ROSAI AND ACKERMAN'S

SURGICAL PATHOLOGY

ROSAI AND ACKERMAN'S

SURGICAL PATHOLOGY

Eleventh Edition

John R. Goldblum, MD
Chairman, Department of Pathology
Cleveland Clinic
Professor of Pathology
Cleveland Clinic Lerner College of Medicine
Cleveland, Ohio

Laura W. Lamps, MD
Professor and Vice-Chair for Academic Affairs
Department of Pathology
University of Arkansas for Medical Sciences
Little Rock, Arkansas

Jesse K. McKenney, MD
Vice-Chair for Faculty Development
Department of Pathology
Cleveland Clinic
Cleveland, Ohio

Jeffrey L. Myers, MD
A. James French Professor of Pathology
Director, Division of Anatomic Pathology and MLabs
University of Michigan School of Medicine
Ann Arbor, Michigan

ELSEVIER

ELSEVIER

1600 John F. Kennedy Blvd.
Ste. 1800
Philadelphia, PA 19103-2899

Rosai and Ackerman's Surgical Pathology, Eleventh Edition **ISBN: 978-0-323-26339-9**
International Edition **ISBN: 978-0-323-44208-4**
Copyright © 2018 by Elsevier Inc.
Previous editions copyrighted 2011, 2004, 1996, 1989, 1981, 1974, 1968, 1964, 1959, 1953 by Mosby Inc., an affiliate of Elsevier Inc.

All rights reserved. No part of this publication may be reproduced or transmitted in any form or by any means, electronic or mechanical, including photocopying, recording, or any information storage and retrieval system, without permission in writing from the publisher. Permissions may be sought directly from Elsevier's Rights Department: phone: (+1) 215 239 3804 (US) or (+44) 1865 843830 (UK); fax: (+44) 1865 853333; e-mail: healthpermissions@elsevier.com. You may also complete your request on-line via the Elsevier website at http://www.elsevier.com/permissions.

Notice

Knowledge and best practice in this field are constantly changing. As new research and experience broaden our knowledge, changes in practice, treatment and drug therapy may become necessary or appropriate. Readers are advised to check the most current information provided (i) on procedures featured or (ii) by the manufacturer of each product to be administered, to verify the recommended dose or formula, the method and duration of administration, and contraindications. It is the responsibility of the practitioner, relying on their own experience and knowledge of the patient, to make diagnoses, to determine dosages and the best treatment for each individual patient, and to take all appropriate safety precautions. To the fullest extent of the law, neither the Publisher nor the Authors assume any liability for any injury and/or damage to persons or property arising out of or related to any use of the material contained in this book.

The Publisher

International Standard Book Number: 978-0-323-26339-9

Executive Content Strategist: Michael Houston
Senior Content Development Manager: Kathryn DeFrancesco
Publishing Services Manager: Patricia Tannian
Senior Project Manager: John Casey
Design Direction: Amy Buxton

Printed in China

9 8 7 6 5 4 3 2 1

To those whom I owe everything: my wife, Asmita; my children, Andrew, Ryan, Janavi, and Raedan; my late parents, Bette and Raymond; and the rest of the Goldblum and Shirali families whom I will always cherish.

JRG

For Paul Ward, with much love and thanks for your unwavering support of my love of writing.

LWL

To my academic mentors: James W. Grau, Shobha Sharma, Mahul B. Amin, Sharon W. Weiss, Michael R. Hendrickson, and Richard L. Kempson. You have all had an enormous impact on my life and career. Thank you.

JKM

To my wife, Eileen McMyler, for her constant support and encouragement despite the costs in nights and weekends lost.

JLM

Contributors

DANIEL A. ARBER, MD
Professor and Chair
Department of Pathology
University of Chicago
Chicago, Illinois

STEVEN D. BILLINGS, MD
Co-Director, Dermatopathology Section
Department of Pathology
Cleveland Clinic
Cleveland, Ohio

LAURA C. COLLINS, MD
Associate Professor
Department of Pathology
Harvard Medical School
Boston, Massachusetts

CHARLES G. EBERHART, MD, PhD
Professor
Departments of Pathology, Ophthalmology, and Oncology
Johns Hopkins University School of Medicine
Baltimore, Maryland

BLAKE GILKS, MD
Professor
Department of Pathology and Laboratory Medicine
Vancouver General Hospital and University of British Columbia
Vancouver, British Columbia, Canada

THOMAS J. GIORDANO, MD, PhD
Henry Clay Bryant Professor of Pathology
Department of Pathology
Michigan Medicine
University of Michigan
Ann Arbor, Michigan

JOHN R. GOLDBLUM, MD
Chairman, Department of Anatomic Pathology
Cleveland Clinic
Professor of Pathology
Cleveland Clinic Lerner College of Medicine
Cleveland, Ohio

NEERAJA KAMBHAM, MD
Professor
Department of Pathology
Stanford University
Stanford, California

B.K. KLEINSCHMIDT-DEMASTERS, MD
Professor
Departments of Neurology, Neurosurgery, and Pathology
University of Colorado School of Medicine
Anschutz Medical Campus
Aurora, Colorado

LAURA W. LAMPS, MD
Professor and Vice-Chair for Academic Affairs
University of Arkansas for Medical Sciences
Little Rock, Arkansas

JONATHAN B. MCHUGH, MD
Associate Professor
Department of Pathology
University of Michigan
Ann Arbor, Michigan

JESSE K. MCKENNEY, MD
Vice-Chair for Faculty Development
Department of Pathology
Cleveland Clinic
Cleveland, Ohio

DYLAN V. MILLER, MD
Professor
Department of Pathology
University of Utah
Intermountain Medical Center
Salt Lake City, Utah

JEFFREY L. MYERS, MD
A. James French Professor of Pathology
Director, Divisions of Anatomic Pathology and MLabs
University of Michigan School of Medicine
Ann Arbor, Michigan

ARIE PERRY, MD
Professor
Departments of Pathology and Neurological Surgery
Chief, Neuropathology Division
University of California–San Francisco
San Francisco, California

JOHN D. REITH, MD
Professor
Departments of Pathology, Immunology, and Laboratory Medicine and Orthopaedics and Rehabilitation
University of Florida
Gainesville, Florida

MARC K. ROSENBLUM, MD
Founder's Chair and Chief
Neuropathology and Autopsy Service
Memorial Sloan Kettering Cancer Center
Professor
Department of Pathology and Laboratory Medicine
Weill Medical College of Cornell University
New York, New York

GIOVANNI TALLINI, MD
Professor of Pathology
Department of Medicine (DIMES)
University of Bologna School of Medicine
Bologna, Italy

Preface

It is a daunting task to continue the incredible tradition of Drs. Rosai and Ackerman's work on this monumental surgical pathology textbook. No single pathologist is capable of tackling the complexities of modern surgical pathology, as the depth and breadth of knowledge required to write such a comprehensive textbook grows with each passing year. In light of this, we decided that a team approach was necessary to uphold the excellent tradition of this textbook and, hence, the 11th edition of *Rosai and Ackerman's Surgical Pathology* was born. The four of us were truly humbled to be invited to continue this tradition, as were our colleagues who joined the team. It was clear to us from the inception that our goal was to maintain Dr. Rosai's style and singular voice as best we could. We are hopeful the reader will notice a continuity of style with the previous editions. Nevertheless, it is impossible to emulate Dr. Rosai's unique voice as the only surgical pathologist in the world who could write multiple editions of this textbook.

The previous edition of *Rosai and Ackerman's Surgical Pathology* was published in 2011. Much has changed in surgical pathology since then, including identification of new entities, reappraisal of older entities, and increasingly sophisticated ancillary techniques, including immunohistochemistry and molecular diagnostics as tools commonly applied in the everyday practice of surgical pathology. We recognized the need for additional help from a number of expert colleagues in different areas of surgical pathology; we are truly grateful to the many authors who have contributed their time and energy to this project. As eloquently stated by Dr. Rosai in the preface of the 10th edition, "A constant attempt has been made to preserve as much as possible the pragmatic flavor initially given to this work by its peerless begetter, Dr. Lauren V. Ackerman."

Each of us is truly grateful to the countless staff pathologists, pathology residents, and fellows at each of our respective institutions who have helped us complete this textbook. We would like to thank Drs. Rahul Jawale, Lani Clinton, Youran Zou, Ryan Berry, Sara Hawes, Hannah Goyne, Ankur Sangoi, Christopher Przybycin, and Amy McKenney for their superb assistance with reviewing and proofreading the text. We would also like to sincerely thank Ms. Kathleen Ranney and Ms. Beth Minors for their outstanding administrative assistance—none of this work would be possible without them. Finally, we would like to thank Ms. Asmita Shirali for her efforts in representing the group of editors.

Most of all, we would like to thank Dr. Juan Rosai for allowing us the opportunity to follow in his enormous footsteps. It goes without saying that Dr. Rosai has been and remains one of the legendary giants of the field of surgical pathology, and it is our greatest professional honor to be able to carry on his tradition in the form of the 11th edition of *Rosai and Ackerman's Surgical Pathology*.

John R. Goldblum, MD
Laura W. Lamps, MD
Jesse K. McKenney, MD
Jeffrey L. Myers, MD

Preface
to the First Edition

This book can be only an introduction to the vast field of surgical pathology: the pathology of the living. It does not pretend to replace in any way the textbooks to general pathology, its purpose being merely to supplement them, assuming that the reader has a background in or access to those texts. The contents are not as complete as they might be because emphasis has been placed on the common rather than the rare lesions and are, to a great extent, based on the author's personal experiences. This book has been written for the medical student as well as for those physicians who are daily intimately concerned with surgical pathology. This must of necessity include not only the surgeon and the pathologist, but also those physicians in other fields who are affected by its decisions, such as the radiologist and the internist. Gross pathology has been stressed throughout with an attempt to correlate the gross findings with the clinical observations. The many illustrations have been selected as typical of the various surgical conditions, although in a few instances the author has been unable to resist showing some of the more interesting rare lesions he has encountered. Concluding each chapter there is a bibliography listing those references which are not only relatively recent and readily available, but also those which will lead the reader to a more detailed knowledge of the subject.

Dr Zola K Cooper, Assistant Professor of Pathology and Surgical Pathology, has written one of the sections on Skin, and Dr David E Smith, Assistant Professor of Pathology and Surgical Pathology, has written the chapter on Central Nervous System. Both of these members of the Department are particularly well qualified for their respective roles because of their background and present responsibilities in these fields. Their efforts on my behalf are most gratefully acknowledged.

Many members of the Surgical Staff at Barnes Hospital have given much help both knowingly and unwittingly. I am particularly grateful to Dr Charles L Eckert, Associate Professor of Surgery, for letting me bother him rather constantly with my questions and for giving freely of his experience. Dr Richard Johnson, who succeeded me as Pathologist at the Ellis Fischel State Cancer Hospital, agreeably made available all the material there, and Dr Franz Leidler, Pathologist at the Veterans Hospital, has been most cooperative.

Thanks must be given to Dr HR McCarroll, Assistant Professor of Orthopedics, for constructively criticizing the chapter on Bone and Joint, and to Dr California Waldron for helping me with the chapters related to the Oral Cavity. Among other faculty friends and colleagues who were especially helpful, I would like to mention Dr Carl E Lischer, Dr Eugene M Bricker, Dr Heinz Haffner, Dr Thomas H Burford, Dr Carl A Moyer, Dr Evarts A Graham, Dr Robert Elman, Dr Edward H Reinhard, Dr J Albert Key, Dr Glover H Copher, Dr Margaret G Smith, and Dr Robert A Moore. Mr Cramer K Lewis, of our Department of Illustration, has been very patient with my demands, and his efforts and skill have been invaluable. Miss Marion Murphy, in charge of our Medical Library, and her associates gave untiringly of their time.

Because of recent advances in anesthesia, antibiotics, and pre- and postoperative care, modern surgery permits the radical excision of portions or all of various organs. There is a need today for contemplative surgeons, men with a rich background in the fundamental sciences, whether chemistry, physiology, or pathology. The modern surgeon should not ask himself, "Can I get away with this operation?" but rather, "What does the future hold for this patient?" It is hoped that this book may contribute in some small fashion toward the acquisition of this attitude.

Lauren V Ackerman MD
St. Louis, Missouri, 1953

Introduction: The Legacies of Dr. Lauren V. Ackerman and Dr. Juan Rosai

1

Jesse K. McKenney

Excellence is an art won by training and habituation. We do not act rightly because we have virtue or excellence, but we rather have those because we have acted rightly. We are what we repeatedly do. Excellence, then, is not an act but a habit.

—Aristotle

The continuous success of this book since the first edition appeared in 1953 is a testament to the incredible careers of Dr. Lauren Ackerman and Dr. Juan Rosai and their unrelenting pursuit for excellence. We find it fitting to begin this 11th edition with their personal stories, so that younger generations will understand the magnitude of their impact on our field of surgical pathology.

Lauren V. Ackerman, MD

Dr. Lauren Ackerman was born in Auburn, New York in 1905. After completing studies at Hamilton College in 1927 and a year of work as an engineer, he entered medical school at the University of Rochester where he received his degree in 1932. At the recommendation of his medical school mentor, Dr. George Whipple, he traveled to the West Coast and completed training in internal medicine at the University of California, San Francisco (a decision that certainly had great influence on his approach to surgical pathology). After working as an Assistant Professor of Medicine focusing on pulmonary disease and autopsy correlation, Dr. Ackerman decided to pursue pathology. From 1936 to 1939 he was a pathology resident at Pondville Hospital in Wrentham, MA, where he studied under the legendary Dr. Shields Warren and developed his lifelong interest in tumor pathology.

In 1940, Dr. Ackerman became the Director of Laboratories at Ellis Fischel State Cancer Hospital in Columbia, MO. With the combination of his clinical background in internal medicine, his growing experience with tumor histology, and a commitment for nothing short of excellence, he helped to shape a model cancer hospital. During this time, he wrote his groundbreaking oncology textbook, with co-author Dr. Juan del Regato, *Cancer: Diagnosis and Treatment*, which served as the premier reference for a generation of oncologists through multiple editions. It was also during his time in Columbia that he described verrucous carcinoma, based on correlation with the unexpected local clinical aggressiveness of the tumor that seemed incongruous with the bland histologic features.

In 1948, Dr. Ackerman was recruited to Washington University in St. Louis as pathologist-in-chief at Barnes Hospital where he spent the next 25 years. During this phase of his career, his influence on other pathologists was enormous. He played a major role in the evolution of surgical pathology into a field that was focused on the clinical implications of histologic findings with regard to prognosis and therapy. Dr. Juan Rosai reminisced on his first experience with an Ackerman case conference; he thought he had entered the wrong room because of the thorough discussion of clinical history and imaging studies that was taking place. Dr. Ackerman codified his approach to the practice of surgical pathology in 1953 with publication of the first edition of this book, *Surgical Pathology*, which greatly increased the worldwide reach of his teaching and has had long-lasting impact on the evolution and current strength of our discipline. In 1973, Dr. Ackerman moved to the Department of Pathology of SUNY at Stony Brook, where he continued to practice pathology for 20 more years until his death at the age of 88.

During his career spanning over 50 years, Dr. Ackerman received enumerable awards for his professional contributions, including the Janeway Medal from the American Radium Society (1970), the Fred W. Stewart Award of the Memorial Sloan Kettering Cancer Center (1986), and the Gold-Headed Cane from the American Association of Pathologists and Bacteriologists (1987). In 1990, the new Surgical Pathology Laboratory at Washington University was dedicated in honor of Lauren V. Ackerman, MD, and, at that time, he also received the Distinguished Service Award from Washington University. In

1992, he received the Prix de Paris Award in recognition of his work at the Institut Gustave-Roussy in Villejuif.

One would be remiss discussing Dr. Ackerman without paying homage to his wit, which "by report" sometimes bordered on irreverent or even abrasive. During one particular dinner, he was given the task of choosing the table's wine, which he certainly enjoyed. After being told that the restaurant did not have either of the first two bottles of wine he requested, he asked for "the list of wines you actually have… not the list of wines you wish you had." On another occasion, after witnessing a young trainee order a "scotch and coke," he noted "I bet you like Tchaikovsky." One can only imagine his response to an improperly handled gross specimen.

Despite all of Dr. Ackerman's accomplishments, his most impressive legacy may be the lasting influence of surgical pathologists he trained. At the time of his death, Dr. Leon Sokoloff, professor emeritus of pathology and orthopedics at Stony Brook said, "He, more than anyone else, changed the character of anatomical pathology by directing the focus toward surgical pathology." The fact that so many leaders in academic surgical pathology emerged from Washington University is a testament to his mentorship and ability to inspire. His emphasis on the ideal that care of the patient be the driving force in surgical pathology continues on. It is unlikely that any practicing surgical pathologist today has not been trained or influenced by one of Ackerman's disciples.

Juan Rosai, MD

Giovanni "Juan" Rosai was born in Poppi, Italy (a small town in Tuscany) in 1940 and emigrated to Argentina with his parents at the age of eight. He attended the School of Medicine at the University of Buenos Aires where he met his first mentor in pathology, Dr. Eduardo Lascano. At the time of his graduation, the Hospital Regional Mar del Plata had just opened with the first formal residency programs in Argentina. Dr. Rosai became their only pathology resident, and he handled every surgical case and autopsy under the tutelage of Dr. Lascano, who had also moved to the new facility. At the time that a complex political situation ended the existence of the teaching hospital, Dr. Rosai met Dr. Lauren Ackerman, who was giving a talk at a medical conference in Buenos Aires. That meeting led to an acceptance of a residency with Dr. Ackerman at the Washington University in St. Louis, where Dr. Rosai completed training and remained as faculty until 1974. Dr. Rosai subsequently led several departments of pathology in the United States, first as: Director of Anatomic Pathology at the University of Minnesota (1974–1985), Director of Anatomic Pathology at Yale University (1985–1991), and Chairman of Pathology at Memorial Sloan Kettering (1991–1999). After a 35-year career in the United States, Dr. Rosai returned to Italy to serve as Chair of Pathology at the Cancer Institute of Milan.

Throughout his career, Dr. Rosai has made enumerable contributions to the field of pathology. His landmark descriptions of distinct entities include Rosai-Dorfman disease (sinus histiocytosis with massive lymphadenopathy), desmoplastic small round cell tumor, sclerosing angiomatoid nodular transformation of the spleen, and spindle epithelial tumor with thymus-like differentiation of the thyroid (SETTLE). To date, he has published over 400 articles, as well as 52 books, book chapters, and monographs. He served as editor in chief for the third series of the AFIP Fascicles and was the founding editor in chief of *The International Journal of Surgical Pathology*. He personally authored two of the third series AFIP Fascicles: *Tumors of the Thymus* and *Tumors of the Thyroid Gland* and edited a book on the history of surgical pathology in America, *Guiding the Surgeon's Hand*. A recent educational milestone was the creation of *The Juan Rosai Collection of Surgical Pathology Seminars,* an open online resource that includes digital images of the original slides and an annotated discussion representing nearly 1500 seminars and over 18,000 individual cases. Of course, one of Dr. Rosai's most renowned contributions has been the authorship of *Rosai and Ackerman's Surgical Pathology*, which he took over for Dr. Ackerman in 1981. Handling this task as a single author will probably stand as one of the monumental accomplishments of modern surgical pathology education and is a feat that we are quite sure will never be duplicated. *In this 11th edition our goal is to preserve what we can of his voice and influence, while acknowledging that there is no one among us who could singlehandedly create this work.*

Dr. Rosai has received numerous professional awards and honors over his career. These include Doctorate Honoris Causa from the University of Bologna (Italy), the University of Santiago de Compostela (Spain), the National University of Cordoba (Argentina), and the University of Ioannina (Greece). He is a Life Trustee of the American Board of Pathology and served for many years creating the Anatomic Pathology examination. His lifetime of service to the United States and Canadian Academy of Pathology (USCAP) and the International Academy of Pathology (IAP) has been acknowledged with the Maude Abbot Lectureship (USCAP 1995), the Distinguished Pathologist Award (USCAP 2010), and the Golden Medal Award (IAP 2011). Other recognition includes an Honorary Membership in the Royal College of Pathologists (England 2001) and the Fred Waldorf Stewart Award of the Memorial Sloan Kettering Cancer Center (New York 2006).

Personal stories can tell measures about a person's abilities, and Dr. Rosai's many trainees over the years all describe in near identical detail an otherworldly consult sign-out experience. On a typical day, as an unusual consult case was reviewed under the microscope (which could be from anywhere on the body), Dr. Rosai would ask someone to pull a specific box of slides off of the wall and another to retrieve a specific file folder containing manuscripts and notes. Of course, the lesions represented by the slides within the box were identical to the case under discussion and the folder contained relevant

articles and personal thoughts. For those with a love of surgical pathology, one cannot imagine a more magical and enlightening experience.

Dr. Rosai is known by many from the hundreds of educational lectures given over his career. His lectures often include philosophical discussions about current tumor classification with an admixture of historical antecedents that clarify the evolution of a specific topic. Of course, he is also masterful at presenting key diagnostic features and pitfalls for everyday practice. The delivery of these lectures is difficult to describe on the written page, but his wit and grace (combined with his incredible depth of knowledge) create a dynamic live experience that is seldom duplicated in surgical pathology conferences. His lectures still create an anticipatory buzz wherever he is speaking.

Today, Dr. Rosai maintains an active diagnostic surgical pathology consultation practice in Milan, Italy at the International Center of Oncologic Pathology Consultations of the Centro Diagnostico Italiano and also serves as a consultant surgical pathologist for ARUP laboratories in Salt Lake City, Utah. His academic activities continue as evidenced by his contributions to four new manuscripts in 2016, covering thyroid and neuroendocrine neoplasia. Dr. Rosai is one of the most distinguished surgical pathologists of the 20th century for his incredible (and unmatched) breadth and depth of knowledge, service to the field, and his remarkable ability to make us all better pathologists.

Bibliography

Ackerman LV. Verrucous carcinoma of the oral cavity. *Surgery*. 1948;23(4):670-678.

Armstrong S. *Conversations with Pathologists. An Interview with Juan Rosai*. http://www.pathsoc.org/conversations/index.php?view=article&catid=66%3Ajuan-rosai&id=86%3Ajuan-rosai-full-transcript&option=com_content&Itemid=123.

Chan JK, Rosai J. Tumors of the neck showing thymic or related branchial pouch differentiation: a unifying concept. *Hum Pathol*. 1991;22(4):349-367.

Gerald WL, Miller HK, Battifora H, et al. Intra-abdominal desmoplastic small round-cell tumor. Report of 19 cases of a distinctive type of high-grade polyphenotypic malignancy affecting young individuals. *Am J Surg Pathol*. 1991;15(6):499-513.

Kempson RL. A tribute to Lauren V. Ackerman. *Cancer*. 1993;72(11):3137-3138.

Martel M, Cheul W, Lombardi L, et al. Sclerosing angiomatoid nodular transformation: a report of 25 cases of a distinctive benign splenic lesion. *Am J Surg Pathol*. 2004;28(10):1268-1279.

Personal communications: Drs. Richard Kempson, Ronald Dorfman, Robert Rouse, and Stacey Mills.

Rosai J, ed. *Guiding the Surgeon's Hand. The History of American Surgical Pathology*. Washington, DC: American Registry of Pathology; 1997.

Rosai J. Obituary. Lauren V. Ackerman. *Am J Surg Pathol*. 1994;18(2):211-213.

Rosai J. Sinus histiocytosis with massive lymphadenopathy. A newly recognized benign clinicopathological entity. *Arch Pathol*. 1969;87(1):63-70.

Saxon W. *Obituary. Lauren Ackerman, 88, Professor and an Author of Medical Texts*. New York Times. July 30, 1993.

Wick MR, ed. A Festschrift for Dr. Juan Rosai. *Sem Diag Pathol*. 2016;33(5):243-356.

2 Dermatoses

Steven D. Billings

CHAPTER CONTENTS

Introduction to dermatopathology, *6*
Normal anatomy, *7*
Inflammatory dermatoses, *8*
Inflammatory dermatoses with epidermal change, *8*
Spongiotic dermatitis, *8*
Stasis dermatitis, *10*
Psoriasiform dermatitis, *10*
Interface dermatitis, *11*
Inflammatory dermatoses with dermal but not epidermal change, *15*
Perivascular dermatoses, *15*
Nodular and diffuse dermatoses, *19*
Palisading granulomatous disease, *20*
Sclerosing disorders, *22*
Scleroderma/morphea, *22*
Eosinophilic fasciitis, *23*
Lichen sclerosus, *23*
Panniculitis, *23*
Erythema nodosum, *23*
Nodular vasculitis/erythema induratum, *24*
Lipodermatosclerosis, *24*
Vesiculobullous diseases, *25*
Subepidermal bullous disease, *25*
Intraepidermal bullous disease, *28*
Infections, *29*
Viral diseases, *29*
Bacterial diseases, *30*
Fungal diseases, *34*
Miscellaneous disorders, *35*
Foreign body reaction, *35*
Pyoderma gangrenosum, *35*
Elastosis perforans, *35*
Pseudoxanthoma elasticum, *35*
Cutaneous mucinosis, *36*
Acanthosis nigricans, *36*
Darier disease, *36*
Dermatoses in HIV-infected patients, *37*

Introduction to Dermatopathology

The entities described in this section are a select group taken from the large number of diseases that affect the skin. They have been chosen to encompass the types of non-neoplastic material generally seen in surgical pathology laboratories. Many of the infrequently biopsied, histologically nonspecific, and rare dermatoses are excluded. Their characteristics are described in texts devoted wholly to dermatopathology and in the dermatologic literature.[1–12]

The fact that isolated histopathologic analysis has distinct limitations becomes more evident in the evaluation of the reactive processes associated with diseases of the skin than in most other organs. It is imperative that the clinical differential diagnosis be correlated with the gross and microscopic observations to render a clinically meaningful diagnosis.[13]

Skin biopsies are often small and have minimal gross changes. Ideally, the lesion should be examined by the pathologist on the patient, but, in lieu of this, an accurate clinical description and differential diagnosis should accompany each biopsy. With the ease of digital photography, the inclusion of a clinical image can be extremely useful in the interpretation of the biopsy findings. All biopsies should be taken from grossly characteristic areas. It is a waste of time and money to biopsy ruptured bullae, secondarily infected or heavily scratched areas, or the incipient or involuting lesion. Multiple biopsies may be advisable when the lesions present differing forms and stages. In diseases in which the expected changes are quantitative rather than qualitative (i.e. hyperkeratosis, acanthosis, increase in dermal thickness), the evaluation of these changes is best made by taking a punch biopsy also of clinically normal skin nearby, which represents the best possible control. Formalin, 10% buffered, is an adequate and widely available fixative. Bouin and Zenker fixatives may be used but have no unique merits. Incisional and punch biopsies can be kept from curling during fixation by placing them on a piece of file card prior to immersion. When the specimen is 0.3 mm or less in diameter, it is best processed into paraffin in one piece. It may then be sampled at various levels in the block. This prevents loss of tissue during the facing-up of the

Abstract

This chapter focuses on inflammatory diseases, infectious diseases, and miscellaneous disorders of the skin. For inflammatory disorders of the skin, the entities are classified according to reaction patterns. Entities with significant epidermal change are categorized into spongiotic, psoriasiform, and interface patterns. For entities without significant epidermal change, they are classified into perivascular, nodular and diffuse, palisading granulomatous, and sclerosing patterns. Panniculitis is subdivided into septal and lobular patterns, and bullous disease is divided into subepidermal and intraepidermal bullous dermatoses. Infections are categorized by nature of the infectious agent. At the end of the chapter is a group of miscellaneous disorders that are not easily classified in the aforementioned groups.

Keywords

Spongiotic dermatitis,
psoriasiform dermatitis,
interface dermatitis,
perivascular dermatitis,
nodular and diffuse dermatoses,
palisading granulomatous dermatitis,
scleroderma/morphea,
panniculitis,
vesiculobullous disease,
infection,
pyoderma gangrenosum

block and allows more adequate sampling. These technical niceties prevent delays, mishaps, and some mistakes.

Normal Anatomy

The skin or integument is a complex organ with many functions and with three main anatomic components: epidermis and skin adnexa, melanocytic system, and dermis and subcutis.[14–17]

The epidermis is a stratified squamous epithelium that differentiates to form the outer protective layer of keratin. It is composed of keratinocytes arranged in four layers: basal, squamous (prickle, malpighian), granular, and cornified (horny). The basal cells are the mitotically active cells that give rise to all other keratinocytes; they contain low-molecular-weight keratin and are separated from the dermis by a continuous basal layer, to which they are attached by hemidesmosomes. The basal membrane is a complex antigenic structure that plays an important role in many cutaneous diseases.[18] The dermoepidermal junction is thrown into undulating folds of interlocking ridges of epidermis (rete ridges) and dermal papillae. Thus the undersurface of the epidermis seen in whole mounts presents an anastomosing and reticulated pattern of ridges and valleys. The pattern and size of these ridges vary from area to area. With age, they diminish in size, and the dermoepidermal junction becomes flattened.

The squamous layer is composed of several layers of cells, which become larger, more flattened, and more eosinophilic as they approach the surface. This correlates with the intracytoplasmic accumulation of filaments, which are the precursors of keratin, and a diminution of ribosomes. Some cells in the squamous layer exhibit a clear, vacuolated cytoplasm (sometimes resulting in nuclear indentation), which should not be confused with melanocytes or Paget cells. Melanocytes and Paget cells, unlike vacuolated keratinocytes, have cytoplasm clinging to their nuclei. When the cells are separated, as a result of fixation and dehydration or intercellular edema, these areas of attachment are seen via the light microscope as fine spiny ("intercellular") bridges, with a dot-like structure at their center (Bizzozero nodule), representing the desmosome. The epidermal cells are not a syncytium, and true intercellular bridges do not exist. Destruction of these attachments causes the cells to lose their cohesion. This process, termed acantholysis, is seen in pemphigus vulgaris and related diseases. The granular layer is composed of one to three layers of flattened cells containing keratohyaline granules. These coarse, intensely basophilic granules are rich in histidine and represent the precursors of the protein filaggrin, which is responsible for the aggregation of keratin filaments. The cornified layer contains multiple layers of polyhedral cells that have lost their nuclei and that are arranged in a basket-weave pattern (except for the acral regions, in which this layer is thick and compact). The skin from the palms and soles features an additional layer—the stratum lucidum—located between the granular and the cornified layers and appearing as a homogeneous eosinophilic zone.

The major proteins of basal keratinocytes are keratins 5 and 14, which form an extensive network of 10-nm cytoskeletal filaments. As keratinocytes differentiate, they downregulate this pair of keratins and switch on expression of other pairs, the nature of which is dependent on the site. In the epidermis, terminally differentiated keratinocytes express keratins 1 and 10.

The keratinization cycle usually takes 30–45 days. Many dermatoses result in alterations in the pattern and speed of this process. Abnormal keratinization may be manifest by hyperkeratosis, in which the stratum corneum is thickened, usually in association with a more prominent granular layer, or by parakeratosis, in which the cells of the stratum corneum retain their nuclei and the granular layer is diminished or absent.

Certain descriptive terms are applied to alterations in the pattern of the epidermis. It may become *atrophic* or thinned with age or disease. It may be thickened, and as it proliferates the rete ridges extend deeper into the dermis, a process known as *acanthosis*. Outward overgrowth of the epidermis accompanied by elongation of the dermal papillae is *papillomatosis*. A degenerative process in which the basal cells become vacuolated, separated, and disorganized is called *liquefactive* or *hydropic degeneration*. Various combinations of these changes are seen in the dermatoses, and this descriptive jargon allows succinct communication.

In addition to keratinocytes, the normal epidermis contains melanocytes, Langerhans cells, and Merkel cells. Melanocytes are described in more detail in the chapter on cutaneous neoplasms. Langerhans cells are bone marrow–derived dendritic cells whose function is to present antigens to immunologically competent T cells. They are scattered throughout the upper part of the squamous layer and are difficult to identify in routinely stained sections. Ultrastructurally, they have a characteristic organelle—the Birbeck granule—a rod-shaped structure with zipper-like striations and sometimes a bulbous end. Immunohistochemically, they express CD1a, langherin, and S-100 protein; they have receptor sites for the Fc portion of the immunoglobulin G (IgG) molecule and the third component of complement.[15]

Merkel cells, also extremely difficult to identify in hematoxylin and eosin (H&E) sections and even with special stains, are concentrated in the glabrous skin of the digits, lips, outer root sheath of hair follicles, and tactile hair disks. Ultrastructurally, they contain cytoplasmic dense core (neurosecretory-type) granules, often arranged beneath the cell membrane or located within unmyelinated neurites. Spinous processes projecting from the cytoplasm anchor these cells to adjacent keratinocytes. Immunohistochemically, Merkel cells are reactive for neuron-specific enolase (NSE), neurofilaments, keratin (including CK20), chromogranin, and synaptophysin.[15,19,20]

The skin adnexa are represented by the hair follicles, sebaceous glands, sweat (eccrine) glands, and apocrine glands. The hair follicle, sebaceous gland, erector pili muscle, and (in certain regions) the apocrine gland constitute a functional complex known as the *pilar unit*.

The hair follicle is responsible for the formation of hair, a cyclic process that proceeds in three phases: *anagen* or growing phase, *catagen* or involuting phase, and *telogen* or resting phase. The mitotically active cells of the hair follicles lining the dermal papilla are the matrix (generative) cells. These cells give rise to the hair shaft and the *inner root sheath*. The outer layer of the latter structure is surrounded by a layer of large clear (glycogen-rich) cells known as the *outer root sheath*. At the level of the isthmus, these cells undergo an abrupt type of keratinization, which occurs without the interposition of a granular layer; this is referred to as *trichilemmal keratinization* and, by extension, the layer itself is known as the *trichilemmal sheath*. By contrast, the keratinization in the infundibular portion of the follicle is similar to that of the adjacent epidermis. It is not unusual to find *Demodex* folliculorum mites, clumps of *Staphylococcus epidermidis*, and yeasts of *Malassezia* (formerly *Pityrosporum*) inside the pilar infundibulum.

The sebaceous glands are lobulated structures containing an outer layer of germinative cells that, as they differentiate, move toward the inside and accumulate intracytoplasmic lipid droplets. These result in a typical multivacuolated appearance, with multiple indentations of the centrally located nucleus. The excretory duct of the sebaceous glands opens into the infundibulum of the hair follicle.

Sweat glands are of three types: *eccrine* (responsible for thermoregulation and therefore the only "true" sweat glands), *apocrine*, and *mixed* (apoeccrine glands). Eccrine sweat glands are tubular structures with a secretory and an excretory portion. The secretory coil, located

in the deep dermis or sometimes in the subcutis, is composed of secretory cells (further divided into clear and dark cells) and myoepithelial cells. The excretory portion is composed of a dermal (straight) and an intraepidermal (spiral) portion, the latter also known as the *acrosyringium*.

Although the apocrine glands are concentrated in the axillae, groin, and perineum, they also occur in small numbers on the face and elsewhere. Like eccrine glands, they have a secretory and an excretory component. It is the former that gives them their highly characteristic appearance. The cells have an abundant acidophilic cytoplasm, which may contain lipid, iron, and lipofuscin.

Immunohistochemically, the various epithelial components of eccrine and apocrine glands stain for carcinoembryonic antigen (CEA), epithelial membrane antigen (EMA), keratin, S-100 protein, the enzyme carbonic anhydrase, ferritin, secretory immunoglobulin, and pregnancy-specific β-I-glycoprotein (SPI). In addition, apocrine glands express the marker known as gross cystic disease fluid protein (GCDFP)-15.[21] The myoepithelial cells stain for actin, calponin, caldesmon, S-100 protein, and Sox10.[21–28]

The epidermal adnexa are seldom the sites of primary changes. However, diagnostic changes do occur: heterotopias as in nevus sebaceous of Jadassohn, in which apocrine glands are found in the scalp; pigmentation of eccrine gland basement membranes in argyria and hemochromatosis; atrophy, as in scleroderma; duct obstruction with subsequent retention, as in the various forms of miliaria; and deposition of aggregates of granules of mucoprotein in the eccrine gland cells in myxedematous patients.

The dermis is a connective tissue structure composed of collagen and elastic fibers bathed in ground substance and containing adnexal structures, vessels, and nerves. It is divided into two layers: adventitial and reticular. The adventitial dermis comprises the superficial layer located immediately beneath the epidermis—the papillary dermis—and that located around adnexal structures—the periadnexal dermis.[15]

The *adventitial dermis* is largely composed of a delicate network of collagen fibers (mainly type I, with a scattering of type III or "reticulin" fibers), whereas the *reticular dermis* is made up of thick bundles of type I collagen intermixed with thick elastic fibers.

The thickness of the dermis varies considerably from area to area; it is particularly thick in the back, a feature that is sometimes misinterpreted as being abnormal in biopsies.

The subcutaneous tissue (subcutis) is composed of lobules of mature adipose tissue separated by thin bands of connective tissue interlobular septa. The dermal blood vessels are divided into a deep plexus (located in the reticular dermis) and a superficial plexus (located in the papillary dermis), with communicating vessels in between. From the superficial vascular plexus, capillary loops extend into the dermal papillae. The acral skin contains specialized arteriovenous anastomoses—the *Sucquet–Hoyer canals*—surrounded by a row of modified smooth muscle—the *glomus cells*—which have a round shape, clear cytoplasm, and well-defined cytoplasmic borders. The lymphatics of the skin are also divided into a deep and a superficial plexus.

Specialized nerve end organs present in the skin are the *Wagner–Meissner corpuscles* (with a tactile function; mainly located in the papillary dermis of the palms and soles) and *Pacinian corpuscles* (sensitive to pressure; mainly located in the deep dermis and subcutis of weight-bearing areas). With age, and more so in areas exposed to sunlight, the collagen and elastica undergo structural and tinctorial changes called *solar (actinic) elastosis*. These changes should not be attributed to some suspect disease and should be distinguished from pathologic connective tissue changes, such as increased dermal mucin deposition.

The dermis is the site of inflammatory reactions. In normal skin, a few fibroblasts, macrophages, mast cells, lymphocytes, and dermal dendrocytes are present. The latter represent a population of mononuclear dendritic cells located in the papillary and upper reticular dermis and are thought to function as antigen-presenting cells. They express the coagulation factor XIIIa (also known as fibrin stabilizing factor) and are known to increase in number in a large number of inflammatory and neoplastic disorders.[29]

The perivascular and periadnexal spaces and the papillary layer of the dermis are the usual sites in which inflammatory cells aggregate. Certain dermatoses, such as lichen planus and chronic discoid lupus erythematosus, have distinct patterns of inflammatory reaction. Others, such as urticaria pigmentosa, have a specific cellular population. Changes in the nerves, visible in sections stained with H&E, are infrequent but when present are of note (see section on leprosy).

Inflammatory Dermatoses

As previously mentioned, a thorough and detailed discussion of inflammatory dermatoses is beyond the scope of this text and the reader should seek texts devoted to dermatopathology for a complete discussion of inflammatory diseases of the skin. Nevertheless, biopsies of inflammatory diseases are still encountered with relative frequency by surgical pathologists. Therefore some familiarity with these entities is necessary. Approaching inflammatory dermatoses based on the pattern of inflammation is a rational approach that results in more refined diagnoses. Multiple different patterns exist. For the purposes of this text, a simplified approach will be used. Broadly speaking, the inflammatory reaction patterns can be divided into five groups: (1) dermatoses with significant epidermal changes, (2) dermatoses with dermal inflammation without significant epidermal change, (3) sclerosing diseases, (4) panniculitis, and (5) immunobullous/vesiculobullous disease. These will be discussed in turn. There are also a variety of diseases with specific etiologies (e.g. infections) and miscellaneous disorders that will be described separately at the end of the chapter.

Inflammatory Dermatoses With Epidermal Change

There are three primary patterns within this group: spongiotic, psoriasiform, and interface dermatitis. Spongiotic dermatitis is characterized by the accumulation of edema fluid within the epidermis, resulting in the epidermal keratinocytes being pulled apart by hydrostatic forces. The psoriasiform pattern is characterized by epidermal acanthosis (hyperplasia) without significant spongiosis. There is often overlap between these patterns. The interface pattern is characterized by a dermal infiltrate, either lichenoid or perivascular, that is associated with damage to the epidermis along the dermoepidermal junction with basal vacuolization and dyskeratotic keratinocytes. Select entities within these groups will be discussed.

Spongiotic Dermatitis

Spongiotic dermatitis is a reaction pattern that is most commonly seen in the clinical spectrum of eczematous dermatitis, including allergic contact dermatitis, nummular dermatitis, atopic dermatitis, dyshidrotic eczema, stasis dermatitis, and eczematous drug reactions. All of these dermatoses are characterized by the presence of intraepidermal edema (spongiosis). Histologically, these entities resemble one another and differentiating them relies on knowledge of the clinical presentation rather than histologic features in most cases. That being said, this group of clinical disorders is frequently biopsied and have common histologic features.[29]

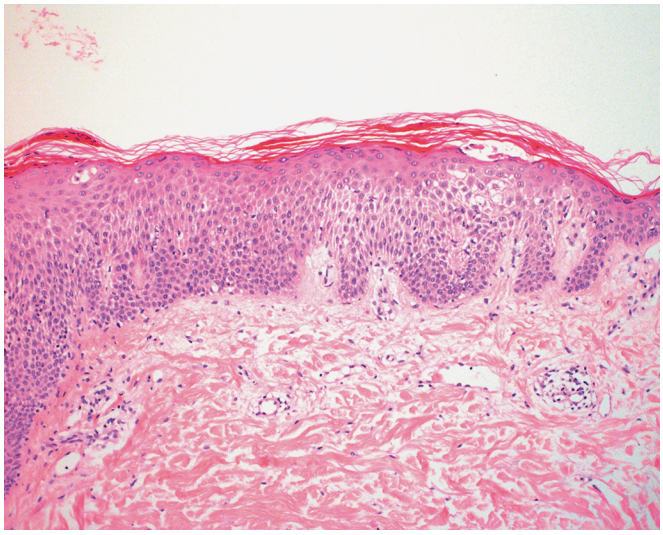

Figure 2.1 Acute Spongiotic Dermatitis. The stratum corneum is largely normal, and there is intraepidermal edema *(spongiosis)* and a superficial perivascular inflammatory infiltrate.

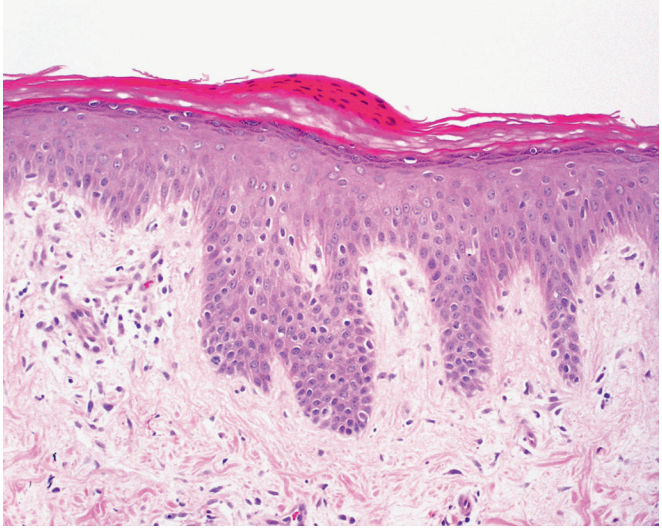

Figure 2.3 Chronic Spongiotic Dermatitis. There is compact hyperkeratosis, a thickened granular layer, minimal spongiosis, and a sparse perivascular infiltrate.

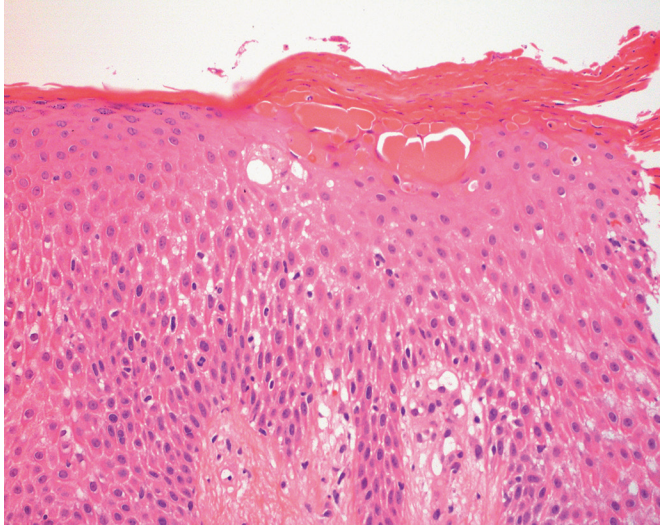

Figure 2.2 Subacute Spongiotic Dermatitis. The epidermis is acanthotic and spongiotic with overlying parakeratosis.

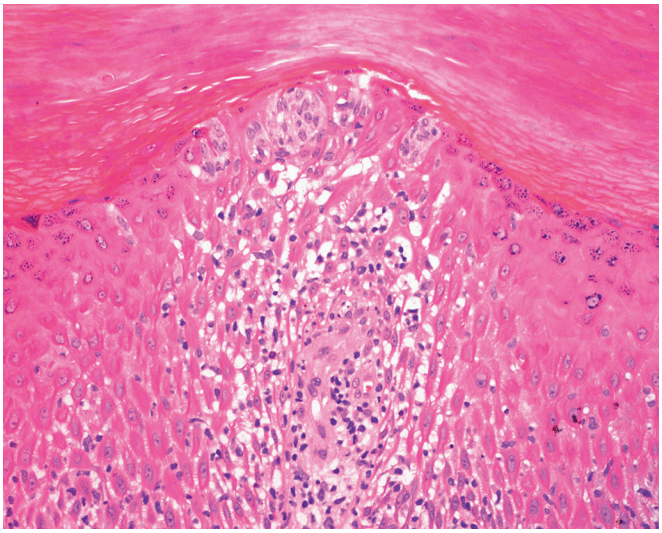

Figure 2.4 Langerhans Cell Microabscess. Intraepidermal collections of Langerhans cells are often found in allergic contact dermatitis.

The histologic features are somewhat dependent on when the biopsy is taken during the disease process. The range of histologic features can be divided into three phases, although one should recognize that these phases exist along a continuum. In *acute spongiotic dermatitis*, there is accumulation of edema fluid in the epidermis, sometimes with spongiotic microvesicle formation. The stratum corneum often retains its normal basket-weave configuration or may have some focal parakeratosis. Acanthosis is absent or mild. Within the dermis there is a variable superficial perivascular infiltrate of lymphocytes often admixed with eosinophils (Fig. 2.1). In the *subacute* form, there is associated parakeratosis, often with a diminished granular layer, acanthosis of the epidermis, variable spongiosis, and a similar superficial perivascular dermal inflammatory infiltrate (Fig. 2.2). In the *chronic* phase, there is often compact hyperkeratosis, a thickened granular layer, acanthosis, minimal spongiosis, and mild superficial inflammatory infiltrate (Fig. 2.3). The subacute and chronic phases can have significant histologic overlap with entities in the psoriasiform dermatitis category. In addition to spongiosis, there is variable parakeratosis, hyperkeratosis, and irregular acanthosis.

Allergic Contact Dermatitis

Allergic contact dermatitis is a common entity that is biopsied with some frequency. Typical examples of common allergens include detergents, nickel, and plants, such as poison ivy, but a whole host of potential allergens exist. Microscopically, it is a spongiotic dermatitis that is indistinguishable from other forms of spongiotic dermatitis. Some cases have Langerhans cell microabscesses in the epidermis (Fig. 2.4). This is a clue to possible allergic contact dermatitis but is not entirely specific.

Nummular Dermatitis

Nummular dermatitis presents as round to oval plaques, commonly on the extremities. Clinically, it may get confused with psoriasis.

Microscopically, most cases show features of subacute spongiotic dermatitis. Clues that help to distinguish it from psoriasis include serum in the parakeratotic scale, epidermal spongiosis, and, when present, eosinophils in the dermal infiltrate.

Atopic Dermatitis

This is a chronic eczematous dermatitis that runs in families and is associated with allergic rhinitis and asthma. It is infrequently biopsied and typically shows features of a subacute to chronic spongiotic dermatitis.

Dyshidrotic Eczema

Also called pompholyx, this is a recurrent dermatitis that affects the hands and feet, and many are in actuality an allergic contact dermatitis. Clinically, it often has a vesicular appearance. Microscopically, it resembles a typical spongiotic dermatitis. Spongiotic microvesicles are relatively common. It is important to exclude a dermatophyte infection, especially in lesions from the feet.

Eczematous Drug Reactions

A small subset of drug eruptions may be eczematous in nature. Histologically, they are not distinguishable from other forms of spongiotic dermatitis. Rather correlation with onset related to a medication is required.

Summary

As a general rule, pathologists can render only a descriptive diagnosis of spongiotic dermatitis because the histologic features themselves are not specific. That being said, it is important to exclude more specific diagnoses, such as psoriasis and dermatophyte infection, which can have overlapping features and are discussed later. If information is known about the clinical presentation, a more specific diagnosis can be suggested in a comment.

Stasis Dermatitis

A more distinct form of dermatitis that can have either a spongiotic or psoriasiform pattern is stasis dermatitis. Stasis dermatitis occurs on the lower legs of older and/or obese patients. Often it is bilateral but sometimes presents as an isolated lesion that can mimic a neoplasm clinically.[30] Microscopically, it is associated with variable acanthosis and spongiosis. The key feature is the presence of a lobular proliferation of relatively thick-walled blood vessels in the papillary dermis (Fig. 2.5). Frequently there are extravasated erythrocytes and siderophages. In longstanding cases there may be significant dermal fibrosis with an associated fibroblastic proliferation, called *acroangiodermatitis*, a condition that can superficially mimic Kaposi sarcoma.[30] It should be remembered that other forms of eczematous dermatitis, such as contact dermatitis, can be superimposed on patients with underlying stasis change.

Psoriasiform Dermatitis

The most common entities in this group include psoriasis and lichen simplex chronicus/prurigo nodularis. This group is characterized by prominent epidermal hyperplasia. That being said, there may be considerable overlap with subacute to chronic spongiotic dermatitis, which also is associated with epidermal hyperplasia. In that regard, placing subacute to chronic spongiotic dermatitis in the spongiotic pattern is somewhat arbitrary.

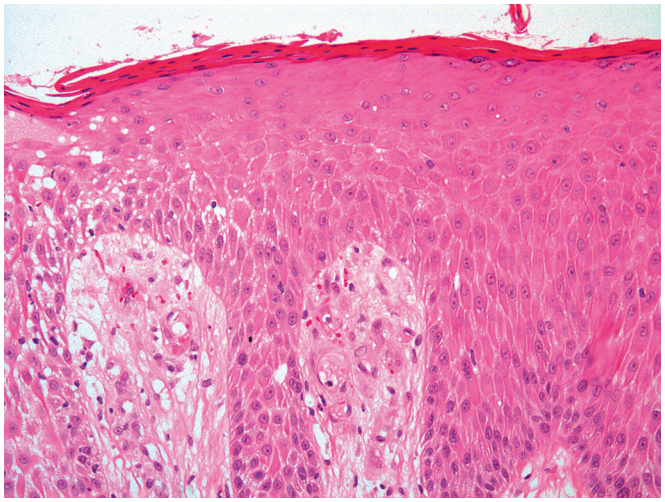

Figure 2.5 Stasis Dermatitis. Within the superficial dermis there is a lobular proliferation of relatively thick-walled vessels with hemorrhage and overlying spongiosis in the epidermis.

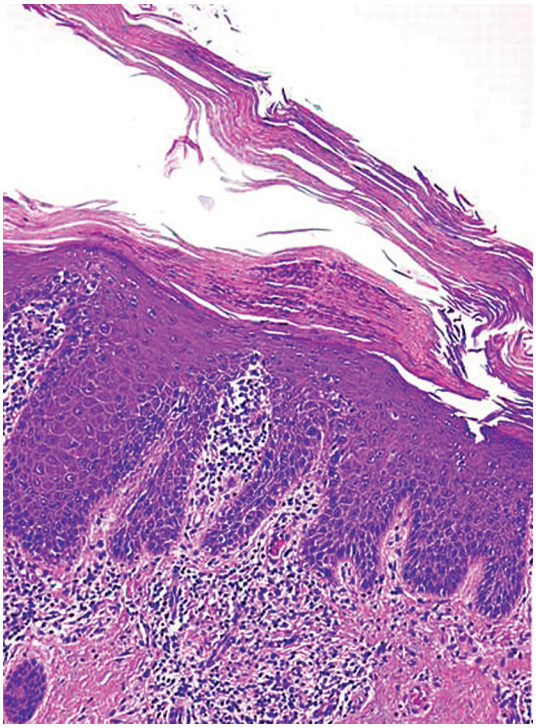

Figure 2.6 Typical Appearance of Psoriasis. Note the engorgement of papillae and Munro microabscesses.

Psoriasis

Psoriasis is one of the more common dermatoses. Estimates of its incidence vary between 0.5% and 1.5% of the population.[31] In its most common form, *psoriasis vulgaris*, it is a chronic, bilaterally symmetric, nonpruritic lesion formed by erythematous plaques covered by fine silvery scales.[32–34] Typically, it involves the extensor surfaces, such as the elbows, knees, back, and scalp. Generalized lesions also occur. The morphologic characteristics are those of uniform acanthosis of the epidermis with prominent parakeratosis and attenuation of the epidermis overlying the dermal papillae, a feature known as "suprapapillary thinning" (Fig. 2.6). Within the

parakeratosis and sometimes the epidermis, there are collections of neutrophils. Within the dermal papillae, the capillaries are dilated and tortuous. There is also a polymorphic inflammatory infiltrate composed of lymphocytes, macrophages, and neutrophils.[35] Psoriasis may also be induced by tumor necrosis factor-α inhibitors, typically in the setting of inflammatory bowel disease.[35] In our experience, drug-induced psoriasis in this setting often has eosinophils, in contrast to conventional psoriasis in which eosinophils are typically absent. Eosinophils are usually absent with the exception of drug-induced forms of psoriasis, usually secondary to tumor necrosis factor-α inhibitors. The hyperproliferation appears to be caused by overexpression of cytokines (e.g. tumor necrosis factor-α, interferon gamma, and various interleukins), as well as chemokines and chemokine receptors (e.g. CCL2, CCL3, CCL4, CXCL1, CXCL8), suggesting a Th1 disorder.[36,37]

Other variants of psoriasis lack the prototypical uniform hyperplasia but will be discussed in this section. *Pustular psoriasis* is a variant in which the subcorneal abscesses are particularly prominent.[31,32,36,38] In pustular psoriasis, there is less prominent epidermal hyperplasia. *Guttate psoriasis* is a special type of psoriasis that is characterized by a rapid onset of small papules and plaques, typically after an antecedent streptococcal pharyngitis. It lacks the epidermal hyperplasia, and the granular layer is often retained. It is characterized by discrete mounds of parakeratosis with collections of neutrophils overlying the epidermis (Fig. 2.7).[38]

The differential diagnosis of psoriasis typically centers on subacute forms of spongiotic dermatitis, usually nummular. In contrast to spongiotic dermatitis, the epidermis in psoriasis is more uniformly acanthotic and the parakeratosis is "dry," lacking the serum present in the overlying crust scale in spongiotic dermatitis. Psoriasis also typically lacks eosinophils (with the exception noted previously), which are frequently present in spongiotic dermatitis. Dermatophyte infections can have similarity to psoriasis. Both have collections of neutrophils in the parakeratosis, but dermatophyte infections usually lack the uniform acanthosis and may have eosinophils in the infiltrate. A periodic acid–Schiff (PAS) or Gomori methenamine silver (GMS) stain can help with this differential diagnosis. *Pityriasis rubra pilaris* is a rare disorder that can closely resemble psoriasis with a similar pattern of acanthosis and parakeratosis. However, collections of neutrophils in the parakeratotic scale are not seen. Finally, partially treated psoriasis may lack some of the typical histologic features. The presence of dilated and tortuous papillary dermal blood vessels can be a clue in partially treated psoriasis. As in all inflammatory dermatoses, clinical correlation is essential.

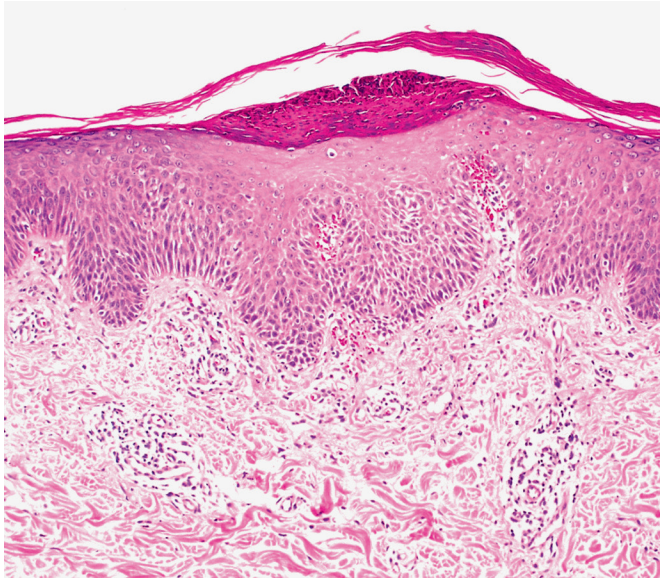

Figure 2.7 Guttate Psoriasis. Note the discrete mound of parakeratosis with overlying collections of neutrophils.

Lichen Simplex Chronicus and Prurigo Nodularis

Lichen simplex chronicus and *prurigo nodularis*, sometimes clinically referred to as neurodermatitis, are ends of a spectrum of a dermatosis that are the result of persistent excoriation rather than inflammation. They are often seen in patients with medical conditions that result in pruritus (e.g. renal failure) and in a subset of patients with psychiatric disorders.[39] They present as plaques (lichen simplex chronicus) or nodules (prurigo nodularis). The clinical location is a clue to the diagnosis in that lesions are only seen in areas that can be readily reached. This condition is most commonly encountered on the extremities, abdomen, genitalia, and scalp, but they may present at any easily accessible location on the body. Lichen simplex chronicus involving perianal and genital skin is often biopsied with a clinical diagnosis of lichen sclerosus. These disorders can also be seen as a complication of a chronic eczematous process, such as a persistent contact dermatitis (see earlier).

Microscopically, they demonstrate marked acanthosis of the epidermis, marked hyperkeratosis, a thickened granular layer, and vertical fibrosis of the papillary dermal collagen (Fig. 2.8).[40] Occasional cases may show pseudoepitheliomatous hyperplasia or focal parakeratosis. Typically, there is little inflammation unless it is superimposed on an underlying chronic eczematous process.

Interface Dermatitis

Interface dermatitis is characterized by basal vacuolization and dyskeratosis. The presence of dyskeratotic keratinocytes is important, as some cases of spongiotic dermatitis have basilar spongiosis that mimics vacuolar change. Broadly speaking, interface dermatitis can be grouped in two patterns: lichenoid and perivascular, although entities within this group may have overlapping features.

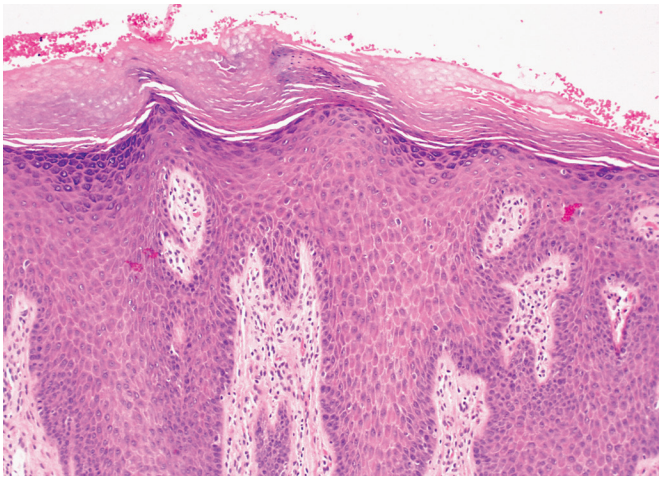

Figure 2.8 Lichen Simplex Chronicus. There is compact hyperkeratosis overlying an acanthotic epidermis with a thickened granular layer. Vertically oriented, thickened collagen bundles are present in the superficial dermis.

Interface Dermatitis With Perivascular Pattern

Erythema Multiforme, Stevens-Johnson Syndrome, and Toxic Epidermal Necrosis

This group of disorders forms of spectrum of dermatoses that are histologically similar. Specific diagnosis requires knowledge of the clinical presentation.[41,42] *Erythema multiforme* is a self-limiting episodic eruption that usually affects acral surfaces and oral mucosa of young adults. It is associated with herpes simplex virus and *Mycoplasma* infections, as well as a variety of medications.[41,42]

Stevens-Johnson syndrome and *toxic epidermal necrolysis* involve both mucosa and epidermis. By definition, Stevens-Johnson syndrome affects ≤10% of the total body surface area and toxic epidermal necrolysis ≥30% of the body surface area, leaving an intermediate category between the two ends of the spectrum. Both Stevens-Johnson syndrome and toxic epidermal necrolysis are almost invariably triggered by adverse reactions to medications. They are considered true emergencies, and there is an associated mortality rate ranging from 10% to 40%. Recognition of Stevens-Johnson syndrome and toxic epidermal necrolysis is therefore critical because these patients may need to be managed in specialized burn units.

Microscopically, all of these entities show similar features. There is interface change characterized by basal vacuolization of the epidermis and frequent necrotic keratinocytes at all levels of the epidermis with exocytosis of lymphocytes into the overlying epidermis (Fig. 2.9).[43] In some cases there is complete necrosis of the epidermis. There is typically a relatively sparse to mild superficial perivascular lymphocytic infiltrate that may contain a few eosinophils.[44] The infiltrate is typically disproportionately mild compared with the amount of epidermal damage. Reactive epidermal changes, such as acanthosis, parakeratosis, and hyperkeratosis, are notably absent, and this absence is a clue to differentiating this group from other dermatoses with interface change. Some cases may have a bullous appearance due to detachment of the epidermis secondary to the marked interface change.[45]

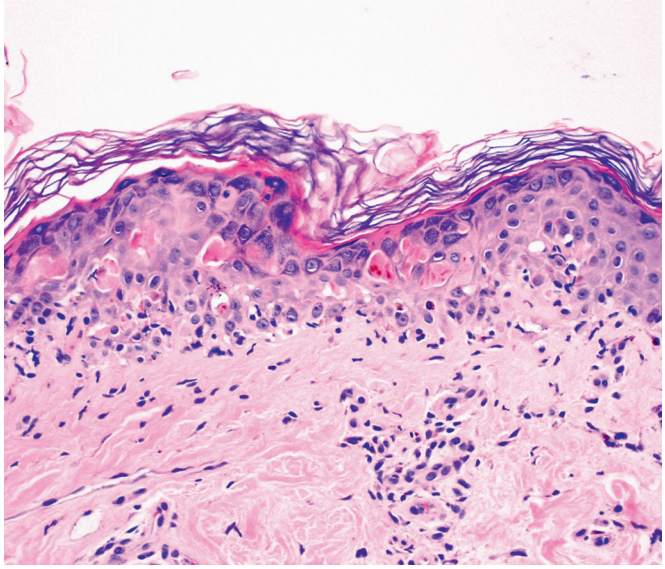

Figure 2.9 Erythema Multiforme. There is interface change with basal vacuolization, numerous dyskeratotic keratinocytes, and a sparse perivascular infiltrate.

Graft-Versus-Host Disease

Graft-versus-host disease is an important cause of morbidity and mortality following bone marrow transplantation. The acute form is characterized microscopically by vacuolization of the basal layer, spongiosis, and individual cell necrosis, associated with mononuclear cell infiltration of the upper dermis (Fig. 2.10).[46,47] Sometimes these epidermal changes occur in the absence of an inflammatory infiltrate.[47] The amount of inflammation seems to be the most important prognostic determinator.[48] This has been quantitated through the Lerner grading system, which has a high degree of interobserver concordance,[49] but which is of limited use in predicting the likelihood of a skin rash progressing to a clinically more significant disease.[50] In this system, grade 1 acute graft-versus-host disease is characterized by basal vacuolization with a superficial perivascular lymphocytic infiltrate without dyskeratotic keratinocytes. Grade 2 has the features of grade 1 graft-versus-host disease but with dyskeratotic keratinocytes and satellite cell necrosis. Grade 3 is associated with cleft formation between the epidermis and dermis, and grade 4 is characterized by complete loss of the epidermis. In general, most cases of acute graft-versus-host disease are grade 2.

The chronic form of graft-versus-host disease has been divided into a predominantly lichenoid form and sclerodermoid form.[51,52] In lichenoid chronic graft-versus-host disease the epidermis shows thickening of the granular layer like lichen planus, but the inflammatory infiltrate is usually less dense. The sclerodermoid form is essentially indistinguishable from scleroderma/morphea with marked sclerosis of dermal collagen.

Lupus Erythematosus

Cutaneous lupus erythematosus can be divided into the chronic/discoid, acute/systemic, and subacute forms.[53–55] *Chronic discoid lupus erythematosus* is a relatively common condition with a distinct preference for women, presenting as delimited erythematous to hyperkeratotic to atrophic patches and plaques on the face, neck, scalp, and, less frequently, the arms and trunk (Fig. 2.11). *Systemic lupus erythematosus* is an immune-mediated disease caused by antibodies to homologous and heterologous DNA. It manifests a protean symptomatology usually characterized by fatigue, fever, arthritis, various cutaneous lesions of which the erythematous bimalar

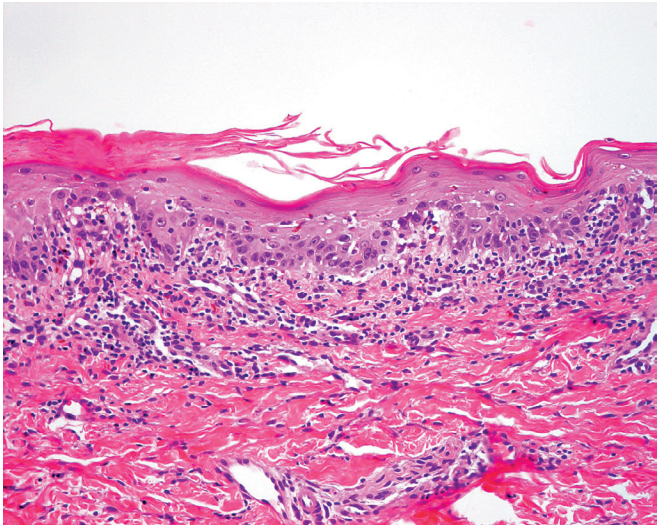

Figure 2.10 Microscopic changes of acute graft-versus-host reaction.

Figure 2.11 Extensive facial lesions of chronic discoid lupus erythematosus.

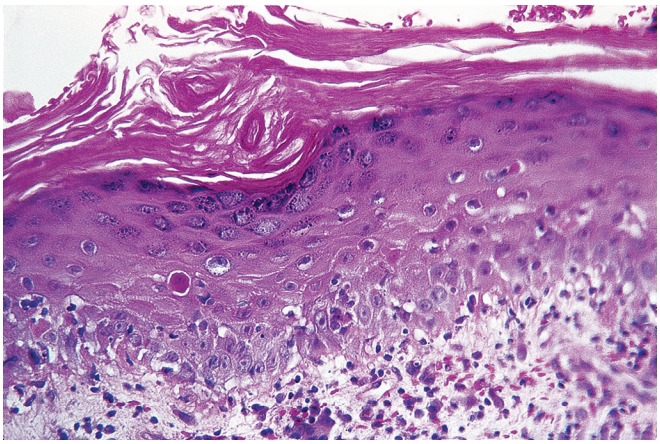

Figure 2.12 Lesion of chronic discoid lupus erythematosus showing hyperkeratosis and interface change with hydropic degeneration along basal layer.

"butterfly" blush is most common, signs of renal involvement, lymphadenopathy, and panserositis. Sunlight may cause exacerbations. *Subacute lupus erythematosus* usually presents as plaques, often annular, on sun-exposed skin of the extremities and trunk. The face is usually spared. Histologically, there is overlap between the subtypes. They all have basal vacuolization with interface change and scattered dyskeratotic cells associated with a superficial or superficial and deep perivascular lymphocytic infiltrate with increased dermal mucin. In the discoid form there is often follicular plugging, epidermal atrophy, a thickened basement membrane, and periadnexal inflammation (Fig. 2.12).[55–58] Eosinophils are absent, and their presence argues against the diagnosis.[59] *Tumid lupus erythematosus* is a form of chronic lupus erythematosus without interface change and may represent the same process that has also been termed *Jessner lymphocytic infiltration of the skin*.[58] Clusters of CD123-positive plasmacytoid dendritic cells are present in lupus erythematosus and their presence can support the diagnosis.[60]

Direct immunofluorescence will show the presence of immunoglobulins (usually IgG and IgM) and so-called membrane attack complex (C5b, C6, C7, C8, and C9) in approximately 90% of specimens obtained from clinically involved skin of patients with either systemic or chronic discoid lupus erythematosus.[61,62] The deposition consists of coalescing clumps along the dermoepidermal junction, resulting in the formation of an irregular band (so-called *lupus band test*), a finding that is not entirely specific for this entity.[63] Clinically uninvolved areas will show deposition of immunoglobulins in approximately half of the patients with systemic lupus erythematosus but no deposition of the membrane attack complex.[61,64] Direct immunofluorescence may be helpful in selected cases but is generally not necessary to establish the diagnosis. Histologic examination and correlation with clinical history usually allows accurate diagnosis.

Dermatomyositis

Dermatomyositis is an inflammatory disorder affecting skeletal muscle and skin, characterized clinically by proximal, symmetric muscle weakness, and cutaneous lesions. There are cutaneous forms without muscle involvement, termed dermatomyositis sine myositis. Microscopically, the skin changes may be those of a nonspecific chronic dermatitis or may acquire features very similar to those of systemic lupus erythematosus, although typically with less inflammation.[65,66] By immunofluorescence, features favoring dermatomyositis over lupus erythematosus are a negative "lupus band test" and deposition of C5b–q (the membrane attack complex of complement).[64] Biopsies of the afflicted muscles show distinct myositis with necrosis of myofibers, fragmentation, phagocytosis, and some sarcolemmal nuclear proliferation. In the later stages, fibrosis, fat infiltration, and fascicular atrophy appear.[67,68]

Much has been written about the incidence or coincidence of adenocarcinoma with dermatomyositis.[69–71] A review of the literature carried out by Williams many years ago found that 15% of dermatomyositis patients had neoplasms of the stomach, breast, ovary, lung, or colon. Remissions of the dermatomyositis have occurred following resection of the neoplasm.[71] Therefore careful investigation of adults with dermatomyositis for undetected carcinoma is certainly worthwhile. However, in the majority none will be found.

Interface Dermatitis With Lichenoid Pattern

Lichen Planus

Lichen planus is a pruritic, violaceous, subacute to chronic, papulosquamous dermatitis of unknown etiology (Fig. 2.13).[72–74] It usually involves the flexor surfaces of the arms and the legs, but it may be found in many other sites. Lesions may be confined to the oral mucosa, or they may precede or accompany the skin changes.[75] Histologically, the well-developed lesions are rather distinct (Fig. 2.14). The epidermis is hyperkeratotic, the granular layer is prominent, and the hyperplastic epithelium forms irregular sawtooth acanthotic pegs. Within the dermis there is a dense band-like (lichenoid) lymphocytic infiltrate that may contain a few eosinophils and histiocytes. Dyskeratotic keratinocytes, also referred to as *Civatte bodies*, are often seen in the basal layer and sometimes also in the upper dermis and malpighian layer. On occasion, subepidermal cleavage occurs with the formation of bullae. In oral lichen planus, there is may be parakeratosis, subtle formation of keratohyaline granules. Prominent hyperkeratosis and hypergranulosis are absent in *oral lichen planus*. Histologically, the dyskeratotic cells and absence of atypia in oral lichen planus assists in distinguishing it from dysplasia (see Chapter 4). Clinicopathologic variants of lichen planus include bullous, pemphigoid, hypertrophic, atrophic, and follicular (lichen planopilaris) forms.[76–79]

A morphologic pattern akin to that of lichen planus and designated as lichenoid dermatitis, lichenoid tissue reaction or

Figure 2.13 Clinical Appearance of Lichen Planus Affecting the Dorsum of the Hand. One of the lesions has been biopsied.

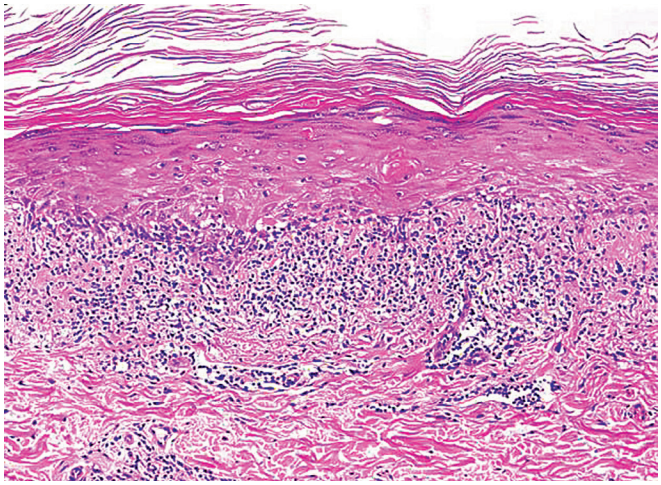

Figure 2.14 Microscopic Appearance of Lichen Planus. There is orthotopic hyperkeratosis, hypergranulosis, basal vacuolization, and a band-like inflammatory infiltrate with melanophages.

interface dermatitis can be seen in a variety of conditions, including lichenoid drug eruptions (see later), lichenoid actinic keratosis, benign lichenoid keratosis, solitary lichen planus, lupus erythematosus, acute graft-versus-host reaction, and several other conditions.[80–87] A lichenoid reaction is the rule in regressing melanoma (a notorious pitfall) and can also be seen in the epidermis overlying a dermatofibroma.[88,89]

Lichenoid Drug Eruption

Lichenoid drug eruptions present as widespread papular eruptions. A variety of agents can trigger lichenoid drug eruptions, including common agents, such as thiazide diuretics. The eruption can develop soon after ingestion of the drug or weeks after.

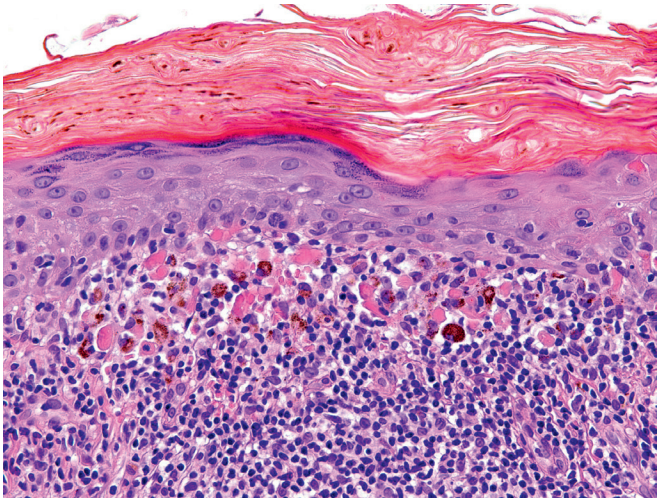

Figure 2.15 Lichenoid Tissue Reaction. Lichenoid drug reactions resemble lichen planus, but typically have parakeratosis, which is usually absent in lichen planus. (Courtesy of Dr Fabio Facchetti, Brescia, Italy.)

Figure 2.16 Fixed Drug Eruption. The infiltrate is rich in eosinophils and is accompanied by necrotic keratinocytes.

Microscopically, lichenoid drug eruptions are very similar to lichen planus. There is a lichenoid lymphocytic infiltrate with prominent epidermal damage. The epidermis has a thickened granular layer. The presence of parakeratosis and conspicuous eosinophils help to distinguish lichenoid drug eruption from lichen planus (Fig. 2.15).[80,87]

Fixed Drug Eruption

Fixed drug eruption is an unusual localized type of adverse medication reaction that recurs in the same location on subsequent exposures.[90–93] Microscopically, it is an interface dermatitis with a lichenoid or perivascular infiltrate and basal vacuolization with dyskeratotic keratinocytes (Fig. 2.16). The overlying stratum corneum usually has a normal basket-weave configuration but may have some parakeratosis. The infiltrate contains lymphocytes, histiocytes, and eosinophils. Melanophages are frequently present.

Pityriasis Lichenoides

Pityriasis lichenoides occurs in two clinical forms: *pityriasis lichenoides acuta et varioliformis acuta* (PLEVA; also known as *Mucha-Habermann disease*) and *pityriasis lichenoides chronica* (PLC).[94–97] The etiology is uncertain but may be related to a hypersensitivity reaction to various

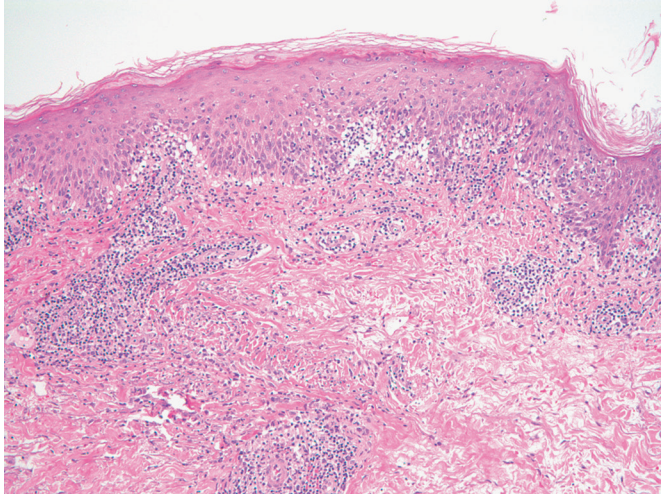

Figure 2.17 Pityriasis Lichenoides Et Varioliformis Acuta. There is interface change with basal vacuolization and a superficial and deep lymphocytic infiltrate with papillary dermal hemorrhage.

infectious agents or drugs.[98–100] It has also been associated with autoimmune disease. PLEVA is associated with the appearance of numerous, small papules that ulcerate and heal, leaving behind smallpox-like (varioliformis) scars. The eruption is predominately on the extremities but may also involve the trunk and buttocks. In PLC the eruption is characterized by brownish-red papules that typically do not result in scarring. Some patients may have overlapping features of both PLEVA and PLC.

Histologically, pityriasis lichenoides shows overlapping features of a lichenoid interface dermatitis and a perivascular interface dermatitis.[101,102] The features somewhat depend on the timing of the biopsy during the evolution of the disease. In fully developed, nonulcerated lesions of PLEVA, there is a superficial perivascular to lichenoid infiltrate with an accompanying wedge-shaped perivascular infiltrate extending into the underlying dermis. There is interface change with basal vacuolization, dyskeratosis, and papillary dermal hemorrhage (Fig. 2.17). The hemorrhage is likely due to a lymphocytic vasculitis, and vasculitic changes can sometimes be seen. In addition to interface change, the epidermis is spongiotic with parakeratosis-prominent exocytosis of lymphocytes and often exocytosis of erythrocytes. Although some authors prefer to classify this as a lymphocytic vasculitis, considering it in the family of interface dermatitis is prudent given the more consistent histologic findings of interface damage. In older lesions, the epidermis may be completely ulcerated. From a pathologic standpoint, ulcerated lesions are histologically nonspecific. Early lesions may show considerably less interface and epidermal change. PLC is similar to PLEVA but with less pronounced histologic features.[102] There is less interface damage, less inflammation, and little to no hemorrhage. Again, a given patient may have lesions that histologically span the spectrum of both PLEVA and PLC.

The differential diagnosis includes other interface dermatitides, as outlined previously. PLEVA has a distinct clinical presentation, which aids in its diagnosis. PLEVA also typically has extravasation of erythrocytes, which is not a conspicuous feature of the aforementioned entities. The presence of spongiosis helps to distinguish it from chronic interface dermatitides, such as lupus erythematosus. Lichen planus and lichenoid drug eruptions have a lichenoid pattern without a deeper perivascular extension. Graft-versus-host disease has much less inflammation. As with all inflammatory diseases, knowledge of the clinical presentation is very helpful.

However, one entity may have a very similar clinical presentation to PLEVA: lymphomatoid papulosis (LYP).[103–106] LYP is actually considered an indolent T-cell lymphoma. There are multiple different histologic types, ranging from type A to E.[107–111] Types A, B, and C are the classic forms. Type A can show considerable histologic overlap with PLEVA but also has numerous large, atypical $CD30^+$ lymphocytes that are not seen in PLEVA admixed within the infiltrate. Type B LYP resembles mycosis fungoides microscopically. Type C histologically resembles cutaneous anaplastic large cell lymphoma, with sheets of large atypical, $CD30^+$ lymphocytes. The primary way to differentiate types B and C LYP from their mimics is knowledge of the clinical history of waxing and waning papulonecrotic lesions.

Inflammatory Dermatoses With Dermal but Not Epidermal Change

This section will encompass a wide variety of entities and by necessity is somewhat superficial, mostly concentrating on more common dermatoses. The patterns discussed will include perivascular, nodular and diffuse, palisading granulomatous and sclerosing dermatoses.

Perivascular Dermatoses

This pattern is typified by an inflammatory infiltrate that is predominantly in a perivascular distribution. Some entities in this pattern will have overlapping features with the nodular and diffuse pattern. This further highlights how inflammatory diseases and their patterns are on a biologic continuum that we by necessity categorize as discrete entities.

Dermal Hypersensitivity Reactions

Dermal hypersensitivity reaction is a somewhat wastebasket term that encompasses a variety of entities, most commonly morbilliform drug eruptions, urticaria, and arthropod bite reactions. Although clinically distinct, these entities may be histologically indistinguishable. Morbilliform drug eruptions tend to be widespread, erythematous maculopapular eruptions associated with ingestion of a new medication, although sometime it may take weeks after initiation of a new medication, complicating the clinicopathologic correlation. Urticaria, or hives, classically presents as transient wheals that resolve in 24 hours, although occasionally they may be more persistent. Arthropod bite reactions may present as solitary lesions or numerous papules.

Morbilliform drug eruptions are the most common type of adverse medication reaction.[112] They are usually characterized by a mild superficial or superficial and deep, perivascular mixed inflammatory infiltrate of lymphocytes with a few eosinophils (Fig. 2.18). Some cases may show mild basal vacuolization, therefore overlapping with the interface pattern. *Urticaria* is almost identical with a mild perivascular infiltrate of lymphocytes, eosinophils, and sometimes neutrophils.[113,114] In urticaria, there may also be margination of neutrophils in the vascular lumens. In chronic cases, there may be subtle vascular damage resulting in urticarial vasculitis.[113,115] *Arthropod bite reactions* have a similar pattern of inflammation with eosinophils but typically a denser inflammatory infiltrate (Fig. 2.19). In the setting of underlying hematologic malignancies, such as chronic lymphocytic leukemia, reactions to arthropod assaults can be quite pronounced.[116]

Vasculitis

There is a large group of cutaneous diseases in which the basic alteration is an inflammatory change in the wall of the dermal and/

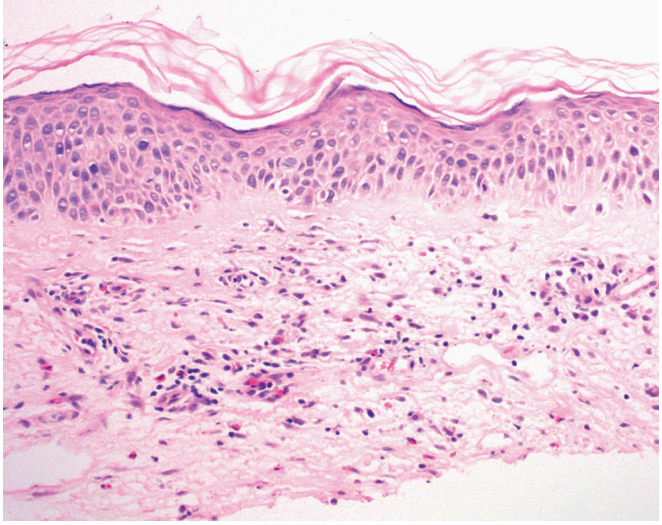

Figure 2.18 Morbilliform Drug Eruption. The epidermis is relatively normal. Within the dermis there is a mild perivascular infiltrate of lymphocytes and eosinophils.

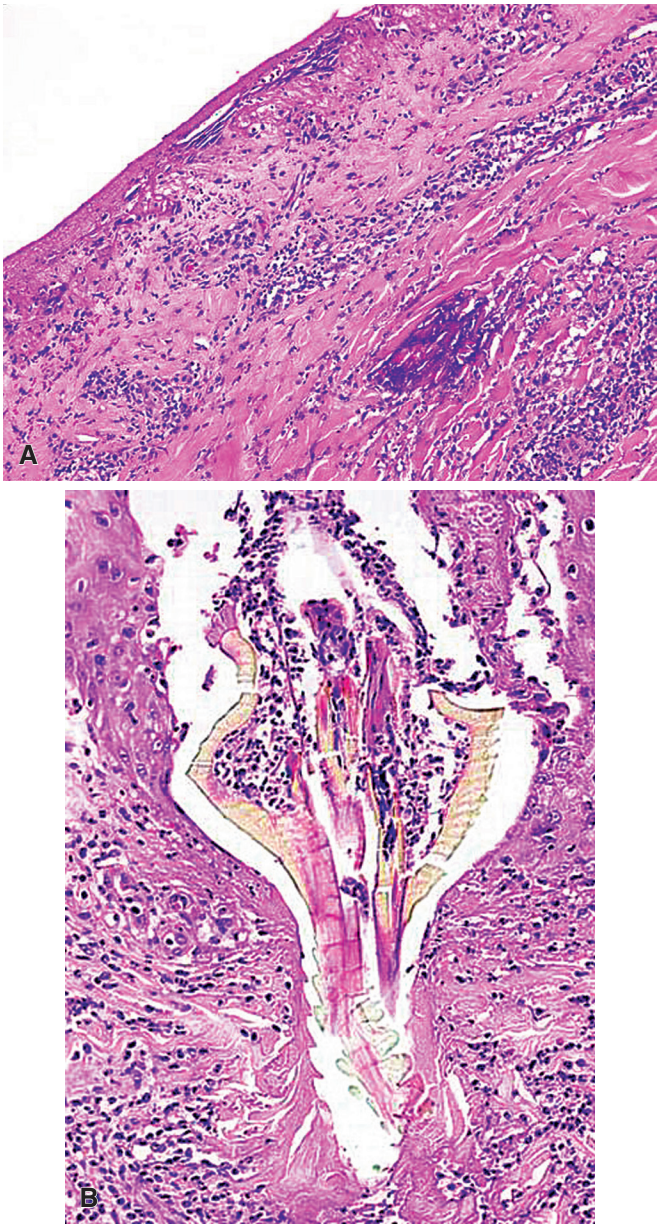

Figure 2.19 Arthropod Bite. A, Heavy inflammatory dermal infiltrate around necrotic focus. **B,** Section of the arthropod. (Courtesy of Dr Raffaele Gianotti, Milan, Italy.)

or subcutaneous vessels (i.e. a vasculitis).[117–120] The mechanism is in all likelihood immune mediated for the majority of them, through the action of immune complexes.[121,122] The disease can be restricted to the skin or also involve internal organs; if limited to the skin, it may be generalized or localized to a single focus.[123] The vessels involved may be the capillaries of the papillary dermis, arterioles, and venules of the deep dermis and subcutaneous tissue, or deep-seated medium-sized vessels. Erythrocytes extravasation is a constant feature.

The inflammatory infiltrate can be predominantly neutrophilic (usually accompanied by leukocytoclasis), lymphocytic, eosinophilic, or granulomatous.[124,125] Necrotizing changes (usually of fibrinoid type) of the vessel wall may be present or absent. Secondary changes in the overlying epidermis and in the sweat glands are frequent.[126] Direct immunofluorescence often shows granular deposits of immunoglobulins, complement, and fibrin in and about vessel walls, although with the exception of Henoch-Schönlein purpura, direct immunofluorescence plays little role in the diagnosis.[127,128]

Taking into account all of the foregoing features, morphologic classifications of cutaneous vasculitides have been proposed that correlate well with a variety of clinical conditions.[125,129–131]

Leukocytoclastic (neutrophilic, allergic) *vasculitis* is a neutrophilic vasculitis of small vessels accompanied by fibrinoid necrosis and leukocytoclasis (Fig. 2.20).[125] It usually presents as purpuric palpable lesions, most commonly on the lower part of the legs. Systemic involvement, particularly of the kidneys, is frequently found in the form known as Henoch-Schönlein purpura (IgA vasculitis).[128,132] *Henoch-Schönlein purpura* resembles conventional leukocytoclastic vasculitis but on direct immunofluorescence has prominent perivascular deposits of IgA and variable deposits of complement C3. Other distinct subtypes of leukocytoclastic vasculitis are those associated with chronic idiopathic urticaria, hypocomplementemia, and essential mixed cryoglobulinemia.[133,134] The presence of systemic disease is more likely when the vasculitis extends deeply into the reticular dermis or subcutaneous fat,[135] but in general the morphologic features of the systemic and the purely cutaneous form are the same.[136–138]

Etiologic agents include infections, foreign proteins, chemicals, drugs, and a variety of diseases. Some patients with acute leukemia develop cutaneous vasculitis, the suggestion having been made that the vascular injury is mediated by the leukemic blasts.[139]

Involvement of larger vessels, often accompanied by necrotizing changes, is seen in allergic granulomatosis of Churg and Strauss, polyarteritis nodosa (systemic or limited to the skin), giant cell arteritis, and granulomatosis polyangiitis (formerly Wegener granulomatosis).[140–143] Prominent vascular involvement without necrotizing changes is also seen in the cutaneous lesions of lymphomatoid granulomatosis, a form of B-cell lymphoma.[144,145] Angiodestruction can be seen in type E LYP.[110]

Other entities associated with vascular injury that do not fit in the category of leukocytoclastic vasculitis include pigmented purpuric dermatosis, perniosis, malignant atrophic papulosis, and segmented hyalinizing vasculitis (atrophie blanche of Milian).

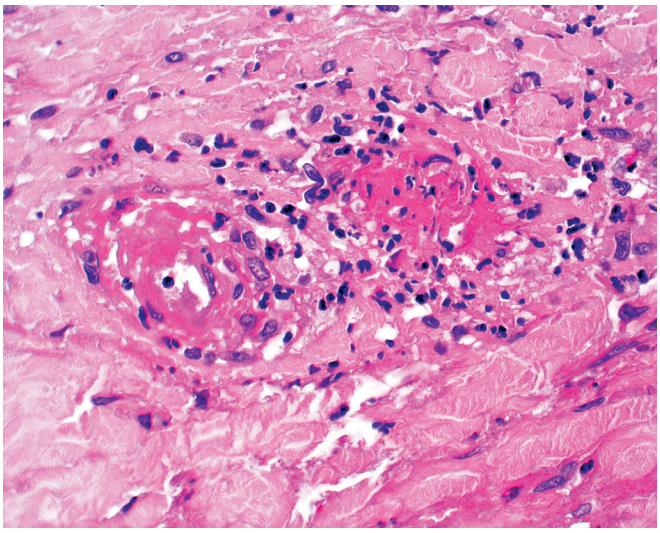

Figure 2.20 Acute Necrotizing Changes in Leukocytoclastic Vasculitis.

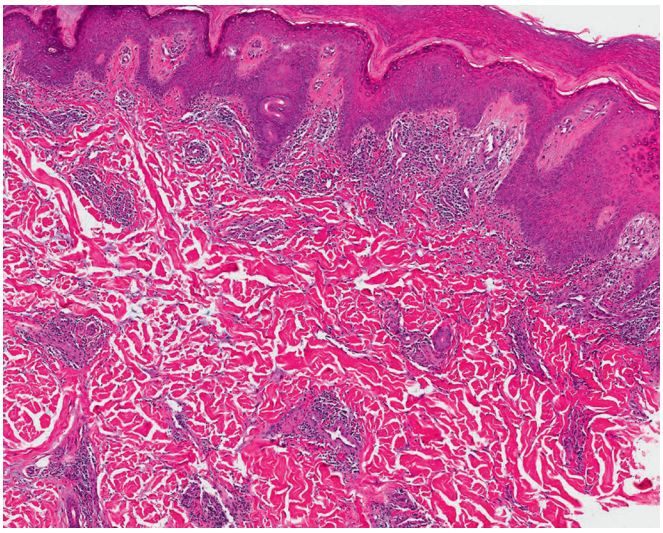

Figure 2.22 Perniosis is characterized by a superficial and deep perivascular lymphocytic vasculitis.

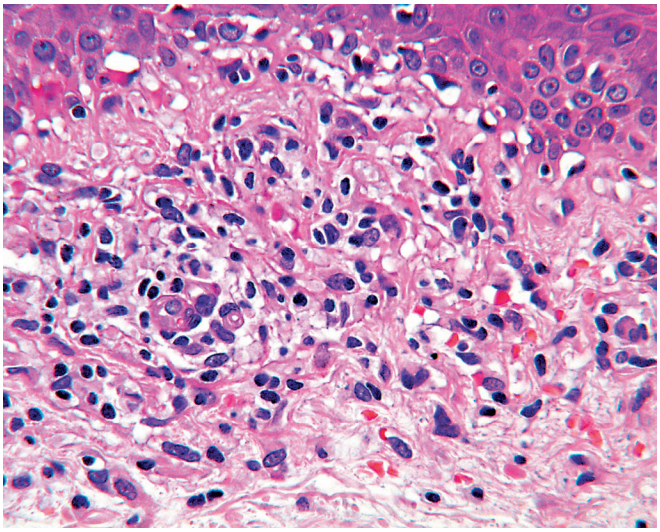

Figure 2.21 Chronic Non-Necrotizing Vasculitis in Pigmented Purpuric Dermatosis.

Pigmented Purpuric Dermatosis

Pigmented purpuric dermatosis has a variety of clinical forms, the most common of which is *Schamberg disease*. Schamberg disease most commonly presents in men and is characterized by asymptomatic, bilateral purpura and petechiae, most commonly involving the lower extremities. Clinically, it may be confused with leukocytoclastic vasculitis but lacks the indurated nature of the lesions seen in leukocytoclastic vasculitis. Microscopically, it consists of a superficial perivascular infiltrate of lymphocytes with extravasated erythrocytes and sometimes siderophages (Fig. 2.21).[146,147] The vessels can show endothelial swelling, and the condition is considered by some a form of lymphocytic vasculitis, although fibrinoid necrosis of vessels is not seen.

Perniosis/Chilblains

Perniosis usually occurs in cold, damp weather and most commonly presents as painful, erythematous nodules on the fingers or toes. It is a form of lymphocytic vasculitis. Microscopically, there is a superficial and deep perivascular and perieccrine lymphocytic infiltrate (Fig. 2.22). The vessels often demonstrate fibrinoid change that has been described as having a fluffy appearance. Papillary dermal edema is often marked.[148,149]

Malignant Atrophic Papulosis (Degos Disease)

This disorder usually occurs in young adult men and is characterized by papules and patches with a central, depressed white area surrounded by an erythematous rim. It has been associated with lupus erythematosus and may represent a reaction pattern rather than a distinct entity. Microscopically, the main change is an ischemic, wedge-shaped infarct of the skin resulting from intimal proliferation of a deep-seated arteriole with or without a lymphocytic infiltrate.[150–152]

Atrophie Blanche

In atrophie blanche (segmented hyalinizing vasculitis) the dermal capillaries show focal endothelial proliferation, marked thickening of the wall by PAS-positive eosinophilic hyaline material, and eventually occlusion of the lumen by a fibrin thrombus (Fig. 2.23).[153,154] This condition has been associated with a variety of hypercoagulable states, and the presence of numerous thrombosed vessels should prompt the pathologist to recommend an appropriate evaluation to exclude those possibilities.

Calciphylaxis

Calciphylaxis usually presents in patients with chronic renal failure as bilateral, painful ulcers involving the thighs. Involvement of the breasts, buttocks, and penis has also been described. This is a medical emergency with a mortality rate greater than 50%.[155–157] Histologically, most of the findings are in the subcutis. Therefore it is important that any diagnostic biopsy be of adequate depth. Calciphylaxis is characterized by calcium deposition in small- to medium-sized arterioles, associated with thrombosis and extensive fat necrosis of the subcutis (Fig. 2.24). The calcium deposits are usually evident in routine H&E sections, but von Kossa stains may be useful in selected cases. Vascular thrombosis of vessels in the overlying dermis may also be seen.

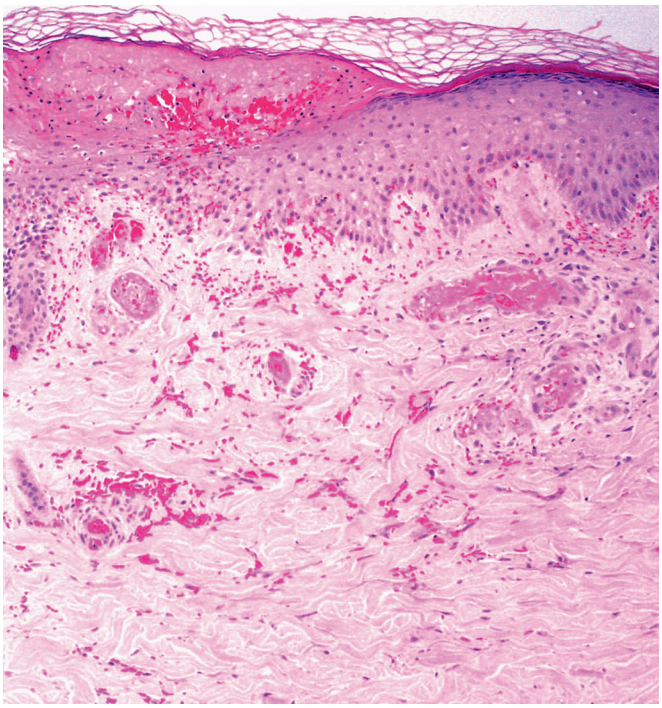

Figure 2.23 Atrophie blanche is characterized by intravascular fibrin thrombi without a true vasculitis.

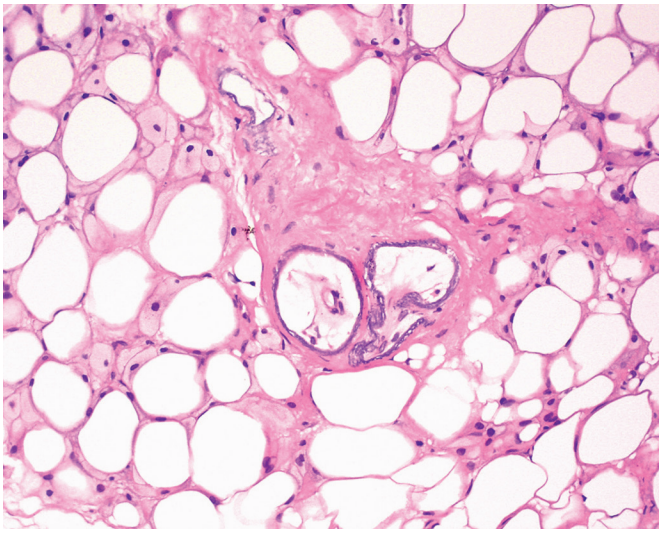

Figure 2.24 **Calciphylaxis.** There is calcium deposition affecting vessels in the subcutis and associated fat necrosis.

Mastocytosis

Mastocytosis of the skin can manifest in the form of *urticaria pigmentosa*, (solitary) *mastocytoma*, *diffuse and erythrodermic cutaneous mastocytosis*, and *telangiectasia macularis eruptiva perstans*.[158–161] Urticaria pigmentosa, accounting for approximately 80% of cutaneous mastocytosis, usually has its onset during childhood in the form of multiple brown macules.[158,162] On occasion, it makes its first appearance in adults.[162] The brown macules may be diffusely distributed or, less frequently, may be single.[160,163] When the lesions are stroked, the skin urticates because of the release of histamine.

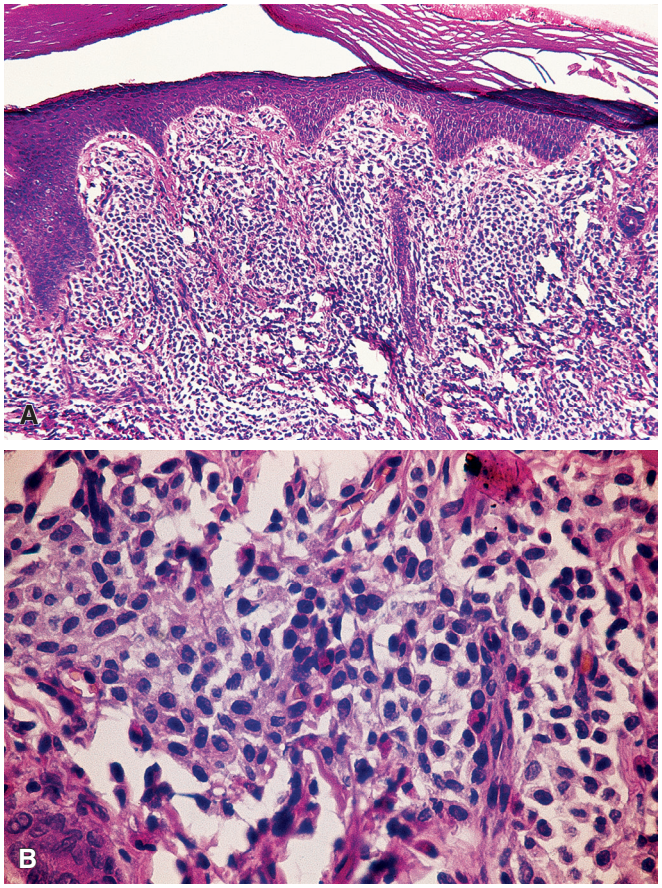

Figure 2.25 **Urticaria Pigmentosa. A,** Diffuse dermal infiltrate of mast cells admixed with eosinophils. **B,** High-power view of the infiltrate. (Courtesy of Dr Raffaele Gianotti, Milan, Italy.)

Systemic mastocytosis accounts for approximately 20% of cases and may have involvement of the spleen, liver, bone marrow, and lymph nodes, with or without cutaneous lesions.[164,165] Most behave in an indolent fashion, but aggressive forms with a malignant clinical course, including mast cell leukemia, do occur. In general, it is not possible on morphologic grounds to distinguish urticaria pigmentosa with systemic involvement from that having skin disease only,[166] but expression of CD2 or CD25 on mast cells is more common in patients with systemic disease.[167] Aberrant expression of CD30 is also associated with more aggressive disease.[168]

The diagnosis of mastocytosis in a skin biopsy can be easily missed unless the cytologic features of mast cells in sections stained with H&E are remembered (Fig. 2.25).[169] Some of the cells have large, pale nuclei, distinct cytoplasmic boundaries, and a faintly granular cytoplasm. Others are elongated and closely simulate fibroblasts or perithelial cells. Mast cells can be highlighted with toluidine blue, Giemsa, or Leder cytochemical stains. They can also be highlighted with immunohistochemical stains for tryptase, calretinin, and CD117 (c-kit) (Fig. 2.26).[170–173] The mast cells are often admixed with eosinophils, a feature that may induce confusion with Langerhans cell histiocytosis, but the latter often has involvement of the epidermis and is positive for S100 protein, langerin, and CD1a. Mutations of KIT have been documented in a significant proportion of cases.[174,175] Therefore patients with systemic disease may respond to treatment with imatinib mesylate.[176,177]

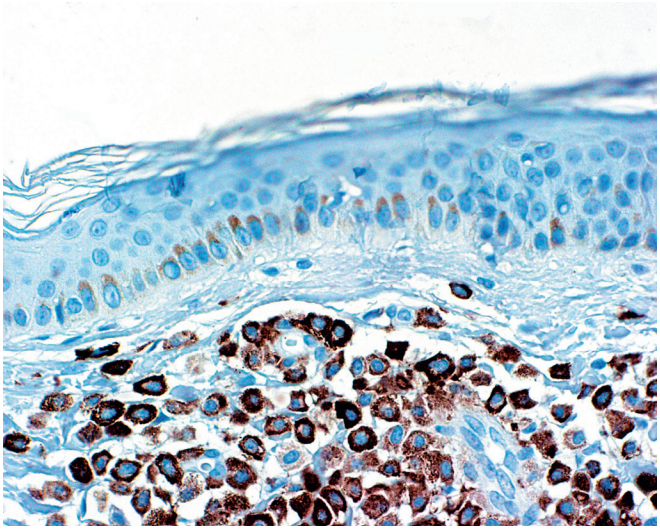

Figure 2.26 Urticaria Pigmentosa. Immunohistochemical demonstration of mast cells with tryptase.

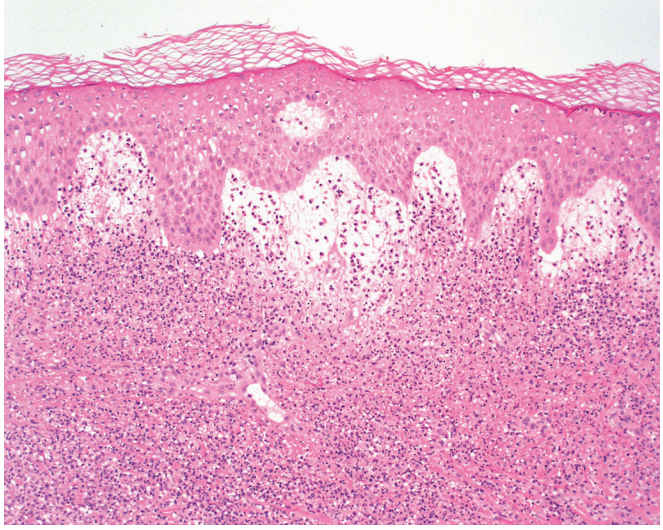

Figure 2.27 Sweet Syndrome. Diffuse dermal infiltrate of neutrophils with leukocytoclasis but without vasculitis.

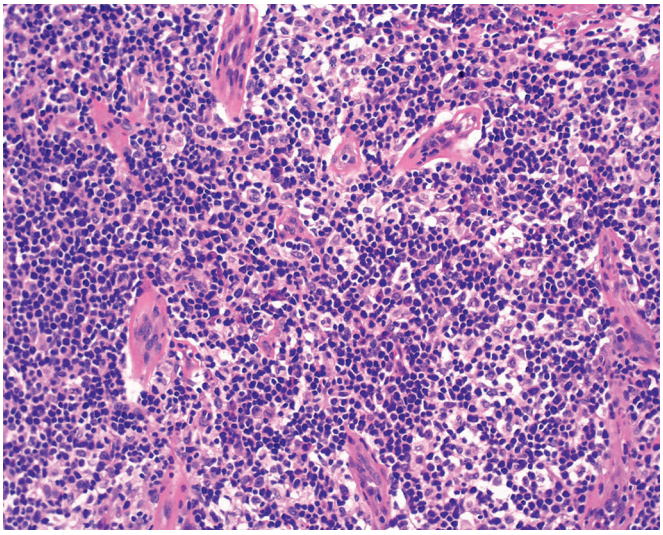

Figure 2.28 Cutaneous B-Lymphoid Hyperplasia. Dense infiltrate of reactive lymphocytes and histiocytes. Variable number of eosinophils or plasma cells may be present.

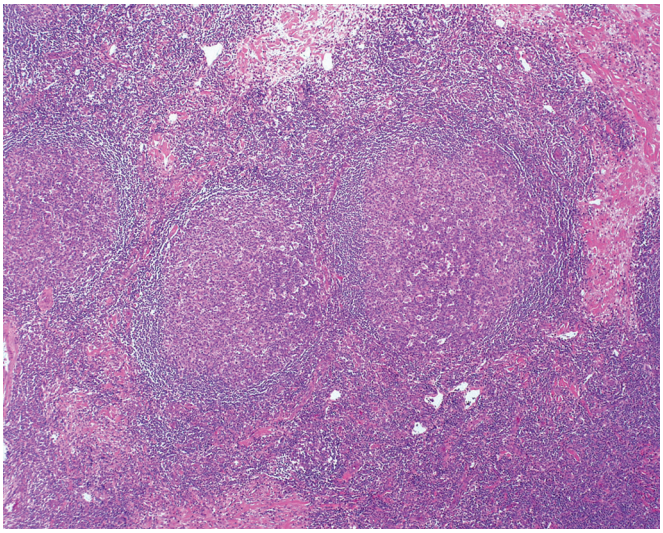

Figure 2.29 Cutaneous B-Lymphoid Hyperplasia. Reactive germinal centers with frequent tingible body macrophages may be present.

Nodular and Diffuse Dermatoses

Entities in this reaction pattern involve the dermis that is not concentrated around vessels. In selected entities there can be histologic overlap with perivascular inflammatory dermatoses.

Acute Febrile Neutrophilic Dermatosis (Sweet Syndrome)

Acute febrile neutrophilic dermatosis, most commonly referred to as *Sweet syndrome*, is characterized by acute onset of fever, leukocytosis, arthralgias, and erythematous plaques that often involve the extremities and face. It is most common in middle-aged women, but any age group can be affected.[178] It can be associated with underlying inflammatory bowel disease, connective tissue disease, infection, and, in a small subset, malignancies, usually hematologic malignancies but also solid tumors.[178,179] Microscopically, there is a dense infiltrate of neutrophils in a nodular to sheet-like pattern (Fig. 2.27). Leukocytoclasis is common, but vascular damage is not a feature, distinguishing it from leukocytoclastic vasculitis, described previously.[180,181] There may be prominent dermal edema, sometimes giving rise to a bullous appearance to the process.[182]

B-Cutaneous Lymphoid Hyperplasia

B-cutaneous lymphoid hyperplasia, also known as *lymphocytoma cutis* and *pseudolymphoma*, most commonly presents in the head and neck as solitary erythematous to violaceous plaques or nodules in adults.[183] Although most cases are idiopathic, such triggering agents as arthropod bites, *Borrelia* infections, drugs, and jewelry have all been implicated.[184,185]

Histologic examination reveals a nodular to sheet-like lymphoid proliferation that can mimic a B-cell lymphoma (Fig. 2.28). Lymphoid follicles with reactive germinal centers containing centroblasts, centrocytes, and tingible body macrophages may be present (Fig. 2.29).[186–188] These are surrounded by a proliferation of small reactive

Figure 2.30 Clinical Appearance of Granuloma Faciale. The lesion appears as thickened purplish patches.

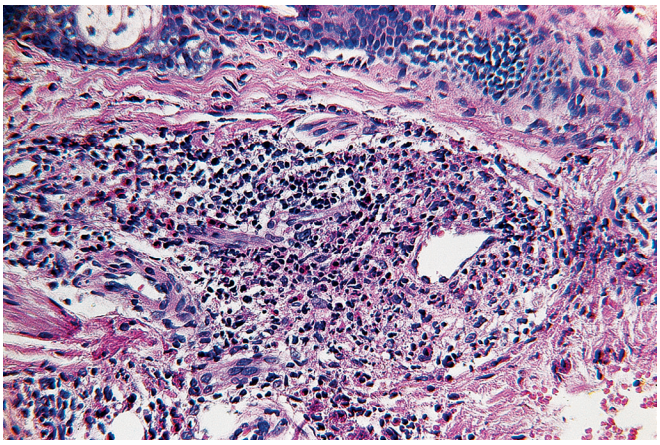

Figure 2.31 Vascular changes in granuloma faciale.

T-cells. The B-cells in the lymphoid follicles can be highlighted by stains for CD20, bcl-6, and CD10. The interfollicular cells are largely negative for these markers. Stains for CD21 will highlight an intact dendritic network in the germinal centers.

The main differential diagnosis includes cutaneous marginal zone lymphoma and cutaneous follicle center lymphoma, which are discussed in more detail in the chapter on cutaneous neoplasms. Briefly, in cutaneous marginal zone lymphoma there is a sheet-like proliferation of monocytoid B cells with variable numbers of monotypic plasma cells in the interfollicular zone. The monocytoid B cells disrupt reactive follicles, resulting in expansion of the follicular dendritic network. The neoplastic B cells may also have aberrant CD43 expression. In primary cutaneous follicle center lymphoma, the germinal centers are more monomorphous with few to no tingible body macrophages.

Granuloma Faciale

Granuloma faciale typically presents on the face of adults as a thickened, purplish brownish patch, which clinically may be confused with infected nevus, tumor, or sarcoid (Fig. 2.30).[189] For this reason, it is often excised or biopsied, and acquaintance with its histologic appearance is helpful. The generally unaltered epidermis is separated from the zone of dermal inflammation by a narrow band of uninvolved dermis. The inflammatory reaction is nodular to sheet-like and formed by lymphocytes, histiocytes, neutrophils, and often large numbers of eosinophils. The infiltrate is frequently prominent, and there is overlap with entities with a nodular or diffuse pattern of inflammation, such as acute febrile neutrophilic dermatosis and arthropod bite reactions. It is considered a chronic vasculitis, and in early lesions evidence of a leukocytoclastic vasculitis may be present (Fig. 2.31).[190] It has been suggested that eosinophilic angiocentric fibrosis of the larynx and other portions of the sinonasal tract is the mucosal equivalent of cutaneous granuloma faciale. Indeed, they look very similar microscopically and can coexist.[191]

Erythema elevatum diutinum shares some morphologic features with granuloma faciale and is thought to be pathogenetically related to it.[192,193] It generally presents in systemically ill patients as bilaterally symmetrical plaques, papules, or nodules, often over the dorsa of joints. Microscopically, it initially presents as a leukocytoclastic vasculitis and later resolves with storiform or concentric fibrosis that imparts a more diffuse pattern to the inflammatory process.[194] In contrast to granuloma faciale, eosinophils are scanty or absent. Sometimes the disease has a nodular quality that mimics a neoplastic process.[195]

Sarcoidosis

Sarcoidosis can present as an acute self-limiting disease, chronic cutaneous disease, or systemic disease that also involves lymph nodes and viscera. The clinical manifestations of cutaneous sarcoidosis are multifarious, earning the disease a site among the "great imitators in medicine."[196,197] Clinically, the cutaneous manifestations of the disease vary a great deal from case to case. The lesions can be single or multiple and can range from macules to large plaques and nodules.[196–199]

Microscopically, the dermis is infiltrated by nests and clusters of noncaseating epithelioid granulomas almost devoid of associated inflammatory cells (Fig. 2.32). In particular, Langhans giant cells are scarce. The often-mentioned asteroid bodies, seen in giant cells, and the calcified Schaumann bodies are uncommon and nonspecific.

Sarcoidosis is a diagnosis of exclusion, inasmuch as granulomas with an identical microscopic appearance can also appear in the skin in a variety of infectious diseases, including tuberculosis, atypical mycobacteriosis, and syphilis; as a reaction to zirconium, beryllium, and tattoos; and as a secondary change in malignant lymphoma. Therefore, at a minimum, stains for infectious organisms should be performed the first time a biopsy from a given patient with possible sarcoidosis is encountered.

Palisading Granulomatous Disease

This group of disorders is characterized by a histiocytic infiltrate that surrounds zones of altered collagen. Granuloma annulare and necrobiosis lipoidica are the prototypical examples in this category.

Granuloma Annulare

Granuloma annulare occurs most frequently on the dorsum of the hands and arms as circinate or grouped clusters of pink nodules with slight central depressions (Fig. 2.33). Occasionally, the disease

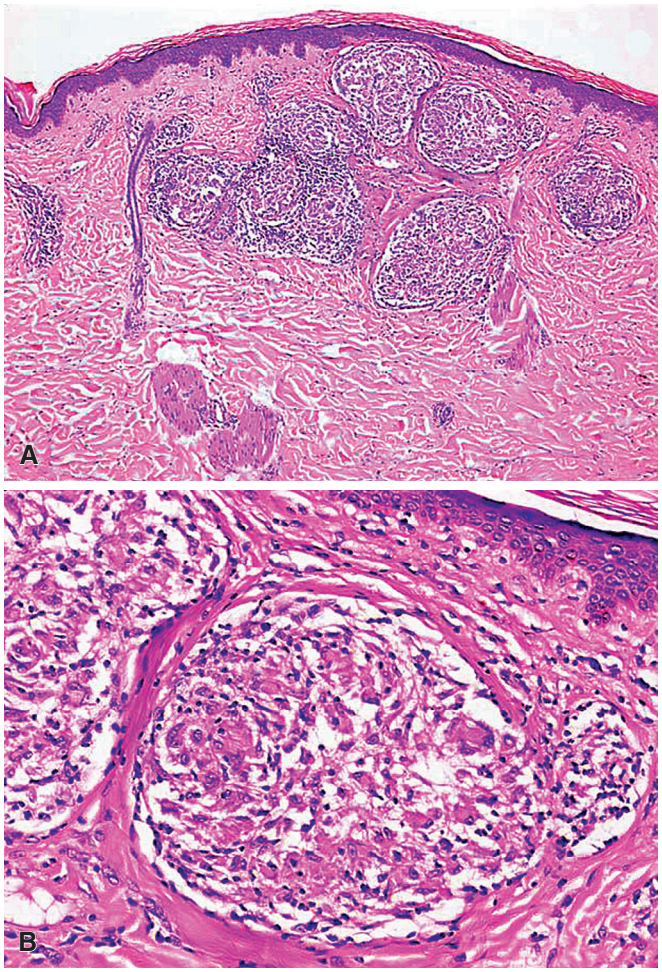

Figure 2.32 **A** and **B,** Low- and Higher-Power Views of Cutaneous Sarcoidosis.

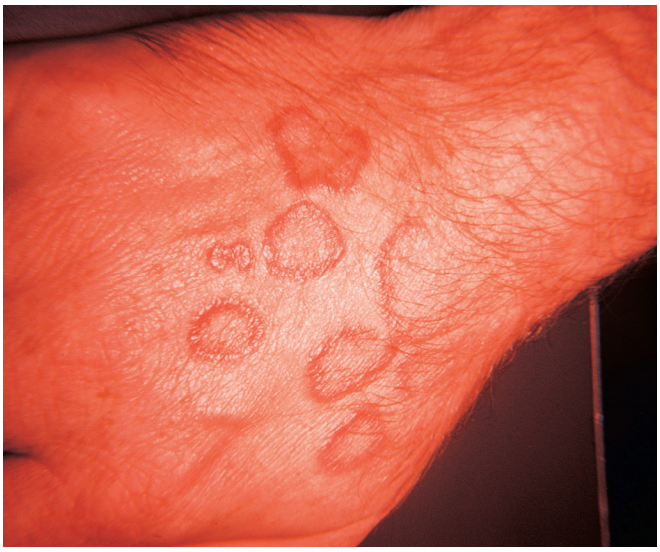

Figure 2.33 Clinical Appearance of Multiple Lesions of Granuloma Annulare of Dorsum of Hand.

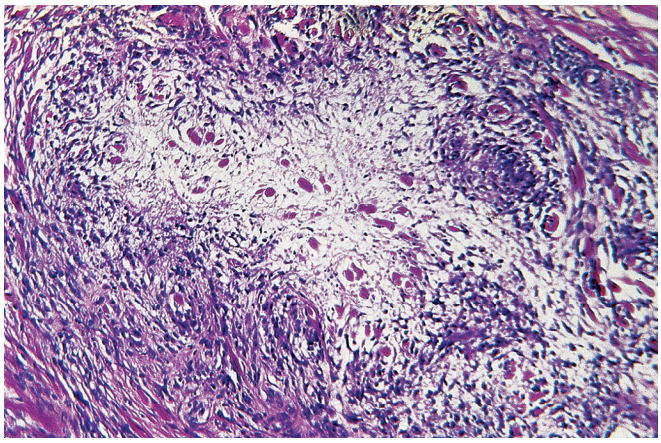

Figure 2.34 Typical Lesion of Granuloma Annulare, With Palisading of Histiocytes Around "Necrobiotic Collagen" Center.

is generalized.[200] Associated systemic diseases are present only exceptionally.[201,202] Histologically, the key component of the lesion is the so-called necrobiotic or palisading granuloma.[203] This is characterized by a well-demarcated zone of disintegrating extracellular material with the appearance of collagen mixed with dermal mucin and cellular debris that is found in the mid-dermis surrounded by a cuff of radially oriented fibroblasts mixed with lymphocytes and histiocytes (Fig. 2.34). Occasional foreign body giant cells and foci of vasculitis may be found. In many lesions the palisading granuloma is not as well developed and has a more interstitial pattern.[204] Multiple sections may be necessary to arrive at a specific diagnosis in this setting.

Immunohistochemically, the "histiocytes" of granuloma annulare stain for vimentin and lysozyme but not for other histiocytic markers, such as HAM-56 or KP-1 (CD68).[205] Ultrastructural studies have shown a prominent component of degenerated elastic (rather than collagen) fibers.[206] Isolated, large, rather deep, necrobiotic collagen granulomas are sometimes seen on the extremities or occiput in children[204] and sometimes in adults.[207,208] They have been referred to as deep, subcutaneous, or giant granuloma annulare and as pseudorheumatoid nodule.[209,210]

An entity histologically similar to granuloma annulare that occurs on heavily sun-damaged skin has been designated as *O'Brien actinic granuloma*, *Miescher granuloma*, and *annular elastolytic giant cell granuloma*.[211,212] Histologically it is almost identical to conventional granuloma annulare and is considered by some to represent the same disease, just occurring in sun-damaged skin. The presence of elastic fibers in the giant cells, as seen by light and electron microscopy, is one of its most important distinguishing features.[213–215]

The subcutaneous nodules of rheumatoid arthritis and rheumatic fever share with granuloma annulare the presence of the necrobiotic collagen granuloma, but the combination of clinical and microscopic features usually allows an easy distinction.[209,216] Rheumatoid nodules are usually deeper and the central zone of the palisading granuloma contains fibrin rather than dermal mucin.

Necrobiosis Lipoidica

Necrobiosis lipoidica typically presents as atrophic, yellow, depressed plaques involving the lower legs (Fig. 2.35).[217,218] Necrobiosis lipoidica is associated with diabetes mellitus and hypothyroidism, but the association with underlying endocrine disordered is less frequent than originally thought.[219] Although most cases involve the legs, presentation outside this location may occur.[219–221] Microscopically,

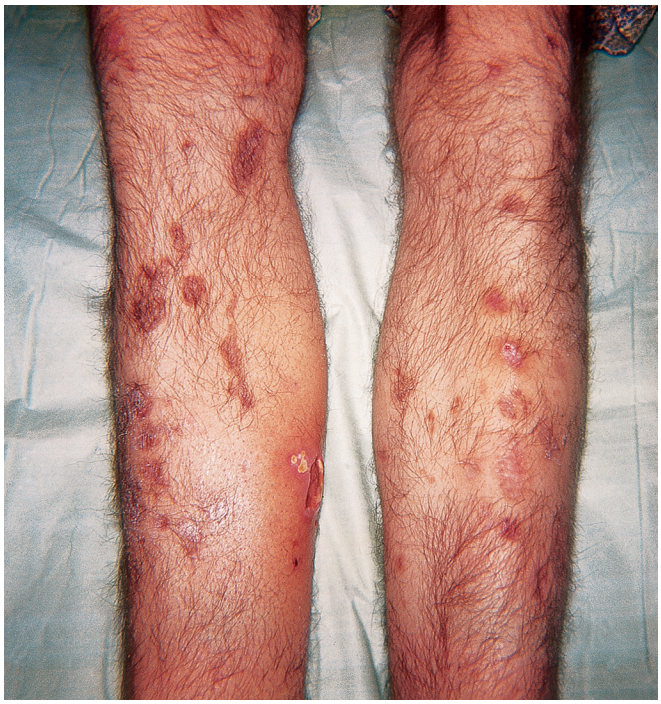

Figure 2.35 Clinical Appearance of Lesions of Necrobiosis Lipoidica.

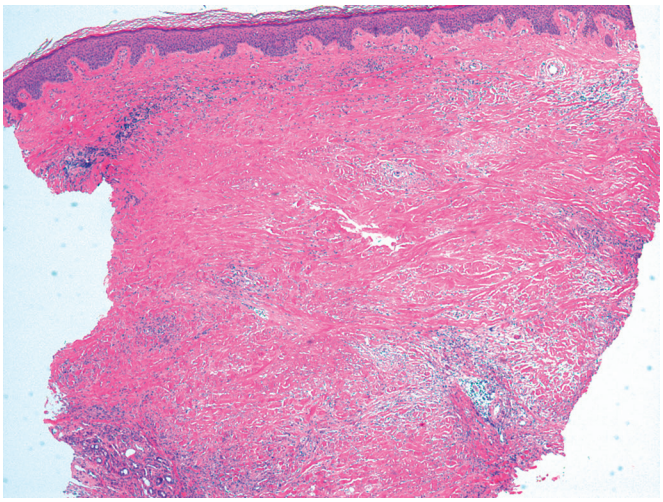

Figure 2.36 **Necrobiosis Lipoidica.** Tiered arrangement of inflammatory cells and altered collagen.

ill-defined areas of disintegrating dermal collagen are seen surrounded by a lymphohistiocytic infiltrate, often arranged in a tiered or layered pattern (Fig. 2.36).[220,221] This has been likened to the appearance of a layer cake or bacon. Lymphoid aggregates with plasma cells are typical (Fig. 2.37). Thickening of the blood vessel wall is usually prominent. It may also have a deeper component with the features of septal panniculitis. Granuloma annulare tends to have a more circumscribed pattern of palisading granulomas and plasma cells are typically absent in granuloma annulare. In addition, in contrast with granuloma annulare, stains for mucin and immunoreactivity for lysozyme tend to be negative, although these stains are not generally necessary to distinguish these entities.[222] The differential diagnosis also includes *necrobiotic xanthogranuloma*, a disease occurring in the head, neck, and trunk of patients in association with paraproteinemia.[223]

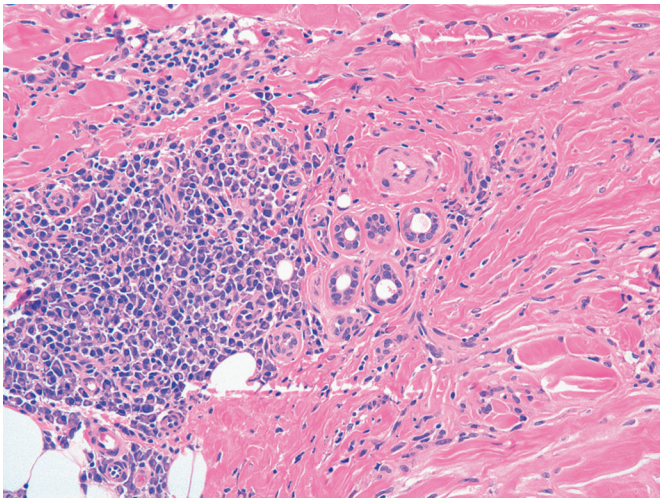

Figure 2.37 Necrobiosis lipoidica usually has lymphoplasmacytic aggregates.

Sclerosing Disorders

This group of disorders is characterized by dermal sclerosis, usually with comparatively little inflammation. Included in this group are scleroderma/morphea, eosinophilic fasciitis, and lichen sclerosus.

Scleroderma/Morphea

Scleroderma is manifest in two distinct forms: *localized scleroderma*, or morphea, and *systemic scleroderma*, in which the skin, particularly of the face, the upper trunk, hands, and arms (acrosclerosis), the esophagus, the heart, and the lungs are diseased.[224–226] Most patients are adults, but the disease can also present in childhood.[227,228] Morphea is the most common form of scleroderma in childhood.[229] Sometimes, visceral disease typical of systemic scleroderma occurs in the absence of cutaneous involvement. A few cases of morphea have been associated with generalized or systemic disease.

The dominant microscopic change in scleroderma is an increase in the amount of collagen, which is morphologically, ultrastructurally, and biochemically unremarkable.[230,231] The relative proportions and distribution of type I and type III collagens are also closely similar to those found in the normal dermis.[232] The histologic appearance is that of enlarged, swollen collagen fibers with a decrease in the normal spacing between the collagen bundles of the reticular dermis (Fig. 2.38). The sclerosis may extend in depth to encircle the secretory coils of the eccrine sweat glands. Concomitantly, the epidermis becomes atrophic. Varying amounts of a mild lymphoplasmacytic infiltrate may be seen in the dermis. In well-developed lesions, the infiltrate may be absent or present at the leading deep edge of the sclerotic change. Early lesions may have little collagen change and a superficial and deep perivascular lymphoplasmacytic infiltrate, suggesting that the fibrosis may represent a secondary phenomenon.[233,234] One should not mistake the normally relatively thick collagen bundles of the back for scleroderma. The collagen bundles of the back will still have retained spaces between the fibers. Dystrophic calcification may occur in scleroderma, and in some patients the dominant patterns is that of acrosclerosis preceded by, or associated with, Raynaud phenomenon.

Scleroderma is usually distinguishable from lichen sclerosus (discussed in more detail later) by the depth of dermal involvement, but in some cases coexisting features of lichen sclerosus

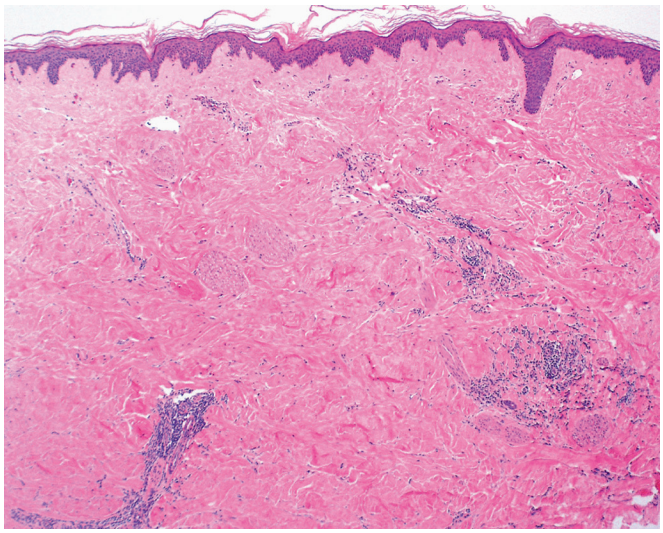

Figure 2.38 Scleroderma. Thickened collagen bundles with decreased spaces between the collagen bundles of the reticular dermis.

may be present and the diseases may represent a spectrum.[235] Scleroderma should also be differentiated from eosinophilic fasciitis (see later).

Eosinophilic Fasciitis

Eosinophilic fasciitis (Shulman disease) is characterized clinically by swelling, tenderness, and stiffness of an extremity, often involving the lower forearm and sometimes associated with carpal tunnel syndrome and peripheral eosinophilia.[235–239] The most important difference between scleroderma and eosinophilic fasciitis on histologic grounds is that in the latter condition there is marked inflammation and thickening of the deep fascia (with or without eosinophils), whereas in scleroderma this structure tends to show minimal or no abnormalities.

Lichen Sclerosus

Lichen sclerosus, also called *lichen sclerosus et atrophicus*, occurs most often on the anogenital areas, upper trunk and neck, and flexor surface of the wrist. When this disease is located in the vulva or glans penis, it is also designated as *kraurosis* and *balanitis xerotica obliterans*, respectively. The disease occurs most commonly in women, often at or around menopause, but it can also be seen in children and young adults.[240] The lesions present as white papules and plaques with a wrinkly surface. Patients have an increased risk of development of high-grade squamous intraepithelial lesions of the differentiated or simplex type, and squamous cell carcinoma in the affected sites, but the risk is relatively low (<10%). The etiology is unknown, but there is a strong association with autoimmune disorders and a link with HLA DQ7.[241] The microscopic features vary depending on the timing of the biopsy. Early lesions may demonstrate an interface dermatitis that can mimic lichen planus.[242] More established lesions have the characteristic edematous, homogenization of the papillary dermis with atrophy of the overlying epidermis (Fig. 2.39). A variable perivascular to lichenoid lymphocytic infiltrate is frequently at the leading edge of the dermal change. Varying degrees of non-necrotizing vasculitis may be seen.[243] As previously mentioned, lichen sclerosus should be distinguished from scleroderma/morphea, although the two diseases may coexist and distinction may not always be possible.[234,244]

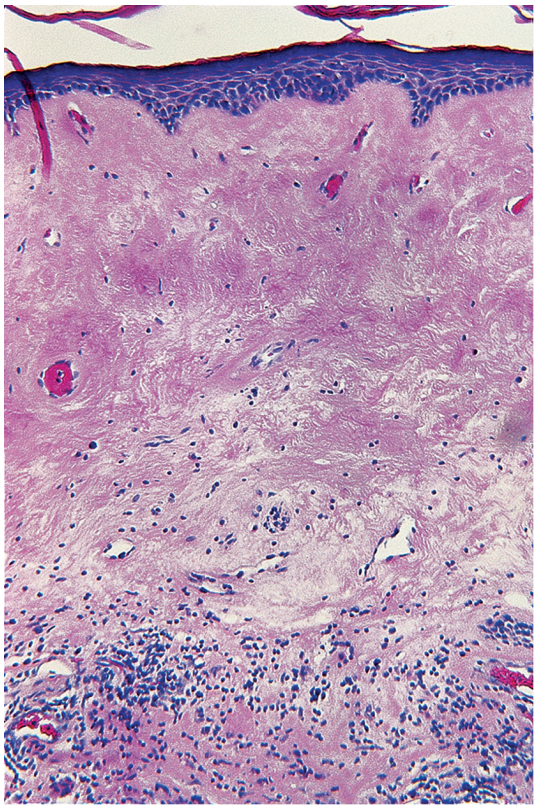

Figure 2.39 Lichen Sclerosus.

Panniculitis

Panniculitis exists in a predominantly septal or lobular pattern, although there is considerable histologic overlap in both of these patterns. It is important to examine the biopsy at low magnification to assess for where the predominant pattern of inflammation/alteration of the subcutis is present. Erythema nodosum is the prototypical septal panniculitis, whereas nodular vasculitis is the prototypical lobular panniculitis.

Erythema Nodosum

Erythema nodosum is the most common form of primary panniculitis, accounting for approximately 70%–80% of cases of panniculitis. The lesions present as painful, red, subcutaneous nodules on the anterior surface of the legs.[245] Typically, they involute within a few days or weeks, leaving slightly depressed pigmented areas. They do not ulcerate, as do the lesions of erythema induratum. It seems certain that the pathogenesis is immune mediated, but the precise mechanism is unknown.[246] In an old series of a British population with erythema nodosum, 45% of the patients had antecedent streptococcal infections, 6% had tuberculosis, 36% had sarcoid, and 13% had a variety of lesions.[247] Several other infectious agents can be involved.[248] Some cases are associated with chronic ulcerative colitis and others with Behçet syndrome.[249–253] In the endemic areas of the United States, coccidioidomycosis is a common antecedent.

Histologically, the junction of the dermis and the subcutis is inflamed. An inflammatory infiltrate extends along the fibrous septa between the fat and about the vessels of the dermis (Fig. 2.40). There is usually spillover into the adjacent lobules, but it is concentrated at the periphery. The composition of the inflammatory infiltrate

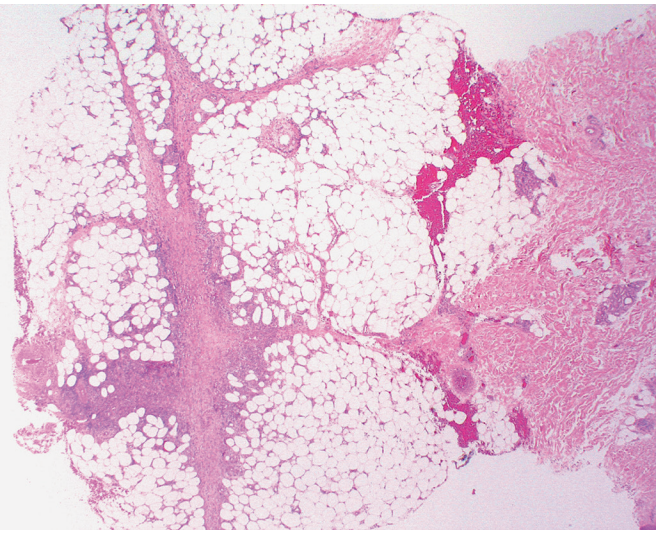

Figure 2.40 Erythema Nodosum. The inflammation predominantly affects the subcutaneous septae.

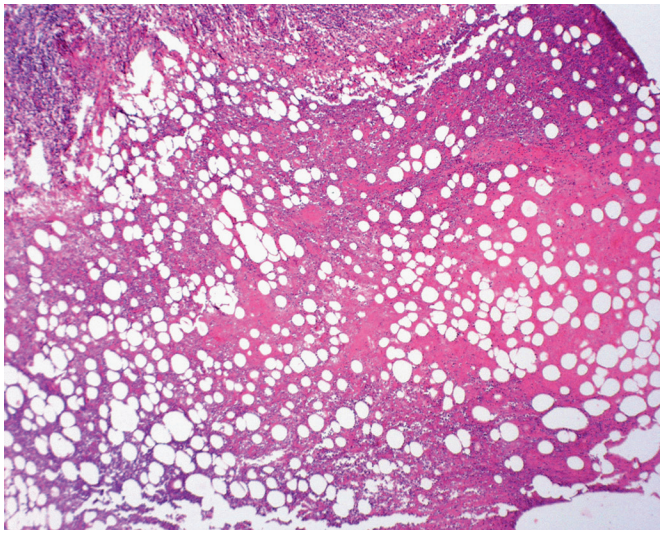

Figure 2.42 Nodular Vasculitis/Erythema Induratum. The inflammation predominantly affects the subcutaneous lobule.

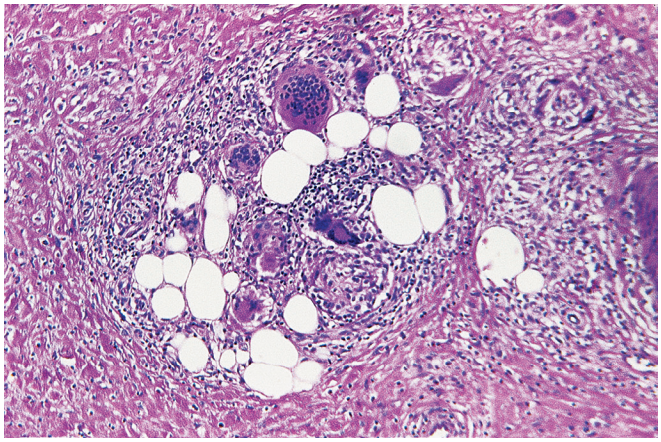

Figure 2.41 Panniculitis With Scattered Multinucleated Giant Cells in Erythema Nodosum.

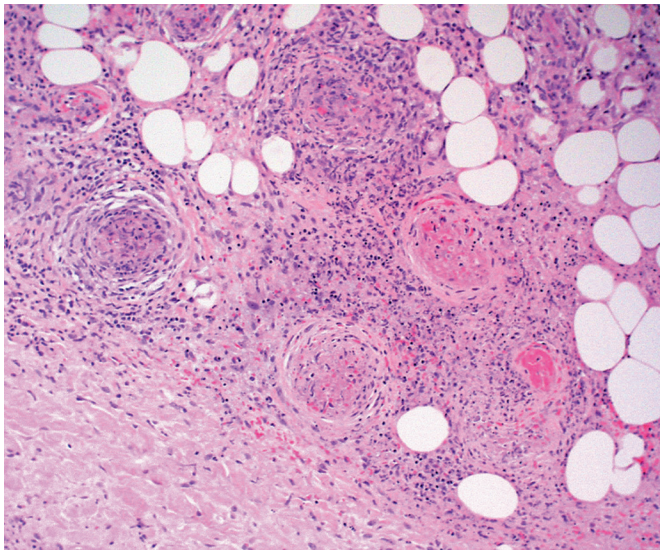

Figure 2.43 Vasculitis in Nodular Vasculitis.

depends largely on the age of the lesion. It may be predominantly neutrophilic, lymphocytic, or histiocytic, with isolated giant cells or noncaseating granulomas (Fig. 2.41).[245,254–256] A characteristic lesion seen in the early stages of the disease is represented by a cluster of small histiocytes radially arranged around a central cleft (Miescher radial granuloma).[255]

Nodular Vasculitis/Erythema Induratum

Both terms are used for the same condition. This condition usually presents on the calves of young to middle-aged women.[257] They present as painful violaceous nodules that may be complicated by ulceration. Some cases represent a manifestation of underlying tuberculosis (Bazin disease) and is a form of tuberculin hypersensitivity.[258] Acid-fast bacilli are not seen in special stains, but mycobacterial DNA has been found in these lesions by polymerase chain reaction (PCR) by some authors but not by others.[259] In the United States, most cases of erythema induratum are idiopathic and are not related to underlying tuberculosis. The etiopathogenesis of this disease and its relation to tuberculosis remain controversial.

Nodular vasculitis/erythema induratum is predominantly a lobular panniculitis, although some septal involvement may also be seen (Fig. 2.42). The inflammatory infiltrate is variably composed of lymphocytes, histiocytes, and neutrophils. Granulomas may be present. In most cases there is an associated leukocytoclastic vasculitis involving medium-sized vessels of the septum or lobule (Fig. 2.43).[257] The differential diagnosis includes erythema nodosum and infection. Erythema nodosum has a distinctly different clinical presentation, lacks the vasculitis, and is predominantly a septal panniculitis. Infectious processes usually lack the associated vasculitis, but infectious stains should be used if there is a question of infection.

Lipodermatosclerosis

Lipodermatosclerosis, or sclerosing panniculitis, is a type of panniculitis that is the result of chronic venous insufficiency. It occurs in elderly or morbidly obese patients and presents as woody

induration of the lower legs.[260,261] Microscopically, unlike other panniculitides, it is relatively noninflammatory. There is lobular alteration of the fat, with hyalinization, microcyst formation, and membranocystic fat necrosis that has been compared with the appearance of frost on a windowpane (Fig. 2.44). The septa are typically spared. The overlying dermis usually shows evidence of stasis change. It may also be seen as a result of vascular compromise due to radiation therapy.[261]

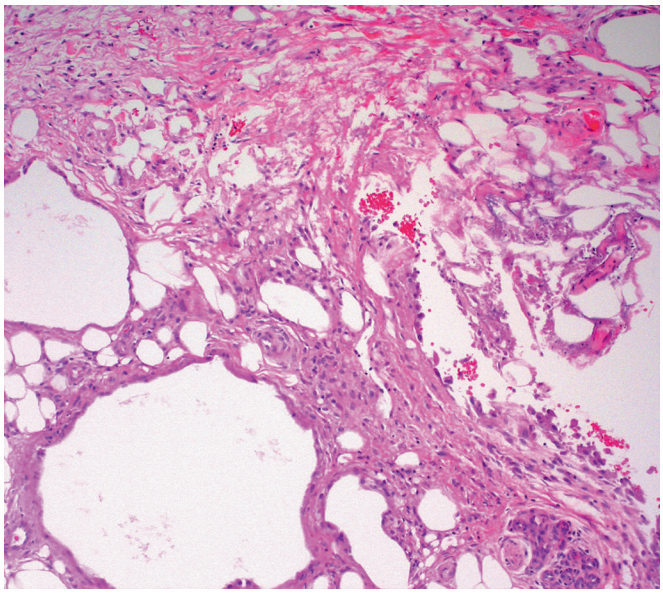

Figure 2.44 **Membranocystic Fat Necrosis of Lipodermatosclerosis.**

Vesiculobullous Diseases

The key morphologic features in the microscopic evaluation of vesiculobullous lesions are the level of the plane of separation and the type of cellular change seen, particularly the presence or absence of acantholysis—as masterfully described in the classic monograph by Lever[262] (Table 2.1), now supplemented by their immunofluorescent pattern (Table 2.2). Vesicles and bullae (large vesicles) are divided according to their location into subepidermal and intraepidermal, which in turn may be suprabasal or subcorneal. In making this distinction, one should be aware that a bulla that was originally subepidermal can become intraepidermal because of regrowth of epithelium across its base, a process that can be very rapid. Actually, large intraepidermal bullae unassociated with acantholytic changes should be suspected of being healed subepidermal bullae. Biopsying early lesions (<24 hours old) minimizes this problem. Biopsies for complimentary direct immunofluorescence studies should be perilesional and submitted in Michel's solution rather than formalin. A complete discussion of the wide range of bullous dermatoses is beyond the scope of this text, but selected entities will be emphasized.

Subepidermal Bullous Disease

Subepidermal bullous dermatoses include a wide range of entities, including *bullous pemphigoid, cicatricial pemphigoid, epidermolysis bullosa*

Table 2.1 Grouping of cutaneous bullous diseases according to the location and mechanism of formation of the bullae

INTRAEPIDERMAL	SUBEPIDERMAL
Subcorneal/Glandular	**Basal Keratinocyte Necrosis, Cytologic, or Damage**
Miliaria crystalline	Epidermolysis bullosa simplex
Staphylococcal scalded skin syndrome	Thermal injury (some)
Pemphigus foliaceus and variants	Erythema multiforme
Bullous impetigo	Herpes gestationis
IgA pemphigus	**Epidermal Basement Membrane Zone Destruction or Disruption**
Subcorneal pustular dermatosis	Lamina lucida
Erythema toxicum neonatorum	Bullous pemphigoid
Transient neonatal pustular melanosis	Cicatricial pemphigoid
Acropustulosis of infancy	Herpes gestationis
Spinous	Dermatitis herpetiformis
Spongiotic dermatitis	Linear IgA dermatosis
Friction blister (may extend into dermis)	Epidermolysis bullosa acquisita
Miliaria rubra	Porphyria cutanea tarda
Incontinentia pigmenti	Epidermolysis bullosa letalis (junctional)
IgA pemphigus	Suction blister
Epidermolytic hyperkeratosis	Thermal injury (some)
Hailey-Hailey disease	Sublamina densa
Suprabasal	Cicatricial pemphigoid
Pemphigus vulgaris and variants	Linear IgA dermatosis
Paraneoplastic pemphigus	Epidermolysis bullosa dystrophica
Darier disease	Epidermolysis bullosa acquisita
	Bullous systemic lupus erythematosus
	Dermal
	Penicillamine-induced blisters (iatrogenic)

Ig, Immunoglobulin.

Table 2.2 Usual immunofluorescence patterns in the various types of vesicobullous dermatoses.*

DERMATOSIS	PRINCIPAL IMMUNOREACTANT	LOCATION	PATTERN
Pemphigus			
All types except below	IgG	ISR	Lace-like
IgA type	IgA	ISR	Lace-like
Paraneoplastic type	IgG C3, IgG C3, IgG	ISR EBMZ EBMZ	Lace-like Linear Granular
Bullous pemphigoid	C3, IgG	EBMZ	Linear
Cicatricial pemphigoid	C3, IgG	EBMZ	Linear
Herpes gestationis	C3	EBMZ	Linear
Epidermolysis bullosa acquisita	C3, IgG	EBMZ	Linear
Bullous systemic lupus erythematosus	C3, IgG C3, IgG	EBMZ EBMZ	Linear Granular
Dermatitis herpetiformis	IgA	EBMZ	Granular
Linear IgA dermatosis	IgA	EBMZ	Linear
Erythema multiforme	C3, IgM C3, IgM	EBMZ Vessels	Granular Granular

*It should be noted that immunoglobulins other than those listed above may also be present, although less commonly and less intensely.
EBMZ, Epidermal basement membrane zone; Ig, immunoglobulin; *ISR*, intercellular squamous region.

Figure 2.45 Clinical Lesions of Dermatitis Herpetiformis. Note the small size of the vesicles and their symmetric distribution.

Figure 2.46 Clinical Appearance of Bullous Pemphigoid. Large bullae are present, some of which have ruptured.

dermatitis herpetiformis, and *porphyria cutanea tarda* (Figs. 2.45 and 2.46).[263] They can also be seen as a secondary event in any dermatosis associated with liquefactive degeneration of the basal layer, such as lupus erythematosus, erythema multiforme, scleroderma, and lichen planus (see earlier).[264]

Microscopically, a distinction between these various subepidermal processes is not always possible; however, careful evaluation of a set of criteria as seen in routinely stained sections results in a high level of concordance with the clinical diagnosis (see Tables 2.1 and 2.2).[265]

Bullous Pemphigoid

A number of clinical forms exist. The most common form, *generalized cutaneous pemphigoid*, presents as tense blisters involving the skin of older patients.[265,266] In a minority, there may also be mucosal involvement.[267] The most consistent histologic features of bullous pemphigoid is a subepidermal blister above the basement membrane that contains numerous inflammatory cells, including frequent eosinophils, in the blister cavity (Fig. 2.47). Direct immunofluorescence on specimens submitted in Michel's solution will reveal linear deposition of

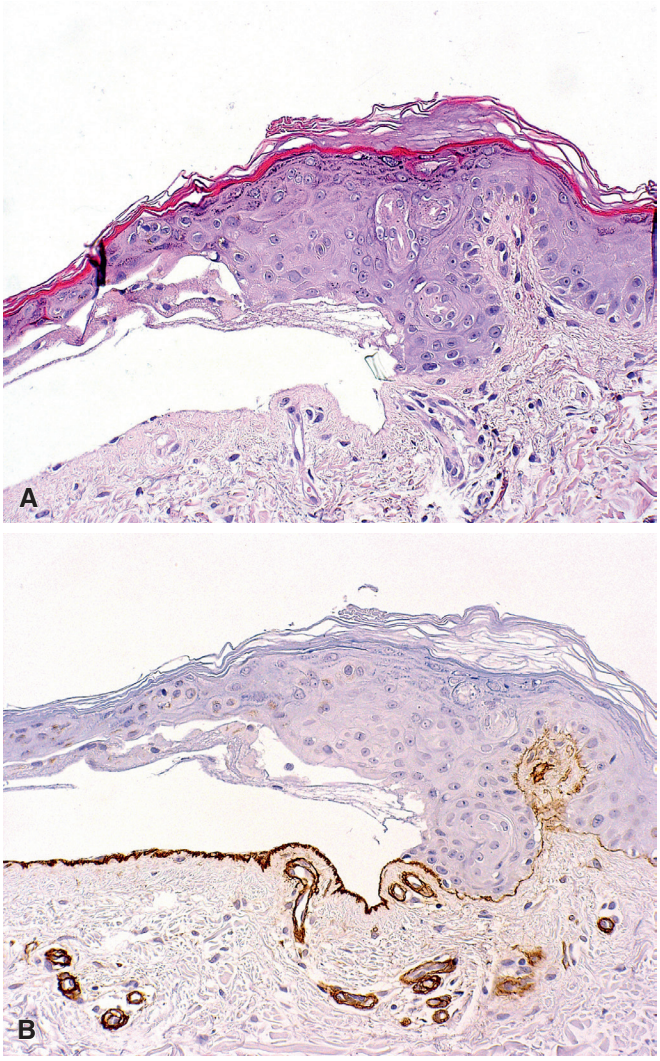

Figure 2.47 **A,** Bullous pemphigoid. A net separation is present between the epidermis and dermis, with protrusion of dermal papillae into the bulla. The inflammatory infiltrate is very scanty. **B,** Immunostaining for type IV collagen shows that the basement membrane is at the base of the bulla. (Courtesy Dr Fabio Facchetti, Brescia, Italy.)

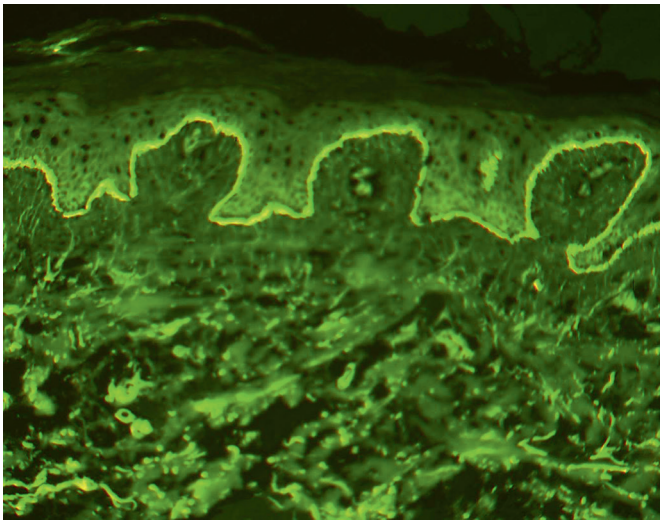

Figure 2.48 Linear deposition of complement C3 in bullous pemphigoid.

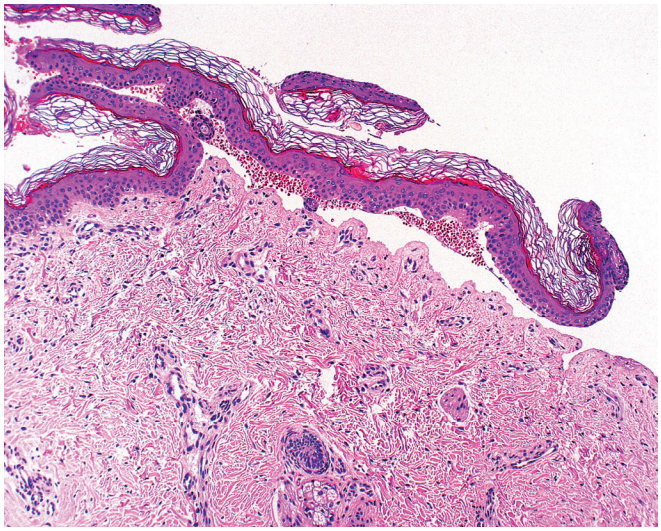

Figure 2.49 Clean subepidermal bulla of epidermolysis bullosa.

complement C3 and usually IgG along the basement membrane zone (Fig. 2.48).

Cicatricial Pemphigoid (Mucous Membrane Pemphigoid)

This rare form of pemphigoid involves ocular and oral mucosa and is often associated with scarring, especially ocular lesions.[266,267] Involvement of genital mucosa is relatively common in female patients with this condition. Histologically, they can be indistinguishable from generalized cutaneous pemphigoid, but the inflammatory infiltrate is often much less intense. In older or recurrent lesions, an underlying scar is often present. Direct immunofluorescence is similar to bullous pemphigoid, although IgA deposits may also be seen in a minority of cases.

Epidermolysis Bullosa Acquisita

There are multiple different variants and only the classical variant will be discussed.[268–272] Patients present with marked skin fragility at sites prone to trauma, such as the hands. Patients easily develop blisters and erosions, and milia are frequently present.

Microscopically, cell-poor subepidermal blisters are characteristic, although occasional cases will show some inflammatory cells in the blister cavity (Fig. 2.49). By direct immunofluorescence, linear deposits of IgG and complement C3 are present, similar to pemphigoid. Salt-split skin preparations examined with direct immunofluorescence will demonstrate the immune deposits on the floor of the blister in epidermolysis bullosa acquisita rather than the roof of the blister in pemphigoid.[272]

Dermatitis Herpetiformis

Dermatitis herpetiformis usually presents in young adults as an intensely pruritic papulovesicular eruption often on extensor surfaces. Clinically, it is closely related to celiac disease. Histologically, the most useful criterion for the diagnosis of dermatitis herpetiformis is the presence of papillary microabscesses forming a multilocular subepidermal bulla (Fig. 2.50).[273] Direct immunofluorescence demonstrates granular deposits of IgA along the basement membrane zone that are typically

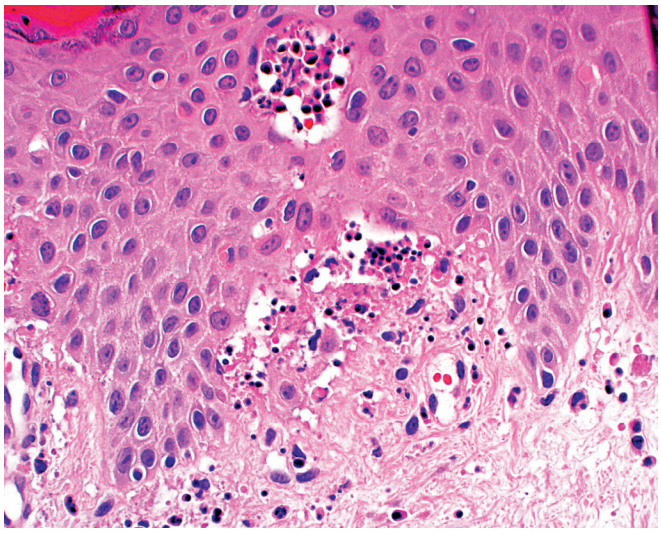

Figure 2.50 Typical appearance of early lesion of dermatitis herpetiformis.

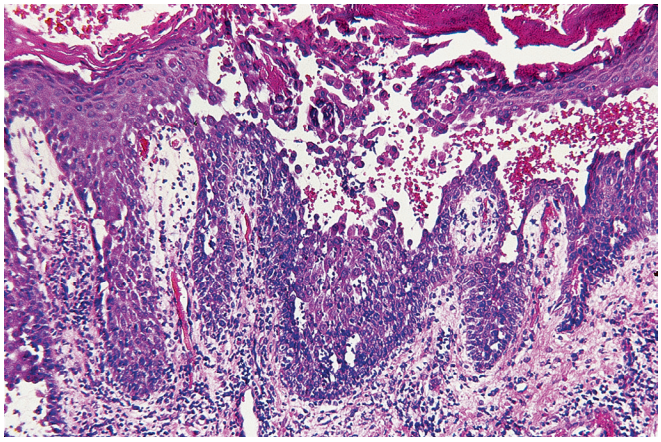

Figure 2.51 Pemphigus Vulgaris. The bulla is in a suprabasal location.

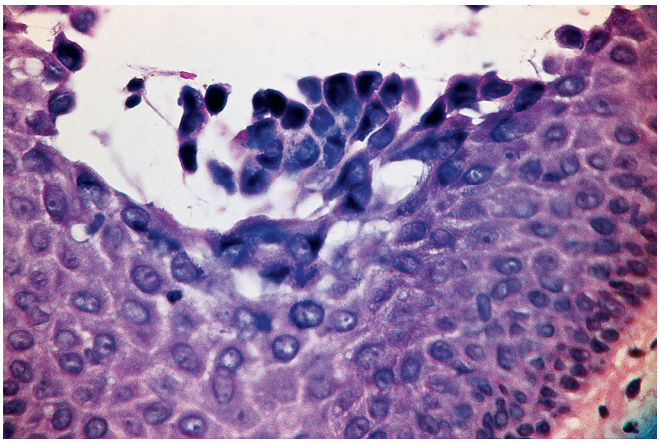

Figure 2.52 Pemphigus Erythematosus. The acantholytic cells are in a superficial location.

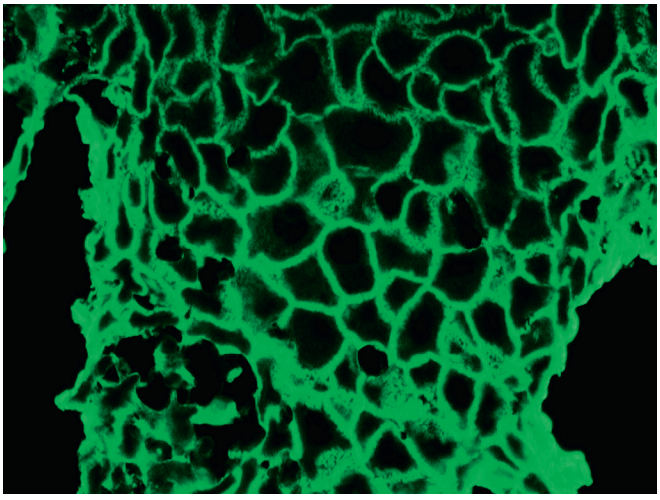

Figure 2.53 Immunofluorescent Demonstration of Anti-Pemphigus Vulgaris Antibody.

more intense in the dermal papillae. *Linear IgA disease* can be histologically and clinically indistinguishable from dermatitis herpetiformis.[274] Like dermatitis herpetiformis, it is characterized by subepidermal blisters with neutrophils along the dermoepidermal junction. It differs by having a linear pattern of IgA deposition along the dermoepidermal junction. Linear IgA bullous dermatosis is frequently triggered by adverse drug reactions.[274]

Intraepidermal Bullous Disease

Intraepidermal bullous dermatoses are characterized by acantholysis and intraepidermal blisters. These disorders include a variety of conditions, including the pemphigus group (pemphigus vulgaris, pemphigus vegetans, pemphigus foliaceus and pemphigus erythematosus), Darier disease, Hailey-Hailey disease, and Grover disease.

Pemphigus

The pemphigus group consists of a variety of related diseases. In *pemphigus vulgaris* and *vegetans*, the pattern of acantholysis results in a cleavage plane just above the basal layer (Fig. 2.51), whereas in *pemphigus foliaceus* and *pemphigus erythematosus* the split is in or just below the granular layer (Fig. 2.52).[262,275–277] Indirect immunofluorescent stains performed with sera of patients with pemphigus demonstrate the presence of antiepithelial autoantibodies in most cases, although the test may be negative in the early stages (Fig. 2.53).[278,279] In addition, IgG and complement C3 can be detected in more than 90% of cases in the epidermal intercellular spaces by a direct immunofluorescence technique.[280] These autoantibodies directed against desmogleins play an important role in the pathogenesis of pemphigus.[281–286] Some cases of pemphigus are seen in association with internal organ malignancies (paraneoplastic pemphigus).[286–288] A statistically increased incidence of internal malignancies has been observed in patients with pemphigus, in addition to the well-known association between pemphigus and thymoma.[288]

Acantholysis can be seen in several other dermatologic conditions, such as *familial benign pemphigus* or *Hailey-Hailey disease* (often located in inguinal folds and clinically resembling candidiasis and condylomas),[289] viral vesicles, the pemphigus-like lesions induced by D-penicillamine,[290] actinic keratosis, and the type of squamous cell carcinoma arising from it (adenoid or pseudoglandular), *Darier disease, warty dyskeratoma*, and *transient acantholytic dermatosis (Grover disease)*. The latter is characterized by transient edematous and

excoriated papules and vesicles located predominantly on the trunk, thought to be the result of the combined action of heat and sweating.[291–293] According to Chalet et al. the most important clue to the diagnosis is the association of acantholysis and spongiosis.[293] In addition, focal acantholytic dyskeratotic changes (sometimes limited to a single rete ridge) totally devoid of clinical significance can be found in association with a variety of localized lesions, such as dermatofibroma, basal cell carcinoma, melanocytic nevus, and malignant melanoma.[294,295]

In subcorneal pustular dermatosis, the vesicles are just beneath the keratin layer, as they are in *impetigo contagiosa*.[296,297] Another subcorneal vesicular lesion that has been mistaken clinically for junctional nevus is the blood blister, in which the erythrocytes are trapped beneath the thick stratum corneum of the toes or fingers. This has been termed talon noir and is commonly seen in athletes.[298]

Infections

Viral Diseases

The viral lesions of skin most commonly seen histologically are warts and condylomas. Molluscum contagiosum and herpesvirus infections are also commonly biopsied.

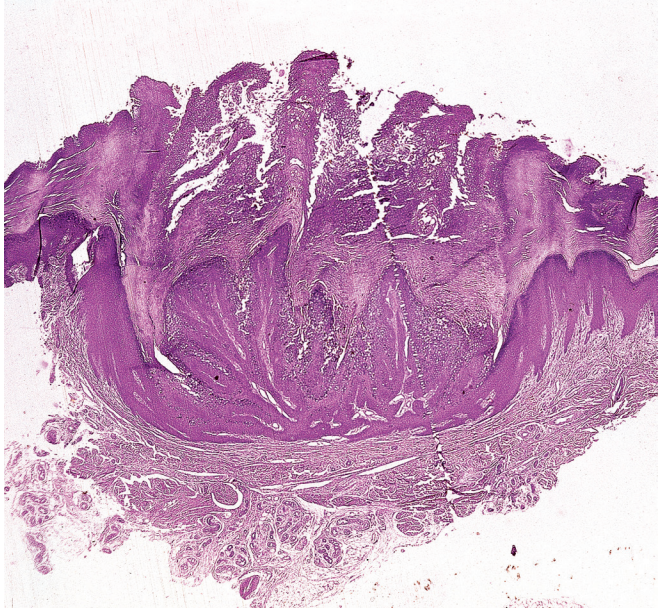

Figure 2.54 Verruca Vulgaris. The lesion is cup-shaped and highly keratotic.

Warts

Warts are cutaneous (and sometimes mucosal) lesions caused by one of the several human papilloma viruses (HPVs), papovavirus.[299–301] Several variants of warts occur, depending primarily on the HPV subtype, but also on the anatomic features of the region.[302–304] *Verruca vulgaris* (generally associated with HPV-2) usually occurs on the hands as an elevated, hard, rough, flesh-colored lesion. The top may be peeled off, leaving a pink granular surface. *Verruca plantaris* occurs on the sole of the foot, is covered by a callus, and is often painful. *Verruca plana* (usually associated with HPV-10) is, as its name indicates, a flatter lesion usually seen in crops or clusters on the face and hands. Flat warts disseminated throughout the body are a feature of the genetically determined *epidermodysplasia verruciformis*.[305,306] *Condyloma acuminatum* or "venereal wart" (usually caused by HPV-6 and HPV-11) occurs around the anus and vulva, on the glans penis, and sometimes in other mucosal membranes, such as the oral cavity. Genital warts with increased risk for developing dysplasia and subsequent carcinoma are predominantly caused by HPV-16 and HPV-18.

The histologic characteristics of these lesions are those of focal epidermal hyperplasia manifested by hyperkeratosis and parakeratosis, varying degrees of acanthosis, and (except for verruca plana) papillomatosis (Fig. 2.54). A trichilemmal type of keratinization may be present.[307] Distinct vacuolization of the cells in the upper portion of the malpighian layer is a feature in early lesions; some of these abnormal cells have large cytoplasmic eosinophilic aggregates. Smaller vacuolated cells with pyknotic nuclei may also be seen in the lower portions of the thickened stratum corneum. In condyloma acuminatum, acanthosis may be florid, and tangential cuts can show isolated nests of squamous cells surrounded by inflamed dermis. Care should be taken not to overdiagnose such lesions as squamous cell carcinoma. Older verrucae may not show the microscopic changes that allow their recognition; they may appear simply as papillomas or keratoses. Flat warts undergoing involution exhibit marked mononuclear dermal and intraepidermal inflammation associated with degenerative epidermal changes.[308,309] The viral nuclear inclusions are basophilic, Feulgen positive, and DNase resistant. They can be demonstrated immunohistochemically and with an in situ hybridization techniques.[310] The eosinophilic cytoplasmic masses are not made of viral material but rather represent accumulations of tonofilaments.

Occasionally, benign or malignant skin tumors and tumor-like conditions of various types (e.g. seborrheic keratosis, squamous cell carcinoma in situ [Bowen disease], and invasive squamous cell carcinoma) are seen superimposed on HPV-induced lesions, suggesting a causal relationship.[311–313] In our experience, this is most common in elderly and immunocompromised patients (e.g. solid organ transplant patients). Epidermodysplasia verruciformis is another example.[314,315] Changes in keratin expression occur in the keratinocytes as a result of the viral infection, and further changes develop when a neoplastic process supervenes.[315,316]

Molluscum Contagiosum

Molluscum contagiosum is a skin disease produced by a *Molluscipoxvirus*, a virus specific to humans, present worldwide, and passed by direct skin to skin contact.[317,318] It occurs often in young individuals and may even be congenital.[319,320] Clinically, it is characterized by small, firm, usually multiple nodules that, when fully developed, have central cores from which white keratinous material can be expressed (Fig. 2.55). The microscopic picture is characteristic. The dermis is indented by a sharply delimited and lobulated mass of proliferating epithelium. As the cells differentiate within the mass, their cytoplasm gradually is filled by a faintly granular eosinophilic inclusion that displaces the nucleus and enlarges the cells (see Fig. 2.55). These molluscum bodies are formed of viral particles that are similar in size and mode of formation to the poxviruses.[321] Inflammation in the surrounding dermis is intense, sometimes in the form of an abscess[322] and sometimes in the form of a pleomorphic T-cell infiltrate that can simulate a lymphomatous/leukemic process.[323,324] Metaplastic ossification has been occasionally observed.[325]

Herpes Virus

Herpes zoster is a painful disease caused by the same virus that causes chickenpox (varicella). It may vary from relatively benign

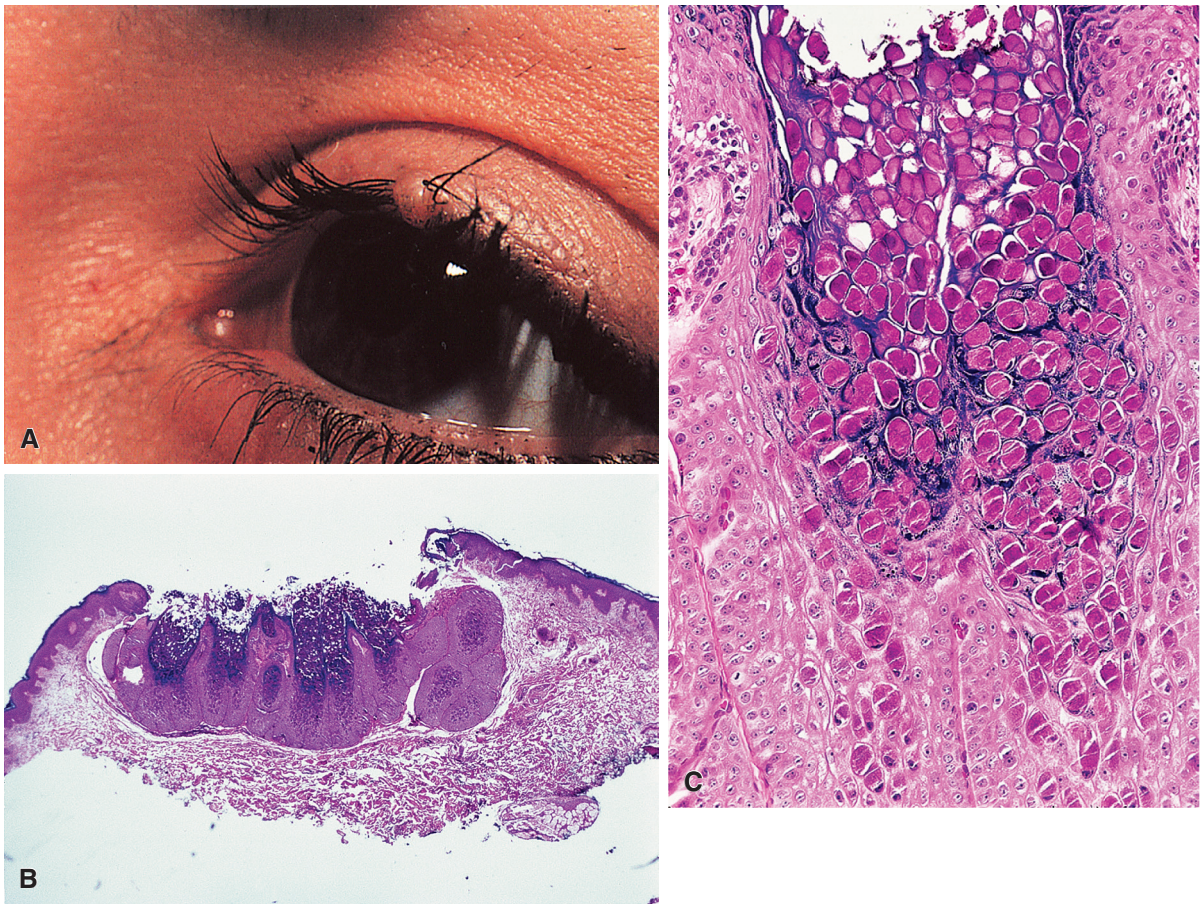

Figure 2.55 Molluscum Contagiosum. A, Clinical appearance of lesion located in eyelid. **B,** Low-power view of cup-shaped lesion. **C,** High-power view showing numerous molluscum bodies. (**A** courtesy Dr Carlos Ramos, Belleville, Illinois.)

pruritic lesions on the trunk, usually unilateral and in the distribution of a single dermatome, to severe involvement of the first division of the trigeminal nerve with herpetic keratitis and corneal ulceration.[326,327] Postherpetic neuralgia is the unpleasant sequela. Patients with leukemia and malignant lymphoma are particularly prone to develop herpes zoster infection.[328]

Oral and genital herpes are typically caused by herpes simplex virus 1 (HSV1) and HSV2, respectively, although either virus can be found in either location. Infection with both HSV1 and HSV2 results in recurrent, painful blistering eruptions.

The histopathologic features of varicella–herpes zoster are essentially identical to herpes simplex lesions, although it has been suggested that the lesions of zoster have a more prominent inflammatory infiltrate than herpes simplex lesions.[329] In both conditions, there are intradermal blisters with acantholysis and multinucleated keratinocytes with the characteristic intranuclear steel gray viral inclusions with peripheral margination of nuclear chromatin (Fig. 2.56). In some cases the dermal lymphocytic infiltrate can be of an intensity and atypia such as to simulate a malignant lymphoma.[330]

Bacterial Diseases

Folliculitis

The term folliculitis refers to an inflammatory process distributed around hair follicles and involving the follicular opening or adjacent perifollicular skin.[331] A fair number of cases are drug induced.[332] They have been divided microscopically into the following:

1. Infectious

   Superficial (usually suppurative): resulting from fungi, bacteria, syphilis, or viruses
   Deep (usually granulomatous): resulting from fungi or bacteria

2. Noninfectious

   Superficial (usually suppurative): acne vulgaris, rosacea, follicular mucinosis, steroid induced, etc.
   Deep (usually granulomatous): acne vulgaris (conglobate and keloidal forms), perforating forms, etc.
   Spongiotic: Fox-Fordyce disease, atopic dermatitis, pruritic folliculitis of pregnancy

3. Perifolliculitis

   Predominantly lymphocytic: lichen planopilaris, pityriasis rubra pilaris, rosacea, etc.
   Predominantly granulomatous: perioral dermatitis, rosacea, etc.

Demodex mites are more frequent in inflamed follicles than in normal ones, but it is not clear whether they play an etiologic role.[333] *Eosinophilic folliculitis*, as seen in adults and infants, is usually a human immunodeficiency virus (HIV)-related dermatosis.[334,335] The

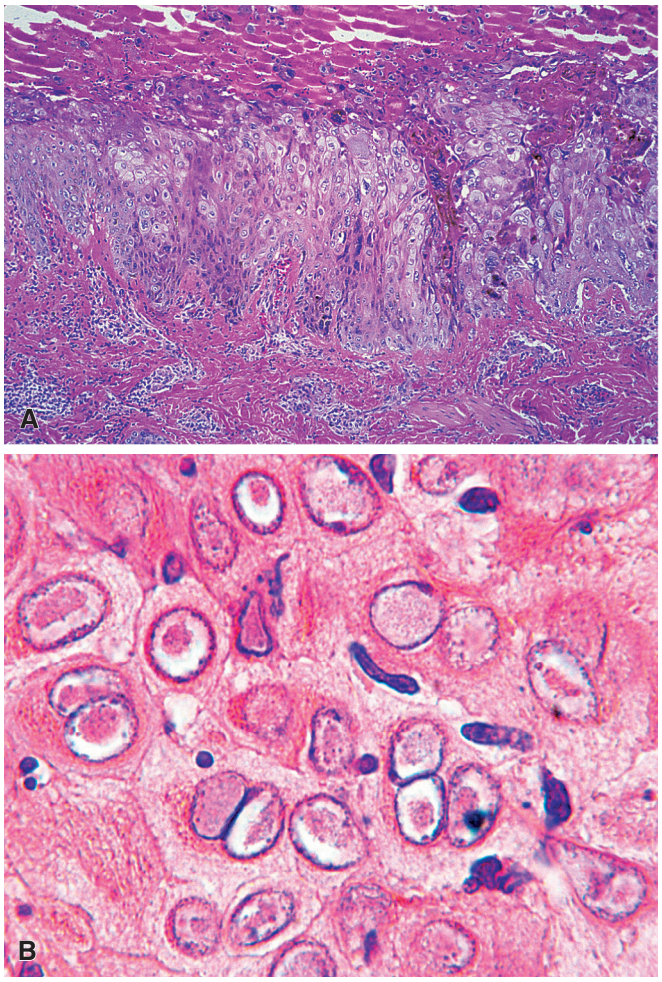

Figure 2.56 A, Medium-power image of herpes simplex infection. **B,** High-power image of herpes simplex infection demonstrating large intranuclear inclusions.

term *pseudolymphomatous folliculitis* has been proposed for a skin lesion usually located in the face and characterized histologically by a dense lymphocytic infiltrate of mixed nature centered around hair follicles, with infiltration of the follicular epithelium.[336] The suggestion has been made that some cases diagnosed as solitary sclerotic fibroma of the skin may be the end stage of a folliculitis.[337]

Hidradenitis Suppurativa

Hidradenitis suppurativa is caused by bacterial infection in and about apocrine glands, usually in the axilla but occasionally involving the perineum or vulva (Fig. 2.57).[338] Anaerobic organisms are the most important pathogens. Abscesses, sinuses, and perianal fistulas occur with subsequent scarring.[339] The process tends toward chronicity, and in refractory cases excision of the involved skin may be required.[340] The follicles into which the apocrine glands open are plugged by keratin and infection develops following stasis. At present, hidradenitis suppurativa is considered a disease of follicular occlusion (acne inversa) rather than a primary inflammatory/infectious process of apocrine glands.[341,342]

Tuberculosis and Atypical Mycobacteriosis

Cutaneous tuberculosis is an uncommon disease in the United States, although its incidence is on the rise.[343] It has various clinical and

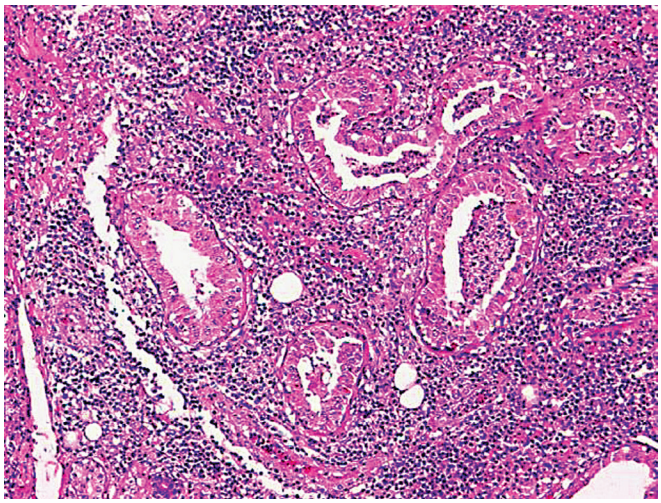

Figure 2.57 Hidradenitis Suppurativa. A heavy neutrophilic infiltrate is present around apocrine glands and in their dilated lumina. (Courtesy of Dr Raffaele Gianotti, Milano, Italy.)

Figure 2.58 Clinical Appearance of Lupus Vulgaris. The lesion presents in the form of an irregularly shaped red patch with elevated borders.

morphologic forms depending on the mode of entry and whether it is a primary or secondary infection.[343,344]

Lupus vulgaris is a reactivation type of tuberculosis. It generally involves the face, and the lesions are formed of red patches in which small, firm nodules reside (Fig. 2.58).[345] When pressed with a glass slide (diascopy), these nodules have a pale tan color. Microscopically, non-necrotic (sarcoid-like) and—less commonly—necrotic granulomas are found in the dermis (Fig. 2.59). Acid-fast bacilli are difficult to demonstrate but may be found. Cultures are recommended. The organisms can also be demonstrated with PCR methods.[346] Ulceration of the skin may occur. In longstanding cases, frank squamous cell carcinoma may arise from these lesions.

Papulonecrotic tuberculid is a skin lesion associated with tuberculosis but typically devoid of organisms; it is seen in both adults and children and is characterized microscopically by dermal necrosis, a poorly formed granulomatous infiltrate, vasculitis, and edema.[347,348] Rarely, the vasculitis is in the form of a nodular granulomatous phlebitis.[349]

Atypical mycobacteriosis can also affect the skin and result in a variety of lesions, including ulceration, abscesses, granulomas, diffuse histiocytic reactions, panniculitis, and rheumatoid-like nodules.[350–353]

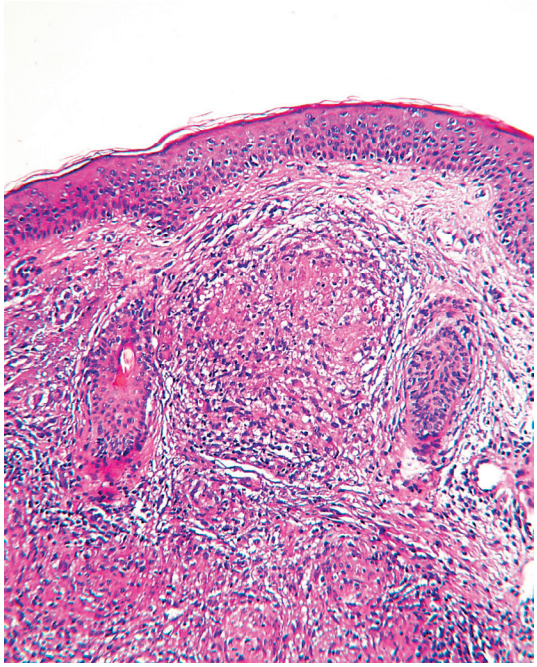

Figure 2.59 Tuberculosis of Skin (Lupus Vulgaris). Well-formed granulomas with necrotic centers are present in the dermis.

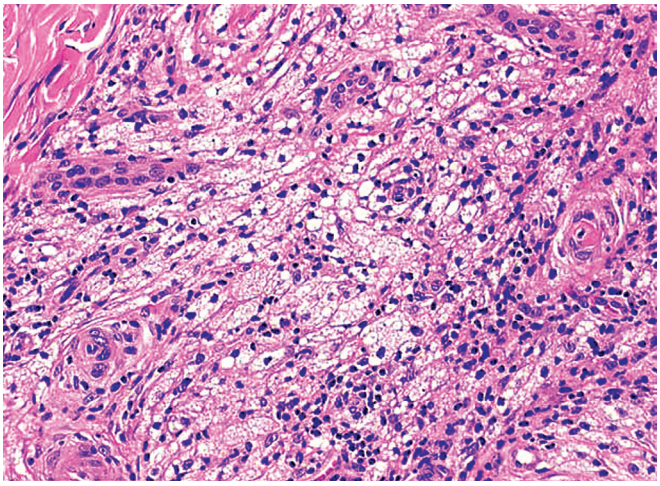

Figure 2.60 Lepromatous Leprosy. Large collections of foamy macrophages *(Virchow cells)* infiltrate the dermis.

Mycobacterium kansasii, M. marinum, and *M. ulcerans* are the organisms most commonly implicated.[350–353] Infection with atypical mycobacteria should be considered whenever routine bacterial cultures are negative.

Leprosy

In most regions of the United States, leprosy, or Hansen disease, is a rarity. However, an increased number of cases have been seen during as the result of the influx of immigrants from Asia and other regions of the world in which the disease is still endemic. Therefore the pathologist should consider it in the differential diagnosis of dermal granulomas and histiocytic tumors. In *lepromatous* and *dimorphic leprosy* the lepra or Virchow cells, filled with acid-fast bacilli, are plentiful (Figs. 2.60 and 2.61), whereas in *tuberculoid* and

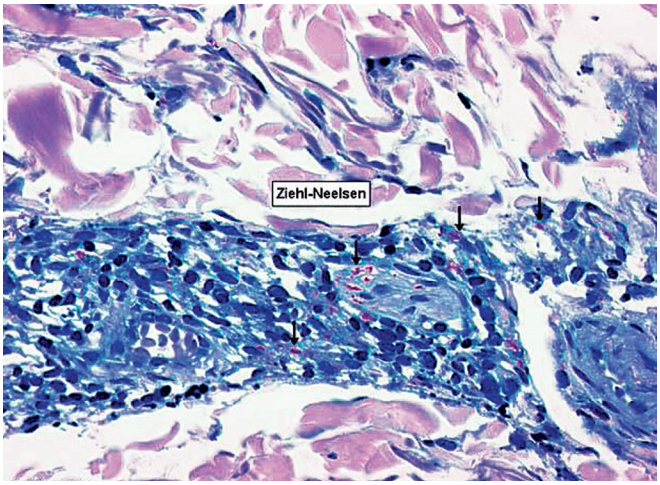

Figure 2.61 Acid-fast stain shows leprosy organisms *(arrows)* in a perineurial inflammatory infiltrate. (Courtesy of Dr Raffaele Gianotti, Milan, Italy.)

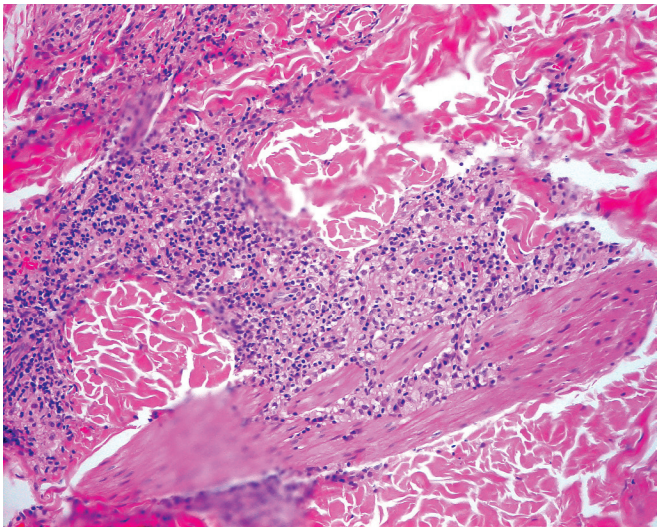

Figure 2.62 Infiltration of the Arrectores Pilorum Muscle by Inflammatory Cells. This is a diagnostic clue for the diagnosis of leprosy.

indeterminate leprosy, bacilli are very scanty.[354] As for tuberculosis, a PCR-based diagnosis of leprosy is now available.[355] A diagnosis of leprosy should be suspected whenever the granulomas or the lymphocytic infiltration is located in and around the cutaneous nerves or when seen infiltrating and destroying arrectores pilorum muscle (Fig. 2.62).[354,356] Histoid leprosy (a bad term) is regarded by most workers as a variant of lepromatous leprosy which follows resistance to dapsone therapy.[357] It presents clinically as sudden eruptions of dome-shaped nodules that can simulate keratoacanthomas or cutaneous metastases.[358] Microscopically, the dermis shows sheets of round to spindle-shaped histiocytes, with a pattern resembling benign fibrous histiocytoma.

Syphilis

The cutaneous lesions of secondary syphilis are of the maculopapular type and can be confused clinically with drug eruption, lichen planus, psoriasis, and other dermatoses (Fig. 2.63). Secondary syphilis can also present in the form of moth-eaten alopecia.[359] The microscopic

appearance can be nonspecific, especially in the macular lesions. The late papular lesions are more likely to exhibit the distinctive microscopic appearance of a dense perivascular or diffuse lichenoid infiltrate predominantly or almost exclusively composed of plasma cells (Fig. 2.64).[360] Noncaseating granulomas may also be present. The blood vessels characteristically show marked endothelial swelling and often proliferation. The cutaneous lesions of syphilis occurring in HIV-infected individuals do not differ significantly at the microscopic level from those seen in immunocompetent persons.[361]

Although the organisms can be detected by Steiner silver stains, immunohistochemistry is a significantly more sensitive and superior technique (Fig. 2.65).[362] Of interest, in primary syphilis, the spirochetes show a mixed epitheliotropic and vasculotropic pattern, whereas in secondary syphilis, the spirochetes are almost confined to lower levels of the epidermis in an intercellular distribution.[363] PCR methods to detect *Treponema pallidum* in biopsies and biologic fluid is also available.[364]

Lyme Disease

Lyme disease, a multisystem disorder caused by the spirochete *Borrelia burgdorferi*, is most commonly transmitted to humans by a tick

Figure 2.63 Palmar Lesions of Secondary Syphilis.

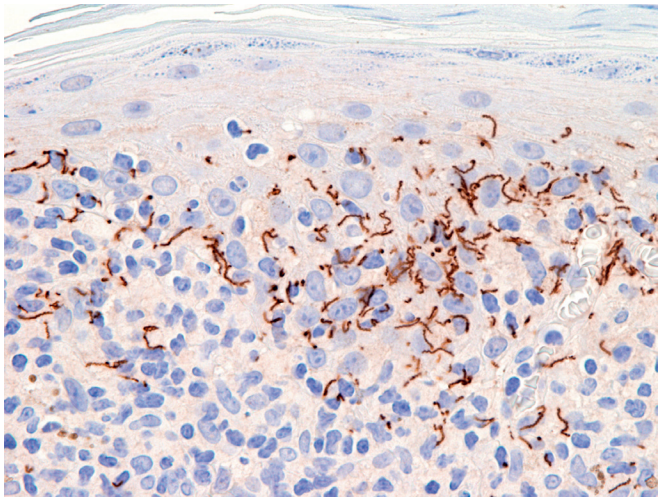

Figure 2.65 Numerous *Treponema* organisms are seen in this immunostain in a case of secondary syphilis. (Courtesy of Dr Fabio Facchetti, Brescia, Italy.)

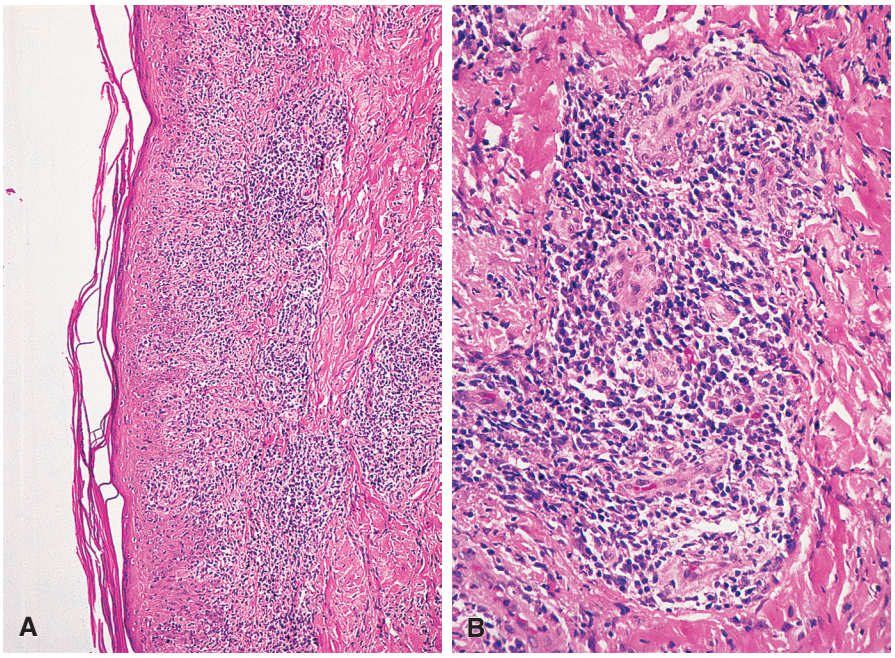

Figure 2.64 **Secondary Syphilis. A,** Low-power view showing a dense infiltrate predominantly affecting the upper dermis. **B,** High-power view showing markedly hyperplastic blood vessels surrounded by a lymphoplasmacytic infiltrate.

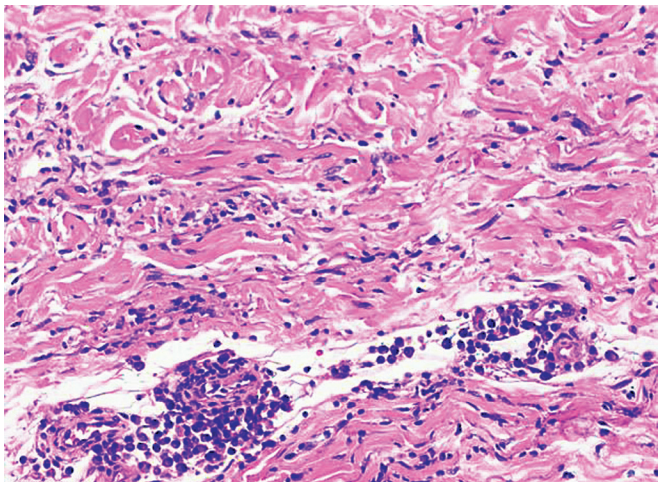

Figure 2.66 Lyme Disease. A perivascular infiltrate of lymphocytes and plasma cells is seen in the dermis.

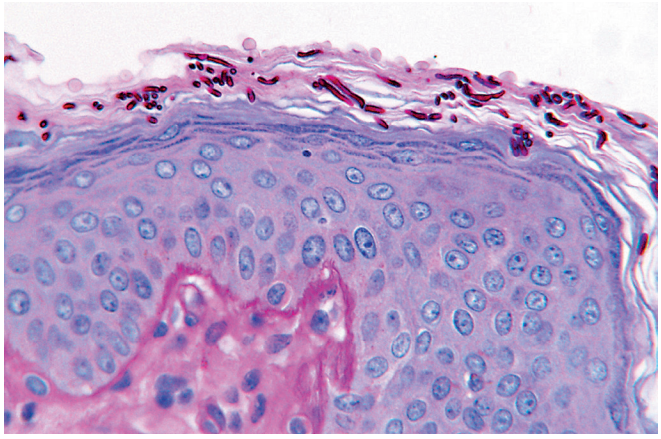

Figure 2.67 Dermatophytosis due to *Trichophyton*, demonstrated by periodic acid–Schiff stain.

bite.[365,366] It may be manifest in the skin as *erythema chronicum migrans* (currently regarded as pathognomonic of the disease), *acrodermatitis chronica atrophicans*, and *cutaneous lymphoid hyperplasia* ("borrelial lymphocytoma").[367–371] In the early stages the predominant microscopic finding is a superficial and deep perivascular infiltrate largely composed of lymphocytes but also containing plasma cells and/or eosinophils (Fig. 2.66). Spirochetes can be demonstrated with the Warthin-Starry silver stain.[372] The organisms have also been detected by PCR in synovial fluid.[373] Other organs that may be involved by Lyme disease in addition to skin include the heart, joints, and nervous system.

It has been suggested that some cases of morphea, lichen sclerosus et atrophicus, anetoderma, and atrophoderma of Pasini and Pierini may also be caused by borrelial organisms, but this remains controversial.[374,375]

Fungal Diseases

Tinea (Dermatophytoses)

In the dermatophytoses, the fungal spores and hyphae are found in the stratum corneum and in or about hair shafts (Fig. 2.67).[376] Mild epidermal changes, such as focal intercellular edema and varying amounts of dermal inflammation, may be seen. The fungal elements are readily seen in sections stained by the PAS or GMS methods. Occasionally, atypical clinical forms of tinea are biopsied, and the fungi are readily missed if not sought. Bacterial folliculitis and perifolliculitis may be superimposed on tinea of the scalp and beard. These lesions are known as *kerion celsi* and *sycosis barbae*, respectively, and may, on occasion, be mistaken for infected tumors. Histologically, cellulitis, abscesses, pseudoepitheliomatous hyperplasia, and a few fungi in the hair follicles and adjacent tissues are seen. A related disorder is *Majocchi granuloma (nodular granulomatous perifolliculitis)*, in which inflammation of dermal and subcutaneous tissue by dermatophytes is present; *Trichophyton rubrum* is the organism most commonly involved.[377]

It should be kept in mind that dermatophytes can be found superimposed on an inflammatory (pyoderma, scabies) or neoplastic lesion of the skin.[378] We have seen cases of mycosis fungoides that were missed originally because the atypical dermal lymphoid infiltrate was attributed to the fungi seen in the horny layer.

Figure 2.68 Clinical Appearance of North American Blastomycosis.

North American Blastomycosis

Isolated cutaneous blastomycosis is an uncommon lesion. Usually the skin lesion is secondary to pulmonary involvement, which may be subclinical.[379] Overall, approximately 20% of patients with blastomycosis have cutaneous lesions.[380] The causative organism, *Blastomyces dermatitidis*, is a spheric, double-contoured 12 µm ± 4 µm yeast. It reproduces by budding, and this characteristic allows its identification in sections. The skin lesions are slowly enlarging verrucous plaques in which numerous small abscesses are present (Fig. 2.68).[380] Microscopically, they are characterized by marked pseudoepitheliomatous hyperplasia and a mixed granulomatous and acute polymorphonuclear infiltrate (Fig. 2.69).[380] The accompanying pseudoepitheliomatous hyperplasia may cause diagnostic confusion with squamous cell carcinoma. The organism is generally found in giant cells. Smears and cultures are recommended diagnostic adjuncts (Fig. 2.70).

Chromoblastomycosis

Chromoblastomycosis is an indolent cutaneous disease with a verrucous or nodular gross appearance, often misdiagnosed clinically as carcinoma and therefore excised.[381–383] It is an occupation-related disease, mainly affecting individuals in tropical and temperate regions.[383] Hematogenous dissemination occurs very rarely.[384] The spores are

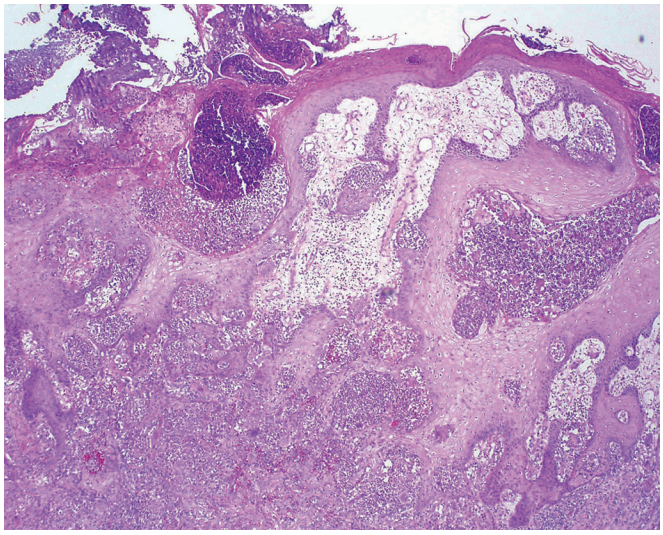

Figure 2.69 Blastomycosis. Pseudoepitheliomatous hyperplasia and dense neutrophilic infiltrate.

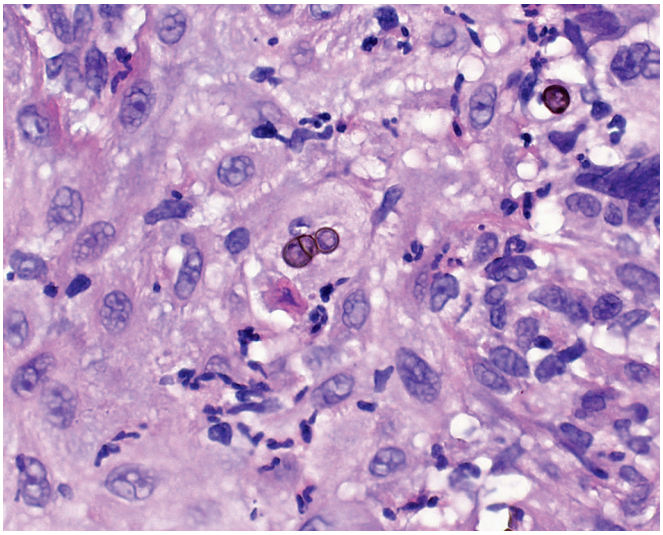

Figure 2.71 Chromoblastomycosis. Pigmented septate organisms.

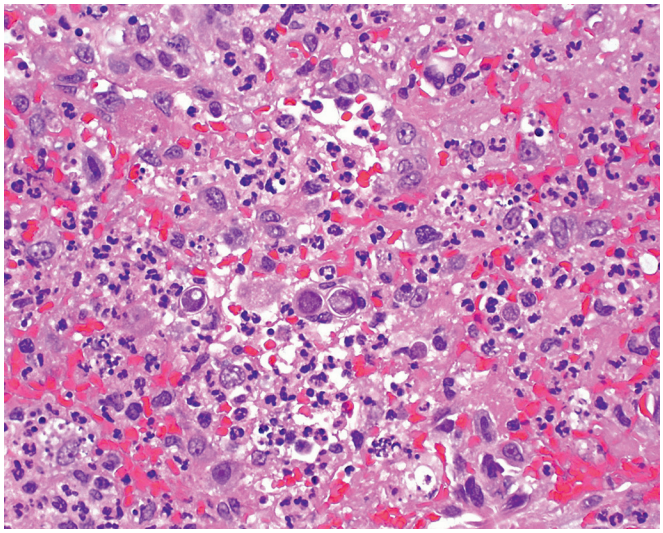

Figure 2.70 Blastomycosis. Budding yeast with thick refractile cell walls.

brown, hence their name, and the tissue reaction is similar to that seen in blastomycosis (Fig. 2.71). These fungi, closely related species of *Phialophora*, *Fonsecaea* and *Cladosporium*, multiply by cross wall formation and splitting. Their color, cross walls, and lack of budding distinguish them from *B. dermatitidis*. Sometimes, fungi with an identical appearance are found in subcutaneous abscesses.[385]

Miscellaneous Disorders

Foreign Body Reaction

Silica, talc, exogenous lipids, zirconium, beryllium, and aluminum induce granulomatous reactions within the dermis.[386–389] Residual particles of talc, silica, and lipids are demonstrable in tissue by routine or polariscopic microscopy. Beryllium, previously a component of the phosphorus in fluorescent lights, induces a distinct necrotizing and granulomatous reaction. Aluminum, used for vaccination and allergen desensitization, can induce a variety of changes in the injection site, including fat necrosis, panniculitis, prominent lymphoid follicle formation, and perifollicular lymphoid infiltrate. A clue to the diagnosis is the finding of histiocytes with a violaceous granular cytoplasm.[390]

Pyoderma Gangrenosum

Pyoderma gangrenosum is associated with a systemic disorder (such as inflammatory bowel disease) in approximately half of the cases.[391,392] It begins with an acute-phase necrotic pustule or furuncle and can evolve to a large and deep necrotic ulcer with a violaceous border and a surrounding halo of erythema.[392] Most lesions are found on the extremities. The majority are deeply seated, but they can also be superficial and vegetant.[393] Microscopically, the changes are those of hemorrhagic necrosis with abscess formation in the early stage and represented by a heavy infiltrate of lymphocytes and plasma cells in the late stage. Marked epidermal hyperplasia can be seen at the edges. The pathogenesis is probably immune mediated. Histologically, pyoderma gangrenosum does not have specific features but requires clinical correlation for diagnosis.

Elastosis Perforans

Elastosis perforans (serpiginosa) typically involves the back of the neck in adolescent boys.[394] Microscopically, clumps and strands of abnormally coarse elastic fibers penetrate the epidermis and produce a focal epidermal hyperplasia.[395,396] The altered elastica in the papillary dermis is easily missed and recognition usually requires elastic tissue stains.

Elastosis perforans needs to be distinguished from other perforating dermatoses, such as *reactive perforating collagenosis*, *perforating folliculitis*, and *Kyrle disease*.[397–400] The nosologic identity of the latter two disorders and their relationship to each other remains controversial. A high proportion of them are seen in patients with chronic renal failure (in hemodialysis) or diabetes mellitus.[401,402]

Pseudoxanthoma Elasticum

The dermal changes in *pseudoxanthoma elasticum* are manifestations of a heritable disease also having ocular and vascular lesions resulting from degeneration of elastic fibers and due to mutations of the

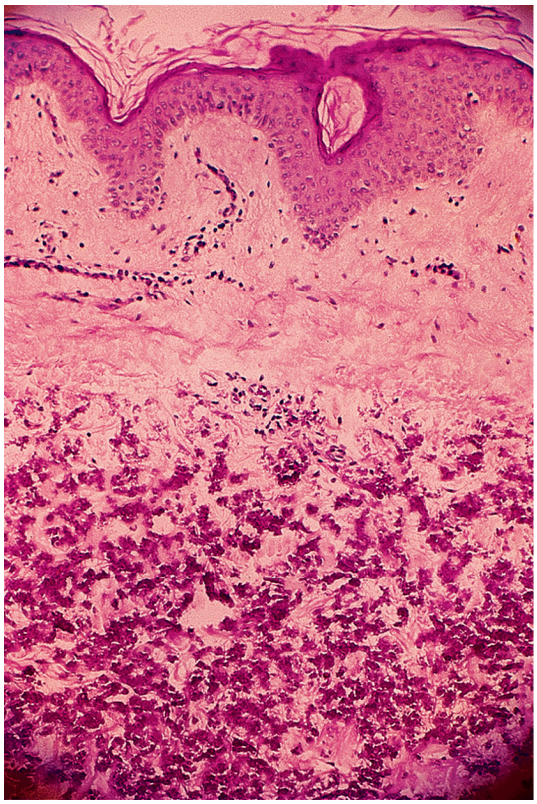

Figure 2.72 Pseudoxanthoma Elasticum.

Figure 2.73 Clinical Appearance of Darier Disease. The lesion typically affects the back and presents in the form of reticulated keratotic lesions.

ABCC/MRP6 gene (which codes for an ATP-binding protein).[403–405] Angioid streaks in the retina and degenerative changes in arteries leading to occlusion or rupture are described.[406] Yellow streaks and plaques of the skin, particularly in areas of creases, such as the neck, axillae, and groin, account for the name pseudoxanthoma. Histologically, the mid and lower dermis contains clumps and strands of altered, basophilic connective tissue that stain intensely with aldehyde fuchsin and Verhoeff elastic tissue stain (Fig. 2.72). The basophilic staining quality of the elastic material is due to dystrophic calcification of the fibers.

Cutaneous Mucinosis

Pretibial myxedema is characterized by sometimes large nodular lesions that occur on the legs of patients who are or have been thyrotoxic.[407] When particularly extreme, the disease has been referred to as *elephantiasic*.[408] The accumulation of mucopolysaccharides in the dermis is similar to that in the orbital tissues, which is caused by excess thyroid-stimulating hormone (TSH) secretion by the pituitary gland. Histologically, the dermal collagen is separated by aggregates of faintly basophilic material that stains with Mayer mucicarmine, Hale colloidal iron, and PAS (diastase resistant).

Other conditions associated with the deposition of large amounts of acid mucopolysaccharides in the dermis are the generalized myxedema of hypothyroidism, papular mucinosis (lichen myxedematosus), myxoid cyst, cutaneous focal mucinosis, and follicular mucinosis.[409–418] The latter condition is a reaction pattern of follicular epithelium that is particularly prominent in alopecia mucinosa but that can also be seen in a variety of other diseases, including mycosis fungoides.[419] Morphologically, the idiopathic and mycosis fungoides-related forms of the disease are similar; follow-up studies on patients with the idiopathic form have shown little or no progression toward mycosis fungoides, despite the presence in some cases of a clonal T-cell population.[419] *Cutaneous myxomas* (superficial angiomyxomas) are an important component of Carney complex, which also includes cardiac myxomas, spotty hyperpigmentation, and endocrine hyperactivity.[420]

Acanthosis Nigricans

Acanthosis nigricans manifests clinically as brown, velvety plaques most often found in the axillae, back of the neck, and other flexural areas. Two major forms exist, one associated with internal malignant neoplasms (particularly of the gastrointestinal tract) and the other with a heterogeneous group of disorders having as common denominator the presence of tissue resistance to insulin.[421–424] The latter form includes diabetes, obesity, and Cushing syndrome. Microscopically, the changes are similar in both types and are characterized by papillomatosis and hyperkeratosis (rather than by acanthosis and hyperpigmentation, as suggested by the name). In the cases associated with malignancy, the disease may be the result of production of epidermal growth factors by the tumor cells.[425,426]

Darier Disease

Although Darier disease has bullous features, it is not an autoimmune inflammatory bullous dermatosis. Darier disease is an uncommon genodermatosis caused by germline mutation of the *ATP2A2* gene.[427,428] It usually presents with a symmetrical distribution of keratotic reddish-brown papules over the seborrheic areas of the body (Fig. 2.73). Unilateral and localized variants have been described.[429] Microscopically, the skin lesions are characterized by suprabasal

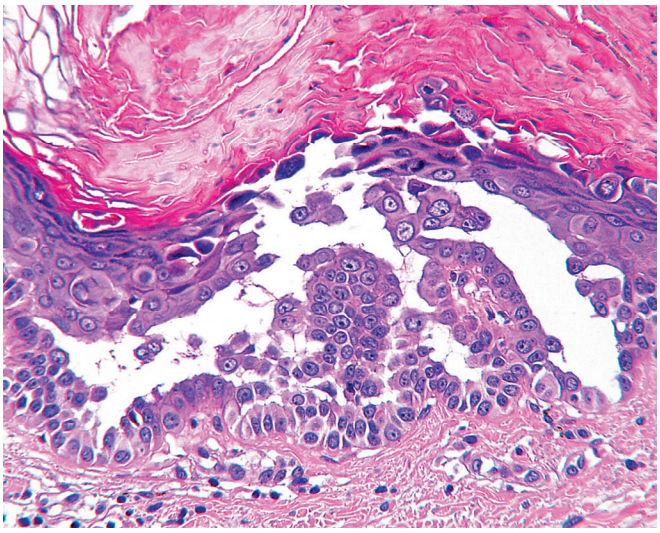

Figure 2.74 Darier Disease.

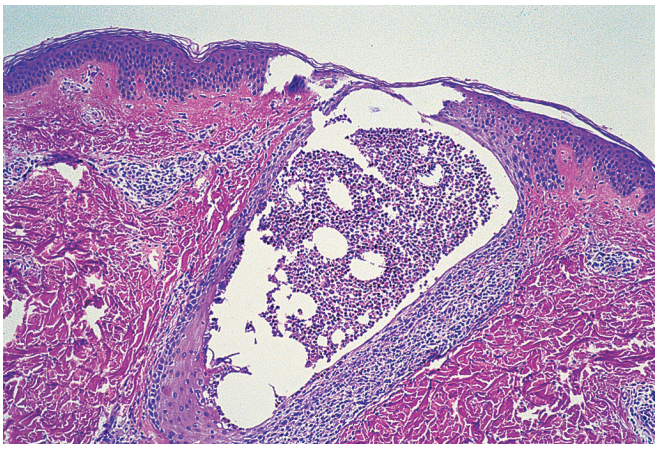

Figure 2.75 Eosinophilic Folliculitis in a Human Immunodeficiency Virus-Infected Patient.

clefts in which acantholytic cells called grains are found (Fig. 2.74).[430] The dermal papillae covered by a layer of basal cells form small villi at the base of the lesion. In addition, within the epidermis, large individually dyskeratotic cells called *corps ronds* are found. When the lesions are closely spaced, the skin assumes a verrucous appearance. The back is the most common site of involvement. The oral mucosa and hairless skin may be involved, showing that the disease is not limited to the hair follicle, as suggested by the synonym keratosis follicularis. *Warty dyskeratoma*, an isolated follicular lesion, is histologically similar but unrelated to Darier disease.

Dermatoses in HIV-Infected Patients

HIV-infected patients may develop a large variety of skin diseases, ranging from inconspicuous macular rashes to Kaposi sarcoma, the latter being the condition that contributed in the mid-1980s to the recognition of this immune deficiency syndrome.[431–434]

Non-neoplastic skin manifestations of HIV infection include the following:

1. Maculopapular eruptions. In acute HIV disease, approximately one-fourth of patients develop a maculopapular erythematous eruption in the trunk that may extend to involve the extremities. Microscopically, there is a nonspecific perivascular collection of lymphocytes and histiocytes in the upper dermis, sometimes associated with small papulovesicular foci with necrotic keratinocytes and a few neutrophils.[435,436]
2. Papular pruritic eruptions. These lesions, which may develop after the acute HIV phase, have a tendency for waxing and waning and can occur anywhere in the body. Microscopically, there is a superficial and mid-dermal perivascular lymphocytic dermatitis, often featuring eosinophils, acanthosis, and parakeratosis.[437]
3. Vasculitis. A few cases of leukocytoclastic vasculitis have been reported. Some have been said to be the direct result of HIV infection[438] and others of cytomegalovirus (CMV) infection.[439]
4. Folliculitis and syringitis. The clinical observation has been made that full-blown AIDS is often preceded by some manifestation of folliculitis.[440] Microscopically, the usual appearance is that of a mixed perifollicular chronic inflammatory infiltrate, sometimes associated with follicle rupture. In some cases the inflammation has a prominent eosinophilic component (HIV-associated eosinophilic folliculitis) (Fig. 2.75).[441] Herpetic syringitis (i.e. inflammation of the acrosyringium of the sweat glands) has been described, sometimes accompanied by squamous syringometaplasia.[442]
5. Seborrheic dermatitis. This common complication of HIV infection differs from that seen in immunocompetent individuals in that it tends to involve the trunk and extremities and is clinically more severe.[443,444] Microscopically, the changes depend on the stage of the lesion and are qualitatively similar to those seen in the usual form of the disease.
6. Psoriasis.
7. Drug reaction.
8. Parasitic (scabies), fungal (cryptococcosis, histoplasmosis, dermatophytosis), and bacterial (mycobacteriosis, syphilis, bacillary angiomatosis) infections.
9. Viral infections (other than these already mentioned). Herpes simplex occurs in approximately 20% of HIV-infected patients, usually in the form of a painful ulcer in the perianal or perioral regions (see Fig. 2.56).[445] Varicella–herpes zoster infection can be severe and widespread, sometimes with involvement of numerous dermatomes.[446,447] CMV may be detected in ulcerative lesions at mucocutaneous junctions. Other viral infections include measles,[448] molluscum contagiosum, oral hairy leukoplakia, and HPV-induced lesions (such as anal warts and bowenoid papulosis).[449]
10. Papular neutrophilic xanthoma. This HIV-associated lesion is characterized by collections of foamy macrophages, extracellular nuclear dust, and hyaline necrosis of collagen fibers.[450]

References

1. Ackerman AB. *Histologic Diagnosis of Inflammatory Skin Disease*. 2nd ed. Baltimore: Williams & Williams; 1997.
2. Ackerman AB. *Differential Diagnosis in Dermatopathology II*. 2nd ed. New York, NY: Ardor Scribendi; 2001.
3. Demis D, ed. *Clinical Dermatology*. Hagerstown, MD: Harper & Row; 1972.
4. Elder DE, Elenitasas R, Johnson BL, et al. *Lever's Histopathology of the Skin*. 9th ed. Philadelphia, PA: Lippincott Williams & Wilkins; 2005.
5. Farmer ER, Hood AF, eds. *Pathology of the Skin*. 2nd ed. New York, NY: McGraw-Hill; 2000.
6. Fitzpatrick TB, Freedberg I, eds. *Fitzpatrick's Dermatology in General Medicine*. 6th ed. New York, NY: McGraw-Hill; 2003.

7. Johnson BLJ, Honig PJ, Jaworsky C. *Pediatric Dermatopathology*. Boston: Butterworth-Heinemann; 1994.
8. Kempf W, Hantschke M, Kutzner H, Burgdoff WHC. *Dermatopathology*. Berlin: Springer; 2008.
9. McKee P. *Essential Skin Pathology*. London: Mosby; 1999.
10. Mehregan AH. *Pinkus' Guide to Dermatohistopathology*. 6th ed. Norwalk, CT: Appleton & Lange; 1995.
11. Rook A, Wilkinson DS, Ebling FJG, Champion RH. *Rook/Wilkinson/Ebling Textbook of Dermatology*. 6th ed. Oxford: Blackwell Science; 1998.
12. Weedon D. *Weedon's Skin Pathology*. 3rd ed. Edinburgh: Churchill Livingstone; 2010.
13. Rajaratnam R, Smith AG, Biswas A, Stephens M. The value of skin biopsy in inflammatory dermatoses. *Am J Dermatopathol*. 2009;31:350-353.
14. Horstman E. Die Haut. In: Möllendorff WV, ed. *Handbuch der Microskopichen Anatomie des Menschen*. Vol 3. *Part 3*. Berlin: Springer; 1957:1-488.
15. Li M, Urmacher CD. Normal skin. In: Mills SE, ed. *Histology for Pathologists*. 3rd ed. Philadelphia, PA: Lippincott Williams & Wilkins; 2007.
16. Montagna W, Parakkal PF. *The Structure and Function of the Skin*. 3rd ed. New York, NY: Academic Press; 1974.
17. Montagna W, Kligman AM, Carlisle KS. *Atlas of Normal Human Skin*. New York, NY: Springer; 1992.
18. Fine JD. Structure and antigenicity of the skin basement membrane zone. *J Cutan Pathol*. 1991;18:401-409.
19. Gould VE, Moll R, Moll I, et al. Neuroendocrine (Merkel) cells of the skin: hyperplasias, dysplasias, and neoplasms. *Lab Invest*. 1985;52:334-353.
20. Moll R, Moll I, Franke WW. Identification of Merkel cells in human skin by specific cytokeratin antibodies: changes of cell density and distribution in fetal and adult plantar epidermis. *Differentiation*. 1984;28:136-154.
21. Pagani A, Eusebi V, Bussolati G. Detection of PIP-GCDFP-15 gene expression in apocrine epithelium of the breast and salivary glands. *Appl Immunohistochem*. 1994;2:29-35.
22. Foschini MP, Scarpellini F, Gown AM, Eusebi V. Differential expression of myoepithelial markers in salivary, sweat and mammary glands. *Int J Surg Pathol*. 2000;8:29-37.
23. Maiorana A, Nigrisoli E, Papotti M. Immunohistochemical markers of sweat gland tumors. *J Cutan Pathol*. 1986;13:187-196.
24. Noda Y, Oosumi H, Morishima T, et al. Immunohistochemical study of carbonic anhydrase in mixed tumours and adenomas of sweat and sebaceous glands. *J Cutan Pathol*. 1987;14:285-290.
25. Penneys NS, Zlatkiss I. Immunohistochemical demonstration of ferritin in sweat gland and sweat gland neoplasms. *J Cutan Pathol*. 1990;17:32-36.
26. Tamaki K, Furue M, Matsukawa A, et al. Presence and distribution of carcinoembryonic antigen and lectin-binding sites in benign apocrine sweat gland tumours. *Br J Dermatol*. 1985;113:565-571.
27. Tsubura A, Senzaki H, Sasaki M, et al. Immunohistochemical demonstration of breast-derived and/or carcinoma-associated glycoproteins in normal skin appendages and their tumors. *J Cutan Pathol*. 1992;19: 73-79.
28. Miettinen M, McCue PA, Sarlomo-Rikala M, et al. Sox10—a marker for not only schwannian and melanocytic neoplasms but also myoepithelial cell tumors of soft tissue: a systematic analysis of 5134 tumors. *Am J Surg Pathol*. 2015;39:826-835.
29. Houck G, Saeed S, Stevens GL, Morgan MB. Eczema and the spongiotic dermatoses: a histologic and pathogenic update. *Semin Cutan Med Surg*. 2004;23:39-45.
30. Weaver J, Billings SD. Initial presentation of stasis dermatitis mimicking solitary lesions: a previously unrecognized clinical scenario. *J Am Acad Dermatol*. 2009;61:1028-1032.
31. Schon MP, Boehncke WH. Psoriasis. *N Engl J Med*. 2005;352:1899-1912.
32. Fox BJ, Odom RB. Papulosquamous diseases: a review. *J Am Acad Dermatol*. 1985;12:597-624.
33. Helwig EB. Pathology of psoriasis. *Ann N Y Acad Sci*. 1958;73(5):924-935.
34. Boehncke WH, Wortmann S, Kaufmann R, et al. A subset of macrophages located along the basement membrane ('lining cells') is a characteristic histopathologic feature of psoriasis. *Am J Dermatopathol*. 1995;17:139-144.
35. Guerra I, Algaba A, Pérez-Calle JL, et al. Induction of psoriasis with anti-TNF agents in patients with inflammatory bowel disease: a report of 21 cases. *J Crohns Colitis*. 2012;6:518-523.
36. Nestle FO, Kaplan DH, Barker J. Psoriasis. *N Engl J Med*. 2009;361:496-509.
37. Lowes MA, Bowcock AM, Krueger JG. Pathogenesis and therapy of psoriasis. *Nature*. 2007;445:866-873.
38. Kim BY, Choi JW, Kim BR, Youn SW. Histopathological findings are associated with the clinical types of psoriasis but not with the corresponding lesional psoriasis severity index. *Ann Dermatol*. 2015;27:26-31.
39. Lotti T, Buggiani G, Prignano F. Prurigo nodularis and lichen simplex chronicus. *Dermatol Ther*. 2008;21:42-46.
40. Leighton PC, Langley FA. A clinico-pathological study of vulval dermatoses. *J Clin Pathol*. 1975;28:394-402.
41. Bastuji-Garin S, Rzany B, Stern RS, et al. Clinical classification of cases of toxic epidermal necrolysis, Stevens-Johnson syndrome, and erythema multiforme. *Arch Dermatol*. 1993;129:92-96.
42. Forman R, Koren G, Shear NH. Erythema multiforme, Stevens-Johnson syndrome and toxic epidermal necrolysis in children: a review of 10 years' experience. *Drug Saf*. 2002;25:965-972.
43. Bedi TR, Pinkus H. Histopathological spectrum of erythema multiforme. *Br J Dermatol*. 1976;95:243-250.
44. Patterson JW, Parsons JM, Blaylock WK, Mills AS. Eosinophils in skin lesions of erythema multiforme. *Arch Pathol Lab Med*. 1989;113:36-39.
45. Imamura S, Horio T, Yanase K, et al. Erythema multiforme: pathomechanism of papular erythema and target lesion. *J Dermatol*. 1992;19:524-533.
46. Snover DC. Biopsy interpretation in bone marrow transplantation. *Pathol Annu*. 1989;24(Pt 2):63-101.
47. Elliott CJ, Sloane JP, Sanderson KV, et al. The histological diagnosis of cutaneous graft versus host disease: relationship of skin changes to marrow purging and other clinical variables. *Histopathology*. 1987;11:145-155.
48. Hymes SR, Farmer ER, Lewis PG, et al. Cutaneous graft-versus-host reaction: prognostic features seen by light microscopy. *J Am Acad Dermatol*. 1985;12:468-474.
49. Massi D, Franchi A, Pimpinelli N, et al. A reappraisal of the histopathologic criteria for the diagnosis of cutaneous allogeneic acute graft-vs-host disease. *Am J Clin Pathol*. 1999;112:791-800.
50. Kohler S, Hendrickson MR, Chao NJ, Smoller BR. Value of skin biopsies in assessing prognosis and progression of acute graft-versus-host disease. *Am J Surg Pathol*. 1997;21:988-996.
51. Hausermann P, Walter RB, Halter J, et al. Cutaneous graft-versus-host disease: a guide for the dermatologist. *Dermatology*. 2008;216:287-304.
52. Spielvogel RL, Goltz RW, Kersey JH. Scleroderma-like changes in chronic graft vs host disease. *Arch Dermatol*. 1977;113:1424-1428.
53. Callen JP. Systemic lupus erythematosus in patients with chronic cutaneous (discoid) lupus erythematosus. Clinical and laboratory findings in seventeen patients. *J Am Acad Dermatol*. 1985;12(2 Pt 1):278-288.
54. Walling HW, Sontheimer RD. Cutaneous lupus erythematosus: issues in diagnosis and treatment. *Am J Clin Dermatol*. 2009;10:365-381.
55. Bangert JL, Freeman RG, Sontheimer RD, Gilliam JN. Subacute cutaneous lupus erythematosus and discoid lupus erythematosus. Comparative histopathologic findings. *Arch Dermatol*. 1984;120:332-337.
56. Hood AF. Pathology of cutaneous lupus erythematosus. *Adv Dermatol*. 1987;2:153-170.
57. Jerdan MS, Hood AF, Moore GW, Callen JP. Histopathologic comparison of the subsets of lupus erythematosus. *Arch Dermatol*. 1990;126:52-55.
58. Crowson AN, Magro C. The cutaneous pathology of lupus erythematosus: a review. *J Cutan Pathol*. 2001;28:1-23.
59. Sharon VR, Konia TH, Barr KL, Fung MA. Assessment of the 'no eosinophils' rule: are eosinophils truly absent in pityriasis lichenoides, connective tissue disease, and graft-vs.-host disease? *J Cutan Pathol*. 2012;39:413-418.
60. McNiff JM, Kaplan DH. Plasmacytoid dendritic cells are present in cutaneous dermatomyositis lesions in a pattern distinct from lupus erythematosus. *J Cutan Pathol*. 2008;35:452-456.
61. Biesecker G, Lavin L, Ziskind M, Koffler D. Cutaneous localization of the membrane attack complex in discoid and systemic lupus erythematosus. *N Engl J Med*. 1982;306:264-270.
62. Williams RE, Mackie RM, O'Keefe R, Thomson W. The contribution of direct immunofluorescence to the diagnosis of lupus erythematosus. *J Cutan Pathol*. 1989;16:122-125.
63. Wojnarowska F, Bhogal B, Black MM. The significance of an IgM band at the dermo-epidermal junction. *J Cutan Pathol*. 1986;13:359-362.
64. Magro CM, Crowson AN. The immunofluorescent profile of dermatomyositis: a comparative study with lupus erythematosus. *J Cutan Pathol*. 1997;24:543-552.
65. Golitz LE. Collagen diseases. *J Cutan Pathol*. 1985;12:358-365.
66. Janis JF, Winkelmann RK. Histopathology of the skin in dermatomyositis. A histopathologic study of 55 cases. *Arch Dermatol*. 1968;97:640-650.
67. Dalakas MC. Muscle biopsy findings in inflammatory myopathies. *Rheum Dis Clin North Am*. 2002;28:779-798, vi.
68. Mastaglia FL, Garlepp MJ, Phillips BA, Zilko PJ. Inflammatory myopathies: clinical, diagnostic and therapeutic aspects. *Muscle Nerve*. 2003;27:407-425.
69. Franks AG Jr. Skin manifestations of internal disease. *Med Clin North Am*. 2009;93:1265-1282.
70. Sigurgeirsson B, Lindelof B, Edhag O, Allander E. Risk of cancer in patients with dermatomyositis or polymyositis. A population-based study. *N Engl J Med*. 1992;326:363-367.

71. Williams RC Jr. Dermatomyositis and malignancy: a review of the literature. *Ann Intern Med*. 1959;50:1174-1181.
72. Boyd AS, Neldner KH. Lichen planus. *J Am Acad Dermatol*. 1991;25:593-619.
73. Lehman JS, Tollefson MM, Gibson LE. Lichen planus. *Int J Dermatol*. 2009;48:682-694.
74. Scully C, el-Kom M. Lichen planus: review and update on pathogenesis. *J Oral Pathol*. 1985;14:431-458.
75. Bagan-Sebastian JV, Milian-Masanet MA, Penarrocha-Diago M, Jimenez Y. A clinical study of 205 patients with oral lichen planus. *J Oral Maxillofac Surg*. 1992;50:116-118.
76. Assouly P, Reygagne P. Lichen planopilaris: update on diagnosis and treatment. *Semin Cutan Med Surg*. 2009;28:3-10.
77. Mehregan DA, Van Hale HM, Muller SA. Lichen planopilaris: clinical and pathologic study of forty-five patients. *J Am Acad Dermatol*. 1992;27(6 Pt 1):935-942.
78. Ragaz A, Ackerman AB. Evolution, maturation, and regression of lesions of lichen planus. New observations and correlations of clinical and histologic findings. *Am J Dermatopathol*. 1981;3:5-25.
79. Willsteed E, Bhogal BS, Das AK, et al. Lichen planus pemphigoides. A clinicopathologic study of nine cases. *Histopathology*. 1991;19:147-154.
80. Patterson JW. The spectrum of lichenoid dermatitis. *J Cutan Pathol*. 1991;18:67-74.
81. Sontheimer RD. Lichenoid tissue reaction/interface dermatitis: clinical and histological perspectives. *J Invest Dermatol*. 2009;129:1088-1099.
82. Frigy AF, Cooper PH. Benign lichenoid keratosis. *Am J Clin Pathol*. 1985;83:439-443.
83. Lumpkin LR, Helwig EB. Solitary lichen planus. *Arch Dermatol*. 1966;93:54-55.
84. Prieto VG, Casal M, McNutt NS. Lichen planus-like keratosis. A clinical and histological reexamination. *Am J Surg Pathol*. 1993;17:259-263.
85. Pinkus H. Lichenoid tissue reactions. A speculative review of the clinical spectrum of epidermal basal cell damage with special reference to erythema dyschromicum perstans. *Arch Dermatol*. 1973;107:840-846.
86. Sale GE, Lerner KG, Barker EA, et al. The skin biopsy in the diagnosis of acute graft-versus-host disease in man. *Am J Pathol*. 1977;89:621-636.
87. Weedon D. The lichenoid tissue reaction. *J Cutan Pathol*. 1985;12:279-281.
88. Dalton SR, Baptista MA, Libow LF, Elston DM. Lichenoid tissue reaction in malignant melanoma: a potential diagnostic pitfall. *Am J Clin Pathol*. 2002;117:766-770.
89. Sanchez Yus E, Soria L, de Eusebio E, Requena L. Lichenoid, erosive and ulcerated dermatofibromas. Three additional clinico-pathologic variants. *J Cutan Pathol*. 2000;27:112-117.
90. Flowers H, Brodell R, Brents M, Wyatt JP. Fixed drug eruptions: presentation, diagnosis, and management. *South Med J*. 2014;107:724-727.
91. Korkij W, Soltani K. Fixed drug eruption. A brief review. *Arch Dermatol*. 1984;120:520-524.
92. Hindsén M, Christensen OB, Gruic V, Löfberg H. Fixed drug eruption: an immunohistochemical investigation of the acute and healing phase. *Br J Dermatol*. 1987;116:351-360.
93. Van Voorhees A, Stenn KS. Histological phases of Bactrim-induced fixed drugeruption. The report of one case. *Am J Dermatopathol*. 1987;9:528-532.
94. Gray AM. Pityriasis lichenoides et varioliformis acuta. *Proc R Soc Med*. 1927;20:341-344.
95. Davis H. Pityriasis lichenoides chronica. *Proc R Soc Med*. 1920;13(Dermatol Sect):119.
96. Roenigk HH Jr. Pityriasis lichenoides et varioliformis acuta (Mucha-Habermann). *Arch Dermatol*. 1971;104:102-103.
97. Geller L, Antonov NK, Lauren CT, et al. Pityriasis lichenoides in childhood: review of clinical presentation and treatment options. *Pediatr Dermatol*. 2015;32:579-592.
98. Castro BA, Pereira JM, Meyer RL, et al. Pityriasis lichenoides et varioliformis acuta after influenza vaccine. *An Bras Dermatol*. 2015;90(3 suppl 1):181-184.
99. Terraneo L, Lava SA, Camozzi P, et al. Unusual eruptions associated with mycoplasma pneumoniae respiratory infections: review of the literature. *Dermatology*. 2015;231:152-157.
100. Echeverri AF, Vidal A, Cañas CA, et al. Etanercept-induced pityriasis lichenoides chronica in a patient with rheumatoid arthritis. *Case Rep Dermatol Med*. 2015;2015:168063.
101. Hood AF, Mark EJ. Histopathologic diagnosis of pityriasis lichenoides et varioliformis acuta and its clinical correlation. *Arch Dermatol*. 1982;118:478-482.
102. Benmamán O, Sánchez JL. Comparative clinicopathological study on pityriasis lichenoides chronica and small plaque parapsoriasis. *Am J Dermatopathol*. 1988;10:189-196.
103. Black MM. Lymphomatoid papulosis and pityriasis lichenoides: are they related? *Br J Dermatol*. 1982;106:717-721.
104. Willemze R, Scheffer E. Clinical and histologic differentiation between lymphomatoid papulosis and pityriasis lichenoides. *J Am Acad Dermatol*. 1985;13:418-428.
105. Varga FJ, Vonderheid EC, Olbricht SM, Kadin ME. Immunohistochemical distinction of lymphomatoid papulosis and pityriasis lichenoides et varioliformis acuta. *Am J Pathol*. 1990;136:979-987.
106. Kempf W, Kazakov DV, Palmedo G, et al. Pityriasis lichenoides et varioliformis acuta with numerous CD30(+) cells: a variant mimicking lymphomatoid papulosis and other cutaneous lymphomas. A clinicopathologic, immunohistochemical, and molecular biological study of 13 cases. *Am J Surg Pathol*. 2012;36:1021-1029.
107. Kempf W. CD30+ lymphoproliferative disorders: histopathology, differential diagnosis, new variants, and simulators. *J Cutan Pathol*. 2006;33(suppl 1):58-70.
108. Guitart J, Querfeld C. Cutaneous CD30 lymphoproliferative disorders and similar conditions: a clinical and pathologic prospective on a complex issue. *Semin Diagn Pathol*. 2009;26:131-140.
109. Bertolotti A, Pham-Ledard AL, Vergier B, et al. Lymphomatoid papulosis type D: an aggressive histology for an indolent disease. *Br J Dermatol*. 2013;169:1157-1159.
110. Kempf W, Kazakov DV, Schärer L, et al. Angioinvasive lymphomatoid papulosis: a new variant simulating aggressive lymphomas. *Am J Surg Pathol*. 2013;37:1-13.
111. Martires KJ, Ra S, Abdulla F, Cassarino DS. Characterization of primary cutaneous CD8+/CD30+ lymphoproliferative disorders. *Am J Dermatopathol*. 2015;37:822-833.
112. Swanbeck G, Dahlberg E. Cutaneous drug reactions. An attempt to quantitative estimation. *Arch Dermatol Res*. 1992;284:215-218.
113. Jones RR, Bhogal B, Dash A, Schifferli J. Urticaria and vasculitis: a continuum of histological and immunopathological changes. *Br J Dermatol*. 1983;108:695-703.
114. Winkelmann RK, Wilson-Jones E, Smith NP, et al. Neutrophilic urticaria. *Acta Derm Venereol*. 1988;68:129-133.
115. Jones RR, Eady RA. Endothelial cell pathology as a marker for urticarial vasculitis: a light microscopic study. *Br J Dermatol*. 1984;110:139-149.
116. Davis MD, Perniciaro C, Dahl PR, et al. Exaggerated arthropod-bite lesions in patients with chronic lymphocytic leukemia: a clinical, histopathologic, and immunopathologic study of eight patients. *J Am Acad Dermatol*. 1998;39:27-35.
117. Ackerman AB, Jones RE Jr. Making chronic nonspecific dermatitis specific. How to make precise diagnoses of superficial perivascular dermatitides devoid of epidermal involvement. *Am J Dermatopathol*. 1985;7:307-323.
118. Carlson JA. The histological assessment of cutaneous vasculitis. *Histopathology*. 2010;56:3-23.
119. Crowson AN, Mihm MC Jr, Magro CM. Cutaneous vasculitis: a review. *J Cutan Pathol*. 2003;30(3):161-173.
120. Lie JT. Systemic and isolated vasculitis. A rational approach to classification and pathologic diagnosis. *Pathol Annu*. 1989;24(Pt 1):25-114.
121. Mackel SE, Jordon RE. Leukocytoclastic vasculitis. A cutaneous expression of immune complex disease. *Arch Dermatol*. 1982;118(5):296-301.
122. Ryan TJ. Cutaneous vasculitis. *J Cutan Pathol*. 1985;12(3-4):381-387.
123. Fiorentino DF. Cutaneous vasculitis. *J Am Acad Dermatol*. 2003;48(3):311-340.
124. Carlson JA, Chen KR. Cutaneous vasculitis update: neutrophilic muscular vessel and eosinophilic, granulomatous, and lymphocytic vasculitis syndromes. *Am J Dermatopathol*. 2007;29(1):32-43.
125. Carlson JA, Chen KR. Cutaneous vasculitis update: small vessel neutrophilic vasculitis syndromes. *Am J Dermatopathol*. 2006;28(6):486-506.
126. Akosa AB, Lampert IA. The sweat gland in cutaneous vasculitis. *Histopathology*. 1991;18(6):553-558.
127. Boom BW, Mommaas AM, Vermeer BJ. Presence and interpretation of vascular immune deposits in human skin: the value of direct immunofluorescence. *J Dermatol Sci*. 1992;3(1):26-34.
128. Alalwani M, Billings SD, Gota CE. Clinical significance of immunoglobulin deposition in leukocytoclastic vasculitis: a 5-year retrospective study of 88 patients at Cleveland Clinic. *Am J Dermatopathol*. 2014;36(9):723-729.
129. Copeman PWM, Ryan TJ. The problems of classification of cutaneous angiitis with reference to histopathology and pathogenesis. *Br J Dermatol*. 1970;82:2-14.
130. Gibson LE. Cutaneous vasculitis update. *Dermatol Clin*. 2001;19(4):603-615, vii.
131. Gilliam JN, Smiley JD. Cutaneous necrotizing vasculitis and related disorders. *Ann Allergy*. 1976;37(5):328-339.
132. Jennette JC, Falk RJ. Small-vessel vasculitis. *N Engl J Med*. 1997;337(21):1512-1523.
133. Mehregan DR, Hall MJ, Gibson LE. Urticarial vasculitis: a histopathologic and clinical review of 72 cases. *J Am Acad Dermatol*. 1992;26(3 Pt 2):441-448.
134. Peteiro C, Toribio J. Incidence of leukocytoclastic vasculitis in chronic idiopathic urticaria. Study of 100 cases. *Am J Dermatopathol*. 1989;11(6):528-533.
135. Sanchez NP, Van Hale HM, Su WP. Clinical and histopathologic spectrum of necrotizing vasculitis. Report of findings in 101 cases. *Arch Dermatol*. 1985;121(2):220-224.
136. Churg J, Churg A. Idiopathic and secondary vasculitis: a review. *Mod Pathol*. 1989;2(2):144-160.
137. Cribier B, Couilliet D, Meyer P, Grosshans E. The severity of histopathological changes of leukocytoclastic vasculitis is not predictive of

extracutaneous involvement. *Am J Dermatopathol*. 1999;21(6):532-536.
138. Hodge SJ, Callen JP, Ekenstam E. Cutaneous leukocytoclastic vasculitis: correlation of histopathological changes with clinical severity and course. *J Cutan Pathol*. 1987;14(5):279-284.
139. Jones D, Dorfman DM, Barnhill RL, Granter SR. Leukemic vasculitis: a feature of leukemia cutis in some patients. *Am J Clin Pathol*. 1997;107(6):637-642.
140. Chumbley LC, Harrison EG Jr, DeRemee RA. Allergic granulomatosis and angiitis (Churg-Strauss syndrome). Report and analysis of 30 cases. *Mayo Clin Proc*. 1977;52(8):477-484.
141. Diri E, Buscemi DM, Nugent KM. Churg-Strauss syndrome: diagnostic difficulties and pathogenesis. *Am J Med Sci*. 2003;325(2):101-105.
142. Finan MC, Winkelmann RK. The cutaneous extravascular necrotizing granuloma (Churg-Strauss granuloma) and systemic disease: a review of 27 cases. *Medicine (Baltimore)*. 1983;62(3):142-158.
143. Barksdale SK, Hallahan CW, Kerr GS, et al. Cutaneous pathology in Wegener's granulomatosis. A clinicopathologic study of 75 biopsies in 46 patients. *Am J Surg Pathol*. 1995;19(2):161-172.
144. James WD, Odom RB, Katzenstein AL. Cutaneous manifestations of lymphomatoid granulomatosis. Report of 44 cases and a review of the literature. *Arch Dermatol*. 1981;117(4):196-202.
145. Kessler S, Lund HZ, Leonard DD. Cutaneous lesions of lymphomatoid granulomatosis. Comparison with lymphomatoid papulosis. *Am J Dermatopathol*. 1981;3(2):115-127.
146. Schamberg JF. A peculiar progressive pigmentary disease of the skin. *Br J Dermatol*. 1901;13:1-5.
147. Randall SJ, Kierland RR, Montgomery H. Pigmented purpuric eruptions. *AMA Arch Derm Syphilol*. 1951;64:177-191.
148. Wall LM, Smith NP. Perniosis: a histopathological review. *Clin Exp Dermatol*. 1981;6(3):263-271.
149. Goette DK. Chilblains (perniosis). *J Am Acad Dermatol*. 1990;23(2 Pt1):257-262.
150. Black MM, Jones EW. Malignant atrophic papulosis (Degos' syndrome). *Br J Dermatol*. 1971;85(3):290-292.
151. Magrinat G, Kerwin KS, Gabriel DA. The clinical manifestations of Degos' syndrome. *Arch Pathol Lab Med*. 1989;113(4):354-362.
152. Molenaar WM, Rosman JB, Donker AJ, Houthoff HJ. The pathology and pathogenesis of malignant atrophic papulosis (Degos' disease). A case study with reference to other vascular disorders. *Pathol Res Pract*. 1987;182(1):98-106.
153. Gray HR, Graham JH, Johnson W, Burgoon CF Jr. Atrophie blanche: periodic painful ulcers of lower extremities. A clinical and histopathological entity. *Arch Dermatol*. 1966;93(2):187-193.
154. Maessen-Visch MB, Koedam MI, Hamulyak K, Neumann HA. Atrophie blanche. *Int J Dermatol*. 1999;38(3):161-172.
155. Oh DH, Eulau D, Tokugawa DA, et al. Five cases of calciphylaxis and a review of the literature. *J Am Acad Dermatol*. 1999;40(6 Pt 1):979-987.
156. Karpman E, Das S, Kurzrock EA. Penile calciphylaxis: analysis of risk factors and mortality. *J Urol*. 2003;169(6):2206-2209.
157. Daudén E, Oñate MJ. Calciphylaxis. *Dermatol Clin*. 2008;26(4):557-568, ix.
158. Briley LD, Phillips CM. Cutaneous mastocytosis: a review focusing on the pediatric population. *Clin Pediatr*. 2008;47(8):757-761.
159. Escribano L, Akin C, Castells M, et al. Mastocytosis: current concepts in diagnosis and treatment. *Ann Hematol*. 2002;81(12):677-690.
160. Johnson WC, Helwig EB. Solitary mastocytosis (urticaria pigmentosa). *Arch Dermatol*. 1961;84:806-815.
161. Soter NA. The skin in mastocytosis. *J Invest Dermatol*. 1991;96(suppl 3):32S-38S, discussion 8S-9S, 60S-65S.
162. Caplan RM. The natural course of urticaria pigmentosa. Analysis and follow-up of 112 cases. *Arch Dermatol*. 1963;87:146-157.
163. Wolff K, Komar M, Petzelbauer P. Clinical and histopathological aspects of cutaneous mastocytosis. *Leuk Res*. 2001;25(7): 519-528.
164. Brunning RD, McKenna RW, Rosai J, et al. Systemic mastocytosis. Extracutaneous manifestations. *Am J Surg Pathol*. 1983;7(5):425-438.
165. Lennert K, Parwaresch MR. Mast cells and mast cell neoplasia: a review. *Histopathology*. 1979;3(5):349-365.
166. Travis WD, Li CY, Su WP. Adult-onset urticaria pigmentosa and systemic mast cell disease. *Am J Clin Pathol*. 1985;84(6):710-714.
167. Sotlar K, Horny HP, Simonitsch I, et al. CD25 indicates the neoplastic phenotype of mast cells: a novel immunohistochemical marker for the diagnosis of systemic mastocytosis (SM) in routinely processed bone marrow biopsy specimens. *Am J Surg Pathol*. 2004;28(10):1319-1325.
168. Valent P, Sotlar K, Horny HP. Aberrant expression of CD30 in aggressive systemic mastocytosis and mast cell leukemia: a differential diagnosis to consider in aggressive hematopoietic CD30-positive neoplasms. *Leuk Lymphoma*. 2011;52(5):740-744.
169. Mihm MC, Clark WH, Reed RJ, Caruso MG. Mast cell infiltrates of the skin and the mastocytosis syndrome. *Hum Pathol*. 1973;4(2):231-239.
170. Arber DA, Tamayo R, Weiss LM. Paraffin section detection of the c-kit gene product (CD117) in human tissues: value in the diagnosis of mast cell disorders. *Hum Pathol*. 1998;29(5):498-504.
171. Horny HP, Sillaber C, Menke D, et al. Diagnostic value of immunostaining for tryptase in patients with mastocytosis. *Am J Surg Pathol*. 1998;22(9):1132-1140.
172. Li CY. Diagnosis of mastocytosis: value of cytochemistry and immunohistochemistry. *Leuk Res*. 2001;25(7):537-541.
173. Mangini J, Silverman JF, Dabbs DJ, et al. Diagnostic value of calretinin in mast cell lesions of the skin. *Int J Surg Pathol*. 2000;8(2):119-122.
174. Feger F, Ribadeau Dumas A, Leriche L, et al. Kit and c-kit mutations in mastocytosis: a short overview with special reference to novel molecular and diagnostic concepts. *Int Arch Allergy Immunol*. 2002;127(2): 110-114.
175. Garcia-Montero AC, Jara-Acevedo M, Teodosio C, et al. KIT mutation in mast cells and other bone marrow hematopoietic cell lineages in systemic mast cell disorders: a prospective study of the Spanish Network on Mastocytosis (REMA) in a series of 113 patients. *Blood*. 2006;108(7):2366-2372.
176. Morren MA, Hoppé A, Renard M, et al. Imatinib mesylate in the treatment of diffuse cutaneous mastocytosis. *J Pediatr*. 2013;162(1):205-207.
177. Gotlib J. Tyrosine kinase inhibitors and therapeutic antibodies in advanced eosinophilic disorders and systemic mastocytosis. *Curr Hematol Malig Rep*. 2015;10(4):351-361.
178. Callen JP. Neutrophilic dermatoses. *Dermatol Clin*. 2002;20(3):409-419.
179. Cohen PR, Holder WR, Tucker SB, et al. Sweet syndrome in patients with solid tumors. *Cancer*. 1993;72(9):2723-2731.
180. Jordaan HF. Acute febrile neutrophilic dermatosis. A histopathological study of 37 patients and a review of the literature. *Am J Dermatopathol*. 1989;11(2):99-111.
181. Ratzinger G, Burgdorf W, Zelger BG, Zelger B. Acute febrile neutrophilic dermatosis: a histopathologic study of 31 cases with review of literature. *Am J Dermatopathol*. 2007;29(2):125-133.
182. Voelter-Mahlknecht S, Bauer J, Metzler G, et al. Bullous variant of Sweet's syndrome. *Int J Dermatol*. 2005;44(11):946-947.
183. Cerio R, MacDonald DM. Benign cutaneous lymphoid infiltrates. *J Cutan Pathol*. 1985;12(5):442-452.
184. Caro WA, Helwig HB. Cutaneous lymphoid hyperplasia. *Cancer*. 1969;24(3):487-502.
185. Boudova L, Kazakov DV, Sima R, et al. Cutaneous lymphoid hyperplasia and other lymphoid infiltrates of the breast nipple: a retrospective clinicopathologic study of fifty-six patients. *Am J Dermatopathol*. 2005;27(5):375-386.
186. Mach KW, Wilgram GF. Characteristic histopathology of cutaneous lymphoplasia (lymphocytoma). *Arch Dermatol*. 1966;94(1):26-32.
187. Wirt DP, Grogan TM, Jolley CS, et al. The immunoarchitecture of cutaneous pseudolymphoma. *Hum Pathol*. 1985;16(5):492-510.
188. Arai E, Shimizu M, Hirose T. A review of 55 cases of cutaneous lymphoid hyperplasia: reassessment of the histopathologic findings leading to reclassification of 4 lesions as cutaneous marginal zone lymphoma and 19 as pseudolymphomatous folliculitis. *Hum Pathol*. 2005;36(5):505-511.
189. Pedace FJ, Perry HO. Granuloma faciale. A clinical and histopathologic review. *Arch Dermatol*. 1966;94(4):387-395.
190. Johnson WC, Higdon RS, Helwig EB. Granuloma faciale. *AMA Arch Derm*. 1959;79:42-52.
191. Holme SA, Laidler P, Holt PJ. Concurrent granuloma faciale and eosinophilic angiocentric fibrosis. *Br J Dermatol*. 2005;153(4):851-853.
192. Wahl CE, Bouldin MB, Gibson LE. Erythema elevatum diutinum: clinical, histopathologic, and immunohistochemical characteristics of six patients. *Am J Dermatopathol*. 2005;27(5):397-400.
193. Yiannias JA, el-Azhary RA, Gibson LE. Erythema elevatum diutinum: a clinical and histopathologic study of 13 patients. *J Am Acad Dermatol*. 1992;26(1):38-44.
194. Sangueza OP, Pilcher B, Martin Sangueza J. Erythema elevatum diutinum: a clinicopathological study of eight cases. *Am J Dermatopathol*. 1997;19(3):214-222.
195. Shanks JH, Banerjee SS, Bishop PW, et al. Nodular erythema elevatum diutinum mimicking cutaneous neoplasms. *Histopathology*. 1997;31(1):91-96.
196. Lodha S, Sanchez M, Prystowsky S. Sarcoidosis of the skin: a review for the pulmonologist. *Chest*. 2009;136(2):583-596.
197. Tchernev G. Cutaneous sarcoidosis: the "great imitator": etiopathogenesis, morphology, differential diagnosis, and clinical management. *Am J Clin Dermatol*. 2006;7(6):375-382.
198. Mayock RL, Bertrand P, Morrison CE, Scott JH. Manifestations of sarcoidosis. Analysis of 145 patients, with a review of nine series selected from the literature. *Am J Med*. 1963;35: 67-89.
199. Cronin E. Skin changes in sarcoidosis. *Postgrad Med J*. 1970;46(538):507-509.

200. Friedman-Birnbaum R, Weltfriend S, Munichor M, Lichtig C. A comparative histopathologic study of generalized and localized granuloma annulare. *Am J Dermatopathol*. 1989;11(2):144-148.
201. Magro CM, Crowson AN, Regauer S. Granuloma annulare and necrobiosis lipoidica tissue reactions as a manifestation of systemic disease. *Hum Pathol*. 1996;27(1):50-56.
202. Wells RS, Smith MA. The natural history of granuloma annulare. *Br J Dermatol*. 1963;75:199-205.
203. Johnson WC. Necrobiotic granulomas. *J Cutan Pathol*. 1984;12:289-299.
204. Tanyildizi T, Akarsu S, Ilknur T, et al. Disseminated eruptive interstitial granuloma annulare mimicking lichen nitidus. *Eur J Dermatol*. 2011;21(4):644-645.
205. Mullans E, Helm KF. Granuloma annulare: an immunohistochemical study. *J Cutan Pathol*. 1994;21(2):135-139.
206. Hanna WM, Moreno-Merlo F, Andrighetti L. Granuloma annulare: an elastic tissue disease? Case report and literature review. *Ultrastruct Pathol*. 1999;23(1):33-38.
207. Mesara BW, Brody GL, Oberman HA. "Pseudorheumatoid" subcutaneous nodules. *Am J Clin Pathol*. 1966;45(6):684-691.
208. Barzilai A, Huszar M, Shpiro D, et al. Pseudorheumatoid nodules in adults: a juxta-articular form of nodular granuloma annulare. *Am J Dermatopathol*. 2005;27(1):1-5.
209. Patterson JW. Rheumatoid nodule and subcutaneous granuloma annulare. A comparative histologic study. *Am J Dermatopathol*. 1988;10(1):1-8.
210. Requena L, Fernandez-Figueras MT. Subcutaneous granuloma annulare. *Semin Cutan Med Surg*. 2007;26(2):96-99.
211. Lindlbauerm SR, Gschnait F. Annular elastolytic giant cell granuloma. *J Cutan Pathol*. 1990;10:321-326.
212. Schwarz T, Lindlbauer R, Gschnait F. Annular elastolytic giant cell granuloma. *J Cutan Pathol*. 1983;10(5):321-326.
213. Al-Hoqail IA, Al-Ghamdi AM, Martinka M, Crawford RI. Actinic granuloma is a unique and distinct entity: a comparative study with granuloma annulare. *Am J Dermatopathol*. 2002;24(3):209-212.
214. Limas C. The spectrum of primary cutaneous elastolytic granulomas and their distinction from granuloma annulare: a clinicopathological analysis. *Histopathology*. 2004;44(3):277-282.
215. Yanagihara M, Kato F, Mori S. Extra- and intra-cellular digestion of elastic fibers by macrophages in annular elastolytic giant cell granuloma. An ultrastructural study. *J Cutan Pathol*. 1987;14(5):303-308.
216. Wood MG, Beerman H. Necrobiosis lipoidica, granuloma annulare, and rheumatoid nodule. *J Invest Dermatol*. 1960;34:139-147.
217. Ferringer T, Miller F 3rd. Cutaneous manifestations of diabetes mellitus. *Dermatol Clin*. 2002;20(3):483-492.
218. Sibbald RG, Landolt SJ, Toth D. Skin and diabetes. *Endocrinol Metab Clin North Am*. 1996;25(2):463-472.
219. Reid SD, Ladizinski B, Lee K, et al. Update on necrobiosis lipoidica: a review of etiology, diagnosis, and treatment options. *J Am Acad Dermatol*. 2013;69(5):783-791.
220. Muller SA, Winkelmann RK. Necrobiosis lipoidica diabeticorum histopathologic study of 98 cases. *Arch Dermatol*. 1966;94(1):1-10.
221. Peyri J, Moreno A, Marcoval J. Necrobiosis lipoidica. *Semin Cutan Med Surg*. 2007;26(2):87-89.
222. Padilla RS, Mukai K, Dahl MV, et al. Differential staining pattern of lysozyme in palisading granulomas: an immunoperoxidase study. *J Am Acad Dermatol*. 1983;8(5): 634-638.
223. Wood AJ, Wagner MV, Abbott JJ, Gibson LE. Necrobiotic xanthogranuloma: a review of 17 cases with emphasis on clinical and pathologic correlation. *Arch Dermatol*. 2009;145(3):279-284.
224. Asboe-Hansen G. Scleroderma. *J Am Acad Dermatol*. 1987;17:102-108.
225. Winkelmann RK. Classification and pathogenesis of scleroderma. *Mayo Clinic Proc*. 1971;46(2):83-91.
226. Young EM Jr, Barr RJ. Sclerosing dermatoses. *J Cutan Pathol*. 1985;12(5):426-441.
227. Krafchik BR. Localized cutaneous scleroderma. *Semin Dermatol*. 1992;11(1):65-72.
228. Singsen BH. Scleroderma in childhood. *Pediatr Clin North Am*. 1986;33(5):1119-1139.
229. Zulian F. New developments in localized scleroderma. *Curr Opin Rheumatol*. 2008;20(5):601-607.
230. Fisher ER, Rodnan GP. Pathologic observations concerning the cutaneous lesion of progressive systemic sclerosis: an electron microscopic histochemical and immunohistochemical study. *Arthritis Rheum*. 1960;3:536-545.
231. Fleischmajer R. The collagen in scleroderma. *Arch Dermatol*. 1964;89:437-441.
232. Lovell CR, Nicholls AC, Duance VC, Bailey AJ. Characterization of dermal collagen in systemic sclerosis. *Br J Dermatol*. 1979;100(4):359-369.
233. Doyle JA, Connolly SM, Winkelmann RK. Cutaneous and subcutaneous inflammatory sclerosis syndromes. *Arch Dermatol*. 1982;118(11):886-890.
234. Fleischmajer R, Perlish JS, Duncan M. Scleroderma. A model for fibrosis. *Arch Dermatol*. 1983;119(12):957-962.
235. Shono S, Imura M, Ota M, et al. Lichen sclerosus et atrophicus, morphea, and coexistence of both diseases. Histological studies using lectins. *Arch Dermatol*. 1991;127(9):1352-1356.
236. Barnes L, Rodnan GP, Medsger TA, Short D. Eosinophilic fasciitis. A pathologic study of twenty cases. *Am J Pathol*. 1979;96(2):493-518.
237. Jones HR Jr, Beetham WP Jr, Silverman ML, Margles SW. Eosinophilic fasciitis and the carpal tunnel syndrome. *J Neurol Neurosurg Psychiatry*. 1986;49(3):324-327.
238. Moutsopoulos HM, Webber BL, Pavlidis NA, et al. Diffuse fasciitis with eosinophilia. A clinicopathologic study. *Am J Med*. 1980;68(5):701-709.
239. Michet CJ Jr, Doyle JA, Ginsburg WW. Eosinophilic fasciitis: report of 15 cases. *Mayo Clinic Proc*. 1981;56(1):27-34.
240. Helm KF, Gibson LE, Muller SA. Lichen sclerosus et atrophicus in children and young adults. *Pediatr Dermatol*. 1992;9:311.
241. Tasker GL, Wojnarowska F. Lichen sclerosus. *Clin Exp Dermatol*. 2003;28(2):128-133.
242. Fung MA, LeBoit PE. Light microscopic criteria for the diagnosis of early vulvar lichen sclerosus: a comparison with lichen planus. *Am J Surg Pathol*. 1998;22(4):473-478.
243. Regauer S, Liegl B, Reich O, Beham-Schmid C. Vasculitis in lichen sclerosus: an under recognized feature? *Histopathology*. 2004;45(3):237-244.
244. Patterson JAK, Ackerman AB. Lichen sclerosus et atrophicus is not related to morphea. A clinical and histologic study of 24 patients in whom both conditions were reputed to be present simultaneously. *Am J Dermatopathol*. 1984;6:323-335.
245. Requena L, Yus ES. Erythema nodosum. *Dermatol Clin*. 2008;26(4):425-438, v.
246. White WL, Wieselthier JS, Hitchcock MG. Panniculitis: recent developments and observations. *Semin Cutan Med Surg*. 1996;15(4):278-299.
247. Vesey CMR, Wilkinson DS. Erythema nodosum. A study of 70 cases. *Br J Dermatol*. 1959;71:139-155.
248. Patterson JW, Brown PC, Broecker AH. Infection-induced panniculitis. *J Cutan Pathol*. 1989;16(4):183-193.
249. Boh EE, al-Smadi RM. Cutaneous manifestations of gastrointestinal diseases. *Dermatol Clin*. 2002;20(3):533-546.
250. Chun SI, Su WP, Lee S, Rogers RS 3rd. Erythema nodosum-like lesions in Behcet's syndrome: a histopathologic study of 30 cases. *J Cutan Pathol*. 1989;16(5):259-265.
251. Crawford GH, Kim S, James WD. Skin signs of systemic disease: an update. *Adv Dermatol*. 2002;18:1-27.
252. Mir-Madjlessi SH, Taylor JS, Farmer RG. Clinical course and evolution of erythema nodosum and pyoderma gangrenosum in chronic ulcerative colitis: a study of 42 patients. *Am J Gastroenterol*. 1985;80(8):615-620.
253. Forstrom L, Winkelmann RK. Acute panniculitis: a clinical and histopathologic study of 34 cases. *Arch Dermatol*. 1977;113(7):909-917.
254. Winkelmann RK, Forstrom L. New observations in the histopathology of erythema nodosum. *J Invest Dermatol*. 1975;65(5):441-446.
255. Sanchez Yus E, Sanz Vico MD, de Diego V. Miescher's radial granuloma. A characteristic marker of erythema nodosum. *Am J Dermatopathol*. 1989;11(5):434-442.
256. Requena L, Yus ES. Panniculitis. Part I. Mostly septal panniculitis. *J Am Acad Dermatol*. 2001;45(2):163-183, quiz 84–6.264.
257. Requena L, Sanchez Yus E. Panniculitis. Part II. Mostly lobular panniculitis. *J Am Acad Dermatol*. 2001;45(3):325-361, quiz 62–64.
258. Cho KH, Lee DY, Kim CW. Erythema induratum of Bazin. *Int J Dermatol*. 1996;35(11):802-808.
259. Schneider JW, Jordaan HF, Geiger DH, et al. Erythema induratum of Bazin. A clinicopathological study of 20 cases and detection of Mycobacterium tuberculosis DNA in skin lesions by polymerase chain reaction. *Am J Dermatopathol*. 1995;17(4):350-356.
260. Demitsu T, Okada O, Yoneda K, Manabe M. Lipodermatosclerosis—report of three cases and review of the literature. *Dermatology*. 1999;199(3):271-273.
261. Sroa N, Bartholomew DA, Magro CM. Lipodermatosclerosis as a form of vascular compromise-associated radiation recall dermatitis: case report and a review of literature. *J Cutan Pathol*. 2006;33(suppl 2):55-59.
262. Lever WF. *Pemphigus and Pemphigoid*. Springfield, IL: Charles C Thomas; 1965.
263. Farmer ER. Subepidermal bullous diseases. *J Cutan Pathol*. 1985;12(3-4):316-321.
264. Rencic A, Goyal S, Mofid M, et al. Bullous lesions in scleroderma. *Int J Dermatol*. 2002;41(6):335-339.
265. Saxe N, Kahn LB. Subepidermal bullous disease. A correlated clinico-pathologic study of 51 cases. *J Cutan Pathol*. 1976;3(2):88-94.
266. Person JR, Rogers RS 3rd. Bullous and cicatricial pemphigoid. Clinical, histopathologic, and immunopathologic correlations. *Mayo Clin Proc*. 1977;52(1):54-66.
267. Chan LS. Ocular and oral mucous membrane pemphigoid (cicatricial pemphigoid). *Clin Dermatol*. 2012;30(1):34-37.
268. Dunnill MG, Leigh IM. The molecular basis of inherited skin disorders. *Prog Pathol*. 2001;5:103-119.
269. Eady RA. Epidermolysis bullosa: scientific advances and therapeutic challenges. *J Dermatol*. 2001;28(11):638-640.
270. Pai S, Marinkovich MP. Epidermolysis bullosa: new and emerging trends. *Am J Clin Dermatol*. 2002;3(6):371-380.
271. Mallipeddi R. Epidermolysis bullosa and cancer. *Clin Exp Dermatol*. 2002;27(8): 616-623.

272. Valeski JE, Kumar V, Beutner EH, et al. Differentiation of bullous pemphigoid from epidermolysis bullosa acquisita on frozen skin biopsies. *Int J Dermatol*. 1992;31(1):37-41.
273. Imber MJ, Kibbi AG, Mihm MC Jr. Dermatitis herpetiformis: histopathologic findings. *Clin Dermatol*. 1991;9(3):289-293.
274. Lings K, Bygum A. Linear IgA bullous dermatosis: a retrospective study of 23 patients in Denmark. *Acta Derm Venereol*. 2015;95(4):466-471.
275. Perry HO, Brunsting LA. Pemphigus foliaceus. Further observations. *Arch Dermatol*. 1965;91:10-23.
276. Amerian ML, Ahmed AR. Pemphigus erythematosus. Senear-Usher syndrome. *Int J Dermatol*. 1985;24(1):16-25.
277. Jordon RE. "An unusual type of pemphigus combining features of lupus erythematosus" by Senear and Usher, June 1926. Commentary: Pemphigus erythematosus, a unique member of the pemphigus group. *Arch Dermatol*. 1982;118(10):723-742.
278. Devries DT, Warren SJ. Recent advances in intraepidermal blistering diseases. *Adv Dermatol*. 2002;18:203-245.
279. Tuffanelli DL. "Clinical significance of autoantibodies in pemphigus" by Chorzelski, Von Weiss and Lever, May 1966. Commentary: clinical importance of autoantibodies in pemphigus. *Arch Dermatol*. 1982;118(10):837-845.
280. Thivolet J, Faure M. Immunohistochemistry in cutaneous pathology. *J Cutan Pathol*. 1983;10(1):1-32.
281. Chidgey M. Desmosomes and disease: an update. *Histol Histopathol*. 2002;17(4):1179-1192.
282. Hertl M, Veldman C. Pemphigus—paradigm of autoantibody-mediated autoimmunity. *Skin Pharmacol Appl Skin Physiol*. 2001;14(6):408-418.
283. Korman NJ, Eyre RW, Klaus-Kovtun V, Stanley JR. Demonstration of an adhering-junction molecule (plakoglobin) in the autoantigens of pemphigus foliaceus and pemphigus vulgaris. *N Engl J Med*. 1989;321(10):631-635.
284. James KA, Culton DA, Diaz LA. Diagnosis and clinical features of pemphigus foliaceus. *Dermatol Clin*. 2011;29(3):405-412, viii.
285. Venugopal SS, Murrell DF. Diagnosis and clinical features of pemphigus vulgaris. *Immunol Allergy Clin North Am*. 2012;32(2):233-243, v-vi.
286. Anhalt GJ, Kim SC, Stanley JR, et al. Paraneoplastic pemphigus. An autoimmune mucocutaneous disease associated with neoplasia. *N Engl J Med*. 1990;323(25):1729-1735.
287. Mehregan DR, Oursler JR, Leiferman KM, et al. Paraneoplastic pemphigus: a subset of patients with pemphigus and neoplasia. *J Cutan Pathol*. 1993;20(3):203-210.
288. Younus J, Ahmed AR. The relationship of pemphigus to neoplasia. *J Am Acad Dermatol*. 1990;23(3 Pt 1):498-502.
289. Langenberg A, Berger TG, Cardelli M, et al. Genital benign chronic pemphigus (Hailey-Hailey disease) presenting as condylomas. *J Am Acad Dermatol*. 1992;26(6):951-955.
290. Santa Cruz DJ, Prioleau PG, Marcus MD, Uitto J. Pemphigus-like lesions induced by D-penicillamine. Analysis of clinical, histopathological, and immunofluorescence features in 34 cases. *Am J Dermatopathol*. 1981;3(1):85-92.
291. Hu CH, Michel B, Farber EM. Transient acantholytic dermatosis (Grover's disease). A skin disorder related to heat and sweating. *Arch Dermatol*. 1985;121(11):1439-1441.
292. Parsons JM. Transient acantholytic dermatosis (Grover's disease): a global perspective. *J Am Acad Dermatol*. 1996;35(5 Pt 1):653-666, quiz 67–70.
293. Chalet M, Grover R, Ackerman AB. Transient acantholytic dermatosis. A re-evaluation. *Arch Dermatol*. 1977;113:431-435.
294. Ackerman AB. Focal acantholytic dyskeratosis. *Arch Dermatol*. 1972;106(5):702-706.
295. Waldo ED, Ackerman AB. Epidermolytic hyperkeratosis and focal acantholytic dyskeratosis: a unified concept. *Pathol Annu*. 1978;13(Pt 1):149-175.
296. Sneddon IB, Wilkinson DS. Subcorneal pustular dermatosis. *Br J Dermatol*. 1956;68(12):385-394.
297. Hirschmann JV. Impetigo: etiology and therapy. *Curr Clin Top Infect Dis*. 2002;22:42-51.
298. Bender TW 3rd. Cutaneous manifestations of disease in athletes. *Skinmed*. 2003;2(1):34-40.
299. Brentjens MH, Yeung-Yue KA, Lee PC, Tyring SK. Human papilloma virus: a review. *Dermatol Clin*. 2002;20:315-351.
300. Nebesio CL, Mirowski GW, Chuang TY. Human papillomavirus: clinical significance and malignant potential. *Int J Dermatol*. 2001;40(6):373-379.
301. Dvoretzky I, Lowy DR. Infections by human papillomavirus (warts). *Am J Dermatopathol*. 1982;4(1):85-89.
302. Egawa K, Inaba Y, Yoshimura K, Ono T. Varied clinical morphology of HPV-1-induced warts, depending on anatomical factors. *Br J Dermatol*. 1993;128(3):271-276.
303. Gross G, Pfister H, Hagedorn M, Gissmann L. Correlation between human papillomavirus (HPV) type and histology of warts. *J Invest Dermatol*. 1982;78(2):160-164.
304. Nuovo GJ, Lastarria DA, Smith S, et al. Human papillomavirus segregation patterns in genital and nongenital warts in prepubertal children and adults. *Am J Clin Pathol*. 1991;95(4):467-474.
305. Kawashima M. Epidermodysplasia verruciformis. *J Dermatol*. 1992;19(11):707-709.
306. Obalek S, Favre M, Szymanczyk J, et al. Human papillomavirus (HPV) types specific of epidermodysplasia verruciformis detected in warts induced by HPV3 or HPV3-related types in immunosuppressed patients. *J Invest Dermatol*. 1992;98(6):936-941.
307. Kimura S, Komatsu T, Ohyama K. Common and plantar warts with trichilemmal keratinization-like keratinizing process: a possible existence of pseudo-trichilemmal keratinization. *J Cutan Pathol*. 1982;9(6):391-395.
308. Aiba S, Rokugo M, Tagami H. Immunohistologic analysis of the phenomenon of spontaneous regression of numerous flat warts. *Cancer*. 1986;58(6):1246-1251.
309. Iwatsuki K, Tagami H, Takigawa M, Yamada M. Plane warts under spontaneous regression. Immunopathologic study on cellular constituents leading to the inflammatory reaction. *Arch Dermatol*. 1986;122(6):655-659.
310. Mullink H, Jiwa NM, Walboomers JM, et al. Demonstration of changes in cytokeratin expression in condylomata accuminata in relation to the presence of human papilloma virus as shown by a combination of immunohistochemistry and in situ hybridization. *Am J Dermatopathol*. 1991;13(6):530-537.
311. Inaba Y, Egawa K, Yoshimura K, Ono T. Demonstration of human papillomavirus type 1 DNA in a wart with bowenoid histologic changes. *Am J Dermatopathol*. 1993;15(2):172-175.
312. Phillips ME, Ackerman AB. "Benign" and "malignant" neoplasms associated with verrucae vulgares. *Am J Dermatopathol*. 1982;4(1):61-84.
313. Dhillon I, Zouzias D, Geronemus R. Invasive squamous cell carcinoma in a patient with epidermodysplasia verruciformis. *J Dermatol Surg Oncol*. 1991;17(3):300-302.
314. Jacyk WK, Dreyer L, de Villiers EM. Seborrheic keratoses of black patients with epidermodysplasia verruciformis contain human papillomavirus DNA. *Am J Dermatopathol*. 1993;15(1):1-6.
315. Majewski S, Jablonska S. Do epidermodysplasia verruciformis human papillomaviruses contribute to malignant and benign epidermal proliferations? *Arch Dermatol*. 2002;138(5):649-654.
316. Proby CM, Churchill L, Purkis PE, et al. Keratin 17 expression as a marker for epithelial transformation in viral warts. *Am J Pathol*. 1993;143(6):1667-1678.
317. Coloe J, Burkhart CN, Morrell DS. Molluscum contagiosum: what's new and true? *Pediatr Ann*. 2009;38(6):321-325.
318. Smith KJ, Skelton H. Molluscum contagiosum: recent advances in pathogenic mechanisms, and new therapies. *Am J Clin Dermatol*. 2002;3(8):535-545.
319. Brown J, Janniger CK, Schwartz RA, Silverberg NB. Childhood molluscum contagiosum. *Int J Dermatol*. 2006;45(2):93-99.
320. Connell CO, Oranje A, Van Gysel D, Silverberg NB. Congenital molluscum contagiosum: report of four cases and review of the literature. *Pediatr Dermatol*. 2008;25(5):553-556.
321. Sutton JS, Burnett JW. Ultrastructural changes in dermal and eipidermal cells of skin infected with Molluscum contagiosum virus. *J Ultrastruct Resh*. 1969;26(3):177-196.
322. Cribier B, Scrivener Y, Grosshans E. Molluscum contagiosum: histologic patterns and associated lesions. A study of 578 cases. *Am J Dermatopathol*. 2001;23(2):99-103.
323. Ackerman AB, Tanski EV. Pseudoleukemia cutis: report of a case in association with molluscum contagiosum. *Cancer*. 1977;40(2):813-817.
324. Guitart J, Hurt MA. Pleomorphic T-cell infiltrate associated with molluscum contagiosum. *Am J Dermatopathol*. 1999;21(2):178-180.
325. Naert F, Lachapelle JM. Multiple lesions of molluscum contagiosum with metaplastic ossification. *Am J Dermatopathol*. 1989;11(3):238-241.
326. Gnann JW Jr, Whitley RJ. Clinical practice. Herpes zoster. *N Engl J Med*. 2002;347(5):340-346.
327. Molin L. Aspects of the natural history of herpes zoster. A follow-up investigation of outpatient material. *Acta Derm Venereol*. 1969;49(6):569-583.
328. Merselis JG Jr, Kaye D, Hook EW. Disseminated herpes zoster. A report of 17 cases. *Arch Int Med*. 1964;113:679-686.
329. McSorley J, Shapiro L, Brownstein MH, Hsu KC. Herpes simplex and varicella-zoster: comparative histopathology of 77 cases. *Int J Dermatol*. 1974;13(2):69-75.
330. Leinweber B, Kerl H, Cerroni L. Histopathologic features of cutaneous herpes virus infections (herpes simplex, herpes varicella/zoster): a broad spectrum of presentations with common pseudolymphomatous aspects. *Am J Surg Pathol*. 2006;30(1):50-58.
331. Herman LE, Harawi SJ, Ghossein RA, Kurban AK. Folliculitis. A clinicopathologic review. *Pathol Annu*. 1991;26(Pt 2):201-246.
332. Ramdial PK, Naidoo DK. Drug-induced cutaneous pathology. *J Clin Pathol*. 2009;62(6):493-504.
333. Vollmer RT. Demodex-associated folliculitis. *Am J Dermatopathol*. 1997;18:589-591.
334. McCalmont TH, Althemus D, Maurer T, Berger TG. Eosinophilic folliculitis: the histologic

spectrum. *Am J Dermatopathol*. 1996;17:439-446.
335. Ramdial PK, Morar N, Dlova NC, Aboobaker J. HIV-associated eosinophilic folliculitis in an infant. *Am J Dermatopathol*. 1999;21(3):241-246.
336. Arai E, Okubo H, Tsuchida T, et al. Pseudolymphomatous folliculitis: a clinicopathologic study of 15 cases of cutaneous pseudolymphoma with follicular invasion. *Am J Surg Pathol*. 1999;23(11):1313-1319.
337. Chang SN, Chun SI, Moon TK, Park WH. Solitary sclerotic fibroma of the skin: degenerated sclerotic change of inflammatory conditions, especially folliculitis. *Am J Dermatopathol*. 2000;22(1):22-25.
338. Heller DS, Haefner HK, Hameed M, Lieberman RW. Vulvar hidradenitis suppurativa. Immunohistochemical evaluation of apocrine and eccrine involvement. *J Reprod Med*. 2002;47(9):695-700.
339. Jemec GB. Hidradenitis suppurativa. *J Cutan Med Surg*. 2003;7(1):47-56.
340. Mitchell KM, Beck DE. Hidradenitis suppurativa. *Surg Clin North Am*. 2002;82(6):1187-1197.
341. Alikhan A, Lynch PJ, Eisen DB. Hidradenitis suppurativa: a comprehensive review. *J Am Acad Dermatol*. 2009;60(4):539-561 [quiz 62–63].
342. Buimer MG, Wobbes T, Klinkenbijl JH. Hidradenitis suppurativa. *Br J Surg*. 2009;96(4):350-360.
343. Barbagallo J, Tager P, Ingleton R, et al. Cutaneous tuberculosis: diagnosis and treatment. *Am J Clin Dermatol*. 2002;3(5):319-328.
344. Bravo FG, Gotuzzo E. Cutaneous tuberculosis. *Clin Dermatol*. 2007;25(2):173-180.
345. Marcoval J, Servitje O, Moreno A, et al. Lupus vulgaris. Clinical, histopathologic, and bacteriologic study of 10 cases. *J Am Acad Dermatol*. 1992;26(3 Pt 2):404-407.
346. Victor T, Jordaan HF, Van Niekerk DJ, et al. Papulonecrotic tuberculid. Identification of *Mycobacterium tuberculosis* DNA by polymerase chain reaction. *Am J Dermatopathol*. 1992;14(6):491-495.
347. Jordaan HF, Schneider JW, Schaaf HS, et al. Papulonecrotic tuberculid in children. A report of eight patients. *Am J Dermatopathol*. 1996;18(2):172-185.
348. Jordaan HF, Van Niekerk DJ, Louw M. Papulonecrotic tuberculid. A clinical, histopathological, and immunohistochemical study of 15 patients. *Am J Dermatopathol*. 1994;16(5):474-485.
349. Hara K, Tsuzuki T, Takagi N, Shimokata K. Nodular granulomatous phlebitis of the skin: a fourth type of tuberculid. *Histopathology*. 1997;30(2):129-134.
350. Beyt BE Jr, Ortbals DW, Santa Cruz DJ, et al. Cutaneous mycobacteriosis: analysis of 34 cases with a new classification of the disease. *Medicine (Baltimore)*. 1981;60(2):95-109.
351. Santa Cruz DJ, Strayer DS. The histologic spectrum of the cutaneous mycobacterioses. *Hum Pathol*. 1982;13(5):485-495.
352. Saxe N. Mycobacterial skin infections. *J Cutan Pathol*. 1985;12(3-4):300-312.
353. Elston D. Nontuberculous mycobacterial skin infections: recognition and management. *Am J Clin Dermatol*. 2009;10(5):281-285.
354. Bhatia AS, Katoch K, Narayanan RB, et al. Clinical and histopathological correlation in the classification of leprosy. *Int J Lepr Other Mycobact Dis*. 1993;61(3):433-438.
355. Torres P, Camarena JJ, Gomez JR, et al. Comparison of PCR mediated amplification of DNA and the classical methods for detection of *Mycobacterium leprae* in different types of clinical samples in leprosy patients and contacts. *Lepr Rev*. 2003;74(1):18-30.
356. Porichha D, Misra AK, Dhariwal AC, et al. Ambiguities in leprosy histopathology. *Int J Lepr Other Mycobact Dis*. 1993;61(3):428-432.
357. Kaur I, Dogra S, De D, Saikia UN. Histoid leprosy: a retrospective study of 40 cases from India. *Br J Dermatol*. 2009;160(2):305-310.
358. Sehgal VN, Srivastava G, Singh N. Histoid leprosy: histopathological connotations' relevance in contemporary context. *Am J Dermatopathol*. 2009;31(3):268-271.
359. Jordaan HF, Louw M. The moth-eaten alopecia of secondary syphilis. A histopathological study of 12 patients. *Am J Dermatopathol*. 1995;17(2):158-162.
360. Alessi E, Innocenti M, Ragusa G. Secondary syphilis. Clinical morphology and histopathology. *Am J Dermatopathol*. 1983;5(1):11-17.
361. McBroom RL, Styles AR, Chiu MJ, et al. Secondary syphilis in persons infected with and not infected with HIV-1: a comparative immunohistologic study. *Am J Dermatopathol*. 1999;21:432-441.
362. Hoang MP, High WA, Molberg KH. Secondary syphilis: a histologic and immunohistochemical evaluation. *J Cutan Pathol*. 2004;31(9):595-599.
363. Martin-Ezquerra G, Fernandez-Casado A, Barco D, et al. *Treponema pallidum* distribution patterns in mucocutaneous lesions of primary and secondary syphilis: an immunohistochemical and ultrastructural study. *Human Pathol*. 2009;40(5):624-630.
364. Liu H, Rodes B, Chen CY, Steiner B. New tests for syphilis: rational design of a PCR method for detection of *Treponema pallidum* in clinical specimens using unique regions of the DNA polymerase I gene. *J Clin Microbiol*. 2001;39(5):1941-1946.
365. Baumgarten JM, Montiel NJ, Sinha AA. Lyme disease—part 1: epidemiology and etiology. *Cutis*. 2002;69:349-352.
366. Mullegger RR, Glatz M. Skin manifestations of lyme borreliosis: diagnosis and management. *Am J Clin Dermatol*. 2008;9(6):355-368.
367. Edlow JA. Erythema migrans. *Med Clin North Am*. 2002;86(2):239-260.
368. Abele DC, Anders KH. The many faces and phases of borreliosis. I. Lyme disease. *J Am Acad Dermatol*. 1990;23(2 Pt 1):167-186.
369. Abele DC, Anders KH. The many faces and phases of borreliosis II. *J Am Acad Dermatol*. 1990;23(3 Pt 1):401-410.
370. Asbrink E. Cutaneous manifestations of Lyme borreliosis. Clinical definitions and differential diagnoses. *Scand J Infect Dis Suppl*. 1991;77:44-50.
371. Montiel NJ, Baumgarten JM, Sinha AA. Lyme disease—part II: clinical features and treatment. *Cutis*. 2002;69(6):443-448.
372. Berger BW, Clemmensen OJ, Ackerman AB. Lyme disease is a spirochetosis. A review of the disease and evidence for its cause. *Am J Dermatopathol*. 1983;5(2):111-124.
373. Nocton JJ, Dressler F, Rutledge BJ, et al. Detection of Borrelia burgdorferi DNA by polymerase chain reaction in synovial fluid from patients with Lyme arthritis. *N Engl J Med*. 1994;330(4):229-234.
374. Aberer E, Stanek G. Histological evidence for spirochetal origin of morphea and lichen sclerosus et atrophicans. *Am J Dermatopathol*. 1987;9(5):374-379.
375. Malane MS, Grant-Kels JM, Feder HM Jr, Luger SW. Diagnosis of Lyme disease based on dermatologic manifestations. *Ann Int Med*. 1991;114(6):490-498.
376. Graham JH, Johnson WC, Burgoon CF Jr, Helwig EB. Tinea capitis. A histopathological and histochemical study. *Arch Dermatol*. 1964;89:528-544.
377. Smith KJ, Neafie RC, Skelton HG 3rd, et al. Majocchi's granuloma. *J Cutan Pathol*. 1991;18(1):28-35.
378. Andrews RM, McCarthy J, Carapetis JR, Currie BJ. Skin disorders, including pyoderma, scabies, and tinea infections. *Pediatr Clin North Am*. 2009;56(6):1421-1440.
379. Lemos LB, Baliga M, Guo M. Blastomycosis: the great pretender can also be an opportunist. Initial clinical diagnosis and underlying diseases in 123 patients. *Ann Diagn Pathol*. 2002;6(3):194-203.
380. Lemos LB, Guo M, Baliga M. Blastomycosis: organ involvement and etiologic diagnosis. A review of 123 patients from Mississippi. *Ann Diagn Pathol*. 2000;4(6):391-406.
381. Bonifaz A, Carrasco-Gerard E, Saul A. Chromoblastomycosis: clinical and mycologic experience of 51 cases. *Mycoses*. 2001;44(1-2):1-7.
382. Minotto R, Bernardi CD, Mallmann LF, et al. Chromoblastomycosis: a review of 100 cases in the state of Rio Grande do Sul, Brazil. *J Am Acad Dermatol*. 2001;44(4):585-592.
383. Queiroz-Telles F, Esterre P, Perez-Blanco M, et al. Chromoblastomycosis: an overview of clinical manifestations, diagnosis and treatment. *Med Mycol*. 2009;47(1):3-15.
384. Azulay RD, Serruya J. Hematogenous dissemination in chromoblastomycosis. Report of a generalized case. *Arch Dermatol*. 1967;95(1):57-60.
385. Kempson RL, Sternberg WH. Chronic subcutaneous abscesses caused by pigmented fungi, a lesion distinguishable from cutaneous chromoblastomycosis. *Am J Clin Pathol*. 1963;39:598-606.
386. Epstein E. Silica granuloma of the skin. *Arch Dermatol*. 1955;71:24-35.
387. Newcomer VD, Graham JH, Schaffert RR, Kaplan L. Sclerosing lipogranuloma resulting from exogenous lipids. *AMA Arch Dermatol*. 1956;73(4):361-372.
388. Shelley WB, Hurley HJ. The pathogenesis of silica granulomas in man: a non-allergic collidial phenomenon. *J Invest Dermatol*. 1960;34:107-123.
389. Helwig EB. Chemical (beryllium) granulomas of skin. *Mil Surg*. 1951;109(4):540-558.
390. Chong H, Brady K, Metze D, Calonje E. Persistent nodules at injection sites (aluminium granuloma)—clinicopathological study of 14 cases with a diverse range of histological reaction patterns. *Histopathology*. 2006;48(2):182-188.
391. Ruocco E, Sangiuliano S, Gravina AG, et al. Pyoderma gangrenosum: an updated review. *J Eur Acad Dermatol Venereol*. 2009;23(9):1008-1017.
392. Powell FC, Schroeter AL, Su WP, Perry HO. Pyoderma gangrenosum: a review of 86 patients. *Q J Med*. 1985;55(217):173-186.
393. Wilson-Jones E, Winkelmann RK. Superficial granulomatous pyoderma: a localized vegetative form of pyoderma gangrenosum. *J Am Acad Dermatol*. 1988;18(3):511-521.
394. Mehta RK, Burrows NP, Payne CM, et al. Elastosis perforans serpiginosa and associated disorders. *Clin Exp Dermatol*. 2001;26(6):521-524.
395. Golitz L. Follicular and perforating disorders. *J Cutan Pathol*. 1985;12(3-4):282-288.
396. Reed RJ, Clark WH, Mihm MC. The cutaneous elastoses. *Hum Pathol*. 1973;4(2):187-199.
397. Millard PR, Young E, Harrison DE, Wojnarowska F. Reactive perforating collagenosis: light, ultrastructural and immunohistological studies. *Histopathology*. 1986;10(10):1047-1056.
398. Patterson JW. The perforating disorders. *J Am Acad Dermatol*. 1984;10(4):561-581.
399. Poliak SC, Lebwohl MG, Parris A, Prioleau PG. Reactive perforating collagenosis associated with diabetes mellitus. *N Engl J Med*. 1982;306(2):81-84.

400. Sehgal VN, Jain S, Thappa DM, et al. Perforating dermatoses: a review and report of four cases. *J Dermatol*. 1993;20(6):329-340.
401. White CR Jr, Heskel NS, Pokorny DJ. Perforating folliculitis of hemodialysis. *Am J Dermatopathol*. 1982;4(2):109-116.
402. Hood AF, Hardegen GL, Zarate AR, et al. Kyrle's disease in patients with chronic renal failure. *Arch Dermatol*. 1982;118(2):85-88.
403. Finger RP, Charbel Issa P, Ladewig MS, et al. Pseudoxanthoma elasticum: genetics, clinical manifestations and therapeutic approaches. *Surv Ophthalmol*. 2009;54(2):272-285.
404. Hu X, Plomp A, Wijnholds J, et al. ABCC6/MRP6 mutations: further insight into the molecular pathology of pseudoxanthoma elasticum. *Eur J Hum Genet*. 2003;11(3):215-224.
405. Ohtani T, Furukawa F. Pseudoxanthoma elasticum. *J Dermatol*. 2002;29(10):615-620.
406. Li Q, Jiang Q, Pfendner E, et al. Pseudoxanthoma elasticum: clinical phenotypes, molecular genetics and putative pathomechanisms. *Exp Dermatol*. 2009;18(1):1-11.
407. Niepomniszcze H, Amad RH. Skin disorders and thyroid diseases. *J Endocrinol Invest*. 2001;24(8):628-638.
408. Rapoport B, Alsabeh R, Aftergood D, McLachlan SM. Elephantiasic pretibial myxedema: insight into and a hypothesis regarding the pathogenesis of the extrathyroidal manifestations of Graves' disease. *Thyroid*. 2000;10(8):685-692.
409. Farmer ER, Hambrick GW Jr, Shulman LE. Papular mucinosis. A clinicopathologic study of four patients. *Arch Dermatol*. 1982;118(1):9-13.
410. Hempstead RW, Ackerman AB. Follicular mucinosis. A reaction pattern in follicular epithelium. *Am J Dermatopathol*. 1985;7(3):245-257.
411. Hierholzer K, Finke R. Myxedema. *Kidney Int Suppl*. 1997;59:S82-S89.
412. Jackson EM, English JC 3rd. Diffuse cutaneous mucinoses. *Dermatol Clin*. 2002;20(3):493-501.
413. Johnson WC, Graham JH, Helwig EB. Cutaneous myxoid cyst. A clinicopathological and histochemical study. *JAMA*. 1965;191:15-20.
414. Johnson WC, Helwig EB. Cutaneous focal mucinosis. A clinicopathological and histochemical study. *Arch Dermatol*. 1966;93(1):13-20.
415. Mehregan DA, Gibson LE, Muller SA. Follicular mucinosis: histopathologic review of 33 cases. *Mayo Clinic Proc*. 1991;66(4):387-390.
416. Reed RJ, Clark WH, Mihm MC. The cutaneous mucinoses. *Hum Pathol*. 1973;4(2):201-205.
417. Rongioletti F, Rebora A. Updated classification of papular mucinosis, lichen myxedematosus, and scleromyxedema. *J Am Acad Dermatol*. 2001;44(2):273-281.
418. Brown HA, Gibson LE, Pujol RM, et al. Primary follicular mucinosis: long-term follow-up of patients younger than 40 years with and without clonal T-cell receptor gene rearrangement. *J Am Acad Dermatol*. 2002;47(6):856-862.
419. Cerroni L, Fink-Puches R, Back B, Kerl H. Follicular mucinosis: a critical reappraisal of clinicopathologic features and association with mycosis fungoides and Sezary syndrome. *Arch Dermatol*. 2002;138(2):182-189.
420. Carney JA, Headington JT, Su WP. Cutaneous myxomas. A major component of the complex of myxomas, spotty pigmentation, and endocrine overactivity. *Arch Dermatol*. 1986;122(7):790-798.
421. Brown J, Winkelmann RK. Acanthosis nigricans: a study of 90 cases. *Medicine (Baltimore)*. 1968;47(1):33-51.
422. Stuart CA, Driscoll MS, Lundquist KF, et al. Acanthosis nigricans. *J Basic Clin Physiol Pharmacol*. 1998;9(2-4):407-418.
423. Reference deleted in proofs.
424. Taylor SI, Arioglu E. Syndromes associated with insulin resistance and acanthosis nigricans. *J Basic Clin Physiol Pharmacol*. 1998;9(2-4):419-439.
425. Ellis DL, Kafka SP, Chow JC, et al. Melanoma, growth factors, acanthosis nigricans, the sign of Leser-Trelat, and multiple acrochordons. A possible role for alpha-transforming growth factor in cutaneous paraneoplastic syndromes. *N Engl J Med*. 1987;317(25):1582-1587.
426. Torley D, Bellus GA, Munro CS. Genes, growth factors and acanthosis nigricans. *Br J Dermatol*. 2002;147(6):1096-1101.
427. Ahn W, Lee MG, Kim KH, Muallem S. Multiple effects of SERCA2b mutations associated with Darier's disease. *J Biol Chem*. 2003;278(23):20795-20801.
428. Sakuntabhai A, Burge S, Monk S, Hovnanian A. Spectrum of novel ATP2A2 mutations in patients with Darier's disease. *Hum Mol Genet*. 1999;8(9):1611-1619.
429. O'Malley MP, Haake A, Goldsmith L, Berg D. Localized Darier disease. Implications for genetic studies. *Arch Dermatol*. 1997;133(9):1134-1138.
430. Gottlieb SK, Lutzner MA. Darier's disease. An electron microscopic study. *Arch Dermatol*. 1973;107(2):225-230.
431. Gottlieb GJ, Ragaz A, Vogel JV, et al. A preliminary communication on extensively disseminated Kaposi's sarcoma in young homosexual men. *Am J Dermatopathol*. 1981;3(2):111-114.
432. Francis N. Non-neoplastic, cutaneous and mucocutaneous manifestations of HIV infection. *Histopathology*. 1993;23(4):297-305.
433. Grayson W. The HIV-positive skin biopsy. *J Clin Pathol*. 2008;61(7):802-817.
434. Harawi SJ, Ghossein RA, Kurban RS, Kurban AK. Cutaneous diseases associated with HIV infection. *Pathol Ann*. 1991;26(Pt 1):265-309.
435. Balslev E, Thomsen HK, Weismann K. Histopathology of acute human immunodeficiency virus exanthema. *J Clin Pathol*. 1990;43(3):201-202.
436. Brehmer-Andersson E, Torssander J. The exanthema of acute (primary) HIV infection. Identification of a characteristic histopathological picture? *Acta Derm Venereol*. 1990;70(1):85-87.
437. Hevia O, Jimenez-Acosta F, Ceballos PI, et al. Pruritic papular eruption of the acquired immunodeficiency syndrome: a clinicopathologic study. *J Am Acad Dermatol*. 1991;24(2 Pt 1):231-235.
438. Farthing CF, Staughton RC, Rowland Payne CM. Skin disease in homosexual patients with acquired immune deficiency syndrome (AIDS) and lesser forms of human T cell leukaemia virus (HTLV III) disease. *Clin Exp Dermatol*. 1985;10(1):3-12.
439. Penneys NS, Hicks B. Unusual cutaneous lesions associated with acquired immunodeficiency syndrome. *J Am Acad Dermatol*. 1985;13(5 Pt 1):845-852.
440. Muhlemann MF, Anderson MG, Paradinas FJ, et al. Early warning skin signs in AIDS and persistent generalized lymphadenopathy. *Br J Dermatol*. 1986;114(4):419-424.
441. Rosenthal D, LeBoit PE, Klumpp L, Berger TG. Human immunodeficiency virus-associated eosinophilic folliculitis. A unique dermatosis associated with advanced human immunodeficiency virus infection. *Arch Dermatol*. 1991;127(2):206-209.
442. Munoz E, Valks R, Fernandez-Herrera J, Fraga J. Herpetic syringitis associated with eccrine squamous syringometaplasia in HIV-positive patients. *J Cutan Pathol*. 1997;24(7):425-428.
443. Mathes BM, Douglass MC. Seborrheic dermatitis in patients with acquired immunodeficiency syndrome. *J Am Acad Dermatol*. 1985;13(6):947-951.
444. Soeprono FF, Schinella RA, Cockerell CJ, Comite SL. Seborrheic-like dermatitis of acquired immunodeficiency syndrome. A clinicopathologic study. *J Am Acad Dermatol*. 1986;14(2 Pt 1):242-248.
445. Siegal FP, Lopez C, Hammer GS, et al. Severe acquired immunodeficiency in male homosexuals, manifested by chronic perianal ulcerative herpes simplex lesions. *N Engl J Med*. 1981;305(24):1439-1444.
446. Hoppenjans WB, Bibler MR, Orme RL, Solinger AM. Prolonged cutaneous herpes zoster in acquired immunodeficiency syndrome. *Arch Dermatol*. 1990;126(8):1048-1050.
447. Jacobson MA, Berger TG, Fikrig S, et al. Acyclovir-resistant varicella zoster virus infection after chronic oral acyclovir therapy in patients with the acquired immunodeficiency syndrome (AIDS). *Ann Int Med*. 1990;112(3):187-191.
448. McNutt NS, Kindel S, Lugo J. Cutaneous manifestations of measles in AIDS. *J Cutan Pathol*. 1992;19(4):315-324.
449. Rolighed J, Sorensen IM, Jacobsen NO, Lindeberg H. The presence of HPV types 6/11, 13, 16 and 33 in bowenoid papulosis in an HIV-positive male, demonstrated by DNA in situ hybridization. *APMIS*. 1991;99(7):583-585.
450. Smith KJ, Yeager J, Skelton HG. Histologically distinctive papular neutrophilic xanthomas in HIV-1 + patients. *Am J Surg Pathol*. 1997;21(5):545-549.

Tumors and Tumorlike Conditions of the Skin

3

Steven D. Billings

CHAPTER CONTENTS

Epidermis, *46*
Seborrheic keratosis, *46*
Benign lichenoid keratosis, *46*
Acrochordon, *46*
Actinic keratosis, *46*
Cutaneous horn, *47*
Bowen disease, *47*
Squamous cell carcinoma, *48*
General features, *48*
Microscopic features, *48*
Immunohistochemical and molecular genetic features, *49*
Other microscopic types, *49*
Treatment, *50*
Prognosis, *50*
Pseudoepitheliomatous hyperplasia, *50*
Basal cell carcinoma, *50*
General features, *50*
Microscopic features, *51*
Histochemical and immunohistochemical features, *52*
Molecular genetic features, *53*
Other microscopic types, *53*
Spread and metastases, *53*
Treatment, *53*
Skin adnexa, *54*
Eccrine sweat glands, *54*
Apocrine glands, *61*
Sebaceous glands, *61*
Hair follicles, *62*
Melanocytes, *67*
Nevi, *68*
Malignant melanoma, *77*
Neuroendocrine cells, *87*
Merkel cell carcinoma, *87*
Other neuroendocrine tumors, *89*
Dermis, *90*
Fibroblastic tumors and tumorlike conditions, *90*
Fibrohistiocytic tumors and tumorlike conditions, *91*
Smooth muscle tumors, *96*
Skeletal muscle tumors, *97*
Peripheral nerve sheath tumors, *97*
Vascular tumors and tumorlike conditions, *98*
Hemangioma, *98*
Lymphangioma, *99*
Pyogenic granuloma, *100*
Acquired tufted angioma, *100*
Masson hemangioma, *101*
Epithelioid hemangioma, *101*
Kaposi sarcoma, *101*
Bacillary angiomatosis and verruga peruana, *103*
Angiosarcoma, *104*
Lymphoid tumors and tumorlike conditions, *105*
Cutaneous lymphoid hyperplasia, *105*
Mycosis fungoides and related peripheral T-cell lymphomas, *107*
Lymph nodes in mycosis fungoides, *109*
Lymphomatoid papulosis and anaplastic large cell lymphoma, *109*
Other malignant lymphomas, *110*
Leukemia, *111*
Other primary tumors and tumorlike conditions, *111*
Metastatic tumors, *111*

The skin is, contrary to the ubiquitous simplistic concept, a remarkably heterogeneous organ. The nodular lesions (hamartomatous, reactive, and neoplastic) that occur in the skin are more numerous than those produced by any other organ. For example, the eccrine sweat gland alone gives rise to 10 or more histologically distinct adenomas. This diversity, combined with a body of descriptive data (clinical, histologic, histochemical, immunohistochemical, and ultrastructural) amassed over the past century and dispersed in varying literatures, produces confusion, chiefly in the area of nomenclature. Within the limits inherent in a textbook that covers a breadth of surgical pathology specialties, it is impossible to pursue finite segmentation, interesting and accurate as it may be. The more common lesions will be discussed in some detail and pertinent references provided for the rare lesions.

Most of the mesenchymal tumors that may involve the dermis are discussed in the chapter on soft tissues. Only those showing exclusive or preferential involvement of the skin are included in this chapter.

Abstract

This chapter focuses on cutaneous tumors and tumorlike conditions of the skin. Epidermal tumors, adnexal tumors, melanocytic tumors, neuroendocrine tumors, cutaneous soft tissue tumors, and lymphoproliferative/hematopoietic lesions will be covered.

Keywords

Seborrheic keratosis,
squamous cell carcinoma,
basal cell carcinoma,
adnexal tumor,
melanocytic nevus,
melanoma,
Merkel cell carcinoma,
dermatofibrosarcoma protuberans,
atypical fibroxanthoma,
lymphoma

Epidermis

Seborrheic Keratosis

Seborrheic keratoses are common, benign, pigmented, predominantly basal keratinocytic proliferations occurring chiefly on the trunk of adults. They may be single or multiple. The sudden appearance of, or increase in the number and size of, seborrheic keratoses in association with internal malignant disease is known as the *Leser–Trélat sign*.[1]

Grossly, the lesions of seborrheic keratosis protrude above the surface of the skin, are soft, and vary in color from tan to black. The single, heavily pigmented seborrheic keratoses may be confused clinically with malignant melanoma.

Microscopically, the number of epidermal basal cells is greatly increased, presumably as a result of a maturation defect. The acanthotic pattern is the most frequent, in which a thick layer of basal cells is seen interspersed with pseudohorn cysts (Fig. 3.1). Some of these cells contain melanin, as the result of transfer from neighboring melanocytes. Other microscopic variants of seborrheic keratosis are the *hyperkeratotic*, *adenoid*, *acantholytic*,[2] and *desmoplastic*. The latter may simulate invasive squamous cell carcinoma.[3] *Psoriasiform keratosis* is a recently described condition combining features of seborrheic keratosis and psoriasis, the true nature of which still needs to be determined.[4,5]

Immunohistochemically, the keratinocytes of seborrheic keratosis invariably express low-molecular-weight keratin but often exhibit a deficiency of the high-molecular-weight keratins.[6,7]

In *irritated seborrheic keratosis*, squamous metaplasia is pronounced, often in the form of so-called squamous eddies. This phenomenon, presumably arising from the acrotrichia, should not be overdiagnosed as basosquamous carcinoma.[8] It does not seem to be related to human papilloma virus (HPV).[9] Instead, HPV can be identified in the seborrheic keratosis-like lesions of patients with *epidermodysplasia verruciformis*[10,11] and in those exhibiting bowenoid changes.[12,13] The latter should probably be interpreted as condylomas rather than as true seborrheic keratoses.[14]

Malignant skin neoplasms of various types (particularly basal cell carcinoma) may be seen contiguous or adjacent to lesions of seborrheic keratosis.[15] Seborrheic keratoses are genetically stable but frequently have mutations in a variety of oncogenes in the *FGFR3-RAS-mitogen-activated protein kinase (MAPK)* pathway but not tumor suppressor genes.[16]

Benign Lichenoid Keratosis

Benign lichenoid keratosis (lichenoid keratosis, lichen planus–like keratosis) presents as a solitary lesion, most commonly on the trunk or extremities of middle-aged and older patients. Clinically, they are often confused with basal cell carcinomas. Microscopically, the epidermis is acanthotic with hyperkeratosis and a thickened granular layer in association with a dense lichenoid lymphocytic infiltrate with interface change reminiscent of lichen planus.[17]

Acrochordon

Acrochordon is the preferred name for a common and inconsequential skin lesion also known as fibroepithelial papilloma, fibroepithelial polyp, fibroma molle, and skin tag. As these various names indicate, it is a polypoid lesion composed of varying amounts of stroma covered by a papillomatous epidermis. A clue to the diagnosis is the absence of adnexal structures in the underlying dermis.

A distinctive variant of this exophytic fibroepithelial process is represented by the *acquired (digital) fibrokeratoma*, characterized by collagenous protrusions covered by hyperkeratotic epidermis, usually occurring around interphalangeal joints but sometimes in other sites.[18]

Actinic Keratosis

In that portion of the epidermis exposed to sunlight, chiefly that of the near ultraviolet (UV) spectrum, a sequence of atrophic, hyperplastic, and eventually dysplastic changes known as actinic keratosis may develop.[19] The term "senile" keratosis, often used as a synonym, is inappropriate. An increased incidence of these changes has been found in renal transplant recipients, particularly in the lip region.[20] Histologically, actinic keratoses involve the interfollicular epidermis, sparing the follicular apparatus and the intraepidermal portion of the sweat duct, as demonstrated in the classic article by Pinkus.[21] The stratum corneum is replaced by a parakeratotic scale. Excessive production and accumulation of this scale lead to the formation of cutaneous horns. The granular layer is generally absent except at and about the follicular orifices. The malpighian layer shows disorderly maturation, as well as individually dysplastic and dyskeratotic cells (Fig. 3.2). Morphologic variations on the theme of actinic keratosis include basaloid proliferations resembling early basal cell carcinomas, changes along the dermoepidermal junction resembling lichen planus

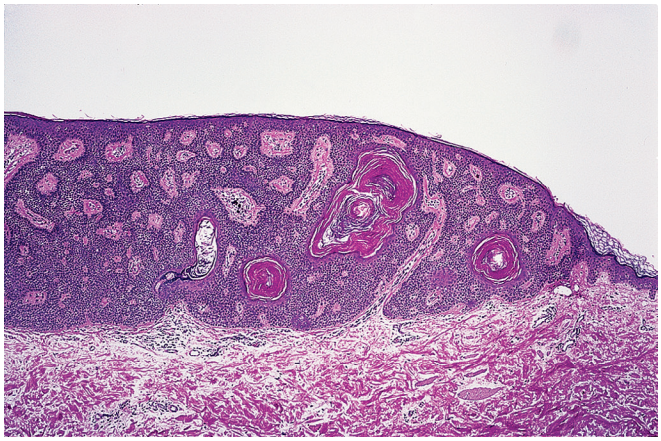

Figure 3.1 Seborrheic keratosis with mild pigmentation in the skin of a senior pathologist. Pseudohorny cysts are evident.

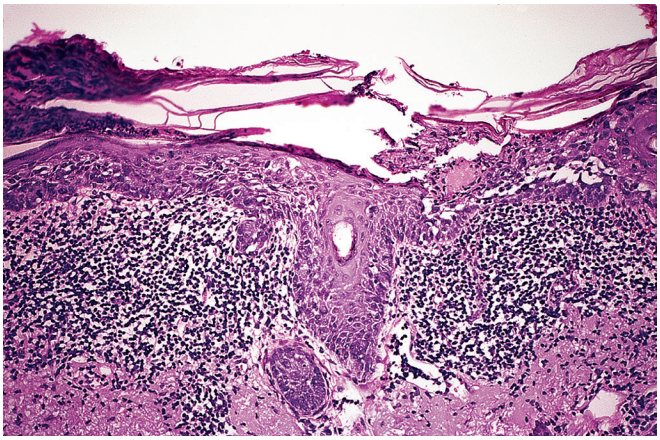

Figure 3.2 Actinic Keratosis. Note the hyperparakeratosis, moderate malpighian atypia, and dermal inflammatory infiltrate.

(lichenoid actinic keratosis), suprabasal acantholysis producing vesicles similar to those of pemphigus vulgaris, a marked degree of keratinocytic atypia throughout the malpighian layer (bowenoid actinic keratosis), and the presence of large atypical clear cells (pagetoid actinic keratosis).[22] Not infrequently, the basal melanocytes participate in the proliferation and atypia, resulting in a combination of actinic keratosis and actinic melanosis. Such cases appear clinically as heavily pigmented lesions.[23]

The papillary dermis is often chronically inflamed, and basophilic degenerative changes are prominent in the elastic fibers (solar elastosis). In florid forms of actinic keratosis, the atypical epithelial proliferation produces irregularly elongated acanthotic ridges, and this process extends down the external root sheaths of the hair follicles. In such cases, the differential diagnosis with superficially invasive squamous carcinoma inevitably arises.

Accumulation of p53 protein, presumably as a result of mutation, has been found in almost three-fourths of actinic keratosis lesions and found to correlate with the degree of atypia.[24] Genetically, mutation of TP53 is found in 50% of cases, being less frequent than in cutaneous squamous cell carcinoma.[25] The mutations in TP53 are predominantly C to T transitions, in keeping with ultraviolet radiation damage.[25] In addition, loss of heterozygosity at multiple chromosome sites is common.[26,27] Progression to squamous cell carcinoma may be mediated by inactivation of INK4A (p16).[28]

Actinic keratoses may be treated by a variety of methods—freezing, superficial curettage, application of antineoplastic chemotherapeutic agents, and surgical excision. Excision is unnecessarily radical therapy except for the more florid and infiltrative types and those not responding to topical 5-fluorouracil.[29]

Cutaneous Horn

Cutaneous horn (cornu cutaneum) is the traditional picturesque term for a protruding skin lesion largely composed of keratin and resembling a horn in shape.[30] The lesion can reach a gigantic size and truly resemble an animal horn.[31] Because the clinical appearance of cutaneous horn can result from a variety of diseases, cutaneous horn should not be used as a pathologic term. Most cases are caused by actinic keratosis, but others may be the result of verruca, seborrheic keratosis, inverted follicular keratosis, or squamous cell carcinoma.[32] The keratin formed is usually of epidermal type, but occasionally it has trichilemma-like features (i.e., it contains deep red granules). When this is the case, the lesion has been referred to as trichilemmal keratosis, verrucous trichilemmal tumor, and trichilemmal horn.[33,34]

Bowen Disease

Bowen disease is a form of squamous cell carcinoma in situ that consists clinically of indolent, scaly, erythematous plaques occurring predominantly on non-chronically sun-exposed skin (Fig. 3.3). Histologically, the lesions show a variety of atypical epithelial changes, such as cytoplasmic vacuolization, nuclear hyperchromasia, multinucleated keratinocytes, individual cell dyskeratosis, and increased number of mitoses, including atypical forms (Fig. 3.4). The maturation pattern is markedly altered (as made very apparent with the Mib-1 stain),[35] but some surface flattening and keratinization are almost always present. Extension of the process into the eccrine sweat glands may occur.[36] In its fully developed stage, Bowen disease can be regarded as a carcinoma in situ of the skin or as a form of squamous intraepidermal neoplasia, a concept supported by the presence of mutant p53 protein,[37,38] and of distinct aneuploidy in flow cytometric studies.[39] It should be emphasized that the diagnosis of Bowen disease is a clinicopathologic one.[40] Lesions showing similar microscopic changes but located in sun-exposed areas and having the clinical appearance of actinic keratosis should not be diagnosed as Bowen disease but rather as *bowenoid actinic keratosis*. An important difference between the two conditions is that in actinic keratosis there are atypical squamous cells in the lower portions of the epidermis including the basal layer, whereas in Bowen disease there are atypical squamous cells in all portions of the epidermis but with preservation of the basal cells, which are arranged in palisades. Differences can also be appreciated at the immunohistochemical level.[41]

Occasionally, lesions of Bowen disease have a papillated appearance,[42] others show a verrucous–hyperkeratotic pattern, and still others contain large atypical clear cells simulating Paget disease *(pagetoid Bowen disease)*[43]; even more rarely, the latter two processes coexist.

Figure 3.3 Clinical Appearance of Bowen Disease. A slightly elevated red patch of irregular contours is seen. This clinical appearance conforms to the syndrome originally described by Bowen.

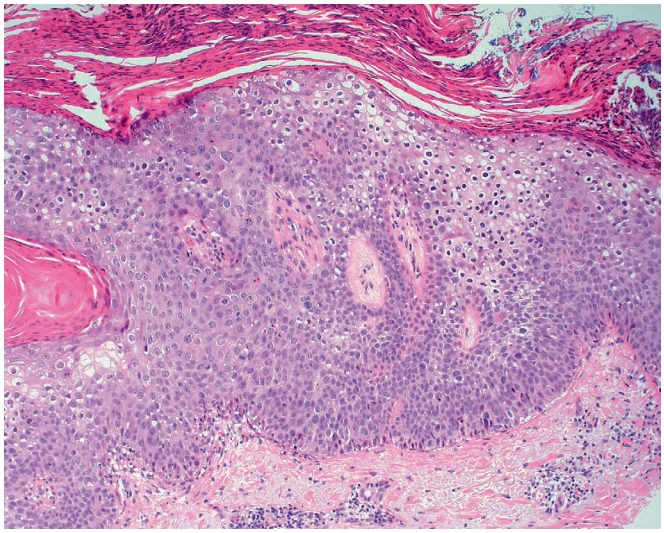

Figure 3.4 Microscopic Appearance of Bowen Disease. The atypia involves the full thickness of the epithelium. This example also has focal clear cell change.

Some studies have shown an apparent increase in the incidence of visceral cancer in patients with Bowen disease,[44,45] but others have failed to document such an association. Because arsenic is capable of inducing hyperplastic and dysplastic epidermal changes that may lead to the development of invasive squamous cell carcinoma, this element has been looked for in lesions of Bowen disease, but the search has proved inconclusive.[46]

Squamous Cell Carcinoma

General Features

The large majority of squamous cell (epidermoid) carcinomas of the skin are actinically induced,[47–49] one of the postulated pathogenetic mechanisms being the induction of TP53 mutations by ultraviolet light (Fig. 3.5).[50] The incidence of this tumor is directly related to the amount of exposure to the sun and the lack of pigmentation of the skin. Blond, blue-eyed, fair-skinned people living in Texas have a higher incidence of skin cancer than do their counterparts in Minnesota. Squamous cell carcinoma in black people is a very rare disease. In urban populations, frankly invasive squamous cell carcinoma is uncommon, whereas in rural populations it is common.[51] Nearly all of these actinic-induced tumors are preceded and accompanied by lesions of actinic keratosis.[52]

Squamous cell carcinomas of the skin can also be seen as a complication of the following:

1. Xeroderma pigmentosum, a genetically determined condition characterized by a diminished capacity for DNA repair following ultraviolet light irradiation.[53,54] These patients may also develop basal cell carcinomas and malignant melanomas.
2. Epidermodysplasia verruciformis, a generalized virally induced dermatosis.[55,56]
3. Cutaneous scars of various types: from burns (Marjolin ulcer), x-rays, epidermolysis bullosa, chronic osteomyelitic sinuses, necrobiosis lipoidica, acne aggregata seu conglobata, or hidradenitis suppurativa.[57–64]
4. Chemical exposure: arsenic, coal tars, soot, and a variety of oils and distillation products.[46]
5. Immunocompromise. In organ transplant recipients the carcinomas are often associated with severe actinic keratosis or, less commonly, widespread warts.[65,66] HPV has been detected in these lesions.[67,68] The clinical course can be very aggressive.[69] In the human immunodeficiency virus (HIV)-infected population there is an increased risk for both squamous cell and basal cell carcinoma.[70] The tumors tend to be larger, less differentiated, and more deeply invasive.[71]
6. PUVA-treated psoriatic patients, in whom the risk is dose dependent.[72,73]
7. Ichthyosis,[74] epidermal nevus,[75] porokeratosis,[76] and congenital lymphedema.[77,78] Only a few cases have been reported in each of these disorders.

Smoller et al.[79] have shown that an "activated" keratinocyte phenotype—characterized by a particular staining pattern for ψ-3, involucrin, filaggrin, and keratins—is the common denominator for the conditions that predispose to squamous cell carcinoma.

Microscopic Features

More than 80% of squamous cell carcinomas are well differentiated and, as such, produce large amounts of keratin (Fig. 3.6). Some of this is seen in the form of horn pearls, particularly in the better differentiated tumors; characteristically, keratohyaline granules within

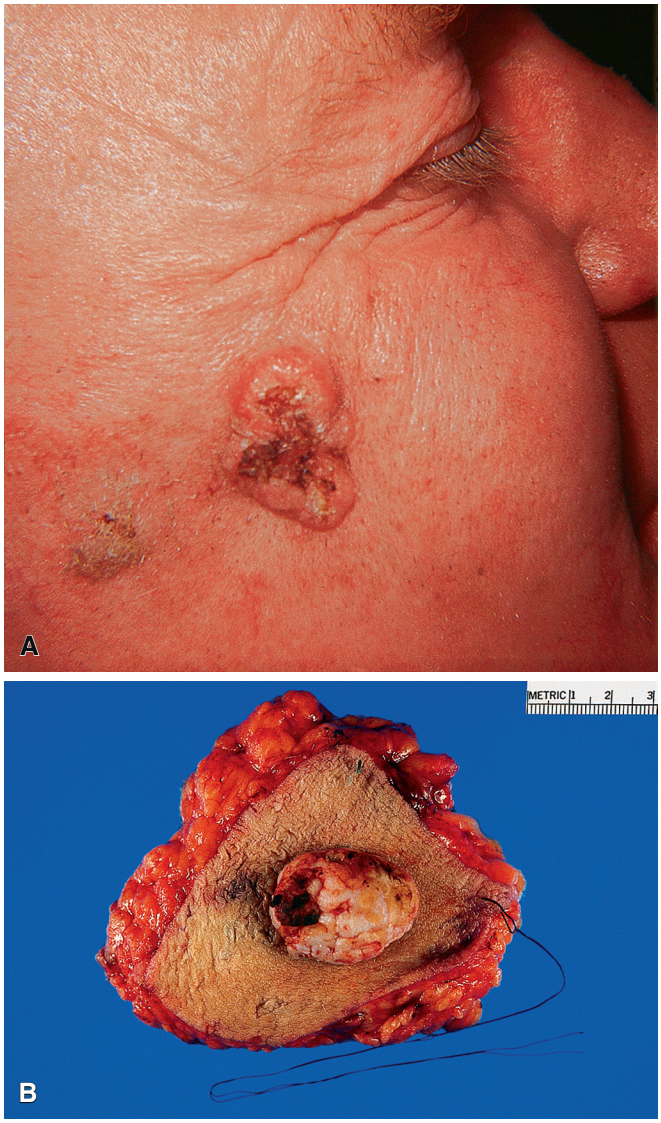

Figure 3.5 Squamous Cell Carcinoma. A, Tumor of the face with rolled edges and depressed center. **B,** Tumor of the leg with exophytic appearance.

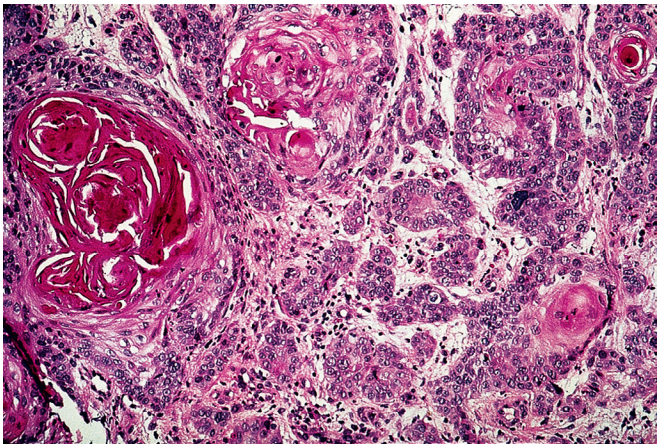

Figure 3.6 Deeply invasive, well-differentiated squamous cell carcinoma.

these pearls are sparse or absent. So-called intercellular bridges can be found with ease in most cases. The pattern of growth may be polypoid or even papillary[80] or may have a deep penetrating quality. Sometimes the tumors are cup-shaped in the manner of keratoacanthomas.

Invasion of the dermis is sine qua non for the diagnosis, but this may be a very subjective evaluation in the early stages. A lesion interpreted by some as florid actinic keratosis may be interpreted by others as a superficially invasive squamous cell carcinoma.[81,82] This is a reflection of the fact that actinic keratosis and squamous cell carcinoma are part of a continuous spectrum of squamous neoplasia. Fortunately, the issue is of no great practical importance, because the treatment and prognosis for these borderline lesions are essentially the same.

Squamous cell carcinoma may contain a population of non-neoplastic dendritic melanocytes, with transfer of some of the melanin granules into the cytoplasm of the tumor cells (pigmented squamous cell carcinoma); this phenomenon is analogous to that seen more commonly in basal cell carcinoma.[83]

Occasionally, the tumor has a clear cell appearance throughout, raising the differential diagnosis with a variety of adnexal tumors,[84,85] as well as suggesting the possibility that the change may reflect an abortive attempt at trichilemmal differentiation in the squamous cell carcinoma.[86] Even more rarely, the tumor may have a component of signet ring cells.[87]

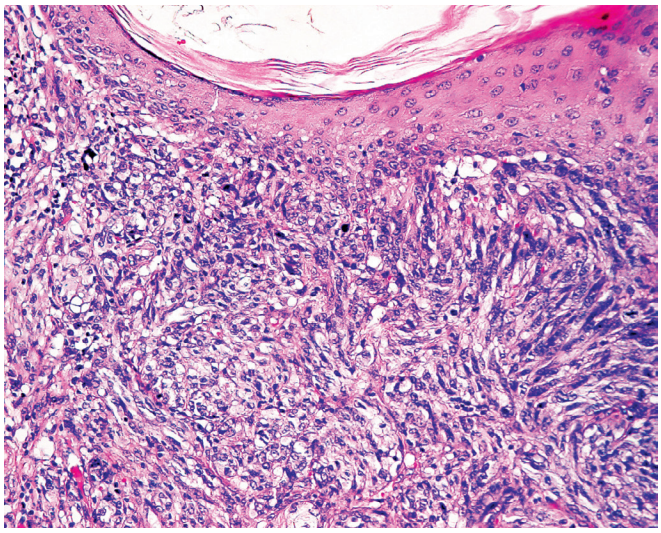

Figure 3.7 Squamous cell carcinoma with spindle metaplastic features.

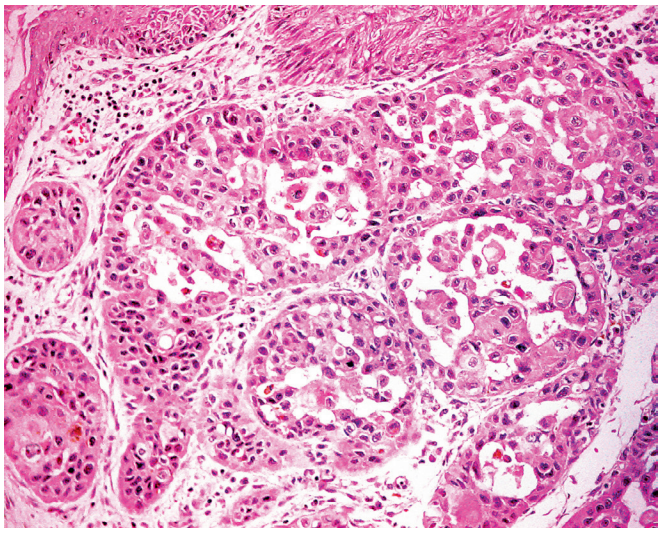

Figure 3.8 Adenoid (acantholytic) squamous cell carcinoma, resulting in a pseudoglandular appearance.

Immunohistochemical and Molecular Genetic Features

Squamous cell carcinomas of the skin exhibit immunoreactivity for high-molecular-weight keratins, involucrin (a precursor of the cross-linked envelope protein of the stratum corneum), epithelial membrane antigen (EMA), and often also carcinoembryonic antigen (CEA) and p63.[88–91] Poorly differentiated tumors can also be immunoreactive for vimentin.[92] In contrast to basal cell carcinomas, squamous cell carcinomas tend to be negative for Ber-EP4 and CD10.[93–95] Basement membrane components, such as laminin and type IV collagen, can be found surrounding some of the tumor nests.[96]

Accumulation of p53 protein has been detected in close to half of cases.[97]

Up to 90% of cutaneous squamous cell carcinomas harbor the TP53 mutation, with frequent C→T or CC→TT transitions as signatures of ultraviolet radiation–induced mutagenesis.[98] The frequent presence of the TP53 mutation in the precursor lesion actinic keratosis, as well as normal-looking epidermal cells adjacent to squamous cell carcinoma, suggests that this genetic alteration is an early event in carcinogenesis.[98] Inactivation of the RB/P16 pathway through mutation or promoter hypermethylation of INK4A also appears to play a role.[99,100] Recent studies also implicate activation of the NF-κB pathway to contribute to the malignant phenotype of cutaneous squamous cell carcinoma.[101–103] Activating mutations in HRAS and KRAS are found in 46% and 4%–12% of cases, respectively.[104,105] Promoter hypermethylation of the E-cadherin gene CDH1 is reported in 95% of cases.[100]

Other Microscopic Types

Spindle squamous cell carcinoma (metaplastic sarcomatoid squamous cell carcinoma) usually occurs in sun-exposed areas and is relatively common in the lip (Fig. 3.7). The differential diagnosis includes malignant melanoma and atypical fibroxanthoma. Continuity of tumor cells with the basal layer of the epidermis, foci of clear-cut squamous change, and high-molecular-weight keratin immunoreactivity are the most important distinguishing features.[106–108] Vimentin is consistently coexpressed by these tumors.[109] *Carcinosarcoma* is the term used when there is a sharp segregation between the epithelial and the sarcoma-like components.[110] When the distinction between spindle cell carcinoma and a mesenchymal tumor is not possible (a not uncommon occurrence), the noncommittal term *sarcoma-like tumor of the skin* may be used.[111]

Adenoid (pseudoglandular; acantholytic) *squamous cell carcinoma* results from acantholysis (i.e., lack of cell cohesiveness caused by a desmosomal defect) (Fig. 3.8). Sometimes the pattern simulates an angiosarcoma (pseudoangiosarcomatous carcinoma).[112,113] Nearly all cases occur in sun-exposed areas, and many are associated with actinic keratosis with acantholysis. Immunohistochemically, there is a preferential reduction of the cell adhesion molecule syndecan-1.[114] The differential diagnosis includes primary and metastatic adenocarcinoma, true adenosquamous carcinoma of the skin (a rare aggressive neoplasm that exhibits squamous differentiation and mucin production),[115,116] and mucoepidermoid carcinoma (an even rarer tumor of probable sweat gland derivation).[117]

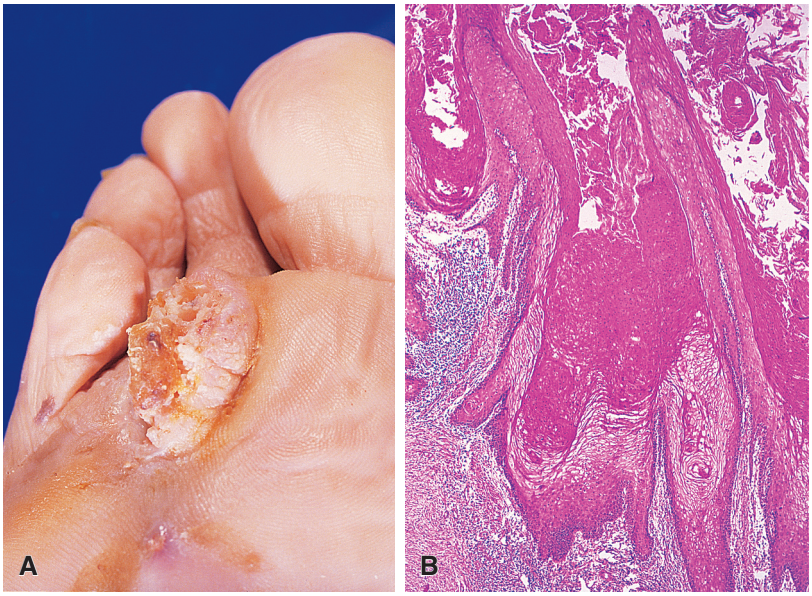

Figure 3.9 Verrucous Carcinoma of Skin. A, Typical appearance of lesion located in sole of foot. **B,** Papillomatous growth associated with hyperkeratosis and pushing type of invasion into the underlying dermis. (Courtesy Dr Daniel Santa Cruz, St. Louis.)

Verrucous carcinoma is an extremely well-differentiated type of squamous cell carcinoma, also known in the skin as carcinoma or *epithelioma cuniculatum*.[118,119] It appears as an ulcerated, fungating, and polypoid mass with openings of sinus tracts onto the skin surface. Most cases are located in the sole of the foot (Fig. 3.9). Local invasion is the rule, and extension to bone is frequent, but nodal metastases are exceptional.[120,121] It is regarded as the cutaneous counterpart of the more common verrucous carcinoma of the oral cavity and other mucosal membranes, and, like them, it may be positive for HPV.[122]

Treatment

Complete excision remains the treatment of choice for most squamous cell carcinomas.[123,124] Careful pathologic examination, including inked surgical margins, allows identification of those cases in which the tumor has been transected. Depending on the size and location of the tumor and the general condition of the patient, alternative therapies include curettage and electrodessication, cryotherapy, and radiation therapy.[47]

Prognosis

The overall prognosis of squamous cell carcinoma is excellent, particularly for the actinic-induced tumors.[125] Superficially invasive cancers (less than 1.5 cm) metastasize only occasionally.[126] Even in lesions larger than 2 cm with unequivocal invasion into the reticular dermis, the incidence of regional lymph node metastases is less than 5%. The best prognostic factors are staging, level of dermal invasion, and vertical tumor thickness.[127,128] In one series, all tumors that recurred were 4 mm or more thick and involved the deep half of the dermis or deeper; all tumors that proved fatal were at least 1 cm in maximum thickness, and most extended into the subcutaneous fat or beyond.[127] In another series, the prototypical metastatic squamous cell carcinoma had a width of at least 1.5 cm, a vertical tumor thickness of at least 2 mm, poor differentiation, desmoplasia, and a mixed inflammatory infiltrate.[129] The presence or absence of actinic keratosis at the edge of a squamous cell carcinoma is not as useful a predictor of behavior as tumor thickness or level of invasion.[130]

Pseudoepitheliomatous Hyperplasia

At sites of trauma, chronic irritation, and ulcers, the reparative hyperplasia of the epidermis may produce seemingly invasive tongues of epithelial cells. This abnormality, known as *pseudoepitheliomatous* (pseudocarcinomatous) *hyperplasia*, can also be caused by mycotic infections (particularly North American blastomycosis), bromoderma, pyoderma vegetans, tuberculosis, syphilis, granular cell tumor, and melanocytic lesions (particularly Spitz nevi but also malignant melanoma).[131,132] The epithelial proliferation is generally associated with a dermal fibroblastic and vascular proliferation and a prominent acute or subacute inflammatory infiltrate. Characteristically, the proliferating strands of epithelium are thin, markedly elongated, anastomosing, and heavily infiltrated by inflammatory cells (Fig. 3.10).[133]

Clear separation of pseudoepitheliomatous hyperplasia from squamous cell carcinoma is not always easy. The width of the strands (thin in hyperplasia and broad in carcinomas) and the degree of keratinocytic atypia (greater in the carcinoma) are the main distinguishing features. It should be kept in mind that the presence of an intraepidermal inflammatory infiltrate, no matter how heavy, does not rule out the diagnosis of squamous cell carcinoma. We have seen several cases with clear-cut architectural and cytologic features of carcinoma that were repeatedly underdiagnosed as pseudoepitheliomatous hyperplasia because of their association with a prominent lymphocytic, neutrophilic, eosinophilic, or granulomatous infiltrate.

Basal Cell Carcinoma

General Features

Basal cell carcinoma derives its name from the cytologic similarity of the tumor cells to the normal basal cells of the epidermis and the

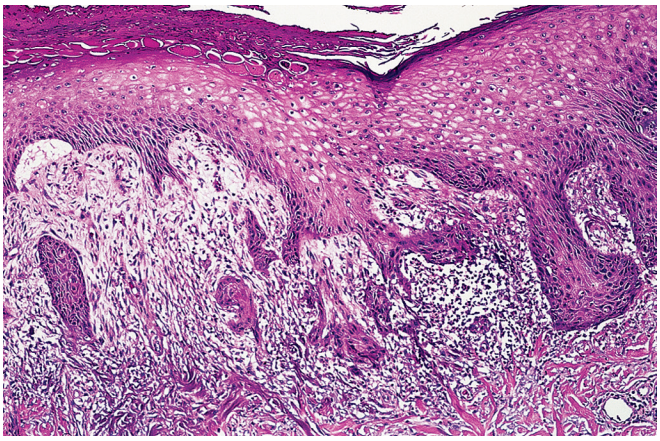

Figure 3.10 Pseudoepitheliomatous hyperplasia following removal of a benign nevus.

Figure 3.11 Gross appearance of basal cell carcinoma of forehead. The lesion is nodular and pigmented.

traditional belief that it arises from them. In our opinion, all basal cell carcinomas attempt to differentiate toward adnexal structures (particularly pilosebaceous units), but most of them remain at a stage so primitive as to render this recognition not immediately apparent.[134] The belief that basal cell carcinomas represent primitive "adnexal" carcinomas has been voiced over the years by several authors[135,136] and is supported by the marked immunohistochemical similarities that exist between basal cell carcinoma and tumors of indubitable hair follicle derivation,[137–141] among them the common immunoreactivity for CD10.[142] Some authorities who initially denied the concept have now gone as far as flatly stating that basal cell carcinoma is a trichoblastic carcinoma.[143]

Basal cell carcinoma is the most frequent form of skin cancer; it occurs predominantly on sun-exposed skin[144] in direct proportion to the number of pilosebaceous units present therein, a feature supporting the previously stated histogenetic interpretation.[145,146] Fair-skinned, blue-eyed persons engaged in outdoor occupations suffer a higher incidence of these tumors.[147,148] Synchronous and metachronous tumors are frequent.[149] Exceptionally, children and young adults are affected.[150,151]

Basal cell carcinomas may also develop in sunlight-protected skin,[152] in nevus sebaceus of Jadassohn, in the lower leg in association with chronic venous stasis and other preexistent conditions,[153–155] over arteriovenous malformations,[156] and following arsenic ingestion, x-ray exposure, skin injury, chickenpox scars, tattoos, hair transplantation scars, and immune suppression.

The clinical appearance of basal cell carcinoma is as variable as its histologic patterns. *Nodular*, *ulcerative*, *superficial*, *erythematous*, *sclerosing* (morphea-like), and *keloidal* forms occur (Fig. 3.11).[144,157]

Basal cell nevus syndrome *(Gorlin syndrome)* is characterized by multiple basal cell carcinomas, palmar pits, calcification of dura, keratocysts of the jaws, skeletal anomalies, and occasional abnormalities of the central nervous system, mesentery, and endocrine organs (Fig. 3.12).[158,159] Microscopically, the basal cell carcinomas in this setting exhibit a broader spectrum of subtypes than the sporadic tumors.[160,161] The syndrome should be suspected when basal cell carcinomas are seen in young people who have multiple tumors, many of which are of the superficial multicentric type and in which osteoid is an occasional finding. It is caused by a germline inactivating mutation in the *PTCH1* gene located at chromosome 9q22.3–q31.[160] Mutations in *PTCH1* are also found in a significant number of sporadic basal cell carcinomas.[144]

Figure 3.12 Multiple basal cell carcinomas in the skin of the back of an elderly patient.

Microscopic Features

As stated in the preceding section, basal cell carcinomas arise from basally located cells of the epidermis and pilosebaceous units and differentiate incompletely in the direction of adnexal (primarily follicular) structures.[162] Epidermal attachment is present in nearly all cases. The tumors may have solid, cystic, adenoid, keratotic, pigmented, infiltrating, and sclerosing (morphea-like) patterns (Fig. 3.13).[144,163,164] The keratotic pattern probably represents an expression of differentiation toward the infundibular portion of hair follicles, has no clinical significance, and should be distinguished from so-called basosquamous carcinoma.

The nests of basal cell carcinoma show prominent palisading and are surrounded by a typical loose stroma, which contains myofibroblasts and often exhibits myxoid change.[144,165] Cleft-like retraction spaces, some of artifactual nature and others resulting from the accumulation of stromal mucin, are often seen between

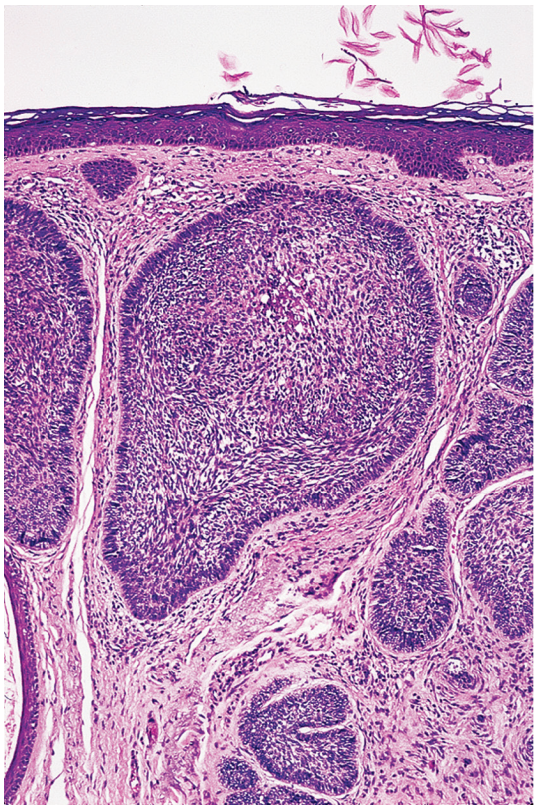

Figure 3.13 Typical nodular appearance with peripheral palisading of cutaneous basal cell carcinoma.

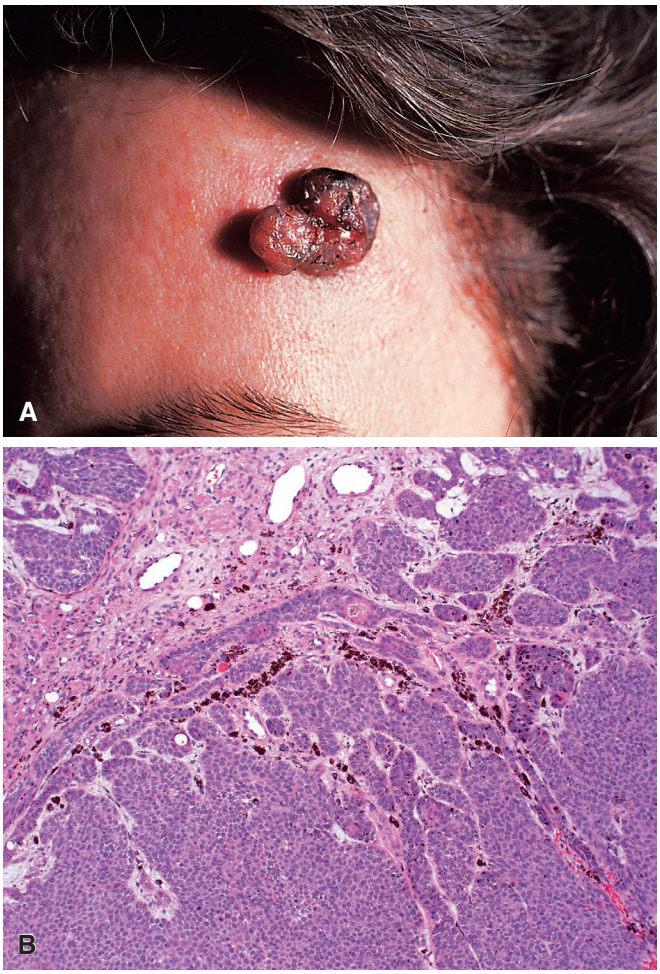

Figure 3.14 **A** and **B,** Clinical and microscopic appearance of pigmented basal cell carcinoma. Melanin is largely present in macrophages located in the stroma between tumor lobules.

the epithelial nests and the stroma.[166] Melanin can accumulate in dermal macrophages between the tumor nests and result in a "pigmented" appearance clinically and histologically (Fig. 3.14). Langerhans cells can also be present.[167] Intercellular amyloid material is not infrequent, sometimes accompanied by the deposition of immunoglobulins.[168,169] Oval to spindle tumor cells with hyaline eosinophilic cytoplasm have been found in a few cases[170] and interpreted by some authors as evidence of myoepithelial differentiation (see also section "Other Microscopic Types" later).[171] Mitotic activity (sometimes accompanied by atypical forms), marked atypia with the appearance of bizarre ("monster") tumor cells, and giant cell formation may occur, but there is no convincing evidence that any of these features carries prognostic significance.[144,172–174] In other instances the atypia is present in the reactive stromal cells and is equally inconsequential.[175] The stroma may undergo osseous metaplasia, sometimes to a considerable degree[176]; in other instances, it may contain peculiar collagen crystal-like structures.[177]

Rarely, matrical (shadow cell formation), eccrine, or sebaceous differentiation or markedly thickened basement membrane is seen in otherwise typical basal cell carcinoma, further supporting the close relationship of these tumors with adnexal structures.[178–182] Perineurial or endoneurial invasion by tumor cells is rarely present and is more common in the infiltrating/morpheaform variants.[183] Sometimes, a basal cell carcinoma is seen adjacent to a benign melanocytic nevus, the juxtaposition being a coincidental event.[184]

The differential diagnosis of basal cell carcinoma includes the areas of highly organoid basaloid proliferation sometimes seen in the epidermis overlying dermatofibromas[185] and the more atypical foci of basaloid proliferation that may be found in association with actinic keratosis and Bowen disease (see respective discussions).

Histochemical and Immunohistochemical Features

Immunohistochemically, the cells of basal cell carcinoma are positive for keratin (particularly low-molecular-weight type)[7,186,187] but usually negative for EMA, CEA, and involucrin.[88,90] Other markers commonly expressed are CD10 (as mentioned previously), Ber-EP4, and androgen receptors.[188] The basement membrane that surrounds the tumor nests reacts with antibodies against laminin, types IV and V collagen, and bullous pemphigoid antigen.[189,190] The pattern of staining for these markers tends to be attenuated and discontinuous, as an expression of the disruption of this structure.[191,192] This feature is more prominent in the aggressive tumors.[193]

A suggestion was made some years ago that basal cell carcinomas may show neuroendocrine differentiation, with immunoreactivity for CD56, chromogranin, and synaptophysin[194]; although the relatively common finding of argyrophilia may seem to support this contention, immunoreactivity for neuroendocrine markers, such as chromogranin or neuron-specific enolase (NSE), is uncommon.[195,196] Importantly, basal cell carcinoma is negative for cytokeratin 20, which allows distinction from Merkel cell carcinoma and trichoepitheliomas, which typically have scattered retained Merkel cells in the tumor islands.[197] It has been shown that most basal cell carcinomas stain for Ber-EP4, whereas most squamous cell carcinomas do not.[93,94,198] They also

commonly express BCL2, a feature of alleged value in the differential diagnosis with actinic keratosis and squamous cell carcinoma.[199,200]

Molecular Genetic Features

More than 80% of basal cell carcinomas overexpress p53 protein,[201] and this figure is even higher in the more aggressive types (see later). Clonal chromosome aberrations are frequent, most often represented by the numerical changes +18, +9, +20, +7, and +5.[202] Dysregulation of the Hedgehog pathway is a key pathogenetic event in basal cell carcinoma.[203] In the absence of Hedgehog ligands, protein patched homolog 1 (encoded by *PTCH1*) normally inhibits the transmembrane protein Smoothened (encoded by *SMOH*), leading to a cascade that represses expression of the Hedgehog downstream target genes. In basal cell carcinomas, inactivating somatic mutation and allelic loss of *PTCH1*, the gene implicated in the basal cell nevus syndrome, are common (67% and 53% of cases, respectively).[204–207] In 10% of cases, activating mutations of *SMOH* are present instead.[206,208] These genetic changes result in activation of the Hedgehog pathway. A recent study has successfully used GDC-0449, a small-molecule inhibitor of smoothened, for treatment of advanced basal cell carcinoma.[209] Vismodegib and sonidegib, both inhibitors of the Hedgehog pathway, have activity against basal cell carcinoma with significant antitumor effect in large unresectable tumors and rare cases of metastatic basal cell carcinoma.[210] Mutation in *TP53* is found in approximately 30%–40% of cases.[205,206] Presence of trisomy 6 has been correlated with the metastatic potential of the tumor.[211]

Other Microscopic Types

Superficial basal cell carcinoma arises in skin with sparse, fine hairs and epidermis that is thin, such as that of the trunk. It grows chiefly in a lateral direction, beneath a relatively flat epidermis, and exhibits a high recurrence rate.[144,212,213]

Basosquamous (metatypical) carcinoma has the general configuration of a basal cell carcinoma, but it also contains atypical squamous cells. This variant is more aggressive than conventional basal cell carcinoma. A high proportion of the metastasizing basal cell tumors belong to this type, which should be distinguished from the keratotic form of basal cell carcinoma.[214,215]

Granular cell basal cell carcinoma contains tumor cells with cytoplasmic granules analogous in every way to those seen in granular cell tumor of the dermis and other locations.[216,217] No clinical significance is ascribed to this variety.

Clear cell basal cell carcinoma contains tumor cells with prominent cytoplasmic vacuoles[218–220]; in other cases the tumor cells may even have a signet ring configuration,[221] perhaps indicative of myoepithelial cell differentiation.[222]

Infundibulocystic basal cell carcinoma is a variant of basal cell carcinoma in which evidence of hair follicle differentiation is much more evident and advanced than in the ordinary type; it could be viewed as being situated between the latter and trichoepithelioma in terms of the differentiation spectrum.[223]

Fibroepithelioma of Pinkus (fibroepithelial tumor; Pinkus tumor) often occurs on the back (Fig. 3.15). It has been traditionally regarded as a polypoid variant of basal cell carcinoma, and it has been suggested that the fibroadenoma-like pattern of this tumor is the result of eccrine duct spread.[224] Other authors view it as a "fenestrated" variant of trichoblastoma.[225] To us, this tumor provides yet another piece of evidence of the intimate relationship of basal cell carcinoma with the pilosebaceous unit.

Sarcomatoid basal cell carcinoma is a relatively new variant, characterized by areas of conventional basal cell carcinoma intimately admixed with heterologous bone formation (termed osteosarcomatous differentiation by the authors).[226] Its behavior does not seem particularly aggressive.

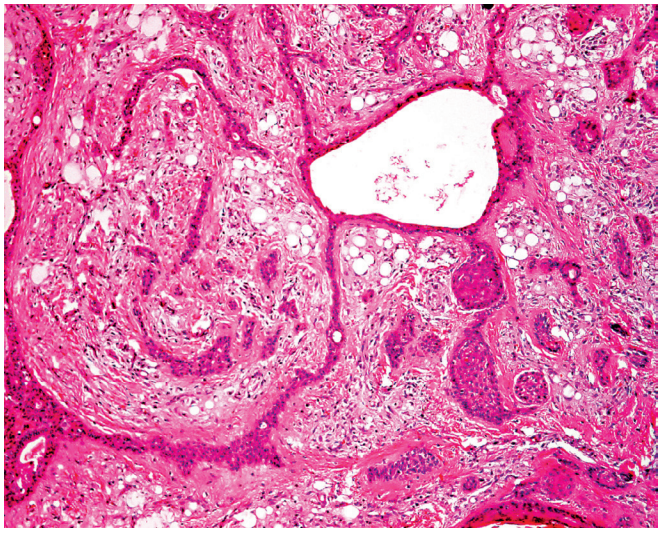

Figure 3.15 Highly organoid appearance of fibroepithelioma of Pinkus.

Spread and Metastases

Basal cell carcinoma usually grows in a slow and indolent fashion. However, if untreated, the tumor may invade the subcutaneous fat, skeletal muscle, and bone *("ulcus rodens")*. Tumors of the face may invade skull, nares, orbit, or temporal bone via the auditory canal. They can thus reach the central nervous system and produce lethal meningitis. Microscopically, the locally more aggressive tumors tend to show loss of peripheral palisading and a dense, fibrous stroma rather than a loose myxoid stroma.[227] At a statistical level, they also show decreased expression of syndecan-1[228] and BCL2,[229] greater expression of p53,[230] higher AgNOR count,[231] and higher incidence of aneuploidy[232] than the others.

In terms of location, local recurrence is more common in tumors of the nasolabial fold, inner canthus, and postauricular region.[163] This is probably the combined result of the highly irregular infiltrative pattern that these tumors often exhibit, and the fact that in these locations the distance to the surgical margins tends to be rather close.[233,234] In general, the microscopic appearance of the recurrence is not substantially different from that of the original tumor.[235] Distant metastases are extraordinarily rare, but more than 100 cases have been reported.[236–238] These include cases associated with the basal cell nevus syndrome.[239] Approximately 60%–75% of these metastases involved the regional lymph nodes, and the others affect such organs as lung, bone, and liver. Metastases in basal cell carcinoma are more likely in the basosquamous types, in those with perineurial spread, and in tumors located on sunlight-protected skin.[152]

Treatment

Excision, curettage and desiccation, and irradiation used appropriately cure most basal cell carcinomas.[123,148,240,241] Even when these tumors extend to the margin of surgical excision (an occurrence of approximately 5% in large series), only one-third will show evidence of recrudescence over the ensuing 2–5 years.[242] Thus immediate reexcision is not always indicated under these circumstances. Actually, it has been suggested that evaluation of the pattern of tumor growth (widely dispersed vs. tightly clustered nests) is a better predictor of local

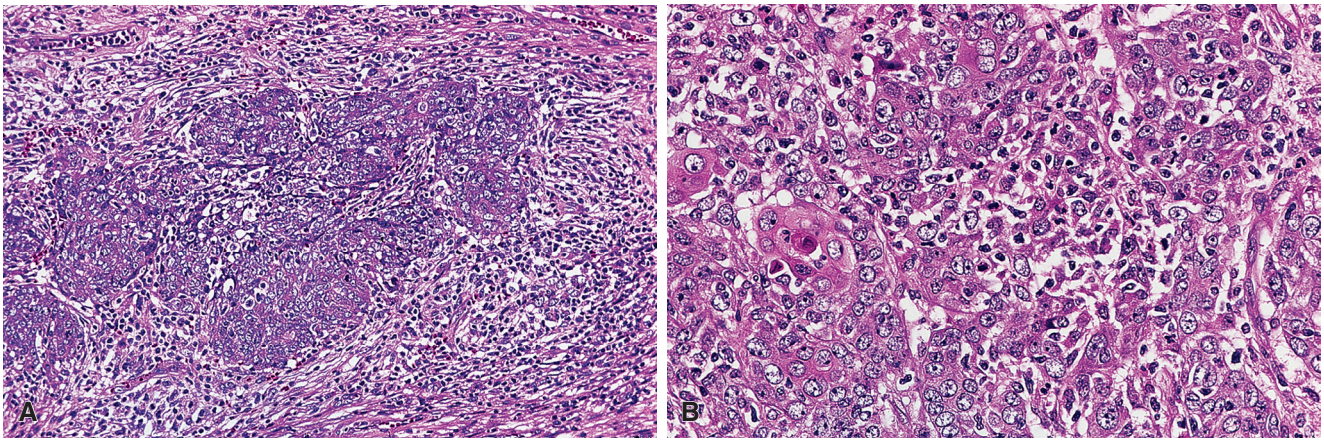

Figure 3.16 **A** and **B,** Low- and high-power views of lymphoepithelioma-like carcinoma.

recurrence than presence or absence of tumor at the surgical margins.[243]

Recurrent basal cell carcinomas can be treated with radiation therapy or surgical reexcision.[244] In some institutions, these recurrent tumors (and increasingly, many others, whether recurrent or not) are being treated by a procedure known as Mohs micrographic surgery.[245–247] In this setting the Mohs surgeon reviews complete en face surgical margins by frozen section, to ensure complete evaluation of the margins intraoperatively. In the United States, this technique has been advocated for certain basal cell carcinoma subtypes and for basal cell carcinomas in cosmetically sensitive locations.[241] While there is literature that supports the concept that this results in a decrease in local recurrence, use of this technique does need to be balanced with cost because it is significantly more costly than conventional excision for a relatively indolent tumor.

Skin Adnexa

The large majority of skin adnexal tumors differentiate only along one adnexal line, and this results in the formation of reasonably distinct types whose structure, cytochemistry, and immunohistochemistry can be correlated with those of the corresponding adnexa or even a subdivision thereof.[248–253] However, because all cutaneous adnexa share the same origin, it is not surprising that the tumors arising from them have many features in common, not only among themselves, but also with those of surface epidermal type. As a matter of fact, it is not unusual to find evidence of differentiation along two or more adnexal lines in different tumors occurring in the same individual or sometimes even within the same neoplasm, whether benign or malignant.[254–257] The tumors described as cutaneous adnexal carcinomas with divergent differentiation are an expression of the latter phenomenon.[258]

Lymphoepithelioma-like carcinoma of the skin may also represent a primitive adnexal neoplasm. As the name indicates, this lesion shows a morphologic resemblance to the tumor of the upper respiratory tract that bears that name, but it also exhibits features suggestive of early sweat gland and/or follicular differentiation (Fig. 3.16).[259,260] It does not seem to be related to Epstein–Barr virus (EBV).[261]

Eccrine Sweat Glands

Eccrine Poroma

Eccrine poromas occur chiefly on the palms and soles but have been reported in many other sites. They often show a moat and hillock pattern and, histologically, are characterized by a sharp junction between the proliferating, nonpigmented, small keratinocytes and the adjacent epidermis (Fig. 3.17). Within these cords and nests, ducts and sharply outlined squamous islands may be formed.[262] The tumor may be purely intraepidermal, purely intradermal (also referred to as *dermal duct tumor*), or (more commonly) involve both areas.[263] Purely intraepidermal poromas have been described in the past as *hydroacanthoma simplex*.[264] Heavily pigmented and clear cell variants of this tumor have been reported.[265] Ultrastructural, enzymatic, histochemical, and immunohistochemical studies show that the predominant cell of eccrine poroma has features similar to those of the eccrine gland acrosyringium.[266,267] However, cases have been described with divergent differentiation toward apocrine structures.[268] EMA immunoreactivity is consistently present, and this stain helps in identification of duct lumens.[269] The dermis beneath often shows a distinct proliferation of reactive vessels and some inflammation. The main differential diagnosis of eccrine poroma is with basal cell carcinoma and seborrheic keratosis.

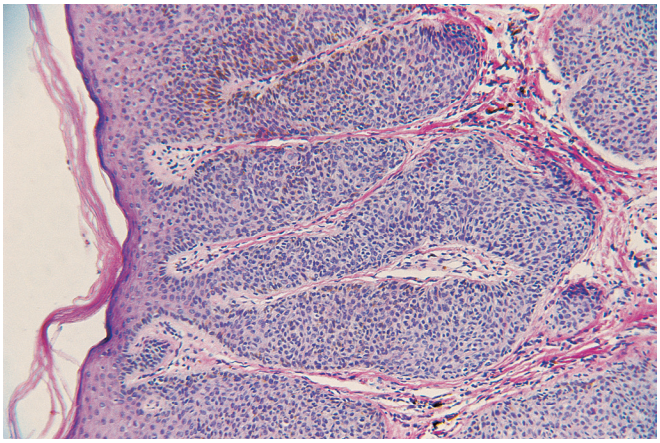

Figure 3.17 **Eccrine Poroma.** The tumor characteristically grows in the form of cords and nests of small tumor cells attached to the epidermis.

Eccrine poroma should also be distinguished from *acrosyringeal adenomatosis* (eccrine syringofibroadenoma), a peculiar condition in which papular lesions spread gradually and symmetrically to cover large areas of the body. Microscopically, they are formed by a diffuse proliferation of acrosyringium-related cells in the epidermis and dermis.[270,271]

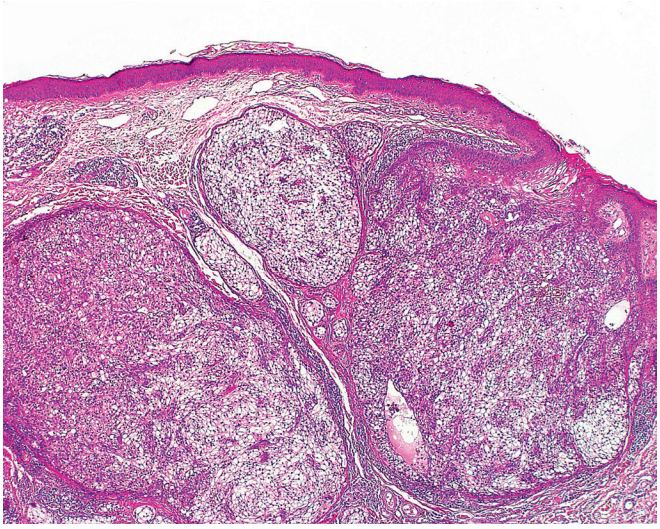

Figure 3.18 Hidradenoma. The lesion is lobulated and shows a prominent clear cell component.

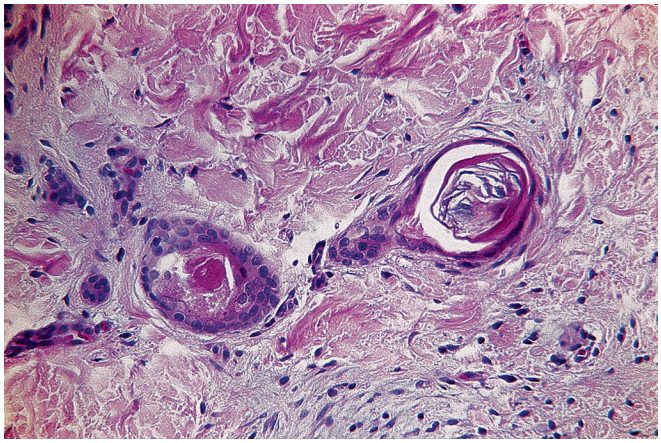

Figure 3.19 Syringoma. Small glandular structures with little "tails" are typical of this entity.

The behavior of eccrine poroma is benign, but a malignant counterpart of the tumor, known as eccrine porocarcinoma, exists.[272]

Hidradenoma

Hidradenoma, also known as *eccrine acrospiroma*, arises from the distal excretory duct.[273] It forms nodules with occasional cystic foci high in the dermis (Fig. 3.18). Some of the proliferating cells are cytologically similar to those of the poroma. Others have an abundant clear cytoplasm (hence the other synonym, *clear cell hidradenoma*), and still others exhibit prominent squamous metaplasia.[274] Immunohistochemically, there is reactivity for keratin, EMA, CEA, S-100 protein, and vimentin, although immunostains are not necessary for the diagnosis.[275] Johnson and Helwig[276] regard eccrine poroma as a subtype of eccrine acrospiroma (hidradenoma), although they are widely considered distinct entities currently. The differential diagnosis of hidradenoma can include glomus tumor because of the presence in both entities of round clear cells and marked vascularity; the distinction between the two entities is easily made by immunohistochemical evaluation.[275]

Syringoma

Syringomas are generally multiple, yellowish, papulonodular lesions that occur chiefly on the neck and face (particularly lower eyelids) of women. Other forms are *vulvar* syringoma, *acral* syringoma (limited to the dorsal proximal and middle phalanges of the hand), and *eruptive* syringoma (see later). Microscopically, these tumors are formed by clusters of small ducts lined by epithelium two cells thick, occasionally with comma-shaped extensions (Fig. 3.19). A clear cell variety has been described, resulting from intracellular accumulation of glycogen.[277]

The ultrastructural[278] and histochemical (enzymatic)[279] findings indicate that syringomas are of eccrine rather than apocrine nature. Specifically, the pattern of cytokeratin expression suggests differentiation toward the portion of the sweat duct located in the uppermost portion of the dermis and lower portion of the epidermis (sweat duct ridge).[280]

Eruptive syringoma appears as multiple yellow–brown papules on the neck, anterior trunk, axillae, shoulder, anterior surfaces of the arms, abdomen, and pubic areas of young people[281]; the process may be reactive rather than neoplastic.[282]

Mixed Tumor (Chondroid Syringoma) and Myoepithelioma

Mixed tumors are benign, nodular, nonulcerated tumors that occur predominantly on the face, head, and neck but also on the extremities and trunk.[283] Histologically, immunohistochemically, and ultrastructurally, their appearance is comparable to that of mixed tumors of salivary gland origin.[284–286] This includes the presence of cells with an abundant hyaline cytoplasm.[287,288] Sometimes, eosinophilic globules with radiating fibrillary structures are seen within and around the lumina, their appearance being analogous to that seen in collagenous spherulosis of the breast.[289,290] Immunohistochemically, the inner layer cells express cytokeratin, CEA, and EMA; the outer cell layers show variable staining for myoepithelial markers, such as vimentin, S-100 protein, actin, calponin, p63, and glial fibrillary acidic protein.[291–294] Although most of these tumors are thought to be of eccrine type, a variety exhibiting clear-cut evidence of apocrine differentiation has been well documented; this is often admixed with follicular and sebaceous components.[295,296] Despite the occasionally atypical appearance of the cartilaginous component, the large majority of these tumors are benign.

Tumors having a similar myoepithelial cell component but lacking the epithelial element are known as *myoepitheliomas* (Fig. 3.20)[297]; some of these behave in a malignant fashion, apparently with a higher frequency than the homologous salivary gland neoplasms.[293]

Tumors with an appearance similar to cutaneous chondroid syringomas and myoepitheliomas can also arise in the deep soft tissue.[298]

Cylindroma

Classically, *cylindroma* of the skin has been described as a large, multicentric tumor of the scalp (turban tumor) (Fig. 3.21). In fact, the majority of these slow-growing adenomas are solitary and small, and approximately 10% occur on sites other than the head and neck.[299] Exceptionally, they are seen in association with microscopically identical tumors in the major salivary glands.[300] Microscopically, the heavy accumulation of basement membrane material around and within the tumor lobules is the most important distinguishing feature (Fig. 3.22). The ultrastructural and immunohistochemical features indicate differentiation toward the intradermal coiled duct

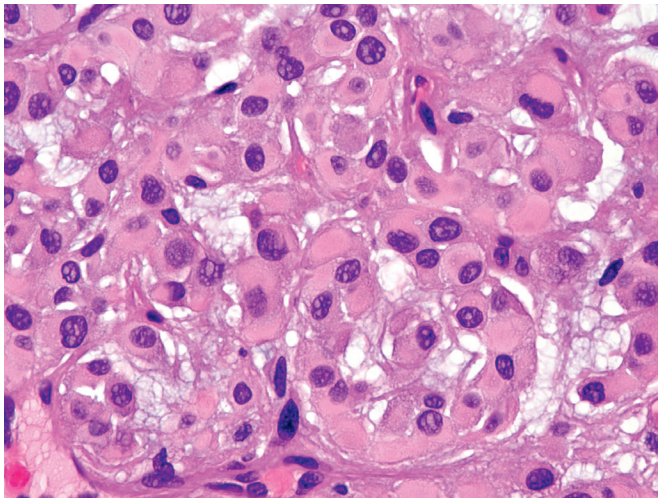

Figure 3.20 Myoepithelioma of skin consistent with sweat gland origin. The tumor cells have a typical hyaline cytoplasm. (Courtesy Dr Fabio Facchetti, Brescia, Italy.)

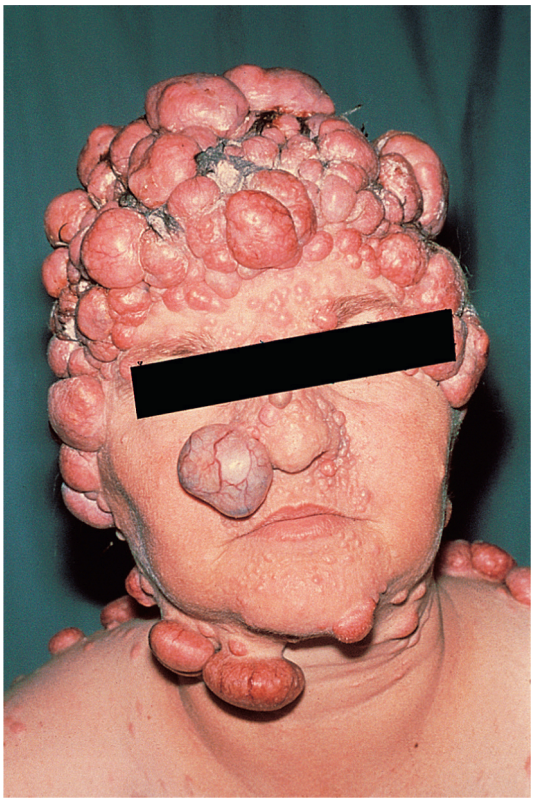

Figure 3.21 Clinical appearance of multiple dermal eccrine cylindroma extensively involving the scalp and other sites of the head and neck. This is sometimes referred to as turban tumor.

region of eccrine sweat glands,[301–303] provide evidence for the participation of myoepithelial cells,[304–306] and are very similar to those of eccrine spiradenoma.[307] Sometimes, features of cylindroma and eccrine spiradenoma coexist in the same lesion *(spiradenocylindromas)*.[308,309] Several examples of eccrine cylindroma undergoing malignant transformation are on record.

Multiple cylindromas are caused by a mutation in the *CYLD* gene, found on chromosome 16; both copies of this tumor-suppressor gene must be inactivated for the syndrome to occur.[310]

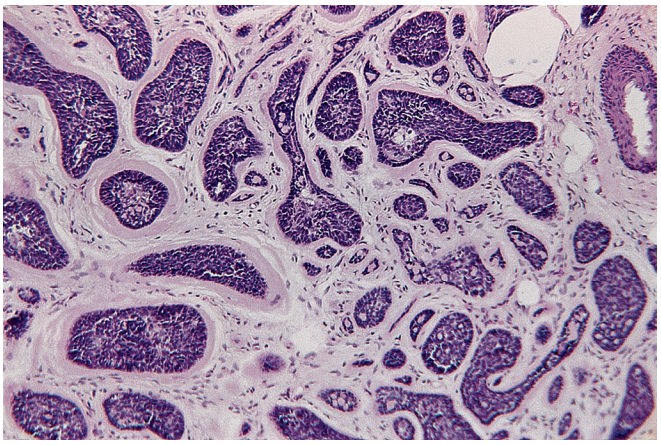

Figure 3.22 Eccrine Dermal Cylindroma. Compact nests of tumor cells surrounded by thick basement membrane.

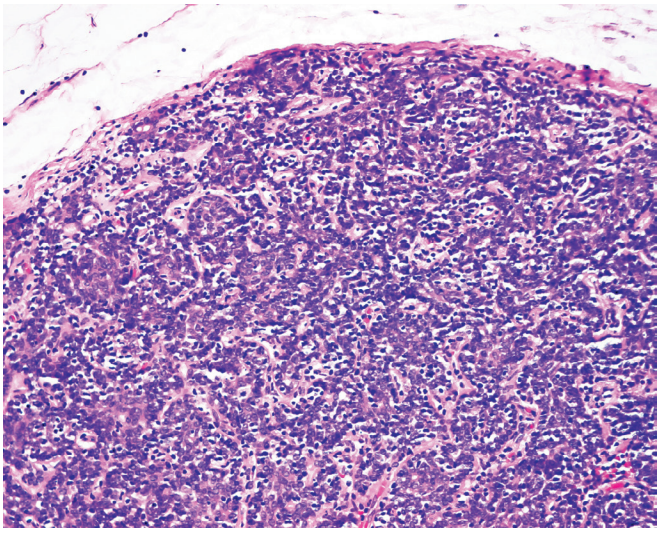

Figure 3.23 Eccrine Spiradenoma. The lesion is highly cellular and infiltrated by lymphocytes.

Spiradenoma

Spiradenomas are sharply delimited, lobular sweat gland adenomas that can occur almost anywhere in the body and can be extremely painful. They originate from the lower portion of the eccrine duct and are microscopically very cellular (Fig. 3.23).[311,312] The scanty cytoplasm and marked cellularity may lead the unwary to an erroneous diagnosis of malignancy.[313] We have seen them confused with synovial sarcoma and with metastatic carcinoma. They can also be confused clinically and microscopically with vascular tumors because of their high degree of vascularity (Fig. 3.24).[314] Ultrastructural and immunohistochemical studies have shown that these tumors contain an admixture of epithelial (secretory) and myoepithelial cells.[315–317]

In some spiradenomas, a heavy infiltration by lymphocytes (mainly of T-cell type) is present between the tumor cells; the resulting appearance is reminiscent of a thymoma. The analogy is accentuated by the presence of perivascular spaces containing lymphocytes.[317]

The tumor entity known as *cutaneous lymphadenoma* (not to be confused with cutaneous lymphoepithelioma-like carcinoma; see earlier) seems to represent a closely related phenomenon. It presents as multiple rounded lobules of basaloid cells with some peripheral palisading, foci of keratinization, and sometimes duct formation,

Figure 3.24 Clinical appearance of eccrine spiradenoma of the knee associated with a prominent vascular component that resulted in a hemangioma-like appearance clinically.

which are admixed with an intense infiltrate of small lymphocytes.[318,319] The immunohistochemical profile of this tumor has suggested to some authors a histogenetic link with trichoblastoma.[320]

On rare occasions, eccrine spiradenoma shows a focal atypical adenomatous component, the significance of which has not yet been ascertained.[321] In other instances it has been seen to undergo transformation to a high-grade malignancy.[322]

Syringocystadenoma Papilliferum

Syringocystadenoma papilliferum is a verrucous, moist tumor that occurs chiefly on the scalp, neck, and face but may be found elsewhere on the skin. It is seen from childhood to senescence, and often there is a history of slow growth or of a recent change in a "birthmark." Microscopically, a glandular papillary proliferation connected to the skin surface is seen. Dense plasma cell infiltration is common. These plasma cells are predominantly of the IgG and IgA classes.[323,324] Juxtaposed nevus sebaceus was found in one-third and basal cell carcinoma in one-tenth of the patients reported in the classic article by Helwig and Hackney.[325]

A malignant counterpart of this neoplasm *(syringocystadenocarcinoma papilliferum)* has been described,[326] as well as a variant containing a prominent fibrous component, known as *eccrine syringofibroadenoma* and sometimes developing in peristomal skin.[327,328]

Papillary Eccrine Adenoma

Papillary eccrine adenoma is a distinctive sweat gland tumor, most often located on the distal extremities of black people.[329] Microscopically, tubular structures resembling eccrine ducts are seen; many are dilated and exhibit intraluminal papillomatosis. Local recurrence may supervene, but none of the reported lesions has metastasized. Immunohistochemically and ultrastructurally, the pattern suggests differentiation toward the secretory epithelium of sweat glands.[330–333] The main differential diagnosis is with low-grade eccrine carcinoma.[334,335]

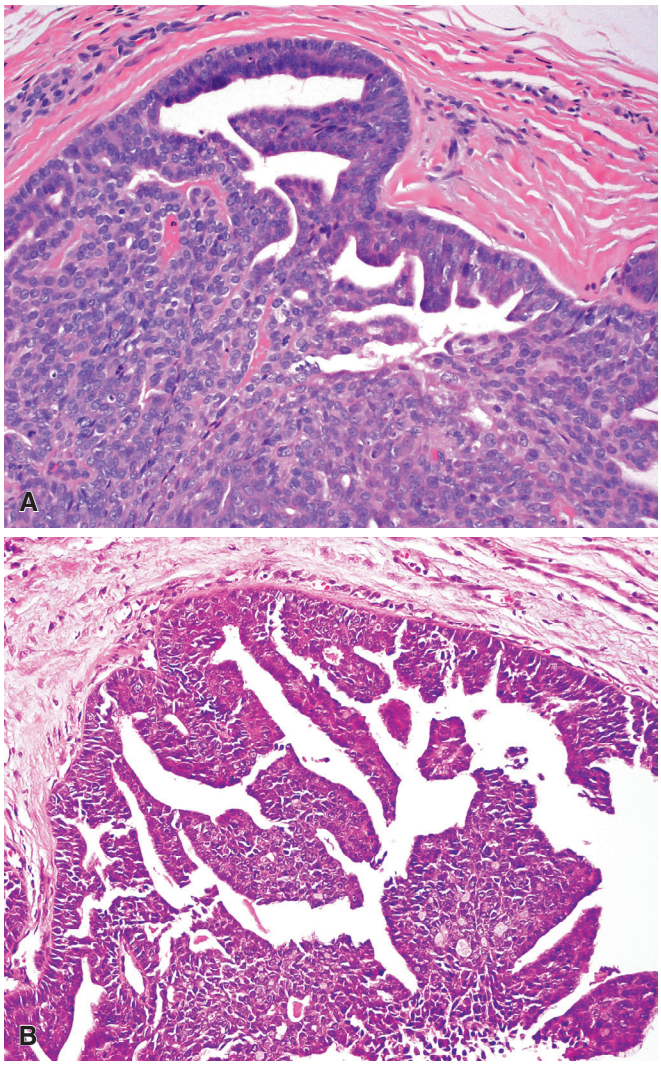

Figure 3.25 **Aggressive Digital Papillary Adenocarcinoma. A,** Primary tumor with areas of back to back glands as well as papillary areas. **B,** Metastatic tumor involving a lymph node.

Digital Papillary Adenocarcinoma

Another sweat gland neoplasm with a marked predilection for the digits is *digital papillary adenocarcinoma*.[336,337] Formerly subdivided into adenoma and adenocarcinoma based on histologic features, it is now recognized that histologic features are not predictive of behavior and that all are considered carcinomas with metastatic potential.[337] Microscopically, tubuloalveolar and ductal structures alternate with areas of papillary projections protruding into cystic lumina (Fig. 3.25). The appearance is somewhat reminiscent of carcinoma of the breast. Local recurrence is common, and there is risk of metastasis to regional lymph nodes and the lungs.[337]

Clear Cell Acanthoma and Other "Acanthomas"

Degos clear cell acanthoma[328] is a morphologically distinct intraepithelial lesion composed of clear, glycogen-filled keratinocytes

associated with dermal inflammation. A minor melanocytic population may also be present.[338,339] Clear cell acanthoma is seen almost invariably in the leg of females, is occasionally multiple, and is thought to arise from intraepidermal eccrine ducts. Similar cytologic changes ("pale cell acanthosis") can be seen focally in seborrheic keratosis and several other skin disorders as an expression of a reaction pattern of epidermal epithelium.[340] As a matter of fact, clear cell acanthoma itself may be an exaggerated form of this process rather than a true neoplasm.

One could mention here that acanthoma is a generic term that has been used for "benign tumors of epidermal keratinocytes."[333] It comprises a large number of probably unrelated lesions, such as seborrheic keratosis, verrucous acanthoma, epidermolytic hyperkeratosis, warty dyskeratoma, acantholytic acanthoma, epidermolytic acanthoma, and large cell acanthoma.[333,335,341–345] Consequently, the term "acanthoma" has very little meaning when used without a qualifier.

Intraepidermal Epithelioma

The lesion traditionally known as *intraepithelial epithelioma of Borst–Jadassohn* is probably composed of a heterogeneous group of disorders, the two most common being irritated seborrheic keratosis and eccrine poroma (and related intraepidermal sweat gland tumors).[346,347]

Sweat Gland Carcinoma

Adenocarcinomas arising from eccrine glands constitute only a minute fraction of sweat gland neoplasms (Figs. 3.26 and 3.27).[348–350] Most occur in adults, but they have also been reported in children.[351] They can be very difficult to recognize at the microscopic level. Those with well-developed ductal differentiation simulate metastatic carcinoma, particularly from the breast,[352,353] a similarity highlighted by the fact that they can exhibit immunoreactivity for gross cystic disease fluid protein (GCDF-15) and estrogen receptor protein[354] (although usually not for HER2/neu)[355] The sweat gland carcinomas with large clear cells may resemble metastatic renal cell carcinoma,[356] and those with prominent basaloid formations may be confused with basal cell carcinoma.[357]

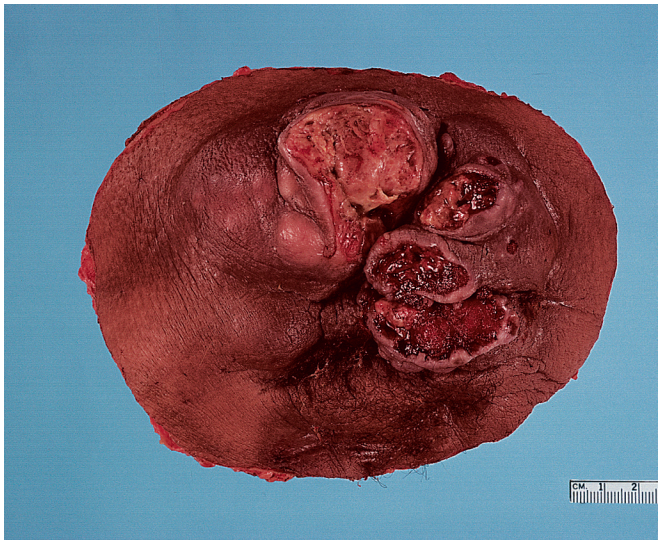

Figure 3.26 Gross appearance of resected specimen of sweat gland carcinoma of the axilla. The tumor grows in a multinodular fashion and shows several areas of ulceration.

Some sweat gland carcinomas retain morphologic features that allow them to be recognized as the malignant counterparts of the various types of sweat gland adenomas, as already alluded to in some of the previous sections.[358–360]

Porocarcinoma (malignant eccrine poroma) is the most frequent member of this group.[361,362] Most cases occur in the lower extremities, like their benign counterparts. Some of the lesions are pedunculated. Microscopically, the architecture is similar to that of eccrine poroma, but there is obvious atypia and high mitotic activity. Epidermotropism is a common feature of this tumor, the resulting picture being that of extramammary Paget disease.[363,364] Foci of squamous differentiation and clear cell features may be present.[365,366] Pigmentation may occur and lead to a mistaken diagnosis of malignant melanoma.[367] Metastases occur most frequently in the regional lymph nodes, this often following repeated local recurrences.[368]

Other distinct varieties of sweat gland carcinoma include malignant chondroid syringoma (malignant mixed tumor[369]) and the closely related myoepithelial carcinoma (Fig. 3.28),[297] malignant dermal cylindroma,[370,371] malignant syringoma (syringoid eccrine carcinoma),[372–374] hidradenocarcinoma (malignant acrospiroma),[360,375] digital papillary adenocarcinoma (see Fig. 3.25B),[337] and apocrine carcinoma.[376,377]

In addition to these presumably de novo lesions, eccrine acrospiroma, spiradenoma, syringoma, and cylindroma can undergo malignant transformation, the phenomenon manifesting clinically as enlargement of a cutaneous nodule of long standing.[378–382] This transformation is usually in the form of a high-grade carcinoma, including the variant known as sarcomatoid carcinoma or carcinosarcoma.[383]

Several other distinctive types of sweat gland carcinoma occur. One is *primary mucinous carcinoma*, often appearing in the scalp and the head and neck of elderly patients, especially involving the eyelids.[384–386] Its microscopic appearance resembles mucinous carcinoma of the breast by virtue of the presence of clusters of tumor cells floating in lakes of mucin. The similarity is reinforced by the fact that, on occasion, the mucinous pattern is associated with an infiltrating ductal pattern.[386] Both pure and mixed forms exist.[383,384] It appears likely to be related to *endocrine mucin-producing sweat gland carcinoma*, which shares clinical, morphologic, and immunophenotypic features.[387] The immunohistochemical profile of mucinous carcinoma suggests differentiation toward the eccrine secretory coil,[371,388] but some cases have been thought to exhibit apocrine-type features.[389,390] They may also contain a myoepithelial cell component, a useful feature in the differential diagnosis with metastatic carcinoma.[391]

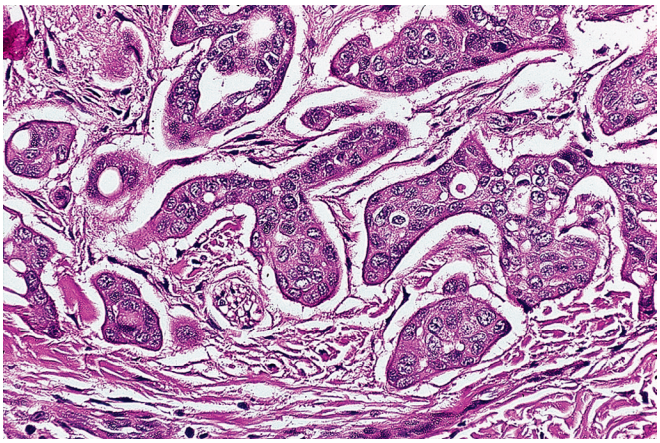

Figure 3.27 Typical branching configuration of sweat gland carcinoma.

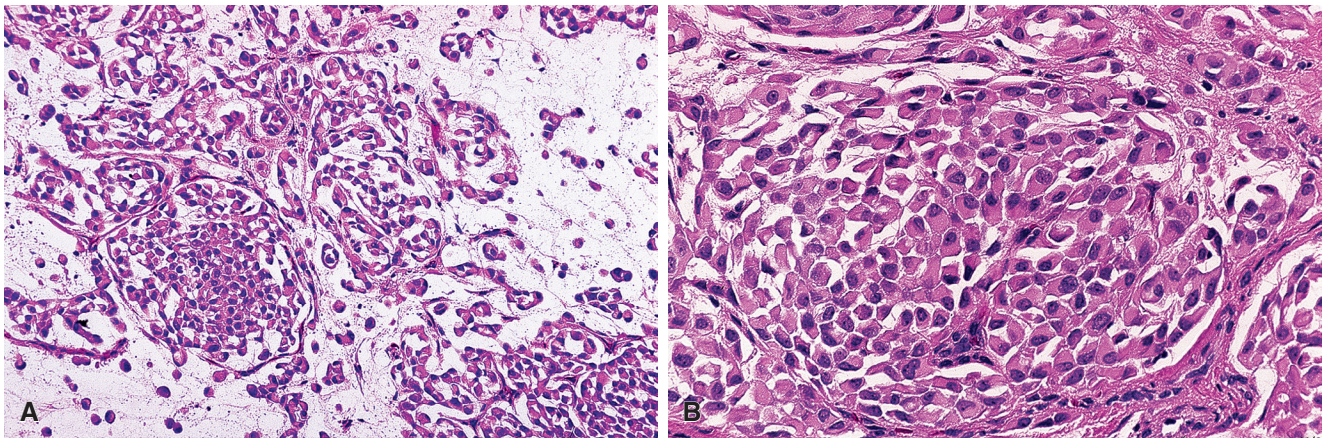

Figure 3.28 **A** and **B,** Sweat gland carcinoma of myoepithelial type located in the toe.

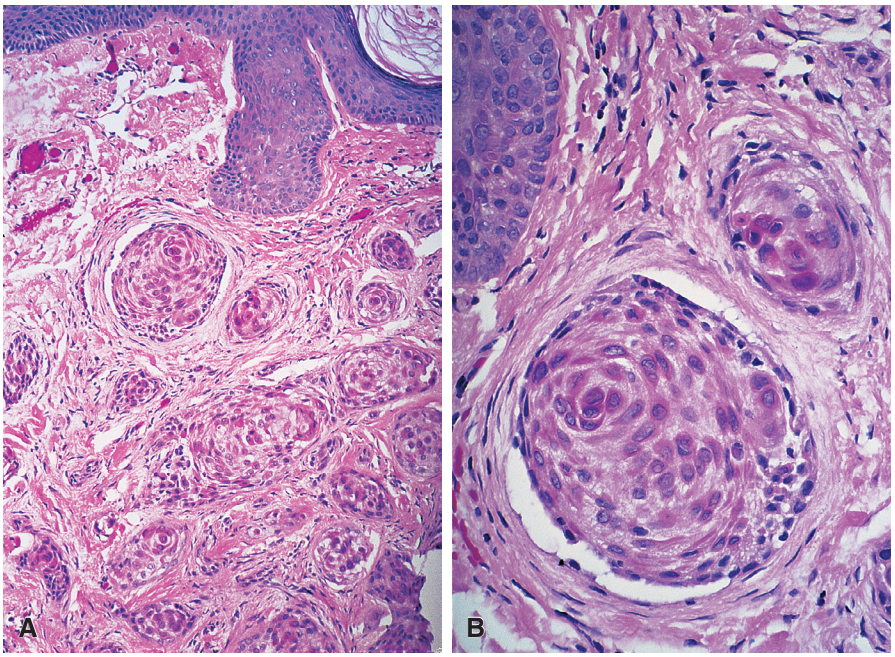

Figure 3.29 **A** and **B,** Microcystic adnexal carcinoma composed of nests of keratinocytes in a whorling pattern. This tumor was located in skin of upper lip in a 28-year-old woman.

This tumor should be distinguished from the even rarer primary *adenoid cystic carcinoma* and *mucoepidermoid carcinoma* of the skin, two tumors morphologically and immunohistochemically equivalent to the salivary gland neoplasms that bear those names.[392–396] More important, it should be distinguished from *mucinous syringometaplasia*, a non-neoplastic reactive change that can be accompanied by prominent epithelial hyperplasia.[397]

Another variant of sweat gland carcinoma, *microcystic adnexal carcinoma*, also termed *sclerosing sweat duct carcinoma*, appears as a slow-growing, indurated nodule or plaque, usually on the face.[398–400] The upper lip is a particularly common location. Microscopically and immunohistochemically, the tumor shares several features with benign syringoma and desmoplastic trichoepithelioma, and it may be impossible to distinguish on superficial biopsies.[401] Cords and nests of uniform keratinocytes, keratin-containing cysts, and foci of ductal differentiation are present (Figs. 3.29 and 3.30). Exceptionally, there is sebaceous differentiation.[402] The stroma has a dense, collagenous quality. There is often CK15 positivity, a potentially useful feature in the differential diagnosis with basal and squamous cell carcinoma.[403] The tumor has invasive properties, sometimes extending into the subcutaneous fat, perineurial spaces, and/or mandibular bone.[398–401,404] Recurrence is common, but metastases are extremely rare.[405]

Nearly all types of sweat gland carcinoma exhibit immunoreactivity for cytokeratin, CEA, and EMA, like their benign counterparts.[406,407]

Extramammary Paget Disease

Extramammary Paget disease results from the presence in the epidermis of carcinoma cells with signs of glandular differentiation. Concomitant involvement of eccrine glands and/or hair follicles is nearly always present, whereas dermal invasion is seen in a minority of cases, the frequency varying according to the location (extremely rare in the vulva and more common in the perianal region).[408] Cases limited to the epidermis are explained by postulating an origin from the intraepidermal portion of the sweat glands or from primitive basal cells with the capacity to differentiate toward glandular elements.[409,410]

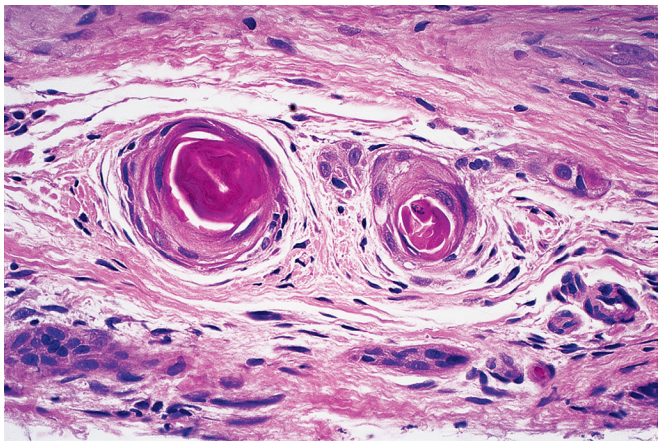

Figure 3.30 Microcystic adnexal carcinoma.

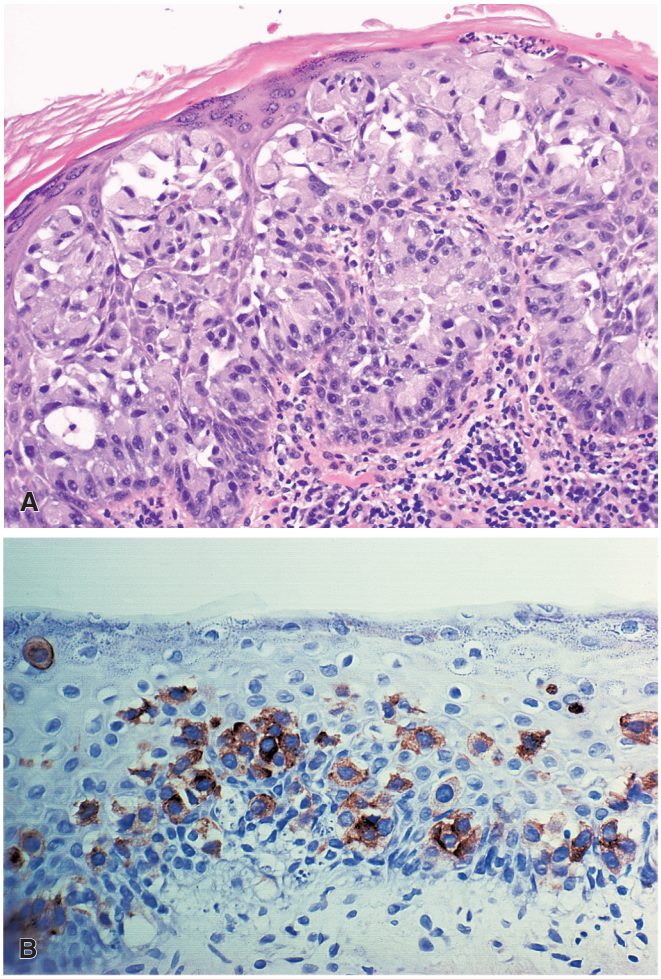

Figure 3.31 Extramammary Paget Disease of the Skin. A, The tumor consists of intraepidermal collections of neoplastic cells with small hyperchromatic nuclei and relatively abundant cytoplasm. The tumor cells typically spare the basal layer. **B,** Extramammary Paget disease immunostained for epithelial membrane antigen.

The labia majora, scrotum, and perineum are the most frequent sites, with adjacent areas following. The lesions are grossly circinate, annular, erythematous, and eczematoid plaques. Histologically, large, pale, vacuolated cells are seen concentrated just above the basal layer (Fig. 3.31). They may be single or arranged in rows, small nests, or glandular formations. A cleft-like separation is often seen between the Paget cells and the adjacent non-neoplastic keratinocytes. Electron microscopic examination shows that Paget cells are not altered keratinocytes or melanocytes but rather cells with glandular differentiation.[411] In contrast to Paget disease of the breast, the extramammary form is consistently positive for mucin stains.[412,413] Immunohistochemically, the tumor cells show reactivity for EMA, CEA, CK7, and CK19 (regarded as a marker or follicular stem cells)[414] and the types of low-molecular-weight cytokeratin present in simple epithelia (Fig. 3.31).[390,415–418]

The theme common to all forms of Paget disease is the origin of the tumor from epithelial cells with the capacity to differentiate toward the glandular structures of the region. These are the mammary glands in the breast, the apocrine glands in the vulva, and the perianal and/or rectal glands in the perianal region. This probably explains the fact that there is heterogeneity in the immunohistochemical profile of Paget disease depending on the site of occurrence but in concordance with that of the corresponding normal glands and adenocarcinomas of the region. Thus, vulvar Paget disease is positive for GCDFP-15 and hormone receptors (curiously, androgen rather than estrogen or progesterone)[416,419–421] and shows a pattern of lectin-binding sites similar to that of apocrine glands.[422,423] Conversely, perianal Paget disease often shows positivity for cytokeratin 20, a feature of colorectal glands.[421,424] Patients with perianal Paget disease that is positive for cytokeratin 20 usually have an underlying rectal adenocarcinoma with secondary involvement of the skin.

Complete surgical excision is the treatment of choice, but this may be difficult to achieve because of the ill-defined gross edges of the lesion.

The differential diagnosis of extramammary Paget disease includes pagetoid Bowen disease, pagetoid actinic keratosis, benign and malignant melanocytic lesions, metastatic epidermotropic carcinomas from breast and other sites,[425,426] and so-called clear cell papulosis.[427] Most of the reported cases of the latter condition have been in children younger than 4 years and have been characterized by multiple small whitish maculopapular lesions that, microscopically, are seen to contain pale cells with a similar immunohistochemical profile to that of Paget cells (Fig. 3.32).[428] These cells are probably related to the so-called Toker cells as seen in the nipple.

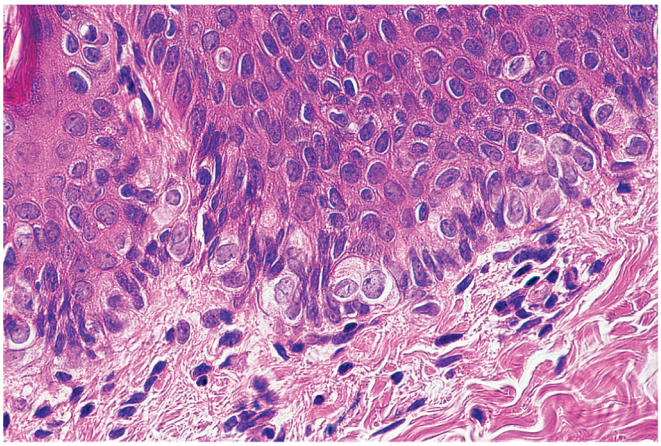

Figure 3.32 Clear Cell Papulosis of Skin. Large clear cells arranged singly or in small clusters are seen in the basal portions of the epidermis. (Slide contributed by Dr TT Kuo, Taipei, Taiwan.)

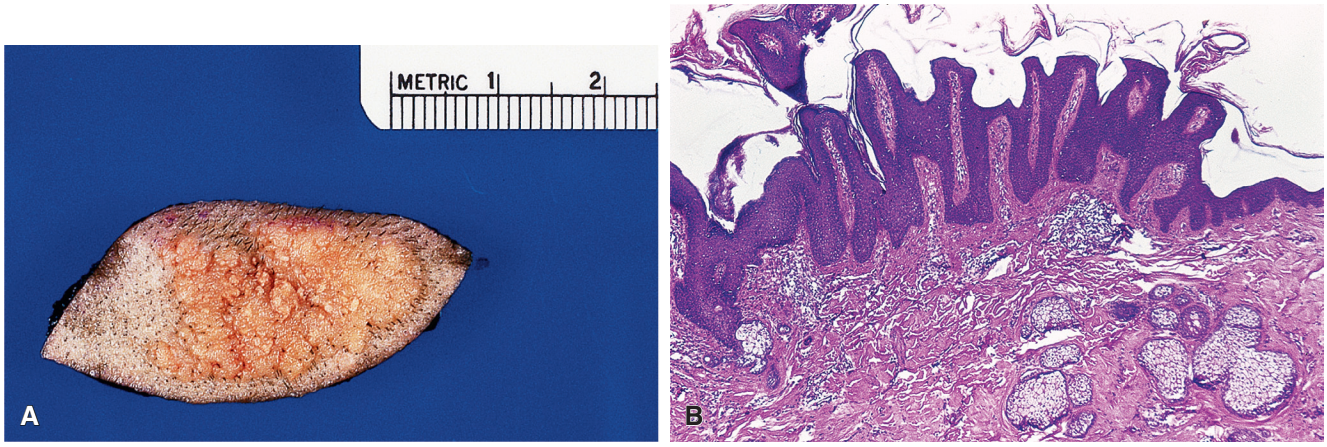

Figure 3.33 Nevus Sebaceus of Jadassohn. A, Gross appearance. **B,** Microscopic appearance, showing epidermal papillomatous hyperplasia and increased number of sebaceous glands.

Apocrine Glands

It is possible that some of the sweat gland tumors already described, particularly syringocystadenoma papilliferum, cylindroma, and mixed tumor, exhibit apocrine differentiation.[429] As a matter of fact, the existence of eccrine and apocrine forms of the latter has been proposed. Furthermore, stains for the apocrine marker GCDFP-15 are often positive in sweat gland neoplasms.[429] However, tumors composed exclusively of apocrine glands are extremely rare.

Apocrine cystadenoma is discussed in a different section.

Tubular apocrine adenoma is characterized by dermal and subcutaneous tubular structures of apocrine type arranged in a lobular fashion.[430] The lesion is very similar to syringocystadenoma papilliferum.[431]

Papillary hidradenoma and *ceruminous adenoma* have been traditionally regarded as tumors of apocrine glands.

Sebaceous Glands

Sebaceous Hyperplasia

The most common nodular lesion of the sebaceous glands is due to hyperplasia. It occurs chiefly on the nose and cheeks of elderly persons, hence the name senile sebaceous hyperplasia or, preferably, *sebaceous hyperplasia*.[432] The lesion consists of enlarged but otherwise relatively normal sebaceous glands.

Nevus Sebaceus of Jadassohn and Epidermal Nevus

Nevus sebaceus of Jadassohn is a distinct clinicopathologic type of epithelial nevus.[433] It is composed of a hamartomatous conglomerate of large sebaceous glands associated with heterotopic apocrine glands, defective hair follicles, acanthosis, and papillomatosis (Fig. 3.33). The lesions occur on the scalp and face, are present from infancy, and gradually enlarge.[434] Basal cell carcinomas, a variety of adnexal tumors (particularly trichoblastomas) and, very rarely, squamous cell carcinomas can arise within this lesion.[435,436]

Epithelial nevi without an adnexal component are generically referred to as *epidermal nevi*. They are characterized microscopically by hyperkeratosis, papillomatosis, and acanthosis and are sharply demarcated from the adjacent skin. Several clinicopathologic varieties exist, one of them having a characteristic linear distribution *(linear epidermal nevus)*.[437] Histologically they are similar to seborrheic keratosis. The history of presence since childhood may be the only way to distinguish epidermal nevus from a seborrheic keratosis.

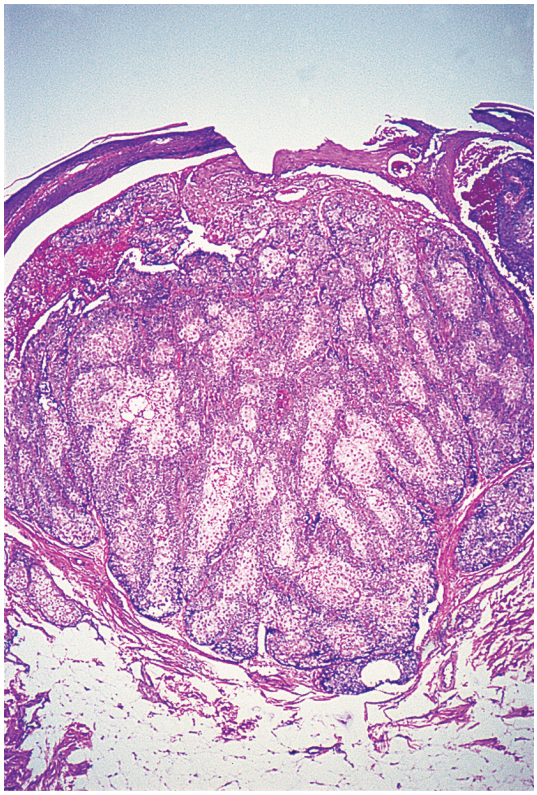

Figure 3.34 Sebaceous Adenoma. The tumor has a distinctly lobular architecture. The light and dark areas correspond to well-differentiated sebaceous cells and generative cells, respectively.

Sebaceous Adenoma

Sebaceous adenoma presents as a nodular lobulated growth with generative cells at the periphery and cells showing varying degrees of sebaceous differentiation toward the center (Fig. 3.34).[438] Although well differentiated, it lacks the distinctly organoid quality of sebaceous hyperplasia. It should be realized that the so-called sebaceous adenoma occurring on the face of patients with the tuberous sclerosis syndrome is not a sebaceous neoplasm but a fibrovascular proliferative process *("angiofibroma")* accompanied by a mild degree of sebaceous hyperplasia. *Sebaceoma* represents a morphologic variant of sebaceous adenoma in which the germinative basaloid cells predominate over

mature sebocytes but lacks the infiltrative growth of sebaceous carcinoma.[439,440] Some of these tumors have a pattern of growth vaguely mimicking that of carcinoid tumors.[441] Immunoreactivity for adipophilin is helpful for confirming the presence of intracytoplasmic lipid vesicles and hence sebaceous differentiation.[442]

Sebaceous Carcinoma

Bona fide sebaceous carcinoma is extremely rare.[438] Those occurring in the eyelids, in caruncles, and in the orbit may be more aggressive than those located elsewhere in the skin,[443,444] but an unfavorable clinical course can occasionally also be seen with the latter.[445] Some of the cases have followed irradiation therapy to the area,[446] and others have arisen in lesions of nevus sebaceus of Jadassohn.[447] Microscopically, sebaceous carcinomas exhibit, together with evidence of sebaceous differentiation, prominent atypia, increased mitotic activity, and invasive features (Fig. 3.35). The invasiveness criterion should be emphasized because sebaceous tumors with marked cellular atypia but good circumscription or encapsulation usually do well.[448] Immunoreactivity for keratin and cytokeratin, EMA, Leu-M1 (CD15), androgen receptor, and adipophilin is present in sebaceous carcinoma, whereas CEA and S-100 protein are absent.[442,449,450] Sebaceous carcinoma shows a greater expression of the Thomsen–Friedenreich (T) antigen than sebaceous adenoma, and it may show reactivity for androgen receptors, a feature that it shares with sebaceous adenomas.[450] Although other quantitative differences exist in the immunohistochemical profile between sebaceous adenomas and carcinoma, they are not sharp enough to be of great diagnostic assistance, and one must rely on histologic features to make the distinction.[451]

Sebaceous carcinoma should be distinguished from basal cell carcinomas with sebaceous differentiation,[452] and from squamous cell carcinomas accompanied by hydropic changes in the tumor cells.[453] Necrosis and lack of lymphoid cell reaction have been found to be associated with a more aggressive course.[454]

Sebaceous adenoma and carcinoma may be seen as a component of *Muir–Torre syndrome*, a clinical subset of hereditary nonpolyposis colorectal cancer syndrome which is caused by germline mutation in a mismatch repair gene, most commonly MSH2.[455–458] In this condition, multiple cutaneous tumors exhibiting varying degrees of sebaceous and hair follicle differentiation occur in association with multiple internal malignancies.[458–460] The tumors, whether benign or malignant, may have a cystic or keratoacanthoma-like growth pattern, which should be a clue to the association.[461,462] Because of the strong association of sebaceous neoplasm with Muir–Torre syndrome, it has been suggested that routine immunohistochemistry (looking for loss of mismatch repair protein expression) be performed in all sebaceous neoplasms regardless of the patient's age or other clinical characteristics.[458,463]

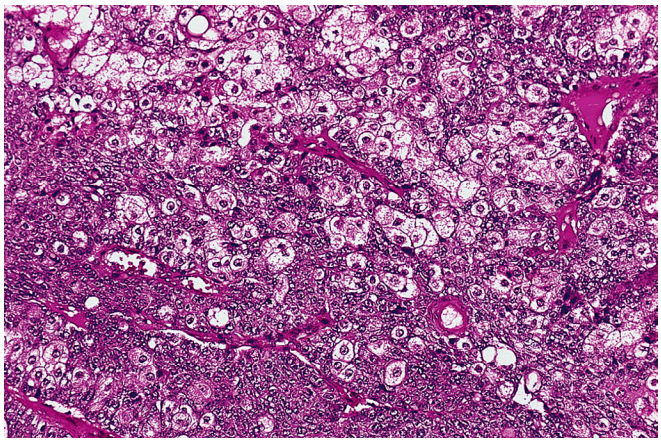

Figure 3.35 Sebaceous Carcinoma. The tumor is composed of an increased number of atypical basaloid cells with some cells exhibiting evident sebaceous differentiation.

Hair Follicles

A myriad of neoplasms, hamartomas, and cysts can develop from the hair follicle. In an exhaustive review of the subject, Headington[464] listed 26 entries, and several additional ones have been described since.[465–470] One could wonder how useful or sensible it will be to further continue this subdivision, which is largely irrelevant on clinical grounds, as opposed to using a more encompassing term, such as *benign trichogenic tumor*.[471] In any event, only the more common and better established varieties of hair follicle tumors will be described here.

Inverted Follicular Keratosis

The lesions of inverted follicular keratosis occur mostly on the face of elderly patients, the eyelid being a preferred location. Clinically, they present as a papule or nodule, practically always single, usually projecting from the surface. Microscopically, they resemble an endophytic seborrheic keratosis, with the most distinctive feature being the presence of squamous eddies (Fig. 3.36).[472] They usually have a papillomatous as well as an acanthotic inverted component. In contrast to keratoacanthoma, the borders are sharply outlined, and inflammation is usually lacking.[473]

The histogenesis and pathogenesis are controversial. Some view it as a unique keratotic lesion of the infundibular portion of the hair follicle (hence the name),[474] whereas others regard it as an irritated form of seborrheic keratosis or verruca vulgaris.[475]

Trichoepithelioma

Trichoepitheliomas are hair follicle tumors of long standing,[476] a good number of which occur in children.[477] They are often multiple, do not ulcerate, and may attain a huge size.[478] Some are seen in a familial setting.[479] Histologically, a stromal element surrounds abortive pilar differentiation (Fig. 3.37). The main differential diagnosis is with basal cell carcinoma, which is histogenetically a closely related tumor; the most helpful features are the frondlike arrangement of

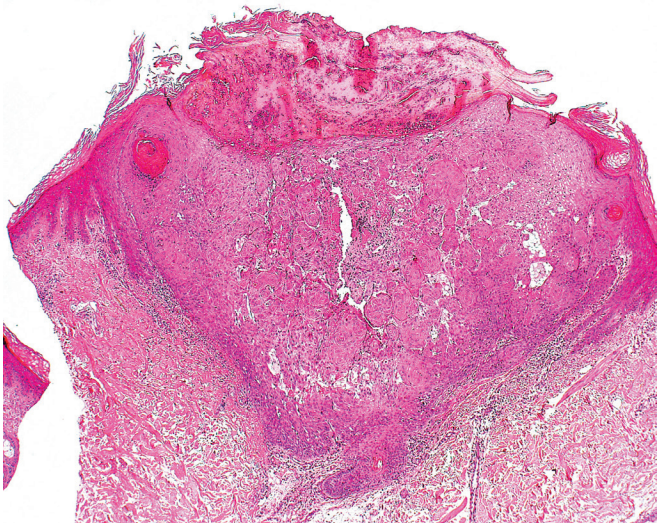

Figure 3.36 Inverted Follicular Keratosis. There are numerous "keratotic eddies."

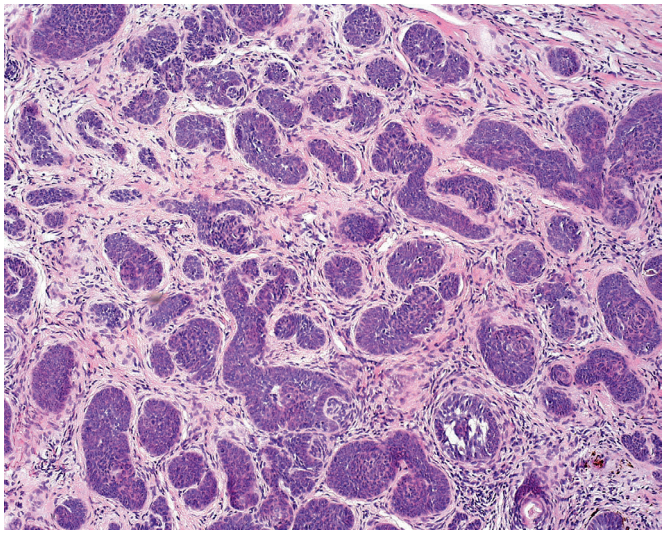

Figure 3.37 Organoid pattern in trichoepithelioma with islands of basaloid cells surrounded by a fibroblastic stroma. Focal papillary mesenchymal bodies are present.

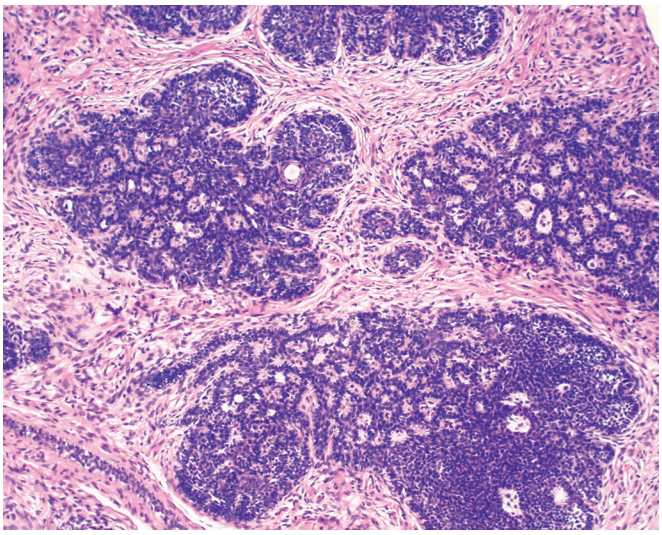

Figure 3.39 Trichoblastoma. This tumor is morphologically similar to trichoepithelioma and is composed of islands of basaloid epithelium surrounded by a fibroblastic stroma.

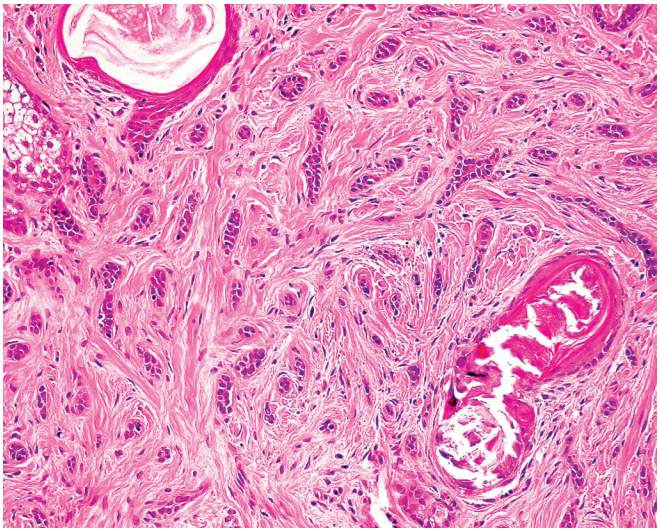

Figure 3.38 Desmoplastic Trichoepithelioma. This benign tumor is not to be confused with basal cell carcinoma.

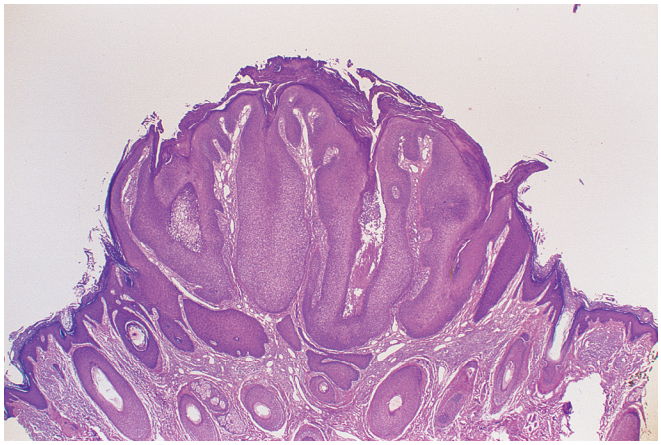

Figure 3.40 Trichilemmoma. The tumor presents as an endophytic lobular growth of glycogen-rich clear cells. (Courtesy Dr D Santa Cruz, St Louis.)

the basaloid cells, the presence of epithelial tracts comprising two or more layers of basaloid cells, and the formation of papillary mesenchymal bodies, which represent attempts to form the papillary mesenchyme responsible for hair follicle induction.[480] A variant of this tumor, appropriately known as *desmoplastic trichoepithelioma*, is accompanied by extensive fibrous proliferation that surrounds and distorts the epithelial islands (Fig. 3.38).[481] In contrast with the conventional form, this variant is usually single. Its main differential diagnosis is with the morphea-like form of basal cell carcinoma.[482] Immunostaining for cytokeratin 20 may be helpful because most trichoepitheliomas have retained, scattered Merkel cells, whereas they are absent in basal cell carcinomas.[197] Stains for bcl-2 have also been highlighted as a useful marker. In trichoepitheliomas, bcl-2 stains highlight the periphery of the tumor, whereas the staining pattern is diffuse in basal cell carcinoma.[140] Immunostaining for stromelysin-3 (a matrix metalloproteinase) is also said to be of help in this regard, in the sense of being always negative in desmoplastic trichoepithelioma and positive in most cases of basal cell carcinoma.[483]

Trichoblastoma

Trichoblastoma is a benign hair follicle tumor related to trichoepithelioma composed of aggregates of basaloid epithelial cells associated with a distinctive trichogenic stroma (Fig. 3.39). As already indicated, we view this tumor as being very closely related to basal cell carcinoma and trichoepithelioma; indeed foci of typical basal cell carcinoma may be present.[484] A prominent component of Merkel cells is usually present, and a clear cell variant has been described.[485] Like many other hair follicle tumors, it may undergo malignant transformation into a high-grade carcinoma, a sarcomatoid carcinoma (carcinosarcoma) and possibly a true sarcoma.[470,486,487]

Trichilemmoma

Trichilemmoma (tricholemmoma) is a benign solid tumor that presents as a lobular formation or plate-like growth of glycogen-rich clear cells, often surrounded by palisading and sometimes exhibiting central keratinization (Fig. 3.40). Multiple trichilemmomas are associated with acral keratoses, sclerotic fibromas of skin, papillomas

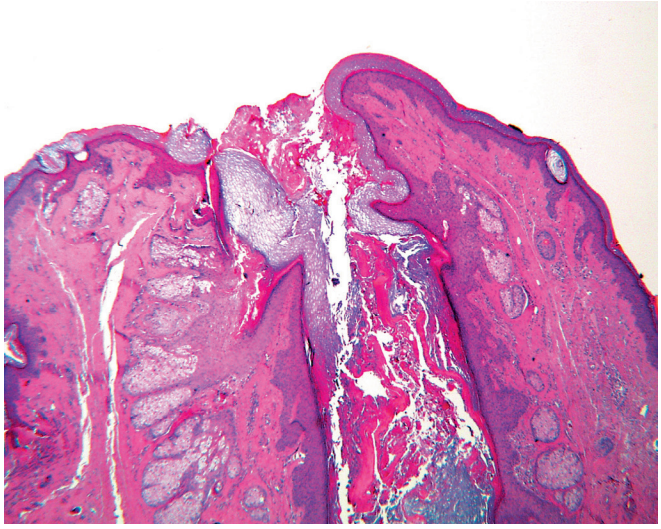

Figure 3.41 Highly organoid pattern of trichofolliculoma.

of the oral mucosa, and, occasionally, tumors of the breast, thyroid, and gastrointestinal tract—a condition known as Cowden disease or multiple hamartoma syndrome.[488,489]

A *desmoplastic* variety of trichilemmoma that simulates an invasive carcinoma has been described.[490] This variety still has tumor cells with clear cytoplasm with peripheral palisading typical of conventional trichilemmoma.

Trichilemmal (tricholemmal) carcinoma is a tumor that combines features of trichilemma-type keratinization with atypical features, such as brisk mitotic activity, invasion of reticular dermis, and ulceration.[491,492] The clinical course of trichilemmal carcinoma is very indolent, and the incidence of metastatic behavior is extremely low.[493,494]

Trichofolliculoma

Trichofolliculomas are solitary, nodular, highly organoid hamartomatous lesions that recapitulate the anagen, catagen, and telogen phases of the normal hair follicle. They should be distinguished from trichoepitheliomas and basal cell carcinomas.[495] Their characteristic dilated central follicle is surrounded by proliferating epithelium showing various stages of pilar formation (Fig. 3.41). Merkel cells are often present,[496] as they also are in other hair follicle tumors, such as trichoepithelioma and trichoblastoma.[197,497]

The occurrence of multiple fibrofolliculomas in association with trichodiscomas (another type of benign hair follicle tumor) and acrochordons (fibroepithelial polyps) constitutes a genetically determined syndrome.[498]

Keratoacanthoma

Keratoacanthoma typically presents as a dome-shaped lesion with a central crater filled with keratin (Fig. 3.42). It occurs in males 3 or 4 times more frequently than in females. When compared with conventional squamous cell carcinoma of the skin, keratoacanthoma is seen to occur in a somewhat younger population and to have a similar but not identical site distribution.[499] The most important microscopic feature is the architecture of the lesion as seen on cross section on low-power examination: overhanging edges, a keratin-filled crater, and hemispheric shape that is buttressed by a normal-appearing epidermis (Fig. 3.43). Cytologic criteria are of less use in the differential diagnosis with conventional squamous cell carcinoma.[500]

Figure 3.42 Clinical appearance of keratoacanthoma.

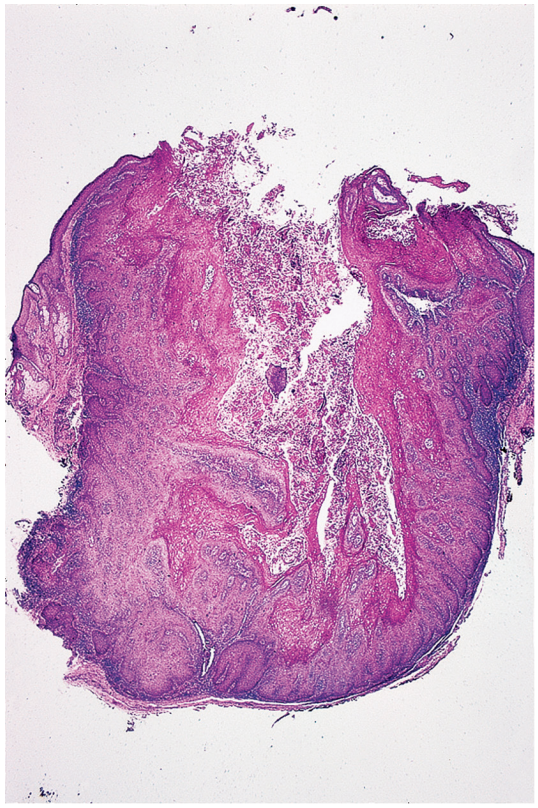

Figure 3.43 Low-power appearance of keratoacanthoma.

Most of the epithelium is well differentiated, with abundant ground-glass cytoplasm, but nuclear abnormalities and mitotic activity can be prominent. The growing edge is usually of the pushing type, a feature accentuated by the heavy rim of inflammatory cells, in which eosinophils may be prominent. However, in some instances there is extension into the underlying skeletal muscle, perineurial invasion,

or even blood vessel invasion.[501–503] It should be noted that eosinophilic infiltration can also occur in squamous cell carcinoma and may actually be more frequent in it.[504] Florid proliferation of sweat ducts entrapped by the keratoacanthomas is a common feature of probable reactive nature.

Many special techniques have been used in the differential diagnosis between keratoacanthoma and conventional squamous cell carcinoma. These include immunohistochemical staining for filaggrin (a histidine-rich protein normally present in the granular and horny layers of the epidermis),[505] transforming growth factor alpha expression,[506] vascular cell adhesion molecule (VCAM) and intercellular adhesion molecule (ICAM),[507] MIB-1 expression,[508] proliferating cell nuclear antigen (PCNA) distribution,[509] DNA content,[510,511] p53 expression,[510,512,513] P2X7 expression (a marker for the initiation of apoptosis),[514] microsatellite instability, and loss of heterozygosity,[515] but it is doubtful whether any of these achieves a sharp separation between the two entities (perhaps simply because such a sharp morphologic separation does not exist). Keratoacanthomas are molecularly distinct from squamous cell carcinomas, but these studies have not to date revealed a simple means to distinguish keratoacanthoma from squamous cell carcinoma.[516]

Keratoacanthoma is thought to represent a proliferation of the infundibular portion of hair follicles rather than of the epidermis. In its most typical form, it arises from previously normal skin, grows rapidly for 4–6 weeks, and then undergoes spontaneous regression over the following 4–6 weeks to leave a slightly depressed, annular scar.[517] However, many variations exist. Some lesions grow slowly, some lesions do not regress spontaneously, some develop at the site of previous trauma,[518] and some lesions (referred to as *actinic keratoacanthomas*) are seen in sun-exposed skin in association with typical changes of actinic keratosis.[519] Some have been reported in association with inflammatory dermatoses, congenital skin lesions, genetic diseases, and scars. Some patients have numerous eruptive lesions *(Grzybowski type)*, and others have multiple ulcerating tumors with atypical distribution *(Ferguson–Smith type)*.[520] Some lesions considered keratoacanthomas may actually represent a subtype of well-differentiated squamous cell carcinomas or perhaps misdiagnosed squamous cell carcinoma, as supported by the chromosomal aberrations they exhibit.[521] This would explain the fact that, occasionally, lesions with the characteristic clinical and microscopic features of keratoacanthoma have been found to grow to huge sizes and/or to metastasize to regional lymph nodes, particularly when the patient's immunity is impaired.[522,523] However, to state that keratoacanthoma is simply a squamous cell carcinoma is to ignore its distinctive clinical behavior and molecular differences from conventional squamous cell carcinoma. At the very least, it should be regarded as a distinct/(abortive) subtype of squamous cell carcinoma. Similarly, to insist that keratoacanthoma is always a benign squamous proliferation[524] is to ignore all the other clinical, biologic, and behavioral evidence pointing towards a neoplastic process.[525–528]

In closing, yet another manifestation of this process should be mentioned. This is the so-called *subungual keratoacanthoma*, thought to arise from the nail matrix, which presents as a rapidly growing mass in the tip of a finger or toe, often associated with a lytic cup-shaped defect of the distal phalanx.[529,530]

Keratinous Cyst

Keratinous cysts have been known for many years as sebaceous cysts, a misnomer born of a mistaken gross interpretation of the cyst content and perpetuated by uncritical repetition.[531,532]

Two types of keratinous cyst occur, with occasional hybrid forms. The more common (90%), known as the *epidermal* or *epidermoid type*, is lined by cornified epithelium, has a distinct granular layer, and contains lamellated keratin without calcification (Fig. 3.44). Although some of these cysts (particularly those located in the fingers)[533] result from traumatic inclusion of the epidermis—hence the term *epidermal inclusion cyst*—the majority probably arise from cystic dilation of the infundibular portion of hair follicles. A few of these cysts exhibit seborrheic keratosis–like changes in their wall.[534]

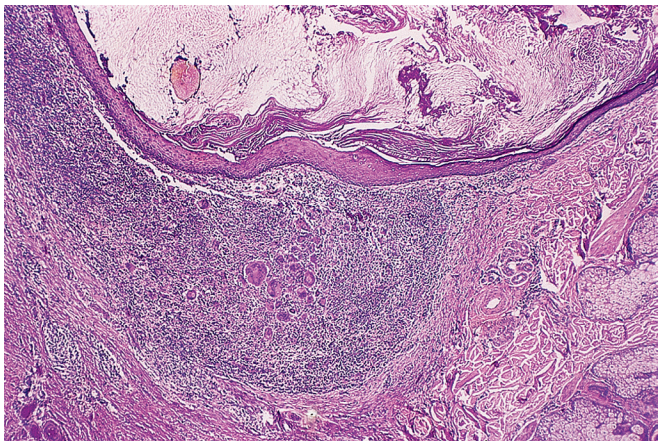

Figure 3.44 Keratinous cyst of epidermal type with secondary inflammation.

Figure 3.45 Gross appearance of keratinous cyst of trichilemmal type. Grumous material composed of pilar-type keratin occupies the lumen.

The other keratinous cyst is the *pilar*, or *trichilemmal type*, (Fig. 3.45).[535,536] It occurs preferentially on the scalp and is microscopically characterized by a trichilemmal type of keratinization, that is, sudden keratinization without the formation of a granular layer and an uneven interphase between the keratinized and nonkeratinized cells (Fig. 3.46). The keratin inside the cyst is not lamellated, some of the nuclei

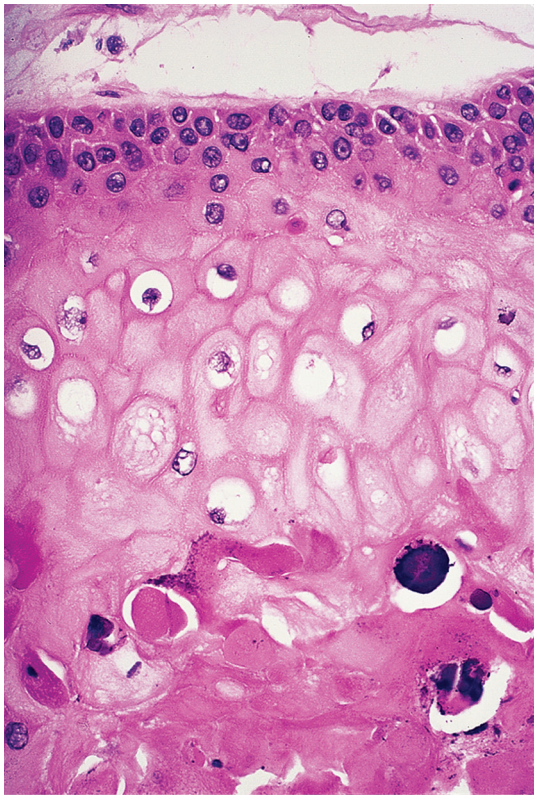

Figure 3.46 Keratinous cyst of pilar type showing trichilemmal pattern of keratinization.

are retained, and focal calcification is frequent. Ultrastructural and immunohistochemical studies also support a trichilemmal derivation for this lesion.[537]

HPV (usually type 57 or 60) has been found in cases of keratinous cysts of palmoplantar and other locations, suggesting that it may play an etiologic role.[538]

Other Cutaneous Cysts

Several other varieties of cutaneous cysts occur, sometimes in combination.[539–541] Although some of them are not of hair follicle derivation, they are listed here for comparison purposes.

1. *Dermoid cyst*. These are microscopically similar in most respects to keratinous cysts of the epidermal type except for the fact that they contain hair adnexa in their wall opening into the cavity.[542] Most of them are found in the face of children near the eyebrow, along lines of embryonic closure.
2. *Steatocystoma*. This is lined by a thin layer of stratified squamous epithelium resembling the ductal portion of a sebaceous gland; lobules of sebaceous glands and small hair follicles are present and the cyst lining has a crenulated appearance. It may occur as a solitary lesion,[543] as multiple lesions on the face,[544] or in the more common disseminated form known as *steatocystoma multiplex*.[545]
3. *Hydrocystoma* (solitary or multiple, usually on the face) and *apocrine cystadenoma*. Both of these are lined by a layer of sweat duct–like epithelium, which usually has apocrine features.[546,547]
4. *Cutaneous ciliated cyst (cystadenoma)*. This is usually seen in the extremities of young females shortly after puberty and is thought by some to be of müllerian derivation.[548–550] Rare cases have been described in males.[551]

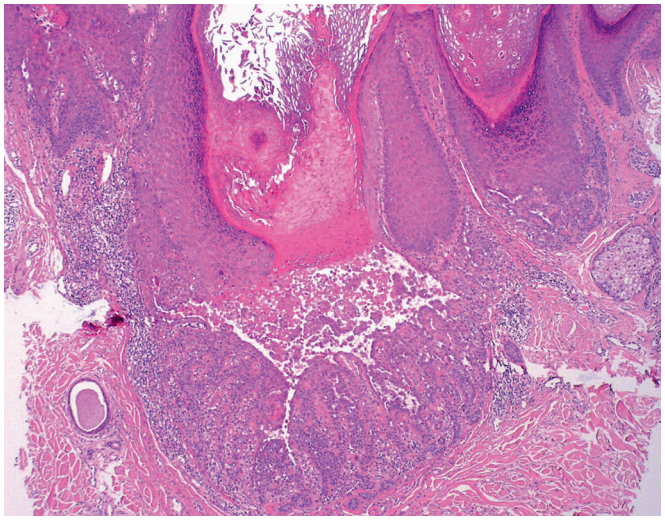

Figure 3.47 **Warty Dyskeratoma.** There is an inverted proliferation of keratinocytes with prominent acantholysis.

5. *Vellus hair cyst*. This presents as small, multiple, eruptive cysts over the chest wall and extremities of young individuals. It is lined by a layer of flattened, follicular sheath epithelium and contains numerous vellus hairs and soft keratinous material.[552]
6. *Pigmented follicular cyst*. This is a hyperpigmented lesion with epidermal-type keratinization, which contains laminated keratin, many pigmented hair shafts, and some growing hair follicles.[553]
7. So-called *bronchogenic cyst*. This is usually discovered at birth or soon thereafter in the suprasternal notch.[554] The lining is made up of pseudostratified columnar ciliated epithelium. Despite its name, the lesion is probably of branchial cleft derivation rather than of bronchial origin.[555] Therefore a more appropriate name would be *branchiogenic cyst*.

Warty Dyskeratoma

Warty dyskeratoma is a small papulonodular lesion usually occurring in sun-exposed skin and characterized microscopically by a peculiar follicular acantholysis and dyskeratosis (Fig. 3.47). Despite the microscopic similarities with Darier disease, it does not represent an isolated manifestation of the latter (which is not a follicle-based process). Instead, it is probably a primary proliferative process of hair follicles, which has been viewed either as the follicular counterpart of actinic keratosis *(isolated follicular keratosis)* or, more likely, as a sui generis follicular neoplasm *(follicular dyskeratoma)*.[556]

Proliferating Pilar Tumor (Proliferating Trichilemmal Cyst)

Pilar tumor represents the neoplastic counterpart of the pilar (trichilemmal) cyst, and it therefore exhibits the same predilection for the scalp and base of neck of women.[557] All types of transitional forms can be found between the ordinary pilar cyst and the full-blown proliferating pilar tumor. In some instances the pilar tumor presents as a mural nodule in a lesion having otherwise the appearance of a pilar cyst, and in others the two lesions coexist in the same individual.[558] The overlying epidermis is usually uninvolved, but in some cases the lesion opens into the surface. Proliferating pilar tumor can reach huge proportions (Fig. 3.48).[559] These lesions should not be misinterpreted as squamous cell carcinomas arising from sebaceous cysts.

Figure 3.48 Cut surface of a proliferating pilar tumor. It has a multinodular appearance, with both an exophytic and an endophytic component.

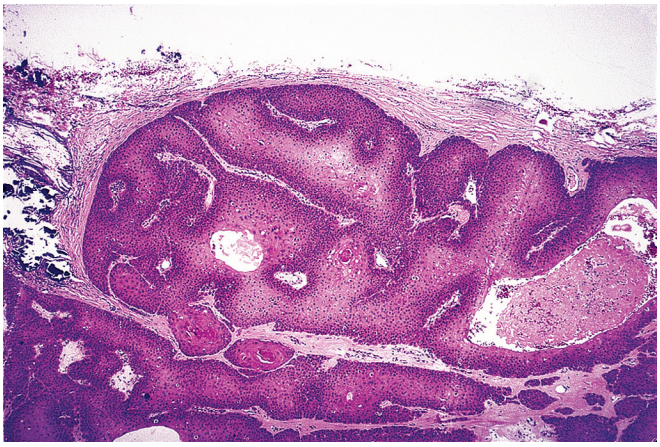

Figure 3.49 Low-power appearance of proliferating pilar tumor. The lobulated contour is characteristic.

Microscopically, pilar tumors have a predominantly solid appearance and generally pushing borders. Interlacing bands of squamous epithelium exhibiting trichilemma-type keratinization are characteristic (Fig. 3.49). Nuclear atypia may be prominent, and some irregularities at the interphase between epithelium and stroma can be observed. Sometimes focal invasion of the stroma is identified.[560] This lesion is neoplastic rather than hyperplastic, a hypothesis supported by the finding of nondiploid DNA content in some of the cases.[561] The behavior is generally benign; several instances of local recurrence have been reported, but metastases are exceptionally rare.[562,563] The few well-documented instances of metastases have occurred in tumors with clear-cut malignant microscopic features.[564–566] The malignant component may have the appearance of a focal trichilemmal carcinoma or, exceptionally, a spindle cell (sarcomatoid) carcinoma.[559,567,568]

Pilomatrixoma

Pilomatrixoma (pilomatricoma), formerly known as *calcified epithelioma of Malherbe*, is a nodular, benign tumor arising from the hair matrix (Fig. 3.50). It occurs predominantly in children and young adults, and most of the cases are located on the head, neck, and upper extremities.[569] Microscopically, it is composed of solid nests of small basaloid cells that may lead to a mistaken diagnosis of basal cell carcinoma,[570] particularly on cytologic examination.[571,572] The key

Figure 3.50 Gross appearance of pilomatrixoma.

feature is the fact that these basaloid cells undergo abrupt keratinization, leading to the formation of "ghost" and "shadow" cells (Fig. 3.51). Pigmentation may occur as a result of colonization by melanocytes.[573] Foreign body reaction, calcification, and ossification are common secondary events. This may be accompanied by extramedullary hematopoiesis.[574] Transepidermal elimination or perforation can occur.[575] The histochemical, immunohistochemical, and ultrastructural features are in keeping with an origin from the hair matrix.[576–579] Most cases of pilomatrixoma show activating mutations of the β-catenin gene *CTNNB1*.[580] It should be remarked that focal features of hair matrix differentiation can sometimes be seen in lesions other than pilomatrixoma.[581]

Cases of pilomatrixoma with atypical histologic features and a tendency for local invasiveness and local recurrence have been designated as *aggressive* pilomatrixomas.[575,582] *Malignant* pilomatrixoma *(pilomatrix carcinoma)* exhibits cytologic atypia, an infiltrating border, transitions to squamous cells, clear cells, necrosis, and mitoses.[583] Cytologic atypia and infiltration are the key features, as mitotic activity may be prominent in typical pilomatrixomas. Sarcomatoid features may be present.[584] Local recurrence is common, and metastases to distant sites can occur.[580,585–588]

Nails

Because the nail bed epithelium is comparable to the outer root sheath or trichilemma of the hair follicle,[589] it follows that if a malignant tumor were to develop from it, that tumor should resemble a trichilemmoma or a trichilemmal carcinoma. Inevitably, such tumors have now been described, under the terms of *onychomatricoma* and *onycholemmal carcinoma*.[590–592] In retrospect, it is possible that some cases reported in the old literature as squamous cell carcinoma, verrucous carcinoma, or keratoacanthoma of the nail bed belong to the same category.

Melanocytes

Melanocytes are neural crest–derived cells located in the basal layer of skin, hair follicles, most squamous-covered mucosal membranes,

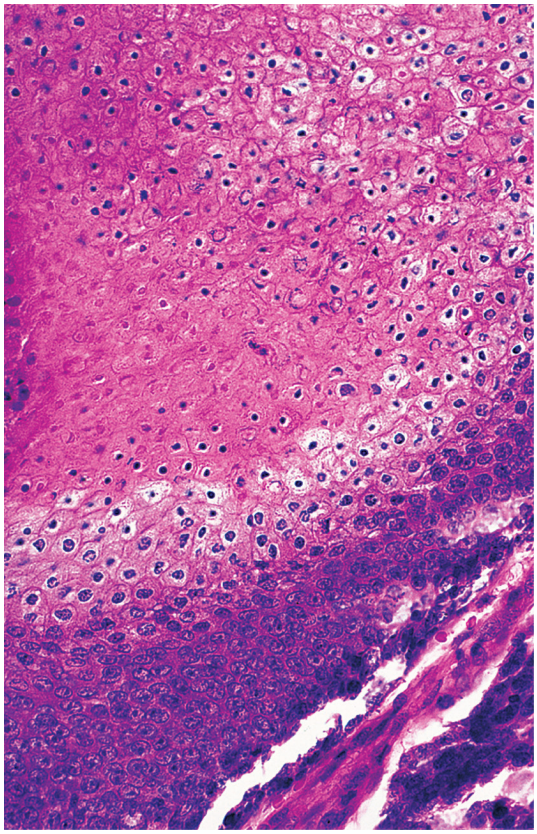

Figure 3.51 Microscopic Appearance of Pilomatrixoma. The basal cells keratinize as does cortex of hair (without granular layer) and produce "ghost" cells.

leptomeninges, and several other sites. Their function is to produce an insoluble pigment known as melanin, using tyrosine as a substrate, and to transfer this product through the process of cytocrinia to the adjacent epithelial cells. The neuroectodermal origin of melanocytes, proposed many years ago by Masson and others,[593] has been supported by a variety of techniques, among which the chick–quail chimera of Le Douarin is the most elegant and convincing, at least for this particular cell type.[594]

The ratio of melanocytes to keratinocytes in the epidermal basal layer varies from 1 : 4 to 1 : 10, depending on the site of the body. Racial differences in skin pigmentation are due to differences in the amount of melanin contained in the keratinocytes rather than the number of melanocytes. The functional unit composed of a melanocyte and the adjacent keratinocytes receiving melanin from it is referred to as the epidermal–melanin unit.

Normal melanocytes with scant pigment appear as pale cells in routinely stained sections (hence the former name "Masson clear cells"), but other intraepidermal clear cells are of keratinocytic nature.[595] Melanocytes possess slender cytoplasmic processes (dendrites) that emanate from the cell body and extend between keratinocytes; these become particularly apparent when containing increased melanin pigment through either increased production or a block in the transfer mechanism.

Melanocytes are generally positive for melanin stains (such as the Fontana–Masson silver stain), tyrosinase, DOPA reaction, S-100 protein, NSE, Mart-1/MelanA (A103), microphthalmia transcription factor (MiTF), Sox10 (a neural crest transcription factor crucial for specification, maturation, and maintenance of Schwann cells and melanocytes), PAX3 (a transcription factor with an important role in the development of melanocytes during embryogenesis), and vimentin; the intensity of these reactions shows marked variability, possibly depending on the functional status of the cell.[596–601] Stains for neurofilaments and glial fibrillary acidic protein are negative.[602] Stains for HMB-45 are generally negative in normal resting melanocytes but positive in activated melanocytes, including those of some nevi and malignant melanoma.[603,604] Keratin is another marker that is consistently absent in normal melanocytes but sometimes expressed aberrantly in their neoplastic counterparts. Other melanocytic markers are discussed in the section on malignant melanoma.

Ultrastructurally, the hallmark of the melanocyte is the melanin-synthesizing organelle known as the *melanosome*. The development of this Golgi-derived structure, which has a specific appearance in its fully developed form because of the striated appearance of its electron-dense content, is preceded by the ultrastructurally nonspecific *premelanosome* and followed by the mature melanin granule.

The term melanocyte should be reserved for the mature melanin-forming cell. Its immature counterpart is the *melanoblast*. Dermal macrophages with phagocytosed melanin are *melanophages*. *Nevus cell* and *nevocyte* are terms that have been traditionally used for the cells of benign ordinary nevi; some authors regard them as nothing but melanocytes and have suggested abandoning the term altogether.[605] We fear that this may be too simplistic a view of the origin and nature of these cells.

Nevi

The word *nevus* (*Leucoraja naevus,* birthmark) can be properly applied to any circumscribed growth of the skin of congenital nature. However, in common practice it is usually used as a synonym for *mole* (L. moles, a shapeless mass) to designate a localized benign abnormality of the melanocytic system. The adjectives *melanocytic* (which we prefer), *nevocellular*, and *pigmented* refer specifically to this type of nevus.

Melanocytic nevi are usually acquired, in the sense that they become clinically apparent after the first year of life. Most of them will appear between the second and sixth years, and nearly all will have become manifest by the age of 20 years. They follow a rather predictable evolution, which only rarely is upset by some dramatic event, such as spontaneous regression, activation, or malignant transformation.[606] Their proliferative activity roughly correlates with the age of the patient.[607] Every white person has a variable number of nevi, the average being between 20 and 30.[608] Their distribution frequency is different from that of malignant melanoma. They are much more common in the skin of the head, neck, and trunk, whereas a high percentage of malignant melanomas occur in the lower extremities. Nevi of every conceivable size, shape, and degree of pigmentation occur, and they may be more or less hairy. Nevi have been variously classified, but it is best to divide them according to the location of the melanocytes inasmuch as their position bears a definite relationship to the likelihood of malignant transformation and perhaps to their histogenesis.

It has been suggested that melanocytic nevi straddle the fence between malformation (hamartoma) and neoplasia.[609] However, the finding that these lesions are clonal and that they exhibit loss of heterozygosity speaks in favor of a neoplastic nature.[610,611] In melanocytic nevi, activating mutations of *BRAF* are frequent, most commonly T1799A (V600E) mutation.[612–614] *NRAS* mutation is uncommon, and *CDKN2A* mutation is not found.[613]

Masson suggested that the ordinary compound mole has a dual origin from intraepidermal melanoblasts, some of which become intradermal through the Abtropfung (dropping off) process, and dermal Schwann cell–related dermal cells.[615,616] Many ultrastructural, histochemical, immunohistochemical, and experimental studies support his proposal that the cells from the upper portion of

compound nevi have melanocytic properties, whereas those in the deep portion have features strongly suggesting differentiation toward specialized peripheral nerve structures.[617–619]

The overwhelming majority of nevi are located in the skin, but they can also be found in any mucosal membrane covered by squamous epithelium (see respective sections). Clusters of benign nevus cells can also be seen in the dermis, subcutaneous tissue, and in the capsule of lymph nodes, the axillary region being the most common location for the latter event.[620,621] These nests, which typically do not penetrate into the node itself, should not be confused with metastatic malignant melanoma, a mistake particularly likely to occur when they are found in specimens from axillary lymphadenectomy or sentinel node biopsy performed because of cutaneous melanoma.

Junctional, Intradermal, and Compound Nevi

Ordinary nevi are classified according to the location of the nevus cells in relation to the major epidermal and dermal landmarks. *Junctional nevus* is defined as a nevus in which the melanocytic proliferation is restricted to the basal portion of the epidermis ("junctional" area). Nevi of the palms and soles are frequently of the junctional type,[622] with most of the intraepidermal melanocytes concentrated in the skin furrows.[623] Grossly, junctional nevus is flat or slightly elevated, non-hairy, and fawn colored. Microscopically, it is characterized by the presence of melanocytic nests ("theques") on the epidermal side of the dermoepidermal junction (Fig. 3.52). Malignant melanomas may arise from this lesion.

Lentigo simplex is generally regarded as the first phase in the evolution of common nevi ("nevi incipientes") and therefore a precursor of junctional nevus. It consists of a proliferation of melanocytes in the epidermal basal layer, and it differs from junctional nevus in that the melanocytes are individually arranged rather than in theques. Multiple lentigines occur in Peutz–Jeghers syndrome, centrofacial lentiginosis, Moynahan syndrome, LEOPARD syndrome, Carney syndrome, and xeroderma pigmentosum.[624] Basal cell hyperpigmentation microscopically resembling lentigo is commonly seen in the epidermis overlying dermatofibromas (see section on dermatofibroma). Exceptionally, a nevus or a melanoma is found on top of a dermatofibroma.[625]

Intradermal nevus is the term given to a nevus in which all the melanocytes are in the dermis. This is the common adult type of nevus. It may be papillomatous, pedunculated, or flat, and it is often hairy. Microscopically, small nests or bundles of melanocytes are seen in the upper dermis, with a tendency to concentrate around pilosebaceous units.[626] The degree of pigmentation and cellularity varies widely. The lower half of the lesion tends to be less cellular and less pigmented and is composed of spindle cells with fibrillary cytoplasm arranged in bundles.[616] Sometimes, structures resembling tactile (Wagner–Meissner) corpuscles are present. Although these areas are immunohistochemically different from neurofibromas,[627] we favor the interpretation that they represent the expression of the neural component of the nevus; it is hard for us to dismiss these highly organoid structures as simply the result of atrophy, as others have done.[628] Occasionally, a storiform pattern of growth is present in this deep portion, establishing a link—at least on morphologic grounds—with the dermal tumor known as storiform neurofibroma.[629,630] Multinucleated melanocytes can be seen scattered throughout the nevus, particularly in the upper half; many of these cells have a characteristic "mulberry" shape. Ultrastructurally and immunohistochemically, the intradermal nevus cells are surrounded by basement membrane components.[631,632] Malignant melanomas rarely arise from purely intradermal nevi, although a few convincing examples are on record.[633]

Compound nevus combines the features of the junctional and intradermal types, i.e., it has both an epidermal and a dermal component. The percentage of nevi with junctional changes decreases as the age of the patient increases.[634] As for the other types of nevi, the amount of melanin deposition is highly variable and sometimes very abundant (hypermelanotic nevus)[635]; as a general rule, it is concentrated in the superficial half of the lesion, particularly the intraepidermal portion. As with other nevi, lymphocytes and other mononuclear cells may be seen at the base of the lesion[636]; they tend to be in clusters rather than exhibiting the bandlike quality more commonly seen in melanoma.

The microscopic appearance of nevi shows some interesting variations depending on the site in which they occur. Nevi of the palms and soles tend to remain junctional throughout life. Nevi of the scalp often exhibit a prominent neural component. Nevi located on the vulvar skin (vulvar or genital nevi) tend to have larger, more irregularly shaped, and more irregular theques than those located elsewhere, and they have a tendency to be accompanied by lentiginous melanocytic hyperplasia; because of these features, they can be misdiagnosed as malignant melanomas.[637,638] Other body sites prone to harbor nevi with atypical features are breast, flexural skin, and acral region, especially ankle.[639–641]

Many morphologic variations have been observed in otherwise typical compound or intradermal nevi. These include the presence of marked sclerosis (desmoplastic or sclerotic nevus),[642] nodular myxoid changes,[643] amyloid deposition, elastosis, metaplastic bone in the stroma; folliculitis and abscess formation; association with keratinous cysts[644] and psammoma bodies; cytoplasmic vacuolization (sometimes resulting in lipoblast-like cells); oncocytic changes[645]; and eczematous or focal acantholytic keratotic changes in the overlying or adjacent epidermis.[646,647]

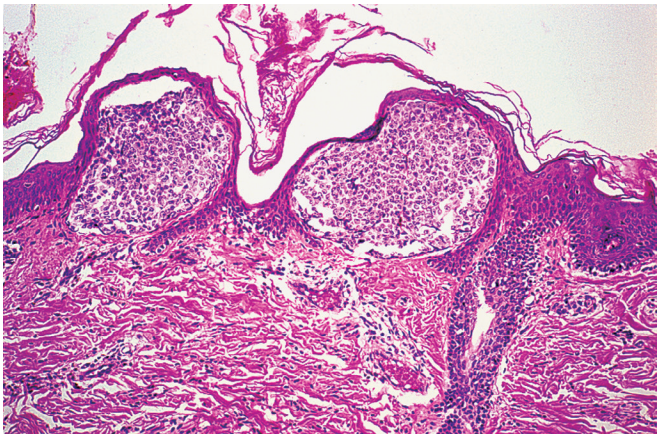

Figure 3.52 Typical Junctional Nevus. Two large theques of melanocytes expand the basal layer of the epidermis.

Blue Nevi and Related Lesions

Blue nevus of the *ordinary (usual, common)* type is usually small and located in the head, neck, or upper extremity.[648] Microscopically, it is characterized by an ill-defined deep dermal proliferation of elongated and/or dendritic dermal melanocytes, sometimes extending into the subcutis. Melanin pigment is usually abundant (Fig. 3.53), although hypopigmented variants occur. There is a band of uninvolved dermis between the epidermis and the lesion, and junctional activity is consistently absent. Blue nevi are sometimes misdiagnosed as benign fibrous histiocytomas because the melanin present in them is misinterpreted as hemosiderin. They are positive for melanin

stains, S-100 protein, and all other melanocytic stains, including HMB-45.[649]

Blue nevi have also been reported in the sclera, hard palate,[650] breast, vagina, cervix,[651] prostate,[652] spermatic cord, and lymph nodes.[653] Blue nevi do not show *BRAF* and *NRAS* mutations, as found in conventional melanocytic nevi, but instead show frequent somatic mutations (83%) in the heterotrimeric G protein alpha subunit, *GNAQ*, a gene also frequently implicated in uveal melanoma. The mutations occur in codon 209 in the RAS-like domain, resulting in constitutive activation.[630]

The differential diagnosis of blue nevus includes dermatofibroma (if the melanin pigment is mistaken for hemosiderin) and—more importantly—metastatic melanoma from the skin or eye, which can simulate it closely.[654,655]

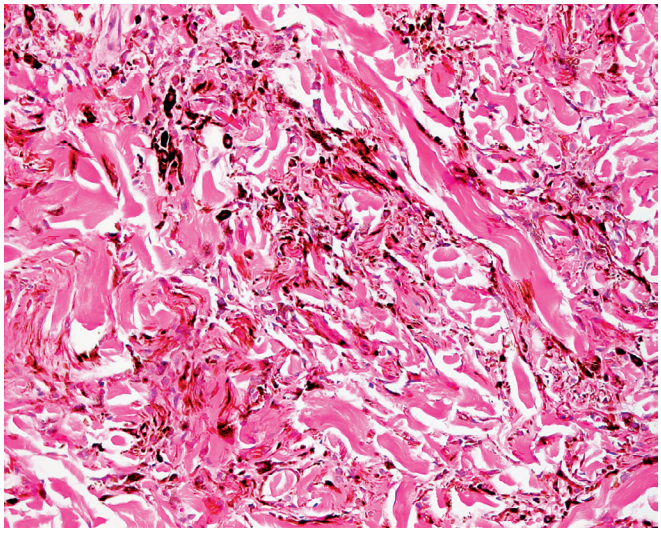

Figure 3.53 Blue Nevus of the Ordinary Type. The cells are spindle-shaped and heavily pigmented.

Cellular blue nevus is a distinctive variety of blue nevus, often clinically suspected of being malignant because of its large size and intense pigmentation.[656,657] The most common locations are the buttock and sacrococcygeal areas; less common sites include the scalp, face, and dorsa of hands and feet.[657] Microscopically, these lesions are extremely cellular, with a pushing border that has been likened to the silhouette of a dumbbell. Extension into the subcutis is the rule, and pigment can be easily found. They differ microscopically from malignant melanomas by the absence of junctional activity, epidermal invasion, peripheral inflammation, and necrosis; the presence of pushing margins, biphasic pattern, fasciculation, and neuroid structures; the inconspicuousness of the nucleoli; and the relative lack of atypia and mitotic figures (Fig. 3.54).[657]

Morphologic variations that cellular blue nevi can exhibit on occasion include the presence of a prominent cellular stroma between the tumor nests (*desmoplastic* cellular blue nevus),[658] focal balloon cell change,[659] paucity of pigmentation (*amelanotic* cellular blue nevus),[660] and degenerative changes in the stroma, including pseudoangiomatous foci (*ancient* blue nevus).[661]

Immunohistochemically, cellular blue nevi are positive for S-100 protein, Melan-A, and HMB-45. Some congenital cellular blue nevi have also been found to be reactive for CD34.[662] Like other melanocytic nevi, cellular blue nevi do not exhibit chromosomal aberrations on analysis by comparative genomic hybridization.[663]

The behavior of cellular blue nevus is nearly always benign, but a few cases with local recurrence or involvement of regional lymph nodes have been documented.[657] However, even these patients are cured by excision of the primary lesion and involved nodes, in the sense that the disease does not progress further.

These cases should be distinguished from malignant melanoma arising from cellular blue nevus and from a type of malignant tumor that has most of the morphologic features of cellular blue nevus but that exhibits a malignant behavior.[664–666] The latter, which has also been referred to as *blue melanoma*, is more common in the scalp and foot (especially heel). Microscopic features that should raise this possibility in a lesion with the architectural features of a cellular blue nevus are marked nuclear atypia, numerous mitoses, atypical

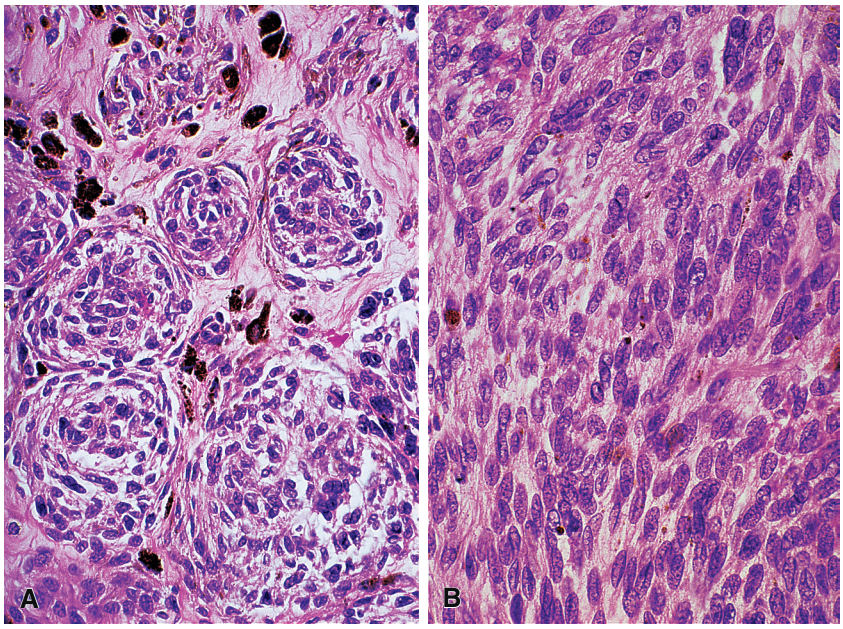

Figure 3.54 Large Cellular Blue Nevus. A, A distinct nesting pattern is present, with most of the melanin being located in macrophages situated in the intervening stroma. **B,** Numerous oval to spindle tumor cells with indistinct nucleoli. There is no mitotic activity.

mitoses, necrosis (sometimes with palisading at the edges), and the occurrence of epithelioid tumor cells.[665,667] It has been claimed that malignant blue nevi have higher AgNOR counts and higher proliferative activity (as measured by PCNA) than cellular blue nevi.[668] Melanomas resembling blue nevi have molecular abnormalities similar to conventional melanoma when interrogated by fluorescence in situ hybridization (FISH).[669] Melanomas arising in blue nevi have also been demonstrated by FISH to have chromosomal alterations associated with conventional melanoma in the malignant component.[670]

Cellular blue nevi with architectural and/or cytologic atypia but not sufficient to be placed in one of the two former malignant categories have been designated as *atypical*,[671] a term which has been violently attacked by some authorities.[672] In a series of nine cases, there were no recurrences or metastases, indicating that a conservative diagnostic and therapeutic approach is justified for these morphologically borderline lesions, especially considering the fact that the agreement rate for the diagnosis of "atypical cellular blue nevus" remains distressingly low.[673]

Both ordinary and cellular blue nevi are usually immunoreactive for S-100 protein, HMB-45, and the other melanocytic markers,[649,674] but exceptions occur.[675]

Variations on the theme of either ordinary or cellular blue nevus include cases forming large plaques (up to 17 cm in diameter),[676] cases with a target-like appearance,[677] and cases in which there is a second component of ordinary type (junctional, compound, or intradermal). The latter represents the most common type of *combined nevi*.[678,679]

Epithelioid blue nevus is a multicentric familial form of blue nevus that is part of the Carney complex together with cardiac myxoma, psammomatous melanotic schwannoma, and other abnormalities. Microscopically, these nevi are heavily pigmented, poorly circumscribed dermal lesions composed of two types of melanocyte: one intensely pigmented and globular, and the other lightly pigmented, polygonal, and spindle.[680] Epithelioid blue nevi can also be seen outside the Carney complex,[681,682] and their status as a distinct subtype of blue nevus has been questioned.[683] The observation has been made that epithelioid blue nevus is morphologically indistinguishable from so-called *animal-type melanoma*, and the proposal has been made to designate this allegedly distinct type of low-grade malignant tumor as *pigmented epithelioid melanocytoma*.[684]

Paraganglioma-like dermal melanocytic tumor is likely to represent another variation in the theme of cellular/epithelioid blue nevus. It is usually found in the extremities of adult females, is centered in the dermis, and presents as a nodule composed of nests of clear to amphophilic oval cells with mild atypia and low mitotic activity, apparently devoid of melanin at the hematoxylin and eosin (H&E) level but expressing all the usual melanocytic markers at the immunohistochemical level. The evolution of the few reported cases has so far been benign.[685]

Other benign skin lesions containing deeply seated dendritic melanocytes include *mongolian spot* (an ill-defined area of bluish discoloration, up to several centimeters in size, usually in the lumbosacral region), *Ota nevus* (located in the ophthalmomaxillary area), *Ito nevus* (located in the shoulder region), and *Sun nevus* (a bilateral speckled pigmentation of the zygomatic region in Chinese people).[686,687]

Spitz Nevus and Related Melanocytic Tumors

Spitz nevus (spindle and/or epithelioid cell nevus) characteristically occurs before puberty, but it may also appear in adult life.[688–690] The most typical presentation is in the form of a raised, pink or red nodule in the skin of the face that clinically resembles a hemangioma. It may be multiple, in either a clustered *(agminate)* or disseminated fashion[691]; this should not be mistaken for the satellite lesions of malignant melanoma.

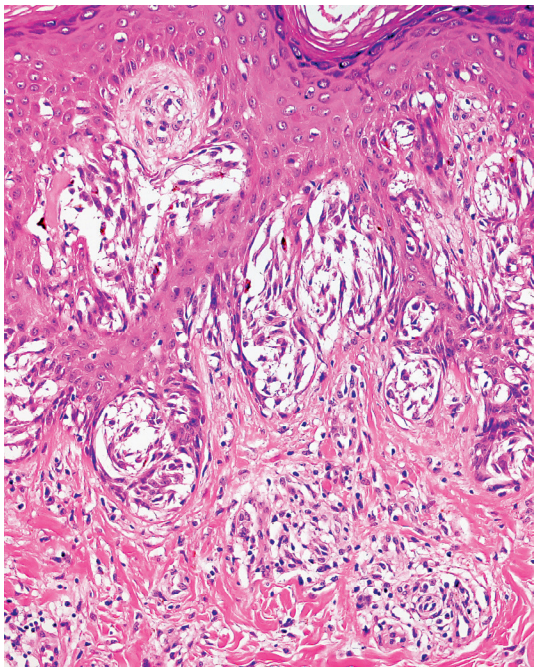

Figure 3.55 Spitz Nevus of Spindle Cell Type. This example is predominantly junctional in location.

Microscopically, most Spitz nevi are of the compound type, with a prominent intraepidermal component. Approximately 5%–10% are junctional, and 20% or more are intradermal.[692,693] They are composed of spindle cells, epithelioid cells, or an admixture of both.

The spindle cell variant is characterized by cigar-shaped cells with large nuclei and prominent nucleoli (Fig. 3.55). The cells of the epithelioid type have similar nuclei and a large, polygonal cytoplasm with distinct borders (Fig. 3.56). A variant of the latter is a multinucleated giant melanocyte containing up to 10–20 nuclei. Mitoses are found in approximately half of the cases,[694,695] but atypical mitoses are exceptional. Pigmentation is usually scanty, but a deeply pigmented variant (often of recent onset and located on the proximal extremities of young adults) exists; this is referred to as *pigmented spindle cell nevus (Reed nevus)* and is regarded by many authors as a separate entity from Spitz nevus (Fig. 3.57).[696–699]

Sometimes, Spitz nevi of predominantly dermal location are accompanied by an extensive stromal desmoplasia, which encircles the individual cells and simulates an invasive pattern (*desmoplastic* Spitz nevus).[700] This feature is more commonly seen in adults, which adds to the diagnostic difficulty. Other features occasionally present in Spitz nevi are predominantly intraepidermal growth (*pagetoid* Spitz nevus),[701] invasion of lymph vessels,[702] florid pseudoepitheliomatous hyperplasia (Fig. 3.58),[132] "tubular" pattern of growth,[703] plexiform pattern of growth (*plexiform* Spitz nevus),[704,705] halo reaction,[706] and prominent vasculature (*angiomatoid* Spitz nevus).[707] Features that favor a diagnosis of Spitz nevus over one of malignant melanoma are symmetric shape; sharp lateral demarcation; maturation in depth; arrangement of the spindle cells perpendicularly to the skin surface; presence of tadpole and multinucleated giant cells; lack of upward epidermal spread of single melanocytes (see earlier); presence of telangiectasia, edema, and fibrosis; presence of eosinophilic hyaline bodies along the dermoepidermal junction thought to be made of basement membrane material (Kamino bodies); and lack of ulceration.[708–712] In addition, the cytoplasm of benign

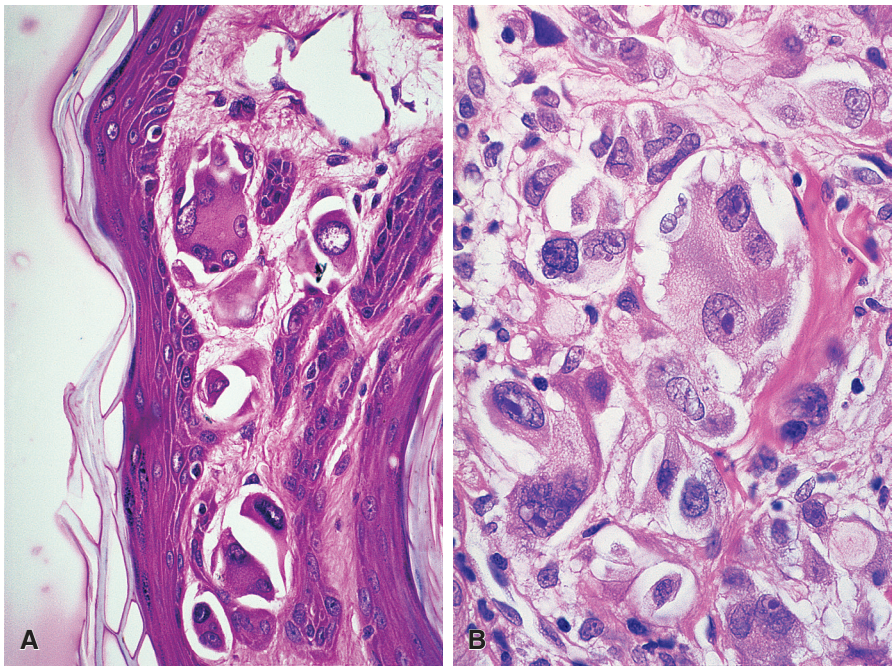

Figure 3.56 **A** and **B,** Spitz nevus of epithelioid type. The tumor cells feature large size, polygonal shape, occasional multinucleation, and a strongly eosinophilic cytoplasm.

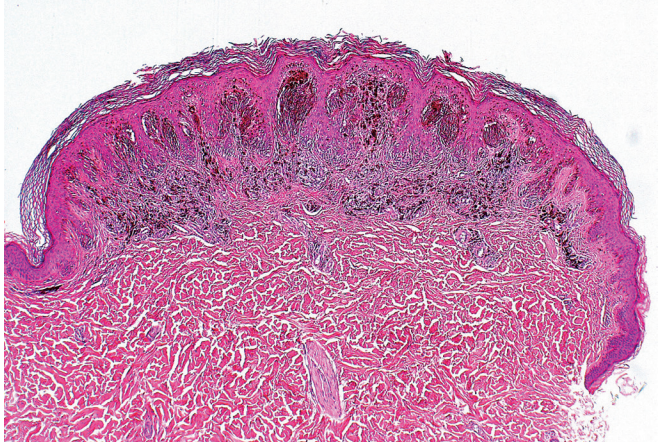

Figure 3.57 **Reed Nevus.** The tumor is heavily pigmented, in contrast to the usual type of Spitz nevus.

epithelioid nevi has a homogeneous acidophilic ground-glass appearance, whereas that of melanoma cells tends to be more irregular in configuration and staining reaction. An additional feature said to be in favor of the diagnosis of melanoma is so-called consumption of the epidermis, as defined by thinning of the epidermis with attenuation of the basal and suprabasal layers and loss of rete ridges in the areas of direct contact with neoplastic melanocytes.[713] Unfortunately, immunohistochemical stains have proved of very little value in this important differential diagnosis.[714] Immunostains for S100A6 protein expression have been touted as an effective adjunct in the differential diagnosis, but this has not widely been adopted.[715] Consistent immunostaining for p16 in desmoplastic Spitz nevus has been reported to differ from the infrequent p16 staining (18.2%) in desmoplastic melanoma, but there remains overlap.[716] Unfortunately, the same can be said for other immunohistochemical stains, and immunohistochemistry is at best supportive in nature but not reliably discriminatory.

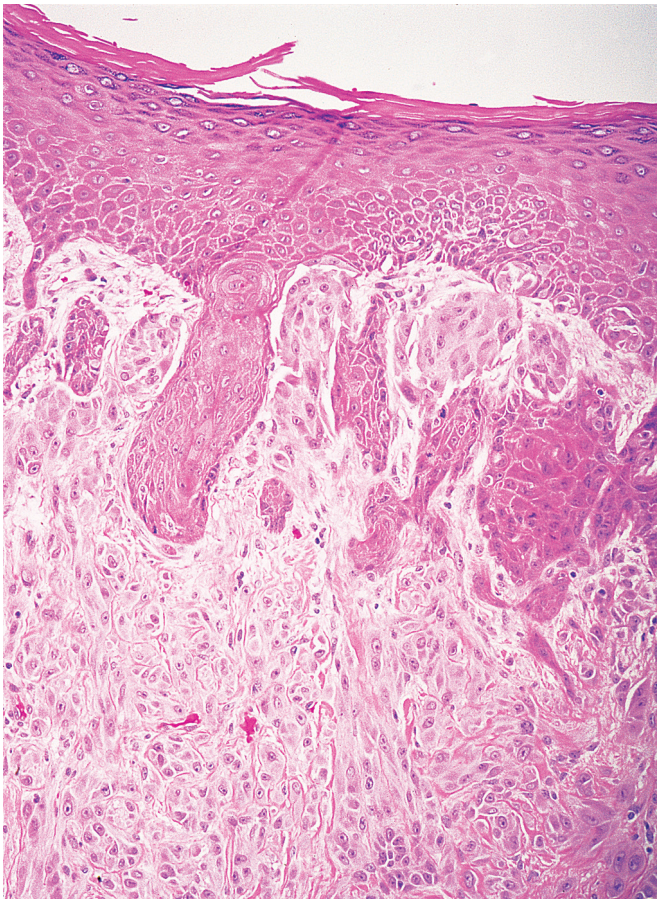

Figure 3.58 Spitz nevus of the spindle cell type that is predominantly intradermal.

Comparative genomic hybridization shows that most cases of Spitz nevi do not exhibit chromosomal aberrations, and only 25% show gain of chromosome 11p.[717] *HRAS* (located on 11p) mutations are common in cases with 11p abnormality.[718] In contrast to malignant melanoma, mutations in *BRAF* and *NRAS* genes are not typically found in Spitz nevus.[719] More recently, kinase fusions involving *ROS1*, *NTRK1*, *ALK*, *BRAF*, and *RET* have been described in Spitz nevi, atypical Spitz tumors, and spitzoid melanomas, suggesting that these genetic rearrangements may impart particular histologic features.[699,720,721]

The behavior of Spitz nevi is almost uniformly benign, but local recurrences may result from incomplete excision; these may show greater architectural irregularities than the original lesion.[722] That being said, several cases of "Spitz nevi" associated with regional lymph node involvement have been reported.[712,723] These "malignant Spitz nevi" tend to be large and deep, with pushing penetration of the dermis and subcutis. None of the patients reported by Smith et al.[125] went on to develop distant disease. However, we have seen a clinically and histologically typical case of Spitz nevus in the cheek of a young girl previously affected by acute leukemia that recurred locally, then metastasized to a regional node, and eventually led to widespread metastases and death.[724]

The argument as to whether or not malignant Spitz tumor exists is largely semantic. There is no question—as the cases previously described illustrate—that, on occasion, cutaneous melanocytic tumors with morphologic features of Spitz tumor behave in a malignant fashion. Whether one calls them malignant Spitz tumor, Spitz-type malignant melanoma, or spitzoid melanoma is immaterial, but to call them malignant melanomas without a qualifier does not fully convey the clinicopathologic identity of this rare but important entity.[725] In this scheme, and following a reasoning similar to that adopted for cellular blue nevus (see previous section), Spitz nevi that show worrisome microscopic features not sufficient to place them in a straightforward malignant category have been designated as *atypical Spitz tumors* or *melanocytic tumors of uncertain malignant potential (MELTUMP)*.[726–728] At a practical level, one should be aware of the fact that a significant percentage of these borderline tumors (especially those in the Spitz category; 33%–50% of the cases) show involvement of the sentinel nodes.[729–731] None of the patients reported by Smith et al.[724] went on to develop distant disease, and therefore may not truly represent malignancy despite involvement of lymph nodes. However, aggressive tumors with Spitz features have resulted in mortality. Recently, it has been demonstrated that a subset of atypical Spitz tumors with homozygous deletion of 9p21 are aggressive tumors worthy of being considered a type of spitzoid melanoma.[732]

A recently described subset of atypical Spitz tumors have deletions of *BAP1*. This results in intradermal tumors composed of large epithelioid melanocytes admixed with more conventional appearing melanocytes. An inflammatory infiltrate is frequently present. These appear to be benign, but patients with germline mutations of *BAP1* are prone to development of melanoma.[733] This further highlights how the group of lesions that have been designated Spitz tumors is biologically and molecularly diverse.

Congenital Nevus

Congenital nevus differs from the more common acquired variety because of its generally larger size (Fig. 3.59); tendency to involve the reticular dermis and subcutaneous tissue; single cell permeation of dermal collagen bundles; and involvement of skin adnexa, arrector pili muscles, nerves, and vessels.[734–736] However, there are too many exceptions to allow for an absolute distinction based on microscopic criteria alone.[734] Neuroid differentiation, such as the formation of Wagner–Meissner-like corpuscles, is common. The term *neuronevus* has been applied to congenital (and some acquired) nevi in which this feature is particularly prominent. When looking at these formations, one marvels at the fact that some authors deny the participation of specialized peripheral nerve structures in the formation of these lesions. The arrangement of round nevus cells in and around vessel walls may simulate the appearance of a glomus tumor (Fig. 3.60).[737] In some cases a nodular or hyperpigmented area develops within the nevus, which may be a cause of great concern both clinically and histologically. These proliferative nodules may show pagetoid intraepidermal proliferation of melanocytes, simulating the appearance of superficially spreading melanoma,[738] but typically regress if left alone.[739] Some congenital nevi also resemble melanoma at the clinical level, especially when located in acral sites[740] or when growing in a very rapid fashion.[741]

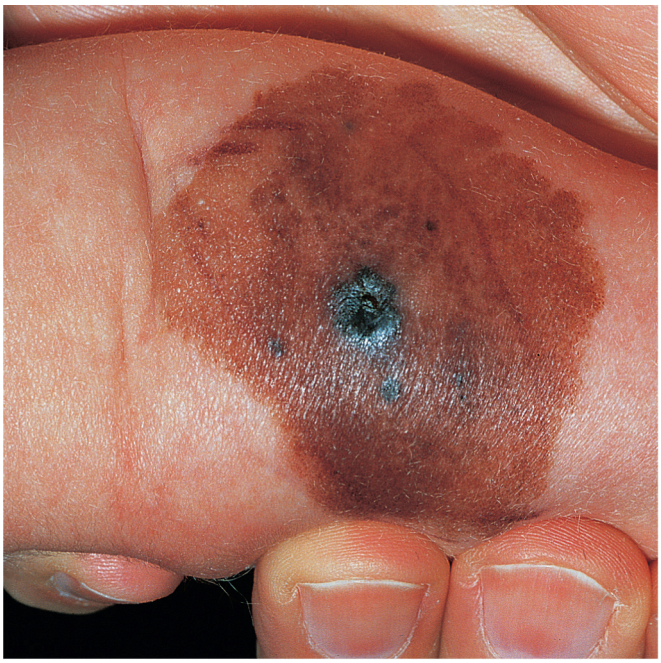

Figure 3.59 Congenital nevus with central hyperpigmented area. This corresponded microscopically to a pagetoid intraepidermal proliferation of melanocytes.

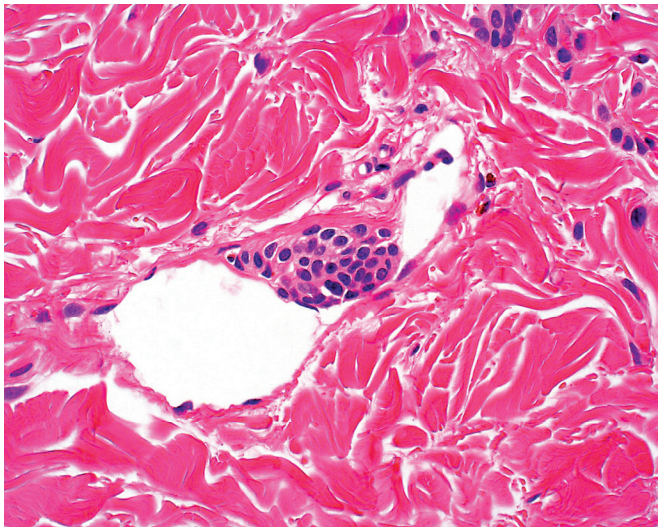

Figure 3.60 Vascular involvement in congenital nevus. This is not a sign of malignancy.

Like most melanocytic nevi, and in contrast to Spitz nevi and blue nevi, congenital nevi commonly show *BRAF* mutation.[614] There are no chromosomal aberrations.

Giant congenital nevus is a variant of congenital nevus characterized by its extensive size, its surface area being by definition 144 cm^2 or larger. It has also been defined as a nevus that measures more than 20 cm in diameter in an adult or that occupies 20% or more of the body surface area.[742] It has a tendency to distribute along a dermatome and often has a "bathing trunk" or "garment" configuration. It is also referred to as *giant pigmented nevus* and *giant hairy nevus*. It may involve a whole extremity, the entire scalp, and most of the trunk and even extend into the placenta.[743] It is often associated with smaller ("satellite") nevi and with nevi in mucosal membranes.[744] When in the scalp, it may result in convoluted folds of greatly thickened skin; this is known as *cerebriform* congenital nevus and is the usual histologic substratum of so-called *cutis verticis gyrata*.[745] Its microscopic appearance is qualitatively similar to that of the more common (non-giant) congenital nevus; occasionally, it has a component of pigmented large epithelioid cells similar to those seen in epithelioid blue nevus.[746]

Giant congenital nevus is sometimes associated with meningeal or cerebral melanosis (so-called *neurocutaneous melanosis or melanocytosis*),[747,748] or it may occur as a component of *melanophakomatosis*, together with numerous satellite nevi. Dissemination to the peritoneal surface by ventriculoperitoneal shunting has been exceptionally observed.[749] Neurocutaneous melanosis may give rise to malignant melanoma of the skin or central nervous system and to related malignant neuroectodermal tumors with a variety of patterns, including malignant peripheral nerve sheath tumor (MPNST), so-called *cutaneous malignant melanotic neurocristic tumor*, rhabdomyosarcoma, liposarcoma, and round cell or spindle cell undifferentiated forms.[750–753] Exceptionally, this malignancy occurs outside the region of the congenital nevus.[754,755] Whether the smaller congenital nevi are also subject to an increased risk of malignant transformation has not yet been established with certainty.[756,757]

Active, Dysplastic, and Atypical Nevi

Active nevus ("hot nevus") is a term that has been applied to benign melanocytic nevi that show prominence of the junctional component and hyperplasia of individual basal melanocytes, often associated with increased overall cellularity and dermal inflammatory infiltrate. Activation of nevi, thus defined, has been reported as a result of sunlight exposure[758] or ultraviolet irradiation,[759] in pregnancy,[760,761] following the use of contraceptive pills, in association with malignant melanoma elsewhere in the skin,[762] in recurrent nevi,[763] and sometimes for no obvious reason. It has been suggested that HIV infection is yet another cause of melanocytic activation.[764] Exceptionally, a myriad of "eruptive" nevi with the microscopic signs of activation unassociated with any recognizable cause will appear in an adult.[765]

Dysplastic nevus remains a highly controversial concept.[766] This lesion seems to blend or at least exhibit some morphologic similarities with the phenomenon of activation of nevi as already described. In its better-defined form, it occurs as a genetically determined syndrome in families prone to develop malignant melanoma (dysplastic nevus syndrome).[767,768] The nevi are clinically atypical, with a relatively large size (>5 mm), irregular outline, and variegated appearance; they appear in adolescence and continue to develop in adult life (Fig. 3.61).[769,770] Microscopically, most dysplastic nevi are compound nevi exhibiting marked lentiginous proliferation of melanocytes at the dermoepidermal junction, with or without nests. The latter are irregularly sized and shaped. These nests bridge adjacent rete ridges, which are themselves of irregular shape and orientation. If a dermal component is present, the junctional component is seen to extend beyond its lateral margins. The dermis shows eosinophilic and lamellar fibroplasia, focal perivascular lymphocytic infiltrate, and vascular dilation.[771,772] These features, collectively referred to as *architectural atypia*, are usually matched by a mild to moderate degree of cytologic atypia, manifested by nuclear hyperchromasia, prominent nucleoli, and dusty melanin pigment.[773] The melanocytes can be spindle shaped or epithelioid; the former tend to be arranged parallel to the skin surface (Fig. 3.62).[774]

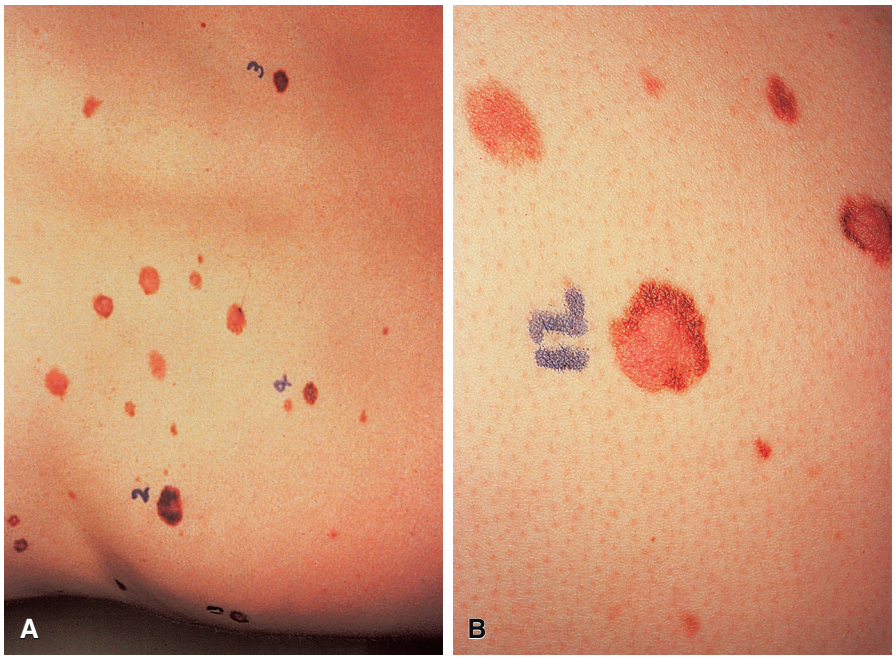

Figure 3.61 **A** and **B,** Clinical appearance of dysplastic nevi in patient with the dysplastic nevus syndrome. These nevi are large, have an irregular outline, and feature a variegated appearance. (Courtesy Dr D Santa Cruz, St Louis.)

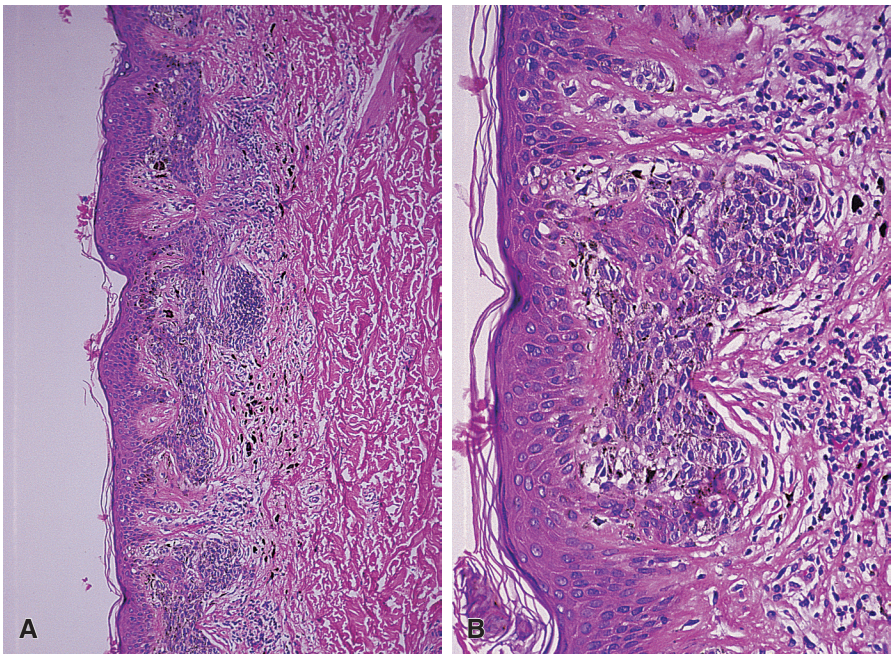

Figure 3.62 **A** and **B,** So-called dysplastic nevus. There is dermal fibrosis, inflammation, and a proliferation of melanocytes at the dermoepidermal junction, with bridging of rete ridges.

Proposals have been made to grade dysplastic nevi depending on the severity of atypia, but the criteria are far from standardized.[775–777] It has been further suggested that the degree of atypia in these nevi correlates with the risk for developing melanoma.[778] It should be remarked that only a minority of the clinically atypical nevi fulfill the microscopic criteria for dysplastic nevus.[779,780]

Ultrastructurally, a variety of melanosomal alterations have been described in these lesions.[781] DNA ploidy studies have shown that nearly all dysplastic nevi are diploid,[755] despite previous claims to the contrary.

Although the importance of having identified a familial syndrome with a predisposition toward melanoma cannot be overemphasized, the application of this concept to the solitary pigmented lesions remains questionable in terms of morphologic criteria, molecular markers, and biologic significance.[782–785] On the basis of present evidence, we think that solitary melanocytic nevi with "dysplastic" features should be regarded as clinically benign. That being said, many clinicians advocate conservative reexcision of dysplastic nevi with moderate to severe dysplasia. At the very least those patients probably should have continued clinical surveillance.

A more general approach to the problem can be taken by acknowledging the fact that one encounters, not infrequently, a melanocytic nevus (usually of the compound type) with atypical changes of the intraepidermal component. If the atypia is of a degree such as to indicate the emergence of a bona fide malignant neoplasm, we designate such a lesion as an in situ malignant melanoma arising in a compound nevus. For the considerably more common cases in which the atypia is below the threshold of melanoma (fully acknowledging the subjective nature of this determination), descriptive terms can be used. A descriptive diagnosis such as "atypical junctional or compound melanocytic proliferation" or "nevus with cytologic atypia" can be used as long as the pathologist acknowledges the diagnostic uncertainty and recommends that the lesion be conservatively but completely reexcised, comforted by the knowledge that a complete surgical excision will be curative in practically every instance.

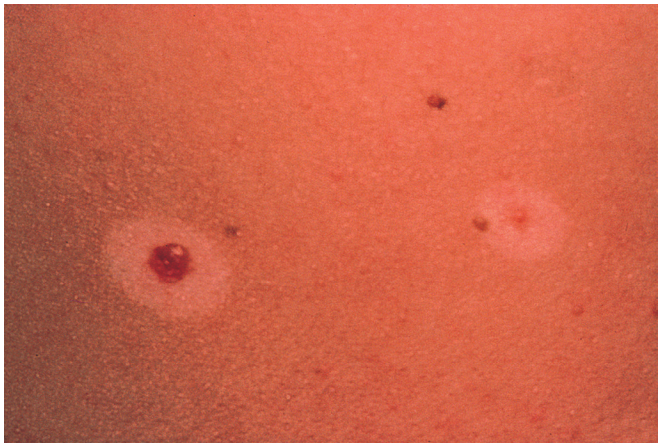

Figure 3.63 **Typical Clinical Appearance of Halo Nevus.** Heavily pigmented center is surrounded by sharply defined oval area of depigmentation. Pigmented nevus may be situated in center, as here, or be eccentric. (Courtesy Dr AW Kopf, New York.)

Other Nevi

Halo nevus (leukoderma acquisitum centrifugum) is the clinical term used to describe a melanocytic nevus surrounded by a zone of depigmented skin (Fig. 3.63).[786] It is most commonly found on the trunk of young patients, and it can be multiple.[787] Microscopically, it is characterized by a heavy infiltration of the nevus by lymphocytes and histiocytes and is thought to represent the expression of a host immune response (Figs. 3.64 and 3.65). The lesion can be confused with melanoma, lymphoma, and dermatitis. Ultrastructurally, melanocytes in various stages of degeneration can be identified amid the lymphohistiocytic elements.[787] It should be mentioned that malignant melanoma may also be surrounded by a halo of depigmented skin.[788] However, in this instance the halo tends to be irregular, and the pigmented spot is usually off center.

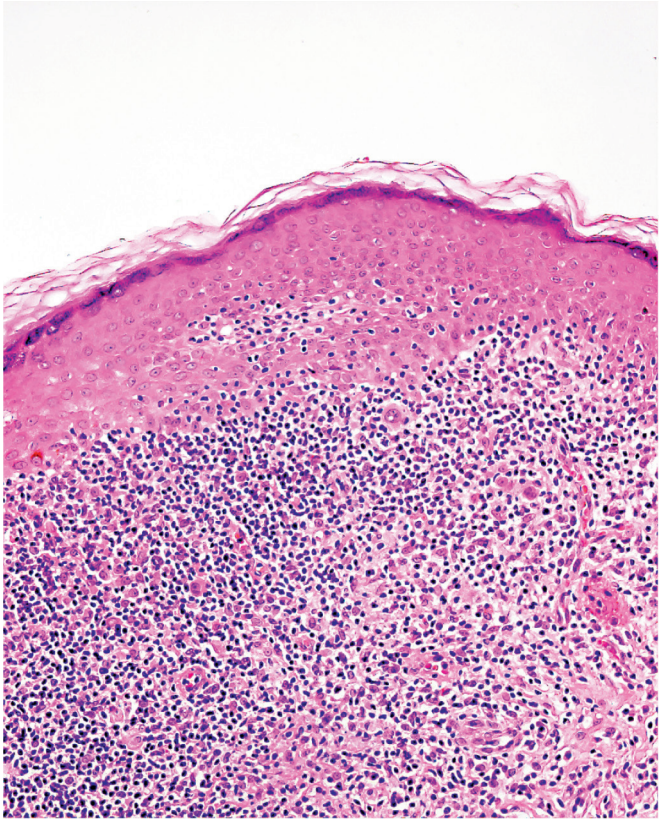

Figure 3.64 Halo Nevus. The low-power view is that of an inflammatory dermal nodule.

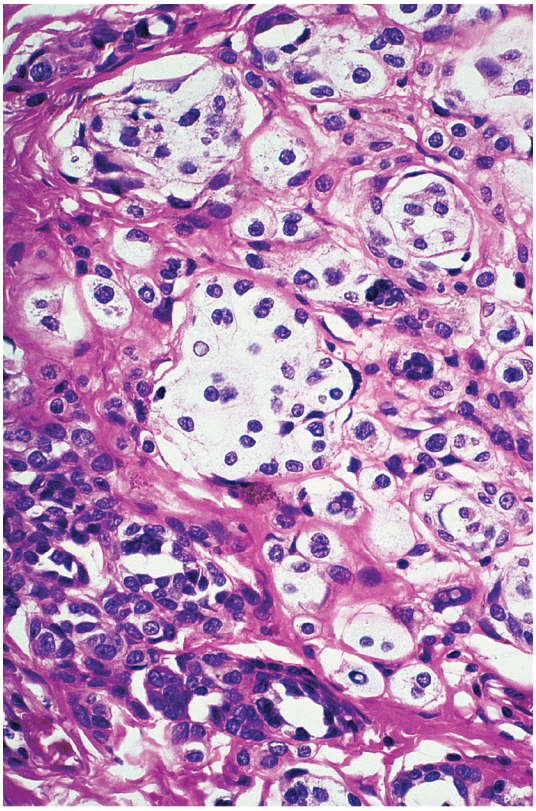

Figure 3.66 Balloon Cell Nevus. The tumor cells are arranged in nests and have a voluminous pale cytoplasm.

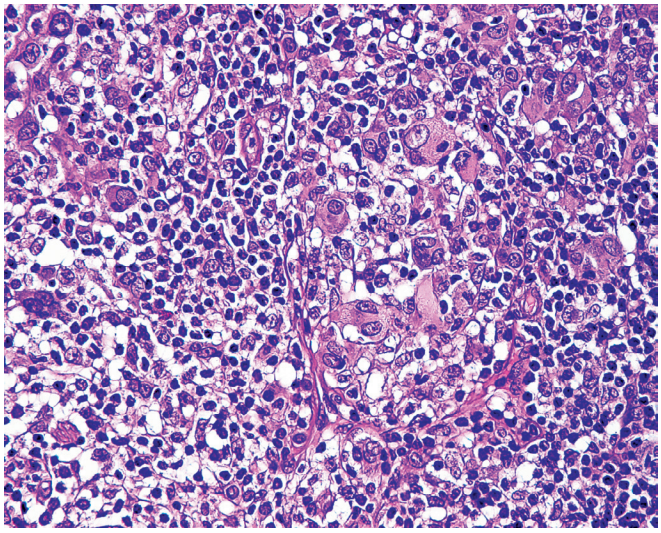

Figure 3.65 Halo Nevus. High-power view showing residual melanocytes amid a heavy inflammatory infiltrate.

Balloon cell nevus is another unusual variety of nevus, identified by the presence of large pale melanocytes with foamy cytoplasm, perhaps the result of a biochemical alteration in melanin synthesis (Fig. 3.66).[789] Balloon cells also can occur in blue nevi and malignant melanomas.[790]

Cockarde nevus is characterized clinically by a concentric pattern of pigmentation; a central pink to darkly pigmented papule is surrounded by a stippled pigmented circle, with a clear zone in between.[791] Microscopically, the central lesion is a junctional or compound nevus without inflammatory changes, the peripheral portion (ring) shows multiple junctional melanocytic nests, and the intermediate zone is basically unremarkable.

Deep penetrating nevus is the name given to a variant of compound nevus morphologically similar to blue nevi, in which the dermal component extends deeply into the reticular dermis and sometimes even into the subcutaneous fat.[792] The junctional component is usually inconspicuous, whereas the dermal component is cellular, nested or fascicular, abundantly pigmented, and cytologically mildly atypical. Mitoses are nil, and there is little or no inflammatory infiltrate. Sometimes deep penetrating nevus is seen admixed with other types of nevi, as a form of combined nevus.[793]

Treatment

Because every white adult has, on average, 20–30 nevi, it is obvious that specific indications are needed for their removal, other than those dictated by cosmetic considerations. The presence of a junctional component per se is not an indication; most plantar and palmar nevi are junctional, but they are too common and the possibility of malignant transformation too remote to warrant routine removal.[794,795] Definite indications for excision include the appearance of a pigmented lesion in an adult, chronic mechanical irritation of a nevus, or the appearance of any of the following changes in a preexisting nevus: deepening of pigmentation or spread of the pigment beyond the gross confines of the lesion, appearance of flat areas of depigmentation within the nevus, appearance of a red inflamed zone around the nevus, rapid growth, ulceration, itching, oozing of serum, or bleeding with trivial trauma.[796]

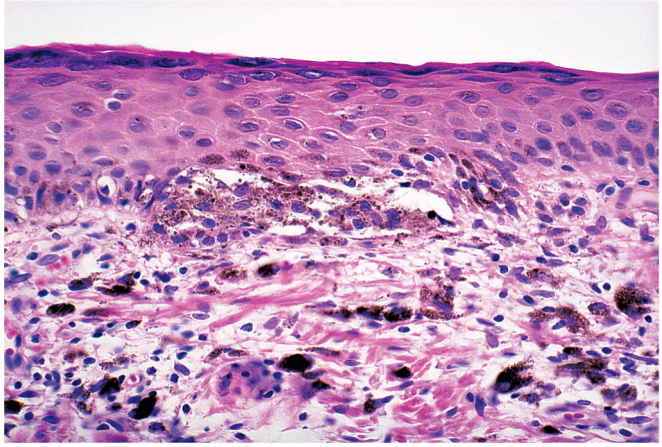

Figure 3.67 Recurrent Nevus Following Shave Excision. There is an irregular proliferation of melanocytes along the dermoepidermal junction, associated with some dermal fibrosis and clusters of melanin-laden macrophages. This lesion should not be overdiagnosed as malignant melanoma.

Removal of a nevus should be carried out with a cold knife rather than a cautery to prevent the distortion of tissue and peculiar staining reactions associated with the latter. Incomplete removal may result in local recurrence.[797–799] The recurrent lesion often shows junctional activity, even if this feature was not present in the original excision.[800] This, together with the nuclear enlargement and nucleolar prominence that often accompany these recurrences, has sometimes resulted in a mistaken diagnosis of malignant melanoma with regression (Fig. 3.67).[763,801] Parenthetically, another pseudomalignant feature that may be seen in a reexcision skin specimen is the growth of squamous epithelium in the perineurial spaces, mimicking perineurial invasion.[802]

Early surgical removal of the giant form of congenital nevus is also recommended because of their greater tendency to undergo malignant transformation; unduly large lesions have to be excised in the course of several sessions.

Malignant Melanoma

General Features

The large majority of melanomas are associated with sunlight exposure and thought to be due to ultraviolet radiation.[803,804] Therefore, most are found in the head and neck area and on the lower extremities, the latter location being particularly more common in women.[805,806] Rare but well-known locations of cutaneous melanomas are the subungual region ("melanotic whitlow")[807–809] and the palms and soles. White people, particularly those of fair complexion, red hair, and a tendency to burn or develop freckles after exposure to sunlight,[810] are particularly susceptible to the development of melanomas. The few melanomas developing in blacks tend to occur in the palms, soles, nail beds, or mucous membranes.

The overwhelming majority of melanomas arise after puberty. However, there is no question that they can also occur in children.[811–816] Most of these melanomas have the same microscopic pattern as those in adults and, therefore, can be distinguished in most cases on morphologic grounds from Spitz nevi.[817,818]

The presence of a large number of melanocytic nevi represents a risk factor for melanoma, even if these nevi are not of the dysplastic type.[819–821] The genetically determined disease *xeroderma pigmentosum* predisposes to the development of melanoma. Cases of melanoma have been reported in association with type I Recklinghausen disease[822] and in solid organ transplant recipients, the latter setting also associated with increased lethality.[823,824]

Malignant melanomas can present as multiple primary tumors.[825,826] In a series of 712 patients with melanomas, 38 (5.3%) had more than one primary melanoma: 24 had 2 primary lesions, 11 had 3, 2 had 4, and one had 8.[827] The prognosis was more dependent on the type and stage of the largest lesion than on the number of primary lesions. Multiple primary melanomas should be distinguished from the admittedly controversial phenomenon of nevus activation in patients with melanomas.[762]

The existence of hereditary forms of malignant melanoma has been known for a long time.[828] Members of melanoma-prone families often exhibit numerous atypical melanocytic lesions ("dysplastic nevi") that serve as a cutaneous marker of those at higher risk.[829] A proportion of cases of hereditary melanoma are caused by germline inactivating mutation in *CDKN2A* on chromosome 9p21 (encoding two tumor suppressor gene products, p16INK4a and p14ARF) or less commonly, activating mutation in *CDK4*.[830–835] Germline mutations in the tumor suppressor gene *BAP1* have been associated with an increased risk for developing cutaneous and uveal melanoma, as well as malignant mesothelioma.[836–838]

The fact that malignant melanomas can develop from nevi can be no longer denied, but the exact percentage is not clear. It is obvious that only an infinitesimal portion of acquired nevi become malignant. The percentage is higher for congenital nevi and for dysplastic nevi, but the exact figures are again unknown. Remnants of dysplastic nevi are said to be present in anywhere from less than 5% to almost half of all melanomas, this wide range undoubtedly reflecting the difficulties in distinguishing lateral melanoma spread from a preexisting precursor lesion.[839]

Clinical Appearance and Major Clinicopathologic Types

For the purposes of clinical and microscopic description, it is useful to divide melanomas into different types. The most common forms of melanoma can be divided into four categories[840-844] while acknowledging the fact that the clinicopathologic or prognostic differences among them are not as sharp as originally claimed.[845,846] These categories are *lentigo maligna* melanoma, *superficially spreading* melanoma, *nodular* melanoma, and *acral lentiginous* melanoma. A high degree of accuracy in the differential diagnosis among these types is possible on the basis of location and gross appearance.[847]

Lentigo maligna (Hutchinson freckle) typically occurs in the sun-exposed areas of elderly white persons, most commonly on the cheek.[848,849] It is a flat, slowly growing lesion, its color varying from tan to black.[850] Microscopically, it is characterized by a proliferation of atypical melanocytes in the basal layer, distributed individually as well as in nests (Fig. 3.68). Retraction of the cytoplasm is common and pleomorphism may be prominent.[850] Upward migration is less prominent than in other types of melanoma. The proliferation of atypical basal melanocytes in the deep portion of the rete ridges can simulate invasion, especially in a tangential section. It is advisable to be very conservative in the evaluation of this lesion, just as one should be in actinic keratosis. When confined to the epidermis, it is considered *lentigo maligna*, a form of melanoma in situ. When a dermal component is present, the term *lentigo maligna melanoma* is used. The term *lentiginous melanoma* has been proposed for a lesion that seems to us to represent a variation in the theme of lentigo maligna, but this terminology is not widely used.[851,852]

Another type of invasive melanoma that can develop within lentigo maligna is *desmoplastic melanoma* (see later).[853] This tumor tends to recur locally, as well as to metastasize distantly.[854] It can also be seen in connection with other pigmented lesions.[855]

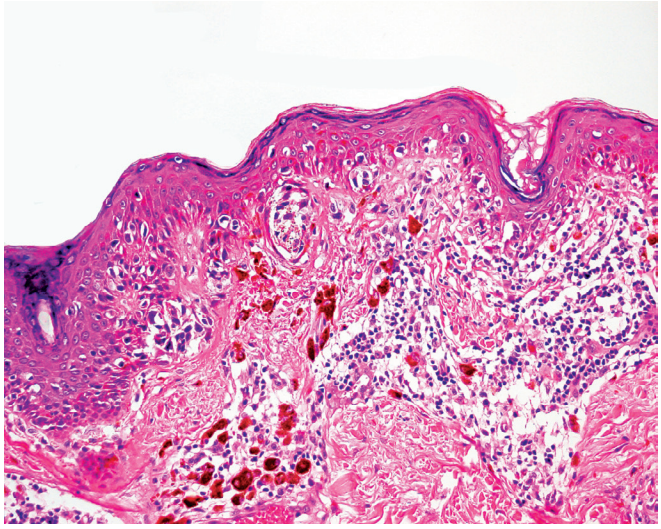

Figure 3.68 So-Called Lentigo Maligna. The atypical melanocytes are present along the basal layer individually and in theques.

Figure 3.69 Clinical appearance of melanoma of superficially spreading type. The nodular light area corresponds to a focus of amelanotic malignant melanoma featuring deep dermal invasion.

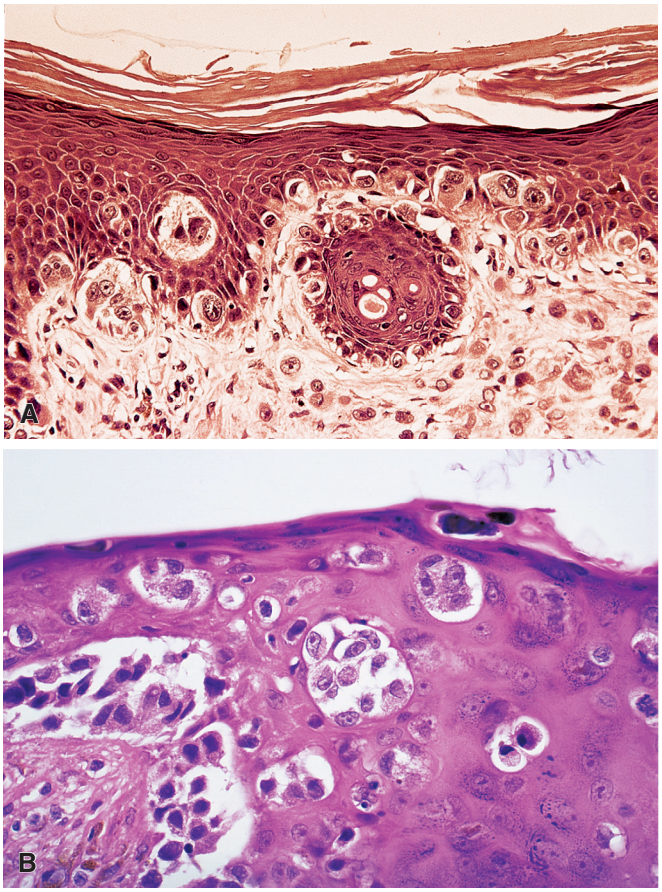

Figure 3.70 A, Pagetoid appearance of melanocytes in superficially spreading malignant melanoma. **B,** Malignant melanoma showing transepidermal migration. There is also individual necrosis of neoplastic melanocytes. Some of the melanin has reached the horny layer (so-called pigmented parakeratosis).

Superficial spreading melanoma is the most common form of melanoma. It has also been previously called premalignant melanosis and pagetoid melanoma, and it can occur anywhere on the body surface. It has a variegated appearance, the colors including hues of tan, brown, black, blue, pink, and white. The telltale color of early superficially spreading melanoma is most frequently a shade of blue admixed with tan, brown, or dark brown.[847] The surface is slightly elevated, and the margins are barely palpable (Fig. 3.69). The white areas correspond to areas of spontaneous regression; they are related to tumor size but not to the level of invasion or prognosis.[856] Pink and blue areas also correspond to areas of tumor regression, associated with dermal fibrosis and accumulation of melanin-laden macrophages. The borders of the lesion are irregular and usually include a prominent indentation or notch. Deep invasion generally is accompanied by the appearance of an elevated nodule on the surface. Microscopically, the noninvasive areas are composed of uniform atypical melanocytes with nest formation and pagetoid appearance (Fig. 3.70).

Nodular melanoma can present as a smooth nodule covered by normal epidermis, as an elevated blue–black plaque, or as a polypoid, frequently ulcerated mass.[857] A lateral flat component is not seen clinically or microscopically. This type of melanoma affects all body surfaces, is usually of short duration, and occurs in a younger age group than either of the foregoing two categories.

Acral lentiginous melanoma has an intraepidermal component of lentiginous type, which is similar in many respects to that seen in lentigo maligna.[844,846,858] In contrast to the latter, however, the intraepidermal melanocytes tend to be dendritic and bizarre, the involved epidermis is markedly hyperplastic rather than atrophic, and the papillary dermis in this region is widened and inflamed. Tumors with these features have been seen on the palms, soles, subungual areas, mucocutaneous junction of the oral and nasal cavities, and anus.[859] This type of melanoma is more common in blacks and Asian people.[860,861]

The clinical differential diagnosis of malignant melanoma includes a wide variety of lesions, particularly those containing melanin or hemosiderin pigment: benign nevi of various types, benign fibrous histiocytoma, inflamed or thrombosed hemangioma, pigmented seborrheic keratosis, and pigmented basal cell carcinoma.[862] Conversely, malignant melanomas that are amelanotic or covered by a thick layer of keratin can simulate a pyogenic granuloma or a callus, respectively.

Microscopic Features and Other Melanoma Types

The typical example of malignant melanoma is easily identified microscopically because of its junctional activity; prominent melanin

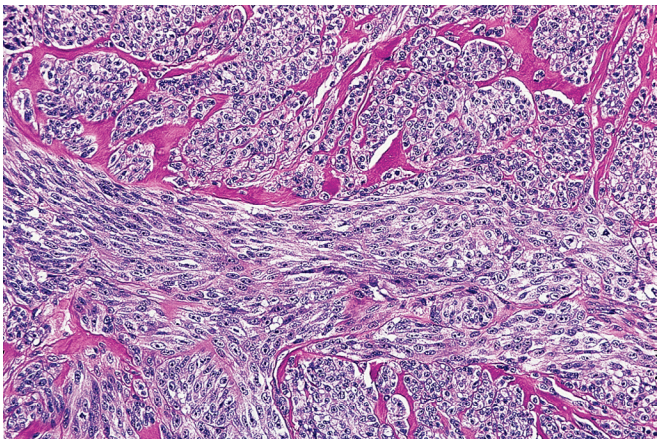

Figure 3.71 Malignant melanoma in the region of the Achilles tendon showing prominent spindling. This is a common finding in tumors at this site.

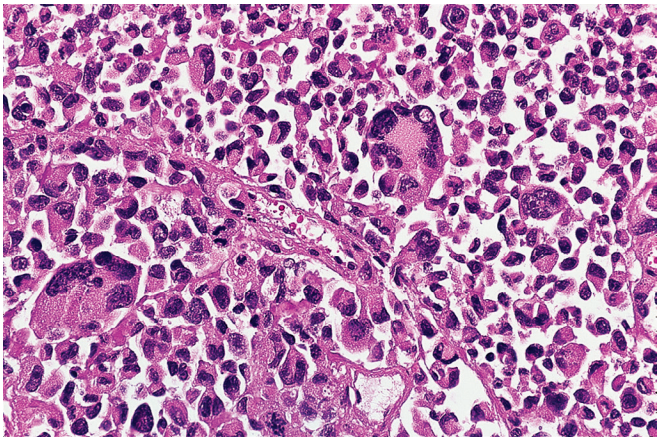

Figure 3.72 Melanoma containing highly anaplastic tumor cells.

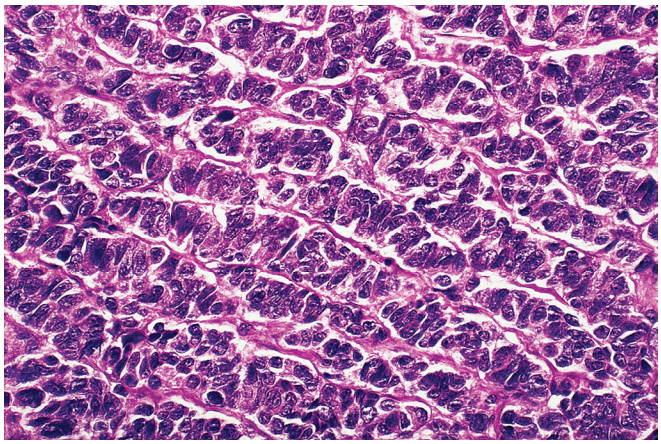

Figure 3.73 Prominent trabecular pattern of growth in melanoma.

pigmentation; invasion of the surrounding tissue; marked cytologic atypia; nuclear grooves, folds, and pseudoinclusions; large eosinophilic nucleoli; and abundant mitotic figures, some of them atypical.[863] Alas, this is not always the case. As a matter of fact, malignant melanoma is notorious for the great microscopic variability that it may exhibit.[864–866] The cells can be epithelioid, spindle shaped, or extremely bizarre ("monster cells").[867] Their size can range from small (lymphocyte-like)[868] to spindled to giant multinucleated forms (Figs. 3.71 and 3.72). The cytoplasm can be eosinophilic, basophilic, foamy, of signet ring type,[869,870] rhabdoid,[871–873] oncocytic[874] or completely clear (balloon cell melanoma).[875] Melanin can be abundant, scanty, or absent (amelanotic melanoma).

Sometimes the amount of melanin production is so massive as to obscure the cellular details; such cases have been inelegantly called *animal-type melanoma* on the grounds that they resemble melanocytic neoplasms in horses and other mammals.[876] Their behavior is that of low-grade neoplasms, with the potential for local recurrence, nodal metastases, and very exceptionally distant metastases.[877] The claim has been advanced that this animal-type melanoma is the same entity as epithelioid blue nevus, and the proposal has been made to rename it *pigmented epithelioid melanocytoma*.[687]

The pattern of growth of melanoma may be pseudoglandular, pseudopapillary, peritheliomatous, hemangiopericytoma-like, resembling Spitz nevus (spitzoid melanoma), rosette-like, trabecular (Fig. 3.73), verrucous (nevoid or pseudonevoid melanoma) (Fig. 3.74), carcinoid-like, or follicular (i.e., centered in the hair follicle and the adjacent dermis).[866,878–884] The tumor can be accompanied by marked fibroblastic response, myxoid changes (Fig. 3.75),[885,886] osteoclast-like giant cells,[887–889] Touton-like giant cells,[890] pseudoepitheliomatous hyperplasia of the overlying epidermis,[131] and a variety of divergent differentiations, including osteocartilaginous, rhabdomyoblastic, and neuroendocrine.[891–894] Occasionally, formations suggesting differentiation toward Schwann cells, tactile corpuscles, ganglion cells, and other neuroid structures are observed.[895–897] Sometimes the lymph node and other metastases of a melanoma acquire an appearance that is practically indistinguishable from that of an MPNST.[898] The knowledge that MPNSTs rarely metastasize to lymph nodes is helpful in the distinction.

Desmoplastic melanoma, which has already been mentioned, represents a distinct subtype of spindle cell melanoma.[899] The head and neck is the most commonly affected region.[900] This is an important subtype of melanoma because of the fact that it can be easily misdiagnosed, sometimes with serious consequences. An overlying junctional component consisting of melanocytic hyperplasia to lentigo maligna is frequently, but not invariably, present. The dermal component is formed of spindle cells arranged in short fascicles surrounded by a heavy desmoplastic stroma. The tumor cells can be very scanty and not overly atypical. The difficulty is compounded by the fact that these cells are positive for S-100 protein but usually not for HMB-45, Melan-A, or any of the other more specific melanoma markers, while sometimes acquiring mesenchymal markers, such as actin.[901,902]

Desmoplastic melanomas can be "pure" or represent a portion of an otherwise conventional melanoma.[903] More cellular examples with less collagenous stroma are better regarded as spindle cell melanoma rather than desmoplastic melanoma. The differential diagnosis of desmoplastic melanoma includes hypertrophic scar (which may contain S-100 protein–positive cells),[904] atypical fibroxanthoma, spindle squamous cell carcinoma, and peripheral nerve sheath tumors. Clues to the diagnosis at the H&E level are focal fascicular pattern of growth, deep invasion, infiltration of nerves, and lymphoid aggregates at the tumor periphery (sometimes so prominent as to resemble cutaneous lymphoid hyperplasia/pseudolymphoma), and the presence of a lesion with the features lentigo maligna in the overlying epidermis (Fig. 3.76).[905] Alas, many of these features will often be absent in the individual case. *Neurotropic melanoma* is a variant of desmoplastic/spindle cell melanoma growing in a peripheral nerve sheath pattern, either because the tumors invade preexisting nerves or because they differentiate along peripheral nerve structures.[906–909] Along these lines, it is interesting that spindle cell melanomas have often been found to express the p75 neurotrophin

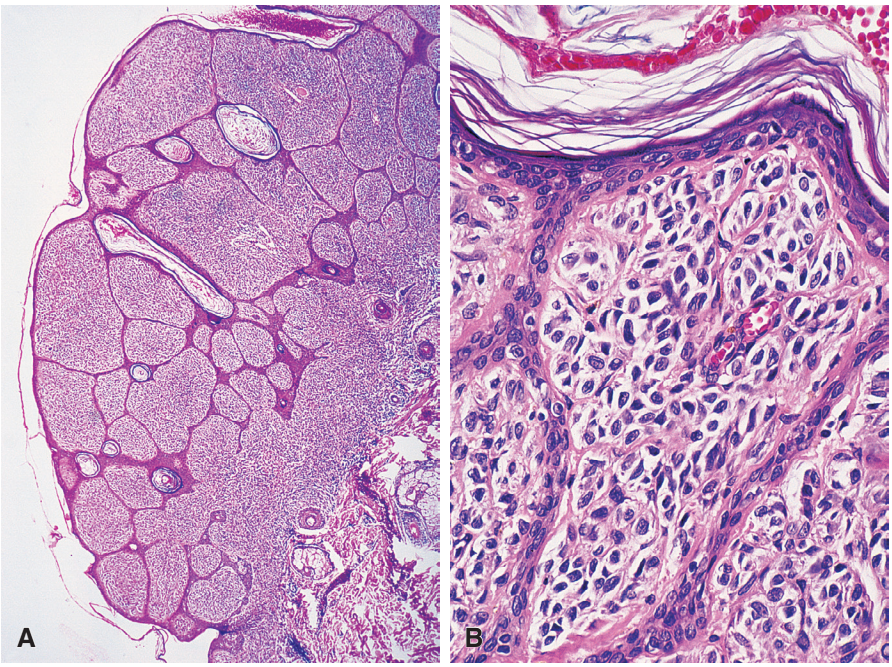

Figure 3.74 Malignant Melanoma With Nevoid Pattern of Growth. A, Low-power view showing a polypoid configuration suggestive of a benign intradermal nevus. **B,** High-power view showing only minimal atypicality of the tumor cells. This tumor recurred locally and eventually metastasized to regional lymph nodes. (Slide contributed by Dr Paul Duray, Bethesda, MD.)

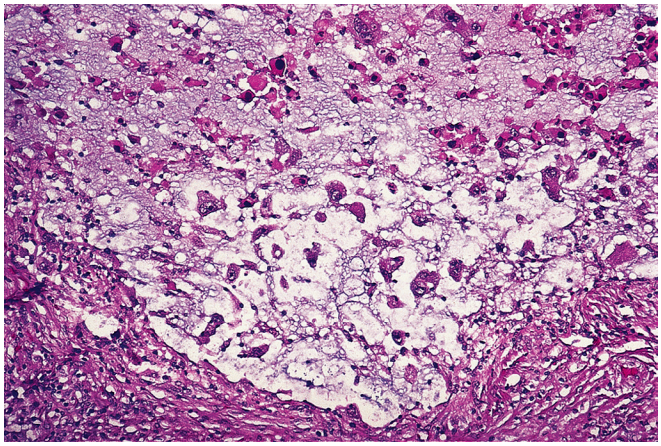

Figure 3.75 Myxoid Changes in Malignant Melanoma. This secondary alteration is more common at metastatic sites but can also be seen in the primary lesion.

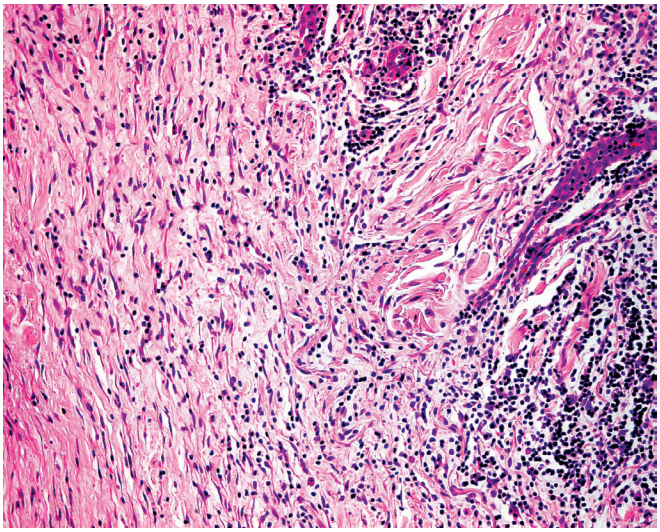

Figure 3.76 Desmoplastic Malignant Melanoma. The spindle cells have a deceptively bland appearance. The collections of lymphocytes are a characteristic feature.

receptor and nerve growth factor receptor (NGFR) (a marker of schwannian differentiation), two features further supporting a differentiation along neural lines.[910,911]

Borderline or *minimal deviation melanoma* is yet another proposed subtype of melanoma, a controversial concept that includes the previously cited verrucous and spitzoid melanoma, as well as a halo nevus–like type.[912–914] As a result of all these variations, malignant melanoma can simulate carcinoma, various types of sarcoma, malignant lymphoma, and several other neoplasms.

Nearly all primary melanomas exhibit an intraepidermal component ("junctional activity") during their initial phase. Therefore a melanoma lying entirely within the dermis should be suspected of being metastatic. However, many well-documented cases of primary intradermal melanoma exist, the possible explanations for their occurrence being total regression of the intraepidermal component or origin from an intradermal nevus. When encountering a purely intradermal primary melanoma, it should be distinguished from *cutaneous clear cell sarcoma*.[915]

At a practical level, there are two major diagnostic challenges in this field. The first is how to identify as melanoma an obviously malignant tumor when melanin formation is not apparent in routine sections. Features suggestive of melanoma in H&E sections are: cells with abundant acidophilic, finely granular cytoplasm; pseudonuclear inclusions; a combination of epithelial and spindle cell patterns of growth; a fascicular arrangement of tumor cells; and pseudoalveolar arrangement. Special stains, immunohistochemical stains, and

ultrastructural examination are of great utility in establishing the diagnosis in difficult cases (see next section). The other important diagnostic problem is the determination of whether a skin lesion of obvious melanocytic nature is benign or malignant. Benign lesions most commonly overdiagnosed as melanomas are Spitz nevi (especially the desmoplastic type of pure epithelioid nevus), halo nevi, activated and dysplastic nevi, vulvar (genital-type) nevi, and nevi that have recurred following incomplete excision. Conversely, the type of melanoma that is more likely to be underdiagnosed as benign is a level I or II superficially spreading type, especially if occurring in sites such as the plantar and the subungual regions.[916–918] We have found the criteria listed here to be the most useful for the identification of early malignant melanoma.[919,920] Unfortunately, none of them is pathognomonic. The diagnosis of melanoma can be made only on the basis of a combination of features.

1. Poor circumscription (lack of cohesiveness) of the intraepidermal melanocytic component. The nests are not as sharply defined as those of benign lesions, and the individual cells within the nests are separated from each other. A related phenomenon of similar diagnostic significance is subepidermal cleft formation, i.e., the presence of clefting of at least 0.3 mm in length between the epidermal layer and the underlying melanocytic proliferation.[921]
2. Lateral extension of individual melanocytes. Benign lesions usually exhibit a sharp cutoff, whereas in most malignant lesions there is a trailing off of atypical melanocytes spreading from the center of the lesion.
3. Extension of melanocytes, individually and in nests, throughout the malpighian layer and within adnexal epithelium. This phenomenon of transepidermal migration results in a pagetoid appearance of the lesion, hence the term "pagetoid melanoma" that is sometimes used. The melanin pigment can reach the horny layer, a process known as pigmented parakeratosis; this is rare in benign nevi, but appears with some frequency in some variants of benign lentigo and in "activated" benign lesions.
4. Size variation, shape variation, and confluence of melanocytic nests.
5. Asymmetry. This pertains to many of the items described in this list, such as lateral extension, the extent of the dermal component, architectural features of the nests, cell type, the distribution and appearance of the melanin, and the degree of inflammation and fibrosis.
6. Lack of maturation of dermal melanocytes. In benign nevi, the nests and individual melanocytes become smaller with descent into the dermis, whereas this is usually absent in melanoma.
7. Melanocytic atypia, evidenced by the prominence of nuclei and nucleoli and an increase of the nucleocytoplasmic ratio.
8. Mitotic activity. Most benign nevi have a very small number of mitotic figures, although some spindle and epithelioid cell nevi may contain many. The presence of atypical mitoses and dermal mitoses (especially deeply located) are strong indicators that the lesion is malignant. The same is true for the presence of mitoses in the dermal component of melanocytic lesions other than Spitz nevi. Some benign and malignant melanocytic lesions are associated with marked hyperplasia of the epidermis: in these cases, one should be careful to distinguish mitoses in keratinocytes from mitoses in melanocytes.
9. Melanocytes with an abundant clear cytoplasm having a finely dispersed ("dusty") chromatin. This has been interpreted as a sign of degeneration and is a particularly useful sign.
10. Necrosis of individual melanocytes. This phenomenon should be distinguished from the eosinophilic hyaline bodies (Kamino bodies) seen most often in Spitz nevi.
11. Dermal infiltrate of chronic inflammatory cells, mainly lymphocytes. This is particularly prominent in early lesions and tends to have a bandlike distribution instead of the patchy appearance usually seen in irritated nevi.

So far, no completely reliable ultrastructural, immunohistochemical, or molecular genetic features distinguishing between benign and malignant melanocytic lesions have been described.[922] At the ultrastructural level, there is a greater tendency for abnormal melanosome formation in malignant melanomas than in the benign lesion, but there is a great degree of overlap.[923]

Histochemical and Immunohistochemical Features

At the outset, it should be restated that all of the markers listed in this section are useful (to a greater or lesser degree) to distinguish normal or neoplastic melanocytes from other cell types, but none of them is of great utility in the separation between benign and malignant melanocytic neoplasms.

Melanin stains are silver based and rely on the reducing properties of melanin granules. These argentaffin stains (of which the Fontana–Masson is the most widely used) are particularly useful in two situations: detecting finely dispersed granules that are not immediately apparent in H&E sections or demonstrating (when used in conjunction with a negative iron stain) that the brown pigment seen in the routine sections is melanin rather than hemosiderin.

Immunohistochemically, the typical melanoma is reactive for S-100 protein, HMB-45, Melan-A, tyrosinase, MiTF, and SOX10.[599,924–926] Positivity for S-100 protein, although nonspecific, is of greater practical importance because it is negative in many of the tumors that enter in the differential diagnosis (Fig. 3.77).[927,928] This reactivity is both nuclear and cytoplasmic and is present in more than 90% of the cases.[929] However, it should be noted that melanomas (particularly in their metastases) can lose their immunoreactivity for S-100 protein (and most of the markers discussed next) as a consequence of phenotypic dedifferentiation.[930–932]

HMB-45 is a much more specific marker than S-100 protein (Fig. 3.78).[603] It is particularly useful when the differential diagnosis includes a nonmelanocytic tumor that can also be S-100 protein positive, such as breast carcinoma.[933] It may be detected in S-100 protein–negative melanomas, but on the whole it is less sensitive than the latter. It recognizes a premelanosomal glycoprotein (gp100) related to the tyrosinase system, which explains why it may be negative in undifferentiated amelanotic neoplasms.[934–937]

Melan-A (Mart-1; A103) is a melanocyte differentiation antigen originally identified as a target for cytotoxic T cells, which is detected with the monoclonal antibody A103. It is positive in approximately

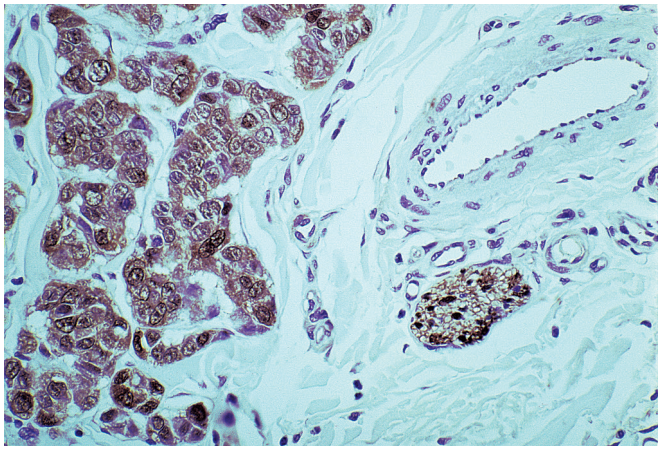

Figure 3.77 Malignant melanoma of skin immunostained for S-100 protein. Strong nuclear and cytoplasmic reactivity is present.

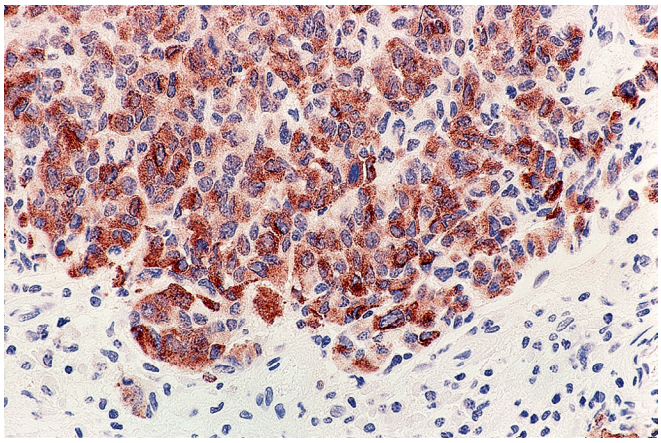

Figure 3.78 HMB-45 immunoreactivity in melanoma.

Figure 3.79 Stage 2 and stage 3 melanosomes with characteristic lattice arrangement in malignant melanoma of skin metastatic to lung (×81,000).

80% of melanomas and has become a widely used marker for this tumor; however, it also stains steroid-producing cells from adrenal cortex, ovary, and testis and the tumors originating from them.[597]

Tyrosinase is a key enzyme for the production of melanin from tyrosine; it can be detected with conventional enzyme histochemical methods (which require fresh tissue) but now also with immunohistochemistry or reverse transcription-polymerase chain reaction (RT-PCR) in paraffin-embedded material.[596,938,939] At the immunohistochemical level, the positivity is in the range of 80%–90%.

MiTF is a nuclear protein needed for the development and postnatal viability of melanocytes, through its function as a master regulator of extracellular signals. It stains nearly all melanomas of conventional type,[598] but—like most other markers—it fails to stain most spindle cell/desmoplastic melanomas,[940] despite early statements to the contrary; furthermore, it can also be positive in a variety of nonmelanocytic spindle cell tumors, including dermatofibroma and smooth muscle tumors.[940]

SOX10 is a nuclear transcription factor that is widely expressed in melanocytic and nerve sheath tumors. It stains nearly all melanocytic tumors, including desmoplastic melanomas, but will also stain myoepithelial cells.[602,926]

SM5-1 and *PNL2* are two relatively new antibodies said to offer significant advantages in terms of sensitivity, a claim that needs independent confirmation.[941,942]

MAGE-1 (melanoma antigen-encoding gene) has also been introduced as a sensitive marker for melanoma, but its diagnostic utility seems very limited.[943,944] NK1/C3 has also been advocated for the identification of melanoma but suffers from considerable cross-reactivity with many other neoplasms.[945,946]

NSE also stains melanoma cells, in keeping with the neuroectodermal nature of these cells, but the stain is of little practical utility. *WT1* is negative in most nevi and positive in most melanomas (including the desmoplastic variety), but its potential utility is diminished by the fact that most Spitz nevi and a third of dysplastic nevi are also positive.[947]

It is important to recognize that, contrary to previous claims, a significant number of melanomas exhibit immunoreactivity for low-molecular-weight keratins (such as those demonstrated with the CAM 5.2 antibody)[948,949]; some cases are also positive for CEA, EMA, α1-antichymotrypsin, and CD68 (KP-1).[948–952]

Electron Microscopic Features

Electron microscopy has previously contributed greatly to the confirmation of a diagnosis of malignant melanoma through the identification of melanosomes and the less specific premelanosomes (Fig. 3.79),[953–955] and it still may in rare cases, but its diagnostic utility is of limited value following the advent of immunohistochemistry.[956] The utility of this technique was brought dramatically to light in a case we examined in an axillary lymph node, which was very suggestive of melanoma in the H&E section but which was negative for S-100 protein and HMB-45 while being positive for low-molecular-weight keratin. Ultrastructurally, the tumor cells had well-developed melanosomes and lacked epithelial features. A regressed primary tumor in the adjacent skin was later detected.

Molecular Genetic Features

Cytogenetic or comparative genomic hybridization studies reveal aberrations of multiple chromosomes in malignant melanoma, whereas they are absent in melanocytic nevi, except some cases of Spitz nevi showing gain of 11p alone.[957] The commoner changes include losses of 6q, 8p, 9p, and 10q and gains of 1q, 6p, 7, 8q, 11q, 17q, and 20q.[957] Of interest, the patterns of chromosomal aberrations seem to differ markedly depending on anatomic location and sun-exposure pattern; for example, acral sites have significantly more aberrations involving chromosomes 5p, 11q, 12q, and 15, whereas lentigo maligna melanomas or melanomas occurring on severely sun-damaged skin show more frequent losses of 17p and 13q.[957]

In melanomas, the MAPK signaling pathway and PTEN/AKT pathway are commonly activated by somatic alterations in the involved genes (Fig. 3.80).[958,959] For the MAPK pathway, there are documented alterations in *KIT* (mutation or amplification in 0%–40%), *NRAS* (mutation in 20%), *BRAF* (mutation in 60%, at a frequency similar to that of melanocytic nevi except Spitz nevi), and *MiTF* (amplification in 20%).[958–961] Of note, in melanomas occurring in acral and chronic sun-damaged skin, *BRAF* and *NRAS* mutations are uncommon, whereas *KIT* alteration is relatively common.[962,963] On the other hand, *KIT* alteration is very rare in melanomas occurring in skin without chronic sun damage.[963] For the PTEN/AKT pathway, *PTEN* shows inactivation by deletion, hypermethylation or mutation in 50% of cases, and *AKT* shows amplification or activation in 60% of cases.[959] This information provides the theoretical framework for targeted therapy to abrogate the pathways (see Fig. 3.80).[959,964]

CDKN2A, the gene implicated in the genesis of some hereditary melanomas, shows inactivating mutation or allelic loss in a small proportion of cases of sporadic melanomas but in almost all melanoma

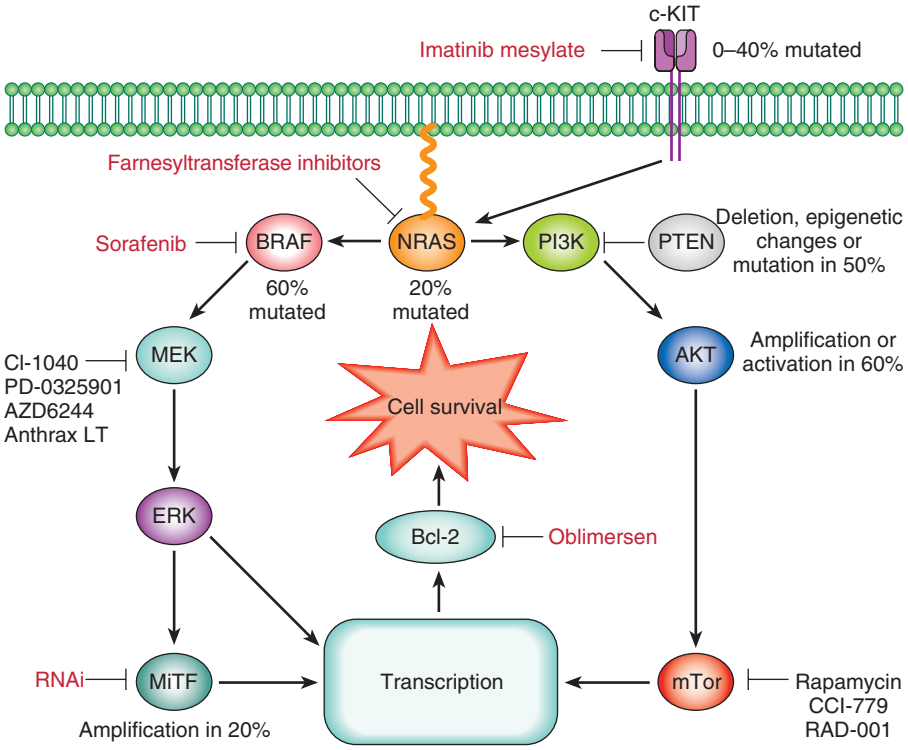

Figure 3.80 Targeted Therapies in Melanoma. Advances in our understanding of the genetics of melanoma have led to the development of targeted therapeutic agents that are directed at commonly observed molecular aberrations in melanoma involved in tumor proliferation and resistance to chemotherapy. *MiTF*, Microphthalmia transcription factor. (Adapted from Singh M, Lin J, Hocker TL, Tsao H. Genetics of melanoma tumorigenesis. *Br J Dermatol*. 2008;158(1):15–21.)

cell lines.[965–968] Mutations in telomerase reverse transcriptase (TERT) promoters are common in melanomas with *CDKN2A* and *BRAF* alterations and in melanomas from intermittently and chronically sun-exposed sites.[969] The combination of *TERT* promoter and *BRAF* mutations is associated with more aggressive behavior.[970]

FISH technique can aid in the distinction between melanoma and nevi by detecting chromosomal aberrations associated with melanoma looking for gain in 6p, loss in 6q, and gain in 11q to support the former diagnosis.[971–974] The discriminatory utility of FISH seems improved with additional probes directed against 9p21 and 8q24.[974] However, not all melanomas have chromosomal aberrations detectable by this technique, and the technique may not have the same degree of sensitivity or specificity in ambiguous lesions.[975] A genetic signature assay has been developed that appears to behave with a similar degree of sensitivity and specificity to FISH on non-ambiguous lesions, but it remains to be seen how well it will perform in routine practice.[976]

Biopsy and Frozen Section

Whenever feasible, an elliptical excisional biopsy with narrow margins (down to the subcutaneous fat) constitutes the best procedure for the initial evaluation of suspicious pigmented skin lesions.[977] However, that is a relatively uncommon practice. Fortunately, there is no evidence that incisional biopsy of a malignant melanoma increases the probability of spread.[978,979] Punch biopsies or incisional biopsies are indicated for extensive lesions (such as giant congenital nevi or lentigo maligna) or for lesions located in certain areas (such as the subungual region). If the lesion proves malignant, a reexcision should be carried out. In experienced hands, the diagnosis of malignant melanoma by frozen section is reliable.[980–982] However, one can hardly justify its routine use on practical grounds, other than for the evaluation of surgical margins.[983] That being said, it is more desirable to evaluate margins on permanent sections.

Regression

Partial regression is a common feature in melanoma. Total regression is much less common, but numerous cases in which the primary tumor regressed completely after giving rise to nodal and distant metastases have been documented.[984–986] This phenomenon may also explain some apparent discrepancies between expected and observed prognosis based on tumor thickness[987,988] and also the fact that in 5%–15% of patients with metastatic melanoma the primary tumor is never found.[989,990]

Clinically, spontaneous regression of melanoma is often heralded by the sudden onset of an irregular halo around the tumor. Microscopically, the early stage of regression is characterized by a dense infiltrate of lymphocytes similar to that seen in spontaneously disappearing nevi. This change may be partial or complete. In the late stage, vascular scar tissue with a variable number of melanin-laden macrophages is present (Fig. 3.81). Several distinctive clinical patterns result from this process. It has been pointed out that only melanomas with an intraepidermal component have been found to undergo spontaneous regression.[991]

Atypical In Situ Melanocytic Lesions

One of the most controversial aspects in the pathology of the melanocytic system is the evaluation and nomenclature of atypical

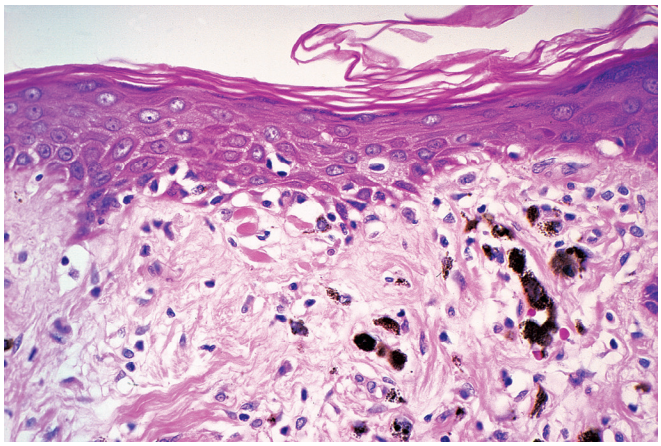

Figure 3.81 Area of Regression in Malignant Melanoma. There is extensive dermal fibrosis, epidermal atrophy, numerous dermal melanophages, and dyskeratotic cells in the dermoepidermal junction. Viable tumor was present in other areas.

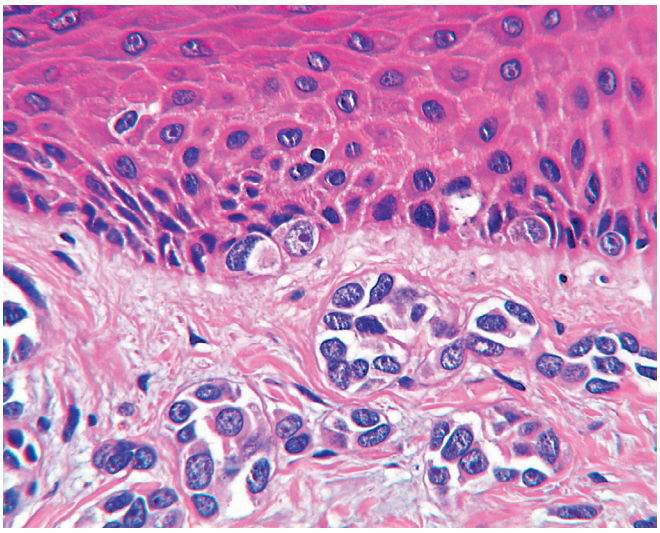

Figure 3.82 Metastatic malignant melanoma with secondary epidermal involvement.

melanocytic lesions that are limited to the epidermis. Such changes may be seen at the periphery of an obvious malignant melanoma,[992,993] in the epidermal component of a compound nevus, or as an isolated finding. Terms such as *atypical* (intraepidermal, premalignant) *melanocytic hyperplasia*, *lentiginous dysplastic nevus*, *melanocytic dysplasia*, *melanocytic intraepidermal neoplasia (MIN)*, *premalignant melanosis*, and *melanoma in situ* have been used for this process, depending on location, some variations in morphologic appearance, and—most of all—the observer's bias.[992–997] In such a situation, it is important to word your report in a way to ensure proper treatment of the patient so that the lesion is completely excised if there is significant concern about the biologic potential regarding the lesion. As mentioned previously, lesions falling short of criteria for melanoma in situ should be diagnosed descriptively with such terms as intraepithelial atypical melanocytic proliferation and intraepithelial melanocytic neoplasia, with the recommendation of complete but conservative reexcision.[998]

Spread and Metastases

Malignant melanoma spreads by growing along the dermoepidermal junction and upper dermis and later by invading the deep dermis and eventually the subcutis and deeper structures, the latter feature being evaluated in a semiquantitative manner by determining the Clark level and Breslow thickness (see later). The deeper the melanoma extends into the dermis or subcutis, the higher the risk of metastasis. Metastases in regional lymph nodes are common even if the nodes appear clinically negative (see next section).

Distant metastases occur most often in the liver, lungs, gastrointestinal tract, bone, and central nervous system but can occur anywhere, including within other tumors.[999,1000] At autopsy, metastases to the heart are found in one-half of the patients.[1001] A certain pattern in the distribution of these metastases, presumably related to the embryologic origin of the organs involved, has been noted.[1002] Cutaneous metastases are also common. Many of them are located close to the tumor ("satellite nodules"), suggesting a lymphatic rather than a blood vessel mechanism. Cutaneous and subcutaneous metastases located between the site of the primary tumor and the regional lymph node are referred to as "*in-transit metastases*." Both satellite nodules and in-transit metastases are usually indicators of disseminated systemic disease.[1003] Cutaneous metastases from melanoma can be difficult to distinguish from a primary lesion because the metastases may develop a secondary intraepidermal component ("epidermotropic" metastases) (Fig. 3.82).[1004] A useful differential feature is the fact that in metastatic carcinoma melanoma with secondary intraepithelial spread, the dermal component is much wider than the epidermal one, whereas the opposite is generally true for the primary lesion.[1005] However, some epidermotropic metastatic malignant melanomas are primarily intraepidermal, simulating malignant melanoma in situ.[1006] Phenotype profile comparison between the primary melanoma and its metastasis usually shows a close concordance, but some markers are lost in the latter as a side effect of tumor progression.[1007]

The behavior of malignant melanoma is very unpredictable. Deaths from metastatic melanoma have been documented 15 years or more after the initial therapy.[1008] Conversely, some patients with widespread satellite nodules in one extremity may survive for many years without evidence of tumor spread beyond that extremity. Immunologic factors likely play a role in the varying behavior of individual tumors. Although the interactions between the tumor and the immune system are incompletely understood, expression of PD-L1 appears to play an important role in the ability of melanoma to downregulate immunosurveillance and contribute to the development of metastasis.[1009,1010] Current therapeutic strategies using immune checkpoint inhibitors are showing great promise in the treatment of this disease.[1011–1014]

Sentinel Lymph Node

The performance of sentinel lymph node biopsy in melanoma has become routine.[1015,1016] This procedure is based on the mechanistic concept that the pattern of metastatic spread of melanoma to the nodes is orderly, and that if the sentinel node (defined as the first node on the direct lymphatic drainage path from the primary tumor) is negative, the likelihood is very high that this will also be true for the other nodes of that region (especially if the tumor burden in the sentinel node is considerable and/or the primary tumor has a high Breslow thickness).[1017,1018] Therefore, if the sentinel node is positive, a lymphadenectomy is carried out. Although there are strong voices of dissent,[1019] most workers in the field maintain that sentinel node biopsy is an accurate staging procedure and a powerful prognostic indicator.[1020–1022]

Sentinel node biopsy is recommended for all melanomas measuring 1 mm or more in thickness or in thinner melanomas with dermal mitotic figures or ulceration.[1023] The node is identified with a dye or an isotope[1024] and sent to the pathology department, where preferably it will be submitted in toto for paraffin embedding serial sectioning, rather than subjecting it to frozen section, acknowledging the fact that discrepant opinions exist regarding the usefulness of the latter procedure in this situation.[1025] In our practice, we do not do frozen sections on sentinel lymph nodes for metastatic melanoma.

Controversy also exists as to the best method for the pathologic evaluation of the sentinel node that will ensure a high detection rate while preventing the other activities of the histology laboratory coming to a full halt. In general, the recommendation is for the examination of a certain number of H&E step sections plus one or more immunostains.[1026–1028] Following an exhaustive pathologic study of 105 sentinel lymph node procedures carried out at the Memorial Sloan Kettering Cancer Center, we concluded that the performance of three levels at 250-µm intervals, each level being composed of a set of three sections stained with H&E, S-100 protein, and HMB-45, will detect the overwhelming majority of the nodal metastases present.[1029] At the Sydney Melanoma Unit, four sequential sections of both halves of each node are examined; the first and fourth sections are stained with H&E, the second is stained for S-100 protein, and the third section is stained for HMB-45.[1030] We would regard as the absolute minimum the performance of three "step" H&E sections (with approximately 10 discarded sections in between) plus one immunostain, among which we and most others prefer HMB-45 (Fig. 3.83).[1031] The addition of immunostains for SOX10 can also be useful in the evaluation of sentinel lymph nodes. Perhaps it should be added here that there is no evidence of a predilection of metastatic melanoma for a particular region of the node.[1032]

It remains to be seen whether molecular techniques for the detection of isolated tumor cells (such as the RT-PCR procedure for tyrosinase) will be a useful adjunct to the combined morphologic and immunohistochemical method just described.[1033,1034] Currently, these methods are not the standard of care and should be considered investigational.

The differential diagnosis of metastatic melanoma to lymph node includes benign nevus cells (nodal nevi) and histiocytes.[1035] Benign nevus cell inclusions are usually limited to the nodal capsule (although they can also be intraparenchymal),[1036] have a typical semilunar shape, lack nuclear atypia, and stain for S-100 protein and Melan-A but weakly or not at all for HMB-45, IMP3, or MIB-1 (Ki-67).[1037,1038] Histiocytes and other cells of the accessory immune system can be a problem because of their immunoreactivity for S-100 protein and occasional positivity for HMB-45, as well as the fact that melanomas can be positive for some of the histiocyte-associated markers.[1039,1040] However, histiocytes should lack nuclear atypia and be positive for CD68/PG-M1 (which melanoma cells usually are not).[1040] Immunostains for SOX10 can help in this situation because melanocytes are positive for SOX10 and histiocytes are not.[1041]

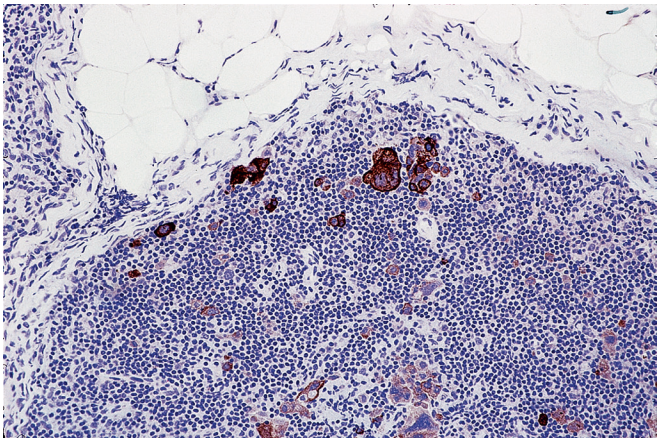

Figure 3.83 Isolated melanoma cells in sentinel lymph node, demonstrated with HMB-45 immunostain.

Treatment

The treatment of choice of most malignant melanomas is wide excision of the primary lesion.[1042] A margin of 3 cm or perhaps even 1 cm is probably sufficient for the average-sized tumor, even if some surgeons in the past have recommended a margin of 5 cm.[1042–1046] Balch et al.[1047] recommended a margin of 2 cm for thin melanomas (less than 0.76 mm in thickness) and a margin of 3–5 cm for thicker lesions, but even this proposal has been questioned in view of the fact that survival in melanoma is unrelated to the width of the margins, irrespective of the width of the tumor.[1048–1051] Indeed, the same group of authors has shown that even in intermediate-thickness melanoma (1–4 mm), a surgical margin of 2 cm is sufficient.[1052] In a randomized clinical trial, Thomas et al.[1053] found that a 1-cm margin for thick (>2 mm) melanomas was associated with a significantly greater risk of regional recurrence than a 3-cm margin but that the overall survival rate was the same.

If the regional lymph nodes are clinically considered to be involved, a radical lymph node dissection should be performed. Removal of clinically negative lymph nodes has always been a very controversial subject. Some authors have been in favor of the procedure based on the finding of microscopic foci of malignant melanoma in almost a fourth of clinically negative nodes.[1054] However, most series have failed to show an improvement of survival in the patients so treated.[1055–1057] A prospective randomized study of stage I melanoma of the limbs showed no differences in survival between the patients who had regional node dissection at the time of the original excision and those who had it only when clinically detectable metastases appeared.[1058–1060] As already indicated in the preceding section, the field has been revolutionized with the introduction of the sentinel lymph node biopsy as a guide for planning therapy and gauging prognosis.

Topical imiquimod appears to be a viable option for treatment of lentigo maligna, especially in patients with persistently positive margins or who are poor surgical candidates.[1061] For disseminated disease, interleukin, biochemotherapy, and interferon have given good results but only in a small percentage of patients.[1062,1063] More recently, targeted therapy directed against melanomas with specific mutations has shown significant effect. Vemurafenib targets the V600E *BRAF*–mutated melanomas, and imatinib mesylate has activity against melanomas with activating *KIT* mutations.[1014,1064,1065] As previously mentioned, checkpoint inhibitors targeting CTLA-4 and PD-1/PD-L1 have shown significant efficacy in the adjuvant setting.[1010–1014]

Prognosis

The death rate for malignant melanoma is still unacceptably high if one considers the fact that this lesion is diagnosable at a stage when it can be cured in nearly every instance. In a series of nearly 3000 patients with melanoma in Norway, published in 1977, the overall 5-year relative survival rate was approximately 60%.[1066] There are many clinical and pathologic factors that have been studied in regard to their influence on prognosis.[1067,1068] Before subjecting the reader to this imposing list, we should mention as an introduction that an analysis of 17,600 patients with melanoma showed that in the tumor (T) staging category, the most powerful predictors of

survival were tumor thickness (Breslow level) and ulceration.[1069] This large study is a powerful validation of the seminal work of Dr. Clark and colleagues and Dr. Breslow.[1070–1072]

Clark and colleagues noted a correlation of adverse prognosis depending on the anatomic level of the skin involved by melanoma. The level of invasion *(Clark's level)* is defined as: *level I* epidermis (melanoma in situ), *level II* papillary dermis, *level III* filling the papillary dermis, *level IV* reticular dermis, and *level V* subcutis.[1073] A direct relationship exists between the level of invasion and the incidence of lymph node metastases and therefore the prognosis.[1074] In one series, regional node metastases were present in 32% of the patients with level III invasion, 67% with level IV, and 66% with level V[1075,1076]; patients with level I and level II did not undergo node dissection, but none of them had clinical evidence of metastases. In the series of Wanebo et al., the 5-year disease-free survival after surgery was 100% in patients with level II invasion, 88% in those with level III, 66% in those with level IV, and 15% in those with level V.[1077,1078]

The concept of anatomic level of invasion was refined in a quantitative manner by Dr. Breslow.[1071,1072] The tumor is measured with an ocular micrometer at right angles to the surface of the adjacent normal skin, from the top of the granular layer of the overlying epidermis or from the ulcer base over the deepest point of invasion to the deepest invasive tumor cells in ulcerated tumors. In the original version, the system assigned the melanomas into low-, intermediate-, and high-risk categories depending on whether their depth is less than 0.76 mm, between 0.76 and 1.5 mm, or greater than 1.5 mm, respectively.[1073] The 5-year disease-free survival is 98% for the first group, 44%–63% for the third, and somewhere in between for the second.[1073,1077–1079] In one series, the 3-year actuarial incidence of subsequent regional metastases in patients initially treated by wide local excision of the melanoma was 0% for lesions less than 0.76 mm, 25% for 0.76–1.50 mm lesions, 51% for 1.51–3.99 mm lesions, and 62% for lesions greater than 4 mm in thickness.[1079]

Note should be taken of the fact that, in recent publications (including the new staging system of melanoma), the groups are divided according to 1-mm increments rather than in the fashion originally devised by Breslow and his followers.[1073] Due to its more reproducible nature, measuring thickness has largely supplanted the use of Clark's level, although the original work of Dr. Clark and colleagues was seminal in our understanding of pathologic staging of melanoma.[1070]

In addition to thickness, the presence of ulceration—however minimal—has emerged as one of the most important prognostic factors in melanoma, as reflected in the AJCC staging system.[1073] The prognostic value remains after the tumor is matched with nonulcerated lesions by thickness, type, and stage.[1080,1081]

Most authors have shown a relationship between dermal mitotic activity and prognosis independently from other parameters.[1082] As a matter of fact, a study of 3661 patients from a single center showed that tumor mitotic rate is a more powerful prognostic indicator than ulceration.[1083] Even a single dermal mitotic figure in a thin melanoma (≤1.0 mm) should prompt consideration of sentinel lymph node biopsy.[1023] In the current staging system, dermal mitoses upstage the tumor stage in thin (pT1) melanomas but not for thicker melanomas.[1073] It should be noted that mitotic figures in melanocytes within the epidermis of adnexal epithelium are not used in determining the mitotic rate. It should also be pointed out that pathologists should assess for mitotic figures as they would routinely and to not go to exhaustive efforts by multiple deeper levels or special stains as the prognostic information is based on routine practice.

Other factors associated with prognosis:

1. *Gender*. In one large series,[1067] the 5-year survival rate was 50.5% for males and 70.5% for females. This improved survival for females results from a variety of factors, such as location and depth of invasion.[1084] However, it seems to remain somewhat better even after these factors have been corrected.
2. *Age*. It has been claimed that younger age is associated with a more favorable prognosis in males but not in females.[1085] One study has shown the adverse prognostic significance of old age, but this is at least partially due to the large percentage of thick melanomas in this age group.[1086]
3. *Pregnancy*. This remains a controversial subject. Isolated case reports have strongly suggested an adverse effect, but several large studies showed no statistical differences in prognosis.[1087,1088] Perhaps part of the difficulty resides in the fact that this alleged influence may be dependent on the stage of the melanoma. Shiu et al.[1089,1190] found no statistical difference in stage I disease but a significantly lower survival rate in pregnant patients (29%) with stage II lesions as compared with nonparous (51%) or nulliparous (55%) patients. Parenthetically, malignant melanoma cells do not contain hormone receptors at the immunohistochemical level, and this also applies to pregnant patients.[1087]
4. *Anatomic location*. Rogers et al.[1091] have defined the following as high-risk sites: scalp, mandibular area, midline of trunk, upper medial thighs, hands, feet, popliteal fossae, and genitalia. These differences may be attributable to their association with thickness. Subungual melanomas have a notoriously bad prognosis, which is probably largely due to their late detection.
5. *Clinicopathologic type*. Early articles describing the three major types of malignant melanoma claimed a better prognosis for lentigo maligna melanoma, a worse prognosis for nodular melanoma, and an intermediate prognosis for superficially spreading melanoma.[1070,1092] More recent studies have shown that, once depth of invasion is entered into the equation, most of these differences are erased. The behavior of acral lentiginous melanoma is particularly aggressive, but again this may be the consequence of its propensity for deep invasion and ulceration: in the series of Coleman et al.,[1093] the average 3-year survival rate was 11%.
6. *Cytologic features*. Whether the melanoma cells are spindle, epithelioid, or any other shape seems to bear no direct relationship to the prognosis.[1094,1095]
7. *Cell proliferative activity*. Melanomas have been stained for cell proliferation markers, such as MIB-1 (Ki-67) and PCNA, the latter rarely used at present. A relationship has been demonstrated between this parameter and the thickness of the tumor, but there is controversy as to whether it offers independent prognostic information.[1096–1099] We do not recommend routine use of proliferative markers in the assessment of melanomas.
8. *Dermal inflammatory infiltrate*. It has been found that a dense lymphocytic infiltrate around the melanoma is associated with a better prognosis, particularly if the lymphocytes are closely intermingled with the neoplastic melanocytes ("tumor-infiltrating lymphocytes").[1100,1101] The intensity of this reaction has been graded using the odd terminology brisk, non-brisk, and absent and found to have a strong predictive value in melanomas with a vertical growth phase.[1102] Conversely, the presence of numerous plasma cells in the infiltrate is said to correlate with an increased probability of lymph node metastases.[1103] Although some of the significance of these findings may diminish after correcting for tumor thickness, tumor infiltrating lymphocytes have been shown to be an independent prognostic factor.[1104]
9. *Regression*. The significance of regression is controversial. It has been claimed that the presence of focal areas of regression in a malignant melanoma may modify the significance of the level or thickness of the residual tumor (Fig. 3.81). Regression, even

if focal, may explain why relatively superficial melanomas exhibiting focal regression may be associated with an incidence of lymph node metastases higher than that expected on the basis of these determinations.[988] However, other studies have failed to confirm this claim.[1105–1107] These discordant results likely reflect our poor understanding of the complex interactions of melanoma with the immune system.

10. *Angiotropism*. Angiotropism (defined not as conventional blood vessel invasion but as growth of melanoma cells along the external surface of blood vessels) has been found to be a predictor of local recurrence and in-transit metastases.[1108]
11. *Microscopic satellites*. The presence of microscopic satellites, defined as tumor nests greater than 50 μm in diameter separate from the main tumor mass, shows a high association with regional lymph node metastases and therefore with prognosis.[1109]
12. *Metastases to sentinel node*. The prognostic value of this procedure is well established and may constitute the reason why its performance has become so ubiquitous. Among cases with positive sentinel nodes, the prognosis is related to the tumor burden and to the presence of extranodal extension.[1110,1111] It has been suggested that isolated HMB-45 or Melan-A-positive cells do not impact behavior,[1112] but this has not been widely accepted and currently any amount of tumor involving a lymph node is still considered significant.[1073]

Other Pigmented Skin Lesions

There are several types of benign and (less commonly) malignant skin lesions that are neither melanocytic nevi nor malignant melanoma.

Hyperpigmentation, whether regional or generalized, is the result of stimulation of melanocytes by a variety of stimuli, such as sunlight, heat, drugs, hormones (as in pregnancy), dietary deficiency (as in kwashiorkor), metabolic disorders (such as Gaucher disease), scars, and a variety of dermatoses (generically referred to as postinflammatory hyperpigmentation).[1113] The only microscopic change (rarely seen because of the infrequency of biopsies in this group of conditions) is increased pigmentation of basal melanocytes, accompanied by increased transfer of melanin into the adjacent keratinocytes and melanophages in the dermis.

Ephelis (freckle) arises in sun-exposed skin of susceptible individuals and shows microscopically mild hyperpigmentation of basal melanocytes and basal keratinocytes, associated with a normal epidermal *architecture*.

Solar lentigo shows elongation of rete ridges and increased pigmentation of the basal and suprabasal layers; this lesion is related to keratosis rather than to simple lentigo, and it may have a reticulated appearance (Fig. 3.84).[1114]

Café au lait spot, as seen in Recklinghausen disease but also in other genetically determined diseases and in 10% of the general population, is characterized microscopically by basal hyperpigmentation of the epidermis and, at the ultrastructural level, by the presence of macromelanosomes.

Becker nevus, typically seen in the shoulder, chest, or lower back, shows increased epidermal pigmentation associated with mild acanthosis and sometimes hypertrichosis. Some Becker nevi have an increased number of smooth muscle bundles in the dermis.[1115]

Pigmentation can also occur in several types of nonmelanocytic skin neoplasms because of increased activity of melanocytes or increased retention of pigment in the epithelial cells. The most striking example is *melanoacanthoma*, in which dendritic melanocytes and keratinocytes participate in the formation of this benign lesion, which some authors regard as an entity and others (including ourselves) as a variant of seborrheic keratosis.[1116]

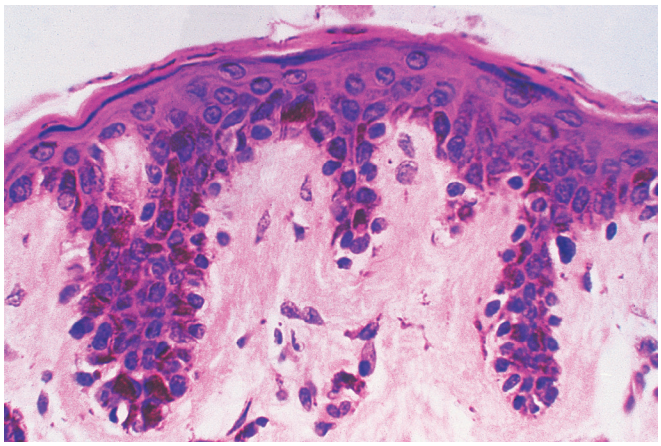

Figure 3.84 Microscopic Appearance of Solar Lentigo. There is elongation of rete ridges associated with hyperpigmentation of the basal layer.

Malignant basomelanocytic tumor is a rare lesion having a dual neoplastic cellular composition, one of melanocytic and the other made up of basal cell carcinoma–like cells.[1117,1118] The basal cell component of these tumors tends to be of high grade. In one of the reported cases, the tumor metastasized as a malignant melanoma.[1119] *Malignant squamomelanocytic tumor* is another lesion having a dual neoplastic population, one (like the former) of melanocytic nature and the other made up of squamous cell carcinoma–like keratinocytes.[1120,1121]

Other lesions that may be heavily pigmented are ordinary seborrheic keratosis, acrochordon, dermatosis papulosa nigra, actinic keratosis, Bowen disease and bowenoid papulosis, basal cell carcinoma, and some adnexal tumors (particularly trichoepithelioma, pilomatrixoma, and eccrine poroma). In pigmented basal cell carcinoma, both participation of dendritic melanocytes and retention of pigment in the neoplastic epithelial cells occur.

Neuroendocrine Cells

Merkel Cell Carcinoma

Merkel cell carcinoma is the currently preferred term for a distinctive cutaneous malignancy originally described as trabecular carcinoma,[1122,1123] but now referred to as Merkel cell carcinoma.[1124,1125] It occurs mainly in adults and elderly individuals, with rare cases described in children.[1126] The face and extremities are the most common locations (Figs. 3.85 and 3.86).[1127,1128] Clinically, it appears as a nodular, sometimes ulcerated lesion with a reddish or violaceous hue. Microscopically, the tumor is centered in the dermis or sometimes in the subcutaneous tissue, with the overlying epidermis being usually uninvolved.[1129] The monotonous nature of the dermal round cell infiltrate and the diffuse pattern of infiltration of the subcutaneous fat are responsible for its occasional misdiagnosis as malignant lymphoma (Fig. 3.87).[1130,1131] The pattern of growth can also be trabecular, but it is rare for this to be the predominant feature (hence the inappropriateness of the term trabecular carcinoma).[1132] The diagnosis of Merkel cell carcinoma can be made on the basis of the cytologic features as seen in a good H&E-stained slide (Fig. 3.88). The cytoplasm is scanty but visible as a thin acidophilic rim; the nuclei are round and vesicular, with a typically fine granular ("dusty") chromatin and multiple nucleoli. Mitotic figures and fragmented nuclei (probably as the result of apoptosis) are plentiful. Necrosis may be present, sometimes accompanied by the Azzopardi phenomenon (hematoxyphilic staining of vessel walls and fibrous

Figure 3.85 Merkel Cell Carcinoma. This unfortunate patient had involvement of almost the entire face by an extensively ulcerated neoplasm that failed to respond with chemotherapy after an initial diagnosis of malignant lymphoma.

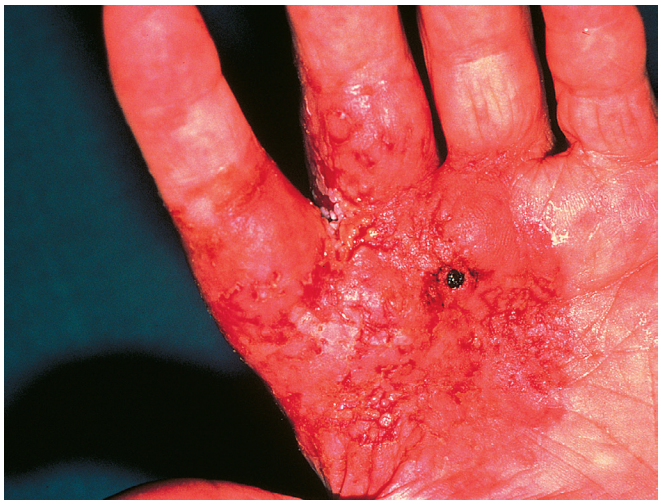

Figure 3.86 Merkel Cell Carcinoma Involving the Hand. This particular lesion was associated with Bowen disease of the overlying epidermis.

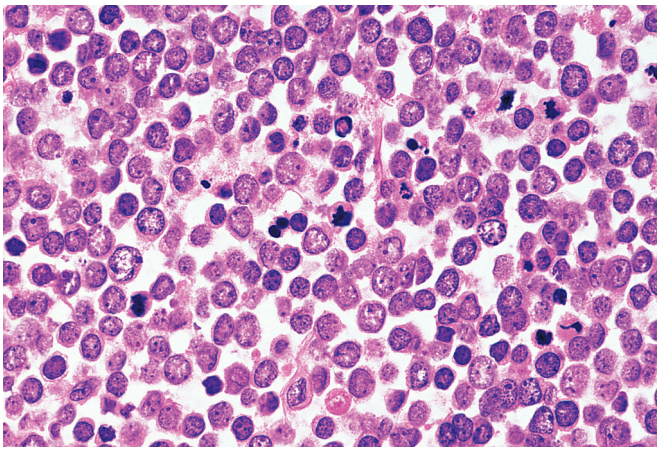

Figure 3.87 Medium-power view of Merkel cell carcinoma.

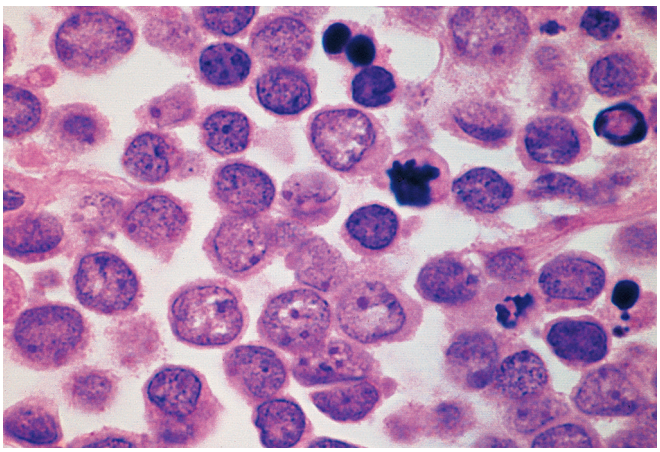

Figure 3.88 High-power view of the same tumor shown in Fig. 4.135. Note the finely granular, dusty quality of the chromatin and the small nucleoli.

septa).[1133] The stroma often contains proliferated vessels with plump endothelial cells, a feature that these tumors share with many other malignant neoplasms having a primitive neural phenotype.[1133,1134]

Merkel cell carcinoma can be seen in association with in situ or invasive squamous cell carcinoma, with duct-like structures of eccrine type, and with basal cell carcinoma-like areas, suggesting that it originates from a multipotential stem cell of ectodermal derivation.[1076,1135–1138] Rarely, it exhibits focal or extensive intraepidermal pagetoid spread (Fig. 3.89).[1139] Even more rarely, the entire tumor can be intraepidermal, either pure or associated with squamous cell carcinoma in situ.[1140,1141]

Exceptionally, Merkel cell carcinoma can show foci resembling leiomyosarcoma, rhabdomyosarcoma, or atypical fibroxanthoma, either in the primary tumor or in the recurrences as a result of dedifferentiation/divergent differentiation.[1142–1144] The differential diagnosis includes the reciprocal phenomenon, i.e., rhabdomyosarcomas with aberrant expression of neuroendocrine markers.[1145]

When examined ultrastructurally, the tumor cells are seen to contain dense-core neurosecretory granules (sometimes arranged immediately beneath the cell membrane) and tightly packed perinuclear intermediate filaments (Fig. 3.90).[1130,1146,1147] Filament-rich rigid spinous processes ("cytoplasmic spikes") similar to those seen in normal Merkel cells have been detected in a few cases.[1148–1150]

Immunohistochemically, positivity for low-molecular-weight keratin, neurofilaments, and NSE is usually obtained (Fig. 3.91).[1151–1154] Notably, the positivity for keratin is predominantly for cytokeratin 20[1154,1155] and often has a distinct perinuclear dot-like quality, a feature found only exceptionally in small cell carcinomas of internal organs (we have seen it in isolated cases of neuroendocrine tumors of the salivary gland, pancreas, and thyroid).[1156] The consistent positivity for CK20 and neurofilaments and the negativity for TTF-1 (allowing for the inevitable exceptions)[1157,1158] are important in the differential diagnosis with metastatic small cell neuroendocrine carcinoma of

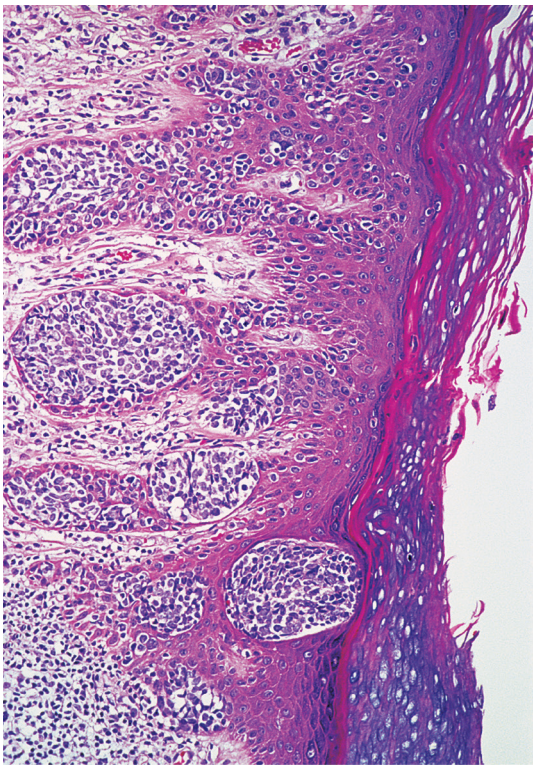

Figure 3.89 Merkel cell carcinoma showing marked degree of epidermotropism. (Slide contributed by Dr Philip LeBoit, San Francisco.)

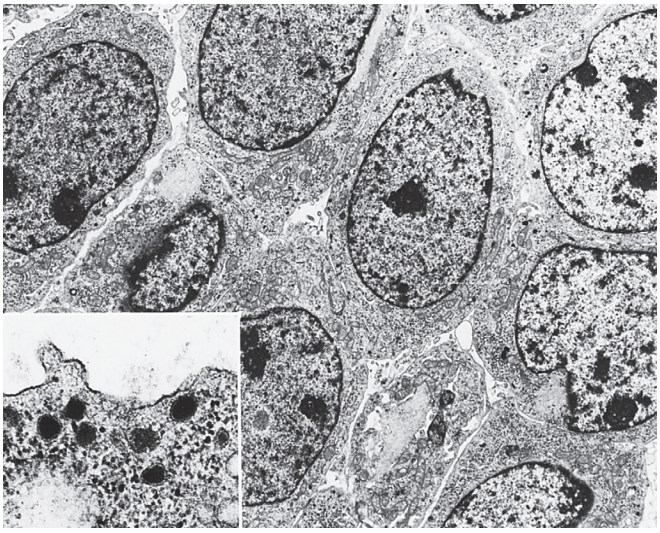

Figure 3.90 Same Tumor Shown in Figs. 3.87 and 3.88. Ultrastructurally, neurosecretory-type granules are seen in periphery of cytoplasm beneath cell membrane (×4400; inset ×41,100).

lung.[1090,1159–1161] However, exceptions occur, such as cases that are positive for CK7 while negative for CK20.[1162]

In addition to the markers just listed, cases of Merkel cell carcinoma have shown reactivity for chromogranin, synaptophysin, vasoactive intestinal peptide, pancreatic polypeptide, calcitonin, substance P, somatostatin, ACTH, other peptide hormones, PAX-5 (a B-cell related transcription factor and therefore a potential source of confusion with lymphoma),[1163] TdT (the same warning applies),[1164,1165] glypican-3,[1166] and CD117.[1167–1169]

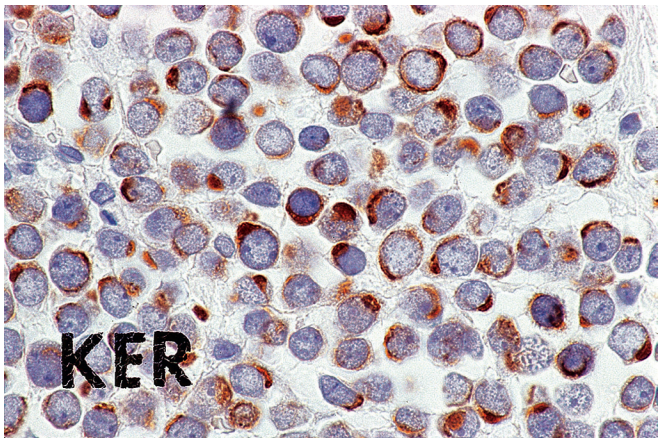

Figure 3.91 Dot-like immunoreactivity for keratin in Merkel cell carcinoma.

A most interesting development has been the demonstration that a new polyoma virus is clonally integrated in the genome of the majority of Merkel cell carcinomas, with truncating mutations in the viral large T antigen gene.[1170] This can be demonstrated by PCR or immunohistochemistry.[1171,1172] The virus is present in approximately 75%–80% of the cases in the United States, but much less frequently in cases from Australia, where UV radiation is the more important etiologic factor.[1173]

Merkel cell carcinoma is an aggressive neoplasm. Regional nodal metastases are common, and distant metastases also occur, particularly to the lungs, liver, and bones,[1174,1175] but also to unusual sites, such as the testis.[1176] Occasionally, a morphologically and genetically typical Merkel cell carcinoma is found in a lymph node (most often inguinal) in the absence of a primary skin tumor.[1177] The most likely explanation for this occurrence is spontaneous regression of the primary tumor (a phenomenon analogous to that which has been well documented in melanoma).[1178–1180]

Previously, the recommended treatment for Merkel cell carcinoma was wide resection of the primary site and regional lymph node dissection.[1181,1182] Current guidelines incorporate the use of sentinel lymph node biopsy with lymph node dissection reserved for patients with positive sentinel lymph nodes or obvious metastasis at presentation.[1183] Radiation therapy can be effective as an adjunct,[1183–1186] and chemotherapy has been used for metastatic tumors.[1183,1186–1188] Locoregional recurrence carries an ominous prognostic significance.[1189]

Other Neuroendocrine Tumors

Sometimes, tumors with an appearance similar to pulmonary small cell neuroendocrine carcinoma and large cell neuroendocrine carcinoma[1190] are found in the skin. They probably represent morphologic variants of Merkel cell carcinoma, but the possibility of a metastasis from an internal organ should always be ruled out.[1191] Like otherwise typical Merkel cell carcinomas, these neuroendocrine carcinomas of skin may show divergent differentiation along skeletal muscle or other mesenchymal lines.[1192]

Most cases reported in the past as peripheral neuroblastomas of skin fit into the category of Merkel cell carcinoma; others are clearly different and of unquestionable neural derivation.[1193] Still others belong to the Ewing sarcoma and Ewing sarcoma-like family of tumors.[1194] Carcinoid tumors of both insular and trabecular types, allegedly primary in the skin, have also been reported.[1195–1197] These should be distinguished from skin metastases from carcinoid tumor of internal organs, particularly lung.

Figure 3.92 Gross appearance of keloid of ear. The lesion has a polypoid shape.

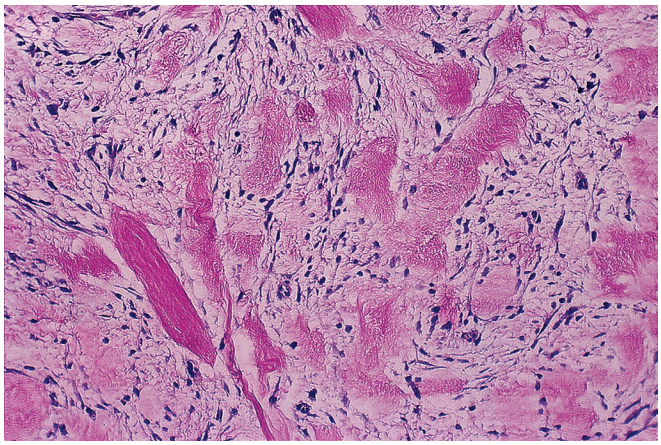

Figure 3.93 Microscopic appearance of keloid, with characteristic wide bands of hyalinized collagen.

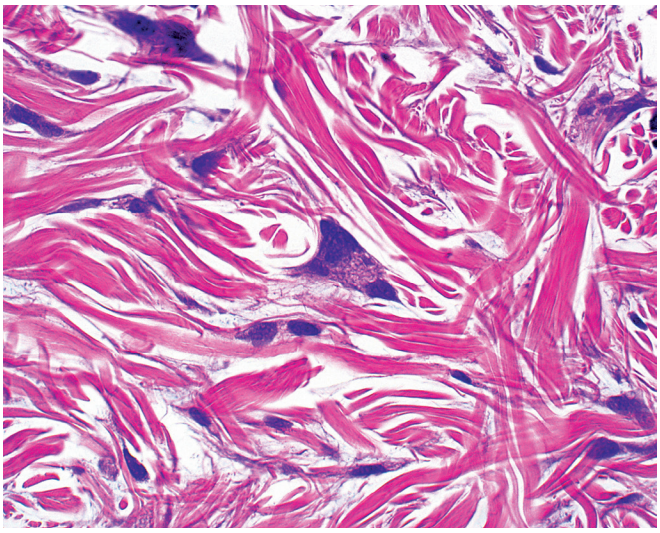

Figure 3.94 Pleomorphic Fibroma. A large triangular cell with hyperchromatic nuclei is encased within dense fibrous tissue.

Dermis

Fibroblastic Tumors and Tumorlike Conditions

Keloid is an abnormal pattern of dermal reaction to injury that results in an unusual hypertrophic scar, seen most commonly in African-American persons (Fig. 3.92). The earlobe is one of the most common locations. It is characterized by the formation of wide acidophilic bands of collagen, with seven fibroblasts and myofibroblasts running in parallel between them (Fig. 3.93).[1198–1200] The immunohistochemical profile also shows some differences.[1201] This distinction is useful in estimating the probability of recrudescence, which is much higher for keloids than for hypertrophic scars. Another differential diagnosis is with so-called keloidal dermatofibroma, in which an otherwise typical dermatofibroma exhibits an area similar to keloid in its superficial portion.[1202] A keloid-type change is sometimes also seen as a complication of acne ("acne keloidalis").[1203] In keloids that have been injected with steroids, a common treatment, pools of mucinous material can be found.[1204]

Acrochordon (soft fibroma, fibroepithelial polyp, cutaneous tag) is a non-neoplastic polypoid lesion composed of a loose connective tissue core covered by a normal to slightly hyperplastic (sometimes hyperkeratotic) epidermis. The absence of adnexal structures in the underlying dermis is a clue to the diagnosis.

Pleomorphic fibroma has a denser collagenous background, and it contains scattered bizarre cells with hyperchromatic nuclei and stellate cytoplasm, usually unaccompanied by mitotic activity (Fig. 3.94)[1205]; the lesion is the cutaneous equivalent of the more common polypoid lesion seen in squamous-covered mucosal membranes, such as nasal cavity, oral cavity, and urogenital tract[1206] (see respective chapters). It is probably closely related to giant cell collagenoma[1207] but distinct (also on immunohistochemical grounds) from dermatofibroma with monster cells.[1208] Other variations on the theme of benign pseudosarcomatous polypoid lesions of the skin have been described.[1209]

Fibrous papule of the face appears clinically as a solitary, dome-shaped, firm lesion that is frequently mistaken for basal cell carcinoma, clinically. The nose is by far the most common site (hence the alternative term "fibrous papule of the nose").[1210] Microscopically, there are increased vessels with a dilated lumen separated by a fibroblastic stroma containing stellate and sometimes multinucleated cells similar to those of pleomorphic fibroma.[1211] The numerous hair follicles are surrounded by a concentric array of collagen fibers. Expression of NKI/C3 is common.[1212] This lesion, which anatomically is best described as an angiofibroma, should be distinguished from a fibrosing (involuting) melanocytic nevus, a not always easy but practically inconsequential task.[1213]

Sclerotic fibroma (storiform collagenoma) is characterized by the heavy deposition of collagen with a so-called wood-grain pattern in a markedly hypocellular lesion having well-circumscribed outlines.[1214] The collagen is predominantly of type I,[1215] and there is expression of CD34.[1216] This is probably a heterogeneous condition, with some of the cases representing the end stage of a folliculitis.[1217] Multiple fibromas of the face, scalp, and subungual region are seen in tuberous sclerosis, together with angiofibroma of the face and "shagreen patches" in the lumbosacral region. Multiple sclerotic fibromas are also a marker for Cowden disease.[489]

Collagenous fibroma (desmoplastic fibroblastoma) is a different lesion from sclerosing (sclerotic) fibroma despite the misleadingly similar terminology. It is typically subcutaneous, sometimes associated with fascial involvement, and is characterized microscopically by bland stellate and spindle-shaped fibroblasts embedded in a collagenous or myxocollagenous matrix.[1218–1220]

Dermatomyofibroma (cutaneous myofibroma) is a benign cutaneous, plaque-like proliferation of fibroblasts and myofibroblasts (the identity of the latter having been confirmed ultrastructurally) centered in the deep dermis and subcutis.[1221] It is most commonly found in and

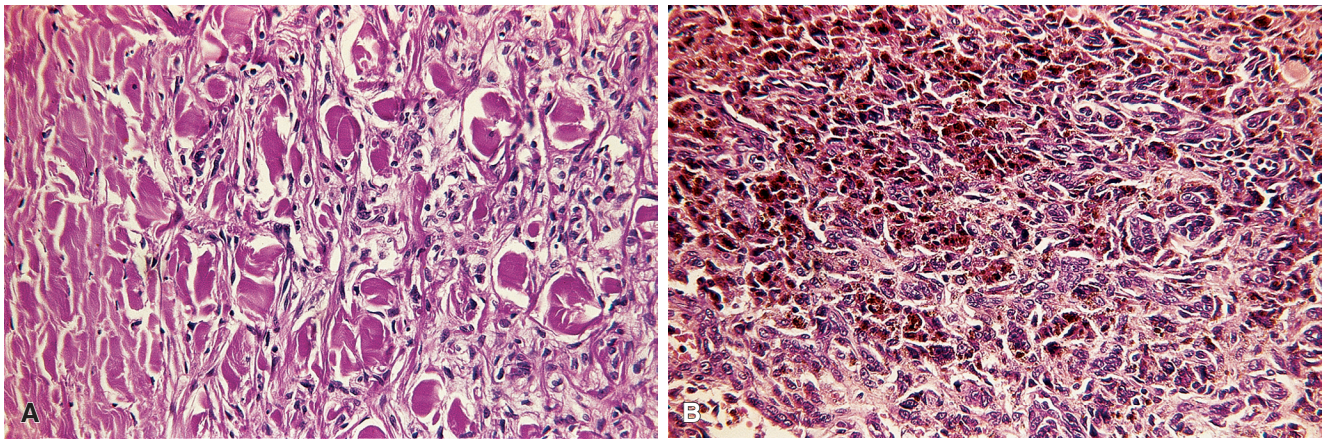

Figure 3.95 Benign Fibrous Histiocytoma of Skin. The tumor depicted in **A** is predominantly fibrous, whereas that shown in **B** is mainly composed of hemosiderin-laden macrophages.

around the shoulder of young women.[1222–1224] When hemorrhagic, it may simulate plaque-stage Kaposi sarcoma.[1225] Focal positivity for smooth muscle actin and CD34 is the rule. The behavior is benign.[1226] It may be related to the recently described fibroblastic connective tissue nevus which has significant histologic and immunophenotypic overlap.[1227]

Solitary fibrous tumor and *nodular fasciitis* have been reported in the skin, their microscopic appearance being similar to those of their more common deep-seated counterparts.[1228,1229] However, some lesions reported to be cutaneous solitary fibrous tumors may in fact be spindle cell lipomas with little mature adipose tissue.[1230]

Fibrohistiocytic Tumors and Tumorlike Conditions

Benign Fibrous Histiocytoma

Benign fibrous histiocytoma (also known as dermatofibroma, histiocytoma, and sclerosing hemangioma) refers to a spectrum of firm, nodular, nonencapsulated, often pigmented lesions that occur chiefly on the extremities.[1231,1232] Clinically, they may be single or multiple and have a flat, polypoid, or depressed shape. Most of them are less than 1 cm in diameter, but some can reach huge proportions. When heavily pigmented, they may be confused clinically with nevi, malignant melanoma, Kaposi sarcoma, and other vascular tumors. On transection, they are usually solid and rather well circumscribed but not encapsulated, the color ranging from white to yellow to dark brown, depending on the relative amounts of fibrous tissue, fat, and hemosiderin. Microscopically, there is a cellular fibroblastic-like proliferation with varying amounts of collagen deposition, admixed with a variable number of macrophages, most of which may contain fat (thereby acquiring a foamy appearance) or hemosiderin. Some of these histiocytes are multinucleated and may acquire the features of Touton giant cells. Much more rarely, they have osteoclast-like features, with or without accompanying bone formation.[1233,1234] Mitotic activity and MIB-1–measured proliferative index are typically low.[1235]

The lesion is characteristically centered in the upper dermis, but it can involve the deep dermis and occasionally extend into the subcutis.[1236–1238] The fibrohistiocytic proliferation is set in a fine vascular network, which can be very prominent (Fig. 3.95). The presence of this vascular component is responsible for this lesion having been regarded in the past as a sclerosing hemangioma and

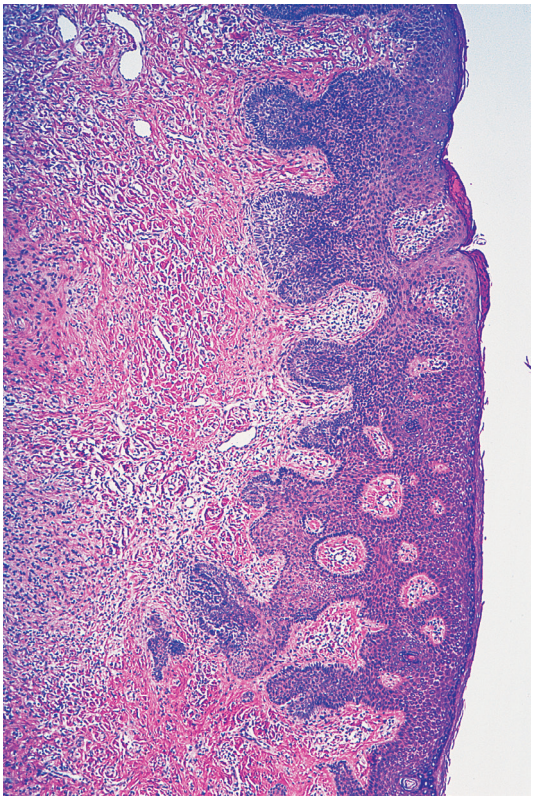

Figure 3.96 Benign Fibrous Histiocytoma. This lesion is associated with basaloid proliferation of the overlying skin. This change does not represent a basal cell carcinoma.

for the fact that it is still occasionally misdiagnosed as Kaposi sarcoma, especially when occurring in HIV-infected individuals. Focal storiform features may be seen, but they are rarely as well developed as in dermatofibrosarcoma protuberans (DFSP).

The overlying epidermis is often acanthotic but can be normal or atrophic. Sometimes there is a proliferation of hair germ–like structures in the basal layer of the epidermis (follicular induction), and rarely a full-blown basal cell carcinoma develops (Fig. 3.96)[1239,1240]; the epidermal growth factor receptor is said to play a role in this interesting phenomenon.[1241] More rarely, there is sebaceous hyperplasia[1242] or even a squamous cell carcinoma in situ.[1243]

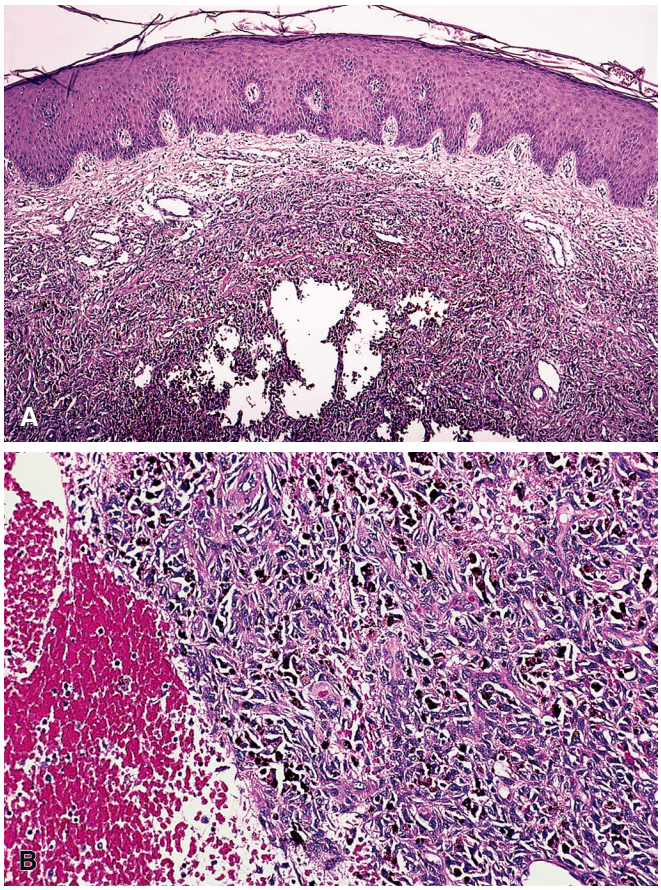

Figure 3.97 Aneurysmal Fibrous Histiocytoma. A, Low-power appearance. The empty space in the center of the lesion was occupied by blood. **B,** Higher-power view, showing recent and old hemorrhage.

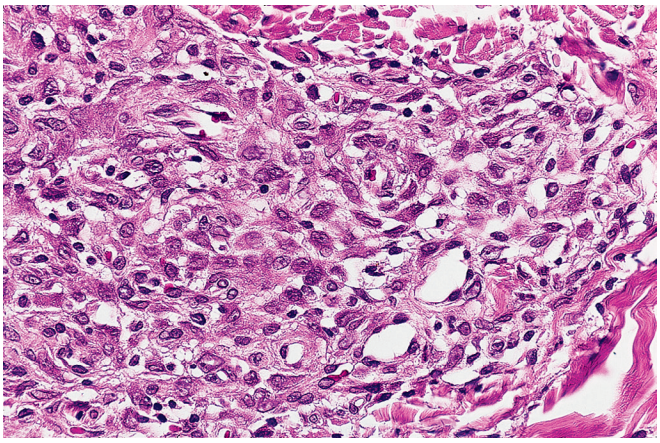

Figure 3.98 Epithelioid fibrous histiocytoma.

Morphologic variations of dermatofibroma include prominent palisading similar to that seen in peripheral nerve tumors,[1244] keloid-like changes,[1202] myxoid changes,[1245] granular cells,[1246–1248] markedly lipidized cells,[1249] clear cells,[1250,1251] balloon cells,[1252] signet ring cells,[1253] diffuse eosinophilic infiltrate,[1254] and lichenoid, erosive, and ulcerated features.[1255] Sometimes two or more of these variations coexist.[1256] Marked focal cellular atypia (manifested by the presence of "monster cells"),[1257–1259] extreme cellularity (sometimes associated with necrosis),[1260] and the presence of large cystic changes filled with blood may also occur. The latter lesion, referred to as hemorrhagic, aneurysmal (Fig. 3.97), or angiomatoid, should be distinguished from the *angiomatoid fibrous histiocytoma* seen in deeper sites in younger patients (see chapter on soft tissue tumors).[1261,1262] Due to nomenclature similarity with angiomatoid fibrous histiocytoma, a completely different neoplasm, the use of the term *angiomatoid* when describing benign fibrous histiocytomas with hemorrhage is strongly discouraged. *Epithelioid* fibrous histiocytoma (epithelioid cell histiocytoma) is yet another variation on the theme, characterized by the presence of large "angulated" epithelioid cells as the main constituent (Fig. 3.98).[1263–1266] This tumor is notorious for its ability to simulate vascular and melanocytic neoplasms.[1266] This variant has rearrangements of *ALK*, and immunohistochemical stains can be a useful adjunct to the diagnosis.[1267]

Immunohistochemically, dermatofibromas are positive for factor XIIIa, a proenzyme known to be present in so-called dermal dendrocytes,[1268,1269] and for HMGA1/HMGA2 (members of the high mobility group protein family genes).[1270] In contrast with DFSP, they are negative for CD34.[1268,1270,1271] Another group of markers that dermatofibromas often exhibit are those associated with smooth muscle/myofibroblastic differentiation, such as actin, desmin, and myosin; this is not generally known and has led to misdiagnoses, such as leiomyoma or—worse—leiomyosarcoma.[1272,1273] However, truth be told, immunohistochemical stains are rarely needed in the diagnosis of dermatofibromas, except in partially sampled lesions in superficial biopsies.

There was a longstanding controversy as to whether dermatofibroma is a neoplastic or reactive condition, but the occurrence of aggressive and even metastasizing forms of the disease (see later) and the evidence of clonality at the molecular level have effectively disproven the idea that dermatofibromas are reactive in nature.[1274–1276]

The behavior of dermatofibroma is generally very indolent, to the extent that local recurrence is very rare even if the margins are inadequate. However, cases with locally aggressive behavior and even with distant metastases are on record.[1277–1281] This is seen more commonly with lesions located in the face and those exhibiting deep extension into the subcutaneous tissue and/or cellular fascicles of mitotically active spindle cells, but it remains an exceptionally rare occurrence, and histologic features are not predictive of aggressive behavior. It does appear that dermatofibromas with metastatic potential may have increased chromosomal aberrations compared with conventional dermatofibromas, but these changes are not reflective in histologic features and are not practical for routine use.[1282,1283]

Atypical Fibroxanthoma

Atypical fibroxanthomas are nodular, sometimes ulcerated tumors that typically occur on the sun-exposed skin of elderly persons and are often clinically confused with cutaneous carcinomas (Fig. 3.99).[1284–1286] Histologically, the tumor is often polypoid and ulcerated, especially when occurring at the classical sites (Fig. 3.100). Bizarre tumor cells are seen scattered within a spindle cell stroma with varying amounts of inflammation (Fig. 3.101). Mitoses are plentiful, some of them being atypical. However, in some instances there is little pleomorphism and a predominance of spindle cells.[1287] The overlying epidermis may be normal, atrophic, hyperplastic, or ulcerated, but by definition it should not show continuity with the tumor. Morphologic variations include tumors with pigmentation,[1288] with osteoclast-like giant cells,[1289,1290] with clear cells,[1291,1292] (which should be distinguished from other dermal clear cell mesenchymal neoplasms),[1293] and with granular cells.[1294,1295]

Immunohistochemically, the various components of the lesion may show reactivity for vimentin, actin, calponin, h-caldesmon, CD68 (detected with monoclonal antibody KP-1), α1-antitrypsin,

Figure 3.99 Clinical appearance of atypical fibroxanthoma. The lesion is characteristically elevated, reddish, and ulcerated.

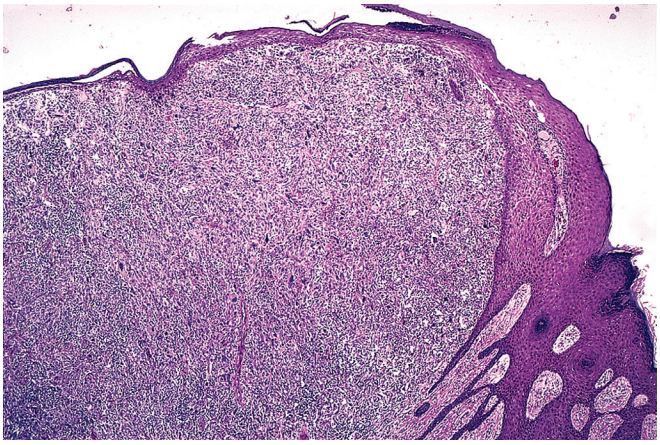

Figure 3.100 Low-power view of atypical fibroxanthoma. The lesion is typically polypoid and ulcerated.

α1-antichymotrypsin, cathepsin-B, FXIIIa (focal), S-100 protein (focal), CD10, CD117, and CD99 and negativity for keratin, EMA, and desmin.[1296–1301] From a practical standpoint, the absence of any keratin expression and absence of diffuse S100 protein expression is more important than any positive marker. There are rare reports in the literature of so-called keratin-positive atypical fibroxanthomas, which in our opinion are more likely sarcomatoid squamous cell carcinomas.[1302]

Despite the bizarre microscopic features that suggest a high-grade lesion, atypical fibroxanthomas are relatively indolent lesions that are usually cured by local excision.[1303] However, some cases have resulted in local recurrence, and a few have metastasized.[1304,1305]

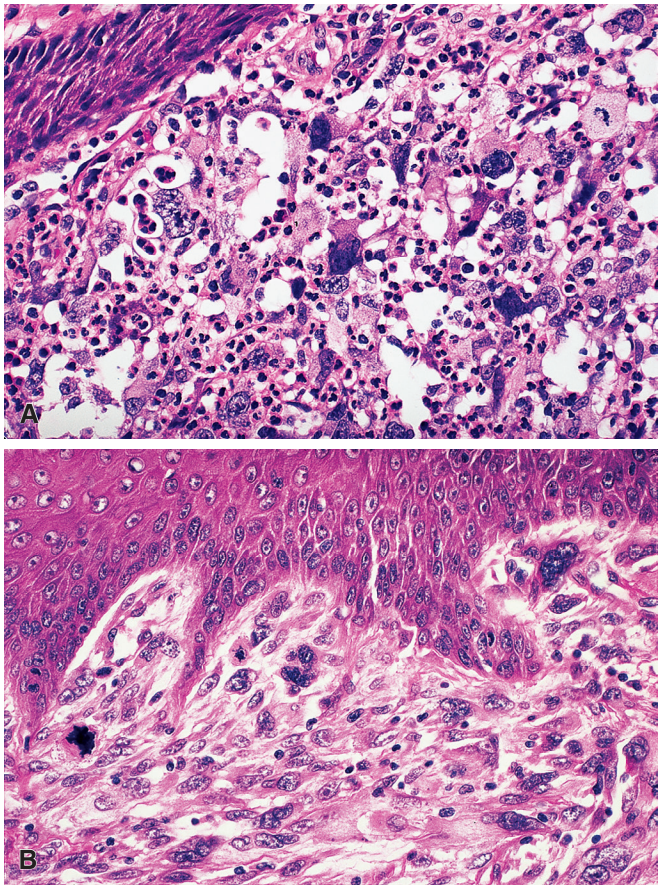

Figure 3.101 **A** and **B,** High-power views of atypical fibroxanthoma, showing highly anaplastic cells in the dermis surrounded by an inflammatory infiltrate.

Factors that portend aggressive behavior and possible metastases in atypical fibroxanthoma are vascular invasion, extension into deep tissues, tumor necrosis, local recurrence, and history of immunosuppression,[1304] but rare cases without these features may behave in an aggressive fashion.[1305] Cases with the aforementioned histologic features are probably best classified as *pleomorphic dermal sarcoma*, a tumor that shares demographic features with atypical fibroxanthoma but is infiltrative and has a significant risk of metastasis.[1306]

Dermatofibrosarcoma Protuberans

DFSP are slow-growing, nodular, polypoid neoplasms that are found almost exclusively in the dermis, from which they often invade the subcutaneous tissue (Fig. 3.102). However, sometimes they are entirely subcutaneous, with little or no dermal involvement.[1307] Most of the cases occur in adults, but they have also been seen in infancy and childhood.[1308] As a group, these tumors are much larger than benign fibrous histiocytomas; however, the diagnosis of DFSP should not be made or ruled out on the basis of size alone. Microscopically, the appearance of radial whorls of spindle cells producing the storiform or cartwheel pattern is characteristic although not pathognomonic (Fig. 3.103). Other features of diagnostic importance are the high cellularity, monomorphic appearance, diffuse infiltration of subcutaneous fat (Fig. 3.104), lack of foamy or hemosiderin-laden macrophages and/or multinucleated giant cells, and lack of peripheral collagen trapping characteristic of dermatofibroma. Myxoid features can be present focally and sometimes be the dominant feature of the tumor.[1309–1311] Bundles of plumper spindle cells of myoid

Figure 3.102 Gross appearance of dermatofibrosarcoma protuberans, showing typical bulging above the skin.

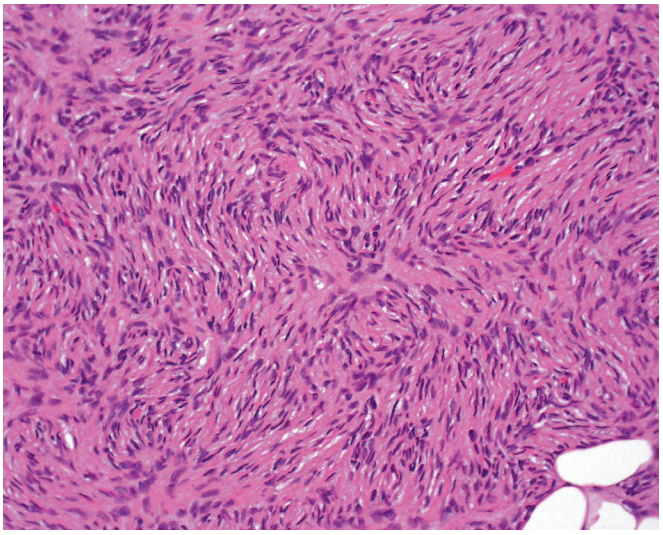

Figure 3.103 Storiform or cartwheel pattern of dermatofibrosarcoma protuberans.

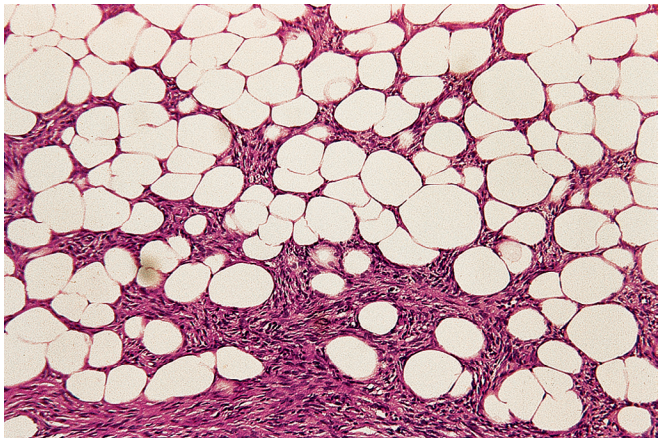

Figure 3.104 Typical pattern of invasion of subcutaneous fat by dermatofibrosarcoma protuberans.

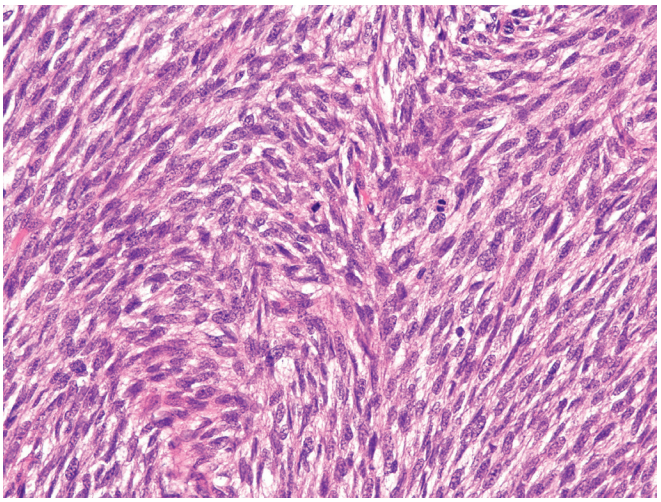

Figure 3.105 Fibrosarcomatous area in a dermatofibrosarcoma protuberans. A storiform pattern of growth is no longer evident in this component. (Courtesy Dr Fabio Facchetti, Brescia, Italy.)

appearance can be seen.[1312] Regressive areas with atrophy may also occur, and these are likely to be underdiagnosed.[1313,1314] Granular cell change may be present in areas.[1315]

Immunohistochemically, these tumors are positive for vimentin, actin (focally and inconstantly), and CD34 (strongly and consistently).[1316,1317] Conversely, they are negative for S-100 protein, HMB-45, keratin, and Factor XIIIa (although some dendritic cells that are reactive for the latter marker are usually found).[1268,1298,1318]

Cytogenetically, DFSP shows supernumerary rings derived from chromosome 22 or a linear translocation in the same chromosome in the form of *t*(17;22)(q22;q13), both of them leading to the gene fusion *COL1A1* with *PDGFB*.[1319,1320] This molecular alteration is also found in the morphologic variants of this tumor, including the high-grade areas (fibrosarcomatous transformation) when present.[1321,1322] Detection of the gene fusion by RT-PCR or FISH is helpful for confirming a diagnosis of DFSP in difficult cases.[1322]

The natural history of DFSP is characterized by an extremely high tendency for local recurrence following limited resection.[1323,1324] Very rare instances of metastases to regional nodes and/or internal organs have also been documented.[1325,1326] Thus, DFSP is generally placed in the category of tumors of intermediate malignancy.[1327]

DFSP and *giant cell fibroblastoma of infancy* are related tumors representing ends of a spectrum. This is supported by the occurrence of hybrid or combined tumors, either simultaneously or sequentially and by their common molecular alterations.[1328–1331]

DFSP can undergo fibrosarcomatous transformation, the latter areas acquiring the typical herringbone appearance of that tumor type and no longer exhibiting a storiform pattern of growth (Fig. 3.105). There has been an argument as to whether this morphologic change is reflected in a more aggressive clinical form,[1332–1334] but most recent evidence indicates that it does.[1335] Occasionally, the tumor progression is toward a more pleomorphic neoplasm with the appearance of an undifferentiated pleomorphic sarcoma (referred to historically as malignant fibrous histiocytoma).[1336,1337]

Pigmented DFSP (Bednar tumor, pigmented storiform neurofibroma) is a neoplasm having the overall appearance of an ordinary DFSP but containing, in addition, a variable (but usually small and patchy) population of dendritic cells containing large amounts of melanin pigment (Fig. 3.106).[1338] Although this finding obviously raises the possibility of schwannian/melanocytic derivation, the tumor is negative for S-100 protein and other melanocyte-related

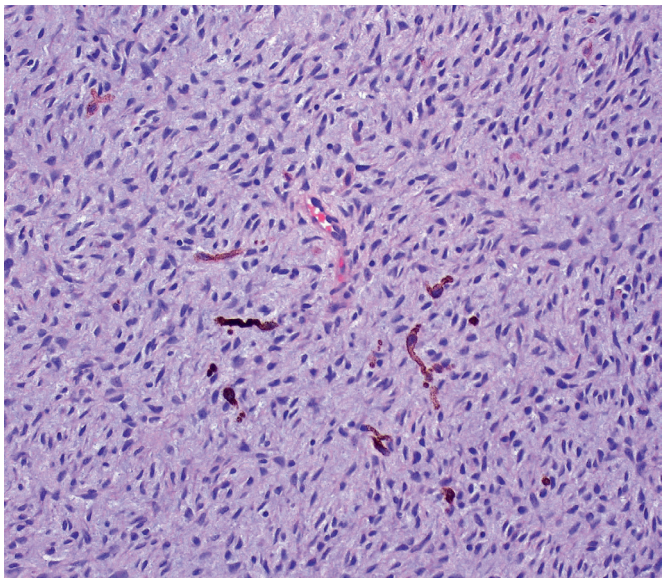

Figure 3.106 Pigmented dermatofibrosarcoma protuberans (Bednar tumor).

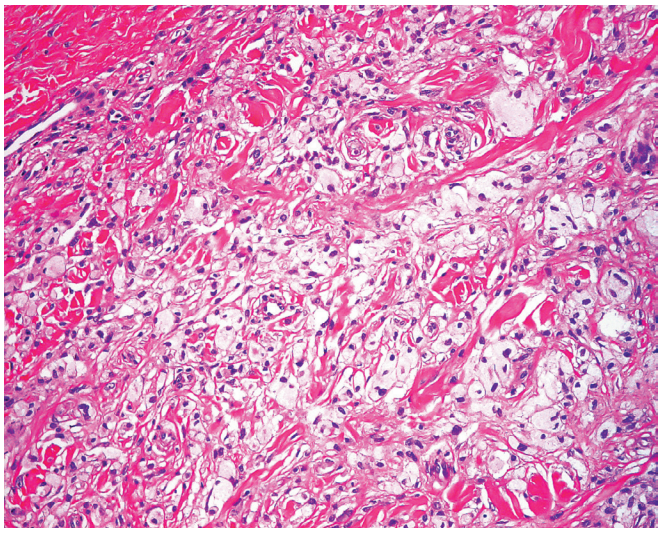

Figure 3.107 Cutaneous xanthoma showing ill-defined collection of foamy macrophages in the dermis.

markers and should not be equated with malignant melanoma of conventional, desmoplastic, or soft tissue (clear cell sarcoma) types. The similarity with DFSP extends even to the occasional development in Bednar tumor of fibrosarcomatous areas and of distant metastatic spread.[1339]

Undifferentiated Pleomorphic Sarcoma (Malignant Fibrous Histiocytoma) and Pleomorphic Dermal Sarcoma

Undifferentiated pleomorphic sarcoma, a tumor morphologically analogous to the tumor traditionally called pleomorphic-storiform type of malignant fibrous histiocytoma, can sometimes present as a superficial tumor. This term should probably be restricted to those tumors that infiltrate deeply into the subcutis, fascia, or muscle and arise outside of the head and neck.[1306,1340] Some of the reported cases have occurred in chronic ulcers or scars,[1341] and others have shown the features of the myxoid variant (myxofibrosarcoma).[1342,1343] They should not be confused with atypical fibrous histiocytoma/dermatofibroma with monster cells, tumors that have marked cytologic atypia but overall features of dermatofibromas.[1257,1258,1344] A more detailed discussion of these entities is present in the chapter on soft tissue tumors. The term *pleomorphic dermal sarcoma* has been suggested for pleomorphic sarcomas that arise in sun-damaged skin of the head and neck of elderly patients.[1306] As previously mentioned, they differ from atypical fibroxanthoma by having an infiltrative growth pattern, necrosis, and perineural invasion. Of these features, infiltrative growth is the most important. These tumors have a relatively high rate of recurrence and metastatic rate of approximately 10%, with metastases most commonly involving the skin of the head and neck. The possibilities of sarcomatoid squamous cell carcinomas and spindle cell melanoma should be excluded with appropriate cytokeratin stains and a stain for S100 protein or SOX10.[1306]

Xanthoma

Xanthomas are non-neoplastic nodules resulting from the accumulation of fat-laden histiocytes in the dermis and subcutis or deeply in the tendons, synovium, and bone (Fig. 3.107). They are usually periarticular and few in number, but disseminated forms occur.[1345] They are often associated with hyperlipidemia, either primary (familial) or secondary to diabetes mellitus, hypothyroidism, multiple myeloma, malignant lymphoma, leukemia, and obstructive liver disease. Flat xanthomas of the eyelid, referred to as *xanthelasma*, show a similar microscopic appearance. Only a minority of these patients have hyperlipidemia. *Papular xanthoma* is usually found in the trunk or extremities of males.[1346] In *eruptive xanthoma*, there is an abrupt onset of crops of yellowish papules with erythematous halos on the extensor surfaces. It can be confused with granuloma annulare at the microscopic level.[1347] In *verruciform xanthoma*, there is a papillomatous, verruca-like change of the overlying epidermis.[1348,1349]

Xanthogranuloma

Xanthogranuloma occurs most often in the skin, but it can also be found in the subcutaneous tissue, skeletal muscle,[1350,1351] ocular globe, peripheral nerves,[1352] testis,[1353] breast,[1354] and other sites.[1350,1351,1355,1356] It usually presents in infants *(juvenile xanthogranuloma)*, but it also occurs in adults, having in them a slightly different microscopic appearance.[1357] The upper part of the body is most commonly involved. The skin lesions are multiple in approximately 20% of cases[1358]; adult cases are more often solitary. Glaucoma and amblyopia, caused by involvement of the iris and ciliary body, can sometimes be seen as the initial manifestation of the disease. It has been reported in association with type 1 neurofibromatosis, epilepsy, Niemann–Pick disease, urticaria pigmentosa, and cytomegalovirus (CMV) infection.[1357]

Microscopically, the lesion is characterized by a histiocytic proliferation that in later stages is accompanied by foamy and Touton giant cell forms (Figs. 3.108 and 3.109). Lymphocytes, eosinophils, proliferating vessels, and fibroblasts may also be present. Ultrastructurally, the histiocytes do not contain Birbeck granules; some have instead a variable number of cytoplasmic lipid vacuoles.[1358] Immunohistochemically, most cases show positivity for CD68, α1-antichymotrypsin, lysozyme, and other histiocytic markers, whereas S-100 protein is essentially negative.[1359,1360] The lesion is thought to be a proliferation of (non-Langerhans) cells belonging to the so-called accessory immune system, whether conventional macrophages or plasmacytoid monocytes.[1361–1363] Xanthogranulomas with scanty foamy macrophages and giant cells may closely mimic malignant melanoma, but xanthogranulomas are negative for melanocyte-specific

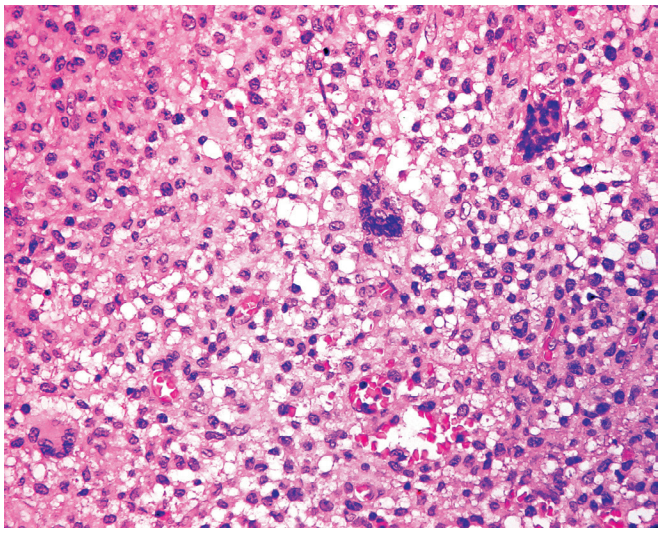

Figure 3.108 Juvenile Xanthogranuloma. Scattered multinucleated histiocytes are seen among numerous mononuclear elements.

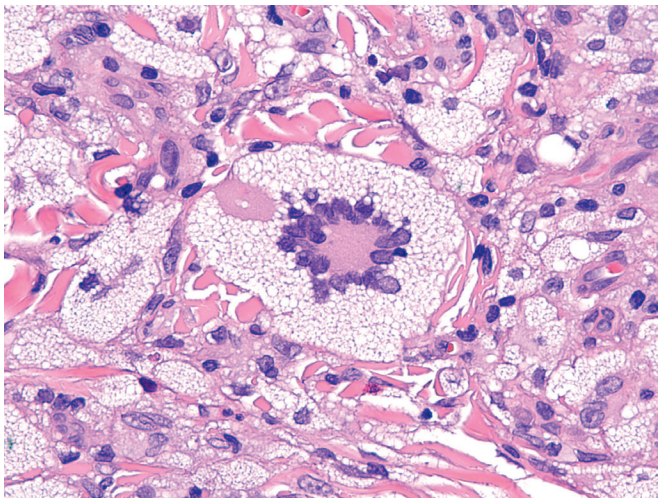

Figure 3.109 A spectacular Touton giant cell in a case of juvenile xanthogranuloma. (Courtesy Dr Fabio Facchetti, Brescia, Italy.)

markers like Melan-A.[1364] There is a variant of xanthogranuloma predominantly composed of spindle cells; solitary and generalized forms have been described.[1365]

Other Histiocytic Proliferations

Many other types of histiocytic infiltrates of the skin occur, a high percentage of them in children.[1358,1366,1367] *Giant cell reticulohistiocytoma* can present in a solitary or multicentric form, the latter sometimes associated with articular involvement ("lipoid dermatoarthritis").[1368,1369] Microscopically, there is an infiltration of mononuclear and multinucleated histiocytes with a characteristic ground-glass cytoplasm, admixed with other inflammatory cells.[1370] Immunohistochemically, the main proliferating cells have markers of histiocytes, with an important secondary component of dermal dendrocytes.[1371,1372] Some authors believe that reticulohistiocytoma and multicentric reticulohistiocytosis represent different entities.[1373]

In *Langerhans cell histiocytosis*, scattered ordinary histiocytes are seen admixed with eosinophils and S-100 protein– and CD1a-positive Langerhans cells, the latter defining the nature of the disorder, covered elsewhere in this text. Invasion of the epidermis by the infiltrate is an important diagnostic sign.

Figure 3.110 Clinical Appearance of Rosai–Dorfman Disease of the Skin. In this case the lesion presented in the form of multiple elevated erythematous nodules.

Rosai–Dorfman disease (sinus histiocytosis with massive lymphadenopathy) may involve the skin (Figs. 3.110 and 3.111).[1374] In some instances the diagnosis is obvious because of the presence of prominent cervical lymphadenopathy; however, in the majority of cases the cutaneous lesions represent the predominant or exclusive manifestation of the disease.[1375–1378]

Smooth Muscle Tumors

Leiomyomas of skin can be divided into three distinct types: the *genital* leiomyoma located in the nipple or scrotum; the multiple superficial nodules of *nevoid* or *hamartomatous* type derived from arrectores pilorum muscle (*pilar* leiomyoma)[1379]; and the *solitary angioleiomyoma* (vascular leiomyoma), which is usually subcutaneous rather than dermal (see soft tissue chapter).[1380]

Cutaneous leiomyomas can be very painful. Microscopically, they show intersecting fascicles of smooth muscle, without atypia, mitotic activity, or necrosis. Occasionally, scattered bizarre hyperchromatic nuclei are present both in angioleiomyomas[1381] and pilar leiomyomas.[1382] As in analogous situations in other parts of the body, these tumors—which behave in a benign fashion—are variously called pleomorphic, symplasmic, or atypical. *Familial cutaneous leiomyomatosis* is a genetically determined condition, sometimes associated with a distinct morphologic type of renal cell carcinoma, a condition associated with mutations in fumarate hydratase.[1383,1384]

Leiomyosarcomas are larger, more cellular, cytologically atypical, mitotically active and may contain areas of necrosis.[1385–1387] Some of them exhibit a prominent vascular pattern, suggesting that they may represent the malignant counterpart of vascular leiomyoma.[1388]

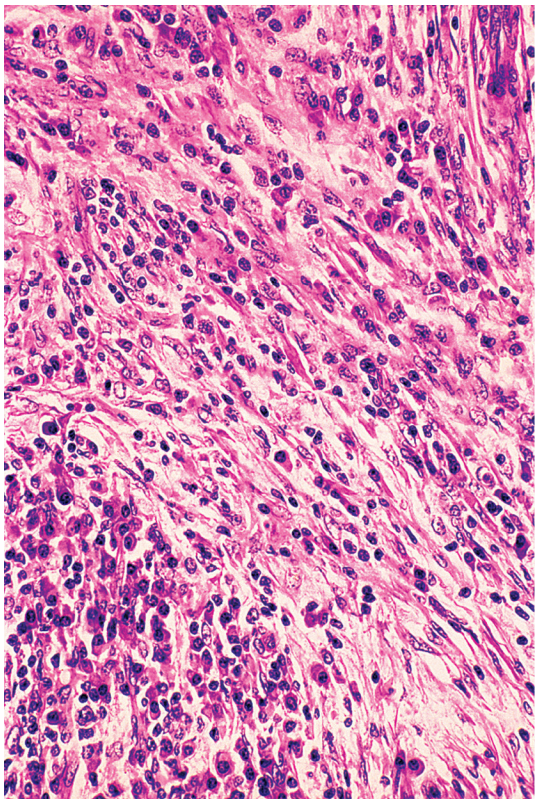

Figure 3.111 Microscopic Appearance of Cutaneous Rosai–Dorfman Disease. A polymorphic infiltrate composed of lymphocytes, plasma cells, and histiocytes is present. As is often the case in extranodal lesions, there is a moderate degree of fibrosis.

Others have clear cell ("leiomyoblastomatous") features[1389,1390] and still others have a desmoplastic quality.[1391] Cutaneous leiomyosarcomas may recur, but they metastasize only exceptionally if at all, in stark contrast with their subcutaneous counterpart.[1386,1392,1393] Some have argued that the name should be changed to "atypical intradermal smooth muscle tumor" to reflect the indolent nature of the tumor.[1394] However, this approach has been questioned, suggesting that this approach may inject a proliferation of confusing and ultimately meaningless nomenclature.[1395] Multiple smooth muscle tumors in HIV-infected patients are associated with EBV and appear to be biologically different from other cutaneous leiomyomas.[1396] No such association has been found in similar tumors in immunocompetent individuals.[1397]

Skeletal Muscle Tumors

Rhabdomyomatous mesenchymal hamartoma (striated muscle hamartoma) is a benign process of infants usually located centrally on the chin or near the ala of the nose, sometimes in association with other congenital abnormalities. Microscopically, the lesion is formed by a central core containing bundles and individual fibers of skeletal muscle and other mesenchymal elements.[1398,1399] Occasionally, lesions with a similar appearance (and also of presumed choristomatous or hamartomatous nature) present as multiple nodules in the skin.[1400,1401]

Adult rhabdomyoma has been reported in the lip and eyelid.[1402]

Primary cutaneous rhabdomyosarcomas are rare. Tumors arising in young patients tend to be of the embryonal or alveolar type, whereas those arising in older adults are usually pleomorphic rhabdomyosarcomas.[1403] Cutaneous rhabdomyosarcomas, like their deep soft tissue counterparts, can be aggressive neoplasms.[1403] Rhabdomyosarcoma can also arise in represent the malignant component of a congenital melanocytic nevus.[1404]

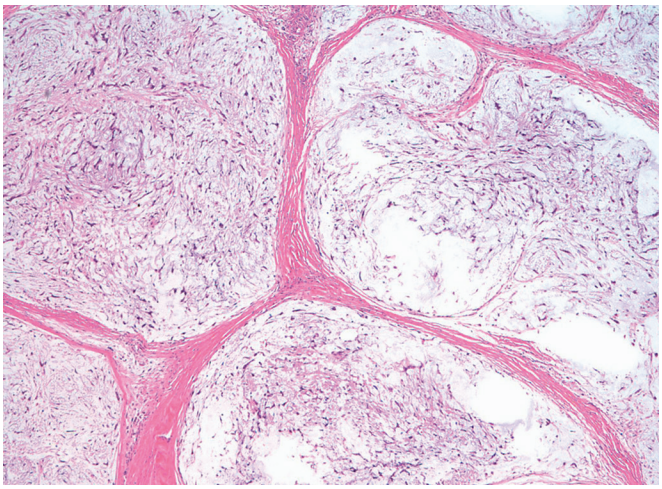

Figure 3.112 Dermal Nerve Sheath Myxoma. The tumor is characterized by bland spindled cells arranged in discrete myxoid nodules separated by fibrous septae.

Peripheral Nerve Sheath Tumors

Of the various types of peripheral nerve sheath tumor, those with a predilection for cutaneous (dermal)—as opposed to subcutaneous or deeper—involvement are *neurofibroma*, *granular cell tumor* (not all of which are neural),[1405,1406] *dermal nerve sheath myxoma* (myxoid neurothekeoma), and *palisaded encapsulated neuroma* (solitary circumscribed neuroma).[1407] The first two tumors are discussed in the chapter on soft tissue tumors, but it should be mentioned here that dermal neurofibromas can result in proliferation of entrapped sweat glands or folliculosebaceous structures, which can be confusing,[1408] and that reexcision specimens may show a reparative perineurial proliferation which may simulate perineurial invasion by tumor.[1409,1410]

Dermal nerve sheath myxoma (myxoid neurothekeoma) is characterized by distinct nests of spindled to slightly epithelioid cells in a myxoid stroma separated by fibrous septa (Fig. 3.112).[1411–1413] It is a benign tumor but prone to local recurrence if incompletely excised. This tumor is positive for S100 protein, unlike the unrelated cellular neurothekeoma (see later).

The so-called *cellular neurothekeoma* was originally considered an entity related to dermal nerve sheath myxoma due to overlapping histologic features. The tumor is composed of a nested population of epithelioid cells within a somewhat hyalinized stroma (Fig. 3.113). Some myxoid stroma may be present. It was originally thought to be related to dermal nerve sheath myxoma due to the overlapping appearance of the nested pattern. However, convincing evidence of true nerve sheath differentiation is lacking, and there is growing consensus that cellular neurothekeoma is best considered a fibroblastic/fibrohistiocytic tumor.[1414–1416] Cellular neurothekeoma is negative for S-100 protein, Melan-A, and HMB-45; positive for S-100A6, protein gene product (PGP) 9.5, MiTF, NKI/C3, NSE, and CD10; and variable for smooth muscle actin.[1414–1420] The combination of NKI/C3 and CD10 may be the most helpful positive stains, although neither is tremendously specific.[1420] Cellular neurothekeoma can be confused with malignant melanoma and other melanocytic tumors,[1343,1421] particularly when exhibiting atypical features.[1420,1422] We have seen several cases in which typical cellular neurothekeoma areas blended with a pattern very similar to that of plexiform

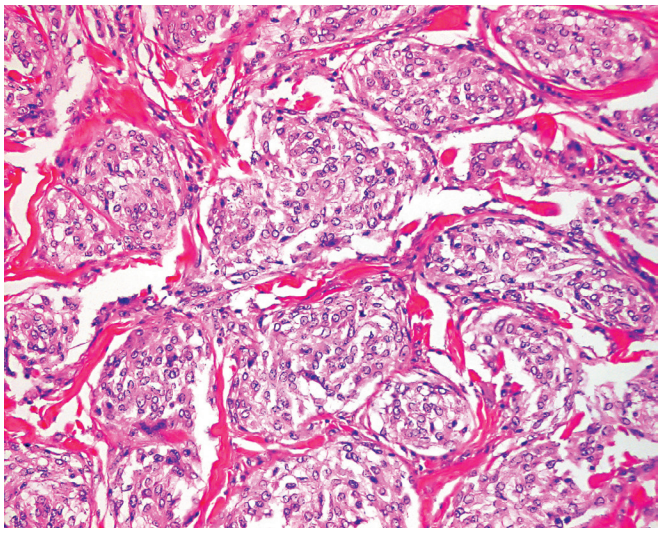

Figure 3.113 Cellular Neurothekeoma. The tumor cells are arranged in compact nests.

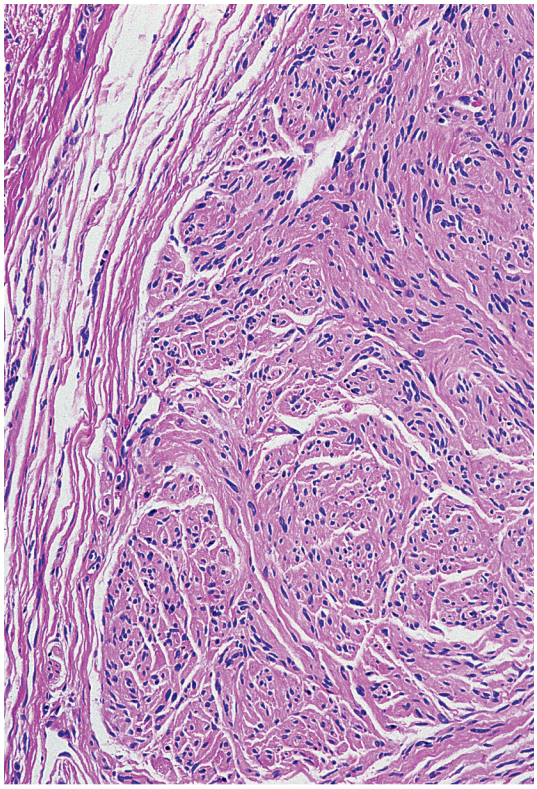

Figure 3.114 Palisaded Encapsulated Neuroma. The fascicular pattern is well developed. This lesion should not be confused with leiomyoma of skin.

fibrohistiocytic tumor, suggesting a relationship between the two entities, although a relationship has not been definitively proven.[1423] The behavior is generally benign. Local recurrences have been rarely described, but no instances of metastatic spread.[1415,1416]

Palisaded encapsulated neuroma (solitary circumscribed neuroma) presents as a small solitary papule, usually located on the face.[1424] Microscopically, it is a spindle cell lesion exhibiting varying degrees of nuclear palisading and characteristic intratumoral clefts (Fig. 3.114).[1425] Occasionally, the cells are epithelioid rather than spindle.[1426] Misinterpretation of this lesion as a schwannoma or leiomyoma is

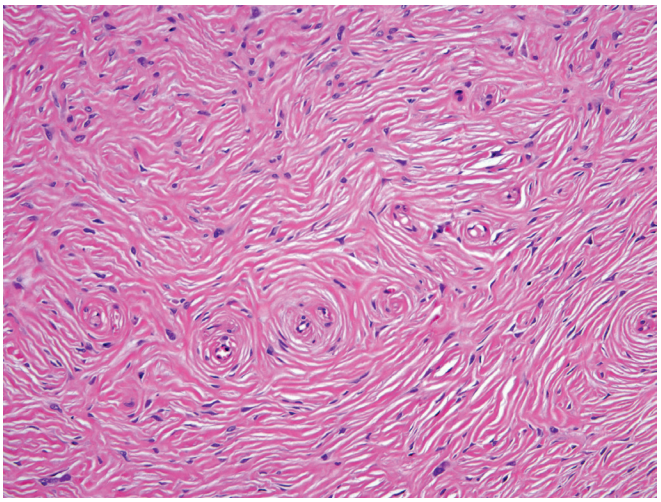

Figure 3.115 Cutaneous Perineurioma. The very elongated shape of the tumor cells and the whorling arrangement are typical features of this benign peripheral nerve sheath tumor. (Courtesy Dr Fabio Facchetti, Brescia, Italy.)

common. Immunohistochemically, the spindle cells are strongly reactive for S-100 protein, in keeping with their presumed schwannian nature.[1427,1428] Axons can be demonstrated with special stains, distinguishing it from schwannoma.

Epithelial sheath neuroma is a most peculiar skin lesion characterized by a proliferation of nerve fibers coated by squamous epithelium.[1429,1430] This process probably represents an unusual reactive process with squamous metaplasia of the nerve sheath.

Perineurioma can occur in the skin and soft tissues with a variety of patterns: *epithelioid* (often misdiagnosed as epithelioid histiocytoma), *sclerosing* (which simulates a fibroma and is usually acral in location), *reticular*, and *plexiform* (Fig. 3.115).[1431–1434] EMA immunoreactivity is an important clue to the diagnosis.

Although the large majority of MPNSTs are located in the deep soft tissues, cutaneous examples have been described in patients with or without type I Recklinghausen disease.[1356,1435,1436] In MPNST, a precursor neurofibroma remnant is often present.

Vascular Tumors and Tumorlike Conditions

A large variety of tumors and ectasias arising from blood and lymph vessels of the skin exists,[1437,1438] and several new types have been described.[1439] Most of these lesions are discussed in the chapter on soft tissue tumors. Only those features pertaining to their cutaneous location will be mentioned in this section.

Hemangioma

The more distinctive types of benign blood vessel tumors of skin[1440] are *capillary* hemangioma, *infantile* hemangioma (benign [infantile] hemangioendothelioma) (Fig. 3.116), *cavernous* hemangioma, *angiokeratomas* of various types,[1441] *verrucous* hemangioma,[1442] *acral arteriovenous tumor/arteriovenous hemangioma* (Fig. 3.117),[1443,1444] *microvenular* hemangioma (Fig. 3.118),[1445–1447] *glomeruloid* hemangioma (Fig. 3.119; a distinctive vascular proliferation rich in hyaline globules, seen in Castleman disease associated with the POEMS [polyneuropathy, organomegaly, endocrinopathy, monoclonal plasma proliferative disorder, skin changes] syndrome),[1448–1451] *papillary* hemangioma (also containing hyaline globules),[1452,1453] *hobnail* hemangioma (targetoid hemosiderotic hemangioma) (Fig. 3.120),[1454,1455] *acquired*

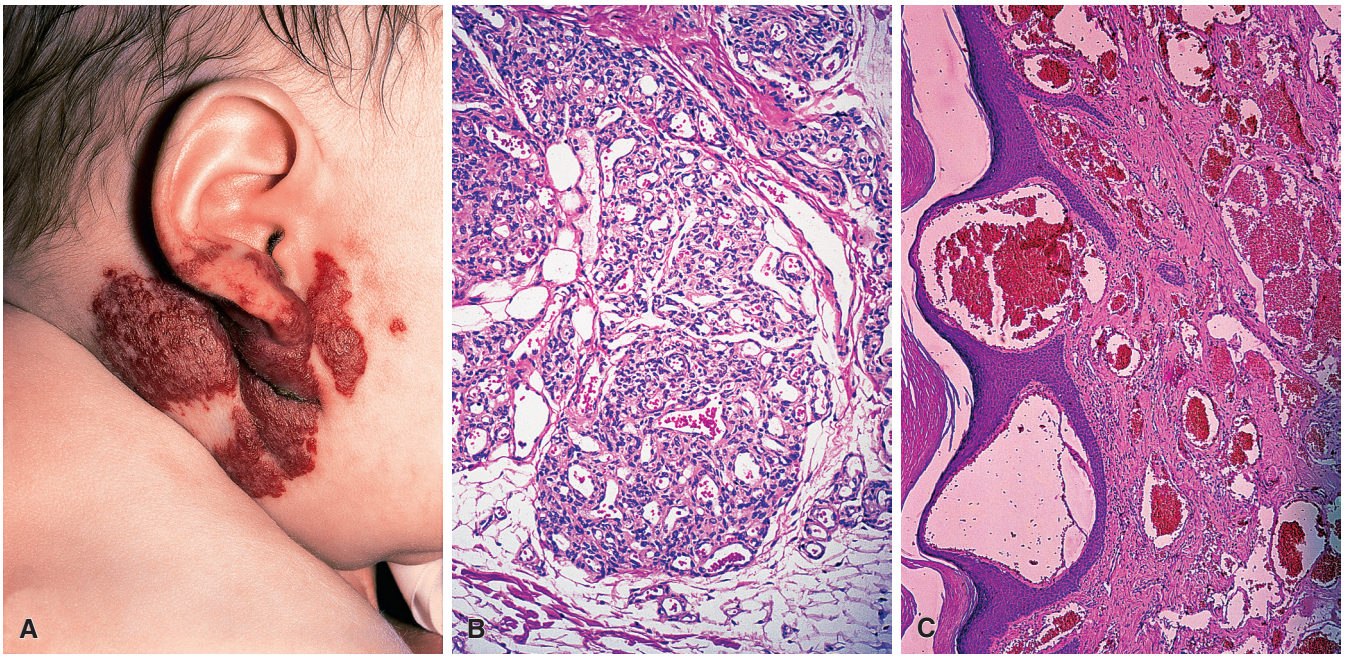

Figure 3.116 **A,** Clinical appearance of infantile hemangioma (benign hemangioendothelioma). **B,** Benign hemangioendothelioma. Note marked hypercellularity and lobular configuration. **C,** Cavernous hemangioma of skin. Vessels are markedly dilated and result in elevation of the overlying atrophic epidermis. (**A** courtesy Dr RA Cooke, Brisbane, Australia; From Cooke RA, Stewart B. *Colour Atlas of Anatomical Pathology*. Edinburgh: Churchill Livingstone; 2004.)

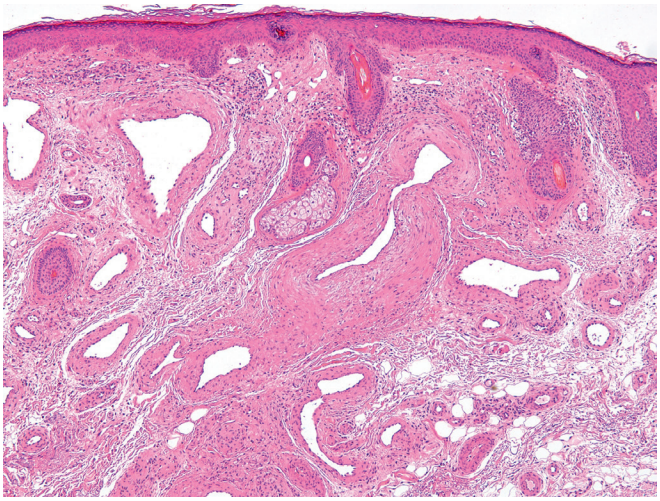

Figure 3.117 **Arteriovenous Hemangioma.** Large vessels with arterial, venous, and hybrid features occupy the dermis. (Courtesy Dr Fabio Facchetti, Brescia, Italy.)

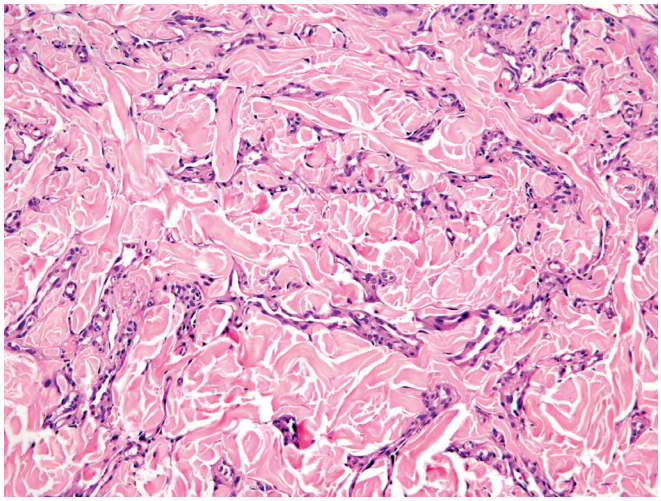

Figure 3.118 **Microvenular Hemangioma.** The vessels, which contain a muscle wall, are widely scattered in between the dermal collagen fibers. (Courtesy Dr Fabio Facchetti, Brescia, Italy.)

elastotic hemangioma,[1456] *symplastic* hemangioma,[1457] *cutaneous epithelioid angiomatoid nodule*,[1458] *glomus tumor*, and *myopericytoma* (see chapter on soft tissue tumors).[1459]

Spider angioma, venous lake, capillary aneurysm, angioma serpiginosum, and the lesion of hereditary hemorrhagic telangiectasia are not true neoplasms but rather telangiectatic processes of either hamartomatous or acquired nature.[1356] This may also be true for some of the lesions listed in the preceding paragraph.

Lymphangioma

Cutaneous lymphangiomas usually present in infancy, the majority being present by the age of 5 years.[1459] Sites of predilection are the neck, axilla, breasts, chest, buttocks, and thighs. The lesions are divided into *superficial* (lymphangioma circumscriptum), *deep* (lymphangioma cavernosum), and *cystic* (cystic hygroma) varieties (Fig. 3.121). Recurrence develops in about 25% of cases.[1460] This is apparently caused by the presence of large muscle-coated lymphatic cisterns lying deep in the subcutis and feeding the superficial vesicles.[1461]

Benign lymphangioendothelioma is the name that has been proposed for the benign lymph vessel tumor originally described as acquired progressive lymphangioma.[1462,1463] It presents as a bruise-like lesion and simulates angiosarcoma because of the presence of anastomosing vascular channels. However, atypia of endothelial cells is totally absent.[1464] Before this diagnosis is made, care should be exercised in ruling out the lymphangioma-like form of Kaposi sarcoma.[1465,1466]

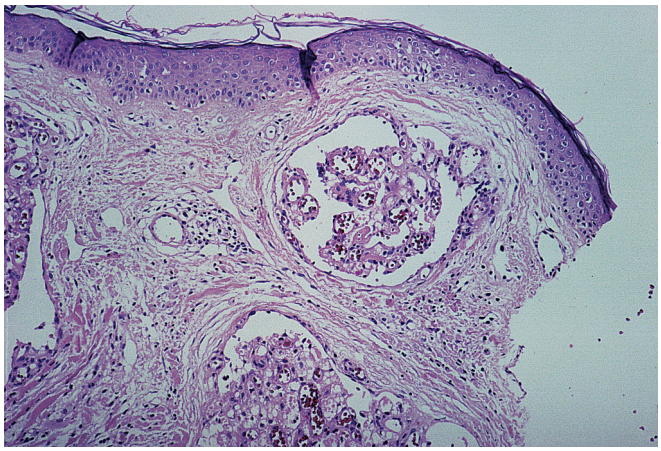

Figure 3.119 Glomeruloid hemangioma in a patient with POEMS syndrome. Microscopic appearance of the individual lesions is reminiscent of renal glomeruli.

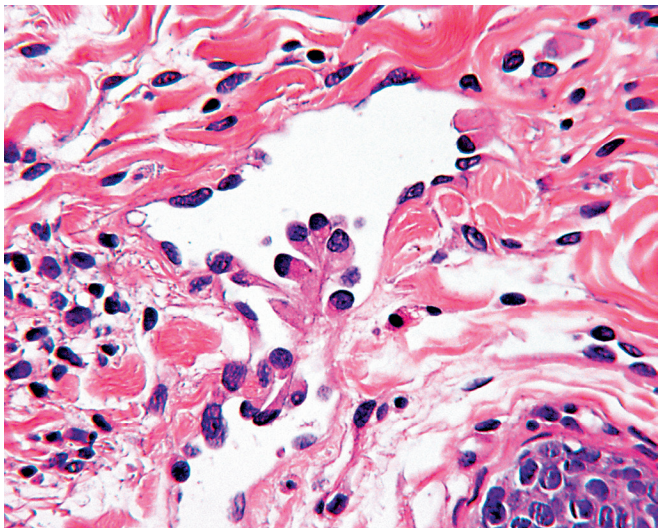

Figure 3.120 **Hobnail Hemangioma.** The endothelial cells protrude into the vessel lumina.

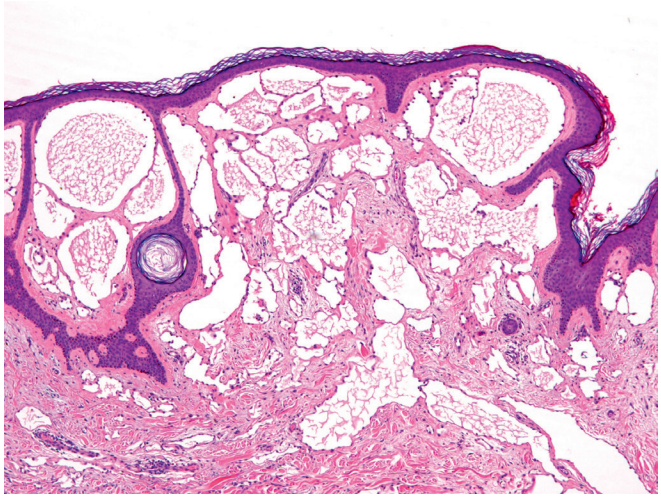

Figure 3.121 **Superficial Lymphangioma of Skin.** Cystically dilated vascular spaces are lined by flattened endothelial cells. Red blood cells are nearly absent. (Courtesy Dr Fabio Facchetti, Brescia, Italy.)

Figure 3.122 Clinical appearance of typical pyogenic granuloma.

A curious condition mentioned here despite the fact that it is not a lymph vessel neoplasm is *cutaneous intralymphatic histiocytosis*. As the name indicates, this process is characterized by the presence of dilated lymph vessels packed with CD68-positive histiocytes, usually seen in patients with rheumatoid arthritis.[1467,1468]

Pyogenic Granuloma

Pyogenic granuloma (granuloma pyogenicum, lobular capillary hemangioma) presents clinically as a rapidly growing polypoid red mass, surrounded by a collarette of thickened epidermis. The fingers and lips are the most common locations (Fig. 3.122). Sometimes it appears in connection with a keratinous cyst.[1469] Microscopically, there is vascular proliferation, edema, and inflammation. The epidermis is thinned and sometimes ulcerated at the top, and there is acanthosis and hyperkeratosis at the sides (Fig. 3.123). The most distinctive feature is the so-called vascular (capillary) lobule, a central branching vessel, surrounded by a hypercellular proliferation of newly formed endothelial and perithelial cells (Fig. 3.124).[1470,1471] High cellularity and abundant mitotic activity may be present (particularly in lesions of the lips), but these are not indicative of an aggressive behavior.[1472,1473] The lesion is self-limited, and spontaneous regression is the rule. Excision is usually curative, although some examples located on the trunk may recur as multiple satellites.[1474] Lobular capillary hemangioma can also occur in a disseminated form,[1475] develop within port-wine stains,[1476] be located in the deep dermis or subcutaneous tissue,[1477] or present as an intravascular proliferation.[1478] Deeply seated lesions usually lack the edema and inflammation seen in the more superficial examples.

Acquired Tufted Angioma

Acquired tufted angioma (angioblastoma) typically presents as multiple red plaques on the shoulders and upper back of children and

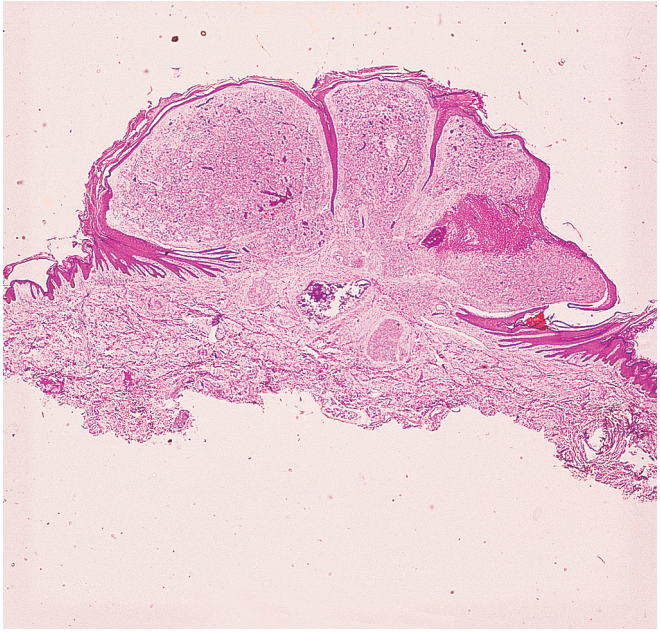

Figure 3.123 Low-power microscopic view of typical pyogenic granuloma.

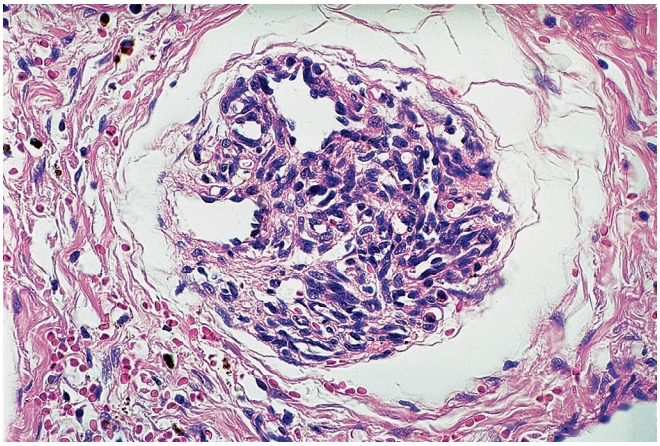

Figure 3.124 **So-Called Capillary or Vascular Lobule.** This formation is almost always an indicator of a benign process.

adolescents and is characterized microscopically by multiple vascular lobules, which tend to be more cellular than those of pyogenic granuloma and to have a semilunar vessel at the periphery rather than a more open one at the center.[1479,1480] Acquired tufted angioma shares histologic and immunophenotypic features with kaposiform hemangioendothelioma and is likely part of the spectrum of that tumor.[1481]

Masson Hemangioma

Masson hemangioma (vegetant intravascular hemangioendothelioma; Masson pseudoangiosarcoma; intravascular papillary endothelial hyperplasia) is in all likelihood the result of exuberant organization and recanalization of a thrombus.[1482] It may develop in a previously normal vessel as a result of trauma, or it may superimpose itself on a pyogenic granuloma or cavernous hemangioma.[1483–1485] It is characterized microscopically by a papillary proliferation of endothelial cells (which are plump but lack atypia) located entirely within the lumen of a dilated vessel. The core of the papillae has a deeply acidophilic quality, resulting at least in part from fibrin deposition.

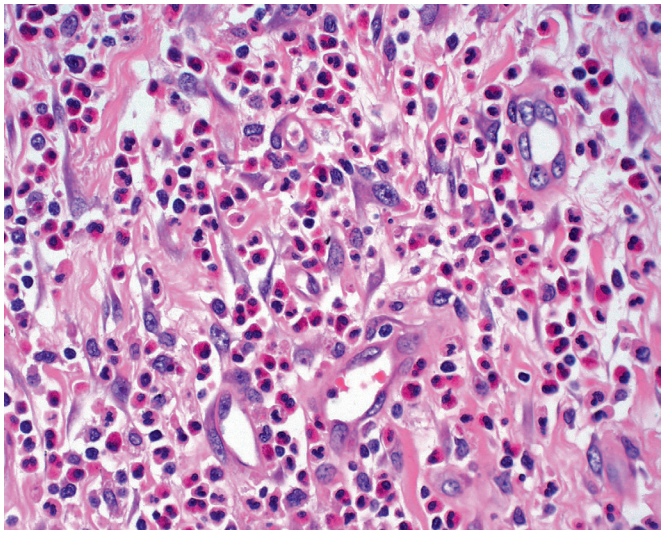

Figure 3.125 Epithelioid hemangioma is benign cutaneous vascular tumor largely composed of vessels lined by epithelioid endothelial cells. An associated infiltrate of eosinophils and lymphocytes is usually present.

The immunohistochemical profile of the predominant element is that of activated endothelial cells.[1486]

Epithelioid Hemangioma

Epithelioid hemangioma (histiocytoid hemangioma, angiolymphoid hyperplasia with eosinophilia) presents clinically as inflammatory-looking nodules, the head and neck (particularly the periauricular region) being the preferred locations.[1487,1488] Despite earlier claims to the contrary, this disease is clearly distinct from Kimura disease.[1410,1489,1490] Microscopically, a central area of proliferated blood vessels is infiltrated and surrounded by a heavy inflammatory infiltrate rich in eosinophils and containing lymphoid follicles with germinal centers. In a variation of the theme, the proliferation may acquire a lobular solid pattern that has been termed *cutaneous epithelioid angiomatous nodule*.[1458] The defining feature of this entity is the peculiar epithelioid or histiocytoid appearance of the endothelial cells (Fig. 3.125). Sometimes the inflammatory infiltrate is nil or absent.[1491] These lesions, as they occur in the skin, are of an indolent nature, and there is controversy as to whether they are reactive or neoplastic.[1492] They represent the "benign" end of the spectrum of a family of vascular proliferations having as a common denominator the presence of epithelioid (histiocytoid) endothelial cells, which also includes epithelioid hemangioendothelioma and epithelioid angiosarcoma.[1493] A distinction among these entities is possible in the majority of the cases on the basis of location (most epithelioid hemangiomas are cutaneous, whereas most epithelioid hemangioendotheliomas and angiosarcomas are not), cellularity, atypia, and some architectural features.[1494] That being said, epithelioid hemangioendothelioma[1495,1496] and epithelioid angiosarcoma[1497] can occur in the skin, whereas tumors with the appearance of epithelioid hemangioma can be seen in deep sites, such as bone.[1498]

Kaposi Sarcoma

In its classic form, Kaposi sarcoma is infrequent in the United States but relatively common in some regions of the Mediterranean basin and even more so in equatorial Africa, where it comprises 10% of all malignant tumors.[1499–1501] The incidence of Kaposi sarcoma in the United States increased several hundred-fold during the 1980s through

Figure 3.126 Clinical Appearance of Kaposi Sarcoma. A, Diffuse violaceous lesions in skin of foot and ankle. This is the most common location of the classic form. **B,** Early lesion of Kaposi sarcoma in an HIV-infected patient.

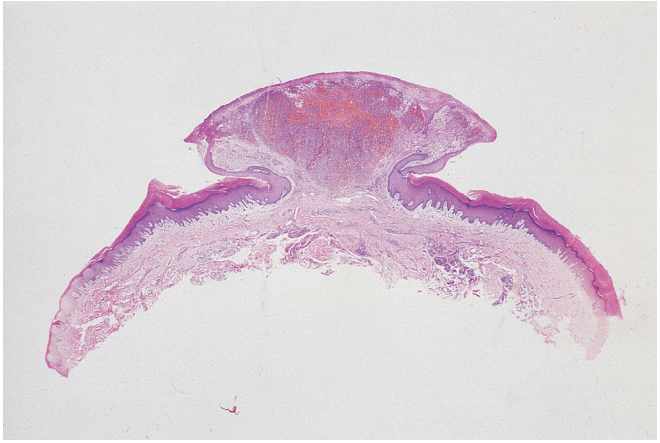

Figure 3.127 Low-power view of a lesion of Kaposi sarcoma having a prominent polypoid shape that simulates pyogenic granuloma.

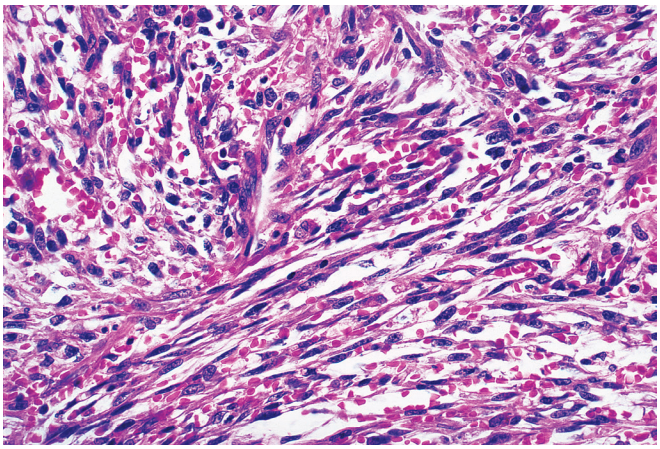

Figure 3.128 Microscopic Appearance of Kaposi Sarcoma. Elongated spindle cells showing minimal atypia are separated by slits containing red blood cells.

its occurrence in the acquired immunodeficiency syndrome (AIDS) population and, to a lesser degree, in persons with other forms of immunosuppression, such as organ transplant recipients.[1500–1504] An association with the systemic form of Castleman disease and with angioimmunoblastic lymphadenopathy (two disorders of the immune system) has also been reported.[1505,1506] In patients with AIDS, Kaposi sarcoma is predominantly a feature of the homosexual population, although it has also been seen in heterosexual drug users.[1507]

In classic Kaposi sarcoma, the disease manifests itself by multiple blue dermal plaques or nodules starting on the feet and legs (Fig. 3.126).[1500,1501] These nodules progress up the extremity and occasionally assume a pedunculated appearance reminiscent of pyogenic granuloma (Fig. 3.127). By angiographic techniques, clinically inapparent subcutaneous nodules can be identified. Temporary control is effected by irradiation, chemotherapy, or, if the lesion is sharply delimited, excision. The course of Kaposi sarcoma is variable although usually prolonged. Some elderly persons die of intercurrent disease. An increased incidence of malignant tumors, particularly of lymphoid type, has been documented.[1508] In patients in whom the disease runs its full course, widespread visceral involvement may be found.[1509] Lymph nodes and the gastrointestinal tract are the organs most commonly involved.[1510] Visceral involvement can precede the development of skin lesions or occur in their absence.[1511] Indicators of poor outcome in classic Kaposi sarcoma are immunosuppression and age greater than 50 years.[1512,1513]

Other clinical forms of Kaposi sarcoma have been described in African cases.[1514] In the AIDS population, the lesions of Kaposi sarcoma have a more erratic distribution, a wider variety of clinical appearance, and a more rapidly aggressive clinical course,[1515,1516] with frequent involvement of the lymph nodes, lung, and/or gastrointestinal tract.[1517]

Microscopically, the most typical feature of Kaposi sarcoma is the presence of spindle cells forming slits containing red blood cells (Fig. 3.128). Mitotic activity is only moderate, and pleomorphism is usually absent. Admixed in this lesion are lymphocytes, hemosiderin-laden macrophages, and other inflammatory cells. Variously sized hyaline bodies, which are periodic acid–Schiff (PAS) positive, are often seen in the cytoplasm of the proliferating cells and sometimes extracellularly. These probably represent the result of ingestion and degradation of erythrocytes and—although diagnostically useful—are not specific for Kaposi sarcoma.[1518,1519]

In early lesions, the spindle proliferation may be limited to the papillary dermis and to the vascular plexus with the neoplastic vessels

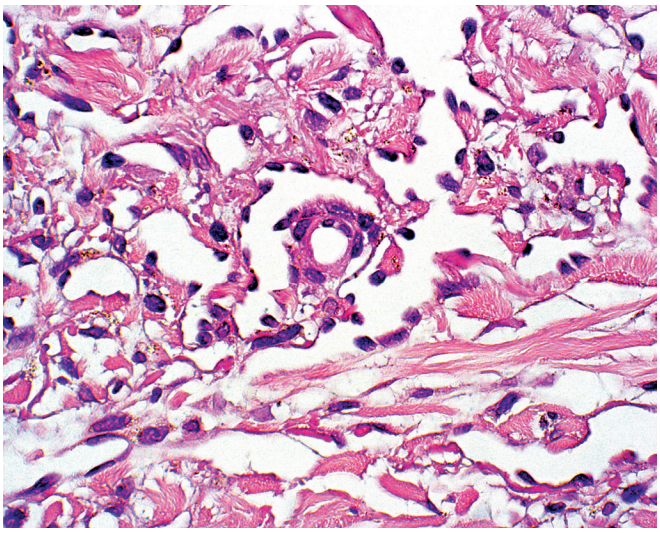

Figure 3.129 Early changes of Kaposi sarcoma, manifested by vascular proliferation in the dermis. These changes often center around skin adnexae.

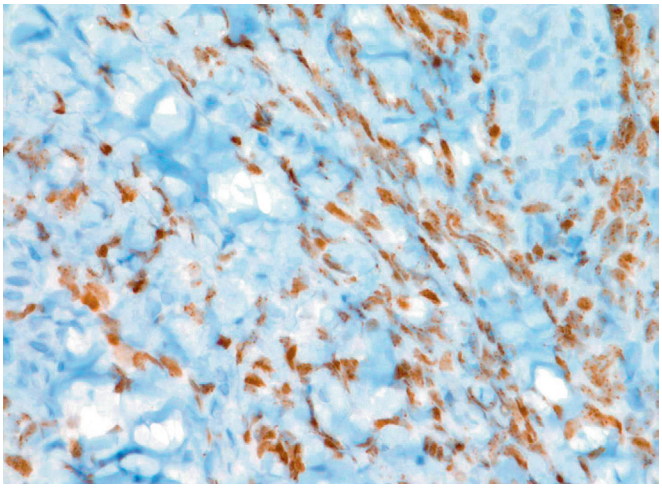

Figure 3.130 Immunoreactivity for HHV8 latent nuclear antigen.

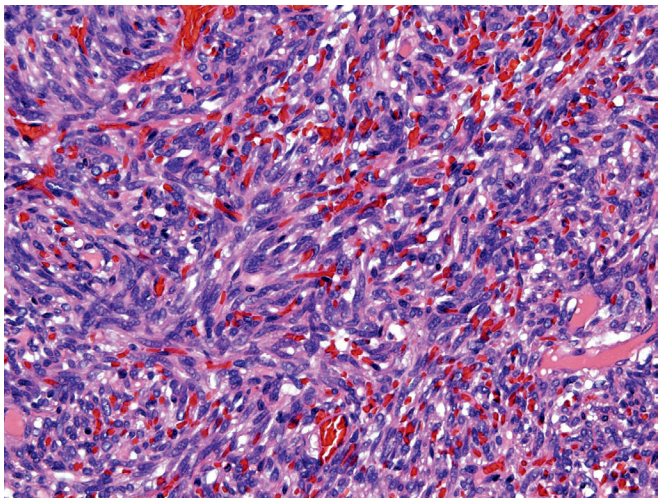

Figure 3.131 Kaposiform Hemangioendothelioma in an Infant. The lesion is composed of uniform spindled cells arranged in fascicles. There are no hyaline bodies and the tumor cells are negative for HHV8. (Courtesy Dr Fabio Facchetti, Brescia, Italy.)

dissecting around dermal structures, such as the secretory coil of sweat glands or blood vessels (Fig. 3.129).[1520] This has been termed the promontory sign. The changes can be very subtle and limited to a few irregularly dilated vascular spaces and aggregates of plumper (epithelioid) cells[1521]; at this stage, the microscopic appearance may be nondiagnostic in the absence of doing immunostains for human herpesvirus 8 (HHV8) (see later).

Histochemical, immunohistochemical, and ultrastructural studies have shown that Kaposi sarcoma is derived from endothelial cells,[1522] probably of lymphatic origin.[1523,1524] Indeed, FVIII-related antigen, CD31, CD34, angiotensin-converting enzyme, thrombomodulin, leukocyte adhesion molecule-1, and other endothelial markers have been detected in at least some of the cases,[1525–1528] The consistent immunoreactivity for podoplanin (D2-40), a lymphatic endothelial marker, provides additional support for the lymphatic nature of the lesion.[1524,1529]

The most important recent development in this field has been the discovery that HHV8 is present in almost 100% of Kaposi sarcoma lesions, whether HIV-related, classic, endemic, or iatrogenic.[1530] HHV8, also known as Kaposi sarcoma–associated herpesvirus (KSHV), is a gamma-herpesvirus closely related to EBV.[1531] It is believed to be necessary but not sufficient to cause the disease, with immunosuppression playing a major contributory role. Parenthetically, HHV8 is also involved in the pathogenesis of multicentric Castleman disease and primary effusion lymphoma.[1532–1534] Immunostains for HHV8 latent nuclear antigen are consistently positive in Kaposi sarcoma and are a valuable tool in confirming the diagnosis (Fig. 3.130).[1535–1537]

There is controversy concerning the pathogenesis of Kaposi sarcoma, particularly whether it should be regarded as a multicentric hyperplastic or as a neoplastic process.[1538] The fact that nearly all these lesions have been found to be diploid on flow cytometric studies[1539] would seem to favor the former mechanism, which could be mediated by the action of oncogenes and growth factors that stimulate local angiogenesis.[1540–1542] The clonal nature of the lesions and their sometimes markedly aggressive behavior favor instead a neoplastic nature.[1543,1544] Remarkably, it has been shown that post-transplant Kaposi sarcoma originates from the seeding of donor-derived progenitors.[1545] More recently, it has been shown that Kaposi sarcoma in individual patients is actually a multiclonal process, arguing again in favor of a reactive/infectious rather than neoplastic process.[1546]

In terms of differential diagnosis, benign lesions that can be microscopically confused with Kaposi sarcoma include arteriovenous malformations, acroangiodermatitis, pyogenic granuloma and other vascular proliferations exhibiting a lobular pattern of growth (such as tufted angioma), intranodal hemorrhagic spindle cell tumor with amianthoid fibers (nearly always located in inguinal nodes), bacillary angiomatosis, pigmented purpuric dermatosis, kaposiform hemangioendothelioma (Fig. 3.131), and the predominantly vascular or hemorrhagic forms of benign fibrous histiocytoma.[1474,1547–1551]

Bacillary Angiomatosis and Verruga Peruana

Bacillary angiomatosis is due to infection by a rickettsia-like organism of the *Rochalimaea* species now known as *Bartonella henselae*.[1552,1553] The cutaneous lesions, which present clinically as reddish papules and nodules, are characterized microscopically by lobules of capillaries with plump (epithelioid or histiocytoid) endothelial cells (Fig. 3.132A).[1554] Thus, this entity shows some of the architectural features of pyogenic granuloma and some of the cytologic features of epithelioid hemangioma. Clues to the diagnosis are represented by clusters of neutrophils (many of them fragmented) and the presence

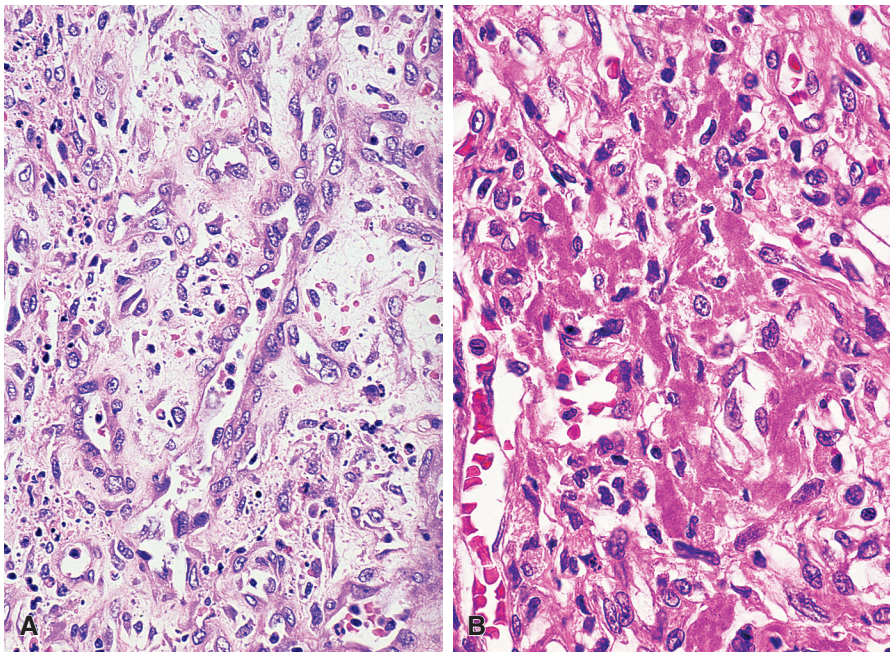

Figure 3.132 Bacillary Angiomatosis. A, Note epithelioid appearance of the endothelial cells in the proliferating vessels and neutrophilic infiltrate with marked karyorrhexis. **B,** An amphophilic granular material is seen in the stroma, due to the accumulation of myriads of microorganisms.

of a granular purplish-staining extracellular material (see Fig. 3.132B). The latter results from the accumulation of a myriad of organisms, as demonstrated with silver stains, immunohistochemistry, or electron microscopy.[1555–1557]

Bacillary angiomatosis can also involve soft tissues (sometimes in the absence of skin disease),[1558] lymph nodes,[1559] and internal organs.[1560,1561] It can also be seen in association with Kaposi sarcoma.[1562]

The differential diagnosis of bacillary angiomatosis includes verruga peruana, another vascular proliferative process induced by an infectious organism, in this instance *B. bacilliformis*.[1563] Identification of Rocha-Lima inclusions is the most important clue for the diagnosis of this disease, which is endemic to Peru.

Angiosarcoma

Angiosarcoma of the skin is largely restricted to sun-damaged skin of the head and neck of elderly persons,[1564–1566] if the varieties associated with longstanding lymphedema or radiation therapy are excluded.[1567–1569] It characteristically presents as a violaceous flat lesion of ill-defined margins, on which elevated nodules may develop.[1570] Occasionally, the tumor acquires a verrucous appearance because of hyperplasia of the overlying epidermis.[1571] Microscopically, three distinct patterns are seen, singly or in combination: undifferentiated foci, which can simulate carcinoma or malignant melanoma; freely anastomosing channels lined by atypical endothelial cells, surrounding skin adnexa, and dissecting dermal collagen fibers; and areas resembling Kaposi sarcoma (Fig. 3.133).[1565,1572] The tumor cells have ultrastructural and immunohistochemical features of endothelial cells, although these can be lost in the poorly differentiated tumors.[1570,1573,1574]

Occasionally, the tumor cells have an epithelioid morphology *(epithelioid angiosarcoma)*.[1497,1575,1576] This tumor should be distinguished from epithelioid hemangioendothelioma and—more importantly—from epithelioid hemangioma.[1494] In contrast to Kaposi sarcoma, flow cytometric studies of angiosarcoma show a nondiploid pattern.[1576] Angiosarcoma is a slow growing but highly aggressive neoplasm that stubbornly recurs following surgery or radiation therapy to involve extensive areas of the scalp and face and eventually metastasizes to the regional lymph nodes, the lung, and other organs.[1555,1571] Older patient age, anatomic site, necrosis, and epithelioid features correlate with increased mortality.[1577] Any vascular lesion of the skin diagnosed as angiosarcoma in a young patient or not located in the head and neck should be suspected of being something else and, more often than not, a benign process.[1578] Tumors notorious for their ability to simulate angiosarcoma are squamous cell carcinoma,[113] epithelioid sarcoma,[1579] and pseudoangiomatous atypical fibroxanthoma.[1580]

A distinctive and increasingly common type of angiosarcoma is that developing following irradiation to the area, usually as part of the therapy for breast carcinoma.[1581,1582] It can be viewed as analogous to post-mastectomy angiosarcoma (Stewart–Treves syndrome, see Chapter 36), from which it differs because of its shorter latency period and lack of association with lymphedema. Its morphologic appearance is similar to that of de novo angiosarcoma, its main differential diagnosis being with the *atypical vascular lesion*, a lesion that often accompanies it and precedes it, and which may on occasion therefore be seen as its precursor.[1583] The distinction, which can be very difficult because of the considerable overlap, is mainly based on the greater degree of atypia seen in the full-blown angiosarcoma.[1584] A particularly treacherous feature in this situation is the capillary (vascular) lobule pattern of postradiation angiosarcoma.[1585] Whereas in all other situations we are aware of this as a sign of benignancy, when seen in the context of a postradiation atypical vascular lesion it is an indicator of the high probability of an angiosarcoma developing (if it has not already).[1586] Recently, it has been shown that amplification of *MYC* and expression of MYC is a consistent feature of postradiation angiosarcoma that is not seen in atypical vascular lesion.[1587] It should be stressed that this same feature is not typically seen in conventional angiosarcomas.

Retiform hemangioendothelioma is a distinctive vascular tumor of intermediate malignancy that resembles well-differentiated

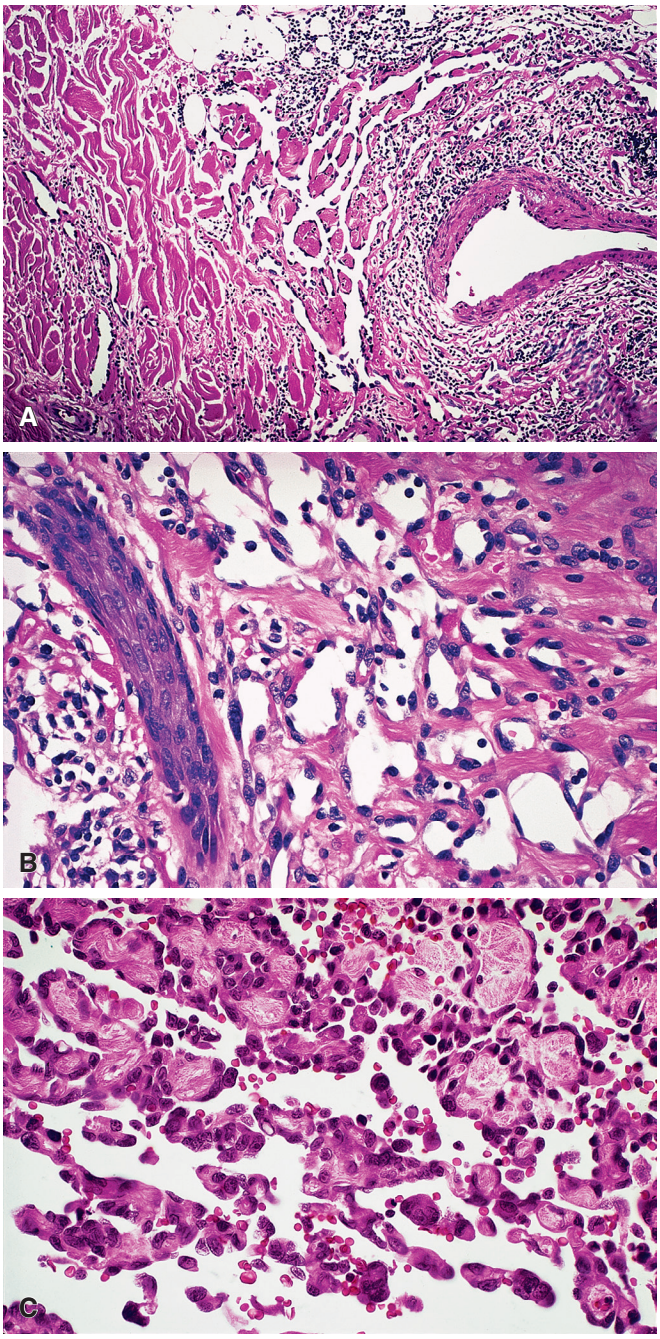

Figure 3.133 Angiosarcoma of Skin. A, Dissection of dermal collagen fibers by neoplastic vessels. **B,** Freely anastomosing vessels lined by atypical cells. **C,** Papillary projections.

angiosarcoma. It usually occurs in the distal extremities of young individuals, sometimes associated with hyperkeratotic changes in the overlying epidermis.[1588] Microscopically, there is a complex ("retiform") network of vessels in the dermis and subcutaneous tissue, lined by endothelial cells having round (lymphocyte-like) nuclei and scanty cytoplasm. These cells protrude into the lumen of the neoplastic vessels in a hobnail fashion. Similar areas are sometimes seen in angiosarcomas, but here they are accompanied by a greater degree of atypia and pleomorphism. Immunohistochemically, retiform hemangioendotheliomas are positive for CD31, CD34, and FVIII-related antigen but usually not for the lymph vessel markers D2-40 and vascular endothelial growth factor receptor-3 (VEGFR-3).[1589]

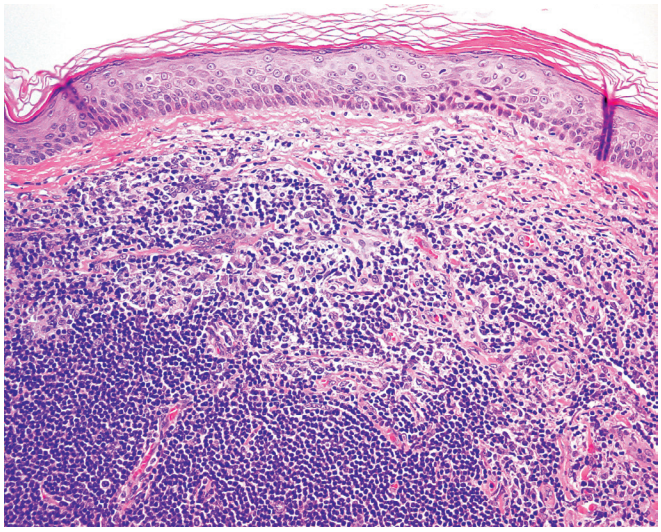

Figure 3.134 Cutaneous Lymphoid Hyperplasia. Note the numerous hyperplastic vessels with plump endothelial cells.

Lymphoid Tumors and Tumorlike Conditions

Cutaneous Lymphoid Hyperplasia

Cutaneous lymphoid hyperplasia (also known as lymphoplasia, lymphadenoma, lymphocytoma benigna cutis, lymphadenosis benigna cutis, and Spiegler–Fendt sarcoid) was briefly discussed in the section on inflammatory diseases of the skin. It will also be discussed here as it figures prominently in the differential diagnoses of cutaneous lymphomas. It occurs predominantly on the face as solitary violaceous nodules or plaques, most commonly in women.[1590] It probably represents a response to trauma, insect bites, and other undetermined stimuli.[1591] Microscopically, the infiltrate is predominantly composed of lymphocytes and histiocytes in the dermis (Fig. 3.134).[1592] Classically, the upper portion of the dermis is more involved than the deep dermis, but this is not a consistent feature. The morphologic and immunoarchitectural features of the lesion are very similar to those of reactive lymph nodes.[1593] Cases in which the lymphoid infiltrates centers around follicles have been designated *pseudolymphomatous folliculitis*.[1594] They can be associated with hyperplasia of hair follicles and other adnexal structures. Although the latter finding favors benignancy, it can also occur in cutaneous lymphoma.[1595]

Microscopically, features are variable. Most cases show a top-heavy, wedge-shaped infiltrate with a distinct grenz zone.[1596,1597] In some cases, there are distinct lymphoid follicles composed of CD20-positive B cells with or without germinal centers typically surrounded by a population of reactive CD3-positive T cells. When present the germinal centers are frequently polarized and contain tingible body macrophages, which can aid in the distinction form cutaneous follicle center cell lymphoma (see later) (Fig. 3.135).[1513,1598]

The primary differential diagnostic considerations include primary cutaneous marginal zone lymphoma and primary cutaneous follicle center lymphoma, discussed in more detail later. Histologic features that have traditionally been used to favor a diagnosis of lymphoid hyperplasia over one of malignant lymphoma are the following: multiplicity of cell types, including plasma cells and eosinophils; formation of lymphoid follicles, with or without germinal centers; polarized germinal centers (when germinal center formation is present); tingible body macrophages; vascular proliferation; predominantly perivascular or periadnexal distribution of the infiltrate; and

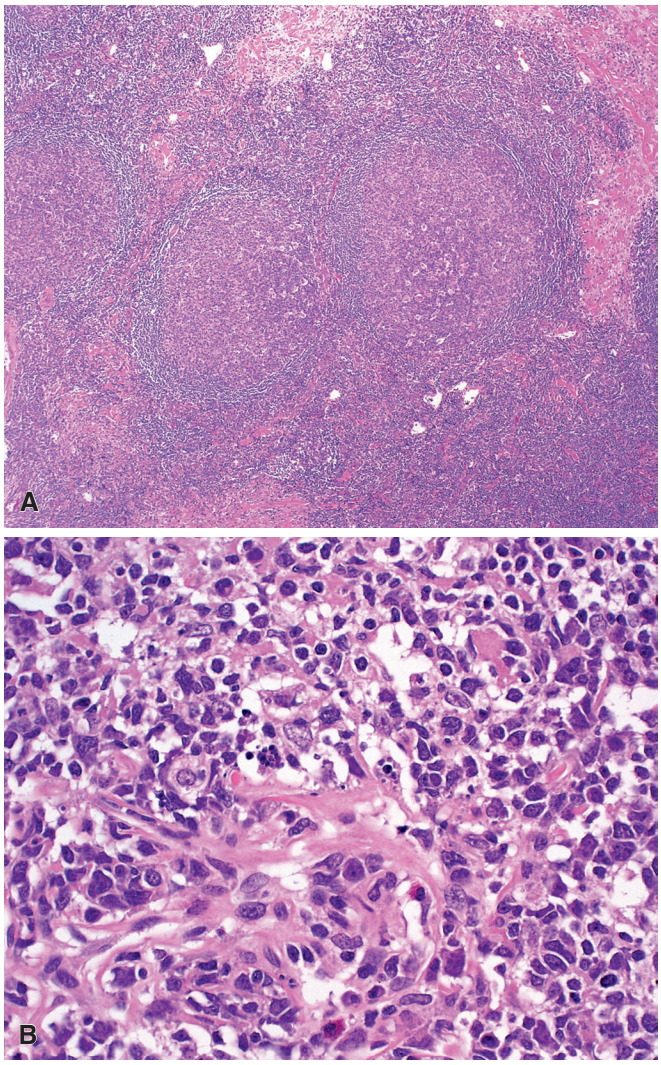

Figure 3.135 **A,** In this case of cutaneous lymphoid hyperplasia, there are distinct reactive germinal centers with a polarized appearance surrounded by a reactive proliferation of T-cells. **B,** The reactive germinal centers contain tingible body macrophages.

prominent epidermal hyperplasia.[1513,1596–1599] Immunohistochemistry is also valuable. By immunohistochemistry, the germinal centers retain immunoreactivity for BCL6 and CD10 but do not show coexpression of BCL2. The CD20-positive B cells do not show aberrant expression of CD43. Immunostains for CD21 can highlight intact dendritic cell networks in the reactive germinal centers.[1513,1598–1600] Plasma cells in the infiltrate lack light chain restriction by immunohistochemistry.[1598] The germinal centers in reactive lymphoid hyperplasia have a high Ki-67 nuclear labeling index. In selected cases clonality studies may be pursued, and cutaneous lymphoid hyperplasia is typically polyclonal. Molecular genetic analysis may be useful for the differential diagnosis with malignant lymphoma.[1598,1601]

Most lesions of cutaneous lymphoid hyperplasia are characterized by a benign clinical course, with resolution following antibiotic, steroid, or x-ray therapy or resolving spontaneously. However, some cases have been documented to progress to malignant lymphoma.[1602,1603]

Other clinically benign lymphocytic infiltrates that can microscopically simulate malignant lymphoma are related to molluscum contagiosum,[1604] syphilis,[1605] nodular scabies,[1606] and actinic reticuloid.[1607] Those that simulate microscopically the appearance of mycosis fungoides have been generically referred to as cutaneous pseudo–T-cell lymphomas.[1608,1609]

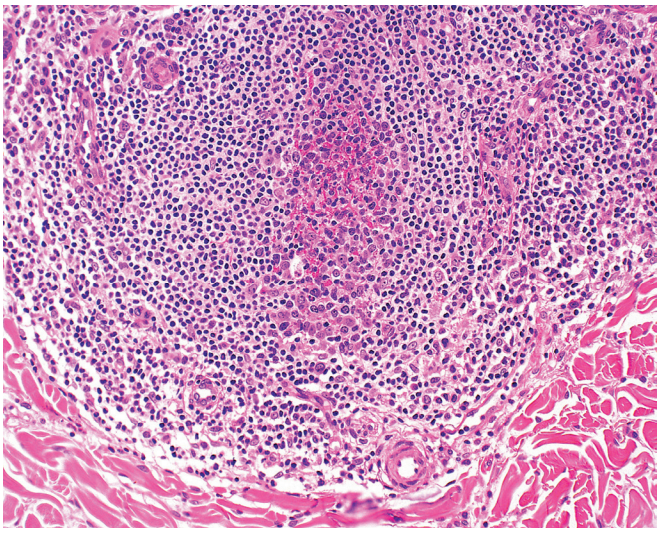

Figure 3.136 **Marginal Zone B-Cell Lymphoma of Skin.** There is a proliferation of neoplastic monocytoid tumor cells colonizing a germinal center.

Primary Cutaneous Marginal Zone Lymphoma

Primary cutaneous marginal zone lymphoma usually arises on the extremities or trunk, with a predominance in young males.[1513] Microscopically, primary cutaneous marginal zone lymphoma has a nodular to diffuse pattern and the epidermis is uninvolved. The infiltrate is predominantly composed of marginal zone cells (centrocyte-like cells), monocytoid B cells and plasma cells. Reactive germinal centers may be present, and they are frequently colonized by the neoplastic monocytoid B cells (Fig. 3.136).[1513,1600] In the lymphoplasmacytic variant, the majority of cells are lymphoplasmacytoid and plasma cells with few monocytoid B cells. The plasmacytic variant is composed predominantly of plasma cells.

The neoplastic cells express CD20 and CD79a, and stains for CD79a often highlight more of the neoplastic cells, including plasma cells.[1513] Stains for BCL6 and CD10 are negative, helping to distinguish it from primary cutaneous follicle center lymphoma. Stains for CD21 can highlight disrupted dendritic cell networks in reactive germinal centers colonized by the neoplastic cells.[1513,1610] The plasma cells are light chain restricted by immunohistochemistry (>3 : 1 kappa:lambda or >1 : 1 lambda:kappa), and the neoplasm demonstrates clonality by molecular testing.[1513,1598,1600,1603]

The primary differential diagnosis includes cutaneous lymphoid hyperplasia and primary cutaneous follicle center lymphoma. Primary cutaneous marginal zone lymphoma has larger, pale-staining cells that colonize germinal centers. Sheets of CD20- and CD79a-postive lymphocytes outside the germinal centers also favor primary cutaneous marginal zone lymphoma, as does light chain restriction of the plasma cell component. Distinguishing primary cutaneous marginal zone lymphoma from primary cutaneous follicle center lymphoma can be challenging. The germinal centers in the latter are neoplastic and typically lack tingible body macrophages. The interfollicular B cells in primary follicle center lymphoma are positive for BCL6. Cutaneous involvement by underlying chronic lymphocytic leukemia/small lymphocytic lymphoma can also be a consideration. The neoplastic B cells of this latter condition coexpress CD5, unlike primary cutaneous marginal zone lymphoma. Secondary involvement

by extranodal marginal zone lymphoma can be histologically indistinguishable. Expression of CD43 on the neoplastic cells favors secondary cutaneous involvement.

Primary cutaneous marginal zone lymphoma has an excellent prognosis with a greater than 90% 5-year survival. Most patients can be treated with localized therapy, either excision or radiation therapy.[1598]

Primary Cutaneous Follicle Center Lymphoma

Most patients present with an erythematous to violaceous nodule on the head and neck (most common site) or trunk (Fig. 3.137). Women are more commonly affected. Microscopically, this lymphoma may be follicular, diffuse, or follicular and diffuse (Fig. 3.138).[1513,1611,1612] In the follicular pattern, the tumor is composed of neoplastic follicles with a combination of centrocytes, centroblasts, and immunoblasts. The neoplastic follicles lack polarization and lack tingible body macrophages. The surrounding mantle zone is reduced to absent. In the diffuse pattern, the neoplastic cells have a sheet-like pattern in the dermis. Some cases have a combination of neoplastic follicles and a sheet-like pattern of neoplastic cells.

By immunohistochemistry, the neoplastic cells are positive for CD20, CD79a, and BCL6. Occasional cases are also positive for BCL2 and CD10. The tumor cells are negative for MUM1. Unlike the nodal counterpart, it is rare to see a *t*(14;18) in primary cutaneous follicle center lymphoma. Molecular studies typically reveal a clonal population of B-cells.[1598,1610–1612]

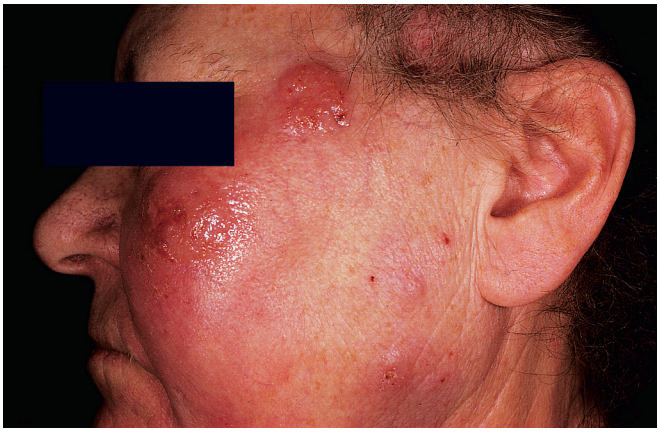

Figure 3.137 Malignant Lymphoma of Skin. The lesion appears in the form of markedly erythematous nodules on the face.

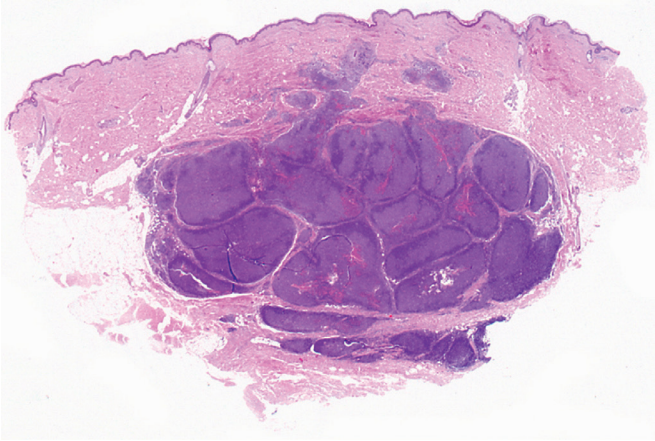

Figure 3.138 Panoramic view of follicular lymphoma of the skin, showing its deep location, nodular architecture, and sparing of papillary dermis and epidermis.

In the follicular and combined and diffuse and follicular patterns, the differential diagnosis includes cutaneous lymphoid hyperplasia and cutaneous marginal zone lymphoma.[1513,1610–1612] Cutaneous lymphoid hyperplasia is more heterogeneous with admixed eosinophils and plasma cells. The germinal centers in cutaneous lymphoid hyperplasia tend to be polarized and have tingible body macrophages. In cutaneous marginal zone lymphoma, the germinal centers are reactive in nature, like in cutaneous lymphoid hyperplasia. The neoplastic cells are negative for BCL6 in cutaneous marginal zone lymphoma. In the diffuse pattern, a rare aggressive form of cutaneous B-cell lymphoma, *diffuse large B-cell lymphoma, leg type* needs to be considered. This lymphoma usually presents on the lower legs of older patients. It consists of a sheet-like proliferation of enlarged centroblasts and immunoblasts. The tumor cells of diffuse large B-cell lymphoma, leg type are positive for MUM1, which is negative or only focally positive in primary follicle center lymphoma. BCL6 and CD10 immunoreactivity favor primary cutaneous follicle center lymphoma. It is also prudent to exclude the possibility of secondary cutaneous involvement by systemic follicular lymphoma, generally accomplished by a clinical examination.[1513,1610–1612]

Like primary cutaneous marginal zone lymphoma, primary follicle center lymphoma has an excellent prognosis with a greater than 90% 5-year survival. Surgical excision or radiotherapy are effective means of treatment.[1513]

Mycosis Fungoides and Related Peripheral T-Cell Lymphomas

Mycosis fungoides is a distinct clinicopathologic type of peripheral T-cell lymphoma and the most common cutaneous lymphoma subtype (Fig. 3.139).[1542,1613–1617] The large majority of cases occur in adult and elderly individuals, but adolescents and young adults can also be affected.[1617,1618] Traditionally, mycosis fungoides is divided into three stages: *premycotic*, *mycotic*, and *tumorous*. In the premycotic stage, the skin is erythematous, scaly, and pruritic. Clinical variations characterized by solitary, follicular, granulomatous, pustular, bullous, hyperkeratotic, verrucous, and hypopigmented forms exist.[1615,1616,1619–1626]

In the premycotic stage, the microscopic appearance may be nondiagnostic and represented by a nonspecific psoriasiform dermatitis.[1627] In the mycotic stage, infiltrative plaques appear, and biopsies show a polymorphous inflammatory infiltrate in the dermis that contains small numbers of frankly atypical lymphoid cells.[1628] These cells may invade the epidermis to form Pautrier microabscesses or, more often, to line up individually along the epidermal basal layer (Figs. 3.140 and 3.141).[1629] The latter finding, if unaccompanied by spongiosis, is strongly suggestive of mycosis fungoides. The lymphoid infiltrate may be predominantly located around hair follicles and can be accompanied by follicular mucinosis.[1630–1633] In rare instances there is infiltration of the eccrine sweat glands.[1634] In the tumorous stage, dense infiltrates of atypical lymphoid cells expand the dermis. The characteristic cell of mycosis fungoides is a small- or medium-sized lymphocyte with a cerebroid nucleus. This term refers to the highly irregular contour of the thick nuclear membrane, which results in an appearance somewhat reminiscent of brain convolutions (Fig. 3.142).[1635] Thin, well-prepared sections are necessary to identify this feature. These cerebroid cells are of T-cell type; their phenotype is usually that of helper T cells (CD4+), but sometimes it is suppressor/cytotoxic (CD8+) or aberrant.[1636,1637] Interestingly, several differences in antigen expression have been found between intraepidermal and intradermal lymphocytes.[1638–1640] In advanced stages of the disease, these cells may express CD15.[1641]

Figure 3.139 Clinical appearance of mycosis fungoides showing infiltrative plaques over virtually entire body.

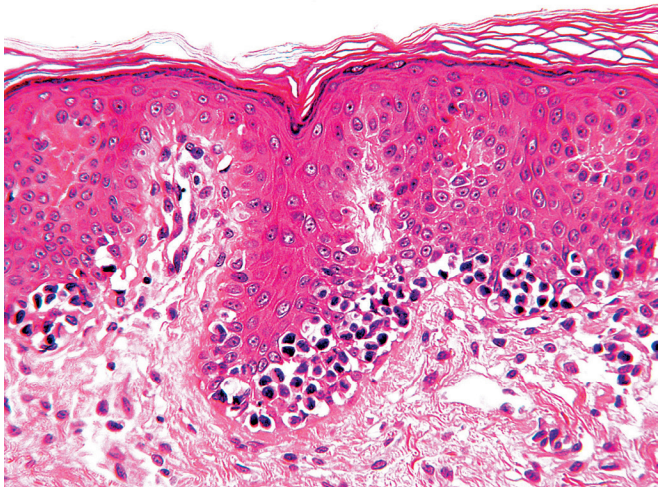

Figure 3.140 Epidermotropism of neoplastic lymphoid cells in mycosis fungoides.

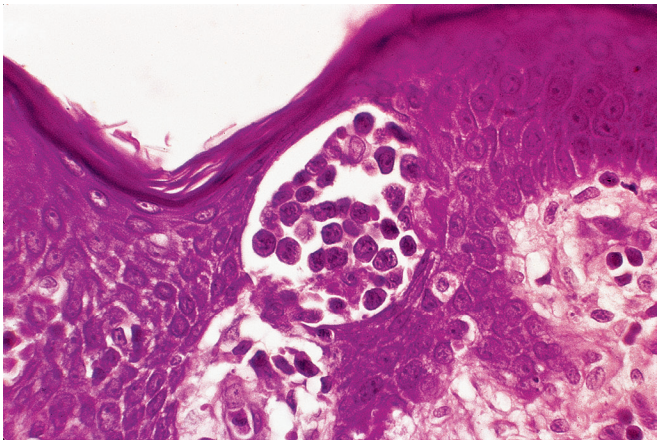

Figure 3.141 So-called Pautrier microabscess in mycosis fungoides.

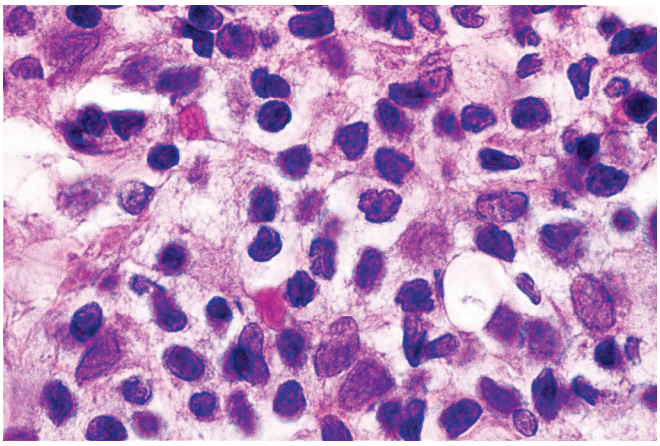

Figure 3.142 High-power view of mycosis fungoides cell, showing marked nuclear irregularities.

Although the presence of cerebroid cells is necessary to make a diagnosis of mycosis fungoides, they are not pathognomonic of the disease. Scattered cells with these nuclear features can be seen in other lymphomas and in some types of spongiotic acute and chronic dermatitis.[1642–1645] Conversely, it should be noted that a reactive B-cell component (with plasma cells and follicle formation) can accompany the T-cell neoplastic infiltrate of mycosis fungoides.[1639]

On the basis of immunocytochemical studies of the T-cell population performed, it has been suggested that loss of the T-lineage antigens CD2, CD3, CD5, and CD7 occurs in neoplastic T lymphocytes but not in reactive conditions.[1646–1648] Greater diagnostic assistance is provided by molecular studies (such as the analysis of T-cell receptor genes) for the identification of T-cell clones in skin biopsy specimens from patients with early disease.[1649–1651] It should be pointed out that other processes such as pityriasis lichenoides can have an abnormal clone of T-cells.[1652,1653] Therefore clonality by itself is not diagnostic. The histologic features must be analyzed in the appropriate clinical context, and significant weight is given to the clinical information in order to arrive at a diagnosis of mycosis fungoides, especially in early lesions.[1654]

The course of mycosis fungoides is usually protracted over a period of years. Clinical signs associated with poor prognosis are the presence of generalized plaques or tumors, diffuse erythema, and lymphadenopathy.[1655,1656] A correlation exists between the histologic findings and the clinical course,[1657] which applies primarily to the number and cytologic features of the neoplastic T cells, but the prognostic significance of the microscopic features as seen in a single biopsy is negligible.[1658] Parenthetically, Langerhans cells have been implicated in the pathogenesis of the disease, together with dermal dendrocytes.[1638,1659]

In approximately one-half to two-thirds of patients with mycosis fungoides of the skin, involvement of lymph nodes and internal viscera occurs. In most instances, the internal disease is microscopically still recognizable as mycosis fungoides by the polymorphism of the infiltrate and, most important, the cerebroid quality of the

nuclei of the tumor cells.[1660,1661] The internal infiltrates of mycosis fungoides can be found in the lymph nodes, lung, spleen, liver, kidney, bone marrow, central nervous system, and practically every other organ.[1661–1663]

Sepsis is a frequent terminal complication. The forms of therapy for disease limited to the skin include total skin electron beam irradiation, topical chemotherapy, and PUVA.[1664] More recently, targeted therapies are also being incorporated into the management of mycosis fungoides.[1665]

Sézary syndrome is a variant of mycosis fungoides characterized clinically by infiltrative erythroderma with pruritus, lymphadenopathy, and the presence of large or small cerebroid cells (Sézary and Lutzner cells, respectively) in the peripheral blood.[1666–1668] PAS-positive cytoplasmic granules are present in their cytoplasm. The distinction between mycosis fungoides and Sézary syndrome is to some extent artificial because circulating cerebroid cells of the same phenotype are found in approximately 20% of patients with mycosis fungoides. However, minor morphologic differences exist, such as a smaller number of cerebroid cells in the epidermis and fewer lymphocytes aligned within the basal layer, which may render the diagnosis more difficult.[1669]

Woringer–Kolopp disease (pagetoid reticulosis) is another T-cell cutaneous proliferative disorder which is characterized morphologically by a monomorphic intraepidermal infiltrate of cells with cerebroid nuclei, indistinguishable from those of the usual mycosis fungoides and Sézary syndrome.[1670,1671] The lesion presents clinically as a solitary erythematosquamous patch, typically on the extremities. The evolution is extremely slow.

Lymph Nodes in Mycosis Fungoides

Lymphadenopathy is common in patients with mycosis fungoides. The pathologic changes may be those of dermatopathic lymphadenitis, involvement by mycosis fungoides, or both.[1672,1673] The distinction between these processes can be extremely difficult to make. Preservation or distortion of the nodal architecture and the number of atypical lymphoid cells in T cell–dependent paracortical areas are the two most important diagnostic features.[1674,1675] Immunophenotyping and determination of clonal rearrangement of T-cell receptor genes offer a more sensitive and reliable means to make the distinction. (see Chapter 37).[1676,1677]

Lymphomatoid Papulosis and Anaplastic Large Cell Lymphoma

Lymphomatoid papulosis (LYP) is the original term given to a self-healing, recurrent papular eruption with a generally indolent clinical course and characterized microscopically by a polymorphic dermal infiltrate usually located superficially (Figs. 3.143 and 3.144). There are multiple different histologic types, ranging from type A to E.[1678–1682] Types A, B, and C are the classic forms. Type A can show considerable histologic overlap with pityriasis lichenoides et varioliformis acuta (PLEVA), discussed previously in the section on inflammatory dermatoses. It is composed of a superficial and deep perivascular mixed infiltrate with numerous large, atypical CD30+ lymphocytes admixed with avariable numbers of lymphocytes, eosinophils, and/or neutrophils (Fig. 3.145). Type B LYP resembles mycosis fungoides microscopically. Type C histologically resembles cutaneous anaplastic large cell lymphoma, with sheets of large atypical, CD30+ lymphocytes. More recently, types D and E have been described. Type D LYP has the typical clinical presentation of LYP but histologically and immunophenotypically resembles cutaneous aggressive epidermotropic CD8+ cytotoxic T-cell lymphoma.[1683] Knowledge of the clinical presentation is the only way to reliably distinguish these

Figure 3.143 Clinical Appearance of Lymphomatoid Papulosis. Multiple lesions are present, the larger ones showing ulceration.

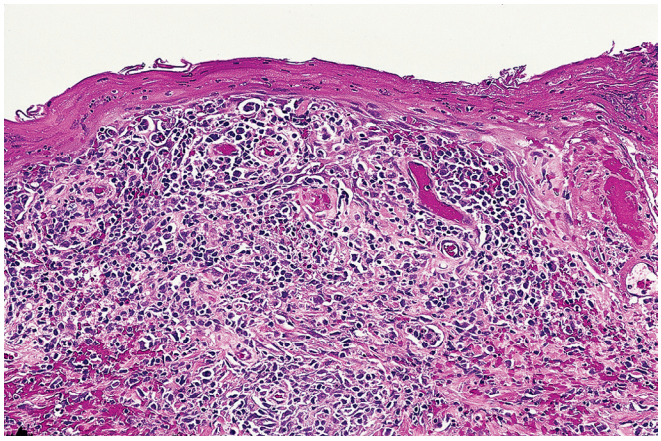

Figure 3.144 Low-power view of lymphomatoid papulosis showing heavy dermal infiltrate with epidermal thinning.

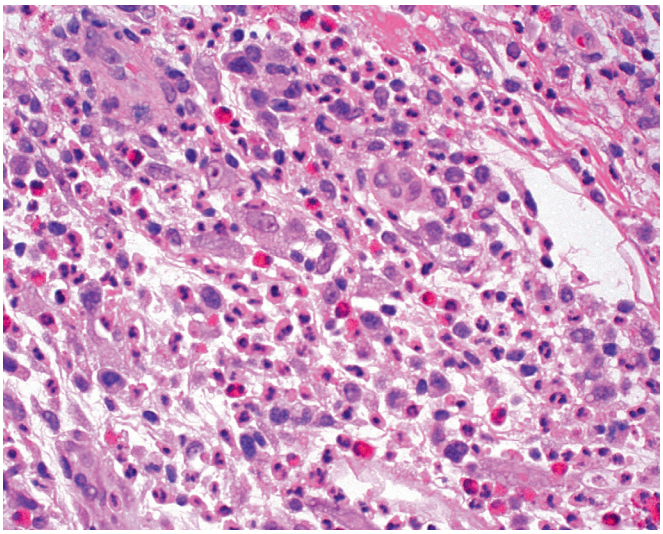

Figure 3.145 Lymphomatoid Papulosis Type A. High-power view, showing large atypical lymphoid cells admixed with eosinophils.

entities. Type E LYP is associated with a perivascular infiltrate of atypical CD30-positive and often CD8-positive lymphocytes with destruction of the vessel wall. Clinically, patients develop ulcers and large eschar-like lesions that eventually resolve spontaneously in this rare form of LYP.[1681]

The nature of LYP has been controversial. It was originally regarded either as a specific dermatosis or as a variant of PLEVA (Mucha–Habermann disease). The fact that there is a clonal population of T cells,[1684,1685] and that in 10%–20% of cases there is an association with, or evolution into, an obvious malignant lymphoma[1686] supports the current classification of LYP as a CD30-positive lymphoproliferative disorder closely related to anaplastic large cell lymphoma.[1687,1688]

The histologic differential diagnosis of LYP is variable. As previously mentioned, type A LYP can be confused with PLEVA or an arthropod bite reaction, although these conditions do not typically have significant numbers of CD30-positive atypical lymphocytes.[1689] Type B LYP histologically resembles mycosis fungoides. Type C LYP is indistinguishable from anaplastic large cell lymphoma (see later). Type D LYP is indistinguishable from cutaneous aggressive epidermotropic CD8+ cytotoxic T-cell lymphoma. In type E LYP, other forms of angioinvasive T-cell lymphoma need to be considered. This highlights the critical importance of correlation of the histologic findings with clinical presentation to arrive at an accurate diagnosis in LYP.[1690]

Anaplastic large cell lymphoma of skin presents clinically as solitary or multiple, often ulcerated skin lesions, and it affects predominantly elderly males.[1679,1688] Some cases have occurred in a post-transplant setting.[1691] Microscopically, there is a diffuse dermal and subcutaneous infiltration by a polymorphic infiltrate containing large anaplastic tumor cells with an appearance similar to those described in LYP.[1679,1688,1692] Pseudoepitheliomatous hyperplasia is a common accompanying feature.[1693] Morphologic variants include myxoid, sarcomatoid, and neutrophil-rich.[1694–1696]

The large lymphoid cells show strong positivity for CD30 in the form of diffuse membrane staining, as well as a paranuclear dot-like reaction in the Golgi area. Lineage markers are usually of T-cell type, but they can also be null.[1695,1697] They are by definition not of B-cell type, but it should be noted that some cutaneous large B-cell lymphomas are CD30 positive.[1698]

Three clinicopathologic forms of anaplastic large cell lymphoma are recognized: *primary cutaneous*, *primary systemic ALK+*, and *primary systemic ALK–*.[1688,1695,1699] The primary cutaneous form is associated with a good prognosis, as secondary systemic dissemination is only rarely observed. In contrast to systemic ALK+ anaplastic large cell lymphoma, the chromosomal translocation t(2;5), which generates the chimeric NPM–ALK transcript, is not found in primary cutaneous anaplastic large cell lymphoma.[1688,1700–1702] Instead, 20%–57% of cases show DUSP22-IRF4 translocation.[1703–1707] Rarely this translocation is seen in LYP.[1706,1707]

It needs to be pointed out that the presence of CD30-positive atypical lymphoid cells in a skin lesion is not diagnostic of LYP/anaplastic large cell lymphoma, inasmuch as they can also be seen in a variety of non-neoplastic cutaneous infiltrates.[1708]

Other Malignant Lymphomas

Other forms and subtypes of T-cell lymphoma that involve the skin are adult T-cell leukemia–lymphoma, subcutaneous panniculitis-like T-cell lymphoma, extranodal natural killer (NK)/T-cell lymphoma, nasal type; cutaneous ϒ/δ+ T-cell lymphoma, primary cutaneous CD4+ small/medium-sized pleomorphic T-cell lymphoma, primary cutaneous aggressive epidermotropic CD8+ T-cell lymphoma and primary cutaneous peripheral T-cell lymphoma, unspecified.[1688]

Subcutaneous panniculitis-like T-cell lymphoma is characterized by a primary involvement of the subcutaneous tissue (Fig. 3.146).[1688,1709]

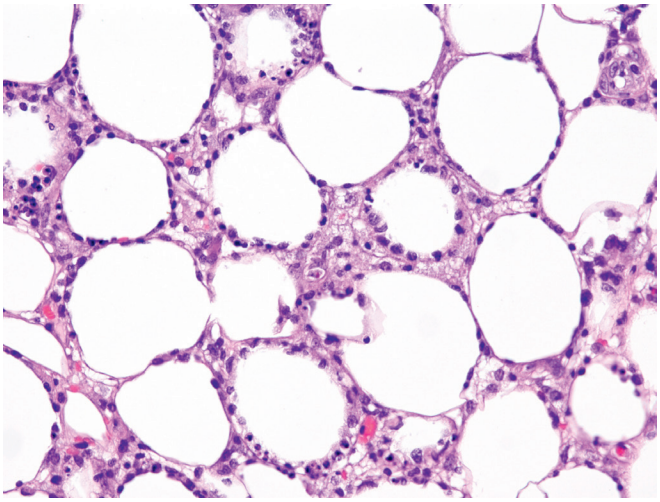

Figure 3.146 Panniculitis-Like T-Cell Lymphoma. Note the rimming of individual melanocytes by atypical lymphoid cells. (Courtesy Dr Fabio Facchetti, Brescia, Italy.)

The predominant phenotype is CD3+/CD4–/CD8+/β-F1+ (TCR α/β subtype)/CD56–.[1688,1710–1712] Rimming of adipocytes by the neoplastic lymphocytes is an important morphologic, albeit not totally specific, clue.[1713] There is significant histologic overlap with cutaneous ϒ/δ+ T-cell lymphoma, but this subcutaneous lymphoma has a ϒ/δ TCR and is CD3+/CD4–/CD8–/CD56+.[1688] The distinction is not trivial as subcutaneous panniculitis-like T-cell lymphoma is indolent with an excellent 5-year survival and cutaneous ϒ/δ+ T-cell lymphoma is a very aggressive lymphoma.

Primary cutaneous CD4+ small/medium-sized pleomorphic T-cell lymphoproliferative disorder usually presents as a solitary nodule with a dermal infiltrate of small- to medium-sized atypical lymphocytes that represent a proliferation of neoplastic follicular T-helper cells. In addition to being positive for CD4, they express CXCL-13 and PD-1.[1688] This is an indolent tumor, and some have questioned its inclusion as a true cutaneous lymphoma.[1714] Due to its indolent behavior, it has been reclassified as a lymphoproliferative disorder rather than a true lymphoma.[1715]

Lymphoblastic lymphoma is very uncommon, but it represents the predominant type of cutaneous lymphoma in children.[1716–1718]

Blastic plasmacytoid dendritic cell neoplasm (also known as blastic NK cell lymphoma) is a CD4+/CD56+/CD123+ systemic malignancy with frequent cutaneous involvement and a highly aggressive clinical course.[1719–1723]

Hodgkin lymphoma of the skin is exceptionally rare and presents in most instances as papules and nodules forming distally to involved lymph nodes; they are an indication of stage IV disease and probably result from retrograde lymphatic spread.[1724] A few well-documented cases of primary Hodgkin lymphoma of the skin have been reported,[1725,1726] some of them in HIV-infected patients,[1726] but many of the cases published in the past under this rubric were examples of LYP or cutaneous anaplastic large cell lymphoma.

True histiocytic and *Langerhans cells sarcomas* of the skin exists,[1727–1729] but most cases previously reported as malignant histiocytosis would probably be reclassified as anaplastic large cell lymphoma at present.

Intravascular (angiotropic) lymphoma is the currently preferred term for the disease originally described as malignant (systemic, proliferating, neoplastic) angioendotheliomatosis and characterized by accumulations of large, round, malignant cells in the lumen (and sometimes wall) of vessels (Fig. 3.147).[1730] The cutaneous and neurologic manifestations dominate the clinical presentation, but the disease may present initially in the uterine cervix, prostate, nasal cavity, bone, skeletal muscle, or other sites.[1731,1732] It was originally

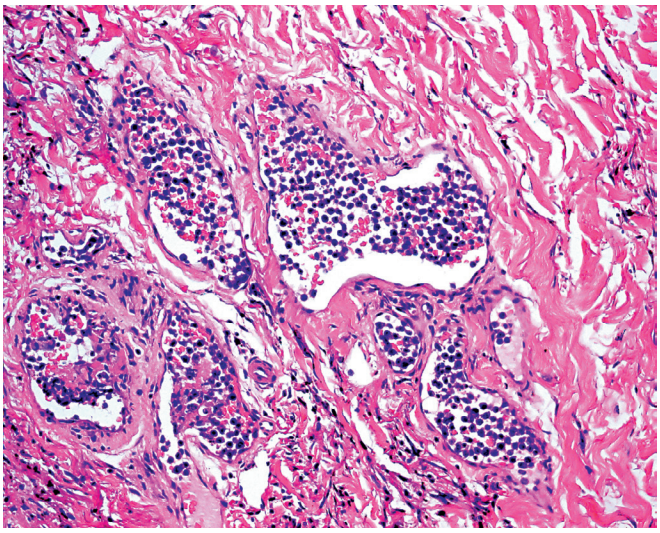

Figure 3.147 Angiotropic Malignant Lymphoma. The dermal vessels are packed with malignant lymphoid cells.

regarded as a systemic malignancy of vascular endothelium, but immunocytochemical studies have shown that it represents an angiotropic form of malignant lymphoma, usually of B-cell but sometimes of T- or NK-cell type, the latter being usually associated with EBV infection.[1733–1736] The term "angiotropic lymphoma" should not be equated with that of "angiocentric lymphoma," a T- or NK-cell malignancy with a different organ distribution and microscopic appearance (see Chapter 7).

Leukemia

Involvement of the skin in the form of multiple papules or nodules ("leukemia cutis") occurs in approximately 10% of patients with monocytic leukemia, 8% with chronic lymphocytic leukemia, and 5% with chronic granulocytic leukemia.[1737–1739] Most patients have an abnormal blood count at the time of diagnosis, but in some instances the skin lesions represent the first clinical manifestation of the disease and are accompanied by a normal peripheral blood ("aleukemic" forms).[1738,1739] Granulocytic leukemia of skin is usually a manifestation of recurrence in treated patients or a late development in association with widespread dissemination.[1740] Rarely, the disease manifests initially as multiple tumors in the skin: these cases tend to be misdiagnosed as large cell lymphoma.[1741] In chronic lymphocytic leukemia, the dermal infiltrate can be perivascular and periadnexal, nodular/diffuse, or bandlike.[1742] Immunohistochemical evaluation plays an important role in the identification of this process.[1743,1744] This includes the use of TdT and lymphocyte lineage markers for acute lymphoblastic leukemia, myeloperoxidase for acute myelogenous leukemia, and lysozyme (muramidase), the latter seemingly the most sensitive for acute myelogenous leukemias.[1743,1744]

It is well to remember that a large proportion of the skin lesions occurring in leukemic patients are histologically nonspecific inflammatory reactions and are not caused by infiltration by neoplastic cells.[1745] This includes leukemic vasculitis, although in this condition it is not clear whether the cells infiltrating the vessel walls are reactive or neoplastic.[1746]

Other Primary Tumors and Tumorlike Conditions

Endometriosis can present in women of reproductive age in the skin of the umbilicus or groin without antecedent surgery. When present in other cutaneous sites, there is nearly always an associated surgical scar.[1747] Microscopically, the combination of endometrial glands and stroma is characteristic; the lesion should not be confused with a sweat gland tumor or, worse, with a metastatic adenocarcinoma. Marked hemorrhage or myxoid decidual changes in the stroma may render the recognition difficult and lead to an overdiagnosis of malignancy.[1748,1749]

Meningioma can occur as a skin nodule, either in the scalp or along the vertebral axis, with or without an associated skin defect (see Chapter 46). *Hamartoma of the scalp with ectopic meningothelial elements* (rudimentary meningocele) is pathogenetically related to meningioma of the skin; it appears as a scalp nodule, usually during infancy, and is characterized by a dermal and subcutaneous proliferation of polygonal to spindle meningothelial cells, sometimes arranged in whorls and sometimes dissecting collagen fibers in a fashion reminiscent of angiosarcoma (Fig. 3.148). Psammoma bodies and islands of cartilage may be present. A long cleft is sometimes seen in the center of the lesion, in keeping with its presumed malformative pathogenesis. The ectopic meningothelial cells are immunoreactive for vimentin, EMA, and p63 and negative for CD31 and FVIII-related antigen.[1750–1752]

Nasal glioma is a form of glial heterotopia that is seen in neonates at the root of the nose, sometimes immediately beneath the skin (see Chapter 4).[1753]

Ganglioneuroma can exceptionally present as a primary cutaneous neoplasm.[1754]

Osteoma cutis of skin is not a neoplasm but rather a reactive process. It can be seen as metaplastic ossification of other lesions, such as pilomatrixomas or melanocytic nevi, or the result of inflammatory processes, often linked to prior acne.[1755,1756]

Metaplastic synovial cyst (synovial metaplasia of the skin) is a peculiar postsurgical intradermal cystic formation associated with transepidermal fistulas and lined microscopically by tissue resembling hyperplastic synovium.[1756–1759] The rare *cutaneous ganglion cyst* probably has a similar pathogenesis.[1760]

Inflammatory pseudotumor presents as a small, deeply seated dermal nodule; microscopically, it has a fibrosed (sometimes hyalinized) and vascularized center containing a polymorphic infiltrate rich in plasma cells surrounded by a rim of lymphoid follicles, the overall appearance resembling a lymph node on low-power examination.[1761] The process is probably truly inflammatory and not related to so-called inflammatory myofibroblastic tumor.

PEComa, an unusual tumor of melanocytic and smooth muscle differentiation related to angiomyolipoma, can rarely present in a superficial (cutaneous or subcutaneous) location.[1762–1764] As in other sites, they may be predominantly composed of clear cells. They should be distinguished from metastatic renal cell carcinoma, true melanocytic lesions, and other clear cell mesenchymal neoplasms.[1293]

Soft tissue-type tumors of various types can sometimes present as cutaneous (dermal) neoplasms. In addition to those that have already been mentioned, the list includes spindle cell lipoma,[1765] pleomorphic liposarcoma,[1766] giant cell tumor,[1767] Ewing sarcoma/primitive neuroectodermal tumor (PNET),[1768] synovial sarcoma,[1769] and clear cell sarcoma[915] to highlight a few.

Metastatic Tumors

In men, the most common sources of metastatic tumor to the skin are lung (25%), large bowel, skin (melanoma), kidney, and upper aerodigestive tract. In females, the breast is the most common source (69%), followed by the lung, skin (melanoma), kidney, and ovary.[1770–1772] Unusual sites include adrenal gland, liver, pancreas, uterus, and thyroid.[1773–1776] Most cases are multiple and appear as firm, nonulcerated nodules.[1776] When solitary, they may be misdiagnosed

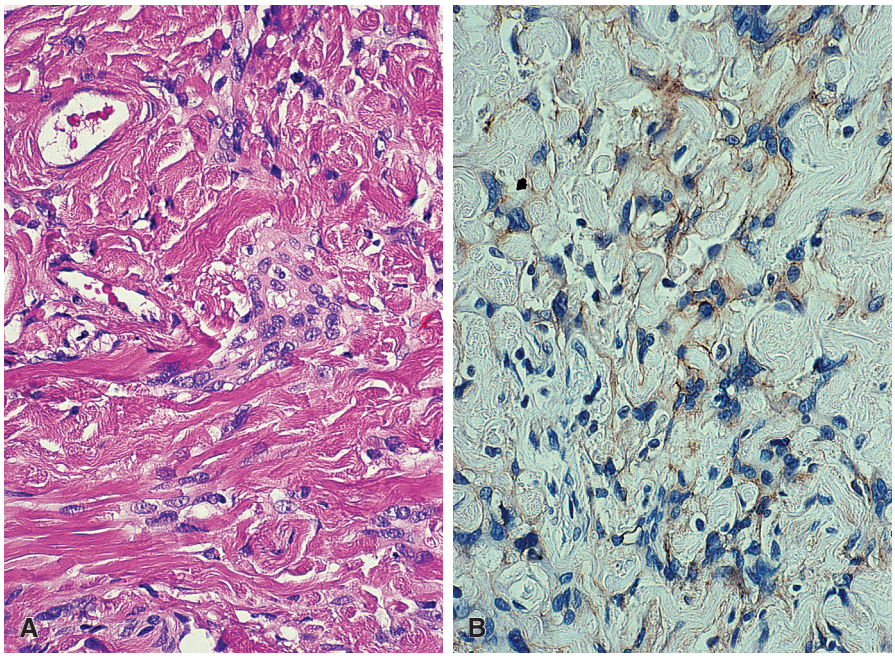

Figure 3.148 Hamartoma of the Scalp With Ectopic Meningothelial Elements. A, Meningothelial cells are present in the deep dermis, some of them arranged in clusters and others individually among collagen fibers. **B,** Positive immunostain for epithelial membrane antigen (EMA).

as primary skin tumors (Fig. 3.149). This is particularly true for renal cell carcinoma, which is often misinterpreted as a sweat gland tumor; the presence of dilated sinusoidal vessels, extravasated red blood cells in the glandular lumina, and nuclear atypia should suggest the correct diagnosis.[1777,1778] Immunostains for markers such as PAX8 can aid in recognition of metastatic renal cell carcinoma.[1779,1780] Occasionally, metastatic signet ring carcinomas from the stomach or other sites elicit a brisk fibroblastic reaction with storiform features, thus closely resembling the appearance of a DFSP. Staining with antibody HIK1083 (which detects gastric O-glycan) is useful in the distinction between cutaneous metastases of gastric carcinoma (positive) and primary sweat gland carcinoma (negative),[1781] whereas podoplanin (D2-40), p63, and p40 have been proposed as a means to distinguishing sweat gland carcinoma (positive) from metastatic carcinoma from various sites (negative).[1782–1784]

The metastatic tumor may be predominantly confined to lymphatic vessels. This is especially true in metastatic carcinomas of the breast, which can impart a diffuse erythematous appearance to the affected skin (so-called inflammatory carcinoma) (Fig. 3.150). Occasionally, the metastatic dermal nodules invade the overlying epidermis, simulating the appearance of a primary tumor ("epidermotropic carcinomas").[1785,1786] Another source of error is the solitary cutaneous metastasis from a small cell carcinoma of the lung, endocrine tumor of the pancreas, or carcinoid tumor of the small bowel that is misdiagnosed as Merkel cell carcinoma or some other primary neuroendocrine carcinoma of skin, but Merkel cell carcinoma is positive for cytokeratin 20.[1787]

The most common sites for skin metastases are the chest and abdomen, followed by the head and neck; location in the extremities is rare. Those metastases situated in the scalp can be associated with alopecia ("alopecia neoplastica"). The interesting observation has been made that the skin metastases tend to be close to the site of the primary tumor: chest in lung carcinoma, abdominal wall in gastrointestinal tumors, and lower back in renal cell carcinoma.[1771]

Figure 3.149 Squamous cell carcinoma of uterine cervix metastatic to skin of arm.

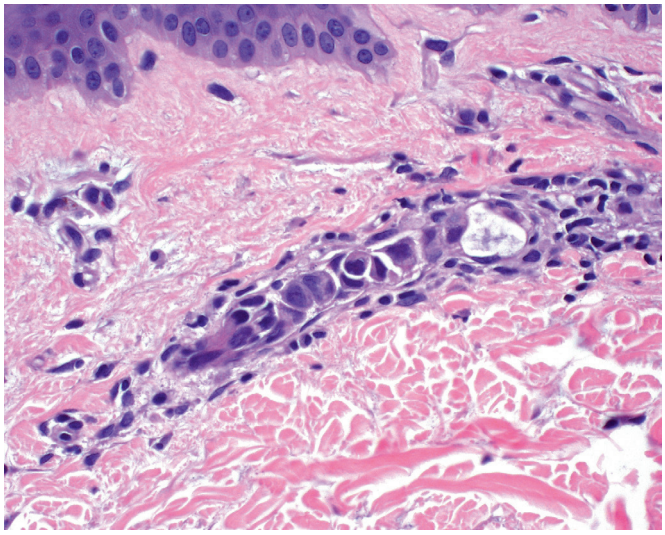

Figure 3.150 Metastatic Adenocarcinoma of Breast to Skin. The tumor cells are filling the vascular lumen of a dermal lymphatic vessel.

References

1. Holdiness MR. The sign of Leser-Trelat. *Int J Dermatol*. 1986;25(9):564-572.
2. Chen M, Shinmori H, Takemiya M, Miki Y. Acantholytic variant of seborrheic keratosis. *J Cutan Pathol*. 1990;17(1):27-31.
3. King R, Page RN, Googe PB. Desmoplastic seborrheic keratosis. *Am J Dermatopathol*. 2003;25(3):210-214.
4. Mutasim DF. Psoriasiform keratosis: a lesion mimicking psoriasis. *Am J Dermatopathol*. 2007;29(5):482-484.
5. Walsh SN, Hurt MA, Santa Cruz DJ. Psoriasiform keratosis. *Am J Dermatopathol*. 2007;29(2):137-140.
6. Nindl M, Nakagawa H, Furue M, Ishibashi Y. Simple epithelial cytokeratin-expression in seborrheic keratosis. *J Cutan Pathol*. 1992;19(5):415-422.
7. Shimizu N, Ito M, Tazawa T, Sato Y. Immunohistochemical study on keratin expression in certain cutaneous epithelial neoplasms. Basal cell carcinoma, pilomatricoma, and seborrheic keratosis. *Am J Dermatopathol*. 1989;11(6):534-540.
8. Choi HJ, Yun SK, Kim HU, Ihm CW. Squamous eddies in irritated seborrheic keratosis. *Am J Dermatopathol*. 2007;29(1):28-31.
9. Zhu WY, Leonardi C, Kinsey W, Penneys NS. Irritated seborrheic keratoses and benign verrucous acanthomas do not contain papillomavirus DNA. *J Cutan Pathol*. 1991;18(6):449-452.
10. Jacyk WK, Dreyer L, de Villiers EM. Seborrheic keratoses of black patients with epidermodysplasia verruciformis contain human papillomavirus DNA. *Am J Dermatopathol*. 1993;15(1):1-6.
11. Roncalli de Oliveira W, Neto CF, Rady PL, Tyring SK. Seborrheic Keratosis-like lesions in patients with epidermodysplasia verruciformis. *J Dermatol*. 2003;30(1):48-53.
12. Rahbari H. Bowenoid transformation of seborrhoeic verrucae (keratoses). *Br J Dermatol*. 1979;101(4):459-463.
13. Zhao YK, Lin YX, Luo RY, et al. Human papillomavirus (HPV) infection in seborrheic keratosis. *Am J Dermatopathol*. 1989;11(3):209-212.
14. Li J, Ackerman AB. Seborrheic keratoses" that contain human papillomavirus are condylomata acuminata. *Am J Dermatopathol*. 1994;16(4):398-405, discussion 6-8.
15. Cascajo CD, Reichel M, Sanchez JL. Malignant neoplasms associated with seborrheic keratoses. An analysis of 54 cases. *Am J Dermatopathol*. 1996;18(3):278-282.
16. Hafner C, Toll A, Fernández-Casado A, et al. Multiple oncogenic mutations and clonal relationship in spatially distinct benign human epidermal tumors. *Proc Natl Acad Sci USA*. 2010;107:20780-20785.
17. Morgan MB, Stevens GL. Switlyk S. Benign lichenoid keratosis: a clinical and pathologic reappraisal of 1040 cases. *Am J Dermatopathol*. 2005;27(5):387-392.
18. Cooper PH, Mackel SE. Acquired fibrokeratoma of the heel. *Arch Dermatol*. 1985;121(3):386-388.
19. Fu W, Cockerell CJ. The actinic (solar) keratosis: a 21st-century perspective. *Arch Dermatol*. 2003;139(1):66-70.
20. King GN, Healy CM, Glover MT, et al. Increased prevalence of dysplastic and malignant lip lesions in renal-transplant recipients. *N Engl J Med*. 1995;332(16):1052-1057.
21. Pinkus H. Keratosis senilis; a biologic concept of its pathogenesis and diagnosis based on the study of normal epidermis and 1730 seborrheic and senile keratoses. *Am J Clin Pathol*. 1958;29(3):193-207.
22. Mai KT, Alhalouly T, Landry D, et al. Pagetoid variant of actinic keratosis with or without squamous cell carcinoma of sun-exposed skin: a lesion simulating extramammary Paget's disease. *Histopathology*. 2002;41(4):331-336.
23. James MP, Wells GC, Whimster IW. Spreading pigmented actinic keratoses. *Br J Dermatol*. 1978;98(4):373-379.
24. Sim CS, Slater S, McKee PH. Mutant p53 expression in solar keratosis: an immunohistochemical study. *J Cutan Pathol*. 1992;19(4):302-308.
25. Nelson MA, Einspahr JG, Alberts DS, et al. Analysis of the p53 gene in human precancerous actinic keratosis lesions and squamous cell cancers. *Cancer Lett*. 1994;85(1):23-29.
26. Kushida Y, Miki H, Ohmori M. Loss of heterozygosity in actinic keratosis, squamous cell carcinoma and sun-exposed normal-appearing skin in Japanese: difference between Japanese and Caucasians. *Cancer Lett*. 1999;140(1-2):169-175.
27. Rehman I, Takata M, Wu YY, Rees JL. Genetic change in actinic keratoses. *Oncogene*. 1996;12(12):2483-2490.
28. Mortier L, Marchetti P, Delaporte E, et al. Progression of actinic keratosis to squamous cell carcinoma of the skin correlates with deletion of the 9p21 region encoding the p16(INK4a) tumor suppressor. *Cancer Lett*. 2002;176(2):205-214.
29. Dinehart SM. The treatment of actinic keratoses. *J Am Acad Dermatol*. 2000; 42(1 Pt 2):25-28.
30. Bondeson J. Everard Home, John Hunter, and cutaneous horns: a historical review. *Am J Dermatopathol*. 2001;23(4): 362-369.
31. Michal M, Bisceglia M, Di Mattia A, et al. Gigantic cutaneous horns of the scalp: lesions with a gross similarity to the horns of animals: a report of four cases. *Am J Surg Pathol*. 2002;26(6):789-794.
32. Yu RC, Pryce DW, Macfarlane AW, Stewart TW. A histopathological study of 643 cutaneous horns. *Br J Dermatol*. 1991;124(5):449-452.
33. DiMaio DJ, Cohen PR. Trichilemmal horn: case presentation and literature review. *J Am Acad Dermatol*. 1998;39(2 Pt 2): 368-371.
34. Kimura S. Trichilemmal keratosis (horn): a light and electron microscopic study. *J Cutan Pathol*. 1983;10(1):59-67.
35. Oh CW, Penneys N. P27 and mib1 expression in actinic keratosis, Bowen disease, and squamous cell carcinoma. *Am J Dermatopathol*. 2004;26(1):22-26.
36. Argenyi ZB, Hughes AM, Balogh K, Vo TL. Cancerization of eccrine sweat ducts in Bowen's disease as studied by light microscopy, DNA spectrophotometry and immunohistochemistry. *Am J Dermatopathol*. 1990;12(5):433-440.
37. Kuo TT, Hu S, Lo SK, Chan HL. p53 expression and proliferative activity in Bowen's disease with or without chronic arsenic exposure. *Hum Pathol*. 1997;28(7):786-790.

38. Sim CS, Slater SD, McKee PH. Mutant p53 protein is expressed in Bowen's disease. *Am J Dermatopathol*. 1992;14(3):195-199.
39. Newton JA, Camplejohn RS, McGibbon DH. Aneuploidy in Bowen's disease. *Br J Dermatol*. 1986;114(6):691-694.
40. Kossard S, Rosen R. Cutaneous Bowen's disease. An analysis of 1001 cases according to age, sex, and site. *J Am Acad Dermatol*. 1992;27(3):406-410.
41. Saglam O, Salama M, Meier F, et al. Immunohistochemical staining of palisading basal cells in Bowen's disease and basal involvement in actinic keratosis: contrasting staining patterns suggest different cells of origin. *Am J Dermatopathol*. 2008;30(2): 123-126.
42. Sun JD, Barr RJ. Papillated Bowen disease, a distinct variant. *Am J Dermatopathol*. 2006;28(5):395-398.
43. Williamson JD, Colome MI, Sahin A, et al. Pagetoid Bowen disease: a report of 2 cases that express cytokeratin 7. *Arch Pathol Lab Med*. 2000;124(3):427-430.
44. Callen JP, Headington J. Bowen's and non-Bowen's squamous intraepidermal neoplasia of the skin. Relationship to internal malignancy. *Arch Dermatol*. 1980;116(4):422-426.
45. Graham JH, Helwig EB. Bowen's disease and its relationship to systemic cancer. *AMA Arch Dermatol*. 1959;80(2):133-159.
46. Centeno JA, Mullick FG, Martinez L, et al. Pathology related to chronic arsenic exposure. *Environ Health Perspect*. 2002;110(suppl 5):883-886.
47. Alam M, Ratner D. Cutaneous squamous-cell carcinoma. *N Engl J Med*. 2001;344(13): 975-983.
48. Marks R. An overview of skin cancers. Incidence and causation. *Cancer*. 1995; 75(2 suppl):607-612.
49. Preston DS, Stern RS. Nonmelanoma cancers of the skin. *N Engl J Med*. 1992;327(23):1649-1662.
50. Brash DE, Rudolph JA, Simon JA, et al. A role for sunlight in skin cancer: UV-induced p53 mutations in squamous cell carcinoma. *Proc Natl Acad Sci USA*. 1991;88(22):10124-10128.
51. Urbach F, ed. *Geographic Pathology of Skin Cancer. The Biologic Effects of Ultraviolet Radiation (With Emphasis on the Skin)*. New York, NY: Pergamon Press; 1969.
52. Sober AJ, Burstein JM. Precursors to skin cancer. *Cancer*. 1995;75(2 suppl):645-650.
53. Cleaver JE, Crowley E. UV damage, DNA repair and skin carcinogenesis. *Front Biosci*. 2002;7:d1024-d1043.
54. Tsao H. Genetics of nonmelanoma skin cancer. *Arch Dermatol*. 2001;137(11):1486-1492.
55. Dubina M, Goldenberg G. Viral-associated nonmelanoma skin cancers: a review. *Am J Dermatopathol*. 2009;31(6):561-573.
56. Majewski S, Jablonska S. Do epidermodysplasia verruciformis human papillomaviruses contribute to malignant and benign epidermal proliferations? *Arch Dermatol*. 2002;138(5):649-654.
57. Alexander SJ. Squamous cell carcinoma in chronic hydradenitis suppurativa: a case report. *Cancer*. 1979;43(2):745-748.
58. Barr LH, Menard JW. Marjolin's ulcer. The LSU experience. *Cancer*. 1983;52(1):173-175.
59. Johnson LL, Kempson RL. Epidermoid carcinoma in chronic osteomyelitis: diagnostic problems and management. *J Bone Joint Surg Am*. 1965;47:133-145.
60. Kim JM, Su WP, Kurtin PJ, Ziesmer S. Marjolin's ulcer: immunohistochemical study of 17 cases and comparison with common squamous cell carcinoma and basal cell carcinoma. *J Cutan Pathol*. 1992;19(4):278-285.
61. McGrath JA, Schofield OM, Mayou BJ, et al. Epidermolysis bullosa complicated by squamous cell carcinoma: report of 10 cases. *J Cutan Pathol*. 1992;19(2):116-123.
62. Mallipeddi R. Epidermolysis bullosa and cancer. *Clin Exp Dermatol*. 2002;27(8): 616-623.
63. Schwartz RA, Birnkrant AP, Rubenstein DJ, et al. Squamous cell carcinoma in dominant type epidermolysis bullosa dystrophica. *Cancer*. 1981;47(3):615-620.
64. Ueda A, Suda K, Matsumoto T, et al. A clinicopathological and immunohistochemical comparison of squamous cell carcinoma arising in scars versus nonscar SCC in Japanese patients. *Am J Dermatopathol*. 2006;28(6):472-477.
65. Mullen DL, Silverberg SG, Penn I, Hammond WS. Squamous cell carcinoma of the skin and lip in renal homograft recipients. *Cancer*. 1976;37(2):729-734.
66. Rubel JR, Milford EL, Abdi R. Cutaneous neoplasms in renal transplant recipients. *Eur J Dermatol*. 2002;12(6):532-535.
67. Euvrard S, Kanitakis J, Claudy A. Skin cancers after organ transplantation. *N Engl J Med*. 2003;348(17):1681-1691.
68. Soler C, Chardonnet Y, Allibert P, et al. Detection of mucosal human papillomavirus types 6/11 in cutaneous lesions from transplant recipients. *J Invest Dermatol*. 1993;101(3):286-291.
69. Martinez JC, Otley CC, Stasko T, et al. Defining the clinical course of metastatic skin cancer in organ transplant recipients: a multicenter collaborative study. *Arch Dermatol*. 2003;139(3):301-306.
70. Wang CY, Brodland DG, Su WP. Skin cancers associated with acquired immunodeficiency syndrome. *Mayo Clin Proc*. 1995;70(8): 766-772.
71. Valentino C, Krouse R, Bradely-Dunlop D, et al. Immunopathological features of cutaneous squamous cell carcinomas in immunocompromised patients. *Lab Invest*. 2009;89:111A.
72. Gasparro FP. The role of PUVA in the treatment of psoriasis. Photobiology issues related to skin cancer incidence. *Am J Clin Dermatol*. 2000;1(6):337-348.
73. Stern RS, Laird N, Melski J, et al. Cutaneous squamous-cell carcinoma in patients treated with PUVA. *N Engl J Med*. 1984;310(18):1156-1161.
74. Madariaga J, Fromowitz F, Phillips M, Hoover HC Jr. Squamous cell carcinoma in congenital ichthyosis with deafness and keratitis. A case report and review of the literature. *Cancer*. 1986;57(10): 2026-2029.
75. Levin A, Amazon K, Rywlin AM. A squamous cell carcinoma that developed in an epidermal nevus. Report of a case and a review of the literature. *Am J Dermatopathol*. 1984;6(1):51-55.
76. Otsuka F, Umebayashi Y, Watanabe S, et al. Porokeratosis large skin lesions are susceptible to skin cancer development: histological and cytological explanation for the susceptibility. *J Cancer Res Clin Oncol*. 1993;119(7):395-400.
77. Epstein JI, Mendelsohn G. Squamous carcinoma of the foot arising in association with long-standing verrucous hyperplasia in a patient with congenital lymphedema. *Cancer*. 1984;54(5):943-947.
78. Furukawa H, Yamamoto Y, Minakawa H, Sugihara T. Squamous cell carcinoma in chronic lymphedema: case report and review of the literature. *Dermatol Surg*. 2002;28(10):951-953.
79. Smoller BR, Krueger J, McNutt NS, Hsu A. "Activated" keratinocyte phenotype is unifying feature in conditions which predispose to squamous cell carcinoma of the skin. *Mod Pathol*. 1990;3(2): 171-175.
80. Landman G, Taylor RM, Friedman KJ. Cutaneous papillary squamous cell carcinoma. A report of two cases. *J Cutan Pathol*. 1990;17(2):105-110.
81. Jones RE Jr. What is the boundary that separates a thick solar keratosis and a thin squamous-cell carcinoma? *Am J Dermatopathol*. 1984;6(3):301-306.
82. Kessler GM, Ackerman AB. Nomenclature for very superficial squamous cell carcinoma of the skin and of the cervix: a critique in historical perspective. *Am J Dermatopathol*. 2006;28(6):537-545.
83. Satter EK. Pigmented squamous cell carcinoma. *Am J Dermatopathol*. 2007;29(5): 486-489.
84. Forman SB, Ferringer TC. Clear-cell basal cell carcinoma: differentiation from other clear-cell tumors. *Am J Dermatopathol*. 2007;29(2):208-209.
85. Requena L, Sanchez M, Requena I, et al. Clear cell squamous cell carcinoma. A histologic, immunohistologic, and ultrastructural study. *J Dermatol Surg Oncol*. 1991;17(8):656-660.
86. Dalton SR, LeBoit PE. Squamous cell carcinoma with clear cells: how often is there evidence of tricholemmal differentiation? *Am J Dermatopathol*. 2008;30(4):333-339.
87. Cramer SF, Heggeness LM. Signet-ring squamous cell carcinoma. *Am J Clin Pathol*. 1989;91(4):488-491.
88. Heyderman E, Graham RM, Chapman DV, et al. Epithelial markers in primary skin cancer: an immunoperoxidase study of the distribution of epithelial membrane antigen (EMA) and carcinoembryonic antigen (CEA) in 65 primary skin carcinomas. *Histopathology*. 1984;8(3):423-434.
89. Perkins W, Campbell I, Leigh IM, MacKie RM. Keratin expression in normal skin and epidermal neoplasms demonstrated by a panel of monoclonal antibodies. *J Cutan Pathol*. 1992;19(6):476-482.
90. Said JW, Sassoon AF, Shintaku IP, Banks-Schlegel S. Involucrin in squamous and basal cell carcinomas of the skin: an immunohistochemical study. *J Invest Dermatol*. 1984;82(5):449-452.
91. Gleason BC, Calder KB, Cibull TL, et al. Utility of p63 in the differential diagnosis of atypical fibroxanthoma and spindle cell squamous cell carcinoma. *J Cutan Pathol*. 2009;36:543-547.
92. Iyer PV, Leong AS. Poorly differentiated squamous cell carcinomas of the skin can express vimentin. *J Cutan Pathol*. 1992;19(1):34-39.
93. Beer TW, Shepherd P, Theaker JM. Ber EP4 and epithelial membrane antigen aid distinction of basal cell, squamous cell and basosquamous carcinomas of the skin. *Histopathology*. 2000;37(3):218-223.
94. Swanson PE, Fitzpatrick MM, Ritter JH, et al. Immunohistologic differential diagnosis of basal cell carcinoma, squamous cell carcinoma, and trichoepithelioma in small cutaneous biopsy specimens. *J Cutan Pathol*. 1998;25(3):153-159.
95. Wagoner J, Keehn C, Morgan MB. CD-10 immunostaining differentiates superficial basal cell carcinoma from cutaneous squamous cell carcinoma. *Am J Dermatopathol*. 2007;29(6):555-558.
96. Gusterson BA, Clinton S, Gough G. Studies of early invasive and intraepithelial squamous cell carcinomas using an antibody to type IV collagen. *Histopathology*. 1986;10(2):161-169.
97. Helander SD, Peters MS, Pittelkow MR. Expression of p53 protein in benign and

malignant epidermal pathologic conditions. *J Am Acad Dermatol*. 1993;29(5 Pt 1): 741-748.
98. Leffell DJ. The scientific basis of skin cancer. *J Am Acad Dermatol*. 2000;42(1 Pt 2):18-22.
99. Kubo Y, Murao K, Matsumoto K, Arase S. Molecular carcinogenesis of squamous cell carcinomas of the skin. *J Med Invest*. 2002;49(3-4):111-117.
100. Murao K, Kubo Y, Ohtani N, et al. Epigenetic abnormalities in cutaneous squamous cell carcinomas: frequent inactivation of the RB1/p16 and p53 pathways. *Br J Dermatol*. 2006;155(5):999-1005.
101. Chen Z, Lee TL, Yang XP, et al. cDNA microarray and bioinformatic analysis of nuclear factor-kappaB related genes in squamous cell carcinoma. *Methods Mol Biol*. 2007;383:81-99.
102. Kobielak A, Fuchs E. Links between alpha-catenin, NF-kappaB, and squamous cell carcinoma in skin. *Proc Natl Acad Sci USA*. 2006;103(7):2322-2327.
103. Loercher A, Lee TL, Ricker JL, et al. Nuclear factor-kappaB is an important modulator of the altered gene expression profile and malignant phenotype in squamous cell carcinoma. *Cancer Res*. 2004;64(18):6511-6523.
104. Pierceall WE, Goldberg LH, Tainsky MA, et al. Ras gene mutation and amplification in human nonmelanoma skin cancers. *Mol Carcinog*. 1991;4(3):196-202.
105. Spencer JM, Kahn SM, Jiang W, et al. Activated RAS genes occur in human actinic keratoses, premalignant precursors to squamous cell carcinomas. *Arch Dermatol*. 1995;131(7):796-800.
106. Eusebi V, Ceccarelli C, Piscioli F, et al. Spindle cell tumours of the skin of debatable origin. An immunocytochemical study. *J Pathol*. 1984;144(3):189-199.
107. Folpe AL, Cooper K. Best practices in diagnostic immunohistochemistry: pleomorphic cutaneous spindle cell tumors. *Arch Pathol Lab Med*. 2007;131(10):1517-1524.
108. Kuwano H, Hashimoto H, Enjoji M. Atypical fibroxanthoma distinguishable from spindle cell carcinoma in sarcoma-like skin lesions. A clinicopathologic and immunohistochemical study of 21 cases. *Cancer*. 1985;55(1):172-180.
109. Smith KJ, Skelton HG III, Morgan AM, et al. Spindle cell neoplasms coexpressing cytokeratin and vimentin (metaplastic squamous cell carcinoma). *J Cutan Pathol*. 1992;19(4):286-293.
110. Izaki S, Hirai A, Yoshizawa Y, et al. Carcinosarcoma of the skin: immunohistochemical and electron microscopic observations. *J Cutan Pathol*. 1993;20(3):272-278.
111. Evans HL, Smith JL. Spindle cell squamous carcinomas and sarcoma-like tumors of the skin: a comparative study of 38 cases. *Cancer*. 1980;45(10):2687-2697.
112. Banerjee SS, Eyden BP, Wells S, et al. Pseudoangiosarcomatous carcinoma: a clinicopathological study of seven cases. *Histopathology*. 1992;21(1):13-23.
113. Nappi O, Wick MR, Pettinato G, et al. Pseudovascular adenoid squamous cell carcinoma of the skin. A neoplasm that may be mistaken for angiosarcoma. *Am J Surg Pathol*. 1992;16(5):429-438.
114. Bayer-Garner IB, Smoller BR. The expression of syndecan-1 is preferentially reduced compared with that of E-cadherin in acantholytic squamous cell carcinoma. *J Cutan Pathol*. 2001;28(2):83-89.
115. Banks ER, Cooper PH. Adenosquamous carcinoma of the skin: a report of 10 cases. *J Cutan Pathol*. 1991;18(4):227-234.
116. Weidner N, Foucar E. Adenosquamous carcinoma of the skin. An aggressive mucin- and gland-forming squamous carcinoma. *Arch Dermatol*. 1985;121(6): 775-779.
117. Landman G, Farmer ER. Primary cutaneous mucoepidermoid carcinoma: report of a case. *J Cutan Pathol*. 1991;18(1):56-59.
118. Brownstein MH, Shapiro L. Verrucous carcinoma of skin: epithelioma cuniculatum plantare. *Cancer*. 1976;38(4):1710-1716.
119. Reingold IM, Smith BR, Graham JH. Epithelioma cuniculatum pedis, a variant of squamous cell carcinoma. *Am J Clin Pathol*. 1978;69(5):561-565.
120. Kao GF, Graham JH, Helwig EB. Carcinoma cuniculatum (verrucous carcinoma of the skin): a clinicopathologic study of 46 cases with ultrastructural observations. *Cancer*. 1982;49(11):2395-2403.
121. McKee PH, Wilkinson JD, Black MM, Whimster IW. Carcinoma (epithelioma) cuniculatum: a clinico-pathological study of nineteen cases and review of the literature. *Histopathology*. 1981;5(4):425-436.
122. Garven TC, Thelmo WL, Victor J, Pertschuk L. Verrucous carcinoma of the leg positive for human papillomavirus DNA 11 and 18: a case report. *Hum Pathol*. 1991;22(11): 1170-1173.
123. Fleming ID, Amonette R, Monaghan T, Fleming MD. Principles of management of basal and squamous cell carcinoma of the skin. *Cancer*. 1995;75(2 suppl): 699-704.
124. Sober AJ. Diagnosis and management of skin cancer. *Cancer*. 1983;51(12 suppl): 2448-2452.
125. Smoller BR. Squamous cell carcinoma: from precursor lesions to high-risk variants. *Mod Pathol*. 2006;19(suppl 2):S88-S92.
126. Lund HZ. How often does squamous cell carcinoma of the skin metastasize? *Arch Dermatol*. 1965;92(6):635-637.
127. Friedman HI, Cooper PH, Wanebo HJ. Prognostic and therapeutic use of microstaging of cutaneous squamous cell carcinoma of the trunk and extremities. *Cancer*. 1985;56(5):1099-1105.
128. Immerman SC, Scanlon EF, Christ M, Knox KL. Recurrent squamous cell carcinoma of the skin. *Cancer*. 1983;51(8):1537-1540.
129. Quaedvlieg PJ, Creytens DH, Epping GG, et al. Histopathological characteristics of metastasizing squamous cell carcinoma of the skin and lips. *Histopathology*. 2006;49(3):256-264.
130. Dinehart SM, Nelson-Adesokan P, Cockerell C, et al. Metastatic cutaneous squamous cell carcinoma derived from actinic keratosis. *Cancer*. 1997;79(5):920-923.
131. Kamino H, Tam ST, Alvarez L. Malignant melanoma with pseudocarcinomatous hyperplasia—an entity that can simulate squamous cell carcinoma. A light-microscopic and immunohistochemical study of four cases. *Am J Dermatopathol*. 1990;12(5):446-451.
132. Scott G, Chen KT, Rosai J. Pseudoepitheliomatous hyperplasia in Spitz nevi. A possible source of confusion with squamous cell carcinoma. *Arch Pathol Lab Med*. 1989;113(1):61-63.
133. Civatte J. Pseudo-carcinomatous hyperplasia. *J Cutan Pathol*. 1985;12(3-4):214-223.
134. Rosai J. Basal cell carcinoma with follicular differentiation [Letters to the Editor I and II]. *Am J Dermatopathol*. 1988;10(5):458-459. [1989;11:479-480].
135. Foot NC. Adnexal carcinoma of the skin. *Am J Pathol*. 1947;23(1):1-27.
136. Masson P. *Human Tumors: Histology, Diagnosis, and Technique*. 2nd ed. Detroit, MI: Wayne State University Press; 1970.
137. Jih DM, Lyle S, Elenitsas R, et al. Cytokeratin 15 expression in trichoepitheliomas and a subset of basal cell carcinomas suggests they originate from hair follicle stem cells. *J Cutan Pathol*. 1999;26(3):113-118.
138. Kore-eda S, Horiguchi Y, Ueda M, et al. Basal cell carcinoma cells resemble follicular matrix cells rather than follicular bulge cells: immunohistochemical and ultrastructural comparative studies. *Am J Dermatopathol*. 1998;20(4):362-369.
139. Kurzen H, Esposito L, Langbein L, Hartschuh W. Cytokeratins as markers of follicular differentiation: an immunohistochemical study of trichoblastoma and basal cell carcinoma. *Am J Dermatopathol*. 2001;23(6):501-509.
140. Poniecka AW, Alexis JB. An immunohistochemical study of basal cell carcinoma and trichoepithelioma. *Am J Dermatopathol*. 1999;21(4):332-336.
141. Schirren CG, Rutten A, Kaudewitz P, et al. Trichoblastoma and basal cell carcinoma are neoplasms with follicular differentiation sharing the same profile of cytokeratin intermediate filaments. *Am J Dermatopathol*. 1997;19(4):341-350.
142. Yada K, Kashima K, Daa T, et al. Expression of CD10 in basal cell carcinoma. *Am J Dermatopathol*. 2004;26(6):463-471.
143. Misago N, Ackerman AB. Trichoblastic (basal-cell) carcinoma with tricholemmal (at the bulb) differentiation. *Dermatopathol Pract Concept*. 1999;5:200-204.
144. Crowson AN. Basal cell carcinoma: biology, morphology and clinical implications. *Mod Pathol*. 2006;19(suppl 2):S127-S147.
145. Graham PG, McGavran MH. Basal-cell carcinomas and sebaceous glands. *Cancer*. 1964;17(6):803-806.
146. Miller SJ. Biology of basal cell carcinoma (Parts I, II). *J Am Acad Dermatol*. 1991;24(1):1-13, 161-75.
147. Gellin GA, Kopf AW, Garfinkel L. Basal cell epithelioma. A controlled study of associated factors. *Arch Dermatol*. 1965;91:38-45.
148. Rubin AI, Chen EH, Ratner D. Basal-cell carcinoma. *N Engl J Med*. 2005;353(21):2262-2269.
149. Robinson JK. Risk of developing another basal cell carcinoma. A 5-year prospective study. *Cancer*. 1987;60(1):118-120.
150. Milstone EB, Helwig EB. Basal cell carcinoma in children. *Arch Dermatol*. 1973;108(4):523-527.
151. Rahbari H, Mehregan AH. Basal cell epithelioma (carcinoma) in children and teenagers. *Cancer*. 1982;49(2):350-353.
152. Mehregan AH. Aggressive basal cell epithelioma on sunlight-protected skin. Report of eight cases, one with pulmonary and bone metastases. *Am J Dermatopathol*. 1983;5(3):221-229.
153. Black MM, Walkden VM. Basal cell carcinomatous changes on the lower leg: a possible association with chronic venous stasis. *Histopathology*. 1983;7(2):219-227.
154. Nogita T, Kamikawa T, Kawashima M. Significance of pre-existent conditions in basal cell carcinoma on the lower extremities. *Int J Dermatol*. 1993;32(5):350-353.
155. Ryan JF. Basal cell carcinoma and chronic venous stasis. *Histopathology*. 1989;14(6):657-659.
156. Feinmesser M, Taube E, Badani E, Kristt D. Basal cell carcinomas arising over arteriovenous malformations: some speculations on the theme. *Am J Dermatopathol*. 1997;19(6):575-579.
157. Lewis JE. Keloidal basal cell carcinoma. *Am J Dermatopathol*. 2007;29(5):485.
158. Gorlin RJ, Vickers RA, Kellen E, Williamson JJ. Multiple basal-cell Nevi syndrome. An analysis of a syndrome consisting of multiple

nevoid basal-cell carcinoma, jaw cysts, skeletal anomalies, medulloblastoma, and hyporesponsiveness to parathormone. *Cancer*. 1965;18:89-104.
159. Howell JB, Anderson DE. Commentary: the nevoid basal cell carcinoma syndrome. *Arch Dermatol*. 1982;118(10):824-826.
160. Lindeberg H, Jepsen FL. The nevoid basal cell carcinoma syndrome. Histopathology of the basal cell tumors. *J Cutan Pathol*. 1983;10(1):68-72.
161. Mason JK, Helwig EB, Graham JH. Pathology of the nevoid basal cell carcinoma syndrome. *Arch Pathol*. 1965;79:401-408.
162. Kint A. Histogenetic study of the basal cell epithelioma. *Curr Probl Dermatol*. 1970;3:82-123.
163. McGibbon DH. Malignant epidermal tumours. *J Cutan Pathol*. 1985;12(3-4):224-238.
164. Maloney ME, Jones DB, Sexton FM. Pigmented basal cell carcinoma: investigation of 70 cases. *J Am Acad Dermatol*. 1992;27(1):74-78.
165. Nagao S, Nemoto H, Suzuki M, et al. Myofibroblasts in basal cell epithelioma: with special reference to the phagocytic function of myofibroblasts. *J Cutan Pathol*. 1986;13(4):261-267.
166. McArdle JP, Roff BT, Muller HK. Characterization of retraction spaces in basal cell carcinoma using an antibody to type IV collagen. *Histopathology*. 1984;8(3):447-455.
167. Florell SR, Zone JJ, Gerwels JW. Basal cell carcinomas are populated by melanocytes and Langerhans [correction of Langerhan's] cells. *Am J Dermatopathol*. 2001;23(1): 24-28.
168. Looi LM. Localized amyloidosis in basal cell carcinoma. A pathologic study. *Cancer*. 1983;52(10):1833-1836.
169. Satti MB, Azzopardi JG. Amyloid deposits in basal cell carcinoma of the skin. A pathologic study of 199 cases. *J Am Acad Dermatol*. 1990;22(6 Pt 1):1082-1087.
170. Sahin AA, Ro JY, Grignon DJ, Ordonez NG. Basal cell carcinoma with hyaline inclusions. *Arch Pathol Lab Med*. 1989;113(9):1015-1018.
171. Suster S, Ramon y, Cajal S. Myoepithelial differentiation in basal cell carcinoma. *Am J Dermatopathol*. 1991;13(4):350-357.
172. Cutlan RT, Maluf HM. Immunohistochemical characterization of pleomorphic giant cells in basal cell carcinoma. *J Cutan Pathol*. 1999;26(7):353-356.
173. Elston DM, Bergfeld WF, Petroff N. Basal cell carcinoma with monster cells. *J Cutan Pathol*. 1993;20(1):70-73.
174. Pritchard BN, Youngberg GA. Atypical mitotic figures in basal cell carcinoma. A review of 208 cases. *Am J Dermatopathol*. 1993;15(6):549-552.
175. Meehan SA, Egbert BM, Rouse RV. Basal cell carcinoma with tumor epithelial and stromal giant cells: a variant of pleomorphic basal cell carcinoma. *Am J Dermatopathol*. 1999;21(5):473-478.
176. Shoji T, Burlage AM, Bhawan J. Basal cell carcinoma with massive ossification. *Am J Dermatopathol*. 1999;21(1):34-36.
177. Zamecnik M, Skalova A, Michal M. Basal cell carcinoma with collagenous crystalloids. *Arch Pathol Lab Med*. 1996;120(6):581-582.
178. Ambrojo P, Aguilar A, Simón P, et al. Basal cell carcinoma with matrical differentiation. *Am J Dermatopathol*. 1992;14(4):293-297.
179. Del Sordo R, Cavaliere A, Sidoni A. Basal cell carcinoma with matrical differentiation: expression of beta-catenin [corrected] and osteopontin. *Am J Dermatopathol*. 2007;29(5):470-474.
180. El-Shabrawi L, LeBoit PE. Basal cell carcinoma with thickened basement membrane: a variant that resembles some benign adnexal neoplasms. *Am J Dermatopathol*. 1997;19(6):568-574.
181. Heenan PJ, Bogle MS. Eccrine differentiation in basal cell carcinoma. *J Invest Dermatol*. 1993;100(3):295s-299s.
182. Misago N, Suse T, Uemura T, Narisawa Y. Basal cell carcinoma with sebaceous differentiation. *Am J Dermatopathol*. 2004;26(4):298-303.
183. Mark GJ. Basal cell carcinoma with intraneural invasion. *Cancer*. 1977;40(5):2181-2187.
184. Boyd AS, Rapini RP. Cutaneous collision tumors. An analysis of 69 cases and review of the literature. *Am J Dermatopathol*. 1994;16(3):253-257.
185. Cheng L, Amini SB, Tarif Zaim M. Follicular basal cell hyperplasia overlying dermatofibroma. *Am J Surg Pathol*. 1997;21(6):711-718.
186. Thomas P, Said JW, Nash G, Banks-Schlegel S. Profiles of keratin proteins in basal and squamous cell carcinomas of the skin. An immunohistochemical study. *Lab Invest*. 1984;50(1):36-41.
187. Viac J, Reano A, Thivolet J. Cytokeratins in human basal and squamous cell carcinomas: biochemical, immunohistological findings and comparisons with normal epithelia. *J Cutan Pathol*. 1982;9(6):377-390.
188. Izikson L, Bhan A, Zembowicz A. Androgen receptor expression helps to differentiate basal cell carcinoma from benign trichoblastic tumors. *Am J Dermatopathol*. 2005;27(2):91-95.
189. Rasmussen HB, Teisner B, Andersen JA, et al. Immunohistochemical studies on the localization of fetal antigen 2 (FA2), laminin, and collagen type 4 in basal cell carcinoma. *J Cutan Pathol*. 1991;18(3):215-219.
190. Van Cauwenberge D, Pierard GE, Foidart JM, Lapiere CM. Immunohistochemical localization of laminin, type IV and type V collagen in basal cell carcinoma. *Br J Dermatol*. 1983;108(2):163-170.
191. Kirihara Y, Haratake J, Horie A. Clinicopathological and immunohistochemical study of basal cell carcinoma with reference to the features of basement membrane. *J Dermatol*. 1992;19(3):161-169.
192. Stanley JR, Beckwith JB, Fuller RP, Katz SI. A specific antigenic defect of the basement membrane is found in basal cell carcinoma but not in other epidermal tumors. *Cancer*. 1982;50(8):1486-1490.
193. De Rosa G, Barra E, Guarino M, et al. Fibronectin, laminin, type IV collagen distribution, and myofibroblastic stromal reaction in aggressive and nonaggressive basal cell carcinoma. *Am J Dermatopathol*. 1994;16(3):258-267.
194. Eusebi V, Mambelli V, Tison V, et al. Endocrine differentiation in basal cell carcinoma. *Tumori*. 1979;65(2):191-199.
195. George E, Swanson PE, Wick MR. Neuroendocrine differentiation in basal cell carcinoma. An immunohistochemical study. *Am J Dermatopathol*. 1989;11(2):131-135.
196. Terada T. Expression of NCAM (CD56), chromogranin A, synaptophysin, c-KIT (CD117) and PDGFRA in normal non-neoplastic skin and basal cell carcinoma: an immunohistochemical study of 66 consecutive cases. *Med Oncol*. 2013;30:1-5.
197. Katona TM, Perkins SM, Billings SD. Does the panel of cytokeratin 20 and androgen receptor antibodies differentiate desmoplastic trichoepithelioma from morpheaform/infiltrative basal cell carcinoma? *J Cutan Pathol*. 2008;35:174-179.
198. Tellechea O, Reis JP, Domingues JC, Baptista AP. Monoclonal antibody Ber EP4 distinguishes basal-cell carcinoma from squamous-cell carcinoma of the skin. *Am J Dermatopathol*. 1993;15(5):452-455.
199. Mills AE. Solar keratosis can be distinguished from superficial basal cell carcinoma by expression of bcl-2. *Am J Dermatopathol*. 1997;19(5):443-445.
200. Gaballah MA, Ahmed RA. Diagnostic value of CD10 and Bcl2 expression in distinguishing cutaneous basal cell carcinoma from squamous cell carcinoma and seborrheic keratosis. *Pathol Res Pract*. 2015;211(12):931-938.
201. Shea CR, McNutt NS, Volkenandt M, et al. Overexpression of p53 protein in basal cell carcinomas of human skin. *Am J Pathol*. 1992;141(1):25-29.
202. Jin Y, Mertens F, Persson B, et al. Nonrandom numerical chromosome abnormalities in basal cell carcinomas. *Cancer Genet Cytogenet*. 1998;103(1):35-42.
203. Lupi O. Correlations between the Sonic Hedgehog pathway and basal cell carcinoma. *Int J Dermatol*. 2007;46(11):1113-1117.
204. Gailani MR, Stahle-Backdahl M, Leffell DJ, et al. The role of the human homologue of Drosophila patched in sporadic basal cell carcinomas. *Nat Genet*. 1996;14(1):78-81.
205. Kim MY, Park HJ, Baek SC, et al. Mutations of the p53 and PTCH gene in basal cell carcinomas: UV mutation signature and strand bias. *J Dermatol Sci*. 2002;29(1):1-9.
206. Reifenberger J, Wolter M, Knobbe CB, et al. Somatic mutations in the PTCH, SMOH, SUFUH and TP53 genes in sporadic basal cell carcinomas. *Br J Dermatol*. 2005;152(1):43-51.
207. Shen T, Park WS, Boni R, et al. Detection of loss of heterozygosity on chromosome 9q22.3 in microdissected sporadic basal cell carcinoma. *Hum Pathol*. 1999;30(3): 284-287.
208. Xie J, Murone M, Luoh SM, et al. Activating smoothened mutations in sporadic basal-cell carcinoma. *Nature*. 1998;391(6662):90-92.
209. Von Hoff DD, LoRusso PM, Rudin CM, et al. Inhibition of the hedgehog pathway in advanced basal-cell carcinoma. *N Engl J Med*. 2009;361(12):1164-1172.
210. Wahid M, Jawed A, Mandal RK, et al. Vismodegib,itraconazole and sonidegib as hedgehog pathway inhibitors and their relative competencies in the treatment of basal cell carcinomas. *Crit Rev Oncol Hematol*. 2016;98:235-241.
211. Nangia R, Sait SN, Block AW, Zhang PJ. Trisomy 6 in basal cell carcinomas correlates with metastatic potential: a dual color fluorescence in situ hybridization study on paraffin sections. *Cancer*. 2001;91(10):1927-1932.
212. Imayama S, Yashima Y, Higuchi R, Urabe H. A new concept of basal cell epitheliomas based on the three-dimensional growth pattern of the superficial multicentric type. *Am J Pathol*. 1987;128(3):497-504.
213. Rippey JJ. Why classify basal cell carcinomas? *Histopathology*. 1998;32(5):393-398.
214. Farmer ER, Helwig EB. Metastatic basal cell carcinoma: a clinicopathologic study of seventeen cases. *Cancer*. 1980;46(4):748-757.
215. de Faria JL, Navarrete MA. The histopathology of the skin basal cell carcinoma with areas of intermediate differentiation. A metatypical carcinoma? *Pathol Res Pract*. 1991;187(8):978-985.
216. Barr RJ, Graham JH. Granular cell basal cell carcinoma. A distinct histopathologic entity. *Arch Dermatol*. 1979;115(9):1064-1067.
217. Garcia Prats MD, Lopez Carreira M, Martinez-Gonzalez MA, et al. Granular cell basal cell carcinoma. Light microscopy, immunohistochemical and ultrastructural study. *Virchows Arch A Pathol Anat Histopathol*. 1993;422(2):173-177.

218. Barnadas MA, Freeman RG. Clear cell basal cell epithelioma: light and electron microscopic study of an unusual variant. *J Cutan Pathol*. 1988;15(1):1-7.
219. Barr RJ, Alpern KS, Santa Cruz DJ, Fretzin DF. Clear cell basal cell carcinoma: an unusual degenerative variant. *J Cutan Pathol*. 1993;20(4):308-316.
220. Starink TM, Blomjous CE, Stoof TJ, Van Der Linden JC. Clear cell basal cell carcinoma. *Histopathology*. 1990;17(5):401-405.
221. White GM, Barr RJ, Liao S-Y. Signet ring cell basal cell carcinoma. *Am J Dermatopathol*. 1991;13(3):288-292.
222. Kim YC, Vandersteen DP, Chung YJ, Myong NH. Signet ring cell basal cell carcinoma: a basal cell carcinoma with myoepithelial differentiation. *Am J Dermatopathol*. 2001;23(6):525-529.
223. Walsh N, Ackerman AB. Infundibulocystic basal cell carcinoma: a newly described variant. *Mod Pathol*. 1990;3(5):599-608.
224. Stern JB, Haupt HM, Smith RR. Fibroepithelioma of Pinkus. Eccrine duct spread of basal cell carcinoma. *Am J Dermatopathol*. 1994;16(6):585-587.
225. Bowen AR, LeBoit PE. Fibroepithelioma of pinkus is a fenestrated trichoblastoma. *Am J Dermatopathol*. 2005;27(2):149-154.
226. Mc Menamin ME, Goh SG, Poblet E, et al. Sarcomatoid basal cell carcinoma—predilection for osteosarcomatous differentiation: a series of 11 cases. *Am J Surg Pathol*. 2006;30(10):1299-1308.
227. Jacobs GH, Rippey JJ, Altini M. Prediction of aggressive behavior in basal cell carcinoma. *Cancer*. 1982;49(3):533-537.
228. Bayer-Garner IB, Dilday B, Sanderson RD, Smoller BR. Syndecan-1 expression is decreased with increasing aggressiveness of basal cell carcinoma. *Am J Dermatopathol*. 2000;22(2):119-122.
229. Ramdial PK, Madaree A, Reddy R, Chetty R. bcl-2 protein expression in aggressive and non-aggressive basal cell carcinomas. *J Cutan Pathol*. 2000;27(6):283-291.
230. Auepemkiate S, Boonyaphiphat P, Thongsuksai P. p53 expression related to the aggressive infiltrative histopathological feature of basal cell carcinoma. *Histopathology*. 2002;40(6):568-573.
231. De Rosa G, Staibano S, Barra E, et al. Nucleolar organizer regions in aggressive and nonaggressive basal cell carcinoma of the skin. *Cancer*. 1992;69(1):123-126.
232. Herzberg AJ, Garcia JA, Kerns BJ, et al. DNA ploidy of basal cell carcinoma determined by image cytometry of fresh smears. *J Cutan Pathol*. 1993;20(3):216-222.
233. Breuninger H, Dietz K. Prediction of subclinical tumor infiltration in basal cell carcinoma. *J Dermatol Surg Oncol*. 1991;17(7):574-578.
234. Dixon AY, Lee SH, McGregor DH. Histologic features predictive of basal cell carcinoma recurrence: results of a multivariate analysis. *J Cutan Pathol*. 1993;20(2):137-142.
235. Dixon AY, Lee SH, McGregor DH. Histologic evolution of basal cell carcinoma recurrence. *Am J Dermatopathol*. 1991;13(3):241-247.
236. Andrews RJ, Sercarz JA, Fu YS, Calcaterra TC. Metastatic basal cell carcinoma from head and neck primary lesions. *Int J Surg Pathol*. 1998;6(1):17-22.
237. Ionescu DN, Arida M, Jukic DM. Metastatic basal cell carcinoma: four case reports, review of literature, and immunohistochemical evaluation. *Arch Pathol Lab Med*. 2006;130(1):45-51.
238. Snow SN, Sahl W, Lo JS, et al. Metastatic basal cell carcinoma. Report of five cases. *Cancer*. 1994;73(2):328-335.
239. Berardi RS, Korba J, Melton J, Chen H. Pulmonary metastasis in nevoid basal cell carcinoma syndrome. *Int Surg*. 1991;76(1):64-66.
240. Wilder RB, Kittelson JM, Shimm DS. Basal cell carcinoma treated with radiation therapy. *Cancer*. 1991;68(10):2134-2137.
241. Ad Hoc Task Force, Connolly SM, Baker DR, et al. AAD/ACMS/ASDSA/ASMS 2012 appropriate use criteria for Mohs micrographic surgery: a report of the American Academy of Dermatology, American College of Mohs Surgery, American Society for Dermatologic Surgery Association, and the American Society for Mohs Surgery. *J Am Acad Dermatol*. 2012;67:531-550.
242. Gooding CA, White G, Yatsuhashi M. Significance of marginal extension in excised basal-cell carcinoma. *N Engl J Med*. 1965;273(17):923-924.
243. Seidman JD, Berman JJ, Moore GW. Basal cell carcinoma: importance of histologic discontinuities in the evaluation of resection margins. *Mod Pathol*. 1991;4(3):325-330.
244. Wilder RB, Shimm DS, Kittelson JM, et al. Recurrent basal cell carcinoma treated with radiation therapy. *Arch Dermatol*. 1991;127(11):1668-1672.
245. Headington JT. A dermatopathologist looks at Mohs micrographic surgery [editorial]. *Arch Dermatol*. 1990;126(7):950-951.
246. Mikhail G, ed. *Mohs Micrographic Surgery*. Philadelphia, PA: WB Saunders; 1991.
247. Miller PK, Roenigk RK, Brodland DG, Randle HW. Cutaneous micrographic surgery: Mohs procedure. *Mayo Clin Proc*. 1992;67(10):971-980.
248. Abenoza PAAB. *Neoplasms With Eccrine Differentiation*. Philadelphia, PA: Lea & Febiger; 1990.
249. Crowson AN, Magro CM, Mihm MC. Malignant adnexal neoplasms. *Mod Pathol*. 2006;19(suppl 2):S93-S126.
250. Massa MC, Medenica M. Cutaneous adnexal tumors and cysts: a review. Part I. Tumors with hair follicular and sebaceous glandular differentiation and cysts related to different parts of the hair follicle. *Pathol Ann*. 1985;20(Pt 2):189-233.
251. Massa MC, Medenica M. Cutaneous adnexal tumors and cysts: a review. Part II.Tumors with apocrine and eccrine glandular differentiation and miscellaneous cutaneous cysts. *Pathol Ann*. 1987;22(Pt 1): 225-276.
252. Smith KJ, Skelton HG, Holland TT. Recent advances and controversies concerning adnexal neoplasms. *Dermatol Clin*. 1992;10(1):117-160.
253. Wick MRSPE. *Cutaneous Adnexal Tumors: A Guide to Pathologic Diagnosis*. Chicago, IL: ASCP Press; 1991.
254. Buchi ER, Peng Y, Eng AM, Tso MO. Eccrine acrospiroma of the eyelid with oncocytic, apocrine and sebaceous differentiation. Further evidence for pluripotentiality of the adnexal epithelia. *Eur J Ophthalmol*. 1991;1(4):187-193.
255. Kazakov DV, Calonje E, Rutten A, et al. Cutaneous sebaceous neoplasms with a focal glandular pattern (seboapocrine lesions): a clinicopathological study of three cases. *Am J Dermatopathol*. 2007;29(4):359-364.
256. Sanchez Yus E, Requena L, Simon P, Sanchez M. Complex adnexal tumor of the primary epithelial germ with distinct patterns of superficial epithelioma with sebaceous differentiation, immature trichoepithelioma, and apocrine adenocarcinoma. *Am J Dermatopathol*. 1992;14(3):245-252.
257. Wong TY, Suster S, Cheek RF, Mihm MC Jr. Benign cutaneous adnexal tumors with combined folliculosebaceous, apocrine, and eccrine differentiation. Clinicopathologic and immunohistochemical study of eight cases. *Am J Dermatopathol*. 1996;18(2):124-136.
258. Nakhleh RE, Swanson PE, Wick MR. Cutaneous adnexal carcinomas with divergent differentiation. *Am J Dermatopathol*. 1990;12(4):325-334.
259. Carr KA, Bulengo-Ransby SM, Weiss LM, Nickoloff BJ. Lymphoepitheliomalike carcinoma of the skin. A case report with immunophenotypic analysis and in situ hybridization for Epstein-Barr viral genome. *Am J Surg Pathol*. 1992;16(9):909-913.
260. Wick MR, Swanson PE, LeBoit PE, et al. Lymphoepithelioma-like carcinoma of the skin with adnexal differentiation. *J Cutan Pathol*. 1991;18(2):93-102.
261. Shek TWH, Leung EYF, Luk ISC, et al. Lymphoepithelioma-like carcinoma of the skin. *Am J Dermatopathol*. 1996;18(6):637-644.
262. Kohda M, Manabe T, Ueki H. Squamous islands in eccrine neoplasms. *Am J Dermatopathol*. 1990;12(4):344-349.
263. Kakinuma H, Miyamoto R, Iwasawa U, et al. Three subtypes of poroid neoplasia in a single lesion: eccrine poroma, hidroacanthoma simplex, and dermal duct tumor. Histologic, histochemical, and ultrastructural findings. *Am J Dermatopathol*. 1994;16(1):66-72.
264. Rahbari H. Hidroacanthoma simplex—a review of 15 cases. *Br J Dermatol*. 1983;109(2):219-225.
265. Rutten A, Hantschke M, Angulo J, Requena L. Clear-cell dermal duct tumour: another distinctive, previously underrecognized cutaneous adnexal neoplasm. *Histopathology*. 2007;51(6):805-813.
266. Hashimoto K, Lever WF. Eccrine poroma; histochemical and electron microscopic studies. *J Invest Dermatol*. 1964;43: 237-247.
267. Watanabe S, Mogi S, Ichikawa E, et al. Immunohistochemical analysis of keratin distribution in eccrine poroma. *Am J Pathol*. 1993;142(1):231-239.
268. Harvell JD, Kerschmann RL, LeBoit PE. Eccrine or apocrine poroma? Six poromas with divergent adnexal differentiation. *Am J Dermatopathol*. 1996;18(1):1-9.
269. Takanashi M, Urabe A, Nakayama J, Hori Y. Distribution of epithelial membrane antigen in eccrine poroma. *Dermatologica*. 1991;183(3):187-190.
270. Hara K, Mizuno E, Nitta Y, Ikeya T. Acrosyringeal adenomatosis (eccrine syringofibroadenoma of Mascaro). A case report and review of the literature. *Am J Dermatopathol*. 1992;14(4):328-339.
271. Lui H, Stewart WD, English JC, Wood WS. Eccrine syringofibroadenomatosis: a clinical and histologic study and review of the literature. *J Am Acad Dermatol*. 1992;26(5 Pt 2):805-813.
272. Robson A, Greene J, Ansari N, et al. Eccrine porocarcinoma (malignant eccrine poroma): a clinicopathologic study of 69 cases. *Am J Surg Pathol*. 2001;25(6):710-720.
273. Winkelmann RK, Wolff K. Solid-cystic hidradenoma of the skin. Clinical and histopathologic study. *Arch Dermatol*. 1968;97(6):651-661.
274. Stanley RJ, Sanchez NP, Massa MC, et al. Epidermoid hidradenoma. A clinicopathologic study. *J Cutan Pathol*. 1982;9(5):293-302.
275. Haupt HM, Stern JB, Berlin SJ. Immunohistochemistry in the differential diagnosis of nodular hidradenoma and glomus tumor. *Am J Dermatopathol*. 1992;14(4):310-314.
276. Johnson BL, Helwig EB. Eccrine acrospiroma: a clinicopathologic study. *Cancer*. 1969;23(3):641-657.
277. Feibelman CE, Maize JC. Clear-cell syringoma. A study by conventional and

electron microscopy. *Am J Dermatopathol*. 1984;6(2):139-150.
278. Hashimoto K, Nelson RG, Lever WF. Calcifying epithelioma of Malherbe. Histochemical and electron microscopic studies. *J Invest Dermatol*. 1966;46(4):391-408.
279. Winkelmann RK, Gottlieb BF. Syringoma: an enzymatic study. *Cancer*. 1963;16:665-669.
280. Eckert F, Nilles M, Schmid U, Altmannsberger M. Distribution of cytokeratin polypeptides in syringomas. An immunohistochemical study on paraffin-embedded material. *Am J Dermatopathol*. 1992;14(2):115-121.
281. Soler-Carrillo J, Estrach T, Mascaro JM. Eruptive syringoma: 27 new cases and review of the literature. *J Eur Acad Dermatol Venereol*. 2001;15(3):242-246.
282. Guitart J, Rosenbaum MM, Requena L. Eruptive syringoma': a misnomer for a reactive eccrine gland ductal proliferation? *J Cutan Pathol*. 2003;30(3):202-205.
283. Kunikane H, Ishikura H, Yamaguchi J, et al. Chondroid syringoma (mixed tumor of the skin). A clinicopathological study of 13 cases. *Acta Pathol Jpn*. 1987;37(4):615-625.
284. Hirsch P, Helwig EB. Chondroid syringoma: mixed tumor of skin, salivary gland type. *Arch Dermatol*. 1961;84(5):835-847.
285. Jaworski RC. The ultrastructure of chondroid syringoma (mixed tumor of skin). *Ultrastruct Pathol*. 1984;6(2-3):153-159.
286. Yoneda K, Kitajima Y, Furuta H, et al. The distribution of keratin type intermediate-sized filaments in so-called mixed tumour of the skin. *Br J Dermatol*. 1983;109(4):393-400.
287. Argenyi ZB, Goeken JA, Balogh K. Hyaline cells in chondroid syringomas. A light-microscopic, immunohistochemical, and ultrastructural study. *Am J Dermatopathol*. 1989;11(5):403-412.
288. Ferreiro JA, Nascimento AG. Hyaline-cell rich chondroid syringoma. A tumor mimicking malignancy. *Am J Surg Pathol*. 1995;19(8):912-917.
289. Argenyi ZB, Balogh K. Collagenous spherulosis in chondroid syringomas. *Am J Dermatopathol*. 1991;13(2):115-121.
290. Banerjee SS, Harris M, Eyden BP, et al. Chondroid syringoma with hyaline cell change. *Histopathology*. 1993;22(3): 235-245.
291. Hafezi-Bakhtiari S, Al-Habeeb A, Ghazarian D. Benign mixed tumor of the skin, hypercellular variant: a case report. *J Cutan Pathol*. 2010;37(9):e46-e49.
292. Hassab-el-Naby HM, Tam S, White WL, Ackerman AB. Mixed tumors of the skin. A histological and immunohistochemical study. *Am J Dermatopathol*. 1989;11(5):413-428.
293. Nakayama H, Miyazaki E, Hiroi M, et al. So-called neoplastic myoepithelial cells in chondroid syringomas/mixed tumors of the skin: their subtypes and immunohistochemical analysis. *Pathol Int*. 1998;48(4):245-253.
294. Wiley EL, Milchgrub S, Freeman RG, Kim ES. Sweat gland adenomas: immunohistochemical study with emphasis on myoepithelial differentiation. *J Cutan Pathol*. 1993;20(4):337-343.
295. Requena L, Sanchez Yus E, Santa Cruz DJ. Apocrine type of cutaneous mixed tumor with follicular and sebaceous differentiation. *Am J Dermatopathol*. 1992;14(3):186-194.
296. Salama ME, Azam M, Ma CK, et al. Chondroid syringoma. Cytokeratin 20 immunolocalization of Merkel cells and reappraisal of apocrine folliculo-sebaceous differentiation. *Arch Pathol Lab Med*. 2004;128(9):986-990.
297. Hornick JL, Fletcher CD. Cutaneous myoepithelioma: a clinicopathologic and immunohistochemical study of 14 cases. *Hum Pathol*. 2004;35(1):14-24.
298. Kilpatrick SE, Hitchcock MG, Kraus MD, et al. Mixed tumors and myoepitheliomas of soft tissue: a clinicopathologic study of 19 cases with a unifying concept. *Am J Surg Pathol*. 1997;21(1):13-22.
299. Crain RC, Helwig EB. Dermal cylindroma (dermal eccrine cylindroma). *Am J Clin Pathol*. 1961;35:504-515.
300. Reingold IM, Keasbey LE, Graham JH. Multicentric dermal-type cylindromas of the parotid glands in a patient with florid turban tumor. *Cancer*. 1977;40(4):1702-1710.
301. Cotton DW, Braye SG. Dermal cylindromas originate from the eccrine sweat gland. *Br J Dermatol*. 1984;111(1):53-61.
302. Kallioinen M. Immunoelectron microscope demonstration of the basement membrane components laminin and type IV collagen in the dermal cylindroma. *J Pathol*. 1985;147(2):97-102.
303. Penneys NS, Kaiser M. Cylindroma expresses immunohistochemical markers linking it to eccrine coil. *J Cutan Pathol*. 1993;20(1):40-43.
304. Eckert F, Betke M, Schmoeckel C, et al. Myoepithelial differentiation in benign sweat gland tumors. Demonstrated by a monoclonal antibody to alpha-smooth muscle actin. *J Cutan Pathol*. 1992;19(4):294-301.
305. Tellechea O, Reis JP, Ilheu O, Baptista AP. Dermal cylindroma. An immunohistochemical study of thirteen cases. *Am J Dermatopathol*. 1995;17(3):260-265.
306. Wollina U, Rulke D, Schaarschmidt H. Dermal cylindroma. Expression of intermediate filaments, epithelial and neuroectodermal antigens. *Histol Histopathol*. 1992;7(4):575-582.
307. Meybehm M, Fischer HP. Spiradenoma and dermal cylindroma: comparative immunohistochemical analysis and histogenetic considerations. *Am J Dermatopathol*. 1997;19(2):154-161.
308. Goette DK, McConnell MA, Fowler VR. Cylindroma and eccrine spiradenoma coexistent in the same lesion. *Arch Dermatol*. 1982;118(4):273-274.
309. Michal M, Lamovec J, Mukensnabl P, Pizinger K. Spiradenocylindromas of the skin: tumors with morphological features of spiradenoma and cylindroma in the same lesion: report of 12 cases. *Pathol Int*. 1999;49(5):419-425.
310. Bignell GR, Warren W, Seal S, et al. Identification of the familial cylindromatosis tumour-suppressor gene. *Nat Genet*. 2000;25(2):160-165.
311. Hashimoto K, Gross BG, Nelson RG, Lever WF. Eccrine spiradenoma. Histochemical and electron microscopic studies. *J Invest Dermatol*. 1966;46(4):347-365.
312. Mambo NC. Eccrine spiradenoma: clinical and pathologic study of 49 tumors. *J Cutan Pathol*. 1983;10(5):312-320.
313. Kersting DW, Helwig EB. Eccrine spiradenoma. *JAMA Arch Dermatol*. 1956;73(3):199-227.
314. Cotton DW, Slater DN, Rooney N, et al. Giant vascular eccrine spiradenomas: a report of two cases with histology, immunohistology and electron microscopy. *Histopathology*. 1986;10(10):1093-1099.
315. al-Nafussi A, Blessing K, Rahilly M. Non-epithelial cellular components in eccrine spiradenoma: a histological and immunohistochemical study of 20 cases. *Histopathology*. 1991;18(2):155-160.
316. Jitsukawa K, Sueki H, Sato S, Anzai T. Eccrine spiradenoma. An electron microscopic study. *Am J Dermatopathol*. 1987;9(2):99-108.
317. van den Oord JJ, De Wolf-Peeters C. Perivascular spaces in eccrine spiradenoma. A clue to its histological diagnosis. *Am J Dermatopathol*. 1995;17(3):266-270.
318. Requena L, Sanchez Yus E. Cutaneous lymphadenoma with ductal differentiation. *J Cutan Pathol*. 1992;19(5):429-433.
319. Santa Cruz DJ, Barr RJ, Headington JT. Cutaneous lymphadenoma. *Am J Surg Pathol*. 1991;15(2):101-110.
320. McNiff JM, Eisen RN, Glusac EJ. Immunohistochemical comparison of cutaneous lymphadenoma, trichoblastoma, and basal cell carcinoma: support for classification of lymphadenoma as a variant of trichoblastoma. *J Cutan Pathol*. 1999;26(3):119-124.
321. Kazakov DV, Magro G, Kutzner H, et al. Spiradenoma and spiradenocylindroma with an adenomatous or atypical adenomatous component: a clinicopathological study of 6 cases. *Am J Dermatopathol*. 2008;30(5):436-441.
322. Kazakov DV, Zelger B, Rutten A, et al. Morphologic diversity of malignant neoplasms arising in preexisting spiradenoma, cylindroma, and spiradenocylindroma based on the study of 24 cases, sporadic or occurring in the setting of Brooke-Spiegler syndrome. *Am J Surg Pathol*. 2009;33(5):705-719.
323. Mambo NC. Immunohistochemical study of the immunoglobulin classes of the plasma cells in papillary syringadenoma. *Virchows Arch A Pathol Anat Histol*. 1982;397(1):1-6.
324. Vanatta PR, Bangert JL, Freeman RG. Syringocystadenoma papilliferum. A plasmacytotropic tumor. *Am J Surg Pathol*. 1985;9(9):678-683.
325. Helwig EB, Hackney CC. Syringadenoma papilliferum: lesions with and without naevus sebaceous and basal cell carcinoma. *AMA Arch Dermatol*. 1955;71(3):361-372.
326. Bondi R, Urso C. Syringocystadenocarcinoma papilliferum. *Histopathology*. 1996;28(5):475-477.
327. Clarke LE, Ioffreda M, Abt AB. Eccrine syringofibroadenoma arising in peristomal skin: a report of two cases. *Int J Surg Pathol*. 2003;11(1):61-63.
328. Brownstein MH, Fernando S, Shapiro L. Clear cell acanthoma: clinicopathologic analysis of 37 new cases. *Am J Clin Pathol*. 1973;59(3):306-311.
329. Rulon DB, Helwig EB. Papillary eccrine adenoma. *Arch Dermatol*. 1977;113(5):596-598.
330. Guccion JG, Patterson RH, Nayar R, Saini NB. Papillary eccrine adenoma: an ultrastructural and immunohistochemical study. *Ultrastruct Pathol*. 1998;22(3):263-269.
331. Ichikawa E, Okabe S, Umebayashi Y, et al. Papillary eccrine adenoma: immunohistochemical studies of keratin expression. *J Cutan Pathol*. 1997;24(9):564-570.
332. Mizuoka H, Senzaki H, Shikata N, et al. Papillary eccrine adenoma: immunohistochemical study and literature review. *J Cutan Pathol*. 1998;25(1):59-64.
333. Brownstein MH. The benign acanthomas. *J Cutan Pathol*. 1985;12(3-4):172-188.
334. Nova M, Kress Y, Jennings T, et al. Papillary eccrine adenoma and low-grade eccrine carcinoma. A comparative histologic, ultrastructural, and immunohistochemical study. *Surg Pathol*. 1990;3:179-188.
335. Giannotti M, Alves A, Silva M, Giannotti Filho O. Epidermolytic acanthoma. A study of 45 cases. *Mod Pathol*. 2003;16:91a.
336. Kao GF, Helwig EB, Graham JH. Aggressive digital papillary adenoma and adenocarcinoma. A clinicopathological study of 57 patients, with histochemical,

immunopathological, and ultrastructural observations. *J Cutan Pathol*. 1987;14(3):129-146.
337. Duke WH, Sherrod TT, Lupton GP. Aggressive digital papillary adenocarcinoma (aggressive digital papillary adenoma and adenocarcinoma revisited). *Am J Surg Pathol*. 2000;24(6):775-784.
338. Fanti PA, Passarini B, Varotti C. Melanocytes in clear cell acanthoma. *Am J Dermatopathol*. 1990;12(4):373-376.
339. Langer K, Wuketich S, Konrad K. Pigmented clear cell acanthoma. *Am J Dermatopathol*. 1994;16(2):134-139.
340. Fukushiro S, Takei Y, Ackerman AB. Pale-cell acanthosis. A distinctive histologic pattern of epidermal epithelium. *Am J Dermatopathol*. 1985;7(6):515-527.
341. Megahed M, Scharffetter-Kochanek K. Acantholytic acanthoma. *Am J Dermatopathol*. 1993;15(3):283-285.
342. Cohen PR, Ulmer R, Theriault A, et al. Epidermolytic acanthomas: clinical characteristics and immunohistochemical features. *Am J Dermatopathol*. 1997;19(3):232-241.
343. Argenyi ZB, Huston BM, Argenyi EE, et al. Large-cell acanthoma of the skin. A study by image analysis cytometry and immunohistochemistry. *Am J Dermatopathol*. 1994;16(2):140-144.
344. Mehregan DR, Hamzavi F, Brown K. Large cell acanthoma. *Int J Dermatol*. 2003;42(1):36-39.
345. Roewert HJ, Ackerman AB. Large-cell acanthoma is a solar lentigo. *Am J Dermatopathol*. 1992;14(2):122-132.
346. Mehregan AH, Pinkus H. Intraepidermal epithelioma: a critical study. *Cancer*. 1964;17:609-636.
347. Steffen C, Ackerman AB. Intraepidermal epithelioma of Borst-Jadassohn. *Am J Dermatopathol*. 1985;7(1):5-24.
348. Cooper P. Carcinomas of sweat glands. *Pathol Ann*. 1987;22(Pt 1):83-124.
349. Cruz DJ. Sweat gland carcinomas: a comprehensive review. *Semin Diagn Pathol*. 1987;4(1):38-74.
350. Urso C, Bondi R, Paglierani M, et al. Carcinomas of sweat glands: report of 60 cases. *Arch Pathol Lab Med*. 2001;125(4):498-505.
351. Chow CW, Campbell PE, Burry AF. Sweat gland carcinomas in children. *Cancer*. 1984;53(5):1222-1227.
352. Urso C, Paglierani M, Bondi R. Histologic spectrum of carcinomas with eccrine ductal differentiation (sweat-gland ductal carcinomas). *Am J Dermatopathol*. 1993;15(5):435-440.
353. Wick MR, Goellner JR, Wolfe JT III, Su WP. Adnexal carcinomas of the skin. I. Eccrine carcinomas. *Cancer*. 1985;56(5):1147-1162.
354. Swanson PE, Mazoujian G, Mills SE, et al. Immunoreactivity for estrogen receptor protein in sweat gland tumors. *Am J Surg Pathol*. 1991;15(9):835-841.
355. Hiatt KM, Pillow JL, Smoller BR. Her-2 expression in cutaneous eccrine and apocrine neoplasms. *Mod Pathol*. 2004;17(1):28-32.
356. Cooper PH, Robinson CR, Greer KE. Low-grade clear cell eccrine carcinoma. *Arch Dermatol*. 1984;120(8):1076-1078.
357. Mendoza S, Helwig EB. Mucinous (adenocystic) carcinoma of the skin. *Arch Dermatol*. 1971;103(1):68-78.
358. Berg J, McDivitt R. Pathology of sweat gland carcinoma. *Pathol Ann*. 1968;3:123-144.
359. Dissanayake RV, Salm R. Sweat-gland carcinomas: prognosis related to histological type. *Histopathology*. 1980;4(4):445-466.
360. Liegl B, Leibl S, Okcu M, et al. Malignant transformation within benign adnexal skin tumours. *Histopathology*. 2004;45(2):162-170.
361. Mehregan AH, Hashimoto K, Rahbari H. Eccrine adenocarcinoma. A clinicopathologic study of 35 cases. *Arch Dermatol*. 1983;119(2):104-114.
362. Shaw M, McKee PH, Lowe D, Black MM. Malignant eccrine poroma: a study of twenty-seven cases. *Br J Dermatol*. 1982;107(6):675-680.
363. Landa NG, Winkelmann RK. Epidermotropic eccrine porocarcinoma. *J Am Acad Dermatol*. 1991;24(1):27-31.
364. Misago N, Toda S, Hikichi Y, et al. A unique case of extramammary Paget's disease. Derivation from eccrine porocarcinoma? *Am J Dermatopathol*. 1992;14(6):553-559.
365. Pena J, Suster S. Squamous differentiation in malignant eccrine poroma. *Am J Dermatopathol*. 1993;15(5):492-496.
366. Wong TY, Suster S, Nogita T, et al. Clear cell eccrine carcinomas of the skin. A clinicopathologic study of nine patients. *Cancer*. 1994;73(6):1631-1643.
367. Hara K, Kamiya S. Pigmented eccrine porocarcinoma: a mimic of malignant melanoma. *Histopathology*. 1995;27(1): 86-88.
368. Kolde G, Macher E, Grundmann E. Metastasizing eccrine porocarcinoma. Report of two cases with fatal outcome. *Pathol Res Pract*. 1991;187(4):477-481.
369. Ishimura E, Iwamoto H, Kobashi Y, et al. Malignant chondroid syringoma. Report of a case with widespread metastasis and review of pertinent literature. *Cancer*. 1983;52(10):1966-1973.
370. Lo JS, Peschen M, Snow SN, et al. Malignant cylindroma of the scalp. *J Dermatol Surg Oncol*. 1991;17(11):897-901.
371. Rockerbie N, Solomon AR, Woo TY, et al. Malignant dermal cylindroma in a patient with multiple dermal cylindromas, trichoepitheliomas, and bilateral dermal analogue tumors of the parotid gland. *Am J Dermatopathol*. 1989;11(4):353-359.
372. Alessi E, Caputo R. Syringomatous carcinoma of the scalp presenting as a slowly enlarging patch of alopecia. *Am J Dermatopathol*. 1993;15(5):503-505.
373. McKee PH, Fletcher CD, Rasbridge SA. The enigmatic eccrine epithelioma (eccrine syringomatous carcinoma). *Am J Dermatopathol*. 1990;12(6):552-561.
374. Ohnishi T, Kaneko S, Egi M, et al. Syringoid eccrine carcinoma: report of a case with immunohistochemical analysis of cytokeratin expression. *Am J Dermatopathol*. 2002;24(5):409-413.
375. Headington JT, Niederhuber JE, Beals TF. Malignant clear cell acrospiroma. *Cancer*. 1978;41(2):641-647.
376. Nishikawa Y, Tokusashi Y, Saito Y, et al. A case of apocrine adenocarcinoma associated with hamartomatous apocrine gland hyperplasia of both axillae. *Am J Surg Pathol*. 1994;18(8):832-836.
377. Paties C, Taccagni GL, Papotti M, et al. Apocrine carcinoma of the skin. A clinicopathologic, immunocytochemical, and ultrastructural study. *Cancer*. 1993;71(2):375-381.
378. Argenyi ZB, Nguyen AV, Balogh K, et al. Malignant eccrine spiradenoma. A clinicopathologic study. *Am J Dermatopathol*. 1992;14(5):381-390.
379. Cooper PH, Frierson HF, Morrison AG. Malignant transformation of eccrine spiradenoma. *Arch Dermatol*. 1985;121(11):1445-1448.
380. Gerretsen AL, van der Putte SC, Deenstra W, van Vloten WA. Cutaneous cylindroma with malignant transformation. *Cancer*. 1993;72(5):1618-1623.
381. Lin PY, Fatteh SM, Lloyd KM. Malignant transformation in a solitary dermal cylindroma. *Arch Pathol Lab Med*. 1987;111(8):765-767.
382. Wick MR, Swanson PE, Kaye VN, Pittelkow MR. Sweat gland carcinoma ex eccrine spiradenoma. *Am J Dermatopathol*. 1987;9(2):90-98.
383. McKee PH, Fletcher CD, Stavrinos P, Pambakian H. Carcinosarcoma arising in eccrine spiradenoma. A clinicopathologic and immunohistochemical study of two cases. *Am J Dermatopathol*. 1990;12(4):335-343.
384. Kazakov DV, Suster S, LeBoit PE, et al. Mucinous carcinoma of the skin, primary, and secondary: a clinicopathologic study of 63 cases with emphasis on the morphologic spectrum of primary cutaneous forms: homologies with mucinous lesions in the breast. *Am J Surg Pathol*. 2005;29(6):764-782.
385. Santa-Cruz DJ, Meyers JH, Gnepp DR, Perez BM. Primary mucinous carcinoma of the skin. *Br J Dermatol*. 1978;98(6):645-654.
386. Yamamoto O, Nakayama K, Asahi M. Sweat gland carcinoma with mucinous and infiltrating duct-like patterns. *J Cutan Pathol*. 1992;19(4):334-339.
387. Zembowicz A, Garcia CF, Tannous ZS, et al. Endocrine mucin-producing sweat gland carcinoma: twelve new cases suggest that it is a precursor of some invasive mucinous carcinomas. *Am J Surg Pathol*. 2005;29(10):1330-1339.
388. Eckert F, Schmid U, Hardmeier T, Altmannsberger M. Cytokeratin expression in mucinous sweat gland carcinomas: an immunohistochemical analysis of four cases. *Histopathology*. 1992;21(2):161-165.
389. Wako M, Nishimaki K, Kawamura N, et al. Mucinous carcinoma of the skin with apocrine-type differentiation: immunohistochemical studies. *Am J Dermatopathol*. 2003;25(1):66-70.
390. Helm KF, Goellner JR, Peters MS. Immunohistochemical stains in extramammary Paget's disease. *Am J Dermatopathol*. 1992;14(5):402-407.
391. Qureshi HS, Salama ME, Chitale D, et al. Primary cutaneous mucinous carcinoma: presence of myoepithelial cells as a clue to the cutaneous origin. *Am J Dermatopathol*. 2004;26(5):353-358.
392. Cooper PH, Adelson GL, Holthaus WH. Primary cutaneous adenoid cystic carcinoma. *Arch Dermatol*. 1984;120(6):774-777.
393. Fukai K, Ishii M, Kobayashi H, et al. Primary cutaneous adenoid cystic carcinoma: ultrastructural study and immunolocalization of types I, III, IV, V collagens and laminin. *J Cutan Pathol*. 1990;17(6):374-380.
394. Kuramoto Y, Tagami H. Primary adenoid cystic carcinoma masquerading as syringoma of the scalp. *Am J Dermatopathol*. 1990;12(2):169-174.
395. Riedlinger WF, Hurley MY, Dehner LP, Lind AC. Mucoepidermoid carcinoma of the skin: a distinct entity from adenosquamous carcinoma: a case study with a review of the literature. *Am J Surg Pathol*. 2005;29(1):131-135.
396. Wick MR, Swanson PE. Primary adenoid cystic carcinoma of the skin. A clinical, histological, and immunocytochemical comparison with adenoid cystic carcinoma of salivary glands and adenoid basal cell carcinoma. *Am J Dermatopathol*. 1986;8(1):2-13.
397. Madison JF, Cooper PH, Burgdorf WH. Mucinous syringometaplasia with prominent epithelial hyperplasia and deep dermal involvement. *J Cutan Pathol*. 1990;17(4):220-224.
398. Cooper PH, Mills SE, Leonard DD, et al. Sclerosing sweat duct (syringomatous) carcinoma. *Am J Surg Pathol*. 1985;9(6):422-433.

399. Goldstein DJ, Barr RJ, Santa Cruz DJ. Microcystic adnexal carcinoma: a distinct clinicopathologic entity. *Cancer*. 1982;50(3):566-572.
400. Ohtsuka H, Nagamatsu S. Microcystic adnexal carcinoma: review of 51 Japanese patients. *Dermatology*. 2002;204(3):190-193.
401. Kato H, Mizuno N, Nakagawa K, et al. Microcystic adnexal carcinoma: a light microscopic, immunohistochemical and ultrastructural study. *J Cutan Pathol*. 1990;17(2):87-95.
402. Pujol RM, LeBoit PE, Su WP. Microcystic adnexal carcinoma with extensive sebaceous differentiation. *Am J Dermatopathol*. 1997;19(4):358-362.
403. Hoang MP, Dresser KA, Kapur P, et al. Microcystic adnexal carcinoma: an immunohistochemical reappraisal. *Mod Pathol*. 2008;21(2):178-185.
404. Nagatsuka H, Rivera RS, Gunduz M, et al. Microcystic adnexal carcinoma with mandibular bone marrow involvement: a case report with immunohistochemistry. *Am J Dermatopathol*. 2006;28(6):518-522.
405. Chiller K, Passaro D, Scheuller M, et al. Microcystic adnexal carcinoma: forty-eight cases, their treatment, and their outcome. *Arch Dermatol*. 2000;136(11):1355-1359.
406. Penneys NS, Nadji M, Ziegels J, et al. Carcinoembryonic antigen in sweat-gland carcinomas. *Cancer*. 1982;50(8):1608-1611.
407. Swanson PE, Cherwitz DL, Neumann MP, Wick MR. Eccrine sweat gland carcinoma: an histologic and immunohistochemical study of 32 cases. *J Cutan Pathol*. 1987;14(2): 65-86.
408. Jones RE Jr, Austin C, Ackerman AB. Extramammary Paget's disease. A critical reexamination. *Am J Dermatopathol*. 1979;1(2):101-132.
409. Guarner J, Cohen C, DeRose PB. Histogenesis of extramammary and mammary Paget cells. An immunohistochemical study. *Am J Dermatopathol*. 1989;11(4):313-318.
410. Helwig EB, Graham JH. Anogenital (extramammary) Paget's disease. A clinicopathological study. *Cancer*. 1963;16:387-403.
411. Koss LG, Brockunier A Jr. Ultrastructural aspects of Paget's disease of the vulva. *Arch Pathol*. 1969;87(6):592-600.
412. Battles OE, Page DL, Johnson JE. Cytokeratins, CEA, and mucin histochemistry in the diagnosis and characterization of extramammary Paget's disease. *Am J Clin Pathol*. 1997;108(1):6-12.
413. Inokuchi K, Sasai Y. Histochemical analysis of sialomucin in Paget cells of mammary and extramammary Paget's disease. *Acta Histochem*. 1992;92(2):216-223.
414. Regauer S. Extramammary Paget's disease—a proliferation of adnexal origin? *Histopathology*. 2006;48(6):723-729.
415. Guldhammer B, Norgaard T. The differential diagnosis of intraepidermal malignant lesions using immunohistochemistry. *Am J Dermatopathol*. 1986;8(4):295-301.
416. Kariniemi AL, Ramaekers F, Lehto VP, Virtanen I. Paget cells express cytokeratins typical of glandular epithelia. *Br J Dermatol*. 1985;112(2):179-183.
417. Nagle RB, Lucas DO, McDaniel KM, Clark VA. Schmalzel GM. Paget's cells. New evidence linking mammary and extramammary Paget cells to a common cell phenotype. *Am J Clin Pathol*. 1985;83(4):431-438.
418. Shah KD, Tabibzadeh SS, Gerber MA. Immunohistochemical distinction of Paget's disease from Bowen's disease and superficial spreading melanoma with the use of monoclonal cytokeratin antibodies. *Am J Clin Pathol*. 1987;88(6):689-695.
419. Diaz de Leon E, Carcangiu ML, Prieto VG, et al. Extramammary Paget disease is characterized by the consistent lack of estrogen and progesterone receptors but frequently expresses androgen receptor. *Am J Clin Pathol*. 2000;113(4):572-575.
420. Fujimoto A, Takata M, Hatta N, Takehara K. Expression of structurally unaltered androgen receptor in extramammary Paget's disease. *Lab Invest*. 2000;80(9):1465-1471.
421. Nowak MA, Guerriere-Kovach P, Pathan A, et al. Perianal Paget's disease: distinguishing primary and secondary lesions using immunohistochemical studies including gross cystic disease fluid protein-15 and cytokeratin 20 expression. *Arch Pathol Lab Med*. 1998;122(12):1077-1081.
422. Ordonez NG, Awalt H, Mackay B. Mammary and extramammary Paget's disease. An immunocytochemical and ultrastructural study. *Cancer*. 1987;59(6):1173-1183.
423. Vanstapel MJ, Gatter KC, De Wolf-Peeters C, et al. Immunohistochemical study of mammary and extra-mammary Paget's disease. *Histopathology*. 1984;8(6): 1013-1023.
424. Ramalingam P, Hart WR, Goldblum JR. Cytokeratin subset immunostaining in rectal adenocarcinoma and normal anal glands. *Arch Pathol Lab Med*. 2001;125(8):1074-1077.
425. Kohler S, Rouse RV, Smoller BR. The differential diagnosis of pagetoid cells in the epidermis. *Mod Pathol*. 1998;11(1):79-92.
426. Requena L, Sanchez Yus E, Nunez C, et al. Epidermotropically metastatic breast carcinomas. Rare histopathologic variants mimicking melanoma and Paget's disease. *Am J Dermatopathol*. 1996;18(4):385-395.
427. Kuo TT, Chan HL, Hsueh S. Clear cell papulosis of the skin. A new entity with histogenetic implications for cutaneous Paget's disease. *Am J Surg Pathol*. 1987;11(11):827-834.
428. Mohanty SK, Arora R, Kakkar N, Kumar B. Clear cell papulosis of the skin. *Ann Diagn Pathol*. 2002;6(6):385-388.
429. Mazoujian G, Margolis R. Immunohistochemistry of gross cystic disease fluid protein (GCDFP-15) in 65 benign sweat gland tumors of the skin. *Am J Dermatopathol*. 1988;10(1):28-35.
430. Umbert P, Winkelmann RK. Tubular apocrine adenoma. *J Cutan Pathol*. 1976;3(2):75-87.
431. Ishiko A, Shimizu H, Inamoto N, Nakmura K. Is tubular apocrine adenoma a distinct clinical entity? *Am J Dermatopathol*. 1993;15(5):482-487.
432. Mehregan AH. Sebaceous tumors of the skin. *J Cutan Pathol*. 1985;12(3-4):196-199.
433. Mehregan AH, Pinkus H. Life history of organoid nevi. Special reference to nevus sebaceus of Jadassohn. *Arch Dermatol*. 1965;91:574-588.
434. Alessi E, Sala F. Nevus sebaceus. A clinicopathologic study of its evolution. *Am J Dermatopathol*. 1986;8(1):27-31.
435. Jaqueti G, Requena L, Sanchez Yus E. Trichoblastoma is the most common neoplasm developed in nevus sebaceus of Jadassohn: a clinicopathologic study of a series of 155 cases. *Am J Dermatopathol*. 2000;22(2):108-118.
436. Jones EW, Heyl T. Naevus sebaceus. A report of 140 cases with special regard to the development of secondary malignant tumours. *Br J Dermatol*. 1970;82(2):99-117.
437. Su WP. Histopathologic varieties of epidermal nevus. A study of 160 cases. *Am J Dermatopathol*. 1982;4(2):161-170.
438. Rulon DB, Helwig EB. Cutaneous sebaceous neoplasms. *Cancer*. 1974;33(1):82-102.
439. Misago N, Mihara I, Ansai S, Narisawa Y. Sebaceoma and related neoplasms with sebaceous differentiation: a clinicopathologic study of 30 cases. *Am J Dermatopathol*. 2002;24(4):294-304.
440. Troy JL, Ackerman AB. Sebaceoma. A distinctive benign neoplasm of adnexal epithelium differentiating toward sebaceous cells. *Am J Dermatopathol*. 1984;6(1):7-13.
441. Kazakov DV, Kutzner H, Rutten A, et al. Carcinoid-like pattern in sebaceous neoplasms: another distinctive, previously unrecognized pattern in extraocular sebaceous carcinoma and sebaceoma. *Am J Dermatopathol*. 2005;27(3):195-203.
442. Muthusamy K, Halbert G, Roberts F. Immunohistochemical staining for adipophilin, perilipin and TIP47. *J Clin Pathol*. 2006;59(11):1166-1170.
443. Bailet JW, Zimmerman MC, Arnstein DP, et al. Sebaceous carcinoma of the head and neck. Case report and literature review. *Arch Otolaryngol Head Neck Surg*. 1992;118(11):1245-1249.
444. Wick MR, Goellner JR, Wolfe JT III, Su WP. Adnexal carcinomas of the skin. II. Extraocular sebaceous carcinomas. *Cancer*. 1985;56(5):1163-1172.
445. Moreno C, Jacyk WK, Judd MJ, Requena L. Highly aggressive extraocular sebaceous carcinoma. *Am J Dermatopathol*. 2001;23(5):450-455.
446. Hood IC, Qizilbash AH, Salama SS, et al. Sebaceous carcinoma of the face following irradiation. *Am J Dermatopathol*. 1986;8(6):505-508.
447. Kazakov DV, Calonje E, Zelger B, et al. Sebaceous carcinoma arising in nevus sebaceus of Jadassohn: a clinicopathological study of five cases. *Am J Dermatopathol*. 2007;29(3):242-248.
448. Kazakov DV, Kutzner H, Spagnolo DV, et al. Discordant architectural and cytological features in cutaneous sebaceous neoplasms—a classification dilemma: report of 5 cases. *Am J Dermatopathol*. 2009;31(1):31-36.
449. Ansai S, Hashimoto H, Aoki T, et al. A histochemical and immunohistochemical study of extra-ocular sebaceous carcinoma. *Histopathology*. 1993;22(2):127-133.
450. Bayer-Garner IB, Givens V, Smoller B. Immunohistochemical staining for androgen receptors: a sensitive marker of sebaceous differentiation. *Am J Dermatopathol*. 1999;21(5):426-431.
451. Cabral ES, Auerbach A, Killian JK, et al. Distinction of benign sebaceous proliferations from sebaceous carcinomas by immunohistochemistry. *Am J Dermatopathol*. 2006;28(6):465-471.
452. Friedman KJ, Boudreau S, Farmer ER. Superficial epithelioma with sebaceous differentiation. *J Cutan Pathol*. 1987;14(4):193-197.
453. Kuo T. Clear cell carcinoma of the skin. A variant of the squamous cell carcinoma that simulates sebaceous carcinoma. *Am J Surg Pathol*. 1980;4(6):573-583.
454. Hasebe T, Mukai K, Yamaguchi N, et al. Prognostic value of immunohistochemical staining for proliferating cell nuclear antigen, p53, and c-erbB-2 in sebaceous gland carcinoma and sweat gland carcinoma: comparison with histopathological parameter. *Mod Pathol*. 1994;7(1):37-43.
455. Graham R, McKee P, McGibbon D, Heyderman E. Torre-Muir syndrome. An association with isolated sebaceous carcinoma. *Cancer*. 1985;55(12): 2868-2873.
456. Misago N, Narisawa Y. Sebaceous neoplasms in Muir-Torre syndrome. *Am J Dermatopathol*. 2000;22(2):155-161.
457. Paraf F, Sasseville D, Watters AK, et al. Clinicopathological relevance of the association between gastrointestinal and

sebaceous neoplasms: the Muir-Torre syndrome. *Hum Pathol*. 1995;26(4):422-427.
458. Shalin SC, Lyle S, Calonje E, Lazar AJ. Sebaceous neoplasia and the Muir-Torre syndrome: important connections with clinical implications. *Histopathology*. 2010;56(1):133-147.
459. Burgdorf WH, Pitha J, Fahmy A. Muir-Torre syndrome. Histologic spectrum of sebaceous proliferations. *Am J Dermatopathol*. 1986;8(3):202-208.
460. Finan MC, Connolly SM. Sebaceous gland tumors and systemic disease: a clinicopathologic analysis. *Medicine (Baltimore)*. 1984;63(4):232-242.
461. Rutten A, Burgdorf W, Hugel H, et al. Cystic sebaceous tumors as marker lesions for the Muir-Torre syndrome: a histopathologic and molecular genetic study. *Am J Dermatopathol*. 1999;21(5):405-413.
462. Singh RS, Grayson W, Redston M, et al. Site and tumor type predicts DNA mismatch repair status in cutaneous sebaceous neoplasia. *Am J Surg Pathol*. 2008;32(6):936-942.
463. Orta L, Klimstra DS, Qin J, et al. Towards identification of hereditary DNA mismatch repair deficiency: sebaceous neoplasm warrants routine immunohistochemical screening regardless of patient's age or other clinical characteristics. *Am J Surg Pathol*. 2009;33(6):934-944.
464. Headington JT. Tumors of the hair follicle. A review. *Am J Pathol*. 1976;85(2):479-514.
465. Barr RJ, Goodman MM. Neurofollicular hamartoma: a light microscopic and immunohistochemical study. *J Cutan Pathol*. 1989;16(6):336-341.
466. Mehregan AH. Hair follicle tumors of the skin. *J Cutan Pathol*. 1985;12(3-4):189-195.
467. Mehregan AH, Brownstein MH. Pilar sheath acanthoma. *Arch Dermatol*. 1978;114(10):1495-1497.
468. Rosen LB. A review and proposed new classification of benign acquired neoplasms with hair follicle differentiation. *Am J Dermatopathol*. 1990;12(5):496-516.
469. Sau P, Lupton GP, Graham JH. Trichogerminoma. Report of 14 cases. *J Cutan Pathol*. 1992;19(5):357-365.
470. Kazakov DV, Vittay G, Michal M, Calonje E. High-grade trichoblastic carcinosarcoma. *Am J Dermatopathol*. 2008;30(1):62-64.
471. Wong TY, Reed JA, Suster S, et al. Benign trichogenic tumours: a report of two cases supporting a simplified nomenclature. *Histopathology*. 1993;22(6):575-580.
472. Sim-Davis D, Marks R, Wilson-Jones E. The inverted follicular keratosis. A surprising variant of seborrheic wart. *Acta Derm Venereol*. 1976;56(5):337-344.
473. Azzopardi JG, Laurini R. Inverted follicular keratosis. *J Clin Pathol*. 1975;28(6):465-471.
474. Mehregan AH. Inverted follicular keratosis. *Arch Dermatol*. 1964;89:229-235.
475. Spielvogel RL, Austin C, Ackerman AB. Inverted follicular keratosis is not a specific keratosis but a verruca vulgaris (or seborrheic keratosis) with squamous eddies. *Am J Dermatopathol*. 1983;5(5):427-442.
476. Gray HR, Helwig EB. Epithelioma adenoides cysticum and solitary trichoepithelioma. *Arch Dermatol*. 1963;87:102-114.
477. Marrogi AJ, Wick MR, Dehner LP. Benign cutaneous adnexal tumors in childhood and young adults, excluding pilomatrixoma: review of 28 cases and literature. *J Cutan Pathol*. 1991;18(1):20-27.
478. Lorenzo MJ, Yebra-Pimentel MT, Peteiro C, Toribio J. Cystic giant solitary trichoepithelioma. *Am J Dermatopathol*. 1992;14(2):155-160.
479. Clarke J, Ioffreda M, Helm KF. Multiple familial trichoepitheliomas: a folliculosebaceous-apocrine genodermatosis. *Am J Dermatopathol*. 2002;24(5):402-405.
480. Bettencourt MS, Prieto VG, Shea CR. Trichoepithelioma: a 19-year clinicopathologic re-evaluation. *J Cutan Pathol*. 1999;26(8):398-404.
481. Brownstein MH, Shapiro L. Desmoplastic trichoepithelioma. *Cancer*. 1977;40(6):2979-2986.
482. Takei Y, Fukushiro S, Ackerman AB. Criteria for histologic differentiation of desmoplastic trichoepithelioma (sclerosing epithelial hamartoma) from morphea-like basal-cell carcinoma. *Am J Dermatopathol*. 1985;7(3):207-221.
483. Thewes M, Worret WI, Engst R, Ring J. Stromelysin-3: a potent marker for histopathologic differentiation between desmoplastic trichoepithelioma and morphealike basal cell carcinoma. *Am J Dermatopathol*. 1998;20(2):140-142.
484. Misago N, Satoh T, Miura Y, et al. Merkel cell-poor trichoblastoma with basal cell carcinoma-like foci. *Am J Dermatopathol*. 2007;29(3):249-255.
485. Kazakov DV, Mentzel T, Erlandson RA, et al. Clear cell trichoblastoma: a clinicopathological and ultrastructural study of two cases. *Am J Dermatopathol*. 2006;28(3):197-201.
486. Rosso R, Lucioni M, Savio T, Borroni G. Trichoblastic sarcoma: a high-grade stromal tumor arising in trichoblastoma. *Am J Dermatopathol*. 2007;29(1):79-83.
487. Schulz T, Proske S, Hartschuh W, et al. High-grade trichoblastic carcinoma arising in trichoblastoma: a rare adnexal neoplasm often showing metastatic spread. *Am J Dermatopathol*. 2005;27(1):9-16.
488. Carlson GJ, Nivatvongs S, Snover DC. Colorectal polyps in Cowden's disease (multiple hamartoma syndrome). *Am J Surg Pathol*. 1984;8(10):763-770.
489. Requena L, Gutierrez J, Sanchez Yus E. Multiple sclerotic fibromas of the skin. A cutaneous marker of Cowden's disease. *J Cutan Pathol*. 1992;19(4):346-351.
490. Hunt SJ, Kilzer B, Santa Cruz DJ. Desmoplastic trichilemmoma: histologic variant resembling invasive carcinoma. *J Cutan Pathol*. 1990;17(1):45-52.
491. Reis JP, Tellechea O, Cunha MF, Baptista AP. Trichilemmal carcinoma: review of 8 cases. *J Cutan Pathol*. 1993;20(1):44-49.
492. Swanson PE, Marrogi AJ, Williams DJ, et al. Tricholemmal carcinoma: clinicopathologic study of 10 cases. *J Cutan Pathol*. 1992;19(2): 100-109.
493. Boscaino A, Terracciano LM, Donofrio V, et al. Tricholemmal carcinoma: a study of seven cases. *J Cutan Pathol*. 1992;19(2):94-99.
494. Wong TY, Suster S. Tricholemmal carcinoma. A clinicopathologic study of 13 cases. *Am J Dermatopathol*. 1994;16(5):463-473.
495. Gray HR, Helwig EB. Trichofolliculoma. *Arch Dermatol*. 1962;86(5):619-625.
496. Hartschuh W, Schulz T. Immunohistochemical investigation of the different developmental stages of trichofolliculoma with special reference to the Merkel cell. *Am J Dermatopathol*. 1999;21(1):8-15.
497. Collina G, Eusebi V, Capella C, Rosai J. Merkel cell differentiation in trichoblastoma. *Virchows Arch*. 1998;433(4):291-296.
498. Fujita WH, Barr RJ, Headley JL. Multiple fibrofolliculomas with trichodiscomas and acrochordons. *Arch Dermatol*. 1981;117(1):32-35.
499. Rook A, Champion RH. Keratoacanthoma. *Natl Cancer Inst Monogr*. 1963;10:257-274.
500. Fisher ER, McCoy MM 2nd, Wechsler HL. Analysis of histopathologic and electron microscopic determinants of keratoacnthoma and squamous cell carcinoma. *Cancer*. 1972;29(5):1387-1397.
501. Calonje E, Jones EW. Intravascular spread of keratoacanthoma. An alarming but benign phenomenon. *Am J Dermatopathol*. 1992;14(5):414-417.
502. Janecka IP, Wolff M, Crikelair GF, Cosman B. Aggressive histological features of keratoacanthoma. *J Cutan Pathol*. 1977;4(6):342-348.
503. Lapins NA, Helwig EB. Perineural invasion by keratoacanthoma. *Arch Dermatol*. 1980;116(7):791-793.
504. Lowe D, Fletcher CD, Shaw MP, McKee PH. Eosinophil infiltration in keratoacanthoma and squamous cell carcinoma of the skin. *Histopathology*. 1984;8(4):619-625.
505. Klein-Szanto AJ, Barr RJ, Reiners JJ Jr, Mamrack MD. Filaggrin distribution in keratoacanthomas and squamous cell carcinoma. *Arch Pathol Lab Med*. 1984;108(11):888-890.
506. Ho T, Horn T, Finzi E. Transforming growth factor alpha expression helps to distinguish keratoacanthomas from squamous cell carcinomas. *Arch Dermatol*. 1991;127(8):1167-1171.
507. Melendez ND, Smoller BR, Morgan M. VCAM (CD-106) and ICAM (CD-54) adhesion molecules distinguish keratoacanthomas from cutaneous squamous cell carcinomas. *Mod Pathol*. 2003;16(1):8-13.
508. Biesterfeld S, Josef J. Differential diagnosis of keratoacanthoma and squamous cell carcinoma of the epidermis by MIB-1 immunohistometry. *Anticancer Res*. 2002;22(5):3019-3023.
509. Phillips P, Helm KF. Proliferating cell nuclear antigen distribution in keratoacanthoma and squamous cell carcinoma. *J Cutan Pathol*. 1993;20(5):424-428.
510. Pilch H, Weiss J, Heubner C, Heine M. Differential diagnosis of keratoacanthomas and squamous cell carcinomas: diagnostic value of DNA image cytometry and p53 expression. *J Cutan Pathol*. 1994;21(6):507-513.
511. Randall MB, Geisinger KR, Kute TE, et al. DNA content and proliferative index in cutaneous squamous cell carcinoma and keratoacanthoma. *Am J Clin Pathol*. 1990;93(2):259-262.
512. Cain CT, Niemann TH, Argenyi ZB. Keratoacanthoma versus squamous cell carcinoma. An immunohistochemical reappraisal of p53 protein and proliferating cell nuclear antigen expression in keratoacanthoma-like tumors. *Am J Dermatopathol*. 1995;17(4):324-331.
513. Lee YS, Teh M. p53 expression in pseudoepitheliomatous hyperplasia, keratoacanthoma, and squamous cell carcinoma of skin. *Cancer*. 1994;73(9):2317-2323.
514. Slater M, Barden JA. Differentiating keratoacanthoma from squamous cell carcinoma by the use of apoptotic and cell adhesion markers. *Histopathology*. 2005;47(2):170-178.
515. Peris K, Magrini F, Keller G, et al. Analysis of microsatellite instability and loss of heterozygosity in keratoacanthoma. *Arch Dermatol Res*. 1997;289(4):185-188.
516. Ra SH, Su A, Li X, et al. Keratoacanthoma and squamous cell carcinoma are distinct from a molecular perspective. *Mod Pathol*. 2015;28(6):799-806.
517. Blessing K, al Nafussi A, Gordon PM. The regressing keratoacanthoma. *Histopathology*. 1994;24(4):381-384.
518. Pattee SF, Silvis NG. Keratoacanthoma developing in sites of previous trauma: a report of two cases and review of the

literature. *J Am Acad Dermatol*. 2003;48(2 suppl):S35-S38.
519. Reed RJ. Actinic keratoacanthoma. *Arch Dermatol*. 1972;106(6):858-864.
520. Kingman J, Callen JP. Keratoacanthoma. A clinical study. *Arch Dermatol*. 1984;120(6):736-740.
521. Clausen OP, Beigi M, Bolund L, et al. Keratoacanthomas frequently show chromosomal aberrations as assessed by comparative genomic hybridization. *J Invest Dermatol*. 2002;119(6):1367-1372.
522. Hodak E, Jones RE, Ackerman AB. Solitary keratoacanthoma is a squamous-cell carcinoma: three examples with metastases. *Am J Dermatopathol*. 1993;15(4):332-342, discussion 43-52.
523. Piscioli F, Boi S, Zumiani G, Cristofolini M. A gigantic, metastasizing keratoacanthoma. Report of a case and discussion on classification. *Am J Dermatopathol*. 1984;6(2):123-129.
524. Mandrell JC, Santa Cruz D. Keratoacanthoma: hyperplasia, benign neoplasm, or a type of squamous cell carcinoma? *Semin Diagn Pathol*. 2009;26(3):150-163.
525. Beham A, Regauer S, Soyer HP, Beham-Schmid C. Keratoacanthoma: a clinically distinct variant of well differentiated squamous cell carcinoma. *Adv Anat Pathol*. 1998;5(5):269-280.
526. LeBoit PE. Can we understand keratoacanthoma? *Am J Dermatopathol*. 2002;24(2):166-168.
527. Sanchez Yus E, Simon P, Requena L, et al. Solitary keratoacanthoma: a self-healing proliferation that frequently becomes malignant. *Am J Dermatopathol*. 2000;22(4):305-310.
528. Sleater JP, Beers BB, Stephens CA, Hendricks JB. Keratoacanthoma: a deficient squamous cell carcinoma? Study of bcl-2 expression. *J Cutan Pathol*. 1994;21(6):514-519.
529. Allen CA, Stephens M, Steel WM. Subungual keratoacanthoma. *Histopathology*. 1994;25(2):181-183.
530. Cramer SF. Subungual keratoacanthoma. A benign bone-eroding neoplasm of the distal phalanx. *Am J Clin Pathol*. 1981;75(3):425-429.
531. Kligman AM. The myth of the sebaceous cyst. *Arch Dermatol*. 1964;89:253-256.
532. Pinkus H. "Sebaceous cysts" are trichilemmal cysts. *Arch Dermatol*. 1969;99(5):544-555.
533. Lucas GL. Epidermoid inclusion cysts of the hand. *J South Orthop Assoc*. 1999;8(3): 188-192.
534. Rahbari H. Epidermoid cysts with seborrheic verruca-like cyst walls. *Arch Dermatol*. 1982;118(5):326-328.
535. Leppard BJ, Sanderson KV. The natural history of trichilemmal cysts. *Br J Dermatol*. 1976;94(4):379-390.
536. McGavran MH, Binnington B. Keratinous cysts of the skin. Identification and differentiation of pilar cysts from epidermal cysts. *Arch Dermatol*. 1966;94(4):499-508.
537. Cotton DW, Kirkham N, Young BJ. Immunoperoxidase anti-keratin staining of epidermal and pilar cysts. *Br J Dermatol*. 1984;111(1):63-68.
538. Lee S, Lee W, Chung S, et al. Detection of human papillomavirus 60 in epidermal cysts of nonpalmoplantar location. *Am J Dermatopathol*. 2003;25(3):243-247.
539. Ahn SK, Chung J, Lee WS, et al. Hybrid cysts showing alternate combination of eruptive vellus hair cyst, steatocystoma multiplex, and epidermoid cyst, and an association among the three conditions. *Am J Dermatopathol*. 1996;18(6):645-649.
540. Andersen WK, Rao BK, Bhawan J. The hybrid epidermoid and apocrine cyst. A combination of apocrine hidrocystoma and epidermal inclusion cyst. *Am J Dermatopathol*. 1996;18(4):364-366.
541. Kurban RS, Bhawan J. Cutaneous cysts lined by nonsquamous epithelium. *Am J Dermatopathol*. 1991;13(5):509-517.
542. Yamaki T, Higuchi R, Sasaki K, Nozaki M. Multiple dermoid cysts on the forehead. Case report. *Scand J Plast Reconstr Surg Hand Surg*. 1996;30(4):321-324.
543. Brownstein MH. Steatocystoma simplex. A solitary steatocystoma. *Arch Dermatol*. 1982;118(6):409-411.
544. Requena L, Martin L, Renedo G, et al. A facial variant of steatocystoma multiplex. *Cutis*. 1993;51(6):449-452.
545. Cho S, Chang SE, Choi JH, et al. Clinical and histologic features of 64 cases of steatocystoma multiplex. *J Dermatol*. 2002;29(3):152-156.
546. de Viragh PA, Szeimies RM, Eckert F. Apocrine cystadenoma, apocrine hidrocystoma, and eccrine hidrocystoma: three distinct tumors defined by expression of keratins and human milk fat globulin 1. *J Cutan Pathol*. 1997;24(4):249-255.
547. Mehregan AH. Apocrine cystadenoma: a clinicopathologic study with special reference to the pigmented variety. *Arch Dermatol*. 1964;90(3):274-279.
548. al-Nafussi AI, Carder P. Cutaneous ciliated cyst: a case report and immunohistochemical comparison with fallopian tube. *Histopathology*. 1990;16(6):595-598.
549. Farmer ER, Helwig EB. Cutaneous ciliated cysts. *Arch Dermatol*. 1978;114(1):70-73.
550. Fontaine DG, Lau H, Murray SK, et al. Cutaneous ciliated cyst of the abdominal wall: a case report with a review of the literature and discussion of pathogenesis. *Am J Dermatopathol*. 2002;24(1):63-66.
551. Trotter SE, Rassl DM, Saad M, et al. Cutaneous ciliated cyst occurring in a male. *Histopathology*. 1994;25(5):492-493.
552. Esterly NB, Fretzin DF, Pinkus H. Eruptive vellus hair cysts. *Arch Dermatol*. 1977;113(4):500-503.
553. Mehregan AH, Medenica M. Pigmented follicular cysts. *J Cutan Pathol*. 1982;9(6):423-427.
554. Fraga S, Helwig EB, Rosen SH. Bronchogenic cysts in the skin and subcutaneous tissue. *Am J Clin Pathol*. 1971;56(2):230-238.
555. Shareef DS, Salm R. Ectopic vestigial lesions of the neck and shoulders. *J Clin Pathol*. 1981;34(10):1155-1162.
556. Kaddu S, Dong H, Mayer G, et al. Warty dyskeratoma—"follicular dyskeratoma": analysis of clinicopathologic features of a distinctive follicular adnexal neoplasm. *J Am Acad Dermatol*. 2002;47(3):423-428.
557. Mann B, Salm R, Azzopardi JG. Pilar tumour: a distinctive type of trichilemmoma. *Diagn Histopathol*. 1982;5(3):157-167.
558. Hendricks DL, Liang MD, Borochovitz D, Miller T. A case of multiple pilar tumors and pilar cysts involving the scalp and back. *Plast Reconstruct Surg*. 1991;87(4):763-767.
559. Mori O, Hachisuka H, Sasai Y. Proliferating trichilemmal cyst with spindle cell carcinoma. *Am J Dermatopathol*. 1990;12(5): 479-484.
560. Lopez-Rios F, Rodriguez-Peralto JL, Aguilar A, et al. Proliferating trichilemmal cyst with focal invasion: report of a case and a review of the literature. *Am J Dermatopathol*. 2000;22(2):183-187.
561. Sleater J, Beers B, Stefan M, et al. Proliferating trichilemmal cyst. Report of four cases, two with nondiploid DNA content and increased proliferation index. *Am J Dermatopathol*. 1993;15(5):423-428.
562. Jones E. Proliferating epidermoid cysts. *Arch Dermatol*. 1966;94(1):11-19.
563. Reed RJ, Lamar LM. Invasive hair matrix tumors of the scalp. Invasive pilomatrixoma. *Arch Dermatol*. 1966;94(3):310-316.
564. Amaral AL, Nascimento AG, Goellner JR. Proliferating pilar (trichilemmal) cyst. Report of two cases, one with carcinomatous transformation and one with distant metastases. *Arch Pathol Lab Med*. 1984;108(10):808-810.
565. Rutty GN, Richman PI, Laing JH. Malignant change in trichilemmal cysts: a study of cell proliferation and DNA content. *Histopathology*. 1992;21(5):465-468.
566. Ye J, Nappi O, Swanson PE, et al. Proliferating pilar tumors: a clinicopathologic study of 76 cases with a proposal for definition of benign and malignant variants. *Am J Clin Pathol*. 2004;122(4):566-574.
567. Haas N, Audring H, Sterry W. Carcinoma arising in a proliferating trichilemmal cyst expresses fetal and trichilemmal hair phenotype. *Am J Dermatopathol*. 2002;24(4):340-344.
568. Takata M, Rehman I, Rees JL. A trichilemmal carcinoma arising from a proliferating trichilemmal cyst: the loss of the wild-type p53 is a critical event in malignant transformation. *Hum Pathol*. 1998;29(2):193-195.
569. Forbis R Jr, Helwig EB. Pilomatrixoma (calcifying epithelioma). *Arch Dermatol*. 1961;83:606-618.
570. Kaddu S, Soyer HP, Wolf IH, Kerl H. Proliferating pilomatricoma. A histopathologic simulator of matrical carcinoma. *J Cutan Pathol*. 1997;24(4):228-234.
571. Solanki P, Ramzy I, Durr N, Henkes D. Pilomatrixoma. Cytologic features with differential diagnostic considerations. *Arch Pathol Lab Med*. 1987;111(3):294-297.
572. Wang J, Cobb CJ, Martin SE, et al. Pilomatrixoma: clinicopathologic study of 51 cases with emphasis on cytologic features. *Diagn Cytopathol*. 2002;27(3):167-172.
573. Aly Z, Pozo L, Diaz-Cano SJ. Colonization of epithelial pilar neoplasms by melanocytes. *Histopathology*. 2006;48(2):213-217.
574. Kaddu S, Beham-Schmid C, Soyer HP, et al. Extramedullary hematopoiesis in pilomatricomas. *Am J Dermatopathol*. 1995;17(2):126-130.
575. Marrogi AJ, Wick MR, Dehner LP. Pilomatrical neoplasms in children and young adults. *Am J Dermatopathol*. 1992;14(2):87-94.
576. Kaddu S, Soyer HP, Hodl S, Kerl H. Morphological stages of pilomatricoma. *Am J Dermatopathol*. 1996;18(4):333-338.
577. Kusama K, Katayama Y, Oba K, et al. Expression of hard alpha-keratins in pilomatrixoma, craniopharyngioma, and calcifying odontogenic cyst. *Am J Clin Pathol*. 2005;123(3):376-381.
578. McGavran MH. Ultrastructure of pilomatrixoma (calcifying epithelioma). *Cancer*. 1965;18(11):1445-1456.
579. Tateyama H, Eimoto T, Tada T, Niwa T. Malignant pilomatricoma. An immunohistochemical study with antihair keratin antibody. *Cancer*. 1992;69(1):127-132.
580. Chan EF, Gat U, McNiff JM, Fuchs E. A common human skin tumour is caused by activating mutations in beta-catenin. *Nat Genet*. 1999;21(4):410-413.
581. LeBoit PE, Parslow TG, Choy SH. Hair matrix differentiation. Occurrence in lesions other than pilomatricoma. *Am J Dermatopathol*. 1987;9(5):399-405.
582. Wickremaratchi T, Collins CMP. Pilomatrixoma or calcifying epithelioma of Malherbe invading bone. *Histopathology*. 1992;21(1):79-81.

583. Hardisson D, Linares MD, Cuevas-Santos J, Contreras F. Pilomatrix carcinoma: a clinicopathologic study of six cases and review of the literature. *Am J Dermatopathol*. 2001;23(5):394-401.
584. Hanly MG, Allsbrook WC, Pantazis CG, et al. Pilomatrical carcinosarcoma of the cheek with subsequent pulmonary metastases. A case report. *Am J Dermatopathol*. 1994;16(2):196-200.
585. De Galvez-Aranda MV, Herrera-Ceballos E, Sanchez-Sanchez P, et al. Pilomatrix carcinoma with lymph node and pulmonary metastasis: report of a case arising on the knee. *Am J Dermatopathol*. 2002;24(2):139-143.
586. O'Donovan DG, Freemont AJ, Adams JE, Markham DE. Malignant pilomatrixoma with bone metastasis. *Histopathology*. 1993;23(4):385-386.
587. Sau P, Lupton GP, Graham JH. Pilomatrix carcinoma. *Cancer*. 1993;71(8):2491-2498.
588. Wood MG, Parhizgar B, Beerman H. Malignant pilomatricoma. *Arch Dermatol*. 1984;120(6):770-773.
589. Conejo-Mir J, Nail RL. Mills SE, eds *Histology for Pathologists*. 3rd ed. Philadelphia, PA: Lippincott Williams & Wilkins; 2007.
590. Alessi E, Coggi A, Gianotti R, et al. Onycholemmal carcinoma. *Am J Dermatopathol*. 2004;26(5):397-402.
591. Inaoki M, Makino E, Adachi M, Fujimoto W. Onycholemmal carcinoma. *J Cutan Pathol*. 2006;33(8):577-580.
592. Perrin C, Baran R, Balaguer T, et al. Onychomatricoma: new clinical and histological features. A review of 19 tumors. *Am J Dermatopathol*. 2010;32(1):1-8.
593. Masson P. Pigment cells in man. In: Miner RW, ed. *The Biology of Melanomas (Special Publication)*. Vol. 4. New York, NY: The New York Academy of Sciences; 1948:15-51.
594. Le Douarin N. Cell migration in early vertebrate development studied in inter-specific chimaeras. In: *Embryogenesis in Mammals Ciba Foundation Symposium*. Amsterdam: Elsevier Excerpta Medica–North Holland; 1976:71-101.
595. Clark WH Jr, Watson MC, Watson BE. Two kinds of "clear" cells in the human epidermis; with a report of a modified DOPA reaction for electron microscopy. *Am J Pathol*. 1961;39:333-344.
596. Boyle JL, Haupt HM, Stern JB, Multhaupt HA. Tyrosinase expression in malignant melanoma, desmoplastic melanoma, and peripheral nerve tumors. *Arch Pathol Lab Med*. 2002;126(7):816-822.
597. Jungbluth AA, Busam KJ, Gerald WL, et al. A103: An anti-melan-a monoclonal antibody for the detection of malignant melanoma in paraffin-embedded tissues. *Am J Surg Pathol*. 1998;22(5):595-602.
598. King R, Weilbaecher KN, McGill G, et al. Microphthalmia transcription factor. A sensitive and specific melanocyte marker for MelanomaDiagnosis. *Am J Pathol*. 1999;155(3):731-738.
599. Mangini J, Li N, Bhawan J. Immunohistochemical markers of melanocytic lesions: a review of their diagnostic usefulness. *Am J Dermatopathol*. 2002;24(3):270-281.
600. Nonaka D, Chiriboga L, Rubin BP. Sox10: a pan-schwannian and melanocytic marker. *Am J Surg Pathol*. 2008;32(9):1291-1298.
601. Plummer RS, Shea CR, Nelson M, et al. PAX3 expression in primary melanomas and nevi. *Mod Pathol*. 2008;21(5):525-530.
602. Miettinen M, Lehto VP, Virtanen I. Presence of fibroblast-type intermediate filaments (vimentin) and absence of neurofilaments in pigmented nevi and malignant melanomas. *J Cutan Pathol*. 1983;10(3):188-192.
603. Bacchi CE, Bonetti F, Pea M, et al. HMB-45: a review. *Appl Immunohistochem*. 1996;4:73-85.
604. Smoller BR, McNutt NS, Hsu A. HMB-45 recognizes stimulated melanocytes. *J Cutan Pathol*. 1989;16(2):49-53.
605. Magana-Garcia M, Ackerman AB. What are nevus cells? *Am J Dermatopathol*. 1990;12(1):93-102.
606. Cochran AJ, Bailly C, Paul E, Dolbeau D. Nevi, other than dysplastic and Spitz nevi. *Semin Diagn Pathol*. 1993;10(1):3-17.
607. Lu D, Hoch B, Dehner LP, Lind AC. Proliferative activity in melanocytic nevi from patients grouped by age. *Mod Pathol*. 2003;16:94a.
608. MacKie RM, English J, Aitchison TC, et al. The number and distribution of benign pigmented moles (melanocytic naevi) in a healthy British population. *Br J Dermatol*. 1985;113(2):167-174.
609. Krengel S. Nevogenesis—new thoughts regarding a classical problem. *Am J Dermatopathol*. 2005;27(5):456-465.
610. Hui P, Perkins A, Glusac E. Assessment of clonality in melanocytic nevi. *J Cutan Pathol*. 2001;28(3):140-144.
611. Maitra A, Gazdar AF, Moore TO, Moore AY. Loss of heterozygosity analysis of cutaneous melanoma and benign melanocytic nevi: laser capture microdissection demonstrates clonal genetic changes in acquired nevocellular nevi. *Hum Pathol*. 2002;33(2):191-197.
612. Bloethner S, Snellman E, Bermejo JL, et al. Differential gene expression in melanocytic nevi with the V600E BRAF mutation. *Genes Chromosome Cancer*. 2007;46(11):1019-1027.
613. Kumar R, Angelini S, Snellman E, Hemminki K. BRAF mutations are common somatic events in melanocytic nevi. *J Invest Dermatol*. 2004;122(2):342-348.
614. Pollock PM, Harper UL, Hansen KS, et al. High frequency of BRAF mutations in nevi. *Nat Genet*. 2003;33(1):19-20.
615. Masson P. Les naevi pigmentaires, tumeurs nerveuses. *Ann Anat Pathol (Paris)*. 1926;3:417-453, 657-696.
616. Masson P. My conception of cellular nevi. *Cancer*. 1951;4(1):9-38.
617. Argenyi ZB, Rodgers J, Wick M. Expression of nerve growth factor and epidermal growth factor receptors in neural nevi with nevic corpuscles. *Am J Dermatopathol*. 1996;18(5):460-464.
618. Kroumpouzos G, Cohen LM. Intradermal melanocytic nevus with prominent schwannian differentiation. *Am J Dermatopathol*. 2002;24(1):39-42.
619. Misago N. The relationship between melanocytes and peripheral nerve sheath cells (Part I): melanocytic nevus (excluding so-called "blue nevus") with peripheral nerve sheath differentiation. *Am J Dermatopathol*. 2000;22(3):217-229.
620. Johnson WT, Helwig EB. Benign nevus cells in the capsule of lymph nodes. *Cancer*. 1969;23(3):747-753.
621. Ridolfi RL, Rosen PP, Thaler H. Nevus cell aggregates associated with lymph nodes: estimated frequency and clinical significance. *Cancer*. 1977;39(1):164-171.
622. Fallowfield ME, Collina G, Cook MG. Melanocytic lesions of the palm and sole. *Histopathology*. 1994;24(5):463-467.
623. Signoretti S, Annessi G, Puddu P, Faraggiana T. Melanocytic nevi of palms and soles: a histological study according to the plane of section. *Am J Surg Pathol*. 1999;23(3):283-287.
624. Mooi WJ, Krausz T. *Biopsy Pathology of Melanocytic Disorders. Biopsy Pathology Series*. London: Chapman & Hall; 1992.
625. King R, Googe PB, Page RN, Mihm MC Jr. Melanocytic lesions associated with dermatofibromas: a spectrum of lesions ranging from junctional nevus to malignant melanoma in situ. *Mod Pathol*. 2005;18(8):1043-1047.
626. Sowa J, Kobayashi H, Ishii M, Kimura T. Histopathologic findings in Unna's nevus suggest it is a tardive congenital nevus. *Am J Dermatopathol*. 2008;30(6):561-566.
627. Gray MH, Smoller BR, McNutt NS, Hsu A. Neurofibromas and neurotized melanocytic nevi are immunohistochemically distinct neoplasms. *Am J Dermatopathol*. 1990;12(3):234-241.
628. Van Paesschen MA, Goovaerts G, Buyssens N. A study of the so-called neurotization of nevi. *Am J Dermatopathol*. 1990;12(3):242-248.
629. Bednar B. Storiform neurofibroma in the core of naevocellular naevi. *J Pathol*. 1970;101(2):199-201.
630. Van Raamsdonk CD, Bezrookove V, Green G, et al. Frequent somatic mutations of GNAQ in uveal melanoma and blue naevi. *Nature*. 2009;457(7229):599-602.
631. Schaumburg-Lever G, Lever I, Fehrenbacher B, et al. Melanocytes in nevi and melanomas synthesize basement membrane and basement membrane-like material. An immunohistochemical and electron microscopic study including immunoelectron microscopy. *J Cutan Pathol*. 2000;27(2):67-75.
632. Yaar M, Woodley DT, Gilchrest BA. Human nevocellular nevus cells are surrounded by basement membrane components. Immunohistologic studies of human nevus cells and melanocytes in vivo and in vitro. *Lab Invest*. 1988;58(2):157-162.
633. Tajima Y, Nakajima T, Sugano I, et al. Malignant melanoma within an intradermal nevus. *Am J Dermatopathol*. 1994;16(3):301-306.
634. Stegmaier OC Jr, Montgomery H. Histopathologic studies of pigmented nevi in children. *J Invest Dermatol*. 1953;20(1):51-64.
635. Cohen LM, Bennion SD, Johnson TW, Golitz LE. Hypermelanotic nevus: clinical, histopathologic, and ultrastructural features in 316 cases. *Am J Dermatopathol*. 1997;19(1):23-30.
636. Benz G, Holzel D, Schmoeckel C. Inflammatory cellular infiltrates in melanocytic nevi. *Am J Dermatopathol*. 1991;13(6):538-542.
637. Clark WH Jr, Hood AF, Tucker MA, Jampel RM. Atypical melanocytic nevi of the genital type with a discussion of reciprocal parenchymal-stromal interactions in the biology of neoplasia. *Hum Pathol*. 1998;29(1 suppl 1):S1-S24.
638. Gleason BC, Hirsch MS, Nucci MR, et al. Atypical genital nevi. A clinicopathologic analysis of 56 cases. *Am J Surg Pathol*. 2008;32(1):51-57.
639. Elder DE. Precursors to melanoma and their mimics: nevi of special sites. *Mod Pathol*. 2006;19(suppl 2):S4-S20.
640. Khalifeh I, Taraif S, Reed JA, et al. A subgroup of melanocytic nevi on the distal lower extremity (ankle) shares features of acral nevi, dysplastic nevi, and melanoma in situ: a potential misdiagnosis of melanoma in situ. *Am J Surg Pathol*. 2007;31(7):1130-1136.
641. McKee PH. Clues to the diagnosis of atypical melanocytic lesions. *Histopathology*. 2010;56(1):100-111.
642. Harris GR, Shea CR, Horenstein MG, et al. Desmoplastic (sclerotic) nevus: an underrecognized entity that resembles dermatofibroma and desmoplastic melanoma. *Am J Surg Pathol*. 1999;23(7):786-794.
643. Mehregan DR, Mehregan DA, Mehregan AH. Nodular myxoid change in melanocytic nevi.

A report of two cases. *Am J Dermatopathol*. 1996;18(4):400-402.
644. Cohen PR, Rapini RP. Nevus with cyst. A report of 93 cases. *Am J Dermatopathol*. 1993;15(3):229-234.
645. Jih DM, Morgan MB, Bass J, et al. Oncocytic metaplasia occurring in a spectrum of melanocytic nevi. *Am J Dermatopathol*. 2002;24(6):468-472.
646. Conlin PA, Rapini RP. Epidermolytic hyperkeratosis associated with melanocytic nevi: a report of 53 cases. *Am J Dermatopathol*. 2002;24(1):23-25.
647. Weedon D. Unusual features of nevocellular nevi. *J Cutan Pathol*. 1982;9(5):284-292.
648. Gonzalez-Campora R, Galera-Davidson H, Vazquez-Ramirez FJ, Diaz-Cano S. Blue nevus: classical types and new related entities. A differential diagnostic review. *Pathol Res Pract*. 1994;190(6):627-635.
649. Sun J, Morton TH Jr, Gown AM. Antibody HMB-45 identifies the cells of blue nevi. An immunohistochemical study on paraffin sections. *Am J Surg Pathol*. 1990;14(8):748-751.
650. Harper JC, Waldron CA. Blue nevus of palate: report of a case. *Oral Surg Oral Med Oral Pathol*. 1965;20:145-149.
651. Goldman RL, Friedman NB. Blue nevus of the uterine cervix. *Cancer*. 1967;20(2):210-214.
652. Jao W, Fretzin DF, Christ ML, Prinz LM. Blue nevus of the prostate gland. *Arch Pathol*. 1971;91(2):187-191.
653. Epstein JI, Erlandson RA, Rosen PP. Nodal blue nevi. A study of three cases. *Am J Surg Pathol*. 1984;8(12):907-915.
654. Busam KJ. Metastatic melanoma to the skin simulating blue nevus. *Am J Surg Pathol*. 1999;23(3):276-282.
655. Wieselthier JS, White WL. Cutaneous metastasis of ocular malignant melanoma. An unusual presentation simulating blue nevi. *Am J Dermatopathol*. 1996;18(3):289-295.
656. Masson P. Blue neuro-nevi. *Arch de Vecchi Anat Patol*. 1950;14(1):1-28.
657. Rodriguez HA, Ackerman LV. Cellular blue nevus: clinicopathologic study of forty-five cases. *Cancer*. 1968;21(3):393-405.
658. Michal M, Kerekes Z, Kinkor Z, et al. Desmoplastic cellular blue nevi. *Am J Dermatopathol*. 1995;17(3):230-235.
659. Perez MT, Suster S. Balloon cell change in cellular blue nevus. *Am J Dermatopathol*. 1999;21(2):181-184.
660. Zembowicz A, Granter SR, McKee PH, Mihm MC. Amelanotic cellular blue nevus: a hypopigmented variant of the cellular blue nevus: clinicopathologic analysis of 20 cases. *Am J Surg Pathol*. 2002;26(11):1493-1500.
661. Cerroni L, Borroni RG, Massone C, Kerl H. Ancient" blue nevi (cellular blue nevi with degenerative stromal changes). *Am J Dermatopathol*. 2008;30(1):1-5.
662. Smith K, Germain M, Williams J, Skelton H. CD34-positive cellular blue nevi. *J Cutan Pathol*. 2001;28(3):145-150.
663. Maize JC Jr, McCalmont TH, Carlson JA, et al. Genomic analysis of blue nevi and related dermal melanocytic proliferations. *Am J Surg Pathol*. 2005;29(9):1214-1220.
664. Connelly J, Smith JL Jr. Malignant blue nevus. *Cancer*. 1991;67(10):2653-2657.
665. Granter SR, McKee PH, Calonje E, et al. Melanoma associated with blue nevus and melanoma mimicking cellular blue nevus: a clinicopathologic study of 10 cases on the spectrum of so-called 'malignant blue nevus'. *Am J Surg Pathol*. 2001;25(3):316-323.
666. Temple-Camp CR, Saxe N, King H. Benign and malignant cellular blue nevus. A clinicopathological study of 30 cases. *Am J Dermatopathol*. 1988;10(4):289-296.
667. Kao GF, Graham JH, Helwig EB. Cutaneous malignant blue melanoma [abstract]. *Lab Invest*. 1981;44:33.
668. Pich A, Chiusa L, Margaria E, Aloi F. Proliferative activity in the malignant cellular blue nevus. *Hum Pathol*. 1993;24(12):1323-1329.
669. Pouryazdanparast P, Newman M, Mafee M, et al. Distinguishing epithelioid blue nevus from blue nevus-like cutaneous melanoma metastasis using fluorescence in situ hybridization. *Am J Surg Pathol*. 2009;33(9):1396-1400.
670. Gerami P, Pouryazdanparast P, Vemula S, Bastian BC. Molecular analysis of a case of nevus of Ota showing progressive evolution to melanoma with intermediate stages resembling cellular blue nevus. *Am J Dermatopathol*. 2010;32(3):301-305.
671. Tran TA, Carlson JA, Basaca PC, Mihm MC. Cellular blue nevus with atypia (atypical cellular blue nevus): a clinicopathologic study of nine cases. *J Cutan Pathol*. 1998;25(5):252-258.
672. Mones JM, Ackerman AB. "Atypical" blue nevus, "malignant" blue nevus, and "metastasizing" blue nevus: a critique in historical perspective of three concepts flawed fatally. *Am J Dermatopathol*. 2004;26(5):407-430.
673. Barnhill RL, Argenyi Z, Berwick M, et al. Atypical cellular blue nevi (cellular blue nevi with atypical features): lack of consensus for diagnosis and distinction from cellular blue nevi and malignant melanoma ("malignant blue nevus"). *Am J Surg Pathol*. 2008;32(1):36-44.
674. Wood WS, Tron VA. Analysis of HMB-45 immunoreactivity in common and cellular blue nevi. *J Cutan Pathol*. 1991;18(4):261-263.
675. Dei Tos AP, Khurana JS, Kurtin PJ, Nascimento AG. Absence of S-100 protein immunoreactivity in cellular blue nevus: a potential diagnostic pitfall. *Appl Immunohistochem Mol Morphol*. 1999;7(4):255.
676. Tsoitis G, Kanitakis C, Kapetis E. Naevus bleu multinodulaire en plaque, superficiel et neuroide. *Ann Dermatol Venereol*. 1983;110:231-235.
677. Bondi EE, Elder D, Guerry D 4th, Clark WH Jr. Target blue nevus. *Arch Dermatol*. 1983;119(11):919-920.
678. Leopold JG, Richards DB. The interrelationship of blue and common naevi. *J Pathol Bacteriol*. 1968;95(1):37-46.
679. Pulitzer DR, Martin PC, Cohen AP, Reed RJ. Histologic classification of the combined nevus. Analysis of the variable expression of melanocytic nevi. *Am J Surg Pathol*. 1991;15(12):1111-1122.
680. Carney JA, Ferreiro JA. The epithelioid blue nevus. A multicentric familial tumor with important associations, including cardiac myxoma and psammomatous melanotic schwannoma. *Am J Surg Pathol*. 1996;20(3):259-272.
681. Moreno C, Requena L, Kutzner H, et al. Epithelioid blue nevus: a rare variant of blue nevus not always associated with the Carney complex. *J Cutan Pathol*. 2000;27(5):218-223.
682. O'Grady TC, Barr RJ, Billman G, Cunningham BB. Epithelioid blue nevus occurring in children with no evidence of Carney complex. *Am J Dermatopathol*. 1999;21(5):483-486.
683. Groben PA, Harvell JD, White WL. Epithelioid blue nevus: neoplasm Sui generis or variation on a theme? *Am J Dermatopathol*. 2000;22(6):473-488.
684. Zembowicz A, Carney JA, Mihm MC. Pigmented epithelioid melanocytoma: a low-grade melanocytic tumor with metastatic potential indistinguishable from animal-type melanoma and epithelioid blue nevus. *Am J Surg Pathol*. 2004;28(1):31-40.
685. Deyrup AT, Althof P, Zhou M, et al. Paraganglioma-like dermal melanocytic tumor: a unique entity distinct from cellular blue nevus, clear cell sarcoma, and cutaneous melanoma. *Am J Surg Pathol*. 2004;28(12):1579-1586.
686. Hirayama T, Suzuki T. A new classification of Ota's nevus based on histopathological features. *Dermatologica*. 1991;183(3):169-172.
687. Zembowicz A, Mihm MC. Dermal dendritic melanocytic proliferations: an update. *Histopathology*. 2004;45(5):433-451.
688. Cesinaro AM, Foroni M, Sighinolfi P, et al. Spitz nevus is relatively frequent in adults: a clinico-pathologic study of 247 cases related to patient's age. *Am J Dermatopathol*. 2005;27(6):469-475.
689. Echevarria R, Ackerman LV. Spindle and epitheloid cell nevi in the adult. Clinicopathologic report of 26 cases. *Cancer*. 1967;20(2):175-189.
690. Kernen JA, Ackerman LV. Spindle cell nevi and epithelioid cell nevi (so-called juvenile melanomas) in children and adults: a clinicopathological study of 27 cases. *Cancer*. 1960;13:612-625.
691. Hamm H, Happle R, Brocker EB. Multiple agminate Spitz naevi: review of the literature and report of a case with distinctive immunohistological features. *Br J Dermatol*. 1987;117(4):511-522.
692. Mooi WJ. Spitz nevus and its histologic simulators. *Adv Anat Pathol*. 2002;9(4):209-221.
693. Paniago-Pereira C, Maize JC, Ackerman AB. Nevus of large spindle and/or epithelioid cells (Spitz's nevus). *Arch Dermatol*. 1978;114(12):1811-1823.
694. Tu P, Miyauchi S, Miki Y. Proliferative activities in Spitz nevus compared with melanocytic nevus and malignant melanoma using expression of PCNA/cyclin and mitotic rate. *Am J Dermatopathol*. 1993;15(4): 311-314.
695. Weedon D, Little JH. Spindle and epithelioid cell nevi in children and adults. A review of 211 cases of the Spitz nevus. *Cancer*. 1977;40(1):217-225.
696. Barnhill RL, Barnhill MA, Berwick M, Mihm MC Jr. The histologic spectrum of pigmented spindle cell nevus: a review of 120 cases with emphasis on atypical variants. *Hum Pathol*. 1991;22(1):52-58.
697. Sagebiel RW, Chinn EK, Egbert BM. Pigmented spindle cell nevus. Clinical and histologic review of 90 cases. *Am J Surg Pathol*. 1984;8(9):645-653.
698. Smith NP. The pigmented spindle cell tumor of Reed: an underdiagnosed lesion. *Semin Diagn Pathol*. 1987;4(1):75-87.
699. Busam KJ, Kutzner H, Cerroni L, Wiesner T. Clinical and pathologic findings of Spitz nevi and atypical Spitz tumors with ALK fusions. *Am J Surg Pathol*. 2014;38(7):925-933.
700. Barr RJ, Morales RV, Graham JH. Desmoplastic nevus: a distinct histologic variant of mixed spindle cell and epithelioid cell nevus. *Cancer*. 1980;46(3):557-564.
701. Busam KJ, Barnhill RL. Pagetoid Spitz nevus. Intraepidermal Spitz tumor with prominent pagetoid spread. *Am J Surg Pathol*. 1995;19(9):1061-1067.
702. Howat AJ, Variend S. Lymphatic invasion in Spitz nevi. *Am J Surg Pathol*. 1985;9(2):125-128.
703. Burg G, Kempf W, Hochli M, et al. Tubular' epithelioid cell nevus: a new variant of Spitz's nevus. *J Cutan Pathol*. 1998;25(9):475-478.
704. Clarke B, Essa A, Chetty R. Plexiform spitz nevus. *Int J Surg Pathol*. 2002;10(1):69-73.

705. Spatz A, Peterse S, Fletcher CD, Barnhill RL. Plexiform spitz nevus: an intradermal spitz nevus with plexiform growth pattern. *Am J Dermatopathol*. 1999;21(6):542-546.
706. Harvell JD, Meehan SA, LeBoit PE. Spitz's nevi with halo reaction: a histopathologic study of 17 cases. *J Cutan Pathol*. 1997;24(10):611-619.
707. Diaz-Cascajo C, Borghi S, Weyers W. Angiomatoid Spitz nevus: a distinct variant of desmoplastic Spitz nevus with prominent vasculature. *Am J Dermatopathol*. 2000;22(2):135-139.
708. Binder SW, Asnong C, Paul E, Cochran AJ. The histology and differential diagnosis of Spitz nevus. *Semin Diagn Pathol*. 1993;10(1):36-46.
709. Peters MS, Goellner JR. Spitz naevi and malignant melanomas of childhood and adolescence. *Histopathology*. 1986;10(12):1289-1302.
710. Skelton HG, Miller ML, Lupton GP, Smith KJ. Eosinophilic globules in spindle cell and epithelioid cell nevi: composition and possible origin. *Am J Dermatopathol*. 1998;20(6):547-550.
711. Walsh N, Crotty K, Palmer A, McCarthy S. Spitz nevus versus spitzoid malignant melanoma: an evaluation of the current distinguishing histopathologic criteria. *Hum Pathol*. 1998;29(10):1105-1112.
712. Weedon D. Borderline melanocytic tumors. *J Cutan Pathol*. 1985;12(3-4):266-270.
713. Hantschke M, Bastian BC, LeBoit PE. Consumption of the epidermis: a diagnostic criterion for the differential diagnosis of melanoma and Spitz nevus. *Am J Surg Pathol*. 2004;28(12):1621-1625.
714. Kanter-Lewensohn L, Hedblad MA, Wejde J, Larsson O. Immunohistochemical markers for distinguishing Spitz nevi from malignant melanomas. *Mod Pathol*. 1997;10(9):917-920.
715. Ribe A, McNutt NS. S100A6 protein expression is different in Spitz nevi and melanomas. *Mod Pathol*. 2003;16(5):505-511.
716. Hilliard NJ, Krahl D, Sellheyer K. p16 expression differentiates between desmoplastic Spitz nevus and desmoplastic melanoma. *J Cutan Pathol*. 2009;36(7):753-759.
717. Bastian BC, Wesselmann U, Pinkel D, Leboit PE. Molecular cytogenetic analysis of Spitz nevi shows clear differences to melanoma. *J Invest Dermatol*. 1999;113(6):1065-1069.
718. Bastian BC, LeBoit PE, Pinkel D. Mutations and copy number increase of HRAS in Spitz nevi with distinctive histopathological features. *Am J Pathol*. 2000;157(3):967-972.
719. Gill M, Cohen J, Renwick N, et al. Genetic similarities between Spitz nevus and Spitzoid melanoma in children. *Cancer*. 2004;101(11):2636-2640.
720. Wiesner T, He J, Yelensky R, et al. Kinase fusions are frequent in Spitz tumours and spitzoid melanomas. *Nat Commun*. 2014;5:3116.
721. Yeh I, de la Fouchardiere A, Pissaloux D, et al. Clinical, histopathologic, and genomic features of Spitz tumors with ALK fusions. *Am J Surg Pathol*. 2015;39(5):581-591.
722. Harvell JD, Bastian BC, LeBoit PE. Persistent (recurrent) Spitz nevi: a histopathologic, immunohistochemical, and molecular pathologic study of 22 cases. *Am J Surg Pathol*. 2002;26(5):654-661.
723. Goldes J, Holmes S, Satz M, et al. Melanoma masquerading as Spitz nevus following acute lymphoblastic leukemia. *Pediatr Dermatol*. 1984;1(4):295-298.
724. Smith KJ, Barrett TL, Skelton HG 3rd, et al. Spindle cell and epithelioid cell nevi with atypia and metastasis (malignant Spitz nevus). *Am J Surg Pathol*. 1989;13(11):931-939.
725. Lee DA, Cohen JA, Twaddell WS, et al. Are all melanomas the same? Spitzoid melanoma is a distinct subtype of melanoma. *Cancer*. 2006;106(4):907-913.
726. Barnhill RL, Argenyi ZB, From L, et al. Atypical Spitz nevi/tumors: lack of consensus for diagnosis, discrimination from melanoma, and prediction of outcome. *Hum Pathol*. 1999;30(5):513-520.
727. Barnhill RL. The spitzoid lesion: the importance of atypical variants and risk assessment. *Am J Dermatopathol*. 2006;28(1):75-83.
728. Cerroni L, Barnhill R, Elder D, et al. Melanocytic tumors of uncertain malignant potential: results of a tutorial held at the XXIX Symposium of the International Society of Dermatopathology in Graz, October 2008. *Am J Surg Pathol*. 2010;34(3):314-326.
729. Lohmann CM, Coit DG, Brady MS, et al. Sentinel lymph node biopsy in patients with diagnostically controversial spitzoid melanocytic tumors. *Am J Surg Pathol*. 2002;26(1):47-55.
730. Su LD, Fullen DR, Sondak VK, et al. Sentinel lymph node biopsy for patients with problematic spitzoid melanocytic lesions: a report on 18 patients. *Cancer*. 2003;97(2):499-507.
731. Urso C, Borgognoni L, Saieva C, et al. Sentinel lymph node biopsy in patients with "atypical Spitz tumors." A report on 12 cases. *Hum Pathol*. 2006;37(7):816-823.
732. Gerami P, Scolyer RA, Xu X, et al. Risk assessment for atypical spitzoid melanocytic neoplasms using FISH to identify chromosomal copy number aberrations. *Am J Surg Pathol*. 2013;37(5):676-684.
733. Wiesner T, Murali R, Fried I, et al. A distinct subset of atypical Spitz tumors is characterized by BRAF mutation and loss of BAP1 expression. *Am J Surg Pathol*. 2012;36(6):818-830.
734. Rhodes AR, Silverman RA, Harrist TJ, Melski JW. A histologic comparison of congenital and acquired nevomelanocytic nevi. *Arch Dermatol*. 1985;121(10):1266-1273.
735. Silvers DN, Helwig EB. Melanocytic nevi in neonates. *J Am Acad Dermatol*. 1981;4(2):166-175.
736. Walsh MY, MacKie RM. Histological features of value in differentiating small congenital melanocytic naevi from acquired naevi. *Histopathology*. 1988;12(2):145-154.
737. Kaye VM, Dehner LP. Cutaneous glomus tumor. A comparative immunohistochemical study with pseudoangiomatous intradermal melanocytic nevi. *Am J Dermatopathol*. 1991;13(1):2-6.
738. Mancianti ML, Clark WH, Hayes FA, Herlyn M. Malignant melanoma simulants arising in congenital melanocytic nevi do not show experimental evidence for a malignant phenotype. *Am J Pathol*. 1990;136(4):817-829.
739. Herron MD, Vanderhooft SL, Smock K, et al. Proliferative nodules in congenital melanocytic nevi: a clinicopathologic and immunohistochemical analysis. *Am J Surg Pathol*. 2004;28(8):1017-1025.
740. Botet MV, Caro FR, Sanchez JL. Congenital acral melanocytic nevi clinically stimulating acral lentiginous melanoma. *J Am Acad Dermatol*. 1981;5(4):406-410.
741. Angelucci D, Natali PG, Amerio PL, et al. Rapid perinatal growth mimicking malignant transformation in a giant congenital melanocytic nevus. *Hum Pathol*. 1991;22(3):297-301.
742. Chung C, Forte AJ, Narayan D, Persing J. Giant nevi: a review. *J Craniofac Surg*. 2006;17(6):1210-1215.
743. Demian SD, Donnelly WH, Frias JL, Monif GR. Placental lesions in congenital giant pigmented nevi. *Am J Clin Pathol*. 1974;61(3):438-442.
744. Ruiz-Maldonado R, Tamayo L, Laterza AM, Duran C. Giant pigmented nevi: clinical, histopathologic, and therapeutic considerations. *J Pediatr*. 1992;120(6):906-911.
745. Jeanfils S, Tennstedt D, Lachapelle JM. Cerebriform intradermal nevus. A clinical pattern resembling cutis verticis gyrata. *Dermatology*. 1993;186(4):294-297.
746. Martinez-Barba E, Polo-Garcia LA, Ferri-Niguez B, et al. Congenital giant melanocytic nevus with pigmented epithelioid cells: a variant of epithelioid blue nevus. *Am J Dermatopathol*. 2002;24(1):30-35.
747. Kadonaga JN, Frieden IJ. Neurocutaneous melanosis: definition and review of the literature. *J Am Acad Dermatol*. 1991;24(5 Pt 1):747-755.
748. Slaughter JC, Hardman JM, Kempe LG, Earle KM. Neurocutaneous melanosis and leptomeningeal melanomatosis in children. *Arch Pathol*. 1969;88(3):298-304.
749. Cajaiba MM, Benjamin D, Halaban R, Reyes-Mugica M. Metastatic peritoneal neurocutaneous melanocytosis. *Am J Surg Pathol*. 2008;32(1):156-161.
750. Hendrickson MR, Ross JC. Neoplasms arising in congenital giant nevi: morphologic study of seven cases and a review of the literature. *Am J Surg Pathol*. 1981;5(2):109-135.
751. Pearson JP, Weiss SW, Headington JT. Cutaneous malignant melanotic neurocristic tumors arising in neurocristic hamartomas. A melanocytic tumor morphologically and biologically distinct from common melanoma. *Am J Surg Pathol*. 1996;20(6):665-677.
752. Reed WB, Becker SW Sr, Becker SW Jr, Nickel WR. Giant pigmented nevi, melanoma, and leptomeningeal melanocytosis: a clinical and histopathological study. *Arch Dermatol*. 1965;91:100-119.
753. Schmitt FC, Bittencourt A, Mendonca N, Dorea M. Rhabdomyosarcoma in a congenital pigmented nevus. *Pediatr Pathol*. 1992;12(1):93-98.
754. Roth MJ, Medeiros LJ, Kapur S, et al. Malignant schwannoma with melanocytic and neuroepithelial differentiation in an infant with congenital giant melanocytic nevus: a complex neurocristopathy. *Hum Pathol*. 1993;24(12):1371-1375.
755. Sangueza OP, Hyder DM, Bakke AC, White CR Jr. DNA determination in dysplastic nevi. A comparative study between flow cytometry and image analysis. *Am J Dermatopathol*. 1993;15(2):99-105.
756. Alper JC. Congenital nevi. The controversy rages on. *Arch Dermatol*. 1985;121(6):734-735.
757. Mark GJ, Mihm MC, Liteplo MG, et al. Congenital melanocytic nevi of the small and garment type. Clinical, histologic, and ultrastructural studies. *Human Pathol*. 1973;4(3):395-418.
758. Holman CD, Heenan PJ, Caruso V, et al. Seasonal variation in the junctional component of pigmented naevi. *Int J Cancer*. 1983;31(2):213-215.
759. Tronnier M, Wolff HH. UV-irradiated melanocytic nevi simulating melanoma in situ. *Am J Dermatopathol*. 1995;17(1):1-6.
760. Chan MP, Chan MM, Tahan SR. Superficial micronodules of pregnancy (SMOPs) and MIB-1 (Ki67) proliferation index in benign nevi excised during pregnancy. *Lab Invest*. 2009;89:101A.
761. Foucar E, Bentley TJ, Laube DW, Rosai J. A histopathologic evaluation of nevocellular nevi in pregnancy. *Arch Dermatol*. 1985;121(3):350-354.

762. Tucker SB, Horstmann JP, Hertel B, et al. Activation of nevi in patients with malignant melanoma. *Cancer*. 1980;46(4):822-827.
763. Kornberg R, Ackerman AB. Pseudomelanoma: recurrent melanocytic nevus following partial surgical removal. *Arch Dermatol*. 1975;111(12):1588-1590.
764. Smith KJ, Skelton HG, Heimer W, et al. Melanocytic activation in HIV-1 disease: HMB-45 staining in common acquired nevi. Military Medical Consortium for the Advancement of Retroviral Research. *J Am Acad Dermatol*. 1993;29(4):539-544.
765. Eady RA, Gilkes JJ, Jones EW. Eruptive naevi: report of two cases, with enzyme histochemical, light and electron microscopical findings. *Br J Dermatol*. 1977;97(3):267-278.
766. Cockerell CJ. A rational approach to the understanding and management of the dysplastic nevus syndrome concept. *Pathol Ann*. 1993;28(Pt 1):121-144.
767. Greene MH, Clark WH Jr, Tucker MA, et al. Acquired precursors of cutaneous malignant melanoma. The familial dysplastic nevus syndrome. *N Engl J Med*. 1985;312(2):91-97.
768. Lynch HT, Fusaro RM, Pester J, Lynch JF. Familial atypical multiple mole melanoma (FAMMM) syndrome: genetic heterogeneity and malignant melanoma. *Br J Cancer*. 1980;42(1):58-70.
769. McBride A, Rivers JK, Kopf AW, et al. Clinical features of dysplastic nevi. *Dermatol Clin*. 1991;9(4):717-722.
770. Tucker MA, Fraser MC, Goldstein AM, et al. A natural history of melanomas and dysplastic nevi: an atlas of lesions in melanoma-prone families. *Cancer*. 2002;94(12):3192-3209.
771. Brodell RT, Santa Cruz DJ. Borderline and atypical melanocytic lesions. *Semin Diagn Pathol*. 1985;2(1):63-86.
772. Elder DE, Clark WH Jr, Elenitsas R, et al. The early and intermediate precursor lesions of tumor progression in the melanocytic system: common acquired nevi and atypical (dysplastic) nevi. *Semin Diagn Pathol*. 1993;10(1):18-35.
773. Elder DE. Dysplastic naevi: an update. *Histopathology*. 2010;56(1):112-120.
774. Barnhill RL, Roush GC, Duray PH. Correlation of histologic architectural and cytoplasmic features with nuclear atypia in atypical (dysplastic) nevomelanocytic nevi. *Hum Pathol*. 1990;21(1):51-58.
775. Hastrup N, Clemmensen OJ, Spaun E, Sondergaard K. Dysplastic naevus: histological criteria and their inter-observer reproducibility. *Histopathology*. 1994;24(6):503-509.
776. Rivers JK, Cockerell CJ, McBride A, Kopf AW. Quantification of histologic features of dysplastic nevi. *Am J Dermatopathol*. 1990;12(1):42-50.
777. Smoller BR, Egbert BM. Dysplastic nevi can be diagnosed and graded reproducibly: a longitudinal study. *J Am Acad Dermatol*. 1992;27(3):399-402.
778. Arumi-Uria M, McNutt NS, Finnerty B. Grading of atypia in nevi: correlation with melanoma risk. *Mod Pathol*. 2003;16(8):764-771.
779. Black WC, Hunt WC. Histologic correlations with the clinical diagnosis of dysplastic nevus. *Am J Surg Pathol*. 1990;14(1): 44-52.
780. Peter RU, Worret WI, Nickolay-Kiesthardt J. Prevalence of dysplastic nevi in healthy young men. *Int J Dermatol*. 1992;31(5):327-330.
781. Rhodes AR, Seki Y, Fitzpatrick TB, Stern RS. Melanosomal alterations in dysplastic melanocytic nevi. A quantitative, ultrastructural investigation. *Cancer*. 1988;61(2):358-369.
782. Ackerman AB, Mihara I. Dysplasia, dysplastic melanocytes, dysplastic nevi, the dysplastic nevus syndrome, and the relation between dysplastic nevi and malignant melanomas. *Hum Pathol*. 1985;16(1):87-91.
783. Hussein MR, Wood GS. Molecular aspects of melanocytic dysplastic nevi. *J Mol Diagn*. 2002;4(2):71-80.
784. Roth ME, Grant-Kels JM, Ackerman AB, et al. The histopathology of dysplastic nevi. Continued controversy. *Am J Dermatopathol*. 1991;13(1):38-51.
785. Urso C. Atypical histologic features in melanocytic nevi. *Am J Dermatopathol*. 2000;22(5):391-396.
786. Wayte DM, Helwig EB. Halo nevi. *Cancer*. 1968;22(1):69-90.
787. Hashimoto K. Ultrastructural studies of halo nevus. *Cancer*. 1974;34(5):1653-1666.
788. Mooney MA, Barr RJ, Buxton MG. Halo nevus or halo phenomenon? A study of 142 cases. *J Cutan Pathol*. 1995;22(4):342-348.
789. Schrader WA, Helwig EB. Balloon cell nevi. *Cancer*. 1967;20(9):1502-1514.
790. Gardner WA Jr, Vazquez MD. Balloon cell melanoma. *Arch Pathol*. 1970;89(5):470-472.
791. Guzzo C, Johnson B, Honig P. Cockarde nevus: a case report and review of the literature. *Pediatr Dermatol*. 1988;5(4):250-253.
792. Seab JA Jr, Graham JH, Helwig EB. Deep penetrating nevus. *Am J Surg Pathol*. 1989;13(1):39-44.
793. Cooper PH. Deep penetrating (plexiform spindle cell) nevus. A frequent participant in combined nevus. *J Cutan Pathol*. 1992;19(3):172-180.
794. Mundth ED, Guralnick EA, Raker JW. Malignant melanoma: a clinical study of 427 cases. *Ann Surg*. 1965;162:15-28.
795. Wilson FC Jr, Anderson PC. A dissenting view on the prophylactic removal of plantar and palmar nevi. *Cancer*. 1961;14: 102-104.
796. Davis NC, Herron J, McLeod GR. The macroscopic appearance of malignant melanoma of the skin. *Med J Aust*. 1966;2(19):883-886.
797. Arrese Estrada J, Pierard-Franchimont C, Pierard GE. Histogenesis of recurrent nevus. *Am J Dermatopathol*. 1990;12(4):370-372.
798. Park HK, Leonard DD, Arrington JH 3rd, Lund HZ. Recurrent melanocytic nevi: clinical and histologic review of 175 cases. *J Am Acad Dermatol*. 1987;17(2 Pt 1): 285-292.
799. Sexton M, Sexton CW. Recurrent pigmented melanocytic nevus. A benign lesion, not to be mistaken for malignant melanoma. *Arch Pathol Lab Med*. 1991;115(2):122-126.
800. Cox AJ, Walton RG. The induction of junctional changes in pigmented nevi. *Arch Pathol*. 1965;79:428-434.
801. King R, Hayzen BA, Page RN, et al. Recurrent nevus phenomenon: a clinicopathologic study of 357 cases and histologic comparison with melanoma with regression. *Mod Pathol*. 2009;22(5):611-617.
802. Beer TW. Reexcision perineural invasion: a mimic of malignancy. *Am J Dermatopathol*. 2006;28(5):423-425.
803. Gilchrest BA, Eller MS, Geller AC, Yaar M. The pathogenesis of melanoma induced by ultraviolet radiation. *N Engl J Med*. 1999;340(17):1341-1348.
804. Miller AJ, Mihm MC Jr. Melanoma. *N Engl J Med*. 2006;355(1):51-65.
805. Gussack GS, Reintgen D, Cox E, et al. Cutaneous melanoma of the head and neck. A review of 399 cases. *Arch Otolaryngol*. 1983;109(12):803-808.
806. Urist MM, Balch CM, Soong SJ, et al. Head and neck melanoma in 534 clinical Stage I patients. A prognostic factors analysis and results of surgical treatment. *Ann Surg*. 1984;200(6):769-775.
807. Blessing K, Kernohan NM, Park KG. Subungual malignant melanoma: clinicopathological features of 100 cases. *Histopathology*. 1991;19(5):425-429.
808. Patterson RH, Helwig EB. Subungual malignant melanoma: a clinical-pathologic study. *Cancer*. 1980;46(9):2074-2087.
809. Takematsu H, Obata M, Tomita Y, et al. Subungual melanoma. A clinicopathologic study of 16 Japanese cases. *Cancer*. 1985;55(11):2725-2731.
810. Beral V, Evans S, Shaw H, Milton G. Cutaneous factors related to the risk of malignant melanoma. *Br J Dermatol*. 1983;109(2):165-172.
811. Bader JL, Li FP, Olmstead PM, et al. Childhood malignant melanoma. Incidence and etiology. *Am J Pediatr Hematol Oncol*. 1985;7(4):341-345.
812. Ceballos PI, Ruiz-Maldonado R, Mihm MC Jr. Melanoma in children. *N Engl J Med*. 1995;332(10):656-662.
813. Crotty KA, McCarthy SW, Palmer AA, et al. Malignant melanoma in childhood: a clinicopathologic study of 13 cases and comparison with Spitz nevi. *World J Surg*. 1992;16(2):179-185.
814. McCarthy SW, Crotty KA, Palmer AA, et al. Cutaneous malignant melanoma in teenagers. *Histopathology*. 1994;24(5):453-461.
815. Mones JM, Ackerman AB. Melanomas in prepubescent children: review comprehensively, critique historically, criteria diagnostically, and course biologically. *Am J Dermatopathol*. 2003;25(3):223-238.
816. Tate PS, Ronan SG, Feucht KA, et al. Melanoma in childhood and adolescence: clinical and pathological features of 48 cases. *J Pediatr Surg*. 1993;28(2):217-222.
817. Barnhill RL. Childhood melanoma. *Semin Diagn Pathol*. 1998;15(3):189-194.
818. Helwig EB *Malignant Melanoma in Children. Neoplasms of the Skin and Malignant Melanoma Proceedings of the 20th Annual Clinical Conferences on Cancer, Houston, Texas, 1975*. Chicago, IL: Year Book Medical Publishers; 1976:11-26.
819. Grob JJ, Gouvernet J, Aymar D, et al. Count of benign melanocytic nevi as a major indicator of risk for nonfamilial nodular and superficial spreading melanoma. *Cancer*. 1990;66(2):387-395.
820. Holly EA, Kelly JW, Shpall SN, Chiu SH. Number of melanocytic nevi as a major risk factor for malignant melanoma. *J Am Acad Dermatol*. 1987;17(3):459-468.
821. Swerdlow AJ, English J, MacKie RM, et al. Benign melanocytic naevi as a risk factor for malignant melanoma. *Br Med J*. 1986;292(6535):1555-1559.
822. Stokkel MP, Kroon BB, van der Sande JJ, Neering H. Malignant cutaneous melanoma associated with neurofibromatosis in two sisters from a family with familial atypical multiple mole melanoma syndrome. Case reports and review of the literature. *Cancer*. 1993;72(8):2370-2375.
823. Hollenbeak CS, Todd MM, Billingsley EM, et al. Increased incidence of melanoma in renal transplantation recipients. *Cancer*. 2005;104(9):1962-1967.
824. Whiteman DC, Olsen CM. Melanoma incidence and lethality is increased following solid organ transplantation. *J Invest Dermatol*. 2015;135(11):2560-2562.
825. Blackwood MA, Holmes R, Synnestvedt M, et al. Multiple primary melanoma revisited. *Cancer*. 2002;94(8):2248-2255.
826. Kang S, Barnhill RL, Mihm MC, Sober AJ. Multiple primary cutaneous melanomas. *Cancer*. 1992;70(7):1911-1916.

827. Moseley HS, Giuliano AE, Storm FK 3rd, et al. Multiple primary melanoma. *Cancer*. 1979;43(3):939-944.
828. Anderson DE, Smith JL Jr, McBride CM. Hereditary aspects of malignant melanoma. *JAMA*. 1967;200(9):741-746.
829. Carey WP Jr, Thompson CJ, Synnestvedt M, et al. Dysplastic nevi as a melanoma risk factor in patients with familial melanoma. *Cancer*. 1994;74(12):3118-3125.
830. Goldstein AM, Chidambaram A, Halpern A, et al. Rarity of CDK4 germline mutations in familial melanoma. *Melanoma Res*. 2002;12(1):51-55.
831. Goldstein AM. Familial melanoma, pancreatic cancer and germline CDKN2A mutations. *Hum Mutat*. 2004;23(6):630.
832. Holland EA, Schmid H, Kefford RF, Mann GJ. CDKN2A (P16(INK4a)) and CDK4 mutation analysis in 131 Australian melanoma probands: effect of family history and multiple primary melanomas. *Genes Chromosomes Cancer*. 1999;25(4):339-348.
833. Laud K, Marian C, Avril MF, et al. Comprehensive analysis of CDKN2A (p16INK4A/p14ARF) and CDKN2B genes in 53 melanoma index cases considered to be at heightened risk of melanoma. *J Med Genet*. 2006;43(1):39-47.
834. Meyle KD, Guldberg P. Genetic risk factors for melanoma. *Hum Genet*. 2009;126(4):499-510.
835. Soufir N, Avril MF, Chompret A, et al. Prevalence of p16 and CDK4 germline mutations in 48 melanoma-prone families in France. The French Familial Melanoma Study Group. *Hum Mol Genet*. 1998;7(2):209-216.
836. Wiesner T, Obenauf AC, Murali R, et al. Germline mutations in BAP1 predispose to melanocytic tumors. *Nat Genet*. 2011;43(10):1018-1021.
837. Carbone M, Ferris LK, Baumann F, et al. BAP1 cancer syndrome: malignant mesothelioma, uveal and cutaneous melanoma, and MBAITs. *J Transl Med*. 2012;10:179.
838. Gerami P, Yélamos O, Lee CY, et al. Multiple cutaneous melanomas and clinically atypical moles in a patient with a novel germline BAP1 mutation. *JAMA Dermatol*. 2015;151(11):1235-1239.
839. Hastrup N, Osterlind A, Drzewiecki KT, Hou-Jensen K. The presence of dysplastic nevus remnants in malignant melanomas. A population-based study of 551 malignant melanomas. *Am J Dermatopathol*. 1991;13(4):378-385.
840. Clark WH Jr, Elder DE, Van Horn M. The biologic forms of malignant melanoma. *Hum Pathol*. 1986;17(5):443-450.
841. Mihm MC Jr, Clark WH Jr, From L. The clinical diagnosis, classification and histogenetic concepts of the early stages of cutaneous malignant melanomas. *N Engl J Med*. 1971;284(19):1078-1082.
842. McGovern VJ. *Malignant Melanoma: Clinical and Histological Diagnosis*. New York, NY: Wiley; 1976.
843. McGovern VJ, Cochran AJ, Van der Esch EP, et al. The classification of malignant melanoma, its histological reporting and registration: a revision of the 1972 Sydney classification. *Pathology*. 1986;18(1):12-21.
844. Arrington JH III, Reed RJ, Ichinose H, Krementz ET. Plantar lentiginous melanoma: a distinctive variant of human cutaneous malignant melanoma. *Am J Surg Pathol*. 1977;1(2):131-143.
845. Ackerman AB, David KM. A unifying concept of malignant melanoma: biologic aspects. *Hum Pathol*. 1986;17(5):438-440.
846. Sondergaard K. Histological type and biological behavior of primary cutaneous malignant melanoma. 1. An analysis of 1916 cases. *Virchows Arch A Pathol Anat Histopathol*. 1983;401(3):315-331.
847. Mihm MC Jr, Fitzpatrick TB. Early detection of malignant melanoma. *Cancer*. 1976;37(1 suppl):597-603.
848. McGovern VJ. The nature of melanoma. A critical review. *J Cutan Pathol*. 1982;9(2):61-81.
849. Wayte DM, Helwig EB. Melanotic freckle of Hutchinson. *Cancer*. 1968;21(5):893-911.
850. Clark WH Jr, Mihm MC Jr. Lentigo maligna and lentigo-maligna melanoma. *Am J Pathol*. 1969;55(1):39-67.
851. Ferrara G, Zalaudek I, Argenziano G. Lentiginous melanoma: a distinctive clinicopathological entity. *Histopathology*. 2008;52(4):523-525.
852. King R, Page RN, Googe PB, Mihm MC Jr. Lentiginous melanoma: a histologic pattern of melanoma to be distinguished from lentiginous nevus. *Mod Pathol*. 2005;18(10):1397-1401.
853. Conley J, Lattes R, Orr W. Desmoplastic malignant melanoma (a rare variant of spindle cell melanoma). *Cancer*. 1971;28(4):914-936.
854. Labrecque PG, Hu CH, Winkelmann RK. On the nature of desmoplastic melanoma. *Cancer*. 1976;38(3):1205-1213.
855. Bruijn JA, Mihm MC Jr, Barnhill RL. Desmoplastic melanoma. *Histopathology*. 1992;20(3):197-205.
856. McLean DI, Lew RA, Sober AJ, et al. On the prognostic importance of white depressed areas in the primary lesion of superficial spreading melanoma. *Cancer*. 1979;43(1):157-161.
857. Manci EA, Balch CM, Murad TM, Soong SJ. Polypoid melanoma, a virulent variant of the nodular growth pattern. *Am J Clin Pathol*. 1981;75(6):810-815.
858. Krementz ET, Feed RJ, Coleman WP III, et al. Acral lentiginous melanoma. A clinicopathologic entity. *Ann Surg*. 1982;195(5):632-645.
859. Paladugu RR, Winberg CD, Yonemoto RH. Acral lentiginous melanoma. A clinicopathologic study of 36 patients. *Cancer*. 1983;52(1):161-168.
860. Kwon IH, Lee JH, Cho KH. Acral lentiginous melanoma in situ: a study of nine cases. *Am J Dermatopathol*. 2004;26(4):285-289.
861. Mishima Y, Nakanishi T. Acral lentiginous melanoma and its precursor—heterogeneity of palmo-plantar melanomas. *Pathology*. 1985;17(2):258-265.
862. Levene A. An experience of malignant melanoma. *Pathology*. 1985;17(2):266-270.
863. Barnhill RL, Mihm MC Jr. The histopathology of cutaneous malignant melanoma. *Semin Diagn Pathol*. 1993;10(1):47-75.
864. Banerjee SS, Harris M. Morphological and immunophenotypic variations in malignant melanoma. *Histopathology*. 2000;36(5):387-402.
865. Levene A. On the histological diagnosis and prognosis of malignant melanoma. *J Clin Pathol*. 1980;33(2):101-124.
866. Magro CM, Crowson AN, Mihm MC. Unusual variants of malignant melanoma. *Mod Pathol*. 2006;19(suppl 2):S41-S70.
867. Boyd AS, Wu H, Shyr Y. Monster cells in malignant melanoma. *Am J Dermatopathol*. 2005;27(3):208-210.
868. Hanson IM, Banerjee SS, Menasce LP, Prescott RJ. A study of eleven cutaneous malignant melanomas in adults with small-cell morphology: emphasis on diagnostic difficulties and unusual features. *Histopathology*. 2002;40(2):187-195.
869. al-Talib RK, Theaker JM. Signet-ring cell melanoma: light microscopic, immunohistochemical and ultrastructural features. *Histopathology*. 1991;18(6):572-575.
870. Sheibani K, Battifora H. Signet-ring cell melanoma. A rare morphologic variant of malignant melanoma. *Am J Surg Pathol*. 1988;12(1):28-34.
871. Abbott JJ, Amirkhan RH, Hoang MP. Malignant melanoma with a rhabdoid phenotype: histologic, immunohistochemical, and ultrastructural study of a case and review of the literature. *Arch Pathol Lab Med*. 2004;128(6): 686-688.
872. Borek BT, McKee PH, Freeman JA, et al. Primary malignant melanoma with rhabdoid features: a histologic and immunocytochemical study of three cases. *Am J Dermatopathol*. 1998;20(2):123-127.
873. Chang ES, Wick MR, Swanson PE, Dehner LP. Metastatic malignant melanoma with "rhabdoid" features. *Am J Clin Pathol*. 1994;102(4):426-431.
874. Jih DM, Morgan MB, Bass J, et al. Oncocytic metaplasia occurring in melanoma. *Semin Cutan Med Surg*. 2004;23(1):73-79.
875. Kao GF, Helwig EB, Graham JH. Balloon cell malignant melanoma of the skin. A clinicopathologic study of 34 cases with histochemical, immunohistochemical, and ultrastructural observations. *Cancer*. 1992;69(12):2942-2952.
876. Crowson AN, Magro CM, Mihm MC Jr. Malignant melanoma with prominent pigment synthesis: "animal type" melanoma—a clinical and histological study of six cases with a consideration of other melanocytic neoplasms with prominent pigment synthesis. *Hum Pathol*. 1999;30(5):543-550.
877. Antony FC, Sanclemente G, Shaikh H, et al. Pigment synthesizing melanoma (so-called animal type melanoma): a clinicopathological study of 14 cases of a poorly known distinctive variant of melanoma. *Histopathology*. 2006;48(6):754-762.
878. Mirzabeigi M, Guitart J, Gerami P. Primary cutaneous malignant melanoma with pseudorosettes features. An unusual morphological manifestation. *Am J Dermatopathol*. 2009;31(4):403-405.
879. Hantschke M, Mentzel T, Kutzner H. Follicular malignant melanoma: a variant of melanoma to be distinguished from lentigo maligna melanoma. *Am J Dermatopathol*. 2004;26(5):359-363.
880. Kacerovska D, Michal M, Sosna B, et al. Carcinoid-like pattern in melanoma: report of 4 cases. *Am J Dermatopathol*. 2009;31(6):542-550.
881. Kuehnl-Petzoldt C, Berger H, Wiebelt H. Verrucous-keratotic variations of malignant melanoma: a clinicopathological study. *Am J Dermatopathol*. 1982;4(5):403-410.
882. Nakhleh RE, Wick MR, Rocamora A, et al. Morphologic diversity in malignant melanomas. *Am J Clin Pathol*. 1990;93(6):731-740.
883. Wong TY, Suster S, Duncan LM, Mihm MC Jr. Nevoid melanoma: a clinicopathological study of seven cases of malignant melanoma mimicking spindle and epithelioid cell nevus and verrucous dermal nevus. *Hum Pathol*. 1995;26(2):171-179.
884. Zembowicz A, McCusker M, Chiarelli C, et al. Morphological analysis of nevoid melanoma: a study of 20 cases with a review of the literature. *Am J Dermatopathol*. 2001;23(3):167-175.
885. Hitchcock MG, McCalmont TH, White WL. Cutaneous melanoma with myxoid features: twelve cases with differential diagnosis. *Am J Surg Pathol*. 1999;23(12):1506-1513.
886. Urso C, Giannotti B, Bondi R. Myxoid melanoma of the skin. *Arch Pathol Lab Med*. 1990;114(5):527-528.

887. Al-Brahim N, Salama S. Malignant melanoma with osteoclast-like giant cells: an unusual host response: immunohistochemical and ultrastructural study of three cases and literature review. *Am J Dermatopathol*. 2005;27(2):126-129.
888. Daroca PJ, Reed RJ, Martin PC. Metastatic amelanotic melanoma simulating giant-cell tumor of bone. *Hum Pathol*. 1990;21(9):978-980.
889. Denton KJ, Stretch J, Athanasou N. Osteoclast-like giant cells in malignant melanoma. *Histopathology*. 1992;20(2):179-181.
890. Lee JS, Kossard S. Atypical fibroxanthoma-like melanoma with Touton-like giant cells. *Am J Dermatopathol*. 2007;29(5):480-481.
891. Banerjee SS, Eyden B. Divergent differentiation in malignant melanomas: a review. *Histopathology*. 2008;52(2): 119-129.
892. Gharpuray-Pandit D, Coyne J, Eyden B, Banerjee SS. Rhabdomyoblastic differentiation in malignant melanoma in adults: report of 2 cases. *Int J Surg Pathol*. 2007;15(1):20-25.
893. Lucas DR, Tazelaar HD, Unni KK, et al. Osteogenic melanoma. A rare variant of malignant melanoma. *Am J Surg Pathol*. 1993;17(4):400-409.
894. Nakagawa H, Imakado S, Nogita T, Ishibashi Y. Osteosarcomatous changes in malignant melanoma. Immunohistochemical and ultrastructural studies of a case. *Am J Dermatopathol*. 1990;12(2):162-168.
895. DiMaio SM, Mackay B, Smith JL Jr, Dickersin GR. Neurosarcomatous transformation in malignant melanoma: an ultrastructural study. *Cancer*. 1982;50(11):2345-2354.
896. Grayson W, Mare LR. Ganglioneuroblastic differentiation in a primary cutaneous malignant melanoma. *Am J Dermatopathol*. 2003;25(1):40-44.
897. Reed RJ, Leonard DD. Neurotropic melanoma. A variant of desmoplastic melanoma. *Am J Surg Pathol*. 1979;3(4):301-311.
898. King R, Busam K, Rosai J. Metastatic malignant melanoma resembling malignant peripheral nerve sheath tumor: report of 16 cases. *Am J Surg Pathol*. 1999;23(12):1499-1505.
899. Reiman HM, Goellner JR, Woods JE, Mixter RC. Desmoplastic melanoma of the head and neck. *Cancer*. 1987;60(9):2269-2274.
900. Kay PA, Pinheiro AD, Lohse CM, et al. Desmoplastic melanoma of the head and neck: histopathologic and immunohistochemical study of 28 cases. *Int J Surg Pathol*. 2004;12(1):17-24.
901. Kucher C, Zhang PJ, Pasha T, et al. Expression of Melan-A and Ki-67 in desmoplastic melanoma and desmoplastic nevi. *Am J Dermatopathol*. 2004;26(6):452-457.
902. Riccioni L, Di Tommaso L, Collina G. Actin-rich desmoplastic malignant melanoma: report of three cases. *Am J Dermatopathol*. 1999;21(6):537-541.
903. Busam KJ, Mujumdar U, Hummer AJ, et al. Cutaneous desmoplastic melanoma: reappraisal of morphologic heterogeneity and prognostic factors. *Am J Surg Pathol*. 2004;28(11):1518-1525.
904. Robson A, Allen P, Hollowood K. S100 expression in cutaneous scars: a potential diagnostic pitfall in the diagnosis of desmoplastic melanoma. *Histopathology*. 2001;38(2):135-140.
905. Kaneishi NK, Cockerell CJ. Histologic differentiation of desmoplastic melanoma from cicatrices. *Am J Dermatopathol*. 1998;20(2):128-134.
906. Carlson JA, Dickersin GR, Sober AJ, Barnhill RL. Desmoplastic neurotropic melanoma. A clinicopathologic analysis of 28 cases. *Cancer*. 1995;75(2):478-494.
907. Quinn MJ, Crotty KA, Thompson JF, et al. Desmoplastic and desmoplastic neurotropic melanoma: experience with 280 patients. *Cancer*. 1998;83(6):1128-1135.
908. Su LD, Fullen DR, Lowe L, et al. Desmoplastic and neurotropic melanoma. *Cancer*. 2004;100(3):598-604.
909. Warner TF, Lloyd RV, Hafez GR, Angevine JM. Immunocytochemistry of neurotropic melanoma. *Cancer*. 1984;53(2): 254-257.
910. Iwamoto S, Burrows RC, Agoff SN, et al. The p75 neurotrophin receptor, relative to other Schwann cell and melanoma markers, is abundantly expressed in spindled melanomas. *Am J Dermatopathol*. 2001;23(4):288-294.
911. Radfar A, Stefanato CM, Ghosn S, Bhawan J. NGFR-positive desmoplastic melanomas with focal or absent S-100 staining: further evidence supporting the use of both NGFR and S-100 as a primary immunohistochemical panel for the diagnosis of desmoplastic melanomas. *Am J Dermatopathol*. 2006;28(2):162-167.
912. Blessing K, Evans AT, al-Nafussi A. Verrucous naevoid and keratotic malignant melanoma: a clinico-pathological study of 20 cases. *Histopathology*. 1993;23(5):453-458.
913. Phillips ME, Margolis RJ, Merot Y, et al. The spectrum of minimal deviation melanoma: a clinicopathologic study of 21 cases. *Hum Pathol*. 1986;17(8):796-806.
914. Reed RJ, Webb SV, Clark WH Jr. Minimal deviation melanoma (halo nevus variant). *Am J Surg Pathol*. 1990;14(1):53-68.
915. Hantschke M, Mentzel T, Rutten A, et al. Cutaneous clear cell sarcoma: a clinicopathologic, immunohistochemical, and molecular analysis of 12 cases emphasizing its distinction from dermal melanoma. *Am J Surg Pathol*. 2010;34(2):216-222.
916. Amin B, Nehal KS, Jungbluth AA, et al. Histologic distinction between subungual lentigo and melanoma. *Am J Surg Pathol*. 2008;32(6):835-843.
917. Massi G, Vellone VG, Pagliarello C, Fabrizi G. Plantar melanoma that mimics melanocytic nevi: a report of 4 cases with lymph node metastases and with review of positive and negative controls. *Am J Dermatopathol*. 2009;31(2):117-131.
918. Tan KB, Moncrieff M, Thompson JF, et al. Subungual melanoma: a study of 124 cases highlighting features of early lesions, potential pitfalls in diagnosis, and guidelines for histologic reporting. *Am J Surg Pathol*. 2007;31(12):1902-1912.
919. Price NM, Rywlin AM, Ackerman AB. Histologic criteria for the diagnosis of superficial spreading malignant melanoma: formulated on the basis of proven metastatic lesions. *Cancer*. 1976;38(6):2434-2441.
920. Smoller BR. Histologic criteria for diagnosing primary cutaneous malignant melanoma. *Mod Pathol*. 2006;19(suppl 2):S34-S40.
921. Braun-Falco M, Friedrichson E, Ring J. Subepidermal cleft formation as a diagnostic marker for cutaneous malignant melanoma. *Hum Pathol*. 2005;36(4):412-415.
922. Mintzis MM, Silvers DN. Ultrastructural study of superficial spreading melanoma and benign simulants. *Cancer*. 1978;42(2):502-511.
923. Hunter JA, Zaynoun S, Paterson WD, et al. Cellular fine structure in the invasive nodules of different histogenetic types of malignant melanoma. *Br J Dermatol*. 1978;98(3):255-272.
924. de Wit NJ, van Muijen GN, Ruiter DJ. Immunohistochemistry in melanocytic proliferative lesions. *Histopathology*. 2004;44(6):517-541.
925. Yaziji H, Gown AM. Immunohistochemical markers of melanocytic tumors. *Int J Surg Pathol*. 2003;11(1):11-15.
926. Tacha D, Qi W, Ra S, et al. A newly developed mouse monoclonal SOX10 antibody is a highly sensitive and specific marker for malignant melanoma, including spindle cell and desmoplastic melanomas. *Arch Pathol Lab Med*. 2015;139(4):530-536.
927. Nakajima T, Watanabe S, Sato Y, et al. Immunohistochemical demonstration of S100 protein in malignant melanoma and pigmented nevus, and its diagnostic application. *Cancer*. 1982;50(5):912-918.
928. Springall D, Gu J, Cocchia D, et al. The value of S-100 immunostaining as a diagnostic tool in human malignant melanomas. *Vichows Arch A Pathol Anat Histopathol*. 1983;400(3):331-343.
929. Argenyi ZB, Cain C, Bromley C, et al. S-100 protein-negative malignant melanoma: fact or fiction? A light-microscopic and immunohistochemical study. *Am J Dermatopathol*. 1994;16(3):233-240.
930. Aisner DL, Maker A, Rosenberg SA, Berman DM. Loss of S100 antigenicity in metastatic melanoma. *Hum Pathol*. 2005;36(9):1016-1019.
931. Plaza JA, Suster D, Perez-Montiel D. Expression of immunohistochemical markers in primary and metastatic malignant melanoma: a comparative study in 70 patients using a tissue microarray technique. *Appl Immunohistochem Mol Morphol*. 2007;15(4):421-425.
932. Zubovits J, Buzney E, Yu L, Duncan LM. HMB-45, S-100, NK1/C3, and MART-1 in metastatic melanoma. *Hum Pathol*. 2004;35(2):217-223.
933. Colombari R, Bonetti F, Zamboni G, et al. Distribution of melanoma specific antibody (HMB-45) in benign and malignant melanocytic tumours. An immunohistochemical study on paraffin sections. *Virchows Arch A Pathol Anat Histopathol*. 1988;413(1):17-24.
934. Kapur RP, Bigler SA, Skelly M, Gown AM. Anti-melanoma monoclonal antibody HMB45 identifies an oncofetal glycoconjugate associated with immature melanosomes. *J Histochem Cytochem*. 1992;40(2):207-212.
935. Schaumburg-Lever G, Metzler G, Kaiserling E. Ultrastructural localization of HMB-45 binding sites. *J Cutan Pathol*. 1991;18(6):432-435.
936. Wagner SN, Wagner C, Hofler H, et al. Expression cloning of the cDNA encoding a melanoma-associated Ag recognized by mAb HMB-45. Identification as melanocyte-specific Pmel 17 cDNA. *Lab Invest*. 1995;73(2):229-235.
937. Adema GJ, de Boer AJ, van't Hullenaar R, et al. Melanocyte lineage-specific antigens recognized by monoclonal antibodies NKI-beteb, HMB-50, and HMB-45 are encoded by a single cDNA. *Am J Pathol*. 1993;143(6):1579-1585.
938. Guo J, Cheng L, Wen DR, et al. Detection of tyrosinase mRNA in formalin-fixed, paraffin-embedded archival sections of melanoma, using the reverse transcriptase in situ polymerase chain reaction. *Diagn Mol Pathol*. 1998;7(1):10-15.
939. Hofbauer GF, Kamarashev J, Geertsen R, et al. Tyrosinase immunoreactivity in formalin-fixed, paraffin-embedded primary and metastatic melanoma: frequency and distribution. *J Cutan Pathol*. 1998;25(4):204-209.
940. Granter SR, Weilbaecher KN, Quigley C, et al. Microphthalmia transcription factor: not a

sensitive or specific marker for the diagnosis of desmoplastic melanoma and spindle cell (non-desmoplastic) melanoma. *Am J Dermatopathol*. 2001;23(3):185-189.
941. Busam KJ, Kucukgol D, Sato E, et al. Immunohistochemical analysis of novel monoclonal antibody PNL2 and comparison with other melanocyte differentiation markers. *Am J Surg Pathol*. 2005;29(3):400-406.
942. Reinke S, Königer P, Herberth G, et al. Differential expression of MART-1, tyrosinase, and SM5-1 in primary and metastatic melanoma. *Am J Dermatopathol*. 2005;27(5):401-406.
943. Gajjar NA, Cochran AJ, Binder SW. Is MAGE-1 expression in metastatic malignant melanomas really helpful? *Am J Surg Pathol*. 2004;28(7):883-888.
944. Kazakov DV, Kutzner H, Rutten A, et al. The anti-MAGE antibody B57 as a diagnostic marker in melanocytic lesions. *Am J Dermatopathol*. 2004;26(2):102-107.
945. Nakanishi T, Hashimoto K. The differential reactivity of benign and malignant nevomelanocytic lesions with mouse monoclonal antibody TNKH1. *Cancer*. 1987;59(7):1340-1344.
946. Vennegoor C, Hageman P, Van Nouhuijs H, et al. A monoclonal antibody specific for cells of the melanocyte lineage. *Am J Pathol*. 1988;130(1):179-192.
947. Wilsher M, Cheerala B. WT1 as a complementary marker of malignant melanoma: an immunohistochemical study of whole sections. *Histopathology*. 2007;51(5):605-610.
948. Miettinen M, Franssila K. Immunohistochemical spectrum of malignant melanoma. The common presence of keratins. *Lab Invest*. 1989;61(6):623-628.
949. Zarbo RJ, Gown AM, Nagle RB, et al. Anomalous cytokeratin expression in malignant melanoma: one- and two-dimensional western blot analysis and immunohistochemical survey of 100 melanomas. *Mod Pathol*. 1990;3(4):494-501.
950. Selby WL, Nance KV, Park HK. CEA immunoreactivity in metastatic malignant melanoma. *Mod Pathol*. 1992;5(4):415-419.
951. Leader M, Patel J, Collins M, Henry K. Anti-alpha 1-antichymotrypsin staining of 194 sarcomas, 38 carcinomas, and 17 malignant melanomas. Its lack of specificity as a tumour marker. *Am J Pathol*. 1987;11(2):133-139.
952. Facchetti F, Bertalot G, Grigolato PG. KP1 (CD 68) staining of malignant melanomas. *Histopathology*. 1991;19(2):141-145.
953. Bhuta S. Electron microscopy in the evaluation of melanocytic tumors. *Semin Diagn Pathol*. 1993;10(1):92-101.
954. Erlandson RA. Ultrastructural diagnosis of amelanotic malignant melanoma: aberrant melanosomes, myelin figures or lysosomes? *Ultrastruct Pathol*. 1987;11(2-3):191-208.
955. Mazur MT, Katzenstein AL. Metastatic melanoma: the spectrum of ultrastructural morphology. *Ultrastruct Pathol*. 1980;1(3):337-356.
956. Herrera GA, Turbat-Herrera EA. Current role of electron microscopy in the diagnosis of pigmented tumors. *Semin Diagn Pathol*. 2003;20(1):60-71.
957. Bastian BC, Olshen AB, LeBoit PE, Pinkel D. Classifying melanocytic tumors based on DNA copy number changes. *Am J Pathol*. 2003;163(5):1765-1770.
958. Dahl C, Guldberg P. The genome and epigenome of malignant melanoma. *APMIS*. 2007;115(10):1161-1176.
959. Singh M, Lin J, Hocker TL, Tsao H. Genetics of melanoma tumorigenesis. *Br J Dermatol*. 2008;158(1):15-21.
960. Blokx WA, van Dijk MC, Ruiter DJ. Molecular cytogenetics of cutaneous melanocytic lesions—diagnostic, prognostic and therapeutic aspects. *Histopathology*. 2010;56(1):121-132.
961. van Dijk MC, Bernsen MR, Ruiter DJ. Analysis of mutations in B-RAF, N-RAS, and H-RAS genes in the differential diagnosis of Spitz nevus and spitzoid melanoma. *Am J Surg Pathol*. 2005;29(9):1145-1151.
962. Beadling C, Jacobson-Dunlop E, Hodi FS, et al. KIT gene mutations and copy number in melanoma subtypes. *Clin Cancer Res*. 2008;14(21):6821-6828.
963. Curtin JA, Busam K, Pinkel D, Bastian BC. Somatic activation of KIT in distinct subtypes of melanoma. *J Clin Oncol*. 2006;24(26):4340-4346.
964. Sullivan RJ. The role of mitogen-activated protein targeting in melanoma beyond BRAFV600. *Curr Opin Oncol*. 2016;28(2):185-191.
965. Cachia AR, Indsto JO, McLaren KM, et al. CDKN2A mutation and deletion status in thin and thick primary melanoma. *Clin Cancer Res*. 2000;6(9):3511-3515.
966. Flores JF, Walker GJ, Glendening JM, et al. Loss of the p16INK4a and p15INK4b genes, as well as neighboring 9p21 markers, in sporadic melanoma. *Cancer Res*. 1996;56(21):5023-5032.
967. Gonzalgo ML, Bender CM, You EH, et al. Low frequency of p16/CDKN2A methylation in sporadic melanoma: comparative approaches for methylation analysis of primary tumors. *Cancer Res*. 1997;57(23):5336-5347.
968. Kumar R, Smeds J, Lundh Rozell B, Hemminki K. Loss of heterozygosity at chromosome 9p21 (INK4-p14ARF locus): homozygous deletions and mutations in the p16 and p14ARF genes in sporadic primary melanomas. *Melanoma Res*. 1999;9(2):138-147.
969. Heidenreich B, Nagore E, Rachakonda PS, et al. Telomerase reverse transcriptase promoter mutations in primary cutaneous melanoma. *Nat Commun*. 2014;5:3401.
970. Macerola E, Loggini B, Giannini R, et al. Coexistence of TERT promoter and BRAF mutations in cutaneous melanoma is associated with more clinicopathological features of aggressiveness. *Virchows Arch*. 2015;467(2):177-184.
971. Dalton SR, Gerami P, Kolaitis NA, et al. Use of fluorescence in situ hybridization (FISH) to distinguish intranodal nevus from metastatic melanoma. *Am J Surg Pathol*. 2010;34(2):231-237.
972. Gerami P, Jewell SS, Morrison LE, et al. Fluorescence in situ hybridization (FISH) as an ancillary diagnostic tool in the diagnosis of melanoma. *Am J Surg Pathol*. 2009;33(8):1146-1156.
973. Gerami P, Wass A, Mafee M, et al. Fluorescence in situ hybridization for distinguishing nevoid melanomas from mitotically active nevi. *Am J Surg Pathol*. 2009;33(12):1783-1788.
974. Gerami P, Li G, Pouryazdanparast P, et al. A highly specific and discriminatory FISH assay for distinguishing between benign and malignant melanocytic neoplasms. *Am J Surg Pathol*. 2012;36(6):808-817.
975. Gaiser T, Kutzner H, Palmedo G, et al. Classifying ambiguous melanocytic lesions with FISH and correlation with clinical long-term follow up. *Mod Pathol*. 2010;23(3):413-419.
976. Clarke LE, Warf BM, Flake DD 2nd, et al. Clinical validation of a gene expression signature that differentiates benign nevi from malignant melanoma. *J Cutan Pathol*. 2015;42(4):244-252.
977. Swanson NA, Lee KK, Gorman A, Lee HN. Biopsy techniques. Diagnosis of melanoma. *Dermatol Clin*. 2002;20(4):677-680.
978. Epstein E, Bragg K, Linden G. Biopsy and prognosis of malignant melanoma. *JAMA*. 1969;208(8):1369-1371.
979. Lees VC, Briggs JC. Effect of initial biopsy procedure on prognosis in Stage 1 invasive cutaneous malignant melanoma: review of 1086 patients. *Br J Surg*. 1991;78(9):1108-1110.
980. Braun-Falco O, Korting HC, Konz B. Histological and cytological criteria in the diagnosis of malignant melanomas by cryostat sections. *Virchows Arch A Pathol Anat Histol*. 1981;393(1):115-121.
981. Little JH, Davis NC. Frozen section diagnosis of suspected malignant melanoma of the skin. *Cancer*. 1974;34(4):1163-1172.
982. Shafir R, Hiss J, Tsur H, Bubis JJ. Pitfalls in frozen section diagnosis of malignant melanoma. *Cancer*. 1983;51(6):1168-1170.
983. Zitelli JA, Moy RL, Abell E. The reliability of frozen sections in the evaluation of surgical margins for melanoma. *J Am Acad Dermatol*. 1991;24(1):102-106.
984. Avril MF, Charpentier P, Margulis A, Guillaume JC. Regression of primary melanoma with metastases. *Cancer*. 1992;69(6):1377-1381.
985. Emanuel PO, Mannion M, Phelps RG. Complete regression of primary malignant melanoma. *Am J Dermatopathol*. 2008;30(2):178-181.
986. Smith JL Jr, Stehlin JS Jr. Spontaneous regression of primary malignant melanomas with regional metastases. *Cancer*. 1965;18(11):1399-1415.
987. Blessing K, McLaren KM, McLean A, Davidson P. Thin malignant melanomas (<1.5 mm) with metastasis. A histological study and survival analysis. *Histopathology*. 1990;17:397-400.
988. Gromet MA, Epstein WL, Blois MS. The regressing thin malignant melanoma: a distinctive lesion with metastatic potential. *Cancer*. 1978;42(5):2282-2292.
989. Anbari KK, Schuchter LM, Bucky LP, et al. Melanoma of unknown primary site: presentation, treatment, and prognosis—a single institution study. University of Pennsylvania Pigmented Lesion Study Group. *Cancer*. 1997;79(9):1816-1821.
990. Chang P, Knapper WH. Metastatic melanoma of unknown primary. *Cancer*. 1982;49(6):1106-1111.
991. McGovern VJ. Spontaneous regression of melanoma. *Pathology*. 1975;7(2):91-99.
992. Cook MG, Robertson I. Melanocytic dysplasia and melanoma. *Histopathology*. 1985;9(6):647-658.
993. McGovern VJ, Shaw HM, Milton GW. Histogenesis of malignant melanoma with an adjacent component of the superficial spreading type. *Pathology*. 1985;17(2):251-254.
994. Ackerman AB. Malignant melanoma in situ: the flat, curable stage of malignant melanoma. *Pathology*. 1985;17(2):298-300.
995. Everett MA. Early melanoma. Histologic terms. *J Cutan Pathol*. 1991;18:477-479.
996. Dubow BE, Ackerman AB. Ideas in pathology. Malignant melanoma in situ: the evolution of a concept. *Mod Pathol*. 1990;3(6): 734-744.
997. Kossard S, Commens C, Symons M, Doyle J. Lentinginous dysplastic naevi in the elderly: a potential precursor for malignant melanoma. *Australas J Dermatol*. 1991;32(1):27-37.
998. Rywlin AM. Intraepithelial melanocytic neoplasia (IMN) versus intraepithelial atypical melanocytic proliferation (IAMP). *Am J Dermatopathol*. 1988;10(1):92-93.

999. Adair C, Ro JY, Sahin AA, et al. Malignant melanoma metastatic to gastrointestinal tract: a clinicopathologic study. *Int J Surg Pathol*. 1994;2(1):3-9.
1000. Di Tommaso L, Rahal D, Bresciani G, Roncalli M. Cutaneous melanoma metastatic to uterine adenomyoma: report of a case. *Int J Surg Pathol*. 2005;13(2):223-225.
1001. Gibbs P, Cebon JS, Calafiore P, Robinson WA. Cardiac metastases from malignant melanoma. *Cancer*. 1999;85(1):78-84.
1002. de la Monte SM, Moore GW, Hutchins GM. Patterned distribution of metastases from malignant melanoma in humans. *Cancer Res*. 1983;43(7):3427-3433.
1003. Roses DF, Harris MN, Rigel D, et al. Local and in-transit metastases following definitive excision for primary cutaneous malignant melanoma. *Ann Surg*. 1983;198(1):65-69.
1004. Plaza JA, Torres-Cabala C, Evans H, et al. Cutaneous metastases of malignant melanoma: a clinicopathologic study of 192 cases with emphasis on the morphologic spectrum. *Am J Dermatopathol*. 2010;32(2):129-136.
1005. Kornberg R, Harris M, Ackerman AB. Epidermotropically metastatic malignant melanoma. Differentiating malignant melanoma metastatic to the epidermis from malignant melanoma primary in the epidermis. *Arch Dermatol*. 1978;114(1): 67-69.
1006. Abernethy JL, Soyer HP, Kerl H, et al. Epidermotropic metastatic malignant melanoma simulating melanoma in situ. A report of 10 examples from two patients. *Am J Surg Pathol*. 1994;18(11):1140-1149.
1007. Meije CB, Swart GW, Lepoole C, et al. Antigenic profiles of individual-matched pairs of primary and melanoma metastases. *Hum Pathol*. 2009;40(10):1399-1407.
1008. Steiner A, Wolf C, Pehamberger H, Wolff K. Late metastases of cutaneous malignant melanoma. *Br J Dermatol*. 1986;114(6):737-740.
1009. Massi D, Brusa D, Merelli B, et al. PD-L1 marks a subset of melanomas with a shorter overall survival and distinct genetic and morphological characteristics. *Ann Oncol*. 2014;25(12):2433-2442.
1010. Oba J, Nakahara T, Abe T, et al. Expression of programmed death receptor ligand 1 in melanoma may indicate tumor progression and poor patient survival. *J Am Acad Dermatol*. 2014;70(5):954-956.
1011. Robert C, Long GV, Brady B, et al. Nivolumab in previously untreated melanoma without BRAF mutation. *N Engl J Med*. 2015;372(4):320-330.
1012. Larkin J, Chiarion-Sileni V, Gonzalez R, et al. Combined nivolumab and ipilimumab or monotherapy in untreated melanoma. *N Engl J Med*. 2015;373(1):23-34.
1013. Márquez-Rodas I, Cerezuela P, Soria A, et al. Immune checkpoint inhibitors: therapeutic advances in melanoma. *Ann Transl Med*. 2015;3(18):267.
1014. Singh BP, Salama AK. Updates in therapy for advanced melanoma. *Cancers (Basel)*. 2016;8(1):E17.
1015. Gennari R, Bartolomei M, Testori A, et al. Sentinel node localization in primary melanoma: preoperative dynamic lymphoscintigraphy, intraoperative gamma probe, and vital dye guidance. *Surgery*. 2000;127(1):19-25.
1016. Morton DL. Lymphatic mapping and sentinel lymphadenectomy for melanoma: past, present, and future. *Ann Surg Oncol*. 2001;8(9 suppl):22s-28s.
1017. Cochran AJ, Wen DR, Huang RR, et al. Prediction of metastatic melanoma in nonsentinel nodes and clinical outcome based on the primary melanoma and the sentinel node. *Mod Pathol*. 2004;17(7):747-755.
1018. Scolyer RA, Li LX, McCarthy SW, et al. Micromorphometric features of positive sentinel lymph nodes predict involvement of nonsentinel nodes in patients with melanoma. *Am J Dermatopathol*. 2004;122(4):532-539.
1019. Medalie NS, Ackerman AB. Sentinel lymph node biopsy has no benefit for patients with primary cutaneous melanoma metastatic to a lymph node: an assertion based on comprehensive, critical analysis: part I. *Am J Dermatopathol*. 2003;25(5):399-417.
1020. Balch CM, Morton DL, Gershenwald JE, et al. Sentinel node biopsy and standard of care for melanoma. *J Am Acad Dermatol*. 2009;60(5):872-875.
1021. Gershenwald JE, Thompson W, Mansfield PF, et al. Multi-institutional melanoma lymphatic mapping experience: the prognostic value of sentinel lymph node status in 612 stage I or II melanoma patients. *J Clin Oncol*. 1999;17(3):976-983.
1022. Kanzler MH. Sentinel node biopsy and standard of care for melanoma: a re-evaluation of the evidence. *J Am Acad Dermatol*. 2010;62(5):880-884.
1023. Piris A, Mihm MC Jr, Duncan LM. AJCC melanoma staging update: impact on dermatopathology practice and patient management. *J Cutan Pathol*. 2011;38(5):394-400.
1024. Czerniecki BJ, Bedrosian I, Faries M, Alavi A. Revolutionary impact of lymphoscintigraphy and intraoperative sentinel node mapping in the clinical practice of oncology. *Semin Nucl Med*. 2001;31(2):158-164.
1025. Prieto VG. Use of frozen sections in the examination of sentinel lymph nodes in patients with melanoma. *Semin Diagn Pathol*. 2008;25(2):112-115.
1026. Hauschild A, Christophers E. Sentinel node biopsy in melanoma. *Virchows Arch*. 2001;438(2):99-106.
1027. Lawrence WD. Association of Directors of Anatomic and Surgical Pathology. ADASP recommendations for processing and reporting of lymph node specimens submitted for evaluation of metastatic disease. *Virchows Arch*. 2001;439(5): 601-603.
1028. Prieto VG, Clark SH. Processing of sentinel lymph nodes for detection of metastatic melanoma. *Ann Diagn Pathol*. 2002;6(4):257-264.
1029. Spanknebel K, Coit DG, Bieligk SC, et al. Characterization of micrometastatic disease in melanoma sentinel lymph nodes by enhanced pathology: recommendations for standardizing pathologic analysis. *Am J Surg Pathol*. 2005;29(3):305-317.
1030. Scolyer RA, Murali R, McCarthy SW, Thompson JF. Pathologic examination of sentinel lymph nodes from melanoma patients. *Semin Diagn Pathol*. 2008;25(2):100-111.
1031. Baisden BL, Askin FB, Lange JR, Westra WH. HMB-45 immunohistochemical staining of sentinel lymph nodes: a specific method for enhancing detection of micrometastases in patients with melanoma. *Am J Surg Pathol*. 2000;24(8):1140-1146.
1032. Riber-Hansen R, Nyengaard JR, Hamilton-Dutoit SJ, Steiniche T. The nodal location of metastases in melanoma sentinel lymph nodes. *Am J Surg Pathol*. 2009;33(10):1522-1528.
1033. Bostick PJ, Morton DL, Turner RR, et al. Prognostic significance of occult metastases detected by sentinel lymphadenectomy and reverse transcriptase-polymerase chain reaction in early-stage melanoma patients. *J Clin Oncol*. 1999;17(10):3238-3244.
1034. Gutzmer R, Kaspari M, Brodersen JP, et al. Specificity of tyrosinase and HMB45 PCR in the detection of melanoma metastases in sentinel lymph node biopsies. *Histopathology*. 2002;41(6):510-518.
1035. Brennick JB, Yan S. False-positive cells in sentinel lymph nodes. *Semin Diagn Pathol*. 2008;25(2):116-119.
1036. Biddle DA, Evans HL, Kemp BL, et al. Intraparenchymal nevus cell aggregates in lymph nodes: a possible diagnostic pitfall with malignant melanoma and carcinoma. *Am J Surg Pathol*. 2003;27(5):673-681.
1037. Lohmann CM, Iversen K, Jungbluth AA, et al. Expression of melanocyte differentiation antigens and ki-67 in nodal nevi and comparison of ki-67 expression with metastatic melanoma. *Am J Surg Pathol*. 2002;26(10):1351-1357.
1038. Mentrikoski MJ, Ma L, Pryor JG, et al. Diagnostic utility of IMP3 in segregating metastatic melanoma from benign nevi in lymph nodes. *Mod Pathol*. 2009;22(12):1582-1587.
1039. Pernick NL, DaSilva M, Gangi MD, et al. "Histiocytic markers" in melanoma. *Mod Pathol*. 1999;12(11):1072-1077.
1040. Groisman GM, Amar M, Schafer I. The histiocytic marker PG-M1 is helpful in differentiating histiocytes and histiocytic tumors from melanomas. *Appl Immunohistochem Mol Morphol*. 2002;10(3):205-209.
1041. Willis BC, Johnson G, Wang J, Cohen C. SOX10: a useful marker for identifying metastatic melanoma in sentinel lymph nodes. *Appl Immunohistochem Mol Morphol*. 2015;23(2):109-112.
1042. Tsao H, Atkins MB, Sober AJ. Management of cutaneous melanoma. *N Engl J Med*. 2004;351(10):998-1012.
1043. Aitken DR, Clausen K, Klein JP, James AG. The extent of primary melanoma excision. A re-evaluation—how wide is wide? *Ann Surg*. 1983;198(5):634-641.
1044. Kelly JW, Sagebiel RW, Calderon W, et al. The frequency of local recurrence and microsatellites as a guide to reexcision margins for cutaneous malignant melanoma. *Ann Surg*. 1984;200(6):759-763.
1045. Khayat D, Rixe O, Martin G, et al. Surgical margins in cutaneous melanoma (2 cm versus 5 cm for lesions measuring less than 2.1-mm thick). *Cancer*. 2003;97(8):1941-1946.
1046. Landthaler M, Braun-Falco O, Leitl A, et al. Excisional biopsy as the first therapeutic procedure versus primary wide excision of malignant melanoma. *Cancer*. 1989;64(8):1612-1616.
1047. Balch CM, Murad TM, Soong SJ, et al. Tumor thickness as a guide to surgical management of clinical stage I melanoma patients. *Cancer*. 1979;43(3):883-888.
1048. Ackerman AB, Scheiner AM. How wide and deep is wide and deep enough? A critique of surgical practice in excisions of primary cutaneous malignant melanoma. *Hum Pathol*. 1983;14(9):743-744.
1049. Cosimi AB, Sober AJ, Mihm MC, Fitzpatrick TB. Conservative surgical management of superficially invasive cutaneous melanoma. *Cancer*. 1984;53(6):1256-1259.
1050. Heenan PJ, English DR, Holman CD, Armstrong BK. The effects of surgical treatment on survival and local recurrence of cutaneous malignant melanoma. *Cancer*. 1992;69(2):421-426.
1051. Urist MM, Balch CM, Soong S, et al. The influence of surgical margins and prognostic factors predicting the risk of local recurrence in 3445 patients with primary cutaneous melanoma. *Cancer*. 1985;55(6): 1398-1402.

1052. Balch CM, Urist MM, Karakousis CP, et al. Efficacy of 2-cm surgical margins for intermediate-thickness melanomas (1 to 4 mm). Results of a multi-institutional randomized surgical trial. *Ann Surg*. 1993;218(3):262-267, discussion 7-9.
1053. Thomas JM, Newton-Bishop J, A'Hern R, et al. Excision margins in high-risk malignant melanoma. *N Engl J Med*. 2004;350(8):757-766.
1054. Cochran AJ, Wen DR, Morton DL. Occult tumor cells in the lymph nodes of patients with pathological stage I malignant melanoma. An immunohistological study. *Am J Surg Pathol*. 1988;12(8):612-618.
1055. Elder DE, Guerry D 4th, VanHorn M, et al. The role of lymph node dissection for clinical stage I malignant melanoma of intermediate thickness (1.51-3.99 mm). *Cancer*. 1985;56(2):413-418.
1056. Sim FH, Taylor WF, Ivins JC, et al. A prospective randomized study of the efficacy of routine elective lymphadenectomy in management of malignant melanoma. Preliminary results. *Cancer*. 1978;41(3):948-956.
1057. Sim FH, Taylor WF, Pritchard DJ, Soule EH. Lymphadenectomy in the management of stage I malignant melanoma: a prospective randomized study. *Mayo Clin Proc*. 1986;61(9):697-705.
1058. Veronesi U, Adamus J, Aubert C, et al. A randomized trial of adjuvant chemotherapy and immunotherapy in cutaneous melanoma. *N Engl J Med*. 1982;307(15):913-916.
1059. Veronesi U, Adamus J, Bandiera DC, et al. Stage I melanoma of the limbs. Immediate versus delayed node dissection. *Tumori*. 1980;66(3):373-396.
1060. Veronesi U, Adamus J, Bandiera DC, et al. Delayed regional lymph node dissection in stage I melanoma of the skin of the lower extremities. *Cancer*. 1982;49(11):2420-2430.
1061. Swetter SM, Chen FW, Kim DD, Egbert BM. Imiquimod 5% cream as primary or adjuvant therapy for melanoma in situ, lentigo maligna type. *J Am Acad Dermatol*. 2015;72(6):1047-1053.
1062. Garbe C, Eigentler TK. Diagnosis and treatment of cutaneous melanoma: state of the art 2006. *Melanoma Res*. 2007;17(2):117-127.
1063. Nashan D, Muller ML, Grabbe S, et al. Systemic therapy of disseminated malignant melanoma: an evidence-based overview of the state-of-the-art in daily routine. *J Eur Acad Dermatol Venereol*. 2007;21(10):1305-1318.
1064. Olszanski AJ. Current and future roles of targeted therapy and immunotherapy in advanced melanoma. *J Manag Care Spec Pharm*. 2014;20(4):346-356.
1065. Zhu Z, Liu W, Gotlieb V. The rapidly evolving therapies for advanced melanoma—towards immunotherapy, molecular targeted therapy, and beyond. *Crit Rev Oncol Hematol*. 2015;99:91-99.
1066. Magnus K. Prognosis in malignant melanoma of the skin. Significance of stage of disease, anatomical site, sex, age and period of diagnosis. *Cancer*. 1977;40(1):389-397.
1067. Garbe C, Buttner P, Bertz J, et al. Primary cutaneous melanoma. Identification of prognostic groups and estimation of individual prognosis for 5093 patients. *Cancer*. 1995;75(10):2484-2491.
1068. Wick MR. Prognostic factors for cutaneous melanoma. *Am J Clin Pathol*. 1998;110(6):713-718.
1069. Balch CM, Soong SJ, Gershenwald JE, et al. Prognostic factors analysis of 17,600 melanoma patients: validation of the American Joint Committee on Cancer melanoma staging system. *J Clin Oncol*. 2001;19(16):3622-3634.
1070. Clark WH Jr, From L, Bernardino EA, Mihm MC. The histogenesis and biologic behavior of primary human malignant melanomas of the skin. *Cancer Res*. 1969;29(3):705-727.
1071. Breslow A. Tumor thickness, level of invasion and node dissection in stage I cutaneous melanoma. *Ann Surg*. 1975;182(5):572-575.
1072. Breslow A. Thickness, cross-sectional areas and depth of invasion in the prognosis of cutaneous melanoma. *Ann Surg*. 1970;172(5):902-908.
1073. *AJCC Cancer Staging Handbook*. 7th ed. New York, NY: Springer; 2010:387-415.
1074. Buttner P, Garbe C, Bertz J, et al. Primary cutaneous melanoma. Optimized cutoff points of tumor thickness and importance of Clark's level for prognostic classification. *Cancer*. 1995;75(10):2499-2506.
1075. Holmes EC, Clark W, Morton DL, et al. Regional lymph node metastases and the level of invasion of primary melanoma. *Cancer*. 1976;37(1):199-201.
1076. Saeb-Lima M, Montante-Montes de Oca D, Albores-Saavedra J. Merkel cell carcinoma with eccrine differentiation: a clinicopathologic study of 7 cases. *Ann Diagn Pathol*. 2008;12(6):410-414.
1077. Wanebo HJ, Fortner JG, Woodruff J, et al. Selection of the optimum surgical treatment of stage I melanoma by depth of microinvasion: use of the combined microstage technique (Clark-Breslow). *Ann Surg*. 1975;182(3):302-315.
1078. Wanebo HJ, Woodruff J, Fortner JG. Malignant melanoma of the extremities: a clinicopathologic study using levels of invasion (microstage). *Cancer*. 1975;35(3):666-676.
1079. Balch CM, Murad TM, Soong SJ, et al. A multifactorial analysis of melanoma: prognostic histopathological features comparing Clark's and Breslow's staging methods. *Ann Surg*. 1978;188(6):732-742.
1080. McGovern VJ, Shaw HM, Milton GW, McCarthy WH. Ulceration and prognosis in cutaneous malignant melanoma. *Histopathology*. 1982;6(4):399-407.
1081. Shaw HM, Balch CM, Soong SJ, et al. Prognostic histopathological factors in malignant melanoma. *Pathology*. 1985;17(2):271-274.
1082. Van Der Esch EP, Cascinelli N, Preda F, et al. Stage I melanoma of the skin: evaluation of prognosis according to histologic characteristics. *Cancer*. 1981;48(7):1668-1673.
1083. Azzola MF, Shaw HM, Thompson JF, et al. Tumor mitotic rate is a more powerful prognostic indicator than ulceration in patients with primary cutaneous melanoma: an analysis of 3661 patients from a single center. *Cancer*. 2003;97(6):1488-1498.
1084. O'Doherty CJ, Prescott RJ, White H, et al. Sex differences in presentation of cutaneous malignant melanoma and in survival from stage I disease. *Cancer*. 1986;58(3): 788-792.
1085. Thorn M, Ponten F, Bergstrom R, et al. Clinical and histopathologic predictors of survival in patients with malignant melanoma: a population-based study in Sweden. *J Natl Cancer Inst*. 1994;86(10):761-769.
1086. Cohen HJ, Cox E, Manton K, Woodbury M. Malignant melanoma in the elderly. *J Clin Oncol*. 1987;5(1):100-106.
1087. Duncan LM, Travers RL, Koerner FC, et al. Estrogen and progesterone receptor analysis in pregnancy-associated melanoma: absence of immunohistochemically detectable hormone receptors. *Hum Pathol*. 1994;25(1):36-41.
1088. White LP, Linden G, Breslow L, Harzfeld L. Studies on melanoma. The effect of pregnancy on survival in human melanoma. *JAMA*. 1961;177:235-238.
1089. Shiu MH, Schottenfeld D, Maclean B, Fortner JG. Adverse effect of pregnancy on melanoma: a reappraisal. *Cancer*. 1976;37(1):181-187.
1090. Byrd-Gloster AL, Khoor A, Glass LF, et al. Differential expression of thyroid transcription factor 1 in small cell lung carcinoma and Merkel cell tumor. *Hum Pathol*. 2000;31(1):58-62.
1091. Rogers GS, Kopf AW, Rigel DS, et al. Effect of anatomical location on prognosis in patients with clinical stage I melanoma. *Arch Dermatol*. 1983;119(8):644-649.
1092. Clark WH Jr, Goldman LI, Mastrangelo MJ. *Human Malignant Melanoma*. New York, NY: Grune & Stratton; 1979.
1093. Coleman WP III, Loria PR, Reed RJ, Krementz ET. Acral lentiginous melanoma. *Arch Dermatol*. 1980;116(7):773-776.
1094. Cochran AJ. Histology and prognosis in malignant melanoma. *J Pathol*. 1969;97(3):459-468.
1095. McGovern VJ, Shaw HM, Milton GW, Farago GA. Prognostic significance of the histological features of malignant melanoma. *Histopathology*. 1979;3(5):385-393.
1096. Frahm SO, Schubert C, Parwaresch R, Rudolph P. High proliferative activity may predict early metastasis of thin melanomas. *Hum Pathol*. 2001;32(12):1376-1381.
1097. Hazan C, Melzer K, Panageas KS, et al. Evaluation of the proliferation marker MIB-1 in the prognosis of cutaneous malignant melanoma. *Cancer*. 2002;95(3):634-640.
1098. Rieger E, Hofmann-Wellnhof R, Soyer HP, et al. Comparison of proliferative activity as assessed by proliferating cell nuclear antigen (PCNA) and Ki-67 monoclonal antibodies in melanocytic skin lesions. *J Cutan Pathol*. 1993;20(3):229-236.
1099. Soyer HP. Ki 67 immunostaining in melanocytic skin tumors. Correlation with histologic parameters. *J Cutan Pathol*. 1991;18(4):264-272.
1100. Rao UN, Lee SJ, Luo W, et al. Presence of tumor-infiltrating lymphocytes and a dominant nodule within primary melanoma are prognostic factors for relapse-free survival of patients with thick (t4) primary melanoma: pathologic analysis of the e1690 and e1694 intergroup trials. *Am J Clin Pathol*. 2010;133(4):646-653.
1101. Sondergaard K, Schou G. Therapeutic and clinico-pathological factors in the survival of 1,469 patients with primary cutaneous malignant melanoma in clinical stage I. A multivariate regression analysis. *Virchows Arch A Pathol Anat Histopathol*. 1985;408(2-3):249-258.
1102. Clemente CG, Mihm MC Jr, Bufalino R, et al. Prognostic value of tumor infiltrating lymphocytes in the vertical growth phase of primary cutaneous melanoma. *Cancer*. 1996;77(7):1303-1310.
1103. Mascaro JM, Molgo M, Castel T, Castro J. Plasma cells within the infiltrate of primary cutaneous malignant melanoma of the skin. A confirmation of its histoprognostic value. *Am J Dermatopathol*. 1987;9(6): 497-499.
1104. Tuthill RJ, Unger JM, Liu PY, et al. Southwest Oncology Group. Risk assessment in localized primary cutaneous melanoma: a Southwest Oncology Group study evaluating nine factors and a test of the Clark logistic regression prediction model. *Am J Clin Pathol*. 2002;118(4):504-511.
1105. Cooper PH, Wanebo HJ, Hagar RW. Regression in thin malignant melanoma. Microscopic diagnosis and

prognostic importance. *Arch Dermatol*. 1985;121(9):1127-1131.
1106. Kelly JW, Sagebiel RW, Blois MS. Regression in malignant melanoma. A histologic feature without independent prognostic significance. *Cancer*. 1985;56(9):2287-2291.
1107. McGovern VJ, Shaw HM, Milton GW. Prognosis in patients with thin malignant melanoma: influence of regression. *Histopathology*. 1983;7(5):673-680.
1108. Van Es SL, Colman M, Thompson JF, et al. Angiotropism is an independent predictor of local recurrence and in-transit metastasis in primary cutaneous melanoma. *Am J Surg Pathol*. 2008;32(9):1396-1403.
1109. Harrist TJ, Rigel DS, Day CL Jr, et al. "Microscopic satellites" are more highly associated with regional lymph node metastases than is primary melanoma thickness. *Cancer*. 1984;53(10):2183-2187.
1110. Lauer S, Yaar R, Page A, et al. Percentage of sentinel lymph node involvement by metastatic melanoma as measured by ACIS cytometric image analysis is associated with survival. *Lab Invest*. 2009;89:104A.
1111. Satzger I, Volker B, Al Ghazal M, et al. Prognostic significance of histopathological parameters in sentinel nodes of melanoma patients. *Histopathology*. 2007;50(6): 764-772.
1112. Satzger I, Volker B, Meier A, et al. Prognostic significance of isolated HMB45 or Melan A positive cells in melanoma sentinel lymph nodes. *Am J Surg Pathol*. 2007;31(8):1175-1180.
1113. Duve S, Schmoeckel C, Burgdorf WH. Melanocytic hyperplasia in scars. A histopathological investigation of 722 cases. *Am J Dermatopathol*. 1996;18(3):236-240.
1114. Bolognia JL. Reticulated black solar lentigo ('ink spot' lentigo). *Arch Dermatol*. 1992;128(7):934-940.
1115. Happle R. The group of epidermal nevus syndromes Part I. Well defined phenotypes. *J Am Acad Dermatol*. 2010;63(1):1-22, quiz 23-24.
1116. Mishima Y, Pinkus H. Benign mixed tumor of melanocytes and malpighian cells. Melanoacanthoma: its relationship to Bloch's benign non-nevoid melanoepithelioma. *Arch Dermatol*. 1960;81:539-550.
1117. Rodriguez J, Nonaka D, Kuhn E, et al. Combined high-grade basal cell carcinoma and malignant melanoma of the skin ("malignant basomelanocytic tumor"): report of two cases and review of the literature. *Am J Dermatopathol*. 2005;27(4):314-318.
1118. Satter EK, Metcalf J, Lountzis N, Elston DM. Tumors composed of malignant epithelial and melanocytic populations: a case series and review of the literature. *J Cutan Pathol*. 2009;36(2):211-219.
1119. Erickson LA, Myers JL, Mihm MC, et al. Malignant basomelanocytic tumor manifesting as metastatic melanoma. *Am J Surg Pathol*. 2004;28(10):1393-1396.
1120. Miteva M, Herschthal D, Ricotti C, et al. A rare case of a cutaneous squamomelanocytic tumor: revisiting the histogenesis of combined neoplasms. *Am J Dermatopathol*. 2009;31(6):599-603.
1121. Pouryazdanparast P, Yu L, Johnson T, Fullen D. An unusual squamo-melanocytic tumor of uncertain biologic behavior: a variant of melanoma? *Am J Dermatopathol*. 2009;31(5):457-461.
1122. Tang CK, Toker C. Trabecular carcinoma of the skin: an ultrastructural study. *Cancer*. 1978;42(5):2311-2321.
1123. Toker C. Trabecular carcinoma of the skin. *Arch Dermatol*. 1972;105(1):107-110.
1124. Pulitzer MP, Amin BD, Busam KJ. Merkel cell carcinoma: review. *Adv Anat Pathol*. 2009;16(3):135-144.
1125. Silva EG, Mackay B, Goepfert H, et al. Endocrine carcinoma of the skin (Merkel cell carcinoma). *Pathol Ann*. 1984;19(Pt 2):1-30.
1126. Schmid C, Beham A, Feichtinger J, et al. Recurrent and subsequently metastasizing Merkel cell carcinoma in a 7-year-old girl. *Histopathology*. 1992;20(5):437-439.
1127. Ratner D, Nelson BR, Brown MD, Johnson TM. Merkel cell carcinoma. *J Am Acad Dermatol*. 1993;29(2 Pt 1):143-156.
1128. Sibley RK, Dahl D. Primary neuroendocrine (Merkel cell?) carcinoma of the skin. II. An immunocytochemical study of 21 cases. *Am J Surg Pathol*. 1985;9(2):109-116.
1129. Bayrou O, Avril MF, Charpentier P, et al. Primary neuroendocrine carcinoma of the skin. Clinicopathologic study of 18 cases. *J Am Acad Dermatol*. 1991;24(2 Pt 1):198-207.
1130. Sidhu GS, Feiner H, Flotte TJ, et al. Merkel cell neoplasms. Histology, electron microscopy, biology, and histogenesis. *Am J Dermatopathol*. 1980;2(2):101-119.
1131. Wick MR, Kaye VN, Sibley RK, et al. Primary neuroendocrine carcinoma and small-cell malignant lymphoma of the skin. A discriminant immunohistochemical comparison. *J Cutan Pathol*. 1986;13(5):347-358.
1132. Walsh NM. Primary neuroendocrine (Merkel cell) carcinoma of the skin: morphologic diversity and implications thereof. *Hum Pathol*. 2001;32(7):680-689.
1133. Vazmitel M, Michal M, Shelekhova KV, et al. Vascular changes in merkel cell carcinoma based on a histopathological study of 92 cases. *Am J Dermatopathol*. 2008;30(2):106-111.
1134. Gaudin PB, Rosai J. Florid vascular proliferation associated with neural and neuroendocrine neoplasms. A diagnostic clue and potential pitfall. *Am J Surg Pathol*. 1995;19(6):642-652.
1135. Cerroni L, Kerl H. Primary cutaneous neuroendocrine (Merkel cell) carcinoma in association with squamous- and basal-cell carcinoma. *Am J Dermatopathol*. 1997;19(6):610-613.
1136. Gomez LG, DiMaio S, Silva EG, Mackay B. Association between neuroendocrine (Merkel cell) carcinoma and squamous carcinoma of the skin. *Am J Surg Pathol*. 1983;7(2):171-177.
1137. Gould E, Albores-Saavedra J, Dubner B, et al. Eccrine and squamous differentiation in Merkel cell carcinoma. An immunohistochemical study. *Am J Surg Pathol*. 1988;12(10):768-772.
1138. Heenan PJ, Cole JM, Spagnolo DV. Primary cutaneous neuroendocrine carcinoma (Merkel cell tumor). An adnexal epithelial neoplasm. *Am J Dermatopathol*. 1990;12(1):7-16.
1139. Hashimoto K, Lee MW, D'Annunzio DR, et al. Pagetoid Merkel cell carcinoma: epidermal origin of the tumor. *J Cutan Pathol*. 1998;25(10):572-579.
1140. Al-Ahmadie HA, Mutasim DF, Mutema GK. A case of intraepidermal Merkel cell carcinoma within squamous cell carcinoma in-situ: Merkel cell carcinoma in-situ? *Am J Dermatopathol*. 2004;26(3):230-233.
1141. Brown HA, Sawyer DM, Woo T. Intraepidermal Merkel cell carcinoma with no dermal involvement. *Am J Dermatopathol*. 2000;22(1):65-69.
1142. Boutilier R, Desormeau L, Cragg F, et al. Merkel cell carcinoma: squamous and atypical fibroxanthoma-like differentiation in successive local tumor recurrences. *Am J Dermatopathol*. 2001;23(1):46-49.
1143. Cooper L, Debono R, Alsanjari N, Al-Nafussi A. Merkel cell tumour with leiomyosarcomatous differentiation. *Histopathology*. 2000;36(6):540-543.
1144. Fernandez-Figueras MT, Puig L, Gilaberte M, et al. Merkel cell (primary neuroendocrine) carcinoma of the skin with nodal metastasis showing rhabdomyosarcomatous differentiation. *J Cutan Pathol*. 2002;29(10):619-622.
1145. Bahrami A, Gown AM, Baird GS, et al. Aberrant expression of epithelial and neuroendocrine markers in alveolar rhabdomyosarcoma: a potentially serious diagnostic pitfall. *Mod Pathol*. 2008;21(7):795-806.
1146. Frigerio B, Capella C, Eusebi V, et al. Merkel cell carcinoma of the skin: the structure and origin of normal Merkel cells. *Histopathology*. 1983;7(2):229-249.
1147. Silva E, Mackay B. Neuroendocrine (Merkel cell) carcinomas of the skin: an ultrastructural study of nine cases. *Ultrastruct Pathol*. 1981;2(1):1-9.
1148. Sibley RK, Rosai J, Foucar E, et al. Neuroendocrine (Merkel cell) carcinoma of the skin. A histologic and ultrastructural study of two cases. *Am J Surg Pathol*. 1980;4(3):211-221.
1149. Sidhu GS, Chandra P, Cassai ND. Merkel cells, normal and neoplastic: an update. *Ultrastruct Pathol*. 2005;29(3-4):287-294.
1150. Warner TF, Uno H, Hafez GR, et al. Merkel cells and Merkel cell tumors. Ultrastructure, immunocytochemistry and review of the literature. *Cancer*. 1983;52(2):238-245.
1151. Hofler H, Kerl H, Lackinger E, et al. The intermediate filament cytoskeleton of cutaneous neuroendocrine carcinoma (Merkel cell tumour). Immunohistochemical and biochemical analyses. *Virchows Arch A Pathol Anat Histopathol*. 1985;406(3): 339-350.
1152. Leff EL, Brooks JS, Trojanowski JQ. Expression of neurofilament and neuron-specific enolase in small cell tumors of skin using immunohistochemistry. *Cancer*. 1985;56(3):625-631.
1153. Wick MR, Scheithauer BW, Kovacs K. Neuron-specific enolase in neuroendocrine tumors of the thymus, bronchus, and skin. *Am J Clin Pathol*. 1983;79(6):703-707.
1154. Chan JK, Suster S, Wenig BM, et al. Cytokeratin 20 immunoreactivity distinguishes Merkel cell (primary cutaneous neuroendocrine) carcinomas and salivary gland small cell carcinomas from small cell carcinomas of various sites. *Am J Surg Pathol*. 1997;21(2):226-234.
1155. Scott MP, Helm KF. Cytokeratin 20: a marker for diagnosing Merkel cell carcinoma. *Am J Dermatopathol*. 1999;21(1):16-20.
1156. Bobos M, Hytiroglou P, Kostopoulos I, et al. Immunohistochemical distinction between merkel cell carcinoma and small cell carcinoma of the lung. *Am J Dermatopathol*. 2006;28(2):99-104.
1157. Ralston J, Chiriboga L, Nonaka D. MASH1: a useful marker in differentiating pulmonary small cell carcinoma from Merkel cell carcinoma. *Mod Pathol*. 2008;21(11):1357-1362.
1158. Sierakowski A, Al-Janabi K, Dam H, Sood M. Metastatic Merkel cell carcinoma with positive expression of thyroid transcription factor-1—a case report. *Am J Dermatopathol*. 2009;31(4):384-386.
1159. Cheuk W, Kwan MY, Suster S, Chan JK. Immunostaining for thyroid transcription factor 1 and cytokeratin 20 aids the distinction of small cell carcinoma from Merkel cell carcinoma, but not pulmonary from extrapulmonary small cell carcinomas. *Arch Pathol Lab Med*. 2001;125(2):228-231.
1160. Schmidt U, Muller U, Metz KA, Leder LD. Cytokeratin and neurofilament protein staining in Merkel cell carcinoma of the small cell type and small cell

carcinoma of the lung. *Am J Dermatopathol*. 1998;20(4):346-351.
1161. Shah IA, Netto D, Schlageter MO, et al. Neurofilament immunoreactivity in Merkel-cell tumors: a differentiating feature from small-cell carcinoma. *Mod Pathol*. 1993;6(1):3-9.
1162. Calder KB, Coplowitz S, Schlauder S, Morgan MB. A case series and immunophenotypic analysis of CK20–/CK7+ primary neuroendocrine carcinoma of the skin. *J Cutan Pathol*. 2007;34(12):918-923.
1163. Dong HY, Liu W, Cohen P, et al. B-cell specific activation protein encoded by the PAX-5 gene is commonly expressed in merkel cell carcinoma and small cell carcinomas. *Am J Surg Pathol*. 2005;29(5):687-692.
1164. Buresh CJ, Oliai BR, Miller RT. Reactivity with TdT in Merkel cell carcinoma: a potential diagnostic pitfall. *Am J Clin Pathol*. 2008;129(6):894-898.
1165. Sur M, AlArdati H, Ross C, Alowami S. TdT expression in Merkel cell carcinoma: potential diagnostic pitfall with blastic hematological malignancies and expanded immunohistochemical analysis. *Mod Pathol*. 2007;20(11):1113-1120.
1166. He H, Fang W, Liu X, et al. Frequent expression of glypican-3 in Merkel cell carcinoma: an immunohistochemical study of 55 cases. *Appl Immunohistochem Mol Morphol*. 2009;17(1):40-46.
1167. Feinmesser M, Halpern M, Kaganovsky E, et al. c-kit expression in primary and metastatic merkel cell carcinoma. *Am J Dermatopathol*. 2004;26(6):458-462.
1168. Silva EG, Ordonez NG, Lechago J. Immunohistochemical studies in endocrine carcinoma of the skin. *Am J Clin Pathol*. 1984;81(5):558-562.
1169. Su LD, Fullen DR, Lowe L, et al. CD117 (KIT receptor) expression in Merkel cell carcinoma. *Am J Dermatopathol*. 2002;24(4):289-293.
1170. Feng H, Shuda M, Chang Y, Moore PS. Clonal integration of a polyomavirus in human Merkel cell carcinoma. *Science*. 2008;319(5866):1096-1100.
1171. Busam KJ, Jungbluth AA, Rekthman N, et al. Merkel cell polyomavirus expression in Merkel cell carcinomas and its absence in combined tumors and pulmonary neuroendocrine carcinomas. *Am J Surg Pathol*. 2009;33(9):1378-1385.
1172. Ly TY, Walsh NM, Pasternak S. The spectrum of Merkel cell polyomavirus expression in Merkel cell carcinoma, in a variety of cutaneous neoplasms, and in neuroendocrine carcinomas from different anatomical sites. *Hum Pathol*. 2012;43(4):557-566.
1173. Wong SQ, Waldeck K, Vergara IA, et al. UV-associated mutations underlie the etiology of MCV-negative Merkel cell carcinomas. *Cancer Res*. 2015;75(24):5228-5234.
1174. Goepfert H, Remmler D, Silva E, Wheeler B. Merkel cell carcinoma (endocrine carcinoma of the skin) of the head and neck. *Arch Otolaryngol*. 1984;110(11):707-712.
1175. Wick MR, Goellner JR, Scheithauer BW, et al. Primary neuroendocrine carcinomas of the skin (Merkel cell tumors). A clinical, histologic, and ultrastructural study of thirteen cases. *Am J Clin Pathol*. 1983;79(1):6-13.
1176. Ro JY, Ayala AG, Tetu B, et al. Merkel cell carcinoma metastatic to the testis. *Am J Clin Pathol*. 1990;94(4):384-389.
1177. Eusebi V, Capella C, Cossu A, Rosai J. Neuroendocrine carcinoma within lymph nodes in the absence of a primary tumor, with special reference to Merkel cell carcinoma. *Am J Surg Pathol*. 1992;16(7):658-666.
1178. Kayashima K, Ono T, Johno M, et al. Spontaneous regression in Merkel cell (neuroendocrine) carcinoma of the skin. *Arch Dermatol*. 1991;127(4):550-553.
1179. Takenaka H, Kishimoto S, Shibagaki R, et al. Merkel cell carcinoma with partial spontaneous regression: an immunohistochemical, ultrastructural, and TUNEL labeling study. *Am J Dermatopathol*. 1997;19(6):614-618.
1180. Wooff JC, Trites JR, Walsh NM, Bullock MJ. Complete spontaneous regression of metastatic merkel cell carcinoma: a case report and review of the literature. *Am J Dermatopathol*. 2010;32(6):614-617.
1181. Gollard R, Weber R, Kosty MP, et al. Merkel cell carcinoma: review of 22 cases with surgical, pathologic, and therapeutic considerations. *Cancer*. 2000;88(8):1842-1851.
1182. Raaf JH, Urmacher C, Knapper WK, et al. Trabecular (Merkel cell) carcinoma of the skin. Treatment of primary, recurrent, and metastatic disease. *Cancer*. 1986;57(1):178-182.
1183. Lebbe C, Becker JC, Grob JJ, et al. Diagnosis and treatment of Merkel Cell Carcinoma. European consensus-based interdisciplinary guideline. *Eur J Cancer*. 2015;51(16):2396-2403.
1184. Marks ME, Kim RY, Salter MM. Radiotherapy as an adjunct in the management of Merkel cell carcinoma. *Cancer*. 1990;65(1):60-64.
1185. McAfee WJ, Morris CG, Mendenhall CM, et al. Merkel cell carcinoma: treatment and outcomes. *Cancer*. 2005;104(8):1761-1764.
1186. Fenig E, Brenner B, Katz A, et al. The role of radiation therapy and chemotherapy in the treatment of Merkel cell carcinoma. *Cancer*. 1997;80(5):881-885.
1187. Sharma D, Flora G, Grunberg SM. Chemotherapy of metastatic Merkel cell carcinoma: case report and review of the literature. *Am J Clin Oncol*. 1991;14(2):166-169.
1188. Tai PT, Yu E, Winquist E, et al. Chemotherapy in neuroendocrine/Merkel cell carcinoma of the skin: case series and review of 204 cases. *J Clin Oncol*. 2000;18(12):2493-2499.
1189. Llombart B, Monteagudo C, Lopez-Guerrero JA, et al. Clinicopathological and immunohistochemical analysis of 20 cases of Merkel cell carcinoma in search of prognostic markers. *Histopathology*. 2005;46(6): 622-634.
1190. Kasami M, Muramatsu K, Kawahata K, et al. Large-cell neuroendocrine carcinoma of the skin, with lymphoid stroma. *Am J Dermatopathol*. 2007;29(6):578-580.
1191. Gould VE, Moll R, Moll I, et al. Neuroendocrine (Merkel) cells of the skin: hyperplasias, dysplasias, and neoplasms. *Lab Invest*. 1985;52(4):334-353.
1192. Eusebi V, Damiani S, Pasquinelli G, et al. Small cell neuroendocrine carcinoma with skeletal muscle differentiation: report of three cases. *Am J Surg Pathol*. 2000;24(2):223-230.
1193. Van Nguyen A, Argenyi ZB. Cutaneous neuroblastoma. Peripheral neuroblastoma. *Am J Dermatopathol*. 1993;15(1):7-14.
1194. Hasegawa SL, Davison JM, Rutten A, et al. Primary cutaneous Ewing's sarcoma: immunophenotypic and molecular cytogenetic evaluation of five cases. *Am J Surg Pathol*. 1998;22(3):310-318.
1195. Collina G, Quarto F, Eusebi V. Trabecular carcinoid of the skin with cellular stroma. *Am J Dermatopathol*. 1988;10(5):430-435.
1196. Courville P, Joly P, Thomine E, et al. Primary cutaneous carcinoid tumour. *Histopathology*. 2000;36(6):566-567.
1197. Smith PA, Chappell RH. Another possible primary carcinoid tumour of skin? *Virchows Arch A Pathol Anat Histopathol*. 1985;408(1):99-103.
1198. Blackburn WR, Cosman B. Histologic basis of keloid and hypertrophic scar differentiation. Clinicopathologic correlation. *Arch Pathol*. 1966;82(1):65-71.
1199. Ehrlich HP, Desmouliere A, Diegelmann RF, et al. Morphological and immunochemical differences between keloid and hypertrophic scar. *Am J Pathol*. 1994;145(1):105-113.
1200. Lee JY, Yang CC, Chao SC, Wong TW. Histopathological differential diagnosis of keloid and hypertrophic scar. *Am J Dermatopathol*. 2004;26(5):379-384.
1201. Santucci M, Borgognoni L, Reali UM, Gabbiani G. Keloids and hypertrophic scars of Caucasians show distinctive morphologic and immunophenotypic profiles. *Virchows Arch*. 2001;438(5):457-463.
1202. Kuo TT, Hu S, Chan HL. Keloidal dermatofibroma: report of 10 cases of a new variant. *Am J Surg Pathol*. 1998;22(5):564-568.
1203. Herzberg AJ, Dinehart SM, Kerns BJ, Pollack SV. Acne keloidalis. Transverse microscopy, immunohistochemistry, and electron microscopy. *Am J Dermatopathol*. 1990;12(2):109-121.
1204. Santa Cruz DJ, Ulbright TM. Mucin-like changes in keloids. *Am J Clin Pathol*. 1981;75(1):18-22.
1205. Chen TM, Purohit SK, Wang AR. Pleomorphic sclerotic fibroma: a case report and literature review. *Am J Dermatopathol*. 2002;24(1):54-58.
1206. Kamino H, Lee JY, Berke A. Pleomorphic fibroma of the skin: a benign neoplasm with cytologic atypia. A clinicopathologic study of eight cases. *Am J Surg Pathol*. 1989;13(2):107-113.
1207. Rudolph P, Schubert C, Harms D, Parwaresch R. Giant cell collagenoma: a benign dermal tumor with distinctive multinucleate cells. *Am J Surg Pathol*. 1998;22(5):557-563.
1208. Rudolph P, Schubert C, Zelger BG, et al. Differential expression of CD34 and Ki-M1p in pleomorphic fibroma and dermatofibroma with monster cells. *Am J Dermatopathol*. 1999;21(5):414-419.
1209. Cathro HP, Patterson JW, Wick MR. Cutaneous pseudosarcomatous polyp: a recently described lesion. *Ann Diagn Pathol*. 2008;12(6):440-444.
1210. Graham JH, Sanders JB, Johnson WC, Helwig EB. Fibrous papule of the nose: a clinicopathological study. *J Invest Dermatol*. 1965;45(3):194-203.
1211. Meigel WN, Ackerman AB. Fibrous papule of the face. *Am J Dermatopathol*. 1979;1(4):329-340.
1212. Lee AN, Stein SL, Cohen LM. Clear cell fibrous papule with NKI/C3 expression: clinical and histologic features in six cases. *Am J Dermatopathol*. 2005;27(4):296-300.
1213. Cerio R, Rao BK, Spaull J, Jones EW. An immunohistochemical study of fibrous papule of the nose: 25 cases. *J Cutan Pathol*. 1989;16(4):194-198.
1214. Metcalf JS, Maize JC, LeBoit PE. Circumscribed storiform collagenoma (sclerosing fibroma). *Am J Dermatopathol*. 1991;13(2):122-129.
1215. Shitabata PK, Crouch EC, Fitzgibbon JF, et al. Cutaneous sclerotic fibroma. Immunohistochemical evidence of a fibroblastic neoplasm with ongoing type I collagen synthesis. *Am J Dermatopathol*. 1995;17(4):339-343.
1216. Hanft VN, Shea CR, McNutt NS, et al. Expression of CD34 in sclerotic ("plywood") fibromas. *Am J Dermatopathol*. 2000;22(1):17-21.
1217. Chang SN, Chun SI, Moon TK, Park WH. Solitary sclerotic fibroma of the skin:

degenerated sclerotic change of inflammatory conditions, especially folliculitis. *Am J Dermatopathol*. 2000;22(1):22-25.
1218. Fukunaga M, Ushigome S. Collagenous fibroma (desmoplastic fibroblastoma): a distinctive fibroblastic soft tissue tumor. *Adv Anat Pathol*. 1999;6(5):275-280.
1219. Hasegawa T, Shimoda T, Hirohashi S, et al. Collagenous fibroma (desmoplastic fibroblastoma): report of four cases and review of the literature. *Arch Pathol Lab Med*. 1998;122(5):455-460.
1220. Miettinen M, Fetsch JF. Collagenous fibroma (desmoplastic fibroblastoma): a clinicopathologic analysis of 63 cases of a distinctive soft tissue lesion with stellate-shaped fibroblasts. *Hum Pathol*. 1998;29(7):676-682.
1221. Ng WK, Cheung MF, Ma L. Dermatomyofibroma: further support of its myofibroblastic nature by electronmicroscopy. *Histopathology*. 1996;29(2):181-183.
1222. Guitart J, Ritter JH, Wick MR. Solitary cutaneous myofibromas in adults: report of six cases and discussion of differential diagnosis. *J Cutan Pathol*. 1996;23(5):437-444.
1223. Kamino H, Reddy VB, Gero M, Greco MA. Dermatomyofibroma. A benign cutaneous, plaque-like proliferation of fibroblasts and myofibroblasts in young adults. *J Cutan Pathol*. 1992;19(2):85-93.
1224. Smith KJ, Skelton HG, Barrett TL, et al. Cutaneous myofibroma. *Mod Pathol*. 1989;2(6):603-609.
1225. Mentzel T, Kutzner H. Haemorrhagic dermatomyofibroma (plaque-like dermal fibromatosis): clinicopathological and immunohistochemical analysis of three cases resembling plaque-stage Kaposi's sarcoma. *Histopathology*. 2003;42(6):594-598.
1226. Mentzel T, Kutzner H. Dermatomyofibroma: clinicopathologic and immunohistochemical analysis of 56 cases and reappraisal of a rare and distinct cutaneous neoplasm. *Am J Dermatopathol*. 2009;31(1):44-49.
1227. de Feraudy S, Fletcher CD. Fibroblastic connective tissue nevus: a rare cutaneous lesion analyzed in a series of 25 cases. *Am J Surg Pathol*. 2012;36(10):1509-1515.
1228. Cowper SE, Kilpatrick T, Proper S, Morgan MB. Solitary fibrous tumor of the skin. *Am J Dermatopathol*. 1999;21(3): 213-219.
1229. Soldano AC, Meehan SA. Cutaneous solitary fibrous tumor: a report of 2 cases and review of the literature. *Am J Dermatopathol*. 2008;30(1):54-58.
1230. Sigel JE, Goldblum JR. Solitary fibrous tumor of the skin. *Am J Dermatopathol*. 2001;23(3):275-278.
1231. Calonje E, Fletcher CD. Cutaneous fibrohistiocytic tumors. An update. *Adv Anat Pathol*. 1994;1:2-15.
1232. Zelger B, Zelger BG, Burgdorf WH. Dermatofibroma—a critical evaluation. *Int J Surg Pathol*. 2004;12(4):333-344.
1233. Kuo TT, Chan HL. Ossifying dermatofibroma with osteoclast-like giant cells. *Am J Dermatopathol*. 1994;16(2):193-195.
1234. Kutchemeshgi M, Barr RJ, Henderson CD. Dermatofibroma with osteoclast-like giant cells. *Am J Dermatopathol*. 1992;14(5):397-401.
1235. Hanly AJ, Jorda M, Elgart GW, et al. High proliferative activity excludes dermatofibroma: report of the utility of MIB-1 in the differential diagnosis of selected fibrohistiocytic tumors. *Arch Pathol Lab Med*. 2006;130(6):831-834.
1236. Kamino H, Jacobson M. Dermatofibroma extending into the subcutaneous tissue. Differential diagnosis from dermatofibrosarcoma protuberans. *Am J Surg Pathol*. 1990;14(12):1156-1164.
1237. Luzar B, Calonje E. Cutaneous fibrohistiocytic tumours—an update. *Histopathology*. 2010;56(1):148-165.
1238. Zelger B, Sidoroff A, Stanzl U, et al. Deep penetrating dermatofibroma versus dermatofibrosarcoma protuberans. A clinicopathologic comparison. *Am J Surg Pathol*. 1994;18(7):677-686.
1239. Dalziel K, Marks R. Hair follicle-like change over histiocytomas. *Am J Dermatopathol*. 1986;8(6):462-466.
1240. Goette DK, Helwig EB. Basal cell carcinomas and basal cell carcinoma-like changes overlying dermatofibromas. *Arch Dermatol*. 1975;111(5):589-592.
1241. Morgan MB, Howard HG, Everett MA. Epithelial induction in dermatofibroma: a role for the epidermal growth factor (EGF) receptor. *Am J Dermatopathol*. 1997;19(1):35-40.
1242. Davis TT, Calilao G, Fretzin D. Sebaceous hyperplasia overlying a dermatofibroma. *Am J Dermatopathol*. 2006;28(2):155-157.
1243. Herman KL, Kantor GR, Katz SM. Squamous cell carcinoma in situ overlying dermatofibroma. *J Cutan Pathol*. 1990;17(6):385-387.
1244. Schwob VS, Santa Cruz DJ. Palisading cutaneous fibrous histiocytoma. *J Cutan Pathol*. 1986;13(6):403-407.
1245. Zelger BG, Calonje E, Zelger B. Myxoid dermatofibroma. *Histopathology*. 1999;34(4):357-364.
1246. Lee J. Epithelioid cell histiocytoma with granular cells (another nonneural granular cell neoplasm). *Am J Dermatopathol*. 2007;29(5):475-476.
1247. Soyer HP, Metze D, Kerl H. Granular cell dermatofibroma. *Am J Dermatopathol*. 1997;19(2):168-173.
1248. Zelger BG, Steiner H, Kutzner H, et al. Granular cell dermatofibroma. *Histopathology*. 1997;31(3):258-262.
1249. Iwata J, Fletcher CD. Lipidized fibrous histiocytoma: clinicopathologic analysis of 22 cases. *Am J Dermatopathol*. 2000;22(2):126-134.
1250. Paties C, Vassallo G, Taccagni GL. Clear cell dermatofibroma. *Am J Surg Pathol*. 1997;21(2):250-252.
1251. Wambacher-Gasser B, Zelger B, Zelger BG, Steiner H. Clear cell dermatofibroma. *Histopathology*. 1997;30(1):64-69.
1252. Tran TA, Hayner-Buchan A, Jones DM, et al. Cutaneous balloon cell dermatofibroma (fibrous histiocytoma). *Am J Dermatopathol*. 2007;29(2):197-200.
1253. Garrido-Ruiz MC, Carrillo R, Enguita AB, Peralto JL. Signet-ring cell dermatofibroma. *Am J Dermatopathol*. 2009;31(1):84-87.
1254. Aiba S, Terui T, Tagami H. Dermatofibroma with diffuse eosinophilic infiltrate. *Am J Dermatopathol*. 2000;22(3):281-284.
1255. Sanchez Yus E, Soria L, de Eusebio E, Requena L. Lichenoid, erosive and ulcerated dermatofibromas. Three additional clinico-pathologic variants. *J Cutan Pathol*. 2000;27(3):112-117.
1256. Zelger BG, Sidoroff A, Zelger B. Combined dermatofibroma: co-existence of two or more variant patterns in a single lesion. *Histopathology*. 2000;36(6):529-539.
1257. Leyva WH, Santa Cruz DJ. Atypical cutaneous fibrous histiocytoma. *Am J Dermatopathol*. 1986;8(6):467-471.
1258. Tamada S, Ackerman AB. Dermatofibroma with monster cells. *Am J Dermatopathol*. 1987;9(5):380-387.
1259. Wilk M, Zelger BG, Nilles M, Zelger B. The value of immunohistochemistry in atypical cutaneous fibrous histiocytoma. *Am J Dermatopathol*. 2004;26(5):367-371.
1260. Calonje E, Mentzel T, Fletcher CD. Cellular benign fibrous histiocytoma. Clinicopathologic analysis of 74 cases of a distinctive variant of cutaneous fibrous histiocytoma with frequent recurrence. *Am J Surg Pathol*. 1994;18(7):668-676.
1261. Calonje E, Fletcher CD. Aneurysmal benign fibrous histiocytoma. Clinicopathological analysis of 40 cases of a tumour frequently misdiagnosed as a vascular neoplasm. *Histopathology*. 1995;26:323-332.
1262. Santa Cruz DJ, Kyriakos M. Aneurysmal ("angiomatoid") fibrous histiocytoma of the skin. *Cancer*. 1981;47(8):2053-2061.
1263. Glusac EJ, Barr RJ, Everett MA, et al. Epithelioid cell histiocytoma. A report of 10 cases including a new cellular variant. *Am J Surg Pathol*. 1994;18(6):583-590.
1264. Singh Gomez C, Calonje E, Fletcher CD. Epithelioid benign fibrous histiocytoma of skin: clinico-pathological analysis of 20 cases of a poorly known variant. *Histopathology*. 1994;24(2):123-129.
1265. Jones EW, Cerio R, Smith NP. Epithelioid cell histiocytoma: a new entity. *Br J Dermatol*. 1989;120(2):185-195.
1266. Glusac EJ, McNiff JM. Epithelioid cell histiocytoma: a simulant of vascular and melanocytic neoplasms. *Am J Dermatopathol*. 1999;21(1):1-7.
1267. Doyle LA, Mariño-Enriquez A, Fletcher CD, Hornick JL. ALK rearrangement and overexpression in epithelioid fibrous histiocytoma. *Mod Pathol*. 2015;28(7):904-912.
1268. Abenoza P, Lillemoe T. CD34 and factor XIIIa in the differential diagnosis of dermatofibroma and dermatofibrosarcoma protuberans. *Am J Dermatopathol*. 1993;15(5):429-434.
1269. Prieto VG, Reed JA, Shea CR. Immunohistochemistry of dermatofibromas and benign fibrous histiocytomas. *J Cutan Pathol*. 1995;22(4):336-341.
1270. Li N, McNiff J, Hui P, et al. Differential expression of HMGA1 and HMGA2 in dermatofibroma and dermatofibrosarcoma protuberans: potential diagnostic applications, and comparison with histologic findings, CD34, and factor XIIIa immunoreactivity. *Am J Dermatopathol*. 2004;26(4):267-272.
1271. Kutzner H. Expression of the human progenitor cell antigen CD34 (HCPA-1) distinguishes dermatofibrosarcoma protuberans from fibrous histiocytoma in formalin-fixed, paraffin-embedded tissue. *J Am Acad Dermatol*. 1993;28:613-617.
1272. Bruecks AK, Trotter MJ. Expression of desmin and smooth muscle myosin heavy chain in dermatofibromas. *Arch Pathol Lab Med*. 2002;126(10):1179-1183.
1273. Zelger BW, Zelger BG, Rappersberger K. Prominent myofibroblastic differentiation. A pitfall in the diagnosis of dermatofibroma. *Am J Dermatopathol*. 1997;19(2): 138-146.
1274. Calonje E. Is cutaneous benign fibrous histiocytoma (dermatofibroma) a reactive inflammatory process or a neoplasm? *Histopathology*. 2000;37(3):278-280.
1275. Chen TC, Kuo T, Chan HL. Dermatofibroma is a clonal proliferative disease. *J Cutan Pathol*. 2000;27(1):36-39.
1276. Vanni R, Fletcher CD, Sciot R, et al. Cytogenetic evidence of clonality in cutaneous benign fibrous histiocytomas: a report of the CHAMP study group. *Histopathology*. 2000;37(3):212-217.
1277. Bisceglia M, Attino V, Bacchi CE. Metastasizing "benign" fibrous histiocytoma of the skin: a report of two additional cases and review of the literature. *Adv Anat Pathol*. 2006;13(2):89-96.

1278. Guillou L, Gebhard S, Salmeron M, Coindre JM. Metastasizing fibrous histiocytoma of the skin: a clinicopathologic and immunohistochemical analysis of three cases. *Mod Pathol*. 2000;13(6):654-660.
1279. Kaddu S, McMenamin ME, Fletcher CD. Atypical fibrous histiocytoma of the skin: clinicopathologic analysis of 59 cases with evidence of infrequent metastasis. *Am J Surg Pathol*. 2002;26(1):35-46.
1280. Mentzel T, Kutzner H, Rutten A, Hugel H. Benign fibrous histiocytoma (dermatofibroma) of the face: clinicopathologic and immunohistochemical study of 34 cases associated with an aggressive clinical course. *Am J Dermatopathol*. 2001;23(5):419-426.
1281. Gleason BC, Fletcher CD. Deep "benign" fibrous histiocytoma: clinicopathologic analysis of 69 cases of a rare tumor indicating occasional metastatic potential. *Am J Surg Pathol*. 2008;32(3):354-362.
1282. Mentzel T, Wiesner T, Cerroni L, et al. Malignant dermatofibroma: clinicopathological, immunohistochemical, and molecular analysis of seven cases. *Mod Pathol*. 2013;26(2):256-267.
1283. Charli-Joseph Y, Saggini A, Doyle LA, et al. DNA copy number changes in tumors within the spectrum of cellular, atypical, and metastasizing fibrous histiocytoma. *J Am Acad Dermatol*. 2014;71(2):256-263.
1284. Kempson RL, McGavran MH. Atypical fibroxanthomas of the skin. *Cancer*. 1964;17:1463-1471.
1285. Hudson AW, Winkelmann RK. Atypical fibroxanthoma of the skin: a reappraisal of 19 cases in which the original diagnosis was spindle-cell squamous carcinoma. *Cancer*. 1972;29(2):413-422.
1286. Fretzin DF, Helwig EB. Atypical fibroxanthoma of the skin. A clinicopathologic study of 140 cases. *Cancer*. 1973;31(6):1541-1552.
1287. Calonje E, Wadden C, Wilson-Jones E, Fletcher CD. Spindle-cell non-pleomorphic atypical fibroxanthoma: analysis of a series and delineation of a distinctive variant. *Histopathology*. 1993;22(3):247-254.
1288. Diaz-Cascajo C, Weyers W, Borghi S. Pigmented atypical fibroxanthoma: a tumor that may be easily mistaken for malignant melanoma. *Am J Dermatopathol*. 2003;25(1):1-5.
1289. Khan ZM, Cockerell CJ. Atypical fibroxanthoma with osteoclast-like multinucleated giant cells. *Am J Dermatopathol*. 1997;19(2):174-179.
1290. Tomaszewski MM, Lupton GP. Atypical fibroxanthoma. An unusual variant with osteoclast-like giant cells. *Am J Surg Pathol*. 1997;21(2):213-218.
1291. Crowson AN, Carlson-Sweet K, Macinnis C, et al. Clear cell atypical fibroxanthoma:a clinicopathologic study. *J Cutan Pathol*. 2002;29(6):374-381.
1292. Requena L, Sangueza OP, Sanchez Yus E, Furio V. Clear-cell atypical fibroxanthoma: an uncommon histopathologic variant of atypical fibroxanthoma. *J Cutan Pathol*. 1997;24(3):176-182.
1293. Lazar AJ, Fletcher CD. Distinctive dermal clear cell mesenchymal neoplasm: clinicopathologic analysis of five cases. *Am J Dermatopathol*. 2004;26(4):273-279.
1294. Orosz Z, Kelemen J, Szentirmay Z. Granular cell variant of atypical fibroxanthoma. *Pathol Oncol Res*. 1996;2(4):244-247.
1295. Rios-Martin JJ, Delgado MD, Moreno-Ramirez D, et al. Granular cell atypical fibroxanthoma: report of two cases. *Am J Dermatopathol*. 2007;29(1):84-87.
1296. de Feraudy S, Mar N, McCalmont TH. Evaluation of CD10 and procollagen 1 expression in atypical fibroxanthoma and dermatofibroma. *Am J Surg Pathol*. 2008;32(8):1111-1122.
1297. Longacre TA, Smoller BR, Rouse RV. Atypical fibroxanthoma. Multiple immunohistologic profiles. *Am J Surg Pathol*. 1993;17(12):1199-1209.
1298. Ma CK, Zarbo RJ, Gown AM. Immunohistochemical characterization of atypical fibroxanthoma and dermatofibrosarcoma protuberans. *Am J Clin Pathol*. 1992;97(4):478-483.
1299. Mathew RA, Schlauder SM, Calder KB, Morgan MB. CD117 immunoreactivity in atypical fibroxanthoma. *Am J Dermatopathol*. 2008;30(1):34-36.
1300. Sakamoto A, Oda Y, Yamamoto H, et al. Calponin and h-caldesmon expression in atypical fibroxanthoma and superficial leiomyosarcoma. *Virchows Arch*. 2002;440(4):404-409.
1301. Silvis NG, Swanson PE, Manivel JC, et al. Spindle-cell and pleomorphic neoplasms of the skin. A clinicopathologic and immunohistochemical study of 30 cases, with emphasis on "atypical fibroxanthomas. *Am J Dermatopathol*. 1988;10(1):9-19.
1302. Bansal C, Sinkre P, Stewart D, Cockerell CJ. Two cases of cytokeratin positivity in atypical fibroxanthoma. *J Clin Pathol*. 2007;60(6):716-717.
1303. Dahl I. Atypical fibroxanthoma of the skin. A clinico-pathological study of 57 cases. *Acta Pathol Microbiol Scand [A]*. 1976;84(2):183-197.
1304. Helwig EB, May D. Atypical fibroxanthoma of the skin with metastasis. *Cancer*. 1986;57(2):368-376.
1305. Wang WL, Torres-Cabala C, Curry JL, et al. Metastatic atypical fibroxanthoma: a series of 11 cases including with minimal and no subcutaneous involvement. *Am J Dermatopathol*. 2015;37(6):455-461.
1306. Miller K, Goodlad JR, Brenn T. Pleomorphic dermal sarcoma: adverse histologic features predict aggressive behavior and allow distinction from atypical fibroxanthoma. *Am J Surg Pathol*. 2012;36(9):1317-1326.
1307. Bague S, Folpe AL. Dermatofibrosarcoma protuberans presenting as a subcutaneous mass: a clinicopathological study of 15 cases with exclusive or near-exclusive subcutaneous involvement. *Am J Dermatopathol*. 2008;30(4):327-332.
1308. McKee PH, Fletcher CD. Dermatofibrosarcoma protuberans presenting in infancy and childhood. *J Cutan Pathol*. 1991;18(4):241-246.
1309. Frierson HF, Cooper PH. Myxoid variant of dermatofibrosarcoma protuberans. *Am J Surg Pathol*. 1983;7(5):445-450.
1310. Sigel JE, Bergfeld WF, Goldblum JR. A morphologic study of dermatofibrosarcoma protuberans: expansion of a histologic profile. *J Cutan Pathol*. 2000;27(4):159-163.
1311. Mentzel T, Schärer L, Kazakov DV, Michal M. Myxoid dermatofibrosarcoma protuberans: clinicopathologic, immunohistochemical, and molecular analysis of eight cases. *Am J Dermatopathol*. 2007;29(5):443-448.
1312. Calonje E, Fletcher CD. Myoid differentiation in dermatofibrosarcoma protuberans and its fibrosarcomatous variant: clinicopathologic analysis of 5 cases. *J Cutan Pathol*. 1996;23(1):30-36.
1313. Davis DA, Sanchez RL. Atrophic and plaquelike dermatofibrosarcoma protuberans. *Am J Dermatopathol*. 1998;20(5):498-501.
1314. Zelger BW, Ofner D, Zelger BG. Atrophic variants of dermatofibroma and dermatofibrosarcoma protuberans. *Histopathology*. 1995;26(6):519-527.
1315. Banerjee SS, Harris M, Eyden BP, Hamid BN. Granular cell variant of dermatofibrosarcoma protuberans. *Histopathology*. 1990;17(4):375-378.
1316. Dominguez-Malagon HR, Ordonez NG, Mackay B. Dermatofibrosarcoma protuberans: ultrastructural and immunocytochemical observations. *Ultrastruct Pathol*. 1995;19(4):281-289.
1317. Goldblum JR, Tuthill RJ. CD34 and factor-XIIIa immunoreactivity in dermatofibrosarcoma protuberans and dermatofibroma. *Am J Dermatopathol*. 1997;19(2):147-153.
1318. Dominguez-Malagon H, Valdez-Carrillo Mdel C, Cano-Valdez AM. Dermatofibroma and dermatofibrosarcoma protuberans: a comparative ultrastructural study. *Ultrastruct Pathol*. 2006;30(4):283-291.
1319. Sandberg AA, Bridge JA. Updates on the cytogenetics and molecular genetics of bone and soft tissue tumors. Dermatofibrosarcoma protuberans and giant cell fibroblastoma. *Cancer Genet Cytogenet*. 2003;140(1):1-12.
1320. Sirvent N, Maire G, Pedeutour F. Genetics of dermatofibrosarcoma protuberans family of tumors: from ring chromosomes to tyrosine kinase inhibitor treatment. *Genes Chromosomes Cancer*. 2003;37(1):1-19.
1321. Maire G, Pedeutour F, Coindre JM. COL1A1-PDGFB gene fusion demonstrates a common histogenetic origin for dermatofibrosarcoma protuberans and its granular cell variant. *Am J Surg Pathol*. 2002;26(7):932-937.
1322. Patel KU, Szabo SS, Hernandez VS, et al. Dermatofibrosarcoma protuberans COL1A1-PDGFB fusion is identified in virtually all dermatofibrosarcoma protuberans cases when investigated by newly developed multiplex reverse transcription polymerase chain reaction and fluorescence in situ hybridization assays. *Hum Pathol*. 2008;39(2):184-193.
1323. Bowne WB, Antonescu CR, Leung DH, et al. Dermatofibrosarcoma protuberans: A clinicopathologic analysis of patients treated and followed at a single institution. *Cancer*. 2000;88(12):2711-2720.
1324. Taylor HB, Helwig EB. Dermatofibrosarcoma protuberans. A study of 115 cases. *Cancer*. 1962;15:717-725.
1325. Adams JT, Saltzstein SL. Metastasizing dermatofibrosarcoma protuberans: report of two cases. *Am Surg*. 1963;29:878-886.
1326. Rutkowski P, Van Glabbeke M, Rankin CJ, et al. Imatinib mesylate in advanced dermatofibrosarcoma protuberans: pooled analysis of two phase II clinical trials. *J Clin Oncol*. 2010;28(10):1772-1779.
1327. Billings SD, Folpe AL. Cutaneous and subcutaneous fibrohistiocytic tumors of intermediate malignancy: an update. *Am J Dermatopathol*. 2004;26(2):141-155.
1328. Alguacil-Garcia A. Giant cell fibroblastoma recurring as dermatofibrosarcoma protuberans. *Am J Surg Pathol*. 1991;15(8):798-801.
1329. Beham A, Fletcher CD. Dermatofibrosarcoma protuberans with areas resembling giant cell fibroblastoma: report of two cases. *Histopathology*. 1990;17(2):165-167.
1330. Shmookler BM, Enzinger FM, Weiss SW. Giant cell fibroblastoma. A juvenile form of dermatofibrosarcoma protuberans. *Cancer*. 1989;64(10):2154-2161.
1331. Rubin BP, Fletcher JA, Fletcher CD. The histologic, genetic, and biological relationships between dermatofibrosarcoma protuberans and giant cell fibroblastoma: an unexpected story. *Adv Anat Pathol*. 1997;4:336-341.
1332. Connelly JH, Evans HL. Dermatofibrosarcoma protuberans. A clinicopathologic review with emphasis on

fibrosarcomatous areas. *Am J Surg Pathol*. 1992;16(10):921-925.
1333. Goldblum JR, Reith JD, Weiss SW. Sarcomas arising in dermatofibrosarcoma protuberans: a reappraisal of biologic behavior in eighteen cases treated by wide local excision with extended clinical follow up. *Am J Surg Pathol*. 2000;24(8):1125-1130.
1334. Mentzel T, Beham A, Katenkamp D, et al. Fibrosarcomatous ("high-grade") dermatofibrosarcoma protuberans: clinicopathologic and immunohistochemical study of a series of 41 cases with emphasis on prognostic significance. *Am J Surg Pathol*. 1998;22(5):576-587.
1335. Abbott JJ, Oliveira AM, Nascimento AG. The prognostic significance of fibrosarcomatous transformation in dermatofibrosarcoma protuberans. *Am J Surg Pathol*. 2006;30(4):436-443.
1336. O'Dowd J, Laidler P. Progression of dermatofibrosarcoma protuberans to malignant fibrous histiocytoma: report of a case with implications for tumor histogenesis. *Hum Pathol*. 1988;19(3):368-370.
1337. Eisen RN, Tallini G. Metastatic dermatofibrosarcoma protuberans with fibrosarcomatous change in the absence of local recurrence. A case report of simultaneous occurrence with a malignant giant cell tumor of soft parts. *Cancer*. 1993;72(2):462-468.
1338. Ding JA, Hashimoto H, Sugimoto T, et al. Bednar tumor (pigmented dermatofibrosarcoma protuberans). An analysis of six cases. *Acta Pathol Jpn*. 1990;40(10):744-754.
1339. Onoda N, Tsutsumi Y, Kakudo K, et al. Pigmented dermatofibrosarcoma protuberans (Bednar tumor). An autopsy case with systemic metastasis. *Acta Pathol Jpn*. 1990;40(12):935-940.
1340. Wick MR, Fitzgibbon J, Swanson PE. Cutaneous sarcomas and sarcomatoid neoplasms of the skin. *Semin Diagn Pathol*. 1993;10(2):148-158.
1341. Routh A, Hickman BT, Johnson WW. Malignant fibrous histiocytoma arising from chronic ulcer. *Arch Dermatol*. 1985;121(4):529-531.
1342. Mansoor A, White CR Jr. Myxofibrosarcoma presenting in the skin: clinicopathological features and differential diagnosis with cutaneous myxoid neoplasms. *Am J Dermatopathol*. 2003;25(4):281-286.
1343. Husain S, Silvers DN, Halperin AJ, McNutt NS. Histologic spectrum of neurothekeoma and the value of immunoperoxidase staining for S-100 protein in distinguishing it from melanoma. *Am J Dermatopathol*. 1994;16(5):496-503.
1344. Marrogi AJ, Dehner LP, Coffin CM, Wick MR. Atypical fibrous histiocytoma of the skin and subcutis in childhood and adolescence. *J Cutan Pathol*. 1992;19(4):268-277.
1345. Altman J, Winkelman RI. Xanthoma disseminatum. *Arch Dermatol Res*. 1962;86:582-596.
1346. Breier F, Zelger B, Reiter H, et al. Papular xanthoma: a clinicopathological study of 10 cases. *J Cutan Pathol*. 2002;29(4): 200-206.
1347. Cooper PH. Eruptive xanthoma: a microscopic simulant of granuloma annulare. *J Cutan Pathol*. 1986;13(3):207-215.
1348. Duray PH, Johnston YE. Verruciform xanthoma of the nose in an elderly male. *Am J Dermatopathol*. 1986;8(3):237-240.
1349. Mohsin SK, Lee MW, Amin MB, et al. Cutaneous verruciform xanthoma: a report of five cases investigating the etiology and nature of xanthomatous cells. *Am J Surg Pathol*. 1998;22(4):479-487.
1350. Dehner LP. Juvenile xanthogranulomas in the first two decades of life: a clinicopathologic study of 174 cases with cutaneous and extracutaneous manifestations. *Am J Surg Pathol*. 2003;27(5):579-593.
1351. Janney CG, Hurt MA, Santa Cruz DJ. Deep juvenile xanthogranuloma. Subcutaneous and intramuscular forms. *Am J Surg Pathol*. 1991;15(2):150-159.
1352. George DH, Scheithauer BW, Hilton DL, et al. Juvenile xanthogranuloma of peripheral nerve: a report of two cases. *Am J Surg Pathol*. 2001;25(4):521-526.
1353. Senger C, Gonzalez-Crussi F. Testicular juvenile xanthogranuloma: a case report. *J Urol Pathol*. 1999;10:159-168.
1354. Shin SJ, Scamman W, Gopalan A, Rosen PP. Mammary presentation of adult-type "juvenile" xanthogranuloma. *Am J Surg Pathol*. 2005;29(6):827-831.
1355. Sonoda T, Hashimoto H, Enjoji M. Juvenile xanthogranuloma. Clinicopathologic analysis and immunohistochemical study of 57 patients. *Cancer*. 1985;56(9):2280-2286.
1356. Sangueza OP, Requena L. Neoplasms with neural differentiation: a review. Part II: Malignant neoplasms. *Am J Dermatopathol*. 1998;20(1):89-102.
1357. Zelger B, Cerio R, Orchard G, Wilson-Jones E. Juvenile and adult xanthogranuloma. A histological and immunohistochemical comparison. *Am J Surg Pathol*. 1994;18(2):126-135.
1358. Tahan SR, Pastel-Levy C, Bhan AK, Mihm MC Jr. Juvenile xanthogranuloma. Clinical and pathologic characterization. *Arch Pathol Lab Med*. 1989;113(9):1057-1061.
1359. Sangueza OP, Salmon JK, White CR Jr, Beckstead JH. Juvenile xanthogranuloma: a clinical, histopathologic and immunohistochemical study. *J Cutan Pathol*. 1995;22(4):327-335.
1360. Marrogi AJ, Dehner LP, Coffin CM, Wick MR. Benign cutaneous histiocytic tumors in childhood and adolescence, excluding Langerhans' cell proliferations. A clinicopathologic and immunohistochemical analysis. *Am J Dermatopathol*. 1992;14(1):8-18.
1361. Janssen D, Harms D. Juvenile xanthogranuloma in childhood and adolescence: a clinicopathologic study of 129 patients from the Kiel pediatric tumor registry. *Am J Surg Pathol*. 2005;29(1):21-28.
1362. Kraus MD, Haley JC, Ruiz R, et al. "Juvenile" xanthogranuloma: an immunophenotypic study with a reappraisal of histogenesis. *Am J Dermatopathol*. 2001;23(2):104-111.
1363. Nascimento AG. A clinicopathologic and immunohistochemical comparative study of cutaneous and intramuscular forms of juvenile xanthogranuloma. *Am J Surg Pathol*. 1997;21(6):645-652.
1364. Busam KJ, Rosai J, Iversen K, Jungbluth AA. Xanthogranulomas with inconspicuous foam cells and giant cells mimicking malignant melanoma: a clinical, histologic, and immunohistochemical study of three cases. *Am J Surg Pathol*. 2000;24(6):864-869.
1365. Zelger BW, Staudacher C, Orchard G, et al. Solitary and generalized variants of spindle cell xanthogranuloma (progressive nodular histiocytosis). *Histopathology*. 1995;27(1):11-19.
1366. Alexis JB, Poppiti RJ, Turbat-Herrera E, Smith MD. Congenital self-healing reticulohistiocytosis. Report of a case with 7-year follow-up and a review of the literature. *Am J Dermatopathol*. 1991;13(2):189-194.
1367. Caputo R, Alessi E, Berti E. Cutaneous histiocytoses in children. Histopathologic, ultrastructural, and immunohistochemical findings. *Prog Surg Pathol*. 1989;10:111-126.
1368. Barrow MV, Holubar K. Multicentric reticulohistiocytosis. A review of 33 patients. *Medicine (Baltimore)*. 1969;48(4):287-305.
1369. Luz FB, Gaspar TAP, Kalil-Gaspar N, Ramos-e-Silva M. Multicentric reticulohistiocytosis. *J Eur Acad Dermatol Venereol*. 2001;15(6):524-531.
1370. Purvis WE 3rd, Helwig EB. Reticulohistiocytic granuloma (reticulohistiocytoma) of the skin. *Am J Clin Pathol*. 1954;24(9):1005-1015.
1371. Salisbury JR, Hall PA, Williams HC, et al. Multicentric reticulohistiocytosis. Detailed immunophenotyping confirms macrophage origin. *Am J Surg Pathol*. 1990;14(7):687-693.
1372. Perrin C, Lacour JP, Michiels JF, et al. Multicentric reticulohistiocytosis. Immunohistological and ultrastructural study: a pathology of dendritic cell lineage. *Am J Dermatopathol*. 1992;14(5):418-425.
1373. Zelger B, Cerio R, Soyer HP, et al. Reticulohistiocytoma and multicentric reticulohistiocytosis. Histopathologic and immunophenotypic distinct entities. *Am J Dermatopathol*. 1994;16(6):577-584.
1374. Thawerani H, Sanchez RL, Rosai J, Dorfman RF. The cutaneous manifestations of sinus histiocytosis with massive lymphadenopathy. *Arch Dermatol*. 1978;114(2):191-197.
1375. Brenn T, Calonje E, Granter SR, et al. Cutaneous rosai-dorfman disease is a distinct clinical entity. *Am J Dermatopathol*. 2002;24(5):385-391.
1376. Chu P, LeBoit PE. Histologic features of cutaneous sinus histiocytosis (Rosai-Dorfman disease): study of cases both with and without systemic involvement. *J Cutan Pathol*. 1992;19(3):201-206.
1377. Kong YY, Kong JC, Shi DR, et al. Cutaneous rosai-dorfman disease: a clinical and histopathologic study of 25 cases in China. *Am J Surg Pathol*. 2007;31(3):341-350.
1378. Lu CI, Kuo TT, Wong WR, Hong HS. Clinical and histopathologic spectrum of cutaneous Rosai-Dorfman disease in Taiwan. *J Am Acad Dermatol*. 2004;51(6):931-939.
1379. Raj S, Calonje E, Kraus M, et al. Cutaneous pilar leiomyoma: clinicopathologic analysis of 53 lesions in 45 patients. *Am J Dermatopathol*. 1997;19(1):2-9.
1380. Hachisuga T, Hashimoto H, Enjoji M. Angioleiomyoma. A clinicopathologic reappraisal of 562 cases. *Cancer*. 1984;54(1):126-130.
1381. Kawagishi N, Kashiwagi T, Ibe M, et al. Pleomorphic angioleiomyoma. *Am J Dermatopathol*. 2000;22(3):268-271.
1382. Mahalingam M, Goldberg LJ. Atypical pilar leiomyoma: cutaneous counterpart of uterine symplastic leiomyoma? *Am J Dermatopathol*. 2001;23(4):299-303.
1383. Kiuru M, Launonen V, Hietala M, et al. Familial cutaneous leiomyomatosis is a two-hit condition associated with renal cell cancer of characteristic histopathology. *Am J Pathol*. 2001;159(3):825-829.
1384. Martínek P, Grossmann P, Hes O, et al. Genetic testing of leiomyoma tissue in women younger than 30 years old might provide an effective screening approach for the hereditary leiomyomatosis and renal cell cancer syndrome (HLRCC). *Virchows Arch*. 2015;467(2):185-191.
1385. Dahl I, Angervall L. Cutaneous and subcutaneous leiomyosarcoma. A clinicopathologic study of 47 patients. *Pathol Eur*. 1974;9(4):307-315.
1386. Fields JP, Helwig EB. Leiomyosarcoma of the skin and subcutaneous tissue. *Cancer*. 1981;47(1):156-169.
1387. Kaddu S, Beham A, Cerroni L, et al. Cutaneous leiomyosarcoma. *Am J Surg Pathol*. 1997;21(9):979-987.
1388. Varela-Duran J, Oliva H, Rosai J. Vascular leiomyosarcoma: the malignant

counterpart of vascular leiomyoma. *Cancer*. 1979;44(5):1684-1691.
1389. Massi D, Biancalani M, Franchi A, Santucci M. Clear-cell smooth muscle tumor of the skin. *Mod Pathol*. 1998;11(10):1021-1025.
1390. Suster S. Epithelioid leiomyosarcoma of the skin and subcutaneous tissue. Clinicopathologic, immunohistochemical, and ultrastructural study of five cases. *Am J Surg Pathol*. 1994;18(3):232-240.
1391. Diaz-Cascajo C, Borghi S, Weyers W. Desmoplastic leiomyosarcoma of the skin. *Am J Dermatopathol*. 2000;22(3):251-255.
1392. Bellezza G, Sidoni A, Cavaliere A, et al. Primary cutaneous leiomyosarcoma: a clinicopathological and immunohistochemical study of 7 cases. *Int J Surg Pathol*. 2004;12(1):39-44.
1393. Massi D, Franchi A, Alos L, et al. Primary cutaneous leiomyosarcoma: clinicopathological analysis of 36 cases. *Histopathology*. 2010;56(2):251-262.
1394. Kraft S, Fletcher CD. Atypical intradermal smooth muscle neoplasms: clinicopathologic analysis of 84 cases and a reappraisal of cutaneous "leiomyosarcoma". *Am J Surg Pathol*. 2011;35(4):599-607.
1395. McCalmont TH. What's in a name? *J Cutan Pathol*. 2013;40(7):621-622.
1396. Orlow SJ, Kamino H, Lawrence RL. Multiple subcutaneous leiomyosarcomas in an adolescent with AIDS. *Am J Pediatr Hematol Oncol*. 1992;14(3):265-268.
1397. Fernanadez MP. No evidence of Epstein–Barr virus association with angioleiomyomas, pilar leiomyomas or cutaneous leiomyosarcomas in immunocompetent individuals. *Lab Invest*. 2009;89:103A.
1398. Farris PE, Manning S, Vuitch F. Rhabdomyomatous mesenchymal hamartoma. *Am J Dermatopathol*. 1994;16(1):73-75.
1399. Sanchez RL, Raimer SS. Clinical and histologic features of striated muscle hamartoma: possible relationship to Delleman's syndrome. *J Cutan Pathol*. 1994;21(1):40-46.
1400. O'Connell JX, Rosenberg AE. Multiple cutaneous neuromuscular choristomas. Report of a case and a review of the literature. *Am J Surg Pathol*. 1990;14(1):93-96.
1401. Sahn EE, Garen PD, Pai GS, et al. Multiple rhabdomyomatous mesenchymal hamartomas of skin. *Am J Dermatopathol*. 1990;12(5):485-491.
1402. Verdolini R, Goteri G, Brancorsini D, et al. Adult rhabdomyoma: report of two cases of rhabdomyoma of the lip and of the eyelid. *Am J Dermatopathol*. 2000;22(3):264-267.
1403. Marburger TB, Gardner JM, Prieto VG, Billings SD. Primary cutaneous rhabdomyosarcoma: a clinicopathologic review of 11 cases. *J Cutan Pathol*. 2012;39(11):987-995.
1404. Hoang MP, Sinkre P, Albores-Saavedra J. Rhabdomyosarcoma arising in a congenital melanocytic nevus. *Am J Dermatopathol*. 2002;24(1):26-29.
1405. Chaudhry IH, Calonje E. Dermal non-neural granular cell tumour (so-called primitive polypoid granular cell tumour): a distinctive entity further delineated in a clinicopathological study of 11 cases. *Histopathology*. 2005;47(2):179-185.
1406. Lazar AJ, Fletcher CD. Primitive nonneural granular cell tumors of skin: clinicopathologic analysis of 13 cases. *Am J Surg Pathol*. 2005;29(7):927-934.
1407. Requena L, Sangueza OP. Benign neoplasms with neural differentiation: a review. *Am J Dermatopathol*. 1995;17(1):75-96.
1408. del Rio E, Sanchez Yus E, Simon P, Vazquez Veiga HA. Stimulation of folliculo-sebaceous proliferations by neurofibromas: a report of two cases. *J Cutan Pathol*. 1998;25(4):228-232.
1409. Beer TW. Reparative perineural hyperplasia: a series of 10 cases. *Am J Dermatopathol*. 2009;31(1):50-52.
1410. Urabe A, Tsuneyoshi M, Enjoji M. Epithelioid hemangioma versus Kimura's disease. A comparative clinicopathologic study. *Am J Surg Pathol*. 1987;11(10):758-766.
1411. Gallager RL, Helwig EB. Neurothekeoma—a benign cutaneous tumor of neural origin. *Am J Clin Pathol*. 1980;74(6):759-764.
1412. Holden CA, Wilson-Jones E, MacDonald DM. Cutaneous lobular neuromyxoma. *Br J Dermatol*. 1982;106(2):211-215.
1413. Fletcher CD, Chan JK, McKee PH. Dermal nerve sheath myxoma: a study of three cases. *Histopathology*. 1986;10(2):135-145.
1414. Argenyi ZB, LeBoit PE, Santa Cruz D, et al. Nerve sheath myxoma (neurothekeoma) of the skin: light microscopic and immunohistochemical reappraisal of the cellular variant. *J Cutan Pathol*. 1993;20(4):294-303.
1415. Fetsch JF, Laskin WB, Hallman JR, et al. Neurothekeoma: an analysis of 178 tumors with detailed immunohistochemical data and long-term patient follow-up information. *Am J Surg Pathol*. 2007;31(7):1103-1114.
1416. Hornick JL, Fletcher CD. Cellular neurothekeoma: detailed characterization in a series of 133 cases. *Am J Surg Pathol*. 2007;31(3):329-340.
1417. Page RN, King R, Mihm MC Jr, Googe PB. Microphthalmia transcription factor and NKI/C3 expression in cellular neurothekeoma. *Mod Pathol*. 2004;17(2):230-234.
1418. Plaza JA, Torres-Cabala C, Evans H, et al. Immunohistochemical expression of S100A6 in cellular neurothekeoma: clinicopathologic and immunohistochemical analysis of 31 cases. *Am J Dermatopathol*. 2009;31(5):419-422.
1419. Wang AR, May D, Bourne P, Scott G. PGP9.5: a marker for cellular neurothekeoma. *Am J Surg Pathol*. 1999;23(11):1401-1407.
1420. Stratton J, Billings SD. Cellular neurothekeoma: analysis of 37 cases emphasizing atypical histologic features. *Mod Pathol*. 2014;27(5):701-710.
1421. Barnhill RL, Mihm MC Jr. Cellular neurothekeoma. A distinctive variant of neurothekeoma mimicking nevomelanocytic tumors. *Am J Surg Pathol*. 1990;14(2):113-120.
1422. Busam KJ, Mentzel T, Colpaert C, et al. Atypical or worrisome features in cellular neurothekeoma: a study of 10 cases. *Am J Surg Pathol*. 1998;22(9):1067-1072.
1423. Jaffer S, Ambrosini-Spaltro A, Mancini AM, et al. Neurothekeoma and plexiform fibrohistiocytic tumor: mere histologic resemblance or histogenetic relationship? *Am J Surg Pathol*. 2009;33(6):905-913.
1424. Megahed M. Palisaded encapsulated neuroma (solitary circumscribed neuroma). A clinicopathologic and immunohistochemical study. *Am J Dermatopathol*. 1994;16(2):120-125.
1425. Reed RJ, Fine RM, Meltzer HD. Palisaded, encapsulated neuromas of the skin. *Arch Dermatol*. 1972;106(6):865-870.
1426. Tsang WY, Chan JK. Epithelioid variant of solitary circumscribed neuroma of the skin. *Histopathology*. 1992;20(5):439-441.
1427. Argenyi ZB. Immunohistochemical characterization of palisaded, encapsulated neuroma. *J Cutan Pathol*. 1990;17(6):329-335.
1428. Fletcher CD. Solitary circumscribed neuroma of the skin (so-called palisaded, encapsulated neuroma). A clinicopathologic and immunohistochemical study. *Am J Surg Pathol*. 1989;13(7):574-580.
1429. Requena L, Grosshans E, Kutzner H, et al. Epithelial sheath neuroma: a new entity. *Am J Surg Pathol*. 2000;24(2):190-196.
1430. Lin TY, Zhang AY, Bayer-Garner IB, et al. Epithelial sheath neuroma: a case report and discussion of the literature. *Am J Dermatopathol*. 2006;28(3):216-219.
1431. Mentzel T, Kutzner H. Reticular and plexiform perineurioma:clinicopathological and immunohistochemical analysis of two cases and review of perineurial neoplasms of skin and soft tissues. *Virchows Arch*. 2005;447(4):677-682.
1432. Pina-Oviedo S, Ortiz-Hidalgo C. The normal and neoplastic perineurium: a review. *Adv Anat Pathol*. 2008;15(3):147-164.
1433. Fetsch JF, Miettinen M. Sclerosing perineurioma: a clinicopathologic study of 19 cases of a distinctive soft tissue lesion with a predilection for the fingers and palms of young adults. *Am J Surg Pathol*. 1997;21(12):1433-1442.
1434. Robson AM, Calonje E. Cutaneous perineurioma: a poorly recognized tumour often misdiagnosed as epithelioid histiocytoma. *Histopathology*. 2000;37(4):332-339.
1435. Allison KH, Patel RM, Goldblum JR, Rubin BP. Superficial malignant peripheral nerve sheath tumor: a rare and challenging diagnosis. *Am J Clin Pathol*. 2005;124(5):685-692.
1436. Thomas C, Somani N, Owen LG, et al. Cutaneous malignant peripheral nerve sheath tumors. *J Cutan Pathol*. 2009;36(8): 896-900.
1437. Johnson WC. Pathology of cutaneous vascular tumors. *Int J Dermatol*. 1976;15(4):239-270.
1438. Ryan TJ, Cherry GW. *Vascular Birthmarks. Pathogenesis and Management*. New York, NY: Oxford University Press; 1987.
1439. Tsang WY, Chan JK, Fletcher CD. Recently characterized vascular tumours of skin and soft tissues. *Histopathology*. 1991;19(6):489-501.
1440. Goh SG, Calonje E. Cutaneous vascular tumours: an update. *Histopathology*. 2008;52(6):661-673.
1441. Imperial R, Helwig EB. Angiokeratoma. A clinicopathological study. *Arch Dermatol*. 1967;95(2):166-175.
1442. Imperial R, Helwig EB. Verrucous hemangioma. A clinicopathologic study of 21 cases. *Arch Dermatol*. 1967;96(3):247-253.
1443. Connelly MG, Winkelmann RK. Acral arteriovenous tumor. A clinicopathologic review. *Am J Surg Pathol*. 1985;9(1):15-21.
1444. Koutlas IG, Jessurun J. Arteriovenous hemangioma: a clinicopathological and immunohistochemical study. *J Cutan Pathol*. 1994;21(4):343-349.
1445. Aloi F, Tomasini C, Pippione M. Microvenular hemangioma. *Am J Dermatopathol*. 1993;15(6):534-538.
1446. Hunt SJ, Santa Cruz DJ, Barr RJ. Microvenular hemangioma. *J Cutan Pathol*. 1991;18(4):235-240.
1447. Napekoski KM, Fernandez AP, Billings SD. Microvenular hemangioma: a clinicopathologic review of 13 cases. *J Cutan Pathol*. 2014;41(11):816-822.
1448. Chan JK, Fletcher CD, Hicklin GA, Rosai J. Glomeruloid hemangioma. A distinctive cutaneous lesion of multicentric Castleman's disease associated with POEMS syndrome. *Am J Surg Pathol*. 1990;14(11):1036-1046.
1449. Kishimoto S, Takenaka H, Shibagaki R, et al. Glomeruloid hemangioma in POEMS syndrome shows two different immunophenotypic endothelial cells. *J Cutan Pathol*. 2000;27(2):87-92.

1450. Lee H, Meier FA, Ma CK, et al. Eosinophilic globules in 3 cases of glomeruloid hemangioma of the head and neck: a characteristic offering more evidence for thanatosomes with or without POEMS. *Am J Dermatopathol*. 2008;30(6):539-544.
1451. Yuri T, Yamazaki F, Takasu K, et al. Glomeruloid hemangioma. *Pathol Int*. 2008;58(6):390-395.
1452. Suurmeijer AJ, Fletcher CD. Papillary haemangioma. A distinctive cutaneous haemangioma of the head and neck area containing eosinophilic hyaline globules. *Histopathology*. 2007;51(5):638-648.
1453. Suurmeijer AJ. Papillary hemangiomas and glomeruloid hemangiomas are distinct clinicopathological entities. *Int J Surg Pathol*. 2010;18(1):48-54.
1454. Guillou L, Calonje E, Speight P, et al. Hobnail hemangioma: a pseudomalignant vascular lesion with a reappraisal of targetoid hemosiderotic hemangioma. *Am J Surg Pathol*. 1999;23(1):97-105.
1455. Mentzel T, Partanen TA, Kutzner H. Hobnail hemangioma ("targetoid hemosiderotic hemangioma"): clinicopathologic and immunohistochemical analysis of 62 cases. *J Cutan Pathol*. 1999;26(6):279-286.
1456. Requena L, Kutzner H, Mentzel T. Acquired elastotic hemangioma: a clinicopathologic variant of hemangioma. *J Am Acad Dermatol*. 2002;47(3):371-376.
1457. Goh SG, Dayrit JF, Calonje E. Symplastic hemangioma: report of two cases. *J Cutan Pathol*. 2006;33(11):735-740.
1458. Brenn T, Fletcher CD. Cutaneous epithelioid angiomatous nodule: a distinct lesion in the morphologic spectrum of epithelioid vascular tumors. *Am J Dermatopathol*. 2004;26(1):14-21.
1459. Mentzel T, Dei Tos AP, Sapi Z, Kutzner H. Myopericytoma of skin and soft tissues: clinicopathologic and immunohistochemical study of 54 cases. *Am J Surg Pathol*. 2006;30(1):104-113.
1460. Peachey RD, Lim CC, Whimster IW. Lymphangioma of skin. A review of 65 cases. *Br J Dermatol*. 1970;83(5):519-527.
1461. Flanagan BP, Helwig EB. Cutaneous lymphangioma. *Arch Dermatol*. 1977;113(1):24-30.
1462. Whimster IW. The pathology of lymphangioma circumscriptum. *Br J Dermatol*. 1976;94(5):473-486.
1463. Guillou L, Fletcher CDM. Benign lymphangioendothelioma (acquired progressive lymphangioma): a lesion not to be confused with well-differentiated angiosarcoma and patch stage Kaposi's sarcoma: clinicopathologic analysis of a series. *Am J Surg Pathol*. 2000;24:1047-1057.
1464. Watanabe M, Kishiyama K, Ohkawara A. Acquired progressive lymphangioma. *J Am Acad Dermatol*. 1983;8(5):663-667.
1465. Cossu S, Satta R, Cottoni F, Massarelli G. Lymphangioma-like variant of Kaposi's sarcoma: clinicopathologic study of seven cases with review of the literature. *Am J Dermatopathol*. 1997;19(1):16-22.
1466. Gange RW, Jones EW. Lymphangioma-like Kaposi's sarcoma. A report of three cases. *Br J Dermatol*. 1979;100(3):327-334.
1467. Requena L, El-Shabrawi-Caelen L, Walsh SN, et al. Intralymphatic histiocytosis. A clinicopathologic study of 16 cases. *Am J Dermatopathol*. 2009;31(2):140-151.
1468. Takiwaki H, Adachi A, Kohno H, Ogawa Y. Intravascular or intralymphatic histiocytosis associated with rheumatoid arthritis: a report of 4 cases. *J Am Acad Dermatol*. 2004;50(4):585-590.
1469. Hunt SJ. Two pyogenic granulomas arising in an epidermoid cyst. *Am J Dermatopathol*. 1989;11(4):360-363.
1470. Mills SE, Cooper PH, Fechner RE. Lobular capillary hemangioma: the underlying lesion of pyogenic granuloma. A study of 73 cases from the oral and nasal mucous membranes. *Am J Surg Pathol*. 1980;4(5):470-479.
1471. Nichols GE, Gaffey MJ, Mills SE, Weiss LM. Lobular capillary hemangioma. An immunohistochemical study including steroid hormone receptor status. *Am J Clin Pathol*. 1992;97(6):770-775.
1472. Kapadia SB, Heffner DK. Pitfalls in the histopathologic diagnosis of pyogenic granuloma. *Eur Arch Otorhinolaryngol*. 1992;249(4):195-200.
1473. Renshaw AA, Rosai J. Benign atypical vascular lesions of the lip. A study of 12 cases. *Am J Surg Pathol*. 1993;17(6):557-565.
1474. Warner J, Jones EW. Pyogenic granuloma recurring with multiple satellites. A report of 11 cases. *Br J Dermatol*. 1968;80(4):218-227.
1475. Nappi O, Wick MR. Disseminated lobular capillary hemangioma (pyogenic granuloma). A clinicopathologic study of two cases. *Am J Dermatopathol*. 1986;8(5):379-385.
1476. Swerlick RA, Cooper PH. Pyogenic granuloma (lobular capillary hemangioma) within port-wine stains. *J Am Acad Dermatol*. 1983;8(5):627-630.
1477. Cooper PH, Mills SE. Subcutaneous granuloma pyogenicum. Lobular capillary hemangioma. *Arch Dermatol*. 1982;118(1):30-33.
1478. Cooper PH, McAllister HA, Helwig EB. Intravenous pyogenic granuloma. A study of 18 cases. *Am J Surg Pathol*. 1979;3(3):221-228.
1479. Padilla RS, Orkin M, Rosai J. Acquired "tufted" angioma (progressive capillary hemangioma). A distinctive clinicopathologic entity related to lobular capillary hemangioma. *Am J Dermatopathol*. 1987;9(4):292-300.
1480. Jones EW, Orkin M. Tufted angioma (angioblastoma). A benign progressive angioma, not to be confused with Kaposi's sarcoma or low-grade angiosarcoma. *J Am Acad Dermatol*. 1989;20(2 Pt 1):214-225.
1481. Le Huu AR, Jokinen CH, Rubin BP, et al. Expression of prox1, lymphatic endothelial nuclear transcription factor, in Kaposiform hemangioendothelioma and tufted angioma. *Am J Surg Pathol*. 2010;34(11):1563-1573.
1482. Barr RJ, Graham JH, Sherwin LA. Intravascular papillary endothelial hyperplasia. A benign lesion mimicking angiosarcoma. *Arch Dermatol*. 1978;114(5):723-726.
1483. Clearkin KP, Enzinger FM. Intravascular papillary endothelial hyperplasia. *Arch Pathol Lab Med*. 1976;100(8):441-444.
1484. Hashimoto H, Daimaru Y, Enjoji M. Intravascular papillary endothelial hyperplasia. A clinicopathologic study of 91 cases. *Am J Dermatopathol*. 1983;5(6):539-546.
1485. Kuo T, Sayers CP, Rosai J. Masson's "vegetant intravascular hemangioendothelioma:" a lesion often mistaken for angiosarcoma: study of seventeen cases located in the skin and soft tissues. *Cancer*. 1976;38(3):1227-1236.
1486. Albrecht S, Kahn HJ. Immunohistochemistry of intravascular papillary endothelial hyperplasia. *J Cutan Pathol*. 1990;17(1): 16-21.
1487. Castro C, Winkelmann RK. Angiolymphoid hyperplasia with eosinophilia in the skin. *Cancer*. 1974;34(5):1696-1705.
1488. Olsen TG, Helwig EB. Angiolymphoid hyperplasia with eosinophilia. A clinicopathologic study of 116 patients. *J Am Acad Dermatol*. 1985;12(5 Pt 1):781-796.
1489. Chan JK, Hui PK, Ng CS, et al. Epithelioid haemangioma (angiolymphoid hyperplasia with eosinophilia) and Kimura's disease in Chinese. *Histopathology*. 1989;15(6):557-574.
1490. Chen H, Thompson LD, Aguilera NS, Abbondanzo SL. Kimura disease: a clinicopathologic study of 21 cases. *Am J Surg Pathol*. 2004;28(4):505-513.
1491. Burrall BA, Barr RJ, King DF. Cutaneous histiocytoid hemangioma. *Arch Dermatol*. 1982;118(3):166-170.
1492. Fetsch JF, Weiss SW. Observations concerning the pathogenesis of epithelioid hemangioma (angiolymphoid hyperplasia). *Mod Pathol*. 1991;4(4):449-455.
1493. Ko JS, Billings SD. Diagnostically challenging epithelioid vascular tumors. *Surg Pathol Clin*. 2015;8(3):331-351.
1494. Mentzel T, Beham A, Calonje E, et al. Epithelioid hemangioendothelioma of skin and soft tissues: clinicopathologic and immunohistochemical study of 30 cases. *Am J Surg Pathol*. 1997;21(4):363-374.
1495. Quante M, Patel NK, Hill S, et al. Epithelioid hemangioendothelioma presenting in the skin: a clinicopathologic study of eight cases. *Am J Dermatopathol*. 1998;20(6):541-546.
1496. Resnik KS, Kantor GR, Spielvogel RL, Ryan E. Cutaneous epithelioid hemangioendothelioma without systemic involvement. *Am J Dermatopathol*. 1993;15(3):272-276.
1497. Marrogi AJ, Hunt SJ, Cruz DJ. Cutaneous epithelioid angiosarcoma. *Am J Dermatopathol*. 1990;12(4):350-356.
1498. O'Connell JX, Kattapuram SV, Mankin HJ, et al. Epithelioid hemangioma of bone. A tumor often mistaken for low-grade angiosarcoma or malignant hemangioendothelioma. *Am J Surg Pathol*. 1993;17(6):610-617.
1499. Ackerman LV, Murray JF. Symposium on Kaposi's sarcoma. *Acta Un Int Cancer*. 1962;18:312-511.
1500. Hiatt KM, Nelson AM, Lichy JH, Fanburg-Smith JC. Classic Kaposi Sarcoma in the United States over the last two decades: a clinicopathologic and molecular study of 438 non-HIV-related Kaposi Sarcoma patients with comparison to HIV-related Kaposi Sarcoma. *Mod Pathol*. 2008;21(5):572-582.
1501. Iscovich J, Boffetta P, Franceschi S, et al. Classic kaposi sarcoma: epidemiology and risk factors. *Cancer*. 2000;88(3):500-517.
1502. Akhtar M, Bunuan H, Ali MA, Godwin JT. Kaposi's sarcoma in renal transplant recipients. Ultrastructural and immunoperoxidase study of four cases. *Cancer*. 1984;53(2):258-266.
1503. Antman K, Chang Y. Kaposi's sarcoma. *N Engl J Med*. 2000;342(14):1027-1038.
1504. Stribling J, Weitzner S, Smith GV. Kaposi's sarcoma in renal allograft recipients. *Cancer*. 1978;42(2):442-446.
1505. Frizzera G, Banks PM, Massarelli G, Rosai J. A systemic lymphoproliferative disorder with morphologic features of Castleman's disease. Pathological findings in 15 patients. *Am J Surg Pathol*. 1983;7(3):211-231.
1506. Varsano S, Manor Y, Steiner Z, et al. Kaposi's sarcoma and angioimmunoblastic lymphadenopathy. *Cancer*. 1984;54(8):1582-1585.
1507. Garrett TJ, Lange M, Ashford A, Thomas L. Kaposi's sarcoma in heterosexual intravenous drug users. *Cancer*. 1985;55(5):1146-1148.
1508. Safai B, Mike V, Giraldo G, et al. Association of Kaposi's sarcoma with second primary malignancies: possible etiopathogenic implications. *Cancer*. 1980;45(6):1472-1479.
1509. Ioachim HL, Adsay V, Giancotti FR, et al. Kaposi's sarcoma of internal organs. A multiparameter study of 86 cases. *Cancer*. 1995;75(6):1376-1385.
1510. Parfitt JR, Rodriguez-Justo M, Feakins R, Novelli MR. Gastrointestinal Kaposi's

sarcoma: CD117 expression and the potential for misdiagnosis as gastrointestinal stromal tumour. *Histopathology*. 2008;52(7): 816-823.
1511. Sunter JP. Visceral Kaposi's sarcoma. Occurrence in a patient suffering from celiac disease. *Arch Pathol Lab Med*. 1978;102(10):543-545.
1512. Brenner B, Weissmann-Brenner A, Rakowsky E, et al. Classical Kaposi sarcoma: prognostic factor analysis of 248 patients. *Cancer*. 2002;95(9):1982-1987.
1513. Baldassano MF, Bailey EM, Ferry JA, et al. Cutaneous lymphoid hyperplasia and cutaneous marginal zone lymphoma: comparison of morphologic and immunophenotypic features. *Am J Surg Pathol*. 1999;23(1):88-96.
1514. Taylor JF, Templeton AC, Vogel CL, Ziegler JL. Kyalwazi SK. Kaposi's sarcoma in Uganda: a clinico-pathological study. *Int J Cancer*. 1971;8(1):122-135.
1515. Krigel RL, Friedman-Kien AE. Epidemic Kaposi's sarcoma. *Semin Oncol*. 1990;17(3):350-360.
1516. Ziegler JL, Templeton AC, Vogel CL. Kaposi's sarcoma: a comparison of classical, endemic, and epidemic forms. *Semin Oncol*. 1984;11(1):47-52.
1517. Lee WA, Hutchins GM. Cluster analysis of the metastatic patterns of human immunodeficiency virus-associated Kaposi's sarcoma. *Hum Pathol*. 1992;23(3):306-311.
1518. Fukunaga M, Silverberg SG. Hyaline globules in Kaposi's sarcoma: a light microscopic and immunohistochemical study. *Mod Pathol*. 1991;4(2):187-190.
1519. Kao GF, Johnson FB, Sulica VI. The nature of hyaline (eosinophilic) globules and vascular slits of Kaposi's sarcoma. *Am J Dermatopathol*. 1990;12(3):256-267.
1520. Ruszczak Z, Mayer-Da Silva A, Orfanos CE. Kaposi's sarcoma in AIDS. Multicentric angioneoplasia in early skin lesions. *Am J Dermatopathol*. 1987;9(5):388-398.
1521. Niedt GW, Myskowski PL, Urmacher C, et al. Histology of early lesions of AIDS-associated Kaposi's sarcoma. *Mod Pathol*. 1990;3(1):64-70.
1522. Way DL, Witte MH, Fiala M, et al. Endothelial transdifferentiated phenotype and cell-cycle kinetics of AIDS-associated Kaposi sarcoma cells. *Lymphology*. 1993;26(2):79-89.
1523. Folpe AL, Veikkola T, Valtola R, Weiss SW. Vascular endothelial growth factor receptor-3 (VEGFR-3): a marker of vascular tumors with presumed lymphatic differentiation, including Kaposi's sarcoma, kaposiform and Dabska-type hemangioendotheliomas, and a subset of angiosarcomas. *Mod Pathol*. 2000;13(2):180-185.
1524. Weninger W, Partanen TA, Breiteneder-Geleff S, et al. Expression of vascular endothelial growth factor receptor-3 and podoplanin suggests a lymphatic endothelial cell origin of Kaposi's sarcoma tumor cells. *Lab Invest*. 1999;79(2):243-251.
1525. Guarda LG, Silva EG, Ordonez NG, Smith JL Jr. Factor VIII in Kaposi's sarcoma. *Am J Clin Pathol*. 1981;76(2):197-200.
1526. Hoerl HD, Goldblum JR. Immunoreactivity pattern of CD31 and CD68 in 28 cases of Kaposi's sarcoma: evidence supporting endothelial differentiation in the spindle cell component. *Appl Immunohistochem*. 1997;5:173-178.
1527. Scully PA, Steinman HK, Kennedy C, et al. AIDS-related Kaposi's sarcoma displays differential expression of endothelial surface antigens. *Am J Pathol*. 1988;130(2):244-251.
1528. Zhang YM, Bachmann S, Hemmer C, et al. Vascular origin of Kaposi's sarcoma. Expression of leukocyte adhesion molecule-1, thrombomodulin, and tissue factor. *Am J Pathol*. 1994;144(1):51-59.
1529. Kahn HJ, Bailey D, Marks A. Monoclonal antibody D2-40, a new marker of lymphatic endothelium, reacts with Kaposi's sarcoma and a subset of angiosarcomas. *Mod Pathol*. 2002;15(4):434-440.
1530. Ablashi DV, Chatlynne LG, Whitman JE Jr, Cesarman E. Spectrum of Kaposi's sarcoma-associated herpesvirus, or human herpesvirus 8, diseases. *Clin Microbiol Rev*. 2002;15(3):439-464.
1531. Martinelli PT, Tyring SK. Human herpesvirus 8. *Dermatol Clin*. 2002;20(2):307-314, vii-viii.
1532. Geraminejad P, Memar O, Aronson I, et al. Kaposi's sarcoma and other manifestations of human herpesvirus 8. *J Am Acad Dermatol*. 2002;47(5):641-655, quiz 56-58.
1533. Parravicini C, Chandran B, Corbellino M, et al. Differential viral protein expression in Kaposi's sarcoma-associated herpesvirus-infected diseases: Kaposi's sarcoma, primary effusion lymphoma, and multicentric Castleman's disease. *Am J Pathol*. 2000;156(3):743-749.
1534. Sarid R, Klepfish A, Schattner A. Virology, pathogenetic mechanisms, and associated diseases of Kaposi sarcoma-associated herpesvirus (human herpesvirus 8). *Mayo Clin Proc*. 2002;77:941-949.
1535. Cheuk W, Wong KO, Wong CS, et al. Immunostaining for human herpesvirus 8 latent nuclear antigen-1 helps distinguish Kaposi sarcoma from its mimickers. *Am J Clin Pathol*. 2004;121(3):335-342.
1536. Patel RM, Goldblum JR, Hsi ED. Immunohistochemical detection of human herpes virus-8 latent nuclear antigen-1 is useful in the diagnosis of Kaposi sarcoma. *Mod Pathol*. 2004;17(4):456-460.
1537. Robin YM, Guillou L, Michels JJ, Coindre JM. Human herpesvirus 8 immunostaining: a sensitive and specific method for diagnosing Kaposi sarcoma in paraffin-embedded sections. *Am J Clin Pathol*. 2004;121(3):330-334.
1538. Auerbach HE, Brooks JJ. Kaposi's sarcoma. Neoplasia or hyperplasia? *Surg Pathol*. 1989;2:19-28.
1539. Fukunaga M, Silverberg SG. Kaposi's sarcoma in patients with acquired immune deficiency syndrome. A flow cytometric DNA analysis of 26 lesions in 21 patients. *Cancer*. 1990;66(4):758-764.
1540. Huang YQ, Li JJ, Moscatelli D, et al. Expression of int-2 oncogene in Kaposi's sarcoma lesions. *J Clin Invest*. 1993;91(3):1191-1197.
1541. Sinkovics JG. Kaposi's sarcoma: its 'oncogenes' and growth factors. *Crit Rev Oncol Hematol*. 1991;11(2):87-107.
1542. Kerl H, Cerroni L, Burg G. The morphologic spectrum of T-cell lymphomas of the skin: a proposal for a new classification. *Semin Diagn Pathol*. 1991;8(2):55-61.
1543. Rabkin CS, Janz S, Lash A, et al. Monoclonal origin of multicentric Kaposi's sarcoma lesions. *N Engl J Med*. 1997;336(14):988-993.
1544. Reitz MS Jr, Nerurkar LS, Gallo RC. Perspective on Kaposi's sarcoma: facts, concepts, and conjectures. *J Natl Cancer Inst*. 1999;91(17):1453-1458.
1545. Barozzi P, Luppi M, Facchetti F, et al. Post-transplant Kaposi sarcoma originates from the seeding of donor-derived progenitors. *Nat Med*. 2003;9(5):554-561.
1546. Duprez R, Lacoste V, Brière J, et al. Evidence for a multiclonal origin of multicentric advanced lesions of Kaposi sarcoma. *J Natl Cancer Inst*. 2007;99(14):1086-1094.
1547. Blumenfeld W, Egbert BM, Sagebiel RW. Differential diagnosis of Kaposi's sarcoma. *Arch Pathol Lab Med*. 1985;109(2):123-127.
1548. Chor PJ, Santa Cruz DJ. Kaposi's sarcoma. A clinicopathologic review and differential diagnosis. *J Cutan Pathol*. 1992;19(1): 6-20.
1549. Marshall ME, Hatfield ST, Hatfield DR. Arteriovenous malformation simulating Kaposi's sarcoma (pseudo-Kaposi's sarcoma). *Arch Dermatol*. 1985;121(1):99-101.
1550. Strutton G, Weedon D. Acro-angiodermatitis. A simulant of Kaposi's sarcoma. *Am J Dermatopathol*. 1987;9(2):85-89.
1551. Suster S, Rosai J. Intranodal hemorrhagic spindle-cell tumor with "amianthoid" fibers. Report of six cases of a distinctive mesenchymal neoplasm of the inguinal region that simulates Kaposi's sarcoma. *Am J Surg Pathol*. 1989;13(5):347-357.
1552. Koehler JE, Quinn FD, Berger TG, et al. Isolation of Rochalimaea species from cutaneous and osseous lesions of bacillary angiomatosis. *N Engl J Med*. 1992;327(23):1625-1631.
1553. Tsang WY, Chan JK. Bacillary angiomatosis. A "new" disease with a broadening clinicopathologic spectrum. *Histol Histopathol*. 1992;7(1):143-152.
1554. LeBoit PE, Berger TG, Egbert BM, et al. Bacillary angiomatosis. The histopathology and differential diagnosis of a pseudoneoplastic infection in patients with human immunodeficiency virus disease. *Am J Surg Pathol*. 1989;13(11):909-920.
1555. Kostianovsky M, Lamy Y, Greco MA. Immunohistochemical and electron microscopic profiles of cutaneous Kaposi's sarcoma and bacillary angiomatosis. *Ultrastruct Pathol*. 1992;16(6):629-640.
1556. Reed JA, Brigati DJ, Flynn SD, et al. Immunocytochemical identification of Rochalimaea henselae in bacillary (epithelioid) angiomatosis, parenchymal bacillary peliosis, and persistent fever with bacteremia. *Am J Surg Pathol*. 1992;16(7):650-657.
1557. Relman DA, Loutit JS, Schmidt TM, et al. The agent of bacillary angiomatosis. An approach to the identification of uncultured pathogens. *N Engl J Med*. 1990;323(23):1573-1580.
1558. Schinella RA, Greco MA. Bacillary angiomatosis presenting as a soft-tissue tumor without skin involvement. *Hum Pathol*. 1990;21(5):567-569.
1559. Chan JK, Lewin KJ, Lombard CM, et al. Histopathology of bacillary angiomatosis of lymph node. *Am J Surg Pathol*. 1991;15(5):430-437.
1560. Finet JF, Abdalsamad I, Bakdach H, et al. Intrathoracic localization of bacillary angiomatosis. *Histopathology*. 1996;28(2):183-185.
1561. Steeper TA, Rosenstein H, Weiser J, et al. Bacillary epithelioid angiomatosis involving the liver, spleen, and skin in an AIDS patient with concurrent Kaposi's sarcoma. *Am J Clin Pathol*. 1992;97(5):713-718.
1562. Arias-Stella J, Lieberman PH, Garcia-Caceres U, et al. Verruga peruana mimicking malignant neoplasms. *Am J Dermatopathol*. 1987;9(4):279-291.
1563. Cooper PH. Angiosarcomas of the skin. *Semin Diagn Pathol*. 1987;4(1):2-17.
1564. Maddox JC, Evans HL. Angiosarcoma of skin and soft tissue: a study of forty-four cases. *Cancer*. 1981;48(8):1907-1921.
1565. Rosai J, Sumner HW, Kostianovsky M, Perez-Mesa C. Angiosarcoma of the skin. A clinicopathologic and fine structural study. *Hum Pathol*. 1976;7(1):83-109.
1566. Chen KT, Gilbert EF. Angiosarcoma complicating generalized lymphangiectasia. *Arch Pathol Lab Med*. 1979;103(2):86-88.
1567. Moskaluk CA, Merino MJ, Danforth DN, Medeiros LJ. Low-grade angiosarcoma of the skin of the breast: a complication of

lumpectomy and radiation therapy for breast carcinoma. *Hum Pathol*. 1992;23(6):710-714.
1568. Otis CN, Peschel R, McKhann C, et al. The rapid onset of cutaneous angiosarcoma after radiotherapy for breast carcinoma. *Cancer*. 1986;57(11):2130-2134.
1569. Holden CA, Spaull J, Das AK, et al. The histogenesis of angiosarcoma of the face and scalp: an immunohistochemical and ultrastructural study. *Histopathology*. 1987;11(1):37-51.
1570. Diaz-Cascajo C, Weyers W, Borghi S, Reichel M. Verrucous angiosarcoma of the skin: a distinct variant of cutaneous angiosarcoma. *Histopathology*. 1998;32(6):556-561.
1571. Jones EW. Dowling oration 1976. Malignant vascular tumours. *Clin Exp Dermatol*. 1976;1(4):287-312.
1572. Leader M, Collins M, Patel J, Henry K. Staining for factor VIII related antigen and Ulex europaeus agglutinin I (UEA-I) in 230 tumours. An assessment of their specificity for angiosarcoma and Kaposi's sarcoma. *Histopathology*. 1986;10(11):1153-1162.
1573. Orchard GE, Zelger B, Jones EW, Jones RR. An immunocytochemical assessment of 19 cases of cutaneous angiosarcoma. *Histopathology*. 1996;28(3):235-240.
1574. Bacchi CE, Silva TR, Zambrano E, et al. Epithelioid angiosarcoma of the skin: a study of 18 cases with emphasis on its clinicopathologic spectrum and unusual morphologic features. *Am J Surg Pathol*. 2010;34(9):1334-1343.
1575. Prescott RJ, Banerjee SS, Eyden BP, Haboubi NY. Cutaneous epithelioid angiosarcoma: a clinicopathological study of four cases. *Histopathology*. 1994;25(5):421-429.
1576. Dictor M, Ferno M, Baldetorp B. Flow cytometric DNA content in Kaposi's sarcoma by histologic stage. Comparison with angiosarcoma. *Anal Quant Cytol Histol*. 1991;13(3):201-208.
1577. Deyrup AT, McKenney JK, Tighiouart M, et al. Sporadic cutaneous angiosarcomas: a proposal for risk stratification based on 69 cases. *Am J Surg Pathol*. 2008;32(1):72-77.
1578. Connors RC, Ackerman AB. Histologic pseudomalignancies of the skin. *Arch Dermatol*. 1976;112(12):1767-1780.
1579. von Hochstetter AR, Meyer VE, Grant JW, et al. Epithelioid sarcoma mimicking angiosarcoma: the value of immunohistochemistry in the differential diagnosis. *Virchows Arch A Pathol Anat Histopathol*. 1991;418(3):271-278.
1580. Thum C, Husain EA, Mulholland K, et al. Atypical fibroxanthoma with pseudoangiomatous features: a histological and immunohistochemical mimic of cutaneous angiosarcoma. *Ann Diagn Pathol*. 2013;17(6):502-507.
1581. Billings SD, McKenney JK, Folpe AL, et al. Cutaneous angiosarcoma following breast-conserving surgery and radiation: an analysis of 27 cases. *Am J Surg Pathol*. 2004;28(6):781-788.
1582. Brenn T, Fletcher CD. Postradiation vascular proliferations: an increasing problem. *Histopathology*. 2006;48(1):106-114.
1583. Brenn T, Fletcher CD. Radiation-associated cutaneous atypical vascular lesions and angiosarcoma: clinicopathologic analysis of 42 cases. *Am J Surg Pathol*. 2005;29(8):983-996.
1584. Weaver J, Billings SD. Postradiation cutaneous vascular tumors of the breast: a review. *Semin Diagn Pathol*. 2009;26(3):141-149.
1585. Di Tommaso L, Rosai J. The capillary lobule: a deceptively benign feature of post-radiation angiosarcoma of the skin: report of three cases. *Am J Dermatopathol*. 2005;27(4):301-305.
1586. Mentzel T, Schildhaus HU, Palmedo G, et al. Postradiation cutaneous angiosarcoma after treatment of breast carcinoma is characterized by MYC amplification in contrast to atypical vascular lesions after radiotherapy and control cases: clinicopathological, immunohistochemical and molecular analysis of 66 cases. *Mod Pathol*. 2012;25(1):75-85.
1587. Fernandez AP, Sun Y, Tubbs RR, et al. FISH for MYC amplification and anti-MYC immunohistochemistry: useful diagnostic tools in the assessment of secondary angiosarcoma and atypical vascular proliferations. *J Cutan Pathol*. 2012;39(2):234-242.
1588. Calonje E, Fletcher CD, Wilson-Jones E, Rosai J. Retiform hemangioendothelioma. A distinctive form of low-grade angiosarcoma delineated in a series of 15 cases. *Am J Surg Pathol*. 1994;18(2):115-125.
1589. Parsons A, Sheehan DJ, Sangueza OP. Retiform hemangioendotheliomas usually do not express D2-40 and VEGFR-3. *Am J Dermatopathol*. 2008;30(1):31-33.
1590. Cerio R, MacDonald DM. Benign cutaneous lymphoid infiltrates. *J Cutan Pathol*. 1985;12(5):442-452.
1591. Caro WA, Helwig HB. Cutaneous lymphoid hyperplasia. *Cancer*. 1969;24(3):487-502.
1592. Mach KW, Wilgram GF. Characteristic histopathology of cutaneous lymphoplasia (lymphocytoma). *Arch Dermatol*. 1966;94(1):26-32.
1593. Wirt DP, Grogan TM, Jolley CS, et al. The immunoarchitecture of cutaneous pseudolymphoma. *Hum Pathol*. 1985;16(5):492-510.
1594. Arai E, Shimizu M, Hirose T. A review of 55 cases of cutaneous lymphoid hyperplasia: reassessment of the histopathologic findings leading to reclassification of 4 lesions as cutaneous marginal zone lymphoma and 19 as pseudolymphomatous folliculitis. *Hum Pathol*. 2005;36(5):505-511.
1595. Kazakov DV, Belousova IE, Kacerovska D, et al. Hyperplasia of hair follicles and other adnexal structures in cutaneous lymphoproliferative disorders: a study of 53 cases, including so-called pseudolymphomatous folliculitis and overt lymphomas. *Am J Surg Pathol*. 2008;32(10):1468-1478.
1596. Rijlaarsdam JU, Meijer CJ, Willemze R. Differentiation between lymphadenosis benigna cutis and primary cutaneous follicular center cell lymphomas. A comparative clinicopathologic study of 57 patients. *Cancer*. 1990;65(10): 2301-2306.
1597. Sarantopoulos GP, Palla B, Said J, et al. Mimics of cutaneous lymphoma: report of the 2011 Society for Hematopathology/ European Association for Haematopathology workshop. *Am J Clin Pathol*. 2014;139(4):536-551.
1598. Sundram U. Primary cutaneous B-cell lymphomas. *Surg Pathol Clin*. 2014;7(2):253-283.
1599. Eckert F, Schmid U, Kaudewitz P, et al. Follicular lymphoid hyperplasia of the skin with high content of Ki-1 positive lymphocytes. *Am J Dermatopathol*. 1989;11(4):345-352.
1600. Li C, Inagaki H, Kuo TT, et al. Primary cutaneous marginal zone B-cell lymphoma: a molecular and clinicopathologic study of 24 asian cases. *Am J Surg Pathol*. 2003;27(8):1061-1069.
1601. Schmid U, Eckert F, Griesser H, et al. Cutaneous follicular lymphoid hyperplasia with monotypic plasma cells. A clinicopathologic study of 18 patients. *Am J Surg Pathol*. 1995;19(1):12-20.
1602. Nihal M, Mikkola D, Horvath N, et al. Cutaneous lymphoid hyperplasia: a lymphoproliferative continuum with lymphomatous potential. *Hum Pathol*. 2003;34(6):617-622.
1603. Wood GS, Ngan BY, Tung R, et al. Clonal rearrangements of immunoglobulin genes and progression to B cell lymphoma in cutaneous lymphoid hyperplasia. *Am J Pathol*. 1989;135(1):13-19.
1604. Ackerman AB, Tanski EV. Pseudoleukemia cutis: report of a case in association with molluscum contagiosum. *Cancer*. 1977;40(2):813-817.
1605. Cochran RE, Thomson J, Fleming KA, Strong AM. Histology simulating reticulosis in secondary syphilis. *Br J Dermatol*. 1976;95(3):251-254.
1606. Thomson J, Cochrane T, Cochran R, McQueen A. Histology simulating reticulosis in persistent nodular scabies. *Br J Dermatol*. 1974;90(4):421-429.
1607. Ive FA, Magnus IA, Warin RP, Jones EW. "Actinic reticuloid"; a chronic dermatosis associated with severe photosensitivity and the histological resemblance to lymphoma. *Br J Dermatol*. 1969;81(7):469-485.
1608. Rijlaarsdam JU, Scheffer E, Meijer CJ, Willemze R. Cutaneous pseudo-T-cell lymphomas. A clinicopathologic study of 20 patients. *Cancer*. 1992;69(3):717-724.
1609. Smolle J, Torne R, Soyer HP, Kerl H. Immunohistochemical classification of cutaneous pseudolymphomas: delineation of distinct patterns. *J Cutan Pathol*. 1990;17(3):149-159.
1610. Leinweber B, Colli C, Chott A, et al. Differential diagnosis of cutaneous infiltrates of B lymphocytes with follicular growth pattern. *Am J Dermatopathol*. 2004;26(1):4-13.
1611. Suárez A, Pulitzer M, Horwitz S, et al. Primary cutaneous B-cell lymphomas, part 1; clinical features, diagnosis, and classification. *J Am Acad Dermatol*. 2013;69(3):329.e1-329. e13, quiz 341-342.
1612. Suárez A, Pulitzer M, Horwitz S, et al. Primary cutaneous B-cell lymphomas, part 2; therapy; biologic, molecular and genetic advances. *J Am Acad Dermatol*. 2013;69(3):343.e1-343.e11, quiz 355-356.
1613. Girardi M, Heald PW, Wilson LD. The pathogenesis of mycosis fungoides. *N Engl J Med*. 2004;350(19):1978-1988.
1614. Willemze R, Beljaards RC, Meijer CJ. Classification of primary cutaneous T-cell lymphomas. *Histopathology*. 1994;24(5):405-415.
1615. Agar NS, Wedgeworth E, Crichton S, et al. Survival outcomes and prognostic factors in mycosis fungoides/Sezary syndrome: validation of the revised International Society for Cutaneous Lymphomas/European Organisation for Research and Treatment of Cancer staging proposal. *J Clin Oncol*. 2010;28(31):4730-4739.
1616. Olsen E, Vonderheid E, Pimpinelli N, et al. Revisions to the staging and classification of mycosis fungoides and Sezary syndrome: a proposal of the International Society for Cutaneous Lymphomas (ISCL) and the cutaneous lymphoma task force of the European Organization of Research and Treatment of Cancer (EORTC). *Blood*. 2007;110(6):1713-1722.
1617. Burns MK, Ellis CN, Cooper KD. Mycosis fungoides—type cutaneous T-cell lymphoma arising before 30 years of age. Immunophenotypic, immunogenotypic and clinicopathologic analysis of nine cases. *J Am Acad Dermatol*. 1992;27(6 Pt 1):974-978.
1618. Gordon BG, Weisenburger DD, Warkentin PI, et al. Peripheral T-cell lymphoma in childhood and adolescence. A

clinicopathologic study of 22 patients. *Cancer*. 1993;71(1):257-263.
1619. Argenyi ZB, Goeken JA, Piette WW, Madison KC. Granulomatous mycosis fungoides. Clinicopathologic study of two cases. *Am J Dermatopathol*. 1992;14(3):200-210.
1620. Breathnach SM, McKee PH, Smith NP. Hypopigmented mycosis fungoides: report of five cases with ultrastructural observations. *Br J Dermatol*. 1982;106(6):643-649.
1621. Cerroni L, Fink-Puches R, El-Shabrawi-Caelen L, et al. Solitary skin lesions with histopathologic features of early mycosis fungoides. *Am J Dermatopathol*. 1999;21(6):518-524.
1622. El-Shabrawi-Caelen L, Cerroni L, Medeiros LJ, McCalmont TH. Hypopigmented mycosis fungoides: frequent expression of a CD8+ T-cell phenotype. *Am J Surg Pathol*. 2002;26(4):450-457.
1623. Kartsonis J, Brettschneider F, Weissmann A, Rosen L. Mycosis fungoides bullosa. *Am J Dermatopathol*. 1990;12(1):76-80.
1624. Lacour JP, Castanet J, Perrin C, Ortonne JP. Follicular mycosis fungoides. A clinical and histologic variant of cutaneous T-cell lymphoma: report of two cases. *J Am Acad Dermatol*. 1993;29(2 Pt 2):330-334.
1625. LeBoit PE. Variants of mycosis fungoides and related cutaneous T-cell lymphomas. *Semin Diagn Pathol*. 1991;8(2):73-81.
1626. LeBoit PE, Zackheim HS, White CR Jr. Granulomatous variants of cutaneous T-cell lymphoma. The histopathology of granulomatous mycosis fungoides and granulomatous slack skin. *Am J Surg Pathol*. 1988;12(2):83-95.
1627. Glusac EJ. Criterion by criterion, mycosis fungoides. *Am J Dermatopathol*. 2003;25(3):264-269.
1628. Shum DT, Roberts JT, Smout MS, et al. The value of nuclear contour index in the diagnosis of mycosis fungoides. An assessment of current ultrastructural morphometric diagnostic criteria. *Cancer*. 1986;57(2):298-304.
1629. Sanchez JL, Ackerman AB. The patch stage of mycosis fungoides. Criteria for histologic diagnosis. *Am J Dermatopathol*. 1979;1(1):5-26.
1630. Boer A, Guo Y, Ackerman AB. Alopecia mucinosa is mycosis fungoides. *Am J Dermatopathol*. 2004;26(1):33-52.
1631. Mehregan DA, Gibson LE, Muller SA. Follicular mucinosis: histopathologic review of 33 cases. *Mayo Clin Proc*. 1991;66(4):387-390.
1632. van Doorn R, Scheffer E, Willemze R. Follicular mycosis fungoides, a distinct disease entity with or without associated follicular mucinosis: a clinicopathologic and follow-up study of 51 patients. *Arch Dermatol*. 2002;138(2):191-198.
1633. Gerami P, Rosen S, Kuzel T, et al. Folliculotropic mycosis fungoides; an aggressive variant of cutaneous T-cell lymphoma. *Arch Dermatol*. 2008;144(6):738-746.
1634. Hitchcock MG, Burchette JL Jr, Olsen EA, et al. Eccrine gland infiltration by mycosis fungoides. *Am J Dermatopathol*. 1996;18(5):447-453.
1635. Barcos M. Mycosis fungoides. Diagnosis and pathogenesis. *Am J Clin Pathol*. 1993;99(4):452-458.
1636. Ralfkiaer E, Wantzin GL, Mason DY, et al. Phenotypic characterization of lymphocyte subsets in mycosis fungoides. Comparison with large plaque parapsoriasis and benign chronic dermatoses. *Am J Clin Pathol*. 1985;84(5):610-619.
1637. Wood GS, Edinger A, Hoppe RT, Warnke RA. Mycosis fungoides skin lesions contain CD8+ tumor-infiltrating lymphocytes expressing an activated, MHC-restricted cytotoxic T-lymphocyte phenotype. *J Cutan Pathol*. 1994;21(2):151-156.
1638. Cooper KD. Skin-infiltrating lymphocytes in normal and disordered skin: activation signals and functional roles in psoriasis and mycosis fungoides-type cutaneous T cell lymphoma. *J Dermatol*. 1992;19(11):731-737.
1639. Michie SA, Abel EA, Hoppe RT, et al. Discordant expression of antigens between intraepidermal and intradermal T cells in mycosis fungoides. *Am J Pathol*. 1990;137(6):1447-1451.
1640. Nickoloff BJ, Griffiths CE. Intraepidermal but not dermal T lymphocytes are positive for a cell-cycle-associated antigen (Ki-67) in mycosis fungoides. *Am J Pathol*. 1990;136(2):261-266.
1641. Wieczorek R, Suhrland M, Ramsay D, et al. Leu-M1 antigen expression in advanced (tumor) stage mycosis fungoides. *Am J Clin Pathol*. 1986;86(1):25-32.
1642. Fisher ER, Horvat BL, Wechsler HL. Ultrastructural features of mycosis fungoides. *Am J Clin Pathol*. 1972;58(2):99-110.
1643. Flaxman BA, Zelazny G, Van Scott EJ. Nonspecificity of characteristic cells in mycosis fungoides. *Arch Dermatol*. 1971;104(2):141-147.
1644. Santucci M, Biggeri A, Feller AC, et al. Efficacy of histologic criteria for diagnosing early mycosis fungoides: an EORTC cutaneous lymphoma study group investigation. European Organization for Research and Treatment of Cancer. *Am J Surg Pathol*. 2000;24(1):40-50.
1645. Yeh YA, Hudson AR, Prieto VG, et al. Reassessment of lymphocytic atypia in the diagnosis of mycosis fungoides. *Mod Pathol*. 2001;14(4):285-288.
1646. Chu A, Patterson J, Berger C, et al. In situ study of T-cell subpopulations in cutaneous T-cell lymphoma. Diagnostic criteria. *Cancer*. 1984;54(11):2414-2422.
1647. Nasu K, Said J, Vonderheid E, et al. Immunopathology of cutaneous T-cell lymphomas. *Am J Pathol*. 1985;119(3):436-447.
1648. van der Putte SC, Toonstra J, van Wichen DF, et al. Aberrant immunophenotypes in mycosis fungoides. *Arch Dermatol*. 1988;124(3):373-380.
1649. Weinberg JM, Rook AH, Lessin SR. Molecular diagnosis of lymphocytic infiltrates of the skin. *Arch Dermatol*. 1993;129(11):1491-1500.
1650. Whittaker SJ, Smith NP, Jones RR, Luzzatto L. Analysis of beta, gamma, and delta T-cell receptor genes in mycosis fungoides and Sezary syndrome. *Cancer*. 1991;68(7):1572-1582.
1651. Zelickson BD, Peters MS, Muller SA, et al. T-cell receptor gene rearrangement analysis: cutaneous T cell lymphoma, peripheral T cell lymphoma, and premalignant and benign cutaneous lymphoproliferative disorders. *J Am Acad Dermatol*. 1991;25(5 Pt 1):787-796.
1652. Chen M, Deng A, Crowson AN, et al. Assessment of T-cell clonality via T-cell receptor-gamma rearrangements in cutaneous T-cell-dominant infiltrates using polymerase chain reaction and single-stranded DNA conformational polymorphism assay. *Appl Immunohistochem Mol Morphol*. 2004;12(4):373-379.
1653. Magro C, Crowson AN, Kovatich A, Burns F. Pityriasis lichenoides: a clonal T-cell lymphoproliferative disorder. *Hum Pathol*. 2002;33(8):788-795.
1654. Pimpinelli N, Olsen EA, Santucci M, et al. Defining early mycosis fungoides. *J Am Acad Dermatol*. 2005;53(6):1053-1063.
1655. Fuks ZY, Bagshaw MA, Farber EM. Prognostic signs and the management of the mycosis fungoides. *Cancer*. 1973;32(6):1385-1395.
1656. Green SB, Byar DP, Lamberg SI. Prognostic variables in mycosis fungoides. *Cancer*. 1981;47(11):2671-2677.
1657. Vonderheid EC, Tam DW, Johnson WC, et al. Prognostic significance of cytomorphology in the cutaneous T-cell lymphomas. *Cancer*. 1981;47(1):119-125.
1658. Smoller BR, Detwiler SP, Kohler S, et al. Role of histology in providing prognostic information in mycosis fungoides. *J Cutan Pathol*. 1998;25(6):311-315.
1659. Fivenson DP, Douglass MC, Nickoloff BJ. Cutaneous expression of Thy-1 in mycosis fungoides. *Am J Pathol*. 1992;141(6):1373-1380.
1660. Long JC, Mihm MC. Mycosis fungoides with extracutaneous dissemination: a distinct clinicopathologic entity. *Cancer*. 1974;34(5):1745-1755.
1661. Rappaport H, Thomas LB. Mycosis fungoides: the pathology of extracutaneous involvement. *Cancer*. 1974;34(4):1198-1229.
1662. Bodensteiner DC, Skikne B. Central nervous system involvement in mycosis fungoides: diagnosis, treatment and literature review. *Cancer*. 1982;50(6):1181-1184.
1663. Huberman MS, Bunn PA Jr, Matthews MJ, et al. Hepatic involvement in the cutaneous T-cell lymphomas: results of percutaneous biopsy and peritoneoscopy. *Cancer*. 1980;45(7):1683-1688.
1664. Kuzel TM, Roenigk HH Jr, Rosen ST. Mycosis fungoides and the Sezary syndrome: a review of pathogenesis, diagnosis, and therapy. *J Clin Oncol*. 1991;9(7):1298-1313.
1665. Kaplan JB, Guitart J, Giles FJ. Targeted therapies for cutaneous T-cell lymphomas. *Expert Rev Hematol*. 2014;7(4):481-493.
1666. Buechner SA, Winkelmann RK. Sezary syndrome. A clinicopathologic study of 39 cases. *Arch Dermatol*. 1983;119(12):979-986.
1667. Kim YH, Hoppe RT. Mycosis fungoides and the Sezary syndrome. *Semin Oncol*. 1999;26(3):276-289.
1668. Trotter MJ, Whittaker SJ, Orchard GE, Smith NP. Cutaneous histopathology of Sezary syndrome: a study of 41 cases with a proven circulating T-cell clone. *J Cutan Pathol*. 1997;24(5):286-291.
1669. Kohler S, Kim YH, Smoller BR. Histologic criteria for the diagnosis of erythrodermic mycosis fungoides and Sezary syndrome: a critical reappraisal. *J Cutan Pathol*. 1997;24(5):292-297.
1670. Degreef H, Holvoet C, Van Vloten WA, et al. Woringer-Kolopp disease. An epidermotropic variant of mycosis fungoides. *Cancer*. 1976;5:2154-2165.
1671. Lever WF. Localized mycosis fungoides with prominent epidermotropism: Woringer-Kolopp disease. *Arch Dermatol*. 1977;113(9):1254-1256.
1672. Colby TV, Burke JS, Hoppe RT. Lymph node biopsy in mycosis fungoides. *Cancer*. 1981;47(2):351-359.
1673. Scheffer E, Meijer CJ, Van Vloten WA. Dermatopathic lymphadenopathy and lymph node involvement in mycosis fungoides. *Cancer*. 1980;45(1):137-148.
1674. Sausville EA, Worsham GF, Matthews MJ, et al. Histologic assessment of lymph nodes in mycosis fungoides/Sezary syndrome (cutaneous T-cell lymphoma): clinical correlations and prognostic import of a new classification system. *Hum Pathol*. 1985;16(11):1098-1109.
1675. Schechter GP, Bunn PA, Fischmann AB, et al. Blood and lymph node T lymphocytes in cutaneous T cell lymphoma: evaluation by light microscopy. *Cancer Treat Rep*. 1979;63(4):571-574.
1676. Weiss LM, Hu E, Wood GS, et al. Clonal rearrangements of T-cell receptor genes in mycosis fungoides and dermatopathic

lymphadenopathy. *N Engl J Med*. 1985;313(9):539-544.
1677. Weiss LM, Wood GS, Warnke RA. Immunophenotypic differences between dermatopathic lymphadenopathy and lymph node involvement in mycosis fungoides. *Am J Pathol*. 1985;120(2):179-185.
1678. Kempf W. CD30+ lymphoproliferative disorders: histopathology, differential diagnosis, new variants, and simulators. *J Cutan Pathol*. 2006;33(suppl 1):58-70.
1679. Guitart J, Querfeld C. Cutaneous CD30 lymphoproliferative disorders and similar conditions: a clinical and pathologic prospective on a complex issue. *Semin Diagn Pathol*. 2009;26(3):131-140.
1680. Bertolotti A, Pham-Ledard AL, Vergier B, et al. Lymphomatoid papulosis type D: an aggressive histology for an indolent disease. *Br J Dermatol*. 2013;169(5):1157-1159.
1681. Kempf W, Kazakov DV, Schärer L, et al. Angioinvasive lymphomatoid papulosis: a new variant simulating aggressive lymphomas. *Am J Surg Pathol*. 2013;37(1):1-13.
1682. Martires KJ, Ra S, Abdulla F, Cassarino DS. Characterization of primary cutaneous CD8+/CD30+ lymphoproliferative disorders. *Am J Dermatopathol*. 2015;37(11): 822-833.
1683. Saggini A, Gulia A, Argenyi Z, et al. A variant of lymphomatoid papulosis simulating primary cutaneous aggressive epidermotropic CD8+ cytotoxic T-cell lymphoma. Description of 9 cases. *Am J Surg Pathol*. 2010;34(8):1168-1175.
1684. Kadin ME, Vonderheid EC, Sako D, et al. Clonal composition of T cells in lymphomatoid papulosis. *Am J Pathol*. 1987;126(1):13-17.
1685. Weiss LM, Wood GS, Trela M, et al. Clonal T-cell populations in lymphomatoid papulosis. Evidence of a lymphoproliferative origin for a clinically benign disease. *N Engl J Med*. 1986;315(8):475-479.
1686. Wantzin GL, Thomsen K, Brandrup F, Larsen JK. Lymphomatoid papulosis. Development into cutaneous T-cell lymphoma. *Arch Dermatol*. 1985;121(6):792-794.
1687. Drews R, Samel A, Kadin ME. Lymphomatoid papulosis and anaplastic large cell lymphomas of the skin. *Semin Cutan Med Surg*. 2000;19(2):109-117.
1688. Kempf W, Sander CA. Classification of cutaneous lymphomas—an update. *Histopathology*. 2010;56(1):57-70.
1689. Smoller BR, Longacre TA, Warnke RA. Ki-1 (CD30) expression in differentiation of lymphomatoid papulosis from arthropod bite reactions. *Mod Pathol*. 1992;5(5):492-496.
1690. Cockerell CJ, Stetler LD. Accuracy in diagnosis of lymphomatoid papulosis. *Am J Dermatopathol*. 1991;13(1):20-25.
1691. Coyne JD, Banerjee SS, Bromley M, et al. Post-transplant T-cell lymphoproliferative disorder/T-cell lymphoma: a report of three cases of T-anaplastic large-cell lymphoma with cutaneous presentation and a review of the literature. *Histopathology*. 2004;44(4):387-393.
1692. Kaudewitz P, Stein H, Dallenbach F, et al. Primary and secondary cutaneous Ki-1+ (CD30+) anaplastic large cell lymphomas. Morphologic, immunohistologic, and clinical-characteristics. *Am J Pathol*. 1989;135(2):359-367.
1693. Zayour M, Gilmore E, Heald P, et al. A distinct entity in the spectrum of the CD30+ cutaneous lymphoproliferative diseases: oligolesional nodules with pseudoepitheliomatous hyperplasia followed by spontaneous resolution. *Am J Dermatopathol*. 2009;31(1):37-43.
1694. Chan JK, Buchanan R, Fletcher CD. Sarcomatoid variant of anaplastic large-cell Ki-1 lymphoma. *Am J Surg Pathol*. 1990;14(10):983-988.
1695. Kinney MC, Kadin ME. The pathologic and clinical spectrum of anaplastic large cell lymphoma and correlation with ALK gene dysregulation. *Am J Clin Pathol*. 1999;111(1 suppl 1):S56-S67.
1696. Mann KP, Hall B, Kamino H, et al. Neutrophil-rich, Ki-1-positive anaplastic large-cell malignant lymphoma. *Am J Surg Pathol*. 1995;19(4):407-416.
1697. Stein H, Foss HD, Durkop H, et al. CD30(+) anaplastic large cell lymphoma: a review of its histopathologic, genetic, and clinical features. *Blood*. 2000;96(12):3681-3695.
1698. Magro CM, Nash JW, Werling RW, et al. Primary cutaneous CD30+ large cell B-cell lymphoma: a series of 10 cases. *Appl Immunohistochem Mol Morphol*. 2006;14(1):7-11.
1699. Macgrogan G, Vergier B, Dubus P, et al. CD30-positive cutaneous large cell lymphomas. A comparative study of clinicopathologic and molecular features of 16 cases. *Am J Clin Pathol*. 1996;105(4):440-450.
1700. Beylot-Barry M, Lamant L, Vergier B, et al. Detection of t(2;5)(p23;q35) translocation by reverse transcriptase polymerase chain reaction and in situ hybridization in CD30-positive primary cutaneous lymphoma and lymphomatoid papulosis. *Am J Pathol*. 1996;149(2):483-492.
1701. Herbst H, Sander C, Tronnier M, et al. Absence of anaplastic lymphoma kinase (ALK) and Epstein-Barr virus gene products in primary cutaneous anaplastic large cell lymphoma and lymphomatoid papulosis. *Br J Dermatol*. 1997;137(5):680-686.
1702. Kadin ME, Morris SW. The t(2;5) in human lymphomas. *Leuk Lymphoma*. 1998;29(3-4):249-256.
1703. Feldman AL, Law M, Remstein ED, et al. Recurrent translocations involving the IRF4 oncogene locus in peripheral T-cell lymphomas. *Leukemia*. 2009;23(3):574-580.
1704. Pham-Ledard A, Prochazkova-Carlotti M, Laharanne E, et al. IRF4 gene rearrangements define a subgroup of CD30-positive cutaneous T-cell lymphoma: a study of 54 cases. *J Invest Dermatol*. 2010;130(3):816-825.
1705. Wada DA, Law ME, Hsi ED, et al. Specificity of IRF4 translocations for primary cutaneous anaplastic large cell lymphoma: a multicenter study of 204 skin biopsies. *Mod Pathol*. 2011;24(4):596-605.
1706. Onaindia A, Montes-Moreno S, Rodríguez-Pinilla SM, et al. Primary cutaneous anaplastic large cell lymphomas with 6p25.3 rearrangement exhibit particular histological features. *Histopathology*. 2015;66(6):846-855.
1707. Karai LJ, Kadin ME, Hsi ED, et al. Chromosomal rearrangements of 6p25.3 define a new subtype of lymphomatoid papulosis. *Am J Surg Pathol*. 2013;37(8):1173-1181.
1708. Cepeda LT, Pieretti M, Chapman SF, Horenstein MG. CD30-positive atypical lymphoid cells in common non-neoplastic cutaneous infiltrates rich in neutrophils and eosinophils. *Am J Surg Pathol*. 2003;27(7):912-918.
1709. Aronson IK, West DP, Variakojis D, et al. Panniculitis associated with cutaneous T-cell lymphoma and cytophagocytic histiocytosis. *Br J Dermatol*. 1985;112(1):87-96.
1710. Kong YY, Dai B, Kong JC, et al. Subcutaneous panniculitis-like T-cell lymphoma: a clinicopathologic, immunophenotypic, and molecular study of 22 Asian cases according to WHO-EORTC classification. *Am J Surg Pathol*. 2008;32(10):1495-1502.
1711. Takeshita M, Imayama S, Oshiro Y, et al. Clinicopathologic analysis of 22 cases of subcutaneous panniculitis-like CD56– or CD56+ lymphoma and review of 44 other reported cases. *Am J Clin Pathol*. 2004;121(3):408-416.
1712. Willemze R, Jansen PM, Cerroni L, et al. Subcutaneous panniculitis-like T-cell lymphoma: definition, classification, and prognostic factors: an EORTC Cutaneous Lymphoma Group Study of 83 cases. *Blood*. 2008;111(2):838-845.
1713. Lozzi GP, Massone C, Citarella L, et al. Rimming of adipocytes by neoplastic lymphocytes: a histopathologic feature not restricted to subcutaneous T-cell lymphoma. *Am J Dermatopathol*. 2006;28(1):9-12.
1714. James E, Sokhn JG, Gibson JF, et al. CD4+ primary cutaneous small/medium-sized pleomorphic T-cell lymphoma: a retrospective case series and review of literature. *Leuk Lymphoma*. 2015;56(4):951-957.
1715. Swerdlow SH, Campo E, Pileri SA, et al. The 2016 revision of the World Health Organization classification of lymphoid neoplasms. *Blood*. 2016;127(20):2375-2390.
1716. Grumayer ER, Ladenstein RL, Slavc I, et al. B-cell differentiation pattern of cutaneous lymphomas in infancy and childhood. *Cancer*. 1988;61(2):303-308.
1717. Sander CA, Medeiros LJ, Abruzzo LV, et al. Lymphoblastic lymphoma presenting in cutaneous sites. A clinicopathologic analysis of six cases. *J Am Acad Dermatol*. 1991;25(6 Pt 1):1023-1031.
1718. Zaatari GS, Chan WC, Kim TH, et al. Malignant lymphoma of the skin in children. *Cancer*. 1987;59(5):1040-1045.
1719. Cota C, Vale E, Viana I, et al. Cutaneous manifestations of blastic plasmacytoid dendritic cell neoplasm-morphologic and phenotypic variability in a series of 33 patients. *Am J Surg Pathol*. 2010;34(1): 75-87.
1720. DiGiuseppe JA, Louie DC, Williams JE, et al. Blastic natural killer cell leukemia/lymphoma: a clinicopathologic study. *Am J Surg Pathol*. 1997;21(10):1223-1230.
1721. Khoury JD, Medeiros LJ, Manning JT, et al. CD56(+) TdT(+) blastic natural killer cell tumor of the skin: a primitive systemic malignancy related to myelomonocytic leukemia. *Cancer*. 2002;94(9):2401-2408.
1722. Massone C, Chott A, Metze D, et al. Subcutaneous, blastic natural killer (NK), NK/T-cell, and other cytotoxic lymphomas of the skin: a morphologic, immunophenotypic, and molecular study of 50 patients. *Am J Surg Pathol*. 2004;28(6):719-735.
1723. Kim JH, Park HY, Lee JH, et al. Blastic plasmacytoid dendritic cell neoplasm: analysis of clinicopathological feature and treatment outcome of seven cases. *Ann Dermatol*. 2015;27(6):727-737.
1724. White RM, Patterson JW. Cutaneous involvement in Hodgkin's disease. *Cancer*. 1985;55(5):1136-1145.
1725. Sioutos N, Kerl H, Murphy SB, Kadin ME. Primary cutaneous Hodgkin's disease. Unique clinical, morphologic, and immunophenotypic findings. *Am J Dermatopathol*. 1994;16(1):2-8.
1726. Shaw MT, Jacobs SR. Cutaneous Hodgkin's disease in a patient with human immunodeficiency virus infection. *Cancer*. 1989;64(12):2585-2587.
1727. Soria C, Orradre JL, Garcia-Almagro D, et al. True histiocytic lymphoma (monocytic sarcoma). *Am J Dermatopathol*. 1992;14(6):511-517.
1728. Deng A, Lee W, Pfau R, et al. Primary cutaneous Langerhans cell sarcoma without Birbeck granules: indeterminate cell sarcoma? *J Cutan Pathol*. 2008;35(9):849-854.
1729. Sagransky MJ, Deng AC, Magro CM. Primary cutaneous langerhans cell sarcoma: a report of four cases and review of the literature. *Am J Dermatopathol*. 2013;35(2):196-204.

1730. Scott PW, Silvers DN, Helwig EB. Proliferating angioendotheliomatosis. *Arch Pathol*. 1975;99(6):323-326.
1731. Stroup RM, Sheibani K, Moncada A, et al. Angiotropic (intravascular) large cell lymphoma. A clinicopathologic study of seven cases with unique clinical presentations. *Cancer*. 1990;66(8): 1781-1788.
1732. Wick MR, Mills SE. Intravascular lymphomatosis: clinicopathologic features and differential diagnosis. *Semin Diagn Pathol*. 1991;8(2):91-101.
1733. Cerroni L, Massone C, Kutzner H, et al. Intravascular large T-cell or NK-cell lymphoma: a rare variant of intravascular large cell lymphoma with frequent cytotoxic phenotype and association with Epstein-Barr virus infection. *Am J Surg Pathol*. 2008;32(6):891-898.
1734. Kuo TT, Chen MJ, Kuo MC. Cutaneous intravascular NK-cell lymphoma: report of a rare variant associated with Epstein-Barr virus. *Am J Surg Pathol*. 2006;30(9):1197-1201.
1735. Molina A, Lombard C, Donlon T, et al. Immunohistochemical and cytogenetic studies indicate that malignant angioendotheliomatosis is a primary intravascular (angiotropic) lymphoma. *Cancer*. 1990;66(3):474-479.
1736. Sheibani K, Battifora H, Winberg CD, et al. Further evidence that "malignant angioendotheliomatosis" is an angiotropic large-cell lymphoma. *N Engl J Med*. 1986;314(15):943-948.
1737. Greenwood R, Barker DJ, Tring FC, et al. Clinical and immunohistological characterization of cutaneous lesions in chronic lymphocytic leukaemia. *Br J Dermatol*. 1985;113(4):447-453.
1738. Sepp N, Radaszkiewicz T, Meijer CJ, et al. Specific skin manifestations in acute leukemia with monocytic differentiation. A morphologic and immunohistochemical study of 11 cases. *Cancer*. 1993;71(1):124-132.
1739. Cho-Vega JH, Medeiros LJ, Prieto VG, Vega F. Leukemia cutis. *Am J Clin Pathol*. 2008;129(1):130-142.
1740. Kaiserling E, Horny HP, Geerts ML, Schmid U. Skin involvement in myelogenous leukemia: morphologic and immunophenotypic heterogeneity of skin infiltrates. *Mod Pathol*. 1994;7(7): 771-779.
1741. Long JC, Mihm MC. Multiple granulocytic tumors of the skin: report of six cases of myelogenous leukemia with initial manifestations in the skin. *Cancer*. 1977;39(5):2004-2016.
1742. Cerroni L, Zenahlik P, Hofler G, et al. Specific cutaneous infiltrates of B-cell chronic lymphocytic leukemia: a clinicopathologic and prognostic study of 42 patients. *Am J Surg Pathol*. 1996;20(8):1000-1010.
1743. Ratnam KV, Su WP, Ziesmer SC, Li CY. Value of immunohistochemistry in the diagnosis of leukemia cutis: study of 54 cases using paraffin-section markers. *J Cutan Pathol*. 1992;19(3):193-200.
1744. Cibull TL, Thomas AB, O'Malley DP, Billings SD. Myeloid leukemia cutis: a histologic and immunohistochemical review. *J Cutan Pathol*. 2008;35(2):180-185.
1745. Desch JK, Smoller BR. The spectrum of cutaneous disease in leukemias. *J Cutan Pathol*. 1993;20(5):407-410.
1746. Jones D, Dorfman DM, Barnhill RL, Granter SR. Leukemic vasculitis: a feature of leukemia cutis in some patients. *Am J Clin Pathol*. 1997;107(6):637-642.
1747. Steck WD, Helwig EB. Cutaneous endometriosis. *JAMA*. 1965;191:167-170.
1748. Nogales FF, Martin F, Linares J, et al. Myxoid change in decidualized scar endometriosis mimicking malignancy. *J Cutan Pathol*. 1993;20(1):87-91.
1749. Pellegrini AE. Cutaneous decidualized endometriosis. A pseudomalignancy. *Am J Dermatopathol*. 1982;4(2):171-174.
1750. Suster S, Rosai J. Hamartoma of the scalp with ectopic meningothelial elements. A distinctive benign soft tissue lesion that may simulate angiosarcoma. *Am J Surg Pathol*. 1990;14(1):1-11.
1751. Miedema JR, Zedek D. Cutaneous meningioma. *Arch Pathol Lab Med*. 2012;136(2):208-211.
1752. Fox MD, Billings SD, Gleason BC, et al. Cutaneous meningioma: a potential diagnostic pitfall in p63 positive cutaneous neoplasms. *J Cutan Pathol*. 2013;40(10):891-895.
1753. Argenyi ZB. Cutaneous neural heterotopias and related tumors relevant for the dermatopathologist. *Semin Diagn Pathol*. 1996;13(1):60-71.
1754. Wallace CA, Hallman JR, Sangueza OP. Primary cutaneous ganglioneuroma: a report of two cases and literature review. *Am J Dermatopathol*. 2003;25(3):239-242.
1755. Conlin PA, Jimenez-Quintero LP, Rapini RP. Osteomas of the skin revisited: a clinicopathologic review of 74 cases. *Am J Dermatopathol*. 2002;24(6):479-483.
1756. Myllylä RM, Haapasaari KM, Palatsi R, et al. Multiple miliary osteoma cutis is a distinct disease entity: four case reports and review of the literature. *Br J Dermatol*. 2011;164(3):544-552.
1757. Beham A, Fletcher CD, Feichtinger J, et al. Synovial metaplasia of the skin. *Virchows Arch A Pathol Anat Histopathol*. 1993;423(4):315-318.
1758. Bhawan J, Dayal Y, Gonzalez-Serva A, Eisen R. Cutaneous metaplastic synovial cyst. *J Cutan Pathol*. 1990;17(1):22-26.
1759. Gonzalez JG, Ghiselli RW, Santa Cruz DJ. Synovial metaplasia of the skin. *Am J Surg Pathol*. 1987;11(5):343-350.
1760. Radice F, Gianotti R. Cutaneous ganglion cell tumor of the skin. Case report and review of the literature. *Am J Dermatopathol*. 1993;15(5):488-491.
1761. Hurt MA, Santa Cruz DJ. Cutaneous inflammatory pseudotumor. Lesions resembling "inflammatory pseudotumors" or "plasma cell granulomas" of extracutaneous sites. *Am J Surg Pathol*. 1990;14(8): 764-773.
1762. Mentzel T, Reisshauer S, Rutten A, et al. Cutaneous clear cell myomelanocytic tumour: a new member of the growing family of perivascular epithelioid cell tumours (PEComas). Clinicopathological and immunohistochemical analysis of seven cases. *Histopathology*. 2005;46(5): 498-504.
1763. Walsh SN, Sangueza OP. PEComas: a review with emphasis on cutaneous lesions. *Semin Diagn Pathol*. 2009;26(3):123-130.
1764. Liegl B, Hornick JL, Fletcher CD. Primary cutaneous PEComa: distinctive clear cell lesions of skin. *Am J Surg Pathol*. 2008;32(4):608-614.
1765. French CA, Mentzel T, Kutzner H, Fletcher CD. Intradermal spindle cell/pleomorphic lipoma: a distinct subset. *Am J Dermatopathol*. 2000;22(6):496-502.
1766. Gardner JM, Dandekar M, Thomas D, et al. Cutaneous and subcutaneous pleomorphic liposarcoma: a clinicopathologic study of 29 cases with evaluation of MDM2 gene amplification in 26. *Am J Surg Pathol*. 2012;36(7):1047-1051.
1767. Hoang MP, Rogers BB, Albores-Saavedra J. Giant cell tumor of the skin: a morphologic and immunohistochemical study of five cases. *Ann Diagn Pathol*. 2002;6(5):288-293.
1768. Terrier-Lacombe MJ, Guillou L, Chibon F, et al. Superficial primitive Ewing's sarcoma: a clinicopathologic and molecular cytogenetic analysis of 14 cases. *Mod Pathol*. 2009;22(1):87-94.
1769. Pollock AM, Sweeney EC. Primary cutaneous synovial sarcoma: a case report. *Am J Dermatopathol*. 1998;20:509-512.
1770. Brownstein MH, Helwig EB. Metastatic tumors of the skin. *Cancer*. 1972;29(5):1298-1307.
1771. Brownstein MH, Helwig EB. Patterns of cutaneous metastasis. *Arch Dermatol*. 1972;105(6):862-868.
1772. Sittart JA, Senise M. Cutaneous metastasis from internal carcinomas: a review of 45 years. *An Bras Dermatol*. 2013;88(4): 541-544.
1773. Kim ES, Lee DP, Lee MW, et al. Cutaneous metastasis of uterine papillary serous carcinoma. *Am J Dermatopathol*. 2005;27(5):436-438.
1774. Quinn TR, Duncan LM, Zembowicz A, Faquin WC. Cutaneous metastases of follicular thyroid carcinoma: a report of four cases and a review of the literature. *Am J Dermatopathol*. 2005;27(4):306-312.
1775. Royer MC, Rush WL, Lupton GP. Hepatocellular carcinoma presenting as a precocious cutaneous metastasis. *Am J Dermatopathol*. 2008;30(1):77-80.
1776. McKee PH. Cutaneous metastases. *J Cutan Pathol*. 1985;12(3-4):239-250.
1777. Connor DH, Taylor HB, Helwig EB. Cutaneous metastasis of renal cell carcinoma. *Arch Pathol*. 1963;76:339-346.
1778. Menter A, Boyd AS, McCaffree DM. Recurrent renal cell carcinoma presenting as skin nodules: two case reports and review of the literature. *Cutis*. 1989;44(4):305-308.
1779. Li H, Hes O, MacLennan GT, et al. Immunohistochemical distinction of metastases of renal cell carcinoma to the adrenal from primary adrenal nodules, including oncocytic tumor. *Virchows Arch*. 2015;466(5):581-588.
1780. Fujiwara M, Taube J, Sharma M, et al. PAX8 discriminates ovarian metastases from adnexal tumors and other cutaneous metastases. *J Cutan Pathol*. 2010;37(9):938-943.
1781 Iijima M, Nakayama J, Nishizawa T, et al. Usefulness of monoclonal antibody HIK1083 specific for gastric O-glycan in differentiating cutaneous metastasis of gastric cancer from primary sweat gland carcinoma. *Am J Dermatopathol*. 2007;29(5):452-456.
1782. Liang H, Wu H, Giorgadze TA, et al. Podoplanin is a highly sensitive and specific marker to distinguish primary skin adnexal carcinomas from adenocarcinomas metastatic to skin. *Am J Surg Pathol*. 2007;31(2): 304-310.
1783. Plaza JA, Ortega PF, Stockman DL, Suster S. Value of p63 and podoplanin (D2-40) immunoreactivity in the distinction between primary cutaneous tumors and adenocarcinomas metastatic to the skin: a clinicopathologic and immunohistochemical study of 79 cases. *J Cutan Pathol*. 2010;37(4):403-410.
1784. Lee JJ, Mochel MC, Piris A, et al. p40 exhibits better specificity than p63 in distinguishing primary skin adnexal carcinomas from cutaneous metastases. *Hum Pathol*. 2014;45(5):1078-1083.
1785. Aguilar A, Schoendorff C, Lopez Redondo MJ, et al. Epidermotropic metastases from internal carcinomas. *Am J Dermatopathol*. 1991;13(5):452-458.
1786. Youngberg GA, Berro J, Young M, Leicht SS. Metastatic epidermotropic squamous carcinoma histologically simulating primary carcinoma. *Am J Dermatopathol*. 1989;11(5):457-465.
1787. Rodriguez G, Villamizar R. Carcinoid tumor with skin metastasis. *Am J Dermatopathol*. 1992;14(3):263-269.

4 Upper Aerodigestive Tract

Jonathan B. McHugh

CHAPTER CONTENTS

Oral cavity and oropharynx, *146*
Normal anatomy, *146*
Congenital abnormalities, *147*
Inflammatory diseases, *147*
Other non-neoplastic lesions, *149*
Tumors and tumorlike conditions of surface epithelium, *150*
Tumors and other lesions of minor salivary glands, *157*
Tumors of odontogenic epithelium, *159*
Tumors of melanocytes, *159*
Tumors and tumorlike conditions of lymphoid tissue, *160*
Other tumors and tumorlike conditions, *161*
Respiratory tract, *164*
Normal anatomy, *164*
Inflammatory (including "allergic") polyp, *165*
Other inflammatory lesions, *165*
Tumors, *167*
Larynx, *183*
Normal anatomy, *183*
Cysts and laryngocele, *184*
Inflammation, *185*
Vocal cord nodule and contact ulcer, *185*
Other non-neoplastic lesions, *186*
Tumors and tumorlike conditions, *186*
Trachea, *196*
Non-neoplastic lesions, *196*
Tumors, *196*

Oral Cavity and Oropharynx

Normal Anatomy

The oral cavity and oropharyngeal region represent the upper portion of the digestive tract; in addition, the oropharynx constitutes a portion of the upper respiratory tract. The oropharynx and hypopharynx share many of the diseases of the two adjacent digestive tract organs—oral cavity and esophagus—whereas the nasopharynx shares them with the two other components of the upper respiratory tract, that is, the nasal cavity and paranasal sinuses.

For the purposes of the topographic characterization of lesions that occur in this area (particularly squamous cell carcinoma), the oral cavity and oropharyngeal region is divided into the following regions: (1) *lip*, including only the vermilion surface and comprising an upper and lower lip joined at the commissures of the mouth; (2) *floor of the mouth*, a U-shaped area bounded by the lower gingiva and the oral tongue; (3) *oral tongue*, defined as the portion of the tongue anterior to the circumvallate papillae; (4) *buccal mucosa*, which covers the inner surface of the cheeks and lips; (5) *gingiva* (alveolar ridge), the mucosa covering the mandible or maxilla from the gingivobuccal gutter to the origin of the mobile mucosa; (6) *retromolar trigone*, a small triangular surface behind the third molar covering the ascending ramus of the mandible; (7) *hard palate*, a semilunar area located between the upper alveolar ridge and the mucous membrane covering the palatine process of the maxillary bones; (8) *base of the tongue*, bound anteriorly by the circumvallate papillae, laterally by the glossotonsillar sulci, and posteriorly by the valleculae; (9) *tonsillar area*, which includes the anterior and posterior tonsillar pillars and the tonsillar fossa; (10) *soft palate*; and (11) *pharyngeal walls.*[1,2]

The surface epithelium of this region is of stratified squamous type throughout, with greater depth than the epithelium of the skin. It lacks hair follicles and sweat glands but may contain scattered sebaceous glands, melanocytes, and Merkel cells.[3] It keratinizes in the areas most exposed to mastication (gingivae, hard palate, and dorsum of tongue) but not in others. The lamina propria is composed of loose connective tissue and contains mucous and serous glands of minor salivary gland type. Minor but distinctive variations exist among the various areas of this region.

The oral cavity and oropharynx are the sites of numerous diseases, both congenital and acquired, affecting a large variety of tissues and systems. Only those that occur commonly enough to be of interest to the surgical pathologist are discussed here. For a more thorough discussion of these diseases and the rarer diseases, the reader is referred to specialized textbooks on the subject.[3–6]

Abstract

This chapter reviews pathology of the upper aerodigestive tract. The chapter is organized by subsite beginning with the oral cavity/oropharynx followed by sinonasal cavities, larynx, and trachea. Each subsite section discusses the relevant anatomy and histology, followed by non-neoplastic and neoplastic entities.

Keywords

Oral cavity neoplasms,
oropharyngeal neoplasms,
sinonasal neoplasms,
laryngeal neoplasms

Congenital Abnormalities

Dermoid cysts are seen in the midline of the floor of the mouth. Although present at birth, they may become evident only later when secondarily inflamed.[7] They are lined by squamous epithelium and contain skin adnexa.[8] **Heterotopic gastric** or **intestinal epithelium** has been reported in the tongue and floor of the mouth, sometimes resulting in cystic formations.[9] Minute **cysts of odontogenic origin** are commonly seen in the alveolar and palatal mucosa of newborns and older infants; they need not be biopsied. Nodules of **heterotopic nerve tissue** in the palate or parapharyngeal space, mainly composed of glial elements and ependyma-lined clefts, have been reported as *glial choristomas*[10,11]; in rare cases, a neoplasm may arise from them.[12] **White sponge nevus,** an autosomal dominantly inherited disease, is characterized by large white plaques in the oral mucosa with preferential involvement of the buccal mucosa (Fig. 4.1). Mutations of the keratin 4 or 13 genes, which are expressed in the malpighian layer of the mucosa, is responsible for the clinical and histologic abnormalities. Microscopically there is striking intracellular glycogen accumulation throughout the malpighian layer with overlying parakeratosis (Fig. 4.2).[13] **Fordyce granule** refers to the presence of normal sebaceous glands inside the oral cavity, a very common occurrence. Sometimes these glands undergo hyperplastic changes and appear as discrete nodules.[14] The entity **lingual thyroid** is discussed in Chapter 8.

Figure 4.1 Clinical Appearance of White Sponge Nevus. (Courtesy of Dr. James Sciubba, Long Island Jewish Medical Center, Long Island, New York.)

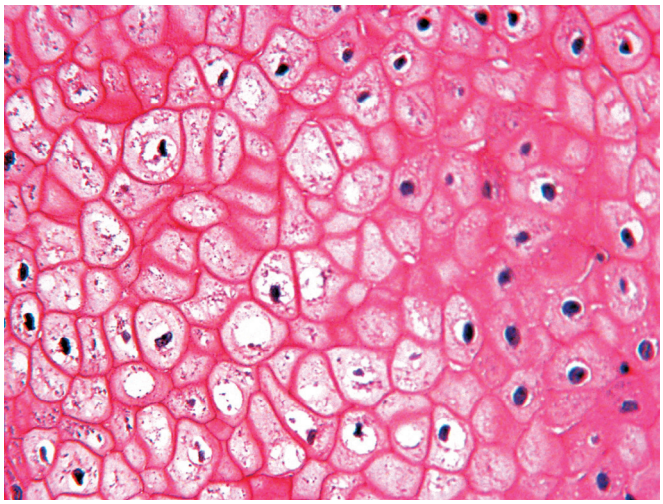

Figure 4.2 White Sponge Nevus. There is a marked pallor of the cytoplasm due to intracellular edema.

Although it does not represent a congenital anomaly, the occurrence of **epithelial nests** in intraoral sensory nerve endings should be mentioned here.[15,16] Their importance relates to the fact that pathologists unaware of their existence might easily confuse them with perineurial invasion by squamous cell carcinoma. These formations are normally occurring neuroepithelial structures of alleged receptor function, known by anatomists as the *organ of Chievitz*, Chievitz paraparotid organ, and juxtaoral organ (Fig. 4.3).[17] They lie deep to the internal pterygoid muscle near the pterygomandibular raphe and are associated with small branches from the buccal nerve. These structures can undergo nodular hyperplasia.[18]

Inflammatory Diseases

Chronic inflammatory lesions of nonspecific type are produced in the oral cavity by ill-fitting denture, ragged, sharp teeth, and poor dental hygiene. Removal of the offending agent allows the pathologic process to subside. Microscopically, a combination of hyperplastic epithelium (including pseudoepitheliomatous hyperplasia), fibrous tissue, and inflammatory cells in varying proportions is seen. In a classic article, Bhaskar et al.[19] described 341 such cases, all associated with the use of dentures, under the term *inflammatory papillary hyperplasia*; 82.7% of the lesions were located in the palate. Localized overgrowth of the epithelium with or without ulceration is frequent, and it is not rare to see large pseudotumors made up of fibrous tissue and chronic inflammatory cells, among which plasma cells may be prominent. Lesions in which the fibrous proliferation predominates are sometimes referred to, somewhat inaccurately, as *irritation fibromas*. Scattered stellate and multinucleated giant cells can be seen throughout the fibrous tissue, in which case the term *giant cell fibroma* has been used.[20,21]

Geographic tongue (benign migratory glossitis, glossitis migrans) is a relatively common condition (affecting 1%–2% of the population) of unknown cause, which is usually asymptomatic. Most patients are adults, but it has also been seen in children. It often occurs in association with fissured tongue. Clinically, it appears as an erythematous flat zone on the dorsum of the tongue resulting from loss of the filiform papillae (Fig. 4.4). The microscopic appearance is that of a psoriasiform process; there is acanthosis with migration of neutrophils throughout the epithelium to form microabscesses near the surface, accompanied by a mild inflammatory infiltrate in the lamina propria.[22]

Tuberculosis is a rare lesion within the oral cavity. It is usually seen on the tongue as a painful ulcer, but it also may occur on the buccal mucosa. It nearly always is associated with advanced pulmonary disease. Microscopically, there are typical tubercles.[23]

Syphilis may produce a gumma in the tongue or palate appearing as a painless indurated mass. Microscopically, there are granulomas with giant cells, numerous plasma cells, and prominent vascular changes.

Histoplasmosis can occur anywhere in the oral cavity and can closely simulate squamous cell carcinoma on clinical examination. Indurated ulcers, nodular lesions, or verrucous masses can be present. The usual microscopic appearance is that of a granuloma, although sometimes only a nonspecific inflammatory reaction is seen. Special stains (Gomori methenamine silver or periodic acid–Schiff [PAS]–Gridley) are necessary for the identification of the fungi.[24]

Crohn disease can involve the oral cavity and pharynx, sometimes as the initial manifestation.[25,26] Oral lesions develop in about 6% of patients with Crohn disease at some stage of this disorder. The

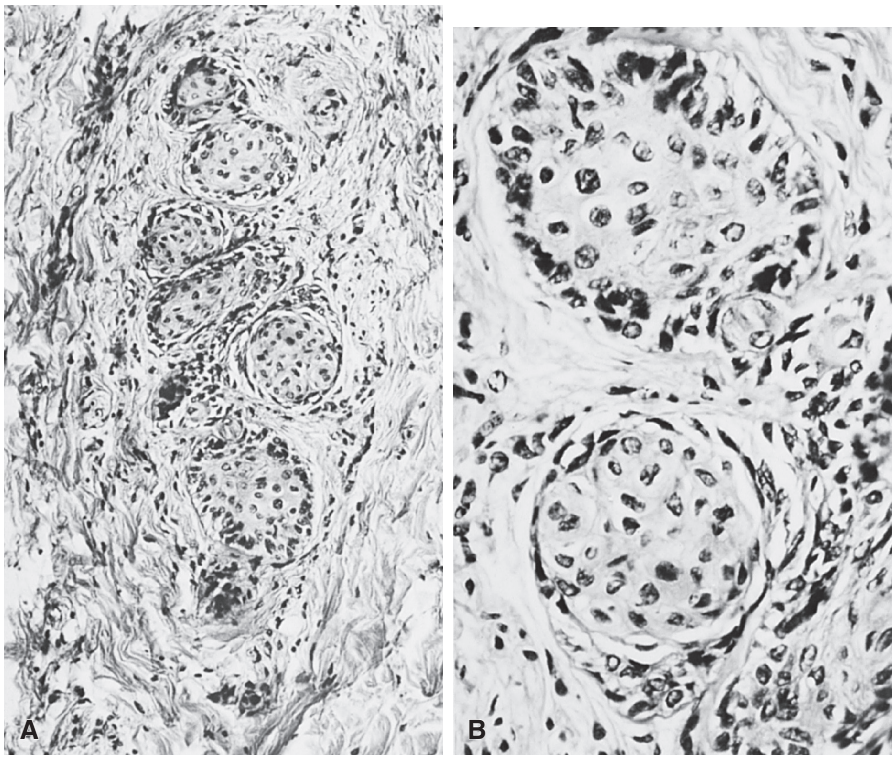

Figure 4.3 Low-power **(A)** and high-power **(B)** views of juxtaoral organ of Chievitz. (From Tschen JA, Fechner RE. The juxtaoral organ of Chievitz. *Am J Surg Pathol*. 1979;3:147–150.)

Figure 4.4 Clinical Appearance of Geographic Tongue. (Courtesy of Dr. James Sciubba, Long Island Jewish Medical Center, Long Island, New York.)

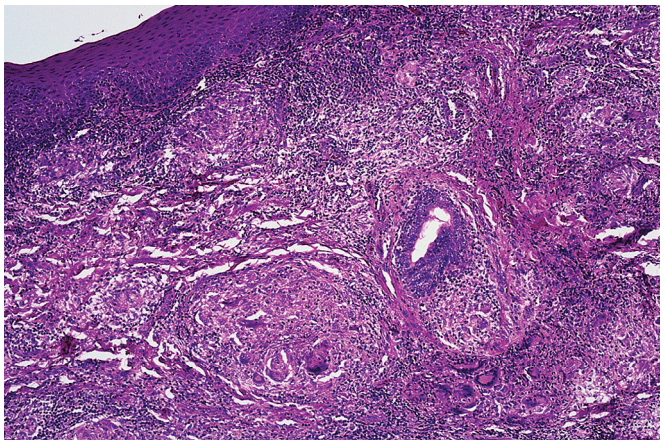

Figure 4.5 Lip Biopsy in a Patient With Melkersson–Rosenthal Syndrome. Numerous non-necrotizing granulomas are seen beneath a normal epithelium.

most common locations are lips, gingiva, vestibular sulci, and buccal mucosa.[26] The lesions can manifest as edema, ulcers, or in the form of a polypoid papulous hyperplastic mucosa. Microscopically, there are edema, dilation of lymph vessels, chronic inflammation, scattered giant cells, and, rarely, noncaseating granulomas.[27]

Sarcoidosis may affect the oral mucosa, gingiva, tongue, hard palate, and major salivary glands. Random biopsy of the lower lip has been successfully used to support a diagnosis of sarcoidosis; in a series of 75 consecutive patients, noncaseating granulomas were found by this procedure in 58%.[28]

Melkersson–Rosenthal syndrome is composed of the triad of orofacial swelling, peripheral facial nerve paralysis, and plicated tongue. *Cheilitis granulomatosa* is probably an abortive variant of this syndrome, the etiology and pathogenesis of which remain obscure.[29] Microscopically, there is a granulomatous inflammation primarily involving the stroma of the lip (Fig. 4.5). The differential diagnosis includes sarcoidosis and Crohn disease.

Granulomatous tonsillitis is occasionally found in specimens of tonsillectomy performed because of chronic recurrent tonsillar enlargement; in most cases, no specific organism is recovered, and the course is benign.[30]

Waldeyer ring lymphoid hyperplasia is a common symptomatic complication of HIV infection. Characteristically, the process is accompanied by a scattering of multinucleated giant cells adjacent

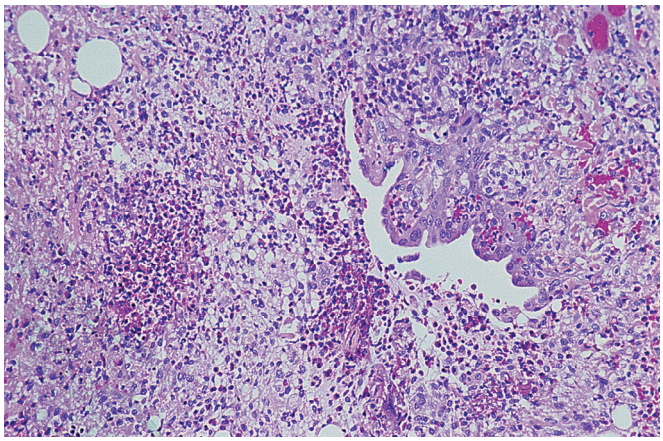

Figure 4.6 Tongue Ulceration With Eosinophilia. A mixed inflammatory infiltrate rich in eosinophils is present.

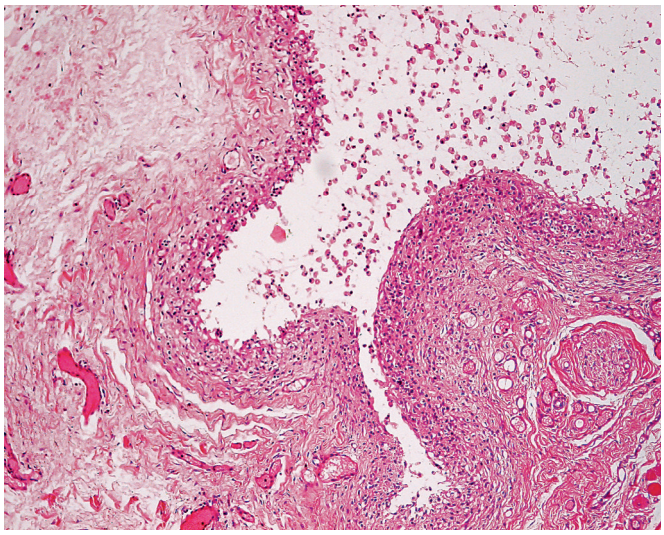

Figure 4.7 Extravasation Mucocele. The lining of the mucus-filled cyst is made up of histiocytes rather than epithelial cells.

to the tonsillary crypt of surface epithelium.[31] These cells, which harbor significant amounts of HIV, exhibit histiocytic markers and probably belong to the accessory immune system.[32]

Granulomatosis with polyangiitis (Wegener) may manifest in the oral cavity as a red to purple hyperplastic gingiva; in about 5% of the cases this is the first manifestation of the disease.[33] On microscopic examination, there are epithelioid histiocytes, giant cells, eosinophils, pseudoepitheliomatous hyperplasia, and, in rare cases, vasculitis.[34]

Behçet disease affects primarily skin, oral mucosa, and eyes and is characterized microscopically by a leukocytoclastic vasculitis.[35] **Cytomegalovirus infection** can manifest in the oral cavity as an ulcerated lesion.[36]

Tongue ulceration with eosinophilia (eosinophilic ulcer; ulcerative eosinophilic granuloma; traumatic ulcerative granuloma with stromal eosinophilia [TUGSE], Riga–Fede disease) may mimic carcinoma clinically.[37] Microscopically, it shows a polymorphic inflammatory infiltrate rich in eosinophils, extending into the submucosa, muscle, and minor salivary glands[38] (Fig. 4.6). The initiating event is presumably traumatic (crush injury to the tongue muscle), hence its alternative designation as *traumatic (ulcerative) granuloma*.[39] Some cases have shown T-cell receptor rearrangement and/or CD30 immunoreactivity, but the clinical behavior is benign.[40]

Chronic graft-versus-host disease (GVHD) frequently involves the oral cavity and presents with xerostomia if the salivary glands are involved as well as with lichen planus-like lesions involving the buccal mucosa and tongue.[41] Histologically, the mucosal lesions demonstrate intracellular edema with basal cell degeneration, scattered dyskeratotic cells, and a lichenoid chronic inflammatory infiltrate.

Pulse granuloma, an odd lesion also known by a variety of synonyms, is discussed in Chapter 5.

Other Non-Neoplastic Lesions

Leukoedema presents as a diffuse opalescent lesion of the cheek mucosa that can extend to the lips; microscopically, the main alteration is vacuolization or intracellular edema of the malpighian cells, a change of a probably degenerative nature.[42]

Diffuse fibrous hyperplasia of the gingiva has been traditionally described as a complication of diphenylhydantoin (Dilantin) therapy, but most cases seen today are genetically inherited, idiopathic, or associated with other drugs, such as cyclosporin A.[43,44] The gingival thickening can be so extreme as to necessitate surgical removal.

Oral submucosal fibrosis, as seen mainly in Indians and Pakistanis, is a reactive process characterized microscopically by subepithelial fibrosis and chronic inflammation, accompanied by hyalinization and loss of vascularity.[45] The overlying epithelium may be either atrophic or hyperplastic and is often hyperkeratotic. The pathogenesis is unknown. The disease is thought to predispose the patient to the development of squamous cell carcinoma.[46]

Mucous cyst (mucocele), when applied to a lesion of the oral cavity, has been used for two different processes. The first and more common is referred to as *extravasation mucocele* and represents a focus of stromal reaction to spillage of mucus from a traumatically injured minor salivary gland.[47] It is often seen in young individuals, the lower lip being the classic location, and the microscopic pattern is that of granulation tissue surrounding one or more spaces containing mucin[48] (Fig. 4.7). Sometimes the cysts are very superficial and simulate vesicobullous diseases clinically.[49]

The second type, named *retention mucocele*, occurs most often in older patients and in other locations in the oral cavity, such as the floor of the mouth and the inside of the cheek. Microscopically, a mucus-filled cyst completely lined by cylindric, cuboidal, or flattened epithelial cells is seen.[50]

An anatomic variant of either extravasation or retention mucocele is known as *ranula* when it occurs as a blue-domed cyst in a sublingual location, and as *plunging ranula* when it extends into the neck above the hyoid bone.[51,52]

Oral focal mucinosis is the oral counterpart of the more common cutaneous focal mucinosis[53]; this condition is located in oral cavity sites other than the lip and lacks the granulation tissue wall and inflammatory cells consistently seen in extravasation mucocele.

Necrotizing sialometaplasia is a reactive condition involving minor or—less commonly—major salivary glands; its importance lies in the fact that it can be confused histologically with squamous cell or mucoepidermoid carcinoma.[54,55] The disease usually presents as an ulcerating lesion of the hard palate characterized by vascular proliferation, prominent inflammatory infiltrate, and partial necrosis of salivary glands, associated with regeneration and squamous metaplasia of the adjacent ducts and acini. Cases also have been described in the nasal cavity, gingiva, lip, hypopharynx, and maxillary sinus. The morphologic changes are somewhat similar to those seen in this region after radiation therapy. The pathogenesis is probably ischemic, and some cases have been seen as a complication of

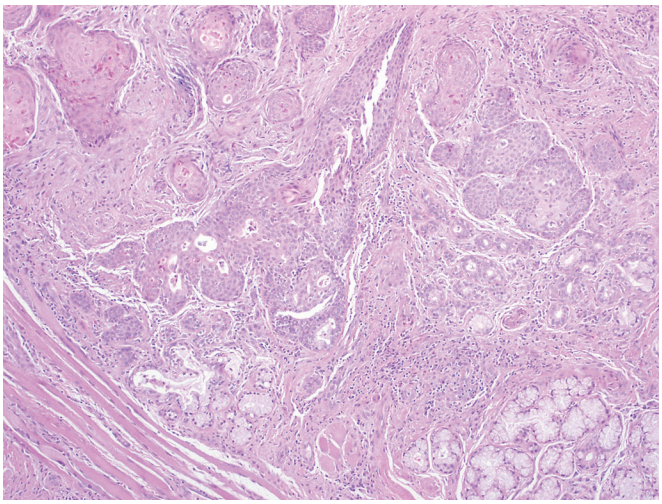

Figure 4.8 Necrotizing sialometaplasia. The retained lobular configuration is an important diagnostic clue.

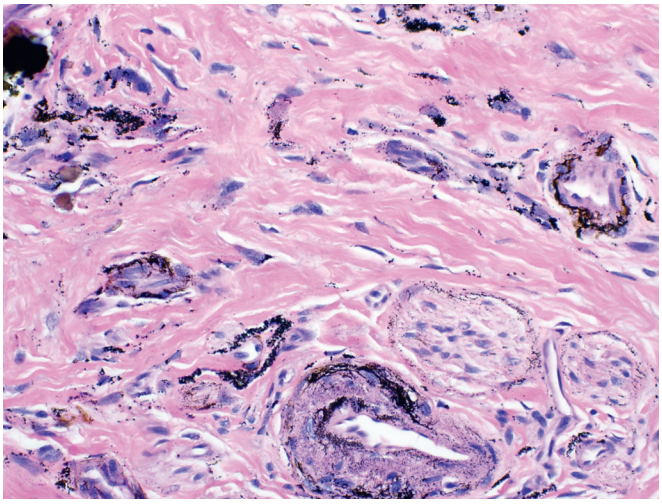

Figure 4.9 Amalgam Tattoo. The pigment is seen surrounding vessels and nerves as well as adhering to the connective stroma fibers.

vasculitis and other primary vascular disorders. The lobular configuration that these lesions exhibit on low-power examination is an important sign in the differential diagnosis with squamous cell carcinoma[56] (Fig. 4.8). The presence of calponin-positive myoepithelial cells is a supporting diagnostic feature.[57,58]

Amyloidosis of the tongue may be an isolated event (localized amyloidosis) but is often involved as a manifestation of systemic amyloidosis.[59] Only in a small proportion of cases are the deposits extensive enough to result in clinically evident disease in the form of diffuse macroglossia or a localized tumor.[60,61] Patients with lingual amyloidosis should be worked up for systemic disease; 15% of those with systemic disease will have underlying multiple myeloma.

Amalgam tattoos result from amalgam alloys being inadvertently deposited in subepithelial connective tissues of the gingiva, buccal mucosa, and/or alveolar ridge. They appear as blue-black macules ranging from 1 to 20 mm.[62] They are typically biopsied to rule out melanocytic lesions. Histologically, fine golden-brown or black granules are deposited on connective tissue fibers and around vessels and nerves (Fig. 4.9). Larger particles can be seen in foreign body giant cells.

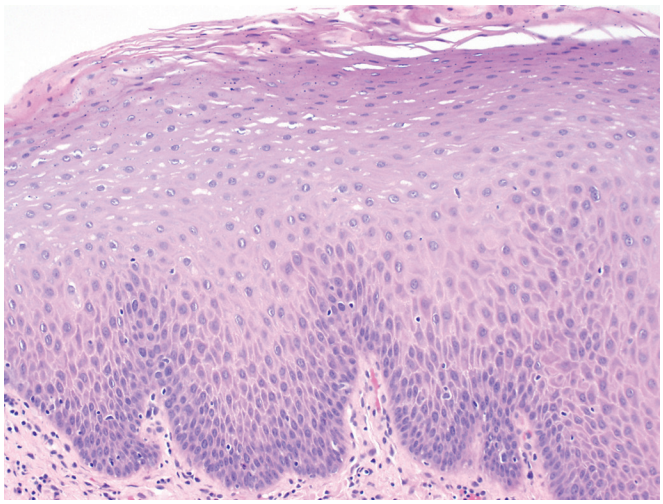

Figure 4.10 Keratosis Without Dysplasia.

Dermatologic disorders of various types can involve the oral cavity, including *lichen planus* (but beware of lichenoid dysplasia, see next section),[63,64] *lupus erythematosus*,[64] and *pemphigus vulgaris*.

Tumors and Tumorlike Conditions of Surface Epithelium

Intraepithelial Squamoproliferative Lesions

It has been rightly pointed out that the lesions grouped under this generic term "continue to be among the most widely discussed, reclassified, and semantically tortured conditions in the medical literature."[65] Part of the problem resides in the fact that different clinical and pathologic terms have been introduced haphazardly over the years and that the correlations between them—although certainly present, as will be shown later—are less than perfect. Among the clinical terms, **leukoplakia** remains the most widely used.[65,66] It has been defined as "a white patch or plaque, not less than 5 mm in diameter, that cannot be removed by rubbing and cannot be classified as any other diagnosable disease," and it implies nothing about the histologic appearance. It is equivalent to the term *keratosis* as used more often at other sites (such as larynx) and is sometimes subclassified (always on clinical grounds) as homogeneous, nonhomogeneous (speckled; nodular; erythroleukoplakia), erythroplakia (which is red rather than white), and proliferative verrucous leukoplakia.[65,67] The most common location of leukoplakia, as defined previously, are the buccal gingival gutter and tongue.

At the histopathologic level, terms such as keratosis, squamous hyperplasia, and verrucous hyperplasia have been used interchangeably, the choice depending on minor architectural differences but mainly on personal preference. When *dysplasia* is present, this is added to the diagnosis and the changes are graded as *mild*, *moderate*, and *severe*, the latter merging with squamous cell carcinoma in situ (CIS) and therefore often grouped with it, as it is at other sites (Figs. 4.10–4.13).[68,69] The microscopic criteria for the diagnosis of severe dysplasia/CIS are the same as for other mucosal membranes: epithelial disarray with full-thickness atypia, no flattening or horizontal elongation of the surface layer, and a basement membrane that appears intact in routinely stained sections.

The atypical proliferative changes characteristically involve the surface epithelium, but they can also extend to the ducts of minor salivary glands. When the dysplastic changes are accompanied by hyperkeratosis, prominent granular layer, irregular basal layer,

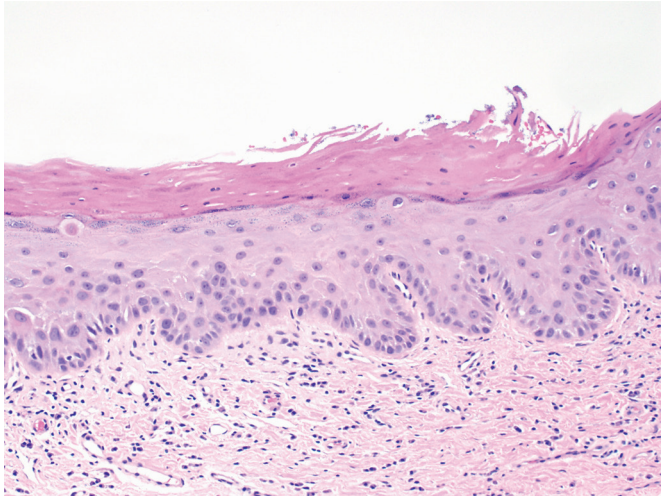

Figure 4.11 Mild Dysplasia.

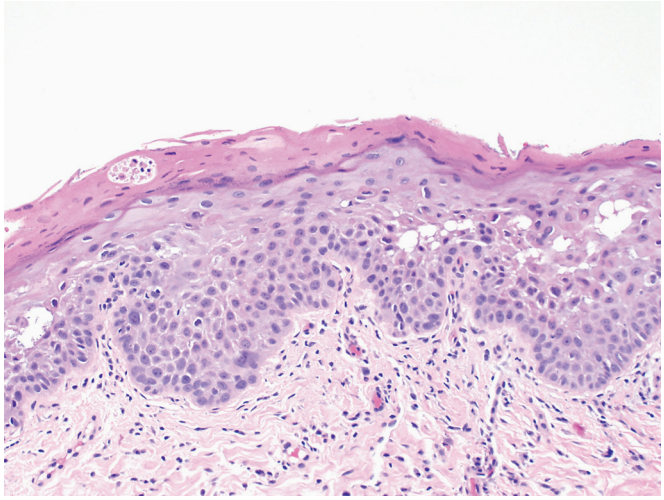

Figure 4.12 Moderate Dysplasia.

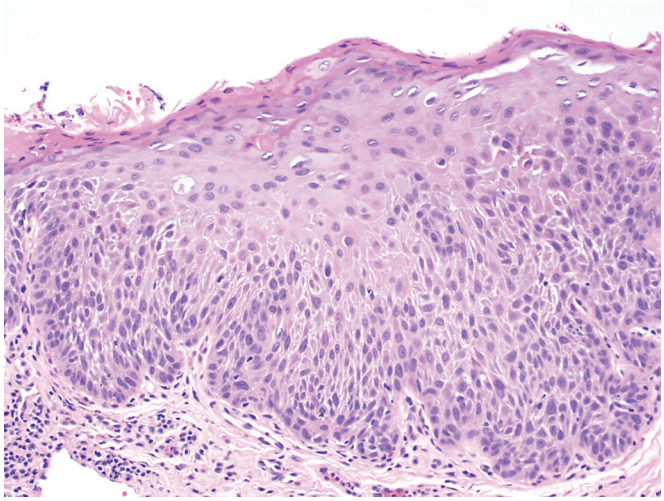

Figure 4.13 Severe Dysplasia.

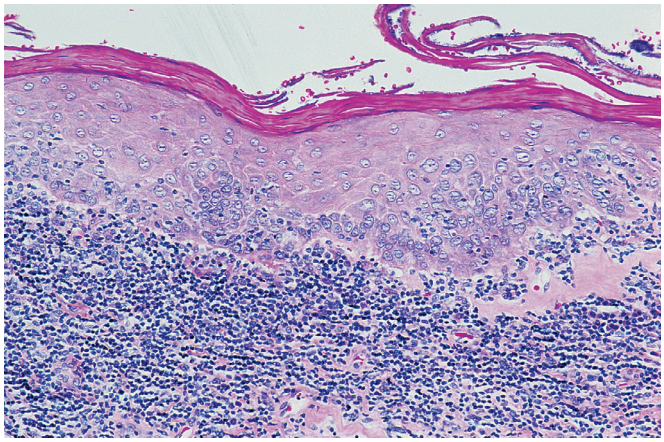

Figure 4.14 **Lichenoid Dysplasia.** There is a bandlike lymphocytic infiltrate beneath the squamous epithelium, with some infiltration of lymphocytes in the lower third. This lesion is commonly underdiagnosed.

Table 4.1 Classification of keratosis

GENERIC TERM	QUALIFIERS	DYSPLASIA
Keratosis	Papillary	Absent
	Lichenoid	Mild
	Verrucous	Moderate
	Proliferative verrucous	Severe/CIS

Examples:
- Keratosis, with no dysplasia
- Keratosis, lichenoid, with mild dysplasia
- Keratosis, with severe dysplasia/CIS

CIS, Carcinoma in situ.

sawtoothed rete pegs, and bandlike lymphocytic infiltrate, the condition is referred to as *lichenoid dysplasia* (Fig. 4.14).[70] Because of the often subtle degree of the dysplastic changes, this condition is frequently underdiagnosed as lichen planus, a mistake that may have serious consequences.[71,72]

The alternative terminology that has been proposed for this group of lesions is that of *oral intraepithelial neoplasia* (*OIN*), grade I (equivalent to mild dysplasia), grade II (equivalent to moderate dysplasia), and grade III (equivalent to severe dysplasia/CIS). Until the latter terminology is widely adopted (and there is no sign that it will happen soon), our preference is to use *keratosis* as the generic term, to qualify it if indicated and—most importantly—to indicate the presence and degree of dysplasia, according to the scheme in Table 4.1. It should be acknowledged that, no matter what terminology is used, the determination is subjective and marred by a marked degree of interobserver variability.

At the immunohistochemical level, the main distinction between keratosis without and with dysplasia is a quantitative one: whereas in the former the expressions of keratin 19, p53, and proliferation-related antigens (such as Ki-67) are all limited to the basal layer, in the latter they are also expressed in suprabasal cells. A similar distinction is appreciated with $p16^{INK4A}$, the protein product of a tumor suppressor gene.[73] Of these markers, Ki-67 (MIB-1) seems the most consistent and therefore the most useful for the identification and grading of the dysplasia.[74] DNA ploidy studies have shown that

about one-third of "leukoplakic" lesions are hyperploid or aneuploid but that the relationship of this parameter with the grade of dysplasia is poor.[75,76] Overexpression of p53 has been found in only a small minority of dysplasias, in keeping with the known late occurrence of this event in the carcinogenesis chain.[77] In summary, no immunohistochemical marker, or set of markers, is adequate in making a diagnosis of dysplasia or grading dysplasia but, in conjunction with the morphology, can be useful as an adjunctive measure in making these distinctions.

In terms of clinicopathologic correlations, severe dysplastic changes are much more likely to be present in lesions with the clinical appearance of erythroplakia than those of homogeneous leukoplakia, with erythroleukoplakia occupying an intermediate position.[78] Thus, of 158 "early" asymptomatic squamous cell carcinomas studied by Mashberg et al.,[79] 143 (90.5%) had red velvety ("erythroplastic") components, whereas only 10 (9.8%) had white components; only four lesions were solely white, and there was no color distinction between in situ and invasive carcinoma. The presence of induration almost guaranteed the presence of stromal invasion.

There is also a correlation between the location of the leukoplakia and the chance of finding dysplastic changes microscopically; the probability of dysplasia is much higher for lesions located in the floor of the mouth.[80]

The most important issue concerning this group of lesions is the likelihood of them evolving into invasive carcinomas of either squamous or verrucous type. There is no question that this prediction is more accurate when made on the basis of the severity of the dysplasia as judged microscopically than when attempted on the basis of clinical features. If all cases fitting the clinical definition of leukoplakia are included, the incidence of subsequent malignancy is very low. Pindborg et al.[81] followed 248 patients with oral leukoplakia (mostly of the speckled type) for 1–10 years and found that only 4.4% developed squamous cell carcinoma. In Einhorn and Wersäll's series[82] of 782 patients with a mean follow-up of 11.7 years, the incidence of invasive carcinoma was 2.4% after 10 years and 4% after 20 years. Most other series quote figures ranging from less than 1% to 6%.[83]

From a microscopic standpoint, the implicit assumption is that the greater the atypia, the higher the premalignant potential. It is, however, important to remember that some squamous cell carcinomas of the mouth present without any evidence of adjacent or preceding dysplasia[68] and that a lesion with the features of severe dysplasia/CIS may simply be the peripheral expression of an invasive carcinoma that has not been properly sampled.

There is hope that some special procedure will eventually allow a more accurate and reproducible prediction of the premalignant potential of these lesions.[84]

Actinic cheilitis is the equivalent in the lip vermilion of actinic keratosis of the skin on morphologic, pathogenetic, and behavioral grounds; it should therefore not be equated with the leukoplakic–dysplastic conditions within the oral cavity previously discussed. An increased prevalence of dysplastic and malignant lip lesions has been documented in renal transplant recipients and other immunosuppressed individuals.[85]

Oral/Oropharyngeal Lesions and Human Papilloma Virus

The oral cavity can be the site of a variety of human papilloma virus (HPV)-related lesions, some of which are microscopically and behaviorally analogous to those located in the genital tract.[86] These include *focal epithelial hyperplasia (Heck disease)*,[87] *verruca vulgaris*,[88] *condyloma acuminatum*,[89] and the relatively common *squamous papilloma*[90] (Fig. 4.15).

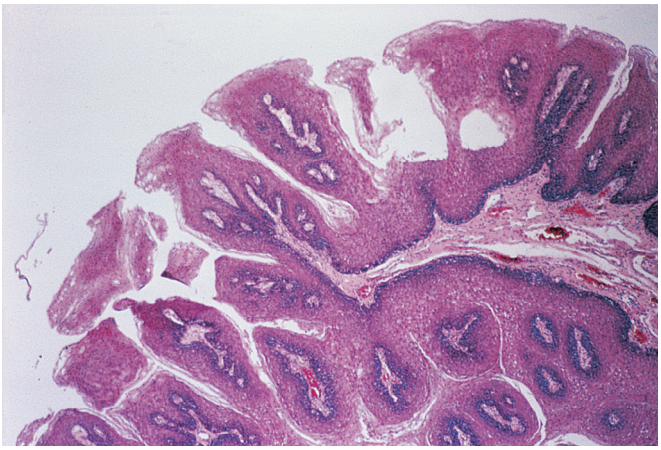

Figure 4.15 Squamous Papilloma of the Oral Cavity.

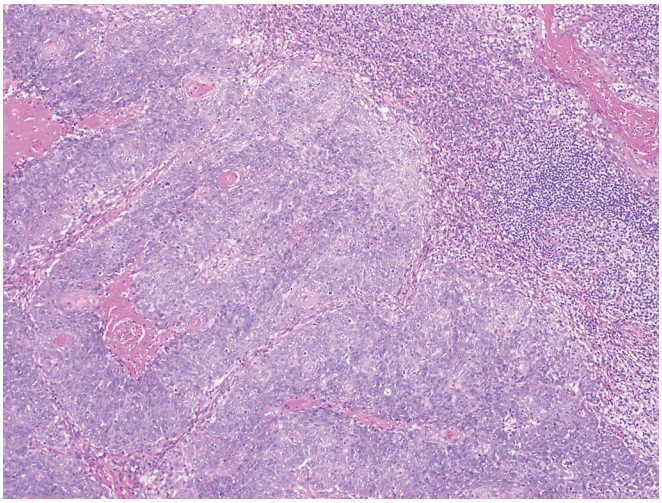

Figure 4.16 Infiltrative lobules composed of poorly differentiated basaloid cells with focal keratinization (so-called non-keratinizing squamous cell carcinoma) are typical of HPV-related oropharyngeal squamous cell carcinomas.

Heck disease presents clinically as a well-circumscribed, sessile, pale elevation of the buccal mucosa. Microscopically, the most prominent feature is the presence of balloon cells in the malpighian layers. The balloon cells often demonstrate irregular nuclear karyorrhectic degeneration resembling mitotic figures (mitosoid bodies) that are suggestive of the diagnosis. This disorder is more common among Native Americans and Eskimos.[87]

The verrucae, condylomas, and papillomas often exhibit koilocytosis as a sign of cytopathic effect.

An etiologic role for HPV has also been suggested for verrucous carcinoma[91] and squamous cell carcinoma, including some of its precursors (high-grade dysplasia/CIS) and variants, but these are inconsistent findings.[92] The benign oral lesions are statistically associated with HPV types 2, 4, 6, 11, 13, and 32, and the malignant ones with HPV types 16, 18, and 33.[86,93,94] Among the carcinomas, those with the highest incidence of HPV detection are the poorly differentiated nonkeratinizing squamous cell carcinomas of the oropharynx (palatine and lingual tonsil) seen in sexually active young individuals (Fig. 4.16).[95–97] Parenthetically, many of the latter tumors express p16 protein, a surrogate marker for high-risk

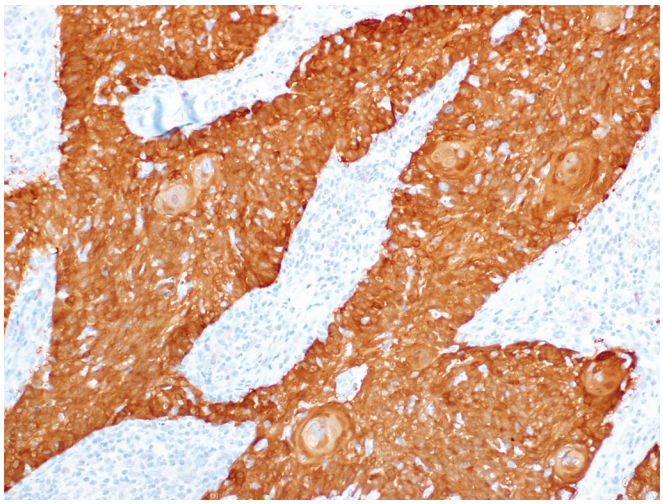

Figure 4.17 A p16 immunohistochemical stain is strongly positive in the entire tumor including both nuclear and cytoplasmic staining. This pattern of staining, in conjunction with the morphology, supports that this is a high-risk HPV-related carcinoma.

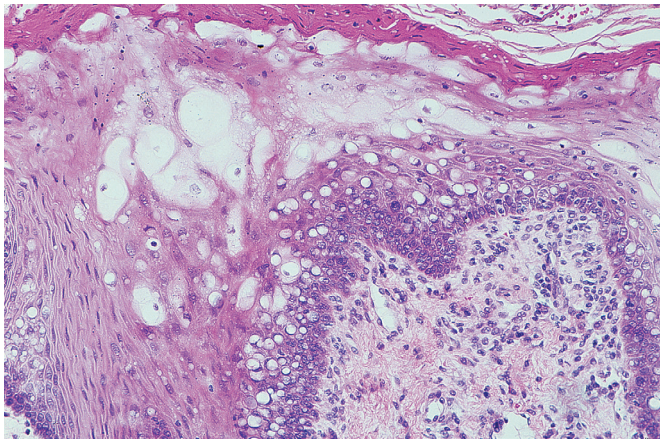

Figure 4.18 Hairy Leukoplakia. There is prominent ballooning of the squamous cells in the upper half of the epithelium, associated with mild inflammation in the underlying stroma.

HPV infection (Fig. 4.17).[98] HPV-positive oropharyngeal cancers are also more likely to exhibit a "basaloid" morphology and to have cystic lymph node metastasis.[99] It is important to recognize these cancers as they are associated with a favorable response to chemoradiation therapy and are associated with a much improved survival compared with conventional squamous cell carcinoma of the head and neck.

Not all squamous papillomas of the oral cavity are virally induced. Some may be the result of mechanical irritation, and others (although possibly viral related) are genetically determined, such as those occurring as a component of Cowden syndrome.[100,101]

Hairy leukoplakia was originally thought to be associated with HPV but is now believed to be due to Epstein–Barr virus (EBV) lytic infection.[102,103] This lesion develops in patients with HIV infection and is characteristically located along the lateral edges of the tongue.[104] Microscopically, it shows parakeratosis, acanthosis, and intranuclear inclusions in keratinocytes, associated with ballooned or ground-glass cytoplasm (Fig. 4.18).[105,106] There is a high incidence of superinfection by *Candida* organisms.

Squamous Cell Carcinoma

General Features

Practically speaking, cancer of the oral cavity mucosa is synonymous with squamous cell (epidermoid) carcinoma. Known predisposing factors vary according to the location of the tumor. Most carcinomas of the oral cavity are strongly associated with tobacco use, and there is a synergistic effect with alcohol. For carcinoma of the lip, they include sunlight, fair complexion, and—to less extent—smoking and mechanical irritation.[107] Transplant recipients and HIV-positive patients are also at an increased risk, presumably as a result of immunosuppression.[108,109] This risk is greater among younger patients.[109] Interestingly, carcinomas developing in HIV-positive individuals are only infrequently associated with HPV infection.[108]

Oropharyngeal carcinomas have been related mainly to tobacco and alcohol, but also to syphilis, oral sepsis, iron deficiency, oral candidiasis, and Fanconi anemia.[110–114] Currently, most oropharyngeal squamous cell carcinomas are now known to be related to infection with high-risk HPV. Most cases occur in men over the age of 50, although the relative incidence among women and younger patients seems to be increasing.[92,115–118]

Location

In a large series from the M.D. Anderson Cancer Center in Houston, Texas,[119] the location of squamous cell carcinomas within the oral cavity was listed as follows: lip, 45%; tongue, 16%; floor of mouth, 12%; buccal mucosa, 10%; lower gingiva, 12%; and upper gingiva and hard palate, 5%. Of the lip tumors, over 90% involved the lower lip. In a careful study of early asymptomatic squamous cell carcinomas of the oral cavity proper, Mashberg and Meyers[120] found that the overwhelming majority of them occurred in three locations: floor of the mouth (especially at the papilla at the Wharton duct exit), soft palate–anterior pillar–retromolar complex, and ventrolateral aspect of the mobile portion of the tongue (Fig. 4.19). These "high-risk areas" have in common a lining of thin nonkeratinized squamous epithelium, with short or absent rete ridges and a narrow lamina propria.

Multiplicity of tumors is common; in such cases, the tongue is one of the most commonly affected sites.[121] Patients with carcinoma of the oral cavity have a 100-fold probability of developing a second primary tumor in the region.[122] The chances of this occurrence are particularly high when the carcinoma is associated with dysplastic changes elsewhere in the oral cavity, which are the morphologic indicators of the important biologic phenomenon known as *field cancerization*.[123]

The analysis of the karyotype and pattern of *TP53* mutation in these multiple tumors has shown that in some cases they are clonally related (taken to indicate that they represent metastases from a single lesion), whereas others—probably the majority—are truly multiple primary tumors.[124,125]

Microscopic Features

Intraoral squamous cell carcinomas range widely in their degree of differentiation. Histologic evidence of squamous differentiation is typically manifest as intercellular bridges and/or squamous pearls. Those located at the base of the tongue or in the tonsil tend to be undifferentiated and solid with less prominent evidence of keratinization, thereby creating diagnostic confusions with large cell malignant lymphoma. Perineurial and vascular invasion are common. The epithelium adjacent to the invasive tumor often shows dysplastic changes of various degrees, all the way to CIS.[126] Some variations in the microscopic appearance of this tumor exist. A few squamous cell carcinomas are massively infiltrated with mature eosinophils, a feature that may create diagnostic

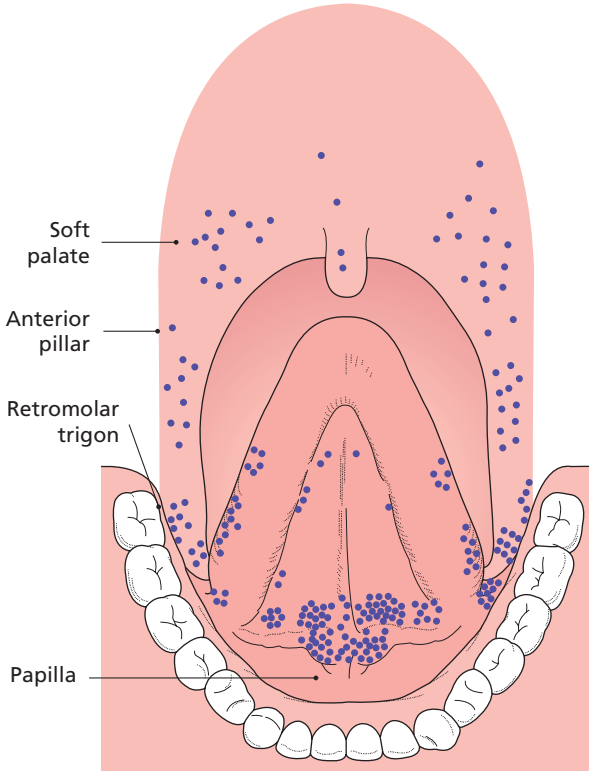

Figure 4.19 Scattergram indicating site of origin of over 200 asymptomatic early squamous cell carcinomas. Note concentration of lesions around papilla at exit of Wharton duct, ventrolateral aspect of tongue, lingual aspect of retromolar trigone, anterior pillar, and soft palate. (Adapted from Mashberg A, Meyers H. Anatomic site and size of 222 early asymptomatic oral squamous cell carcinomas. A continuing prospective study of oral cancer. II. *Cancer*. 1976;37:2149–2157.)

difficulties and that is said to be associated with an improved prognosis.[127,128]

Histochemical and Immunohistochemical Features

Immunohistochemically, these tumors are invariably positive for keratin. In the study by Suo et al.,[129] all cases expressed CK8 and 19, most expressed 5/6 and 13 (the latter only in the metastases), and none expressed CK20.

For the special features of the tonsillar tumors associated with cystic metastases in cervical lymph nodes, see under "Spread and Metastases."

Molecular Genetic Features

The most common oncogene alterations identified in oral squamous cell carcinoma involve p16 (approximately 80% of the cases), p53 (50%, with mutation being more common in smokers), cyclin D1 (30%), p63 (30%), phosphatase and tensin homolog (PTEN) (10%), Rb (<10%), and epidermal growth factor receptor (EGFR, <10%).[115,130,131] The critically altered pathways include p53 (inactivation by mutation, HPV-16 E6 protein inhibition, or aberrations of other genes in the pathway), EGFR (frequent overexpression through gene amplification, transcriptional activation or mutation in ligand-binding domain), signal transducer and activator of transcription 3 (STAT3) and vascular endothelial growth factor receptor (VEGFR).[132] There are ongoing clinical trials on the usefulness of drugs that specifically target these pathways, such as EGFR inhibitor and VEGF or VEGFR inhibitor.[132]

Evaluation of these changes has led to the proposal of a model of molecular progression, which is conceptually appealing but which should be viewed only as a working hypothesis.[133,134]

Gene expression profiling studies have identified transcriptional signatures in oral squamous cell carcinomas that are said to predict the overall survival, recurrence-free survival, and likelihood of lymph node metastasis.[135–137]

Biopsy, Cytology, and Frozen Section

Dentists have the best opportunity to discover early lesions of the oral cavity, especially those in "hidden" sites such as the posterolateral tongue. It is their responsibility to examine the oral cavity carefully and to refer patients with suspicious lesions for proper evaluation and possible biopsy.[121] The diagnosis is usually obvious in a well-taken sample. A biopsy specimen that is often much more difficult to interpret is the one taken from an abnormal-appearing mucosa sometime after irradiation therapy has been completed for an invasive squamous cell carcinoma. Under these circumstances, it is better to refrain from making a diagnosis of carcinoma unless there is definite stromal invasion, because from a cytologic standpoint it is often challenging to distinguish residual CIS from radiation atypia. Generally speaking, it is better to wait a minimum of 4–8 weeks after completion of the therapy before taking a new biopsy.

Fine-needle aspiration is a very convenient and efficient way to confirm the presence of cervical lymph node metastases. As mentioned, p16 immunohistochemistry is helpful in supporting the diagnosis of metastatic oropharyngeal squamous cell carcinoma if positive.

The main role of frozen section in oropharyngeal squamous cell carcinoma is in the evaluation of surgical margins.[138] A good correlation has been found between presence or closeness of the tumor at the margin and the probability of local recurrence and mortality.[139]

Spread and Metastases

The pattern of direct spread of oropharyngeal carcinoma is dictated by the anatomic features of the primary site.[2] Carcinoma of the lip invades adjacent skin, the orbicular muscle, and—when advanced—the buccal mucosa, the adjacent mandible, and the mental nerve. Tumors of the floor of the mouth penetrate early beneath the mucosa into the sublingual gland, into the midline muscles, and extend toward the gingiva and mandible.[140] Tumors of the oral tongue, which usually arise on the lateral surfaces and ventral side, tend to remain localized for long periods but eventually invade the floor of the mouth, mandible, and root of the tongue, resulting in fixation of the organ. Tumors of the buccal mucosa invade the underlying muscles and may eventually penetrate into the skin. Tumors of gingiva extend quickly into the periosteum, the adjacent buccal mucosa, and the floor of mouth. Tumors of the hard palate may spread into the underlying bone, but extension into the maxillary antrum is very rare. Tumors of the retromolar trigone spread to adjacent buccal mucosa, anterior tonsillar pillar, maxilla, pterygomandibular space, medial pterygoid muscle (resulting in trismus), and buccinator muscle.

Invasion of the mandible usually involves the body of the bone, from which it may spread to the ramus; direct invasion of the latter structure may also occur, particularly after radiation therapy.[141] Metastases occur primarily by the lymphatic route, the distribution of lymph node involvement depending on the location of the primary tumor.[142] The more anterior the tumor, the lower the position of the cervical nodal metastasis. Carcinomas of the base of the tongue and oropharynx tend to metastasize to the upper cervical (jugulodigastric; level II) lymph nodes. These metastases are notoriously cystic and frequently present before the identification of the primary carcinoma.

Metastases to the posterior triangle region (level V) are rare; they occur in only 6% of the oropharyngeal tumors and 1% of the oral tumors.[143] Features of the primary tumor associated with the likelihood of nodal metastases in the neck are location (higher for the posterior portion of the tongue and oropharynx, intermediate for the anterior portion of the tongue, and lower for the lip, floor of mouth, cheek mucosa, hard palate, and gingiva), poor microscopic differentiation, and depth of invasion.[144,145] Lip carcinomas associated with metastases tend to be wide, deep, not well differentiated, and accompanied by an inflammatory and desmoplastic response.[146]

Occasionally, the cervical node metastases from these squamous cell carcinomas undergo cystic degeneration. This, plus the well-differentiated nature of the lesion, may easily lead to a mistaken diagnosis of branchial cyst with malignant transformation ("branchial carcinoma").[96] The occult primary lesion is often located in the lingual or palatine (faucial) tonsil, and it may take 10 years or more for it to be detected.[147] Another peculiar morphologic pattern that squamous cell carcinoma can exhibit when metastasizing to cervical nodes is that of an extensive foreign body giant cell reaction around clumps of keratin, without viable tumor cells; this is particularly common if the tumor has been previously irradiated.[148]

Treatment

The two pillars of therapy for oropharyngeal carcinoma are surgery and radiation therapy, used either singly or in combination.[149] For most early stage lesions, the results of irradiation and surgery are very similar, so that the final decision as to which to use often depends on factors such as functional and cosmetic results, the patient's general status, and the physician's bias.[150,151] Advanced cases are treated by a combination of radiation therapy and chemotherapy.[115] Most other sites are treated with primary surgery for resectable cases with adjuvant radiation therapy with or without concomitant chemotherapy. Patients with unresectable tumors can be treated with radiation or chemoradiation therapy with palliative intent.

The treatment of metastatic squamous cell carcinoma to the cervical lymph nodes without detectable primary is largely dependent on the specific location of the lymphadenopathy.[152]

Prognosis

Listed below are the most important prognostic determinants in carcinomas of the oral cavity.

1. **Location**. The overall 5-year survival rates are about 90% for carcinomas of the lower lip; 60% for tumors of the anterior tongue; 40% for tumors of the posterior tongue, floor of mouth, tonsil, gingiva, and hard palate; and 20%–30% for tumors of the soft palate.[144,153] However, these figures are heavily influenced by, and largely dependent upon, the tumor stage. HPV-related oropharyngeal squamous cell carcinomas are associated with a favorable outcome compared with conventional head and neck squamous cell carcinoma.
2. **Stage**. As usual, this parameter is of the utmost significance. Thus, the recurrence-free 5-year survival rates for "mucosal cancer" of this region in a series of over 3000 cases were: stage I, 91.0%; stage II, 77.2%; stage III, 61.2%; stage IVA, 32.4%; stage IVB, 25.3%; stage IVC, 3.6%.[154]
3. **Grade**. This parameter has proved to be of independent prognostic value.[155] It has been noted that grading of the deep invasive margins of the tumor provides better prognostic information than grading of the entire tumor.[156]
4. **Depth of invasion**. This is an important factor, at least in some locations.[144,157] This feature is incorporated into the staging systems and often dictates whether a lymph node dissection will be performed, especially for oral cavity carcinomas.
5. **Tumor size**. This feature does not correlate closely with clinical outcome, except for the very small tumors.[158]
6. **Tissue eosinophilia**. Intense infiltration of the carcinoma by eosinophils is said to be a favorable prognostic factor.[159]
7. **Lymph node involvement**. Naturally, presence of lymph node metastases is an important prognostic criterion and, as such, it is a key feature of the staging system. Extracapsular spread (i.e., spread of the metastases beyond the lymph node capsule) is an indicator of a further decrease in survival rates being associated with higher rates of locoregional failure.[156]
8. **High-risk HPV**. HPV-16 and -18 positivity in squamous cell carcinomas of the oral cavity and other head and neck sites has been recognized to be a powerful indicator of improved survival.[160] In a recently completed study, it was confirmed that tumor HPV status is a strong and independent prognostic factor for survival among patients with oropharyngeal cancer.[161] This survival advantage is tempered in those individuals who smoke.
9. ***P21* gene**. Overexpression of this gene (the product of which is the downstream regulatory protein of *TP53*) was found to be an independent indicator of unfavorable prognosis in lingual squamous cell carcinoma.[162]
10. **p16**. Overexpression of p16 was found by Kato et al. to be a favorable prognostic factor in oropharyngeal carcinoma.[163] This is related to the fact that p16 is a surrogate marker for high-risk HPV, a known favorable prognostic factor.

Verrucous Carcinoma

Verrucous carcinoma (Ackerman tumor) is a variant of well-differentiated squamous cell carcinoma endowed with enough clinical, pathologic, and behavioral peculiarities to justify its being regarded as a specific tumor entity.[164,165] The oral cavity is its classic location, but this lesion also has been reported in the larynx, nasal cavity, esophagus, penis, anorectal region, vulva, vagina, uterine cervix, and skin (particularly in the sole of the foot). Within the oral cavity, the most common sites are the buccal mucosa and lower gingiva.[166] Most patients are elderly males, and there is a close connection with the use of tobacco, especially chewing or snuff dipping.[167] Grossly, it presents as a large, fungating, soft papillary growth that tends to become infected and slowly invades contiguous structures (Fig. 4.20). It may grow through the soft tissues of the cheek, penetrate into the mandible or maxilla, and invade perineurial spaces. Regional lymph node metastases are exceedingly rare and are presumably related to an undetected well-differentiated conventional squamous cell component. Distant metastases have not been reported.

The microscopic diagnosis of verrucous carcinoma may be difficult because of its well-differentiated character. A superficial biopsy will

Figure 4.20 Gross Appearance of Verrucous Carcinoma With Extensive Involvement of the Tongue.

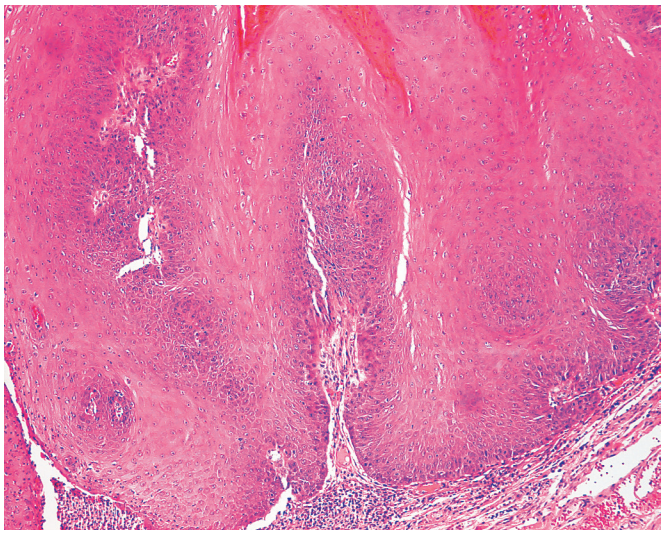

Figure 4.21 Verrucous Carcinoma of Tongue. Extremely well-differentiated squamous rete pegs push into the underlying stroma.

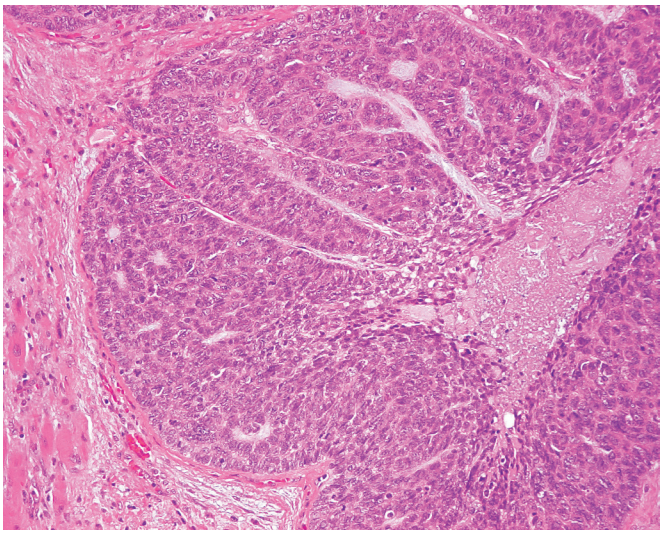

Figure 4.22 Basaloid Squamous Cell Carcinoma. Note the lobular configuration, pseudoglandular spaces, and the deposition of basement membrane material.

show only hyperkeratosis, acanthosis, and benign-appearing papillomatosis. Sections of an adequate biopsy show swollen, rounded, and voluminous rete pegs that extend into the deeper tissues (Fig. 4.21). Additional features include parakeratin plugs (invaginations) and a band of lymphoplasmacytic inflammation at the advancing front. The most important differential feature with squamous cell carcinoma is the good cytologic differentiation *throughout* the tumor. Dr. Lauren Ackerman, who first described the entity, used to express this fact by stating: "If a lesion looks cytologically like carcinoma, it is not verrucous carcinoma." Significantly, in about one-fifth of the cases, cytologically identifiable foci of squamous cell carcinoma occur within a lesion that looks otherwise like a verrucous carcinoma, hence the importance of thorough sampling.[168] These *hybrid* (*verrucous–squamous*) *tumors* are said to be associated with a higher recurrence rate than pure verrucous carcinomas.[168]

Resection is the treatment of choice. If surgery is inadequate, the tumor will recur.[164] Radiation therapy is not recommended, since it may alter the nature of the tumor to a highly malignant, rapidly metastasizing, poorly differentiated squamous cell carcinoma.[169] This has occurred in as many as 30% of the cases in some series, the average postirradiation interval being 6 months.

It is likely that most of the cases reported in the past as *oral florid papillomatosis* represent early and noninvasive stages of verrucous carcinoma. Along the same lines, the similar if not identical conditions known as *verrucous hyperplasia*, *proliferative verrucous leukoplakia*,[170] *verrucous keratosis*, and *leukoplakia verrucosa* can be regarded as precursor lesions of verrucous carcinoma, from which they are distinguished by the fact that the verrucous process is *superficial* to the adjacent squamous epithelium.

Other Microscopic Types

Carcinomas of surface epithelial origin other than squamous cell carcinoma of either the conventional or verrucous carcinoma types include the following:

1. **Adenoid (pseudoglandular) squamous cell carcinoma**. This tumor exhibits a pseudoglandular or alveolar appearance because of acantholysis. Most examples are located in the lip and, like their more common cutaneous counterparts, are associated with, and probably induced by, actinic radiation; however, a few have been seen in the gingiva or tongue, where an actinic pathogenesis cannot be invoked.[171]
2. **Adenosquamous carcinoma**. In contrast to the type listed previously, the rare adenosquamous carcinoma shows areas of squamous differentiation admixed with others having true glandular differentiation.[172] Some of these cases may be of minor salivary gland derivation, but they are substantially different from mucoepidermoid carcinomas.[173]
3. **Basaloid squamous cell carcinoma**. This is an aggressive variant of squamous cell carcinoma that has a predilection for the upper aerodigestive tract (oral cavity, oropharynx, esophagus, and larynx) but also occurs in other sites such as lung.[174] In basaloid carcinoma, areas with obvious squamous differentiation are admixed with solid tumor islands composed of undifferentiated basaloid cells that exhibit peripheral palisading and a thick basement membrane (Fig. 4.22).[175] Small cystic spaces containing mucoid or hyaline material are present, resulting in a resemblance to adenoid cystic carcinoma. The prominence of basal lamina material is one of the most striking attributes of this tumor at both the ultrastructural and immunohistochemical level. Immunoreactivity for high-molecular-weight keratin (detected with the 34βE12 antibody) and p63 is a consistent feature of this tumor.[176] Occasional examples have a spindle cell component.[177] The differential diagnosis includes minor salivary gland tumors (particularly adenoid cystic carcinoma)[178] and peripheral ameloblastoma.

   Adenoid cystic carcinoma shows a lower nuclear grade and exhibits focal glandular differentiation, whereas basaloid squamous cell carcinoma shows squamous differentiation. Both adenoid cystic carcinoma and basaloid squamous cell carcinoma are immunoreactive for 34βE12 and p63.[154]

   HPV-16 is detectable in the large majority of oropharyngeal basaloid squamous cell carcinomas, but only in few of those arising in other sites. The absence of HPV-16 in these tumors is associated with a decreased overall survival.[160]
4. **Papillary squamous cell carcinoma.** This is an uncommon variant in the oral cavity. It is seen most frequently in the oropharynx and larynx of elderly individuals and shows a frequent association with HPV infection.[179] Papillary squamous cell carcinoma of the oral cavity and oropharynx is associated with a good prognosis.

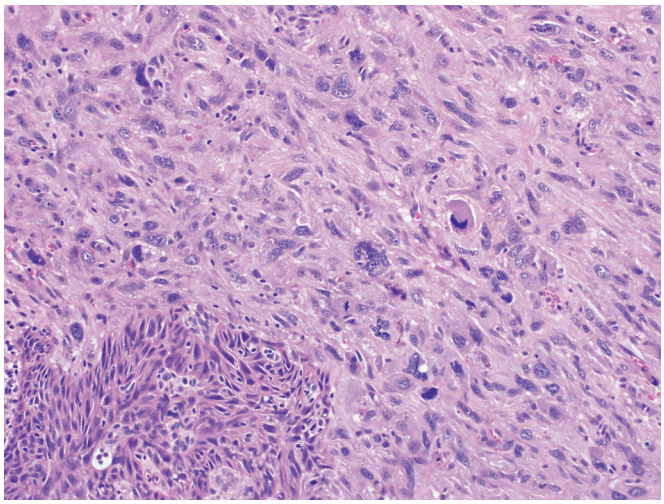

Figure 4.23 Spindle Cell (Sarcomatoid) Carcinoma. The island in the bottom left is clearly identifiable as squamous cell carcinoma, whereas the remaining component has a pleomorphic sarcoma-like appearance.

5. **Spindle cell (sarcomatoid) carcinoma**. This may appear as an ulcerated and infiltrative mass or as a polypoid growth in the lip, tongue, or other portions of the oral cavity. Sometimes the sarcoma-like formation blends with areas of obvious squamous cell carcinoma or represents the recurrence of what originally was an obvious squamous cell carcinoma (Fig. 4.23).[180] Other tumors are associated with squamous CIS or severe dysplasia. These findings, plus a wealth of electron microscopic, immunohistochemical, and molecular data, indicate that the sarcoma-like component represents a metaplastic change of an originally epithelial neoplasm.[181] Immunostains helpful in the distinction between sarcomatoid carcinoma and sarcoma (in the sense of favoring the former if positive) are keratin 5/6, epithelial membrane antigen (EMA), membranous epithelial cadherin, and nuclear p63.[182] Unfortunately, even a broad panel of epithelial immunohistochemical markers will be negative in a significant percentage of cases.

   The sarcoma-like component may look like an undifferentiated pleomorphic sarcoma or fibrosarcoma of soft tissue or it may show evidence of specific mesenchymal differentiation, particularly along muscle lines.[183] The nodal and distal metastases of this tumor may be purely carcinomatous, have a mixed appearance as in the primary neoplasm, or, in rare cases, be entirely composed of sarcoma-like elements. The prognosis is closely related to the stage and depth of invasion and is not significantly different from ordinary squamous cell carcinoma of equivalent stage and thickness.[184]
6. **Small cell carcinoma**. The appearance is similar to that of the homonymous lung carcinoma.[185] It may be pure or associated with a squamous component and its behavior is very aggressive.[186]
7. **Lymphoepithelioma-like carcinoma**. A tumor microscopically similar to the lymphoepithelioma of the nasopharynx and tonsil is occasionally found in the oral cavity or oropharynx.[187,188]
8. **NUT (midline) carcinoma**. This newly recognized type of carcinoma is defined by a molecular genetic alteration, but its diagnosis can be suspected on the basis of its clinicopathologic features.[189] Clinically it affects midlines structures, particularly those in the head and neck areas. Most of the initial reported cases were in children and young adults, but they were subsequently seen in all age groups. The most typical morphologic pattern is represented by foci of undifferentiated carcinoma showing islands of keratinization, *with a sharp interphase between the two*, accentuated by the immunohistochemical profile (CK8/18 positive in the undifferentiated areas and CK5/6 or p63 positive in the keratinizing areas). Prior to its recognition, this tumor was usually interpreted as sinonasal undifferentiated carcinomas, poorly differentiated squamous cell carcinoma, small cell carcinomas, or the basaloid squamous cell carcinomas.[189]

   At the molecular level, the tumor is defined by rearrangement of the *NUT* gene on chromosome 15q14.[190] The diagnosis is confirmed by documenting nuclear expression of NUT in the nuclei of the undifferentiated cells by immunohistochemistry (with the C52 monoclonal antibody) or by detecting the chromosome translocation *BRD4-NUT* or one of its variants (such as *BRD3-NUT*) by fluorescent in situ hybridization or reverse transcriptase-polymerase chain reaction (RT-PCR).[190,191] This tumor runs an extremely aggressive clinical course but has been found to respond well to the chemotherapeutic regimen used for Ewing sarcoma/primitive neuroectodermal tumor (PNET).[192]

Tumors and Other Lesions of Minor Salivary Glands

Minor salivary glands, present in practically all compartments of the oral cavity, participate in many of the diseases affecting their major counterparts, a feature that can be exploited for diagnostic purposes. Thus biopsy of the lower lip has shown involvement of the minor salivary glands in cases of *cystic fibrosis*[193] and *Sjögren syndrome*[194] and has also been used to diagnose end-stage *chronic GVHD*.[195]

Adenomatoid hyperplasia is a term used for a localized hyperplastic process of minor salivary glands appearing clinically as a nodule, usually in the hard palate but occasionally in the retromolar area.[196]

Intraoral minor salivary glands can give rise to a variety of benign and malignant tumors. The hard palate is the most common location, but similar tumors also occur in the soft palate, cheek, tonsil, floor of the mouth, tongue, lip (usually the upper), gingiva, and jaw. It is important to remember that tumors arising in the deep lobe of the parotid gland may present as primary intraoral masses. With a few exceptions, minor salivary gland tumors are morphologically analogous to those located in the major glands[197,198]; however, they differ from the latter in their relative incidence and, to some extent, in their natural history.[199]

Pleomorphic adenomas (benign mixed tumor), which constitute over 75% of all parotid neoplasms, make up about half of the salivary gland tumors of the palate but are otherwise similar to major salivary gland pleomorphic adenomas.[200–202] They may be overdiagnosed as malignant because of increased cellularity, nuclear atypia in the often predominant myoepithelial component (see under "Myoepithelioma"), or pseudoepitheliomatous hyperplasia of the overlying mucosa.[203]

Adenoid cystic carcinoma, mucoepidermoid carcinoma, and **polymorphous low-grade adenocarcinoma** (see later section) comprise the large majority of intraoral malignant salivary gland tumors, in contrast to the more even distribution of tumor types seen in the parotid gland. Rare cases of **acinic cell carcinoma** and of **epithelial–myoepithelial carcinoma** (to be distinguished from pure myoepithelioma, see later) have also been described.[204,205] The prognosis of adenoid cystic carcinoma is said to be better when the tumor is located in the palate than when arising in the parotid or submandibular gland,[201] but this may be at least partially due to the inclusion among the palatal tumors of some cases of

polymorphous low-grade adenocarcinomas. The prognostic difference among the various morphologic subtypes of this tumor, which has been noted for the major salivary gland, seems to apply also to this location.[206] Of the salivary gland tumors located in the lip, about 80% are benign. Among the malignant types, adenoid cystic carcinoma and mucoepidermoid carcinoma are the most frequent.[207]

Some types of salivary gland tumor occur predominantly or, in some instances, almost exclusively in the minor salivary glands of the oral cavity. They include the following:

1. **Canalicular adenoma**. This tumor, characterized by a canalicular pattern of growth (Fig. 4.24), has a predilection for the upper lip, buccal mucosa, and palate (often at the junction between the hard and soft regions), where it is sometimes confused with adenoid cystic carcinoma.[202,208,209] In contrast to adenoid cystic carcinoma, canalicular adenomas are diffusely positive for S-100 and demonstrate only focal and weak p63 staining if positive.
2. **Myoepithelioma**. This lesion, composed of hyaline or plasmacytoid cells, usually involves the hard palate (Fig. 4.25). The differential diagnosis includes plasmacytoma, oncocytoma, and even skeletal muscle neoplasms. Despite its high cellularity and the occasional presence of atypical hyperchromatic nuclei and intravascular tumor cells, the behavior is generally benign.[210,211]
3. **Sialadenoma papilliferum**. This is a papillary tumor of the oral cavity, usually located in the hard palate or buccal mucosa and characterized microscopically by a biphasic composition. An exophytic mass of well-differentiated squamous epithelium is seen covering a glandular component consisting of cleft-like cystic spaces lined by cuboidal or columnar epithelium; some of these glands may contain oncocytic cells, and others may exhibit squamous metaplasia.[212] The stroma is usually rich in plasma cells. The appearance is reminiscent of both Warthin tumor of the parotid gland and papillary syringocystadenoma of skin, both at the light and electron microscopic level.
4. **Inverted ductal papilloma**. This tumor has a pattern of growth similar to that of inverted papilloma of the nasal cavity. It appears clinically as a small submucosal mass in the oral cavity of adults. Microscopically, there are complex invaginations formed by well-differentiated, predominantly squamous epithelium–associated microcysts, occasional mucous cells, and a lining of columnar cells. The behavior is benign.[213]
5. **Clear cell carcinoma.** This is a low-grade carcinoma that predominantly occurs in intraoral minor salivary glands of adults.[214] The palate is most frequently involved, but all oral sites can be involved such as alveolar ridge, tongue, tonsil, floor of mouth, and buccal mucosa. Microscopically, they are composed of sheets or nodules of large polygonal cells with abundant cytoplasmic glycogen and lacking in atypia or mitotic activity (Fig. 4.26). The stroma can be hyalinized and paucicelluar or composed of a cellular spindled myofibroblastic stroma. The cells are positive for keratin and p63 with variable S-100 staining. They may be associated with recurrence and regional lymph node metastasis, but they rarely metastasize distantly or result in death. Recently these tumors have been shown to have a consistent *EWSR1-ATF1* fusion.[215]
6. **Polymorphous low-grade adenocarcinoma.**[216,217] This is the currently preferred term for a low-grade malignant tumor that has also been called *low-grade papillary adenocarcinoma*,[218,219] *terminal duct carcinoma*,[220] and *lobular carcinoma*.[221] Adult females are most

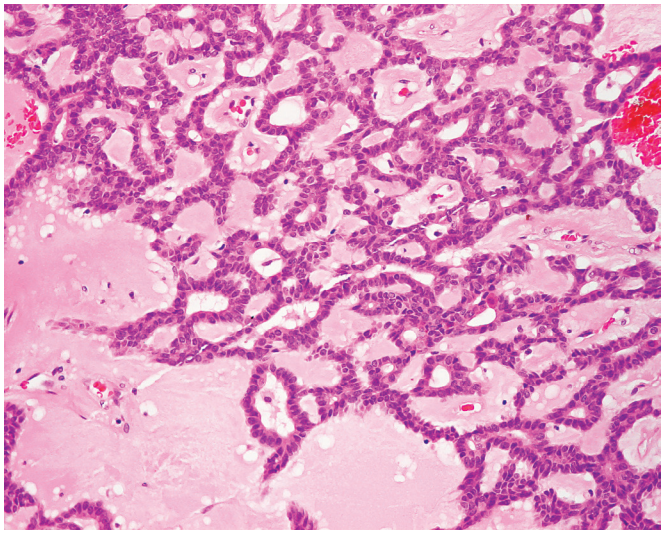

Figure 4.24 Canalicular Adenoma. This type of benign salivary gland tumor is particularly common in the lip.

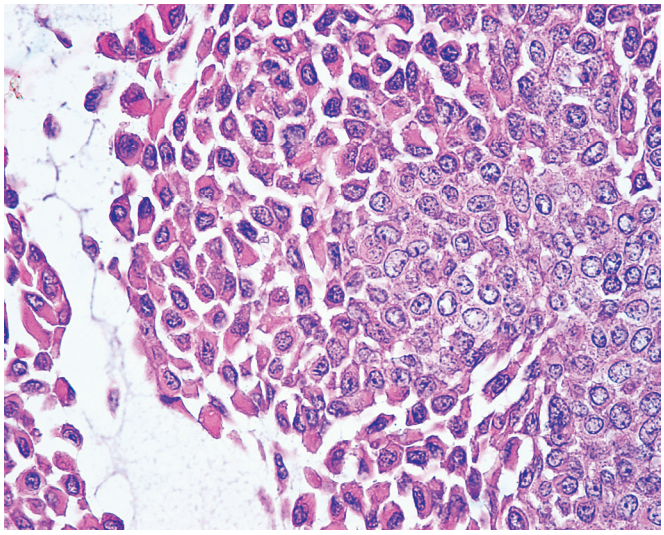

Figure 4.25 Myoepithelioma exclusively composed of so-called hyaline or plasmacytoid cells.

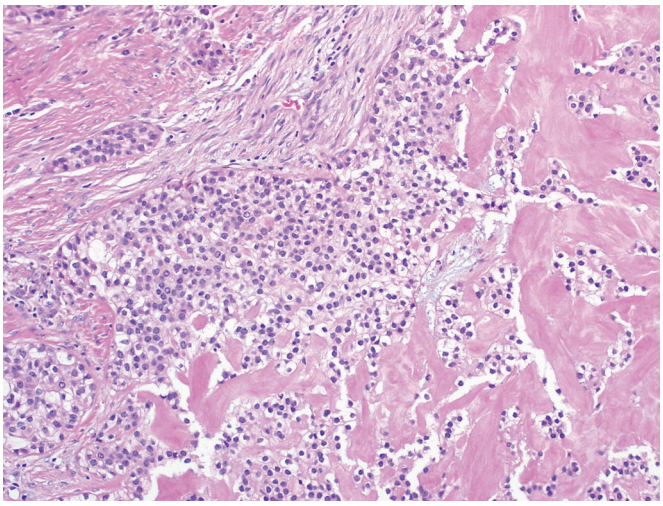

Figure 4.26 Clear Cell Carcinoma of Minor Salivary Glands. These typically arise in intraoral minor salivary gland and are composed of irregular islands composed of large clear cells associated with a hyalinized to spindled stroma.

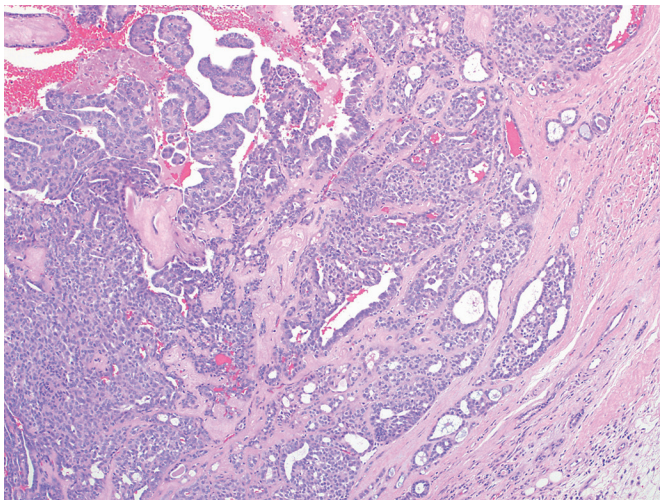

Figure 4.27 Polymorphous Low-Grade Adenocarcinoma. At low power, multiple architectural patterns can be seen including solid, tubular and papillary in this example.

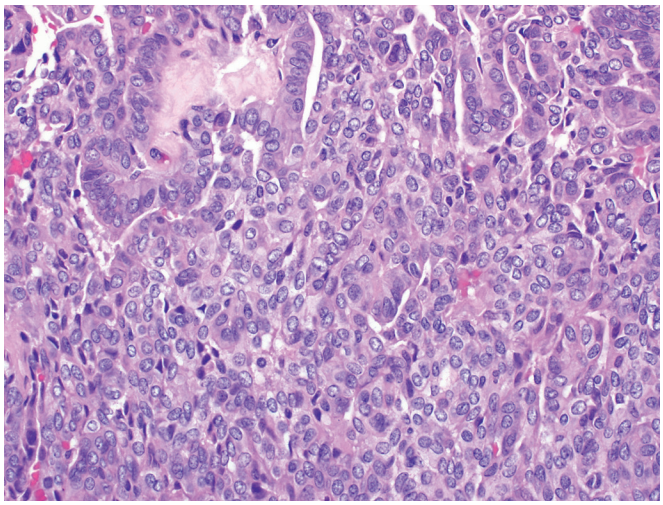

Figure 4.28 Polymorphous Low-Grade Adenocarcinoma. The cells are monotonous with oval nuclei containing pale chromatin, somewhat resembling the nuclei seen in papillary thyroid carcinoma.

commonly affected.[216] The palate is the most common location, but all intraoral sites can be involved. Polymorphous low-grade adenocarcinoma is the second most common type of salivary gland carcinoma in this location following adenoid cystic carcinoma.[222] Microscopically, there is uniformity of cell type but a marked variation in architectural patterns, which is responsible for the various names that this tumor has received.[223] Tubular, cribriform, papillary, solid, and fascicular formations may appear, with frequent combinations and transitions (Figs. 4.27 and 4.28). The tumor nuclei are typically oval with pale chromatin and occasional nuclear grooves imparting a resemblance to papillary thyroid carcinoma. The periphery of the tumor has invasive features, sometimes in an Indian-file pattern, which has led to a strained analogy with invasive lobular carcinoma of the breast. Perineurial invasion is also common and may have a targetoid appearance. Mitotic activity is inconspicuous. Extensive S-100 protein immunoreactivity is present, suggesting possible derivation from intercalated ducts.[224] They are often p63 positive, but the staining is focal and of variable intensity. C-kit is often positive in polymorphous low-grade adenocarcinoma, limiting its utility in the differential diagnosis. The differential diagnosis includes benign mixed tumor, canalicular adenoma, basal cell adenoma (all of which lack infiltrative features), and in particular adenoid cystic carcinoma.[220] However, the last lacks the plump and columnar cells of polymorphous low-grade adenocarcinoma, as well as its papillary and fascicular growth patterns. In addition, adenoid cystic carcinomas are not diffusely S-100 positive and have diffuse strong p63 staining in the myoepithelial/basal cell component. The behavior of this tumor is that of a low-grade malignancy. In one series of 69 cases, recurrences developed in 12% and regional lymph node metastases in 10%, but there were no distant metastases, and there was only one tumor-related death.[224] In another series, consisting of 164 cases, 97.6% of the patients were either alive or had died of other diseases.[216] Tumors with a conspicuous papillary component are associated with a higher incidence of lymph node metastases.[217] Rarely, polymorphous low-grade adenocarcinoma may undergo transformation to a high-grade tumor.[225,226] A majority of polymorphous low-grade adenocarcinomas have recently been shown to have *PRKD1* activating mutations.[227]

The recently described *cribriform adenocarcinoma of minor salivary glands* (cribriform adenocarcinoma of the tongue) is mentioned here despite its obscure histogenesis and also because its differential diagnosis includes several types of salivary gland tumor. Morphologically, it resembles the solid and follicular variants of papillary thyroid carcinoma (to the point of raising the possibility of an origin from the thyroglossal duct anlage), but thyroglobulin stains are negative.[228] Some consider this a variant of polymorphous low-grade adenocarcinoma due to significant histologic and immunophenotypic overlap. This is supported by recent molecular evidence demonstrating translocations involving the *PRKD1* gene and the related *PRKD2* and *PRKD3* genes.[227] In contrast to polymorphous low-grade adenocarcinoma, cribriform adenocarcinoma of minor salivary glands most often arises in the tongue base and more often presents with cervical lymph node metastasis. Despite this latter fact, they are associated with an overall favorable prognosis.

The treatment of minor salivary gland tumors is primarily surgical. It has been emphasized that the first excision should be the most definitive and comprehensive and that treatment of recurrent disease is rarely curative.[229] Postoperative irradiation is generally recommended for all high-grade malignancies, including adenoid cystic carcinoma.[229]

Tumors of Odontogenic Epithelium

Peripheral ameloblastoma is a tumor of the oral cavity, not involving bone but exhibiting microscopic features of ameloblastic differentiation (Fig. 4.29). As a matter of fact, its appearance is indistinguishable from that of ameloblastoma of the jaw (see Chapter 5).[230] Most of the reported cases have occurred in the gingiva, and several have been published in the past as basal cell carcinomas. A desmoplastic variety has been described.[231] Theoretically, peripheral ameloblastomas could arise from remnants of the dental lamina within the gingiva ("rests of Serres") or from surface epithelium that has retained the capacity to differentiate along odontogenic structures. They are more indolent than their counterparts in the jaw and are generally cured by local excision.[230]

Tumors of Melanocytes

Ephelis and **lentigo** (melanotic macules) can present as solitary lesions of the oral cavity, usually the lower lip.[232] They are more

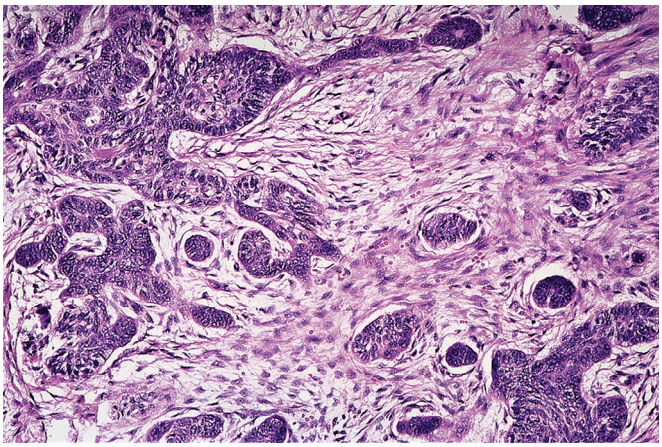

Figure 4.29 Peripheral Ameloblastoma. This tumor connected with the lining epithelium of the gingival mucosa and did not involve the jawbones but is otherwise identical to intraosseous ameloblastomas.

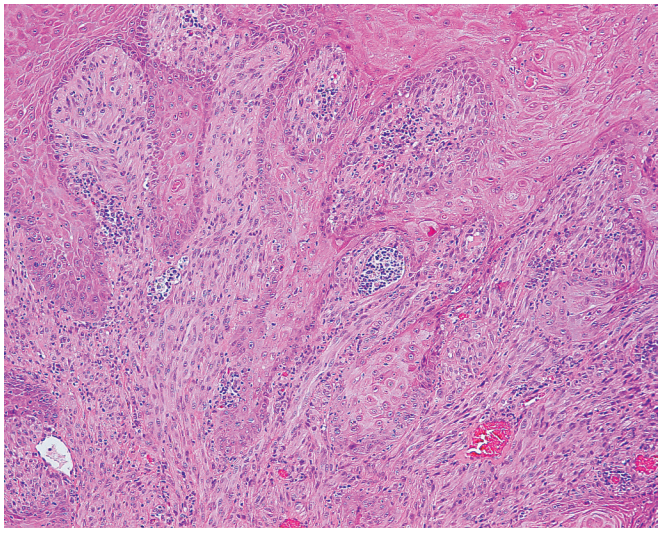

Figure 4.30 Spitz nevus of tongue accompanied by intense pseudoepitheliomatous hyperplasia of the overlying squamous epithelium.

common in females and are characterized microscopically by hyperpigmentation of the basal layer, associated in the case of lentigo with elongation of the rete ridges. The term *melanoacanthoma* has been used when the melanocytic proliferation extends above the basal layer and is found intimately admixed with the keratinocytes.[233] Multiple pigmented macules of the lip are one of the components of the Peutz–Jeghers syndrome and Carney complex. The presence of pigmented patches within the oral cavity (usually located in the hard palate or gingiva) is known as **melanosis**.

Melanocytic nevi may involve the lips and, in rare cases, the inside of the oral cavity.[234–236] In one series, there were 3 junctional, 30 compound, 32 submucosal (equivalent of the cutaneous intradermal), and 6 blue nevi.[237]

Spitz nevus may involve the tongue and be associated with pseudoepitheliomatous hyperplasia of the overlying squamous epithelium, to a degree that may simulate both malignant melanoma and squamous cell carcinoma (Fig. 4.30).[238]

Malignant melanoma of the oral cavity is particularly common in people of Japanese and black African origin. The hard palate and gingiva are the most common locations.[239] Both pigmented and amelanotic varieties occur.[240] Some of the tumors have desmoplastic features, especially when occurring in the lower lip. These are often underdiagnosed because of their scarce cellularity and sometimes less than prominent atypia. The diagnosis should be suspected in the presence of a spindle cell proliferation in the lamina propria with a fascicular pattern of growth, particularly if accompanied by prominent clusters of lymphocytes in the peripheral portion.[241] The diagnosis is supported by the S-100 protein positivity; however, this is usually accompanied by negativity for Melan-A and HMB-45.[242] Conventional melanoma, by contrast, is usually positive for all three markers.[242]

Oral "melanosis" adjacent to the area of invasive melanoma is found in about 30% of the cases; in most instances, there is some degree of atypia in this intraepithelial component. Lymph node and distant metastases are common, and the prognosis is extremely poor.[243] The histologic parameters used for predicting prognosis of cutaneous melanomas do not apply as well.[244]

Tumors and Tumorlike Conditions of Lymphoid Tissue

Benign nodules made of mature small lymphocytes, with or without an admixture of histiocytes, are not uncommon in the oral cavity. They may represent enlarged buccal lymph nodes or hypertrophic buccal tonsils, or may be associated with cystic glandular structures (*"lymphoepithelial cysts"*).[245] The most prominent of these benign lymphoid proliferations occur in the palatine tonsils and are designated *lymphoid polyps* or *pseudolymphomas*, but it is better to avoid the latter term.[246]

Malignant lymphoma most commonly occurs in the Waldeyer ring, particularly in the palatine and lingual tonsil, but it can also develop in the gingival area, buccal mucosa, palate, or lips. Most patients are in their sixth or seventh decade, but cases have been reported in younger patients and even in children.[247] The typical clinical presentation is that of a soft, bulky mass covered by normal or ulcerated mucosa. Microscopically, most cases are of B-lineage and follicular center cell origin, of large size and with a generally diffuse pattern of growth.[248–252] In about 40% of the cases, there is evidence of disease outside the oral cavity, particularly in the cervical lymph nodes and gastrointestinal tract.[253] A high proportion of the latter represent cases of marginal zone lymphoma.[249,254] T-cell lymphomas can also occur in this location[255] (including mycosis fungoides[256]), as well as anaplastic large cell lymphomas.

As for malignant lymphomas elsewhere, clinical staging and microscopic typing are the two most important prognostic factors.[248]

Plasmacytomas can occur in the soft tissues of the oral cavity, although not so commonly as in the upper air passages.[257] It is important to distinguish them from the more common *plasma cell granulomas* of reactive nature,[258] including so-called *mucous membrane plasmacytosis*[259] or *plasma cell mucositis*.[260] These disorders are composed of mature plasma cells, have a mixture of other inflammatory cells, and are associated with fibrosis. Immunohistochemical staining for immunoglobulin light chains may help in this differential diagnosis as plasmacytomas will demonstrate a monoclonal population of either kappa- or lambda-expressing cells.

Hodgkin disease presenting initially in the oral cavity is extremely rare, but several reported cases are on record.[261] Most of them were located in the Waldeyer ring, and there was a predilection for the lymphocyte-rich classical subtype.[262]

Leukemia of acute myelocytic or myelomonocytic type is associated with gingival involvement in about 4% of the cases, with or without concomitant skin involvement.[263] In rare cases, oral cavity disease is the first manifestation of extramedullary myeloid sarcoma.[264]

Langerhans cell histiocytosis can involve the oral cavity, either as an isolated focus or as an expression of multisystem disease.[265]

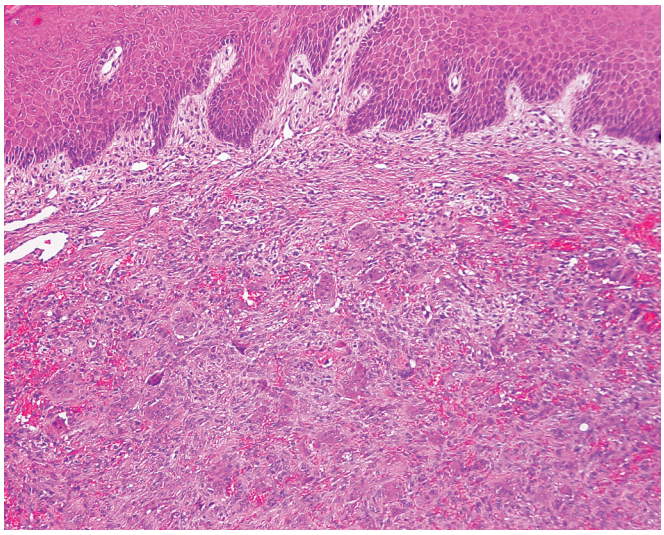

Figure 4.31 Peripheral giant cell granuloma beneath a slightly hyperplastic squamous epithelium.

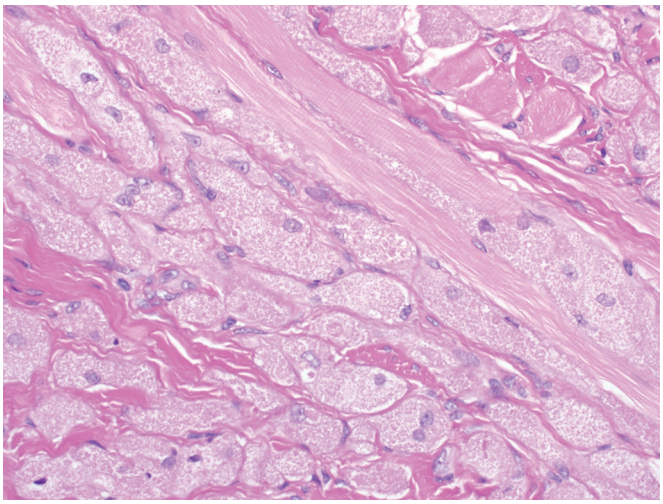

Figure 4.32 **Granular Cell Tumor.** The lesion shows an infiltrative pattern with growth along muscle fibers. The cells are large and polygonal with abundant granular eosinophilic cytoplasm.

Although most often found in the gingiva, the lesions can also affect the hard palate.[266]

Follicular dendritic cell tumors (dendritic reticulum cell tumors) and **histiocytic sarcomas** have been observed in the palate and tonsil.[267] These are fully discussed in Chapter 37.

Other Tumors and Tumorlike Conditions

Hamartomas of the tongue blend with some of the congenital malformations mentioned previously. They are predominantly submucosal and can be roughly divided according to their predominant composition into neurovascular, smooth muscle predominant, fat predominant, and smooth muscle and fat containing.[268]

Peripheral giant cell granuloma (giant cell epulis) is seen in all age groups and is more common in females.[269] Maxilla and mandible are affected with equal frequency. A soft-to-firm mass forms in the gingiva, often displaces adjacent teeth, and may erode the underlying bone. Microscopically, the lesion shows numerous osteoclast-like giant cells, a cellular highly vascularized stroma, and, at times, small amounts of neoformed osteoid and bone (Fig. 4.31). This common lesion is benign and probably of reactive nature.

Peripheral ossifying fibroma is a reactive lesion composed of a proliferation of bland fibroblasts with a collagenous stroma that may contain dystrophic calcification and reactive bone, the latter typically located at the deep aspect. Most occur in young adults, but a wide age range is described.[270] They occur in the gingiva, particularly near the incisors, and present as sessile mucosal covered nodules often with ulceration. Although benign, recurrences occur in about 20% of patients, necessitating excision down to the periosteum to prevent such an event.

Granular cell tumor can involve any portion of the oral cavity, the tongue being the most common site (and the one in which it was originally described by Abrikosoff) (Fig. 4.32). The overlying epithelium often shows florid pseudoepitheliomatous hyperplasia.[271] An exceptionally rare malignant counterpart of this lesion has also been described.[272] A lesion morphologically similar to granular cell tumor is seen occasionally in the gingiva of newborn infants and is called *congenital (granular cell) epulis* (Fig. 4.33). This lesion occurs almost exclusively in females and behaves in a benign fashion even if incompletely excised.[273] Histologically, it is comprised of sheets of large polygonal cells with abundant granular eosinophilic cytoplasm. The tumor has a prominent vascular stroma, and they do not induce pseudoepitheliomatous hyperplasia, features which differ from granular cell tumor. Ultrastructural studies have suggested a mesenchymal (fibroblastic, pericytic, or smooth muscle) rather than an odontogenic origin.[274,275] Staining for S-100 protein, NGFr/p75, and PGP 9.5 is negative, in contrast to the adult form of this lesion.[276]

Figure 4.33 **Clinical Appearance of Congenital Granular Cell Epulis.** (Courtesy of Dr. R.A. Cooke, Brisbane, Australia; From Cooke RA, Stewart B. *Colour Atlas of Anatomical Pathology*. Edinburgh: Churchill Livingstone; 2004.)

Verruciform xanthoma presents in middle-aged persons as a raised, granular, or verrucous lesion of the oral cavity, usually in the gingiva or alveolar ridge.[277,278] Collections of foamy macrophages in the lamina propria are covered by a verrucous and acanthotic epithelium (Fig. 4.34). The lesion is probably a reactive process rather than a true neoplasm.

Congenital dermoid (hairy polyp) is a rare congenital malformation arising from the oropharynx or nasopharynx. Microscopically, the lesion is polypoid and composed of epidermis, hair follicles, sebaceous glands, and eccrine sweat glands. Adipose tissue, smooth muscle, striated muscle, and cartilage may be present within the polyp core.[279] Excision is curative.

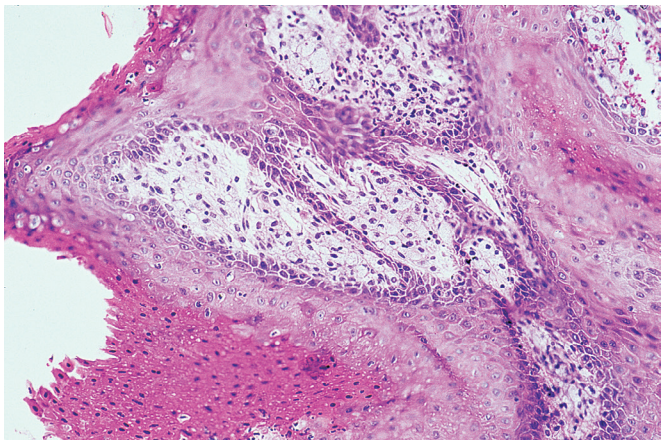

Figure 4.34 Verruciform Xanthoma. Clusters of foamy macrophages are seen expanding the stroma beneath a hyperkeratotic epithelium.

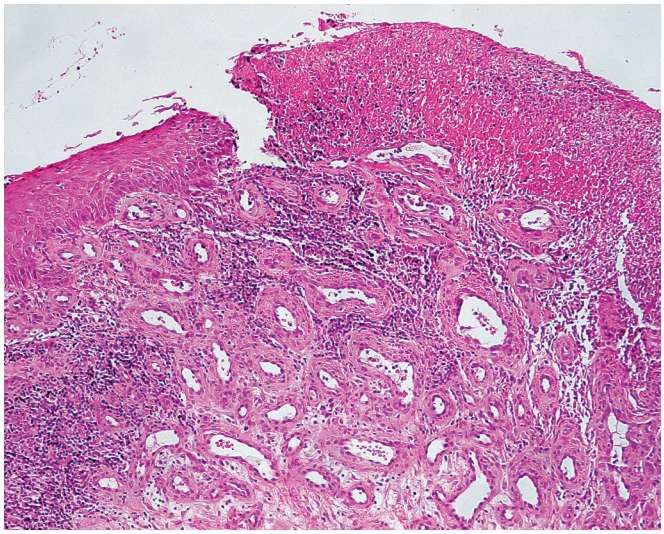

Figure 4.35 Pyogenic Granuloma. Numerous neoformed vessels are separated from each other by an inflamed and edematous stroma. The overlying mucosa is partially ulcerated.

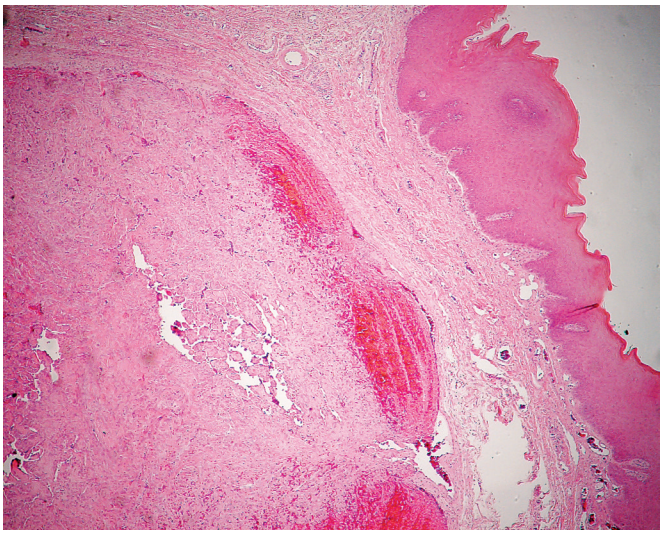

Figure 4.36 Intravascular Papillary Endothelial Hyperplasia. Remnants of the original thrombus can be seen in the more superficial portion of the nodule.

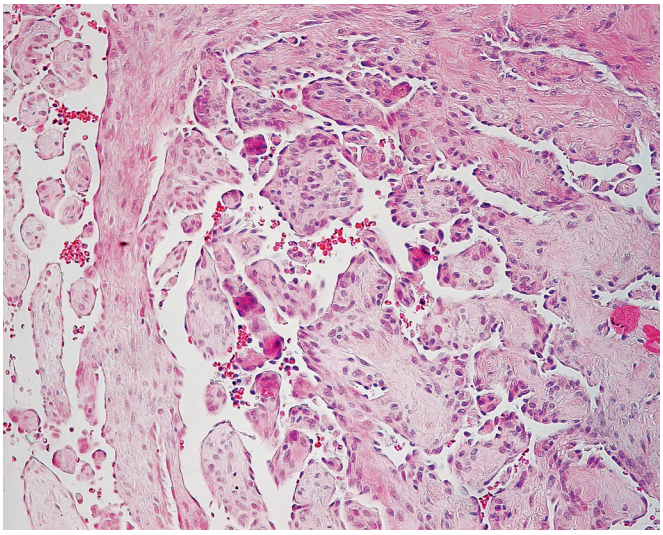

Figure 4.37 Intravascular Papillary Endothelial Hyperplasia. Papillary projections lined by endothelial cells are seen within the vascular lumen.

Vascular proliferations of the oral cavity are benign in the vast majority of cases. Two of the most common types are probably not even neoplastic, although their ability to simulate a malignant process is not to be underestimated.[280] The first is *pyogenic granuloma (lobular capillary hemangioma)*, which appears as an elevated, dark red lesion that may or may not be ulcerated (Fig. 4.35).[281] Large masses of proliferating endothelial and perithelial cells are separated by an edematous stroma containing inflammatory cells, imparting a lobular configuration to the vascular proliferation. Characteristically, the covering epithelium makes a collarette and almost meets at the base of the lesion. The lesion may regress completely or heal as a residual fibrous mass or fibroepithelial papilloma.[282] An identical lesion occurring during pregnancy has been referred to as granuloma gravidarum or pregnancy tumor.[283]

The second most common benign and probably non-neoplastic intraoral vascular lesion is *intravascular papillary endothelial hyperplasia (Masson hemangioma)*. It can occur de novo or be superimposed on a preexisting hemangioma (Figs. 4.36 and 4.37).[284] Both this lesion and pyogenic granuloma occur most commonly in the lip, their features sometimes overlapping.[280]

Benign vascular tumors are largely represented by *hemangiomas* and *lymphangiomas*.[285] Most of these are located in the tongue, where they can result in soft cystic masses large enough to interfere with speech and mastication. Microscopically, most of these lesions have markedly dilated ("cavernous") vascular or lymphatic channels. The treatment is surgical. *Tonsillar lymphangiomatous polyps* present as unilateral tonsillar masses composed of dilated lymph channels covered by hyperplastic squamous epithelium, resulting in a typical polypoid configuration.[286] Other benign or borderline vascular tumors that may present intraorally are *glomus tumor*,[287] *epithelioid hemangioma* (angiolymphoid hyperplasia with eosinophilia) (Fig. 4.38),[288,289] and *epithelioid hemangioendothelioma*.[290]

Kaposi sarcoma of the oral cavity can be seen in individuals with HIV infection and sometimes represents the first manifestation of the disease. The palate is the most common site. Clinically, the lesions may appear as small, well-delineated macular lesions or as larger, infiltrative nodules.[291] Microscopically and immunohistochemically, the features are generally similar to those of its cutaneous

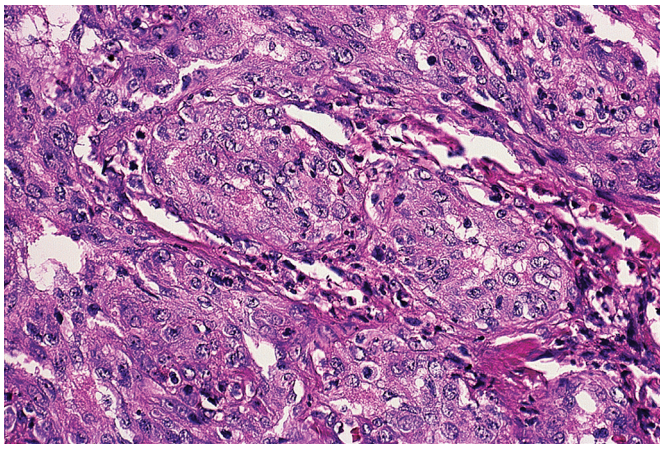

Figure 4.38 Epithelioid Hemangioma of Soft Tissues of Oral Cavity. This lesion tends to be overdiagnosed as a malignant vascular neoplasm and sometimes is confused with carcinoma.

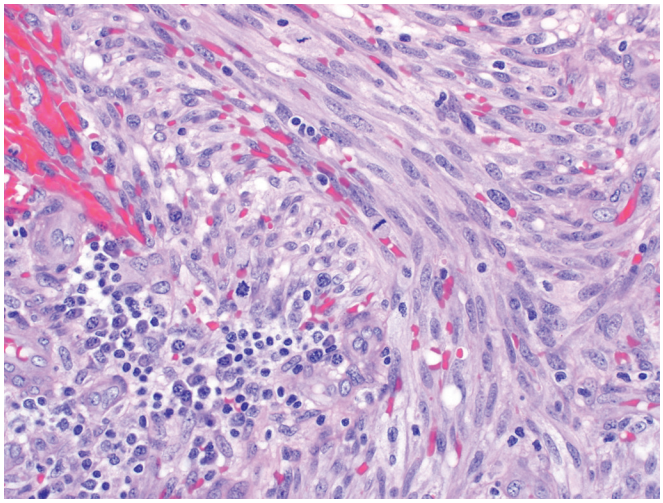

Figure 4.39 Kaposi Sarcoma of Oral Cavity. Atypical spindle cells form slit-like vascular channels containing red blood cells.

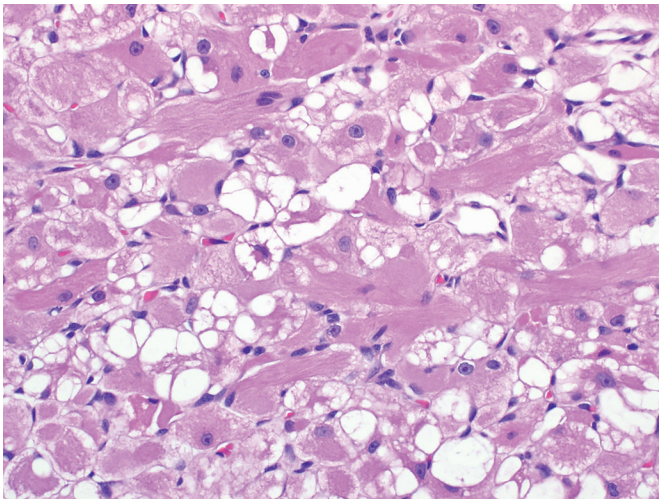

Figure 4.40 Adult Rhabdomyoma of Oral Cavity. Large eosinophilic cells contain cytoplasmic vacuoles, some of which resemble "spider cells." Cross striations can be seen focally in many cases.

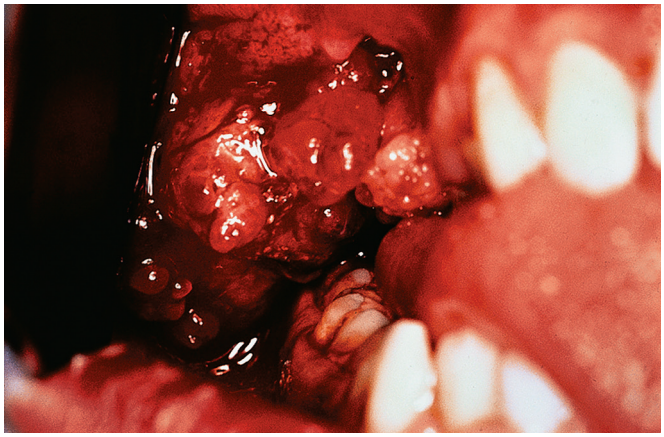

Figure 4.41 Clinical appearance of embryonal rhabdomyosarcoma of oral cavity in an infant.

counterpart (Fig. 4.39).[292] *Angiosarcoma* of the oral cavity is very rare.[293–295] Before making a diagnosis of angiosarcoma in the oral cavity (particularly if the lesion is in the lip or tongue), the much more likely possibility of a benign vascular process of one of the types previously described should be considered.[280]

Solitary fibrous tumor may present in the oral cavity as a well-circumscribed submucosal mass; the behavior of the reported cases has been benign.[296]

Rhabdomyomas have a special predilection for the oral cavity and neck. The floor of the mouth is the most common location,[297,298] but they also occur in the tongue.[299] Both adult and fetal forms have been described, as well as intermediate ("juvenile") forms.[300] The adult type is the most common and is usually well circumscribed and may be multiple.[301] It may recur locally and display cytogenetic abnormalities, features more in keeping with a neoplastic than a hamartomatous process.[302] Histologically, they are composed of sheets of very large eosinophilic cells with a low nuclear-to-cytoplasmic ratio. Cytoplasmic vacuolization results in a characteristic "spider" cell morphology, and cross striations can be seen (Fig. 4.40). Fetal rhabdomyomas resemble embryonal rhabdomyosarcoma but typically are circumscribed and lack cytologic atypia and mitotic activity.

Embryonal rhabdomyosarcomas have been described in the tongue and most other oral sites in children (Figs. 4.41 and 4.42).

Peripheral nerve tumors and tumorlike conditions of the oral cavity and pharynx include *schwannoma* (often located in the tongue),[303,304] *neurofibroma*,[305] *traumatic neuroma* (sometimes containing mature ganglion cells),[306] and the *multiple mucosal neuromas* seen as a component of multiple endocrine adenomatosis type IIb. These lesions resemble plexiform neurofibromas and may be found in the lips, tongue, conjunctiva, nasal cavity, and larynx.[307] They are made up of all the elements of the normal nerve, including a thickened EMA-positive perineurial layer.[308] *Malignant peripheral nerve sheath tumors* of the oral cavity, some of which are pigmented, have also been described.[309]

Other **benign soft tissue tumors** that have been reported in this location are *lipoma* (including variants such as myxoid lipoma, spindle cell lipoma, sialolipoma,[310] and lipoma with osseous and chondroid metaplasia)[311–314] *chondroma*,[315] *angiolipoma*,[316] and *PEComa*.[317]

A unique intraoral neoplasm exhibiting myxochondroid features has been termed *ectomesenchymal chondromyxoid tumor*; most have occurred in the anterior tongue (Fig. 4.43).[318] Microscopically, they are characterized by a lobular proliferation of oval and spindle cells in a chondromyxoid background. Immunohistochemically, the tumor

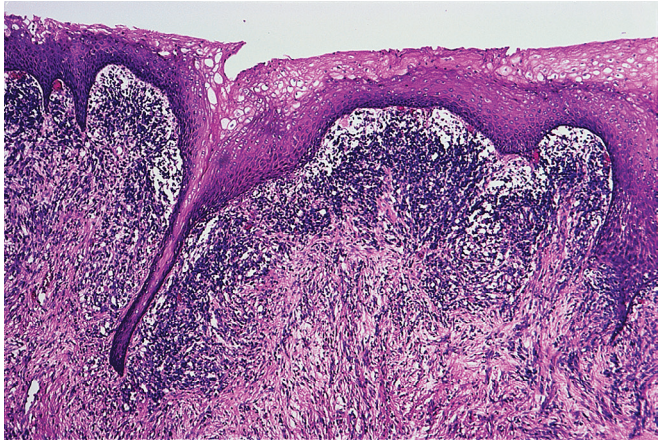

Figure 4.42 Low-Power Appearance of Embryonal Rhabdomyosarcoma of Oral Cavity. A prominent cambium layer is present.

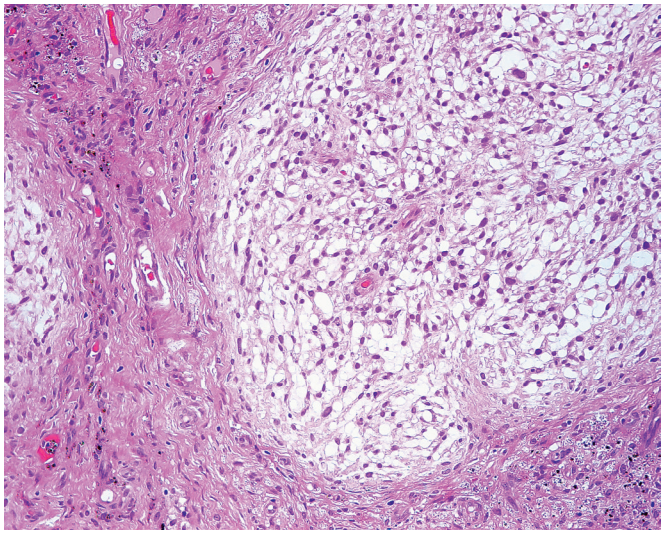

Figure 4.43 Ectomesenchymal Chondromyxoid Tumor of Tongue. (Slide courtesy of Dr. D. Heffner, Washington, DC.)

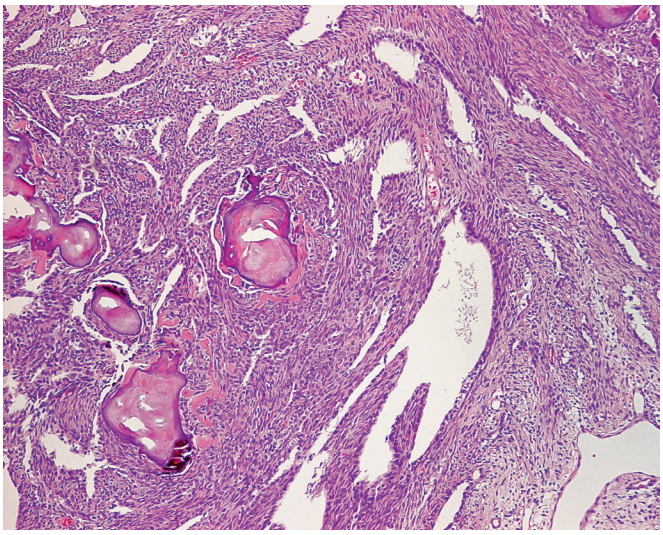

Figure 4.44 Synovial Sarcoma of Pharynx. Note the hemangiopericytoma-like areas and the foci of calcification/ossification.

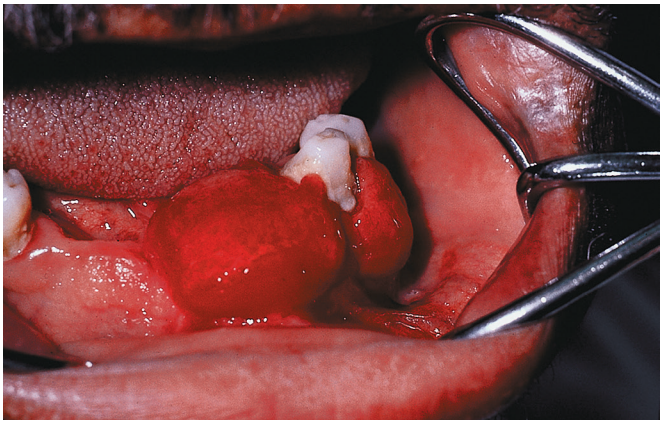

Figure 4.45 Clinical appearance of primary fibrosarcoma of the oral cavity, presenting as a sessile polypoid mass in the gingiva.

cells are reactive for glial fibrillary acidic protein (GFAP) and keratin and less frequently for smooth muscle actin and S-100 protein (but not for EMA and desmin). These are benign tumors that tend not to recur following excision.

Synovial sarcomas can occur as primary tumors in the pharynx, tonsil, cheek, tongue, or palate of young adults[319,320]; the main differential diagnosis is with salivary gland tumors, particularly cellular pleomorphic adenoma, epithelial–myoepithelial carcinoma, and carcinoma ex pleomorphic adenoma (Fig. 4.44).

Other reported sarcoma types of the oral cavity include **alveolar soft part sarcoma,**[294] **extraskeletal osteosarcoma,**[321] **fibrosarcoma** (Fig. 4.45), and **liposarcoma/atypical lipomatous tumor** (including the dedifferentiated form of the latter).[322,323]

Metastatic tumors may present as primary intraoral masses. The gingiva is the classic location, with or without bone involvement. The lung is the most common site of the primary lesion.[324,325] Metastatic renal cell carcinoma can masquerade clinically and microscopically as a pyogenic granuloma. Other sites for the primary tumor include breast, kidney, skin (melanoma and squamous cell carcinoma), prostate, endometrium, large bowel, and pleura (mesothelioma).[326–329]

Respiratory Tract

Normal Anatomy

The nasal cavity, paranasal sinuses, and nasopharynx form a functional unity that is reflected in the commonality of the pathologic processes that involve the region. This is particularly the case for the first two sites, which are often grouped under the term *sinonasal*.

The two main types of epithelia lining these structures are stratified squamous and respiratory-type pseudostratified columnar. The interphase between them is sharp in some areas, whereas in others there is an intervening zone of transitional (intermediate) epithelium. The latter resembles the urothelium of bladder and related structures at the light microscopic level but is ultrastructurally distinct from it.[1]

Each of these types of epithelia has its own distinctive cytokeratin profile as evaluated immunohistochemically.[330]

Numerous submucosal seromucinous glands are present throughout; they are particularly numerous in the region of the eustachian tube opening in the nasopharynx. Focal oncocytic metaplasia of these glands is common with advancing age. In *melanocytic oncocytic metaplasia*, a pigmented patch is seen around the eustachian tube

in which oncocytic metaplasia of the seromucinous glands is associated with melanin pigmentation.[331]

The roof of the nasal cavity contains the olfactory mucosa. In the normal human fetus this mucosa extends to the midportion of the nasal septum and onto the superior turbinate in a continuous fashion, whereas in adults many of these areas are replaced by respiratory epithelium.[332] The olfactory mucosa consists of three types of cell: olfactory nerve cells (bipolar cells whose axons pass through the cribriform plate to end in the olfactory bulb); sustentacular or supporting cells (microvilli-containing cylindrical cells); and basal cells (basally located small conical cells thought to be stem cells). Beneath the mucosa lie the olfactory glands of Bowman.[333]

Organized lymphoid tissue is present throughout the nasopharynx, which forms part of the Waldeyer ring. In addition to the pharyngeal tonsil (commonly referred to as the adenoid), lymphoid cells are abundant in the rim of the eustachian tube opening *(Gerlach tonsil)*. Conversely, lymphoid cells are scanty in the sinonasal region.

Inflammatory (Including "Allergic") Polyp

Nasal polyps are not true neoplasms. Their formation is associated with inflammation, allergy, or mucoviscidosis. Clinically, they appear as soft exophytic masses that extend laterally from the mucosa into the anterior part of the middle meatus.[334] Bilaterality is the rule. With time, they can fill the entire nasal cavity and even extend upward into the cranial cavity.[335] A morphologically similar type of polyp can be seen arising from one of the paranasal sinuses; this is referred to as *choanal polyp* and is subdivided according to its specific location into antrochoanal (the most common), sphenochoanal, and ethmoidochoanal.[336] Microscopically, the polyps are composed of a loose myxoid or hyaline stroma surrounding mucous glands and are covered by respiratory epithelium, which often exhibits foci of squamous metaplasia. They are infiltrated by lymphocytes, plasma cells, mast cells, neutrophils, and eosinophils.[337] Among the lymphocytes, there is a predominance of CD8+ (suppressor/cytotoxic) over CD4+ (helper/inducer) cells.[338] The eosinophils are immunoreactive for E62 (an activation marker), suggesting that they play a role in the pathogenesis of these polyps.[339] Eosinophils are not restricted to the polyps having a presumed allergic pathogenesis, although they are more numerous in them (Fig. 4.46).[340] Prominent thickening of the basal membrane is a common accompanying finding.

Occasionally, the stromal cells are large and pleomorphic, with bizarre hyperchromatic nuclei, and can simulate rhabdomyosarcoma or other malignancies (Fig. 4.47).[341] These cells are of a reactive nature and are similar to those sometimes seen in polyps of the oral cavity, vagina, and other mucosa-covered sites. Choanal polyps may show a prominent component of dilated vessels ("angiomatous or angiectatic polyps"), sometimes associated with thrombosis and infarct.[342]

From 6% to 10% of patients with mucoviscidosis (cystic fibrosis) develop polyps in the nasal cavity and paranasal sinuses. Therefore children presenting with nasal polyps should be investigated for this genetically determined condition. Microscopically, the polyps differ from the ordinary variety by the presence of large cystic glands with inspissated secretion in their lumina, degranulation of mast cells, preponderance of acid mucin, lack of extensive infiltration by eosinophils, and scanty submucosal hyalinization.[343,344] Nasal polyps can also develop as a complication of mucopolysaccharidosis (Hurler–Scheie syndrome).[345]

Local recurrence is common following the surgical removal of sinonasal polyps, probably because of persistence of the inciting pathogenetic factors.

Other Inflammatory Lesions

Chronic sinusitis has been traditionally divided into purulent and nonpurulent types. The maxillary sinus is by far the most commonly involved site. The disease is caused by various microbial organisms. The main microscopic features are inflammatory infiltrate, edema, glandular hyperplasia, basement membrane thickening, and squamous metaplasia.[346] Eosinophils may also be present and are occasionally numerous.[347] The underlying bone may show thickening and remodeling, with prominent osteoblastic rimming and fibrosis of the bone marrow spaces.

Mucocele of the maxillary sinus represents a complication of chronic sinusitis in which the accumulation of inflammatory exudate and the mucin secreted by the hyperplastic glands lifts the epithelial lining of the sinus and the periosteum away from the underlying bone. It is also sometimes referred to as *pseudocyst*.[348] The process gradually expands the cavity and causes destruction of contiguous bones, to the point that it can be mistaken for a malignant neoplasm.

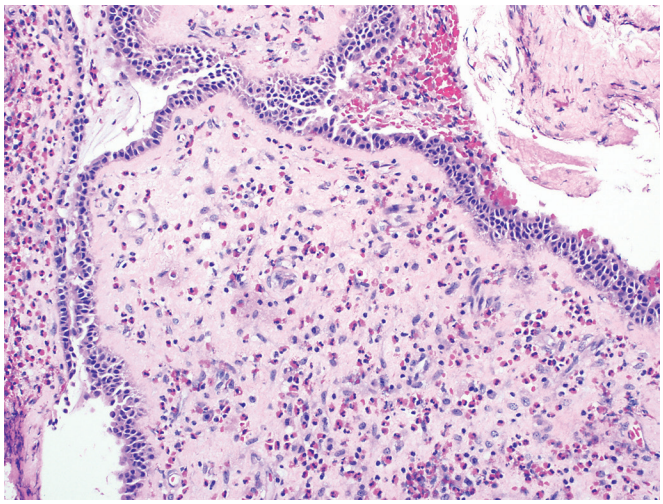

Figure 4.46 Allergic nasal polyp showing a large number of eosinophils and associated chronic inflammation.

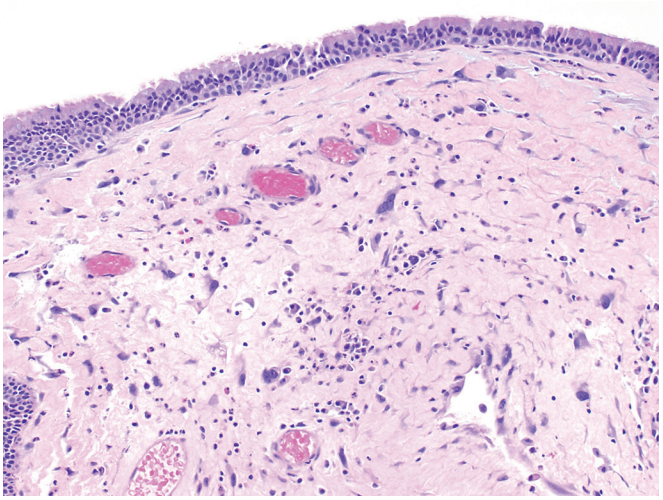

Figure 4.47 Bizarre stromal cells in a nasal polyp, set against an edematous and inflammatory background.

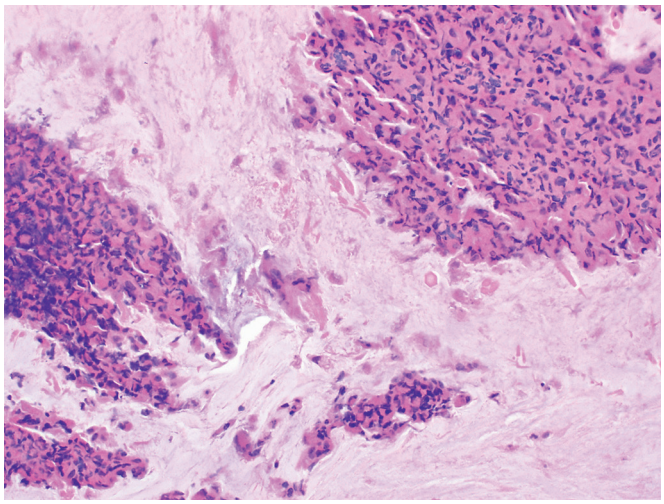

Figure 4.48 Allergic mucin with aggregates of eosinophils and sloughed epithelial cells. Within the acellular mucin, numerous Charcot–Leyden crystals are seen.

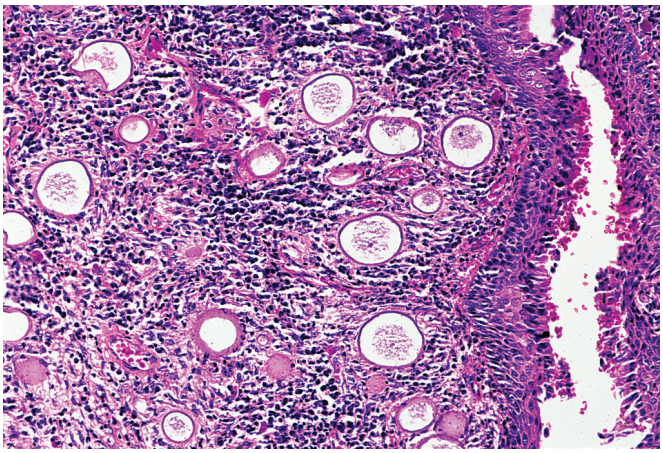

Figure 4.49 **Rhinosporidiosis.** Large globular cysts are present surrounded by a heavy inflammatory reaction.

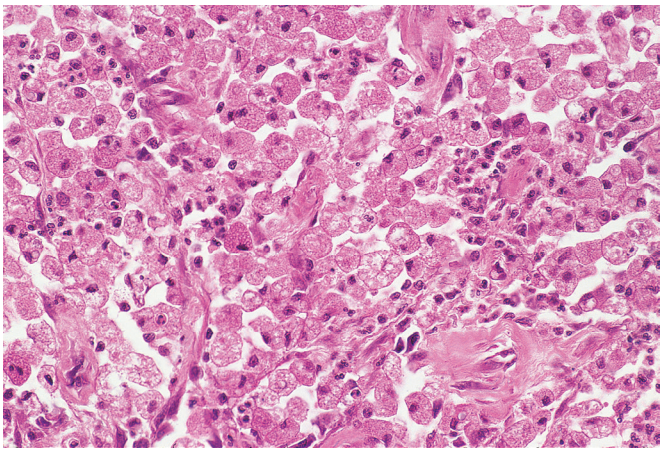

Figure 4.50 **Rhinoscleroma.** The infiltrate is mainly of histiocytic character, some of the cells having foamy features. The main differential diagnosis is with nasal involvement by Rosai–Dorfman disease.

Mycotic infections of the upper respiratory tract are usually located in the paranasal sinuses.[349] *Mucormycosis* is one of the most frequent, but other organisms such as *Aspergillus* can be involved as well. It usually occurs in association with poorly controlled diabetes mellitus, especially when complicated with ketoacidosis. It is also seen in the immunocompromised population. The infection may result in the formation of noninvasive mycetomas/fungus balls or spread rapidly to involve orbit and brain ("invasive fungal sinusitis").[350,351] In mucormycosis, the organisms characteristically invade blood vessels and cause thrombosis, hemorrhage, and infarction.

Allergic fungal sinusitis is a term used for an infection of the sinus caused by *Aspergillus*, *Curvularia*, or other fungal organisms that results in the formation of so-called allergic mucin (Fig. 4.48), made up of pools of mucin-containing sloughed epithelial cells, eosinophils, Charcot–Leyden crystals, and fungal hyphae[352–354] Allergic fungal sinusitis is not to be equated with *paranasal mucocele*, which results from the accumulation of mucus in a sinus because of obstruction.[355]

Rhinosporidiosis is an inflammatory disease endemic in India, but it has also been reported in other parts of the world.[356] It is characterized by hyperplastic polypoid lesions of the nasal cavity and—rarely—other mucous membranes. The diagnosis is readily made by the identification of numerous globular cysts measuring up to 200 nm in diameter (Fig. 4.49). Each of these cysts represents a thick-walled sporangium containing numerous spores. The precise nature of this organism remains enigmatic.[357] Molecular studies indicate that *Rhinosporidium seeberi* clusters with a novel group of fish parasites referred to as the DRIP clade (*Dermocystidium*, rosette agent, *Ichthyophonus*, and *Psorospermium*), near the animal–fungal divergence.[358]

Tuberculosis can involve the nasal cavity, nasopharynx, or paranasal sinuses. Many of the cases are associated with cervical lymphadenopathy; most seem to represent an isolated upper respiratory tract infection rather than secondary spread from pulmonary infection.[359]

Sarcoidosis may first present with nasal manifestations and may result in perforation of the septum.[360]

Rhinoscleroma (scleroma) is an inflammatory disease of the nose, pharynx, and larynx caused by an organism of the *Klebsiella* group. Microscopically, the predominant cells are foamy macrophages (Mikulicz cells) and plasma cells (Fig. 4.50). Vasculitis, ulceration, and pseudoepitheliomatous hyperplasia may be present.[361] The organisms can be identified using PAS or Hotchkiss–McManus stains or by an immunocytochemical technique.[362]

Rosai–Dorfman disease (sinus histiocytosis with massive lymphadenopathy) can affect various head and neck sites, including the nasal cavity (in the form of polyps), paranasal sinuses, and nasopharynx. Concomitant cervical nodal involvement may or may not be present.[363,364]

Granulomatosis with polyangiitis (Wegener granulomatosis) in its classic form is a rapidly progressive condition in which nasal involvement is accompanied by pulmonary and renal disease. Microscopically, a leukocytoclastic vasculitis with geographic necrosis surrounded by palisaded histiocytes, lymphocyte-poor granulomatous reaction, and epithelial ulceration is seen.[365]

In one series,[366] vasculitis, necrosis, and granulomatous inflammation *together* were seen in only 16% of head and neck biopsy specimens; both vasculitis and granulomatous inflammation were seen in 21%, and vasculitis and necrosis in 23%. In another series,[367] the nasal biopsy was diagnostic of granulomatosis with polyangiitis in 53% of the patients; samples larger than 5 mm in greatest diameter were more likely to contain diagnostic features than smaller samples. Elastic tissue stains are helpful in identifying remnants of badly damaged vessels. Granulomatosis with polyangiitis should be

distinguished from tuberculosis and other specific infections; from malignant lymphoma, especially natural killer (NK)/T-cell lymphoma; from so-called eosinophilic angiocentric fibrosis (see later); from cocaine-induced lesions[368]; and from other immune-mediated diseases, such as lupus erythematosus.

It should be remembered that granulomatosis with polyangiitis is not a lymphocyte-rich process, whether in the upper respiratory tract or in the lung; therefore a biopsy from the sinonasal region containing a dense lymphocytic infiltrate renders such a diagnosis less likely, and the alternative possibility of a malignant lymphoma is a real one.[369]

Eosinophilic angiocentric fibrosis is an inflammatory disease of unknown cause characterized by a perivascular "onion-skin" fibrosis and a mixed inflammatory infiltrate rich in eosinophils.[370] There are no granulomas, necrosis, or vasculitis. It has been viewed as the mucosal counterpart of granuloma faciale and can involve any portion of the upper respiratory tract.[371]

Myospherulosis is an iatrogenically induced granulomatous condition of the nose and paranasal sinuses. It is a form of lipogranuloma that develops after hemostatic packing with petrolatum-based ointments and gauze, and is microscopically analogous to a disease previously described in the subcutaneous tissues of East Africans.[372] Microscopically, its distinctive feature is the presence of large tissue spaces containing saclike structures with brown "spherules" resembling fungi (Fig. 4.51). It turns out that these mysterious formations are simply erythrocytes that have been altered and clumped by the action of the petrolatum.[373]

Tumors

Sinonasal (Schneiderian) Papilloma

Sinonasal papillomas are benign neoplasms of the sinonasal respiratory mucosa (the schneiderian membrane) most commonly presenting with nasal congestion, nasal obstruction, and/or epistaxis. Most cases are seen in adult men, but they can also occur in children.[374] In rare cases, they may extend into the cranial cavity.[375] Many adjectives have been attached to them, such as inverted, cylindrical cell, transitional, squamous, and schneiderian. There are three distinct clinicopathologic subtypes: exophytic (fungiform), inverted, and oncocytic. Excluded from this group are the verrucous hyperkeratotic squamous papillomas arising from the stratified squamous epithelium lining the nasal vestibule, which are analogous to tumors occurring elsewhere in the skin. In contrast to inflammatory polyps, sinonasal papillomas are unilateral in the large majority of cases.[376] Microscopically, papillomas are composed of proliferating columnar and/or squamous epithelial cells, with an admixture of mucin-containing cells and numerous microcysts (Fig. 4.52).[377] The microcysts are typically filled with neutrophils (neutrophilic microabscesses) and epithelial transmigration of neutrophils is a distinct histologic feature (Fig. 4.53). Downward growth into the sinonasal seromucous glands results in the inverted growth pattern of inverted papillomas. Some tumors are partially or entirely composed of swollen, granular, eosinophilic cells with features of oncocytes (oncocytic papilloma) (Fig. 4.54).[378] Occasional mitoses are present in the basal layer. Atypia is mild to moderate, and there is an orderly maturation pattern. The dual composition of columnar and squamous cells is also apparent at the immunohistochemical level, in the sense that there is expression of keratin corresponding to both cell types.[379] The inverted and oncocytic papillomas occur almost exclusively on the lateral nasal wall and are unilateral.

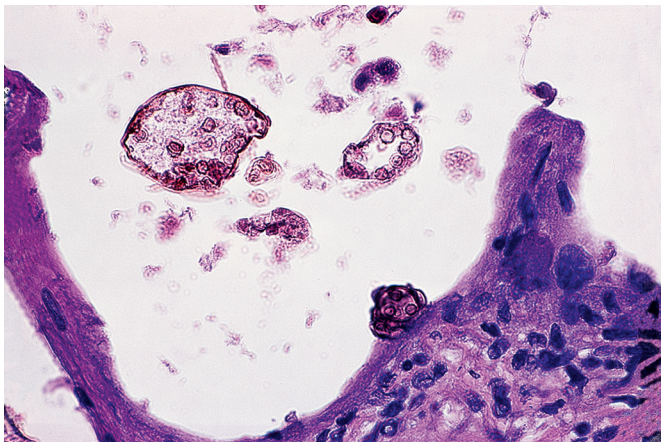

Figure 4.51 Myospherulosis of paranasal sinus following an operation in the region for fibromatosis. A "bag" containing round structures is seen floating in a tissue cavity surrounded by fibrous tissue.

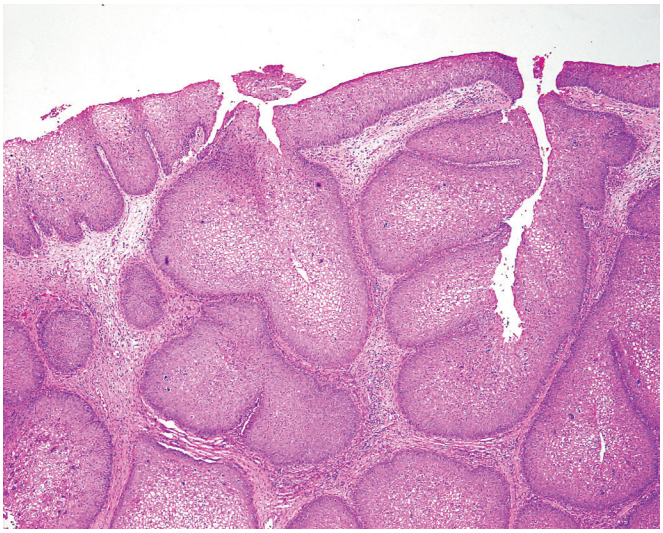

Figure 4.52 Sinonasal Papilloma With Inverted Pattern of Growth.

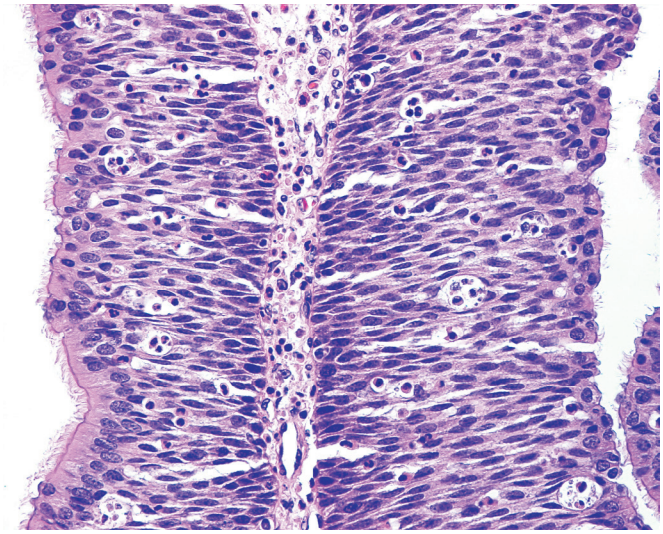

Figure 4.53 Stratified Lining by Cylindrical Cells in Sinonasal Papilloma. Note the transmigration of neutrophils and neutrophilic microabscesses.

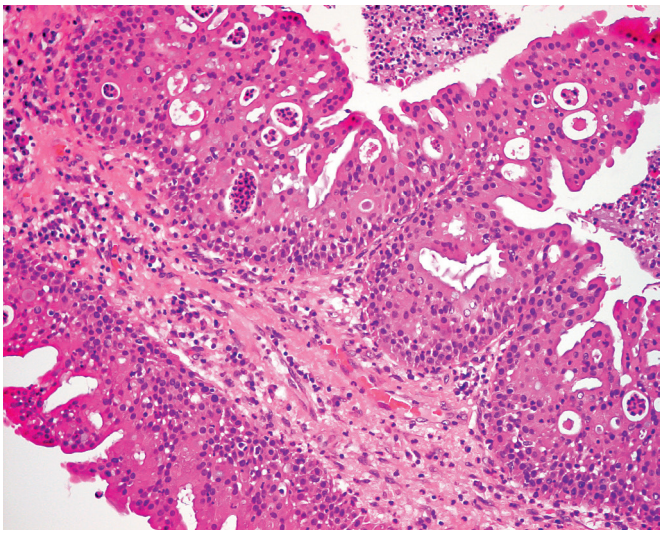

Figure 4.54 Sinonasal Papilloma Lined by Oncocytic Epithelium. Note the transmigration of neutrophils and neutrophilic microabscesses.

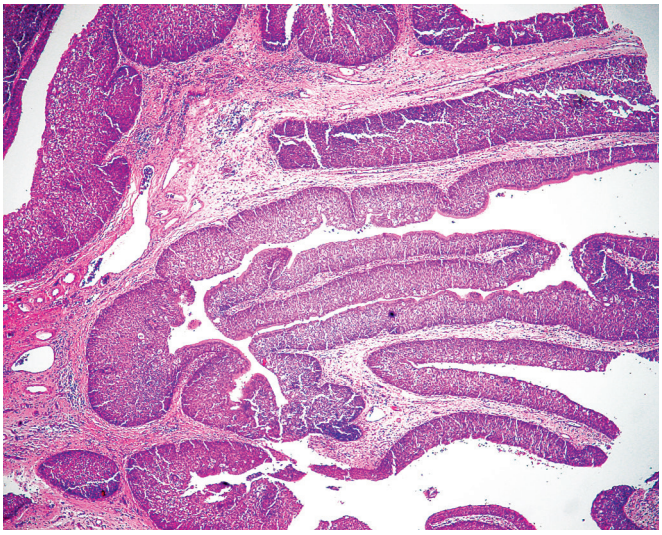

Figure 4.55 Sinonasal Papilloma With Exophytic (Fungiform) Pattern of Growth.

Papillomas arising in the nasal septum are usually exophytic and mushroom shaped ("fungiform" or "everted"). They are lined by similar epithelium as inverted papillomas but are arranged in exophytic fronds with a thin central core of connective tissue (Fig. 4.55). They lack the neutrophilic microabscesses and epithelial transmigration of neutrophils seen in inverted and oncocytic papillomas.

Sinonasal papillomas have a tendency to recur, this feature being particularly common with the inverted and oncocytic types.[377] They also have a complex and often misunderstood relationship with malignancy, most commonly squamous cell carcinoma, which may manifest in three ways:

1. Development of obvious carcinoma months or years after the excision of a papilloma, with or without recurrences of the papilloma in the interim.[380] This event occurs in about 3% of all papillomas and is associated with a 25% survival rate.
2. Presence of focal invasive carcinoma in an otherwise typical papilloma at the time of the first excision.[381] This complication, seen in about 3% of the cases, is associated with an excellent prognosis.
3. Occurrence of a tumor having a pattern of growth very similar to that of papilloma but with subtle cytologic features indicative of malignancy (see next section). The survival rate for this group is as poor as for carcinoma developing after excision of a papilloma (that is, in the neighborhood of 25%).

Many studies have been done in recent years with in situ hybridization or PCR techniques demonstrating the presence of HPV in sinonasal papillomas, even if the detection rate varied considerably.[382–384] HPV 6/11 has been the type most often detected.[385] In several of the series the incidence of positivity was notably higher for the fungiform than for the inverted papillomas, which often show histologic evidence of viral infection in the form of koilocytosis.[382,386] Despite early claims to the contrary,[387] EBV is not present in sinonasal papillomas.[382] A recent study demonstrated activating EGFR mutations in 88% of inverted papillomas and 77% of squamous cell carcinomas arising in inverted papillomas. These were not identified in oncocytic or exophytic papillomas, implicating a distinct role of activating EGFR mutations in inverted papilloma pathogenesis.[388]

The treatment of sinonasal papillomas is surgical removal. CT scanning is routinely used in management planning. The standard therapy has been lateral rhinotomy and en bloc excision of the lateral nasal wall, followed by removal of all the mucosa in the ipsilateral paranasal sinuses.[389] Endoscopic sinus surgery approaches are now replacing open surgical resection as the mainstay of therapy for inverted and oncocytic papillomas.[390] Exophytic papillomas can be conservatively excised.

Sinonasal Carcinoma

General Features

Sinonasal carcinomas are an uncommon group of tumors responsible for less than 1% of cancer deaths in the United States.[391] A marked left-sided preponderance has been noted for ethmoid tumors, suggestive of an exogenous pathogenesis.[392] An occupational group known to be at an increased risk is nickel refiners.[391] Studies from Europe, Australia, and North America have shown that another profession at risk is that of woodworkers, with most of the tumors in this group being adenocarcinomas.[393–396] In contrast to sinonasal papilloma, only a small minority of the carcinomas of this region that have been investigated for evidence of HPV infection have yielded positive results; most of these positive cases are of the cylindrical cell carcinoma type (see below).[397] They lack evidence of EBV infection, regardless of their histologic subtype.[398]

Location and Spread

Intranasal carcinomas occur more commonly in the vestibule and lateral wall and only rarely in the septum.[399–401] In one series of paranasal sinus tumors, 76% occurred in the ethmoid sinus, 16% in the sphenoid sinus, and 2% in the frontal sinus.[402] Sinonasal carcinomas often are diagnosed late in their course, when extensive bone destruction is already present. Intranasal tumors may extend into the medial wall of the antrum, ethmoid sinuses, orbit, anterior skull bone, and upper lip. Tumors of the infrastructure of the maxillary sinus spread inferiorly into the alveolar process or gingivobuccal sulcus, anteriorly into the soft tissues of the cheek beneath the zygoma, or medially into the nasal cavity and hard palate. Those of the suprastructure may extend superiorly and medially into the orbit, ethmoid sinus, and cribriform plate; posterolaterally into the pterygoid space, sphenoid sinus, or base of the skull; anterolaterally into the zygoma; or posterolaterally into the infratemporal fossa.[2]

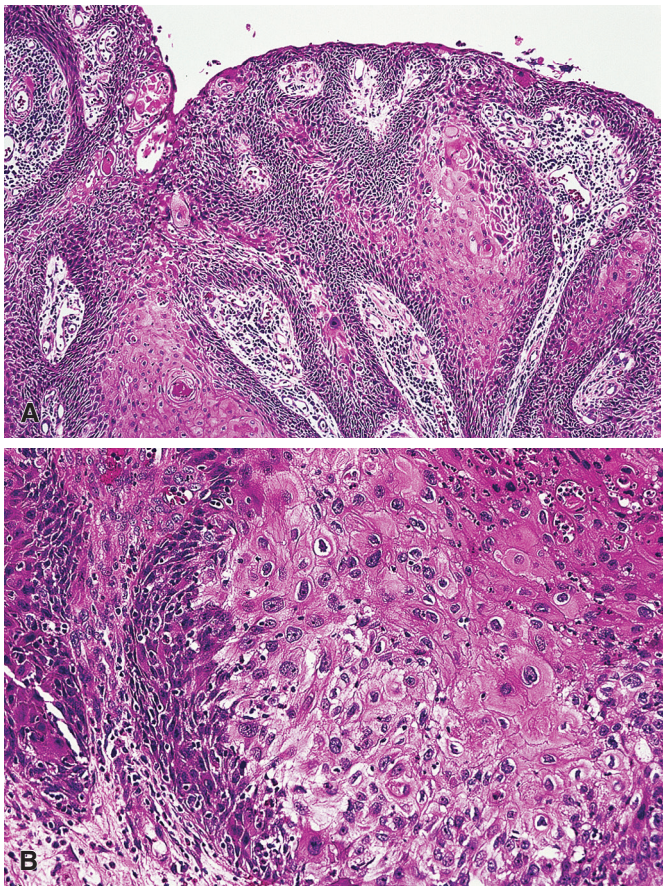

Figure 4.56 Low- **(A)** and high- **(B)** power views of sinonasal keratinizing squamous cell carcinoma.

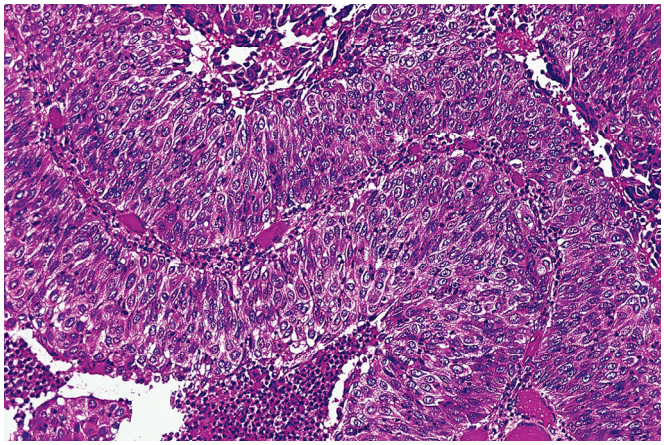

Figure 4.57 Nonkeratinizing squamous cellinonasal carcinoma of "transitional" type.

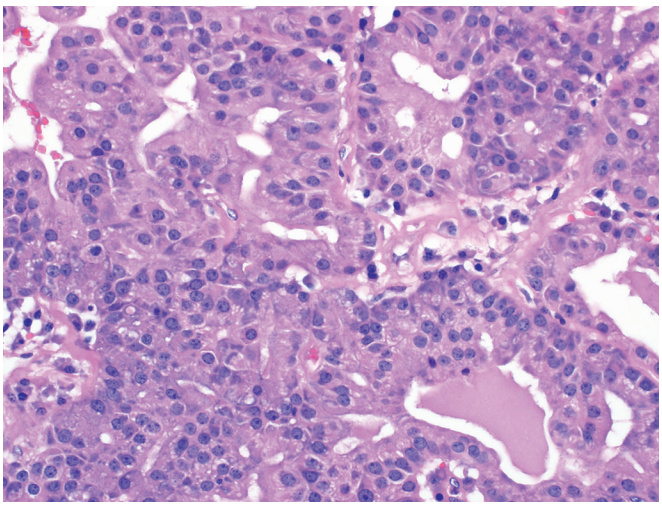

Figure 4.58 Low-grade nonintestinal type sinonasal adenocarcinoma with complex arborizing tubular and papillary pattern and extremely well-differentiated cytologic appearance.

Microscopic Features

Conventional squamous cell carcinoma (the term often preceded by the qualifier ***keratinizing***) is the most common microscopic type of sinonasal carcinoma, as already shown in the monumental study by Ringertz in 1938.[403] Most of the cases are high-grade lesions, with varying degrees of keratinization (Fig. 4.56).[404]

Nonkeratinizing squamous cell carcinoma (transitional; cylindrical; schneiderian) carcinoma is closely related to conventional squamous cell carcinoma. The cells have scant cytoplasm imparting a basaloid appearance of typically have occasional keratin pearl formation. Foci of intracellular mucin production may be present. The proliferation often has an undulating or ribbon-like growth pattern. In most instances the microscopic diagnosis is obvious because of the atypicality and stromal infiltration. In others the identification is more difficult because the growth pattern is similar to that of a papilloma in the sense that stromal invasion is not immediately apparent. The differential diagnosis must be made on the basis of cellular abnormalities, such as gross disturbance of polarity, increased mitotic rates, and atypical nuclear changes (Fig. 4.57).[377,405] However, mitoses and some degree of nuclear hyperchromasia also can be present in benign lesions such as inverted papillomas.

The differential diagnosis of keratinizing and nonkeratinizing squamous cell carcinoma also includes the sometimes bizarre atypical epithelial changes that can develop following chemotherapy.[406]

Verrucous carcinoma, basaloid squamous cell carcinoma, and **sarcomatoid carcinoma (spindle cell carcinoma, carcinosarcoma)** are three types of malignant tumor that have been rarely observed in the sinonasal region. They are similar in all regards to their more common counterparts in the upper digestive tract and larynx.

Adenocarcinomas of the sinonasal tract can be of salivary gland type or of non-salivary gland type. The latter are divided into intestinal type and nonintestinal type. Adenocarcinoma without a specific salivary gland pattern usually arises on the middle turbinate or in the ethmoid sinus and from there extends laterally into the orbit and upward into the anterior cranial fossa. These tumors may arise from the surface epithelium (the majority) or from the subjacent seromucous glands.[407,408] Microscopically, nonintestinal-type adenocarcinomas show a wide range of differentiation and patterns, most of them having a well-differentiated seromucinous composition and tubulopapillary architecture (Figs. 4.58 and 4.59).[408,409] These low-grade adenocarcinomas can be distinguished from benign mimics by the lack of a myoepithelial layer, presence of infiltrative growth, and complex growth pattern. High-grade nonintestinal-type adenocarcinomas more often have a solid growth pattern with marked nuclear atypia, necrosis, and high mitotic activity.

Intestinal-type sinonasal adenocarcinomas have an appearance strongly reminiscent of colorectal carcinoma or adenoma, including the presence of goblet cells.[410–413] Others resemble small intestinal mucosa, with the formation of resorptive, goblet, Paneth, and

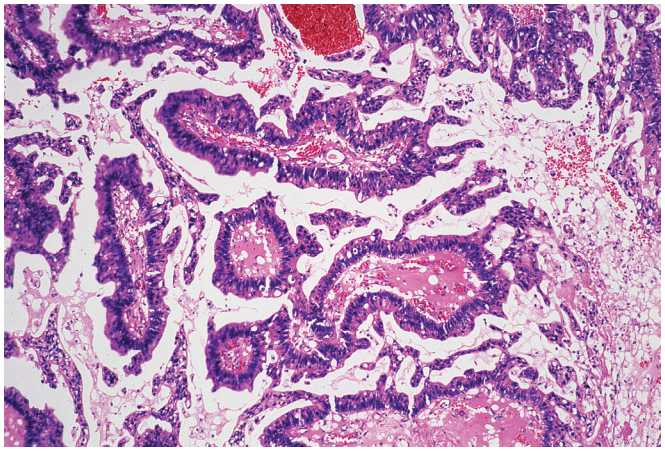

Figure 4.59 Nonintestinal Type Adenocarcinoma of the Nasal Cavity. The tumor is well differentiated and has a distinctly papillary configuration.

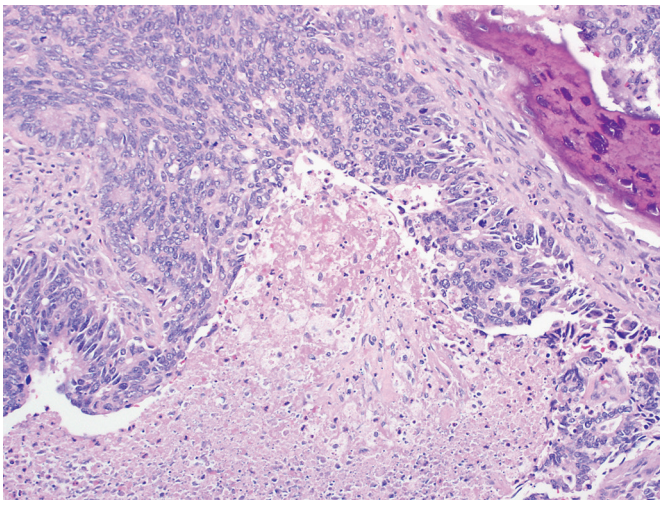

Figure 4.61 Moderately differentiated ITAC resembled conventional colorectal adenocarcinoma with "dirty" necrosis.

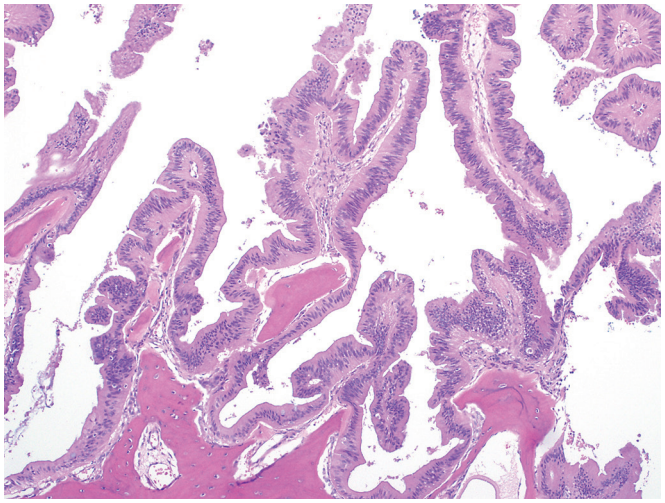

Figure 4.60 Well-Differentiated Intestinal-Type Sinonasal Adenocarcinoma (ITAC). The lesion resembles a villous adenoma of the colon. Note the bone invasion at the bottom.

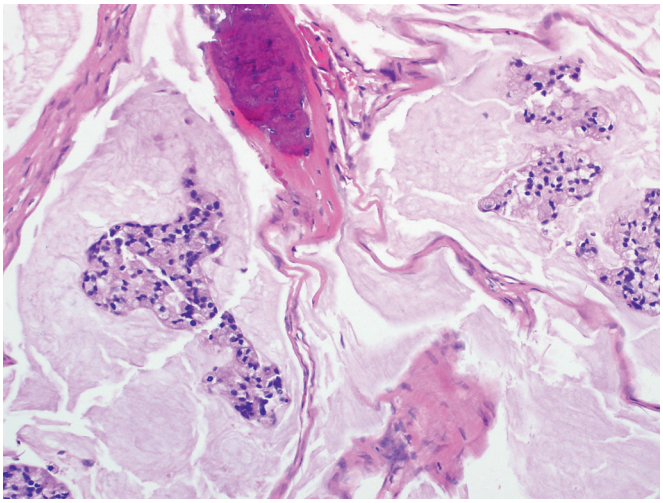

Figure 4.62 Mucinous ITAC typically consist of pools of mucin with malignant cells either within the mucin or lining the mucous pools.

neuroendocrine cells.[414] In rare cases the latter component is present in the form of atypical carcinoid, resulting in the formation of a composite neoplasm. Tumors that resemble colonic adenomas are considered well differentiated (Fig. 4.60) and those that resemble typical colorectal adenocarcinoma are considered moderately differentiated (Fig. 4.61). Those with a solid growth pattern are considered poorly differentiated. Finally, some tumors are considered mucinous if they resemble mucinous colorectal adenocarcinoma or if they have a signet ring cell morphology (Fig. 4.62). The morphologic similarities between colorectal adenocarcinoma and sinonasal intestinal-type adenocarcinomas are matched immunophenotypically (with positivity for CK20, CDX2, villin, and MUC2)[415–417] but usually not at the molecular level in terms of *KRAS* and *TP53* abnormalities.[418] Sinonasal adenocarcinomas are locally aggressive tumors, with a propensity for local recurrence.[419] Lymph node metastases are rare. Low-grade (well-differentiated) tumors typically have an indolent course, whereas high-grade tumors have a very poor outcome.

Small cell neuroendocrine carcinoma has a morphologic, immunohistochemical, and ultrastructural appearance similar to that of its pulmonary homolog.[420] The main differential diagnosis is with undifferentiated (anaplastic) carcinoma (see below) and with olfactory neuroblastoma.

Sinonasal undifferentiated (anaplastic) carcinoma (SNUC) of the nasal cavity or paranasal sinuses is characterized microscopically by nests, trabeculae, and sheets of medium-sized cells having a high mitotic rate, extensive necrosis, and prominent vascular invasion.[421] SNUC does not show evidence of neuroendocrine, squamous, or glandular differentiation.[399,422] SNUC express simple keratins (CK7, CK8, and CK19) but are negative for complex keratins (CK14 and CK5/6) and neuroendocrine markers. They present in adults as locally advanced sinonasal or skull-based tumors and are associated with a median survival of under 2 years. ***NUT midline carcinoma*** accounts for a proportion of cases conventionally diagnosed as SNUC; the diagnosis has to be confirmed by immunostaining with a NUT-specific antibody or by molecular techniques.[191]

Treatment and Prognosis

The recommended treatment for most sinonasal carcinomas is a combination of surgery and radiation therapy with or without

chemotherapy.[423] The 5-year survival rates with this modality have been in the neighborhood of 60%.[424] Relapse occurs almost always within 2 years after the initial treatment. As usual, the most important prognostic factor is tumor stage.[425] In a multivariate analysis of a large retrospective cohort, extension to the pterygomaxillary fossa and invasion of the dura remained independent prognostic factors.[424]

Histology-wise, it would seem that adenocarcinoma carries a slightly better prognosis than squamous cell carcinoma.[424] As mentioned, among the adenocarcinomas, there is a relationship between degree of differentiation and prognosis.[425] Tubulopapillary tumors showing minimal atypia run an indolent clinical course.[411] The prognosis of high-grade adenocarcinoma, SNUC, and NUT midline carcinoma are extremely poor.[426]

Nasopharyngeal Carcinoma

General Features

Squamous cell carcinoma of the nasopharynx is a leading cause of death for large populations in Southeast Asia and, to less degree, in northern Africa,[427,428] The age–incidence curve is bimodal, with a peak occurring between 15 and 25 years and another between 60 and 69 years.[429] Cases showing familial aggregation have been reported both in the United States and in the Southeast Asia.[430] The accumulated evidence strongly suggests that this tumor results from the combined action of genetic predisposition, environmental factors, and the EBV.[431–433] Specifically, it has been proposed that tumor initiation requires EBV expression but that the induction of preneoplastic events and maintenance of tumor-cell phenotype require critical cellular genes.[434] It should be noted that the association with EBV is much stronger in endemic areas (such as Southeast Asia) than in other parts of the world.

Within the tumor, the EBV DNA is homogeneous and clonal with regard to terminal repeat sequences.[435] Expression of specific viral messenger RNAs or gene products is consistently detected within all of the tumor cells.[436]

The virus can be demonstrated in the tumor tissue with in situ hybridization and immunohistochemical techniques, the former being much more reliable (Fig. 4.63).[437,438] It has also been detected with the PCR technique in materials obtained by fine-needle aspiration of metastatic cervical nodes.[439] The virus has been found in all microscopic types of nasopharyngeal carcinoma—including cases exhibiting glandular differentiation—although with different frequencies (see below). The consistent detection of IgG antibodies (which are directed against the early EBV antigen) and of IgA antibodies (which are directed against the capsid viral antigen) has been used in the United States to support a presumptive diagnosis of nasopharyngeal carcinoma.[440] However, the presence of 30% false-positive results for the former test and 9%–18% for the latter indicates that the diagnosis of nasopharyngeal carcinoma cannot be based solely on serologic tests. These tests have also been used in areas with a high incidence of nasopharyngeal carcinoma as a risk predictor. In one such study, carried out in Taiwan, in which almost 10,000 men were enrolled, blood samples were examined for IgA antibodies against EBV-specific capsid antigen and neutralizing antibodies against EBV-specific DNase. It was found that the risk for cancer development was 4.0 for subjects with one marker and 32.8 for subjects with both markers, as compared with subjects with neither marker.[441] Increasingly, assay of plasma EBV DNA is used in place of serologic studies to aid in diagnosis, prognostication, assessment of post-treatment residual tumor load, and detection of relapse of nasopharyngeal carcinoma.[442]

Gross Features

Grossly, the tumor may be very difficult to detect. Random ("blind") biopsies from the nasopharyngeal area should be taken whenever the diagnosis is suspected, particularly from the fossa of Rosenmüller.[443]

Microscopic Features

Microscopically, the crucial distinction to be made in nasopharyngeal carcinoma is between tumors that show clear-cut evidence of keratinization and those that do not.[444] The former, designated **keratinizing squamous cell carcinomas**, do not show as high an association with EBV as the others and occur in an older age group (Fig. 4.64).[445] The tumors in the second category, which represent the large majority, have been designated **nonkeratinizing carcinomas** and are subdivided into *differentiated* and *undifferentiated* types.[446] The former have a stratified or pavemented arrangement and well-defined cell margins and are histologically identical to sinonasal nonkeratinizing squamous cell carcinomas (Fig. 4.65). The latter exhibit a syncytial appearance and indistinct cell margins (Fig. 4.66). A high proportion of these tumors (particularly in the undifferentiated subgroup) is accompanied by a prominent inflammatory infiltrate rich in lymphocytes, a fact responsible for the designation

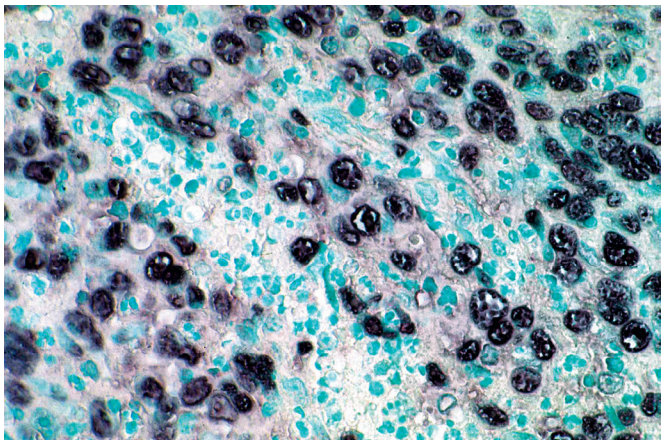

Figure 4.63 Demonstration by in situ hybridization of EBER in nasopharyngeal undifferentiated carcinoma.

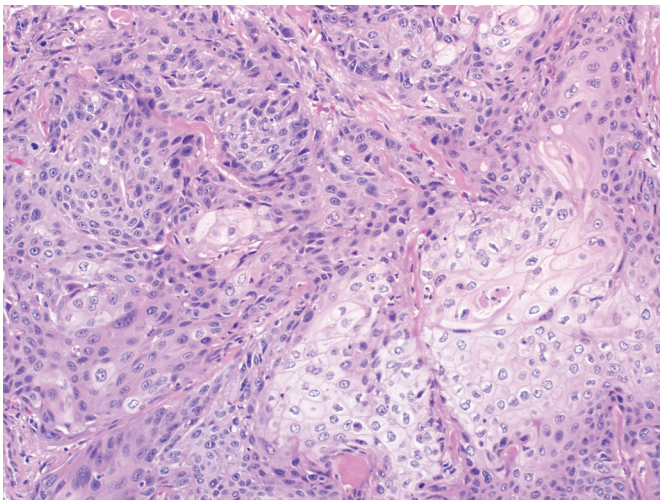

Figure 4.64 Nasopharyngeal carcinoma of keratinizing squamous cell type.

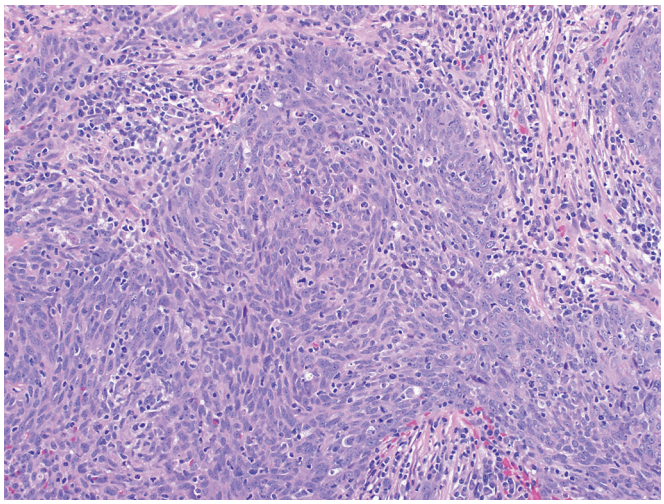

Figure 4.65 Differentiated nonkeratinizing nasopharyngeal carcinoma.

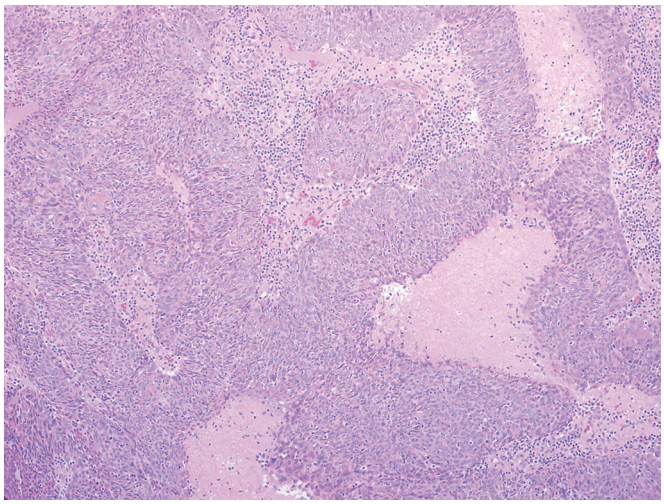

Figure 4.66 Undifferentiated nonkeratinizing nasopharyngeal carcinoma with areas of necrosis.

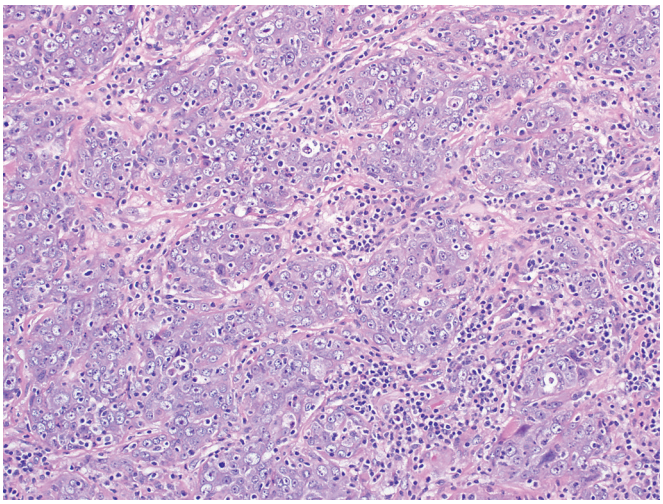

Figure 4.67 Undifferentiated nasopharyngeal carcinoma composed of tumor cells arranged in compact nests (so-called Regaud-type growth pattern).

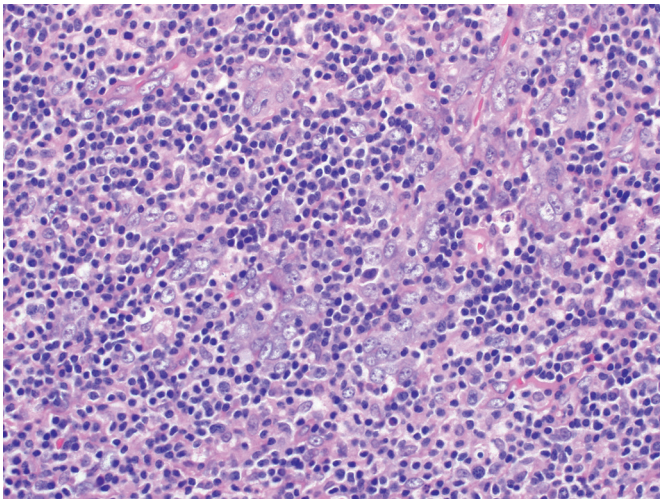

Figure 4.68 Undifferentiated nasopharyngeal carcinoma composed of single carcinoma cells growing in the lymphoid stroma of the nasopharyngeal tonsil (so-called Schmincke-type growth pattern). This growth pattern of nasopharyngeal carcinoma imparts a lymphoma-like appearance.

lymphoepithelioma that these neoplasms have traditionally received. The term is a misnomer inasmuch as the lymphocytic population is not neoplastic. As a matter of fact, it may be accompanied by other inflammatory cells, such as plasma cells, eosinophils, and—on rare occasions—epithelioid histiocytes and multinucleated giant cells; however, the term "lymphoepithelioma," inaccurate as it may be, should perhaps be retained in view of the characteristic appearance of this neoplasm.

Two patterns of growth may be seen in undifferentiated nasopharyngeal carcinoma, sometimes in combination. The first, referred to as *Regaud type*, consists of well-defined aggregates of epithelial cells surrounded by fibrous tissue and lymphoid cells (Fig. 4.67). In the second, designated as *Schmincke type*, the neoplastic epithelial cells grow diffusely and are closely intermingled with inflammatory cells. The latter type is apt to be confused with large cell malignant lymphoma (Fig. 4.68). Careful examination of the tumor cell nuclei should establish the diagnosis in most instances. The nuclei of undifferentiated nasopharyngeal carcinoma are characteristically large and vesicular, with a smooth outline and a single, large, sharply etched eosinophilic nucleolus. The nuclei of malignant lymphoma are usually more irregularly shaped, the chromatin is coarser, and the nucleoli are smaller and either basophilic or amphophilic. Occasionally, the tumor cells have an oval or spindle shape that may be confusing (Fig. 4.69). Amyloid globule deposition is not uncommon in nasopharyngeal carcinoma.[447]

An in situ carcinoma component can be identified in only a minority of cases. Even rarer but well documented is the nasopharyngeal carcinoma that is *entirely* in situ (nasopharyngeal intraepithelial lesion).[448]

Rare microscopic forms of nasopharyngeal carcinoma include **basaloid squamous cell carcinoma**[449] and **papillary adenocarcinoma**.[450] The adenocarcinomas may be of salivary gland type (the most common) or arise from the surface epithelium.[451] The latter are papillary, mucin producing, immunoreactive for keratin and carcinoembryonic antigen (CEA), and associated with an excellent prognosis.[450] Rare examples of nasopharyngeal adenocarcinoma closely mimic the appearance of papillary thyroid

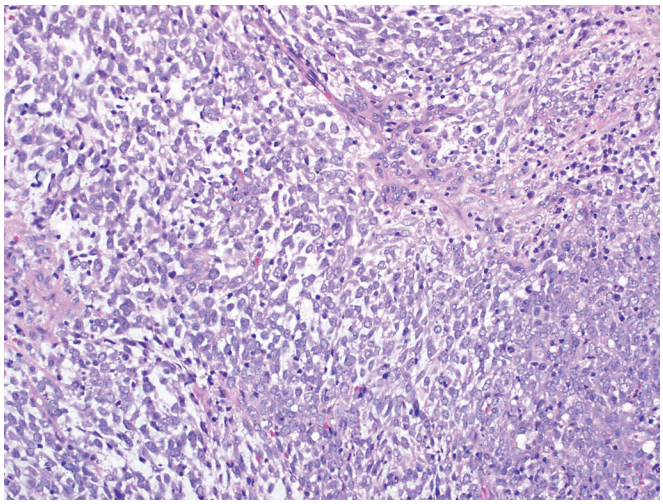

Figure 4.69 Undifferentiated nasopharyngeal carcinoma composed of oval and spindle tumor cells.

carcinoma and can even be immunoreactive for TTF-1 (but not for thyroglobulin).[452]

Immunohistochemical Features

Immunohistochemically, nasopharyngeal carcinoma (including the lymphoepithelioma type) shows reactivity for keratin (always), EMA (usually), and CEA (occasionally).[453,454] Thus keratin is the most reliable marker for the identification of this neoplasm. About 10% of the cases stain for CD30, a potential source of misdiagnosis.[455] A population of S-100 protein–positive dendritic cells may also be present.

Electron Microscopic Features

Ultrastructurally, tonofilaments and complex desmosomes are present in the tumor cells.[456] The electron microscopic features suggest an origin from the cells of the basal layers of pseudostratified and stratified epithelia.[457]

Molecular Genetic Features

The etiology of nasopharyngeal carcinoma is complex, involving genetic susceptibility, EBV infection, and exposure to chemical carcinogens. Multiple somatic genetic and epigenetic changes are required for tumor development.[458] *EBV-LMP1* appears to be the principal oncogene—it is required for cell immortalization and is present in 80%–90% of the tumors.[459] In the carcinoma cells, there is upregulation of cellular proliferation pathways such as the Akt pathway, mitogen-activated protein kinases, and the Wnt pathway. Cell adhesion is compromised due to abnormal E-cadherin and β-catenin function. Aberrations in cell cycle are due to dysregulation of factors such as P16, cyclin D1, and cyclin E. Anti-apoptotic mechanisms are also upregulated.[460]

Allelic loss of chromosome 3p (particularly the 3p21.3 region) is found in 95%–100% of nasopharyngeal carcinomas, indicating that this region harbors tumor suppressor genes that are important in tumorigenesis. Several genes have been implicated, including *RASSF1A*, *LTF*, *BLU*, and *LARS2*.[460] Another common site of allelic loss is 9p21, implicating the *P16*, *P15*, and *P14/ARF* genes.[458] Downregulation of E-cadherin is common, and results from aberrant promoter methylation of the E-cadherin gene.[459] While P53 is commonly overexpressed, the *TP53* gene is usually not mutated.

Some oncogenes are found to be variably overexpressed, sometimes attributable to gene amplification, such as *A20/TNFAIP3* (6q23), *BCL2* (18q21), *CCND1* (11q13), *EGFR* (7p12), *EVI1* (3q26), *HER2* (17q12), *HRAS* (11p15), *NRAS* (1p13), *ID1* (20q11), *INT2/FGF3* (11q13), *NMYC* (8q24), and *PIK3CA* (3q26).[458]

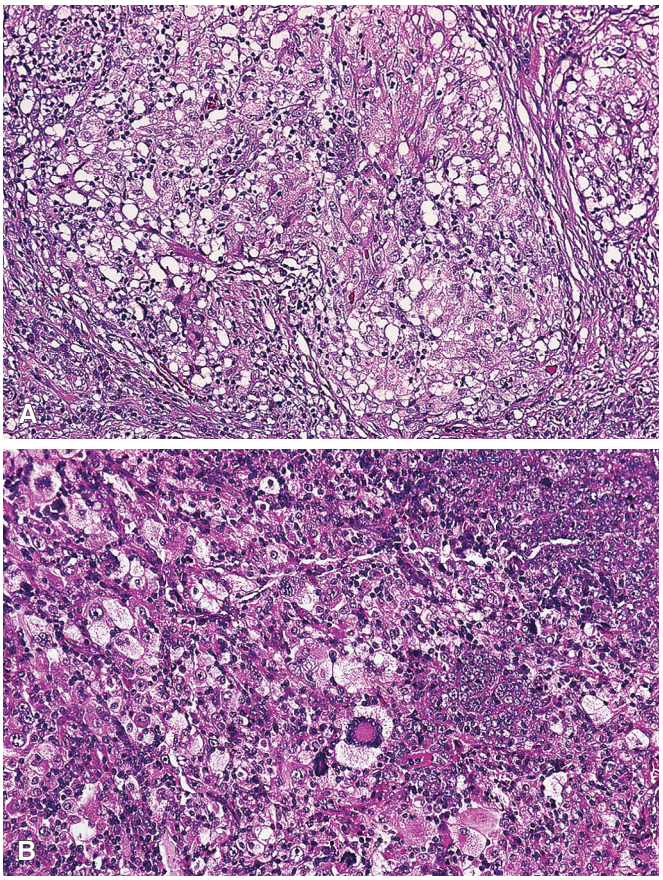

Figure 4.70 **A** and **B,** Patterns of nasopharyngeal undifferentiated carcinoma metastatic to cervical lymph node: **A,** associated with granuloma formation; **B,** associated with xanthogranulomatous reaction.

Staging and Grading

Several staging systems for nasopharyngeal carcinoma have been proposed. In a comparative study, it was concluded that the system devised by Ho was the best predictor of prognosis.[461]

Spread and Metastases

Nasopharyngeal carcinoma arising from the fossa of Rosenmüller frequently extends to the paranasopharyngeal space, from which it can grow along the perineurial space of the trigeminal nerve.[462]

Nasopharyngeal carcinoma has a great propensity to metastasize to regional nodes; in fact, the appearance of unilateral cervical lymphadenopathy is the most common form of presentation. A unique feature of nasopharyngeal carcinoma is its propensity to metastasize to the posterior cervical triangle (level V) and many patients present with bilateral level V metastases. Microscopically, these nodal metastases may closely simulate a large cell lymphoma. Diagnostic clues include the focal (predominantly sinusal) nature of the involvement and the large vesicular nuclei with a single prominent nucleolus. In some cases the metastatic tumor is accompanied by a marked infiltration by eosinophils, which may result in a mistaken diagnosis of Hodgkin lymphoma.[463] In other cases the lymph node metastases are accompanied by a granulomatous reaction with varying degrees of necrosis (Fig. 4.70).[464] In yet others,

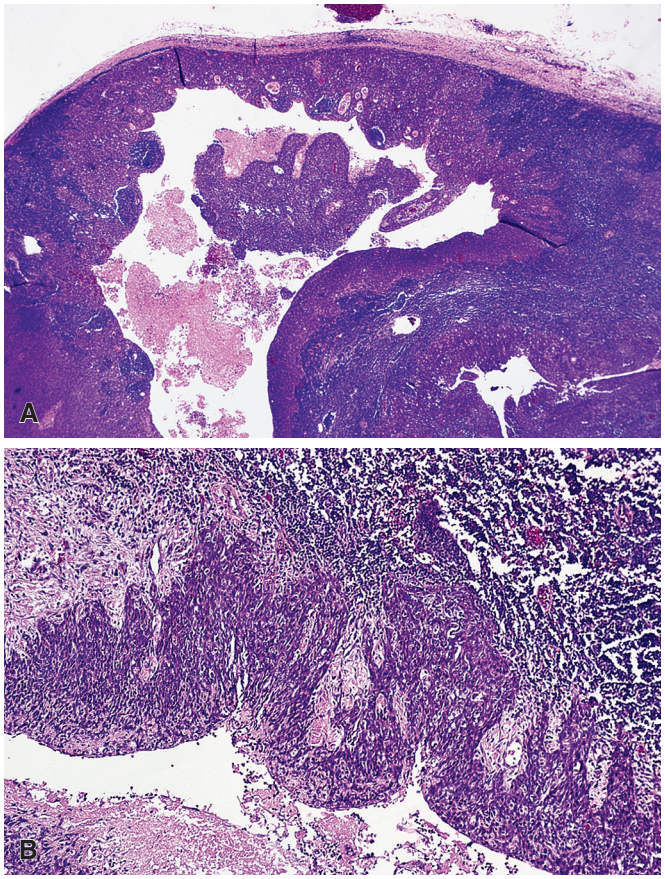

Figure 4.71 **A** and **B,** Cystic metastasis of nasopharyngeal undifferentiated carcinoma to cervical lymph node simulating the pattern of growth of branchial cleft cyst.

it undergoes marked cystic changes, simulating a benign branchial cleft cyst (Fig. 4.71).

Metastases can also develop in distant sites, such as the skeletal system.[465]

Treatment and Prognosis

The treatment of choice for nasopharyngeal carcinoma is radiation therapy, which some authors suggest combining with chemotherapy.[466] In a series of over 5000 cases from Hong Kong, complete remission after radiation therapy was obtained in 83%; the overall actuarial 10-year survival rate was 43%, and the corresponding failure-free survival was 34%.[467] Survival is significantly affected by patient age (better in young individuals), clinical staging,[468,469] and the location of the regional metastases (better for homolateral rather than contralateral metastases and for metastases that are limited to the upper neck as opposed to the lower cervical regions). Cranial nerve, orbit, and intracranial involvement confer a particularly unfavorable prognosis.[468]

At a microscopic level, survival has been found to be worse for the keratinizing squamous cell carcinoma than for the others.[470,471] For the latter category, it has been claimed that the prognosis is worse for tumors exhibiting one or more of the following features:

1. Marked anaplasia and/or pleomorphism[472]
2. High cell proliferation rate (measured with mitotic count or with proliferation-related immunomarkers)[473]
3. Lack of lymphocytic infiltrate[472]
4. High density of S-100 protein–positive dendritic cells[472]
5. High microvessel count[474]
6. HER2/neu overexpression.[474]

Salivary Gland Tumors

Tumors of minor salivary gland origin occur in the nasal cavity as well as in the sinuses but much less commonly in the nasopharynx. Their relative frequency conforms to the density and distribution of the seromucous (salivary gland type) glands of the region—hence their predilection for the nasal (septum and turbinates) or ostial regions.[475] Of the paranasal tumors, the majority are found in the maxillary sinus antrum. Of 37 cases reviewed by Rafla,[476] 21 were in the antrum, 9 in the ethmoid, 5 in the nasal fossa, and 2 in the sphenoid. Most tumors of the paranasal sinuses are malignant; **adenoid cystic carcinoma** is the most common variety.[476] Like its more common counterpart in the major salivary glands, this tumor may undergo dedifferentiation.[477]

In the nasal cavity there is a relatively high proportion of benign neoplasms in the form of **pleomorphic adenoma** (benign mixed tumor). The large majority arise from the mucosa overlying the bony or cartilaginous septum.[478] Their microscopic appearance is similar to that of their homologs in the major salivary glands, but they are unencapsulated in minor salivary gland sites.[479] Recurrence is rare if adequately excised and rare cases may undergo malignant transformation (carcinoma ex pleomorphic adenoma).

Several other types of salivary gland tumor have been reported in the sinonasal region, including **mucoepidermoid carcinoma**, **acinic cell carcinoma**, and **epithelial–myoepithelial carcinoma**, and **myoepithelioma**.[475] Most are low-grade lesions, but local recurrence is a common event given the difficulty in obtaining tumor-free margins in this location.[475] In contrast to the oral cavity, polymorphous low-grade adenocarcinomas are very uncommon in the sinonasal region.

Salivary gland anlage tumor is the term proposed for a distinctive polypoid lesion of the nasopharynx that presents at birth or soon thereafter with respiratory distress. Microscopically, it is characterized by a biphasic pattern of squamous nests and duct-like structures at the periphery of the lesion that blend into solid nodules centrally (Fig. 4.72). It is a benign, perhaps hamartomatous process, but it can be life-threatening because of its location.[481]

Neurogenous and Related Tumors and Tumorlike Conditions

Encephaloceles and **glial heterotopias** (commonly called *nasal gliomas*) are related malformational tumorlike conditions usually affecting newborns and older infants.[482] They may present as subcutaneous masses at the base of the nose or as intranasal polyps. Microscopically, they are composed of mature glial tissue, with occasional multinucleated glial cells that may simulate neurons (Fig. 4.73). Immunohistochemically, there is reactivity for both S-100 protein and GFAP. In some cases a true neuronal component is also present. Associated bony defects are the rule with the encephaloceles, but they are unusual with the glial heterotopias, a feature to be evaluated at the time of removal or with preoperative imaging.

Meningiomas located intracranially may invade the sphenoid or frontal sinuses secondarily. They can also present as primary intranasal or paranasal masses.[483] The key diagnostic features are a whorled growth pattern, psammoma bodies, and a combined EMA, progesterone receptor, and vimentin immunoreactivity.

Astrocytomas and other glial tumors can also extend into the root of the nasal cavity from their initial intracranial location.[484]

Olfactory neuroblastoma (esthesioneuroblastoma) is a specific type of malignant neuroectodermal tumor arising from neuroepithelial

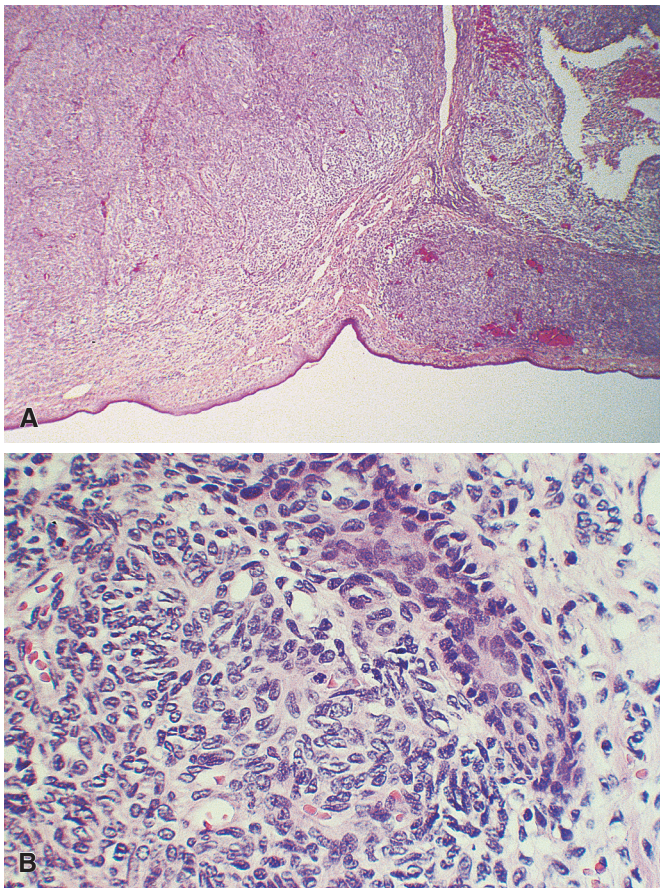

Figure 4.72 Salivary Gland Anlage Tumor. A, The solid, multinodular growth with a focal cyst is the characteristic appearance of this polypoid growth. **B,** A solid focus is composed of stromal cells with interspersed small duct-like structures. Solid or duct-like structures adjacent to the nodules are typically present in the loose fibrous stroma between the solid nodules.

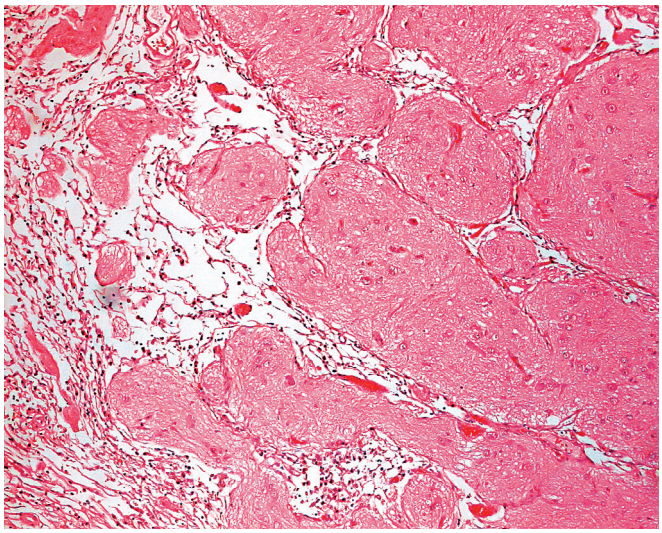

Figure 4.73 Glial Heterotopia in Nasal Cavity.

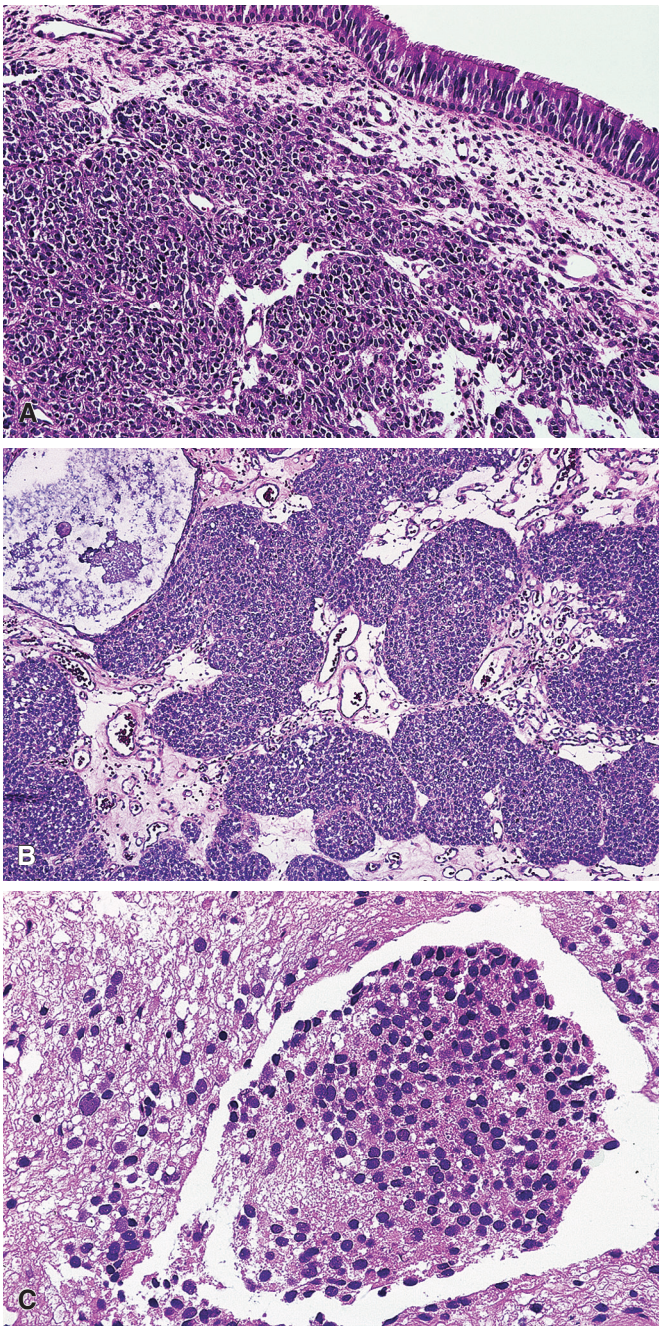

Figure 4.74 Olfactory Neuroblastoma. Both **A** and **B** show a lobular pattern of growth. The tumor depicted in **C** shows typical neurofibrillary background.

elements in the olfactory mucosa.[485] Olfactory neuroblastoma shows a wide range of age distribution (3–79 years), the median age being about 50 years.[486] Grossly, the tumor appears as a reddish gray, highly vascular polypoid mass of generally soft consistency located in the roof of the nasal fossa. Rare cases have been described as arising in the nasopharynx, maxillary sinus, and ethmoid sinus.[487] Microscopically, several patterns have been described, which often merge with each other (Fig. 4.74).[488] The most easily recognizable and common appearance is that of a cellular tumor arranged in lobules and composed of uniform small cells with round nuclei, scanty cytoplasm, indistinct nuclear membranes, and a prominent eosinophilic fibrillary or reticular background, similar to that seen

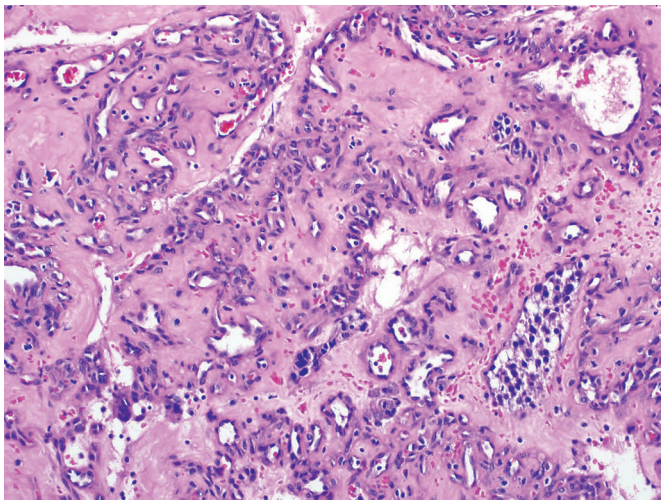

Figure 4.75 Olfactory neuroblastoma associated with a striking lobular proliferation of blood vessels. This proliferation is a feature often seen in neuroepithelial and neuroendocrine neoplasms and may be mistaken for a vascular neoplasm. Note the small foci of residual olfactory neuroblastoma.

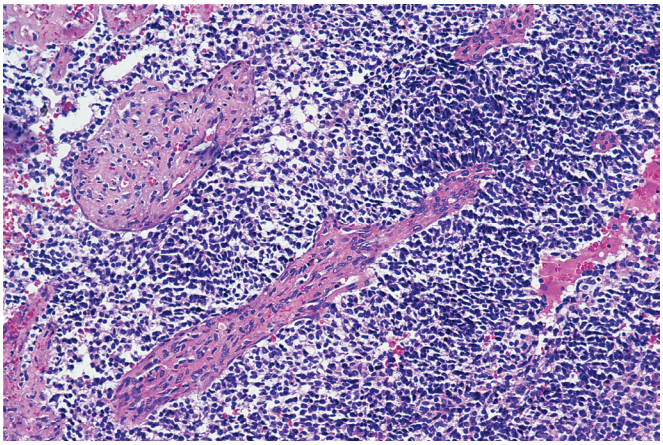

Figure 4.76 Some high-grade olfactory neuroblastomas resemble small cell carcinoma of the nasal cavity. The lesion is extremely cellular and monotonous, with no obvious evidence of neural differentiation.

in some other neurogenic tumors (such as ganglioneuroblastoma) (see Fig. 4.74C). Rosettes (actually pseudorosettes) of the Homer Wright type may be present (and identifiable in cytologic preparations[489]) in up to 30% of tumors, but differentiation into mature ganglion cells takes place only in rare cases.[490] True neural rosettes (Flexner–Wintersteiner) are also uncommon being present in only about 5% of tumors. Fibrovascular stroma may be abundant and separates the tumor cells in distinct lobular pattern. The vascular proliferation can be so florid as to obscure the true nature of the tumor (Fig. 4.75).[491] Melanin may in some cases be found in the cytoplasm of the tumor cells.[492] The differential diagnosis of tumors with this appearance includes malignant lymphoma, plasmacytoma, embryonal/alveolar rhabdomyosarcoma, and the Ewing sarcoma/PNET tumor family (see later).

In other examples the tumor cells are larger, have more abundant cytoplasm with less fibrillary stroma, and grow in solid nests, thus exhibiting an epithelial appearance. This type is often confused with SNUC, nasopharyngeal carcinoma, and small neuroendocrine carcinoma. The suggestion has been made that these two patterns may correspond to two different tumor types, the former being similar (although not identical) to *neuroblastoma* and the latter being similar to *small cell neuroendocrine carcinoma* (Fig. 4.76) (see p. 297).[493] The fact that in some of these tumors there is a component of adenocarcinoma or squamous cell carcinoma (so-called dedifferentiated olfactory neuroblastoma) would seem to support this contention. Other authors have described a similar morphologic dichotomy but favored the existence of a spectrum of differentiation rather than the existence of two separate neoplasms, in view of the many shared ultrastructural and immunohistochemical features.[494] These considerations notwithstanding, in most cases the distinction between olfactory neuroblastoma and small cell neuroendocrine carcinoma is possible and that it has significant therapeutic connotations.[495] Strong expression of cytokeratin is a useful marker in distinguishing these two as olfactory neuroblastoma are invariable negative or show weak and focal staining.

Another contentious issue has been the relationship between olfactory neuroblastoma and tumors in the Ewing sarcoma/PNET family. Despite early claims to the contrary, it has been shown that olfactory neuroblastoma lacks the *EWS–FLI1* gene fusion that characterizes the latter, and therefore it should be considered distinct from it.[496]

Historically, catecholamines have been demonstrated in olfactory neuroblastoma by fluorescent techniques after formaldehyde vapor or glyoxylic acid treatment,[497] whereas the enzyme dopamine β-hydroxylase and the hormone ACTH have been detected by biochemical and immunocytochemical methods.[498] Parenthetically, a case has been described of Cushing syndrome secondary to olfactory neuroblastoma.[499] Other substances detected immunohistochemically in the tumor include synaptophysin, chromogranin, CD56, neuron-specific enolase, neurofilaments, and Hu (Fig. 4.77).[494,500–502] As mentioned, cytokeratin reactivity is uncommon and, when present, is typically weak and focal. In addition, S-100 protein has been found in isolated cells, often surrounding the tumor nests (sustentacular cells), and GFAP has been detected in scattered astrocyte-like cells.[501]

Electron microscopy shows the consistent presence of neurofilaments, neurotubules, and dense-core neurosecretory cytoplasmic granules and may be of help in difficult cases.[503]

Olfactory neuroblastoma shows complex karyotypic changes.[504] An array-based comparative genomic hybridization study showed that gene copy gains are more common than losses, with the most changes being gains at 7q, 9p, 20p/q, and Xp/q and losses at 2q, 6q, 22q, and Xp/q.[505]

The behavior of olfactory neuroblastoma is mainly characterized by local invasiveness into the paranasal sinuses, nasopharynx, palate, orbit, base of skull, and brain.[506] Distant metastases occur in about one-fifth of cases, the most common sites being the cervical lymph nodes and lungs. The 5-year survival rate is between 50% and 66%.[507,508] Late recurrence is common. This tumor has been shown to be radiosensitive, and a combination of surgery and radiation therapy offers the best chances of cure.[507,509,510] From the surgical standpoint, endoscopic removal results in outcomes comparable to those obtained with open surgery.[511] A four-tiered grading system proposed by Hyams shows poor interobserver reproducibility and poor correlation with prognosis. Most olfactory neuroblastomas can be segregated into low and high grade based on the previously mentioned features. Systemic spread is more common in the high-grade (small cell neuroendocrine carcinoma-like) tumors than among the low-grade (neuroblastoma-type) neoplasms.[495]

Carcinoid tumor has been found in rare cases to present as an intranasal or paranasal sinus tumor. These well-differentiated neuroendocrine tumors can show marked immunophenotypic overlap

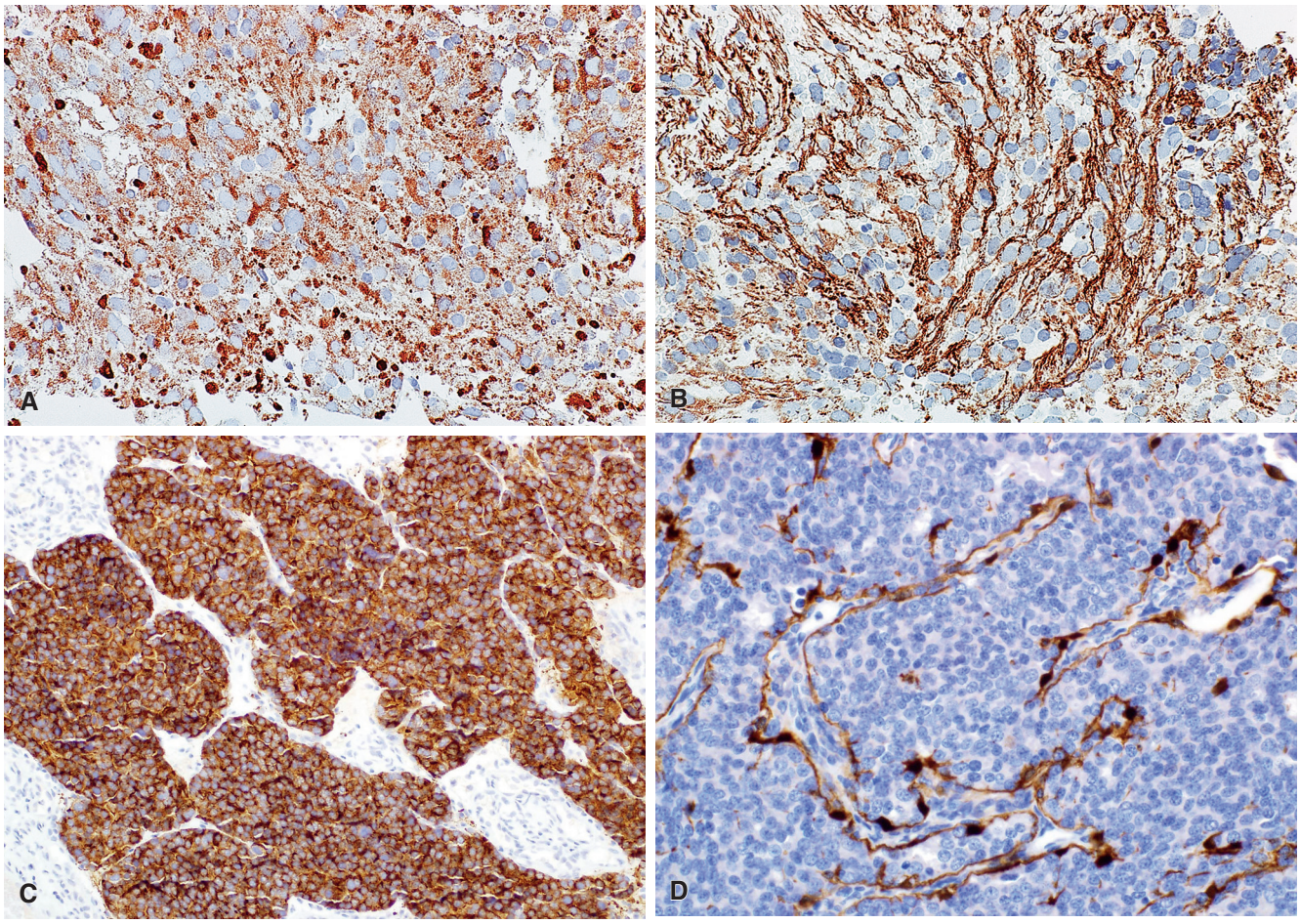

Figure 4.77 Olfactory Neuroblastoma. A, Chromogranin; **B,** neurofilament; **C,** synaptophysin; and **D,** S-100 protein.

with olfactory neuroblastoma but will invariably express cytokeratin as opposed to olfactory neuroblastoma.

Pituitary adenoma can present as a primary lesion of the nasopharynx, sphenoid sinus, or nasal cavity, presumably arising from ectopic anterior pituitary-like cells. These tumors, which are typically of the chromophobe type, should be distinguished from pituitary adenomas that have extended downward from the sella through the sphenoid bone.[512] One should suspect the diagnosis when confronted with a ribbony or rosettoid pattern of growth and a prominent delicate vascularized stroma.[513] These tumors will express cytokeratins, neuroendocrine markers and typically one or more pituitary hormones. Null cell (pituitary hormone negative) cases are common though.

Paragangliomas have been reported both intranasally and in the nasopharynx.[514] These are morphologically and immunophenotypically identical to those occurring elsewhere and lack the fibrillary stroma that is characteristic of olfactory neuroblastoma.

Peripheral nerve tumors of the sinonasal region are extremely rare.[515] They presumably arise from the ophthalmic and maxillary branches of the trigeminal nerve and from branches of the autonomic nervous system. The most common type is the schwannoma, which may cause diagnostic problems because of hypercellularity and the fact that—in contrast to its more common counterpart in the soft tissue—it is often unencapsulated.[516] Neurofibromas (including the plexiform variety) and malignant peripheral nerve sheath tumors have also been observed.[517] Some of the latter have exhibited focal skeletal muscle differentiation ("Triton tumor").[517] Some peripheral nerve tumors occur in association with neurofibromatosis 1 (von Recklinghausen disease).

Tumors of Melanocytes

Primary sinonasal malignant melanomas usually present as solid polypoid growths.[518] Their most common location is the nasal cavity, followed by antrum, ethmoid, and frontal sinuses.[518] They arise from melanocytes located in the epithelium and stroma of the respiratory mucosa.[519] Most sinonasal melanomas are easily recognizable microscopically, but some can be missed because of their lack of pigmentation, pleomorphic features, pseudopapillary configuration, or prominent spindle cell appearance (Fig. 4.78).[518,520] Occasional examples have shown prominent myxoid features[521] and others have been accompanied by metaplastic bone formation.[522] The epithelial basal layer should be searched for the presence of theque-like growth or "junctional" activity to support a diagnosis of primary sinonasal melanoma. However, this features is often obscured the presence of surface mucosal ulceration. Immunohistochemically, these tumors are reactive for vimentin, S-100 protein, Melan-A (Mart-1), and HMB-45, that is, they have a profile similar to that of their cutaneous counterparts. The prognosis is extremely poor, with most patients dying of metastatic tumor in less than 5 years.[518,523]

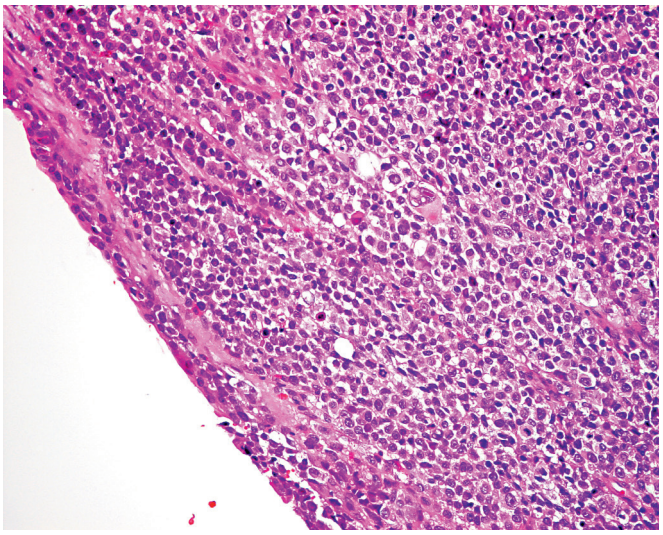

Figure 4.78 Malignant Melanoma of Nasal Cavity. The diffuse pattern of growth and lack of pigmentation often result in misdiagnoses.

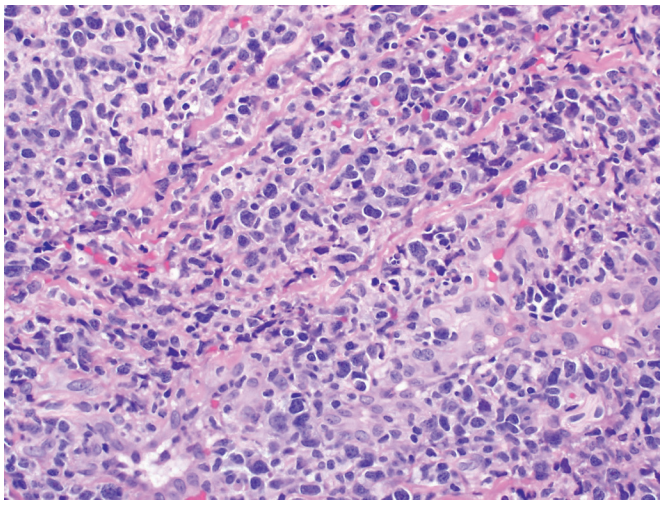

Figure 4.80 Most extranodal NK/T-cell lymphomas are composed of a heterogeneous proliferation of atypical lymphocytes.

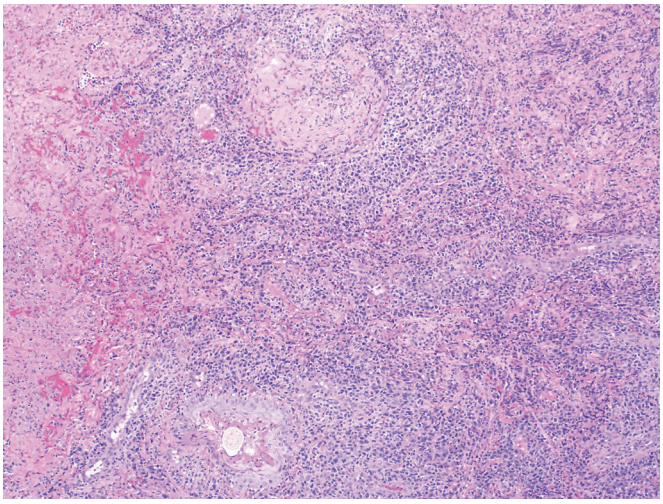

Figure 4.79 Extranodal NK/T-cell lymphoma demonstrating necrosis *(left)* and vessel involvement *(upper center)* with focal pseudoepitheliomatous hyperplasia *(bottom left)*.

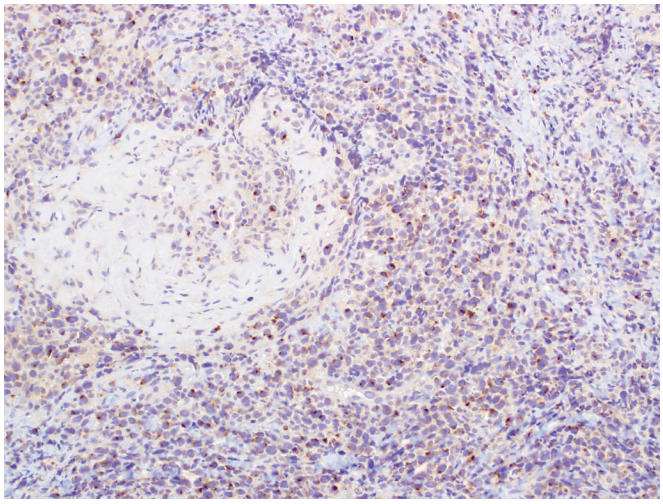

Figure 4.81 Immunohistochemical demonstration of NK marker expression such as TIA-1 help to confirm the diagnosis.

Lymphoid Tumors and Tumorlike Conditions

Malignant lymphoma can present initially as a mass in the sinonasal region or nasopharynx.[524,525] Nearly all cases are of non-Hodgkin type[526,527] and the large majority fall into one of three categories: (1) NK/T-cell type; (2) B-cell type; and (3) peripheral T-cell type.[528] There is a marked geographic difference in their relative frequency: B-cell lymphomas predominate in series from the United States and Western Europe, whereas NK/T-cell lymphomas are prevalent in series from the Far East and Latin America.[528–531]

Extranodal NK/T-cell lymphoma is a distinct clinicopathologic entity which is highly associated with EBV.[442] Morphologically, it is characterized by a broad cytologic spectrum, ranging from small or medium-sized to large transformed cells (Figs. 4.79 and 4.80).[532] Necrosis is nearly always present. Angioinvasion by tumor cells is a very frequent and diagnostically important feature, sometimes accompanied by epitheliotropism reminiscent of that seen in mycosis fungoides. An admixture of reactive histiocytes, some exhibiting erythrophagocytosis, is a frequent feature. Because of the remarkable pattern of blood vessel involvement, this type of lymphoma is sometimes referred to as *angiocentric lymphoma*. However, angiocentric growth is not always present, while it can also be seen in other types of lymphoma. The immunophenotype of NK/T-cell lymphoma is characteristic: positive for cytoplasmic CD3 (as detected in paraffin sections), CD2, and CD56 but usually negative for surface CD3 (as detected by flow cytometry or on frozen section).[533] Cytotoxic markers, such as TIA-1 (Fig. 4.81) and granzyme B, are detectable in most cases.[534] Tumors with a similar phenotype occurring at other extranodal sites (such as skin, subcutaneous tissue, gastrointestinal tract, and testis) or in the lymph nodes themselves are referred to as nasal-type NK/T-cell lymphoma. While CD56 positivity is a key diagnostic feature, it should be kept in mind that this can also be seen in other lymphoma types and in a variety of nonlymphoid neoplasms, including Ewing sarcoma/PNET.[535] It has been hypothesized that the necrotizing features of this tumor type are mediated by perforin and the Fas–Fas ligand (CD95/CD95L) mechanism.[536] There is also frequent overexpression of P53.[537]

In extranodal NK/T-cell lymphomas, the T-cell receptor genes are usually not rearranged, but they are rearranged in a proportion

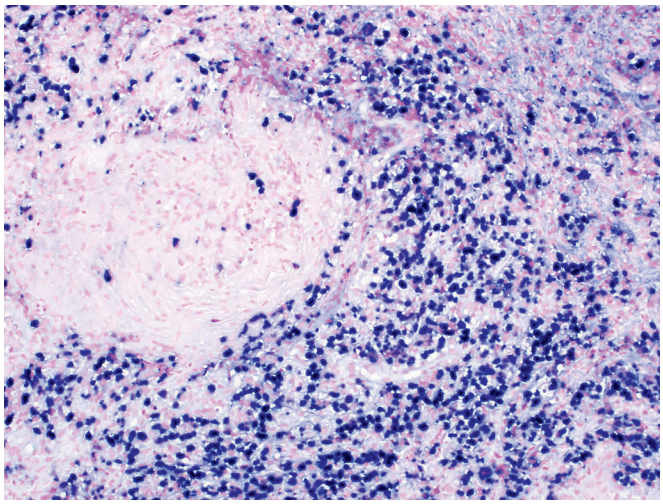

Figure 4.82 The atypical lymphocytes are positive for EBER confirming the presence of Epstein–Barr virus. Note the EBER positive cells in the vessel on the left.

Figure 4.83 **A,** A young female with a clinical diagnosis of lethal midline granuloma. **B,** Same patient a few years later. There was no evidence of systemic disease at the time. This unfortunate individual died a few weeks after this second photograph was taken.

of cases with the cytotoxic T-cell rather than the genuine NK-cell phenotype.[538] There is a consistent association with EBV, which is practically a definitional feature.[539] The most reliable way to demonstrate EBV is in situ hybridization for EBV early RNA (EBER), whereby clusters and sheets of cells exhibit nuclear labeling (Fig. 4.82). This can aid in the differential diagnosis, including in the distinction from reactive lymphoid infiltration (EBER negative) and from other lymphoma types with CD56 expression (usually EBER negative).[540]

The commonest genetic changes are −6q21 (with *PRDM1* being the most likely target gene), −17p11–p13, +1q31–qter, and +20pter–qter.[541,542] Recurrent chromosomal translocations have not been recognized.

It has become apparent that a high percentage of cases of so-called *lethal midline granuloma* (a clinical syndrome characterized by slowly progressive ulceration and destruction of the nose and paranasal cavities, with frequent erosion of the soft tissues, bone, and cartilage of the region) (Fig. 4.83) are due to NK/T-cell lymphoma.[543] In the past, these cases have been diagnosed with terms such as polymorphic reticulosis,[543] malignant histiocytosis,[544] and midline malignant reticulosis. Other cases having the clinical features of lethal midline granuloma represent particularly aggressive examples of granulomatosis with polyangiitis. Still others have been found to be the result of cocaine abuse and are characterized microscopically by nonspecific inflammation and necrosis without vasculitis.[545,546] A clue to this possibility is the presence of polarizable foreign material with an associated giant cell reaction.

Although nasal NK/T-cell lymphomas had been linked by some authors to pulmonary lymphomatoid granulomatosis (because of their angiocentric qualities, association with EBV, and other shared morphologic features) under the term *angiocentric immunoproliferative lesion*, this is no longer thought to be appropriate in view of the current belief that lymphomatoid granulomatosis is an EBV-linked B-cell lymphoma with a florid T-cell reaction.

B-cell lymphoma of the sinonasal region usually presents as a large cell lymphoma with a diffuse pattern of growth and a relatively monomorphic appearance. It is much more common in the paranasal sinuses than in the nasal cavity (an important point in the differential diagnosis with NK/T-cell lymphoma) and constitutes the most common type of sinonasal lymphoma in the United States and western Europe.[547] Burkitt lymphoma is the predominant form of sinonasal lymphoma in the pediatric US population.[548]

Peripheral T-cell lymphoma is uncommon in the sinonasal region and does not express CD56 and usually lacks the necrotizing and angiocentric features of NK/T-cell lymphoma.[549] In contrast to the latter, it usually lacks an association with EBV and shows rearrangement of the T-cell receptor gene.[549]

The behavior of sinonasal lymphoma is difficult to assess because of the fact that one of its major types (NK/T-cell) has been only recently defined, that some of the reported series do not include a thorough immunophenotypic evaluation, and that many cases of NK/T-cell lymphoma go unrecognized for years. In the Far East (where NK/T-cell lymphoma predominates), about 70%–80% of patients with sinonasal lymphoma present with stage IE or IIE disease, have a complete response rate of 75%, and a 2-year overall survival of 50%.[528] In one series from the United States (where B-cell lymphoma is prevalent), the overall survival rate was 52%.[550]

Plasmacytoma (extramedullary plasmacytoma) arising in the nasal cavity or nasopharynx may present primarily as a soft bleeding mass.[551] Microscopic examination shows a monomorphic infiltration by plasma cells which can range in appearance from mature to immature and anaplastic.[257] Amyloid deposition among the neoplastic cells is sometimes present. Approximately 10%–20% of patients with apparently solitary plasmacytomas of the upper air passages subsequently develop disseminated myeloma. In some patients, this process takes 10 or more years to become manifest. Local control of the disease can usually be achieved with radiation therapy.[552]

Angiotropic (intravascular) lymphoma is not to be confused with angiocentric (NK/T-cell) lymphoma (see Chapter 37). In this condition, the neoplastic lymphocytes are predominantly within the lumen of the vessels rather than infiltrating the vessel wall and are usually of B lineage. This unusual type of lymphoma can present initially as an intranasal lesion.[553]

Hodgkin lymphoma presenting as a primary disease in this region is exceptional, but isolated cases of this occurrence have been reported.[554]

Myeloid (granulocytic) sarcoma has been seen limited to the sinonasal region and simulating malignant lymphoma in routinely stained sections.[555]

Pseudolymphoma (reactive lymphoid hyperplasia) may present as a polypoid intranasal mass.[556]

Angiofibroma (Nasopharyngeal Angiofibroma)

Angiofibroma occurs almost exclusively in males between 10 and 25 years of age[557]; however, well-documented cases in older patients are on record. Several cases have been reported in patients with familial adenomatous polyposis (FAP), but alterations of the *APC* gene have not been found in the tumors.[558] The great predilection for young males strongly suggests that this lesion is androgen dependent, a theory confirmed by the fact that stromal and endothelial nuclear immunostaining for androgen receptors is found in 75% of cases; by contrast, very few are positive for progesterone receptors and estrogen receptors.[559] It has also been found that nasopharyngeal angiofibroma contains protein basic fibroblast growth factor (bFGF)[560] and that there is a strong nuclear expression of β-catenin.[561] Concordant with this latter feature, sporadic (not associated with FAP) angiofibromas often have activating mutations of the *CTTNB* gene.[562]

This neoplasm arises from a distinctive erectile-like fibrovascular stroma located in the posterolateral wall of the roof of the nose, where the sphenoidal process of the palatine bone meets the horizontal ala of the vomer and the root of the pterygoid process of the sphenoid bone. Because of this, these are now simply referred to as angiofibroma instead of nasopharyngeal angiofibroma. Grossly, it presents as a polypoid mass that bleeds severely on manipulation and biopsy (Fig. 4.84). It can grow to occlude the involved nares completely. It may protrude below the free edge of the soft palate, extend into the antrum, and grow to the external orifice of the nares, posteriorly into the nasopharynx, or even into the orbit and cranial cavity.[556] Selective carotid arteriograms were often used to determine the gross confines of the tumor, but this method has been replaced by noninvasive techniques such as CT scan and MRI.

Microscopically, nasopharyngeal angiofibroma is composed of an intricate mixture of blood vessels and fibrous stroma (Fig. 4.85). The latter varies from loose and edematous, with stellate fibroblasts and numerous mast cells, to a dense, acellular, and highly collagenized tissue. The latter is particularly striking and diagnostic. The cellularity varies between tumors but is often homogeneous in a given tumor. The vessels range from capillary size to venous size; the larger vessels are located at the base of the lesion, whereas the smaller capillary-like vessels with plump endothelial cells are particularly common at the "growing edge" of the tumor.[563] The large vessels may have an irregular or incomplete smooth muscle coat, but they lack elastic fibers. Many examples have a "hemangiopericytomous" vascular pattern. It is important to distinguish angiofibromas from lobular capillary hemangiomas because of the different natural history of these lesions. In general, hemangiomas are accompanied by less fibrous tissue, show some degree of lobulation, and their vessels do not have the "erectile tissue" appearance so characteristic of nasopharyngeal angiofibroma. Location of the tumor is very important in this regard; a diagnosis of angiofibroma should be questioned for any tumor not located in the area described in the preceding paragraph, and particularly for those limited to the nasal cavity. Solitary fibrous tumors can be confused with angiofibromas, but they are much more cellular with marked variations in cellularity and denser collagen bundles.

There is no doubt that some large angiofibromas regress after puberty, especially after incomplete surgical removal or radiation

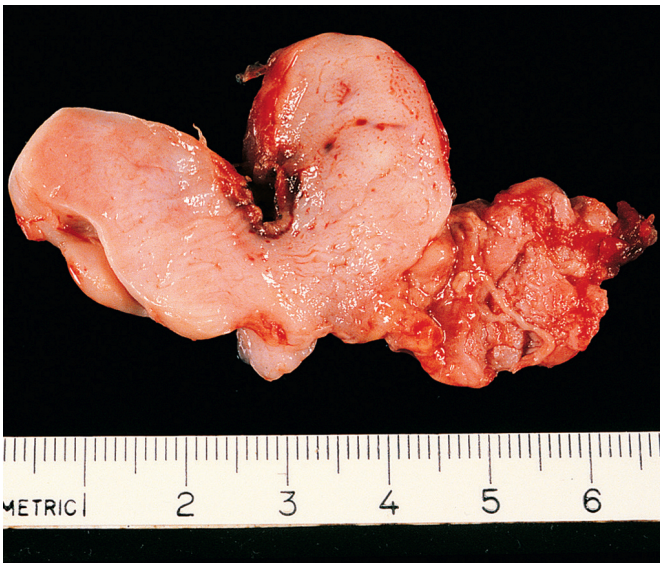

Figure 4.84 Nasopharyngeal Angiofibroma. The cut surface shows the characteristic spongy appearance and well-circumscribed outline.

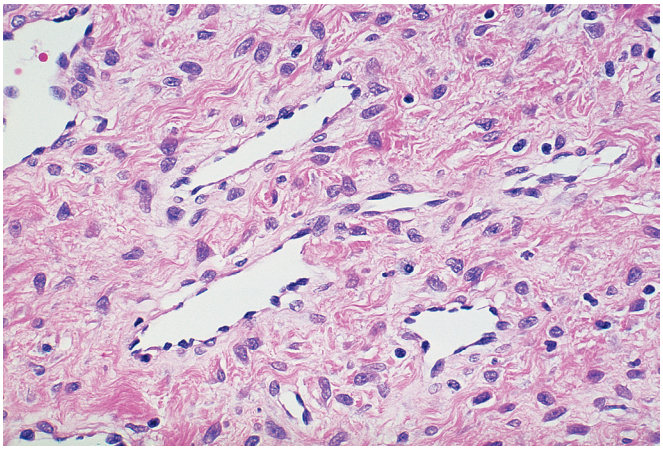

Figure 4.85 Nasopharyngeal Angiofibroma. The dense fibrous quality of the stroma and the numerous thin-walled vessels are characteristic of this entity.

therapy. Spontaneous total regression, however, is very rare[564]; therefore, in a patient with symptoms, treatment is indicated. There is controversy as to whether surgery or radiation is the treatment of choice, but most writers favor surgical resection for early lesions.[565,566] Preoperative embolization is used in most cases to control intraoperative and perioperative bleeding.[567] Radiation therapy or even chemotherapy may be necessary for more advanced and aggressive tumors.[568] Most post-therapy recurrences develop within the first year.[569] Meticulous removal of the angiofibroma is essential to prevent recurrence, particularly the portion of the tumor which infiltrates the pterygoid canal and basisphenoid.[570] A multidisciplinary approach may be necessary to achieve cure.[571] A few cases of sarcomatous transformation after radiation therapy have been described.[572]

Other Tumors and Tumorlike Conditions

Dermoid cysts are dorsal developmental anomalies located in the midline and histologically composed of benign ectodermal and mesodermal elements. Most are located in the subcutaneous tissue of the supraorbital ridge and nose and less commonly in the glabella and columella. Rare examples occur in the paranasal sinuses. They may be associated with bony defects and sinus tracts.[573] They can extend intracranially and result in CNS infection.[574]

True teratomas have been reported in the sinuses and nasopharynx of infants and children. The large majority are histologically mature and clinically benign.[575]

Nasal chondromesenchymal hamartoma is a benign and probably non-neoplastic process which presents as an intranasal or paranasal polypoid mass in infants and occasionally in older children and adults.[576,577] It is composed microscopically of mature cartilage, myxoid stroma, and aneurysmal bone cyst-like formations, and it has been regarded as the upper respiratory tract homolog of chest wall mesenchymal hamartoma.

Respiratory epithelial adenomatoid hamartoma (REAH) is the cumbersome name that has been proposed for a well-differentiated proliferation of glands lined by ciliated epithelium originating from the mucosal surface; the glands often have a thickened basement membrane (Fig. 4.86). The most common location they arise from is the nasal septum, particularly along its posterior aspect.[578] Although originally described as a hamartomatous condition, REAH is now thought by some to be a neoplastic process and possibly related to low-grade (nonintestinal) sinonasal adenocarcinoma.[579]

Vascular tumors are relatively common and include a large variety of types. Care must be taken to not over diagnose the normal heavily vascularized connective tissue of the nasal cavity as a vascular neoplasm. *Lobular capillary hemangioma* is a common tumor of the nasal cavity, where it can reach a large size (Fig. 4.87). This tumor is often misinterpreted as a nasopharyngeal angiofibroma, or—worse—as an angiosarcoma, the latter because of the marked cellularity and high mitotic activity that it may exhibit. Detection of a *lobular* pattern of growth within the lesion (as opposed to freely anastomosing vascular channels) is a key diagnostic feature. Support for the diagnosis is obtained by the immunohistochemical demonstration of the presence of CD31-positive endothelial cells and actin-positive prethelial/smooth muscle cells, the latter predominating.[580]

Glomangiopericytoma *(sinonasal-type hemangiopericytoma, hemangiopericytoma-like tumor)* is a vascular mesenchymal neoplasm that is clinically and histologically distinct. They may arise either in a paranasal sinus or in the nasal cavity, the latter predominating.[581,582] The clinical diagnosis is often that of allergic polyp. Microscopically, the lesions appear vascular and highly cellular, but they have little atypia, necrosis, or mitotic activity (Fig. 4.88). The cells are ovoid or spindled with monotonous nuclei and scant amounts of pale eosinophilic cytoplasm. They array around staghorn-type vessels in areas and are associated with a patchy inflammatory infiltrate and extravasated red blood cells. The proliferation of spindle cells are arranged in short fascicles, but other patterns such as storiform and whorled patters can be seen. A distinct features is the presence of an acellular, hyalinized zone located around small blood vessels (Fig. 4.89). Cytologic atypia, mitotic activity, and necrosis are not present. Immunohistochemically, there is strong reactivity for vimentin, smooth muscle actin, and muscle specific actin.[582] The cells are negative for S-100 and desmin and typically for CD34. CD34 is very focal in the rare cases that are positive. Ultrastructurally, the most consistent features are basal lamina material enwrapping the individual cells, tapered cytoplasmic extensions, and orderly bundles of filaments.[582] Most view this tumor as being closer to Stout's original concept of hemangiopericytoma than most other tumors that have received this term, in the sense that it is composed of vascular myoid cells similar to glomus cells.[583] Glomangiopericytomas

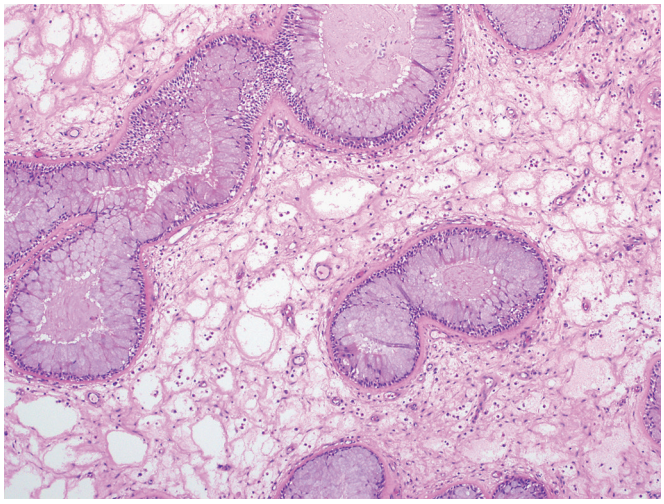

Figure 4.86 Respiratory Epithelial Adenomatoid Hamartoma. While these resemble inverted papillomas, the epithelial lining consists of normal surface respiratory mucosa with thickened basement membranes.

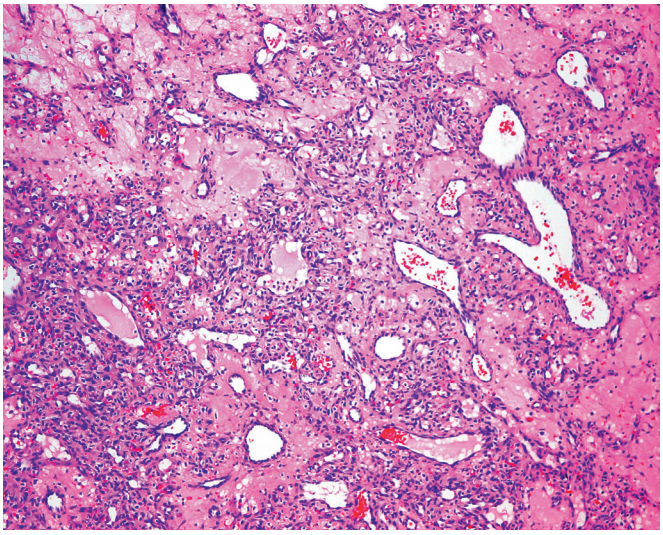

Figure 4.87 Lobular Capillary Hemangioma of Nasal Cavity. Numerous capillary lobules are seen. This lesion should not be confused with nasopharyngeal angiofibroma.

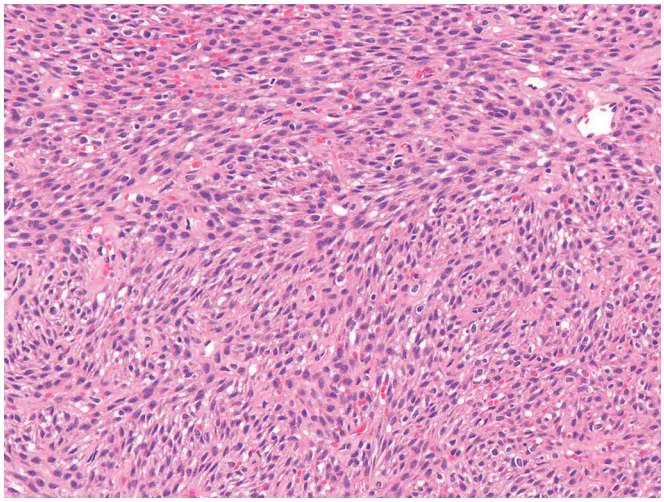

Figure 4.88 Glomangiopericytoma (Hemangiopericytoma-Like Tumor) of Nasal Cavity. Predominantly oval tumor cells arrange themselves around blood vessels forming small fascicles.

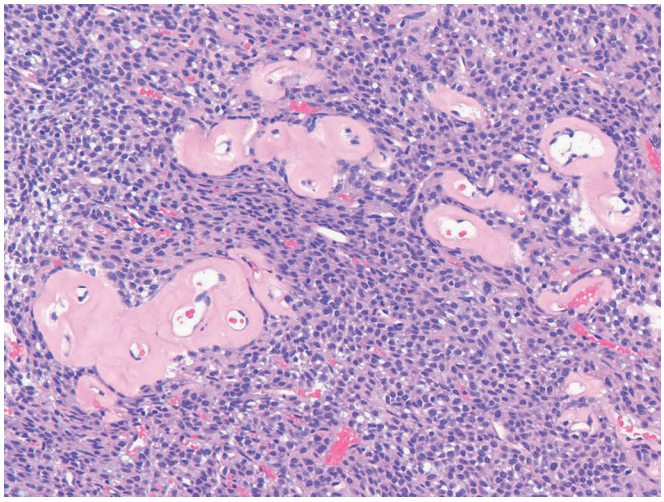

Figure 4.89 Perivascular hyalinization is frequently seen in glomangiopericytomas.

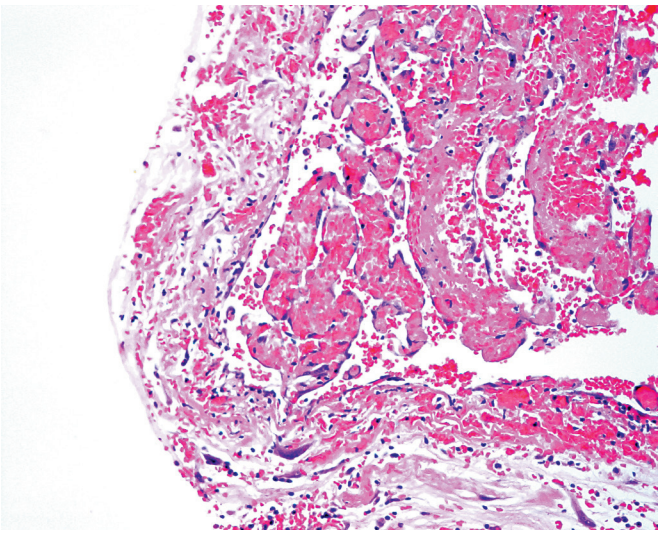

Figure 4.90 So-Called Masson Hemangioma (Papillary Endothelial Hyperplasia). The intraluminal papillary fronds have a fibrin core and are covered by endothelial cells.

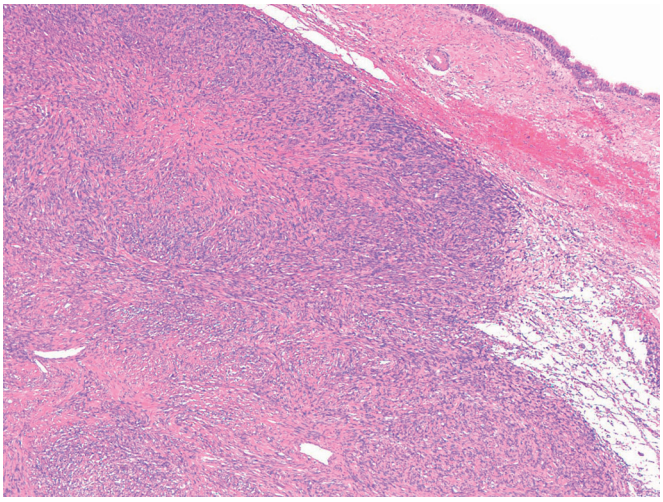

Figure 4.91 Solitary Fibrous Tumor of Paranasal Sinus. The tumor is highly vascularized and shows an alternation of hypercellular and hypocellular foci.

are low-grade lesions that tend to have an excellent long-term prognosis. Local recurrences may develop, but metastases do not occur.[581,582]

Other vascular tumors of the region include *hemangioma*, *lymphangioma*, conventional *glomus tumor*, *Masson hemangioma* (Fig. 4.90) (papillary endothelial hyperplasia), *angioleiomyoma* (vascular leiomyoma), *Kaposi sarcoma*, and the exceptionally rare *angiosarcoma*.[584] Before making the latter diagnosis in the nasal cavity, other possibilities should be considered, such as a particularly florid form of lobular capillary hemangioma, the reactive vascular changes in cocaine abusers,[585] and the prominent angiectatic changes sometimes seen in nasal polyps.[342]

Solitary fibrous tumor (formerly hemangiopericytoma) is uncommon in the upper respiratory tract accounting for less than 0.1% of neoplasms. Most occur in adults, and all sites can be affected, with the nasal cavity and paranasal sinuses being most frequent. They are morphologically, genetically, and immunohistochemically analogous to non-sinonasal solitary fibrous tumors (Figs. 4.91 and 4.92).[586] Most behave in a benign fashion but recurrences can be seen especially in lesions that have been inadequately excised. Rare cases may have histologic and clinical features of a high-grade malignancy.

Low-grade sinonasal sarcoma with neural and myogenic features (biphenotypic sinonasal sarcoma) is a recently described spindle cell sarcoma occurring in the sinonasal region and demonstrating immunophenotypic evidence of both neural and myoid differentiation.[587] Most patients are adults, and there is a female predilection. Morphologically, they are infiltrative and highly cellular being composed of uniform spindle cells arranged in fascicles with a herringbone-type appearance. They are usually associated with a benign respiratory epithelial proliferation with cystic change that is likely hyperplastic in nature. They uniformly express S-100 protein and actin, typically in a patchy distribution. Cytokeratin and desmin can be focally positive in rare cases. The original authors reported two of their tumors to have the chromosomal translocation t(2;4) resulting in a *PAX3-MAML3* fusion.[588] Nearly half of patients will develop recurrence, but none have developed metastasis or died of disease.

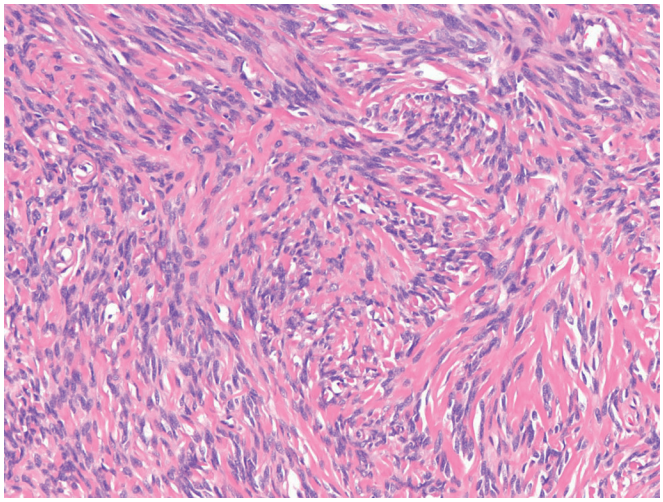

Figure 4.92 Solitary Fibrous Tumor of the Nasal Cavity. Bland spindle cells associated with ropey collagen bundles arranged in short fascicles are typical.

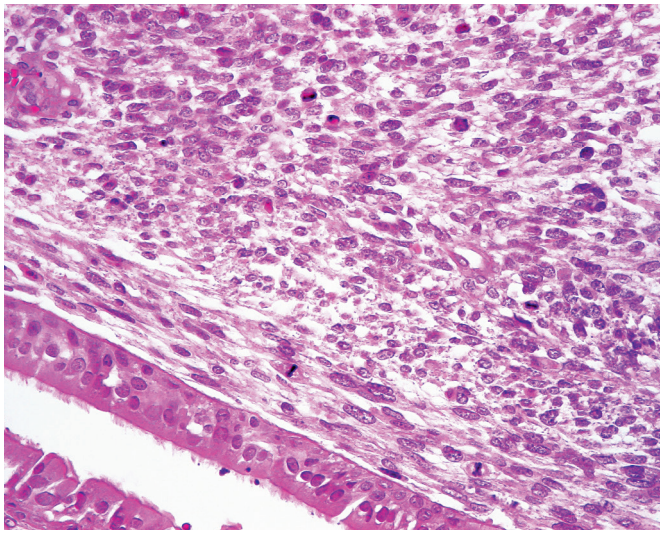

Figure 4.93 Embryonal Rhabdomyosarcoma of Nasopharynx. The lesion is extremely cellular and mitotically active.

Ameloblastoma having a microscopic appearance indistinguishable from that of its more common counterpart in the jaw can present as a primary tumor in the sinonasal tract, predominantly located in the maxillary sinus. The fact that there is often continuity of the tumor with the surface epithelium suggests that most of these tumors are primary in this region rather than extensions of jaw neoplasms.[589] As such, they are analogous to the peripheral ameloblastomas of the oral cavity (see Chapter 5). The differential diagnosis includes sinonasal extension of craniopharyngioma, the nature of which should be apparent on MRI or CT scan.[589]

Chordoma of the sphenoid region is another example of a primary cranial/intracranial tumor that can secondarily invade the nasopharynx.[590]

Rhabdomyosarcoma of the embryonal type is one of the three most common types of nasopharyngeal malignancy in children, the other two being lymphoepithelioma and malignant lymphoma (Fig. 4.93).[591] Both embryonal and alveolar rhabdomyosarcoma can also develop in the sinonasal tract in adults.[592] The alveolar type (including its solid variant) is the most common[593]; it often develops clear cell changes because of glycogen accumulation, thus simulating other neoplasms. They most frequently arise in the ethmoid sinus followed by the maxillary sinus and nasopharynx. They are genetically and immunophenotypically identical to alveolar rhabdomyosarcoma occurring elsewhere and are associated with a poor prognosis.

Teratocarcinosarcoma (teratoid carcinosarcoma) is a unique sinonasal tract neoplasm that combines features of carcinosarcoma and teratoma, the latter including primitive neuroepithelial elements with well-formed rosettes and fetal-type squamous differentiation (Fig. 4.94).[594] The histogenesis remains uncertain, but it has been proposed on the basis of cytogenetic, ultrastructural, and immunohistochemical observations that it represents a neuroectodermal tumor with divergent differentiation.[595,596] Most patients are adults, and the prognosis is poor, with 60% of the patients not surviving beyond 3 years.[597]

Soft tissue tumors of this region include, in addition to the entities already described, the following types: osseous and fibro-osseous lesions,[598] cartilaginous tumors,[599] smooth muscle tumors,[600,601] fibroblastic and myofibroblastic tumors (fibromatosis, "fibromas," and fibrosarcomas),[602] myxomas,[603] adipose tissue tumors,[604] fibrous histiocytomas,[605] synovial sarcomas,[320] extraskeletal Ewing sarcoma/PNET (Fig. 4.95),[606] phosphaturic mesenchymal tumor,[607] and desmoplastic small cell tumor.[608]

Follicular dendritic cell tumor/sarcoma is a malignant neoplasm arising from the follicular subset of the dendritic/reticulum cells family. Its features are similar to those of its more common counterpart in the lymph nodes. In the nasopharynx, its misdiagnosis as lymphoepithelioma-like carcinoma is likely. The nucleoli are not as large or eosinophilic as in the latter, and there is immunoreactivity for CD21 and/or CD35 instead of keratin.[609] Some cases have arisen against a background of Castleman disease of the hyaline–vascular type.[610]

Metastatic tumors to this region are exceptional, but well-documented cases are on record. As usual, renal cell carcinoma, malignant melanoma, and breast carcinoma head the list.[611]

Larynx

Normal Anatomy

The larynx is a complex organ composed of various stromal and epithelial tissues. The supraglottic portion is derived from the third and fourth branchial pouches, whereas the glottis and subglottis originate from the sixth branchial pouch. The major cartilages of the larynx (cricoid, thyroid, and arytenoids) are of hyaline type, whereas the epiglottis is of elastic type, with numerous fenestrations. Calcification of the thyroid and cricoid cartilages increases with age; the thyroid cartilage also undergoes ossification.

The larynx is usually divided into three major compartments:

1. **Supraglottic**, which extends from the tip of the epiglottis to the true cord and includes the aryepiglottic folds, false vocal cords, and ventricles (including its saccules)
2. **Glottic**, which extends from the top of the true vocal cords and extends caudal for 1 cm and consists of the true vocal cords and the anterior commissure that bridges them anteriorly
3. **Subglottic**, which is the area between the lower border of the glottis (where the squamous epithelium ends) and the inferior border of the cricoid cartilage.

The epithelium of the normal larynx varies from stratified squamous to respiratory-type ciliated, depending on the location, according to the scheme outlined in Table 4.2.

The junction between the two epithelial types may be abrupt or separated by a transitional zone. Patches of squamous epithelium are frequently seen within the respiratory-type epithelial regions;

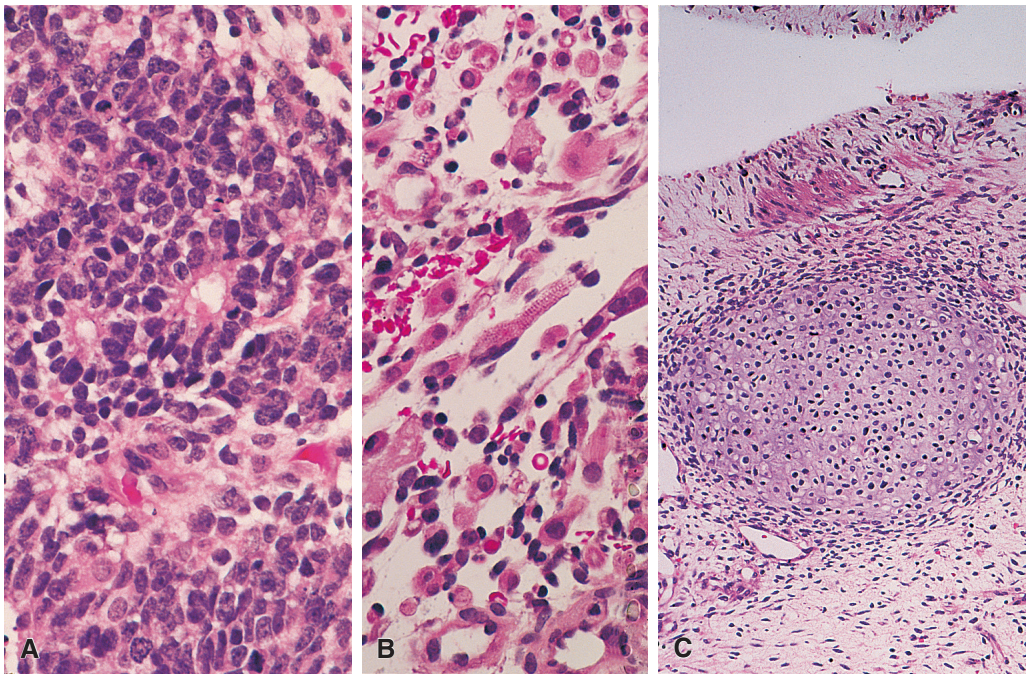

Figure 4.94 Teratocarcinosarcoma of Sinonasal Region. This composite photomicrograph shows three different components: **A,** adenocarcinomatous with neural-type rosette formations; **B,** myosarcomatous areas; and **C,** cartilaginous foci. (Courtesy of Dr. Dennis K. Heffner, Washington, DC.)

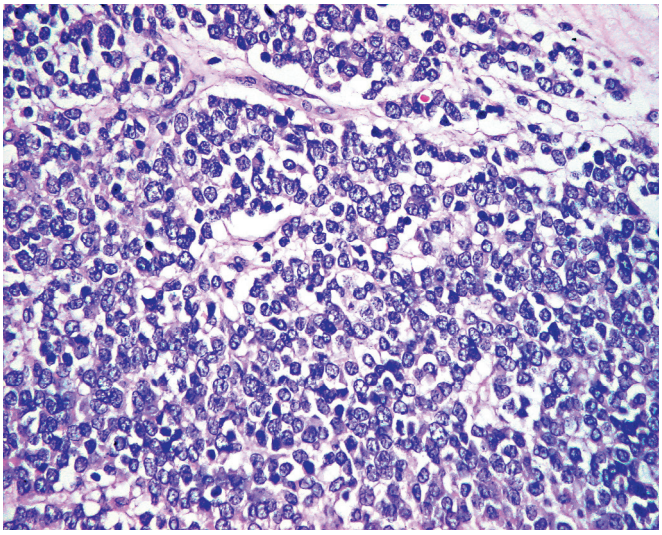

Figure 4.95 Ewing Sarcoma/PNET of Sinonasal Region. This tumor type is distinct from olfactory neuroblastoma.

Table 4.2 Classification of the laryngeal epithelium

Epiglottis	
Lingual (anterior) surface	Stratified squamous
Laryngeal (posterior) surface	Mixed stratified squamous and respiratory type
Larynx	
Supraglottic portion	Respiratory type
Glottis	Stratified squamous
Intraglottic portion	Respiratory type

these are particularly prominent in smokers. Dendritic melanocytes may be seen in the basal layer, particularly in blacks.

Seromucinous glands are present in most of the larynx; these often show oncocytic metaplasia in older individuals.[612]

Reinke space is the term used for the lamina propria of the true vocal cord, bound by the base of the squamous epithelium on one side and the vocal ligament on the other. It contains a few capillaries but lacks lymph vessels.

Biopsy specimens from the larynx may show *normal* or *metaplastic cartilaginous formations* that can be confused with cartilaginous neoplasms. One is the *vocal process of the arytenoid cartilage*, which may be seen as a sharply circumscribed nodule of uniformly mature elastic-type cartilage in biopsies from the posterior portion of the true cord. Another is *chondroid metaplasia* of the true cord, a common asymptomatic finding in the mid or posterior portion of this structure; it is characterized by blurred margins and a peripheral zone of myxoid connective tissue.[613]

Two pairs of paraganglia are normally found in the larynx, sometimes in ectopic or aberrant positions.[614]

It is not unusual to find microscopic islands of *thyroid tissue* within the fibrous capsule of the larynx and trachea, just external to the cricothyroid membrane.[615]

Cysts and Laryngocele

The two most common types of **cyst** of the larynx have been divided by DeSanto et al.[616] according to their mechanism of formation into *saccular* (24%) and *ductal* (75%). The former arise from cystic distention of the laryngeal saccule. They are usually large and deep and are often found inside the ventricle. Saccular cysts differ from laryngoceles only in that they contain mucus, whereas the latter

contain air as they still are connected to the endolarynx. Ductal cysts, which are the result of dilation of mucous glands, are small and superficial and are usually located in the true cord or epiglottis. Both types can be lined by either squamous or respiratory epithelium or a combination of both. Saccular cysts may be a cause of neonatal airway obstruction.[617]

A third type of laryngeal cyst, which probably represents a subtype of the ductal cyst, is referred to as *oncocytic cyst* (oncocytic papillary "cystadenoma") because of the fact that it is lined partially or completely by oncocytes.[618] Papillary infoldings are usually present, but the condition is regarded as a metaplastic and hyperplastic change rather than a true neoplasia. In rare cases the entire larynx is involved in a diffuse fashion by this process.[619] Oncocytic cysts have a tendency to recur.

A fourth type of laryngeal cyst is the *tonsillar cyst*.[620] It has squamous-lined crypt-like structures and abundant follicular lymphoid tissue in the wall.

The term **laryngocele** refers to an air-containing dilation of the tip of the laryngeal ventricle that communicates with the lumen of the ventricle by a narrow stalk.[621] The *internal* variety causes hoarseness, dyspnea, or reflex cough, whereas the *external* type appears as a soft mass in the lateral aspect of the neck. Combined forms occur. Laryngoceles may became infected and accumulate purulent material *(laryngopyoceles)*.

Inflammation

Chronic (nonspecific) laryngitis can be the result of infection, overuse of the voice, exposure to chemical or physical agents, or irritation by tobacco and alcohol. Microscopically, a lymphocytic infiltrate is seen beneath the mucosa with an inconstant admixture of plasma cells and histiocytes, accompanied by some hyperplasia of the overlying epithelium.

Acute epiglottitis (acute supraglottitis) is a relatively rare but potentially lethal disease because of respiratory tract obstruction caused by massive edema. It is usually a disease of children but also occurs in adults.[622] It is a bacterial infection, and *Haemophilus influenzae* type B is the most common organism involved. Grossly, the epiglottis appears red and edematous; microscopically, there is an intense acute inflammatory infiltrate associated with edema that extends to the adjacent soft tissues.

Tuberculosis of the larynx begins with edema of the posterior interarytenoid space, from which it spreads to the epiglottis, aryepiglottic fold, and vocal cords.[623,624] It can simulate carcinoma on laryngoscopic examination. Imaging studies of the chest may show active advanced tuberculosis, although not as frequently as in the past.[625] Laryngeal biopsy shows typical granulomas, with or without caseation necrosis, but granulomas can be poorly formed. Demonstration of acid-fast bacilli or their DNA sequences is necessary to document the diagnosis.

Histoplasmosis and **blastomycosis** are the two most common types of mycotic laryngitis in the United States.[626] In histoplasmosis, the early lesions are frequently located in the vocal cords and epiglottis.[24] A granulomatous lesion involving *only* the anterior portions of the larynx (especially the epiglottis) or having associated oral lesions is more likely to be histoplasmosis than tuberculosis. **Aspergillosis** and **cryptococcosis** may also involve this organ.[627,628] **Actinomycosis** of the larynx is extremely rare; only a handful of cases have been reported.[629] Several of these mycotic infections (particularly histoplasmosis and blastomycosis, but also aspergillosis) can induce a marked pseudoepitheliomatous hyperplasia of the overlying epithelium that can be confused microscopically with carcinoma.

Leprosy of the larynx is not rare in areas of the world where the disease is endemic.[630]

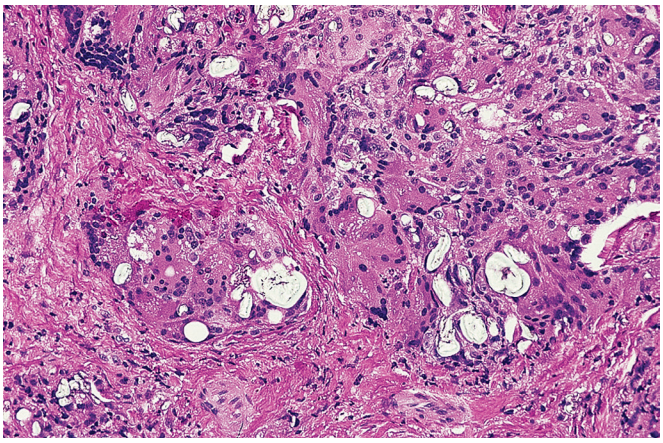

Figure 4.96 So-Called Teflonoma of Larynx. A foreign body giant cell reaction is seen around Teflon fragments. These are polarizable using polarized light microscopy.

Crohn disease can be accompanied by ulcerative and granulomatous lesions in the larynx, particularly the epiglottis.[631]

Sarcoidosis can involve the larynx and has been reported to present as epiglottic enlargement.[632]

Laryngeal granulomas resulting from endotracheal trauma caused by intubation can occur bilaterally on the vocal process of the arytenoid cartilage and may be mistaken for a neoplasm. Injection of *Teflon* into paralyzed vocal cords, used as a means of augmentation in cases of recurrent nerve paralysis, may lead to the formation of an exuberant **foreign body granuloma** ("teflonoma") (Fig. 4.96).[633] Cases of laryngeal **malakoplakia** and **Kimura disease** have been described.[634,635] **Radiation changes** may present in the form of granulation tissue–type reactions with bizarre mesenchymal cells that can simulate malignancy.[636] **Arthritis** of the cricoarytenoid joint is commonly associated with generalized rheumatoid arthritis.[637] **Pemphigus vulgaris** may rarely involve the supraglottic larynx.[638] **Gout** may result in the deposit of tophi in the true vocal cords.[639] **Rosai–Dorfman disease (sinus histiocytosis with massive lymphadenopathy)** can affect the subglottic region and trachea.[362]

Vocal Cord Nodule and Contact Ulcer

Vocal cord (laryngeal) nodule represents a peculiar noninflammatory reaction to injury causing hoarseness, which is seen more commonly in people who misuse their voices. It occurs chiefly on the anterior third of the vocal cords and has also been called singer's nodule, amyloid tumor, vocal cord polyp, and varix.

The microscopic appearance varies depending on the stage of evolution, as carefully recorded in the classic article by Ash and Schwartz on the subject (Fig. 4.97).[640] In the early stages, there is edema and proliferation of young fibroblasts (myxoid stage). Later, dilated blood vessels and hyalinization of the stroma appear (fibrous stage). Cases with a prominent vascular component may be mistaken for hemangioma (vascular stage). The hyaline stage was previously designated as "amyloid tumor." This is a misnomer because the material is fibrin rather than amyloid. Mixed types occur as well.

Contact granuloma (contact ulcer, granulomatous ulcer, intubation granuloma, posterior commissure ulcer) is a lesion sometimes erroneously equated with laryngeal nodule but having a different presentation, microscopic appearance, and behavior. Most are caused by severe phonotrauma, gastroesophageal reflux disease, and intubation. It is almost always found at the level of the posterior commissure, in the area of the vocal process of the arytenoid cartilage, at a site

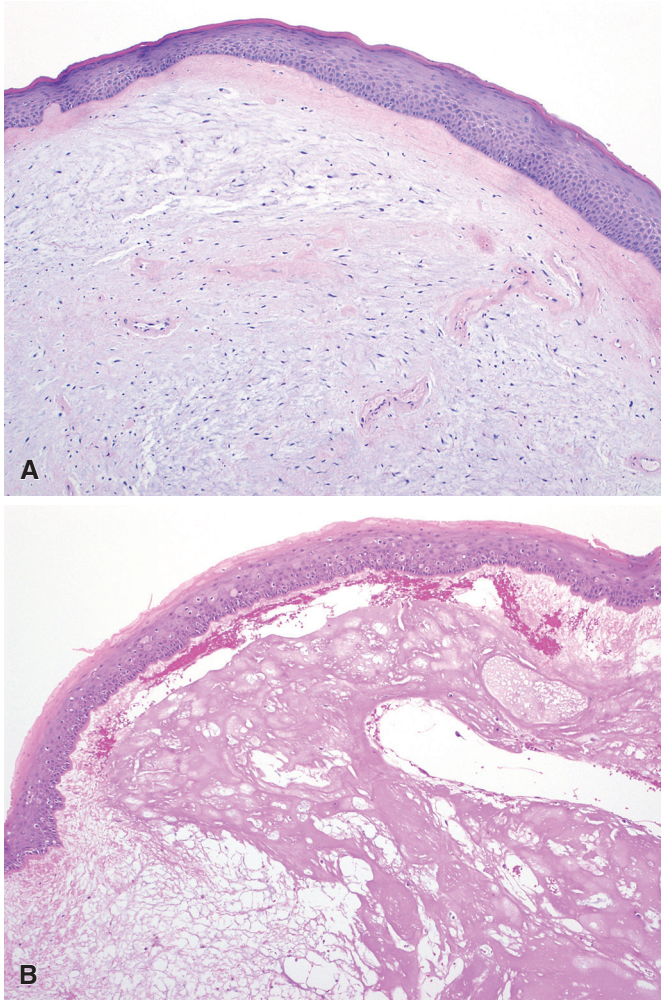

Figure 4.97 Vocal Nodule. The lesion shown in **A** has a fibromyxoid quality, whereas that depicted in **B** has fibrinoid features.

where the amount of subepithelial stroma is scantier. Microscopically, it has the appearance of exuberant granulation tissue; it is often confused with a pyogenic granuloma but lacks the characteristic lobular pattern of the latter.[641] The epithelium may be ulcerated or exhibit hyperplastic changes, sometimes of a pseudoepitheliomatous degree (Fig. 4.98).[642] The lesion stubbornly recurs after local excision but eventually subsides. Conservative management is strongly recommended, inasmuch as the trauma associated with the surgical excision can induce further recurrences.

Other Non-Neoplastic Lesions

Amyloidosis may involve the tracheobronchial tree as a localized phenomenon.[643] It is usually asymptomatic but may result in hoarseness and bleeding. The false vocal cords are the most common site, but any portion of the larynx can be involved, often in a multifocal fashion. Monoclonal light chain deposition can be detected in most cases. The disease can recur locally and become systemic or multicentric, but none of the patients studied by Thompson et al.[644] developed myeloma or lymphoma.

Eosinophilic angiocentric fibrosis is a peculiar inflammatory lesion of the upper respiratory tract thought to represent a mucosal variant of granuloma faciale and which occurs more commonly in the nasal cavity[369]; some of the reported cases have involved the

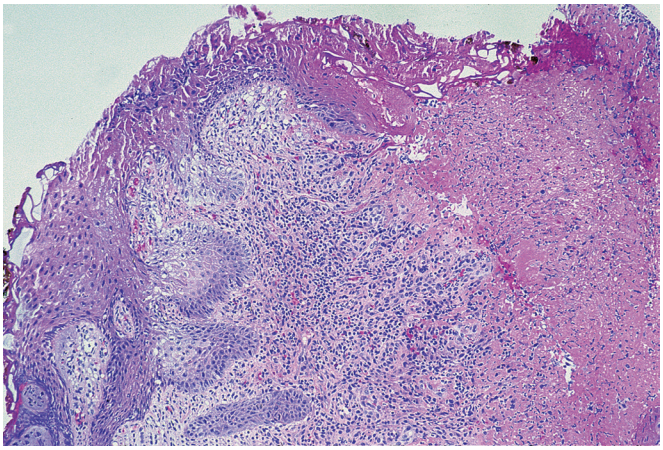

Figure 4.98 Contact Ulcer of Larynx. A polypoid mass is seen resulting from a heavily inflamed stroma covered by a partially ulcerated epithelium.

subglottic region of the trachea and the larynx.[645] The differential diagnosis includes granulomatosis with polyangiitis, Churg–Strauss syndrome, and specific infections.

Focal mucinosis has been rarely reported in the larynx and other portions of the upper aerodigestive tract.[646]

Necrotizing sialometaplasia similar to that more commonly seen in the oral cavity can occur in the larynx.[647]

Tumors and Tumorlike Conditions

Papilloma and Papillomatosis

Juvenile laryngeal papillomas present in children or adolescents with multiple papillary tumors on the true cords, from which they may spread to the false cords, epiglottis, subglottic area, and in rare cases, even the trachea and bronchi. When extensive, papillomatosis may cause extreme respiratory difficulty and even death (Fig. 4.99).

The viral etiology of juvenile laryngeal papillomatosis has been proven by ultrastructural examination,[648] immunohistochemical demonstration of HPV antigens,[649] and in situ hybridization.[650,651] Viral DNA has also been found in uninvolved sites in patients with active disease and also in patients in remission.[651] The types of HPV that have been specifically associated with laryngeal papillomas are HPV-11 and HPV-6.[652]

The microscopic appearance is that of a papillary or acanthotic growth of well-differentiated squamous cells that retain an orderly maturation pattern (Fig. 4.100).[653] Mitotic activity is common, and some degree of koilocytosis and mild nuclear atypia are the rule (Fig. 4.101). When the process involves the respiratory mucosa, the maturation pattern, which is constant in the squamous epithelium, is not so apparent. This may lead to an overdiagnosis of CIS. Mild chronic inflammation and hyperemia are usually present beneath the epithelium.[654]

These tumors tend to recur over a long period. It has been pointed out that the recurrences occur more often at junctions of stratified squamous and respiratory-type epithelium.[654] Treatment has included hormones, HPV vaccines, cautery, cryosurgery, CO_2 laser, interferon, and photodynamic therapy, with mixed but generally limited results.[655,656] In cases with very extensive involvement, laryngectomy may become necessary.

Rarely, squamous cell carcinoma develops in association with laryngeal papillomatosis. In practically all the reported cases of this complication, irradiation therapy had been administered previously

Figure 4.99 Extensive Papillomatosis in an 18-Year-Old Boy. The patient had had almost 50 resections of this process, beginning at 7 years of age, and finally died of suffocation.

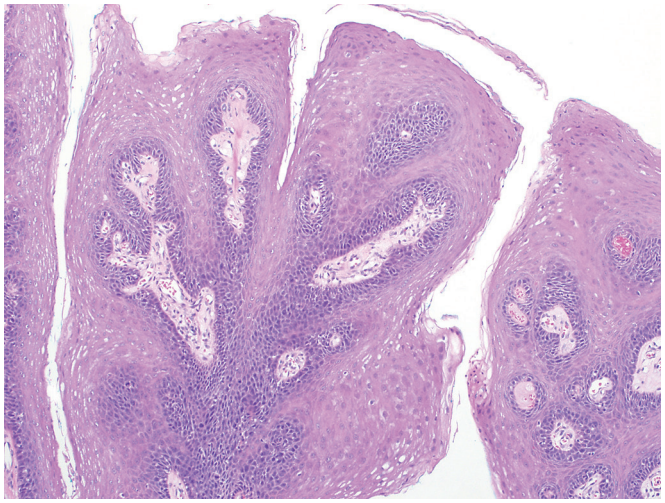

Figure 4.100 Squamous papilloma of larynx with a typical arborizing papillary appearance.

for the papillomas; however, a few cases have been documented in which malignancy developed in the absence of radiation therapy.[657] The carcinoma is usually located in the larynx, but in cases with extensive papillomatosis of the tracheobronchial tree, it may also be found in the trachea or bronchi.[658] Interestingly, in all of the reported cases of juvenile-onset respiratory papillomatosis complicated by the development of pulmonary squamous cell carcinoma, HPV-11 was identified in association with the malignant tumor.[659]

Adult laryngeal papillomas have a male predominance, are most commonly solitary, show a greater degree of inflammatory reaction, do not tend to spread, and recur less frequently than the juvenile form. As for the juvenile form, the involved viral types are usually HPV-6 and HPV-11.[662]

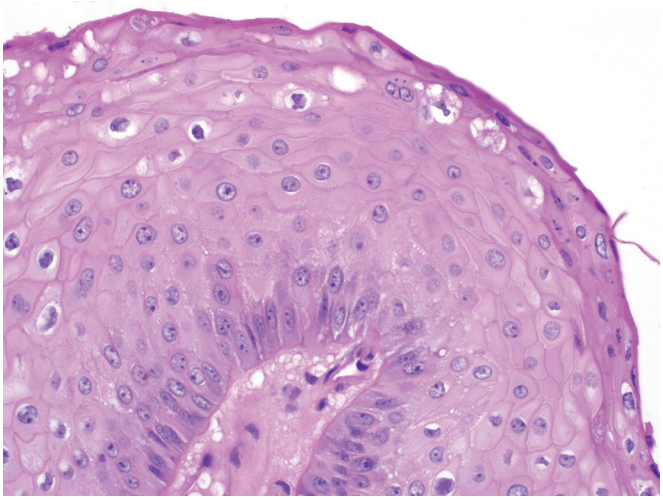

Figure 4.101 Squamous papillomas show an orderly pattern of maturation with koilocytes near the surface.

Verruca vulgaris is another HPV-related lesion that may occur in the larynx and be confused with squamous cell or verrucous carcinoma.[663]

Squamous Intraepithelial Lesions

Keratosis of the larynx involves most commonly the true cords and interarytenoid area. It is also designated as simple hyperplasia, epithelial hyperplasia, squamous hyperplasia, and leukoplakia, even if the latter term is not used as often by the clinicians as in the oral cavity. It often occurs in smokers, singers, and others who use their voices excessively. Patients may complain of hoarseness, and laryngoscopic examination may show white thickening of the involved areas. Presence of reddening should alert the clinician to the possible existence of a more significant lesion (dysplasia/CIS, see later). Cases of keratosis that exhibit an undulating warty configuration are referred to as *verrucous keratosis* or *papillary keratosis*. Microscopically, benign keratotic lesions are characterized by hyperkeratotic epithelium (often with a granular layer) and acanthosis, without atypia.

As in other sites, cases of keratosis characterized by varying degrees of cellular atypia, loss of normal maturation, and loss of stratification are grouped under generic terms such as *squamous intraepithelial lesion* (*SIL*), *squamous intraepithelial neoplasia* (*SIN*), and *laryngeal intraepithelial neoplasia* (*LIN*), these embracing the traditional categories of dysplasia and CIS. These changes are graded on the basis of the degree of nuclear abnormalities (including changes in polarity)[664] and the level of the epithelium showing loss of stratification. The World Health Organization (WHO) Classification of Tumors described and illustrated the criteria for their grading system (referred to as the "dysplasia system") as follows[665] (Figs. 4.102 to 4.105):

1. **Mild dysplasia.** The nuclear abnormalities are slight and are most marked in the basal third of the epithelial thickness. They are minimal in the upper layers where the cells show maturation and stratification. A few mitoses may be present in the parabasal layers. Keratosis and chronic inflammation are usually present.
2. **Moderate dysplasia.** The nuclear abnormalities are more marked than in mild dysplasia, and nucleoli tend to be prominent. These changes are most marked in the lower two-thirds of the epithelial thickness. Moderate nuclear abnormalities may persist up to the surface, but cell maturation and stratification are evident in the upper layers. Mitoses are present in the parabasal and intermediate layers. The lesion may be associated with keratosis.

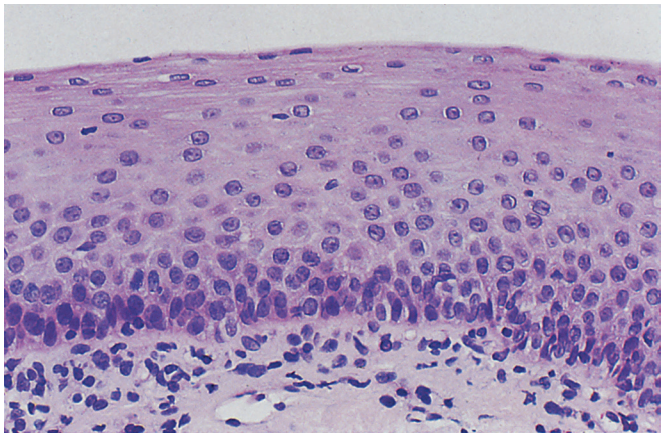

Figure 4.102 Mild Dysplasia of Larynx. There is mild nuclear atypia with retained maturation and stratification of upper layers. (From Shanmugaratnam K, Sobin H. *Histological Typing of Tumours of the Upper Respiratory Tract and Ear*. 2nd ed. New York, NY: Springer; 1991.)

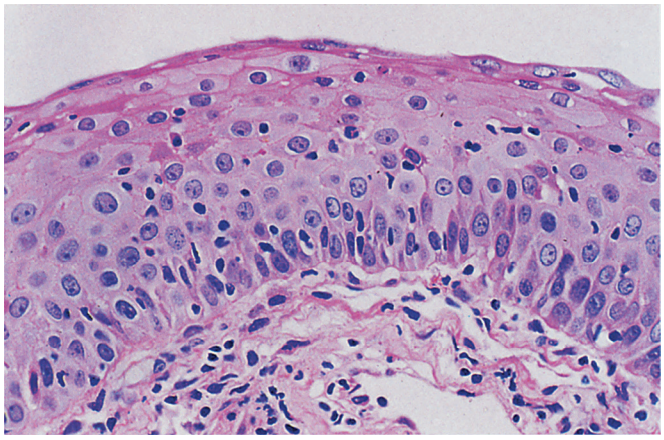

Figure 4.103 Moderate Dysplasia of Larynx. There is moderate nuclear atypia with prominent nuclei, but the stratification of the upper layers is retained. (From Shanmugaratnam K, Sobin H. *Histological Typing of Tumours of the Upper Respiratory Tract and Ear*. 2nd ed. New York, NY: Springer; 1991.)

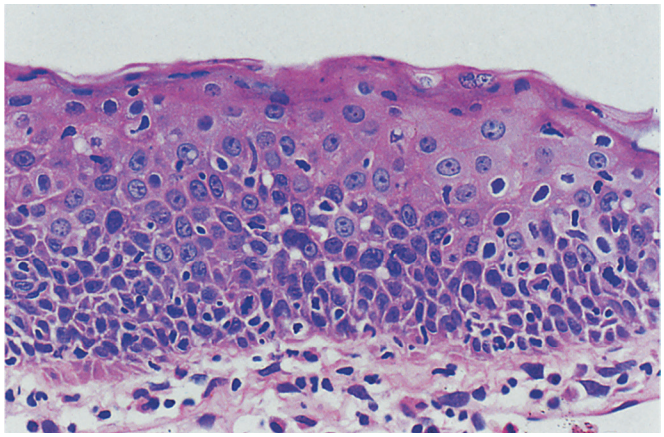

Figure 4.104 Severe Dysplasia of Larynx. There is severe nuclear atypia and increased mitotic activity, associated with some maturation and stratification of the most superficial layers. (From Shanmugaratnam K, Sobin H. *Histological Typing of Tumours of the Upper Respiratory Tract and Ear*. 2nd ed. New York, NY: Springer; 1991.)

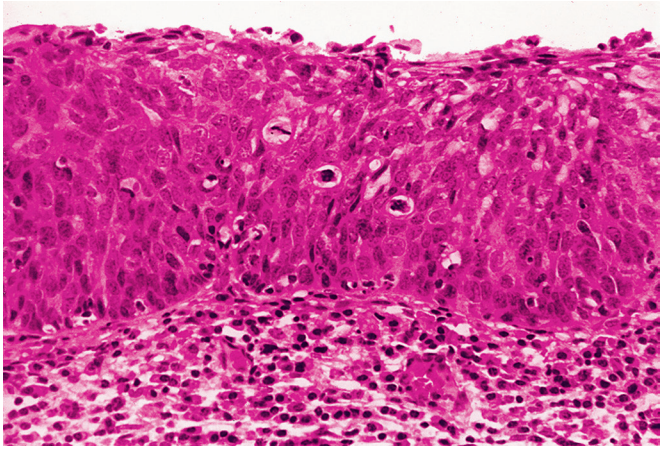

Figure 4.105 Squamous Cell Carcinoma in situ of Larynx.

3. **Severe dysplasia.** The epithelium shows marked nuclear abnormalities and loss of maturation involving more than two-thirds of the epithelial thickness with some of the stratification of the most superficial layers. Nuclear pleomorphism is common, and some of the cells may have bizarre nuclei. In some areas the nucleoli are very prominent, but in others all the nuclei are hyperchromatic. Mitoses are present high up in the epithelium, and atypical mitoses may be found. The presence of some maturation and stratification of the cells in the most superficial layers distinguishes the lesion from CIS. The lesion is frequently associated with keratosis.
4. **CIS.** A lesion in which the full thickness of the squamous epithelium shows the cellular features of carcinoma without stromal invasion.

It should be noted that the WHO scheme reproduced here makes a distinction between severe dysplasia and CIS (discussed later), whereas in most other sites these two conditions are currently grouped because of the considerable difficulty in distinguishing them consistently and because of their seemingly similar natural history.

Most cases of CIS of the larynx are composed of keratinized cells (spinous or well-differentiated type), whereas a minority are formed of basal-like cells similar to those seen in CIS of the uterine cervix (basal type). There is no evidence that these two subcategories differ from the point of view of their clinical significance.

Papillary CIS is a variant of CIS characterized by papillary fronds with a fibrovascular stroma covered by squamous epithelium with cytologic features similar to those seen in the conventional variety.[665] Going back to the latter, it needs to be pointed out again that its boundaries with severe dysplasia are very blurred, to the point that the two diagnoses should be regarded as essentially equivalent for clinical purposes. It should also be kept in mind that a lesion of dysplasia/CIS may simply represent the peripheral portion of an invasive carcinoma. Indeed, about 75% of invasive squamous cell carcinomas of the larynx have an associated in situ component.[666]

An alternative grading system, referred to as the Ljubljana classification, divides the classes as follows[667,668]:

1. Squamous hyperplasia
2. Basal–parabasal hyperplasia
3. Atypical hyperplasia
4. CIS.

The first two categories are viewed as benign, the third as potentially malignant, and the fourth as actually malignant. The authors stress the lack of significance of the presence of a surface keratin

layer in the differential diagnosis between CIS and lesser lesions, an important difference with the WHO scheme. The Ljubljana types are not easily translatable into those in the WHO system, and no compelling evidence has been brought forward that this system will improve the admittedly unsatisfactory rate of interobserver agreement with the WHO system[669] or that it can provide more accurate prognostic information.

A third proposal is that of a binary system, by which lesions are divided as follows[662]:

1. Hyperplasia/keratosis, SIN I (low grade)
2. SIN II (high grade).

A correlation exists between the grade of dysplasia/CIS and the incidence of aneuploidy,[68] immunohistochemical reactivity for EGFR,[663] cell proliferation (as measured by Ki-67 immunostaining),[670] and expression of the P53 product.[670] Obviously, the most important question in this group of patients is the estimation of the risk for the development of invasive squamous cell carcinoma. On the whole, the risk is rather small, but this is probably because there is a great predominance of patients with low-grade lesions. In a classic study by McGavran et al.,[671] of 84 patients with laryngeal keratosis with varying degrees of dysplasia followed between 5 and 15 years, only three developed carcinoma and only one of these patients died as a result. In the series of Hellquist et al.,[672] 7% of the patients with mild dysplasia progressed to more severe dysplasia or carcinoma, 24% of those with moderate dysplasia progressed to CIS or invasive carcinoma, and 25% of those with severe dysplasias progressed to invasive carcinoma. Similar results were obtained by Gillis et al.[673] and Kambic et al.[674] In the series of Stenersen et al.,[664] 46% of untreated CIS developed invasive carcinoma within 4 years. The progression of the disease can be very slow; it is not unusual for patients to have documented CIS for 5 years or more without an invasive component developing in this period.[675] None of the special techniques that have been applied to these lesions up to now has proved superior to simple morphologic assessment, as subjective and unsatisfactory this assessment may be.

The treatment of these conditions needs to be individualized in the basis of the patient's age, reliability, extent of the lesion, and—last but not least—the presence and degree of microscopic changes of dysplasia/CIS. Cases of keratosis without dysplasia or mild dysplasia can be simply watched.[676] Cases with more significant changes can be treated with vocal cord stripping, endoscopic laser resection, extensive surgery, or radiation therapy.[677]

Invasive Carcinoma

General Features

Carcinoma of the larynx accounts for 2.2% of all cancers in men and 0.4% in women. Most patients are in their fifth decade of life or beyond, but cases occurring in much younger patients are on record.[678] A large majority of the patients are males; however, the incidence in females is increasing. Smoking is the main risk factor, this risk being enhanced by heavy alcohol consumption.[679,680] In some studies, up to 25% of laryngeal squamous cell carcinomas harbor HPV, most commonly HPV-16, and less commonly HPV-18.[681] The high-risk HPV seems to be biologically relevant in a subset of laryngeal carcinogenesis, manifesting with viral integration in the cancer cell genome and increased expression of P16 protein. The HPV-associated cancers tend to occur in younger patients who are nonsmokers.[682] In general, HPV now appears to have a minor role in overall laryngeal carcinogenesis.

Interestingly, a difference in the incidence of the location of the tumor within the larynx has been found depending on the site of residence of the patient.[2] Hoarseness is a common early symptom for glottic tumors but not for those located elsewhere.

Patients with laryngeal carcinoma are at an increased risk for the development of a second tumor in the upper aerodigestive tract or lung.[122]

The "T" classification for cancer of the larynx is based on a combination of clinical, endoscopic, and radiologic parameters.

Types, Spread, and Therapy

Spread of laryngeal carcinoma can be accurately predicted from the site of origin and knowledge of the anatomic barriers produced by the different laryngeal compartments.[2] Accordingly, these tumors have been traditionally divided, depending on their location, into four major types (Figs. 4.106–4.109). This classification has been largely based on laryngoscopic evaluation, but the use of CT scan and MRI has resulted in greater accuracy. MRI is more sensitive but less specific than CT in detecting cartilage invasion by tumor; it

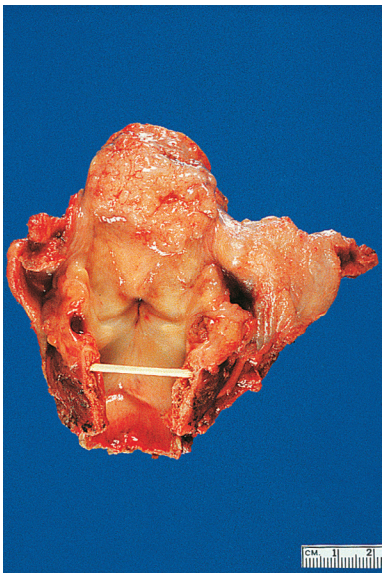

Figure 4.106 Supraglottic carcinoma of the larynx replacing most of the epiglottis.

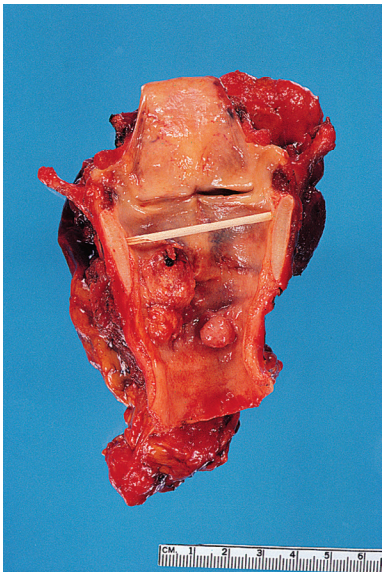

Figure 4.107 Subglottic carcinoma appearing as multiple polypoid masses.

tends to overestimate it, whereas CT tends to underestimate it.[683] The four types are as follows:

1. **Glottic** (60%–65% of all cases). These tumors arise from the true vocal cords, the anterior third of the glottis being the most common location. They tend to remain localized for long periods because of the surrounding cartilaginous wall and the paucity of lymphatic vessels in Reinke's space. In time they may spread across the anterior commissure to the opposite cord, posteriorly to involve the arytenoids, superiorly to involve the supraglottic portion, inferiorly to extend into the subglottic area, and anteriorly to penetrate the thyroid cartilage with subsequent growth into the soft tissues of the anterior neck. In one series, ipsilateral lymph node metastases were not found in any of 41 T1 lesions and in only 7.3% of T2 tumors[684]; therefore prophylactic lymph node dissection is not indicated.

   Early cases can be treated by irradiation therapy with excellent results.[685] If irradiation fails, surgery still saves most of the patients.[686] Small, superficially invasive squamous cell carcinomas of the true cord can also be cured by endoscopic removal (cordectomy) alone with results essentially identical to those obtained in CIS.[687] T2 glottic cancers can be treated by hemilaryngectomy.[688]

2. **Supraglottic** (30%–35% of all cases). These tumors involve the false cord, the ventricle (including those arising in a laryngocele), aryepiglottic fold, and/or the laryngeal or lingual surface of the epiglottis.[689] One-third of the supraglottic cancers arise from the latter structure. These tumors have a marked tendency to spread toward the pre-epiglottic space, but the oropharynx is protected by the thick hyoepiglottic ligament.[690] Only 1% of supraglottic carcinomas invade inferiorly to involve the glottis. Invasion of cartilage is also rare and is largely restricted to cases in which the cartilage had undergone osseous metaplasia.[691]

   The incidence of lymph node metastases averages 40%. About 20%–35% of patients with clinically negative nodes harbor occult metastases on microscopic examination.[2] Supraglottic tumors can be treated by irradiation or laryngectomy.[685]

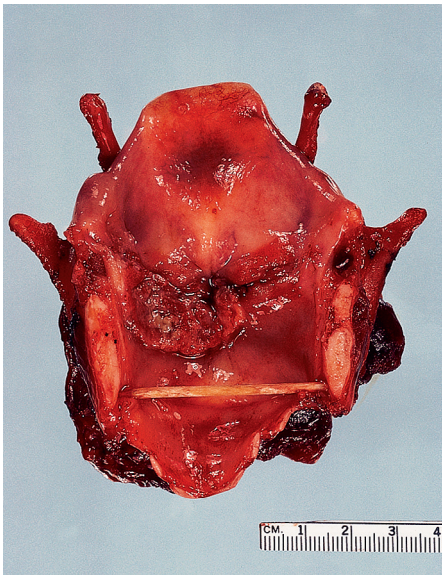

Figure 4.108 Gross appearance of transglottic carcinoma.

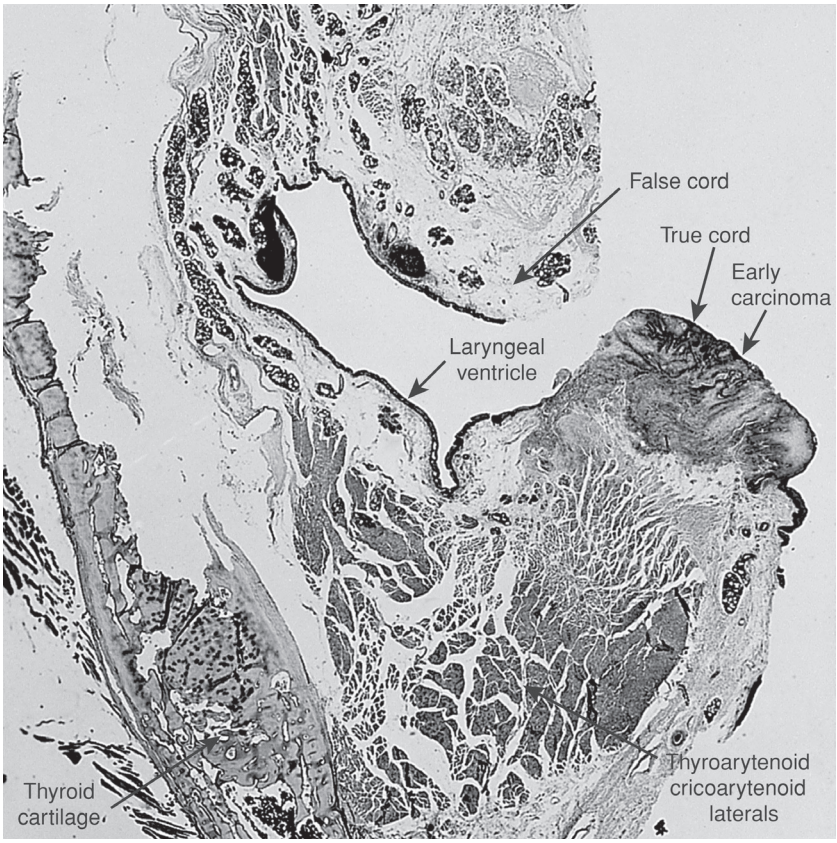

Figure 4.109 Superficial carcinoma of true vocal cord (glottic carcinoma), as seen in a sagittal section. This lesion is equally curable by resection or radiation therapy.

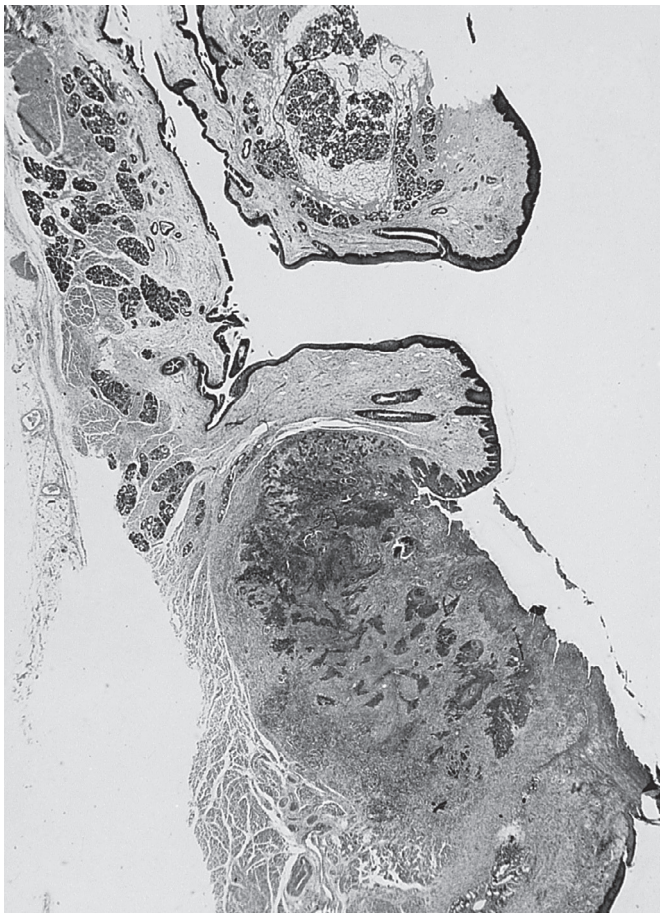

Figure 4.110 True Subglottic Squamous Cell Carcinoma in a 42-Year-Old Man. Hemilaryngectomy was performed. All margins were free. This was the third infraglottic carcinoma out of 600 consecutive laryngectomies.

3. **Transglottic** (less than 5% of all cases). This term is applied to cancers that cross the laryngeal ventricle.[684] They have the highest incidence of lymph node involvement (52%). Of 16 transglottic cancers examined by McGavran et al.,[692] five (31%) had clinically undetected node metastases. This figure indicates that elective lymph node dissection should be performed for tumors in this location, in addition to a total laryngectomy.[693]
4. **Subglottic** (infraglottic) (less than 5% of all cases). Under this category are included cancers involving the true cord with a subglottic extension of more than 1 cm (Fig. 4.110) as well as tumors entirely confined to the subglottic area. The latter are very unusual.[694] Lateral spread to the cricoid cartilage is the rule. Also common is destruction by tumor of the weak interthyrocricoid membrane, with invasion of the prelaryngeal wall and thyroid gland.[695] Because of the frequent extension to the trachea, this structure should be resected as distally as possible. Metastases to cervical nodes occur in 15%–20% of the cases, and metastases to paratracheal nodes occur in about 50%.[76] Therefore radical node dissection with clearance of paratracheal nodes is indicated.

   Tumors situated on the pyriform sinus or postcricoid areas are considered of hypopharyngeal origin.

   The most common sites of metastases from laryngeal carcinoma, regardless of site of the primary tumor, are the regional lymph nodes, followed by the lungs. Thyroid gland and jugular vein involvement are usually the result of direct extension; the latter is seen only in the presence of extensive nodal involvement and indicates a high probability of systemic dissemination.[696]

Pathologic Features

Grossly, laryngeal carcinomas are generally described as a protruding pink to gray mass that is often ulcerated. Vocal cord lesions tend to have a keratotic appearance.

Microscopically, over 90% of laryngeal carcinomas are of the squamous cell type. They are graded into well, moderately, and poorly differentiated on the basis of the degree of differentiation, cellular pleomorphism, and mitotic activity. Most glottic carcinomas are well to moderately differentiated, whereas a high percentage of those located in other regions of the larynx (particularly in the subglottis) are moderately to poorly differentiated. In general, the smaller the tumor, the better differentiated its appearance. Those neoplasms in which the stromal invasion is limited to the most superficial layers just below the basement membrane (according to some authors, within 0.5 mm from the basement membrane level) are designated as *superficially invasive*, *minimally invasive*, *microinvasive*, or *"early."* The last term should be avoided, not only because it may be inaccurate chronologically speaking, but also because it is used by clinicians with a somewhat different meaning; specifically, to indicate that the mobility of the cord is not impaired. Tumors involving the anterior commissure are treacherous in the sense that significant invasion may be clinically inapparent.

Occasionally, the tumor extends over a large surface of the larynx while retaining its superficial character.[697]

Papillary squamous cell carcinoma is a variant of squamous cell carcinoma with an exophytic pattern of growth and the features of CIS associated with foci of invasion. These foci can be inconspicuous and require thorough sampling for their identification. This tumor is distinguished from verrucous carcinoma on the basis of the cytologic atypia it exhibits. It shows a greater degree of association with HPV than ordinary squamous cell carcinoma, and it has a relatively good outlook (in contrast to its counterpart in the sinonasal region).[698]

The diagnosis of postirradiation persistence of squamous cell carcinoma is often difficult to make. If dysplastic or atypical cells are present but limited to the mucosa it is better to err on the conservative side because of the great difficulty in distinguishing tumor recurrence from postirradiation atypia.[68]

Molecular Genetic Features

The genetic changes of laryngeal squamous cell carcinomas are generally similar to those of squamous cell carcinomas of other head and neck sites. Multiple genetic alterations are necessary to drive the progression from a normal cell to invasive cancer.[699] Allelic losses of 3p (harboring *FHIT*), 9p21 (harboring *CDKN2A*), and 17p13 (harboring *TP53*) are considered to be early events in carcinogenesis, since they are found in 60%–80% of cases of preneoplastic lesions and invasive carcinomas.[699,700] Other common genetic changes include gains or amplifications of 3p, 5p, 8q, 11q13 (harboring *CCND1*, among others), and 18p, and losses of 5q, 8p, 11q23–24, 13q, and 18q. A proportion of cases strongly express transforming growth factor alpha (TGF-α, a ligand for EGFR), with activation of the EGFR pathway and associated with a very poor prognosis.[701]

The HPV-associated subgroup appears to be genetically different. There is strong immunohistochemical expression of p16, *TP53* gene mutation is generally absent, and allelic losses at 3p, 9p, and 17p are uncommon.[699]

Other Microscopic Types

Verrucous carcinoma (Ackerman tumor) is a rare variant of squamous cell carcinoma with a distinctly polypoid pattern of growth and an

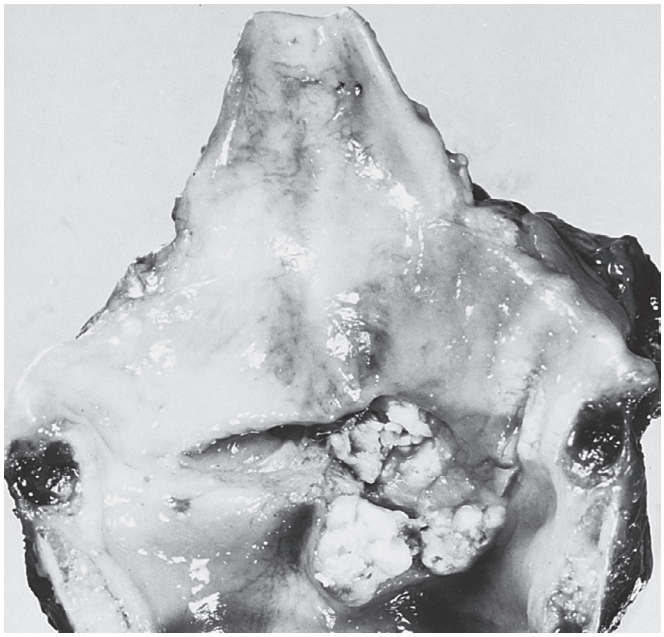

Figure 4.111 Verrucous carcinoma of larynx with obliteration of right vocal cord and extension into subglottis. (From Kraus FT, Perez-Mesa C. Verrucous carcinoma. Clinical and pathologic study of 105 cases involving oral cavity, larynx, and genitalia. *Cancer*. 1966;19:26–28.)

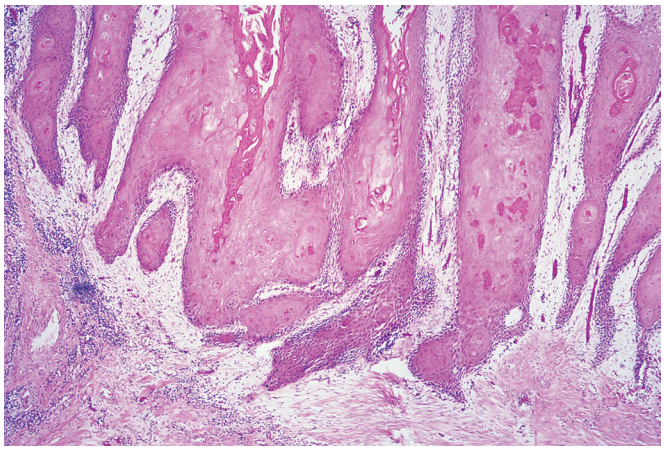

Figure 4.112 Verrucous Carcinoma. Well-differentiated tongues of squamous epithelium impinge on the underlying stroma.

extremely well-differentiated microscopic appearance (Figs. 4.111 and 4.112).[702] Like its counterpart in the oral cavity and other locations, it may show extensive local invasion but practically never metastasizes.[169] HPV sequences have been demonstrated both in the tumor and in adjacent normal tissues in some studies but not in others.[703] Verrucous carcinoma should be distinguished from the verrucous form of keratosis (verrucous hyperplasia). The differential diagnosis is based on the presence or absence of invasion and can therefore be impossible to make on a small biopsy.[649] Sometimes verrucous carcinoma coexists with conventional squamous cell carcinoma *(hybrid carcinoma)*.[704] The primary treatment of verrucous carcinoma is surgical. Radiation therapy may be followed by anaplastic transformation of the tumor.[705] Hybrid carcinomas should be treated as conventional squamous cell carcinomas.

Small cell (neuroendocrine) carcinoma is an unusual type of laryngeal carcinoma (less than 0.5% of all cases) that most often

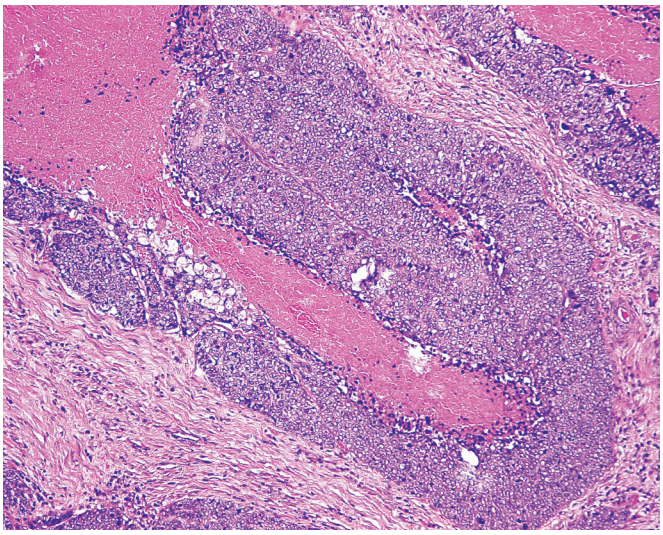

Figure 4.113 Basaloid Squamous Cell Carcinoma of Larynx. The basophilic staining quality and the high-grade nature of the tumor are evident with central comedonecrosis.

presents in the sixth and seventh decades in men who are heavy smokers.[706] Although all laryngeal sites can be involved, most (>90%) arise in the supraglottic larynx. Its microscopic appearance is identical to that of its pulmonary counterpart. Like the latter, it usually contains a few dense-core secretory granules on ultrastructural examination and exhibits a variable (sometimes very scanty) degree of immunoreactivity for neural/neuroendocrine markers.[707] As in other sites, it may be pure or associated with other patterns.[708] Cervical, nodal, and distal metastases are very common, and the prognosis is poor.[708] It should be distinguished from atypical carcinoid/large cell neuroendocrine carcinoma.

Basaloid squamous cell carcinoma is a highly malignant laryngeal tumor characterized by areas of typical in situ and/or invasive squamous cell carcinoma associated with nests of small crowded cells (Fig. 4.113). These cells have hyperchromatic nuclei, scant cytoplasm, small cystic spaces, necrosis, prominent hyalinization, and peripheral palisading.[175] The overall appearance suggests an attempt of differentiation toward adnexal (glandular) structures. This tumor, which also occurs in the tongue, pharynx, and esophagus, should not be confused with true adenoid cystic carcinoma, which has a different clinical course.[178] Most of the patients with basaloid squamous cell carcinoma are heavy smokers who present with advanced disease and sometimes with other primary tumors in the area.[709] The supraglottic larynx is preferentially involved. The behavior is extremely aggressive.[174]

Lymphoepithelioma-like carcinoma (lymphoepithelial carcinoma) of the larynx is often accompanied by (and sometimes presents initially with) cervical lymph node metastases. Alterations of *TP53* are common, but no relationship with EBV has been found. The clinical course is aggressive.[710]

Adenosquamous carcinoma consists of conventional squamous cell carcinoma and adenocarcinoma. The squamous component is typically invasive but can be *in situ*. The adenocarcinoma component is typically at the base of the tumor. Adenosquamous carcinoma has the same demographics as conventional squamous cell carcinoma but appears be more aggressive.

Sarcomatoid carcinoma (spindle-cell carcinoma; carcinoma with sarcoma-like stroma; carcinosarcoma; pseudosarcoma) is a peculiar neoplasm with a high predilection for the upper aerodigestive tract.[711] Tumors of this type located in the larynx, as elsewhere, often have

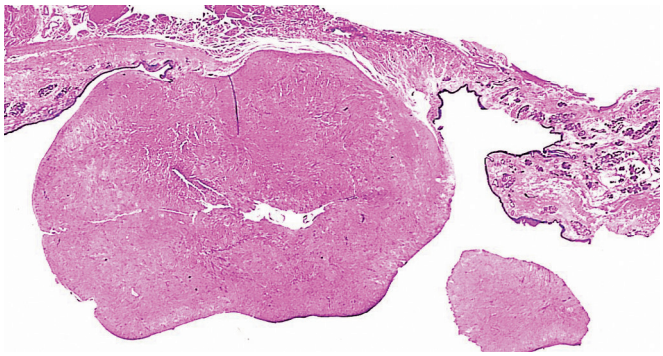

Figure 4.114 Whole mount of laryngeal sarcomatoid squamous cell carcinoma, showing typical polypoid shape.

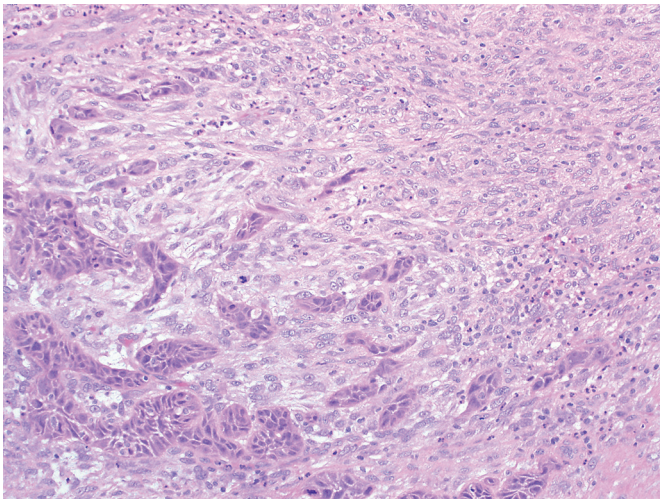

Figure 4.115 Sarcomatoid carcinoma of larynx with conventional squamous cell carcinoma at the bottom left.

a polypoid configuration[712] (Fig. 4.114) and may simulate a laryngeal polyp. Most are located in the supraglottic region. Microscopically, they have an element of squamous cell carcinoma (often inconspicuous and frequently in situ) and a pleomorphic sarcoma-like or fibrosarcoma-like component, which makes up the bulk of the lesion. The sarcomatoid component may be so bland as to simulate granulation tissue or have a bizarre appearance reminiscent of so-called malignant fibrous histiocytoma, malignant giant cell tumor of soft parts, or osteosarcoma (Fig. 4.115).

Lymph node metastases may be composed of the carcinomatous component alone, both patterns as in the primary tumor, or—in rare cases—the sarcoma-like elements exclusively. Whether the sarcoma-like stroma is of mesenchymal derivation or a carcinoma in disguise has been a matter of controversy since the entity was first defined in the classic paper by Lane.[713] Current evidence strongly favors the latter interpretation. Immunohistochemical markers of epithelial differentiation such as keratin and p63 are detected in at least some of the spindle cells in most cases, even in those with a relatively monomorphic appearance.[714] However, a significant number of cases are completely negative for epithelial markers. Thus a high index of suspicion is required for sarcomatoid malignancies involving the mucosal surface. The presence of a conventional squamous cell carcinoma component or overlying CIS/dysplasia should suggest the possibility of sarcomatoid carcinoma. The fact that the two tumor components harbor the same *TP53* mutation and share a variety of chromosome markers is further proof of their common pathway of tumorigenesis.[181,715]

Surgical excision is the treatment of choice.[712] The prognosis is better for the polypoid tumors than for deeply invasive neoplasms with similar microscopic features.[184] Stage by stage, it does not seem to be significantly different from that of conventional squamous cell carcinoma.[714]

Prognosis

The factors found to be of prognostic significance in laryngeal squamous cell carcinoma are the following:

1. *Clinical stage* and *site*. These two factors are interrelated and are therefore usually evaluated together.[716] The approximate 5-year survival rates for the different types are the following, allowing for the usual differences from series to series:

   Glottic: 80%
   I: 90%; II: 85%; III: 60%; IV: less than 5%
   Supraglottic: 65% (with those located in the aryepiglottic folds having the worst prognosis)[717]
   I: 85%; II: 75%; III: 45%; IV: less than 5%
   Transglottic: 50%
   Subglottic: 40%

   Among the T1 glottic tumors, the microinvasive type needs to be segregated from the others because its natural history is basically equivalent to that of CIS (in a manner analogous to that operating between microinvasive and in situ squamous cell carcinoma of the uterine cervix).
2. *Microscopic grade*. While this parameter is related to the clinical stage of the tumor, it has been shown that it is an independent prognostic determinator.[718]
3. *Field size*. Among T1 glottic carcinomas treated with radiation therapy, a large tumor field size is associated with an increased risk of local recurrence.[719]
4. *Lymph nodes*. In patients with metastatic lymph nodes, the prognosis is affected by the number of involved nodes, their size, and the presence or absence of extranodal extension.[720]
5. *Host reaction*. It has been claimed that a high density of S-100 protein–positive Langerhans cells in the tumor stroma is a favorable prognostic sign.[721]
6. *Keratin expression*. No prognostic significance seems to be attached to the type of keratin expression by the tumor, as evaluated immunohistochemically.[722]
7. *p53 overexpression*. It has been proposed that this parameter is an independent prognostic factor,[723] the claim has not been substantiated by others.[724]
8. *Survivin expression*. A high level of expression of this marker is said to be associated with p53 accumulation and poor survival.[725]

Salivary Gland–Type Tumors

The most common form of salivary gland–type tumor of the larynx is **adenoid cystic carcinoma**.[726] Almost all of these tumors are located in areas other than the true vocal cords, in keeping with the distribution of normal salivary glands in the region. They grow slowly but eventually prove fatal in most instances.[727] This tumor should be distinguished from the more rapidly growing basaloid squamous cell carcinoma.

Other neoplasms in this category include mucoepidermoid carcinoma,[728] acinic cell carcinoma,[729] benign mixed tumor (pleomorphic adenoma),[730] and myoepithelial neoplasms.[731,732]

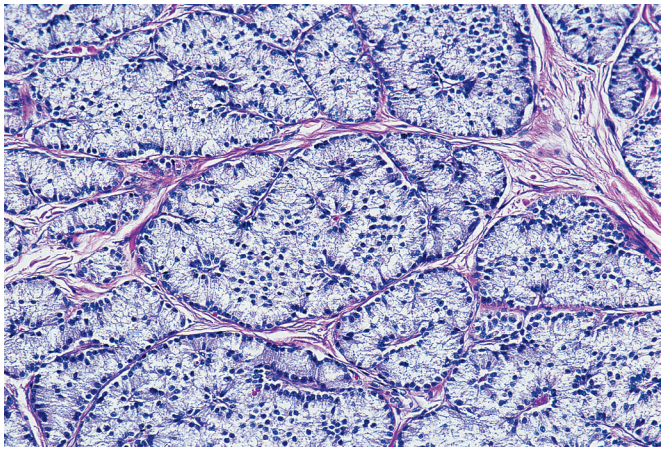

Figure 4.116 Carcinoid tumor of the larynx showing marked cytoplasmic clear change.

Neuroendocrine Tumors

In addition to the already mentioned small cell neuroendocrine carcinoma, the larynx can be the site of several other types of neuroendocrine tumor.[733,734]

Carcinoid tumor of the *typical* variety, which is very rare in this location, looks in all respects like its more common bronchial counterpart at the morphologic, immunohistochemical, and ultrastructural levels.[735] Some are predominantly composed of oncocytic cells *(oncocytic carcinoid tumors)*,[736] others have an appearance indistinguishable from that of medullary thyroid carcinoma[737] (but are negative for TTF-1),[738] and still others are composed of clear cells (Fig. 4.116). Most of these tumors are located in the supraglottic region, particularly in the arytenoid and aryepiglottic folds.[739] The prognosis for true laryngeal carcinoid tumors is generally good.

The larynx is much more commonly the site of *atypical carcinoid tumor* (moderately differentiated neuroendocrine carcinoma) and *large cell neuroendocrine carcinoma*.[734,740] Both of these tumor types are characterized by pleomorphism, mitotic activity, and necrosis (Fig. 4.117). The distinction between them, not always attempted in the articles that have been written on the subject, is made using the same guidelines as those used for the homonymous pulmonary tumors. Argyrophilia, immunoreactivity for chromogranin and synaptophysin, and presence of dense-core neurosecretory granules on ultrastructural examination are the rule.[741,742] They are also positive for cytokeratin and up to 80% express calcitonin but, in contrast to medullary thyroid carcinoma, they are typically negative for TTF-1. Most patients are elderly males with a history of heavy smoking. Nearly all tumors are located in the supraglottic region, particularly on the arytenoid cartilage.[743] They run an aggressive clinical course, with frequent metastases to lymph nodes and distant sites. Mortality is approximately 50%.

Paraganglioma of the larynx is usually located in the supraglottic region, from where it often extends to the ipsilateral aryepiglottic fold.[744] However, it can also present as a subglottic tumor.[745] Metastases have been documented in about a fifth of the reported cases, but these studies might include lesions that could be classified as atypical carcinoid tumors. Most tumors are nonfunctioning.[746] Calcitonin and vasoactive intestinal peptide (VIP) have been detected in some of the cases, in addition to the usual panendocrine markers.[747] In contrast to carcinoid tumors and other types of neuroendocrine carcinoma, they are keratin negative. Sustentacular cells, which are immunoreactive for S-100 protein and GFAP, are present at the periphery of the nests and constitute an important diagnostic sign.[748]

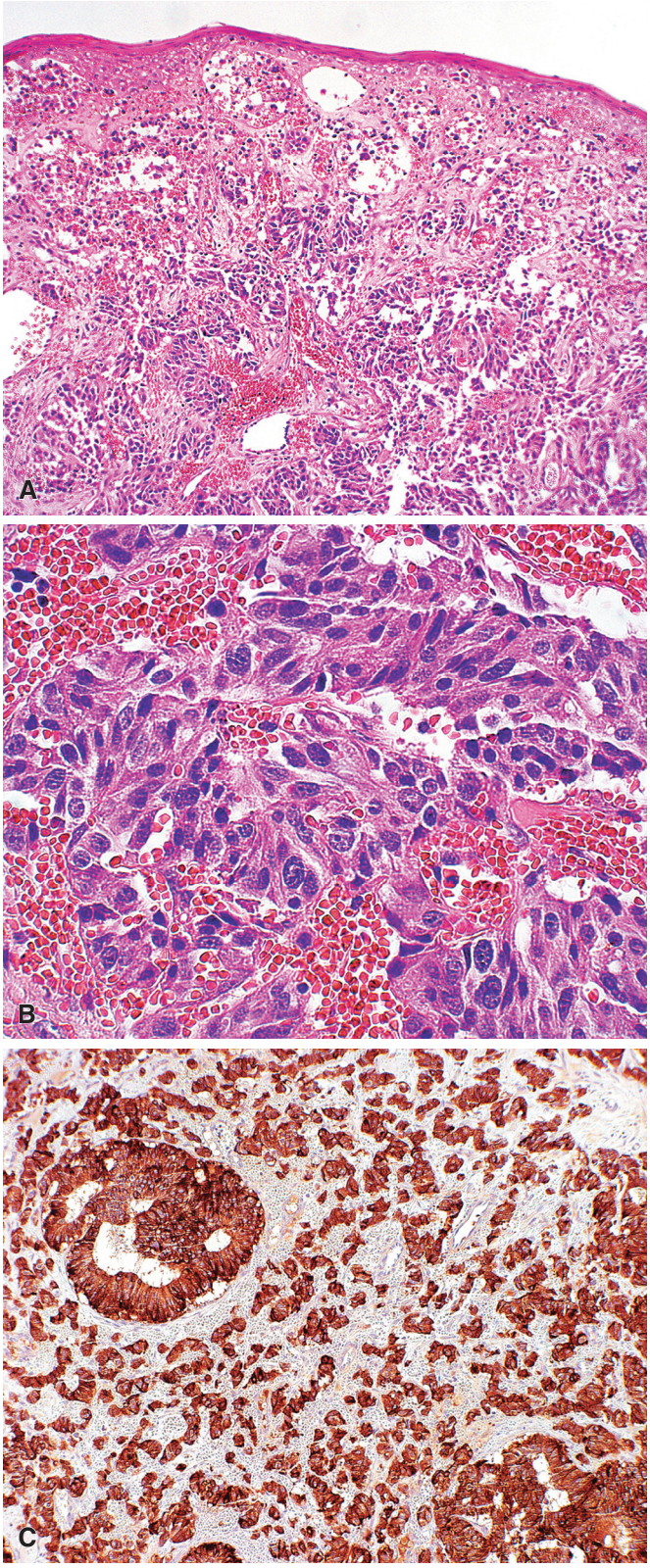

Figure 4.117 Atypical Carcinoid Tumor (Moderately Differentiated Neuroendocrine Carcinoma) of Larynx. A, Low-power view; **B,** high-power view; and **C,** chromogranin stain.

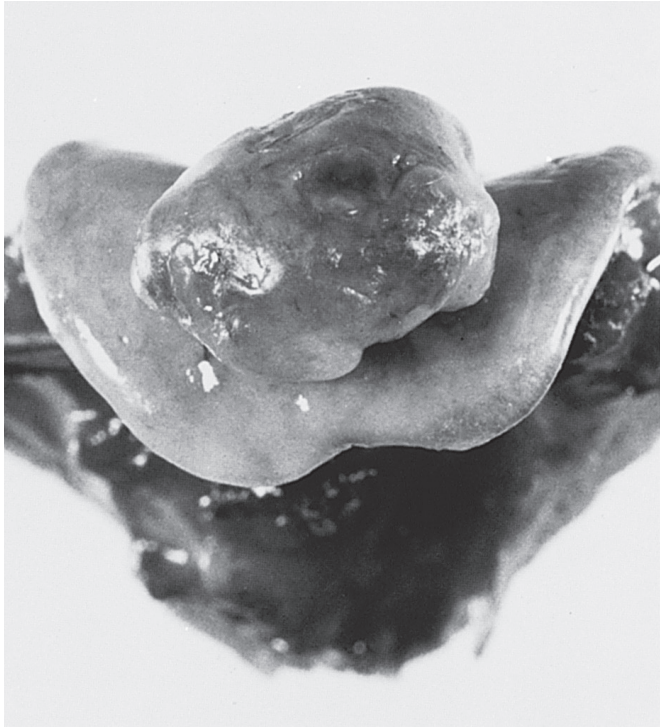

Figure 4.118 Well-Differentiated Angiosarcoma of Epiglottis. The tumor has a distinctly polypoid appearance and is partially ulcerated. (Courtesy of Dr. J. Costa, Lausanne, Switzerland.)

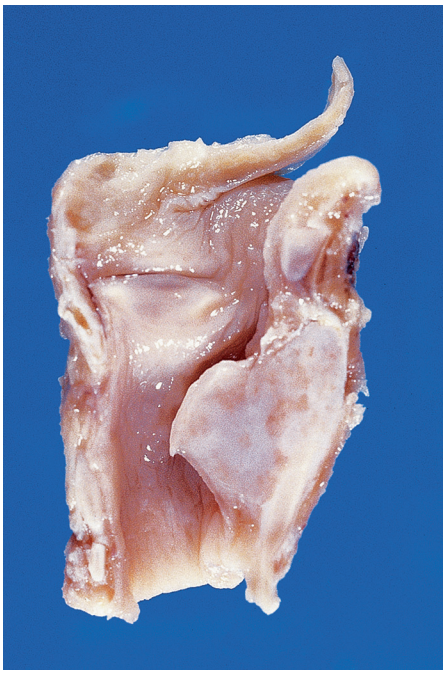

Figure 4.119 Gross appearance of well-differentiated chondrosarcoma of larynx arising in the posterior cricoid cartilage.

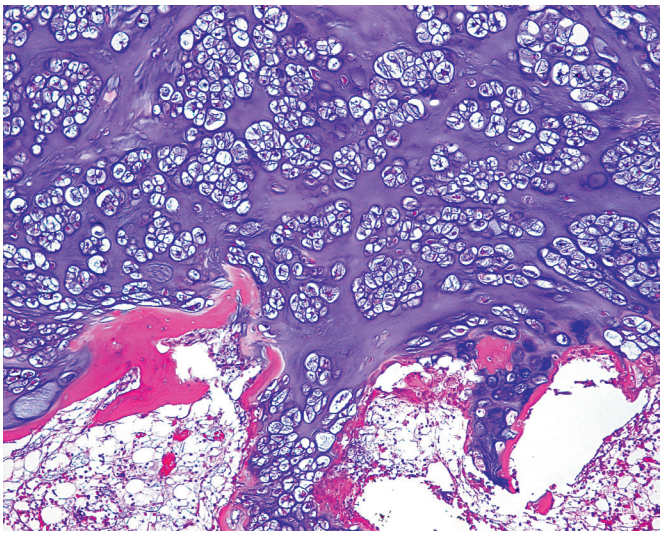

Figure 4.120 Low-Power Microscopic View of Chondrosarcoma of Larynx. Most of these tumors are very well differentiated.

Other Tumors and Tumorlike Conditions

Hemangioma of the larynx characteristically presents in infants as a sessile, poorly circumscribed mass in the subglottic area, immediately beneath the true vocal cord. Symptoms of upper respiratory tract obstruction may be severe. One-half of the patients have associated hemangiomas in the skin, an important diagnostic sign. Biopsy can precipitate massive bleeding. Treatment modalities include endoscopic excision with CO_2 laser, systemic steroids, interferon, and intralesional corticosteroid injection with short-term intubation.[749] Hemangiomas of the larynx are exceptionally also seen in adults.[750]

Angiosarcoma can present as a polypoid mass in the epiglottis (Fig. 4.118) or elsewhere in the larynx. Some of the reported cases have been associated with previous radiation to the area.[751]

Granular cell tumor may involve the true cord or other sites in the larynx.[752] Some of the reported cases have been in children. Most are located posteriorly. They are small and yellow and are covered by epithelium. The clinical diagnosis is usually that of laryngeal papilloma or nodule. Their microscopic appearance is typical, but they can be mistaken microscopically for invasive squamous cell carcinoma because of the pseudoepitheliomatous hyperplasia that often accompanies this lesion.

Myofibromatosis of the larynx in the neonate may result in severe laryngeal obstruction.[753]

Inflammatory myofibroblastic tumor (inflammatory pseudotumor) can involve the larynx and be confused with a clinically more aggressive process, particularly spindle cell (sarcomatoid) carcinoma.[754]

Rhabdomyoma has a predilection for the head and neck area, including the larynx. Cross striations are often found in the tumor cells, in addition to characteristic "spinder" cells and peculiar crystal-like intracytoplasmic particles. The adult type is more common than the fetal variety.[56]

Rhabdomyosarcoma also occurs; it is mostly restricted to infancy and childhood and is almost always of the embryonal variety, including the botryoid subtype.[756] The larynx is a common location for pleomorphic rhabdomyosarcoma. This is an aggressive variant of rhabdomyosarcoma that is restricted to adults.

Leiomyomas and **leiomyosarcomas** are extremely unusual; some of the former have been of epithelioid or atypical (bizarre) types.[757,758]

Cartilaginous tumors are the most common mesenchymal neoplasms of the larynx.[759,760] They usually arise from the cricoid cartilage and appear posteriorly in the subglottic region (Figs. 4.119 and 4.120). Chondrosarcomas far outnumbers cases of laryngeal chondroma. Goethals et al.[761] classified four of their 22 cases as *chondromas* and all of the others as *chondrosarcomas* by applying

the microscopic criteria used for the homonymous skeletal tumors; none of the tumors metastasized, and only six recurred locally. Although subsequently there have been reported cases with pulmonary metastases, these findings indicate that surgery should be as conservative as possible for cartilaginous neoplasms occurring in this location, nearly all of which are well differentiated.[762] Rarely, chondrosarcomas may be of the clear cell variety or exhibit dedifferentiated foci.[763,764] Although they are rare, well-documented cases of chondroma do arise in the larynx. In contrast to chondrosarcomas, these are small (<1–2 cm) tumors without any chondrocyte atypia. Laryngeal cartilaginous tumors should be distinguished from the non-neoplastic condition known as *chondrometaplasic nodules.*[762]

Osteosarcomas also occur; they should be distinguished from chondrosarcomas with osseous metaplasia and from sarcomatoid carcinomas (carcinosarcomas).[765]

Lipoma of the spindle cell variety was reported in the larynx by Nonaka et al.,[766] and **hibernoma** has been seen in the pre-epiglottic area.[767]

Well-differentiated liposarcoma (atypical lipomatous tumor) can present as a pedunculated laryngeal mass, almost always located in the supraglottic portion of the hypopharynx.[768] As in other sites it can undergo dedifferentiation.[769]

Undifferentiated pleomorphic sarcomas (malignant fibrous histiocytoma) of the larynx also have been described,[770] but one wonders how many of them actually represent sarcomatoid carcinomas in which the epithelial component (which may be very inconspicuous) has either been overlooked or else has been destroyed by tumor ulceration.

Isolated cases of **giant cell tumor**,[771,772] **aneurysmal bone cyst**,[773] osteoblastoma,[774] **polypoid xanthoma**,[775] **solitary fibrous tumor**,[776] and **synovial sarcoma**[777] have been reported.

Malignant melanoma can be primary in the larynx,[778] but the possibility of metastasis should always be ruled out before entertaining such a diagnosis.

Lymphoid tumors and tumorlike conditions can also involve the larynx, although the event is rare.[779] Reported cases include non-Hodgkin lymphoma (including the "lethal midline granuloma" type of probable NK/T-cell nature), and plasmacytoma. Although the latter lesion may be initially localized, dissemination is likely to occur.[780] Plasmacytoma should be distinguished from chronic inflammation and so-called *mucous membrane plasmacytosis*, a reactive condition of unknown cause. *Acute leukemia* can present initially with laryngeal obstruction.[781]

Metastatic tumors to the larynx can arise from various sites; skin (melanoma), kidney, breast, and lung are the most common.[782]

Trachea

Non-Neoplastic Lesions

Chondromalacia is characterized by necrosis and softening of the tracheal cartilage. It may result in fibrous strictures and tracheal deformation owing to the collapse of the necrotic plates of cartilage. It may be due to the ischemic damage and mechanical effects induced by prolonged intubation, prior infection, tumors, trauma, vasculitis, and relapsing perichondritis. Cases in which no inciting factor can be identified are referred to as *idiopathic tracheal stenosis*.[783]

Tracheopathia osteochondroplastica presents as multiple submucosal nodules composed of mature bone and cartilage.[784] Its etiology is unknown.

Amyloidosis of the tracheobronchial tree is characterized by the formation of solitary or multiple nodules and is usually asymptomatic.

Figure 4.121 Extensive Papillomatosis of Trachea and Bronchi.

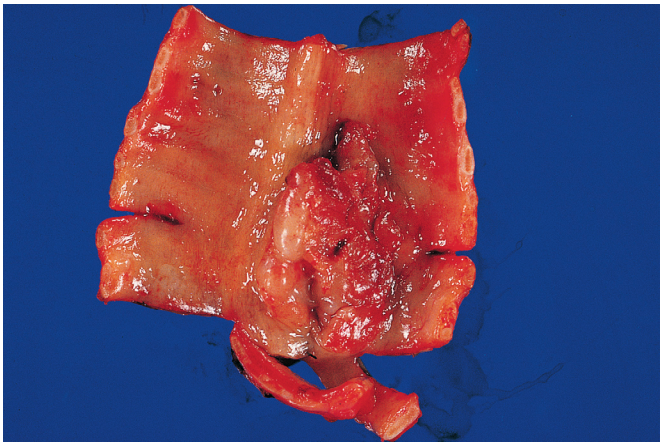

Figure 4.122 Squamous Cell Carcinoma of Trachea Growing as a Polypoid Mass. The tumor was treated by segmental resection.

Necrotizing sialometaplasia similar to that more commonly seen in the palate has been described in the trachea after prolonged translaryngeal intubation.[785]

Rheumatoid nodules are occasionally seen in the trachea of patients with rheumatoid arthritis.[786]

Tumors

Papilloma and **papillomatosis** of the trachea are morphologically similar to the homonymous lesions seen in the larynx (Fig. 4.121). Cases seen in conjunction with laryngeal lesions usually begin in infancy and have a very low incidence of malignant transformation. Those limited to the trachea and bronchi usually begin in adulthood and have a greater tendency for malignant change.

Squamous cell carcinoma is the most common primary malignant tumor of the trachea (Fig. 4.122).[787] The majority arise in adult (mean age of 65) men and preferentially involve the lower third of the trachea. The clinical course is rapid, and the prognosis is poor. The primary treatment is surgical, usually consisting of circumferential resection of the involved segment with end-to-end anastomosis.[788] Radiation therapy is used for advanced cases. Tumor extension into the thyroid gland and lymph vessel invasion are two important unfavorable prognostic factors.[789]

Adenoid cystic carcinoma is the second most common type of primary tracheal malignancy. Its appearance is similar to that of the

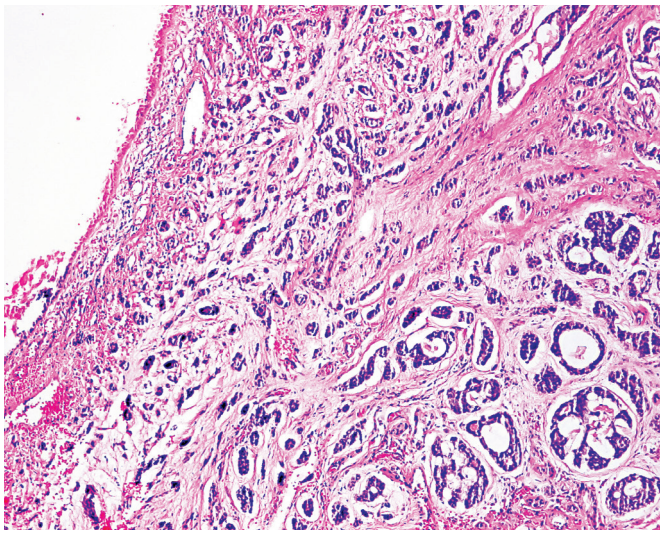

Figure 4.123 Adenoid cystic carcinoma of trachea growing beneath normal epithelium and showing typical cribriform pattern of growth.

homonymous tumor in the major salivary glands (Fig. 4.123). Most cases are located in the upper third of the trachea with equal sex incidence and occur in younger individuals (mean age 45–50) compared with squamous cell carcinoma.[790] The clinical course is very slow, but the long-term prognosis is poor.

Small cell (neuroendocrine) carcinoma has an appearance and a behavior similar to that of the bronchial tumor of the same type, an extension from which should always be considered in the differential diagnosis.

Adenocarcinoma (mucin-producing) and **lymphoepithelioma-like carcinoma** have been observed in the lower third of the organ.[790]

Carcinoid tumor may arise in the trachea and be cured by segmental resection with primary reconstruction.[791]

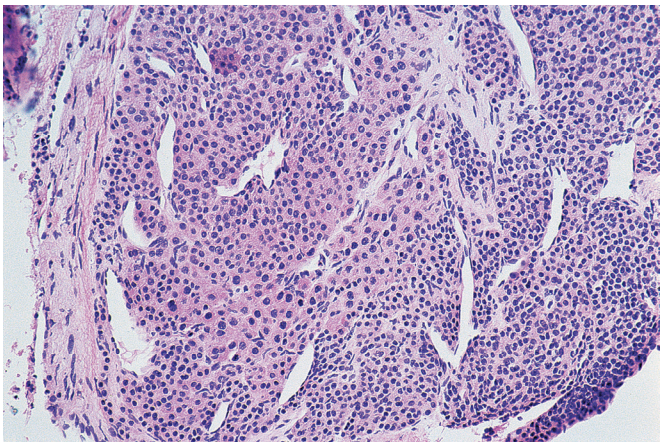

Figure 4.124 Glomus Tumor of Trachea. The microscopic appearance is identical to that of the homonymous tumor of the skin.

Benign mixed tumors (pleomorphic adenomas) and other salivary gland-type tumors occur, but not nearly as often as adenoid cystic carcinoma.[792]

Other primary tumors of the trachea, all exceptionally rare, include glomus tumor (Fig. 4.124)[793] (including its oncocytic variety),[794] solitary fibrous tumor (hemangiopericytoma),[795] juvenile hemangioma,[796] granular cell tumor,[797] "fibromyxoma," schwannoma,[798] paraganglioma,[799] benign clear cell tumor ("sugar tumor"),[800] fibrosarcoma,[788] benign and malignant fibrous histiocytoma,[801] plasmacytoma, and malignant lymphoma.[802] Hodgkin lymphoma can present initially as a tracheal mass as a result of invasion from adjacent nodes.

Secondary tumors are much more common than primary neoplasms. Most of them arise in the bronchi, esophagus, or larynx and involve the trachea by direct extension. Metastasis to the trachea is uncommon with most being from breast, skin, kidney, and colorectal primaries.

References

1. Balogh K, Pantanowitz L. Mouth, nose and paranasal sinuses. In: Mills SE, ed. *Histology for Pathologists*. 3rd ed. Philadelphia, PA: Lippincott Williams & Wilkins; 2007:403-430.
2. Barnes L, Johnson JT. Pathologic and clinical considerations in the evaluation of major head and neck specimens resected for cancer. Part I. *Pathol Annu*. 1986;21(Pt 1):173-250.
3. Righi A, Betts CM, Marchetti C, et al. Merkel cells in the oral mucosa. *Int J Surg Pathol*. 2006;14(3):206-211.
4. Neville B, Damm D, Allen CM, Bouquot J, eds. *Oral and Maxillofacial Pathology*. Philadelphia, PA: WB Saunders; 1995.
5. Regezi JA, Sciubba JJ, Jordan RCK. *Oral Pathology: Clinical Pathologic Correlations*. 5th ed. St Louis, MO: Saunders; 2008.
6. Soames JV, Southam JC. *Oral Pathology*. 3rd ed. Oxford: Oxford University Press; 1998.
7. Gibson WS Jr, Fenton NA. Congenital sublingual dermoid cyst. *Arch Otolaryngol*. 1982;108(11):745-748.
8. Meyer I. Dermoid cysts (dermoids) of the floor of the mouth. *Oral Surg Oral Med Oral Pathol*. 1955;8(11):1149-1164.
9. Gorlin RJ, Jirasek JE. Oral cysts containing gastric or intestinal mucosa. An unusual embryological accident or heterotopia. *Arch Otolaryngol*. 1970;91(6):594-597.
10. al-Nafussi A, Hancock K, Sommerlad B, Carder PJ. Heterotopic brain presenting as a cystic mass of the palate. *Histopathology*. 1990;17(1):81-84.
11. Sun LS, Sun ZP, Ma XC, Li TJ. Glial choristoma in the oral and maxillofacial region: a clinicopathologic study of 6 cases. *Arch Pathol Lab Med*. 2008;132(6):984-988.
12. Bossen EH, Hudson WR. Oligodendroglioma arising in heterotopic brain tissue of the soft palate and nasopharynx. *Am J Surg Pathol*. 1987;11(7):571-574.
13. Simpson HE. White sponge nevus: report of three cases. *J Oral Surg*. 1966;24(5): 463-466.
14. Daley T. Pathology of intraoral sebaceous glands. *J Oral Pathol Med*. 1993;22(6): 241-245.
15. Dunlap CL, Barker BF. Diagnostic problems in oral pathology. *Semin Diagn Pathol*. 1985;2(1):16-30.
16. Lutman GB. Epithelial nests in intraoral sensory nerve endings simulating perineural invasion in patients with oral carcinoma. *Am J Clin Pathol*. 1974;61(2):275-284.
17. Tschen JA, Fechner RE. The juxtaoral organ of Chievitz. *Am J Surg Pathol*. 1979;3(2):147-150.
18. Leibl W, Pfluger H, Kerjaschki D. A case of nodular hyperplasia of the juxtaoral organ in man. *Virchows Arch A Pathol Anat Histol*. 1976;371(4):389-391.
19. Bhaskar SN, Beasley JD, Cutright DE. Inflammatory papillary hyperplasia of the oral mucosa: report of 341 cases. *J Am Dent Assoc*. 1970;81(4):949-952.
20. Houston GD. The giant cell fibroma. A review of 464 cases. *Oral Surg Oral Med Oral Pathol*. 1982;53(6):582-587.
21. Regezi JA, Courtney RM, Kerr DA. Fibrous lesions of the skin and mucous membranes which contain stellate and multinucleated cells. *Oral Surg Oral Med Oral Pathol*. 1975;39(4):605-614.
22. Weathers DR, Baker G, Archard HO, Burkes EJ Jr. Psoriasiform lesions of the oral mucosa (with emphasis on "ectopic geographic tongue"). *Oral Surg Oral Med Oral Pathol*. 1974;37(6):872-888.
23. Eveson JW. Granulomatous disorders of the oral mucosa. *Semin Diagn Pathol*. 1996;13(2):118-127.
24. Bennett DE. Histoplasmosis of the oral cavity and larynx. A clinicopathologic study. *Arch Intern Med*. 1967;120(4):417-427.
25. Halme L, Meurman JH, Laine P, et al. Oral findings in patients with active or inactive Crohn's disease. *Oral Surg Oral Med Oral Pathol*. 1993;76(2):175-181.
26. Plauth M, Jenss H, Meyle J. Oral manifestations of Crohn's disease. An analysis of 79 cases. *J Clin Gastroenterol*. 1991;13(1):29-37.
27. Schnitt SJ, Antonioli DA, Jaffe B, Peppercorn MA. Granulomatous inflammation of minor

salivary gland ducts: a new oral manifestation of Crohn's disease. *Hum Pathol*. 1987;18(4):405-407.
28. Nessan VJ, Jacoway JR. Biopsy of minor salivary glands in the diagnosis of sarcoidosis. *N Engl J Med*. 1979;301(17):922-924.
29. Worsaae N, Christensen KC, Schiodt M, Reibel J. Melkersson-Rosenthal syndrome and cheilitis granulomatosa. A clinicopathological study of thirty-three patients with special reference to their oral lesions. *Oral Surg Oral Med Oral Pathol*. 1982;54(4):404-413.
30. Taxy JB. Granulomatous tonsillitis. An unusual host response with benign clinical evolution. *Int J Surg Pathol*. 1995;3:23-28.
31. Kapadia SB, Wiley CA, Soontornniyomkij V, et al. HIV-associated Waldeyer's ring lymphoid hyperplasias: characterization of multinucleated giant cells and the role of Epstein-Barr virus. *Hum Pathol*. 1999;30(11):1383-1388.
32. Dargent JL, Lespagnard L, Kornreich A, et al. HIV-associated multinucleated giant cells in lymphoid tissue of the Waldeyer's ring: a detailed study. *Mod Pathol*. 2000;13(12):1293-1299.
33. Patten SF, Tomecki KJ. Wegener's granulomatosis: cutaneous and oral mucosal disease. *J Am Acad Dermatol*. 1993;28(5 Pt 1):710-718.
34. Handlers JP, Waterman J, Abrams AM, Melrose RJ. Oral features of Wegener's granulomatosis. *Arch Otolaryngol*. 1985;111(4):267-270.
35. Helm TN, Camisa C, Allen C, Lowder C. Clinical features of Behcet's disease. Report of four cases. *Oral Surg Oral Med Oral Pathol*. 1991;72(1):30-34.
36. Jones AC, Freedman PD, Phelan JA, et al. Cytomegalovirus infections of the oral cavity. A report of six cases and review of the literature. *Oral Surg Oral Med Oral Pathol*. 1993;75(1):76-85.
37. Hirshberg A, Amariglio N, Akrish S, et al. Traumatic ulcerative granuloma with stromal eosinophilia: a reactive lesion of the oral mucosa. *Am J Clin Pathol*. 2006;126(4):522-529.
38. el-Mofty SK, Swanson PE, Wick MR, Miller AS. Eosinophilic ulcer of the oral mucosa. Report of 38 new cases with immunohistochemical observations. *Oral Surg Oral Med Oral Pathol*. 1993;75(6):716-722.
39. Elzay RP. Traumatic ulcerative granuloma with stromal eosinophilia (Riga-Fede's disease and traumatic eosinophilic granuloma). *Oral Surg Oral Med Oral Pathol*. 1983;55(5): 497-506.
40. Salisbury CL, Budnick SD, Li S. T-cell receptor gene rearrangement and CD30 immunoreactivity in traumatic ulcerative granuloma with stromal eosinophilia of the oral cavity. *Am J Clin Pathol*. 2009;132(5):722-727.
41. Soares AB, Faria PR, Magna LA, et al. Chronic GVHD in minor salivary glands and oral mucosa: histopathological and immunohistochemical evaluation of 25 patients. *J Oral Pathol Med*. 2005;34(6):368-373.
42. van Wyk CW, Ambrosio SC. Leukoedema: ultrastructural and histochemical observations. *J Oral Pathol*. 1983;12(5):319-329.
43. Takagi M, Yamamoto H, Mega H, et al. Heterogeneity in the gingival fibromatoses. *Cancer*. 1991;68(10):2202-2212.
44. Wysocki GP, Gretzinger HA, Laupacis A, et al. Fibrous hyperplasia of the gingiva: a side effect of cyclosporin A therapy. *Oral Surg Oral Med Oral Pathol*. 1983;55(3):274-278.
45. Isaac U, Issac JS, Ahmed Khoso N. Histopathologic features of oral submucous fibrosis: a study of 35 biopsy specimens. *Oral Surg Oral Med Oral Pathol Oral Radiol Endod*. 2008;106(4):556-560.
46. Pillai R, Balaram P, Reddiar KS. Pathogenesis of oral submucous fibrosis. Relationship to risk factors associated with oral cancer. *Cancer*. 1992;69(8):2011-2020.
47. Praetorius F, Hammarstrom L. A new concept of the pathogenesis of oral mucous cysts based on a study of 200 cases. *J Dent Assoc S Afr*. 1992;47(5):226-231.
48. Lattanand A, Johnson WC, Graham JH. Mucous cyst (mucocele). A clinicopathologic and histochemical study. *Arch Dermatol*. 1970;101(6):673-678.
49. Jensen JL. Superficial mucoceles of the oral mucosa. *Am J Dermatopathol*. 1990;12(1):88-92.
50. Harrison JD. Salivary mucoceles. *Oral Surg Oral Med Oral Pathol*. 1975;39(2):268-278.
51. Langlois NE, Kolhe P. Plunging ranula: a case report and a literature review. *Hum Pathol*. 1992;23(11):1306-1308.
52. McClatchey KD, Appelblatt NH, Zarbo RJ, Merrel DM. Plunging ranula. *Oral Surg Oral Med Oral Pathol*. 1984;57(4):408-412.
53. Tomich CE. Oral focal mucinosis. A clinicopathologic and histochemical study of eight cases. *Oral Surg Oral Med Oral Pathol*. 1974;38(5):714-724.
54. Abrams AM, Melrose RJ, Howell FV. Necrotizing sialometaplasia. A disease simulating malignancy. *Cancer*. 1973;32(1):130-135.
55. Dunlap CL, Barker BF. Necrotizing sialometaplasia. Report of five additional cases. *Oral Surg Oral Med Oral Pathol*. 1974;37(5):722-727.
56. Fechner RE. Necrotizing sialometaplasia: a source of confusion with carcinoma of the palate. *Am J Clin Pathol*. 1977;67(4):315-317.
57. Carlson DL. Necrotizing sialometaplasia: a practical approach to the diagnosis. *Arch Pathol Lab Med*. 2009;133(5):692-698.
58. Rizkalla H, Toner M. Necrotizing sialometaplasia versus invasive carcinoma of the head and neck: the use of myoepithelial markers and keratin subtypes as an adjunct to diagnosis. *Histopathology*. 2007;51(2):184-189.
59. Madani M, Harwick RD, Chen SY, Miller AS. Amyloidosis of the oral cavity: report of five cases. *Compendium*. 1991;12(5):336, 338-342.
60. van der Wal N, Henzen-Logmans S, van der Kwast WA, van der Waal I. Amyloidosis of the tongue: a clinical and postmortem study. *J Oral Pathol*. 1984;13(6):632-639.
61. Yamaguchi A, Nasu M, Esaki Y, et al. Amyloid deposits in the aged tongue: a postmortem study of 107 individuals over 60 years of age. *J Oral Pathol*. 1982;11(3):237-244.
62. Amano H, Tamura A, Yasuda M, et al. Amalgam tattoo of the oral mucosa mimics malignant melanoma. *J Dermatol*. 2011;38(1):101-103.
63. Bouquot JE, Gorlin RJ. Leukoplakia, lichen planus, and other oral keratoses in 23,616 white Americans over the age of 35 years. *Oral Surg Oral Med Oral Pathol*. 1986;61(4):373-381.
64. Konttinen YT, Malmstrom M, Reitamo S, et al. Oral lesions in lichen planus and systemic lupus erythematosus. A histochemical and immunohistochemical study. *Acta Pathol Microbiol Immunol Scand [A]*. 1982;90(4):295-299.
65. Suarez P, Batsakis JG, el-Naggar AK. Leukoplakia: still a gallimaufry or is progress being made?—a review. *Adv Anat Pathol*. 1998;5(3):137-155.
66. Fischman SL, Ulmansky M, Sela J, et al. Correlative clinico-pathological evaluation of oral premalignancy. *J Oral Pathol*. 1982;11(4):283-289.
67. Batsakis JG, Suarez P, el-Naggar AK. Proliferative verrucous leukoplakia and its related lesions. *Oral Oncol*. 1999;35(4):354-359.
68. Crissman JD, Gnepp DR, Goodman ML, et al. Preinvasive lesions of the upper aerodigestive tract: histologic definitions and clinical implications (a symposium). *Pathol Annu*. 1987;22(Pt 1):311-352.
69. Katz HC, Shear M, Altini M. A critical evaluation of epithelial dysplasia in oral mucosal lesions using the Smith-Pindborg method of standardization. *J Oral Pathol*. 1985;14(6):476-482.
70. Eisenberg E, Krutchkoff DJ. Lichenoid lesions of oral mucosa. Diagnostic criteria and their importance in the alleged relationship to oral cancer. *Oral Surg Oral Med Oral Pathol*. 1992;73(6):699-704.
71. Al-Hashimi I, Schifter M, Lockhart PB, et al. Oral lichen planus and oral lichenoid lesions: diagnostic and therapeutic considerations. *Oral Surg Oral Med Oral Pathol Oral Radiol Endod*. 2007;103(suppl):S25.e1-S25.e12.
72. Krutchkoff DJ, Eisenberg E. Lichenoid dysplasia: a distinct histopathologic entity. *Oral Surg Oral Med Oral Pathol*. 1985;60(3):308-315.
73. Gologan O, Barnes EL, Hunt JL. Potential diagnostic use of p16INK4A, a new marker that correlates with dysplasia in oral squamoproliferative lesions. *Am J Surg Pathol*. 2005;29(6):792-796.
74. Coltrera MD, Zarbo RJ, Sakr WA, Gown AM. Markers for dysplasia of the upper aerodigestive tract. Suprabasal expression of PCNA, p53, and CK19 in alcohol-fixed, embedded tissue. *Am J Pathol*. 1992;141(4):817-825.
75. Saito T, Notani K, Miura H, et al. DNA analysis of oral leukoplakia by flow cytometry. *Int J Oral Maxillofac Surg*. 1991;20(5):259-263.
76. Sudbo J, Kildal W, Risberg B, et al. DNA content as a prognostic marker in patients with oral leukoplakia. *N Engl J Med*. 2001;344(17):1270-1278.
77. Nishioka H, Hiasa Y, Hayashi I, et al. Immunohistochemical detection of p53 oncoprotein in human oral squamous cell carcinomas and leukoplakias: comparison with proliferating cell nuclear antigen staining and correlation with clinicopathological findings. *Oncology*. 1993;50(6):426-429.
78. Amagasa T, Yokoo E, Sato K, et al. A study of the clinical characteristics and treatment of oral carcinoma in situ. *Oral Surg Oral Med Oral Pathol*. 1985;60(1):50-55.
79. Mashberg A, Morrissey JB, Garfinkel L. A study of the appearance of early asymptomatic oral squamous cell carcinoma. *Cancer*. 1973;32(6):1436-1445.
80. Waldron CA, Shafer WG. Leukoplakia revisited. A clinicopathologic study 3256 oral leukoplakias. *Cancer*. 1975;36(4):1386-1392.
81. Pindborg JJ, Jolst O, Renstrup G, Roed-Petersen B. Studies in oral leukoplakia: a preliminary report on the period pervalence of malignant transformation in leukoplakia based on a follow-up study of 248 patients. *J Am Dent Assoc*. 1968;76(4):767-771.
82. Einhorn J, Wersall J. Incidence of oral carcinoma in patients with leukoplakia of the oral mucosa. *Cancer*. 1967;20(12): 2189-2193.
83. Silverman S, Bhargava K, Smith LW, Malaowalla AM. Malignant transformation and natural history of oral leukoplakia in 57,518 industrial workers of Gujarat, India. *Cancer*. 1976;38(4):1790-1795.
84. Scully C, Burkhardt A. Tissue markers of potentially malignant human oral epithelial lesions. *J Oral Pathol Med*. 1993;22(6):246-256.
85. King GN, Healy CM, Glover MT, et al. Increased prevalence of dysplastic and malignant lip lesions in renal-transplant recipients. *N Engl J Med*. 1995;332(16):1052-1057.

86. Garlick JA, Taichman LB. Human papillomavirus infection of the oral mucosa. *Am J Dermatopathol*. 1991;13(4):386-395.
87. Pilgard G. Focal epithelial hyperplasia. Report of nine cases from Sweden and review of the literature. *Oral Surg Oral Med Oral Pathol*. 1984;57(5):540-543.
88. Eversole LR, Laipis PJ, Green TL. Human papillomavirus type 2 DNA in oral and labial verruca vulgaris. *J Cutan Pathol*. 1987;14(6):319-325.
89. Swan RH, McDaniel RK, Dreiman BB, Rome WC. Condyloma acuminatum involving the oral mucosa. *Oral Surg Oral Med Oral Pathol*. 1981;51(5):503-508.
90. Abbey LM, Page DG, Sawyer DR. The clinical and histopathologic features of a series of 464 oral squamous cell papillomas. *Oral Surg Oral Med Oral Pathol*. 1980;49(5):419-428.
91. Eisenberg E, Rosenberg B, Krutchkoff DJ. Verrucous carcinoma: a possible viral pathogenesis. *Oral Surg Oral Med Oral Pathol*. 1985;59(1):52-57.
92. Mork J, Lie AK, Glattre E, et al. Human papillomavirus infection as a risk factor for squamous-cell carcinoma of the head and neck. *N Engl J Med*. 2001;344(15): 1125-1131.
93. Bouda M, Gorgoulis VG, Kastrinakis NG, et al. "High risk" HPV types are frequently detected in potentially malignant and malignant oral lesions, but not in normal oral mucosa. *Mod Pathol*. 2000;13(6):644-653.
94. Chen PC, Pan CC, Kuo C, Lin CP. Risk of oral nonmalignant lesions associated with human papillomavirus infection, betel quid chewing, and cigarette smoking in Taiwan: an integrated molecular and epidemiologic study. *Arch Pathol Lab Med*. 2006;130(1):57-61.
95. El-Mofty SK, Lu DW. Prevalence of human papillomavirus type 16 DNA in squamous cell carcinoma of the palatine tonsil, and not the oral cavity, in young patients: a distinct clinicopathologic and molecular disease entity. *Am J Surg Pathol*. 2003;27(11):1463-1470.
96. McHugh JB. Association of cystic neck metastases and human papillomavirus-positive oropharyngeal squamous cell carcinoma. *Arch Pathol Lab Med*. 2009;133(11):1798-1803.
97. Wilczynski SP, Lin BT, Xie Y, Paz IB. Detection of human papillomavirus DNA and oncoprotein overexpression are associated with distinct morphological patterns of tonsillar squamous cell carcinoma. *Am J Pathol*. 1998;152(1):145-156.
98. Klussmann JP, Gultekin E, Weissenborn SJ, et al. Expression of p16 protein identifies a distinct entity of tonsillar carcinomas associated with human papillomavirus. *Am J Pathol*. 2003;162(3):747-753.
99. Gillison ML, Koch WM, Capone RB, et al. Evidence for a causal association between human papillomavirus and a subset of head and neck cancers. *J Natl Cancer Inst*. 2000;92(9):709-720.
100. Swart JG, Lekkas C, Allard RH. Oral manifestations in Cowden's syndrome. Report of four cases. *Oral Surg Oral Med Oral Pathol*. 1985;59(3):264-268.
101. Welch TB, Barker BF, Williams C. Peroxidase-antiperoxidase evaluation of human oral squamous cell papillomas. *Oral Surg Oral Med Oral Pathol*. 1986;61(6):603-606.
102. Adler-Storthz K, Ficarra G, Woods KV, et al. Prevalence of Epstein-Barr virus and human papillomavirus in oral mucosa of HIV-infected patients. *J Oral Pathol Med*. 1992;21(4):164-170.
103. Becker J, Leser U, Marschall M, et al. Expression of proteins encoded by Epstein-Barr virus trans-activator genes depends on the differentiation of epithelial cells in oral hairy leukoplakia. *Proc Natl Acad Sci USA*. 1991;88(19):8332-8336.
104. Eversole LR, Jacobsen P, Stone CE, Freckleton V. Oral condyloma planus (hairy leukoplakia) among homosexual men: a clinicopathologic study of thirty-six cases. *Oral Surg Oral Med Oral Pathol*. 1986;61(3):249-255.
105. Fernandez JF, Benito MA, Lizaldez EB, Montanes MA. Oral hairy leukoplakia: a histopathologic study of 32 cases. *Am J Dermatopathol*. 1990;12(6):571-578.
106. Southam JC, Felix DH, Wray D, Cubie HA. Hairy leukoplakia—a histological study. *Histopathology*. 1991;19(1):63-67.
107. Chen J, Katz RV, Krutchkoff DJ, Eisenberg E. Lip cancer. Incidence trends in Connecticut, 1935–1985. *Cancer*. 1992;70(8):2025-2030.
108. Alos L, Moyano S, Diaz A, et al. Squamous cell carcinoma of the head and neck in HIV-positive patients. A neoplasm infrequently associated with human papillomavirus infection. *Lab Invest*. 2009;89:244A.
109. Curtis RE, Rowlings PA, Deeg HJ, et al. Solid cancers after bone marrow transplantation. *N Engl J Med*. 1997;336(13):897-904.
110. Binnie WH, Rankin KV. Epidemiological and diagnostic aspects of oral squamous cell carcinoma. *J Oral Pathol*. 1984;13(4):333-341.
111. Binnie WH, Rankin KV, Mackenzie IC. Etiology of oral squamous cell carcinoma. *J Oral Pathol*. 1983;12(1):11-29.
112. Chen JK, Katz RV, Krutchkoff DJ. Intraoral squamous cell carcinoma. Epidemiologic patterns in Connecticut from 1935 to 1985. *Cancer*. 1990;66(6):1288-1296.
113. Neville BW, Day TA. Oral cancer and precancerous lesions. *CA Cancer J Clin*. 2002;52(4):195-215.
114. Rich AM, Radden BG. Squamous cell carcinoma of the oral mucosa: a review of 244 cases in Australia. *J Oral Pathol*. 1984;13(5):459-471.
115. Forastiere A, Koch W, Trotti A, Sidransky D. Head and neck cancer. *N Engl J Med*. 2001;345(26):1890-1900.
116. Ildstad ST, Tollerud DJ, Bigelow ME, Remensnyder JP. Squamous cell carcinoma of the head and neck at the Massachusetts General Hospital: a comparison of biologic characteristics in men and women. *Surgery*. 1986;99(1):7-14.
117. Muir C, Weiland L. Upper aerodigestive tract cancers. *Cancer*. 1995;75(1 suppl):147-153.
118. Newman AN, Rice DH, Ossoff RH, Sisson GA. Carcinoma of the tongue in persons younger than 30 years of age. *Arch Otolaryngol*. 1983;109(5):302-304.
119. MacComb WS, Fletcher GH, Healey JE. Intra-oral cavity. In: MacComb WS, Fletcher GH, eds. *Cancer of the Head and Neck*. Baltimore, MD: Williams & Wilkins; 1967:89-151.
120. Mashberg A, Meyers H. Anatomical site and size of 222 early asymptomatic oral squamous cell carcinomas: a continuing prospective study of oral cancer. II. *Cancer*. 1976;37(5):2149-2157.
121. Jovanovic A, Schulten EA, Kostense PJ, et al. Squamous cell carcinoma of the lip and oral cavity in The Netherlands; an epidemiological study of 740 patients. *J Craniomaxillofac Surg*. 1993;21(4):149-152.
122. Boysen M, Loven JO. Second malignant neoplasms in patients with head and neck squamous cell carcinomas. *Acta Oncol*. 1993;32(3):283-288.
123. van Rees BP, Cleton-Jansen AM, Cense HA, et al. Molecular evidence of field cancerization in a patient with 7 tumors of the aerodigestive tract. *Hum Pathol*. 2000;31(2):269-271.
124. Braakhuis BJ, Tabor MP, Leemans CR, et al. Second primary tumors and field cancerization in oral and oropharyngeal cancer: molecular techniques provide new insights and definitions. *Head Neck*. 2002;24(2):198-206.
125. Tabor MP, Brakenhoff RH, Ruijter-Schippers HJ, et al. Multiple head and neck tumors frequently originate from a single preneoplastic lesion. *Am J Pathol*. 2002;161(3):1051-1060.
126. Wright A, Shear M. Epithelial dysplasia immediately adjacent to oral squamous cell carcinomas. *J Oral Pathol*. 1985;14(7):559-564.
127. Falconieri G, Luna MA, Pizzolitto S, et al. Eosinophil-rich squamous carcinoma of the oral cavity: a study of 13 cases and delineation of a possible new microscopic entity. *Ann Diagn Pathol*. 2008;12(5):322-327.
128. Lowe D, Fletcher CD. Eosinophilia in squamous cell carcinoma of the oral cavity, external genitalia and anus—clinical correlations. *Histopathology*. 1984;8(4):627-632.
129. Suo Z, Holm R, Nesland JM. Squamous cell carcinomas. An immunohistochemical study of cytokeratins and involucrin in primary and metastatic tumours. *Histopathology*. 1993;23(1):45-54.
130. El-Naggar AK, Lai S, Clayman GL, et al. Expression of p16, Rb, and cyclin D1 gene products in oral and laryngeal squamous carcinoma: biological and clinical implications. *Hum Pathol*. 1999;30(9):1013-1018.
131. Warnakulasuriya KA, Johnson NW. Expression of p53 mutant nuclear phosphoprotein in oral carcinoma and potentially malignant oral lesions. *J Oral Pathol Med*. 1992;21(9):404-408.
132. Klein JD, Grandis JR. The molecular pathogenesis of head and neck cancer. *Cancer Biol Ther*. 2010;9(1):1-7.
133. Califano J, van der Riet P, Westra W, et al. Genetic progression model for head and neck cancer: implications for field cancerization. *Cancer Res*. 1996;56(11):2488-2492.
134. Califano J, Westra WH, Meininger G, et al. Genetic progression and clonal relationship of recurrent premalignant head and neck lesions. *Clin Cancer Res*. 2000;6(2):347-352.
135. Belbin TJ, Singh B, Barber I, et al. Molecular classification of head and neck squamous cell carcinoma using cDNA microarrays. *Cancer Res*. 2002;62(4):1184-1190.
136. O'Donnell RK, Kupferman M, Wei SJ, et al. Gene expression signature predicts lymphatic metastasis in squamous cell carcinoma of the oral cavity. *Oncogene*. 2005;24(7): 1244-1251.
137. Roepman P, Wessels LF, Kettelarij N, et al. An expression profile for diagnosis of lymph node metastases from primary head and neck squamous cell carcinomas. *Nat Genet*. 2005;37(2):182-186.
138. Olson SM, Lewis JS, Hussaini M. Frozen section analysis of head and neck tumor resection margins: methods, trends, and error rates at a large academic institution. *Lab Invest*. 2009;89:250A.
139. Looser KG, Shah JP, Strong EW. The significance of "positive" margins in surgically resected epidermoid carcinomas. *Head Neck Surg*. 1978;1(2):107-111.
140. O'Brien CJ, Carter RL, Soo KC, et al. Invasion of the mandible by squamous carcinomas of the oral cavity and oropharynx. *Head Neck Surg*. 1986;8(4):247-256.
141. McGregor AD, MacDonald DG. Patterns of spread of squamous cell carcinoma to the ramus of the mandible. *Head Neck*. 1993;15(5):440-444.
142. Shah JP, Candela FC, Poddar AK. The patterns of cervical lymph node metastases from squamous carcinoma of the oral cavity. *Cancer*. 1990;66(1):109-113.

143. Davidson BJ, Kulkarny V, Delacure MD, Shah JP. Posterior triangle metastases of squamous cell carcinoma of the upper aerodigestive tract. *Am J Surg*. 1993;166(4):395-398.
144. Frierson HF Jr, Cooper PH. Prognostic factors in squamous cell carcinoma of the lower lip. *Hum Pathol*. 1986;17(4):346-354.
145. Umeda M, Yokoo S, Take Y, et al. Lymph node metastasis in squamous cell carcinoma of the oral cavity: correlation between histologic features and the prevalence of metastasis. *Head Neck*. 1992;14(4):263-272.
146. Quaedvlieg PJ, Creytens DH, Epping GG, et al. Histopathological characteristics of metastasizing squamous cell carcinoma of the skin and lips. *Histopathology*. 2006;49(3):256-264.
147. Thompson LD, Heffner DK. The clinical importance of cystic squamous cell carcinomas in the neck: a study of 136 cases. *Cancer*. 1998;82(5):944-956.
148. Safall H, Azar HA. Keratin granulomas in irradiated squamous cell carcinoma of various sites. *Cancer Res*. 1966;26(3):500-508.
149. Parsons JT, Mendenhall WM, Stringer SP, et al. Squamous cell carcinoma of the oropharynx: surgery, radiation therapy, or both. *Cancer*. 2002;94(11):2967-2980.
150. Korb LJ, Spaulding CA, Constable WC. The role of definitive radiation therapy in squamous cell carcinoma of the oral tongue. *Cancer*. 1991;67(11):2733-2737.
151. Vokes EE, Weichselbaum RR, Lippman SM, Hong WK. Head and neck cancer. *N Engl J Med*. 1993;328(3):184-194.
152. de Braud F, al-Sarraf M. Diagnosis and management of squamous cell carcinoma of unknown primary tumor site of the neck. *Semin Oncol*. 1993;20(3):273-278.
153. Bryne M, Thrane PS, Dabelsteen E. Loss of expression of blood group antigen H is associated with cellular invasion and spread of oral squamous cell carcinomas. *Cancer*. 1991;67(3):613-618.
154. Iro H, Waldfahrer F. Evaluation of the newly updated TNM classification of head and neck carcinoma with data from 3247 patients. *Cancer*. 1998;83(10):2201-2207.
155. Bryne M, Nielsen K, Koppang HS, Dabelsteen E. Reproducibility of two malignancy grading systems with reportedly prognostic value for oral cancer patients. *J Oral Pathol Med*. 1991;20(8):369-372.
156. Odell EW, Jani P, Sherriff M, et al. The prognostic value of individual histologic grading parameters in small lingual squamous cell carcinomas. The importance of the pattern of invasion. *Cancer*. 1994;74(3):789-794.
157. Stein AL, Tahan SR. Histologic correlates of metastasis in primary invasive squamous cell carcinoma of the lip. *J Cutan Pathol*. 1994;21(1):16-21.
158. Moore C, Flynn MB, Greenberg RA. Evaluation of size in prognosis of oral cancer. *Cancer*. 1986;58(1):158-162.
159. Dorta RG, Landman G, Kowalski LP, et al. Tumour-associated tissue eosinophilia as a prognostic factor in oral squamous cell carcinomas. *Histopathology*. 2002;41(2):152-157.
160. Begum S, Westra WH. Basaloid squamous cell carcinoma of the head and neck is a mixed variant that can be further resolved by HPV status. *Am J Surg Pathol*. 2008;32(7):1044-1050.
161. Ang KK, Harris J, Wheeler R, et al. Human papillomavirus and survival of patients with oropharyngeal cancer. *N Engl J Med*. 2010;363(1):24-35.
162. Yuen PW, Chow V, Choy J, et al. The clinicopathologic significance of p53 and p21 expression in the surgical management of lingual squamous cell carcinoma. *Am J Clin Pathol*. 2001;116(2):240-245.
163. Kato H, Shi W, Hui A, et al. P16 over-expression is a favorable prognostic factor in squamous cell carcinoma of the oropharynx. *Lab Invest*. 2009;89(249A).
164. Ackerman LV. Verrucous carcinoma of the oral cavity. *Surgery*. 1948;23(4):670-678.
165. Koch BB, Trask DK, Hoffman HT, et al. National survey of head and neck verrucous carcinoma: patterns of presentation, care, and outcome. *Cancer*. 2001;92(1):110-120.
166. McCoy JM, Waldron CA. Verrucous carcinoma of the oral cavity. A review of forty-nine cases. *Oral Surg Oral Med Oral Pathol*. 1981;52(6):623-629.
167. Sundstrom B, Mornstad H, Axell T. Oral carcinomas associated with snuff dipping. Some clinical and histological characteristics of 23 tumours in Swedish males. *J Oral Pathol*. 1982;11(3):245-251.
168. Medina JE, Dichtel W, Luna MA. Verrucous-squamous carcinomas of the oral cavity. A clinicopathologic study of 104 cases. *Arch Otolaryngol*. 1984;110(7):437-440.
169. Kraus FT, Perezmesa C. Verrucous carcinoma. Clinical and pathologic study of 105 cases involving oral cavity, larynx and genitalia. *Cancer*. 1966;19(1):26-38.
170. Hansen LS, Olson JA, Silverman S Jr. Proliferative verrucous leukoplakia. A long-term study of thirty patients. *Oral Surg Oral Med Oral Pathol*. 1985;60(3):285-298.
171. Takagi M, Sakota Y, Takayama S, Ishikawa G. Adenoid squamous cell carcinoma of the oral mucosa: report of two autopsy cases. *Cancer*. 1977;40(5):2250-2255.
172. Martinez-Madrigal F, Baden E, Casiraghi O, Micheau C. Oral and pharyngeal adenosquamous carcinoma. A report of four cases with immunohistochemical studies. *Eur Arch Otorhinolaryngol*. 1991;248(5):255-258.
173. Seethala RR, Zhang X, Turner S, et al. Adenosquamous carcinomas of the head and neck: an analysis of MDM2, p53 expression and MAML2 rearrangements. *Lab Invest*. 2009;89:251A.
174. Banks ER, Frierson HF Jr, Mills SE, et al. Basaloid squamous cell carcinoma of the head and neck. A clinicopathologic and immunohistochemical study of 40 cases. *Am J Surg Pathol*. 1992;16(10):939-946.
175. Wain SL, Kier R, Vollmer RT, Bossen EH. Basaloid-squamous carcinoma of the tongue, hypopharynx, and larynx: report of 10 cases. *Hum Pathol*. 1986;17(11):1158-1166.
176. Serrano MF, El-Mofty SK, Gnepp DR, Lewis JS Jr. Utility of high molecular weight cytokeratins, but not p63, in the differential diagnosis of neuroendocrine and basaloid carcinomas of the head and neck. *Hum Pathol*. 2008;39(4):591-598.
177. Muller S, Barnes L. Basaloid squamous cell carcinoma of the head and neck with a spindle cell component. An unusual histologic variant. *Arch Pathol Lab Med*. 1995;119(2):181-182.
178. Tsang WY, Chan JK, Lee KC, et al. Basaloid-squamous carcinoma of the upper aerodigestive tract and so-called adenoid cystic carcinoma of the oesophagus: the same tumour type? *Histopathology*. 1991;19(1): 35-46.
179. Jo VY, Mills SE, Stoler MH, Stelow EB. Papillary squamous cell carcinoma of the head and neck: frequent association with human papillomavirus infection and invasive carcinoma. *Am J Surg Pathol*. 2009;33(11):1720-1724.
180. Batsakis JG, Suarez P. Sarcomatoid carcinomas of the upper aerodigestive tracts. *Adv Anat Pathol*. 2000;7(5):282-293.
181. Choi HR, Sturgis EM, Rosenthal DI, et al. Sarcomatoid carcinoma of the head and neck: molecular evidence for evolution and progression from conventional squamous cell carcinomas. *Am J Surg Pathol*. 2003;27(9):1216-1220.
182. Cates JM, Dupont WD, Barnes JW, et al. Markers of epithelial-mesenchymal transition and epithelial differentiation in sarcomatoid carcinoma: utility in the differential diagnosis with sarcoma. *Appl Immunohistochem Mol Morphol*. 2008;16(3):251-262.
183. Nakhleh R, Zarbo R, Ewing S, et al. Myogenic differentiation in spindle cell (sarcomatoid) carcinomas of the upper aerodigestive tract. *Appl Immunohistochem*. 1993;1:58-68.
184. Weidner N. Sarcomatoid carcinoma of the upper aerodigestive tract. *Semin Diagn Pathol*. 1987;4(2):157-168.
185. Baugh RF, Wolf GT, McClatchey KD. Small cell carcinoma of the head and neck. *Head Neck Surg*. 1986;8(5):343-354.
186. Hull MT, Eble JN, Warfel KA. Extrapulmonary oat-cell carcinoma of the tongue: an electron-microscopic study. *J Oral Pathol*. 1984;13(5):489-496.
187. Evans AT, Guthrie W. Lymphoepithelioma-like carcinoma of the uvula and soft palate: a rare lesion in an unusual site. *Histopathology*. 1991;19(2):184-186.
188. Singhi AD, Stelow EB, Mills SE, Westra WH. Lymphoepithelial-like carcinoma of the oropharynx: a morphologic variant of HPV-related head and neck carcinoma. *Am J Surg Pathol*. 2010;34(6):800-805.
189. Stelow EB, Bellizzi AM, Taneja K, et al. NUT rearrangement in undifferentiated carcinomas of the upper aerodigestive tract. *Am J Surg Pathol*. 2008;32(6):828-834.
190. Stelow EB, French CA. Carcinomas of the upper aerodigestive tract with rearrangement of the nuclear protein of the testis (NUT) gene (NUT midline carcinomas). *Adv Anat Pathol*. 2009;16(2):92-96.
191. Haack H, Johnson LA, Fry CJ, et al. Diagnosis of NUT midline carcinoma using a NUT-specific monoclonal antibody. *Am J Surg Pathol*. 2009;33(7):984-991.
192. Mertens F, Wiebe T, Adlercreutz C, et al. Successful treatment of a child with t(15;19)-positive tumor. *Pediatr Blood Cancer*. 2007;49(7):1015-1017.
193. Warwick WJ, Bernard B, Meskin LH. The involvement of the labial mucous salivary gland in patients with cystic fibrosis. *Pediatrics*. 1964;34:621-628.
194. Chisholm DM, Mason DK. Labial salivary gland biopsy in Sjogren's disease. *J Clin Pathol*. 1968;21(5):656-660.
195. Sale GE, Shulman HM, Schubert MM, et al. Oral and ophthalmic pathology of graft versus host disease in man: predictive value of the lip biopsy. *Hum Pathol*. 1981;12(11):1022-1030.
196. Arafat A, Brannon RB, Ellis GL. Adenomatoid hyperplasia of mucous salivary glands. *Oral Surg Oral Med Oral Pathol*. 1981;52(1):51-55.
197. Isacsson G, Shear M. Intraoral salivary gland tumors: a retrospective study of 201 cases. *J Oral Pathol*. 1983;12(1):57-62.
198. Regezi JA, Lloyd RV, Zarbo RJ, McClatchey KD. Minor salivary gland tumors. A histologic and immunohistochemical study. *Cancer*. 1985;55(1):108-115.
199. Chaudhry AP, Vickers RA, Gorlin RJ. Intraoral minor salivary gland tumors. An analysis of 1,414 cases. *Oral Surg Oral Med Oral Pathol*. 1961;14:1194-1226.
200. Coates HL, Devine KD, DeSanto LW, Weiland LH. Glandular tumors of the palate. *Surg Gynecol Obstet*. 1975;140(4):589-593.
201. Eneroth CM. Incidence and prognosis of salivary-gland tumours at different sites. A study of parotid, submandibular and palatal tumours in 2632 patients. *Acta Otolaryngol Suppl*. 1969;263:174-178.
202. Eveson JW, Cawson RA. Tumours of the minor (oropharyngeal) salivary glands: a

demographic study of 336 cases. *J Oral Pathol*. 1985;14(6):500-509.
203. Takeda Y, Sasou S, Obata K. Pleomorphic adenoma of the minor salivary gland with pseudoepitheliomatous hyperplasia of the overlying oral mucosa: report of two cases. *Pathol Int*. 1998;48(5):389-395.
204. Anavi Y, Calderon S, Gal G, Sandbank J. Intraoral acinic cell carcinoma. *Ann Dent*. 1993;52(1):26-29.
205. Seethala RR, Barnes EL, Hunt JL. Epithelial-myoepithelial carcinoma: a review of the clinicopathologic spectrum and immunophenotypic characteristics in 61 tumors of the salivary glands and upper aerodigestive tract. *Am J Surg Pathol*. 2007;31(1):44-57.
206. Chomette G, Auriol M, Tranbaloc P, Vaillant JM. Adenoid cystic carcinoma of minor salivary glands. Analysis of 86 cases. Clinico-pathological, histoenzymological and ultrastructural studies. *Virchows Arch A Pathol Anat Histol*. 1982;395(3):289-301.
207. Owens OT, Calcaterra TC. Salivary gland tumors of the lip. *Arch Otolaryngol*. 1982;108(1):45-47.
208. Batsakis JG. Oral monomorphic adenomas. *Ann Otol Rhinol Laryngol*. 1991;100(4 Pt 1):348-350.
209. Suarez P, Hammond HL, Luna MA, Stimson PG. Palatal canalicular adenoma: report of 12 cases and review of the literature. *Ann Diagn Pathol*. 1998;2(4):224-228.
210. Coleman H, Altini M. Intravascular tumour in intra-oral pleomorphic adenomas: a diagnostic and therapeutic dilemma. *Histopathology*. 1999;35(5):439-444.
211. Lomax-Smith JD, Azzopardi JG. The hyaline cell: a distinctive feature of "mixed" salivary tumours. *Histopathology*. 1978;2(2): 77-92.
212. Freedman PD, Lumerman H. Sialadenoma papilliferum. *Oral Surg Oral Med Oral Pathol*. 1978;45(1):88-94.
213. White DK, Miller AS, McDaniel RK, Rothman BN. Inverted ductal papilloma: a distinctive lesion of minor salivary gland. *Cancer*. 1982;49(3):519-524.
214. Weinreb I. Hyalinizing clear cell carcinoma of salivary gland: a review and update. *Head Neck Pathol*. 2013;7(1S):20-29.
215. Antonescu CR, Katabi N, Zhang L, et al. EWSR1-ATF1 fusion is a novel and consistent finding in hyalinizing clear-cell carcinoma of salivary gland. *Genes Chromosomes Cancer*. 2011;50(7):559-570.
216. Castle JT, Thompson LD, Frommelt RA, et al. Polymorphous low grade adenocarcinoma: a clinicopathologic study of 164 cases. *Cancer*. 1999;86(2):207-219.
217. Evans HL, Luna MA. Polymorphous low-grade adenocarcinoma: a study of 40 cases with long-term follow up and an evaluation of the importance of papillary areas. *Am J Surg Pathol*. 2000;24(10):1319-1328.
218. Allen MS Jr, Fitz-Hugh GS, Marsh WL Jr. Low-grade papillary adenocarcinoma of the palate. *Cancer*. 1974;33(1):153-158.
219. Mills SE, Garland TA, Allen MS Jr. Low-grade papillary adenocarcinoma of palatal salivary gland origin. *Am J Surg Pathol*. 1984;8(5):367-374.
220. Frierson HF Jr, Mills SE, Garland TA. Terminal duct carcinoma of minor salivary glands. A nonpapillary subtype of polymorphous low-grade adenocarcinoma. *Am J Clin Pathol*. 1985;84(1):8-14.
221. Aberle AM, Abrams AM, Bowe R, et al. Lobular (polymorphous low-grade) carcinoma of minor salivary glands. A clinicopathologic study of twenty cases. *Oral Surg Oral Med Oral Pathol*. 1985;60(4):387-395.
222. Evans HL, Batsakis JG. Polymorphous low-grade adenocarcinoma of minor salivary glands. A study of 14 cases of a distinctive neoplasm. *Cancer*. 1984;53(4):935-942.
223. Perez-Ordonez B, Linkov I, Huvos AG. Polymorphous low-grade adenocarcinoma of minor salivary glands: a study of 17 cases with emphasis on cell differentiation. *Histopathology*. 1998;32(6):521-529.
224. Luna MA, Batsakis JG, Ordonez NG, et al. Salivary gland adenocarcinomas: a clinicopathologic analysis of three distinctive types. *Semin Diagn Pathol*. 1987;4(2):117-135.
225. Pelkey TJ, Mills SE. Histologic transformation of polymorphous low-grade adenocarcinoma of salivary gland. *Am J Clin Pathol*. 1999;111(6):785-791.
226. Simpson RH, Pereira EM, Ribeiro AC, et al. Polymorphous low-grade adenocarcinoma of the salivary glands with transformation to high-grade carcinoma. *Histopathology*. 2002;41(3):250-259.
227. Weinreb I, Piscuoglio S, Martelotto LG, et al. Hotspot activating PRKD1 somatic mutations in polymorphous low-grade adenocarcinomas of the salivary glands. *Nat Genet*. 2014;46(11):1166-1169.
228. Michal M, Skalova A, Simpson RH, et al. Cribriform adenocarcinoma of the tongue: a hitherto unrecognized type of adenocarcinoma characteristically occurring in the tongue. *Histopathology*. 1999;35(6):495-501.
229. Gates GA. Current concepts in otolaryngology: malignant neoplasms of the minor salivary glands. *N Engl J Med*. 1982;306(12):718-722.
230. Gardner DG. Peripheral ameloblastoma: a study of 21 cases, including 5 reported as basal cell carcinoma of the gingiva. *Cancer*. 1977;39(4):1625-1633.
231. Smullin SE, Faquin W, Susarla SM, Kaban LB. Peripheral desmoplastic ameloblastoma: report of a case and literature review. *Oral Surg Oral Med Oral Pathol Oral Radiol Endod*. 2008;105(1):37-40.
232. Kaugars GE, Heise AP, Riley WT, et al. Oral melanotic macules. A review of 353 cases. *Oral Surg Oral Med Oral Pathol*. 1993;76(1):59-61.
233. Fornatora ML, Reich RF, Haber S, et al. Oral melanoacanthoma: a report of 10 cases, review of the literature, and immunohistochemical analysis for HMB-45 reactivity. *Am J Dermatopathol*. 2003;25(1):12-15.
234. Buchner A, Hansen LS. Pigmented nevi of the oral mucosa: a clinicopathologic study of 32 new cases and review of 75 cases from the literature. Part I. A clinicopathologic study of 32 new cases. *Oral Surg Oral Med Oral Pathol*. 1979;48(2):131-142.
235. Buchner A, Hansen LS. Pigmented nevi of the oral mucosa: a clinicopathologic study of 32 new cases and review of 75 cases from the literature. Part II. Analysis of 107 cases. *Oral Surg Oral Med Oral Pathol*. 1980;49(1):55-62.
236. Devildos LR, Langlois CC. Intramucosal cellular nevi. *Oral Surg Oral Med Oral Pathol*. 1981;52(2):162-166.
237. Trodahl JN, Sprague WG. Benign and malignant melanocytic lesions of the oral mucosa. An analysis of 135 cases. *Cancer*. 1970;25(4):812-823.
238. Dorji T, Cavazza A, Nappi O, Rosai J. Spitz nevus of the tongue with pseudoepitheliomatous hyperplasia: report of three cases of a pseudomalignant condition. *Am J Surg Pathol*. 2002;26(6):774-777.
239. Lourenco SV, A MS, Sotto MN, et al. Primary oral mucosal melanoma: a series of 35 new cases from South America. *Am J Dermatopathol*. 2009;31(4):323-330.
240. Batsakis JG, Suarez P. Mucosal melanomas: a review. *Adv Anat Pathol*. 2000;7(3): 167-180.
241. Kilpatrick SE, White WL, Browne JD. Desmoplastic malignant melanoma of the oral mucosa. An underrecognized diagnostic pitfall. *Cancer*. 1996;78(3):383-389.
242. Prasad ML, Jungbluth AA, Iversen K, et al. Expression of melanocytic differentiation markers in malignant melanomas of the oral and sinonasal mucosa. *Am J Surg Pathol*. 2001;25(6):782-787.
243. Eisen D, Voorhees JJ. Oral melanoma and other pigmented lesions of the oral cavity. *J Am Acad Dermatol*. 1991;24(4):527-537.
244. Prasad ML, Patel S, Hoshaw-Woodard S, et al. Prognostic factors for malignant melanoma of the squamous mucosa of the head and neck. *Am J Surg Pathol*. 2002;26(7):883-892.
245. Bernier JL, Bhaskar SN. Lymphoepithelial lesions of salivary glands; histogenesis and classification based on 186 cases. *Cancer*. 1958;11(6):1156-1179.
246. Barreto I, Juliano P, Chagas C, Altemani A. Lymphoid polyps of the palatine tonsil. *Int J Surg Pathol*. 2007;15(2):155-159.
247. Zambrano E, Mejia-Mejia O, Bifulco C, et al. Extranodal marginal zone B-cell lymphoma/maltoma of the lip in a child: case report and review of cutaneous lymphoid proliferations in childhood. *Int J Surg Pathol*. 2006;14(2):163-169.
248. Barton JH, Osborne BM, Butler JJ, et al. Non-Hodgkin's lymphoma of the tonsil. A clinicopathologic study of 65 cases. *Cancer*. 1984;53(1):86-95.
249. Chan JK, Ng CS, Lo ST. Immunohistological characterization of malignant lymphomas of the Waldeyer's ring other than the nasopharynx. *Histopathology*. 1987;11(9):885-899.
250. Handlers JP, Howell RE, Abrams AM, Melrose RJ. Extranodal oral lymphoma. Part I. A morphologic and immunoperoxidase study of 34 cases. *Oral Surg Oral Med Oral Pathol*. 1986;61(4):362-367.
251. Kemp S, Gallagher G, Kabani S, et al. Oral non-Hodgkin's lymphoma: review of the literature and World Health Organization classification with reference to 40 cases. *Oral Surg Oral Med Oral Pathol Oral Radiol Endod*. 2008;105(2):194-201.
252. Solomides CC, Miller AS, Christman RA, et al. Lymphomas of the oral cavity: histology, immunologic type, and incidence of Epstein-Barr virus infection. *Hum Pathol*. 2002;33(2):153-157.
253. Saul SH, Kapadia SB. Primary lymphoma of Waldeyer's ring. Clinicopathologic study of 68 cases. *Cancer*. 1985;56(1):157-166.
254. Paulsen J, Lennert K. Low-grade B-cell lymphoma of mucosa-associated lymphoid tissue type in Waldeyer's ring. *Histopathology*. 1994;24(1):1-11.
255. Sirois DA, Miller AS, Harwick RD, Vonderheid EC. Oral manifestations of cutaneous T-cell lymphoma. A report of eight cases. *Oral Surg Oral Med Oral Pathol*. 1993;75(6):700-705.
256. Brousset P, Pages M, Chittal SM, Gorguet B. Tumour phase of mycosis fungoides in the tongue. *Histopathology*. 1992;20(1):87-89.
257. Batsakis JG, Medeiros JL, Luna MA, El-Naggar AK. Plasma cell dyscrasias and the head and neck. *Ann Diagn Pathol*. 2002;6(2):129-140.
258. Ballesteros E, Osborne BM, Matsushima AY. Plasma cell granuloma of the oral cavity: a report of two cases and review of the literature. *Mod Pathol*. 1998;11(1):60-64.
259. Ferreiro JA, Egorshin EV, Olsen KD, et al. Mucous membrane plasmacytosis of the upper aerodigestive tract. A clinicopathologic study. *Am J Surg Pathol*. 1994;18(10):1048-1053.
260. Solomon LW, Wein RO, Rosenwald I, Laver N. Plasma cell mucositis of the oral cavity: report of a case and review of the literature. *Oral Surg Oral Med Oral Pathol Oral Radiol Endod*. 2008;106(6):853-860.

261. Sidhu JS, Rigotti R, Schotanus P. Primary adenoidal Hodgkin's disease: report of a case with an unusual morphology and review of the literature. *Int J Surg Pathol*. 2000;8(3):241-246.
262. Quinones-Avila Mdel P, Gonzalez-Longoria AA, Admirand JH, Medeiros LJ. Hodgkin lymphoma involving Waldeyer ring: a clinicopathologic study of 22 cases. *Am J Clin Pathol*. 2005;123(5):651-656.
263. Dreizen S, McCredie KB, Keating MJ, Luna MA. Malignant gingival and skin "infiltrates" in adult leukemia. *Oral Surg Oral Med Oral Pathol*. 1983;55(6):572-579.
264. Castella A, Davey FR, Elbadawi A, Gordon GB. Granulocytic sarcoma of the hard palate: report of the first case. *Hum Pathol*. 1984;15(12):1190-1192.
265. Hartman KS. Histiocytosis X: a review of 114 cases with oral involvement. *Oral Surg Oral Med Oral Pathol*. 1980;49(1):38-54.
266. Gorsky M, Silverman S Jr, Lozada F, Kushner J. Histiocytosis X: occurrence and oral involvement in six adolescent and adult patients. *Oral Surg Oral Med Oral Pathol*. 1983;55(1):24-28.
267. Chan JK, Tsang WY, Ng CS, et al. Follicular dendritic cell tumors of the oral cavity. *Am J Surg Pathol*. 1994;18(2):148-157.
268. Kreiger PA, Ernst LM, Elden LM, et al. Hamartomatous tongue lesions in children. *Am J Surg Pathol*. 2007;31(8):1186-1190.
269. Giansanti JS, Waldron CA. Peripheral giant cell granuloma: review of 720 cases. *J Oral Surg*. 1969;27(10):787-791.
270. ZE C, RB B. Peripheral ossifying fibroma—a clinical evaluation of 134 pediatric cases. *Pediatr Dent*. 2001;23(3):245-248.
271. Slootweg P, de Wilde P, Vooijs P, Ramaekers F. Oral granular cell lesions. An immunohistochemical study with emphasis on intermediate-sized filaments proteins. *Virchows Arch A Pathol Anat Histopathol*. 1983;402(1):35-45.
272. Wetzel W, Leipzig B, Grunow W, et al. Malignant granular cell tumor of the tongue. *Arch Otolaryngol*. 1982;108(9):603-605.
273. Lack EE, Worsham GF, Callihan MD, et al. Gingival granula cell tumors of the newborn (congenital "epulis"): a clinical and pathologic study of 21 patients. *Am J Surg Pathol*. 1981;5(1):37-46.
274. Kameyama Y, Mizohata M, Takehana S, et al. Ultrastructure of the congenital epulis. *Virchows Arch A Pathol Anat Histopathol*. 1983;401(3):251-260.
275. Lack EE, Perez-Atayde AR, McGill TJ, Vawter GF. Gingival granular cell tumor of the newborn (congenital "epulis"): ultrastructural observations relating to histogenesis. *Hum Pathol*. 1982;13(7):686-689.
276. Tucker MC, Rusnock EJ, Azumi N, et al. Gingival granular cell tumors of the newborn. An ultrastructural and immunohistochemical study. *Arch Pathol Lab Med*. 1990;114(8):895-898.
277. Mostafa KA, Takata T, Ogawa I, et al. Verruciform xanthoma of the oral mucosa: a clinicopathological study with immunohistochemical findings relating to pathogenesis. *Virchows Arch A Pathol Anat Histopathol*. 1993;423(4):243-248.
278. Nowparast B, Howell FV, Rick GM. Verruciform xanthoma. A clinicopathologic review and report of fifty-four cases. *Oral Surg Oral Med Oral Pathol*. 1981;51(6):619-625.
279. Sexton M. Hairy polyp of the oropharynx. A case report with speculation on nosology. *Am J Dermatopathol*. 1990;12(3):294-298.
280. Renshaw AA, Rosai J. Benign atypical vascular lesions of the lip. A study of 12 cases. *Am J Surg Pathol*. 1993;17(6):557-565.
281. Toida M, Hasegawa T, Watanabe F, et al. Lobular capillary hemangioma of the oral mucosa: clinicopathological study of 43 cases with a special reference to immunohistochemical characterization of the vascular elements. *Pathol Int*. 2003;53(1):1-7.
282. Kerr DA. Granuloma pyogenicum. *Oral Surg Oral Med Oral Pathol*. 1951;4(2):158-176.
283. MacVicar J, Dunn MF. Pregnancy tumour of the gums. A report of two cases. *J Obstet Gynaecol Br Commonw*. 1969;76(3):260-263.
284. Bodner L, Dayan D. Intravascular papillary endothelial hyperplasia of the mandibular mucosa. *Int J Oral Maxillofac Surg*. 1991;20(5):273-274.
285. Batsakis JG, Rice DH. The pathology of head and neck tumors: vasoformative tumors, part 9A. *Head Neck Surg*. 1981;3(3):231-239.
286. Kardon DE, Wenig BM, Heffner DK, Thompson LD. Tonsillar lymphangiomatous polyps: a clinicopathologic series of 26 cases. *Mod Pathol*. 2000;13(10):1128-1133.
287. Saku T, Okabe H, Matsutani K, Sasaki M. Glomus tumor of the cheek: an immunohistochemical demonstration of actin and myosin. *Oral Surg Oral Med Oral Pathol*. 1985;60(1):65-71.
288. Peters E, Altini M, Kola AH. Oral angiolymphoid hyperplasia with eosinophilia. *Oral Surg Oral Med Oral Pathol*. 1986;61(1):73-79.
289. Razquin S, Mayayo E, Citores MA, Alvira R. Angiolymphoid hyperplasia with eosinophilia of the tongue: report of a case and review of the literature. *Hum Pathol*. 1991;22(8):837-839.
290. Flaitz CM, McDaniel RK, Mackay B, et al. Primary intraoral epithelioid hemangioendothelioma presenting in childhood: review of the literature and case report. *Ultrastruct Pathol*. 1995;19(4):275-279.
291. Regezi JA, MacPhail LA, Daniels TE, et al. Oral Kaposi's sarcoma: a 10-year retrospective histopathologic study. *J Oral Pathol Med*. 1993;22(7):292-297.
292. Regezi JA, MacPhail LA, Daniels TE, et al. Human immunodeficiency virus-associated oral Kaposi's sarcoma. A heterogeneous cell population dominated by spindle-shaped endothelial cells. *Am J Pathol*. 1993;143(1):240-249.
293. Batsakis JG, Rice DH. The pathology of head and neck tumors: vasoformative tumors, part 9B. *Head Neck Surg*. 1981;3(4):326-339.
294. Fanburg-Smith JC, Furlong MA, Childers EL. Oral and salivary gland angiosarcoma: a clinicopathologic study of 29 cases. *Mod Pathol*. 2003;16(3):263-271.
295. Oliver AJ, Gibbons SD, Radden BG, et al. Primary angiosarcoma of the oral cavity. *Br J Oral Maxillofac Surg*. 1991;29(1):38-41.
296. Alawi F, Stratton D, Freedman PD. Solitary fibrous tumor of the oral soft tissues: a clinicopathologic and immunohistochemical study of 16 cases. *Am J Surg Pathol*. 2001;25(7):900-910.
297. Corio RL, Lewis DM. Intraoral rhabdomyomas. *Oral Surg Oral Med Oral Pathol*. 1979;48(6):525-531.
298. Gardner DG, Corio RL. Fetal rhabdomyoma of the tongue, with a discussion of the two histologic variants of this tumor. *Oral Surg Oral Med Oral Pathol*. 1983;56(3):293-300.
299. Sangueza O, Sangueza P, Jordan J, White CR Jr. Rhabdomyoma of the tongue. *Am J Dermatopathol*. 1990;12(5):492-495.
300. Crotty PL, Nakhleh RE, Dehner LP. Juvenile rhabdomyoma. An intermediate form of skeletal muscle tumor in children. *Arch Pathol Lab Med*. 1993;117(1):43-47.
301. Gardner DG, Corio RL. Multifocal adult rhabdomyoma. *Oral Surg Oral Med Oral Pathol*. 1983;56(1):76-78.
302. Gibas Z, Miettinen M. Recurrent parapharyngeal rhabdomyoma. Evidence of neoplastic nature of the tumor from cytogenetic study. *Am J Surg Pathol*. 1992;16(7):721-728.
303. Lopez JI, Ballestin C. Intraoral schwannoma. A clinicopathologic and immunohistochemical study of nine cases. *Arch Anat Cytol Pathol*. 1993;41(1):18-23.
304. Williams HK, Cannell H, Silvester K, Williams DM. Neurilemmoma of the head and neck. *Br J Oral Maxillofac Surg*. 1993;31(1):32-35.
305. Oberman HA, Sullenger G. Neurogenous tumors of the head and neck. *Cancer*. 1967;20(11):1992-2001.
306. Daneshvar A. Pharyngeal traumatic neuromas and traumatic neuromas with mature ganglion cells (pseudoganglioneuromas). *Am J Surg Pathol*. 1990;14(6):565-570.
307. Gorlin RJ, Sedano HO, Vickers RA, Cervenka J. Multiple mucosal neuromas, pheochromocytoma and medullary carcinoma of the thyroid—a syndrome. *Cancer*. 1968;22(2):293-299. passim.
308. Cangiarella J, Jagirdar J, Adelman H, et al. Mucosal neuromas and plexiform neurofibromas: an immunocytochemical study. *Pediatr Pathol*. 1993;13(3):281-288.
309. Janzer RC, Makek M. Intraoral malignant melanotic schwannoma. Ultrastructural evidence for melanogenesis by Schwann's cells. *Arch Pathol Lab Med*. 1983;107(6):298-301.
310. Okada H, Yokoyama M, Hara M, et al. Sialolipoma of the palate: a rare case and review of the literature. *Oral Surg Oral Med Oral Pathol Oral Radiol Endod*. 2009;108(4):571-576.
311. Allard RH, Blok P, van der Kwast WA, van der Waal I. Oral lipomas with osseous and chondrous metaplasia; report of two cases. *J Oral Pathol*. 1982;11(1):18-25.
312. Billings SD, Henley JD, Summerlin DJ, et al. Spindle cell lipoma of the oral cavity. *Am J Dermatopathol*. 2006;28(1):28-31.
313. Chen SY, Fantasia JE, Miller AS. Myxoid lipoma of oral soft tissue. A clinical and ultrastructural study. *Oral Surg Oral Med Oral Pathol*. 1984;57(3):300-307.
314. Said-Al-Naief N, Zahurullah FR, Sciubba JJ. Oral spindle cell lipoma. *Ann Diagn Pathol*. 2001;5(4):207-215.
315. Munro JM, Singh MP. Chondroma of the tongue. Report of a case and a consideration of the histogenesis of such lesions. *Arch Pathol Lab Med*. 1990;114(5):541-542.
316. Flaggert JJ 3rd, Heldt LV, Keaton WM. Angiolipoma of the palate. Report of a case. *Oral Surg Oral Med Oral Pathol*. 1986;61(4):333-336.
317. Koutlas IG, Pambuccian SE, Jessurun J, et al. Perivascular epithelioid cell tumor of the oral mucosa. *Arch Pathol Lab Med*. 2005;129(5):690-693.
318. Smith BC, Ellis GL, Meis-Kindblom JM, Williams SB. Ectomesenchymal chondromyxoid tumor of the anterior tongue. Nineteen cases of a new clinicopathologic entity. *Am J Surg Pathol*. 1995;19(5):519-530.
319. Massarelli G, Tanda F, Salis B. Synovial sarcoma of the soft palate: report of a case. *Hum Pathol*. 1978;9(3):341-345.
320. Shmookler BM, Enzinger FM, Brannon RB. Orofacial synovial sarcoma: a clinicopathologic study of 11 new cases and review of the literature. *Cancer*. 1982;50(2):269-276.
321. Reyes JM, Vangore SK, Putong PB, et al. Osteogenic sarcoma of the tongue. *Oral Surg Oral Med Oral Pathol*. 1981;51(4):421-425.
322. Fanburg-Smith JC, Furlong MA, Childers EL. Liposarcoma of the oral and salivary gland region: a clinicopathologic study of 18 cases with emphasis on specific sites, morphologic subtypes, and clinical outcome. *Mod Pathol*. 2002;15(10):1020-1031.

323. Nascimento AF, McMenamin ME, Fletcher CD. Liposarcomas/atypical lipomatous tumors of the oral cavity: a clinicopathologic study of 23 cases. *Ann Diagn Pathol*. 2002;6(2):83-93.
324. Kaugars GE, Svirsky JA. Lung malignancies metastatic to the oral cavity. *Oral Surg Oral Med Oral Pathol*. 1981;51(2):179-186.
325. Kim RY, Perry SR, Levy DS. Metastatic carcinoma to the tongue: a report of two cases and a review of the literature. *Cancer*. 1979;43(1):386-389.
326. Baden E, Duvillard P, Micheau C. Metastatic papillary endometrial carcinoma of the tongue. Case report and review of the literature. *Arch Pathol Lab Med*. 1992;116(9):965-968.
327. Rusthoven JJ, Fine S, Thomas G. Adenocarcinoma of the rectum metastatic to the oral cavity. Two cases and a review of the literature. *Cancer*. 1984;54(6):1110-1112.
328. Zanconati F, DelConte A, Bonifacio-Gori D, Falconieri G. Metastatic pleural mesothelioma presenting with solitary involvement of the tongue: report of a new case and review of the literature. *Int J Surg Pathol*. 2003;11(1):51-55.
329. Zohar Y, Ben-Tovim R, Gal R, Laurian N. Metastatic carcinoma of oral soft tissue. *Head Neck Surg*. 1985;7(6):484-486.
330. Stosiek P, Kasper M, Moll R. Changes in cytokeratin expression accompany squamous metaplasia of the human respiratory epithelium. *Virchows Arch A Pathol Anat Histopathol*. 1992;421(2):133-141.
331. Sakaki M, Shek TW, Hirokawa M, et al. Melanotic oncocytic metaplasia of the nasopharynx: a report of seven cases and review of the literature. *Virchows Arch*. 2004;444(4):345-349.
332. Nakashima T, Kimmelman CP, Snow JB Jr. Structure of human fetal and adult olfactory neuroepithelium. *Arch Otolaryngol*. 1984;110(10):641-646.
333. Martinez J, Duma RJ, Nelson EC, Moretta FL. Experimental naegleria meningoencephalitis in mice. Penetration of the olfactory mucosal epithelium by Naegleria and pathologic changes produced: a light and electron microscope study. *Lab Invest*. 1973;29(2):121-133.
334. Larsen PL, Tos M. Origin of nasal polyps. *Laryngoscope*. 1991;101(3):305-312.
335. Yazbak PA, Phillips JM, Ball PA, Rhodes CH. Benign nasal polyposis presenting as an intracranial mass: case report. *Surg Neurol*. 1991;36(5):380-383.
336. Batsakis JG, Sneige N. Choanal and angiomatous polyps of the sinonasal tract. *Ann Otol Rhinol Laryngol*. 1992;101(7):623-625.
337. Kawabori S, Denburg JA, Schwartz LB, et al. Histochemical and immunohistochemical characteristics of mast cells in nasal polyps. *Am J Respir Cell Mol Biol*. 1992;6(1):37-43.
338. Stoop AE, van der Heijden HA, Biewenga J, van der Baan S. Lymphocytes and nonlymphoid cells in human nasal polyps. *J Allergy Clin Immunol*. 1991;87(2):470-475.
339. Stoop AE, van der Heijden HA, Biewenga J, van der Baan S. Eosinophils in nasal polyps and nasal mucosa: an immunohistochemical study. *J Allergy Clin Immunol*. 1993;91(2):616-622.
340. Davidsson A, Hellquist HB. The so-called 'allergic' nasal polyp. *ORL J Otorhinolaryngol Relat Spec*. 1993;55(1):30-35.
341. Kindblom LG, Angervall L. Nasal polyps with atypical stroma cells: a pseudosarcomatous lesion. A light and electron-microscopic and immunohistochemical investigation with implications on the type and nature of the mesenchymal cells. *Acta Pathol Microbiol Immunol Scand [A]*. 1984;92(1):65-72.
342. Yfantis HG, Drachenberg CB, Gray W, Papadimitriou JC. Angiectatic nasal polyps that clinically simulate a malignant process: report of 2 cases and review of the literature. *Arch Pathol Lab Med*. 2000;124(3):406-410.
343. Henderson WR Jr, Chi EY. Degranulation of cystic fibrosis nasal polyp mast cells. *J Pathol*. 1992;166(4):395-404.
344. Oppenheimer EH, Rosenstein BJ. Differential pathology of nasal polyps in cystic fibrosis and atopy. *Lab Invest*. 1979;40(4):445-449.
345. MacArthur CJ, Gliklich R, McGill TJ, Perez-Atayde A. Sinus complications in mucopolysaccharidosis IH/S (Hurler-Scheie syndrome). *Int J Pediatr Otorhinolaryngol*. 1993;26(1):79-87.
346. Stierna P, Carlsöö B. Histopathological observations in chronic maxillary sinusitis. *Acta Otolaryngol*. 1990;110(5-6):450-458.
347. Hamilos DL, Leung DY, Wood R, et al. Chronic hyperplastic sinusitis: association of tissue eosinophilia with mRNA expression of granulocyte-macrophage colony-stimulating factor and interleukin-3. *J Allergy Clin Immunol*. 1993;92(1 Pt 1):39-48.
348. Gardner DG. Pseudocysts and retention cysts of the maxillary sinus. *Oral Surg Oral Med Oral Pathol*. 1984;58(5):561-567.
349. deShazo RD, Chapin K, Swain RE. Fungal sinusitis. *N Engl J Med*. 1997;337(4):254-259.
350. Granville L, Chirala M, Cernoch P, et al. Fungal sinusitis: histologic spectrum and correlation with culture. *Hum Pathol*. 2004;35(4):474-481.
351. Taxy JB. Paranasal fungal sinusitis: contributions of histopathology to diagnosis: a report of 60 cases and literature review. *Am J Surg Pathol*. 2006;30(6):713-720.
352. Das A, Bal A, Chakrabarti A, et al. Spectrum of fungal rhinosinusitis; histopathologist's perspective. *Histopathology*. 2009;54(7):854-859.
353. Katzenstein AL, Sale SR, Greenberger PA. Pathologic findings in allergic aspergillus sinusitis. A newly recognized form of sinusitis. *Am J Surg Pathol*. 1983;7(5):439-443.
354. Torres C, Ro JY, el-Naggar AK, et al. Allergic fungal sinusitis: a clinicopathologic study of 16 cases. *Hum Pathol*. 1996;27(8):793-799.
355. Heffner DK. Allergic fungal sinusitis is a histopathologic diagnosis; paranasal mucocele is not. *Ann Diagn Pathol*. 2004;8(5):316-323.
356. van der Coer JM, Marres HA, Wielinga EW, Wong-Alcala LS. Rhinosporidiosis in Europe. *J Laryngol Otol*. 1992;106(5):440-443.
357. Ahluwalia KB. New interpretations in rhinosporidiosis, enigmatic disease of the last nine decades. *J Submicrosc Cytol Pathol*. 1992;24(1):109-114.
358. Herr RA, Ajello L, Taylor JW, et al. Phylogenetic analysis of Rhinosporidium seeberi's 18S small-subunit ribosomal DNA groups this pathogen among members of the protoctistan Mesomycetozoa clade. *J Clin Microbiol*. 1999;37(9):2750-2754.
359. Waldron J, Van Hasselt CA, Skinner DW, Arnold M. Tuberculosis of the nasopharynx: clinicopathological features. *Clin Otolaryngol Allied Sci*. 1992;17(1):57-59.
360. Patey O, Bonnieux P, Roucayrol AM, Lafaix C. Sarcoidosis of the nose: report of a case with nasal perforation. *Sarcoidosis*. 1990;7(2):123-124.
361. Batsakis JG, el-Naggar AK. Rhinoscleroma and rhinosporidiosis. *Ann Otol Rhinol Laryngol*. 1992;101(10):879-882.
362. Meyer PR, Shum TK, Becker TS, Taylor CR. Scleroma (Rhinoscleroma). A histologic immunohistochemical study with bacteriologic correlates. *Arch Pathol Lab Med*. 1983;107(7):377-383.
363. Foucar E, Rosai J, Dorfman RF. Sinus histiocytosis with massive lymphadenopathy. *Arch Otolaryngol*. 1978;104(12):687-693.
364. Wenig BM, Abbondanzo SL, Childers EL, et al. Extranodal sinus histiocytosis with massive lymphadenopathy (Rosai-Dorfman disease) of the head and neck. *Hum Pathol*. 1993;24(5):483-492.
365. Matsubara O, Yoshimura N, Doi Y, et al. Nasal biopsy in the early diagnosis of Wegener's (pathergic) granulomatosis. Significance of palisading granuloma and leukocytoclastic vasculitis. *Virchows Arch*. 1996;428(1):13-19.
366. Devaney KO, Travis WD, Hoffman G, et al. Interpretation of head and neck biopsies in Wegener's granulomatosis. A pathologic study of 126 biopsies in 70 patients. *Am J Surg Pathol*. 1990;14(6):555-564.
367. Del Buono EA, Flint A. Diagnostic usefulness of nasal biopsy in Wegener's granulomatosis. *Hum Pathol*. 1991;22(2):107-110.
368. Trimarchi M, Gregorini G, Facchetti F, et al. Cocaine-induced midline destructive lesions: clinical, radiographic, histopathologic, and serologic features and their differentiation from Wegener granulomatosis. *Medicine (Baltimore)*. 2001;80(6):391-404.
369. Noorduyn LA, Torenbeek R, van der Valk P, et al. Sinonasal non-Hodgkin's lymphomas and Wegener's granulomatosis: a clinicopathological study. *Virchows Arch A Pathol Anat Histopathol*. 1991;418(3):235-240.
370. Nigar E, Dhillon R, Carr E, Matin RN. Eosinophilic angiocentric fibrosis and extrafacial granuloma faciale. *Histopathology*. 2007;51(5):729-731.
371. Thompson LD, Heffner DK. Sinonasal tract eosinophilic angiocentric fibrosis. A report of three cases. *Am J Clin Pathol*. 2001;115(2):243-248.
372. McClatchie S, Warambo MW, Bremner AD. Myospherulosis: a previously unreported disease? *Am J Clin Pathol*. 1969;51(6):699-704.
373. Travis WD, Li CY, Weiland LH. Immunostaining for hemoglobin in two cases of myospherulosis. *Arch Pathol Lab Med*. 1986;110(8):763-765.
374. D'Angelo AJ Jr, Marlowe A, Marlowe FI, McFarland M. Inverted papilloma of the nose and paranasal sinuses in children. *Ear Nose Throat J*. 1992;71(6):264-266.
375. Peterson IM, Heim C. Inverted squamous papilloma with neuro-ophthalmic features. *J Clin Neuroophthalmol*. 1991;11(1):35-38.
376. Hyams VJ. Papillomas of the nasal cavity and paranasal sinuses. A clinicopathological study of 315 cases. *Ann Otol Rhinol Laryngol*. 1971;80(2):192-206.
377. Michaels L. Benign mucosal tumors of the nose and paranasal sinuses. *Semin Diagn Pathol*. 1996;13(2):113-117.
378. Barnes L, Bedetti C. Oncocytic Schneiderian papilloma: a reappraisal of cylindrical cell papilloma of the sinonasal tract. *Hum Pathol*. 1984;15(4):344-351.
379. Schwerer MJ, Kraft K, Baczako K, Maier H. Coexpression of cytokeratins typical for columnar and squamous differentiation in sinonasal inverted papillomas. *Am J Clin Pathol*. 2001;115(5):747-754.
380. Nielsen PL, Buchwald C, Nielsen LH, Tos M. Inverted papilloma of the nasal cavity: pathological aspects in a follow-up study. *Laryngoscope*. 1991;101(10):1094-1101.
381. Benninger MS, Roberts JK, Sebek BA, et al. Inverted papillomas and associated squamous cell carcinomas. *Otolaryngol Head Neck Surg*. 1990;103(3):457-461.
382. Gaffey MJ, Frierson HF, Weiss LM, et al. Human papillomavirus and Epstein-Barr virus in sinonasal Schneiderian papillomas. An in situ hybridization and polymerase chain reaction study. *Am J Clin Pathol*. 1996;106(4):475-482.
383. McLachlin CM, Kandel RA, Colgan TJ, et al. Prevalence of human papillomavirus in sinonasal papillomas: a study using polymerase chain reaction and in situ hybridization. *Mod Pathol*. 1992;5(4):406-409.

384. Sarkar FH, Visscher DW, Kintanar EB, et al. Sinonasal Schneiderian papillomas: human papillomavirus typing by polymerase chain reaction. *Mod Pathol*. 1992;5(3):329-332.
385. Fu YS, Hoover L, Franklin M, et al. Human papillomavirus identified by nucleic acid hybridization in concomitant nasal and genital papillomas. *Laryngoscope*. 1992;102(9):1014-1019.
386. Judd R, Zaki SR, Coffield LM, Evatt BL. Sinonasal papillomas and human papillomavirus: human papillomavirus 11 detected in fungiform Schneiderian papillomas by in situ hybridization and the polymerase chain reaction. *Hum Pathol*. 1991;22(6):550-556.
387. Macdonald MR, Le KT, Freeman J, et al. A majority of inverted sinonasal papillomas carries Epstein-Barr virus genomes. *Cancer*. 1995;75(9):2307-2312.
388. Udager AM, Rolland DC, McHugh JB, et al. High-frequency targetable EGFR mutations in sinonasal squamous cell carcinomas arising from inverted sinonasal papilloma. *Cancer Res*. 2015;75(13):2600-2606.
389. Myers EN, Fernau JL, Johnson JT, et al. Management of inverted papilloma. *Laryngoscope*. 1990;100(5):481-490.
390. Carta F, Verillaud B, Herman P. Role of endoscopic approach in the management of inverted papilloma. *Curr Opin Otolaryngol Head Neck Surg*. 2011;19(1):21-24.
391. Roush GC. Epidemiology of cancer of the nose and paranasal sinuses: current concepts. *Head Neck Surg*. 1979;2(1):3-11.
392. Robin PE, Shortridge RT. Lateralisation of tumours of the nasal cavity and paranasal sinuses and its relationship to aetiology. *Lancet*. 1979;1(8118):695-696.
393. Ironside P, Matthews J. Adenocarcinoma of the nose and paranasal sinuses in woodworkers in the state of Victoria, Australia. *Cancer*. 1975;36(3):1115-1124.
394. Kleinsasser O, Schroeder HG. What's new in tumours of the nasal cavity? Adenocarcinomas arising after exposure to wood dust. *Pathol Res Pract*. 1989;184(5):554-558.
395. Moran CA, Wenig BM, Mullick FG. Primary adenocarcinoma of the nasal cavity and paranasal sinuses. *Ear Nose Throat J*. 1991;70(12):821-828.
396. Nunez F, Suarez C, Alvarez I, et al. Sino-nasal adenocarcinoma: epidemiological and clinico-pathological study of 34 cases. *J Otolaryngol*. 1993;22(2):86-90.
397. El-Mofty SK, Lu DW. Prevalence of high-risk human papillomavirus DNA in nonkeratinizing (cylindrical cell) carcinoma of the sinonasal tract: a distinct clinicopathologic and molecular disease entity. *Am J Surg Pathol*. 2005;29(10):1367-1372.
398. Cerilli LA, Holst VA, Brandwein MS, et al. Sinonasal undifferentiated carcinoma: immunohistochemical profile and lack of EBV association. *Am J Surg Pathol*. 2001;25(2):156-163.
399. Fradis M, Podoshin L, Gertner R, Sabo E. Squamous cell carcinoma of the nasal septum mucosa. *Ear Nose Throat J*. 1993;72(3):217-221.
400. Patel P, Tiwari R, Karim AB, et al. Squamous cell carcinoma of the nasal vestibule. *J Laryngol Otol*. 1992;106(4):332-336.
401. Taxy JB. Squamous carcinoma of the nasal vestibule: an analysis of five cases and literature review. *Am J Clin Pathol*. 1997;107(6):698-703.
402. Cheng VS, Wang CC. Carcinomas of the paranasal sinuses: a study of sixty-six cases. *Cancer*. 1977;40(6):3038-3041.
403. Ringertz N. Pathology of malignant tumors arising in the nasal and paranasal cavities and maxilla. *Acta Otolaryngol*. 1938;27(suppl):1-405.
404. Batsakis JG, Rice DH, Solomon AR. The pathology of head and neck tumors: squamous and mucous-gland carcinomas of the nasal cavity, paranasal sinuses, and larynx, part 6. *Head Neck Surg*. 1980;2(6):497-508.
405. Osborn DA. Nature and behavior of transitional tumors in the upper respiratory tract. *Cancer*. 1970;25(1):50-60.
406. Westra WH, Holmes GF, Eisele DW. Bizarre epithelial atypia of the sinonasal tract after chemotherapy. *Am J Surg Pathol*. 2001;25(5):652-656.
407. Gnepp DR, Heffner DK. Mucosal origin of sinonasal tract adenomatous neoplasms. *Mod Pathol*. 1989;2(4):365-371.
408. Neto AG, Pineda-Daboin K, Luna MA. Sinonasal tract seromucous adenocarcinomas: a report of 12 cases. *Ann Diagn Pathol*. 2003;7(3):154-159.
409. Heffner DK, Hyams VJ, Hauck KW, Lingeman C. Low-grade adenocarcinoma of the nasal cavity and paranasal sinuses. *Cancer*. 1982;50(2):312-322.
410. Barnes L. Intestinal-type adenocarcinoma of the nasal cavity and paranasal sinuses. *Am J Surg Pathol*. 1986;10(3):192-202.
411. Franquemont DW, Fechner RE, Mills SE. Histologic classification of sinonasal intestinal-type adenocarcinoma. *Am J Surg Pathol*. 1991;15(4):368-375.
412. McKinney CD, Mills SE, Franquemont DW. Sinonasal intestinal-type adenocarcinoma: immunohistochemical profile and comparison with colonic adenocarcinoma. *Mod Pathol*. 1995;8(4):421-426.
413. Sanchez-Casis G, Devine KD, Weiland LH. Nasal adenocarcinomas that closely simulate colonic carcinomas. *Cancer*. 1971;28(3):714-720.
414. Batsakis JG, Mackay B, Ordonez NG. Enteric-type adenocarcinoma of the nasal cavity. An electron microscopic and immunocytochemical study. *Cancer*. 1984;54(5):855-860.
415. Cathro HP, Mills SE. Immunophenotypic differences between intestinal-type and low-grade papillary sinonasal adenocarcinomas: an immunohistochemical study of 22 cases utilizing CDX2 and MUC2. *Am J Surg Pathol*. 2004;28(8):1026-1032.
416. Choi HR, Sturgis EM, Rashid A, et al. Sinonasal adenocarcinoma: evidence for histogenetic divergence of the enteric and nonenteric phenotypes. *Hum Pathol*. 2003;34(11):1101-1107.
417. Ortiz-Rey JA, Alvarez C, San Miguel P, et al. Expression of CDX2, cytokeratins 7 and 20 in sinonasal intestinal-type adenocarcinoma. *Appl Immunohistochem Mol Morphol*. 2005;13(2):142-146.
418. Yom SS, Rashid A, Rosenthal DI, et al. Genetic analysis of sinonasal adenocarcinoma phenotypes: distinct alterations of histogenetic significance. *Mod Pathol*. 2005;18(3): 315-319.
419. Mills SE, Fechner RE, Cantrell RW. Aggressive sinonasal lesion resembling normal intestinal mucosa. *Am J Surg Pathol*. 1982;6(8):803-809.
420. Perez-Ordonez B, Caruana SM, Huvos AG, Shah JP. Small cell neuroendocrine carcinoma of the nasal cavity and paranasal sinuses. *Hum Pathol*. 1998;29(8):826-832.
421. Houston GD, Gillies E. Sinonasal undifferentiated carcinoma: a distinctive clinicopathologic entity. *Adv Anat Pathol*. 1999;6(6):317-323.
422. Frierson HF Jr, Mills SE, Fechner RE, et al. Sinonasal undifferentiated carcinoma. An aggressive neoplasm derived from schneiderian epithelium and distinct from olfactory neuroblastoma. *Am J Surg Pathol*. 1986;10(11):771-779.
423. Giri SP, Reddy EK, Gemer LS, et al. Management of advanced squamous cell carcinomas of the maxillary sinus. *Cancer*. 1992;69(3):657-661.
424. Dulguerov P, Jacobsen MS, Allal AS, et al. Nasal and paranasal sinus carcinoma: are we making progress? A series of 220 patients and a systematic review. *Cancer*. 2001;92(12):3012-3029.
425. Franchi A, Gallo O, Santucci M. Clinical relevance of the histological classification of sinonasal intestinal-type adenocarcinomas. *Hum Pathol*. 1999;30(10):1140-1145.
426. Mills SE, Fechner RE. "Undifferentiated" neoplasms of the sinonasal region: differential diagnosis based on clinical, light microscopic, immunohistochemical, and ultrastructural features. *Semin Diagn Pathol*. 1989;6(4):316-328.
427. Fandi A, Altun M, Azli N, et al. Nasopharyngeal cancer: epidemiology, staging, and treatment. *Semin Oncol*. 1994;21(3):382-397.
428. Wenig BM. Nasopharyngeal carcinoma. *Ann Diagn Pathol*. 1999;3(6):374-385.
429. Easton JM, Levine PH, Hyams VJ. Nasopharyngeal carcinoma in the United States. A pathologic study of 177 US and 30 foreign cases. *Arch Otolaryngol*. 1980;106(2):88-91.
430. Coffin CM, Rich SS, Dehner LP. Familial aggregation of nasopharyngeal carcinoma and other malignancies. A clinicopathologic description. *Cancer*. 1991;68(6):1323-1328.
431. Gaffey MJ, Weiss LM. Association of Epstein-Barr virus with human neoplasia. *Pathol Annu*. 1992;27(Pt 1):55-74.
432. Liebowitz D. Nasopharyngeal carcinoma: the Epstein-Barr virus association. *Semin Oncol*. 1994;21(3):376-381.
433. Lopategui JR, Gaffey MJ, Frierson HF Jr, et al. Detection of Epstein-Barr viral RNA in sinonasal undifferentiated carcinoma from Western and Asian patients. *Am J Surg Pathol*. 1994;18(4):391-398.
434. Sun Y, Hegamyer G, Cheng YJ, et al. An infrequent point mutation of the p53 gene in human nasopharyngeal carcinoma. *Proc Natl Acad Sci USA*. 1992;89(14):6516-6520.
435. Pathmanathan R, Prasad U, Sadler R, et al. Clonal proliferations of cells infected with Epstein-Barr virus in preinvasive lesions related to nasopharyngeal carcinoma. *N Engl J Med*. 1995;333(11):693-698.
436. Deyrup AT. Epstein-Barr virus-associated epithelial and mesenchymal neoplasms. *Hum Pathol*. 2008;39(4):473-483.
437. Stewart JP, Arrand JR. Expression of the Epstein-Barr virus latent membrane protein in nasopharyngeal carcinoma biopsy specimens. *Hum Pathol*. 1993;24(3):239-242.
438. Tsai ST, Jin YT, Mann RB, Ambinder RF. Epstein-Barr virus detection in nasopharyngeal tissues of patients with suspected nasopharyngeal carcinoma. *Cancer*. 1998;82(8):1449-1453.
439. Feinmesser R, Miyazaki I, Cheung R, et al. Diagnosis of nasopharyngeal carcinoma by DNA amplification of tissue obtained by fine-needle aspiration. *N Engl J Med*. 1992;326(1):17-21.
440. Pearson GR, Weiland LH, Neel HB 3rd, et al. Application of Epstein-Barr virus (EBV) serology to the diagnosis of North American nasopharyngeal carcinoma. *Cancer*. 1983;51(2):260-268.
441. Chien YC, Chen JY, Liu MY, et al. Serologic markers of Epstein-Barr virus infection and nasopharyngeal carcinoma in Taiwanese men. *N Engl J Med*. 2001;345(26):1877-1882.
442. Chan JK, Yip TT, Tsang WY, et al. Detection of Epstein-Barr viral RNA in malignant lymphomas of the upper aerodigestive tract. *Am J Surg Pathol*. 1994;18(9):938-946.
443. Wei WI, Sham JS, Zong YS, et al. The efficacy of fiberoptic endoscopic examination and

biopsy in the detection of early nasopharyngeal carcinoma. *Cancer*. 1991;67(12):3127-3130.
444. Nicholls JM. Nasopharyngeal carcinoma: classification and histologic appearances. *Adv Anat Pathol*. 1997;4:71-84.
445. Tsai ST, Jin YT, Su IJ. Expression of EBER1 in primary and metastatic nasopharyngeal carcinoma tissues using in situ hybridization. A correlation with WHO histologic subtypes. *Cancer*. 1996;77(2):231-236.
446. Micheau C. What's new in histological classification and recognition of naso-pharyngeal carcinoma (N.P.C.). *Pathol Res Pract*. 1986;181(2):249-253.
447. Prathap K, Looi LM, Prasad U. Localized amyloidosis in nasopharyngeal carcinoma. *Histopathology*. 1984;8(1):27-34.
448. Cheung FM, Pang SW, Yau TK, et al. Nasopharyngeal intraepithelial lesion: latent Epstein-Barr virus infection with malignant potential. *Histopathology*. 2004;45(2):171-179.
449. Zaatari GS, Santoianni RA. Adenoid squamous cell carcinoma of the nasopharynx and neck region. *Arch Pathol Lab Med*. 1986;110(6):542-546.
450. Wenig BM, Hyams VJ, Heffner DK. Nasopharyngeal papillary adenocarcinoma. A clinicopathologic study of a low-grade carcinoma. *Am J Surg Pathol*. 1988;12(12):946-953.
451. Pineda-Daboin K, Neto A, Ochoa-Perez V, Luna MA. Nasopharyngeal adenocarcinomas: a clinicopathologic study of 44 cases including immunohistochemical features of 18 papillary phenotypes. *Ann Diagn Pathol*. 2006;10(4):215-221.
452. Carrizo F, Luna MA. Thyroid transcription factor-1 expression in thyroid-like nasopharyngeal papillary adenocarcinoma: report of 2 cases. *Ann Diagn Pathol*. 2005;9(4):189-192.
453. Gusterson BA, Mitchell DP, Warburton MJ, Carter RL. Epithelial markers in the diagnosis of nasopharyngeal carcinoma: an immunocytochemical study. *J Clin Pathol*. 1983;36(6):628-631.
454. Oppedal BR, Bohler PJ, Marton PF, Brandtzaeg P. Carcinoma of the nasopharynx. Histopathological examination with supplementary immunohistochemistry. *Histopathology*. 1987;11(11):1161-1169.
455. Kneile JR, Tan G, Suster S, Wakely PE Jr. Expression of CD30 (Ber-H2) in nasopharyngeal carcinoma, undifferentiated type and lymphoepithelioma-like carcinoma. A comparison study with anaplastic large cell lymphoma. *Histopathology*. 2006;48(7):855-861.
456. Taxy JB, Hidvegi DF, Battifora H. Nasopharyngeal carcinoma: antikeratin immunohistochemistry and electron microscopy. *Am J Clin Pathol*. 1985;83(3):320-325.
457. Lin HS, Lin CS, Yeh S, Tu SM. Fine structure of nasopharyngeal carcinoma with special reference to the anaplastic type. *Cancer*. 1969;23(2):390-405.
458. Tao Q, Chan AT. Nasopharyngeal carcinoma: molecular pathogenesis and therapeutic developments. *Expert Rev Mol Med*. 2007;9(12):1-24.
459. Chou J, Lin YC, Kim J, et al. Nasopharyngeal carcinoma—review of the molecular mechanisms of tumorigenesis. *Head Neck*. 2008;30(7):946-963.
460. Zhou W, Feng X, Li H, et al. Inactivation of LARS2, located at the commonly deleted region 3p21.3, by both epigenetic and genetic mechanisms in nasopharyngeal carcinoma. *Acta Biochim Biophys Sin (Shanghai)*. 2009;41(1):54-62.
461. Teo PM, Leung SF, Yu P, et al. A comparison of Ho's, International Union Against Cancer, and American Joint Committee stage classifications for nasopharyngeal carcinoma. *Cancer*. 1991;67(2):434-439.
462. Su CY, Lui CC. Perineural invasion of the trigeminal nerve in patients with nasopharyngeal carcinoma. Imaging and clinical correlations. *Cancer*. 1996;78(10):2063-2069.
463. Zarate-Osorno A, Jaffe ES, Medeiros LJ. Metastatic nasopharyngeal carcinoma initially presenting as cervical lymphadenopathy. A report of two cases that resembled Hodgkin's disease. *Arch Pathol Lab Med*. 1992;116(8):862-865.
464. Rennke H, Lennert K. [Caseous necrosis and epithelioid cell reaction in lymph node metastases of lymphoepithelial carcinoma (Schmincke-Tumor)]. *Virchows Arch A Pathol Pathol Anat*. 1973;358(3):241-247.
465. Zen HG, Jame JM, Chang AY, et al. Nasopharyngeal carcinoma with bone marrow metastasis. *Am J Clin Oncol*. 1991;14(1):66-70.
466. Tsujii H, Kamada T, Tsuji H, et al. Improved results in the treatment of nasopharyngeal carcinoma using combined radiotherapy and chemotherapy. *Cancer*. 1989;63(9):1668-1672.
467. Lee AW, Poon YF, Foo W, et al. Retrospective analysis of 5037 patients with nasopharyngeal carcinoma treated during 1976–1985: overall survival and patterns of failure. *Int J Radiat Oncol Biol Phys*. 1992;23(2):261-270.
468. Heng DM, Wee J, Fong KW, et al. Prognostic factors in 677 patients in Singapore with nondisseminated nasopharyngeal carcinoma. *Cancer*. 1999;86(10):1912-1920.
469. Sham JS, Choy D. Prognostic factors of nasopharyngeal carcinoma: a review of 759 patients. *Br J Radiol*. 1990;63(745):51-58.
470. Hsu HC, Chen CL, Hsu MM, et al. Pathology of nasopharyngeal carcinoma. Proposal of a new histologic classification correlated with prognosis. *Cancer*. 1987;59(5):945-951.
471. Shanmugaratnam K, Chan SH, de-The G, et al. Histopathology of nasopharyngeal carcinoma: correlations with epidemiology, survival rates and other biological characteristics. *Cancer*. 1979;44(3):1029-1044.
472. Giannini A, Bianchi S, Messerini L, et al. Prognostic significance of accessory cells and lymphocytes in nasopharyngeal carcinoma. *Pathol Res Pract*. 1991;187(4):496-502.
473. Faccioli S, Cavicchi O, Caliceti U, et al. Cell proliferation as an independent predictor of survival for patients with advanced nasopharyngeal carcinoma. *Mod Pathol*. 1997;10(9):884-894.
474. Roychowdhury DF, Tseng A Jr, Fu KK, et al. New prognostic factors in nasopharyngeal carcinoma. Tumor angiogenesis and C-erbB2 expression. *Cancer*. 1996;77(8):1419-1426.
475. Manning JT, Batsakis JG. Salivary-type neoplasms of the sinonasal tract. *Ann Otol Rhinol Laryngol*. 1991;100(8):691-694.
476. Rafla S. Mucous gland tumors of paranasal sinuses. *Cancer*. 1969;24(4):683-691.
477. Goepfert H, Luna MA, Lindberg RD, White AK. Malignant salivary gland tumors of the paranasal sinuses and nasal cavity. *Arch Otolaryngol*. 1983;109(10):662-668.
478. Sato K, Ueda Y, Sakurai A, et al. Adenoid cystic carcinoma of the maxillary sinus with gradual histologic transformation to high-grade adenocarcinoma: a comparative report with dedifferentiated carcinoma. *Virchows Arch*. 2006;448(2):204-208.
479. Compagno J, Wong RT. Intranasal mixed tumors (pleomorphic adenomas): a clinicopathologic study of 40 cases. *Am J Clin Pathol*. 1977;68(2):213-218.
480. Reference deleted in proofs.
481. Dehner LP, Valbuena L, Perez-Atayde A, et al. Salivary gland anlage tumor ("congenital pleomorphic adenoma"). A clinicopathologic, immunohistochemical and ultrastructural study of nine cases. *Am J Surg Pathol*. 1994;18(1):25-36.
482. Fletcher CD, Carpenter G, McKee PH. Nasal glioma. A rarity. *Am J Dermatopathol*. 1986;8(4):341-346.
483. Perzin KH, Pushparaj N. Nonepithelial tumors of the nasal cavity, paranasal sinuses, and nasopharynx. A clinicopathologic study. XIII: Meningiomas. *Cancer*. 1984;54(9):1860-1869.
484. Chan JK, Lau WH. Nasal astrocytoma or nasal glial heterotopia? *Arch Pathol Lab Med*. 1989;113(8):943-945.
485. Devaney K, Wenig BM, Abbondanzo SL. Olfactory neuroblastoma and other round cell lesions of the sinonasal region. *Mod Pathol*. 1996;9(6):658-663.
486. Mills SE, Frierson HF Jr. Olfactory neuroblastoma. A clinicopathologic study of 21 cases. *Am J Surg Pathol*. 1985;9(5):317-327.
487. Oberman HA, Rice DH. Olfactory neuroblastomas: a clinicopathologic study. *Cancer*. 1976;38(6):2494-2502.
488. Ordonez NG, Mackay B. Neuroendocrine tumors of the nasal cavity. *Pathol Annu*. 1993;28(Pt 2):77-111.
489. Bellizzi AM, Bourne TD, Mills SE, Stelow EB. The cytologic features of sinonasal undifferentiated carcinoma and olfactory neuroblastoma. *Am J Clin Pathol*. 2008;129(3):367-376.
490. Chan JK, Lau WH, Yuen RW. Ganglioneuroblastic transformation of olfactory neuroblastoma. *Histopathology*. 1989;14(4):425-428.
491. Gaudin PB, Rosai J. Florid vascular proliferation associated with neural and neuroendocrine neoplasms. A diagnostic clue and potential pitfall. *Am J Surg Pathol*. 1995;19(6):642-652.
492. Curtis JL, Rubinstein LJ. Pigmented olfactory neuroblastoma: a new example of melanotic neuroepithelial neoplasm. *Cancer*. 1982;49(10):2136-2143.
493. Silva EG, Butler JJ, Mackay B, Goepfert H. Neuroblastomas and neuroendocrine carcinomas of the nasal cavity: a proposed new classification. *Cancer*. 1982;50(11):2388-2405.
494. Taxy JB, Bharani NK, Mills SE, et al. The spectrum of olfactory neural tumors. A light-microscopic immunohistochemical and ultrastructural analysis. *Am J Surg Pathol*. 1986;10(10):687-695.
495. Rosenthal DI, Barker JL Jr, El-Naggar AK, et al. Sinonasal malignancies with neuroendocrine differentiation: patterns of failure according to histologic phenotype. *Cancer*. 2004;101(11):2567-2573.
496. Argani P, Perez-Ordonez B, Xiao H, et al. Olfactory neuroblastoma is not related to the Ewing family of tumors: absence of EWS/FLI1 gene fusion and MIC2 expression. *Am J Surg Pathol*. 1998;22(4):391-398.
497. Hirano T, Aida T, Moriyama M, et al. Primary neuroblastoma of the nasal cavity and review of literature. *Acta Pathol Jpn*. 1985;35(1):183-191.
498. Micheau C. A new histochemical approach to olfactory esthesioneuroma. A nasal tumor of neural crest origin. *Cancer*. 1977;40(1):314-318.
499. Arnesen MA, Scheithauer BW, Freeman S. Cushing's syndrome secondary to olfactory neuroblastoma. *Ultrastruct Pathol*. 1994;18(1-2):61-68.
500. Axe S, Kuhajda FP. Esthesioneuroblastoma. Intermediate filaments, neuroendocrine, and

tissue-specific antigens. *Am J Clin Pathol*. 1987;88(2):139-145.
501. Choi HS, Anderson PJ. Immunohistochemical diagnosis of olfactory neuroblastoma. *J Neuropathol Exp Neurol*. 1985;44(1):18-31.
502. Trojanowski JQ, Lee V, Pillsbury N, Lee S. Neuronal origin of human esthesioneuroblastoma demonstrated with anti-neurofilament monoclonal antibodies. *N Engl J Med*. 1982;307(3):159-161.
503. Lloreta-Trull J, Mackay B, Troncoso P, et al. Neuroendocrine tumors of the nasal cavity: an ultrastructural and morphometric study of 24 cases. *Ultrastruct Pathol*. 1992;16(1-2):165-175.
504. Holland H, Koschny R, Krupp W, et al. Comprehensive cytogenetic characterization of an esthesioneuroblastoma. *Cancer Genet Cytogenet*. 2007;173(2):89-96.
505. Guled M, Myllykangas S, Frierson HF Jr, et al. Array comparative genomic hybridization analysis of olfactory neuroblastoma. *Mod Pathol*. 2008;21(6):770-778.
506. Meneses MS, Thurel C, Mikol J, et al. Esthesioneuroblastoma with intracranial extension. *Neurosurgery*. 1990;27(5):813-819, discussion 9-20.
507. Chao KS, Kaplan C, Simpson JR, et al. Esthesioneuroblastoma: the impact of treatment modality. *Head Neck*. 2001;23(9):749-757.
508. Olsen KD, DeSanto LW. Olfactory neuroblastoma. Biologic and clinical behavior. *Arch Otolaryngol*. 1983;109(12):797-802.
509. Kadish S, Goodman M, Wang CC. Olfactory neuroblastoma. A clinical analysis of 17 cases. *Cancer*. 1976;37(3):1571-1576.
510. Ozsahin M, Gruber G, Olszyk O, et al. Outcome and prognostic factors in olfactory neuroblastoma: a rare cancer network study. *Int J Radiat Oncol Biol Phys*. 2010;78(4):992-997.
511. Devaiah AK, Andreoli MT. Treatment of esthesioneuroblastoma: a 16-year meta-analysis of 361 patients. *Laryngoscope*. 2009;119(7):1412-1416.
512. Iwai Y, Hakuba A, Khosla VK, et al. Giant basal prolactinoma extending into the nasal cavity. *Surg Neurol*. 1992;37(4):280-283.
513. Luk IS, Chan JK, Chow SM, Leung S. Pituitary adenoma presenting as sinonasal tumor: pitfalls in diagnosis. *Hum Pathol*. 1996;27(6):605-609.
514. Schuller DE, Lucas JG. Nasopharyngeal paraganglioma. Report of a case and review of literature. *Arch Otolaryngol*. 1982;108(10):667-670.
515. Perzin KH, Panyu H, Wechter S. Nonepithelial tumors of the nasal cavity, paranasal sinuses and nasopharynx. A clinicopathologic study. XII: Schwann cell tumors (neurilemoma, neurofibroma, malignant schwannoma). *Cancer*. 1982;50(10):2193-2202.
516. Buob D, Wacrenier A, Chevalier D, et al. Schwannoma of the sinonasal tract: a clinicopathologic and immunohistochemical study of 5 cases. *Arch Pathol Lab Med*. 2003;127(9):1196-1199.
517. Heffner DK, Gnepp DR. Sinonasal fibrosarcomas, malignant schwannomas, and "Triton" tumors. A clinicopathologic study of 67 cases. *Cancer*. 1992;70(5):1089-1101.
518. Holdcraft J, Gallagher JC. Malignant melanomas of the nasal and paranasal sinus mucosa. *Ann Otol Rhinol Laryngol*. 1969;78(1):5-20.
519. Uehara T, Matsubara O, Kasuga T. Melanocytes in the nasal cavity and paranasal sinus. Incidence and distribution in Japan. *Acta Pathol Jpn*. 1987;37(7):1105-1114.
520. Prasad ML, Busam KJ, Patel SG, et al. Clinicopathologic differences in malignant melanoma arising in oral squamous and sinonasal respiratory mucosa of the upper aerodigestive tract. *Arch Pathol Lab Med*. 2003;127(8):997-1002.
521. Chetty R, Slavin JL, Pitson GA, Dowling JP. Melanoma botryoides: a distinctive myxoid pattern of sino-nasal malignant melanoma. *Histopathology*. 1994;24(4):377-379.
522. Friedmann I. Osteoid and bone formation in a nasal mucosal melanoma and its metastasis. *Histopathology*. 1998;33(1):88.
523. Thompson LD, Wieneke JA, Miettinen M. Sinonasal tract and nasopharyngeal melanomas: a clinicopathologic study of 115 cases with a proposed staging system. *Am J Surg Pathol*. 2003;27(5):594-611.
524. Robbins KT, Fuller LM, Vlasak M, et al. Primary lymphomas of the nasal cavity and paranasal sinuses. *Cancer*. 1985;56(4):814-819.
525. Vega F, Lin P, Medeiros LJ. Extranodal lymphomas of the head and neck. *Ann Diagn Pathol*. 2005;9(6):340-350.
526. Abbondanzo SL, Wenig BM. Non-Hodgkin's lymphoma of the sinonasal tract. A clinicopathologic and immunophenotypic study of 120 cases. *Cancer*. 1995;75(6):1281-1291.
527. Ferry JA, Sklar J, Zukerberg LR, Harris NL. Nasal lymphoma. A clinicopathologic study with immunophenotypic and genotypic analysis. *Am J Surg Pathol*. 1991;15(3):268-279.
528. Cheung MM, Chan JK, Lau WH, et al. Primary non-Hodgkin's lymphoma of the nose and nasopharynx: clinical features, tumor immunophenotype, and treatment outcome in 113 patients. *J Clin Oncol*. 1998;16(1):70-77.
529. Aozasa K, Zaki MA. Epidemiology and pathogenesis of nasal NK/T-cell lymphoma: a mini-review. *ScientificWorldJournal*. 2011;11:422-428.
530. Cuadra-Garcia I, Proulx GM, Wu CL, et al. Sinonasal lymphoma: a clinicopathologic analysis of 58 cases from the Massachusetts General Hospital. *Am J Surg Pathol*. 1999;23(11):1356-1369.
531. Gaal K, Sun NC, Hernandez AM, Arber DA. Sinonasal NK/T-cell lymphomas in the United States. *Am J Surg Pathol*. 2000;24(11):1511-1517.
532. Kuo TT, Shih LY, Tsang NM. Nasal NK/T cell lymphoma in Taiwan: a clinicopathologic study of 22 cases, with analysis of histologic subtypes, Epstein-Barr virus LMP-1 gene association, and treatment modalities. *Int J Surg Pathol*. 2004;12(4):375-387.
533. Chan WC, Hans CP. Genetic and molecular genetic studies in the diagnosis of T and NK cell neoplasia. *Hum Pathol*. 2003;34(4):314-321.
534. Schwartz EJ, Molina-Kirsch H, Zhao S, et al. Immunohistochemical characterization of nasal-type extranodal NK/T-cell lymphoma using a tissue microarray: an analysis of 84 cases. *Am J Clin Pathol*. 2008;130(3): 343-351.
535. Ko YH, Cho EY, Kim JE, et al. NK and NK-like T-cell lymphoma in extranasal sites: a comparative clinicopathological study according to site and EBV status. *Histopathology*. 2004;44(5):480-489.
536. Ng CS, Lo ST, Chan JK. Peripheral T and putative natural killer cell lymphomas commonly coexpress CD95 and CD95 ligand. *Hum Pathol*. 1999;30(1):48-53.
537. Takahara M, Kishibe K, Bandoh N, et al. P53, N- and K-Ras, and beta-catenin gene mutations and prognostic factors in nasal NK/T-cell lymphoma from Hokkaido, Japan. *Hum Pathol*. 2004;35(1):86-95.
538. Chiang AK, Chan AC, Srivastava G, Ho FC. Nasal T/natural killer (NK)-cell lymphomas are derived from Epstein-Barr virus-infected cytotoxic lymphocytes of both NK- and T-cell lineage. *Int J Cancer*. 1997;73(3):332-338.
539. Ott G, Kalla J, Ott MM, Muller-Hermelink HK. The Epstein-Barr virus in malignant non-Hodgkin's lymphoma of the upper aerodigestive tract. *Diagn Mol Pathol*. 1997;6(3):134-139.
540. Chan AT, Lo YM, Zee B, et al. Plasma Epstein-Barr virus DNA and residual disease after radiotherapy for undifferentiated nasopharyngeal carcinoma. *J Natl Cancer Inst*. 2002;94(21):1614-1619.
541. Iqbal J, Kucuk C, Deleeuw RJ, et al. Genomic analyses reveal global functional alterations that promote tumor growth and novel tumor suppressor genes in natural killer-cell malignancies. *Leukemia*. 2009;23(6):1139-1151.
542. Nakashima Y, Tagawa H, Suzuki R, et al. Genome-wide array-based comparative genomic hybridization of natural killer cell lymphoma/leukemia: different genomic alteration patterns of aggressive NK-cell leukemia and extranodal Nk/T-cell lymphoma, nasal type. *Genes Chromosomes Cancer*. 2005;44(3):247-255.
543. Ho FC, Choy D, Loke SL, et al. Polymorphic reticulosis and conventional lymphomas of the nose and upper aerodigestive tract: a clinicopathologic study of 70 cases, and immunophenotypic studies of 16 cases. *Hum Pathol*. 1990;21(10):1041-1050.
544. Aozasa K. Biopsy findings in malignant histiocytosis presenting as lethal midline granuloma. *J Clin Pathol*. 1982;35(6):599-605.
545. Daggett RB, Haghighi P, Terkeltaub RA. Nasal cocaine abuse causing an aggressive midline intranasal and pharyngeal destructive process mimicking midline reticulosis and limited Wegener's granulomatosis. *J Rheumatol*. 1990;17(6):838-840.
546. Sercarz JA, Strasnick B, Newman A, Dodd LG. Midline nasal destruction in cocaine abusers. *Otolaryngol Head Neck Surg*. 1991;105(5):694-701.
547. Ye YL, Zhou MH, Lu XY, et al. Nasopharyngeal and nasal malignant lymphoma: a clinicopathological study of 54 cases. *Histopathology*. 1992;20(6):511-516.
548. Wollner N, Mandell L, Filippa D, et al. Primary nasal-paranasal oropharyngeal lymphoma in the pediatric age group. *Cancer*. 1990;65(6):1438-1444.
549. Jaffe ES, Chan JK, Su IJ, et al. Report of the workshop on nasal and related extranodal angiocentric T/natural killer cell lymphomas. Definitions, differential diagnosis, and epidemiology. *Am J Surg Pathol*. 1996;20(1):103-111.
550. Liu Q, Ohshima K, Sumie A, et al. Nasal CD56 positive small round cell tumors. Differential diagnosis of hematological, neurogenic, and myogenic neoplasms. *Virchows Arch*. 2001;438(3):271-279.
551. Alexiou C, Kau RJ, Dietzfelbinger H, et al. Extramedullary plasmacytoma: tumor occurrence and therapeutic concepts. *Cancer*. 1999;85(11):2305-2314.
552. Kapadia SB, Desai U, Cheng VS. Extramedullary plasmacytoma of the head and neck. A clinicopathologic study of 20 cases. *Medicine (Baltimore)*. 1982;61(5):317-329.
553. Stroup RM, Sheibani K, Moncada A, et al. Angiotropic (intravascular) large cell lymphoma. A clinicopathologic study of seven cases with unique clinical presentations. *Cancer*. 1990;66(8):1781-1788.
554. MacNaughton DM, Tewfik TL, Bernstein ML. Hodgkin's disease in the nasopharynx. *J Otolaryngol*. 1990;19(4):282-284.
555. Fellbaum C, Hansmann ML. Immunohistochemical differential diagnosis of granulocytic sarcomas and malignant lymphomas on formalin-fixed material. *Virchows Arch A Pathol Anat Histopathol*. 1990;416(4):351-355.

556. Rimarenko S, Schwartz IS. Polypoid nasal pseudolymphoma. *Am J Clin Pathol*. 1985;83(4):507-509.
557. Hicks JL, Nelson JF. Juvenile nasopharyngeal angiofibroma. *Oral Surg Oral Med Oral Pathol*. 1973;35(6):807-817.
558. Guertl B, Beham A, Zechner R, et al. Nasopharyngeal angiofibroma: an APC-gene-associated tumor? *Hum Pathol*. 2000;31(11):1411-1413.
559. Hwang HC, Mills SE, Patterson K, Gown AM. Expression of androgen receptors in nasopharyngeal angiofibroma: an immunohistochemical study of 24 cases. *Mod Pathol*. 1998;11(11):1122-1126.
560. Schiff M, Gonzalez AM, Ong M, Baird A. Juvenile nasopharyngeal angiofibroma contain an angiogenic growth factor: basic FGF. *Laryngoscope*. 1992;102(8):940-945.
561. Zhang PJ, Weber R, Liang HH, et al. Growth factors and receptors in juvenile nasopharyngeal angiofibroma and nasal polyps: an immunohistochemical study. *Arch Pathol Lab Med*. 2003;127(11):1480-1484.
562. Abraham SC, Montgomery EA, Giardiello FM, Wu TT. Frequent beta-catenin mutations in juvenile nasopharyngeal angiofibromas. *Am J Pathol*. 2001;158(3):1073-1078.
563. Beham A, Beham-Schmid C, Regauer S, et al. Nasopharyngeal angiofibroma: true neoplasm or vascular malformation? *Adv Anat Pathol*. 2000;7(1):36-46.
564. Dohar JE, Duvall AJ 3rd. Spontaneous regression of juvenile nasopharyngeal angiofibroma. *Ann Otol Rhinol Laryngol*. 1992;101(6):469-471.
565. Deschler DG, Kaplan MJ, Boles R. Treatment of large juvenile nasopharyngeal angiofibroma. *Otolaryngol Head Neck Surg*. 1992;106(3):278-284.
566. Kasper ME, Parsons JT, Mancuso AA, et al. Radiation therapy for juvenile angiofibroma: evaluation by CT and MRI, analysis of tumor regression, and selection of patients. *Int J Radiat Oncol Biol Phys*. 1993;25(4):689-694.
567. Gullane PJ, Davidson J, O'Dwyer T, Forte V. Juvenile angiofibroma: a review of the literature and a case series report. *Laryngoscope*. 1992;102(8):928-933.
568. Fields JN, Halverson KJ, Devineni VR, et al. Juvenile nasopharyngeal angiofibroma: efficacy of radiation therapy. *Radiology*. 1990;176(1):263-265.
569. McCombe A, Lund VJ, Howard DJ. Recurrence in juvenile angiofibroma. *Rhinology*. 1990;28(2):97-102.
570. Howard DJ, Lloyd G, Lund V. Recurrence and its avoidance in juvenile angiofibroma. *Laryngoscope*. 2001;111(9):1509-1511.
571. Roche PH, Paris J, Regis J, et al. Management of invasive juvenile nasopharyngeal angiofibromas: the role of a multimodality approach. *Neurosurgery*. 2007;61(4):768-777, discussion 77.
572. Spagnolo DV, Papadimitriou JM, Archer M. Postirradiation malignant fibrous histiocytoma arising in juvenile nasopharyngeal angiofibroma and producing alpha-1-antitrypsin. *Histopathology*. 1984;8(2): 339-352.
573. Heffner DK. Problems in pediatric otorhinolaryngic pathology, III. Teratoid and neural tumors of the nose, sinonasal tract, and nasopharynx. *Int J Pediatr Otorhinolaryngol*. 1983;6(1):1-21.
574. Brydon HL. Intracranial dermoid cysts with nasal dermal sinuses. *Acta Neurochir (Wien)*. 1992;118(3-4):185-188.
575. Tharrington CL, Bossen EH. Nasopharyngeal teratomas. *Arch Pathol Lab Med*. 1992;116(2):165-167.
576. McDermott MB, Ponder TB, Dehner LP. Nasal chondromesenchymal hamartoma: an upper respiratory tract analogue of the chest wall mesenchymal hamartoma. *Am J Surg Pathol*. 1998;22(4):425-433.
577. Ozolek JA, Carrau R, Barnes EL, Hunt JL. Nasal chondromesenchymal hamartoma in older children and adults: series and immunohistochemical analysis. *Arch Pathol Lab Med*. 2005;129(11):1444-1450.
578. Wenig BM, Heffner DK. Respiratory epithelial adenomatoid hamartomas of the sinonasal tract and nasopharynx: a clinicopathologic study of 31 cases. *Ann Otol Rhinol Laryngol*. 1995;104(8):639-645.
579. Jo VY, Mills SE, Cathro HP, et al. Low-grade sinonasal adenocarcinomas: the association with and distinction from respiratory epithelial adenomatoid hamartomas and other glandular lesions. *Am J Surg Pathol*. 2009;33(3):401-408.
580. Nichols GE, Gaffey MJ, Mills SE, Weiss LM. Lobular capillary hemangioma. An immunohistochemical study including steroid hormone receptor status. *Am J Clin Pathol*. 1992;97(6):770-775.
581. Compagno J, Hyams VJ. Hemangiopericytoma-like intranasal tumors. A clinicopathologic study of 23 cases. *Am J Clin Pathol*. 1976;66(4):672-683.
582. Eichhorn JH, Dickersin GR, Bhan AK, Goodman ML. Sinonasal hemangiopericytoma. A reassessment with electron microscopy, immunohistochemistry, and long-term follow-up. *Am J Surg Pathol*. 1990;14(9):856-866.
583. Thompson LD, Miettinen M, Wenig BM. Sinonasal-type hemangiopericytoma: a clinicopathologic and immunophenotypic analysis of 104 cases showing perivascular myoid differentiation. *Am J Surg Pathol*. 2003;27(6):737-749.
584. Holsinger FC, Hafemeister AC, Hicks MJ, et al. Differential diagnosis of pediatric tumors of the nasal cavity and paranasal sinuses: a 45-year multi-institutional review. *Ear Nose Throat J*. 2010;89(11):534-540.
585. Alameda F, Fontane J, Corominas JM, et al. Reactive vascular lesion of nasal septum simulating angiosarcoma in a cocaine abuser. *Hum Pathol*. 2000;31(2):239-241.
586. Witkin GB, Rosai J. Solitary fibrous tumor of the upper respiratory tract. A report of six cases. *Am J Surg Pathol*. 1991;15(9):842-848.
587. Lewis J, Oliveira A, Nascimento A, et al. Low-grade sinonasal sarcoma with neural and myogenic features: a clinicopathologic analysis of 28 cases. *Am J Surg Pathol*. 2012;36(4):517-525.
588. Wang X, Bledsoe KL, Graham RP, et al. Recurrent PAX3-MAML3 fusion in biphenotypic sinonasal sarcoma. *Nat Genet*. 2014;46(7):666-668.
589. Schafer DR, Thompson LD, Smith BC, Wenig BM. Primary ameloblastoma of the sinonasal tract: a clinicopathologic study of 24 cases. *Cancer*. 1998;82(4):667-674.
590. Batsakis JG, Solomon AR, Rice DH. The pathology of head and neck tumors: neoplasms of cartilage, bone, and the notochord, part 7. *Head Neck Surg*. 1980;3(1):43-57.
591. Kapadia SB, Popek EJ, Barnes L. Pediatric otorhinolaryngic pathology: diagnosis of selected lesions. *Pathol Annu*. 1994;29(Pt 1):159-209.
592. Nakhleh RE, Swanson PE, Dehner LP. Juvenile (embryonal and alveolar) rhabdomyosarcoma of the head and neck in adults. A clinical, pathologic, and immunohistochemical study of 12 cases. *Cancer*. 1991;67(4):1019-1024.
593. Ahmed AA, Tsokos M. Sinonasal rhabdomyosarcoma in children and young adults. *Int J Surg Pathol*. 2007;15(2):160-165.
594. Pai SA, Naresh KN, Masih K, et al. Teratocarcinosarcoma of the paranasal sinuses: a clinicopathologic and immunohistochemical study. *Hum Pathol*. 1998;29(7):718-722.
595. Salem F, Rosenblum MK, Jhanwar SC, et al. Teratocarcinosarcoma of the nasal cavity and paranasal sinuses: report of 3 cases with assessment for chromosome 12p status. *Hum Pathol*. 2008;39(4):605-609.
596. Shimazaki H, Aida S, Tamai S, et al. Sinonasal teratocarcinosarcoma: ultrastructural and immunohistochemical evidence of neuroectodermal origin. *Ultrastruct Pathol*. 2000;24(2):115-122.
597. Heffner DK, Hyams VJ. Teratocarcinosarcoma (malignant teratoma?) of the nasal cavity and paranasal sinuses A clinicopathologic study of 20 cases. *Cancer*. 1984;53(10):2140-2154.
598. Fu Y-S, Perzin KH. Nonepithelial tumors of the nasal cavity, paranasal sinuses and nasopharynx. A clinicopathologic study. II. Osseous and fibroosseous lesions, including osteoma, fibrous dysplasia, ossifying fibroma, osteoblastoma, giant cell tumor, and osteosarcoma. *Cancer*. 1974;33:1289-1305.
599. Fu YS, Perzin KH. Non-epithelial tumors of the nasal cavity, paranasal sinuses, and nasopharynx: a clinicopathologic study. 3. Cartilaginous tumors (chondroma, chondrosarcoma). *Cancer*. 1974;34(2):453-463.
600. Fu YS, Perzin KH. Nonepithelial tumors of the nasal cavity, paranasal sinuses, and nasopharynx: a clinicopathologic study. IV. Smooth muscle tumors (leiomyoma, leiomyosarcoma). *Cancer*. 1975;35(5):1300-1308.
601. Huang HY, Antonescu CR. Sinonasal smooth muscle cell tumors: a clinicopathologic and immunohistochemical analysis of 12 cases with emphasis on the low-grade end of the spectrum. *Arch Pathol Lab Med*. 2003;127(3):297-304.
602. Fu YS, Perzin KH. Nonepithelial tumors of the nasal cavity, paranasal sinuses, and nasopharynx. A clinicopathologic study. VI. Fibrous tissue tumors (fibroma, fibromatosis, fibrosarcoma). *Cancer*. 1976;37(6):2912-2928.
603. Fu YS, Perzin KH. Non-epithelial tumors of the nasal cavity, paranasal sinuses and nasopharynx: a clinico-pathologic study. VII. Myxomas. *Cancer*. 1977;39(1):195-203.
604. Fu YS, Perzin KH. Non-epithelial tumors of the nasal cavity, paranasal sinuses and nasopharynx: a clinicopathologyic study. VIII. Adipose tissue tumors (lipoma and liposarcoma). *Cancer*. 1977;40(3):1314-1317.
605. Rice DH, Batsakis JG, Headington JT, Boles R. Fibrous histiocytomas of the nose and paranasal sinuses. *Arch Otolaryngol*. 1974;100(5):398-401.
606. Cordes B, Williams MD, Tirado Y, et al. Molecular and phenotypic analysis of poorly differentiated sinonasal neoplasms: an integrated approach for early diagnosis and classification. *Hum Pathol*. 2009;40(3):283-292.
607. Shelekhova KV, Kazakov DV, Michal M. Sinonasal phosphaturic mesenchymal tumor (mixed connective tissue variant): report of 2 cases. *Am J Surg Pathol*. 2010;34(4):596-597.
608. Finke NM, Lae ME, Lloyd RV, et al. Sinonasal desmoplastic small round cell tumor: a case report. *Am J Surg Pathol*. 2002;26(6):799-803.
609. Beham-Schmid C, Beham A, Jakse R, et al. Extranodal follicular dendritic cell tumour of the nasopharynx. *Virchows Arch*. 1998;432(3):293-298.
610. Chan AC, Chan KW, Chan JK, et al. Development of follicular dendritic cell sarcoma in hyaline-vascular Castleman's disease of the nasopharynx: tracing its evolution by sequential biopsies. *Histopathology*. 2001;38(6):510-518.
611. Wanamaker JR, Kraus DH, Eliachar I, Lavertu P. Manifestations of metastatic breast

carcinoma to the head and neck. *Head Neck*. 1993;15(3):257-262.
612. Ritter JH, Nappi O. Oxyphilic proliferations of the respiratory tract and paranasal sinuses. *Semin Diagn Pathol*. 1999;16(2):105-116.
613. Hill MJ, Taylor CL, Scott GB. Chondromatous metaplasia in the human larynx. *Histopathology*. 1980;4(2):205-214.
614. Lawson W, Zak FG. The glomus bodies ("paraganglia") of the human larynx. *Laryngoscope*. 1974;84(1):98-111.
615. Richardson GM, Assor D. Thyroid tissue within the larynx. Case report. *Laryngoscope*. 1971;81(1):120-125.
616. DeSanto LW, Devine KD, Weiland LH. Cysts of the larynx—classification. *Laryngoscope*. 1970;80(1):145-176.
617. Weber PC, Kenna MA, Casselbrant ML. Laryngeal cysts: a cause of neonatal airway obstruction. *Otolaryngol Head Neck Surg*. 1993;109(1):129-134.
618. Oliveira CA, Roth JA, Adams GL. Oncocytic lesions of the larynx. *Laryngoscope*. 1977;87(10 Pt 1):1718-1725.
619. Martin-Hirsch DP, Lannigan FJ, Irani B, Batman P. Oncocytic papillary cystadenomatosis of the larynx. *J Laryngol Otol*. 1992;106(7):656-658.
620. Newman BH, Taxy JB, Laker HI. Laryngeal cysts in adults: a clinicopathologic study of 20 cases. *Am J Clin Pathol*. 1984;81(6):715-720.
621. Giovanniello J, Grieco RV, Bartone NF. Laryngocele. *Am J Roentgenol Radium Ther Nucl Med*. 1970;108(4):825-829.
622. Hawkins DB, Miller AH, Sachs GB, Benz RT. Acute epiglottitis in adults. *Laryngoscope*. 1973;83(8):1211-1220.
623. Bailey CM, Windle-Taylor PC. Tuberculous laryngitis: a series of 37 patients. *Laryngoscope*. 1981;91(1):93-100.
624. Richter B, Fradis M, Kohler G, Ridder GJ. Epiglottic tuberculosis: differential diagnosis and treatment. Case report and review of the literature. *Ann Otol Rhinol Laryngol*. 2001;110(2):197-201.
625. Hunter AM, Millar JW, Wightman AJ, Horne NW. The changing pattern of laryngeal tuberculosis. *J Laryngol Otol*. 1981;95(4):393-398.
626. Reder PA, Neel HB 3rd. Blastomycosis in otolaryngology: review of a large series. *Laryngoscope*. 1993;103(1 Pt 1):53-58.
627. Browning DG, Schwartz DA, Jurado RL. Cryptococcosis of the larynx in a patient with AIDS: an unusual cause of fungal laryngitis. *South Med J*. 1992;85(7):762-764.
628. Kheir SM, Flint A, Moss JA. Primary aspergillosis of the larynx simulating carcinoma. *Hum Pathol*. 1983;14(2):184-186.
629. Nelson EG, Tybor AG. Actinomycosis of the larynx. *Ear Nose Throat J*. 1992;71(8): 356-358.
630. Soni NK. Leprosy of the larynx. *J Laryngol Otol*. 1992;106(6):518-520.
631. Ulnick KM, Perkins J. Extraintestinal Crohn's disease: case report and review of the literature. *Ear Nose Throat J*. 2001;80(2):97-100.
632. McHugh K, deSilva M, Kilham HA. Epiglottic enlargement secondary to laryngeal sarcoidosis. *Pediatr Radiol*. 1993;23(1):71.
633. Wenig BM, Heffner DK, Oertel YC, Johnson FB. Teflonomas of the larynx and neck. *Hum Pathol*. 1990;21(6):617-623.
634. Cho MS, Kim ES, Kim HJ, Yang WI. Kimura's disease of the epiglottis. *Histopathology*. 1997;30(6):592-594.
635. Gabrielides CG, Karkavelas G, Triarides C, Kouloulas A. Malakoplakia of the larynx. *Pathol Res Pract*. 1981;172(1-2):53-57.
636. Weidner N, Askin FB, Berthrong M, et al. Bizarre (pseudomalignant) granulation-tissue reactions following ionizing-radiation exposure. A microscopic, immunohistochemical, and flow-cytometric study. *Cancer*. 1987;59(8):1509-1514.
637. Geterud A, Bake B, Berthelsen B, et al. Laryngeal involvement in rheumatoid arthritis. *Acta Otolaryngol*. 1991;111(5):990-998.
638. Saunders MS, Gentile RD, Lobritz RW. Primary laryngeal and nasal septal lesions in pemphigus vulgaris. *J Am Osteopath Assoc*. 1992;92(7):933-937.
639. Guttenplan MD, Hendrix RA, Townsend MJ, Balsara G. Laryngeal manifestations of gout. *Ann Otol Rhinol Laryngol*. 1991;100(11):899-902.
640. Ash JE, Schwartz L. The laryngeal (vocal cord) nodule. *Trans Am Acad Ophthalmol Otolaryngol*. 1944;48:323-332.
641. Fechner RE, Cooper PH, Mills SE. Pyogenic granuloma of the larynx and trachea. A causal and pathologic misnomer for granulation tissue. *Arch Otolaryngol*. 1981;107(1):30-32.
642. Wenig BM, Heffner DK. Contact ulcers of the larynx. A reacquaintance with the pathology of an often underdiagnosed entity. *Arch Pathol Lab Med*. 1990;114(8):825-828.
643. Hui AN, Koss MN, Hochholzer L, Wehunt WD. Amyloidosis presenting in the lower respiratory tract. Clinicopathologic, radiologic, immunohistochemical, and histochemical studies on 48 cases. *Arch Pathol Lab Med*. 1986;110(3):212-218.
644. Thompson LD, Derringer GA, Wenig BM. Amyloidosis of the larynx: a clinicopathologic study of 11 cases. *Mod Pathol*. 2000;13(5):528-535.
645. Fageeh NA, Mai KT, Odell PF. Eosinophilic angiocentric fibrosis of the subglottic region of the larynx and upper trachea. *J Otolaryngol*. 1996;25(4):276-278.
646. Gnepp DR, Vogler C, Sotelo-Avila C, Kielmovitch IH. Focal mucinosis of the upper aerodigestive tract in children. *Hum Pathol*. 1990;21(8):856-858.
647. Wenig BM. Necrotizing sialometaplasia of the larynx. A report of two cases and a review of the literature. *Am J Clin Pathol*. 1995;103(5):609-613.
648. Incze JS, Lui PS, Strong MS, et al. The morphology of human papillomas of the upper respiratory tract. *Cancer*. 1977;39(4):1634-1646.
649. Costa J, Howley PM, Bowling MC, et al. Presence of human papilloma viral antigens in juvenile multiple laryngeal papilloma. *Am J Clin Pathol*. 1981;75(2):194-197.
650. Rimell F, Maisel R, Dayton V. In situ hybridization and laryngeal papillomas. *Ann Otol Rhinol Laryngol*. 1992;101(2 Pt 1):119-126.
651. Steinberg BM, Topp WC, Schneider PS, Abramson AL. Laryngeal papillomavirus infection during clinical remission. *N Engl J Med*. 1983;308(21):1261-1264.
652. Byrne JC, Tsao MS, Fraser RS, Howley PM. Human papillomavirus-11 DNA in a patient with chronic laryngotracheobronchial papillomatosis and metastatic squamous-cell carcinoma of the lung. *N Engl J Med*. 1987;317(14):873-878.
653. Nikolaidis ET, Trost DC, Buchholz CL, Wilkinson EJ. The relationship of histologic and clinical factors in laryngeal papillomatosis. *Arch Pathol Lab Med*. 1985;109(1):24-29.
654. Kashima H, Mounts P, Leventhal B, Hruban RH. Sites of predilection in recurrent respiratory papillomatosis. *Ann Otol Rhinol Laryngol*. 1993;102(8 Pt 1):580-583.
655. Derkay CS, Darrow DH. Recurrent respiratory papillomatosis of the larynx: current diagnosis and treatment. *Otolaryngol Clin North Am*. 2000;33(5):1127-1142.
656. Forster G, Boltze C, Seidel J, et al. [Juvenile laryngeal papillomatosis—immunisation with the polyvalent vaccine gardasil]. *Laryngorhinootologie*. 2008;87(11):796-799.
657. Rehberg E, Kleinsasser O. Malignant transformation in non-irradiated juvenile laryngeal papillomatosis. *Eur Arch Otorhinolaryngol*. 1999;256(9):450-454.
658. Guillou L, Sahli R, Chaubert P, et al. Squamous cell carcinoma of the lung in a nonsmoking, nonirradiated patient with juvenile laryngotracheal papillomatosis. Evidence of human papillomavirus-11 DNA in both carcinoma and papillomas. *Am J Surg Pathol*. 1991;15(9):891-898.
659. Cook JR, Hill DA, Humphrey PA, et al. Squamous cell carcinoma arising in recurrent respiratory papillomatosis with pulmonary involvement: emerging common pattern of clinical features and human papillomavirus serotype association. *Mod Pathol*. 2000;13(8):914-918.
660. Reference deleted in proofs.
661. Reference deleted in proofs.
662. Sakr WA, Gale N, Gnepp DR. Squamous intraepithelial neoplasia of the upper aerodigestive tract. In: Gnepp DR, ed. *Diagnostic Surgical Pathology of the Head and Neck*. 2nd ed. Philadelphia, PA: WB Saunders; 2009.
663. Miyaguchi M, Olofsson J, Hellquist HB. Immunohistochemical study of epidermal growth factor receptor in severe dysplasia and carcinoma in situ of the vocal cords. *Acta Otolaryngol*. 1991;111(1):149-152.
664. Stenersen TC, Boysen M, Juhng SW, Reith A. Quantitative histopathological evaluation of vocal cord dysplasia with particular emphasis on nuclear orientation. *Pathol Res Pract*. 1992;188(4-5):524-530.
665. Gale N, Pilch BZ, Sidransky D, et al. Epithelial precursor lesions. In: Barnes L, Eveson JW, Reichart P, Sidransky D, eds. *World Health Organization Classification of Tumours Pathology and Genetics of Head and Neck Tumours*. Lyon: IARC Press; 2005:140-143.
666. Bauer WC, McGavran MH. Carcinoma in situ and evaluation of epithelial changes in laryngopharyngeal biopsies. *JAMA*. 1972;221(1):72-75.
667. Gale N, Kambic V, Michaels L, et al. The Ljubljana classification: a practical strategy for the diagnosis of laryngeal precancerous lesions. *Adv Anat Pathol*. 2000;7(4):240-251.
668. Gale N, Michaels L, Luzar B, et al. Current review on squamous intraepithelial lesions of the larynx. *Histopathology*. 2009;54(6): 639-656.
669. McLaren KM, Burnett RA, Goodlad JR, et al. Consistency of histopathological reporting of laryngeal dysplasia. The Scottish Pathology Consistency Group. *Histopathology*. 2000;37(5):460-463.
670. Gallo O, Franchi A, Chiarelli I, et al. Potential biomarkers in predicting progression of epithelial hyperplastic lesions of the larynx. *Acta Otolaryngol Suppl*. 1997;527:30-38.
671. McGavran MH, Bauer WC, Ogura JH. Isolated laryngeal keratosis. Its relation to carcinoma of the larynx based on a clinicopathologic study of 87 consecutive cases with long-term follow-up. *Laryngoscope*. 1960;70:932-951.
672. Hellquist H, Lundgren J, Olofsson J. Hyperplasia, keratosis, dysplasia and carcinoma in situ of the vocal cords—a follow-up study. *Clin Otolaryngol Allied Sci*. 1982;7(1):11-27.
673. Gillis TM, Incze J, Strong MS, et al. Natural history and management of keratosis, atypia, carcinoma-in situ, and microinvasive cancer of the larynx. *Am J Surg*. 1983;146(4):512-516.
674. Kambic V, Gale N, Ferluga D. Laryngeal hyperplastic lesions, follow-up study and application of lectins and anticytokeratins for their evaluation. *Pathol Res Pract*. 1992;188(8):1067-1077.

675. Helliwell TR. 'Risky' epithelium in the larynx—a practical diagnosis? *Histopathology*. 1999;34(3):262-265.
676. Hintz BL, Kagan AR, Nussbaum H, et al. A 'watchful waiting' policy for in situ carcinoma of the vocal cords. *Arch Otolaryngol*. 1981;107(12):746-751.
677. Le QT, Takamiya R, Shu HK, et al. Treatment results of carcinoma in situ of the glottis: an analysis of 82 cases. *Arch Otolaryngol Head Neck Surg*. 2000;126(11):1305-1312.
678. Lee SS, Ro JY, Luna MA, Batsakis JG. Squamous cell carcinoma of the larynx in young adults. *Semin Diagn Pathol*. 1987;4(2):150-152.
679. Muscat JE, Wynder EL. Tobacco, alcohol, asbestos, and occupational risk factors for laryngeal cancer. *Cancer*. 1992;69(9):2244-2251.
680. Rafferty MA, Fenton JE, Jones AS. The history, aetiology and epidemiology of laryngeal carcinoma. *Clin Otolaryngol Allied Sci*. 2001;26(6):442-446.
681. Gorgoulis VG, Zacharatos P, Kotsinas A, et al. Human papilloma virus (HPV) is possibly involved in laryngeal but not in lung carcinogenesis. *Hum Pathol*. 1999;30(3):274-283.
682. Baumann JL, Cohen S, Evjen AN, et al. Human papillomavirus in early laryngeal carcinoma. *Laryngoscope*. 2009;119(8):1531-1537.
683. Zbaren P, Becker M, Lang H. Pretherapeutic staging of laryngeal carcinoma. Clinical findings, computed tomography, and magnetic resonance imaging compared with histopathology. *Cancer*. 1996;77(7):1263-1273.
684. Ogura JH, Biller HF, eds. *Neck Dissection for Carcinoma of the Larynx and Hypopharynx. Proceedings of the Sixth National Cancer Conference*. Philadelphia, PA: JB Lippincott; 1970.
685. DeSanto LW. The options in early laryngeal carcinoma. *N Engl J Med*. 1982;306(15):910-912.
686. Fisher AJ, Caldarelli DD, Chacko DC, Holinger LD. Glottic cancer. Surgical salvage for radiation failure. *Arch Otolaryngol Head Neck Surg*. 1986;112(5):519-521.
687. Olsen KD, Thomas JV, DeSanto LW, Suman VJ. Indications and results of cordectomy for early glottic carcinoma. *Otolaryngol Head Neck Surg*. 1993;108(3):277-282.
688. Ogura JH, Sessions DG, Spector GJ. Analysis of surgical therapy for epidermoid carcinoma of the laryngeal glottis. *Laryngoscope*. 1975;85(9):1522-1530.
689. Johns ME, Farrior E, Boyd JC, Cantrell RW. Staging of supraglottic cancer. *Arch Otolaryngol*. 1982;108(11):700-702.
690. Micheau C, Luboinski B, Sancho H, Cachin Y. Modes of invasion of cancer of the larynx. A statistical, histological, and radioclinical analysis of 120 cases. *Cancer*. 1976;38(1):346-360.
691. Dyess CL, Carter D, Kirchner JA, Baron RE. A morphometric comparison of the changes in the laryngeal skeleton associated with invasion by tumor and by external-beam radiation. *Cancer*. 1987;59(6):1117-1122.
692. McGavran MH, Bauer WC, Ogura JH. The incidence of cervical lymph node metastases from epidermoid carcinoma of the larynx and their relationship to certain characteristics of the primary tumor. A study based on the clinical and pathological findings for 96 patients treated by primary en bloc laryngectomy and radical neck dissection. *Cancer*. 1961;14:55-65.
693. Robbins KT, Michaels L. Feasibility of subtotal laryngectomy based on whole-organ examination. *Arch Otolaryngol*. 1985;111(6):356-360.
694. Sessions DG, Ogura JH, Fried MP. Carcinoma of the subglottic area. *Laryngoscope*. 1975;85(9):1417-1423.
695. Lam KH. Extralaryngeal spread of cancer of the larynx: a study with whole-organ sections. *Head Neck Surg*. 1983;5(5):410-424.
696. Djalilian M, Weiland LH, Devine KD, Beahrs OH. Significance of jugular vein invasion by metastatic carcinoma in radical neck dissection. *Am J Surg*. 1973;126(4):566-569.
697. Carbone A, Volpe R, Barzan L. Superficial extending carcinoma (SEC) of the larynx and hypopharynx. *Pathol Res Pract*. 1992;188(6):729-735.
698. Suarez PA, Adler-Storthz K, Luna MA, et al. Papillary squamous cell carcinomas of the upper aerodigestive tract: a clinicopathologic and molecular study. *Head Neck*. 2000;22(4):360-368.
699. Makitie AA, Monni O. Molecular profiling of laryngeal cancer. *Expert Rev Anticancer Ther*. 2009;9(9):1251-1260.
700. Loyo M, Pai SI. The molecular genetics of laryngeal cancer. *Otolaryngol Clin North Am*. 2008;41(4):657-672, v.
701. Chung CH, Parker JS, Karaca G, et al. Molecular classification of head and neck squamous cell carcinomas using patterns of gene expression. *Cancer Cell*. 2004;5(5):489-500.
702. Ferlito A, Recher G. Ackerman's tumor (verrucous carcinoma) of the larynx: a clinicopathologic study of 77 cases. *Cancer*. 1980;46(7):1617-1630.
703. Lopez-Amado M, Garcia-Caballero T, Lozano-Ramirez A, Labella-Caballero T. Human papillomavirus and p53 oncoprotein in verrucous carcinoma of the larynx. *J Laryngol Otol*. 1996;110(8):742-747.
704. Orvidas LJ, Olsen KD, Lewis JE, Suman VJ. Verrucous carcinoma of the larynx: a review of 53 patients. *Head Neck*. 1998;20(3):197-203.
705. Hagen P, Lyons GD, Haindel C. Verrucous carcinoma of the larynx: role of human papillomavirus, radiation, and surgery. *Laryngoscope*. 1993;103(3):253-257.
706. Gnepp DR. Small cell neuroendocrine carcinoma of the larynx. A critical review of the literature. *ORL J Otorhinolaryngol Relat Spec*. 1991;53(4):210-219.
707. Benisch BM, Tawfik B, Breitenbach EE. Primary oat cell carcinoma of the larynx: an ultrastructural study. *Cancer*. 1975;36(1):145-148.
708. Mills SE, Cooper PH, Garland TA, Johns ME. Small cell undifferentiated carcinoma of the larynx. Report of two patients and review of 13 additional cases. *Cancer*. 1983;51(1):116-120.
709. Seidman JD, Berman JJ, Yost BA, Iseri OA. Basaloid squamous carcinoma of the hypopharynx and larynx associated with second primary tumors. *Cancer*. 1991;68(7):1545-1549.
710. MacMillan C, Kapadia SB, Finkelstein SD, et al. Lymphoepithelial carcinoma of the larynx and hypopharynx: study of eight cases with relationship to Epstein-Barr virus and p53 gene alterations, and review of the literature. *Hum Pathol*. 1996;27(11):1172-1179.
711. Appelman HD, Oberman HA. Squamous cell carcinoma of the larynx with sarcoma-like stroma. A clinicopathologic assessment of spindle cell carcinoma and "pseudosarcoma". *Am J Clin Pathol*. 1965;44:135-145.
712. Randall G, Alonso WA, Ogura JH. Spindle cell carcinoma (pseudosarcoma) of the larynx. *Arch Otolaryngol*. 1975;101(1): 63-66.
713. Lane N. Pseudosarcoma (polypoid sarcoma-like masses) associated with squamous-cell carcinoma of the mouth, fauces, and larynx; report of ten cases. *Cancer*. 1957;10(1):19-41.
714. Lewis JE, Olsen KD, Sebo TJ. Spindle cell carcinoma of the larynx: review of 26 cases including DNA content and immunohistochemistry. *Hum Pathol*. 1997;28(6):664-673.
715. Ansari-Lari MA, Hoque MO, Califano J, Westra WH. Immunohistochemical p53 expression patterns in sarcomatoid carcinomas of the upper respiratory tract. *Am J Surg Pathol*. 2002;26(8):1024-1031.
716. Manni JJ, Mulder JJ, Schaafsma HE, van Haelst UJ. Inflammatory pseudotumor of the subglottis. *Eur Arch Otorhinolaryngol*. 1992;249(1):16-19.
717. Silvestri F, Bussani R, Stanta G, et al. Supraglottic versus glottic laryngeal cancer: epidemiological and pathological aspects. *ORL J Otorhinolaryngol Relat Spec*. 1992;54(1):43-48.
718. Wiernik G, Millard PR, Haybittle JL. The predictive value of histological classification into degrees of differentiation of squamous cell carcinoma of the larynx and hypopharynx compared with the survival of patients. *Histopathology*. 1991;19(5): 411-417.
719. Small W Jr, Mittal BB, Brand WN, et al. Results of radiation therapy in early glottic carcinoma: multivariate analysis of prognostic and radiation therapy variables. *Radiology*. 1992;183(3):789-794.
720. Barona de Guzman R, Martorell MA, Basterra J, et al. Prognostic value of histopathological parameters in 51 supraglottic squamous cell carcinomas. *Laryngoscope*. 1993;103(5):538-540.
721. Nakashima T, Yano G, Hayashi I, Katsuta Y. Epithelial membrane antigen and S-100 protein-labeled cells in primary and metastatic laryngeal carcinomas. *Head Neck*. 1992;14(6):445-451.
722. Mallofre C, Cardesa A, Campo E, et al. Expression of cytokeratins in squamous cell carcinomas of the larynx: immunohistochemical analysis and correlation with prognostic factors. *Pathol Res Pract*. 1993;189(3):275-282.
723. Narayana A, Vaughan AT, Gunaratne S, et al. Is p53 an independent prognostic factor in patients with laryngeal carcinoma? *Cancer*. 1998;82(2):286-291.
724. Friedman M, Lim JW, Manders E, et al. Prognostic significance of Bcl-2 and p53 expression in advanced laryngeal squamous cell carcinoma. *Head Neck*. 2001;23(4):280-285.
725. Pizem J, Cor A, Gale N. Survivin expression is a negative prognostic marker in laryngeal squamous cell carcinoma and is associated with p53 accumulation. *Histopathology*. 2004;45(2):180-186.
726. Spiro RH, Hajdu SI, Lewis JS, Strong EW. Mucus gland tumors of the larynx and laryngopharynx. *Ann Otol Rhinol Laryngol*. 1976;85(4 Pt 1):498-503.
727. Olofsson J, van Nostrand AW. Adenoid cystic carcinoma of the larynx: a report of four cases and a review of the literature. *Cancer*. 1977;40(3):1307-1313.
728. Tomita T, Lotuaco L, Talbott L, Watanabe I. Mucoepidermoid carcinoma of the subglottis. An ultrastructural study. *Arch Pathol Lab Med*. 1977;101(3):145-148.
729. Squires JE, Mills SE, Cooper PH, et al. Acinic cell carcinoma: its occurrence in the laryngotracheal junction after thyroid radiation. *Arch Pathol Lab Med*. 1981;105(5):266-268.
730. MacMillan RH 3rd, Fechner RE. Pleomorphic adenoma of the larynx. *Arch Pathol Lab Med*. 1986;110(3):245-247.
731. Ibrahim R, Bird DJ, Sieler MW. Malignant myoepithelioma of the larynx with massive metastatic spread to the liver: an

ultrastructural and immunocytochemical study. *Ultrastruct Pathol*. 1991;15(1):69-76.
732. Martinez-Madrigal F, Santiago Payan H, Meneses A, et al. Plasmacytoid myoepithelioma of the laryngeal region: a case report. *Hum Pathol*. 1995;26(7):802-804.
733. Batsakis JG, el-Naggar AK, Luna MA. Neuroendocrine tumors of larynx. *Ann Otol Rhinol Laryngol*. 1992;101(8):710-714.
734. Ferlito A, Devaney KO, Rinaldo A. Neuroendocrine neoplasms of the larynx: advances in identification, understanding, and management. *Oral Oncol*. 2006;42(8):770-788.
735. Tamai S, Iri H, Maruyama T, et al. Laryngeal carcinoid tumor: light and electron microscopic studies. *Cancer*. 1981;48(10):2256-2259.
736. Stanley RJ, DeSanto LW, Weiland LH. Oncocytic and oncocytoid carcinoid tumors (well-differentiated neuroendocrine carcinomas) of the larynx. *Arch Otolaryngol Head Neck Surg*. 1986;112(5):529-535.
737. el-Naggar AK, Batsakis JG, Vassilopoulou-Sellin R, et al. Medullary (thyroid) carcinoma-like carcinoids of the larynx. *J Laryngol Otol*. 1991;105(8):683-686.
738. Hirsch MS, Faquin WC, Krane JF. Thyroid transcription factor-1, but not p53, is helpful in distinguishing moderately differentiated neuroendocrine carcinoma of the larynx from medullary carcinoma of the thyroid. *Mod Pathol*. 2004;17:631-636.
739. el-Naggar AK, Batsakis JG. Carcinoid tumor of the larynx. A critical review of the literature. *ORL J Otorhinolaryngol Relat Spec*. 1991;53(4):188-193.
740. Mills SE. Neuroectodermal neoplasms of the head and neck with emphasis on neuroendocrine carcinomas. *Mod Pathol*. 2002;15(3):264-278.
741. McCluggage WG, Cameron CH, Arthur K, Toner PG. Atypical carcinoid tumor of the larynx: an immunohistochemical, ultrastructural, and flow cytometric analysis. *Ultrastruct Pathol*. 1997;21(5):431-438.
742. Woodruff JM, Senie RT. Atypical carcinoid tumor of the larynx. A critical review of the literature. *ORL J Otorhinolaryngol Relat Spec*. 1991;53(4):194-209.
743. Laccourreye O, Brasnu D, Carnot F, et al. Carcinoid (neuroendocrine) tumor of the arytenoid. *Arch Otolaryngol Head Neck Surg*. 1991;117(12):1395-1399.
744. Gallivan MV, Chun B, Rowden G, Lack EE. Laryngeal paraganglioma. Case report with ultrastructural analysis and literature review. *Am J Surg Pathol*. 1979;3(1):85-92.
745. Peterson KL, Fu YS, Calcaterra T. Subglottic paraganglioma. *Head Neck*. 1997;19(1):54-56.
746. Barnes L. Paraganglioma of the larynx. A critical review of the literature. *ORL J Otorhinolaryngol Relat Spec*. 1991;53(4):220-234.
747. Sneige N, Mackay B, Ordonez NG, Batsakis JG. Laryngeal paraganglioma. Report of two tumors with immunohistochemical and ultrastructural analysis. *Arch Otolaryngol*. 1983;109(2):113-117.
748. Wasserman PG, Savargaonkar P. Paragangliomas: classification, pathology, and differential diagnosis. *Otolaryngol Clin North Am*. 2001;34(5):845-862, v-vi.
749. Hughes CA, Rezaee A, Ludemann JP, Holinger LD. Management of congenital subglottic hemangioma. *J Otolaryngol*. 1999;28(4):223-228.
750. Lomeo P, McDonald J, Finneman J. Adult laryngeal hemangioma: report of four cases. *Ear Nose Throat J*. 2000;79(8):594, 7-8.
751. Loos BM, Wieneke JA, Thompson LD. Laryngeal angiosarcoma: a clinicopathologic study of five cases with a review of the literature. *Laryngoscope*. 2001;111(7): 1197-1202.
752. Compagno J, Hyams VJ, Ste-Marie P. Benign granular cell tumors of the larynx: a review of 36 cases with clinicopathologic data. *Ann Otol Rhinol Laryngol*. 1975;84(3 Pt 1):308-314.
753. Rosenberg HS, Vogler C, Close LG, Warshaw HE. Laryngeal fibromatosis in the neonate. *Arch Otolaryngol*. 1981;107(8):513-517.
754. Idrees MT, Huan Y, Woo P, Wang BY. Inflammatory myofibroblastic tumor of larynx: a benign lesion with variable morphological spectrum. *Ann Diagn Pathol*. 2007;11(6):433-439.
755. Reference deleted in proofs.
756. Libera DD, Falconieri G, Zanella M. Embryonal "Botryoid" rhabdomyosarcoma of the larynx: a clinicopathologic and immunohistochemical study of two cases. *Ann Diagn Pathol*. 1999;3(6):341-349.
757. Hellquist HB, Hellquist HH, Vejlens L, Lindholm CE. Epithelioid leiomyoma of the larynx. *Histopathology*. 1994;24:155-160.
758. Matsumoto T, Nishiya M, Ichikawa G, Fujii H. Leiomyoma with atypical cells (atypical leiomyoma) in the larynx. *Histopathology*. 1999;34(6):532-536.
759. Nicolai P, Ferlito A, Sasaki CT, Kirchner JA. Laryngeal chondrosarcoma: incidence, pathology, biological behavior, and treatment. *Ann Otol Rhinol Laryngol*. 1990;99(7 Pt 1):515-523.
760. Thompson LD, Gannon FH. Chondrosarcoma of the larynx: a clinicopathologic study of 111 cases with a review of the literature. *Am J Surg Pathol*. 2002;26(7):836-851.
761. Goethals PL, Dahlin DC, Devine KD. Cartilaginous tumors of the larynx. *Surg Gynecol Obstet*. 1963;117:77-82.
762. Casiraghi O, Martinez-Madrigal F, Pineda-Daboin K, et al. Chondroid tumors of the larynx: a clinicopathologic study of 19 cases, including two dedifferentiated chondrosarcomas. *Ann Diagn Pathol*. 2004;8(4):189-197.
763. Brandwein M, Moore S, Som P, Biller H. Laryngeal chondrosarcomas: a clinicopathologic study of 11 cases, including two "dedifferentiated" chondrosarcomas. *Laryngoscope*. 1992;102(8):858-867.
764. Kleist B, Poetsch M, Lang C, et al. Clear cell chondrosarcoma of the larynx: a case report of a rare histologic variant in an uncommon localization. *Am J Surg Pathol*. 2002;26(3):386-392.
765. Madrigal FM, Godoy LM, Daboin KP, et al. Laryngeal osteosarcoma: a clinicopathologic analysis of four cases and comparison with a carcinosarcoma. *Ann Diagn Pathol*. 2002;6(1):1-9.
766. Nonaka S, Enomoto K, Kawabori S, et al. Spindle cell lipoma within the larynx: a case report with correlated light and electron microscopy. *ORL J Otorhinolaryngol Relat Spec*. 1993;55(3):147-149.
767. Sellari Franceschini S, Segnini G, Berrettini S, et al. Hibernoma of the larynx. Review of the literature and a new case. *Acta Otorhinolaryngol Belg*. 1993;47(1):51-53.
768. Wenig BM, Weiss SW, Gnepp DR. Laryngeal and hypopharyngeal liposarcoma. A clinicopathologic study of 10 cases with a comparison to soft-tissue counterparts. *Am J Surg Pathol*. 1990;14(2):134-141.
769. Gonzalez-Lois C, Ibarrola C, Ballestin C, Martanez-Tello FJ. Dedifferentiated liposarcoma of the pyriform sinus: report of a case and review of the literature. *Int J Surg Pathol*. 2002;10(1):75-79.
770. Ferlito A. Histiocytic tumors of the larynx: a clinicopathological study with review of the literature. *Cancer*. 1978;42(2):611-622.
771. Murrell GL, Lantz HJ. Giant cell tumor of the larynx. *Ear Nose Throat J*. 1993;72(5):360-361.
772. Wieneke JA, Gannon FH, Heffner DK, Thompson LD. Giant cell tumor of the larynx: a clinicopathologic series of eight cases and a review of the literature. *Mod Pathol*. 2001;14(12):1209-1215.
773. Della Libera D, Redlich G, Bittesini L, Falconieri G. Aneurysmal bone cyst of the larynx presenting with hypoglottic obstruction. *Arch Pathol Lab Med*. 2001;125(5):673-676.
774. Ledeboer QC, Kerrebijn JD, Govaere F, den Bakker MA. Osteoblastoma of the larynx: a case report. *Int J Surg Pathol*. 2005;13(4):365-367.
775. Matsumoto T, Nobukawa B, Kobayashi K, et al. Solitary polypoid xanthoma in the larynx. *Histopathology*. 1999;34(5):475-477.
776. Safneck JR, Alguacil-Garcia A, Dort JC, Phillips SM. Solitary fibrous tumour: report of two new locations in the upper respiratory tract. *J Laryngol Otol*. 1993;107(3):252-256.
777. Ferlito A, Caruso G. Endolaryngeal synovial sarcoma. An update on diagnosis and treatment. *ORL J Otorhinolaryngol Relat Spec*. 1991;53(2):116-119.
778. Wenig BM. Laryngeal mucosal malignant melanoma. A clinicopathologic, immunohistochemical, and ultrastructural study of four patients and a review of the literature. *Cancer*. 1995;75(7):1568-1577.
779. Horny HP, Kaiserling E. Involvement of the larynx by hemopoietic neoplasms. An investigation of autopsy cases and review of the literature. *Pathol Res Pract*. 1995;191(2):130-138.
780. Weissman JL, Myers JN, Kapadia SB. Extramedullary plasmacytoma of the larynx. *Am J Otolaryngol*. 1993;14(2):128-131.
781. Ti M, Villafuerte R, Chase PH, Dosik H. Acute leukemia presenting as laryngeal obstruction. *Cancer*. 1974;34(2):427-430.
782. Batsakis JG, Luna MA, Byers RM. Metastases to the larynx. *Head Neck Surg*. 1985;7(6):458-460.
783. Mark EJ, Meng F, Kradin RL, et al. Idiopathic tracheal stenosis: a clinicopathologic study of 63 cases and comparison of the pathology with chondromalacia. *Am J Surg Pathol*. 2008;32(8):1138-1143.
784. Ashley DJ. Bony metaplasia in trachea and bronchi. *J Pathol*. 1970;102(3):186-188.
785. Romagosa V, Bella MR, Truchero C, Moya J. Necrotizing sialometaplasia (adenometaplasia) of the trachea. *Histopathology*. 1992;21(3):280-282.
786. Ip MS, Wong MP, Wong KL. Rheumatoid nodules in the trachea. *Chest*. 1993;103(1):301-303.
787. Allen MS. Malignant tracheal tumors. *Mayo Clin Proc*. 1993;68(7):680-684.
788. Olmedo G, Rosenberg M, Fonseca R. Primary tumors of the trachea. Clinicopathologic features and surgical results. *Chest*. 1982;81(6):701-706.
789. Honings J, Gaissert HA, Ruangchira-Urai R, et al. Pathologic characteristics of resected squamous cell carcinoma of the trachea: prognostic factors based on an analysis of 59 cases. *Virchows Arch*. 2009;455(5): 423-429.
790. Hajdu SI, Huvos AG, Goodner JT, et al. Carcinoma of the trachea. Clinicopathologic study of 41 cases. *Cancer*. 1970;25(6):1448-1456.
791. Briselli M, Mark GJ, Grillo HC. Tracheal carcinoids. *Cancer*. 1978;42(6): 2870-2879.
792. Ma CK, Fine G, Lewis J, Lee MW. Benign mixed tumor of the trachea. *Cancer*. 1979;44(6):2260-2266.
793. Garcia-Prats MD, Sotelo-Rodriguez MT, Ballestin C, et al. Glomus tumour of the trachea: report of a case with microscopic, ultrastructural and immunohistochemical examination and

review of the literature. *Histopathology*. 1991;19(5):459-464.
794. Shin DH, Park SS, Lee JH, et al. Oncocytic glomus tumor of the trachea. *Chest*. 1990;98(4):1021-1023.
795. Ballard RW, Yarington CT Jr. Hemangiopericytoma of the tracheal wall. *Arch Otolaryngol*. 1981;107(9):558-560.
796. Messineo A, Wesson DE, Filler RM, Smith CR. Juvenile hemangiomas involving the thoracic trachea in children: report of two cases. *J Pediatr Surg*. 1992;27(10): 1291-1293.
797. Burton DM, Heffner DK, Patow CA. Granular cell tumors of the trachea. *Laryngoscope*. 1992;102(7):807-813.
798. Pang LC. Primary neurilemoma of the trachea. *South Med J*. 1989;82(6):785-787.
799. Liew SH, Leong AS, Tang HM. Tracheal paraganglioma: a case report with review of the literature. *Cancer*. 1981;47(6):1387-1393.
800. Kung M, Landa JF, Lubin J. Benign clear cell tumor ("sugar tumor") of the trachea. *Cancer*. 1984;54(3):517-519.
801. Sandstrom RE, Proppe KH, Trelstad RL. Fibrous histiocytoma of the trachea. *Am J Clin Pathol*. 1978;70(3):429-433.
802. Fidias P, Wright C, Harris NL, et al. Primary tracheal non-Hodgkin's lymphoma. A case report and review of the literature. *Cancer*. 1996;77(11):2332-2338.

5 Mandible and Maxilla

Jonathan B. McHugh

CHAPTER CONTENTS

Normal anatomy, *212*
Inflammatory diseases, *213*
Simple bone cyst, *213*
Central giant cell lesion and other giant cell-containing lesions, *214*
Benign fibro-osseous lesions, *215*
Fibrous dysplasia and related lesions, *215*
Osseous dysplasias (cementoma) and related lesions, *216*
Epithelial cysts, *217*
Odontogenic tumors, *221*
Benign odontogenic tumors, *221*
Borderline odontogenic tumors, *224*
Malignant odontogenic tumors, *227*
Other tumors and tumorlike conditions, *228*
Diseases of the temporomandibular joint, *230*

Normal Anatomy

In most respects, the microscopic features of the mandible and maxilla differ in no significant way from those of any other bones. Their peculiarity is derived from their close proximity to the mucosal surface of the oral cavity and the fact that they enclose the odontogenic apparatus, a highly specialized structure that gives rise to a large variety of malformative, inflammatory, and neoplastic conditions.

The odontogenic compartment is unique in the sense that it contains primitive embryonic structures from early fetal development to approximately 25 years of age. They have a combined ectodermal and mesodermal derivation; the mesodermal component has the added peculiarity that it originates from the neural crest (the so-called *ectomesenchyme*).[1]

The odontogenic development as seen in a tooth germ is a striking example of reciprocal inductive phenomena between two different types of tissue. The first is composed of an invagination of the ectodermally derived primitive oral cavity *(dental lamina)*, which subsequently acquires a bell shape and develops along its inner (concave) aspects a layer of cuboidal to columnar cells, the *ameloblasts*, which are responsible for the secretion of enamel matrix. At this stage, it is also referred to as the *enamel organ*.

The second component, which is mesodermally derived and enclosed within the previously described bell, is formed by the *dental papilla*, having initially the appearance of a loose myxoid mesenchyme and later undergoing a maturation of its outer aspect (i.e. that contiguous to the ameloblastic layer) that results in the emergence of *odontoblasts* (i.e. the cells responsible for the formation of the dentinal matrix).

An increase in the cellularity of the dental papilla adjacent to the maturing ameloblastic (enamel-forming) epithelium subsequently leads to the formation of the *dental sac* or *follicle* surrounding the developing tooth, which is in turn responsible for the formation of a dense fibrous sheath enveloping the tooth roots known as *periodontium*. In addition, the inner cells of this sac become *cementoblasts* and deposit cement over the newly formed dentin, whereas the more peripheral cells of this structure are thought to become osteoblasts and to contribute to the production of alveolar bone.

The major extracellular components of the tooth are dentin, enamel, and cementum. *Dentin* is easily recognized because of its radially striated appearance caused by the presence of innumerable minute canals (the *dentinal tubules*) containing cytoplasmic processes from the odontoblasts. When these canals are absent, it may be difficult to distinguish between atypical poorly mineralized dentin (dentinoid) and osteoid. *Enamel* consists of thin rods or prisms that on cross section are separated by concentric lines *(lines of Retzius)*. *Cementum* is very similar to bone in physicochemical characteristics and is indeed regarded as a special type of bone. It may be cellular or acellular, and it is identified microscopically mainly because of its intense basophilia. When less than entirely typical, its distinction from conventional bone may become impossible. It must be recognized that cementum-like material may be encountered in parts of the skeletal system other than the maxilla or mandible, in which participation of odontogenic tissue would seem out of the question.

The presence of rounded, strongly basophilic *cementicles* within the periodontal ligament is a normal feature.

The *dental pulp* has a myxoid hypocellular appearance that is similar to that of myxoma and that sometimes can be confused with

Abstract

This chapter reviews the development of teeth and the normal anatomy and histology of teeth and gnathic bones. Inflammatory disorders and nonodontogenic tumors are discussed as well. Odontogenic tumors and jaw cysts are reviewed using the general classification adopted by the WHO. Disorders of the temporomandibular joint are also discussed.

Keywords

Odontogenic tumors,
nonodontogenic tumors

it. It differs from the latter grossly because of its most compact appearance and microscopically because a layer of odontoblasts may be recognizable at the periphery. Sometimes a thin layer of eosinophilic dentin is seen adjacent to the layer of odontoblasts.

Nests of odontogenic epithelium (with or without their associated mesenchymal counterpart) are normally found in the jaw and gingiva and have the potential to develop into cysts or tumors. Those nests located in the alveolar mucosa and resulting from the breakup of the dental lamina are referred to as *rests of Serres*, whereas those embedded within the periodontium are known as *rests of Malassez*.

Another source of cysts and tumors in this region is related to the breakdown of ectodermal lining cells during the union or fusion of the various embryonic processes of the region, through the formation of entrapped epithelium-lined nests.

The surgical pathology of the maxilla and mandible encompasses the spectrum of pathology, because both systemic and unique diseases occur in these locations. This discussion concentrates on commonly encountered and surgically related conditions of the jaws. A more detailed discussion of these conditions, as well as of others that are less common, may be found in specialized texts.[2–7]

Inflammatory Diseases

The majority of inflammatory conditions of the jaws have a dental origin. Untreated dental caries eventually leads to inflammation of the pulpal or soft tissue portions of teeth that are unable to respond and heal adequately. This results in inflammation of the cancellous bone and connective tissue surrounding the dental root apices that follows a predictable, albeit variable, clinical and pathologic course.

Periapical granuloma appears as a lytic lesion at the apex of a nonvital tooth and is ordinarily detected in a dental roentgenogram. Grossly, the lesion rarely measures over 1.5 cm in diameter. Microscopically, it consists of a rounded collection of acute and chronic inflammatory cells rich in histiocytes and surrounded by dense fibrous tissue. Degeneration can occur in the center, leading to cavity formation and the development of a *radicular* or *periapical* cyst resulting from stimulation of the rests of Malassez.[8]

Pulse granulomas may be seen in areas of chronic periostitis. These ring-like structures enclose vegetable particles, giant cells, other inflammatory cells, and bundles of collagen fibrils (Fig. 5.1). This inconsequential microscopic oddity, variously referred to as *hyaline ring–like structures*, *lentil granuloma*, *oral vegetable granuloma*, and *giant cell hyaline angiopathy*, has given rise to numerous theories about its nature, as can be deduced from the names it has received.[9,10] The two leading hypotheses are a reaction to legume parenchymatous cells at various stages of digestion ("pulse" being the edible seed of legumes), and a degenerative change in vessel walls resulting from localized vasculitis. The former explanation seems much more reasonable. Structures of similar appearance have been described in many other sites, including gallbladder, rectum, fallopian tube, skin, and prostate.[11]

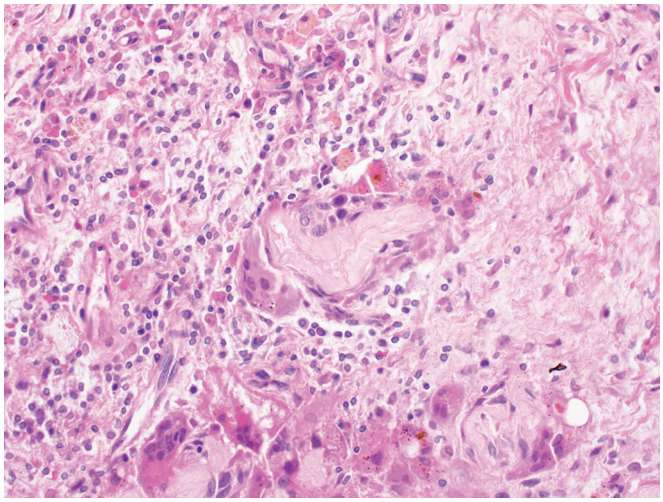

Figure 5.1 Pulse granuloma. Foreign body giant cells surround residual plant material (pulse) with associated fibrosis and chronic inflammation.

Osteomyelitis of the jaws of bacterial etiology usually represents an additional consequence and extension of dental or periodontal infection.[12] Acute, subacute, and chronic forms exist. Some of the chronic forms are of the sclerosing *(Garré)* type.[13] Hematogenous osteomyelitis is encountered more rarely. Symptoms such as pain, fever, and soft tissue swelling or redness in later stages are usually present. Smooth, regular, and atrophic loss of the covering mucosa is a late finding, and the exposed bone appears dull and devitalized. Radiographic features of osteomyelitis are subtle, irregular, ill-defined, and predominantly radiolucent lesions. A *sequestrum* is more often identified at the time of surgical exploration than during examination of x-ray films. Acute suppurative inflammation and resorptive scalloping of margins of nonvital bone within a large portion of maxilla or mandible are the main microscopic findings of acute and subacute osteomyelitis. *Staphylococcus aureus* is the organism most commonly cultured. Anaerobic bacteria have also been demonstrated to be important.[14] Tuberculosis, mucormycosis, aspergillosis, and candidiasis have also been causally identified in osteomyelitis of the jaws.[15]

Chronic forms of osteomyelitis generally appear histologically as benign fibro-osseous lesions with patchy chronic inflammation. The diagnosis often depends on the constellation of clinical, radiographic, and histologic findings. Another form of osteomyelitis of the jaw is that associated with the so-called SAPHO syndrome (synovitis, acne, pustulosis, hyperostosis, and osteitis).[16] This variety is nonsuppurative and antibiotic therapy is usually not effective.[16]

Osteonecrosis of the jaw bones can be seen following radiation therapy (osteoradionecrosis)[17] or in patients being treated with bisphosphonates (osteochemonecrosis, bisphosphonate-related osteonecrosis).[18] The mandible is affected more commonly than the maxilla and the lesions present as a painful mucosal ulcer with exposed underlying dead bone. Pathologic fractures may occur in the weakened bone. They are histologically similar with necrotic bone surrounded by acute and chronic inflammatory cells with superimposed colonization by oral microbial flora.

Simple Bone Cyst

Simple bone cyst usually occurs in young patients as a sharply outlined, unilocular, radiolucent mass (Fig. 5.2). It is usually located in the body or symphyseal area of the mandible and can assume a large size.[19] In older patients it may also involve the maxilla.[20] It is also known as *traumatic*, *solitary*, or *hemorrhagic cyst*, but there is a history of trauma in only one-half of the cases, and the content of the cyst is rarely hemorrhagic. Actually, little is observed within the cavity at surgery in the typical case; this feature is analogous to that seen in solitary (unicameral) bone cysts, of which simple bone cyst may be the gnathic counterpart. Morphologically, the cavity is entirely intraosseous and not lined by epithelium. Surgical samples from the periphery show instead a delicate fibrovascular lining of unremarkable appearance. A few osteoclast-like giant cells and hemosiderin-laden macrophages may be present. Surgical exploration with thorough curettage is the treatment of choice and is typically curative.

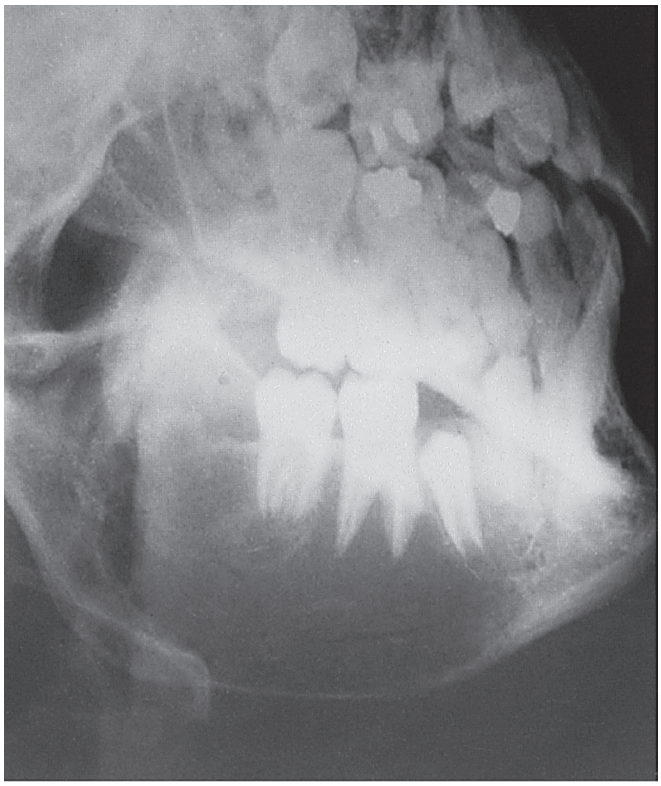

Figure 5.2 Simple bone cyst of mandible in an 11-year-old girl. Note thin shell of remaining bone at the inferior aspect of the mandible.

The differential diagnosis of simple bone cyst includes aneurysmal bone cyst (particularly when the latter is associated with a benign fibro-osseous lesion) and so-called *latent bone cavity*, a symptomless open cavity situated below and behind the inferior dental canal near the angle of the mandible and often containing salivary gland tissue.[21]

Central Giant Cell Lesion and Other Giant Cell-Containing Lesions

Lesions of the jaws that feature large numbers of osteoclast-like, multinucleated giant cells include the following major entities: central giant cell lesion (granuloma), cherubism, giant cell tumor (osteoclastoma), fibro-osseous lesions, the bone lesion of hyperparathyroidism (brown tumor), hereditary hyperparathyroidism–jaw tumor syndrome, and aneurysmal bone cyst. **Central giant cell granuloma** is by far the most common. Its pathogenesis is unknown. Because a history of trauma is often ascertained, it has been suggested that it is the result of the organization of slow, minute, recurrent hemorrhages, hence the alternative name *reparative giant cell granuloma* coined by Jaffe in his classic paper on the subject.[22] A benign neoplastic nature seems a more likely explanation given the fact that some do recur.

This condition affects children and young adults, predominantly females, and occurs almost twice as frequently in the mandible as in the maxilla, particularly in the anterior region.[22,23] It produces a lytic lesion of the bone, which microscopically shows large numbers of multinucleated giant cells, hemosiderin, a cellular vascular stroma, and often new bone formation (Figs. 5.3 and 5.4). The osteoclast-like giant cells have a patchy distribution, usually associated with areas of hemorrhage. Cases have been reported in association with central odontogenic fibroma.[24]

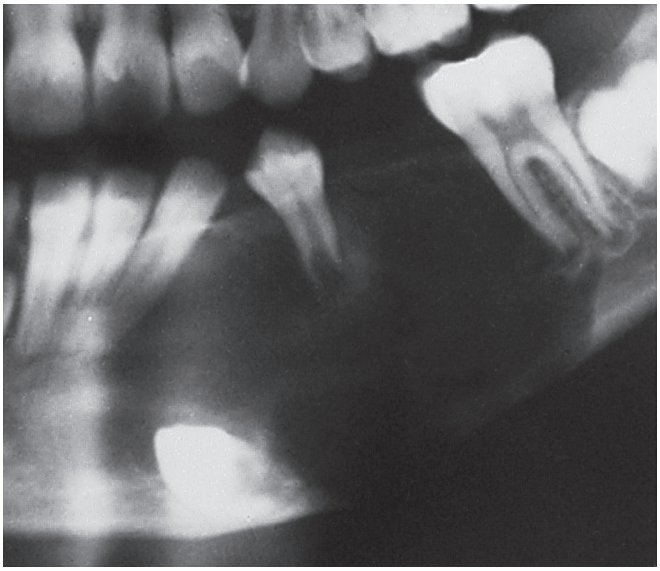

Figure 5.3 Radiographic appearance of recurrent central giant cell granuloma in a 10-year-old girl. The inferior border of mandible has been eroded and the involved teeth are displaced.

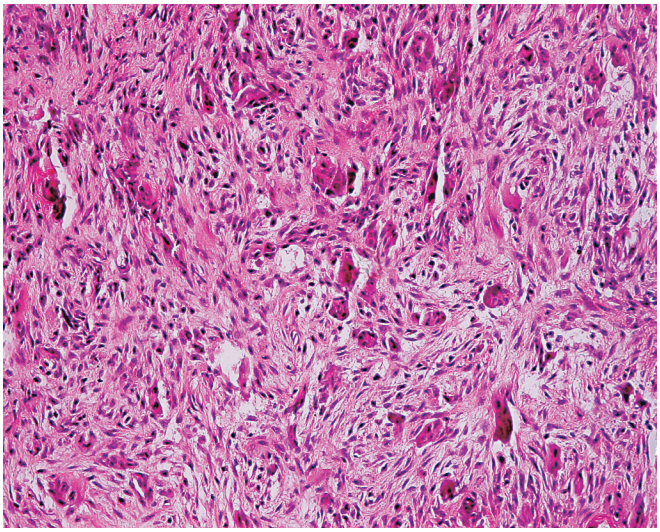

Figure 5.4 Central giant cell granuloma. Osteoclast-like giant cells are scattered within a fibroblastic matrix.

These lesions are treated by surgical removal or thorough curettage.[25,26] Recurrence, which occurs in approximately one-fourth of the cases, is treated similarly but only after the diagnosis has been confirmed.

Cherubism (hereditary and intraosseous fibrous swellings of the jaws) is indistinguishable microscopically from the lesions of central giant cell granuloma.[27] However, the bilateral presentation of mandibular and maxillary involvement in a young individual with an autosomal dominant mode of inheritance, the sometimes more delicate fibrovascular stroma with less consistent bone formation, and the differing behavior and response to treatment clearly justify a nosologic separation between the two. The gene responsible for cherubism has been mapped to chromosome 4p16.3,[28] and identified as encoding c-Abl–binding protein SH3BP2.[29]

Hyperparathyroidism,[30] aneurysmal bone cyst, and other conditions containing areas resembling giant cell granuloma (especially

Box 5.1 Common benign fibro-osseous lesions of the jaw bones

- Fibrous dysplasia
  - Monostotic
  - Polyostotic
  - Syndromic (McCune–Albright)
- Ossifying fibroma
  - Conventional
  - Psammomatous (juvenile)
  - Trabecular (juvenile)
- Cementoblastoma
- Osseous dysplasia
  - Periapical
  - Focal
  - Florid

at the periphery) may also constitute a basis for histologic misinterpretation. Fortunately, these are encountered much less commonly and are usually associated with additional clinical or laboratory information that aids delineation.[31] Giant cell tumor only rarely, if ever, occurs in the jaw bones.

Benign Fibro-Osseous Lesions

Several types of tumor and tumorlike conditions composed of benign fibro-osseous tissue exist. Their histologic features are very similar, whereas their clinical behavior can be very different.[32] Their accurate diagnosis depends on an integration of the microscopic picture with the medical, family, and dental history, the radiographic and operative appearance, skeletal survey, and laboratory tests; furthermore, it may need to be revised on the basis of the course of the disease and response to treatment. The pathologist who relies on histology alone for the interpretation of these lesions is less likely to contribute to the successful management of these patients. Common benign fibro-osseous lesions of the jaw bones are listed in Box 5.1.

Fibrous Dysplasia and Related Lesions

Fibrous dysplasia can be polyostotic or monostotic, the microscopic appearance of the two forms being essentially the same. The polyostotic form may be accompanied by pigmented skin lesions, endocrine dysfunction presenting with precocious puberty in females, and other anomalies *(McCune–Albright syndrome)*. Both monostotic fibrous dysplasia and Albright syndrome are associated with a somatic mutation of the *GNAS1* gene.[33,34] Fibrous dysplasia confined to jawbones is sometimes referred to as the *craniofacial form* of the disease. Approximately 10% of patients with monostotic fibrous dysplasia present with involvement of the craniofacial skeleton. In contrast, a vast majority of those with polyostotic disease have involvement of the craniofacial bones. Congenital or hereditary fibrous dysplasia in siblings has been reported[35] and should not be confused with cherubism.

Clinically, painless and sometimes dramatic swellings of the maxilla or mandible are observed that are characteristically unilateral. Young individuals are usually affected, the mean age at time of diagnosis in most series being from 25 to 35 years. The lesions tend to become static as skeletal maturity is reached. The radiographic appearance varies from cystic or radiolucent to sclerotic or radiopaque, and the margins tend to be ill-defined.

The histologic appearance of fibrous dysplasia in its usual, most recognizable form is characterized by the presence of curvilinear trabeculae of woven or immature bone within a proliferating benign fibroblastic stroma (Fig. 5.5). Osteoblastic rimming of these trabeculae is usually absent, but its presence focally (particularly at the periphery of the lesion) does not rule out a diagnosis of fibrous dysplasia. Two main morphologic variations on this theme are represented by lesions in which there is deposition of either lamellar bone with prominent osteoblastic rimming or rounded psammoma-like masses resembling cement. These two variations can be seen in lesions of the craniofacial skeleton but are typically not seen in lesions involving the long bones.

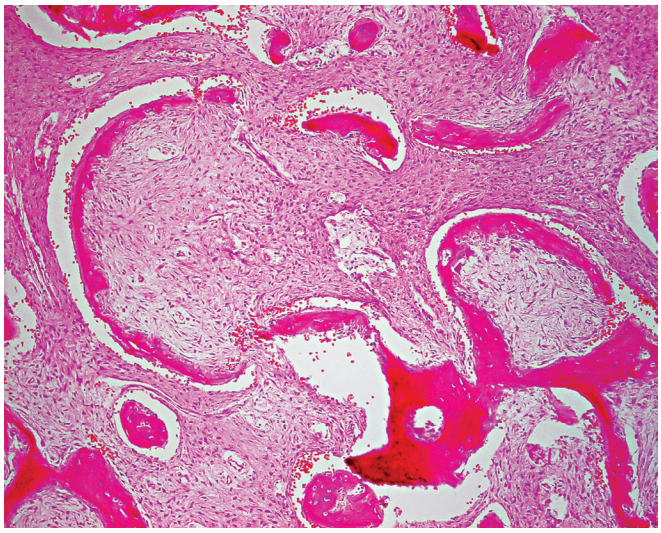

Figure 5.5 Fibrous dysplasia. Curvilinear bone trabeculae are surrounded by a dense fibrous stroma. Osteoclasts are lacking.

Figure 5.6 Ossifying fibroma in a 17-year-old girl. Note the sharp border of the lesion. (Courtesy of Dr. C.A. Waldron, Atlanta.)

Ossifying fibroma (cementifying fibroma, cemento-ossifying fibroma) is a benign neoplasm occurring in the tooth-bearing regions of the jaw bones.[36–39] They occur most often in the mandible of adults, and there is a female predilection. They present as an expansile lytic or mixed lytic-sclerotic bone lesion or are discovered incidentally in imaging studies and are well demarcated in contrast to fibrous dysplasia (Figs. 5.6 and 5.7). Histologically, they consist of a collagenous spindled stroma associated with varying amounts and types of mineralized tissues (Fig. 5.8). These can include

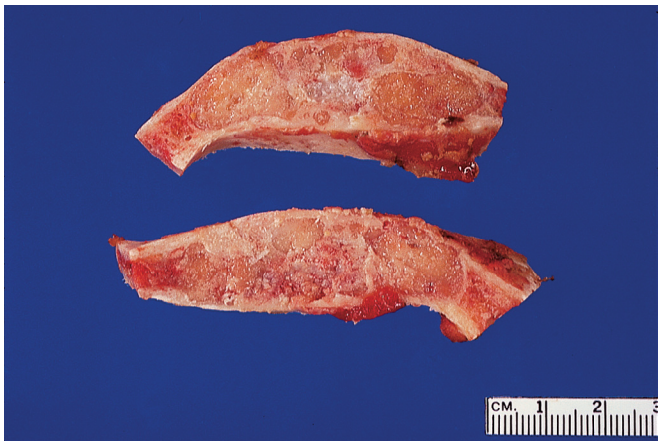

Figure 5.7 Gross appearance of ossifying fibroma. The lesion is hard, whitish, and well defined.

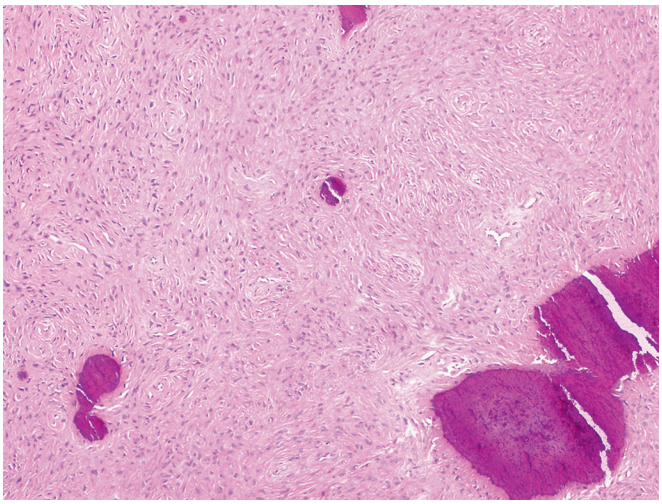

Figure 5.8 Conventional ossifying fibroma is less homogeneous compared to fibrous dysplasia and contains irregular globoid bone with a bland cellular spindled stroma.

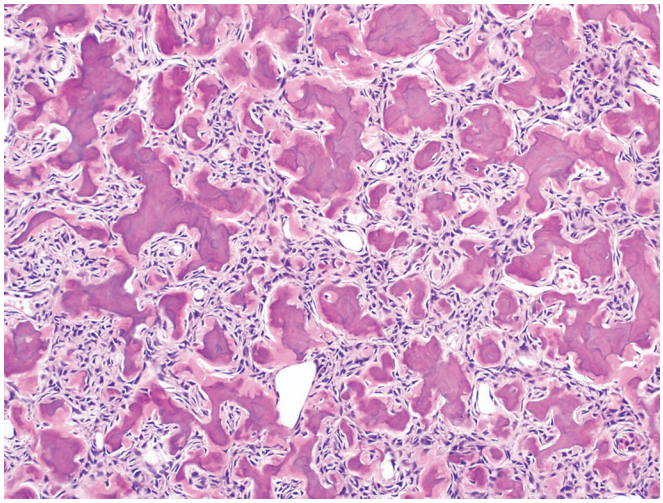

Figure 5.9 Psammomatous ossifying fibroma are more cellular and have psammoma-like ossicles and trabeculae.

globules of dense bone, trabeculae of woven or lamellar bone, and cementum-like calcifications. In contrast to fibrous dysplasia, there is less histologic uniformity in a given lesion; however, significant histologic overlap exists requiring correlation with imaging and clinical findings.

Two variants of ossifying fibroma have been described, and these typically present in children with rapidly growing bone tumors of the craniofacial skeleton. As such, they have been referred to as "aggressive" and "juvenile" ossifying fibroma. They are the psammomatoid and trabecular variants, but they may be unrelated to conventional ossifying fibroma. The *psammomatoid ossifying* fibromas usually occur in older children and involve the periorbital bones and paranasal sinuses preferentially but do occur in the mandible.[40] Radiologically, they are well circumscribed and typically lytic. Histologically, there is a cellular, benign, spindled stroma associated with numerous, round, basophilic ossicles that resemble psammoma bodies (Fig. 5.9). Simple excision is the treatment of choice, but lesions can recur. *Trabecular ossifying fibromas* occur in younger children and present with a rapidly growing tumor involving the maxilla most often followed by the mandible.[41] Microscopically, they consist of a cellular spindled stroma with bundles of osteoid that matures to woven bone and lamellar bone with a zonal-type appearance. Stromal hemorrhage and aggregates of osteoclast are scattered throughout. Aneurysmal bone cyst changes and cystic degeneration are not uncommon. They are treated by simple excision but frequently recur.

It seems likely that all of these lesions might have a periodontal ligament origin. Overall, these lesions show a marked predilection for females and for the molar–premolar region of the mandible. Some authors have stressed the importance of separating fibrous dysplasia from the ossifying fibroma group of lesions because the latter are better-demarcated lesions that are more amenable to surgical enucleation or to curettage.[38,42,43] These practical considerations justify a segregation for therapeutic and prognostic purposes, which are backed by immunohistochemical and molecular genetic data. Thus, fibrous dysplasia (whether gnathic or extragnathic) has been found to exhibit a much stronger immunoreactivity for osteocalcin and to consistently harbor mutations of the *GNAS1* gene, whereas ossifying fibroma does not.[44]

Osseous Dysplasias (Cementoma) and Related Lesions

There are additional fibrous and ossifying, calcifying, or cementifying conditions of the jaws that may be linked to fibro-osseous lesions because of their histologic resemblance, although some of them may be of odontogenic nature.

Osseous dysplasia (periapical, focal, and florid) is a relatively common disorder, being detectable radiographically in 0.3% of the adult population. It is usually multiple and asymptomatic, is limited to small regions surrounding apices of teeth, and ordinarily does not require treatment. It is thought to be of periodontal ligament origin and non-neoplastic in nature.[45] An autosomal dominant form of this disorder has been described.[46]

Mandibular incisor regions of black female adults usually are involved, but there are some differences among the three variants. Occasionally, a single tooth is affected, and this may become a surgical specimen. Periapical osseous dysplasia occurs in middle-aged black women and involves the apex of a single tooth, usually a mandibular incisor. Focal osseous dysplasia is similar to the periapical type but involves multiple teeth in the posterior mandible. Florid osseous dysplasia is similar to the focal type except that multiple jaw quadrants are involved and the lesions are more often

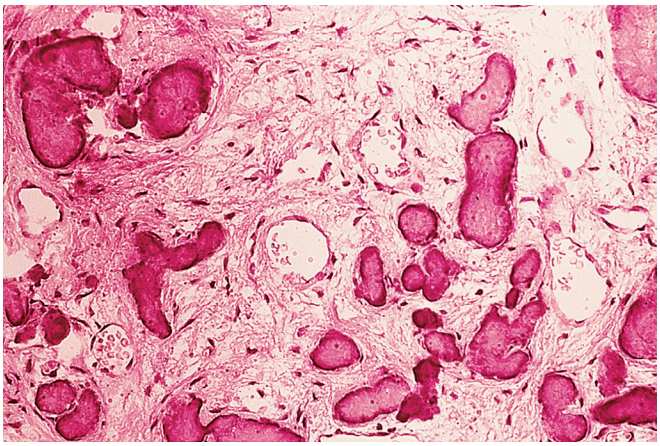

Figure 5.10 Periapical cemental dysplasia. (From Pindborg JJ, Kramer IRH, Torloni H. *Histological Typing of Odontogenic Tumours, Jaw Cysts, and Allied Lesions*. Geneva: World Health Organization, 1971.)

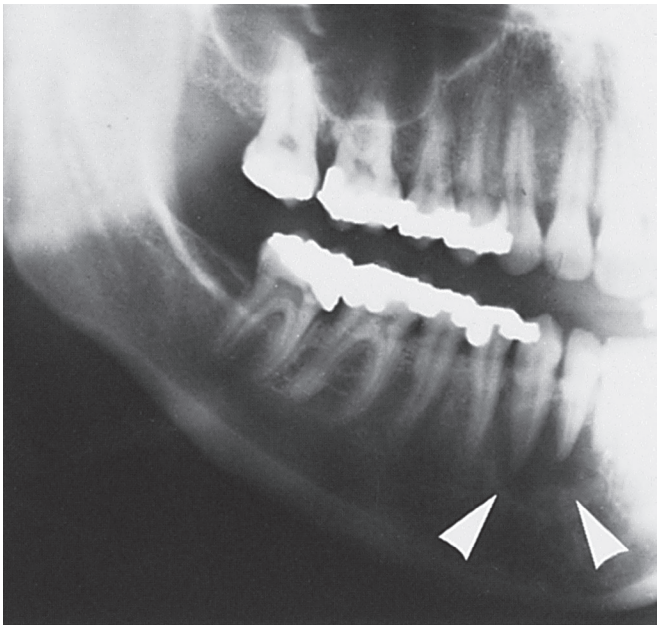

Figure 5.11 Radiograph illustrating mandibular benign osteoblastoma or cementoblastoma without calcification that was associated with periapical regions of permanent premolars *(arrows)*.

symptomatic. Microscopically all three are identical; the most typical feature is the presence of curvilinear trabeculae ("ginger root" pattern) or irregularly shaped cementum-like masses set within a vascular stroma (Fig. 5.10). The main differential diagnosis is with ossifying fibroma, which is well-circumscribed and shows thin isolated trabeculae with prominent osteoblastic rimming; however, significant histologic overlap exists.[2,47]

Benign osteoblastoma can occur in the jaw, sometimes in intimate relationship to a dental root surface.[48] When the latter is the case, the alternative designations of *(benign) cementoblastoma* and *true cementoma* are sometimes used (Figs. 5.11 and 5.12).[49]

The clinical course is usually innocuous, the lesion often stabilizing as a heavily calcified nodule. However, the fact that some lesions are locally aggressive indicates that surgical excision is the treatment of choice.

Figure 5.12 Typical radiographic appearance of cementoblastoma. A dense, homogeneous mass is seen in continuity with the tooth root. (Courtesy of Dr. C.A. Waldron, Atlanta.)

Microscopically, this lesion features irregular osteoid and bone formation (or cementum) within proliferative fibrovascular connective tissues.[37] Plump benign-appearing osteoblasts are seen rimming the newly formed trabeculae (Fig. 5.13). Osteoblastomas exhibiting a prominent epithelioid configuration of the osteoblasts are referred to as *aggressive* and are regarded by some as low-grade (nonmetastasizing) malignancies given the increased rate of recurrence.

Other lesions of the jaw featuring bone or cementum formation within proliferative fibrous connective tissue include solitary **large** or **"gigantiform" cementomas**,[50] and **osteomas** (especially those observed in patients with Gardner syndrome).[51] Inflammatory lesions of the jaws during their sclerotic or healing phases and Paget disease also enter in the differential diagnosis.[52]

Epithelial Cysts

Epithelium-lined cysts of the maxilla or mandible are among the more commonly encountered jaw diseases from both the clinician's and the pathologist's perspective.[19] Most cannot be identified specifically on the basis of their histologic appearance alone. Therefore, integration of radiographic, surgical, and microscopic findings is necessary to reach a specific diagnosis.

Two major categories of epithelial cyst exist: odontogenic and fissural (nonodontogenic). *Odontogenic* cysts arise from the odontogenic epithelium and are located within the jaw (or, rarely, in the adjacent soft tissues). *Fissural (nonodontogenic) cysts* are thought to arise from epithelial inclusions within soft or bony portions of the region that lack the embryologic and tooth-forming heritage of odontogenic epithelium. They occur along embryologic fissure lines

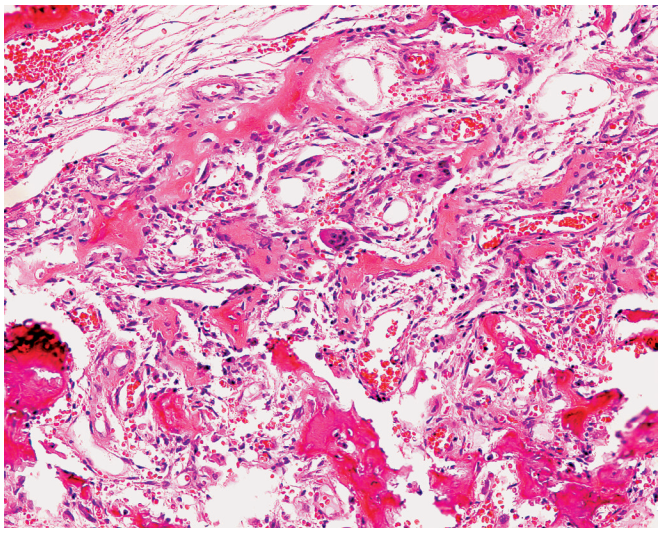

Figure 5.13 Cementoblastoma. Numerous neoformed osteoid trabeculae are lined by osteoblasts and separated by a highly vascularized matrix.

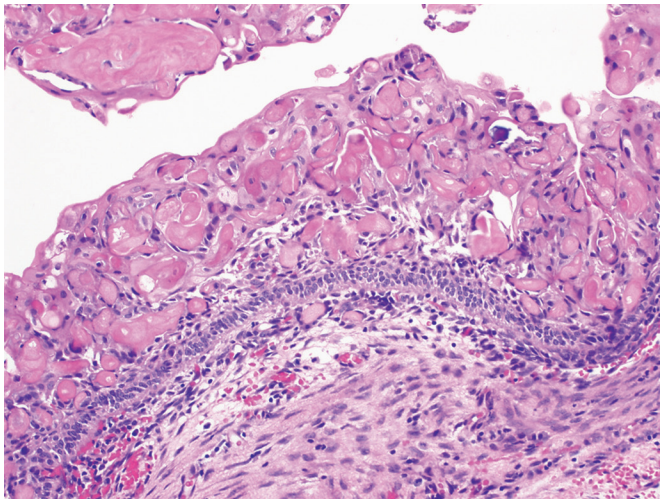

Figure 5.14 Calcifying cystic odontogenic tumor (CCOT). The epithelial cells resemble cystic ameloblastoma but the presence of ghost keratinocytes, some of which calcify, easily distinguish CCOT from ameloblastomas which lack them.

Box 5.2 Epithelial cysts of the maxilla or mandible

Odontogenic cysts
- Dentigerous cyst
- Eruption cyst
- Gingival cyst

Lateral periodontal and botryoid odontogenic cysts
Calcifying cystic odontogenic tumor
Radicular or periapical cyst (including residual cyst)
Keratocystic odontogenic tumor
- Solitary or primordial
- Multiple (nevoid basal cell carcinoma syndrome)

Orthokeratinized odontogenic cyst
Glandular odontogenic cyst

Fissural and other nonodontogenic cysts

Nasolabial (Klestadt or nasoalveolar) cyst
Nasopalatine duct (median anterior palatal) cyst
Palatal cyst

and, therefore, usually occur outside of the jaw bones. Several subtypes of these two major categories are listed in Box 5.2.

Dentigerous cysts surround or are associated with unerupted teeth and usually are found in young adults. They are found in almost 1% of individuals having complete dental roentgenograms and are often discovered incidentally.[53] They arise from alterations of reduced enamel epithelium after development of enamel and are associated with the tooth crown, at least initially. They develop from fluid accumulating between the crown of the tooth and the reduced enamel epithelium which is just beneath the dental follicle connective tissue. Swelling and, rarely, pain are symptoms, but they occur late or with infection and inflammation.

Microscopically, the uncomplicated dentigerous cyst has a thin fibrous wall (dental follicle connective tissue) lined by stratified squamous epithelium.[53] Secondary changes in the form of chronic inflammation, ulceration, reactive hyperplasia, metaplasia (squamous and mucinous), calcification, and clusters of histiocytes containing hemosiderin and lipofuscin are common.[54] Dysplasia and carcinoma can also develop in them, but this is exceedingly uncommon.[55] Although uncommon, they are more likely to give rise to cystic ameloblastomas.

Surgical excision is the treatment of choice for dentigerous cysts. Recurrence is very unusual. When it occurs, incomplete removal or the alternative possibilities of keratocystic odontogenic tumor and early or cystic examples of ameloblastomas should be considered.

Eruption cyst is a subtype of dentigerous cyst that may be unilateral or bilateral, single or multiple. It presents as a gingival swelling above erupting primary or, rarely, permanent teeth. Surgical exposure of the affected tooth reveals a subacutely inflamed and hemorrhagic cyst wall lined by usually thin and nonkeratinizing stratified squamous epithelium.

Gingival cysts of newborn infants *(Bohn nodules)* present as minute cystic or nodular formations; they are seen in most neonates and gradually disappear, usually in a matter of weeks. Microscopically, they are lined by stratified squamous epithelium that are sometimes parakeratotic.[56] Occasionally, gingival cysts are seen in adults.

Lateral periodontal and **botryoid odontogenic cysts** probably represent cystic remnants of the dental lamina. They are remarkable by virtue of their anatomic location, usually apposing gingival or root surfaces of teeth in adults.[57] Mandibular premolar regions are the most frequent sites of occurrence. They are usually unilocular but can present as a multilocular cyst. The latter have been termed botryoid odontogenic cysts. Microscopically, they are lined by an extremely thin stratified squamous epithelium, one or two layers thick.[58] Small nodular collections of glycogen-containing epithelial clusters can be seen, especially in the botryoid odontogenic cysts.

Calcifying cystic odontogenic tumor (keratinizing and calcifying odontogenic cyst, Gorlin cyst) is characterized by a cyst lining of ameloblastic epithelium with prominent basal palisading and large masses of keratinized "ghost" cells (Fig. 5.14). The ghost cells undergo varying degrees of dystrophic calcification. Some of the cells may exhibit clear cell changes, and others may contain melanin pigment.[59] The epithelium can induce dentinoid matrix production in the underlying stroma. Some examples show a remarkable similarity with ameloblastoma and craniopharyngioma, from which they are distinguished by the presence of the characteristic ghost cells and dentinoid, respectively.[60,61] It has been proposed that lesions in which

Figure 5.15 Periapical/radicular cyst demonstrating continuity with pulp canal of nonvital tooth.

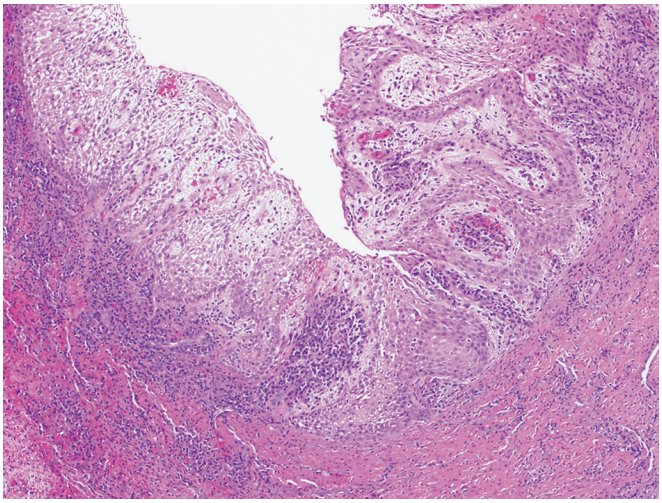

Figure 5.16 Periapical/radicular cyst. These are squamous lined cysts with marked inflammation and epithelial proliferation, the latter manifesting as elongated rete-like pegs.

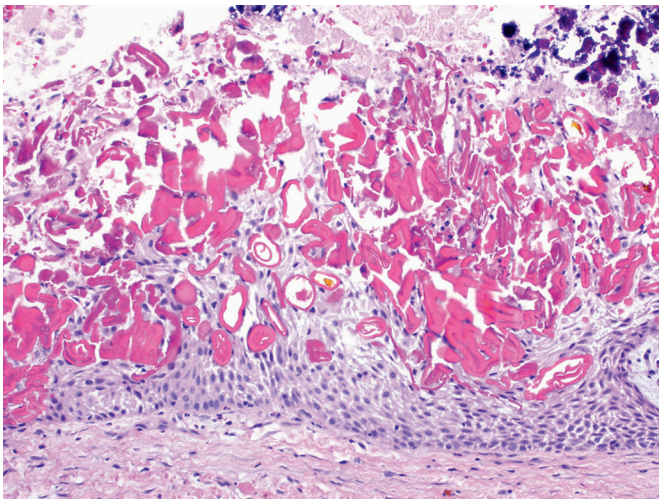

Figure 5.17 Periapical/radicular cyst with numerous intraepithelial eosinophilic Rushton bodies.

this proliferation is solid represent the neoplastic counterpart of the calcifying cystic odontogenic tumor, and the term *dentinogenic ghost cell tumor* has been proposed for them.[62,63] Indeed, it may well be that all of the lesions in this category are tumors exhibiting varying (and sometimes very extensive) degrees of cystic change, a possibility supported by the common presence of molecular alterations in the form of β-catenin gene mutations.[64] Aberrant nuclear accumulation of β-catenin is a characteristic finding, attributable to the presence of somatic mutations in the encoding gene *CTNNB1*.[64] Enucleation is the treatment of choice which is associated with a very low recurrence risk.

Radicular or periapical cysts are a sequela of dental inflammatory disease and represent the most frequently encountered cyst of the jaws.[8] They occur in all age groups but are more commonly diagnosed during the third and fourth decades. Those observed within the maxilla or the mandible after tooth extraction are called *residual cysts*. Radiographically, periapical cysts present as a well-circumscribed radiolucency at the apex of affected nonvital teeth (Figs. 5.15 and 5.16). Microscopically, they are lined by stratified squamous epithelium, the thickness of which varies according to the degree of inflammation present. Ulceration is common, and epithelium may be difficult to identify. When present, it may exhibit metaplasia, calcification, and hyaline (Rushton) bodies (Fig. 5.17). The inflammatory infiltrate in the wall may be acute, chronic, or mixed. Aggregates of cholesterol crystals, foamy macrophages, multinucleated giant cells, and plasma cells are common. The cyst usually is easily curetted from the surrounding bone, and recurrence is rare. At surgery, the cyst may be found attached to the apex of the extracted tooth.

Keratocystic odontogenic tumor (odontogenic keratocyst) constitutes approximately 10% of cysts of the jaw and ordinarily can be diagnosed on the basis of their histologic features.[65,66] Although they can occur in any portion of the jaw, most are found in the posterior mandibular regions. They have been divided into *solitary* or *primordial* (90%) and *multiple* (10%). The latter are a component of the nevoid basal cell carcinoma syndrome *(Gorlin syndrome)*, together with cutaneous nevoid basal cell carcinomas, palmar/plantar pits, calcification of the falx cerebri, cutaneous epidermoid cysts, and numerous types of skeletal abnormalities.[67,68] This syndrome is transmitted by an autosomal dominant gene having high penetrance and variable expressivity.[69,70] Germline mutation of the human homologue of *Drosophila* patched *(PTCH1)*, a tumor suppressor gene located at 9q22.3–q31, is the underlying molecular defect in this syndrome.[71]

Keratocysts occur most frequently in the third molar region of the mandible (Figs. 5.18 and 5.19). The mean age of the patients is 40 years. The cysts are more frequently multilocular and more commonly associated with swelling and pain than are dentigerous cysts.

Grossly, the cyst cavity contains a cheesy material consisting of keratinous debris that, when flushed away, reveals a white, subtly wrinkled surface. Microscopically, the epithelial lining is of uniform thickness and approximately 5–7 cells thick. It is a parakeratinized

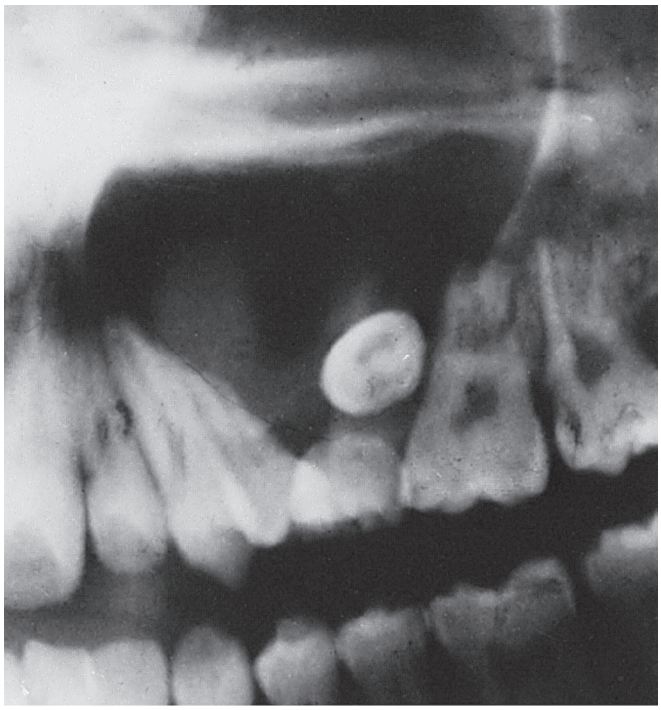

Figure 5.18 Radiograph demonstrating portion of maxillary odontogenic keratocyst in a 15-year-old with a 2-week history of facial swelling.

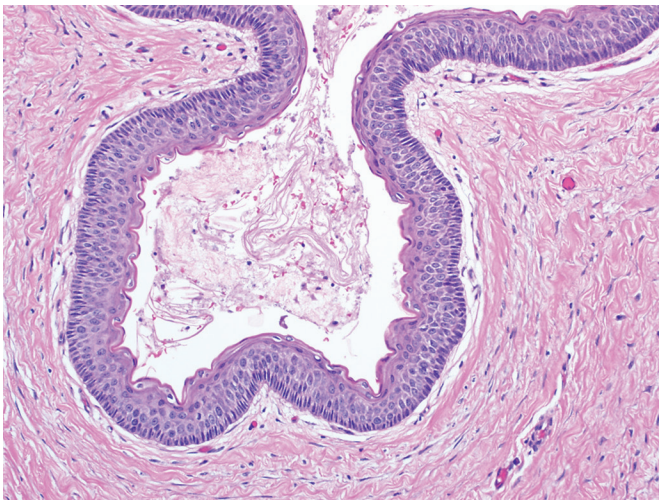

Figure 5.19 Odontogenic keratocyst. Note the corrugated parakeratinized surface and prominent palisaded basal cell layer.

squamous epithelium with prominent palisading of the basal cell layer and a wavy, corrugated, or mildly verrucous surface of parakeratin. Secondary inflammation can obscure these characteristic histologic findings. Small "daughter" cysts and basaloid odontogenic rests can be seen in the connective tissue stroma. These should be separated from the cystic lesions exhibiting an orthokeratinized lining, on the basis of less aggressiveness associated with the latter *(orthokeratinized odontogenic cysts)*.[72,73] The majority of keratocystic odontogenic tumors have been found to harbor chromosomal abnormalities, supporting the supposition that they are of neoplastic nature, resulting in the renaming of the entity from "odontogenic keratocyst."[74,75] The Sonic Hedgehog *(SHH)* signaling pathway plays

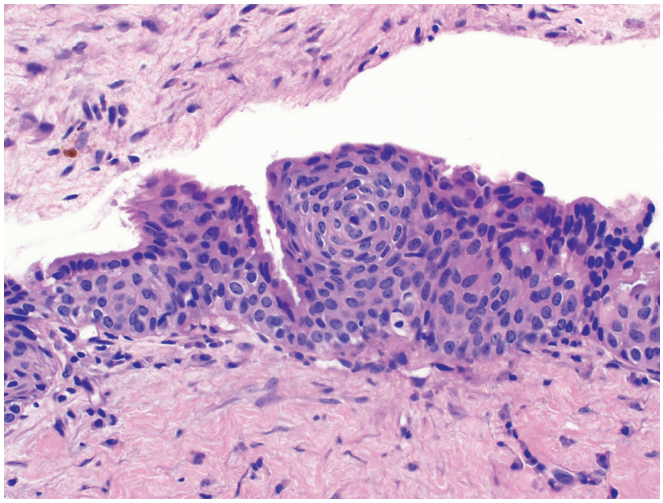

Figure 5.20 Glandular odontogenic cysts can be unilocular or multilocular. They are lined by squamoid epithelial cells with occasional thickened plaques. Other features include eosinophilic surface cells, mucous cells, and intraepithelial glandular lumens.

a critical role in tooth development. *PTCH1* combines with Smoothened *(SMO)* to form a receptor complex for the *SHH* ligand. Inactivating mutation and allelic loss of *PTCH1* resulting in aberrant activation of the *SHH* signaling pathway represent the key genetic event of both sporadic and nevoid basal cell carcinoma syndrome-related keratocysts.[76,77]

Keratocystic odontogenic tumors have a high rate of recurrence, which has ranged from 23% to 60% in the various series.[78] This has been variously attributed to technical difficulties with curettement due to the multilocularity of the cysts and the friability of the material, presence of epithelial remnants in the wall, and budding of the epithelial lining within the cyst wall.

Glandular odontogenic cysts (sialo-odontogenic cysts) are most often seen in adults and have a predilection for the anterior jaw, especially the mandible. They can be unilocular or multilocular and have a recurrence risk similar to keratocystic odontogenic tumors. Microscopically, they are lined by stratified squamous epithelium with eosinophilic cuboidal surface cells in areas (Fig. 5.20). They contain mucous cells and duct-like structures as well and can therefore be confused with mucoepidermoid carcinoma.[79] Small nodular collections of glycogen-containing epithelial clusters can be seen, similar to those in lateral periodontal/botryoid odontogenic cysts.

Nasolabial (Klestadt or **nasoalveolar) cyst** predominantly occurs in females and is commonly bilateral. Originally thought to arise from epithelial rests at the embryologic junction of the globular, lateral nasal, and maxillary processes, development from the caudal end of the nasolacrimal rod or duct is currently favored.[80] The nasoalveolar cyst occurs near the base of the nostril, outside the alveolar process of the maxilla. It eventually obliterates the nasolabial fold and gently presses its way toward the nasal mucosa. Microscopically, the lining may be of stratified squamous or respiratory type.

Nasopalatine duct (incisive canal) cyst may be intraosseous or be located within the soft tissues of the palatine papilla. It represents cyst formation of embryologic remnants of the incisive canal joining the oral and nasal cavities[81] and is the most common type of fissural or nonodontogenic cyst. Microscopically, it is lined by respiratory or stratified squamous epithelium (sometimes pigmented) or a combination of both.[82] Frequently, the nasopalatine neurovascular bundle is present in the stroma adjacent to the cyst epithelium, as well as minor salivary gland, adipose, and cartilage tissues.

Box 5.3 Classification of odontogenic tumors

Benign tumors

Adenomatoid odontogenic tumor (adenoameloblastoma)
Calcifying epithelial odontogenic tumor (Pindborg tumor)
Squamous odontogenic tumor
Ameloblastic fibroma and fibro-odontoma
Odontoma
- Complex
- Compound

Odontogenic myxoma, fibroma, and myxofibroma
Ameloblastoma

Malignant tumors

Ameloblastic carcinoma
Clear cell odontogenic carcinoma
Dentinogenic ghost cell carcinoma
- Ameloblastic fibrosarcoma

Palatal cysts in newborn infants *(Epstein pearls)* are located at the junction of the hard and soft palate and are microscopically similar to gingival cysts.[56]

Odontogenic Tumors

Odontogenic tumors are neoplasms of the jaws which differentiate toward tooth structures. Despite their rarity, there is a great variety of types, with numerous transitional forms. This has resulted in many classification attempts, beginning with the histologic scheme proposed by Broca in 1867. Thoma and Goldman[83] in 1946 classified them histogenetically into epithelial, mesodermal, and mixed, whereas Pindborg and Clausen[84] in 1958 stressed the phenomenon of induction (as a mechanism of differentiation) over histogenesis. Subsequent authors have slightly rearranged these types and added a few, most of which are included in the current classification scheme from the World Health Organization (WHO).[2]

The following grouping (Box 5.3) presents odontogenic tumors in a simplified fashion for the general surgical pathologist. It emphasizes their clinical behavior, which is benign for most types.

It should be noted that peripheral (extraosseous) equivalents of most central odontogenic tumors have been described, located in the mandibular or maxillary gingiva, arising either from the surface mucosa or from dental lamina nests in the submucosa, or in the sinonasal tract.[85]

Benign Odontogenic Tumors

Adenomatoid Odontogenic Tumor (Adenoameloblastoma)

Adenomatoid odontogenic tumor is a benign lesion that probably arises from the odontogenic epithelium of the dental lamina complex or its remnants.[86,87] It is more common in females, occurs most frequently in the second decade of life, and the most frequent location is the anterior maxilla.[86] It is often associated with an unerupted canine tooth ("follicular" type) (Fig. 5.21), but it can also be extrafollicular and may appear cystic radiographically.[88] A peripheral variety of this tumor exists.[87] Although the tumor expands, it is not invasive and does not recur after conservative surgical therapy.[89]

Grossly, it is rounded and predominantly solid with cystic areas. Some are very cystic to the point of simulating an odontogenic cyst. The low-power microscopic appearance is that of a multinodular tumor composed of cuboidal to columnar cells forming small nests with occasional duct-like structures. The duct-like structures are filled with eosinophilic material or are empty, and the outer cells can demonstrate reverse polarization (Fig. 5.22). Some tumors can have so-called convoluted structures, which are similar to the duct-like structures except that they are lined by very tall columnar cells arranged in a convoluted manner. Homogeneous zones of hyaline material and calcified deposits may be scattered throughout the epithelial lining.[2,90,91] Between the solid epithelial nodules, the epithelial cells often have a more cystic configuration and there is little stroma. The lesion is typically surrounded by a thick fibrous capsule.

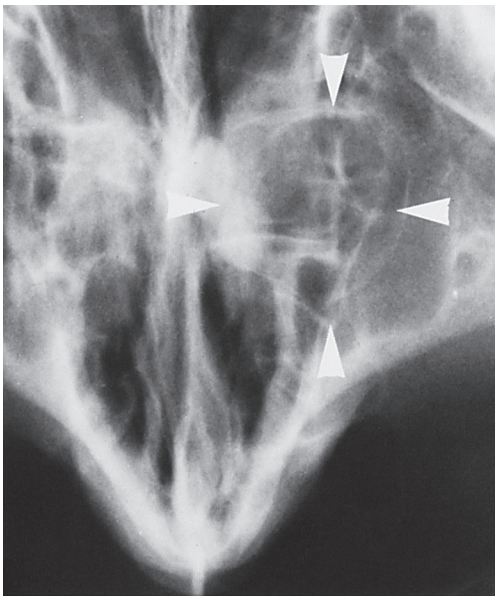

Figure 5.21 Adenomatoid odontogenic tumor of maxilla in an edentulous patient. Radiographically, a dentigerous cyst is suggested *(arrows)*.

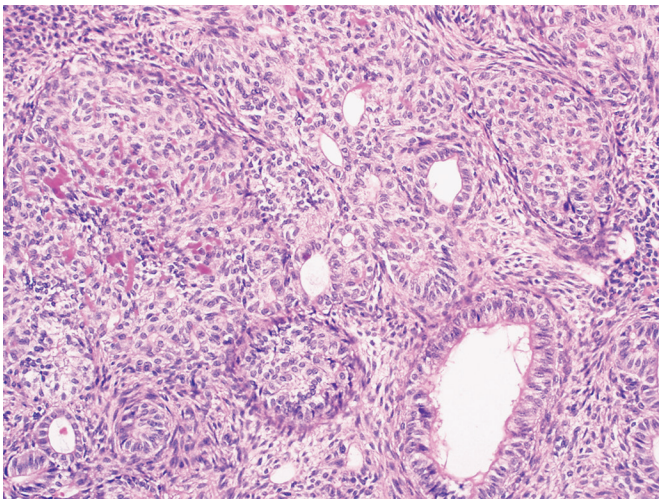

Figure 5.22 Adenomatoid odontogenic tumor. Gland-like structures are present with more cellular solid areas. Eosinophilic tumor droplets are present on the left.

Calcifying Epithelial Odontogenic Tumor

Calcifying epithelial odontogenic tumor (Pindborg tumor) occurs more commonly in the fourth and fifth decades.[92] There is no gender

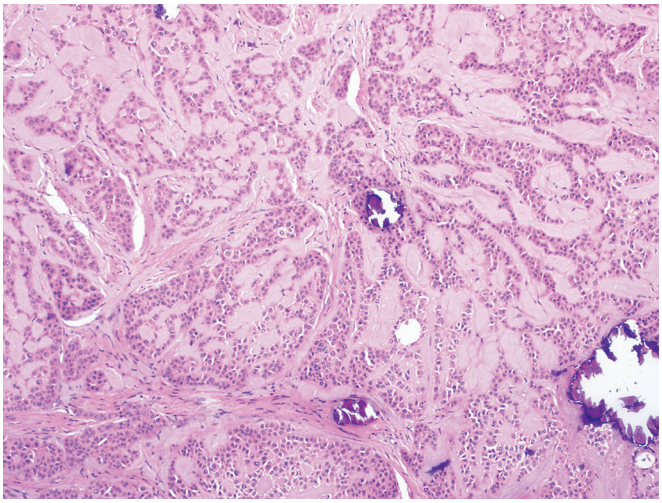

Figure 5.23 Calcifying epithelial odontogenic tumor. Nests of eosinophilic epithelial cells are set within an amyloid stroma with areas of dystrophic calcification.

predilection. Most of the reported cases have arisen in the mandibular premolar–molar area in association with an embedded tooth,[93] and a few have been found peripherally located in the gingiva.[94]

Grossly it is usually solid, but a cystic variety has been described.[95] Microscopically, the tumor is composed of closely packed polyhedral epithelial cells accompanied by variable amounts of stroma (Fig. 5.23). The epithelial cells frequently demonstrate nuclear pleomorphism and have abundant eosinophilic cytoplasm. Some tumors contain a predominance of clear cells. Although the nuclei demonstrate pleomorphism, they typically lack mitotic activity. Intracellular degeneration results in numerous spherical spaces filled with eosinophilic homogeneous material that in time becomes calcified. This has been shown to be amyloid or a substance with similar physicochemical properties.[96,97] Some tumors are quite cellular with minimal amyloid, whereas others are paucicellular and rich in amyloid. Despite the name, some tumors are actually noncalcified. High activity of alkaline phosphatase and adenosine triphosphatase has been found in the cytoplasm, an enzyme histochemical profile similar to that of the stratum intermedium cells of the normal dental germ.[98] Hybrids of this neoplasm and adenomatoid odontogenic tumor have been described.[99]

Calcifying epithelial odontogenic tumor may be invasive and recur locally, but on the whole it is a less aggressive lesion than ameloblastoma.[2] Small tumors can be enucleated but larger lesions require resection with tumor-free margins. Exceptional instances of metastasis to regional lymph nodes and to the lungs have been reported.[100]

Squamous Odontogenic Tumor

Squamous odontogenic tumor is a very rare benign neoplasm that occurs over a wide age range and has a predilection for the anterior maxilla and posterior mandible. Tumors in the former location tend to recur more often due to incomplete removal.[101–103] Radiographically, the lesion appears as a well-circumscribed semicircular radiolucency between the roots of teeth and surrounded by a sclerotic border. Microscopically, it is composed of nests and islands of well-differentiated squamous epithelium lacking atypia or mitotic activity, located within a collagenous stroma of low to moderate cellularity (Fig. 5.24).[102] An extraosseous variety of this tumor has been described.[101]

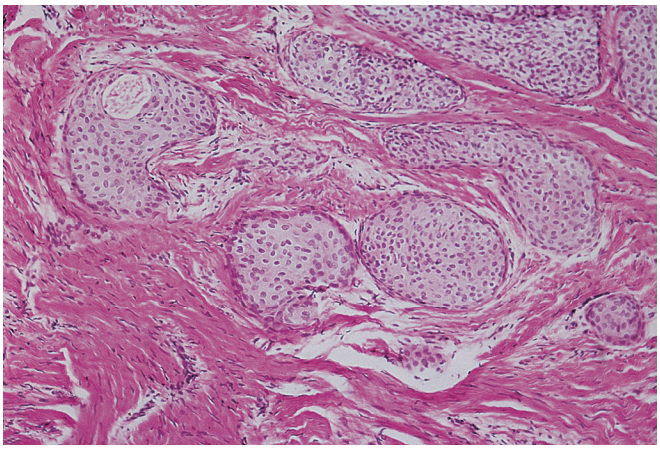

Figure 5.24 Squamous odontogenic tumor. Well-defined nests of monotonous clear cells are separated by an abundant collagen stroma.

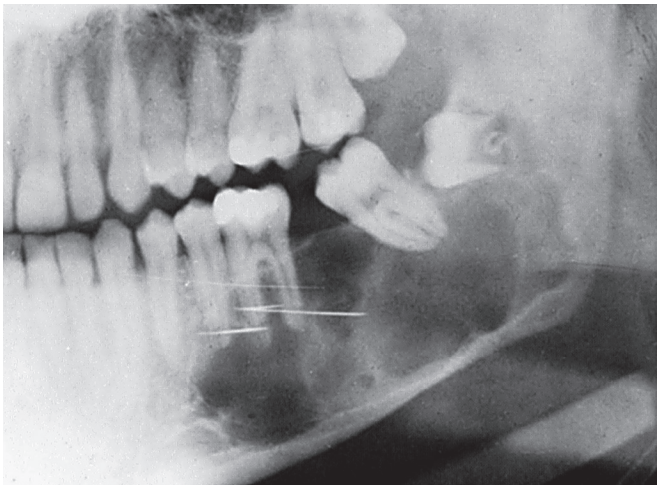

Figure 5.25 Radiographic appearance of ameloblastic fibroma of mandible in a 17-year-old youth. The defect is multilocular but suggests irregularity.

Ameloblastic Fibroma

Ameloblastic fibroma often resembles a cyst radiographically (Fig. 5.25). In contrast to ameloblastoma (the tumor with which it is most commonly mistaken), ameloblastic fibroma usually occurs in a young age group, rarely being seen in individuals older than 21 years of age. It is usually solid, although a cystic variety has been described.[104]

Microscopically, it is composed of strands and buds of ameloblastic epithelial cells embedded in a cellular myxoid connective tissue stroma (Fig. 5.26). The presence of this mesenchymal component is the main distinguishing feature with ameloblastoma. Hard tooth structures such as dentin may be present (ameloblastic fibrodentinoma), but this does not impart a biologic difference.[105] For the most part, the cells composing the epithelial strands are cuboidal and two cell layers thick. Only occasionally a stellate reticulum is present, but larger aggregates are often found as well. A *granular cell variety* of ameloblastic fibroma has been described.[106] Ameloblastic fibro-odontoma consist of an ameloblastic fibroma with areas resembling small odontomas.

The clinical behavior of ameloblastic fibroma and ameloblastic fibro-odontoma is benign. Therefore, and in contrast to ameloblastoma, simple curettage is usually adequate.[107]

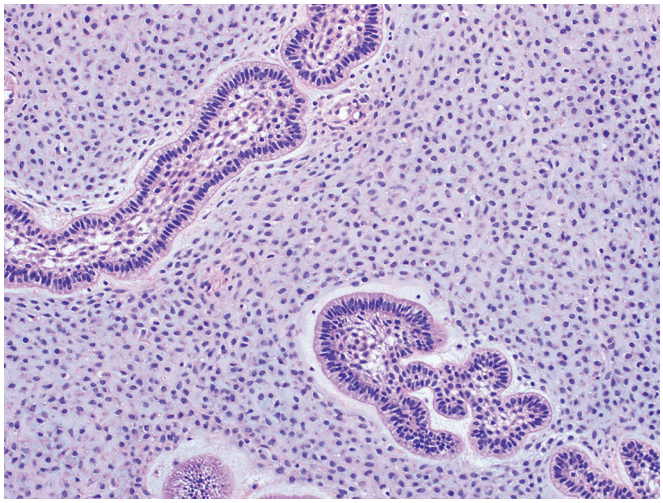

Figure 5.26 Ameloblastic fibroma. The neoplastic fibrous stroma encloses thin strips of ameloblastic epithelium.

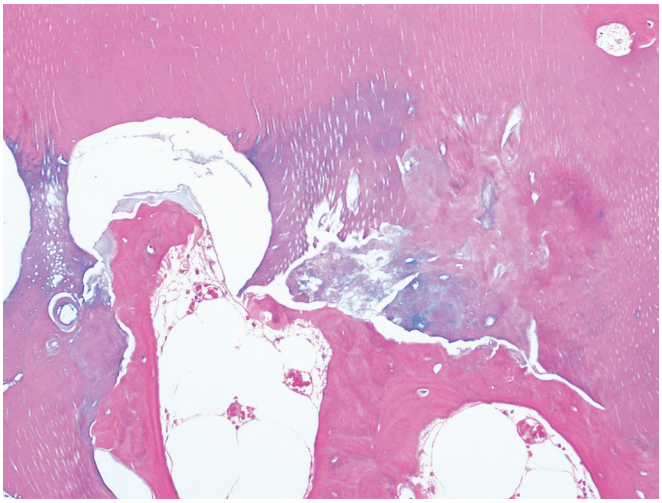

Figure 5.28 Complex odontomas contain a disorganized proliferation of enamel, dentin, and cementum (bone).

Figure 5.27 Radiograph illustrating benign complex odontoma involving posterior maxilla of a 16-year-old girl. Note molar superiorly and absence of one molar.

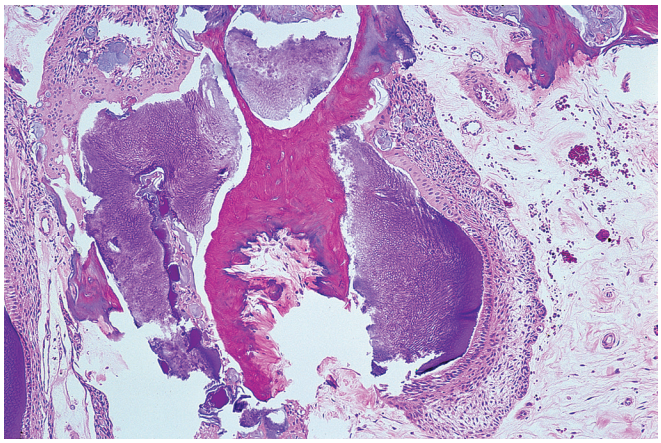

Figure 5.29 Compound odontomas are more organized than complex odontomas having the appearance of a misshapen tooth.

Odontoma

Odontomas are defined as odontogenic tumors featuring production of calcified parts of teeth. They are the most common odontogenic tumor. They occur in the tooth-bearing regions of the mandible or maxilla. Two main subtypes of odontoma are recognized.

Complex odontoma is an architecturally disorganized lesion, with a variety of calcified patterns but not enough coordinated production of enamel, dentin, or cementum to reach a point where an actual tooth can be identified (Fig. 5.27). It is more frequent in molar areas of the mandible in female patients (Fig. 5.28). Although the tumors occasionally achieve considerable proportions, they are entirely benign and usually represent incidental findings in routine radiographic examinations.

Compound odontoma exhibits a higher degree of differentiation than does complex odontoma, so that the individual lesion characteristically consists of masses of small misshapen teeth known as *denticles* (Fig. 5.29). Most lesions have only a few of these structures, but cases containing as many as 2000 (!) are on record. Compound odontomas behave in an entirely benign fashion. They are more commonly encountered in the anterior regions of the jaws and are more frequent in the maxilla than in the mandible.

Odontoameloblastoma

Odontoameloblastoma (ameloblastic odontoma, odontoblastoma) is a solid or cystic lesion characterized by the presence of a prominent epithelial component resembling ameloblastoma in addition to dental hard and soft tissues, such as enamel and dentin (Fig. 5.30).[2,108] The presence of dental hard tissues distinguished this lesion from ameloblastoma. Some have considered it a variant of odontoma, but it appears to be a distinct entity.[109] It is generally benign, but on occasion it behaves aggressively and recurs locally after conservative surgical removal.[2] Therefore, it is typically treated in a similar manner as ameloblastoma.

Odontogenic Myxoma, Myxofibroma, and Fibroma

Myxoma of the jaws is generally regarded as of tooth germ origin and specifically derived from the dental papilla, hence the qualifier *odontogenic* usually applied to it.[110] It may be associated with

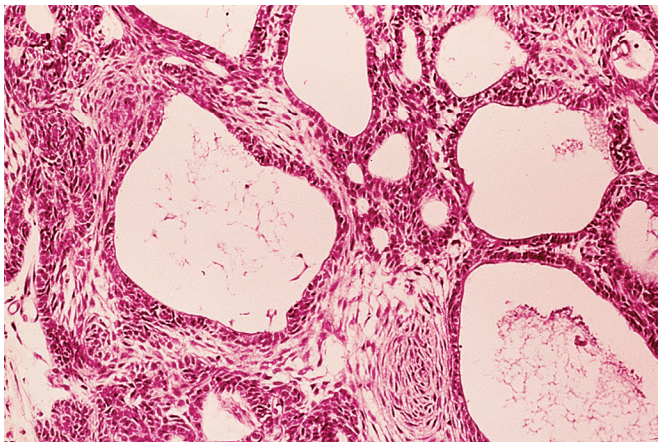

Figure 5.30 Odontoameloblastoma. (From Pindborg JJ, Kramer IRH, Torloni H. *Histological Typing of Odontogenic Tumours, Jaw Cysts, and Allied Lesions*. Geneva: World Health Organization; 1971.)

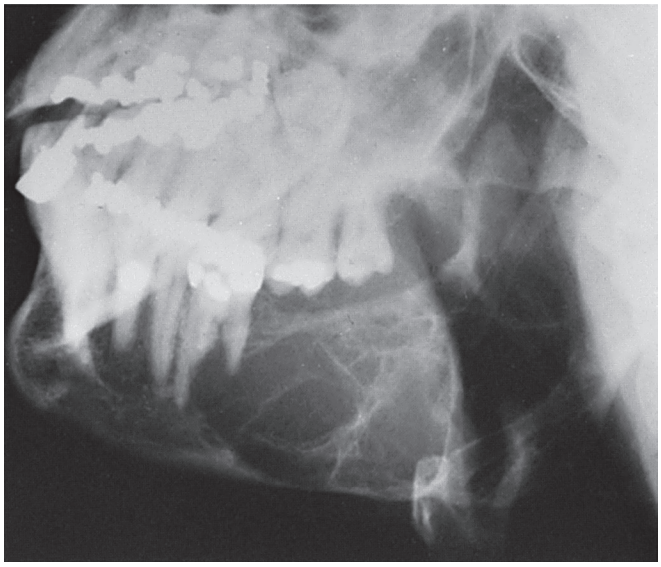

Figure 5.31 Radiograph illustrating a large recurrent odontogenic myxoma of mandible in male adult.

malformed or missing teeth. Approximately 60% occur during the second or third decades, and there is an equal incidence of mandible and maxilla involvement. Radiographically, these tumors often present as lytic lesions, but they can attain a large size and result in marked facial deformity. Recurrence after conservative removal is not unusual, probably because of its poorly defined margins (Fig. 5.31).[111] Therefore, resection with tumor-free margins is indicated. Small lesions can be more conservatively excised.

Microscopically, myxoma consists of loose stellate cells with long, branching, eosinophilic cytoplasmic processes that are set within a paucivascular myxoid stroma (Fig. 5.32). Occasionally, strands of odontogenic epithelium thought to represent rests of Malassez are noted. Spicules of bone trabeculae are often entrapped by this infiltrative tumor. The myxoma cells are immunohistochemically reactive for vimentin and often smooth muscle actin but are negative for S-100 protein. In contrast to intramuscular myxoma, activating mutations in the *GNAS1* gene are not found.[112]

Odontogenic myxoma can be closely simulated microscopically by the normal dental papilla of an unerupted tooth. Although the

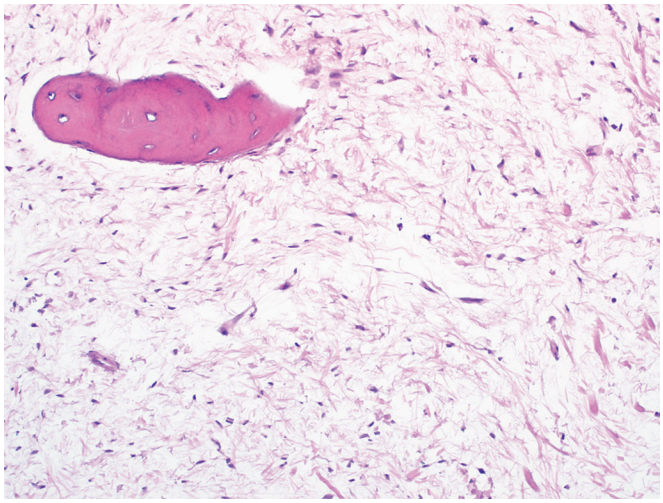

Figure 5.32 Odontogenic myxoma. The lesion is highly myxoid, hypocellular, and devoid of atypia. Native bone trabeculae are entrapped indicative of infiltrative growth.

histology can be similar, the clinical and radiographic appearances easily distinguish these two processes.

Odontogenic fibroma differs microscopically from myxoma by the presence of fibrous tissue and the more frequent occurrence of odontogenic epithelial rests.[113] This lesion occurs most frequently in the mandible and displays a female predilection.[114] Tumors in which the myxomatous and the fibrous components are equally represented can be designated as *myxofibromas*.[115] Cases combining features of odontogenic fibroma and central giant cell granulomas exist (see p. 276).[116] Odontogenic fibroma can be simulated microscopically by the normal dental follicle around the crown of an unerupted tooth (see p. 276).[113,117] In contrast to myxomas, they tend not to recur and can be treated more conservatively.

Peripheral counterparts of these lesions occurring in the gingiva have been described.[118]

Borderline Odontogenic Tumors

Ameloblastoma

General and Clinical Features

Ameloblastoma is the most common of the epithelial odontogenic tumors,[119] but it is still comparatively rare, comprising approximately 1% of tumors and cysts arising in the jaws. It may arise from the epithelial lining of a dentigerous cyst, from the remnants of the dental lamina and enamel organ, or from the basal layer of the oral mucosa, sometimes in a multicentric fashion.[120]

Ameloblastoma appears most commonly in the third to fifth decades, but it has also been described in children.[121] No gender or racial preference has been noted. More than 80% occur in the mandible, with 70% of these arising in the molar–ramus area. The usual radiographic appearance is that of a lytic expansile lesion. Clinical duration may range from a few weeks to 50 years (Fig. 5.33). The diagnosis can be made by fine-needle aspiration. Some arise in the maxillary sinus and have no connection with the maxillary bone.

Morphologic Features

Traditionally, ameloblastoma has been divided into solid and (multi) cystic types, but this distinction is arbitrary inasmuch as nearly all ameloblastomas demonstrate some degree of cystic change (Fig. 5.34). Therefore, they are now grouped together as solid/

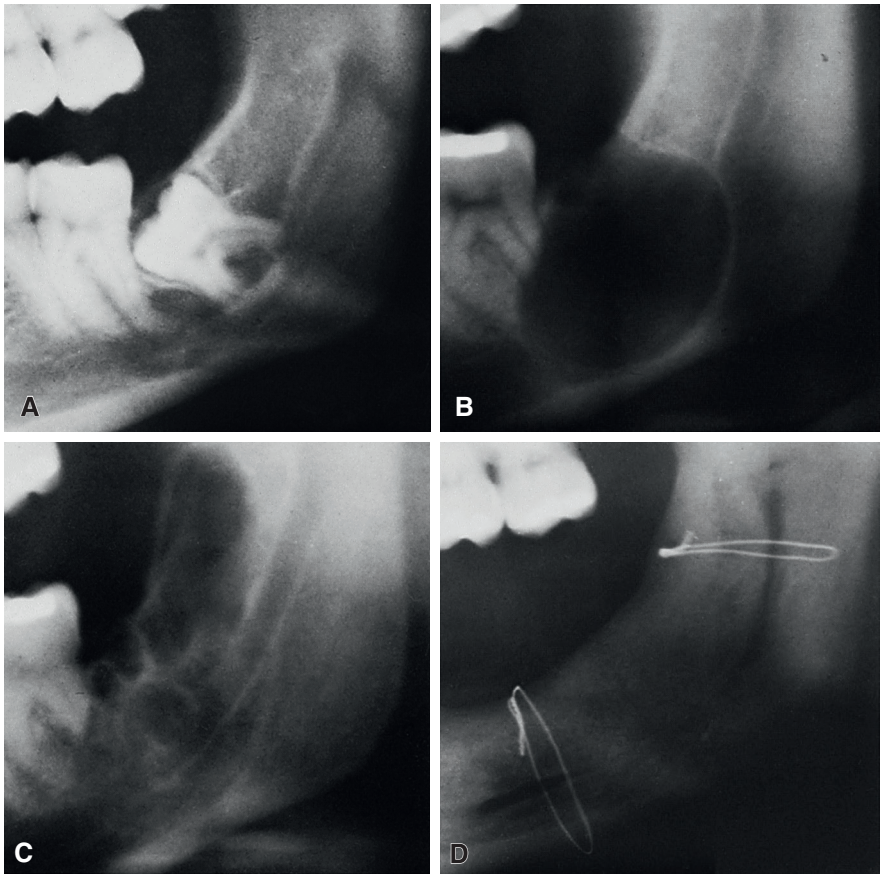

Figure 5.33 Four radiographs illustrating history of ameloblastoma associated with impacted third molar tooth in a 19-year-old female patient. **A** (April 1971), Subtle, atypical radiolucency can be discerned below tooth. Tooth was surgically removed. No surgical specimen was obtained. **B** (September 1974), Routine dental roentgenogram revealed residual or recurrent cystic lesion. Surgical curettage was performed and "early" ameloblastoma demonstrated. No further treatment was given. **C** (February 1978), Multilocular radiolucency of more typical character. Tumor was resected. **D** (December 1978), There is no evidence of residual tumor. (Courtesy of Dr. William Randall and Dr. Clark Borstad, Minneapolis.)

Figure 5.34 Gross appearance of ameloblastoma showing an expansile solid and cystic mass in the posterior mandible and ramus.

multicystic ameloblastomas. Microscopically, many subtypes or patterns have been described: follicular, plexiform (Fig. 5.35), acanthomatous (Fig. 5.36), basaloid, granular cell (Fig. 5.37), and desmoplastic.[122–126] Two or more types may coexist within the same tumor, and there is little evidence to suggest that one subtype is more aggressive than another.

The two predominant patterns are follicular and plexiform. In the follicular type, there is an attempt to mimic the dental organ epithelium. The outermost cells resemble those of the inner dental epithelium of the developing tooth follicle (i.e. the ameloblastic layer). The cells are tall columnar, with polarization of the nuclei away from the basement membrane. The plexiform pattern demonstrates irregular masses and interdigitating cords of epithelial cells but otherwise are similar to the follicular type.[2,127] The central portion of the epithelial island is composed of a loose network of cells resembling stellate reticulum. Squamous metaplasia within the stellate reticulum gives rise to the acanthomatous type and is a common histologic finding. The epithelial islands demonstrate little inductive influence on the fibrous connective tissue stroma. Enamel and dentin are not formed by ameloblastoma. The desmoplastic variant is uncommon and is characterized by dense sclerotic stroma with compressed islands of ameloblastoma. They tend to lose the polarization of the peripheral palisaded columnar cells and the stellate reticulum appears more condensed and cellular.

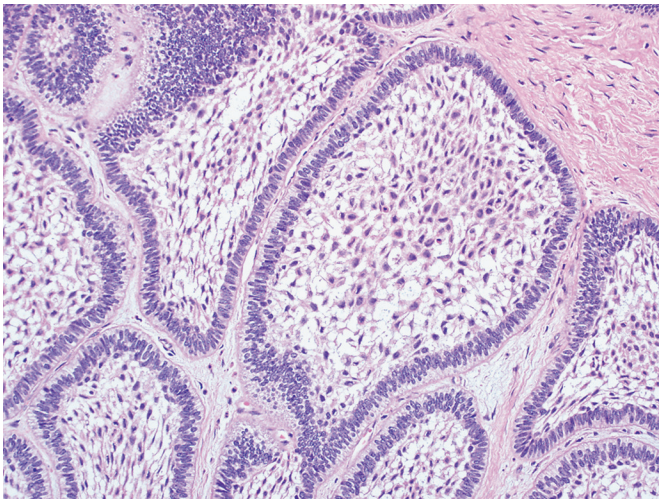

Figure 5.35 Ameloblastoma exhibiting the classic "follicular" appearance with central stellate reticulum and peripheral palisaded columnar cells with so-called reverse polarization.

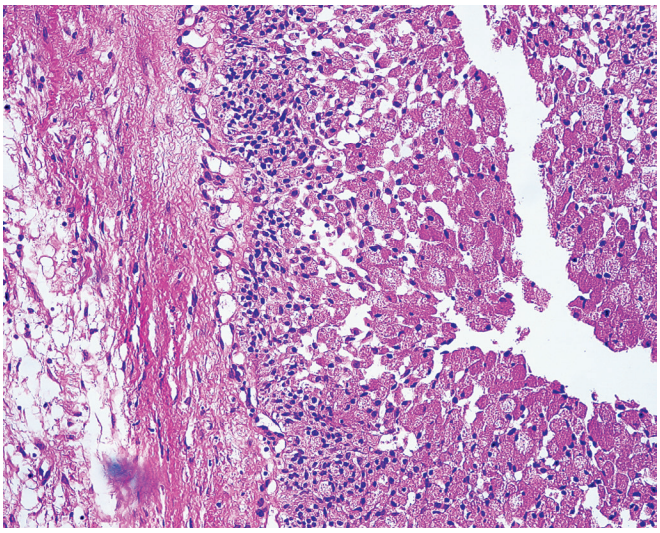

Figure 5.37 Granular cell ameloblastoma. Most of the tumor cells in the stellate reticulum area have an abundant, deeply granular cytoplasm.

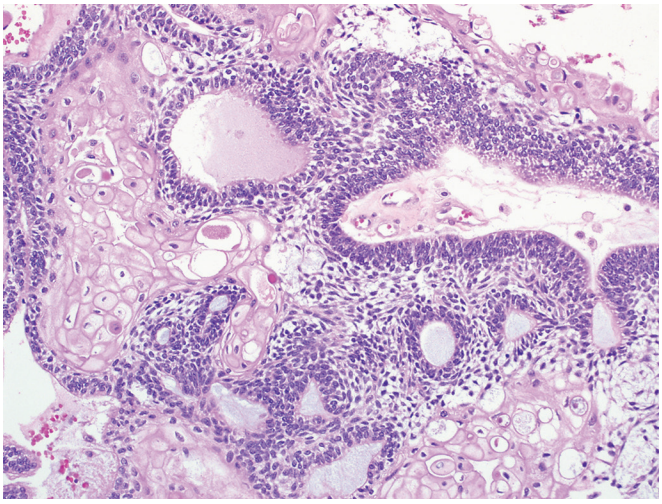

Figure 5.36 Acanthotic ameloblastoma. Ameloblastic epithelium surrounds large keratin-filled cavities.

Immunohistochemical and Molecular Genetic Features

Immunohistochemically, the tumor cells exhibit strong reactivity for keratin and are surrounded by a continuous layer of laminin in a pattern similar to that seen in the developing tooth.[128] The major keratins expressed are CK5 and CK14, whereas coexpression of CK8, CK18, and CK19 is a feature of the cells in the stellate reticulum-like areas.[129] Notably, calretinin has been found to be positive in the overwhelming majority of solid and multicystic ameloblastomas (as well as in the unicystic tumors, see later).[130] The staining, which is almost always restricted to the stellate reticulum-like epithelium, may be of diagnostic aid for the identification of these tumors, particularly in the differential diagnosis with keratocyst, which is consistently negative for this marker.[131]

Granular cell ameloblastoma is positive for keratin and negative for S-100 protein, in keeping with its ameloblastic nature and in contrast to the ordinary granular cell tumor; however, and like the latter, it is also positive for CD68, indicating that the granular cell change here is also due to lysosomal overload.[132]

Ameloblastoma commonly shows aberrant nuclear accumulation of β-cateinin.[64,133,134] To explain this phenomenon, mutations of genes involved in the Wnt signaling pathway have been sought. Mutations in the β-catenin gene *CTNNB1* are rare, mutations in the *APC* gene are found in 0%–50% of cases, and mutations in *AXIN1* and *AXIN2* are absent.[64,133–135] Gene expression profiling studies reveal overexpression of the oncogene *FOS* and tumor necrosis factor (TNF) receptor 1 *(TNFRSF1A)*, as well as underexpression of a variety of genes, such as genes for *SHH*, TNF receptor-associated factor 3 *(TRAF3)* and transforming growth factor (TGF)-β_1 *(TGFB1)*.[136] Recently, somatic activating *BRAF* V600E mutations have been identified in 62% of ameloblastomas in a large series of 80 tumors.[137] *BRAF* VE1 immunohistochemical stain was 100% sensitive and specific in these mutated cases. *BRAF*-mutated tumors show lower recurrence risk. Mutually exclusive somatic activating mutations of FGFR2 were also identified, as well as rare mutations of SMO, CTNNB1, PIK3CA, and SMARCB1.

Spread and Metastasis

Ameloblastoma has invasive properties and a tendency to recur. As such, they are treated by complete surgical resection with tumor-free margins.

Furthermore, distant metastases have been documented in rare instances, especially to the lungs but also to the central nervous system.[138,139] The term *malignant ameloblastoma* is accepted by the WHO for those metastasizing tumors that retain the typical morphology of ameloblastoma (as opposed to ameloblastic carcinoma, see next section). In the majority of these cases, the distant metastases have been preceded by several local recurrences.[140]

Differential Diagnosis

A particularly vexing problem in this area is the differential diagnosis between focal reactive hyperplasia in a dentigerous cyst and so-called *unicystic ameloblastoma*, the latter representing either ameloblastic transformation from a dentigerous cyst or a predominantly cystic form of ameloblastoma. In unicystic ameloblastomas that have ameloblastomatous epithelium confined to the cyst lining (so-called luminal and intraluminal types), simple enucleation is effective treatment. If ameloblastomatous epithelium extends into the underlying stroma of a unicystic ameloblastoma (so-called mural type), they should be treated like conventional solid/multicystic ameloblastomas because they have a recurrence risk.

The minimal criterion for the diagnosis of ameloblastoma under these circumstances is the finding of a palisaded basal layer with

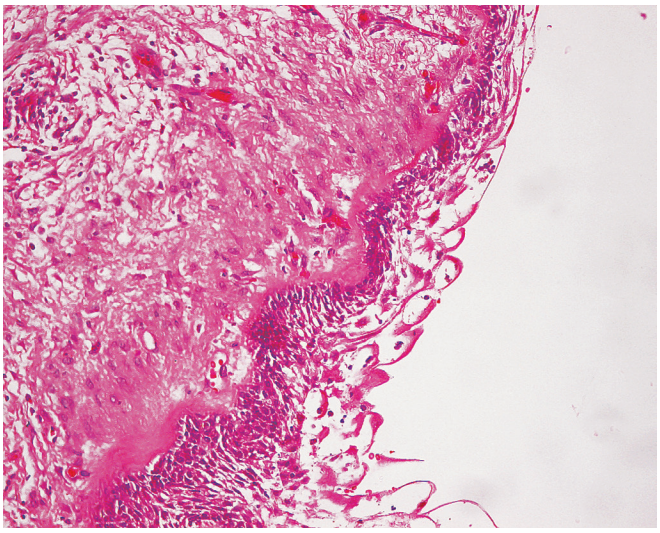

Figure 5.38 Unicystic ameloblastoma fulfilling the minimum criteria for this entity, which should be distinguished from reactive epithelial changes in a radicular cyst.

stellate reticulum-like epithelium above (Fig. 5.38).[141,142] Immunoreactivity for calretinin may help to support the diagnosis.[143] Enucleation of the lesion is usually curative, but local recurrence may develop, particularly if there are ameloblastic islands embedded in the cyst wall.[144]

Malignant Odontogenic Tumors

Ameloblastic Carcinoma

Ameloblastic carcinoma is defined as a tumor having the overall microscopic architectural features of ameloblastoma but also manifesting malignant morphologic features, such as lack of differentiation, hypercellularity, marked nuclear atypia, numerous mitotic figures, vascular invasion, and neural invasion (Fig. 5.39).[145] It is possible that at least some of the reported *intraosseous squamous cell carcinomas* of the jaw represent ameloblastic carcinomas with a marked degree of squamous change[146–148]; others appear to arise in keratocysts and other types of odontogenic cyst.[149] Hypermethylation of *P16* may mediate the malignant transformation of ameloblastoma.[150] These are aggressive tumors with approximately one-third resulting in distant metastasis and death.

Odontogenic Carcinoma

Odontogenic carcinoma is a generic term used for primary intraosseous carcinomas thought to be of odontogenic origin, either de novo or through the malignant transformation of an odontogenic cyst.[151] The term is generally restricted to carcinomas other than those having an ameloblastoma-like pattern (see previous section) and is usually accompanied by a qualifier.

Clear cell odontogenic carcinoma is a rare epithelial lesion of the jaw of putative odontogenic origin that may simulate a clear cell carcinoma of salivary gland type or of metastatic origin. The clear cells are arranged in nests surrounded by a mature collagenous stroma, are devoid of mucin, and contain glycogen (Fig. 5.40).[152] These tumors are morphologically and immunophenotypically very similar to clear cell carcinoma of minor salivary gland origin. In support of their relatedness is that a majority of clear cell odontogenic carcinomas demonstrate the *EWSR1-ATF1* fusion identified in clear

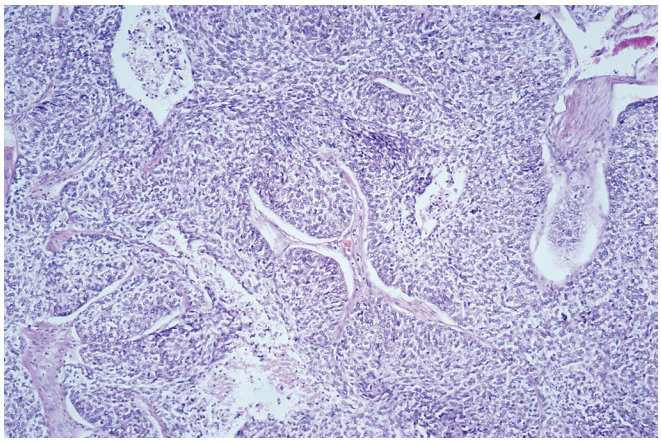

Figure 5.39 Ameloblastic carcinoma. The geographic configuration of the tumor nests and the overall basophilic staining quality give this lesion a distinctly basaloid quality. Other areas had a more typical ameloblastoma appearance.

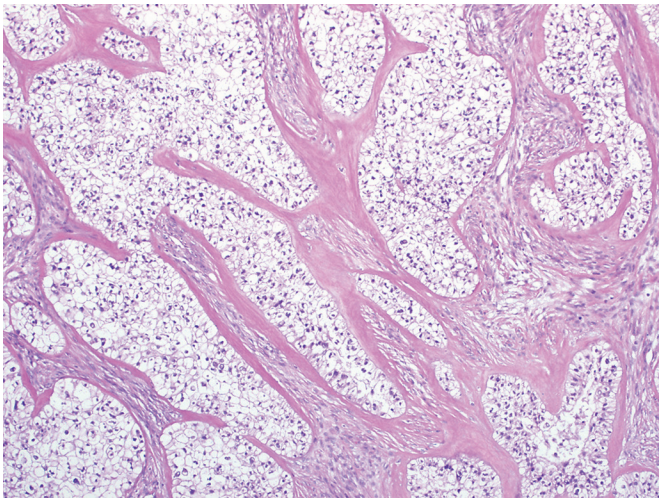

Figure 5.40 Clear cell odontogenic carcinoma. Infiltrative nests of large polygonal clear cells are set within a hyalinized to cellular spindled stroma.

cell carcinoma of minor salivary gland origin.[153] Although originally regarded as benign, it is now considered malignant, with occasional examples having metastasized to regional lymph nodes.[154,155]

Sclerosing odontogenic carcinoma is characterized by the presence of small nests and thin cords of small polygonal epithelial cells, occasionally clear and relatively monomorphic, often exhibiting skeletal muscle and neural infiltration, embedded in an abundant sclerohyaline stroma.[156]

Ghost cell odontogenic carcinoma is the malignant variant of dentinogenic ghost cell tumor. These are rare tumors whose behavior is difficult to predict but, overall, are associated with a 73% 5-year survival.[157]

Ameloblastic Fibrosarcoma

Ameloblastic fibrosarcoma (odontogenic sarcoma; odontogenic fibrosarcoma) shows histopathologic features similar to those of ameloblastic fibroma but differs from it by virtue of cytologic atypia and increased cellularity of the mesenchymal component with diminution or absence of the epithelial component, and aggressive

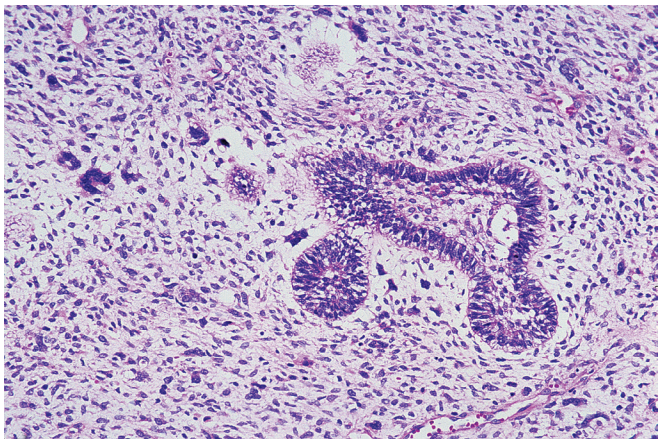

Figure 5.41 Ameloblastic fibrosarcoma. Islands of well-differentiated ameloblastic epithelium are separated by a neoplastic stroma showing marked pleomorphism and mitotic activity.

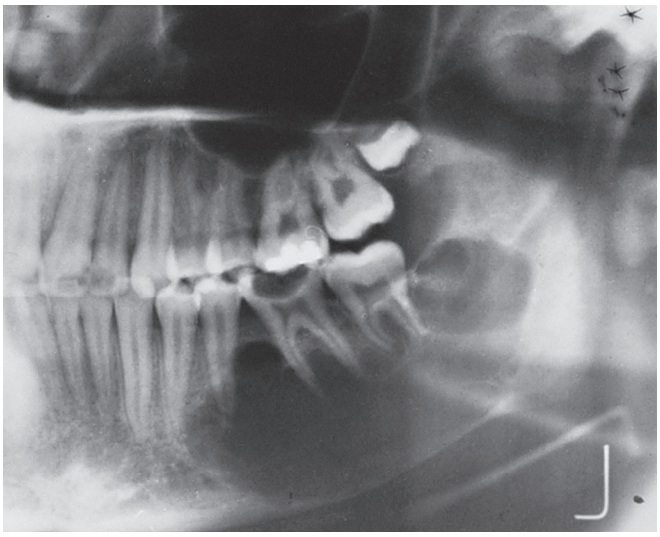

Figure 5.42 Radiograph illustrating cystlike appearance of aneurysmal bone cyst of mandible in a 19-year-old man.

clinical behavior (Fig. 5.41).[158,159] Sometimes these features appear in recurrences of tumors originally diagnosed as ameloblastic fibromas.

Pain is a common symptom, in contrast with most other odontogenic tumors. Death follows extensive local recurrence and extension. Distant metastases from this tumor are exceptionally rare.

Cases combining features of ameloblastic carcinoma and ameloblastic fibrosarcoma *(ameloblastic carcinosarcoma)* have been described, sometimes arising in ameloblastic fibroma.[160]

Other Tumors and Tumorlike Conditions

Paget disease of the mandible and maxilla can occur as a dominant clinical expression of a generalized process or as the only localization in the monostotic form of the disease. The process may be complicated by the appearance of osteosarcoma or giant cell tumor. Actually, the possibility of Paget disease should always be investigated when either of these two neoplasms is found in the jaw. As a note of caution, normal cementicles within the periodontal ligament should not be confused with Paget disease.

Langerhans cell histiocytosis (eosinophilic granuloma; histiocytosis X) of bone has a marked predilection for the jaw—more often the mandible—where it can cause a localized ragged zone of destruction (see Chapter 37).[161]

Aneurysmal bone cyst can produce massive expansion of the mandible. Radiographic studies reveal a multiloculated lytic lesion with fluid-fluid levels (Fig. 5.42). Because of its high content of giant cells, the lesion can be confused microscopically with central giant cell granuloma.[162]

Benign tumors of the jaw include, among others, hemangioma of either cavernous or Masson type,[163] benign peripheral nerve tumors,[164] nonossifying fibroma (not to be confused with the ossifying fibroma),[165] desmoplastic fibroma (which has a definite predilection for the mandible and histologically resembles desmoid fibromatosis),[166] chondromyxoid fibroma,[167] chondroblastoma,[168] the already mentioned osteoblastoma, osteochondroma (often located in the coronoid process of the mandible),[169] and osteoma. The last lesion occurs almost exclusively in the jaw and is present in more than 80% of patients with Gardner syndrome.[170]

Salivary gland tumors may present as primary intraosseous masses, usually in the mandible. Mucoepidermoid carcinoma is the most common type[171]; other types include adenoid cystic carcinoma, acinic cell carcinoma, and hyalinizing clear cell carcinoma.[172]

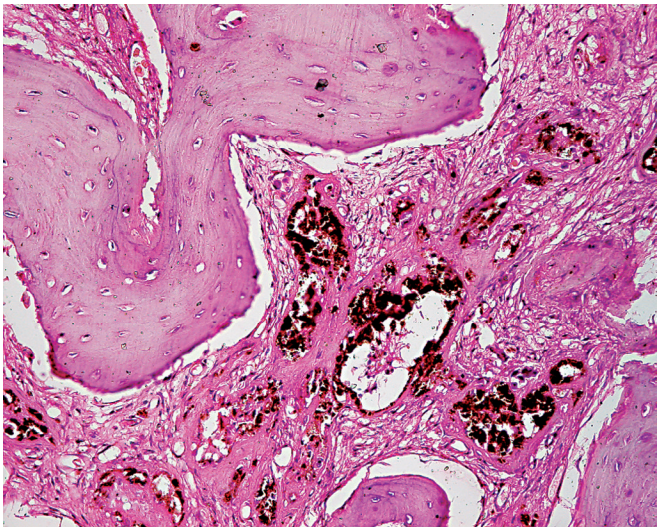

Figure 5.43 Melanotic neuroectodermal tumor of infancy. The neoplastic islands located between the bone trabeculae contain abundant melanin pigment.

Meningioma has been seen in the mandible, presumably arising from ectopic nests of arachnoidal cells or related perineurial cells.[173] Most are of the meningothelial, fibroblastic or transitional types histologically.

Melanotic neuroectodermal tumor of infancy (melanotic progonoma; retinal anlage tumor) is a rare neoplasm of neuroectodermal derivation previously thought to arise from odontogenic epithelium (Figs. 5.43 and 5.44).[174,175] The maxilla is the most common location; however, it also occurs in the mandible, skull, long bones, epididymis, mediastinum, and soft tissues of extremities. They are composed of a dual population of small round neuroblastic cells arranged in nests and surrounded by melanin-containing epithelial cells that are separated by a dense fibrous stroma. The small neuroblastic cells are positive for NSE and CD57, often with expression of synaptophysin and GFAP. The epithelial cells are positive for cytokeratin, HMB-45, and vimentin. Ultrastructural studies and the demonstration of both neuronal differentiation and

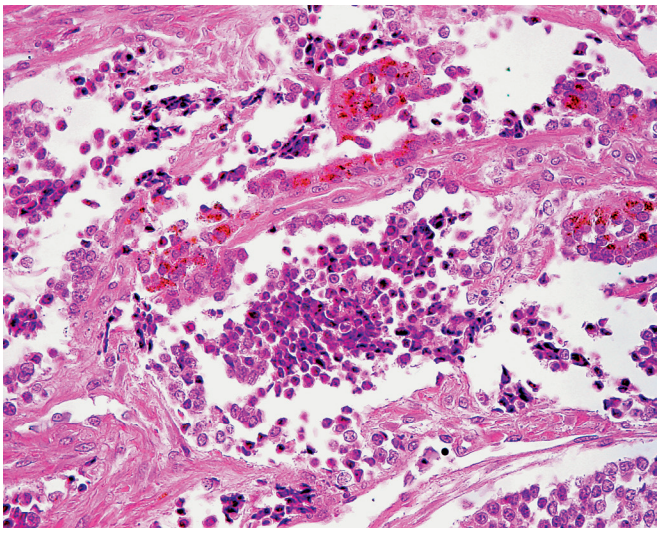

Figure 5.44 Melanotic neuroectodermal tumor of infancy. This example shows the classic pattern of neuroblast-like cells surrounded by larger melanin-containing epithelial cells.

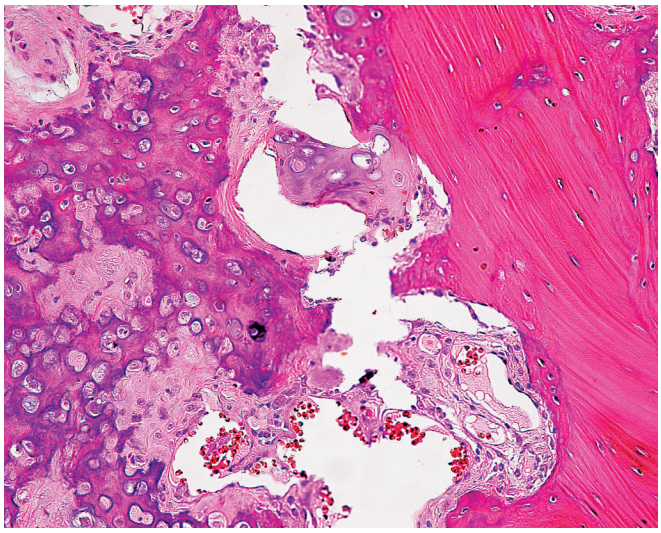

Figure 5.46 Osteosarcoma of jaw. The neoplastic bone *(left)* is clearly distinguishable from the residual normal bone *(right)*.

Figure 5.45 Gross appearance of a destructive osteosarcoma of mandible.

vanillylmandelic acid production have confirmed the neural nature of this neoplasm.[176] The behavior is generally benign, but some cases with aggressive local behavior and a few that have resulted in distant metastases have been documented.[177]

Myofibroma is another proliferative process that may involve the mandible of infants or children.[178] Morphologically they resemble those seen in soft tissue sites. They can be solitary bone tumors or can be associated with other sites of involvement in the multicentric form of myofibromatosis.

Osteosarcoma is the most common primary malignant tumor of the jaw. The mandible is affected slightly more often than the maxilla (Fig. 5.45).[179] The majority of the maxillary tumors occur in the alveolar ridge.[180] Most cases arise de novo, but others represent complications of radiation therapy, Paget disease, or fibrous dysplasia.[181] The majority are of the usual intramedullary type, but parosteal examples have been reported.[182] Microscopically, most have a conventional appearance, with many exhibiting a prominent chondroblastic component (Fig. 5.46). Others have a telangiectatic quality that may lead to confusion with aneurysmal bone cyst.[183] The prognosis for osteosarcoma of the jaw is, as a group, more favorable than for osteosarcoma of long bones. It is best for the tumors located in the mandibular symphysis and worst for those involving the maxillary antrum.[184] Multimodality therapy similar to that used for osteosarcomas of the extremities is used for them.

Chondrosarcoma of the jaw shows a marked predilection for the maxilla.[185] It can be central or peripheral, and microscopically it may exhibit conventional, mesenchymal, or dedifferentiated features.[186]

Ewing sarcoma/primitive neuroectodermal tumor (PNET) can present as a primary tumor of the jaw; most of the reported cases have been located in the maxilla.[187]

Kaposi sarcoma of the oral cavity may erode the underlying jawbone; in exceptional cases it presents as a primary intraosseous lesion.[188]

Other reported cases of sarcoma of the jaw are *leiomyosarcoma*,[189] *rhabdomyosarcoma*,[190] *myofibroblastic sarcoma* (myofibrosarcoma),[191,192] *malignant peripheral nerve sheath tumor*[193] (including its melanotic variant[194]), *angiosarcoma* (including the epithelioid variant[195]), and *pleomorphic undifferentiated sarcoma* (malignant fibrous histiocytoma).[196] The last is a very aggressive neoplasm, similar to those arising in deep soft tissues.

Malignant lymphoma that involves the jaws is nearly always of the non-Hodgkin type.[197] In adults, most cases represent diffuse large B-cell lymphoma, whereas in children there is a predominance of Burkitt lymphoma.[198] The high frequency of jaw involvement in the latter is well known.[198]

Hodgkin lymphoma with primary presentation in the jaw is a curiosity; less than a handful of cases have been reported.[199]

Acute leukemia may involve the jaw and oral cavity in children, sometimes as the initial sign of the disease.[200]

Plasma cell neoplasms can present in the jaw, either as part of a generalized process (multiple myeloma) or as the only manifestation of the disease (plasmacytoma).[201]

Direct invasion of the mandible by squamous cell carcinoma of the oral cavity is not uncommon. Extension along the mandibular canal, which contains the inferior alveolar nerve, artery, and vein, can be seen at a great distance from the primary tumor.[202]

Metastatic tumors to the jaw in adults most often originate from breast, lung, large bowel, prostate, kidney, thyroid, or testis.[203,204] In children, metastases to the jaw originate most frequently from adrenal neuroblastoma, embryonal rhabdomyosarcoma, and Wilms tumor.[205,206]

The tooth-bearing area of the body and molar regions of the mandible are the most frequent sites for these metastases, possibly because of greater blood supply in these regions. In approximately half of the cases, oral metastasis is the first sign of systemic disease. Swelling, pain, and anesthesia are the most common symptoms.[205,207,208]

Diseases of the Temporomandibular Joint

Hypoplasia of the mandibular condyle may be unilateral or bilateral. It is characterized by facial asymmetry and abnormality of function. It often represents diminished or retarded development and may be associated with anomalies of the ear or temporal bone and with macrostomia. It may also be the result of acquired conditions, especially mandibular fracture or other traumas during the growth period.

Hyperplasia of the mandibular condyle usually manifests as an isolated finding in the form of unilateral facial enlargement in adults, but it may be also seen in association with hemihypertrophy. Grossly, the condyle appears larger than normal. Microscopic examination reveals a thick and irregular layer of hyaline or fibrohyaline cartilage covering the articular surface of the condyle. This disease is probably related to, if not identical with, *synovial chondromatosis* or *osteochondromatosis*.[209,210] When the cellularity of the cartilaginous nodules is marked, the possibility of overdiagnosing the case as chondrosarcoma exists.

Tophaceous pseudogout (tumoral calcium pyrophosphate dihydrate crystal deposition disease [CPDCDD]) results from the deposition of calcium pyrophosphate dihydrate crystals.[211] Microscopically, the presence of chondromyxoid tissue with atypical chondrocytes can result in a mistaken diagnosis of chondrosarcoma. The identification by polarized light of birefringent crystals associated with a granulomatous reaction is the clue to the diagnosis (Fig. 5.47).[212] The chemical nature of the crystals can be confirmed by crystallography, but this is not typically necessary from a diagnostic standpoint.[213]

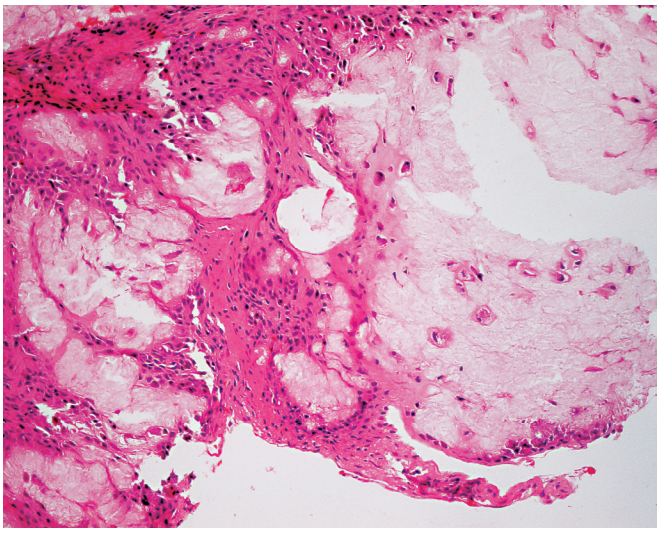

Figure 5.47 Tophaceous pseudogout. The lobules of deposited soft tissue uric acid have the appearance of slightly atypical cartilage and are surrounded by foreign body giant cells.

Traumatic, inflammatory, and degenerative conditions may all result in the so-called *temporomandibular joint pain–dysfunction syndrome*. The features of this syndrome include limitation of jaw movement with discomfort or pain, tenderness of masticatory muscles, and, sometimes, clicking of the joint during mastication. The gross and microscopic anatomy of joint components (capsule, articulating portions of the mandibular condyle, and the meniscus) display markedly altered relationships in such instances. Less altered, individual components of the temporomandibular joint, such as a meniscus or condylar head, may be surgically removed and submitted for pathologic examination. Although it is sometimes possible to demonstrate specific inflammatory or degenerative conditions of this joint, such as rheumatoid arthritis, osteoarthritis (osteoarthrosis), or osteochondromatosis, in most cases the pathologic features are nonspecific.[214]

Tenosynovial giant cell tumor (pigmented villonodular synovitis) can occur in the region of the temporomandibular joint. Lack of familiarity with this fact, coupled with the high cellularity of the lesion, may result in overinterpretation as a malignant process.[215]

Other conditions that have been reported in the temporomandibular joint include osteoma and osteoblastoma, ganglion and synovial cyst, aneurysmal bone cyst, epidermal inclusion cyst, hemangioma, nonossifying fibroma, Langerhans cell histiocytosis, and plasma cell myeloma.[215]

References

1. Slootweg PJ. Lesions of the jaws. *Histopathology*. 2009;54(4):401-418.
2. Barnes L, Eveson JW, Reichart P, Sidransky D. *World Health Organization Classification of Tumors: Pathology and Genetics of Head and Neck Tumors*. Lyon: IARC Press; 2005.
3. Cawson RA. *Oral Diseases: Clinical and Pathologic Correlations*. 3rd ed. Edinburgh: Mosby; 2001.
4. Cawson RA. *Lucas's Pathology of Tumors of the Oral Tissues*. 5th ed. London: Churchill Livingstone; 1998.
5. Neville BW, Damm DD, Allen CM, Bouquot J. *Oral & Maxillofacial Pathology*. 2nd ed. Philadelphia: W.B. Saunders; 2002.
6. Regezi JA, Sciubba JJ, Jordan RCK. *Oral Pathology: Clinical Pathologic Correlations*. 5th ed. Philadelphia: WB Saunders; 2008.
7. Sciubba JJ, Fantasia JE, Khan LB. *Tumors and Cysts of the Jaws. Atlas of Tumor Pathology*. Series 3, Fascicle 29. Washington, DC: Armed Forces Institute of Pathology; 2001.
8. Mortensen H, Winther JE, Birn H. Periapical granulomas and cysts. An investigation of 1,600 cases. *Scand J Dent Res*. 1970;78(3):241-250.
9. Barker BF, Dunlap CL. Hyaline rings of the oral cavity: the so-called "pulse" granuloma redefined. *Semin Diagn Pathol*. 1987;4(3):237-242.
10. McMillan MD, Kardos TB, Edwards JL, et al. Giant cell hyalin angiopathy or pulse granuloma. *Oral Surg Oral Med Oral Pathol*. 1981;52(2):178-186.
11. Karamurzin YS, Narula S, Khanifar E, et al. Pulse granulomas in highly unusual sites. *Histopathology*. 2009;54(2):268-269.
12. Lieblich SE, Piecuch JF. Infections of the jaws, including infected fractures, osteomyelitis, and osteoradionecrosis. *Atlas Oral Maxillofac Surg Clin North Am*. 2000;8(1):121-132.
13. Ellis DJ, Winslow JR, Indovina AA. Garre's osteomyelitis of the mandible. Report of a case. *Oral Surg Oral Med Oral Pathol*. 1977;44(2):183-189.
14. Kannangara DW, Thadepalli H, McQuirter JL. Bacteriology and treatment of dental infections. *Oral Surg Oral Med Oral Pathol*. 1980;50(2):103-109.
15. Gorlin RJ, Goldman HM, eds. *Thoma's Oral Pathology*. 6th ed. St Louis: Mosby; 1970.
16. Suei Y, Taguchi A, Tanimoto K. Diagnosis and classification of mandibular osteomyelitis. *Oral Surg Oral Med Oral Pathol Oral Radiol Endod*. 2005;100(2):207-214.
17. Nabil S, Samman N. Risk factors for osteoradionecrosis after head and neck radiation: a systematic review. *Oral Surg Oral Med Oral Pathol Oral Radiol*. 2012;113(1):54-69.
18. Kumar V, Sinha RK. Bisphosphonate related osteonecrosis of the jaw: an update. *J Maxillofac Oral Surg*. 2014;13(4):386-393.
19. Regezi JA, Courtney RM, Batsakis JG. The pathology of head and neck tumors: cysts of the jaws, part 12. *Head Neck Surg*. 1981;4(1):48-57.

20. Saito Y, Hoshina Y, Nagamine T, et al. Simple bone cyst. A clinical and histopathologic study of fifteen cases. *Oral Surg Oral Med Oral Pathol*. 1992;74(4):487-491.
21. Howe GL. 'Haemorrhagic cysts' of the mandible. I. *Br J Oral Surg*. 1965;3(1):55-76.
22. Jaffe HL. Giant-cell reparative granuloma, traumatic bone cyst, and fibrous (fibro-oseous) dysplasia of the jawbones. *Oral Surg Oral Med Oral Pathol*. 1953;6(1):159-175.
23. Waldron CA, Shafer WG. The central giant cell reparative granuloma of the jaws. An analysis of 38 cases. *Am J Clin Pathol*. 1966;45(4):437-447.
24. Mosqueda Taylor A, Bermudez Flores V, Diaz Franco MA. Combined central odontogenic fibroma and giant cell granuloma-like lesion of the mandible: report of a case and review of the literature. *J Oral Maxillofac Surg*. 1999;57(10):1258-1262.
25. de Lange J, van den Akker HP, van den Berg H. Central giant cell granuloma of the jaw: a review of the literature with emphasis on therapy options. *Oral Surg Oral Med Oral Pathol Oral Radiol Endod*. 2007;104(5): 603-615.
26. De Lange J, Van den Akker HP. Clinical and radiological features of central giant-cell lesions of the jaw. *Oral Surg Oral Med Oral Pathol Oral Radiol Endod*. 2005;99(4):464-470.
27. Yamaguchi T, Dorfman HD, Eisig S. Cherubism: clinicopathologic features. *Skeletal Radiol*. 1999;28(6):350-353.
28. Mangion J, Rahman N, Edkins S, et al. The gene for cherubism maps to chromosome 4p16.3. *Am J Hum Genet*. 1999;65(1):151-157.
29. Ueki Y, Tiziani V, Santanna C, et al. Mutations in the gene encoding c-Abl-binding protein SH3BP2 cause cherubism. *Nat Genet*. 2001;28(2):125-126.
30. Masson EA, MacFarlane IA, Bodmer CW, Vaughan ED. Parathyroid carcinoma presenting with a brown tumour of the mandible in a young man. *Br J Oral Maxillofac Surg*. 1993;31(2):117-119.
31. Dorfman HD, Czerniak B. *Bone Tumors*. St. Louis: Mosby; 1998.
32. Waldron CA, Giansanti JS. Benign fibro-osseous lesions of the jaws: a clinical-radiologic-histologic review of sixty-five cases. II. Benign fibro-osseous lesions of periodontal ligament origin. *Oral Surg Oral Med Oral Pathol*. 1973;35(3):340-350.
33. Cohen MM Jr, Howell RE. Etiology of fibrous dysplasia and McCune-Albright syndrome. *Int J Oral Maxillofac Surg*. 1999;28(5):366-371.
34. Lania A, Mantovani G, Spada A. G protein mutations in endocrine diseases. *Eur J Endocrinol*. 2001;145(5):543-559.
35. Pierce AM, Wilson DF, Goss AN. Inherited craniofacial fibrous dysplasia. *Oral Surg Oral Med Oral Pathol*. 1985;60(4):403-409.
36. Eversole LR, Sabes WR, Rovin S. Fibrous dysplasia: a nosologic problem in the diagnosis of fibro-osseous lesions of the jaws. *J Oral Pathol*. 1972;1(5):189-220.
37. El-Mofty SK. Cemento-ossifying fibroma and benign cementoblastoma. *Semin Diagn Pathol*. 1999;16(4):302-307.
38. Eversole LR, Leider AS, Nelson K. Ossifying fibroma: a clinicopathologic study of sixty-four cases. *Oral Surg Oral Med Oral Pathol*. 1985;60(5):505-511.
39. Hamner JE 3rd, Scofield HH, Cornyn J. Benign fibro-osseous jaw lesions of periodontal membrane origin. An analysis of 249 cases. *Cancer*. 1968;22(4):861-878.
40. Granados R, Carrillo R, Najera L, et al. Psammomatoid ossifying fibromas: immunohistochemical analysis and differential diagnosis with psammomatous meningiomas of craniofacial bones. *Oral Surg Oral Med Oral Pathol Oral Radiol Endod*. 2006;101(5):614-619.
41. Williams HK, Mangham C, Speight PM. Juvenile ossifying fibroma. An analysis of eight cases and a comparison with other fibro-osseous lesions. *J Oral Pathol Med*. 2000;29(1):13-18.
42. Brannon RB, Fowler CB. Benign fibro-osseous lesions: a review of current concepts. *Adv Anat Pathol*. 2001;8(3):126-143.
43. Voytek TM, Ro JY, Edeiken J, Ayala AG. Fibrous dysplasia and cemento-ossifying fibroma. A histologic spectrum. *Am J Surg Pathol*. 1995;19(7):775-781.
44. Toyosawa S, Yuki M, Kishino M, et al. Ossifying fibroma vs fibrous dysplasia of the jaw: molecular and immunological characterization. *Mod Pathol*. 2007;20(3):389-396.
45. Summerlin DJ, Tomich CE. Focal cemento-osseous dysplasia: a clinicopathologic study of 221 cases. *Oral Surg Oral Med Oral Pathol*. 1994;78(5):611-620.
46. Sedano HO, Kuba R, Gorlin RJ. Autosomal dominant cemental dysplasia. *Oral Surg Oral Med Oral Pathol*. 1982;54(6):642-646.
47. Su L, Weathers DR, Waldron CA. Distinguishing features of focal cemento-osseous dysplasias and cemento-ossifying fibromas: I. A pathologic spectrum of 316 cases. *Oral Surg Oral Med Oral Pathol Oral Radiol Endod*. 1997;84(3):301-309.
48. Jones AC, Prihoda TJ, Kacher JE, et al. Osteoblastoma of the maxilla and mandible: a report of 24 cases, review of the literature, and discussion of its relationship to osteoid osteoma of the jaws. *Oral Surg Oral Med Oral Pathol Oral Radiol Endod*. 2006;102(5):639-650.
49. Slootweg PJ. Cementoblastoma and osteoblastoma: a comparison of histologic features. *J Oral Pathol Med*. 1992;21(9):385-389.
50. Abdelsayed RA, Eversole LR, Singh BS, Scarbrough FE. Gigantiform cementoma: clinicopathologic presentation of 3 cases. *Oral Surg Oral Med Oral Pathol Oral Radiol Endod*. 2001;91(4):438-444.
51. Kaplan I, Nicolaou Z, Hatuel D, Calderon S. Solitary central osteoma of the jaws: a diagnostic dilemma. *Oral Surg Oral Med Oral Pathol Oral Radiol Endod*. 2008;106(3):e22-e29.
52. Jacobsson S, Heyden G. Chronic sclerosing osteomyelitis of the mandible. Histologic and histochemical findings. *Oral Surg Oral Med Oral Pathol*. 1977;43(3):357-364.
53. Cabrini RL, Barros RE, Albano H. Cysts of the jaws: a statistical analysis. *J Oral Surg*. 1970;28(7):485-489.
54. Wright JM Jr. Squamous odontogenic tumorlike proliferations in odontogenic cysts. *Oral Surg Oral Med Oral Pathol*. 1979;47(4):354-358.
55. Eversole LR, Sabes WR, Rovin S. Aggressive growth and neoplastic potential of odontogenic cysts: with special reference to central epidermoid and mucoepidermoid carcinomas. *Cancer*. 1975;35(1):270-282.
56. Fromm A. Epstein's pearls, Bohn's nodules and inclusion-cysts of the oral cavity. *J Dent Child*. 1967;34(4):275-287.
57. Kerezoudis NP, Donta-Bakoyianni C, Siskos G. The lateral periodontal cyst: aetiology, clinical significance and diagnosis. *Endod Dent Traumatol*. 2000;16(4):144-150.
58. Formoso Senande MF, Figueiredo R, Berini Aytes L, Gay Escoda C. Lateral periodontal cysts: a retrospective study of 11 cases. *Med Oral Patol Oral Cir Bucal*. 2008;13(5):E313-E317.
59. Soames JV. A pigmented calcifying odontogenic cyst. *Oral Surg Oral Med Oral Pathol*. 1982;53(4):395-400.
60. Gorlin RJ, Pindborg JJ, Odont, et al. The calcifying odontogenic cyst: a possible analogue of the cutaneous calcifying epithelioma of Malherbe. An analysis of fifteen cases. *Oral Surg Oral Med Oral Pathol*. 1962;15:1235-1243.
61. Li TJ, Yu SF. Clinicopathologic spectrum of the so-called calcifying odontogenic cysts: a study of 21 intraosseous cases with reconsideration of the terminology and classification. *Am J Surg Pathol*. 2003;27(3):372-384.
62. Ellis GL. Odontogenic ghost cell tumor. *Semin Diagn Pathol*. 1999;16(4):288-292.
63. Yoshida M, Kumamoto H, Ooya K, Mayanagi H. Histopathological and immunohistochemical analysis of calcifying odontogenic cysts. *J Oral Pathol Med*. 2001;30(10):582-588.
64. Sekine S, Sato S, Takata T, et al. Beta-catenin mutations are frequent in calcifying odontogenic cysts, but rare in ameloblastomas. *Am J Pathol*. 2003;163(5):1707-1712.
65. Brannon RB. The odontogenic keratocyst. A clinicopathologic study of 312 cases. Part I. Clinical features. *Oral Surg Oral Med Oral Pathol*. 1976;42(1):54-72.
66. Hodgkinson DJ, Woods JE, Dahlin DC, Tolman DE. Keratocysts of the jaw. Clinicopathologic study of 79 patients. *Cancer*. 1978;41(3):803-813.
67. Gorlin RJ, Vickers RA, Kellen E, Williamson JJ. Multiple basal-cell nevi syndrome. An analysis of a syndrome consisting of multiple nevoid basal-cell carcinoma, jaw cysts, skeletal anomalies, medulloblastoma, and hyporesponsiveness to parathormone. *Cancer*. 1965;18:89-104.
68. Rayner CR, Towers JF, Wilson JS. What is Gorlin's syndrome? The diagnosis and management of the basal cell naevus syndrome, based on a study of thirty-seven patients. *Br J Plast Surg*. 1977;30(1):62-67.
69. Donatsky O, Hjorting-Hansen E, Philipsen HP, Fejerskov O. Clinical, radiologic, and histopathologic aspects of 13 cases of nevoid basal cell carcinoma syndrome. *Int J Oral Surg*. 1976;5(1):19-28.
70. Gorlin RJ, Pindborg JJ, Cohen MM Jr. *Syndromes of the Head and Neck*. 2nd ed. New York: McGraw-Hill; 1976.
71. Zedan W, Robinson PA, High AS. A novel polymorphism in the PTC gene allows easy identification of allelic loss in basal cell nevus syndrome lesions. *Diagn Mol Pathol*. 2001;10(1):41-45.
72. Dong Q, Pan S, Sun LS, Li TJ. Orthokeratinized odontogenic cyst: a clinicopathologic study of 61 cases. *Arch Pathol Lab Med*. 2010;134(2):271-275.
73. Li TJ, Kitano M, Chen XM, et al. Orthokeratinized odontogenic cyst: a clinicopathological and immunocytochemical study of 15 cases. *Histopathology*. 1998;32(3):242-251.
74. Henley J, Summerlin DJ, Tomich C, et al. Molecular evidence supporting the neoplastic nature of odontogenic keratocyst: a laser capture microdissection study of 15 cases. *Histopathology*. 2005;47(6):582-586.
75. Madras J, Lapointe H. Keratocystic odontogenic tumour: reclassification of the odontogenic keratocyst from cyst to tumour. *J Can Dent Assoc*. 2008;74(2):165-165h.
76. Gomes CC, Diniz MG, Gomez RS. Review of the molecular pathogenesis of the odontogenic keratocyst. *Oral Oncol*. 2009;45(12):1011-1014.
77. Barreto DC, Gomez RS, Bale AE, et al. PTCH gene mutations in odontogenic keratocysts. *J Dent Res*. 2000;79(6):1418-1422.
78. Chirapathomsakul D, Sastravaha P, Jansisyanont P. A review of odontogenic keratocysts and the behavior of recurrences. *Oral Surg Oral Med Oral Pathol Oral Radiol Endod*. 2006;101(1):5-9, discussion 10.

79. Koppang HS, Johannessen S, Haugen LK, et al. Glandular odontogenic cyst (sialo-odontogenic cyst): report of two cases and literature review of 45 previously reported cases. *J Oral Pathol Med*. 1998;27(9):455-462.
80. Karmody CS, Gallagher JC. Nasoalveolar cysts. *Ann Otol Rhinol Laryngol*. 1972;81(2):278-283.
81. Abrams AM, Howell FV, Bullock WK. Nasopalatine cysts. *Oral Surg Oral Med Oral Pathol*. 1963;16:306-332.
82. Buchner A, Mlinek A. Palatal opening of the nasopalatine duct: a developmental anomaly. Report of a case. *Oral Surg Oral Med Oral Pathol*. 1972;34(3):440-444.
83. Thoma KH, Goldman HM. Odontogenic tumors: a classification based on observations of the epithelial, mesenchymal, and mixed varieties. *Am J Pathol*. 1946;22(3):433-471.
84. Pindborg JJ, Clausen FP. Classification of odontogenic tumors. Suggestion. *Acta Odontol Scand*. 1958;16:293-301.
85. Schafer DR, Thompson LD, Smith BC, Wenig BM. Primary ameloblastoma of the sinonasal tract: a clinicopathologic study of 24 cases. *Cancer*. 1998;82(4):667-674.
86. Courtney RM, Kerr DA. The odontogenic adenomatoid tumor. A comprehensive study of twenty new cases. *Oral Surg Oral Med Oral Pathol*. 1975;39(3):424-435.
87. Philipsen HP, Samman N, Ormiston IW, et al. Variants of the adenomatoid odontogenic tumor with a note on tumor origin. *J Oral Pathol Med*. 1992;21(8):348-352.
88. Swasdison S, Dhanuthai K, Jainkittivong A, Philipsen HP. Adenomatoid odontogenic tumors: an analysis of 67 cases in a Thai population. *Oral Surg Oral Med Oral Pathol Oral Radiol Endod*. 2008;105(2):210-215.
89. Philipsen HP, Reichart PA, Zhang KH, et al. Adenomatoid odontogenic tumor: biologic profile based on 499 cases. *J Oral Pathol Med*. 1991;20(4):149-158.
90. Abrams AM, Melrose RJ, Howell FV. Adenoameloblastoma. A clinical pathologic study of ten new cases. *Cancer*. 1968;22(1):175-185.
91. el-Labban NG. The nature of the eosinophilic and laminated masses in the adenomatoid odontogenic tumor: a histochemical and ultrastructural study. *J Oral Pathol Med*. 1992;21(2):75-81.
92. Ai-Ru L, Zhen L, Jian S. Calcifying epithelial odontogenic tumors: a clinicopathologic study of nine cases. *J Oral Pathol*. 1982;11(5):399-406.
93. Pindborg JJ. The calcifying epithelial odontogenic tumor. Review of the literature and report of an extra-osseous case. *Acta Odontol Scand*. 1966;24:419-430.
94. Takeda Y, Suzuki A, Sekiyama S. Peripheral calcifying epithelial odontogenic tumor. *Oral Surg Oral Med Oral Pathol*. 1983;56(1):71-75.
95. Gopalakrishnan R, Simonton S, Rohrer MD, Koutlas IG. Cystic variant of calcifying epithelial odontogenic tumor. *Oral Surg Oral Med Oral Pathol Oral Radiol Endod*. 2006;102(6):773-777.
96. El-Labban NG, Lee KW, Kramer IR, Harris M. The nature of the amyloid-like material in a calcifying epithelial odontogenic tumour: an ultrastructural study. *J Oral Pathol*. 1983;12(5):366-374.
97. Franklin CD, Martin MV, Clark A, et al. An investigation into the origin and nature of 'amyloid' in a calcifying epithelial odontogenic tumour. *J Oral Pathol*. 1981;10(6):417-429.
98. Chomette G, Auriol M, Guilbert F. Histoenzymological and ultrastructural study of a bifocal calcifying epithelial odontogenic tumor. Characteristics of epithelial cells and histogenesis of amyloid-like material. *Virchows Arch [A]*. 1984;403:67-76.
99. Damm DD, White DK, Drummond JF, et al. Combined epithelial odontogenic tumor: adenomatoid odontogenic tumor and calcifying epithelial odontogenic tumor. *Oral Surg Oral Med Oral Pathol*. 1983;55(5):487-496.
100. Kawano K, Ono K, Yada N, et al. Malignant calcifying epithelial odontogenic tumor of the mandible: report of a case with pulmonary metastasis showing remarkable response to platinum derivatives. *Oral Surg Oral Med Oral Pathol Oral Radiol Endod*. 2007;104(1):76-81.
101. Baden E, Doyle J, Mesa M, et al. Squamous odontogenic tumor. Report of three cases including the first extraosseous case. *Oral Surg Oral Med Oral Pathol*. 1993;75(6):733-738.
102. Goldblatt LI, Brannon RB, Ellis GL. Squamous odontogenic tumor. Report of five cases and review of the literature. *Oral Surg Oral Med Oral Pathol*. 1982;54(2):187-196.
103. Pullon PA, Shafer WG, Elzay RP, et al. Squamous odontogenic tumor. Report of six cases of a previously undescribed lesion. *Oral Surg Oral Med Oral Pathol*. 1975;40(5):616-630.
104. Meyers AD, Poulson T, Pettigrew J, Clark M. Cystic ameloblastic fibroma. *Ear Nose Throat J*. 1991;70(10):729-732.
105. van Wyk CW, van der Vyver PC. Ameloblastic fibroma with dentinoid formation/immature dentinoma. A microscopic and ultrastructural study of the epithelial-connective tissue interface. *J Oral Pathol*. 1983;12(1):37-46.
106. Couch RD, Morris EE, Vellios F. Granular cell ameloblastic fibroma. Report of 2 cases in adults, with observations of its similarity to congenital epulis. *Am J Clin Pathol*. 1962;37:398-404.
107. Trodahl JN. Ameloblastic fibroma. A survey of cases from the Armed Forces Institute of Pathology. *Oral Surg Oral Med Oral Pathol*. 1972;33(4):547-558.
108. Dunlap CL, Fritzlen TJ. Cystic odontoma with concomitant adenoameloblastoma (adenoameloblastic odontoma). *Oral Surg Oral Med Oral Pathol*. 1972;34(3):450-456.
109. Slootweg PJ. An analysis of the interrelationship of the mixed odontogenic tumors: ameloblastic fibroma, ameloblastic fibro-odontoma, and the odontomas. *Oral Surg Oral Med Oral Pathol*. 1981;51(3):266-276.
110. Barker BF. Odontogenic myxoma. *Semin Diagn Pathol*. 1999;16(4):297-301.
111. Li TJ, Sun LS, Luo HY. Odontogenic myxoma: a clinicopathologic study of 25 cases. *Arch Pathol Lab Med*. 2006;130(12):1799-1806.
112. Boson WL, Gomez RS, Araujo L, et al. Odontogenic myxomas are not associated with activating mutations of the Gs alpha gene. *Anticancer Res*. 1998;18(6a):4415-4417.
113. Dunlap CL. Odontogenic fibroma. *Semin Diagn Pathol*. 1999;16(4):293-296.
114. Handlers JP, Abrams AM, Melrose RJ, Danforth R. Central odontogenic fibroma: clinicopathologic features of 19 cases and review of the literature. *J Oral Maxillofac Surg*. 1991;49(1):46-54.
115. Zimmerman DC, Dahlin DC. Myxomatous tumors of the jaws. *Oral Surg Oral Med Oral Pathol*. 1958;11(10):1069-1080.
116. Odell EW, Lombardi T, Barrett AW, et al. Hybrid central giant cell granuloma and central odontogenic fibroma-like lesions of the jaws. *Histopathology*. 1997;30(2):165-171.
117. Fellegara G, Mody K, Kuhn E, Rosai J. Normal dental papilla simulating odontogenic myxoma. *Int J Surg Pathol*. 2007;15(3):282-285.
118. Gardner DG. The peripheral odontogenic fibroma: an attempt at clarification. *Oral Surg Oral Med Oral Pathol*. 1982;54(1):40-48.
119. Larsson A, Almeren H. Ameloblastoma of the jaws. An analysis of a consecutive series of all cases reported to the Swedish Cancer Registry during 1958–1971. *Acta Pathol Microbiol Scand A Pathol*. 1978;86a(5):337-349.
120. Gardner DG. Peripheral ameloblastoma: a study of 21 cases, including 5 reported as basal cell carcinoma of the gingiva. *Cancer*. 1977;39(4):1625-1633.
121. Daramola JO, Ajagbe HA, Oluwasanmi JO. Ameloblastoma of the jaws in Nigerian children. A review of sixteen cases. *Oral Surg Oral Med Oral Pathol*. 1975;40(4):458-463.
122. Altini M, Slabbert HD, Johnston T. Papilliferous keratoameloblastoma. *J Oral Pathol Med*. 1991;20(1):46-48.
123. Higuchi Y, Nakamura N, Ohishi M, Tashiro H. Unusual ameloblastoma with extensive stromal desmoplasia. *J Craniomaxillofac Surg*. 1991;19(7):323-327.
124. Nasu M, Takagi M, Yamamoto H. Ultrastructural and histochemical studies of granular-cell ameloblastoma. *J Oral Pathol*. 1984;13(4):448-456.
125. Slabbert H, Altini M, Crooks J, Uys P. Ameloblastoma with dentinoid induction: dentinoameloblastoma. *J Oral Pathol Med*. 1992;21(1):46-48.
126. Whitt JC, Dunlap CL, Sheets JL, Thompson ML. Keratoameloblastoma: a tumor sui generis or a chimera? *Oral Surg Oral Med Oral Pathol Oral Radiol Endod*. 2007;104(3):368-376.
127. Gorlin RJ. Odontogenic tumors. In: Gorlin RJ, Goldman HM, eds. *Thoma's Oral Pathology*. 6th ed. St Louis: Mosby; 1970.
128. Thesleff I, Ekblom P. Distribution of keratin and laminin in ameloblastoma. Comparison with developing tooth and epidermoid carcinoma. *J Oral Pathol*. 1984;13(1):85-96.
129. Vigneswaran N, Whitaker SB, Budnick SD, Waldron CA. Expression patterns of epithelial differentiation antigens and lectin-binding sites in ameloblastomas: a comparison with basal cell carcinomas. *Hum Pathol*. 1993;24(1):49-57.
130. Alaeddini M, Etemad-Moghadam S, Baghaii F. Comparative expression of calretinin in selected odontogenic tumours: a possible relationship to histogenesis. *Histopathology*. 2008;52(3):299-304.
131. DeVilliers P, Liu H, Suggs C, et al. Calretinin expression in the differential diagnosis of human ameloblastoma and keratocystic odontogenic tumor. *Am J Surg Pathol*. 2008;32(2):256-260.
132. Dina R, Marchetti C, Vallania G, et al. Granular cell ameloblastoma. An immunocytochemical study. *Pathol Res Pract*. 1996;192(6):541-546.
133. Siriwardena BS, Kudo Y, Ogawa I, et al. Aberrant beta-catenin expression and adenomatous polyposis coli gene mutation in ameloblastoma and odontogenic carcinoma. *Oral Oncol*. 2009;45(2):103-108.
134. Tanahashi J, Daa T, Yada N, et al. Mutational analysis of Wnt signaling molecules in ameloblastoma with aberrant nuclear expression of beta-catenin. *J Oral Pathol Med*. 2008;37(9):565-570.
135. Kawabata T, Takahashi K, Sugai M, et al. Polymorphisms in PTCH1 affect the risk of ameloblastoma. *J Dent Res*. 2005;84(9):812-816.
136. Heikinheimo K, Jee KJ, Niini T, et al. Gene expression profiling of ameloblastoma and human tooth germ by means of a cDNA microarray. *J Dent Res*. 2002;81(8): 525-530.
137. Brown NA, Rolland D, McHugh JB, et al. Activating FGFR2-RAS-BRAFT mutations in ameloblastoma. *Clin Cancer Res*. 2014;20(21):5517-5526.
138. Ikemura K, Tashiro H, Fujino H, et al. Ameloblastoma of the mandible with metastasis to the lungs and lymph nodes. *Cancer*. 1972;29(4):930-940.

139. Phillips SD, Corio RL, Brem H, Mattox D. Ameloblastoma of the mandible with intracranial metastasis. A case study. *Arch Otolaryngol Head Neck Surg*. 1992;118(8):861-863.
140. Kunze E, Donath K, Luhr HG, et al. Biology of metastasizing ameloblastoma. *Pathol Res Pract*. 1985;180(5):526-535.
141. Gardner DG, Corio RL. The relationship of plexiform unicystic ameloblastoma to conventional ameloblastoma. *Oral Surg Oral Med Oral Pathol*. 1983;56(1):54-60.
142. Leider AS, Eversole LR, Barkin ME. Cystic ameloblastoma. A clinicopathologic analysis. *Oral Surg Oral Med Oral Pathol*. 1985;60(6):624-630.
143. Coleman H, Altini M, Ali H, et al. Use of calretinin in the differential diagnosis of unicystic ameloblastomas. *Histopathology*. 2001;38(4):312-317.
144. Li TJ, Wu YT, Yu SF, Yu GY. Unicystic ameloblastoma: a clinicopathologic study of 33 Chinese patients. *Am J Surg Pathol*. 2000;24(10):1385-1392.
145. Hall JM, Weathers DR, Unni KK. Ameloblastic carcinoma: an analysis of 14 cases. *Oral Surg Oral Med Oral Pathol Oral Radiol Endod*. 2007;103(6):799-807.
146. Bruce RA, Jackson IT. Ameloblastic carcinoma. Report of an aggressive case and review of the literature. *J Craniomaxillofac Surg*. 1991;19(6):267-271.
147. Huang JW, Luo HY, Li Q, Li TJ. Primary intraosseous squamous cell carcinoma of the jaws. Clinicopathologic presentation and prognostic factors. *Arch Pathol Lab Med*. 2009;133(11):1834-1840.
148. Nagai N, Takeshita N, Nagatsuka H, et al. Ameloblastic carcinoma: case report and review. *J Oral Pathol Med*. 1991;20(9): 460-463.
149. Muller S, Waldron CA. Primary intraosseous squamous carcinoma. Report of two cases. *Int J Oral Maxillofac Surg*. 1991;20(6):362-365.
150. Abiko Y, Nagayasu H, Takeshima M, et al. Ameloblastic carcinoma ex ameloblastoma: report of a case-possible involvement of CpG island hypermethylation of the p16 gene in malignant transformation. *Oral Surg Oral Med Oral Pathol Oral Radiol Endod*. 2007;103(1):72-76.
151. Chaisuparat R, Coletti D, Kolokythas A, et al. Primary intraosseous odontogenic carcinoma arising in an odontogenic cyst or de novo: a clinicopathologic study of six new cases. *Oral Surg Oral Med Oral Pathol Oral Radiol Endod*. 2006;101(2):194-200.
152. Xavier FC, Rodini CO, Ramalho LM, et al. Clear cell odontogenic carcinoma: case report with immunohistochemical findings adding support to the challenging diagnosis. *Oral Surg Oral Med Oral Pathol Oral Radiol Endod*. 2008;106(3):403-410.
153. Bilodeau EA, Weinreb I, Antonescu CR, et al. Clear cell odontogenic carcinomas show EWSR1 rearrangements: a novel finding and a biologic link to salivary clear cell carcinomas. *Am J Surg Pathol*. 2013;37:1001-1005.
154. Li TJ, Yu SF, Gao Y, Wang EB. Clear cell odontogenic carcinoma: a clinicopathologic and immunocytochemical study of 5 cases. *Arch Pathol Lab Med*. 2001;125(12):1566-1571.
155. Maiorano E, Altini M, Viale G, et al. Clear cell odontogenic carcinoma. Report of two cases and review of the literature. *Am J Clin Pathol*. 2001;116(1):107-114.
156. Koutlas IG, Allen CM, Warnock GR, Manivel JC. Sclerosing odontogenic carcinoma: a previously unreported variant of a locally aggressive odontogenic neoplasm without apparent metastatic potential. *Am J Surg Pathol*. 2008;32(11):1613-1619.
157. Lu Y, Mock D, Takata T, Jordan RC. Odontogenic ghost cell carcinoma: report of four new cases and review of the literature. *J Oral Pathol Med*. 1999;28(7):323-329.
158. Chomette G, Auriol M, Guilbert F, Delcourt A. Ameloblastic fibrosarcoma of the jaws: report of three cases. Clinico-pathologic, histoenzymological and ultrastructural study. *Pathol Res Pract*. 1983;178(1):40-47.
159. Sozeri B, Ataman M, Ruacan S, Gedikoglu G. Ameloblastic fibrosarcoma. *Int J Pediatr Otorhinolaryngol*. 1993;25(1-3):255-259.
160. DeLair D, Bejarano PA, Peleg M, El-Mofty SK. Ameloblastic carcinosarcoma of the mandible arising in ameloblastic fibroma: a case report and review of the literature. *Oral Surg Oral Med Oral Pathol Oral Radiol Endod*. 2007;103(4):516-520.
161. Domboski ML. Eosinophilic granuloma of bone manifesting mandibular involvement. *Oral Surg Oral Med Oral Pathol*. 1980;50(2):116-123.
162. Matt BH. Aneurysmal bone cyst of the maxilla: case report and review of the literature. *Int J Pediatr Otorhinolaryngol*. 1993;25(1-3):217-226.
163. Komori A, Koike M, Kinjo T, et al. Central intravascular papillary endothelial hyperplasia of the mandible. *Virchows Arch A Pathol Anat Histopathol*. 1984;403(4):453-459.
164. Ellis GL, Abrams AM, Melrose RJ. Intraosseous benign neural sheath neoplasms of the jaws. Report of seven new cases and review of the literature. *Oral Surg Oral Med Oral Pathol*. 1977;44(5):731-743.
165. Elzay RP, Mills S, Kay S. Fibrous defect (nonossifying fibroma) of the mandible. *Oral Surg Oral Med Oral Pathol*. 1984;58(4):402-407.
166. Inwards CY, Unni KK, Beabout JW, Sim FH. Desmoplastic fibroma of bone. *Cancer*. 1991;68(9):1978-1983.
167. Lingen MW, Solt DB, Polverini PJ. Unusual presentation of a chondromyxoid fibroma of the mandible. Report of a case and review of the literature. *Oral Surg Oral Med Oral Pathol*. 1993;75(5):615-621.
168. Spahr J, Elzay RP, Kay S, Frable WJ. Chondroblastoma of the temporomandibular joint arising from articular cartilage: a previously unreported presentation of an uncommon neoplasm. *Oral Surg Oral Med Oral Pathol*. 1982;54(4):430-435.
169. Kerscher A, Piette E, Tideman H, Wu PC. Osteochondroma of the coronoid process of the mandible. Report of a case and review of the literature. *Oral Surg Oral Med Oral Pathol*. 1993;75(5):559-564.
170. Ida M, Nakamura T, Utsunomiya J. Osteomatous changes and tooth abnormalities found in the jaw of patients with adenomatosis coli. *Oral Surg Oral Med Oral Pathol*. 1981;52(1):2-11.
171. Brookstone MS, Huvos AG. Central salivary gland tumors of the maxilla and mandible: a clinicopathologic study of 11 cases with an analysis of the literature. *J Oral Maxillofac Surg*. 1992;50(3):229-236.
172. Martinez-Madrigal F, Pineda-Daboin K, Casiraghi O, Luna MA. Salivary gland tumors of the mandible. *Ann Diagn Pathol*. 2000;4(6):347-353.
173. Landini G, Kitano M. Meningioma of the mandible. *Cancer*. 1992;69(12):2917-2920.
174. Kapadia SB, Frisman DM, Hitchcock CL, et al. Melanotic neuroectodermal tumor of infancy. Clinicopathological, immunohistochemical, and flow cytometric study. *Am J Surg Pathol*. 1993;17(6):566-573.
175. Kruse-Losler B, Gaertner C, Burger H, et al. Melanotic neuroectodermal tumor of infancy: systematic review of the literature and presentation of a case. *Oral Surg Oral Med Oral Pathol Oral Radiol Endod*. 2006;102(2):204-216.
176. Borello ED, Gorlin RJ. Melanotic neuroectodermal tumor of infancy: a neoplasm of neural crese origin. Report of a case associated with high urinary excretion of vanilmandelic acid. *Cancer*. 1966;19(2):196-206.
177. Navas Palacios JJ. Malignant melanotic neuroectodermal tumor: light and electron microscopic study. *Cancer*. 1980;46(3):529-536.
178. Vigneswaran N, Boyd DL, Waldron CA. Solitary infantile myofibromatosis of the mandible. Report of three cases. *Oral Surg Oral Med Oral Pathol*. 1992;73(1):84-88.
179. Mark RJ, Sercarz JA, Tran L, et al. Osteogenic sarcoma of the head and neck. The UCLA experience. *Arch Otolaryngol Head Neck Surg*. 1991;117(7):761-766.
180. Bertoni F, Dallera P, Bacchini P, et al. The Istituto Rizzoli-Beretta experience with osteosarcoma of the jaw. *Cancer*. 1991;68(7):1555-1563.
181. Present D, Bertoni F, Enneking WF. Osteosarcoma of the mandible arising in fibrous dysplasia. A case report. *Clin Orthop Relat Res*. 1986;204:238-244.
182. Roca AN, Smith JL Jr, Jing BS. Osteosarcoma and parosteal osteogenic sarcoma of the maxilla and mandible: study of 20 cases. *Am J Clin Pathol*. 1970;54(4):625-636.
183. Chan CW, Kung TM, Ma L. Telangiectatic osteosarcoma of the mandible. *Cancer*. 1986;58(9):2110-2115.
184. Garrington GE, Scofield HH, Cornyn J, Hooker SP. Osteosarcoma of the jaws. Analysis of 56 cases. *Cancer*. 1967;20(3):377-391.
185. Hackney FL, Aragon SB, Aufdemorte TB, et al. Chondrosarcoma of the jaws: clinical findings, histopathology, and treatment. *Oral Surg Oral Med Oral Pathol*. 1991;71(2):139-143.
186. Takahashi K, Sato K, Kanazawa H, et al. Mesenchymal chondrosarcoma of the jaw: report of a case and review of 41 cases in the literature. *Head Neck*. 1993;15(5):459-464.
187. Arafat A, Ellis GL, Adrian JC. Ewing's sarcoma of the jaws. *Oral Surg Oral Med Oral Pathol*. 1983;55(6):589-596.
188. Langford A, Pohle HD, Reichart P. Primary intraosseous AIDS-associated Kaposi's sarcoma. Report of two cases with initial jaw involvement. *Int J Oral Maxillofac Surg*. 1991;20(6):366-368.
189. Kratochvil FJ 3rd, MacGregor SD, Budnick SD, et al. Leiomyosarcoma of the maxilla. Report of a case and review of the literature. *Oral Surg Oral Med Oral Pathol*. 1982;54(6):647-655.
190. Loducca SV, Mantesso A, de Oliveira EM, de Araujo VC. Intraosseous rhabdomyosarcoma of the mandible: a case report. *Int J Surg Pathol*. 2003;11(1):57-60.
191. Bisceglia M, Tricarico N, Minenna P, et al. Myofibrosarcoma of the upper jawbones: a clinicopathologic and ultrastructural study of two cases. *Ultrastruct Pathol*. 2001;25(5):385-397.
192. Montgomery E, Goldblum JR, Fisher C. Myofibrosarcoma: a clinicopathologic study. *Am J Surg Pathol*. 2001;25(2):219-228.
193. Kameyama Y, Maeda H, Nakane S, et al. Malignant schwannoma of the maxilla in a patient without neurofibromatosis. *Histopathology*. 1987;11(11):1205-1208.
194. Gratz KW, Makek M, Sailer HF. Malignant melanotic schwannoma of the oral cavity. *Int J Oral Maxillofac Surg*. 1991;20(4): 236-238.
195. Freedman PD, Kerpel SM. Epithelioid angiosarcoma of the maxilla. A case report and review of the literature. *Oral Surg Oral Med Oral Pathol*. 1992;74(3):319-325.
196. Abdul-Karim FW, Ayala AG, Chawla SP, et al. Malignant fibrous histiocytoma of jaws. A clinicopathologic study of 11 cases. *Cancer*. 1985;56(7):1590-1596.

197. Pileri SA, Montanari M, Falini B, et al. Malignant lymphoma involving the mandible. Clinical, morphologic, and immunohistochemical study of 17 cases. *Am J Surg Pathol*. 1990;14(7):652-659.
198. Eisenbud L, Sciubba J, Mir R, Sachs SA. Oral presentations in non-Hodgkin's lymphoma: a review of thirty-one cases. Part II. Fourteen cases arising in bone. *Oral Surg Oral Med Oral Pathol*. 1984;57(3):272-280.
199. Cohen MA, Bender S, Struthers PJ. Hodgkin's disease of the jaws. Review of the literature and report of a case. *Oral Surg Oral Med Oral Pathol*. 1984;57(4):413-417.
200. Stafford R, Sonis S, Lockhart P, Sonis A. Oral pathoses as diagnostic indicators in leukemia. *Oral Surg Oral Med Oral Pathol*. 1980;50(2):134-139.
201. Kanazawa H, Shoji A, Yokoe H, et al. Solitary plasmacytoma of the mandible. Case report and review of the literature. *J Craniomaxillofac Surg*. 1993;21(5):202-206.
202. Lukinmaa PL, Hietanen J, Soderholm AL, Lindqvist C. The histologic pattern of bone invasion by squamous cell carcinoma of the mandibular region. *Br J Oral Maxillofac Surg*. 1992;30(1):2-7.
203. al-Ani S. Metastatic tumors to the mouth: report of two cases. *J Oral Surg*. 1973;31(2):120-122.
204. Meyer I, Shklar G. Malignant tumors metastatic to mouth and jaws. *Oral Surg Oral Med Oral Pathol*. 1965;20: 350-362.
205. Clausen F, Poulsen H. Metastatic carcinoma of the jaws. *Acta Pathol Microbiol Scand*. 1963;57:361-374.
206. Dehner LP. Tumors of the mandible and maxilla in children. II. A study of 14 primary and secondary malignant tumors. *Cancer*. 1973;32(1):112-120.
207. Ellis GL, Jensen JL, Reingold IM, Barr RJ. Malignant neoplasms metastatic to gingivae. *Oral Surg Oral Med Oral Pathol*. 1977;44(2):238-245.
208. McDaniel RK, Luna MA, Stimson PG. Metastatic tumors in the jaws. *Oral Surg Oral Med Oral Pathol*. 1971;31(3): 380-386.
209. Blankestijn J, Panders AK, Vermey A, Scherpbier AJ. Synovial chondromatosis of the temporo-mandibular joint. Report of three cases and a review of the literature. *Cancer*. 1985;55(2):479-485.
210. Sanders B, McKelvy B. Osteochondromatous exostosis of the condyle. *J Am Dent Assoc*. 1977;95(6):1151-1153.
211. Yamakawa K, Iwasaki H, Ohjimi Y, et al. Tumoral calcium pyrophosphate dihydrate crystal deposition disease. A clinicopathologic analysis of five cases. *Pathol Res Pract*. 2001;197(7):499-506.
212. Ishida T, Dorfman HD, Bullough PG. Tophaceous pseudogout (tumoral calcium pyrophosphate dihydrate crystal deposition disease). *Hum Pathol*. 1995;26(6):587-593.
213. Mikami T, Takeda Y, Ohira A, et al. Tumoral calcium pyrophosphate dihydrate crystal deposition disease of the temporomandibular joint: identification on crystallography. *Pathol Int*. 2008;58(11):723-729.
214. Shapiro BL. Disorders of the temporomandibular joint. In: Gorlin RJ, Goldman HM, eds. *Thoma's Oral Pathology*. 6th ed. St Louis: Mosby; 1970.
215. Warner BF, Luna MA, Robert Newland T. Temporomandibular joint neoplasms and pseudotumors. *Adv Anat Pathol*. 2000;7(6):365-381.

Major and Minor Salivary Glands

6

Jonathan B. McHugh

CHAPTER CONTENTS

Normal anatomy, *235*
Heterotopia, *236*
Sialolithiasis, *236*
Sialadenitis, *236*
Benign lymphoepithelial cysts and HIV-related lesions, *237*
Lymphoepithelial sialadenitis (Mikulicz disease) and Sjögren syndrome, *238*
Irradiation effect, *239*
Other non-neoplastic lesions, *239*
Epithelial tumors, *240*
Classification, *240*
Tumors with stromal metaplasia, *240*
Tumors with oncocytic (oxyphilic) change, *243*
"Monomorphic" adenoma, *245*
Tumors with sebaceous differentiation, *247*
Tumors with myoepithelial differentiation, *247*
Tumors with clear cell change, *248*
Mucoepidermoid carcinoma, *249*
Acinic cell carcinoma and mammary analogue secretory carcinoma, *250*
Adenoid cystic carcinoma, *252*
Salivary duct tumors, *253*
Polymorphous low-grade adenocarcinoma, *254*
Cystadenocarcinoma (papillary cystadenocarcinoma), *254*
Squamous cell carcinoma, *255*
Small cell carcinoma and other neuroendocrine carcinomas, *255*
Lymphoepithelioma-like carcinoma, *255*
Other primary carcinomas, *256*
Malignant lymphoma, *256*
Other primary tumors, *256*
Metastatic tumors, *257*
General features of salivary gland tumors, *257*
Relative incidence and malignancy, *257*
Clinical diagnosis, *257*
Staging, *257*
Biopsy and cytology, *257*
Frozen section, *258*
Treatment, *258*
Prognosis, *258*

Normal Anatomy

The major salivary glands are the paired parotid, submandibular (submaxillary), and sublingual glands. The parotid gland weighs 14–28 g, the submandibular gland weighs 7–8 g, and the sublingual gland weighs 3 g. The main duct of the parotid gland (Stensen duct) empties into the oral cavity opposite the crown of the second maxillary molar. The main ducts of both the submandibular glands (Wharton duct) and sublingual glands (Bartholin duct) open in the floor of the mouth, on each side of the frenulum of the tongue. Several minor sublingual gland ducts (Rivinus ducts) drain into the main duct or empty into the oral cavity along the plica sub lingualis on either side of the frenulum.

The parotid gland is composed of a broad superficial lobe and a smaller deep lobe, with the facial nerve running between, and artificially separating, the two lobes. Variations of this anatomy and the distribution of the facial nerve occur.[1]

Minor salivary gland tissue is present in many other locations in the head and neck region, where it may give rise to inflammatory conditions, benign tumors, and malignant tumors. They are found in the lips (more in the upper than the lower lip), gingiva, floor of mouth, cheek, hard and soft palates, tongue, tonsillar areas, oropharynx, and upper respiratory tract.

Microscopically, salivary glands are compound exocrine glands composed of a ductal and an acinar portion, the latter of either serous or mucinous type.[2] The parotid gland is exclusively serous, the submandibular gland is mixed with serous predominance, and the sublingual gland is mixed with mucinous predominance. Minor salivary glands can be pure mucinous (anterior tongue, palate), pure serous (posterior tongue), or mixed (lip, buccal, sinonasal tract, nasopharynx). The intercalated ducts and acini represent the terminal portion of the system (ductoacinar unit). Under normal conditions, rare sebaceous glands are annexed to the duct system in the parotid and, less commonly, the submandibular glands. The reserve cells of the intercalated ducts are the source of regeneration of the acinar tissue and the terminal duct system and are thought to be the progenitors (together with the closely apposed myoepithelial cells) of most salivary gland tumors.[3] However, it has been pointed out that basal

Abstract

This chapter reviews the normal anatomy and histology of the three paired major salivary glands and the minor salivary glands. Inflammatory disorders and developmental disorders of salivary glands are briefly discussed. Salivary gland tumors make up for most of the chapter content, using the general classification adopted by the WHO. However, certain neoplasms are discussed together as they relate to differential diagnosis.

Keywords

salivary gland neoplasms,
salivary gland inflammation

and luminal cells at all levels of the duct system and even acinar cells are capable of DNA synthesis and mitosis, and therefore they all have the potential to give rise to neoplasms.[4]

Immunohistochemically, the luminal cells stain for low-molecular-weight keratin (including CK7), CD117, carcinoembryonic antigen (CEA), and epithelial membrane antigen (EMA). The intercalated duct luminal cells are also positive for lysozyme but not for S-100 protein.[5] Serous acinar cells are positive for low-molecular-weight keratin and DOG-1.[6] The myoepithelial cell component can show some minor differences in its immunohistochemical profile depending on its location, but this is an inconsistent finding: in the parotid gland the myoepithelial cells express mainly calponin and h-caldesmon; in the submaxillary glands they also express smooth muscle actin; and in the minor salivary glands there is an additional expression of smooth muscle myosin heavy chain. Myoepithelial cells also stain for p63, p40, CD10, and maspin, as do the basal cells.[7]

The lymphoid tissue of the parotid region is represented by small nodes located near or within the parotid gland and by scattered lymphoid cells located in the connective tissue around the acini and ducts. The latter are part of the mucosa-associated lymphoid tissue (MALT).[8] Periparotid lymph nodes often contain benign salivary gland inclusions. No lymph nodes are present within the submandibular or sublingual glands.

Heterotopia

Heterotopia of salivary gland tissue has been divided into *intranodal* and *extranodal* types.[2] The intranodal variety is more frequent. Almost all lymph nodes located within or near the parotid gland in infants contain salivary gland tissue. The finding is not as prevalent in adults, but it is still very frequent. The salivary gland tissue is usually located in the medullary portion of the node and is predominantly composed of intercalated and intralobular ducts; it may also contain acini (mainly of serous type) and small ducts of immature type.[9]

Extranodal heterotopia has been divided into *high* and *low* forms, depending on its location in the head and neck region. Sites of high heterotopia include the mandible, ear, palatine tonsil, mylohyoid muscle, pituitary gland, and cerebellopontine angle; these are probably all the result of abnormalities in the embryonic migration of the salivary glands. Low heterotopia is related to the branchial pouches and is found in association with cysts and sinuses in the lower neck and in the thyroid gland.[10,11] The most common location is along the medial border of the right sternomastoid muscle near the sternoclavicular joint. In this location, the ectopic glands can secrete saliva onto the skin during feeding.

Heterotopic salivary tissue is subject to the same pathologic changes as its orthotopic counterpart, including cystic formation, oncocytic metaplasia, ductal hyperplasia, and neoplasms.[9] Among the latter, Warthin tumor is the most frequent, but several other benign and malignant types have been described.[12]

Sialolithiasis

Calculi may form in the major ducts of the submandibular, sublingual, and parotid glands, sometimes in a multicentric and bilateral fashion.[13] They are more common in the submandibular gland than in the parotid gland, presumably because in the former the saliva is more saturated with calcium salts and the duct is longer with a sharp upward angle prior to its termination onto the floor of the mouth (Fig. 6.1).[14] Rarely, they affect minor salivary glands.[15] Some of the stones have a foreign body or bacterial nidus. Others do not have an identifiable nidus, are laminated, and are composed of the crystalline compound carbonate apatite.[16] The formation of calculi

Figure 6.1 Sialolithiasis with secondary chronic sialadenitis. A large stone is blocking a major salivary duct.

blocks secretion and produces swelling of the distal salivary gland tissue. If ductal obstruction persists, the gland becomes inflamed and atrophic as acinar tissue is destroyed. With obstructed ducts of the submandibular and sublingual glands, marked induration can occur in the floor of the mouth that may be mistaken for neoplasm by palpation. The duct orifices become erythematous and swollen. Radiographic examination may demonstrate a radiopaque mass, and sialography will show partial or total blockage of the duct. The stones can also be demonstrated by ultrasound.[17] Microscopic examination of glands that have been affected by stones shows dilation of ducts with intraluminal neutrophils, at times squamous metaplasia of the epithelium, moderate to prominent chronic inflammation, and a variable destruction of acinar tissue (Fig. 6.2). Degenerative changes in the secretory and myoepithelial cells are also apparent at the immunohistochemical and ultrastructural levels.[18]

The treatment of symptomatic sialolithiasis consists of surgical removal or disintegration of the calculus. The latter is achieved with techniques such as intracorporeal or extracorporeal shock-wave lithotripsy.[19] In most cases the gland can be preserved, but surgical resection is occasionally necessary.[20]

Sialadenitis

Acute sialadenitis can be localized to one salivary gland (usually parotid or submandibular) or be the expression of a systemic infection. *Viral* sialadenitis (rarely seen as a surgical specimen or biopsy) can be caused by paramyxovirus (mumps), cytomegalovirus, Epstein–Barr virus (EBV), coxsackievirus, and influenza A and parainfluenza viruses.[21] *Acute suppurative sialadenitis* is generally caused by *Staphylococcus aureus*, *Streptococcus* species, and gram-negative bacteria. Dehydration, malnutrition, immunosuppression, and sialolithiasis are

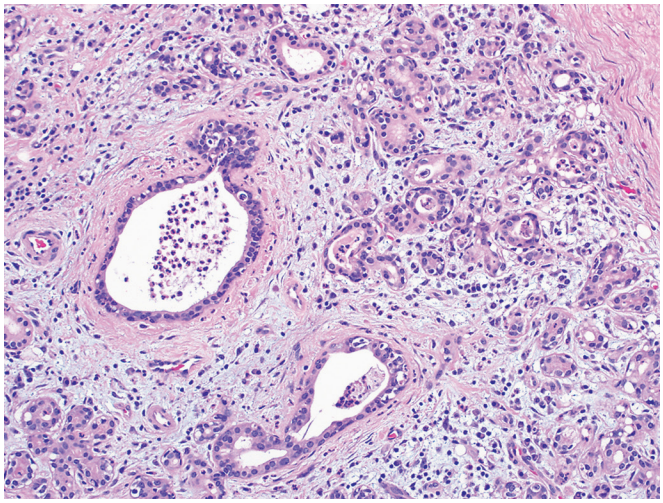

Figure 6.2 Obstructive sialadenitis associated with submandibular gland sialolithiasis. The parenchyma is atrophic with mixed acute and chronic inflammation including intraluminal neutrophils.

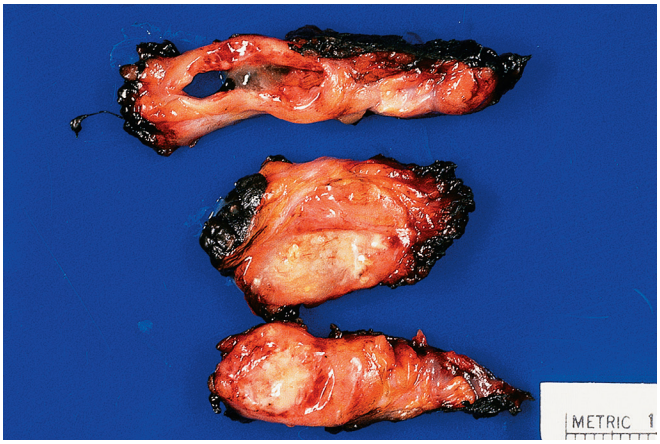

Figure 6.3 Gross appearance of suppurative sialadenitis.

predisposing factors. Once an abscess has formed, surgical drainage may be necessary (Fig. 6.3).[21]

Chronic sialadenitis in the form of mild lymphocytic infiltration of the major salivary gland unaccompanied by clinical symptoms is relatively common. Some cases are of focal obstructive nature and are accompanied by various degrees of parenchymal atrophy, fibrosis, and microliths[22]; others, more common in females, are age related, have a high statistical association with rheumatoid arthritis and Sjögren syndrome, and are probably immune mediated.[23,24] In clinically apparent cases, sialolithiasis is the most common cause.

Kuttner tumor is a chronic sclerosing sialadenitis of the submandibular gland.[25,26] This disorder, which is usually unilateral, is characterized by a plasmacytic and lymphocytic periductal infiltrate eventually leading to encasement of ducts in thick fibrous tissue. The lobular architecture is preserved and obliterative phlebitis is frequently seen. The lymphocytes that infiltrate the epithelial component are mainly B cells. The plasma cells contain abundant immunoglobulin G4 (IgG4), suggesting that Kuttner tumor is part of the widening spectrum of IgG4-associated diseases.[27,28] Cases in which the lymphoid infiltrate is very florid can simulate marginal zone B-cell lymphoma.[29] Surgical excision may be necessary in some cases.[30]

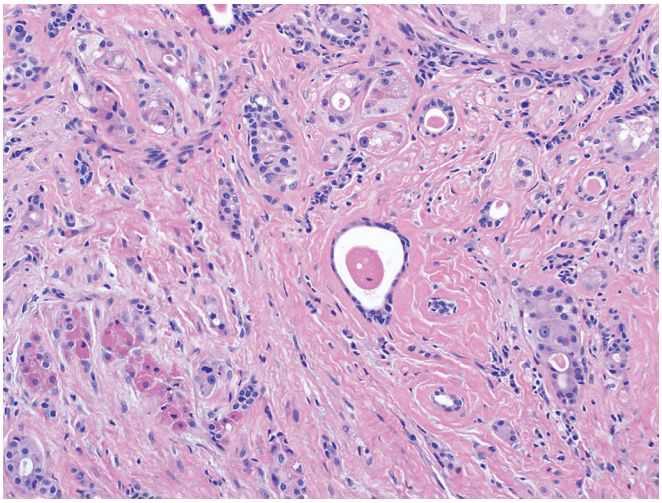

Figure 6.4 Sclerosing polycystic adenosis. Small tubules and epithelial nests composed of cells with apocrine cytology are present within a collagenous stroma. Note the eosinophilic cytoplasmic granules in the bottom left.

Sclerosing polycystic adenosis is characterized by the presence of a discrete mass (usually in the parotid gland) formed by fibrohyaline stroma enclosing dilated and hyperplastic ductal and acinar structures (Fig. 6.4). Apocrine-like metaplasia and transluminal bridges with a cribriform pattern of growth are present.[31,32] The appearance resembles that of sclerosing adenosis and fibrocystic disease of the breast. Some of the epithelial cells contain large, brightly eosinophilic cytoplasmic granules. The behavior is characteristically indolent.[33] Although initially reported as a reactive inflammatory process, most authors now believe this is a low-grade neoplasm,[34] and a study with the HUMARA technique has shown that the disease is of clonal nature.[35]

Granulomatous sialadenitis is uncommon and can result from tuberculosis, fungal infection, sarcoidosis, or duct obstruction from calculi or malignant tumors. In the latter instance, the granulomas result from rupture of ducts and may contain small pools of mucin.[36] A *xanthogranulomatous* variant of sialadenitis has also been described.[37]

Kimura disease can involve the salivary glands (especially the parotid) by spread from adjacent lymph nodes.[38]

Benign Lymphoepithelial Cysts and HIV-Related Lesions

Benign lymphoepithelial cysts are lesions of the parotid or upper cervical lymph nodes characterized by unilocular or multilocular cystic formations lined by glandular or squamous epithelium surrounded by a florid lymphoid hyperplasia with prominent germinal centers.[39] The amount of the lymphoid component is variable,[40] and the cyst lining is often infiltrated by lymphocytes.[41] This is likely an acquired process resulting from the proliferation of branchial pouch-derived or analogous epithelium (e.g. intranodal salivary gland inclusions) induced by the lymphoid hyperplasia, probably through a specific interaction between the epithelial cells and a subset of lymphocytes.[42] Other examples of this phenomenon in the head and neck area are branchial cleft cyst, the branchial cleft cyst-like formations sometimes seen in Hashimoto thyroiditis, and multilocular thymic cyst.

Another salivary gland lesion that merits mention in this context is **human immunodeficiency virus (HIV)-associated lymphoepithelial cyst** (Fig. 6.5).[43,44] The morphologic changes in

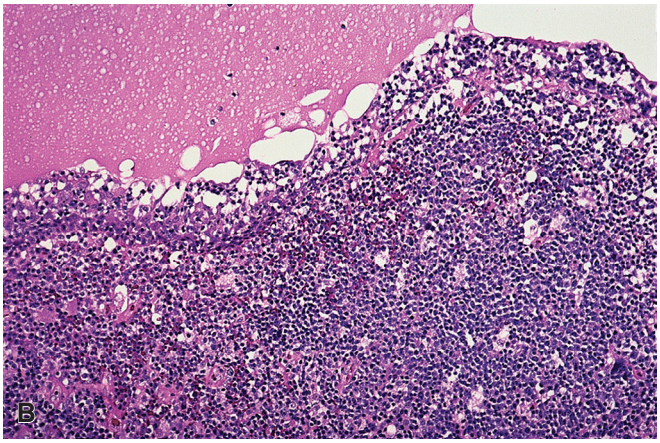

Figure 6.5 **A,** Lymphoepithelial cysts in parotid gland removed from an HIV-infected patient. The solid tan areas correspond to infiltration by lymphoid tissue. **B,** Lymphoepithelial cyst of parotid gland in an HIV-infected patient. Note the lymphocytic infiltration of the epithelium.

this condition include multiloculated lymphoepithelial cysts similar to those previously described, solid lymphoepithelial lesions (so-called epimyoepithelial islands) similar to those seen in Mikulicz disease (see next section), and a combination of both.[44,45] These lesions can be unilateral but are often bilateral. The more prominent the combination of these changes, the more likely that HIV infection is the causative factor. Three-dimensional reconstructions have shown that the cysts arise from the intralobular duct system rather than from intraparotid lymph nodes.[46]

The lymphoid follicles of HIV-induced salivary gland disease show a prominent network of follicular dendritic cells and numerous intrafollicular CD8+ lymphocytes. The follicular dendritic cells show a strong expression of HIV-1 major core protein and HIV-1 RNA, indicating that there is active replication of the virus within them.[47]

There are two other polycystic diseases of the salivary glands that need to be mentioned here for differential diagnosis purposes. The first is *polycystic (dysgenetic) disease*, a developmental disorder so far reported only in females and characterized by bilateral parotid gland enlargement.[48,49] The lesion is characterized by small epithelial cysts replacing most of the parotid gland parenchyma with small foci of residual acini interspersed throughout. The other is the already mentioned *sclerosing polycystic adenosis*. One should also keep in mind that some neoplasms of salivary gland may undergo prominent cystic changes. This is particularly true of mucoepidermoid carcinoma, acinic cell carcinoma, basal cell adenoma, sebaceous lymphadenoma, and, occasionally, benign mixed tumor.

Lymphoepithelial Sialadenitis (Mikulicz Disease) and Sjögren Syndrome

Lymphoepithelial sialadenitis (Mikulicz disease, benign lymphoepithelial lesion) most often presents as a slowly increasing and eventually striking enlargement of the salivary and/or lacrimal glands. This enlargement is usually bilateral and symmetric, but it can also be unilateral and localized, at least at the clinical level. If an infection develops, the process may subside only to recur when the infection is gone.

Grossly, the gland is enlarged and whitish, sometimes admixed with occasional cysts (Fig. 6.6A). Microscopically, the two cardinal changes are marked lymphoid infiltration and so-called epimyoepithelial islands.[50] This combination of findings has been used to create a synonym for the disease associated with a catchy acronym, that is, *myoepithelial sialadenitis* (*MESA*), recently modified to *lymphoepithelial sialadenitis (LESA)*.[51] The lymphoid tissue contains numerous well-formed germinal centers and is composed of a mixed population of B and T lymphocytes, accompanied by scattered histiocytes and dendritic cells. The so-called epimyoepithelial islands appear as solid epithelial nests surrounded and infiltrated by lymphoid cells, which are mainly of monocytoid B type (see Fig. 6.6B). A hyaline substance is deposited between the cells, which is shown ultrastructurally to represent basement membrane material, including type IV collagen.[52] The nature of the cells within the islands, that is, whether ductal, basal or myoepithelial, remains a controversial subject.[53,54] Current evidence suggests a lack of myoepithelial cell participation, which—if true—would make the term "epimyoepithelial islands" inaccurate and the alternative "lymphoepithelial lesions" more appropriate.[55]

LESA can remain localized to the salivary gland but more often is a manifestation of a generalized symptom complex known as **Sjögren syndrome**, the other components of which are keratoconjunctivitis, xerostomia, rheumatoid arthritis, and hypergammaglobulinemia.[56] In this condition, lymphoid infiltrates similar to those present in the major salivary glands are also seen in the lacrimal glands and minor salivary glands of the oral cavity. This fact is of diagnostic utility, in the sense that biopsy of the labial glands is often used to document the diagnosis of this condition.[57] It should be noted, however, that so-called epimyoepithelial islands are usually scanty or absent at these sites. Occasionally, the lymphoid infiltrates extend to other organ systems, such as lymph nodes, lung, kidney, bone marrow, skeletal muscle, skin, or liver.[58]

The etiology of LESA, with or without Sjögren syndrome, remains enigmatic. The incidence of the disease is markedly increased in HIV-infected patients. As a matter of fact, there is a marked morphologic similarity (and probably a close pathogenetic relationship) between Sjögren syndrome as seen in this population and the HIV-related changes described in the previous section. Interestingly, a chronic lymphocytic sialadenitis morphologically very similar to Mikulicz disease occurs in hepatitis C virus (HCV)-related chronic liver disease.[59]

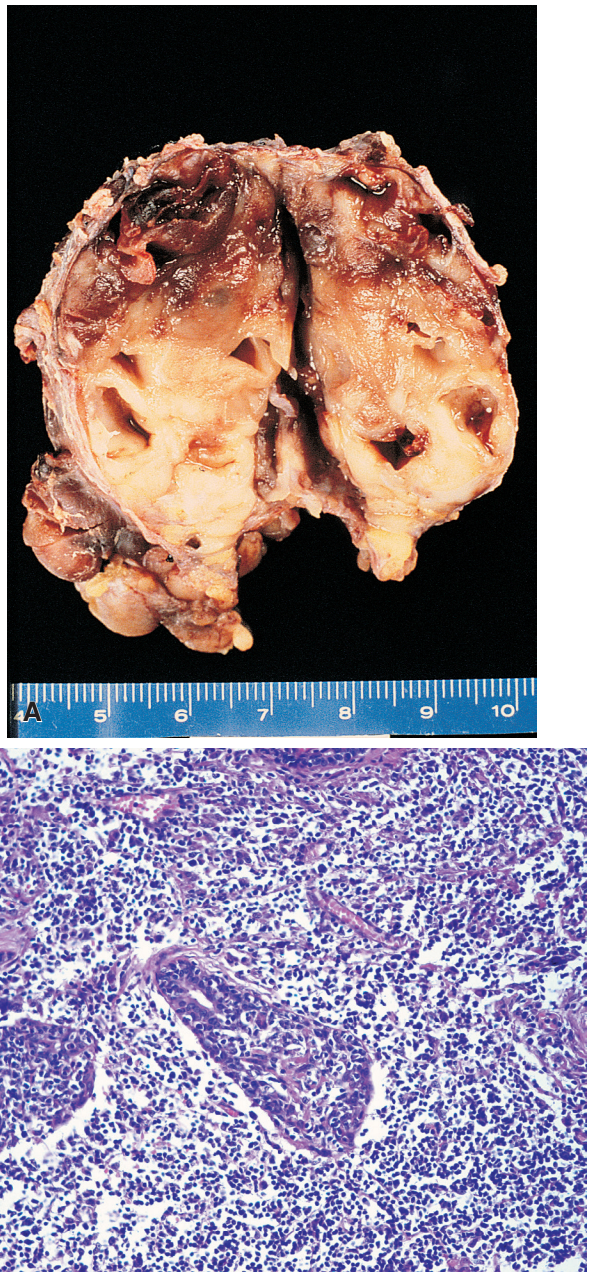

Figure 6.6 **A,** Gross appearance of lymphoepithelial sialadenitis (LESA) of parotid gland. There is a combination of solid areas resulting from infiltration by lymphocytes and small cystic formations representing dilated ductal lumina. **B,** Prominent proliferation of duct epithelium in a patient with LESA disease.

The prevalent view is that LESA is a systemic autoimmune process. In the typical case the lymphocyte population is polytypic, in keeping with a reactive process. However, this population may undergo small clonal expansions, detectable on Southern blots.[56,60–62] In some cases, these evolve into full-blown lymphomas, whether in the salivary gland or in extraglandular locations.[62,63] Some of these are large B-cell lymphomas (often with an immunoblastic appearance), whereas others are small lymphocytic lymphomas with or without plasmacytoid features (see later), and exceptional cases of Hodgkin lymphoma and peripheral T-cell lymphoma have been reported.[64–66] When one of these lymphoma types develops, there is usually not much difficulty in identifying it. The vexing problem is how to interpret the usual case of LESA that is composed of a morphologic mature ("benign-looking") lymphocytic population, especially if a monotypic component has been detected with molecular techniques. Is it a reactive, possibly autoimmune process with a tendency to evolve into a recognizable malignant lymphoma, or is it a malignant lymphoma already?[67–69] Some authors have taken the latter view and have placed LESA in the ever-expanding MALT lymphoma category, mainly on the basis of the molecular findings. It seems to us that to label a process as malignant at a stage at which it shows neither clinical nor morphologic signs of malignancy is neither conceptually nor medically sound.[51] At the present state of knowledge, it is probably wiser to restrict the diagnosis of lymphoma to those cases showing some *morphologic* evidence of such. The most important feature in this regard is the number and distribution of the monocytoid B cells. The presence of these cells outside of the lymphoepithelial lesions, and especially as broad anastomosing strands, is in favor of lymphoma; the same is true for sheets of plasma cells, with or without Dutcher bodies.[70,71] In fact, probably the earliest morphologic feature of MALT lymphoma arising in LESA is the presence of a "halo" of pale-staining sheets of monocytoid B cells surrounding the "epimyoepithelial" islands.

Irradiation Effect

The submandibular glands, which are often included in the field of irradiation for tumors of the oral cavity, swell and become firm as a result of the therapy. These changes may be mistaken clinically for metastatic carcinoma in submandibular lymph nodes and sometimes have led to unnecessary radical surgery. Not surprisingly, these changes are frequently seen in cervical lymph node dissection specimens in patients previously treated with radiation therapy. Microscopic examination shows atrophy of acinar elements with associated fibrosis and chronic inflammatory cells in the stroma. The lining of the duct epithelium may show prominent squamous metaplasia and degenerative-type atypia.

Other Non-Neoplastic Lesions

Lymphoid disorders of reactive nature can involve the intraparotid lymph nodes and be confused clinically with a primary salivary gland tumor. These include nonspecific follicular hyperplasia, healed abscesses, and granulomatous inflammations, such as those produced by cat-scratch disease.

Amyloidosis may involve the salivary gland as part of a generalized process or as a localized pseudotumoral mass ("amyloid tumor"), and it may result in the sicca syndrome.[72]

Nodular fasciitis can present as a primary intraparotid or periparotid lesion; its microscopic appearance is identical to that of its more common soft tissue counterpart.[73]

Inflammatory pseudotumor is composed of a predominant population of myofibroblast-like cells in an edematous and inflammatory background.[74] As in other sites where this entity occurs, there is a question as to whether it may represent a neoplastic condition, hence the alternative designation of *inflammatory myofibroblastic tumor*.

Rosai–Dorfman disease (sinus histiocytosis with massive lymphadenopathy) can involve the major salivary glands, with or without accompanying lymph node enlargement.[75]

Intercalated duct hyperplasia of major salivary glands may coexist with salivary gland tumors of various types (especially epithelial–myoepithelial carcinomas) and with chronic parotitis.[5] It is composed of intercalated duct epithelium and therefore different from the adenomatoid acinar hyperplasia found predominantly in intraoral salivary glands.[76] It has been suggested that intercalated duct

hyperplasia may be a precursor lesion of some salivary gland neoplasms (see next section).

Epithelial Tumors

Classification

The classification of salivary gland tumors has proved a most difficult and frustrating exercise. If anything, it is even more complex than that of the somewhat related breast and sweat gland tumors. One of the major stumbling blocks is that most of the salivary gland tumors arise from—or differentiate toward—the same cell lines: epithelial (ductal and/or acinar) and abluminal (myoepithelial and/or basal cell). This results in a considerable overlap at all levels, compounded by the fact that each of these cells can undergo a variety of metaplastic changes (e.g. oncocytic, clear cell, sebaceous, squamous, chondroid). In addition, with some exceptions, these lesions are uncommon. The World Health Organization (WHO) classification stresses the distinction between benign and malignant tumors (i.e. adenomas and carcinomas).[77–79] In this chapter, a somewhat different approach has been used. The tumors have been grouped, whenever possible, according to their predominant line of differentiation; this has been followed by a discussion of the benign and malignant members within each group.

Tumors With Stromal Metaplasia

Pleomorphic Adenoma (Benign Mixed Tumor)

Pleomorphic adenoma is the most common neoplasm of the salivary glands. It is most frequent in women in the fourth decade of life, but it can be seen in children and in elderly persons of either gender.[80] It is approximately 10 times more common in the parotid than in the submandibular gland and is very rare in the sublingual gland. In the parotid gland, most tumors arise within the superficial lobe, from either the tail (50%) or the anterior portion (25%). The remaining 25% arise from the deep lobe and often present as a parapharyngeal mass.[81] They are also seen in various minor salivary gland sites (e.g. palate).

Grossly, the tumor forms a rubbery, tan-white, firm mass with a bosselated surface and may grow to a large size but are usually between 2 and 5 cm (Fig. 6.7). The consistency depends on the relative amount of epithelial cells and stroma and the type of the latter. Although the tumor tends to be well circumscribed, small extensions (so-called pseudopodia) can often be seen protruding into the adjacent normal tissue. Islands of cartilage can be recognized by their glistening, translucent appearance. In rare cases, foci of mature bone are identified.

The typical pleomorphic adenoma has a biphasic appearance resulting from the intimate admixture of epithelium and stroma (Figs. 6.8 and 6.9). Most of the epithelial component is of a glandular nature, but foci of squamous metaplasia are common, sometimes accompanied by keratinized epithelial plugs in the lumen. The neoplastic glands have a lining composed of two cell types, the basally located cells displaying morphologic features of myoepithelial and basal cells.[82] They may be cuboidal, oncocytic, clear, spindled, or "hyaline" (see Fig. 6.8).[83] The latter cells are also referred to as plasmacytoid myoepithelial cells and are frequently seen in pleomorphic adenomas. The stroma may have a nonspecific myxoid appearance, sometimes containing abundant elastic tissue[84] or extensive adipose tissue[85]; however, areas of clear-cut cartilaginous differentiation are usually found. There is convincing morphologic, ultrastructural, immunohistochemical, and molecular evidence to suggest that these mesenchymal elements share the same origin as the epithelial cells[86–88] and that they represent modified myoepithelial cells.[89] Ultrastructurally, a continuum of cytoplasmic features from epithelial to mesenchymal cells is also present.[90–92]

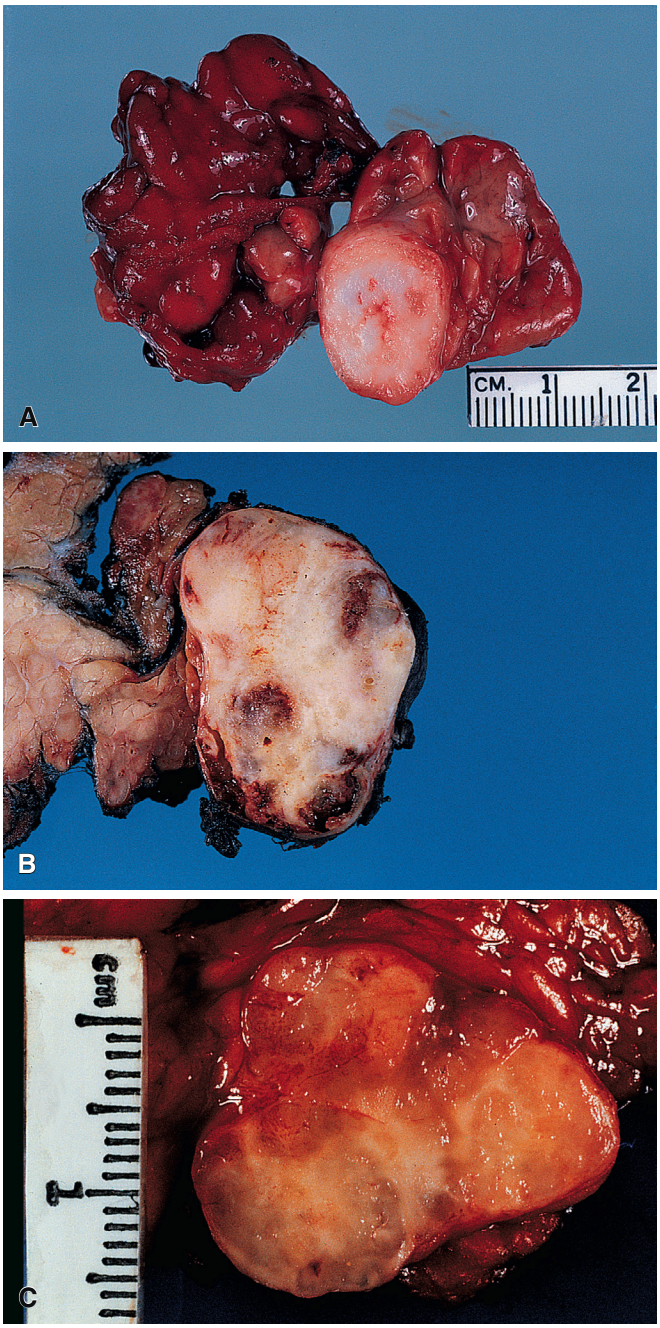

Figure 6.7 A–C, Gross appearance of three benign mixed tumors of parotid gland. Note the sharply outlined character and predominantly solid cut surface. The tumors shown in **A** and **B** have a glistening surface indicative of cartilaginous differentiation, whereas the tumor in **C** has a more myxoid or gelatinous appearance.

Additional stromal changes seen in pleomorphic adenoma include osseous metaplasia and areas of fibrosis. Cutaneous adnexal differentiation can be seen in pleomorphic adenomas, especially those arising in the palate and lip.[93] This is most commonly manifest as trichilemmal differentiation, infundibulocystic structures, and trichohyalin granules. Other substances sometimes found in pleomorphic adenomas include tyrosine-rich crystalloids in the myxoid

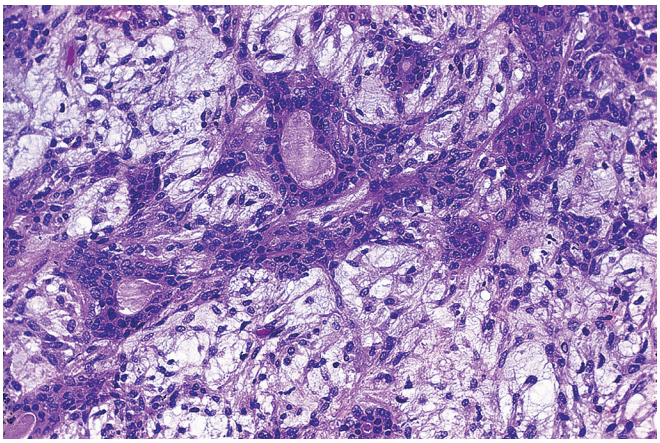

Figure 6.8 Microscopic appearance of benign mixed tumor. Epithelial and myoepithelial cells can be easily distinguished.

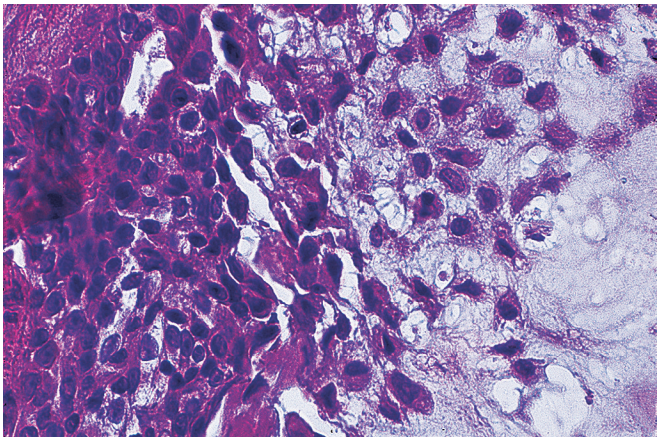

Figure 6.9 Benign mixed tumor. The myoepithelial cells are undergoing cartilaginous metaplasia and appear to "melt" into the chondromyxoid stroma they are producing.

areas,[94,95] collagenous spherules,[96] calcium oxalate crystals, intraductal birefringent crystalloids of unknown chemical composition,[97] and melanin.[98]

Some benign pleomorphic adenomas are extremely cellular, the tumor cells being either round or spindle shaped (Fig. 6.10). Others may show cytologic atypia in the form of scattered large hyperchromatic nuclei (which have been shown to be polyploid).[99] Follow-up studies have indicated that these tumors do not behave differently from the ordinary variety. The rarity of mitotic figures and absence of necrosis aid in the differential diagnosis with true malignant neoplasms. Something similar can be said of pleomorphic adenomas with foci that superficially resemble the adenoid cystic carcinoma pattern. The presence of these foci does not influence the prognosis and therefore should be disregarded.

Immunohistochemically, the ductal epithelial component is positive for keratin, EMA, and CEA. The keratins most frequently expressed are CK7, CK8/18, and CK19 (with or without CK14) in the luminal cells of the tubular structures, and CK14 in the abluminal cells.[100] The myoepithelial component is immunoreactive for low-molecular-weight keratins (CK7, CK8/18, and CK14), actin, myosin, other smooth muscle-specific proteins, p63, p40, and sometimes S-100 protein.[101–106] The latter marker is also strongly expressed in the cartilaginous areas and in subpopulations of the epithelial ductal cells. The demonstration in some of the tumors of glial fibrillary

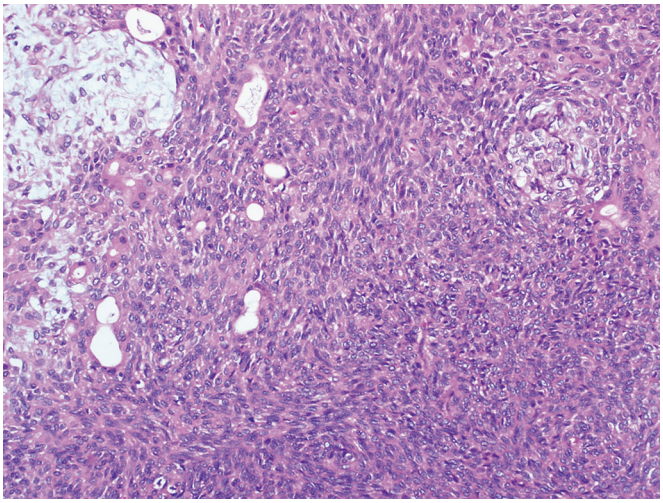

Figure 6.10 Benign mixed tumor with a markedly hypercellular appearance.

acidic protein and astroprotein, two glial markers, is more difficult to explain[107,108]; it has been suggested that it is the result of cross-reactivity with other intermediate filaments of similar structure and chemical composition.[109] Regardless of the reason for this occurrence, it seems to be related to the capacity of this tumor for cartilaginous differentiation, and it therefore may be useful in the differential diagnosis with adenoid cystic carcinoma and basal cell adenoma, in which such a differentiation does not occur.[110]

Cytogenetically, pleomorphic adenoma shows distinctive chromosomal translocations involving 8q12 or 12q13–15.[111,112] The *PLAG1* gene at 8q12 can be fused with *CTNNB1* (β-catenin), *LIFR* (leukemia inhibitory factor receptor), or *SII* (transcription elongation factor SII), or is overexpressed due to intrachromosomal 8q rearrangements.[25,113–115] The *HMGA2* gene at 12q13–15 can be fused with *FHIT* (fragile histidine triad) or *NFIB* (nuclear protein involved in transcriptional regulation).[116,117] Overexpression of p53 or mutation in the *TP53* gene is rare in pleomorphic adenoma, in contrast to its malignant counterpart.[118]

The *recurrence rate* of pleomorphic adenoma depends almost entirely on the adequacy of the primary excision, as several classic studies have conclusively demonstrated.[119] Recurrence is very high if the tumor is removed by a simple enucleation (Fig. 6.11). This is because small inconspicuous nodules (pseudopodia) attached by threadlike filaments of neoplastic tissue may be present surrounding the main mass.[120] They may have the shape and appearance of lymph nodes and may be mistaken for nodal metastases by both the surgeon and the pathologist. If the tumor is enucleated, these small remnants may be left behind and will provide the nidus for recurrence.[121] Most of these recurrences will appear during the first 18 months after surgery, but others supervene over an exceedingly long period (50 years or more). Because of this, long-term follow-up is essential. It has been proposed that patients with tumor spillage at operation or residual tumor left behind should have radiation therapy immediately to minimize the possibility of recurrence.[122] Usually the microscopic pattern of the recurrent tumor exactly mimics that of the original neoplasm (Fig. 6.12). Surgery for recurrent tumor often fails. In approximately one-fourth of cases, further recurrences develop, often in the form of multiple foci.[123] The proper therapy for pleomorphic adenoma is its total surgical removal, along with a margin of normal salivary tissue that surrounds it. For the tumors located in the superficial lobe of the parotid gland, which represent the majority, the standard surgery is a superficial parotidectomy with

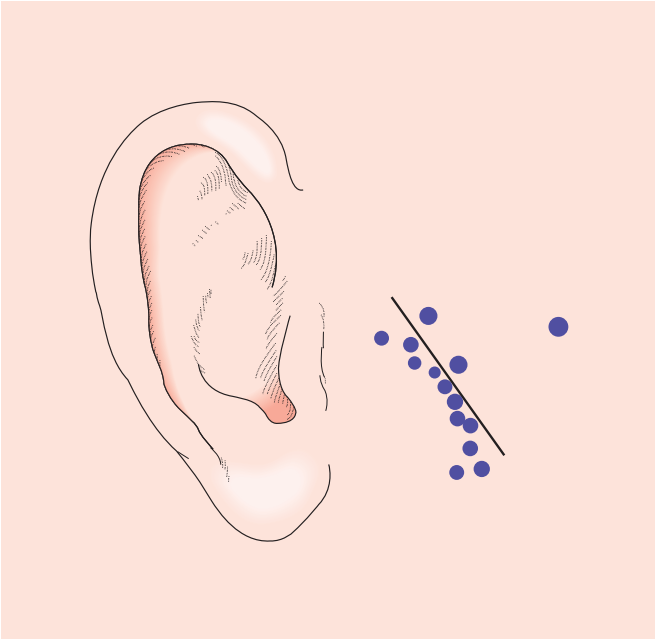

Figure 6.11 Distribution of recurrent tumor nodules (shown as *dots*) as demonstrated by careful histologic study of reexcision of benign mixed tumor of parotid gland, which at time of first operation had apparently been enucleated. Surgical scar measured 3.5 cm. (Courtesy of Dr. F. Leidler, Houston.)

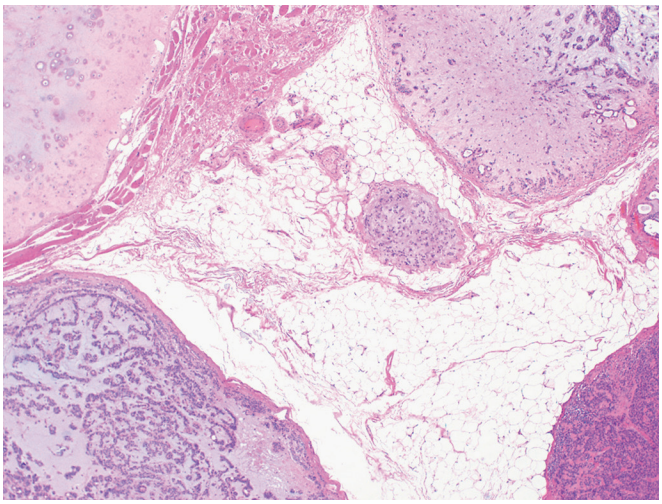

Figure 6.12 Recurrent benign mixed tumors typically appear as multiple small tumors distributed in residual gland tissue, as well as periglandular soft tissue.

preservation of the facial nerve. The incidence of recurrence after this procedure is almost zero, and the long-term prognosis for properly treated pleomorphic adenoma is excellent.

Under rare circumstances, a pleomorphic adenoma of ordinary microscopic appearance will metastasize to the lymph nodes, lungs, bone, or other organs, with the metastases appearing as benign as the original tumor ("benign" metastasizing pleomorphic adenoma).[124,125] Some of these cases have occurred in immunologically compromised patients and have followed a rapidly aggressive clinical course.[126] Usually these metastases are preceded by one or more local recurrences.[127] Curiously, a good number of these metastases have presented as isolated masses in the kidney.[128]

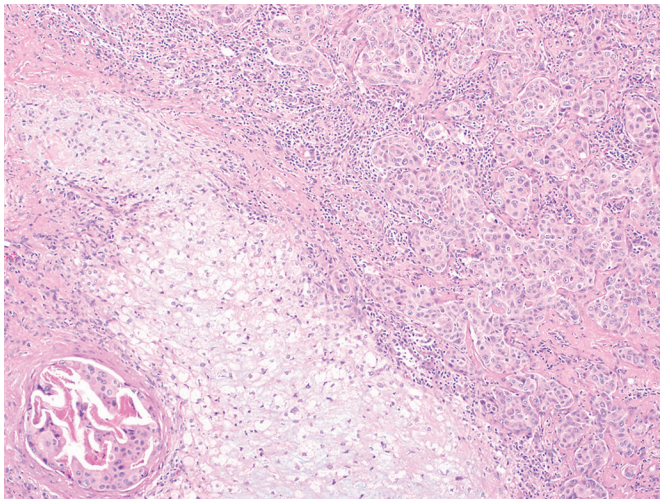

Figure 6.13 Benign mixed tumor with area of malignant transformation in the form of poorly differentiated carcinoma (*upper right* and *bottom left*). As with this tumor, the histology of the carcinoma is most often salivary duct carcinoma.

Malignant Mixed Tumor

Two major categories of malignant mixed tumor exist.[129,130] The first and more common can be viewed as a malignant transformation of a preexisting pleomorphic adenoma (carcinoma ex pleomorphic adenoma). This complication occurs in approximately 5%–10% of these neoplasms.[131] Clinical features that suggest this event in a long-standing tumor are sudden increase in growth, pain, and facial paralysis.[132,133] Documentation that a malignant salivary gland tumor arose from a preexistent pleomorphic adenoma may be difficult to obtain. The clinical history, although suggestive of the process, is not by itself diagnostic. It is necessary to have microscopic evidence of a previously existing benign tumor or to have benign and malignant tumor in the same neoplasm. This may require thorough sampling of the tumor. Sometimes the preexisting benign lesion is represented only by a totally hyalinized round nodule surrounded by carcinoma. Features said to indicate a greater likelihood of malignant transformation of a pleomorphic adenoma are submandibular (as opposed to parotid) location, long duration, older patient age, large tumor size, and—at the microscopic level—prominent zones of hyalinization and a moderate degree of mitotic activity.[134]

The malignant component of this tumor typically has an epithelial appearance usually comparable to that of the luminal cells, less commonly that of the myoepithelial cells, or both (Fig. 6.13). It has been stated that these malignant areas often assume the appearance of one of the well-recognized variants of salivary gland carcinoma (such as mucoepidermoid carcinoma or adenoid cystic carcinoma), but salivary duct carcinoma and adenocarcinoma, not otherwise specified (N.O.S.) type, appear to be the most common.[135] For example, in the series of Tortoledo et al.,[130] the malignant component was classified as salivary ductal carcinoma in 13 cases, undifferentiated carcinoma in 10, terminal duct carcinoma in 9, myoepithelial carcinoma in 3, and unclassified in 2. Most of the tumors have a poorly differentiated appearance. As a matter of fact, whenever a high-grade adenocarcinoma that is difficult to classify is found in the salivary gland, the possibility of it having arisen from a pleomorphic adenoma should be considered.[135] In a high percentage of early cases the malignant change is restricted to foci of intraductal carcinoma, with an intact layer of neoplastic myoepithelial cells on the outside.[136]

In most cases, the immunohistochemical profile of the malignant cells is comparable to that of the ductal luminal cells of the benign component.[137] In the malignant areas there is often overexpression of *TP53* (as a result of mutation) and of *HER2*.[138–140] However, this is also true in a small subset of pleomorphic adenoma lacking malignant change.[141] Genetic alterations that mediate malignant transformation may include amplification of genes at 12q13–15 (including *CDK4*, *HMGA2*, *MDM2*), *TP53* mutation, or *HER2* amplification.[142–144]

LiVolsi and Perzin[129] have pointed out that if the cytologically malignant foci are found entirely within a pleomorphic adenoma (i.e. intracapsular or in situ) they are not associated with clinical malignancy if the tumor is completely excised. Only when invasion occurs beyond the capsule of the original neoplasm will the lesion potentially behave clinically in a malignant fashion. For invasive tumors, the extent of invasion beyond the capsule is of importance: minimally invasive (≤1.5 mm from the tumor capsule) versus widely or frankly invasive (<1.5 mm), as defined by the WHO.[7] In one series, all patients whose malignant neoplasms extended for more than 8 mm beyond the capsule died of tumor.[130] Therefore, the importance of thorough sampling cannot be overemphasized. The prognosis also depends on the histologic type of carcinoma, the microscopic grade (which is related to the former), and the proliferative index.[130,145]

The most common sites of metastases are regional lymph nodes, lungs, bone (especially the vertebral column), and abdominal organs.[146]

The second type of malignant mixed tumor has a biphasic composition similar to that of pleomorphic adenoma, but both the epithelial and the mesenchyme-like elements have a malignant appearance, the former often in the form of a ductal carcinoma and the latter in the form of chondrosarcoma or undifferentiated pleomorphic sarcoma. Because no preexisting benign tumor is found, the designation of *carcinoma ex pleomorphic adenoma*, which has been suggested as an alternative term for malignant mixed tumor, is inappropriate.[133] Names such as *true malignant mixed tumor* and *carcinosarcoma* have been proposed instead.[147–149] This is an aggressive, often rapidly lethal neoplasm.

Tumors With Oncocytic (Oxyphilic) Change

Oncocytes or oxyphilic cells are large ductal epithelial cells with a granular, deeply eosinophilic cytoplasm crowded with mitochondria.[150] Their number in the normal salivary gland increases with age, and their secretory activity is minimal, suggesting that they are the expression of a degenerative change.[151] Sometimes one finds multiple parotid cysts lined by oncocytic epithelium, associated with tyrosine crystals in the lumen.[152] In other instances, oncocytes form well-defined clusters scattered throughout the gland. It is not clear whether these clusters represent an exaggeration of the age-related hyperplastic process or the emergence of a neoplasm, an uncertainty reflected by the terms that have been used to designate this process: *oncocytosis*,[153] *multinodular oncocytoma*,[154] *multinodular oncocytic hyperplasia*, and *multifocal adenomatous oncocytic hyperplasia*.[155,156]

The two major tumor types composed of oncocytes are oncocytic adenoma and Warthin tumor.[157,158] There are no transitional forms between these two tumors, suggesting that their pathogenesis is different.

Oncocytic Adenoma and Oncocytic Carcinoma

Oncocytic adenoma (oncocytoma; oxyphilic adenoma) is defined, since the classic works of Hamperl, as a benign tumor exclusively composed of oncocytic cells.[159] The majority occur in the parotid, but they are also well documented in the submandibular gland.[160] In one large series, 20% of patients had either a history of radiation therapy to the region or of long-term occupational exposure.[161] Grossly, the tumor presents as a solid, well-circumscribed mass, usually small and with a characteristic tan or brown color (Fig. 6.14). Microscopically, it is composed of large cells with small, central, round nuclei and abundant granular acidophilic cytoplasm (Fig. 6.15). Ultrastructurally, the cytoplasm is packed with mitochondria (Fig. 6.16). Mitotic figures are absent, and cellular transition from

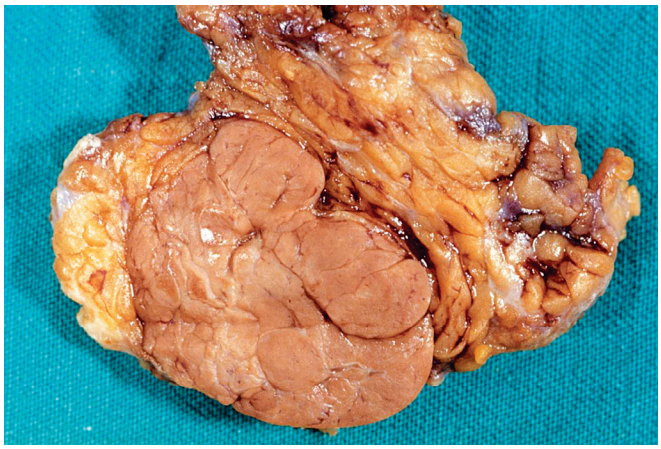

Figure 6.14 Gross appearance of oxyphilic adenoma. The tumor is well circumscribed, solid, and light brown. (Courtesy of Dr. F. Facchetti, Brescia, Italy.)

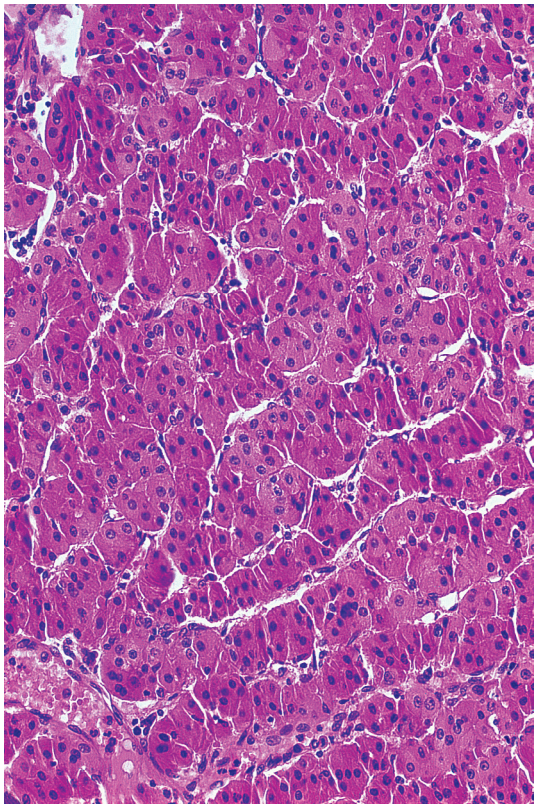

Figure 6.15 Low-power microscopic view of oxyphilic adenoma. The pattern of growth is solid, with a suggestion of trabecular formations. The tumor cells have a uniform granular eosinophilic staining quality.

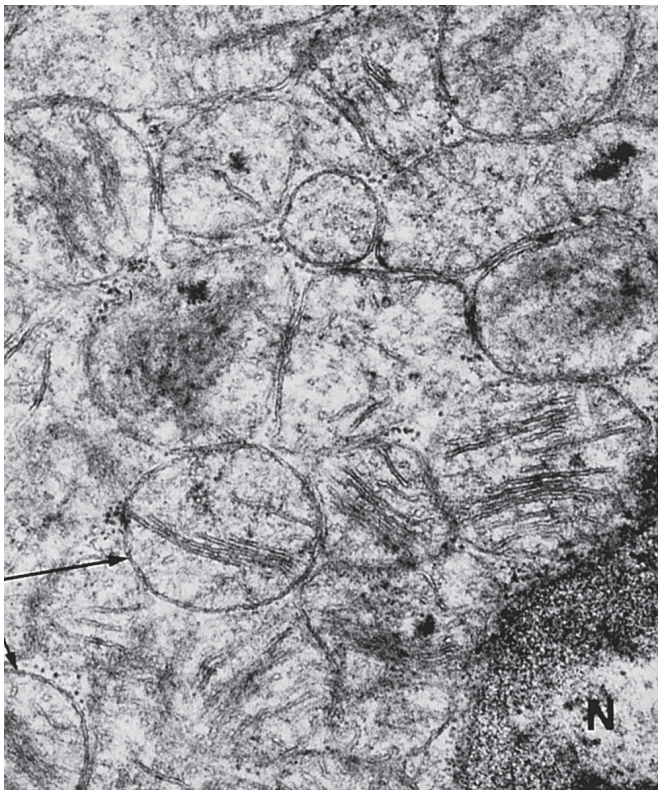

Figure 6.16 Electron micrograph of oxyphilic adenoma showing cytoplasm packed with mitochondria *(arrow)*. A portion of the nucleus *(N)* is at bottom right. (×31,000.)

Figure 6.17 Gross appearance of Warthin tumor of parotid gland. The presence of multiple large cystic spaces is characteristic of this lesion. (Courtesy of Dr. J. Carvalho, Ann Arbor, MI.)

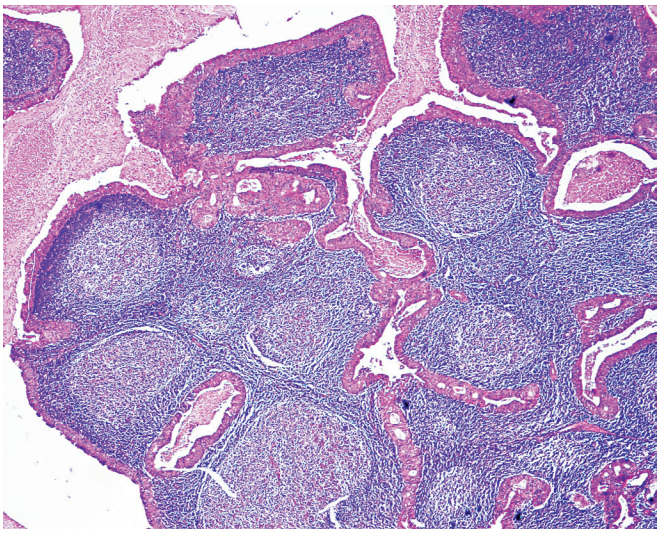

Figure 6.18 Low-power appearance of Warthin tumor. Germinal centers are very prominent.

normal lining cells of the ducts may be seen. Occasionally, the cells undergo a clear change as a result of cytoplasmic glycogenation. The lumen of the glandular spaces formed by these tumors may contain psammoma bodies[162] or tyrosine-rich crystals.[163] Focal collections of oncocytes may be present in the adjacent normal gland. Local excision is usually curative.[164] The tumor cells diffusely express keratin, and p63 highlights a subset of the cells in a distribution suggestive of basal-type cells.[165] The latter is helpful in distinguishing oncocytic adenoma from metastatic renal cell carcinoma, which are always p63 negative.

The presence of cytoplasmic mucin or of mucin-containing cystic spaces is not a typical feature of oncocytic adenoma but can be seen occasionally; such a finding should raise the suspicion that the tumor is an oncocytic variant of mucoepidermoid carcinoma (see later). Occasionally, multiple oncocytic nodules, often with clear cell change, can be appreciated. In these cases, the term *multinodular oncocytic* hyperplasia is appropriate.

Oncocytic carcinoma (malignant oncocytoma; oxyphilic carcinoma) is the malignant counterpart of oncocytic adenoma, a tumor type so rare as to represent a pathologic curiosity.[161] It is characterized by cytologic atypia, mitotic activity, and infiltrative growth. These are typically high-grade neoplasms with aggressive clinical behavior.

Warthin Tumor

Warthin tumor (cystadenoma lymphomatosum papilliferum) is found exclusively in the parotid gland and periparotid lymph nodes.[166] Warthin tumor is more common in males, and a near-universal relationship with smoking has been found.[167,168] It is often multicentric and is bilateral in 10%–15% of cases. It comprises 70% of all bilateral salivary gland neoplasms.[169] Grossly, it appears as a lobulated brown mass and has a typical multicystic appearance, with fluid-filled spaces filled with dark brown fluid (often likened to motor oil) (Fig. 6.17). Occasionally the entire tumor undergoes necrotic changes consistent with hemorrhagic infarct. These changes can occur spontaneously but are more common following fine-needle biopsy.[170]

Microscopically, lymphoid tissue is prominent, often with germinal centers; this has led to the time-honored suggestion that the lesion originates from excretory ducts located within intraparotid lymph nodes (Fig. 6.18).[171] This lymphoid stroma is predominantly composed of B lymphocytes,[172] but it also contains T lymphocytes, mast cells, and S-100 protein–positive dendritic cells.[173] Covering the surface of this lymphoid tissue are large epithelial cells with oncocytic features, similar in most respects to those seen in oncocytic adenoma (Fig. 6.19). These cells are arranged in two layers, with some morphologic and immunohistochemical differences between them.[174] The luminal cells are more columnar and the outer cells more polygonal. Both stain equally with keratin, and the outer cells are p63 positive, suggesting a basal cell phenotype. These oncocytic cells are also reactive for mitochondria-associated markers (Fig. 6.20).[175,176] The keratins

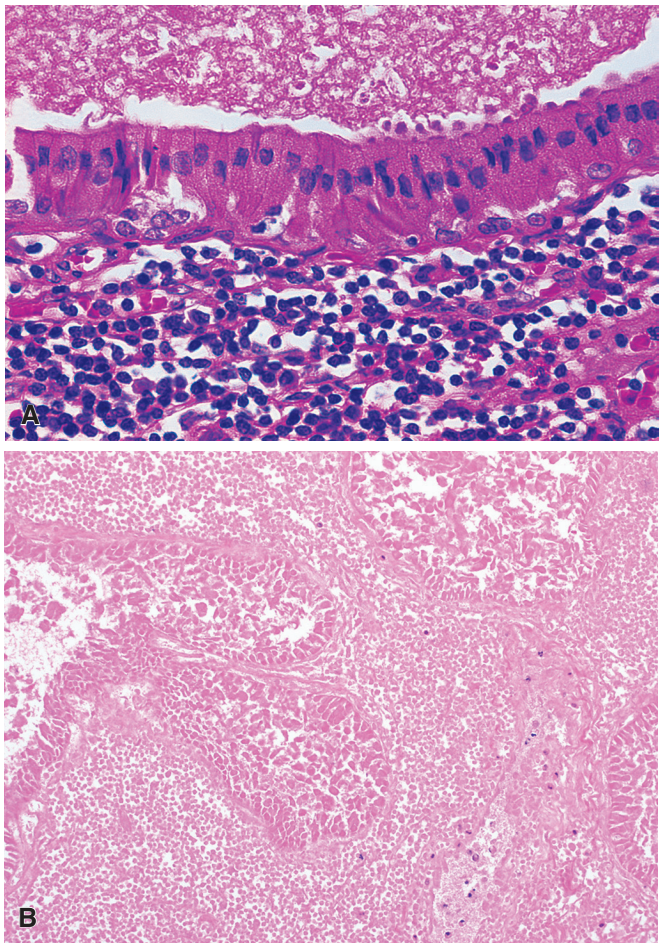

Figure 6.19 **A,** High-power view of the lining of one of the cysts of Warthin tumor. The epithelium is tall and oxyphilic, with a discontinuous layer of small cells at the base. The stroma beneath contains a monotonous lymphocytic infiltrate. **B,** Infarcted Warthin tumor following fine-needle aspiration. Ghost outlines of necrotic epithelial papillae can be seen adjacent to necrotic lymphocytic stroma.

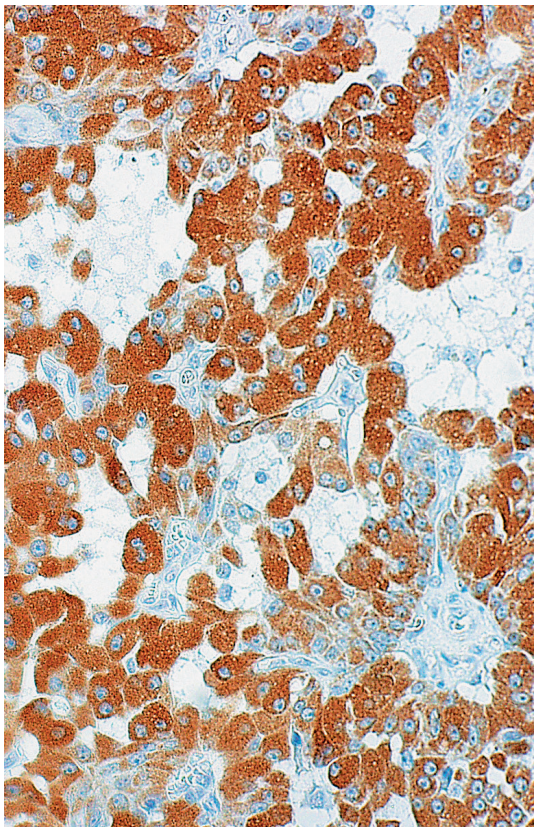

Figure 6.20 Positive immunostaining for antimitochondrial antibody in oncocytes. (Courtesy of Dr. F. Facchetti, Brescia, Italy.)

expressed are those typical for columnar differentiation, that is, CK7, 8, 18, and 19.[177] Mucin-secreting cells and groups of sebaceous cells may also be present.[178,179] There is no evidence for a myoepithelial cell component.[180] Occasionally, the lymphoid component is scanty or absent.[166] By electron microscopy, the cytoplasm of the granular epithelial cells is packed with mitochondria.

The cases associated with infarct-like necrosis may exhibit focal squamous metaplasia (see Fig. 6.19B), sometimes with features analogous to those of necrotizing sialometaplasia in the oral cavity,[181] and are just as likely to be overinterpreted as squamous cell carcinoma.[182]

The typical treatment of Warthin tumor is surgical excision; the incidence of local recurrence is extremely low.

Malignant transformation of Warthin tumor is a rare event but has been documented both in terms of the lymphoid component evolving into malignant lymphoma[183–185] and the epithelial component evolving into adenocarcinoma, mucoepidermoid carcinoma, squamous cell carcinoma, oncocytic carcinoma, Warthin adenocarcinoma,[186] or Merkel cell carcinoma.[187–190]

Warthin tumor has been generally regarded as a true neoplasm, hence its inclusion in this section. However, some have made the suggestion that it may belong instead to the group of acquired multicystic reactive conditions of the head and neck that also includes benign lymphoepithelial cyst and other lesions of branchial pouch derivation.[42] The fact that the epithelial component of this lesion has been found to be polyclonal and that it tends to be associated with salivary ductal inclusions in parotid lymph nodes support this contention.[191,192] If this interpretation is correct, one should regard the parotid lesions having a multicystic oncocytic-lined component but lacking a lymphoid stroma *(oncocytic papillary cystadenomas)* as belonging to a different category.[166]

"Monomorphic" Adenoma

The outdated term *monomorphic adenoma* was originally proposed for any benign epithelial salivary gland tumor other than pleomorphic adenoma. It therefore included tumors as disparate as oncocytic adenoma, Warthin tumor, sebaceous lymphadenoma, canalicular adenoma, and basal cell adenoma.[193,194] The very inclusiveness of the term when so defined, and the fact that some people have used it instead as a synonym for only one member of the group (i.e. for basal cell adenoma), has resulted in confusion. Therefore it is probably advisable to regard monomorphic adenoma not as a specific pathologic diagnosis but rather as the expression of a nosologic grouping.[195] The term "monomorphic adenoma" does not appear in the new WHO classification of salivary gland tumors and should not be used as a specific pathologic diagnosis.[79]

Basal Cell Adenoma and Adenocarcinoma

Basal cell adenomas usually occur in adult patients, and there is a slight predilection for females.[196] Most cases occur in the

parotid but a few have been reported within periparotid lymph nodes, as well as in minor salivary gland sites.[197] Grossly, these tumors are encapsulated and often cystic; as a group, they tend to be smaller than pleomorphic adenomas. Microscopically, they are composed of basaloid epithelial cells, arranged in a variety of architectural patterns, and lacking in cartilage and chondromyxoid stroma. This acknowledges the fact that pleomorphic adenomas and basal cell adenomas have overlapping histology. Most basal cell adenomas have scattered ductal structures filled with eosinophilic secretions. The ducts often undergo cystic change. Surrounding the ducts are varying amounts of basaloid cells that may have a true basal cell immunophenotype, as well as true myoepithelial cells. Therefore, these tumors contain varying amounts of ductal, basal, and myoepithelial cells. An important distinguishing feature seen in most basal cell adenomas is the palisading at the periphery of the epithelial nests, also giving the tumor a "basaloid" appearance. The pattern of growth may be predominantly tubular, trabecular, cribriform, or solid.[195,198,199] In a variant of the latter designated as **membranous** or **dermal analogue tumor**, there is deposition of abundant basal lamina material around and within the epithelial nests, in a pattern nearly identical to that of the cutaneous sweat gland tumor known as eccrine dermal cylindroma (Fig. 6.21).[200,201] Actually, there have been cases of multiple dermal cylindromas coexisting with multiple parotid tumors with the same microscopic appearance.[202–204] Furthermore, the same cytogenetic abnormality in the chromosome 16q region has been found in the two tumors.[205] The mutated gene involved in this syndrome (Brooke–Spiegler syndrome) is the *CYLD* gene, which can also be mutated in sporadic basal cell adenomas.

Basal cell adenocarcinoma is the malignant counterpart of basal cell adenoma.[206–208] Like its benign counterpart, it can arise either in the major or the minor salivary glands.[209] It has a similar architecture and immunohistochemical profile,[210] but it differs by virtue of its infiltrative quality, perineurial spread, and vascular invasion, as well as a variable degree of cytologic atypia and mitotic activity. Although most basal cell adenocarcinomas are cytologically low grade, high-grade examples do occur. It also tends to express p53, BCL2, and epidermal growth factor receptor (EGFR), but this is not necessarily helpful in the diagnosis.[211] The parotid gland is the predominant site, and the peak incidence is in the sixth decade of life. Solid, membranous, trabecular, and tubular patterns of growth have been described. The aggressiveness of the tumor can be manifested by local recurrence or metastases to the lymph nodes and lung. Like its benign counterpart, it can be associated with dermal cylindromas in the Brooke–Spiegler syndrome.[206]

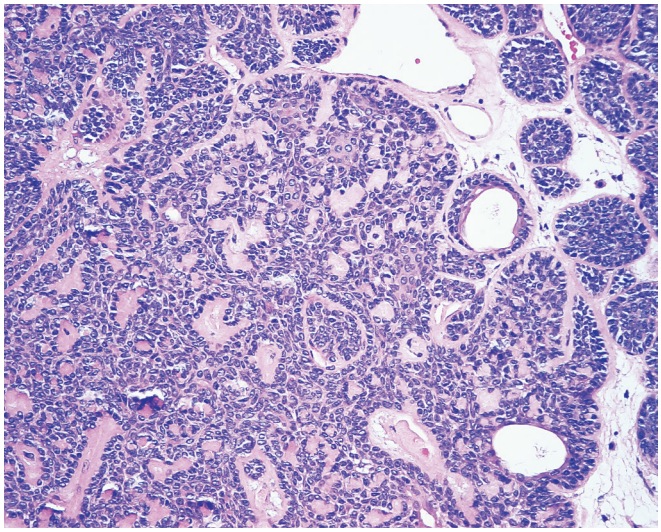

Figure 6.21 Basal cell adenoma of parotid gland. The appearance is reminiscent of that of a skin adnexal tumor (cylindroma).

Canalicular Adenoma

Another tumor formerly considered a variant of monomorphic adenoma is characterized by the presence of bilayered strands or ribbons of columnar epithelial cells separated by a loose, well-vascularized, paucicellular-myxoid stroma. This has been referred to as **canalicular adenoma** and is now regarded as an entity separate from basal cell adenoma[195,212] because of its unique morphology and immunophenotype and greater tendency to arise from intraoral minor salivary glands.[213] The "canalicular" description stems from the appearance imparted by the bilayered epithelial cells alternately opposing each other (Fig. 6.22). In some tumors, nodules of basaloid cells are present in between the columnar epithelial cells. A unique feature of canalicular adenomas is diffuse S100 reactivity. They are strongly positive for cytokeratin and have weak and focal staining

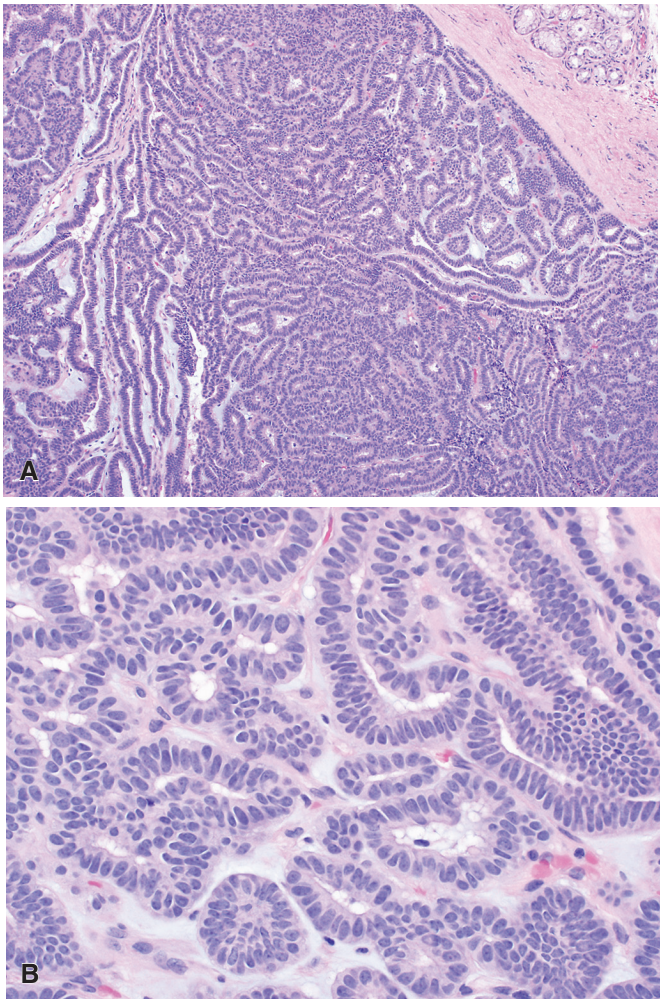

Figure 6.22 Canalicular adenoma of the buccal minor salivary glands. **A,** Parallel rows of columnar epithelial cells appose each other in areas imparting a beaded or canalicular pattern. The stroma is scant and predominantly myxoid. **B,** The columnar cells are uniform and cytologically bland.

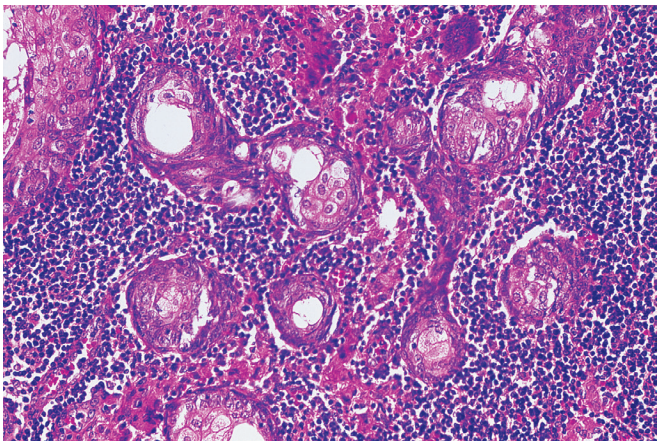

Figure 6.23 So-called sebaceous lymphadenoma. Ductal structures merge with well-differentiated sebaceous glands, which in turn are surrounded by a heavy lymphocytic infiltrate.

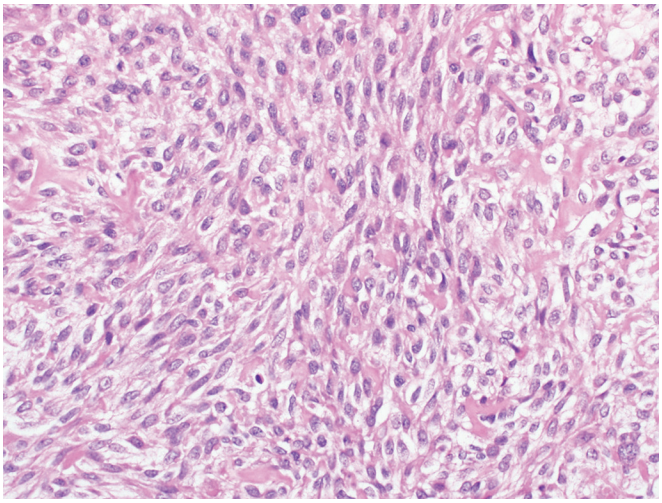

Figure 6.24 Spindle cell myoepithelioma of parotid gland. It would be very difficult to distinguish this tumor from a soft tissue neoplasm on purely morphologic grounds.

with p63 and myoepithelial markers at most. A vast majority of canalicular adenomas occur in the upper lip (80%) and buccal mucosa (10%) of adults. They are benign neoplasms that rarely recur with complete excision.

The main differential diagnosis of basal cell adenoma is with basal cell adenocarcinoma (see later discussion), pleomorphic adenoma, and adenoid cystic carcinoma.[214] Basal cell adenoma lacks the chondromyxoid mesenchyme-like component of pleomorphic adenoma. In contrast to adenoid cystic carcinoma, it is encapsulated and devoid of stromal and perineurial invasion. Immunohistochemically, the duct-lining cells express keratins and CEA with variable S-100 protein reactivity; the basaloid cells in the trabecular and solid areas express vimentin, actin, and p63, indicative of myoepithelial cell participation.[215,216] Basal cell adenoma behaves in a benign fashion, analogous to that of pleomorphic adenoma, and excision is curative. The recurrence risk is not as high as it is for pleomorphic adenomas with the exception of the membranous type in which up to 25% of tumors recur.

Malignant transformation of basal cell adenoma is a rare but well-documented event; the membranous type is said to be particularly at risk (up to 25%).[217] In six cases of this phenomenon reported by Luna et al.,[218] the malignant component was diagnosed as adenoid cystic carcinoma in three and as basal cell adenocarcinoma in the other three.

Tumors With Sebaceous Differentiation

Cells of a sebaceous type are often found within otherwise normal parotid glands. They are also found in a variety of salivary gland tumors. They are relatively common in Warthin tumor but may also appear in pleomorphic adenoma, mucoepidermoid carcinoma, adenoid cystic carcinoma, and epithelial–myoepithelial carcinoma.[219–222]

Benign tumors with a predominant sebaceous component have been designated as **sebaceous adenoma** when pure and **sebaceous lymphadenoma** when accompanied by a prominent lymphoid stroma (Fig. 6.23).[223,224] The latter tumor may present as a unilocular cystic mass on gross inspection.[225] When the tumor contains the same admixture of epithelial glandular cells and lymphocytes but lacks sebaceous differentiation, it is simply designated as *lymphadenoma*.[226,227] Rare malignant counterparts of these tumors exist; these have been called **sebaceous carcinoma** and **sebaceous lymphadenocarcinoma**, respectively.[223]

Tumors With Myoepithelial Differentiation

Myoepithelial cells are a component of many types of benign and malignant salivary gland tumors, particularly pleomorphic adenoma, epithelial–myoepithelial carcinoma, adenoid cystic carcinoma, and basal cell neoplasms.[228–231] Benign neoplasms composed exclusively of myoepithelial cells are referred to as **myoepitheliomas**.[232] Grossly, they are well circumscribed and typically encapsulated. A variety of morphologic types have been described: spindle cell, hyaline (plasmacytoid), epithelioid, and clear cell. However, it should be noted that combined and intermediate forms exist, and that the myoepithelial nature of the hyaline cell type has been questioned by some.[233]

The *spindle cell type* tumors have a stromalike appearance and can be confused with lesions of fibroblasts, Schwann cells, or smooth muscle cells (Fig. 6.24).[234] The *epithelioid type* is composed of uniform round cells with moderate amounts of cytoplasm. As with other myoepitheliomas, immunohistochemical demonstration of myoepithelial differentiation is required to confirm the diagnosis. In the variant known as *oncocytic myoepithelioma*, the cytoplasm has a granular oxyphilic quality. In all myoepitheliomas, collagen stroma is scanty, microcystic formations may be present, and various degrees of secondary myxoid change or lipomatous metaplasia of the stroma may be seen.[235,236] Collagenous crystalloids may be present in some tumors.[237] Ultrastructurally and immunohistochemically, microfilaments of both actin and keratin type can be demonstrated (Fig. 6.25).[238] Most myoepitheliomas also demonstrate p63 and p40 reactivity, whereas S100 can be positive or negative. The *hyaline (plasmacytoid) cell–type* tumors are composed of cells with eccentric nuclei, some degree of pleomorphism and hyperchromasia, but scanty or no mitotic activity. The cytoplasm is abundant, with a *diffuse* eosinophilia that is very different from the fine granular quality seen in oncocytes. The cell margins are polygonal and sharply outlined (Fig. 6.26). The appearance of hyaline cells may simulate that of neoplastic plasma cells or even skeletal muscle cells. Ultrastructurally, their main feature is the presence of abundant, uniformly dispersed microfilaments measuring 50–100 Å in diameter.[239] Although this type has ultrastructural evidence of myoepithelial differentiation, they are typically negative for traditional myoepithelial markers (actin, p63) but do stain with keratin and S-100. The *clear cell type* tumors are composed of sheets or nests of small cuboidal cells with moderate amounts

Figure 6.25 Electron micrograph of a myoepithelioma of parotid gland. Portion of a neoplastic myoepithelial cell illustrating *(left to right)* extracellular space with collagen fibrils and basement membrane, electron-dense attachment plaques on the cell membrane, linear arrays of 6-nm actin microfilaments, perinuclear bundles of tonofilaments (indicative of squamous metaplasia), and a portion of the nucleus. (×22,900.) (Courtesy of Dr. Robert A. Erlandson, Memorial Sloan-Kettering Cancer Center.)

of clear cytoplasm. These clear cells contain variable amounts of glycogen but no fat or mucin.

Immunohistochemically, in general, the neoplastic myoepithelial cells show reactivity for keratin, both forms of S-100 protein, p63, p40, actin, and, in some cases, vimentin, calponin, and myosin.[101,240–246] In this regard, it is important to point out that many myoepitheliomas fail to react with smooth muscle actin.[247] It is important to remember that there are differences in the immunohistochemical profile related to the myoepithelioma subtype, as well as a great deal of heterogeneity within each category.[244,248]

Most of the reported cases of spindle cell, epithelioid, and clear cell myoepitheliomas have occurred in the parotid gland, whereas most pure examples of hyaline myoepitheliomas have been described in minor salivary glands, particularly those in the palate.[249,250]

There is a range of differentiation among these tumors, with both benign and malignant variants represented. The majority of cases with a hyaline cell morphology have behaved in a benign fashion,[251] although well-documented exceptions exist.[249] Many malignant examples of the spindle cell and particularly of the clear cell types have been described.[252–256] Malignant tumors have been referred to as both malignant myoepithelioma and myoepithelial carcinoma. In general, these have been characterized by infiltrative growth, increased cellularity, mitotic activity, necrosis, and cytologic atypia.[251] A frequent growth pattern is composed of large invasive lobules with central necrosis. These malignant myoepitheliomas can arise de novo or as a malignant transformation of a myoepithelioma, benign mixed tumor, or a basal cell adenoma.[257,258] They are uncommon, accounting for approximately 2% of salivary gland malignancies. They are most common in the parotid gland but can be seen in all salivary gland sites. Although no formal grading system exists, tumors with high mitotic activity, necrosis, and pleomorphism tend to behave as high-grade carcinomas. Following treatment, approximately one-third of patients will die of disease, one-third will be alive with disease, and one-third will be alive and disease free.[256] Although most myoepitheliomas are reportedly negative for *EWSR1* rearrangements,[259] clear cell myoepithelial carcinomas show *EWSR1* gene rearrangements in approximately 40% of cases.[260]

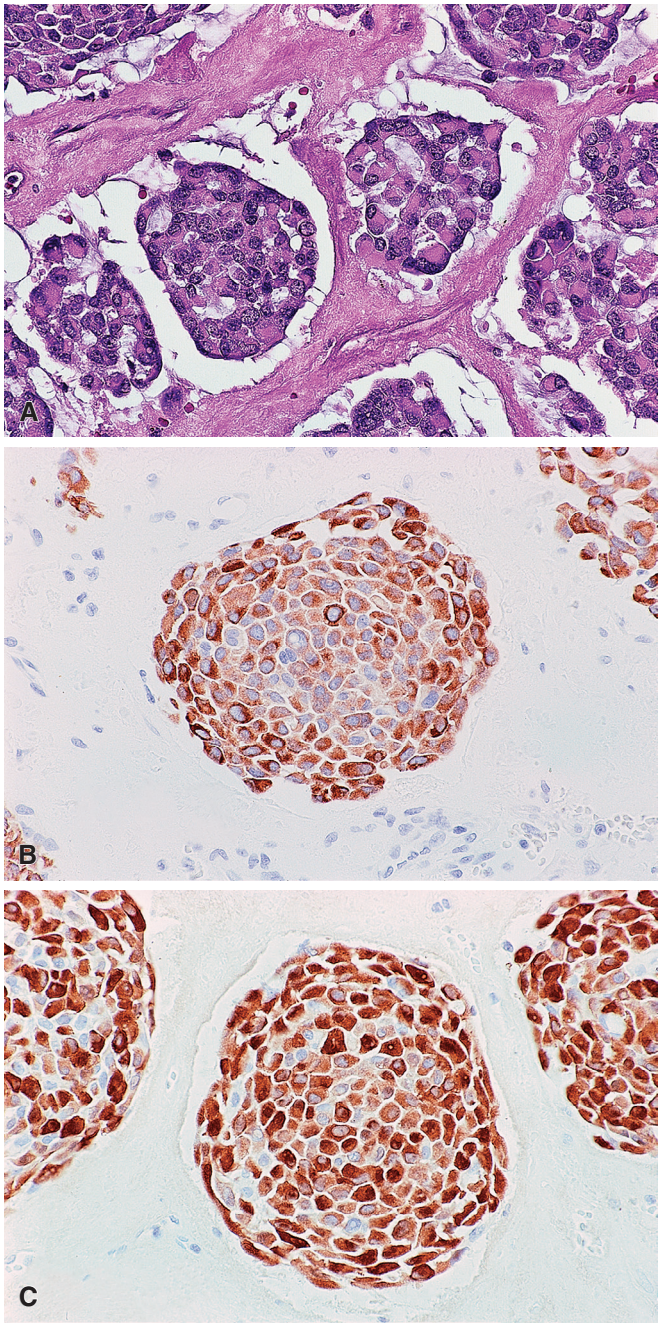

Figure 6.26 Myoepithelioma composed of so-called hyaline cells. (**A,** H&E; **B,** keratin; **C,** S-100 protein.)

Tumors With Clear Cell Change

As is true in most other organs, clear cell–containing neoplasms of the salivary gland do not constitute a homogeneous or specific type.[261–264] In the presence of such feature, the differential diagnosis should include clear cell myoepithelioma and myoepithelial

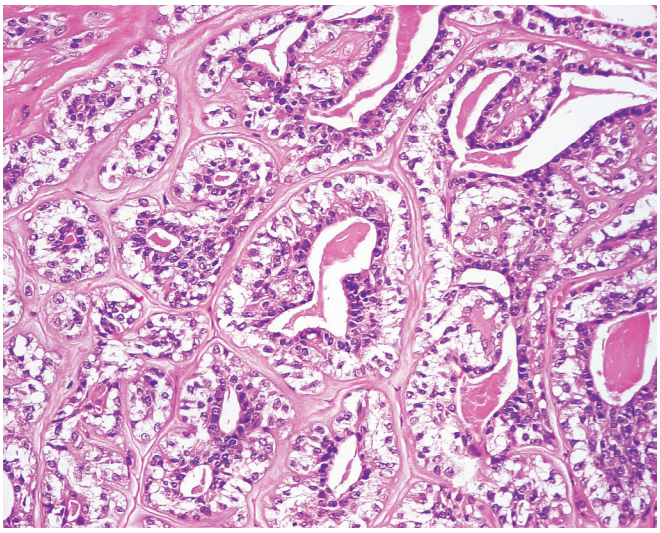

Figure 6.27 Epithelial–myoepithelial carcinoma. The myoepithelial component is represented by the cells with clear cytoplasm. Infiltrative growth was present in other areas of this tumor. Benign mixed tumors can have similar appearing areas, but they lack infiltrative growth.

carcinoma (positive for glycogen), sebaceous neoplasms (positive for fat), mucoepidermoid carcinoma (positive for mucin), acinic cell carcinoma, clear cell change in oncocytic tumors, and metastatic renal cell carcinoma.[265–267] There are some malignant salivary gland tumors composed of clear cells that cannot be placed into any of those categories and for which the descriptive term *clear cell* carcinoma has been used.[268,269] Most of these tumors occur in the oral cavity rather than in the major salivary glands and are accompanied by a prominent fibrohyaline stroma (hence the proposed term *hyalinizing clear cell carcinoma* for them).[268]

Epithelial–myoepithelial carcinoma is an uncommon salivary gland carcinoma that most often occurs in the parotid gland but can occur in other major salivary glands and minor salivary gland sites, especially the sinonasal region.[270] As the name implies, they are composed of a dual population of eosinophilic ductal cells surrounded by myoepithelial cells that most often have prominent clear cytoplasm (Fig. 6.27). The proportions of ductal and myoepithelial cells varies from tumor to tumor. The stroma can be scant but often contains variable amounts of myxoid and/or basement membrane–type material. Because most are low-grade, demonstration of infiltrative growth is required to make this diagnosis. Some tumors can have significant mitotic activity, pleomorphism, and necrosis. The invasive lobules are typically solid, but papillary and cystic growth patterns are not uncommon. Several "variants" have recently been described, including double clear, oncocytic-sebaceous, and apocrine.[270,271] In addition, some may arise in a preexisting pleomorphic adenoma (carcinoma ex pleomorphic adenoma). The ductal cells react with low-molecular-weight cytokeratin, whereas the myoepithelial cells react with high-molecular-weight cytokeratin, p63, p40, actin, and calponin. S-100 staining, as is often the case in salivary gland neoplasia, is unpredictable. Although approximately 40% of tumors recur, metastases are seen in only 15% (mostly cervical lymph nodes) and disease-related mortality is less than 10%, with 5-year survival rates of 80%.[270,272]

Mucoepidermoid Carcinoma

Mucoepidermoid carcinoma is the most common salivary gland malignancy. Most cases of mucoepidermoid carcinoma are located in the parotid gland, and half of cases occur in the major salivary glands (Fig. 6.28).[273] They also arise from minor salivary gland sites with the palate, buccal mucosa, and tongue being relatively common sites. This lesion also represents the most common malignant salivary gland tumor in children.[80,274] Microscopically, three main cell types can be identified: mucin-producing, squamous (epidermoid), and intermediate (Fig. 6.29). The intermediate cells tend to predominate and are characterized as small cuboidal cells with minimal eosinophilic cytoplasm, resembling basal cells. The three cell types are

Figure 6.28 Gross appearance of mucoepidermoid carcinoma. This particular tumor is entirely solid, without the cystic formations commonly seen in low-grade lesions.

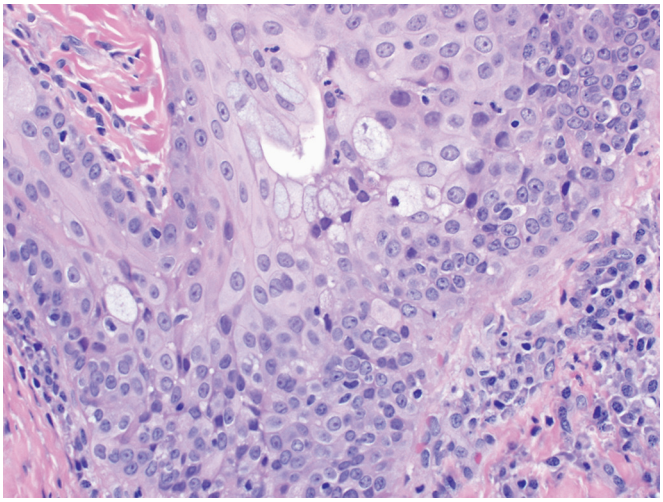

Figure 6.29 Mucoepidermoid carcinoma. Mucous, squamous, and intermediate cells can be seen.

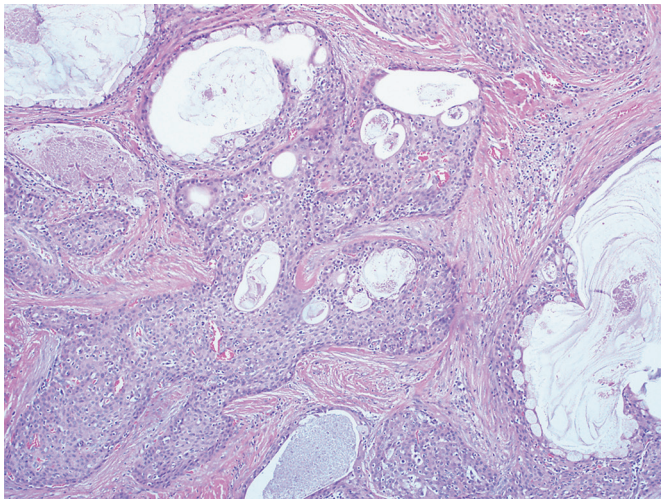

Figure 6.30 Low-grade mucoepidermoid carcinoma has a predominantly cystic areas as well as infiltrative growth.

present in variable proportions from tumor to tumor and can form sheets and nests with duct-like structures or cysts. The better differentiated forms present grossly as a relatively well-circumscribed mass with cystic areas containing mucinous material (Fig. 6.30). Microscopically, well-differentiated mucinous cells predominate in these low-grade lesions. The high-grade varieties are more solid and have a more infiltrative pattern of growth. In the high-grade tumors, squamous and intermediate predominate over the mucin-producing cells. It should be pointed out that marked nuclear atypia, frequent mitoses, extensive keratinization, and extensive necrosis are not typical of mucoepidermoid carcinoma of any grade. When these features are present, the alternative possibilities of poorly differentiated adenocarcinoma and adenosquamous carcinoma should be considered.[275]

Morphologic variants of mucoepidermoid carcinoma include forms with a component of sebaceous cells,[276] cases with prominent oncocytic change *(oncocytic mucoepidermoid carcinoma)*,[277–279] tumors with extensive clear cell change, forms with intense sclerosis of the stroma *(sclerosing mucoepidermoid carcinoma)*, and an extremely rare variant characterized by sclerosis, focal epidermoid features, and eosinophilic infiltration *(sclerosing mucoepidermoid carcinoma with eosinophilia)*, the latter being similar to the homonymous tumor of the thyroid gland.[7,280] In addition, cases of mucoepidermoid carcinoma with a dedifferentiated component have been reported, the change being accompanied by an accelerated clinical course.[281]

When the mucin or keratin formed by mucoepidermoid carcinoma escapes into the interstitial tissue, it causes an inflammatory reaction. Although true post-traumatic sialoceles and mucoceles certainly occur,[282] in the presence of mucin-filled cystic spaces in the parotid region the possibility of a well-differentiated mucoepidermoid carcinoma should always be ruled out by taking additional sections. Sometimes, extensive fibrosis accompanies the spillage of mucin.[283]

Immunohistochemically, simple mucin-type carbohydrate antigens (T, Tn, and syalosyl-Tn) have been detected in this tumor.[284] The mucins expressed by mucoepidermoid carcinoma include MUC1, MUC2, MUC4, MUC5AC, and MUC5B, but not MUC3 (which is expressed instead by adenoid cystic carcinoma; see later). Significantly, MUC1 predominates in the high-grade tumors, whereas MUC4 is more prevalent in low-grade tumors.[285,286]

In terms of keratin expression, the usual profile of mucoepidermoid carcinoma is CK7+/CK14+/CK20–.[287,288] The pattern of staining with these markers recapitulates that of normal striated duct cells.[289] Myoepithelial cell markers are usually negative and focal with weak staining if present.[289] The exception is p63, which is positive in the epidermoid and intermediate cells.

In a majority of cases of mucoepidermoid carcinomas, a distinctive chromosomal translocation t(11;19)(q21;p13), which fuses the *CRTC1* (formerly known as *MECT1*) gene with the *MAML2* gene, is found.[290–292] The translocation results in activation of the Notch pathway.[293] Of interest, mucoepidermoid carcinomas occurring in other sites, such as skin, breast, lung, and cervix, have also demonstrated the *CRTC1* translocation.[294–297] In 6% of cases, *CRTC3–MAML2* gene fusion is present instead of *CRTC1–MAML2*.[292] Mucoepidermoid carcinomas harboring *CRTC1–MAML2* or *CRTC3–MAML2* fusion exhibit a more favorable prognosis compared with those lacking the gene fusion.[291,292,298–300]

There is a marked difference in prognosis depending on the grade of the tumor, whether one uses the traditional two-tier system (low grade and high grade) or the three-grade scheme proposed by the Armed Forces Institute of Pathology (AFIP) authors, which is the one currently favored.[301–303] This is based on a weighted points system: cystic component less than 20%, 2 points; neural invasion, 2 points; necrosis, 3 points; four or more mitoses per 10 high-power fields, 3 points; anaplasia, 4 points. A total score between 0 and 4 defines a low-grade tumor, a score of 5–6 applies to an intermediate-grade tumor, and a score of 7 or more indicates a high-grade tumor.[304]

In the series reported by Jakobsson et al.[305] the determinate 5-year survival rate was 98% for the low-grade variety and 56% for the high-grade variety. Most of the latter tumors showed their malignant behavior within the first 5 years after surgery, in contrast with the continuous fall in survival rate over a 20-year period seen with adenoid cystic carcinoma and acinic cell carcinoma. In another series involving 69 cases, all but 2 of the 14 deaths and all 6 instances of distant metastases occurred in high-grade tumors, which were also associated with an increased incidence of local recurrence and regional lymph node metastases.[275] A correlation has also been found between prognosis and the following parameters: age (better in younger patients), gender (better in females), location (better in the parotid than in the submandibular gland), extraglandular extension, vascular invasion, necrosis, mitotic rate, cell proliferation as measured by MIB-1 antibody, DNA ploidy, and activation of the ERK-1/ERK-2 pathway.[301,302,306–308]

Acinic Cell Carcinoma and Mammary Analogue Secretory Carcinoma

Acinic cell carcinoma comprises 1%–3% of all salivary gland tumors. There is a male predominance and a peak incidence in the fifth decade of life, but there is a broad age distribution.[309] In fact, following mucoepidermoid carcinoma, it the second most common salivary gland malignancy in children. It is the most common bilateral salivary gland malignancy. A few familial cases have been described.[310] The majority (80%) are located in the parotid gland, but many examples in the minor salivary glands have been recorded.[311–313]

Grossly, the tumor presents as an encapsulated round mass with a solid, friable, grayish-white cut surface, usually measuring less than 3 cm in diameter.[309] Occasionally it undergoes marked cystic degeneration.

The microscopic appearance shows considerable variation from case to case. The pattern of growth may be predominantly solid, microcystic, papillary–cystic, or follicular.[309] There is also marked variability in the appearance of the tumor cells. The most characteristic cell, known as acinic, has a cytoplasmic appearance (granular and basophilic) and ultrastructural morphology analogous to that of acinic cells of normal salivary glands (Fig. 6.31).[314,315] The cytoplasmic granules demonstrate periodic acid–Schiff (PAS) positivity that is

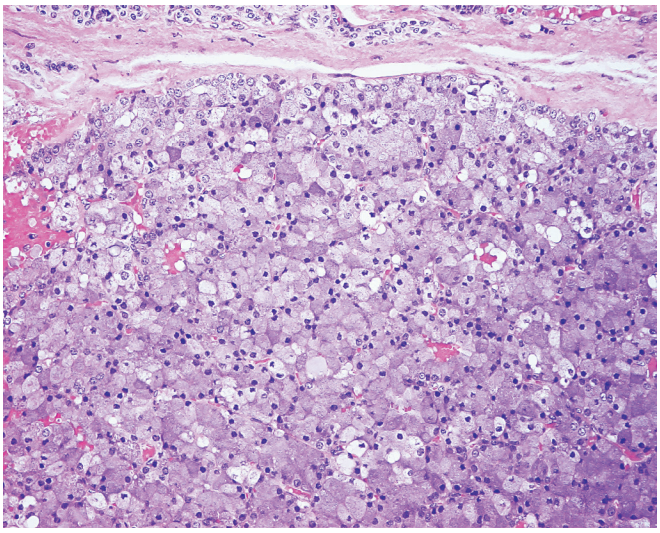

Figure 6.31 Acinic cell carcinoma. The cells have an abundant cytoplasm filled with basophilic zymogen granules.

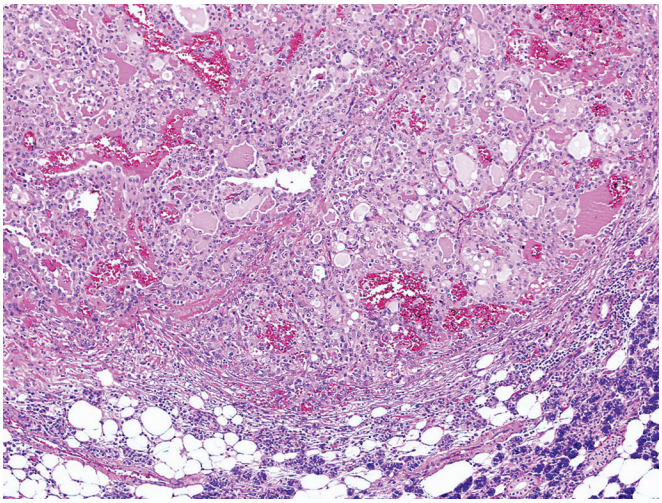

Figure 6.32 Mammary analogue secretory carcinoma of parotid gland. These low-grade infiltrative carcinomas are comprised of large nests with a microcystic appearance. The lumens are filled with eosinophilic to basophilic secretions.

resistant to diastase. Other cell types have been designated as intercalated duct, clear, vacuolated, and nonspecific glandular.[309] When the clear cell component predominates, the tumor acquires a "hypernephroid" appearance reminiscent of renal cell carcinoma. These clear cells do not contain fat or mucin but may have variable amounts of glycogen. However, focal mucin positivity can be encountered in the papillary–cystic or follicular areas.[316] The occurrence of these cytologic and architectural variations indicates that this neoplasm differentiates in the direction of the terminal ductular–acinar unit of the salivary gland, which includes secretory acinar (luminal) cells, intercalated duct cells, pluripotential reserve (basal) cells, and myoepithelial cells.[317] Lymphoid follicles with germinal centers may be prominent at the periphery of the tumor[318] and laminated concretions with the appearance of psammoma bodies may be seen within the lumina.[309]

Immunohistochemically, there is positivity for keratin and also focal reactivity for amylase, α1-antichymotrypsin, transferrin, lactoferrin, IgA, secretory component, and proline-rich protein.[319,320] Patchy S-100 protein reactivity can be seen in some tumors. Apical membrane reactivity for DOG-1 has been identified in acinic cell carcinomas and is helpful in distinguishing this tumor from its mimics.[6]

In a classic study of 37 cases reported by Eneroth et al.,[314] there was local recurrence in 11 cases and metastases in 7 cases; 4 recurrences were in regional lymph nodes. The determinate survival rate at 5 years was 89%, but it fell to 56% after 20 years. In a larger series reported by Ellis and Corio,[321] there was a recurrence rate of 12%, a metastatic rate of 7.8%, and a death rate of 6.1%. The regional lymph nodes are the most common site of metastases.[321]

Features of prognostic importance are pain or fixation, gross extraglandular invasion, desmoplasia, cytologic atypia, increased mitotic activity, and adequacy of initial excision.[322] The latter is of particular importance.[323,324] In the series of Perzin and LiVolsi,[324] recurrent tumor was found in 14 of 15 patients treated with limited local excision but in only 3 of 28 patients who had wide local excision. Local recurrence was associated with an increased incidence of locally uncontrollable and metastatic disease. Neck dissection does not appear warranted unless the nodes are clinically involved. The role of radiation therapy for this tumor remains controversial; most series have not shown clear-cut beneficial effects.[325]

A particularly ominous but fortunately rare event in acinic cell carcinoma is the emergence of an anaplastic (dedifferentiated) component in the form of a high-grade adenocarcinoma, poorly differentiated carcinoma, or undifferentiated carcinoma.[7,326] This development is associated with aneuploidy on flow cytometry, appearance of peculiar helioid inclusions at the ultrastructural level, and an accelerated clinical tempo.[327,328] *TP53* gene mutation and *HER2* amplification have not been detected in dedifferentiated acinic cell carcinoma.[329]

Mammary analogue secretory carcinoma is a recently described salivary gland carcinoma that was frequently diagnosed as acinic cell carcinoma but is now known to be a distinct entity that is identical to secretory carcinoma of the breast, confirmed by the morphologic, immunohistochemical, and genetic similarities between the two entities. The entity was reported by Skalova et al., taking advantage of the fact that mammary secretory carcinoma is associated with the t(12;15)(p13;q25) translocation leading to the *ETV6–NTRK3* gene fusion. Given the histologic similarity to acinic cell carcinoma, a key question, of course, was whether acinic cell carcinoma of salivary glands carried the same translocation. Reis-Filho et al.,[330] and Skalova et al.,[331] working with 14 suitable cases, found the same cytogenetic aberration *in all of them* (but not in conventional acinic cell carcinomas or other salivary gland tumors). On the basis of this remarkable finding, the authors postulated the existence of a distinct entity among salivary gland tumors that they proposed to call mammary analogue secretory carcinoma of salivary glands (MASC). Most occur in the parotid gland, but intraoral minor salivary gland sites can also be involved. Morphologically, the cases representing this new entity are characterized by the presence of microcystic and glandular spaces with abundant eosinophilic secretion positive for PAS, mucicarmine, MUC1, MUC4, and mammaglobin (Fig. 6.32). The cells have an apocrine appearance with vacuolated, eosinophilic cytoplasm and uniform vesicular nuclei with small nucleoli (Fig. 6.33). Similar to mammary secretory carcinoma of the breast, the cells are positive for cytokeratin, S-100 protein, BRST-2, and mammaglobin but negative for androgen receptor, p63, and DOG-1. They are low-grade carcinomas that recur in approximately 30% of cases but only rarely metastasize or result in death. Rare examples with high-grade transformation (dedifferentiation) have been described and behave more aggressively.

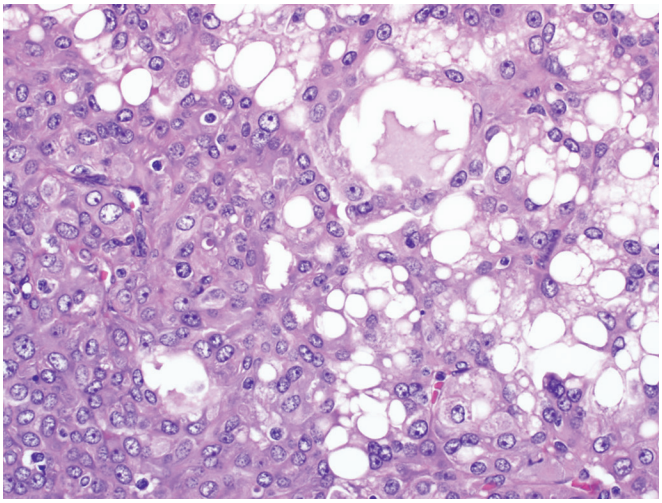

Figure 6.33 Mammary analogue secretory carcinomas contain monotonous cells with an apocrine appearance and vacuolated cytoplasm.

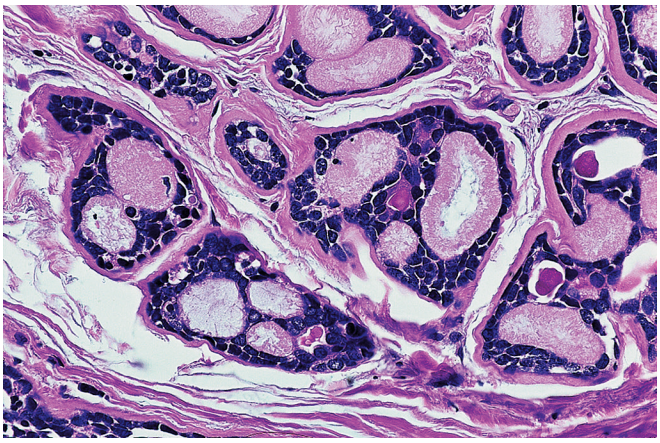

Figure 6.35 Adenoid cystic carcinoma. Numerous "cylinders" containing a homogeneous acidophilic material can be seen.

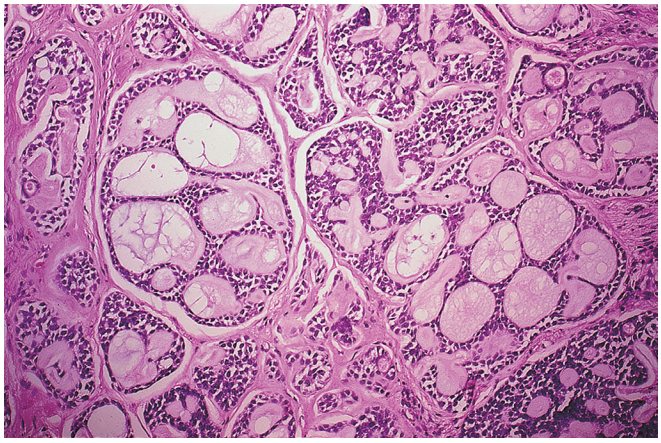

Figure 6.34 Adenoid cystic carcinoma. Typical low-power appearance.

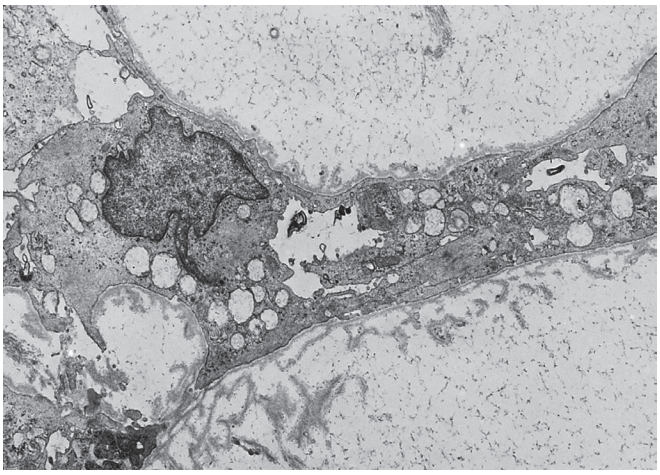

Figure 6.36 Ultrastructural appearance of adenoid cystic carcinoma of oral minor salivary gland. The tumor is made up of myoepithelial cells covered by reduplicated basal lamina. False lumina are thus formed. (×7450.)

Adenoid Cystic Carcinoma

Adenoid cystic carcinoma is a generally slow-growing but highly malignant neoplasm with a remarkable capacity for recurrence. In the parotid gland it is less common than mucoepidermoid carcinoma and acinic cell carcinoma, but in the minor salivary glands it is the most common malignant tumor.

Grossly, it usually has a solid appearance and an infiltrative pattern of growth, although some examples can be well circumscribed. Microscopically, the typical adenoid cystic carcinoma has a pattern described as *cribriform:* nests and columns of cells of rather bland appearance are arranged concentrically around glandlike spaces ("pseudocysts") filled with homogeneous eosinophilic PAS-positive material or granular myxoid material (Figs. 6.34 and 6.35). Most of these are not true glandular spaces; they represent instead extracellular cavities containing reduplicated basal lamina material and mucin produced by the tumor cells (Fig. 6.36).[332] Small true glandular lumina are also formed. Indeed, identification of *both* pseudocysts and true glandular lumina is required to make a diagnosis of adenoid cystic carcinoma. The rare small glandular lumina are lined by a monolayer of eosinophilic epithelial cells. These are surrounded by varying amounts of small myoepithelial cells with scant cytoplasm and hyperchromatic, angulated nuclei. This tumor has a remarkable tendency for invasion of perineurial spaces, to the degree that the diagnosis of adenoid cystic carcinoma should be questioned if an adequate sample taken from the periphery of the tumor does not exhibit this feature (Fig. 6.37).[333]

Some adenoid cystic carcinomas have a predominantly *tubular* pattern of growth, whereas others are mainly *solid*[334,335] and yet others (exceptionally rare) are *sclerosing*.[336] The solid pattern is characterized by overgrowth of the epithelial (glandular) component and frequently displays more mitotic activity with increased cytologic atypia with or without small foci of necrosis. Combined patterns of growth are common, whether in the original tumor or in the recurrences (Fig. 6.38).[337]

Immunohistochemically, the tumor cells located in recognizable duct structures express a phenotype similar to that of the intercalated duct (positive for keratin, CEA, lysozyme, lactoferrin, α1-antichymotrypsin, S-100 protein, and CD117 [c-KIT]), and those around pseudocysts have a phenotype suggestive of myoepithelial cell differentiation (positive for S-100 protein, p63, and actin and variably positive for keratin).[338–343]

Cytogenetically, there is a high incidence of loss of heterozygosity (LOH) at chromosome 6q23–35.[344,345] Alterations of *TP53* are

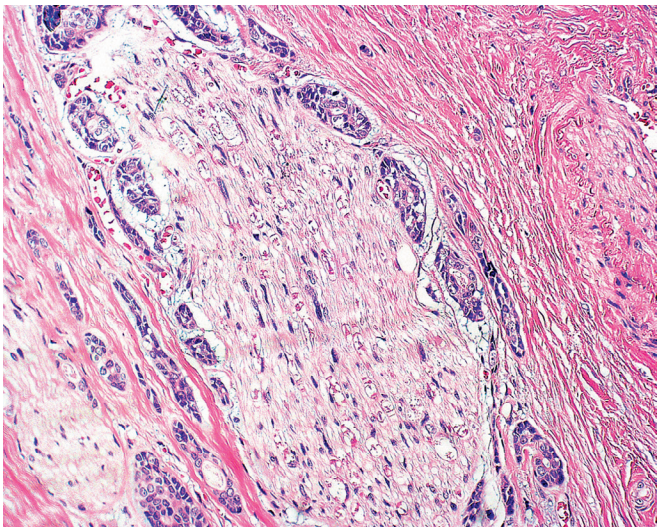

Figure 6.37 Adenoid cystic carcinoma with prominent perineurial invasion.

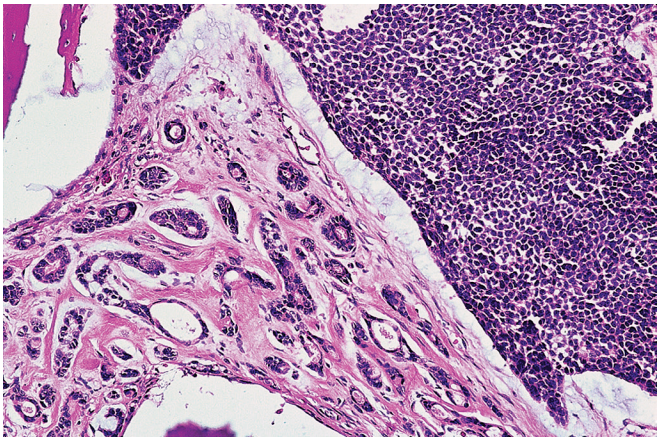

Figure 6.38 Adenoid cystic carcinoma combining tubular *(left)* and solid *(right)* features.

uncommon,[346] except in dedifferentiated cases (see later). A microarray analysis has demonstrated the common expression of genes indicative of myoepithelial differentiation, transcription factors 50 × 4 and AP-2y, and members of the Wnt/β-catenin signaling pathway.[347] A proportion of cases (approximately 30%) of adenoid cystic carcinomas exhibit a distinctive chromosomal translocation resulting in *MYB–NKIB* fusion.[348]

The differential diagnosis with benign mixed tumor can be difficult. Important points to remember are that adenoid cystic carcinoma is invariably invasive and often associated with perineurial invasion, and that chondromyxoid stroma and foci of squamous metaplasia are consistently absent. In addition, papillary growth and true cyst formation are not a feature of adenoid cystic carcinoma.

Another important differential diagnosis is with polymorphous low-grade adenocarcinoma, which is rendered easier by the realization that the latter is almost nonexistent in the *major* salivary glands. At the microscopic level, the nuclei of adenoid cystic carcinoma tend to be hyperchromatic and angulated rather than bland and uniform. Furthermore, as already stated, adenoid cystic carcinoma is usually strongly immunoreactive for CD117 (c-KIT), whereas polymorphous low-grade adenocarcinoma is either negative or shows a lesser intensity of staining.[343] The latter fact makes this stain suboptimal as a distinguishing feature. In contrast, diffuse S-100 protein staining would support a diagnosis of polymorphous low-grade adenocarcinoma over adenoid cystic carcinoma, whereas strong p63 staining would support the latter.

Because the prognosis of adenoid cystic carcinoma is greatly influenced by its pattern of growth, this feature has been used as a grading system.[334,349–351] In one series, the recurrence rate was 59% for the tubular tumors, 89% for the classic cribriform lesions, and 100% for the solid variety.[334] In another series in which a somewhat similar grading system was used, the cumulative survival rates at 15 years were 39%, 26%, and 5%, respectively.[351] The solid or anaplastic type of adenoid cystic carcinoma is associated with a higher incidence of metastases and a rapid clinical course.[349,352] Based on these findings, adenoid cystic carcinomas can be graded as follows: grade 1—tubular or mixed cribriform and tubular; grade 2—pure cribriform or those with a solid component less than 30%; grade 3—tumors with 30% or more solid component. A behavior just as aggressive (if not more so) is to be expected in the rare instances in which a conventional adenoid cystic carcinoma undergoes dedifferentiation or high-grade transformation,[353,354] an event that is accompanied by *TP53* gene mutation.[355] Other factors that influence the prognosis of adenoid cystic carcinoma are stage (very important), presence of tumor at the margins, anatomic site, size of the primary lesion, degree of atypia, and lymph node metastases.[334,351,356]

Adenoid cystic carcinomas frequently metastasize to the lungs. These metastases are usually silent, and it is not unusual to find multiple nodules in the chest x-ray film of a totally asymptomatic individual. Lymph node metastases are rare, at least at the time of the initial presentation; many of them seem to represent direct extension from the perinodal soft tissues rather than true embolic deposits.[357]

In the treatment of adenoid cystic carcinoma, a radical surgical approach should be used, no matter how well differentiated the tumor appears under the microscope.[358] Cures after tumor recurrence are very difficult to achieve. Radiation therapy is rarely curative, but it may improve results when combined with surgery,[349] and it may produce excellent temporary regression of inoperable recurrences.[350,359]

Salivary Duct Tumors

Salivary duct papilloma usually arises within minor salivary glands, but a few cases have been reported in the parotid.[360–363]

Salivary duct carcinoma is usually seen in elderly males, most commonly in the parotid gland but also in the submandibular gland.[250,364–366] Some cases develop on the basis of a preexisting pleomorphic adenoma and salivary duct carcinoma is the most common carcinoma seen in carcinoma ex pleomorphic adenoma. Microscopically, it resembles high-grade in situ and invasive apocrine ductal carcinoma of the breast, whether comedo, solid, cribriform, papillary, invasive micropapillary, mucinous (mucin-rich), the usual invasive form, or even sarcomatoid (Fig. 6.39).[7,367–375] In other words, it spans the same wide range of differentiation as its more common mammary counterpart.[376–378] The immunohistochemical profile is similar to that of a ductal-type adenocarcinoma and just as diverse as its morphologic appearance.[379] There is expression of keratin (including low- and high-molecular-weight keratins),[380] HER2/neu (approximately 40% of cases),[381,382] CEA, and EMA.[383,384] It also frequently expresses androgen receptors (approximately 90%) but negative for estrogen receptor. Some tumors express CD117 (c-KIT), GCDFP-15 (especially in the intraductal component), and prostate-specific antigen and other prostate-related markers.[385,386–388] They

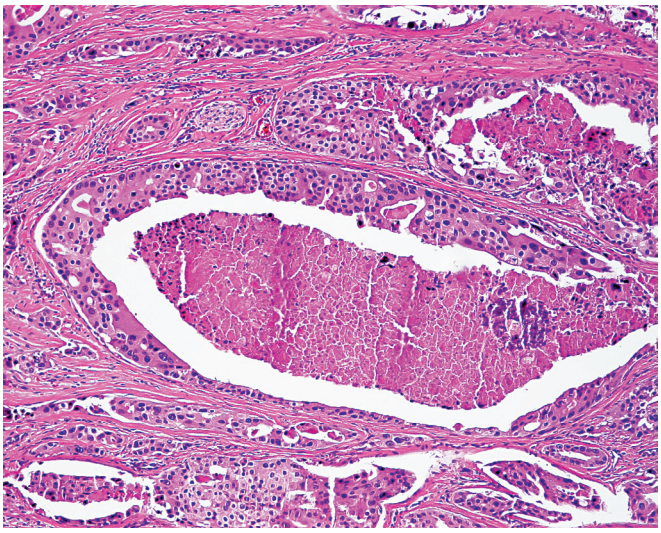

Figure 6.39 High-grade ductal-type carcinoma of parotid gland. There is some degree of cytoplasmic apocrine-like change.

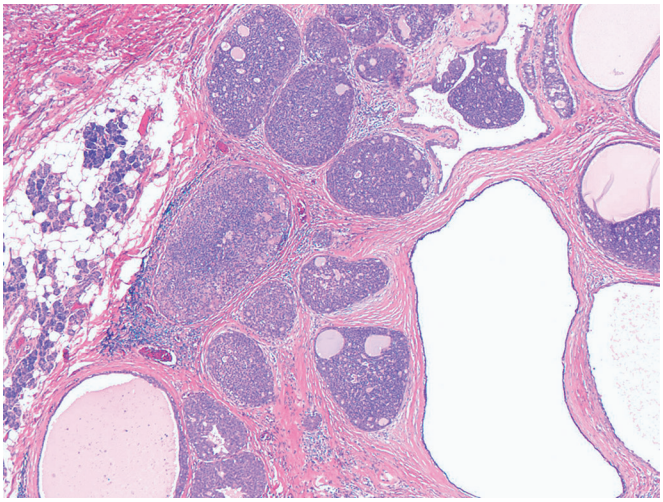

Figure 6.40 Low-grade cribriform cystadenocarcinoma of parotid gland. A mixture of solid and cystic nodules is typical.

are negative for S-100 protein and p63 (rare weak positivity can be seen).[389]

Mutation of *TP53* is a common finding in salivary duct carcinoma, and *HER2* amplification is present is approximately one-third of cases.[365,382] Gene expression profiling study shows overexpression of apoptosis-related genes *CASP10* and *MMP11*.[390]

This high-grade carcinoma is markedly aggressive, with frequent metastases to both regional nodes and distant organs, and a mortality rate of 70%, with most patients dying within 3 years of diagnosis.[250,391] The presence of a micropapillary or sarcomatoid component is said to be associated with an aggressive behavior.[392] Rare pure intraductal tumors treated by simple excision recur frequently, either with the same intraductal pattern or as invasive tumor.[393,394]

It should be emphasized that the term "salivary duct carcinoma" refers to the pattern of growth of the tumor rather than to its anatomic location. Most reported carcinomas of Stensen duct have not been salivary duct carcinomas but rather mucoepidermoid, squamous cell, or undifferentiated carcinomas.[395]

Low-grade cribriform cystadenocarcinoma is a recently described indolent salivary gland carcinoma that resembles a spectrum of low-grade breast lesions ranging from atypical ductal hyperplasia to micropapillary and cribriform ductal carcinoma in situ (Fig. 6.40). Most occur in adults and are located in the parotid gland.[396] They were originally referred to as "low-grade salivary duct carcinoma,"[376] but this term should be avoided to obviate confusion with the aggressive salivary duct carcinoma. Most lesions are entirely in situ, based on both morphologic and immunohistochemical features. Small foci of infiltrative growth can be identified in rare lesions. The tumor is characterized by solid and cystic lobules composed of bland cuboidal cells with minimal mitotic activity. Some tumors have cells with prominent apocrine cytology.[375] The solid lobules contain numerous microcysts imparting a cribriform appearance (Fig. 6.41). The microcysts are filled with pale eosinophilic or basophilic secretions. The cystic lobules may contain both papillary and cribriform growth. The neoplastic cells are positive for keratin and S-100 protein but negative for p63 and myoepithelial markers. The latter highlight a single layer of myoepithelial cells in the majority of the tumor lobules. Androgen receptor and HER2/neu are negative. Given the low-grade cytology and in situ nature of the tumor, the prognosis is excellent, with low recurrence risk and only rare cases of metastasis, with essentially no disease-related mortality.

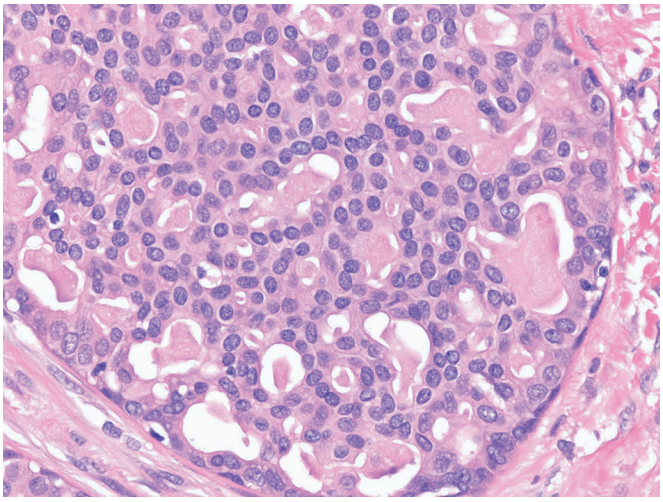

Figure 6.41 Low-grade cribriform cystadenocarcinomas resemble low-grade breast epithelial lesions, such as atypical ductal hyperplasia and low-grade ductal carcinoma in situ.

Polymorphous Low-Grade Adenocarcinoma

Polymorphous low-grade adenocarcinoma is usually restricted to the minor salivary glands of the oral cavity and is therefore discussed in Chapter 4.[397–399] Those occurring in the major salivary glands nearly always arise against a background of benign mixed tumor, but rare primary examples do occur.[400,401] The main differential diagnosis is with adenoid cystic carcinoma and benign mixed tumor.[402,403]

Cystadenocarcinoma (Papillary Cystadenocarcinoma)

Cystadenocarcinoma comprises less than 3% of all parotid tumors, but they also occur in the sublingual gland.[363,404] It may grow large and be accompanied by hemorrhage and necrosis. Similar cases have been described in the oral cavity.[405,406] Microscopically, the presence of invasive cystic nodules with well-defined papillary structures is the most important distinguishing feature. Mucin production is usually present, but there are no squamous or intermediate

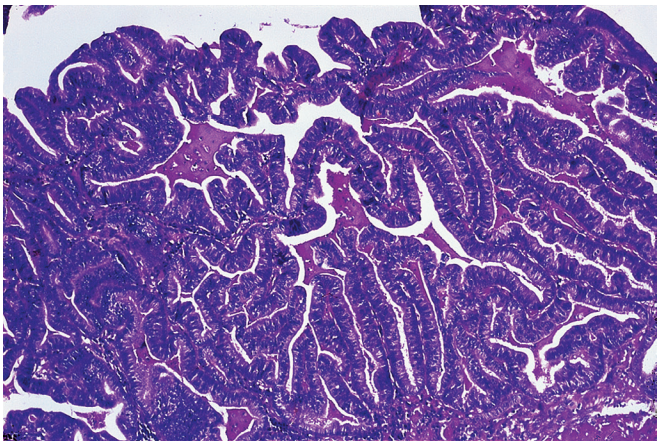

Figure 6.42 Papillary cystadenocarcinoma of parotid gland.

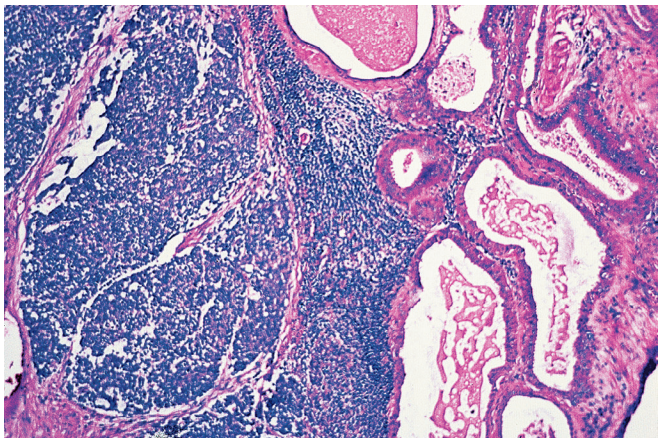

Figure 6.43 Collision between Warthin tumor *(right)* and small cell (Merkel cell) carcinoma *(left)*.

components (Fig. 6.42). If there is a prominent papillary component, the tumors can be designated as *(papillary) cystadenocarcinomas*.[407,408] Sometimes the malignant papillary component is a focal feature in an otherwise benign-looking mucinous cystadenoma.[409] The differential diagnosis includes mucoepidermoid carcinoma, acinic cell carcinoma, the papillary subtype of polymorphous low-grade adenocarcinoma, and metastatic carcinoma, particularly from the thyroid. Blanck et al.[404] divided their cases into high- and low-grade varieties based on the presence or absence of stromal invasion. The former had a poor prognosis, comparable with that of adenoid cystic carcinoma, whereas the latter did not differ prognostically from low-grade mucoepidermoid carcinoma.

Squamous Cell Carcinoma

Most squamous cell carcinomas in the parotid region represent metastases in the intraparotid lymph nodes of tumors located in the oral cavity, some other region in the upper aerodigestive tract, or the skin.[410]

True pure squamous cell carcinomas of the salivary gland are very rare. Some represent the malignant component of a mixed tumor; others are predominantly squamous cell types of high-grade mucoepidermoid tumors, as shown by their focal positivity for mucin stains. An in situ malignant ductal component has been occasionally encountered and can support the concept of primary salivary gland squamous cell carcinoma but could also represent secondary invasion from a metastasis.[411] These tumors grow rapidly and infiltrate surrounding structures. The treatment of choice is radical surgery, but radiation therapy is also effective. The overall 5-year survival rate in a series of 18 cases from the Mayo Clinic was 50%.[412]

Small Cell Carcinoma and Other Neuroendocrine Carcinomas

There are malignant tumors of the salivary gland that are entirely composed of a solid population of small cells with a darkly staining nucleus, high mitotic activity, and scanty cytoplasm.[413,414] Some of these tumors are indistinguishable from small cell carcinomas of the lung. They may be pure or associated with areas of glandular or squamous differentiation.[415–418] Ultrastructurally, dense-core granules consistent with endocrine differentiation are found in most but not all of the cases.[419] Immunohistochemically, all of the cases studied by two groups of authors[420,421] expressed one or more neuroendocrine markers, such as Leu7, neuron-specific enolase (NSE), chromogranin, or synaptophysin. Keratin (often dot-like pattern) and EMA are also regularly expressed.

In approximately half of the cases these tumors have been found to have features analogous to those of Merkel cell carcinoma of skin, including immunoreactivity for CK20 and polyomavirus.[421,422] Rarely, small cell carcinoma can be the malignant component arising in a background Warthin tumor (Fig. 6.43).[423] On the basis of the above findings, some authors have proposed to divide small cell carcinomas of salivary glands into Merkel cell type and pulmonary type, the latter being negative for CK20. It remains to be seen whether this distinction carries a clinical significance, but preliminary studies suggest that the Merkel cell type is associated with a better survival.[7,421] Overall, recurrence and metastasis occur in more than half of patients, with 5-year survival ranging from 15% to 50%.

Large cell neuroendocrine carcinoma of the salivary gland has also been described, the criteria for its recognition being the same as for the homologous lung tumor.[424]

Lymphoepithelioma-Like Carcinoma

Lymphoepithelioma-like carcinoma is the preferred term for a type of salivary gland carcinoma that has also been reported as a malignant lymphoepithelial lesion and lymphoepithelial carcinoma.[425–428] This tumor is particularly frequent among Eskimos and Chinese, in whom it may show evidence of familial clustering.[427,429] It presents as a unilateral mass, in either the parotid or submaxillary glands, in adult patients without any of the peripheral manifestations of Sjögren syndrome. Its low-power appearance is reminiscent of Mikulicz disease because of the mixture of epithelial solid islands and lymphoid tissue. However, high-power examination shows that the islands have malignant cytologic features throughout. The appearance is that of a nonkeratinizing large cell carcinoma, with occasional spindle-shaped areas, analogous by light and electron microscopy to the nasopharyngeal tumor classically known as lymphoepithelioma.[426,430] That the analogy may be more than morphologic is suggested by the fact that many of these patients have serologic evidence of EBV infection[427] and that EBV DNA has been found in the tumors by in situ hybridization and other molecular techniques.[431–434] Perineurial invasion may be present.[427] Immunohistochemically, there is strong positivity for keratin.[427] The reactive lymphoid tissue forms germinal centers and may exhibit focally a starry sky pattern. Regional lymph node metastases are very common, and distant metastases (particularly to the lung, liver, and bone) also occur.[429] Wide variations in mortality rates have been reported, but the overall outcome in the better documented cases seems to

be relatively good, with 5-year survival rates ranging from 75% to 85%.[427,435]

Other Primary Carcinomas

Some *adenocarcinomas* of salivary gland combine features of two histologically distinct types. They are referred to as **hybrid carcinomas**, and one of the two components is often of myoepithelial nature, but any combination of histologic subtypes is possible.[436,437] Other adenocarcinomas do not fit into any of the previously described patterns and are referred to as adenocarcinoma, N.O.S.[438,439] Following the description of salivary duct carcinoma, polymorphous low-grade adenocarcinoma, MASC, low-grade cribriform cystadenocarcinoma, and epithelial–myoepithelial carcinoma, the number of adenocarcinomas, N.O.S. has shrunk considerably.[438]

Malignant Lymphoma

Malignant lymphoma in the parotid region may arise from an intraparotid lymph node or in the gland itself. In the former instance, the histologic features and natural history of the disease are those of nodal lymphoma in general. When the salivary gland tissue is involved, this may represent the expression of disseminated involvement or, more commonly, a primary process of this organ. The large majority of primary lymphomas of salivary gland involve the parotid gland, but the submaxillary gland can also be affected.[440–443] Clinically, most present as unilateral masses. The large majority of salivary gland lymphomas are of B-cell derivation, most commonly MALT lymphoma, followed by follicular lymphoma and diffuse large B-cell lymphoma.[440,442,444]

Some salivary gland lymphomas are of follicular type and feature the t(14;18) characteristic of follicular lymphoma.[444,445] Some have sclerosing features and simulate chronic sclerosing sialadenitis (Kuttner tumor; but see later).[446] Others—the majority—are composed of small lymphocytes and cells resembling monocytoid B cells. These tumors are currently regarded as belonging to the MALT/marginal zone type.[447,448] They often arise against a background of Mikulicz disease or other immune-mediated diseases (see earlier).[444] They are characterized by a very slow evolution and an excellent long-term prognosis[444,447,449]; it is not unusual for recurrent disease to supervene in the contralateral parotid, skin, or in some other location a decade or more after the initial diagnosis.[450] In contrast, lymphomas composed of large cells run a rapidly progressive clinical course.[451]

Cases of malignant lymphoma have also been observed in association with Warthin tumor,[183,452] in transplant recipients,[453] and following chronic sclerosing sialadenitis (Kuttner tumor).[454]

Isolated cases of **plasmacytoma** of the salivary gland have been reported, some later developing typical radiographic bone changes of multiple myeloma.[455,456]

T-cell lymphomas of the salivary gland are rare but well documented.[457] These include tumors of T/natural killer cells. They may show prominent lymphoepithelial lesions and cannot therefore be reliably distinguished from B-cell tumors on morphologic grounds.[458]

Hodgkin lymphoma presenting as a primary salivary gland neoplasm is very rare.[459] Most cases so diagnosed in the past would probably be reclassified today.

Other Primary Tumors

Benign vascular tumors of blood vessel and lymph vessel type (lymphangiomas) occur in the parotid gland.[460]

Infantile (juvenile) hemangioma is the most common salivary gland tumor in infants and children.[461] It is often congenital and usually involves the parotid gland. It forms a diffuse soft mass without fixation to the overlying skin. Microscopically, it is made up of anastomosing thin-walled capillaries growing between salivary ducts and acini (Fig. 6.44). The solid proliferation of endothelial cells and the presence of mitotic figures may lead to a mistaken diagnosis of malignancy.[462] These lesions practically never become malignant and can regress spontaneously. Some of the cases have been associated with the Kasabach–Merritt syndrome.[463] Immunohistochemical reactivity for GLUT1 distinguishes this lesion from its mimics, particularly vascular malformations, because the former demonstrate diffuse cytoplasmic reactivity.[464] This distinction is important because infantile hemangiomas can be followed clinically without surgical intervention. Vascular malformations, in contrast, need to be treated because they tend to grow slowly over time.

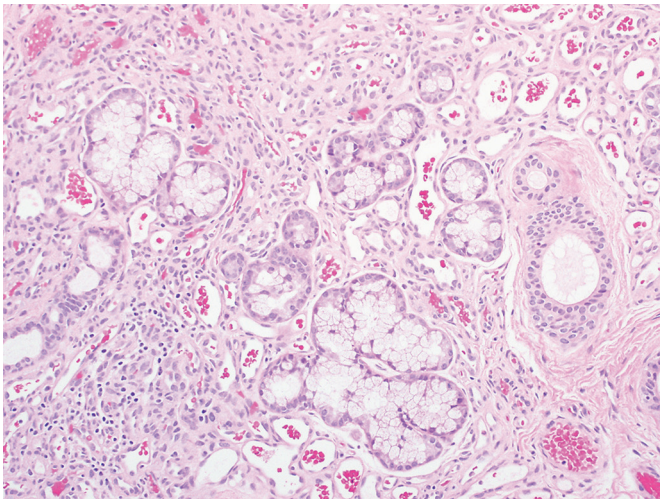

Figure 6.44 Infantile hemangiomas are composed of small capillary-sized blood vessels that infiltrate the glandular parenchyma.

Lipoma rarely involves the region of the parotid salivary gland.[465] It should be distinguished from *lipomatosis*, which is a diffuse nontumoral deposition of adipose tissue throughout the gland accompanied by enlargement of the organ. The latter has been seen in association with diabetes, cirrhosis, chronic alcoholism, malnutrition, and hormonal disturbances.[466] In some cases, this has been preceded by hypertrophy of the serous acinar cells, interstitial edema, and ductal atrophy, a process known as *sialosis* or *sialadenosis*.[467]

Schwannoma can arise from one of the fine radicles of the facial nerve and present clinically as a primary salivary gland tumor.[468] It is grossly encapsulated, and its microscopic appearance is similar to that of schwannomas elsewhere. Failure to recognize this neoplasm as benign may result in needless sacrifice of the facial nerve.

Adult rhabdomyoma often presents in the soft tissues of the submandibular area, but the gland itself is rarely affected.[469]

Solitary fibrous tumor has been reported in the parotid and in the submandibular gland.[470,471] Its histology and clinical course is similar to that of its soft tissue counterpart.[472]

Sialolipoma is a benign tumor composed of mature adipose tissue and glandular elements, which are probably entrapped.[473]

Granular cell tumor has been reported within the parotid gland.[474]

Sialoblastoma (embryoma) is a term used for an extremely rare, highly cellular epithelial parotid tumor of neonates and infants having an embryonal or "blastomatous" appearance.[475–477] The neoplastic cells typically are reactive for keratin, p63, S-100, and actin. The biologic behavior is difficult to predict on histologic

grounds. Some of the sialoblastomas have recurred locally, several had regional lymph node involvement, and one case resulted in lung metastases.[478]

Salivary gland anlage tumor is another congenital tumor of minor salivary gland type that has been described only in the nasopharynx.[479]

Sarcomas are very rare and need to be distinguished from epithelial, myoepithelial, and melanocytic tumors with a spindle cell pattern.[480] The types described in adults include *malignant peripheral nerve sheath tumor*, *fibrosarcoma*, *synovial sarcoma*, *Kaposi sarcoma*, *angiosarcoma*,[481] *Ewing sarcoma/primitive neuroectodermal tumor* (*PNET*), desmoplastic small round cell tumor,[482] and *undifferentiated malignant fibrous histiocytoma*.[480,483–486] In children, *embryonal rhabdomyosarcoma* can arise in the parotid region and can secondarily invade the gland.[487]

Metastatic Tumors

Most metastatic tumors to this region are centered in intraparotid or submandibular lymph nodes.[488] As the tumor grows, it closely mimics a primary neoplasm of the salivary gland. It should be remembered that the most common malignant tumor in the submandibular and parotid gland region is a metastatic carcinoma in the submandibular or parotid lymph nodes rather than a primary salivary gland carcinoma. The most common types are squamous cell carcinoma (from the upper aerodigestive tract or skin) and malignant melanoma (including the desmoplastic variant).[489–491] Of the distant tumors metastasizing to the major salivary glands, lung, kidney, and breast tumors are the most common.[488,492,493] Other reported sites include prostate and large bowel.[491,494]

General Features of Salivary Gland Tumors

Relative Incidence and Malignancy

Salivary gland tumors are 12 times more frequent in the parotid than in the submandibular gland, a difference that cannot be explained on the basis of gland size alone. The majority are benign and largely represented by the pleomorphic adenoma.[495,496]

In a series of 2632 salivary gland tumors reported by Eneroth,[497] the incidence of malignancy was 17% for the parotid gland, 38% for the submandibular gland, and 44% for the palate. The incidence of malignancy is highest for tumors of the sublingual gland and benign sublingual gland neoplasms are exceedingly uncommon.[495]

Most tumors of major salivary glands are unilateral and single. Bilaterality and multiplicity are common only in Warthin tumor but can also be seen with pleomorphic adenoma and acinic cell carcinoma.[498] Acinic cell carcinoma is the most common bilateral salivary gland malignancy.

Tumors of minor salivary glands can be found anywhere in the oral cavity, including the hard and soft palate, cheek, gingiva, tonsillar area, and tongue.[499] Their frequency seems to be approximately proportional to the amount of normal glandular tissue in this area, which may explain their marked predilection for the hard palate. They can also occur in the lip (particularly upper lip), nasal cavity and paranasal sinuses, ear, jaw, pharynx, larynx, trachea, and bronchi. Furthermore, tumors of the salivary gland type may arise from a variety of glandular structures, particularly breast and sweat glands.

Finally, salivary gland tumors of various types have been described as arising from lymph nodes located in or around the parotid gland, presumably on the basis of ectopic salivary tissue. Warthin tumor is by far the most common type, but examples of sebaceous lymphadenoma, pleomorphic adenoma, basal cell adenoma, acinic cell carcinoma, and mucoepidermoid carcinoma have also been reported.[197,500]

Little is known about the etiology of salivary gland tumors, and high-risk populations have not been identified except for the rare lymphoepithelioma-like carcinoma.[501] An increased incidence of benign mixed tumors and other neoplasms has been observed following therapeutic childhood irradiation,[502,503] and a possible increase in carcinomas (particularly of mucoepidermoid type) has been noted among atomic bomb survivors.[504]

In children, the most common salivary gland tumor is benign mixed tumor, but the proportion of malignant tumors is higher than in adults. Among the malignant neoplasms, mucoepidermoid carcinoma, adenoid cystic carcinoma, and acinic cell carcinoma are the most common.[80,505–507]

Clinical Diagnosis

Benign tumors of the salivary glands usually can be distinguished from the high-grade malignant varieties on the basis of their clinical and gross characteristics. The presence of facial nerve paralysis is almost diagnostic of malignancy. These criteria do not apply for the low-grade acinic cell carcinomas and mucoepidermoid carcinomas because their clinical presentation is usually indistinguishable from that of benign neoplasms. The reverse also may be true, although only in rare cases. Warthin tumor, for instance, may be clinically thought to be malignant because of its adherence to the skin.

Staging

A clinical staging system using the TNM classification scheme for major salivary gland tumors has been established. It is based on: size of the primary tumor, local extension with involvement of adjacent structures (bone, skin, ear canal, facial nerve, skull base, pterygoid plates, carotid artery), involvement of the regional lymph nodes (number, size, and laterality), and the presence or absence of distant metastases. Importantly, extraglandular extension is based on gross or clinical evidence and not microscopic evidence alone. Salivary gland carcinomas of minor salivary glands are staged according to the site from which they arise.

Biopsy and Cytology

Tumors of the submandibular gland are usually treated by removal of the gland without previous biopsy. For tumors of the parotid glands, several choices are available depending on the size and location of the tumor, clinical features, and expertise of the pathologist. Tumors involving the superficial parotid lobe lacking clinical features of malignancy can be properly handled by a superficial lobectomy with frozen section, any subsequent therapy depending on the diagnosis of the frozen section. Obviously malignant tumors with skin invasion can usually be diagnosed with a small incisional biopsy and treated accordingly. Other options are core needle biopsy and fine-needle aspiration. Although the former usually provides diagnostic material, the possibility of implantation along the needle track and the difficulty sometimes encountered in the differential diagnosis (particularly among adenoid cystic carcinoma, monomorphic adenoma, and benign mixed tumor) have resulted in a less than enthusiastic response from clinicians and pathologists. Instead, fine-needle aspiration has been used successfully by several European institutions (particularly the Karolinska Institute in Sweden) and has now become widespread in the United States (Figs. 6.45 and 6.46). The overall accuracy rate has been greater than 90% in most reported series.[508,509] The fine-needle aspiration procedure can induce necrotic and reparative changes in the tumor, particularly if composed

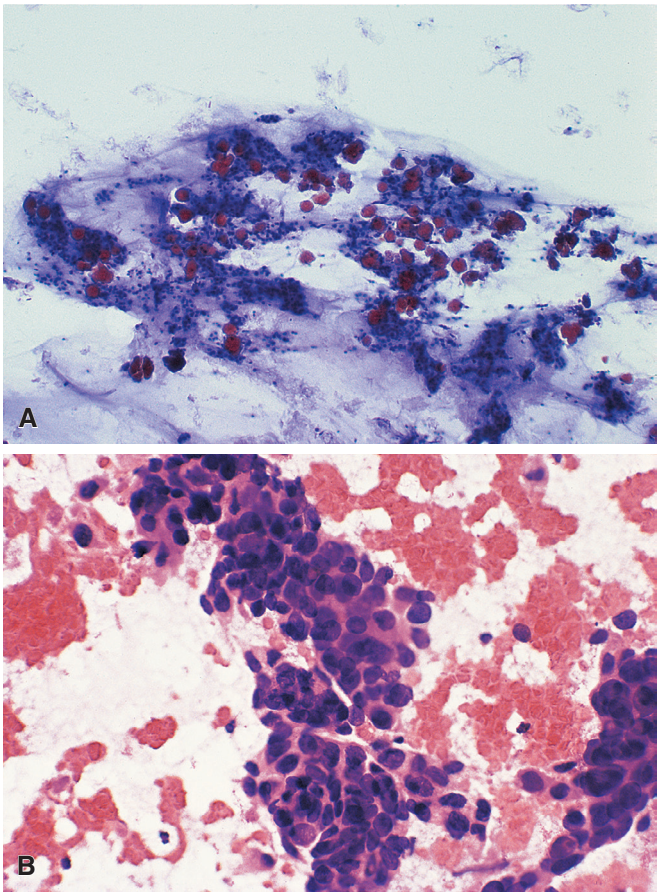

Figure 6.45 **A,** Fine-needle aspiration specimen from a benign mixed tumor of parotid. Clusters of benign-appearing epithelial cells are seen against a bluish myxoid matrix. Tyrosine-rich crystals are also present. **B,** Fine-needle aspiration of mucoepidermoid carcinoma of parotid gland. Most of the cells are of the so-called third cell type, and some exhibit focal squamous differentiation. (**A,** Courtesy of Dr. Maureen Zakowski, Memorial Sloan-Kettering Cancer Center.)

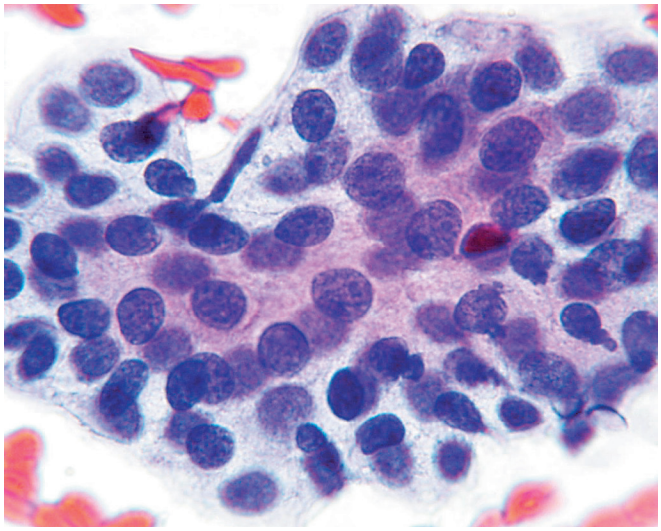

Figure 6.46 Typical appearance of adenoid cystic carcinoma on fine-needle aspiration. The nuclei are small and hyperchromatic. There is a pink amorphous basement membrane–like material, which corresponds to the "cylinders" seen in the histologic sections.

of oncocytes[510]; however, the subsequent microscopic evaluation of the case is not significantly compromised.[511]

Frozen Section

Intraoperative examination of salivary gland tumors is an accurate procedure that can help the surgeon determine the extent of the surgery needed, particularly for parotid neoplasms.[512,513] Obviously, the usefulness of this procedure depends on the expertise of the pathologist in providing accurate diagnoses and the wisdom of the surgeon in applying this information.[514]

Treatment

The extent of surgical treatment of parotid tumors is determined by their microscopic type, histologic grade, and the anatomic peculiarities of the parotid gland, particularly its intimate relationship with the facial nerve.[515,516]

Fortunately, most parotid pleomorphic adenomas arise from the superficial lobe, so a superficial or partial parotidectomy with preservation of the nerve can be performed; actually, the nerve can be preserved in selected cases even if the entire gland is removed.[517]

Most low-grade malignant tumors of mucoepidermoid or acinic cell type can be treated in a similar fashion. If the carcinoma is advanced and/or high grade, total parotidectomy with sacrifice of the facial nerve is usually necessary. If there is clinical evidence of nodal involvement, this procedure needs to be coupled with selective or radical neck dissection. Elective wide dissection should be considered in malignant tumors that are of high grade and/or larger than 4 cm.[518]

The surgical treatment of submandibular tumors, whether benign or malignant, is total removal of the gland. The recurrence rate of carcinomas of this particular gland is relatively high because of the close relation of the gland to the mandible.

Patients who develop postoperative recurrence of high-grade malignant salivary gland tumors do poorly; most have a relatively short survival, and subsequent treatment is effective in only one of four cases.

Radiation therapy has been used as the primary form of therapy in inoperable tumors and as a postoperative modality in cases selected on the basis of the microscopic features and surgical procedure.[519,520] There is evidence that this may result in a decrease in the incidence of local recurrence.[521–523]

Prognosis

The prognosis of salivary gland tumors is determined by the clinical staging, location, and microscopic features (Fig. 6.47).[524–527] Malignant tumors of the submandibular gland have a higher incidence of recurrence and metastases than parotid tumors of the same type.[528,529] For adenoid cystic carcinoma, the prognosis is best when located in the palate, intermediate when in the parotid gland, and worst in the submaxillary gland. For parotid malignant tumors, the presence of facial nerve paralysis is an ominous prognostic sign. In regard to microscopic types, the prognosis is best for the low-grade variants of mucoepidermoid and acinic cell carcinoma and worst for the high-grade variants of these tumors and for adenoid cystic carcinoma, malignant mixed tumor, salivary duct carcinoma, and squamous cell carcinoma. Additional prognostic parameters are discussed in connection with the respective tumor types.

Amplification of *HER2* oncogene[530] and p53 oncoprotein expression[531] have been claimed to correlate with aggressive behavior, but it is not clear that these parameters represent independent prognostic determinators.[142,532,533]

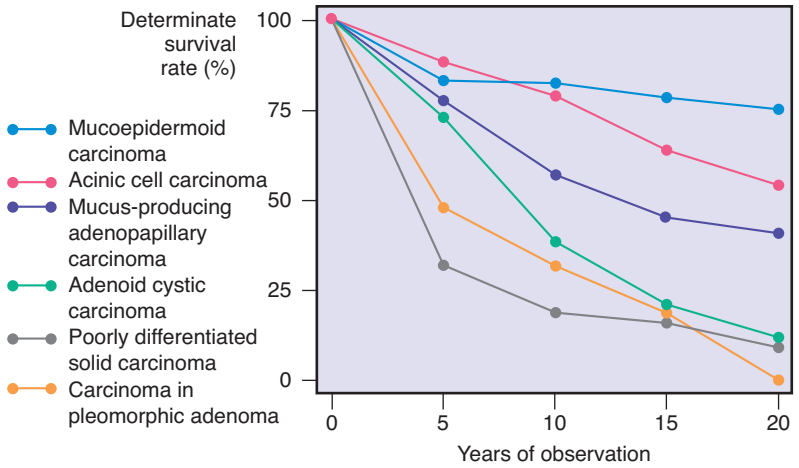

Figure 6.47 Survival rates in malignant salivary gland tumors. (From Eneroth CM, Hamberger CA. Principles of treatment of different types of parotid tumors. *Laryngoscope*. 1974;84:1732–1740.)

References

1. Conley J. *Salivary Glands and the Facial Nerve*. New York: Grune & Stratton; 1975.
2. Martínez-Madrigal F, Bosq J, Casiraghi O. Major salivary glands. In: Mills SE, ed. *Histology for Pathologists*. 3rd ed. Philadelphia: Lippincott Williams & Wilkins; 2007:445-469.
3. Dardick I, van Nostrand AW. Morphogenesis of salivary gland tumors. A prerequisite to improving classification. *Pathol Annu*. 1987;22(Pt 1):1-53.
4. Dardick I, Byard RW, Carnegie JA. A review of the proliferative capacity of major salivary glands and the relationship to current concepts of neoplasia in salivary glands. *Oral Surg Oral Med Oral Pathol*. 1990;69(1):53-67.
5. Weinreb I, Seethala RR, Hunt JL, et al. Intercalated duct lesions of salivary gland: a morphologic spectrum from hyperplasia to adenoma. *Am J Surg Pathol*. 2009;33(9):1322-1329.
6. Chenevert J, Duvvuri U, Chiosea S, et al. DOG1: a novel marker of salivary acinar and intercalated duct differentiation. *Mod Pathol*. 2012;25(7):919-929.
7. Cheuk W, Chan JK. Advances in salivary gland pathology. *Histopathology*. 2007;51(1): 1-20.
8. Seifert G. The pathology of the salivary gland immune system. Diseases and correlations with other organ systems. *Surg Pathol*. 1993;5:161-180.
9. Shinohara M, Harada T, Nakamura S, et al. Heterotopic salivary gland tissue in lymph nodes of the cervical region. *Int J Oral Maxillofac Surg*. 1992;21(3):166-171.
10. Carney JA. Salivary heterotopia, cysts, and the parathyroid gland: branchial pouch derivatives and remnants. *Am J Surg Pathol*. 2000;24(6):837-845.
11. Singer MI, Applebaum EL, Loy KD. Heterotopic salivary tissue in the neck. *Laryngoscope*. 1979;89(11): 1772-1778.
12. Luna M, Monheit J. Salivary gland neoplasms arising in lymph nodes. A clinicopathologic analysis of 13 cases [abstract]. *Lab Invest*. 1988;58:58A.
13. Raymond AK, Batsakis JG. Angiolithiasis and sialolithiasis in the head and neck. *Ann Otol Rhinol Laryngol*. 1992;101(5):455-457.
14. Husted E. Sialolithiasis. *Acta Chir Scand*. 1953;105(1-4):161-171.
15. Ho V, Currie WJ, Walker A. Sialolithiasis of minor salivary glands. *Br J Oral Maxillofac Surg*. 1992;30(4):273-275.
16. Blatt IM, Denning RM, Zumberge JH, Maxwell JH. Studies in sialolithiasis. I. The structure and mineralogical composition of salivary gland calculi. *Ann Otol Rhinol Laryngol*. 1958;67(3):595-617.
17. Bruneton JN, Mourou MY. Ultrasound in salivary gland disease. *ORL J Otorhinolaryngol Relat Spec*. 1993;55(5): 284-289.
18. Shinohara M, Oka M, Yamada K, et al. Immunohistochemical and electronmicroscopic studies of obstructive lesions in submandibular glands. *J Oral Pathol Med*. 1992;21(8):370-375.
19. Konigsberger R, Feyh J, Goetz A, Kastenbauer E. Endoscopically-controlled electrohydraulic intracorporeal shock wave lithotripsy (EISL) of salivary stones. *J Otolaryngol*. 1993;22(1):12-13.
20. Iro H, Zenk J, Escudier MP, et al. Outcome of minimally invasive management of salivary calculi in 4,691 patients. *Laryngoscope*. 2009;119(2):263-268.
21. Brook I. Diagnosis and management of parotitis. *Arch Otolaryngol Head Neck Surg*. 1992;118(5):469-471.
22. Harrison JD, Epivatianos A, Bhatia SN. Role of microliths in the aetiology of chronic submandibular sialadenitis: a clinicopathological investigation of 154 cases. *Histopathology*. 1997;31(3):237-251.
23. Kurashima C, Hirokawa K. Age-related increase of focal lymphocytic infiltration in the human submandibular glands. *J Oral Pathol*. 1986;15(3):172-178.
24. Seifert G. Aetiological and histological classification of sialadenitis. *Pathologica*. 1997;89(1):7-17.
25. Astrom AK, Voz ML, Kas K, et al. Conserved mechanism of PLAG1 activation in salivary gland tumors with and without chromosome 8q12 abnormalities: identification of SII as a new fusion partner gene. *Cancer Res*. 1999;59(4):918-923.
26. Seifert G. Tumour-like lesions of the salivary glands. The new WHO classification. *Pathol Res Pract*. 1992;188(7):836-846.
27. Geyer JT, Ferry JA, Harris NL, et al. Chronic sclerosing sialadenitis (Kuttner tumor) is an IgG4-associated disease. *Am J Surg Pathol*. 2010;34(2):202-210.
28. Kitagawa S, Zen Y, Harada K, et al. Abundant IgG4-positive plasma cell infiltration characterizes chronic sclerosing sialadenitis (Kuttner's tumor). *Am J Surg Pathol*. 2005;29(6):783-791.
29. Kojima M, Nakamura S, Itoh H, et al. Kuttner's tumor of salivary glands resembling marginal zone B-cell lymphoma of the MALT type: a histopathologic and immunohistochemical study of 7 cases. *Int J Surg Pathol*. 2004;12(4):389-393.
30. O'Brien CJ, Murrant NJ. Surgical management of chronic parotitis. *Head Neck*. 1993;15(5):445-449.
31. Batsakis JG. Sclerosing polycystic adenosis: newly recognized salivary gland lesion—a form of chronic sialadenitis? *Adv Anat Pathol*. 1996;3:298-304.
32. Smith BC, Ellis GL, Slater LJ, Foss RD. Sclerosing polycystic adenosis of major salivary glands. A clinicopathologic analysis of nine cases. *Am J Surg Pathol*. 1996;20(2):161-170.
33. Gnepp DR, Wang LJ, Brandwein-Gensler M, et al. Sclerosing polycystic adenosis of the salivary gland: a report of 16 cases. *Am J Surg Pathol*. 2006;30(2):154-164.
34. Skalova A, Michal M, Simpson RH, et al. Sclerosing polycystic adenosis of parotid gland with dysplasia and ductal carcinoma in situ. Report of three cases with immunohistochemical and ultrastructural examination. *Virchows Arch*. 2002;440(1):29-35.
35. Skalova A, Gnepp DR, Simpson RH, et al. Clonal nature of sclerosing polycystic adenosis of salivary glands demonstrated by using the polymorphism of the human androgen receptor (HUMARA) locus as a marker. *Am J Surg Pathol*. 2006;30(8):939-944.
36. van der Walt JD, Leake J. Granulomatous sialadenitis of the major salivary glands. A clinicopathological study of 57 cases. *Histopathology*. 1987;11(2):131-144.
37. Padfield CJ, Choyce MQ, Eveson JW. Xanthogranulomatous sialadenitis. *Histopathology*. 1993;23(5):488-491.
38. Gao Y, Chen Y, Yu GY. Clinicopathologic study of parotid involvement in 21 cases of eosinophilic hyperplastic lymphogranuloma

(Kimura's disease). *Oral Surg Oral Med Oral Pathol Oral Radiol Endod*. 2006;102(5):651-658.
39. Pieterse AS, Seymour AE. Parotid cysts. An analysis of 16 cases and suggested classification. *Pathology*. 1981;13(2):225-234.
40. Wu L, Cheng J, Maruyama S, et al. Lymphoepithelial cyst of the parotid gland: its possible histopathogenesis based on clinicopathologic analysis of 64 cases. *Hum Pathol*. 2009;40(5):683-692.
41. Elliott JN, Oertel YC. Lymphoepithelial cysts of the salivary glands. Histologic and cytologic features. *Am J Clin Pathol*. 1990;93(1):39-43.
42. Suster S, Rosai J. Multilocular thymic cyst: an acquired reactive process. Study of 18 cases. *Am J Surg Pathol*. 1991;15(4):388-398.
43. Finfer MD, Schinella RA, Chiriboga LA, et al. Cystic lesions of the parotid gland in patients at risk for AIDS. An immunohistochemical study. *Surg Pathol*. 1991;4:35-45.
44. Schiodt M. HIV-associated salivary gland disease: a review. *Oral Surg Oral Med Oral Pathol*. 1992;73(2):164-167.
45. Maiorano E, Favia G, Viale G. Lymphoepithelial cysts of salivary glands: an immunohistochemical study of HIV-related and HIV-unrelated lesions. *Hum Pathol*. 1998;29(3):260-265.
46. Ihrler S, Zietz C, Riederer A, et al. HIV-related parotid lymphoepithelial cysts. Immunohistochemistry and 3-D reconstruction of surgical and autopsy material with special reference to formal pathogenesis. *Virchows Arch*. 1996;429:139-148.
47. Labouyrie E, Merlio JP, Beylot-Barry M, et al. Human immunodeficiency virus type 1 replication within cystic lymphoepithelial lesion of the salivary gland. *Am J Clin Pathol*. 1993;100(1):41-46.
48. Seifert G, Thomsen S, Donath K. Bilateral dysgenetic polycystic parotid glands. Morphological analysis and differential diagnosis of a rare disease of the salivary glands. *Virchows Arch A Pathol Anat Histol*. 1981;390(3):273-288.
49. Smyth AG, Ward-Booth RP, High AS. Polycystic disease of the parotid glands: two familial cases. *Br J Oral Maxillofac Surg*. 1993;31(1):38-40.
50. Morgan WS, Castleman B. A clinicopathologic study of Mikulicz's disease. *Am J Pathol*. 1953;29(3):471-503.
51. Hsi ED, Siddiqui J, Schnitzer B, et al. Analysis of immunoglobulin heavy chain gene rearrangement in myoepithelial sialadenitis by polymerase chain reaction. *Am J Clin Pathol*. 1996;106(4):498-503.
52. Palmer RM, Eveson JW, Gusterson BA. Epimyoepithelial' islands in lymphoepithelial lesions. An immunocytochemical study. *Virchows Arch A Pathol Anat Histopathol*. 1986;408(6):603-609.
53. Caselitz J, Osborn M, Wustrow J, et al. Immunohistochemical investigations on the epimyoepithelial islands in lymphoepithelial lesions. Use of monoclonal keratin antibodies. *Lab Invest*. 1986;55(4):427-432.
54. Chaudhry AP, Cutler LS, Yamane GM, et al. Light and ultrastructural features of lymphoepithelial lesions of the salivary glands in Mikulicz's disease. *J Pathol*. 1986;148(3):239-250.
55. Ihrler S, Zietz C, Sendelhofert A, et al. Lymphoepithelial duct lesions in Sjogren-type sialadenitis. *Virchows Arch*. 1999;434(4):315-323.
56. Fox RI, Kang HI. Pathogenesis of Sjogren's syndrome. *Rheum Dis Clin North Am*. 1992;18(3):517-538.
57. Bodeutsch C, de Wilde PC, Kater L, et al. Quantitative immunohistologic criteria are superior to the lymphocytic focus score criterion for the diagnosis of Sjogren's syndrome. *Arthritis Rheum*. 1992;35(9):1075-1087.
58. Constantopoulos SH, Tsianos EV, Moutsopoulos HM. Pulmonary and gastrointestinal manifestations of Sjogren's syndrome. *Rheum Dis Clin North Am*. 1992;18(3):617-635.
59. Scott CA, Avellini C, Desinan L, et al. Chronic lymphocytic sialoadenitis in HCV-related chronic liver disease: comparison of Sjogren's syndrome. *Histopathology*. 1997;30(1):41-48.
60. Fishleder A, Tubbs R, Hesse B, Levine H. Uniform detection of immunoglobulin-gene rearrangement in benign lymphoepithelial lesions. *N Engl J Med*. 1987;316(18): 1118-1121.
61. Lasota J, Miettinen MM. Coexistence of different B-cell clones in consecutive lesions of low-grade MALT lymphoma of the salivary gland in Sjogren's disease. *Mod Pathol*. 1997;10(9):872-878.
62. McCurley TL, Collins RD, Ball E, Collins RD. Nodal and extranodal lymphoproliferative disorders in Sjogren's syndrome: a clinical and immunopathologic study. *Hum Pathol*. 1990;21(5):482-492.
63. Anderson LG, Talal N. The spectrum of benign to malignant lymphoproliferation in Sjogren's syndrome. *Clin Exp Immunol*. 1972;10(2):199-221.
64. Chevalier X, Gaulard P, Voisin MC, et al. Peripheral T cell lymphoma with Sjogren's syndrome: a report with immunologic and genotypic studies. *J Rheumatol*. 1991;18(11):1744-1746.
65. Schmid U, Helbron D, Lennert K. Development of malignant lymphoma in myoepithelial sialadenitis (Sjogren's syndrome). *Virchows Arch A Pathol Anat Histol*. 1982;395(1):11-43.
66. Vivancos J, Bosch X, Grau JM, et al. Development of Hodgkin's disease in the course of primary Sjogren's syndrome. *Br J Rheumatol*. 1992;31(8):561-563.
67. Diss TC, Wotherspoon AC, Speight P, et al. B-cell monoclonality, Epstein Barr virus, and t(14;18) in myoepithelial sialadenitis and low-grade B-cell MALT lymphoma of the parotid gland. *Am J Surg Pathol*. 1995;19(5):531-536.
68. Falzon M, Isaacson PG. The natural history of benign lymphoepithelial lesion of the salivary gland in which there is a monoclonal population of B cells. A report of two cases. *Am J Surg Pathol*. 1991;15(1):59-65.
69. Zulman J, Jaffe R, Talal N. Evidence that the malignant lymphoma of Sjogren's syndrome is a monoclonal B-cell neoplasm. *N Engl J Med*. 1978;299(22):1215-1220.
70. Harris NL. Lymphoid proliferations of the salivary glands. *Am J Clin Pathol*. 1999;111(1 suppl 1):S94-S103.
71. Quintana PG, Kapadia SB, Bahler DW, et al. Salivary gland lymphoid infiltrates associated with lymphoepithelial lesions: a clinicopathologic, immunophenotypic, and genotypic study. *Hum Pathol*. 1997;28(7):850-861.
72. Myssiorek D, Alvi A, Bhuiya T. Primary salivary gland amyloidosis causing sicca syndrome. *Ann Otol Rhinol Laryngol*. 1992;101(6):487-490.
73. Fischer JR, Abdul-Karim FW, Robinson RA. Intraparotid nodular fasciitis. *Arch Pathol Lab Med*. 1989;113(11):1276-1278.
74. Williams SB, Foss RD, Ellis GL. Inflammatory pseudotumors of the major salivary glands. Clinicopathologic and immunohistochemical analysis of six cases. *Am J Surg Pathol*. 1992;16(9):896-902.
75. Foucar E, Rosai J, Dorfman R. Sinus histiocytosis with massive lymphadenopathy (Rosai-Dorfman disease): review of the entity. *Semin Diagn Pathol*. 1990;7(1):19-73.
76. Arafat A, Brannon RB, Ellis GL. Adenomatoid hyperplasia of mucous salivary glands. *Oral Surg Oral Med Oral Pathol*. 1981;52(1):51-55.
77. Seifert G, Brocheriou C, Cardesa A, Eveson JW. WHO international histological classification of tumours. Tentative histological classification of salivary gland tumours. *Pathol Res Pract*. 1990;186(5):555-581.
78. Seifert G, Sobin LH. The World Health Organization's histological classification of salivary gland tumors. A commentary on the second edition. *Cancer*. 1992;70(2):379-385.
79. Simpson RH. Classification of tumours of the salivary glands. *Histopathology*. 1994;24(2):187-191.
80. Krolls SO, Trodahl JN, Boyers RC. Salivary gland lesions in children. A survey of 430 cases. *Cancer*. 1972;30(2):459-469.
81. Chu W, Strawitz JG. Parapharyngeal growth of parotid tumors: report of two cases. *Arch Surg*. 1977;112(6):709-711.
82. Dardick I, van Nostrand AW, Phillips MJ. Histogenesis of salivary gland pleomorphic adenoma (mixed tumor) with an evaluation of the role of the myoepithelial cell. *Hum Pathol*. 1982;13(1):62-75.
83. Lomax-Smith JD, Azzopardi JG. The hyaline cell: a distinctive feature of "mixed" salivary tumours. *Histopathology*. 1978;2(2):77-92.
84. David R, Buchner A. Elastosis in benign and malignant salivary gland tumors. A histochemical and ultrastructural study. *Cancer*. 1980;45(9):2301-2310.
85. Haskell HD, Butt KM, Woo SB. Pleomorphic adenoma with extensive lipometaplasia: report of three cases. *Am J Surg Pathol*. 2005;29(10):1389-1393.
86. Debiec-Rychter M, Van Valckenborgh I, Van den Broeck C, et al. Histologic localization of PLAG1 (pleomorphic adenoma gene 1) in pleomorphic adenoma of the salivary gland: cytogenetic evidence of common origin of phenotypically diverse cells. *Lab Invest*. 2001;81(9):1289-1297.
87. Lee PS, Sabbath-Solitare M, Redondo TC, Ongcapin EH. Molecular evidence that the stromal and epithelial cells in pleomorphic adenomas of salivary gland arise from the same origin: clonal analysis using human androgen receptor gene (HUMARA) assay. *Hum Pathol*. 2000;31(4):498-503.
88. Noguchi S, Aihara T, Yoshino K, et al. Demonstration of monoclonal origin of human parotid gland pleomorphic adenoma. *Cancer*. 1996;77(3):431-435.
89. Erlandson RA, Cardon-Cardo C, Higgins PJ. Histogenesis of benign pleomorphic adenoma (mixed tumor) of the major salivary glands. An ultrastructural and immunohistochemical study. *Am J Surg Pathol*. 1984;8(11):803-820.
90. Dardick I, Van Nostrand AW, Jeans MT, et al. Pleomorphic adenoma, II: ultrastructural organization of "stromal" regions. *Hum Pathol*. 1983;14(9):798-809.
91. Lam RM. An electron microscopic histochemical study of the histogenesis of major salivary gland pleomorphic adenoma. *Ultrastruct Pathol*. 1985;8(2-3):207-223.
92. Mills SE, Cooper PH. An ultrastructural study of cartilaginous zones and surrounding epithelium in mixed tumors of salivary glands and skin. *Lab Invest*. 1981;44(1):6-12.
93. Schmidt LA, Olsen SH, McHugh JB. Cutaneous adnexal differentiation and stromal metaplasia in palate pleomorphic adenomas: a potential diagnostic pitfall that may be mistaken for malignancy. *Am J Surg Pathol*. 2010;34(8):1205-1210.
94. Chaplin AJ, Darke P, Patel S. Tyrosine-rich crystals in pleomorphic adenomas of parotid glands. *J Oral Pathol*. 1983;12(5):342-346.
95. Harris BR, Shipkey F. Tyrosine-rich crystalloids in neoplasms and tissues of the head and

neck. *Arch Pathol Lab Med*. 1986;110(8):709-712.
96. Skalova A, Leivo I, Michal M, Saksela E. Analysis of collagen isotypes in crystalloid structures of salivary gland tumors. *Hum Pathol*. 1992;23(7):748-754.
97. Humphrey PA, Ingram P, Tucker A, Shelburne JD. Crystalloids in salivary gland pleomorphic adenomas. *Arch Pathol Lab Med*. 1989;113(4):390-393.
98. Takeda Y, Satoh M, Nakamura S. Pigmented pleomorphic adenoma, a novel melanin-pigmented benign salivary gland tumor. *Virchows Arch*. 2004;445(2):199-202.
99. Thunnissen FB, Peterse JL, Buchholtz R, et al. Polyploidy in pleomorphic adenomas with cytological atypia. *Cytopathology*. 1992;3(2):101-109.
100. Ogawa Y, Toyosawa S, Ishida T, Ijuhin N. Keratin 14 immunoreactive cells in pleomorphic adenomas and adenoid cystic carcinomas of salivary glands. *Virchows Arch*. 2000;437(1):58-68.
101. Dardick I, Ostrynski VL, Ekem JK, et al. Immunohistochemical and ultrastructural correlates of muscle-actin expression in pleomorphic adenomas and myoepitheliomas based on comparison of formalin and methanol fixation. *Virchows Arch A Pathol Anat Histopathol*. 1992;421(2):95-104.
102. Luo M, Takagi H, Tsubone M, et al. Fibronectin expression in salivary gland pleomorphic adenoma. *Arch Anat Cytol Pathol*. 1993;41(2):68-74.
103. Palmer RM, Lucas RB, Knight J, Gusterson B. Immunocytochemical identification of cell types in pleomorphic adenoma, with particular reference to myoepithelial cells. *J Pathol*. 1985;146(3):213-220.
104. Savera AT, Gown AM, Zarbo RJ. Immunolocalization of three novel smooth muscle-specific proteins in salivary gland pleomorphic adenoma: assessment of the morphogenetic role of myoepithelium. *Mod Pathol*. 1997;10(11):1093-1100.
105. Takai Y, Mori M, Dardick I, et al. Myofilament localization and immunoelectron microscopic detection of muscle-specific actin in neoplastic myoepithelial cells in pleomorphic adenomas and myoepitheliomas. *Ultrastruct Pathol*. 1994;18:575-592.
106. Zarbo RJ, Bacchi CE, Gown AM. Muscle-specific protein expression in normal salivary glands and pleomorphic adenomas: an immunocytochemical study with biochemical confirmation. *Mod Pathol*. 1991;4(5):621-626.
107. Nakazato Y, Ishizeki J, Takahashi K, et al. Localization of S-100 protein and glial fibrillary acidic protein-related antigen in pleomorphic adenoma of the salivary glands. *Lab Invest*. 1982;46(6):621-626.
108. Stead RH, Qizilbash AH, Kontozoglou T, et al. An immunohistochemical study of pleomorphic adenomas of the salivary gland: glial fibrillary acidic protein-like immunoreactivity identifies a major myoepithelial component. *Hum Pathol*. 1988;19(1):32-40.
109. Anderson C, Knibbs DR, Abbott SJ, et al. Glial fibrillary acidic protein expression in pleomorphic adenoma of salivary gland: an immunoelectron microscopic study. *Ultrastruct Pathol*. 1990;14(3):263-271.
110. Nishimura T, Furukawa M, Kawahara E, Miwa A. Differential diagnosis of pleomorphic adenoma by immunohistochemical means. *J Laryngol Otol*. 1991;105(12):1057-1060.
111. Bullerdiek J, Wobst G, Meyer-Bolte K, et al. Cytogenetic subtyping of 220 salivary gland pleomorphic adenomas: correlation to occurrence, histological subtype, and in vitro cellular behavior. *Cancer Genet Cytogenet*. 1993;65(1):27-31.
112. Stenman G, Sahlin P, Mark J, Landys D. Structural alterations of the c-mos locus in benign pleomorphic adenomas with chromosome abnormalities of 8q12. *Oncogene*. 1991;6(7):1105-1108.
113. Asp J, Persson F, Kost-Alimova M, Stenman G. CHCHD7-PLAG1 and TCEA1-PLAG1 gene fusions resulting from cryptic, intrachromosomal 8q rearrangements in pleomorphic salivary gland adenomas. *Genes Chromosomes Cancer*. 2006;45(9):820-828.
114. Voz ML, Agten NS, Van de Ven WJ, Kas K. PLAG1, the main translocation target in pleomorphic adenoma of the salivary glands, is a positive regulator of IGF-II. *Cancer Res*. 2000;60(1):106-113.
115. Voz ML, Astrom AK, Kas K, et al. The recurrent translocation t(5;8)(p13;q12) in pleomorphic adenomas results in upregulation of PLAG1 gene expression under control of the LIFR promoter. *Oncogene*. 1998;16(11):1409-1416.
116. Geurts JM, Schoenmakers EF, Roijer E, et al. Identification of NFIB as recurrent translocation partner gene of HMGIC in pleomorphic adenomas. *Oncogene*. 1998;16(7):865-872.
117. Geurts JM, Schoenmakers EF, Roijer E, et al. Expression of reciprocal hybrid transcripts of HMGIC and FHIT in a pleomorphic adenoma of the parotid gland. *Cancer Res*. 1997;57(1):13-17.
118. Deguchi H, Hamano H, Hayashi Y. c-myc, ras p21 and p53 expression in pleomorphic adenoma and its malignant form of the human salivary glands. *Acta Pathol Jpn*. 1993;43(7-8):413-422.
119. Patey DH, Thackray AC. The treatment of parotid tumours in the light of a pathological study of parotidectomy material. *Br J Surg*. 1958;45(193):477-487.
120. Henriksson G, Westrin KM, Carlsoo B, Silfversward C. Recurrent primary pleomorphic adenomas of salivary gland origin: intrasurgical rupture, histopathologic features, and pseudopodia. *Cancer*. 1998;82(4):617-620.
121. Mallett KJ, Harrison MS. The recurrence of salivary gland tumours. *J Laryngol Otol*. 1971;85(5):439-448.
122. Barton J, Slevin NJ, Gleave EN. Radiotherapy for pleomorphic adenoma of the parotid gland. *Int J Radiat Oncol Biol Phys*. 1992;22(5):925-928.
123. Maran AG, Mackenzie IJ, Stanley RE. Recurrent pleomorphic adenomas of the parotid gland. *Arch Otolaryngol*. 1984;110(3):167-171.
124. Chen KT. Metastasizing pleomorphic adenoma of the salivary gland. *Cancer*. 1978;42(5):2407-2411.
125. Cresson DH, Goldsmith M, Askin FB, et al. Metastasizing pleomorphic adenoma with myoepithelial cell predominance. *Pathol Res Pract*. 1990;186(6):795-800, discussion 1–2.
126. Sampson BA, Jarcho JA, Winters GL. Metastasizing mixed tumor of the parotid gland: a rare tumor with unusually rapid progression in a cardiac transplant recipient. *Mod Pathol*. 1998;11(11):1142-1145.
127. Wenig BM, Hitchcock CL, Ellis GL, Gnepp DR. Metastasizing mixed tumor of salivary glands. A clinicopathologic and flow cytometric analysis. *Am J Surg Pathol*. 1992;16(9):845-858.
128. Czader M, Eberhart CG, Bhatti N, et al. Metastasizing mixed tumor of the parotid: initial presentation as a solitary kidney tumor and ultimate carcinomatous transformation at the primary site. *Am J Surg Pathol*. 2000;24(8):1159-1164.
129. LiVolsi VA, Perzin KH. Malignant mixed tumors arising in salivary glands. I. Carcinomas arising in benign mixed tumors: a clinicopathologic study. *Cancer*. 1977;39(5):2209-2230.
130. Tortoledo ME, Luna MA, Batsakis JG. Carcinomas ex pleomorphic adenoma and malignant mixed tumors. Histomorphologic indexes. *Arch Otolaryngol*. 1984;110(3):172-176.
131. Nagao K, Matsuzaki O, Saiga H, et al. Histopathologic studies on carcinoma in pleomorphic adenoma of the parotid gland. *Cancer*. 1981;48(1):113-121.
132. Gnepp DR. Malignant mixed tumors of the salivary glands: a review. *Pathol Annu*. 1993;28(Pt 1):279-328.
133. Spiro RH, Huvos AG, Strong EW. Malignant mixed tumor of salivary origin: a clinicopathologic study of 146 cases. *Cancer*. 1977;39(2):388-396.
134. Auclair PL, Ellis GL. Atypical features in salivary gland mixed tumors: their relationship to malignant transformation. *Mod Pathol*. 1996;9(6):652-657.
135. Lewis JE, Olsen KD, Sebo TJ. Carcinoma ex pleomorphic adenoma: pathologic analysis of 73 cases. *Hum Pathol*. 2001;32(6):596-604.
136. Ihrler S, Weiler C, Hirschmann A, et al. Intraductal carcinoma is the precursor of carcinoma ex pleomorphic adenoma and is often associated with dysfunctional p53. *Histopathology*. 2007;51(3):362-371.
137. Altemani A, Martins MT, Freitas L, et al. Carcinoma ex pleomorphic adenoma (CXPA): immunoprofile of the cells involved in carcinomatous progression. *Histopathology*. 2005;46(6):635-641.
138. Di Palma S, Skalova A, Vanieek T, et al. Non-invasive (intracapsular) carcinoma ex pleomorphic adenoma: recognition of focal carcinoma by HER-2/neu and MIB1 immunohistochemistry. *Histopathology*. 2005;46(2):144-152.
139. Rosa JC, Fonseca I, Felix A, Soares J. Immunohistochemical study of c-erbB-2 expression in carcinoma ex-pleomorphic adenoma. *Histopathology*. 1996;28(3): 247-252.
140. Yamamoto Y, Kishimoto Y, Wistuba II, et al. DNA analysis at p53 locus in carcinomas arising from pleomorphic adenomas of salivary glands: comparison of molecular study and p53 immunostaining. *Pathol Int*. 1998;48(4):265-272.
141. DeRoche TC, Hoschar AP, Hunt JL. Immunohistochemical evaluation of androgen receptor, HER-2/neu, and p53 in benign pleomorphic adenomas. *Arch Pathol Lab Med*. 2008;132(12):1907-1911.
142. Muller S, Vigneswaran N, Gansler T, et al. c-erbB-2 oncoprotein expression and amplification in pleomorphic adenoma and carcinoma ex pleomorphic adenoma: relationship to prognosis. *Mod Pathol*. 1994;7(6):628-632.
143. Nordkvist A, Roijer E, Bang G, et al. Expression and mutation patterns of p53 in benign and malignant salivary gland tumors. *Int J Oncol*. 2000;16(3):477-483.
144. Roijer E, Nordkvist A, Strom AK, et al. Translocation, deletion/amplification, and expression of HMGIC and MDM2 in a carcinoma ex pleomorphic adenoma. *Am J Pathol*. 2002;160(2):433-440.
145. Xin W, Paulino AF. Prognostic factors in malignant mixed tumors of the salivary gland: correlation of immunohistochemical markers with histologic classification. *Ann Diagn Pathol*. 2002;6(4):205-210.
146. Thomas WH, Coppola ED. Distant metastases from mixed tumors of the salivary glands. *Am J Surg*. 1965;109:724-730.
147. Bleiweiss IJ, Huvos AG, Lara J, Strong EW. Carcinosarcoma of the submandibular salivary gland. Immunohistochemical findings. *Cancer*. 1992;69(8):2031-2035.
148. Stephen J, Batsakis JG, Luna MA, et al. True malignant mixed tumors (carcinosarcoma) of

salivary glands. *Oral Surg Oral Med Oral Pathol*. 1986;61(6):597-602.
149. Yamashita T, Kameda N, Katayama K, et al. True malignant mixed tumor of the submandibular gland. *Acta Pathol Jpn*. 1990;40(2):137-142.
150. Chang A, Harawi SJ. Oncocytes, oncocytosis, and oncocytic tumors. *Pathol Annu*. 1992;27(Pt 1):263-304.
151. Muller-Hocker J. Random cytochrome-C-oxidase deficiency of oxyphil cell nodules in the parathyroid gland. A mitochondrial cytopathy related to cell ageing? *Pathol Res Pract*. 1992;188(6):701-706.
152. Chaushu G, Buchner A, David R. Multiple oncocytic cysts with tyrosine-crystalloids in the parotid gland. *Hum Pathol*. 1999;30(2):237-239.
153. Schwartz IS, Feldman M. Diffuse multinodular oncocytoma ("oncocytosis") of the parotid gland. *Cancer*. 1969;23(3):636-640.
154. Ghandur-Mnaymneh L. Multinodular oncocytoma of the parotid gland: a benign lesion simulating malignancy. *Hum Pathol*. 1984;15(5):485-486.
155. Palmer TJ, Gleeson MJ, Eveson JW, Cawson RA. Oncocytic adenomas and oncocytic hyperplasia of salivary glands: a clinicopathological study of 26 cases. *Histopathology*. 1990;16(5):487-493.
156. Sorensen M, Baunsgaard P, Frederiksen P, Haahr PA. Multifocal adenomatous oncocytic hyperplasia of the parotid gland (unusual clear cell variant in two female siblings. *Pathol Res Pract*. 1986;181(2):254-259.
157. Paulino AF, Huvos AG. Oncocytic and oncocytoid tumors of the salivary glands. *Semin Diagn Pathol*. 1999;16(2):98-104.
158. Tallini G. Oncocytic tumours. *Virchows Arch*. 1998;433(1):5-12.
159. Hamperl H. Benign and malignant oncocytoma. *Cancer*. 1962;15:1019-1027.
160. Thompson LD, Wenig BM, Ellis GL. Oncocytomas of the submandibular gland. A series of 22 cases and a review of the literature. *Cancer*. 1996;78(11):2281-2287.
161. Brandwein MS, Huvos AG. Oncocytic tumors of major salivary glands. A study of 68 cases with follow-up of 44 patients. *Am J Surg Pathol*. 1991;15(6):514-528.
162. Feiner HD, Goldstein S, Ittman M, et al. Oncocytic adenoma of the parotid gland with psammoma bodies. *Arch Pathol Lab Med*. 1986;110(7):640-644.
163. Gilcrease MZ, Nelson FS, Guzman-Paz M. Tyrosine-rich crystals associated with oncocytic salivary gland neoplasms. *Arch Pathol Lab Med*. 1998;122(7):644-649.
164. Gray SR, Cornog JL Jr, Seo IS. Oncocytic neoplasms of salivary glands: a report of fifteen cases including two malignant oncocytomas. *Cancer*. 1976;38(3):1306-1317.
165. McHugh JB, Hoschar AP, Dvorakova M, et al. p63 immunohistochemistry differentiates salivary gland oncocytoma and oncocytic carcinoma from metastatic renal cell carcinoma. *Head Neck Pathol*. 2007;1(2):123-131.
166. Eveson JW, Cawson RA. Warthin's tumor (cystadenolymphoma) of salivary glands. A clinicopathologic investigation of 278 cases. *Oral Surg Oral Med Oral Pathol*. 1986;61(3):256-262.
167. Kotwall CA. Smoking as an etiologic factor in the development of Warthin's tumor of the parotid gland. *Am J Surg*. 1992;164(6):646-647.
168. Monk JS Jr, Church JS. Warthin's tumor. A high incidence and no sex predominance in central Pennsylvania. *Arch Otolaryngol Head Neck Surg*. 1992;118(5):477-478.
169. Turnbull AD, Frazell EL. Multiple tumors of the major salivary glands. *Am J Surg*. 1969;118(5):787-789.
170. Di Palma S, Simpson RH, Skalova A, Michal M. Metaplastic (infarcted) Warthin's tumour of the parotid gland: a possible consequence of fine needle aspiration biopsy. *Histopathology*. 1999;35(5):432-438.
171. Thompson AS, Bryant HC Jr. Histogenesis of papillary cystadenoma lymphomatosum (Warthin's tumor) of the parotid salivary gland. *Am J Pathol*. 1950;26(5):807-849.
172. Cossman J, Deegan MJ, Batsakis JG. Warthin tumor. B-lymphocytes within the lymphoid infiltrate. *Arch Pathol Lab Med*. 1977;101(7):354-356.
173. Yamamoto H, Caselitz J, Seifert G. Cystadenolymphoma: an immunohistochemical study with special reference to Ig E and mastcells. *Pathol Res Pract*. 1985;180(4):364-368.
174. Hsu S-M, Raine L. Warthin's tumor. Epithelial cell differences. *Am J Clin Pathol*. 1982;77:78-81.
175. Orito T, Shinohara H, Okada Y, Mori M. Heterogeneity of keratin expression in epithelial tumor cells of adenolymphoma in paraffin sections. *Pathol Res Pract*. 1989;184(6):600-608.
176. Shintaku M, Honda T. Identification of oncocytic lesions of salivary glands by anti-mitochondrial immunohistochemistry. *Histopathology*. 1997;31(5):408-411.
177. Schwerer MJ, Kraft K, Baczako K, Maier H. Cytokeratin expression and epithelial differentiation in Warthin's tumour and its metaplastic (infarcted) variant. *Histopathology*. 2001;39(4):347-352.
178. Dreyer T, Battmann A, Silberzahn J, et al. Unusual differentiation of a combination tumor of the parotid gland. A case report. *Pathol Res Pract*. 1993;189(5):577-581, discussion 81–85.
179. Gnepp DR. Warthin tumor exhibiting sebaceous differentiation and necrotizing sialometaplasia. *Virchows Arch A Pathol Anat Histol*. 1981;391(3):267-273.
180. Gustafsson H, Kjorell U, Carlsoo B. Cytoskeletal proteins in oncocytic tumors of the parotid gland. *Arch Otolaryngol*. 1985;111(2):99-105.
181. Taxy JB. Necrotizing squamous/mucinous metaplasia in oncocytic salivary gland tumors. A potential diagnostic problem. *Am J Clin Pathol*. 1992;97(1):40-45.
182. Donath K, Seifert G. Tumour-simulating squamous cell metaplasia (SCM) in necrotic areas of salivary gland tumours. *Pathol Res Pract*. 1997;193(10):689-693.
183. Banik S, Howell JS, Wright DH. Non-Hodgkin's lymphoma arising in adenolymphoma – a report of two cases. *J Pathol*. 1985;146(3):167-177.
184. Bunker ML, Locker J. Warthin's tumor with malignant lymphoma. DNA analysis of paraffin-embedded tissue. *Am J Clin Pathol*. 1989;91(3):341-344.
185. Shikhani AH, Shikhani LT, Kuhajda FP, Allam CK. Warthin's tumor-associated neoplasms: report of two cases and review of the literature. *Ear Nose Throat J*. 1993;72(4):264-269, 72–73.
186. Bell D, Luna MA. Warthin adenocarcinoma: analysis of 2 cases of a distinct salivary neoplasm. *Ann Diagn Pathol*. 2009;13(3):201-207.
187. Bengoechea O, Sanchez F, Larrinaga B, Martinez-Penuela JM. Oncocytic adenocarcinoma arising in Warthin's tumor. *Pathol Res Pract*. 1989;185(6):907-911, discussion 11–14.
188. Damjanov I, Sneff EM, Delerme AN. Squamous cell carcinoma arising in Warthin's tumor of the parotid gland. A light, electron microscopic, and immunohistochemical study. *Oral Surg Oral Med Oral Pathol*. 1983;55(3):286-290.
189. Nagao T, Sugano I, Ishida Y, et al. Mucoepidermoid carcinoma arising in Warthin's tumour of the parotid gland: report of two cases with histopathological, ultrastructural and immunohistochemical studies. *Histopathology*. 1998;33(4):379-386.
190. Williamson JD, Simmons BH, el-Naggar A, Medeiros LJ. Mucoepidermoid carcinoma involving Warthin tumor. A report of five cases and review of the literature. *Am J Clin Pathol*. 2000;114(4):564-570.
191. Cope W, Naugler CT, Vyas T, Bullock MJ. Prevalence of salivary ductal inclusions in parotid lymph nodes of patients with Warthin tumor. *Lab Invest*. 2009;89(suppl 1):247A.
192. Honda K, Kashima K, Daa T, et al. Clonal analysis of the epithelial component of Warthin's tumor. *Hum Pathol*. 2000;31(11):1377-1380.
193. Cho KJ, Kim YI. Monomorphic adenomas of the salivary glands. A clinico-pathologic study of 12 cases with immunohistochemical observation. *Pathol Res Pract*. 1989;184(6):614-620.
194. Mintz GA, Abrams AM, Melrose RJ. Monomorphic adenomas of the major and minor salivary glands. Report of twenty-one cases and review of the literature. *Oral Surg Oral Med Oral Pathol*. 1982;53(4):375-386.
195. Gardner DG, Daley TD. The use of the terms monomorphic adenoma, basal cell adenoma, and canalicular adenoma as applied to salivary gland tumors. *Oral Surg Oral Med Oral Pathol*. 1983;56(6):608-615.
196. Batsakis JG, Brannon RB, Sciubba JJ. Monomorphic adenomas of major salivary glands: a histologic study of 96 tumours. *Clin Otolaryngol Allied Sci*. 1981;6(2):129-143.
197. Luna MA, Tortoledo ME, Allen M. Salivary dermal analogue tumors arising in lymph nodes. *Cancer*. 1987;59(6):1165-1169.
198. Crumpler C, Scharfenberg JC, Reed RJ. Monomorphic adenomas of salivary glands. Trabecular-tubular, canalicular, and basaloid variants. *Cancer*. 1976;38(1):193-200.
199. Dardick I, Lytwyn A, Bourne AJ, Byard RW. Trabecular and solid-cribriform types of basal cell adenoma. A morphologic study of two cases of an unusual variant of monomorphic adenoma. *Oral Surg Oral Med Oral Pathol*. 1992;73(1):75-83.
200. Batsakis JG. Basal cell adenoma of the parotid gland. *Cancer*. 1972;29(1):226-230.
201. Batsakis JG, Brannon RB. Dermal analogue tumours of major salivary glands. *J Laryngol Otol*. 1981;95(2):155-164.
202. Batsakis JG, Luna MA, el-Naggar AK. Basaloid monomorphic adenomas. *Ann Otol Rhinol Laryngol*. 1991;100(8):687-690.
203. Herbst EW, Utz W. Multifocal dermal-type basal cell adenomas of parotid glands with co-existing dermal cylindromas. *Virchows Arch A Pathol Anat Histopathol*. 1984;403(1):95-102.
204. Reingold IM, Keasbey LE, Graham JH. Multicentric dermal-type cylindromas of the parotid glands in a patient with florid turban tumor. *Cancer*. 1977;40(4):1702-1710.
205. Choi HR, Batsakis JG, Callender DL, et al. Molecular analysis of chromosome 16q regions in dermal analogue tumors of salivary glands: a genetic link to dermal cylindroma? *Am J Surg Pathol*. 2002;26(6):778-783.
206. Ellis GL, Wiscovitch JG. Basal cell adenocarcinomas of the major salivary glands. *Oral Surg Oral Med Oral Pathol*. 1990;69(4):461-469.
207. Gallimore AP, Spraggs PD, Allen JP, Hobsley M. Basaloid carcinomas of salivary glands. *Histopathology*. 1994;24(2):139-144.
208. Muller S, Barnes L. Basal cell adenocarcinoma of the salivary glands. Report of seven cases and review of the literature. *Cancer*. 1996;78(12):2471-2477.

209. Fonseca I, Soares J. Basal cell adenocarcinoma of minor salivary and seromucous glands of the head and neck region. *Semin Diagn Pathol*. 1996;13(2):128-137.
210. Williams SB, Ellis GL, Auclair PL. Immunohistochemical analysis of basal cell adenocarcinoma. *Oral Surg Oral Med Oral Pathol*. 1993;75(1):64-69.
211. Nagao T, Sugano I, Ishida Y, et al. Basal cell adenocarcinoma of the salivary glands: comparison with basal cell adenoma through assessment of cell proliferation, apoptosis, and expression of p53 and bcl-2. *Cancer*. 1998;82(3):439-447.
212. Daley TD, Gardner DG, Smout MS. Canalicular adenoma: not a basal cell adenoma. *Oral Surg Oral Med Oral Pathol*. 1984;57(2):181-188.
213. Suarez P, Hammond HL, Luna MA, Stimson PG. Palatal canalicular adenoma: report of 12 cases and review of the literature. *Ann Diagn Pathol*. 1998;2(4):224-228.
214. Nagao K, Matsuzaki O, Saiga H, et al. Histopathologic studies of basal cell adenoma of the parotid gland. *Cancer*. 1982;50(4):736-745.
215. Ferreiro JA. Immunohistochemistry of basal cell adenoma of the major salivary glands. *Histopathology*. 1994;24(6):539-542.
216. Takahashi H, Fujita S, Okabe H, et al. Immunohistochemical characterization of basal cell adenomas of the salivary gland. *Pathol Res Pract*. 1991;187(2-3):145-156.
217. Batsakis JG, Luna MA. Basaloid salivary carcinoma. *Ann Otol Rhinol Laryngol*. 1991;100(9 Pt 1):785-787.
218. Luna MA, Batsakis JG, Tortoledo ME, del Junco GW. Carcinomas ex monomorphic adenoma of salivary glands. *J Laryngol Otol*. 1989;103(8):756-759.
219. Cramer SF, Gnepp DR, Kiehn CL, Levitan J. Sebaceous differentiation in adenoid cystic carcinoma of the parotid gland. *Cancer*. 1980;46(6):1405-1410.
220. Gnepp DR. Sebaceous neoplasms of salivary gland origin: a review. *Pathol Annu*. 1983;18(Pt 1):71-102.
221. Rawson AJ, Horn RC Jr. Sebaceous glands and sebaceous gland-containing tumors of the parotid salivary gland; with a consideration of the histogenesis of papillary cystadenoma lymphomatosum. *Surgery*. 1950;27(1):93-101. [illust].
222. Shinozaki A, Nagao T, Endo H, et al. Sebaceous epithelial-myoepithelial carcinoma of the salivary gland: clinicopathologic and immunohistochemical analysis of 6 cases of a new histologic variant. *Am J Surg Pathol*. 2008;32(6):913-923.
223. Gnepp DR, Brannon R. Sebaceous neoplasms of salivary gland origin. Report of 21 cases. *Cancer*. 1984;53(10):2155-2170.
224. McGavran MH, Bauer WC, Ackerman LV. Sebaceous lymphadenoma of the parotid salivary gland. *Cancer*. 1960;13:1185-1187.
225. Merwin WH Jr, Barnes L, Myers EN. Unilocular cystic sebaceous lymphadenoma of the parotid gland. *Arch Otolaryngol*. 1985;111(4):273-275.
226. Dardick I, Thomas MJ. Lymphadenoma of parotid gland: two additional cases and a literature review. *Oral Surg Oral Med Oral Pathol Oral Radiol Endod*. 2008;105(4):491-494.
227. Ma J, Chan JK, Chow CW, Orell SR. Lymphadenoma: a report of three cases of an uncommon salivary gland neoplasm. *Histopathology*. 2002;41(4):342-350.
228. Batsakis JG, el-Naggar AK. Myoepithelium in salivary and mammary neoplasms is host-friendly. *Adv Anat Pathol*. 1999;6(4):218-226.
229. Dardick I, Thomas MJ, van Nostrand AW. Myoepithelioma—new concepts of histology and classification: a light and electron microscopic study. *Ultrastruct Pathol*. 1989;13(2-3):187-224.
230. Hubner G, Klein HJ, Kleinsasser O, Schiefer HG. Role of myoepithelial cells in the development of salivary gland tumors. *Cancer*. 1971;27(5):1255-1261.
231. Prasad AR, Savera AT, Gown AM, Zarbo RJ. The myoepithelial immunophenotype in 135 benign and malignant salivary gland tumors other than pleomorphic adenoma. *Arch Pathol Lab Med*. 1999;123(9):801-806.
232. Simpson RH, Jones H, Beasley P. Benign myoepithelioma of the salivary glands: a true entity? *Histopathology*. 1995;27(1):1-9.
233. Franquemont DW, Mills SE. Plasmacytoid monomorphic adenoma of salivary glands. Absence of myogenous differentiation and comparison to spindle cell myoepithelioma. *Am J Surg Pathol*. 1993;17(2):146-153.
234. Chaudhry AP, Satchidanand S, Peer R, Cutler LS. Myoepithelial cell adenoma of the parotid gland: a light and ultrastructural study. *Cancer*. 1982;49(2):288-293.
235. Sciubba JJ, Brannon RB. Myoepithelioma of salivary glands: report of 23 cases. *Cancer*. 1982;49(3):562-572.
236. Skálová A, Stárek I, Simpson RH, et al. Spindle cell myoepithelial tumours of the parotid gland with extensive lipomatous metaplasia. A report of four cases with immunohistochemical and ultrastructural findings. *Virchows Arch*. 2001;439:762-767.
237. Bellizzi AM, Mills SE. Collagenous crystalloids in myoepithelial carcinoma: report of a case and review of the literature. *Am J Clin Pathol*. 2008;130(3):355-362.
238. Takai Y, Mori M, Dardick I, et al. Myofilament localization and immunoelectron microscopic detection of muscle-specific actin in neoplastic myoepithelial cells in pleomorphic adenomas and myoepitheliomas. *Ultrastruct Pathol*. 1994;18(6):575-591.
239. Stromeyer FW, Haggitt RC, Nelson JF, Hardman JM. Myoepithelioma of minor salivary gland origin. Light and electron microscopical study. *Arch Pathol*. 1975;99(5):242-245.
240. Hara K, Ito M, Takeuchi J, et al. Distribution of S-100b protein in normal salivary glands and salivary gland tumors. *Virchows Arch A Pathol Anat Histopathol*. 1983;401(2):237-249.
241. Hasegawa M, Hagiwara S, Sato T, et al. CD109, a new marker for myoepithelial cells of mammary, salivary, and lacrimal glands and prostate basal cells. *Pathol Int*. 2007;57(5):245-250.
242. Kahn HJ, Baumal R, Marks A, et al. Myoepithelial cells in salivary gland tumors. An immunohistochemical study. *Arch Pathol Lab Med*. 1985;109(2):190-195.
243. Luna MA, Ordonez NG, Mackay B, et al. Salivary epithelial-myoepithelial carcinomas of intercalated ducts: a clinical, electron microscopic, and immunocytochemical study. *Oral Surg Oral Med Oral Pathol*. 1985;59(5):482-490.
244. Mori M, Ninomiya T, Okada Y, Tsukitani K. Myoepitheliomas and myoepithelial adenomas of salivary gland origin. Immunohistochemical evaluation of filament proteins, S-100 alpha and beta, glial fibrillary acidic proteins, neuron-specific enolase, and lactoferrin. *Pathol Res Pract*. 1989;184(2):168-178.
245. Nilsen R, Donath K. Actin containing cells in normal human salivary glands. An immunohistochemical study. *Virchows Arch A Pathol Anat Histol*. 1981;391(3): 315-322.
246. Palmer RM. The identification of myoepithelial cells in human salivary glands. A review and comparison of light microscopical methods. *J Oral Pathol*. 1986;15(4):221-229.
247. Jones H, Moshtael F, Simpson RH. Immunoreactivity of alpha smooth muscle actin in salivary gland tumours: a comparison with S100 protein. *J Clin Pathol*. 1992;45(10):938-940.
248. Morinaga S, Nakajima T, Shimosato Y. Normal and neoplastic myoepithelial cells in salivary glands: an immunohistochemical study. *Hum Pathol*. 1987;18(12):1218-1226.
249. Kuwabara H, Uda H, Miyabe K, et al. Malignant plasmacytoid myoepithelioma of the palate: histological observations compared to benign predominant plasmacytoid myoepithelial cells in pleomorphic adenoma of the palate. *Ultrastruct Pathol*. 1998;22(2):153-160.
250. Luna MA, Batsakis JG, Ordonez NG, et al. Salivary gland adenocarcinomas: a clinicopathologic analysis of three distinctive types. *Semin Diagn Pathol*. 1987;4(2): 117-135.
251. Barnes L, Appel BN, Perez H, El-Attar AM. Myoepithelioma of the head and neck: case report and review. *J Surg Oncol*. 1985;28(1):21-28.
252. Brocheriou C, Auriol M, de Roquancourt A, et al. [Epithelial-myoepithelial carcinoma of the salivary glands. Study of 15 cases and review of the literature]. *Ann Pathol*. 1991;11(5-6):316-325.
253. Crissman JD, Wirman JA, Harris A. Malignant myoepithelioma of the parotid gland. *Cancer*. 1977;40(6):3042-3049.
254. Fonseca I, Soares J. Epithelial-myoepithelial carcinoma of the salivary glands. A study of 22 cases. *Virchows Arch A Pathol Anat Histopathol*. 1993;422(5):389-396.
255. Nagao T, Sugano I, Ishida Y, et al. Salivary gland malignant myoepithelioma: a clinicopathologic and immunohistochemical study of ten cases. *Cancer*. 1998;83(7):1292-1299.
256. Savera AT, Sloman A, Huvos AG, Klimstra DS. Myoepithelial carcinoma of the salivary glands: a clinicopathologic study of 25 patients. *Am J Surg Pathol*. 2000;24(6):761-774.
257. Di Palma S, Guzzo M. Malignant myoepithelioma of salivary glands: clinicopathological features of ten cases. *Virchows Arch A Pathol Anat Histopathol*. 1993;423(5):389-396.
258. Suzuki H, Inoue K, Fujioka Y, et al. Myoepithelial carcinoma with predominance of plasmacytoid cells arising in a pleomorphic adenoma of the parotid gland. *Histopathology*. 1998;32(1):86-87.
259. Shah AA, LeGallo RD, van Zante A, et al. EWSR1 genetic rearrangements in salivary gland tumors a specific and very common feature of hyalinizing clear cell carcinoma. *Am J Surg Pathol*. 2013;37(4):571-578.
260. Skalova A, Weinreb I, Hyrcza M, et al. Clear cell myoepithelial carcinoma of salivary glands showing EWSR1 rearrangement: molecular analysis of 94 salivary gland carcinomas with prominent clear cell component. *Am J Surg Pathol*. 2015;39(3):338-348.
261. Batsakis JG. Clear cell tumors of salivary glands. *Ann Otol Rhinol Laryngol*. 1980;89(2 Pt 1):196-197.
262. Ellis GL. Clear cell neoplasms in salivary glands: clearly a diagnostic challenge. *Ann Diagn Pathol*. 1998;2(1):61-78.
263. Maiorano E, Altini M, Favia G. Clear cell tumors of the salivary glands, jaws, and oral mucosa. *Semin Diagn Pathol*. 1997;14(3):203-212.
264. Ogawa I, Nikai H, Takata T, et al. Clear cell tumors of minor salivary gland origin. An immunohistochemical and ultrastructural analysis. *Oral Surg Oral Med Oral Pathol*. 1991;72(2):200-207.

265. Rezende RB, Drachenberg CB, Kumar D, et al. Differential diagnosis between monomorphic clear cell adenocarcinoma of salivary glands and renal (clear) cell carcinoma. *Am J Surg Pathol*. 1999;23(12):1532-1538.
266. Seifert G. Classification and differential diagnosis of clear and basal cell tumors of the salivary glands. *Semin Diagn Pathol*. 1996;13(2):95-103.
267. Wang B, Brandwein M, Gordon R, et al. Primary salivary clear cell tumors—a diagnostic approach: a clinicopathologic and immunohistochemical study of 20 patients with clear cell carcinoma, clear cell myoepithelial carcinoma, and epithelial-myoepithelial carcinoma. *Arch Pathol Lab Med*. 2002;126(6):676-685.
268. Milchgrub S, Gnepp DR, Vuitch F, et al. Hyalinizing clear cell carcinoma of salivary gland. *Am J Surg Pathol*. 1994;18(1):74-82.
269. Simpson RH, Sarsfield PT, Clarke T, Babajews AV. Clear cell carcinoma of minor salivary glands. *Histopathology*. 1990;17(5):433-438.
270. Seethala RR, Barnes EL, Hunt JL. Epithelial-myoepithelial carcinoma: a review of the clinicopathologic spectrum and immunophenotypic characteristics in 61 tumors of the salivary glands and upper aerodigestive tract. *Am J Surg Pathol*. 2007;31(1):44-57.
271. Seethala RR, Richmond JA, Hoschar AP, Barnes EL. New variants of epithelial-myoepithelial carcinoma: oncocytic-sebaceous and apocrine. *Arch Pathol Lab Med*. 2009;133(6):950-959.
272. Fonseca I, Soares J. Proliferating cell nuclear antigen immunohistochemistry in epithelial-myoepithelial carcinoma of the salivary glands. *Arch Pathol Lab Med*. 1993;117(10):993-995.
273. Nascimento AG, Amaral LP, Prado LA, et al. Mucoepidermoid carcinoma of salivary glands: a clinicopathologic study of 46 cases. *Head Neck Surg*. 1986;8(6):409-417.
274. Luna MA, Batsakis JG, el-Naggar AK. Salivary gland tumors in children. *Ann Otol Rhinol Laryngol*. 1991;100(10):869-871.
275. Evans HL. Mucoepidermoid carcinoma of salivary glands: a study of 69 cases with special attention to histologic grading. *Am J Clin Pathol*. 1984;81(6):696-701.
276. Hayes MM, Cameron RD, Jones EA. Sebaceous variant of mucoepidermoid carcinoma of the salivary gland. A case report with cytohistologic correlation. *Acta Cytol*. 1993;37(2):237-241.
277. Hamed G, Shmookler BM, Ellis GL, et al. Oncocytic mucoepidermoid carcinoma of the parotid gland. *Arch Pathol Lab Med*. 1994;118(3):313-314.
278. Jahan-Parwar B, Huberman RM, Donovan DT, et al. Oncocytic mucoepidermoid carcinoma of the salivary glands. *Am J Surg Pathol*. 1999;23(5):523-529.
279. Weinreb I, Seethala RR, Perez-Ordonez B, et al. Oncocytic mucoepidermoid carcinoma: clinicopathologic description in a series of 12 cases. *Am J Surg Pathol*. 2009;33(3):409-416.
280. Veras EF, Sturgis E, Luna MA. Sclerosing mucoepidermoid carcinoma of the salivary glands. *Ann Diagn Pathol*. 2007;11(6):407-412.
281. Nagao T, Gaffey TA, Kay PA, et al. Dedifferentiation in low-grade mucoepidermoid carcinoma of the parotid gland. *Hum Pathol*. 2003;34(10):1068-1072.
282. Cholankeril JV, Scioscia PA. Post-traumatic sialoceles and mucoceles of the salivary glands. *Clin Imaging*. 1993;17(1):41-45.
283. Chan JK, Saw D. Sclerosing mucoepidermoid tumour of the parotid gland: report of a case. *Histopathology*. 1987;11(2):203-207.
284. Fonseca I, Costa Rosa J, Felix A, et al. Simple mucin-type carbohydrate antigens (T, Tn and sialosyl-Tn) in mucoepidermoid carcinoma of the salivary glands. *Histopathology*. 1994;25(6):537-543.
285. Alos L, Lujan B, Castillo M, et al. Expression of membrane-bound mucins (MUC1 and MUC4) and secreted mucins (MUC2, MUC5AC, MUC5B, MUC6 and MUC7) in mucoepidermoid carcinomas of salivary glands. *Am J Surg Pathol*. 2005;29(6):806-813.
286. Handra-Luca A, Lamas G, Bertrand JC, Fouret P. MUC1, MUC2, MUC4, and MUC5AC expression in salivary gland mucoepidermoid carcinoma: diagnostic and prognostic implications. *Am J Surg Pathol*. 2005;29(7):881-889.
287. Meer S, Altini M. CK7+/CK20- immunoexpression profile is typical of salivary gland neoplasia. *Histopathology*. 2007;51(1):26-32.
288. Nikitakis NG, Tosios KI, Papanikolaou VS, et al. Immunohistochemical expression of cytokeratins 7 and 20 in malignant salivary gland tumors. *Mod Pathol*. 2004;17(4):407-415.
289. Foschini MP, Marucci G, Eusebi V. Low-grade mucoepidermoid carcinoma of salivary glands: characteristic immunohistochemical profile and evidence of striated duct differentiation. *Virchows Arch*. 2002;440(5):536-542.
290. Martins C, Cavaco B, Tonon G, et al. A study of MECT1-MAML2 in mucoepidermoid carcinoma and Warthin's tumor of salivary glands. *J Mol Diagn*. 2004;6(3):205-210.
291. Miyabe S, Okabe M, Nagatsuka H, et al. Prognostic significance of p27Kip1, Ki-67, and CRTC1-MAML2 fusion transcript in mucoepidermoid carcinoma: a molecular and clinicopathologic study of 101 cases. *J Oral Maxillofac Surg*. 2009;67(7):1432-1441.
292. Nakayama T, Miyabe S, Okabe M, et al. Clinicopathological significance of the CRTC3-MAML2 fusion transcript in mucoepidermoid carcinoma. *Mod Pathol*. 2009;22(12):1575-1581.
293. Tonon G, Modi S, Wu L, et al. t(11;19)(q21;p13) translocation in mucoepidermoid carcinoma creates a novel fusion product that disrupts a Notch signaling pathway. *Nat Genet*. 2003;33(2):208-213.
294. Achcar Rde O, Nikiforova MN, Dacic S, et al. Mammalian mastermind like 2 11q21 gene rearrangement in bronchopulmonary mucoepidermoid carcinoma. *Hum Pathol*. 2009;40(6):854-860.
295. Camelo-Piragua SI, Habib C, Kanumuri P, et al. Mucoepidermoid carcinoma of the breast shares cytogenetic abnormality with mucoepidermoid carcinoma of the salivary gland: a case report with molecular analysis and review of the literature. *Hum Pathol*. 2009;40(6):887-892.
296. Lennerz JK, Perry A, Dehner LP, et al. CRTC1 rearrangements in the absence of t(11;19) in primary cutaneous mucoepidermoid carcinoma. *Br J Dermatol*. 2009;161(4):925-929.
297. Lennerz JK, Perry A, Mills JC, et al. Mucoepidermoid carcinoma of the cervix: another tumor with the t(11;19)-associated CRTC1-MAML2 gene fusion. *Am J Surg Pathol*. 2009;33(6):835-843.
298. Behboudi A, Enlund F, Winnes M, et al. Molecular classification of mucoepidermoid carcinomas-prognostic significance of the MECT1-MAML2 fusion oncogene. *Genes Chromosomes Cancer*. 2006;45(5):470-481.
299. Fehr A, Meyer A, Heidorn K, et al. A link between the expression of the stem cell marker HMGA2, grading, and the fusion CRTC1-MAML2 in mucoepidermoid carcinoma. *Genes Chromosomes Cancer*. 2009;48(9):777-785.
300. Okabe M, Miyabe S, Nagatsuka H, et al. MECT1-MAML2 fusion transcript defines a favorable subset of mucoepidermoid carcinoma. *Clin Cancer Res*. 2006;12(13):3902-3907.
301. Brandwein MS, Ivanov K, Wallace DI, et al. Mucoepidermoid carcinoma: a clinicopathologic study of 80 patients with special reference to histological grading. *Am J Surg Pathol*. 2001;25(7):835-845.
302. Goode RK, Auclair PL, Ellis GL. Mucoepidermoid carcinoma of the major salivary glands: clinical and histopathologic analysis of 234 cases with evaluation of grading criteria. *Cancer*. 1998;82(7):1217-1224.
303. Guzzo M, Andreola S, Sirizzotti G, Cantu G. Mucoepidermoid carcinoma of the salivary glands: clinicopathologic review of 108 patients treated at the National Cancer Institute of Milan. *Ann Surg Oncol*. 2002;9(7):688-695.
304. Ellis GL, Auclair PL. Tumors of the salivary glands. In: Silverberg SG, Sobin LH, eds. *Atlas of Tumor Pathology, Series 4, Fascicle 9*. Washington, DC: American Registry of Pathology; 2008.
305. Jakobsson PA, Blanck C, Eneroth CM. Mucoepidermoid carcinoma of the parotid gland. *Cancer*. 1968;22(1):111-124.
306. Auclair PL, Goode RK, Ellis GL. Mucoepidermoid carcinoma of intraoral salivary glands. Evaluation and application of grading criteria in 143 cases. *Cancer*. 1992;69(8):2021-2030.
307. Fonseca I, Clode AL, Soares J. Mucoepidermoid carcinoma of major and minor salivary glands. A survey of 43 cases with study of prognostic indicators. *Int J Surg Pathol*. 1993;1:3-12.
308. Skalova A, Lehtonen H, von Boguslawsky K, Leivo I. Prognostic significance of cell proliferation in mucoepidermoid carcinomas of the salivary gland: clinicopathological study using MIB 1 antibody in paraffin sections. *Hum Pathol*. 1994;25(9):929-935.
309. Abrams AM, Cornyn J, Scofield HH, Hansen LS. Acinic cell adenocarcinoma of the major salivary glands. A clinicopathologic study of 77 cases. *Cancer*. 1965;18:1145-1162.
310. Depowski PL, Setzen G, Chui A, et al. Familial occurrence of acinic cell carcinoma of the parotid gland. *Arch Pathol Lab Med*. 1999;123(11):1118-1120.
311. Batsakis JG, Chinn EK, Weimert TA, et al. Acinic cell carcinoma: a clinicopathologic study of thirty-five cases. *J Laryngol Otol*. 1979;93(4):325-340.
312. Chen SY, Brannon RB, Miller AS, et al. Acinic cell adenocarcinoma of minor salivary glands. *Cancer*. 1978;42(2):678-685.
313. Zbaeren P, Lehmann W, Widgren S. Acinic cell carcinoma of minor salivary gland origin. *J Laryngol Otol*. 1991;105(9):782-785.
314. Eneroth CM, Jakobsson PA, Blanck C. Acinic cell carcinoma of the parotid gland. *Cancer*. 1966;19(12):1761-1772.
315. Gustafsson H, Carlsoo B, Henriksson R. Ultrastructural morphometry and secretory behavior of acinic cell carcinoma. *Cancer*. 1985;55(8):1706-1710.
316. Spiro RH, Huvos AG, Strong EW. Acinic cell carcinoma of salivary origin. A clinicopathologic study of 67 cases. *Cancer*. 1978;41(3):924-935.
317. Chaudhry AP, Cutler LS, Leifer C, et al. Histogenesis of acinic cell carcinoma of the major and minor salivary glands. An ultrastructural study. *J Pathol*. 1986;148(4):307-320.
318. Michal M, Skalova A, Simpson RH, et al. Well-differentiated acinic cell carcinoma of salivary glands associated with lymphoid stroma. *Hum Pathol*. 1997;28(5):595-600.
319. Takahashi H, Fujita S, Okabe H, et al. Distribution of tissue markers in acinic cell

carcinomas of salivary gland. *Pathol Res Pract*. 1992;188(6):692-700.
320. Warner TF, Seo IS, Azen EA, et al. Immunocytochemistry of acinic cell carcinomas and mixed tumors of salivary glands. *Cancer*. 1985;56(9):2221-2227.
321. Ellis GL, Corio RL. Acinic cell adenocarcinoma. A clinicopathologic analysis of 294 cases. *Cancer*. 1983;52(3):542-549.
322. Lewis JE, Olsen KD, Weiland LH. Acinic cell carcinoma. Clinicopathologic review. *Cancer*. 1991;67(1):172-179.
323. Oliveira P, Fonseca I, Soares J. Acinic cell carcinoma of the salivary glands. A long term follow-up study of 15 cases. *Eur J Surg Oncol*. 1992;18(1):7-15.
324. Perzin KH, LiVolsi VA. Acinic cell carcinomas arising in salivary glands: a clinicopathologic study. *Cancer*. 1979;44(4):1434-1457.
325. Spafford PD, Mintz DR, Hay J. Acinic cell carcinoma of the parotid gland: review and management. *J Otolaryngol*. 1991;20(4):262-266.
326. Henley JD, Geary WA, Jackson CL, et al. Dedifferentiated acinic cell carcinoma of the parotid gland: a distinct rarely described entity. *Hum Pathol*. 1997;28(7):869-873.
327. Di Palma S, Corletto V, Lavarino C, et al. Unilateral aneuploid dedifferentiated acinic cell carcinoma associated with bilateral-low grade diploid acinic cell carcinoma of the parotid gland. *Virchows Arch*. 1999;434(4):361-365.
328. Nunes JF, Fonseca I, Soares J. Helioid inclusions in dedifferentiated acinic cell carcinoma of the parotid gland. *Ultrastruct Pathol*. 1996;20(5):443-449.
329. Skalova A, Sima R, Vanecek T, et al. Acinic cell carcinoma with high-grade transformation: a report of 9 cases with immunohistochemical study and analysis of TP53 and HER-2/neu genes. *Am J Surg Pathol*. 2009;33(8):1137-1145.
330. Reis-Filho JS, Natrajan R, Vatcheva R, et al. Is acinic cell carcinoma a variant of secretory carcinoma? A FISH study using ETV6 'split apart' probes. *Histopathology*. 2008;52(7):840-846.
331. Skalova A, Vanecek T, Sima R, et al. Mammary analogue secretory carcinoma of salivary glands, containing the ETV6-NTRK3 fusion gene: a hitherto undescribed salivary gland tumor entity. *Am J Surg Pathol*. 2010;34(5):599-608.
332. Tandler B. Ultrastructure of adenoid cystic carcinoma of salivary gland origin. *Lab Invest*. 1971;24(6):504-512.
333. Kowalski PJ, Paulino AF. Perineural invasion in adenoid cystic carcinoma: its causation/promotion by brain-derived neurotrophic factor. *Hum Pathol*. 2002;33(9):933-936.
334. Perzin KH, Gullane P, Clairmont AC. Adenoid cystic carcinomas arising in salivary glands: a correlation of histologic features and clinical course. *Cancer*. 1978;42(1):265-282.
335. Spiro RH, Huvos AG, Strong EW. Adenoid cystic carcinoma of salivary origin. A clinicopathologic study of 242 cases. *Am J Surg*. 1974;128(4):512-520.
336. Albores-Saavedra J, Wu J, Uribe-Uribe N. The sclerosing variant of adenoid cystic carcinoma: a previously unrecognized neoplasm of major salivary glands. *Ann Diagn Pathol*. 2006;10(1):1-7.
337. Snyder ML, Paulino AF. Hybrid carcinoma of the salivary gland: salivary duct adenocarcinoma adenoid cystic carcinoma. *Histopathology*. 1999;35(4):380-383.
338. Azumi N, Battifora H. The cellular composition of adenoid cystic carcinoma. An immunohistochemical study. *Cancer*. 1987;60(7):1589-1598.
339. Caselitz J, Becker J, Seifert G, et al. Coexpression of keratin and vimentin filaments in adenoid cystic carcinomas of salivary glands. *Virchows Arch A Pathol Anat Histopathol*. 1984;403(4):337-344.
340. Caselitz J, Jaup T, Seifert G. Immunohistochemical detection of carcinoembryonic antigen (CEA) in parotid gland carcinomas. Analysis of 52 cases. *Virchows Arch A Pathol Anat Histol*. 1981;394(1-2):49-60.
341. Chomette G, Auriol M, Vaillant JM, et al. An immunohistochemical study of the distribution of lysozyme, lactoferrin, alpha 1-antitrypsin and alpha 1-antichymotrypsin in salivary adenoid cystic carcinoma. *Pathol Res Pract*. 1991;187(8):1001-1008.
342. Holst VA, Marshall CE, Moskaluk CA, Frierson HF Jr. KIT protein expression and analysis of c-kit gene mutation in adenoid cystic carcinoma. *Mod Pathol*. 1999;12(10):956-960.
343. Penner CR, Folpe AL, Budnick SD. C-kit expression distinguishes salivary gland adenoid cystic carcinoma from polymorphous low-grade adenocarcinoma. *Mod Pathol*. 2002;15(7):687-691.
344. Rutherford S, Yu Y, Rumpel CA, et al. Chromosome 6 deletion and candidate tumor suppressor genes in adenoid cystic carcinoma. *Cancer Lett*. 2006;236(2):309-317.
345. Stallmach I, Zenklusen P, Komminoth P, et al. Loss of heterozygosity at chromosome 6q23–25 correlates with clinical and histologic parameters in salivary gland adenoid cystic carcinoma. *Virchows Arch*. 2002;440(1):77-84.
346. Kiyoshima T, Shima K, Kobayashi I, et al. Expression of p53 tumor suppressor gene in adenoid cystic and mucoepidermoid carcinomas of the salivary glands. *Oral Oncol*. 2001;37(3):315-322.
347. Frierson HF Jr, El-Naggar AK, Welsh JB, et al. Large scale molecular analysis identifies genes with altered expression in salivary adenoid cystic carcinoma. *Am J Pathol*. 2002;161(4):1315-1323.
348. Mitani Y, Li J, Rao PH, et al. Comprehensive analysis of the MYB-NFIB gene fusion in salivary adenoid cystic carcinoma: incidence, variability, and clinicopathologic significance. *Clin Cancer Res*. 2010;16(19):4722-4731.
349. Matsuba HM, Spector GJ, Thawley SE, et al. Adenoid cystic salivary gland carcinoma. A histopathologic review of treatment failure patterns. *Cancer*. 1986;57(3):519-524.
350. Nascimento AG, Amaral AL, Prado LA, et al. Adenoid cystic carcinoma of salivary glands. A study of 61 cases with clinicopathologic correlation. *Cancer*. 1986;57(2):312-319.
351. Szanto PA, Luna MA, Tortoledo ME, White RA. Histologic grading of adenoid cystic carcinoma of the salivary glands. *Cancer*. 1984;54(6):1062-1069.
352. Eby LS, Johnson DS, Baker HW. Adenoid cystic carcinoma of the head and neck. *Cancer*. 1972;29(5):1160-1168.
353. Cheuk W, Chan JK, Ngan RK. Dedifferentiation in adenoid cystic carcinoma of salivary gland: an uncommon complication associated with an accelerated clinical course. *Am J Surg Pathol*. 1999;23(4):465-472.
354. Seethala RR, Hunt JL, Baloch ZW, et al. Adenoid cystic carcinoma with high-grade transformation: a report of 11 cases and a review of the literature. *Am J Surg Pathol*. 2007;31(11):1683-1694.
355. Chau Y, Hongyo T, Aozasa K, Chan JK. Dedifferentiation of adenoid cystic carcinoma: report of a case implicating p53 gene mutation. *Hum Pathol*. 2001;32(12):1403-1407.
356. Spiro RH, Huvos AG. Stage means more than grade in adenoid cystic carcinoma. *Am J Surg*. 1992;164(6):623-628.
357. Allen MS Jr, Marsh WL Jr. Lymph node involvement by direct extension in adenoid cystic carcinoma. Absence of classic embolic lymph node metastasis. *Cancer*. 1976;38(5):2017-2021.
358. Casler JD, Conley JJ. Surgical management of adenoid cystic carcinoma in the parotid gland. *Otolaryngol Head Neck Surg*. 1992;106(4):332-338.
359. Hosokawa Y, Ohmori K, Kaneko M, et al. Analysis of adenoid cystic carcinoma treated by radiotherapy. *Oral Surg Oral Med Oral Pathol*. 1992;74(2):251-255.
360. Franklin CD, Ong TK. Ductal papilloma of the minor salivary gland. *Histopathology*. 1991;19(2):180-182.
361. Ishikawa T, Imada S, Ijuhin N. Intraductal papilloma of the anterior lingual salivary gland. Case report and immunohistochemical study. *Int J Oral Maxillofac Surg*. 1993;22(2):116-117.
362. King PH, Hill J. Intraduct papilloma of parotid gland. *J Clin Pathol*. 1993;46(2):175-176.
363. Nagao T, Sugano I, Matsuzaki O, et al. Intraductal papillary tumors of the major salivary glands: case reports of benign and malignant variants. *Arch Pathol Lab Med*. 2000;124(2):291-295.
364. Grenko RT, Gemryd P, Tytor M, et al. Salivary duct carcinoma. *Histopathology*. 1995;26(3):261-266.
365. Jaehne M, Roeser K, Jaekel T, et al. Clinical and immunohistologic typing of salivary duct carcinoma: a report of 50 cases. *Cancer*. 2005;103(12):2526-2533.
366. Kumar RV, Kini L, Bhargava AK, et al. Salivary duct carcinoma. *J Surg Oncol*. 1993;54(3):193-198.
367. Chen KT, Hafez GR. Infiltrating salivary duct carcinoma. A clinicopathologic study of five cases. *Arch Otolaryngol*. 1981;107(1):37-39.
368. Garland TA, Innes DJ Jr, Fechner RE. Salivary duct carcinoma: an analysis of four cases with review of literature. *Am J Clin Pathol*. 1984;81(4):436-441.
369. Henley JD, Seo IS, Dayan D, Gnepp DR. Sarcomatoid salivary duct carcinoma of the parotid gland. *Hum Pathol*. 2000;31(2):208-213.
370. Nagao T, Gaffey TA, Serizawa H, et al. Sarcomatoid variant of salivary duct carcinoma: clinicopathologic and immunohistochemical study of eight cases with review of the literature. *Am J Clin Pathol*. 2004;122(2):222-231.
371. Nagao T, Gaffey TA, Visscher DW, et al. Invasive micropapillary salivary duct carcinoma: a distinct histologic variant with biologic significance. *Am J Surg Pathol*. 2004;28(3):319-326.
372. Padberg BC, Sasse B, Huber A, Pfaltz M. Sarcomatoid salivary duct carcinoma. *Ann Diagn Pathol*. 2005;9(2):86-92.
373. Simpson RH, Clarke TJ, Sarsfield PT, Babajews AV. Salivary duct adenocarcinoma. *Histopathology*. 1991;18(3):229-235.
374. Simpson RH, Prasad AR, Lewis JE, et al. Mucin-rich variant of salivary duct carcinoma: a clinicopathologic and immunohistochemical study of four cases. *Am J Surg Pathol*. 2003;27(8):1070-1079.
375. Weinreb I, Tabanda-Lichauco R, Van der Kwast T, Perez-Ordonez B. Low-grade intraductal carcinoma of salivary gland: report of 3 cases with marked apocrine differentiation. *Am J Surg Pathol*. 2006;30(8):1014-1021.
376. Delgado R, Klimstra D, Albores-Saavedra J. Low grade salivary duct carcinoma. A distinctive variant with a low grade histology and a predominant intraductal growth pattern. *Cancer*. 1996;78(5):958-967.
377. Lewis JE, McKinney BC, Weiland LH, et al. Salivary duct carcinoma. Clinicopathologic and immunohistochemical review of 26 cases. *Cancer*. 1996;77(2):223-230.

378. Wick MR, Ockner DM, Mills SE, et al. Homologous carcinomas of the breasts, skin, and salivary glands. A histologic and immunohistochemical comparison of ductal mammary carcinoma, ductal sweat gland carcinoma, and salivary duct carcinoma. *Am J Clin Pathol*. 1998;109(1):75-84.
379. Hungermann D, Korsching E, Buerger H, et al. Salivary duct carcinomas comprise phenotypically and genotypically diverse high-grade neoplasms. *Histopathology*. 2007;50(7):956-958.
380. de Araujo VC, Kowalski LP, Soares F, et al. Salivary duct carcinoma: cytokeratin 14 as a marker of in-situ intraductal growth. *Histopathology*. 2002;41(3):244-249.
381. Johnson CJ, Barry MB, Vasef MA, Deyoung BR. Her-2/neu expression in salivary duct carcinoma: an immunohistochemical and chromogenic in situ hybridization study. *Appl Immunohistochem Mol Morphol*. 2008;16(1):54-58.
382. Skalova A, Starek I, Vanecek T, et al. Expression of HER-2/neu gene and protein in salivary duct carcinomas of parotid gland as revealed by fluorescence in-situ hybridization and immunohistochemistry. *Histopathology*. 2003;42(4):348-356.
383. Brandwein MS, Jagirdar J, Patil J, et al. Salivary duct carcinoma (cribriform salivary carcinoma of excretory ducts). A clinicopathologic and immunohistochemical study of 12 cases. *Cancer*. 1990;65(10):2307-2314.
384. Yoshihara T, Shino A, Ishii T, Kawakami M. Ultrastructural and immunohistochemical study of salivary duct carcinoma of the parotid gland. *Ultrastruct Pathol*. 1994;18(6):553-558.
385. Fan CY, Wang J, Barnes EL. Expression of androgen receptor and prostatic specific markers in salivary duct carcinoma: an immunohistochemical analysis of 13 cases and review of the literature. *Am J Surg Pathol*. 2000;24(4):579-586.
386. James GK, Pudek M, Berean KW, et al. Salivary duct carcinoma secreting prostate-specific antigen. *Am J Clin Pathol*. 1996;106(2):242-247.
387. Sato K, Shimode Y, Itoi A, et al. Salivary duct carcinoma of the parotid gland presenting KIT (CD117) overexpression. *Histopathology*. 2007;51(1):114-115.
388. Williams MD, Roberts D, Blumenschein GR Jr, et al. Differential expression of hormonal and growth factor receptors in salivary duct carcinomas: biologic significance and potential role in therapeutic stratification of patients. *Am J Surg Pathol*. 2007;31(11):1645-1652.
389. Butler RT, Spector ME, Thomas D, et al. An immunohistochemical panel for reliable differentiation of salivary duct carcinoma and mucoepidermoid carcinoma. *Head Neck Pathol*. 2014;8(2):133-140.
390. Leivo I, Jee KJ, Heikinheimo K, et al. Characterization of gene expression in major types of salivary gland carcinomas with epithelial differentiation. *Cancer Genet Cytogenet*. 2005;156(2):104-113.
391. Colmenero Ruiz C, Patron Romero M, Martin Perez M. Salivary duct carcinoma: a report of nine cases. *J Oral Maxillofac Surg*. 1993;51(6):641-646.
392. Hong YO, Cho KJ, Ro JY. Salivary duct carcinoma with or without micropapillary components: clinicopathologic and immunohistochemical comparison. *Lab Invest*. 2009;89(suppl 1):248A.
393. Anderson C, Muller R, Piorkowski R, et al. Intraductal carcinoma of major salivary gland. *Cancer*. 1992;69(3):609-614.
394. Simpson RH, Desai S, Di Palma S. Salivary duct carcinoma in situ of the parotid gland. *Histopathology*. 2008;53(4):416-425.
395. Raymond AK, Batsakis JG. Stensen's duct carcinomas. *Ann Otol Rhinol Laryngol*. 1991;100(12):1035-1036.
396. Brandwein-Gensler M, Hille J, Wang BY, et al. Low-grade salivary duct carcinoma: description of 16 cases. *Am J Surg Pathol*. 2004;28(8):1040-1044.
397. Castle JT, Thompson LD, Frommelt RA, et al. Polymorphous low grade adenocarcinoma: a clinicopathologic study of 164 cases. *Cancer*. 1999;86(2):207-219.
398. Evans HL, Luna MA. Polymorphous low-grade adenocarcinoma: a study of 40 cases with long-term follow up and an evaluation of the importance of papillary areas. *Am J Surg Pathol*. 2000;24(10):1319-1328.
399. Norberg L, Dardick I. The need for clinical awareness of polymorphous low-grade adenocarcinoma: a review. *J Otolaryngol*. 1992;21(2):149-152.
400. George MK, Mansour P, Pahor AL. Terminal parotid duct carcinoma. *J Laryngol Otol*. 1991;105(9):780-781.
401. Miliauskas JR. Polymorphous low-grade (terminal duct) adenocarcinoma of the parotid gland. *Histopathology*. 1991;19(6):555-557.
402. Anderson C, Krutchkoff D, Pedersen C, et al. Polymorphous low grade adenocarcinoma of minor salivary gland: a clinicopathologic and comparative immunohistochemical study. *Mod Pathol*. 1990;3(1):76-82.
403. Simpson RH, Clarke TJ, Sarsfield PT, et al. Polymorphous low-grade adenocarcinoma of the salivary glands: a clinicopathological comparison with adenoid cystic carcinoma. *Histopathology*. 1991;19(2):121-129.
404. Blanck C, Eneroth CM, Jakobsson PA. Mucus-producing adenopapillary (non-epidermoid) carcinoma of the parotid gland. *Cancer*. 1971;28(3):676-685.
405. Kardos TB, Ferguson JW, McMillan MD. Mucus-producing adenopapillary carcinoma of the oral cavity. *Int J Oral Maxillofac Surg*. 1992;21(3):160-162.
406. Mostofi R, Wood RS, Christison W, Talerman A. Low-grade papillary adenocarcinoma of minor salivary glands. Case report and literature review. *Oral Surg Oral Med Oral Pathol*. 1992;73(5):591-595.
407. Batsakis JG. Cystadenocarcinoma: a specific diagnosis or just another adenocarcinoma NOS? *Adv Anat Pathol*. 1997;4:252-255.
408. Foss RD, Ellis GL, Auclair PL. Salivary gland cystadenocarcinomas. A clinicopathologic study of 57 cases. *Am J Surg Pathol*. 1996;20(12):1440-1447.
409. Michal M, Skalova A, Mukensnabl P. Micropapillary carcinoma of the parotid gland arising in mucinous cystadenoma. *Virchows Arch*. 2000;437(4):465-468.
410. Taxy JB. Squamous carcinoma in a major salivary gland: a review of the diagnostic considerations. *Arch Pathol Lab Med*. 2001;125(6):740-745.
411. Leader M, Jass JR. In-situ neoplasia in squamous cell carcinoma of the parotid. A case report. *Histopathology*. 1985;9(3):325-329.
412. Gaughan RK, Olsen KD, Lewis JE. Primary squamous cell carcinoma of the parotid gland. *Arch Otolaryngol Head Neck Surg*. 1992;118(8):798-801.
413. Koss LG, Spiro RH, Hajdu S. Small cell (oat cell) carcinoma of minor salivary gland origin. *Cancer*. 1972;30(3):737-741.
414. Wirman JA, Battifora HA. Small cell undifferentiated carcinoma of salivary gland origin: an ultrastructural study. *Cancer*. 1976;37(4):1840-1848.
415. Gnepp DR, Corio RL, Brannon RB. Small cell carcinoma of the major salivary glands. *Cancer*. 1986;58(3):705-714.
416. Hayashi Y, Nagamine S, Yanagawa T, et al. Small cell undifferentiated carcinoma of the minor salivary gland containing exocrine, neuroendocrine, and squamous cells. *Cancer*. 1987;60(7):1583-1588.
417. Leipzig B, Gonzales-Vitale JC. Small cell epidermoid carcinoma of salivary glands. 'Pseudo'-oat cell carcinoma. *Arch Otolaryngol*. 1982;108(8):511-514.
418. Rollins CE, Yost BA, Costa MJ, Vogt PJ. Squamous differentiation in small-cell carcinoma of the parotid gland. *Arch Pathol Lab Med*. 1995;119(2):183-185.
419. Huntrakoon M. Neuroendocrine carcinoma of the parotid gland: a report of two cases with ultrastructural and immunohistochemical studies. *Hum Pathol*. 1987;18(12):1212-1217.
420. Gnepp DR, Wick MR. Small cell carcinoma of the major salivary glands. An immunohistochemical study. *Cancer*. 1990;66(1):185-192.
421. Nagao T, Gaffey TA, Olsen KD, et al. Small cell carcinoma of the major salivary glands: clinicopathologic study with emphasis on cytokeratin 20 immunoreactivity and clinical outcome. *Am J Surg Pathol*. 2004;28(6):762-770.
422. Fisher CA, Harms PW, McHugh JB, et al. Small cell carcinoma in the parotid harboring Merkel cell polyomavirus. *Oral Surg Oral Med Oral Pathol Oral Radiol*. 2014;118(6):703-712.
423. Fornelli A, Eusebi V, Pasquinelli G, et al. Merkel cell carcinoma of the parotid gland associated with Warthin tumour: report of two cases. *Histopathology*. 2001;39(4):342-346.
424. Nagao T, Sugano I, Ishida Y, et al. Primary large-cell neuroendocrine carcinoma of the parotid gland: immunohistochemical and molecular analysis of two cases. *Mod Pathol*. 2000;13(5):554-561.
425. Kott ET, Goepfert H, Ayala AG, Ordonez NG. Lymphoepithelial carcinoma (malignant lymphoepithelial lesion) of the salivary glands. *Arch Otolaryngol*. 1984;110(1):50-53.
426. Nagao K, Matsuzaki O, Saiga H, et al. A histopathologic study of benign and malignant lymphoepithelial lesions of the parotid gland. *Cancer*. 1983;52(6):1044-1052.
427. Saw D, Lau WH, Ho JH, et al. Malignant lymphoepithelial lesion of the salivary gland. *Hum Pathol*. 1986;17(9):914-923.
428. Schneider M, Rizzardi C. Lymphoepithelial carcinoma of the parotid glands and its relationship with benign lymphoepithelial lesions. *Arch Pathol Lab Med*. 2008;132(2):278-282.
429. Hanji D, Gohao L. Malignant lymphoepithelial lesions of the salivary glands with anaplastic carcinomatous change. Report of nine cases and review of literature. *Cancer*. 1983;52(12):2245-2252.
430. Sehested M, Hainau B, Albeck H, et al. Ultrastructural investigation of anaplastic salivary gland carcinomas in Eskimos. *Cancer*. 1985;55(11):2732-2736.
431. Chan JK, Yip TT, Tsang WY, et al. Specific association of Epstein-Barr virus with lymphoepithelial carcinoma among tumors and tumorlike lesions of the salivary gland. *Arch Pathol Lab Med*. 1994;118(10):994-997.
432. Kuo T, Tsang NM. Salivary gland type nasopharyngeal carcinoma: a histologic, immunohistochemical, and Epstein-Barr virus study of 15 cases including a psammomatous mucoepidermoid carcinoma. *Am J Surg Pathol*. 2001;25(1):80-86.
433. Raab-Traub N, Rajadurai P, Flynn K, Lanier AP. Epstein-Barr virus infection in carcinoma of the salivary gland. *J Virol*. 1991;65(12):7032-7036.
434. Tsai CC, Chen CL, Hsu HC. Expression of Epstein-Barr virus in carcinomas of major salivary glands: a strong association with lymphoepithelioma-like carcinoma. *Hum Pathol*. 1996;27(3):258-262.

435. Wang CP, Chang YL, Ko JY, et al. Lymphoepithelial carcinoma versus large cell undifferentiated carcinoma of the major salivary glands. *Cancer*. 2004;101(9):2020-2027.
436. Croitoru CM, Suarez PA, Luna MA. Hybrid carcinomas of salivary glands. Report of 4 cases and review of the literature. *Arch Pathol Lab Med*. 1999;123(8):698-702.
437. Nagao T, Sugano I, Ishida Y, et al. Hybrid carcinomas of the salivary glands: report of nine cases with a clinicopathologic, immunohistochemical, and p53 gene alteration analysis. *Mod Pathol*. 2002;15(7):724-733.
438. Batsakis JG, el-Naggar AK, Luna MA. "Adenocarcinoma, not otherwise specified": a diminishing group of salivary carcinomas. *Ann Otol Rhinol Laryngol*. 1992;101(1):102-104.
439. Li J, Wang BY, Nelson M, et al. Salivary adenocarcinoma, not otherwise specified: a collection of orphans. *Arch Pathol Lab Med*. 2004;128(12):1385-1394.
440. Dunn P, Kuo TT, Shih LY, et al. Primary salivary gland lymphoma: a clinicopathologic study of 23 cases in Taiwan. *Acta Haematol*. 2004;112(4):203-208.
441. Gleeson MJ, Bennett MH, Cawson RA. Lymphomas of salivary glands. *Cancer*. 1986;58(3):699-704.
442. Kojima M, Shimizu K, Nishikawa M, et al. Primary salivary gland lymphoma among Japanese: a clinicopathological study of 30 cases. *Leuk Lymphoma*. 2007;48(9):1793-1798.
443. Mehle ME, Kraus DH, Wood BG, et al. Lymphoma of the parotid gland. *Laryngoscope*. 1993;103(1 Pt 1):17-21.
444. Nakamura S, Ichimura K, Sato Y, et al. Follicular lymphoma frequently originates in the salivary gland. *Pathol Int*. 2006;56(10):576-583.
445. Kojima M, Nakamura S, Ichimura K, et al. Follicular lymphoma of the salivary gland: a clinicopathological and molecular study of six cases. *Int J Surg Pathol*. 2001;9(4):287-293.
446. Kojima M, Nakamura S, Itoh H, et al. Sclerosing variant of follicular lymphoma arising from submandibular glands and resembling "Kuttner tumor": a report of 3 patients. *Int J Surg Pathol*. 2003;11(4):303-307.
447. Abbondanzo SL. Extranodal marginal-zone B-cell lymphoma of the salivary gland. *Ann Diagn Pathol*. 2001;5(4):246-254.
448. Takahashi H, Cheng J, Fujita S, et al. Primary malignant lymphoma of the salivary gland: a tumor of mucosa-associated lymphoid tissue. *J Oral Pathol Med*. 1992;21(7):318-325.
449. Schmid U, Helbron D, Lennert K. Primary malignant lymphomas localized in salivary glands. *Histopathology*. 1982;6(6):673-687.
450. Dunphy CH, Grosso LE, Rodriquez JJ, Dunphy FR. Bilateral mucosa-associated lymphoid tissue lymphomas of parotid glands: a 13-year interval. *Mod Pathol*. 1996;9(5):560-565.
451. Nime FA, Cooper HS, Eggleston JC. Primary malignant lymphomas of the salivary glands. *Cancer*. 1976;37(2):906-912.
452. Miller R, Yanagihara ET, Dubrow AA, Lukes RJ. Malignant lymphoma in the Warthin's tumor. Report of a case. *Cancer*. 1982;50(12):2948-2950.
453. Hsi ED, Singleton TP, Swinnen L, et al. Mucosa-associated lymphoid tissue-type lymphomas occurring in post-transplantation patients. *Am J Surg Pathol*. 2000;24(1):100-106.
454. Ochoa ER, Harris NL, Pilch BZ. Marginal zone B-cell lymphoma of the salivary gland arising in chronic sclerosing sialadenitis (Kuttner tumor). *Am J Surg Pathol*. 2001;25(12):1546-1550.
455. Kerr PD, Dort JC. Primary extramedullary plasmacytoma of the salivary glands. *J Laryngol Otol*. 1991;105(8):687-692.
456. Pascoe HR, Dorfman RF. Extramedullary plasmacytoma of the submaxillary gland. *Am J Clin Pathol*. 1969;51(4):501-507.
457. James M, Norton AJ, Akosa AB, Primary T. cell lymphoma of submandibular salivary gland. *Histopathology*. 1993;22(1):83-85.
458. Chan JK, Tsang WY, Hui PK, et al. T- and T/natural killer-cell lymphomas of the salivary gland: a clinicopathologic, immunohistochemical and molecular study of six cases. *Hum Pathol*. 1997;28(2):238-245.
459. Hyman GA, Wolff M. Malignant lymphomas of the salivary glands. Review of the literature and report of 33 new cases, including four cases associated with the lymphoepithelial lesion. *Am J Clin Pathol*. 1976;65(4):421-438.
460. Livesey JR, Soames JV. Cystic lymphangioma in the adult parotid. *J Laryngol Otol*. 1992;106(6):566-568.
461. Mantravadi J, Roth LM, Kafrawy AH. Vascular neoplasms of the parotid gland. Parotid vascular tumors. *Oral Surg Oral Med Oral Pathol*. 1993;75(1):70-75.
462. Childers EL, Furlong MA, Fanburg-Smith JC. Hemangioma of the salivary gland: a study of ten cases of a rarely biopsied/excised lesion. *Ann Diagn Pathol*. 2002;6(6):339-344.
463. Takato T, Komuro Y, Yonehara Y. Giant hemangioma of the parotid gland associated with Kasabach-Merritt syndrome: a case report. *J Oral Maxillofac Surg*. 1993;51(4):425-428.
464. North PE, Waner M, Mizeracki A, Mihm MC Jr. GLUT1: a newly discovered immunohistochemical marker for juvenile hemangiomas. *Hum Pathol*. 2000;31(1):11-22.
465. Baker SE, Jensen JL, Correll RW. Lipomas of the parotid gland. *Oral Surg Oral Med Oral Pathol*. 1981;52(2):167-171.
466. Davidson D, Leibel BS, Berris B. Asymptomatic parotid gland enlargement in diabetes mellitus. *Ann Intern Med*. 1969;70(1):31-38.
467. Ascoli V, Albedi FM, De Blasiis R, Nardi F. Sialadenosis of the parotid gland: report of four cases diagnosed by fine-needle aspiration cytology. *Diagn Cytopathol*. 1993;9(2):151-155.
468. Katz AD, Passy V, Kaplan L. Neurogenous neoplasms of major nerves of face and neck. *Arch Surg*. 1971;103(1):51-56.
469. Murrell GL, Barnes M, Langford FP, Kenan PD. Submandibular rhabdomyoma. *Ear Nose Throat J*. 1992;71(12):663-664.
470. Ferreiro JA, Nascimento AG. Solitary fibrous tumour of the major salivary glands. *Histopathology*. 1996;28(3):261-264.
471. Guarino M, Giordano F, Pallotti F, Ponzi S. Solitary fibrous tumour of the submandibular gland. *Histopathology*. 1998;32(6):571-573.
472. Carrillo R, Rodriquez-Peralto JL, Batsakis JG, el-Naggar AK. Primary haemangiopericytomas of the parotid gland. *J Laryngol Otol*. 1992;106(7):659-661.
473. Nagao T, Sugano I, Ishida Y, et al. Sialolipoma: a report of seven cases of a new variant of salivary gland lipoma. *Histopathology*. 2001;38(1):30-36.
474. Dimosthenous K, Righi A. Granular cell tumor of the parotid gland: an exceptionally rare occurrence. *Int J Surg Pathol*. 2008;16(2):213-214.
475. Batsakis JG, Frankenthaler R. Embryoma (sialoblastoma) of salivary glands. *Ann Otol Rhinol Laryngol*. 1992;101(11):958-960.
476. Brandwein M, Al-Naeif NS, Manwani D, et al. Sialoblastoma: clinicopathological/immunohistochemical study. *Am J Surg Pathol*. 1999;23(3):342-348.
477. Luna MA. Sialoblastoma and epithelial tumors in children: their morphologic spectrum and distribution by age. *Adv Anat Pathol*. 1999;6(5):287-292.
478. Williams SB, Ellis GL, Warnock GR. Sialoblastoma: a clinicopathologic and immunohistochemical study of 7 cases. *Ann Diagn Pathol*. 2006;10(6):320-326.
479. Dehner LP, Valbuena L, Perez-Atayde A, et al. Salivary gland anlage tumor ("congenital pleomorphic adenoma"). A clinicopathologic, immunohistochemical and ultrastructural study of nine cases. *Am J Surg Pathol*. 1994;18(1):25-36.
480. Auclair PL, Langloss JM, Weiss SW, Corio RL. Sarcomas and sarcomatoid neoplasms of the major salivary gland regions. A clinicopathologic and immunohistochemical study of 67 cases and review of the literature. *Cancer*. 1986;58(6):1305-1315.
481. Fanburg-Smith JC, Furlong MA, Childers EL. Oral and salivary gland angiosarcoma: a clinicopathologic study of 29 cases. *Mod Pathol*. 2003;16(3):263-271.
482. Yin WH, Guo SP, Yang HY, Chan JK. Desmoplastic small round cell tumor of the submandibular gland—a rare but distinctive primary salivary gland neoplasm. *Hum Pathol*. 2010;41(3):438-442.
483. Benjamin E, Wells S, Fox H, et al. Malignant fibrous histiocytomas of salivary glands. *J Clin Pathol*. 1982;35(9):946-953.
484. Castle JT, Thompson LD. Kaposi sarcoma of major salivary gland origin: a clinicopathologic series of six cases. *Cancer*. 2000;88(1):15-23.
485. Deb RA, Desai SB, Amonkar PP, et al. Primary primitive neuroectodermal tumour of the parotid gland. *Histopathology*. 1998;33(4):375-378.
486. Yu FH, Kobos JW, Brooks JSJ. Synovial sarcoma of the parotid gland region: a case report and review of the literature. *Int J Surg Pathol*. 1996–1997;4:239-244.
487. Walterhouse DO, Pappo AS, Baker KS, et al. Rhabdomyosarcoma of the parotid region occurring in childhood and adolescence. A report from the Intergroup Rhabdomyosarcoma Study Group. *Cancer*. 2001;92(12):3135-3146.
488. Seifert G, Hennings K, Caselitz J. Metastatic tumors to the parotid and submandibular glands—analysis and differential diagnosis of 108 cases. *Pathol Res Pract*. 1986;181(6):684-692.
489. Jennings TA, Okby NT, Schroer KR, et al. Parotid involvement by desmoplastic melanoma. *Histopathology*. 1996;29(2):165-170.
490. Shah JP, Kraus DH, Dubner S, Sarkar S. Patterns of regional lymph node metastases from cutaneous melanomas of the head and neck. *Am J Surg*. 1991;162(4):320-323.
491. Simpson RH, Skalova A. Metastatic carcinoma of the prostate presenting as parotid tumour. *Histopathology*. 1997;30(1):70-74.
492. Brodsky G, Rabson AB. Metastasis to the submandibular gland as the initial presentation of small cell ("oat cell") lung carcinoma. *Oral Surg Oral Med Oral Pathol*. 1984;58(1):76-80.
493. Melnick SJ, Amazon K, Dembrow V. Metastatic renal cell carcinoma presenting as a parotid tumor: a case report with immunohistochemical findings and a review of the literature. *Hum Pathol*. 1989;20(2):195-197.
494. Hrebinko R, Taylor SR, Bahnson RR. Carcinoma of prostate metastatic to parotid gland. *Urology*. 1993;41(3):272-273.
495. Eveson JW, Cawson RA. Salivary gland tumours. A review of 2410 cases with particular reference to histological types, site, age and sex distribution. *J Pathol*. 1985;146(1):51-58.
496. Spiro RH. Salivary neoplasms: overview of a 35-year experience with 2,807 patients. *Head Neck Surg*. 1986;8(3):177-184.
497. Eneroth CM. Incidence and prognosis of salivary-gland tumours at different sites. A

study of parotid, submandibular and palatal tumours in 2632 patients. *Acta Otolaryngol Suppl*. 1969;263:174-178.
498. Gnepp DR, Schroeder W, Heffner D. Synchronous tumors arising in a single major salivary gland. *Cancer*. 1989;63(6): 1219-1224.
499. Fine G, Marshall RB, Horn RC Jr. Tumors of the minor salivary glands. *Cancer*. 1960;13:653-669.
500. Smith A, Winkler B, Perzin KH, et al. Mucoepidermoid carcinoma arising in an intraparotid lymph node. *Cancer*. 1985;55(2):400-403.
501. Albeck H, Nielsen NH, Hansen HE, et al. Epidemiology of nasopharyngeal and salivary gland carcinoma in Greenland. *Arctic Med Res*. 1992;51(4):189-195.
502. Shore-Freedman E, Abrahams C, Recant W, Schneider AB. Neurilemomas and salivary gland tumors of the head and neck following childhood irradiation. *Cancer*. 1983;51(12):2159-2163.
503. Spitz MR, Batsakis JG. Major salivary gland carcinoma. Descriptive epidemiology and survival of 498 patients. *Arch Otolaryngol*. 1984;110(1):45-49.
504. Saku T, Hayashi Y, Takahara O, et al. Salivary gland tumors among atomic bomb survivors, 1950–1987. *Cancer*. 1997;79(8):1465-1475.
505. Baker SR, Malone B. Salivary gland malignancies in children. *Cancer*. 1985;55(8):1730-1736.
506. Byers RM, Piorkowski R, Luna MA. Malignant parotid tumors in patients under 20 years of age. *Arch Otolaryngol*. 1984;110(4):232-235.
507. Callender DL, Frankenthaler RA, Luna MA, et al. Salivary gland neoplasms in children. *Arch Otolaryngol Head Neck Surg*. 1992;118(5):472-476.
508. Lussier C, Klijanienko J, Vielh P. Fine-needle aspiration of metastatic nonlymphomatous tumors to the major salivary glands: a clinicopathologic study of 40 cases cytologically diagnosed and histologically correlated. *Cancer*. 2000;90:350-356.
509. MacLeod CB, Frable WJ. Fine-needle aspiration biopsy of the salivary gland: problem cases. *Diagn Cytopathol*. 1993;9(2):216-224, discussion 24–25.
510. Li S, Baloch ZW, Tomaszewski JE, LiVolsi VA. Worrisome histologic alterations following fine-needle aspiration of benign parotid lesions. *Arch Pathol Lab Med*. 2000;124(1):87-91.
511. Mukunyadzi P, Bardales RH, Palmer HE, Stanley MW. Tissue effects of salivary gland fine-needle aspiration. Does this procedure preclude accurate histologic diagnosis? *Am J Clin Pathol*. 2000;114(5):741-745.
512. Granick MS, Erickson ER, Hanna DC. Accuracy of frozen-section diagnosis in salivary gland lesions. *Head Neck Surg*. 1985;7(6):465-467.
513. Heller KS, Attie JN, Dubner S. Accuracy of frozen section in the evaluation of salivary tumors. *Am J Surg*. 1993;166(4):424-427.
514. Rigual NR, Milley P, Lore JM Jr, Kaufman S. Accuracy of frozen-section diagnosis in salivary gland neoplasms. *Head Neck Surg*. 1986;8(6):442-446.
515. Eneroth CM, Hamberger CA. Principles of treatment of different types of parotid tumors. *Laryngoscope*. 1974;84(10):1732-1740.
516. Witten J, Hybert F, Hansen HS. Treatment of malignant tumors in the parotid glands. *Cancer*. 1990;65(11):2515-2520.
517. Yamashita T, Tomoda K, Kumazawa T. The usefulness of partial parotidectomy for benign parotid gland tumors. A retrospective study of 306 cases. *Acta Otolaryngol Suppl*. 1993;500:113-116.
518. Armstrong JG, Harrison LB, Thaler HT, et al. The indications for elective treatment of the neck in cancer of the major salivary glands. *Cancer*. 1992;69(3):615-619.
519. Garden AS, Weber RS, Ang KK, et al. Postoperative radiation therapy for malignant tumors of minor salivary glands. Outcome and patterns of failure. *Cancer*. 1994;73(10):2563-2569.
520. Spiro IJ, Wang CC, Montgomery WW. Carcinoma of the parotid gland. Analysis of treatment results and patterns of failure after combined surgery and radiation therapy. *Cancer*. 1993;71(9):2699-2705.
521. Elkon D, Colman M, Hendrickson FR. Radiation therapy in the treatment of malignant salivary gland tumors. *Cancer*. 1978;41(2):502-506.
522. Shingaki S, Ohtake K, Nomura T, Nakajima T. The role of radiotherapy in the management of salivary gland carcinomas. *J Craniomaxillofac Surg*. 1992;20(5):220-224.
523. Tu G, Hu Y, Jiang P, Qin D. The superiority of combined therapy (surgery and postoperative irradiation) in parotid cancer. *Arch Otolaryngol*. 1982;108(11):710-713.
524. Frankenthaler RA, Luna MA, Lee SS, et al. Prognostic variables in parotid gland cancer. *Arch Otolaryngol Head Neck Surg*. 1991;117(11):1251-1256.
525. Fu KK, Leibel SA, Levine ML, et al. Carcinoma of the major and minor salivary glands: analysis of treatment results and sites and causes of failures. *Cancer*. 1977;40(6):2882-2890.
526. Gallo O, Franchi A, Bottai GV, et al. Risk factors for distant metastases from carcinoma of the parotid gland. *Cancer*. 1997;80(5):844-851.
527. Hickman RE, Cawson RA, Duffy SW. The prognosis of specific types of salivary gland tumors. *Cancer*. 1984;54(8): 1620-1624.
528. Andersen LJ, Therkildsen MH, Ockelmann HH, et al. Malignant epithelial tumors in the minor salivary glands, the submandibular gland, and the sublingual gland. Prognostic factors and treatment results. *Cancer*. 1991;68(11):2431-2437.
529. Eneroth CM, Hjertman L, Moberger G. Malignant tumours of the submandibular gland. *Acta Otolaryngol*. 1967;64(5): 514-536.
530. Sugano S, Mukai K, Tsuda H, et al. Immunohistochemical study of c-erbB-2 oncoprotein overexpression in human major salivary gland carcinoma: an indicator of aggressiveness. *Laryngoscope*. 1992;102(8):923-927.
531. Gallo O, Franchi A, Bianchi S, et al. p53 oncoprotein expression in parotid gland carcinoma is associated with clinical outcome. *Cancer*. 1995;75(8):2037-2044.
532. el-Naggar AK, Hurr K, Kagan J, et al. Genotypic alterations in benign and malignant salivary gland tumors: histogenetic and clinical implications. *Am J Surg Pathol*. 1997;21(6):691-697.
533. Kamio N. Coexpression of p53 and c-erbB-2 proteins is associated with histological type, tumour stage, and cell proliferation in malignant salivary gland tumours. *Virchows Arch*. 1996;428(2): 75-83.

Ear

7

Jonathan B. McHugh

CHAPTER CONTENTS

Introduction, *269*
Normal anatomy, *269*
Diseases of external ear, *269*
Non-neoplastic disorders, *269*
Tumors and tumorlike conditions, *270*
Diseases of middle and inner ear, *272*
Non-neoplastic disorders, *272*
Tumors and tumorlike conditions, *273*

Introduction

Nearly all the diseases that can involve the ear also occur in other sites of the body. However, some of these diseases either have a predilection for the ear or pose special problems when occurring at this site. Only the features of these lesions as they pertain to their location in the ear will be discussed here. The general features of the various entities are dealt with in the respective chapters.

The reader is referred to the specialized books on the subject for an authoritative discussion of the specific diseases of this structure.[1–4]

Normal Anatomy

The ear is divided into the external, middle, and inner segments. The external ear consists of the auricle (pinna) and the external auditory canal, which is further divided into an outer (cartilaginous) portion and an inner (osseous) portion. Microscopically, both the auricle and the canal are covered by skin that differs little from that of the skin elsewhere, except for the fact that in the inner half of the canal the epidermis is very thin and lacks rete pegs. Adnexal structures are present in both areas; they are represented by hair follicles, sebaceous glands, and eccrine sweat glands in the auricle and by hair follicles, sebaceous glands, and a special type of apocrine sweat gland (known as *ceruminous glands*) in the canal, most of which are located in the outer third of this structure.

The inner portion of the canal is separated from the middle ear by the *tympanic membrane*, a thin fibrous structure lined by an attenuated layer of keratinizing squamous epithelium on the outer surface and by a single layer of cuboidal cells on the inner surface.

The middle ear (tympanic cavity) contains the three auditory ossicles (malleus, incus, and stapes); it connects with the pharynx through the eustachian tube and with the mastoid cavity and its contiguous pneumatic spaces. The middle ear proper and the mastoid are lined by a layer of flat epithelium; the eustachian tube is covered by tall ciliated epithelium, with smooth transitions between the two types.[5,6]

The inner ear, which is located in the medial portion of the temporal bone, contains the *cochlea* and the *vestibular labyrinth*. These structures are supplied by the eighth cranial nerve, which enters the region through the internal auditory canal together with the seventh nerve. The vestibular labyrinth includes the blind *endolymphatic sac*, which is located in the middle of the posteromedial plate of the petrous bone. It has an intraosseous *rugose* portion and a *distal* portion that lies within the dura. It is lined by a flat to low columnar epithelium resting on a well-vascularized stroma.[7] The sac is connected to the *utricle* and *saccule* (the two main membranous structures of the vestibule) by the *endolymphatic duct*, which passes across the petrous bone.

Diseases of External Ear

Non-Neoplastic Disorders

Congenital abnormalities of this region are common. *Preauricular sinuses*, *cysts*, and *fistulas* are derived from the first or second branchial clefts.[8,9] They are lined by squamous or respiratory epithelium and often contain lymphoid tissue in the wall. Cartilage and skin adnexa may also be present. Secondary inflammatory features are common.[8,9] The treatment is surgical, and recurrences are common.[10] *Accessory tragi* are unilateral or bilateral nodules present at birth, located anteriorly to the auricle in the pretragal area.[11] Like the previous lesions, they are the expression of a branchial cleft anomaly. Sometimes they are seen as a component of the oculoauriculovertebral syndrome (Goldenhar syndrome).[12] Microscopically they are composed of a covering of skin, numerous tiny, mature hair follicles, and a core of fibrofatty tissue that may contain cartilage.[13] Depending on the relative amounts of these components, these lesions can be variously misdiagnosed as papillomas, fibromas, or soft tissue

Abstract

This chapter reviews normal anatomy and histology of the external, middle, and inner ear compartments. Non-neoplastic and neoplastic pathologies of the external are discussed separately from those of the middle and inner ear.

Keywords

external ear,
middle ear,
inner ear

chondromas. *Ectopic salivary gland tissue* is not uncommon in the region of the middle ear; it can also be found in the external auditory canal.[14]

Keratinous cysts are common in and around the ear. Some are probably developmental anomalies related to the branchial cleft (see preceding discussion), and others are equivalent to those seen elsewhere in the skin and, as such, are either of infundibular hair follicle derivation or of epidermal inclusion type. They are all lined by keratinized squamous epithelium and filled by keratin of epidermal type. Keratinous cysts of pilar type are common in the periauricular area but not in the ear itself.

Cholesteatoma of the external auditory canal is composed of a cystic mass of keratinized squamous epithelium overlying an area of bone sequestration in the inner half of the canal. This rare condition should not be confused with cholesteatoma of the middle ear spaces or with *keratosis obturans*, a disorder characterized by a diffuse acanthosis and hyperkeratosis of the skin of the canal associated with underlying chronic inflammation.[15]

Malignant external otitis, also known as necrotizing granulomatous otitis, is usually caused by *Pseudomonas aeruginosa* and affects mainly elderly patients who have diabetes. It can also be due to fungi, particularly *Aspergillus*. Microscopically, it is characterized by a necrotizing inflammatory reaction involving skin, soft tissue, cartilage, and bone, with invasion of the skull base.[16]

Chondrodermatitis nodularis chronica helicis (Winkler disease) usually involves the upper portion of the helix in older patients, but it can also occur in the antihelix and in younger individuals. Clinically, it presents as a painful, small, round nodule, often covered by a crust.[17] It is often thought clinically to be squamous cell carcinoma or actinic keratosis. Microscopically, there is marked hyperkeratosis and parakeratosis, acanthosis, and hyperplasia of the epidermis, which can reach pseudoepitheliomatous degrees (Fig. 7.1). The center is usually ulcerated and covered by granulation tissue. The underlying inflammation reaches the perichondrium and is characterized by a mononuclear infiltrate and vascular proliferation. The latter may be so pronounced as to simulate a vascular neoplasm, particularly glomus tumor.[18]

Idiopathic pseudocystic chondromalacia results from degeneration of the auricular cartilage and is more commonly seen as a painless localized ear enlargement (sometimes bilaterally) in young males. Grossly, a cystic formation within the external auricular cartilage is filled with a watery fluid. Microscopically, the cyst has no lining, and there is no associated inflammation.[19]

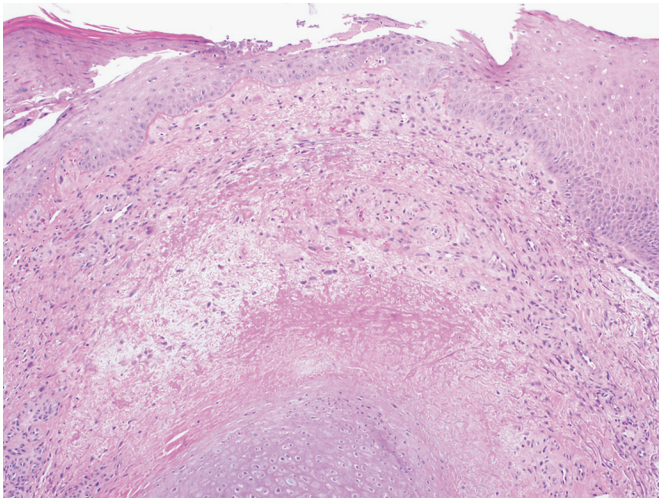

Figure 7.1 Chondrodermatitis Nodularis Helicis. There is fibrosis and vascular proliferation in the dermis, accompanied by pseudoepitheliomatous hyperplasia of the overlying epithelium. The perichondrium demonstrates fibrinoid degeneration.

Relapsing polychondritis is characterized by episodic painful inflammation of cartilage, most commonly in the outer and inner ear, nose, costochondral junctions, a variety of joints, and sometimes the cartilage of the respiratory tract.[20] Aortic insufficiency is a life-threatening complication. The external ear is affected in almost 90% of the patients, and it represents the initial site of involvement in one-third of the cases.[21]

Microscopically, there are degenerative changes in the cartilage (decrease in basophilic staining, loss of lacunae, and eventual replacement by collagen) and an inflammatory infiltrate that is neutrophilic initially and mononuclear in the late stages.[21] The etiology is unknown, but the detection in these patients of antibodies to type II collagen suggests an autoimmune mechanism.[22,23]

Nodular fasciitis can involve the external ear region; its morphologic appearance is similar to that seen at other soft tissue sites.

Localized disorders of the external ear formed by the accumulation of extracellular material include *keloid*, localized *amyloidosis*, uric acid tophi of *gout*, *elastotic nodules*, and *collagenous papules*. Elastotic nodules are small papules and nodules most commonly noted on the antihelix as a result of actinic damage. Microscopically, they are composed of dermal clumps of elastic tissue.[24] Collagenous papules are smooth, firm, small papules, located bilaterally on the inner aspects of the aural pinnae and, in rare cases, in the external auditory canal. Microscopically, there is a dense collagenous mass in which dilated vessels and scattered fibroblasts are identified.[25]

Tumors and Tumorlike Conditions

Keratotic Lesions

The external ear is a common site for *seborrheic keratosis* and *actinic keratosis*. Some ear lesions designated as fibroepithelial papillomas or squamous papillomas are probably variants of seborrheic keratosis. Other *squamous papillomas* present as branching complex polypoid structures in the external auditory canal. Additional types of keratotic lesion that can occur at this site are *keratoacanthoma*, *inverted follicular keratosis*, *verruca vulgaris*, and *molluscum contagiosum*. It has been estimated that 8.5% of all keratoacanthomas involve the skin of the external ear.[26]

Basal Cell Carcinoma

Basal cell carcinoma is a common tumor of the auricle and external auditory canal, the ratio between the two sites being 5 : 1. In the auricle, basal cell carcinoma predominates over squamous cell carcinoma (although not as much as in the rest of the head and neck area[27]), the ratio being reversed in the external auditory canal. The microscopic features and behavior of this lesion are described in Chapter 3. If untreated, basal cell carcinomas of the canal may extend into the middle ear, mastoid, or even the cranial cavity.[28] These tumors may be treated with surgery or radiation therapy, the choice depending on the size and location.

Squamous Cell Carcinoma

Squamous cell carcinoma of the external ear comprises one-fourth of all squamous cell cutaneous carcinomas of the head and neck

Figure 7.2 This squamous cell carcinoma of the auricular concha required the removal of the entire external ear.

region.[29] Most patients are elderly. The tumors are more common in the auricle (particularly the helix) than in the canal. Many of the latter present clinically with symptoms of otitis.[30] Grossly and microscopically, they do not differ significantly from those seen elsewhere in sun-exposed skin (Fig. 7.2). Some are of the *adenoid (pseudoglandular)* variant, others belong to the *verrucous* type, and still others to the *spindle cell* (*sarcomatoid*) variant.[31,32] The pattern of local spread varies depending on the initial location of the tumor. Tumors of the helix spread initially along the helix and then anteriorly to the antihelix and posteriorly to the posterior surface of the ear; tumors of the antihelix spread concentrically; tumors of the posterior surface of the ear spread to the helix and along that structure.[33] Tumors at high risk for regional lymph node involvement are those with a depth of invasion greater than 8 mm or a depth of invasion between 2 and 8 mm in conjunction with destructive cartilage invasion, lymphovascular invasion or a "noncohesive" invasive front.[34] Tumors of the canal tend to invade bone and often destroy the tympanic membrane to penetrate into the middle ear. Like their basal cell counterparts, squamous cell carcinomas can be treated by either surgery (primary resection with or without neck dissection) or radiation therapy, the choice being determined by the size, location, and degree of invasiveness of the lesion.[35]

The prognosis is much better for tumors of the auricle than for those in the canal, a fact that is at least partially related to the earlier diagnosis of the former type of tumor.[33] In one series, tumor-related deaths occurred in only 1 of 17 patients with tumors of the auricle but in 11 of 21 patients with tumors of the canal.[36] Survival is directly correlated with tumor stage. The prognosis is particularly ominous for tumors of the inner portion of the canal exhibiting deep involvement of the temporal bone and beyond.[37]

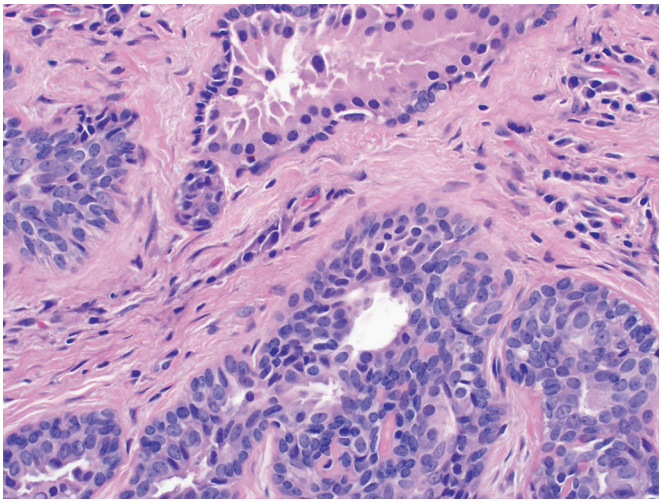

Figure 7.3 **Ceruminous Adenoma.** A benign biphasic epithelial proliferation is seen adjacent to normal ceruminous gland *(top center)*.

Adnexal Tumors

Almost any type of adnexal tumor can involve the skin of the external ear. One of the most common is *pilomatrixoma*, often seen in children and sometimes confused microscopically with basal cell carcinoma. Reported cases of adnexal tumors of this region include other types of *hair-follicle neoplasms*[38] and *sebaceous adenoma*.[39]

Adnexal tumors of the external auditory canal are generally assumed to be of ceruminous gland origin and include both benign and malignant neoplasms. The clinical presentation is similar, although the malignant tumors are more often painful and ulcerated.[40] Four major categories are recognized.

Ceruminous adenoma (ceruminoma) is sharply demarcated but not encapsulated. Variously sized glandular formations arranged in a back-to-back proliferation and lined by apocrine cells are seen microscopically (Fig. 7.3).[41] A myoepithelial layer can be discerned at the base. Mitotic figures, pleomorphism, necrosis, and invasiveness are lacking. Presence of cerumen pigment and positivity for CK7 and p63 are helpful in the differential diagnosis with other neoplasms of the region.[42]

Benign mixed tumor (pleomorphic adenoma, chondroid syringoma) has an appearance similar to that of its cutaneous or salivary gland counterpart. In some cases, the epithelial component exhibits apocrine features similar to those of adenoma.[43]

Syringocystadenoma papilliferum is morphologically equivalent to the tumor occurring elsewhere in the skin, particularly in the scalp. Connection with the surface of the canal is characteristic.

Ceruminous adenocarcinoma may be well differentiated and therefore difficult to distinguish from adenoma. The presence of more than occasional mitotic activity, pleomorphism, the absence of a myoepithelial layer, necrosis, and invasiveness are the main identifying features.[44] The main problem with this tumor is local recurrence; nodal or distant metastases are exceedingly rare.

Some adenocarcinomas of ceruminous gland origin, not surprisingly, are clinically and morphologically identical to salivary gland carcinomas. Adenoid cystic carcinoma and mucoepidermoid carcinoma are the most common histologic subtypes. It is important to exclude extension into the external auditory canal from an adjacent parotid gland primary before making a diagnosis of primary ear salivary gland carcinoma.

Adenoid cystic carcinoma has an appearance similar to that of its more common equivalent in the salivary glands (Fig. 7.4). Like

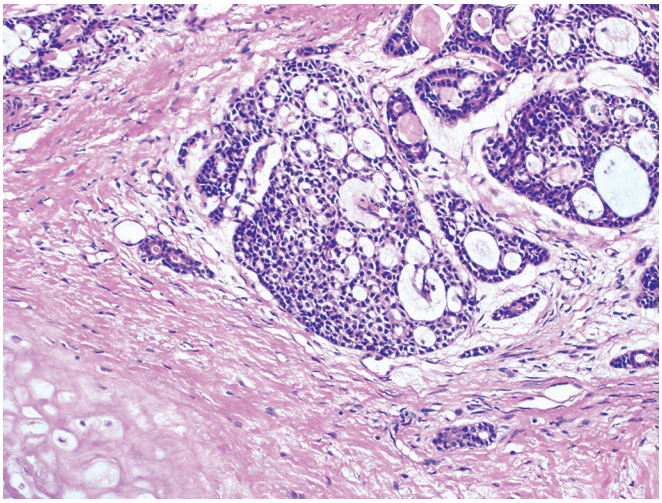

Figure 7.4 Adenoid cystic carcinoma growing beneath the epidermis of the external ear canal and infiltrating close to auricular cartilage *(bottom left).*

the latter, it has a great tendency for local (including perineurial) invasion and distant (rather than nodal) metastases, particularly to the lungs but also to brain.[45] The death rate is approximately 50%. *Mucoepidermoid carcinomas* arising in the ear are typically low-grade but are otherwise similar to those occurring in the salivary glands.

The differential diagnosis of these tumors includes direct invasion from so-called adenomas and paragangliomas of the middle ear and adnexal tumors of the auricle. It is particularly important to distinguish the benign eccrine dermal cylindroma arising from the conchal portion of the auricle from adenoid cystic carcinoma arising from the canal.

Melanocytic Tumors

Melanocytic nevi of any of the known microscopic types can occur in the auricle or, less commonly, in the canal.[46] They may show some disturbing morphologic features, similar to those often seen in the acral, flexural, and genital areas (so-called nevi of special sites).[46]

Malignant melanomas of the external ear comprise approximately 10% of all melanomas of the head and neck region.[47] Nearly all are located in the auricle rather than in the canal.[48] The most common type is superficially spreading. Nodal metastases are to the upper cervical, intraparotid, or occipital groups, depending on the exact location of the tumor in the auricle.

Other Tumors

Osteoma of the external auditory canal presents as a solitary pedunculated osseous mass attached by a narrow pedicle to the tympanosquamous or tympanomastoid suture line of the temporal bone. Microscopically, it is formed by mature lamellar bone containing bone marrow and covered by keratinized squamous epithelium.[49]

Exostoses are sessile, often multiple and bilateral masses that seem to be particularly common in swimmers. Microscopically, the appearance is similar to that of osteoma except for the absence of bone marrow spaces.[49]

Cutaneous myxomas of the external ear (superficial angiomyxoma) occur in patients with Carney complex, sometimes bilaterally. Microscopically, they are nonencapsulated circumscribed nodules composed of scattered stellate and spindle cells set in a myxoid, capillary-rich matrix.[50] A mixed inflammatory infiltrate with a predominance of neutrophils is common and helps to distinguish this lesion from other superficial myxoid tumors. Entrapped epithelial buds, cords, and cysts are seen in approximately 25% of cutaneous myxomas. Although benign, there is a propensity for recurrence.

Vascular tumors and tumorlike conditions include *vascular leiomyoma (angioleiomyoma)*,[51] *epithelioid (histiocytoid) hemangioma* (also known as angiolymphoid hyperplasia with eosinophilia and having a predilection for the skin of the ear, external auditory canal, and periauricular region[52]), and the related *epithelioid angiomatous nodule*.[53] The neoplastic versus inflammatory nature of the last two entities remains debatable.

Other primary tumors of the external ear include *Merkel cell carcinoma*[54,55] and various types of soft tissue neoplasm, including *rhabdomyosarcoma*, *myxoid chondrosarcoma*,[56] and *peripheral nerve sheath tumors*.[57] As already mentioned, the canal can be secondarily involved by tumors of the middle ear or salivary gland.

Exceptionally, *malignant lymphoma* presents initially as an ear lesion.[58]

Diseases of Middle and Inner Ear

Non-Neoplastic Disorders

Developmental anomalies of the middle ear include the presence of brain tissue (as a manifestation of heterotopia or encephalocele)[59] and ectopic salivary gland tissue (sometimes designated as choristoma).[60]

Inflammatory polyp (aural polyp, otic polyp) arises in the middle ear on the basis of a chronic otitis media but often presents in the external auditory canal following perforation of the tympanic membrane. Microscopically, the appearance is that of chronically inflamed stroma, typically with features of granulation tissue. The overlying mucosa may be of columnar respiratory type (consistent with its middle ear origin) or squamous (as a result of metaplasia). Cystically dilated glands may be present in the stroma.

Inflammations of the middle ear (otitis media) are usually of a nonspecific nature microscopically.[61] Although no glands are present in the subepithelial connective tissue of the middle ear, surface invaginations induced by chronic inflammation can result in a pseudoglandular appearance when cut in cross section. This structure can also be involved by specific conditions, such as tuberculosis, aspergillosis, malakoplakia, and granulomatosis with polyangiitis (Wegener).[62,63] *Cholesterol granulomas* can be seen in any inflammatory process involving the middle ear that results in microhemorrhage. These result from a foreign body giant cell reaction to cholesterol crystals that derive from the breakdown of extravasated red blood cells. Morphologically, they appear as empty acicular spaces surrounded by a giant cell reaction and nonspecific chronic inflammation with fibrosis, fresh hemorrhage, and hemosiderin-laden macrophages (Fig. 7.5). They are commonly seen in association with other lesions such as cholesteatoma.

Tympanosclerosis results from dystrophic calcification of the tympanic membrane and/or middle ear mucosa secondary to recurrent bouts of otitis media. Histologically, there is dense mineralization of connective tissues which can undergo ossification. Severe cases can result in ossicular fixation and conductive hearing loss.

Cholesteatoma usually presents during the third or fourth decade, but it may appear at any age. It is the result of chronic otitis media and may involve the middle ear, peritympanic space, mastoid cavities, and petrous portion of the temporal bone. Grossly, the appearance is that of a cyst filled with a granular waxy material. Microscopically, the membrane that bounds the lesion peripherally

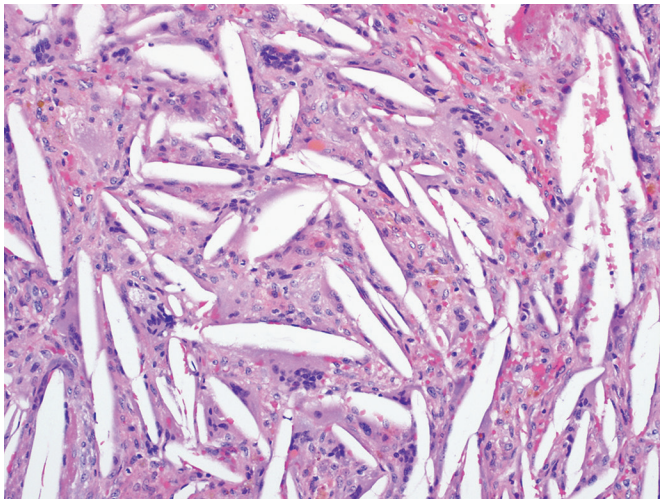

Figure 7.5 Cholesterol granuloma composed of inflammation with hemorrhage and cholesterol crystals with foreign body giant cell reaction.

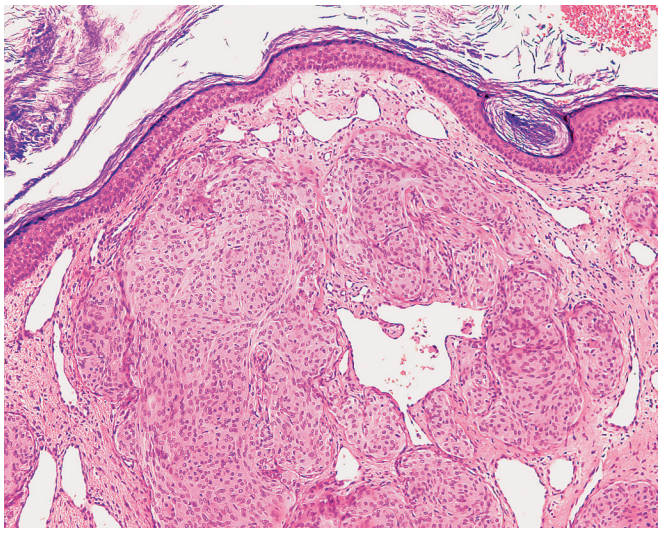

Figure 7.6 Meningioma of Ear. The appearance is identical to that of its counterpart in the central nervous system. Note the overlying cholesteatoma with middle ear epithelium replaced by keratinizing squamous mucosa.

is made up of keratinizing squamous epithelium, and the content is composed of keratin squames. Chronic inflammatory cells, cholesterol clefts, and foreign body–type giant cell granulomas are common. It should be noted that although *cholesterol granulomas* are often seen in the middle ear as a consequence of cholesteatoma, they may also occur independently from it as a result of hemorrhage or otitis media.

The pathogenesis of cholesteatoma is controversial; origin of the squamous epithelium from metaplasia of middle ear mucosa, migration from the external auditory canal, migration from the external surface of the tympanic membrane following a perforation, or retraction of the tympanic membrane into the middle ear have all been considered.[64] In the congenital form, the disease is thought to be the result of inclusions of squamous epithelium in the temporal bone. The matrix-degrading cysteine proteinase cathepsin K may be involved in the bone erosion often seen in this entity.[65]

The treatment is surgical and aimed at removal of the entire lesion, including the limiting membrane.[66]

Otosclerosis is a disorder of abnormal bone remodeling of unknown etiology. Genetic factors are clearly involved, but measles virus infection and autoimmunity may play contributory roles.[67,68] The typical and apparently unique site of involvement is the temporal bone. It is characterized by an initial bone resorption (otospongiosis) followed by bone production (otosclerosis).[69] This results in the formation of Paget disease–like woven bone with prominent cement lines.[70] The disease causes hearing loss because of fixation of the stapes footplate in the oval window. Usually, the only specimens received in the pathology laboratory are portions of the stapes head and crura, which are almost always unaffected by the disease.[70] Microscopic studies done on temporal bones at autopsy have revealed cases of "histologic otosclerosis" that were asymptomatic, but the incidence of this finding seems much lower (approximately 2.5%) than previously claimed.[71]

Tumors and Tumorlike Conditions

Paraganglioma

Paraganglioma of the glomus jugulare or glomus tympanicum is the most common neoplasm of the middle ear.[72] The general features of this tumor are discussed in Chapter 29. It can be found in the jugular bulb area, within the middle ear, in the external auditory canal, or around the eustachian tube.[73] In contrast to paragangliomas of other sites, those of the middle ear region have a marked predilection for females.[74] They can be familial, bilateral, or associated with paragangliomas elsewhere. Clinically, the typical presentation is that of a red mass protruding behind the tympanic membrane or extending in the canal. Profuse bleeding may be encountered at the time of biopsy. This tumor has a tendency to infiltrate adjacent bone; a few cases associated with distant metastases are on record. The initial treatment usually takes the form of local excision, but the incidence of local recurrence is greater than 50%.[74] Radiation therapy has also been used as an adjunct to surgery or as the primary treatment.[75]

Meningioma

Approximately 6% of all meningiomas arise from the surface of the petrous bone, from which they may invade this structure and reach the middle ear. In addition, meningiomas seemingly localized to the middle ear have been described.[76] The tumor may involve the external ear canal, mastoid cavity, or jugular fossa.[77] The microscopic appearance is described in Chapter 43 (Fig. 7.6). The treatment is surgical. The prognosis is substantially better for meningiomas limited to the middle ear than for those reaching this site through invasion of the petrous bone.

Schwannoma (Acoustic Neuroma)

The tumor traditionally known as acoustic neuroma is simply a schwannoma arising from the eighth (or sometimes the seventh) nerve, which grows within the internal auditory canal and can reach the middle ear. These are often submitted to the pathology department as tumors of the cerebello-pontine angle. Its features are described in Chapter 41. Nearly 90% of acoustic neuromas are solitary and not associated with neurofibromatosis 2 (NF2), whereas 5% are bilateral and not associated with NF2 and 4% are NF2 related.[78] The treatment is complete surgical resection, which is associated with a very low recurrence rate.

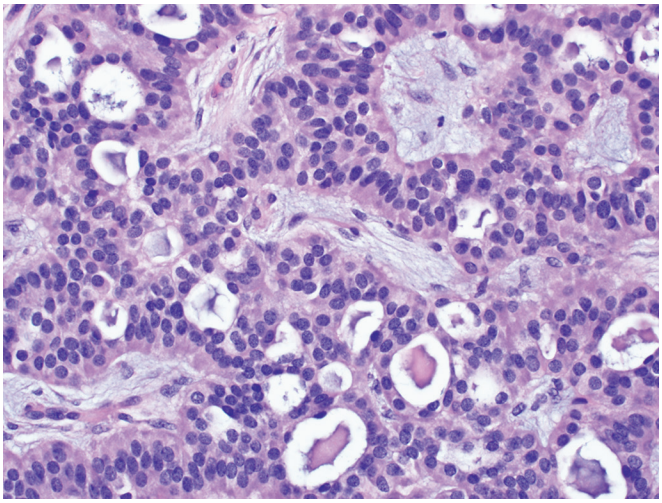

Figure 7.7 So-Called Middle Ear Adenoma. This tumor is closely related and perhaps identical to carcinoid tumor of the ear.

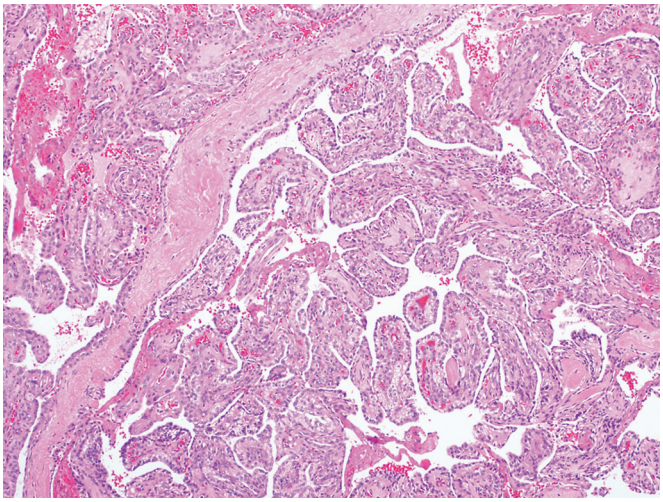

Figure 7.8 Endolymphatic Sac Tumor. The tumor forms papillary and glandular structures lined by clear cells. The papillary structures have well-vascularized connective tissue cores.

Middle Ear Adenoma (Carcinoid Tumor, Neuroendocrine Adenoma)

Middle ear adenoma is the term traditionally used for a distinctive tumor of the middle ear, mostly seen in patients between 20 and 40 years of age. Grossly, the lesion is grayish white and firm, not as vascular as paraganglioma, and relatively well circumscribed. Microscopically, the pattern of growth may be solid, glandular, or trabecular (Fig. 7.7).[79] The tumor cells are uniform, cuboidal or cylindrical, with a moderately abundant acidophilic cytoplasm that sometimes acquires plasmacytoid features.[80] Mitoses are exceedingly rare, pleomorphism is minimal, and necrosis is absent.

Histochemically, there may be intraluminal positivity for mucin and intracytoplasmic argyrophilia. Ultrastructurally, the tumor cells exhibit desmosomes and microvilli; in addition, membrane-bound dense-core granules are present in many of the tumor cells.[81] Immunohistochemically, positivity for keratin, neuroendocrine markers, and lysozyme has been described.[82,83]

The histogenetic problem posed by middle ear adenoma mainly concerns its possible neuroendocrine nature and relationship with the reported cases of **carcinoid tumors** of the middle ear.[84] The latter tumors have many cytoarchitectural features in common with middle ear adenoma but also exhibit undeniable evidence of neuroendocrine differentiation. Some authors like to view middle ear adenomas and carcinoid tumors as separate entities and regard the former as tumors of the middle ear mucosa.[83,85] However, a large number of studies performed in recent years have convincingly shown that these two tumors merge imperceptibly, in the sense of showing various degrees of combined exocrine and neuroendocrine differentiation.[86–90] As such, they could be regarded as analogous to adenocarcinoids or amphicrine neoplasms of other sites and are now all simply regarded as "middle ear adenomas." The presence of a neuroendocrine component is supported by the previously mentioned argyrophilia, demonstration of dense-core granules ultrastructurally, and reported immunoreactivity for neuron-specific enolase, chromogranin, synaptophysin, serotonin, and numerous peptide hormones (such as pancreatic polypeptide, glucagon, cholecystokinin, and leucine-enkephalin).[87] Rare cases associated with systemic manifestations (carcinoid syndrome) are also on record.

The treatment of choice of middle ear adenoma/carcinoid tumor is surgical excision. The prognosis is excellent, with only an occasional example of local recurrence.[87,89,90]

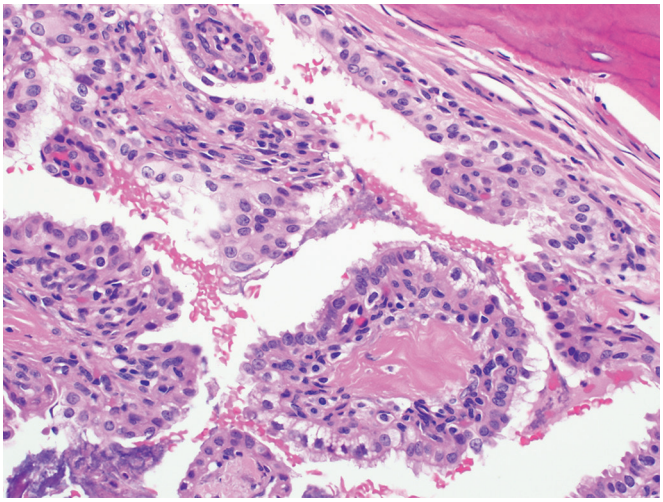

Figure 7.9 Endolymphatic Sac Tumor. The gland and papillary structures are lined by a monolayer of cytologically bland cells with clear cytoplasm, resembling the normal endolymphatic sac organ.

Endolymphatic Sac Tumor (Aggressive Papillary Middle Ear Tumor, Heffner Tumor)

Adenocarcinoma of the middle and inner ear has been a somewhat confusing and controversial entity.[91,92] The term has sometimes been used for papillary adenocarcinomas presenting in the middle ear and for papillary adenocarcinomas and "adenomas" arising in the temporal bone (aggressive papillary tumor of the temporal bone). Most of these lesions are now accepted as and referred to as endolymphatic sac tumors (ELSTs). ELST is an uncommon, locally aggressive but nonmetastasizing neoplasm arising from the endolymphatic sac of the petrous portion of the temporal bone. Most occur in adults and present with hearing loss often associated with tinnitus and vertigo. This is a low-grade papillary and glandular adenocarcinoma (Fig. 7.8) composed of uniform cuboidal cells with clear to acidophilic cytoplasm forming papillary structures that rest on a vascular stroma (Fig. 7.9). Cystic dilation of the glands often occurs, leading to a follicle-like appearance that is very reminiscent of that seen in thyroid tumors.[93–95] Tumors with prominent cytoplasmic clearing

simulate metastatic renal cell carcinoma. They stain positive for cytokeratin with variable GFAP and S-100 staining. They are negative for thyroglobulin and TTF-1. Gaffey et al.[96] who originally referred to this neoplasm as *aggressive papillary middle-ear tumor* (APMET), favored an origin from middle ear/mastoid epithelium. In a subsequent article, they showed that this lesion can occur in the setting of von Hippel–Lindau (VHL) disease, sometimes in association with a microscopically similar tumor in the broad ligament of presumed wolffian (mesonephric) origin.[97,98] APMET was shown to be closely related if not identical to the *low-grade adenocarcinoma of probable endolymphatic sac origin* reported by Heffner[99] and referred to by some as *Heffner tumor*.[100,101] Most of these are now accepted to be of endolymphatic sac origin with a strong association with VHL disease. Patients with ELSTs should be screened for VHL disease, and patients with the syndrome should be screened for ELSTs. Cases of this tumor occurring in the setting of VHL disease are typically bilateral and are associated with germline mutation of the *VHL* gene combined with loss of function of the wild-type allele through genetic deletion.[102] Interestingly, mutations or allelic deletions of the same gene have also been found in most sporadic tumors.[103,104]

ELST has a tendency to invade bone and the middle ear, from which it may spread to the cranial cavity, especially the posterior fossa. The treatment is surgical, but achievement of local control is difficult and associated with recurrences.[96]

Squamous Cell Carcinoma

Squamous cell carcinoma of the middle ear is exceedingly uncommon and typically presents in older patients with a history of long-standing ear discharge, which may be hemorrhagic and is usually associated with pain and hearing loss.[105] Rarely, the process is bilateral.[106] An etiologic role for chronic otitis media has long been suspected.[107] Grossly, the tumor fills the middle ear spaces, from where it may invade the bony walls of the mastoid ear cells, the bone septum that separates the ear from the carotid canal, the internal auditory meatus, the eustachian tube, and the external auditory canal. Eventually, it may reach the intracranial cavity and the soft tissues of the neck.[105] Microscopically, the tumor is an ordinary squamous cell carcinoma of various degrees of differentiation; in rare cases, it may be of *verrucous* type. The differential diagnosis includes secondary invasion of the middle ear by squamous cell carcinomas of the external auditory canal and the eustachian tube. The preferred form of treatment is a combination of surgery and radiation therapy. In the series by Michaels and Wells,[105] the 5-year survival rate was 39%.

Rhabdomyosarcoma

Rhabdomyosarcoma of the middle ear occurs almost exclusively in children. At the time of diagnosis, the tumor has often invaded the external canal, mastoid, and meninges.[108] CT scan is the best method to delineate the tumor and to detect intracranial spread. Microscopically, the neoplasms are most often of embryonal type, including the botryoid variety.[109] The microscopic features are described in Chapter 41 (Fig. 7.10). The treatment is a combination of surgery, radiation therapy, and multidrug chemotherapy.[109,110]

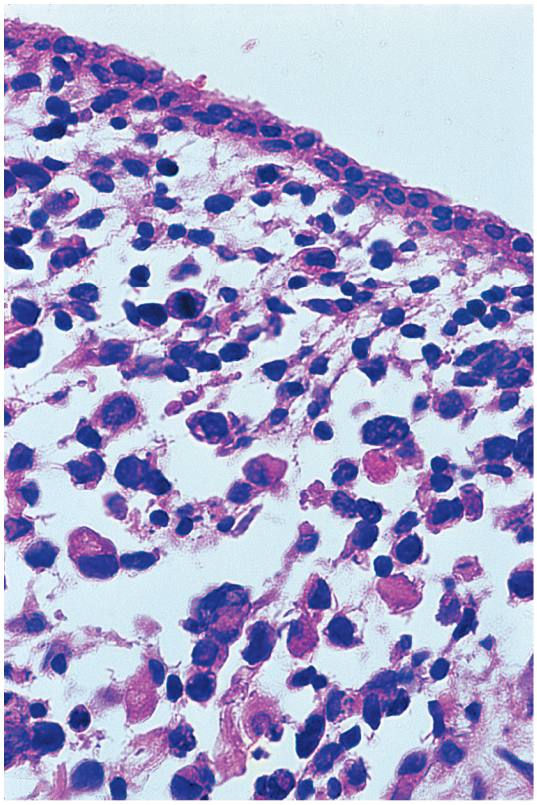

Figure 7.10 Embryonal Rhabdomyosarcoma of the Middle Ear. Neoplastic tumor cells are seen growing beneath a flattened epithelium. Most of the cell population is small, but there are larger elements (rhabdomyoblasts) with more abundant fibrillary acidophilic cytoplasm.

A few cases of rhabdomyosarcoma apparently localized to the external auditory canal have been reported.[109]

Other Primary Tumors

Rare benign primary tumors of the middle ear region include *lipoma*, *hemangioma*, *osteoma*, *ossifying fibroma*, *dermoid cyst* (in the eustachian tube), *teratoma*, and "*glioma*."[111–116] The middle ear can also be involved in cases of *Langerhans cell histiocytosis*.[117,118]

Metastatic Tumors

The temporal bone can be involved by malignant tumors arising elsewhere. This involvement can be in the form of direct extension from tumors of the pharynx, salivary glands, or central nervous system, or as blood-borne distant metastases. In the latter instance, the most common sites of the primary are breast, lung, and kidney.[119,120]

References

1. Friedmann I. *Pathology of the Ear*. Edinburgh: Churchill Livingstone; 1993.
2. Jackler RK, Driscoll CLW. *Tumors of the Ear and Temporal Bone*. Philadelphia, PA: Lippincott Williams & Wilkins; 2000.
3. Schuknecht HF, Merchant SN, Nadol JB. *Schuknecht's Pathology of the Ear*. Maidenhead, Berkshire: McGraw-Hill; 2010.
4. Nager GT, Hyams VJ. *Pathology of the Ear and Temporal Bone*. Baltimore, MD: Williams & Wilkins; 1993.
5. Lim DJ. Functional morphology of the mucosa of the middle ear and Eustachian tube. *Ann Otol Rhinol Laryngol*. 1976;85(2 suppl 25 Pt 2):36-43.
6. Wenig BHM, Michaels L. The ear and temporal bone. In: Mills SE, ed. *Histology for Pathologists*. 3rd ed. Baltimore, MD: Lippincott Williams & Wilkins; 2007: 371-401.
7. Schindler RA. The ultrastructure of the endolymphatic sac in man. *Laryngoscope*. 1980;90(6 Pt 2):1-39.

8. Olsen KD, Maragos NE, Weiland LH. First branchial cleft anomalies. *Laryngoscope*. 1980;90(3):423-436.
9. Work WP. Newer concepts of first branchial cleft defects. *Laryngoscope*. 1972;82(9):1581-1593.
10. Ellies M, Laskawi R, Arglebe C, Altrogge C. Clinical evaluation and surgical management of congenital preauricular fistulas. *J Oral Maxillofac Surg*. 1998;56(7):827-830, discussion 831.
11. Brownstein MH, Wanger N, Helwig EB. Accessory tragi. *Arch Dermatol*. 1971;104(6):625-631.
12. Jansen T, Romiti R, Altmeyer P. Accessory tragus: report of two cases and review of the literature. *Pediatr Dermatol*. 2000;17(5):391-394.
13. Satoh T, Tokura Y, Katsumata M, et al. Histological diagnostic criteria for accessory tragi. *J Cutan Pathol*. 1990;17(4):206-210.
14. Morimoto N, Ogawa K, Kanzaki J. Salivary gland choristoma in the middle ear: a case report. *Am J Otolaryngol*. 1999;20(4):232-235.
15. Naiberg J, Berger G, Hawke M. The pathologic features of keratosis obturans and cholesteatoma of the external auditory canal. *Arch Otolaryngol*. 1984;110(10):690-693.
16. Zaky DA, Bentley DW, Lowy K, et al. Malignant external otitis: a severe form of otitis in diabetic patients. *Am J Med*. 1976;61(2):298-302.
17. Metzger SA, Goodman ML. Chondrodermatitis helicis: a clinical re-evaluation and pathological review. *Laryngoscope*. 1976;86(9):1402-1412.
18. Calnan J, Rossatti B. On the histopathology of chondrodermatitis nodularis helicis chronica. *J Clin Pathol*. 1959;12(2):179-182.
19. Heffner DK, Hyams VJ. Cystic chondromalacia (endochondral pseudocyst) of the auricle. *Arch Pathol Lab Med*. 1986;110(8):740-743.
20. Yetiser S, Inal A, Taser M, Ozkaptan Y. Otolaryngological aspects of relapsing polychondritis: course and outcome. *Rev Laryngol Otol Rhinol (Bord)*. 2001;122(3):195-200.
21. Hughes RA, Berry CL, Seifert M, Lessof MH. Relapsing polychondritis. Three cases with a clinico-pathological study and literature review. *Q J Med*. 1972;41(163):363-380.
22. Herman JH, Dennis MV. Immunopathologic studies in relapsing polychondritis. *J Clin Invest*. 1973;52(3):549-558.
23. McCune WJ, Schiller AL, Dynesius-Trentham RA, Trentham DE. Type II collagen-induced auricular chondritis. *Arthritis Rheum*. 1982;25(3):266-273.
24. Weedon D. Elastotic nodules of the ear. *J Cutan Pathol*. 1981;8(6):429-433.
25. Sanchez JL. Collagenous papules on the aural conchae. *Am J Dermatopathol*. 1983;5(3):231-233.
26. Patterson HC. Facial keratoacanthoma. *Otolaryngology*. 1983;91(3):263-270.
27. Ahmad I, Das Gupta AR. Epidemiology of basal cell carcinoma and squamous cell carcinoma of the pinna. *J Laryngol Otol*. 2001;115(2):85-86.
28. Goodwin WJ, Jesse RH. Malignant neoplasms of the external auditory canal and temporal bone. *Arch Otolaryngol*. 1980;106(11): 675-679.
29. Avila J, Bosch A, Aristizabal S, et al. Carcinoma of the pinna. *Cancer*. 1977;40(6):2891-2895.
30. Paaske PB, Witten J, Schwer S, Hansen HS. Results in treatment of carcinoma of the external auditory canal and middle ear. *Cancer*. 1987;59(1):156-160.
31. Koso-Thomas K, Thompson LDR. Spindle cell (sarcomatoid) carcinoma of the ear: a clinicopathological study of 57 cases [abstract]. *Mod Pathol*. 2003;16.
32. Proops DW, Hawke WM, van Nostrand AW, et al. Verrucous carcinoma of the ear. Case report. *Ann Otol Rhinol Laryngol*. 1984;93(4 Pt 1):385-388.
33. Bailin PL, Levine HL, Wood BG, Tucker HM. Cutaneous carcinoma of the auricular and periauricular region. *Arch Otolaryngol*. 1980;106(11):692-696.
34. Clark RR, Soutar DS, Hunter KD. A retrospective analysis of histological prognostic factors for the development of lymph node metastases from auricular squamous cell carcinoma. *Histopathology*. 2010;57(1):138-146.
35. Kinney SE, Wood BG. Malignancies of the external ear canal and temporal bone: surgical techniques and results. *Laryngoscope*. 1987;97(2):158-164.
36. Chen KT, Dehner LP. Primary tumors of the external and middle ear. I. Introduction and clinicopathologic study of squamous cell carcinoma. *Arch Otolaryngol*. 1978;104(5):247-252.
37. Pfreundner L, Schwager K, Willner J, et al. Carcinoma of the external auditory canal and middle ear. *Int J Radiat Oncol Biol Phys*. 1999;44(4):777-788.
38. Cohen C, Davis TS. Multiple trichogenic adnexal tumors. *Am J Dermatopathol*. 1986;8(3):241-246.
39. Raizada RM, Khan NU. Aural sebaceous adenomas. *J Laryngol Otol*. 1986;100(12):1413-1416.
40. Lynde CW, McLean DI, Wood WS. Tumors of ceruminous glands. *J Am Acad Dermatol*. 1984;11(5 Pt 1):841-847.
41. Cankar V, Crowley H. Tumors of ceruminous glands: a clinicopathological study of 7 cases. *Cancer*. 1964;17:67-75.
42. Thompson LD, Nelson BL, Barnes EL. Ceruminous adenomas: a clinicopathologic study of 41 cases with a review of the literature. *Am J Surg Pathol*. 2004;28(3):308-318.
43. Tang X, Tamura Y, Tsutsumi Y. Mixed tumor of the external auditory canal. *Pathol Int*. 1994;44(1):80-83.
44. Nelson BL, Thompson LDR, Barnes L. Ceruminal gland carcinomas: a clinicopathologic study of 17 cases [abstract]. *Mod Pathol*. 2003;16:221A.
45. Conlin PA, Mira JL, Graham SC, et al. Ceruminous gland adenoid cystic carcinoma with contralateral metastasis to the brain. *Arch Pathol Lab Med*. 2002;126(1):87-89.
46. Saad AG, Patel S, Mutasim DF. Melanocytic nevi of the auricular region: histologic characteristics and diagnostic difficulties. *Am J Dermatopathol*. 2005;27(2):111-115.
47. Byers RM, Smith JL, Russell N, Rosenberg V. Malignant melanoma of the external ear. Review of 102 cases. *Am J Surg*. 1980;140(4):518-521.
48. Pack GT, Conley J, Oropeza R. Melanoma of the external ear. *Arch Otolaryngol*. 1970;92(2):106-113.
49. Graham MD. Osteomas and exostoses of the external auditory canal. A clinical, histopathologic and scanning electron microscopic study. *Ann Otol Rhinol Laryngol*. 1979;88(4 Pt 1):566-572.
50. Ferreiro JA, Carney JA. Myxomas of the external ear and their significance. *Am J Surg Pathol*. 1994;18(3):274-280.
51. Choe KS, Sclafani AP, McCormick SA. Angioleiomyoma of the auricle: a rare tumor. *Otolaryngology*. 2001;125(1):109-110.
52. Thompson JW, Colman M, Williamson C, Ward PH. Angiolymphoid hyperplasia with eosinophilia of the external ear canal. *Arch Otolaryngol*. 1981;107(5):316-319.
53. Fernandez-Flores A, Montero MG, Renedo G. Cutaneous epithelioid angiomatous nodule of the external ear. *Am J Dermatopathol*. 2005;27(2):175-176.
54. Petkovic M, Krstulja M, Radic J, et al. Merkel cell carcinoma arising in the ear canal. *Int J Surg Pathol*. 2008;16(3):337-340.
55. Virtaniemi J, Hirvikoski P, Pukkila M, et al. Merkel cell carcinoma of the auricle. *Eur Arch Otorhinolaryngol*. 2000;257(10):558-560.
56. Worley GA, Wareing MJ, Sergeant RJ. Myxoid chondrosarcoma of the external auditory meatus. *J Laryngol Otol*. 1999;113(8):742-743.
57. Tran Ba Huy P, Hassan JM, Wassef M, et al. Acoustic schwannoma presenting as a tumor of the external auditory canal. Case report. *Ann Otol Rhinol Laryngol*. 1987;96(4):415-418.
58. Darvay A, Russell-Jones R, Acland KM, et al. Systemic B-cell lymphoma presenting as an isolated lesion on the ear. *Clin Exp Dermatol*. 2001;26(2):166-169.
59. Heffner DK. Brain in the middle ear or nasal cavity: heterotopia or encephalocele? *Ann Diagn Pathol*. 2004;8(4):252-257.
60. Saeger KL, Gruskin P, Carberry JN. Salivary gland choristoma of the middle ear. *Arch Pathol Labor Med*. 1982;106(1):39-40.
61. Merchant SN, Nadol JB Jr. *Schuknecht's Pathology of the Ear*. 3rd ed. Maidenhead. Berkshire: McGraw-Hill; 2010.
62. Azadeh B, Dabiri S, Moshfegh I. Malakoplakia of the middle ear. *Histopathology*. 1991;19(3):276-278.
63. Ramages LJ, Gertler R. Aural tuberculosis: a series of 25 patients. *J Laryngol Otol*. 1985;99(11):1073-1080.
64. Soldati D, Mudry A. Knowledge about cholesteatoma, from the first description to the modern histopathology. *Otol Neurotol*. 2001;22(6):723-730.
65. Hansen T, Unger RE, Gaumann A, et al. Expression of matrix-degrading cysteine proteinase cathepsin K in cholesteatoma. *Mod Pathol*. 2001;14(12):1226-1231.
66. Palva T. Surgical treatment of cholesteatomatous ear disease. *J Laryngol Otol*. 1985;99(6):539-544.
67. Chole RA, McKenna M. Pathophysiology of otosclerosis. *Otol Neurotol*. 2001;22(2):249-257.
68. Van Den Bogaert K, Govaerts PJ, Schatteman I, et al. A second gene for otosclerosis, OTSC2, maps to chromosome 7q34–36. *Am J Hum Genet*. 2001;68(2):495-500.
69. Michaels L. The temporal bone: an organ in search of a histopathology. *Histopathology*. 1991;18(5):391-394.
70. Davis GL. Pathology of otosclerosis: a review. *Am J Otolaryngol*. 1987;8(5):273-281.
71. Declau F, Van Spaendonck M, Timmermans JP, et al. Prevalence of otosclerosis in an unselected series of temporal bones. *Otol Neurotol*. 2001;22(5):596-602.
72. Pensak ML. Alford and Guilford: a comprehensive study of tumors of the glomus jugulare. *Laryngoscope*. 1996;106(9 Pt 1):1063-1066.
73. Larson TC 3rd, Reese DF, Baker HL Jr, McDonald TJ. Glomus tympanicum chemodectomas: radiographic and clinical characteristics. *Radiology*. 1987;163(3):801-806.
74. Reddy EK, Mansfield CM, Hartman GV. Chemodectoma of glomus jugulare. *Cancer*. 1983;52(2):337-340.
75. Konefal JB, Pilepich MV, Spector GJ, Perez CA. Radiation therapy in the treatment of chemodectomas. *Laryngoscope*. 1987;97(11):1331-1335.
76. Prayson RA. Middle ear meningiomas. *Ann Diagn Pathol*. 2000;4(3):149-153.
77. Thompson LD, Bouffard JP, Sandberg GD, Mena H. Primary ear and temporal bone meningiomas: a clinicopathologic study of 36 cases with a review of the literature. *Mod Pathol*. 2003;16(3):236-245.

78. Antinheimo J, Sankila R, Carpén O, et al. Population-based analysis of sporadic and type 2 neurofibromatosis-associated meningiomas and schwannomas. *Neurology*. 2000;54(1):71-76.
79. Hyams VJ, Michaels L. Benign adenomatous neoplasm (adenoma) of the middle ear. *Clin Otolaryngol Allied Sci*. 1976;1(1):17-26.
80. Friedmann I. Middle ear adenoma. *Histopathology*. 1998;32(3):279-280.
81. el Naggar AK, Pflatz M, Ordonez NG, Batsakis JG. Tumors of the middle ear and endolymphatic sac. *Pathol Annu*. 1994;29(Pt 2):199-231.
82. McNutt MA, Bolen JW. Adenomatous tumor of the middle ear. An ultrastructural and immunocytochemical study. *Am J Clin Pathol*. 1985;84(4):541-547.
83. Mills SE, Fechner RE. Middle ear adenoma. A cytologically uniform neoplasm displaying a variety of architectural patterns. *Am J Surg Pathol*. 1984;8(9):677-685.
84. Stanley MW, Horwitz CA, Levinson RM, Sibley RK. Carcinoid tumors of the middle ear. *Am J Clin Pathol*. 1987;87(5):592-600.
85. Murphy GF, Pilch BZ, Dickersin GR, et al. Carcinoid tumor of the middle ear. *Am J Clin Pathol*. 1980;73(6):816-823.
86. Davies JE, Semeraro D, Knight LC, Griffiths GJ. Middle ear neoplasms showing adenomatous and neuroendocrine components. *J Laryngol Otol*. 1989;103(4):404-407.
87. Hosoda S, Tateno H, Inoue HK, et al. Carcinoid tumor of the middle ear containing serotonin and multiple peptide hormones. A case report and review of the pathology literature. *Acta Pathol Jpn*. 1992;42(8):614-620.
88. Ruck P, Pfisterer EM, Kaiserling E. Carcinoid tumour of the middle ear. A morphological and immunohistochemical study with comments on histogenesis and differential diagnosis. *Pathol Res Pract*. 1989;185(4):496-503, discussion 504-505.
89. Sakurai M, Mori N, Horiuchi O, et al. Carcinoid tumor of the middle ear. An immunohistochemical and electron microscopic study. Report of a case. *Acta Pathol Jpn*. 1988;38(11):1453-1460.
90. Wassef M, Kanavaros P, Polivka M, et al. Middle ear adenoma. A tumor displaying mucinous and neuroendocrine differentiation. *Am J Surg Pathol*. 1989;13(10):838-847.
91. Glasscock ME 3rd, McKennan KX, Levine SC, Jackson CG. Primary adenocarcinoma of the middle ear and temporal bone. *Arch Otolaryngol*. 1987;113(8):822-824.
92. Schuller DE, Conley JJ, Goodman JH, et al. Primary adenocarcinoma of the middle ear. *Otolaryngol Head Neck Surg*. 1983;91(3):280-283.
93. Bisceglia M, D'Angelo VA, Wenig BM. Endolymphatic sac papillary tumor (Heffner tumor). *Adv Anat Pathol*. 2006;13(3):131-138.
94. Siedentop KH, Jeantet C. Primary adenocarcinoma of the middle ear. Report of three cases. *Ann Otol Rhinol Laryngol*. 1961;70:719-733.
95. Stone HE, Lipa M, Bell RD. Primary adenocarcinoma of the middle ear. *Arch Otolaryngol*. 1975;101(11):702-705.
96. Gaffey MJ, Mills SE, Fechner RE, et al. Aggressive papillary middle-ear tumor. A clinicopathologic entity distinct from middle-ear adenoma. *Am J Surg Pathol*. 1988;12(10):790-797.
97. Gaffey MJ, Mills SE, Boyd JC. Aggressive papillary tumor of middle ear/temporal bone and adnexal papillary cystadenoma. Manifestations of von Hippel-Lindau disease. *Am J Surg Pathol*. 1994;18(12):1254-1260.
98. Lonser RR, Kim HJ, Butman JA, et al. Tumors of the endolymphatic sac in von Hippel-Lindau disease. *N Engl J Med*. 2004;350(24):2481-2486.
99. Heffner DK. Low-grade adenocarcinoma of probable endolymphatic sac origin A clinicopathologic study of 20 cases. *Cancer*. 1989;64(11):2292-2302.
100. Kempermann G, Neumann HP, Volk B. Endolymphatic sac tumours. *Histopathology*. 1998;33(1):2-10.
101. Wenig BM, Heffner DK. Endolymphatic sac tumors: fact or fiction? *Adv Anat Pathol*. 1996;3:378-387.
102. Nevoux J, Nowak C, Vellin JF, et al. Management of endolymphatic sac tumors: sporadic cases and von Hippel-Lindau disease. *Otol Neurotol*. 2014;35(5):899-904.
103. Hamazaki S, Yoshida M, Yao M, et al. Mutation of von Hippel-Lindau tumor suppressor gene in a sporadic endolymphatic sac tumor. *Hum Pathol*. 2001;32(11):1272-1276.
104. Vortmeyer AO, Huang SC, Koch CA, et al. Somatic von Hippel-Lindau gene mutations detected in sporadic endolymphatic sac tumors. *Cancer Res*. 2000;60(21):5963-5965.
105. Michaels L, Wells M. Squamous cell carcinoma of the middle ear. *Clin Otolaryngol Allied Sci*. 1980;5(4):235-248.
106. Milford CA, Violaris N. Bilateral carcinoma of the middle ear. *J Laryngol Otol*. 1987;101(7):711-713.
107. Kenyon GS, Marks PV, Scholtz CL, Dhillon R. Squamous cell carcinoma of the middle ear. A 25-year retrospective study. *Ann Otol Rhinol Laryngol*. 1985;94(3):273-277.
108. Tefft M, Fernandez C, Donaldson M, et al. Incidence of meningeal involvement by rhabdomyosarcoma of the head and neck in children: a report of the Intergroup Rhabdomyosarcoma Study (IRS). *Cancer*. 1978;42(1):253-258.
109. Raney RB Jr, Lawrence W Jr, Maurer HM, et al. Rhabdomyosarcoma of the ear in childhood. A report from the Intergroup Rhabdomyosarcoma Study-I. *Cancer*. 1983;51(12):2356-2361.
110. Hawkins DS, Anderson JR, Paidas CN, et al. Improved outcome for patients with middle ear rhabdomyosarcoma: a children's oncology group study. *J Clin Oncol*. 2001;19(12):3073-3079.
111. Cremers CW. Osteoma of the middle ear. *J Laryngol Otol*. 1985;99(4):383-386.
112. Gourin CG, Sofferman RA. Dermoid of the eustachian tube. *Otolaryngol Head Neck Surg*. 1999;120(5):772-775.
113. Roncaroli F, Scheithauer BW, Pires MM, et al. Mature teratoma of the middle ear. *Otol Neurotol*. 2001;22(1):76-78.
114. Shaida AM, McFerran DJ, da Cruz M, et al. Cavernous haemangioma of the internal auditory canal. *J Laryngol Otol*. 2000;114(6):453-455.
115. Singh SP, Cottingham SL, Slone W, et al. Lipomas of the internal auditory canal. *Arch Pathol Labor Med*. 1996;120(7):681-683.
116. Stegehuis HR, Guy AM, Anderson KR. Middle-ear lipoma presenting as airways obstruction: case report and review of literature. *J Laryngol Otol*. 1985;99(6): 589-591.
117. Stanley RJ, Scheithauer BW, Thompson EI, et al. Endodermal sinus tumor (yolk sac tumor) of the ear. *Arch Otolaryngol Head Neck Surg*. 1987;113(2):200-203.
118. Uchida M, Matsunami T. Malignant amelanotic melanoma of the middle ear. *Arch Otolaryngol Head Neck Surg*. 2001;127(9):1126-1128.
119. Hill BA, Kohut RI. Metastatic adenocarcinoma of the temporal bone. *Arch Otolaryngol*. 1976;102(9):568-571.
120. Schuknecht HF, Allam AF, Murakami Y. Pathology of secondary malignant tumors of the temporal bone. *Ann Otol Rhinol Laryngol*. 1968;77(1):5-22.

8 Thyroid Gland

Giovanni Tallini and Thomas J. Giordano

CHAPTER CONTENTS

Normal anatomy and thyroid gland development, *278*
Congenital abnormalities, *280*
Thyroiditis, *282*
Acute thyroiditis, *282*
Granulomatous (de Quervain) thyroiditis, *282*
Other granulomatous inflammations, *282*
Autoimmune (lymphocytic and Hashimoto) thyroiditis, *283*
Riedel thyroiditis, *286*
Multifocal fibrosing thyroiditis, *287*
Hyperplasia, *287*
Dyshormonogenetic goiter, *288*
Graves disease (diffuse toxic goiter), *289*
Nodular hyperplasia, *291*
Tumors, *293*
Epithelial tumors—specific types, *293*
Epithelial tumors—general features, *326*
Lymphoid tumors and tumorlike conditions, *331*
Mesenchymal tumors, *332*
Other primary tumors and tumorlike conditions, *334*
Metastatic tumors, *334*

Normal Anatomy and Thyroid Gland Development

The thyroid *anlage* appears in the embryo as a midline structure at the site corresponding to the foramen cecum of the adult tongue. From here, it descends as a component of the thyroglossal duct along the midline to reach its final position in the mid neck.[1] Later, the hyoid bone is formed from the second branchial arch. The thyroglossal duct is usually situated *anteriorly* to this bone and is divided by it into a suprahyoid and an infrahyoid portion. In the normal course of events, the thyroglossal duct is obliterated and disappears, leaving as a vestige the pyramidal lobe in approximately 40% of normal individuals.[2] At the same time, the thyroid *anlage* expands laterally to form the thyroid lobes. Microscopically, cords and plates of follicular cells are formed by the 9th week, small follicular lumina appear by the 10th week, and colloid secretion becomes evident by the 12th week. By the 14th week, the gland consists of well-developed follicles lined by follicular cells and containing thyroglobulin-positive colloid in the lumen.

The development of the thyroid gland is controlled by the coordinated action of specific transcription factors such as TTF-1 (Nkx2-1), TTF-2 (FoxE1), PAX8, HHEX, and NKX2-5. Functional maturation requires the activity of thyrotropin (TSH), of the TSH receptor (TSHr) and of the TSHr downstream effector Gsα. Genetic alterations associated with *thyroid dysgenesis* (a term referring to the spectrum of thyroid organogenetic defects) include those of the TSH receptor gene *(TSHR)* in non-syndromic cases, while the Gsα gene *(GNAS)* and the thyroid transcription factors genes *PAX8*, *TTF-1 (Nkx2-1)*, *TTF-2 (FoxE1)*, and *NKX2-5* are typically associated with syndromes that include thyroid dysgenesis as one of the features.[3,4]

The normal adult thyroid gland is composed of two lobes joined by the isthmus, which lies across the trachea anteriorly, below the level of the cricoid cartilage. It is endowed with a rich lymphatic network, not always evident in hematoxylin and eosin (H&E) sections but clearly evident with the D2-40 immunostain.[5] The lymph vessels coalesce in the subcapsular region to give rise to collecting trunks that drain into the following nodes: (1) pericapsular; (2) internal jugular chain; (3) pretracheal, paratracheal, and prelaryngeal (the pretracheal node located near the isthmus is sometimes referred to as the Delphian node); (4) recurrent laryngeal nerve chain; and (5) retropharyngeal and retroesophageal. The anterosuperior mediastinal nodes are secondary to the recurrent laryngeal nerve chain and pretracheal groups, but studies have shown that dye injected into the thyroid isthmus can also drain directly into them.[6]

Microscopically, the thyroid gland is made up of round or oval follicles that vary considerably in size, with an average diameter of 200 μm. They are lined by a single layer of follicular cells whose shape ranges from flattened to low columnar, depending on their degree of activity.[5] The cytoplasm has a pale acidophilic or amphophilic staining quality; the greater the activity of the cell, the greater its amount. Follicular cells with abundant granular acidophilic cytoplasm are referred to as Hürthle cells (a misnomer), Askanazy cells, oxyphilic cells, or oncocytes. Ultrastructurally, this granularity

Abstract

The thyroid gland, from the Greek words *thyreos* (shield) and *eidos* (shape), is one of the largest endocrine organs, with a remarkable potential for growth and enlargement. Diseases due to altered parenchymal function and anatomic abnormalities of this gland are among the most common endocrine disorders in humans. Thyroid carcinoma is the most common endocrine malignancy, and both non-neoplastic and neoplastic abnormalities are a frequent source of specimens for surgical pathology laboratories. Thyroid nodules are highly prevalent and often require cytopathologic evaluation. The general theme is that of the "needle in the haystack": many are thyroid nodules, but few have malignant potential. Of the malignant tumors, few pose a significant threat to life, although some of them, like anaplastic carcinoma, are among the most aggressive forms of human cancer. While most thyroid tumors are sporadic, a few develop in a familial setting or in the context of well-defined tumor syndromes (medullary carcinoma and MEN2 being the prototypical examples for C-cells, follicular carcinoma and Cowden syndrome for follicular cells). Some thyroid lesions pose considerable diagnostic challenges, and Dr. J. Rosai used to quote the words of the famous French pathologist C. L. Pierre Masson (one of the fathers of surgical pathology): "Of all cancers, thyroid epitheliomas teach, perhaps, the greatest lesson of humility to histopathologists." Ancillary techniques, including immunohistochemistry and molecular diagnostics, may help resolve these difficult cases. This chapter covers the relevant topics in the routine surgical pathology practice of the thyroid gland.

Keywords

diffuse thyroid hyperplasia
nodular thyroid hyperplasia
thyroiditis
thyroid tumors
follicular thyroid adenoma
oncocytic (Hürthle cell) tumors
thyroid cancer
follicular thyroid carcinoma
papillary thyroid carcinoma
poorly differentiated thyroid carcinoma
anaplastic thyroid
carcinoma
thyroid molecular pathology
thyroid markers

is due to the accumulation of mitochondria. They can be detected immunohistochemically with antibodies directed against mitochondrial enzymes.[7]

The proliferative activity of follicular cells is related to age, being highest in the prenatal group and lowest in adults.[8]

The main ultrastructural features of follicular cells are abundant granular endoplasmic reticulum, a well-developed Golgi apparatus, lysosomes (particularly numerous in actively secreting cells, and mainly located toward the apical side, not to be confused with secretory granules), and numerous microvilli in the luminal border.[9]

The intraluminal colloid is pale staining, with scalloped borders in follicles with active secretory function and densely eosinophilic in inactive ones. In old age, it tends to be broken up in globular formations. It is variably periodic acid–Schiff (PAS) positive and alcianophilic, depending on the types and relative amounts of carbohydrate components present.[10] Birefringent *calcium oxalate crystals* may be found, always intraluminally, their number increasing with age.[11] Their presence is of practical utility in distinguishing thyroid from parathyroid tissue (which lacks them), particularly at the time of frozen section.[12] They occur in the normal gland and in many pathologic conditions, particularly benign ones.[11] They are thought to represent a sign of functional inactivity on the part of the follicles containing them.[11]

Collections of small follicles protruding into the lumen of larger follicles are commonly seen in actively secreting glands; they are referred to as *Sanderson polsters* and become prominent in hyperplastic conditions.[5]

Immunohistochemically, many markers have been documented in normal follicular cells, most of them being also expressed in well-differentiated tumors of these cells:

1. Reactivity for thyroglobulin, thyroid peroxidase (TPO), triiodothyronine (T3), and thyroxine (T4) is found both in the colloid and in the cytoplasm of the follicular cells. Thyroglobulin is the most widely used of these markers.[5] Less degree of reactivity is found in oncocytic (Hürthle) cells.
2. Immunoreactivity for the sodium iodide symporter (NIS), the ion channel protein that mediates active iodide uptake, is localized to the basolateral plasma membrane of follicular cells. NIS is expressed at higher level in the normal thyroid gland and in benign conditions than in carcinomas, where the localization of the protein is redirected to the intracellular compartment.[13] Pendrin and Anoctamin-1 (ANO1) (also known as Transmembrane Member 16A-TMEM16A or Discovered on GIST1-DOG1), the ion channel proteins that mediate the passive iodide efflux towards the follicular lumen are localized by immunohistochemistry to the apical plasma membrane of follicular cells.[14]
3. Thyroid transcription factor-1 (TTF-1) is expressed in normal follicular and parafollicular cells. It is an extremely useful marker for all types of primary and metastatic thyroid tumors (including medullary carcinoma), except for anaplastic carcinoma. TTF-1 is not expressed in normal, hyperplastic, or adenomatous parathyroid tissue.[5] It is expressed in the normal lung (bronchial cells and pneumocytes) and in most cases of lung carcinoma (including the small cell neuroendocrine type). TTF-1 is occasionally expressed in other sites, such as the normal and neoplastic female genital tract,[15] Wilms tumor,[16] and Merkel cell tumor.[17] Like TTF-1, PAX8 and TTF-2 (FoxE1) are also detectable by routine immunohistochemical methods in thyrocytes and tumors derived from them. PAX8 may be the best to demonstrate the thyroid origin of anaplastic carcinoma.[18]
4. Low-molecular-weight keratins: CK7, CK18, and (to less degree) CK8 and CK19.[19]
5. EMA (epithelial membrane antigen, MUC1).[20]
6. Vimentin.[21]
7. Estrogen and progesterone receptors.[22]
8. Blood group antigens.[23]
9. Metal-binding proteins: ceruloplasmin, lactoferrin, transferrin, metallothionein.[24]
10. Follicular cells are joined by tight junctions containing the known components of these structures, including occludin and the various claudins.[25]
11. The follicles rest on a basement membrane that is immunoreactive for laminin and type IV collagen.[26]

Many of the markers listed previously have been evaluated in normal tissues, benign tumors, and malignant tumors with the hope of finding significantly different values among these groups that could be exploited diagnostically, but the results have generally been those to be expected, that is, disappointing.

The other major epithelial component of the thyroid gland is represented by neuroendocrine cells known as C cells or parafollicular cells. The latter term is a misnomer because immunohistochemical and ultrastructural studies have shown that they occupy a predominantly and perhaps exclusively intrafollicular position. It has been generally believed that mammalian, like avian C cells, derive from the neural crest. Lineage tracing experiments have now provided substantial evidence that they develop under the influence of specific transcription factors (including TTF-1) from the pharyngeal endoderm of the IV pouch and ultimobranchial body (see Solid cell nests next).[27] Because of this fact, C cells are largely restricted to the middle and upper thirds of the lateral lobes along their central axes. The number of C cells varies according to age; they are more numerous in infancy and old age than in adults. Most adult glands contain no more than 10 C cells in a low-power microscopic field. In old age, they may form nodular aggregates.[28]

Ultrastructurally, C cells contain numerous dense-core granules of neurosecretory type. They are argyrophilic with the Grimelius reaction; metachromatic with toluidine blue; positive for lead hematoxylin; and immunoreactive for calcitonin, katacalcin, calcitonin gene–related peptide, neuron-specific enolase (NSE), chromogranins A and B, secretogranin II, and synaptophysin (Fig. 8.1).[5] They are also immunoreactive for carcinoembryonic antigen (CEA), although less so than their neoplastic counterparts in medullary carcinoma.[5]

Solid cell nests *(rests)* are believed to represent remnants of the ultimobranchial body, which in turn is derived from the branchial cleft pouch complex IV–V.[29] They measure 0.1 mm on average and can be detected in almost 90% of neonatal thyroid glands (Fig. 8.2).[30] Exceptionally they reach a large and even a "giant" (tumorlike) size.[31] They are mainly composed of polygonal or oval cells admixed

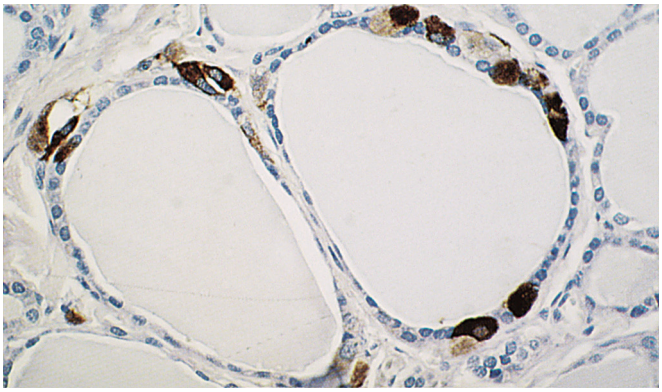

Figure 8.1 Immunoreactivity for calcitonin in thyroid C cells from a case of C-cell hyperplasia.

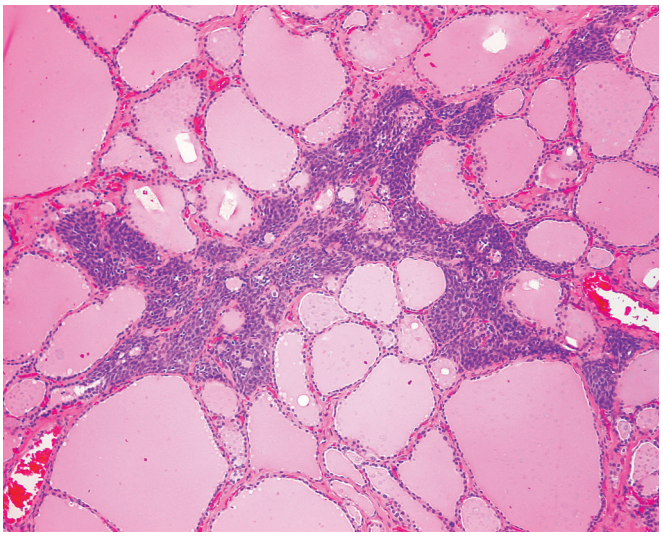

Figure 8.2 Solid cell rest. The irregular branching shape of the nodule is characteristic.

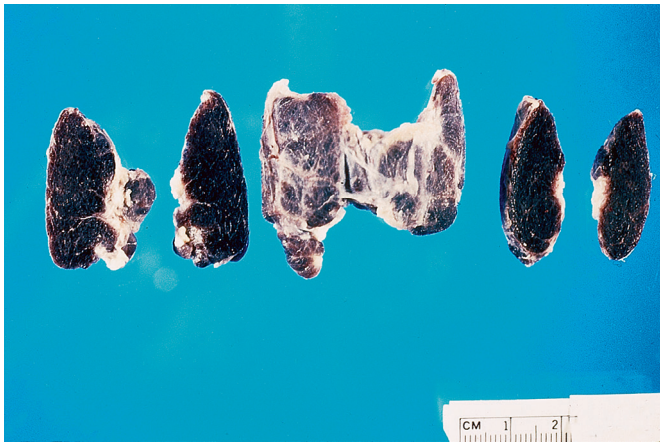

Figure 8.3 Black thyroid following minocycline therapy. (Courtesy of Dr. Maria Merino, Bethesda, Maryland.)

Figure 8.4 Thyroglossal duct cyst. The content of the cyst is gelatinous.

with occasional clear cells. Small glandular lumina containing a mucinous secretion are often present,[32] the nests thus acquiring a combined solid and cystic appearance. A substantial number of C cells may be seen around the nests, in keeping with the well-known relationship that these cells have with the ultimobranchial body.[32] Ultrastructurally, there are microfollicular structures, intracytoplasmic microvacuoles, and ciliated cells, in addition to lymphoid cells.[33] Immunohistochemically, solid cell nests are positive for high-molecular-weight keratin (recognized by the antibody 34bE12) and for CEA.[32,34] Their strong immunoreactivity for p63, telomerase expression, and proliferative activity suggest a stem cell origin.[34] Solid cell nests need to be distinguished from metaplastic follicles, nodular C-cell hyperplasia, and papillary microcarcinoma. Carcinoma of the thyroid showing thymus-like elements (CASTLE) may originate from solid cell nests.[35]

Focal collections of lymphocytes are seen at autopsy in the thyroid of approximately one-half of females and one-fourth of males; this finding is regarded as a subclinical manifestation of focal lymphocytic thyroiditis.[36] Microscopic manifestations of nodular hyperplasia have been reported at autopsy in one-fourth of the cases, but their frequency varies greatly depending on the geographic location of the population being investigated.[37]

Morphologic variations in the anatomy of the thyroid, several of them being the expression of branchial pouch remnants[38] and having no clinical significance, include:

1. Adipose metaplasia of the interfollicular stroma. Only exceptionally will this result in a clinically noticeable mass ("localized adiposity"), to be distinguished from lipoadenoma (see p. 295).[39]
2. Intrathyroidal islands of mature cartilage, presumably of branchial pouch derivation.
3. Intrathyroidal islands of ectopic thymus.[40]
4. Intrathyroidal parathyroid.[5]
5. Intrathyroidal bundles of skeletal muscle.[5]
6. Intrathyroidal salivary gland tissue.[41]
7. Perithyroidal pancreatic tissue, presumably a foregut remnant (see later).[42]
8. Accumulation of melanin-like pigment in the cytoplasm of follicular cells occurs in old age and may become massive after the administration of some medications, such as minocycline.[43] When intense, it is appreciable grossly and is referred to as *melanosis thyroidi* or—less pompously—as *black thyroid* (Fig. 8.3).[43,44] Some of the granules are of classic lipofuscin type, but most of them also contain colloid, thus becoming ambilysosomes.[44]

Congenital Abnormalities

Thyroglossal duct anomalies are the result of a localized persistence of the thyroglossal duct. This may be in the form of a sinus tract connected either to the foramen cecum or to the suprasternal notch, or in the form of a blind tubular structure.[45] It may be accompanied by a cystic dilation, as the result of secretion from the lining cells. When these cystic changes are prominent, the abnormality is designated as a thyroglossal duct cyst. Its usual location is the midline of the neck, in the region of the hyoid bone (Fig. 8.4).[45] Microscopically, the cyst is lined by pseudostratified ciliated or squamous epithelium which is often TTF-1 positive but thyroglobulin negative.[46] Mucous glands and thyroid follicles are commonly seen in the subjacent stroma. Secondary inflammation is common, particularly in cases accompanied by a sinus tract.[47] As a result, the epithelial lining may be partially absent, and the stroma may be infiltrated by inflammatory cells. Most cases are clinically evident during

childhood, but others become apparent only later in life. The treatment is surgical removal. To minimize recurrence, it is important to include in the excision the middle third of the hyoid bone and the entire length of any sinus tract that might be present.[48]

The thyroid tissue present in these anomalies can undergo malignant transformation, usually in the form of papillary carcinoma.[49,50] The prognosis is excellent after surgical removal, which does not need to include the thyroid gland. Other tumor types have been described, including oncocytic (Hürthle cell) carcinoma[51] and undifferentiated (anaplastic) carcinoma.[52]

Heterotopic thyroid tissue can be found not only as a component of thyroglossal duct cyst but anywhere along the course of the thyroglossal duct, sometimes as the sole abnormality (Fig. 8.5). The most frequent location is the base of the tongue, where it may result in difficulty in swallowing and respiratory obstruction, which in a few cases has proven fatal. At a microscopic (subclinical) level, lingual thyroid is found in 10% of normal individuals.[53] This heterotopic thyroid does not differ microscopically from that seen in the main gland. Sometimes a capsule is formed around it; in other instances, the follicles grow between the skeletal muscle of the tongue, a feature that may simulate invasion by tumor. Significantly, in 70% of patients with grossly evident lingual thyroid there is absence of the normal thyroid gland. Therefore, removal of the heterotopic thyroid tissue will lead to hypothyroidism, requiring subsequent medical replacement therapy.

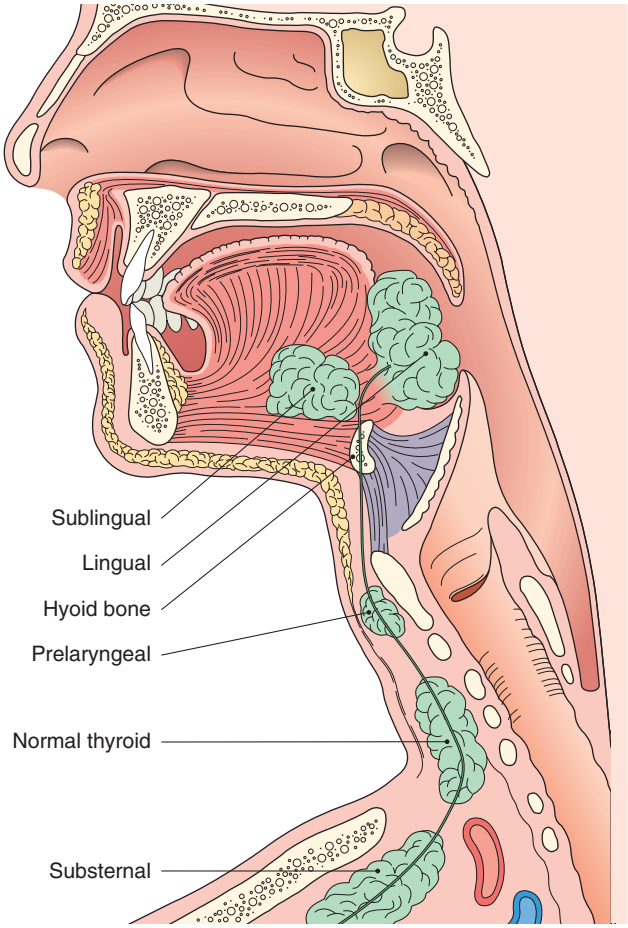

Figure 8.5 Distribution of heterotopic thyroid tissue. (From Lemmon WT, Paschal GW Jr. Lingual thyroid. *Am J Surg*. 1941;52:82–85.)

Other sites of heterotopic thyroid tissue are the anterior tongue, submandibular region, larynx, trachea, mediastinum (usually superior but sometimes posterior), and heart.[54–56] The common denominator in all these sites is their location in or close to the midline, the large majority being found in the so-called *Wölfler area*, described by anatomists as an isosceles triangle with the edge of the mandible at its base and the concavity of the aortic arch at its apex. The possible occurrence of heterotopic thyroid tissue in cervical nodes is discussed elsewhere.

More distant locations in which heterotopic thyroid tissue has been reported include the wall of the duodenum, gallbladder, region of the porta hepatis, adrenal gland, fallopian tube, vagina, and—last but not least—the ovary and other sites as a component of a teratoma (*struma ovarii* being the most spectacular example) (see Chapter 35).[57,58] Heterotopic thyroid tissue in any of these locations is subject to the same diseases that can affect the main gland, including inflammation, hyperplasia, and tumors. Thus, several cases of follicular carcinoma arising from lingual thyroid have been reported,[59] as well as numerous cases of carcinomas of various types arising in struma ovarii (see Chapter 35).[60,61]

Branchial pouch anomalies are not directly related to the thyroid but are discussed here because of their close proximity to the gland. They may present as a patent fistula, a simple sinus, a blind cyst, or an island of cartilage (Fig. 8.6).[62] They are located in the anterolateral region of the neck, their exact position depending on the specific branchial cleft involved. Those related to the *first pouch* appear in the preauricular area or beneath the posterior half of the mandible and may be connected to the external auditory canal. Those related to the *second pouch* appear just anterior to the sternocleidomastoid muscle in the mid neck and may have an open tract communicating with the pharynx near the superior fold of the tonsil. Those related to the *third and fourth pouches* are typically found in the lower neck, in a suprasternal or supraclavicular location. Some of these have been mislabeled as bronchogenic cysts in the past.[63,64]

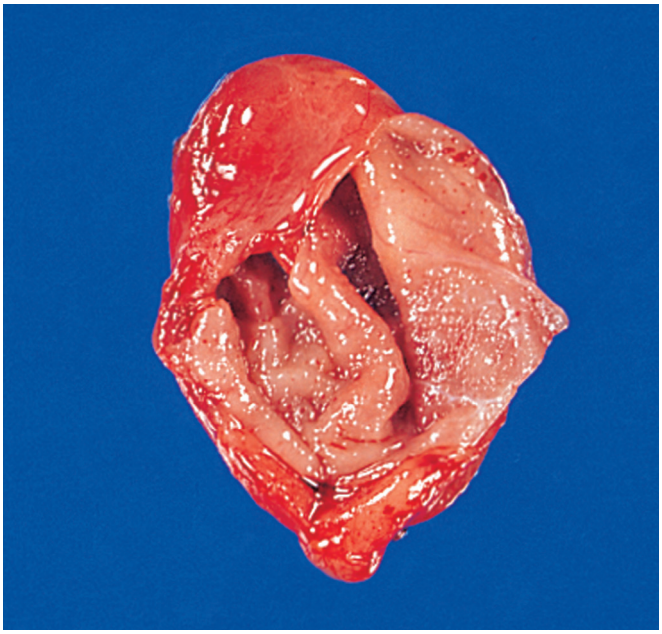

Figure 8.6 Branchial cleft cyst that has been partially opened to expose the inner surface, which is rendered irregular by the presence of innumerable hyperplastic lymphoid follicles.

The lining of these cysts and fistulous tracts is usually squamous epithelium, but columnar ciliated epithelium is also common. Abundant lymphoid tissue, often with germinal centers, is observed beneath. Cysts located in the lower neck may also contain mucinous, seromucinous, and sebaceous glands.[63,64] Secondary infection may complicate the microscopic picture. Squamous cell carcinomas arising in a branchial cleft cyst probably exist, but they are exceptionally rare.[65] Any cystic mass in the lateral neck containing squamous cell carcinoma must be considered a lymph node metastasis with cystic degeneration until proved otherwise, and a search for the primary tumor should be instituted, particularly in the upper aerodigestive tract.[66] Sites notorious for harboring small occult primary tumors include tonsil and posterior tonsillar pillar, retromolar trigone, tongue, and nasopharynx.

Similar comments pertain to the relationship of branchial cleft cysts and papillary carcinomas of thyroid type. Perhaps there exist cases of this tumor type arising in the ectopic thyroid tissue of branchial cleft cysts,[67] but there is no question that the overwhelming majority of the cystic lesions in the lateral neck containing a recognizable focus of papillary thyroid carcinoma represent lymph node metastases from a thyroid primary that have undergone secondary cystic change.

Branchial pouch–related structures are found within the thyroid in the form of the already mentioned solid cell nests (a remnant of the ultimobranchial body or branchial pouch complex IV–V) and—less commonly—in the form of heterotopic cartilage (sharply outlined and often kidney shaped),[68] thymic tissue, parathyroid glands, or epithelial-lined cysts with or without an associated lymphoid component.[69] Most of the latter—sometimes designated as *lymphoepithelial cysts*—are seen in glands affected by Hashimoto thyroiditis, but they can also be found in its absence.[70] Exceptionally, perithyroidal epithelial cysts have been found to contain pancreatic tissue in their wall, as representatives of foregut remnants.[42]

Parenthetically, the presence of normal, cystic, or neoplastic thymic tissue in the neck should also be viewed as the expression of branchial pouch–derived anomalies (see Chapter 12).

Thyroiditis

Acute Thyroiditis

Acute thyroiditis is usually of infectious nature.[71,72] It may be associated with acute infections of the upper aerodigestive tract (e.g., pharyngitis, tonsillitis), generalized sepsis, or major trauma to the neck with an open wound.[73] It tends to affect the malnourished infant, the debilitated elderly, and the immunocompromised patient. *Streptococcus haemolyticus*, *Staphylococcus aureus*, and *Pneumococcus* are the organisms most commonly responsible.[71,72] Other causes include gram-negative bacteria, fungi (particularly *Candida*), and *Pneumocystis*.[74] Viral infection is rare, but several cases of cytomegalovirus infection of the thyroid in patients with AIDS have been documented.[75]

Morphologically, the main changes in acute thyroiditis are neutrophilic infiltration and tissue necrosis. Nonsuppurative and suppurative forms exist, the latter sometimes evolving into an *abscess*.[76] The interesting observation has been made that a large number of cases of recurrent acute suppurative thyroiditis (especially when left sided) are secondary to the presence of a piriform sinus fistula,[77] a structure of presumably ultimobranchial body derivation.[78]

The best method to confirm the diagnosis of acute thyroiditis is a fine-needle biopsy with smear cytologic examination and cultures. The presence of a pyriform sinus fistula can be established by barium meal.[77]

Medical treatment of acute thyroiditis is usually effective, but abscesses need to be drained surgically. Cases associated with pyriform sinus fistula are best treated by fistulectomy.[77]

Granulomatous (de Quervain) Thyroiditis

Granulomatous thyroiditis, also known as de Quervain thyroiditis, giant-cell thyroiditis, subacute thyroiditis, subacute granulomatous thyroiditis, or painful subacute thyroiditis, typically presents in middle-aged women with sore throat, painful deglutition, and marked tenderness on palpation in the thyroid region, often associated with fever and malaise.[72] Once the initial process has subsided, pressure symptoms and/or mild hypothyroidism may develop. However, in the majority of cases there is complete resolution. Because of the sometimes asymmetric involvement of the gland, the disease may be clinically confused with carcinoma. Thyrotoxicosis with elevated serum levels of T4 and T3 in combination with marked suppression of radioactive iodide uptake are typical of the initial phase of this disease,[72] which has been found to be associated with the HLA-B35 haplotype.[79]

Grossly, the process usually involves the entire gland, but the enlargement is often asymmetric. In a typical case, the gland is enlarged to approximately twice its normal size. In the advanced stage, the involved areas are firm. In contrast to Riedel thyroiditis, there is usually little or no adherence to the surrounding structures.

Microscopically, areas of marked inflammation and granulomas containing foreign body giant cells are present. It is characteristic for these granulomas to surround follicles and for the multinucleated giant cells (most of which are of histiocytic nature) to engulf colloid (Fig. 8.7). The granulomas are not very distinct, and caseation necrosis is consistently absent. Areas of fibrosis are also seen, usually in a patchy distribution. Different stages of the same process may be seen in the same gland.[80] Strong immunoreactivity for CA19-9 is found in the late stage of the disease, whereas positivity for CEA in the center of the granuloma is a feature of the acute stage.[81]

The etiology is not known. Although the disease often follows an infection of the upper aerodigestive tract, the thyroiditis itself is of nonbacterial nature. A viral etiology has been often suggested on clinical and epidemiologic grounds but not conclusively proven.[72,82]

Other Granulomatous Inflammations

Palpation thyroiditis is the term that has been proposed for a relatively common, clinically insignificant, and grossly inconspicuous thyroid process (also known as multifocal granulomatous folliculitis)

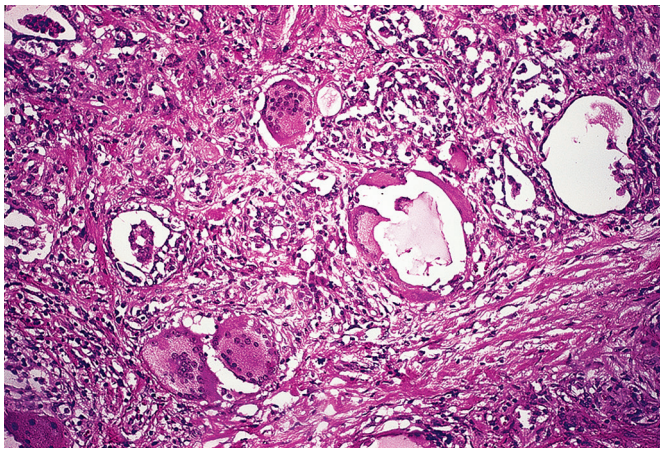

Figure 8.7 Granulomatous thyroiditis showing multiple granulomas centered in thyroid follicles.

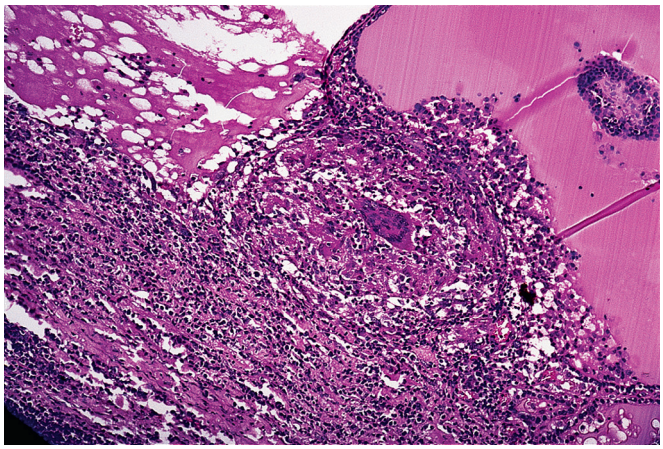

Figure 8.8 So-called palpation thyroiditis is a common incidental finding.

in which collections of histiocytes (some of them foamy), lymphocytes, and a few multinucleated giant cells are seen within the lumen of scattered thyroid follicles (Fig. 8.8).[83] In some of these follicles, the inflammatory infiltrate disrupts the epithelium and extends into the perifollicular region. These changes bear no relationship to granulomatous (de Quervain) thyroiditis. Rather, they seem to be the result of minor trauma to the gland, sometimes spontaneous and sometimes thought to be induced by vigorous palpation on physical examination, hence the term palpation thyroiditis.

Tuberculosis as a primary clinical manifestation within the thyroid gland is a pathologic curiosity.[84] In disseminated miliary tuberculosis, it is common for an occasional tubercle to occur within the gland. It is also possible for tuberculosis of cervical lymph nodes or larynx to involve the thyroid gland secondarily. Many of the cases diagnosed in the past as tuberculosis of the thyroid were actually examples of granulomatous (de Quervain) thyroiditis.

Sarcoidosis may involve the thyroid in the form of interstitial (rather than follicle-centered) noncaseating granulomas in patients with systemic disease. Occasionally it manifests initially as a thyroid mass.[85] Sarcoidosis has been associated with autoimmune thyroid disease (Graves disease and Hashimoto thyroiditis).[86]

Mycoses of various types have been described, most of them occurring in immunocompromised hosts.[87–89] In many of these cases, the tissue changes are characterized by necrosis and acute inflammation rather than granuloma formation.

Postoperative necrotizing granulomas, vaguely simulating rheumatoid nodules and morphologically similar to those more commonly seen in the prostate and bladder, have been observed within the thyroid.[90]

Autoimmune (Lymphocytic and Hashimoto) Thyroiditis

It is now widely accepted that the thyroid diseases traditionally known as lymphocytic thyroiditis and Hashimoto thyroiditis represent different phases or manifestations of an organ-specific, immune-mediated inflammatory disorder generically designated as *autoimmune thyroid disease*. The disorder is common, affects predominantly women, and it is characterized by the production of autoantibodies that alter thyroid function.[72,91,92] It is further believed that autoimmune thyroiditis is one of the two major forms in which autoimmune thyroid disease may manifest, the other being Graves disease.[93] In favor of this interpretation is the existence of cases sharing features of the two diseases (sometimes designated by the picturesque term *hashitoxicosis*), suggesting that one may evolve into the other.[94] According to this interpretation, there is an immune-mediated insult that leads initially to diffuse or nodular hyperactivity of the gland and eventually to exhaustion atrophy, manifested by diffuse oxyphilia of the follicular epithelium. Rarely the sequence is reversed, in the sense that Hashimoto disease with hypothyroidism is followed by Graves disease.[95]

The mechanisms leading to autoimmune thyroid disease are of both humoral and cellular nature. Circulating autoantibodies exist against thyroglobulin and other follicular cell antigens, notably TSHr. The leading pathogenetic event is the breakdown of immune tolerance caused by a combination of immunologic, genetic, and environmental factors. Available evidence indicates that autoimmunity is triggered by inflammatory events in the gland likely related to infection (viral or bacterial), or injury to the thyroid cells from toxins. The injured thyrocytes may exhibit new epitopes (or unmask hidden ones), causing the arrival of major histocompatibility complex (MHC) class II–positive antigen presenting cells (dendritic cells and different subclasses of macrophages). These cells present thyroid-specific antigens to naive lymphocytes within the regional lymph nodes, resulting in clonal expansion of CD4+ T cells, CD8+ cytotoxic T cells, and immunoglobulin (IgG) antibody–producing B cells that are autoreactive. These cells accumulate in the thyroid, resulting in thyroiditis. The intrathyroidal T and B cells, as well as antigen-presenting cells, produce numerous cytokines that alter the behavior of the follicular cells. These start expressing MHC class II, enabling the interaction with antigen-specific T cells that maintains and contributes to the autoimmune inflammatory process.[93,96–98] Genome-wide association studies (GWASs) have identified several susceptibility loci for autoimmune thyroid disease, some of which have been specifically linked to Graves disease (the *TSHR* single nucleotide polymorphism rs2268458) and Hashimoto thyroiditis (e.g., the *FoxE1* single nucleotide polymorphism rs965513).[99]

Morphologically, the common denominator of autoimmune thyroid disease in general and autoimmune thyroiditis in particular is the presence of *lymphocytic infiltration of the gland associated with germinal center formation*. Histologically, it is the *appearance of the intervening follicles that determines the category to which a given case belongs*: Graves disease when the follicles are diffusely hyperplastic, lymphocytic thyroiditis (in various forms) when they are relatively normal, and classic Hashimoto thyroiditis when follicles are lined by severely damaged cells showing extensive oncocytic change. Considerable confusion exists in the use of terminology, depending on whether the emphasis is on tissue inflammation or the clinical findings. Some authors use the term Hashimoto thyroiditis to include any autoimmune thyroid disease characterized by marked lymphocytic infiltration.[100] For practical purposes, autoimmune thyroiditis can be grouped histologically into "lymphocytic thyroiditis," when the evidence of parenchymal damage is limited, and "Hashimoto thyroiditis" when there is marked parenchymal damage, following the original description of the disease by Hakaru Hashimoto in 1912.[101] The practice of using the terms lymphocytic and Hashimoto thyroiditis synonymously is not recommended, one of the reasons being that a good correlation exists between the morphologic appearance of the follicular epithelium and thyroid function.[102,103]

Lymphocytic thyroiditis, thus defined, is characterized by lymphoid infiltration with limited evidence of parenchymal damage. As these forms of thyroiditis rarely require thyroidectomy, few studies have accurately described the histologic alterations following needle biopsy procedures.[102] Germinal centers are few, oncocytic changes are focal, follicular atrophy is absent (there may actually be signs of follicular hyperplasia), and fibrosis is mild or altogether absent. Several clinical entities fall into this category: *painless (or silent, or subacute lymphocytic) thyroiditis* that can be *sporadic*[104] or *postpartum*,[105] the "*juvenile form*" of lymphocytic/autoimmune thyroiditis,[106] and the initial phase in cases of *Hashitoxicosis*.[94] In patients with painless

(silent) thyroiditis, sporadic or postpartum, a transient hyperthyroid phase is followed by hypothyroidism and then, in the majority of cases, by resolution with return to a euthyroid condition.[72] The course of the juvenile form of autoimmune thyroiditis is variable.[106] Drug-induced thyroiditis after treatment with amiodarone and lithium has been related to autoimmunity. Immunomodulatory drugs, cancer immunotherapy, and cancer vaccines have immune-related side effects that include endocrinopathies and thyroiditis.[72,107]

The presence of focal lymphoid infiltration in the thyroid parenchyma is referred to as *focal lymphocytic thyroiditis (or nonspecific thyroiditis, or focal autoimmune thyroiditis)*. Most patients are euthyroid, but a minority has latent/subclinical hypothyroidism.[102] Collections of lymphocytes are common in thyroid glands removed for a variety of reasons and can be found around thyroid tumors (particularly papillary carcinoma), in thyroid glands that have been irradiated (radioactive iodine ablation or external beam therapy), and in autopsy series.[36] Autopsy studies indicate that the finding is more frequent in women, increases with age, and shows racial variation (more common in whites than in black or Japanese individuals). White females have the highest prevalence and the most pronounced increase with aging: focal lymphoid infiltration is found in approximately 55% of white women aged 80 years or older.[108]

Hashimoto thyroiditis, originally described in 1912 by Hakaru Hashimoto as struma lymphomatosa,[101] is characterized by extensive damage to the thyroid parenchyma. It is predominantly a disease of women over 40 years of age. It presents as diffuse firm thyroid enlargement, sometimes accompanied by signs of tracheal or esophageal compression. Initially the disease may be accompanied by mild hyperthyroidism and later by hypothyroidism.[72] At surgery, the thyroid gland is easily separated from other structures. The fascial attachment between the thyroid gland and the tracheal wall is, at times, slightly thickened, but there is no strong fixation (unlike Riedel thyroiditis). Because of the firm character of the lesion, it may be confused with carcinoma, but the diffuse involvement without adherence to the surrounding structures should be strong evidence against it. Grossly, the typical case shows diffuse and symmetrical enlargement of the gland. However, in some instances, one lobe is more enlarged than the other, and in others the disease has a distinctly multinodular quality. The consistency is firm but not stony hard as in Riedel thyroiditis. There is no extension of the process outside the gland. The cut surface is friable, vaguely or distinctly nodular or micronodular, yellowish gray, and greatly resembles a hyperplastic lymph node (Fig. 8.9). Colloid is not clearly discernible. Necrosis and calcification are absent. The texture of the parenchyma infiltrated by lymphoid cells results in a distinctive pattern on ultrasound examination characterized by reduced echogenicity.[100]

Microscopically, the two main abnormalities are lymphocytic infiltration of the stroma and oxyphilic change of the follicular epithelium (Fig. 8.10). The lymphoid tissue is distributed within and around the lobules, and it invariably exhibits large follicles with prominent germinal centers. Lymphocytes predominate, T cells predominating over B cells.[109] Plasma cells, histiocytes, and scattered intrafollicular multinucleated giant cells are also present. Ultrastructurally, some of these giant cells have been found to be of epithelial derivation, but most are of histiocytic nature.[110] The lymphoplasmacytic population has been found to be polyclonal by immunohistochemical and gene rearrangement studies.[109,111] Lymphatic vessels are increased in number and dilated, resulting in characteristic "cracking spaces" (Fig. 8.11).[112]

Most of the thyroid follicles are atrophic, but others show features consistent with regenerative hyperplasia.[113] Most or all of these follicles are lined by variably sized oncocytic (Hürthle) cells. The nuclei of these cells may show enlargement and hyperchromasia or, conversely,

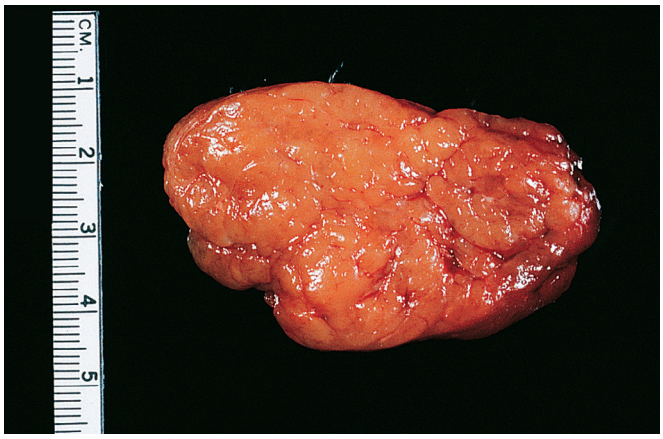

Figure 8.9 Cut surface of thyroid involved by Hashimoto thyroiditis. The appearance is reminiscent of a hyperplastic lymph node.

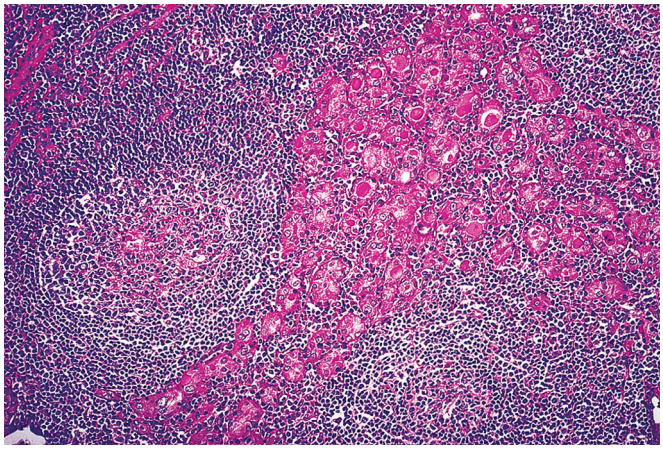

Figure 8.10 Hashimoto thyroiditis showing lymphoid follicles with prominent germinal centers and oncocytic follicular epithelium.

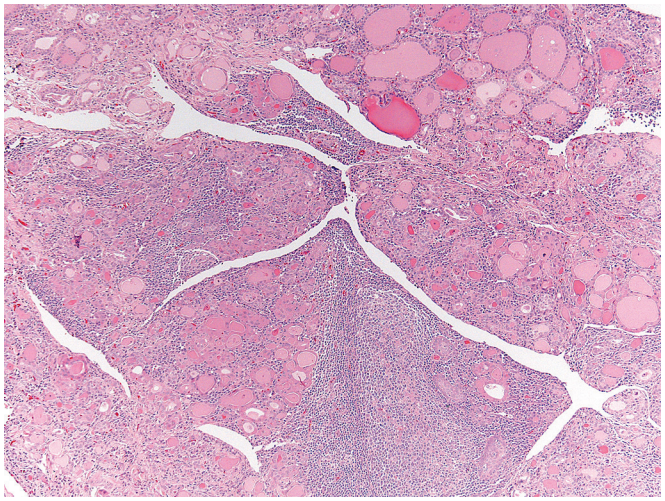

Figure 8.11 Dilated lymphatic vessels in Hashimoto thyroiditis result in characteristic "cracking spaces."

an optically clear appearance and overlapping quality reminiscent of that seen in papillary carcinoma. Immunohistochemically, the follicular cells of autoimmune thyroiditis show greater reactivity for keratin (particularly the high molecular weight types), S-100 protein, HLA-DR, and *N*-acetyl-α-D-galactosamine than the corresponding

normal cells, their immunohistochemical profile thus resembling that of the cells of papillary carcinoma. Biochemically, the oncocytic cells of Hashimoto thyroiditis have defects of cytochrome-c oxidase and the common 4977 base pairs deletion of mitochondrial DNA.[114]

Squamous nests and duct-like structures, thought to arise from metaplasia of follicular cells as a response to the chronic inflammatory injury (and possibly representing a manifestation of phylogenetic regression), are common and can reach sizable proportions (Fig. 8.12).[115] Rarely, large cysts lined by squamous epithelium and bordered by a row of lymphoid follicles are seen, their appearance being highly reminiscent of branchial cleft cysts (Fig. 8.13).[116] Parenthetically, similar cysts can also be seen in the absence of thyroiditis.[70]

In the typical case of Hashimoto thyroiditis, connective tissue is scarce, with slight or moderate thickening of the interlobular septa. In the *fibrous (or fibrosing) variant* of the disease, described by Katz and Vickery in 1974[117] and comprising approximately 10% of all cases, fibrosis is more extensive. In contrast to Riedel thyroiditis, this fibrosis is of dense hyaline type (instead of the active proliferative fibrosis seen in the latter) and does not extend beyond the thyroid capsule. In this regard, it should be remembered that Hashimoto and Riedel thyroiditis can exceptionally coexist.[118,119] The fibrous variant of Hashimoto thyroiditis can also be confused with carcinoma when the fibrosis is associated with epithelial islands showing squamous metaplasia.[117] It typically presents in older women, with hypothyroidism requiring prompt hormone replacement, and may evolve into a severe form of *thyroid atrophy*. In these cases the thyroid gland is not palpable and the symptoms of hypothyroidism are difficult to identify since they overlap with those of aging.[100]

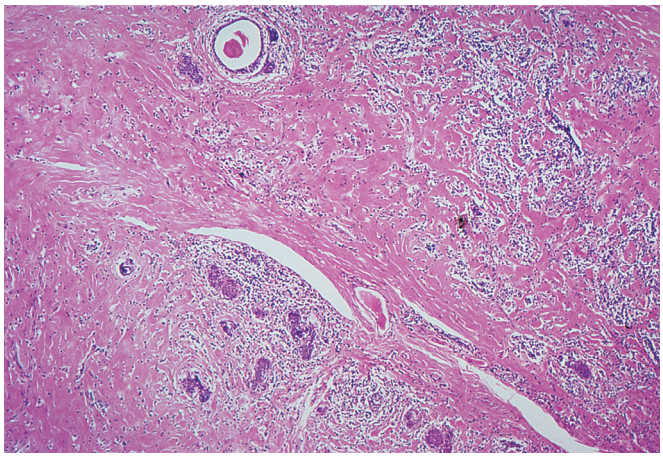

Figure 8.12 Hashimoto thyroiditis with extensive fibrosis, atrophy of follicular epithelium, and squamous metaplasia.

A type of Hashimoto thyroiditis that shows partial overlap with the fibrous variant is the IgG4-related form. It is defined by an increased number of IgG4-positive plasma cells (greater than 20 IgG4-positive plasma/high-power field [×400] and IgG4/IgG ratios greater than 30% by immunohistochemistry). Compared with conventional Hashimoto thyroiditis the IgG4-related variant is associated with high titers of thyroid autoantibodies, runs a more aggressive course, shows greater ultrasound alterations with pronounced hypoechogenicity, develops at a younger age, has a lower female-to-male ratio. Histologically, the lympho-plasmacytic infiltration is extensive and there is a predominantly interfollicular pattern of fibrosis. Similar to the fibrous variant (and unlike Riedel thyroiditis) the inflammatory process does not extend to extrathyroidal tissues, nor is it typically associated with fibroinflammatory lesions in other sites.[100,120,121]

Although Hashimoto thyroiditis typically exhibits a diffuse appearance both grossly and microscopically, cases do occur in which a distinct nodularity is evident, the epithelial component of the nodules having a hyperplastic quality. This could be interpreted as the combination of Hashimoto thyroiditis and nodular hyperplasia, but in all likelihood the two abnormalities are pathogenetically related. A term such as *nodular Hashimoto thyroiditis* would therefore seem more appropriate to designate this relatively common occurrence. A variation on the theme is represented by the Hashimoto thyroiditis in which one or more distinct hyperplastic ("dominant") nodules exclusively composed of oncocytic (Hürthle) cells having either a follicular or a solid configuration are present. Some of these nodules are surrounded by a thick fibrous capsule and therefore fulfill the criteria for follicular, including oncocytic (Hürthle) cell, adenoma, even if their true neoplastic nature is debatable.

Hashimoto thyroiditis (and autoimmune thyroid disease in general) may be seen in association with lymphocytic inflammation

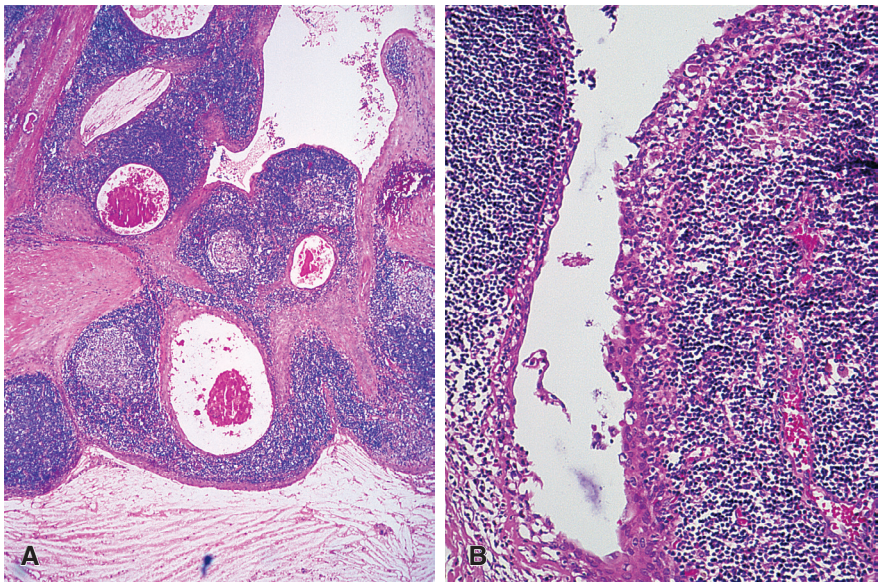

Figure 8.13 **A** and **B,** Hashimoto thyroiditis with branchial cleftlike cysts. In the high-power microphotograph (**B**) one can appreciate the infiltration by the lymphocytes of the lining epithelium.

of other organs, also on an autoimmune basis, as parts of autoimmune polyendocrine syndromes, namely Addison's disease (the combination being known as *Schmidt syndrome*) and diabetes mellitus.[122] Chronic autoimmune thyroiditis, Addison's disease, and type 1A diabetes are the distinctive features of *autoimmune polyendocrine syndrome type II* (the type I characterized by hypoparathyroidism and Addison's disease is not typically associated with thyroid disease). Hashimoto thyroiditis (and other autoimmune thyroid diseases) can also be associated with non-endocrine autoimmune disorders like vitiligo, pernicious anemia, myasthenia gravis, autoimmune gastritis, celiac disease, and hepatitis.[122]

Complications of Hashimoto thyroiditis include thyroid lymphoma,[123] oncocytic (Hürthle cell) neoplasms, and papillary carcinoma.[98] Their identification at an early stage may be extremely difficult. This probably explains the remarkable difference in the reported figures for these complications, particularly the latter two.[124] It is worth noting that follicular cells in Hashimoto thyroiditis can have loss of heterozygosity (LOH) at tumor suppressor gene loci[125] and can become karyotypically abnormal when they form proliferative nodules.[126] Also, the occurrence of sometimes striking nuclear clearing and overlapping in the follicular cells of Hashimoto thyroiditis is of interest; one wonders whether this might not represent a precursor (preneoplastic) stage of papillary carcinoma, as suggested by their similar phenotypic profile.[127] Additional evidence suggests that *RET/PTC* may provide a link between Hashimoto thyroiditis and papillary carcinoma. As a matter of fact, patients exposed to the Chernobyl radioactive fallout not only develop *RET/PTC*-driven papillary cancer but also chronic autoimmune thyroiditis; transgenic mice expressing *RET/PTC* show chronic thyroiditis in addition to papillary carcinoma; and—more importantly—low level *RET/PTC* rearrangement is commonly detectable in non-neoplastic thyrocytes of Hashimoto thyroiditis,[128–130] both in nodular and non-nodular areas of the inflamed gland.[128] This finding is intriguing given the established oncogenic potential of *RET/PTC*. It has to be pointed out that the rearrangement is present in very few cells,[128] that its identification requires highly sensitive methods[128–130] (that need therefore to be avoided for the molecular diagnosis of papillary carcinoma), and that the very restriction of the rearrangement to rare follicular cells does not necessarily anticipate the development of papillary carcinoma. The finding of oncogenic events in non-neoplastic cells is certainly not unique, a good example being the occurrence of *BCL2/JH* rearrangement (the molecular signature of follicular lymphoma) in rare lymphocytes in hyperplastic follicles.[131] Just as the identification of low-level *BCL2/JH* rearrangement does not establish per se a diagnosis of follicular lymphoma, the detection of low level *RET/PTC* does not establish papillary carcinoma. It rather supports the epidemiologic data showing that Hashimoto thyroiditis is associated with a small but real risk of developing papillary carcinoma, by providing a biologic link between the two. Incidentally, *BRAF* p.V600E mutations have not been detected in Hashimoto thyroiditis.[128,132] Medullary carcinoma has also been described in thyroid glands with Hashimoto thyroiditis, but the occurrence is probably coincidental.[133]

The treatment of Hashimoto thyroiditis depends on its severity. In mild cases no therapy is needed. In some instances, thyroid hormone is given to relieve hypothyroidism. In still others, surgery in the form of subtotal thyroidectomy is performed because of large size and/or pressure symptoms. Some cases of Hashimoto thyroiditis are treated surgically simply because they are clinically confused with a neoplastic process.[100]

Riedel Thyroiditis

Riedel thyroiditis, also known as Riedel struma, fibrous thyroiditis, and invasive thyroiditis was originally reported by Bernhard Moritz Riedel in 1896.[134] It is an extremely rare disorder that affects adult and elderly patients and shows a slight predilection for females. It presents with an ill-defined thyroid enlargement often associated with profound dyspnea. The lesion, which is extremely firm, binds the soft tissues of the neck in an iron collar (in the original description Riedel used the words *eisenharte*—iron hard—struma) and may compress the trachea to a slitlike state. Clinically, it is often thought to be carcinoma. In contrast to granulomatous thyroiditis, it is not preceded by an acute inflammatory process or by tenderness of the thyroid gland. The regional lymph nodes are not involved. Grossly, the process is asymmetric and involves only localized areas of the thyroid gland. The affected portion is stony hard and cuts with great resistance. Dense fibrous tracts extend from the thyroid capsule into adjacent muscle so that at surgery the tissue planes are obliterated. On cross section, areas with complete obliteration of the architecture alternate with others having a nearly normal appearance.

Microscopically, fibrous tissue completely replaces the area of the gland involved (Fig. 8.14). The fibrosis is the result of an active proliferative process of fibroblasts and myofibroblasts showing areas of storiform growth, and dense hyaline collagenization in the later stages of the disease. In the resected thyroid glands, hyalinization is frequently extensive, and skeletal muscle cells in the immediate area are often directly infiltrated by fibrous connective tissue. Giant cells are absent. The inflammation present is patchy and of mononuclear type, with a predominance of lymphocytes and plasma cells. The plasma cells are polyclonal, with numerous IgA- and IgG4-producing cells.[121,135] Collections of eosinophils may also be present. Medium-sized veins encased by the fibrosis typically show inflammation of their wall. This process of inflammatory phlebosclerosis is referred to as *obliterative phlebitis* and is important diagnostic feature (Fig. 8.15).[136] Elastic stain may be necessary to recognize fully obliterated veins. Arteries are less likely to be affected.[121]

Riedel thyroiditis is the prototypical manifestation of IgG4-related disease in the thyroid gland. IgG4-related diseases are a group of tumefactive fibro-inflammatory disorders (generically known as *inflammatory fibrosclerosis*) that can affect many organs and sites.[121,135] The group includes retroperitoneal or mediastinal fibrosis, sclerosing cholangitis, and—in the head and neck region—inflammatory pseudotumor of the orbit, eosinophilic angiocentric fibrosis, IgG4-related disease submandibular disease, and Mikulicz's disease.[121] IgG4 is a rare IgG idiotype, inefficient as antibody, with paradoxical anti-inflammatory properties. The diagnosis of IgG4-related diseases is based on distinctive histologic features (lymphoplasmacytic infiltrate, fibrosis—arranged at least focally in a storiform pattern,

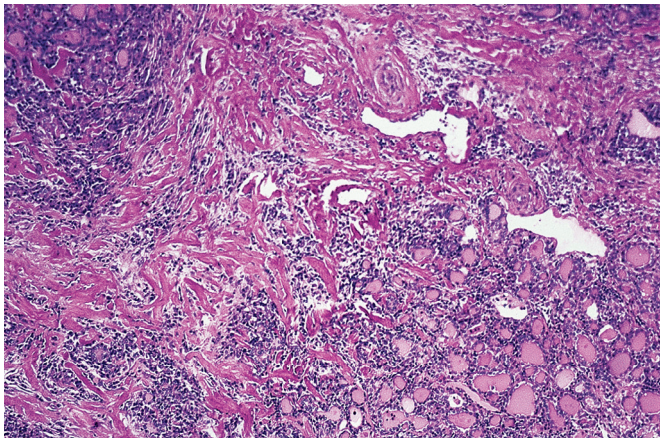

Figure 8.14 Riedel thyroiditis showing sclerosis, chronic inflammation, and parenchymal atrophy.

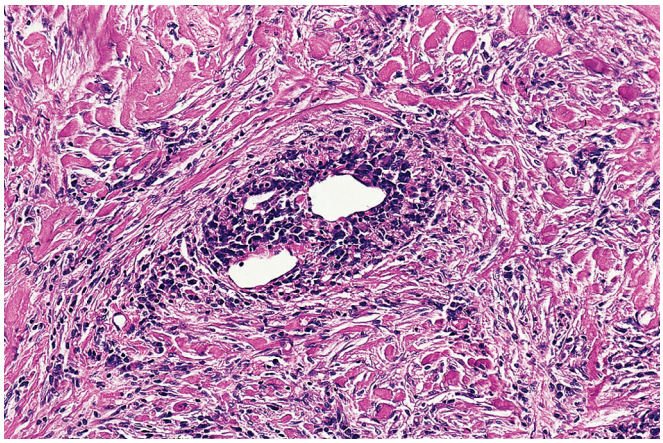

Figure 8.15 Inflammation of a vein in Riedel thyroiditis.

Figure 8.16 Multifocal sclerosing thyroiditis, macroscopic appearance. Multiple fibrotic foci are scattered throughout the bisected thyroid lobe *(arrows)*. (From Fellegara G, Rosai J. Gross appearance of multifocal fibrosing thyroiditis. *Am J Surg Pathol*. 2015;39(6):870.)

and obliterative phlebitis), and on the finding of numerous IgG4-positive plasma cells with an IgG4 to IgG ratio greater than 40% by immunohistochemistry.[121] IgG4-related fibro-inflammatory disorders develop (synchronously or metachronously) in other sites (e.g., the retroperitoneum) in 30%–40% of patients with Riedel thyroiditis.[135]

Riedel thyroiditis is different from granulomatous or Hashimoto thyroiditis, despite the existence of isolated instances in which the two diseases coexist.[118,119] While many cases of fibrous and some cases of conventional Hashimoto thyroiditis are IgG4 related, their histologic and clinical features are different, and they lack the extraglandular infiltration and systemic involvement by IgG4-related disorders in other sites that is typical of Riedel thyroiditis.[135] Riedel thyroiditis needs also to be distinguished from malignancies, particularly the paucicellular variant of anaplastic carcinoma (a challenging distinction in small biopsies), and from lymphoplasmacytic lymphoma.[121]

Steroid therapy has been effective in some cases (particularly those diagnosed at early stages), but most patients need surgical intervention to relieve the compression symptoms and to rule out the presence of carcinoma. The resection is quite difficult because no plane of cleavage exists and aggressive surgery is not recommended due to the risk of complications.[135]

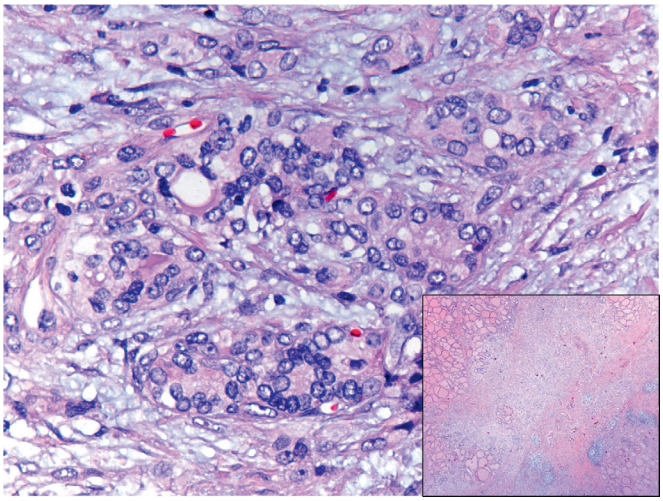

Figure 8.17 Multifocal sclerosing thyroiditis, microscopic appearance. *Reactive atypia* of follicular cells and "nodular fasciitis-like" stroma. The inset shows the irregular starlike fibrotic focus at low power.

Multifocal Fibrosing Thyroiditis

An uncommon but very distinctive form of thyroiditis has been recognized and designated multifocal fibrosing (or sclerosing) thyroiditis by Dr. Rosai in the course of his long and extensive activity as consulting pathologist. As the name implies the condition is characterized by one or more foci of fibrosis throughout the gland (typically foci are multiple, sometimes very numerous), having a stellate, radial configuration, and in a minority of cases a band-like appearance (Fig. 8.16).[137] The size of the foci is quite variable, with a mean diameter of 3 mm. On low power, the appearance can be indistinguishable from that of papillary microcarcinoma, but on high power it is possible to appreciate the lack of a neoplastic glandular component. Although the sclerotic foci are heterogeneous, the individual lesions are similar to each other in composition, characterized by a fibrotic poorly cellular center that merges with a cellular peripheral zone. Some of the follicular structures present at the periphery of the sclerotic focus (i.e., at the interface between the fibrotic core and the normal tissue), and to less extent those entrapped inside it, undergo reactive/regenerative changes (so-called *reactive atypia*) that simulates malignancy (Fig. 8.17). The thyroid follicles entrapped in the more central sclerotic areas are minute, with scant colloid. Those at the periphery appear hyperplastic, are surrounded by stroma that can have a nodular fasciitis-like appearance, and are lined by crowded thyrocytes with overlapping nuclei that sometimes display mild clearing and irregularities of the nuclear membrane contour. There are no nuclear pseudoinclusions or psammoma bodies.[137] *BRAF* p.V600E mutations have not been identified.[138]

The pathogenesis of multifocal fibrosing thyroiditis is obscure. The condition probably represents a peculiar host response to injury that stimulates a localized tissue response followed by a process similar to that of a healing scar. The condition develops predominantly in women (F/M = 12.75) and is often associated with nodular hyperplasia, Hashimoto thyroiditis, and Graves disease. In approximately 30% of cases it coexists with papillary microcarcinoma, and it is possible that some cases may represent a pre-neoplastic condition. As Dr. Rosai has pointed out, an association between fibrosis and malignancy has been reported in other organs (e.g., radial scar leading to ductal breast carcinoma).[137]

Hyperplasia

Hyperplastic disorders of the thyroid have been classified on the basis of their presumed pathogenesis, morphologic features, and

Table 8.1 Major types of thyroid hyperplastic disorders

NAME	MECHANISM	PATHOLOGY	FUNCTIONAL STATUS
Dyshormonogenetic Goiter	Genetically determined error in thyroid hormone synthesis	Nodular or (less frequently) diffuse hyperplasia	Hypothyroid
Graves Disease	Autoimmune	Diffuse hyperplasia	Hyperthyroid
Nodular Hyperplasia			
Endemic goiter	Iodine deficiency	Nodular hyperplasia (preceded by a transient phase of diffuse hyperplasia)	Usually euthyroid; sometimes hypothyroid
Sporadic goiter	Unknown	Nodular hyperplasia	Usually euthyroid; sometimes hyperthyroid or hypothyroid

clinical manifestations. In practice, three major forms of thyroid hyperplasia are recognized by combining these criteria (Table 8.1).

Dyshormonogenetic Goiter

Dyshormonogenetic goiter is a condition in which enlargement of the thyroid gland is due to defects in the synthesis of thyroid hormones. Thyroid dyshormonogenesis (thyroid hormone deficiency resulting from inborn errors of thyroid hormone synthesis) accounts for approximately 20% of cases of primary congenital hypothyroidism, the other 80% being the result of thyroid dysgenesis.[139] Some studies have shown that the incidence of primary congenital hypothyroidism with a normally located (eutopic) thyroid gland and milder dysfunction may be increasing, possibly due to changes in screening thresholds.[140] Dyshormonogenetic goiter is linked to mutations in genes that encode for proteins involved in the steps of thyroid hormone synthesis. Mutations in genes that cause defective iodide transport (*NIS/SCL5A5* encoding the Na/Iodide symporter and *SCL26A4/PDS* encoding pendrin), defective iodide organification (*TPO* encoding thyroid peroxidase, *DUOX2* encoding dual oxidase 2, *DUOXA2* encoding dual oxidase maturation factor 2), defects of thyroglobulin synthesis (*TG* encoding thyroglobulin), or dehalogenation deficiency (*IYD/DEHAL1* encoding iodotyrosine deiodinase) are well characterized. Disease phenotypes are inherited in an autosomal recessive manner and are not associated with other defects, other than deafness in Pendred syndrome (due to *SCL26A4/PDS* mutations).[139–141]

Grossly, the gland is enlarged and multinodular (Fig. 8.18). Microscopically, the most common alteration consists of hypercellular nodules exhibiting a variety of architectural appearances, with a predominance of solid and microfollicular patterns (Fig. 8.19).[142] In some cases there are papillary and insular formations. Fibrosis is a common finding, in some instances resulting in irregularities at the edge of the nodules that can simulate capsular invasion. Other common features include marked nuclear atypia and minimal amounts of colloid. A diagnostically important feature is the fact that the nuclear atypia (in the form of bizarre hyperchromatic nuclei) is present mainly in the tissue *between* the hyperplastic nodules rather than in the nodules themselves.[142] Mitotic figures are often seen, presumably as a result of the continuous TSH stimulation.[142] The suggestion has been made that there is some correlation between the specific molecular defect and the morphologic appearance of the gland.[143]

The histologic features of dyshormonogenetic goiter are characteristic enough that a pathologist may strongly suggest the diagnosis.[142] This is important given the need for genetic counseling to assess

Figure 8.18 Dyshormonogenetic goiter. Gross appearance. Note the multinodular quality and the hemorrhagic changes in the larger nodules. (Courtesy of Dr. Michael Kashgarian, New Haven, Connecticut.)

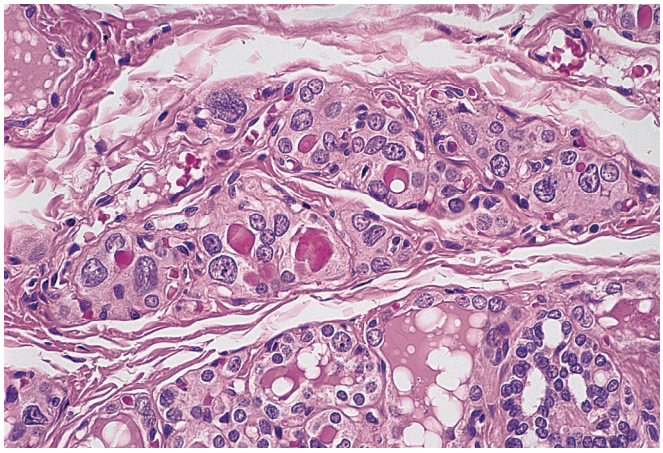

Figure 8.19 Dyshormonogenetic goiter. Microscopic appearance. The follicles are hyperplastic and lined by follicular cells with marked nuclear pleomorphism.

the risk of inheritance and recurrence in the family.[139] Cases of thyroid carcinoma have been reported in patients with dyshormonogenetic goiter, but the number of well-documented cases is very low.[144] Most have been of follicular type, and others have been incidental papillary microcarcinomas.[142] The reported follicular tumors have included adenomas (some developing after T4 replacement therapy) and carcinomas.[142,145]

Because dyshormonogenetic goiter is commonly associated with pleomorphism, hypercellularity, and mitotic activity of the follicular epithelium, one should be particularly strict with the criteria for the diagnosis of follicular carcinoma in this setting. Specifically, nothing short of clear-cut capsular or blood vessel invasion should be accepted.[142,146]

Graves Disease (Diffuse Toxic Goiter)

Graves disease (also known as Basedow disease, diffuse toxic goiter, and exophthalmic goiter) typically presents in young adult females with muscle weakness, weight loss, irritability, heat intolerance, fatigue, tachycardia, goiter, and often a great increase of appetite. It can also develop in children, in whom it constitutes the most common cause of hyperthyroidism. Atrial fibrillation may occur, particularly in older patients.[147,148] The enlargement of the thyroid gland is typically diffuse, but in case of iodide deficiency Graves disease may coexist with multinodular goiter. The goiter is palpable in the majority of hyperthyroid patients who are younger than 60 years, as opposed to less than 50% of older patients.[147]

Graves ophthalmopathy (or orbitopathy) develops in 25%–30% of patients. Cigarette smoking is a risk factor and has been associated with more aggressive ophthalmopathy.[149] This is an autoimmune disorder of the periorbital tissues that results in increased volume of both adipose tissue and extraocular muscles due to inflammation, the accumulation of hydrophilic glycosaminoglycans (typically hyaluronic acid) and related edema, and tissue remodeling with activation of lipogenesis and fibrosis.[149] Exophthalmos (or proptosis, i.e., protrusion of the eyeball) develops in approximately 60% of patients with ophthalmopathy, but imaging can identify subtle orbital connective tissue abnormalities in 70% of patients with Graves disease.[147,149]

Late clinical manifestations of Graves disease are localized dermopathy *(pretibial myxedema)* and so-called *thyroid acropachy*; the latter is characterized by swelling of the extremities and clubbing of fingers and toes resulting from periosteal new bone formation.[147,150]

Laboratory abnormalities include elevation of bound T4, free T4, or bound T3 levels and increased radioactive iodine uptake in the presence of low TSH levels.[147,148] A variant characterized by increased serum levels of T3 in the presence of therapy-induced low levels of T4 has been described as *T3-predominant Graves disease*.

Grossly, the gland shows a mild to moderate symmetric diffuse enlargement. It is succulent and reddish and has the consistency of pancreatic tissue (Fig. 8.20). The cut surface is uniformly gray or red, depending on the degree of vascularity (Fig. 8.21). In longstanding cases, the gland appears friable and dull yellow.

Microscopically, the follicles are markedly hyperplastic, with prominent papillary infolding that may cause confusion with papillary carcinoma (Fig. 8.22).[151,152]

The lining epithelium is columnar, with basally located normochromatic or hyperchromatic nuclei and a clear, sometimes microvacuolated basophilic or amphophilic cytoplasm that may contain fat and glycogen. These features are said to be even more prominent in T3-predominant Graves disease.[153] A variable number of oxyphilic cells may be present, suggesting a possible evolution toward Hashimoto thyroiditis. The colloid is pale and finely vacuolated, with prominent scalloping where it abuts the epithelium. The stroma contains aggregates of lymphoid tissue with germinal center formation (Fig. 8.23). Immunohistochemically, most of these lymphocytes are of T-cell type, the cytotoxic-suppressor subtype predominating in the follicles and the helper-induced subtype in the interstitium.[154] Mild fibrosis is present in longstanding cases. Hyperplastic follicles

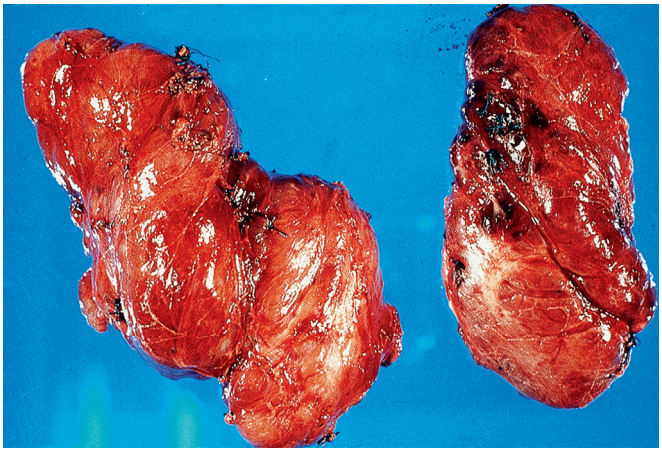

Figure 8.20 Outer aspect of diffuse thyroid hyperplasia in a patient with Graves disease. The gland is diffusely swollen and hyperemic.

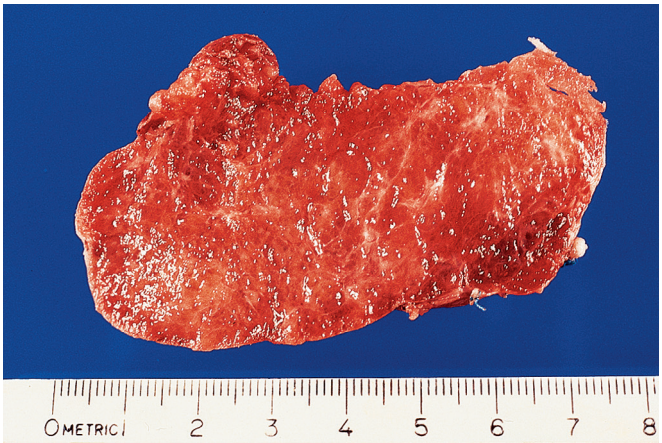

Figure 8.21 Cut surface of thyroid gland with diffuse hyperplasia, showing a hyperemic "juicy" appearance.

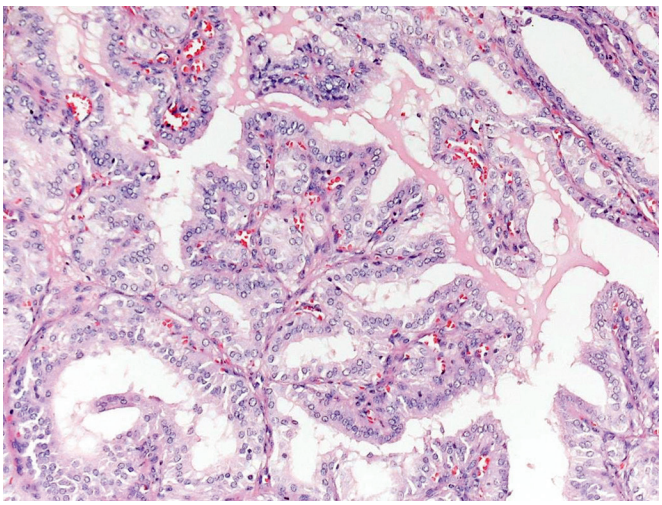

Figure 8.22 Hyperplastic papillae protruding into dilated follicles in diffuse hyperplasia.

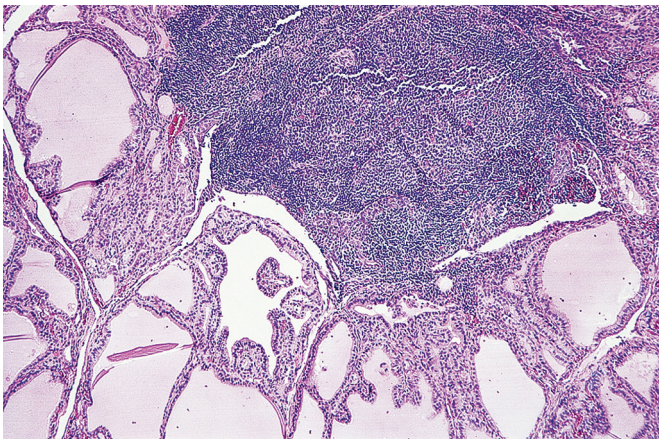

Figure 8.23 Lymphoid follicles with germinal centers and hyperplastic thyroid follicles in diffuse hyperplasia. Note the pale-staining quality of the colloid.

may be seen outside the thyroid gland, sometimes growing into the skeletal muscle of the neck. This may represent extrathyroid extension of the hyperplastic process or—more likely—the expression of hyperplasia in ectopic thyroid follicles, which in the normal situation are so small and scanty as to pass undetected.[155] Whatever the mechanism for their development, they should not be interpreted as evidence of malignancy.

Controversy still exists regarding the incidence, as well as the prognosis, of thyroid cancer associated with Graves disease (and hyperthyroidism in general, e.g., in the case of toxic multinodular goiter), but the numbers are such as not to influence the selection of therapy for Graves disease in the absence of palpable thyroid nodules.[156] Not surprisingly, incidental carcinomas have been found in the pathologic examination of thyroid glands removed for hyperthyroidism, their incidence varying from 1% to 10% in most reported series.[156] These figures are no higher than those reported in otherwise normal glands. Nearly all of the cases have been small papillary carcinomas without clinical significance, although some studies have suggested that carcinomas arising in patients with Graves disease may potentially be more aggressive.[156] The treatment of Graves disease may consist of antithyroid drugs such as propylthiouracil, methimazole, and carbimazole; ablation of the gland with radioactive iodine; or subtotal thyroidectomy.[147] The latter operation provides the specimen most commonly seen by the pathologist in this disorder. It should be noted that the microscopic picture described previously is rarely seen in their pristine state in these organs because of the changes that supervene as a result of therapy with antithyroid drugs and iodine or beta-blockers, which are given routinely in the preoperative period.[147] The glandular enlargement and the lymphoid infiltrate persist, but most of the hyperplastic changes in the follicles regress.[152,157,158] However, thorough sampling will usually reveal residual foci of hyperplasia. After surgery the thyroid remnants regenerate, so that a euthyroid status can be maintained, especially if the amount of thyroid tissue left is approximately 5 g on each side.[159] The greater the lymphocytic infiltration and the larger the number of oxyphilic cells in the operative specimen, the greater the chance that hypothyroidism will develop postoperatively.[160]

Glands treated with radioactive iodine show initially nuclear abnormalities, dissolution of some of the follicles, and vascular alterations. In later stages, nodularity, oncocytic changes, follicular atrophy, and fibrosis occur.[158,161,162] As a consequence, the long-term incidence of hypothyroidism is very high with this therapy. It should be noted that none of these treatments improves the ophthalmopathy associated with hyperthyroidism; rather, in some instances radioactive iodine treatment may provoke or worsen it.[147]

Graves disease is one of the two major forms in which *autoimmune thyroid disease* may manifest, the other being Hashimoto thyroiditis.

In Graves disease, thyroid-stimulating immunoglobulins activate TSHr, causing the overproduction of thyroid hormones and hyperthyroidism.[147,148] The T and B cells, as well as antigen-presenting cells infiltrating the thyroid parenchyma, produce numerous cytokines (including interleukins-1β, -6, and -12 and interferon-γ). These cytokines activate and sustain inflammation and alter the behavior of the follicular cells. Follicular cells start producing cytokines and expressing MHC class II molecules and CD40, allowing for productive interactions between thyroid epithelium and antigen-specific T cells that contribute to the autoimmune inflammatory process. Other antithyroid antibodies (e.g., anti-peroxidase) are also present but are not relevant for the development of the hyperthyroidism.[147]

The occurrence of an immune attack on the thyroid follicle is also evident on electron microscopic examination, which demonstrates deposits consistent with immune complexes in the follicular basement membrane.[163]

Genetic and environmental factors have been associated with the development of Graves disease, but the specific initiating events are unknown: infections and emotional stress are often reported in the patient history.[147,148,164] An increased incidence of Graves disease after irradiation to the neck for lesions such as Hodgkin lymphoma has been observed,[165] and cases have been reported in association with true thymic hyperplasia.[166]

Graves disease is only one of the many disorders—although by far the most common (80% of cases in iodide sufficient areas)[148]—that can lead to clinically evident hyperthyroidism, i.e., hyperfunction due high thyroid hormone levels caused by an increase in their synthesis and secretion by the thyroid parenchyma. Hyperthyroidism is not synonymous with *thyrotoxicosis*, the clinical hypermetabolic syndrome caused by increased free thyroxine-T4 and/or free triiodothyronine-T3 levels that may or may not be due to increased hormone synthesis and secretion by the thyroid. Other causes of hyperthyroidism include the following[148]: (1) "Toxic" sporadic (nodular) goiter; (2) "Toxic" follicular adenoma and the rare hyperfunctioning thyroid carcinoma. In these instances the hyperthyroidism is due to activating mutations in the gene encoding for the TSH receptor or in that for its associated Gsα subunit protein (with or without associated *EZH1* gene mutations); (3) TSH-secreting pituitary adenoma (hyperthyroidism due to stimulation by inappropriate TSH secretion); (4) Trophoblastic tumors (hydatidiform mole, choriocarcinoma) and human chorionic gonadotropin (hCG)-induced gestational hyperthyroidism. In these cases the hyperthyroidism is due to increased stimulation of the TSH receptor by hCG; (5) Struma ovarii (hyperthyroidism due to the autonomous function of thyroid tissue in the ovarian teratoma); (6) Iodine-induced hyperthyroidism (the Jod-Basedow effect—*jod* is the German word for iodine; hyperthyroidism after exposure to excessive amounts of iodide caused by increased hormone synthesis in patients with underlying thyroid disease, particularly those with multinodular goiter containing autonomously hyperfunctioning areas); (7) Familial and sporadic non-autoimmune hyperthyroidism due to gain-of-function germline mutations in the TSH receptor gene.

Thyrotoxicosis without hyperthyroidism is due to the release of stored, preformed iodothyronine hormones into the circulation (follicular cell damage with "hormone leakage") as seen in various types of thyroiditis (e.g., de Quervain or drug-induced thyroiditides), or due to excessive intake of exogenous thyroid hormones (iatrogenic or factitious).[148] *Amiodarone-induced thyroid disease* includes both thyrotoxicosis

and hypothyroidism. Amiodarone is a cardiac antiarrhythmic and antianginal drug containing a large amount of iodine (37% by weight) that is in part released in the blood. Amiodarone-induced thyrotoxicosis type I is a form of iodine-induced hyperthyroidism caused by the exposure to high amounts of iodine; amiodarone-induced thyrotoxicosis type II is due to the direct toxic effect of the drug on thyrocytes, characterized histologically by degenerative and destructive follicular lesions causing the release of iodothyronines, involutional changes, and fibrosis.[72,148,167] Amiodarone-induced hypothyroidism (due to iodine excess) occurs predominantly in patients with preexisting thyroid autoimmune disease.[72]

Autoimmune thyroid diseases like Graves disease and Hashimoto thyroiditis can be components of autoimmune polyendocrine syndromes and can also be associated with non-endocrine autoimmune disorders (e.g., vitiligo, pernicious anemia, myasthenia gravis, autoimmune gastritis, celiac disease, hepatitis).[122]

Nodular Hyperplasia

Nodular hyperplasia (multinodular hyperplasia, nodular or multinodular goiter, adenomatoid goiter, adenomatous hyperplasia) is the most common thyroid disease. Its development is influenced by environmental factors, the most important of which is iodine deficiency, and by genetic factors.[168]

In the form traditionally known as **endemic goiter**, the disease is due to low iodine content of the water and soil, and it can be largely prevented by the addition of iodine to common salt.[169,170] The deficiency in thyroid hormone production induced by iodine deficiency leads to increased TSH secretion, which results initially in a hyperactive thyroid with tall follicular epithelium and small amounts of colloid (so-called *parenchymatous goiter*) and later in follicular atrophy with massive storage of colloid, with or without nodularity (so-called *colloid goiter*). In these endemic areas, the frequency of the disease at post mortem examination is virtually 100%. Although endemic goiter is typically a disease of developing countries, iodine deficiency is a global public health problem and may cause goiter also in developed ones.[169,170]

In the form known as **sporadic (nodular) goiter**, which is the one most commonly seen in the United States and other developed parts of the world, the pathogenesis remains unclear. Mild dietary deficiency of iodine, slight impairment of hormone synthesis, natural goitrogens, smoking, and lack of selenium and iron have been variously suggested.[168] In most patients with nodular hyperplasia, the blood levels of TSH are not elevated. Some cases are associated with lymphocytic or Hashimoto thyroiditis and can be viewed as the nodular forms of these immune-mediated inflammatory diseases. Hereditary predisposition is polygenic and influenced by environmental factors. Single nucleotide polymorphisms at specific chromosomal loci (1p36, 15q21and 16q23) have been linked to thyroid volume by genomewide association studies (GWAS),[171] while polymorphisms at both thyroid-specific genes (encoding for TPO, thyroglobulin, sodium iodine symporter, pendrin, and TSHr) and non thyroid-specific chromosomal loci (e.g., MNG-1 at 14q31, MNG-2 at Xp22, MNG-3 3q26.1-q26.3) have been associated with nodular goiter.[172] Patients with DICER1 syndrome, a rare autosomal dominant cancer syndrome caused by inactivating germline mutations in the gene encoding DICER1, a ribonuclease (RNase) involved in the generation of mature miRNA species, develop pleuropulmonary blastoma, ovarian Sertoli-Leydig cell tumors, cystic nephroma of the kidney and multinodular goiter with adenomatous nodules, and sometimes thyroid carcinoma (often follicular variant papillary carcinoma).[173]

The prevalence of goiter in the general adult population of iodide-sufficient regions is 10% in women and 2% in men,[174] while thyroid nodularity is identified at autopsy in approximately 50% of cases.[175] Clinically, most patients are euthyroid and when first seen have a multinodular gland that may become very large, cause tracheal obstruction, and produce considerable disfigurement. In cases with a single, firm, dominant nodule, the clinical distinction from a true neoplasm becomes impossible. Hemorrhage within a nodule can cause sudden enlargement and pain. A small proportion of patients initially have clinical signs of hyperthyroidism, but the exophthalmos of Graves disease does not occur.[168]

Some cases of nodular hyperplasia are located substernally and enter in the differential diagnosis of superior mediastinal tumors (see Chapter 12). The morphologic changes are similar to those of the nodular form of endemic goiter. As in the latter, the degree of thyroid nodularity is directly related to the duration of the disease.[168,176] On occasion, one or more of the hyperplastic nodules appear in the lateral neck, anatomically separate from the main gland, sometimes simulating metastatic thyroid carcinoma[177]; these are referred to as *parasitic nodules*.

Grossly, the thyroid with nodular hyperplasia is enlarged and its shape distorted, one lobe being frequently larger than the other (Fig. 8.24). The thyroid capsule may be stretched but is intact. On cross section, multiple nodules are seen; most are devoid of a capsule (Fig. 8.25), but some may be partially or even completely encapsulated. Secondary changes in the form of hemorrhage, calcification, and cystic degeneration are common.

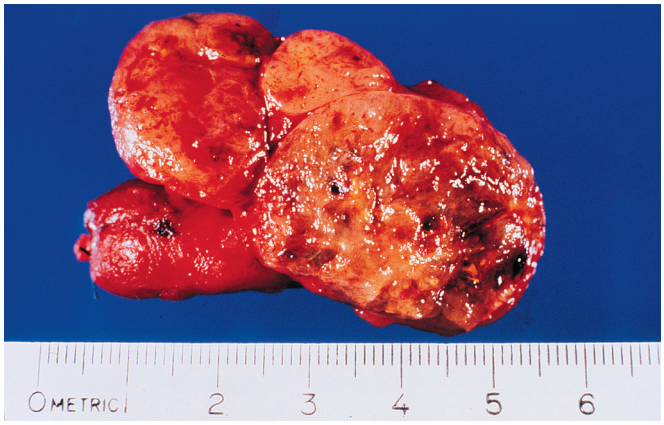

Figure 8.24 Nodular hyperplasia of thyroid gland, with secondary cystic and hemorrhagic areas.

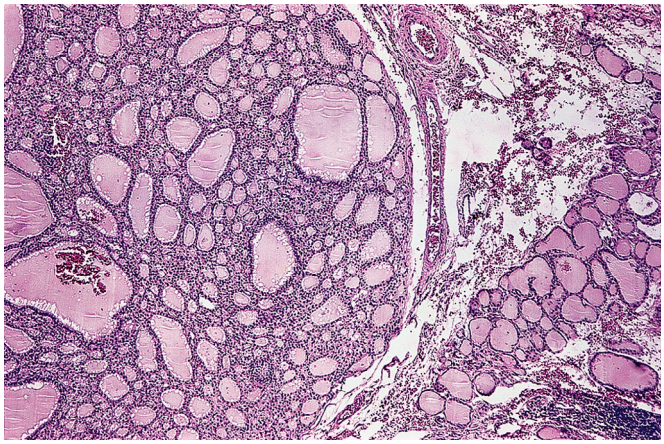

Figure 8.25 Low-power appearance of nodular hyperplasia. The hyperplastic nodules lack a capsule.

Microscopically, the appearance is very variable. Some nodules are composed of huge follicles lined by flattened epithelium, others are extremely cellular and hyperplastic, and still others are composed predominantly or exclusively of oncocytic (Hürthle) cells (Fig. 8.25). Some of the dilated follicles have a conglomerate of small active follicles at one pole (so-called *Sanderson polsters*) (Fig. 8.26). Others have papillary projections facing the lumen of a cystic follicle, a feature that may lead to confusion with papillary carcinoma (Fig. 8.27).[151]

It is not unusual to find, within a nodule predominantly composed of large dilated follicles, sharply outlined solid or microfollicular clusters of follicular cells. It has been suggested that nodular goiters grow by episodic replication of these clusters, which have been referred to as *foci of secondary proliferation*. The proliferative activity in these clusters overlaps with that of neoplastic nodules (follicular adenoma, follicular carcinoma, papillary carcinoma).[178]

Rupture of follicles leads to a granulomatous reaction to the colloid, with appearance of histiocytes and foreign body–type giant cells. Greatly thickened vessels with calcified media, areas of fresh and old hemorrhage, coarse fibrous trabeculation, foci of calcification, and osseous metaplasia may be seen as expression of regressive changes. Exceptionally, foci of extramedullary hematopoiesis are found in patients with known or occult primary myelofibrosis.[179]

Vascularization inside the nodules is usually prominent, sometimes accompanied by reactive endothelial hyperplasia[180] and exceptionally even by the presence of hyperplastic follicles within vascular lumina.[181] Obviously, the latter feature raises the differential diagnosis with angioinvasive follicular carcinoma. Although the distinction can be very difficult, if the overall appearance of the lesion is typical throughout of nodular hyperplasia (including the intravascular component), a benign diagnosis is justified. Conversely, the multinodular pattern of invasion of some widely invasive carcinomas (particularly Hürthle cell carcinomas) may simulate nodular hyperplasia.[177] A variable number of chronic inflammatory cells are present in the stroma in many of the cases, indicating the coexistence of chronic thyroiditis; the larger their number, the higher the incidence of postoperative hypothyroidism.[160] The presence of highly atypical nuclei in a case of nodular hyperplasia should raise the possibility of previous exposure to radioactive substances if present in the nodule themselves, and of dyshormonogenetic goiter if present between the nodules. It is not possible to predict on the basis of the morphologic appearance whether the patient has clinical or laboratory evidence of hyperthyroidism.

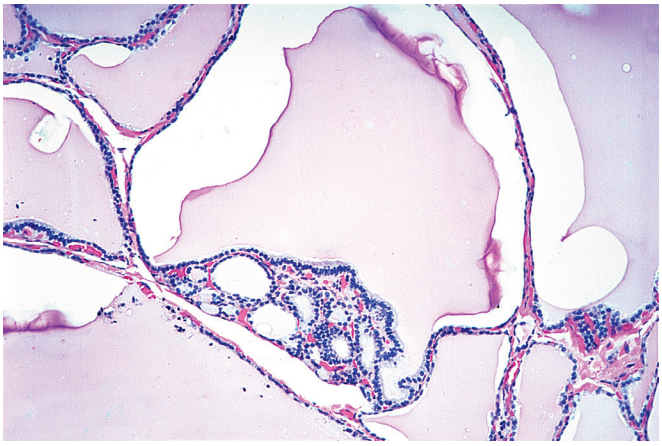

Figure 8.26 Nodular hyperplasia showing so-called Sanderson polster.

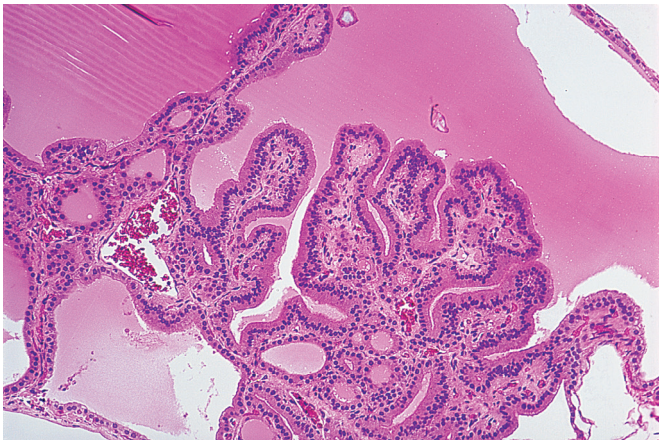

Figure 8.27 Nodular hyperplasia with benign papillary formations protruding toward the center of a cystically dilated follicle. Note the basal position of the nuclei.

The differential diagnosis between a dominant nodule from a case of nodular hyperplasia and a true adenoma is based on a set of admittedly arbitrary criteria. The adenoma is usually single, is totally surrounded by a capsule, is dissimilar from the remaining parenchyma, compresses the adjacent tissue, and is composed mainly of follicles that are smaller than those of the normal gland. The lesion of nodular hyperplasia is almost always one of many nodules, its encapsulation is incomplete, the follicular size is variable, some or all of the follicles are larger than those in the surrounding gland, and there is no compression of the adjacent parenchyma. In some cases, the distinction becomes impossible, inasmuch as lesions with the morphologic features of adenoma may be multiple and/or occur in a setting of nodular hyperplasia.

To address this, the clonality of hyperplastic nodules has been evaluated using X chromosome inactivation patterns: thyroid nodules, particularly the "dominant" adenomatous ones that develop in the background of nodular hyperplasia, may be monoclonal, even when they are partially or completely devoid of a fibrous capsule.[182] These studies have limitations given the large size of the embryonal X chromosome inactivation patch in the thyroid gland (approximately 0.5–1 cm^2),[183] but results consistent with a monoclonal cell population are identical to those obtained in many follicular adenomas (that are typically, but not always, clonal by X chromosome inactivation analysis).[184]

Most hyperplastic nodules have a normal karyotype. However, chromosomal DNA abnormalities detectable by conventional karyotyping and ploidy analysis occur in a minority of hyperplastic nodules, particularly in those with adenomatous features that frequently have extra copies of chromosome 7.[185] Activating mutations of the TSH receptor gene, typically associated with "toxic" adenomas, have been identified in hyperfunctioning, scintigraphically "hot" areas in multinodular goiter[184] and in microscopic, autoradiographically "hot" foci in approximately 30% of euthyroid goiters.[186] Activating *RAS* mutations occur in a few hyperplastic nodules.[184,187] These observations (monoclonal origin of some hyperplastic nodules, the occurrence of cytogenetic abnormalities, of aneuploidy and of oncogenic mutations) have been used to argue that hyperplastic nodules are in fact neoplastic.[184] They certainly reflect the difficulty in drawing the line between hyperplasia and neoplasia, a problem common to all endocrine proliferative lesions.

A longstanding and still unresolved issue is whether nodular hyperplasia is associated with an increased incidence of clinically significant carcinoma, particularly of the follicular type.[168] Suffice it to say that if such an increase really exists, it is small enough to be disregarded for practical purposes.

Mild asymptomatic cases of nodular hyperplasia require no treatment. Suppressive medical therapy with exogenous thyroid hormones is only moderately effective. If the enlargement is such that disfigurement or pressure symptoms develop, bilateral subtotal thyroidectomy is performed.[168]

Tumors

The majority of clinically apparent thyroid neoplasms are primary and epithelial. Traditionally, they have been divided into adenomas and carcinomas, the latter group incorporating the medullary carcinomas together with the more common lesions composed of follicular cells. From a histogenetic/differentiation standpoint, it is preferable to divide thyroid neoplasms into three major categories, depending on the cell types involved, and subdivide them into the various benign and malignant categories:

1. Tumors exhibiting follicular cell differentiation
2. Tumors exhibiting C-cell differentiation
3. Tumors exhibiting follicular and C-cell differentiation.

Lesions in the first category comprise more than 95% of the cases, the remainder being largely made up by tumors in the second category.[188]

Epithelial Tumors—Specific Types

Follicular Adenoma

Follicular adenoma is defined as a benign encapsulated tumor that shows evidence of follicular cell differentiation and lacks: (1) evidence of capsular, vascular, or any other type of invasion; and (2) the nuclear features of the papillary family of neoplasms. It is a common thyroid neoplasm. Most patients are euthyroid adults who initially have a thyroid lump, which on scan is usually "cold," sometimes "cool" or "warm," and only rarely "hot." The large majority of "hot" nodules are benign, but exceptions have been documented.[189]

By ultrasound, follicular adenomas are well circumscribed, usually solid, isoechoic or hypoechoic with a peripheral halo, similar to follicular carcinomas.[190]

Few of the tumors are associated with clinical hyperthyroidism (so-called *toxic* or *Plummer adenomas*).[191,192] The thyroid tissue outside hyperfunctioning nodules often contains intraluminal crystals of calcium oxalate, thought to be a sign of hypofunction.[189]

Adenomas are almost always solitary (except when occurring in genetically determined syndromes). They are characteristically surrounded by a generally thin capsule that is grossly and microscopically complete (Figs. 8.28 and 8.29). The architectural and cytologic features are different from those of the surrounding gland, which usually shows signs of compression. Adenomas may exhibit a variety of patterns, singly or in combination: normofollicular (simple), macrofollicular (colloid), microfollicular (fetal), and solid/trabecular (embryonal) (Fig. 8.30). The morphologic differences among these various patterns may be striking. They have no apparent clinical significance but elicit different differential diagnoses. Thus, as a general rule, the larger the follicles, the less likely that the lesion is a follicular adenoma or a follicular carcinoma (as opposed to a hyperplastic nodule or a papillary carcinoma with a predominantly follicular growth pattern). Instead, a predominance of solid/nesting/trabecular areas should alert one to the alternative possibilities of poorly differentiated or medullary carcinoma (which, however, are usually—but not always—clearly invasive).[193]

Mitoses are rare or absent in the follicular adenomas. They are not necessarily indicators of malignancy, but when they are present in appreciable numbers one should sample and examine the specimen with particular care. Secondary degenerative changes such as hemorrhage, edema, fibrosis, calcification, bone formation, and cystic degeneration are common, especially among the larger tumors. Sometimes the vessels in the capsule of adenomas (and also at the periphery of hyperplastic nodules) show prominent focal thickenings of their wall, referred to as *muscular cushions*.[194] Adenomas may exhibit papillary or pseudopapillary structures, which may prompt confusion with papillary carcinoma. Some authors have referred to these tumors as "papillary adenomas," a term that should be replaced with *follicular adenomas with papillary hyperplasia*.[195] The differential diagnosis, which

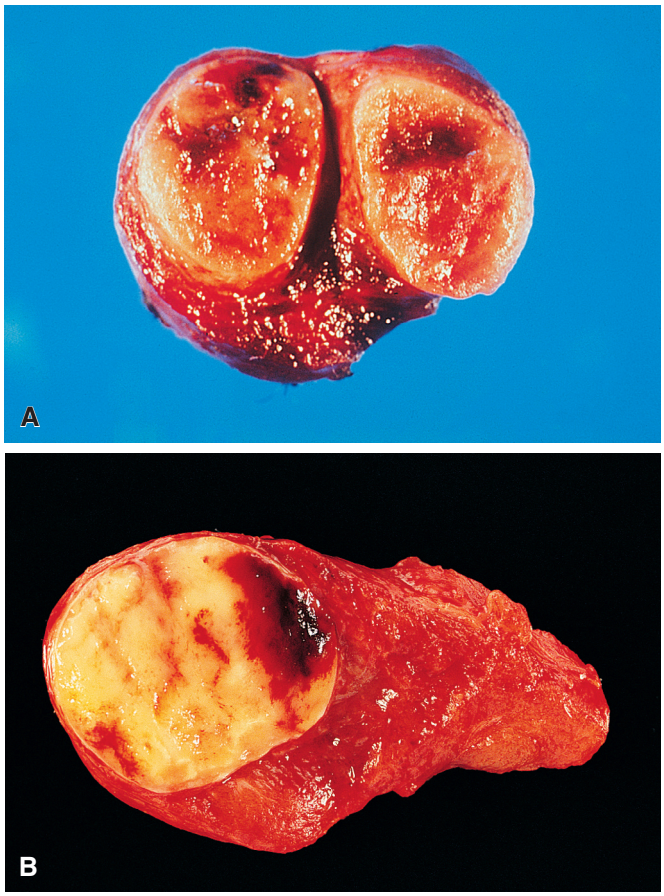

Figure 8.28 **A** and **B**, Gross appearance of two follicular adenomas. Both tumors show focal hemorrhagic areas.

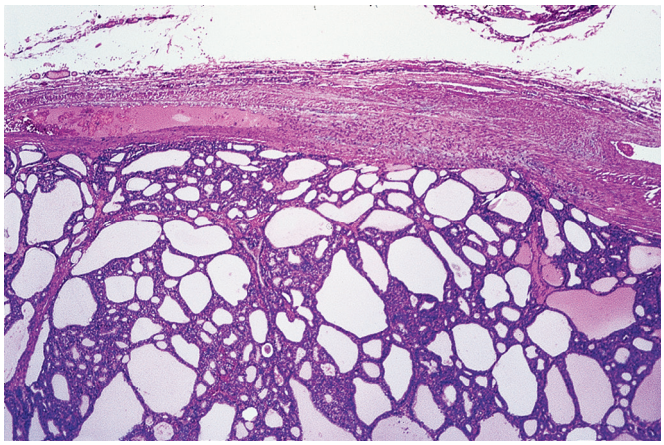

Figure 8.29 Intact fibrous capsule around a follicular adenoma.

includes hyperplastic nodules and encapsulated papillary carcinomas, is discussed later.

Some correlation exists between the microscopic appearance of a follicular adenoma and its activity as judged by the scan appearance.[196,197] In general, hyperfunctioning (hot) adenomas are more cellular and their cells have more abundant cytoplasm (and therefore a decreased nucleocytoplasmic ratio) than nonfunctioning (cold) tumors. However, the range of morphologic appearances that hot thyroid nodules can exhibit is wide, including less well-differentiated and oncocytic patterns. Hyperfunctioning follicular adenomas that are scintigraphically "hot" (and sometimes associated with overt hyperthyroidism, so-called *toxic* or *Plummer adenomas*) typically have activating mutations in the gene encoding the TSH receptor (*TSHR*) or in that encoding its associated Gsα subunit protein *(GNAS)*. *TSHR* mutations are more common (~50%–80%) than those of *GNAS* (~5%).[198,199] *EZH1* gene mutations have been identified in approximately 20%–30% of cases, nearly always in combination with *TSHR* or *GNAS* mutations, or with other presumed alterations in cAMP pathway genes.[200] It should also be remembered that hot thyroid nodules are usually but *not always* benign.[189]

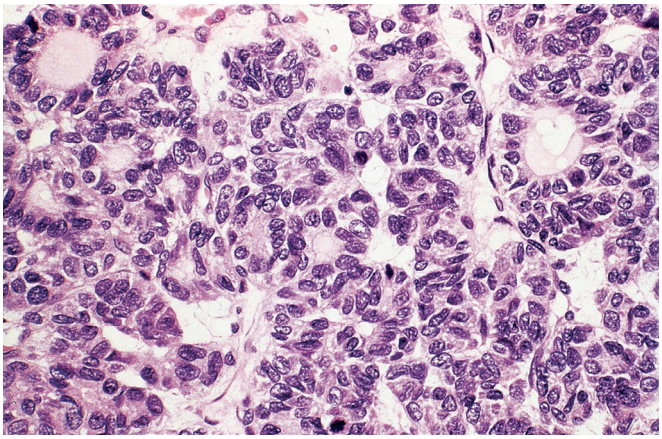

Figure 8.30 Microfollicular pattern of growth in a follicular adenoma.

The enzyme histochemical and immunohistochemical profile of adenomas mirrors that of the normal follicle.[201,202] There is reactivity for low-molecular-weight keratin, TPO, and thyroglobulin in the cytoplasm, for TTF-1 and PAX8 in the nuclei, and for laminin and other basement membrane components around the follicles.[26,202] The use of immunohistochemical markers in the differential diagnosis is discussed later. To date, no molecular test can reliably distinguish between follicular adenoma and follicular carcinoma, since genetic alterations (e.g., chromosomal abnormalities, activating *RAS* mutations, and *PAX8/PPARG* rearrangement) found in the former are also found, albeit with a higher prevalence, in the latter (Table 8.2). This points to a tumorigenic pathway common to all follicular neoplasms (adenomas and carcinomas) as opposed to papillary carcinoma.[203] Reasoning along this line, it may be argued

Table 8.2 Genetic pathology of thyroid tumors of follicular cells[a]

FOLLICULAR ADENOMA	FOLLICULAR CARCINOMA	PAPILLARY CARCINOMA (CONVENTIONAL TYPES)	ENCAPSULATED FOLLICULAR VARIANT OF PAPILLARY CARCINOMA	POORLY DIFFERENTIATED THYROID CARCINOMA	ANAPLASTIC THYROID CARCINOMA
RAS (20%–40%)[b] *PAX8/PPARG* (5%–20%) *TSHr*, *GNAS*, *EZH1*[c] Chromosomally unstable[d] (~35% to 65% karyotypes with simple abnormalities)	*RAS* (30%–50%)[b] *PAX8/PPARG* (20%–50%) *TERT* (10%–35%) *PIK3CA* (0%–10%) *PTEN* (0%–10%) Chromosomally unstable[d] (~65% abnormal karyotypes)	*BRAF* p.V600E (40%–80%) *RET/PTC* (5%–25%)[e] *TERT* (5%–15%) *RAS* (0%–10%)[b] *NTRK* rearrangement (0–10%)[f] Chromosomally stable[d]	*RAS* (25%–45%)[b] *PAX8/PPARG* (0%–30%) *TERT* (5%–15%) *BRAF* p.V600E (0%–10%) *RET/PTC* (0–10%) *EIF1AX* (0%–5%)[g] Chromosomally unstable[d] (similar to follicular neoplasms)	*RAS* (20%–50%)[b] *TERT* (20%–50%) *TP53* (10%–35%) *BRAF* p.V600E (5%–35%)[h] *PTEN* (5–20%) *PIK3CA* (0%–15%) *EIF1AX* (5%–15%)[g] *ALK* rearrangement (0–10) *CTNNB1* (0%–5%)[i] Chromosomally unstable[d] (karyotypes with complex abnormalities)	*TP53* (40%–80%) *TERT* (30%–75%) *RAS* (10%–50%)[b] *BRAF* p.V600E (10%–50%) *PIK3CA* (5%–25%) *PTEN* (10%–15%) *EIF1AX* (5%–15%)[g] *ALK* rearrangement (0–10) *CTNNB1* (0%–5%)[i] Chromosomally unstable and highly aneuploid[d]

[a]The main molecular alterations are reported; in parentheses the mutation prevalence percentage range, as estimated from the literature quoted in the text.
[b]Mutations in *N-*, *H*, *KRAS*; *NRAS* is the gene most frequently mutated.
[c]Hyperfunctioning follicular adenomas and adenomatous nodules have mutations of the TSH gene receptor (*TSHR*) (~50%–80% of cases), of the *GNAS* gene (~5% of cases), of the *EZH1* gene (~20%–30% of cases, nearly always in combination with *TSHR* or *GNAS* mutations, or with other presumed alterations in cAMP pathway genes).
[d]According to conventional cytogenetics, cytometric measurement of DNA content, comparative genomic hybridization, loss of heterozygosity and somatic copy-number alterations studies.
[e]The prevalence of *RET/PTC* is higher in children and much higher in radiation-associated papillary carcinomas (~50%–80%).
[f]The prevalence of *NTRK* rearrangements is variably reported between 0% and 5% for *NTRK1* and *NTRK3* in most series from nonradiation-associated papillary carcinoma in adult patients; the prevalence is higher in children and young patients, and in radiation-associated papillary carcinomas (up to ~15% for *NTRK3/ETV6*).
[g]*EIF1AX* mutations often co-exist with *RAS* mutations; they have been reported in follicular adenomas and rarely in hyperplastic nodules.
[h]The prevalence of *BRAF* p.V600E is approximately 40% in aggressive, radioiodine-refractory and FDG-PET positive tumors
[i]*CTNNB1* is the gene encoding β-catenin (effector of the *wnt* pathway); previous studies reported a higher prevalence of *CTNNB1* mutations in poorly and undifferentiated carcinomas.

that follicular adenomas with *PAX8/PPARG* are in fact noninvasive or preinvasive follicular carcinomas, or that the tumor has not been adequately sampled and that invasion of the capsule or blood vessel was missed. This is supported by the more common occurrence of the rearrangement in follicular carcinomas and also by the high cellularity and atypical features of some follicular adenomas with *PAX8/PPARG*.[204] A similar argument can be made for *RAS* mutations, since *RAS* mutated follicular adenomas may progress to *RAS* mutated follicular carcinomas and undergo further dedifferentiation.[203]

Follicular adenomas are typically (but not always) clonal according to X chromosome inactivation studies.[182,183] Conventional karyotyping identifies aberrations in 35%–65% of cases.[185,204,205] Numerical changes begin with an extra copy of chromosome 7, followed by the acquisition of additional copies of other chromosomes, a sequence that parallels the transition from hyperplastic to adenomatous nodules. Structural abnormalities overlap with those of follicular carcinomas.[185,205,206] Chromosomal translocations that involve 19q13, with the breakpoint corresponding to the *ZNF331* gene locus, and chromosome 2p21, with the breakpoint corresponding to the thyroid adenoma associated (*THADA*) gene locus, have been identified in approximately 10% of cases but are apparently rare in follicular carcinoma.[207,208] Fusion of *THADA* with the LOC389473 pseudo gene (at 7p15.3), leading to increased insulin-like growth factor receptor signaling, has been reported in approximately 5% of papillary carcinomas (follicular variant papillary carcinomas or NIFTP).[209] The PI3K/PTEN/AKT pathway is rarely altered in sporadic follicular adenomas, due to activating mutations of the *PIK3CA* gene that have been identified in a few cases (~5%); *PTEN* gene mutations are also uncommon.[210] This is somewhat surprising, considering that loss of function germline *PTEN* mutations are responsible for the Cowden syndrome (one of the PTEN-hamartoma tumor syndrome, PHTS) that is characterized by multicentric and bilateral thyroid follicular adenomas and hyperplastic/adenomatous nodules.[211] Follicular adenomas and adenomatous nodules also occur in the Carney complex type I[212] (*PRKARIA* germline mutations) and in the McCune–Albright syndrome (sporadic, postzygotic activating mutations of *GNAS*), in which case they are typically hyperfunctioning.[213]

Several variants of follicular adenoma have been described. *Oncocytic (Hürthle cell) adenoma* is discussed later and *hyalinizing trabecular adenoma* in the section that follows. The term *atypical adenoma* has been proposed for adenomas with pronounced cellular proliferation and less regular cytoarchitectural patterns but still lacking evidence of capsular or blood vessel invasion.[214,215]

Adenoma with bizarre nuclei is characterized by the presence of huge hyperchromatic nuclei, usually in clusters, unaccompanied by other features of malignancy (Fig. 8.31). This phenomenon is analogous to that seen in parathyroid adenomas and other endocrine neoplasms.

Other rare types of follicular adenoma are those with clear cell changes (including the signet ring, mucin-producing, and lipid-rich types), adenomas with adipose metaplasia of the stroma (so-called *lipoadenomas* or *adenolipomas*),[216] adenomas with cartilaginous metaplasia (so-called *adenochondromas*),[217] spindle cell adenomas (some vaguely resembling meningiomas),[218] and adenomas with massive deposition of cytoplasmic black pigment following minocycline therapy (so-called *black adenomas*).[219]

The differential diagnosis of follicular adenoma includes a dominant nodule of nodular hyperplasia, noninvasive follicular thyroid neoplasm with papillary-like nuclear features (NIFTP), minimally invasive carcinomas (follicular carcinoma or follicular variant papillary carcinoma), medullary carcinoma, and intrathyroidal parathyroid adenoma. Some follicular adenomas may also be confused with vascular tumors because of their high vascularization.

The lack of immunoreactivity for galectin-3, HBME1, and CITED1 and the retention of CD56 helps to distinguish adenomas from NIFTP and follicular-variant papillary carcinoma (Table 8.3); immunoreactivity for thyroglobulin and lack of calcitonin and CEA distinguishes adenomas with solid/trabecular growth from medullary carcinoma; immunoreactivity for thyroglobulin and TTF-1 and lack of chromogranin and parathyroid hormone distinguishes follicular adenomas from intrathyroidal parathyroid adenomas.[202,220–224]

The standard therapy for follicular adenoma is removal by lobectomy. Enucleation of the adenoma should not be attempted. Suppression of the nodule with levothyroxine and treatment of the toxic adenoma with radioactive iodine have been used, but the results have generally been less than satisfactory.[197]

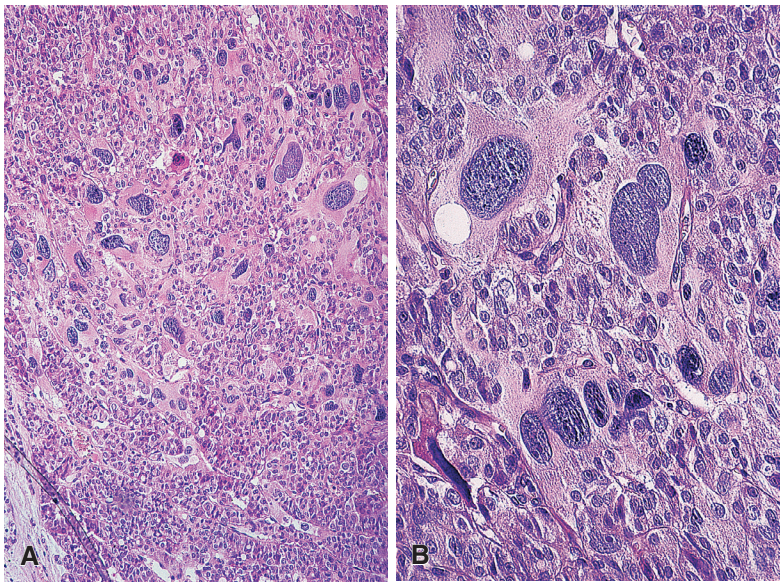

Figure 8.31 Low-power **(A)** and high-power **(B)** views of follicular adenoma with bizarre nuclei. This feature is not a sign of malignancy and is analogous to that seen in many other endocrine tumors.

Table 8.3 Immunohistochemical markers of papillary carcinoma[a]

	HBME-1	GALECTIN-3	CK19	CITED1	CD56	KI-67 LABELING INDEX (% RANGE)
Normal thyroid	~0	~0	0–40	~0	~100	~0.2 (0–0.5)
Nodular hyperplasia	0–20	0–30	0–40	0–10	90–100	~0.7 (0–3)
Follicular adenoma	5–30	10–50	10–50	5–10	90–100	~1.5 (0–5)
Follicular carcinoma	60–80	20–100	20–80	10–20	80–100	~5.0 (1–10)
Papillary carcinoma, follicular variant	80–100	60–100	50–100	50–80	0–30	~2 (0–5)
Papillary carcinoma, conventional	90–100	90–100	80–100	50–90	0–10	~3 (0–5)
Anaplastic carcinoma	0–80	0–100	0–80	~0	~0	~35 (20–70)

[a]Percentage range of positive cases estimated from the literature and proliferative activity (Ki-67 labeling index)
Data from references 202, 220–224.

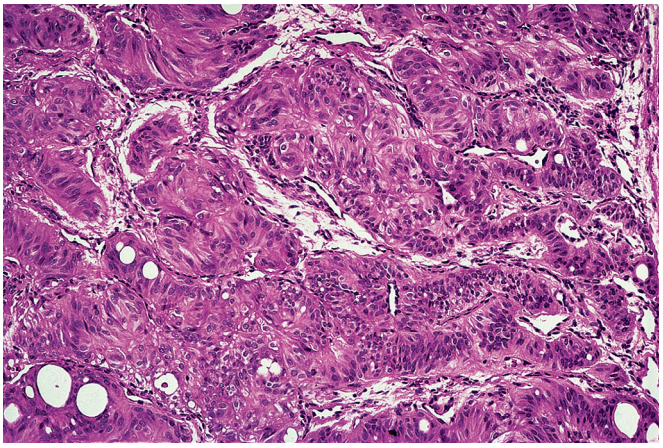

Figure 8.32 Low-power view of hyalinizing trabecular adenoma.

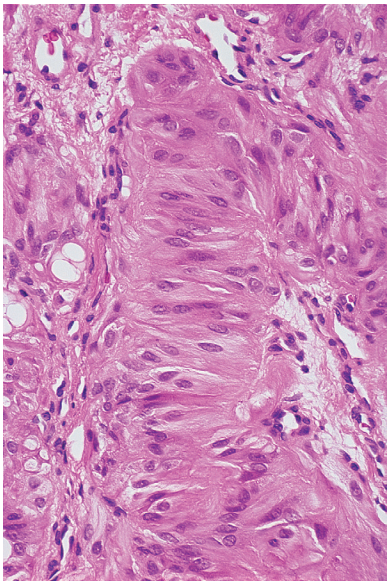

Figure 8.33 Hyalinizing trabecular adenoma. A wide trabecula is seen in the center of the picture, with the tumor cells arranged perpendicular to the longest axis.

Hyalinizing Trabecular Tumor and Related Lesions

Hyalinizing trabecular adenoma was the term given by Dr. J.A. Carney in 1987[226] to a peculiar type of follicular cell neoplasm (apparently first identified by Langhans).[227] Because of its unclear relationship with malignancy and because rare cases may show invasion (of the tumor capsule or vascular spaces) or metastases (see later) the term *hyalinizing trabecular tumor (HTT)* is currently preferred.[225,228,229] The lesion has a very distinctive histologic appearance, characterized by a prominent trabecular arrangement and an equally prominent hyaline appearance (Fig. 8.32). The latter is present both in the cytoplasm of the tumor cells (as the result of the accumulation of intermediate filaments) and in the extracellular space (as the result of heavy deposition of hyalinized collagen fibers and basement membrane material). The trabeculae can be straight or curved, resulting in curious organoid formations (Fig. 8.33). The pattern of growth may simulate that of paraganglioma and medullary carcinoma, whereas the presence of perinucleolar clearing, nuclear grooves, and psammoma bodies may suggest papillary carcinoma, particularly in material from fine-needle aspiration (FNA) (Fig. 8.34).[226] By ultrasound, HTT is typically hypoechoic with a pattern most similar to that of follicular adenoma and the follicular variant papillary carcinoma.[230] Another distinct (but not specific) morphologic feature of HTT is the so-called *cytoplasmic yellow body*, which is a round, 2–5 µm, pale yellow cytoplasmic inclusion body in a paranuclear

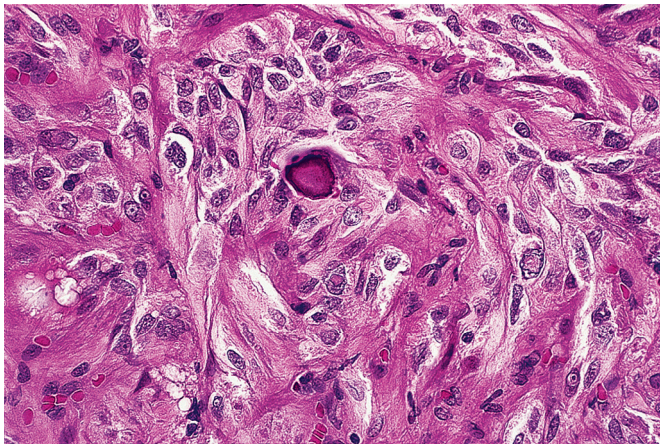

Figure 8.34 Psammoma body formation in hyalinizing trabecular adenoma.

location having a refractile quality and detectable both in tissue sections and in FNA smears.[231,232] These bodies correspond to giant secondary lysosomes[231] and can be found in other thyroid tumors (including papillary and follicular carcinoma), where they are however numerically rare.[232] Immunohistochemically, HTT is positive for thyroglobulin and TTF-1 but not for calcitonin.[226] HBME-1, galectin-3, and cytokeratin 19 are expressed inconsistently.[225,233,234] Focal and inconstant signs of neuroendocrine differentiation have been shown by immunohistochemistry (reactivity for NSE and chromogranin A) and confirmed by the finding of neurosecretory granules by electron microscopy.[227,235]

HTT also shows a peculiar cell membrane and cytoplasmic (instead of nuclear) immunostaining with the monoclonal antibody MIB1 to the proliferation marker Ki-67.[236] The peculiar pattern (likely due to epitope cross reactivity of the MIB1 antibody) is not seen with automated immunostainers which operate at 37°C but only when the reaction is performed at room temperature.[237] Immunostains for type IV collagen and laminin are consistent with heavy deposition of basement membrane material around the tumor cells (partially explaining their "hyaline" appearance) and—surprisingly—in the nuclear pseudoinclusions.[225,235,238]

Considerable controversy has arisen as to whether HTT is a distinct entity or an unusual pattern of growth that can be present in a variety of thyroid lesions.[239,240] It is generally accepted that the "HTT pattern" can be seen as a microscopic incidental finding in nodular hyperplasia,[241] and in rare neoplasms with HTT features accompanied by capsular and/or vascular invasion, which have therefore been designated as hyalinizing trabecular carcinomas.[228,229,242] Intriguing is the apparent link between HTT and papillary carcinoma, which manifests itself by the presence in HTT of morphologic features traditionally associated with papillary carcinoma, such as nuclear alterations (grooves and pseudoinclusions) and the finding of psammoma bodies; by the occurrence of papillary carcinoma merging with HTT (Fig. 8.35)[229,242]; by the association of both conditions with Hashimoto thyroiditis and possibly with radiation exposure.[225,235]

Regardless of this link, in the absence of capsular or vascular invasion there are no well-documented examples of HTT that have metastasized, and the only tumor that developed distant metastases (in the lung) out of a series of 119 cases had both.[225,227]

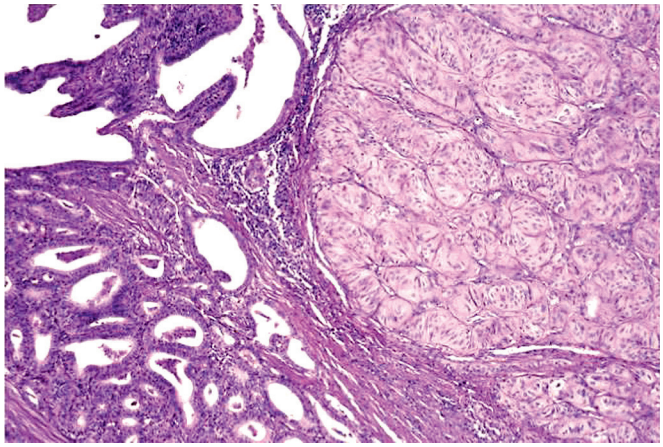

Figure 8.35 Typical hyalinizing trabecular adenoma pattern *(right)*, and a lesion with the features of a papillary carcinoma *(left)* are seen side by side, in a cervical lymph node metastasis. (From Rosai J, DeLellis RA, Carcangiu ML, Frabel WJ, Tallini G. *Tumors of the Thyroid and Parathyroid Glands. AFIP Atlas of Tumor Pathology*. Fourth series, Fascicle 21. Silver Spring, MD: American Registry of Pathology; 2014.)

A small number of cases are aneuploid by flow cytometric DNA analysis[226] or show simple karyotypic alterations.[240] Reports of *RET/PTC* rearrangements[243] are in all likelihood the result of subclonal events that are not diagnostically relevant.[128] *BRAF* p.V600E or *RAS* mutations do not occur, and the miRNA profile is different from that of papillary carcinoma.[243,244]

Papillary Carcinoma

General Features

Papillary carcinoma is defined by the presence of a distinctive set of alterations of nuclear morphology, the PTC-type nuclei (see later), although the presence of either papillae or invasion of the surrounding thyroid parenchyma is generally required for the diagnosis. It is the most common type of thyroid carcinoma and the most common endocrine malignancy.[245]

Females are more affected than males. It can present in any age group, the mean age at the time of initial diagnosis being approximately 40–50 years. Papillary carcinoma accounts for more than 90% of thyroid malignancies in children. In approximately 5% of cases, there is a history of irradiation exposure to the neck, and the non-neoplastic gland may show nuclear aberrations as a result. There is convincing evidence for an increase in the incidence of papillary carcinoma in Hashimoto thyroiditis, but the wide variation in the figures quoted suggests that the diagnostic criteria vary just as widely.[246] Whether the frequency of papillary carcinoma is increased in Graves disease remains a controversial subject.[156,247]

The prevalence of thyroid carcinoma has been increasing globally, mostly due to the increased detection of small papillary carcinomas through neck ultrasound.[245] By ultrasound, papillary carcinoma is usually solid, hypoechoic, with infiltrative or microlobulated margins, microcalcifications, and a "taller than wide" shape.[190] Before the widespread use of ultrasound screening the large majority of patients had clinically evident disease in the neck when they were first seen, localized to the thyroid gland in 67% of cases, thyroid and lymph nodes in 13%, and lymph nodes alone in 20%.[248]

Gross Features

The size of the primary tumor ranges from microscopic to very large. A very high proportion of thyroid cancers measuring less than 1 cm in diameter are of papillary type. Grossly, most cases are solid, whitish, firm, and clearly invasive; 10%–20% are surrounded by a complete capsule (Figs. 8.36 and 8.37).[248,249] Marked cystic changes are seen

Figure 8.36 Gross appearance of a papillary carcinoma.

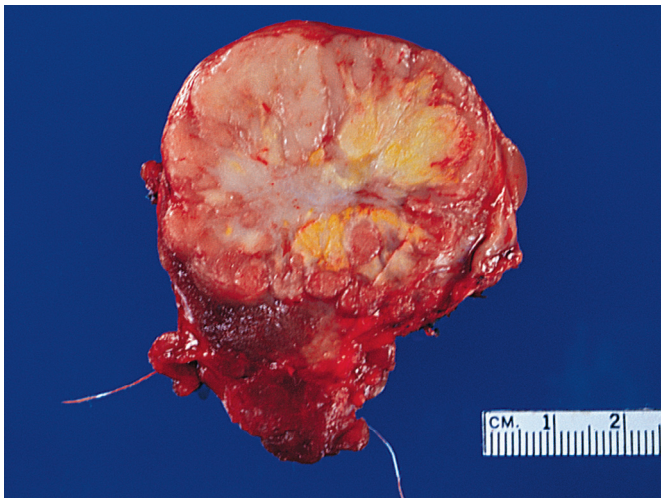

Figure 8.37 Gross appearance of a papillary carcinoma. The tumor shown exhibits a central area of fibrosis.

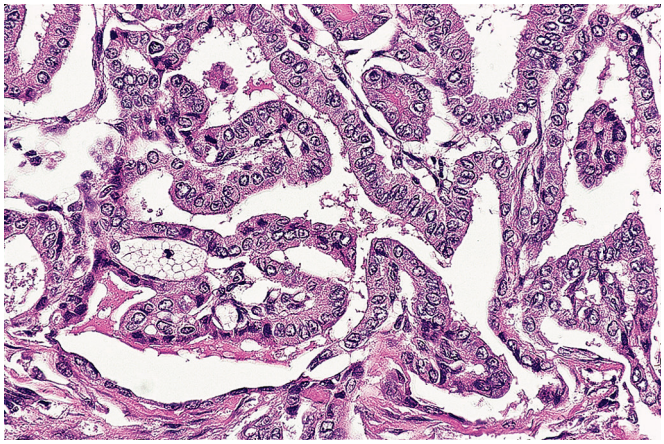

Figure 8.38 Complex branching papillae in classic papillary carcinoma.

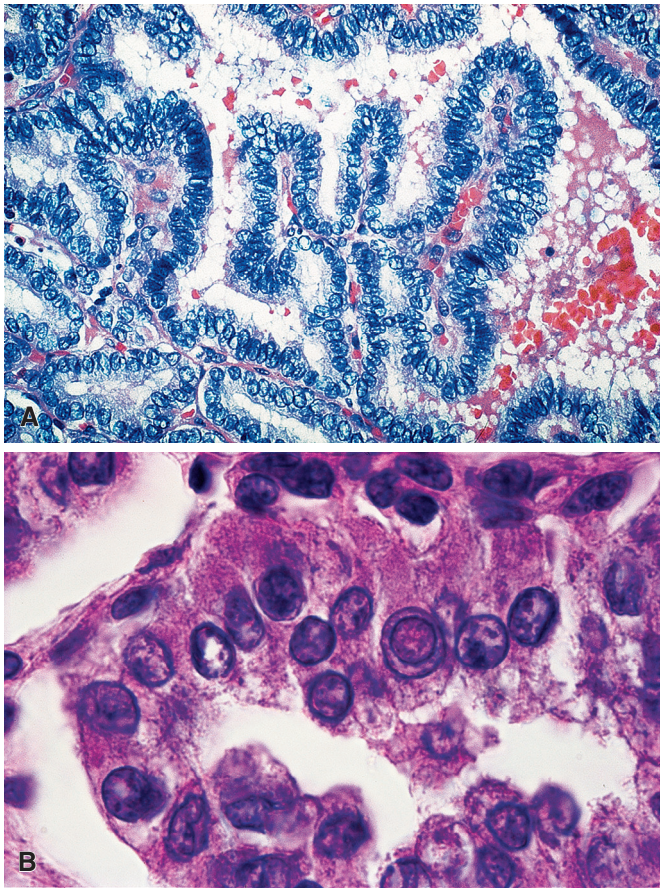

Figure 8.39 Nuclear features of papillary carcinoma: **A,** optically clear nuclei; **B,** nuclear pseudoinclusions.

in approximately 10% of cases. Sometimes the papillary formations are evident to the naked eye.

Microscopic Features

Microscopically, the typical papillary carcinoma contains numerous true papillae, an easily recognizable feature which—as one would have deduced—was the one originally chosen to name the tumor.[250] The papillae are usually complex, branching, and randomly oriented, with a central fibrovascular core and a single or stratified lining of cuboidal cells, some of which may have hobnail features (Fig. 8.38).[251] The stroma of the papillae may be edematous or hyaline and may contain lymphocytes, foamy macrophages, hemosiderin, or—exceptionally—adipose tissue. These papillae are nearly always associated with the formation of follicles, the ratio between the two components varying greatly from case to case. The follicles tend to be irregularly shaped, often tubular and branching. Tumors with a combination of papillary and follicular structures have the biologic behavior of papillary carcinoma and should therefore be classified as such instead of as mixed carcinomas.

The cells of papillary carcinoma have characteristic nuclear features. These have acquired so much relevance that currently the diagnosis of papillary carcinoma is more dependent upon their presence than on the papillary architecture, which may be minor or altogether absent (see under Variants).

These nuclear features (PTC-type nuclei) consist of:

1. Ground-glass (optically clear) nuclei, which often have a large size and an overlapping quality (Fig. 8.39A).[252] The nucleolus is usually inconspicuous and pushed against the nuclear membrane, which appears thickened. This change is present in sections obtained from paraffin-embedded material regardless of the fixative used, but is less apparent or altogether absent in frozen sections or cytology material, and is particularly prominent in tissue fixed in high concentrations of formalin.[253] The mechanism of its formation has not yet been ascertained.[254]
2. Nuclear pseudoinclusions. These represent invaginations of the cytoplasm and appear as sharply outlined (nuclear membrane–bound) round acidophilic vacuoles (see Fig. 8.39B).[255] In contrast to the ground-glass feature, the pseudoinclusions are also readily apparent in specimens from frozen section and aspirations. They should be distinguished from the nuclear "bubbles" that can be seen in a variety of lesions and organs and which are in all likelihood a processing artifact. These "bubbles," when present, tend to affect most nuclei and to be multiple within a single nucleus[177] and have been related to the process of histology section heating at 60°C in the oven before deparafinization (they are absent when sections are dried overnight or with a fan).[256]
3. Nuclear grooves. These tend to occur in oval or spindle nuclei, are usually arranged along the longest nuclear axis, and represent—like the pseudoinclusions—the morphologic expression of infoldings of a redundant nuclear membrane[257] as confirmed by confocal microscope analysis and tridimensional reconstruction.[258]

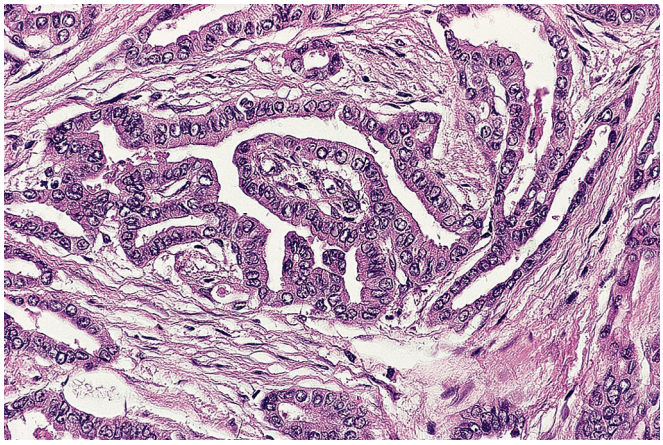

Figure 8.40 Desmoplastic stromal reaction in papillary carcinoma.

These nuclear membrane irregularities are seen to better advantage with markers specific for emerin, a nuclear membrane protein.[259]

4. Nuclear microfilaments. A few cases have been described in which the nuclear clearing is due to the accumulation of fine threadlike fibrils.[260]

Mitoses are usually very scanty or absent in papillary carcinoma.[261] Over half of the cases show extensive fibrosis, usually in the form of sharply outlined bands traversing the tumor; the appearance of this fibrosis may range from sclerohyaline to highly cellular (Fig. 8.40). Elastic tissue is often abundant in the tumor stroma.[262]

Psammoma bodies are seen in approximately half of the cases. These basophilic structures showing concentric laminations stain for mucin, calcium, and iron and appear to arise from necrosis of individual tumor cells, which occasionally may be seen at their very center, and which represent the nidus for their formation, very much the way a grain of sand acts as the nidus for the formation of a pearl in an oyster.[263] They may be located in the papillary stalk, in the fibrous stroma, or between tumor cells in solid foci (Fig. 8.41A). Their presence in a thyroid gland strongly suggests the diagnosis of papillary carcinoma, inasmuch as their occurrence in other thyroid lesions is exceptional[264]; Klinck and Winship[265] found them only once in a review of 2153 benign thyroids. Thus they represent a very important clue to the diagnosis not only in paraffin sections, but also in frozen sections and cytology preparations. If numerous enough they are visible on ultrasound scans.[190]

When psammoma bodies are found in otherwise normal thyroid tissue or lymph nodes from the neck, the chances are high that a papillary carcinoma is present in the immediate vicinity (see Fig. 8.41B).[265] Psammoma bodies should be distinguished from other forms of calcification and from the intraluminal foci of inspissated secretion often seen in oncocytic (Hürthle cell) tumors.[177,250]

Areas with a solid/trabecular pattern of growth are present in 20% of the cases and foci of squamous metaplasia in a similar number; these two patterns often merge and are probably related.[250] The presence of such foci is not per se an indication that the tumor is poorly differentiated unless accompanied by other alterations.

Occasionally, papillary carcinomas are seen to contain a bland-looking spindle cell component; this clinically insignificant metaplastic change (recognizable because of its blending with more typical epithelial cells and its immunoreactivity for thyroglobulin and TTF-1) should not be confused with a mesenchymal neoplasm or with the anaplastic transformation of a papillary carcinoma.[266]

Papillary carcinoma has a rich microvasculature, with high microvessel density. On the other hand, lymphatic vessels are very few inside the tumor, but their density is very high at the interface

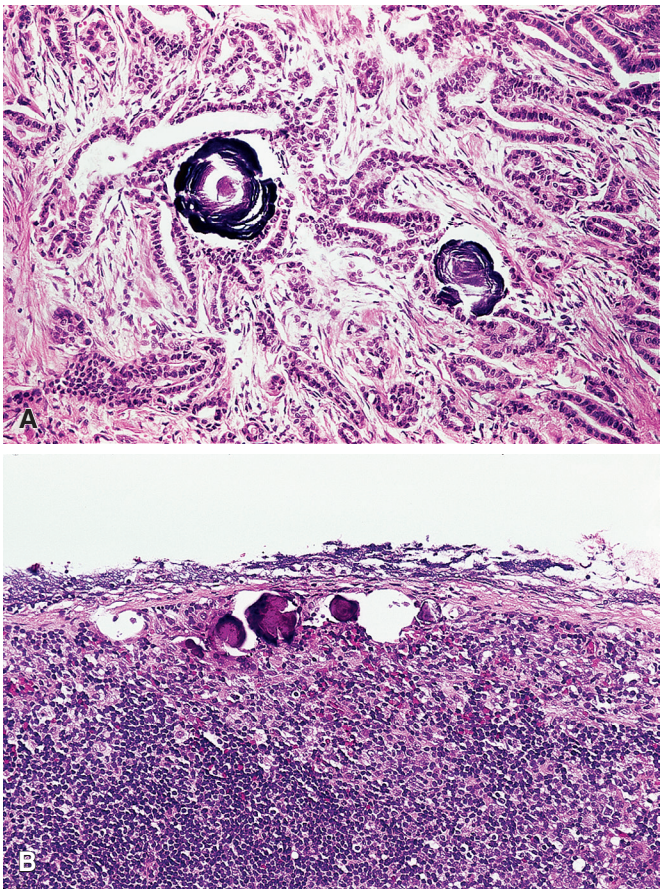

Figure 8.41 Psammoma body formation in papillary carcinoma: **A,** within the stroma of the primary tumor; **B,** beneath the capsule of a cervical lymph node, without identifiable tumor cells.

with the surrounding non-neoplastic thyroid.[267] Blood vessel invasion is found in only 5% of cases, a much lower proportion compared to follicular carcinoma.[248] Lymphocytic infiltration of the stroma is seen in a fourth of cases; it is not clear whether this represents a reaction to the tumor or the expression of preexisting thyroiditis.[268] Many tumors also exhibit a heavy infiltrate of S-100 protein–positive dendritic/Langerhans cells and macrophages.[269] Scattered multinucleated giant cells may be present, often in the lumen of the neoplastic follicles and probably representing a response to leakage of colloid.[270]

Multiple microscopic foci of tumor are found in approximately 20% of cases if a few random sections are taken and in over 75% if step sections of the entire gland are examined.[271] It is not entirely clear whether this represents *multicentricity* (multiple independent primary tumors) as opposed to intrathyroidal lymphatic permeation (*multifocality* due to spread of a single primary tumor). Both mechanisms likely operate: mutation analysis indicates the independent origin of these multiple foci in 30%–60% of cases.[272]

Electron Microscopic Features

Ultrastructurally, the most distinctive feature of the cells of papillary carcinoma is the highly indented nuclear membrane, with formation of pseudoinclusions and multilobation.[255,273] Changes in distribution of chromatin and ribonucleoprotein have been observed.[274] The cytoplasm is rich in mitochondria, lysosomes, and intermediate filaments. The apical surface exhibits microvillous differentiation.[255,273] The abnormal intracellular and extracellular deposition of basement

membrane material (of less degree but otherwise similar to that seen in hyalinizing trabecular carcinoma) is very evident at the ultrastructural level.[238]

Histochemical and Immunohistochemical Features

Papillary carcinoma retains immunoreactivity for pan-follicular cell markers, although these are generally downregulated compared with normal follicular cells.[5] Thus, TTF-1, and the other two transcription factors TTF-2 and PAX8 that are required to maintain the differentiated phenotype of follicular cells show consistent nuclear immunoreactivity in neoplastic cell nuclei.[18] Thyroglobulin is also consistently positive (although less than in well-differentiated follicular neoplasms), while TPO and NIS show reduced expression (in the case of NIS localization is redirected from the membrane to the cytoplasm).[13] Similar to normal follicular cells, those of papillary carcinoma are immunoreactive for keratins (detectable with pan-keratin, CAM 5.2, AE1/3 antibodies), with a CK7 positive/CK20 negative profile.[19,275–277] Unlike normal follicular cells, papillary carcinoma cells are often positive for the low-molecular-weight CK19,[19,275,278] and in keeping with their tendency to undergo squamous metaplasia they express high-molecular-weight keratins recognized by the antibody 34βE12.[277] Unlike normal follicular cells, that infrequently coexpress vimentin and keratin, papillary carcinoma cells are often vimentin positive,[21] although coexpression of both markers does not appear to be diagnostically relevant.[279]

The diagnosis of papillary carcinoma does not routinely require immunohistochemistry. When this is performed it is usually to establish the thyroid origin of a tumor at metastatic sites. Thyroglobulin and TTF-1 are very specific markers, and PAX8 can be used to differentiate papillary carcinoma (positive for both TTF-1 and PAX8) from lung adenocarcinoma and other tumors that are positive for TTF-1 but negative for PAX8.[18]

Another situation, considerably more complex, is the use of immunochemistry for the differential diagnosis of papillary carcinoma from other benign and malignant thyroid lesions. HBME-1 (membrane immunoreactivity), galectin-3 (both nuclear and cytoplasmic immunoreactivity), cytokeratin 19 (cytoplasmic immunoreactivity), and CITED1 (both nuclear and cytoplasmic immunoreactivity) are the markers more frequently overexpressed in papillary carcinoma (HBME-1 followed by galectin-3 are considered the most specific),[202,220–222] while CD56 is typically negative (see Table 8.3).[223,224] While the sensitivity of these markers is high, their specificity is relatively low, thus they are more effective when used in combination (usually HBME-1, galectin-3, cytokeratin 19).[202,220–224] Since results vary from one institution to another, in order to diagnose papillary carcinoma the performance characteristics of the panel need to be established in individual laboratories. Unfortunately, in problematic cases immunohistochemical results tend to be difficult to interpret, even if a panel is utilized, and this is particularly true for the abnormal follicular epithelium of Hashimoto thyroiditis.[177,281]

Traditional mucin stains are positive in many papillary carcinomas whether in the colloid, luminal border, or cytoplasm.[282] This correlates with the immunohistochemical demonstration of EMA (MUC1), mucins, simple mucin antigens, and histo-blood group antigens in papillary carcinoma cells (but also in those of follicular carcinoma).[20] EMA and alcian blue stain the apical membrane of the neoplastic cells lining the papillae but not those of the benign papillae of diffuse or nodular hyperplasia.[283]

A variety of other markers have been shown by immunohistochemistry in papillary carcinoma, including estrogen receptors,[22] S-100 protein,[280] S-100C,[284] HER2/neu,[285] cMet/hepatocyte growth factor receptor,[286] and involucrin,[277] while laminin and type IV collagen are demonstrable immunohistochemically at the interface of the tumor with the stroma.[238] Mutation-specific antibodies are available to detect BRAF p.V600E,[287] although molecular analysis is necessary in those cases with equivocal results.[288] Immunohistochemistry with the D5F3ALK antibody may be used as a surrogate marker to identify those rare papillary carcinomas with *ALK* rearrangement.[289]

Molecular Genetic Features

Activation of the mitogen-activated protein kinase (MAPK) pathway is the defining molecular genetic feature of papillary carcinoma.[203,290–292] This pathway regulates important cellular functions (e.g., proliferation, differentiation, and survival) and is frequently altered in human cancers.

Since the oncogenic events that cause MAPK signaling act sequentially in the same pathway, they are usually mutually exclusive.[203,290,291] One can be identified in the vast majority (~90%) of papillary carcinomas: in three out of four cases the MAPK pathway is activated by point mutations of *BRAF* (~60%) or of *RAS* (~15%), and in ~15% by chromosomal rearrangements that cause aberrant expression of receptor tyrosine kinases (RET, NTRK, and ALK) or of the kinase domain of BRAF.[292] Copy number gene variations likely play a tumorigenic role in approximately two-thirds of the remaining ~10% of cases, leaving less than 5% of papillary carcinoma without a known genetic defect.[292]

The prevalence of the main molecular alterations is shown in Table 8.2. The Cancer Genome Atlas (TCGA) Research Network has published in 2014 an integrated genomic characterization of 496 papillary carcinomas. The work, while confirming previous observations, has provided a clear picture of their molecular landscape.[292] The genome of papillary carcinoma is stable when compared to that of tumors from other organs, with approximately 0.4 non-synonymous somatic mutations per megabase of DNA.[292] Papillary carcinomas typically have a diploid karyotype with low rates of LOH,[292,293] although in ~7% of cases gene copy number variations likely play an important tumorigenic role.[292] They are a heterogeneous group that includes histopathologic variants defined on the basis of size (papillary microcarcinoma), growth pattern (follicular, macrofollicular, cribriform-morular, solid), or cellular characteristics (tall cell, hobnail/micropapillary, columnar cell, oncocytic), each with distinctive sets of molecular alterations (see later).

A general and schematic view that takes into account the four basic morphologic features used to diagnose differentiated thyroid carcinoma—that is, papillary growth pattern, follicular growth pattern, presence of a tumor capsule (with or without invasion, of the capsule itself or of vessels), PTC-type nuclei—identifies the following scenario of diagnostic categories[294]: classic PTC → follicular predominant classic PTC → infiltrative follicular variant PTC → encapsulated follicular variant papillary carcinoma (PTC-EFV, when invasion is present; noninvasive follicular thyroid neoplasm with papillary-like nuclear features, NIFTP, when there is no invasion) → follicular neoplasm (FTC, when invasion is present; FTA, when there is no invasion) (Fig. 8.42).[294] In this schematic scenario, a decrease in the extent of papillary growth and PTC-type nuclei is paralleled by increased follicular growth pattern, the appearance of a defined tumor capsule, and a shift from a *BRAF* p.V600E to a *RAS*-like molecular signature (see Fig. 8.42).[295–298] The unequivocal recognition of these two broad molecular families of papillary carcinoma has been one important result of the TCGA's study.[292] Tumors with a ***BRAF* p.V600E-like** signature have high levels of MAPK pathway signaling, a low thyroid differentiation score (based on the expression of 16 genes involved with follicular cell function and metabolism), a heterogeneous molecular profile (due to the molecular alterations specific to the different histopathologic papillary carcinoma variants), and represent the group of conventional papillary carcinoma.[292] Tumors with a ***RAS*-like** molecular signature have low levels of MAPK pathway signaling, a high thyroid differentiation score, a relatively homogeneous

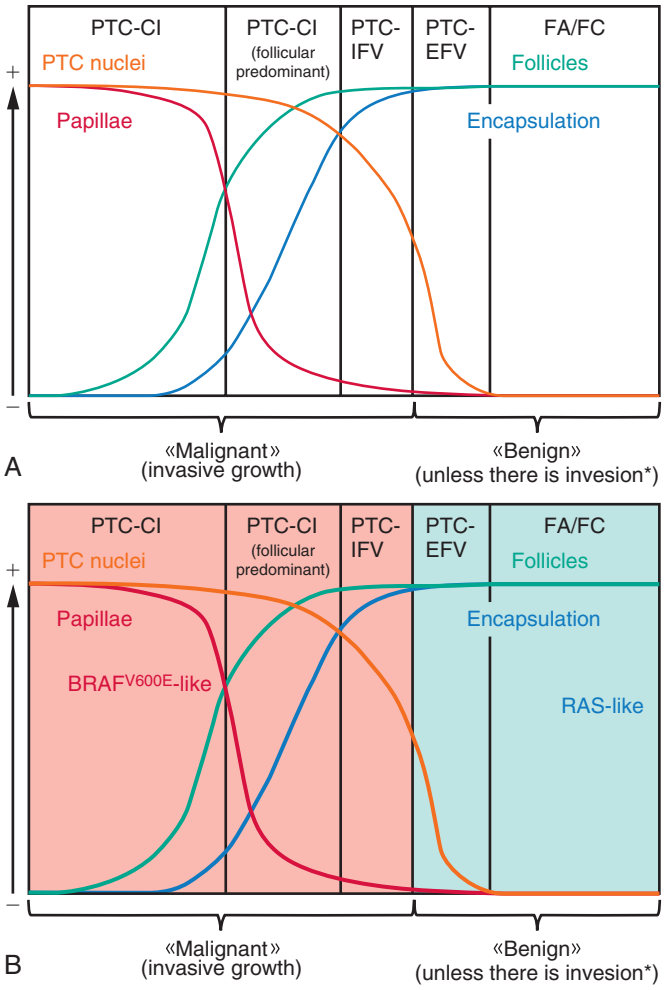

Figure 8.42 Correlation of diagnostic categories (**A**) and molecular alterations (**B**) with the four basic morphologic features used to diagnose tumors of follicular cell derivation: papillary growth pattern, follicular growth pattern, presence of a tumor capsule (with or without invasion, of the capsule itself or of vessels), alterations of nuclear morphology of papillary carcinoma. PTC-CI, classic papillary thyroid carcinoma; PTC-IFV, infiltrative follicular variant of papillary thyroid carcinoma (no tumor capsule); PTC-EFV, encapsulated follicular variant of papillary thyroid carcinoma (with or without invasion of capsule and vascular spaces); FA/FC, follicular adenoma/follicular carcinoma. (From Tallini G, Tuttle RM, Ghossein RA. The history of the follicular variant of papillary thyroid carcinoma. *J Clin Endocrinol Metab*. 2017;102;15–22.)

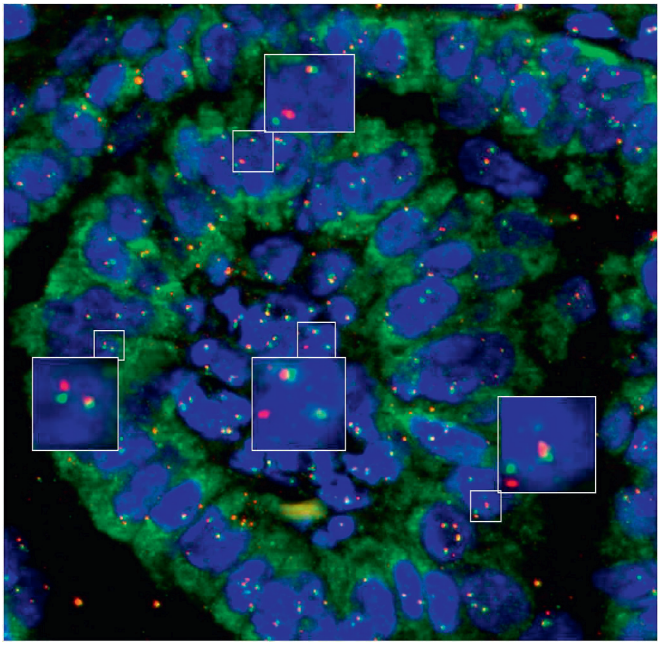

Figure 8.43 Papillary thyroid carcinoma with *RET/PTC* rearrangement visualized using fluorescent probes that cover the *RET* locus at 10q11.2. Split fluorescent in situ hybridization signals indicating *RET* rearrangement are highlighted and magnified in the square insets.

molecular profile, and are follicular variant papillary carcinomas,[292] reclassified as NIFTP when noninvasive (see "Noninvasive Follicular Thyroid Neoplasm with Papillary-Like Nuclear Features," later).[295]

The genetic changes that characterize conventional papillary carcinoma are *BRAF* p.V600E,[288,290–292,299–301] and *RET/PTC* (Fig. 8.43),[128,292,302–312] *NTRK*,[292,309,313–317] or *ALK* rearrangements (fusion oncogene papillary carcinomas).[292,318–322]

***BRAF* p.V600E** is the most common alteration of papillary carcinoma and a very powerful diagnostic marker for those tumors characterized by papillary growth pattern (classic/conventional papillary carcinomas) that carry the mutation in ~40%–80% of cases.[290–292,301,306,323] The mutation is highly specific and has been identified in papillary carcinomas arising within struma ovarii.[324] The strongest association is with the tall cell variant that carries *BRAF* p.V600E in more than 90% of cases.[306,323] *BRAF* p.V600E is an early molecular alteration, in most cases clonally distributed in the majority of neoplastic cells.[288,292] Point mutations other than p.V600E (e.g., p.K601E) and other rare alterations are typically found in the follicular variant and have an oncogenic potential lower than the p.V600E mutation.[292,325] *BRAF* rearrangements, found in up to approximately 10% of radiation-associated papillary carcinomas are *AKAP9/BRAF*[326] and *AGK/BRAF*.[315] *BRAF* p.V600E–specific antibodies are available,[327] but sequencing is the gold standard for molecular diagnosis.[288] The mutation is detectable in the peripheral blood of papillary carcinoma patients, and its identification correlates with the status of disease.[300] The prognostic relevance of *BRAF* p.V600E is controversial. Several studies have associated the p.V600E mutation with poor outcome,[331–333] while other have not confirmed the association.[334–336] *BRAF* p.V600E has been linked to extrathyroid tumor extension and to an increased risk of recurrence (also in patients with low risk tumors),[333,337,338] but the overall prognostic relevance of the mutation appears limited when other factors (e.g., stage, papillary carcinoma variant) are considered.[303,334,339] Clinical response to kinase inhibitors that target the *BRAF* p.V600E mutation (such as dabrafenib[340] and vemurafenib[341]) has been demonstrated in patients with advanced papillary carcinoma.

RET/PTCs represent the prototypical fusion oncogenes of papillary carcinoma. Gene rearrangements occur in up to ~30% of papillary carcinomas, and the majority of them involve *RET*, a transmembrane tyrosine kinase receptor.[312] This oncogene is thus uniquely related to thyroid tumors, with activating *RET point mutations* in medullary carcinoma, and somatic *RET rearrangements* in papillary carcinoma. The latter, called *RET/PTC* (for *p*apillary *t*hyroid *c*arcinoma), are chimeric genes generated by the in-frame fusion of the entire RET tyrosine-kinase domain with other genes, that distinguish the different *RET/PTC* isoforms. The heterologous genes drive the expression of RET (not present at any significant level in normal follicular cells); by causing the chimeric proteins to dimerize, they also induce ligand independent, constitutive activation of the RET tyrosine kinase.[302,304,312]

Sixteen different oncogenic *RET* rearrangements have been identified so far: RET/PTC fusion proteins RET/PTC1 to PTC9, RET/PCM1, RFP/RET, HOOK3/RET, ELKS/RET,[312] DLG5-RET,[328] AFAP1L2/RET, and PPFIBP2/RET (the latter two found in carcinomas of young patients from the Fukushima area).[329] The most common are RET/PTC1 (*CCDC6/RET*), which accounts for approximately 60% of *RET*-rearranged tumors, RET/PTC3 *(NCOA4/RET)* representing approximately 30%, and RET/PTC2 *(PRKAR1A/RET)* representing approximately 5%; the other *RET* rearrangements have been described in a few papillary carcinomas that have characteristically arisen following radiation exposure.[312] *RET* rearrangements (as well as rearrangements of other tyrosine kinase genes e.g., *NTRK3*) typically occur in tumors that develop in children and young patients and in those related to radiation exposure (therapeutic or environmental).[309,312,314] In one large study *RET/PTC* was identified in 62.3% of 191 papillary carcinomas diagnosed after the 1986 Chernobyl nuclear disaster.[309] In the study, *RET/PTC3* was particularly common in tumors that developed after exposure to high radioactivity levels that were of short latency, more aggressive, and classified as solid variants of papillary carcinoma.[309] *RET*-rearranged carcinomas have in general classic papillary histology, with typical alterations of nuclear morphology and psammoma bodies.[306–308,313] The rearrangement is considered an early molecular alteration, and highly sensitive methods detect low-level *RET/PTC* recombination in a variable proportion of papillary [128] with or without other mutational events (e.g., *BRAF*) due to genetic heterogeneity.[310] Clonal *RET/PTC* expression is specific, but low-level *RET/PTC* recombination has been shown in hyperplastic thyroid nodules[311] and in Hashimoto thyroiditis.[128] While very sensitive methods can detect *RET/PTC* in the peripheral blood of patients with papillary carcinoma,[305] they must thus be avoided for routine molecular diagnosis. With appropriate methods, RET/PTC is now detected in ∼5%–25% percent of papillary carcinomas, with a decreasing prevalence among non–radiation-associated tumors over the years.[342] Several studies[307,308,343,344] have failed to correlate *RET/PTC* with increased morbidity and mortality, although *RET* rearranged papillary carcinoma in young patients may present with lymph node metastases and aggressive clinicopathologic features.[313,317] The rearrangement, in particular *RET/PTC1* that largely predominates in papillary carcinomas not associated with radiation exposure, is often found in indolent tumors showing little propensity to progress to poorly differentiated and undifferentiated carcinomas.[307,308,343,344]

In addition to RET, other tyrosine kinases are rearranged in papillary carcinoma. These include the NTRK and ALK kinases. The ***NTRK1*** gene is rearranged with *TPM3*, *TPR* and *TFG*,[309,313,314] ***NTRK3*** with *ETV6*, or less frequently with other genes.[317,329] Some fusion partners of both *NTRK1* and *NTRK3* are still uncharacterized.[314,317] *NTRK* rearrangements have been reported in up to approximately 10% of unselected papillary carcinomas.[314] The general clinicopathologic features of papillary carcinomas with *NTRK* rearrangement are similar to those of *RET/PTC*-positive cases.[313] As in the case of *RET/PTC*, *NTRK* rearrangements have a higher prevalence in children and young adults[313,317,329] and in cases associated with radiation exposure.[315,316,329] *ETV6/NTRK3* has been identified in approximately 15% of radiation-induced papillary carcinomas and after *RET/PTC* is one of the most common forms of oncogenic alteration in radiation-associated tumors.[315,316]

ALK is rearranged in approximately 1%–5% of papillary carcinomas.[319,322] The most common *ALK* recombination is the *STRN/ALK* rearrangement,[319] *EML4/ALK*, typically found in non–small cell lung carcinoma, has been identified in a few cases,[319] including radiation-associated tumors from atomic bomb survivors.[345] *ALK*-rearranged carcinomas have a predominantly follicular, infiltrative pattern, often with areas of solid growth, or have the histologic features of diffuse sclerosing papillary carcinoma.[319,322] *ALK* rearrangement can be identified using the same fluorescent in situ hybridization probes and antibodies used to detect *ALK* rearrangement in non–small cell lung carcinoma.[319–322] *ALK*-rearranged tumors may have extrathyroidal extension and lymph node metastases[319,322] and may develop in papillary carcinomas undergoing dedifferentiation.[319,321] However, one large series has failed to demonstrate a statistical association with aggressive clinicopathologic features.[322]

Patients with *ALK*-rearranged tumors may respond to targeted therapies with ALK inhibitors (e.g., crizotinib).[320,321]

The encapsulated follicular variant of papillary carcinoma, regardless of whether the tumor has capsular or vascular invasion, or is noninvasive and now reclassified as NIFTP (see "Noninvasive Follicular Thyroid Neoplasm with Papillary-Like Nuclear Features," later),[295] has a *RAS*-like molecular signature with a profile of genetic alterations overlapping that of follicular adenomas and carcinomas.[292,295–297] As in the case of follicular adenomas and carcinomas, the most common genetic alterations are point mutations in *NRAS*, followed by *HRAS*, with most mutations in codon 61.[187,298] Up to approximately 30% of follicular variant papillary carcinomas carry *PPARG* rearrangements (*PAX8/PPARG* or, much less frequently, *CREB3L2/PPARG)*.[298,346] Most of the *EIF1AX* mutations identified by the TCGA study in a small subset of papillary carcinoma were of the follicular variant.[292] Fusion of *THADA* (at 2p21) with the LOC389473 pseudo gene (at 7p15.3), 12 kb upstream of *IGF2BP3* leading to overexpression of the full-length IGF2BP3 mRNA and protein, and to increased insulin-like growth factor receptor signaling, has been reported in approximately 5% of papillary carcinomas. All *THADA*-rearranged cases were classified follicular-variant papillary carcinomas or NIFTP.[209]

TERT promoter mutations represent an important marker of poor prognosis in differentiated thyroid carcinoma.[328,347–351] They are identified with a prevalence of approximately 5%–15% in most series of papillary carcinomas,[347–350] and the association with aggressive behavior appears stronger in case of a coexisting *BRAF* p.V600E mutation.[328,347,349–351]

MED12-G44C substitutions, consistent with gain- or change-of-function and *RBM10* mutations (truncating and missense mutations), have been identified in fatal forms of papillary carcinomas (and in poorly differentiated thyroid carcinoma).[328]

MicroRNA expression is dysregulated in papillary carcinoma, with high levels of miRs-146b, -221, and -222.[292,352] A large meta-analysis has found that expression levels of miRs-21, −34b, −130b, −135b, −146b, −151, −181b, −199b-5p, −221, −222, −451, −623, −1271, −2861, and let-7e show a significant association with at least one aggressive feature (large tumor size, extrathyroidal extension, multifocality, lymphovascular invasion, lymph node metastases, distant metastasis, advanced stage, *BRAF* p.V600E).[353] Patients with DICER1 syndrome, a rare autosomal dominant cancer syndrome caused by inactivating germline mutations of *DICER1*, encoding the DICER1 ribonuclease (RNase) necessary to generate mature miRNA species, develop pleuropulmonary blastoma, ovarian Sertoli-Leydig cell tumors, cystic nephroma of the kidney and multinodular goiter with adenomatous nodules.[173] Patients with the syndrome have an increased risk of developing thyroid carcinoma, often follicular-variant papillary carcinoma.[173] Reduced *DICER1* expression has been associated with aggressive clinicopathologic features in non-familial papillary carcinomas.[354]

Variants

The following morphologic variants of papillary carcinoma have been described.[355]

Papillary Microcarcinoma. This is defined as a papillary carcinoma measuring 1 cm or less in diameter (Figs. 8.44 and 8.45). Most cases have a stellate configuration and correspond to the lesions

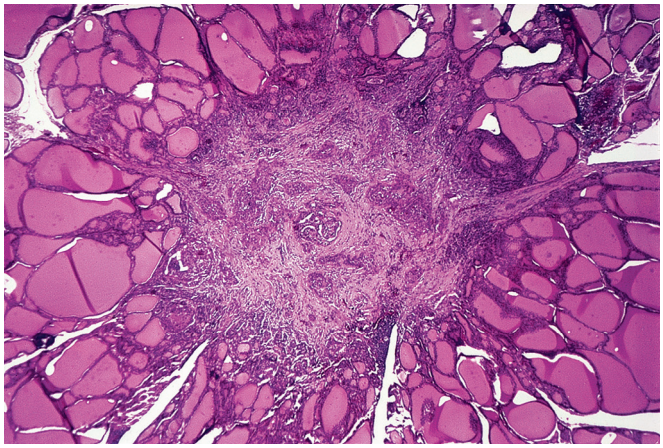

Figure 8.44 Typical stellate appearance of papillary microcarcinoma.

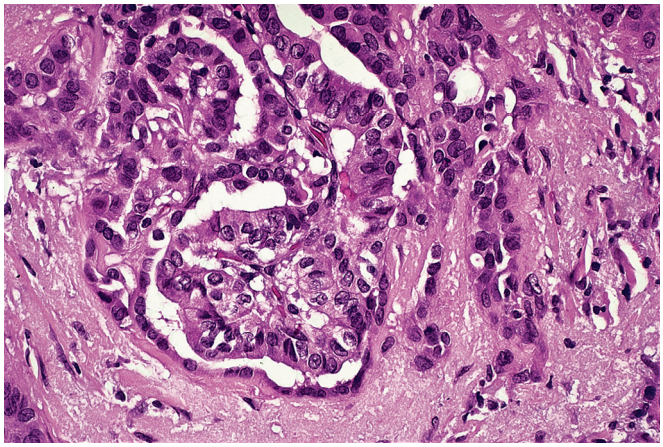

Figure 8.45 On high power, the appearance of papillary microcarcinoma is no different from that of its larger counterpart.

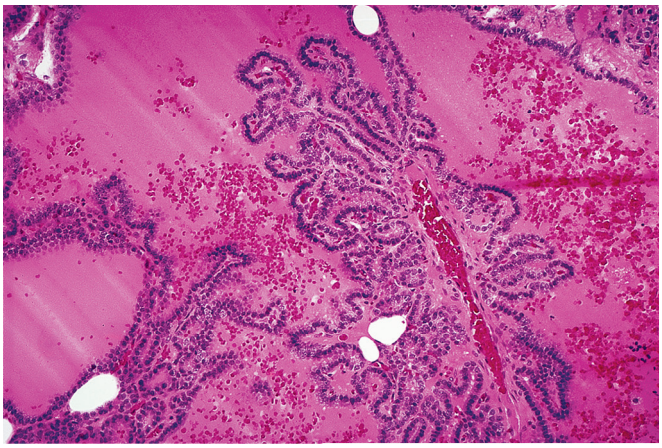

Figure 8.46 The benign papillary formations of nodular hyperplasia point toward the center of the cystically dilated follicles.

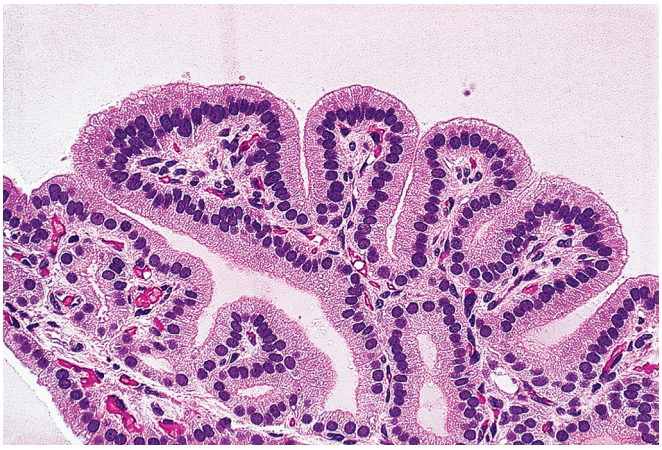

Figure 8.47 Benign papillary formations lined by columnar cells with basally located round normochromatic nuclei. The cytoplasm has a pale basophilic quality.

formerly known as occult sclerosing carcinoma or nonencapsulated sclerosing tumor,[356,357] whereas others show partial or near total encapsulation, with or without tumor outside the capsule. Sometimes the fibrous capsule is extremely thick and may be calcified. The microscopic features and the mutational profile are not different from those of their larger counterpart, and both *BRAF* p.V600E and *RET/PTC* have been identified.[306,308,323]

Papillary microcarcinoma is an extremely common incidental finding depending on the thoroughness of the examination,[358] with figures as high as 35.6% in one autopsy series.[359] A meta-analysis reviewing approximately 1000 microcarcinomas from 15 autopsy series from different parts of the world has found an overall prevalence of 11.5%,[360] compatible with the 12%–13% rate for microcarcinomas diagnosed incidentally in thyroid glands surgically removed for goiter or other reasons.[361] In contrast to its clinically evident counterpart, incidental papillary microcarcinoma seems to be relatively more common in males than females.[358] Despite its small size, the tumor can be identified in FNA specimens, and the increased detection of small papillary carcinomas is largely responsible for the considerable increase of thyroid carcinoma in developed countries.[362] It may be associated with cervical node metastases. However, distant metastases are exceptionally rare and the prognosis is generally excellent.[361] Thus a proposal has been made to replace microcarcinoma with the term "*papillary microtumor*" when occurring in adults and in its typical form.[363] Observational studies are showing that active surveillance is equally effective as immediate surgery to manage patients with low-risk microcarcinoma (no high-grade cytology, extrathyroidal extension, or metastases), while sparing the patients the side effects of surgery.[364] However, a few microcarcinomas can exhibit malignant behavior, particularly if the tumors carry the *BRAF* p.V600E mutation.[323] Rare, but well-documented fatal cases with evidence of tumor progression in cervical lymph node metastases have been reported.[365]

Encapsulated Variant. This is defined as a papillary carcinoma *totally* surrounded by a capsule. It may still be associated with nodal metastases, but the incidence of distant metastases or tumor death is nearly zero.[366,367] The cytoarchitectural (and particularly nuclear) features of this variant are the same as for the conventional invasive type. This lesion should be distinguished from the hyperplastic nodule with central cystic degeneration and papillary or pseudopapillary fronds in the wall (Figs. 8.46 and 8.47). In contrast to papillary carcinomas, these lesions are "hot" on thyroid scan and are characterized microscopically by a pale, vacuolated colloid. The papillary areas are largely limited to the area facing the cystic cavity. The follicular cells tend to be low columnar, with basally located normochromatic or hyperchromatic nuclei (instead of the centrally located, optically clear nuclei of papillary carcinoma).

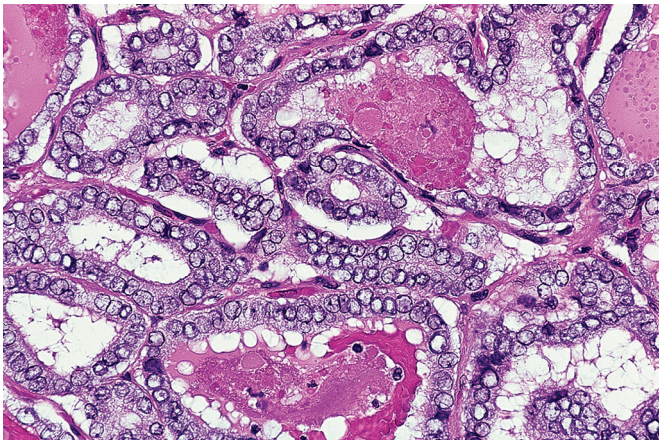

Figure 8.48 Follicular variant of papillary carcinoma. Note the clear overlapping nuclei.

Follicular Variant. This is a papillary carcinoma composed entirely or almost entirely of follicles (Fig. 8.48).[368,369] It is also referred to as *Lindsay tumor*.[370] The diagnosis is based on the presence of PTC-type nuclei. The behavior of these tumors, when infiltrative and not encapsulated, is analogous to that of conventional papillary carcinoma,[371] particularly in regard to the high incidence of nodal metastases.[248,370] Interestingly, these metastases sometimes exhibit well-developed papillary formations.[370]

Based on the outline of the tumor when it grows into the surrounding non-neoplastic tissue, two major groups of follicular variant papillary carcinoma with different histologic, clinical, and molecular features are recognized.

Infiltrative Follicular Variant Papillary Carcinoma. The tumor is characterized by infiltrative growth margins with neoplastic cells pervading the thyroid parenchyma with irregular strands and nests composed of neoplastic follicles. It corresponds to many of the cases originally described by Lindsay and to those reviewed by Chen and Rosai in 1977.[368] It is typically devoid of a fibrous capsule. Only partial remnants of a capsule can sometimes be identified. The tumor is very similar to follicular predominant classic papillary carcinoma, where well-developed papillae are found in the minority of the neoplastic mass that largely consists of follicular structures (see Fig. 8.42). If strict criteria are utilized (i.e., no papillary growth),[371] the infiltrative follicular variant papillary carcinoma is currently uncommon, representing less than 5% of all papillary carcinomas.[294] A rare *diffuse (or multinodular) variant* has been described, where most of a thyroid lobe—or sometimes both lobes—are diffusely infiltrated by the tumor, which is difficult to recognize because of its very diffuseness.[372] The infiltrative follicular-variant papillary carcinoma is characterized by a *BRAF* p.V600E–like molecular signature (see Fig. 8.42).[292,297,373]

Encapsulated Follicular Variant and Noninvasive Follicular Thyroid Neoplasm With Papillary-Like Nuclear Features. The tumor is entirely surrounded by a capsule (or well circumscribed, with a smooth contour facing the adjacent parenchyma),[373] has follicular growth pattern (with no papillae), but the nuclear alterations of papillary carcinoma. As in the case of follicular neoplasms, there may or may not be evidence of capsular and/or blood vessel invasion.

The encapsulated follicular variant has generated considerable controversy. To make a diagnosis, the nuclear alterations should be widespread and well developed, and some supportive features (such as intratumoral sharply defined fibrohyaline bands, elongated and branching follicles, abortive follicles, dense eosinophilic colloid) should be present[374,375]; sometimes minute follicles with the typical nuclear alteration are scattered in a background of normal-appearing follicles (the "sprinkling" sign of the follicular variant of papillary carcinoma).[376]

However, there has been excessive observer variation in the diagnostic weight given to these morphologic changes, with a progressive lowering over the years of the nuclear alteration threshold required to diagnose a tumor as papillary carcinoma.[377–380]

It is possible that noninvasive lesions in which the cytoarchitectural alterations are focal or "incomplete" represent the early development of papillary carcinoma in a preexisting benign nodule. This is suggested by the fact that the expression of galectin-3 and HBME-1 at the immunohistochemical level and the presence of molecular alterations in microdissection experiments may be restricted to these foci.[311,381,382] However, the word "carcinoma" should not be used for these lesions. The diagnostic term *"well-differentiated tumor of uncertain malignant potential (WDT-UMP)"* was proposed in the year 2000 for noninvasive nodules with questionable/incomplete nuclear changes that fall short of a diagnosis of papillary carcinoma, and that of *"well-differentiated carcinoma, not otherwise specified (WDC-NOS)"* for similar cases with invasive features, but neither has been widely utilized.[383]

Since then, two facts have become increasingly clear: that follicular-patterned nodules, when noninvasive and fully excised, are cured by conservative surgery in nearly every instance[380,384,385] and that the encapsulated follicular variant papillary carcinoma is characterized by a *RAS*-like molecular signature.[292,297,373]

To obviate cancer overdiagnosis and overtreatment, a working group of the Endocrine Pathology Society has critically reexamined the encapsulated follicular variant papillary carcinoma: Nikiforov et al. have introduced the diagnostic term *"noninvasive follicular thyroid neoplasm with papillary-like nuclear features"* (NIFTP) for noninvasive nodules previously diagnosed as follicular variant papillary carcinoma.[295] As a result of this effort the histologic features of the follicular variant papillary carcinoma have been redefined. Using molecular alterations as the reference standard, a 0–3 point scoring system based on conventional morphologic features has been shown to define with reasonable reproducibility the degree of nuclear alterations required to diagnose the follicular variant papillary carcinoma (Fig. 8.49).

The diagnostic criteria of NIFTP are:

1. Encapsulation or clear demarcation from the adjacent thyroid tissue
2. Follicular growth pattern with
   - <1% papillae
   - No psammoma bodies
   - <30% solid/trabecular/insular growth pattern
3. Nuclear alterations of papillary carcinoma (with a score of 2–3)
4. No vascular or capsular invasion (after thorough examination of the tumor interface with the surrounding tissues)
5. No tumor necrosis
6. No high mitotic activity (i.e., <3 mitoses per 10 high-power fields [×400])

If these criteria are met (Fig. 8.50) the likelihood of the tumor recurring or metastasizing is less than 1%. On the contrary, if there is invasion of the tumor capsule or of blood vessels, the study demonstrated adverse events (recurrence, metastases, tumor-related death) in 12% of patients after a median follow-up of 3.5 years.[295] In the latter case, to use the word "cancer" is fully justified, and such invasive tumors should be diagnosed as *encapsulated follicular variant of papillary carcinoma with capsular and/or vascular invasion*. If, after careful examination, the invasive features are still questionable the term "WDT-UMP" is appropriate to avoid overdiagnosis for those cases that show the nuclear alterations of papillary carcinoma, while the term "follicular tumor of uncertain malignant potential" (FT-UMP) is applied to those cases devoid of nuclear alterations (Table 8.4).[375]

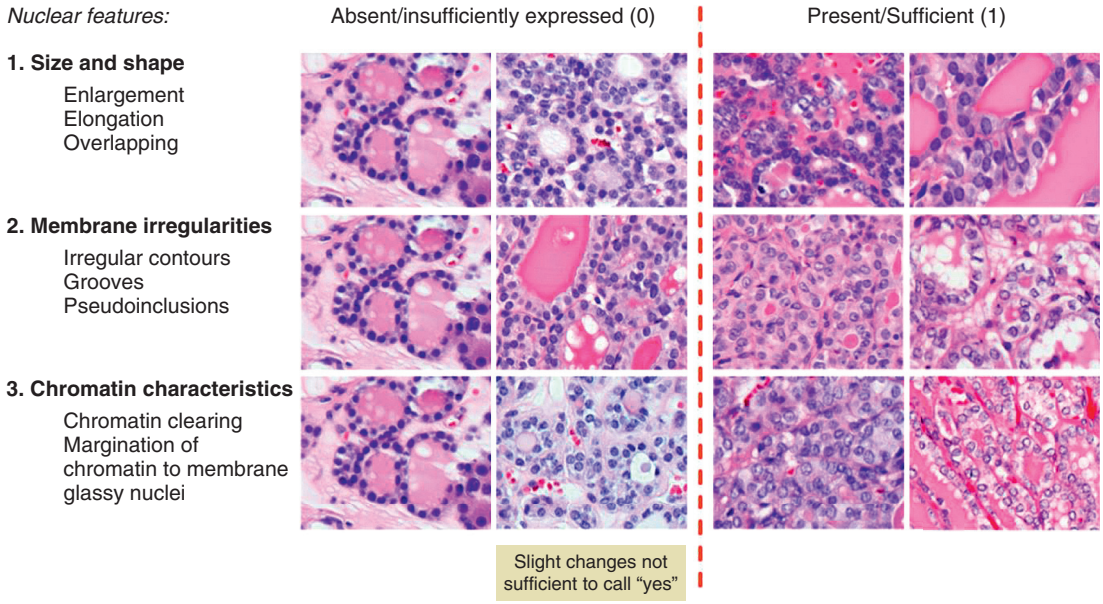

Figure 8.49 Visual guide for scoring the nuclear features of papillary carcinoma using the three-point scoring scale. (From Nikiforov YE, Seethala RR, Tallini G, et al. Nomenclature revision for encapsulated follicular variant of papillary thyroid carcinoma: a paradigm shift to reduce overtreatment of indolent tumors. *JAMA Oncol*. 2016;2(8);1023–1029.)

Table 8.4 Nomenclature for well-differentiated thyroid tumors with a follicular growth pattern

		Capsular or vascular invasion		
		Present	**Questionable**	**Absent**
Nuclear features of papillary thyroid carcinoma	**Present**	Invasive encapsulated FV-PTC	WDT-UMP	NIFTP
	Questionable	WDC-NOS	WDT-UMP	NIFTP
	Absent	FC	FT-UMP	FA

FA, Follicular adenoma; *FC*, follicular carcinoma; *FT-UMP*, Follicular tumor of uncertain malignant potential; *FV-PTC*, papillary thyroid carcinoma, follicular variant; *NIFTP*, noninvasive follicular neoplasm with papillary-like nuclear features; *WDC-NOS*, well-differentiated carcinoma, not otherwise specified; *WDT-UMP*, well differentiated tumor of uncertain malignant potential.
Modified from Rosai J, DeLellis RA, Carcangiu ML, Frable WJ, Tallini G. *Tumors of the Thyroid and Parathyroid Glands. AFIP Atlas of Tumor Pathology*. Fourth series, Fascicle 21. Silver Spring, MD: American Registry of Pathology; 2014.

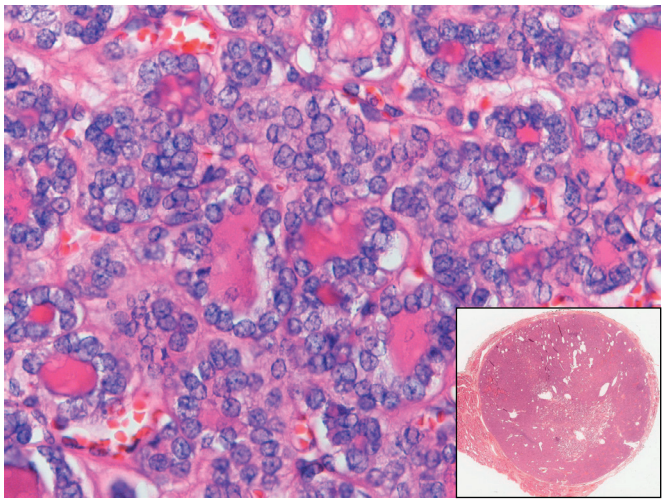

Figure 8.50 Noninvasive follicular thyroid neoplasm with papillary-like nuclear features (NIFTP). This tumor has follicular growth pattern, the nuclear alterations of papillary carcinoma, and is well circumscribed and without invasion (inset).

On pure morphologic grounds, the follicular variant of papillary carcinoma can be viewed as the balanced result of two opposing biologic properties of the tumor cell: differentiation in the form of secretory activity (thereby making colloid-filled follicles), and proliferation. When one of these forces predominates over the other, two additional variants emerge:

Solid Variant. This variant, which is particularly common in children, develops when proliferation predominates over secretion. It is characterized by solid nests of generally round shape that can be viewed as filled-up follicles (Fig. 8.51). It is distinguished from insular carcinoma and other forms of poorly differentiated carcinoma because the nuclear features remain those of papillary carcinoma. This distinction is of great importance, because the behavior of this tumor is essentially that of papillary carcinoma (or perhaps only a little worse) but notably different from that of the truly poorly differentiated neoplasms.[386]

Macrofollicular Variant. This can be viewed as the opposite of the solid variant, in the sense that the secretory activity predominates over proliferation, resulting in large dilated follicles, so that the tumor resembles not so much a follicular neoplasm as a hyperplastic nodule (Fig. 8.52).[387–389]

Diffuse Sclerosing Variant. This uncommon variant is characterized by diffuse involvement of one or both thyroid lobes, dense

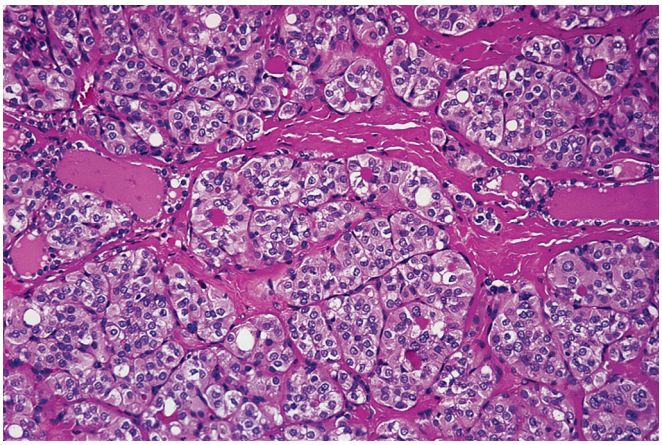

Figure 8.51 Solid variant of papillary carcinoma. The nests are separated by fibrohyaline strands.

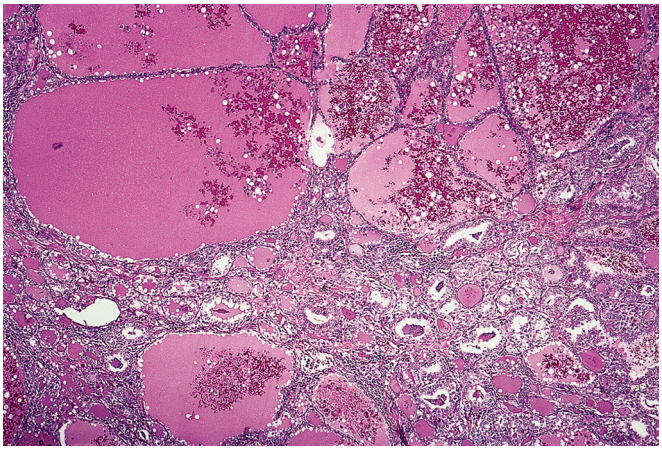

Figure 8.52 So-called macrofollicular variant of papillary carcinoma. This lesion simulates nodular hyperplasia. The nuclear features that allow the diagnosis cannot be seen at this magnification.

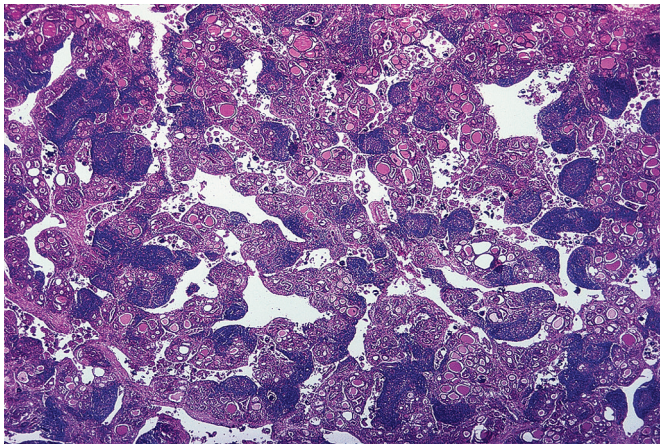

Figure 8.53 Diffuse sclerosing variant of papillary carcinoma. Note the diffuse pattern of growth, the heavy lymphocytic infiltrate, and the sclerosis.

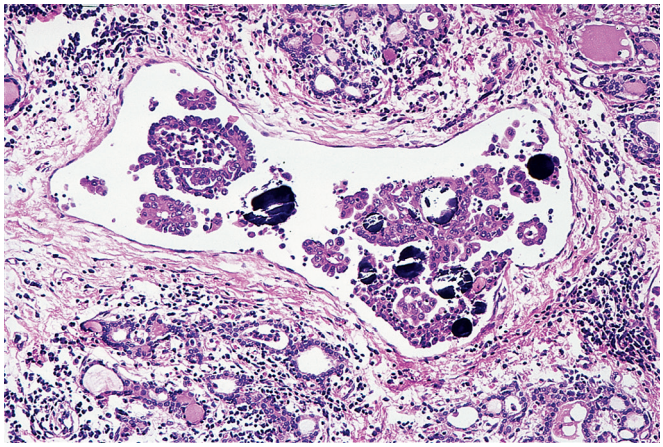

Figure 8.54 Prominent permeation of intrathyroid lymph vessels in diffuse sclerosing papillary carcinoma. Psammoma bodies are evident.

sclerosis, abundant psammoma bodies, extensive solid foci, squamous metaplasia, heavy lymphocytic infiltration, and extensive lymph vessel permeation[390,391] (Figs. 8.53 and 8.54). Clinically, it may be misdiagnosed as Hashimoto thyroiditis. Nodal metastases are nearly always present, lung metastases are common, multiple brain metastases may supervene, and the disease-free survival rate is lower than for conventional papillary carcinoma.[391–395] However, in spite of a lower disease-free survival period, with appropriate treatment the mortality rate is the same of classic papillary carcinoma.[396] Both *RET/PTC1* and *RET/PTC3* have been identified, although *BRAF* mutations appear to be rare.[397]

Oncocytic (Oxyphilic, Warthin-Like) Variant. In this variant, the nuclear features remain those of papillary carcinoma, but the cytoplasm is abundant and has a granular oxyphilic quality.[398] The pattern of growth may be papillary or follicular, and the tumor may be encapsulated or invasive. A variation on the theme is the tumor having a papillary architecture, typical nuclear features, oncocytic cytoplasm, and a heavy lymphocytic infiltrate in the stroma of the papillae, resulting in an appearance reminiscent of Warthin tumor of salivary glands.[399,400] This *Warthin-like papillary carcinoma* may harbor the *BRAF* p.V600E mutation (although with a lower prevalence).[401] The prognosis of Warthin-like papillary carcinomas is generally very good, like that of conventional papillary carcinomas of similar size and stage.[400,402] Oncocytic papillary carcinomas, including Warthin-like papillary carcinoma must be distinguished from tall cell variant papillary carcinomas. It is also worth reminding the reader that a sine qua non for including a tumor in *any* of these subsets of papillary carcinoma is the presence of PTC-type nuclei as defined previously.

Tall Cell Carcinoma. This relatively common variant, originally described by Hawk and Hazard in 1976,[403] is characterized by papillae lined by a single layer of "tall" cells (the height being two to three times the width) and an abundant acidophilic (oncocytoid) cytoplasm (Fig. 8.55). The pattern of growth tends to be highly papillary, the papillae are overly elongated, cord-like, and running side-to-side in a regimented, "tram track" fashion. Nuclear pseudoinclusions are particularly prominent.[404] There may be an extensive lymphocytic infiltration of the stroma.[405] The variant tends to affect older patients more often than the conventional form, extrathyroidal extension is more common, and the clinical course is more aggressive when compared with classical papillary carcinoma,[406,407] even in the absence of extrathyroidal extension.[408] This aggressive behavior correlates with the presence of tall cell features in greater than 30% of the tumor, which may thus be considered a reasonable threshold for the diagnosis of tall cell papillary carcinoma.[409] A considerable proportion of radioactive iodine–refractory and of fatal forms of

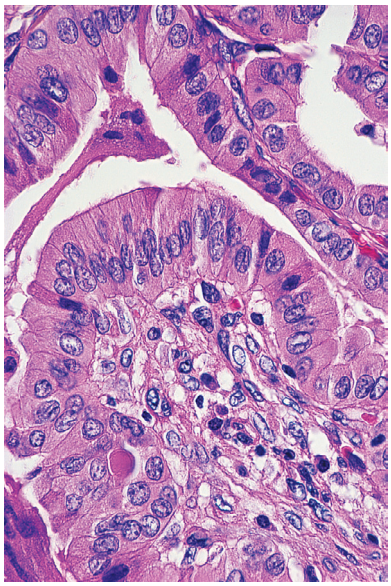

Figure 8.55 Tall cell variant of papillary carcinoma. Note the abundant granular acidophilic cytoplasm with oncocyte-like features.

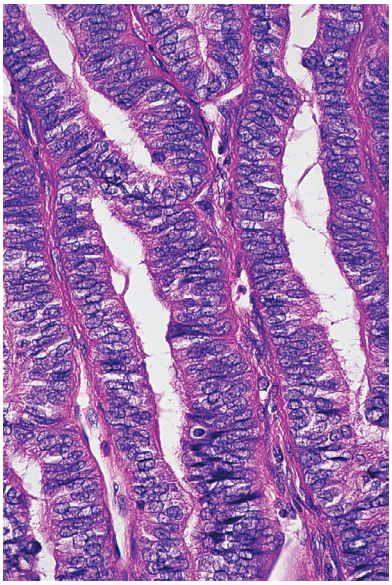

Figure 8.56 Columnar cell variant of papillary carcinoma. The papillae are lined by a pseudostratified layer of spindle tumor cells.

non-anaplastic thyroid carcinomas are tall cell papillary carcinoma variants.[410] Anaplastic transformation of tall cell papillary carcinoma typically occurs in the form of a spindle cell squamoid type of anaplastic carcinoma.[411]

Tall cell papillary carcinoma shows the strongest association with the *BRAF* p.V600E mutation, which is present in the vast majority of cases, including small papillary carcinomas.[306,323] Like other types of aggressive thyroid carcinoma, it often carries *TERT* promoter mutations, found in approximately 30% of cases.[412]

Columnar Cell Carcinoma. This rare variant was originally described by Dr. J.H. Evans in 1986.[413] It is characterized by thin papillae or glandular-like spaces lined by an epithelium with prominent nuclear stratification (Fig. 8.56); the cytoplasm is clear (sometimes with subnuclear vacuolization, reminiscent of early

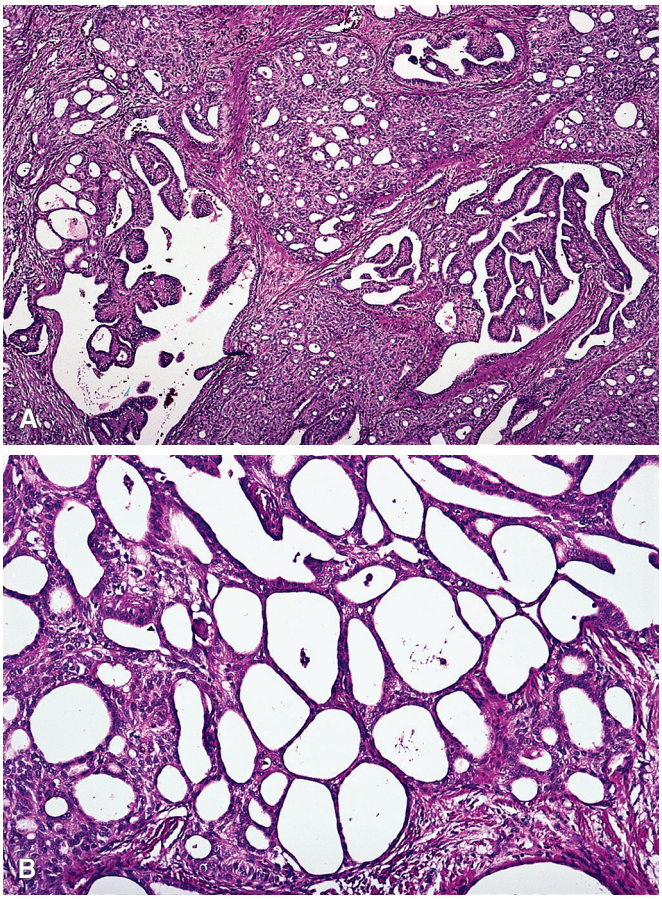

Figure 8.57 **A** and **B,** Cribriform–morular variant of papillary carcinoma. The cribriform quality of the tumor is particularly well appreciated in **B**.

secretory endometrium), rather than acidophilic as in the tall cell variant; squamoid whorls or morules may be present.[413–418] The nuclei usually lack the optically clear appearance, grooves, and pseudoinclusions seen in papillary carcinoma and all of its other variants,[413–418] and therefore it has been questioned whether columnar cell carcinoma is really a variant of papillary carcinoma, as opposed to a different tumor type despite its highly papillary architecture. However, while thyroglobulin may be variably expressed,[416,419] TTF1 is always positive.[419,420] Mitotic figures can be found, and the Ki-67/MIB1 proliferative index may be very high.[417,420] Immunoreactivity for the intestinal differentiation factor CDX2 is common, and the tumor must be differentiated from metastatic colonic adenocarcinoma.[419–421] There is no nuclear immunoreactivity for β-catenin, and that for p53 is weak or entirely lacking.[417,420] Hypercellularity with papillary structures, nuclear superposition, and a paucity of nuclear pseudoinclusions and grooves are the cytologic features in preoperative FNA samples.[419] The initial reports of this entity indicated a poor prognosis,[413–415] but more recent larger series have shown that—once again—the outcome is largely predicated by tumor stage; specifically, encapsulated columnar cell carcinomas are associated with a favorable course.[416–418] *BRAF* p.V600E is present in approximately 30% of cases.[417,420]

Cribriform–Morular Variant. As the name indicates, this variant is characterized by the presence of a cribriform pattern of growth and morular formations (Fig. 8.57). The tumor is very rare, representing 0.16% of 4194 papillary carcinomas in a large Japanese series.[422] It develops in a sporadic form,[423] or as an extraintestinal component of the familial adenomatous polyposis syndrome, of which it may

be the initial clinical manifestation; it is seen almost exclusively in females.[422–425] A few cases have been reported in children.[426] One case with focal neuroendocrine differentiation has been reported.[427] The cribriform–morular variant papillary carcinomas are often encapsulated with an intimate admixture of cribriform, follicular, papillary, trabecular, and solid patterns of growth; round squamoid morular structures are a characteristic finding; intraluminal colloid is scanty or absent altogether; invasion of the tumor capsule or of vessels is common; sporadic cases are usually solitary, while those associated with familial adenomatous polyposis are often multifocal.[422–425] The neoplastic cell nuclei are not particularly clear but exhibit variable amounts of grooves and pseudoinclusions. In the morules, however, neoplastic cells have optically clear nuclei. These are different from those of conventional papillary carcinoma and similar to the nuclei seen in morule-containing tumors at other sites, due to the accumulation of biotin.[428] Thyroglobulin is often weakly expressed, and TTF1 is variably positive within the tumor. Nuclear immunoreactivity for β-catenin, the hallmark of *wnt* pathway activation, is the rule.[423,424] *Wnt* signaling is activated in the familial tumors because of germline loss of function mutations of the *APC* gene, and in the sporadic ones because of somatic *APC* mutations or due to somatic mutations in exon 3 of the β-catenin gene *(CTNNB1)* that stabilize the β-catenin protein, preventing its degradation and promoting its accumulation in the nucleus.[424,429]

Hobnail Variant. This rare variant, as the name implies, is characterized by papillary, micropapillary, and follicular formations lined by neoplastic cells with eosinophilic cytoplasm, altered nuclear/cytoplasmatic ratio, and apically placed nuclei that produce a surface bulge responsible for the typical hobnail appearance (Fig. 8.58). Nucleoli are prominent, there is loss of cellular cohesion, mitoses are common, and necrosis may be present; angiolymphatic invasion and extrathyroidal extension are frequently observed.[251,430–434] The tumor is aggressive with metastases to lymph nodes and to distant organs and frequently recurs.[251,430–434] This aggressive behavior correlates with the presence of hobnail features in at least 30% of the tumor, which is considered the threshold for its diagnosis, although the prognosis may be unfavorable even in cases with a lower proportion of hobnail areas.[432,433] These areas may be present in association with poorly differentiated and even undifferentiated carcinomas, indicating that hobnail cells may be a morphologic marker for tumor progression.[434,435] Immunohistochemistry is positive for TTF1 and typically shows nuclear accumulation of p53 in a significant proportion of cells, the mean of the Ki-67/MIB1 proliferative index is approximately 10%.[251] *BRAF* p.V600E is present in a high proportion (~70%–80%) of cases, inactivating *TP53* mutations, and *TERT* promoter mutation are also very common.[434,436]

Papillary Carcinoma With Exuberant Fibromatosis/Fascitis-Like Stroma. In this variant, the prominence of the stromal reaction of the tumor may obscure the neoplastic epithelial component.[437,438] As a result, a biopsy may be misinterpreted as nodular fasciitis, fibromatosis, or some other proliferative stromal condition.[439,440] In some foci, the interplay of this stromal component with the tumor results in a fibroadenoma-like appearance.[437] Remarkably, exon 3 mutations of the β-catenin gene (*CTNNB1* p.S45P) with nuclear accumulation of β-catenin by immunohistochemistry—a characteristic finding of fibromatosis—has been shown in the mesenchymal (but not in the epithelial) component of some tumors. This indicates that they represent biphasic neoplasms and that papillary carcinoma with nodular fasciitis-like stroma and *CTNNB1* mutations should be renamed papillary carcinoma with desmoid-type fibromatosis.[441]

Spread and Metastases

Extrathyroidal extension into the soft tissues of the neck is found in approximately one-fourth of cases, with occasional spread into the parathyroid glands.[248,442,443] Involvement of cervical lymph nodes is very common (particularly in young patients), and it may be the first manifestation of the disease. The nodal metastases have a tendency to undergo cystic changes (Fig. 8.59). These metastases may not be clinically apparent because of their small size and also because their consistency may not differ from that of a normal node. In a study of 67 patients with clinically negative nodes, 41 (61%) had metastatic tumor on microscopic examination.[444] In rare but well-documented cases with lymph node metastases the primary tumor is not identified in spite of extensive microscopic examination of the thyroid gland.[445]

Blood-borne metastases are less frequent than with other thyroid carcinomas, but they also occur. Although the most common site is the lung, they can also develop in bones, soft tissues, central nervous system, pancreas, breast, and many other organs.[248,446–448] The lung metastases can have a miliary micronodular pattern detectable only on I scintiscans, or they can be rounded and macronodular.[449] *TERT* promoter mutations have been associated with the occurrence of distant metastases.[351]

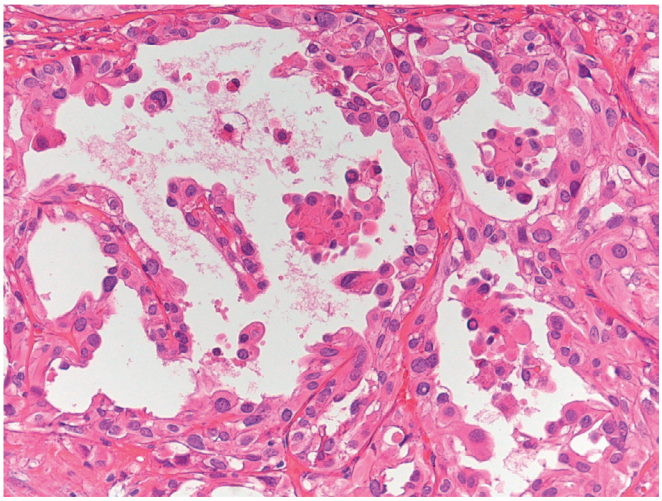

Figure 8.58 Hobnail variant of papillary carcinoma. Atypical nuclei with "hobnail" surface bulges, micropapillae, and discohesive cells (Courtesy of Drs. Asioli and Lloyd)

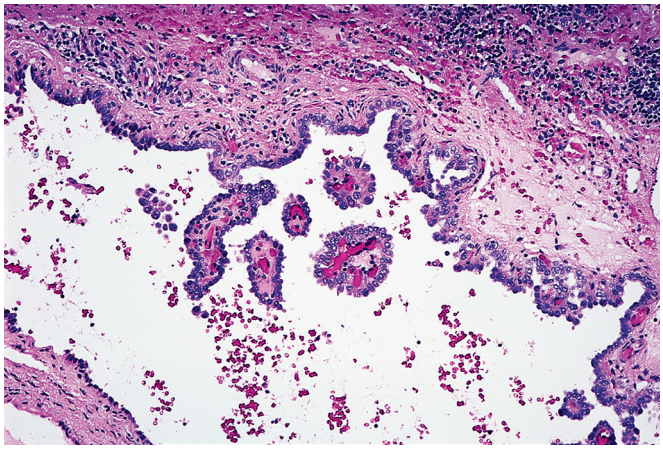

Figure 8.59 Papillary thyroid carcinoma metastatic to cervical lymph node. The tumor has undergone cystic change, simulating on low power the appearance of a branchial cleft cyst; small papillary formations are present.

Treatment

This is discussed together with the other epithelial tumors of the thyroid gland.

Prognosis

The overall survival of patients with papillary carcinoma is excellent, not significantly different from that of the general population.[450,451] Factors relating to prognosis are the following:

1. *Age*. The age of the patient at the time of diagnosis has long been known to be of great prognostic significance. Nearly all the deaths from papillary carcinomas occur when the tumor manifests itself after the age of 40 years.[248,452,453] Conversely, papillary carcinomas developing in children and adolescents are almost uniformly associated with a good outcome.[454]
2. *Sex*. Females are said to have a better prognosis than males, although in some series the difference has not been significant.[248]
3. *Extrathyroidal extension*. This feature adversely affects the prognosis in a very significant fashion.[248,455] Parenthetically, this feature and several others included in this listing have long been incorporated into the staging systems for thyroid carcinoma.[456–458]
4. *Microscopic variants* (see previous sections).
5. *History of previous irradiation*. Despite previous statements to the contrary, the prognosis of tumors in which this antecedent is present does not seem to differ significantly from the others.[459]
6. *Tumor size*. A rough inverse correlation is present between tumor size and prognosis.
7. *Capsule and margins*. Tumors that are encapsulated and/or have pushing margins have a better outcome than the others.[248,460,461]
8. *Multicentricity*. Patients in whom this is a prominent feature have a greater incidence of metastasis and less chance of disease-free survival.[248]
9. *Lymph node metastases*. The prognostic significance of nodal metastases from papillary carcinoma is limited when compared to that of carcinomas of other organs. It can, however, be stratified based on the size and number of metastatic lymph nodes[462,463]; extranodal tumor extension may be an indicator of a greater likelihood of distant metastases and poor prognosis,[462,464] even in patients with microcarcinomas,[465] although interobserver agreement for its identification is poor.[466]
10. *Distant metastases*. Metastases to lung have an adverse influence on prognosis; this influence is even greater for distant metastases in other sites, such as the skeletal system. Cases that present with distant metastases have poor prognosis.[248,467]
11. *Poorly differentiated*, *squamous*, *or anaplastic foci*. These features have a markedly detrimental effect on prognosis. Fortunately, they are present in fewer than 5% of the cases.[248,365,468]
12. *Grading*. This parameter, which is intertwined with the previous, bears a definite relationship with prognosis that we feel has been underestimated.[469,470] However, it needs to be clearly defined in terms of criteria (necrosis, mitotic activity, etc.) and properly standardized for it to reach its full potential.[471]
13. *TERT* promoter mutations have been associated with poor prognosis, and the association with aggressive behavior appears stronger in case of a coexisting *BRAF* p.V600E mutation.[328,347,349,350]
14. *BRAF* p.V600E. The prognostic relevance of this mutation is controversial. Several studies have associated the p.V600E mutation with poor outcome,[331–333] while other have not confirmed the association.[334–336] *BRAF* p.V600E has been linked to extrathyroid tumor extension and to an increased risk of recurrence (also in patients with low-risk tumors),[333,337,338] but the overall prognostic relevance of the mutation appears limited when other factors (e.g., stage, papillary carcinoma variant) are considered.[303,334,339]
15. Factors not generally found to correlate with prognosis are: relative proportion of papillae and follicles; presence or amount of fibrosis; presence or amount of squamous metaplasia or psammoma bodies; and microvessel density.[472] The effect of the type of therapy on prognosis remains controversial, with sometimes little correlation between the two parameters.[248]

Follicular Carcinoma

Generalities and Molecular Genetic Features

Follicular thyroid carcinoma (in a generic sense any malignant thyroid tumor with evidence of follicular cell differentiation) is usually defined as a form of thyroid malignancy arising from follicular cells in which the diagnostic nuclear features of papillary carcinoma are absent. We are not including in this category Hürthle (oncocytic) cell carcinoma, poorly differentiated carcinoma, or the exceptionally rare mixed medullary–follicular carcinoma.

Follicular carcinoma has become a relatively uncommon tumor whose diagnosis depends on the presence of invasion of the capsule, blood vessels, or adjacent thyroid.[203,303,473] It shares with papillary carcinoma the same predilection for females but occurs, on average, in patients who are a decade older.[203] Insufficient dietary iodine is regarded as an important factor for nodular goiter and follicular carcinoma.[203] Dietary iodide supplementation into iodine-insufficient regions has been associated with a decrease in the ratio of follicular to papillary carcinomas.[203]

Its microscopic appearance is extremely variable, ranging from well-formed follicles to a predominantly solid growth pattern. Poorly formed follicles, cribriform areas, or trabecular formations may be present, sometimes in combination. Exceptionally, the tumor may be entirely composed of spindle cells[474] or exhibit prominent glomeruloid formations.[475] Focal or extensive cytoplasmic clear changes can occur. Mitotic activity and nuclear atypia are usually seen but may be entirely lacking. Psammoma bodies are absent, and squamous metaplasia is exceptionally rare. Tumors showing a predominantly solid/trabecular/nesting pattern of growth should be carefully evaluated for mitoses and necrosis in order to rule out the diagnosis of poorly differentiated carcinoma, according to the Turin proposal.

Immunohistochemically, follicular carcinomas are reactive for thyroglobulin, TPO, low-molecular-weight keratins, EMA, basement membrane components such as laminin and type IV collagen, and the thyroid transcription factors TTF1, TTF2 (FOXE1), and PAX8.[202] Their reactivity for these and other markers, as well as their ultrastructural appearance, is not significantly different from that of follicular adenomas.[476] Follicular carcinomas have a higher proliferative index compared to adenomas (see Table 8.3), although this is of limited help in the diagnosis of individual cases. Immunohistochemical reactivity for HBME-1, Galectin-3, CK19, CITED1, and CD56 may be used to distinguish follicular carcinoma (and adenoma) from follicular-variant papillary carcinomas (and NIFTP) (see Table 8.3).

At a molecular genetic level, follicular carcinomas share a common tumorigenic pathway with follicular adenomas, and to date no molecular test can reliably distinguish between the two (see Table 8.2).[203,303] This pathway is different from that of papillary carcinoma and is characterized by aneuploidy and by the frequent occurrence of *RAS* mutations.[203,303] A subset of follicular carcinomas harbors the *PAX8/PPARG* rearrangement, which generates the PAX8/PPARG fusion protein, named PPFP.[477] Conventional karyotyping shows clonal aberrations in approximately 65% of follicular carcinomas, with both numerical changes and structural abnormalities.[205,478] Numerical changes are similar to those of follicular adenomas and include hyperdiploid karyotypes with extra copies of chromosome 7, but chromosomal losses tend to be more frequent in follicular carcinomas, and complex karyotypes are common.[185,205,206,478,479]

Cytometric measurements of DNA content and comparative genomic hybridization (CGH) also identify aneuploidy in both

follicular carcinomas and adenomas.[203] Two pathways have been postulated based on aneuploidy and the pattern of chromosomal DNA alterations in follicular tumors (adenomas and carcinomas): one followed by tumors with prominent aneuploidy, chromosomal gains, and microfollicular/trabecular/solid architecture; the second characterized by diploid/near diploid DNA content with common chromosomal losses and normofollicular architecture.[480] Consistent with the instability of their chromosomal DNA, follicular carcinomas typically have a high average rate of LOH, approximately 20% per chromosome arm, as opposed to the much lower rates of approximately 5% in follicular adenomas and of approximately 2.5% in papillary carcinoma.[481]

The most common oncogenic mutations are those that involve *RAS* and, as in the case of follicular adenomas, *K*-, *N*-, and *HRAS* can all be affected. Most of mutations in follicular carcinomas (and adenomas) are at codon 61 of *NRAS*.[187] *RAS* mutations are a marker of follicular-patterned tumors (follicular carcinoma, follicular variant papillary carcinoma/NIFTP, follicular adenoma), likely promote tumor progression through loss of differentiation, and have been linked to unfavorable clinical features.[203,303,482–485]

The *PAX8/PPARG* rearrangement,[477] caused by the t(2;3)(q13;p25) that fuses *PPARG* at 3p25 with *PAX8*, originally thought to be specific, is also found in a subset of follicular adenomas and in the follicular variant of papillary carcinoma.[204,346,486] *PAX8/PPARG* is not found in hyperplastic thyroid nodules or in aggressive tumors such as poorly differentiated or anaplastic thyroid cancer.[204] It seldom overlaps with *RAS* mutations and is uncommon in oncocytic tumors.[330] In follicular carcinomas, *PAX8/PPARG* has been associated with female gender, younger age, high cellularity, and invasive features.[330] However, the risk of distant metastases may be lower than in *PAX8/PPARG*-negative cases.[486] Thus, *PAX8/PPARG* may be a marker for a distinct subset of tumors characterized by follicular growth and invasive potential but not by overtly aggressive features. Immunohistochemistry with anti-PPARG antibodies shows upregulation of PPARG and can be used to infer the *PAX8/PPARG* rearrangement.[204]

The PI3K/PTEN/AKT pathway is aberrantly activated, due to germline loss of function *PTEN* mutations in patients with the Cowden syndrome, and follicular carcinoma is a manifestation of the disease.[211] The fact that follicular carcinoma develops in the background of benign nodular disease with adenomatous thyroid nodules is an important clue supporting a common tumorigenic pathway for follicular adenoma and carcinoma. In addition to Cowden syndrome, follicular carcinoma has also been reported in Carney complex type I and Werner syndrome (adult progeria).[487]

Inactivating *PTEN* mutations or gain-of-function mutations of the *PIK3CA* gene activate PI3K/PTEN/AKT signaling in a minority of sporadic follicular carcinomas. However, copy number gains of *PIK3CA* and receptor tyrosine kinase *(EGFR, VEGFR1)* genes are common.[210,488] *PTEN* and *PIK3CA* mutations, as well as oncogenic *RAS* activation, rarely coexist in follicular carcinomas (although they can overlap in aggressive tumors), suggesting that each alteration has an independent role.[210,488] *TSHR* mutations are uncommon, but they have been reported in hyperfunctioning follicular carcinomas.[489]

TERT promoter mutations have been reported in approximately 17% of FTC,[350] with a percentage range of approximately 10%–35%.[350,351,412,490,491] In a subset of follicular carcinomas they coexist with *RAS* mutations.[348] As in the case of papillary carcinoma, *TERT* promoter mutations have been linked to poor prognosis.[347,348,350,491]

Follicular Carcinoma Subtypes

Depending on its degree of invasiveness at the gross, macroscopic, level, follicular carcinoma has been traditionally subdivided into "minimally" invasive and "widely" invasive forms. A clinically more valid grouping that overcomes this traditional binary division should take into account the following considerations:

1. There are two major categories, of widely different prognostic import: the encapsulated tumors, in which one has to look for invasion; and the widely invasive tumors, in which one has a look for a capsule.
2. Among the former, there are marked prognostic differences among those that show invasion of *only* the capsule (very low likelihood of distant metastases) and those that show vascular invasion, with or without capsular invasion (greater potential for distant metastases).[492–498]
3. Among those with vascular invasion, there is a prognostic difference depending on the number of vessels involved (with 4 foci of vascular invasion as the cutoff).[497–501]

Accordingly, a prognostically relevant classification scheme is the following:

FOLLICULAR CARCINOMA	INVASION
Minimally invasive	Encapsulated, with capsular invasion only (no vascular invasion)
Encapsulated angioinvasive	With limited vascular invasion (1–3 vessels, with or without capsular invasion)
	With extensive vascular invasion (≥4 vessels, with or without capsular invasion)
Widely invasive	Extensive invasion (macro- and microscopically evident), multinodular growth, no obvious tumor capsule

Encapsulated Follicular Carcinoma (Minimally Invasive and Encapsulated Angioinvasive). The vast majority of follicular carcinoma diagnosed today in developed countries are encapsulated, round-oval thyroid nodules sharply separated from the surrounding normal parenchyma, with a macroscopic appearance virtually indistinguishable from that of follicular adenoma. Only microscopic identification of invasion of the tumor capsule or of blood vessels allows to differentiate between the two. The cut surface is typically solid and fleshy. The pattern of growth usually resembles that of an adenoma of embryonal or fetal type. Indeed, it has been suggested that some of the cases represent malignant transformation of an adenoma. The mean diameter of encapsulated follicular carcinoma is 3–4 cm, nearly double that of papillary carcinoma.[502] Unlike the case of papillary carcinoma, encapsulated follicular carcinomas are almost always solitary, and it is rare to find tumors smaller than 1 cm.[503] Occult follicular carcinomas (i.e., tumors that manifest their presence as a consequence of metastatic spread) are well documented, some of them may be relatively small (1–2 cm)[496]. Malignant behavior in the form of distant metastasis has been documented in follicular carcinomas as small as 0.7 cm.[494]

Since the diagnosis of malignancy depends entirely on the demonstration of blood vessel and/or capsular invasion, one should be very strict about these criteria (Fig. 8.60).[504] The blood vessel invasion is almost never evident grossly. Microscopically, the vessels (typically veins) should be located in or immediately outside the capsule (rather than within the tumor) and contain one or more clusters of tumor cells attached to the wall and protruding into the lumen. These intravascular tumor nests must be covered by endothelium or surrounded by fibrin in a fashion similar to that of an

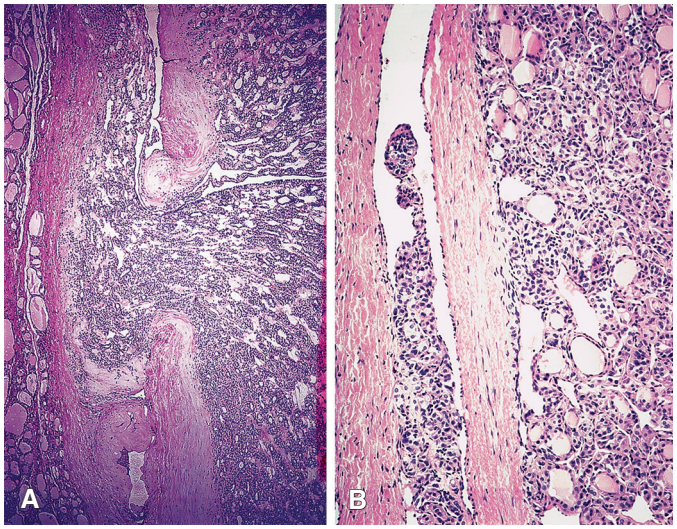

Figure 8.60 Capsular (**A**) and vascular (**B**) invasion in minimally invasive follicular carcinoma.

ordinary thrombus. Due to sectioning, sometimes nests of tumor cells with evidence of thrombus appear to be free-floating into the lumen. Elastic tissue stains of only limited use in identifying these vessels. Immunohistochemical stains for actin are more likely to be positive, but often these peculiar capsular vessels lack an elastic muscular layer altogether, despite their relatively large size. Endothelial markers—such as CD31, CD34, and Fli-1—can be useful, although their use can sometimes be disappointing due to improper fixation, technical reasons, or very low levels of expression. A mimic of vascular invasion is represented by the sometimes extremely florid proliferation of endothelial and smooth muscle cells of capsular vessels, which may look like a papillary endothelial hyperplasia (the "Masson lesion") or may even acquire a Kaposi-like appearance; this peculiar change can also be seen in follicular adenomas, but with a much lower frequency (Fig. 8.61).[177,505]

Interruption of the capsule must be full thickness for the process to qualify as capsular invasion.[506] After it has violated a narrow segment of the capsule, it is common for the tumor to expand in a mushroom-like fashion in the adjacent area. As a result, a tangential section might show a tumor nodule outside the main mass, separated from it by an intact capsule. Deeper sections may demonstrate the actual focus of capsular rupture. Another interesting phenomenon is the occasional formation of a second (or even a third) capsule in the advancing edge of the tumor that has already violated the original capsule. Evans[366] has made the interesting observation, confirmed by others,[507] that the capsule of follicular carcinoma tends to be thicker and more irregular than that of adenoma. Foci of capsular invasion should be distinguished from capsular rupture resulting from an FNA procedure. The latter should be suspected when the area in question has a fissure-like quality, contains foci of recent or old hemorrhage, and exhibits florid stromal reparative changes.[177] Another mimic is represented by the pseudoinvasion resulting from herniation of tumor tissue when the section for histology has been taken perpendicularly to a previous capsule cut made by the surgeon or pathologist on the fresh specimen; to avoid this trap, it is better to disregard the areas at the very edge of the section, in which the tumor appears to be coating an abrupt cross section of the capsule.[177]

There are prognostic differences among encapsulated follicular carcinomas that have vascular invasion and those in which invasion is only limited to the tumor capsule, the former having a greater potential for metastatic spread. Thus, thorough sampling of the

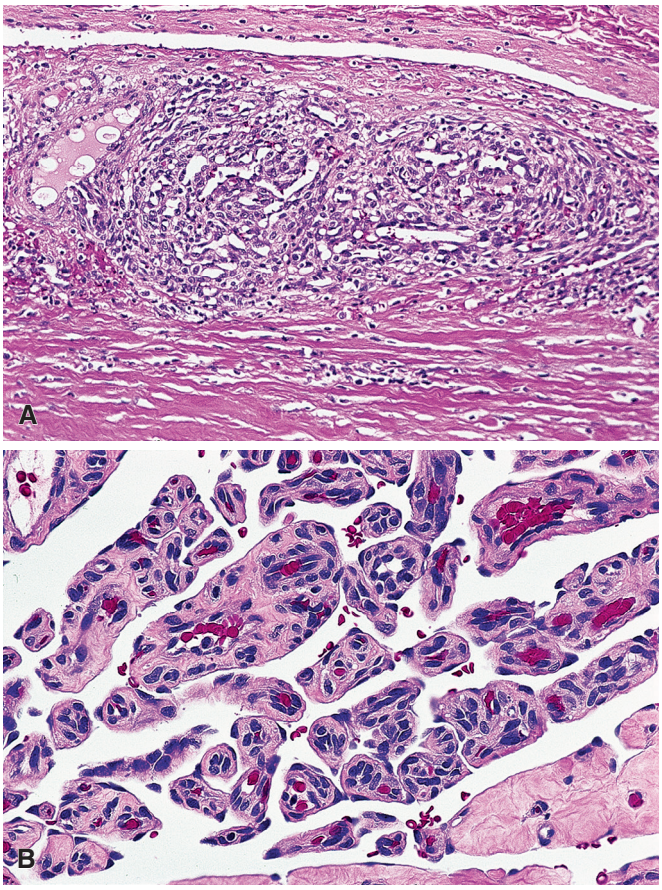

Figure 8.61 **A** and **B,** Reactive vascular proliferation in the capsule of a follicular neoplasm. On high power (**B**) the lesion has a papillary configuration.

interface of the nodule with the surrounding parenchyma is of paramount importance for encapsulated follicular-patterned lesions.[215] Sometimes even after accurate sampling and thorough examination there may still be doubts about true invasion of the tumor capsule or of vascular spaces. Vascular invasion may be questioned when nests of tumor cells abut into or are closely intermixed with vascular spaces, or when they appear inside them without endothelial lining or evidence of thrombus, and one cannot be sure that the findings are mere artifacts due to tumor dislodgement during sampling. Capsular invasion is questionable when tumor cells irregularly mushroom into but not completely through the capsule or when findings are limited to tumor nests in its outer portions. In these instances there can be considerable interobserver variability,[508] and the term "FT-UMP" may be appropriate. Similarly, that of "WDT-UMP" may be used for those cases where there are nuclear alterations of papillary carcinoma (see Table 8.4).[375,383] The "tumor of uncertain malignant potential" is not a "wastebasket" diagnostic category and should be used very sparingly as a pragmatic approach to address problematic cases.

Widely Invasive Follicular Carcinoma. Widely invasive follicular carcinomas used to be common, particularly in iodine-deficient areas, but have now become very rare in developed countries because of the improved diagnostic methods and health care standards. Invasion of the thyroid gland is widespread and immediately apparent on sectioning of the specimen, with multiple, irregular fronts of infiltration and frequent extension into the extrathyroidal soft tissues. Gross (and sometimes even microscopic) evidence of preexisting tumor encapsulation may be missing altogether. Cases with numerous

invasive nodules, the result of intravascular dissemination, may be mistaken for multinodular goiter.[177] Microscopically, vascular invasion is obvious. Many cases show high-grade morphology, at least in part of the tumor, with mitoses, foci of necrosis, and poorly differentiated cytoarchitectural features. Thus, many cases are more appropriately labeled poorly differentiated thyroid carcinomas. Some tumors have mixed histologic appearance, with combined follicular, solid, insular, and even papillary or oncocytic features.

Spread, Metastases, and Prognosis

In contrast to papillary carcinomas, follicular carcinomas of any subtype are almost always solitary and rarely occult. Metastases are blood-borne rather than to regional nodes.[509] The report of true lymph node metastases in a patient with follicular carcinoma should always be questioned, and, particularly if the tumor is not oncocytic, the possibility of a follicular variant of papillary carcinoma or a poorly differentiated carcinoma should be seriously considered.

In keeping with the tendency of follicular carcinoma to diffuse through blood vessels, even early-stage tumors have a small, but definite potential to give rise to distant metastases that can be the first manifestation of the disease. These are found at the time of the initial diagnosis in approximately 5%–10% of patients with encapsulated follicular carcinomas (a much higher proportion compared with papillary carcinoma)[496,499,510] and in a greater percentage (~20%–30%) of those with widely invasive carcinomas.[499,511] In an additional 5%–15% of patients with encapsulated tumors, distant metastases are discovered afterwards, not infrequently more than 10 years after the original diagnosis, underlying the need for a prolonged follow-up.[499,510] It is important to remember that even small tumors can metastasize. In one series five of eight minimally invasive carcinomas with distant metastases measured 2 cm or less.[496]

The most common sites of distant metastases are lungs and bone, but they can be seen in many other places, including kidney and skin.[512] The skeletal metastases are usually multicentric but have a predilection for the shoulder girdle, sternum, skull, and iliac bone.[513] Sometimes they pulsate because of their vascularity, a feature they share with metastatic renal cell carcinoma. These metastases have a strong affinity for radioiodine and—curiously—may exhibit a better differentiated appearance than the primary tumor, to the point of looking like normal thyroid as an expression of terminal differentiation (so-called metastasizing adenoma, malignant adenoma, or metastasizing goiter). The majority, however, have poorly differentiated features, at least at the architectural level.[509] Thyroglobulin and/or TTF-1 staining is essential in confirming the thyroid origin of a metastatic tumor.

Distant metastases are common in the widely invasive type or in encapsulated tumors with extensive angioinvasion, occur in fewer than 5% of the encapsulated tumors *with focal* blood vessel invasion (1–3 foci), and develop in fewer than 1% of the tumors diagnosed as carcinoma *only on the basis of minimal capsular invasion*.[492,494,495,499,501] While the prognosis of patients with follicular carcinoma is directly related to the degree of encapsulation and invasion of vascular spaces,[499,514] encapsulated follicular carcinomas with focal capsular and vascular invasion, without poorly differentiated features and without distant metastases at presentation, are rarely fatal.[384,410]

The prognosis for patients with follicular carcinoma that present with distant metastases is poor.[497,498,511,514,515] In one large series of encapsulated follicular carcinoma the cause-specific survival at 10 years was 55% compared with 97.8% for patients that did not have distant metastases at presentation.[510]

Rare follicular neoplasms show marked cytoarchitectural abnormalities (in the form of solid/trabecular pattern of growth, mitotic activity, necrosis, etc.) in the absence of capsular or blood vessel invasion. Considerations should be given to consider these tumors *noninvasive follicular carcinoma* with high-grade features.[516]

Hürthle Cell (Oncocytic) Tumors

The Oncocyte

Since the presence of oncocytes is the common denominator for all the tumors included in this section, it seems appropriate to begin with a description of these cells, which in the thyroid are usually but inaccurately designated as Hürthle cells (a misnomer, since the oncocytic cells were originally recognized in the thyroid gland by Askanazy in 1898).[517] Oncocyte, oncocytic cell ("swollen" cell, that we consider the more accurate descriptive term), and oxyphilic cell ("acidophilic" or "eosinophilic" cell) are terms, more popular in the European literature, used interchangeably for Hürthle cell.[518] The characteristic cytoplasmic granularity of these cells is due to the accumulation of mitochondria, many of which show a variety of morphologic abnormalities both on transmission and scanning electron microscopy (Fig. 8.62).[519,520] Due to the striking mitochondrial accumulation there is complete loss of cell polarity.[518] It is important, to avoid confusion in diagnostic terminology, to distinguish oncocytic cells from other "mitochondria-rich" cells that do not have total loss of cell polarity and have fewer mitochondria at the ultrastructural level (e.g., the tall cells of tall cell papillary carcinoma that have an eosinophilic "oncocytoid" cytoplasm).[518] It is also good to remember that the granularity of the neoplastic cell cytoplasm should have a deeply eosinophilic quality in H&E-stained sections; otherwise, alternative possibilities such as (oncocytic) medullary carcinoma should be considered. Secondary cytoplasmic clearing is not uncommon in oncocytic cells, usually due to mitochondrial swelling. Immunohistochemically, oncocytes show reactivity many mitochondrial antigens, glucose transporter 4 (GLUT-4), and keratin.[7,521] Marked reduction or loss of expression of complex I subunit genes (e.g., *NDUFS4*) and of complex I enzyme activity is a common feature in oncocytic cells both in the thyroid and in the kidney.[522,523] It is important to remember that the endogenous biotin of mitochondria may result in spurious immunohistochemical staining of oncocytic cells.[524]

The obvious cellular derangement of oncocytic cells causing the accumulation of mitochondria has long been suspected to be due to some form of abnormality in mitochondria biogenesis. Oncocytic tumors have a higher prevalence of mitochondrial DNA mutations than non-oncocytic tumors, ranging from point substitutions, to small insertions or deletions that can lead to frameshifts or premature stop codons, and large-scale deletions, like the "common" 4977-base pairs deletion.[525–529] We now know that the biochemical, metabolic, and phenotypic (i.e., accumulation of mitochondria) alterations of oncocytic tumors are caused by mutations in the genes coding for some of the subunits of the five multimeric complexes of the inner mitochondrial membrane that constitute the oxidative phosphorylation (OXPHOS) system. If these subunits are missing or defective due to the mutation, the entire multimeric complex does not assemble properly, OXPHOS is impaired, and there is a compensatory accumulation of mitochondria.[530,531] In oncocytic thyroid tumors, as well as in those from other organs, greater than 50% of the mutations occur at homoplasmic levels in mitochondrial genes, in more than 70% of cases in the *MT-ND* genes encoding Complex I (NADH coenzyme Q reductase) subunits.[522,523,527,532] Mutations of the Complex I subunit encoded by the *NDUFA13 (GRIM-19)* nuclear gene are the only nuclear gene mutations specific to oncocytic tumors reported to date. They have been found in a few carcinomas, including one patient with a germline mutation who developed an oncocytic variant of papillary carcinoma and multiple benign oncocytic thyroid nodules.[533] While mutations in mitochondrial and nuclear genes affecting OXPHOS function are the cause of the oncocytic phenotype, their relationship with tumor development is complex and there is no definitive proof that the mutations have a direct tumorigenic role.[530,531,534] However, the accumulation of defective mitochondria

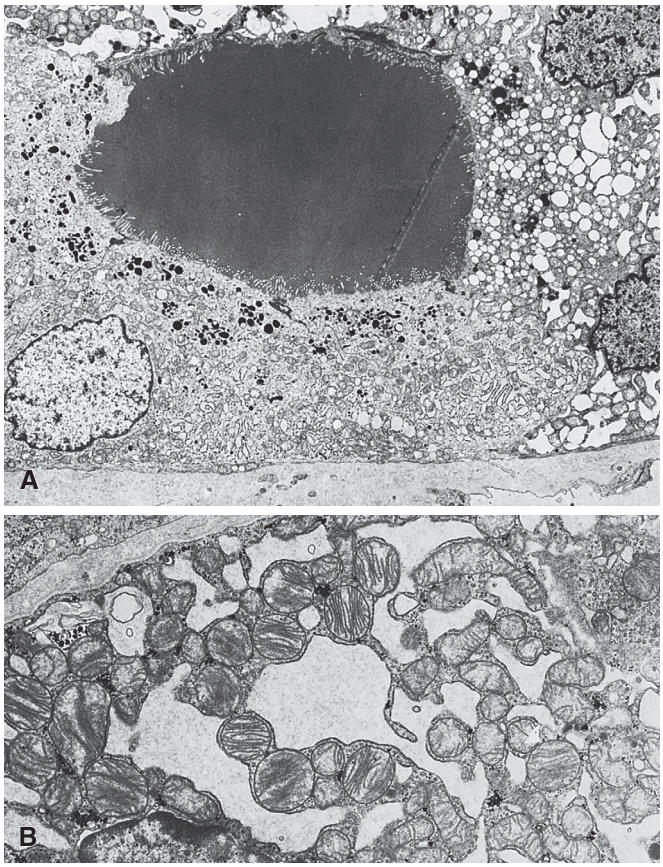

Figure 8.62 Ultrastructural appearance of Hürthle cell (oncocytic) tumor of thyroid gland. **A,** The cytoplasm is packed with mitochondria. Secretory product is located toward the lumen, which is filled with colloid. **B,** Variably sized mitochondria with prominent cristae. (**A**, ×3840; **B**, ×11,230.)

Figure 8.63 Gross appearance of Hürthle cell (oncocytic) carcinoma. The cut surface shows a tan color and a necrotic hemorrhagic center.

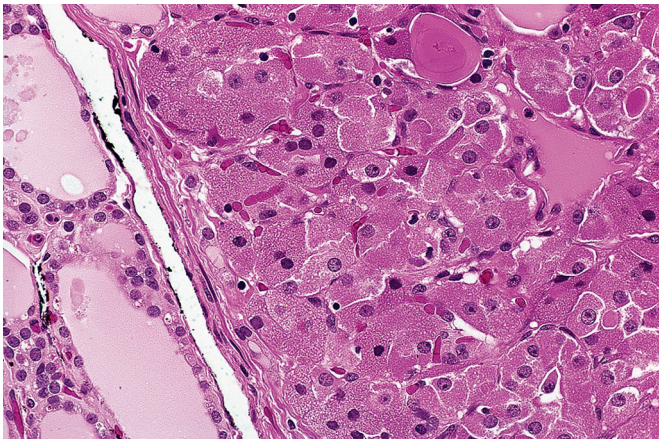

Figure 8.64 Hürthle cell (oncocytic) adenoma showing follicular pattern of growth and intact thin capsule.

explains well one of the distinctive pathologic features of oncocytic tumors, that is their exquisite sensitivity to hypoxia.[530]

Clinicopathologic Features

Hürthle cell (oncocytic) tumors represent approximately 3%–4% of all thyroid carcinomas.[535] Tumors included in this category are those composed exclusively or predominantly (over 75%) of follicular cells exhibiting oncocytic features.[518] In a traditional view Hürthle cell tumors composed of follicular cells have not been regarded as a distinct type and have been placed in one of the existing tumor categories (i.e., follicular or papillary), depending on their pattern of growth. However, their biologic characteristics, morphologic features, and natural history are distinctive enough for them to be regarded as a special group.

Most patients with Hürthle cell thyroid tumors are adults, and there is a predominance of females.[536–538] Grossly, the tumors are characteristically solid, tan, and well vascularized (Fig. 8.63). Most are well encapsulated throughout; the invasive tumors tend to grow into the parenchyma in a multinodular fashion that can be very deceptive in that it can be underinterpreted as nodular hyperplasia. Microscopically, the pattern of growth may be follicular, trabecular/solid, or papillary. The former is the most common. The follicles, when large, are separated by long and thin fibrovascular septa that simulate papillae when cut tangentially. Hürthle cell tumors usually contain little stroma, and discohesive cells in areas of solid growth may also simulate papillary structures. Another diagnostic trap is the presence of inspissated intraluminal colloid with concentric laminations, having an appearance similar to that of the psammoma bodies associated with papillary carcinoma, from which they are distinguished because of their intraluminal location. The nuclei typically show pleomorphism and prominent nucleoli, sometimes with isolated bizarre forms, these not being features of malignancy by themselves.

Immunohistochemically, there is reactivity for thyroglobulin, although in lesser degree than in conventional follicular lesions.

Hürthle cell (oncocytic) tumors with follicular or solid/trabecular patterns—which constitute the large majority—should be evaluated and diagnosed using criteria analogous to those used for follicular neoplasms of non-oncocytic types; that is, capsular and/or blood vessel invasion should be used as the main criterion for malignancy.[536–538] In the past all Hürthle cell (oncocytic) neoplasms were regarded as malignant or potentially malignant.[539] In fact, the majority of them behave in a benign fashion and are properly designated as *Hürthle cell (oncocytic) adenoma* (Fig. 8.64).[536,537] Tumors with clear-cut capsular and/or blood vessel invasion are designated as *Hürthle cell (oncocytic) carcinoma*.[536,537]

As a group, the carcinomas occur in an older age group, show less degree of female predominance, are larger (tumors measuring 3.5 cm or more are carcinomas in approximately two thirds of the

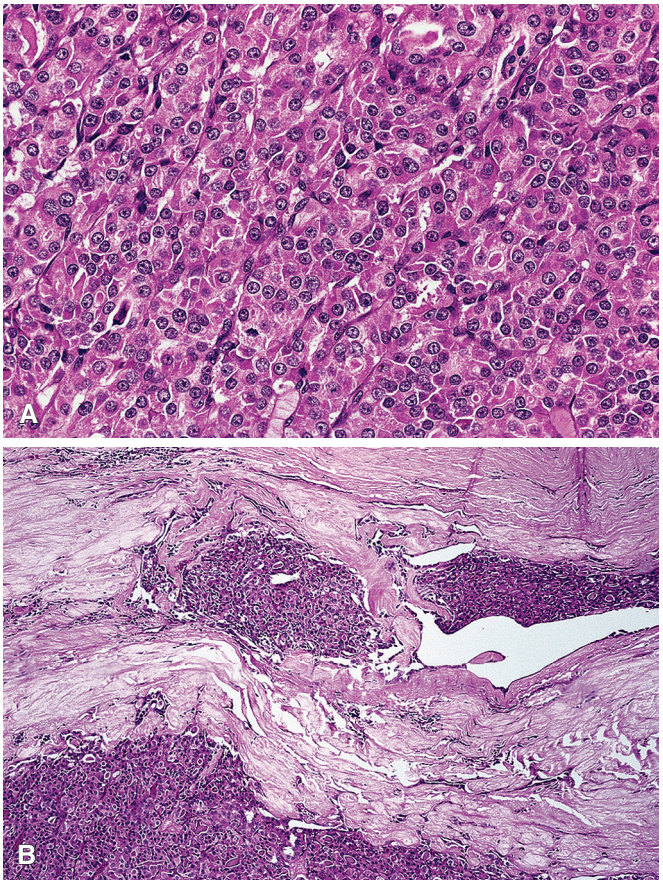

Figure 8.65 Hürthle cell (oncocytic) carcinoma. **A,** The tumor has a predominantly solid pattern of growth. **B,** Extensive vascular invasion.

cases),[540] and tend to have a solid/trabecular rather than a follicular pattern of growth (Fig. 8.65).[536–538] The cells of carcinoma are often smaller than those of adenoma and have a higher nucleocytoplasmic ratio, a feature also noticeable on cytologic examination. In the presence of any of these features, the search for capsular and/or vascular invasion should be particularly thorough (Fig. 8.65).[536–538] However, even small oncocytic nodules should be carefully sampled, as they can show invasive growth and malignant clinical behavior.[541] If no vascular invasion but only equivocal capsular invasion is found in an oncocytic tumor the behavior is usually benign.[538]

At the other end of the spectrum are the Hürthle cell (oncocytic) carcinomas that are highly invasive, with a predominantly or exclusively solid/trabecular pattern of growth, mitotically active, with foci of tumor necrosis; these are to be placed in the poorly differentiated category and regarded as high-risk tumors.[542–544]

One problem of Hürthle cell tumors is their tendency to undergo massive infarct-type necrosis, often following FNA.[545] This phenomenon, which is analogous to that seen in oncocytic tumors at other sites and which the consequence of the great sensitivity of oncocytes to ischemia due to impaired mitochondrial function, can render the identification of the tumor difficult or impossible. However, the shadows of the tumor cells can sometimes still be discerned by simply lowering the microscope condenser, and there can be a surprising retention of immunohistochemical markers, particularly keratin.[546] It is important to realize that under these circumstances the capsule can become very irregular and entrap within its substance thyroid follicles with "regenerative" or "reactive" atypia, including some nuclear clearing and overlapping; these changes should not be overinterpreted as carcinoma.

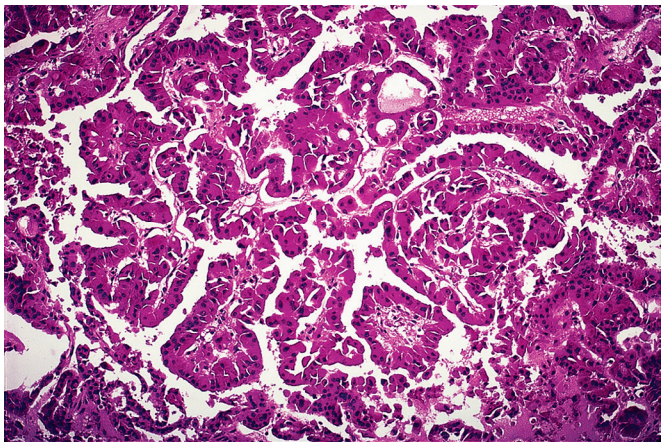

Figure 8.66 Hürthle cell (oncocytic) neoplasm with a papillary pattern of growth. The nuclear features of the papillary family of neoplasms are absent, and therefore this tumor should not be classified as a papillary carcinoma.

A difficult diagnostic problem is represented by the rare Hürthle cell (oncocytic) tumors composed entirely of papillae (as opposed to the more common pseudopapillary formations previously mentioned).[547] Those that have the nuclear features of papillary carcinoma should be placed in the latter category, as already indicated; those that do not should be handled as follicular tumors (Fig. 8.66).[548] In other words, malignancy should be largely based on the presence of capsular and/or vascular invasion. Tumors that are encapsulated behave in a benign fashion,[549] whereas those that are invasive behave in a malignant fashion,[549] perhaps more so than conventional papillary carcinomas.[550]

Hürthle cell (oncocytic) carcinomas have a marked propensity for vascular invasion. True lymph node metastases can occur but are (contrary to past opinion) uncommon.[551] In the large majority of cases locoregional disease in the neck occurs in the form of rounded nodules of carcinoma within the soft tissues. These are the result of endovascular tumor dissemination, and wide excision of the nodules alone, as opposed to formal lymph node dissection, may provide adequate local control.[551] Distant metastases are identified at presentation in approximately 10% of cases, although they may also appear years after the initial diagnosis.[552] Bone is a common metastatic site, but metastases may develop at unusual sites and be misdiagnosed as primary tumors.[509,512]

Hürthle cell (oncocytic) adenomas are cured by lobectomy, if fully excised. The carcinomas are rather aggressive neoplasms. When compared with conventional non-oncocytic carcinomas of follicular cell derivation, Hürthle cell (oncocytic) carcinomas are relatively more common among men and among older patients, have larger tumors, and present with higher disease stage.[553] Importantly, they have lower overall and disease-specific survival,[553] a reflection of their poor iodide uptake (that also limits the efficacy of radioactive iodine scans to identify metastatic disease).[552] Compared to patients with conventional non-oncocytic carcinoma, those with oncocytic carcinomas also have a significantly higher rate of secondary primary malignancies.[553] In a large series, survival of at 5 year was 85%, although for patients with stage III–IV disease the 5-year cumulative probability of clinical recurrence or death was 74% for female and 91% for male patients.[552] Older patient age, large tumor size, extrathyroidal extension, extensive vascular invasion, and metastases represent unfavorable prognostic factors.[552] The extent of vascular invasion (1–3 vs. 4 or more foci) greatly influences prognosis of patients with encapsulated carcinomas.[500,552]

No specific chromosomal abnormalities have been reported in Hürthle cell (oncocytic) tumors. However, aneuploidy is a characteristic feature of both adenomas and carcinomas and typically involves whole chromosomes or large chromosome sections, as if the increased mitochondrial mass were to hinder correct chromosomal segregation.[554–558] Gains at chromosome 12q, 19q, and 20p have been associated with tumor recurrence,[557] while chromosome 22 loss has been associated with patient mortality.[555] Cytometric DNA content analysis has linked aneuploid tumors to invasion, metastases, and poor outcome.[559,560]

The main molecular alterations that characterize non-oncocytic tumors can also be found in Hürthle cell (oncocytic) tumors. Thus, *RAS* mutations occur in tumors with follicular growth (although they are detected much less frequently),[330,486,558] and *BRAF* mutations in the rare oncocytic papillary carcinomas.[291,334] Intriguingly, *TP53* mutations have been reported in 10%–20% of Hürthle cell (oncocytic) tumors lacking high-grade/poorly differentiated features,[561,562] sometimes in association with *PTEN* mutations.[563]

A comprehensive high-throughput molecular study of tumorigenic mutations, DNA copy number changes, and expression profiling of Hürthle cell (oncocytic) tumors has shown that they have a genetic profile different from that of their conventional non-oncocytic counterparts. Carcinomas with extensive vascular invasion (4 foci or more) and aggressive features, unlike tumors with no or limited invasion, have molecular signatures consistent with activation of wnt/β-catenin and PI3K/PTEN/AKT pathways.[558]

Clear Cell Tumors

Clear cell changes can occur in thyroid neoplasms of various microscopic types and as a consequence of a variety of mechanisms, which include cytoplasmic vesicles (of mitochondrial, reticulum endoplasmic, or Golgi origin[564,565]) and accumulation of glycogen, lipid, thyroglobulin, or "mucin" (Fig. 8.67). The natural history of these tumors is determined by their basic nature rather than the presence of, degree of, or mechanism for cytoplasmic clearing in them. Therefore *clear cell carcinoma* should not be viewed as a specific tumor type.[564,566]

The neoplasm most prone to undergo secondary clear cell changes are Hürthle cell (oncocytic) tumors, this being the result of vesicular swelling of mitochondria (Fig. 8.68).[564] The oxyphilic and clear cell changes may be seen in cells facing each other or even in different regions of the same cell (Fig. 8.69).[567] Clear cell changes can also occur in follicular adenomas and carcinomas (usually because of vesicles of either mitochondrial or granular endoplasmic reticulum derivation),[568] papillary carcinoma (usually because of glycogen accumulation),[569] undifferentiated carcinoma (also the result of glycogen overload), and—exceptionally—medullary carcinoma.[570] Except for the latter, thyroglobulin stain is usually positive in these neoplasms, although sometimes in a focal and faint fashion.[564,571] Positive TTF1 immunoreactivity can confirm the thyroidal origin of the clear cells. Although the presence of clear cell change in a follicular neoplasm per se is not an indication of malignancy, it occurs more frequently in carcinomas than in adenomas and should therefore be viewed with suspicion when encountered.

A peculiar variant of thyroid tumor with clear cell changes is the *signet ring type*, in which the formation of variously sized cytoplasmic vacuoles results in a configuration reminiscent of signet ring cells or lipoblasts (Fig. 8.70). Most of these signet ring neoplasms are adenomas, but carcinomas with this appearance also occur.[572–574] Immunohistochemically, the vacuoles contain intracellular thyroglobulin.[564,572–574] The stroma is usually heavily hyalinized and with punctate calcification, suggesting that the signet ring change may be of degenerative nature and the expression of an arrest of folliculogenesis.[572,573] Some of this material has been found to react positively with mucin stains.[574]

Another rare form of clear cell change is that seen in the *lipid-rich cell adenoma*, in which the cytoplasmic vacuolization is due to the accumulation of neutral fat.[575,576]

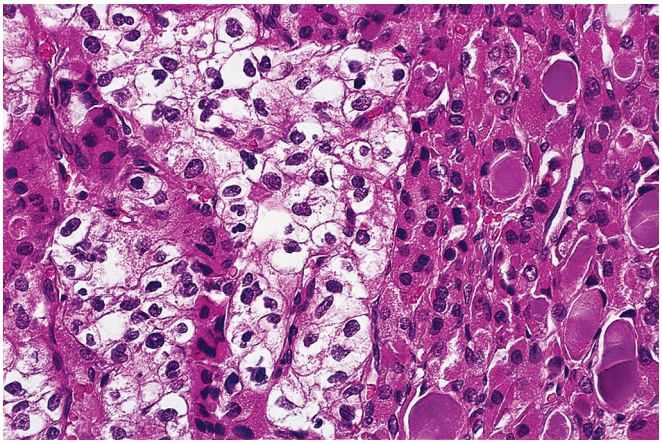

Figure 8.68 Hürthle cell neoplasm with focal cytoplasmic clear change.

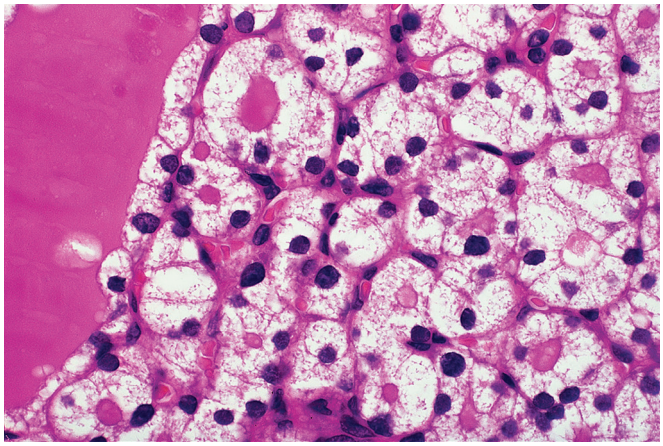

Figure 8.67 Follicular neoplasm with cytoplasmic clear change. The clearing has a finely granular quality.

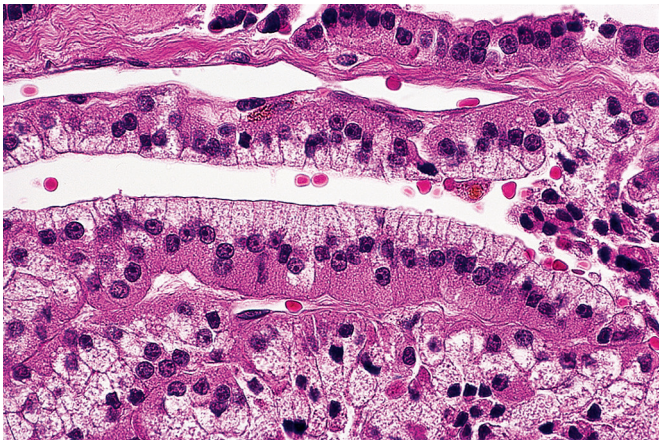

Figure 8.69 Hürthle cell neoplasm showing oncocytic features in the basal half of the tumor cells and clearing of the apical half.

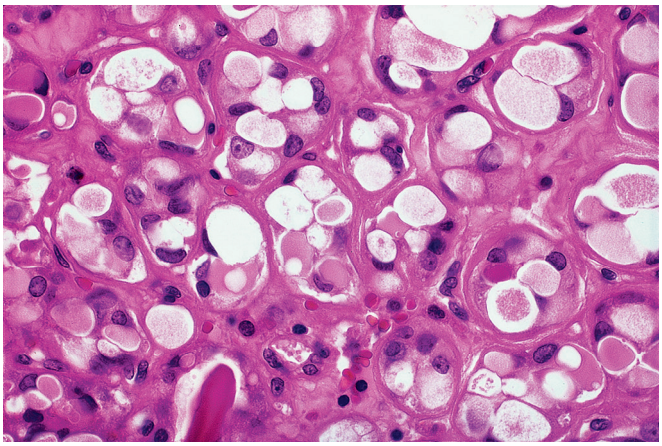

Figure 8.70 So-called signet ring adenoma, resulting from intracytoplasmic accumulation of thyroglobulin.

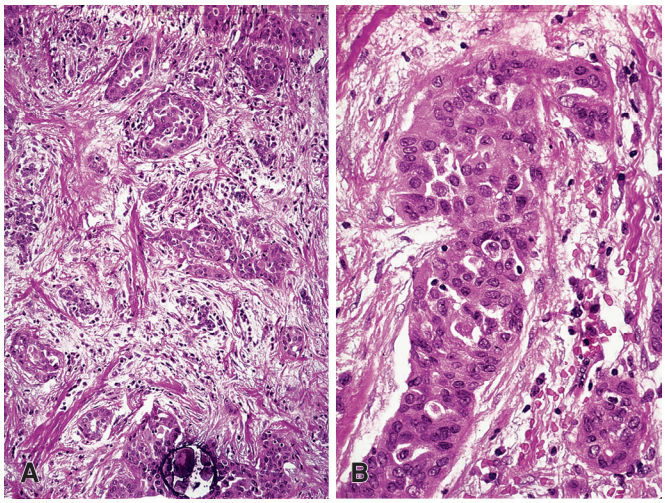

Figure 8.71 **A** and **B,** Mucoepidermoid carcinoma of thyroid. (Courtesy of Dr. K. Franssila, Helsinki.)

The main differential diagnosis of primary thyroid tumors with clear cells is with parathyroid neoplasms and metastatic renal cell carcinoma.[564,566] When struggling with this problem, the pathologist should keep in mind the fact that both of these lesions can be intrathyroidal, whereas thyroid clear cell tumors can occur in ectopic locations.[577] Immunohistochemistry will be of great help in the differential diagnosis.

It should also be noted that cytoplasmic clear cell changes can also occur in non-neoplastic thyroid disorders, including Hashimoto thyroiditis and dyshormonogenetic goiter.[564]

Squamous Cell, Mucinous, and Related Tumors

Squamous cells can be found in the thyroid as a result of persistence of thyroglossal duct or structures derived from the branchial pouch (such as thymic epithelium), or as an expression of squamous metaplasia in Hashimoto thyroiditis, papillary carcinoma, and other conditions. Pure **squamous cell carcinomas** are exceptional.[578,579] Some have been associated with leukocytosis and hypercalcemia[580] (as have anaplastic carcinomas).[581,582] Most high-grade thyroid tumors with squamous foci blend with areas of undifferentiated (anaplastic) carcinoma and are generally placed in the latter category because of their similar natural history.[583] Indeed, many of them are seen to develop from papillary carcinoma in a fashion analogous to that of undifferentiated carcinoma.[468,584] The tall cell variant of papillary carcinoma has a particular tendency to evolve into a spindle cell squamoid type of anaplastic carcinoma.[411] In the presence of an obvious squamous cell carcinoma involving the thyroid, the possibility should also be considered of secondary direct involvement from a tumor of larynx or trachea or a metastasis from lung or other sites. The thyroid differentiation factors TTF1 and TTF2 are usually negative in primary squamous (and anaplastic squamoid) carcinomas of the thyroid gland, but PAX8 immunoreactivity is frequently retained in these primary thyroid tumors, while it is invariably negative in squamous cancers of the head and neck and of the lung.[18,585]

Mucoepidermoid carcinoma (Fig. 8.71) is a rare thyroid neoplasm composed of squamous areas arranged in solid sheets, sometimes with keratin pearl formation, and of mucinous (goblet) cells lining duct-like structures or glandular spaces; mucinous cells may contain intracytoplasmic PAS-positive droplets resembling colloid and are exceptionally ciliated. The squamous and mucinous components are closely intermingled, and the stroma is fibrotic. Accumulation of extracellular mucin with cystic spaces containing mucin and keratin material and a cribriform growth pattern may occur. The mucinous material is positive with Mayer mucicarmine and alcian blue stains.[586–592]

Although an origin from solid cell nests has been suggested,[593] the fact that psammoma bodies, nuclear grooves, and pseudoinclusions can all be sometimes observed in mucoepidermoid carcinoma suggests that it may in fact represent a type of papillary carcinomas with an extreme degree of squamous and mucinous metaplasia.[590–592] Indeed, cases of papillary carcinoma with prominent mucoepidermoid features have been described,[594] and the tumor may be associated with papillary carcinoma.[590–592] Mucoepidermoid carcinoma commonly develops in the background of Hashimoto thyroiditis.[590–592]

Immunohistochemically the tumor is usually positive for thyroglobulin, CEA (polyclonal), TTF1, and PAX8.[590–592]

The behavior is that of a low-grade malignant neoplasm that may metastasize to cervical nodes but rarely spreads to distant sites. Rare fatal cases have been reported, typically in tumors with poorly differentiated or anaplastic components.[590,592,595]

The t(11;19) translocation (*CRTC1/MAML2* fusion) typical of salivary and bronchial gland mucoepidermoid carcinomas has been identified in some cases.[596] Mutations of *BRAF* or of *RAS* genes have not been identified, but *RET/PTC* rearrangements have been found in a combined papillary/mucoepidermoid carcinoma.[597]

Sclerosing mucoepidermoid carcinoma with eosinophilia (SMECE) is a distinctive variant of mucoepidermoid carcinoma arising in thyroid glands affected by Hashimoto thyroiditis, often of the fibrous type (Fig. 8.72).[598] The tumor is believed to originate from the benign squamous nests found in Hashimoto thyroiditis.[598] Microscopically, strands and nests of squamous tumor cells with mild to moderate pleomorphism are seen infiltrating a dense fibrohyaline stroma. Foci of definite squamous differentiation and mucin secretion are often present, sometimes admixed with mucin secretion. There is a constant and often striking infiltration by eosinophils, which tend to congregate around the more atypical tumor cells, thus helping to locate them on low-power examination (Fig. 8.73). In some cases there are prominent glycogen-rich clear squamous cells.[590,598–600] Some of these features can be appreciated in FNA material.[601] Immunohistochemically, there is strong reactivity for cytokeratins and p63, but only limited reactivity for TTF-1, and often none for thyroglobulin.[591,599] The clinical course is generally indolent, but cases with distant metastases and aggressive behavior have been reported.[600] The lymph node metastases may simulate microscopically Hodgkin lymphoma.[602]

A few cases of **mucinous carcinoma** lacking a squamous component and exhibiting varying degrees of differentiation (including poorly differentiated types) have been described.[603–605] In this regard, it is pertinent to note that the thyroglobulin molecule contains variable amounts of carbohydrates that may result in some degree of alcianophilia.[10]

A rare entity occurring in or around the thyroid that may exhibit squamous differentiation is *intrathyroid thymic carcinoma* or *carcinoma showing thymus-like differentiation (CASTLE)*.[40] This tumor is described in more detail in Chapter 12, together with other tumors showing thymic or related branchial pouch differentiation that can occur in the neck, often in close anatomic relationship with the thyroid gland.[40,606,607]

Poorly Differentiated Carcinoma

Malignant tumors of follicular cells are divided into a conventional well-differentiated type, composed of papillary and follicular carcinoma, and an undifferentiated or anaplastic type. There is, however, a group of tumors that shows limited evidence of structural follicular cell differentiation and falls in between these two extremes, in terms of both morphologic appearance and clinical behavior.[608–614] "Insular carcinoma," the prototype of this class of tumors, was originally reported in 1984 by Carcangiu, Zampi, and Rosai.[608] The generally accepted diagnostic criteria for this tumor were outlined in the 2007 report of the international Turin consensus conference (Fig. 8.74).[615]

Figure 8.72 Sclerosing mucoepidermoid carcinoma with eosinophilia occurring in a thyroid gland affected by Hashimoto thyroiditis. The neoplasm, which almost entirely replaces a lobe, has a well-circumscribed quality. (Courtesy of Dr. Josie Zaroway, Edmonton, Canada.)

Poorly differentiated carcinomas are uncommon. If the Turin consensus criteria are utilized they represent a small fraction of thyroid carcinomas, less than 2% in the United States and less than 1% in Japan, although a prevalence of approximately 5% has been reported in the area of Turin in Italy and in some regions of France.[616,617] Iodine deficiency likely represents a risk factor based on the association of poorly differentiated carcinoma with longstanding goiter.[612]

Compared to the well-differentiated tumors, poorly differentiated carcinoma occur in an older group, with a mean age at presentation of 55–65 years (although they have also been reported in children and adolescent,[619] and show a lower predominance of female patients.[608,615,617,620]

On gross examination the tumors are large (in one series 5 cm was the median diameter),[617] with pushing margins and satellite nodules. They may be partially encapsulated but are often indistinguishable from widely invasive follicular carcinoma. Because of multinodular growth, they may simulate thyroid goiter.

Microscopically, the features of insular carcinoma are very characteristic (to the point of instant pattern recognition): a nesting—"insular"—pattern of growth (Fig. 8.75), solid to microfollicular arrangement, small uniform tumor cells (Fig. 8.76), variable mitotic activity, and fresh tumor necrosis, sometimes resulting in a peritheliomatous pattern (Fig. 8.77). "Insular" nests are surrounded by thin fibrovascular septa, which are often separated from tumor cell nests by artefactual clefts. The tumor cells have round hyperchromatic nuclei, indistinct nucleoli, and minimal pleomorphism. Sometimes the nuclei may show irregular, "raisin-like," convoluted features reminiscent of papillary carcinoma, but the chromatin is dark and there are no pseudoinclusions.[608]

Some poorly differentiated cases do not show the classical features of "insular" carcinoma: a trabecular pattern predominates (Fig. 8.78), neoplastic cells have larger more pleomorphic nuclei, and necrosis

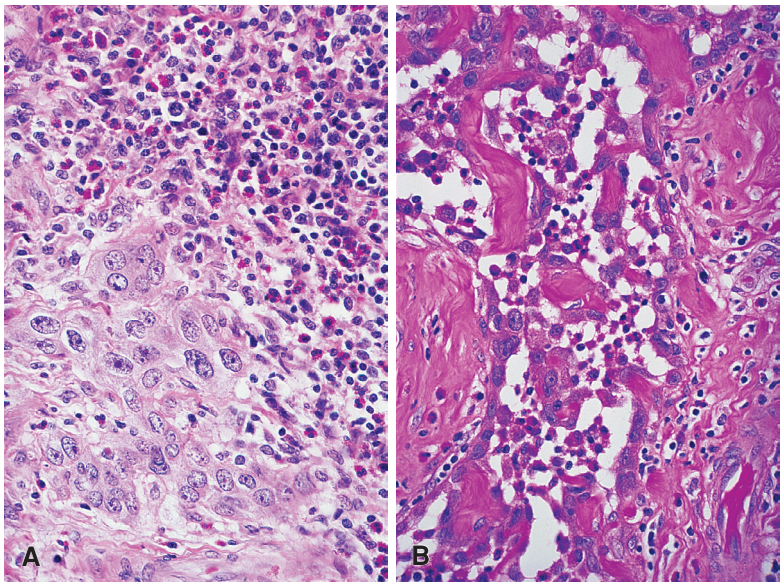

Figure 8.73 Sclerosing mucoepidermoid carcinoma with eosinophilia. **A,** The pattern of growth is solid and squamoid and is associated with a massive eosinophilic infiltration. **B,** The formation of tissue spaces results in a pseudovascular appearance.

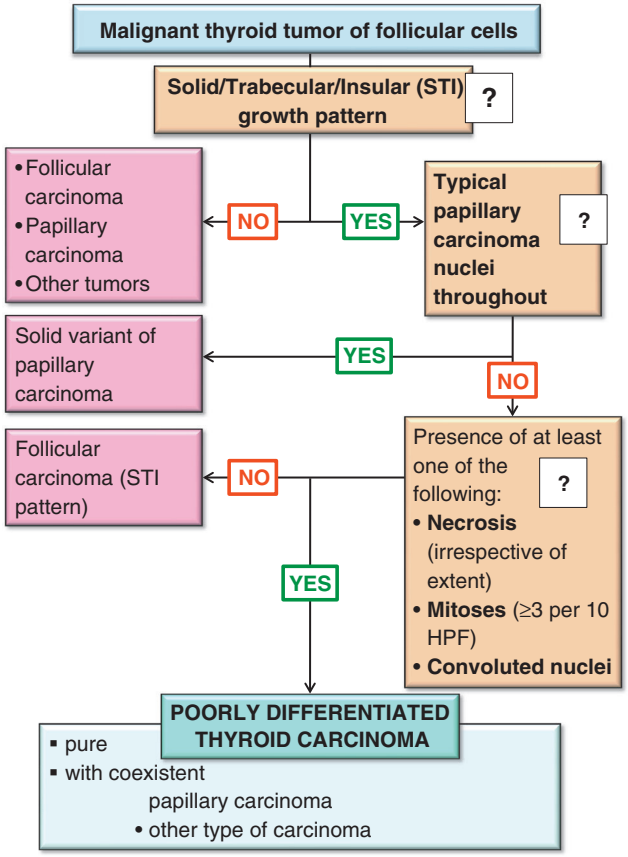

Figure 8.74 Diagnostic criteria for poorly differentiated thyroid carcinoma. HPF: high power field; random mitotic counts in areas with solid/trabecular/insular (STI) growth pattern (From Volante M, Collini P, Nikiforov YE, et al. Poorly differentiated thyroid carcinoma: the Turin proposal for the use of uniform diagnostic criteria and an algorithmic diagnostic approach. *Am J Surg Pathol*. 2007;31(8):1256–1264.)

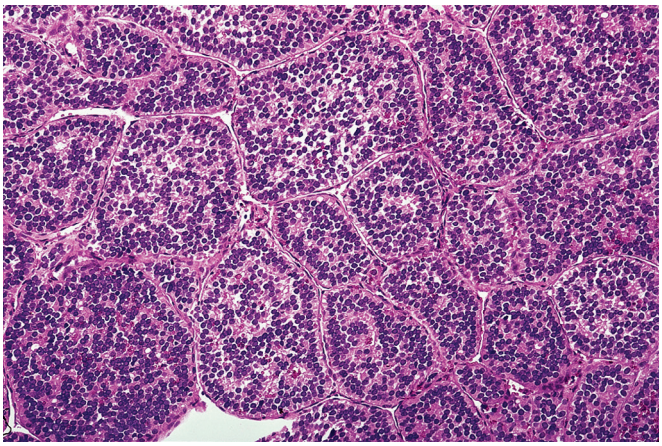

Figure 8.75 Low-power view of poorly differentiated thyroid carcinoma, showing a well-developed insular pattern.

is comedo-like. Vascular invasion is identified in the majority of cases. Extrathyroidal infiltration is common, but it is less pervasive than in anaplastic carcinoma.[608,615,617,618] The Turin consensus criteria,[615] which currently define poorly differentiated carcinoma, represent a generalization of the original concept of insular carcinoma put in the form of a diagnostic algorithm. They are based on (see Fig. 8.74):

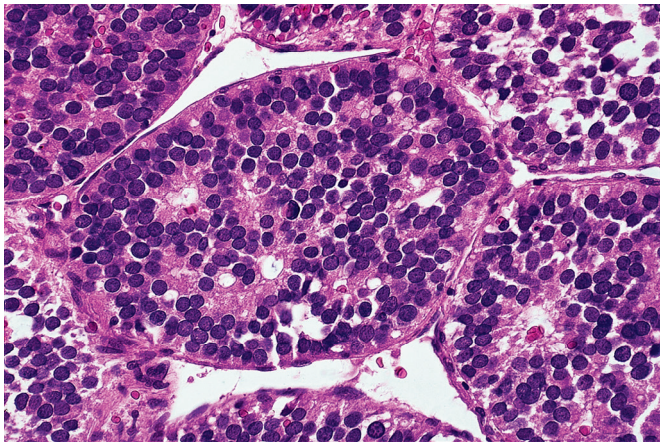

Figure 8.76 On high power, the cells of insular carcinoma show round, medium-sized nuclei with a smooth contour and hyperchromasia.

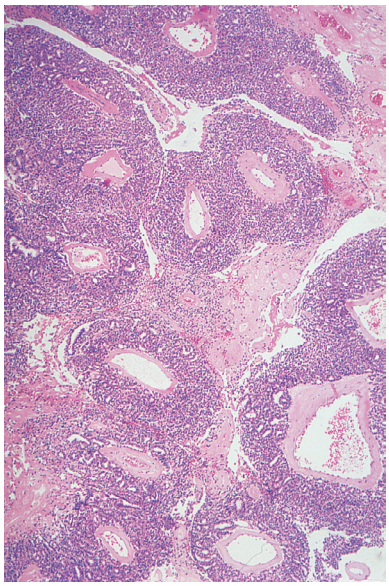

Figure 8.77 Poorly differentiated (insular) carcinoma. The peritheliomatous pattern of growth results from necrosis associated with preservation of the tumor cells that are closer to nutrient vessels.

- Pattern of growth that is nested ("insular")/solid/trabecular.
- Absence of the conventional nuclear features of papillary carcinoma
- Presence of at least one of the following features:
  - mitotic activity (≥3 mitoses per 10 high-power fields)
  - tumor necrosis
  - convoluted nuclei

Some poorly differentiated carcinomas are composed of Hürthle (oncocytic) cells.[542–544]

Clear cells foci,[542] mucinous differentiation,[603] and signet ring[621] or rhabdoid[622] features have been reported. In many cases poorly differentiated tumors exhibit a complex pattern, and poorly differentiated areas can be intermixed with a variety of growth patterns, including areas of well-differentiated papillary or follicular carcinoma. This complexity and the non-standardized use of the term "poorly differentiated" to designate thyroid carcinomas with unfavorable prognosis can produce diagnostic problems.[616] It has been shown that the focal presence (as low as 10%) of poorly differentiated areas in an otherwise well-differentiated papillary or follicular carcinoma may be associated with unfavorable outcome and should therefore

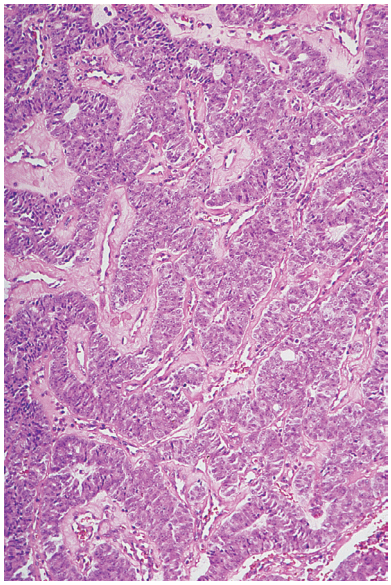

Figure 8.78 Poorly differentiated carcinoma showing trabecular pattern of growth rather than insular formations.

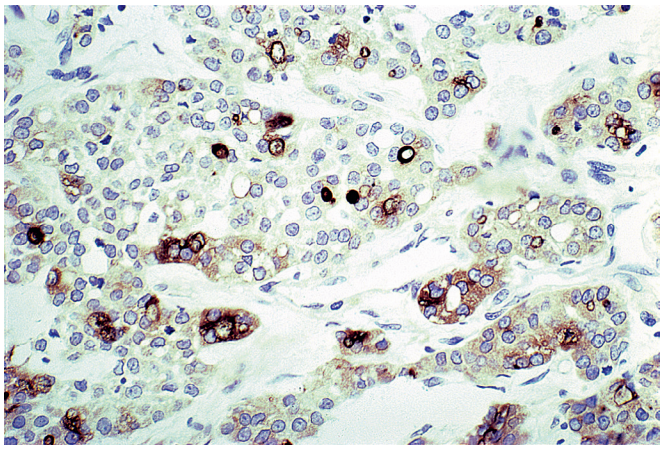

Figure 8.79 Poorly differentiated carcinoma of thyroid of insular type showing immunoreactivity for thyroglobulin.

be reported.[616] Areas of poorly differentiated carcinoma are also encountered in association with tumor histotypes that are characterized by aggressive behavior such as the hobnail variant.[435] Cellular anaplasia and nuclear pleomorphisms mark the transition to anaplastic carcinoma.[623] One fatal case of poorly differentiated carcinoma arising within struma ovarii has been reported.[624]

Immunohistochemically, poorly differentiated carcinoma, like other differentiated thyroid tumors, shows a cytokeratin7+/cytokeratin20– profile.[276] Thyroglobulin expression is reduced and characteristically limited to microfollicular structures and to the paranuclear portion of some of the neoplastic cells (see Fig. 8.79).[611] TTF1 is positive, although with weaker immunoreactivity.[18] Immunoreactivity for p53 may be restricted to areas of infiltrative growth and is not as widespread as in anaplastic carcinoma.[625] The Ki-67/MIB1 labeling index is often 10%–30%.[626]

The differential diagnosis of poorly differentiated carcinoma includes primarily medullary thyroid carcinoma, parathyroid carcinoma, and carcinoma metastatic to the thyroid gland and immunohistochemistry is useful in resolving difficult cases.

Poorly differentiated carcinoma presents as thyroid mass, sometimes as a recent growth in a longstanding goiter. In preoperative FNA samples, cytologic features suggestive of poorly differentiated carcinoma are marked cellular crowding, clusters with insular/solid/trabecular morphology, single cells, and cells with high nuclear/cytoplasmic ratio, but a definitive diagnosis can only be made after histologic examination.[627]

At the time of the initial diagnosis there are distant metastases in approximately 15% of patients, and lymph node metastases are common.[471,608]

Although some tumors may concentrate radioactive iodine, poorly differentiated carcinomas are typically FDG-PET positive[620] and represent approximately 50% of thyroid tumors that are FDG-PET positive and refractory to radioactive iodine treatment.[628] Because of the poor radioactive iodine uptake the survival at 5 years varies between 40% and 70% in most series.[608,615,617,618]

A high density of tumor-associated macrophages (a common finding in advanced thyroid cancers) has been reported as a poor prognostic factor.[629] A favorable prognostic factor is full encapsulation. In one report, completely encapsulated high-grade tumors with mitotic activity or necrosis, and with the features of poorly differentiated carcinoma according to the Turin consensus criteria—but for the lack of invasion—have not recurred or metastasized after a median follow-up greater than 10 years.[516]

It is important to remember that poorly differentiated carcinomas are not the only tumors with a prognosis intermediate between well- and undifferentiated (anaplastic) thyroid malignancies. Follicular tumors with extensive angioinvasion, aggressive papillary carcinoma variants (tall cell, hobnail), and well-differentiated carcinomas that present with distant metastases also have an intermediate prognosis.[616] A simple grading scheme based on the identification of necrosis or high mitotic activity (≥5 mitoses per 10 high-power field) successfully captures thyroid carcinomas with such an intermediate prognosis, irrespective of architectural features or tumor subtype, with good overlap with the Turin consensus criteria for poorly differentiated carcinoma.[471] Other schemes based on the Ki-67/MIB1 labeling index may successfully be applied for the same purpose.[626] Poorly differentiated tumors, defined only on the basis of mitotic activity and necrosis,[471] represent over half of the fatal forms of non-anaplastic thyroid carcinoma.[328]

The molecular alterations are summarized in Table 8.2. Somatic genetic changes that characterize poorly differentiated carcinoma are *TERT* promoter mutations, *TP53* mutation, and dysregulation of the PI3K/PTEN/AKT pathway, although all these alterations are less common than in anaplastic carcinoma. In addition to these "late" molecular events, "early" changes such as *RAS*[630] and *BRAF* p.V600E[301] mutations are also common. The high prevalence of *RAS*-activating mutations (20%–50%) suggests that many poorly differentiated carcinoma develop from follicular carcinomas or from the follicular variant of papillary carcinoma.[482,485,618,630]

Compared to well-differentiated carcinomas, poorly differentiated tumors have a higher mutational load[344] and frequently carry multiple molecular alterations (typically one early change together with a late alteration).[344] In combined tumors with a well-differentiated component, areas with early molecular alterations are found both in the well-differentiated and in the dedifferentiated areas, while the late molecular alterations appear restricted to the dedifferentiated parts of the tumor,[625,631,632] *CTNNB1* mutations,[633] and *ALK* rearrangements,[319,321,344] as well as *EIF1AX* in combination with *RAS* mutations[344] have been reported in poorly differentiated carcinoma subsets (and in anaplastic carcinoma). In one study disruption of the SWI/SNF chromatin remodeling complex, mutation of histone methyltransferases (HMTs) and inactivation of the DNA mismatch repair system have been

reported in 6%, 7%, and 2% of poorly differentiated tumors, respectively, (and in a considerably higher proportion of anaplastic carcinomas).[344]

The tumors are aneuploid with frequent copy number variations,[344] and many of the follicular carcinomas with complex karyotypes reported in the past were poorly differentiated tumors.[478] The microRNA profile of poorly differentiated carcinoma is different from that of well-differentiated tumors and anaplastic carcinomas.[353]

Anaplastic (Undifferentiated) Carcinoma

Anaplastic (undifferentiated) carcinoma typically presents in elderly patients as a rapidly growing firm mass, fixed to the surrounding structures, associated with hoarseness, dysphagia, and dyspnea.[582,634] Extrathyroidal extension is encountered at the time of initial presentation in most of the cases.[583,634] Grossly, a highly necrotic and hemorrhagic solid tumor mass is seen replacing large portions of the organ (Fig. 8.80).

Microscopically, the term anaplastic or undifferentiated carcinoma is used in the thyroid gland in connection with two major categories that sometimes coexist. The first is undifferentiated in the sense that it does not make follicles, papillae, or even trabeculae or nests, but the tumor still retains an unmistakable *epithelial appearance* on morphologic and immunohistochemical grounds. This pattern, which is referred to as **squamoid**, may blend with clear-cut foci of keratinization.[583] A very unusual subset of this tumor type has a lymphoepithelioma-like appearance but does not seem to be related to the Epstein–Barr virus.[635,636]

The second category is actually composed of two patterns which are often seen together and which can be grouped under the qualifier of *sarcomatoid*: **spindle cell** and **giant cell** (the latter showing a degree of pleomorphism substantially greater than that seen in the spindle and squamoid types) (Figs. 8.81 and 8.82). They may exhibit a fascicular or storiform pattern of growth, heavy neutrophilic infiltration, prominent vascularization, and divergent differentiation into bone, cartilage, and skeletal muscle.[637,638] As a result, their appearance may closely simulate a large variety of soft tissue sarcomas, particularly so-called malignant fibrous histiocytoma (including its inflammatory and myxoid variants), angiosarcoma, malignant hemangiopericytoma, rhabdomyosarcoma, and fibrosarcoma.[583,639] Osteoclast-like multinucleated giant cells may be present, giving the tumor an appearance reminiscent of giant cell tumor of bone or soft tissues.[640] As in similar tumors in other organs, these osteoclast-like giant cells are not neoplastic but rather reactive cells of monocytic/histiocytic lineage derived from mononuclear cells through the mechanism of cell fusion.[641,642] In fact, a high density of tumor-associated macrophages, a common finding in advanced thyroid cancer in general, is found in virtually every anaplastic carcinoma.[629]

One variation on the theme of the spindle cell form of undifferentiated carcinoma is the *paucicellular variant*, which mimics Riedel thyroiditis because of the extreme degree of fibrosis and hyalinization, and which is recognized because of the scattered atypia, areas of necrosis, vascular invasion, vascular permeation, and positivity for epithelial markers.[643,644]

The rare *rhabdoid variant* may be considered a variation on the theme of the giant cell form of undifferentiated carcinoma.[645]

It should be kept in mind that the majority of sarcoma-like tumors of the thyroid are, histogenetically speaking, undifferentiated carcinomas. Common and diagnostically useful features are palisading at the necrotic edges and tendency for the tumor cells to invade the wall of veins, replacing the normal smooth muscle. Ultrastructural examination will reveal markers suggestive of epithelial differentiation in approximately half of the cases.[255,583,646]

Immunohistochemically, the most useful marker for confirming the epithelial nature of the tumor (although obviously not for determining its thyroid origin) is keratin, which will be found to

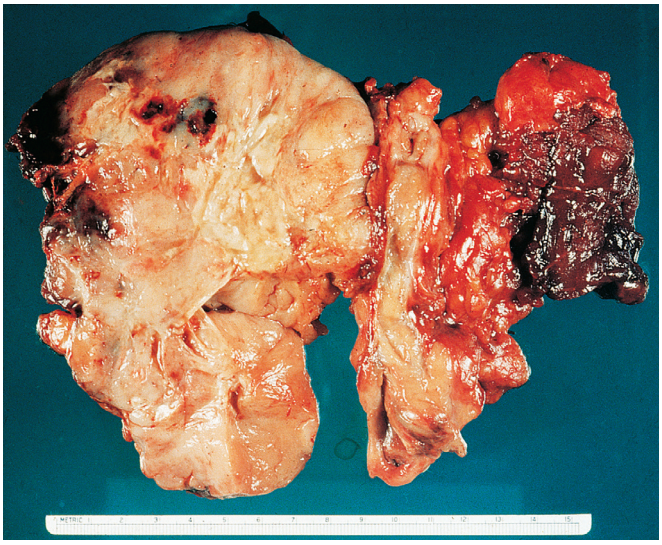

Figure 8.80 Undifferentiated carcinoma of the thyroid entirely replacing the gland and extending into the surrounding skeletal muscle.

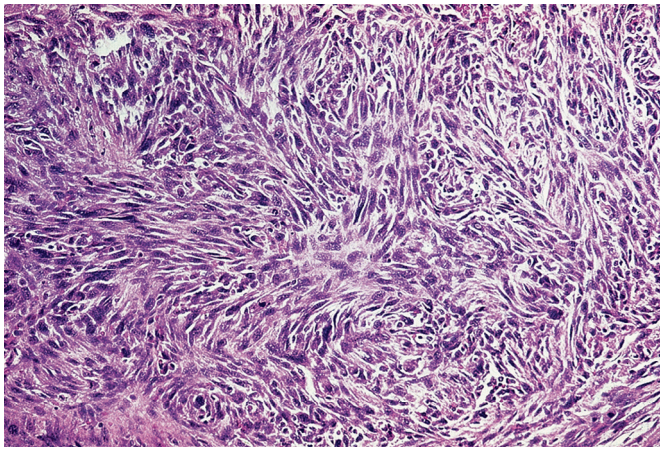

Figure 8.81 Undifferentiated carcinoma of the spindle cell type.

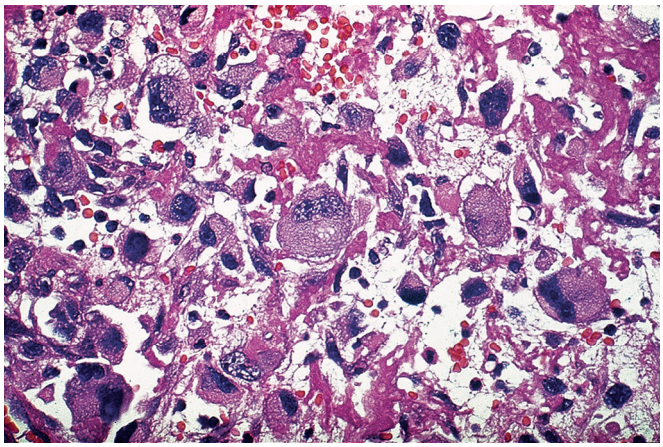

Figure 8.82 Undifferentiated carcinoma of giant cell type.

be expressed in 50%–100% of cases, according to the different series.[583,647,648] However, since cytokeratins are not always positive, negative immunoreactivity does not necessarily rule out a diagnosis of anaplastic carcinoma. Vimentin is consistently present (particularly in the neoplastic spindle cells), there is scattered stromal (basement membrane–related) reactivity for laminin,[26] and focal EMA and CEA positivity may be found, especially in the squamoid type.[583,647,648] Immunoreactivity of thyroglobulin in anaplastic carcinoma is nearly always absent, particularly in those cases that are totally undifferentiated.[583,647,648] False-positive results may be due to entrapment of normal thyroid, residual foci of better differentiated tumor (Fig. 8.83), or diffusion of thyroglobulin from destroyed normal follicles into the tumor cells. Among the thyroid differentiation factors, TTF1 and TTF-2 (FoxE1) are positive only in a minority of anaplastic carcinomas[18,648]; however, positivity for PAX8 is retained in 70%–80% of the cases.[18,585] PAX8 is expressed in carcinomas of the female genital tract and of the kidney (including sarcomatoid renal cell carcinoma), and its positivity in anaplastic carcinoma may be limited to a minority of the tumor cells. In spite of these caveats, it is can be very useful: it is frequently positive in anaplastic carcinomas lacking a well-differentiated component and in the squamoid variant, while it is invariably negative in squamous cancers of the head and neck and of the lung.[18,585] Anaplastic carcinoma (unlike poorly differentiated thyroid carcinomas) is diffusely positive for p53, correlating in part with the frequent occurrence of inactivating *TP53* mutation,[625,649] and has very high proliferative activity (Ki-67/MIB1 labeling index ~35%) (see Table 8.3). Immunohistochemistry is essential in the differential diagnosis of anaplastic carcinoma, which includes a long list of tumors, depending on the pattern of growth they may exhibit. In general, the diagnosis of anaplastic carcinoma should be favored in the presence of any pleomorphic malignant tumor that seems to arise in the thyroid gland, even if no clear-cut evidence of epithelial differentiation is found by any method. This is especially true if the patient is elderly and if there is evidence of a residual better-differentiated epithelial neoplasm in the gland.

Most (if not all) undifferentiated thyroid carcinomas arise as a result of anaplastic transformation ("dedifferentiation") of a preexisting, well-differentiated tumor, as confirmed by molecular studies.[631,632,650] This "dedifferentiation" is fortunately rare, probably less than 1% of cases. In most instances, the anaplastic transformation takes place in the primary tumor, but it may also occur in a recurrence or in a metastasis.[411,582,651] Thorough sampling may be necessary to detect the residual well-differentiated component. It is likely that the sharply outlined sclerohyaline nodules sometimes present within undifferentiated carcinoma represent the burnt-out residue of such components.[583,652] The better-differentiated tumor is usually a papillary carcinoma (Fig. 8.84) or one of its variants (such as the tall cell variant),[411] but it may also be a follicular carcinoma, a Hürthle cell (oncocytic) carcinoma, or a poorly differentiated carcinoma.[484]

There is no clear-cut relationship between the type of well-differentiated carcinoma and the pattern of anaplastic carcinoma that it may give rise to. Exceptions are the link between the tall cell variant of papillary carcinoma and a spindle cell squamoid type of anaplastic carcinoma[411] and between papillary carcinoma with squamous metaplasia and the squamoid type of anaplastic carcinoma.[653]

The evolution of all types of undifferentiated thyroid carcinoma is very rapid, with massive growth in the neck and infiltration of the ribbon muscles, esophagus, trachea, skin, and even contiguous bones. Tracheal extension may simulate a primary tracheal tumor.[411,654]

Preoperative FNA cytology typically shows highly cellular smears, dominated by large, often bizarre cells, with background necrosis and inflammation.[655] Nodal metastases are common and distant metastases are found in 40%–50% of cases at presentation.[634,656] The prognosis is notoriously poor, with only 10%–20% of the patients surviving 12 months after the initial diagnosis, the immediate cause of death usually being the involvement of vital structures in the neck.[582,583,634,656] Favorable prognostic factors on multivariate analysis are younger age and tumor limited to the thyroid, while unfavorable ones are acute symptoms at presentation (sudden appearance of dysphonia, dysphagia, dyspnea, and rapid growth of the tumor),

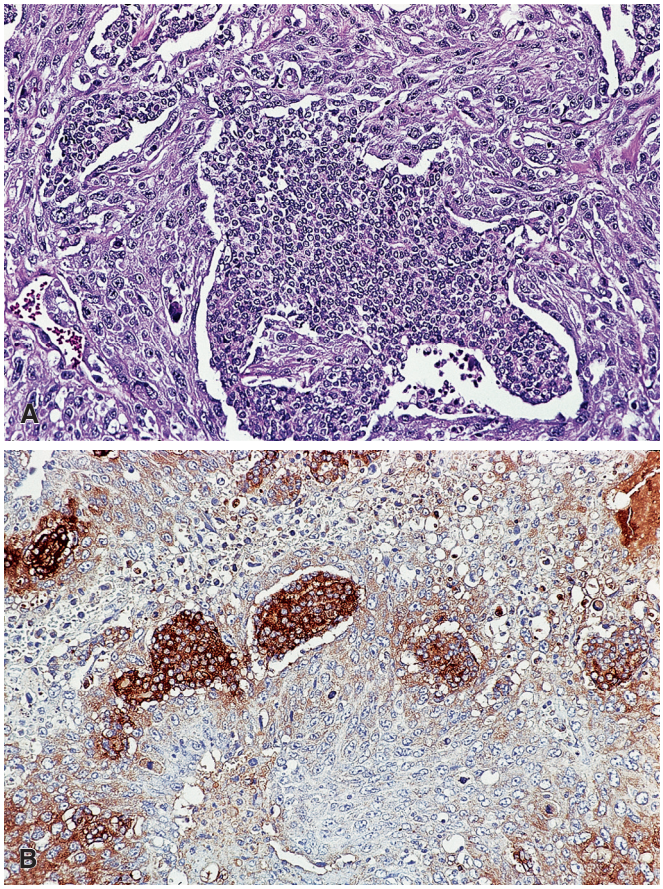

Figure 8.83 **A** and **B,** Combined poorly differentiated and undifferentiated thyroid carcinoma. Immunoreactivity for thyroglobulin is restricted to the poorly differentiated areas (**B**).

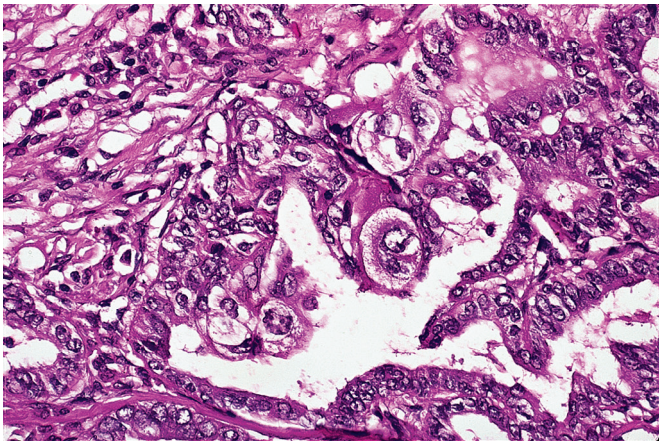

Figure 8.84 Undifferentiated thyroid carcinoma showing residual papillary carcinoma.

leukocytosis (due to the release of leucocyte colony-stimulating factors by the tumor),[581] large tumor size, and distant metastases.[581,656,657] Most anaplastic carcinomas are unresectable, but selected patients may benefit from radical surgery often associated with adjuvant chemotherapy and external beam radiation therapy.[658,659] Those intrathyroidal anaplastic carcinomas discovered incidentally as a focal change in an otherwise well-differentiated tumor are virtually the only cases that can really be cured.[660]

The main molecular genetic alterations of anaplastic carcinoma are shown in Table 8.2. Consistent with the endpoint for thyroid tumor progression, anaplastic carcinomas are characterized by the simultaneous dysregulation of multiple pathways, with a large variety of molecular alterations.[344,661] Even compared to poorly differentiated thyroid carcinoma, anaplastic carcinoma has a very high mutational load, with an average of 121 somatic mutations per sample.[661] They have long been known to be aneuploid,[662] and to show complex karyotypes by conventional cytogenetics.[293]

The alteration most consistently associated with anaplastic carcinoma is *TP53* inactivation.[344,485,632,661,663] The fact that *TP53* mutations are not usually present in residual differentiated components but segregate with the anaplastic one, indicates that they occur *after* the initial development of the tumor and that they have an important role in the progression to anaplastic cancer.[631,632]

TERT promoter mutation[344] and alterations of the PI3K/PTEN/AKT pathway are commonly identified. The PI3K/PTEN/AKT signaling is altered by loss of function *PTEN* mutations or by activating mutations of the *PIK3CA* gene.[210,344,488,661,664] A high prevalence of copy number gains of *PIK3Ca* and *PIK3Cb* (and of receptor tyrosine kinase genes like *EGFR*, *VEGFR1*, *PDGFR-alpha* and *-beta*, *KIT*) has been reported.[210,488] While *PTEN* and *PIK3CA* gene alterations rarely coexist in well-differentiated follicular carcinomas, they can overlap with each other and with either *BRAF* or *RAS* mutations in anaplastic carcinoma.[210,344,488,661,664]

In addition to mutations of *TP53*, *TERT* promoter, and of PI3K/PTEN/AKT pathway effector genes, gene mutations of SWI/SNF subunits and of HMTs appear to be an important feature of anaplastic carcinoma.[344]

Mutations found in conventional papillary and follicular carcinomas are also found in anaplastic carcinomas, a clue to their evolution from preexisting well-differentiated tumors. *RAS* mutations are common,[344,482,484,485,661] as are *BRAF* mutations, particularly in those cases with a papillary carcinoma component.[301,344,661] *RET/PTC* and *PAX8/PPARG* are not usually identified,[344] suggesting that these rearrangements, unlike *RAS* and *BRAF* mutations, do not promote dedifferentiation.

Inactivation of the DNA mismatch repair enzymes has been identified in approximately 10%–20% of cases.[344,661] *EIF1AX* mutations, typically in combination with mutated *RAS*, occur in approximately 5%–15% of anaplastic carcinomas.[344,661] Subsets of anaplastic carcinoma are characterized by *ALK* rearrangements [319,321] or *CTNNB1* mutations.[661,665]

The miRNAs expression profile of anaplastic carcinoma is different from that of other less aggressive thyroid tumor types. Downregulation of miR-30d, -125b, -26a, -30a-5p has been reported,[666] and dysregulated miRNAs expression may influence the epithelial to mesenchymal transition process in anaplastic carcinoma.[667]

Medullary Carcinoma and Related Neuroendocrine Lesions

Medullary Carcinoma

Morphologic Features. Medullary carcinoma is the original and preferred term for a distinctive type of malignant thyroid neoplasm composed of C (parafollicular) cells; prior synonyms include solid carcinoma with amyloid stroma, hyaline carcinoma, and C-cell carcinoma.[668] A benign counterpart of medullary carcinoma is not recognized, although the term medullary microcarcinoma has been used for small tumors (<1 cm) with a low risk of recurrence and metastasis.[669,670] Grossly, the typical tumor is solid, firm, and nonencapsulated but relatively well circumscribed and has a gray to yellowish cut surface (Fig. 8.85). A continuous fibrous capsule envelops an occasional tumor. Most tumors are located in the midportion or upper half of the gland, corresponding to a greater concentration of C cells in these regions.

Microscopically, the classic medullary carcinoma cytoarchitecture is represented by a solid proliferation of round to polygonal cells of granular amphophilic cytoplasm and medium-sized nucleus, separated by a highly vascular stroma, hyalinized collagen, and amyloid (Fig. 8.86).[671] The number of morphologic variations on

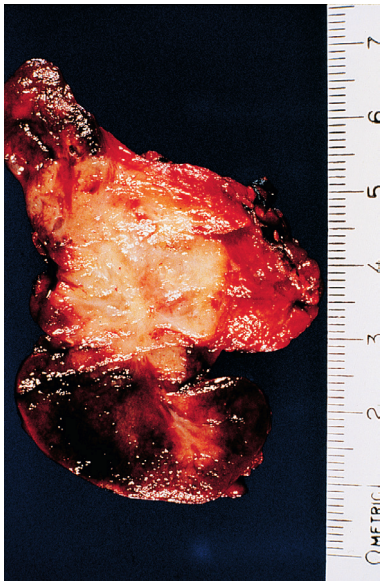

Figure 8.85 Gross appearance of medullary carcinoma. Note its unencapsulated quality, solid appearance, and yellowish tan color.

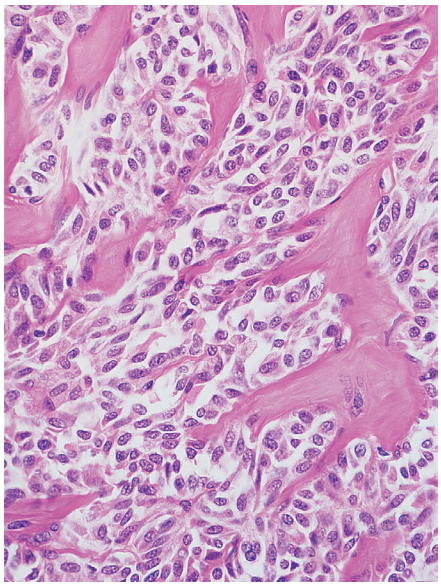

Figure 8.86 Medullary carcinoma. Low-power microscopic view showing solid pattern of growth and deposition of amyloid.

this theme is very large. The pattern of growth can be carcinoid-like, paraganglioma-like, trabecular, glandular (tubular and follicular), or pseudopapillary (Fig. 8.87).[672–675] Therefore, it is prudent to consider medullary carcinoma in the differential diagnosis of any thyroid neoplasm with an unusual morphology. The stroma may be scanty, hemorrhagic, ossified, or edematous. The amyloid deposition may be widespread, limited to small psammomatoid concretions, or altogether absent. Sometimes this amyloid elicits a florid foreign body–type giant cell reaction. True psammoma bodies may be present. A heavy neutrophilic infiltrate is occasionally seen (so-called inflammatory type). The tumor cells may be plasmacytoid (because of nuclear peripheralization), spindle shaped, oncocytic, squamoid, or squamous, or exhibit bizarre features (so-called anaplastic or giant cell type, not to be equated with bona fide undifferentiated carcinoma).[676,677] The oncocytic variety is particularly treacherous because of its uncanny resemblance to Hürthle cell (oncocytic) neoplasms of follicular cell derivation (Fig. 8.88).[678] The diagnosis of oncocytic medullary carcinoma should be suspected if the oncocytic cells are amphophilic rather than brightly eosinophilic and/or if the tumor is divided into nests by sharply outlined fibrous bands. Other unusual varieties of medullary carcinoma include a true papillary form,[679] a type exhibiting luminal differentiation and/or mucinous features (mucinous or amphicrine medullary carcinoma),[680,681] a clear cell variant,[570] a small cell type resembling the homonymous lung tumor, another small cell type with features resembling neuroblastoma,[682] and a pigmented (melanin-producing) variant.[683,684]

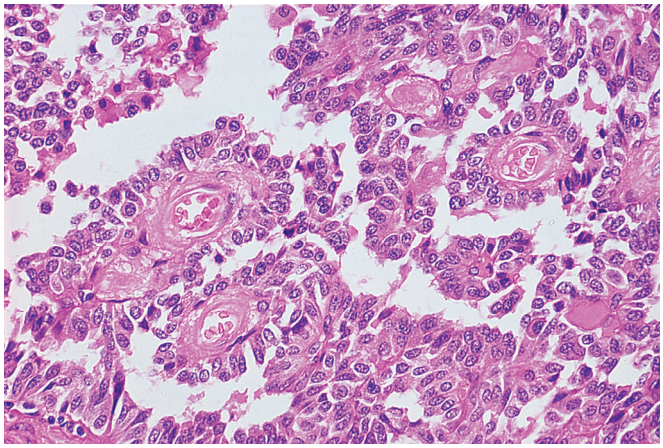

Figure 8.87 Medullary carcinoma with pseudopapillary pattern of growth resulting from lack of cohesiveness of tumor cells.

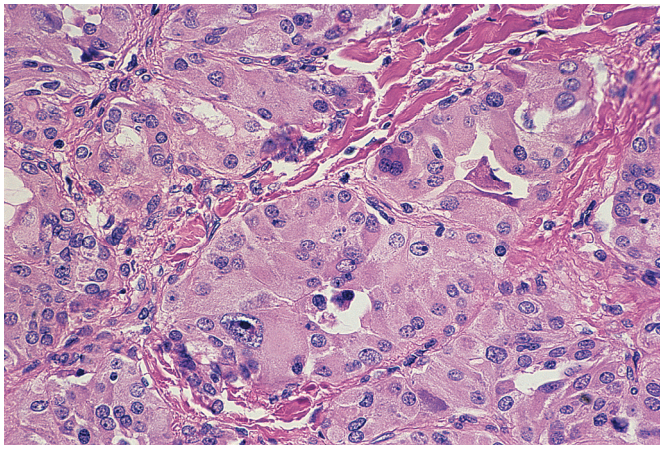

Figure 8.88 Medullary carcinoma of oncocytic type. The appearance closely simulates that of Hürthle cell carcinoma. Clues to the diagnosis are represented by the amphophilic (rather than eosinophilic) staining quality of the cytoplasm and the prominent fibrous septation. This tumor was strongly immunoreactive for calcitonin.

Cytologic Features. In FNA preparations, medullary carcinoma is characterized by eccentric nuclei, salt and pepper (neuroendocrine-type) chromatin, inconspicuous nucleoli, binucleated and multinucleated cells, ill-defined cell borders, and a clean background.[685,686] Amyloid material can be identified in some cases (Fig. 8.89).

Electron Microscopic, Histochemical, and Immunohistochemical Features. Ultrastructurally, cytoplasmic dense-core secretory granules are invariably present. A variability in their sizes has been detected, suggesting the existence of multiple endocrine cell types in this tumor.[687] These granules are usually argyrophilic with the Grimelius stain, especially if the tissue has been fixed in Bouin fluid.[688] Mucin stains are often positive.[689]

Immunohistochemically, the tumor cells are reactive for epithelial markers such as keratin; general thyroid markers such as TTF-1 (although PAX8 is variably expressed and may be negative in medullary carcinoma[690]); panendocrine markers such chromogranin A, B, and C (the latter also known as secretogranin II); synaptophysin; CD56; opioid peptides; and—most important—the specific product of C cells, i.e., calcitonin (Fig. 8.90).[691–694] However, occasional medullary carcinomas display either focal or complete loss of calcitonin expression, a diagnostic pitfall. They are also consistently positive for CEA and negative for thyroglobulin.[695–697] Similar to other neuroendocrine neoplasms, medullary carcinomas have also been reported to express a wide variety of markers, including numerous small peptide products: somatostatin, adrenocorticotropic hormone (ACTH), calcitonin gene–related peptide, serotonin, melanocyte-stimulating hormone (MSH), prostaglandins, bombesin, gastrin-releasing peptide, substance P, L-dopa decarboxylase, histaminase, glucagon, insulin, hCG, the polysialic acid of the neural cell adhesion molecule, galectin-3, hepatocyte growth factor and its receptor, matrix metalloproteinases, prohormone convertases, and progesterone receptors (but virtually no estrogen receptors).[698–715] Accordingly, medullary carcinoma can be associated with various paraneoplastic syndromes, such as Cushing syndrome, depending on the specific hormones produced.[716]

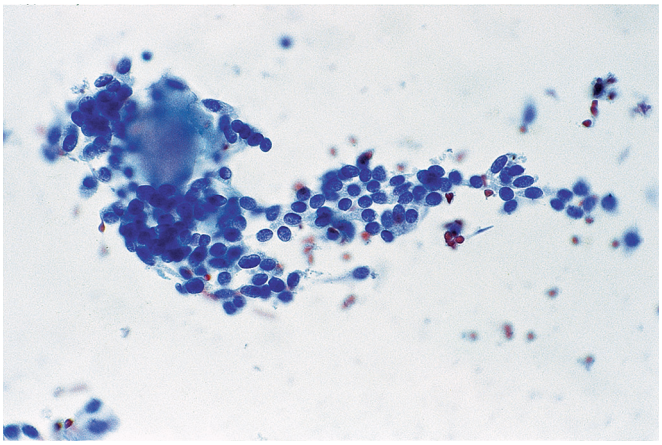

Figure 8.89 Cytologic appearance of medullary carcinoma. The nuclei have clumped chromatin. An amorphous material compatible with amyloid is present.

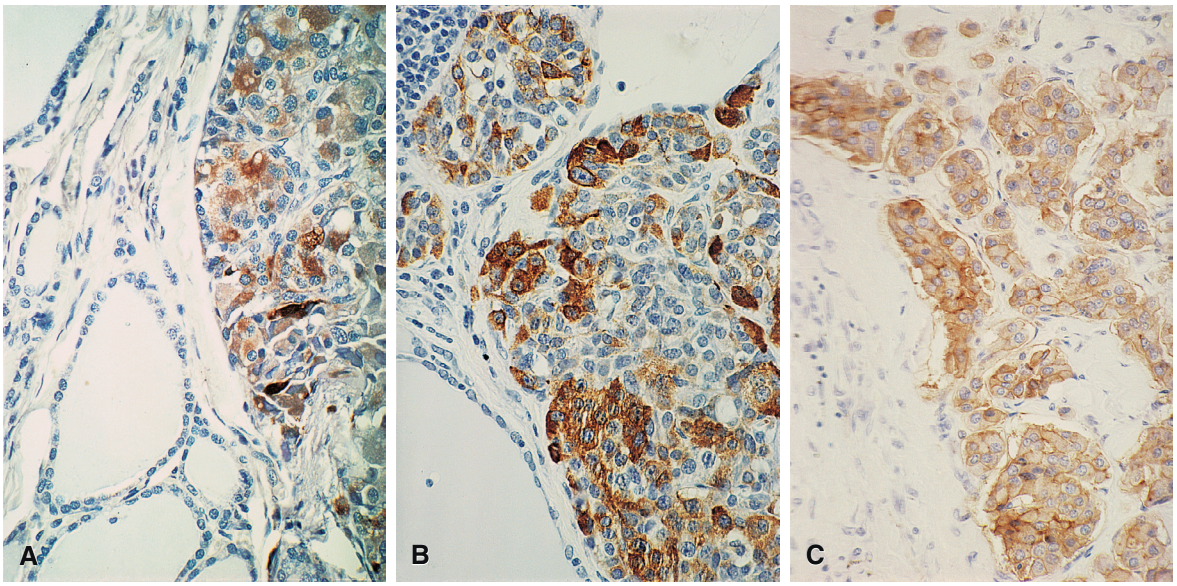

Figure 8.90 Medullary carcinoma showing immunocytochemical positivity for calcitonin (**A**), chromogranin (**B**), and CEA (**C**).

The amyloid of medullary carcinoma reacts with the generic stains for this substance and has a typical microfibrillary appearance ultrastructurally (Fig. 8.91). It also shows reactivity for calcitonin, suggesting that its production may be related to the secretion or degradation of this hormone.[717] Mass spectrometry of medullary carcinoma-related amyloid demonstrates the presence of calcitonin in all cases and secretogranin-1 and calcitonin gene–related peptide in a subset of cases.[718]

Genetics, Hereditary Medullary Carcinoma, and C-cell Hyperplasia. Medullary carcinoma occurs in sporadic and heritable forms. Sporadic medullary carcinoma comprises approximately 70% of the cases, affects adult individuals in their fifth and sixth decades of life (mean age, 45 years), and is almost always solitary.[719] It presents as a thyroid mass that is cold on thyroid scan: in some cases, it is accompanied by intractable diarrhea or Cushing syndrome.[720,721] Only rarely is it clinically occult.[722] Genetically, nonhereditary sporadic medullary carcinoma is characterized by mutations of *RET* in 40%–60% of cases,[723–725] with the *M981T* variant being most common.[723–725] In addition to *RET*, mutations of the *RAS* gene family also occur in a substantial number of cases.[726,727] *RET* and *RAS* family mutations tend to be mutually exclusive, suggesting that these mutations represent alternative drivers for the development of medullary carcinoma.[726] Rare gene fusions involving *RET*[728] and *ALK*[729] have been identified in medullary carcinoma.

Hereditary medullary carcinoma occurs in 30% of patients and follows an autosomal dominant pattern of inheritance with high penetrance, related to germline *RET* mutations. This form of medullary carcinoma becomes clinically apparent in a younger age group (mean age, 35 years), is often multiple and bilateral, and is invariably accompanied by multifocal C-cell hyperplasia in the residual gland. An increasing number of cases are diagnosed when measuring 1 cm or less, i.e., at the stage of medullary microcarcinomas.[730,731] Almost all cases of medullary carcinomas occurring in children belong to this type. Hereditary medullary carcinoma occurs in one of three settings: (1) multiple endocrine neoplasia type 2a (MEN 2A); (2) type 2b (MEN 2B); or (3) familial medullary thyroid carcinoma (FMTC) syndrome.[732–734] In MEN patients, medullary carcinoma is usually the first manifestation of the syndrome.

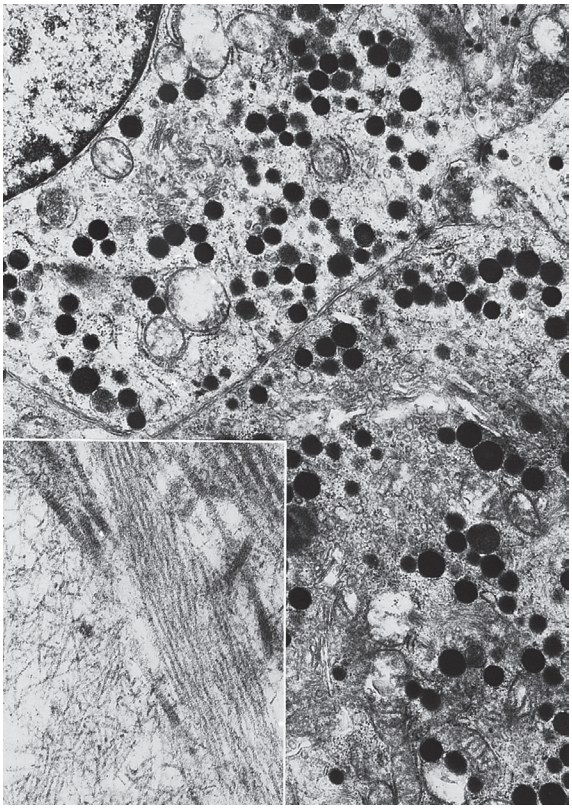

Figure 8.91 Ultrastructural appearance of medullary carcinoma. Portions of two tumor cells show multiple dense secretory granules in the cytoplasm. Each granule is surrounded by a single membrane, and the dense central portion is separated from it by a clear zone. Inset shows both oriented and randomly placed amyloid filaments and may be contrasted with larger banded collagen fibers. (Courtesy of Dr. J.S. Meyer, St Louis.)

The understanding of the genetics of medullary carcinoma has advanced substantially.[735] The gene involved in the development of all forms of inherited medullary carcinoma is *RET*, located on chromosome 10q11.2, which is affected in the form of various activating germline mutations (Table 8.5).[733,736–738] In MEN 2A and FMTC, mutations affect the extracellular cysteine-rich domain of *RET* and are nearly always located on either exons 10 or 11, involving codons 609, 611, 618, 620, 630, 631, or 634 and nearly always involve cysteine residues that are replaced by other amino acids.[733,735] These cysteine residues are normally engaged in intramolecular disulfide bonds in wild-type *RET*. The mutation allows the unpaired cysteine residue in a *RET* monomer to form an aberrant intermolecular disulfide bond with another mutated monomer, causing ligand-independent dimerization and constitutive activation of *RET*.[733,735] In MEN 2A the majority (80% or more) of the mutations are at codon 634, usually in the form of a C634R substitution, not found in FMTC; rare patients with MEN 2A may have mutations in the intracellular tyrosine kinase domain.[733,735] In FMTC the mutations are fairly evenly distributed throughout the various codons of the extracellular domain and in a minority of cases can also be located in the intracellular tyrosine kinase domain (exons 13 and 14).[733,735] In MEN 2B, the *RET* mutations occur in the intracellular tyrosine kinase domain, virtually all of them (>90%) at codon 918 (exon 16) in the form of an *M918T* substitution, the remaining mutations being located at codon 883 (exon 15).[733,735] Mutations in the intracellular tyrosine kinase domain induce structural changes of the catalytic core, causing constitutive activation of the monomeric form of *RET*.[733,735] Given the location of the known clinically relevant mutations, exons 10, 11, 13, 14, 15, and 16 have to be screened in patients with suspected hereditary medullary carcinoma using DNA obtained from peripheral blood samples.[733,739,740]

An important consequence of a heritable medullary carcinoma diagnosis is the need to perform a prophylactic total thyroidectomy in asymptomatic kindreds of patients with hereditary medullary carcinoma that carry germline *RET* mutations, including children.[733] The development of medullary carcinoma is clearly age related, a fact that guides the decision concerning the timing of prophylactic thyroidectomy. Since specific *RET* mutations are related not only to the type of syndrome, but also to the aggressiveness of the medullary carcinoma, *RET* mutations have been stratified into risk levels to guide patient management: level HST, the highest risk category, exemplified by the codon 918 mutation of MEN 2B; level H, the high risk category, exemplified by the codon 634 mutation of MEN 2A; level MOD, the moderate risk category that includes the large majority of mutations.[733,741]

C-cell hyperplasia is the precursor lesion of all these familial syndromes.[742] Its typical location is in the central part of the lateral lobes. It may be diffuse or nodular, and the C cells may be seen in an interfollicular or intrafollicular location. The arbitrary figures of more than six cells per thyroid follicle and/or of greater than 50 intrafollicular calcitonin positive cells in at least one low power field (X100) have been suggested as an indicator of C-cell hyperplasia.[732,743] Because of the extreme difficulty in establishing a clear definition of minimal C-cell hyperplasia based on cell count, it is probably wise to regard the *nodular* form as the only definite precursor for the hereditary type of medullary carcinoma.

As a rule, the hyperplastic C cells exhibit greater CEA immunoreactivity than normal C cells and greater calcitonin immunoreactivity than the cells of medullary carcinoma. The differential diagnosis of this preneoplastic disorder includes on one hand early medullary carcinoma (microcarcinoma) and on the other the reactive or physiologic C-cell hyperplasias that can be seen in a variety of conditions. Medullary carcinoma is recognized because of the nesting expansile pattern with the acquisition of a fibrous stroma, the destruction of the follicular basement membrane, and the diminished intensity of calcitonin immunostaining.[743] Reactive or physiologic C-cell hyperplasias have been described in the immediate periphery of thyroid neoplasms of various microscopic types[744] and in association with lymphocytic thyroiditis[745,746] and secondary hyperparathyroidism.[747] All of these conditions should be distinguished from the normal clusters of C cells seen in relation to solid cell nests.[748]

Patients with thyroid C hyperplasia have elevated serum levels of calcitonin and CEA[741,742]; in addition, patients with medullary carcinoma also have elevated levels of chromogranin A.[749]

Spread and Metastases. Medullary carcinoma invades locally and gives rise to metastases in cervical and mediastinal lymph nodes and also in distant organs, particularly lung, liver, and skeletal system.[750] They are more common in sporadic and MEN 2B-associated tumors than in MEN 2A-associated neoplasms and have been associated with the *M918T* mutation.[733,739,740,751] These metastases may be the first manifestation of the disease and a source of confusion to the pathologist.[752] Microscopically, they tend to resemble the primary tumor and—as a result—usually contain amyloid. The resemblance also applies to their immunohistochemical reactivity, although notable discrepancies occur.[753]

Table 8.5 *RET* point mutations in medullary thyroid carcinoma[a]

RET DOMAIN	*RET* EXON	CODON	MOLECULAR MECHANISM	DISEASE	MEDULLARY CARCINOMA RISK LEVEL[b]
Extracellular cysteine rich	10	609, 611, 618, 620	*RET* dimerization	MEN 2A, FMTC	MOD
Extracellular cysteine rich	11	634	*RET* dimerization	MEN 2A	H
Intracellular tyrosine kinase 1	13	768	Altered substrate specificity	FMTC	MOD
Intracellular tyrosine kinase 1	14	804	Altered substrate specificity	FMTC	MOD
Intracellular tyrosine kinase 2	15	883	Altered substrate specificity	MEN 2B	H
Intracellular tyrosine kinase 2	16	918	Altered substrate specificity	MEN 2B, sporadic medullary carcinoma	HST

[a]The most frequently mutated *RET* codons are reported.
[b]Risk of aggressive medullary carcinoma: MOD, moderate risk; H, high risk; HST, highest risk.
Modified from de Groot JW, Links TP, Plukker JT, Lips CJ, Hofstra RM. RET as a diagnostic and therapeutic target in sporadic and hereditary endocrine tumors. *Endocr Rev*. 2006;27:535–560.

Treatment and Prognosis. The primary treatment of medullary carcinoma is surgical, in the form of total thyroidectomy (particularly important for the familial form because of the multicentricity and C-cell hyperplasia) and cervical lymphadenectomy.[741] Local recurrence supervenes in approximately 35% of patients, and the 5-year survival rate varies between 70% and 80%.[671,754,755] The tumor is not particularly responsive to radioactive iodine, external radiation therapy, or chemotherapy. Several tyrosine kinase inhibitors have recently been approved[756–758] with some success.

Stage of disease and age at diagnosis are the strongest predictors of survival of all medullary carcinoma patients.[719,741,759,760] Indeed, small medullary carcinomas found in prophylactic thyroidectomies are associated with an excellent prognosis.[761] Good prognostic factors are young age, female sex, occurrence in a familial setting, tumor size, and tumor confinement to the gland.[671,741,755,762,763] Microscopically, a greater degree of aggressiveness should be expected of tumors with high mitotic activity, necrosis, squamous pattern, associated with desmoplastic reaction,[764] and/or of the small cell type.[765] It has been claimed that poor immunohistochemical reactivity for calcitonin can serve as a marker of the degree of tumor differentiation and is an indicator of poor prognosis, particularly if coupled with increased reactivity for CEA.[741,765–768]

Other Neuroendocrine Tumors

Medullary (C-cell) adenoma has been suggested as a diagnosis for the rare totally encapsulated forms of C-cell tumors, but they should be regarded as encapsulated variants of medullary carcinomas.[769] The differential diagnosis includes hyalinizing trabecular carcinoma.[770]

Mixed medullary–follicular carcinoma is an extremely rare tumor in which the morphologic features of medullary carcinoma (together with immunoreactivity for calcitonin) coexist with those of a follicular neoplasm (together with immunoreactivity for thyroglobulin).[771,772] Some of the reported cases have been familial.[773] Initial skepticism notwithstanding, sufficient evidence has been advanced to validate the existence of this entity,[774–776] with the added perplexing observation that the two components do not seem to be derived from a single progenitor cell.[777] In any event, it should be kept in mind that most cases in which the diagnosis of mixed medullary–follicular carcinoma has been entertained represent either medullary carcinomas with entrapped follicles and/or secondary incorporation of thyroglobulin by the medullary carcinoma cells or medullary carcinomas with a glandular (tubular and follicular) pattern of growth.

Mixed medullary–papillary carcinoma represents the even more unusual combination of calcitonin-positive medullary carcinoma and thyroglobulin-positive papillary carcinoma, the latter areas having typical ground-glass nuclei.[778–780] This should be distinguished from the more common event of separate medullary and papillary carcinomas in the same gland, which may collide with each other,[781] and the even more bizarre phenomenon of a mixed medullary–follicular carcinoma colliding with a papillary carcinoma.[782]

Paraganglioma can occur adjacent to or within the thyroid, sometimes in association with carotid body tumors.[783–786] The differential diagnosis with medullary carcinoma and follicular adenoma can be very difficult, particularly with the former (Fig. 8.92). Paraganglioma reacts immunohistochemically for panendocrine markers such as chromogranin and opioid peptides but is negative for calcitonin, thyroglobulin, TTF-1, PAX8, and keratin. A particularly useful (although neither constant nor pathognomonic) feature is the presence of S-100 protein–positive sustentacular cells at the periphery of the "Zellballen" (Fig. 8.93).[787] Practically all of the reported cases have been cured by surgical excision.[788,789]

Small cell (neuroendocrine) carcinoma morphologically identical to the homonymous lung tumor has been described in the thyroid. Some of these tumors are calcitonin positive and are therefore regarded as small cell variants of medullary carcinoma. Those that are calcitonin negative probably represent the most undifferentiated members of the spectrum[790]; their behavior is extremely aggressive.[791]

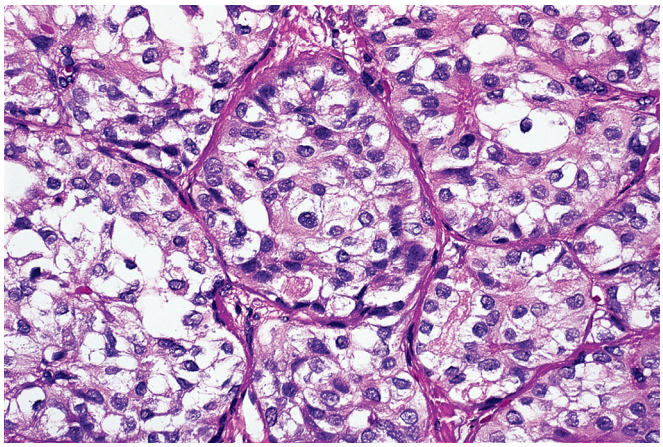

Figure 8.92 Thyroid paraganglioma showing well-formed "Zellballen."

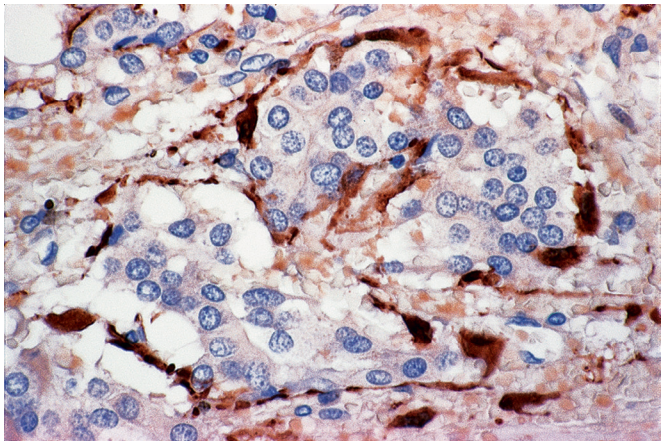

Figure 8.93 S-100 protein–positive sustentacular cells at the periphery of the "Zellballen" in paraganglioma of thyroid.

Neuroendocrine tumors of various types (such as carcinoid tumors of larynx and lung) can invade or metastasize to the thyroid gland and simulate a medullary carcinoma.[792,793] Immunohistochemistry will be of great diagnostic help in the differential diagnosis, with the caveat of TTF-1 immunoreactivity in pulmonary neuroendocrine tumors (and in some cases of extra-pulmonary neuroendocrine carcinomas).[792,793]

Epithelial Tumors—General Features

Geographic Distribution

Most series have shown a statistical correlation between iodine deficiency and an increased incidence of thyroid carcinoma of both follicular and undifferentiated types.[794–800] Because of difficulties in clinical detection related to the background disease, the tumors tend to be more advanced at the time of diagnosis than in nonendemic areas.[801,802] Introduction of iodized salt in iodine-deficient areas can reduce the incidence of some types of thyroid cancer, especially follicular and anaplastic.[803,804]

Papillary carcinoma is the predominant type in areas without iodine deficiency,[802,804] and its frequency is said to be increased in regions with high iodine uptake.[804,805] Developed countries in the

Western and the Eastern Hemispheres appear to have a similar incidence of the major histologic types of thyroid carcinoma.[806]

Thyroid Neoplasia in Childhood

Most thyroid tumors developing in childhood are benign and are examples of either follicular adenoma or nodular hyperplasia. However, the proportion of carcinomas is much higher than that seen in adults, to the point of surpassing the benign processes in some series. Among the malignancies, papillary carcinoma comprises the overwhelming majority of the cases, followed by the hereditary form of medullary carcinoma and Hürthle cell neoplasms.[454,807] In older series there is also an important representation of follicular carcinomas, but most of those would probably be regarded at present as follicular variants of papillary carcinomas.[808,809] *RET/PTC*, NTRK1, and NTRK3 rearrangements are common in papillary carcinoma arising in children and young adults, while activating *BRAF* mutations are relatively uncommon.[306,317,810] Poorly differentiated carcinomas are very rare in this age group, and undifferentiated carcinomas are practically nonexistent.

The papillary carcinomas occurring in children tend to have extensive solid and/or squamous areas and are associated with a high frequency of cervical node metastases.[317,454,811,812] The overall prognosis is excellent, but occasional aggressive and even lethal cases are on record.[317,454,813] Some of these children have a history of previous radiation exposure to the neck (see next section).[814]

Thyroid Neoplasia and Radiation Exposure

Exposure of the thyroid gland to low-dose therapeutic radiation (administered for thymic enlargement, tonsillar hypertrophy, or acne to approximately one million patients in the United States during the early part of the twentieth century) can result in a number of abnormalities later in life.[815] The most common of them are of a benign nature—a fact to remember—and consist of nodular hyperplasia, lymphocytic thyroiditis, and fibrosis.[155,816,817] However, there is also an unquestionable increase in the incidence of carcinoma in this population, the large majority of the tumors being of the papillary type.[818,819] Of patients in this population who have thyroid operations, the incidence of carcinoma ranges from 20% to over 50%.[820,821]

Parenthetically, tumors from other structures of the neck can also develop in individuals with radiation exposure to the area; these include salivary gland, parathyroid, osseous, and neural neoplasms.[822,823] This obviously indicates the need for a continuous surveillance of this population.

High-dose radiation to the neck region, such as that administered for Hodgkin lymphoma, can also result in thyroid carcinoma and other abnormalities of the gland.[459,824,825] There is also conclusive evidence that thyroid carcinoma, dominated by the papillary type,[826] occurs with a much increased incidence in populations accidentally exposed to high radiation doses, such as that resulting from the nuclear accident of Chernobyl in 1986.[309,827–829] The Chernobyl accident exposed residents to high doses of internal radiation due to radioactive iodine, and the health effects related to this exposure have been extensively studied.[309,830,831] Regarding the thyroid gland, it is very clear that there is substantial increased risk of developing thyroid cancer in the Chernobyl population, with children under 15 being especially susceptible.[832–834] A very interesting pattern has emerged from the analysis of these cases.[826,835] Short latent period tumors have a significantly higher proportion of *architecturally less differentiated components* (solid and trabecular) and are more aggressive than long latent period tumors,[309] suggesting that successive waves of carcinoma have occurred in the exposed population. On the other hand, the *type* of differentiation is linked to age at exposure rather than to the latent period, in the sense that a follicular pattern is more common in children exposed at a young age, and a papillary pattern is more frequent in children exposed at a later age.[836] Fortunately, the outcome of children and adolescents in Belarus with post-Chernobyl papillary carcinoma has been favorable.[837]

The Chernobyl nuclear accident has provided insights into the pathogenesis of radiation-induced thyroid cancer. Consistent with a molecular model in which ionizing radiation induces double-stranded DNA breaks, which then leads to chromosomal rearrangements and translocations,[838] these thyroid cancers are highly enriched for oncogenic gene fusions, especially *RET/PTC* and *ETV6/NTRK3* rearrangements.[203,315] *RET/PTC* has been identified in up to 60%–80% of papillary carcinoma from patients exposed to radiation.[203,309,839] The frequency with which *RET* fusion partners (e.g., *CCDC6*) juxtapose in interphase thyrocyte nuclei is likely to predispose the DNA to the rearrangement.[840] In fact, rearrangements other than *RET/PTC1*, *RET/PTC2*, or *RET/PTC3* are enriched in radiation-induced tumors, although the TCGA study identified a variety of gene fusions in papillary carcinoma without a radiation history.[292] In papillary carcinomas that developed after radiation exposure following the Chernobyl accident, *RET/PTC3* has been associated with tumors that arose with shorter latency, in the most heavily contaminated regions and that were more aggressive (larger tumor size, higher stage, solid architecture).[309] Point mutations of *BRAF* and *RAS* are relatively uncommon among radiation associated tumors.[203,315]

The Fukushima nuclear accident in Japan in 2011 has sadly provided another opportunity to learn about radiation-induced thyroid cancer.[320,841,842] Similar to Chernobyl tumors, novel gene fusions involving *RET* and *NTRK3* have been identified.[329] More time and study will be needed to fully evaluate the health impact of this accident on the exposed residents of this region, although there is hope that lower doses of radioactive iodine, compared to Chernobyl, will prevent an excess risk for the development of thyroid cancer.[843,844]

Familial Incidence and Association With Other Conditions

Approximately 3%–9% of thyroid carcinomas of *nonmedullary* type (particularly of the papillary variety) develop in a familial setting.[845–848] Familial nonmedullary thyroid cancer (FNMTC) has been divided into two groups. **Syndromic FNMTC**, in which there is a predominance of nonthyroid tumors and well-defined germline driver mutations, includes familial adenomatous polyposis (including Gardner syndrome), Cowden/PTEN hamartoma tumor syndrome, Carney complex type I, McCune–Albright syndrome, Werner syndrome (adult progeria), MEN type 1, and DICER1 syndrome.[849–855] As already indicated, the thyroid tumors developing in patients with colonic polyposis/Gardner syndrome have a distinctive cribriform-morular appearance.[425,856] **Non-syndromic FNMTC**, in which there is a predominance of thyroid tumors, includes pure familial papillary carcinoma (fPTC) with or without oncocytic features, fPTC with papillary renal cell carcinoma, and fPTC with nodular hyperplasia.[487,848,857] The genetics of non-syndromic FNMTC is less clear. Studies of families with FNMTC have identified numerous associated chromosomal loci, as well as 4 distinct susceptibility genes (*SRGAP1*, *TITF-1/NKX2.1*, *FOXE1*, and *HABP2*).[487,848] None of these genetic susceptibility markers have been implemented in routine clinical practice. Papillary carcinoma has also been reported in patients with ataxia–telangiectasia[858] and acromegaly[859] and in association with parathyroid tumors[860] and paragangliomas of the carotid body.

Evaluation of the Solitary Thyroid Nodule

The most common thyroid problem facing the surgeon and the pathologist is the evaluation of the patient with an apparently single

thyroid mass.[197,861–863] The magnitude of the problem is obvious from the fact that approximately 4% of the population of the United States between the ages of 30 and 60 years have one or more palpable nodules. Using ultrasound examination, this number approaches 50% of adults. These are four times more common in females than in males. Because the majority of these nodules are benign and most are hyperplastic, the goal is to be selective in the cases taken to surgery while at the same time including most of the carcinomas in this group. Factors to consider when making this difficult selection process are the following[863]:

1. Age. The incidence of malignancy is higher in children and the elderly than in young or middle-aged adults.[864,865]
2. Sex. The incidence of malignancy is higher in males.[864]
3. History of familial thyroid cancer (see earlier).
4. Hashimoto thyroiditis. The likelihood of malignancy for a nodule present in Hashimoto thyroiditis is roughly the same as for that occurring in a normal gland.
5. History of radiation. The likelihood of malignancy is higher if there is a history of irradiation to the neck in infancy[865] or total body radiation flowing bone marrow transplantation.[866]
6. Presence of hoarseness and/or vocal cord paralysis.
7. Number. Solitary nodules are more likely to be malignant than multiple ones. It should be kept in mind, however, that approximately one-third of the nodules thought to be solitary on palpation are shown to be multiple on scan and an even higher number on pathologic examination.
8. Rate of nodule growth. Rapid nodule growth is concerning for carcinoma. Most adenomas are very slow growing, but this is also true for most papillary or minimally invasive follicular carcinomas. Rapid enlargement of a longstanding nodule may signify an undifferentiated (anaplastic) transformation or simply the development of hemorrhage within the nodule. Assessment of growth in follow-up of benign nodules has limited ability to predict malignant transformation.[862,867]
9. Cervical lymphadenopathy. This is the strongest clinical indicator of malignancy if present.
10. Thyroid function, including measurement of serum TSH. Nodules that are hyperfunctioning ("toxic") at the clinical level and/or hot on thyroid scintiscan are much less likely to be malignant than the others.
11. Ultrasonography. Cystic and spongiform nodules are less likely to be malignant than solid ones.[868,869]
12. Needle biopsy. In experienced hands, this technique provides the best means of determining the likelihood of malignancy of a thyroid nodule short of surgical excision and pathologic examination (see later section).[870–872]
13. Molecular testing (see later section).

To put these various criteria in perspective, it should be mentioned that even when the nodule is solitary, solid, and cold on scintiscan, it will prove malignant in no more than 10%–20% of the cases and that as many as one-third of the thyroid nodules disappear spontaneously if left untreated.[862,873]

Core Needle Biopsy and Fine-Needle Aspiration (FNA)

Core needle biopsy has been used extensively in a few institutions in the United States and abroad but has failed to gain widespread acceptance.[874] It is particularly helpful in diffuse diseases such as Hashimoto thyroiditis and in confirming the diagnosis of an advanced malignant neoplasm.[875] Most authors have been reluctant to use this technique in the evaluation of the single thyroid nodule not only because of the small but definite risk of complications (bleeding, nerve injury, tracheal perforation, tumor implantation),[876] but also because of the fact that the differential diagnosis between a benign and malignant follicular neoplasm is usually impossible due to the inability of to assess the presence of capsular and lymphovascular invasion on biopsy.[863]

FNA has become instead the gold standard technique for the evaluation of solitary thyroid nodules. Its appeal is obvious: it is quick and inexpensive, it can be carried out in the physician's office, and the risk of complications (including tumor implantation) is minimal.[863,877–880] Furthermore, FNA-derived material is suitable for immunohistochemical and molecular evaluation.[881–883] Published results claim a sensitivity and specificity of over 90%, leading some authors to recommend FNA as the initial test in the evaluation of any thyroid nodule.[863,884–887] Most papillary carcinomas and other types of malignancy other than follicular carcinoma can be identified with ease.[888–891] The same is true for the various types of thyroiditis.[892] The main difficulty, as in the case of core needle biopsy, resides in the identification of follicular carcinoma.[863,893,894]

To standardize the approach and terminology of thyroid FNA procedure, the National Cancer Institute hosted in 2007 the NCI Thyroid FNA State of the Science Conference, which led to the Bethesda Thyroid Atlas Project and constituted the framework for the Bethesda System for Reporting Thyroid Cytopathology.[895] This document recommends that each FNA report begin with one of six diagnostic categories. The categories imply an estimated risk of malignancy and a recommended clinical management. Over the past decade the diagnostic value of the Bethesda system has been clearly demonstrated.[896,897]

The performance of FNA may result in partial or complete infarction of the tumor, with only a thin rim of tissue preserved at the periphery[898]; this complication is particularly common with Hürthle cell tumors and may result in transient elevation of the serum levels of thyroglobulin.[899] Hemorrhage and thrombosis can also develop, with the secondary organization and recanalization sometimes leading to pseudoangiosarcomatous papillary endothelial hyperplastic changes.[898,900] Another complication of the procedure when carried out in cystic lesions has been the development of transient thyrotoxicosis.[901]

Molecular Testing of Fine-Needle Aspiration Specimens

The last decade has witnessed the development of various molecular tests for the diagnostic evaluation of thyroid nodules using cells derived from FNA. The primary goal of such testing is to identify benign nodules that do not require surgical resection, or alternatively, to identify those nodules that are indeed cancerous and do require surgery. According to current American Thyroid Association (ATA) Guidelines, molecular testing of thyroid nodules should be performed in a Clinical Laboratory Improvement Amendments (CLIA)/College of American Pathologists (CLIA/CAP)-certified laboratory and may be considered for nodules with indeterminate FNA results.[863] The implementation of molecular testing currently varies substantially between treatment centers.

A gene expression classifier (GEC) based on the expression of 167 genes has been demonstrated to preoperatively identify benign thyroid nodules[902] and has reduced surgery for benign disease,[903,904] although the clinical utility and performance of the GEC varies across different centers.[867,905,906]

An alternative approach to molecular testing of thyroid nodules is to directly identify the driving mutations present in a given nodule. Recent advances in molecular diagnostics and next-generation DNA sequencing have made this approach feasible and robust. The ThyroSeq assay developed at the University of Pittsburgh represents the prototypical assay of this type,[562,907,908] although several commercial forms are also available. This approach has also been applied to sporadic pediatric nodules, with increased sensitivity compared to

routine molecular diagnostic testing.[909] Evaluations of ThryoSeq performance to date are encouraging,[910] although one of the issues that impacts the performance of all of these molecular tests is the diagnostic threshold of the surgical pathologist, specifically in regard to the diagnosis of the follicular variant of papillary carcinoma. As these tumors are enriched for *RAS* family mutations, the performance of molecular testing is negatively impacted by pathologists who favor benign diagnoses when faced with a follicular-patterned tumor with equivocal diagnostic features.

Frozen Section

The pathologist is often asked to perform a frozen section at the time of exploration of a thyroid mass,[911,912] although with decreasing frequency due to a combination of factors. The specimen may be from an area of extrathyroidal invasion by carcinoma or from a metastatic cervical node. In these instances, the diagnosis is usually obvious, although Riedel thyroiditis, extrathyroidal growth in diffuse hyperplasia, and sequestered thyroid nodule (see next section) represent important diagnostic pitfalls.[913] The most common specimen received for frozen section is a lobectomy carried out because of a nodule. A few of these will be found to be examples of granulomatous thyroiditis, Hashimoto thyroiditis, or malignant lymphoma, each of which may manifest as an apparently single nodule on physical examination. However, in the majority of cases the differential diagnosis will be between a dominant nodule of nodular hyperplasia, adenoma, and carcinoma.[914] An experienced pathologist should have no problem in identifying most cases of undifferentiated carcinomas, poorly differentiated carcinomas, widely invasive follicular carcinomas, conventional papillary carcinomas, or medullary carcinomas. The most difficult problem resides in the distinction between a dominant nodule of nodular hyperplasia, follicular adenoma, minimally invasive follicular carcinoma, and the variant of papillary carcinoma that is both follicular and encapsulated. These considerations also apply to the encapsulated Hürthle cell neoplasms. Capsular and/or blood vessel invasion is typically not evident in the samples chosen for frozen sections but become apparent later in the more thorough sampling of permanent sections.[915–917] The ground-glass nuclear feature that is one of the most distinctive features of papillary carcinoma may not show up at all in the frozen section. For these reasons, the surgeon should accept the fact that a large percentage of well-differentiated carcinomas will not be identifiable on frozen section examination regardless of the experience and diagnostic acumen of the pathologist. Accordingly, many frozen sections are "deferred to permanent sections." This apparent deficiency does not create serious therapeutic problems because, in our opinion, most if not all of the lesions listed in this paragraph are effectively treated by lobectomy or—at the most—subtotal thyroidectomy.

With the increase in popularity in the performance of FNAs, the number of cases in which the surgical planning depends on frozen section results has diminished considerably.[246,918–921] LiVolsi and Baloch have pointed out that frozen sections are most useful in lesions interpreted by FNA as "suspicious for papillary carcinoma" rather than for those diagnosed as "diagnostic of papillary carcinoma," "follicular neoplasm," or Hürthle cell neoplasm."[922] Some centers have instituted expedited routine pathology in lieu of frozen section.[923] Other centers use frozen section to assess extrathyroidal extension.[924] Parenthetically, the performance of a cytologic preparation at the time of the frozen section has proven to be a very useful diagnostic adjunct.[925]

Presence of Thyroid Tissue Outside Gland

There are several circumstances in which normal or abnormal thyroid tissue may be found in the neck outside the confines of the thyroid gland:

1. Ectopic thyroid tissue resulting from faulty embryogenesis. Thyroglossal duct cyst and lingual thyroid are the most common examples.
2. Hyperplastic thyroid tissue outside the gland in Graves disease.
3. Mechanical implantation of thyroid tissue in the neck as a result of surgical intervention or accidental trauma. In the former instance, suture material may be seen adjacent to the thyroid tissue.
4. So-called sequestered thyroid nodule. This phenomenon, also known as parasitic or accessory nodule, refers to the occurrence of a peripherally located thyroid nodule in which either the anatomic connection with the main gland is lost or this connection is missed by the surgeon,[926] the process being probably analogous to that of parasitic uterine leiomyoma.[927,928] The nodule is usually an expression of nodular hyperplasia or nodular Hashimoto thyroiditis, less commonly of diffuse hyperplasia (Graves disease).[929] The diagnosis requires that the tissue reside in the same fascial plane as the thyroid gland, that it be unassociated with lymph nodes, and that it exhibit the same or similar histologic appearance as the main gland, whenever the latter is available. Sequestration also occurs (and may actually be more common) in thyroid nodular hyperplasia located in the mediastinum. The fact that the sequestered nodule is subject to the same morphologic alterations as the main gland may lead to significant interpretive problems in Hashimoto thyroiditis, in which the combination of nuclear atypia (as part of the oncocytic alteration) and heavy lymphoid infiltration (as part of the thyroiditis) may result in an appearance closely simulating a lymph nodal structure containing metastatic tumor (Fig. 8.94).
5. Thyroid tissue within cervical lymph nodes. The determination of the significance of this finding in the presence of an apparently normal thyroid gland can be a very difficult exercise. This phenomenon accounts for most cases of the condition formerly called lateral aberrant thyroid.[930] It is now generally accepted that this may be the result of two unrelated processes and that microscopic examination permits their separation in the majority of the instances.[931]

   The majority of cases represent metastases of clinically undetected thyroid carcinomas, nearly always of the papillary variety. It should be emphasized that detection of the primary neoplasm may require extremely careful microscopic study with embedding of the entire thyroid gland and cutting of the blocks at various levels.[932] The metastatic deposits may replace most of the node, although a peripheral rim of residual lymphoid tissue can usually be found. Secondary cystic changes can be so prominent as to simulate the appearance of a branchial cleft cyst (see Fig. 8.58). The smaller foci of metastatic tumor are frequently located within sinuses. The pattern of growth may be so well differentiated as to simulate normal thyroid tissue. However, close inspection will usually reveal the presence of one or more of the cytoarchitectural features of papillary carcinoma, such as small papillae, psammoma bodies, follicles with darkly staining colloid, and the characteristic nuclear changes of this tumor type. The second situation is the occurrence of normal follicles within nodes, a concept that was originally proposed by Frantz et al.[930] and that some authors still have difficulty in accepting. The best evidence in its favor is the study performed by Meyer and Steinberg.[933] These authors serially sectioned cervical lymph nodes from 106 autopsies and found thyroid tissue in five of them. Serial section of the whole thyroid gland in these cases failed to reveal carcinoma, except for a probably unrelated microscopic papillary carcinoma in the contralateral lobe of one case. In these instances, the ectopic thyroid tissue typically presents as a small conglomerate of follicles lacking all the attributes

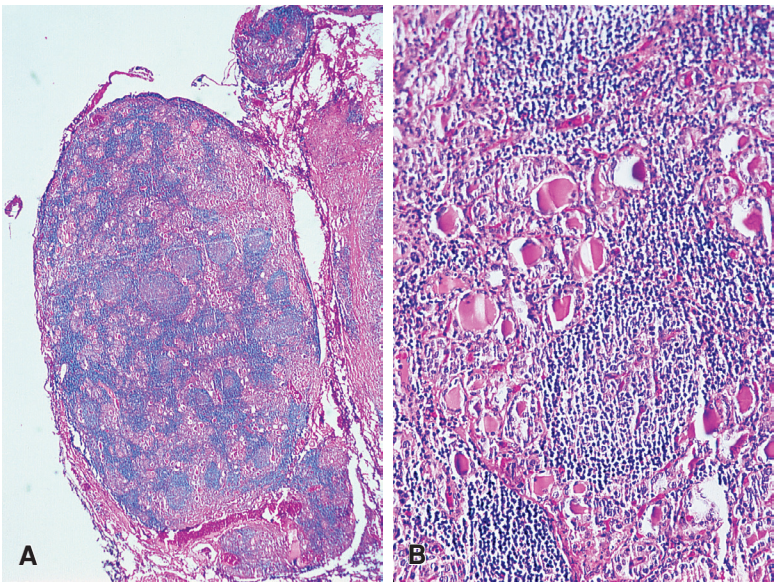

Figure 8.94 **A** and **B,** So-called sequestered (parasitic) thyroid nodule occurring in association with a gland involved by Hashimoto thyroiditis. The combination of oxyphilic change and germinal center formation in the sequestered nodule results in an appearance that can be confused with thyroid carcinoma metastatic to a lymph node.

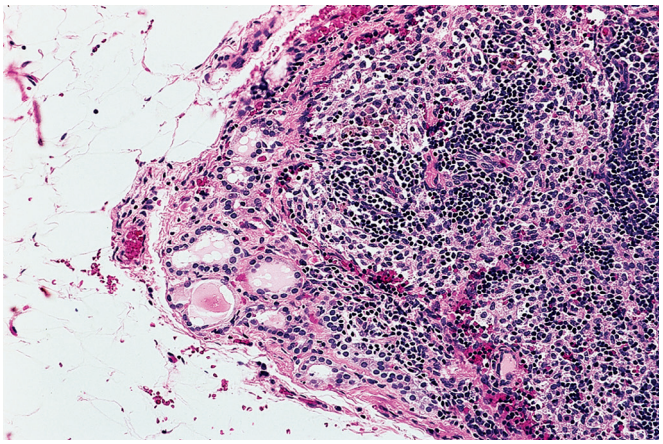

Figure 8.95 Ectopic thyroid follicles in lymph node. The follicles are scanty, centered in the lymph node capsule, and devoid of structural and cytologic abnormalities.

of papillary carcinoma and limited to the periphery of one or two nodes (Fig. 8.95). Any thyroid tissue replacing most of the node and/or involving several nodes is most likely metastatic carcinoma.

A point worth making, despite its apparent obviousness, is that not all metastatic papillary carcinomas with psammoma bodies in a cervical lymph node originate in the thyroid. Cases are on record in which a thoroughly studied specimen of total thyroidectomy failed to reveal tumor in the gland.[934] The possibility of the carcinoma being extrathyroidal (e.g., salivary gland, lung, ovary, and even thymus) should be particularly considered for those tumors lacking the classic nuclear features of papillary carcinoma and devoid of thyroglobulin immunoreactivity.

6. Thyroid as a component of teratoma. Thyroid tissue may be seen as one of the many components of teratoma, particularly those located in the ovary. This thyroid tissue may appear normal, hyperplastic, or—exceptionally—neoplastic. Ovarian teratomas composed predominantly or exclusively of thyroid tissue are referred to as *struma ovarii*. Before accepting any tissue located in an unusual place as representing thyroid, one should keep in mind that a thyroid-like appearance can result from cystically dilated glands of one type or another whenever their epithelium flattens and the intraluminal secretion inspissates.[935] Struma ovarii should also be distinguished from the exceptional thyroid carcinoma that metastasizes to the ovary.[936]

Treatment

The management of thyroid cancer is constantly evolving and thus can be highly variable and controversial.[937,938] The mainstay of treatment of most types of thyroid tumors is primarily surgical. In cases in which the nodule is limited to one lobe, lobectomy (with or without isthmusectomy) is usually done as the first approach, with subsequent therapy depending on the nature of the nodule. Nodulectomy is not an accepted form of therapy for these lesions. Lobectomy or total thyroidectomy is standard of care, depending on the specifics of the pathology, overall assessment of the risk for structural disease recurrence and the desire for treatment with radioiodine.[863] It should be noted that some centers of excellence use active surveillance for select patients with small papillary carcinomas.[939]

The use of radioactive iodine varies considerably across institutions based on a variety of factors.[940] Patient selection and the overall efficacy of radioactive iodine continues to be debated topics.[941] Several targeted therapies for differentiated thyroid cancer have been recently approved.[942,943]

Prognosis

Most of the clinical and pathologic factors that relate to prognosis have been discussed with the specific tumor types. In general terms, the most important are the patient's age (very significant), patient's sex (less so), tumor microscopic type, tumor microscopic grade (to a large extent already included in the microscopic typing), and tumor stage.[944–948] These and other factors have been sometimes combined in rather complex prognostic indices.[492,949,950] Cady et al.[492] grouped

their patients with well-differentiated (papillary or follicular) carcinomas into two categories having strikingly different survival rates: low risk (comprising men under 40 years of age and women under 50 years) and high risk (the others). These findings have been confirmed. For papillary carcinomas Carcangiu et al. found that the prognostic difference is even more striking if the low-risk group includes women 60 years and under.[248] The large majority of deaths from thyroid carcinomas result from undifferentiated, poorly differentiated, Hürthle cell, and medullary tumors. It should be realized that, in many series, several of these tumor types are included among the follicular carcinomas.[951] Conversely, encapsulated well-differentiated follicular-patterned thyroid carcinomas do not play a significant role in the fatality rates from thyroid carcinoma (or, for that matter, their morbidity).[384]

AJCC/UICC TNM staging and diagnostic algorithms (e.g. AGES, patient age, presence of distant metastases, extent and size of the primary tumor; MACIS, metastasis, patient age, completeness of resection, local invasion, and tumor size) adequately predict the risk of tumor related death, but are not designed to predict that of recurrence.[863] The American Thyroid Association (ATA) has developed a three-tiered risk stratification system that groups patients into *low*, *intermediate*, or *high risk* of recurrence based on a series of clinicopathologic parameters that include aggressive histologic types or subtypes of thyroid carcinoma (e.g., tall cell papillary carcinoma), extent of vascular invasion, of extrathyroidal extension, of metastatic disease to the cervical lymph nodes.[863] According to ATA thyroid cancer guidelines initial recurrence risk estimates should be modified during follow-up (dynamic risk stratification), since the risk of recurrence and disease-specific mortality may change over time as a function of the clinical course and the response to therapy. A uniform set of criteria has been proposed to assess response to therapy that groups patients as having: *Excellent response* (no clinical, biochemical, or structural evidence of disease); *Biochemical incomplete response* (abnormal thyroglobulin values or rising anti-thyroglobulin antibodies in the absence of localizable disease); *Structural incomplete response* (persistent or newly identified loco-regional or distant metastases); and *Indeterminate response* (nonspecific biochemical or structural findings that cannot be confidently classified as either benign or malignant).[863]

The tumor mutational profile may add useful prognostic information.[303,339] *TERT* promoter mutations have been associated with aggressive features and unfavorable outcome in differentiated thyroid carcinoma, independent of other clinicopathologic parameters.[348,350,351,412] Inactivating *TP53* mutations have long been known to be a marker for poorly and undifferentiated thyroid carcinomas.[339,632] *BRAF* p.V600E has been associated with decreased iodide uptake, increased risk of recurrence, and poor outcome in papillary carcinoma,[331,332,338,952,953] but the overall prognostic relevance of the mutation may be relatively limited when other factors (e.g. stage, papillary carcinoma variant) are taken into account.[303,334,339] The probability of aggressive behavior is higher in cases that harbor more than one of the mutations known to be relevant for thyroid carcinoma: for instance, the co-occurrence of *BRAF* p.V600E with *TERT* promoter, *PIK3CA* or *TP53* mutations may be an important sign of poor prognosis.[210,347,349,664,952]

Lymphoid Tumors and Tumorlike Conditions

Most cases of primary **malignant lymphoma** of the thyroid are seen in adult or elderly females.[954,955] The thyroid enlargement is often rapid and can lead to symptoms of tracheal or laryngeal compression.[956,957] Most patients are euthyroid, and the tumor presents as one or more cold nodules on thyroid scan.[958] Grossly, the tumor shows a solid white cut surface with a fish-flesh appearance.

Microscopically, the majority of the cases are of *diffuse large B-cell* type (Fig. 8.96).[955,956,959] Sclerosis may be focally prominent. The second largest category is that of the low-grade lymphomas composed of small or "intermediate" lymphocytes, having either a diffuse or a nodular (follicular) pattern of growth.[960,961] Many of these tumors exhibit focal plasmacytoid features,[962] and a few are composed of signet ring cells.[963] It has been proposed that both of these major thyroid lymphoma types belong to the *MALT-type* category ("marginal zone B-cell lymphomas"), despite a follicular architecture in approximately one-fourth of the cases. This architecture is thought to be the result of colonization of the follicles by the tumor cells.[955,960,961,964] This is supported by the fact that large cell lymphomas often show an associated low-grade MALT-type component,[955,965] and that some show a marginal zone

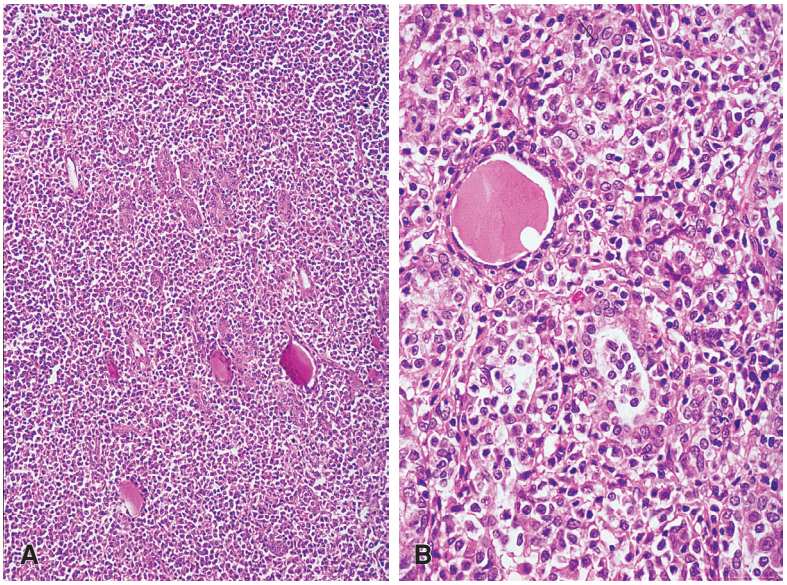

Figure 8.96 Malignant lymphoma of thyroid. **A,** Low-power view showing a diffuse pattern of growth. **B,** Medium-power view showing tumor cells surrounding lymphoid follicles. One of the follicles shows "packing' of the lumen by lymphoid cells, a feature of diagnostic significance.

distribution of the tumor cells.[966] An important diagnostic finding is the packing of follicular lumina by lymphoid cells ("lymphoepithelial lesions"), a feature usually not present in thyroiditis.[955,962]

True *follicular lymphomas* of the thyroid are very rare; interestingly, most of them contain lymphoepithelial lesions similar to those seen in MALT-type lymphomas. Two distinct types have been described, the most common being almost always associated with extrathyroidal disease.[961,967]

Immunohistochemically, all types of thyroid lymphomas exhibit consistent positivity for CD45, and nearly all of them show markers indicative of B-cell derivation,[955,968,969] whereas primary thyroid T-cell lymphomas are vanishingly rare.[970] The differential diagnosis includes the small cell variant of medullary carcinoma and insular carcinoma and may require the use of immunohistochemistry.[971]

A very high proportion of primary thyroid lymphomas arise in a background of lymphocytic or Hashimoto thyroiditis, this association representing one of the better documented examples of the pathogenetic link between immunoproliferation and autoimmune disease.[955,972,973] Accordingly, most of the patients have positive serum tests for antithyroid antibodies.[960] The Epstein–Barr virus does not seem to play a major pathogenetic role.[974]

The tumor may be restricted to the thyroid, may spread to the soft tissues by direct extension, or may involve the regional nodes. The prognosis is better for marginal zone B-cell lymphomas than for diffuse large B-cell lymphomas.[961] Most treatment failures result from distant recurrences.[975] It is not uncommon for this recurrence to be located in the gastrointestinal tract.[976]

The treatment of thyroid lymphoma usually includes thyroidectomy followed by adjuvant therapy that varies depending on the lymphoma subtype[977]; in cases with extrathyroidal involvement, surgical debulking does not seem to be necessary before the administration of adjuvant therapy.[978]

Primary thyroid lymphoma should be distinguished from systemic lymphoma with thyroid involvement, a rather unusual event.

Plasmacytoma of thyroid can be seen as a component of widespread myeloma or as the only manifestation of the disease.[979,980] Immunoglobulin abnormalities may be present in the serum.[981] The term should be restricted to tumors entirely composed of plasma cells of various degrees of maturity; tumors with a lymphoid component should be placed in the malignant lymphoma category.[982] Plasmacytoma should also be distinguished from *plasma cell granuloma*, a non-neoplastic condition in which a polyclonal infiltrate of mature plasma cells is seen admixed with other inflammatory cells in a fibrotic background.[983]

Hodgkin lymphoma involving primarily the thyroid is extremely rare, but its occurrence has been documented.[955,984] Most of the cases have been of the classic type (nodular sclerosis subtype), and some have shown concomitant involvement of cervical lymph nodes (Fig. 8.97).[985,986]

Langerhans cell histiocytosis (histiocytosis X, eosinophilic granuloma) can involve the thyroid gland as an isolated event (Fig. 8.98)[987,988] or associated with papillary carcinoma.[989] Practically all reported cases have occurred against a background of lymphocytic/Hashimoto thyroiditis, and some have also involved the adjacent parathyroid glands.[990]

Rosai–Dorfman disease (sinus histiocytosis with massive lymphadenopathy) can also involve the thyroid gland, either as an isolated event or as a component of multisystem disease.[991,992]

Extramedullary hematopoiesis has been observed within the substance of thyroid nodules in patients with myelofibrosis (agnogenic myeloid metaplasia).[179,993,994]

Mesenchymal Tumors

Benign mesenchymal tumors of thyroid are exceptional. Isolated cases of *lipoma*, *hemangioma*,[995,996] *angiolipoma*,[997,998] *lymphangioma*,[999] *leiomyoma*,[1000,1001] *schwannoma*,[1000,1002] *granular cell tumor*,[1003,1004] *hemangiopericytoma*,[1005] and *solitary fibrous tumor* have been reported, the latter with an increasing frequency.[1006–1009] While on the subject of hemangioma, we thought of mentioning here the strange phenomenon by which severe hypothyroidism can accompany infantile hemangioma of liver and other sites as a result of degradation of thyroid hormone in the tumor tissue by type 3 iodothyronine deiodinase activity.[1010]

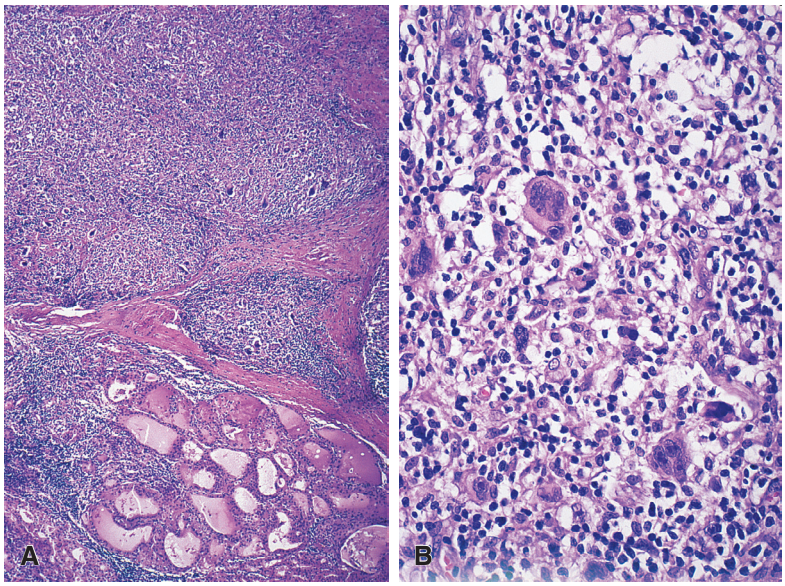

Figure 8.97 Hodgkin lymphoma involving the thyroid gland. **A,** Low-power view showing a nodular pattern of growth. **B,** High-power view showing a polymorphic infiltrate containing Reed–Sternberg cells. (Courtesy of Dr. Juan José Segura, San José, Costa Rica.)

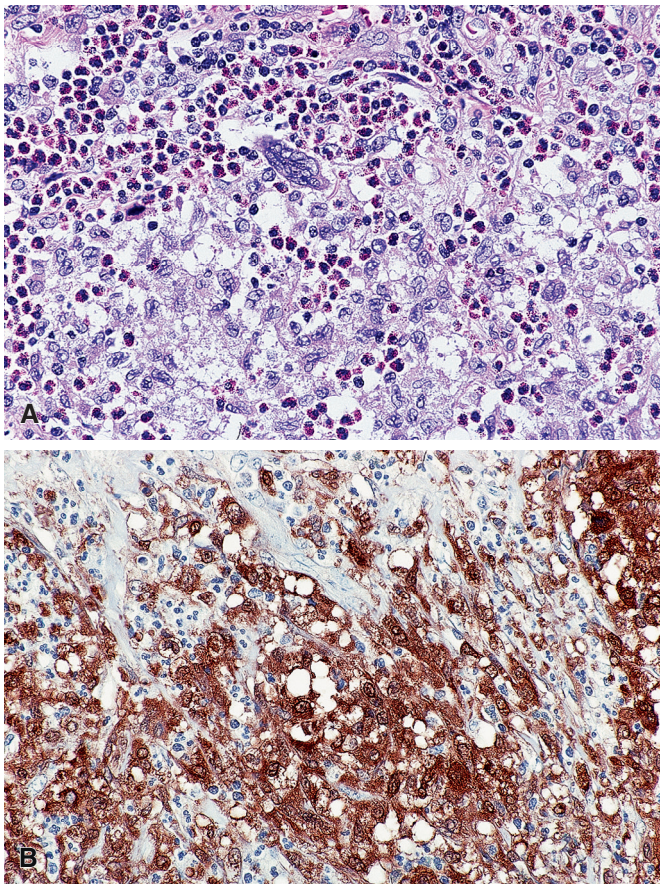

Figure 8.98 Langerhans cell histiocytosis involving the thyroid gland. **A,** Infiltrate composed of Langerhans cells and eosinophils. **B,** S-100 protein immunoreactivity of Langerhans cells.

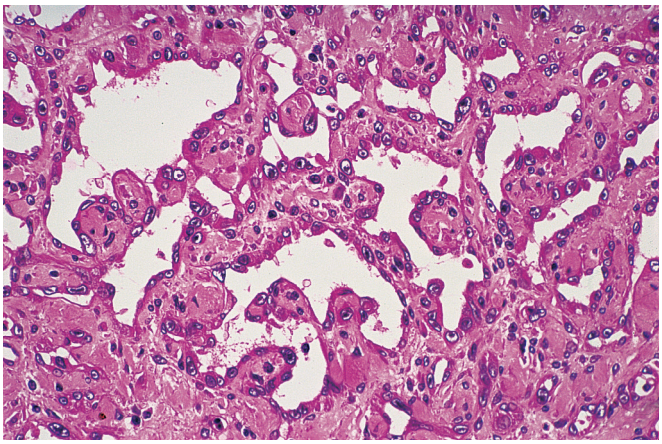

Figure 8.99 Angiosarcoma of thyroid. The tumor is well differentiated and composed of anastomosing vascular channels lined by somewhat epithelioid endothelial cells.

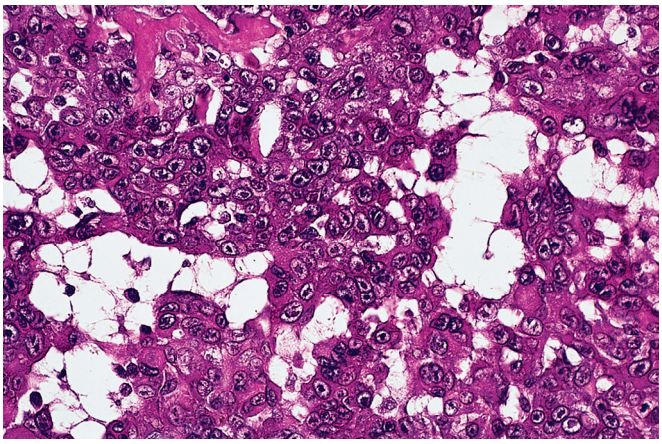

Figure 8.100 Epithelioid angiosarcoma of thyroid. Note the prominent nucleoli.

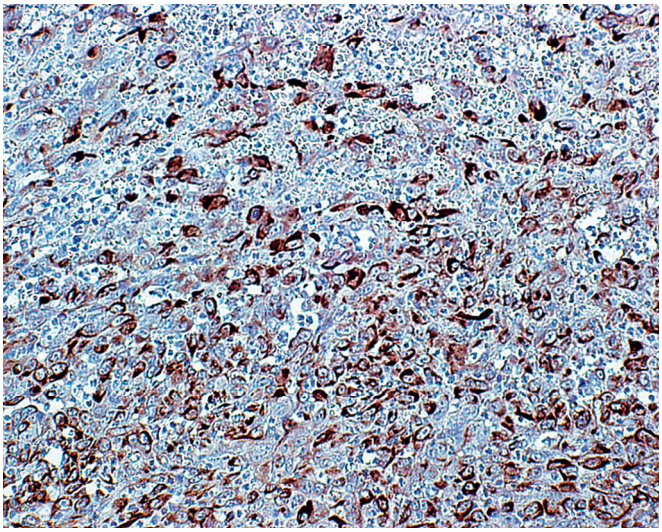

Figure 8.101 Keratin immunoreactivity in thyroid angiosarcoma. There was also positivity for endothelial markers.

Sarcomas of various microscopic types have been reported in the thyroid, usually in the form of individual case reports. These include *fibrosarcoma*,[1011] *liposarcoma*,[1012] *leiomyosarcoma*,[1001,1013,1014] *chondrosarcoma*,[1015] *osteosarcoma*,[1016] and *malignant peripheral nerve sheath tumor* (including triton tumor).[1002,1017,1018] Some of the leiomyosarcomas have occurred in a setting of immunodeficiency in association with the Epstein–Barr virus.[1014] It should be remembered that most sarcoma-like thyroid tumors are examples of the spindle or giant cell types of undifferentiated carcinoma.[1011]

Controversy still exists about the frequency and very existence of thyroid *angiosarcoma*, most early examples of which have been reported from Switzerland and other mountainous regions. There is no question that some of these neoplasms exhibit all the attributes of angiosarcoma, such as anastomosing vascular channels, Weibel–Palade bodies on ultrastructural examination, immunoreactivity for endothelial cell markers, and tendency to produce hemorrhagic pleuropulmonary metastases (Fig. 8.99).[1019–1022] Some of them show, together with a typical angiosarcomatous architecture and immunoreactivity for endothelial markers, an epithelioid morphology, accompanied by marked nucleolar prominence and immunoreactivity for keratin (Figs. 8.100 and 8.101).[1023,1024] These tumors (some of which have occurred in non-Alpine areas)[1025] are keratin-positive *epithelioid angiosarcomas*, in analogy to similar cases reported in other sites, such as skin, bone, and uterine corpus.[1026–1028] They have been regarded, together with related tumors, as anaplastic carcinomas, due to the perennial issue of presumed histogenesis versus phenotype.[1029–1031] Most malignant tumors showing vascular

differentiation have arisen in glands with nodular hyperplasia, and the evolution has usually been fatal.

Low-grade malignant examples of endothelial vascular tumor in the category of *epithelioid hemangioendothelioma* have been reported.[1032]

Other Primary Tumors and Tumorlike Conditions

Teratomas of thyroid usually occur in neonates, infants, or children.[1033] The large majority of the cases have been cystic and benign. Neural tissue is usually the predominant component; the fact that it is often immature is not a sign of clinical malignancy.[1034] However, these teratomas can lead to obstruction of the airway, necessitating emergency surgery because of their location in the mid neck and the huge size that they can attain.[1035]

The few thyroid teratomas that have been described in adults have been malignant[1036]; some of the reported cases have a very primitive neuroepithelial component with rosette formations associated with islands of well-differentiated cartilage.[1033,1037] Another group of reported cases of teratomas[1038] has been reinterpreted as neoplasms showing thymic or related branchial pouch differentiation (see later and Chapter 12).[40]

Neuroblastomas of the thyroid have been reported.[1039] They should be distinguished from the much more common teratomas with immature neural elements.

Parathyroid tumors can occur within the thyroid gland and create problems of differential diagnosis with follicular neoplasms. Unlike follicular neoplasms they are positive for chromogranins and parathyroid hormone, and lack TTF-1 immunoreactivity.[5] Parathyroid tumors are further described in Chapter 9.

Amyloidosis can involve the thyroid as part of a systemic disease or as a localized primary *amyloid tumor* ("amyloid goiter").[1040,1041] The lesion may be unilateral or bilateral and is commonly associated with a foreign body–type reaction. The amyloid deposits are often accompanied by mature adipose tissue.

Malakoplakia and **Wegener granulomatosis** have been described involving the thyroid and mimicking a primary neoplasm clinically.[1042–1044]

Thymic and branchial pouch–derived tumors can involve the thyroid gland and simulate primary thyroid neoplasms.

Metastatic Tumors

Direct extension into the thyroid may occur in carcinomas of pharynx, larynx, trachea, or esophagus, as well as from metastatic lesions from adjacent cervical lymph nodes.[1045] The majority of these tumors are of squamous cell type; therefore the possibility of secondary invasion should be considered when such a tumor type is encountered in a thyroid specimen, especially if the tumor is relatively well differentiated.

Blood-borne metastases represent 0.2% of thyroid malignancies.[1046] Metastases are found in the thyroid at autopsy in approximately 10% of patients dying of malignant tumors; the most common sites for the primary tumor are skin (melanoma) (39%), breast (21%), kidney (12%), and lung (11%) (Fig. 8.102).[1047] These metastases can be solitary (most commonly), multiple, or diffuse.[1048] A fair number of these metastases are found within preexisting thyroid lesions, such as follicular adenoma (the most common), follicular carcinoma, or papillary carcinoma of either the classic or follicular variant type.[1049–1051]

It is rare for metastases to the thyroid to simulate clinically a primary thyroid neoplasm.[1052,1053] The outstanding exception is renal cell carcinoma, which can present as a thyroid mass in the absence of renal symptoms years or decades after the removal of the primary tumor.[250,1054,1055] The differential diagnosis is with

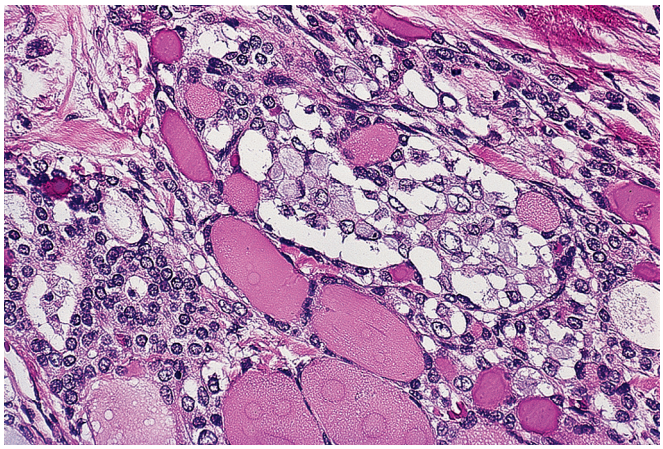

Figure 8.102 Lobular carcinoma of the breast with signet ring features metastatic to thyroid.

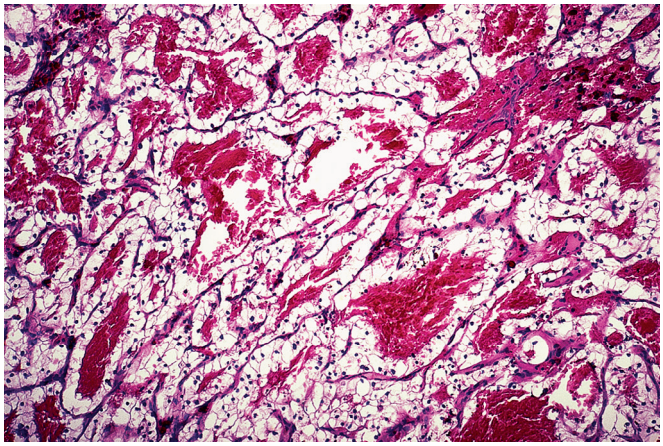

Figure 8.103 Renal cell carcinoma of clear cell type metastatic to thyroid. Note the blood-filled glands.

primary thyroid tumors with clear cell features. Features favoring the diagnosis of metastatic renal cell carcinoma are multiplicity of the nodules, optically clear (as opposed to finely granular) cytoplasm, sinusoidal-type blood vessels, intraluminal fresh hemorrhage ("bloody glands"), and a large amount of cytoplasmic glycogen and fat (Fig. 8.103).[250,1056] Immunohistochemical stains for thyroglobulin, TTF-1, and PAX8 are also helpful, but one should be aware of the fact that diffusion of the former marker from entrapped follicles may occur, with subsequent nonspecific absorption by neighboring tumor cells.[250] If material from the primary renal tumor is available, a molecular comparison with the thyroid clear cell neoplasm can also be helpful.[1057]

For adenocarcinomas of other types, mucin stains are also of some use. Although exceptions certainly occur, the presence of intracytoplasmic mucin of an epithelial type in a malignant tumor located within the thyroid gland points toward a metastatic origin. Similarly, the presence of mucin in a metastatic tumor of unknown source makes very unlikely the possibility that the primary is in the thyroid gland. This traditional approach has been largely superseded by immunohistochemical evaluation for markers such as thyroglobulin, TTF-1, PAX8, CEA, and the various keratins.

The fact that neuroendocrine carcinomas can exceptionally metastasize to the thyroid and simulate a primary thyroid neoplasm (particularly medullary carcinoma)[792,793] is discussed under "Other Neuroendocrine Tumors."

References

1. Hoyes AD, Kershaw DR. Anatomy and development of the thyroid gland. *Ear Nose Throat J*. 1985;64(7):318-333.
2. Sugiyama S. The embryology of the human thyroid gland including ultimobranchial body and others related. *Ergeb Anat Entwicklungsgesch*. 1971;44(2):3-111.
3. Fernández LP, López-Márquez A, Santisteban P. Thyroid transcription factors in development, differentiation and disease. *Nat Rev Endocrinol*. 2015;11(1):29-42.
4. Szinnai G. Clinical genetics of congenital hypothyroidism. *Endocr Dev*. 2014;26: 60-78.
5. Carcangiu ML. Thyroid. In: Mills SE, ed. *Histology for Pathologists*. 4th ed. Philadelphia: Lippincott Williams & Wilkins; 2012:1185-1207.
6. Crile G Jr. The fallacy of the conventional radical neck dissection for papillary carcinoma of the thyroid. *Ann Surg*. 1957;145(3):317-320.
7. Papotti M, Gugliotta P, Forte G, Bussolati G. Immunocytochemical identification of oxyphilic mitochondrion-rich cells. *Appl Immunohistochem*. 1994;2:261-267.
8. Saad AG, Kumar S, Ron E, et al. Proliferative activity of human thyroid cells in various age groups and its correlation with the risk of thyroid cancer after radiation exposure. *J Clin Endocrinol Metab*. 2006;91(7):2672-2677.
9. Klinck GH, Oertel JE, Winship T. Ultrastructure of normal human thyroid. *Lab Invest*. 1970;22(1):2-22.
10. Rigaud C, Bogomoletz WV. "Mucin secreting" and "mucinous" primary thyroid carcinomas: pitfalls in mucin histochemistry applied to thyroid tumours. *J Clin Pathol*. 1987;40(8):890-895.
11. Katoh R, Kawaoi A, Muramatsu A, et al. Birefringent (calcium oxalate) crystals in thyroid diseases. A clinicopathological study with possible implications for differential diagnosis. *Am J Surg Pathol*. 1993;17(7):698-705.
12. Isotalo PA, Lloyd RV. Presence of birefringent crystals is useful in distinguishing thyroid from parathyroid gland tissues. *Am J Surg Pathol*. 2002;26(6):813-814.
13. Dohán O, Baloch Z, Bánrévi Z, et al. Rapid communication: predominant intracellular overexpression of the Na(+)/I(−) symporter (NIS) in a large sampling of thyroid cancer cases. *J Clin Endocrinol Metab*. 2001;86(6):2697-2700.
14. Iosco C, Cosentino C, Sirna L, et al. Anoctamin 1 is apically expressed on thyroid follicular cells and contributes to ATP- and calcium-activated iodide efflux. *Cell Physiol Biochem*. 2014;34(3):966-980.
15. Kubba LA, McCluggage WG, Liu J, et al. Thyroid transcription factor-1 expression in ovarian epithelial neoplasms. *Mod Pathol*. 2008;21(4):485-490.
16. Bisceglia M, Ragazzi M, Galliani CA, et al. TTF-1 expression in nephroblastoma. *Am J Surg Pathol*. 2009;33(3):454-461.
17. Sierakowski A, Al-Janabi K, Dam H, Sood M. Metastatic Merkel cell carcinoma with positive expression of thyroid transcription factor-1—a case report. *Am J Dermatopathol*. 2009;31(4):384-386.
18. Nonaka D, Tang Y, Chiriboga L, et al. Diagnostic utility of thyroid transcription factors Pax8 and TTF-2 (FoxE1) in thyroid epithelial neoplasms. *Mod Pathol*. 2008;21(2):192-200.
19. Fonseca E, Nesland JM, Hoie J, Sobrinho-Simoes M. Pattern of expression of intermediate cytokeratin filaments in the thyroid gland: an immunohistochemical study of simple and stratified epithelial-type cytokeratins. *Virchows Arch*. 1997;430(3): 239-245.
20. Alves P, Soares P, Fonseca E, Sobrinho-Simoes M. Papillary thyroid carcinoma overexpresses fully and underglycosylated mucins together with native and sialylated simple mucin antigens and histo-blood group antigens. *Endocr Pathol*. 1999;10(4):315-324.
21. Henzen-Logmans SC, Mullink H, Ramaekers FC, et al. Expression of cytokeratins and vimentin in epithelial cells of normal and pathologic thyroid tissue. *Virchows Arch A Pathol Anat Histopathol*. 1987;410(4):347-354.
22. Bur M, Shiraki W, Masood S. Estrogen and progesterone receptor detection in neoplastic and non-neoplastic thyroid tissues. *Mod Pathol*. 1993;6(4):469-472.
23. Gonzalez-Campora R, Garcia-Sanatana JA, Jorda i Heras MM, et al. Blood group antigens in differentiated thyroid neoplasms. *Arch Pathol Lab Med*. 1998;122(11):957-965.
24. Schmid KW, Greeff M, Hittmair A, et al. Metallothionein expression in normal, hyperplastic, and neoplastic thyroid follicular and parafollicular C cells using monoclonal antimetallothionein antibody E9. *Endocr Pathol*. 1994;5:114-122.
25. Tzelepi VN, Tsamandas AC, Vlotinou HD, et al. Tight junctions in thyroid carcinogenesis: diverse expression of claudin-1, claudin-4, claudin-7 and occludin in thyroid neoplasms. *Mod Pathol*. 2008;21(1):22-30.
26. Miettinen M, Virtanen I. Expression of laminin in thyroid gland and thyroid tumors: an immunohistologic study. *Int J Cancer*. 1984;34(1):27-30.
27. Kameda Y. Cellular and molecular events on the development of mammalian thyroid C cells. *Dev Dyn*. 2016;245(3):323-341. doi:10.1002/dvdy.24377.
28. O'Toole K, Fenoglio-Preiser C, Pushparaj N. Endocrine changes associated with the human aging process: III. Effect of age on the number of calcitonin immunoreactive cells in the thyroid gland. *Hum Pathol*. 1985;16(10):991-1000.
29. Cameselle-Teijeiro J, Varela-Duran J, Sambade C, et al. Solid cell nests of the thyroid: light microscopy and immunohistochemical profile. *Hum Pathol*. 1994;25(7):684-693.
30. Beckner ME, Shultz JJ, Richardson T. Solid and cystic ultimobranchial body remnants in the thyroid. *Arch Pathol Lab Med*. 1990;114(10):1049-1152.
31. Fellegara G, Dorji T, Bajineta MR, Rosai J. Images in pathology. "Giant" solid cell rest of the thyroid: a hyperplastic change? *Int J Surg Pathol*. 2009;17(3):268-269.
32. Mizukami Y, Nonomura A, Michigishi T, et al. Solid cell nests of the thyroid. A histologic and immunohistochemical study. *Am J Clin Pathol*. 1994;101(2):186-191.
33. Martin V, Martin L, Viennet G, et al. Ultrastructural features of "solid cell nest" of the human thyroid gland: a study of 8 cases. *Ultrastruct Pathol*. 2000;24(1):1-8.
34. Cameselle-Teijeiro J, Preto A, Soares P, Sobrinho-Simoes M. A stem cell role for thyroid solid cell nests. *Hum Pathol*. 2005;36(5):590-591.
35. Reimann JD, Dorfman DM, Nosé V. Carcinoma showing thymus-like differentiation of the thyroid (CASTLE): a comparative study: evidence of thymic differentiation and solid cell nest origin. *Am J Surg Pathol*. 2006;30(8):994-1001.
36. Mitchell JD, Kirkham N, Machin D. Focal lymphocytic thyroiditis in Southampton. *J Pathol*. 1984;144(4):269-273.
37. Scopa CD, Petrohilos J, Spiliotis J, Melachrinou M. Autopsy findings in clinically normal thyroids: a study in southwestern Greek population. *Int J Surg Pathol*. 1993;1:25-32.
38. LiVolsi VA. Branchial and thymic remnants in the thyroid and cervical region: an explanation for unusual tumors and microscopic curiosities. *Endocr Pathol*. 1993;4:115-119.
39. Morizumi H, Sano T, Tsuyuguchi M, et al. Localized adiposity of the thyroid, clinically mimicking an adenoma. *Endocr Pathol*. 1991;2:226-229.
40. Chan JK, Rosai J. Tumors of the neck showing thymic or related branchial pouch differentiation: a unifying concept. *Hum Pathol*. 1991;22(4):349-367.
41. Cameselle-Teijeiro J, Varela-Duran J. Intrathyroid salivary gland-type tissue in multinodular goiter. *Virchows Arch*. 1994;425(3):331-334.
42. Langlois NE, Krukowski ZH, Miller ID. Pancreatic tissue in a lateral cervical cyst attached to the thyroid gland–a presumed foregut remnant. *Histopathology*. 1997;31(4):378-380.
43. Bell CD, Kovacs K, Horvath E, Rotondo F. Histologic, immunohistochemical, and ultrastructural findings in a case of minocycline-associated "black thyroid. *Endocr Pathol*. 2001;12(4):443-451.
44. Veinot JP, Ghadially FN. Melanosis thyroidi. *Ultrastruct Pathol*. 1998;22(5):401-406.
45. Allard RH. The thyroglossal cyst. *Head Neck Surg*. 1982;5(2):134-146.
46. Kreft A, Hansen T, Kirkpatrick CJ. Thyroid transcription factor 1 expression in cystic lesions of the neck: an immunohistochemical investigation of thyroglossal duct cysts, branchial cleft cysts and metastatic papillary thyroid cancer. *Virchows Arch*. 2005;447(1):9-11.
47. Soucy P, Penning J. The clinical relevance of certain observations on the histology of the thyroglossal tract. *J Pediatr Surg*. 1984;19(5):506-509.
48. Ein SH, Shandling B, Stephens CA, Mancer K. The problem of recurrent thyroglossal duct remnants. *J Pediatr Surg*. 1984;19(4):437-439.
49. Falconieri G, Della Libera D, Zanella M. Papillary thyroid carcinoma of the thyroglossal duct cyst: comparative cytohistologic and immunochemical study of 2 new cases and review of the literature. *Int J Surg Pathol*. 2001;9(1):65-71.
50. LiVolsi VA, Perzin KH, Savetsky L. Carcinoma arising in median ectopic thyroid (including thyroglossal duct tissue). *Cancer*. 1974;34(4):1303-1315.
51. Adler M, Freeman JL. Hurthle cell carcinoma of the thyroglossal duct. *Head Neck*. 1991;13(5):446-449.
52. Nussbaum M, Buchwald RP, Ribner A, et al. Anaplastic carcinoma arising from median ectopic thyroid (thyroglossal duct remnant). *Cancer*. 1981;48(12):2724-2728.
53. Sauk JJ Jr. Ectopic lingual thyroid. *J Pathol*. 1970;102(4):239-243.
54. Aguirre A, de la Piedra M, Ruiz R, Portilla J. Ectopic thyroid tissue in the submandibular region. *Oral Surg Oral Med Oral Pathol*. 1991;71(1):73-76.
55. Kantelip B, Lusson JR, De Riberolles C, et al. Intracardiac ectopic thyroid. *Hum Pathol*. 1986;17(12):1293-1296.
56. Osammor JY, Bulman CH, Blewitt RW. Intralaryngotracheal thyroid. *J Laryngol Otol*. 1990;104(9):733-736.
57. Sekine S, Nagata M, Hamada H, Watanabe T. Heterotopic thyroid tissue at the porta

hepatis in a fetus with trisomy 18. *Virchows Arch*. 2000;436(5):498-501.
58. Casadei GP, Bertarelli C, Giorgini E, et al. Ectopic thyroid tissue in the adrenal gland: report of a case. *Int J Surg Pathol*. 2015;23(2):170-175.
59. Diaz-Arias AA, Bickel JT, Loy TS, et al. Follicular carcinoma with clear cell change arising in lingual thyroid. *Oral Surg Oral Med Oral Pathol*. 1992;74(2):206-211.
60. Devaney K, Snyder R, Norris HJ, Tavassoli FA. Proliferative and histologically malignant struma ovarii: a clinicopathologic study of 54 cases. *Int J Gynecol Pathol*. 1993;12(4):333-343.
61. Garg K, Soslow RA, Rivera M, et al. Histologically bland "extremely well differentiated" thyroid carcinomas arising in struma ovarii can recur and metastasize. *Int J Gynecol Pathol*. 2009;28(3):222-230.
62. Bhaskar SN, Bernier JL. Histogenesis of branchial cysts; a report of 468 cases. *Am J Pathol*. 1959;35(2):407-443.
63. Coleman WR, Homer RS, Kaplan RP. Branchial cleft heterotopia of the lower neck. *J Cutan Pathol*. 1989;16(6):353-358.
64. Shareef DS, Salm R. Ectopic vestigial lesions of the neck and shoulders. *J Clin Pathol*. 1981;34(10):1155-1162.
65. Bernstein A, Scardino PT, Tomaszewki MM, Cohen MH. Carcinoma arising in a branchial cleft cyst. *Cancer*. 1976;37(5):2417-2422.
66. Micheau C, Cachin Y, Caillou B. Cystic metastases in the neck revealing occult carcinoma of the tonsil. A report of six cases. *Cancer*. 1974;33(1):228-233.
67. Matsumoto K, Watanabe Y, Asano G. Thyroid papillary carcinoma arising in ectopic thyroid tissue within a branchial cleft cyst. *Pathol Int*. 1999;49(5):444-446.
68. Finkle HI, Goldman RL. Heterotopic cartilage in the thyroid. *Arch Pathol*. 1973;95(1):48-49.
69. Streutker CJ, Murray D, Kovacs K, Higgins HP. Epithelial cyst of thyroid. *Endocr Pathol*. 1997;8(1):75-80.
70. Ryska A, Vokurka J, Michal M, Ludvikova M. Intrathyroidal lymphoepithelial cyst. A report of two cases not associated with Hashimoto's thyroiditis. *Pathol Res Pract*. 1997;193(11-12):777-781.
71. Hazard JB. Thyroiditis: a review. *Am J Clin Pathol*. 1955;25(3):289-298, contd.
72. Pearce EN, Farwell AP, Braverman LE. Thyroiditis. *N Engl J Med*. 2003;348(26):2646-2655.
73. Berger SA, Zonszein J, Villamena P, Mittman N. Infectious diseases of the thyroid gland. *Rev Infect Dis*. 1983;5(1):108-122.
74. Guttler R, Singer PA, Axline SG, et al. Pneumocystis carinii thyroiditis. Report of three cases and review of the literature. *Arch Intern Med*. 1993;153(3):393-396.
75. Frank TS, LiVolsi VA, Connor AM. Cytomegalovirus infection of the thyroid in immunocompromised adults. *Yale J Biol Med*. 1987;60(1):1-8.
76. Herndon MD, Christie DB, Ayoub MM, Duggan AD. Thyroid abscess: case report and review of the literature. *Am Surg*. 2007;73(7):725-728.
77. Skuza K, Rapaport R, Fieldman R, et al. Recurrent acute suppurative thyroiditis. *J Otolaryngol*. 1991;20(2):126-129.
78. Miyauchi A, Matsuzuka F, Kuma K, Katayama S. Piriform sinus fistula and the ultimobranchial body. *Histopathology*. 1992;20(3):221-227.
79. Kramer AB, Roozendaal C, Dullaart RP. Familial occurrence of subacute thyroiditis associated with human leukocyte antigen-B35. *Thyroid*. 2004;14(7):544-547.
80. Stein AA, Hernandez I, McClintock JC. Subacute granulomatous thyroiditis: a clinicopathologic review. *Ann Surg*. 1961;153(1):149-156.
81. Schmid KW, Ofner C, Ramsauer T, et al. CA 19-9 expression in subacute (de Quervain's) thyroiditis: an immunohistochemical study. *Mod Pathol*. 1992;5(3):268-272.
82. Desailloud R, Hober D. Viruses and thyroiditis: an update. *Virol J*. 2009;6:5.
83. Carney JA, Moore SB, Northcutt RC, et al. Palpation thyroiditis (multifocal granulomatour folliculitis). *Am J Clin Pathol*. 1975;64(5):639-647.
84. Sachs MK, Dickinson G, Amazon K. Tuberculous adenitis of the thyroid mimicking subacute thyroiditis. *Am J Med*. 1988;85(4):573-575.
85. Mizukami Y, Nonomura A, Michigishi T, et al. Sarcoidosis of the thyroid gland manifested initially as thyroid tumor. *Pathol Res Pract*. 1994;190(12):1201-1205, discussion 1206-1207.
86. Isern V, Lora-Tamayo J, Capdevila O, et al. Sarcoidosis and autoimmune thyroid disease. A case series of ten patients. *Sarcoidosis Vasc Diffuse Lung Dis*. 2007;24(2):148-152.
87. Kakudo K, Kanokogi M, Mitsunobu M, et al. Acute mycotic thyroiditis. *Acta Pathol Jpn*. 1983;33(1):147-151.
88. Lima MK, Freitas LL, Montandon C, et al. The thyroid in acquired immunodeficiency syndrome. *Endocr Pathol*. 1998;9(3): 217-223.
89. Szporn AH, Tepper S, Watson CW. Disseminated cryptococcosis presenting as thyroiditis. Fine needle aspiration and autopsy findings. *Acta Cytol*. 1985;29(3):449-453.
90. Manson CM, Cross P, De Sousa B. Post-operative necrotizing granulomas of the thyroid. *Histopathology*. 1992;21(4):392-393.
91. Dayan CM, Daniels GH. Chronic autoimmune thyroiditis. *N Engl J Med*. 1996;335(2):99-107.
92. McGrogan A, Seaman HE, Wright JW, de Vries CS. The incidence of autoimmune thyroid disease: a systematic review of the literature. *Clin Endocrinol (Oxf)*. 2008;69(5):687-696. doi:10.1111/j.1365-2265.2008.03338.x.
93. Dong YH, Fu DG. Autoimmune thyroid disease: mechanism, genetics and current knowledge. *Eur Rev Med Pharmacol Sci*. 2014;18(23):3611-3618.
94. Hirota Y, Tamai H, Hayashi Y, et al. Thyroid function and histology in forty-five patients with hyperthyroid Graves' disease in clinical remission more than ten years after thionamide drug treatment. *J Clin Endocrinol Metab*. 1986;62(1):165-169.
95. Takasu N, Yamada T, Sato A, et al. Graves' disease following hypothyroidism due to Hashimoto's disease: studies of eight cases. *Clin Endocrinol*. 1990;33(6):687-698.
96. Davies TF, Kendler DL. Mechanisms of human autoimmune thyroid disease–1992. *Monogr Pathol*. 1993;35:103-117.
97. Menconi F, Monti MC, Greenberg DA, et al. Molecular amino acid signatures in the MHC class II peptide-binding pocket predispose to autoimmune thyroiditis in humans and in mice. *Proc Natl Acad Sci USA*. 2008;105(37):14034-14039.
98. Ahmed R, Al-Shaikh S, Akhtar M. Hashimoto thyroiditis: a century later. *Adv Anat Pathol*. 2012;19(3):181-186.
99. Simmonds MJ. GWAS in autoimmune thyroid disease: redefining our understanding of pathogenesis. *Nat Rev Endocrinol*. 2013;9(5):277-287. doi:10.1038/nrendo.2013.56.
100. Caturegli P, De Remigis A, Rose NR. Hashimoto thyroiditis: clinical and diagnostic criteria. *Autoimmun Rev*. 2014;13(4-5):391-397.
101. Hashimoto H. Zur Kenntniss der lymphomatösen Veränderung der Schilddrüse (Struma lymphomatosa). *Arch Klin Chir*. 1912;97:219-248.
102. Mizukami Y, Michigishi T, Kawato M, et al. Chronic thyroiditis: thyroid function and histologic correlations in 601 cases. *Hum Pathol*. 1992;23(9):980-988.
103. Mizukami Y, Michigishi T, Nonomura A, et al. Pathology of chronic thyroiditis: a new clinically relevant classification. *Pathol Annu*. 1994;29(Pt 1):135-158.
104. Mizukami Y, Michigishi T, Hashimoto T, et al. Silent thyroiditis: a histologic and immunohistochemical study. *Hum Pathol*. 1988;19(4):423-431.
105. Mizukami Y, Michigishi T, Nonomura A, et al. Postpartum thyroiditis. A clinical, histologic, and immunopathologic study of 15 cases. *Am J Clin Pathol*. 1993;100(3):200-205.
106. Gopalakrishnan S, Marwaha RK. Juvenile autoimmune thyroiditis. *J Pediatr Endocrinol Metab*. 2007;20(9):961-970.
107. Corsello SM, Barnabei A, Marchetti P, et al. Endocrine side effects induced by immune checkpoint inhibitors. *J Clin Endocrinol Metab*. 2013;98(4):1361-1375.
108. Okayasu I, Hara Y, Nakamura K, Rose NR. Racial and age-related differences in incidence and severity of focal autoimmune thyroiditis. *Am J Clin Pathol*. 1994;101(6):698-702.
109. Hsi ED, Singleton TP, Svoboda SM, et al. Characterization of the lymphoid infiltrate in Hashimoto thyroiditis by immunohistochemistry and polymerase chain reaction for immunoglobulin heavy chain gene rearrangement. *Am J Clin Pathol*. 1998;110(3):327-333.
110. Knecht H, Hedinger CE. Ultrastructural findings in Hashimoto's thyroiditis and focal lymphocytic thyroiditis with reference to giant cell formation. *Histopathology*. 1982;6(5):511-538.
111. Ben-Ezra J, Wu A, Sheibani K. Hashimoto's thyroiditis lacks detectable clonal immunoglobulin and T cell receptor gene rearrangements. *Hum Pathol*. 1988;19(12):1444-1448.
112. Di Tommaso L, Battista S, Destro A, et al. Cracking spaces in Hashimoto Thyroiditis are lymphatic and prelymphatic vessels: a gift of immunohistochemistry for the centenary of Hashimoto's description. *Am J Surg Pathol*. 2010;34(12):1857-1861.
113. Doganay L, Puyan FO, Oz F, et al. Regenerative hyperplasia of follicular epithelium in chronic lymphocytic thyroiditis. *Appl Immunohistochem Mol Morphol*. 2005;13(4):353-357.
114. Muller-Hocker J, Jacob U, Seibel P. Hashimoto thyroiditis is associated with defects of cytochrome-c oxidase in oxyphil Askanazy cells and with the common deletion (4,977) of mitochondrial DNA. *Ultrastruct Pathol*. 1998;22(1):91-100.
115. Caillou B. Ductal metaplasia in chronic lymphocytic thyroiditis as a manifestation of phylogenic regression to an exocrine structure. *Am J Surg Pathol*. 2006;30(6):774-781.
116. Louis DN, Vickery AL Jr, Rosai J, Wang CA. Multiple branchial cleft-like cysts in Hashimoto's thyroiditis. *Am J Surg Pathol*. 1989;13(1):45-49.
117. Katz SM, Vickery AL Jr. The fibrous variant of Hashimoto's thyroiditis. *Hum Pathol*. 1974;5(2):161-170.
118. Baloch ZW, Feldman MD, LiVolsi VA. Combined riedel's disease and fibrosing hashimoto's thyroiditis: a report of three cases with two showing coexisting papillary

carcinoma. *Endocr Pathol*. 2000;11(2): 157-163.
119. Julie C, Vieillefond A, Desligneres S, et al. Hashimoto's thyroiditis associated with Riedel's thyroiditis and retroperitoneal fibrosis. *Pathol Res Pract*. 1997;193(8):573-577, discussion 578.
120. Li Y, Zhou G, Ozaki T, et al. Distinct histopathological features of Hashimoto's thyroiditis with respect to IgG4-related disease. *Mod Pathol*. 2012;25(8):1086-1097. doi:10.1038/modpathol.2012.68.
121. Deshpande V. IgG4 related disease of the head and neck. *Head Neck Pathol*. 2015;9(1):24-31.
122. Wémeau JL, Proust-Lemoine E, Ryndak A, Vanhove L. Thyroid autoimmunity and polyglandular endocrine syndromes. *Hormones (Athens)*. 2013;12(1):39-45.
123. Holm LE, Blomgren H, Lowhagen T. Cancer risks in patients with chronic lymphocytic thyroiditis. *N Engl J Med*. 1985;312(10):601-604.
124. Lee JH, Kim Y, Choi JW, Kim YS. The association between papillary thyroid carcinoma and histologically proven Hashimoto's thyroiditis: a meta-analysis. *Eur J Endocrinol*. 2013;168(3):343-349.
125. Hunt JL, Baloch ZW, Barnes L, et al. Loss of heterozygosity mutations of tumor suppressor genes in cytologically atypical areas in chronic lymphocytic thyroiditis. *Endocr Pathol*. 2002;13(4):321-330.
126. Vanni R, Marras-Virdis S, Gerosa C, et al. Cytogenetics of thyroid nodules in Hashimoto thyroiditis. *Cancer Genet Cytogenet*. 2000;120(1):87-88.
127. Prasad ML, Huang Y, Pellegata NS, et al. Hashimoto's thyroiditis with papillary thyroid carcinoma (PTC)-like nuclear alterations express molecular markers of PTC. *Histopathology*. 2004;45(1):39-46.
128. Rhoden KJ, Unger K, Salvatore G, et al. RET/papillary thyroid cancer rearrangement in nonneoplastic thyrocytes: follicular cells of Hashimoto's thyroiditis share low-level recombination events with a subset of papillary carcinoma. *J Clin Endocrinol Metab*. 2006;91(6):2414-2423.
129. Sheils OM, O'Eary JJ, Uhlmann V, et al. ret/PTC-1 activation in Hashimoto thyroiditis. *Int J Surg Pathol*. 2000;8(3):185-189.
130. Wirtschafter A, Schmidt R, Rosen D, et al. Expression of the RET/PTC fusion gene as a marker for papillary carcinoma in Hashimoto's thyroiditis. *Laryngoscope*. 1997;107(1):95-100.
131. Limpens J, de Jong D, van Krieken JH, et al. Bcl-2/JH rearrangements in benign lymphoid tissues with follicular hyperplasia. *Oncogene*. 1991;6(12):2271-2276.
132. Sargent R, LiVolsi V, Murphy J, et al. BRAF mutation is unusual in chronic lymphocytic thyroiditis-associated papillary thyroid carcinomas and absent in non-neoplastic nuclear atypia of thyroiditis. *Endocr Pathol*. 2006;17(3):235-241.
133. Weiss LM, Weinberg DS, Warhol MJ. Medullary carcinoma arising in a thyroid with Hashimoto's disease. *Am J Clin Pathol*. 1983;80(4):534-538.
134. Riedel BM. Die chronische zur Bildung eisenharter Tumoren fuehrende Entzuendung der Shilddruese. *Verh Ges Chir*. 1896;25:101-105.
135. Hennessey JV. Clinical review: Riedel's thyroiditis: a clinical review. *J Clin Endocrinol Metab*. 2011;96(10):3031-3041. doi:10.1210/jc.2011-0617.
136. Harach HR, Williams ED. Fibrous thyroiditis–an immunopathological study. *Histopathology*. 1983;7(5):739-751.
137. Fellegara G, Rosai J. Multifocal fibrosing thyroiditis: report of 55 cases of a poorly recognized entity. *Am J Surg Pathol*. 2015;39(3):416-424.
138. Frank R, Baloch ZW, Gentile C, et al. Multifocal fibrosing thyroiditis and its association with papillary thyroid carcinoma using BRAF pyrosequencing. *Endocr Pathol*. 2014;25(3):236-240.
139. Léger J, Olivieri A, Donaldson M, et al. European Society for Paediatric Endocrinology consensus guidelines on screening, diagnosis, and management of congenital hypothyroidism. *J Clin Endocrinol Metab*. 2014;99(2):363-384.
140. Nicholas AK, Serra EG, Cangul H, et al. Comprehensive screening of eight known causative genes in congenital hypothyroidism with gland-in-situ. *J Clin Endocrinol Metab*. 2016;101(12):4521-4531.
141. Szinnai G. Genetics of normal and abnormal thyroid development in humans. *Best Pract Res Clin Endocrinol Metab*. 2014;28(2):133-150.
142. Ghossein RA, Rosai J, Heffess C. Dyshormonogenetic goiter: a clinicopathologic study of 56 cases. *Endocr Pathol*. 1997;8(4):283-292.
143. Camargo RY, Gross JL, Silveiro SP, et al. Pathological findings in dyshormonogenetic goiter with defective iodide transport. *Endocr Pathol*. 1998;9(3):225-233.
144. Cooper DS, Axelrod L, DeGroot LJ, et al. Congenital goiter and the development of metastatic follicular carcinoma with evidence for a leak of nonhormonal iodide: clinical, pathological, kinetic, and biochemical studies and a review of the literature. *J Clin Endocrinol Metabol*. 1981;52(2):294-306.
145. Chertok Shacham E, Ishay A, Irit E, et al. Minimally invasive follicular thyroid carcinoma developed in dyshormonogenetic multinodular goiter due to thyroid peroxidase gene mutation. *Thyroid*. 2012;22(5):542-546.
146. Vickery AL Jr. The diagnosis of malignancy in dyshormonogenetic goitre. *Clin Endocrinol Metab*. 1981;10(2):317-335.
147. Smith TJ, Hegedüs L. Graves' disease. *N Engl J Med*. 2016;375(16):1552-1565.
148. De Leo S, Lee SY, Braverman LE. Hyperthyroidism. *Lancet*. 2016;388(10047):906-918.
149. Bahn RS. Graves' ophthalmopathy. *N Engl J Med*. 2010;362(8):726-738.
150. Nixon DW, Samols E. Acral changes associated with thyroid diseases. *JAMA*. 1970;212(7):1175-1181.
151. Perez-Montiel MD, Suster S. The spectrum of histologic changes in thyroid hyperplasia: a clinicopathologic study of 300 cases. *Hum Pathol*. 2008;39(7):1080-1087.
152. Spjut HJ, Warren WD, Ackerman LV. Clinical-pathologic study of 76 cases of recurrent Graves' disease, toxic (non-exophthalmic) goiter, and nontoxic goiter; does a relation exist between thyroid hyperplasia and struma lymphomatosa? *Am J Clin Pathol*. 1957;27(4):367-392.
153. Ito M, Toyoda N, Nomura E, et al. Type 1 and type 2 iodothyronine deiodinases in the thyroid gland of patients with 3,5,3′-triiodo thyronine-predominant Graves' disease. *Eur J Endocrinol*. 2011;164(1):95-100.
154. Margolick JB, Hsu SM, Volkman DJ, et al. Immunohistochemical characterization of intrathyroid lymphocytes in Graves' disease. Interstitial and intraepithelial populations. *Am J Med*. 1984;76(5):815-821.
155. Hanson GA, Komorowski RA, Cerletty JM, Wilson SD. Thyroid gland morphology in young adults: normal subjects versus those with prior low-dose neck irradiation in childhood. *Surgery*. 1983;94(6):984-988.
156. Pazaitou-Panayiotou K, Michalakis K, Paschke R. Thyroid cancer in patients with hyperthyroidism. *Horm Metab Res*. 2012;44(4):255-262.
157. Eggen PC, Seljelid R. The histological appearance of hyperfunctioning thyroids following various pre-operative treatments. *Acta Pathol Microbiol Scand [A]*. 1973;81(1):16-20.
158. Mizukami Y, Michigishi T, Nonomura A, et al. Histologic changes in Graves' thyroid gland after 131I therapy for hyperthyroidism. *Acta Pathol Jpn*. 1992;42(6):419-426.
159. Bradley EI 3rd, Liechty RD. Modified subtotal thyroidectomy for Graves' disease: a two-institution study. *Surgery*. 1983;94(6):955-958.
160. Hargreaves AW, Garner A. The significance of lymphocytic infiltration of the thyroid gland in thyrotoxicosis. *Br J Surg*. 1968;55(7):543-545.
161. Curran RC, Eckert H, Wilson GM. The thyroid gland after treatment of hyperthyroidism by partial thyroidectomy or iodine 131. *J Pathol Bacteriol*. 1958;76(2):541-560.
162. Friedman NB, Catz B. The reactions of euthyroid and hyperthyroid glands to radioactive iodine. *Arch Pathol Lab Med*. 1996;120(7):660-661.
163. Pfaltz M, Hedinger CE. Abnormal basement membrane structures in autoimmune thyroid disease. *Lab Invest*. 1986;55(5): 531-539.
164. Winsa B, Adami HO, Bergstrom R, et al. Stressful life events and Graves' disease. *Lancet*. 1991;338(8781):1475-1479.
165. Hancock SL, Cox RS, McDougall IR. Thyroid diseases after treatment of Hodgkin's disease. *N Engl J Med*. 1991;325(9):599-605.
166. Judd R, Bueso-Ramos C. Combined true thymic hyperplasia and lymphoid hyperplasia in Graves' disease. *Pediatr Pathol*. 1990;10(5):829-836.
167. Smyrk TC, Goellner JR, Brennan MD, Carney JA. Pathology of the thyroid in amiodarone-associated thyrotoxicosis. *Am J Surg Pathol*. 1987;11(3):197-204.
168. Knobel M. Etiopathology, clinical features, and treatment of diffuse and multinodular nontoxic goiters. *J Endocrinol Invest*. 2016;39(4):357-373.
169. Gaitan E, Nelson NC, Poole GV. Endemic goiter and endemic thyroid disorders. *World J Surg*. 1991;15(2):205-215.
170. Li M, Eastman CJ. The changing epidemiology of iodine deficiency. *Nat Rev Endocrinol*. 2012;8(7):434-440.
171. Teumer A, Rawal R, Homuth G, et al. Genome-wide association study identifies four genetic loci associated with thyroid volume and goiter risk. *Am J Hum Genet*. 2011;88(5):664-673.
172. Knudsen N, Brix TH. Genetic and non-iodine-related factors in the aetiology of nodular goitre. *Best Pract Res Clin Endocrinol Metab*. 2014;28(4):495-506.
173. Khan NE, Bauer AJ, Schultz KAP, et al. Quantification of thyroid cancer and multinodular goiter risk in the dicer1 syndrome: a family-based cohort study. *J Clin Endocrinol Metab*. 2017;102:1614-1622.
174. Vanderpump MP, Tunbridge WM, French JM, et al. The incidence of thyroid disorders in the community: a twenty-year follow-up of the Whickham Survey. *Clin Endocrinol (Oxf)*. 1995;43(1):55-68.
175. Mortensen JD, Woolner LB, Bennett WA. Gross and microscopic findings in clinically normal thyroid glands. *J Clin Endocrinol Metab*. 1955;15(10):1270-1280.
176. Berghout A, Wiersinga WM, Smits NJ, Touber JL. Interrelationships between age, thyroid volume, thyroid nodularity, and thyroid function in patients with sporadic nontoxic goiter. *Am J Med*. 1990;89(5):602-608.

177. Rosai J, Kuhn E, Carcangiu ML. Pitfalls in thyroid tumour pathology. *Histopathology*. 2006;49(2):107-120.
178. Katoh R, Bray CE, Suzuki K, et al. Growth activity in hyperplastic and neoplastic human thyroid determined by an immunohistochemical staining procedure using monoclonal antibody MIB-1. *Hum Pathol*. 1995;26(2):139-146.
179. Lazzi S, Als C, Mazzucchelli L, et al. Extensive extramedullary hematopoiesis in a thyroid nodule. *Mod Pathol*. 1996;9(11):1062-1065.
180. Sapino A, Papotti M, Macri L, et al. Intranodular reactive endothelial hyperplasia in adenomatous goitre. *Histopathology*. 1995;26(5):457-462.
181. Papotti M, Fara E, Ardeleanu C, Bussolati G. Occurrence and significance of vascular invasion in multinodular adenomatous goiter. *Endocr Pathol*. 1994;5:35-39.
182. Chung DH, Kang GH, Kim WH, Ro JY. Clonal analysis of a solitary follicular nodule of the thyroid with the polymerase chain reaction method. *Mod Pathol*. 1999;12(3):265-271.
183. Jovanovic L, Delahunt B, McIver B, et al. Thyroid gland clonality revisited: the embryonal patch size of the normal human thyroid gland is very large, suggesting X-chromosome inactivation tumor clonality studies of thyroid tumors have to be interpreted with caution. *J Clin Endocrinol Metab*. 2003;88(7):3284-3291.
184. Paschke R. Molecular pathogenesis of nodular goiter. *Langenbecks Arch Surg*. 2011;396(8):1127-1136.
185. Belge G, Roque L, Soares J, et al. Cytogenetic investigations of 340 thyroid hyperplasias and adenomas revealing correlations between cytogenetic findings and histology. *Cancer Genet Cytogenet*. 1998;101(1):42-48.
186. Krohn K, Wohlgemuth S, Gerber H, Paschke R. Hot microscopic areas of iodine-deficient euthyroid goitres contain constitutively activating TSH receptor mutations. *J Pathol*. 2000;192(1):37-42.
187. Vasko V, Ferrand M, Di Cristofaro J, et al. Specific pattern of RAS oncogene mutations in follicular thyroid tumors. *J Clin Endocrinol Metab*. 2003;88(6):2745-2752.
188. Zampi G, Carcangiu ML, Rosai J, eds. *Thyroid Tumor Pathology. Proceedings of an International Workshop*; 1985. San Miniato, Italy: Semin Diagn Pathol; 1984.
189. Harach HR, Sanchez SS, Williams ED. Pathology of the autonomously functioning (hot) thyroid nodule. *Ann Diagn Pathol*. 2002;6(1):10-19.
190. Remonti LR, Kramer CK, Leitão CB, et al. Thyroid ultrasound features and risk of carcinoma: a systematic review and meta-analysis of observational studies. *Thyroid*. 2015;25(5):538-550. doi:10.1089/thy.2014.0353.
191. Mizukami Y, Michigishi T, Nonomura A, et al. Autonomously functioning (hot) nodule of the thyroid gland. A clinical and histopathologic study of 17 cases. *Am J Clin Pathol*. 1994;101(1):29-35.
192. Panke TW, Croxson MS, Parker JW, et al. Triiodothyronine-secreting (toxic) adenoma of the thyroid gland: light and electron microscopic characteristics. *Cancer*. 1978;41(2):528-537.
193. Volante M, Papotti M. A practical diagnostic approach to solid/trabecular nodules in the thyroid. *Endocr Pathol*. 2008;19(2):75-81.
194. Sapino A, Cassoni P, Papotti M, Bussolati G. Muscular cushions of the vessel wall at the periphery of thyroid nodules. *Mod Pathol*. 1999;12(9):879-884.
195. Mai KT, Landry DC, Thomas J, et al. Follicular adenoma with papillary architecture: a lesion mimicking papillary thyroid carcinoma. *Histopathology*. 2001;39(1):25-32.
196. Campbell WL, Santiago HE, Perzin KH, Johnson PM. The autonamous thyroid nodule: correlation of scan appearance and histopathology. *Radiology*. 1973;107(1):133-138.
197. Hegedus L. Clinical practice. The thyroid nodule. *N Engl J Med*. 2004;351(17):1764-1771.
198. Parma J, Duprez L, Van Sande J, et al. Diversity and prevalence of somatic mutations in the thyrotropin receptor and Gs alpha genes as a cause of toxic thyroid adenomas. *J Clin Endocrinol Metab*. 1997;82(8):2695-2701.
199. Trulzsch B, Krohn K, Wonerow P, et al. Detection of thyroid-stimulating hormone receptor and Gsalpha mutations: in 75 toxic thyroid nodules by denaturing gradient gel electrophoresis. *J Mol Med*. 2001;78(12):684-691.
200. Calebiro D, Grassi ES, Eszlinger M, et al. Recurrent ezh1 mutations are a second hit in autonomous thyroid adenomas. *J Clin Invest*. 2016;126:3383-3388.
201. Cohen MB, Miller TR, Beckstead JH. Enzyme histochemistry and thyroid neoplasia. *Am J Clin Pathol*. 1986;85(6):668-673.
202. Liu H, Lin F. Application of immunohistochemistry in thyroid pathology. *Arch Pathol Lab Med*. 2015;139(1):67-82.
203. Kondo T, Ezzat S, Asa SL. Pathogenetic mechanisms in thyroid follicular-cell neoplasia. *Nature Rev Cancer*. 2006;6(4):292-306.
204. Nikiforova MN, Biddinger PW, Caudill CM, et al. PAX8-PPARgamma rearrangement in thyroid tumors: RT-PCR and immunohistochemical analyses. *Am J Surg Pathol*. 2002;26(8):1016-1023.
205. Roque L, Rodrigues R, Pinto A, et al. Chromosome imbalances in thyroid follicular neoplasms: a comparison between follicular adenomas and carcinomas. *Genes Chromosomes Cancer*. 2003;36(3):292-302.
206. Herrmann M. Standard and molecular cytogenetics of endocrine tumors. *Am J Clin Pathol*. 2003;119(suppl):S17-S38.
207. Belge G, Rippe V, Meiboom M, et al. Delineation of a 150-kb breakpoint cluster in benign thyroid tumors with 19q13.4 aberrations. *Cytogenet Cell Genet*. 2001;93(1-2):48-51.
208. Rippe V, Drieschner N, Meiboom M, et al. Identification of a gene rearranged by 2p21 aberrations in thyroid adenomas. *Oncogene*. 2003;22(38):6111-6114.
209. Panebianco F, Kelly LM, Liu P, et al. Thada fusion is a mechanism of igf2bp3 activation and igf1r signaling in thyroid cancer. *Proc Natl Acad Sci USA*. 2017;114:2307-2312.
210. Hou P, Liu D, Shan Y, et al. Genetic alterations and their relationship in the phosphatidylinositol 3-kinase/Akt pathway in thyroid cancer. *Clin Cancer Res*. 2007;13(4):1161-1170.
211. Harach HR, Soubeyran I, Brown A, et al. Thyroid pathologic findings in patients with Cowden disease. *Ann Diagn Pathol*. 1999;3(6):331-340.
212. Stratakis CA, Courcoutsakis NA, Abati A, et al. Thyroid gland abnormalities in patients with the syndrome of spotty skin pigmentation, myxomas, endocrine overactivity, and schwannomas (Carney complex). *J Clin Endocrinol Metab*. 1997;82(7):2037-2043.
213. Mastorakos G, Mitsiades NS, Doufas AG, Koutras DA. Hyperthyroidism in McCune-Albright syndrome with a review of thyroid abnormalities sixty years after the first report. *Thyroid*. 1997;7(3):433-439.
214. Hazard JB, Kenyon R. Atypical adenoma of the thyroid. *AMA Arch Pathol*. 1954;58(6):554-563.
215. Lang W, Georgii A, Stauch G, Kienzle E. The differentiation of atypical adenomas and encapsulated follicular carcinomas in the thyroid gland. *Virchows Arch A Pathol Anat Histol*. 1980;385(2):125-141.
216. Gnepp DR, Ogorzalek JM, Heffess CS. Fat-containing lesions of the thyroid gland. *Am J Surg Pathol*. 1989;13(7):605-612.
217. Visona A, Pea M, Bozzola L, et al. Follicular adenoma of the thyroid gland with extensive chondroid metaplasia. *Histopathology*. 1991;18(3):278-279.
218. Magro G, Benkova K, Michal M. Meningioma-like tumor of the thyroid: a previously undescribed variant of follicular adenoma. *Virchows Arch*. 2005;446(6):677-679.
219. Koren R, Bernheim J, Schachter P, et al. Black thyroid adenoma. Clinical, histochemical, and ultrastructural features. *Appl Immunohistochem Mol Morphol*. 2000;8(1):80-84.
220. Saggiorato E, De Pompa R, Volante M, et al. Characterization of thyroid 'follicular neoplasms' in fine-needle aspiration cytological specimens using a panel of immunohistochemical markers: a proposal for clinical application. *Endocr Relat Cancer*. 2005;12(2):305-317.
221. Nakamura N, Erickson LA, Jin L, et al. Immunohistochemical separation of follicular variant of papillary thyroid carcinoma from follicular adenoma. *Endocr Pathol*. 2006;17(3):213-223.
222. Scognamiglio T, Hyjek E, Kao J, Chen YT. Diagnostic usefulness of HBME1, galectin-3, CK19, and CITED1 and evaluation of their expression in encapsulated lesions with questionable features of papillary thyroid carcinoma. *Am J Clin Pathol*. 2006;126(5):700-708.
223. El Demellawy D, Nasr A, Alowami S. Application of CD56, P63 and CK19 immunohistochemistry in the diagnosis of papillary carcinoma of the thyroid. *Diagn Pathol*. 2008;3:5.
224. Park WY, Jeong SM, Lee JH, et al. Diagnostic value of decreased expression of CD56 protein in papillary carcinoma of the thyroid gland. *Basic Appl Pathol*. 2009;2:63-68. doi:10.1111/j.1755-9294.2009.01045.x.
225. Carney JA, Hirokawa M, Lloyd RV, et al. Hyalinizing trabecular tumors of the thyroid gland are almost all benign. *Am J Surg Pathol*. 2008;32(12):1877-1889.
226. Carney JA, Ryan J, Goellner JR. Hyalinizing trabecular adenoma of the thyroid gland. *Am J Surg Pathol*. 1987;11(8):583-591.
227. Carney JA. Hyalinizing trabecular tumors of the thyroid gland: quadruply described but not by the discoverer. *Am J Surg Pathol*. 2008;32(4):622-634.
228. McCluggage WG, Sloan JM. Hyalinizing trabecular carcinoma of thyroid gland. *Histopathology*. 1996;28(4):357-362.
229. Molberg K, Albores-Saavedra J. Hyalinizing trabecular carcinoma of the thyroid gland. *Hum Pathol*. 1994;25(2):192-197.
230. Lee S, Han BK, Ko EY, et al. The ultrasonography features of hyalinizing trabecular tumor of the thyroid are more consistent with its benign behavior than cytology or frozen section readings. *Thyroid*. 2011;21(3):253-259.
231. Rothenberg HJ, Goellner JR, Carney JA. Hyalinizing trabecular adenoma of the thyroid gland: recognition and characterization of its cytoplasmic yellow body. *Am J Surg Pathol*. 1999;23(1):118-125.
232. Rothenberg HJ, Goellner JR, Carney JA. Prevalence and incidence of cytoplasmic

yellow bodies in thyroid neoplasms. *Arch Pathol Lab Med*. 2003;127(6):715-717.
233. Gaffney RL, Carney JA, Sebo TJ, et al. Galectin-3 expression in hyalinizing trabecular tumors of the thyroid gland. *Am J Surg Pathol*. 2003;27(4):494-498.
234. Hirokawa M, Carney JA, Ohtsuki Y. Hyalinizing trabecular adenoma and papillary carcinoma of the thyroid gland express different cytokeratin patterns. *Am J Surg Pathol*. 2000;24(6):877-881.
235. Katoh R, Jasani B, Williams ED. Hyalinizing trabecular adenoma of the thyroid. A report of three cases with immunohistochemical and ultrastructural studies. *Histopathology*. 1989;15(3):211-224.
236. Hirokawa M, Carney JA. Cell membrane and cytoplasmic staining for MIB-1 in hyalinizing trabecular adenoma of the thyroid gland. *Am J Surg Pathol*. 2000;24(4):575-578.
237. Leonardo E, Volante M, Barbareschi M, et al. Cell membrane reactivity of MIB-1 antibody to Ki67 in human tumors: fact or artifact? *Appl Immunohistochem Mol Morphol*. 2007;15(2):220-223.
238. Li M, Carcangiu ML, Rosai J. Abnormal intracellular and extracellular distribution of basement membrane material in papillary carcinoma and hyalinizing trabecular tumors of the thyroid: implication for deregulation of secretory pathways. *Hum Pathol*. 1997;28(12):1366-1372.
239. LiVolsi VA. Hyalinizing trabecular tumor of the thyroid: adenoma, carcinoma, or neoplasm of uncertain malignant potential? *Am J Surg Pathol*. 2000;24(12):1683-1684.
240. Sambade C, Franssila K, Cameselle-Teijeiro J, et al. Hyalinizing trabecular adenoma: a misnomer for a peculiar tumor of the thyroid gland. *Endocr Pathol*. 1991;2:83-91.
241. Chan JK, Tse CC, Chiu HS. Hyalinizing trabecular adenoma-like lesion in multinodular goitre. *Histopathology*. 1990;16(6):611-614.
242. González-Cámpora R, Fuentes-Vaamonde E, Hevia-Vázquez A, et al. Hyalinizing trabecular carcinoma of the thyroid gland: report of two cases of follicular cell thyroid carcinoma with hyalinizing trabecular pattern. *Ultrastruct Pathol*. 1998;22:39-46.
243. Salvatore G, Chiappetta G, Nikiforov YE, et al. Molecular profile of hyalinizing trabecular tumours of the thyroid: high prevalence of RET/PTC rearrangements and absence of B-raf and N-ras point mutations. *Eur J Cancer*. 2005;41(5):816-821.
244. Sheu SY, Vogel E, Worm K, et al. Hyalinizing trabecular tumour of the thyroid-differential expression of distinct miRNAs compared with papillary thyroid carcinoma. *Histopathology*. 2010;56(5):632-640.
245. La Vecchia C, Malvezzi M, Bosetti C, et al. Thyroid cancer mortality and incidence: a global overview. *Int J Cancer*. 2015;136(9):2187-2195. doi:10.1002/ijc.29251.
246. Hundahl SA, Cady B, Cunningham MP, et al. Initial results from a prospective cohort study of 5583 cases of thyroid carcinoma treated in the united states during 1996. U.S. and German Thyroid Cancer Study Group. An American College of Surgeons Commission on Cancer Patient Care Evaluation study. *Cancer*. 2000;89(1):202-217.
247. Karagulle E, Yildirim S, Karakayali F, et al. Malignancy rates in operated patients with hyperthyroidism in an area of endemic goiter. *Int Surg*. 2009;94(4):325-329.
248. Carcangiu ML, Zampi G, Pupi A, et al. Papillary carcinoma of the thyroid. A clinicopathologic study of 241 cases treated at the University of Florence, Italy. *Cancer*. 1985;55(4):805-828.
249. Xu B, Ghossein R. Encapsulated thyroid carcinoma of follicular cell origin. *Endocr Pathol*. 2015;26(3):191-199.
250. Carcangiu ML, Zampi G, Rosai J. Papillary thyroid carcinoma: a study of its many morphologic expressions and clinical correlates. *Pathol Annu*. 1985;20(Pt 1):1-44.
251. Asioli S, Erickson LA, Sebo TJ, et al. Papillary thyroid carcinoma with prominent hobnail features: a new aggressive variant of moderately differentiated papillary carcinoma. A clinicopathologic, immunohistochemical, and molecular study of eight cases. *Am J Surg Pathol*. 2010;34(1):44-52.
252. Gray A, Doniach I. Morphology of the nuclei of papillary carcinoma of the thyroid. *Br J Cancer*. 1969;23(1):49-51.
253. Naganuma H, Murayama H, Ohtani N, et al. Optically clear nuclei in papillary carcinoma of the thyroid: demonstration of one of the fixation artifacts and its practical usefulness. *Pathol Int*. 2000;50(2):113-118.
254. Baloch ZW, LiVolsi VA. Etiology and significance of the optically clear nucleus. *Endocr Pathol*. 2002;13(4):289-299.
255. Johannessen JV, Gould VE, Jao W. The fine structure of human thyroid cancer. *Hum Pathol*. 1978;9(4):385-400.
256. Petrilli G, Fisogni S, Rosai J, et al. Nuclear bubbles (nuclear pseudo-pseudoinclusions): a pitfall in the interpretation of microscopic sections from the thyroid and other human organs. *Am J Surg Pathol*. 2017;41(1):140-141.
257. Batistatou A, Scopa CD. Pathogenesis and diagnostic significance of nuclear grooves in thyroid and other sites. *Int J Surg Pathol*. 2009;17(2):107-110.
258. Papotti M, Manazza AD, Chiarle R, Bussolati G. Confocal microscope analysis and tridimensional reconstruction of papillary thyroid carcinoma nuclei. *Virchows Arch*. 2004;444(4):350-355.
259. Asioli S, Bussolati G. Emerin immunohistochemistry reveals diagnostic features of nuclear membrane arrangement in thyroid lesions. *Histopathology*. 2009;54(5):571-579.
260. Yamashita T, Hosoda Y, Kameyama K, et al. Peculiar nuclear clearing composed of microfilaments in papillary carcinoma of the thyroid. *Cancer*. 1992;70(12):2923-2928.
261. Lee TK, Myers RT, Marshall RB, et al. The significance of mitotic rate: a retrospective study of 127 thyroid carcinomas. *Hum Pathol*. 1985;16(10):1042-1046.
262. Kondo T, Nakazawa T, Murata S, Katoh R. Stromal elastosis in papillary thyroid carcinomas. *Hum Pathol*. 2005;36(5):474-479.
263. Johannessen JV, Sobrinho-Simoes M. The origin and significance of thyroid psammoma bodies. *Lab Invest*. 1980;43(3):287-296.
264. Patchefsky AS, Hoch WS. Psammoma bodies in diffuse toxic goiter. *Am J Clin Pathol*. 1972;57(5):551-556.
265. Klinck GH, Winship T. Psammoma bodies and thyroid cancer. *Cancer*. 1959;12(4):656-662.
266. Vergilio J, Baloch ZW, LiVolsi VA. Spindle cell metaplasia of the thyroid arising in association with papillary carcinoma and follicular adenoma. *Am J Clin Pathol*. 2002;117(2):199-204.
267. Durante C, Tallini G, Puxeddu E, et al. BRAF(V600E) mutation and expression of proangiogenic molecular markers in papillary thyroid carcinomas. *Eur J Endocrinol*. 2011;165(3):455-463. doi:10.1530/EJE-11-0283.
268. Selzer G, Kahn LB, Albertyn L. Primary malignant tumors of the thyroid gland: a clinicopathologic study of 254 cases. *Cancer*. 1977;40(4):1501-1510.
269. Schroder S, Schwarz W, Rehpenning W, et al. Dendritic/Langerhans cells and prognosis in patients with papillary thyroid carcinomas. Immunocytochemical study of 106 thyroid neoplasms correlated to follow-up data. *Am J Clin Pathol*. 1988;89(3):295-300.
270. Guiter GE, DeLellis RA. Multinucleate giant cells in papillary thyroid carcinoma. A morphologic and immunohistochemical study. *Am J Clin Pathol*. 1996;106(6):765-768.
271. Katoh R, Sasaki J, Kurihara H, et al. Multiple thyroid involvement (intraglandular metastasis) in papillary thyroid carcinoma. A clinicopathologic study of 105 consecutive patients. *Cancer*. 1992;70(6):1585-1590.
272. Bansal M, Gandhi M, Ferris RL, et al. Molecular and histopathologic characteristics of multifocal papillary thyroid carcinoma. *Am J Surg Pathol*. 2013;37(10):1586-1591. doi:10.1097/PAS.0b013e318292b780.
273. Beaumont A, Ben Othman S, Fragu P. The fine structure of papillary carcinoma of the thyroid. *Histopathology*. 1981;5(4):377-388.
274. Echeverria OM, Hernandez-Pando R, Vazquez-Nin GH. Ultrastructural, cytochemical, and immunocytochemical study of nuclei and cytoskeleton of thyroid papillary carcinoma cells. *Ultrastruct Pathol*. 1998;22(3):185-197.
275. Schelfhout LJ, Van Muijen GN, Fleuren GJ. Expression of keratin 19 distinguishes papillary thyroid carcinoma from follicular carcinomas and follicular thyroid adenoma. *Am J Clin Pathol*. 1989;92(5):654-658.
276. Bejarano PA, Nikiforov YE, Swenson ES, Biddinger PW. Thyroid transcription factor-1, thyroglobulin, cytokeratin 7, and cytokeratin 20 in thyroid neoplasms. *Appl Immunohistochem Mol Morphol*. 2000;8(3):189-194.
277. Liberman E, Weidner N. Papillary and follicular neoplasms of the thyroid gland. Differential immunohistochemical staining with high-molecular-weight keratin and involucrin. *Appl Immunohistochem Mol Morphol*. 2000;8(1):42-48.
278. Miettinen M, Kovatich AJ, Karkkainen P. Keratin subsets in papillary and follicular thyroid lesions. A paraffin section analysis with diagnostic implications. *Virchows Arch*. 1997;431(6):407-413.
279. Viale G, Dell'Orto P, Coggi G, Gambacorta M. Coexpression of cytokeratins and vimentin in normal and diseased thyroid glands. Lack of diagnostic utility of vimentin immunostaining. *Am J Surg Pathol*. 1989;13:1034-1040.
280. McLaren KM, Cossar DW. The immunohistochemical localization of S100 in the diagnosis of papillary carcinoma of the thyroid. *Hum Pathol*. 1996;27(7):633-636.
281. Arif S, Blanes A, Diaz-Cano SJ. Hashimoto's thyroiditis shares features with early papillary thyroid carcinoma. *Histopathology*. 2002;41(4):357-362.
282. Chan JK, Tse CC. Mucin production in metastatic papillary carcinoma of the thyroid. *Hum Pathol*. 1988;19(2):195-200.
283. Damiani S, Fratamico F, Lapertosa G, et al. Alcian blue and epithelial membrane antigen are useful markers in differentiating benign from malignant papillae in thyroid lesions. *Virchows Arch A Pathol Anat Histopathol*. 1991;419(2):131-135.
284. Torres-Cabala C, Panizo-Santos A, Krutzsch HC, et al. Differential expression of S100C in thyroid lesions. *Int J Surg Pathol*. 2004;12(2):107-115.

285. Utrilla JC, Martin-Lacave I, San Martin MV, et al. Expression of c-erbB-2 oncoprotein in human thyroid tumours. *Histopathology*. 1999;34(1):60-65.
286. Oyama T, Ichimura E, Sano T, et al. c-Met expression of thyroid tissue with special reference to papillary carcinoma. *Pathol Int*. 1998;48(10):763-768.
287. Capper D, Preusser M, Habel A, et al. Assessment of BRAF V600E mutation status by immunohistochemistry with a mutation-specific monoclonal antibody. *Acta Neuropathol*. 2011;122(1):11-19. doi:10.1007/s00401-011-0841-z.
288. de Biase D, Cesari V, Visani M, et al. High-sensitivity BRAF mutation analysis: *BRAF* V600E is acquired early during tumor development but is heterogeneously distributed in a subset of papillary thyroid carcinomas. *J Clin Endocrinol Metab*. 2014;99(8):E1530-E1538. doi:10.1210/jc.2013-4389.
289. Mino-Kenudson M, Chirieac LR, Law K, et al. A novel, highly sensitive antibody allows for the routine detection of ALK-rearranged lung adenocarcinomas by standard immunohistochemistry. *Clin Cancer Res*. 2010;16(5):1561-1571.
290. Kimura ET, Nikiforova MN, Zhu Z, et al. High prevalence of BRAF mutations in thyroid cancer: genetic evidence for constitutive activation of the RET/PTC-RAS-BRAF signaling pathway in papillary thyroid carcinoma. *Cancer Res*. 2003;63(7):1454-1457.
291. Soares P, Trovisco V, Rocha AS, et al. BRAF mutations and RET/PTC rearrangements are alternative events in the etiopathogenesis of PTC. *Oncogene*. 2003;22(29):4578-4580.
292. Cancer Genome Atlas Research Network. Integrated genomic characterization of papillary thyroid carcinoma. *Cell*. 2014;159(3):676-690. doi:10.1016/j.cell.2014.09.050.
293. Jenkins RB, Hay ID, Herath JF, et al. Frequent occurrence of cytogenetic abnormalities in sporadic nonmedullary thyroid carcinoma. *Cancer*. 1990;66(6):1213-1220.
294. Tallini G, Tuttle RM, Ghossein RA. The history of the follicular variant of papillary thyroid carcinoma. *J Clin Endocrinol Metab*. 2017;102:15-22.
295. Nikiforov YE, Seethala RR, Tallini G, et al. Nomenclature revision for encapsulated follicular variant of papillary thyroid carcinoma: a paradigm shift to reduce overtreatment of indolent tumors. *JAMA Oncol*. 2016;2:1023-1029.
296. Zhu Z, Gandhi M, Nikiforova MN, et al. Molecular profile and clinical-pathologic features of the follicular variant of papillary thyroid carcinoma. An unusually high prevalence of ras mutations. *Am J Clin Pathol*. 2003;120:71-77.
297. Rivera M, Ricarte-Filho J, Knauf J, et al. Molecular genotyping of papillary thyroid carcinoma follicular variant according to its histological subtypes (encapsulated vs infiltrative) reveals distinct braf and ras mutation patterns. *Mod Pathol*. 2010;23:1191-1200.
298. McFadden DG, Dias-Santagata D, Sadow PM, et al. Identification of oncogenic mutations and gene fusions in the follicular variant of papillary thyroid carcinoma. *J Clin Endocrinol Metab*. 2014;99:E2457-E2462.
299. Davies H, Bignell GR, Cox C, et al. Mutations of the BRAF gene in human cancer. *Nature*. 2002;417(6892):949-954.
300. Cradic KW, Milosevic D, Rosenberg AM, et al. Mutant BRAF(T1799A) can be detected in the blood of papillary thyroid carcinoma patients and correlates with disease status. *J Clin Endocrinol Metab*. 2009;94(12):5001-5009.
301. Nikiforova MN, Kimura ET, Gandhi M, et al. BRAF mutations in thyroid tumors are restricted to papillary carcinomas and anaplastic or poorly differentiated carcinomas arising from papillary carcinomas. *J Clin Endocrinol Metab*. 2003;88(11):5399-5404.
302. Grieco M, Santoro M, Berlingieri MT, et al. PTC is a novel rearranged form of the ret proto-oncogene and is frequently detected in vivo in human thyroid papillary carcinomas. *Cell*. 1990;60:557-563.
303. Fagin JA, Wells SA Jr. Biologic and clinical perspectives on thyroid cancer. *N Engl J Med*. 2016;375(11):1054-1067. doi:10.1056/NEJMra1501993.
304. Santoro M, Dathan NA, Berlingieri MT, et al. Molecular characterization of RET/PTC3; a novel rearranged version of the RETproto-oncogene in a human thyroid papillary carcinoma. *Oncogene*. 1994;9(2):509-516.
305. Tallini G, Ghossein RA, Emanuel J, et al. Detection of thyroglobulin, thyroid peroxidase, and RET/PTC1 mRNA transcripts in the peripheral blood of patients with thyroid disease. *J Clin Oncol*. 1998;16(3):1158-1166.
306. Adeniran AJ, Zhu Z, Gandhi M, et al. Correlation between genetic alterations and microscopic features, clinical manifestations, and prognostic characteristics of thyroid papillary carcinomas. *Am J Surg Pathol*. 2006;30(2):216-222.
307. Soares P, Fonseca E, Wynford-Thomas D, Sobrinho-Simoes M. Sporadic ret-rearranged papillary carcinoma of the thyroid: a subset of slow growing, less aggressive thyroid neoplasms? *J Pathol*. 1998;185(1):71-78.
308. Tallini G, Santoro M, Helie M, et al. RET/PTC oncogene activation defines a subset of papillary thyroid carcinomas lacking evidence of progression to poorly differentiated or undifferentiated tumor phenotypes. *Clin Cancer Res*. 1998;4(2):287-294.
309. Rabes HM, Demidchik EP, Sidorow JD, et al. Pattern of radiation-induced RET and NTRK1 rearrangements in 191 post-chernobyl papillary thyroid carcinomas: biological, phenotypic, and clinical implications. *Clin Cancer Res*. 2000;6(3):1093-1103.
310. Zhu Z, Ciampi R, Nikiforova MN, et al. Prevalence of RET/PTC rearrangements in thyroid papillary carcinomas: effects of the detection methods and genetic heterogeneity. *J Clin Endocrinol Metab*. 2006;91(9):3603-3610.
311. Fusco A, Chiappetta G, Hui P, et al. Assessment of RET/PTC oncogene activation and clonality in thyroid nodules with incomplete morphological evidence of papillary carcinoma: a search for the early precursors of papillary cancer. *Am J Pathol*. 2002;160(6):2157-2167.
312. Prescott JD, Zeiger MA. The ret oncogene in papillary thyroid carcinoma. *Cancer*. 2015;121:2137-2146.
313. Bongarzone I, Vigneri P, Mariani L, et al. Ret/ntrk1 rearrangements in thyroid gland tumors of the papillary carcinoma family: correlation with clinicopathological features. *Clin Cancer Res*. 1998;4:223-228.
314. Musholt TJ, Musholt PB, Khaladj N, et al. Prognostic significance of ret and ntrk1 rearrangements in sporadic papillary thyroid carcinoma. *Surgery*. 2000;128:984-993.
315. Ricarte-Filho JC, Li S, Garcia-Rendueles ME, et al. Identification of kinase fusion oncogenes in post-chernobyl radiation-induced thyroid cancers. *J Clin Invest*. 2013;123:4935-4944.
316. Leeman-Neill RJ, Kelly LM, Liu P, et al. Etv6-ntrk3 is a common chromosomal rearrangement in radiation-associated thyroid cancer. *Cancer*. 2014;120:799-807.
317. Prasad ML, Vyas M, Horne MJ, et al. Ntrk fusion oncogenes in pediatric papillary thyroid carcinoma in northeast united states. *Cancer*. 2016;122:1097-1107.
318. Demeure MJ, Aziz M, Rosenberg R, et al. Whole-genome sequencing of an aggressive braf wild-type papillary thyroid cancer identified eml4-alk translocation as a therapeutic target. *World J Surg*. 2014;38:1296-1305.
319. Kelly LM, Barila G, Liu P, et al. Identification of the transforming strn-alk fusion as a potential therapeutic target in the aggressive forms of thyroid cancer. *Proc Natl Acad Sci USA*. 2014;111:4233-4238.
320. Perot G, Soubeyran I, Ribeiro A, et al. Identification of a recurrent STRN/ALK fusion in thyroid carcinomas. *PLoS ONE*. 2014;9:e87170.
321. Godbert Y, Henriques de Figueiredo B, Bonichon F, et al. Remarkable response to crizotinib in woman with anaplastic lymphoma kinase-rearranged anaplastic thyroid carcinoma. *J Clin Oncol*. 2015;33:e84-e87.
322. Chou A, Fraser S, Toon CW, et al. A detailed clinicopathologic study of alk-translocated papillary thyroid carcinoma. *Am J Surg Pathol*. 2015;39:652-659.
323. Tallini G, de Biase D, Durante C, et al. Braf v600e and risk stratification of thyroid microcarcinoma: a multicenter pathological and clinical study. *Mod Pathol*. 2015;28:1343-1359.
324. Flavin R, Smyth P, Crotty P, et al. BRAF T1799A mutation occurring in a case of malignant struma ovarii. *Int J Surg Pathol*. 2007;15(2):116-120.
325. Torregrossa L, Viola D, Sensi E, et al. Papillary thyroid carcinoma with rare exon 15 braf mutation has indolent behavior: a single-institution experience. *J Clin Endocrinol Metab*. 2016;101:4413-4420.
326. Ciampi R, Knauf JA, Kerler R, et al. Oncogenic akap9-braf fusion is a novel mechanism of mapk pathway activation in thyroid cancer. *J Clin Invest*. 2005;115:94-101.
327. Koperek O, Kornauth C, Capper D, et al. Immunohistochemical detection of the braf v600e-mutated protein in papillary thyroid carcinoma. *Am J Surg Pathol*. 2012;36:844-850.
328. Ibrahimpasic T, Xu B, Landa I, et al. Genomic alterations in fatal forms of non-anaplastic thyroid cancer: Identification of med12 and rbm10 as novel thyroid cancer genes associated with tumor virulence. *Clin Cancer Res*. 2017;doi:10.1158/1078-0432.CCR-17-1183.
329. Iyama K, Matsuse M, Mitsutake N, et al. Identification of three novel fusion oncogenes, sqstm1/ntrk3, afap1l2/ret, and ppfibp2/ret, in thyroid cancers of young patients in fukushima. *Thyroid*. 2017;27:811-818.
330. Nikiforova MN, Lynch RA, Biddinger PW, et al. RAS point mutations and PAX8-PPAR gamma rearrangement in thyroid tumors: evidence for distinct molecular pathways in thyroid follicular carcinoma. *J Clin Endocrinol Metab*. 2003;88(5):2318-2326.
331. Elisei R, Ugolini C, Viola D, et al. BRAF(V600E) mutation and outcome of patients with papillary thyroid carcinoma: a 15-year median follow-up study. *J Clin Endocrinol Metab*. 2008;93(10):3943-3949.
332. Xing M, Westra WH, Tufano RP, et al. BRAF mutation predicts a poorer clinical prognosis

for papillary thyroid cancer. *J Clin Endocrinol Metab*. 2005;90(12):6373-6379.
333. Elisei R, Viola D, Torregrossa L, et al. The braf(v600e) mutation is an independent, poor prognostic factor for the outcome of patients with low-risk intrathyroid papillary thyroid carcinoma: single-institution results from a large cohort study. *J Clin Endocrinol Metab*. 2012;97:4390-4398.
334. Trovisco V, Soares P, Preto A, et al. Type and prevalence of braf mutations are closely associated with papillary thyroid carcinoma histotype and patients' age but not with tumour aggressiveness. *Virchows Arch*. 2005;446:589-595.
335. Ito Y, Yoshida H, Maruo R, et al. Braf mutation in papillary thyroid carcinoma in a japanese population: Its lack of correlation with high-risk clinicopathological features and disease-free survival of patients. *Endocr J*. 2009;56:89-97.
336. Sancisi V, Nicoli D, Ragazzi M, et al. Brafv600e mutation does not mean distant metastasis in thyroid papillary carcinomas. *J Clin Endocrinol Metab*. 2012;97:E1745-E1749.
337. Basolo F, Torregrossa L, Giannini R, et al. Correlation between the BRAF V600E mutation and tumor invasiveness in papillary thyroid carcinomas smaller than 20 millimeters: analysis of 1060 cases. *J Clin Endocrinol Metab*. 2010;95(9):4197-4205.
338. Xing M, Alzahrani AS, Carson KA, et al. Association between braf v600e mutation and recurrence of papillary thyroid cancer. *J Clin Oncol*. 2015;33:42-50.
339. Tavares C, Melo M, Cameselle-Teijeiro JM, et al. Endocrine tumours. Genetic predictors of thyroid cancer outcome. *Eur J Endocrinol*. 2016;174(4):R117-R126.
340. Falchook GS, Millward M, Hong D, et al. BRAF inhibitor dabrafenib in patients with metastatic BRAF-mutant thyroid cancer. *Thyroid*. 2015;25:71-77.
341. Brose MS, Cabanillas ME, Cohen EE, et al. Vemurafenib in patients with BRAF(V600E)-positive metastatic or unresectable papillary thyroid cancer refractory to radioactive iodine: a non-randomised, multicentre, open-label, phase 2 trial. *Lancet Oncol*. 2016;17:1272-1282.
342. Jung CK, Little MP, Lubin JH, et al. The increase in thyroid cancer incidence during the last four decades is accompanied by a high frequency of braf mutations and a sharp increase in ras mutations. *J Clin Endocrinol Metab*. 2014;99:E276-E285.
343. Santoro M, Papotti M, Chiappetta G, et al. RET activation and clinicopathologic features in poorly differentiated thyroid tumors. *J Clin Endocrinol Metab*. 2002;87(1):370-379.
344. Landa I, Ibrahimpasic T, Boucai L, et al. Genomic and transcriptomic hallmarks of poorly differentiated and anaplastic thyroid cancers. *J Clin Invest*. 2016;126:1052-1066.
345. Hamatani K, Mukai M, Takahashi K, et al. Rearranged anaplastic lymphoma kinase (alk) gene in adult-onset papillary thyroid cancer amongst atomic bomb survivors. *Thyroid*. 2012;22:1153-1159.
346. Castro P, Rebocho AP, Soares RJ, et al. PAX8-PPARgamma rearrangement is frequently detected in the follicular variant of papillary thyroid carcinoma. *J Clin Endocrinol Metab*. 2006;91(1):213-220.
347. Liu X, Qu S, Liu R, et al. TERT promoter mutations and their association with BRAF V600E mutation and aggressive clinicopathological characteristics of thyroid cancer. *J Clin Endocrinol Metab*. 2014;99:E1130-E1136.
348. Melo M, da Rocha AG, Vinagre J, et al. TERT promoter mutations are a major indicator of poor outcome in differentiated thyroid carcinomas. *J Clin Endocrinol Metab*. 2014;99:E754-E765.
349. Xing M, Liu R, Liu X, et al. BRAF V600E and TERT promoter mutations cooperatively identify the most aggressive papillary thyroid cancer with highest recurrence. *J Clin Oncol*. 2014;32:2718-2726.
350. Liu R, Xing M. Tert promoter mutations in thyroid cancer. *Endocr Relat Cancer*. 2016;23:R143-R155.
351. Melo M, Gaspar da Rocha A, Batista R, et al. Tert, braf, and nras in primary thyroid cancer and metastatic disease. *J Clin Endocrinol Metab*. 2017;102:1898-1907.
352. He H, Jazdzewski K, Li W, et al. The role of microrna genes in papillary thyroid carcinoma. *Proc Natl Acad Sci USA*. 2005;102:19075-19080.
353. Aragon Han P, Weng CH, Khawaja HT, et al. Microrna expression and association with clinicopathologic features in papillary thyroid cancer: a systematic review. *Thyroid*. 2015;25:1322-1329.
354. Erler P, Keutgen XM, Crowley MJ, et al. Dicer expression and microrna dysregulation associate with aggressive features in thyroid cancer. *Surgery*. 2014;156:1342-1350, discussion 1350.
355. Chan JK. Papillary carcinoma of thyroid: classical and variants. *Histol Histopathol*. 1990;5(2):241-257.
356. Hazard JB. Small papillary carcinoma of the thyroid. A study with special reference to so-called nonencapsulated sclerosing tumor. *Lab Invest*. 1960;9:86-97.
357. Klinck GH, Winship T. Occult sclerosing carcinoma of the thyroid. *Cancer*. 1955;8(4):701-706.
358. Fink A, Tomlinson G, Freeman JL, et al. Occult micropapillary carcinoma associated with benign follicular thyroid disease and unrelated thyroid neoplasms. *Mod Pathol*. 1996;9(8):816-820.
359. Harach HR, Franssila KO, Wasenius VM. Occult papillary carcinoma of the thyroid. A "normal" finding in Finland. A systematic autopsy study. *Cancer*. 1985;56(3):531-538.
360. Lee YS, Lim H, Chang HS, Park CS. Papillary thyroid microcarcinomas are different from latent papillary thyroid carcinomas at autopsy. *J Korean Med Sci*. 2014;29:676-679.
361. Hay ID, Hutchinson ME, Gonzalez-Losada T, et al. Papillary thyroid microcarcinoma: a study of 900 cases observed in a 60-year period. *Surgery*. 2008;144:980-987, discussion 987-988.
362. Vaccarella S, Franceschi S, Bray F, et al. Worldwide thyroid-cancer epidemic? the increasing impact of overdiagnosis. *N Engl J Med*. 2016;375(7):614-617. doi:10.1056/NEJMp1604412.
363. Rosai J, LiVolsi VA, Sobrinho-Simoes M, Williams ED. Renaming papillary microcarcinoma of the thyroid gland: the Porto proposal. *Int J Surg Pathol*. 2003;11(4):249-251.
364. Oda H, Miyauchi A, Ito Y, et al. Incidences of unfavorable events in the management of low-risk papillary microcarcinoma of the thyroid by active surveillance versus immediate surgery. *Thyroid*. 2016;26(1):150-155. doi:10.1089/thy.2015.0313.
365. Piana S, Ragazzi M, Tallini G, et al. Papillary thyroid microcarcinoma with fatal outcome: evidence of tumor progression in lymph node metastases: report of 3 cases, with morphological and molecular analysis. *Hum Pathol*. 2013;44(4):556-565. doi:10.1016/j.humpath.2012.06.019.
366. Evans HL. Encapsulated papillary neoplasms of the thyroid. A study of 14 cases followed for a minimum of 10 years. *Am J Surg Pathol*. 1987;11(8):592-597.
367. Schroder S, Bocker W, Dralle H, et al. The encapsulated papillary carcinoma of the thyroid. A morphologic subtype of the papillary thyroid carcinoma. *Cancer*. 1984;54(1):90-93.
368. Chen KT, Rosai J. Follicular variant of thyroid papillary carcinoma: a clinicopathologic study of six cases. *Am J Surg Pathol*. 1977;1(2):123-130.
369. Tielens ET, Sherman SI, Hruban RH, Ladenson PW. Follicular variant of papillary thyroid carcinoma. A clinicopathologic study. *Cancer*. 1994;73(2):424-431.
370. Lindsay S. *Carcinoma of the Thyroid Gland: A Clinical and Pathologic Study of 293 Patients at the University of California Hospital*. Springfield Ill: Charles C Thomas; 1960.
371. Liu J, Singh B, Tallini G, et al. Follicular variant of papillary thyroid carcinoma: a clinicopathologic study of a problematic entity. *Cancer*. 2006;107(6):1255-1264.
372. Ivanova R, Soares P, Castro P, Sobrinho-Simoes M. Diffuse (or multinodular) follicular variant of papillary thyroid carcinoma: a clinicopathologic and immunohistochemical analysis of ten cases of an aggressive form of differentiated thyroid carcinoma. *Virchows Arch*. 2002;440(4):418-424.
373. Howitt BE, Jia Y, Sholl LM, Barletta JA. Molecular alterations in partially-encapsulated or well-circumscribed follicular variant of papillary thyroid carcinoma. *Thyroid*. 2013;23(10):1256-1262.
374. Baloch ZW, Livolsi VA. Follicular-patterned lesions of the thyroid: the bane of the pathologist. *Am J Clin Pathol*. 2002;117(1):143-150.
375. Chan J. Strict criteria should be applied in the diagnosis of encapsulated follicular variant of papillary thyroid carcinoma. *Am J Clin Pathol*. 2002;117(1):16-18.
376. Vanzati A, Mercalli F, Rosai J. The "sprinkling" sign in the follicular variant of papillary thyroid carcinoma: a clue to the recognition of this entity. *Arch Pathol Lab Med*. 2013;137(12):1707-1709. doi:10.5858/arpa.2013-0255-LE.
377. Renshaw AA, Gould EW. Why there is the tendency to "overdiagnose" the follicular variant of papillary thyroid carcinoma. *Am J Clin Pathol*. 2002;117(1):19-21.
378. Elsheikh TM, Asa SL, Chan JK, et al. Interobserver and intraobserver variation among experts in the diagnosis of thyroid follicular lesions with borderline nuclear features of papillary carcinoma. *Am J Clin Pathol*. 2008;130(5):736-744.
379. Lloyd RV, Erickson LA, Casey MB, et al. Observer variation in the diagnosis of follicular variant of papillary thyroid carcinoma. *Am J Surg Pathol*. 2004;28(10):1336-1340.
380. Widder S, Guggisberg K, Khalil M, Pasieka JL. A pathologic re-review of follicular thyroid neoplasms: the impact of changing the threshold for the diagnosis of the follicular variant of papillary thyroid carcinoma. *Surgery*. 2008;144(1):80-85.
381. Min HS, Choe G, Cho NY, et al. Immunohistochemical and molecular characteristics of follicular patterned thyroid nodules with incomplete papillary thyroid carcinoma-like nuclei. *Lab Invest*. 2009;89(suppl 1):118A.
382. Papotti M, Rodriguez J, De Pompa R, et al. Galectin-3 and HBME-1 expression in well-differentiated thyroid tumors with follicular architecture of uncertain malignant potential. *Mod Pathol*. 2005;18(4):541-546.

383. Williams ED. Guest editorial: two proposals regarding the terminology of thyroid tumors. *Int J Surg Pathol*. 2000;8(3):181-183.
384. Piana S, Frasoldati A, Di Felice E, et al. Encapsulated well-differentiated follicular-patterned thyroid carcinomas do not play a significant role in the fatality rates from thyroid carcinoma. *Am J Surg Pathol*. 2010;34:868-872.
385. Ganly I, Wang L, Tuttle RM, et al. Invasion rather than nuclear features correlates with outcome in encapsulated follicular tumors: further evidence for the reclassification of the encapsulated papillary thyroid carcinoma follicular variant. *Hum Pathol*. 2015;46(5):657-664. doi:10.1016/j.humpath.2015.01.010.
386. Nikiforov YE, Erickson LA, Nikiforova MN, et al. Solid variant of papillary thyroid carcinoma: incidence, clinical-pathologic characteristics, molecular analysis, and biologic behavior. *Am J Surg Pathol*. 2001;25(12):1478-1484.
387. Albores-Saavedra J, Gould E, Vardaman C, Vuitch F. The macrofollicular variant of papillary thyroid carcinoma: a study of 17 cases. *Hum Pathol*. 1991;22(12):1195-1205.
388. Lugli A, Terracciano LM, Oberholzer M, et al. Macrofollicular variant of papillary carcinoma of the thyroid: a histologic, cytologic, and immunohistochemical study of 3 cases and review of the literature. *Arch Pathol Lab Med*. 2004;128(1):54-58.
389. Nakamura T, Moriyama S, Nariya S, et al. Macrofollicular variant of papillary thyroid carcinoma. *Pathol Int*. 1998;48(6):467-470.
390. Thompson LD, Wieneke JA, Heffess CS. Diffuse sclerosing variant of papillary thyroid carcinoma: a clinicopathologic and immunophenotypic analysis of 22 cases. *Endocr Pathol*. 2005;16(4):331-348.
391. Carcangiu ML, Bianchi S. Diffuse sclerosing variant of papillary thyroid carcinoma. Clinicopathologic study of 15 cases. *Am J Surg Pathol*. 1989;13(12):1041-1049.
392. Chan JK, Tsui MS, Tse CH. Diffuse sclerosing variant of papillary carcinoma of the thyroid: a histological and immunohistochemical study of three cases. *Histopathology*. 1987;11(2):191-201.
393. Fujimoto Y, Obara T, Ito Y, et al. Diffuse sclerosing variant of papillary carcinoma of the thyroid. Clinical importance, surgical treatment, and follow-up study. *Cancer*. 1990;66(11):2306-2312.
394. Imamura Y, Kasahara Y, Fukuda M. Multiple brain metastases from a diffuse sclerosing variant of papillary carcinoma of the thyroid. *Endocr Pathol*. 2000;11(1):97-108.
395. Vickery AL Jr, Carcangiu ML, Johannessen JV, Sobrinho-Simoes M. Papillary carcinoma. *Semin Diagn Pathol*. 1985;2(2):90-100.
396. Akaishi J, Sugino K, Kameyama K, et al. Clinicopathologic features and outcomes in patients with diffuse sclerosing variant of papillary thyroid carcinoma. *World J Surg*. 2015;39(7):1728-1735. doi:10.1007/s00268-015-3021-9.
397. Sheu SY, Schwertheim S, Worm K, et al. Diffuse sclerosing variant of papillary thyroid carcinoma: lack of BRAF mutation but occurrence of RET/PTC rearrangements. *Mod Pathol*. 2007;20(7):779-787.
398. Berho M, Suster S. The oncocytic variant of papillary carcinoma of the thyroid: a clinicopathologic study of 15 cases. *Hum Pathol*. 1997;28(1):47-53.
399. Apel RL, Asa SL, LiVolsi VA. Papillary Hurthle cell carcinoma with lymphocytic stroma. "Warthin-like tumor" of the thyroid. *Am J Surg Pathol*. 1995;19(7):810-814.
400. Baloch ZW, LiVolsi VA. Warthin-like papillary carcinoma of the thyroid. *Arch Pathol Lab Med*. 2000;124(8):1192-1195.
401. Yeo MK, Bae JS, Lee S, et al. The Warthin-like variant of papillary thyroid carcinoma: a comparison with classic type in the patients with coexisting Hashimoto's thyroiditis. *Int J Endocrinol*. 2015;2015:456027. doi:10.1155/2015/456027.
402. Jun HH, Kim SM, Hong SW, et al. Warthin-like variant of papillary thyroid carcinoma: single institution experience. *ANZ J Surg*. 2016;86(6):492-494. doi:10.1111/ans.12725.
403. Hawk WA, Hazard JB. The many appearances of papillary carcinoma of the thyroid. *Cleve Clin Q*. 1976;43(4):207-215.
404. LiVolsi VA. Papillary carcinoma tall cell variant (TCV): a review. *Endocr Pathol*. 2010;21(1):12-15.
405. Ozaki O, Ito K, Mimura T, et al. Papillary carcinoma of the thyroid. Tall-cell variant with extensive lymphocyte infiltration. *Am J Surg Pathol*. 1996;20(6):695-698.
406. Johnson TL, Lloyd RV, Thompson NW, et al. Prognostic implications of the tall cell variant of papillary thyroid carcinoma. *Am J Surg Pathol*. 1988;12(1):22-27.
407. Morris LG, Shaha AR, Tuttle RM, et al. Tall-cell variant of papillary thyroid carcinoma: a matched-pair analysis of survival. *Thyroid*. 2010;20(2):153-158. doi:10.1089/thy.2009.0352.
408. Ghossein RA, Leboeuf R, Patel KN, et al. Tall cell variant of papillary thyroid carcinoma without extrathyroid extension: biologic behavior and clinical implications. *Thyroid*. 2007;17(7):655-661. *Cancer Res*. 2004;64(11):3780-3789.
409. Ganly I, Ibrahimpasic T, Rivera M, et al. Prognostic implications of papillary thyroid carcinoma with tall-cell features. *Thyroid*. 2014;24(4):662-670. doi:10.1089/thy.2013.0503.
410. Xu B, Ibrahimpasic T, Wang L, et al. Clinicopathologic features of fatal non-anaplastic follicular cell-derived thyroid carcinomas. *Thyroid*. 2016;26(11):1588-1597.
411. Gopal PP, Montone KT, Baloch Z, et al. The variable presentations of anaplastic spindle cell squamous carcinoma associated with tall cell variant of papillary thyroid carcinoma. *Thyroid*. 2011;21(5):493-499. doi:10.1089/thy.2010.0338.
412. Liu X, Bishop J, Shan Y, et al. Highly prevalent TERT promoter mutations in aggressive thyroid cancers. *Endocr Relat Cancer*. 2013;20(4):603-610. doi:10.1530/ERC-13-0210.
413. Evans HL. Columnar-cell carcinoma of the thyroid. A report of two cases of an aggressive variant of thyroid carcinoma. *Am J Clin Pathol*. 1986;85(1):77-80.
414. Gaertner EM, Davidson M, Wenig BM. The columnar cell variant of thyroid papillary carcinoma. Case report and discussion of an unusually aggressive thyroid papillary carcinoma. *Am J Surg Pathol*. 1995;19(8):940-947.
415. Sobrinho-Simoes M, Nesland JM, Johannessen JV. Columnar-cell carcinoma. Another variant of poorly differentiated carcinoma of the thyroid. *Am J Clin Pathol*. 1988;89(2):264-267.
416. Wenig BM, Thompson LD, Adair CF, et al. Thyroid papillary carcinoma of columnar cell type: a clinicopathologic study of 16 cases. *Cancer*. 1998;82(4):740-753.
417. Chen JH, Faquin WC, Lloyd RV, Nose V. Columnar cell variant of papillary thyroid carcinoma: a clinicopathologic, molecular and immunophenotypic study of nine cases with a review of the literature. *Mod Pathol*. 2011;24:739-749.
418. Evans HL. Encapsulated columnar-cell neoplasms of the thyroid. A report of four cases suggesting a favorable prognosis. *Am J Surg Pathol*. 1996;20(10):1205-1211.
419. Bongiovanni M, Mermod M, Canberk S, et al. Columnar cell variant of papillary thyroid carcinoma. Cytomorphological characteristics of 11 cases with histological correlation and literature review. *Cancer*. 2017;125(6):389-397.
420. Sujoy V, Pinto A, Nosé V. Columnar cell variant of papillary thyroid carcinoma: a study of 10 cases with emphasis on CDX2 expression. *Thyroid*. 2013;23(6):714-719. doi:10.1089/thy.2012.0455.
421. Bongiovanni M, Piana S, Frattini M, et al. CDX2 expression in columnar variant of papillary thyroid carcinoma. *Thyroid*. 2013;23(11):1498-1499. doi:10.1089/thy.2013.0146.
422. Tomoda C, Miyauchi A, Uruno T, et al. Cribriform-morular variant of papillary thyroid carcinoma: clue to early detection of familial adenomatous polyposis-associated colon cancer. *World J Surg*. 2004;28(9):886-889.
423. Cameselle-Teijeiro J, Chan JK. Cribriform-morular variant of papillary carcinoma: a distinctive variant representing the sporadic counterpart of familial adenomatous polyposis-associated thyroid carcinoma? *Mod Pathol*. 1999;12(4):400-411.
424. Xu B, Yoshimoto K, Miyauchi A, et al. Cribriform-morular variant of papillary thyroid carcinoma: a pathological and molecular genetic study with evidence of frequent somatic mutations in exon 3 of the beta-catenin gene. *J Pathol*. 2003;199(1):58-67.
425. Harach HR, Williams GT, Williams ED. Familial adenomatous polyposis associated thyroid carcinoma: a distinct type of follicular cell neoplasm. *Histopathology*. 1994;25(6):549-561.
426. Rossi ED, Revelli L, Martini M, et al. Cribriformmorular variant of papillary thyroid carcinoma in an 8-year-old girl: a case report with immunohistochemical and molecular testing. *Int J Surg Pathol*. 2012;20:629-632.
427. Cameselle-Teijeiro J, Menasce LP, Yap BK, et al. Cribriform-morular variant of papillary thyroid carcinoma: molecular characterization of a case with neuroendocrine differentiation and aggressive behavior. *Am J Clin Pathol*. 2009;131(1):134-142. doi:10.1309/AJCP7ULS0VSISBEB.
428. Nakatani Y, Masudo K, Nozawa A, et al. Biotin-rich, optically clear nuclei express estrogen receptor-beta: tumors with morules may develop under the influence of estrogen and aberrant beta-catenin expression. *Hum Pathol*. 2004;35(7):869-874.
429. Cameselle-Teijeiro J, Ruiz-Ponte C, Loidi L, et al. Somatic but not germline mutation of the APC gene in a case of cribriform–morular variant of papillary thyroid carcinoma. *Am J Clin Pathol*. 2001;115:486-493.
430. Motosugi U, Murata S, Nagata K, et al. Thyroid papillary carcinoma with micropapillary and hobnail growth pattern: a histological variant with intermediate malignancy? *Thyroid*. 2009;19(5):535-537. doi:10.1089/thy.2008.0271.
431. Kakudo K, Bai Y, Liu Z, et al. Classification of thyroid follicular cell tumors: with special reference to borderline lesions. *Endocr J*. 2012;59(1):1-12.
432. Lino-Silva LS, Domínguez-Malagón HR, Caro-Sánchez CH, Salcedo-Hernández RA.

Thyroid gland papillary carcinomas with "micropapillary pattern," a recently recognized poor prognostic finding: clinicopathologic and survival analysis of 7 cases. *Hum Pathol*. 2012;43(10):1596-1600. doi:10.1016/j.humpath.2011.10.027.
433. Asioli S, Erickson LA, Righi A, Lloyd RV. Papillary thyroid carcinoma with hobnail features: histopathologic criteria to predict aggressive behavior. *Hum Pathol*. 2013;44(3):320-328. doi:10.1016/j.humpath.2012.06.003.
434. Lubitz CC, Economopoulos KP, Pawlak AC, et al. Hobnail variant of papillary thyroid carcinoma: an institutional case series and molecular profile. *Thyroid*. 2014;24(6):958-965. doi:10.1089/thy.2013.0573.
435. Amacher AM, Goyal B, Lewis JS Jr, et al. Prevalence of a hobnail pattern in papillary, poorly differentiated, and anaplastic thyroid carcinoma: a possible manifestation of high-grade transformation. *Am J Surg Pathol*. 2015;39(2):260-265. doi:10.1097/PAS.0000000000000329.
436. Morandi L, Righi A, Maletta F, et al. Somatic mutation profiling of hobnail variant of papillary thyroid carcinoma. *Endocr Relat Cancer*. 2017;24(2):107-117. doi:10.1530/ERC-16-0546.
437. Chan JK, Carcangiu ML, Rosai J. Papillary carcinoma of thyroid with exuberant nodular fasciitis-like stroma. Report of three cases. *Am J Clin Pathol*. 1991;95(3):309-314.
438. Michal M, Chlumska A, Fakan F. Papillary carcinoma of thyroid with exuberant nodular fasciitis-like stroma. *Histopathology*. 1992;21(6):577-579.
439. Naganuma H, Iwama N, Nakamura Y, et al. Papillary carcinoma of the thyroid gland forming a myofibroblastic nodular tumor: report of two cases and review of the literature. *Pathol Int*. 2002;52(1):54-58.
440. Toti P, Tanganelli P, Schurfeld K, et al. Scarring in papillary carcinoma of the thyroid: report of two new cases with exuberant nodular fasciitis-like stroma. *Histopathology*. 1999;35(5):418-422.
441. Rebecchini C, Nobile A, Piana S, et al. Papillary thyroid carcinoma with nodular fasciitis-like stroma and β-catenin mutations should be renamed papillary thyroid carcinoma with desmoid-type fibromatosis. *Mod Pathol*. 2017;30(2):236-245. doi:10.1038/modpathol.2016.173.
442. Cody HS 3rd, Shah JP. Locally invasive, well-differentiated thyroid cancer. 22 years' experience at Memorial Sloan-Kettering Cancer Center. *Am J Surg*. 1981;142(4):480-483.
443. Tang W, Kakudo K, Nakamura MY, et al. Parathyroid gland involvement by papillary carcinoma of the thyroid gland. *Arch Pathol Lab Med*. 2002;126(12):1511-1514.
444. Frazell EL, Foote FW Jr. Papillary thyroid carcinoma: pathological findings in cases with and without clinical evidence of cervical node involvement. *Cancer*. 1955;8(6):1164-1166.
445. Xu B, Scognamiglio T, Cohen PR, et al. Metastatic thyroid carcinoma without identifiable primary tumor within the thyroid gland: a retrospective study of a rare phenomenon. *Hum Pathol*. 2017;65:133-139. doi:10.1016/j.humpath.2017.05.013.
446. Angeles-Angeles A, Chable-Montero F, Martinez-Benitez B, Albores-Saavedra J. Unusual metastases of papillary thyroid carcinoma: report of 2 cases. *Ann Diagn Pathol*. 2009;13(3):189-196.
447. McWilliams RR, Giannini C, Hay ID, et al. Management of brain metastases from thyroid carcinoma: a study of 16 pathologically confirmed cases over 25 years. *Cancer*. 2003;98(2):356-362.
448. Pucci A, Suppo M, Lucchesi G, et al. Papillary thyroid carcinoma presenting as a solitary soft tissue arm metastasis in an elderly hyperthyroid patient. Case report and review of the literature. *Virchows Arch*. 2006;448(6):857-861.
449. Hoie J, Stenwig AE, Kullmann G, Lindegaard M. Distant metastases in papillary thyroid cancer. A review of 91 patients. *Cancer*. 1988;61(1):1-6.
450. DeGroot LJ, Kaplan EL, McCormick M, Straus FH. Natural history, treatment, and course of papillary thyroid carcinoma. *J Clin Endocrinol Metabol*. 1990;71(2):414-424.
451. McConahey WM, Hay ID, Woolner LB, et al. Papillary thyroid cancer treated at the Mayo Clinic, 1946 through 1970: initial manifestations, pathologic findings, therapy, and outcome. *Mayo Clin Proc*. 1986;61(12):978-996.
452. Cady B. Papillary carcinoma of the thyroid. *Semin Surg Oncol*. 1991;7(2):81-86.
453. Vini L, Hyer SL, Marshall J, et al. Long-term results in elderly patients with differentiated thyroid carcinoma. *Cancer*. 2003;97(11):2736-2742.
454. Collini P, Mattavelli F, Pellegrinelli A, et al. Papillary carcinoma of the thyroid gland of childhood and adolescence: morphologic subtypes, biologic behavior and prognosis: a clinicopathologic study of forty two sporadic cases treated at a single institution during a 30-year period. *Am J Surg Pathol*. 2006;30:1420-1426.
455. Torres J, Volpato RD, Power EG, et al. Thyroid cancer. Survival in 148 cases followed for 10 years or more. *Cancer*. 1985;56(9):2298-2304.
456. Utiger RD. Follow-up of patients with thyroid carcinoma. *N Engl J Med*. 1997;337(13):928-930.
457. Cady B. Staging in thyroid carcinoma. *Cancer*. 1998;83(5):844-847.
458. Lerch H, Schober O, Kuwert T, Saur HB. Survival of differentiated thyroid carcinoma studied in 500 patients. *J Clin Oncol*. 1997;15(5):2067-2075.
459. Acharya S, Sarafoglou K, LaQuaglia M, et al. Thyroid neoplasms after therapeutic radiation for malignancies during childhood or adolescence. *Cancer*. 2003;97(10):2397-2403.
460. LiVolsi VA. Papillary neoplasms of the thyroid. Pathologic and prognostic features. *Am J Clin Pathol*. 1992;97(3):426-434.
461. Mai KT, Perkins DG, Yazdi HM, et al. Infiltrating papillary thyroid carcinoma: review of 134 cases of papillary carcinoma. *Arch Pathol Lab Med*. 1998;122(2):166-171.
462. Randolph GW, Duh QY, Heller KS, et al. The prognostic significance of nodal metastases from papillary thyroid carcinoma can be stratified based on the size and number of metastatic lymph nodes, as well as the presence of extranodal extension. *Thyroid*. 2012;22(11):1144-1152.
463. Ricarte-Filho J, Ganly I, Rivera M, et al. Papillary thyroid carcinomas with cervical lymph node metastases can be stratified into clinically relevant prognostic categories using oncogenic BRAF, the number of nodal metastases, and extra-nodal extension. *Thyroid*. 2012;22(6):575-584. doi:10.1089/thy.2011.0431.
464. Yamashita H, Noguchi S, Murakami N, et al. Extracapsular invasion of lymph node metastasis is an indicator of distant metastasis and poor prognosis in patients with thyroid papillary carcinoma. *Cancer*. 1997;80(12):2268-2272.
465. Yamashita H, Noguchi S, Murakami N, et al. Extracapsular invasion of lymph node metastasis. A good indicator of disease recurrence and poor prognosis in patients with thyroid microcarcinoma. *Cancer*. 1999;86(5):842-849.
466. Du E, Wenig BM, Su HK, et al. Inter-observer variation in the pathologic identification of extranodal extension in nodal metastasis from papillary thyroid carcinoma. *Thyroid*. 2016;26(6):816-819. doi:10.1089/thy.2015.0551.
467. Schlumberger M, Tubiana M, De Vathaire F, et al. Long-term results of treatment of 283 patients with lung and bone metastases from differentiated thyroid carcinoma. *J Clin Endocrinol Metabol*. 1986;63(4):960-967.
468. Motoyama T, Watanabe H. Simultaneous squamous cell carcinoma and papillary adenocarcinoma of the thyroid gland. *Hum Pathol*. 1983;14(11):1009-1010.
469. Akslen LA, LiVolsi VA. Prognostic significance of histologic grading compared with subclassification of papillary thyroid carcinoma. *Cancer*. 2000;88(8):1902-1908.
470. Sobrinho-Simoes M. Hail to the histologic grading of papillary thyroid carcinoma? *Cancer*. 2000;88(8):1766-1768.
471. Hiltzik D, Carlson DL, Tuttle RM, et al. Poorly differentiated thyroid carcinomas defined on the basis of mitosis and necrosis: a clinicopathologic study of 58 patients. *Cancer*. 2006;106(6):1286-1295.
472. Akslen LA, Livolsi VA. Increased angiogenesis in papillary thyroid carcinoma but lack of prognostic importance. *Hum Pathol*. 2000;31(4):439-442.
473. Franssila KO, Ackerman LV, Brown CL, Hedinger CE. Follicular carcinoma. *Semin Diagn Pathol*. 1985;2(2):101-122.
474. Giusiano-Courcambeck S, Denizot A, Secq V, et al. Pure spindle cell follicular carcinoma of the thyroid. *Thyroid*. 2008;18(9):1023-1025. doi:10.1089/thy.2008.0058.
475. Cameselle-Teijeiro J, Pardal F, Eloy C, et al. Follicular thyroid carcinoma with an unusual glomeruloid pattern of growth. *Hum Pathol*. 2008;39(10):1540-1547.
476. Johannessen JV, Sobrinho-Simóes M, Finseth I, Pilström L. Ultrastructural morphometry of thyroid neoplasms. *Am J Clin Pathol*. 1983;79(2):166-171.
477. Kroll TG, Sarraf P, Pecciarini L, et al. PAX8-PPARgamma1 fusion oncogene in human thyroid carcinoma [corrected]. *Science (New York, NY)*. 2000;289(5483):1357-1360.
478. Roque L, Clode A, Belge G, et al. Follicular thyroid carcinoma: chromosome analysis of 19 cases. *Genes Chromosomes Cancer*. 1998;21(3):250-255.
479. Ribeiro FR, Meireles AM, Rocha AS, Teixeira MR. Conventional and molecular cytogenetics of human non-medullary thyroid carcinoma: characterization of eight cell line models and review of the literature on clinical samples. *BMC Cancer*. 2008;8:371. doi:10.1186/1471-2407-8-371.
480. Castro P, Eknaes M, Teixeira MR, et al. Adenomas and follicular carcinomas of the thyroid display two major patterns of chromosomal changes. *J Pathol*. 2005;206(3):305-311.
481. Ward LS, Brenta G, Medvedovic M, Fagin JA. Studies of allelic loss in thyroid tumors reveal major differences in chromosomal instability between papillary and follicular carcinomas. *J Clin Endocrinol Metabol*. 1998;83(2):525-530.
482. Garcia-Rostan G, Zhao H, Camp RL, et al. ras mutations are associated with aggressive tumor phenotypes and poor prognosis in

thyroid cancer. *J Clin Oncol*. 2003;21(17):3226-3235.
483. Jang EK, Song DE, Sim SY, et al. NRAS codon 61 mutation is associated with distant metastasis in patients with follicular thyroid carcinoma. *Thyroid*. 2014;24(8):1275-1281. doi:10.1089/thy.2014.0053.
484. Wang HM, Huang YW, Huang JS, et al. Anaplastic carcinoma of the thyroid arising more often from follicular carcinoma than papillary carcinoma. *Ann Surg Oncol*. 2007;14(10):3011-3018.
485. Pita JM, Figueiredo IF, Moura MM, et al. Cell cycle deregulation and tp53 and ras mutations are major events in poorly differentiated and undifferentiated thyroid carcinomas. *J Clin Endocrinol Metab*. 2014;99:E497-E507.
486. Sahin M, Allard BL, Yates M, et al. PPARgamma staining as a surrogate for PAX8/PPARgamma fusion oncogene expression in follicular neoplasms: clinicopathological correlation and histopathological diagnostic value. *J Clin Endocrinol Metabol*. 2005;90(1):463-468.
487. Bonora E, Tallini G, Romeo G. Genetic predisposition to familial nonmedullary thyroid cancer: an update of molecular findings and state-of-the-art studies. *J Oncol*. 2010;385206:2010. doi:10.1155/2010/385206.
488. Liu Z, Hou P, Ji M, et al. Highly prevalent genetic alterations in receptor tyrosine kinases and phosphatidylinositol 3-kinase/akt and mitogen-activated protein kinase pathways in anaplastic and follicular thyroid cancers. *J Clin Endocrinol Metabol*. 2008;93(8):3106-3116.
489. Niepomniszcze H, Suarez H, Pitoia F, et al. Follicular carcinoma presenting as autonomous functioning thyroid nodule and containing an activating mutation of the TSH receptor (T620I) and a mutation of the Ki-RAS (G12C) genes. *Thyroid*. 2006;16(5):497-503.
490. Vinagre J, Almeida A, Populo H, et al. Frequency of tert promoter mutations in human cancers. *Nat Commun*. 2013;4:2185.
491. Liu T, Wang N, Cao J, et al. The age- and shorter telomere-dependent tert promoter mutation in follicular thyroid cell-derived carcinomas. *Oncogene*. 2014;33:4978-4984.
492. Cady B, Rossi R, Silverman M, Wool M. Further evidence of the validity of risk group definition in differentiated thyroid carcinoma. *Surgery*. 1985;98(6):1171-1178.
493. Goldstein NS, Czako P, Neill JS. Metastatic minimally invasive (encapsulated) follicular and Hurthle cell thyroid carcinoma: a study of 34 patients. *Mod Pathol*. 2000;13(2):123-130.
494. Thompson LD, Wieneke JA, Paal E, et al. A clinicopathologic study of minimally invasive follicular carcinoma of the thyroid gland with a review of the English literature. *Cancer*. 2001;91(3):505-524.
495. van Heerden JA, Hay ID, Goellner JR, et al. Follicular thyroid carcinoma with capsular invasion alone: a nonthreatening malignancy. *Surgery*. 1992;112(6):1130-1136, discussion 1136-1138.
496. O'Neill CJ, Vaughan L, Learoyd DL, et al. Management of follicular thyroid carcinoma should be individualised based on degree of capsular and vascular invasion. *Eur J Surg Oncol*. 2011;37(2):181-185.
497. Ito Y, Hirokawa M, Masuoka H, et al. Prognostic factors of minimally invasive follicular thyroid carcinoma: extensive vascular invasion significantly affects patient prognosis. *Endocr J*. 2013;60(5):637-642.
498. Xu B, Wang L, Tuttle RM, et al. Prognostic impact of extent of vascular invasion in low-grade encapsulated follicular cell-derived thyroid carcinomas: a clinicopathologic study of 276 cases. *Hum Pathol*. 2015;46(12):1789-1798. doi:10.1016/j.humpath.2015.08.015.
499. Lang W, Choritz H, Hundeshagen H. Risk factors in follicular thyroid carcinomas. A retrospective follow-up study covering a 14-year period with emphasis on morphological findings. *Am J Surg Pathol*. 1986;10(4):246-255.
500. Ghossein RA, Hiltzik DH, Carlson DL, et al. Prognostic factors of recurrence in encapsulated Hurthle cell carcinoma of the thyroid gland: a clinicopathologic study of 50 cases. *Cancer*. 2006;106(8):1669-1676.
501. Lee YM, Song DE, Kim TY, et al. Risk factors for distant metastasis in patients with minimally invasive follicular thyroid carcinoma. *PLoS ONE*. 2016;11(5):e0155489.
502. Machens A, Holzhausen HJ, Dralle H. The prognostic value of primary tumor size in papillary and follicular thyroid carcinoma. *Cancer*. 2005;103(11):2269-2273.
503. Clerici T, Kolb W, Beutner U, et al. Diagnosis and treatment of small follicular thyroid carcinomas. *Br J Surg*. 2010;97(6):839-844.
504. Fonseca E, Soares P, Cardoso-Oliveira M, Sobrinho-Simoes M. Diagnostic criteria in well-differentiated thyroid carcinomas. *Endocr Pathol*. 2006;17(2):109-117.
505. Papotti M, Arrondini M, Tavaglione V, et al. Diagnostic controversies in vascular proliferations of the thyroid gland. *Endocr Pathol*. 2008;19(3):175-183.
506. Heffess CS, Thompson LD. Minimally invasive follicular thyroid carcinoma. *Endocr Pathol*. 2001;12(4):417-422.
507. Yamashina M. Follicular neoplasms of the thyroid. Total circumferential evaluation of the fibrous capsule. *Am J Surg Pathol*. 1992;16(4):392-400.
508. Hirokawa M, Carney JA, Goellner JR, et al. Observer variation of encapsulated follicular lesions of the thyroid gland. *Am J Surg Pathol*. 2002;26(11):1508-1514.
509. Tickoo SK, Pittas AG, Adler M, et al. Bone metastases from thyroid carcinoma: a histopathologic study with clinical correlates. *Arch Pathol Lab Med*. 2000;124(10):1440-1447.
510. Sugino K, Kameyama K, Ito K, et al. Outcomes and prognostic factors of 251 patients with minimally invasive follicular thyroid carcinoma. *Thyroid*. 2012;22(8):798-804.
511. Lo CY, Chan WF, Lam KY, Wan KY. Follicular thyroid carcinoma: the role of histology and staging systems in predicting survival. *Ann Surg*. 2005;242(5):708-715.
512. Farina E, Monari F, Tallini G, et al. Unusual thyroid carcinoma metastases: a case series and literature review. *Endocr Pathol*. 2016;27(1):55-64.
513. Pittas AG, Adler M, Fazzari M, et al. Bone metastases from thyroid carcinoma: clinical characteristics and prognostic variables in one hundred forty-six patients. *Thyroid*. 2000;10(3):261-268.
514. Brennan MD, Bergstralh EJ, van Heerden JA, McConahey WM. Follicular thyroid cancer treated at the Mayo Clinic, 1946 through 1970: initial manifestations, pathologic findings, therapy, and outcome. *Mayo Clin Proc*. 1991;66(1):11-22.
515. Nixon IJ, Whitcher MM, Palmer FL, et al. The impact of distant metastases at presentation on prognosis in patients with differentiated carcinoma of the thyroid gland. *Thyroid*. 2012;22(9):884-889.
516. Rivera M, Ricarte-Filho J, Patel S, et al. Encapsulated thyroid tumors of follicular cell origin with high grade features (high mitotic rate/tumor necrosis): a clinicopathologic and molecular study. *Hum Pathol*. 2010;41(2):172-180.
517. Askanazy M. Pathologish-anatomische Beiträge zur Kenntnis des Morbus Basedowii, insbesondere über die dabei auftretende Muskelerkrankung. *Dtsch Arch Klin Med*. 1898;61:118-186.
518. Tallini G. Oncocytic tumours. *Virchows Arch*. 1998;433(1):5-12. Review.
519. Ambu R, Riva A, Lai ML, et al. Scanning electron microscopy of the interior of cells in Hurthle cell tumors. *Ultrastruct Pathol*. 2000;24(4):211-219.
520. Nesland JM, Sobrinho-Simoes MA, Holm R, et al. Hurthle-cell lesions of the thyroid: a combined study using transmission electron microscopy, scanning electron microscopy, and immunocytochemistry. *Ultrastruct Pathol*. 1985;8(4):269-290.
521. Muller-Hocker J, Schafer A, Strowitzki T. Glucose transporter 4(GLUT 4) is highly expressed in mitochondria-rich oxyphil cells. *Appl Immunohistochem*. 1998;6:224-227.
522. Zimmermann FA, Mayr JA, Neureiter D, et al. Lack of complex I is associated with oncocytic thyroid tumours. *Br J Cancer*. 2009;100(9):1434-1437.
523. Mayr JA, Meierhofer D, Zimmermann F, et al. Loss of complex I due to mitochondrial DNA mutations in renal oncocytoma. *Clin Cancer Res*. 2008;14(8):2270-2275.
524. Bussolati G, Gugliotta P, Volante M, et al. Retrieved endogenous biotin: a novel marker and a potential pitfall in diagnostic immunohistochemistry. *Histopathology*. 1997;31(5):400-407.
525. Tallini G, Ladanyi M, Rosai J, Jhanwar SC. Analysis of nuclear and mitochondrial DNA alterations in thyroid and renal oncocytic tumors. *Cytogenet Cell Genet*. 1994;66(4):253-259.
526. Maximo V, Soares P, Lima J, et al. Mitochondrial DNA somatic mutations (point mutations and large deletions) and mitochondrial DNA variants in human thyroid pathology: a study with emphasis on Hurthle cell tumors. *Am J Pathol*. 2002;160(5):1857-1865.
527. Gasparre G, Porcelli AM, Bonora E, et al. Disruptive mitochondrial DNA mutations in complex I subunits are markers of oncocytic phenotype in thyroid tumors. *Proc Natl Acad Sci USA*. 2007;104(21):9001-9006.
528. Máximo V, Sobrinho-Simões M. Mitochondrial DNA 'common' deletion in Hürthle cell lesions of the thyroid. *J Pathol*. 2000;192(4):561-562.
529. Máximo V, Sores P, Rocha AS, Sobrinho-Simões M. The common deletion of mitochondrial DNA is found in goiters and thyroid tumors with and without oxyphil cell change. *Ultrastruct Pathol*. 1998;22(3):271-273.
530. Gasparre G, Bonora E, Tallini G, Romeo G. Molecular features of thyroid oncocytic tumors. *Mol Cell Endocrinol*. 2010;321(1):67-76.
531. Máximo V, Lima J, Prazeres H, et al. The biology and the genetics of Hurthle cell tumors of the thyroid. *Endocr Relat Cancer*. 2012;19(4):R131-R147.
532. Bonora E, Porcelli AM, Gasparre G, et al. Defective oxidative phosphorylation in thyroid oncocytic carcinoma is associated with pathogenic mitochondrial DNA mutations affecting complexes I and III. *Cancer Res*. 2006;66(12):6087-6096.
533. Maximo V, Botelho T, Capela J, et al. Somatic and germline mutation in GRIM-19, a dual function gene involved in mitochondrial metabolism and cell death, is linked to mitochondrion-rich (Hurthle cell) tumours of the thyroid. *Br J Cancer*. 2005;92(10):1892-1898.

534. Gasparre G, Kurelac I, Capristo M. A mutation threshold distinguishes the antitumorigenic effects of the mitochondrial gene MTND1, an oncojanus function. *Cancer Res*. 2011;71(19):6220-6229.
535. Hundahl SA, Fleming ID, Fremgen AM, Menck HR. A National Cancer Data Base report on 53,856 cases of thyroid carcinoma treated in the U.S., 1985–1995 [see commetns]. *Cancer*. 1998;83(12): 2638-2648.
536. Carcangiu ML, Bianchi S, Savino D, et al. Follicular Hurthle cell tumors of the thyroid gland. *Cancer*. 1991;68(9):1944-1953.
537. Bronner MP, LiVolsi VA. Oxyphilic (Askanazy/Hürthle cell) tumors of the thyroid. Microscopic features predict biologic behavior. *Surg Pathol*. 1988;1:137-150.
538. Erickson LA, Jin L, Goellner JR, et al. Pathologic features, proliferative activity, and cyclin D1 expression in Hurthle cell neoplasms of the thyroid. *Mod Pathol*. 2000;13(2):186-192.
539. McLeod MK, Thompson NW. Hurthle cell neoplasms of the thyroid. *Otolaryngol Clin North Am*. 1990;23(3):441-452.
540. Chen H, Nicol TL, Zeiger MA, et al. Hürthle cell neoplasms of the thyroid: are there factors predictive of malignancy? *Ann Surg*. 1998;227(4):542-546.
541. Samulski TD, Bai S, LiVolsi VA, et al. Malignant potential of small oncocytic follicular carcinoma/Hürthle cell carcinoma: an institutional experience. *Histopathology*. 2013;63(4):568-573. doi:10.1111/his.12206.
542. Papotti M, Torchio B, Grassi L, et al. Poorly differentiated oxyphilic (Hurthle cell) carcinomas of the thyroid. *Am J Surg Pathol*. 1996;20(6):686-694.
543. Dettmer M, Schmitt A, Steinert H, et al. Poorly differentiated oncocytic thyroid carcinoma–diagnostic implications and outcome. *Histopathology*. 2012;60(7):1045-1051. doi:10.1111/j.1365-2559.2012.04188.x.
544. Bai S, Baloch ZW, Samulski TD, et al. Poorly differentiated oncocytic (hürthle cell) follicular carcinoma: an institutional experience. *Endocr Pathol*. 2015;26(2):164-169. doi:10.1007/s12022-015-9367-6.
545. Kini SR. Post-fine-needle biopsy infarction of thyroid neoplasms: a review of 28 cases. *Diagn Cytopathol*. 1996;15(3):211-220.
546. Judkins AR, Roberts SA, Livolsi VA. Utility of immunohistochemistry in the evaluation of necrotic thyroid tumors. *Hum Pathol*. 1999;30(11):1373-1376.
547. Sobrinho-Simoes MA, Nesland JM, Holm R, et al. Hurthle cell and mitochondrion-rich papillary carcinomas of the thyroid gland: an ultrastructural and immunocytochemical study. *Ultrastruct Pathol*. 1985;8(2-3):131-142.
548. Mai KT, Elmontaser G, Perkins DG, et al. Benign Hurthle cell adenoma with papillary architecture: a benign lesion mimicking oncocytic papillary carcinoma. *Int J Surg Pathol*. 2005;13(1):37-41.
549. Woodford RL, Nikiforov YE, Hunt JL, et al. Encapsulated papillary oncocytic neoplasms of the thyroid: morphologic, immunohistochemical, and molecular analysis of 18 cases. *Am J Surg Pathol*. 2010;34(11):1582-1590. doi:10.1097/PAS.0b013e3181f2d820.
550. Herrera MF, Hay ID, Wu PS, et al. Hurthle cell (oxyphilic) papillary thyroid carcinoma: a variant with more aggressive biologic behavior. *World J Surg*. 1992;16(4):669-674, discussion 774-775.
551. Bishop JA, Wu G, Tufano RP, Westra WH. Histological patterns of locoregional recurrence in Hürthle cell carcinoma of the thyroid gland. *Thyroid*. 2012;22(7):690-694.
552. Chindris AM, Casler JD, Bernet VJ, et al. Clinical and molecular features of Hürthle cell carcinoma of the thyroid. *J Clin Endocrinol Metab*. 2015;100(1):55-62.
553. Goffredo P, Roman SA, Sosa JA. Hurthle cell carcinoma: a population-level analysis of 3311 patients. *Cancer*. 2013;119(3):504-511. doi:10.1002/cncr.27770.
554. Tallini G, Hsueh A, Liu S, et al. Frequent chromosomal DNA unbalance in thyroid oncocytic (Hürthle cell) neoplasms detected by comparative genomic hybridization. *Lab Invest*. 1999;79(5):547-555.
555. Erickson LA, Jalal SM, Goellner JR, et al. Analysis of Hurthle cell neoplasms of the thyroid by interphase fluorescence in situ hybridization. *Am J Surg Pathol*. 2001;25(7):911-917.
556. Dettori T, Frau DV, Lai ML, et al. Aneuploidy in oncocytic lesions of the thyroid gland: diffuse accumulation of mitochondria within the cell is associated with trisomy 7 and progressive numerical chromosomal alterations. *Genes Chromosome Cancer*. 2003;38(1):22-31.
557. Wada N, Duh QY, Miura D, et al. Chromosomal aberrations by comparative genomic hybridization in hurthle cell thyroid carcinomas are associated with tumor recurrence. *J Clin Endocrinol Metabol*. 2002;87(10):4595-4601.
558. Ganly I, Ricarte Filho J, Eng S, et al. Genomic dissection of Hurthle cell carcinoma reveals a unique class of thyroid malignancy. *J Clin Endocrinol Metabol*. 2013;98(5):E962-E972.
559. Flint A, Davenport RD, Lloyd RV, et al. Cytophotometric measurements of Hurthle cell tumors of the thyroid gland. Correlation with pathologic features and clinical behavior. *Cancer*. 1988;61(1):110-113.
560. Schark C, Fulton N, Yashiro T, et al. The value of measurement of ras oncogenes and nuclear DNA analysis in the diagnosis of Hurthle cell tumors of the thyroid. *World J Surg*. 1992;16(4):745-751, discussion 752.
561. Evangelisti C, de Biase D, Kurelac I, et al. A mutation screening of oncogenes, tumor suppressor gene TP53 and nuclear encoded mitochondrial complex I genes in oncocytic thyroid tumors. *BMC Cancer*. 2015;15:157.
562. Nikiforova MN, Wald AI, Roy S, et al. Targeted next-generation sequencing panel (ThyroSeq) for detection of mutations in thyroid cancer. *J Clin Endocrinol Metabol*. 2013;98(11):E1852-E1860.
563. Wei S, LiVolsi VA, Montone KT, et al. PTEN and TP53 Mutations in Oncocytic Follicular Carcinoma. *Endocr Pathol*. 2015;26(4):365-369.
564. Carcangiu ML, Sibley RK, Rosai J. Clear cell change in primary thyroid tumors. A study of 38 cases. *Am J Surg Pathol*. 1985;9(10):705-722.
565. Nishimura R, Noguchi M, Tsujimoto M, et al. Thyroid clear cell adenoma with marked dilatation of membranous structures: electron-microscopic study. *Ultrastruct Pathol*. 2001;25(5):361-366.
566. Schroder S, Bocker W. Clear-cell carcinomas of thyroid gland: a clinicopathological study of 13 cases. *Histopathology*. 1986;10(1):75-89.
567. Dickersin GR, Vickery AL Jr, Smith SB. Papillary carcinoma of the thyroid, oxyphil cell type, "clear cell" variant: a light- and electron-microscopic study. *Am J Surg Pathol*. 1980;4(5):501-509.
568. Mochizuki M, Saito K, Kanazawa K. Benign follicular thyroid nodule composed of signet-ring-like cells with PAS-negative thyroglobulin accumulation in dilated rough endoplasmic reticulum. *Acta Pathol Jpn*. 1992;42:111-114.
569. Variakojis D, Getz ML, Paloyan E, Straus FH. Papillary clear cell carcinoma of the thyroid gland. *Hum Pathol*. 1975;6(3):384-390.
570. Landon G, Ordonez NG. Clear cell variant of medullary carcinoma of the thyroid. *Hum Pathol*. 1985;16(8):844-847.
571. Civantos F, Albores-Saavedra J, Nadji M, Morales AR. Clear cell variant of thyroid carcinoma. *Am J Surg Pathol*. 1984;8(3):187-192.
572. Mendelsohn G. Signet-cell-simulating microfollicular adenoma of the thyroid. *Am J Surg Pathol*. 1984;8(9):705-708.
573. Schroder S, Bocker W. Signet-ring-cell thyroid tumors. Follicle cell tumors with arrest of folliculogenesis. *Am J Surg Pathol*. 1985;9(9):619-629.
574. Rigaud C, Peltier F, Bogomoletz WV. Mucin producing microfollicular adenoma of the thyroid. *J Clin Pathol*. 1985;38(3):277-280.
575. Schroder S, Husselmann H, Bocker W. Lipid-rich cell adenoma of the thyroid gland. Report of a peculiar thyroid tumour. *Virchow Archiv A Pathol Anat Histopathol*. 1984;404(1):105-108.
576. Toth K, Peter I, Kremmer T, Sugar J. Lipid-rich cell thyroid adenoma: histopathology with comparative lipid analysis. *Virchow Archiv A Pathol Anat Histopathol*. 1990;417(3):273-276.
577. Gin D, Gultekin SH, Ward RF, et al. Clear-cell follicular adenoma of ectopic thyroid in the submandibular region. *Endocr Pathol*. 1998;9(1):339-346.
578. Huang TY, Assor D. Primary squamous cell carcinoma of the thyroid gland: a report of four cases. *Am J Clin Pathol*. 1971;55(1):93-98.
579. Lam KY, Lo CY, Liu MC. Primary squamous cell carcinoma of the thyroid gland: an entity with aggressive clinical behaviour and distinctive cytokeratin expression profiles. *Histopathology*. 2001;39(3):279-286.
580. Riddle PE, Dincsoy HP. Primary squamous cell carcinoma of the thyroid associated with leukocytosis and hypercalcemia. *Arch Pathol Lab Med*. 1987;111(4):373-374.
581. Yazawa S, Toshimori H, Nakatsuru K, et al. Thyroid anaplastic carcinoma producing granulocyte-colony-stimulating factor and parathyroid hormone-related protein. *Intern Med*. 1995;34(6):584-588.
582. Sugitani I, Miyauchi A, Sugino K, et al. Prognostic factors and treatment outcomes for anaplastic thyroid carcinoma: ATC Research Consortium of Japan cohort study of 677 patients. *World J Surg*. 2012;36(6):1247-1254.
583. Carcangiu ML, Steeper T, Zampi G, Rosai J. Anaplastic thyroid carcinoma. A study of 70 cases. *Am J Clin Pathol*. 1985;83(2):135-158.
584. Eom TI, Koo BY, Kim BS, et al. Coexistence of primary squamous cell carcinoma of thyroid with classic papillary thyroid carcinoma. *Pathol Int*. 2008;58(12):797-800.
585. Bishop JA, Sharma R, Westra WH. PAX8 immunostaining of anaplastic thyroid carcinoma: a reliable means of discerning thyroid origin for undifferentiated tumors of the head and neck. *Hum Pathol*. 2011;42(12):1873-1877.
586. Franssila KO, Harach HR, Wasenius VM. Mucoepidermoid carcinoma of the thyroid. *Histopathology*. 1984;8(5):847-860.
587. Katoh R, Sugai T, Ono S, et al. Mucoepidermoid carcinoma of the thyroid gland. *Cancer*. 1990;65(9):2020-2027.
588. Mizukami Y, Matsubara F, Hashimoto T, et al. Primary mucoepidermoid carcinoma in the thyroid gland. A case report including an ultrastructural and biochemical study. *Cancer*. 1984;53(8):1741-1745.
589. Sambade C, Franssila K, Basilio-de-Oliveira CA, Sobrinho-Simões M. Mucoepidermoid

carcinoma of the thyroid revisited. *Surg Pathol*. 1990;3:271-280.
590. Baloch ZW, Solomon AC, LiVolsi VA. Primary mucoepidermoid carcinoma and sclerosing mucoepidermoid carcinoma with eosinophilia of the thyroid gland: a report of nine cases. *Mod Pathol*. 2000;13(7):802-807.
591. Wenig BM, Adair CF, Heffess CS. Primary mucoepidermoid carcinoma of the thyroid gland: a report of six cases and a review of the literature of a follicular epithelial-derived tumor. *Hum Pathol*. 1995;26(10):1099-1108.
592. Farhat NA, Faquin WC, Sadow PM. Primary mucoepidermoid carcinoma of the thyroid gland: a report of three cases and review of the literature. *Endocr Pathol*. 2013;24(4):229-233.
593. Harach HR, Vujanic GM, Jasani B. Ultimobranchial body nests in human fetal thyroid: an autopsy, histological, and immunohistochemical study in relation to solid cell nests and mucoepidermoid carcinoma of the thyroid. *J Pathol*. 1993;169(4):465-469.
594. Bondeson L, Bondeson AG, Thompson NW. Papillary carcinoma of the thyroid with mucoepidermoid features. *Am J Clin Pathol*. 1991;95(2):175-179.
595. Cameselle-Teijeiro J, Febles-Pérez C, Sobrinho-Simões M. Papillary and mucoepidermoid carcinoma of the thyroid with anaplastic transformation: a case report with histologic and immunohistochemical findings that support a provocative histogenetic hypothesis. *Pathol Res Pract*. 1995;191(12):1214-1221.
596. Tirado Y, Williams MD, Hanna EY, et al. CRTC1/MAML2 fusion transcript in high grade mucoepidermoid carcinomas of salivary and thyroid glands and Warthin's tumors: implications for histogenesis and biologic behavior. *Genes Chromosome Cancer*. 2007;46(7):708-715.
597. Fulciniti F, Vuttariello E, Calise C, et al. Combined papillary and mucoepidermoid carcinoma of the thyroid gland: a possible collision tumor diagnosed on fine-needle cytology. Report of a case with immunocytochemical and molecular correlations. *Endocr Pathol*. 2015;26(2):140-144.
598. Chan JK, Albores-Saavedra J, Battifora H, et al. Sclerosing mucoepidermoid thyroid carcinoma with eosinophilia. A distinctive low-grade malignancy arising from the metaplastic follicles of Hashimoto's thyroiditis. *Am J Surg Pathol*. 1991;15(5):438-448.
599. Albores-Saavedra J, Gu X, Luna MA. Clear cells and thyroid transcription factor I reactivity in sclerosing mucoepidermoid carcinoma of the thyroid gland. *Ann Diagn Pathol*. 2003;7(6):348-353.
600. Quiroga-Garza G, Lee JH, El-Naggar A, et al. Sclerosing mucoepidermoid carcinoma with eosinophilia of the thyroid: more aggressive than previously reported. *Hum Pathol*. 2015;46(5):725-731.
601. Geisinger KR, Steffee CH, McGee RS, et al. The cytomorphologic features of sclerosing mucoepidermoid carcinoma of the thyroid gland with eosinophilia. *Am J Clin Pathol*. 1998;109(3):294-301.
602. Solomon AC, Baloch ZW, Salhany KE, et al. Thyroid sclerosing mucoepidermoid carcinoma with eosinophilia: mimic of Hodgkin disease in nodal metastases. *Arch Pathol Lab Med*. 2000;124(3):446-449.
603. Kondo T, Kato K, Nakazawa T, et al. Mucinous carcinoma (poorly differentiated carcinoma with extensive extracellular mucin deposition) of the thyroid: a case report with immunohistochemical studies. *Hum Pathol*. 2005;36(6):698-701.
604. Mizukami Y, Nakajima H, Annen Y, et al. Mucin-producing poorly differentiated adenocarcinoma of the thyroid. A case report. *Pathol Res Pract*. 1993;189(5):608-612, discussion 612-615.
605. Sobrinho-Simoes MA, Nesland JM, Johannessen JV. A mucin-producing tumor in the thyroid gland. *Ultrastruct Pathol*. 1985;9(3-4):277-281.
606. Morikawa Y, Ishihara Y, Kawano I, et al. Cystic squamous cell carcinoma of the thyroid a possible new subgroup of intrathyroidal epithelial thymoma. *Endocr Pathol*. 1995;6(1):77-81.
607. Miyauchi A, Kuma K, Matsuzuka F, et al. Intrathyroidal epithelial thymoma: an entity distinct from squamous cell carcinoma of the thyroid. *World J Surg*. 1985;9(1):128-135.
608. Carcangiu ML, Zampi G, Rosai J. Poorly differentiated ("insular") thyroid carcinoma. A reinterpretation of Langhans' "wuchernde Struma. *Am J Surg Pathol*. 1984;8(9): 655-668.
609. Rosai J. Poorly differentiated thyroid carcinoma: introduction to the issue, its landmarks, and clinical impact. *Endocr Pathol*. 2004;15(4):293-296.
610. Rosai J, Saxen EA, Woolner L. Undifferentiated and poorly differentiated carcinoma. *Semin Diagn Pathol*. 1985;2(2):123-136.
611. Papotti M, Botto Micca F, Favero A, et al. Poorly differentiated thyroid carcinomas with primordial cell component. A group of aggressive lesions sharing insular, trabecular, and solid patterns. *Am J Surg Pathol*. 1993;17(3):291-301.
612. Volante M, et al. Poorly differentiated carcinomas of the thyroid with trabecular, insular, and solid patterns: a clinicopathologic study of 183 patients. *Cancer*. 2004;100(5):950-957.
613. Sakamoto A, Kasai N, Sugano H. Poorly differentiated carcinoma of the thyroid. A clinicopathologic entity for a high-risk group of papillary and follicular carcinomas. *Cancer*. 1983;52(10):1849-1855.
614. Cabanne F, Gérard-Marchant R, Heimann R, Williams ED. Tumeurs malignes du corps thyroïde. Problémes de diagnostic histopathologique. A propos de 692 lésions recueillies par le groupe coopérateur des cancers du corps thyroïde de l'OERTC. *Ann Anat Pathol (Paris)*. 1974;19:129-148.
615. Volante M, Collini P, Nikiforov YE, et al. Poorly differentiated thyroid carcinoma: the Turin proposal for the use of uniform diagnostic criteria and an algorithmic diagnostic approach. *Am J Surg Pathol*. 2007;31(8):1256-1264.
616. Tallini G. Poorly differentiated thyroid carcinoma. Are we there yet? *Endocr Pathol*. 2011;22(4):190-194. doi:10.1007/s12022-011-9176-5.
617. Gnemmi V, Renaud F, Do Cao C, et al. Poorly differentiated thyroid carcinomas: application of the Turin proposal provides prognostic results similar to those from the assessment of high-grade features. *Histopathology*. 2014;64(2):263-273. doi:10.1111/his.12246.
618. Asioli S, Erickson LA, Righi A, et al. Poorly differentiated carcinoma of the thyroid: validation of the Turin proposal and analysis of IMP3 expression. *Mod Pathol*. 2010;23(9):1269-1278. doi:10.1038/modpathol.2010.117.
619. Hassoun AA, Hay ID, Goellner JR, Zimmerman D. Insular thyroid carcinoma in adolescents: a potentially lethal endocrine malignancy. *Cancer*. 1997;79(5):1044-1048.
620. Ibrahimpasic T, Ghossein R, Carlson DL, et al. Outcomes in patients with poorly differentiated thyroid carcinoma. *J Clin Endocrinol Metab*. 2014;99(4):1245-1252. doi:10.1210/jc.2013-3842.
621. Fellegara G, Rosai J. Signet ring cells in a poorly differentiated Hurthle cell carcinoma of the thyroid combined with two papillary microcarcinomas. *Int J Surg Pathol*. 2007;15(4):388-390.
622. Albores-Saavedra J, Sharma S. Poorly differentiated follicular thyroid carcinoma with rhabdoid phenotype: a clinicopathologic, immunohistochemical and electron microscopic study of two cases. *Mod Pathol*. 2001;14(2):98-104.
623. Matias-Guiu X, Villanueva A, Cuatrecasas M, et al. p53 in a thyroid follicular carcinoma with foci of poorly differentiated andanaplastic carcinoma. *Pathol Res Pract*. 1996;192(12):1242-1249, discussion 1250-1251.
624. Khunamornpong S, Settakorn J, Sukpan K, et al. Poorly differentiated thyroid carcinoma arising in struma ovarii. *Case Rep Pathol*. 2015;2015:826978. doi:10.1155/2015/826978.
625. Pilotti S, Collini P, Del Bo R, et al. A novel panel of antibodies that segregates immunocytochemically poorlydifferentiated carcinoma from undifferentiated carcinoma of the thyroid gland. *Am J Surg Pathol*. 1994;18(10):1054-1064.
626. Kakudo K, Wakasa T, Ohta Y, et al. Prognostic classification of thyroid follicular cell tumors using Ki-67 labeling index: risk stratification of thyroid follicular cell carcinomas. *Endocr J*. 2015;62(1):1-12. doi:10.1507/endocrj.EJ14-0293.
627. Bongiovanni M, Bloom L, Krane JF, et al. Cytomorphologic features of poorly differentiated thyroid carcinoma: a multi-institutional analysis of 40 cases. *Cancer*. 2009;117(3):185-194.
628. Rivera M, Ghossein RA, Schoder H, et al. Histopathologic characterization of radioactive iodine-refractory fluorodeoxyglucose-positron emission tomography-positive thyroid carcinoma. *Cancer*. 2008;113(1):48-56. doi:10.1002/cncr.23515.
629. Ryder M, Ghossein RA, Ricarte-Filho JC, et al. Increased density of tumor-associated macrophages is associated with decreased survival in advanced thyroid cancer. *Endocr Relat Cancer*. 2008;15(4):1069-1074. doi:10.1677/ERC-08-0036.
630. Volante M, Rapa I, Gandhi M, et al. RAS mutations are the predominant molecular alteration in poorly differentiated thyroid carcinomas and bear prognostic impact. *J Clin Endocrinol Metabol*. 2009;94(12):4735-4741.
631. Quiros RM, Ding HG, Gattuso P, et al. Evidence that one subset of anaplastic thyroid carcinomas are derived from papillary carcinomas due to braf and p53 mutations. *Cancer*. 2005;103:2261-2268.
632. Donghi R, Longoni A, Pilotti S, et al. Gene p53 mutations are restricted to poorly differentiated and undifferentiated carcinomas of the thyroid gland. *J Clin Invest*. 1993;91(4):1753-1760.
633. Garcia-Rostan G, Camp RL, Herrero A, et al. Beta-catenin dysregulation in thyroid neoplasms: down-regulation, aberrant nuclear expression, and CTNNB1 exon 3 mutations are markers for aggressive tumor phenotypes and poor prognosis. *Am J Pathol*. 2001;158(3):987-996.
634. McIver B, Hay ID, Giuffrida DF, et al. Anaplastic thyroid carcinoma: a 50-year experience at a single institution. *Surgery*. 2001;130(6):1028-1034.
635. Dominguez-Malagon H, Flores-Flores G, Vilchis JJ. Lymphoepithelioma-like anaplastic thyroid carcinoma: report of a case not

related to Epstein-Barr virus. *Ann Diagn Pathol*. 2001;5(1):21-24.
636. Shek TW, Luk IS, Ng IO, Lo CY. Lymphoepithelioma-like carcinoma of the thyroid gland: lack of evidence of association with Epstein-Barr virus. *Hum Pathol*. 1996;27(8):851-853.
637. Blasius S, Edel G, Grunert J, et al. Anaplastic thyroid carcinoma with osteosarcomatous differentiation. *Pathol Res Pract*. 1994;190(5):507-510, discussion 511-512.
638. Olthof M, Persoon AC, Plukker JT, et al. Anaplastic thyroid carcinoma with rhabdomyoblastic differentiation: a case report with a good clinical outcome. *Endocr Pathol*. 2008;19(1):62-65.
639. Carda C, Ferrer J, Vilanova M, et al. Anaplastic carcinoma of the thyroid with rhabdomyosarcomatous differentiation: a report of two cases. *Virchows Arch*. 2005;446(1):46-51.
640. Hashimoto H, Koga S, Watanabe H, Enjoji M. Unidifferentiated carcinoma of the thyroid gland with osteoclast-like giant cells. *Acta Pathol Jpn*. 1980;30(2):323-334.
641. Gaffey MJ, Lack EE, Christ ML, Weiss LM. Anaplastic thyroid carcinoma with osteoclast-like giant cells. A clinicopathologic, immunohistochemical, and ultrastructural study. *Am J Surg Pathol*. 1991;15(2):160-168.
642. Deckard-Janatpour K, Kragel S, Teplitz RL, et al. Tumors of the pancreas with osteoclast-like and pleomorphic giant cells: an immunohistochemical and ploidy study. *Arch Pathol Lab Med*. 1998;122(3):266-272.
643. Canos JC, Serrano A, Matias-Guiu X. Paucicellular variant of anaplastic thyroid carcinoma: report of two cases. *Endocr Pathol*. 2001;12(2):157-161.
644. Wan SK, Chan JK, Tang SK. Paucicellular variant of anaplastic thyroid carcinoma. A mimic of Reidel's thyroiditis. *Am J Clin Pathol*. 1996;105(4):388-393.
645. Lai ML, Faa G, Serra S, et al. Rhabdoid tumor of the thyroid gland: a variant of anaplastic carcinoma. *Arch Pathol Lab Med*. 2005;129(3):e55-e57.
646. Newland JR, Mackay B, Hill CS Jr, Hickey RC. Anaplastic thyroid carcinoma: an ultrastructural study of 10 cases. *Ultrastruct Pathol*. 1981;2(2):121-129.
647. Ordóñez NG, El-Naggar AK, Hickey RC, Samaan NA. Anaplastic thyroid carcinoma. Immunocytochemical study of 32 cases. *Am J Clin Pathol*. 1991;96(1):15-24.
648. Miettinen M, Franssila KO. Variable expression of keratins and nearly uniform lack of thyroid transcription factor 1 in thyroid anaplastic carcinoma. *Hum Pathol*. 2000;31(9):1139-1145.
649. Soares P, Cameselle-Teijeiro J, Sobrinho-Simoes M. Immunohistochemical detection of p53 in differentiated, poorly differentiated and undifferentiated carcinomas of the thyroid. *Histopathology*. 1994;24(3):205-210.
650. Hunt JL, Tometsko M, LiVolsi VA, et al. Molecular evidence of anaplastic transformation in coexisting well-differentiated and anaplastic carcinomas of the thyroid. *Am J Surg Pathol*. 2003;27(12):1559-1564.
651. Al-Qsous W, Miller ID. Anaplastic transformation in lung metastases of differentiated papillary thyroid carcinoma: an autopsy case report and review of the literature. *Ann Diagn Pathol*. 2010;14:41-43.
652. Chetty R, Mills A, LiVolsi V. Anaplastic carcinoma of the thyroid with sclerohyaline nodules. *Endocr Pathol*. 1993;4:110-114.
653. Katoh R, Sakamoto A, Kasai N, Yagawa K. Squamous differentiation in thyroid carcinoma. With special reference to histogenesis of squamous cell carcinoma of the thyroid. *Acta Pathol Jpn*. 1989;39(5):306-312.
654. Banville NM, Timon CI, Bermingham NJ, Toner ME. Anaplastic and squamous thyroid carcinoma masquerading as primary mucosal squamous cell carcinoma of the trachea: morphologic and immunohistochemical findings. *Lab Invest*. 2009;89(suppl 1): 245A.
655. Us-Krasovec M, Golouh R, Auersperg M, et al. Anaplastic thyroid carcinoma in fine needle aspirates. *Acta Cytol*. 1996;40:953-958.
656. Kebebew E, Greenspan FS, Clark OH, et al. Anaplastic thyroid carcinoma. Treatment outcome and prognostic factors. *Cancer*. 2005;103(7):1330-1335.
657. Besic N, Hocevar M, Zgajnar J, et al. Prognostic factors in anaplastic carcinoma of the thyroid-a multivariate survival analysis of 188 patients. *Langenbecks Arch Surg*. 2005;390(3):203-208.
658. Sugitani I, Hasegawa Y, Sugasawa M, et al. Super-radical surgery for anaplastic thyroid carcinoma: a large cohort study using the Anaplastic Thyroid Carcinoma Research Consortium of Japan database. *Head Neck*. 2014;36(3):328-333. doi:10.1002/hed.23295.
659. Brignardello E, Gallo M, Baldi I, et al. Anaplastic thyroid carcinoma: clinical outcome of 30 consecutive patients referred to a single institution in the past 5 years. *Eur J Endocrinol*. 2007;156(4):425-430.
660. Yoshida A, Sugino K, Sugitani I, Miyauchi A. Anaplastic thyroid carcinomas incidentally found on postoperative pathological examination. *World J Surg*. 2014;38(9):2311-2316. doi:10.1007/s00268-014-2536-9.
661. Kunstman JW, Juhlin CC, Goh G, et al. Characterization of the mutational landscape of anaplastic thyroid cancer via whole-exome sequencing. *Hum Mol Genet*. 2015;24:2318-2329.
662. Klemi PJ, Joensuu H, Eerola E. DNA aneuploidy in anaplastic carcinoma of the thyroid gland. *Am J Clin Pathol*. 1988;89(2):154-159.
663. Dobashi Y, Sugimura H, Sakamoto A, et al. Stepwise participation of p53 gene mutation during dedifferentiation of human thyroid carcinomas. *Diag Mol Pathol*. 1994;3(1):9-14.
664. Garcia-Rostan G, Costa AM, Pereira-Castro I, et al. Mutation of the PIK3CA gene in anaplastic thyroid cancer. *Cancer Res*. 2005;65(22):10199-10207.
665. Garcia-Rostan G, Tallini G, Herrero A, et al. Frequent mutation and nuclear localization of beta-catenin in anaplastic thyroid carcinoma. *Cancer Res*. 1999;59(8):1811-1815.
666. Visone R, Pallante P, Vecchione A, et al. Specific microRNAs are downregulated in human thyroid anaplastic carcinomas. *Oncogene*. 2007;26:7590-7595.
667. Hebrant A, Floor S, Saiselet M, et al. miRNA expression in anaplastic thyroid carcinomas. *PLoS ONE*. 2014;9:e103871.
668. Hazard JB, Hawk WA, Crile G Jr. Medullary (solid) carcinoma of the thyroid; a clinicopathologic entity. *J Clin Endocrinol Metabol*. 1959;19(1):152-161.
669. Guyetant S, Dupre F, Bigorgne JC, et al. Medullary thyroid microcarcinoma: a clinicopathologic retrospective study of 38 patients with no prior familial disease. *Hum Pathol*. 1999;30(8):957-963.
670. Pillarisetty VG, Katz SC, Ghossein RA, et al. Micromedullary thyroid cancer: how micro is truly micro? *Ann Surg Oncol*. 2009;16(10):2875-2881. doi:10.1245/s10434-009-0595-1.
671. Chong GC, Beahrs OH, Sizemore GW, Woolner LH. Medullary carcinoma of the thyroid gland. *Cancer*. 1975;35(3):695-704.
672. Harach HR, Bergholm U. Medullary carcinoma of the thyroid with carcinoid-like features. *J Clin Pathol*. 1993;46(2):113-117.
673. Harach HR, Williams ED. Glandular (tubular and follicular) variants of medullary carcinoma of the thyroid. *Histopathology*. 1983;7(1):83-97.
674. Horvath E, Kovacs K, Ross RC. Medullary cancer of the thyroid gland and its possible relations to carcinoids. An ultrastructural study. *Virchows Archiv A*. 1972;356(4):281-292.
675. Papotti M, Sambataro D, Pecchioni C, Bussolati G. The pathology of medullary carcinoma of the thyroid: review of the literature and personal experience on 62 cases. *Endocr Pathol*. 1996;7(1):1-20.
676. Kakudo K, Miyauchi A, Ogihara T, et al. Medullary carcinoma of the thyroid. Giant cell type. *Arch Pathol Lab Med*. 1978;102(9):445-447.
677. Mendelsohn G, Baylin SB, Bigner SH, et al. Anaplastic variants of medullary thyroid carcinoma: a light-microscopic and immunohistochemical study. *Am J Surg Pathol*. 1980;4(4):333-341.
678. Dominguez-Malagon H, Delgado-Chavez R, Torres-Najera M, et al. Oxyphil and squamous variants of medullary thyroid carcinoma. *Cancer*. 1989;63(6):1183-1188.
679. Kakudo K, Miyauchi A, Takai S, et al. C cell carcinoma of the thyroid—papillary type. *Acta Pathol Jpn*. 1979;29(4):653-659.
680. Dominguez-Malagon H, Macias-Martinez V, Molina-Cardenas H, Suster S. Amphicrine medullary carcinoma of the thyroid with luminal differentiation: report of an immunohistochemical and ultrastructural study. *Ultrastruct Pathol*. 1997;21(6): 569-574.
681. Golouh R, Us-Krasovec M, Auersperg M, et al. Amphicrine–composite calcitonin and mucin-producing–carcinoma of the thyroid. *Ultrastruct Pathol*. 1985;8(2-3):197-206.
682. Harach HR, Bergholm U. Small cell variant of medullary carcinoma of the thyroid with neuroblastoma-like features. *Histopathology*. 1992;21(4):378-380.
683. Ikeda T, Satoh M, Azuma K, et al. Medullary thyroid carcinoma with a paraganglioma-like pattern and melanin production: a case report with ultrastructural and immunohistochemical studies. *Arch Pathol Lab Med*. 1998;122(6):555-558.
684. Marcus JN, Dise CA, LiVolsi VA. Melanin production in a medullary thyroid carcinoma. *Cancer*. 1982;49(12):2518-2526.
685. Forrest CH, Frost FA, de Boer WB, et al. Medullary carcinoma of the thyroid: accuracy of diagnosis of fine-needle aspiration cytology. *Cancer*. 1998;84(5):295-302.
686. Green I, Ali SZ, Allen EA, Zakowski MF. A spectrum of cytomorphologic variations in medullary thyroid carcinoma. Fine-needle aspiration findings in 19 cases. *Cancer Cytopathol*. 1997;81:40-44.
687. Capella C, Bordi C, Monga G, et al. Multiple endocrine cell types in thyroid medullary carcinoma. Evidence for calcitonin, somatostatin, ACTH, 5HT and small granule cells. *Virchows Arch A Pathol Anat Histol*. 1978;377:111-128.
688. Harach HR, Wilander E, Grimelius L, et al. Chromogranin A immunoreactivity compared with argyrophilia, calcitonin immunoreactivity, and amyloid as tumour markers in the histopathological diagnosis of medullary (C-cell) thyroid carcinoma. *Pathol Res Pract*. 1992;188(1-2):123-130.
689. Zaatari GS, Saigo PE, Huvos AG. Mucin production in medullary carcinoma of the

thyroid. *Arch Pathol Lab Med*. 1983;107(2):70-74.
690. Puglisi F, Cesselli D, Damante G, et al. Expression of Pax-8, p53 and bcl-2 in human benign and malignant thyroid diseases. *Anticancer Res*. 2000;20(1A):311-316.
691. Katoh R, Miyagi E, Nakamura N, et al. Expression of thyroid transcription factor-1 (TTF-1) in human C cells and medullary thyroid carcinomas. *Hum Pathol*. 2000;31(3):386-393.
692. Kimura N, Nakazato Y, Nagura H, Sasano N. Expression of intermediate filaments in neuroendocrine tumors. *Arch Pathol Lab Med*. 1990;114(5):506-510.
693. Roth KA, Bensch KG, Hoffman AR. Characterization of opioid peptides in human thyroid medullary carcinoma. *Cancer*. 1987;59(9):1594-1598.
694. Schmid KW, Kirchmair R, Ladurner D, et al. Immunohistochemical comparison of chromogranins A and B and secretogranin II with calcitonin and calcitonin gene-related peptide expression in normal, hyperplastic and neoplastic C-cells of the human thyroid. *Histopathology*. 1992;21(3):225-232.
695. Dasovic-Knezevic M, Bormer O, Holm R, et al. Carcinoembryonic antigen in medullary thyroid carcinoma: an immunohistochemical study applying six novel monoclonal antibodies. *Mod Pathol*. 1989;2(6):610-617.
696. de Micco C, Chapel F, Dor AM, et al. Thyroglobulin in medullary thyroid carcinoma: immunohistochemical study with polyclonal and monoclonal antibodies. *Hum Pathol*. 1993;24(3):256-262.
697. Lloyd RV, Sisson JC, Marangos PJ. Calcitonin, carcinoembryonic antigen and neuron-specific enolase in medullary thyroid carcinoma. An immunohistochemical study. *Cancer*. 1983;51:2234-2239.
698. Schroder S, Kloppel G. Carcinoembryonic antigen and nonspecific cross-reacting antigen in thyroid cancer. An immunocytochemical study using polyclonal and monoclonal antibodies. *Am J Surg Pathol*. 1987;11(2):100-108.
699. Colomer A, Martinez-Mas JV, Matias-Guiu X, et al. Sex-steroid hormone receptors in human medullary thyroid carcinoma. *Mod Pathol*. 1996;9(1):68-72.
700. Cvejic D, Savin S, Golubovic S, et al. Galectin-3 and carcinoembryonic antigen expression in medullary thyroid carcinoma: possible relation to tumour progression. *Histopathology*. 2001;37:530-535.
701. Engbaek F. Serotonin (5-hydroxytryptamine) in medullary thyroid carcinoma with or without pheochromocytoma. *Eur J Cancer Clin Oncol*. 1985;21(4):469-473.
702. Ghatei MA, Springall DR, Nicholl CG, et al. Gastrin-releasing peptide-like immunoreactivity in medullary thyroid carcinoma. *Am J Clin Pathol*. 1985;84(5):581-586.
703. Holm R, Sobrinho-Simoes M, Nesland JM, et al. Medullary carcinoma of the thyroid gland: an immunocytochemical study. *Ultrastruct Pathol*. 1985;8(1):25-41.
704. Komminoth P, Roth J, Saremaslani P, et al. Polysialic acid of the neural cell adhesion molecule in the human thyroid: a marker for medullary thyroid carcinoma and primary C-cell hyperplasia. An immunohistochemical study on 79 thyroid lesions. *Am J Surg Pathol*. 1994;18(4):399-411.
705. Krisch K, Krisch I, Horvat G, et al. The value of immunohistochemistry in medullary thyroid carcinoma: a systematic study of 30 cases. *Histopathology*. 1985;9(10):1077-1089.
706. Lippman SM, Mendelsohn G, Trump DL, et al. The prognostic and biological significance of cellular heterogeneity in medullary thyroid carcinoma: a study of calcitonin, L-dopa decarboxylase, and histaminase. *J Clin Endocrinol Metabol*. 1982;54(2):233-240.
707. Matsubayashi S, Yanaihara C, Ohkubo M, et al. Gastrin-releasing peptide immunoreactivity in medullary thyroid carcinoma. *Cancer*. 1984;53(11):2472-2477.
708. Mendelsohn G, Eggleston JC, Weisburger WR, et al. Calcitonin and histaminase in C-cell hyperplasia and medullary thyroid carcinoma. A light microscopic and immunohistochemical study. *Am J Pathol*. 1978;92(1):35-52.
709. Papotti M, Olivero M, Volante M, et al. Expression of hepatocyte growth factor (HGF) and its receptor (MET) in medullary carcinoma of the thyroid. *Endocr Pathol*. 2000;11(1):19-30.
710. Reubi JC, Chayvialle JA, Franc B, et al. Somatostatin receptors and somatostatin content in medullary thyroid carcinomas. *Lab Invest*. 1991;64(4):567-573.
711. Sikri KL, Varndell IM, Hamid QA, et al. Medullary carcinoma of the thyroid. An immunocytochemical and histochemical study of 25 cases using eight separate markers. *Cancer*. 1985;56(10):2481-2491.
712. Tomita T. Matrix metalloproteinases and tissue inhibitors of metalloproteinases in thyroid C-cells and medullary thyroid carcinomas. *Histopathology*. 1997;31(2):150-156.
713. Tomita T. Immunocytochemical localization of prohormone convertase 1/3 and 2 in thyroid C-Cells and medullary thyroid carcinomas. *Endocr Pathol*. 2000;11(2):165-172.
714. Uribe M, Fenoglio-Preiser CM, Grimes M, Feind C. Medullary carcinoma of the thyroid gland. Clinical, pathological, and immunohistochemical features with review of the literature. *Am J Surg Pathol*. 1985;9(8):577-594.
715. Wurzel JM, Kourides IA, Brooks JS. Medullary carcinomas of the thyroid contain immunoreactive human chorionic gonadotropin alpha subunit. *Horm Metabol Res*. 1984;16(12):677.
716. Hammami MM, Duaiji N, Mutairi G, et al. Case report of severe Cushing's syndrome in medullary thyroid cancer complicated by functional diabetes insipidus, aortic dissection, jejunal intussusception, and paraneoplastic dysautonomia: remission with sorafenib without reduction in cortisol concentration. *BMC Cancer*. 2015;15:624. doi:10.1186/s12885-015-1620-3.
717. Butler M, Khan S. Immunoreactive calcitonin in amyloid fibrils of medullary carcinoma of the thyroid gland. An immunogold staining technique. *Arch Pathol Lab Med*. 1986;110(7):647-649.
718. Erickson LA, Vrana JA, Theis J, et al. Analysis of amyloid in medullary thyroid carcinoma by mass spectrometry-based proteomic analysis. *Endocr Pathol*. 2015;26(4):291-295. doi:10.1007/s12022-015-9390-7.
719. Raue F, Kotzerke J, Reinwein D, et al. Prognostic factors in medullary thyroid carcinoma: evaluation of 741 patients from the German Medullary Thyroid Carcinoma Register. *Clin Investig*. 1993;71(1):7-12.
720. Hijazi YM, Nieman LK, Medeiros LJ. Medullary carcinoma of the thyroid as a cause of Cushing's syndrome: a case with ectopic adrenocorticotropin secretion characterized by double enzyme immunostaining. *Hum Pathol*. 1992;23(5):592-596.
721. Steinfeld CM, Moertel CG, Woolner LB. Diarrhea and medullary carcinoma of the thyroid. *Cancer*. 1973;31(5): 1237-1239.
722. White IL, Vimadalal SD, Catz B, et al. Occult medullary carcinoma of thyroid: an unusual clinical and pathologic presentation. *Cancer*. 1981;47(6):1364-1368.
723. Dvorakova S, Vaclavikova E, Sykorova V, et al. Somatic mutations in the RET proto-oncogene in sporadic medullary thyroid carcinomas. *Mol Cell Endocrinol*. 2008;284(1-2):21-27. doi:10.1016/j.mce.2007.12.016.
724. Moura MM, Cavaco BM, Pinto AE, et al. Correlation of RET somatic mutations with clinicopathological features in sporadic medullary thyroid carcinomas. *Br J Cancer*. 2009;100(11):1777-1783. doi:10.1038/sj.bjc.6605056.
725. Romei C, Ugolini C, Cosci B, et al. Low prevalence of the somatic M918T RET mutation in micro-medullary thyroid cancer. *Thyroid*. 2012;22(5):476-481. doi:10.1089/thy.2011.0358.
726. Ciampi R, Mian C, Fugazzola L, et al. Evidence of a low prevalence of RAS mutations in a large medullary thyroid cancer series. *Thyroid*. 2013;23(1):50-57. doi:10.1089/thy.2012.0207.
727. Moura MM, Cavaco BM, Leite V. RAS proto-oncogene in medullary thyroid carcinoma. *Endocr Relat Cancer*. 2015;22(5):R235-R252. doi:10.1530/ERC-15-0070.
728. Grubbs EG, Ng PK, Bui J, et al. RET fusion as a novel driver of medullary thyroid carcinoma. *J Clin Endocrinol Metab*. 2015;100(3):788-793. doi:10.1210/jc.2014-4153.
729. Ji JH, Oh YL, Hong M, et al. Identification of Driving ALK Fusion Genes and Genomic Landscape of Medullary Thyroid Cancer. *PLoS Genet*. 2015;11(8):e1005467. doi:10.1371/journal.pgen.1005467.
730. Kaserer K, Scheuba C, Neuhold N, et al. Sporadic versus familial medullary thyroid microcarcinoma: a histopathologic study of 50 consecutive patients. *Am J Surg Pathol*. 2001;25(10):1245-1251.
731. Krueger JE, Maitra A, Albores-Saavedra J. Inherited medullary microcarcinoma of the thyroid: a study of 11 cases. *Am J Surg Pathol*. 2000;24(6):853-858.
732. Bigner SH, Cox EB, Mendelsohn G, et al. Medullary carcinoma of the thyroid in the multiple endocrine neoplasia IIA syndrome. *Am J Surg Pathol*. 1981;5(5): 459-472.
733. de Groot JW, Links TP, Plukker JT, et al. RET as a diagnostic and therapeutic target in sporadic and hereditary endocrine tumors. *Endocr Rev*. 2006;27(5):535-560.
734. Eng C. Seminars in medicine of the Beth Israel Hospital, Boston. The RET proto-oncogene in multiple endocrine neoplasia type 2 and Hirschsprung's disease. *N Engl J Med*. 1996;335(13):943-951.
735. Castellone MD, Santoro M. Dysregulated RET signaling in thyroid cancer. *Endocrinol Metab Clin North Am*. 2008;37(2):363-374. doi:10.1016/j.ecl.2008.02.006.
736. Krampitz GW, Norton JA. RET gene mutations (genotype and phenotype) of multiple endocrine neoplasia type 2 and familial medullary thyroid carcinoma. *Cancer*. 2014;120(13):1920-1931. doi:10.1002/cncr.28661.
737. Matias-Guiu X. RET protooncogene analysis in the diagnosis of medullary thyroid carcinoma and multiple endocrine neoplasia type II. *Adv Anat Pathol*. 1998;5(3):196-201.
738. Wells SA Jr, Baylin SB, Leight GS, et al. The importance of early diagnosis in patients with hereditary medullary thyroid carcinoma. *Ann Surg*. 1982;195(5):595-599.
739. Elisei R, Romei C, Cosci B, et al. RET genetic screening in patients with medullary thyroid

cancer and their relatives: experience with 807 individuals at one center. *J Clin Endocrinol Metab*. 2007;92(12):4725-4729.
740. Elisei R, Cosci B, Romei C, et al. Prognostic significance of somatic RET oncogene mutations in sporadic medullary thyroid cancer: a 10-year follow-up study. *J Clin Endocrinol Metab*. 2008;93(3):682-687.
741. Wells SA Jr, Asa SL, Dralle H, et al. Revised American Thyroid Association guidelines for the management of medullary thyroid carcinoma. *Thyroid*. 2015;25(6):567-610. doi:10.1089/thy.2014.0335.
742. Machens A, Niccoli-Sire P, Hoegel J, et al. Early malignant progression of hereditary medullary thyroid cancer. *N Engl J Med*. 2003;349(16):1517-1525.
743. Hinze R, Holzhausen HJ, Gimm O, et al. Primary hereditary medullary thyroid carcinoma—C-cell morphology and correlation with preoperative calcitonin levels. *Virchows Arch*. 1998;433(3): 203-208.
744. Albores-Saavedra J, Monforte H, Nadji M, Morales AR. C-cell hyperplasia in thyroid tissue adjacent to follicular cell tumors. *Hum Pathol*. 1988;19(7):795-799.
745. Biddinger PW, Brennan MF, Rosen PP. Symptomatic C-cell hyperplasia associated with chronic lymphocytic thyroiditis. *Am J Surg Pathol*. 1991;15(6):599-604.
746. Guyetant S, Wion-Barbot N, Rousselet MC, et al. C-cell hyperplasia associated with chronic lymphocytic thyroiditis: a retrospective quantitative study of 112 cases. *Hum Pathol*. 1994;25(5):514-521.
747. Tomita T, Millard DM. C-cell hyperplasia in secondary hyperparathyroidism. *Histopathology*. 1992;21(5):469-474.
748. Janzer RC, Weber E, Hedinger C. The relation between solid cell nests and C cells of the thyroid gland: an immunohistochemical and morphometric investigation. *Cell Tissue Res*. 1979;197(2):295-312.
749. O'Connor DT, Deftos LJ. Secretion of chromogranin A by peptide-producing endocrine neoplasms. *N Engl J Med*. 1986;314(18):1145-1151.
750. Fletcher JR. Medullary (solid) carcinoma of the thyroid gland. A review of 249 cases. *Arch Surg*. 1970;100(3):257-262.
751. Kakudo K, Carney JA, Sizemore GW. Medullary carcinoma of thyroid. Biologic behavior of the sporadic and familial neoplasm. *Cancer*. 1985;55(12): 2818-2821.
752. Sweeney EC, McDonnell L, O'Brien C. Medullary carcinoma of the thyroid presenting as tumours of the pharynx and larynx. *Histopathology*. 1981;5(3): 263-275.
753. Ruppert JM, Eggleston JC, deBustros A, Baylin SB. Disseminated calcitonin-poor medullary thyroid carcinoma in a patient with calcitonin-rich primary tumor. *Am J Surg Pathol*. 1986;10(7):513-518.
754. Gharib H, McConahey WM, Tiegs RD, et al. Medullary thyroid carcinoma: clinicopathologic features and long-term follow-up of 65 patients treated during 1946 through 1970. *Mayo Clin Proc*. 1992;67(10):934-940.
755. Saad MF, Ordonez NG, Rashid RK, et al. Medullary carcinoma of the thyroid. A study of the clinical features and prognostic factors in 161 patients. *Medicine (Baltimore)*. 1984;63(6):319-342.
756. Durante C, Paciaroni A, Plasmati K, et al. Vandetanib: opening a new treatment practice in advanced medullary thyroid carcinoma. *Endocrine*. 2013;44(2):334-342. doi:10.1007/s12020-013-9943-9.
757. Nix NM, Braun K. Cabozantinib for the treatment of metastatic medullary thyroid carcinoma. *J Adv Pract Oncol*. 2014;5(1): 47-50.
758. Dadu R, Hu MN, Grubbs EG, Gagel RF. Use of tyrosine kinase inhibitors for treatment of medullary thyroid carcinoma. *Recent Results Cancer Res*. 2015;204:227-249. doi:10.1007/978-3-319-22542-5_11.
759. Roman S, Lin R, Sosa JA. Prognosis of medullary thyroid carcinoma: demographic, clinical, and pathologic predictors of survival in 1252 cases. *Cancer*. 2006;107(9):2134-2142.
760. Scopsi L, Sampietro G, Boracchi P, et al. Multivariate analysis of prognostic factors in sporadic medullary carcinoma of the thyroid. A retrospective study of 109 consecutive patients. *Cancer*. 1996;78(10):2173-2183.
761. Etit D, Faquin WC, Gaz R, et al. Histopathologic and clinical features of medullary microcarcinoma and C-cell hyperplasia in prophylactic thyroidectomies for medullary carcinoma: a study of 42 cases. *Arch Pathol Lab Med*. 2008;132(11): 1767-1773.
762. Bergholm U, Bergstrom R, Ekbom A. Long-term follow-up of patients with medullary carcinoma of the thyroid. *Cancer*. 1997;79(1):132-138.
763. Schroder S, Bocker W, Baisch H, et al. Prognostic factors in medullary thyroid carcinomas. Survival in relation to age, sex, stage, histology, immunocytochemistry, and DNA content. *Cancer*. 1988;61(4):806-816.
764. Koperek O, Scheuba C, Cherenko M, et al. Desmoplasia in medullary thyroid carcinoma: a reliable indicator of metastatic potential. *Histopathology*. 2008;52(5):623-630.
765. Franc B, Rosenberg-Bourgin M, Caillou B, et al. Medullary thyroid carcinoma: search for histological predictors of survival (109 proband cases analysis). *Hum Pathol*. 1998;29(10):1078-1084.
766. Mendelsohn G, Wells SA Jr, Baylin SB. Relationship of tissue carcinoembryonic antigen and calcitonin to tumor virulence in medullary thyroid carcinoma. An immunohistochemical study in early, localized, and virulent disseminated stages of disease. *Cancer*. 1984;54(4):657-662.
767. Saad MF, Fritsche HA Jr, Samaan NA. Diagnostic and prognostic values of carcinoembryonic antigen in medullary carcinoma of the thyroid. *J Clin Endocrinol Metab*. 1984;58(5):889-894.
768. Saad MF, Ordonez NG, Guido JJ, Samaan NA. The prognostic value of calcitonin immunostaining in medullary carcinoma of the thyroid. *J Clin Endocrinol Metab*. 1984;59(5):850-856.
769. Driman D, Murray D, Kovacs K, et al. Encapsulated medullary carcinoma of the thyroid. A morphologic study including immunocytochemistry, electron microscopy, flow cytometry, and in situ hybridization. *Am J Surg Pathol*. 1991;15(11):1089-1095.
770. Huss LJ, Mendelsohn G. Medullary carcinoma of the thyroid gland: an encapsulated variant resembling the hyalinizing trabecular (paraganglioma-like) adenoma of thyroid. *Mod Pathol*. 1990;3(5):581-585.
771. Holm R, Sobrinho-Simoes M, Nesland JM, et al. Medullary thyroid carcinoma with thyroglobulin immunoreactivity. A special entity? *Lab Invest*. 1987;57(3):258-268.
772. Pfaltz M, Hedinger CE, Muhlethaler JP. Mixed medullary and follicular carcinoma of the thyroid. *Virchows Arch A Pathol Anat Histopathol*. 1983;400(1):53-59.
773. Mizukami Y, Michigishi T, Nonomura A, et al. Mixed medullary-follicular carcinoma of the thyroid occurring in familial form. *Histopathology*. 1993;22(3):284-287.
774. Papotti M, Negro F, Carney JA, et al. Mixed medullary-follicular carcinoma of the thyroid. A morphological, immunohistochemical and in situ hybridization analysis of 11 cases. *Virchows Arch*. 1997;430(5):397-405.
775. Kostoglou-Athanassiou I, Athanassiou P, Vecchini G, et al. Mixed medullary-follicular thyroid carcinoma. Report of a case and review of the literature. *Horm Res*. 2004;61(6):300-304.
776. Zoroquiain P, Torres J, Goñi I, et al. True mixed medullary papillary carcinoma of the thyroid: a case report with low blood calcitonin levels. *Endocr Pathol*. 2012;23(3):168-171. doi:10.1007/s12022-012-9217-8.
777. Volante M, Papotti M, Roth J, et al. Mixed medullary-follicular thyroid carcinoma. Molecular evidence for a dual origin of tumor components. *Am J Pathol*. 1999;155(5):1499-1509.
778. Apel RL, Alpert LC, Rizzo A, et al. A metastasizing composite carcinoma of the thyroid with distinct medullary and papillary components. *Arch Pathol Lab Med*. 1994;118(11):1143-1147.
779. Lax SF, Beham A, Kronberger-Schonecker D, et al. Coexistence of papillary and medullary carcinoma of the thyroid gland-mixed or collision tumour? Clinicopathological analysis of three cases. *Virchows Arch*. 1994;424(4):441-447.
780. Matias-Guiu X, Caixas A, Costa I, et al. Compound medullary-papillary carcinoma of the thyroid: true mixed versus collision tumour [corrected]. *Histopathology*. 1994;25(2):183-185.
781. Pastolero GC, Coire CI, Asa SL. Concurrent medullary and papillary carcinomas of thyroid with lymph node metastases. A collision phenomenon. *Am J Surg Pathol*. 1996;20(2):245-250.
782. Shimizu M, Hirokawa M, LiVolsi VA, et al. Combined "Mixed Medullary-Follicular" and "Papillary" Carcinoma of the thyroid with lymph node metastasis. *Endocr Pathol*. 2000;11(4):353-358.
783. Gonzalez Poggioli N, Lopez Amado M, Pimentel MT. Paraganglioma of the thyroid gland: a rare entity. *Endocr Pathol*. 2009;20(1):62-65.
784. Hughes JH, El-Mofty S, Sessions D, Liapis H. Primary intrathyroidal paraganglioma with metachronous carotid body tumor: report of a case and review of the literature. *Pathol Res Pract*. 1997;193(11-12):791-796, discussion 797-799.
785. LaGuette J, Matias-Guiu X, Rosai J. Thyroid paraganglioma: a clinicopathologic and immunohistochemical study of three cases. *Am J Surg Pathol*. 1997;21(7):748-753.
786. Pelizzo MR, Conti C, Pennelli G, et al. Thyroid paraganglioma: our experience and systematic review of the literature on a rare tumor. *Am J Clin Oncol*. 2016.
787. Collina G, Maiorana A, Fano RA, et al. Medullary carcinoma of the thyroid gland with sustentacular cell-like cells in a patient with multiple endocrine neoplasia, type IIA. Report of a case with ultrastructural and immunohistochemical studies. *Arch Pathol Lab Med*. 1994;118(10):1041-1044.
788. Mitsudo SM, Grajower MM, Balbi H, Silver C. Malignant paraganglioma of the thyroid gland. *Arch Pathol Lab Med*. 1987;111(4):378-380.
789. Navaratne L, Mathew RG, Kousparos G, McCombe A. The management of locally invasive primary thyroid paraganglioma: a case report and review of the literature. *Head Neck Pathol*. 2017;11(2):139-145. doi:10.1007/s12105-016-0745-2.

790. Schmid KW, Kröll M, Hofstädter F, Ladurner D. Small cell carcinoma of the thyroid. A reclassification of cases originally diagnosed as small cell carcinomas of the thyroid. *Pathol Res Pract*. 1986;181(5):540-543.
791. Eusebi V, Damiani S, Riva C, et al. Calcitonin free oat-cell carcinoma of the thyroid gland. *Virchows Arch A Pathol Anat Histopathol*. 1990;417(3):267-271.
792. Matias-Guiu X, LaGuette J, Puras-Gil AM, Rosai J. Metastatic neuroendocrine tumors to the thyroid gland mimicking medullary carcinoma: a pathologic and immunohistochemical study of six cases. *Am J Surg Pathol*. 1997;21(7):754-762.
793. Sivrikoz E, Ozbey NC, Kaya B, et al. Neuroendocrine tumors presenting with thyroid gland metastasis: a case series. *J Med Case Rep*. 2012;6:73.
794. Cuello C, Correa P, Eisenberg H. Geographic pathology of thyroid carcinoma. *Cancer*. 1969;23(1):230-239.
795. Franssila K, Saxen E, Teppo L, et al. Incidence of different morphological types of thyroid cancer in the Nordic countries. *Acta Pathol Microbiol Scand [A]*. 1981;89(1):49-55.
796. Hedinger C. Geographic pathology of thyroid diseases. *Pathol Res Pract*. 1981;171(3-4):285-292.
797. Hofstadter F. Frequency and morphology of malignant tumours of the thyroid before and after the introduction of iodine-prophylaxis. *Virchows Arch A Pathol Anat Histol*. 1980;385(3):263-270.
798. Pettersson B, Adami HO, Wilander E, Coleman MP. Trends in thyroid cancer incidence in Sweden, 1958-1981, by histopathologic type. *Int J Cancer*. 1991;48(1):28-33.
799. Gyory F, Balazs G, Nagy EV, et al. Differentiated thyroid cancer and outcome in iodine deficiency. *Eur J Surg Oncol*. 2004;30(3):325-331.
800. Dal Maso L, Bosetti C, La Vecchia C, Franceschi S. Risk factors for thyroid cancer: an epidemiological review focused on nutritional factors. *Cancer Causes Control*. 2009;20(1):75-86. doi:10.1007/s10552-008-9219-5.
801. Sarda AK, Kapur MM. Thyroid carcinoma. A report of 206 cases from an area with endemic goitre. *Acta Oncol*. 1990;29(7):863-867.
802. Sarda AK, Kapur MM. Thyroid surgery in an area of iodine deficiency. *Head Neck*. 2005;27(5):383-389.
803. Zimmermann MB. Thyroid gland: Iodine deficiency and thyroid nodules. *Nat Rev Endocrinol*. 2014;10(12):707-708. doi:10.1038/nrendo.2014.187.
804. Zimmermann MB, Galetti V. Iodine intake as a risk factor for thyroid cancer: a comprehensive review of animal and human studies. *Thyroid Res*. 2015;8:8. doi:10.1186/s13044-015-0020-8.
805. Williams ED, Doniach I, Bjarnason O, Michie W. Thyroid cancer in an iodide rich area: a histopathological study. *Cancer*. 1977;39(1):215-222.
806. Nakamura S, Nakamura H, Mizukami Y. Thyroid Carcinoma in Japan and the West: similarities and differences. *Endocr Pathol*. 1996;7(4):251-263.
807. Hayles AB, Kennedy RL, Beahrs OH, Woolner LB. Carcinoma of the thyroid gland in children. *AMA Am J Dis Child*. 1955;90(6):705-715.
808. Bongiovanni AM, Digeorge AM. Cancer of the Thyroid in Childhood and Adolescence. *Am J Med Sci*. 1963;246:734-749.
809. Winship T, Rosvoll RV. Childhood thyroid carcinoma. *Cancer*. 1961;14:734-743.
810. Bongarzone I, Fugazzola L, Vigneri P, et al. Age-related activation of the tyrosine kinase receptor protooncogenes RET and NTRK1 in papillary thyroid carcinoma. *J Clin Endocrinol Metab*. 1996;81(5):2006-2009.
811. Farahati J, Bucsky P, Parlowsky T, et al. Characteristics of differentiated thyroid carcinoma in children and adolescents with respect to age, gender, and histology. *Cancer*. 1997;80(11):2156-2162.
812. Samuel AM, Sharma SM. Differentiated thyroid carcinomas in children and adolescents. *Cancer*. 1991;67(8):2186-2190.
813. Mizukami Y, Michigishi T, Nonomura A, et al. Carcinoma of the thyroid at a young age—a review of 23 patients. *Histopathology*. 1992;20(1):63-66.
814. Harness JK, Thompson NW, McLeod MK, et al. Differentiated thyroid carcinoma in children and adolescents. *World J Surg*. 1992;16(4):547-553, discussion 553-554.
815. Demeter JG, De Jong SA, Lawrence AM, Paloyan E. Anaplastic thyroid carcinoma: risk factors and outcome. *Surgery*. 1991;110(6):956-961, discussion 961-963.
816. Komorowski RA, Hanson GA. Morphologic changes in the thyroid following low-dose childhood radiation. *Arch Pathol Lab Med*. 1977;101(1):36-39.
817. Spitalnik PF, Straus FH 2nd. Patterns of human thyroid parenchymal reaction following low-dose childhood irradiation. *Cancer*. 1978;41(3):1098-1105.
818. Hempelmann LH, Hall WJ, Phillips M, et al. Neoplasms in persons treated with x-rays in infancy: fourth survey in 20 years. *J Natl Cancer Inst*. 1975;55(3):519-530.
819. Schneider AB, Pinsky S, Bekerman C, Ryo UY. Characteristics of 108 thyroid cancers detected by screening in a population with a history of head and neck irradiation. *Cancer*. 1980;46(5):1218-1227.
820. Calandra DB, Shah KH, Lawrence AM, Paloyan E. Total thyroidectomy in irradiated patients. A twenty-year experience in 206 patients. *Ann Surg*. 1985;202(3):356-360.
821. Wilson SD, Komorowski R, Cerletty J, et al. Radiation-associated thyroid tumors: extent of operation and pathology technique influence the apparent incidence of carcinoma. *Surgery*. 1983;94(4):663-669.
822. Schneider AB, Shore-Freedman E, Ryo UY, et al. Radiation-induced tumors of the head and neck following childhood irradiation. Prospective studies. *Medicine (Baltimore)*. 1985;64(1):1-15.
823. Schneider AB, Shore-Freedman E, Weinstein RA. Radiation-induced thyroid and other head and neck tumors: occurrence of multiple tumors and analysis of risk factors. *J Clin Endocrinol Metab*. 1986;63(1):107-112.
824. Carr RF, LiVolsi VA. Morphologic changes in the thyroid after irradiation for Hodgkin's and non-Hodgkin's lymphoma. *Cancer*. 1989;64(4):825-829.
825. Satran L, Sklar C, Dehner L, et al. Thyroid neoplasm after high-dose radiotherapy. *Am J Pediatr Hematol Oncol*. 1983;5(3):307-309.
826. LiVolsi VA, Abrosimov AA, Bogdanova T, et al. The Chernobyl thyroid cancer experience: pathology. *Clin Oncol (R Coll Radiol)*. 2011;23(4):261-267. doi:10.1016/j.clon.2011.01.160.
827. Furmanchuk AW, Averkin JI, Egloff B, et al. Pathomorphological findings in thyroid cancers of children from the Republic of Belarus: a study of 86 cases occurring between 1986 ('post-Chernobyl') and 1991. *Histopathology*. 1992;21(5):401-408.
828. Nikiforov YE, Gnepp DR. Pathomorphology of thyroid gland lesions associated with radiation exposure: the Chernobyl experience and review of the literature. *Adv Anat Pathol*. 1999;6(2):78-91.
829. Tronko MD, Bogdanova TI, Komissarenko IV, et al. Thyroid carcinoma in children and adolescents in Ukraine after the Chernobyl nuclear accident: statistical data and clinicomorphologic characteristics. *Cancer*. 1999;86(1):149-156.
830. Balonov MI, Anspaugh LR, Bouville A, Likhtarev IA. Contribution of internal exposures to the radiological consequences of the Chernobyl accident. *Radiat Prot Dosimetry*. 2007;127(1-4):491-496.
831. Saenko V, Ivanov V, Tsyb A, et al. The Chernobyl accident and its consequences. *Clin Oncol (R Coll Radiol)*. 2011;4:234-243. doi:10.1016/j.clon.2011.01.502.
832. Williams ED, Abrosimov A, Bogdanova T, et al. Morphologic characteristics of Chernobyl-related childhood papillary thyroid carcinomas are independent of radiation exposure but vary with iodine intake. *Thyroid*. 2008;18(8):847-852.
833. Cardis E, Hatch M. The Chernobyl accident—an epidemiological perspective. *Clin Oncol (R Coll Radiol)*. 2011;23(4):251-260. doi:10.1016/j.clon.2011.01.510.
834. Tronko M, Brenner AV, Bogdanova T, et al. Thyroid neoplasia risk is increased nearly 30 years after the Chernobyl accident. *Int J Cancer*. 2017;141(8):1585-1588.
835. Zablotska LB, Nadyrov EA, Polyanskaya ON, et al. Risk of thyroid follicular adenoma among children and adolescents in Belarus exposed to iodine-131 after the Chornobyl accident. *Am J Epidemiol*. 2015;182(9):781-790. doi:10.1093/aje/kwv127.
836. Williams D. Twenty years' experience with post-Chernobyl thyroid cancer. *Best Pract Res Clin Endocrinol Metab*. 2008;22(6):1061-1073. doi:10.1016/j.beem.2008.09.020.
837. Fridman M, Savva N, Krasko O, et al. Initial presentation and late results of treatment of post-Chernobyl papillary thyroid carcinoma in children and adolescents of Belarus. *J Clin Endocrinol Metab*. 2014;99(8):2932-2941. doi:10.1210/jc.2013-3131.
838. Cannan WJ, Pederson DS. Mechanisms and consequences of double-strand DNA break formation in chromatin. *J Cell Physiol*. 2016;231(1):3-14. doi:10.1002/jcp.25048.
839. Bounacer A, Wicker R, Caillou B, et al. High prevalence of activating ret proto-oncogene rearrangements, in thyroid tumors from patients who had received external radiation. *Oncogene*. 1997;15(11):1263-1273.
840. Nikiforova MN, Stringer JR, Blough R, et al. Proximity of chromosomal loci that participate in radiation-induced rearrangements in human cells. *Science*. 2000;290(5489):138-141.
841. Suzuki S, Suzuki S, Fukushima T, et al. Comprehensive survey results of childhood thyroid ultrasound examinations in Fukushima in the first four years after the Fukushima Daiichi nuclear power plant accident. *Thyroid*. 2016;26(6):843-851. doi:10.1089/thy.2015.0564.
842. Ohira T, Takahashi H, Yasumura S, et al. Fukushima Health Management Survey Group. Comparison of childhood thyroid cancer prevalence among 3 areas based on external radiation dose after the Fukushima Daiichi nuclear power plant accident: The Fukushima health management survey. *Medicine (Baltimore)*. 2016;95(35):e4472.
843. Yamashita S, Takamura N, Ohtsuru A, Suzuki S. Radiation exposure and thyroid cancer risk after the Fukushima nuclear power plant accident in comparison with the Chernobyl accident. *Radiat Prot Dosimetry*. 2016;171(1):41-46. doi:10.1093/rpd/ncw189.

844. Saenko VA, Thomas GA, Yamashita S. Meeting report: the 5th International expert symposium in Fukushima on radiation and health. *Environ Health*. 2017;16(1):3. doi:10.1186/s12940-017-0211-y.
845. Ruben Harach H. Familial nonmedullary thyroid neoplasia. *Endocr Pathol*. 2001;12(2):97-112.
846. Lote K, Andersen K, Nordal E, Brennhovd IO. Familial occurrence of papillary thyroid carcinoma. *Cancer*. 1980;46(5):1291-1297.
847. Prazeres H, Torres J, Soares P, Sobrinho-Simoes M. The familial counterparts of follicular cell—derived thyroid tumors. *Int J Surg Pathol*. 2010;18(4):233-242.
848. Peiling Yang S, Ngeow J. Familial non-medullary thyroid cancer: unraveling the genetic maze. *Endocr Relat Cancer*. 2016;23(12):R577-R595.
849. Bell B, Mazzaferri EL. Familial adenomatous polyposis (Gardner's syndrome) and thyroid carcinoma. A case report and review of the literature. *Dig Dis Sci*. 1993;38(1):185-190.
850. Collins MT, Sarlis NJ, Merino MJ, et al. Thyroid carcinoma in the McCune-Albright syndrome: contributory role of activating Gs alpha mutations. *J Clin Endocrinol Metab*. 2003;88(9):4413-4417.
851. Harned RK, Buck JL, Olmsted WW, et al. Extracolonic manifestations of the familial adenomatous polyposis syndromes. *AJR Am J Roentgenol*. 1991;156(3):481-485.
852. Ishikawa Y, Sugano H, Matsumoto T, et al. Unusual features of thyroid carcinomas in Japanese patients with Werner syndrome and possible genotype-phenotype relations to cell type and race. *Cancer*. 1999;85(6):1345-1352.
853. Lever EG, Refetoff S, Straus FH 2nd, et al. Coexisting thyroid and parathyroid disease—are they related? *Surgery*. 1983;94(6):893-900.
854. Plail RO, Bussey HJ, Glazer G, Thomson JP. Adenomatous polyposis: an association with carcinoma of the thyroid. *Br J Surg*. 1987;74(5):377-380.
855. Rutter MM, Jha P, Schultz KA, et al. DICER1 mutations and differentiated thyroid carcinoma: evidence of a direct association. *J Clin Endocrinol Metab*. 2016;101(1):1-5. doi:10.1210/jc.2015-2169.
856. Lam AK, Saremi N. Cribriform-morular variant of papillary thyroid carcinoma: a distinctive type of thyroid cancer. *Endocr Relat Cancer*. 2017;24(4):R109-R121. doi:10.1530/ERC-17-0014.
857. Nose V. Familial non-medullary thyroid carcinoma: an update. *Endocr Pathol*. 2008;19(4):226-240.
858. Narita T, Takagi K. Ataxia-telangiectasia with dysgerminoma of right ovary, papillary carcinoma of thyroid, and adenocarcinoma of pancreas. *Cancer*. 1984;54(6):1113-1116.
859. Barzilay J, Heatley GJ, Cushing GW. Benign and malignant tumors in patients with acromegaly. *Arch Intern Med*. 1991;151(8):1629-1632.
860. Hedman I, Tisell LE. Associated hyperparathyroidism and nonmedullary thyroid carcinoma: the etiologic role of radiation. *Surgery*. 1984;95(4):392-397.
861. Mazzaferri EL. Management of a solitary thyroid nodule. *N Engl J Med*. 1993;328(8):553-559.
862. Durante C, Costante G, Lucisano G, et al. The natural history of benign thyroid nodules. *JAMA*. 2015;313(9):926-935.
863. Haugen BR, Alexander EK, Bible KC, et al. 2015 American Thyroid Association Management Guidelines for Adult Patients with Thyroid Nodules and Differentiated Thyroid Cancer: The American Thyroid Association Guidelines Task Force on Thyroid Nodules and Differentiated Thyroid Cancer. *Thyroid*. 2016;26(1):1-133. doi:10.1089/thy.2015.0020.
864. Belfiore A, La Rosa GL, La Porta GA, et al. Cancer risk in patients with cold thyroid nodules: relevance of iodine intake, sex, age, and multinodularity. *Am J Med*. 1992;93(4):363-369.
865. Davis NL, Gordon M, Germann E, et al. Clinical parameters predictive of malignancy of thyroid follicular neoplasms. *Am J Surg*. 1991;161(5):567-569.
866. Curtis RE, Rowlings PA, Deeg HJ, et al. Solid cancers after bone marrow transplantation. *N Engl J Med*. 1997;336(13):897-904.
867. Singh Ospina N, Maraka S, Espinosa de Ycaza AE, et al. Prognosis of patients with benign thyroid nodules: a population-based study. *Endocrine*. 2016;54(1):148-155.
868. Brito JP, Singh-Ospina N, Gionfriddo MR, et al. Restricting ultrasound thyroid fine needle aspiration biopsy by nodule size: which tumors are we missing? A population-based study. *Endocrine*. 2016;51(3):499-505. doi:10.1007/s12020-015-0713-8.
869. Al Nofal A, Gionfriddo MR, Javed A, et al. Accuracy of thyroid nodule sonography for the detection of thyroid cancer in children: systematic review and meta-analysis. *Clin Endocrinol (Oxf)*. 2016;84(3):423-430. doi:10.1111/cen.12786.
870. Clark OH. Fine-needle aspiration biopsy and management of thyroid tumors. *Am J Clin Pathol*. 1997;108(4 suppl 1):S22-S25.
871. Greenspan FS. The role of fine-needle aspiration biopsy in the management of palpable thyroid nodules. *Am J Clin Pathol*. 1997;108(4 suppl 1):S26-S30.
872. Oertel YC. Fine-needle aspiration in the evaluation of thyroid neoplasms. *Endocr Pathol*. 1997;8(3):215-224.
873. Kuma K, Matsuzuka F, Kobayashi A, et al. Outcome of long standing solitary thyroid nodules. *World J Surg*. 1992;16(4):583-587, discussion 587-588.
874. Lo Gerfo P, Colacchio T, Caushaj F, et al. Comparison of fine-needle and coarse-needle biopsies in evaluating thyroid nodules. *Surgery*. 1982;92(5):835-838.
875. Vickery AL Jr. Needle biopsy pathology. *Clin Endocrinol Metab*. 1981;10(2):275-292.
876. Hawk WA, Crile G Jr, Hazard JB, Barrett DL. Needle biopsy of the thyroid gland. *Surg Gynecol Obstet*. 1966;122(5):1053-1065.
877. Frable WJ, Frable MA. Fine-needle aspiration biopsy of the thyroid. Histopathologic and clinical correlations. In: Fenoglio CM, Wolff M, eds. *Progress in Surgical Pathology*. Vol. 1. New York: Masson Publishing USA; 1980:105-118.
878. Gharib H. Fine-needle aspiration biopsy of thyroid nodules: advantages, limitations, and effect. *Mayo Clin Proc*. 1994;69(1):44-49.
879. Piromalli D, Martelli G, Del Prato I, et al. The role of fine needle aspiration in the diagnosis of thyroid nodules: analysis of 795 consecutive cases. *J Surg Oncol*. 1992;50(4):247-250.
880. Polyzos SA, Anastasilakis AD. Clinical complications following thyroid fine-needle biopsy: a systematic review. *Clin Endocrinol (Oxf)*. 2009;71(2):157-165. doi:10.1111/j.1365-2265.2009.03522.x.
881. Chhieng DC, Ross JS, McKenna BJ. CD44 immunostaining of thyroid fine-needle aspirates differentiates thyroid papillary carcinoma from other lesions with nuclear grooves and inclusions. *Cancer Cytopathol*. 1997;81:157-162.
882. Nasser SM, Pitman MB, Pilch BZ, Faquin WC. Fine-needle aspiration biopsy of papillary thyroid carcinoma: diagnostic utility of cytokeratin 19 immunostaining. *Cancer*. 2000;90(5):307-311.
883. Sack MJ, Astengo-Osuna C, Lin BT, et al. HBME-1 immunostaining in thyroid fine-needle aspirations: a useful marker in the diagnosis of carcinoma. *Mod Pathol*. 1997;10(7):668-674.
884. Amrikachi M, Ramzy I, Rubenfeld S, Wheeler TM. Accuracy of fine-needle aspiration of thyroid. *Arch Pathol Lab Med*. 2001;125(4):484-488.
885. Cramer H. Fine-needle aspiration cytology of the thyroid: an appraisal. *Cancer*. 2000;90(6):325-329.
886. Giard RW, Hermans J. Use and accuracy of fine-needle aspiration cytology in histologically proven thyroid carcinoma: an audit using a national nathology database. *Cancer*. 2000;90:330-334.
887. Ravetto C, Colombo L, Dottorini ME. Usefulness of fine-needle aspiration in the diagnosis of thyroid carcinoma: a retrospective study in 37,895 patients. *Cancer*. 2000;90(6):357-363.
888. Droese M. *Cytological Aspiration Biopsy of the Thyroid Gland*. Stuttgart: Schattauer-Verlag; 1980.
889. Geddie WR, Bedard YC, Strawbridge HT. Medullary carcinoma of the thyroid in fine-needle aspiration biopsies. *Am J Clin Pathol*. 1984;82(5):552-558.
890. Miller JM, Hamburger JI, Kini SR. The needle biopsy diagnosis of papillary thyroid carcinoma. *Cancer*. 1981;48(4):989-993.
891. Sironi M, Collini P, Cantaboni A. Fine needle aspiration cytology of insular thyroid carcinoma. A report of four cases. *Acta Cytol*. 1992;36(3):435-439.
892. Friedman M, Shimaoka K, Rao U, et al. Diagnosis of chronic lymphocytic thyroiditis (nodular presentation) by needle aspiration. *Acta Cytol*. 1981;25(5):513-522.
893. Damiani S, Dina R, Eusebi V. Cytologic grading of aggressive and nonaggressive variants of papillary thyroid carcinoma. *Am J Clin Pathol*. 1994;101(5):651-655.
894. Oertel YC, Oertel JE. Diagnosis of benign thyroid lesions: fine-needle aspiration and histopathologic correlation. *Ann Diagn Pathol*. 1998;2(4):250-263.
895. Cibas ES, Ali SZ. The Bethesda System For Reporting Thyroid Cytopathology. *Am J Clin Pathol*. 2009;132(5):658-665.
896. Naz S, Hashmi AA, Khurshid A, et al. Diagnostic accuracy of Bethesda system for reporting thyroid cytopathology: an institutional perspective. *Int Arch Med*. 2014;7:46. doi:10.1186/1755-7682-7-46.
897. Ozdemir D, Bestepe N, Faki S, et al. Comparison of thyroid fine needle aspiration biopsy results before and after implementation of Bethesda classification. *Cytopathology*. 2017;28(5):400-406.
898. Baloch ZW, LiVolsi VA. Post fine-needle aspiration histologic alterations of thyroid revisited. *Am J Clin Pathol*. 1999;112(3):311-316.
899. Lever EG, Refetoff S, Scherberg NH, Carr K. The influence of percutaneous fine needle aspiration on serum thyroglobulin. *J Clin Endocrinol Metab*. 1983;56(1):26-29.
900. Tsang K, Duggan MA. Vascular proliferation of the thyroid. A complication of fine-needle aspiration. *Arch Pathol Lab Med*. 1992;116(10):1040-1042.
901. Kobayashi A, Kuma K, Matsuzuka F, et al. Thyrotoxicosis after needle aspiration of thyroid cyst. *J Clin Endocrinol Metab*. 1992;75(1):21-24.
902. Alexander EK, Schorr M, Klopper J, et al. Multicenter clinical experience with the Afirma gene expression classifier. *J Clin Endocrinol Metab*. 2014;99(1):119-125. doi:10.1210/jc.2013-2482.

903. Duick DS, Klopper JP, Diggans JC, et al. The impact of benign gene expression classifier test results on the endocrinologist-patient decision to operate on patients with thyroid nodules with indeterminate fine-needle aspiration cytopathology. *Thyroid*. 2012;22(10):996-1001. doi:10.1089/thy.2012.0180.
904. Chaudhary S, Hou Y, Shen R, et al. Impact of the Afirma gene expression classifier result on the surgical management of thyroid nodules with category III/IV cytology and its correlation with surgical outcome. *Acta Cytol*. 2016;60(3):205-210. doi:10.1159/000446797.
905. Aragon Han P, Olson MT, Fazeli R, et al. The impact of molecular testing on the surgical management of patients with thyroid nodules. *Ann Surg Oncol*. 2014;21(6):1862-1869. doi:10.1245/s10434-014-3508-x.
906. Harrell RM, Bimston DN. Surgical utility of Afirma: effects of high cancer prevalence and oncocytic cell types in patients with indeterminate thyroid cytology. *Endocr Pract*. 2014;20(4):364-369. doi:10.4158/EP13330.OR.
907. Nikiforov YE, Carty SE, Chiosea SI, et al. Highly accurate diagnosis of cancer in thyroid nodules with follicular neoplasm/suspicious for a follicular neoplasm cytology by ThyroSeq v2 next-generation sequencing assay. *Cancer*. 2014;120(23):3627-3634. doi:10.1002/cncr.29038.
908. Nikiforov YE, Carty SE, Chiosea SI, et al. Impact of the multi-gene ThyroSeq next-generation sequencing assay on cancer diagnosis in thyroid nodules with typia of undetermined significance/follicular lesion of undetermined significance cytology. *Thyroid*. 2015;25(11):1217-1223. doi:10.1089/thy.2015.0305.
909. Picarsic J, Reyes-Múgica M. Phenotype and immunophenotype of the most common pediatric tumors. *Appl Immunohistochem Mol Morphol*. 2015;23(5):313-326. doi:10.1097/PAI.0000000000000068.
910. Valderrabano P, Khazai L, Leon ME, et al. Evaluation of ThyroSeq v2 performance in thyroid nodules with indeterminate cytology. *Endocr Relat Cancer*. 2017;24(3):127-136. doi:10.1530/ERC-16-0512.
911. Anton RC, Wheeler TM. Frozen section of thyroid and parathyroid specimens. *Arch Pathol Lab Med*. 2005;129(12):1575-1584.
912. Kraemer BB. Frozen section diagnosis and the thyroid. *Semin Diagn Pathol*. 1987;4(2):169-189.
913. Rosai J, Carcangiu ML. Pitfalls in the diagnosis of thyroid neoplasms. *Pathol Res Pract*. 1987;182(2):169-179.
914. Bronner MP, Hamilton R, LiVolsi VA. Utility of frozen section analysis on follicular lesions of the thyroid. *Endocr Pathol*. 1994;5:154-161.
915. Leteurtre E, Leroy X, Pattou F, et al. Why do frozen sections have limited value in encapsulated or minimally invasive follicular carcinoma of the thyroid? *Am J Clin Pathol*. 2001;115(3):370-374.
916. Rosen Y, Rosenblatt P, Saltzman E. Intraoperative pathologic diagnosis of thyroid neoplasms. Report on experience with 504 specimens. *Cancer*. 1990;66(9):2001-2006.
917. Shaha AR, DiMaio T, Webber C, Jaffe BM. Intraoperative decision making during thyroid surgery based on the results of preoperative needle biopsy and frozen section. *Surgery*. 1990;108(6):964-967, discussion 970-971.
918. Hamburger JI, Hamburger SW. Declining role of frozen section in surgical planning for thyroid nodules. *Surgery*. 1985;98(2):307-312.
919. Moon HJ, Kwak JY, Kim EK, et al. The combined role of ultrasound and frozen section in surgical management of thyroid nodules read as suspicious for papillary thyroid carcinoma on fine needle aspiration biopsy: a retrospective study. *World J Surg*. 2009;33(5):950-957.
920. Osamura RY, Hunt JL. Current practices in performing frozen sections for thyroid and parathyroid pathology. *Virchows Arch*. 2008;453(5):433-440.
921. Tworek JA, Giordano TJ, Michael CW. Comparison of intraoperative cytology with frozen sections in the diagnosis of thyroid lesions. *Am J Clin Pathol*. 1998;110(4):456-461.
922. LiVolsi VA, Baloch ZW. Use and abuse of frozen section in the diagnosis of follicular thyroid lesions. *Endocr Pathol*. 2005;16(4):285-293.
923. Berg RW, Yen TW, Evans DB, et al. Analysis of an institutional protocol for thyroid lobectomy: Utility of routine intraoperative frozen section and expedited (overnight) pathology. *Surgery*. 2016;159(2):512-517. doi:10.1016/j.surg.2015.07.031.
924. Hong JC, Seo JW, Jang AL, et al. The utility of intra-operative frozen section for the evaluation of microscopic extrathyroidal extension in papillary thyroid carcinoma. *Clin Otolaryngol*. 2017;doi:10.1111/coa.12843.
925. Basolo F, Baloch ZW, Baldanzi A, et al. Usefulness of Ultrafast Papanicolaou-stained scrape preparations in intraoperative management of thyroid lesions. *Mod Pathol*. 1999;12(6):653-657.
926. Nasrallah MP, Pramick MR, Baloch ZW. Images in endocrine pathology: parasitic nodule of thyroid in neck of patient with family history of papillary thyroid carcinoma. *Endocr Pathol*. 2015;26(3):273-275. doi:10.1007/s12022-014-9329-4.
927. Hathaway BM. Innocuous Accessory Thyroid Nodules. *Arch Surg*. 1965;90:222-227.
928. Sisson JC, Giordano TJ, Jamadar DA, et al. 131-I treatment of micronodular pulmonary metastases from papillary thyroid carcinoma. *Cancer*. 1996;78(10):2184-2192.
929. Shimizu M, Hirokawa M, Manabe T. Parasitic nodule of the thyroid in a patient with Graves' disease. *Virchows Arch*. 1999;434(3):241-244.
930. Frantz VK, Forsythe R, Hanford JM, Rogers WM. LATERAL ABERRANT THYROIDS. *Ann Surg*. 1942;115(2):161-183.
931. Roth LM. Inclusions of non-neoplastic thyroid tissue within cervical lymph nodes. *Cancer*. 1965;18:105-111.
932. Wozencraft P, Foote FWJ, Frazell EL. Occult carcinomas of the thyroid. Their bearings on the concept of lateral aberrant thyroid cancer. *Cancer*. 1948;1:574-583.
933. Meyer JS, Steinberg LS. Microscopically benign thyroid follicles in cervical lymph nodes. Serial section study of lymph node inclusions and entire thyroid gland in 5 cases. *Cancer*. 1969;24(2):302-311.
934. Homan MR, Gharib H, Goellner JR. Metastatic papillary cancer of the neck: a diagnostic dilemma. *Head Neck*. 1992;14(2):113-118.
935. Heffner DK. Low-grade adenocarcinoma of probable endolymphatic sac origin A clinicopathologic study of 20 cases. *Cancer*. 1989;64(11):2292-2302.
936. Young RH, Jackson A, Wells M. Ovarian metastasis from thyroid carcinoma 12 years after partial thyroidectomy mimicking struma ovarii: report of a case. *Int J Gynecol Pathol*. 1994;13(2):181-185.
937. Haymart MR, Banerjee M, Yang D, et al. Variation in the management of thyroid cancer. *J Clin Endocrinol Metab*. 2013;98(5):2001-2008. doi:10.1210/jc.2012-3355.
938. Haymart MR, Esfandiari NH, Stang MT, Sosa JA. Controversies in the Management of Low-Risk Differentiated Thyroid Cancer. *Endocr Rev*. 2017;38(4):351-378.
939. Leboulleux S, Tuttle RM, Pacini F, Schlumberger M. Papillary thyroid microcarcinoma: time to shift from surgery to active surveillance? *Lancet Diabetes Endocrinol*. 2016;4(11):933-942. doi:10.1016/S2213-8587(16)30180-2.
940. Papaleontiou M, Banerjee M, Yang D, et al. Factors that influence radioactive iodine use for thyroid cancer. *Thyroid*. 2013;23(2):219-224. doi:10.1089/thy.2012.0380.
941. Lee SL. Radioactive iodine therapy. *Curr Opin Endocrinol Diabetes Obes*. 2012;19(5):420-428. doi:10.1097/MED.0b013e328357fa0c.
942. Perri F, Pezzullo L, Chiofalo MG, et al. Targeted therapy: a new hope for thyroid carcinomas. *Crit Rev Oncol Hematol*. 2015;94(1):55-63. doi:10.1016/j.critrevonc.2014.10.012.
943. Valerio L, Pieruzzi L, Giani C, et al. Targeted Therapy in Thyroid Cancer: State of the Art. *Clin Oncol (R Coll Radiol)*. 2017;29(5):316-324. doi:10.1016/j.clon.2017.02.009.
944. Akslen LA, Haldorsen T, Thoresen SO, Glattre E. Survival and causes of death in thyroid cancer: a population-based study of 2479 cases from Norway. *Cancer Res*. 1991;51(4):1234-1241.
945. Cunningham MP, Duda RB, Recant W, et al. Survival discriminants for differentiated thyroid cancer. *Am J Surg*. 1990;160(4):344-347.
946. Ito J, Noguchi S, Murakami N, Noguchi A. Factors affecting the prognosis of patients with carcinoma of the thyroid. *Surg Gynecol Obstet*. 1980;150(4):539-544.
947. Lundgren CI, Hall P, Dickman PW, Zedenius J. Clinically significant prognostic factors for differentiated thyroid carcinoma: a population-based, nested case-control study. *Cancer*. 2006;106(3):524-531.
948. Shah JP, Loree TR, Dharker D, et al. Prognostic factors in differentiated carcinoma of the thyroid gland. *Am J Surg*. 1992;164(6):658-661.
949. Pasieka JL, Zedenius J, Auer G, et al. Addition of nuclear DNA content to the AMES risk-group classification for papillary thyroid cancer. *Surgery*. 1992;112(6):1154-1159, discussion 1159-1160.
950. Tennvall J, Biorklund A, Moller T, et al. Is the EORTC prognostic index of thyroid cancer valid in differentiated thyroid carcinoma? Retrospective multivariate analysis of differentiated thyroid carcinoma with long follow-up. *Cancer*. 1986;57(7):1405-1414.
951. Heitz P, Moser H, Staub JJ. Thyroid cancer: a study of 573 thyroid tumors and 161 autopsy cases observed over a thirty-year period. *Cancer*. 1976;37(5):2329-2337.
952. Ricarte-Filho JC, Ryder M, Chitale DA, et al. Mutational profile of advanced primary and metastatic radioactive iodine-refractory thyroid cancers reveals distinct pathogenetic roles for BRAF, PIK3CA, and AKT1. *Cancer Res*. 2009;69(11):4885-4893. doi:10.1158/0008-5472.CAN-09-0727.
953. Durante C, Puxeddu E, Ferretti E, et al. BRAF mutations in papillary thyroid carcinomas inhibit genes involved in iodine metabolism. *J Clin Endocrinol Metab*. 2007;92(7):2840-2843.

954. Pedersen RK, Pedersen NT. Primary non-Hodgkin's lymphoma of the thyroid gland: a population based study. *Histopathology*. 1996;28(1):25-32.
955. Campo E, Chott A, Kinney MC, et al. Update on extranodal lymphomas. Conclusions of the Workshop held by the EAHP and the SH in Thessaloniki, Greece. *Histopathology*. 2006;48(5):481-504.
956. Burke JS, Butler JJ, Fuller LM. Malignant lymphomas of the thyroid: a clinical pathologic study of 35 patients including ultrastructural observations. *Cancer*. 1977;39(4):1587-1602.
957. Rasbach DA, Mondschein MS, Harris NL, et al. Malignant lymphoma of the thyroid gland: a clinical and pathologic study of twenty cases. *Surgery*. 1985;98(6):1166-1170.
958. Devine RM, Edis AJ, Banks PM. Primary lymphoma of the thyroid: a review of the Mayo Clinic experience through 1978. *World J Surg*. 1981;5(1):33-38.
959. Aozasa K, Inoue A, Tajima K, et al. Malignant lymphomas of the thyroid gland. Analysis of 79 patients with emphasis on histologic prognostic factors. *Cancer*. 1986;58(1):100-104.
960. Aozasa K, Inoue A, Yoshimura H, et al. Intermediate lymphocytic lymphoma of the thyroid. An immunologic and immunohistologic study. *Cancer*. 1986;57(9):1762-1767.
961. Derringer GA, Thompson LD, Frommelt RA, et al. Malignant lymphoma of the thyroid gland: a clinicopathologic study of 108 cases. *Am J Surg Pathol*. 2000;24(5):623-639.
962. Compagno J, Oertel JE. Malignant lymphoma and other lymphoproliferative disorders of the thyroid gland. A clinicopathologic study of 245 cases. *Am J Clin Pathol*. 1980;74(1):1-11.
963. Allevato PA, Kini SR, Rebuck JW, et al. Signet ring cell lymphoma of the thyroid: a case report. *Hum Pathol*. 1985;16(10):1066-1068.
964. Anscombe AM, Wright DH. Primary malignant lymphoma of the thyroid—a tumour of mucosa-associated lymphoid tissue: review of seventy-six cases. *Histopathology*. 1985;9(1):81-97.
965. Skacel M, Ross CW, Hsi ED. A reassessment of primary thyroid lymphoma: high-grade MALT-type lymphoma as a distinct subtype of diffuse large B-cell lymphoma. *Histopathology*. 2000;37(1):10-18.
966. Higgins JP, Warnke RA. Large B-cell lymphoma of thyroid. Two cases with a marginal zone distribution of the neoplastic cells. *Am J Clin Pathol*. 2000;114(2):264-270.
967. Bacon CM, Diss TC, Ye H, et al. Follicular lymphoma of the thyroid gland. *Am J Surg Pathol*. 2009;33(1):22-34.
968. Faure P, Chittal S, Woodman-Memeteau F, et al. Diagnostic features of primary malignant lymphomas of the thyroid with monoclonal antibodies. *Cancer*. 1988;61(9):1852-1861.
969. Mizukami Y, Michigishi T, Nonomura A, et al. Primary lymphoma of the thyroid: a clinical, histological and immunohistochemical study of 20 cases. *Histopathology*. 1990;17(3):201-209.
970. Abdul-Rahman ZH, Gogas HJ, Tooze JA, et al. T-cell lymphoma in Hashimoto's thyroiditis. *Histopathology*. 1996;29(5):455-459.
971. Wolf BC, Sheahan K, DeCoste D, et al. Immunohistochemical analysis of small cell tumors of the thyroid gland: an Eastern Cooperative Oncology Group study. *Hum Pathol*. 1992;23(11):1252-1261.
972. Aozasa K. Hashimoto's thyroiditis as a risk factor of thyroid lymphoma. *Acta Pathol Jpn*. 1990;40(7):459-468.
973. Santana V, Rose NR. Neoplastic lymphoproliferation in autoimmune disease: an updated review. *Clinical Immunol Immunopathol*. 1992;63(3):205-213.
974. Lam KY, Lo CY, Kwong DL, et al. Malignant lymphoma of the thyroid. A 30-year clinicopathologic experience and an evaluation of the presence of Epstein-Barr virus. *Am J Clin Pathol*. 1999;112(2):263-270.
975. Ha CS, Shadle KM, Medeiros LJ, et al. Localized non-Hodgkin lymphoma involving the thyroid gland. *Cancer*. 2001;91(4):629-635.
976. Williams ED. Malignant lymphoma of the thyroid. *Clin Endocrinol Metab*. 1981;10(2):379-389.
977. Ansell SM, Grant CS, Habermann TM. Primary thyroid lymphoma. *Semin Oncol*. 1999;26(3):316-323.
978. Pyke CM, Grant CS, Habermann TM, et al. Non-Hodgkin's lymphoma of the thyroid: is more than biopsy necessary? *World J Surg*. 1992;16(4):604-609, discussion 609-610.
979. Avila A, Villalpando A, Montoya G, Luna MA. Clinical features and differential diagnoses of solitary extramedullary plasmacytoma of the thyroid: a case report. *Ann Diagn Pathol*. 2009;13(2):119-123.
980. Shimaoka K, Gailani S, Tsukada Y, Barcos M. Plasma cell neoplasm involving the thyroid. *Cancer*. 1978;41(3):1140-1146.
981. Otto S, Peter I, Vegh S, et al. Gamma-chain heavy-chain disease with primary thyroid plasmacytoma. *Arch Pathol Lab Med*. 1986;110(10):893-896.
982. Aozasa K, Inoue A, Yoshimura H, et al. Plasmacytoma of the thyroid gland. *Cancer*. 1986;58(1):105-110.
983. Holck S. Plasma cell granuloma of the thyroid. *Cancer*. 1981;48(3):830-832.
984. Szczepanek-Parulska E, Szkudlarek M, Majewski P, et al. Thyroid nodule as a first manifestation of Hodgkin lymphoma-report of two cases and literature review. *Diagn Pathol*. 2013;8:116. doi:10.1186/1746-1596-8-116.
985. Feigin GA, Buss DH, Paschal B, et al. Hodgkin's disease manifested as a thyroid nodule. *Hum Pathol*. 1982;13(8):774-776.
986. Wang SA, Rahemtullah A, Faquin WC, et al. Hodgkin's lymphoma of the thyroid: a clinicopathologic study of five cases and review of the literature. *Mod Pathol*. 2005;18(12):1577-1584.
987. Thompson LD, Wenig BM, Adair CF, et al. Langerhans cell histiocytosis of the thyroid: a series of seven cases and a review of the literature. *Mod Pathol*. 1996;9(2):145-149.
988. Tsang WY, Lau MF, Chan JK. Incidental Langerhans' cell histiocytosis of the thyroid. *Histopathology*. 1994;24(4):397-399.
989. Vergez S, Rouquette I, Ancey M, et al. Langerhans cell histiocytosis of the thyroid is a rare entity, but an association with a papillary thyroid carcinoma is often described. *Endocr Pathol*. 2010;21(4):274-276. doi:10.1007/s12022-010-9134-7.
990. Yap WM, Chuah KL, Tan PH. Langerhans cell histiocytosis involving the thyroid and parathyroid glands. *Mod Pathol*. 2001;14(2):111-115.
991. Larkin DF, Dervan PA, Munnelly J, Finucane J. Sinus histiocytosis with massive lymphadenopathy simulating subacute thyroiditis. *Hum Pathol*. 1986;17(3):321-324.
992. Lee FY, Jan YJ, Chou G, et al. Thyroid involvement in Rosai-Dorfman disease. *Thyroid*. 2007;17(5):471-476.
993. Leoni F, Fabbri R, Pascarella A, et al. Extramedullary haematopoiesis in thyroid multinodular goitre preceding clinical evidence of agnogenic myeloid metaplasia. *Histopathology*. 1996;28(6):559-561.
994. Schmid C, Beham A, Seewann HL. Extramedullary haematopoiesis in the thyroid gland. *Histopathology*. 1989;15(4):423-425.
995. Clarke MR, Boppana S. Hemangioma of the thyroid gland in an adolescent with chronic lymphocytic thyroiditis and adenomatous hyperplasia. *Endocr Pathol*. 1998;9:185-190.
996. Pickleman JR, Lee JF, Straus FH 2nd, Paloyan E. Thyroid hemangioma. *Am J Surg*. 1975;129(3):331-333.
997. Dimosthenous K, Righi A, Puccetti M, Lorenzini P. Angiolipoma of the thyroid gland. *Int J Surg Pathol*. 2009;17(1):65-67.
998. Palazzo JP, Cote SA. Primary angiolipoma of the thyroid gland: a case report. *Int J Surg Pathol*. 2005;13(3):305-307.
999. Gardner DF, Frable WJ. Primary lymphangioma of the thyroid gland. *Arch Pathol Lab Med*. 1989;113(9):1084-1085.
1000. Andrion A, Bellis D, Delsedime L, et al. Leiomyoma and neurilemoma: report of two unusual non-epithelial tumours of the thyroid gland. *Virchows Arch A Pathol Anat Histopathol*. 1988;413(4):367-372.
1001. Thompson LD, Wenig BM, Adair CF, et al. Primary smooth muscle tumors of the thyroid gland. *Cancer*. 1997;79(3):579-587.
1002. Thompson LD, Wenig BM, Adair CF, Heffess CS. Peripheral nerve sheath tumors of the thyroid gland: a series of four cases and a review of the literature. *Endocr Pathol*. 1996;7(4):309-318.
1003. Baloch ZW, Martin S, Livolsi VA. Granular cell tumor of the thyroid: a case report. *Int J Surg Pathol*. 2005;13(3):291-294.
1004. Espinosa-de-Los-Monteros-Franco VA, Martinez-Madrigal F, Ortiz-Hidalgo C. Granular cell tumor (Abrikossoff tumor) of the thyroid gland. *Ann Diagn Pathol*. 2009;13(4):269-271.
1005. Hansen T, Gaumann A, Ghalibafian M, et al. Haemangiopericytoma of the thyroid gland in combination with Hashimoto's disease. *Virchows Arch*. 2004;445(3):315-319.
1006. Cameselle-Teijeiro J, Varela-Duran J, Fonseca E, et al. Solitary fibrous tumor of the thyroid. *Am J Clin Pathol*. 1994;101(4):535-538.
1007. Kie JH, Kim JY, Park YN, et al. Solitary fibrous tumour of the thyroid. *Histopathology*. 1997;30(4):365-368.
1008. Rodriguez I, Ayala E, Caballero C, et al. Solitary fibrous tumor of the thyroid gland: report of seven cases. *Am J Surg Pathol*. 2001;25(11):1424-1428.
1009. Tanahashi J, Kashima K, Daa T, et al. Solitary fibrous tumor of the thyroid gland: report of two cases and review of the literature. *Pathol Int*. 2006;56(8):471-477.
1010. Huang SA, Tu HM, Harney JW, et al. Severe hypothyroidism caused by type 3 iodothyronine deiodinase in infantile hemangiomas. *N Engl J Med*. 2000;343(3):185-189.
1011. Shin WY, Aftalion B, Hotchkiss E, et al. Ultrastructure of a primary fibrosarcoma of the human thyroid gland. *Cancer*. 1979;44(2):584-591.
1012. Andrion A, Gaglio A, Dogliani N, et al. Liposarcoma of the thyroid gland. Fine-needle aspiration cytology, immunohistology, and ultrastructure. *Am J Clin Pathol*. 1991;95(5):675-679.
1013. Iida Y, Katoh R, Yoshioka M, et al. Primary leiomyosarcoma of the thyroid gland. *Acta Pathol Jpn*. 1993;43(1-2):71-75.
1014. Tulbah A, Al-Dayel F, Fawaz I, Rosai J. Epstein-Barr virus-associated leiomyosarcoma of the thyroid in a child with congenital

immunodeficiency: a case report. *Am J Surg Pathol*. 1999;23(4):473-476.
1015. Tseleni-Balafouta S, Arvanitis D, Kakaviatos N, Paraskevakou H. Primary myxoid chondrosarcoma of the thyroid gland. *Arch Pathol Lab Med*. 1988;112(1):94-96.
1016. Ohbu M, Kameya T, Wada C, et al. Primary osteogenic sarcoma of the thyroid gland. A case report. *Surg Pathol*. 1989;2:67-72.
1017. Naruse T, Koike A, Suzumura K, et al. Malignant "triton" tumor in the thyroid—a case report. *Jpn J Surg*. 1991;21(4):466-470.
1018. Pallares J, Perez-Ruiz L, Ros S, et al. Malignant peripheral nerve sheath tumor of the thyroid: a clinicopathological and ultrastructural study of one case. *Endocr Pathol*. 2004;15(2):167-174.
1019. Beer TW. Malignant thyroid haemangioendothelioma in a non-endemic goitrous region, with immunohistochemical evidence of a vascular origin. *Histopathology*. 1992;20(6):539-541.
1020. Pfaltz M, Hedinger C, Saremaslani P, Egloff B. Malignant hemangioendothelioma of the thyroid and factor VIII-related antigen. *Virchows Arch A Pathol Anat Histopathol*. 1983;401(2):177-184.
1021. Ruchti C, Gerber HA, Schaffner T. Factor VIII-related antigen in malignant hemangioendothelioma of the thyroid: additional evidence for the endothelial origin of this tumor. *Am J Clin Pathol*. 1984;82(4):474-480.
1022. Totsch M, Dobler G, Feichtinger H, et al. Malignant hemangioendothelioma of the thyroid. Its immunohistochemical discrimination from undifferentiated thyroid carcinoma. *Am J Surg Pathol*. 1990;14(1):69-74.
1023. Eusebi V, Carcangiu ML, Dina R, Rosai J. Keratin-positive epithelioid angiosarcoma of thyroid. A report of four cases. *Am J Surg Pathol*. 1990;14(8):737-747.
1024. Lamovec J, Zidar A, Zidanik B. Epithelioid angiosarcoma of the thyroid gland. Report of two cases. *Arch Pathol Lab Med*. 1994;118(6):642-646.
1025. Maiorana A, Collina G, Cesinaro AM, et al. Epithelioid angiosarcoma of the thyroid. Clinicopathological analysis of seven cases from non-Alpine areas. *Virchows Arch*. 1996;429:131-138.
1026. Gray MH, Rosenberg AE, Dickersin GR, Bhan AK. Cytokeratin expression in epithelioid vascular neoplasms. *Hum Pathol*. 1990;21(2):212-217.
1027. Ryska A, Ludvikova M, Szepe P, Boor A. Epithelioid haemangiosarcoma of the thyroid gland. Report of six cases from a non-Alpine region. *Histopathology*. 2004;44(1):40-46.
1028. van Haelst UJ, Pruszczynski M, ten Cate LN, Mravunac M. Ultrastructural and immunohistochemical study of epithelioid hemangioendothelioma of bone: coexpression of epithelial and endothelial markers. *Ultrastruct Pathol*. 1990;14(2):141-149.
1029. Krisch K, Holzner JH, Kokoschka R, et al. Hemangioendothelioma of the thyroid gland—true endothelioma or anaplastic carcinoma? *Pathol Res Pract*. 1980;170(1-3):230-242.
1030. Mills SE, Gaffey MJ, Watts JC, et al. Angiomatoid carcinoma and 'angiosarcoma' of the thyroid gland. A spectrum of endothelial differentiation. *Am J Clin Pathol*. 1994;102(3):322-330.
1031. Mills SE, Stallings RG, Austin MB. Angiomatoid carcinoma of the thyroid gland. Anaplastic carcinoma with follicular and medullary features mimicking angiosarcoma. *Am J Clin Pathol*. 1986;86(5):674-678.
1032. Siddiqui MT, Evans HL, Ro JY, Ayala AG. Epithelioid haemangioendothelioma of the thyroid gland: a case report and review of literature. *Histopathology*. 1998;32(5):473-476.
1033. Thompson LD, Rosai J, Heffess CS. Primary thyroid teratomas: a clinicopathologic study of 30 cases. *Cancer*. 2000;88(5):1149-1158.
1034. Riedlinger WF, Lack EE, Robson CD, et al. Primary thyroid teratomas in children: a report of 11 cases with a proposal of criteria for their diagnosis. *Am J Surg Pathol*. 2005;29(5):700-706.
1035. Zerella JT, Finberg FJ. Obstruction of the neonatal airway from teratomas. *Surg Gynecol Obstet*. 1990;170(2):126-131.
1036. Bowker CM, Whittaker RS. Malignant teratoma of the thyroid: case report and literature review of thyroid teratoma in adults. *Histopathology*. 1992;21(1):81-83.
1037. Craver RD, Lipscomb JT, Suskind D, Velez MC. Malignant teratoma of the thyroid with primitive neuroepithelial and mesenchymal sarcomatous components. *Ann Diagn Pathol*. 2001;5(5):285-292.
1038. Kingsley DP, Elton A, Bennett MH. Malignant teratoma of the thyroid. Case report and review of the literature. *Br J Cancer*. 1968;22:7-11.
1039. Kumar M, Gupta P, Chaubey A. The thyroid: an extremely rare primary site of neuroblastoma. *Hum Pathol*. 2006;37(10):1357-1360.
1040. Kanoh T, Shimada H, Uchino H, Matsumura K. Amyloid goiter with hypothyroidism. *Arch Pathol Lab Med*. 1989;113(5):542-544.
1041. Moriuchi A, Yokoyama S, Kashima K, et al. Localized primary amyloid tumor of the thyroid developing in the course of Hashimoto's thyroiditis. *Acta Pathol Jpn*. 1992;42(3):210-216.
1042. Katoh R, Ishizaki T, Tomichi N, et al. Malacoplakia of the thyroid gland. *Am J Clin Pathol*. 1989;92(6):813-820.
1043. Schmitz KJ, Baumgaertel MW, Schmidt C, et al. Wegener's granulomatosis in the thyroid mimicking a tumour. *Virchows Arch*. 2008;452(5):571-574.
1044. Vitkovski T, Costales C, Chen S, et al. Malakoplakia of the thyroid gland: a case report and review of literature. *Int J Surg Pathol*. 2015;23(4):308-312. doi:10.1177/1066896915569915.
1045. Zirkin HJ, Tovi F. Tracheal carcinoma presenting as a thyroid tumor. *J Surg Oncol*. 1984;26(4):268-271.
1046. Straccia P, Mosseri C, Brunelli C, et al. Diagnosis and treatment of metastases to the thyroid gland: a meta-analysis. *Endocr Pathol*. 2017;28(2):112-120. doi:10.1007/s12022-017-9475-6.
1047. Shimaoka K, Sokal JE, Pickren JW. Metastatic neoplasms in the thyroid gland. Pathological and clinical findings. *Cancer*. 1962;15:557-565.
1048. Lam KY, Lo CY. Metastatic tumors of the thyroid gland: a study of 79 cases in Chinese patients. *Arch Pathol Lab Med*. 1998;122(1):37-41.
1049. Baloch ZW, LiVolsi VA. Tumor-to-tumor metastasis to follicular variant of papillary carcinoma of thyroid. *Arch Pathol Lab Med*. 1999;123(8):703-706.
1050. Mizukami Y, Saito K, Nonomura A, et al. Lung carcinoma metastatic to microfollicular adenoma of the thyroid. A case report. *Acta Pathol Jpn*. 1990;40(8):602-608.
1051. Ro JY, Guerrieri C, el Naggar AK, et al. Carcinomas metastatic to follicular adenomas of the thyroid gland. Report of two cases. *Arch Pathol Lab Med*. 1994;118(5):551-556.
1052. Ivy HK. Cancer metastatic to the thyroid: a diagnostic problem. *Mayo Clin Proc*. 1984;59(12):856-859.
1053. Nakhjavani MK, Gharib H, Goellner JR, van Heerden JA. Metastasis to the thyroid gland. A report of 43 cases. *Cancer*. 1997;79(3):574-578.
1054. Green LK, Ro JY, Mackay B, et al. Renal cell carcinoma metastatic to the thyroid. *Cancer*. 1989;63(9):1810-1815.
1055. Cesaretti M, Trotta M, Varaldo E, et al. Metastases to the thyroid gland from renal cancer. *Tumori*. 2013;99(3):e107-e110. doi:10.1700/1334.14816.
1056. Heffess CS, Wenig BM, Thompson LD. Metastatic renal cell carcinoma to the thyroid gland: a clinicopathologic study of 36 cases. *Cancer*. 2002;95(9):1869-1878.
1057. Matias-Guiu X, Garcia A, Curell R, Prat J. Renal cell carcinoma metastatic to the thyroid gland: a comparative molecular study between the primary and the metastatic tumor. *Endocr Pathol*. 1998;9(3):255-260.

Parathyroid Glands

9

Thomas J. Giordano

CHAPTER CONTENTS

Normal gross anatomy and embryology, *355*
Normal histology, *355*
Normal physiology, *356*
Adenoma, *356*
Generalities and gross features, *356*
Microscopic features, *357*
Immunohistochemical features, *357*
Molecular genetic features, *358*
Adenoma variants, *358*
Chief cell hyperplasia, *358*
Water-clear cell hyperplasia, *360*
Carcinoma, *360*
Prognosis, *362*
Other lesions, *362*
Hyperparathyroidism, *362*
Primary hyperparathyroidism, *362*
Secondary hyperparathyroidism, *363*
"Tertiary" hyperparathyroidism, *363*
Differential diagnosis, *364*
Treatment, *365*
Frozen section, *365*

Normal Gross Anatomy and Embryology

The parathyroid glands, the last major organ to be recognized in humans, were discovered in 1880 by Ivar Sandstrom, a Swedish medical student, as recounted by Aidan Carney in his delightful essay on the subject.[1]

Normally, there are four oval, pliable parathyroid glands, each averaging 4 × 3 × 1.5 mm. In rare cases, more than four glands are present. In their classic study of 527 autopsy cases, Gilmour and Martin[2] reported two instances in which there were six glands (0.2%) and 31 in which there were five (5.2%). Variations in the weights of the normal glands were studied by the same authors,[2] who found that the mean weight of all four glands was 117.6 ± 4 mg in men and 131.3 ± 5.8 mg in women. The color varies from reddish brown to light tan to yellow, depending on fat content, which in turn depends on age, nutrition, and activity of the individual.

Parathyroid glands are arranged in two pairs. The upper pair arises from the fourth branchial cleft and descends into the neck with the thyroid gland during embryonic life. The lower pair arises from the third branchial cleft and descends into the neck with the thymus. Normally, the upper pair is located on the middle third of the posterolateral border of the thyroid gland, and the lower pair is close to the lower pole of the thyroid gland, near the inferior thyroid artery. The parathyroid glands usually have a symmetric distribution—when one superior parathyroid gland is located in one place, the opposite parathyroid gland will usually be in the contralateral mirror image of that place.[3]

The vascular supply of the lower parathyroid glands comes from branches of the inferior thyroid arteries. This supply is usually independent; a circumstance that may be helpful in locating abnormally placed glands. If one of these arteries is ligated, infarction of the parathyroid gland may result.

Faulty migration of the glands during embryonic life may result in anomalous positions. The upper glands may be found inside the carotid sheath or behind the cervical or thoracic esophagus. The lower glands may continue their descent with the thymus into the anterior portion of the mediastinum.[4] They may also be located inside the thyroid gland (0.2%),[5] in the pharynx,[6] or within the vagus nerve.[7] Interestingly, they can also be found within autonomic ganglia in the neck.[8] Wang[9] has pointed out that despite the wide distribution patterns that parathyroid glands may exhibit, these fall into an orderly scheme and can be uncovered by the experienced surgeon in the great majority of cases, although some patients have required multiple surgeries to identify anomalously located diseased glands.

Normal Histology

In the past a rigid division of cell types has been applied to the normal parathyroid gland; however, evidence suggests that this organ is made up of but one basic cell type, the **chief cell**, and that all the other cells that have been described represent morphologic variations of the former that reflect differences in physiologic activity.[10,11]

The chief cell measures 6–8 μm in diameter and has a centrally located nucleus and a moderate amount of pale granular cytoplasm. Ultrastructurally, there are variable amounts of glycogen particles and secretory droplets, an inverse relationship existing in the amount of these two components.[11] Parathormone (PTH) and PTH-related

Abstract

The essential features of the common parathyroid lesions are presented.

Keywords

Parathyroid
adenoma
hyperplasia
carcinoma
hyperparathyroidism

protein secretion can be demonstrated immunohistochemically.[12,13] There is also cytoplasmic reactivity for various types of keratin, and for chromogranin A, but not for vimentin, glial fibrillary acidic protein, neurofilament, or chromogranin B.[14,15]

The **oxyphil cell** has a more abundant cytoplasm, which is deeply granular and acidophilic. A rich content of oxidative enzymes can be demonstrated histochemically, although the ratio of enzyme content per mitochondrion seems to be decreased.[16] These oxyphilic cells are often present in the form of nodular collections. **Transitional oxyphil cells** have an appearance that is intermediate between chief cells and oxyphil cells. The **water-clear cell** (rarely if ever seen in the normal gland) is characterized by abundant optically clear cytoplasm and sharply defined cell membranes. **Transitional water-clear cells** have an appearance that is intermediate between chief cells and water-clear cells. Both types of transitional cell are more common in hyperfunctioning than in normal glands.

The frequency distribution of the different cells varies with the age of the patient. Until puberty, the gland is composed wholly of chief cells that contain cytoplasmic glycogen but not fat. The latter appears in these cells as very fine droplets soon after puberty at about the same time that the oxyphil cells appear. They appear first singly, then in pairs, and, after 40 years of age, in the form of sharply outlined but not encapsulated islands, which may be large.

After puberty, mature adipose tissue appears in the stroma and increases in amount until about 40 years of age, remaining relatively constant thereafter. Whereas the average percentage of stromal fat cell in the adult parathyroid is about 40%, the variations in the amount of fat present (while the parenchymal cell content remains relatively constant) make it very difficult to distinguish a normal from an abnormal parathyroid solely on the basis of stromal fat content.[17,18] In a classic study, Gilmour[19] demonstrated in 1947 that small parathyroid glands in adult individuals are the result of a decreased amount of stromal fat rather than parenchymal cell mass.

A few follicles and cysts of varying sizes are observed in about half of parathyroid glands after puberty. They may be filled with granular and cellular debris or with a dark blue–staining, finely granular material that is morphologically indistinguishable from thyroid colloid.[20] This material, which sometimes is positive with amyloid stains, is thought to result from a conformational change in the stored PTH polypeptide.[21] When these follicles are present, the distinction between thyroid and parathyroid tissue may become difficult, especially on frozen section. The presence of sizable amounts of cytoplasmic glycogen favors a parathyroid nature. Conversely, the presence of birefringent crystals of calcium oxalate (easily detectable with polarized light) favors thyroid, a feature to remember at the time of frozen section.[22] If doubts persist, immunohistochemical stains (e.g. for thyroglobulin, TTF-1, PTH, and/or chromogranin) should dispel them.

Normal Physiology

The parathyroid glands mediate their endocrine function through the production of PTH, an 84-amino acid polypeptide that results from serial cleavage of preproparathyroid hormone and proparathyroid hormone.[23] There are several forms of circulating PTH. The relationship among them is not clear, but it is known that the structural requirements for the biologic activity reside in the first 34 amino acid residues.[24,25] The chief cells are most critically sensitive to calcium concentrations in vivo and in vitro.[26]

PTH and vitamin D are the primary regulators of mineral metabolism.[27] The primary target organs for PTH activity are the kidneys, intestines, and bones. The most important physiologic actions of PTH are increased renal excretion of phosphate, increased renal tubular reabsorption of calcium, increased intestinal absorption of calcium, and direct effects in bone. The latter are mainly manifested by an increase in the number of osteoclasts and an apparent increase in their phagocytic activity, resulting in resorption of bone tissue.

Adenoma

Generalities and Gross Features

Parathyroid adenomas occur in women and men in a ratio of 3 : 1. They can develop at almost any age, but most occur in patients in the fourth decade. A few cases have been reported in children,[28] and some after radiation therapy to the head and neck region.[29,30] The vast majority are solitary masses. Cases of double or triple adenomas exist,[31-34] but the distinction between multiple adenomas and asymmetrical hyperplasia can be difficult and arbitrary. Accordingly, some of the reported cases of multiple adenomas would be reinterpreted today as examples of chief cell hyperplasia. Their size and weight vary greatly, with the majority being too small to allow detection on palpation of the neck. Some may be recognizable only microscopically ("microadenomas").[35] Adenomas are usually oval, may show slight lobulation, and are surrounded by a thin connective tissue capsule. On section, they are often grayish brown (Fig. 9.1). Foci of hemorrhage, calcification, and cystic change may occur. In terms of location, about 75% involve one of the lower glands (Fig. 9.2), 15% involve one of the upper glands, and 10% occur in anomalous positions. Of the latter, 70% are in the mediastinum,[36,37] 20% are intrathyroidal,[38,39] and the remainder in the soft tissues behind the esophagus or—in rare cases—the esophageal wall itself.[40,41]

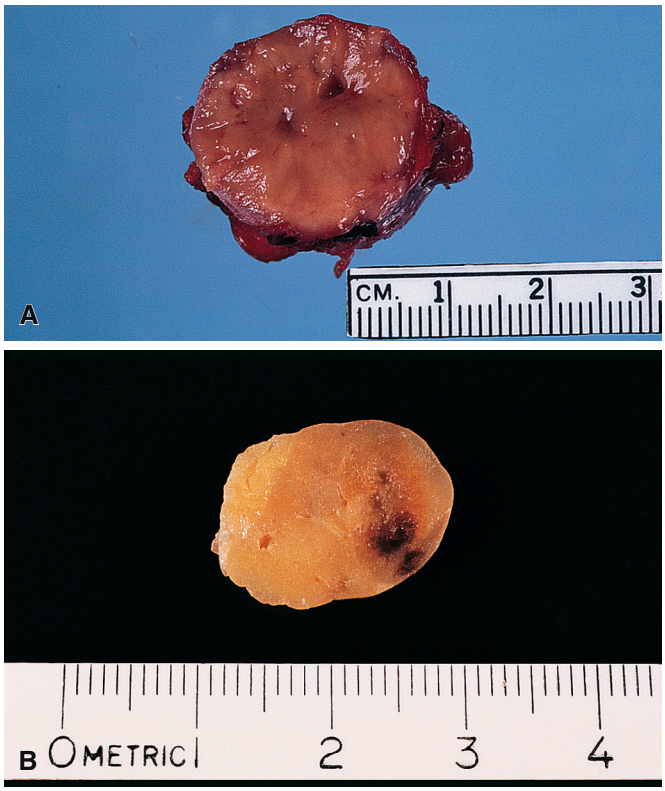

Figure 9.1 **A** and **B,** Gross appearance of two parathyroid adenomas. Note the roundish shape, the homogeneous appearance interrupted by a few foci of fresh hemorrhagic or cystic changes, and the brown to yellowish color.

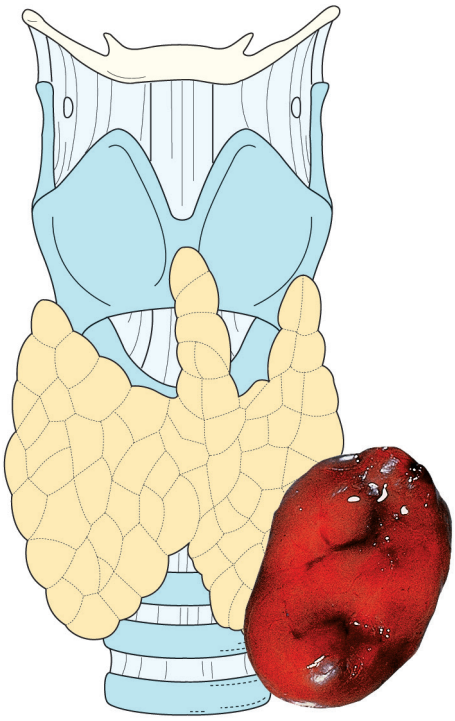

Figure 9.2 Parathyroid adenoma arising from the left lower parathyroid gland.

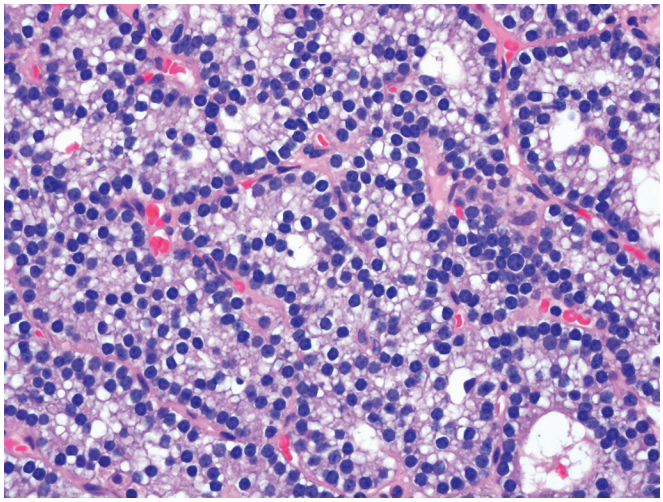

Figure 9.3 Parathyroid adenoma. The tumor is hypercellular, homogeneous, and well vascularized.

Microscopic Features

Microscopically, adenomas are encapsulated and highly cellular (Fig. 9.3). An adjacent rim of compressed non-neoplastic parathyroid tissue can be identified in about 60% of cases. The adenoma itself may be composed of any of the various cell types that make up the normal parathyroid gland (see Fig. 9.3), but chief cells usually predominate.[42] Combinations of chief cells, oxyphil cells, water-clear cells, and transitional elements are common. Variation in nuclear size may be conspicuous, with the presence of tumor cells with isolated or clustered huge hyperchromatic nuclei (Fig. 9.4). Mitotic figures are usually absent, but occasional ones may be found. The pattern of growth is generally diffuse, but it may be nesting, follicular,

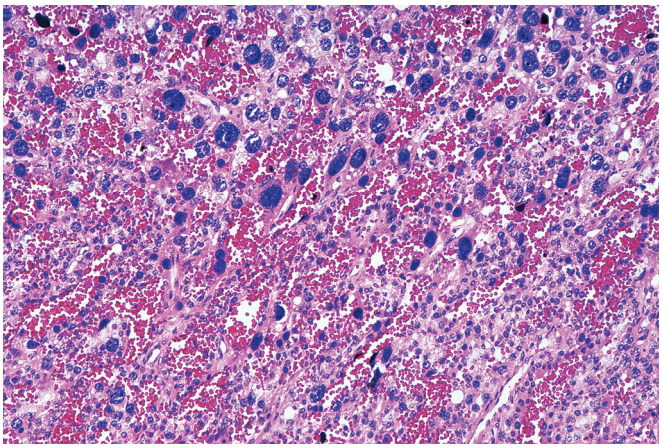

Figure 9.4 Parathyroid adenoma with clusters of bizarre nuclei. This feature is not an indication of malignancy.

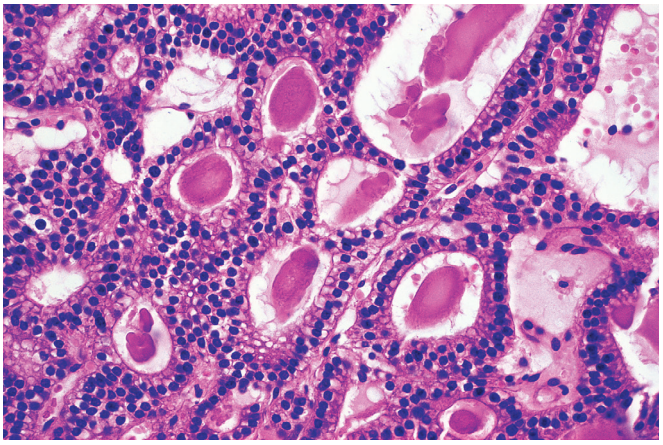

Figure 9.5 Parathyroid adenoma with follicular structures containing a colloid-like material simulating thyroid.

or pseudopapillary (Fig. 9.5).[43] The follicles may contain a colloid-like material. This material sometimes stains for amyloid, as in the normal gland.[44] The presence of follicular structures may closely simulate the appearance of thyroid. Presence of birefringent crystals is a good clue for the identification of the latter. Occasionally, prominent clusters of mature lymphocytes of B and T cell type (sometimes admixed with plasma cells) are seen scattered throughout the tumor (Fig. 9.6).[45] This may be accompanied by degenerative changes in the tumor cells. It is important not to overdiagnose this inconsequential microscopic finding, which may or may not have an autoimmune pathogenesis, as a lymphomatous infiltrate.[46,47]

In the typical case of parathyroid adenoma, the other parathyroid glands have a normal or even atrophic appearance. Indeed, the presence of a *microscopically normal* second gland is thought to represent the best evidence that a given parathyroid lesion is an adenoma rather than chief cell hyperplasia, although the surgical practice of biopsying a second gland to demonstrate its normalcy in order to establish a diagnosis of adenoma has fallen out of favor and has been replaced in part with visualization of the other glands and intraoperative PTH monitoring.[48]

Immunohistochemical Features

Immunohistochemically, there is reactivity for PTH, various types of keratin, and neuroendocrine markers (e.g. chromogranin A and

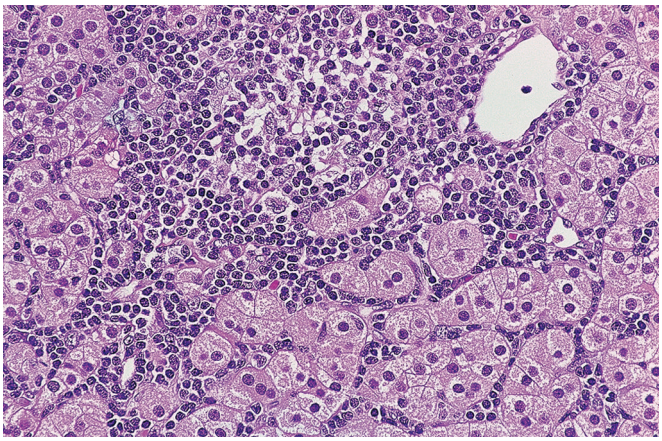

Figure 9.6 Heavy lymphocytic infiltrate within a parathyroid adenoma.

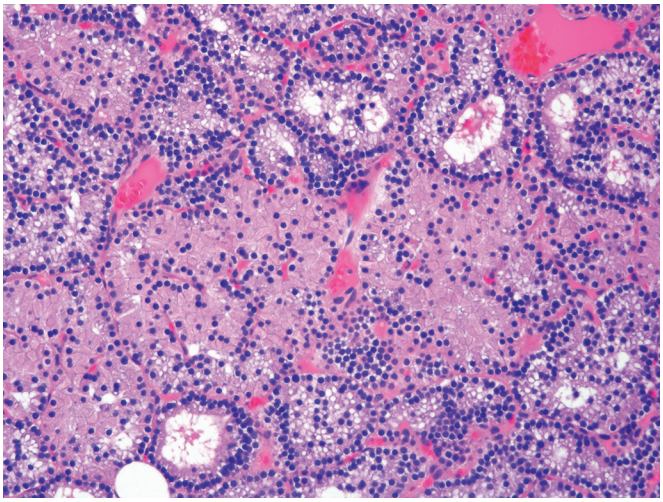

Figure 9.7 Parathyroid adenoma composed of an admixture of chief cells and oncocytic cells.

synaptophysin).[14] The intensity of the PTH staining tends to be weaker in the adenoma than in the peripheral rim of residual normal gland.[49] The adenoma cells express neurofilament, an intermediate filament not found in normal parathyroid cells.[14] Cyclin D1 and bcl-2 expression can be observed in a subset of adenomas,[50-54] whereas immunoreactivity for p53 is rare.[55] Expression of Ki-67 is observed, but the frequency of positive cells is lower compared to carcinoma.[56] The large majority of adenomas express parafibromin, the gene product of *CDC73*, which is lost in the majority of parathyroid carcinomas.[57-60]

Molecular Genetic Features

There has been a steady and substantial increase in the knowledge of the genetics of parathyroid tumors. Several genetic abnormalities have been detected in parathyroid adenomas, most of which are sporadic but can also occur as part of several hereditary syndromes. The primary genetics drivers known to date include somatic alteration of *MEN1*[61-65] and *CCND1/PRAD*.[66-68] Loss of function of the *MEN1* tumor suppressor gene is thought to be an early event in the pathogenesis of parathyroid adenomas, similar to other endocrine tumors.[69] Biallelic inactivation of *MEN1* occurs in about 25%–35% of tumors. Activating mutations of *CCND1/PRAD*, resulting in overexpression of cyclin D1, have been reported in 20%–40% of parathyroid adenomas[70,71] In addition, next-generation sequencing studies have identified low frequency mutation in known cancer genes, including *ZFX* (5%), *CTNNB1* (2%–5%), *EZH2* (1%), and *POT1* (<1%).[67,68]

In addition to genetic alterations, epigenetic alterations such as DNA methylation have emerged as playing a highly significant role in the pathogenesis of sporadic parathyroid adenomas.[72-75] Many of the methylated genes are related to calcium homeostasis, Wnt/β-catenin signaling pathway, cell cycle progression, and transcriptional regulation.[74,76] Reflecting the biologic complexity of gene regulation in cancer, microRNA expression has also been proposed to play a role in parathyroid tumor development.[77,78] Gene expression studies of parathyroid adenomas have identified two main classes of parathyroid adenoma, which may reflect the underlying genotype, specifically loss of 11q13.[79,80]

Adenoma Variants

Oxyphil adenoma is a term that should be restricted to parathyroid adenomas composed entirely or almost entirely of oxyphil cells, inasmuch as a component of oxyphil cells can be found in many adenomas (Fig. 9.7).[81] When thus defined, most oxyphil adenomas are nonfunctioning; however, cases associated with hyperparathyroidism (HPT) have been reported, with secretion of PTH and proparathormone being documented ultrastructurally, immunohistochemically, and biochemically.[82-85]

Lipoadenoma is an unusual morphologic variant of parathyroid adenoma in which the glandular elements are associated with abundant mature adipose tissue, the latter sometimes exhibiting myxoid changes.[86-88] Closely related if not identical lesions have been reported as *parathyroid lipohyperplasia*, *parathyroid hamartoma*, *parathyroid adenoma with myxoid stroma*, and *parathyroid myxoadenoma*. Most lipoadenomas are functioning.[89,90]

Chief Cell Hyperplasia

Chief cell hyperplasia, a condition accompanied by increased production of PTH, can be primary or secondary to impairment of renal function or chronic malabsorption.

Primary chief cell hyperplasia can be observed in several hereditary cancer predisposition syndromes, including multiple endocrine neoplasia types 1, 2A, and 4 (MEN 1, MEN 2A, MEN 4) and hereditary hyperparathyroidism–jaw tumor (HPT-JT).[91,92] In contrast, patients with MEN 2B exhibit normal parathyroid histology during childhood and only a minimal degree of chief cell hyperplasia (consistent with absence of normal involution) during adulthood.[93] MEN 1 is autosomal dominant and caused by inactivating mutations of the *MENIN* tumor suppressor gene at 11q13. Its pathologic phenotype is characterized by multiglandular parathyroid disease, either hyperplasia or multiple adenomas in greater than 90% of cases, along with gastroenteric neuroendocrine tumors in 60% of cases and pituitary adenomas in 30% of cases[94] The histologic distinction between parathyroid hyperplasia and multiple adenomas can be difficult and arbitrary. MEN 2A is caused by activating germline mutations of *RET* at 10q11.2 and its pathologic phenotype is characterized by parathyroid hyperplasia in 30% of cases, as well as medullary thyroid carcinoma in the setting of C cell hyperplasia and pheochromocytomas in the setting of medullary hyperplasia.[95] MEN 4 is a MEN 1–like syndrome, yet without germline *MEN1* mutations. These patients contain inactivating germline mutations of a different tumor suppressor gene located at 12p13.1, *CDKN1B*, which plays a role in cyclin D1 signaling.[94,96,97] HPT-JT syndrome is yet another autosomal dominant syndrome that is phenotypically characterized by multiglandular parathyroid disease,

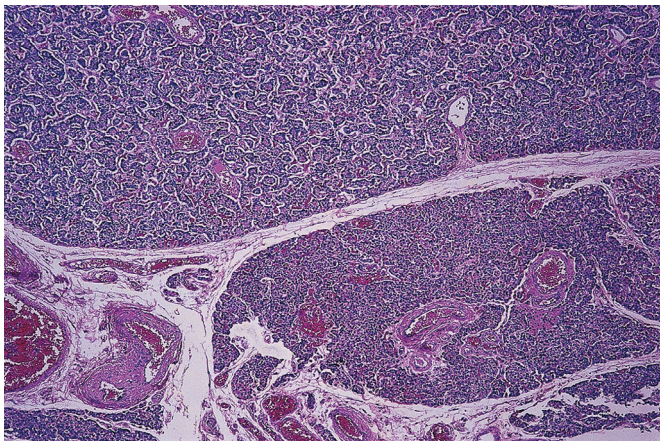

Figure 9.8 Chief cell hyperplasia with multinodular pattern of growth.

often associated with cystic change. These parathyroid lesions are at high risk of progressing to parathyroid carcinoma (up to 20%). These patients may also develop fibro-osseous lesions of the mandible and maxilla, as well as other rare tumors such as Wilms tumor. Molecularly, HPT-JT is related to inactivating germline mutations of *CDC73* (formerly known as *HRPT2*) at 1q31.2,[98] which encodes the parafibromin protein, a vital tumor suppressor in the parathyroid gland.[99]

In a *classic* case of primary chief cell hyperplasia, all glands are enlarged (sometimes weighing 10 g or more) and have a tan to reddish color.[100,101] The upper glands tend to be larger than the lower ones, but the difference is not as striking as in water-clear cell hyperplasia. In other instances, only one gland is visibly enlarged and nodular, whereas the others are nearly normal in size. This latter variant can be confused grossly with an adenoma and is therefore referred to as *pseudoadenomatous*. In still other cases (designated as *occult*) all four glands appear normal in size to the surgeon but are hyperplastic on histologic examination.[102]

Microscopically, the predominant element is the chief cell, but other cell types are also present in most instances. The pattern of growth may be diffuse or nodular, the former being more common among young patients and the latter in the elderly (Fig. 9.8). Glands with nodular chief cell hyperplasia tend to be asymmetric, with a variable cellular arrangement and a high proportion of oxyphil cells.[103] Fibrous septa, acinar formations, and cells with giant hyperchromatic nuclei may be present.[100]

Exceptionally, innumerable microscopic foci of hyperplastic parathyroid tissue are found in the neck in association with primary chief cell hyperplasia of the four glands, in the absence of previous surgery. This phenomenon, called *parathyromatosis*, may be responsible for some cases of recurrent HPT after technically successful surgical therapy.[104] Another rare entity is that of chief cell hyperplasia associated with *chronic parathyroiditis*, interpreted by some as a possible parathyroid equivalent of Hashimoto thyroiditis.[105]

Hyperplastic parathyroid glands surgically transplanted in the forearm as part of the surgical treatment of HPT and which need to be excised because of recurrence of the HPT can exhibit morphologic features, which if present in the orthotopic situation, would have strongly suggested malignancy, such as significant mitotic activity, fibrous strands, and infiltration of the skeletal muscle (Fig. 9.9).

In **secondary chief cell hyperplasia**, all gradations are seen. At one end is the normal-sized gland that is recognized as hyperplastic only because of its tan to reddish color and the microscopic hypercellularity; at the other, there is the gland measuring up to 2 cm

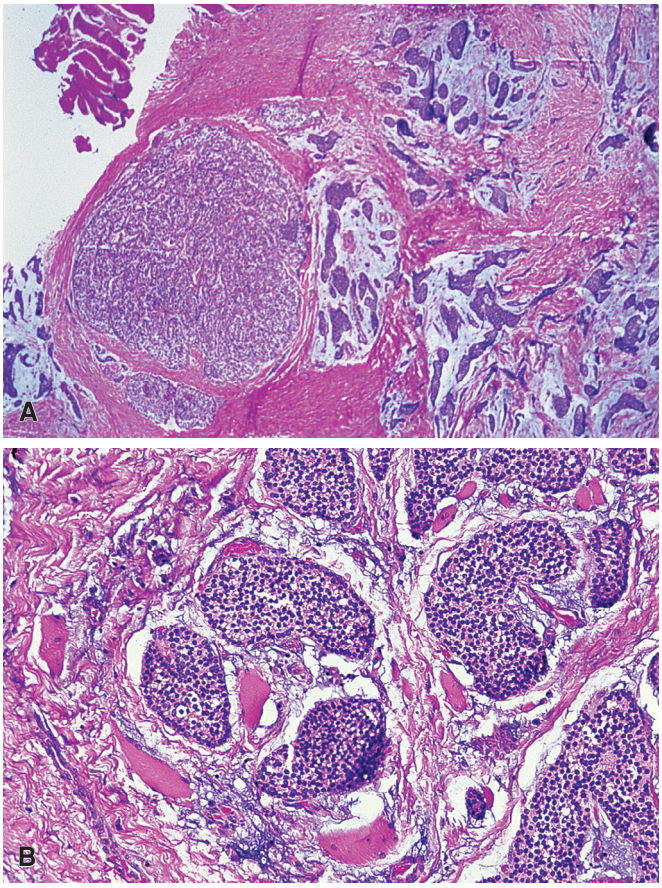

Figure 9.9 **A** and **B,** Parathyroid gland with chief cell hyperplasia that has been surgically transplanted into the forearm. The clusters of hyperplastic chief cells infiltrate the skeletal muscle, thus simulating carcinoma.

and weighing up to 6 g. In general, there is an inverse correlation between the size of the gland and the mean serum calcium level.[106] Microscopically, chief cells predominate, but there may also be increased numbers of oxyphil and transitional oxyphil cells that form nodular collections.

The distinction between primary and secondary chief cell hyperplasia cannot be made on morphologic grounds with any certainty.[107] As a rule, nodularity, fibrous septation, acinar formation, and giant nuclei are more prominent in the primary form, whereas the number of oxyphil cells is higher in the secondary form. However, in the final analysis, the differential diagnosis is made on the basis of the clinical and laboratory findings.[100] Another difficult and more pressing problem is the morphologic distinction between chief cell hyperplasia and adenoma. Size, shape, color, consistency, the cell types present, and their relative frequency are of no help in this regard. The presence of a marked degree of nuclear pleomorphism is said to favor adenoma, but the overlap with hyperplasia is too pronounced for this to represent an absolute criterion.[108] The degree of proliferative activity (as measured by Ki-67 immunostain) is also similar in adenoma and chief cell hyperplasia, the most intense foci in both instances being present in the form of nodular collections.[109] The presence of a rim of normal parenchyma around the mass, visualization of other normal glands, and the normalization of PTH as measured by intraoperative PTH are the only definite criteria by which a diagnosis of adenoma can be made over that of chief cell hyperplasia, but these criteria may be difficult to evaluate.

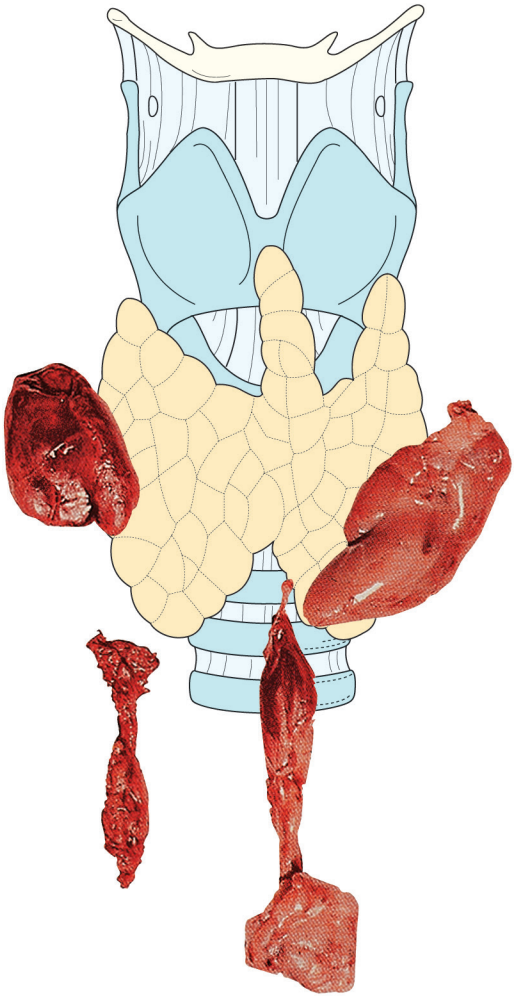

Figure 9.10 Water-clear cell hyperplasia. Note the chocolate brown color, the pseudopods, and the greater involvement of the upper glands. (Redrawn from Castleman B. *Tumors of the Parathyroid Glands. Atlas of Tumor Pathology*, series 1, fascicle 15. Washington, DC: Armed Forces Institute of Pathology; 1952.)

Water-Clear Cell Hyperplasia

In contrast to chief cell hyperplasia, water-clear cell hyperplasia shows no familial incidence and is not associated with multiple endocrine neoplasia or other hereditary syndromes. Interestingly, water-clear cell hyperplasia is strongly associated with blood group O, which may be a prerequisite for development.[110] It is characterized by extreme enlargement of all parathyroid tissue so that the total weight of the glands may exceed 100 g. Strangely, this disorder (which made up a significant proportion of cases of primary HPT in older series) has all but disappeared in recent times, for reasons unknown.[101,103]

Grossly, the superior glands are distinctly larger than the inferior. Moreover, glands may coalesce so that two glands appear as one. They are soft and have a typical chocolate brown color (Fig. 9.10). Cysts and hemorrhages have been observed. Another common gross feature is the formation of pseudopods that may extend a considerable distance from the main mass of the gland. A close correlation exists between the weight of the parathyroid tissue and the severity of the symptoms.

Microscopically, the most characteristic feature is the presence of cells with optically clear cytoplasm throughout the lesion. These cells vary markedly in size, from some no larger than normal parathyroid cells to others that measure up to 40 µm (Fig. 9.11). Thus there is a combination of hyperplasia and hypertrophy. In most regions, the cytoplasm of the cell is water-clear, but in some cells small eosinophilic granules are present. High-power examination of thin sections reveals that the clarity of the cytoplasm is the result of a conglomerate of spherical clear vacuoles surrounded by thin portions of eosinophilic cytoplasmic material. The nuclei average 6–7 µm and are basally oriented, a very distinctive feature. Although their size may vary, giant forms are not seen. The pattern of growth may be alveolar (pseudoglandular) or compact. The connective tissue is delicate and sparse for the most part, but in some areas it may be dense. A chief cell component is occasionally present.

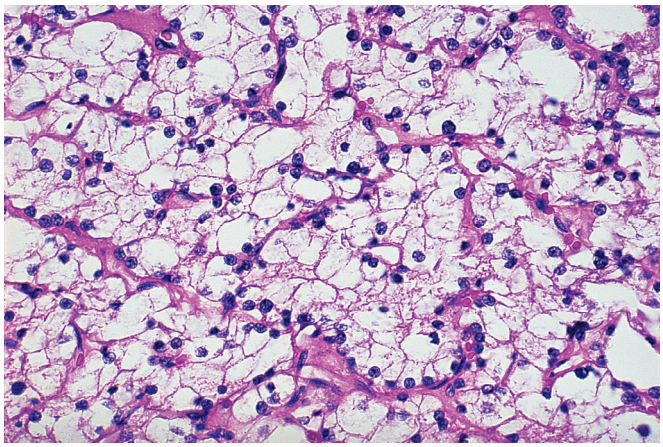

Figure 9.11 Water-clear cell hyperplasia. The cells are very large, optically clear, and have sharply outlined cell membranes.

Carcinoma

Parathyroid carcinoma typically presents with HPT; in an old series, skeletal disease was present in 73% of the patients and renal disease in 26%.[111] A few convincing nonfunctioning cases are on record, and these are said to be more aggressive.[112] The absence of function may be caused by the lack of conversion of the preparathormone to the biologically active compound.[113] Parathyroid carcinoma may coexist with chief cell hyperplasia[114,115] and with adenoma,[116] the former sometimes seen in a familial setting.[117] They have also been seen in the setting of MEN 1.[118]

Clinical features suggestive of parathyroid carcinoma in a hyperparathyroid patient include very high values of serum calcium or PTH, a palpable cervical mass, vocal cord paralysis, and recurrence of HPT a short time after surgery.[54,119,120,121] Some patients present with parathyroid crises.[122] At operation, a parathyroid tumor should be suspected of being carcinoma if it is hard, surrounded by a dense fibrous reaction, and adherent to or infiltrating adjacent structures.[123]

Microscopically, carcinomas differ from adenomas mainly because of their trabecular arrangement, dense fibrous bands (present in 90% of the cases), spindle shape of the tumor cells, presence of mitotic figures (in 81%), capsular invasion (in 67%), and blood vessel invasion (in 12%) (Figs. 9.12 and 9.13).[124,125] Rare parathyroid carcinomas show high-grade histology with numerous mitoses (Fig. 9.14). Some caveats are in order. A certain degree of fibrous banding can also occur in adenoma and in chief cell hyperplasia, particularly the primary form of the latter. Nests of tumor cells may be present within the capsule of a benign tumor as a result of the combined effect of proliferative and regressive changes.[126] Intrathyroidal

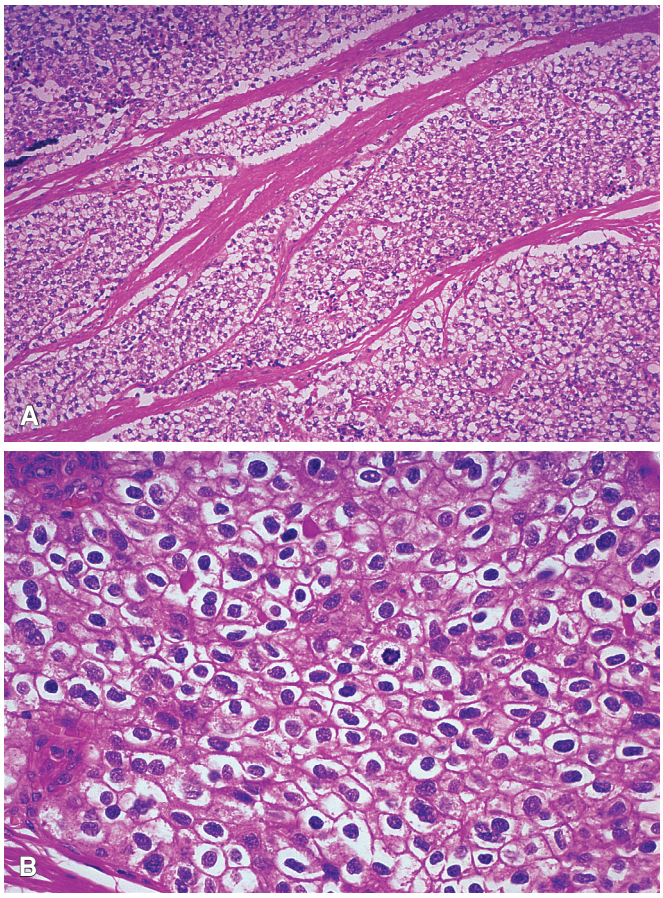

Figure 9.12 Parathyroid carcinoma. **A,** Sharply outlined fibrous bands incompletely dividing the tumor into lobules. **B,** Mitotic features.

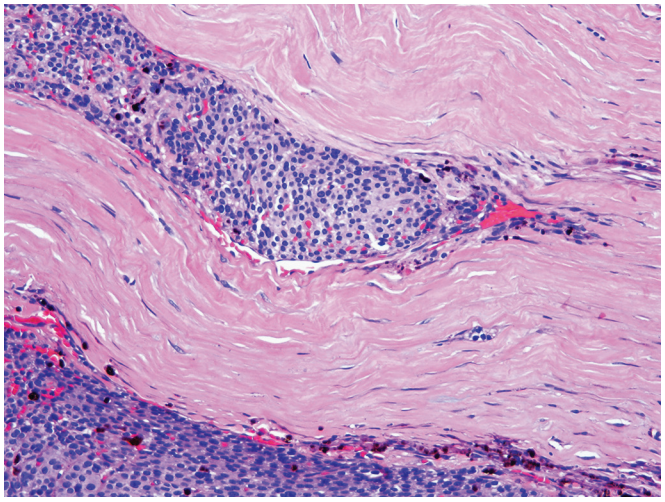

Figure 9.13 Parathyroid carcinoma with lymphovascular invasion.

parathyroid adenomas tend to be associated with fibrosis, sometimes extensive. The residual rim of normal (or hyperplastic) parathyroid tissue of generally semilunar shape often found on the outside of the capsule of a parathyroid neoplasm should not be overinterpreted as evidence of extracapsular invasion. The presence of an occasional mitotic figure in a parathyroid lesion does not necessarily indicate that the lesion in question is a carcinoma. Snover and Foucar[127]

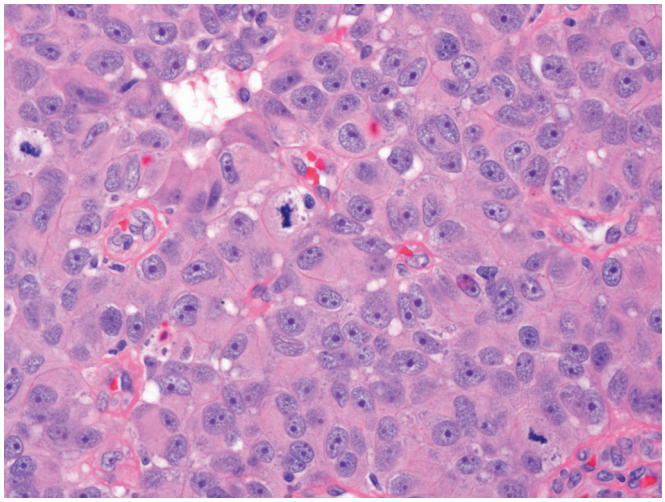

Figure 9.14 High-grade parathyroid carcinoma with abundant mitotic figures.

found rare mitoses by exhaustive search in 71% of adenomas and 80% of the chief cell hyperplasias that they examined. It is also important to be certain that the mitoses are in the tumor cells rather than in the endothelial cells of the prominent hyperplastic blood vessels that so commonly accompany these tumors. Taking everything into account, vascular invasion, obvious extension into the soft tissues, and abundant mitotic figures are the most important indicators of malignancy. As in the thyroid, the diagnosis of vascular invasion can be made only if the tumor tissue is attached to the vessel wall and if the vessel in question is in the capsule or beyond. If doubts persist, a conservative approach is to be recommended. DeLellis[128] has suggested the use of the term *atypical adenoma* for tumors exhibiting some of the features associated with carcinoma but lacking clear-cut evidence of invasion, although this terminology is potentially confusing to clinicians.

In rare cases, parathyroid carcinoma is composed of oxyphil cells.[129,130] In contrast to parathyroid chief cell adenomas, these tumors are usually negative for CK14. They also tend to express a higher Ki-67 labeling index and a lower p27 index than their benign counterparts.[129] If the parathyroid origin of the tumor is questionable—particularly in the absence of function—immunochemical demonstration of PTH should be carried out.[131]

Genetically, somatic inactivating mutations of *CDC73* are found in up to 70% of parathyroid carcinomas.[132,133] The mutations cause absent or decreased expression of parafibromin, which can be demonstrated by immunohistochemistry.[59,133-135] Unexpectedly, rare patients with sporadic parathyroid carcinoma exhibit germline mutation of *CDC73*, suggesting a new proband of HPT-JT syndrome or a phenotypic variant.[132] The allelic losses commonly found in parathyroid adenomas (such as *MEN1* at 11q13) are uncommon in parathyroid carcinomas, suggesting that most parathyroid carcinomas do not arise from preexisting adenomas.[136] Other allelic imbalance studies also support a de novo origin for parathyroid carcinoma.[137]

Special techniques can be of some help in the differential diagnosis between parathyroid adenomas and carcinomas. Most of them are direct or indirect indicators of the rate of cellular proliferation. Thus, a significantly increased mean AgNOR (argyrophilic nucleolar organizer region) number has been found in carcinomatous glands when compared with benign (normal, hyperplastic, or adenomatous) glands.[138-140] Also, Ki-67 expression is significantly higher in carcinomas than in adenomas and hyperplasias.[54,141,142] Overexpression

of cyclin D1 occurs in over 90% of the carcinomas but in less than 40% of the adenomas.[51] An immunohistochemical marker usually expressed by parathyroid carcinomas but not adenomas is galectin-3.[141] Unfortunately, cases of primary and secondary parathyroid hyperplasia are also commonly positive, severely limiting its utility.[143] DNA ploidy studies have shown significant statistical differences between carcinomas and adenomas, and that among the former the presence of aneuploidy is associated with a more aggressive clinical course in carcinomas.[144-148] Kytola et al.[136] found "highly significant differences" by comparative genomic hybridization (CGH) between parathyroid carcinomas and adenomas, but there were no alterations that were specific for one or the other. Allelic loss of the *RB* gene (detected genetically or through absence of the Rb product immunohistochemically) occurs in a variable proportion of carcinomas or otherwise "aggressive" parathyroid tumors but only exceptionally in adenomas.[54,149,150] Finally, mutations of the *CDC73* gene (which can be inferred by a loss or decreased immunostaining for the parafibromin protein[151]) are found in a high percentage of parathyroid carcinoma cases but are rare in parathyroid adenomas.[132]

A few parathyroid carcinomas have been studied at the genomic level. Kasaian et al.[152] determined the genome sequence of a sporadic and recurrent parathyroid carcinoma and identified several novel mutations, such as *MTOR*, *MLL2*, *CDKN2C*, and *PIK3CA*, along with several structural alterations. Additional studies of larger cohorts will expand our understanding of the somatic genetic landscape of parathyroid carcinoma and shine additional light on its pathogenesis.

Prognosis

In a follow-up of 43 patients with parathyroid carcinoma reported by Holmes et al.,[111] it was found that 30 (65%) of the patients were dead, 5 were living with persistent tumor, and 8 were living without evidence of recurrent disease. Of 39 patients studied by Schantz and Castleman,[125] 41% were alive and well, 13% were alive with disease, and 46% were dead of carcinoma. Local recurrence within the first 2 years after surgery was found to be an ominous prognostic sign. Among 286 cases of parathyroid carcinoma collected in the U.S. National Cancer Database, neither tumor size nor lymph node status was found to be a significant prognostic factor. Overall relative survival at 5 years and 10 years was 85.5% and 49.1%, respectively.[153] In a series from M.D. Anderson, the 5-year survival was remarkably similar (85%) but the 10-year survival rate was higher (77%). Adjuvant radiation appeared to improve prognosis independent of the type of surgery and disease stage.[154]

Kameyama et al.[155] have proposed classifying parathyroid carcinomas into *low grade* when local infiltration is minimal and *high grade* when infiltration is widespread, a seemingly sensible approach that should to be tested by other groups.

Other Lesions

Parathyroid cysts usually arise from the lower glands but can be located in the upper region of the neck or in the mediastinum.[156,157] In most cases they cause no symptoms other than those related to pressure. Their mean diameter is 4 cm.[156] They are lined by cuboidal or low columnar epithelial cells and contain parathyroid tissue in their wall. Heterotopic salivary gland tissue can be found around the cyst.[158]

The cyst fluid contains assayable PTH.[159] The few reported cases of parathyroid cysts associated with HPT most likely represent adenomas with cystic degeneration.[160]

Amyloidosis often involves the parathyroid gland, in both primary and "reactive" forms of the disease.[161]

Langerhans cell histiocytosis involving simultaneously the parathyroid and thyroid glands has been reported.[162]

Hemangioma of the parathyroid gland has been described in two patients with HPT, but it is likely that the vascular tumor was simply an incidental finding.[163]

Metastatic carcinoma to the parathyroid glands is very rare, but papillary thyroid carcinoma can invade them in continuity with the main tumor.[164]

Hyperparathyroidism

The term **hyperparathyroidism** (HPT) is applied to any condition associated with the persistent production of parathyroid hormone. It is divided according to the presumed mechanism of production into primary (autonomous), secondary (due to a chronic condition that stimulates the producing of PTH), and tertiary (due to the formation of an autonomous clone in secondary HPT).

Primary Hyperparathyroidism

In primary HPT, there is no evidence of previous parathyroid stimulation by chronic renal or intestinal disease.[165] The pathologic changes in the gland may be those of adenoma, chief cell hyperplasia, carcinoma, or water-clear cell hyperplasia. Multigland disease is responsible for about 15% of cases of primary HPT.[48] Carcinoma constitutes about 1% of cases, and water-clear cell hyperplasia has essentially disappeared; therefore the large majority of cases are caused by either adenoma or chief cell hyperplasia.[166] Adenoma is responsible for over 80% of the cases.

Primary HPT is said to be present in 2.5 per 1000 individuals. It is usually seen in adults but can also be found in children.[167] When seen in a familial setting, the abnormality is usually chief cell hyperplasia, although exceptions occur.[168] It may also be seen, again in a familial form, as a component of MEN or HPT-JT.[169,170] In these syndrome, the parathyroid change is practically always chief cell hyperplasia, perhaps humorally induced.[171] An association between primary HPT and sarcoidosis has been encountered,[172] and a definite increase in the incidence of HPT after irradiation to the neck has been documented.[173,174]

The typical case of primary HPT is biochemically characterized by hypercalcemia, hypophosphatemia, lowering of the renal phosphate threshold, hypercalciuria, elevated levels of immunoreactive PTH, elevated concentrations of 1,25-dihydroxyvitamin D, and enhanced excretion of nephrogenous cyclic AMP. Another associated, albeit inconstant, chemical finding is elevation of the serum alkaline phosphatase level. Although hypercalcemia has traditionally been one of the most constant biochemical markers of parathyroid hyperfunction, well-documented instances of normocalcemic primary HPT do exist.[175] In a series of 84 patients with this variant, parathyroid adenomas were found in 19, chief cell hyperplasia in 39, and normal parathyroid glands in 26; no morphologic differences were detected between patients in this group and patients with conventional primary HPT associated with hypercalcemia.[176] However, at a functional level the glands have a profile closer to normal glands than those associated with conventional hypercalcemic HPT.[177]

According to the clinical presentation, patients with primary HPT have been traditionally classified into: (1) those with osseous manifestations; (2) those with renal manifestations; and (3) those with neither of the foregoing. There is a predominance of the latter group, referred to as "occult" or "asymptomatic."[175,178]

The **skeletal changes** of HPT are always generalized, although they may appear localized clinically or radiographically. The initial lesions show merely a decrease in bone density. In time, they may become very extensive and lead to deformities and fractures. The

Figure 9.15 Historical example of extreme osteitis fibrosa cystica. Note deformity of bone with numerous cysts and brown tumors. (From Hunter D, Turnbull HN. Hyperparathyroidism. Generalized osteitis fibrosa, with observations upon bones, parathyroid tumors, and normal parathyroid glands. *Br J Surg*. 1931;19:203–284.)

full-blown osseous manifestations of HPT have been traditionally known as osteitis fibrosa cystica or Recklinghausen disease (not to be confused with neurofibromatosis, which also carries this eponym) (Figs. 9.15–9.17). The seemingly localized lesions are those more likely to be misinterpreted. They present radiographically as expansile, multilocular masses. The jaw is the preferred location, and this may be the first clinical manifestation of the disease. Grossly, there is an alternation of solid and cystic areas; the latter often have a brown color because of the accumulation of abundant hemosiderin, hence the term *brown tumor* sometimes used for them. Microscopically, there is a combination of osteoblastic and osteoclastic activity, often associated with cyst formation and clusters of hemosiderin-laden macrophages. It is this combination of findings that should suggest the diagnosis (Fig. 9.18).

The differential diagnosis with central giant cell reparative granuloma may be impossible on morphologic grounds because both lesions have a predilection for the jaw and their microscopic appearances are essentially the same; therefore the distinction is based on laboratory findings. The other differential diagnosis is with giant cell tumor, with which brown tumor has often been confused in the past. In giant cell tumor, the osteoclasts are more evenly spaced, the stromal cells are plumper, and osteoblastic activity is less conspicuous.

Removal of the hyperfunctioning gland is usually followed by a spectacular reversal of the bone changes, sometimes in a remarkably short time; however, some of the cystic lesions may persist indefinitely (see Figs. 9.16 and 9.17).

The **renal changes** of primary HPT include renal stones, nephrocalcinosis, polyuria, polydipsia, and impairment of renal function. Renal stones are the most common clinical manifestation of HPT.[165] These renal lesions are frequently associated with hypertension. In contrast to the skeletal changes, the renal abnormalities may still progress after the removal of the parathyroid lesion.

Other manifestations of HPT include hypertension, peptic ulcer, acute and chronic pancreatitis, and mental disturbances. The peptic ulcer is usually in the duodenum and is more common in males[179]; it often heals after removal of the hyperfunctioning gland.

Rarely, acute gastrointestinal, cardiovascular, or central nervous system symptoms develop because of very high serum calcium levels. This condition, designated as **parathyroid crisis**, is fatal unless the offending gland or glands are rapidly excised.[180]

Secondary Hyperparathyroidism

Secondary HPT occurs as a consequence of chronic renal disease or intestinal malabsorption, usually the former. The renal insufficiency leads to elevation of the serum phosphorus level and reciprocal decrease of serum calcium concentrations, with the resulting stimulation of the parathyroid glands.[181] Vitamin D resistance is a characteristic feature of advanced renal disease and also may play a role by contributing to reduced serum calcium concentrations.[182] Determinations of circulating PTH levels have shown these to be roughly proportional to the severity of renal failure. These levels are higher in renal failure than in any form of primary HPT.

The bone changes are qualitatively similar to those seen in primary HPT. They are usually milder, but sometimes extensive changes with cyst formation occur. *Cutaneous calciphylaxis* is an uncommon and potentially lethal disorder characterized by progressive cutaneous vascular calcification. It is mainly seen in the setting of renal failure–associated HPT. Microscopically, the mural vascular calcification is often associated with skin ulceration and calcifying septal panniculitis.[183]

The parathyroid abnormality in secondary HPT is **chief cell hyperplasia** of a generally diffuse but sometimes nodular pattern of growth.

"Tertiary" Hyperparathyroidism

The term **"tertiary" hyperparathyroidism** is applied to cases of HPT secondary to chronic renal disease or intestinal malabsorption, in which one or more of the stimulated parathyroid glands seem to become autonomous.[184] This phenomenon, which is also referred to as **nonsuppressible**, **autonomous**, or **refractory** HPT, is usually detected after correction of the renal disease by hemodialysis or homotransplantation.[185] Follow-up studies seem to indicate that if enough time is given, the parathyroid glands will revert to a normal state in the large majority of cases.[186,187]

Morphologically, the changes in the parathyroid gland are those of chief cell hyperplasia, the main difference with the ordinary case of **suppressible** secondary HPT being a greater tendency to nodularity

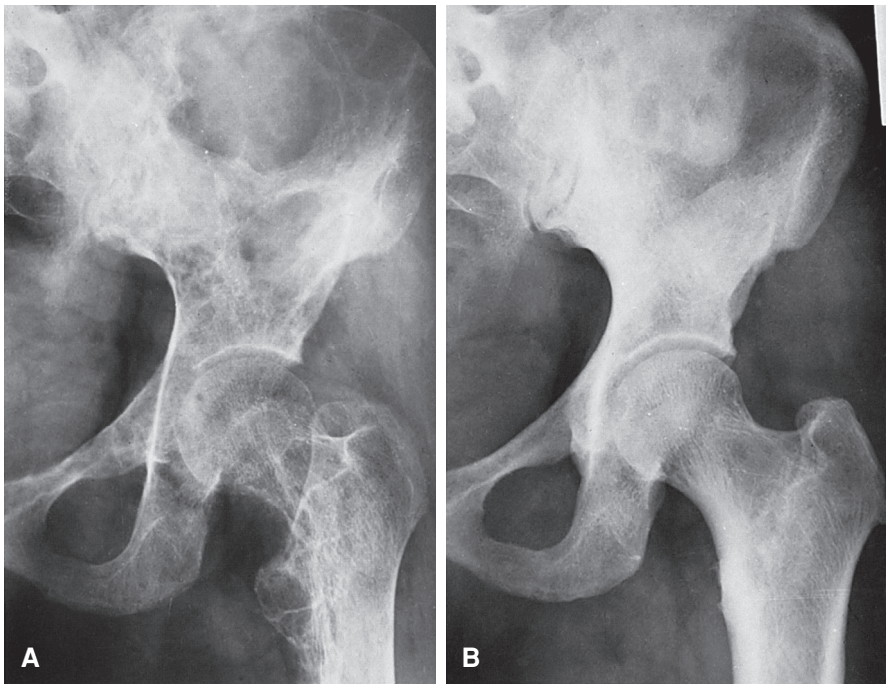

Figure 9.16 **A,** Extensive changes in bones of pelvis and femur caused by functioning parathyroid adenoma. **B,** Same pelvis and femur 8 years after removal of adenoma. Note complete reversion to normal. (From Black BK, Ackerman LV. Tumors of the parathyroid. A review of twenty-three cases. *Cancer*. 1950;3:415–444.)

Figure 9.17 **A,** Cystic changes and cortical alterations in bones of hands of patient with functioning parathyroid adenoma. **B,** Dramatic reparative change evident 9 months after removal of adenoma.

and heterogeneity, in the sense of the nodular components having a higher percentage of oxyphilic cells and acinar cell arrangements, and showing a marked variability of PTH immunoreactivity.[188-190] Sometimes an entire nodule is made up of oxyphilic cells.[190] Even when the hyperplastic changes remain diffuse, the nuclear size has been shown by morphometry to be larger than that of secondary hyperplasia and approaching that of adenoma.[191] It has been demonstrated that the presence of a nodular pattern of growth (especially if coupled with a high Ki-67 fraction) is associated with a higher risk of recurrence of the HPT.[192] These nodules have a high prevalence of *TP53* expression immunohistochemically.[189] In extreme cases, one of these nodules will acquire an appearance that is indistinguishable from that of a true adenoma. However, the finding of allelic losses at chromosomes 7p, 18q, and 2 suggests that its molecular pathways are different from those of the ordinary adenoma.[193]

Differential Diagnosis

Primary HPT must be distinguished clinically from a relatively large number of conditions associated with hypercalcemia. These include sarcoidosis, hyperthyroidism, multiple myeloma, milk–alkali syndrome, vitamin D and vitamin A intoxication, familial hypercalcemic hypocalciuria, and humoral hypercalcemia of malignancy.

Familial hypocalciuric hypercalcemia should be suspected in young patients with a presumptive diagnosis of HPT, especially if there is a family history.[194,195] Determination of the calcium:creatinine

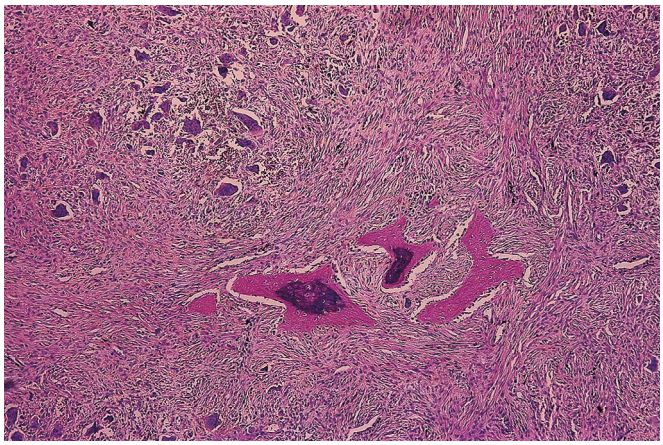

Figure 9.18 Bone changes in hyperparathyroidism. There is marked resorption of bone trabeculae and clustering of osteoclasts.

clearance ratio is the traditional test to identify this disorder. Heterozygous inactivating mutations of calcium-sensing receptor are found in about two-thirds of the patients.[196] Microscopically, the parathyroid glands may appear normal or exhibit a mild degree of chief cell hyperplasia, sometimes with a prominent clear cell component.[197] In other instances they show features of lipohyperplasia.[196]

Humoral hypercalcemia of malignancy. Nonparathyroid tumors may induce hypercalcemia by producing widespread metastases in the skeletal system. In addition, symptoms and signs suggestive of HPT may be seen in malignant tumors of nonparathyroid origin in the absence of significant osseous metastases.[198,199] This condition is sometimes referred to as pseudohyperparathyroidism. Renal cell carcinoma and squamous cell carcinoma of the lung account for 60% of cases.[200] The parathyroid glands appear morphologically normal or only minimally hyperplastic,[201,202] but the serum biochemical parameters clearly indicate a state of suppressed parathyroid function. The mechanism for the hypercalcemia has been found to be the secretion by the tumor cells of a peptide with a partial homology to PTH, known as PTH-related peptide or PTH-related protein.[203-205]

Treatment

According to the most recent guidelines from the American Association of Endocrine Surgeons,[48] parathyroidectomy is the preferred treatment for HPT and is indicated for all symptomatic patients. Surgery is also indicated for asymptomatic patients whose serum calcium level is greater than 1 mg/dL above normal. Parathyroidectomy is also indicated for patients with evidence of renal involvement, osteoporosis, and/or compression fractures, in patients under age 50 regardless of symptoms and clinical findings, and in patients suspected of having parathyroid carcinoma. Patients who elect not to undergo surgery should be evaluated annually. Parathyroidectomy is not indicated when the surgical risks are greater than the expected benefits.

Experienced surgeons, that is, those who perform more than 10 parathyroidectomies per year, have better outcomes. The surgeon embarking on therapy for HPT should have a thorough knowledge of parathyroid physiology and of the variations in the appearance and anatomic locations of the parathyroid glands[206,207] as well as the tumors arising from them.

Several techniques have been used to localize the abnormal gland preoperatively and should be used after deciding to proceed with surgery, as it can guide operative planning. Cervical ultrasonography is the mainstay of localization and can be combined with computed tomography scan and sestamibi radioactive scan. Magnetic resonance imaging and selective venous catheterization can be used in difficult cases. Fine needle biopsy is not recommended for localization.

Adenomas are adequately treated by excision of the tumor.[208] Surgical identification of *all four* parathyroid glands via bilateral exploration remains a widely used approach,[209,210] although minimally invasive parathyroidectomy, that is, a limited neck dissection, has become increasingly used for primary HPT patients with a single adenoma. Advances in the preoperative localization of abnormal parathyroid glands have reduced the number of glands submitted for histologic examination.[211] The use of intraoperative PTH measurement has reduced the surgical failure rate and the need for frozen section. While excision or biopsy at least one other parathyroid gland was once performed to rule out the alternative possibility of chief cell hyperplasia, this approach has been replaced with bilateral exploration with visualization of the glands and intraoperative PTH monitoring.

Primary chief cell hyperplasia and the exceptionally rare water-clear cell hyperplasia are conventionally treated by subtotal parathyroidectomy, as defined by total excision of three glands and partial excision of the fourth, leaving 30–50 mg of viable tissue.[212]

An alternative approach to the treatment of primary or secondary chief cell hyperplasia has been the performance of total parathyroidectomy with autotransplantation of parathyroid tissue into the forearm muscle or chest wall fat pad.[213,214] The transplanted tissue may regrow briskly and lead to recurrence of the HPT.[215,216] The hyperplastic gland may infiltrate the skeletal muscle, simulating a malignant process. The danger of overdiagnosis under these circumstances is made greater by the fact that mitoses can be easily found in this tissue even if absent in the original lesion.

Parathyroid carcinoma is best treated by excision of the tumor and surrounding soft tissues and removal of the ipsilateral lateral thyroid lobe; the indication for ipsilateral node dissection remains controversial,[111,119,217,218] as well as the need for extensive surgery.[219] Surgical resection of isolated metastases is justified because of its marked palliative effect.[220]

The large majority of patients with secondary and "tertiary" HPT respond well to medical treatment[182,221]; however, if bone lesions are severe and if the hypercalcemia is excessive, subtotal parathyroidectomy may become necessary.

Frozen Section

Unless dealing with an exceptionally experienced and gifted surgeon,[222] the pathologist's main role at the time of surgery is to determine by frozen section whether a given nodule removed from the neck is actually parathyroid tissue, since nodules of thyroid gland, small lymph nodes, aberrant thymic tissue, and even fat may be mistaken grossly for parathyroid tissue.[223-225] This determination has an accuracy rate of over 99%.[226,227] With experience, this determination can also be made in imprints stained with polychrome methylene blue, a technique that saves considerable surgical time.[228-230]

As far as the pathologist providing a specific diagnosis is concerned, most cases of water-clear cell hyperplasia and some carcinomas should be identifiable by frozen section, particularly if the carcinoma has invaded local tissues; however, this comprises a very small proportion of cases. The two most common—and unfortunately most difficult—situations faced by the pathologist are to decide whether a gland is normal or abnormal and, if abnormal, whether it is involved by chief cell hyperplasia or adenoma. Fortunately, with the advent of intraoperative PTH measurement, the surgical approach is often guided by visualization of normal glands and normalization of PTH after removal of an enlarged gland, rather than frozen section. Therefore, pathologists are much less often faced with this differential diagnosis and parathyroid frozen section practice has been reduced to confirming the presence of parathyroid tissue.

References

1. Carney JA. The glandulae parathyroideae of Ivar Sandstrom. Contributions from two continents. *Am J Surg Pathol*. 1996;20(9):1123-1144.
2. Gilmour JR, Martin WJ. The weight of the parathyroid glands. *J Pathol Bacteriol*. 1937;44:431-462.
3. Akerstrom G, Malmaeus J, Bergstrom R. Surgical anatomy of human parathyroid glands. *Surgery*. 1984;95(1):14-21.
4. Conn JM, Goncalves MA, Mansour KA, McGarity WC. The mediastinal parathyroid. *Am Surg*. 1991;57(1):62-66.
5. Harach HR, Vujanic GM. Intrathyroidal parathyroid. *Pediatr Pathol*. 1993;13(1):71-74.
6. Herrold KM, Rabson AS, Ketcham AS. Aberrant parathyroid gland in pharyngeal submucosa. *Arch Pathol*. 1961;71:60-62.
7. Lack EE, Delay S, Linnoila RI. Ectopic parathyroid tissue within the vagus nerve. Incidence and possible clinical significance. *Arch Pathol Lab Med*. 1988;112(3):304-306.
8. Michal M. Ectopic parathyroid within a neck paraganglion. *Histopathology*. 1993;22(1):85-87.
9. Wang C. The anatomic basis of parathyroid surgery. *Ann Surg*. 1976;183(3):271-275.
10. Roth SI, Belsley NA, Abu-Jawdeh GM. Parathyroid. In: Mills SE, ed. *Histology for Pathologists*. 3rd ed. Philadelphia: Lippincott Williams & Wilkins; 2007:1149-1166.
11. Roth SI, Capen CC. Ultrastructural and functional correlations of the parathyroid gland. *Int Rev Exp Pathol*. 1974;13(0):161-221.
12. Hellman P, Bjerneroth G, Juhlin C, et al. Immunohistochemical evidence of parathyroid hormone-related protein in human parathyroid tissue. *Endocrinol Pathol*. 1990;1:172-176.
13. Pesce C, Tobia F, Carli F, Antoniotti GV. The sites of hormone storage in normal and diseased parathyroid glands: a silver impregnation and immunohistochemical study. *Histopathology*. 1989;15(2):157-166.
14. Miettinen M, Clark R, Lehto VP, et al. Intermediate-filament proteins in parathyroid glands and parathyroid adenomas. *Arch Pathol Lab Med*. 1985;109(11):986-989.
15. Schmid KW, Hittmair A, Ladurner D, et al. and B in parathyroid tissue of cases of primary hyperparathyroidism: an immunohistochemical study. *Virchows Arch A Pathol Anat Histopathol*. 1991;418(4):295-299.
16. Muller-Hocker J. Random cytochrome-C-oxidase deficiency of oxyphil cell nodules in the parathyroid gland. A mitochondrial cytopathy related to cell ageing? *Pathol Res Pract*. 1992;188(6):701-706.
17. Grimelius L, Bondeson L. Histopathological diagnosis of parathyroid diseases. *Pathol Res Pract*. 1995;191(4):353-365.
18. Obara T, Fujimoto Y, Aiba M. Stromal fat content of the parathyroid gland. *Endocrinol Jpn*. 1990;37(6):901-905.
19. Gilmour JR. *The Parathyroid Glands and Skeleton in Renal Disease*. London: Oxford University Press; 1947.
20. Boquist L. Follicles in human parathyroid glands. *Lab Invest*. 1973;28(3):313-320.
21. Lieberman A, DeLellis RA. Intrafollicular amyloid in normal parathyroid glands. *Arch Pathol*. 1973;95(6):422-423.
22. Isotalo PA, Lloyd RV. Presence of birefringent crystals is useful in distinguishing thyroid from parathyroid gland tissues. *Am J Surg Pathol*. 2002;26(6):813-814.
23. Habener JF, Rosenblatt M, Potts JT Jr. Parathyroid hormone: biochemical aspects of biosynthesis, secretion, action, and metabolism. *Physiol Rev*. 1984;64(3): 985-1053.
24. Martin KJ, Hruska KA, Freitag JJ, et al. The peripheral metabolism of parathyroid hormone. *N Engl J Med*. 1979;301(20):1092-1098.
25. Marx SJ. Hyperparathyroid and hypoparathyroid disorders. *N Engl J Med*. 2000;343(25):1863-1875.
26. Akerstrom G, Rastad J, Ljunghall S, et al. Cellular physiology and pathophysiology of the parathyroid glands. *World J Surg*. 1991;15(6):672-680.
27. Khundmiri SJ, Murray RD, Lederer E. PTH and Vitamin D. *Compr Physiol*. 2016;6(2):561-601.
28. Venail F, Nicollas R, Morin D, et al. Solitary parathyroid adenoma: a rare cause of primary hyperparathyroidism in children. *Laryngoscope*. 2007;117(5):946-949.
29. Schachner SH, Hall A. Parathyroid adenoma and previous head and neck irradiation. *Ann Intern Med*. 1978;88(6):804.
30. Rajatanavin R, Stock JL, Lutton CE, Emerson CH. Radiation-associated recurrent parathyroid adenoma. *Arch Intern Med*. 1985;145(1):154-155.
31. Abboud B, Sleilaty G, Helou E, et al. Existence and anatomic distribution of double parathyroid adenoma. *Laryngoscope*. 2005;115(6):1128-1131.
32. Attie JN, Bock G, Auguste LJ. Multiple parathyroid adenomas: report of thirty-three cases. *Surgery*. 1990;108(6):1014-1019, discussion 1019-1020.
33. Bergson EJ, Heller KS. The clinical significance and anatomic distribution of parathyroid double adenomas. *J Am Coll Surg*. 2004;198(2):185-189.
34. De Gregorio L, Lubitz CC, Hodin RA, et al. The truth about double adenomas: incidence, localization, and intraoperative parathyroid hormone. *J Am Coll Surg*. 2016;222(6):1044-1052.
35. Liechty RD, Teter A, Suba EJ. The tiny parathyroid adenoma. *Surgery*. 1986;100(6):1048-1052.
36. Moran CA, Suster S. Primary parathyroid tumors of the mediastinum: a clinicopathologic and immunohistochemical study of 17 cases. *Am J Clin Pathol*. 2005;124(5):749-754.
37. Callender GG, Grubbs EG, Vu T, et al. The fallen one: the inferior parathyroid gland that descends into the mediastinum. *J Am Coll Surg*. 2009;208(5):887-893, discussion 893-895.
38. Pitsilos SA, Weber R, Baloch Z, LiVolsi VA. Ectopic parathyroid adenoma initially suspected to be a thyroid lesion. *Arch Pathol Lab Med*. 2002;126(12):1541-1542.
39. Yusim A, Aspelund G, Ahrens W, et al. Intrathyroidal parathyroid adenoma. *Thyroid*. 2006;16(6):619-620.
40. Norris EH. The parathyroid adenoma; a study of 322 cases. *Surg Gynecol Obstet*. 1947;84(1):1-41.
41. Sloane JA, Moody HC. Parathyroid adenoma in submucosa of esophagus. *Arch Pathol Lab Med*. 1978;102(5):242-243.
42. Carney JA. Pathology of hyperparathyroidism: a practical approach. *Monogr Pathol*. 1993;35:34-62.
43. Ho KJ. Papillary parathyroid adenoma. A rare occurrence and its importance in differentiation from papillary carcinoma of the thyroid. *Arch Pathol Lab Med*. 1996;120(9):883-884.
44. Leedham PW, Pollock DJ. Intrafollicular amyloid in primary hyperparathyroidism. *J Clin Pathol*. 1970;23(9):811-817.
45. Lawton TJ, Feldman M, LiVolsi V. Lymphocytic infiltrates in solitary parathyroid adenomas. *Int J Surg Pathol*. 1998;6:5-10.
46. Lam KY, Chan AC, Lo CY. Parathyroid adenomas with pronounced lymphocytic infiltration: no evidence of autoimmune pathogenesis. *Endocr Pathol*. 2000;11(1):77-83.
47. Veress B, Nordenstrom J. Lymphocytic infiltration and destruction of parathyroid adenomas: a possible tumour-specific autoimmune reaction in two cases of primary hyperparathyroidism. *Histopathology*. 1994;25(4):373-377.
48. Wilhelm SM, Wang TS, Ruan DT, et al. The American Association of Endocrine Surgeons guidelines for definitive management of primary hyperparathyroidism. *JAMA Surg*. 2016;151(10):959-968.
49. Tomita T. Immunocytochemical staining patterns for parathyroid hormone and chromogranin in parathyroid hyperplasia, adenoma and carcinoma. *Endocr Pathol*. 1999;10:145-156.
50. Ikeda S, Ishizaki Y, Shimizu Y, et al. Immunohistochemistry of cyclin D1 and beta-catenin, and mutational analysis of exon 3 of beta-catenin gene in parathyroid adenomas. *Int J Oncol*. 2002;20(3):463-466.
51. Vasef MA, Brynes RK, Sturm M, et al. Expression of cyclin D1 in parathyroid carcinomas, adenomas, and hyperplasias: a paraffin immunohistochemical study. *Mod Pathol*. 1999;12(4):412-416.
52. Hadar T, Shvero J, Yaniv E, et al. Expression of p53, Ki-67 and Bcl-2 in parathyroid adenoma and residual normal tissue. *Pathol Oncol Res*. 2005;11(1):45-49.
53. Naccarato AG, Marcocci C, Miccoli P, et al. Bcl-2, p53 and MIB-1 expression in normal and neoplastic parathyroid tissues. *J Endocrinol Invest*. 1998;21(3):136-141.
54. Vargas MP, Vargas HI, Kleiner DE, Merino MJ. The role of prognostic markers (MiB-1, RB, and bcl-2) in the diagnosis of parathyroid tumors. *Mod Pathol*. 1997;10(1):12-17.
55. Kishikawa S, Shan L, Ogihara K, et al. Overexpression and genetic abnormality of p53 in parathyroid adenomas. *Pathol Int*. 1999;49(10):853-857.
56. Kumari N, Chaudhary N, Pradhan R, et al. Role of histological criteria and immunohistochemical markers in predicting risk of malignancy in parathyroid neoplasms. *Endocr Pathol*. 2016;27(2):87-96.
57. Guarnieri V, Battista C, Muscarella LA, et al. CDC73 mutations and parafibromin immunohistochemistry in parathyroid tumors: clinical correlations in a single-centre patient cohort. *Cell Oncol (Dordr)*. 2012;35(6):411-422.
58. Juhlin C, Larsson C, Yakoleva T, et al. Loss of parafibromin expression in a subset of parathyroid adenomas. *Endocr Relat Cancer*. 2006;13(2):509-523.
59. Juhlin CC, Villablanca A, Sandelin K, et al. Parafibromin immunoreactivity: its use as an additional diagnostic marker for parathyroid tumor classification. *Endocr Relat Cancer*. 2007;14(2):501-512.
60. Hosny Mohammed K, Siddiqui MT, Willis BC, et al. Parafibromin, APC, and MIB-1 are useful markers for distinguishing parathyroid carcinomas from adenomas. *Appl Immunohistochem Mol Morphol*. 2016.
61. Bergman L, Boothroyd C, Palmer J, et al. Identification of somatic mutations of the MEN1 gene in sporadic endocrine tumours. *Br J Cancer*. 2000;83(8):1003-1008.
62. Dwight T, Twigg S, Delbridge L, et al. Loss of heterozygosity in sporadic parathyroid tumours: involvement of chromosome 1 and the MEN1 gene locus in 11q13. *Clin Endocrinol (Oxf)*. 2000;53(1):85-92.

63. Farnebo F, Teh BT, Kytola S, et al. Alterations of the MEN1 gene in sporadic parathyroid tumors. *J Clin Endocrinol Metab*. 1998;83(8):2627-2630.
64. Heppner C, Kester MB, Agarwal SK, et al. Somatic mutation of the MEN1 gene in parathyroid tumours. *Nat Genet*. 1997;16(4):375-378.
65. Miedlich S, Krohn K, Lamesch P, et al. Frequency of somatic MEN1 gene mutations in monoclonal parathyroid tumours of patients with primary hyperparathyroidism. *Eur J Endocrinol*. 2000;143(1):47-54.
66. Alvelos MI, Mendes M, Soares P. Molecular alterations in sporadic primary hyperparathyroidism. *Genet Res Int*. 2011;2011:275802.
67. Cromer MK, Starker LF, Choi M, et al. Identification of somatic mutations in parathyroid tumors using whole-exome sequencing. *J Clin Endocrinol Metab*. 2012;97(9):E1774-E1781.
68. Newey PJ, Nesbit MA, Rimmer AJ, et al. Whole-exome sequencing studies of nonhereditary (sporadic) parathyroid adenomas. *J Clin Endocrinol Metab*. 2012;97(10):E1995-E2005.
69. Wang EH, Ebrahimi SA, Wu AY, et al. Mutation of the MENIN gene in sporadic pancreatic endocrine tumors. *Cancer Res*. 1998;58(19):4417-4420.
70. Yi Y, Nowak NJ, Pacchia AL, Morrison C. Chromosome 11 genomic changes in parathyroid adenoma and hyperplasia: array CGH, FISH, and tissue microarrays. *Genes Chromosomes Cancer*. 2008;47(8):639-648.
71. Costa-Guda J, Arnold A. Genetic and epigenetic changes in sporadic endocrine tumors: parathyroid tumors. *Mol Cell Endocrinol*. 2014;386(1-2):46-54.
72. Sulaiman L, Juhlin CC, Nilsson IL, et al. Global and gene-specific promoter methylation analysis in primary hyperparathyroidism. *Epigenetics*. 2013;8(6):646-655.
73. Westin G. Molecular genetics and epigenetics of nonfamilial (sporadic) parathyroid tumours. *J Intern Med*. 2016;280(6):551-558.
74. Guarnieri V, Muscarella LA, Verdelli C, Corbetta S. Alterations of DNA methylation in parathyroid tumors. *Mol Cell Endocrinol*. 2017.
75. Arya AK, Bhadada SK, Singh P, et al. Promoter hypermethylation inactivates CDKN2A, CDKN2B and RASSF1A genes in sporadic parathyroid adenomas. *Sci Rep*. 2017;7(1):3123.
76. Verdelli C, Forno I, Vaira V, Corbetta S. Epigenetic alterations in human parathyroid tumors. *Endocrine*. 2015;49(2):324-332.
77. Verdelli C, Forno I, Vaira V, Corbetta S. MicroRNA deregulation in parathyroid tumours suggests an embryonic signature. *J Endocrinol Invest*. 2015;38(4):383-388.
78. Rahbari R, Holloway AK, He M, et al. Identification of differentially expressed microRNA in parathyroid tumors. *Ann Surg Oncol*. 2011;18(4):1158-1165.
79. Morrison C, Farrar W, Kneile J, et al. Molecular classification of parathyroid neoplasia by gene expression profiling. *Am J Pathol*. 2004;165(2):565-576.
80. Forsberg L, Bjorck E, Hashemi J, et al. Distinction in gene expression profiles demonstrated in parathyroid adenomas by high-density oligoarray technology. *Eur J Endocrinol*. 2005;152(3):459-470.
81. Baloch ZW, LiVolsi VA. Oncocytic lesions of the neuroendocrine system. *Semin Diagn Pathol*. 1999;16(2):190-199.
82. Bedetti CD, Dekker A, Watson CG. Functioning oxyphil cell adenoma of the parathyroid gland: a clinicopathologic study of ten patients with hyperparathyroidism. *Hum Pathol*. 1984;15(12):1121-1126.
83. Ordonez NG, Ibanez ML, Mackay B, et al. Functioning oxyphil cell adenomas of parathyroid gland: immunoperoxidase evidence of hormonal activity in oxyphil cells. *Am J Clin Pathol*. 1982;78(5):681-689.
84. Poole GV Jr, Albertson DA, Marshall RB, Myers RT. Oxyphil cell adenoma and hyperparathyroidism. *Surgery*. 1982;92(5):799-805.
85. Wolpert HR, Vickery AL Jr, Wang CA. Functioning oxyphil cell adenomas of the parathyroid gland. A study of 15 cases. *Am J Surg Pathol*. 1989;13(6):500-504.
86. Daboin KP, Ochoa-Perez V, Luna MA. Adenolipomas of the head and neck: analysis of 6 cases. *Ann Diagn Pathol*. 2006;10(2):72-76.
87. Chow LS, Erickson LA, Abu-Lebdeh HS, Wermers RA. Parathyroid lipoadenomas: a rare cause of primary hyperparathyroidism. *Endocr Pract*. 2006;12(2):131-136.
88. Hyrcza MD, Sargin P, Mete O. Parathyroid lipoadenoma: a clinicopathological diagnosis and possible trap for the unaware pathologist. *Endocr Pathol*. 2016;27(1):34-41.
89. Daroca PJ Jr, Landau RL, Reed RJ, Kappelman MD. Functioning lipoadenoma of the parathyroid gland. *Arch Pathol Lab Med*. 1977;101(1):28-29.
90. Ducatman BS, Wilkerson SY, Brown JA. Functioning parathyroid lipoadenoma. Report of a case diagnosed by intraoperative touch preparations. *Arch Pathol Lab Med*. 1986;110(7):645-647.
91. Harach HR, Jasani B. Parathyroid hyperplasia in multiple endocrine neoplasia type 1: a pathological and immunohistochemical reappraisal. *Histopathology*. 1992;20(4):305-313.
92. Giusti F, Cavalli L, Cavalli T, Brandi ML. Hereditary hyperparathyroidism syndromes. *J Clin Densitom*. 2013;16(1):69-74.
93. Carney JA, Roth SI, Heath H 3rd, et al. The parathyroid glands in multiple endocrine neoplasia type 2b. *Am J Pathol*. 1980;99(2):387-398.
94. Thakker RV. Multiple endocrine neoplasia type 1 (MEN1) and type 4 (MEN4). *Mol Cell Endocrinol*. 2014;386(1-2):2-15.
95. Lodish M. Multiple endocrine neoplasia type 2. *Front Horm Res*. 2013;41:16-29.
96. Lee M, Pellegata NS. Multiple endocrine neoplasia type 4. *Front Horm Res*. 2013;41:63-78.
97. Pardi E, Mariotti S, Pellegata NS, et al. Functional characterization of a CDKN1B mutation in a Sardinian kindred with multiple endocrine neoplasia type 4 (MEN4). *Endocr Connect*. 2015;4(1):1-8.
98. Bradley KJ, Cavaco BM, Bowl MR, et al. Parafibromin mutations in hereditary hyperparathyroidism syndromes and parathyroid tumours. *Clin Endocrinol (Oxf)*. 2006;64(3):299-306.
99. Gill AJ. Understanding the genetic basis of parathyroid carcinoma. *Endocr Pathol*. 2014;25(1):30-34.
100. Adams PH, Chalmers T, Peters N, et al. Primary chief cell hyperplasia of the parathyroid glands. *Ann Intern Med*. 1965;63:454-467.
101. Castleman B, Schantz A, Roth S. Parathyroid hyperplasia in primary hyperparathyroidism: a review of 85 cases. *Cancer*. 1976;38(4):1668-1675.
102. Black WC, Haff RC. The surgical pathology of parathyroid chief cell hyperplasia. *Am J Clin Pathol*. 1970;53(5):565-579.
103. Tominaga Y, Grimelius L, Johansson H, et al. Histological and clinical features of non-familial primary parathyroid hyperplasia. *Pathol Res Pract*. 1992;188(1-2):115-122.
104. Fitko R, Roth SI, Hines JR, et al. Parathyromatosis in hyperparathyroidism. *Hum Pathol*. 1990;21(2):234-237.
105. Bondeson AG, Bondeson L, Ljungberg O. Chronic parathyroiditis associated with parathyroid hyperplasia and hyperparathyroidism. *Am J Surg Pathol*. 1984;8(3):211-215.
106. Roth SI, Marshall RB. Pathology and ultrastructure of the human parathyroid glands in chronic renal failure. *Arch Intern Med*. 1969;124(4):397-407.
107. Roth SI. Pathology of the parathyroids in hyperparathyroidism. Discussion of recent advances in the anatomy and pathology of the parathyroid glands. *Arch Pathol*. 1962;73:495-510.
108. Grimelius L, Johansson H. Parathyroid histopathology. *Endocr Pathol*. 1996;7:165-172.
109. Loda M, Lipman J, Cukor B, et al. Nodular foci in parathyroid adenomas and hyperplasias: an immunohistochemical analysis of proliferative activity. *Hum Pathol*. 1994;25(10):1050-1056.
110. Hedback G, Oden A. Parathyroid water clear cell hyperplasia, an O-allele associated condition. *Hum Genet*. 1994;94(2):195-197.
111. Holmes EC, Morton DL, Ketcham AS. Parathyroid carcinoma: a collective review. *Ann Surg*. 1969;169(4):631-640.
112. Aldinger KA, Hickey RC, Ibanez ML, Samaan NA. Parathyroid carcinoma: a clinical study of seven cases of functioning and two cases of nonfunctioning parathyroid cancer. *Cancer*. 1982;49(2):388-397.
113. Baba H, Kishihara M, Tohmon M, et al. Identification of parathyroid hormone messenger ribonucleic acid in an apparently nonfunctioning parathyroid carcinoma transformed from a parathyroid carcinoma with hyperparathyroidism. *J Clin Endocrinol Metab*. 1986;62(2):247-252.
114. Dinnen JS, Greenwoood RH, Jones JH, et al. Parathyroid carcinoma in familial hyperparathyroidism. *J Clin Pathol*. 1977;30(10):966-975.
115. Haghighi P, Astarita RW, Wepsic HT, Wolf PL. Concurrent primary parathyroid hyperplasia and parathyroid carcinoma. *Arch Pathol Lab Med*. 1983;107(7):349-350.
116. Smith JF, Coombs RR. Histological diagnosis of carcinoma of the parathyroid gland. *J Clin Pathol*. 1984;37(12):1370-1378.
117. Streeten EA, Weinstein LS, Norton JA, et al. Studies in a kindred with parathyroid carcinoma. *J Clin Endocrinol Metab*. 1992;75(2):362-366.
118. Shih RY, Fackler S, Maturo S, et al. Parathyroid carcinoma in multiple endocrine neoplasia type 1 with a classic germline mutation. *Endocr Pract*. 2009;15(6):567-572.
119. Cohn K, Silverman M, Corrado J, Sedgewick C. Parathyroid carcinoma: the Lahey Clinic experience. *Surgery*. 1985;98(6):1095-1100.
120. Shane E, Bilezikian JP. Parathyroid carcinoma: a review of 62 patients. *Endocr Rev*. 1982;3(2):218-226.
121. Shortell CK, Andrus CH, Phillips CE Jr, Schwartz SI. Carcinoma of the parathyroid gland: a 30-year experience. *Surgery*. 1991;110(4):704-708.
122. Palnaes Hansen C, Lau Pedersen M, Christensen L. Diagnosis, treatment and outcome of parathyroid cancer. A report of eight patients. *Eur J Surg*. 1991;157(9):517-520.
123. Sandelin K. Parathyroid carcinoma. *Cancer Treat Res*. 1997;89:183-192.
124. Evans HL. Criteria for diagnosis of parathyroid carcinoma. A critical study. *Surg Pathol*. 1991;4:244-265.
125. Schantz A, Castleman B. Parathyroid carcinoma. A study of 70 cases. *Cancer*. 1973;31(3):600-605.

126. Stephenson TJ. Prognostic and predictive factors in endocrine tumours. *Histopathology*. 2006;48(6):629-643.
127. Snover DC, Foucar K. Mitotic activity in benign parathyroid disease. *Am J Clin Pathol*. 1981;75(3):345-347.
128. DeLellis RA. Challenging lesions in the differential diagnosis of endocrine tumors: parathyroid carcinoma. *Endocr Pathol*. 2008;19(4):221-225.
129. Erickson LA, Jin L, Papotti M, Lloyd RV. Oxyphil parathyroid carcinomas: a clinicopathologic and immunohistochemical study of 10 cases. *Am J Surg Pathol*. 2002;26(3):344-349.
130. Obara T, Fujimoto Y, Yamaguchi K, et al. Parathyroid carcinoma of the oxyphil cell type. A report of two cases, light and electron microscopic study. *Cancer*. 1985;55(7):1482-1489.
131. Ordonez NG, Ibanez ML, Samaan NA, Hickey RC. Immunoperoxidase study of uncommon parathyroid tumors. Report of two cases of nonfunctioning parathyroid carcinoma and one intrathyroid parathyroid tumor-producing amyloid. *Am J Surg Pathol*. 1983;7(6):535-542.
132. Shattuck TM, Valimaki S, Obara T, et al. Somatic and germ-line mutations of the HRPT2 gene in sporadic parathyroid carcinoma. *N Engl J Med*. 2003;349(18):1722-1729.
133. Westin G, Bjorklund P, Akerstrom G. Molecular genetics of parathyroid disease. *World J Surg*. 2009;33(11):2224-2233.
134. Cetani F, Ambrogini E, Viacava P, et al. Should parafibromin staining replace HRTP2 gene analysis as an additional tool for histologic diagnosis of parathyroid carcinoma? *Eur J Endocrinol*. 2007;156(5):547-554.
135. Howell VM, Gill A, Clarkson A, et al. Accuracy of combined protein gene product 9.5 and parafibromin markers for immunohistochemical diagnosis of parathyroid carcinoma. *J Clin Endocrinol Metab*. 2009;94(2):434-441.
136. Kytola S, Farnebo F, Obara T, et al. Patterns of chromosomal imbalances in parathyroid carcinomas. *Am J Pathol*. 2000;157(2):579-586.
137. Costa-Guda J, Imanishi Y, Palanisamy N, et al. Allelic imbalance in sporadic parathyroid carcinoma and evidence for its de novo origins. *Endocrine*. 2013;44(2):489-495.
138. Boquist LL. Nucleolar organizer regions in normal, hyperplastic and neoplastic parathyroid glands. *Virchows Arch A Pathol Anat Histopathol*. 1990;417(3):237-241.
139. Kanematsu E, Matsui H, Deguchi T, et al. Significance of AgNOR counts for distinguishing carcinoma from adenoma and hyperplasia in parathyroid gland. *Hum Pathol*. 1997;28(4):421-427.
140. Tuccari G, Abbona GC, Guiffre G, et al. AgNOR quantity as a prognostic tool in hyperplastic and neoplastic parathyroid glands. *Virchows Arch*. 2000;437(3):298-303.
141. Bergero N, De Pompa R, Sacerdote C, et al. Galectin-3 expression in parathyroid carcinoma: immunohistochemical study of 26 cases. *Hum Pathol*. 2005;36(8):908-914.
142. Erickson LA, Jin L, Wollan P, et al. Parathyroid hyperplasia, adenomas, and carcinomas: differential expression of p27Kip1 protein. *Am J Surg Pathol*. 1999;23(3):288-295.
143. Saggiorato E, Bergero N, Volante M, et al. Galectin-3 and Ki-67 expression in multiglandular parathyroid lesions. *Am J Clin Pathol*. 2006;126(1):59-66.
144. Bondeson L, Sandelin K, Grimelius L. Histopathological variables and DNA cytometry in parathyroid carcinoma. *Am J Surg Pathol*. 1993;17(8):820-829.
145. Harlow S, Roth SI, Bauer K, Marshall RB. Flow cytometric DNA analysis of normal and pathologic parathyroid glands. *Mod Pathol*. 1991;4(3):310-315.
146. Howard S, Anderson C, Diels W, et al. Nuclear DNA density of parathyroid lesions. *Pathol Res Pract*. 1992;188(4-5):497-499.
147. Mallette LE. DNA quantitation in the study of parathyroid lesions. A review. *Am J Clin Pathol*. 1992;98(3):305-311.
148. Obara T, Fujimoto Y, Hirayama A, et al. Flow cytometric DNA analysis of parathyroid tumors with special reference to its diagnostic and prognostic value in parathyroid carcinoma. *Cancer*. 1990;65(8):1789-1793.
149. Cryns VL, Thor A, Xu HJ, et al. Loss of the retinoblastoma tumor-suppressor gene in parathyroid carcinoma. *N Engl J Med*. 1994;330(11):757-761.
150. Szijan I, Orlow I, Dalamon V, et al. Alterations in the retinoblastoma pathway of cell cycle control in parathyroid tumors. *Oncol Rep*. 2000;7(2):421-425.
151. Andrici J, Gill AJ, Hornick JL. Next generation immunohistochemistry: emerging substitutes to genetic testing? *Semin Diagn Pathol*. 2017.
152. Kasaian K, Wiseman SM, Thiessen N, et al. Complete genomic landscape of a recurring sporadic parathyroid carcinoma. *J Pathol*. 2013;230(3):249-260.
153. Hundahl SA, Fleming ID, Fremgen AM, Menck HR. Two hundred eighty-six cases of parathyroid carcinoma treated in the U.S. between 1985-1995: a National Cancer Data Base Report. The American College of Surgeons Commission on Cancer and the American Cancer Society. *Cancer*. 1999;86(3):538-544.
154. Clayman GL, Gonzalez HE, El-Naggar A, Vassilopoulou-Sellin R. Parathyroid carcinoma: evaluation and interdisciplinary management. *Cancer*. 2004;100(5):900-905.
155. Kameyama K, Takami H. Proposal for the histological classification of parathyroid carcinoma. *Endocr Pathol*. 2005;16(1):49-52.
156. Calandra DB, Shah KH, Prinz RA, et al. Parathyroid cysts: a report of eleven cases including two associated with hyperparathyroid crisis. *Surgery*. 1983;94(6):887-892.
157. Shields TW, Immerman SC. Mediastinal parathyroid cysts revisited. *Ann Thorac Surg*. 1999;67(2):581-590.
158. Carney JA. Salivary heterotopia, cysts, and the parathyroid gland: branchial pouch derivatives and remnants. *Am J Surg Pathol*. 2000;24(6):837-845.
159. Silverman JF, Khazanie PG, Norris HT, Fore WW. Parathyroid hormone (PTH) assay of parathyroid cysts examined by fine-needle aspiration biopsy. *Am J Clin Pathol*. 1986;86(6):776-780.
160. Rogers LA, Fetter BF, Peete WP. Parathyroid cyst and cystic degeneration of parathyroid adenoma. *Arch Pathol*. 1969;88(5):476-479.
161. Ellis HA, Mawhinney WH. Parathyroid amyloidosis. *Arch Pathol Lab Med*. 1984;108(9):689-690.
162. Yap WM, Chuah KL, Tan PH. Langerhans cell histiocytosis involving the thyroid and parathyroid glands. *Mod Pathol*. 2001;14(2):111-115.
163. Merino MJ, Chuaqui R, Fernandez P. Parathyroid hemangioma: a report of two cases. *Endocr Pathol*. 1996;7(4): 319-322.
164. Tang W, Kakudo K, Nakamura MY, et al. Parathyroid gland involvement by papillary carcinoma of the thyroid gland. *Arch Pathol Lab Med*. 2002;126(12):1511-1514.
165. Pyrah LN, Hodgkinson A, Anderson CK. Primary hyperparathyroidism. *Br J Surg*. 1966;53(4):245-316.
166. Ghandur-Mnaymneh L, Kimura N. The parathyroid adenoma. A histopathologic definition with a study of 172 cases of primary hyperparathyroidism. *Am J Pathol*. 1984;115(1):70-83.
167. Rapaport D, Ziv Y, Rubin M, Huminer D. Dintsman M. Primary hyperparathyroidism in children. *J Pediatr Surg*. 1986;21(5):395-397.
168. Allo M, Thompson NW. Familial hyperparathyroidism caused by solitary adenomas. *Surgery*. 1982;92(3):486-490.
169. Ballard HS, Fame B, Hartsock RJ. Familial multiple endocrine adenoma-peptic ulcer complex. *Medicine (Baltimore)*. 1964;43:481-516.
170. Cutler RE, Reiss E, Ackerman LV. Familial hyperparathyroidism. A kindred involving eleven cases, with a discussion of primary chief-cell hyperplasia. *N Engl J Med*. 1964;270:859-865.
171. Brandi ML, Aurbach GD, Fitzpatrick LA, et al. Parathyroid mitogenic activity in plasma from patients with familial multiple endocrine neoplasia type 1. *N Engl J Med*. 1986;314(20):1287-1293.
172. Winnacker JL, Becker KL, Friedlander M, et al. Sarcoidosis and hyperparathyroidism. *Am J Med*. 1969;46(2):305-312.
173. Netelenbos C, Lips P, van der Meer C. Hyperparathyroidism following irradiation of benign diseases of the head and neck. *Cancer*. 1983;52(3):458-461.
174. Tisell LE, Carlsson S, Fjalling M, et al. Hyperparathyroidism subsequent to neck irradiation. Risk factors. *Cancer*. 1985;56(7):1529-1533.
175. Wills MR. Normocalcaemic primary hyperparathyroidism. *Lancet*. 1971;1: 849-853.
176. Grimelius L, Ejerblad S, Johansson H, Werner I. Parathyroid adenomas and glands in normocalcemic hyperparathyroidism. A light microscopic study. *Am J Pathol*. 1976;83(3):475-484.
177. Yang AH, Hsu CW, Chen JY, et al. Normocalcemic primary hyperparathyroidism in patients with recurrent kidney stones: pathological analysis of parathyroid glands. *Virchows Arch*. 2006;449(1):62-68.
178. Silverberg SJ, Shane E, Jacobs TP, et al. A 10-year prospective study of primary hyperparathyroidism with or without parathyroid surgery. *N Engl J Med*. 1999;341(17):1249-1255.
179. Hellstrom J, Ivemark BI. Primary hyperparathyroidism. Clinical and structural findings in 138 cases. *Acta Chir Scand Suppl*. 1962;Suppl 294:1-113.
180. MacLeod WA, Holloway CK. Hyperparathyroid crisis. A collective review. *Ann Surg*. 1967;166(6):1012-1015.
181. Breslau NA. Update on secondary forms of hyperparathyroidism. *Am J Med Sci*. 1987;294(2):120-131.
182. Bricker NS, Slatopolsky E, Reiss E, Avioli LV. Caclium, phosphorus, and bone in renal disease and transplantation. *Arch Intern Med*. 1969;123(5):543-553.
183. Essary LR, Wick MR. Cutaneous calciphylaxis. An underrecognized clinicopathologic entity. *Am J Clin Pathol*. 2000;113(2):280-287.
184. Davies DR, Dent CE, Watson L. Tertiary hyperparathyroidism. *Br Med J*. 1968;3(5615):395-399.
185. McIntosh DA, Peterson EW, McPhaul JJ Jr. Autonomy of parathyroid function after renal homotransplantation. *Ann Intern Med*. 1966;65(5):900-907.
186. Black WC, Slatopolsky E, Elkan I, Hoffsten P. Parathyroid morphology in suppressible and nonsuppressible renal hyperparathyroidism. *Lab Invest*. 1970;23(5):497-509.
187. Johnson JW, Hattner RS, Hampers CL, et al. Secondary hyperparathyroidism in chronic renal failure. Effects of renal homotransplantation. *JAMA*. 1971;215(3):478-480.

188. Harach HR, Jasani B. Parathyroid hyperplasia in tertiary hyperparathyroidism: a pathological and immunohistochemical reappraisal. *Histopathology*. 1992;21(6):513-519.
189. Martin LN, Kayath MJ, Vieira JG, Nose-Alberti V. Parathyroid glands in uraemic patients with refractory hyperparathyroidism: histopathology and p53 protein expression analysis. *Histopathology*. 1998;33(1):46-51.
190. Misonou J, Ishikura H, Aizawa M, Ohira S. Functioning oxyphil cell adenoma in a patient with secondary hyperparathyroidism. *Acta Pathol Jpn*. 1987;37(8):1357-1366.
191. Banerjee SS, Faragher B, Hasleton PS. Nuclear diameter in parathyroid disease. *J Clin Pathol*. 1983;36(2):143-148.
192. Abbona G, Papotti M, Gasparri G, Bussolati G. Recurrence in parathyroid hyperplasias owing to secondary hyperparathyroidism is predicted by morphological patterns and proliferative activity values. *Endocr Pathol*. 1996;7(1):55-61.
193. Nagy A, Chudek J, Kovacs G. Accumulation of allelic changes at chromosomes 7p, 18q, and 2 in parathyroid lesions of uremic patients. *Lab Invest*. 2001;81(4):527-533.
194. Falko JM, Maeder MC, Conway C, et al. Primary hyperparathyroidism: analysis of 220 patients with special emphasis on familial hypocalciuric hypercalcemia. *Heart Lung*. 1984;13(2):124-131.
195. Marx SJ, Spiegel AM, Levine MA, et al. Familial hypocalciuric hypercalcemia: the relation to primary parathyroid hyperplasia. *N Engl J Med*. 1982;307(7):416-426.
196. Fukumoto S, Chikatsu N, Okazaki R, et al. Inactivating mutations of calcium-sensing receptor results in parathyroid lipohyperplasia. *Diagn Mol Pathol*. 2001;10(4):242-247.
197. Thorgeirsson U, Costa J, Marx SJ. The parathyroid glands in familial hypocalciuric hypercalcemia. *Hum Pathol*. 1981;12(3):229-237.
198. Mundy GR. Pathophysiology of cancer-associated hypercalcemia. *Semin Oncol*. 1990;17(2 suppl 5):10-15.
199. Rosol TJ, Capen CC. Mechanisms of cancer-induced hypercalcemia. *Lab Invest*. 1992;67(6):680-702.
200. Lafferty FW. Pseudohyperparathyroidism. *Medicine (Baltimore)*. 1966;45(3):247-260.
201. Dufour DR, Marx SJ, Spiegel AM. Parathyroid gland morphology in nonparathyroid hormone-mediated hypercalcemia. *Am J Surg Pathol*. 1985;9(1):43-51.
202. Sharp CF Jr, Rude RK, Terry R, Singer FR. Abnormal bone and parathyroid histology in carcinoma patients with pseudohyperparathyroidism. *Cancer*. 1982;49(7):1449-1455.
203. Drucker DJ. Parathyroid hormone-like peptide. *Endocrinol Pathol*. 1991;2:4-11.
204. Singer FR. Pathogenesis of hypercalcemia of malignancy. *Semin Oncol*. 1991;18(4 suppl 5):4-10.
205. Strewler GJ. The physiology of parathyroid hormone-related protein. *N Engl J Med*. 2000;342(3):177-185.
206. Wang CA. Parathyroid re-exploration. A clinical and pathological study of 112 cases. *Ann Surg*. 1977;186(2):140-145.
207. Wang CA. Surgical management of primary hyperparathyroidism. *Curr Probl Surg*. 1985;22(11):1-50.
208. Rudberg C, Akerstrom G, Palmer M, et al. Late results of operation for primary hyperparathyroidism in 441 patients. *Surgery*. 1986;99(6):643-651.
209. Kaplan EL, Yashiro T, Salti G. Primary hyperparathyroidism in the 1990s. Choice of surgical procedures for this disease. *Ann Surg*. 1992;215(4):300-317.
210. Proye CA, Carnaille B, Bizard JP, et al. Multiglandular disease in seemingly sporadic primary hyperparathyroidism revisited: where are we in the early 1990s? A plea against unilateral parathyroid exploration. *Surgery*. 1992;112(6):1118-1122.
211. Johnson SJ. Changing clinicopathological practice in parathyroid disease. *Histopathology*. 2010;56(7):835-851.
212. Wang CA, Castleman B, Cope O. Surgical management of hyperparathyroidism due to primary hyperplasia. *Ann Surg*. 1982;195(4):384-392.
213. Herrera M, Grant C, van Heerden JA, Fitzpatrick LA. Parathyroid autotransplantation. *Arch Surg*. 1992;127(7):825-829, discussion 829-830.
214. Saxe A. Parathyroid transplantation: a review. *Surgery*. 1984;95(5):507-526.
215. Ellis HA. Fate of long-term parathyroid autografts in patients with chronic renal failure treated by parathyroidectomy: a histopathological study of autografts, parathyroid glands and bone. *Histopathology*. 1988;13(3):289-309.
216. Tanaka Y, Seo H, Tominaga Y, et al. Factors related to the recurrent hyperfunction of autografts after total parathyroidectomy in patients with severe secondary hyperparathyroidism. *Surg Today*. 1993;23(3):220-227.
217. Shaha AR, Shah JP. Parathyroid carcinoma: a diagnostic and therapeutic challenge. *Cancer*. 1999;86(3):378-380.
218. Wang CA, Gaz RD. Natural history of parathyroid carcinoma. Diagnosis, treatment, and results. *Am J Surg*. 1985;149(4):522-527.
219. Young S, Wu JX, Li N, et al. More extensive surgery may not improve survival over parathyroidectomy alone in parathyroid carcinoma. *Ann Surg Oncol*. 2016;23(9):2898-2904.
220. Flye MW, Brennan MF. Surgical resection of metastatic parathyroid carcinoma. *Ann Surg*. 1981;193(4):425-435.
221. Goldsmith RS, Furszyfer J, Johnson WJ, et al. Control of secondary hyperparathyroidism during long-term hemodialysis. *Am J Med*. 1971;50(5):692-699.
222. Faquin WC, Roth SI. Frozen section of thyroid and parathyroid specimens. *Arch Pathol Lab Med*. 2006;130(9):1260.
223. LiVolsi VA, Hamilton R. Intraoperative assessment of parathyroid gland pathology. A common view from the surgeon and the pathologist. *Am J Clin Pathol*. 1994;102(3):365-373.
224. Osamura RY, Hunt JL. Current practices in performing frozen sections for thyroid and parathyroid pathology. *Virchows Arch*. 2008;453(5):433-440.
225. Saxe AW, Baier R, Tesluk H, Toreson W. The role of the pathologist in the surgical treatment of hyperparathyroidism. *Surg Gynecol Obstet*. 1985;161(2):101-105.
226. Anton RC, Wheeler TM. Frozen section of thyroid and parathyroid specimens. *Arch Pathol Lab Med*. 2005;129(12):1575-1584.
227. Westra WH, Pritchett DD, Udelsman R. Intraoperative confirmation of parathyroid tissue during parathyroid exploration: a retrospective evaluation of the frozen section. *Am J Surg Pathol*. 1998;22(5):538-544.
228. Geelhoed GW, Silverberg SG. Intraoperative imprints for the identification of parathyroid tissue. *Surgery*. 1984;96(6):1124-1131.
229. Shidham VB, Asma Z, Rao RN, et al. Intraoperative cytology increases the diagnostic accuracy of frozen sections for the confirmation of various tissues in the parathyroid region. *Am J Clin Pathol*. 2002;118(6):895-902.
230. Silverberg SG. Imprints in the intraoperative evaluation of parathyroid disease. *Arch Pathol*. 1975;99(7):375-378.

10 Lung

Jeffrey L. Myers

CHAPTER CONTENTS

Normal anatomy, *372*
Non-neoplastic lesions, *373*
Biopsy, *373*
Cystic diseases, *374*
Bronchopulmonary sequestration, *375*
Bronchiectasis, *376*
Abscess, *376*
Granulomatous inflammation, *377*
Diffuse interstitial lung disease, *385*
Hypersensitivity pneumonia (extrinsic allergic alveolitis), *389*
Langerhans cell histiocytosis and other histiocytic disorders, *390*
Pneumoconiosis, *391*
Lipoid pneumonia, *392*
Aspiration pneumonia, *392*
Eosinophilic pneumonia, *392*
Pulmonary hemorrhage, *394*
Miscellaneous infections, *394*
Lung in AIDS, *396*
Lung and transplantation, *397*
Vascular diseases, *397*
Other non-neoplastic diseases, *398*
Carcinoma, *399*
General and clinical features, *399*
Pathologic and immunohistochemical features, *400*
Adenocarcinoma, *401*
Squamous cell carcinoma, *405*
Neuroendocrine tumors, *407*
Large cell carcinoma, *412*
Adenosquamous carcinoma, *413*
Sarcomatoid carcinoma and carcinosarcoma, *413*
Pulmonary blastoma, *414*
Carcinoma precursors, *415*
Frozen section, *416*
Spread and metastases, *417*
Treatment, *417*
Prognosis, *418*
Other primary tumors, *418*
Hamartoma, *418*
Paraganglioma and other neural neoplasms, *419*
Minute meningothelioid nodules and meningioma, *419*
Sclerosing pneumocytoma, *420*
Inflammatory pseudotumor and inflammatory myofibroblastic tumor, *421*
Vascular tumors, *422*
Lymphoid tumors and tumorlike conditions, *423*
Salivary gland–type tumors, *425*
PEComatous tumors, *426*
Muscle tumors, *427*
Pleuropulmonary blastoma, *428*
Miscellaneous primary tumors, *428*
Metastatic tumors, *429*

Normal Anatomy

Grossly the lungs are subdivided into lobes, three on the right (upper, middle, and lower) and two on the left (upper and lower). Each lobe is supplied by a dedicated lobar bronchus with a companion artery and vein that subdivides into bronchopulmonary segments. Bronchopulmonary segments are of special importance to thoracic surgeons because they are amenable to surgical excision in those patients for whom less than lobectomy is preferred. The cut surface of normal lung is characterized by connective tissue septa that subdivide the parenchyma into polygonal pulmonary lobules (Fig. 10.1).

The two main components of the lung interstitium are the alveolar walls and the extra-alveolar connective tissue affiliated with bronchopulmonary bundles, interlobular septa, and visceral pleura.[1] The alveoli are normally covered primarily by type I pneumocytes with small attenuated nuclei and large cytoplasmic processes and cuboidal type II (granular) pneumocytes with a hobnail appearance; the latter produce surfactant and comprise the minority of alveolar lining cells in normal lungs but are the main proliferating component after alveolar injury.[2] The alveolar walls contain capillaries whose basement membrane fuses with that of the alveolar epithelium to constitute a single alveolar capillary membrane.[2]

The main types of bronchial and bronchiolar epithelial cells are basal cells, neuroendocrine cells, ciliated cells, serous cells, Clara cells, and goblet cells.[1,2] Goblet and ciliated cells decrease in number as one approaches the terminal bronchioles, whereas the number

Abstract

This chapter provides an overview of non-neoplastic and neoplastic disorders of the lung following a brief overview of normal gross and microscopic anatomy. Non-neoplastic diseases include common and uncommon infections, other non-infectious granulomatous diseases, and diffuse diseases that are common sources of diagnostic difficulty in surgical and transbronchial lung biopsies. Neoplastic diseases include mainly malignant epithelial tumors with special emphasis on current diagnostic criteria and the role of immunohistochemical and molecular tools for both classification and management. The chapter concludes with a review of less common tumors that may frequently complicate differential diagnosis in both small and large specimens.

Keywords

Bronchopulmonary sequestration,
bronchiectasis,
granulomatous inflammation,
sarcoidosis,
granulomatosis with polyangiitis (Wegener's),
eosinophilic granulomatosis with polyangiitis (Churg–Strauss),
usual interstitial pneumonia,
nonspecific interstitial pneumonia,
diffuse alveolar damage,
organizing pneumonia,
hypersensitivity pneumonia,
Langerhans cell histiocytosis,
pulmonary alveolar proteinosis,
transplantation,
adenocarcinoma,
squamous cell carcinoma,
small cell carcinoma,
large cell neuroendocrine carcinoma,
carcinoid tumor,
pulmonary blastoma,
sclerosing pneumocytoma,
lymphomatoid granulomatosis,
lymphangioleiomyomatosis

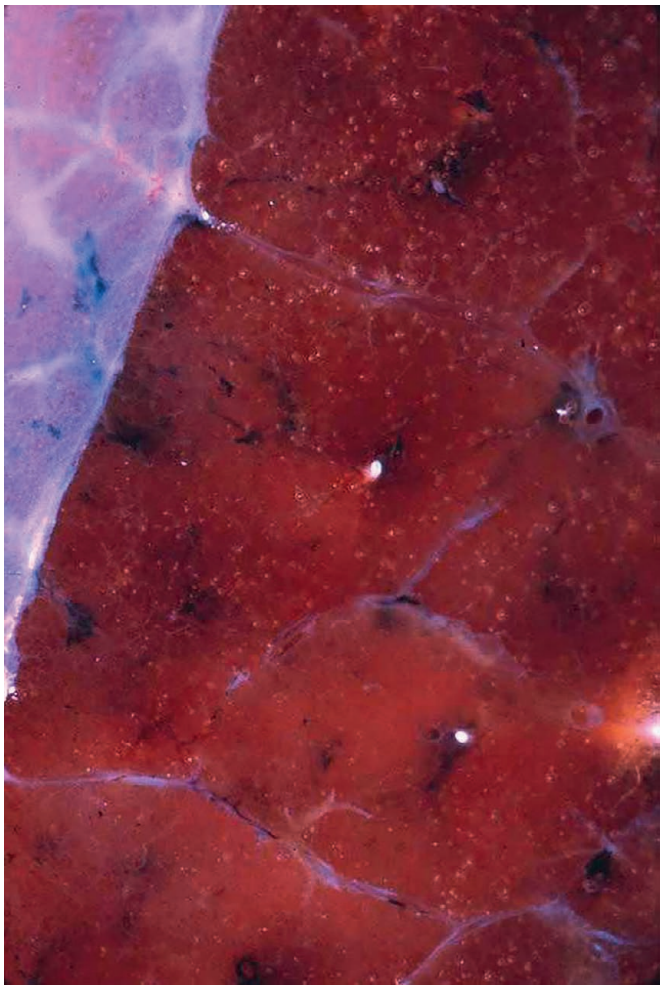

Figure 10.1 Gross appearance of cut surface of normal lung showing pulmonary lobules separated by connective tissue septa.

of Clara cells increases proportionally. Clara cells have a secretory function and represent the main progenitor cells after bronchiolar injury. They are recognized—whether in normal, reactive, or neoplastic conditions—by the presence of apical secretory granules that are periodic acid–Schiff (PAS) positive and diastase resistant and have a dense appearance ultrastructurally. Airway-associated neuroendocrine cells are part of the diffuse neuroendocrine system and are numerous in the fetus and neonate but very scanty and difficult to demonstrate in the adult.[3]

Small clusters of neuroendocrine cells located within the epithelium of bronchi and bronchioles (and sometimes also at the level of alveoli) are referred to as *neuroepithelial bodies*; their function is unknown.[2]

Submucosal glands are associated with the larger bronchi; they are composed of both serous and mucous cells and are invested by a myoepithelial cell layer. In older individuals, these glands may exhibit oncocytic changes.

Structures sometimes seen in alveolar spaces that are of no diagnostic significance include fresh red blood cells (usually the result of surgical trauma), alveolar macrophages that are frequently pigmented in smokers, corpora amylacea (common in elderly people), and blue bodies (composed primarily of calcium carbonate).[4] The lungs of adult city dwellers often contain black anthracotic pigment (carbon); scattered birefringent silica crystals may also be found, a feature which, by itself, is not diagnostic of silicosis.

Megakaryocytes are a common incidental finding in the alveolar walls; the large, hyperchromatic, and distorted nuclei of these cells should not be misinterpreted as evidence of malignancy or viral infection.

Metaplastic bone is an age-related change sometimes seen in the bronchial cartilage; it may be accompanied by calcification and by bone marrow elements.

Lymph vessels follow the bronchovascular structures and are found mainly beneath the pleura and in septa, but not in alveolar walls. They drain to intrapulmonary peribronchial and hilar lymph nodes. The drainage is mainly cephalad, primarily through mediastinal lymph node groups, but also to abdominal lymph nodes.

Intrapulmonary lymph nodes may be found in the peribronchial region and occasionally as individual intraparenchymal nodules in the peripheral, subpleural lung.[5] The vasculature of the lung derives from the pulmonary vessels and bronchial vessels, the latter belonging to the systemic circulation. Pulmonary arteries have both an internal and external elastic membrane, whereas pulmonary veins have a single (outer) elastic layer.

Ectopic tissues sometimes occur in otherwise normal lung or form localized abnormalities and comprise skeletal muscle[6] (sometimes present extensively in the newborn lung, a condition known as rhabdomyomatosis[7]), neuroglial elements,[8] pancreas,[9] and adrenal cortex.[10] Histologically normal thyroid tissue occurs only rarely in the lung; whether all such cases represent metastases from well-differentiated carcinomas remains controversial.[11,12]

Non-Neoplastic Lesions

Biopsy

Lung biopsies performed to evaluate patients suspected of having non-neoplastic lung diseases come in many different shapes and sizes. Small closed biopsies are often done to minimize procedural risk and morbidity. The relative value of different procedures depends on the clinical and radiological setting. It is helpful, especially when interpreting smaller specimens, for the pathologist to know the clinical history and radiological findings before drawing a firm conclusion regarding the diagnosis. Basic facts such as patient age, whether or not the patient is immunocompromised, onset and tempo of disease progression (i.e. acute or chronic), localized versus diffuse radiological distribution of abnormalities, presence and degree of functional impairment, and occupational or travel history can be especially helpful in this regard.

The type of lung biopsy obtained is also important. Wedge biopsies have the highest sensitivity, specificity, and accuracy for nearly all non-neoplastic lung diseases, but smaller biopsies obtained through a bronchoscope using either a biopsy forceps (*transbronchial* biopsy) or a cryoprobe *(cryobiopsy)* are especially helpful in certain diseases like infections, sarcoidosis, diffuse alveolar damage (DAD), pulmonary alveolar proteinosis, eosinophilic pneumonia, and hypersensitivity pneumonia.[13] Histologic findings that complicate interpretation of transbronchial biopsies include a 'holes' or 'bubbles' artifact that mimics the appearance of exogenous lipid pneumonia,[14] procedure-related hemorrhage which is common, and mesothelial cells when the biopsy unintentionally captures pleural tissue.[15] Multiple-step sections are extremely helpful in maximizing the diagnostic yield of transbronchial lung biopsies, especially in patients suspected of having sarcoidosis.[16,17]

Surgical lung biopsies are especially useful in patients suspected of having idiopathic interstitial pneumonias, such as usual or nonspecific interstitial pneumonia (NSIP).[18] The lingula and right middle lobes may be appropriate biopsy targets depending on the

radiological distribution of abnormalities.[19] Areas of extreme scarring and honeycombing are likely to show only end-stage disease and therefore are not very informative. Ideally, samples should be obtained from two or three different areas.[18] A formalin-filled syringe attached to a small (25-gauge) needle may be used to gently infuse fixative into wedge biopsies until fully expanded. A simpler approach is to remove the staple line before teasing apart the lung parenchyma and using a fresh scalpel blade to breadloaf the sample from the nonpleural surface.[4] Routine submission of tissue for microbiologic studies has little value and is a procedure best reserved for patients in whom the clinical suspicion of infection is high.[20]

Cystic Diseases

Cystic lung diseases may be congenital or acquired, and each of these categories can be further subdivided into localized and diffuse diseases. Some of the diffuse diseases in which cysts are a prominent radiological finding (e.g. lymphangioleiomyomatosis, Langerhans cell histiocytosis [LCH]) are reviewed elsewhere.

Congenital Cystic Diseases

Congenital cystic disease is a generic term for any cystic process of the lung thought to be already present at birth.[21] Congenital cystic diseases are generally viewed as diseases of childhood, but they occasionally go undetected until adulthood.[22] The most common types of congenital cystic disease encountered in surgical pathology include congenital lobar overinflation (i.e. congenital lobar *emphysema*), congenital cystic adenomatoid malformation (CCAM) also referred to as congenital pulmonary airway malformation (CPAM), bronchogenic cyst, and pulmonary sequestration.[23] A significant overlap exists between these entities, suggesting a common pathogenesis.[24] Some patients also have extrapulmonary anomalies. Congenital cystic diseases of the lung are frequently diagnosed *in utero* and are associated with excellent postnatal outcomes in the absence of fetal hydrops or other severe congenital abnormalities.[25,26]

Congenital lobar overinflation (congenital lobar emphysema) occurs in young children. It affects only one of the upper lobes or the right middle lobe of the lung. Theories for its occurrence include mucosal folds, mucous plugs, and deficiencies in the bronchial cartilages. The pathologic change consists of massive overdistention of the alveolar spaces, not accompanied by tissue destruction. It is therefore not truly a cystic or an emphysematous process. Severe compression of the other pulmonary lobes may result from this lesion.

CCAM (CPAM) is characterized by the presence of variously sized intercommunicating cysts lined by cuboidal-to-ciliated pseudostratified columnar ('adenomatoid') epithelium (Figs. 10.2 to 10.4).[23,25–27] Those that are not detected prenatally usually present with respiratory distress in early infancy due to compression of lung tissue and mediastinal shift. They are usually solitary and involve a single lobe. Some go undetected until later in life when they may be complicated by mucinous adenocarcinoma with lepidic-predominant *(bronchioloalveolar)* growth patterns.[12,28] Three morphologic variants have been described based on size and number of cysts (Stocker types 1, 2, and 3).[27] These subcategories show significant histologic overlap limiting their value. They can be more simply divided into large (>2 cm) and small (<2 cm) cyst types, roughly corresponding to Stocker types 1 and 2, respectively.[23] Large cyst CCAMs can be unilocular or multilocular and show cystic spaces lined by ciliated respiratory epithelium. Mucinous columnar epithelium resembling gastric mucosa may be present in both the cyst wall lining and adjacent lung tissue. Small cyst CCAMs show a compact

Figure 10.2 Gross appearance of congenital cystic adenomatoid malformation of lung.

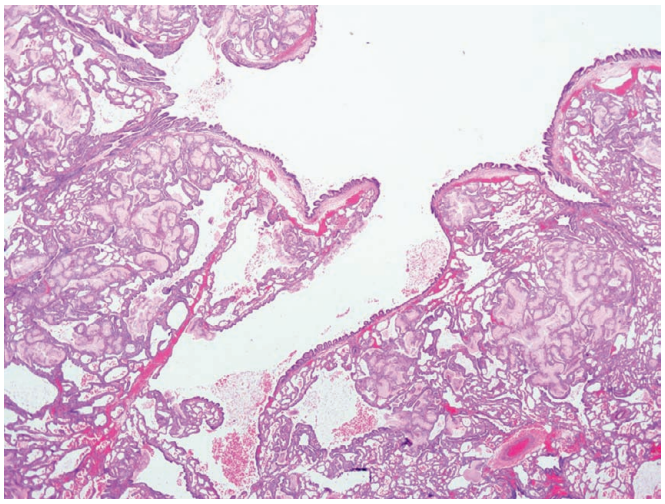

Figure 10.3 Microscopic appearance of large cyst (Stocker type 1) congenital cystic adenomatoid transformation. A large cystic air spaces is lined by ciliated respiratory epithelium and mucinous gastric-like epithelium is scattered throughout the adjacent lung parenchyma.

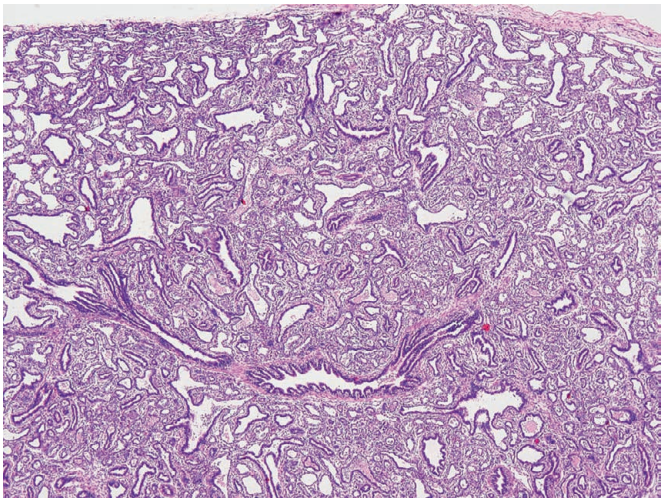

Figure 10.4 Microscopic appearance of small cyst (Stocker type 2) congenital cystic adenomatoid malformation. Microcystic air spaces lined by cuboidal epithelium are associated with tubular bronchiole-like structures lined by columnar respiratory epithelium.

arrangement of irregularly shaped microcystic spaces and variable numbers of tubular bronchiole-like structures that lack companion arteries. Mucinous epithelium is less common than in large cystic variants.

Acquired cystic diseases of the lung are a heterogeneous group of unrelated lesions that have in common the presence of cysts on computed tomography (CT) scans of the chest. **Emphysema** is the most common form of acquired cystic disease and is defined as an increase in the size of airspaces distal to the terminal bronchiole associated with destruction of their walls.[29] Emphysema is the most important morphologic substrate of chronic obstructive pulmonary disease, which in turn is a leading case of disability and death. Emphysema is most commonly encountered as an incidental finding in surgical specimens excised for other reasons, in wedge resections following pneumothorax, as part of volume reduction surgery in patients with severe disease, or in explanted lungs from patients undergoing transplantation.[30–32] Emphysematous *bullae* are large (1 cm or greater) cystic spaces covered by a thin, stretched pleura. Giant bullae can result in an appearance vaguely reminiscent of chorionic villi, a change that has been designated as *placental transmogrification* (Fig. 10.5).[33] Symptoms may result from hemorrhage, infection, compression of adjacent lung, or pneumothorax. *Blebs* are formed by the rupture of an alveolus directly beneath the pleura and the escape of air into the areolar layer of the pleura, which results in interstitial emphysema. They are less than 1 cm in diameter. A bleb may rupture into the free pleural space, causing pneumothorax and *reactive eosinophilic pleuritic*, which is a common finding after pneumothorax of any cause.

Swyer–James (McLeod) syndrome, thought to be the result of repeated episodes of pulmonary infection, is characterized by the development of severe emphysema (occasionally accompanied by placental transmogrification), bronchiectasis, and/or bronchiolitis obliterans.[34]

Pleuropulmonary blebs and cysts (usually basilar) can represent the pulmonary component of the **Birt–Hogg–Dubé syndrome**, a rare genodermatosis associated with an increased risk of renal and colonic neoplasia.[35,36]

Chondroid cystic malformation associated with trisomy 8 mosaicism is a rare form of localized cystic lung malformation in which connective tissue septa contain cartilaginous islands.[37]

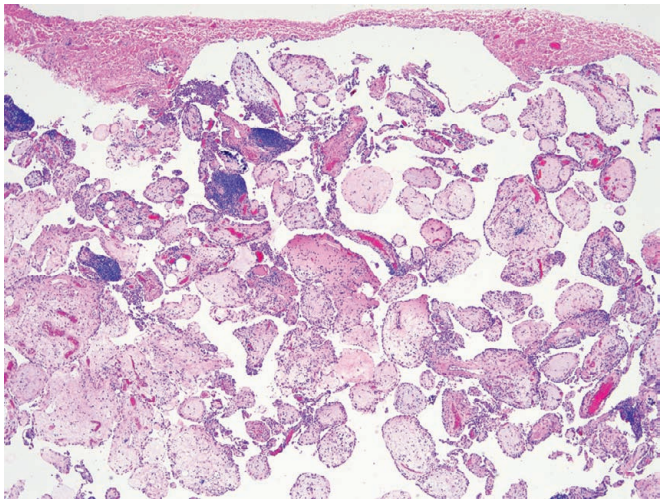

Figure 10.5 Microscopic appearance of placental transmogrification in which connective tissue papillae persist in a giant bulla resulting in an unusual histology that is reminiscent of chorionic villi.

Bronchopulmonary Sequestration

Bronchopulmonary sequestration is characterized by partial or complete separation of a portion of a lobe of the lung with a systemic arterial supply often affiliated with no connection to the functional components of the tracheobronchial tree *(bronchial atresia)*.[23] The pathogenesis of sequestration remains controversial, but most authorities argue persuasively that they are developmental abnormalities rather than acquired lesions.[23]

The **extralobar** variety develops from aberrantly located pulmonary mesenchyme as an extrapulmonary island of lung tissue enveloped by its own pleural covering. Extralobar sequestrations can be located at any level from the thoracic inlet to the diaphragm, or even within the abdominal cavity (Fig. 10.6).[23] About 90% of cases occur in the left side. Other congenital malformations, especially diaphragmatic hernias, occur in approximately 20% of patients. On occasion, the sequestered lung communicates with the foregut. An association with polyhydramnios and edema has been observed. The arterial supply is usually by one or several small arteries from the aorta or one of its branches. The venous drainage is into the azygos system.

The **intralobar** variety is a more heterogeneous group for which the alternative term *bronchial atresia with systemic vascular connection* has been proposed.[23] Intralobar sequestrations are much more likely to be symptomatic. They are characteristically located within the lower lobe, especially in the posterior basal segment, and are also more commonly located in the left lung (Fig. 10.7). Grossly, the sequestered portion may present as a single cyst, as a multicystic area, or as a solid mass. The segment is supplied by a *large* artery arising from the aorta or one of its branches; this artery arises above the diaphragm in 75% of the patients and below the diaphragm in the remainder. Despite its origin, the artery is always of the elastic pulmonary type. Microscopically the findings are relatively nonspecific, reflecting the consequences of proximal bronchial atresia and comprise a combination of chronic inflammation and fibrosis. Key to diagnosis is the surgeon's identification of a large elastic artery representing the systemic vascular connection.

Figure 10.6 Extralobar type of pulmonary sequestration. The lung has a spongy appearance and is covered by normal pleura.

Figure 10.7 Intralobar type of pulmonary sequestration. As is often the case with this variety, there are extensive secondary inflammatory changes. (Courtesy of Dr. J Costa, New Haven, CT.)

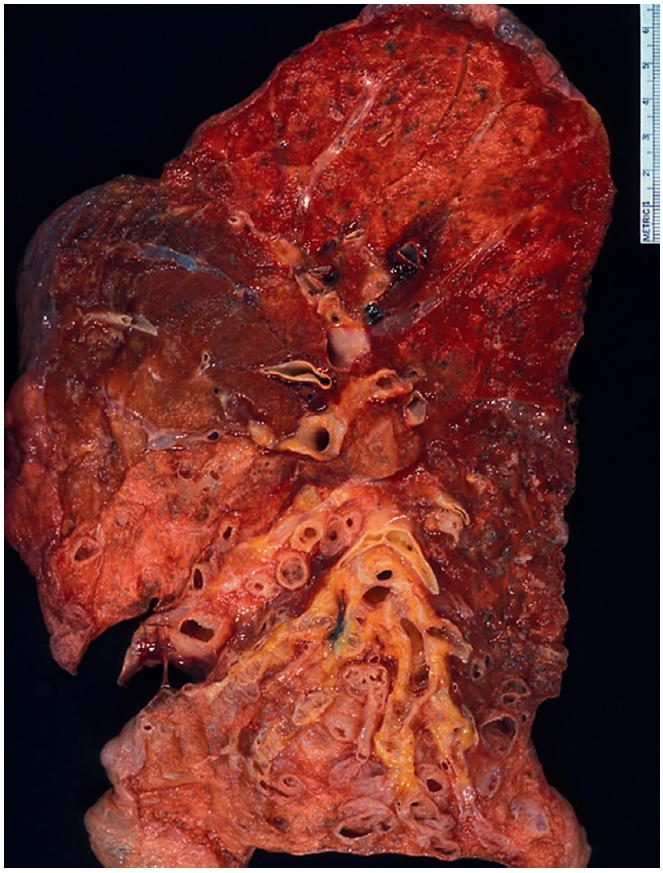

Figure 10.8 Localized bronchiectasis involving the lower lobe in a lung resected from a patient with a centrally obstructing endobronchial neoplasm.

Bronchiectasis

Bronchiectasis refers to the permanent dilation of bronchi usually associated with destruction of some elements of the bronchial wall and inflammatory changes that extend into the surrounding or distal lung parenchyma. It represents the end stage of a variety of unrelated disorders and can be divided into localized and diffuse forms.[38]

Localized bronchiectasis often results from partial or total obliteration of the bronchial lumen by a neoplasm, foreign body, localized inflammatory process, inspissated mucus, or external compression (e.g. broncholithiasis due to a calcified lymph node) (Fig. 10.8). It can occur in any area of the lung and follows the branching pattern of the obstructed bronchus. If the source of obstruction is relieved at an early stage, the bronchiectatic changes will regress; otherwise, the secondary inflammatory and fibrotic changes will render the condition irreversible. Localized bronchiectasis is a common finding in patients with middle lobe syndrome, a condition characterized by fixed radiological abnormalities limited to the right middle lobe and/or lingula.[39]

Diffuse bronchiectasis is a consequence of inflammation and postinflammatory destruction of airway walls that is usually the result of repeated episodes of infection. This is the form of bronchiectasis often seen in patients with cystic fibrosis (Fig. 10.9). Two other disorders associated with chronic sinonasal infection and frequent bronchiectasis are *Kartagener* or *immotile cilia syndrome (primary ciliary dyskinesia)*, associated with complete situs inversus and infertility, and *Young syndrome*, associated with infertility caused by azoospermia but lacking ultrastructural ciliary abnormalities.[40] The distribution of diffuse bronchiectasis depends on the underlying condition. For example, bronchiectasis patients with cystic fibrosis and allergic bronchopulmonary aspergillosis usually presents with upper lobe predominant disease.

Inflammation of the bronchial wall is a constant finding in bronchiectasis of any cause and usually includes a mixed infiltrate of both acute and chronic inflammatory cells. Lymphocytes often predominate and typically include lymphoid aggregates with secondary germinal centers (i.e. lymphoid hyperplasia). Areas of ulceration are common, but the residual epithelium is usually ciliated and otherwise normal; squamous metaplasia can occur, but it is unusual. In a more advanced stage, granulation tissue develops in the lamina propria, the cartilage is fragmented or destroyed, and the muscle is erased or undergoes focal hyperplastic changes. The mucous glands persist longer than other structures. The bronchial arteries often become greatly enlarged, tortuous, and thick walled. Distal lung parenchyma, including smaller airways, usually shows a range of nonspecific postobstructive changes that may include organizing pneumonia. Multiple carcinoid tumorlets may occur in distal lung parenchyma and should not be confused with metastatic disease.[41]

Complications of bronchiectasis such as bronchopleural fistula with empyema, brain abscess, and amyloidosis are no longer frequent. Conservative medical treatment focused on prevention or suppression of infection and early treatment for acute exacerbations is sufficient to control the disease in most patients.[38] Surgical resection is limited primarily to patients with localized disease in whom hemorrhage and/or repeated pulmonary infections cannot be controlled with more conservative measures.[42] Cystic fibrosis with respiratory failure is also an indication for double-lung transplants in highly selected patients.[43]

Abscess

In the pre-antibiotic era, solitary lung abscesses often followed tonsillectomies and other ear, nose, and throat operations. Presently,

Figure 10.9 Diffuse bronchiectasis in lung resected from a patient with cystic fibrosis.

Figure 10.10 Bronchopneumonia with abscess formation in a 2-year-old boy secondary to aspiration of a foreign body (timothy grass inflorescence). The first recorded case of this condition seems to be that recorded in a book entitled *Some account of Lord Boringdon's accident on July 21st, 1817, and its consequences* as follows: 'In 1662, Armand de Boutree, son of the Compte de Nogent, was seized with a violent fever, accompanied by a great difficulty in breathing, a dry cough, afterwards spotting of blood, sleeplessness, and great pain in the right side. A tumor at length appeared on that side, and a surgeon extracted from it an ear of barley almost entire which was quite green and had undergone no change.' (From Kissane JIM. *Pathology of Infancy and Childhood*. 2nd ed. St Louis, MO: Mosby; 1975.)

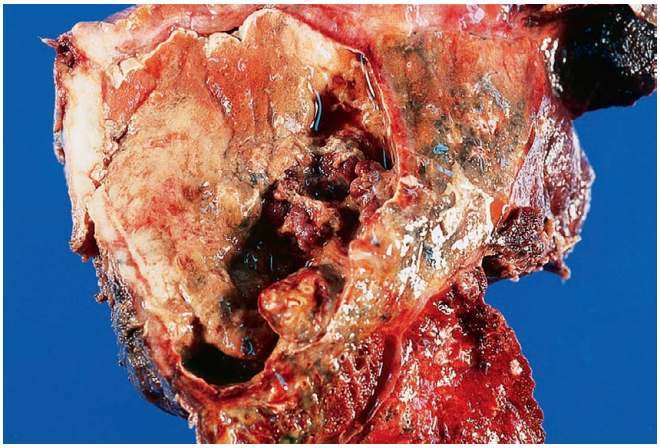

Figure 10.11 Large lung abscess.

most lung abscesses follow the aspiration of foreign material or are a complication of necrotizing pneumonia (Fig. 10.10).[44]

The most common locations of lung abscesses in surgical series are the right lower lobe, the right upper lobe (particularly the subapical segment), and the left lower lobe, in that order of frequency (Fig. 10.11).[44] The apical segment of the lower lobes is particularly vulnerable in patients who must assume a supine position. Anaerobic organisms are the agents that are most commonly responsible. Chronic abscesses have thick fibrotic walls and are surrounded by areas of organizing pneumonia.

Lung abscesses in children are most commonly due to *Streptococcus* species, *Staphylococcus aureus*, and *Klebsiella pneumoniae*.[45]

Complications of untreated lung abscesses include overgrowth of fungi (particularly *Mucor* and *Aspergillus*) in the cavity, spread of the process to other portions of the lung, massive hemorrhage, bronchopleural fistula with empyema, and brain abscess.

Intravenous antibiotics have been used successfully for the treatment of lung abscesses, particularly in children. For small unilocular abscesses, aspiration and drainage or partial resection of the lobe may be curative.[41] For larger lesions, lobectomy is preferable because it is associated with a much lower probability of postoperative complications such as bronchopleural fistula and empyema.

Granulomatous Inflammation

A large number of diseases in which granulomatous inflammation is a dominant feature involve the lung; some of them simulate radiological and gross features of neoplastic processes.[46,47] Microscopic examination is insufficient to establish a specific diagnosis in some patients; therefore it is important to submit a sample for culture and to perform stains for mycobacteria (Ziehl–Neelsen) and fungi (Gomori methenamine silver, GMS) in every case.[48]

Tuberculosis

Tuberculosis is second only to HIV as a cause for fatal infection in the developing world and remains a major global public health challenge.[49] The prevalence of tuberculosis in the United States has fallen dramatically since the early 1990s and is now more commonly

diagnosed in foreign-born rather than native-born persons.[50] Tuberculosis in foreign-born persons is most commonly the result of reactivation of infection with multidrug-resistant organisms acquired before entry into the United States; secondary transmission accounts for fewer newly diagnosed cases.[51] Most patients are diagnosed using a combination of skin testing, cultures, and other emerging techniques applied to sputum or blood.

Specimens harboring tuberculosis that are received in the pathology laboratory are usually from patients in whom some other diagnosis was suspected and may be a biopsy obtained with the fiberoptic bronchoscope, material procured via fine-needle aspiration, a surgical lung biopsy, or a resected lobe. There are still patients with pulmonary tuberculosis who fail medical therapy and therefore become candidates for therapeutic surgical intervention, but this is increasingly rare.[52] Historical indications for pulmonary resection were summarized by Strieder et al. as follows[53]:

1. Open cavity (with or without positive sputum) after a suitable period (4–6 months) on a satisfactory drug regimen
2. Residual caseous or fibrocaseous disease, with or without positive sputum
3. Irreversible destructive lesion, such as bronchostenosis or bronchiectasis
4. Recurrent or persistent hemorrhage, usually arising in a cavity or bronchiectasis
5. Thoracoplasty failure
6. Unexpandable lobe or lung, with associated chronic encapsulated tuberculous empyema
7. Suspected neoplasm.

The gross features of tuberculosis in tissue obtained for diagnosis differ from surgical specimens obtained from patients who have failed medical management in whom most of the resected tissue typically consists of inflamed, fibrotic, and otherwise nonfunctioning lung parenchyma (Fig. 10.12). Peribronchial tuberculous lymph nodes may infect the bronchial mucous glands by direct extension or penetrate the bronchial wall and erode into the lumen, especially when these nodes are calcified (i.e. broncholithiasis).

Tuberculous cavities removed in patients after prolonged antimicrobial therapy may show resolution into a stellate scar. In other patients the lesion stabilizes as a chronic open cavity that may harbor viable organisms in inspissated caseous material. Treated tuberculosis rarely resolves into a sterile cavity with a thin fibrous wall and a smooth surface that has no lining except for a short squamous segment at the point where the bronchus enters the cavity. Examination of these healed cavities for acid-fast organisms is invariably negative.

Tuberculomas, a term referring to localized conglomerates of necrotizing granulomatous infection due to *Mycobacterium tuberculosis* presenting as solitary lung nodules, are usually seen in adults and are a form of tuberculous reinfection. This is the form of tuberculosis most likely to be encountered by the surgical pathologist. Grossly, tuberculomas present as round, discrete, firm nodules (Fig. 10.13); they are usually solitary and located immediately beneath a white or slightly yellowish pleura. On section the lesions show central necrosis that may be complicated by calcification or cavitation. Microscopically, there is often central caseous necrosis characterized by paucicellular, granular, eosinophilic debris surrounded by a mixed inflammatory infiltrate that includes epithelioid and multinucleated giant cells with associated fibrosis (Fig. 10.14). Non-necrotizing granulomas are often present in the adjacent lung tissue. Specific pathogens cannot be reliably predicted on the basis of routine histologic finding in necrotizing granulomatous inflammation and frequently require special stains, cultures, or molecular studies for identification.[48] Organisms are usually present within the central zone of necrosis and can be demonstrated using Ziehl–Neelsen or other comparable stains for acid-fast bacilli (Fig. 10.15).[54] Highly sensitive molecular genetic techniques are available in a limited number of centers and may be helpful in highly selected cases.[55,56]

Atypical Mycobacteriosis

A significant number of granulomatous infections of the lung are caused by 'atypical' or 'unclassified' mycobacteria, such as *M. avium* complex (MAC), *M. kansasii*, *M. xenopi*, and *M. abscessus*.[56] Many of these cases are seen in immunocompromised hosts and/or in patients with preexisting lung disease, including chronic obstructive lung disease, previous tuberculosis, pneumoconiosis, bronchiectasis, and lung carcinoma. Infection due to *MAC* in elderly women may resemble the middle lobe syndrome (Lady Windermere syndrome). *Hot tub*



Figure 10.12 Massive destruction of lung parenchyma by tuberculosis.

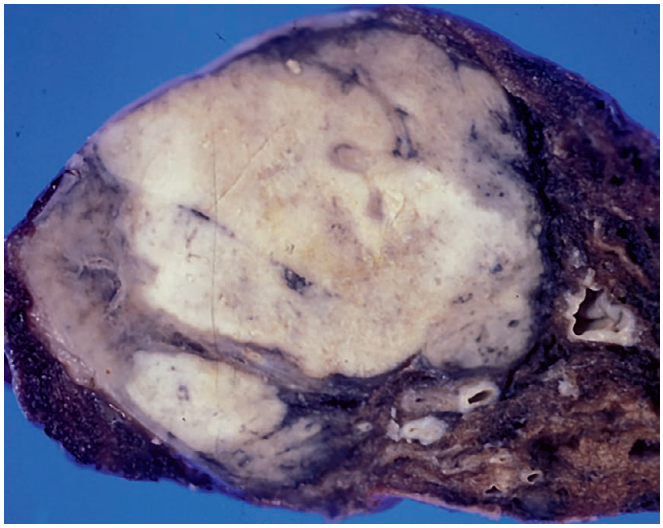

Figure 10.13 Tuberculoma that presented as asymptomatic 3-cm solitary lung nodule.

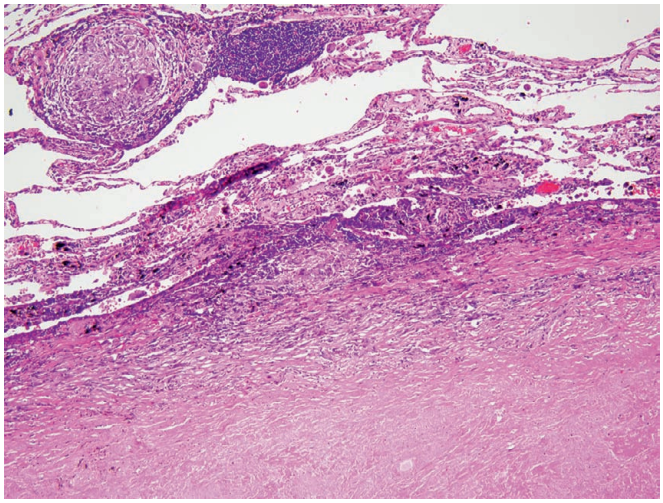

Figure 10.14 Tuberculosis. An area of caseous necrosis is bounded by a mixed inflammatory infiltrate that includes epithelioid and multinucleated histiocytes. A sarcoidal non-necrotizing granuloma accompanied the necrotizing granuloma.

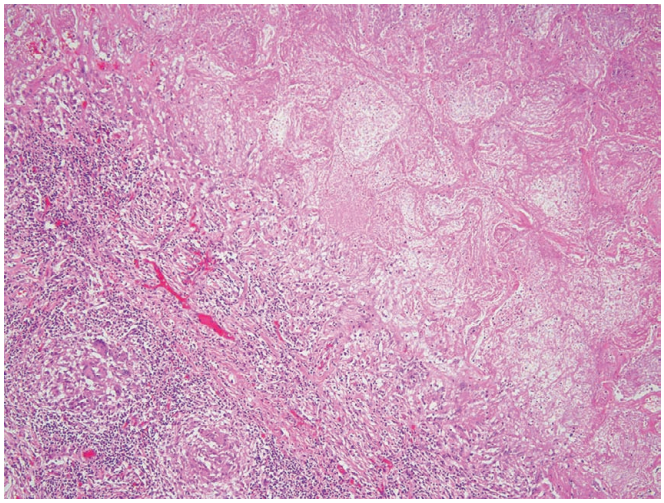

Figure 10.16 Atypical mycobacteriosis due to MAC. An area of necrosis showing 'infarct-like' features is surrounded by an inflammatory infiltrate that includes epithelioid and multinucleated histiocytes. Loose clusters of epithelioid and multinucleated giant cells also form non-necrotizing granulomas at the periphery. These histologic features are indistinguishable from those seen with other infectious granulomatous diseases including tuberculosis. Cultures from this case grew *M. avium* complex.

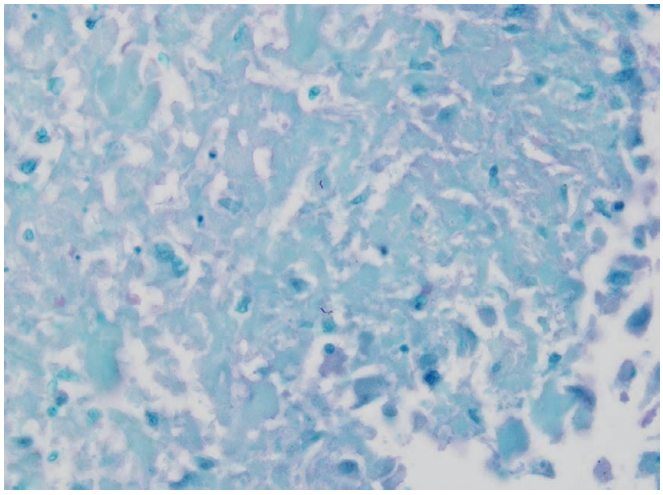

Figure 10.15 Tuberculosis. Ziehl–Neelsen stain demonstrating two acid-fast bacilli.

Figure 10.17 Coccidioidomycotic granuloma. The necrotic center is surrounded by fibrous tissue showing concentric lamination.

lung refers to a syndrome resembling hypersensitivity pneumonia resulting from exposure to hot tubs contaminated with nontuberculous mycobacteria.[46]

Infections by atypical mycobacteria cannot be distinguished from tuberculosis on the basis of their gross or microscopic appearance (Fig. 10.16).[48] The diagnosis may be suspected from the appearance of the organisms in acid-fast preparations, since they tend to be longer (about 20 μm), thicker, more coarsely beaded, and much more bent than tubercle bacilli. However, positive identification of the organism by culture and/or polymerase chain reaction (PCR) techniques is necessary for precise speciation.[56]

Other Granulomatous Infections

Granulomatous infections due to organisms other than tuberculous and nontuberculous mycobacteria likely to be encountered by surgical pathologists comprise mainly fungal infections that target immunocompetent as well as immunocompromised patients. Rates of disease for individual pathogens are linked to geographic variation in prevalence of the organisms. In North America those most likely to present as necrotizing granulomatous inflammation in surgical specimens include histoplasmosis, blastomycosis, cryptococcosis, and coccidioidomycosis.[46] These same organisms have a worldwide distribution, causing disease in Central and South America, parts of Asia, Africa, and Europe.

Granulomatous fungal infections have highly variable clinical manifestations, often presenting as asymptomatic solitary pulmonary nodules (Fig. 10.17). The inflammation in each of these conditions frequently includes a combination of necrotizing and non-necrotizing granulomas with overlapping histologic features making it difficult to predict a specific pathogen on the basis of the histologic findings alone. Diagnosis is dependent on identifying the organisms for which special stains (e.g. GMS) are extremely helpful (Fig. 10.18). *Blastomyces dermatitidis* (Fig. 10.19), *Cryptococcus neoformans* (Figs. 10.20 and 10.21), and *Coccidioides immitis* (Fig. 10.22) are visible on routinely stained sections in which their distinctive morphologic features are sometimes seen to better advantage. *Histoplasma capsulatum* is usually not visible on routinely stained sections except in

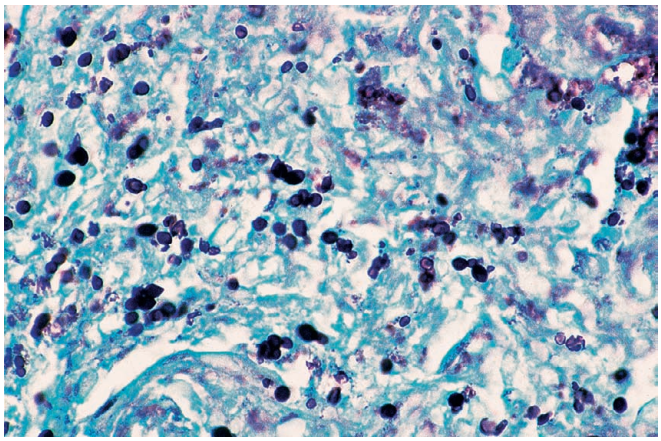

Figure 10.18 Pulmonary histoplasmosis. The organisms are demonstrated with the Grocott stain and are relatively small (1–5 μm) with a characteristic oval or teardrop shape.

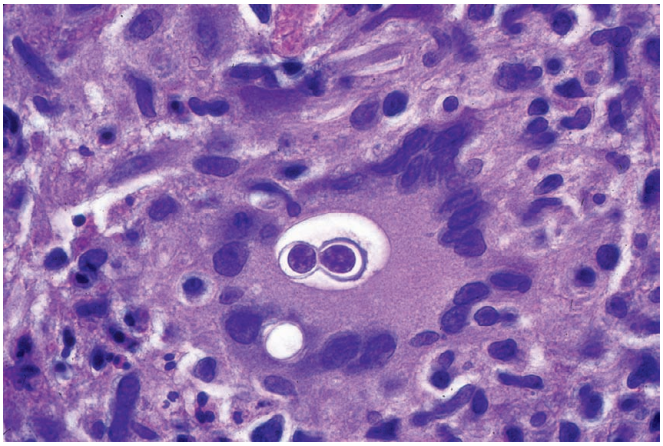

Figure 10.19 Pulmonary blastomycosis. Microscopic appearance of *B. dermatitidis* in a hematoxylin and eosin stain. The organisms are large (8–15 μm) with a doubly refractile wall and basophilic nucleus.

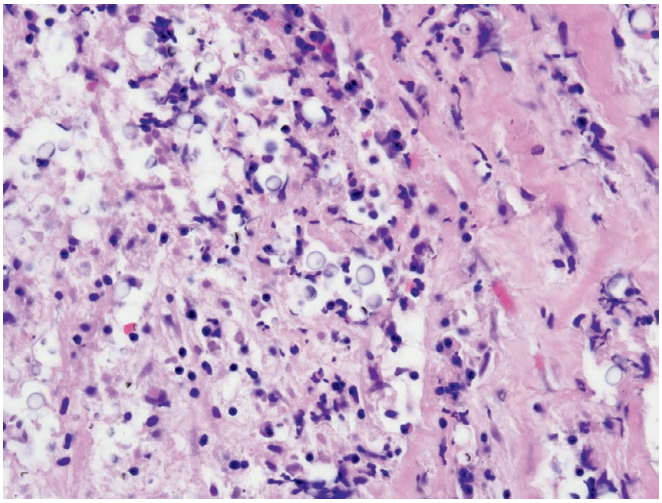

Figure 10.20 Pulmonary cryptococcosis. Microscopic appearance of *C. neoformans* in a hematoxylin and eosin stain. Variably sized, round, and occasionally fractured yeast are intermediate in size (4–7 μm) and have pale staining, thin walls with associated halos.

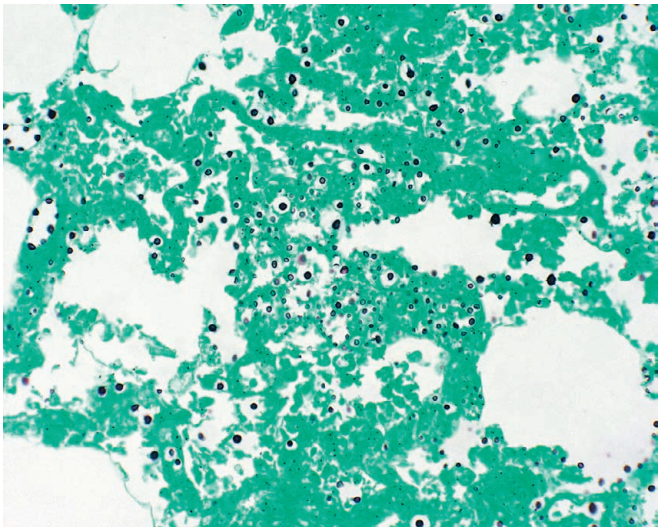

Figure 10.21 Microscopic appearance of cryptococcosis in a Grocott stain. Note the clear halo around the organisms.

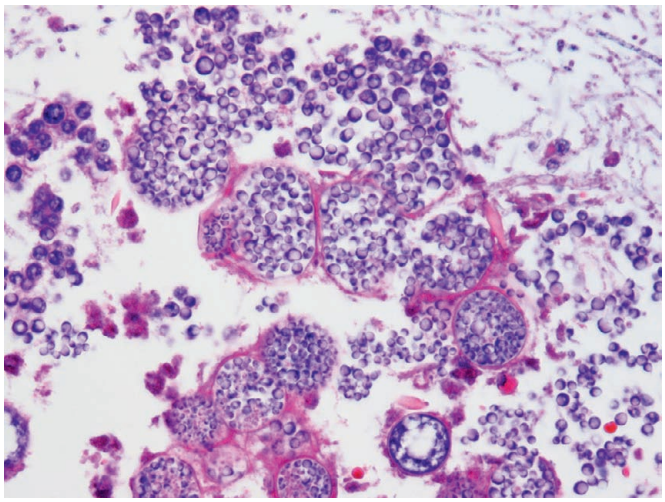

Figure 10.22 Microscopic appearance of *C. immitis* in a hematoxylin and eosin stain. Large (30–60 μm) intact and ruptured spherules contain much smaller (2–5 μm) endospores. In this example there are also mycelia *(upper right)* which is an uncommon finding.

disseminated histoplasmosis in which numerous organisms parasitize dense infiltrates of histiocytes without well-formed granulomas (Fig. 10.23).

Dirofilariasis of the lung usually presents as an incidental asymptomatic solitary nodule on chest radiographs or CT scans performed for other reasons, but it can also be multiple and/or symptomatic (Fig. 10.24). Microscopically, there is a histiocyte-rimmed necrotic nodule with marked eosinophilia containing fragments of *Dirofilaria immitis* (Fig. 10.25).[57]

Sarcoidosis

Sarcoidosis can present in the thoracic cavity in various ways: moderate to marked perihilar lymph node involvement without pulmonary disease, diffuse pulmonary disease without radiographic evidence of node involvement, a combination of lymph node enlargement and diffuse pulmonary disease, pulmonary interstitial fibrosis, and

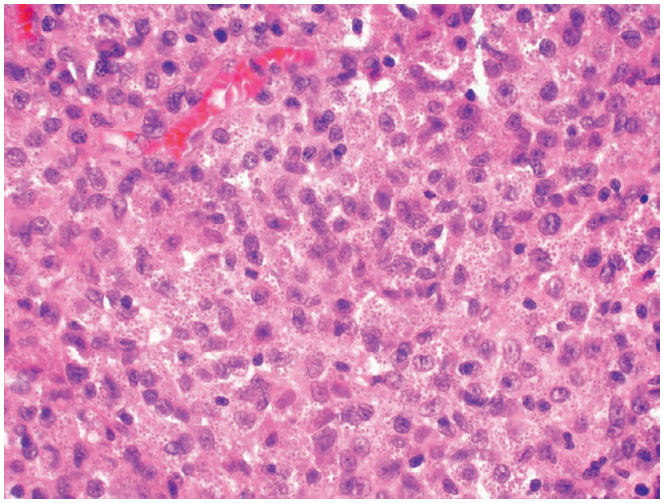

Figure 10.23 Disseminated histoplasmosis. Sheets of histiocytes demonstrate numerous organisms within their cytoplasm.

localized bronchostenosis with distal bronchiectasis and atelectasis.[58–60] The great majority of cases fall into the first and third categories. The etiology of sarcoidosis remains controversial.

Microscopically, the hallmark of the disease is a compact non-caseating granuloma composed of epithelioid cells, Langhans giant cells, and lymphocytes (Fig. 10.26). These compact, well-formed granulomas are confined to the interstitium, where they tend to be distributed along lymphatic pathways and may coalesce to form macroscopic nodules *(nodular sarcoidosis)* (Fig. 10.27).

There are many variations in this morphologic theme. Circumferential fibrosis, central hyalinization, and diffuse interstitial fibrosis in late stage disease may render the diagnosis difficult.[61] Small foci of necrosis having a bright eosinophilic ('fibrinoid') appearance may be found in the center of some granulomas. Intracellular and extracellular inclusions of several kinds may be seen, including birefringent calcium salts, but none is specific.[62] The granulomas often surround bronchioles (but not large bronchi); because of this, transbronchial lung biopsy is positive in more than 80% of the cases.[63] Granulomas are also frequently present around and within

Figure 10.24 Sharply outlined lung infarct resulting from *Dirofilaria* infestation.

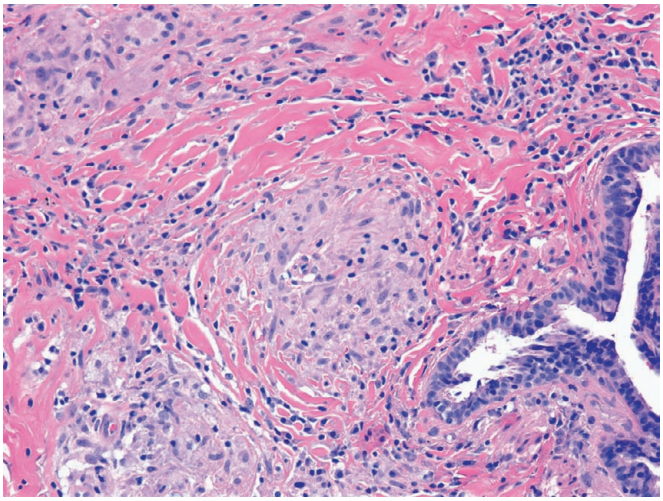

Figure 10.26 Sarcoidosis. Well-formed granuloma characteristic of sarcoidosis with characteristic collaret of coarse collagen bundles.

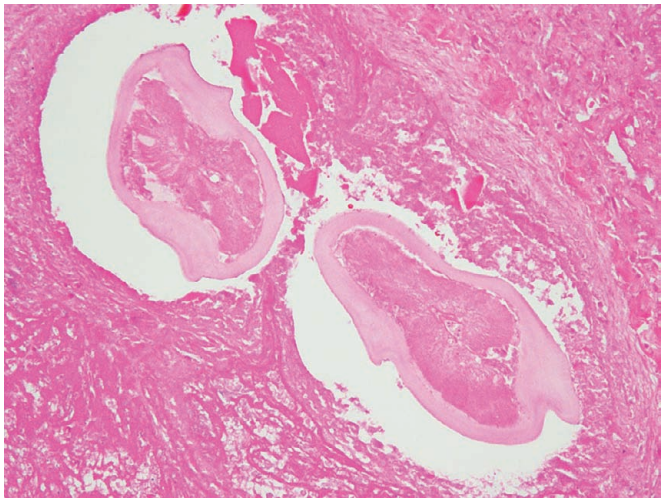

Figure 10.25 Microscopic appearance of *D. immitis* within the necrotic center of a dirofilarial nodule.

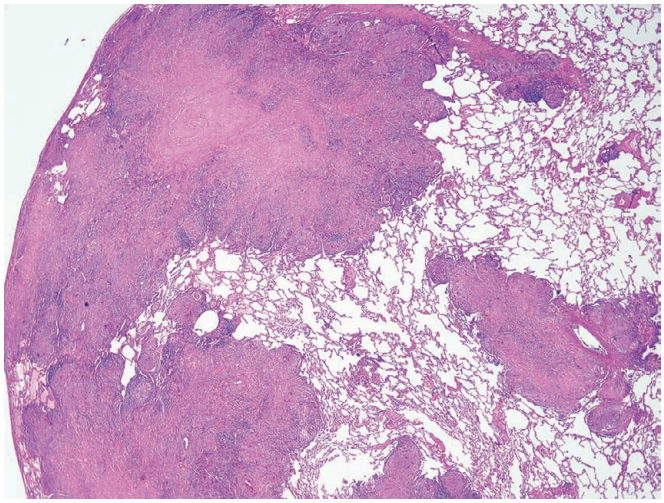

Figure 10.27 Sarcoidosis. Numerous granulomas with associated fibrosis form conglomerate nodules that expand visceral pleura, interlobular septa, and bronchovascular bundles in a characteristic 'lymphangitic' pattern.

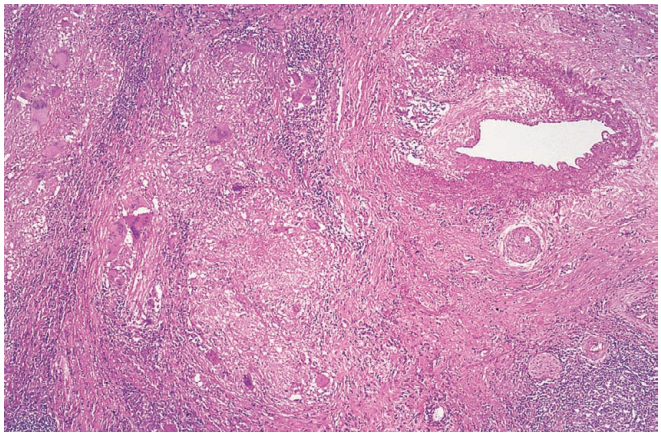

Figure 10.28 Necrotizing sarcoid granulomatosis. There is extensive involvement of large vessels by the inflammatory infiltrate, which has a necrotizing quality. Most authorities consider this a variant of nodular sarcoidosis.

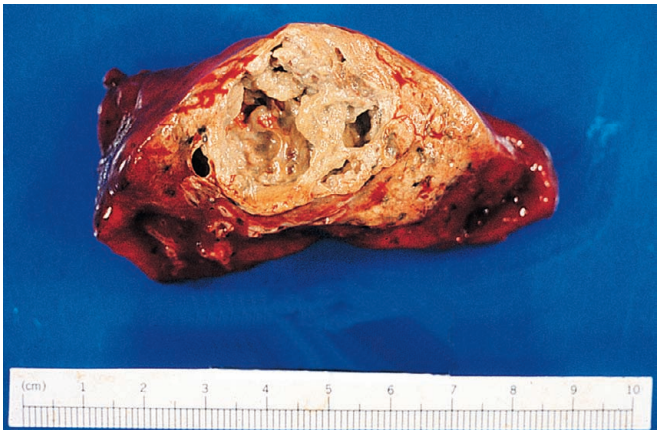

Figure 10.29 Granulomatosis with polyangiitis (Wegener's). The lesion is well circumscribed, with a granulomatous and partially necrotic appearance.

blood vessel walls including predominantly pulmonary veins, and may contribute to pulmonary hypertension.[64] Vascular necrosis, however, is not a feature.

Necrotizing sarcoid granulomatosis is the name given by Liebow to a pulmonary disease characterized by extensive vascular granulomas that infiltrate and occlude pulmonary arteries and veins and are accompanied by widespread necrosis of lung tissue (Fig. 10.28). The preponderance of evidence strongly suggests that this is a variant of nodular sarcoidosis.[65] Response to steroid and immunosuppressive drugs is good, and excision of localized lesions is usually curative.[66]

Granulomatosis With Polyangiitis (Wegener's)

Granulomatosis with polyangiitis (Wegener's), abbreviated *GPA*, is the term endorsed by a number of authoritative medical societies for the syndrome referred to historically as Wegener granulomatosis.[67] GPA is the best known member of the group of heterogeneous diseases designated by Liebow as *pulmonary angiitis and granulomatosis*. It is increasingly clear that this group comprises a number of totally unrelated entities, and it is therefore a term of historical interest but one that should not be retained for current disease classification. It is perhaps more useful to categorize GPA with the other antineutrophil cytoplasmic autoantibody (ANCA)-associated small vessel vasculitides: *microscopic polyangiitis* and *eosinophilic granulomatosis with polyangiitis (EGPA) (Churg–Strauss)*, an asthma-associated vasculitis referred to historically as Churg–Strauss syndrome.[68] ANCA characterized by a *cytoplasmic* (C-ANCA) staining pattern with immunofluorescence and/or corresponding antiproteinase three antibodies with the ELISA test are found in over 90% of classic cases of GPA and in about 60% of patients with limited disease and can be a useful adjunct in diagnostically challenging cases.[67]

GPA is defined by a combination of necrotizing granulomatous inflammation and necrotizing vasculitis targeting small to medium size vessels.[68] **Classic GPA** is characterized by the triad of necrotizing angiitis, aseptic necrosis (involving both the upper respiratory tract and the lungs), and focal glomerulitis.[66] Other vessels may be involved, such as the temporal artery and cutaneous small vessels, resulting in tumefactive lesions at extrapulmonary sites.[69] If untreated, the disease runs an accelerated clinical course; however, it has proved quite responsive to cytotoxic drugs (particularly cyclophosphamide) as first line induction therapy.[69] Current treatment strategies for refractory disease and maintenance therapy include a growing list

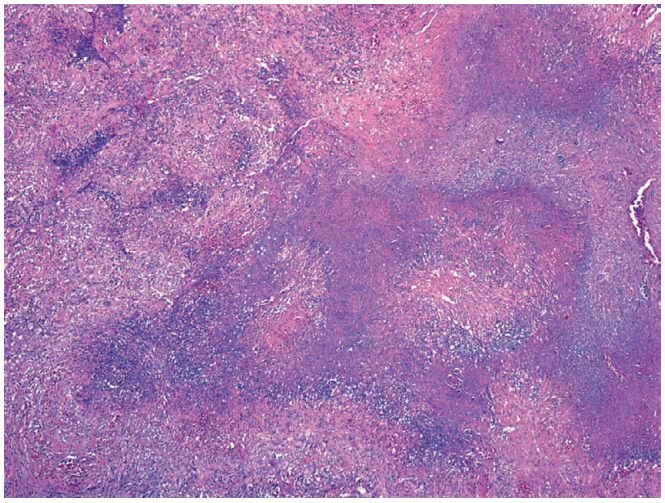

Figure 10.30 Granulomatosis with polyangiitis (Wegener's) demonstrating characteristic 'geographic' pattern of necrosis.

of novel agents such as rituximab which may selectively target vasculitis-associated changes while being relatively ineffective for granulomatous inflammation.[70]

The lungs are commonly involved at the time of diagnosis in patients with GPA. The main morphologic change in the lungs is necrotizing granulomatous inflammation grossly resembling other localized necrotizing processes (Fig. 10.29). The necrotic zones have an irregularly shaped *(geographic)* configuration at low magnification and are occasionally centered on airway lumens, a phenomenon that when dominant is referred to as the *bronchocentric variant* (Figs. 10.30 and 10.31).[71] The necrosis often has a characteristic 'dirty' basophilic appearance due to prominent karyorrhexis of neutrophils. Smaller granulomatous microabscesses with centrally necrotic zones containing nuclear dust surrounded by palisaded histiocytes and multinucleated giant cells are another distinctive form of granulomatous inflammation characteristic of GPA (Fig. 10.32). Well-formed non-necrotizing granulomas like those seen more commonly in granulomatous infections and sarcoidosis are generally not present in GPA.[72] In addition to neutrophils and modified histiocytes, the mixed inflammatory infiltrate invariably includes eosinophils, lymphocytes, and plasma cells in various proportions. Eosinophils are common and when conspicuous account for descriptions of the

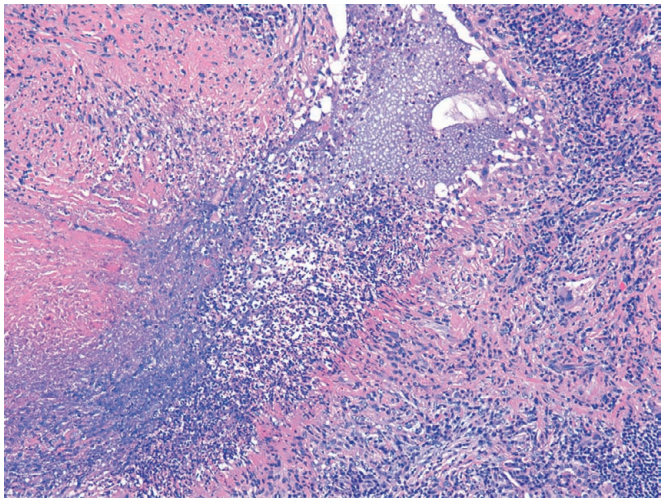

Figure 10.31 Bronchocentric variant of granulomatosis with polyangiitis (Wegener's) in which the necrosis is centered an airway lumen and the airway wall partially replaced by a granulomatous infiltrate comprising palisaded histiocytes.

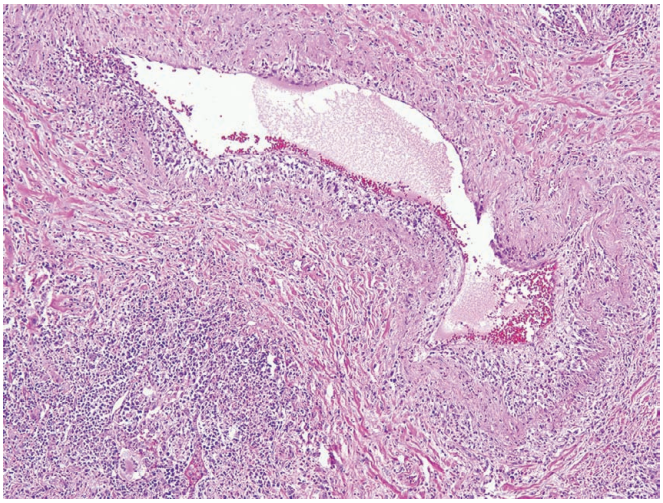

Figure 10.33 Granulomatosis with polyangiitis (Wegener's) showing characteristic pattern of patchy vessel wall inflammation and necrosis.

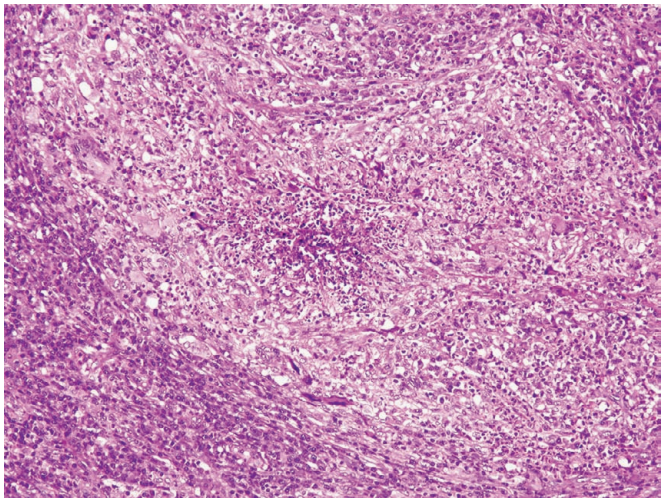

Figure 10.32 Granulomatous microabscess characteristic of granulomatosis with polyangiitis (Wegener's).

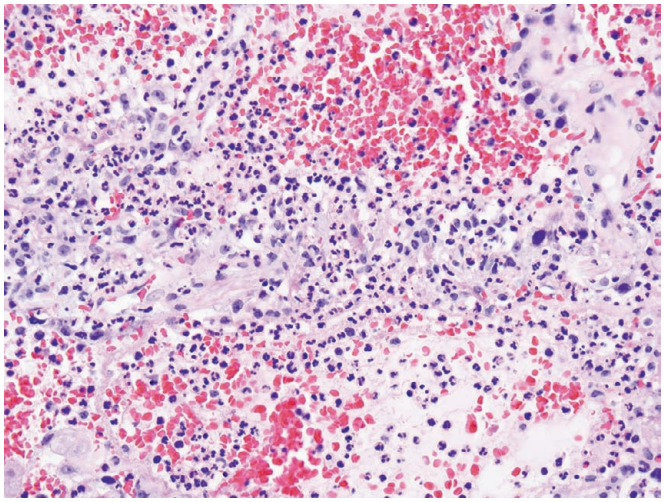

Figure 10.34 Capillaritis and alveolar hemorrhage in a patient with granulomatosis with polyangiitis (Wegener's).

eosinophilic variant.[73] Establishing the diagnosis with confidence requires a destructive leukocytolytic angiitis involving arteries and veins (Fig. 10.33).[73] The vasculitis is patchy in distribution characterized by abrupt transmural neutrophil-rich inflammatory infiltrates with associated karyorrhexis and vessel wall necrosis. Occasionally the necrotizing vasculitis includes granulomatous features in the form of multinucleated giant cells. In rare cases diffuse pulmonary hemorrhage with associated necrotizing capillaritis is a dominant feature, a combination of findings also seen in other vasculitic syndromes, including microscopic polyangiitis and systemic lupus erythematosus (Fig. 10.34).[74,75] The diagnosis of GPA can be made or suggested in transbronchial biopsy specimens.[76]

Limited (localized) GPA is confined to the lungs, more specifically with no renal involvement, and has a more protracted clinical course.[73] Steroids and cytotoxic drugs are highly effective. Grossly, there are multiple bilateral nodules, some round and others infarctlike, frequently located in the lower lobes. Microscopically, the disease is indistinguishable from the classic variety. Necrotizing vasculitis is a requisite for the diagnosis. However, it should be recognized that vessels located within ordinary infectious granulomas can exhibit secondary inflammatory changes that mimic vasculitis.[54] Therefore the presence of angiitis *away* from the areas of necrosis and massive inflammation should be searched for to document the diagnosis. The diagnosis of GPA should be made with caution in granulomas that appear solitary by radiographic examination.[77]

Eosinophilic Granulomatosis With Polyangiitis (Churg–Strauss)

EGPA (Churg–Strauss) is the current term for the disease referred to historically as Churg–Strauss syndrome.[66] EGPA is defined by a combination of necrotizing granulomatous inflammation, eosinophilia, and necrotizing vasculitis involving small and medium-size vessels. It presents a clinical picture of systemic vasculitis resembling polyarteritis nodosa but is associated with asthma, peripheral eosinophilia (up to 80%), and a higher incidence of pulmonary involvement.[78–80] In some patients this asthma-associated vasculitis syndrome may be unmasked or exacerbated when

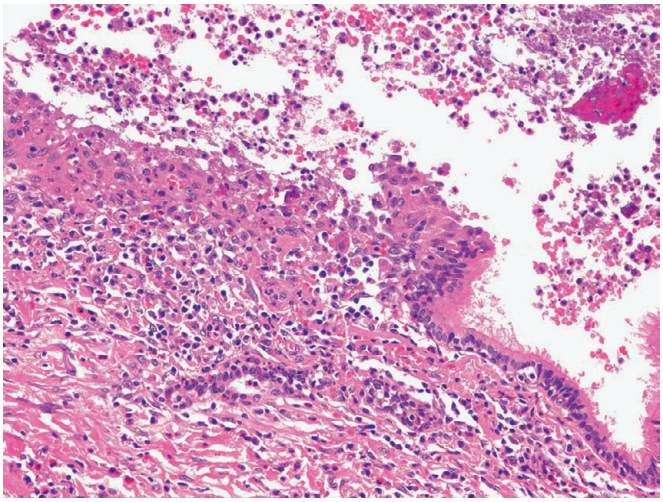

Figure 10.35 Bronchocentric granulomatosis in a patient with allergic bronchopulmonary aspergillosis. The bronchial wall is partially replaced by epithelioid histiocytes with associated eosinophilia.

Figure 10.36 Mucoid impaction of bronchi in a patient with allergic bronchopulmonary aspergillosis. Thick, tenacious secretions expand ectatic bronchi and in this patient formed a hilar mass for which clinical concerns included carcinoma.

transitioning from corticosteroids to steroid-sparing leukotriene receptor antagonists, such as montelukast, although the precise role that these agents have in the pathogenesis of vasculitis remains controversial.[81]

Microscopically, both the pulmonary and the extrapulmonary lesions are characterized by a prominent eosinophilic infiltrate, foci of necrosis (some associated with eosinophils and some unrelated to them), a granulomatous reaction around some of these necrotic foci, and necrotizing vasculitis. Finding all of these features in a single biopsy is uncommon, and therefore establishing the diagnosis on the basis of lung biopsy often requires careful correlation with other clinical and laboratory data. In lung biopsies, for example, the eosinophilic infiltrates often take the form of eosinophilic pneumonia, which is a relatively nonspecific finding in the absence of necrotizing granulomatous inflammation and/or necrotizing vasculitis. About 70% of patients will have a positive P-ANCA corresponding to an anti-myeloperoxidase (MPO) autoantibody by ELISA.[78]

Bronchocentric Granulomatosis, Mucoid Impaction of Bronchi, and Allergic Bronchopulmonary Mycosis

Bronchocentric granulomatosis is a form of necrotizing granulomatous inflammation in which all or nearly all the granulomas are centered on bronchi and bronchioles, leading to their destruction. Broncho- or bronchiolocentric necrotizing granulomatous inflammation is not specific to any one disease and can be seen in GPA as well as granulomatous infections. For that reason the term *bronchocentric granulomatosis* is generally limited to patients with **allergic bronchopulmonary aspergillosis**, a disease occurring almost exclusively in asthmatics and patients with cystic fibrosis in whom the bronchocentric granulomatosis (Fig. 10.35) is usually accompanied by eosinophilic pneumonia and mucoid impaction of bronchi.[82] Globally allergic bronchopulmonary mycosis can be due to other fungi, such as *Candida albicans*, *Bipolaris*, and *Curvularia* organisms.[83]

Mucoid impaction of bronchi is a process in which proximal ectatic bronchi become filled with thick inspissated mucus (Fig. 10.36). This change may cause localized radiological abnormalities for which diagnostic considerations include neoplasms. Occasionally patients expectorate these histologically distinctive plugs that comprise a combination of inspissated mucus, necrotic eosinophils, and Charcot–Leyden crystals distributed in a layered fashion resembling the rings of a tree (Fig. 10.37).

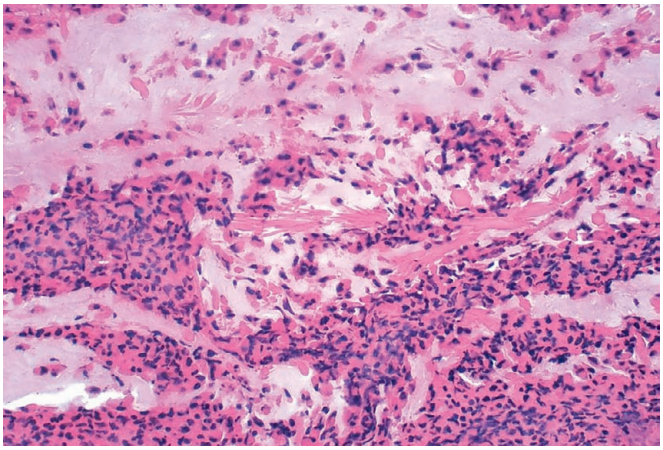

Figure 10.37 Mucoid impaction of bronchi showing the 'allergic mucin' typical of allergic bronchopulmonary aspergillosis including numerous Charcot–Leyden crystals.

Other Granulomatous Inflammations

Granulomas are occasionally seen in other noninfectious conditions, including aspiration of particulates and drug abuse in which inorganic fillers common in the oral medications used instead for intravenous injection elicit a perivascular granulomatous response (Fig. 10.38). Occasionally granulomas are present in diffuse lung diseases other than sarcoidosis, including most commonly hypersensitivity pneumonia, lymphoid interstitial pneumonia, and related forms of lymphoid hyperplasia, and eosinophilic pneumonia.

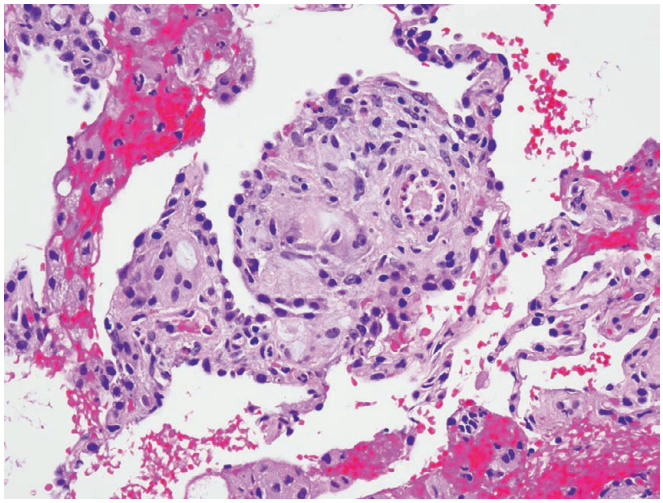

Figure 10.38 Drug abuser's lung in which perivascular granulomas include foreign body giant cells containing birefringent particulates, in this case a combination of talc and cellulose.

Table 10.1 Classification of idiopathic interstitial pneumonias[18]

Chronic fibrosing interstitial pneumonias	UIP NSIP
Smoking-related interstitial pneumonias	RBILD SRIF
Acute/subacute interstitial pneumonias	Diffuse alveolar damage Organizing pneumonia
Rare interstitial pneumonias	LIP Pleuroparenchymal fibroelastosis Unclassifiable interstitial pneumonia

LIP, Lymphoid interstitial pneumonia; *NSIP*, nonspecific interstitial pneumonia; *RBILD*, respiratory bronchiolitis-interstitial lung disease; *SRIF*, smoking-related interstitial fibrosis; *UIP*, usual interstitial pneumonia.

Diffuse Interstitial Lung Disease

This is a complex group of non-neoplastic pulmonary diseases that often require correlation of morphologic, clinical, and radiological findings. High-resolution computed tomography (HRCT) represents a major advance in this area, and a multidisciplinary approach provides at present the highest levels of diagnostic reproducibility.[84]

Idiopathic interstitial pneumonias account for a substantial subset of the diffuse lung diseases that a surgical pathologist is likely to encounter and can be divided into *chronic fibrosing* interstitial pneumonias, *smoking-related* interstitial pneumonias, and the *acute or subacute* interstitial pneumonias (Table 10.1).[18] The chronic fibrosing interstitial pneumonias comprise the largest category and account for over 80% of patients with idiopathic interstitial pneumonia who undergo surgical lung biopsy.[85–88] The same range of histologic abnormalities also occur in patients with underlying connective tissue diseases, a distinction that hinges in large part on clinical and laboratory studies.

Usual interstitial pneumonia (UIP) is the most common of the idiopathic interstitial pneumonias, accounting for nearly two-thirds of patients who undergo biopsy for diffuse lung disease of unknown cause.[85–88] Most patients with UIP fall into the clinical category of idiopathic pulmonary fibrosis (IPF), a syndrome that classically has an insidious onset characterized by a combination of breathlessness and cough with a relentlessly progressive evolution, many of the patients dying of respiratory failure after 3–4 years.[4] Acute exacerbation is increasingly recognized as a common final pathway in patients with underlying UIP and is characterized by sudden worsening of symptoms and more rapid progression of respiratory failure.[89] Some instances of UIP show a familial pattern indicating a heritable predisposition.[90] Others have underlying systemic connective tissue diseases, most commonly rheumatoid arthritis, scleroderma, and systemic lupus erythematosus.

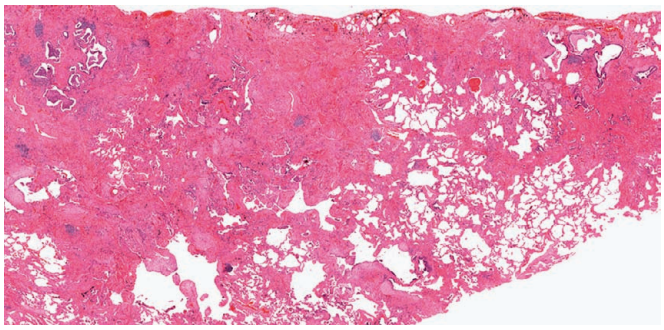

Figure 10.39 Usual interstitial pneumonia. Patchwork pattern of fibrosis with scarring and honeycomb change is characteristic.

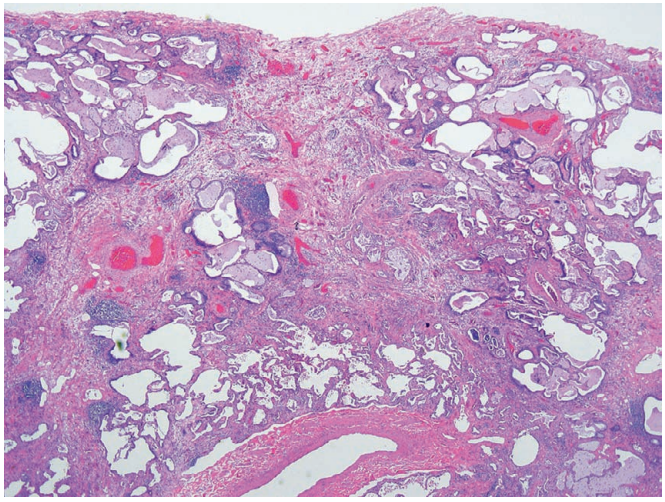

Figure 10.40 Usual interstitial pneumonia. Characteristic appearance of honeycomb change.

Microscopically, UIP is a primarily interstitial fibrosing process. According to Katzenstein et al., the single most important feature that distinguishes UIP from the other interstitial pneumonias (including so-called NSIP) is the marked regional variation in the nature and degree of the fibrosis, with a distinct patchwork distribution and evidence of architectural derangement (Fig. 10.39).[91–93] The architectural derangement takes the form of scarring and *honeycomb change*, the latter referring to cystic spaces situated within distally collapsed, fibrotic lung (Fig. 10.40). Areas of fibrosis in UIP are often most advanced in peripheral, subpleural lung where it is frequently associated with smooth muscle hyperplasia. Small *fibroblast foci* are often sandwiched between surface epithelium and fibrotic scar and are composed of spindled fibroblasts and myofibroblasts organized in a vaguely linear fashion within a pale-staining stroma (Fig. 10.41).[91] These findings are complicated by a superimposed pattern of acute lung injury that usually takes the form of organizing DAD in patients with acute exacerbation.[94] Less commonly patients

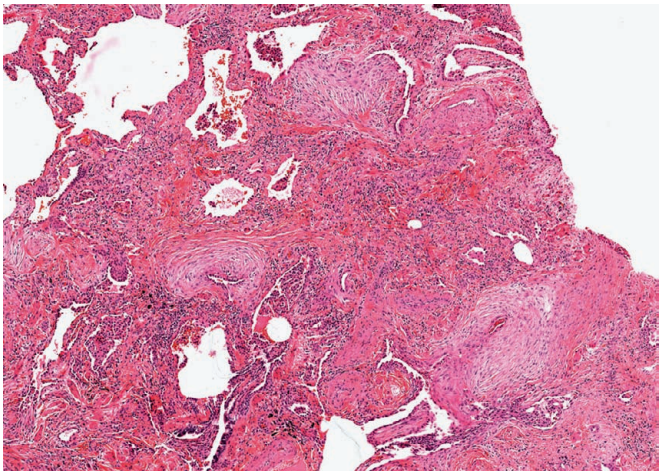

Figure 10.41 Usual interstitial pneumonia with prominent fibroblast foci. Fibroblast foci resemble organizing pneumonia except for their interstitial location.

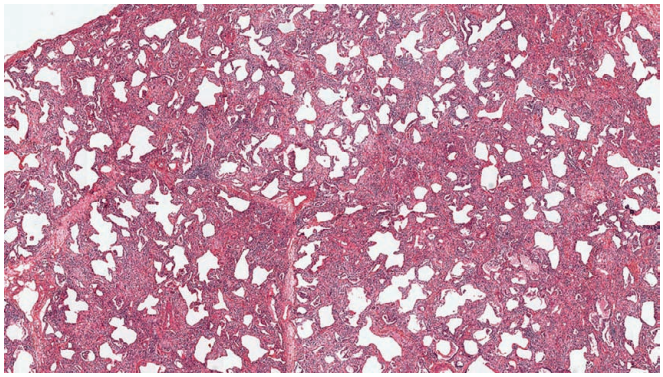

Figure 10.42 Nonspecific interstitial pneumonia demonstrating the diffuse uniform interstitial widening without the patchwork fibrosis or honeycomb change typical of UIP.

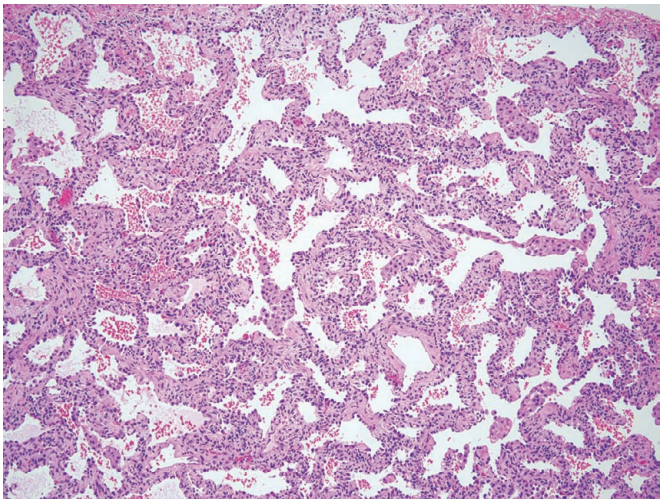

Figure 10.43 Cellular NSIP. Alveolar septa are uniformly expanded by cellular infiltrate with minimal fibrosis.

with acute exacerbation show a combination of UIP and organizing pneumonia. Patchy changes resembling eosinophilic pneumonia have also been described in UIP and appear to have limited clinical significance.[95]

Ultrastructural studies suggest that fibroblast foci are foci of abnormal wound healing in which activated mesenchymal cells migrate from the interstitial into the intraluminal compartment through defects in the basement membrane following epithelial necrosis, resolving through a disordered process of alveolar collapse, reepithelialization, and remodeling.[96,97] Fibroblast foci are characteristic of UIP but are not specific and can be seen in other diffuse lung diseases. They are the consequence of aberrant activation of epithelial cells and fibroblasts in lungs with an aging phenotype leading to accumulation of extracellular matrix and architectural distortion.[98]

NSIP/fibrosis is a term that was originally used for cases that could not be classified into any of the major categories of interstitial pneumonia, but which has now acquired an identity of its own.[18,99,100] Patients with NSIP fall into several different categories, including a subset with underlying systemic connective tissue disorders in which NSIP is the most common form of diffuse fibrotic lung disease.[101] NSIP is the second most common finding in patients with interstitial pneumonias of unknown cause ('idiopathic NSIP').[100] In either circumstance patients with NSIP generally have a better prognosis than patients with UIP.[102]

The main morphologic difference with UIP is that NSIP lacks the heterogeneous pattern of lung involvement characteristic of the former (Fig. 10.42).[18,85,91,99,102–104] The changes in NSIP may be patchy or diffuse but retain a degree of qualitative uniformity in areas of abnormality that set it apart from UIP. Interstitial structure including alveolar septa are expanded by an inflammatory infiltrate with ('fibrotic NSIP') or without ('cellular NSIP') collagen fibrosis (Fig. 10.43). Even with fibrosis, NSIP lacks the architectural derangement typical of UIP and instead is characterized by relative preservation of lung structure. Focal areas resembling NSIP can occur in otherwise classical UIP, which is why deciding that NSIP is a representative finding even in surgical lung biopsies requires careful correlation with clinical and radiological information.[91,92,104]

Respiratory bronchiolitis is a common incidental finding in heavy smokers but in some instances accounts for a form of symptomatic diffuse lung disease referred to as **respiratory bronchiolitis-interstitial lung disease** (RBILD).[105,106] Histologically, respiratory bronchiolitis is characterized by an accumulation of lightly pigmented alveolar macrophages within respiratory bronchioles spilling into neighboring alveoli (Fig. 10.44). The changes differ from the lesion referred to historically as desquamative interstitial pneumonia (DIP) in that the histiocytic accumulation is centriacinar instead of diffuse and lacks an associated interstitial pneumonia. Occasionally, RBILD is accompanied by mild, paucicellular fibrosis in the form of lamellar eosinophilic collagenous thickening of alveolar septa in a patchy, mainly subpleural distribution, a condition referred to as **smoking-related interstitial fibrosis** (SRIF) (Fig. 10.45) that is not to be confused with chronic fibrosing interstitial pneumonias such as UIP and NSIP.[107] The presence or absence of SRIF is not helpful in distinguishing patients with incidental respiratory bronchiolitis from those with RBILD, a distinction that is primarily dependent on clinical and radiological data. It is likely that SRIF in patients with symptomatic lung disease not attributable to COPD includes what would have been referred to historically as DIP.

DIP was defined historically by a filling of the alveolar spaces by large mononuclear cells, associated with relatively minor interstitial changes (Fig. 10.46).[108] Ultrastructurally, the cells that were originally thought to be desquamated pneumocytes have features of macrophages instead, making the term *DIP* a misnomer. Katzenstein and others have proposed that patients previously diagnosed as DIP are more properly categorized today as RBILD, SRIF, or NSIP, and therefore

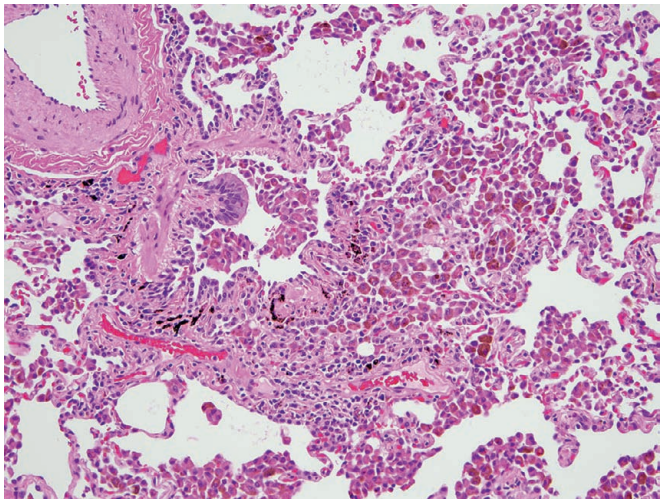

Figure 10.44 Respiratory bronchiolitis. Pigmented (smoker's) macrophages are clustered in the lumens of distal airways and peribronchiolar air spaces. The smoking-associated pigment is positive with Prussian-blue iron stains and should not be confused with hemosiderin.

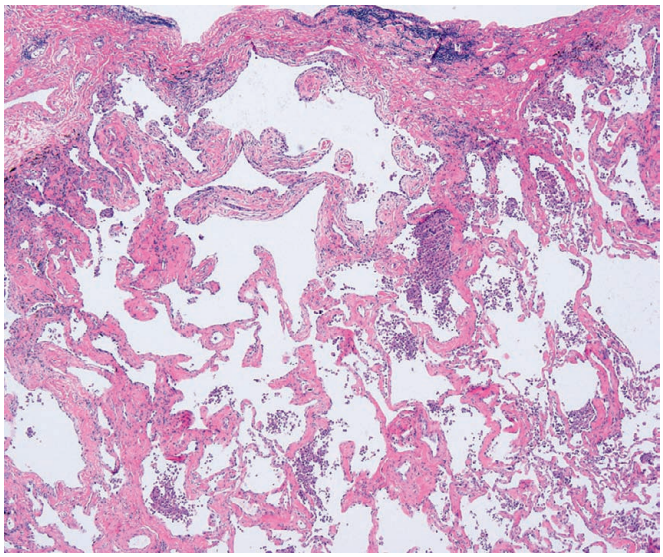

Figure 10.45 Smoking-related interstitial fibrosis. Subpleural septa are expanded by deeply eosinophilic collagen but without the patchwork distribution or honeycomb change characteristic of UIP. There is associated emphysema and respiratory bronchiolitis.

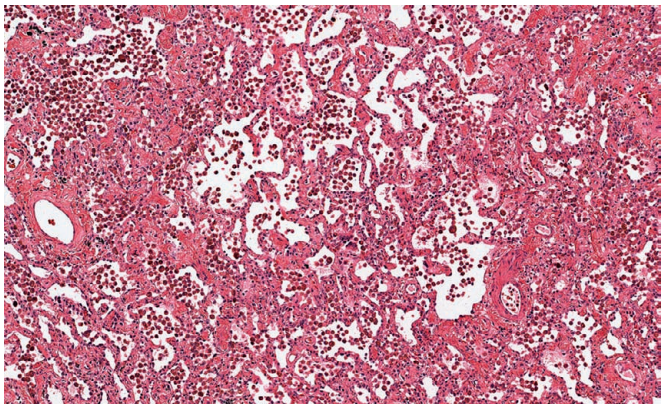

Figure 10.46 Desquamative interstitial pneumonia, an increasingly anachronistic term that should be abandoned in favor of the more modern alternatives NSIP, RBILD, or SRIF with considerable overlap between the latter two. Pigmented ('smoker's') macrophages identical to those illustrated in RBILD are more extensively distributed within alveolar spaces.

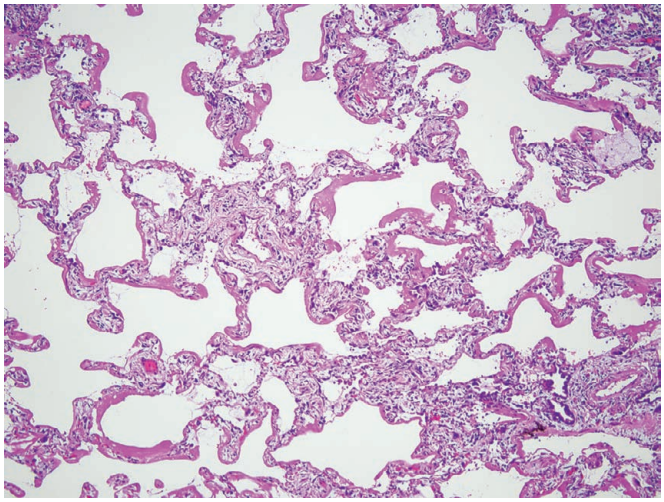

Figure 10.47 Diffuse alveolar damage in the acute phase with well-formed hyaline membranes.

the term DIP should be abandoned (personal communication). Others have argued for continued use of the term, citing potentially important prognostic differences.[109] Whatever terminology one prefers for this uncommon group of overlapping conditions the important point is to avoid confusing them with UIP given that all of them have a better prognosis and frequently benefit from some combination of smoking cessation and steroids.[110]

DAD is usually diffuse and bilateral in patients with the acute respiratory distress syndrome (ARDS).[111] It may be caused by infectious agents (particularly viruses), inhalants (such as oxygen), drugs (especially chemotherapeutic agents), ingestants (such as kerosene or paraquat), shock, sepsis, radiation, and acute exacerbation of UIP.[111,112] With the exception of pathogens detectable on routine histology or with special stains, the cause of DAD cannot be determined from the microscopic picture alone. The earliest stages consist of edema, intra-alveolar hemorrhage, and fibrin deposition. This is followed by hyaline membrane formation (most prominent 3–7 days after the injury), a sparse interstitial inflammatory infiltrate, fibrin thrombi (inconstant), and hyperplasia of the alveolar lining cells (Fig. 10.47). These cells, which are mainly reparative type II (granular) pneumocytes, may exhibit atypia, mitotic activity, and cytoplasmic hyaline bodies. A distinctive form of squamous metaplasia in bronchiolar epithelium combined with cytologic atypia can be pronounced enough to mimic a squamous cell carcinoma.[113] Foamy alveolar macrophages may also be present and may be more common in cases resulting from amiodarone.[114] In a later (organizing) stage, there is interstitial and intraluminal proliferation of organizing fibroblasts and myofibroblasts associated with persistence of the hyperplastic lining cells and collapse of alveolar structures resulting in marked architectural remodeling (Fig. 10.48).[97]

Acute interstitial pneumonia (AIP) is a rapidly progressive form of idiopathic interstitial pneumonia and is synonymous with the *Hamman–Rich syndrome*.[115,116] By definition, there is no identifiable initiating event. The typical patient is a young adult who presents with dyspnea following an influenza-like illness. The prognosis is very poor, with most patients dying within 2 months of onset.

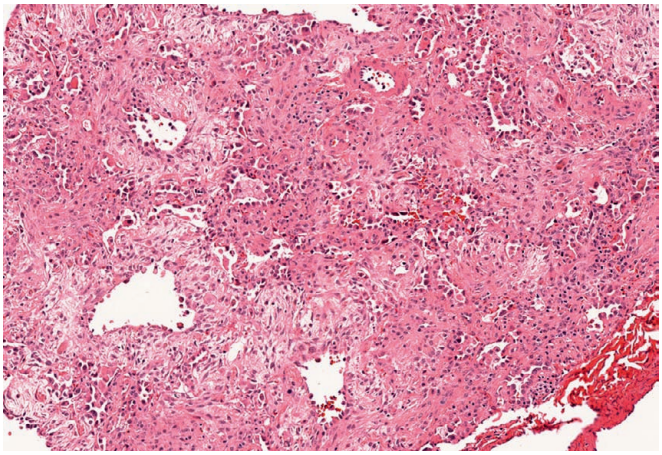

Figure 10.48 Diffuse alveolar damage in the organizing phase accompanied by alveolar collapse.

Microscopically, the appearance is equivalent to that of the organizing phase of DAD, the most striking feature being the interstitial expansion and distortion by organizing fibroblasts and myofibroblasts.

Organizing pneumonia, also termed bronchiolitis obliterans–organizing pneumonia (BOOP), is a nonspecific form of organizing acute or subacute lung injury that is associated with several conditions, including infections, inhalants (including silo-filler's lung), drugs, and collagen-vascular diseases. Organizing pneumonia occasionally occurs as a form of diffuse lung disease of unknown ('idiopathic') cause termed *cryptogenic organizing pneumonia (COP)*, a syndrome referred to historically as idiopathic BOOP.[18,117,118] COP is frequently grouped with the idiopathic interstitial pneumonias, but the clinical and radiological findings at presentation more closely mimic the features of infectious pneumonia. The onset is usually acute and characterized by cough, dyspnea, fever, and malaise. Less commonly COP presents as a solitary radiological opacity that may be asymptomatic and mimic the appearance of a neoplasm, a variant to which some have applied the term *focal organizing pneumonia* (Fig. 10.49).[119] The prognosis is generally excellent; patients requiring treatment often improve with sustained corticosteroids but may relapse when their steroid dose is tapered.[120] Morphologically, the hallmark of organizing pneumonia in any clinical context is represented by fibroblastic plugs ('Masson bodies') filling air spaces (Fig. 10.50). These plugs have a typical elongated to serpiginous, bifurcating shape reflecting the configuration of distal bronchioles and alveolar ducts and are formed by spindle to stellate fibroblasts embedded in a pale-staining matrix. Other changes include clusters of foamy macrophages, a few scattered neutrophils, and thickening of alveolar septa in the areas of intraluminal fibrosis. It is characteristic for the process to have a patchy appearance on low-power examination, a feature of importance in the differential diagnosis with UIP (see earlier). The rare cases of COP with unfavorable outcome (steroid unresponsive) have shown scarring and remodeling of the lung parenchyma on microscopic examination, suggesting an underlying chronic fibrosing lung disease.[121]

Lymphoid (lymphocytic) interstitial pneumonia (LIP) is characterized by a lymphocytic infiltrate with associated lymphoid follicles, often admixed with histiocytes and plasma cells, that expands alveolar septa and peribronchiolar interstitium.[122,123] Although included by some as a rare form of idiopathic interstitial pneumonia, LIP is a lymphoproliferative disorder analogous to reactive lymphoid hyperplasia that overlaps clinically, radiologically, and histologically with follicular bronchiolitis.[122] A third of the cases have been

Figure 10.49 Hilar mass that was considered radiographically to be carcinoma but proved pathologically to be organized pneumonia.

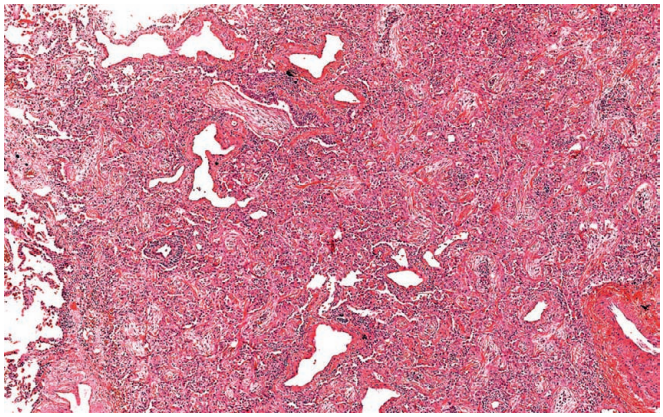

Figure 10.50 Cryptogenic organizing pneumonia showing characteristic intraluminal plugs of organizing fibroblasts and myofibroblasts. The central portion of some of the plugs show an infiltrate of chronic inflammatory cells, a nonspecific finding of no special significance.

associated with Sjögren syndrome, a circumstance in which distinction from marginal zone lymphoma of mucosa-associated lymphoid tissue (MALT) may be challenging. Another large subset of cases are associated with underlying immunodeficiencies, including HIV infection and common variable immunodeficiency. Some of the cases have been incorporated into the ever-enlarging spectrum of IgG4 disease.[124] The radiological appearance is that of interlobular septal lines often accompanied by ground-glass opacities and cysts. Cysts occur especially in patients with underlying Sjögren's syndrome, including some with diffuse variants of MALT lymphoma, often with associated amyloid or non-amyloid light chain deposition.[125] Histologically alveolar septa are expanded by a cellular infiltrate

composed of a combination of lymphocytes and plasma cells with prominent peribronchiolar lymphoid follicles, many of them with secondary germinal centers (Fig. 10.51).[123,126] Non-necrotizing granulomas accompany the infiltrates in some cases. Granulomas are especially common in patients with common variable immunodeficiency for which the term *granulomatous and lymphocytic interstitial lung disease* is sometimes used.[127]

LIP overlaps with **follicular bronchitis and bronchiolitis**, a nonspecific inflammatory reaction in which reactive germinal centers are seen adjacent to airways in the absence of chronic obstructive pulmonary disease. Follicular bronchitis/bronchiolitis is a common secondary finding in bronchiectasis but also occurs as a primary lymphoproliferative disorder in the same clinical circumstances described for LIP.[123,128]

Pleuroparenchymal fibroelastosis (PPFE) is a rare pattern of diffuse lung fibrosis with histologic features that overlap with the much more common *apical cap*, a localized form of fibroelastosis unique to the lung apices and superior segments of the lower lobes.[129] PPFE tends to preferentially affect the upper lobes and is exquisitely localized to peripheral subpleural parenchyma and bronchovascular bundles (Fig. 10.52).[130] PPFE is not a specific disease in that this pattern of fibrosis occurs in a number of clinical scenarios, including lung and stem cell transplants, drug-induced lung disease, and connective tissue disease.[131,132] Importantly this form of peripheral fibroelastosis can also coexist with other forms of diffuse fibrotic lung disease, most importantly UIP.

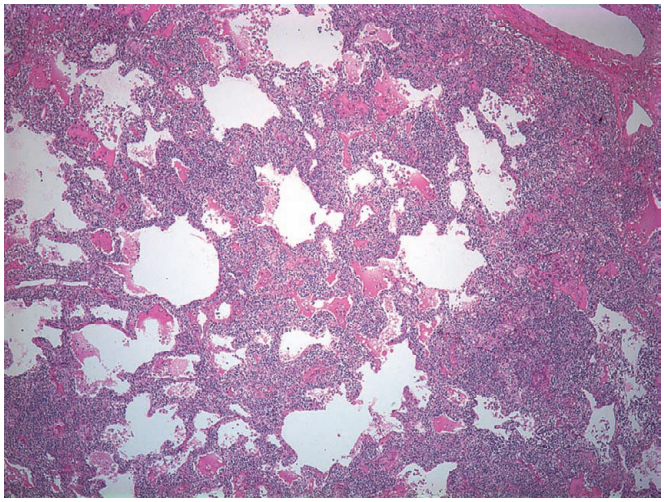

Figure 10.51 Lymphoid interstitial pneumonia in a patient with Sjögren syndrome.

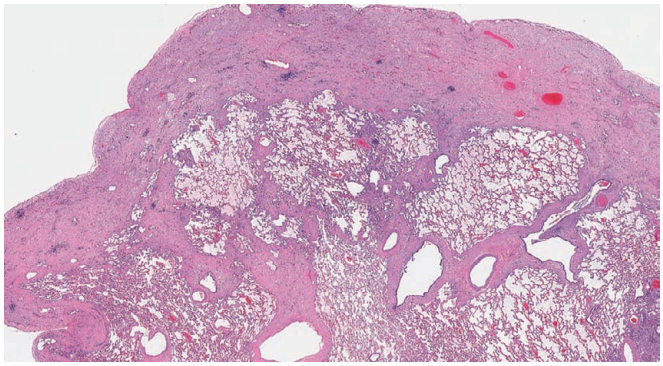

Figure 10.52 Pleuroparenchymal fibroelastosis.

Hypersensitivity Pneumonia (Extrinsic Allergic Alveolitis)

Hypersensitivity pneumonia (extrinsic allergic alveolitis) is the generic term given to an acute, subacute, or chronic inflammatory process representing a tissue reaction to an inhaled allergen.[133] Patients suffering from this condition have both cellular and humoral immune processes directed against the organic allergen. The most common offending antigens include thermophilic bacteria (e.g. farmer's lung, humidifier lung), molds (e.g. Japanese summer type hypersensitivity), and avian proteins (e.g. pigeon breeder's lung). In acute hypersensitivity pneumonia, fever and dyspnea develop a few hours after exposure to relatively high doses of the offending antigen. With repeated exposures, often to relatively low doses of an environmental antigen that may be unknown to the patient, a chronic fibrosing lung disease develops than can mimic many of the features of IPF.

Microscopically, classical hypersensitivity pneumonia is characterized by a combination of a cellular interstitial pneumonia that tends to be accentuated around airways *(bronchiolocentric)*, equally cellular chronic bronchiolitis, and a distinctive pattern of granulomatous inflammation (Figs. 10.53 and 10.54). This combination of findings predicts for the diagnosis of hypersensitivity pneumonia even in patients for whom no exposure was known prior to lung biopsy.[134,135] Fibrosis occurs in some patients and when advanced can closely mimic UIP or the fibrotic stage of NSIP; the presence of isolated giant cells, poorly formed granulomas, and/or Schaumann bodies in a peribronchiolar location should suggest the right diagnosis.[136] Fibrosis is associated with a generally poor prognosis.[137]

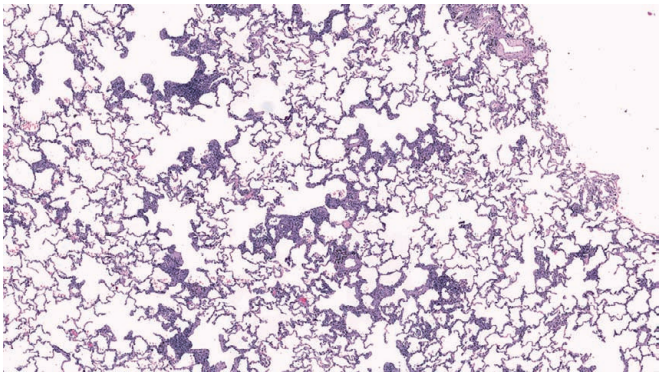

Figure 10.53 Hypersensitivity pneumonia showing patchy interstitial infiltrate of lymphocytes distributed in an exquisitely bronchiolocentric fashion.

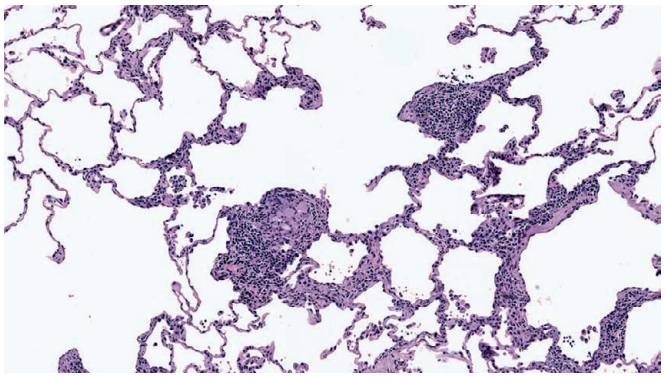

Figure 10.54 Hypersensitivity pneumonia with characteristic loose cluster of multinucleated giant cells in peribronchiolar interstitium.

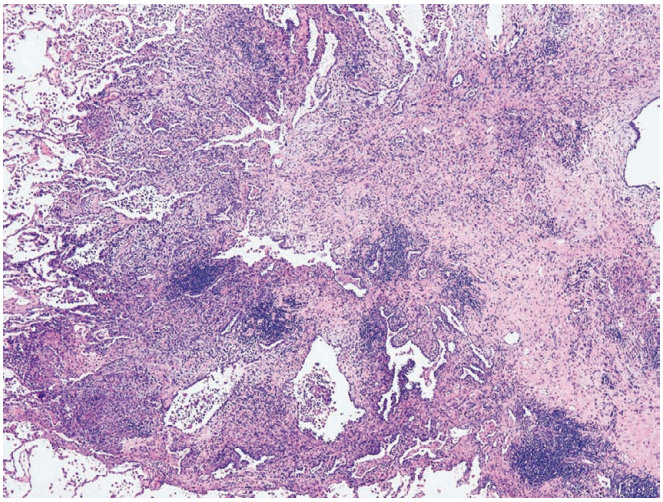

Figure 10.55 Langerhans cell histiocytosis.

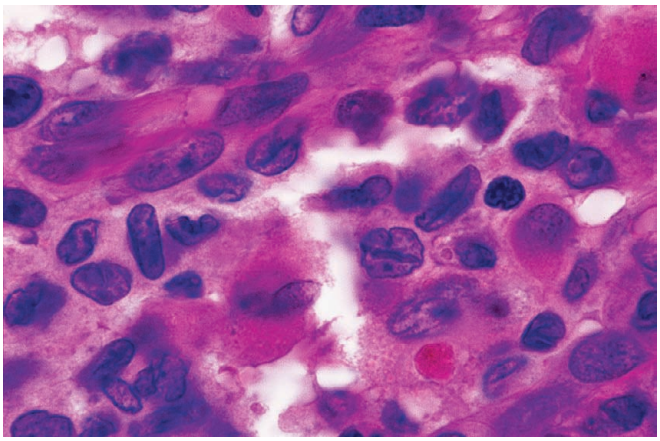

Figure 10.56 Prominent longitudinal grooves in the nuclei of Langerhans cells in a case of pulmonary Langerhans cell histiocytosis.

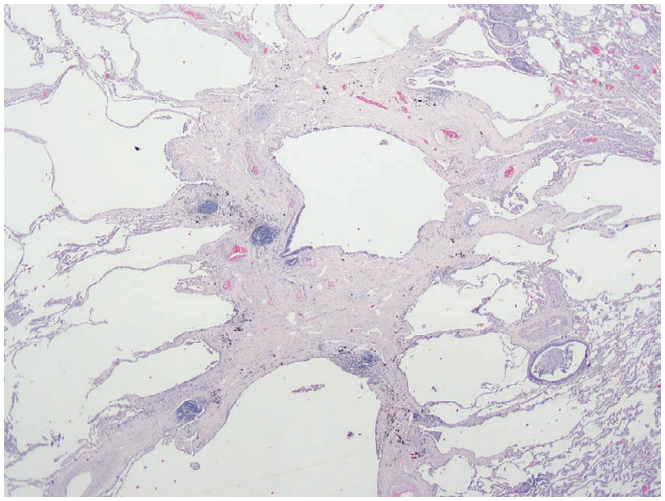

Figure 10.57 Fibrotic Langerhans cell histiocytosis showing characteristic stellate configuration and associated peripheral 'scar emphysema' (paracicatricial air space enlargement).

Silo-filler's disease should be clearly separated from the aforementioned group, since it is a form of acute lung injury secondary to nitrogen dioxide inhalation and is characterized by the presence of DAD without granulomatous inflammation.[138]

Langerhans Cell Histiocytosis and Other Histiocytic Disorders

Pulmonary LCH, referred to historically as Langerhans cell granulomatosis, histiocytosis X, and eosinophilic granuloma of the lung, is most commonly seen in the third and fourth decades of life.[139–141] LCH occurs almost exclusively in cigarette smokers in whom it typically presents as a diffuse process and rarely as a solitary nodule.[142] It predominates in the upper lobes and produces a combination of nodules and cavitary lesions or cysts. In approximately 20% of the patients, there is associated extrapulmonary involvement, usually as isolated lesions in bones or the pituitary region. Spontaneous pneumothorax is a common complication. In most patients with LCH of the lung, the disease resolves or stabilizes. A few patients develop progressive pulmonary disease that is ultimately fatal.

Microscopically, there is a compact interstitial infiltrate that expands peribronchiolar interstitium and is, composed of Langerhans cells, variable numbers of eosinophils, and other mononuclear inflammatory cells (Fig. 10.55). Langerhans cells are the essential element for the diagnosis; they have an abundant acidophilic cytoplasm and a vesicular nucleus, with typical grooves and indentations (caveat: similar grooves also can be seen in reactive mesothelial cells and alveolar macrophages) (Fig. 10.56). Immunohistochemical staining for S-100 protein, CD1a, or langerin can be very helpful in highlighting Langerhans cells and can also be applied to cells in bronchoalveolar lavage fluid.[143] The bronchiolocentric nodules heal through a process of fibrosis that begins in the center eventually extending into peribronchiolar alveolar septa where it is accompanied by a characteristic patter of scar emphysema (paracicatricial air space enlargement). At this late fibrotic stage it may be very difficult to establish a microscopic diagnosis of LCH since the characteristic Langerhans cells may be absent (Fig. 10.57). Correlation with CT scans can be helpful in showing a pattern and distribution of cystic lung disease characteristic of LCH. In the healing stage, the disease may no longer be diagnosable microscopically.

Molecular studies using a variety of techniques suggest that there is a clonal proliferation of Langerhans cells in at least a subset of patients.[144–147] Evidence of clonal evolution in pulmonary LCH includes *BRAF*^{V600E} mutations in 20%–50% of patients.[145,147,148] Some of these patients may benefit from targeted therapy with vemurafenib.[149]

Reactive eosinophilic pleuritis is a nonspecific response to pleural injury that may closely simulate LCH because of the mixture of eosinophils, mesothelial cells, and histiocytes (which can look very similar to Langerhans cells); in contrast to true eosinophilic granuloma, this lesion by itself does not show interstitial lung disease.[150] However, in some instances it may be accompanied by eosinophilic infiltration of the pulmonary vessels.[151]

Erdheim–Chester disease is another histiocytic disorder which can affect the lung, in conjunction with bones (the latter often in the form of symmetric osteosclerosis), soft tissues, and the central nervous system.[139,152] Pulmonary involvement is typically septal (lymphatic) in distribution and characterized by an infiltrate of foamy histiocytes, lymphocytes, and Touton giant cells (Figs. 10.58 and 10.59). The histiocytes are consistently positive for CD68, sometimes reactive for S-100 protein, and negative for CD1a. Recent studies demonstrate *BRAF*^{V600E} mutations in more than half as well as recurrent mutations in *RAS* and *PIK3CA*, indicating that this is a myeloid neoplasm for which targeted therapy with vemurafenib is proving effective in a large number of patients.[153–155]

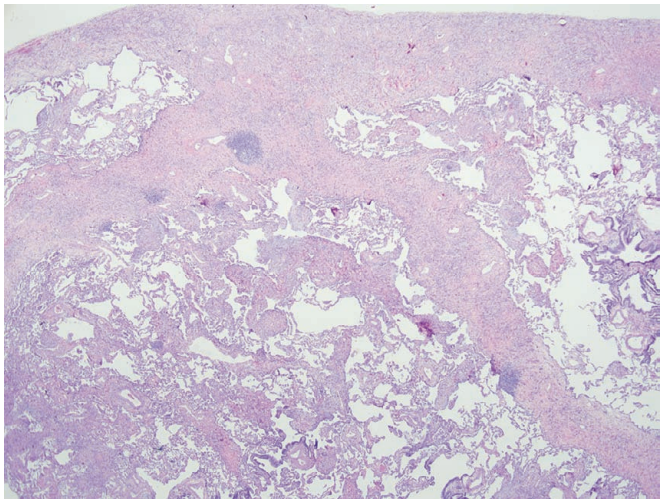

Figure 10.58 Erdheim–Chester disease.

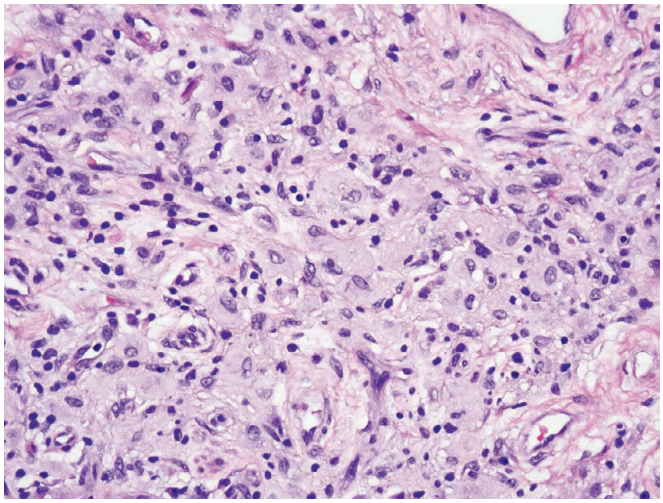

Figure 10.59 Erdheim–Chester disease involving the lung showing histiocyte-rich infiltrate.

Rosai–Dorfman disease (sinus histiocytosis with massive lymphadenopathy) is seen in the lung parenchyma only exceptionally, in contrast to its relatively frequent involvement of the upper respiratory tract.[156–158] The histologic findings overlap with IgG4-related disease, which is a diagnostic pitfall requiring careful correlation with the clinical and radiological findings.[159,160]

Pneumoconiosis

Pneumoconiosis is defined as the non-neoplastic reaction of the lungs to inhaled mineral or organic dust, exclusive of asthma, bronchitis, and emphysema.

Anthracosis is often applied as a general and relatively nonspecific term to black pigment with minimal associated fibrosis in the lungs of heavy smokers and residents of heavily polluted urban environments. Pigmented dust macules also occur in coal workers, however, in whom the term *anthracosis* has a specific and more narrow interpretation, and therefore the term is probably best avoided. *Coal worker's pneumoconiosis* may present either as 'coal nodules' (of little functional significance) or as progressive massive fibrosis (which results in pulmonary function abnormalities).[161–163]

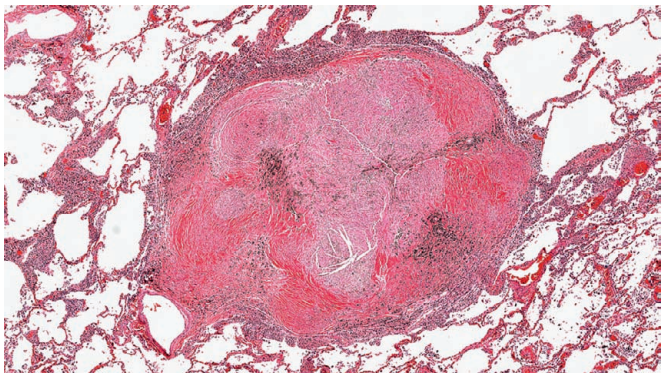

Figure 10.60 Simple silicosis showing classic, uncomplicated silicotic nodule.

Silicosis results from the deposition in the lung of particles of free crystalline silica (quartz, silicon dioxide). The lesions are characterized by micronodular scars with a characteristic pattern of central lamellar fibrosis distributed in a bronchiolocentric pattern with a cellular periphery in which dust-laden macrophages predominate (Fig. 10.60). Complicated silicosis and progressive massive fibrosis result from fusion of nodules to form larger (≥1 cm) macroscopic nodules and masses. Larger nodules may undergo necrosis and cavitate as a result of ischemia, or more commonly superimposed mycobacterial infection; acid-fast stains should be performed when necrosis is identified. Silicotic nodules in patients with rheumatoid arthritis *(Caplan syndrome)* assume some of the morphologic changes characteristic of rheumatoid nodules, including central necrosis with palisaded histiocytes at the periphery.[164]

Silica particles are best demonstrated under polarized light. They appear as weakly birefringent spicules with pointed ends, 5 μm or less in length, and are usually accompanied by more brightly birefringent contaminants. They may be found intracellularly or extracellularly. It should be emphasized that the mere presence of silica particles in a lung specimen does not establish the diagnosis of silicosis. Such a diagnosis should be reserved for cases showing silica in association with characteristic silicotic nodules.[165]

Mixed dust fibrosis is the term used for pneumoconioses resulting from mixed dust exposure, including silica and quartz. It affects foundry workers, arc welders, hematite miners, and boiler scalers. Most cases show a combination of dust macules and fibrotic nodules that may or may not include a minor component of silicotic nodules.[166]

Asbestosis refers to diffuse lung fibrosis attributable to asbestos exposure. Aside from an incriminating occupational history, the clinical and radiological findings may be indistinguishable from other forms of diffuse fibrotic lung disease save for the presence of calcified pleural plaques on imaging studies. Histologic diagnosis requires a combination of diffuse interstitial fibrosis and asbestos bodies in ordinary 5-μm sections.[167–169] The histologic features closely mimic UIP, although there tends to be less inflammation, fewer fibroblast foci, and more visceral pleural fibrosis (Fig. 10.61).[169] The diagnosis of asbestosis in lung biopsy samples requires the identification of asbestos bodies, usually by conventional microscopy although special techniques can be helpful in a limited number of contexts.[170] The typical asbestos body is a long, thin, symmetric, beaded structure with bulbous ends (Fig. 10.62). It is usually straight, but it may be bent or branched. Its core is translucent, a key feature in separating asbestos bodies from other types of non-asbestos ferruginous bodies.[171]

Other pneumoconioses include siderosis (seen in iron workers, hematite miners, and welders), berylliosis, and disorders resulting

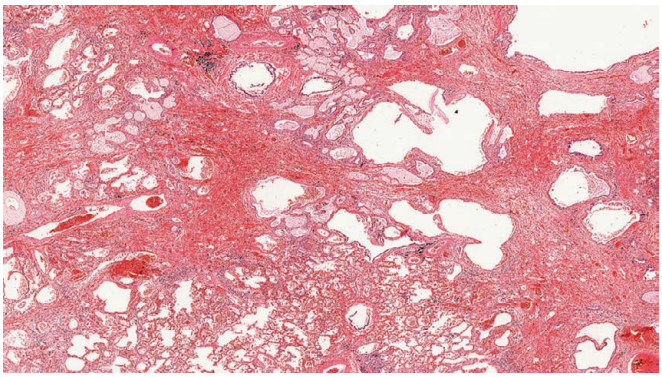

Figure 10.61 Asbestosis showing a pattern of fibrosis resembling UIP.

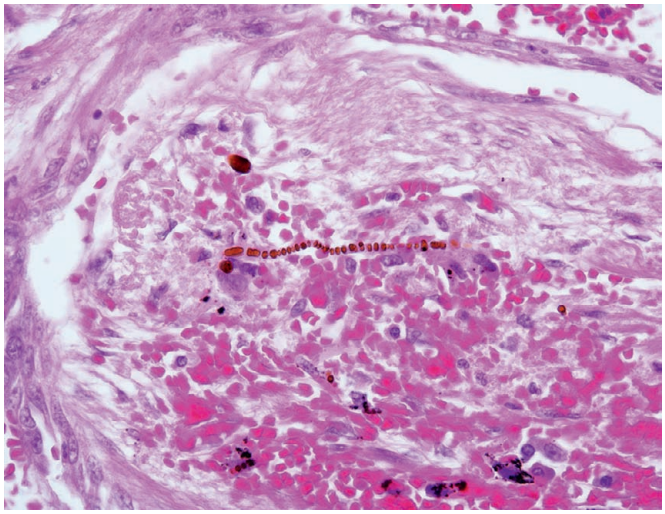

Figure 10.62 Asbestos body in a patient with asbestosis showing characteristic beaded appearance with central translucent core.

from talc and other silicates, aluminum, hard metals, and silicon carbide.

Lipoid Pneumonia

Lipoid pneumonia is often a complication of debilitating disease found as an incidental post mortem finding. However, the local expression of this process may be confused with a malignant neoplasm and consequently may become a surgical problem.

Lipoid pneumonia can be divided into two types: exogenous and endogenous. In the *exogenous* type, now seen only rarely, mineral oil from nasal sprays, laxatives, or other sources reaches the lung through the tracheobronchial tree (Fig. 10.63).[172] Grossly, exogenous lipoid is well circumscribed and firm. Microscopically, coarse lipid vacuoles that vary markedly in size are present within the air spaces and the interstitial compartment where they are accompanied by a combination of inflammation and variable degrees of fibrosis. The inflammatory infiltrate includes multinucleated giant cells that surround and engulf the lipid vacuoles. Identifying the giant cell reaction is extremely helpful in separating exogenous lipoid pneumonia from the 'holes' *(pseudolipoid)* artifact common in both surgical and transbronchial lung biopsies.[14] The much more common *endogenous* type is the consequence of bronchial obstruction by carcinoma or some other process resulting in accumulation of finely vacuolated lipid-laden macrophages in distal air spaces with infrequent involvement of the peribronchiolar interstitium. The gross distribution

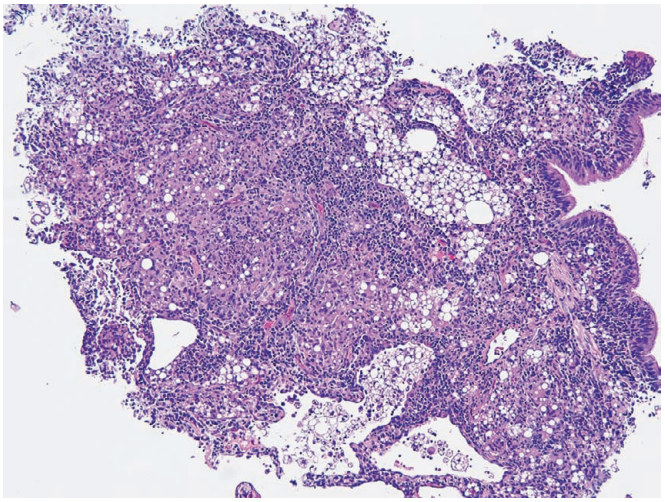

Figure 10.63 Exogenous lipoid pneumonia in a transbronchial biopsy from a patient suspected of having a malignancy.

of the abnormality depends on the level of the obstruction, frequently reflecting the lobar or segmental anatomy of the lung.

Aspiration Pneumonia

Aspiration pneumonia (other than the previously listed exogenous form of lipoid pneumonia) is often due to the aspiration of food and is a well-recognized complication in debilitated patients. Aspiration pneumonia is increasingly recognized as a cause for symptomatic or asymptomatic lung disease that can be multifocal or localized and bilateral or unilateral on radiographs or CT scans of the chest.[173–175] When solitary, aspiration pneumonia can simulate a neoplastic process. Microscopically, the changes are mainly represented by BOOP, usually in combination with multinucleated giant cells, acute bronchopneumonia and/or bronchiolitis, and suppurative granulomas. The key finding is the presence of foreign material, most often food remnants or inorganic fillers (e.g. microcrystalline cellulose, crospovidone) commonly used in oral medications (Figs. 10.64 and 10.65).[174]

Eosinophilic Pneumonia

Eosinophilic pneumonia is a histologically distinct pattern of tissue eosinophilia that may or may not be associated with peripheral eosinophilia (Fig. 10.66). Eosinophilic pneumonia is a common manifestation of drug-induced lung disease and can also occur as a component of a more complex combination of histologic findings in patients with EGPA (Churg–Strauss) and allergic bronchopulmonary aspergillosis. Changes overlapping with eosinophilic pneumonia have also been described in coccidioidomycosis, an important diagnostic consideration in endemic areas.[175] Patients in whom eosinophilic pneumonia is an unexplained primary pathologic abnormality fall into several different clinical categories.[176,177] An acute self-limited form of *simple eosinophilic pneumonia*, characterized by fleeting pulmonary infiltrates accompanied by eosinophilia and lasting no more than a month, is commonly referred to as *Löeffler syndrome*. *Tropical eosinophilic pneumonia*, as the term implies, is limited to patients living in the tropics where it is a well-recognized syndrome of pulmonary infiltrates with eosinophilia thought to be related to filarial infestations. Neither patients with simple or tropical eosinophilic pneumonia are likely to be biopsied.

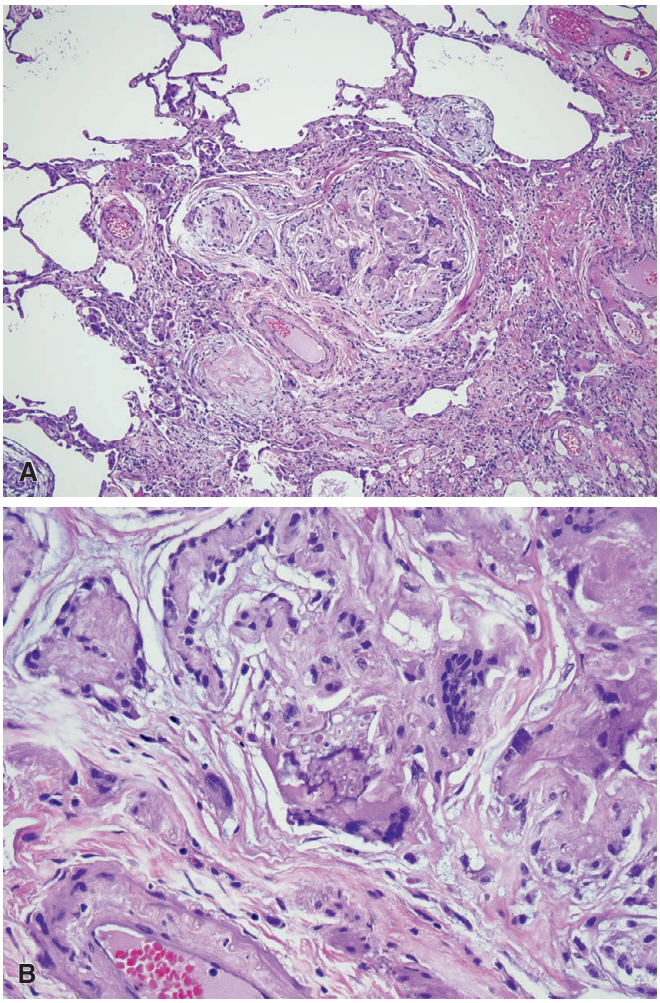

Figure 10.64 Aspiration pneumonia showing a combination of organizing pneumonia with granulomatous inflammation **(A)** and degenerated organic particulates typical of food **(B)**.

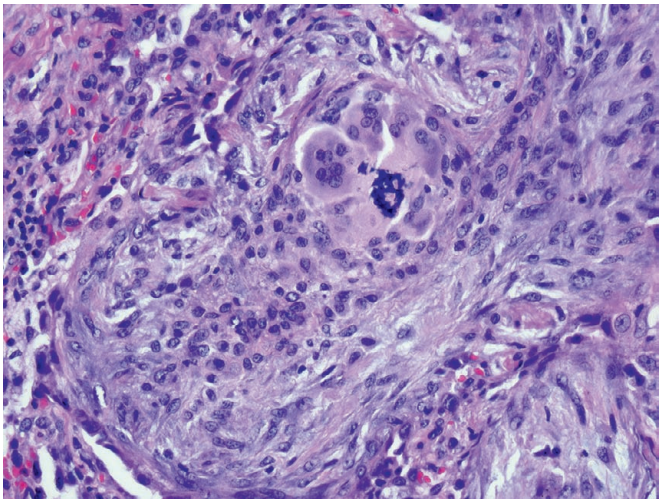

Figure 10.65 Aspiration pneumonia with organizing pneumonia and granulomatous inflammation in which a multinucleated giant cell contains crospovidone, an inorganic filler used in oral medications.

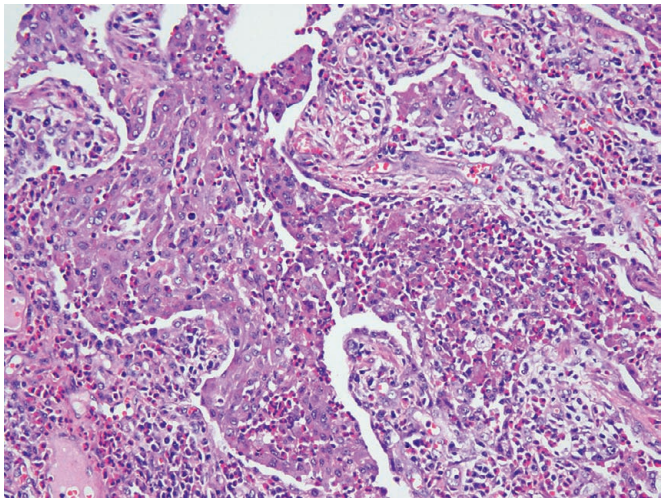

Figure 10.66 Eosinophilic pneumonia. Numerous mature eosinophils are admixed with histiocytes and granular pneumocytes.

Most patients with eosinophilic pneumonia discovered in a diagnostic lung biopsy have a respiratory syndrome characterized by a subacute or chronic onset referred to as *chronic eosinophilic pneumonia*.[178,179] This is a disease that affects women more often than men, usually between the ages of 30 and 50 years. About half of patients have a history of asthma, and most have peripheral eosinophilia. Clinically, the onset is characterized by fever, weight loss, cough, and dyspnea. Chest roentgenograms and CT scans show a characteristic peripheral distribution of infiltrates in about half of patients. As in all other forms of eosinophilic pneumonia the most notable microscopic change is alveolar and interstitial infiltration by eosinophils and histiocytes often with an associated fibrinous exudate (see Fig. 10.66). Charcot–Leyden crystals may be found. Additional features may include mild angiitis, giant cells, and occasionally non-necrotizing granulomas, organizing fibroblasts, and myofibroblasts resembling organizing pneumonia, focal necrosis, mucous plugging, and bronchiolitis.

Acute eosinophilic pneumonia presents as acute respiratory failure, often with profound hypoxemia requiring intubation and mechanical ventilation.[180] As with other forms of eosinophilic pneumonia, however, patients respond quickly and dramatically to corticosteroid therapy. Histologically acute eosinophilic pneumonia shows histologic features that overlap eosinophilic pneumonia and DAD.

Pulmonary alveolar proteinosis (alveolar lipoproteinosis) is a rare disorder characterized by a paucicellular granular air space exudate composed of a combination of surfactant lipids and proteins.[181–183] It affects men more commonly than women, usually in the fourth to fifth decades of life. Pulmonary alveolar proteinosis is rare in neonates in whom it is affiliated with mutations in surfactant protein or granulocyte macrophage-colony stimulating factor (GM-CSF) receptor genes. Conventional chest radiographs show bilateral perihilar infiltrates resembling pulmonary edema. CT scans show a characteristic but nonspecific combination of opacities and septal lines described as *crazy paving*. A large majority (90%) of adult patients with alveolar proteinosis have an autoimmune disorder characterized by high concentrations of neutralizing anti-GM-CSF autoantibodies. In a small subset of patients, pulmonary alveolar proteinosis is secondary to inhalational injuries *(acute silicoproteinosis)* or underlying hematological neoplasms. Whole-lung lavage is the mainstay of therapy. Inhaled or systemically administered GM-CSF and strategies aimed at reducing the levels of circulating anti-GM-CSF autoantibodies may also have value in patients with autoimmune pulmonary alveolar proteinosis.[182,183]

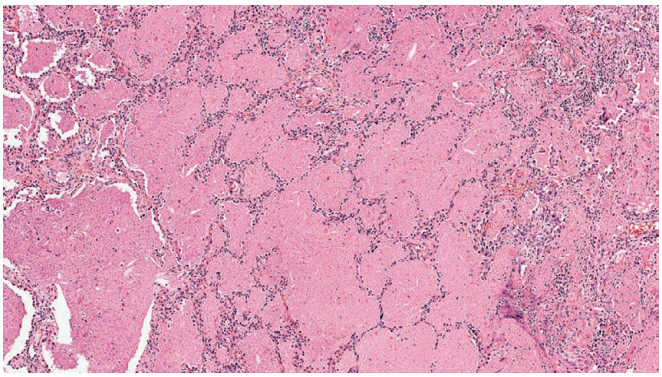

Figure 10.67 Filling of alveolar spaces by amorphous grumous material in alveolar proteinosis.

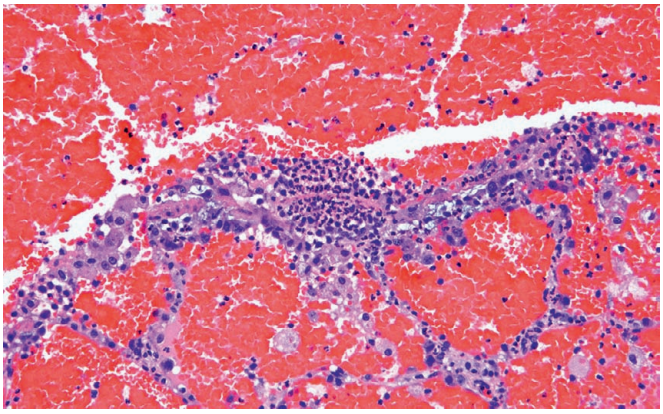

Figure 10.68 Diffuse alveolar hemorrhage with capillaritis in a patient with granulomatosis with polyangiitis (Wegener's).

Microscopically, the hallmark of the process is the accumulation of an amorphous eosinophilic (but sometimes basophilic) PAS-positive material of predominantly phospholipid nature in the alveolar lumina, associated with a minimal infiltrate of lymphocytes, macrophages, and desquamated pneumocytes. The air space exudate is usually affiliated with only mild interstitial abnormalities including a lymphocytic infiltrate with minimal associated fibrosis (Fig. 10.67). In patients who have underlying hematological disorders or are otherwise immunocompromised, alveolar proteinosis may be associated with infections such as nocardiosis, pneumocystis, histoplasmosis, cryptococcosis, aspergillosis, tuberculosis, or cytomegalovirus, making appropriate use of special stains and other microbiologic assays mandatory in this context.

Pulmonary Hemorrhage

Diffuse pulmonary (alveolar) hemorrhage is uncommon. Most patients are symptomatic and complain of a combination of dyspnea, cough, fever, chest pain, and/or hemoptysis. Vasculitic syndromes, anti-glomerular basement membrane disease (**Goodpasture syndrome**) and systemic connective tissue diseases are among the most common causes; affected patients often have concomitant glomerulonephritis (pulmonary-renal syndrome).[184] Patients with underlying vasculitides frequently have circulating ANCA (*ANCA-associated vasculitides*). In Goodpasture syndrome there is an associated glomerulonephritis, circulating antiglomerular basement membrane antibodies, and linear deposits of IgG along glomerular and alveolar basement membranes. Other less common causes of diffuse alveolar hemorrhage include congestive heart failure, occupational exposure to trimellitic anhydride, drug-induced hemorrhage, inhalational lung injury (e.g. crack cocaine), and various clotting diorders.[185] In some patients no underlying cause or immune-mediated disease is identified. Chest roentgenograms and CT scans usually show relatively nonspecific diffuse opacities. Surgical lung biopsies show alveolar hemorrhage, often associated with hemosiderin pigment and organizing pneumonia, with associated small vessel vasculitis *(necrotizing capillaritis)* in those with vasculitis syndromes (most commonly GPA [Wegener's], microscopic polyangiitis, or systemic lupus erythematosus) (Fig. 10.68).

Idiopathic pulmonary hemosiderosis is a rare condition that classically presents in children and young adults with dyspnea, cough, hemoptysis, and refractory anemia.[186] Children who present with diffuse pulmonary hemorrhage show the same range of underlying systemic diseases, including ANCA-associated vasculitides, as adults making idiopathic pulmonary hemosiderosis a diagnosis of exclusion. Down syndrome and celiac disease are common underlying conditions in children with idiopathic pulmonary hemosiderosis. Microscopically, large accumulations of hemosiderin-laden macrophages in the alveolar lumens are accompanied by hyperplastic alveolar pneumocytes lining thickened alveolar septa. Necrosis, vasculitis, granulomas, and lymphoid follicles do not occur, and there are no deposits of IgG on the alveolar basement membranes, an important distinction from Goodpasture syndrome.

Localized pulmonary hemorrhage is usually secondary to some underlying condition, such as a necrotizing primary or metastatic neoplasm, necrotizing infection, or bronchiectasis.[187] **Hematoma** of the lung can present as a distinct round mass that radiographically resembles a neoplasm; it usually develops as a result of nonpenetrating blunt trauma to the thorax.[188]

Miscellaneous Infections

Improved microbiologic assays applied to various noninvasively acquired samples have diminished the role of tissue biopsies in establishing non-granulomatous infectious diagnoses in the lung. Despite these trends there remain a subset of pulmonary infections for which lung biopsy is occasionally required.

Pneumocystis jirovecii Pneumonia

Pneumocystis jirovecii pneumonia is an opportunistic fungal infection.[189,190] Most cases are seen in individuals who are chronically debilitated and immunosuppressed, such as those receiving therapy for neoplastic disease or affected with AIDS. Pneumocystis remains the most prevalent opportunistic infection in AIDS patients. In severely immunocompromised patients, the infection may spread to extrapulmonary sites and become disseminated.

Bronchoalveolar lavage is the most commonly used method for diagnosing pneumocystis pneumonia. Lung biopsy is reserved for those patients in whom bronchoalveolar lavage is unsuccessful or in whom the diagnosis was not anticipated. Microscopically, the typical case is characterized by a foamy or honeycombed intra-alveolar exudate accompanied by a lymphoplasmacytic interstitial infiltrate (Fig. 10.69). However, these features may be inconspicuous or absent in some cases, which may exhibit instead epithelioid granulomas, focal multinucleated giant cells, marked interstitial fibrosis, vasculitis, a marked infiltrate of alveolar macrophages, calcifications, or DAD.[191,192] Given the variability in the histologic findings associated with *P. jirovecii* pneumonia one should have a low threshold for performing special stains in potentially immunocompromised patients.

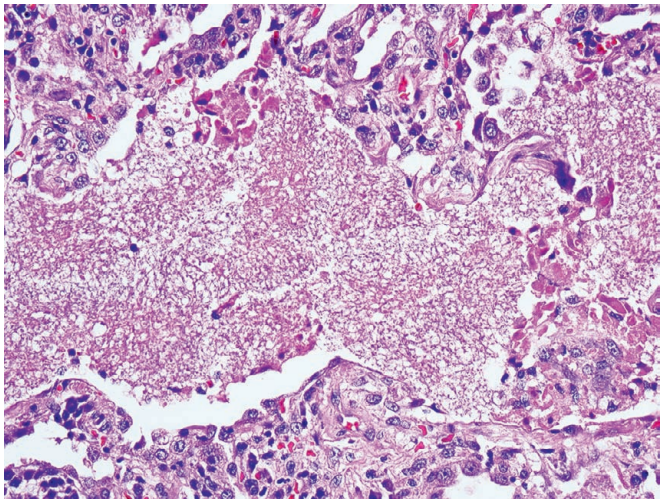

Figure 10.69 Frothy alveolar exudate in *P. jirovecii* pneumonia.

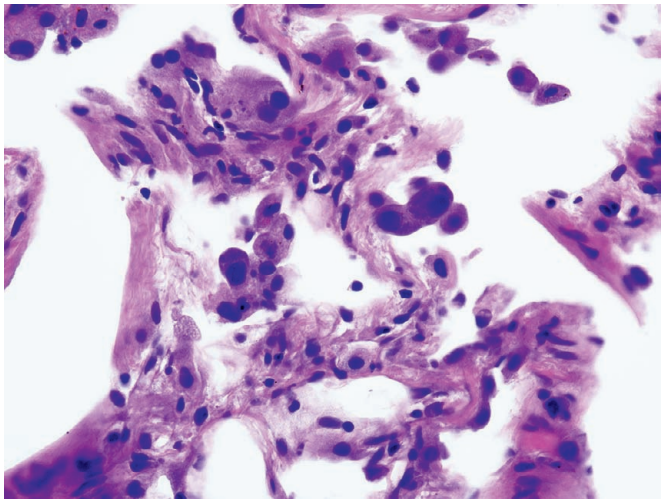

Figure 10.71 Cytomegalovirus infection with characteristic viral cytopathic changes in infected pneumocytes.

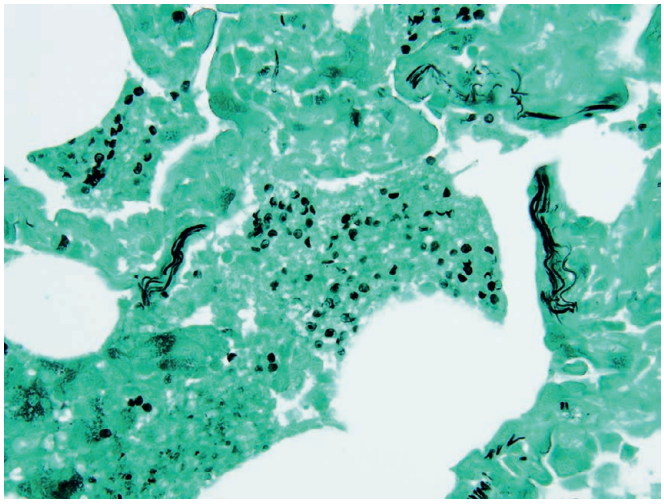

Figure 10.70 GMS stain showing *P. jirovecii* in frothy alveolar exudate.

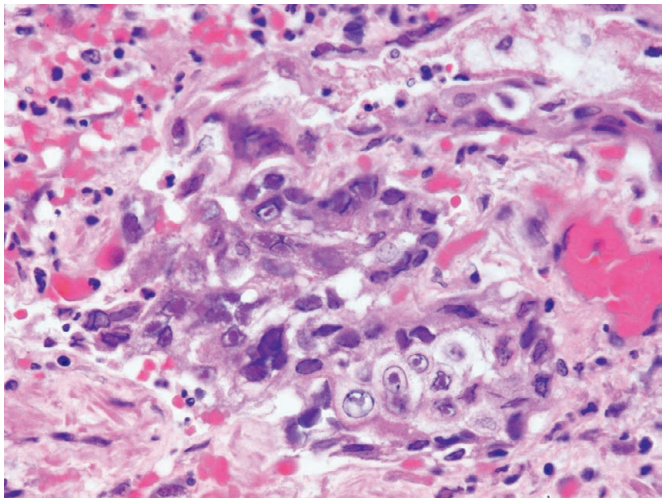

Figure 10.72 Intranuclear inclusions in herpes simplex pneumonia.

The diagnosis of pneumocystic pneumonia depends on identification of the organism.[189] Cytology and biopsy specimens should be cultured (to rule out the possibility of other infectious processes), imprints should be taken, and the rest of the sample processed routinely or subjected to frozen section examination. If *P. jirovecii* is present, the imprints are almost invariably positive. The most reliable stain for detecting the organism is GMS (Fig. 10.70). The cystic forms of the organism appear with the silver stain as round structures, up to 5 µm in diameter, containing single or paired discrete 'intracystic bodies' measuring 1–2 µm. Some of the cysts are crumpled and others are collapsed, with a crescentic shape. False-negative staining with GMS does occur, making careful interpretation of routinely stained sections and use of appropriate positive controls all the more important.[193] Immunoperoxidase techniques using monoclonal antibodies and PCR methods are also available.

Cytomegalovirus pneumonia is usually seen in immunocompromised patients, such as those with AIDS or lymphoid malignancies, transplant recipients, and those receiving cytotoxic drugs.[194] Radiographically, it may present in the form of small (2–4 cm) peripherally located nodules or consolidated opacities, as an acute miliary pattern, or as a diffuse interstitial process. Microscopically, a patchy mixed inflammatory infiltrate is seen in conjunction with an air space exudate and hyperplasia of the alveolar epithelium. In the diffuse pattern, these changes may be associated with focal areas of hemorrhagic necrosis and DAD. Viral inclusion bodies are found in the nucleus and cytoplasm of alveolar macrophages, epithelial cells, and endothelial cells and can be detected in most but not all of the cases (Fig. 10.71). Cytoplasmic inclusions are stained with both PAS and GMS, a fact that may lead to a mistaken diagnosis of *P. jirovecii* pneumonia.[195]

Herpes simplex pneumonia occurs in immunocompromised patients and immunocompetent patients requiring prolonged mechanical ventilation.[196] Microscopically herpes simplex pneumonia usually results in a necrotizing tracheobronchitis and bronchopneumonia that is frequently accompanied by DAD. Intranuclear viral inclusions can be found in airway epithelial cells at the edge of the necrotic areas (Fig. 10.72).

Adenovirus pneumonia also causes a necrotizing bronchiolitis and bronchopneumonia frequently accompanied by DAD, but differs from herpes simplex virus in that adenovirus pneumonia affects previously health immunocompetent as well as immunocompromised patients. The characteristic cytopathic changes include a combination of smudged nuclei and bricklike intranuclear inclusions in epithelial cells (Fig. 10.73).

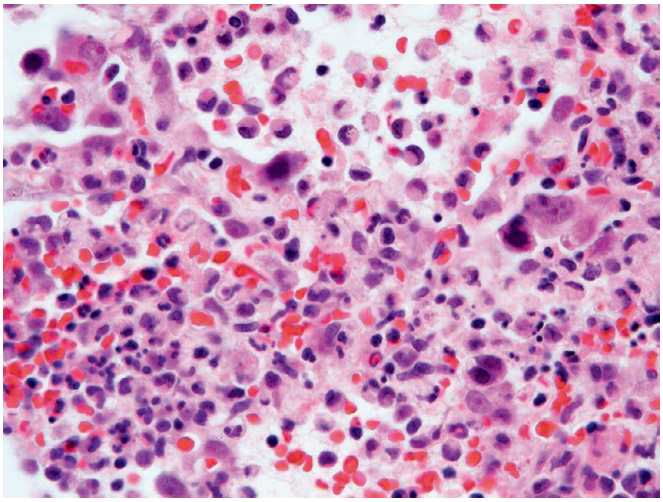

Figure 10.73 Adenovirus showing characteristic smudge cells.

Figure 10.74 Gross appearance of hydatidosis of lung. (Courtesy of Dr. RA Cooke, Brisbane, Australia. From Cooke RA, Stewart B. *Colour Atlas of Anatomical Pathology*. Edinburgh: Churchill Livingstone; 2004.)

Influenza pneumonia can result in a wide range of morphologic changes, most commonly a combination of necrotizing pneumonia and DAD.[197] Mild acute and organizing pneumonia can also occur. Unlike the previously described viral pneumonias there are no characteristic viral cytopathic changes, and diagnosis requires confirmatory cultures or serological studies. Similar changes occur in H1N1 influenza A and are often accompanied by pulmonary hemorrhage, vascular thrombosis, and hemophagocytosis in lung and extrapulmonary sites.[198]

Severe acute respiratory syndrome (SARS) is an infectious condition caused by a coronavirus. It emerged from Guangdong Province in China in November 2002 and resulted in widely publicized outbreaks in Hong Kong, Vietnam, and Singapore. Microscopically, the predominant pattern is that of DAD, often associated with a fibrinous air space exudate resembling that described in acute fibrinous and organizing pneumonia.[199]

Hantavirus pulmonary syndrome is a severe pulmonary disease caused by a previously unrecognized hantavirus.[200] An outbreak has occurred in the southwestern United States. The usual morphologic finding is pulmonary edema and/or DAD with focal hyaline membranes.[201]

Legionnaires' disease became an instant media sensation in 1976, when it occurred in a small epidemic form among persons attending a convention in a hotel in downtown Philadelphia.[202] It turns out that it is anything but a new disease; apparently, sporadic cases have been seen by the thousands over previous decades. Involvement of the hilar lymph nodes occurs in nearly half of autopsied patients, and in about one-fourth of the cases there is hematogenous spread to other organs. Occasionally, an open or transbronchial lung biopsy is performed in these patients. Microscopically, the process is characterized by intra-alveolar accumulation of neutrophils, macrophages, and fibrin as in other bacterial pneumonias.[203] However, many cases also show a leukocytoclastic neutrophilic inflammatory infiltrate, small vessel vasculitis, and necrosis. The Dieterle silver impregnation stain has proved to be the most reliable for identifying the short gram-negative bacillus that is the etiologic agent. Immunostains are also available but carry a risk of falsely negative staining.

Nocardiosis is another opportunistic lung infection sometimes seen in transbronchial or surgical lung biopsies.[204,205] Approximately half of the reported cases have occurred in patients who have a history of organ transplantation, immunosuppression, steroid usage, or chemotherapy. Microscopically, the picture is that of a focal necrotizing bronchopneumonia with microabscesses and a peripheral inflammatory infiltrate that frequently includes palisaded histiocytes resulting in a vaguely granulomatous appearance. Gram and GMS stains show slender, slightly beaded, branching filamentous bacilli.

***Mycoplasma pneumoniae* pneumonia**, formerly known as *atypical pneumonia*, is dominated by upper respiratory tract symptoms and bronchiolitis with shifting pulmonary infiltrates. Disease is usually mild and self-limited, but in some patients *M. pneumoniae* causes pneumonia that may be severe and potentially life-threatening, especially in patients with underlying lung disease.[206] Microscopically, the main change is a severe acute and chronic bronchiolitis with an acute inflammatory exudate in the lumens of small airways.[207] The bronchiolitis may be accompanied by other changes including organizing pneumonia and, in severely ill patients, DAD.

Hydatidosis (echinococcosis) results from infestation by *Echinococcus granulosus* (which is usually cystic) and only rarely by *Echinococcus multilocularis* (which causes alveolar echinococcosis) (Figs. 10.74 and 10.75).[121]

Lung in AIDS

Pulmonary disease occurs frequently during the course of AIDS and may necessitate bronchoalveolar lavage, transbronchial biopsy, or less commonly surgical lung biopsy for appropriate management.[208,209] Surgical lung biopsies are uncommon in AIDS patients but still have value in a highly selected subset of patients, especially those with noninfectious lung diseases.[210,211] Opportunistic infections remain the most common abnormalities, including *Pneumocystis*

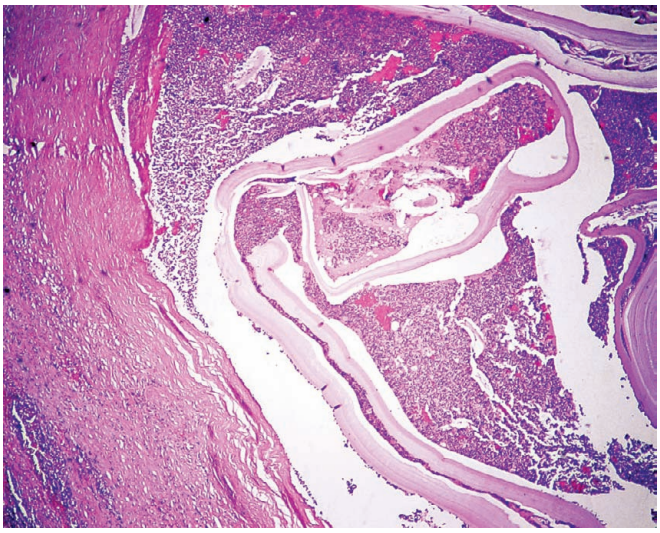

Figure 10.75 Microscopic appearance of pulmonary hydatidosis.

pneumonia, cytomegalovirus pneumonia, atypical mycobacteriosis and tuberculosis, candidiasis, invasive aspergillosis, toxoplasmosis, cryptococcosis, histoplasmosis, blastomycosis, *Rhodococcus equi*, and microsporidiosis.[212] The histologic findings are generally similar to those affiliated with these pathogens in non-AIDS patients. *R. equi* causes a histologically distinct histiocyte-rich inflammatory response indistinguishable from malakoplakia.[213] Noninfectious pulmonary complications include neoplasms, most notably Kaposi sarcoma and lymphomas including lymphomatoid granulomatosis.[214,215] Kaposi sarcoma can be an especially challenging diagnosis in transbronchial biopsies.[216] AIDS patients may get other nonlymphomatous lymphoproliferative lesions that are frequently lumped under the designation of lymphoid interstitial pneumonia.[217] Sometimes the morphologic changes are nonspecific and overlap with the idiopathic interstitial pneumonias.[218]

Lung and Transplantation

Most late nonleukemic deaths after **bone marrow transplantation** are caused by infectious and noninfectious pulmonary diseases, including cytomegalovirus pneumonia, DAD, constrictive (obliterative) bronchiolitis, venoocclusive disease, and various forms of chronic interstitial pneumonia including PPFE.[219–222] Regardless of the histologic findings, late-onset noninfectious pulmonary complications are highly related to, and likely a manifestation of, graft-versus-host disease.

Lung biopsies in patients who are status post **lung transplantation** are most commonly performed to evaluate allograft rejection for which the differential diagnosis is usually infection.[223] Grading of acute and chronic rejection has been standardized by the International Society for Heart and Lung Transplantation, but rates of interobserver agreement remain low.[224,225] Acute cellular rejection is recognized by the accumulation of perivascular and interstitial mononuclear inflammatory cells, often with associated eosinophils. Acute rejection is graded based on the intensity and extent of the inflammatory infiltrate, from A0 (negative) to A4 (severe).[224] Perivascular and interstitial inflammation is often accompanied by a lymphocytic bronchiolitis that is also graded based on the intensity of the inflammatory infiltrate. Perivascular inflammation and bronchiolitis occur commonly in opportunistic infections, most importantly pneumocystis and cytomegalovirus, and therefore infection should be carefully excluded before ascribing these changes to acute rejection.[223] The pathology of acute antibody-mediated rejection has not yet been well defined.[226] Chronic rejection is manifested by fibrosis narrowing the lumen of bronchioles *(obliterative bronchiolitis)*, arteries, and veins and is graded on the basis of the airway changes as either absent (C0) or present (C1).

Vascular Diseases

The term pulmonary hypertension includes a variety of diseases that have different etiologies, but which may have similar clinical presentations, overlapping histologic findings, and variable responses to medical treatment.[227,228] Histopathology plays a less important role in current classification schemes which define phenotypes based on a combination of clinical and physiological findings as well as an expanding list of biomarkers.[227]

Surgical lung biopsies are rarely performed to evaluate otherwise unexplained pulmonary hypertension. Various forms of primary pulmonary hypertension are more likely to be seen in explanted lungs from patients who undergo transplantation. The histologic features unique to pulmonary hypertension were extensively studied in historical studies of patients with congenital heart disease for whom histologic grading of pulmonary hypertension played an important role in determining the potential effectiveness of corrective surgery.[229,230] Elastic tissue stains are very helpful in evaluating the status of arteries, veins, and smaller vessels. In patients with congenital heart disease vascular disease is considered reversible when the arterial lesions are restricted to medial hypertrophy, thickening of longitudinal intimal smooth muscle, post-thrombotic intimal fibrosis, or cellular intimal hyperplasia.[229] Concentric-laminar intimal fibrosis of moderate or severe degree probably does not regress. Fibrinoid necrosis and/or plexiform (plexogenic) lesions are regarded as contraindications to surgery unless the nature of the defect is such that one lung is spared. An increase in the number of neuroendocrine cells has been detected in hypertensive pulmonary vascular diseases.[231] Many of the principles that link histopathologic findings to the severity of pulmonary hypertension in patients with congenital heart disease also apply to patients with primary pulmonary hypertension.[232,233]

Pulmonary veno-occlusive disease (PVOD) accounts for about 10% of patients with idiopathic pulmonary arterial hypertension and affects men and women equally across a wide age range.[234] Radiological findings are distinct compared with other forms of primary pulmonary hypertension and may overlap with the diffuse interstitial diseases.[235] Pulmonary hypertension develops because of widespread occlusion of medium and small-sized branches of the pulmonary veins, accompanied by recanalization and pseudoangiomatous changes. Redundant alveolar septal capillary loops *(capillary hemangiomatosis-like change)* are common and overlap with **capillary hemangiomatosis**, a condition that some have advocated may be indistinguishable from PVOD.[236] Arterial thickening and prominent hemosiderosis are also present. The etiology of idiopathic PVOD is unknown; identical changes are sometimes seen in patients with chronic venous hypertension resulting from primary cardiac disease which should always be excluded. PVOD has also been described as a consequence of drug toxicity and in bone marrow transplant patients with chronic graft-versus-host disease.

Arteriovenous malformations (aneurysms) are radiographically discernible, frequently multiple lesions that occur most often in the lower lobes (Figs. 10.76 and 10.77). Most are congenital, occurring most commonly in patients with hereditary hemorrhagic telangiectasia (Rendu–Osler–Weber syndrome). Because of the shunt, there may be bruits and cyanosis on physical examination accompanied by polycythemia and hypoxemia. Excision is curative. Others can be successfully managed using radiologically guided embolization. They

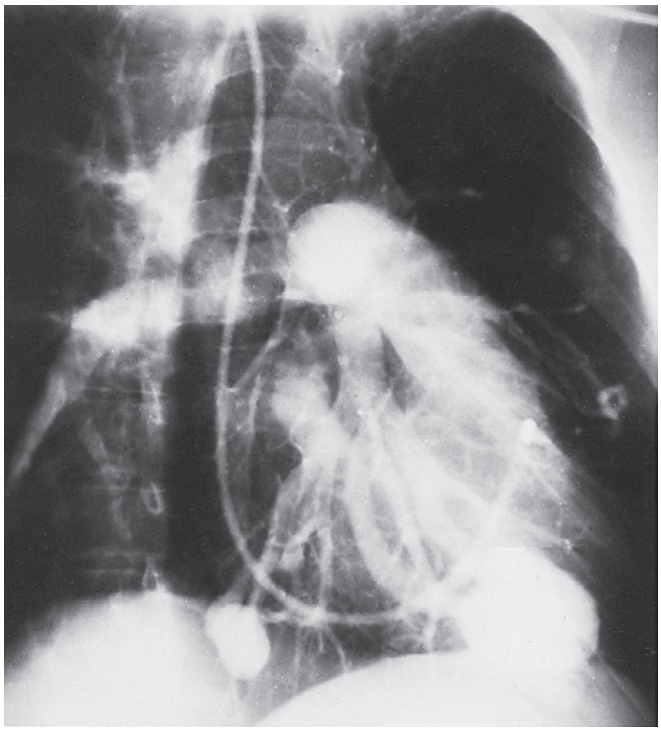

Figure 10.76 Angiogram of a 28-year-old man with multiple arteriovenous malformations. The patient had Rendu–Osler–Weber syndrome (hereditary hemorrhagic telangiectasia). After left lower lobectomy, oxygen saturation rose from 86% to 95%.

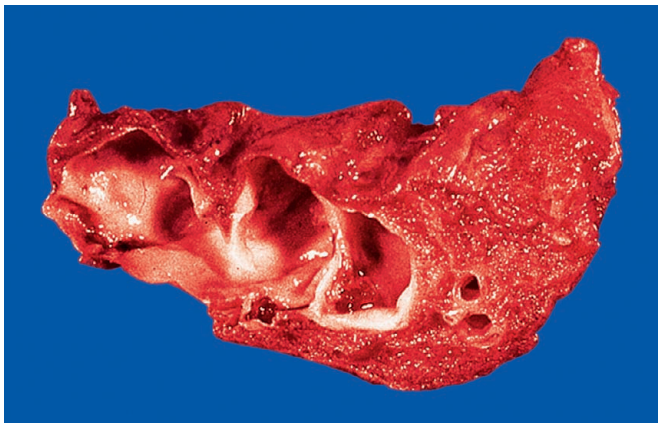

Figure 10.77 Gross appearance of pulmonary arteriovenous malformation.

are made up of large vascular channels with arteriovenous communications. Microscopically, the vessels are abnormal, often showing deficiencies and excesses of muscle, which make it impossible to distinguish artery from vein.

Infarcts resulting from pulmonary thromboembolic disease are usually identified as such on the basis of radiological studies demonstrating a combination of thromboemboli and pleural-based triangular opacities. However, occasionally they simulate a malignant tumor and are either biopsied or resected (Fig. 10.78).[237] Those that come to the attention of a surgical pathologist are less likely to demonstrate the characteristic wedge-shaped configuration on chest imaging studies and instead present as solitary or multiple nodules.[237]

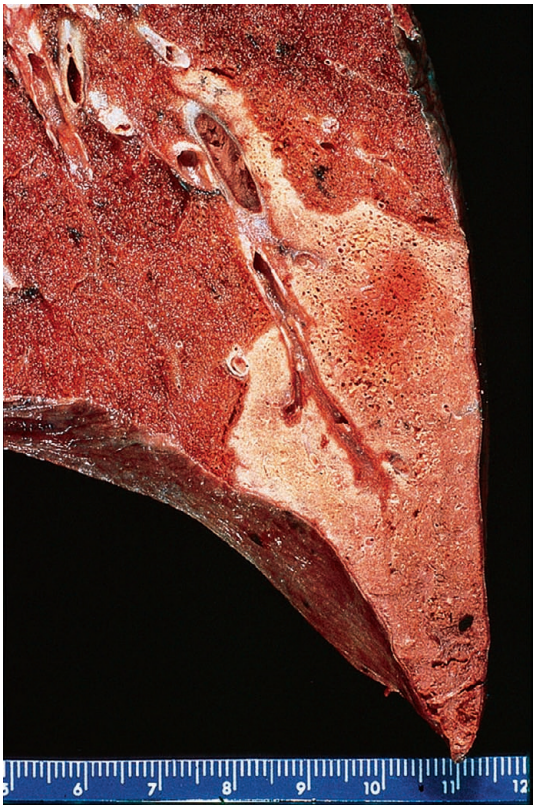

Figure 10.78 Typical wedge-shaped appearance of pleural-based pulmonary infarct. A large occluding thrombus is evident in the vessel leading to the area of the infarct.

Other Non-Neoplastic Diseases

Broncholithiasis is defined as the presence of calcified material within the lumen of a cartilaginous airway and is most commonly a complication of infectious granulomatous diseases (particularly tuberculosis and histoplasmosis) in which a calcified granuloma erodes into a bronchus.[238] Less common causes include calcification of aspirated food or inspissated secretions in bronchiectasis.

Pulmonary hyalinizing granuloma usually presents in minimally symptomatic or asymptomatic adults with multiple, bilateral nodules or infiltrates that may mimic metastatic disease.[239,240] Microscopically, the central portion is made up of hyalinized, keloid-like collagen. This is surrounded by a mixed inflammatory infiltrate comprising mainly lymphocytes, plasma cells, and a minor component of macrophages including rare multinucleated giant cells, the overall appearance simulating nodular amyloidosis (Fig. 10.79). However, special stains for amyloid are negative. Necrotic areas and non-necrotizing epithelioid granulomas are distinctly unusual in this condition, which is of importance in the differential diagnosis. Some patients have evidence of antecedent or concomitant granulomatous infection, but in most the pathogenesis is unknown. Pulmonary hyalinizing granuloma may be associated with sclerosing mediastinitis and/or retroperitoneal fibrosis, with recent evidence suggesting a link to the spectrum of IgG4-related sclerosing diseases.[241]

Endometriosis of the lung may present with recurrent catamenial hemoptysis, or as asymptomatic nodules discovered on routine chest x-ray film.[242] Most of the reported cases have been located on the right side. The disease often extends to the pleural surface.[243]

Pulmonary alveolar microlithiasis is a rare disease characterized by the presence of microliths or calcospherites within the alveoli of an otherwise normal lung.[244] The process is diffuse and bilateral,

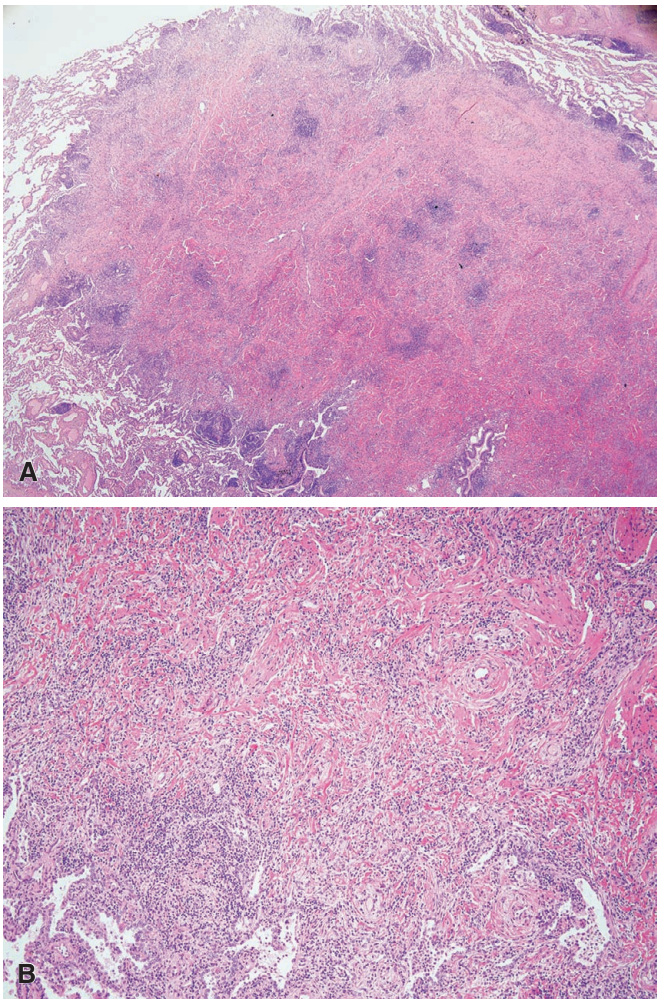

Figure 10.79 Pulmonary hyalinizing granuloma showing circumscribed nodule **(A)** with characteristic pattern of collagen fibrosis and inflammation **(B)**.

and the clinical course is extremely long. The chest radiographic appearance is virtually diagnostic.[245]

Carcinoma

General and Clinical Features

Carcinoma of the lung has become very frequent since the 1930s. The American Cancer Society reported that in 2015 there were 221,200 new cases and 158,040 deaths from lung cancer in the United States. The only hopeful trend in this dreadful situation is the fact that the incidence rates overall are declining in the United States, having peaked in men in the mid-1980s and stabilized in women in the first two decades of the 21st century after steadily increasing through the 1980s and 1990s.[245] The declining trend in men and steady increases in women have converged to a place of near parity across sexes, with a male to female ratio of 1 : 1. These trends are not unique to the United States and have been documented on multiple continents.[246] More than 98% of the patients diagnosed in 2015 are projected to be 45 years of age or older, but cases have also been reported in young adults and adolescents.

Much has been written about the epidemic nature of lung carcinoma, the leading cause of cancer-related deaths. Many factors thought in the past to be of pathogenetic importance—such as tuberculosis, tarring of roads, the 1918 influenza epidemic, anthracosis, and anthracosilicosis—are now considered to be totally unrelated to cancer or to account for only a minimal fraction of cases. Exposure to asbestos; polycyclic aromatic hydrocarbons; arsenic, nickel, and chromium compounds; bis(chloromethyl) ether (BCME); chloromethyl methyl ether (CMME); vinyl chloride; radiation (as seen in uranium workers and in people with high radon concentration in their houses); and other occupational agents undoubtedly account for some of the cases.[247] This is particularly true for asbestos (thought to be responsible for about 5% of all lung carcinoma deaths) and for radon.[248] However, the significance of all these factors pales by comparison with the role played by cigarette smoking, both in males and in females.[245] This is true for all major histologic types of lung carcinoma. The fact that smokers living in urban areas and/or exposed to asbestos are at a higher risk for lung carcinoma than others suggests the potentiating effect of air pollution and asbestos on the carcinogenic effect of tobacco, a possibility that is supported by some experimental models.[249] Significantly, in animals there is a nearly total absence of spontaneously occurring lung tumors that are histologically similar to smoking-related human lung cancers.[250]

The relationship of cigarette smoking with malignant, dysplastic, and metaplastic alterations of the tracheobronchial tree has also been thoroughly documented by the meticulous histologic observations of Auerbach et al.[251] and confirmed by others[252]; at autopsy, Auerbach et al. found an almost linear correlation between the severity of the changes and the amount of cigarette consumption. A similar relationship between smoking and lung cancer precursors has been suggested for marijuana and may be additive with tobacco use.[253]

Approximately 10%–15% of cases of lung carcinoma occur in never-smokers. Among them, three-fourths are women, and a high proportion of cases show an adenocarcinoma histology.[254] Adenocarcinoma occurring in never-smoker women appears to be more prevalent in Asian populations.

Another factor thought to be related to the development of carcinoma is pulmonary fibrosis, through a preceding stage of atypical proliferation of the terminal bronchiolar epithelium. Malignant tumors arising at the site of scars resulting from bullets, other foreign bodies, and old granulomas have been well documented, although in most the cause-and-effect relationship between scar and cancer is uncertain at best.[255] The relationship between lung carcinoma and diffuse fibrosis is more complicated. In a classic study of 153 consecutively resected lung tumors,[256] 21% were associated with—and presumably preceded by—honeycombing and atypical epithelial proliferation. Most of these tumors were in the upper lobe, and one-third of them were adenocarcinomas. Others have documented a clear relationship between UIP and increased lung cancer risk, although the effect of fibrosis *per se* is confounded by the high prevalence of cigarette smoking in these patients.[257] Carcinomas arising in UIP show disproportionate involvement of the lower lobes which mirrors the distribution of the fibrotic changes. Peripheral squamous cell carcinomas are over-represented in UIP patients and are especially common in older male smokers.[258,259]

Atypical adenomatous hyperplasia of type 2 alveolar cells has emerged as an important potential precursor of adenocarcinoma in a subset of patients.[260,261]

Rare examples of squamous cell carcinomas of the lung resulting from human papilloma virus (HPV)-driven malignant transformation of respiratory papillomatosis have been reported.[262,263] On the whole, however, HPV does not seem to play an important role in the genesis of lung cancer.[264]

Lung carcinoma is multiple (either synchronous or metachronous) in about 2%–6% of patients[265,266] and is associated with independent smoking-related cancer of the head and neck region in about 5%–15%

of patients.[267] Molecular genetic studies have shown that a majority of multicentric lung tumors (whether synchronous or metachronous) show evidence of a common clonal origin.[268,269] Despite the molecular evidence, patients thought to have multifocal synchronous or metachronous primary lung carcinomas on the basis of established histologic criteria have a substantially better prognosis than those with intrapulmonary metastases.[270]

Most lung cancers are in a relatively advanced stage by the time of diagnosis; about 60% are inoperable as a result of extensive locoregional spread and/or distant metastases. Symptoms and signs develop relatively late in the course of the disease, are often related to partial or complete bronchial obstruction, and may lead to confusion with a primary inflammatory process. Overall survivals remain low, with about 17% surviving 5 years in a large cohort (2005–2011) from the National Cancer Institute's Surveillance, Epidemiology, and End Results (SEER) Program.[271]

The most common symptoms, in decreasing order of frequency, are cough, weight loss, pain, increased sputum production, hemoptysis, malaise, fever, and those resulting from paraneoplastic manifestations. Peripherally located lesions are clinically silent until they reach a sufficient size to ulcerate into a bronchus or to involve the pleural space. Carcinomas located in the superior pulmonary sulcus result in a clinical picture peculiar to their location, known as *Pancoast syndrome*.[272] This is characterized by pain in the distribution of the ulnar nerve and is often accompanied by Horner syndrome secondary to involvement of the sympathetic chain.

Sometimes lung carcinoma presents as a solitary pulmonary nodule ('coin lesion') on the chest x-ray film or CT scan of an asymptomatic individual. About 35%–50% of solitary pulmonary nodules in adults evaluated using modern imaging techniques represent lung carcinoma.[273] The percentage is higher for patients older than 60 years and for noncalcified lesions. The incidence of malignancy in coin lesions exhibiting obvious calcification is less than 1%.

Lung neoplasms are sometimes associated with extrapulmonary manifestations *(paraneoplastic syndromes)* remote from the sites of primary or metastatic tumor.[274] Although exceptions occur, there is a fairly good correlation between some morphologic parameters of the tumor and the systemic effect produced. These are summarized in Table 10.2. These manifestations are caused by the tumor's secretion of biologically active compounds. In the case of the *Lambert–Eaton syndrome* associated with small cell carcinoma, voltage-gated calcium channel autoantibodies have a pathophysiologic role. Additional substances that have been detected in some cases of lung carcinoma include amylase, calcitonin, CEA, alpha-fetoprotein (AFP), β-pregnancy-specific glycoprotein, and epidermal growth factor receptors (EGFRs). A preponderance of small cell carcinomas exists in this group; however, the correlation between the presence of a tumor marker and the histologic tumor type is generally poor.

Because of the generally late stage of clinically diagnosed lung carcinomas, screening efforts have been mounted over the years at a considerable cost to detect early and potentially curable cases in high-risk individuals.[275] Until now, those efforts have been generally disappointing. At present, extensively publicized multi-institutional studies and a randomized controlled National Lung Screening Trial have indicated an opportunity to reduce lung cancer mortality through thoughtfully implemented screening programs applied to carefully selected high-risk populations. How to implement current screening recommendations in a cost-effective manner remains controversial.[276–278] Parenthetically, the large majority of screening-detected carcinomas—whether solitary or multiple—were adenocarcinomas, including some with doubling times much longer than those historically associated with incident lung carcinomas reflecting the risk of overdiagnosis in this population.[279,280]

Table 10.2 Systemic effects of lung carcinoma and their most commonly related tumor type[275]

SYSTEMIC EFFECT AND HORMONE RESPONSIBLE	TUMOR TYPE
Cushing syndrome (ACTH)	Small cell carcinoma Carcinoid tumor
Carcinoid syndrome	Carcinoid tumor Small cell carcinoma
Hyponatremia (ADH)	Small cell carcinoma
Hypercalcemia (parathyroid hormone-related protein)	Squamous cell carcinoma
Gynecomastia (hCG)	All tumor types
Clubbing of fingers and hypertrophic pulmonary osteoarthropathy	Unrelated to tumor type; mainly dependent on proximity to pleural surface
Mental syndromes (i.e. toxic confusional psychosis)	Small cell carcinoma
Cortical cerebellar degeneration	All tumor types
Encephalomyelitis	Small cell carcinoma
Sensory neuropathy	Small cell carcinoma
Myopathic–myasthenia syndrome (Lambert–Eaton syndrome)	Small cell carcinoma

Pathologic and Immunohistochemical Features

Several microscopic classifications of lung carcinoma exist. The one most widely used derives from the World Health Organization (WHO) Classification of Tumors developed in collaboration with the International Association for the Study of Lung Cancer (IASLC).[281] It includes the following major categories:

1. Adenocarcinoma
2. Squamous cell carcinoma
3. Neuroendocrine tumors (including small cell carcinoma, large cell neuroendocrine carcinoma, typical and atypical carcinoid tumors, and diffuse neuroendocrine cell hyperplasia)
4. Large cell carcinoma
5. Adenosquamous carcinoma
6. Sarcomatoid carcinoma (including pleomorphic, spindle cell and giant cell carcinoma, carcinosarcoma, and pulmonary blastoma).

Several studies have shown the reproducibility of this classification and the close correlation between biopsies and surgical specimens.[283] The current WHO classification of lung tumors differs from its predecessors in including not only criteria based on routine light microscopy but also immunophenotypic criteria based on a limited number of commonly available immunostains.[281]

Larger lung carcinomas often show a combination of histologic patterns which complicates classification. In a study of 100 consecutive cases of lung carcinomas in which either the entire tumor or 10 blocks were examined, just over half were composed of a single histologic type.[284] The immunophenotypes of the main histologic tumor types are relatively stable and highly reproducible, although rare exceptions to the anticipated immunostaining patterns are well documented.[283,285,286]

The relative frequencies of the various microscopic types of lung carcinoma have changed over the years. Adenocarcinomas are now the most common incident lung carcinoma while incidence rates for both squamous cell and small cell carcinoma have declined.[246] The relative frequencies are also influenced by the utilization of immunostains for histologic classification which has sharply reduced those cases assigned to the category of large cell carcinoma.[287]

The histochemical, immunohistochemical, ultrastructural, and molecular genetic features of lung carcinoma are discussed with the respective histologic categories. Suffice it to say here that the most important generic immunomarkers of lung carcinomas are the following:

- *Keratins*. They are present in all types of lung carcinoma, but the expression of individual keratins is dependent upon the tumor subtype.[288]
- *TTF-1*. Thyroid transcription factor 1, which is consistently expressed in normal type 2 pneumocytes and Clara cells, has emerged as one of the most useful markers of epithelial lung tumors.[289,290] It is expressed in over 80% of the adenocarcinomas, a similar proportion of small cell carcinomas, and in a much smaller percentage of the other lung carcinoma types.[285] Given relatively high sensitivity and specificity, the current WHO classification scheme proposes positive staining for TTF-1 (or napsin A) as a criterion for classifying otherwise poorly differentiated non-small cell carcinomas as adenocarcinomas. 'False-positive' results sometimes occur when staining in non-neoplastic respiratory epithelial cells is mistakenly attributed to neoplastic squamous cells, a diagnostic trap especially important to remember when interpreting small biopsies.[291] Detection of TTF-1 in metastases in brain or other extrapulmonary sites is also very helpful in identifying lung as a likely primary site. There is only one major caveat: as its name indicates, the other tissue in which TTF-1 is consistently expressed is the thyroid epithelium. TTF-1 staining has also been described at low frequencies, and usually with a very focal distribution, in small cell carcinomas originating in nonpulmonary sites such as the prostate and bladder and in adenocarcinomas of the breast, colon, ovaries, and endometrium.[289]
- *Napsin A*. Napsin A is an aspartic proteinase involved in the maturation of surfactant protein B. It is detected in the cytoplasm of type II pneumocytes and alveolar macrophages. It is a highly sensitive marker for pulmonary adenocarcinomas (positive in about 80% of cases) and thus is a useful adjunct in TTF-1 negative tumors.[292] Napsin staining is also seen in a subset of renal cell carcinomas and tall cell variants of papillary thyroid carcinomas.[293] Like TTF-1, napsin stains non-neoplastic respiratory epithelial cells that may be intimately admixed with neoplastic squamous cells, a potential diagnostic trap that complicates interpretation.[294]
- *p63 & p40 (ΔNp63)*. *p63* comprises a family of variants (isoforms) including transcriptionally active tumor suppressor genes and transcriptionally inactive oncogenes. The p63 antibody most commonly used for tissue diagnosis is a 'pan-p63' marker while p40 is a nontransactivated isoform (ΔNp63) with greater specificity for squamous/basal-type epithelium.[295] Both are diffusely positive in nearly all squamous cell carcinomas from any site, including the lung, but p63 is less specific in that focal staining is also seen in a third or more of lung adenocarcinomas.[296] The current WHO classification of lung tumors suggests that diffuse staining for p63 or p40 should be used as a criterion for classifying TTF-1 negative poorly differentiated non-small cell lung carcinomas as squamous cell carcinomas.

A selected immunohistochemical profile of the major types of lung carcinoma, extracted from the literature by Pandit et al.,[297] is shown in Table 10.3. A practical approach for classifying poorly differentiated non-small cell carcinomas that are difficult to classify on the basis of routine histology alone that also preserves tissue for molecular testing in small biopsies or cytologies is a combination of TTF-1 and either p63 or p40. Adding immunostains for high-molecular-weight keratins (CK5/6 rather than 34βE12 given greater specificity) and napsin A may have value in cases for which TTF-1 and p63/p40 are insufficient.[290,298] Low rates of discordance with final classification of resected tumors are explained primarily by the impact of sampling rather than fidelity of immunostaining profiles.

Table 10.3 Immunohistochemical profile of the major types of lung carcinoma

	TTF-1 (%)	CD56 (%)	CK5/6 (%)	34βE12 (%)
Adenocarcinoma	77	3	0	46
Squamous carcinoma	7[a]	6	100	97
Small cell carcinoma	88	95	0	12

[a]Ordonez and others hypothesize that TTF-1 (and napsin A) staining in squamous cell carcinomas is limited to non-neoplastic respiratory epithelium.[292,295]
TTF-1, Thyroid transcription factor 1.

Blood vessel and/or lymphatic invasion is seen in about half of resected non-small cell carcinomas and is more frequent in larger tumors.[299] The prognostic significance of vascular and/or lymphatic invasion remains somewhat controversial but both tend to predict a greater likelihood of recurrence and shorter survival and should be included in pathology reports for resected lung carcinomas.[300,301] Visceral pleural invasion occurs in about 20% of resected non-small cell carcinomas and also predicts for shorter overall survival in otherwise early stage node-negative lung carcinomas.[302] Aside from being a prognostic factor, visceral pleural invasion is also important in upstaging (stage IB) small (≤3.0 cm) node-negative tumors that might otherwise be considered earlier stage (stage IA) carcinomas.[303]

Adenocarcinoma

Adenocarcinomas comprise over half of all lung carcinomas in females and nearly 45% of those in males.[304] Incidence rates for adenocarcinoma are higher than for other microscopic type of lung cancer, to the extent that it is now the most common form.[246] In data collected from two large national databases in the United States for the period 2004–2009, adenocarcinomas were 1.7 times more common than squamous cell carcinomas and 2.5 times more common than small cell carcinomas.[305]

Grossly, invasive adenocarcinomas usually present as poorly circumscribed gray–yellow peripheral lesions (Fig. 10.80). They may be single or multiple. If they secrete abundant mucin, they have a gelatinous, glairy appearance. Cavitation is unusual. About 65% of the cases are located peripherally, and often about the visceral pleura at the time of excision, resulting in pleural fibrosis or 'puckering' (Fig. 10.81). Occasionally, a small peripheral adenocarcinoma spreads massively into the pleural space and coats both pleural layers so as to closely simulate the appearance of diffuse mesothelioma *(pseudomesotheliomatous carcinoma)* (Fig. 10.82).[305] Adenocarcinomas only rarely present as endobronchial polypoid masses (Fig. 10.83).[306]

Adenocarcinomas occasionally arise in association with a peripheral scar, including apical caps.[307] In a classic series of 82 'scar cancers' reviewed by Auerbach et al.,[308] 72% were adenocarcinomas and 18%

Figure 10.80 Typical peripheral location of pulmonary adenocarcinoma, in this case puckering and retracting visceral pleura. (Courtesy of Dr. J. Carvalho, Minneapolis, MN.)

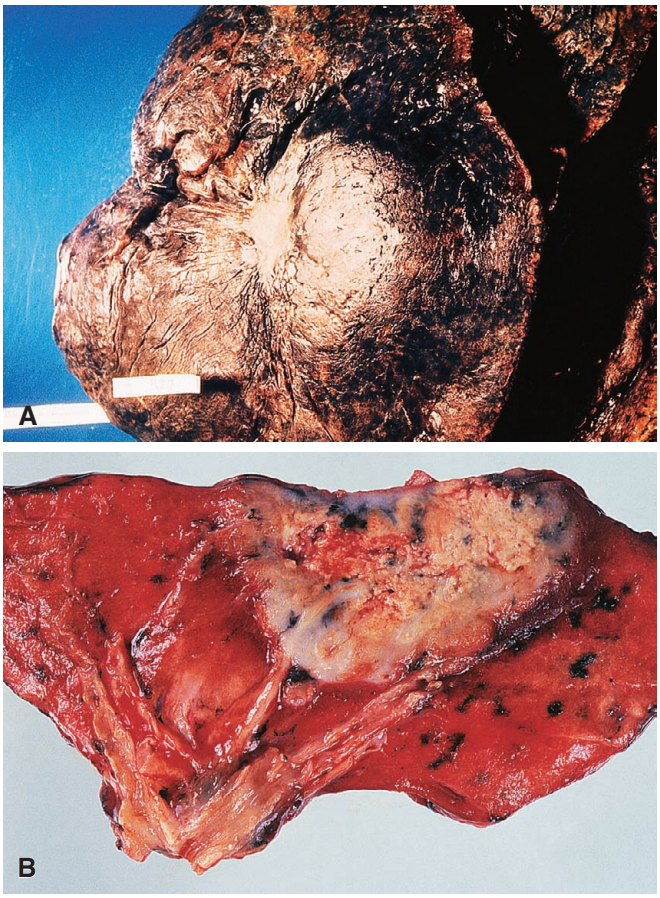

Figure 10.81 **A** and **B,** Outer aspect and cut section of two pulmonary adenocarcinomas showing pleural retraction.

were squamous cell carcinomas, the rest being assigned to the category of large cell undifferentiated carcinomas at a time that immunostains were not used to subclassify poorly differentiated non-small cell lung carcinomas. There were no small cell carcinomas. A number of studies have proposed that many (most?) of these peripheral cancers do not arise from preexisting scars but instead reflect scar formation by the tumor through various combinations of desmoplasia, infarcts, alveolar collapse, and fibroelastosis.[309–311]

Microscopically, adenocarcinomas exhibit a wide range of differentiation, from well-differentiated *in situ* adenocarcinomas formerly termed *bronchioloalveolar carcinoma* to poorly differentiated solid adenocarcinomas that would have been previously classified as large cell carcinoma. The two morphologic signs of glandular differentiation that define adenocarcinoma, often found together, are formation of tubules or papillae and/or secretion of mucin. On occasion, lung adenocarcinoma cells exhibit prominent eosinophilic intracytoplasmic globules that are distinct from mucin globules.[312] Immunoreactivity for pneumocyte markers, most commonly TTF-1 and/or napsin A, is also sufficient to establish the diagnosis of adenocarcinoma in poorly differentiated carcinomas that lack glandular histology or mucin secretion, assuming no compelling histologic features (e.g. keratinization) to suggest an alternative.[261,313]

Adenocarcinomas are histologically heterogeneous with many of them showing a combination of growth patterns. Identifying the predominant growth pattern may have prognostic value in predicting the likelihood of disease-free survival depending on the stage of disease. In patients with small (≤3.0 cm) node-negative tumors, noninvasive *(in situ)*, minimally invasive (≤0.5 cm of invasive carcinoma), and *lepidic* predominant adenocarcinomas (a group of well-differentiated adenocarcinomas referred to in previous iterations of lung tumor classifications as *bronchioloalveolar carcinoma*) (Fig. 10.84) are affiliated with an excellent prognosis.[314] Most early-stage lesions that lack evidence of invasion are composed of nonmucinous columnar cells, although there are rare examples of in situ and minimally invasive adenocarcinomas in which bland, mucinous columnar cells comprise the neoplastic population. Frankly invasive stage 1 adenocarcinomas in which a lepidic *(bronchioloalveolar)* growth pattern comprises at least 50% of the tumor without other adverse histologic findings (i.e. angiolymphatic and/or visceral pleural invasion, a focal micropapillary growth pattern) are affiliated with the same excellent prognosis described for in situ and minimally invasive adenocarcinomas.[315] Indeed some have shown that the presence of even a minor lepidic (bronchioloalveolar) component is associated with better survival compared with adenocarcinomas that lack this distinctive well-differentiated growth pattern.[316] Micropapillary (Fig. 10.85) and solid (Fig. 10.86) adenocarcinomas are more likely to be affiliated with higher-stage disease and portend a poor prognosis.[314,316] The presence of even a minor micropapillary component is worth noting in pathology reports as it implies a more aggressive tumor with greater potential for recurrence and distant relapse.[317] Conventional acinar (Fig. 10.87), papillary (Fig. 10.88), and invasive mucinous (Fig. 10.89) adenocarcinomas are affiliated with an intermediate prognosis.[314] Rare variants of adenocarcinoma

include *signet ring cell adenocarcinoma* (Fig. 10.90),[318] invasive *mucinous carcinoma* (see Fig. 10.89) which includes cases formerly classified as mucinous bronchioloalveolar carcinomas and overlaps with descriptions of colloid carcinoma and cystadenocarcinomas,[319] *adenocarcinoma with enteric (goblet cell)*[320] and *hepatoid*[321] *differentiation*, *adenocarcinoma with rhabdoid features*,[322] *microcystic adenocarcinoma*[323] (a pattern that overlaps with cribriform carcinomas[324]), and *adenocarcinoma with massive lymphocytic infiltration*.[325]

It should be remembered that a lepidic growth pattern (lining of tumor cells along alveolar walls) is not unique to primary adenocarcinomas of the lung and also occurs in metastatic tumor types, including those arising from breast and thyroid which may also be TTF-1 positive.[326] The frequency of TTF-1 staining in adenocarcinomas arising from sites other than lung and thyroid (e.g. breast, colon, pancreaticobiliary tract, ovary, endometrium) is heavily dependent on the antibody clone that is used; of the most commonly used commercially available antibodies 8G7G3/1 (Dako) is less sensitive but more specific than SPT24 (Leica/Novocastra) which is more

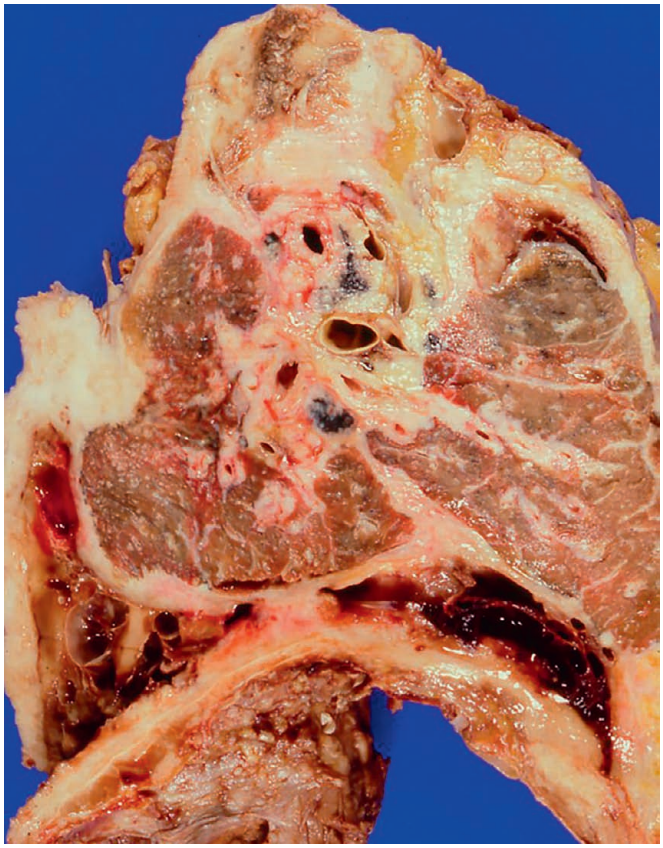

Figure 10.82 Peripheral adenocarcinoma of lung spreading diffusely to pleural surfaces and closely simulating the gross appearance of malignant mesothelioma. Note metastases in intrapulmonary peribronchiolar lymph nodes.

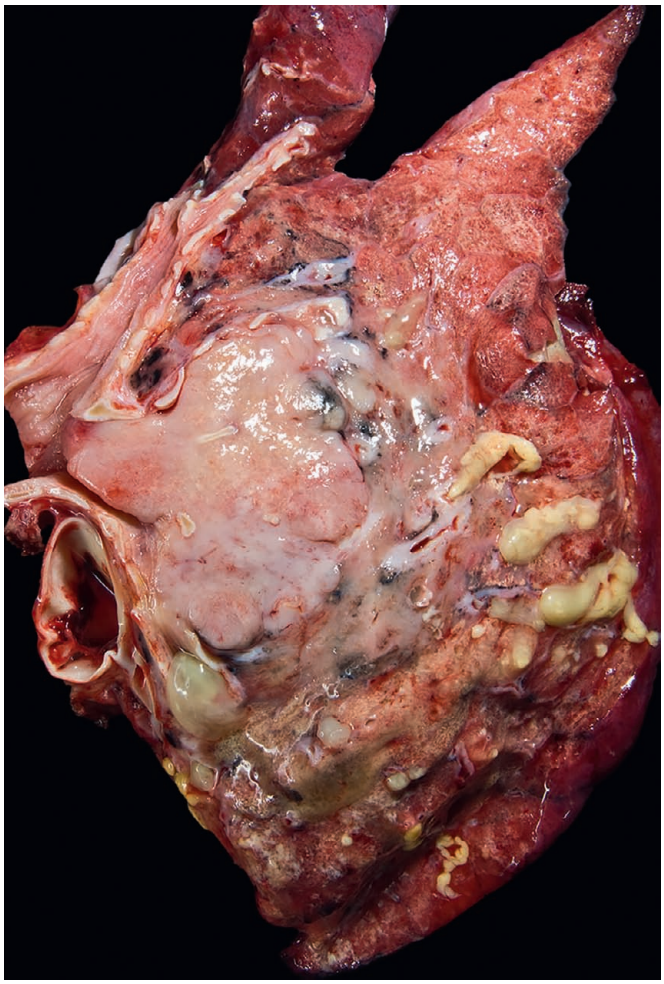

Figure 10.83 Endobronchial polypoid adenocarcinoma with post-obstructive bronchiectasis and obstructive 'golden' *(endogenous lipid)* pneumonia. (Courtesy of Dr. J. Carvalho, Minneapolis, MN.)

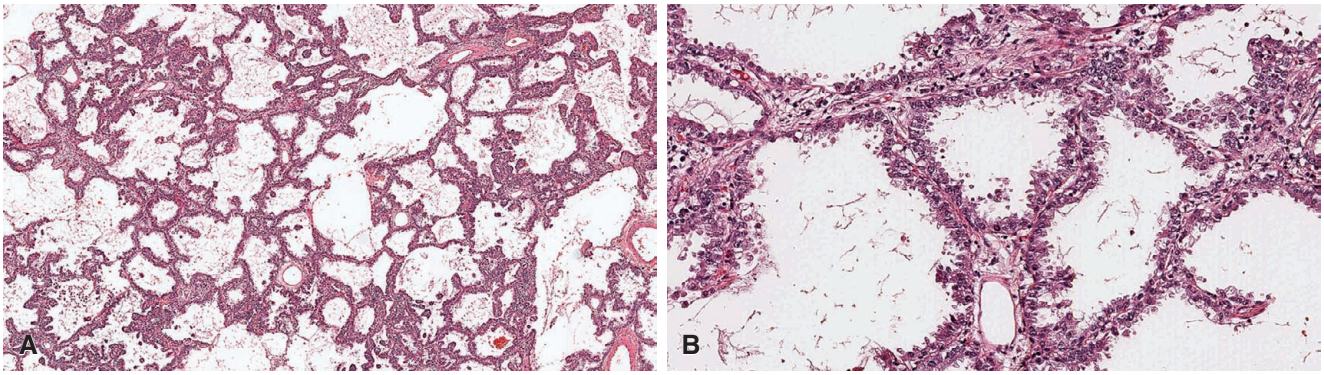

Figure 10.84 Lepidic (bronchioloalveolar) growth pattern that predominated in this minimally invasive adenocarcinoma. Overall architecture is preserved **(A)** with neoplastic nonmucinous columnar cells distributed along interstitial surfaces **(B)**.

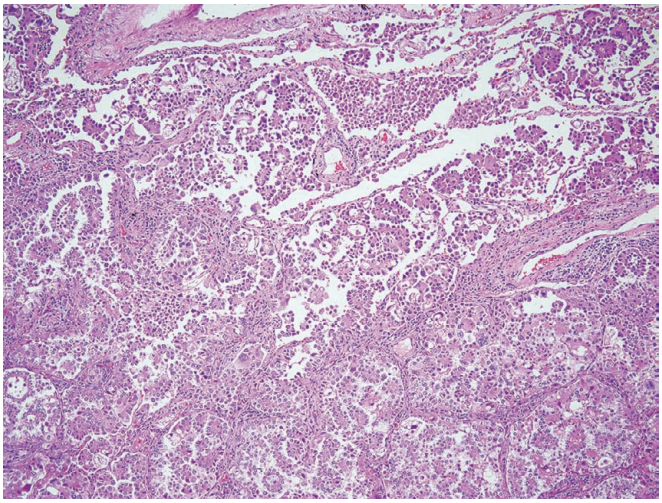

Figure 10.85 Micropapillary adenocarcinoma.

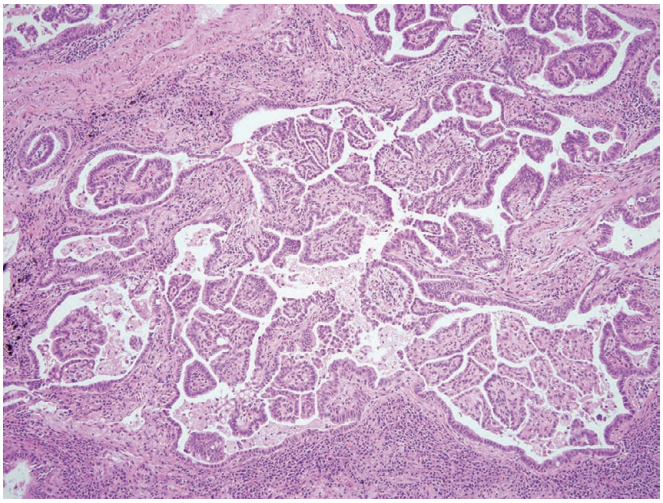

Figure 10.88 Papillary adenocarcinoma.

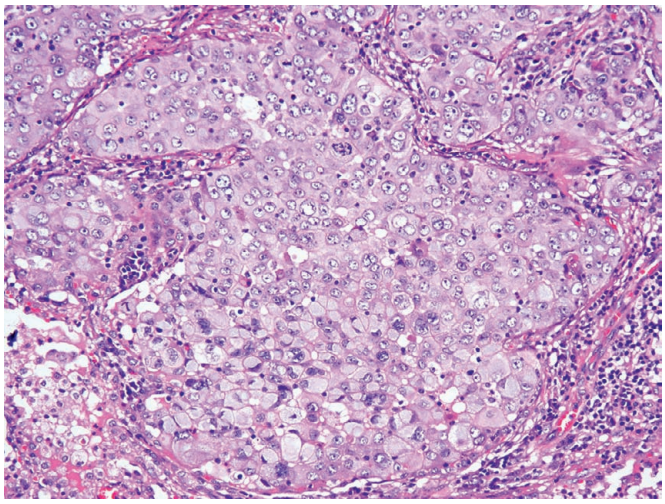

Figure 10.86 Solid adenocarcinoma indistinguishable from large cell carcinoma except for focal positivity with a mucin stain and an immunostain for TTF-1.

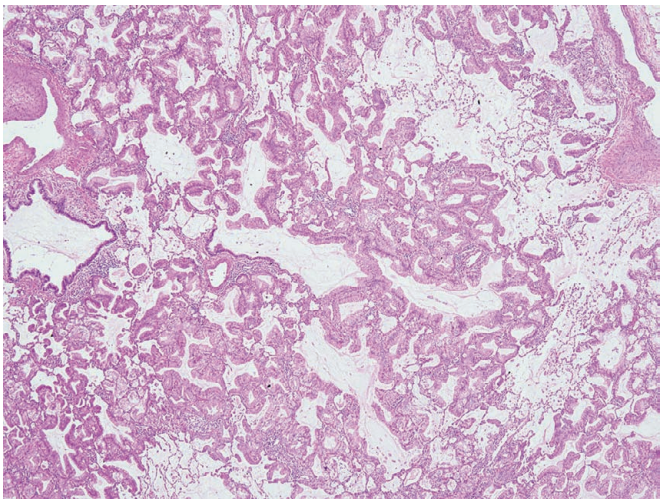

Figure 10.89 Invasive mucinous adenocarcinoma.

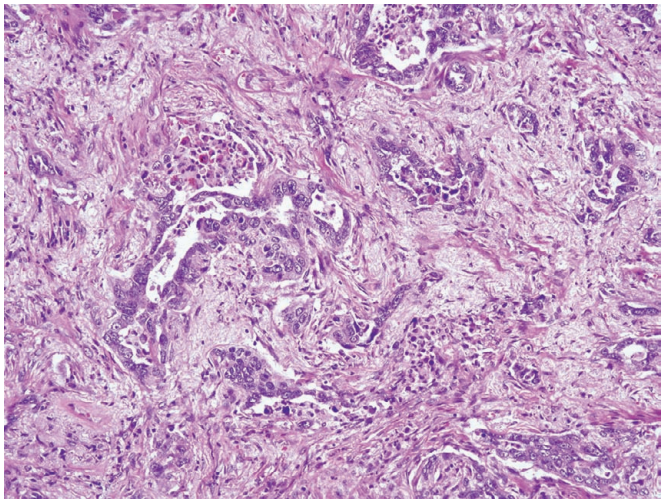

Figure 10.87 Acinar adenocarcinoma with desmoplastic stromal response.

likely to show unanticipated TTF-1 staining in tumors from other sites.[327]

Pagetoid spread within the mucosa of large bronchi has been reported only rarely in primary adenocarcinomas of the lung.[327]

Immunohistochemically, adenocarcinomas of the lung are usually positive for low-molecular-weight keratins (sometimes with coexpression of vimentin[328]), EMA, CEA, secretory components, MOC-31, Ber-EP4, TAG-72, BG-8, and various members of the MUC family.[329] Expression of keratin 7 has been taken as evidence of glandular differentiation in lung carcinoma but is not specific and occurs in a substantial number of squamous cell carcinomas.[286] TTF-1 and napsin A are positive in most cases, as previously summarized. The usual negativity for CDX2 is helpful in the differential diagnosis with metastatic colorectal adenocarcinoma, but this does not apply to a subset of lung adenocarcinomas with enteric differentiation, including some mucinous carcinomas.[319,330] Similarly, their usual negativity for estrogen receptors (ERs) is helpful in the differential diagnosis with metastatic breast carcinoma but is not an absolute criterion given that focal ER positivity occurs in fewer than 10% to nearly 30% of lung adenocarcinomas, depending on the antibody used.[331] In about half of cases there is positivity for surfactant

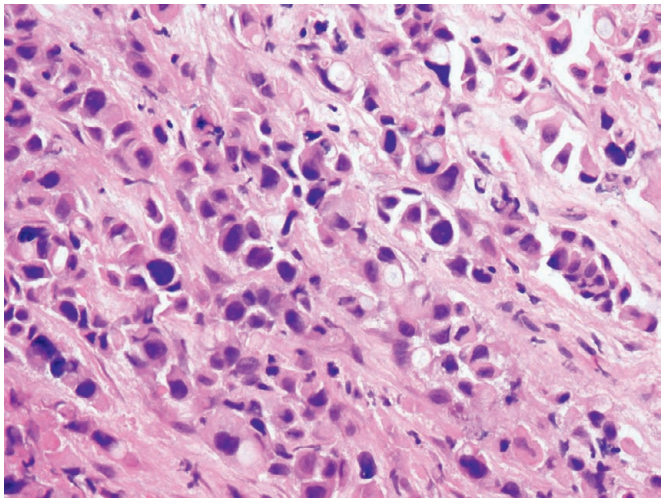

Figure 10.90 TTF-1– and mucin-positive primary pulmonary adenocarcinoma with signet ring cells.

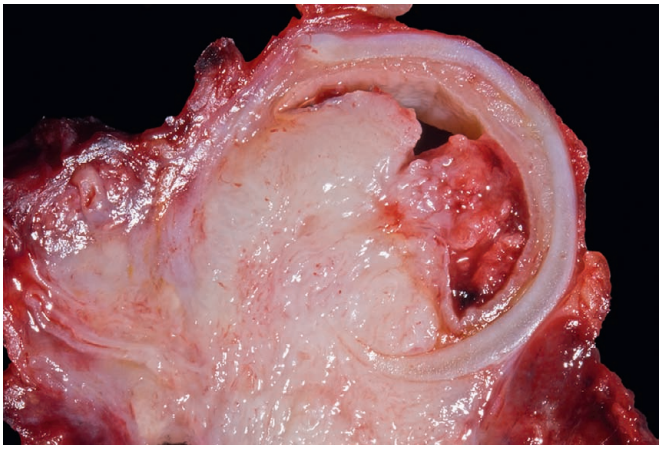

Figure 10.91 Intraluminal bronchial growth of squamous cell carcinoma. (Courtesy of Dr. J. Carvalho, Minneapolis, MN.)

apoprotein (PE-10), a feature of potential utility in the differential diagnosis with other types of primary lung carcinoma and with metastatic adenocarcinoma, although its value as a diagnostic tool has been largely supplanted by TTF-1 which is more sensitive and specific.[332] Lung adenocarcinomas also show consistent expression of Lewis X and Y blood group antigens, a feature that may be of some differential diagnostic value in separating benign from malignant epithelial proliferations.[333] Adenocarcinomas with Clara cell differentiation are immunoreactive for DC-LAMP, a molecule normally expressed in mature dendritic cells that is also expressed in endometrial adenocarcinomas.[334]

Pulmonary adenocarcinomas, like other histologic types of non-small cell carcinomas, harbor multiple genetic and epigenetic alterations.[335,336] *TP53* mutations, most commonly in the form of point mutation and sometimes homozygous deletion, are found in about 50% of cases.[337] Mutations in *KRAS* were second in frequency to *TP53* in the large comprehensive molecular profiling of lung adenocarcinomas performed by The Cancer Genome Atlas (TCGA) Research Network and were associated with cigarette smoking, as were high fractions of C greater than A nucleotide transversions *(transversion-high)* in individual genes and genome wide.[336] The detection of *KRAS* oncogene activation in lung adenocarcinomas from former and current smokers suggests that *KRAS* mutations constitute an early and irreversible event in the development of smoking-related adenocarcinomas. Other driver mutations demonstrated in TCGA analysis of lung adenocarcinomas included *EGFR (14%)*, *BRAF (10%)*, *PIK3CA* (7%), *MET* (7%), *RIT1* (2%); tumor-suppressor genes *STK11* (17%), *KEAP1* (17%), *NF1* (11%), *RB1* (4%), and *CDKN2A* (4%); chromatin-modifying genes *SETD2* (9%), *ARIDIA* (7%), and *SMARCA4* (6%); RNA-splicing genes *RBM10* (8%) and *U2AF1 (3%)*; and *MGA* (8%), a gene encoding a protein important in the MYC pathway.[336] *KRAS* and *EGFR* mutations are also present in *atypical adenomatous hyperplasia*, a putative adenocarcinoma precursor defined as a small (≤0.5 cm) localized proliferation of mildly to moderately atypical nonmucinous columnar cells without significant associated inflammation and/or fibrosis.[337] *EGFR* mutations are mutually exclusive of *KRAS* mutations and occur at a significantly higher frequency in adenocarcinomas from East Asians than from non-Asians, from women than from men, and from never-smokers than from ever-smokers.[338,339] The importance and details of *molecular* testing for specific abnormalities is discussed in a subsequent section on treatment.

There is a rapidly growing list of molecular abnormalities other than single gene mutations that play important roles in the pathogenesis of lung adenocarcinomas. Specific translocations of the *ALK* (anaplastic lymphoma kinase) gene, with the usual fusion partner *(EML4)* also from the 2p chromosome (i.e. inversion), occur in fewer than 10% of lung adenocarcinomas, depending on the population studied.[340] *ALK*-translocated pulmonary adenocarcinomas show the following characteristics: occurrence in never-smokers or light smokers, younger patient age, and lack of mutations in the *EGFR*, *KRAS*, and *TP53* genes.[341–343] These tumors tend to show a solid growth pattern, often with signet ring cell morphology.[342–344] There has been great interest and enthusiasm in this minor subset of adenocarcinomas because inhibitors that target ALK tyrosine kinase yield objective responses in nearly three-fourths of patients and longer progression-free survival on average compared with standard chemotherapy.[345] Given the potential impact of these sorts of targeted approaches to therapy, molecular testing for *EGFR* mutations and *ALK* rearrangements (a list that has expanded to include other potentially targetable genetic and epigenetic abnormalities in many laboratories) are now endorsed by multiple pathology organizations and the American Society of Clinical Oncology as the standard of care for selected patients with adenocarcinoma of the lung.[346,347]

Squamous Cell Carcinoma

Squamous cell carcinomas are the second most common form of lung carcinoma, accounting for a third of incident lung cancers in males and 20%–25% of lung cancers in females.[304] Most cases are centered in segmental bronchi (Fig. 10.91) and therefore present as hilar or perihilar masses in chest radiographs and CT scans. The bronchial mucosa adjacent to the tumor usually shows squamous metaplasia and sometimes carcinoma in situ, occasionally extending several centimeters from the main mass. Rarely, squamous cell carcinoma presents as an endobronchial polypoid mass with only minimal spread beyond the bronchial wall.[348] As a consequence of their tendency to involve central airways, exfoliated malignant cells are more commonly identified in sputum or brushing cytology specimens than for other types of lung carcinoma. Signs of bronchial obstruction, such as obstructive pneumonia or atelectasis, are found in approximately half of the patients presenting with centrally located tumors. The tumors have a special tendency to undergo central necrosis with cavitation (Fig. 10.92). Calcification is unusual. Squamous cell carcinomas can also be found peripherally and even subpleurally.[349,350] When they do, they may fill the alveolar lumens

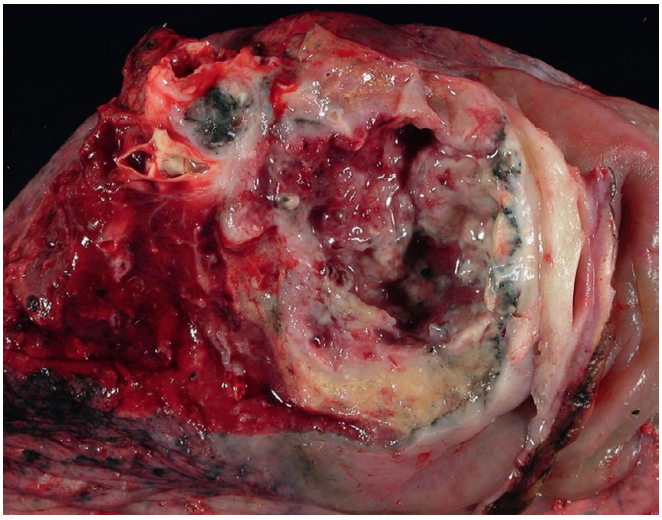

Figure 10.92 Large squamous cell carcinoma associated with central cavitation.

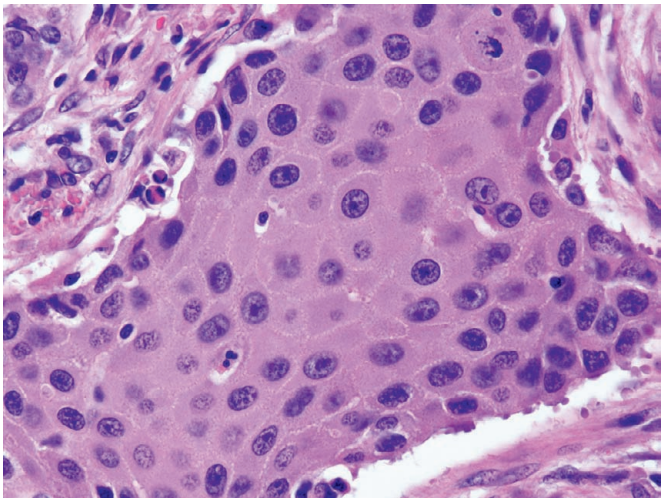

Figure 10.94 Microscopic appearance of squamous cell carcinoma with intercellular bridges.

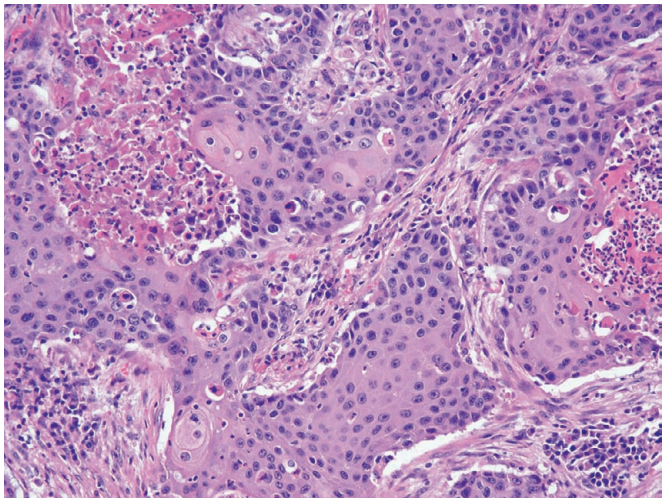

Figure 10.93 Microscopic appearance of squamous cell carcinoma with keratinization and necrosis.

in a lepidic-like fashion, mimicking a growth pattern more typically associated with adenocarcinomas.[351] A predominant alveolar space–filling growth pattern in small, early stage, peripheral tumors may predict a more favorable outcome in squamous cell carcinomas much as a lepidic growth pattern does in adenocarcinomas.[352]

Microscopically, the diagnosis of malignancy is based on cell atypia and invasion, and the diagnosis of squamous cell type on the detection in hematoxylin and eosin sections of keratinization and/or intercellular bridges (Figs. 10.93 and 10.94).[353] Keratin formation may be seen in isolated cells or, more commonly, in the form of 'keratin pearls.' Isolated necrotic cells should not be confused with keratinized cells. Strong, diffuse staining for markers of squamous differentiation such as CK5/6 (high-molecular-weight cytokeratins) and/or p63 or p40 is also sufficient to classify an otherwise nonclassifiable poorly differentiated non-small cell carcinoma as a squamous cell carcinoma.[353]

The finding of an occasional intracytoplasmic mucin droplet in an otherwise typical squamous cell carcinoma should not lead to a reclassification of the tumor. Only when at least 10% of the sampled tumor comprises a histologically distinct adenocarcinomatous component is the designation of *adenosquamous carcinoma* justified.[354]

Other morphologic features that can be encountered in squamous cell carcinoma include oncocytoid appearance of the tumor cells (due to increased mitochondrial density); giant cell foreign body reaction to keratin; palisaded granulomas; and extensive infiltration by neutrophils and other inflammatory cells. Further subclassification into *small cell, clear cell, and papillary variants* is of limited value beyond describing the range of histologic features that may complicate differential diagnosis.

The exception is *basaloid squamous cell carcinoma*, a poorly differentiated carcinoma analogous to the homonymous tumor arising in the upper aerodigestive tract (see Chapter 4) with a characteristically lobulated growth pattern and peripheral palisading of neoplastic cells (Fig. 10.95A).[355] A subset of these tumors show focal and abrupt keratinization; more commonly they are nonkeratinizing carcinomas with a pattern of diffuse immunoreactivity for p63 and/or p40 characteristic of squamous differentiation (see Fig. 10.95B). Immunostains are also positive for antibodies directed against high-molecular keratins such as CK5 or CK5/6 but are negative for TTF-1. Focal staining for neuroendocrine markers is seen in a minority of basaloid squamous cell carcinomas. This is an important subgroup of centrally occurring carcinomas characterized by an aggressive clinical course similar to that seen with other same stage poorly differentiated squamous cell carcinomas.[356,357]

Squamous cell carcinomas are graded into well, moderately, and poorly differentiated on the basis of the amount of keratinization present. Electron microscopic examination shows abundant tonofilaments, complex desmosomes, and basal lamina formation (Fig. 10.96).

Immunohistochemically, there is consistent staining for low- and high-molecular-weight keratins as well as p63 and p40, as previously outlined. Of the most commonly available antibodies directed against high-molecular-weight keratins, CK5/6 shows greater specificity than 34βE12 and is the antibody of choice for distinguishing squamous cell carcinomas from adenocarcinomas in the lung.[284] GATA3 is positive in only about 10% of squamous cell carcinomas of the lung, which may be helpful in distinguishing lung primaries from cutaneous and urothelial metastases.[358] Desmocollin-3 and glypican-3 are additional proteins more commonly expressed in squamous cell carcinomas than adenocarcinomas for which there are commercially available antibodies.[359,360]

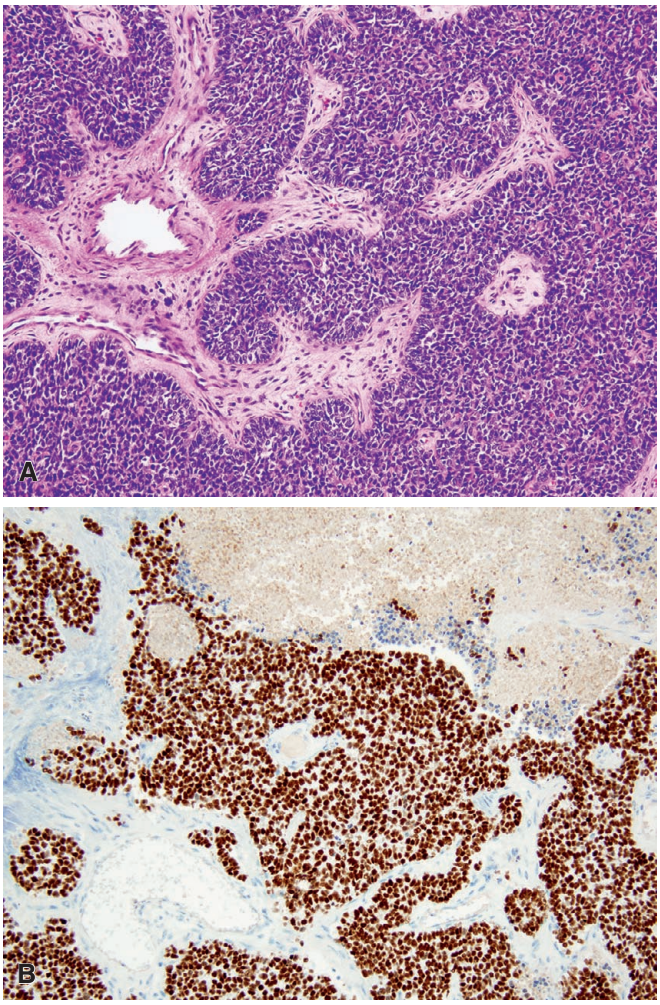

Figure 10.95 Basaloid squamous cell carcinoma with characteristic lobulated growth pattern **(A)** and diffusely positive staining for p63 **(B)**.

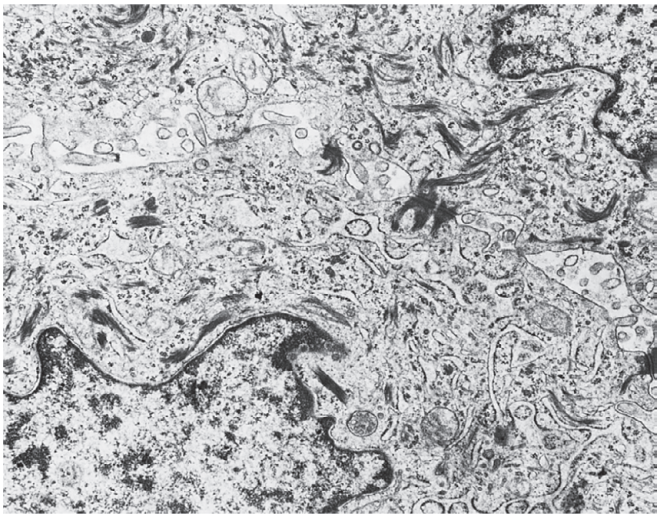

Figure 10.96 Squamous cell carcinoma of lung. Neoplastic cells with numerous tonofilaments, some of them attached to desmosomes. This is characteristic of squamous differentiation (×16,850).

HPV has been documented in a minority of squamous cell carcinomas and in some adenocarcinomas, with a prevalence that is highly variable depending in large part on geographic origin.[361] HPV 16 and 18 are the most commonly detected high-risk genotypes, but their role in carcinogenesis remains uncertain.[264,362]

At the genetic level, the most common alterations are somatic mutations in *TP53* and inactivation of *CDKN2A* through epigenetic silencing, inactivating mutations, and homozygous deletion.[363] Other frequently altered genes include a subset involved in squamous differentiation (*SOX2*, *TP63*, *NOTCH1*, *NOTCH2*, *ASCL4*, *FOXP1*) and another group that regulate the oxidative stress response (*KEAP1*, *CUL3*, and *NFE2L2*).[363]

Neuroendocrine Tumors

Neuroendocrine lung tumors include two high-grade variants, *small cell carcinoma* and *large cell neuroendocrine carcinoma*, an intermediate-grade category termed *atypical carcinoid tumors*, and low-grade *typical carcinoid tumors*. *Tumorlets* and *diffuse neuroendocrine cell hyperplasia* are two overlapping lesions more likely to present as diffuse multifocal disease in contrast to the other neoplasms included in this category. Small cell carcinoma and large cell neuroendocrine carcinoma are high-grade neuroendocrine carcinomas for which there are low rates of interobserver agreement even among experts in consistently separating one from the other.[364] This may be of limited significance given overlapping natural histories in clinical studies, overlapping immunophenotypes, and emerging molecular profiling studies showing that they tend to cluster together but are separate and distinct from atypical and typical carcinoid tumors.[365,366]

Small cell carcinoma comprises 10%–20% of incident lung cancers in the United States.[304] Incidence rates in men and women have been converging toward parity since the 1980s and early 1990s.[246] Small cell carcinoma, like squamous cell carcinoma, shows a very strong dose-dependent association with cigarette smoking; nearly all affected patients are current or former smokers.[367] Small cell carcinoma is disseminated (stage III or IV) at the time of diagnosis in around 90% of patients; 10% have limited stage disease for which therapeutic options may include surgical excision.[368,369]

Small cell carcinoma is typically a lesion of the central portions of the lung, but occasionally it is found in a peripheral location. Grossly, the tumor is white-tan, soft, friable, and extensively necrotic. When centered in a large bronchus (the usual situation), it may involve it in a circumferential fashion and/or spread widely beneath the normal mucosa (Fig. 10.97). The bronchus may be totally occluded in the late stages, but pure or predominant endobronchial involvement is unusual.

Microscopically, small cell carcinoma should be viewed as a distinctive tumor type rather than as an undifferentiated form of lung cancer. The histologic pattern is generally solid or sheetlike, combined with other growth patterns commonly affiliated with neuroendocrine differentiation including a nested or organoid architecture, often with peripheral palisading of neoplastic cells, ribbons trabeculae, and rosettes or pseudorosettes.[370] Necrosis is common and is usually extensive.

The *'pure'* form of small cell carcinoma is characterized by small round or oval cells resembling lymphocytes (Fig. 10.98).[371] The nuclei are finely granular and hyperchromatic, nucleoli are inconspicuous, mitoses are frequent, and the cytoplasm is so scanty as to be almost unrecognizable in routine preparations. In some instances the cells have a spindle shape. Nuclear 'molding,' a change first described in cytologic smears, can also be appreciated in microscopic preparations and is a consequence of scant cytoplasm relatively free of intermediate filaments. In rare cases, small cell carcinomas that are otherwise typical may contain scattered giant tumor cells.[372] A very common

Figure 10.97 Small cell carcinoma of the lung. The tumor is growing diffusely along the wall of a lobar bronchus and its branches.

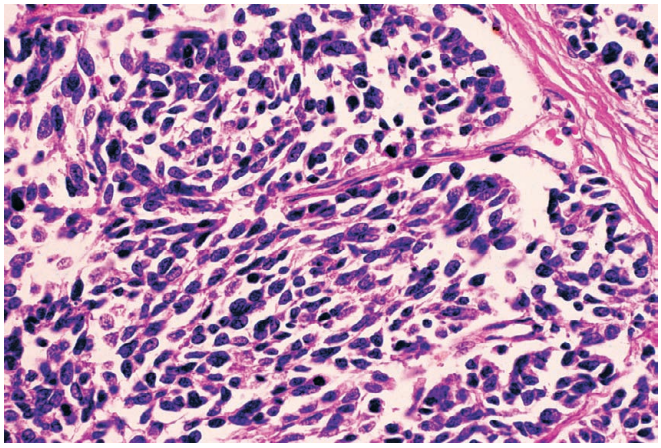

Figure 10.98 Small cell carcinoma showing cells with darkly staining oval to spindle nuclei and extremely scanty cytoplasm.

artifact, particularly prominent in small biopsy specimens, is elongation of the nuclei, with deformation, clumping, and diffusion of the chromatin (Fig. 10.99). If present throughout the specimen, it may make the diagnosis impossible on a biopsy specimen, although correlation with corresponding cytology specimens is often very

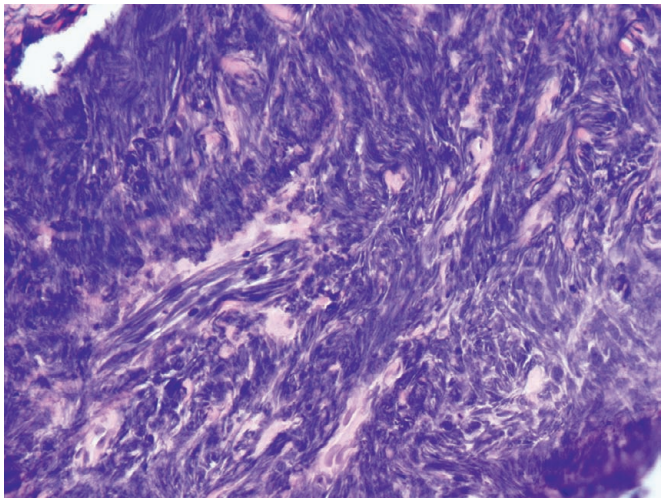

Figure 10.99 Small cell carcinoma in bronchial biopsy with extensive crush artifact making diagnosis all but impossible in this field.

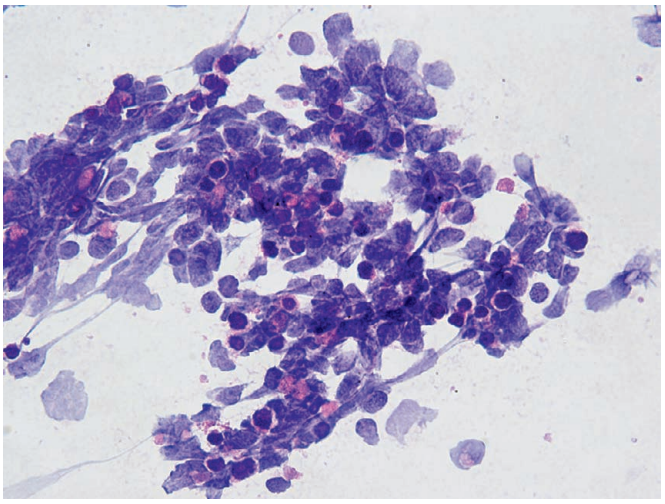

Figure 10.100 Small cell carcinoma smear from endobronchial ultrasound-guided fine-needle aspiration of subcarinal lymph node.

helpful (Fig. 10.100).[373] Another artifact, often referred to as the *Azzopardi effect*, that is sometimes seen in small cell carcinomas is chromatin diffusion and encrustation of blood vessel walls, which appear strongly hematoxyphilic (Fig. 10.101).

Interestingly, the classic appearance of small cell carcinoma is seen almost exclusively in small biopsies. In specimens obtained from lymph node or distant metastases or from the rare resection specimens of the primary tumor, the tumor cells are usually larger and with more abundant cytoplasm.[370] This suggests that some degree of artifactual shrinkage is at least partially responsible for the 'small cell' phenotype which may contribute to the challenge in separating from large cell neuroendocrine carcinoma.

Historical subclassifications of small cell carcinoma were primarily based on cytologic criteria, subdividing small cell carcinomas into *oat cell*, *intermediate cell*, and *mixed small and large cell* categories. These subclassification schemes lacked reproducibility and had no consistent clinical or biologic significance, instead reflecting a range of cytologic heterogeneity in these high-grade neuroendocrine carcinomas heretofore too narrowly defined.[374,375] Both the 2004 and 2015 WHO tumor classification schemes regard small cell carcinoma as a single entity that, like all other forms of lung

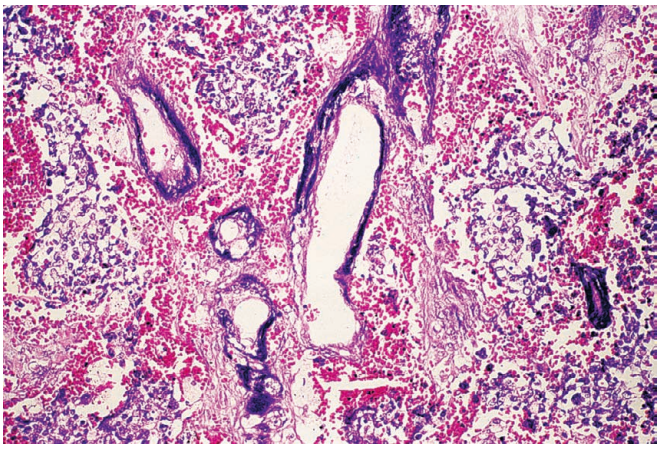

Figure 10.101 Small cell carcinoma with extensive necrosis associated with hematoxyphilic staining of the vessel walls (so-called 'Azzopardi effect').

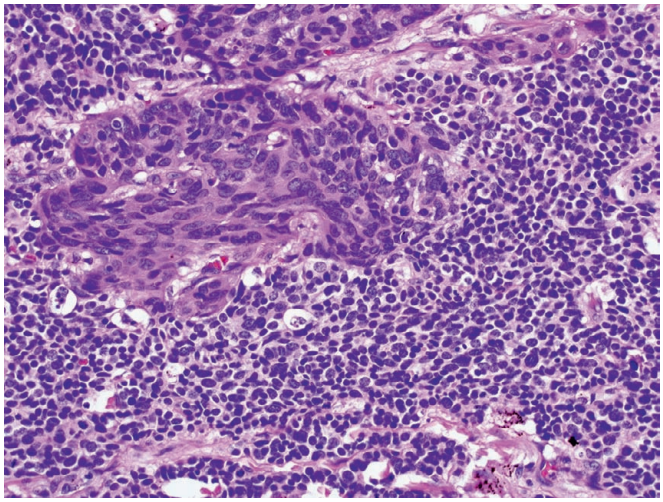

Figure 10.102 Combined small cell–squamous cell carcinoma.

carcinoma, can present in a 'pure' form or admixed ('combined') with other cell types.[371] *Combined small cell carcinoma* is uncommon and is defined as a small cell carcinoma combined with a second component comprising squamous cell carcinoma, adenocarcinoma, or rarely variants of sarcomatoid carcinoma (Fig. 10.102).

The key factor in determining whether a lung tumor belongs to the small cell category or not, in either a pure or a combined form, is not the detection of neuroendocrine differentiation (as discussed in the following paragraph) or the nuclear size, but rather the chromatin and nucleolar patterns as determined by light microscopic examination of routinely stained material.[373] The chromatin should be finely dispersed, without prominent clumps; more importantly, nucleoli should be inconspicuous or absent altogether.

Immunostains are of limited value in establishing a diagnosis of small cell carcinoma but are frequently useful to narrow the differential diagnosis, especially in small biopsies.[373] Nearly all small cell carcinomas are positive for keratins, especially low-molecular-weight keratins.[373,376,377] This is useful in distinguishing small cell carcinoma from lymphoma, a tumor that can mimic the clinical, radiological, histologic, and cytologic features of small cell carcinoma. Immunostains can be especially helpful in separating small cell carcinoma from basaloid variants of squamous cell carcinoma given that small cell carcinomas are usually negative or show only focal staining of isolated tumor cells for high-molecular-weight cytokeratins

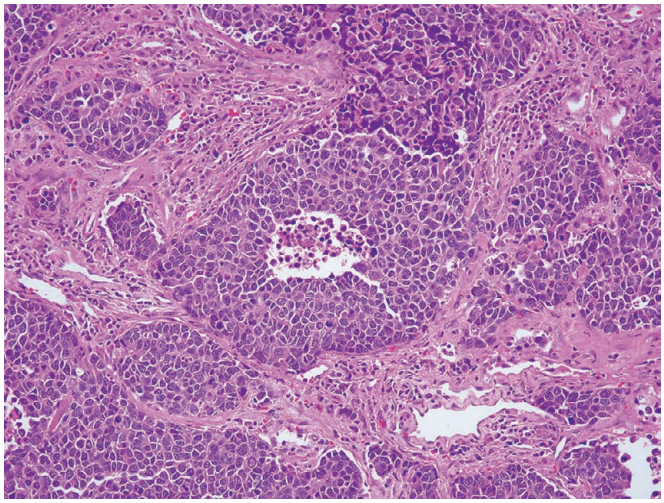

Figure 10.103 Large cell neuroendocrine carcinoma with a nested ('organoid') growth pattern, characteristic pattern of necrosis and numerous mitoses.

(e.g. 34βE12 and CK5/6), p63, and p40.[377] TTF-1 is positive in about 80%–90% of small cell carcinomas, another feature that distinguishes small cell carcinomas from basaloid squamous cell carcinoma.[378] The proliferation rate, as measured with Ki-67 (MIB-1), is almost 100%, a key finding in the differential diagnosis with carcinoid and atypical carcinoid tumor on small biopsies.[379] Stains for neuroendocrine markers are of limited value because as many as 40% of small cell carcinomas may be negative for synaptophysin and chromogranin. CD56 is more sensitive but less specific. At the same time nearly a third or more of conventional non-small cell carcinomas show evidence of neuroendocrine differentiation using a three-antibody panel (chromogranin, synaptophysin, and CD56 or CD57).[380]

At the molecular genetic level, small cell carcinoma is characterized by a deletion in chromosome 3 (p14–p23) in almost 100% of cases, mutation of *TP53* in over 80%, inactivating mutations of the *RB* gene in over half, and amplification of *MYC*, *SOX2*, and *FGFR1* in a minority.[381,382] Mutations in *KRAS* and *EGFR* are rarely found.[382]

Large cell neuroendocrine carcinoma is another form of high-grade neuroendocrine carcinoma with substantial histologic, immunophenotypic, molecular, and clinical overlap with small cell carcinoma. Like small cell carcinoma it is strongly associated with a history of heavy cigarette smoking. Large cell carcinoma is defined by a neuroendocrine architecture under the microscope (i.e. organoid, trabecular, peripheral palisading, and rosette-like structures), relatively large cells with prominent nucleoli and variably abundant cytoplasm, a high (>10 mitoses per 2 mm^2) mitotic rate, necrosis, and immunohistochemical evidence of neuroendocrine differentiation (Fig. 10.103). The neuroendocrine architecture distinguishes large cell neuroendocrine carcinoma from other high-grade non-small cell carcinomas that happen to have neuroendocrine differentiation, the mitotic rate separates it from atypical carcinoid tumors, and the combination of prominent nucleoli and more abundant cytoplasm is what separates large cell neuroendocrine carcinoma from small cell carcinoma. Cell size by itself is of limited value given considerable overlap with small cell carcinoma.[383]

Carcinoid Tumor

Carcinoid tumors comprise less than 1% of primary lung cancers.[384] Pulmonary carcinoid tumors are separated into *typical* and *atypical* categories based on a combination of necrosis and mitotic rate.

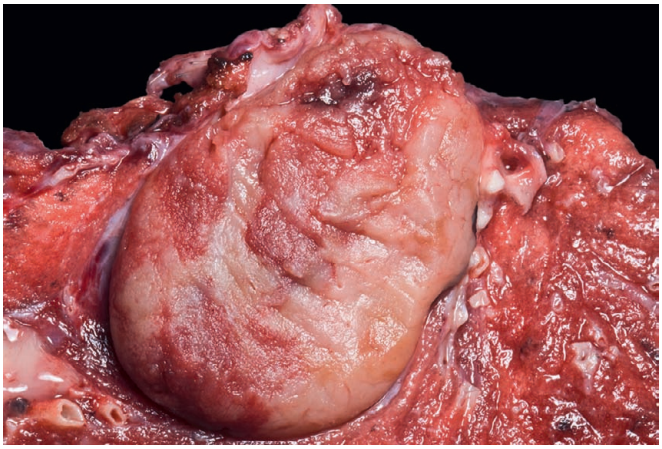

Figure 10.104 Central carcinoid tumor showing well-circumscribed quality situated within a large bronchus. (Courtesy of Dr. J. Carvalho, Minneapolis, MN.)

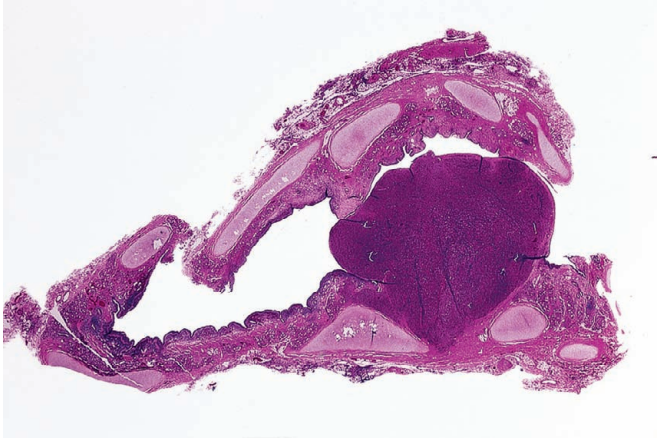

Figure 10.105 Whole mount of central carcinoid tumor showing polypoid endobronchial growth.

Figure 10.106 Peripheral carcinoid tumor showing characteristic subpleural location and well-circumscribed configuration.

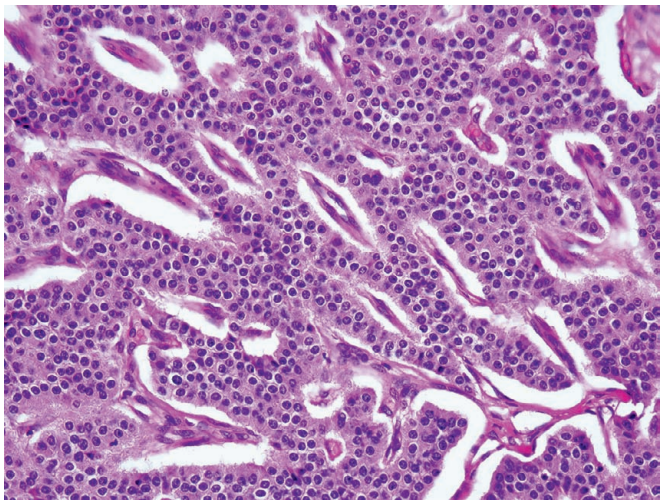

Figure 10.107 Carcinoid tumor showing characteristic architecture and cytology.

Typical carcinoid tumor is the most common of the neuroendocrine lung tumors, known in the distant past as bronchial adenoma.[385] It usually presents as a slow-growing, solitary polypoid mass within a major bronchus (Figs. 10.104 and 10.105); because of its location and highly vascular stroma, hemoptysis and postobstructive pulmonary infection are common. About one-fourth of typical carcinoid tumors occur peripherally and are more likely to be detected as asymptomatic solitary lung nodules. Most cases occur in adults, but they can also develop in children, in whom they are the most common primary malignant lung neoplasm.[386] The gender incidence is almost equal in adults and children. Most cases are endocrinologically silent at the clinical level. However, patients with carcinoid syndrome and elevated urine 5-HIAA have been documented. ACTH-secreting typical and atypical carcinoid tumors are also a rare but important potential cause of Cushing syndrome.[387]

Grossly, typical carcinoid tumors are predominantly endobronchial neoplasms with an intact, nonulcerated mucosal surface and limited infiltration through the bronchial wall to the surrounding parenchyma. Marked invasion of adjacent lung parenchyma is uncommon, however, and more commonly signifies an atypical carcinoid tumor.[388] Peripheral tumors are grossly nonencapsulated but well circumscribed, variegated gray to tan-brown, and focally hemorrhagic nodules with no anatomic relationship to a bronchus (Fig. 10.106).

Microscopically, carcinoid tumors are well circumscribed with limited invasion of adjacent lung tissues.[388] They are composed of intermediate-size uniform cells having central nuclei, small nucleoli, and a moderate amount of finely granular cytoplasm (Fig. 10.107). Occasionally, prominent nuclear *(endocrine-type)* pleomorphism comprising a combination of hyperchromasia and anisonucleosis is seen in the absence of necrosis or mitoses; this feature by itself is not sufficient to place the tumor in the atypical carcinoid category. Neoplastic cells form compact nests, ribbons, and festoons[385]; pseudopapillary or a true papillary growth pattern is rare.[389] Small glands with a rosette-like appearance are only rarely present. Vascularity is pronounced and is the reason that bronchoscopists may choose not to biopsy endobronchial lesions with the gross appearance of a carcinoid. Tumor cells may be seen within lymph vessels in or around the tumor, a finding of no prognostic significance.

Microscopic variants of carcinoid tumor are relatively uncommon but may complicate differential diagnosis. Spindle cell carcinoid tumors are composed predominantly of spindle cells that may closely simulate the appearance of nonepithelial tumors, including smooth muscle neoplasms and monophasic synovial sarcoma (Fig. 10.108).

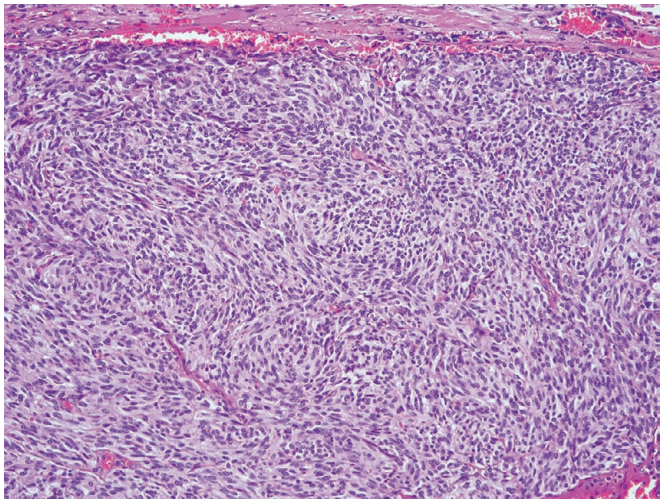

Figure 10.108 Spindle cell appearance of peripheral carcinoid tumor, which may simulate a mesenchymal neoplasm.

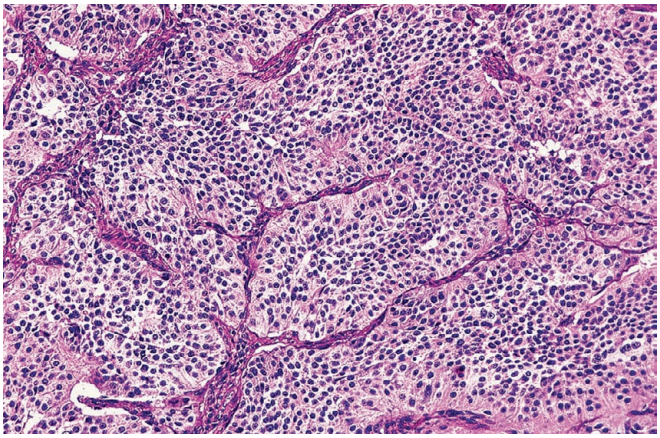

Figure 10.109 Central carcinoid tumor with paraganglioma-like pattern of growth.

The arrangement of the cells is less orderly and the nuclei smaller and more hyperchromatic with finely divided chromatin and higher N:C ratios sometimes mimicking small cell carcinoma.[390] Spindle cell carcinoids are more commonly peripheral in location, frequently presenting as asymptomatic solitary nodules, but can also occur centrally. As in the case of more classical appearing carcinoid tumors, spindle cell carcinoids may acquire paraganglioma-like features, including the presence of S-100 protein–positive sustentacular cells (Fig. 10.109).[391] Oncocytic variants are less common but may be confused with higher-grade lesions, given the tendency toward nuclear pleomorphism and prominent nucleoli (Fig. 10.110).[392] In exceptional cases, carcinoid tumors contain melanin granules in the tumor cells ('melanotic carcinoid tumor').[393] The stroma in carcinoids can be heavily sclerotic or hyalinized and may exhibit focal calcification or ossification.[394]

Immunohistochemically, there is variable but usually positive reactivity for keratin and a broad array of neuroendocrine markers, including neuron-specific enolase, chromogranin A and B, synaptophysin, CD56, and neurofilaments.[384] In addition, many peptide hormones have been detected in individual tumors, sometimes in combination. In addition to many neuroendocrine-type markers, carcinoid tumors display immunoreactivity for the transcription factor TTF-1 in over half of the cases (higher in the peripheral

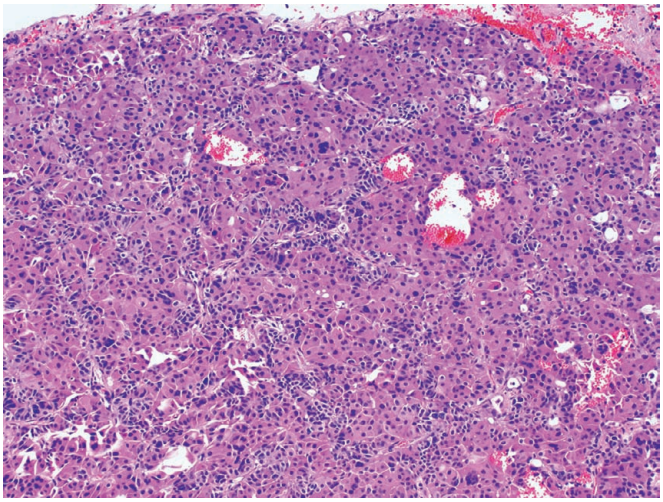

Figure 10.110 Oncocytic variant of carcinoid tumor.

type),[378,395–397] whereas they are consistently negative for CDX2 and PAX8, thus rendering these three markers important tools for the differential diagnosis between primary and metastatic carcinoid tumors in the lung from the gastrointestinal tract and pancreas, respectively.[398,399] Carcinoid tumors with a prominent nesting pattern of growth may acquire a 'paraganglioid' appearance, which is accentuated by the presence of S-100 protein–positive sustentacular cells at the periphery of the nests (see Fig. 10.109).

Carcinoid tumors demonstrate a low mutation burden compared with other higher-grade primary lung neoplasms and usually lack the *TP53* and *RB1* mutations more common in high-grade neuroendocrine lung tumors. Comprehensive molecular profiling has demonstrated mutually exclusive driver mutations in genes affecting histone methylation *(MEN1/PSIP1)* and ATP-dependent chromatin-remodeling (*ARID2*, *SETD1B* and *STAG1*).[400]

From a diagnostic viewpoint, central carcinoid tumors are easily identifiable with the bronchoscope in the majority of cases. Bronchoscopic biopsy is usually positive, although severe hemorrhage may result because of the marked vascularity of the tumors. The microscopic diagnosis is generally easy, although small samples with crush artifact can be confused with small cell carcinoma, as we have seen on several occasions. A Ki-67 (MIB-1) immunostain can be very useful in this circumstance, since it will be positive in nearly all cells of a small cell carcinoma but usually in less than 10% of the cells of a typical carcinoid.[379,401]

The treatment is surgical.[402] Removal through the bronchoscope is not sufficient because of the potentially infiltrative nature of the tumor. Depending on the location of the tumor along the bronchial tree and the status of the distal lung, the operation may be a segmental bronchial resection, a lobectomy (the usual procedure), or a pneumonectomy. Metastases to regional lymph nodes occur in about 5% of the cases and are usually limited to N1 nodes, a finding that has no impact on the generally excellent prognosis affiliated with typical carcinoid tumors.[403]

Atypical carcinoid tumor not only exhibits the overall architectural, ultrastructural, and immunohistochemical features of carcinoid tumor, but also exhibits atypical features in the form of increased mitotic activity (2–10 mitoses per 2 mm^2) and/or foci of necrosis (Fig. 10.111).[404] These have been referred to as *atypical carcinoid tumors*. Like their typical counterparts, they express various neuroendocrine and neural markers with the same relative frequencies[405] and may be occasionally accompanied by amyloid deposition in the stroma.[406] Historically, atypical carcinoid tumors were thought to represent a

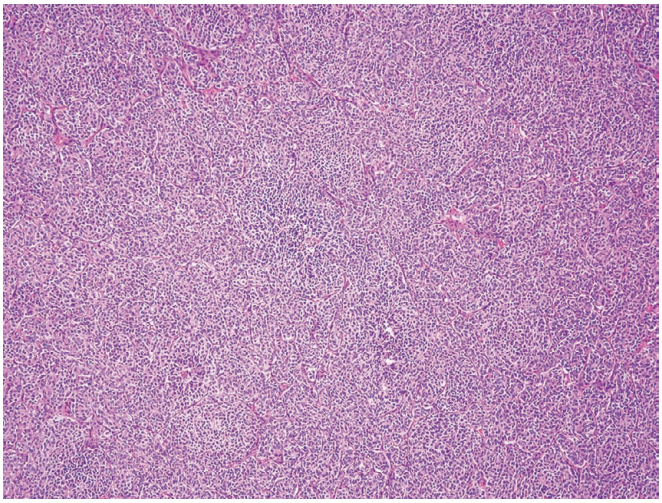

Figure 10.111 Atypical carcinoid tumor.

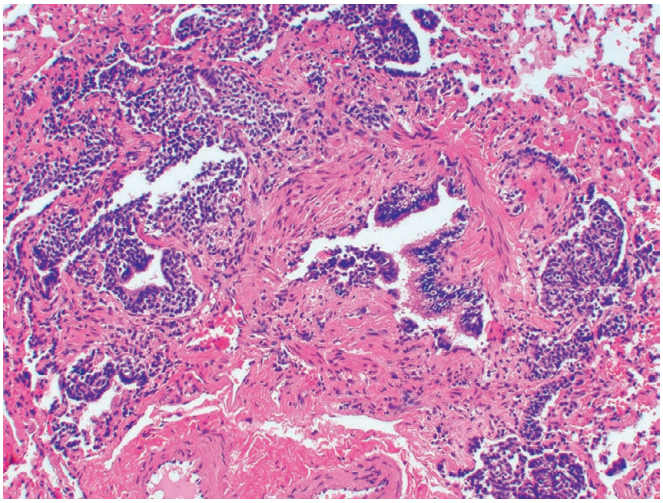

Figure 10.112 So-called pulmonary tumorlet.

link between typical carcinoid tumor and small cell carcinoma. There is now strong molecular evidence against it,[365,366,400] but there is no question that, for prognostic and therapeutic purposes, typical carcinoid tumors should be sharply separated from the atypical variety given marked differences in natural history and survival.[388,404,407] In one surgical series the incidence of lymph node metastases for atypical carcinoid was just over 35%, as opposed to an incidence of about 9% for the typical carcinoid.[408] The authors concluded that the treatment for surgical candidates should be more aggressive and not substantially different from that for ordinary lung carcinoma of non-small cell type, including conventional resection and radical mediastinal lymphadenectomy.[408,409] In this large series, the 5-year survival of atypical carcinoid was 78% and dropped to 60% in those with nodal involvement. Features of adverse prognostic significance are female gender, large tumor size, nodal involvement, higher mitotic rates, marked invasion into adjacent lung parenchyma, and lymph vessel invasion.[388,407,408]

The role of Ki-67 staining in routinely separating carcinoid tumors of the lung into meaningful groups is unresolved. In several studies subclassification using current WHO mitotic rate cutoffs outperformed Ki-67 labeling index in predicting disease progression and survival.[410,411] Others have argued that Ki-67 staining is more reproducible than current histologic criteria for grading neuroendocrine lung tumors and separating them into prognostically useful categories.[412–414]

Tumorlet *(carcinoid tumorlet)* is the term given to a nodular proliferation of small spindle cells seen in relation to bronchioles, often in association with bronchiectasis and other conditions associated with scarring including intralobular sequestration (Fig. 10.112). Tumorlets are frequently multiple and in rare cases are affiliated with a *diffuse* proliferation of airway-associated neuroendocrine cells in a condition referred to as *diffuse idiopathic pulmonary neuroendocrine hyperplasia* (DIPNECH) (Fig. 10.113).[415] Cases with multiple tumorlets may also be affiliated with one or more carcinoid tumors, thus mimicking the radiological appearance of metastatic disease in patients being followed for other malignancies.[416] Exceptionally, one may find tumorlet-like nests of neuroendocrine cells in intrathoracic lymph nodes, a finding that should not be misconstrued as evidence of metastatic disease.[417]

Pulmonary tumorlets closely resemble spindle cell carcinoid tumors, differing mainly in size, distribution, and histologic context. An arbitrary size criterion of 0.5 cm has been used to distinguish between tumorlet and carcinoid tumor given their overlapping histologic and cytologic features. The fact that at the cytogenetic level tumorlets generally lack the 11q13 allelic imbalance that is characteristic of carcinoid tumors suggests a different molecular pathogenesis for the two lesions and provides a potential tool for their distinction.[418]

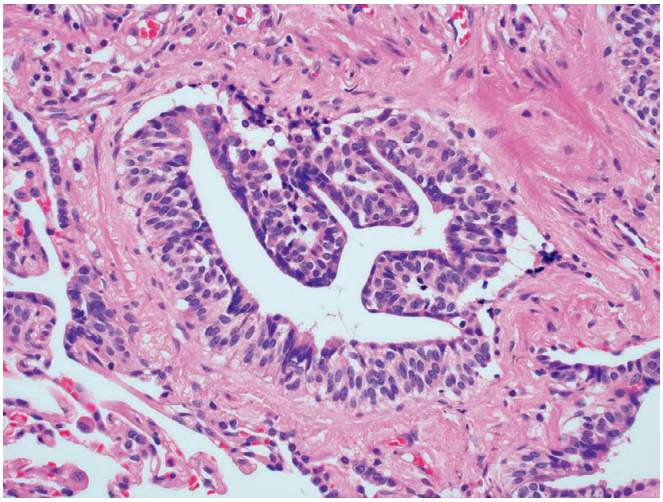

Figure 10.113 Diffuse idiopathic pulmonary neuroendocrine cell hyperplasia in a patient with multiple carcinoid tumorlets.

The behavior of tumorlet is generally benign, although isolated instances of metastatic behavior have been reported. The main practical importance is that they can be misdiagnosed radiographically and microscopically for lung metastases, especially in patients with a history of breast carcinoma.[416,419]

Large Cell Carcinoma

Large cell carcinomas are pleomorphic malignant epithelial tumors without cytologic, histologic, or immunophenotypic features of adenocarcinoma, squamous cell carcinoma, small cell carcinoma, or large cell neuroendocrine carcinoma.[420] The tumor cells are large, at least in comparison with those of small cell carcinoma, and demonstrate marked nuclear pleomorphism and variably abundant cytoplasm mimicking other pleomorphic poorly differentiated tumors, such as melanoma and lymphoma (Fig. 10.114). Many high-grade

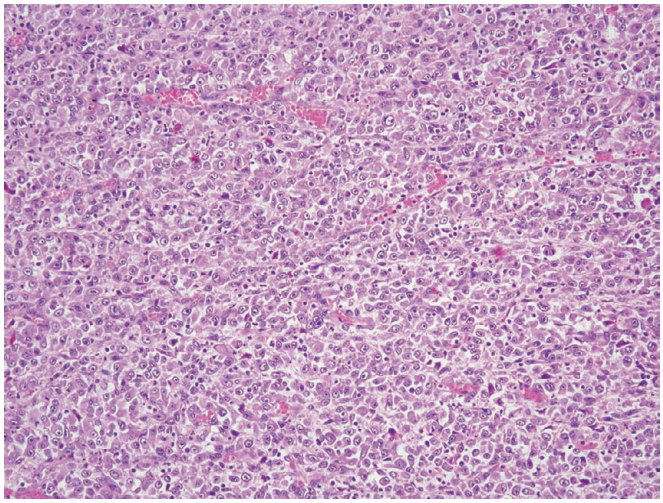

Figure 10.114 Large cell carcinoma.

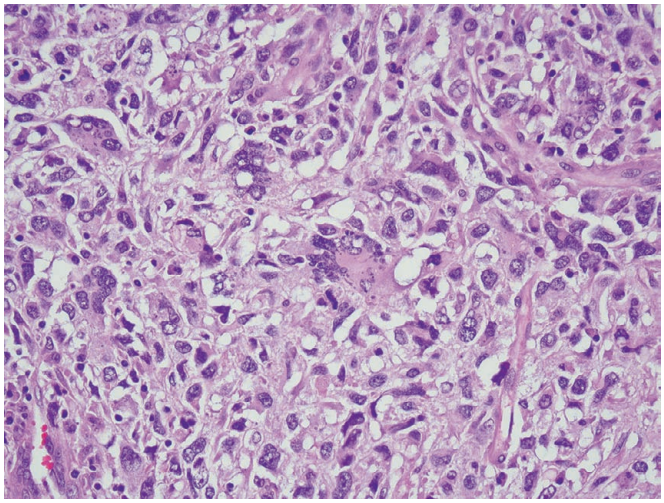

Figure 10.116 Prominent neoplastic giant cells in a sarcomatoid ('giant cell') carcinoma.

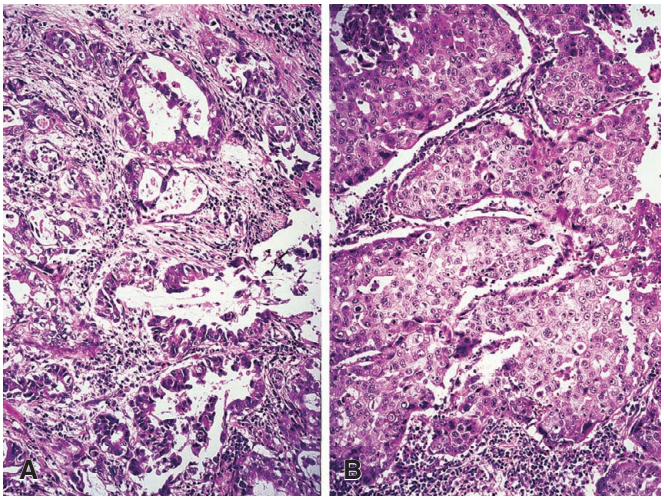

Figure 10.115 Adenosquamous carcinoma of lung showing an admixture of glandular (**A**) and squamous (**B**) components in the same tumor.

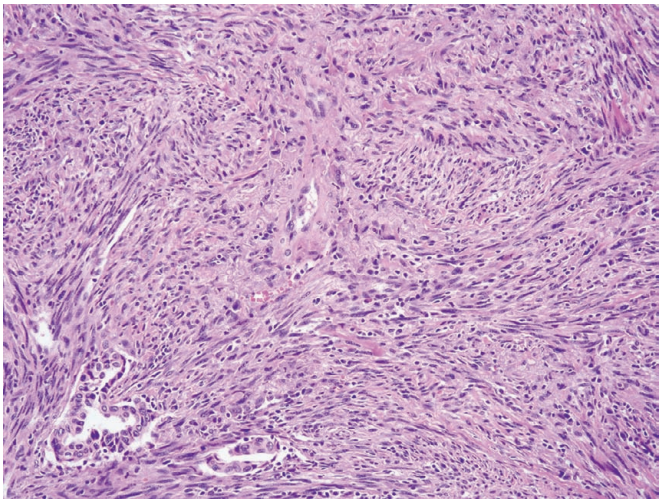

Figure 10.117 Prominent spindle cells in a sarcomatoid ('spindle cell') carcinoma.

non-small cell carcinomas historically assigned to this category are now considered poorly differentiated adenocarcinomas and squamous cell carcinomas based on the results of immunohistochemical and molecular studies. This applies to previously included variants like basaloid carcinomas, lymphoepithelioma-like carcinomas, clear cell carcinomas, and large cell carcinomas with rhabdoid phenotype.[421,422] Large cell neuroendocrine carcinoma has been recategorized with other neuroendocrine lung tumors. As a consequence large cell carcinomas represent a smaller and smaller subset of lung carcinoma types. Large cell carcinomas accounted for only 4% of lung carcinomas in a review of two large national databases accruing incident cases from 2004 to 2009, and declined from a rate of six cases per 100,000 person-years in the 1990s to about 1 case per 100,000 person-years in 2010 in another study.[246]

Adenosquamous Carcinoma

The term adenosquamous carcinoma is used for lung tumors in which distinct areas of squamous and glandular differentiation are found in the same neoplasm, each accounting for at least 10% of the sampled tumor (Fig. 10.115).[354] Squamous cell carcinomas having occasional mucin-producing cells or adenocarcinomas with minute foci of squamous differentiation are named according to their predominant component. Thus defined, adenosquamous carcinomas account for less than 5% of lung cancers. Most of the cases are located peripherally and often are associated with a scar, suggesting a closer relationship with adenocarcinoma than with squamous cell carcinoma.

Sarcomatoid Carcinoma and Carcinosarcoma

As in other organs, there exists in the lung a family of carcinomas having sarcoma-like features referred to generically as *sarcomatoid carcinomas*.[423–425] Further subtyping of these tumors is of limited biologic or clinical significance and is dependent upon minor variations in their microscopic appearance and the histogenetic biases of the observer. When composed predominantly of tumor giant cells, they have been designated as *giant cell carcinomas* (Fig. 10.116). When predominantly composed of spindle cells but still identifiable as epithelial on morphologic, ultrastructural, or immunohistochemical

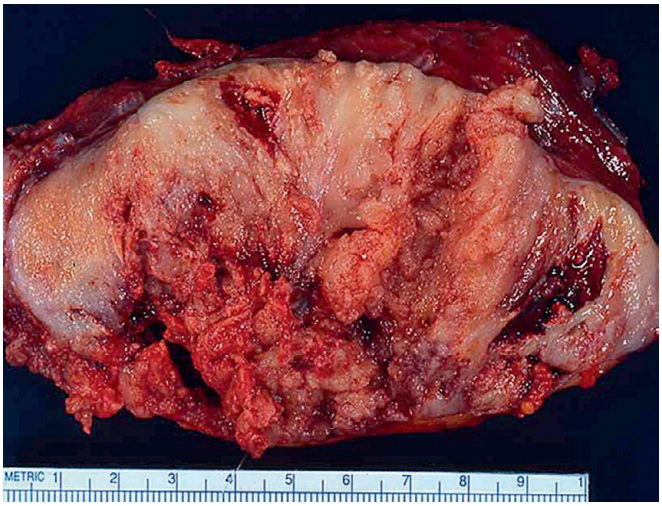

Figure 10.118 Sarcomatoid carcinoma with extensive necrosis.

grounds, they have been called *spindle cell carcinomas* (Fig. 10.117). Some authors have applied the term *pleomorphic carcinoma* to tumors in which there are both giant cell and spindle cell components, often in combination with a more histologically classic component of adenocarcinoma, squamous cell carcinoma, or undifferentiated non-small cell ('large cell') carcinoma. When the carcinomatous and sarcoma-like components are segregated and the latter demonstrates heterologous elements (e.g. chondrosarcoma, osteosarcoma, rhabdomyosarcoma), the term *carcinosarcoma* has been used. Studies of large series of cases with morphologic, immunohistochemical, and molecular techniques have rendered apparent the fact that these represent various manifestations of the same biologic phenomenon, by which neoplastic cells derived from pluripotent stem cells lose in part or completely their epithelial phenotype and acquire characteristics of mesenchymal cells, a phenomenon sometimes referred to as epithelial–mesenchymal transition.[426,427]

Grossly, these tumors can appear either as intraparenchymal or endobronchial polypoid masses that are frequently large and partially necrotic (Fig. 10.118).[425] Microscopically, the identifiable epithelial elements, when present, may show squamous differentiation, glandular differentiation, or be undifferentiated, thus resembling large cell carcinoma (Fig. 10.119). The sarcoma-like component may be nondescript, or resemble chondrosarcoma, osteosarcoma, rhabdomyosarcoma, or angiosarcoma. Osteoclast-like giant cells can be present, resulting in histologic features resembling those seen in giant cell tumor of bone. As indicated, the interface between the carcinomatous and the sarcoma-like components can be indistinct or sharp. Bronchoscopic or needle biopsy may show one or both elements.

The immunostains traditionally used to support the presence of epithelial differentiation in sarcomatoid carcinomas, albeit in a less than specific fashion, are pankeratin, EMA, and p63.[428] Immunostains for TTF-1 are also useful in a surprising number of cases of sarcomatoid lung carcinomas.[423] There remain a minority of cases in which immunostains may fail to show convincing evidence of epithelial differentiation in sarcomatoid components. In this circumstance, knowledge of the radiological distribution of disease is helpful given that sarcomatoid carcinomas often present as large, bulky solitary lung masses with or without intrathoracic adenopathy.

The prognosis of this tumor is poor, overlapping with same-stage poorly differentiated non-small cell carcinomas of other histologic subtypes.[429]

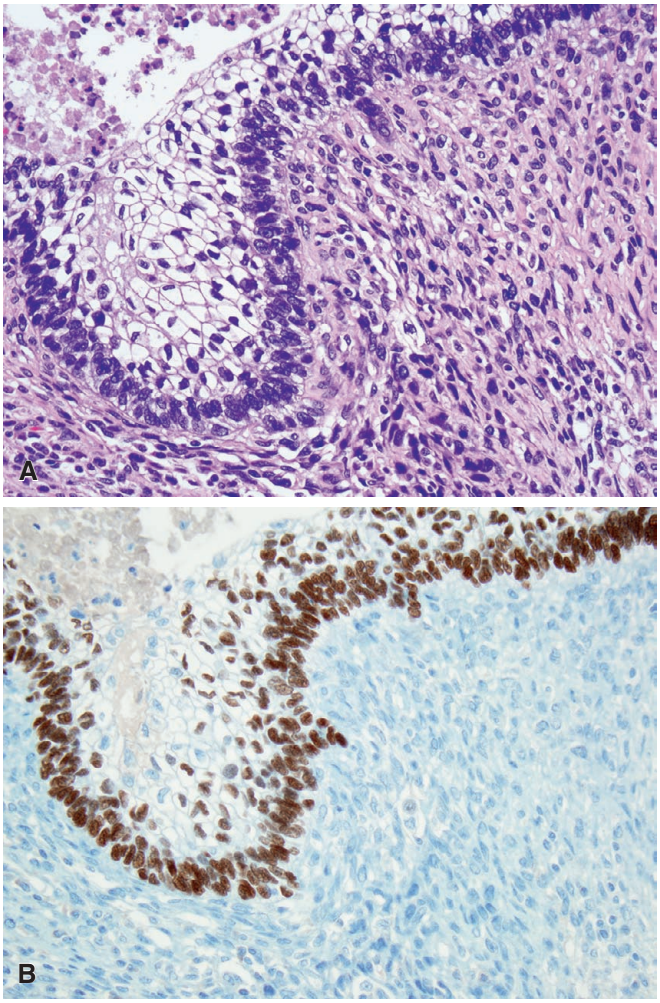

Figure 10.119 Sarcomatoid ('pleomorphic') squamous cell carcinoma showing a spindle cell component and an epithelial component with squamous differentiation demonstrating clear cell change **(A)**; staining for p63 was limited to the squamous component **(B)**.

Pulmonary Blastoma

Pulmonary blastoma typically presents in adults, in contrast to blastomas of other organs. Pulmonary blastoma should not be confused with *pleuropulmonary blastoma (PPB)*, a pediatric malignancy with a totally different presentation and morphologic appearance (see p. 428). Pulmonary blastoma usually presents as a peripherally located, solitary, well-circumscribed, large mass grossly resembling other sarcomatoid carcinomas (Fig. 10.120).[430] Microscopically, it is characterized by the presence of a well-differentiated adenocarcinomatous component in a cellular stroma composed of undifferentiated small ('blastematous') spindle cells (Fig. 10.121).[431] The overall appearance resembles fetal lung between 10 and 16 weeks' gestation and is also reminiscent of Wilms tumor.[432] The glandular cells often show subnuclear and supranuclear cytoplasmic vacuoles and variably abundant cytoplasmic glycogen. Solid balls of cells with abundant acidophilic cytoplasm ('morules') are common, mimicking the appearance of endometrioid adenocarcinomas; curiously, the nuclei in these formations often have a ground-glass (optically clear) appearance, said to be due to the accumulation of biotin.[433] Taken on its own the epithelial component is indistinguishable from *fetal adenocarcinoma* (referred to historically as *pulmonary endodermal tumor resembling fetal lung*) (Fig. 10.122), the only difference being the

Figure 10.120 Pulmonary blastoma forming a large well-circumscribed necrotic mass.

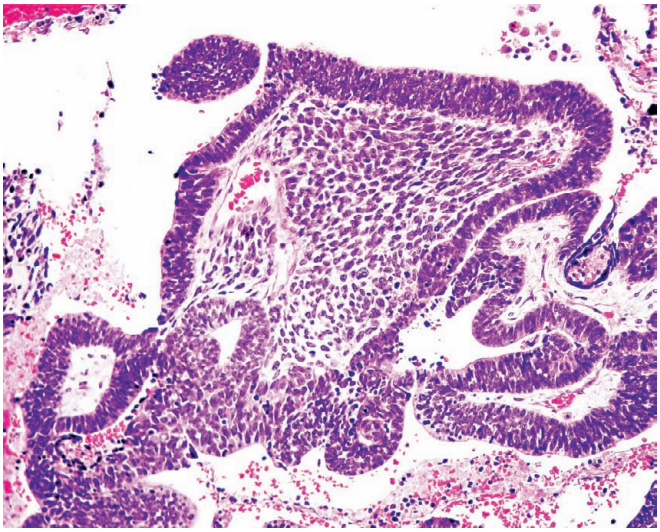

Figure 10.121 Pulmonary blastoma showing typical biphasic pattern of growth and 'fetal' appearance of the epithelial component.

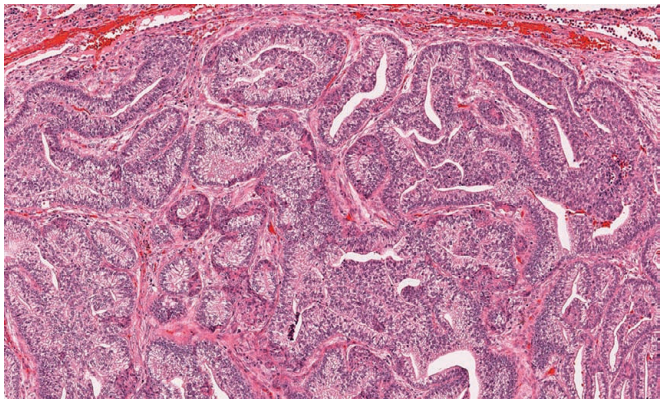

Figure 10.122 Fetal adenocarcinoma (pulmonary endodermal tumor resembling fetal lung). In contrast to pulmonary blastoma, a mesenchymal component is absent.

associated primitive appearing stroma in pulmonary blastoma.[434] Both the stromal component and the epithelial component may show divergent or heterologous differentiation, including skeletal muscle, cartilage, or bone in the former and intestinal, yolk sac, and malignant melanoma in the latter. Like other forms of sarcomatoid carcinoma, classical pulmonary blastoma is an aggressive tumor with greater than 50% mortality at 2 years and median survivals of less than 6 months in a small retrospective cohort.[430]

The occasional presence of combined or transitional forms between pulmonary blastoma and sarcomatoid carcinoma/carcinosarcoma (particularly the latter form) and their similar immunohistochemical and ultrastructural features suggest that they are histogenetically overlapping entities and that in a given case the distinction may not be possible.[435] More recently mutations in the *β-catenin* gene have been identified in fetal adenocarcinoma as well as the epithelial and stromal components of pulmonary blastoma, suggesting that activation of the Wnt signaling pathway may be a distinguishing feature.[436] β-Catenin mutations are associated with aberrant nuclear and cytoplasmic localization of β-catenin by immunohistochemistry, a potentially useful diagnostic tool for separating pulmonary blastoma from other forms of sarcomatoid carcinoma.

Carcinoma Precursors

Dysplasia and carcinoma in situ are the precursors of invasive squamous cell carcinoma. It has been known for a long time that squamous cell carcinomas of the lung have a long preclinical stage in which the lesion progresses from various degrees of dysplasia (mild, moderate, and severe) to carcinoma in situ, microinvasive carcinoma, and frank invasive carcinoma.[437] This progression is neither obligatory nor linear, making it difficult to assess the risk for developing an invasive carcinoma based solely on histologic grading of preinvasive lesions.[438] Detailed morphologic studies of very early cases have demonstrated that most potentially significant squamous cell carcinomas arise unifocally in a segmental bronchus (Fig. 10.123).[439] Grossly, the bronchial mucosa may show slight irregularities in the form of granularity, papillation, and loss of rugae, or it may appear unremarkable. Microscopically, the diagnostic criteria are similar to those applied for this diagnosis elsewhere, including a full-thickness change with an intact basement membrane. There is often extension into the ducts of the submucosal glands, a change that may be difficult to distinguish from broad-based early submucosal invasion. The presence of stromal desmoplasia favors the latter. The proliferative index, as measured with Ki-67 (MIB-1), parallels the morphologic changes.[440] Genetically, early events include loss of heterozygosity at 3p and 9p in squamous metaplasia and dysplasia, followed by *TP53* mutations in carcinoma in situ, and aberrant coexpression of p53 and EGFR.[441,443]

The terms 'early invasive' and 'intramucosal' carcinoma have been used somewhat interchangeably (and somewhat inaccurately) to designate tumors exhibiting superficial invasion of the stroma that does not extend to the level of the bronchial cartilage; most of these are well-differentiated to moderately differentiated tumors (Fig. 10.124).[444] The majority of screening-detected early squamous cell carcinomas show extensive surface involvement with little invasion ('creeping' type); a minority show more deep invasion through the bronchial wall without longitudinal extension along the mucosal surface ('penetrating' type).[445] The observation that penetrating growth patterns are underrepresented in occult squamous cell carcinomas suggests that they may be more rapidly growing and therefore more likely to present as clinically and radiologically significant tumors.

Atypical adenomatous hyperplasia is thought to be the preinvasive precursor of nonmucinous BAC and of some peripheral

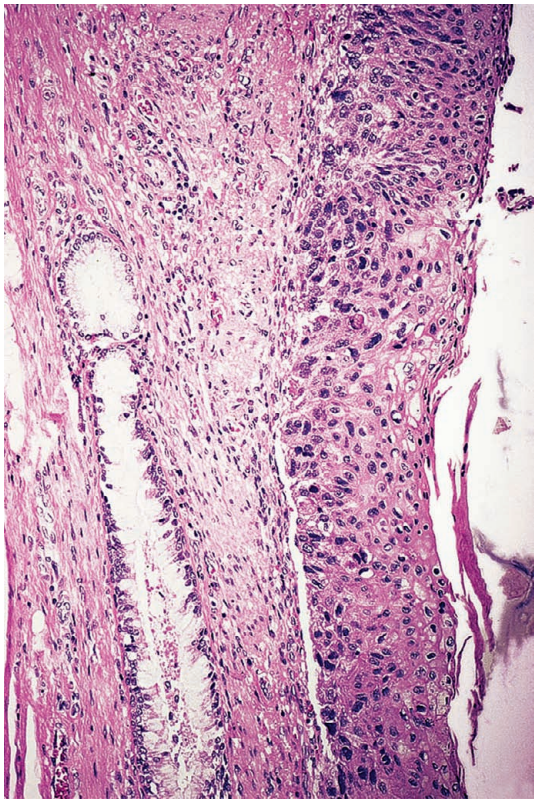

Figure 10.123 Carcinoma in situ of bronchial mucosa.

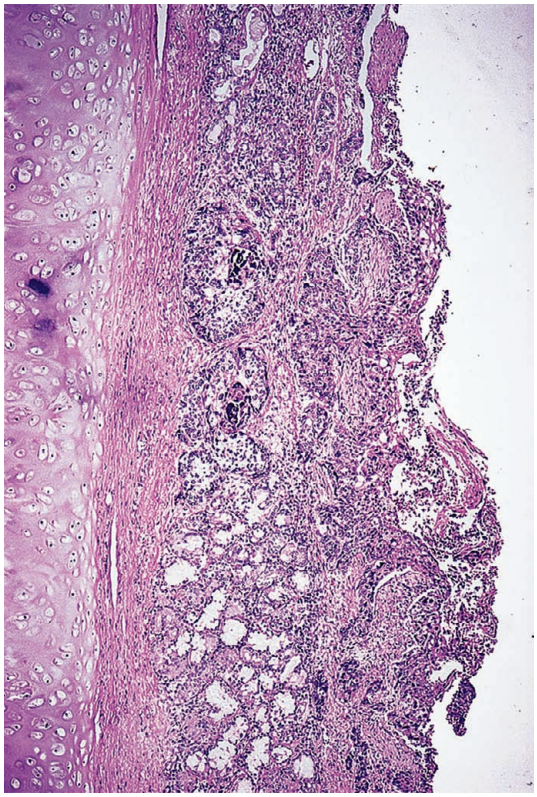

Figure 10.124 Early invasive squamous cell carcinoma of bronchial mucosa.

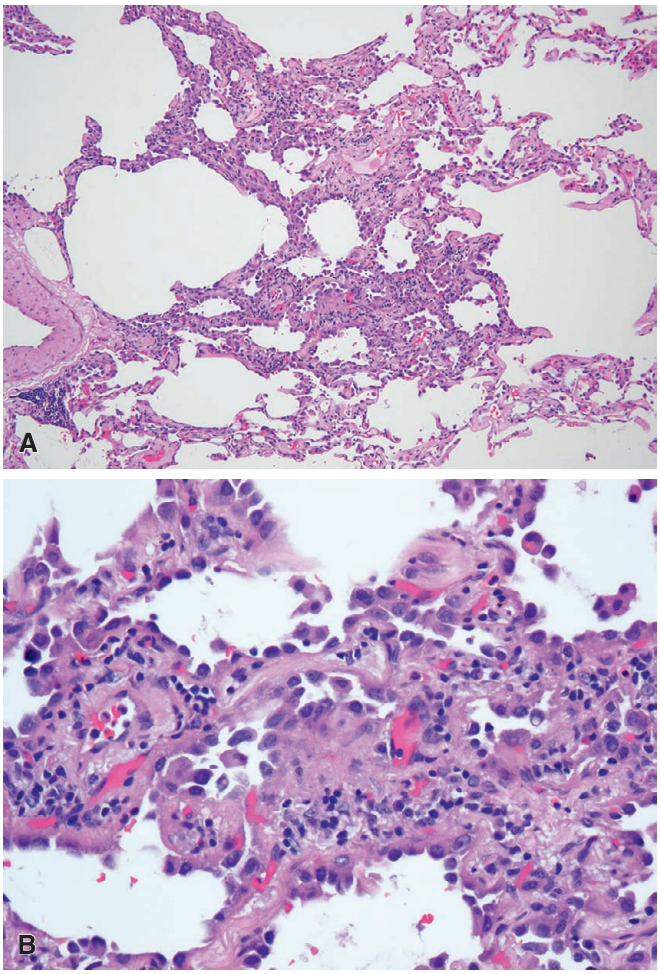

Figure 10.125 Low **(A)** and high **(B)** magnification view of atypical adenomatous hyperplasia.

adenocarcinomas.[262] Atypical adenomatous hyperplasia represents localized proliferations of mildly atypical nonmucinous columnar cells forming small (generally no larger than 5 mm) peripheral nodules in the absence of underlying inflammation or fibrosis (Fig. 10.125). The nodules of atypical adenomatous hyperplasia can be solitary or multiple and are seen more commonly in resected adenocarcinomas (around 15%–20%) than in resected squamous cell carcinomas (fewer than 5%) and occur more commonly in women than in men.[446–450] Importantly, the finding of atypical adenomatous hyperplasia in resected lung carcinomas has no impact on outcomes.[447,451]

Genetically, atypical adenomatous hyperplasia resembles adenocarcinoma in demonstrating mutually exclusive *KRAS* and *EGFR* mutations but differs in that the frequency of the two is markedly different, at least in Asian populations, with *KRAS* mutations more common in atypical adenomatous hyperplasia and *EGFR* mutations more common in adenocarcinoma.[452] This difference is aligned with experiments in genetically engineered mice in whom *KRAS* mutations affecting respiratory epithelial cells is commonly affiliated with atypical adenomatous hyperplasia rather than adenocarcinoma, while the reverse is true for *EGFR* mutations.[453,454]

Frozen Section

Frozen section is an important procedure in debatable lesions of the lung and has its greatest value in peripherally located lesions.

In patients with resectable lung carcinoma, bronchoscopic and/or cytologic examination combined with percutaneous image-guided needle biopsy will yield a diagnosis in the majority of the cases. There remain a number of patients who will undergo surgery for suspected cancer without a definite preoperative diagnosis. For peripheral lesions, it is better to excise them entirely with a margin of normal lung. This is usually in the form of a wedge excision. Frozen section is then done. Sometimes, the lesion proves to be a benign process such as a hamartoma, organizing pneumonia, or granulomatous inflammation, in which case no additional surgery is necessary. If it is carcinoma, the surgeon will decide whether to proceed to completion lobectomy, an especially important decision as less-than lobectomy becomes an increasingly viable option for managing patients with early stage screening-detected lung cancers.[455]

Frozen sections are an accurate method for diagnosing small pulmonary nodules, the chief potential pitfalls being the distinction of carcinoid tumors from other lesions and of early noninvasive or minimally invasive adenocarcinomas from atypical adenomatous hyperplasia and non-neoplastic reactive atypia.[456] Stromal hyalinization, an organoid growth pattern, and spindle cell cytology can be helpful in supporting a diagnosis of carcinoid tumor at the time of frozen section, while a desmoplastic stroma, nuclear pleomorphism, irregular nuclear contours and a mitotic rate above 5 per 10 high powered fields should suggest alternatives.[457] Accurate diagnosis of small in situ or minimally invasive adenocarcinomas at the time of frozen section is especially challenging in smaller (less than 1 cm) lesions and may benefit from more extensive sampling, correlation with findings on CT scans of the chest, and inflation of lung specimens with diluted embedding medium.[458,459] Observation of multiple growth patterns, variation in cell size, extensive atypia involving at least three-fourths of the area of interest, macronucleoli, and atypical mitoses are features that favor well differentiated adenocarcinomas over reactive atypia.[460] It is important that pathologists exercise caution in making a diagnosis of well-differentiated adenocarcinoma in the face of significant inflammation and fibrosis. Uncommon tumors, like sclerosing pneumocytoma, can be accurately diagnosed in most cases, especially when frozen section includes careful examination of the gross specimen.[461]

Two important contributions of frozen section to the surgical handling of lung carcinoma are the mapping of hilar and mediastinal lymph nodes and the evaluation of the bronchial margin. The latter is particularly valuable for central tumors, particularly those of salivary gland–type, and is less valuable in more peripheral tumors.[462,463]

Spread and Metastases

Centrally located lung cancer spreads by direct extension proximally and distally along the bronchus of origin and may reach the trachea at the level of the carina. It also grows into the lung parenchyma, from where it may reach the mediastinum or pleura. The latter event may result in seeding in both pleural layers and extension into the chest wall and diaphragm. Pleural effusion is very common under these circumstances. Occasionally, the entire pleural space is seeded in a fashion mimicking mesothelioma (see Fig. 10.82). Invasion of blood vessels is very common (over 80% of the cases); sometimes, this may lead to extensive tumor emboli and cor pulmonale, an uncommon phenomenon reported with not only primary lung adenocarcinomas but also metastatic adenocarcinomas, for which breast and stomach are the most commonly reported sites.[464] It has been postulated that tumor cells also spread through air spaces, with seeding through the air passages and development of secondary deposits at some distance from the main mass.[465] Indeed observation of spread through air spaces in otherwise low-stage adenocarcinomas may predict for a greater likelihood of locoregional and distant relapse.

Lymph node metastases occur first in the interlobar and hilar region, then in the mediastinal and lower cervical (supraclavicular) groups, and less commonly in axillary and subdiaphragmatic sites. Skip metastases occur in as many as 25% of patients and may reflect the frequency with which micrometastases are clinically and radiologically occult.[466] The site of resection, mediastinal lymph nodes, and supraclavicular fossa remain common sites of locoregional relapse after surgical resection independent of nodal status at the time of diagnosis.

Distant metastases are more common in liver, other areas of lung, adrenal, bone and bone marrow, kidney, and central nervous system.[467] Less common sites include the gastrointestinal tract, pancreas, thyroid, spleen, ovary, pituitary gland, skin, and skeletal muscle. Brain metastases seem to be more common in adenocarcinoma and may be the first manifestation of the disease.[468] The presence of distant metastases at the time of initial diagnosis is particularly high in small cell carcinoma, although the small subset of patients who present without clinical evidence of locoregional or distant spread may benefit from stage-appropriate surgery.[368,469]

Treatment

The standard therapy for operable non-small cell carcinoma of the lung is complete surgical excision through video-assisted thoracoscopic surgery or thoracotomy. The excision can be in the form of pneumonectomy, lobectomy, bilobectomy, or less than lobectomy in highly selected patients, depending on the location and type of the tumor. The first successful lung resection for squamous cell carcinoma was performed by Dr. Evarts A. Graham at Barnes Hospital in St. Louis, Missouri, in 1933. The patient, a physician, died 30 years later of an unrelated disease (Fig. 10.126). Ironically, he survived Dr. Graham, who died as a result of lung carcinoma. As illustrated by this historical patient, surgical therapy is regarded as sufficient in cases of early stage disease, whereas a combined modality therapy is usually applied to patients who present with higher tumor stage.

Radiation therapy can effectively control the local growth of lung cancer and sometimes results in long-term survival[470]; however, like surgery, it fails to cure most patients, mainly because as many as 50% of them have distant metastases when diagnosed or shortly following the initial diagnosis. It also has a limited impact on rates of recurrence in the cases showing microscopic evidence of involvement of the bronchial margin. The role of radiation therapy seems to be greater, whether given alone or as a preoperative measure, for tumors of the superior pulmonary sulcus (Pancoast tumor), as an adjunctive measure in the treatment of small cell carcinoma, and when administrated as adjuvant therapy in combination with chemotherapy.

A significant advance in the treatment of lung cancer is exemplified by the success story of tyrosine kinase inhibitors (such as gefitinib, erlotinib, afatinib), which is a showcase of the new paradigm in targeted therapy for cancer. Analysis of several phase III clinical trials has demonstrated that tyrosine kinase inhibitors outperform standard combination chemotherapy in patient with advanced stage non-small cell lung carcinomas harboring *EGFR*-activating mutations.[471] The same effect has been demonstrated using crizotinib, a small molecule inhibitor of ALK, MET, and ROS1 kinases, as first line therapy in patients with advanced stage non-small cell carcinomas positive for *ALK* translocations.[345] Promising results have also been demonstrated in a phase I trial of crizotinib in patients with *ROS1* rearrangements who have failed conventional therapy.[472] These results are the exemplars for the rapidly evolving field of precision ('personalized') medicine and serve as the underpinnings for current recommendations

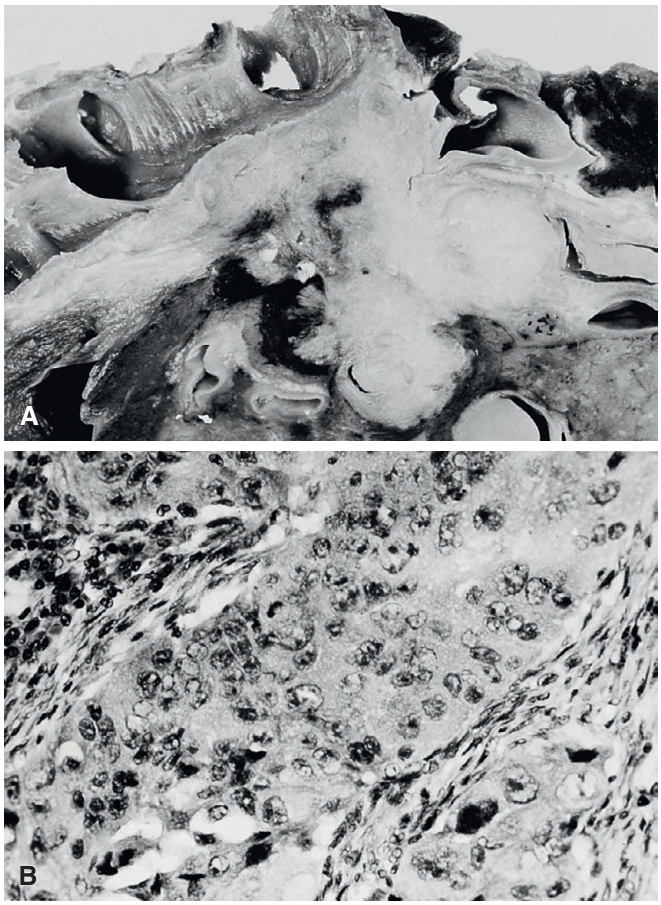

Figure 10.126 **A,** Squamous cell carcinoma of lung resected by Dr. Evarts A. Graham in 1933. Note extension into surrounding lung and involvement of two regional lymph nodes. The patient died in 1962 without evidence of cancer. **B,** Poorly differentiated squamous cell carcinoma shown in **A**.

regarding routine application of molecular testing in patients with advanced or recurrent non-small cell carcinomas.[346] Given that small biopsies with insufficient tissue remain a key impediment to molecular testing in these patients it is increasingly important that surgical pathologists remain stewards of these precious patient assets, minimizing utilization of immunostains unlikely to add substantial value and focusing instead on preservation of tissue for the sorts of testing likely to impact important decisions regarding treatment.[339] This is an important paradigm shift in the role of surgical pathologists in not only diagnosing but also managing patients with lung cancer. This shift will apply to a larger and larger pool of patients as new molecular targets are identified in not only adenocarcinomas but also squamous cell carcinomas for which immunotherapy (nivolumab) has already been approved as a potential therapy, although the role of companion diagnostics relevant to surgical pathology is less clear.[473]

Prognosis

The long-term prognosis of lung carcinoma remains disappointingly poor, with limited improvement having been made in recent years in long-term survival rates. In a recent review of data from the United States collected in the SEER program, 1-year survival rates had increased from 34.4% in 1975–1977 to 44.7% in 2006–2009. But overall 5-year survival rates remained low, at 18.2% for non-small cell lung carcinomas and 6.3% for small cell carcinoma.[474]

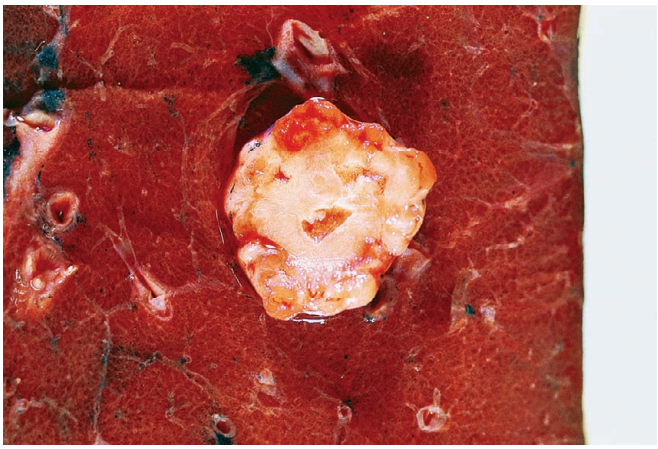

Figure 10.127 Lobulated shape and shiny cut surface of pulmonary hamartoma. (Courtesy of Dr. RA Cooke, Brisbane, Australia. From Cooke RA, Stewart B. *Colour Atlas of Anatomical Pathology*. Edinburgh: Churchill Livingstone; 2004.)

The prognosis of lung carcinomas has been related to a large number of factors, tumor stage chief among them including tumor size and presence or absence of visceral pleural and lymphatic space invasion in those with apparently localized node-negative disease who undergo resection with curative intent.[475,476] Older age, male gender, and low performance status at the time of diagnosis also influence natural history and prognosis.[477] Subtyping or grading of non-small cell carcinomas may have value, particularly in cases of early-stage adenocarcinoma in which solid and micropapillary growth patterns predict for lower rates of disease-specific survival.[478]

A burgeoning list of biomarkers suggests a complex interplay of factors that may affect outcome, including selected genetic markers. For example, *KRAS* mutations have been associated with lower overall survival rates in patients with earlier stage (stage I–IIIa) adenocarcinomas.[479] Survival of patients with activating *EGFR* mutations who are treated with tyrosine kinase inhibitors is influenced by the specific type of mutation, with cases characterized by deletions in exon 19 surviving longer than cases with L858R point mutations.[480] *ALK*-rearranged cases are overrepresented in patients who present with advanced-stage disease, suggesting that it may predict for a subset of more aggressive adenocarcinomas that tend to affect younger nonsmokers.[342]

Other Primary Tumors

Hamartoma

Hamartoma is the most common benign neoplasm encountered in surgical pathology and generally occurs in adults and is more common in males.[481] It is usually solitary but can be multiple. Its most common location is the peripheral lung parenchyma just beneath the pleura, and it presents in most instances as an asymptomatic solitary pulmonary nodule. Endobronchial hamartomas account for only about 10% of cases and are more likely to present with cough or symptoms related to obstruction.[482] Hamartomas are usually small, measuring less than 2.0 cm on average. Radiographically, a characteristic popcorn pattern of calcification is seen in two-thirds of the cases.[483] Grossly, it is sharply delineated and lobulated (Fig. 10.127). The cut surface is characterized by glistening nodules of cartilage separated by ill-defined clefts. A less common presentation is as a polypoid mass inside a large bronchus (Fig. 10.128).[483]

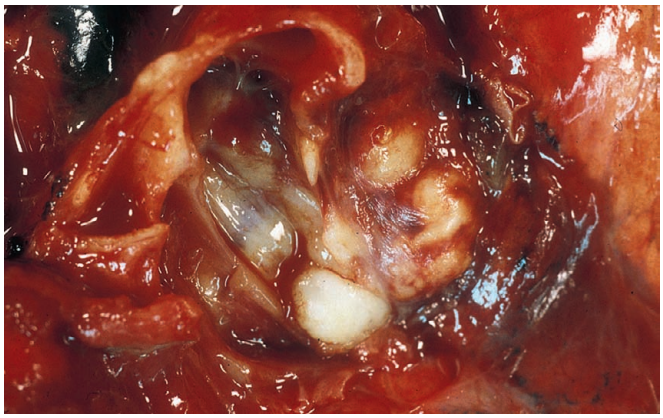

Figure 10.128 Endobronchial hamartoma.

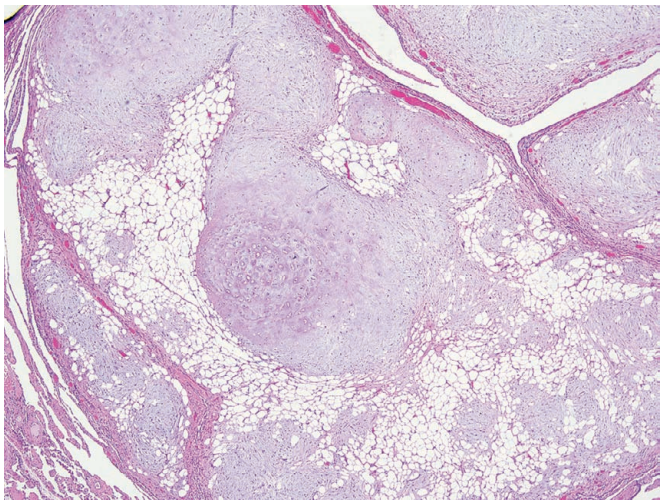

Figure 10.129 Pulmonary hamartoma showing intermingling of hyaline cartilage, fat, myxoid stroma, and non-neoplastic respiratory epithelium.

Microscopically, hamartoma is made up of normal cartilage arranged in islands, fat, smooth muscle, a characteristic myxoid stroma, and clefts lined by ciliated or nonciliated respiratory epithelium (Fig. 10.129). Any one of these components can predominate in any individual tumor, resulting in a range of histologies that include leiomyomas and lipoma. Sometimes exaggerated invagination of non-neoplastic epithelium results in a pattern resembling so-called *placental transmogrification*, characterized by the formation of placental villus-like papillations.[484]

Immunohistochemically, some of the spindle cells of this lesion have features of myoepithelial cells, such as positivity for actin and S-100 protein. The spindle cells in myxoid areas are unique in expressing glial fibrillary acidic protein (GFAP), a finding they have in common with fetal cartilage.[485] There is also common expression of ER, progesterone receptor (PR), and androgen receptor (the latter only in males), most of it in the myoepithelial-like cells.[486] We have seen two salivary gland–type tumors with a myoepithelial cell component and a well-differentiated liposarcoma arising from pulmonary hamartoma.[487,488]

Hamartomas are acquired nonepithelial neoplasms characterized by clonal rearrangements of chromosome 6p21 (implicating the *HMGA1* gene) or chromosome 12q14–15 (implicating the *HMGA2* gene).[489,490]

The treatment of hamartoma is in the form of conservative surgery usually performed as a diagnostic procedure: wedge resection or enucleation of peripheral lesions and sleeve resection of endobronchial lesions.

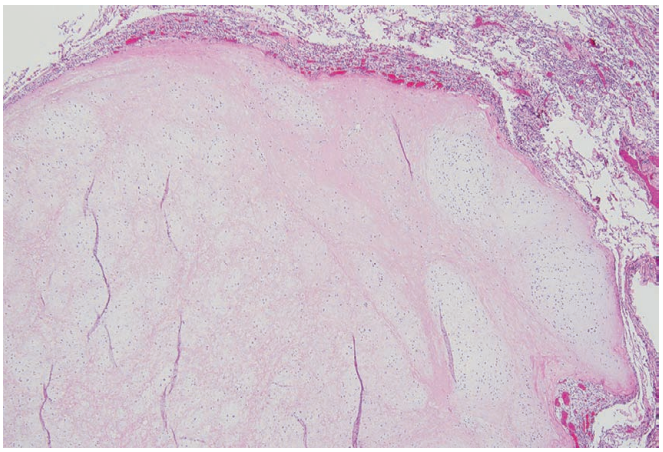

Figure 10.130 Pulmonary chondroma.

Carney has identified a nonfamilial syndrome ('Carney triad') in which pulmonary chondromas (usually multiple) are associated with gastric epithelioid leiomyosarcomas (most of which would be currently categorized as gastrointestinal stromal tumors, [GISTs]), and functioning extra-adrenal paragangliomas.[491] Pulmonary chondromas differ from the usual hamartomas in being purely cartilaginous with a more sharply circumscribed fibrous pseudocapsule without entrapped, invaginated epithelium (Fig. 10.130).[492] Pulmonary chondromas also show a broader range of cellularity and cytologic atypia in the neoplastic cartilage.

Paraganglioma and Other Neural Neoplasms

Paragangliomas have been exceptionally described in the lung, presenting as solitary (usually peripheral but sometimes endobronchial) masses.[493] Their histologic appearance is identical to that of paragangliomas in other sites. The differential diagnosis with carcinoid tumor may be extremely difficult, even after applying electron microscopic and immunohistochemical techniques, and this had led some authors to doubt the very existence of pulmonary paragangliomas. The presence of ribbons, festoons, rosettes, and positivity for mucin, CEA, and especially keratin, favor carcinoid, whereas a prominent 'Zellballen' pattern throughout the tumor and the presence of a population of S-100 protein–positive sustentacular cells at the periphery of the nests favor paraganglioma.[494] Excision is usually curative, but metastasizing cases have also been reported.

Other neural tumors that have been described in the lung include *ganglioneuroblastoma*[495] (one combined with carcinoid tumor[496]) and *gangliocytic paraganglioma*[497,498] (one associated with Cushing syndrome[499]). It is difficult to escape from the suspicion that these are histogenetically closely related tumors that have been interpreted and named just a little differently. A single example of a purported primary pulmonary ependymoma has been reported.[500]

Minute Meningothelioid Nodules and Meningioma

Meningothelial-like nodule (MLN) is the term currently preferred for a curious, usually clinically inconsequential pulmonary lesion originally misinterpreted as pulmonary paraganglioma (chemodectoma).[501,502] It is generally seen as an incidental finding in surgically

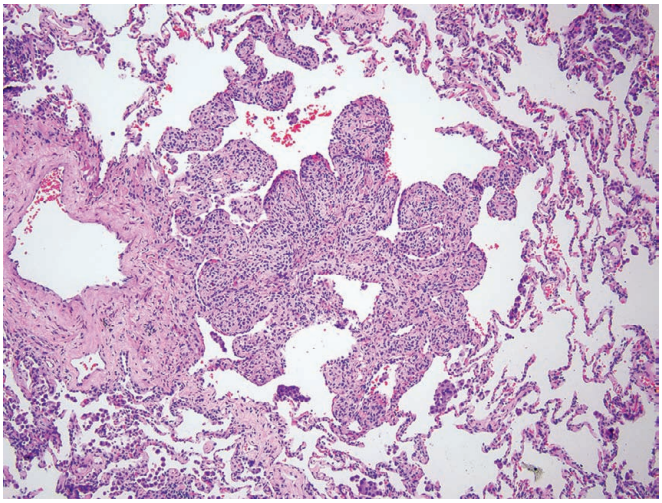

Figure 10.131 Incidentally discovered meningothelial-like nodule.

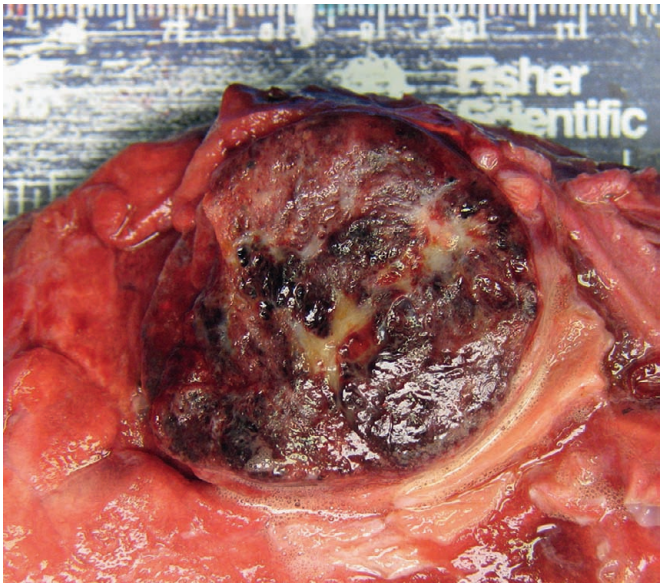

Figure 10.132 Sclerosing pneumocytoma. Yellow solid areas alternate with foci of fresh hemorrhage and fibrosis. (Courtesy of Dr. J. Carvalho, Minneapolis, MN.)

excised lungs, the lesions presenting as one or more 1–3 mm tan-yellow nodules randomly distributed within the interstitium (Fig. 10.131).[502] Occasionally, the lesions are disseminated and bilateral, associated with symptoms of restrictive pulmonary disease.[503] Ultrastructural studies have shown a total lack of neurosecretory granules or other features suggestive of neuroendocrine differentiation. The cells have instead an appearance similar to that of normal arachnoidal cells and the cells of meningioma.[504] Immunohistochemically, they are negative for keratin and positive for vimentin, EMA, CEA, CD56, and PR, a profile again similar to that of meningothelial cells.[502] Their genotypic features, however, are different from those of CNS meningiomas[505] and more in keeping with a reactive than a neoplastic process.

True *meningioma* of lung presenting as a primary solitary nodule has also been described,[506] including a chordoid[507] and a malignant variety.[508] These should be distinguished from 'benign metastasizing meningioma,' a rare but well-documented occurrence.[509,510]

Sclerosing Pneumocytoma

Sclerosing pneumocytoma, referred to historically as *sclerosing hemangioma*, is a distinctive lesion that occurs mostly in younger adult females, usually detected as an asymptomatic small, solitary nodule on a chest radiograph or CT scan.[511–516] On serial films, the lesion is found to be stable or, at the most, very slow growing. Grossly, it is a well circumscribed but not encapsulated, solid peripheral, subpleural mass with a variegated tan, yellow, and frequently hemorrhagic cut surface (Fig. 10.132). Microscopically, sclerosing pneumocytoma is characterized by a combination of architectural and cytological heterogeneity, with growth patterns that may be solid, papillary, sclerosing, and hemorrhagic, resulting in a variegated appearance at low magnification (Fig. 10.133). At higher magnification the cytologic heterogeneity results from a combination of bland interstitial round cells that represent the neoplastic population and incorporated non-neoplastic respiratory epithelial cells that line papillary surfaces in a manner analogous to that seen with other slowly growing lesions such as hamartoma (Fig. 10.134).

The histogenesis of this lesion has been highly controversial since its description as an entity, which has been variously proposed to be of endothelial, histiocytic, mesothelial, and epithelial nature.[514] Immunohistochemically, there are two distinct components. One

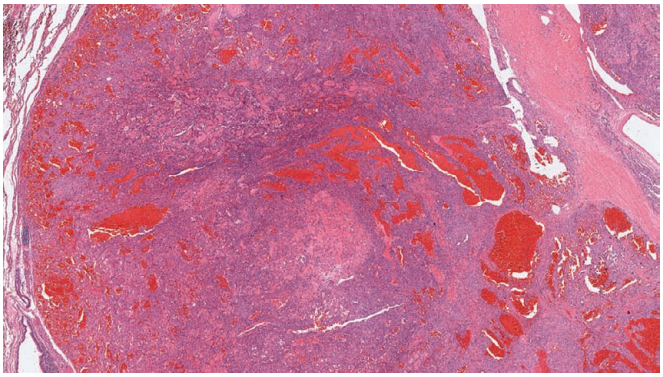

Figure 10.133 Sclerosing pneumocytoma. A variety of growth patterns is appreciated on low-power examination resulting in a characteristic variegated appearance.

(referred to as *surface cells*) is of clearly epithelial nature and reactive for EMA, keratin, CD15, Ber-EP4, apocrine epithelial antigen, surfactant apoprotein, TTF-1, napsin A, and ER beta.[511–513,516–521] Some of these reactivities correspond to those of type 2 pneumocytes, as supported by the ultrastructural finding of a microvillous-like folding of the cell membrane and lamellar inclusions. The second—and numerically more prominent—component (referred to as *round* or *stromal cells*) is negative for many of these markers except EMA, ER beta, and TTF-1, features that suggest an origin from primitive respiratory epithelium. The similar pattern of allelic loss that has been found between sclerosing hemangioma and bronchioloalveolar carcinoma also suggests an origin from the terminal lobular unit.[522] These observations served as the drivers for adoption of the term *sclerosing pneumocytoma* in the most recent WHO classification scheme.[523]

From a clinical standpoint, sclerosing hemangioma is a benign lesion cured by conservative surgery. There are rare reports of local lymph node deposits, but these patients have done well without evidence of distant metastases or tumor-related death.[512,524]

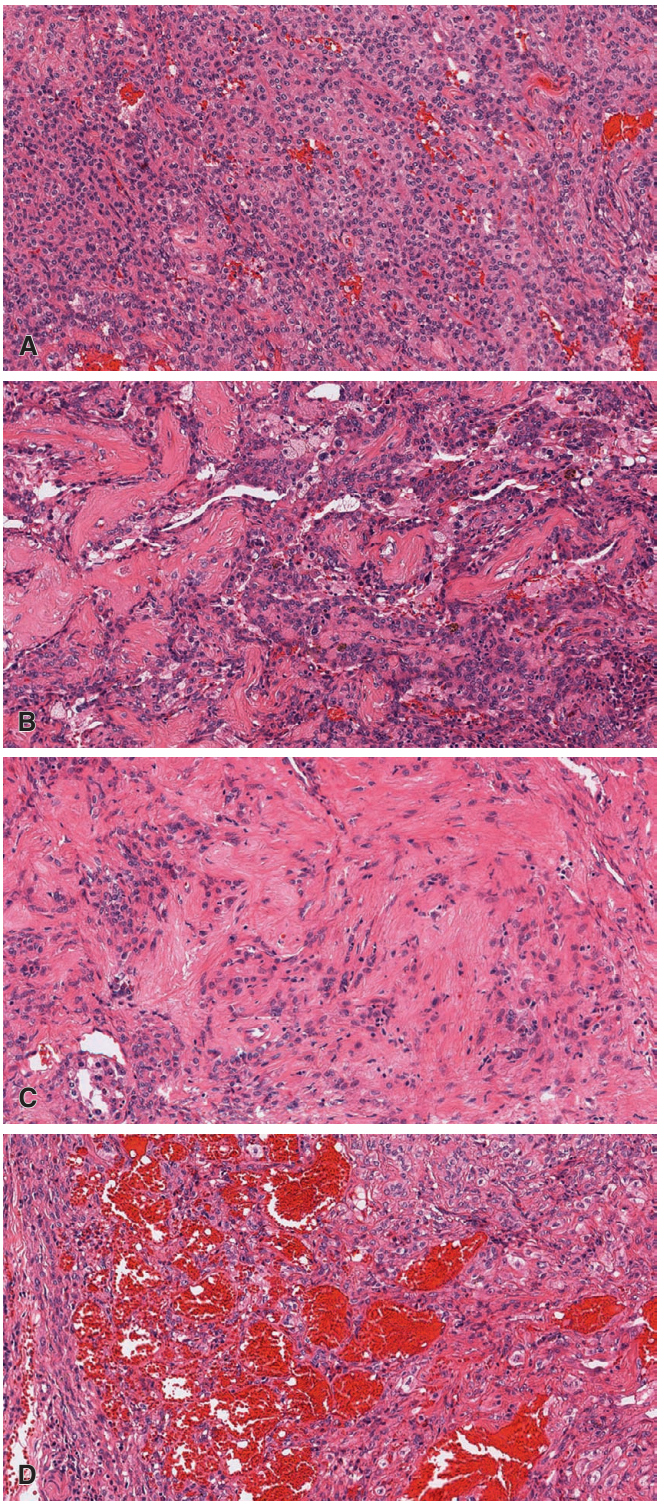

Figure 10.134 Sclerosing pneumocytoma. Higher-magnification views of tumor illustrated in Fig. 10.133 show solid **(A)**, papillary **(B)**, sclerotic **(C)**, and hemorrhagic **(D)** areas. Areas of solid growth **(A)** show neoplastic round cells while papillary areas **(B)** show non-neoplastic bronchiolar epithelium lining papillary surfaces.

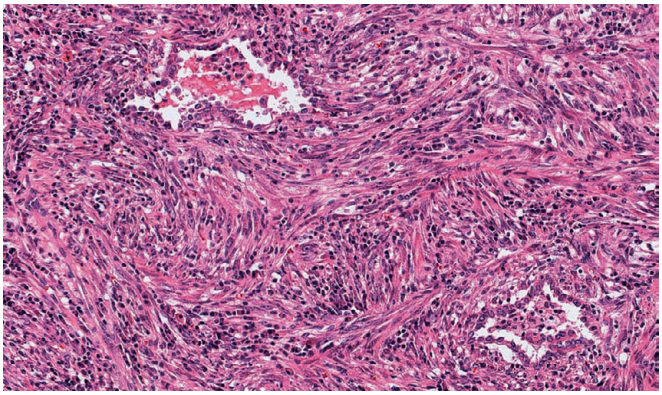

Figure 10.135 Inflammatory myofibroblastic tumor. Elongated myoid cells are heavily infiltrated by plasma cells. Incorporated non-neoplastic respiratory epithelium results in a 'pseudobiphasic' appearance.

Inflammatory Pseudotumor and Inflammatory Myofibroblastic Tumor

There is a group of pulmonary lesions presenting as more or less circumscribed nodules, having as a common denominator the presence of large numbers of mononuclear inflammatory cells. Wide variations on this basic theme occur from case to case or even within the same case and are responsible for the many names and histogenetic interpretations that this group of lesions has received. In addition to inflammatory cells, these variations include vascular proliferation, fibrosis that may take the form of organizing pneumonia, hyalinization, myxoid change, fat accumulation with the formation of xanthoma cells, hemosiderin deposition and proliferation of non-neoplastic respiratory epithelial cells.

It seems likely that within the heterogeneous group of lesions diagnosed as inflammatory pseudotumor is a subset with a reasonably distinct morphologic appearance for which the term *inflammatory myofibroblastic tumor* has been proposed.[525] In this condition, the predominant element is a spindle cell with immunohistochemical and ultrastructural features (actin reactivity, cytoplasmic filaments) consistent with those of myofibroblastic cells, or—alternatively—the cells of the accessory immune system known as fibroblastic (myoid) reticulum (dendritic) cells.[526,527] These are accompanied by a heavy mononuclear infiltrate in which plasma cells often predominate and are intimately admixed with the spindle cells in a fashion reminiscent of that seen in other reticulum (dendritic) cell tumors (Fig. 10.135). The consistent finding of chromosomal rearrangements involving 2p23 (harboring the *ALK* gene), including *EML4-ALK* inversions analogous to those described in adenocarcinomas, in about half of these lesions supports the neoplastic nature of this subset.[528] Other kinase fusions involving *ROS1* and *RET* occur in a smaller number of cases, bringing to two-thirds the total number of inflammatory myofibroblastic tumors that may be amenable to treatment with appropriately targeted kinase inhibitors.[529] Interestingly this applies mainly to inflammatory myofibroblastic tumors in children in whom sensitizing kinase fusions are more common and less so to those diagnosed in adults in whom kinase fusions are rare. HHV8 has been detected in only rare cases.[526,530]

Most cases diagnosed as inflammatory pseudotumors of the lung occur in adults, but a good number of those rich in plasma cells ('plasma cell granulomas') are seen in children. Actually, they constitute the most common isolated primary lesion of the lung in patients under 16 years of age. The majority present as asymptomatic solitary, small peripheral nodules, yellow and firm, covered by an intact pleura. In rare instances there is extension to the pleura or

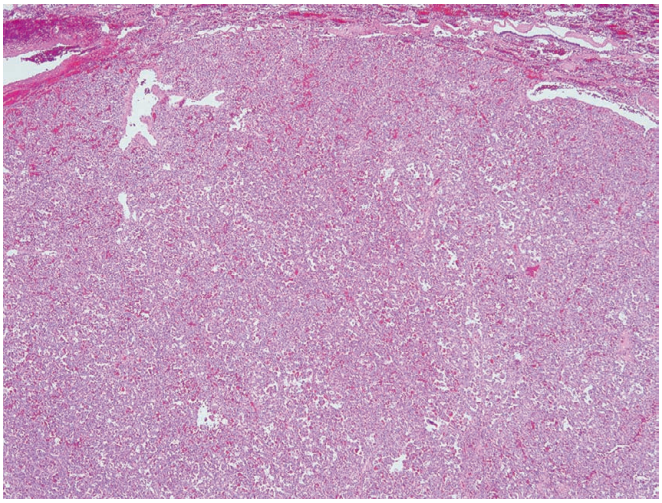

Figure 10.136 Capillary hemangioma presenting as solitary mass in a child.

Figure 10.137 Endobronchial glomus tumor.

mediastinum. Other cases present as polypoid endobronchial masses and may lead to distal inflammatory changes. Interestingly, some cases show many IgG4-positive plasma cells, suggesting an immune-mediated pathogenesis or at least overlap with IgG4-related sclerosing disease. There is emerging evidence that the presence of significantly increased IgG4-positive plasma cells is a feature that distinguishes inflammatory pseudotumor, a non-neoplastic proliferation, from inflammatory myofibroblastic tumor.[531–533]

Surgical excision is usually curative, but some aggressive examples have been described, especially when the appearance corresponds to that of an inflammatory myofibroblastic tumor.

Vascular Tumors

Vascular tumors of the lung are extremely rare. Bona fide **hemangioma** is seen more commonly in children; it can be either endobronchial or parenchymal and should not be equated with the lesion formerly referred to as sclerosing hemangioma (now termed sclerosing pneumocytoma), a nonvascular lesion. Microscopically, most are of the capillary type (Fig. 10.136).[534]

Hemangiomatosis, which is by definition multifocal or diffuse, presents with symptoms and signs of pulmonary hypertension *(pulmonary capillary hemangiomatosis)* accompanied by radiological findings more typical of diffuse interstitial lung disease.[535] The histologic findings include not only the 'capillary hemangiomatosis-like change' previously described in PVOD, but also nodular proliferation of capillary size vessels that infiltrate the interstitium and vessel walls in a manner more characteristic of a neoplastic process.[236]

Hemangiopericytoma (including its *lipomatous variant*) has been described as a primary lung tumor, but most such cases would be placed in other categories at present, particularly cellular solitary fibrous tumor. A particularly notorious trap is the misdiagnosis of a solitary lung metastasis of endometrial stromal sarcoma as a hemangiopericytoma.[536]

Glomus tumor can exceptionally involve the lung, its appearance being similar to that of its more common cutaneous and soft tissue counterparts.[537,538] Most of the few reported cases presented as asymptomatic peripheral nodules with a median diameter of 2.0 cm but with a broad size range (1.1–6.5 cm). Symptomatic endobronchial tumors are even more rare but mimic the appearance of carcinoid tumor at bronchoscopy (Fig. 10.137). It can also be confused with carcinoid tumor histologically; immunostains are helpful with negative staining for cytokeratins and neuroendocrine markers in glomus tumors that are instead positive for smooth muscle actin and desmin. Three reports of malignant glomus tumors *(glomangiosarcoma)* included follow-up in two; one died a year and a half after surgery and the other was alive with disease 5 years after resection.[537]

Kaposi sarcoma primary in the lung is usually a manifestation of AIDS but can also occur in immunocompetent individuals.[217] The distribution of the disease typically follows lymphatic channels.

Angiosarcoma can present as a single mass or as diffuse pulmonary infiltrates as an expression of a primary lung malignancy but in most patients represents metastatic disease of nonpulmonary origin for which potential primary sites include the heart and great vessels.[539] A subset of patients with metastatic angiosarcoma may have a clinical presentation that mimics diffuse alveolar hemorrhage syndromes.[540]

Lymphangioma and **diffuse lymphangiomatosis** are extremely rare; both of these conditions are more common in children but occasionally present in adulthood.[541,542]

Epithelioid hemangioendothelioma is the term for the neoplastic process originally described in the lung as *intravascular bronchioloalveolar tumor* (IV-BAT) that typically presents as multiple nodules.[543] Many of the patients are young adults, and females outnumber males by 3–4 : 1.[543–545] Microscopically, the most common growth pattern is multiple centrally hyalinized and/or necrotic nodules in which there are variably conspicuous acidophilic endothelial cells that may resemble epithelium, histiocytes, or decidualized stromal cells. The surprisingly bland neoplastic cells are distributed individually, in small solid cords, and in a vaguely lobulated pattern often as a thin rim surrounding an eosinophilic or basophilic ('chondroid') mass of hyalinized stroma, which is sometimes calcified (Figs. 10.138 and 10.139). These polypoid formations fill alveoli and occasionally bronchioles. The walls and lumen of both arteries and veins may also be occupied by tumor, even at a distance from the main mass, as the tumor spreads in a lymphangitic pattern. Grading into low and intermediate grades based on mitotic rate, necrosis, and nuclear pleomorphism can separate them into subsets that differ in prognosis, but that together are better than high-grade epithelioid angiosarcoma.[546] Unusual growth patterns include rare reports of solitary nodules and diffuse pleural disease mimicking mesothelioma.[547] Although originally interpreted as a variant of bronchioloalveolar carcinoma, ultrastructural and immunohistochemical studies have shown that the tumor is composed of endothelial cells and that it represents the pulmonary version of epithelioid hemangioendothelioma. Neoplastic cells are positive for vascular markers such as

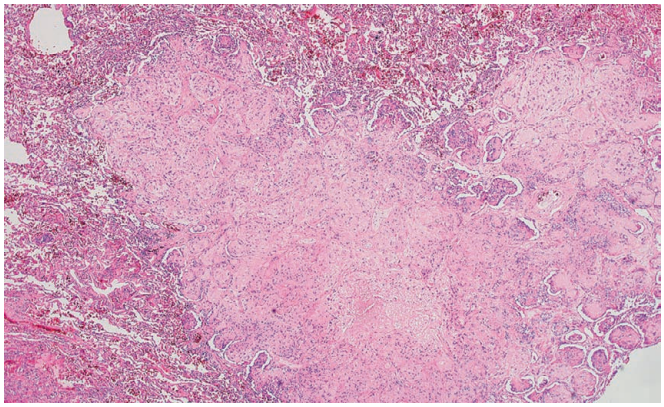

Figure 10.138 Epithelioid hemangioendothelioma. Nodular intra-alveolar aggregates of tumor cells are seen enclosing an amorphous eosinophilic material.

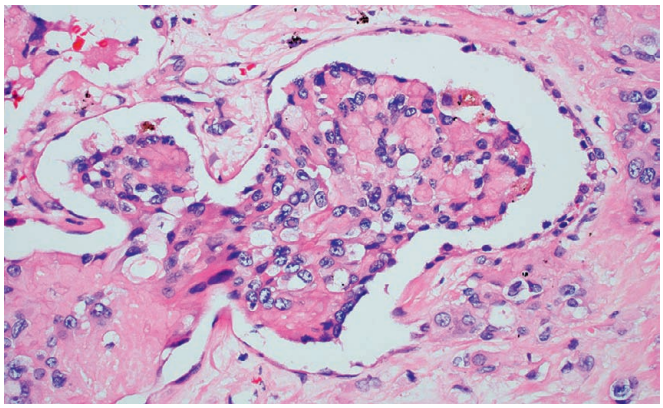

Figure 10.139 Prominent intracytoplasmic lumen formation and cytoplasmic intranuclear pseudoinclusions in epithelioid hemangioendothelioma.

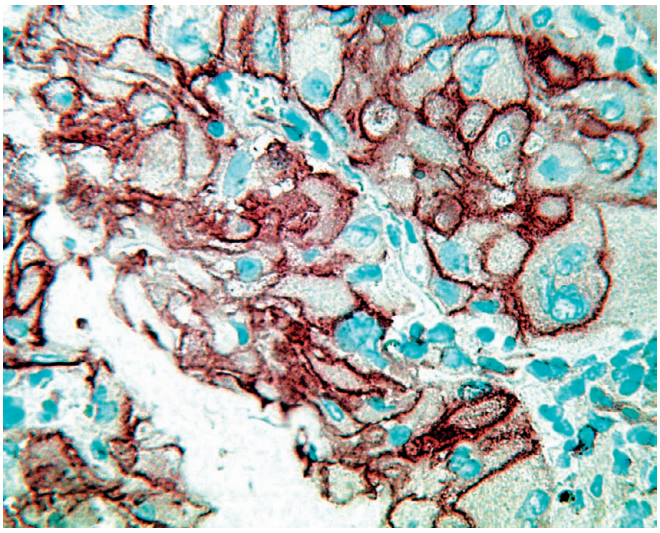

Figure 10.140 Strong immunoreactivity for CD31 in epithelioid hemangioendothelioma.

CD31, ERG, and CD34 but can also be positive for keratins, a potential diagnostic trap (Fig. 10.140).[546,548] Thoracic epithelioid hemangioendotheliomas, like their soft tissue counterparts, show recurrent translocations corresponding to *WWTR1-CAMTA1* and *YAP1-TFE3* gene fusions. Nuclear expression of CAMTA1 in tumors with *WWTR1-CAMTA1* fusions (85%–90%) and strong nuclear staining for TFE3 in the minority with *YAP1-TFE3* fusions is relatively specific and offers another diagnostically useful immunostain.[549]

The tumor grows in a very slow but progressive fashion, with a tendency to remain restricted to the thoracic cavity. Some patients die as a result of pulmonary insufficiency. Poor prognostic factors at the time of diagnosis include respiratory symptoms and/or pleural effusion, and intermediate histologic grade.[544–546] Most of these tumors are primary in the lung, but others with an identical appearance have been interpreted as metastases from epithelioid hemangioendotheliomas located elsewhere, particularly liver.

Epithelioid hemangioma (angiolymphoid hyperplasia with eosinophilia) has been reported in the lung.[550] As in other sites in which it is more frequent, its neoplastic versus inflammatory nature remains controversial.

Lymphoid Tumors and Tumorlike Conditions

The lung can be involved by various types of lymphoproliferative processes, either secondarily or as the only manifestation of the disease.[551,552] Secondary lung involvement can be peribronchial/perivascular, nodular alveolar, interstitial, pleural, or (more commonly) a combination of them. **Leukemic involvement** of the lung is found at autopsy in 30%–40% of the chronic lymphocytic forms, in about 15%–20% of the chronic myelogenous types, and in over 60% of the adult acute forms, but most of them do not result in clinical manifestations.[553–556] Occasionally, however, significant pulmonary impairment results from the infiltrate of chronic lymphocytic leukemia acquiring a selective bronchiolocentric distribution.[555] In rare cases, acute myeloid leukemia presents with widespread pulmonary nodules or infiltrates *(myeloid sarcoma)*.[557,558]

For purposes of discussion, lymphoproliferative disorders presenting in the lung can be divided into four main categories: extranodal marginal zone lymphomas of MALT lymphoma, lymphomas of conventional type spanning the spectrum of phenotypes and histologies including intravascular large B-cell lymphoma, lymphomatoid granulomatosis, and Hodgkin lymphoma.

Small lymphocytic proliferations forming pulmonary nodules are often difficult to interpret. This broad and historically nebulous category comprises predominantly MALT lymphomas, the most common form of primary pulmonary lymphoma.[559] Most patients are in the sixth and seventh decades of life and asymptomatic at the time of diagnosis, the lesion presenting as a solitary nodule or infiltrate on a chest x-ray film or CT scan without associated lymphadenopathy. Underlying autoimmune diseases (especially Sjögren syndrome) and monoclonal gammopathies are common.[559] MALT lymphomas may also complicate pulmonary lymphoid hyperplasia in patients with common variable immunodeficiency.[560]

Grossly, they appear as a relatively well-defined but unencapsulated mass, which on cut surface has a homogeneous white to gray appearance (Fig. 10.141). Microscopic features are similar to those described in other extranodal marginal zone lymphomas and include a tumefactive infiltrate of small lymphocytes, monocytoid B cells, and plasma cells with associated germinal centers scattered throughout and variably well-developed lymphoepithelial complexes (Fig. 10.142). Occasional cases have associated amyloid; in fact, most cases of nodular amyloidosis in the lung are MALT lymphomas in which amyloid deposits overrun the clonal lymphoplasmacytic infiltrate.[561] Histologically indistinguishable nodules composed of non-amyloid light chain may also complicate MALT lymphoma.[562] Nodular hyperplasia is extremely uncommon but the main differential diagnosis for MALT lymphoma.[552,563] Features in favor of malignancy are the monomorphic nature of the infiltrate; the presence of plasmacytoid features with associated intranuclear Dutcher bodies;

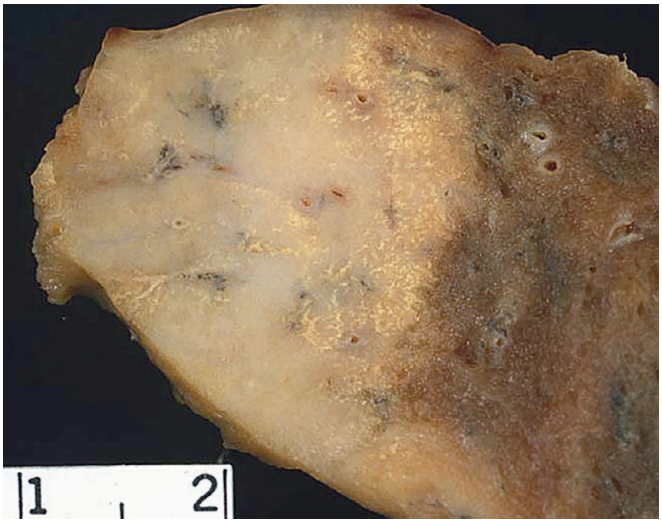

Figure 10.141 Gross appearance of a MALT lymphoma in a surgical lung biopsy.

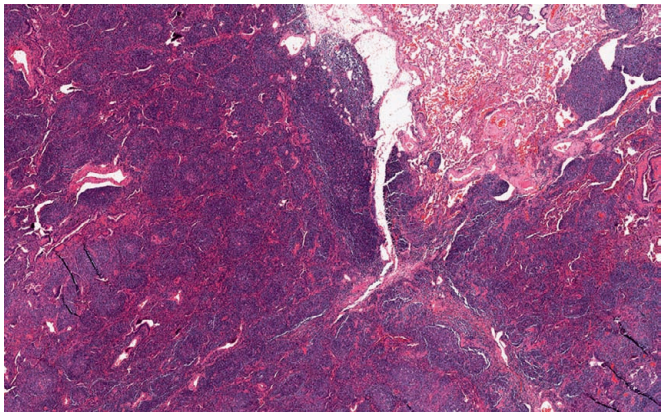

Figure 10.142 MALT lymphoma of lung showing a tumefactive and vaguely nodular configuration on the left with extension along lymphatic pathways on the right.

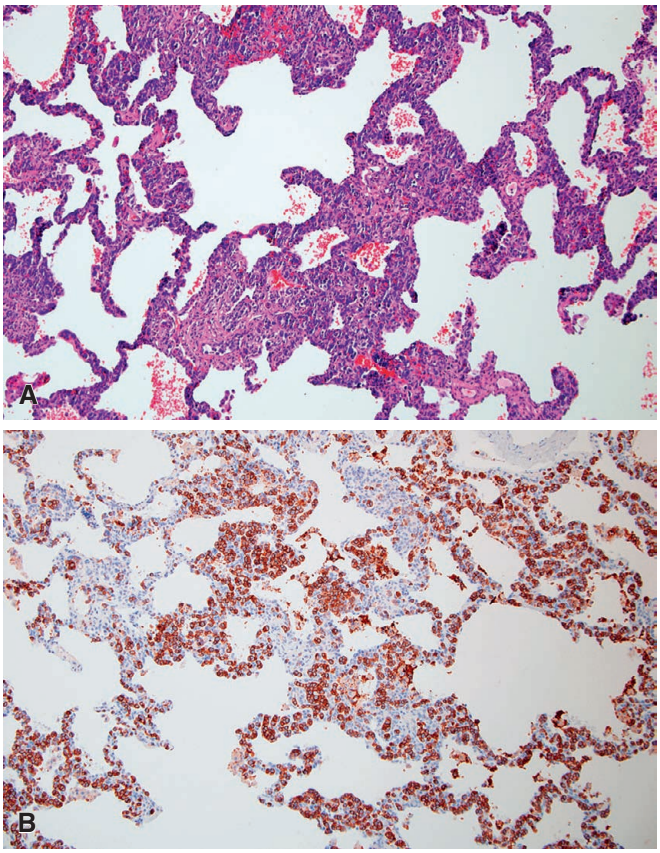

Figure 10.143 **A,** Intravascular lymphoma in a patient with unexplained breathlessness. **B,** An immunostain for CD20 shows neoplastic large B cell exquisitely localized to alveolar septal capillaries.

the presence of amyloid in the stroma; the invasion of bronchial cartilage, wall of large vessels, or visceral pleura; a lymphangitic pattern of infiltration at the periphery; and light chain restriction and/or clonal rearrangements of the immunoglobulin heavy chain gene.[552,559]

Amyloidosis of the lung can be divided into four categories on the basis of distribution: nodular (for which previous comments regarding overlap with MALT lymphoma are relevant), tracheobronchial, diffuse alveolar septal (usually in patients with systemic disease), and vascular (never a serious clinical problem when it occurs in isolation).[564] Radiographically, lesions in the first and second categories can be solitary or multiple and can simulate granulomatous infection or a metastatic neoplasm. Diffuse alveolar septal amyloidosis may lead to a severe impairment of lung function, a diffuse infiltrate on radiographic examination, and a poor prognosis. The amyloid material is mostly made up of AL protein. There are rare reports of localized deposits of non-amyloid light chain forming nodules that are indistinguishable from amyloidosis in routinely stained sections.[562] *Crystal storing histiocytosis* is a related condition resulting from massive accumulation of crystallized immunoglobulin in the cytoplasm of non-neoplastic histiocytes. The disease, which is usually a manifestation of a MALT lymphoma or plasma cell neoplasm, can be localized to the lung or other sites, or systemic.[565]

Plasmacytoma should be used as a diagnostic term only for neoplastic lesions composed entirely of neoplastic, light chain restricted plasma cells. Plasmacytic tumors with a lymphoid component should be classified with the MALT lymphomas; it is likely that some of the tumors previously regarded as primary pulmonary plasmacytomas were instead MALT lymphomas.[566] CD56 can be a helpful immunostain in distinguishing MALT lymphomas from plasmacytomas, as it tends to be positive in the latter and negative in the former.[566] Plasmacytomas of lung may be intraparenchymal or endobronchial, may be associated with nodal or bone involvement, and may exhibit production of light chain protein,[567] which may appear in the tissue in the form of diffuse or nodular deposits that resemble amyloid but are not congophilic.[568]

Large cell lymphoma of conventional type presents as a large mass, sometimes occupying most of a lobe, and is often accompanied by foci of necrosis.[569] Occasionally the pattern of growth is predominantly endobronchial. Microscopically, a monomorphic infiltrate of large lymphoid cells is present. Most cases are diffuse large B-cell lymphomas, with rare examples resembling primary mediastinal large B-cell lymphoma.[570] Intravascular lymphoma is a form of extranodal large B-cell lymphoma that sometimes presents with lung involvement, often in symptomatic patients with minimally abnormal imaging studies (Fig. 10.143)[571,572]; central nervous system, skin, and bone marrow are other commonly affected sites. Anaplastic large cell lymphomas can also occur in the lung.[573]

Lymphomatoid granulomatosis, originally included by Liebow in his *pulmonary angiitis and granulomatosis* group,[574] is now placed among the B-cell lymphoproliferative disorders.[575] It usually presents

in middle age with bilateral rounded mass densities, which radiographically may resemble metastases.[576,577] Cases of lymphomatoid granulomatosis and similar atypical lymphoproliferative processes have been reported in immunosuppressed transplant recipients in whom it represents a form of post-transplant lymphoproliferative disorder, and in HIV-infected patients.[216] The key microscopic picture is the presence of a polymorphic infiltrate comprising a combination of plasma cells, small lymphocytes in which T-cells predominate, immunoblasts, and atypical large lymphoid cells, with a tendency to form centrally necrotic nodules and to involve the walls of pulmonary vessels as transmural, circumferential infiltrates (Fig. 10.144). The multinucleated giant cells and necrotizing vasculitis of GPA (Wegener) are not present. Lymphomatoid granulomatosis can be graded according to the relative proportion of atypical large cells (grades 1–3), although the criteria proposed and the relationship to prognosis are inconsistent.[576,578,579]

Extrapulmonary involvement occurs in over a third of the cases.[577] The most common sites are the skin (particularly in the lower extremities) and central nervous system. Other less commonly involved sites include kidneys, liver, spleen, adrenal glands, heart, and gastrointestinal tract. The histologic appearance is similar in all of these sites. In rare cases the microscopic changes of lymphomatoid granulomatosis are seen in an extrapulmonary site in the absence of pulmonary involvement.

It has become increasingly evident that both the morphologic features of lymphomatoid granulomatosis and its clinical course are more in keeping with a malignant than a reactive process and that it is common for large cell lymphomas of the lung to exhibit vascular infiltration. Accordingly, lymphomatoid granulomatosis is currently viewed as a primary EBV-related lymphoproliferative disease that either is or has a great tendency to become malignant lymphoma.[575,577] On the basis of combined immunohistochemical and in situ hybridization studies, most cases of lymphomatoid granulomatosis represent a proliferation of EBV-infected B cells associated with a prominent T-cell reaction with prominent vascular involvement.[580–583]

Response to steroids is poor, but multidrug chemotherapy induces complete remission in about half of cases.[584] Novel treatments including a combination of immunotherapy and chemotherapy have been effective in some cases.[585] Despite treatment advances, lymphomatoid granulomatosis remains an aggressive disease with relatively high disease-related mortality.[577]

Hodgkin lymphoma involving the lung parenchyma is usually associated with nodal involvement, direct extension from the mediastinum (thymus) being frequent in the nodular sclerosis form. However, rare cases of primary pulmonary Hodgkin lymphoma have been well documented.[586–588] They are reported with slightly greater frequency in women over a broad age ranges and usually appear as solitary or multiple nodular lesions on chest x-rays and/or CT scans.[586–588] Endobronchial involvement can also occur, either in the form of a plaquelike infiltrate or as a polypoid mass.

Salivary Gland–Type Tumors

Several types of epithelial tumor with patterns analogous to those of salivary gland neoplasms occur in the lung, probably arising from submucous bronchial glands. Most of them are located within the trachea or the main cartilaginous bronchi.[589]

Adenoid cystic carcinoma is the most common type. It is usually centered in the major bronchi (Fig. 10.145) and often involves the trachea, although peripheral examples are also on record.[590] Metastases to regional lymph nodes occur in a minority of cases.[589,591] The histologic, immunohistochemical, and cytogenetic findings are indistinguishable from those described for adenoid cystic carcinomas arising in extrathoracic salivary glands (see Chapter 6), including a characteristic t(6:9)(q22–23;p23–24) translocation resulting in fusion of the *MYB* oncogene and *NFIB* transcription factor in about half of cases.[591] TTF-1 and napsin A staining have been reported in lung metastases from extrapulmonary primaries but is rare in primary pulmonary adenoid cystic carcinomas, making these stains of little value in separating primary from metastatic tumors.[592] The primary treatment is surgical excision. Irradiation therapy may induce marked regression, but it is not curative. The total duration of the disease is long, but the ultimate prognosis is poor.[589]

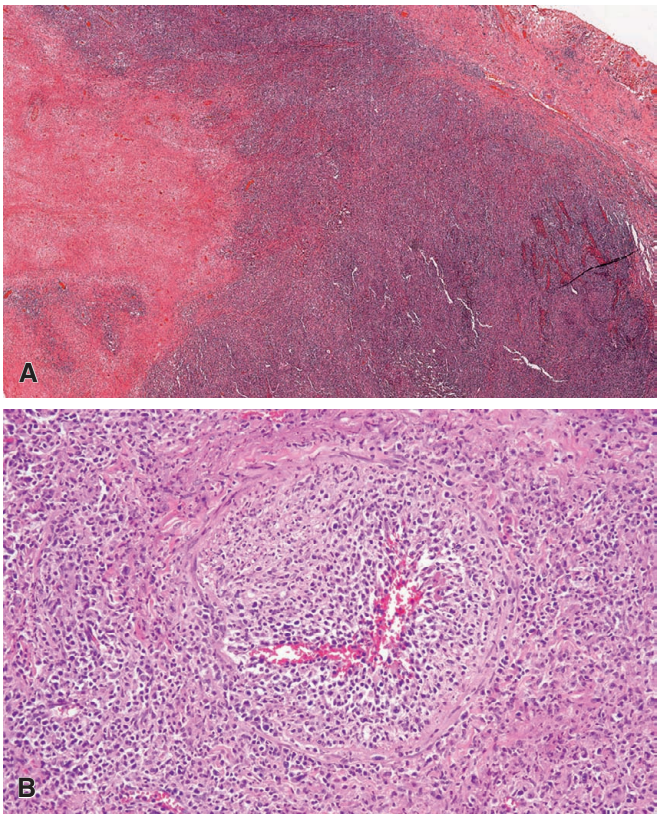

Figure 10.144 Lymphomatoid granulomatosis showing polymorphic infiltrate forming centrally necrotic nodule **(A)** and characteristic angioinvasive growth pattern **(B)**.

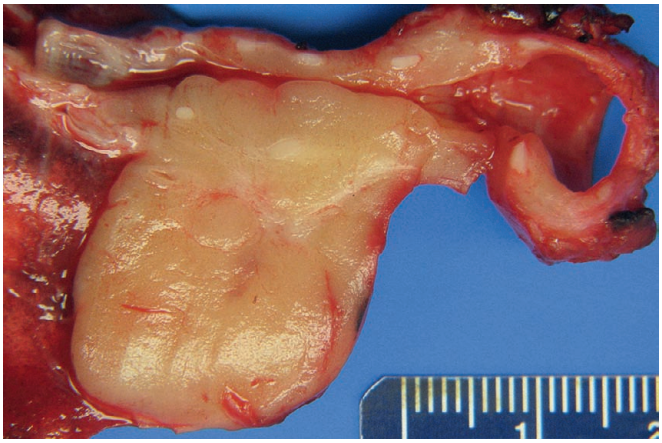

Figure 10.145 Adenoid cystic carcinoma presenting as an endobronchial mass invading adjacent lung parenchyma.

Figure 10.146 Endobronchial growth of mucoepidermoid carcinoma.

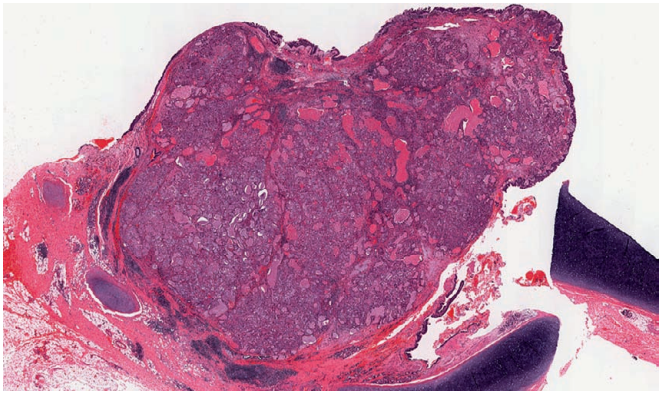

Figure 10.147 Endobronchial mucoepidermoid carcinoma showing characteristic low-grade histology.

Mucoepidermoid carcinomas of the lung affect males and females equally across a broad age range, including children, and usually present as an exophytic endobronchial mass (Fig. 10.146).[589,593,594] They can be divided into low-grade and high-grade varieties, like their salivary gland counterparts.[594] High-grade variants are rare and not easily separated from adenosquamous carcinoma. As in their more common extrathoracic salivary gland location, they are composed of a combination of mucus-secreting cells, squamous cells, and cells of intermediate type (Fig. 10.147). Rarely, they are accompanied by a heavy lymphoplasmacytic infiltrate.[595] Immunohistochemical stains show a profile identical to that described in mucoepidermoid carcinomas arising in other sites (see Chapter 6), including negative staining for TTF-1 and napsin A.[593] Pulmonary mucoepidermoid carcinomas demonstrate the same t(11;19)(q21;p13) translocation of the *mucoepidermoid carcinoma translocated 1 (MECT1)* and *mammalian mastermind-like 2 (MAML2)* genes resulting in the MECT1–MAML2 fusion oncoprotein unique to all mucoepidermoid carcinomas of salivary gland origin.[596]

Low-grade mucoepidermoid carcinoma has a low malignant potential, characterized mainly by local invasion and a relatively good prognosis[589,593,594,597] The rare cases of high-grade mucoepidermoid carcinoma have a stage-dependent prognosis resembling that seen with other forms of high-grade non-small cell carcinoma.[594] These tumors, like adenoid cystic carcinomas, lack the sensitizing *EGFR* mutations that occur in a subset of conventional lung adenocarcinomas.[598]

Cases of lung carcinoma with adenosquamous features, a suggestion of myoepithelial cell differentiation (such as positivity for S-100 protein), and amyloid-like stroma made up of basement membrane material have been reported and may represent a unique subset of lung carcinomas with features resembling salivary gland neoplasms.[599]

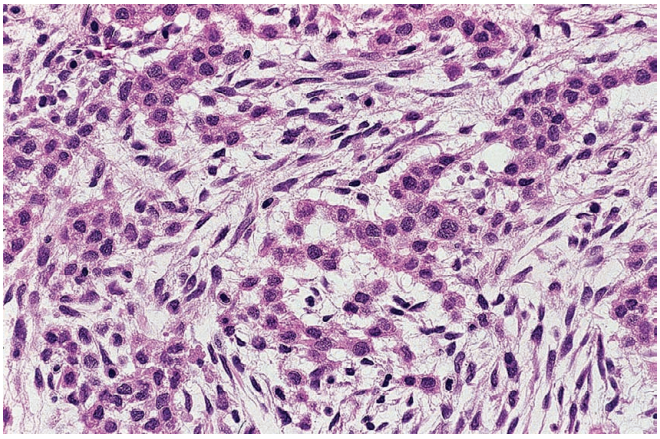

Figure 10.148 Myoepithelioma of lung. This particular tumor had arisen from a typical hamartoma.

Other less common tumors belonging to this rather generic category of salivary gland or salivary gland–like neoplasms include:

- **Pleomorphic adenoma** (benign mixed tumor)[600]
- **Malignant mixed tumor**[600,601]
- **Myoepithelial tumors**
  Epithelial–myoepithelial carcinoma[602]
  Pneumocytic adenomyoepithelioma[603]
  Myoepithelioma arising in hamartoma (Fig. 10.148)[487]
- Acinic cell carcinoma[604]
  Combined with typical carcinoid tumor[605]
- **Oncocytoma**.[606] This tumor, which can be malignant, is analogous to oncocytomas of salivary gland origin and should be distinguished from oncocytic neuroendocrine tumors and adenocarcinomas, a task that may require immunohistochemical evaluation[392,607]

PEComatous Tumors

Clear cell tumor ('sugar tumor') is analogous to PEComas arising in other nonpulmonary sites. In the lung, these rare tumors present as a round or ovoid solitary peripheral lung nodule usually measuring no more than 2 cm in greatest dimension.[608] It usually occurs in adults, but it has also been reported in children.[609] Microscopically, it is made up of large cells with clear to eosinophilic granular cytoplasm crowded with glycogen granules (Fig. 10.149). Some cells have a 'spidery' appearance. Fat is absent. Mitoses are not seen. There is scanty intervening stroma, but thin-walled vessels may be prominent, as well as extracellular amorphous eosinophilic material (sometimes calcified).

Immunohistochemically, clear cell tumors of the lung show the same expression of melanogenesis-associated markers affiliated with PEComas elsewhere, including staining for HMB-45, S-100 protein, and cathepsin B accompanied by focal and inconstant positivity for actin, neuron-specific enolase, and synaptophysin.[608,610] By electron microscopy, most of the glycogen is membrane bound in lysosome-like organelles.[608] Intracytoplasmic filaments may be present. Dense-core granules compatible with premelanosomes have been found in a few of the cells; in rare cases, well-developed melanosomes occur.[608] Basal lamina often surrounds the tumor cells.

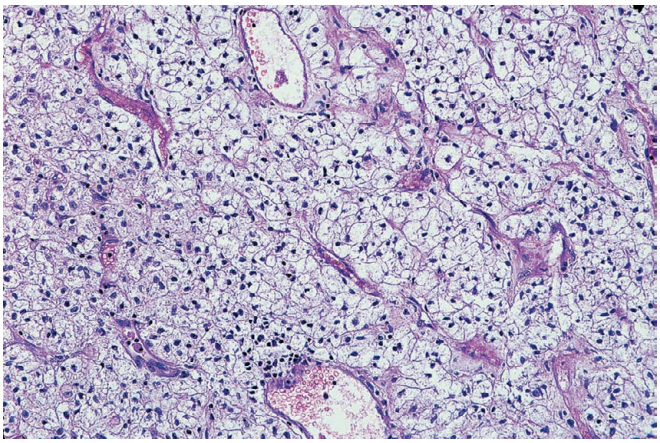

Figure 10.149 Clear cell tumor (PEComa) of lung. Medium-sized clear cells grow in a solid pattern, separated by a prominent vasculature.

The histogenesis of this tumor has been a source of great controversy. Pericytes, smooth muscle cells, neuroendocrine cells, Clara cells, and epithelial cells have all been proposed at one time or another. The HMB-45 immunoreactivity, occasional detection of melanosomes, and other similarities with renal angiomyolipoma suggest that it belongs to a family of tumors thought to be derived from perivascular epithelioid cells (so-called PEComas), a family of tumors that includes lymphangioleiomyomatosis.[611–613]

Lymphangioleiomyomatosis involves both lungs, usually presenting as diffuse cystic lung disease in young women who present with spontaneous pneumothorax and/or pulmonary symptoms, most commonly dyspnea on exertion.[614,615] It occurs only very rarely in men.[616,617] Some patients are affected by tuberous sclerosis (including nearly all of the rare cases reported in men), renal angiomyolipomas, and PEComas of uterus and other sites.[614,618] Grossly, early cases may simply suggest emphysematous changes, whereas more advanced cases show widespread cystic spaces separated by thick, whitish-gray septa (Fig. 10.150). The microscopic features include a combination of cystic spaces associated with interstitial spindled and epithelioid cells with cytologic characteristics typical of other PEComatous lesions (Fig. 10.151). These findings are often accompanied by hemosiderosis, an especially conspicuous feature in more advanced disease.[619] The proliferating ('LAM') cells are immunoreactive for HMB-45 and other melanocytic markers such as melan-A and microphthalmia transcription factor (MiTF) in a patchy distribution with more widespread staining for smooth muscle markers (e.g. smooth muscle actin, desmin) as well as ER and PR. LAM cells are also immunoreactive for β-catenin, which may be a more sensitive marker than HMB-45.[620] LAM cells demonstrate the same complement of mutations in tumor suppressor genes *tuberous sclerosis complex (TSC) 1* or *TSC2* as other PEComatous lesions with clonal identity across sites in cases with multiorgan involvement, including some who develop recurrent pulmonary disease after lung transplant.[621] These observations suggest that lymphangioleiomyomatosis is a low-grade metastasizing neoplasm. Transplantation and, more recently, sirolimus are the mainstays of therapy for cases of lymphangioleiomyomatosis.[622] The prognosis of lymphangiomyomatosis is variable, but survivals measured in decades are the rule rather than the exception.[623] Respiratory symptoms and/or pleural disease (i.e. pneumothorax or chylous effusion) at presentation predict shorter transplant-free survivals.

Muscle Tumors

Leiomyoma presenting as a primary solitary pulmonary mass is rare.[624] Peripheral lesions are more common and typically present as asymptomatic nodules; endobronchial lesions are more likely to be affiliated with findings related to postobstructive bronchiectasis and pneumonia. Multiple EBV-associated leiomyomas and leiomyosarcomas involving the lungs and gastrointestinal tract have been described in HIV-infected children and in MEN 1 patients.[625,626]

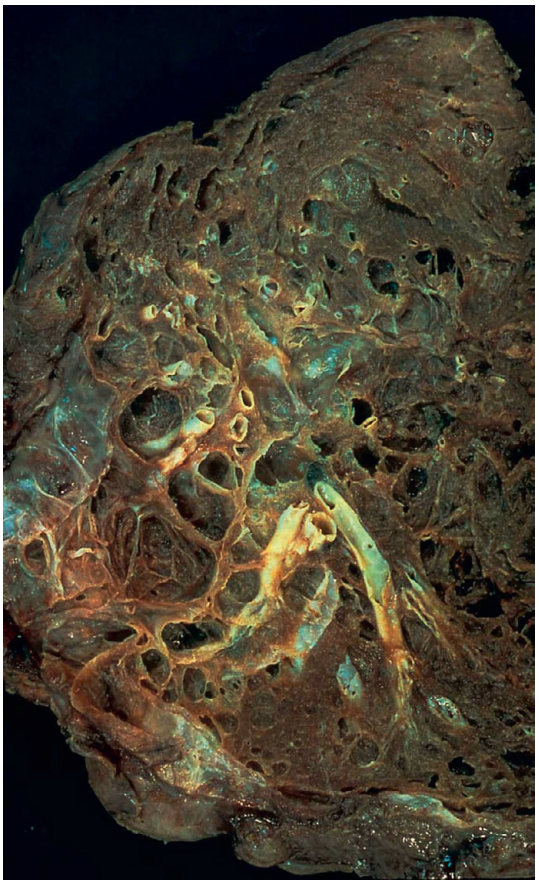

Figure 10.150 Explanted lung showing lymphangioleiomyomatosis in a woman whose pretransplant diagnosis was emphysema.

Occasionally, a middle-aged asymptomatic or minimally symptomatic female is seen with multiple small pulmonary nodules composed of well-differentiated smooth muscle, sometimes enclosing epithelial-lined clefts in a condition referred to most commonly as *benign metastasizing leiomyoma* (Fig. 10.152).[627] Concomitant or preexistent uterine smooth muscle tumors are invariably present. In most cases the pulmonary nodules likely represent clonally related metastases from well-differentiated uterine smooth muscle neoplasms.

Leiomyosarcoma primary in the lung does occur both in adults and children,[628] but in the presence of a malignant smooth muscle tumor in the lung—even if solitary—the chances are overwhelming that the lesion is metastatic. Most are intraparenchymal masses, some associated with an endobronchial component. Leiomyosarcomas arising from the pulmonary veins can invade secondarily the lung parenchyma.[629]

Some cases originally reported as congenital leiomyosarcomas have been reinterpreted as *myofibroblastic tumors* and have been found to be characterized by an indolent clinical course.[630]

Rhabdomyosarcoma can present in its *pleomorphic* form in the lungs of adults (exceptionally rare)[631] or as an expression of the *embryonal* variety in the lungs of children. In children, it tends to occur against a background of cystic changes and blends with the PPBs having a prominent rhabdomyoblastic component (see later).[632]

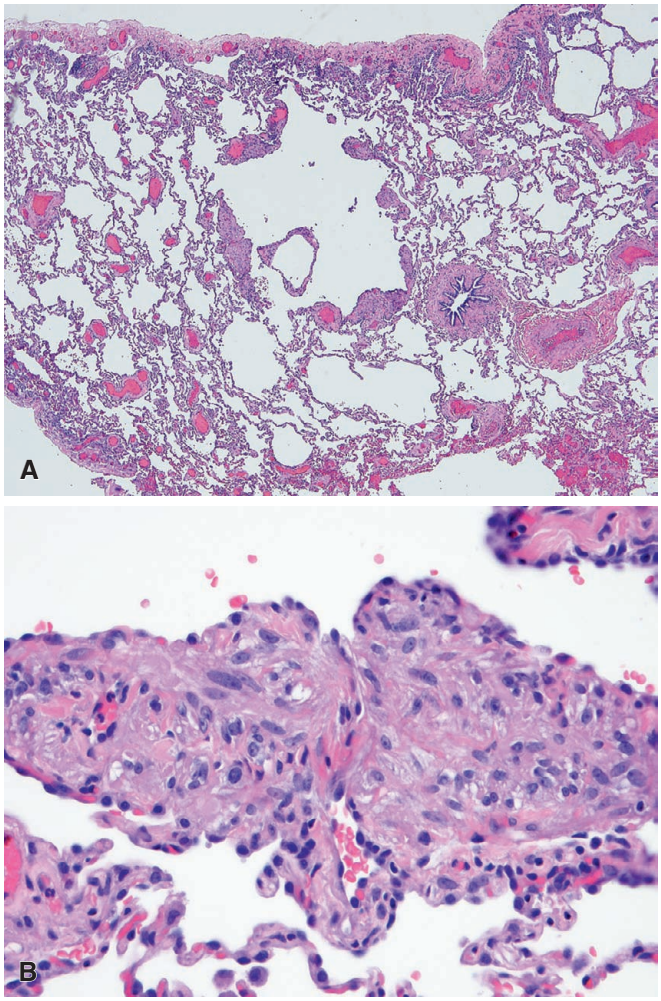

Figure 10.151 Lymphangioleiomyomatosis in which cystic space **(A)** is associated with loose interstitial aggregates of lesional smooth muscle-like (LAM) cells **(B)**.

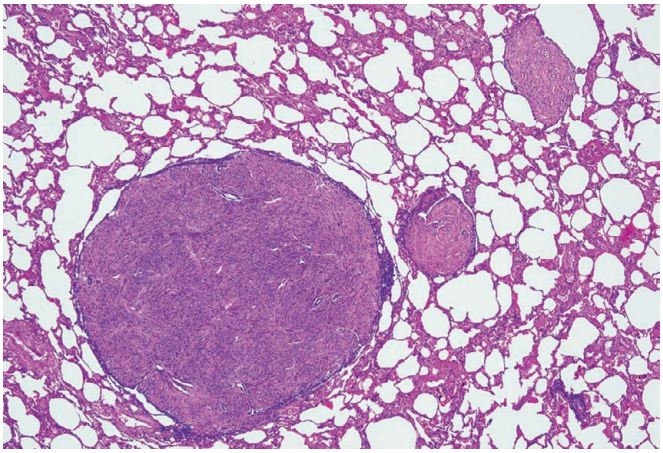

Figure 10.152 Benign metastasizing leiomyoma.

Pleuropulmonary Blastoma

PPB is a dysontogenetic (embryonal, blastomatous) malignant pediatric neoplasm that is pulmonary and/or pleural based.[633] It is unrelated to pulmonary blastoma, which is described elsewhere in this chapter as a histologically distinct form of high-grade sarcomatoid carcinoma in adults. PPB is characterized histologically by an admixture of primitive blastomatous and sarcomatous elements.[634,635] The latter may exhibit evidence of skeletal muscle and cartilaginous differentiation. An epithelial component is either lacking or present only in the form of benign-looking, presumably entrapped epithelium. A three-type system has been proposed for this entity, type I tumors being predominantly cystic and type III tumors almost entirely solid. Care should be exercised to avoid underdiagnosing type I tumors as a developmental cystic malformation.[636] Mutations of the *DICER1* gene have been detected in about two-thirds of cases.[634] The behavior of this tumor is potentially aggressive, particularly for the more solid forms (i.e. types II and III).[634,637]

The recently described **fetal lung interstitial tumor** may or may not be related to the cystic form of (type I) PPB.[638]

Miscellaneous Primary Tumors

Squamous papillomas account for about 70% of solitary lung papillomas, the others showing glandular or mixed types of epithelial lining cells.[639] Squamous papillomas are more common in men and more likely to be associated with cigarette smoking and HPV infection. The prognosis for solitary papillomas is excellent independent of the epithelial type.[639] Multiple squamous papillomas may involve the lower respiratory tract in patients with recurrent respiratory papillomatosis and are more likely to be associated with an aggressive course including progression to squamous cell carcinoma.[640]

Granular cell tumor can present either as a polypoid endobronchial mass with signs of bronchial obstruction or as an asymptomatic peripheral lung nodule.[641] Most are solitary, but multicentric lesions have been described.

Benign lung tumors other than those already mentioned are rare and include intrapulmonary *thymoma*,[642] *schwannoma*,[643] *ganglioneuroblastoma*,[644] *endobronchial blue nevus*,[645] *microcystic fibromyxoma*,[646] *ciliated muconodular papillary tumor* (a benign or low-grade tumors frequently associated with *BRAF-V600E* or *EGFR* mutations)[647,648] and *lipoma* (*endobronchial*, *peripheral*, and *atypical*),[649–651] a lesion probably related to the more conventional hamartoma described elsewhere in this chapter. We have seen a case of *multifocal microcysts and papillary cystadenoma* of the lung associated with striking vascular proliferation in a patient with von Hippel–Lindau disease, and a similar case has been reported.[652]

Solitary fibrous tumor, although usually pleural based (see Chapter 11), can be entirely intrapulmonary and should therefore be considered in the differential diagnosis of spindle cell tumors of this organ.[653]

Synovial sarcoma is now recognized as one of the most common types of primary pulmonary sarcoma. The large majority are of the monophasic spindle type, a relatively high percentage (higher than in the soft tissue) are poorly differentiated, and extremely few are biphasic (Fig. 10.153).[654] Sometimes they are cystic and present with recurrent pneumothorax.[655]

Primary sarcomas of lung other than those already mentioned are rare. *Fibrosarcoma* affecting pediatric age patients,[656] so-called *undifferentiated pleomorphic sarcoma* (previously termed *malignant fibrous histiocytoma*),[657] *low-grade fibromyxoid sarcoma* (including the related *hyalinizing spindle cell tumor with giant rosettes*),[658] *chondrosarcoma*[659] (including the *mesenchymal* variety[660]), *osteosarcoma*,[661] *malignant peripheral nerve sheath tumor* (including *malignant triton tumor*),[662] *Ewing sarcoma/PNET*,[663] *desmoplastic small cell tumor*,[664] and *follicular dendritic cell tumor/sarcoma*[665] have been described in the lung. *Primary pulmonary myxoid sarcoma* is a more recently described form of lung sarcoma that tends to target younger adults and has a characteristic *EWSR1-CREB1* fusion (Fig. 10.154).[666] Primary pulmonary myxoid sarcoma shares morphologic and molecular

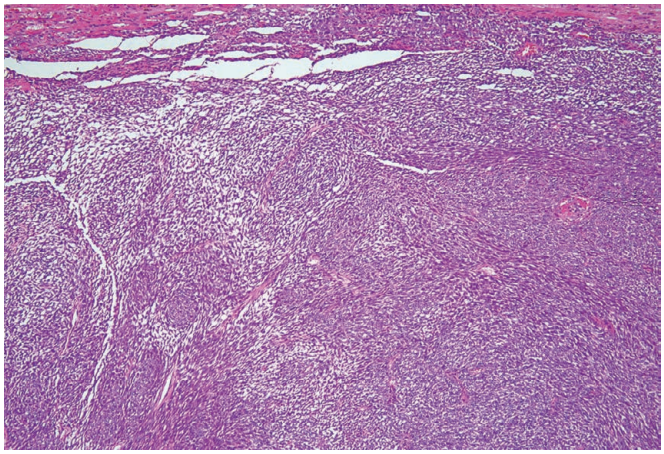

Figure 10.153 Primary monophasic synovial sarcoma of lung. Some areas have a fibroblastic appearance, whereas in others the cells are slightly plumper, although still lacking an identifiable epithelial organization. There was focal immunoreactivity for keratin.

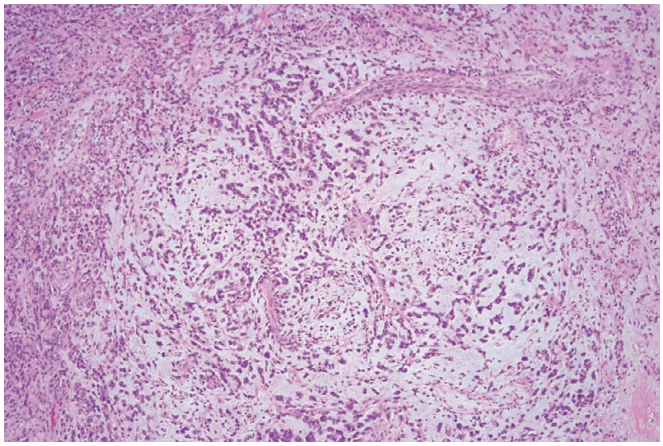

Figure 10.154 Primary pulmonary myxoid sarcoma with a *EWSR1-CREB1* fusion.

features with *angiomatoid fibrous histiocytoma,* leading some to conclude that they may be overlapping entities.[667] In the presence of any of these tumors, all efforts should be made to rule out the possibility of a primary tumor elsewhere and/or of a primary lung carcinoma with a sarcoma-like appearance. This applies particularly to the cases reported as *rhabdoid tumor* or *rhabdoid sarcoma* of lung, most of which are dedifferentiated forms of lung carcinoma.[323]

Malignant melanoma primary in the lung is yet another tumor type that should be diagnosed with great caution. Although reasonably convincing examples exist (supported by the presence of a 'junctional' bronchial component),[668] the large majority represent metastatic deposits from known or occult primaries.

Germ cell tumors of choriocarcinomatous, yolk sac, and other (nonseminomatous) types allegedly primary in the lung have been described.[669–671] They need to be distinguished from pulmonary metastases of gonadal germ cell tumors[672] and from primary lung carcinomas with germ cell–like features, both of which are much more common. Lung carcinomas have the capacity to secrete a number of proteins more commonly associated with germ cell tumors including the alpha subunit of hCG[673] and AFP,[674,675] the latter particularly in association with rare cases of adenocarcinoma resembling hepatocellular carcinoma *(hepatoid adenocarcinoma*[676]*)*.

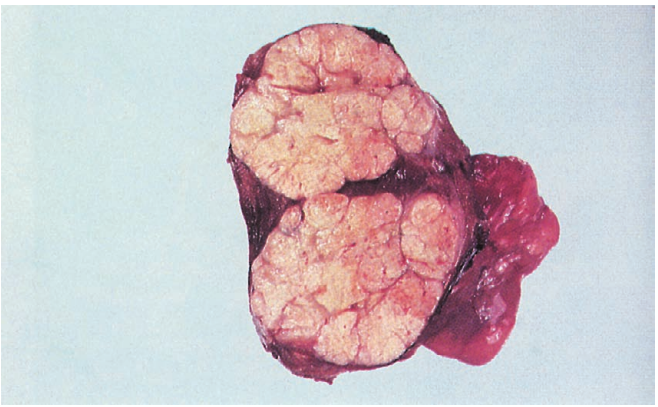

Figure 10.155 Metastatic renal cell carcinoma to lung. The lesion is well circumscribed, multinodular, and golden yellow.

Metastatic Tumors

The lung is a very common site of metastatic disease, sometimes as the only expression of distant tumor spread. Most metastases are multiple, bilateral, sharply outlined, and rapidly growing; this is particularly true for metastases from some types of carcinoma (breast, gastrointestinal tract, and kidney), sarcomas, and melanomas. They range from miliary nodules to 'cannonball' lesions and are more common in the lower lobes. Other metastases (particularly from carcinomas of stomach, breast, pancreas, and prostate) tend to present as widespread neoplastic involvement of the pulmonary perivascular and peribronchial lymphatics (so-called *lymphangitic carcinomatosis*), which may result in severe dyspnea and pulmonary hypertension *(tumor-related thrombotic pulmonary microangiopathy)*, sometimes in the absence of chest x-ray abnormalities.[677]

In other instances the metastases present as isolated nodules and may simulate the appearance of primary tumors (Figs. 10.155 to 10.159). Central cavitation can occur in them; this is particularly common in squamous cell carcinomas of the upper aerodigestive tract and adenocarcinomas of colorectal origin.

Another type of lung metastasis that can be confused with a primary tumor results from the penetration of intraparenchymal or nodal deposits into the wall of a major bronchus and their presentation as polypoid endobronchial masses mimicking primary lung carcinomas.[678] The most common primary sites of origin for endobronchial metastases are breast, large bowel, kidney, stomach, prostate, and melanoma and in some cases is the first manifestation of malignancy.

The differential diagnosis between primary and metastatic lung carcinoma can be difficult and sometimes impossible. Multiplicity of lesions and extensive lymphatic permeation favor a metastasis. The presence of atypical or in situ changes in the bronchial mucosa adjacent to a squamous cell carcinoma, and of honeycombing and atypical hyperplasia of bronchiolar epithelium in the parenchyma surrounding an adenocarcinoma, favor a primary tumor. However, it should be remembered that many metastatic cancers to the lung (particularly from large bowel and pancreas) can line the alveolar walls in a 'lepidic' fashion, simulating well differentiated adenocarcinomas of the lung.[679] One of least common forms of metastatic lung involvement by adenocarcinomas from the gastrointestinal tract is the form associated with pseudomyxoma peritonei which accounts for rare reports of parenchymal deposits resembling primary colloid carcinomas.[680]

Immunohistochemical staining may provide great assistance in some situations as summarized earlier in this chapter. Depending on suspected extrapulmonary primary sites, TTF-1 and napsin A can

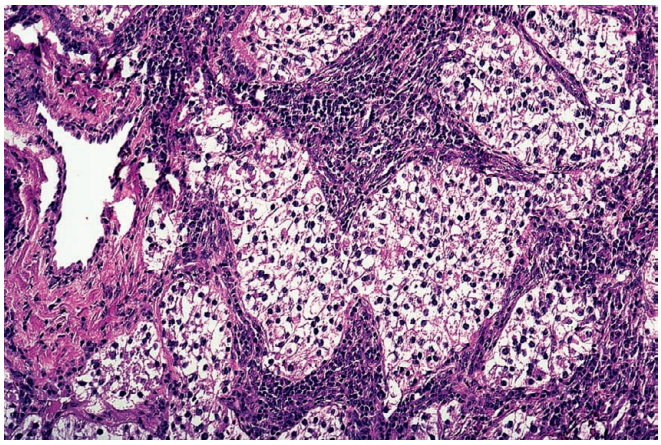

Figure 10.156 Renal cell carcinoma of clear cell type metastatic to lung.

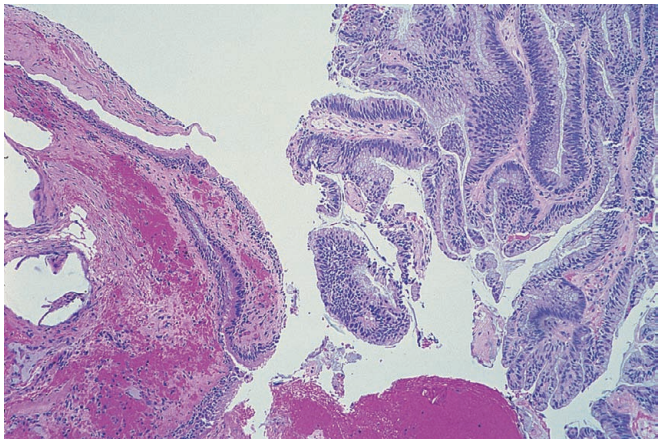

Figure 10.157 Well-differentiated colonic adenocarcinoma metastatic to lung, diagnosed in a bronchial biopsy.

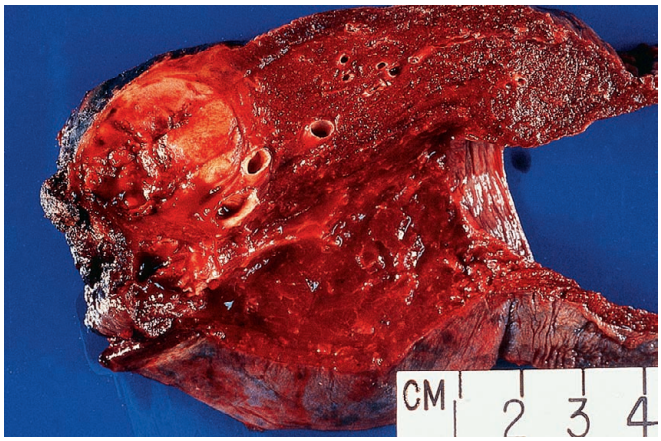

Figure 10.158 Malignant melanoma metastatic to lung.

be especially helpful in supporting pulmonary origin, while staining for PAX8, GATA3, and other selected markers often signify origin from elsewhere.

Among the sarcomas, there are some that are notorious for their ability to simulate primary lung processes. Some metastatic spindle cell sarcomas grow extensively along bronchi and vessels, a pattern that Liebow referred to as *pulmonary sarcomatosis*. Some metastatic angiosarcomas masquerade either as primary vascular tumors or as

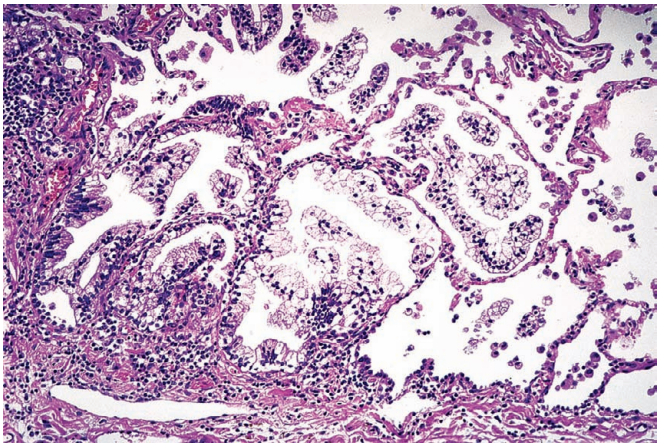

Figure 10.159 Metastatic prostatic adenocarcinoma simulating the appearance of a well differentiated lepidic-predominant adenocarcinoma of the lung.

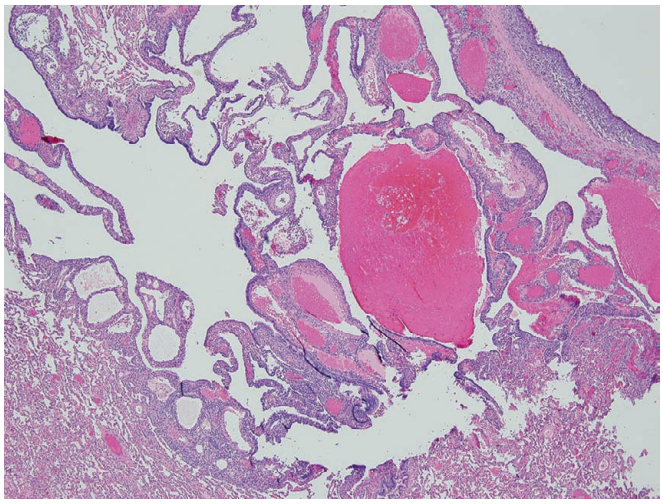

Figure 10.160 Metastatic cellular fibrous histiocytoma of cutaneous origin *(cystic fibrohistiocytic tumors)* forming multiple bilateral cystic masses in a young woman with a preoperative diagnosis of lymphangioleiomyomatosis.

diffuse pulmonary hemorrhage.[540,681] Among uterine tumors, well-differentiated leiomyosarcomas are well known for their ability to simulate leiomyomatous hamartomas, and endometrial stromal sarcomas have often been confused with primary hemangiopericytomas, spindle carcinoid tumors, and other lung primary neoplasms. The fact that the interval between the removal of the original tumors and the appearance of the (often single) lung metastasis can be measured in years or decades contributes to the potential diagnostic pitfall.[536] Another potential diagnostic pitfall pertains to cystic metastases from low-grade nonepithelial tumors (Fig. 10.160), such as cutaneous fibrous histiocytomas *(cystic fibrohistiocytic tumors*[682]*)*, dermatofibrosarcoma protuberans, and low-grade smooth muscle tumors, that may mimic other forms of cystic lung disease such as lymphangioleiomyomatosis or LCH.

When the pulmonary metastatic foci are few *(oligometastases)* and sharply circumscribed, they may be amenable to surgical excision (metastasectomy).[683–685] Poor prognostic signs are multiplicity and size of metastases and presence of extrapulmonary disease. A particularly aggressive approach has been taken toward lung metastases in children, often including some combination of metastasectomy, radiation, and chemotherapy. Five-year survival rates of 25%–40% have been obtained, which is a remarkable achievement.[686]

References

1. Albertine KH. Anatomy of the lungs. In: Mason RJ, Broaddus VC, Martin TR, et al, eds. *Murray and Nadel's Textbook of Respiratory Medicine*. Vol. 1. 5th ed. Philadelphia, PA: Saunders/Elsevier; 2010:3-25.
2. Kuhn CI, Wright JL. The normal lung. In: Churg AM, ed. *Thurlbeck's Pathology of the Lung*. New York, NY: Thieme; 2005:1-38.
3. Linnoila RI. Functional facets of the pulmonary neuroendocrine system. *Lab Invest*. 2006;86(5):425-444.
4. Katzenstein AL. *Katzenstein and Askin's Surgical Pathology of Non-neoplastic Lung Disease*. 4th ed. Philadelphia, PA: Saunders/Elsevier; 2006.
5. Wang CW, Teng YH, Huang CC, et al. Intrapulmonary lymph nodes: computed tomography findings with histopathologic correlations. *Clin Imaging*. 2013;37(3):487-492.
6. Fraggetta F, Davenport M, Magro G, et al. Striated muscle cells in non-neoplastic lung tissue: a clinicopathologic study. *Hum Pathol*. 2000;31(12):1477-1481.
7. Hardisson D, Garcia-Jimenez JA, Jimenez-Heffernan JA, Nistal M. Rhabdomyomatosis of the newborn lung unassociated with other malformations. *Histopathology*. 1997;31(5):474-479.
8. Kershisnik MM, Kaplan C, Craven CM, et al. Intrapulmonary neuroglial heterotopia. *Arch Pathol Lab Med*. 1992;116(10):1043-1046.
9. de Krijger RR, Albers MJ, Bogers AJ, Mooi WJ. Heterotopic pancreatic tissue presenting as a solid and cystic lung lesion: a very unusual bronchopulmonary foregut malformation. *Pediatr Dev Pathol*. 2004;7(2):204-209.
10. Armin A, Castelli M. Congenital adrenal tissue in the lung with adrenal cytomegaly. Case report and review of the literature. *Am J Clin Pathol*. 1984;82(2):225-228.
11. Ryu HS, Chung YJ, Chong S, Lee JI. Ectopic intrapulmonary thyroid tissue mimicking metastatic tissue. *Thyroid*. 2012;22(7):755-759.
12. Sato M, Shames DS, Girard L, et al. Molecular basis of lung cancer. In: Mendelsohn J, Howley PM, Israel MA, et al, eds. *The Molecular Basis of Cancer*. 3rd ed. Philadelphia, PA: Saunders; 2008:397-407.
13. Leslie KO, Gruden JF, Parish JM, Scholand MB. Transbronchial biopsy interpretation in the patient with diffuse parenchymal lung disease. *Arch Pathol Lab Med*. 2007;131(3):407-423.
14. Colby TV, Yousem SA. Pulmonary histology for the surgical pathologist. *Am J Surg Pathol*. 1988;12(3):223-239.
15. Bejarano PA, Garcia MT, Ganjei-Azar P. Mesothelial cells in transbronchial biopsies: a rare complication with a potential for a diagnostic pitfall. *Am J Surg Pathol*. 2007;31(6):914-918.
16. Nagata N, Hirano H, Takayama K, et al. Step section preparation of transbronchial lung biopsy. Significance in the diagnosis of diffuse lung disease. *Chest*. 1991;100(4):959-962.
17. Takayama K, Nagata N, Miyagawa Y, et al. The usefulness of step sectioning of transbronchial lung biopsy specimen in diagnosing sarcoidosis. *Chest*. 1992;102(5):1441-1443.
18. Travis WD, Costabel U, Hansell DM, et al. An official American Thoracic Society/European Respiratory Society statement: update of the international multidisciplinary classification of the idiopathic interstitial pneumonias. *Am J Respir Crit Care Med*. 2013;188(6):733-748.
19. Miller RR, Nelems B, Muller NL, et al. Lingular and right middle lobe biopsy in the assessment of diffuse lung disease. *Ann Thorac Surg*. 1987;44(3):269-273.
20. Fibla JJ, Brunelli A, Allen MS, et al. Microbiology specimens obtained at the time of surgical lung biopsy for interstitial lung disease: clinical yield and cost analysis. *Eur J Cardiothorac Surg*. 2012;41(1):36-38.
21. Luck SR, Reynolds M, Raffensperger JG. Congenital bronchopulmonary malformations. *Curr Probl Surg*. 1986;23(4):245-314.
22. Zylak CJ, Eyler WR, Spizarny DL, Stone CH. Developmental lung anomalies in the adult: radiologic-pathologic correlation. *Radiographics*. 2002;22(Spec No):S25-S43.
23. Langston C. New concepts in the pathology of congenital lung malformations. *Semin Pediatr Surg*. 2003;12(1):17-37.
24. Shanti CM, Klein MD. Cystic lung disease. *Semin Pediatr Surg*. 2008;17(1):2-8.
25. Davenport M, Warne SA, Cacciaguerra S, et al. Current outcome of antenally diagnosed cystic lung disease. *J Pediatr Surg*. 2004;39(4):549-556.
26. Pumberger W, Hormann M, Deutinger J, et al. Longitudinal observation of antenatally detected congenital lung malformations (CLM): natural history, clinical outcome and long-term follow-up. *Eur J Cardiothorac Surg*. 2003;24(5):703-711.
27. Stocker JT, Madewell JE, Drake RM. Congenital cystic adenomatoid malformation of the lung. Classification and morphologic spectrum. *Hum Pathol*. 1977;8(2):155-171.
28. Feng A, Cai H, Sun Q, et al. Congenital cystic adenomatoid malformation of lung in adults: 2 rare cases report and review of the literature. *Diagn Pathol*. 2012;7:37.
29. Fletcher CM, Pride NB. Definitions of emphysema, chronic bronchitis, asthma, and airflow obstruction: 25 years on from the Ciba symposium. *Thorax*. 1984;39(2):81-85.
30. Trow TK. Lung-volume reduction surgery for severe emphysema: appraisal of its current status. *Curr Opin Pulm Med*. 2004;10(2):128-132.
31. Sauter JL, Butnor KJ. Pathological findings in spontaneous pneumothorax specimens: does the incidence of unexpected clinically significant findings justify routine histological examination? *Histopathology*. 2015;66(5):675-684.
32. Gunes A, Aboyoun CL, Morton JM, et al. Lung transplantation for chronic obstructive pulmonary disease at St Vincent's Hospital. *Intern Med J*. 2006;36(1):5-11.
33. Fidler ME, Koomen M, Sebek B, et al. Placental transmogrification of the lung, a histologic variant of giant bullous emphysema. Clinicopathological study of three further cases. *Am J Surg Pathol*. 1995;19(5):563-570.
34. Mukhopadhyay S, Wilcox BE, Myers JL, et al. Pulmonary necrotizing granulomas of unknown cause: clinical and pathologic analysis of 131 patients with completely resected nodules. *Chest*. 2013;144(3):813-824.
35. Butnor KJ, Guinee DG Jr. Pleuropulmonary pathology of Birt-Hogg-Dube syndrome. *Am J Surg Pathol*. 2006;30(3):395-399.
36. Koga S, Furuya M, Takahashi Y, et al. Lung cysts in Birt-Hogg-Dube syndrome: histopathological characteristics and aberrant sequence repeats. *Pathol Int*. 2009;59(10):720-728.
37. Bouron-Dal Soglio D, Rougemont AL, De Buys Roessingh AS, et al. Chondroid cystic malformation of the lung with trisomy 8 mosaicism: a new cystic lung malformation. *Am J Surg Pathol*. 2008;32(7):1095-1100.
38. Barker AF. Bronchiectasis. *N Engl J Med*. 2002;346(18):1383-1393.
39. Kwon KY, Myers JL, Swensen SJ, Colby TV. Middle lobe syndrome: a clinicopathological study of 21 patients. *Hum Pathol*. 1995;26(3):302-307.
40. Morillas HN, Zariwala M, Knowles MR. Genetic causes of bronchiectasis: primary ciliary dyskinesia. *Respiration*. 2007;74(3):252-263.
41. Canessa PA, Santini D, Zanelli M, Capecchi V. Pulmonary tumourlets and microcarcinoids in bronchiectasis. *Monaldi Arch Chest Dis*. 1997;52(2):138-139.
42. Mansharamani NG, Koziel H. Chronic lung sepsis: lung abscess, bronchiectasis, and empyema. *Curr Opin Pulm Med*. 2003;9(3):181-185.
43. Bech B, Pressler T, Iversen M, et al. Long-term outcome of lung transplantation for cystic fibrosis—Danish results. *Eur J Cardiothorac Surg*. 2004;26(6):1180-1186.
44. Hagan JL, Hardy JD. Lung abscess revisited. A survey of 184 cases. *Ann Surg*. 1983;197(6):755-762.
45. Patradoon-Ho P, Fitzgerald DA. Lung abscess in children. *Paediatr Respir Rev*. 2007;8(1):77-84.
46. El-Zammar OA, Katzenstein AL. Pathological diagnosis of granulomatous lung disease: a review. *Histopathology*. 2007;50(3):289-310.
47. Hutton Klein JR, Tazelaar HD, Leslie KO, Colby TV. One hundred consecutive granulomas in a pulmonary pathology consultation practice. *Am J Surg Pathol*. 2010;34(10):1456-1464.
48. Mukhopadhyay S, Gal AA. Granulomatous lung disease: an approach to the differential diagnosis. *Arch Pathol Lab Med*. 2010;134(5):667-690.
49. Nunn P, Williams B, Floyd K, et al. Tuberculosis control in the era of HIV. *Nat Rev Immunol*. 2005;5(10):819-826.
50. Olson NA, Davidow AL, Winston CA, et al. A national study of socioeconomic status and tuberculosis rates by country of birth, United States, 1996-2005. *BMC Public Health*. 2012;12:365.
51. Reves R, Schluger NW. Update in tuberculosis and nontuberculous mycobacterial infections 2013. *Am J Respir Crit Care Med*. 2014;189(8):894-898.
52. Raymond D. Surgical intervention for thoracic infections. *Surg Clin North Am*. 2014;94(6):1283-1303.
53. Strieder JW, Laforet EG, Lynch JP. The surgery of pulmonary tuberculosis. *N Engl J Med*. 1967;276(17):960-965.
54. Ulbright TM, Katzenstein AL. Solitary necrotizing granulomas of the lung: differentiating features and etiology. *Am J Surg Pathol*. 1980;4(1):13-28.
55. Schulz S, Cabras AD, Kremer M, et al. Species identification of mycobacteria in paraffin-embedded tissues: frequent detection of nontuberculous mycobacteria. *Mod Pathol*. 2005;18(2):274-282.
56. McShane PJ, Glassroth J. Pulmonary disease due to nontuberculous mycobacteria: current state and new insights. *Chest*. 2015;148(6):1517-1527.
57. Tazelaar HD, Linz LJ, Colby TV, et al. Acute eosinophilic pneumonia: histopathologic findings in nine patients. *Am J Respir Crit Care Med*. 1997;155(1):296-302.
58. Iannuzzi MC, Rybicki BA, Teirstein AS. Sarcoidosis. *N Engl J Med*. 2007;357(21):2153-2165.
59. Judson MA. Sarcoidosis: clinical presentation, diagnosis, and approach to treatment. *Am J Med Sci*. 2008;335(1):26-33.
60. Ma Y, Gal A, Koss MN. The pathology of pulmonary sarcoidosis: update. *Semin Diagn Pathol*. 2007;24(3):150-161.
61. Zhang C, Chan KM, Schmidt LA, Myers JL. Histopathology of explanted lungs from

patients with a diagnosis of pulmonary sarcoidosis. *Chest*. 2016;149(2):499-507.
62. Visscher D, Churg A, Katzenstein AL. Significance of crystalline inclusions in lung granulomas. *Mod Pathol*. 1988;1(6):415-419.
63. Koerner SK, Sakowitz AJ, Appelman RI, et al. Transbronchinal lung biopsy for the diagnosis of sarcoidosis. *N Engl J Med*. 1975;293(6):268-270.
64. Rosen Y, Moon S, Huang CT, et al. Granulomatous pulmonary angiitis in sarcoidosis. *Arch Pathol Lab Med*. 1977;101(4):170-174.
65. Rosen Y. Four decades of necrotizing sarcoid granulomatosis: what do we know now? *Arch Pathol Lab Med*. 2015;139(2):252-262.
66. Koss MN, Hochholzer L, Feigin DS, et al. Necrotizing sarcoid-like granulomatosis: clinical, pathologic, and immunopathologic findings. *Hum Pathol*. 1980;11(5 suppl):510-519.
67. Jennette JC, Falk RJ, Bacon PA, et al. 2012 revised International Chapel Hill Consensus Conference nomenclature of vasculitides. *Arthritis Rheum*. 2013;65(1):1-11.
68. Yi ES, Colby TV. Wegener's granulomatosis. *Semin Diagn Pathol*. 2001;18(1):34-46.
69. Goulart RA, Mark EJ, Rosen S. Tumefactions as an extravascular manifestation of Wegener's granulomatosis. *Am J Surg Pathol*. 1995;19(2):145-153.
70. Lynch JP 3rd, Tazelaar H. Wegener granulomatosis (granulomatosis with polyangiitis): evolving concepts in treatment. *Semin Respir Crit Care Med*. 2011;32(3):274-297.
71. Yousem SA. Bronchocentric injury in Wegener's granulomatosis: a report of five cases. *Hum Pathol*. 1991;22(6):535-540.
72. Heffner DK. Wegener's granulomatosis is not a granulomatous disease. *Ann Diagn Pathol*. 2002;6(5):329-333.
73. Yousem SA, Lombard CM. The eosinophilic variant of Wegener's granulomatosis. *Hum Pathol*. 1988;19(6):682-688.
74. Travis WD, Hoffman GS, Leavitt RY, et al. Surgical pathology of the lung in Wegener's granulomatosis. Review of 87 open lung biopsies from 67 patients. *Am J Surg Pathol*. 1991;15(4):315-333.
75. Myers JL, Katzenstein AL. Wegener's granulomatosis presenting with massive pulmonary hemorrhage and capillaritis. *Am J Surg Pathol*. 1987;11(11):895-898.
76. Green RJ, Ruoss SJ, Kraft SA, et al. Pulmonary capillaritis and alveolar hemorrhage. Update on diagnosis and management. *Chest*. 1996;110(5):1305-1316.
77. Lombard CM, Duncan SR, Rizk NW, Colby TV. The diagnosis of Wegener's granulomatosis from transbronchial biopsy specimens. *Hum Pathol*. 1990;21(8):838-842.
78. Katzenstein AL, Locke WK. Solitary lung lesions in Wegener's granulomatosis. Pathologic findings and clinical significance in 25 cases. *Am J Surg Pathol*. 1995;19(5):545-552.
79. Jennette JC, Falk RJ. Small-vessel vasculitis. *N Engl J Med*. 1997;337(21):1512-1523.
80. Katzenstein AL. Diagnostic features and differential diagnosis of Churg-Strauss syndrome in the lung. A review. *Am J Clin Pathol*. 2000;114(5):767-772.
81. Kaliterna DM, Perkovic D, Radic M. Churg-Strauss syndrome associated with montelukast therapy. *J Asthma*. 2009;46(6):604-605.
82. Bosken CM, Myers JL, Greenberger PA, Katzenstein AL. Pathologic features of allergic bronchopulmonary aspergillosis. *Am J Surg Pathol*. 1988;12(3):216-222.
83. Chowdhary A, Agarwal K, Kathuria S, et al. Allergic bronchopulmonary mycosis due to fungi other than *Aspergillus*: a global overview. *Crit Rev Microbiol*. 2014;40(1):30-48.
84. Quigley M, Hansell DM, Nicholson AG. Interstitial lung disease—the new synergy between radiology and pathology. *Histopathology*. 2006;49(4):334-342.
85. Bjoraker JA, Ryu JH, Edwin MK, et al. Prognostic significance of histopathologic subsets in idiopathic pulmonary fibrosis. *Am J Respir Crit Care Med*. 1998;157(1):199-203.
86. Nicholson AG, Colby TV, du Bois RM, et al. The prognostic significance of the histologic pattern of interstitial pneumonia in patients presenting with the clinical entity of cryptogenic fibrosing alveolitis. *Am J Respir Crit Care Med*. 2000;162(6):2213-2217.
87. Flaherty KR, Toews GB, Travis WD, et al. Clinical significance of histological classification of idiopathic interstitial pneumonia. *Eur Respir J*. 2002;19(2):275-283.
88. Riha RL, Duhig EE, Clarke BE, et al. Survival of patients with biopsy-proven usual interstitial pneumonia and nonspecific interstitial pneumonia. *Eur Respir J*. 2002;19(6):1114-1118.
89. Collard HR, Yow E, Richeldi L, et al. investigators IP. Suspected acute exacerbation of idiopathic pulmonary fibrosis as an outcome measure in clinical trials. *Respir Res*. 2013;14:73.
90. Lee HL, Ryu JH, Wittmer MH, et al. Familial idiopathic pulmonary fibrosis: clinical features and outcome. *Chest*. 2005;127(6):2034-2041.
91. Katzenstein AL, Mukhopadhyay S, Myers JL. Diagnosis of usual interstitial pneumonia and distinction from other fibrosing interstitial lung diseases. *Hum Pathol*. 2008;39(9):1275-1294.
92. Katzenstein AL, Zisman DA, Litzky LA, et al. Usual interstitial pneumonia: histologic study of biopsy and explant specimens. *Am J Surg Pathol*. 2002;26(12):1567-1577.
93. Katzenstein AL, Myers JL. Nonspecific interstitial pneumonia and the other idiopathic interstitial pneumonias: classification and diagnostic criteria. *Am J Surg Pathol*. 2000;24(1):1-3.
94. Parambil JG, Myers JL, Ryu JH. Histopathologic features and outcome of patients with acute exacerbation of idiopathic pulmonary fibrosis undergoing surgical lung biopsy. *Chest*. 2005;128(5):3310-3315.
95. Yousem SA. Eosinophilic pneumonia-like areas in idiopathic usual interstitial pneumonia. *Mod Pathol*. 2000;13(12):1280-1284.
96. Myers JL, Katzenstein AL. Epithelial necrosis and alveolar collapse in the pathogenesis of usual interstitial pneumonia. *Chest*. 1988;94(6):1309-1311.
97. Katzenstein AL. Pathogenesis of "fibrosis" in interstitial pneumonia: an electron microscopic study. *Hum Pathol*. 1985;16(10):1015-1024.
98. Selman M, Pardo A. Revealing the pathogenic and aging-related mechanisms of the enigmatic idiopathic pulmonary fibrosis. an integral model. *Am J Respir Crit Care Med*. 2014;189(10):1161-1172.
99. Katzenstein AL, Fiorelli RF. Nonspecific interstitial pneumonia/fibrosis. Histologic features and clinical significance. *Am J Surg Pathol*. 1994;18(2):136-147.
100. Travis WD, Hunninghake G, King TE Jr, et al. Idiopathic nonspecific interstitial pneumonia: report of an American Thoracic Society project. *Am J Respir Crit Care Med*. 2008;177(12):1338-1347.
101. Tansey D, Wells AU, Colby TV, et al. Variations in histological patterns of interstitial pneumonia between connective tissue disorders and their relationship to prognosis. *Histopathology*. 2004;44(6):585-596.
102. Myers JL. Nonspecific interstitial pneumonia: pathologic features and clinical implications. *Semin Diagn Pathol*. 2007;24(3):183-187.
103. Katzenstein AL, Myers JL. Idiopathic pulmonary fibrosis: clinical relevance of pathologic classification. *Am J Respir Crit Care Med*. 1998;157(4 Pt 1):1301-1315.
104. Myers JL, Katzenstein AL. Beyond a consensus classification for idiopathic interstitial pneumonias: progress and controversies. *Histopathology*. 2009;54(1):90-103.
105. Myers JL, Veal CF Jr, Shin MS, Katzenstein AL. Respiratory bronchiolitis causing interstitial lung disease. A clinicopathologic study of six cases. *Am Rev Respir Dis*. 1987;135(4):880-884.
106. Fraig M, Shreesha U, Savici D, Katzenstein AL. Respiratory bronchiolitis: a clinicopathologic study in current smokers, ex-smokers, and never-smokers. *Am J Surg Pathol*. 2002;26(5):647-653.
107. Katzenstein AL, Mukhopadhyay S, Zanardi C, Dexter E. Clinically occult interstitial fibrosis in smokers: classification and significance of a surprisingly common finding in lobectomy specimens. *Hum Pathol*. 2010;41(3):316-325.
108. Liebow AA, Steer A, Billingsley JG. Desquamative interstitial pneumonia. *Am J Med*. 1965;39:369-404.
109. Tazelaar HD, Wright JL, Churg A. Desquamative interstitial pneumonia. *Histopathology*. 2011;58(4):509-516.
110. Ryu JH, Myers JL, Capizzi SA, et al. Desquamative interstitial pneumonia and respiratory bronchiolitis-associated interstitial lung disease. *Chest*. 2005;127(1):178-184.
111. Parambil JG, Myers JL, Aubry MC, Ryu JH. Causes and prognosis of diffuse alveolar damage diagnosed on surgical lung biopsy. *Chest*. 2007;132(1):50-57.
112. Katzenstein AL, Bloor CM, Leibow AA. Diffuse alveolar damage—the role of oxygen, shock, and related factors. A review. *Am J Pathol*. 1976;85(1):209-228.
113. Ogino S, Franks TJ, Yong M, Koss MN. Extensive squamous metaplasia with cytologic atypia in diffuse alveolar damage mimicking squamous cell carcinoma: a report of 2 cases. *Hum Pathol*. 2002;33(10):1052-1054.
114. Myers JL, Kennedy JI, Plumb VJ. Amiodarone lung: pathologic findings in clinically toxic patients. *Hum Pathol*. 1987;18(4):349-354.
115. Katzenstein AL, Myers JL, Mazur MT. Acute interstitial pneumonia. A clinicopathologic, ultrastructural, and cell kinetic study. *Am J Surg Pathol*. 1986;10(4):256-267.
116. Olson J, Colby TV, Elliott CG. Hamman-Rich syndrome revisited. *Mayo Clin Proc*. 1990;65(12):1538-1548.
117. Katzenstein AL, Myers JL, Prophet WD, et al. Bronchiolitis obliterans and usual interstitial pneumonia. A comparative clinicopathologic study. *Am J Surg Pathol*. 1986;10(6):373-381.
118. Epler GR, Colby TV, McLoud TC, et al. Bronchiolitis obliterans organizing pneumonia. *N Engl J Med*. 1985;312(3):152-158.
119. Lohr RH, Boland BJ, Douglas WW, et al. Organizing pneumonia. Features and prognosis of cryptogenic, secondary, and focal variants. *Arch Intern Med*. 1997;157(12):1323-1329.
120. Lazor R, Vandevenne A, Pelletier A, et al. Cryptogenic organizing pneumonia. Characteristics of relapses in a series of 48 patients. The Groupe d'Etudes et de Recherche sur les Maladles "Orphelines" Pulmonaires (GERM"O"P). *Am J Respir Crit Care Med*. 2000;162(2 Pt 1):571-577.
121. Morar R, Feldman C. Pulmonary echinococcosis. *Eur Respir J*. 2003;21(6):1069-1077.

122. Nicholson AG, Wotherspoon AC, Diss TC, et al. Reactive pulmonary lymphoid disorders. *Histopathology*. 1995;26(5):405-412.
123. Liebow AA, Carrington CB. Diffuse pulmonary lymphoreticular infiltrations associated with dysproteinemia. *Med Clin North Am*. 1973;57(3):809-843.
124. Zen Y, Inoue D, Kitao A, et al. IgG4-related lung and pleural disease: a clinicopathologic study of 21 cases. *Am J Surg Pathol*. 2009;33(12):1886-1893.
125. Watanabe M, Naniwa T, Hara M, et al. Pulmonary manifestations in Sjogren's syndrome: correlation analysis between chest computed tomographic findings and clinical subsets with poor prognosis in 80 patients. *J Rheumatol*. 2010;37(2):365-373.
126. Koss MN, Hochholzer L, Langloss JM, et al. Lymphoid interstitial pneumonia: clinicopathological and immunopathological findings in 18 cases. *Pathology*. 1987;19(2):178-185.
127. Rao N, Mackinnon AC, Routes JM. Granulomatous and lymphocytic interstitial lung disease: a spectrum of pulmonary histopathologic lesions in common variable immunodeficiency—histologic and immunohistochemical analyses of 16 cases. *Hum Pathol*. 2015;46(9):1306-1314.
128. Yousem SA, Colby TV, Carrington CB. Follicular bronchitis/bronchiolitis. *Hum Pathol*. 1985;16(7):700-706.
129. Yousem SA. Pulmonary apical cap: a distinctive but poorly recognized lesion in pulmonary surgical pathology. *Am J Surg Pathol*. 2001;25(5):679-683.
130. Rosenbaum JN, Butt YM, Johnson KA, et al. Pleuroparenchymal fibroelastosis: a pattern of chronic lung injury. *Hum Pathol*. 2015;46(1):137-146.
131. Camus P, von der Thusen J, Hansell DM, Colby TV. Pleuroparenchymal fibroelastosis: one more walk on the wild side of drugs? *Eur Respir J*. 2014;44(2):289-296.
132. Reddy TL, Tominaga M, Hansell DM, et al. Pleuroparenchymal fibroelastosis: a spectrum of histopathological and imaging phenotypes. *Eur Respir J*. 2012;40(2):377-385.
133. Myers JL. Hypersensitivity pneumonia: the role of lung biopsy in diagnosis and management. *Mod Pathol*. 2012;25(suppl 1):S58-S67.
134. Trahan S, Hanak V, Ryu JH, Myers JL. Role of surgical lung biopsy in separating chronic hypersensitivity pneumonia from usual interstitial pneumonia/idiopathic pulmonary fibrosis: analysis of 31 biopsies from 15 patients. *Chest*. 2008;134(1):126-132.
135. Coleman A, Colby TV. Histologic diagnosis of extrinsic allergic alveolitis. *Am J Surg Pathol*. 1988;12(7):514-518.
136. Churg A, Muller NL, Flint J, Wright JL. Chronic hypersensitivity pneumonitis. *Am J Surg Pathol*. 2006;30(2):201-208.
137. Vourlekis JS, Schwarz MI, Cherniack RM, et al. The effect of pulmonary fibrosis on survival in patients with hypersensitivity pneumonitis. *Am J Med*. 2004;116(10):662-668.
138. Douglas WW, Hepper NG, Colby TV. Silo-filler's disease. *Mayo Clin Proc*. 1989;64(3):291-304.
139. Allen TC. Pulmonary Langerhans cell histiocytosis and other pulmonary histiocytic diseases: a review. *Arch Pathol Lab Med*. 2008;132(7):1171-1181.
140. Travis WD, Borok Z, Roum JH, et al. Pulmonary Langerhans cell granulomatosis (histiocytosis X). A clinicopathologic study of 48 cases. *Am J Surg Pathol*. 1993;17(10):971-986.
141. Vassallo R, Ryu JH, Colby TV, et al. Pulmonary Langerhans'-cell histiocytosis. *N Engl J Med*. 2000;342(26):1969-1978.
142. Khoor A, Myers JL, Tazelaar HD, Swensen SJ. Pulmonary Langerhans cell histiocytosis presenting as a solitary nodule. *Mayo Clin Proc*. 2001;76(2):209-211.
143. Sholl LM, Hornick JL, Pinkus JL, et al. Immunohistochemical analysis of langerin in langerhans cell histiocytosis and pulmonary inflammatory and infectious diseases. *Am J Surg Pathol*. 2007;31(6):947-952.
144. Dacic S, Trusky C, Bakker A, et al. Genotypic analysis of pulmonary Langerhans cell histiocytosis. *Hum Pathol*. 2003;34(12):1345-1349.
145. Roden AC, Hu X, Kip S, et al. BRAF V600E expression in Langerhans cell histiocytosis: clinical and immunohistochemical study on 25 pulmonary and 54 extrapulmonary cases. *Am J Surg Pathol*. 2014;38(4):548-551.
146. Yousem SA, Colby TV, Chen YY, et al. Pulmonary Langerhans' cell histiocytosis: molecular analysis of clonality. *Am J Surg Pathol*. 2001;25(5):630-636.
147. Yousem SA, Dacic S, Nikiforov YE, Nikiforova M. Pulmonary Langerhans cell histiocytosis: profiling of multifocal tumors using next-generation sequencing identifies concordant occurrence of BRAF V600E mutations. *Chest*. 2013;143(6):1679-1684.
148. Chilosi M, Facchetti F, Calio A, et al. Oncogene-induced senescence distinguishes indolent from aggressive forms of pulmonary and non-pulmonary Langerhans cell histiocytosis. *Leuk Lymphoma*. 2014;55(11):2620-2626.
149. Hyman DM, Puzanov I, Subbiah V, et al. Vemurafenib in multiple nonmelanoma cancers with BRAF V600 mutations. *N Engl J Med*. 2015;373(8):726-736.
150. Askin FB, McCann BG, Kuhn C. Reactive eosinophilic pleuritis: a lesion to be distinguished from pulmonary eosinophilic granuloma. *Arch Pathol Lab Med*. 1977;101(4):187-191.
151. Luna E, Tomashefski JF Jr, Brown D, et al. Reactive eosinophilic pulmonary vascular infiltration in patients with spontaneous pneumothorax. *Am J Surg Pathol*. 1994;18(2):195-199.
152. Arnaud L, Pierre I, Beigelman-Aubry C, et al. Pulmonary involvement in Erdheim-Chester disease: a single-center study of thirty-four patients and a review of the literature. *Arthritis Rheum*. 2010;62(11):3504-3512.
153. Emile JF, Diamond EL, Helias-Rodzewicz Z, et al. Recurrent RAS and PIK3CA mutations in Erdheim-Chester disease. *Blood*. 2014;124(19):3016-3019.
154. Haroche J, Charlotte F, Arnaud L, et al. High prevalence of BRAF V600E mutations in Erdheim-Chester disease but not in other non-Langerhans cell histiocytoses. *Blood*. 2012;120(13):2700-2703.
155. Haroche J, Cohen-Aubart F, Charlotte F, et al. The histiocytosis Erdheim-Chester disease is an inflammatory myeloid neoplasm. *Expert Rev Clin Immunol*. 2015;11(9):1033-1042.
156. Ali A, Mackay D. Rosai-Dorfman disease of the lung. *Thorax*. 2009;64(10):908-909.
157. Cartin-Ceba R, Golbin JM, Yi ES, et al. Intrathoracic manifestations of Rosai-Dorfman disease. *Respir Med*. 2010;104(9):1344-1349.
158. Foucar E, Rosai J, Dorfman R. Sinus histiocytosis with massive lymphadenopathy (Rosai-Dorfman disease): review of the entity. *Semin Diagn Pathol*. 1990;7(1): 19-73.
159. El-Kersh K, Perez RL, Guardiola J. Pulmonary IgG4+ Rosai-Dorfman disease. *BMJ Case Rep*. 2013;2013:bcr2012008324.
160. Shrestha B, Sekiguchi H, Colby TV, et al. Distinctive pulmonary histopathology with increased IgG4-positive plasma cells in patients with autoimmune pancreatitis: report of 6 and 12 cases with similar histopathology. *Am J Surg Pathol*. 2009;33(10):1450-1462.
161. Pathology standards for coal workers' pneumoconiosis. Report of the Pneumoconiosis Committee of the College of American Pathologists to the National Institute for Occupational Safety and Health. *Arch Pathol Lab Med*. 1979;103(8):375-432.
162. Green FH, Vallyathan V. Coal workers' pneumoconiosis and pneumoconiosis due to other carbonaceous dusts. In: Churg A, Green FH, eds. *Pathology of Occupational Lung Disease*. 2nd ed. Baltimore, MD: Williams & Wilkins; 1988:129-207.
163. Davis JM, Chapman J, Collings P, et al. Variations in the histological patterns of the lesions of coal workers' pneumoconiosis in Britain and their relationship to lung dust content. *Am Rev Respir Dis*. 1983;128(1):118-124.
164. Schreiber J, Koschel D, Kekow J, et al. Rheumatoid pneumoconiosis (Caplan's syndrome). *Eur J Intern Med*. 2010;21(3):168-172.
165. Gibbs AR, Wagner JC. Diseases due to silica. In: Churg A, Green FH, eds. *Pathology of Occupational Lung Disease*. Baltimore, MD: Williams & Wilkins; 1988:209-233.
166. Honma K, Abraham JL, Chiyotani K, et al. Proposed criteria for mixed-dust pneumoconiosis: definition, descriptions, and guidelines for pathologic diagnosis and clinical correlation. *Hum Pathol*. 2004;35(12):1515-1523.
167. Craighead JE, Abraham JL, Churg A, et al. The pathology of asbestos-associated diseases of the lungs and pleural cavities: diagnostic criteria and proposed grading schema. Report of the Pneumoconiosis Committee of the College of American Pathologists and the National Institute for Occupational Safety and Health. *Arch Pathol Lab Med*. 1982;106(11):544-596.
168. Churg A. Noneoplastic disease caused by asbestos. In: Churg A, Green FH, eds. *Pathology of Occupational Lung Disease*. Baltimore, MD: Williams & Wilkins; 1988:277-338.
169. Roggli VL, Gibbs AR, Attanoos R, et al. Pathology of asbestosis—an update of the diagnostic criteria: report of the asbestosis committee of the college of american pathologists and pulmonary pathology society. *Arch Pathol Lab Med*. 2010;134(3):462-480.
170. Schneider F, Sporn TA, Roggli VL. Asbestos fiber content of lungs with diffuse interstitial fibrosis: an analytical scanning electron microscopic analysis of 249 cases. *Arch Pathol Lab Med*. 2010;134(3):457-461.
171. Crouch E, Churg A. Ferruginous bodies and the histologic evaluation of dust exposure. *Am J Surg Pathol*. 1984;8(2):109-116.
172. Marchiori E, Zanetti G, Mano CM, Hochhegger B. Exogenous lipoid pneumonia. Clinical and radiological manifestations. *Respir Med*. 2011;105(5):659-666.
173. Barnes TW, Vassallo R, Tazelaar HD, et al. Diffuse bronchiolar disease due to chronic occult aspiration. *Mayo Clin Proc*. 2006;81(2):172-176.
174. Mukhopadhyay S, Katzenstein AL. Pulmonary disease due to aspiration of food and other particulate matter: a clinicopathologic study of 59 cases diagnosed on biopsy or resection specimens. *Am J Surg Pathol*. 2007;31(5):752-759.
175. Yousem SA, Faber C. Histopathology of aspiration pneumonia not associated with food or other particulate matter: a clinicopathologic study of 10 cases diagnosed on biopsy. *Am J Surg Pathol*. 2011;35(3):426-431.

176. Lombard CM, Tazelaar HD, Krasne DL. Pulmonary eosinophilia in coccidioidal infections. *Chest*. 1987;91(5):734-736.
177. Katzenstein AL, Liebow AA, Friedman PJ. Bronchocentric granulomatosis, mucoid impaction, and hypersensitivity reactions to fungi. *Am Rev Respir Dis*. 1975;111(4):497-537.
178. Liebow AA, Carrington CB. The eosinophilic pneumonias. *Medicine (Baltimore)*. 1969;48(4):251-285.
179. Carrington CB, Addington WW, Goff AM, et al. Chronic eosinophilic pneumonia. *N Engl J Med*. 1969;280(15):787-798.
180. Jederlinic PJ, Sicilian L, Gaensler EA. Chronic eosinophilic pneumonia. A report of 19 cases and a review of the literature. *Medicine (Baltimore)*. 1988;67(3):154-162.
181. Rosen SH, Castleman B, Liebow AA. Pulmonary alveolar proteinosis. *N Engl J Med*. 1958;258(23):1123-1142.
182. Wang T, Lazar CA, Fishbein MC, Lynch JP 3rd. Pulmonary alveolar proteinosis. *Semin Respir Crit Care Med*. 2012;33(5):498-508.
183. Borie R, Danel C, Debray MP, et al. Pulmonary alveolar proteinosis. *Eur Respir Rev*. 2011;20(120):98-107.
184. Krause ML, Cartin-Ceba R, Specks U, Peikert T. Update on diffuse alveolar hemorrhage and pulmonary vasculitis. *Immunol Allergy Clin North Am*. 2012;32(4):587-600.
185. de Prost N, Parrot A, Cuquemelle E, et al. Diffuse alveolar hemorrhage in immunocompetent patients: etiologies and prognosis revisited. *Respir Med*. 2012;106(7):1021-1032.
186. Taytard J, Nathan N, de Blic J, et al. New insights into pediatric idiopathic pulmonary hemosiderosis: the French RespiRare(®) cohort. *Orphanet J Rare Dis*. 2013;8:161.
187. Larici AR, Franchi P, Occhipinti M, et al. Diagnosis and management of hemoptysis. *Diagn Interv Radiol*. 2014;20(4):299-309.
188. Errion AR, Houk VN, Kettering DL. Pulmonary hematoma due to blunt, nonpenetrating thoracic trauma. *Am Rev Respir Dis*. 1963;88:384-392.
189. Krajicek BJ, Thomas CF Jr, Limper AH. Pneumocystis pneumonia: current concepts in pathogenesis, diagnosis, and treatment. *Clin Chest Med*. 2009;30(2):265-278, vi.
190. Thomas CF Jr, Limper AH. Pneumocystis pneumonia. *N Engl J Med*. 2004;350(24):2487-2498.
191. Hartel PH, Shilo K, Klassen-Fischer M, et al. Granulomatous reaction to *Pneumocystis jirovecii*: clinicopathologic review of 20 cases. *Am J Surg Pathol*. 2010;34(5):730-734.
192. Travis WD, Pittaluga S, Lipschik GY, et al. Atypical pathologic manifestations of Pneumocystis carinii pneumonia in the acquired immune deficiency syndrome. Review of 123 lung biopsies from 76 patients with emphasis on cysts, vascular invasion, vasculitis, and granulomas. *Am J Surg Pathol*. 1990;14(7):615-625.
193. Nassar A, Zapata M, Little JV, Siddiqui MT. Utility of reflex Gomori methenamine silver staining for *Pneumocystis jirovecii* on bronchoalveolar lavage cytologic specimens: a review. *Diagn Cytopathol*. 2006;34(11):719-723.
194. Ison MG, Fishman JA. Cytomegalovirus pneumonia in transplant recipients. *Clin Chest Med*. 2005;26(4):691-705, viii.
195. Gorelkin L, Chandler FW, Ewing EP Jr. Staining qualities of cytomegalovirus inclusions in the lungs of patients with the acquired immunodeficiency syndrome: a potential source of diagnostic misinterpretation. *Hum Pathol*. 1986;17(9):926-929.
196. Schuller D. Lower respiratory tract reactivation of herpes simplex virus. Comparison of immunocompromised and immunocompetent hosts. *Chest*. 1994;106(1 suppl):3S-7S, discussion 34S-35S.
197. Yeldandi AV, Colby TV. Pathologic features of lung biopsy specimens from influenza pneumonia cases. *Hum Pathol*. 1994;25(1):47-53.
198. Harms PW, Schmidt LA, Smith LB, et al. Autopsy findings in eight patients with fatal H1N1 influenza. *Am J Clin Pathol*. 2010;134(1):27-35.
199. Hwang DM, Chamberlain DW, Poutanen SM, et al. Pulmonary pathology of severe acute respiratory syndrome in Toronto. *Mod Pathol*. 2005;18(1):1-10.
200. Klein SL, Calisher CH. Emergence and persistence of hantaviruses. *Curr Top Microbiol Immunol*. 2007;315:217-252.
201. Zaki SR, Greer PW, Coffield LM, et al. Hantavirus pulmonary syndrome. Pathogenesis of an emerging infectious disease. *Am J Pathol*. 1995;146(3):552-579.
202. Blackmon JA, Hicklin MD, Chandler FW. Legionnaires' disease. Pathological and historical aspects of a 'new' disease. *Arch Pathol Lab Med*. 1978;102(7):337-343.
203. Winn WC Jr, Myerowitz RL. The pathology of the Legionella pneumonias. A review of 74 cases and the literature. *Hum Pathol*. 1981;12(5):401-422.
204. Frazier AR, Rosenow EC 3rd, Roberts GD. Nocardiosis. A review of 25 cases occurring during 24 months. *Mayo Clin Proc*. 1975;50(11):657-663.
205. Oddo D, Gonzalez S. Actinomycosis and nocardiosis. A morphologic study of 17 cases. *Pathol Res Pract*. 1986;181(3):320-326.
206. Murray HW, Masur H, Senterfit LB, Roberts RB. The protean manifestations of *Mycoplasma pneumoniae* infection in adults. *Am J Med*. 1975;58(2):229-242.
207. Rollins S, Colby T, Clayton F. Open lung biopsy in *Mycoplasma pneumoniae* pneumonia. *Arch Pathol Lab Med*. 1986;110(1):34-41.
208. Griffiths MH, Kocjan G, Miller RF, Godfrey-Faussett P. Diagnosis of pulmonary disease in human immunodeficiency virus infection: role of transbronchial biopsy and bronchoalveolar lavage. *Thorax*. 1989;44(7):554-558.
209. Blumenfeld W, Wagar E, Hadley WK. Use of the transbronchial biopsy for diagnosis of opportunistic pulmonary infections in acquired immunodeficiency syndrome (AIDS). *Am J Clin Pathol*. 1984;81(1):1-5.
210. Lee CH, Lee JM, Hung CC, et al. The impact of open lung biopsy on diffuse pulmonary infiltrates in patients with AIDS. *Am Surg*. 2009;75(2):157-162.
211. Miller RF, Pugsley WB, Griffiths MH. Open lung biopsy for investigation of acute respiratory episodes in patients with HIV infection and AIDS. *Genitourin Med*. 1995;71(5):280-285.
212. Marchevsky A, Rosen MJ, Chrystal G, Kleinerman J. Pulmonary complications of the acquired immunodeficiency syndrome: a clinicopathologic study of 70 cases. *Hum Pathol*. 1985;16(7):659-670.
213. Kwon KY, Colby TV. *Rhodococcus equi* pneumonia and pulmonary malakoplakia in acquired immunodeficiency syndrome. Pathologic features. *Arch Pathol Lab Med*. 1994;118(7):744-748.
214. Fouret PJ, Touboul JL, Mayaud CM, et al. Pulmonary Kaposi's sarcoma in patients with acquired immune deficiency syndrome: a clinicopathological study. *Thorax*. 1987;42(4):262-268.
215. Haque AK, Myers JL, Hudnall SD, et al. Pulmonary lymphomatoid granulomatosis in acquired immunodeficiency syndrome: lesions with Epstein-Barr virus infection. *Mod Pathol*. 1998;11(4):347-356.
216. Purdy LJ, Colby TV, Yousem SA, Battifora H. Pulmonary Kaposi's sarcoma. Premortem histologic diagnosis. *Am J Surg Pathol*. 1986;10(5):301-311.
217. Travis WD, Fox CH, Devaney KO, et al. Lymphoid pneumonitis in 50 adult patients infected with the human immunodeficiency virus: lymphocytic interstitial pneumonitis versus nonspecific interstitial pneumonitis. *Hum Pathol*. 1992;23(5):529-541.
218. Wang JY, Chang YL, Lee LN, et al. Diffuse pulmonary infiltrates after bone marrow transplantation: the role of open lung biopsy. *Ann Thorac Surg*. 2004;78(1):267-272.
219. Yousem SA. The histological spectrum of pulmonary graft-versus-host disease in bone marrow transplant recipients. *Hum Pathol*. 1995;26(6):668-675.
220. Palmas A, Tefferi A, Myers JL, et al. Late-onset noninfectious pulmonary complications after allogeneic bone marrow transplantation. *Br J Haematol*. 1998;100(4):680-687.
221. Takeuchi Y, Miyagawa-Hayashino A, Chen F, et al. Pleuroparenchymal fibroelastosis and non-specific interstitial pneumonia: frequent pulmonary sequelae of haematopoietic stem cell transplantation. *Histopathology*. 2015;66(4):536-544.
222. Marboe CC. Pathology of lung transplantation. *Semin Diagn Pathol*. 2007;24:188-198.
223. Stewart S, Fishbein MC, Snell GI, et al. Revision of the 1996 working formulation for the standardization of nomenclature in the diagnosis of lung rejection. *J Heart Lung Transplant*. 2007;26(12):1229-1242.
224. Bhorade SM, Husain AN, Liao C, et al. Interobserver variability in grading transbronchial lung biopsy specimens after lung transplantation. *Chest*. 2013;143(6):1717-1724.
225. Berry G, Burke M, Andersen C, et al. Pathology of pulmonary antibody-mediated rejection: 2012 update from the Pathology Council of the ISHLT. *J Heart Lung Transplant*. 2013;32(1):14-21.
226. Dweik RA, Rounds S, Erzurum SC, et al. An official American Thoracic Society Statement: pulmonary hypertension phenotypes. *Am J Respir Crit Care Med*. 2014;189(3):345-355.
227. Stewart S, Rassl D. Advances in the understanding and classification of pulmonary hypertension. *Histopathology*. 2009;54(1):104-116.
228. Wagenvoort CA. Open lung biopsies in congenital heart disease for evaluation of pulmonary vascular disease. Predictive value with regard to corrective operability. *Histopathology*. 1985;9(4):417-436.
229. Wagenvoort CA, Heath D, Edwards JE. *The Pathology of the Pulmonary Vasculature*. Springfield, IL: Charles C. Thomas; 1964.
230. Heath D, Yacoub M, Gosney JR, et al. Pulmonary endocrine cells in hypertensive pulmonary vascular disease. *Histopathology*. 1990;16(1):21-28.
231. Bjornsson J, Edwards WD. Primary pulmonary hypertension: a histopathologic study of 80 cases. *Mayo Clin Proc*. 1985;60(1):16-25.
232. Hughes JD, Rubin LJ. Primary pulmonary hypertension. An analysis of 28 cases and a review of the literature. *Medicine (Baltimore)*. 1986;65(1):56-72.
233. Dai Z, Matsui Y. Pulmonary veno-occlusive disease: an 80-year-old mystery. *Respiration*. 2014;88(2):148-157.
234. Swensen SJ, Tashjian JH, Myers JL, et al. Pulmonary venoocclusive disease: CT findings in eight patients. *AJR Am J Roentgenol*. 1996;167(4):937-940.
235. Lantuejoul S, Sheppard MN, Corrin B, et al. Pulmonary veno-occlusive disease and pulmonary capillary hemangiomatosis: a

clinicopathologic study of 35 cases. *Am J Surg Pathol*. 2006;30(7):850-857.
236. Parambil JG, Savci CD, Tazelaar HD, Ryu JH. Causes and presenting features of pulmonary infarctions in 43 cases identified by surgical lung biopsy. *Chest*. 2005;127(4):1178-1183.
237. Yousem SA. The surgical pathology of pulmonary infarcts: diagnostic confusion with granulomatous disease, vasculitis, and neoplasia. *Mod Pathol*. 2009;22(5):679-685.
238. Seo JB, Song KS, Lee JS, et al. Broncholithiasis: review of the causes with radiologic-pathologic correlation. *Radiographics*. 2002;22(Spec No):S199-S213.
239. Engleman P, Liebow AA, Gmelich J, Friedman PJ. Pulmonary hyalinizing granuloma. *Am Rev Respir Dis*. 1977;115(6):997-1008.
240. Yousem SA, Hochholzer L. Pulmonary hyalinizing granuloma. *Am J Clin Pathol*. 1987;87(1):1-6.
241. Chapman EM, Gown A, Mazziotta R, Churg A. Pulmonary hyalinizing granuloma with associated elevation in serum and tissue IgG4 occurring in a patient with a history of sarcoidosis. *Am J Surg Pathol*. 2012;36(5):774-778.
242. Alifano M, Trisolini R, Cancellieri A, Regnard JF. Thoracic endometriosis: current knowledge. *Ann Thorac Surg*. 2006;81(2):761-769.
243. Flieder DB, Moran CA, Travis WD, et al. Pleuro-pulmonary endometriosis and pulmonary ectopic deciduosis: a clinicopathologic and immunohistochemical study of 10 cases with emphasis on diagnostic pitfalls. *Hum Pathol*. 1998;29(12):1495-1503.
244. Mariotta S, Ricci A, Papale M, et al. Pulmonary alveolar microlithiasis: report on 576 cases published in the literature. *Sarcoidosis Vasc Diffuse Lung Dis*. 2004;21(3):173-181.
245. Lewis DR, Check DP, Caporaso NE, et al. US lung cancer trends by histologic type. *Cancer*. 2014;120(18):2883-2892.
246. Lortet-Tieulent J, Soerjomataram I, Ferlay J, et al. International trends in lung cancer incidence by histological subtype: adenocarcinoma stabilizing in men but still increasing in women. *Lung Cancer*. 2014;84(1):13-22.
247. Sankila RJ, Karjalainen ES, Oksanen HM, et al. Relationship between occupation and lung cancer as analyzed by age and histologic type. *Cancer*. 1990;65(7):1651-1656.
248. Mollo F, Magnani C, Bo P, et al. The attribution of lung cancers to asbestos exposure: a pathologic study of 924 unselected cases. *Am J Clin Pathol*. 2002;117(1):90-95.
249. Humphrey EW, Ewing SL, Wrigley JV, et al. The production of malignant tumors of the lung and pleura in dogs from intratracheal asbestos instillation and cigarette smoking. *Cancer*. 1981;47(8):1994-1999.
250. Ilgren EB, Griner L, Benirschke K, Pang LS. A comparative study of pulmonary tumors from the San Diego Zoological Gardens and the Tumor Reference Collection, Imperial Cancer Research Fund, London. *Pathol Annu*. 1982;17(Pt 2):331-351.
251. Auerbach O, Forman JB, Gere JB, et al. Changes in the bronchial epithelium in relation to smoking and cancer of the lung; a report of progress. *N Engl J Med*. 1957;256(3):97-104.
252. Peters EJ, Morice R, Benner SE, et al. Squamous metaplasia of the bronchial mucosa and its relationship to smoking. *Chest*. 1993;103(5):1429-1432.
253. Fligiel SE, Roth MD, Kleerup EC, et al. Tracheobronchial histopathology in habitual smokers of cocaine, marijuana, and/or tobacco. *Chest*. 1997;112(2):319-326.
254. Toh CK, Wong EH, Lim WT, et al. The impact of smoking status on the behavior and survival outcome of patients with advanced non-small cell lung cancer: a retrospective analysis. *Chest*. 2004;126(6):1750-1756.
255. Yoneda K. Scar carcinomas of the lung in a histoplasmosis endemic area. *Cancer*. 1990;65(1):164-168.
256. Meyer EC, Liebow AA. Relationship of interstitial pneumonia honeycombing and atypical epithelial proliferation to cancer of the lung. *Cancer*. 1965;18:322-351.
257. Harris JM, Johnston ID, Rudd R, et al. Cryptogenic fibrosing alveolitis and lung cancer: the BTS study. *Thorax*. 2010;65(1):70-76.
258. Aubry MC, Myers JL, Douglas WW, et al. Primary pulmonary carcinoma in patients with idiopathic pulmonary fibrosis. *Mayo Clin Proc*. 2002;77(8):763-770.
259. Khan KA, Kennedy MP, Moore E, et al. Radiological characteristics, histological features and clinical outcomes of lung cancer patients with coexistent idiopathic pulmonary fibrosis. *Lung*. 2015;193(1):71-77.
260. Travis WD, Brambilla E, Noguchi M, et al. International association for the study of lung cancer/american thoracic society/european respiratory society international multidisciplinary classification of lung adenocarcinoma. *J Thorac Oncol*. 2011;6(2):244-285.
261. Noguchi M, Yatabe Y, Brambilla E, et al. Preinvasive lesions: atypical adenomatous hyperplasia, adenocarcinoma in situ. In: Travis WD, Brambilla E, Burke AP, et al, eds. *WHO Classification of Tumours of the Lung, Pleura, Thymus and Heart*. 4th ed. Lyon: IARC; 2015.
262. Cook JR, Hill DA, Humphrey PA, et al. Squamous cell carcinoma arising in recurrent respiratory papillomatosis with pulmonary involvement: emerging common pattern of clinical features and human papillomavirus serotype association. *Mod Pathol*. 2000;13(8):914-918.
263. Lele SM, Pou AM, Ventura K, et al. Molecular events in the progression of recurrent respiratory papillomatosis to carcinoma. *Arch Pathol Lab Med*. 2002;126(10):1184-1188.
264. Chang SY, Keeney M, Law M, et al. Detection of human papillomavirus in non-small cell carcinoma of the lung. *Hum Pathol*. 2015;46(11):1592-1597.
265. Carey FA, Donnelly SC, Walker WS, et al. Synchronous primary lung cancers: prevalence in surgical material and clinical implications. *Thorax*. 1993;48(4):344-346.
266. Loukeri AA, Kampolis CF, Ntokou A, et al. Metachronous and synchronous primary lung cancers: diagnostic aspects, surgical treatment, and prognosis. *Clin Lung Cancer*. 2015;16(1):15-23.
267. Douglas WG, Rigual NR, Loree TR, et al. Current concepts in the management of a second malignancy of the lung in patients with head and neck cancer. *Curr Opin Otolaryngol Head Neck Surg*. 2003;11(2):85-88.
268. Wang X, Wang M, MacLennan GT, et al. Evidence for common clonal origin of multifocal lung cancers. *J Natl Cancer Inst*. 2009;101(8):560-570.
269. Warth A, Macher-Goeppinger S, Muley T, et al. Clonality of multifocal nonsmall cell lung cancer: implications for staging and therapy. *Eur Respir J*. 2012;39(6):1437-1442.
270. Jiang L, He J, Shi X, et al. Prognosis of synchronous and metachronous multiple primary lung cancers: systematic review and meta-analysis. *Lung Cancer*. 2015;87(3):303-310.
271. *Institute NC*. SEER Stat Fact Sheets: Lung and Bronchus Cancer. <http://seer.cancer.gov/statfacts/html/lungb.html>; 2015 Accessed 22 December 2015.
272. Arcasoy SM, Jett JR. Superior pulmonary sulcus tumors and Pancoast's syndrome. *N Engl J Med*. 1997;337(19):1370-1376.
273. Perandini S, Soardi GA, Motton M, et al. Solid pulmonary nodule risk assessment and decision analysis: comparison of four prediction models in 285 cases. *Eur Radiol*. 2015;26(9):3071-3076.
274. Pelosof LC, Gerber DE. Paraneoplastic syndromes: an approach to diagnosis and treatment. *Mayo Clin Proc*. 2010;85(9):838-854.
275. Midthun DE, Jett JR. Screening for lung cancer: the US studies. *J Surg Oncol*. 2013;108(5):275-279.
276. Black WC, Gareen IF, Soneji SS, et al. Cost-effectiveness of CT screening in the National Lung Screening Trial. *N Engl J Med*. 2014;371(19):1793-1802.
277. Goulart B. Lung cancer CT screening is cost-effective but implementation matters. *Evid Based Med*. 2015;20(2):78.
278. Wiener RS, Slatore CG. Framing discussions about CT scan screening for lung cancer so that patients see the whole picture. *Chest*. 2013;144(6):1749-1750.
279. Flieder DB, Vazquez M, Carter D, et al. Pathologic findings of lung tumors diagnosed on baseline CT screening. *Am J Surg Pathol*. 2006;30(5):606-613.
280. Lindell RM, Hartman TE, Swensen SJ, et al. Five-year lung cancer screening experience: CT appearance, growth rate, location, and histologic features of 61 lung cancers. *Radiology*. 2007;242(2):555-562.
281. Travis WD, Brambilla E, Burke AP, et al, eds. *WHO Classification of Tumours of the Lung, Pleura, Thymus and Heart*. 4th ed. Lyon: IARC; 2015.
282. Reference deleted in proofs.
283. Mukhopadhyay S, Katzenstein AL. Subclassification of non-small cell lung carcinomas lacking morphologic differentiation on biopsy specimens: utility of an immunohistochemical panel containing TTF-1, napsin A, p63, and CK5/6. *Am J Surg Pathol*. 2011;35(1):15-25.
284. Roggli VL, Vollmer RT, Greenberg SD, et al. Lung cancer heterogeneity: a blinded and randomized study of 100 consecutive cases. *Hum Pathol*. 1985;16(6):569-579.
285. Warth A, Muley T, Herpel E, et al. Large-scale comparative analyses of immunomarkers for diagnostic subtyping of non-small-cell lung cancer biopsies. *Histopathology*. 2012;61(6):1017-1025.
286. Pelosi G, Fabbri A, Tamborini E, et al. Challenging lung carcinoma with coexistent DeltaNp63/p40 and thyroid transcription factor-1 labeling within the same individual tumor cells. *J Thorac Oncol*. 2015;10(10):1500-1502.
287. Hwang DH, Szeto DP, Perry AS, et al. Pulmonary large cell carcinoma lacking squamous differentiation is clinicopathologically indistinguishable from solid-subtype adenocarcinoma. *Arch Pathol Lab Med*. 2014;138(5):626-635.
288. Johansson L. Histopathologic classification of lung cancer: relevance of cytokeratin and TTF-1 immunophenotyping. *Ann Diagn Pathol*. 2004;8(5):259-267.
289. Ordonez NG. Value of thyroid transcription factor-1 immunostaining in tumor diagnosis: a review and update. *Appl Immunohistochem Mol Morphol*. 2012;20(5):429-444.
290. Rekhtman N, Ang DC, Sima CS, et al. Immunohistochemical algorithm for differentiation of lung adenocarcinoma and squamous cell carcinoma based on large series of whole-tissue sections with validation in

small specimens. *Mod Pathol*. 2011;24(10):1348-1359.
291. Ordonez NG. Thyroid transcription factor-1 is not expressed in squamous cell carcinomas of the lung: an immunohistochemical study with review of the literature. *Appl Immunohistochem Mol Morphol*. 2012;20(6):525-530.
292. Ordonez NG. Napsin A expression in lung and kidney neoplasia: a review and update. *Adv Anat Pathol*. 2012;19(1):66-73.
293. Bishop JA, Sharma R, Illei PB. Napsin A and thyroid transcription factor-1 expression in carcinomas of the lung, breast, pancreas, colon, kidney, thyroid, and malignant mesothelioma. *Hum Pathol*. 2010;41(1): 20-25.
294. Ordonez NG. A word of caution regarding napsin A expression in squamous cell carcinomas of the lung. *Am J Surg Pathol*. 2012;36(3):396-401.
295. Bishop JA, Teruya-Feldstein J, Westra WH, et al. p40 (DeltaNp63) is superior to p63 for the diagnosis of pulmonary squamous cell carcinoma. *Mod Pathol*. 2012;25(3): 405-415.
296. Wang BY, Gil J, Kaufman D, et al. P63 in pulmonary epithelium, pulmonary squamous neoplasms, and other pulmonary tumors. *Hum Pathol*. 2002;33(9):921-926.
297. Pandit D, Griffiths D, Edwards J. Bronchial biopsies—in praise of an H&E section. *Histopathology*. 2006;49(1):96-97.
298. Zachara-Szczakowski S, Verdun T, Churg A. Accuracy of classifying poorly differentiated non-small cell lung carcinoma biopsies with commonly used lung carcinoma markers. *Hum Pathol*. 2015;46(5):776-782.
299. Hashizume S, Nagayasu T, Hayashi T, et al. Accuracy and prognostic impact of a vessel invasion grading system for stage IA non-small cell lung cancer. *Lung Cancer*. 2009;65(3):363-370.
300. Wang J, Chen J, Chen X, et al. Blood vessel invasion as a strong independent prognostic indicator in non-small cell lung cancer: a systematic review and meta-analysis. *PLoS ONE*. 2011;6(12):e28844.
301. Wang J, Wang B, Zhao W, et al. Clinical significance and role of lymphatic vessel invasion as a major prognostic implication in non-small cell lung cancer: a meta-analysis. *PLoS ONE*. 2012;7(12):e52704.
302. Jiang L, Liang W, Shen J, et al. The impact of visceral pleural invasion in node-negative non-small cell lung cancer: a systematic review and meta-analysis. *Chest*. 2015;148(4):903-911.
303. *AJCC Cancer Staging Manual*. 7th ed. New York, NY: Springer; 2010.
304. Houston KA, Henley SJ, Li J, et al. Patterns in lung cancer incidence rates and trends by histologic type in the United States, 2004-2009. *Lung Cancer*. 2014;86(1):22-28.
305. Koss MN, Fleming M, Przygodzki RM, et al. Adenocarcinoma simulating mesothelioma: a clinicopathologic and immunohistochemical study of 29 cases. *Ann Diagn Pathol*. 1998;2(2):93-102.
306. Hishida T, Ishii G, Kodama T, et al. Centrally located adenocarcinoma with endobronchial polypoid growth: clinicopathological analysis of five cases. *Pathol Int*. 2011;61(2):73-79.
307. Bakris GL, Mulopulos GP, Korchik R, et al. Pulmonary scar carcinoma. A clinicopathologic analysis. *Cancer*. 1983;52(3):493-497.
308. Auerbach O, Garfinkel L, Parks VR. Scar cancer of the lung: increase over a 21 year period. *Cancer*. 1979;43(2):636-642.
309. Barsky SH, Huang SJ, Bhuta S. The extracellular matrix of pulmonary scar carcinomas is suggestive of a desmoplastic origin. *Am J Pathol*. 1986;124(3):412-419.
310. Kolin A, Koutoulakis T. Role of arterial occlusion in pulmonary scar cancers. *Hum Pathol*. 1988;19(10):1161-1167.
311. Kung IT, Lui IO, Loke SL, et al. Pulmonary scar cancer. A pathologic reappraisal. *Am J Surg Pathol*. 1985;9(6):391-400.
312. Scroggs MW, Roggli VL, Fraire AE, Sanfilippo F. Eosinophilic intracytoplasmic globules in pulmonary adenocarcinomas: a histochemical, immunohistochemical, and ultrastructural study of six cases. *Hum Pathol*. 1989;20(9):845-849.
313. Travis WD, Noguchi M, Yatabe Y, et al. Adenocarcinoma. In: Travis WD, Brambilla E, Burke AP, et al, eds. *WHO Classification of Tumours of the Lung, Pleura, Thymus and Heart*. 4th ed. Lyon: IARC; 2015.
314. Yoshizawa A, Sumiyoshi S, Sonobe M, et al. Validation of the IASLC/ATS/ERS lung adenocarcinoma classification for prognosis and association with EGFR and KRAS gene mutations: analysis of 440 Japanese patients. *J Thorac Oncol*. 2013;8(1): 52-61.
315. Kadota K, Villena-Vargas J, Yoshizawa A, et al. Prognostic significance of adenocarcinoma in situ, minimally invasive adenocarcinoma, and nonmucinous lepidic predominant invasive adenocarcinoma of the lung in patients with stage I disease. *Am J Surg Pathol*. 2014;38(4):448-460.
316. Makinen JM, Laitakari K, Johnson S, et al. Nonpredominant lepidic pattern correlates with better outcome in invasive lung adenocarcinoma. *Lung Cancer*. 2015;90(3):568-574.
317. Lee G, Lee HY, Jeong JY, et al. Clinical impact of minimal micropapillary pattern in invasive lung adenocarcinoma: prognostic significance and survival outcomes. *Am J Surg Pathol*. 2015;39(5):660-666.
318. Merchant SH, Amin MB, Tamboli P, et al. Primary signet-ring cell carcinoma of lung: immunohistochemical study and comparison with non-pulmonary signet-ring cell carcinomas. *Am J Surg Pathol*. 2001;25(12):1515-1519.
319. Rossi G, Murer B, Cavazza A, et al. Primary mucinous (so-called colloid) carcinomas of the lung: a clinicopathologic and immunohistochemical study with special reference to CDX-2 homeobox gene and MUC2 expression. *Am J Surg Pathol*. 2004;28(4):442-452.
320. Inamura K, Satoh Y, Okumura S, et al. Pulmonary adenocarcinomas with enteric differentiation: histologic and immunohistochemical characteristics compared with metastatic colorectal cancers and usual pulmonary adenocarcinomas. *Am J Surg Pathol*. 2005;29(5):660-665.
321. Hayashi Y, Takanashi Y, Ohsawa H, et al. Hepatoid adenocarcinoma in the lung. *Lung Cancer*. 2002;38(2):211-214.
322. Tamboli P, Toprani TH, Amin MB, et al. Carcinoma of lung with rhabdoid features. *Hum Pathol*. 2004;35(1):8-13.
323. Yeh YC, Chou TY. Pulmonary adenocarcinoma with microcystic histology and intratumoral heterogeneity of EGFR gene polymorphism. *Histopathology*. 2010;57(1):112-120.
324. Kadota K, Yeh YC, Sima CS, et al. The cribriform pattern identifies a subset of acinar predominant tumors with poor prognosis in patients with stage I lung adenocarcinoma: a conceptual proposal to classify cribriform predominant tumors as a distinct histologic subtype. *Mod Pathol*. 2014;27(5):690-700.
325. Tsuta K, Ishii G, Kim E, et al. Primary lung adenocarcinoma with massive lymphocyte infiltration. *Am J Clin Pathol*. 2005;123(4):547-552.
326. Rosenblatt MB, Lisa JR, Collier F. Primary and metastatic bronchiolo-alveolar carcinoma. *Dis Chest*. 1967;52(2):147-152.
327. Higashiyama M, Doi O, Kodama K, et al. Extramammary Paget's disease of the bronchial epithelium. *Arch Pathol Lab Med*. 1991;115(2):185-188.
328. Upton MP, Hirohashi S, Tome Y, et al. Expression of vimentin in surgically resected adenocarcinomas and large cell carcinomas of lung. *Am J Surg Pathol*. 1986;10(8):560-567.
329. Ordonez NG. Application of immunohistochemistry in the diagnosis of epithelioid mesothelioma: a review and update. *Hum Pathol*. 2013;44(1):1-19.
330. Mazziotta RM, Borczuk AC, Powell CA, Mansukhani M. CDX2 immunostaining as a gastrointestinal marker: expression in lung carcinomas is a potential pitfall. *Appl Immunohistochem Mol Morphol*. 2005;13(1):55-60.
331. Gomez-Fernandez C, Mejias A, Walker G, Nadji M. Immunohistochemical expression of estrogen receptor in adenocarcinomas of the lung: the antibody factor. *Appl Immunohistochem Mol Morphol*. 2010;18(2):137-141.
332. Bejarano PA, Baughman RP, Biddinger PW, et al. Surfactant proteins and thyroid transcription factor-1 in pulmonary and breast carcinomas. *Mod Pathol*. 1996;9(4):445-452.
333. Shimizu T, Yonezawa S, Tanaka S, Sato E. Expression of Lewis X-related antigens in adenocarcinomas of lung. *Histopathology*. 1993;22(6):549-555.
334. Zhu LC, Yim J, Chiriboga L, et al. DC-LAMP stains pulmonary adenocarcinoma with bronchiolar Clara cell differentiation. *Hum Pathol*. 2007;38(2):260-268.
335. Chang JT, Lee YM, Huang RS. The impact of the Cancer Genome Atlas on lung cancer. *Transl Res*. 2015;166(6):568-585.
336. Cancer Genome Atlas Research Network. Comprehensive molecular profiling of lung adenocarcinoma. *Nature*. 2014;511(7511):543-550.
337. Sartori G, Cavazza A, Bertolini F, et al. A subset of lung adenocarcinomas and atypical adenomatous hyperplasia-associated foci are genotypically related: an EGFR, HER2, and K-ras mutational analysis. *Am J Clin Pathol*. 2008;129(2):202-210.
338. Bell DW, Brannigan BW, Matsuo K, et al. Increased prevalence of EGFR-mutant lung cancer in women and in East Asian populations: analysis of estrogen-related polymorphisms. *Clin Cancer Res*. 2008;14(13):4079-4084.
339. Sholl LM, Aisner DL, Varella-Garcia M, et al. Multi-institutional oncogenic driver mutation analysis in lung adenocarcinoma: the Lung Cancer Mutation Consortium experience. *J Thorac Oncol*. 2015;10(5):768-777.
340. Soda M, Choi YL, Enomoto M, et al. Identification of the transforming EML4-ALK fusion gene in non-small-cell lung cancer. *Nature*. 2007;448(7153):561-566.
341. Kwak EL, Bang YJ, Camidge DR, et al. Anaplastic lymphoma kinase inhibition in non-small-cell lung cancer. *N Engl J Med*. 2010;363(18):1693-1703.
342. Rodig SJ, Mino-Kenudson M, Dacic S, et al. Unique clinicopathologic features characterize ALK-rearranged lung adenocarcinoma in the western population. *Clin Cancer Res*. 2009;15(16):5216-5223.
343. Shaw AT, Yeap BY, Mino-Kenudson M, et al. Clinical features and outcome of patients with non-small-cell lung cancer who harbor EML4-ALK. *J Clin Oncol*. 2009;27(26):4247-4253.
344. Yoshida A, Tsuta K, Watanabe S, et al. Frequent ALK rearrangement and TTF-1/p63

co-expression in lung adenocarcinoma with signet-ring cell component. *Lung Cancer*. 2011;72(3):309-315.
345. Solomon BJ, Mok T, Kim DW, et al. First-line crizotinib versus chemotherapy in ALK-positive lung cancer. *N Engl J Med*. 2014;371(23):2167-2177.
346. Leighl NB, Rekhtman N, Biermann WA, et al. Molecular testing for selection of patients with lung cancer for epidermal growth factor receptor and anaplastic lymphoma kinase tyrosine kinase inhibitors: American Society of Clinical Oncology endorsement of the College of American Pathologists/International Association for the study of lung cancer/ association for molecular pathology guideline. *J Clin Oncol*. 2014;32(32):3673-3679.
347. Lindeman NI, Cagle PT, Beasley MB, et al. Molecular testing guideline for selection of lung cancer patients for EGFR and ALK tyrosine kinase inhibitors: guideline from the College of American Pathologists, International Association for the Study of Lung Cancer, and Association for Molecular Pathology. *Arch Pathol Lab Med*. 2013;137(6):828-860.
348. Cooper L, Hagenschneider JK, Banky S, et al. Papillary endobronchial squamous cell carcinoma. *Ann Diagn Pathol*. 2005;9(5):284-288.
349. Funai K, Yokose T, Ishii G, et al. Clinicopathologic characteristics of peripheral squamous cell carcinoma of the lung. *Am J Surg Pathol*. 2003;27(7):978-984.
350. Tomashefski JF Jr, Connors AF Jr, Rosenthal ES, Hsiue IL. Peripheral vs central squamous cell carcinoma of the lung. A comparison of clinical features, histopathology, and survival. *Arch Pathol Lab Med*. 1990;114(5):468-474.
351. Yousem SA. Peripheral squamous cell carcinoma of lung: patterns of growth with particular focus on airspace filling. *Hum Pathol*. 2009;40(6):861-867.
352. Watanabe Y, Yokose T, Sakuma Y, et al. Alveolar space filling ratio as a favorable prognostic factor in small peripheral squamous cell carcinoma of the lung. *Lung Cancer*. 2011;73(2):217-221.
353. Tsao MS, Brambilla E, Nicholson AG, et al. Squamous cell carcinoma. In: Travis WD, Brambilla E, Burke AP, et al, eds. *WHO Classification of Tumours of the Lung, Pleura, Thymus and Heart*. 4th ed. Lyon: IARC; 2015:51-62.
354. Yatabe Y, Brambilla E, Rekhtman N, et al. Adenosquamous carcinoma. In: Travis WD, Brambilla E, Burke AP, et al, eds. *WHO Classification of Tumours of the Lung, Pleura, Thymus and Heart*. 4th ed. Lyon: IARC; 2015:86-87.
355. Brambilla E, Lantuejoul S, Nicholson AG, et al. Basaloid squamous cell carcinoma. In: Travis WD, Brambilla E, Burke AP, et al, eds. *WHO Classification of Tumours of the Lung, Pleura, Thymus and Heart*. Lyon: IARC; 2015:56-58.
356. Moro D, Brichon PY, Brambilla E, et al. Basaloid bronchial carcinoma. A histologic group with a poor prognosis. *Cancer*. 1994;73(11):2734-2739.
357. Wang LC, Wang L, Kwauk S, et al. Analysis on the clinical features of 22 basaloid squamous cell carcinoma of the lung. *J Cardiothorac Surg*. 2011;6:10.
358. Miettinen M, McCue PA, Sarlomo-Rikala M, et al. GATA3: a multispecific but potentially useful marker in surgical pathology: a systematic analysis of 2500 epithelial and nonepithelial tumors. *Am J Surg Pathol*. 2014;38(1):13-22.
359. Monica V, Ceppi P, Righi L, et al. Desmocollin-3: a new marker of squamous differentiation in undifferentiated large-cell carcinoma of the lung. *Mod Pathol*. 2009;22(5):709-717.
360. Aviel-Ronen S, Lau SK, Pintilie M, et al. Glypican-3 is overexpressed in lung squamous cell carcinoma, but not in adenocarcinoma. *Mod Pathol*. 2008;21:817-825.
361. Syrjanen K. Detection of human papillomavirus in lung cancer: systematic review and meta-analysis. *Anticancer Res*. 2012;32(8):3235-3250.
362. Ragin C, Obikoya-Malomo M, Kim S, et al. HPV-associated lung cancers: an international pooled analysis. *Carcinogenesis*. 2014;35(6):1267-1275.
363. Cancer Genome Atlas Research Network. Comprehensive genomic characterization of squamous cell lung cancers. *Nature*. 2012;489(7417):519-525.
364. den Bakker MA, Willemsen S, Grunberg K, et al. Small cell carcinoma of the lung and large cell neuroendocrine carcinoma interobserver variability. *Histopathology*. 2010;56(3):356-363.
365. Project CLCG. A genomics-based classification of human lung tumors. *Sci Transl Med*. 2013;5(209):209ra153.
366. Jones MH, Virtanen C, Honjoh D, et al. Two prognostically significant subtypes of high-grade lung neuroendocrine tumours independent of small-cell and large-cell neuroendocrine carcinomas identified by gene expression profiles. *Lancet*. 2004;363(9411):775-781.
367. Khuder SA. Effect of cigarette smoking on major histological types of lung cancer: a meta-analysis. *Lung Cancer*. 2001;31(2-3):139-148.
368. Shepherd FA, Crowley J, Van Houtte P, et al. The International Association for the Study of Lung Cancer lung cancer staging project: proposals regarding the clinical staging of small cell lung cancer in the forthcoming (seventh) edition of the tumor, node, metastasis classification for lung cancer. *J Thorac Oncol*. 2007;2(12):1067-1077.
369. Rea F, Callegaro D, Favaretto A, et al. Long term results of surgery and chemotherapy in small cell lung cancer. *Eur J Cardiothoracic Surg*. 1998;14(4):398-402.
370. Nicholson SA, Beasley MB, Brambilla E, et al. Small cell lung carcinoma (SCLC): a clinicopathologic study of 100 cases with surgical specimens. *Am J Surg Pathol*. 2002;26(9):1184-1197.
371. Brambilla E, Beasley MB, Austin JH, et al. Small cell carcinoma. In: Travis WD, Brambilla E, Burke AP, et al, eds. *WHO Classification of Tumours of the Lung, Pleura, Thymus and Heart*. Lyon: IARC; 2015.
372. Begin P, Sahai S, Wang NS. Giant cell formation in small cell carcinoma of the lung. *Cancer*. 1983;52(10):1875-1879.
373. Travis WD. Update on small cell carcinoma and its differentiation from squamous cell carcinoma and other non-small cell carcinomas. *Mod Pathol*. 2012;25(suppl 1):S18-S30.
374. Vollmer RT. The effect of cell size on the pathologic diagnosis of small and large cell carcinomas of the lung. *Cancer*. 1982;50(7):1380-1383.
375. Vollmer RT, Birch R, Ogden L, Crissman JD. Subclassification of small cell cancer of the lung: the Southeastern Cancer Study Group experience. *Hum Pathol*. 1985;16(3):247-252.
376. Guinee DG Jr, Fishback NF, Koss MN, et al. The spectrum of immunohistochemical staining of small-cell lung carcinoma in specimens from transbronchial and open-lung biopsies. *Am J Clin Pathol*. 1994;102(4):406-414.
377. Zhang C, Schmidt LA, Hatanaka K, et al. Evaluation of napsin A, TTF-1, p63, p40, and CK5/6 immunohistochemical stains in pulmonary neuroendocrine tumors. *Am J Clin Pathol*. 2014;142(3):320-324.
378. Sturm N, Rossi G, Lantuejoul S, et al. Expression of thyroid transcription factor-1 in the spectrum of neuroendocrine cell lung proliferations with special interest in carcinoids. *Hum Pathol*. 2002;33(2): 175-182.
379. Pelosi G, Rodriguez J, Viale G, Rosai J. Typical and atypical pulmonary carcinoid tumor overdiagnosed as small-cell carcinoma on biopsy specimens: a major pitfall in the management of lung cancer patients. *Am J Surg Pathol*. 2005;29(2):179-187.
380. Schleusener JT, Tazelaar HD, Jung SH, et al. Neuroendocrine differentiation is an independent prognostic factor in chemotherapy-treated nonsmall cell lung carcinoma. *Cancer*. 1996;77(7):1284-1291.
381. Wistuba II, Gazdar AF, Minna JD. Molecular genetics of small cell lung carcinoma. *Semin Oncol*. 2001;28(2 suppl 4):3-13.
382. Umemura S, Tsuchihara K, Goto K. Genomic profiling of small-cell lung cancer: the era of targeted therapies. *Jpn J Clin Oncol*. 2015;45(6):513-519.
383. Marchevsky AM, Gal AA, Shah S, Koss MN. Morphometry confirms the presence of considerable nuclear size overlap between "small cells" and "large cells" in high-grade pulmonary neuroendocrine neoplasms. *Am J Clin Pathol*. 2001;116(4):466-472.
384. Beasley MB, Brambilla E, Chirieac LR, et al. Carcinoid tumour. In: Travis WD, Brambilla E, Burke AP, et al, eds. *WHO Classification of Tumours of the Lung, Pleura, Thymus and Heart*. 4th ed. Lyon, France: IARC; 2015:73-77.
385. Carter D. The neuroendocrine tumors of the lung, 1926-1998: some historical observations. *Semin Diagn Pathol*. 2008;25(3):154-165.
386. Dishop MK, Kuruvilla S. Primary and metastatic lung tumors in the pediatric population: a review and 25-year experience at a large children's hospital. *Arch Pathol Lab Med*. 2008;132(7):1079-1103.
387. Limper AH, Carpenter PC, Scheithauer B, Staats BA. The Cushing syndrome induced by bronchial carcinoid tumors. *Ann Intern Med*. 1992;117(3):209-214.
388. Ha SY, Lee JJ, Cho J, et al. Lung parenchymal invasion in pulmonary carcinoid tumor: an important histologic feature suggesting the diagnosis of atypical carcinoid and poor prognosis. *Lung Cancer*. 2013;80(2):146-152.
389. Mark EJ, Quay SC, Dickersin GR. Papillary carcinoid tumor of the lung. *Cancer*. 1981;48(2):316-324.
390. Tsuta K, Kalhor N, Wistuba II, Moran CA. Clinicopathological and immunohistochemical analysis of spindle-cell carcinoid tumour of the lung. *Histopathology*. 2011;59(3):526-536.
391. Min KW. Spindle cell carcinoids of the lung with paraganglioid features: a reappraisal of their histogenetic origin from paraganglia using immunohistochemical and electronmicroscopic techniques. *Ultrastruct Pathol*. 2001;25(3):207-217.
392. Tsuta K, Kalhor N, Raso MG, et al. Oncocytic neuroendocrine tumors of the lung: histopathologic spectrum and immunohistochemical analysis of 15 cases. *Hum Pathol*. 2011;42(4):578-585.
393. Gal AA, Koss MN, Hochholzer L, et al. Pigmented pulmonary carcinoid tumor. An immunohistochemical and ultrastructural study. *Arch Pathol Lab Med*. 1993;117(8):832-836.
394. Kalhor N, Suster S, Moran CA. Primary sclerosing neuroendocrine carcinomas of the lung: a clinicopathologic and

immunohistochemical study of 10 cases. *Am J Clin Pathol*. 2010;133(4):618-622.
395. Folpe AL, Gown AM, Lamps LW, et al. Thyroid transcription factor-1: immunohistochemical evaluation in pulmonary neuroendocrine tumors. *Mod Pathol*. 1999;12(1):5-8.
396. Du EZ, Goldstraw P, Zacharias J, et al. TTF-1 expression is specific for lung primary in typical and atypical carcinoids: TTF-1-positive carcinoids are predominantly in peripheral location. *Hum Pathol*. 2004;35(7):825-831.
397. Oliveira AM, Tazelaar HD, Myers JL, et al. Thyroid transcription factor-1 distinguishes metastatic pulmonary from well-differentiated neuroendocrine tumors of other sites. *Am J Surg Pathol*. 2001;25(6):815-819.
398. Saqi A, Alexis D, Remotti F, Bhagat G. Usefulness of CDX2 and TTF-1 in differentiating gastrointestinal from pulmonary carcinoids. *Am J Clin Pathol*. 2005;123(3):394-404.
399. Weissferdt A, Tang X, Wistuba II, Moran CA. Comparative immunohistochemical analysis of pulmonary and thymic neuroendocrine carcinomas using PAX8 and TTF-1. *Mod Pathol*. 2013;26(12):1554-1560.
400. Fernandez-Cuesta L, Peifer M, Lu X, et al. Frequent mutations in chromatin-remodelling genes in pulmonary carcinoids. *Nat Commun*. 2014;5:3518.
401. Aslan DL, Gulbahce HE, Pambuccian SE, et al. Ki-67 immunoreactivity in the differential diagnosis of pulmonary neuroendocrine neoplasms in specimens with extensive crush artifact. *Am J Clin Pathol*. 2005;123(6):874-878.
402. Filosso PL, Rena O, Donati G, et al. Bronchial carcinoid tumors: surgical management and long-term outcome. *J Thorac Cardiovasc Surg*. 2002;123(2):303-309.
403. Cardillo G, Sera F, Di Martino M, et al. Bronchial carcinoid tumors: nodal status and long-term survival after resection. *Ann Thorac Surg*. 2004;77(5):1781-1785.
404. Travis WD, Rush W, Flieder DB, et al. Survival analysis of 200 pulmonary neuroendocrine tumors with clarification of criteria for atypical carcinoid and its separation from typical carcinoid. *Am J Surg Pathol*. 1998;22(8):934-944.
405. Yeh YC, Chou TY. Pulmonary neuroendocrine tumors: study of 90 cases focusing on clinicopathological characteristics, immunophenotype, preoperative biopsy, and frozen section diagnoses. *J Surg Oncol*. 2014;109(3):280-286.
406. Abe Y, Utsunomiya H, Tsutsumi Y. Atypical carcinoid tumor of the lung with amyloid stroma. *Acta Pathol Jpn*. 1992;42(4):286-292.
407. Beasley MB, Thunnissen FB, Brambilla E, et al. Pulmonary atypical carcinoid: predictors of survival in 106 cases. *Hum Pathol*. 2000;31(10):1255-1265.
408. Garcia-Yuste M, Matilla JM, Cueto A, et al. Typical and atypical carcinoid tumours: analysis of the experience of the Spanish Multi-centric Study of Neuroendocrine Tumours of the Lung. *Eur J Cardiothorac Surg*. 2007;31(2):192-197.
409. Pusceddu S, Lo Russo G, Macerelli M, et al. Diagnosis and management of typical and atypical lung carcinoids. *Crit Rev Oncol Hematol*. 2016;100:167-176.
410. Joseph MG, Shibani A, Panjwani N, et al. Usefulness of Ki-67, mitoses, and tumor size for predicting metastasis in carcinoid tumors of the lung: a study of 48 cases at a tertiary care centre in Canada. *Lung Cancer Int*. 2015;2015:545601.
411. Walts AE, Ines D, Marchevsky AM. Limited role of Ki-67 proliferative index in predicting overall short-term survival in patients with typical and atypical pulmonary carcinoid tumors. *Mod Pathol*. 2012;25(9):1258-1264.
412. Swarts DR, van Suylen RJ, den Bakker MA, et al. Interobserver variability for the WHO classification of pulmonary carcinoids. *Am J Surg Pathol*. 2014;38(10):1429-1436.
413. Warth A, Fink L, Fisseler-Eckhoff A, et al. Interobserver agreement of proliferation index (Ki-67) outperforms mitotic count in pulmonary carcinoids. *Virchows Arch*. 2013;462(5):507-513.
414. Pelosi G, Fabbri A, Cossa M, et al. What clinicians are asking pathologists when dealing with lung neuroendocrine neoplasms? *Semin Diagn Pathol*. 2015;32(6):469-479.
415. Marchevsky AM, Walts AE. Diffuse idiopathic pulmonary neuroendocrine cell hyperplasia (DIPNECH). *Semin Diagn Pathol*. 2015;32(6):438-444.
416. Aubry MC, Thomas CF Jr, Jett JR, et al. Significance of multiple carcinoid tumors and tumorlets in surgical lung specimens: analysis of 28 patients. *Chest*. 2007;131(6):1635-1643.
417. Li F, Wang X, Xu H, Roggli VL. Small neuroendocrine lesions in intrathoracic lymph nodes of patients with primary lung adenocarcinoma: real metastasis? *Am J Surg Pathol*. 2010;34(11):1701-1707.
418. Finkelstein SD, Hasegawa T, Colby T, Yousem SA. 11q13 allelic imbalance discriminates pulmonary carcinoids from tumorlets. A microdissection-based genotyping approach useful in clinical practice. *Am J Surg Pathol*. 1999;155(2):633-640.
419. Darvishian F, Ginsberg MS, Klimstra DS, Brogi E. Carcinoid tumorlets simulate pulmonary metastases in women with breast cancer. *Hum Pathol*. 2006;37(7):839-844.
420. Nicholson AG, Brambilla E, Beasley MB, et al. Large cell carcinoma. In: Travis WD, Brambilla E, Burke AP, et al, eds. *WHO Classification of Tumours of the Lung, Pleura, Thymus and Heart*. 4th ed. Lyon: IARC; 2015.
421. Yousem SA. Immunohistochemical and molecular characterization of clear cell carcinoma of the lung. *Hum Pathol*. 2013;44(11):2467-2474.
422. Rossi G, Mengoli MC, Cavazza A, et al. Large cell carcinoma of the lung: clinically oriented classification integrating immunohistochemistry and molecular biology. *Virchows Arch*. 2014;464(1):61-68.
423. Rossi G, Cavazza A, Sturm N, et al. Pulmonary carcinomas with pleomorphic, sarcomatoid, or sarcomatous elements: a clinicopathologic and immunohistochemical study of 75 cases. *Am J Surg Pathol*. 2003;27(3):311-324.
424. Travis WD. Sarcomatoid neoplasms of the lung and pleura. *Arch Pathol Lab Med*. 2010;134(11):1645-1658.
425. Koss MN, Hochholzer L, Frommelt RA. Carcinosarcomas of the lung: a clinicopathologic study of 66 patients. *Am J Surg Pathol*. 1999;23(12):1514-1526.
426. Dacic S, Finkelstein SD, Sasatomi E, et al. Molecular pathogenesis of pulmonary carcinosarcoma as determined by microdissection-based allelotyping. *Am J Surg Pathol*. 2002;26(4):510-516.
427. Holst VA, Finkelstein S, Colby TV, et al. p53 and K-ras mutational genotyping in pulmonary carcinosarcoma, spindle cell carcinoma, and pulmonary blastoma: implications for histogenesis. *Am J Surg Pathol*. 1997;21(7):801-811.
428. Lewis JS, Ritter JH, El-Mofty S. Alternative epithelial markers in sarcomatoid carcinomas of the head and neck, lung, and bladder-p63, MOC-31, and TTF-1. *Mod Pathol*. 2005;18(11):1471-1481.
429. Nakajima M, Kasai T, Hashimoto H, et al. Sarcomatoid carcinoma of the lung: a clinicopathologic study of 37 cases. *Cancer*. 1999;86(4):608-616.
430. Koss MN, Hochholzer L, O'Leary T. Pulmonary blastomas. *Cancer*. 1991;67(9):2368-2381.
431. Nakatani Y, Koss MN, Kerr KM, et al. Pulmonary blastoma. In: Travis WD, Brambilla E, Burke AP, et al, eds. *WHO Classification of Tumours of the Lung, Pleura, Thymus and Heart*. 4th ed. Lyon: IARC; 2015.
432. Yousem SA, Wick MR, Randhawa P, Manivel JC. Pulmonary blastoma. An immunohistochemical analysis with comparison with fetal lung in its pseudoglandular stage. *Am J Clin Pathol*. 1990;93(2):167-175.
433. Nakatani Y, Kitamura H, Inayama Y, Ogawa N. Pulmonary endodermal tumor resembling fetal lung. The optically clear nucleus is rich in biotin. *Am J Surg Pathol*. 1994;18(6):637-642.
434. Nakatani Y, Kitamura H, Inayama Y, et al. Pulmonary adenocarcinomas of the fetal lung type: a clinicopathologic study indicating differences in histology, epidemiology, and natural history of low-grade and high-grade forms. *Am J Surg Pathol*. 1998;22(4):399-411.
435. Olenick SJ, Fan CC, Ryoo JW. Mixed pulmonary blastoma and carcinosarcoma. *Histopathology*. 1994;25(2):171-174.
436. Nakatani Y, Miyagi Y, Takemura T, et al. Aberrant nuclear/cytoplasmic localization and gene mutation of beta-catenin in classic pulmonary blastoma: beta-catenin immunostaining is useful for distinguishing between classic pulmonary blastoma and a blastomatoid variant of carcinosarcoma. *Am J Surg Pathol*. 2004;28(7):921-927.
437. Hirano T, Franzen B, Kato H, et al. Genesis of squamous cell lung carcinoma. Sequential changes of proliferation, DNA ploidy, and p53 expression. *Am J Surg Pathol*. 1994;144(2):296-302.
438. Breuer RH, Pasic A, Smit EF, et al. The natural course of preneoplastic lesions in bronchial epithelium. *Clin Cancer Res*. 2005;11(2 Pt 1):537-543.
439. Melamed MR, Zaman MB, Flehinger BJ, Martini N. Radiologically occult in situ and incipient invasive epidermoid lung cancer: detection by sputum cytology in a survey of asymptomatic cigarette smokers. *Am J Surg Pathol*. 1977;1(1):5-16.
440. Meert AP, Feoli F, Martin B, et al. Ki67 expression in bronchial preneoplastic lesions and carcinoma in situ defined according to the new 1999 WHO/IASLC criteria: a preliminary study. *Histopathology*. 2004;44(1):47-53.
441. Yousem S, Dacic S, eds. Molecular pulmonary pathology. In: Tubbs RR, Stoler MH, eds. *Cell and Tissue Based Molecular Pathology*. Philadelphia: Churchill Livingstone; 2009.
442. Reference deleted in proofs.
443. Rusch V, Klimstra D, Linkov I, Dmitrovsky E. Aberrant expression of p53 or the epidermal growth factor receptor is frequent in early bronchial neoplasia and coexpression precedes squamous cell carcinoma development. *Cancer Res*. 1995;55(6):1365-1372.
444. Woolner LB, Fontana RS, Cortese DA, et al. Roentgenographically occult lung cancer: pathologic findings and frequency of multicentricity during a 10-year period. *Mayo Clinic Proc*. 1984;59(7):453-466.
445. Nagamoto N, Saito Y, Suda H, et al. Relationship between length of longitudinal extension and maximal depth of transmural invasion in roentgenographically occult squamous cell carcinoma of the bronchus (nonpolypoid type). *Am J Surg Pathol*. 1989;13(1):11-20.

446. Miller RR. Bronchioalveolar cell adenomas. *Am J Surg Pathol*. 1990;14:904-912.
447. Chapman AD, Kerr KM. The association between atypical adenomatous hyperplasia and primary lung cancer. *Br J Cancer*. 2000;83(5):632-636.
448. Maeshima AM, Tochigi N, Yoshida A, et al. Clinicopathologic analysis of multiple (five or more) atypical adenomatous hyperplasias (AAHs) of the lung: evidence for the AAH-adenocarcinoma sequence. *J Thorac Oncol*. 2010;5(4):466-471.
449. Nakahara R, Yokose T, Nagai K, et al. Atypical adenomatous hyperplasia of the lung: a clinicopathological study of 118 cases including cases with multiple atypical adenomatous hyperplasia. *Thorax*. 2001;56(4):302-305.
450. Kohno T, Kunitoh H, Suzuki K, et al. Association of KRAS polymorphisms with risk for lung adenocarcinoma accompanied by atypical adenomatous hyperplasias. *Carcinogenesis*. 2008;29(5):957-963.
451. Suzuki K, Nagai K, Yoshida J, et al. The prognosis of resected lung carcinoma associated with atypical adenomatous hyperplasia: a comparison of the prognosis of well-differentiated adenocarcinoma associated with atypical adenomatous hyperplasia and intrapulmonary metastasis. *Cancer*. 1997;79(8):1521-1526.
452. Sakamoto H, Shimizu J, Horio Y, et al. Disproportionate representation of KRAS gene mutation in atypical adenomatous hyperplasia, but even distribution of EGFR gene mutation from preinvasive to invasive adenocarcinomas. *J Pathol*. 2007;212(3):287-294.
453. Collado M, Gil J, Efeyan A, et al. Tumour biology: senescence in premalignant tumours. *Nature*. 2005;436(7051):642.
454. Politi K, Zakowski MF, Fan PD, et al. Lung adenocarcinomas induced in mice by mutant EGF receptors found in human lung cancers respond to a tyrosine kinase inhibitor or to down-regulation of the receptors. *Genes Dev*. 2006;20(11):1496-1510.
455. Altorki NK, Yip R, Hanaoka T, et al. Sublobar resection is equivalent to lobectomy for clinical stage 1A lung cancer in solid nodules. *J Thorac Cardiovasc Surg*. 2014;147(2):754-762, discussion 762-754.
456. Marchevsky AM, Changsri C, Gupta I, et al. Frozen section diagnoses of small pulmonary nodules: accuracy and clinical implications. *Ann Thorac Surg*. 2004;78(5):1755-1759.
457. Gupta R, Dastane A, McKenna RJ Jr, Marchevsky AM. What can we learn from the errors in the frozen section diagnosis of pulmonary carcinoid tumors? An evidence-based approach. *Hum Pathol*. 2009;40(1):1-9.
458. Walts AE, Marchevsky AM. Root cause analysis of problems in the frozen section diagnosis of in situ, minimally invasive, and invasive adenocarcinoma of the lung. *Arch Pathol Lab Med*. 2012;136(12):1515-1521.
459. Xu X, Chung JH, Jheon S, et al. The accuracy of frozen section diagnosis of pulmonary nodules: evaluation of inflation method during intraoperative pathology consultation with cryosection. *J Thorac Oncol*. 2010;5(1):39-44.
460. Gupta R, McKenna R Jr, Marchevsky AM. Lessons learned from mistakes and deferrals in the frozen section diagnosis of bronchioloalveolar carcinoma and well-differentiated pulmonary adenocarcinoma: an evidence-based pathology approach. *Am J Clin Pathol*. 2008;130(1):11-20, quiz 146.
461. Chan AC, Chan JK. Can pulmonary sclerosing haemangioma be accurately diagnosed by intra-operative frozen section? *Histopathology*. 2002;41(5):392-403.
462. Maygarden SJ, Detterbeck FC, Funkhouser WK. Bronchial margins in lung cancer resection specimens: utility of frozen section and gross evaluation. *Mod Pathol*. 2004;17(9):1080-1086.
463. Owen RM, Force SD, Gal AA, et al. Routine intraoperative frozen section analysis of bronchial margins is of limited utility in lung cancer resection. *Ann Thorac Surg*. 2013;95(6):1859-1865, discussion 1865-1856.
464. Roberts KE, Hamele-Bena D, Saqi A, et al. Pulmonary tumor embolism: a review of the literature. *Am J Med*. 2003;115(3):228-232.
465. Morales-Oyarvide V, Mino-Kenudson M. Tumor islands and spread through air spaces: distinct patterns of invasion in lung adenocarcinoma. *Pathol Int*. 2016;66(1): 1-7.
466. Kim AW. Lymph node drainage patterns and micrometastasis in lung cancer. *Semin Thorac Cardiovasc Surg*. 2009;21(4):298-308.
467. Onuigbo WIB. Patterns in metastasis in lung cancer. A review. *Cancer Res*. 1961;21:1077-1085.
468. Trillet V, Catajar JF, Croisile B, et al. Cerebral metastases as first symptom of bronchogenic carcinoma. A prospective study of 37 cases. *Cancer*. 1991;67(11):2935-2940.
469. Vallieres E, Shepherd FA, Crowley J, et al. The IASLC Lung Cancer Staging Project: proposals regarding the relevance of TNM in the pathologic staging of small cell lung cancer in the forthcoming (seventh) edition of the TNM classification for lung cancer. *J Thorac Oncol*. 2009;4(9):1049-1059.
470. Jassem J. The role of radiotherapy in lung cancer: where is the evidence? *Radiother Oncol*. 2007;83(2):203-213.
471. Haaland B, Tan PS, de Castro G Jr, Lopes G. Meta-analysis of first-line therapies in advanced non-small-cell lung cancer harboring EGFR-activating mutations. *J Thorac Oncol*. 2014;9(6):805-811.
472. Shaw AT, Ou SH, Bang YJ, et al. Crizotinib in ROS1-rearranged non-small-cell lung cancer. *N Engl J Med*. 2014;371(21):1963-1971.
473. Socinski MA. Incorporating immunotherapy into the treatment of non-small cell lung cancer: practical guidance for the clinic. *Semin Oncol*. 2015;42(suppl 2):S19-S28.
474. DeSantis CE, Lin CC, Mariotto AB, et al. Cancer treatment and survivorship statistics, 2014. *CA Cancer J Clin*. 2014;64(4):252-271.
475. Wu CY, Fu JY, Wu CF, et al. Survival prediction model using clinico-pathologic characteristics for nonsmall cell lung cancer patients after curative resection. *Medicine (Baltimore)*. 2015;94(45):e2013.
476. Maeda R, Yoshida J, Ishii G, et al. Risk factors for tumor recurrence in patients with early-stage (stage I and II) non-small cell lung cancer: patient selection criteria for adjuvant chemotherapy according to the seventh edition TNM classification. *Chest*. 2011;140(6):1494-1502.
477. Nakamura H, Ando K, Shinmyo T, et al. Female gender is an independent prognostic factor in non-small-cell lung cancer: a meta-analysis. *Ann Thorac Cardiovasc Surg*. 2011;17(5):469-480.
478. Yoshizawa A, Motoi N, Riely GJ, et al. Impact of proposed IASLC/ATS/ERS classification of lung adenocarcinoma: prognostic subgroups and implications for further revision of staging based on analysis of 514 stage I cases. *Mod Pathol*. 2011;24(5):653-664.
479. Meng D, Yuan M, Li X, et al. Prognostic value of K-RAS mutations in patients with non-small cell lung cancer: a systematic review with meta-analysis. *Lung Cancer*. 2013;81(1):1-10.
480. Jackman DM, Miller VA, Cioffredi LA, et al. Impact of epidermal growth factor receptor and KRAS mutations on clinical outcomes in previously untreated non-small cell lung cancer patients: results of an online tumor registry of clinical trials. *Clin Cancer Res*. 2009;15(16):5267-5273.
481. Gjevre JA, Myers JL, Prakash UBS. Pulmonary hamartomas. *Mayo Clin Proc*. 1996;71(1):14-20.
482. Tomashefski JF Jr. Benign endobronchial mesenchymal tumors: their relationship to parenchymal pulmonary hamartomas. *Am J Surg Pathol*. 1982;6(6):531-540.
483. Siegelman SS, Khouri NF, Scott WW, et al. Pulmonary hamartoma: CT findings. *Radiology*. 1986;160(2):313-317.
484. Xu R, Murray M, Jagirdar J, et al. Placental transmogrification of the lung is a histologic pattern frequently associated with pulmonary fibrochondromatous hamartoma. *Arch Pathol Lab Med*. 2002;126(5):562-566.
485. Viale G, Doglioni C, Dell'Orto P, et al. Glial fibrillary acidic protein immunoreactivity in human respiratory tract cartilages and pulmonary chondromatous hamartomas. *Am J Pathol*. 1988;133(2):363-373.
486. Pelosi G, Rosai J, Viale G. Immunoreactivity for sex steroid hormone receptors in pulmonary hamartomas. *Am J Surg Pathol*. 2006;30(7):819-827.
487. Pelosi G, Rodriguez J, Viale G, Rosai J. Salivary gland-type tumors with myoepithelial differentiation arising in pulmonary hamartoma: report of 2 cases of a hitherto unrecognized association. *Am J Surg Pathol*. 2006;30(3):375-387.
488. Trahan S, Erickson-Johnson MR, Rodriguez F, et al. Formation of the 12q14-q15 amplicon precedes the development of a well-differentiated liposarcoma arising from a nonchondroid pulmonary hamartoma. *Am J Surg Pathol*. 2006;30(10):1326-1329.
489. Kazmierczak B, Wanschura S, Rommel B, et al. Ten pulmonary chondroid hamartomas with chromosome 6p21 breakpoints within the HMG-I(Y) gene or its immediate surroundings. *J Natl Cancer Inst*. 1996;88(17):1234-1236.
490. von Ahsen I, Rogalla P, Bullerdiek J. Expression patterns of the LPP-HMGA2 fusion transcript in pulmonary chondroid hamartomas with t(3;12)(q27 approximately 28;q14 approximately 15). *Cancer Genet Cytogenet*. 2005;163(1):68-70.
491. Carney JA. Gastric stromal sarcoma, pulmonary chondroma, and extra-adrenal paraganglioma (Carney Triad): natural history, adrenocortical component, and possible familial occurrence. *Mayo Clin Proc*. 1999;74(6):543-552.
492. Rodriguez FJ, Aubry MC, Tazelaar HD, et al. Pulmonary chondroma: a tumor associated with Carney triad and different from pulmonary hamartoma. *Am J Surg Pathol*. 2007;31(12):1844-1853.
493. Aubertine CL, Flieder DB. Primary paraganglioma of the lung. *Ann Diagn Pathol*. 2004;8(4):237-241.
494. Shibahara J, Goto A, Niki T, et al. Primary pulmonary paraganglioma: report of a functioning case with immunohistochemical and ultrastructural study. *Am J Surg Pathol*. 2004;28(6):825-829.
495. Hochholzer L, Moran CA, Koss MN. Primary pulmonary ganglioneuroblastoma: a clinicopathologic and immunohistochemical study of two cases. *Ann Diagn Pathol*. 1998;2(3):154-158.
496. Freeman JK, Otis CN. Combined carcinoid tumor and ganglioneuroblastoma of the lung: a case report. *Int J Surg Pathol*. 2001;9(2):169-173.

497. Hironaka M, Fukayama M, Takayashiki N, et al. Pulmonary gangliocytic paraganglioma: case report and comparative immunohistochemical study of related neuroendocrine neoplasms. *Am J Surg Pathol*. 2001;25(5):688-693.
498. Kee AR, Forrest CH, Brennan BA, et al. Gangliocytic paraganglioma of the bronchus: a case report with follow-up and ultrastructural assessment. *Am J Surg Pathol*. 2003;27(10):1380-1385.
499. Palau MA, Merino MJ, Quezado M. Corticotropin-producing pulmonary gangliocytic paraganglioma associated with Cushing's syndrome. *Hum Pathol*. 2006;37(5):623-626.
500. Crotty TB, Hooker RP, Swensen SJ, et al. Primary malignant ependymoma of the lung. *Mayo Clin Proc*. 1992;67(4):373-378.
501. Mizutani E, Tsuta K, Maeshima AM, et al. Minute pulmonary meningothelial-like nodules: clinicopathologic analysis of 121 patients. *Hum Pathol*. 2009;40(5):678-682.
502. Mukhopadhyay S, El-Zammar OA, Katzenstein AL. Pulmonary meningothelial-like nodules: new insights into a common but poorly understood entity. *Am J Surg Pathol*. 2009;33(4):487-495.
503. Suster S, Moran CA. Diffuse pulmonary meningotheliomatosis. *Am J Surg Pathol*. 2007;31(4):624-631.
504. Kuhn C 3rd, Askin FB. The fine structure of so-called minute pulmonary chemodectomas. *Hum Pathol*. 1975;6(6):681-691.
505. Ionescu DN, Sasatomi E, Aldeeb D, et al. Pulmonary meningothelial-like nodules: a genotypic comparison with meningiomas. *Am J Surg Pathol*. 2004;28(2):207-214.
506. Moran CA, Hochholzer L, Rush W, Koss MN. Primary intrapulmonary meningiomas. A clinicopathologic and immunohistochemical study of ten cases. *Cancer*. 1996;78(11):2328-2333.
507. Rowsell C, Sirbovan J, Rosenblum MK, Perez-Ordonez B. Primary chordoid meningioma of lung. *Virchows Arch*. 2005;446(3):333-337.
508. Prayson RA, Farver CF. Primary pulmonary malignant meningioma. *Am J Surg Pathol*. 1999;23(6):722-726.
509. Asioli S, Senetta R, Maldi E, et al. Benign" metastatic meningioma: clinico-pathological analysis of one case metastasising to the lung and overview on the concepts of either primitive or metastatic meningiomas of the lung. *Virchows Arch*. 2007;450(5):591-594.
510. Psaras T, Pantazis G, Steger V, et al. Benign meningioma developing late lung metastases: case report and review of the literature. *Clin Neuropathol*. 2009;28(6):453-459.
511. Chan AC, Chan JK. Pulmonary sclerosing hemangioma consistently expresses thyroid transcription factor-1 (TTF-1): a new clue to its histogenesis. *Am J Surg Pathol*. 2000;24(11):1531-1536.
512. Devouassoux-Shisheboran M, Hayashi T, Linnoila RI, et al. A clinicopathologic study of 100 cases of pulmonary sclerosing hemangioma with immunohistochemical studies: TTF-1 is expressed in both round and surface cells, suggesting an origin from primitive respiratory epithelium. *Am J Surg Pathol*. 2000;24(7):906-916.
513. Iyoda A, Hiroshima K, Shiba M, et al. Clinicopathological analysis of pulmonary sclerosing hemangioma. *Ann Thorac Surg*. 2004;78(6):1928-1931.
514. Katzenstein AL, Gmelich JT, Carrington CB. Sclerosing hemangioma of the lung: a clinicopathologic study of 51 cases. *Am J Surg Pathol*. 1980;4(4):343-356.
515. Nagata N, Dairaku M, Ishida T, et al. Sclerosing hemangioma of the lung. Immunohistochemical characterization of its origin as related to surfactant apoprotein. *Cancer*. 1985;55(1):116-123.
516. Wu CT, Chang YL, Lee YC. Expression of the estrogen receptor beta in 37 surgically treated pulmonary sclerosing hemangiomas in comparison with non-small cell lung carcinomas. *Hum Pathol*. 2005;36(10):1108-1112.
517. Illei PB, Rosai J, Klimstra DS. Expression of thyroid transcription factor-1 and other markers in sclerosing hemangioma of the lung. *Arch Pathol Lab Med*. 2001;125(10):1335-1339.
518. Ohori NP, Yousem SA, Sonmez-Alpan E, Colby TV. Estrogen and progesterone receptors in lymphangioleiomyomatosis, epithelioid hemangioendothelioma, and sclerosing hemangioma of the lung. *Am J Clin Pathol*. 1991;96(4):529-535.
519. Rodriguez-Soto J, Colby TV, Rouse RV. A critical examination of the immunophenotype of pulmonary sclerosing hemangioma. *Am J Surg Pathol*. 2000;24(3):442-450.
520. Schmidt LA, Myers JL, McHugh JB. Napsin A is differentially expressed in sclerosing hemangiomas of the lung. *Arch Pathol Lab Med*. 2012;136(12):1580-1584.
521. Yamazaki K. Type-II pneumocyte differentiation in pulmonary sclerosing hemangioma: ultrastructural differentiation and immunohistochemical distribution of lineage-specific transcription factors (TTF-1, HNF-3 alpha, and HNF-3 beta) and surfactant proteins. *Virchows Arch*. 2004;445(1): 45-53.
522. Dacic S, Sasatomi E, Swalsky PA, et al. Loss of heterozygosity patterns of sclerosing hemangioma of the lung and bronchioloalveolar carcinoma indicate a similar molecular pathogenesis. *Arch Pathol Lab Med*. 2004;128(8):880-884.
523. Beasley MB, Travis WD. Sclerosing pneumocytoma. In: Travis WD, Brambilla E, Burke AP, et al, eds. *WHO Classification of Tumours of the Lung, Pleura, Thymus and Heart*. 4th ed. Lyon: IARC; 2015:110-111.
524. Miyagawa-Hayashino A, Tazelaar HD, Langel DJ, Colby TV. Pulmonary sclerosing hemangioma with lymph node metastases: report of 4 cases. *Arch Pathol Lab Med*. 2003;127(3):321-325.
525. Pettinato G, Manivel JC, De Rosa N, Dehner LP. Inflammatory myofibroblastic tumor (plasma cell granuloma). Clinicopathologic study of 20 cases with immunohistochemical and ultrastructural observations. *Am J Clin Pathol*. 1990;94(5):538-546.
526. Farris AB 3rd, Mark EJ, Kradin RL. Pulmonary "inflammatory myofibroblastic" tumors: a critical examination of the diagnostic category based on quantitative immunohistochemical analysis. *Virchows Arch*. 2007;450(5):585-590.
527. Nonaka D, Birbe R, Rosai J. So-called inflammatory myofibroblastic tumour: a proliferative lesion of fibroblastic reticulum cells? *Histopathology*. 2005;46(6):604-613.
528. Cessna MH, Zhou H, Sanger WG, et al. Expression of ALK1 and p80 in inflammatory myofibroblastic tumor and its mesenchymal mimics: a study of 135 cases. *Mod Pathol*. 2002;15(9):931-938.
529. Antonescu CR, Suurmeijer AJ, Zhang L, et al. Molecular characterization of inflammatory myofibroblastic tumors with frequent ALK and ROS1 gene fusions and rare novel RET rearrangement. *Am J Surg Pathol*. 2015;39(7):957-967.
530. Tavora F, Shilo K, Ozbudak IH, et al. Absence of human herpesvirus-8 in pulmonary inflammatory myofibroblastic tumor: immunohistochemical and molecular analysis of 20 cases. *Mod Pathol*. 2007;20(9):995-999.
531. Yamamoto H, Yamaguchi H, Aishima S, et al. Inflammatory myofibroblastic tumor versus IgG4-related sclerosing disease and inflammatory pseudotumor: a comparative clinicopathologic study. *Am J Surg Pathol*. 2009;33(9):1330-1340.
532. Bhagat P, Bal A, Das A, et al. Pulmonary inflammatory myofibroblastic tumor and IgG4-related inflammatory pseudotumor: a diagnostic dilemma. *Virchows Arch*. 2013;463(6):743-747.
533. Chougule A, Bal A, Das A, et al. A Comparative study of inflammatory myofibroblastic tumors and tumefactive IgG4-related inflammatory lesions: the relevance of IgG4 plasma cells. *Appl Immunohistochem Mol Morphol*. 2016;24(10):721-728.
534. Fugo K, Matsuno Y, Okamoto K, et al. Solitary capillary hemangioma of the lung: report of 2 resected cases detected by high-resolution CT. *Am J Surg Pathol*. 2006;30(6):750-753.
535. Faber CN, Yousem SA, Dauber JH, et al. Pulmonary capillary hemangiomatosis. A report of three cases and a review of the literature. *Am Rev Respir Dis*. 1989;140(3):808-813.
536. Aubry MC, Myers JL, Colby TV, et al. Endometrial stromal sarcoma metastatic to the lung: a detailed analysis of 16 patients. *Am J Surg Pathol*. 2002;26(4):440-449.
537. Dalfior D, Parisi A, Cannizzaro C, et al. Pulmonary glomus tumor. *Int J Surg Pathol*. 2008;16(1):81-84.
538. Gaertner EM, Steinberg DM, Huber M, et al. Pulmonary and mediastinal glomus tumors—report of five cases including a pulmonary glomangiosarcoma: a clinicopathologic study with literature review. *Am J Surg Pathol*. 2000;24(8):1105-1114.
539. Yousem SA. Angiosarcoma presenting in the lung. *Arch Pathol Lab Med*. 1986;110(2):112-115.
540. Adem C, Aubry MC, Tazelaar HD, Myers JL. Metastatic angiosarcoma masquerading as diffuse pulmonary haemorrhage: clinicopathologic analysis of seven new patients. *Arch Pathol Lab Med*. 2001;125:1562-1565.
541. Boland JM, Tazelaar HD, Colby TV, et al. Diffuse pulmonary lymphatic disease presenting as interstitial lung disease in adulthood: report of 3 cases. *Am J Surg Pathol*. 2012;36(10):1548-1554.
542. Tazelaar HD, Kerr D, Yousem SA, et al. Diffuse pulmonary lymphangiomatosis. *Hum Pathol*. 1993;24(12):1313-1322.
543. Dail DH, Liebow AA, Gmelich JT, et al. Intravascular, bronchiolar, and alveolar tumor of the lung (IVBAT). An analysis of twenty cases of a peculiar sclerosing endothelial tumor. *Cancer*. 1983;51(3):452-464.
544. Amin RM, Hiroshima K, Kokubo T, et al. Risk factors and independent predictors of survival in patients with pulmonary epithelioid haemangioendothelioma. Review of the literature and a case report. *Respirology*. 2006;11(6):818-825.
545. Kitaichi M, Nagai S, Nishimura K, et al. Pulmonary epithelioid haemangioendothelioma in 21 patients, including three with partial spontaneous regression. *Eur Res J*. 1998;12(1):89-96.
546. Anderson T, Zhang L, Hameed M, et al. Thoracic epithelioid malignant vascular tumors: a clinicopathologic study of 52 cases with emphasis on pathologic grading and molecular studies of WWTR1-CAMTA1 fusions. *Am J Surg Pathol*. 2015;39(1):132-139.
547. Yousem SA, Hochholzer L. Unusual thoracic manifestations of epithelioid hemangioendothelioma. *Arch Pathol Lab Med*. 1987;111(5):459-463.

548. Flucke U, Vogels RJ, de Saint Aubain Somerhausen N, et al. Epithelioid Hemangioendothelioma: clinicopathologic, immunhistochemical, and molecular genetic analysis of 39 cases. *Diagn Pathol*. 2014; 9:131.
549. Doyle LA, Fletcher CD, Hornick JL. Nuclear Expression of CAMTA1 Distinguishes Epithelioid Hemangioendothelioma From Histologic Mimics. *Am J Surg Pathol*. 2016;40(1):94-102.
550. Moran CA, Suster S. Angiolymphoid hyperplasia with eosinophilia (epithelioid hemangioma) of the lung: a clinicopathologic and immunohistochemical study of two cases. *Am J Clin Pathol*. 2005;123(5):762-765.
551. Costa MB, Siqueira SA, Saldiva PH, et al. Histologic patterns of lung infiltration of B-cell, T-cell, and Hodgkin lymphomas. *Am J Clin Pathol*. 2004;121(5):718-726.
552. Koss MN. Malignant and benign lymphoid lesions of the lung. *Ann Diagn Pathol*. 2004;8(3):167-187.
553. Doran HM, Sheppard MN, Collins PW, et al. Pathology of the lung in leukaemia and lymphoma: a study of 87 autopsies. *Histopathology*. 1991;18(3):211-219.
554. Hill BT, Weil AC, Kalaycio M, Cook JR. Pulmonary involvement by chronic lymphocytic leukemia/small lymphocytic lymphoma is a specific pathologic finding independent of inflammatory infiltration. *Leuk Lymphoma*. 2012;53(4):589-595.
555. Rollins SD, Colby TV. Lung biopsy in chronic lymphocytic leukemia. *Arch Pathol Lab Med*. 1988;112(6):607-611.
556. Koh TT, Colby TV, Muller NL. Myeloid leukemias and lung involvement. *Semin Res Crit Care Med*. 2005;26(5):514-519.
557. Callahan M, Wall S, Askin F, et al. Granulocytic sarcoma presenting as pulmonary nodules and lymphadenopathy. *Cancer*. 1987;60(8):1902-1904.
558. Kottaridis PD, Ketley N, Peggs K, et al. An unusual case of intrapulmonary granulocytic sarcoma presenting as interstitial pneumonitis following allogeneic bone marrow transplantation for acute myeloid leukaemia and responding to donor lymphocyte infusion. *Bone Marrow Transplant*. 1999;24(7):807-809.
559. Kurtin PJ, Myers JL, Adlakha H, et al. Pathologic and clinical features of primary pulmonary extranodal marginal zone B-cell lymphoma of MALT type. *Am J Surg Pathol*. 2001;25(8):997-1008.
560. Aghamohammadi A, Parvaneh N, Tirgari F, et al. Lymphoma of mucosa-associated lymphoid tissue in common variable immunodeficiency. *Leuk Lymphoma*. 2006;47(2):343-346.
561. Grogg KL, Aubry MC, Vrana JA, et al. Nodular pulmonary amyloidosis is characterized by localized immunoglobulin deposition and is frequently associated with an indolent B-cell lymphoproliferative disorder. *Am J Surg Pathol*. 2013;37(3):406-412.
562. Khoor A, Myers JL, Tazelaar HD, Kurtin PJ. Amyloid-like pulmonary nodules, including localized light-chain deposition: clinicopathologic analysis of three cases. *Am J Clin Pathol*. 2004;121(2):200-204.
563. Abbondanzo SL, Rush W, Bijwaard KE, Koss MN. Nodular lymphoid hyperplasia of the lung: a clinicopathologic study of 14 cases. *Am J Surg Pathol*. 2000;24(4):587-597.
564. Utz JP, Swensen SJ, Gertz MA. Pulmonary amyloidosis. The Mayo Clinic experience from 1980 to 1993. *Ann Intern Med*. 1996;124(4):407-413.
565. Zhang C, Myers JL. Crystal-storing histiocytosis complicating primary pulmonary marginal zone lymphoma of mucosa-associated lymphoid tissue. *Arch Pathol Lab Med*. 2013;137(9):1199-1204.
566. Seegmiller AC, Xu Y, McKenna RW, Karandikar NJ. Immunophenotypic differentiation between neoplastic plasma cells in mature B-cell lymphoma vs plasma cell myeloma. *Am J Clin Pathol*. 2007;127(2):176-181.
567. Koss MN, Hochholzer L, Moran CA, Frizzera G. Pulmonary plasmacytomas: a clinicopathologic and immunohistochemical study of five cases. *Ann Diagn Pathol*. 1998;2(1):1-11.
568. Piard F, Yaziji N, Jarry O, et al. Solitary plasmacytoma of the lung with light chain extracellular deposits: a case report and review of the literature. *Histopathology*. 1998;32(4):356-361.
569. Cordier JF, Chailleux E, Lauque D, et al. Primary pulmonary lymphomas. A clinical study of 70 cases in nonimmunocompromised patients. *Chest*. 1993;103(1):201-208.
570. Chen G, Yim AP, Ma L, et al. Primary pulmonary large B-cell lymphoma—mediastinal type? *Histopathology*. 2011;58(2):324-326.
571. Kaku N, Seki M, Doi S, et al. A case of intravascular large B-cell lymphoma (IVLBCL) with no abnormal findings on chest computed tomography diagnosed by random transbronchial lung biopsy. *Intern Med*. 2010;49(24):2697-2701.
572. Yousem SA, Colby TV. Intravascular lymphomatosis presenting in the lung. *Cancer*. 1990;65(2):349-353.
573. Rush WL, Andriko JA, Taubenberger JK, et al. Primary anaplastic large cell lymphoma of the lung: a clinicopathologic study of five patients. *Mod Pathol*. 2000;13(12):1285-1292.
574. Liebow AA, Carrington CR, Friedman PJ. Lymphomatoid granulomatosis. *Hum Pathol*. 1972;3(4):457-558.
575. Pittaluga S, Wilson WH, Jaffe E. Lymphomatoid granulomatosis. In: Swerdlow SH, Campo E, Harris NL, et al, eds. *WHO Classification of Tumours of the Haematopoietic and Lymphoid Tissues*. 4th ed. Lyon: IARC; 2008:247-249.
576. Katzenstein AL, Carrington CB, Liebow AA. Lymphomatoid granulomatosis: a clinicopathologic study of 152 cases. *Cancer*. 1979;43(1):360-373.
577. Katzenstein AL, Doxtader E, Narendra S. Lymphomatoid granulomatosis: insights gained over 4 decades. *Am J Surg Pathol*. 2010;34(12):e35-e48.
578. Lipford EH Jr, Margolick JB, Longo DL, et al. Angiocentric immunoproliferative lesions: a clinicopathologic spectrum of post-thymic T-cell proliferations. *Blood*. 1988;72(5):1674-1681.
579. Guinee DG Jr, Perkins SL, Travis WD, et al. Proliferation and cellular phenotype in lymphomatoid granulomatosis: implications of a higher proliferation index in B cells. *Am J Surg Pathol*. 1998;22(9):1093-1100.
580. Morice WG, Kurtin PJ, Myers JL. Expression of cytolytic lymphocyte-associated antigens in pulmonary lymphomatoid granulomatosis. *Am J Clin Pathol*. 2002;118(3):391-398.
581. Myers JL, Kurtin PJ, Katzenstein AL, et al. Lymphomatoid granulomatosis. Evidence of immunophenotypic diversity and relationship to Epstein-Barr virus infection. *Am J Surg Pathol*. 1995;19(11):1300-1312.
582. Guinee D Jr, Jaffe E, Kingma D, et al. Pulmonary lymphomatoid granulomatosis. Evidence for a proliferation of Epstein-Barr virus infected B-lymphocytes with a prominent T-cell component and vasculitis. *Am J Surg Pathol*. 1994;18(8):753-764.
583. Katzenstein AL, Peiper SC. Detection of Epstein–Barr virus genomes in lymphomatoid granulomatosis. Analysis of 29 cases by the polymerase chain reaction technique. *Mod Pathol*. 1990;3:435-441.
584. Fauci AS, Haynes BF, Costa J, et al. Lymphomatoid Granulomatosis. Prospective clinical and therapeutic experience over 10 years. *N Engl J Med*. 1982;306(2):68-74.
585. Dunleavy K, Roschewski M, Wilson WH. Lymphomatoid granulomatosis and other Epstein-Barr virus associated lymphoproliferative processes. *Curr Hematol Malig Rep*. 2012;7(3):208-215.
586. Lluch-Garcia R, Briones-Gomez A, Castellano EM, et al. Primary pulmonary Hodgkin's lymphoma. *Can Respir J*. 2010;17(6):e106-e108.
587. Rodriguez J, Tirabosco R, Pizzolitto S, et al. Hodgkin lymphoma presenting with exclusive or preponderant pulmonary involvement: a clinicopathologic study of 5 new cases. *Ann Diagn Pathol*. 2006;10(2):83-88.
588. Yousem SA, Weiss LM, Colby TV. Primary pulmonary Hodgkin's disease. A clinicopathologic study of 15 cases. *Cancer*. 1986;57(6):1217-1224.
589. Molina JR, Aubry MC, Lewis JE, et al. Primary salivary gland-type lung cancer: spectrum of clinical presentation, histopathologic and prognostic factors. *Cancer*. 2007;110(10):2253-2259.
590. Inoue H, Iwashita A, Kanegae H, et al. Peripheral pulmonary adenoid cystic carcinoma with substantial submucosal extension to the proximal bronchus. *Thorax*. 1991;46(2):147-148.
591. Roden AC, Greipp PT, Knutson DL, et al. Histopathologic and cytogenetic features of pulmonary adenoid cystic carcinoma. *J Thorac Oncol*. 2015;10(11):1570-1575.
592. An J, Park S, Sung SH, et al. Unusual expression of thyroid transcription factor 1 and napsin A in metastatic adenoid cystic carcinoma of extrapulmonary origin in the lung. *Am J Clin Pathol*. 2014;141(5):712-717.
593. Liu X, Adams AL. Mucoepidermoid carcinoma of the bronchus: a review. *Arch Pathol Lab Med*. 2007;131(9):1400-1404.
594. Yousem SA, Hochholzer L. Mucoepidermoid tumors of the lung. *Cancer*. 1987;60(6):1346-1352.
595. Shilo K, Foss RD, Franks TJ, et al. Pulmonary mucoepidermoid carcinoma with prominent tumor-associated lymphoid proliferation. *Am J Surg Pathol*. 2005;29(3):407-411.
596. Achcar Rde O, Nikiforova MN, Dacic S, et al. Mammalian mastermind like 2 11q21 gene rearrangement in bronchopulmonary mucoepidermoid carcinoma. *Hum Pathol*. 2009;40(6):854-860.
597. Ishikawa Y, Alvarez-Fernandez E, Aubry MC, et al. Mucoepidermoid carcinoma. In: Travis WD, Brambilla E, Burke AP, et al, eds. *WHO Classification of Tumours of the Lung, Pleura, Thymus and Heart*. 4th ed. Lyon: IARC; 2015:99-100.
598. Macarenco RS, Uphoff TS, Gilmer HF, et al. Salivary gland-type lung carcinomas: an EGFR immunohistochemical, molecular genetic, and mutational analysis study. *Mod Pathol*. 2008;21(9):1168-1175.
599. Yousem SA. Pulmonary adenosquamous carcinomas with amyloid-like stroma. *Mod Pathol*. 1989;2(5):420-426.
600. Moran CA, Suster S, Askin FB, Koss MN. Benign and malignant salivary gland-type mixed tumors of the lung. Clinicopathologic and immunohistochemical study of eight cases. *Cancer*. 1994;73(10):2481-2490.
601. Hayes MM, van der Westhuizen NG, Forgie R. Malignant mixed tumor of bronchus: a biphasic neoplasm of epithelial and myoepithelial cells. *Mod Pathol*. 1993;6(1):85-88.

602. Nguyen CV, Suster S, Moran CA. Pulmonary epithelial-myoepithelial carcinoma: a clinicopathologic and immunohistochemical study of 5 cases. *Hum Pathol*. 2009;40(3):366-373.
603. Chang T, Husain AN, Colby T, et al. Pneumocytic adenomyoepithelioma: a distinctive lung tumor with epithelial, myoepithelial, and pneumocytic differentiation. *Am J Surg Pathol*. 2007;31(4):562-568.
604. Moran CA, Suster S, Koss MN. Acinic cell carcinoma of the lung ("Fechner tumor"). A clinicopathologic, immunohistochemical, and ultrastructural study of five cases. *Am J Surg Pathol*. 1992;16(11):1039-1050.
605. Rodriguez J, Diment J, Lombardi L, et al. Combined typical carcinoid and acinic cell tumor of the lung: a heretofore unreported occurrence. *Hum Pathol*. 2003;34(10):1061-1065.
606. Santos-Briz A, Terron J, Sastre R, et al. Oncocytoma of the lung. *Cancer*. 1977;40(3):1330-1336.
607. Solis LM, Raso MG, Kalhor N, et al. Primary oncocytic adenocarcinomas of the lung: a clinicopathologic, immunohistochemical, and molecular biologic analysis of 16 cases. *Am J Clin Pathol*. 2010;133(1):133-140.
608. Gaffey MJ, Mills SE, Zarbo RJ, et al. Clear cell tumor of the lung. Immunohistochemical and ultrastructural evidence of melanogenesis. *Am J Surg Pathol*. 1991;15(7):644-653.
609. Fukuda T, Machinami R, Joshita T, Nagashima K. Benign clear cell tumor of the lung in an 8-year-old girl. *Arch Pathol Lab Med*. 1986;110(7):664-666.
610. Gal AA, Koss MN, Hochholzer L, Chejfec G. An immunohistochemical study of benign clear cell ('sugar') tumor of the lung. *Arch Pathol Lab Med*. 1991;115(10):1034-1038.
611. Bonetti F, Pea M, Martignoni G, et al. Clear cell ("sugar") tumor of the lung is a lesion strictly related to angiomyolipoma—the concept of a family of lesions characterized by the presence of the perivascular epithelioid cells (PEC). *Pathology*. 1994;26(3):230-236.
612. Folpe AL, Kwiatkowski DJ. Perivascular epithelioid cell neoplasms: pathology and pathogenesis. *Hum Pathol*. 2010;41(1): 1-15.
613. Fetsch PA, Fetsch JF, Marincola FM, et al. Comparison of melanoma antigen recognized by T cells (MART-1) to HMB-45: additional evidence to support a common lineage for angiomyolipoma, lymphangiomyomatosis, and clear cell sugar tumor. *Mod Pathol*. 1998;11(8):699-703.
614. Ryu JH, Moss J, Beck GJ, et al. The NHLBI lymphangioleiomyomatosis registry: characteristics of 230 patients at enrollment. *Am J Res Crit Care Med*. 2006;173(1):105-111.
615. Zhang X, Travis WD. Pulmonary lymphangioleiomyomatosis. *Arch Pathol Lab Med*. 2010;134(12):1823-1828.
616. Aubry MC, Myers JL, Ryu JH, et al. Pulmonary lymphangioleiomyomatosis in a man. *Am J Res Crit Care Med*. 2000;162(2 Pt 1):749-752.
617. Schiavina M, Di Scioscio V, Contini P, et al. Pulmonary lymphangioleiomyomatosis in a karyotypically normal man without tuberous sclerosis complex. *Am J Res Crit Care Med*. 2007;176(1):96-98.
618. Yavuz E, Cakr C, Tuzlal S, et al. Uterine perivascular epithelioid cell tumor coexisting with pulmonary lymphangioleiomyomatosis and renal angiomyolipoma: a case report. *Appl Immunohistochem Mol Morphol*. 2008;16(4):405-409.
619. Matsui K, Beasley MB, Nelson WK, et al. Prognostic significance of pulmonary lymphangioleiomyomatosis histologic score. *Am J Surg Pathol*. 2001;25(4):479-484.
620. Flavin RJ, Cook J, Fiorentino M, et al. β-Catenin is a useful adjunct immunohistochemical marker for the diagnosis of pulmonary lymphangioleiomyomatosis. *Am J Clin Pathol*. 2011;135(5):776-782.
621. McCormack FX, Travis WD, Colby TV, et al. Lymphangioleiomyomatosis: calling it what it is: a low-grade, destructive, metastasizing neoplasm. *Am J Res Crit Care Med*. 2012;186(12):1210-1212.
622. McCormack FX, Inoue Y, Moss J, et al. Efficacy and safety of sirolimus in lymphangioleiomyomatosis. *N Engl J Med*. 2011;364(17):1595-1606.
623. Oprescu N, McCormack FX, Byrnes S, Kinder BW. Clinical predictors of mortality and cause of death in lymphangioleiomyomatosis: a population-based registry. *Lung*. 2013;191(1):35-42.
624. White SH, Ibrahim NB, Forrester-Wood CP, Jeyasingham K. Leiomyomas of the lower respiratory tract. *Thorax*. 1985;40(4):306-311.
625. Chadwick EG, Connor EJ, Hanson IC, et al. Tumors of smooth-muscle origin in HIV-infected children. *JAMA*. 1990;263(23):3182-3184.
626. McKeeby JL, Li X, Zhuang Z, et al. Multiple leiomyomas of the esophagus, lung, and uterus in multiple endocrine neoplasia type 1. *Am J Pathol*. 2001;159(3):1121-1127.
627. Miller J, Shoni M, Siegert C, et al. Benign metastasizing leiomyomas to the lungs: an institutional case series and a review of the recent literature. *Ann Thorac Surg*. 2016;101(1):253-258.
628. Moran CA, Suster S, Abbondanzo SL, Koss MN. Primary leiomyosarcomas of the lung: a clinicopathologic and immunohistochemical study of 18 cases. *Mod Pathol*. 1997;10(2):121-128.
629. Oliai BR, Tazelaar HD, Lloyd RV, et al. Leiomyosarcoma of the pulmonary veins. *Am J Surg Pathol*. 1999;23(9):1082-1088.
630. Alobeid B, Beneck D, Sreekantaiah C, et al. Congenital pulmonary myofibroblastic tumor: a case report with cytogenetic analysis and review of the literature. *Am J Surg Pathol*. 1997;21(5):610-614.
631. Comin CE, Santucci M, Novelli L, Dini S. Primary pulmonary rhabdomyosarcoma: report of a case in an adult and review of the literature. *Ultrastruct Pathol*. 2001;25(3):269-273.
632. Allan BT, Day DL, Dehner LP. Primary pulmonary rhabdomyosarcoma of the lung in children. Report of two cases presenting with spontaneous pneumothorax. *Cancer*. 1987;59(5):1005-1011.
633. Dehner LP. Pleuropulmonary blastoma is THE pulmonary blastoma of childhood. *Semin Diagn Pathol*. 1994;11(2):144-151.
634. Messinger YH, Stewart DR, Priest JR, et al. Pleuropulmonary blastoma: a report on 350 central pathology-confirmed pleuropulmonary blastoma cases by the International Pleuropulmonary Blastoma Registry. *Cancer*. 2015;121(2):276-285.
635. Priest JR, McDermott MB, Bhatia S, et al. Pleuropulmonary blastoma: a clinicopathologic study of 50 cases. *Cancer*. 1997;80(1):147-161.
636. Hill DA, Jarzembowski JA, Priest JR, et al. Type I pleuropulmonary blastoma: pathology and biology study of 51 cases from the international pleuropulmonary blastoma registry. *Am J Surg Pathol*. 2008;32(2):282-295.
637. Priest JR, Hill DA, Williams GM, et al. Type I pleuropulmonary blastoma: a report from the International Pleuropulmonary Blastoma Registry. *J Clin Oncol*. 2006;24(27):4492-4498.
638. Dishop MK, McKay EM, Kreiger PA, et al. Fetal lung interstitial tumor (FLIT): a proposed newly recognized lung tumor of infancy to be differentiated from cystic pleuropulmonary blastoma and other developmental pulmonary lesions. *Am J Surg Pathol*. 2010;34(12):1762-1772.
639. Flieder DB, Koss MN, Nicholson A, et al. Solitary pulmonary papillomas in adults: a clinicopathologic and in situ hybridization study of 14 cases combined with 27 cases in the literature. *Am J Surg Pathol*. 1998;22(11):1328-1342.
640. Harada H, Miura K, Tsutsui Y, et al. Solitary squamous cell papilloma of the lung in a 40-year-old woman with recurrent laryngeal papillomatosis. *Pathol Int*. 2000;50(5):431-439.
641. Deavers M, Guinee D, Koss MN, Travis WD. Granular cell tumors of the lung. Clinicopathologic study of 20 cases. *Am J Surg Pathol*. 1995;19(6):627-635.
642. Moran CA, Suster S, Fishback NF, Koss MN. Primary intrapulmonary thymoma. A clinicopathologic and immunohistochemical study of eight cases. *Am J Surg Pathol*. 1995;19(3):304-312.
643. Bosch X, Ramirez J, Font J, et al. Primary intrapulmonary benign schwannoma. A case with ultrastructural and immunohistochemical confirmation. *Eur Res J*. 1990;3(2):234-237.
644. Cooney TP. Primary pulmonary ganglioneuroblastoma in an adult: maturation, involution and the immune response. *Histopathology*. 1981;5(4):451-463.
645. Ferrara G, Boscaino A, De Rosa G. Bronchial blue naevus. A previously unreported entity. *Histopathology*. 1995;26(6):581-583.
646. Shilo K, Miettinen M, Travis WD, et al. Pulmonary microcystic fibromyxoma: report of 3 cases. *Am J Surg Pathol*. 2006;30(11):1432-1435.
647. Kamata T, Sunami K, Yoshida A, et al. Frequent BRAF or EGFR mutations in ciliated muconodular papillary tumors of the lung. *J Thorac Oncol*. 2016;11(2):261-265.
648. Kamata T, Yoshida A, Kosuge T, et al. Ciliated muconodular papillary tumors of the lung: a clinicopathologic analysis of 10 cases. *Am J Surg Pathol*. 2015;39(6):753-760.
649. Hirata T, Reshad K, Itoi K, et al. Lipomas of the peripheral lung—a case report and review of the literature. *Thorac Cardiovasc Surg*. 1989;37(6):385-387.
650. Matsuba K, Saito T, Ando K, Shirakusa T. Atypical lipoma of the lung. *Thorax*. 1991;46(9):685.
651. Moran CA, Suster S, Koss MN. Endobronchial lipomas: a clinicopathologic study of four cases. *Mod Pathol*. 1994;7(2):212-214.
652. Klein J, Zhuang Z, Lubensky I, et al. Multifocal microcysts and papillary cystadenoma of the lung in von Hippel-Lindau disease. *Am J Surg Pathol*. 2007;31(8):1292-1296.
653. Rao N, Colby TV, Falconieri G, et al. Intrapulmonary solitary fibrous tumors: clinicopathologic and immunohistochemical study of 24 cases. *Am J Surg Pathol*. 2013;37(2):155-166.
654. Hartel PH, Fanburg-Smith JC, Frazier AA, et al. Primary pulmonary and mediastinal synovial sarcoma: a clinicopathologic study of 60 cases and comparison with five prior series. *Mod Pathol*. 2007;20(7):760-769.
655. Cummings NM, Desai S, Thway K, et al. Cystic primary pulmonary synovial sarcoma presenting as recurrent pneumothorax: report of 4 cases. *Am J Surg Pathol*. 2010;34(8):1176-1179.
656. Pettinato G, Manivel JC, Saldana MJ, et al. Primary bronchopulmonary fibrosarcoma of childhood and adolescence: reassessment of a low-grade malignancy. Clinicopathologic

study of five cases and review of the literature. *Hum Pathol*. 1989;20(5):463-471.
657. Halyard MY, Camoriano JK, Culligan JA, et al. Malignant fibrous histiocytoma of the lung. Report of four cases and review of the literature. *Cancer*. 1996;78(12):2492-2497.
658. Kim L, Yoon YH, Choi SJ, et al. Hyalinizing spindle cell tumor with giant rosettes arising in the lung: report of a case with FUS-CREB3L2 fusion transcripts. *Pathol Int*. 2007;57(3):153-157.
659. Kalhor N, Suster S, Moran CA. Primary pulmonary chondrosarcomas: a clinicopathologic study of 4 cases. *Hum Pathol*. 2011;42(11):1629-1634.
660. Kurotaki H, Tateoka H, Takeuchi M, et al. Primary mesenchymal chondrosarcoma of the lung. A case report with immunohistochemical and ultrastructural studies. *Acta Pathol Jpn*. 1992;42(5):364-371.
661. Colby TV, Bilbao JE, Battifora H, Unni KK. Primary osteosarcoma of the lung. A reappraisal following immunohistologic study. *Arch Pathol Lab Med*. 1989;113(10):1147-1150.
662. Moran CA, Suster S, Koss MN. Primary malignant 'triton' tumour of the lung. *Histopathology*. 1997;30(2):140-144.
663. Tsuji S, Hisaoka M, Morimitsu Y, et al. Peripheral primitive neuroectodermal tumour of the lung: report of two cases. *Histopathology*. 1998;33(4):369-374.
664. Syed S, Haque AK, Hawkins HK, et al. Desmoplastic small round cell tumor of the lung. *Arch Pathol Lab Med*. 2002;126(10):1226-1228.
665. Denning KL, Olson PR, Maley RH Jr, et al. Primary pulmonary follicular dendritic cell neoplasm: a case report and review of the literature. *Arch Pathol Lab Med*. 2009;133(4):643-647.
666. Thway K, Nicholson AG, Lawson K, et al. Primary pulmonary myxoid sarcoma with EWSR1-CREB1 fusion: a new tumor entity. *Am J Surg Pathol*. 2011;35(11):1722-1732.
667. Smith SC, Palanisamy N, Betz BL, et al. At the intersection of primary pulmonary myxoid sarcoma and pulmonary angiomatoid fibrous histiocytoma: observations from three new cases. *Histopathology*. 2014;65(1):144-146.
668. Wilson RW, Moran CA. Primary melanoma of the lung: a clinicopathologic and immunohistochemical study of eight cases. *Am J Surg Pathol*. 1997;21(10):1196-1202.
669. Pelosi G, Petrella F, Sandri MT, et al. A primary pure yolk sac tumor of the lung exhibiting CDX-2 immunoreactivity and increased serum levels of alkaline phosphatase intestinal isoenzyme. *Int J Surg Pathol*. 2006;14(3):247-251.
670. Hunter S, Hewan-Lowe K, Costa MJ. Primary pulmonary alpha-fetoprotein-producing malignant germ cell tumor. *Hum Pathol*. 1990;21(10):1074-1076.
671. Pushchak MJ, Farhi DC. Primary choriocarcinoma of the lung. *Arch Pathol Lab Med*. 1987;111(5):477-479.
672. Mazur MT. Metastatic gestational choriocarcinoma. Unusual pathologic variant following therapy. *Cancer*. 1989;63(7):1370-1377.
673. Dirnhofer S, Freund M, Rogatsch H, et al. Selective expression of trophoblastic hormones by lung carcinoma: neuroendocrine tumors exclusively produce human chorionic gonadotropin alpha-subunit (hCGalpha). *Hum Pathol*. 2000;31:966-972.
674. Yoshino I, Hayashi I, Yano T, et al. Alpha-fetoprotein-producing adenocarcinoma of the lung. *Lung Cancer*. 1996;15(1):125-130.
675. Yoshimoto T, Higashino K, Hada T, et al. A primary lung carcinoma producing alpha-fetoprotein, carcinoembryonic antigen, and human chorionic gonadotropin. Immunohistochemical and biochemical studies. *Cancer*. 1987;60(11):2744-2750.
676. Haninger DM, Kloecker GH, Bousamra Ii M, et al. Hepatoid adenocarcinoma of the lung: report of five cases and review of the literature. *Mod Pathol*. 2014;27(4):535-542.
677. Shields DJ, Edwards WD. Pulmonary hypertension attributable to neoplastic emboli. An autopsy study of 20 cases and a review of the literature. *Cardiovasc Pathol*. 1992;1:279-287.
678. Marchioni A, Lasagni A, Busca A, et al. Endobronchial metastasis: an epidemiologic and clinicopathologic study of 174 consecutive cases. *Lung Cancer*. 2014;84(3):222-228.
679. Bisceglia M, Galliani C, Rosai J. TTF-1 expression in breast carcinoma-the chosen clone matters. *Am J Surg Pathol*. 2011;35(7):1087-1088.
680. Geisinger KR, Levine EA, Shen P, Bradley RF. Pleuropulmonary involvement in pseudomyxoma peritonei: morphologic assessment and literature review. *Am J Clin Pathol*. 2007;127(1):135-143.
681. Bocklage T, Leslie K, Yousem S, Colby T. Extracutaneous angiosarcomas metastatic to the lungs: clinical and pathologic features of twenty-one cases. *Mod Pathol*. 2001;14(12):1216-1225.
682. Osborn M, Mandys V, Beddow E, et al. Cystic fibrohistiocytic tumours presenting in the lung: primary or metastatic disease? *Histopathology*. 2003;43(6):556-562.
683. Zheng Y, Fernando HC. Surgical and nonresectional therapies for pulmonary metastasis. *Surg Clin North Am*. 2010;90(5):1041-1051.
684. Hornbech K, Ravn J, Steinbruchel DA. Outcome after pulmonary metastasectomy: analysis of 5 years consecutive surgical resections 2002-2006. *J Thorac Oncol*. 2011;6(10):1733-1740.
685. Casson AG, Putnam JB, Natarajan G, et al. Five-year survival after pulmonary metastasectomy for adult soft tissue sarcoma. *Cancer*. 1992;69(3):662-668.
686. van Geel AN, Pastorino U, Jauch KW, et al. Surgical treatment of lung metastases: The European Organization for Research and Treatment of Cancer-Soft Tissue and Bone Sarcoma Group study of 255 patients. *Cancer*. 1996;77(4):675-682.

11 Pleura

Jeffrey L. Myers

CHAPTER CONTENTS

Normal anatomy of the pleura, *444*
Pleuritis and other non-neoplastic lesions, *444*
Asbestos and the pleura, *445*
Tumors, *445*
Benign mesothelioma, *445*
Malignant mesothelioma, *445*
Solitary fibrous tumor, *450*
Other primary tumors, *452*
Metastatic tumors, *453*
Biopsy and cytology, *453*

Normal Anatomy of the Pleura

Both the visceral and parietal pleural layers have a lining of mesothelial cells endowed with a continuous basement membrane and resting on a layer of well-vascularized fibroelastic connective tissue matrix.[1,2] The submesothelial connective tissue is divided by superficial and deep elastic lamina.[3] All of these elements are mesodermally derived. The normal mesothelial cell is flat or low cuboidal. Ultrastructurally, it features apical tight junctions, desmosomes, long and slender surface microvilli, and bundles of cytoplasmic tonofilaments. Immunohistochemically, it shows reactivity for both low- and high-molecular-weight keratins[4] and for many other markers, which are discussed in the section on mesothelioma.

The normal subserosal cells have ultrastructural features of fibroblasts and express the intermediate filament vimentin but not keratin; however, when these "multipotential subserosal cells" or "submesothelial fibroblasts" proliferate in reactive conditions, they coexpress keratin and vimentin and develop surface differentiation, consistent with the notion that they are progenitors of mesothelial cells.[4]

The pleural space is drained by three adjacent lymphatic pathways that connect separately into hilar, retroperitoneal, and lower mediastinal lymph node groups. In normal physiological conditions, fluid is drained primarily through lymphatic stomata in the parietal pleural surface.[1]

Pleuritis and Other Non-Neoplastic Lesions

Infectious and noninfectious inflammatory diseases of the lung may also involve the pleura.[2] The vast majority of pleural space infections, including those resulting in a potentially life-threatening suppurative acute inflammatory exudate (i.e. empyema), are caused by infectious lung disease. The pulmonary lesion may completely resolve but leave a pleural *symphysis* (fusion between the two pleural layers) secondary to prominent pleural fibrosis, which can be several centimeters thick. The underlying lung parenchyma may be perfectly normal after recovery from infection, but its expansion is prevented by the surrounding rigid and contracted thickened pleura. If this dense fibrous layer is peeled off, pulmonary function improves markedly. It is likely that the process designated *shrinking pleuritis with atelectasis*, *folded lung syndrome*, or *rounded atelectasis* represents a variation on this theme.[5,6]

Tuberculosis can involve the pleura in various ways: as a complication of a subpleural primary lung infection, by direct extension from reinfection pulmonary disease, and as a result of hematogenous spread.[2]

Systemic connective tissue diseases, especially rheumatoid arthritis and systemic lupus erythematosus, are a common cause of noninfectious pleuritis. The microscopic appearance of the inflammatory infiltrate is often nonspecific, usually comprising a combination of lymphocytes and plasma cells. In some instances, however, the presence of palisaded spindle histiocytes underlying a layer of fibrin and arranged perpendicularly to the pleural surface should make the pathologist suspect a rheumatoid arthritis.[7] Rheumatoid nodules may also involve the pleura, usually as subpleural lung nodules that erode into and sometimes through the visceral pleura (Fig. 11.1).[3]

Endometriosis of the pleura and diaphragm has been reported, accounting for rare reports of catamenial pneumothorax and, less commonly, hemoptysis.[8,9] Most of the cases have occurred in the right hemithorax and are often associated with pelvic endometriosis. Histologic evidence of endometriosis is not always documented in pleural tissue from patients with catamenial pneumothorax.[10]

Amyloidosis can involve the pleura; the diagnosis is possible with needle biopsy.

Abstract

This chapter reviews pathology of the visceral and parietal pleura. It begins with a brief review of normal anatomy followed by inflammatory, non-neoplastic diseases. The relationship between asbestos and both benign and malignant pleural diseases is summarized. The bulk of this chapter is devoted to pleural tumors with a focus on mesothelioma. Other, less common primary pleural neoplasms are discussed, followed by an overview of metastatic tumors.

Keywords

Mesothelioma,
immunohistochemistry,
solitary fibrous tumor,
calcifying fibrous pseudotumor,
epithelioid hemangioendothelioma,
pyothorax-associated lymphoma,
primary effusion lymphoma,
pleural effusion

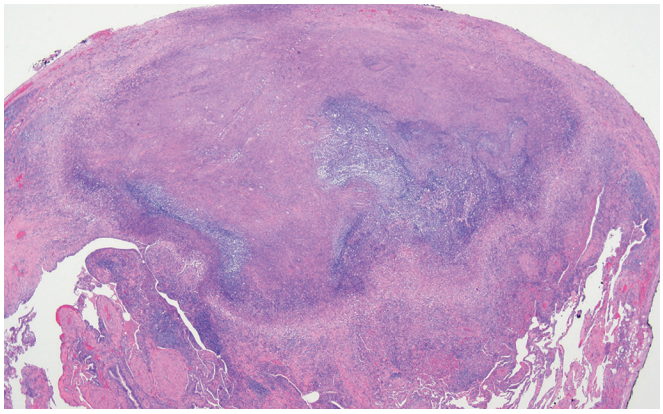

Figure 11.1 Rheumatoid nodule extending into visceral pleura in a patient with rheumatoid arthritis.

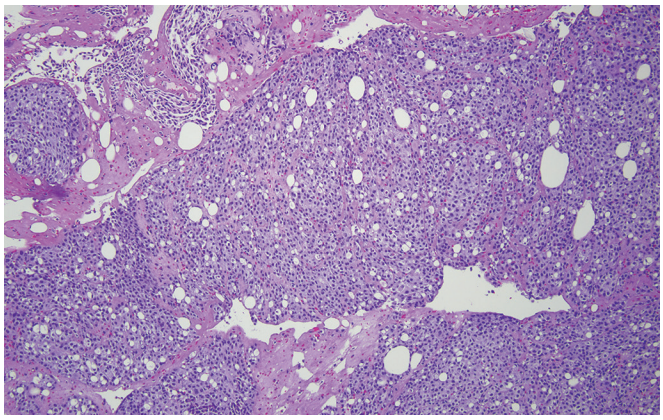

Figure 11.2 Nodular histiocytic/mesothelial hyperplasia forming a cellular aggregate loosely attached to visceral pleura in a patient with lymphangioleiomyomatosis who suffered pneumothorax.

Reactive eosinophilic pleuritis is secondary to pneumothorax of any cause and is discussed in greater detail in Chapter 10.

Nodular histiocytic/mesothelial hyperplasia is a reactive process composed of histiocytes/monocytes and mesothelial cells. It is more common in hernia sacs and heart (where it is known acronymically as MICE for mesothelial/monocytic incidental cardiac excrescence) but can also occur in the lung and pleura, where it may be confused with a neoplastic proliferation (Fig. 11.2).[11]

Asbestos and the Pleura

Asbestos is a family of fibrous hydrated silicates that are divided into two groups: the serpentines and amphiboles.[12] Those of commercial importance are chrysolite in the first group and amosite and crocidolite in the second. These minerals were a component of a large variety of manufactured products, particularly in the construction industry, until their use from insulation products was banned in 1972.[13] Proof of the widespread use of this material until that time is the finding of asbestos bodies in lung smears (particularly in the lower lobes) in approximately 40% of persons autopsied in the United States.[14] Inhalation of these fibers can result in various pathologic processes, which depend on the type of mineral, the dimensions and concentration of the fibers, and the duration of the exposure. The main pleural manifestations of asbestos exposure are pleural plaques, pleural fibrosis, and mesothelioma.

Pleural plaques are made up of hyalinized fibrous tissue. They are usually but not always associated with asbestos (mainly amosite and crocidolite) exposure.[15] The occurrence of these plaques correlates well with the duration and intensity of exposure. They are not topographically related to so-called *pleural black spots* (i.e. foci of accumulation of inhaled particles), suggesting that there is no pathogenetic connection between the two processes.[16]

Pleural plaques are characteristically located on the parietal side, mainly in the intercostal spaces on the anterior and posterolateral aspects of the chest wall and on the dome of the diaphragm, at sites where the visceral and parietal pleura approximate during respiratory excursions. Over time, they become calcified and therefore detectable on chest x-ray films and computed tomography (CT) scans.

The relationship between asbestos and **mesothelioma**, first identified by Wagner et al.[17] in South Africa, has now been documented all over the world. The average prevalence of mesothelioma in people with prolonged heavy exposure to asbestos is 2%–3% but has reached up to 10% in some series. The latency period is usually 20 years or longer, the incidence in the United States having apparently peaked in the 1990s as a result of the banning of asbestos use in 1972.[18] It should be pointed out, however, that a substantial minority of pleural mesotheliomas are not associated with a history of asbestos exposure, and for that reason the presence or absence of a history of exposure should play no part in the histopathologic diagnosis of mesothelioma.[19] Furthermore, the risk of asbestos exposure leading to mesothelioma may vary depending on the genetic makeup of the individual or because of exposure to other carcinogens, such as SV40.[20]

Amosite and crocidolite are the fiber types found in most cases of asbestos-related mesothelioma.[13] There can be superimposed deposition of oxalate salts.[21] Asbestos bodies are more commonly found in the underlying lung parenchyma than within the mesothelioma. They can also be found in pulmonary hilar nodes.[22] Microscopic examination using asbestos bodies as surrogates for uncoated asbestos fibers is a very insensitive and nonspecific method for detection and identification of asbestos fiber burden. Extraction methods to increase the yield combined with biophysical techniques (such as electron microprobe analysis) are necessary to properly study their true incidence and composition.

Tumors

Benign Mesothelioma

Benign (papillary) mesothelioma is a term applied historically to solitary lesions of the peritoneum and tunica vaginalis with histologic features that overlap with well-differentiated papillary mesothelioma, which is discussed elsewhere in this chapter.[23] Analogous localized lesions occur rarely if at all in the pleura.

Two types of benign mesothelial proliferation that are common in the peritoneal cavity and genital region, respectively, but very uncommon in the pleura, are so-called **benign multicystic mesothelioma** and **adenomatoid tumor**. However, a few convincing cases of both conditions in this location are on record.[24,25]

Malignant Mesothelioma

Generalities

Malignant mesothelioma is usually seen in older adults, although well-documented cases in young individuals are on record.[26] In some instances familial clustering has been demonstrated.[27] Cases have been reported following radiation therapy for Hodgkin lymphoma.[28] Typically, the tumor presents with chest pain and pleural effusion which may be hemorrhagic. In most instances the initial involvement is in

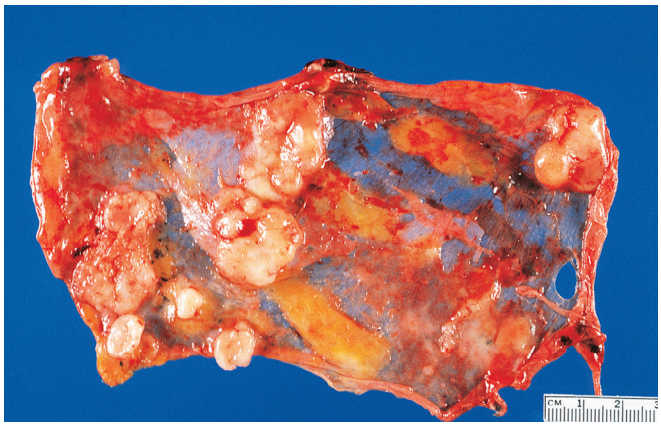

Figure 11.3 Malignant mesothelioma growing as multiple nodules on the parietal pleura.

the lower half of a hemithorax, but spread to the rest of the pleural cavity is the rule. Circumferential pleural thickening with involvement of mediastinal pleura combined with pleural nodules on CT scans tend to favor malignant over benign mesothelial proliferations.[29] Serum levels of osteopontin and mesothelin are potentially useful diagnostic biomarkers, but they are not yet widely available.[30]

Morphologic Features

Grossly, the classic presentation is that of multiple gray or white ill-defined nodules in a diffusely thickened pleura (Figs. 11.3 and 11.4). It is much rarer for it to present as a localized pleural mass.[31,32] Microscopically, diffuse pleural mesothelioma can be divided into purely epithelioid tumors, purely sarcomatoid tumors, and biphasic or mixed tumors. Epithelioid mesotheliomas comprise the majority and in their most classic form are characterized by neoplastic formations with a tubulopapillary architecture, accompanied by solid nests in some cases (Fig. 11.5).[33] The cytoplasm is abundant and acidophilic, sometimes resulting in a histiocytoid appearance. Variations on this classical histology account for myriad histologic variants, as summarized elsewhere in this chapter.

Sarcomatoid mesotheliomas are much less common than epithelioid tumors, accounting for 10%–20% of cases, and are composed of neoplastic spindle cells without an identifiable epithelial element.[34] Pleural effusion is less common, and distant metastases are more frequent at diagnosis in sarcomatoid mesothelioma cases. Grossly they show the same diffuse growth pattern characteristic of epithelioid mesotheliomas with a tendency to encase the lung.[34] Microscopically, the tumor is highly cellular, formed by interwoven bundles of spindle cells (Fig. 11.6). Nuclear atypia is present, and mitotic figures are common. Rarely they are associated with heterologous elements (i.e. rhabdo-, osteo-, and/or chondrosarcomatous differentiation), a finding that is more common in, but not unique to, sarcomatoid variants.[35] Biphasic mesotheliomas occur more frequently than purely sarcomatoid tumors and are characterized by a combination of epithelioid and spindle cell components (Fig. 11.7), resulting in a histologic appearance that may mimic synovial sarcoma. The World Health Organization (WHO) tumor classification proposes that an epithelioid and sarcomatoid component should comprise at least 10% of a mesothelioma to merit the designation of *biphasic*.[36]

Mesothelioma Variants

Well-differentiated papillary mesotheliomas that are multicentric, extensive, and/or associated with pleural effusion should be regarded with great caution, given that these features can be seen focally in otherwise typical epithelioid mesotheliomas. In rare cases, however, the histologic features throughout are identical to those described in patients with the much more common well-differentiated papillary mesotheliomas of the peritoneum: prominent formation of papillae lined by bland mesothelial cells with minimal or no invasion (Fig. 11.8). They are generally associated with an indolent clinical course and long survival but have the capacity to spread widely and behave more aggressively than their peritoneal counterparts.[37]

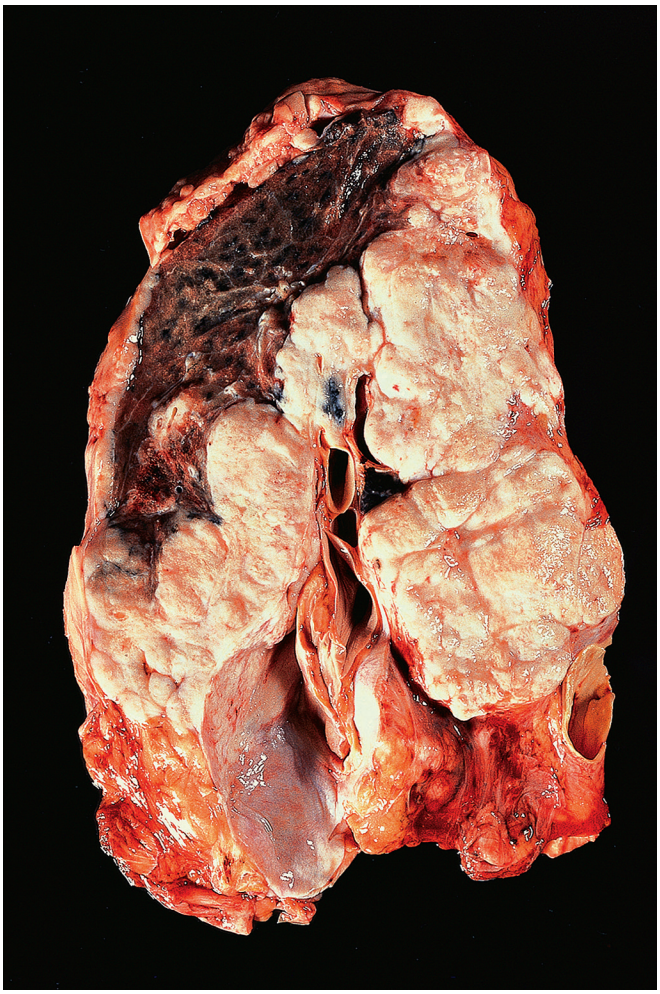

Figure 11.4 Classic pattern of spread of advanced pleural mesothelioma. (Courtesy of Dr. R.A. Cooke, Brisbane, Australia. From Cooke RA, Stewart B. *Colour Atlas of Anatomical Pathology*. Edinburgh: Churchill Livingstone; 2004.)

Deciduoid mesothelioma is characterized by the presence of large tumor cells with an abundant ground-glass cytoplasm that simulates the appearance of decidual cells.[38,39] Originally described in the abdominal cavity of young women, it has now also been seen in the pleural cavity, in an older age group, and in patients of both sexes. In a small retrospective cohort study of 21 cases including 17 pleural tumors, high-grade cytology predicted shorter survivals.[38]

Mesothelioma with clear cell features can be confused with lung carcinoma and metastatic carcinoma, particularly from the kidney.[40] The cytoplasmic clearing is most often due to the accumulation of glycogen, in which case the alternative term *glycogen-rich mesothelioma* has been used.

Mesothelioma with rhabdoid features combines areas of typical mesothelioma (usually of the epithelioid type) with areas rich in

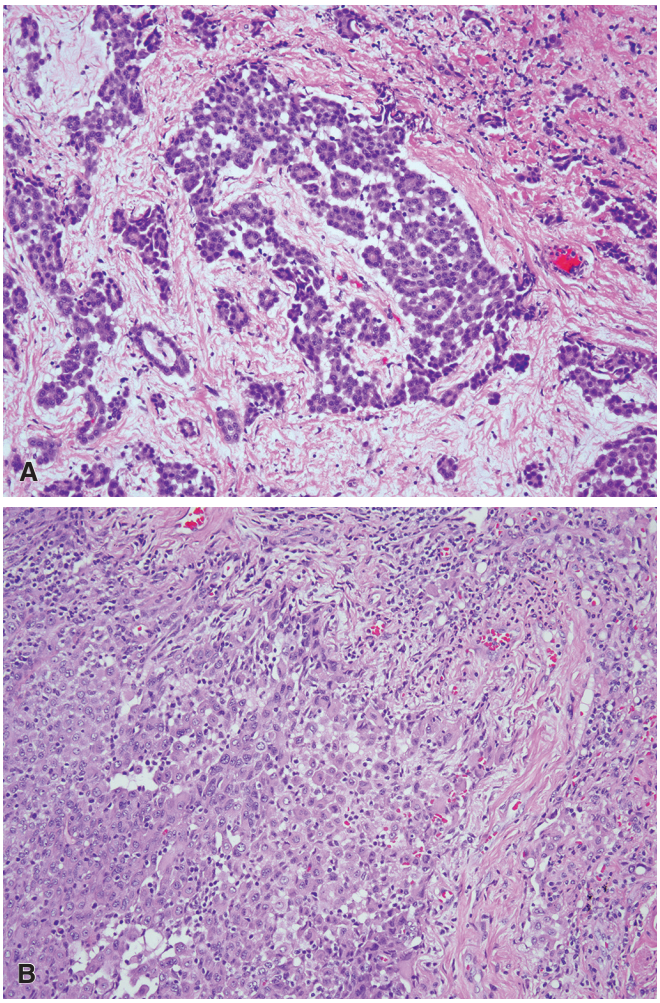

Figure 11.5 Histologically classic malignant pleural mesothelioma with a predominantly tubulopapillary **(A)** and focally solid **(B)** growth pattern.

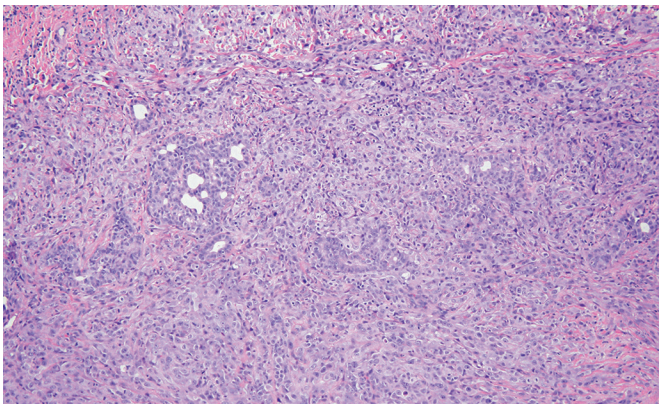

Figure 11.7 Biphasic mesothelioma with both epithelioid and spindle cell components.

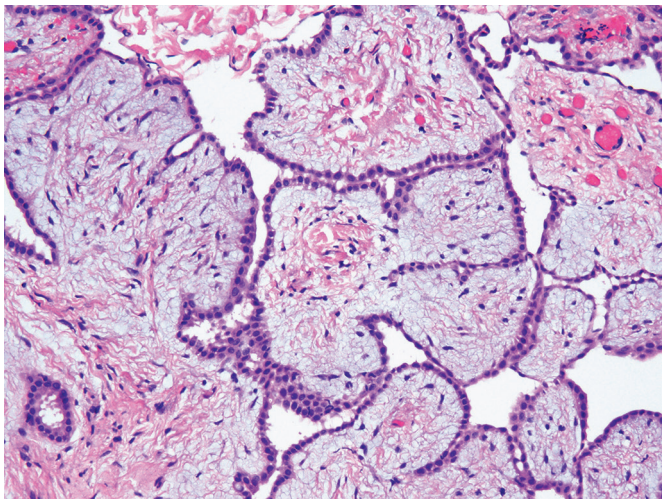

Figure 11.8 **Well-Differentiated Papillary Mesothelioma.**

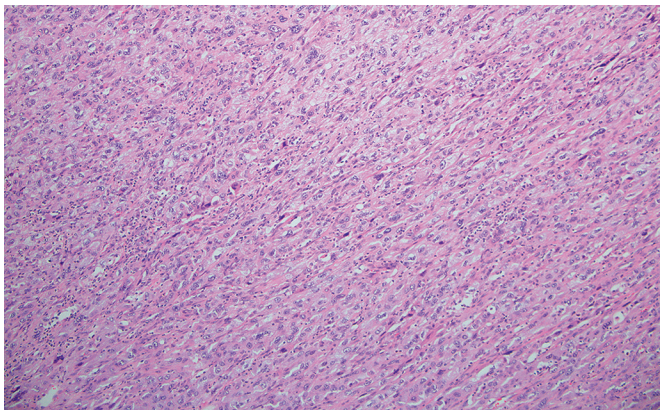

Figure 11.6 Sarcomatoid mesothelioma composed of neoplastic spindle cells.

rhabdoid cells. As it is true for rhabdoid cell-containing tumors in most other sites, this mesothelioma variant runs a markedly aggressive course.[41]

A small cell variant of malignant mesothelioma has been described.[42,43] The small cell component may predominate in small biopsies but is invariably overshadowed by histologically classical features in more thoroughly sampled surgical specimens. Most of the reported cases have been immunoreactive for keratin and mesothelial markers, including calretinin, CK5/6, WT1, and podoplanin; some cases also stained for neuron-specific enolase and occasionally Leu7 (CD57).[42,43]

Lymphohistiocytoid mesothelioma is characterized microscopically by a diffuse proliferation of atypical histiocyte-like malignant mesothelial cells admixed with numerous lymphocytes (almost exclusively of T-cell type) and a lesser number of plasma cells.[44] The phenotype of the histiocyte-like elements reflects their mesothelial nature. The behavior of this tumor is aggressive, as is true for nearly all diffuse mesotheliomas of the pleura, but more closely matches that of conventional epithelioid tumors, suggesting to some that this be considered a variant of epithelioid, rather than sarcomatoid, mesothelioma.[44,45]

Pleomorphic mesothelioma is currently considered a variant of epithelioid mesothelioma in the WHO classification scheme that is characterized by highly pleomorphic large cells with abundant eosinophilic cytoplasm and single or multiple nuclei with marked variation in size and shape and large nucleoli.[46,47] They are consistently positive for pankeratin and cytokeratin 7, but staining for traditional mesothelioma markers like calretinin, CK5/6, and WT1 is variable.[47] A number of authors have advocated that this be considered a variant of sarcomatoid or biphasic, rather than epithelioid, mesothelioma

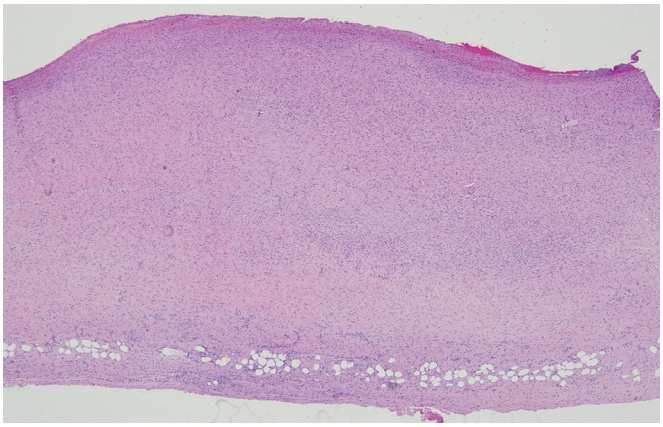

Figure 11.9 Desmoplastic mesothelioma showing characteristic random variation in cellularity, "patternless pattern of Stout," and invasion of chest wall fat.

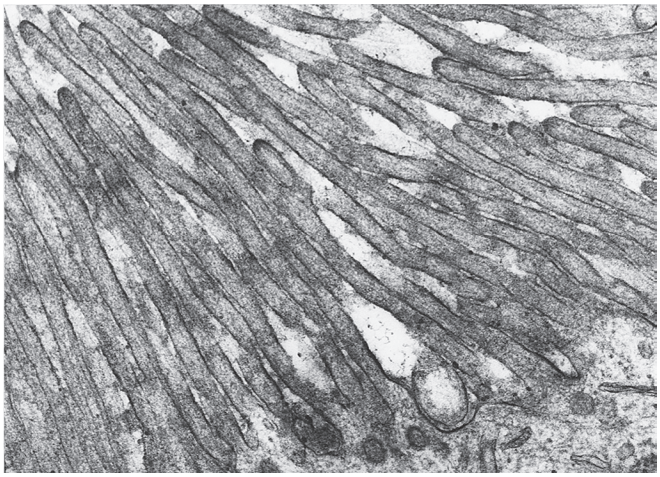

Figure 11.10 Electron Micrograph of a Malignant Mesothelioma of the Pleura. Detail of profuse, long, thin, nonintestinal-type microvilli devoid of a glycocalyx and actin rootlets. (×37,800). (Courtesy of Dr. Robert E. Erlandson, Memorial Sloan-Kettering Cancer Center.)

based on a characteristically aggressive course more typical of sarcomatoid tumors.[46,48]

Desmoplastic mesothelioma is a subtype of sarcomatoid mesothelioma accompanied by abundant deposition of fibrous tissue demonstrating a storiform or "patternless pattern of Stout" arrangement of neoplastic spindle cells (Fig. 11.9). The main differential diagnosis is with benign fibrous lesions of the pleura and more cellular types of solitary fibrous tumors, some of which may be malignant themselves. Immunohistochemical positivity for keratin, calretinin, and WT1 is the best evidence in favor of mesothelioma over solitary fibrous tumor but does not establish a diagnosis of malignancy, given that reactive submesothelial fibroblasts frequently acquire a mesothelial immunophenotype.[49] Histologic features helpful in separating desmoplastic mesothelioma from benign fibrous proliferations include invasion of chest wall soft tissue or lung parenchyma, bland necrosis, frankly sarcomatoid areas with cytologic atypia, and the characteristic storiform growth pattern in the context of random variation in cellularity.[50]

Differential Diagnosis and the Role of Histochemistry, Immunohistochemistry, Electron Microscopy, and Molecular Testing

Early cases of epithelioid mesothelioma must be distinguished from reactive mesothelial hyperplasia, as seen in association with inflammatory or neoplastic diseases of the underlying lung, or sometimes with no apparent cause. Features in favor of malignancy include stromal invasion, full-thickness involvement, expansile nodules, random variation in cellularity, architectural complexity, and irregular distribution of vessels.[29] Of these, invasion is regarded as the most reliable criterion of malignancy. The diagnosis of malignant mesothelioma in the absence of detectable invasion ("mesothelioma in situ") is problematic in the absence of invasive disease elsewhere and should be made with great caution if at all. Homozygous deletion of *p16^{INK4a} (CDKN2A)* detected using a fluorescent in situ hybridization (FISH) assay and loss of BAP1 expression by immunohistochemistry may be helpful in separating benign from malignant mesothelial proliferations, including desmoplastic mesothelioma.[51,52] Other immunostains, such as epithelial membrane antigen (EMA), p53, GLUT1, and IMP3, proposed for separating benign from malignant mesothelial proliferations, are of considerably less value with sensitivities and specificities that make them difficult to apply in any individual case.[53,54] When in doubt, a conservative approach is indicated, reflected by a terminology such as *atypical mesothelial proliferation*.[55] If the lesion is a mesothelioma, usually this will become apparent in a few months.

Obviously malignant epithelioid mesotheliomas need to be distinguished from metastatic carcinoma, particularly pulmonary adenocarcinomas with a pseudomesotheliomatous growth pattern.[56,57] This may be a very difficult or even impossible task at the hematoxylin and eosin–level in a biopsy specimen and sometimes even in a surgical specimen. In general, the cells of mesothelioma are more uniform and regular than those of adenocarcinoma, with a more constant nuclear to cytoplasmic ratio. Their shape is usually cuboidal; presence of a substantial number of columnar-shaped cells favors a diagnosis of adenocarcinoma. Cellular crowding and nuclear molding also favor adenocarcinoma. Given the limitations of routine histology, immunohistochemistry can be very useful in making this distinction and has supplanted a role for histochemistry and electron microscopy in most but not all cases. The role of immunohistochemistry is considerably more limited in separating sarcomatoid mesotheliomas from sarcomatoid carcinomas and soft tissue sarcomas, a distinction that relies in large part on knowing the distribution of disease given that sarcomatoid carcinomas and soft tissue sarcomas rarely if ever grow as diffuse pleural lesions.

Mesotheliomas usually produce large amounts of hyaluronic acid, which can be demonstrated with the alcian blue or colloidal iron stains.[58] This material is nearly always mucicarmine negative, and the alcian blue positivity can be removed almost entirely by pretreatment with hyaluronidase. The presence of obvious droplets of mucicarmine-positive or periodic acid–Schiff (PAS)-positive material *in the cytoplasm of the tumor cells* makes the diagnosis of mesothelioma very unlikely, although it does not rule it out completely inasmuch as the existence of rare mucin-positive mesotheliomas has been documented.[59]

At one time electron microscopy played a pivotal role in the differential diagnosis between mesothelioma and metastatic carcinoma, to the point of being considered the gold standard.[60,61] This was primarily based on the appearance of the microvilli in the apical surface of the tumor cells, which in mesothelioma are longer and more slender than those in adenocarcinoma (Fig. 11.10). The validity of this observation stands, but its practical utility has decreased markedly as a result of the development of immunohistochemical stains that achieve the distinction in the large majority of the cases.[62]

Immunostains are most useful for distinguishing epithelioid mesotheliomas from metastatic carcinomas, particularly in small

biopsies. The staining strategy depends to some extent on the differential diagnosis, given variability in the sensitivity and specificity of commonly used carcinoma markers and the potential role for organ-specific stains. Lung adenocarcinomas account for the majority of cases presenting with a pseudomesotheliomatous growth pattern and is therefore the most likely primary site in the absence of a history of prior or concomitant extrathoracic malignancy. Other metastatic carcinomas that can cause a pseudomesotheliomatous pattern include breast, urothelial, renal cell, pancreatic ductal, prostate, and squamous cell carcinomas from a variety of sites.[56] The following is an incomplete summary of available immunostains, focusing on those that are most commonly available and utilized.

1. *Epithelial markers that are usually present in both tumors:* pankeratins, EMA, basement membrane components (also demonstrable ultrastructurally),[63] and S-100 protein (variable). Many metastatic adenocarcinomas likely to be confused with mesothelioma are positive for cytokeratin 7, as are epithelioid mesotheliomas, making cytokeratin 7 and 20 of limited value except in the very specific context of metastases from the gastrointestinal tract.[64]
2. *Markers that are usually expressed in carcinoma but not in mesothelioma:* MOC-31, Ber-EP4, carcinoembryonic antigen (CEA), B72.3, BG8, CD15, MUC4, and claudin-4.[65,66] Sensitivity and specificity of these markers are dependent on origin and histology of the carcinoma.
3. *Organ-associated and lineage-specific markers that are often expressed in metastatic carcinoma (most common sites highlighted in parentheses) but not mesothelioma:* TTF-1 (lung and thyroid), napsin A (lung and kidney), PAX8 (kidney, müllerian, thymus), CDX2 (gastrointestinal, pancreaticobiliary), GCDFP (breast), mammaglobin (breast), estrogen receptor (ER) (breast, müllerian), p63/p40 (squamous cell, urothelial), and GATA3 (breast, urothelial, squamous cell),[65,67,68] It is important that the TTF-1 antibody used for this differential diagnosis is the 8G7G3/1 rather than the SP141 clone given the greater specificity of the former. A recent report described staining for TTF-1 using the SP141 monoclonal antibody in a subset of sarcomatoid mesotheliomas.[69]
4. *Markers that are usually expressed in mesothelioma but not in carcinoma (with important exceptions highlighted in parentheses)*: calretinin (breast, müllerian serous), WT1 (breast, müllerian serous), keratin 5/6 (squamous cell, urothelial), D2-40/podoplanin (müllerian serous, squamous cell), and thrombomodulin (squamous cell) (Fig. 11.11).[65,67]

As useful as these markers are in this difficult diagnosis, it should be realized that few, if any, of them are 100% sensitive or specific. It should also be remembered as a practical rule that a negative immunoreaction never rules out a diagnosis.

Taking into account the plethora of available markers and variations in their performance characteristics, a selection needs to be made. Several authors have suggested that a limited panel of immunostains should suffice in most cases, depending on the differential diagnosis predicated on the history, distribution of disease, and histologic features. Ordonez has suggested, for example, that a panel of four markers—calretinin, cytokeratin 5/6 (or WT1), CEA, and MOC-31 (or B72.3)—enables a correct diagnosis in nearly every instance if the issue is mesothelioma versus pulmonary adenocarcinoma.[70] Mohammad et al. similarly showed that a combination of calretinin, cytokeratin 5/6, CEA, and CD15 was highly effective in separating mesothelioma from adenocarcinoma of the lung.[71] Yaziji et al. prefer instead a panel composed of calretinin, MOC-31, and BG8 (Lewis Y blood group), which demonstrated 96% sensitivity and specificity for distinguishing epithelioid mesothelioma and adenocarcinoma.[72]

It should be restated that immunostains are useful primarily for cases in which the diagnostic issue is epithelioid mesothelioma versus metastatic carcinoma. Immunostains are much less useful in differentiating sarcomatoid mesothelioma from other sarcomatoid or frankly sarcomatous tumors. Keratin stains are usually positive, at least focally, in sarcomatoid mesotheliomas using pancytokeratin antibodies or antibody cocktails, but as many as 5%–10% may be negative, including those with heterologous elements.[36] Antibodies directed against

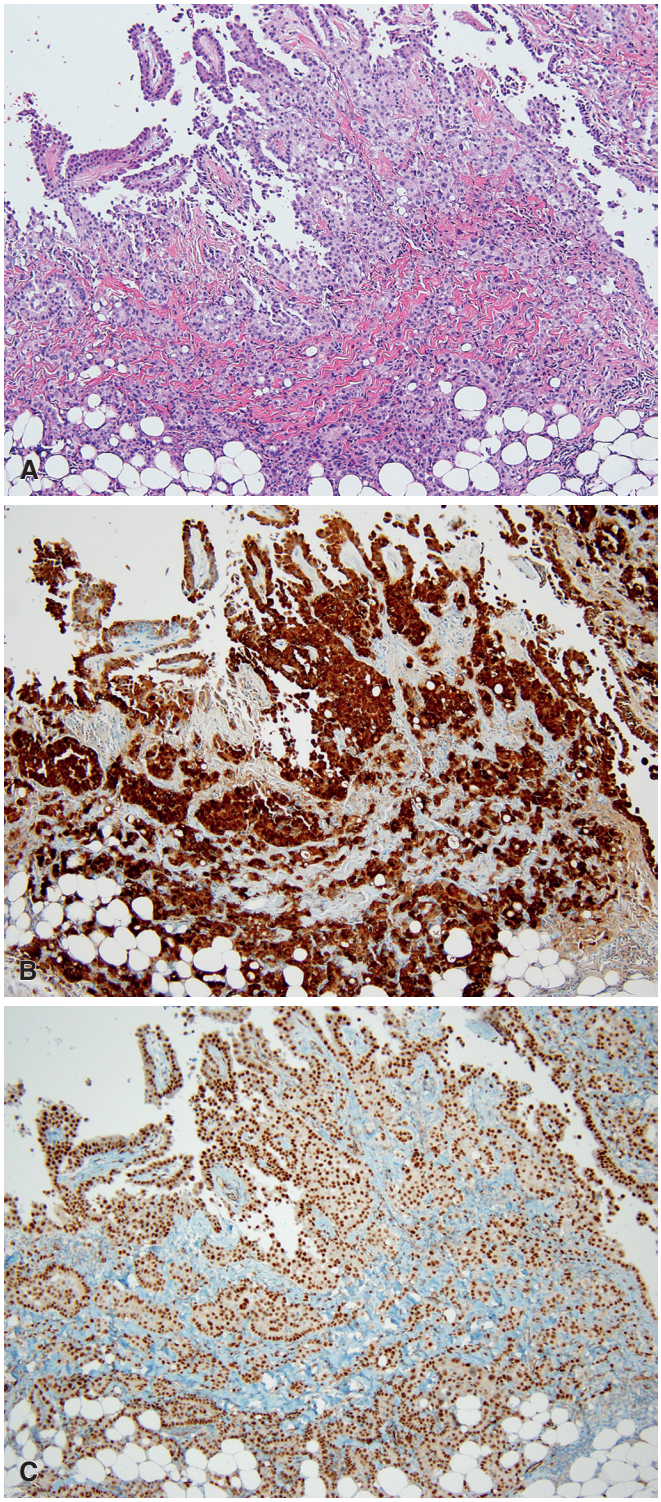

Figure 11.11 Epithelioid mesothelioma **(A)** showing strong nuclear and cytoplasmic immunoreactivity for calretinin **(B)** and nuclear staining for WT1 **(C)**.

podoplanin (i.e. D2-40, antipodoplanin) are more sensitive than calretinin for sarcomatoid mesothelioma.[73] Other mesothelioma markers, such as WT1 and CK5/6, are relatively insensitive.

Molecular Genetic Features

The most common recurrent somatic mutations in malignant mesothelioma target three genes functioning as tumor suppressors: cyclin-dependent kinase inhibitor 2A (*CDKN2A)*, BRCA1-associated protein 1 *(BAP1)*, and neurofibromin 2 (merlin) *(NF2)*.[74,75] Mutations in the *TP53* gene are uncommon. Homozygous deletion of *p16^{INK4a} (CDKN2A)* occurs in 60%–80% of mesotheliomas and, as previously referenced, is a useful diagnostic tool for separating benign from malignant mesothelial proliferations; it is less useful in differentiating mesothelioma from carcinoma.[52–54,76–79] *CDKN2A* deletion is also a potential biomarker that has been linked to a more aggressive course in some studies.[80,81] Loss of BAP1 expression by immunohistochemistry is less sensitive, occurring in around 70% of epithelioid mesotheliomas but in fewer (20%–30%) sarcomatoid and biphasic mesotheliomas.

Spread and Metastases

The typical pattern of spread of malignant mesothelioma is by contiguity and perhaps implantation. Through either mechanism it may spread to the entire pleural space, both pleurae, interlobular septa, pericardium, chest wall, diaphragm, and even the peritoneum.[82] Extension into the subpleural portions of the lung is also common, and intraparenchymal spread can occur,[83] but the presence of nodular masses within the lung parenchyma favors a primary lung cancer with prominent pleural spread. Exceptionally, mesothelioma grows in an intrapulmonary lepidic fashion that can simulate minimally invasive ("bronchioloalveolar") adenocarcinoma.[84,85] Distant extrathoracic metastases in mesothelioma generally occur only in the late stages of the disease, if at all.[86] Therefore, presence of prominent hilar and supraclavicular lymphadenopathy at the time of initial presentation favors carcinoma over mesothelioma. However, we and others have seen pleural mesotheliomas that have presented initially with lymph node involvement in the cervical or axillary region.[87] We have also seen cases of mesothelioma presenting with distant metastases in unusual places, such as the tongue.[88]

Treatment and Prognosis

There is no universally effective treatment for malignant mesothelioma at present. Surgical excision is often attempted, sometimes of heroic proportions (pneumonectomy, parietal and mediastinal pleurectomy, diaphragmectomy), but on the whole the results have been disappointing. On the other hand, bulk resection of the tumor combined with radiation and systemic chemotherapy ("trimodality therapy") has sometimes resulted in long-term remissions in a very small subset of highly selected patients with epithelioid histology, early stage disease, gross total removal of tumor by either extrapleural pneumonectomy or pleurectomy/decortication, and a measurable response to radiation therapy.[89–95] Patterns of relapse after aggressive trimodality therapy are variable and may include miliary involvement of the contralateral lung.[96] Radiation therapy can induce the appearance of bizarre multinucleated tumor cells and intense polymorphic inflammation, whereas the use of chemical (talc) pleurodesis can result in a marked pseudosarcomatous fibroblastic proliferation.[97]

Prognostic factors that need to be mentioned in relation to malignant mesothelioma are the following:

1. *Stage:* There is a definite relationship between tumor stage, including N2 disease at presentation, and prognosis, acknowledging that the prognosis is generally poor in all patients.
2. *Gender:* The prognosis seems to be poorer in males than in females.
3. *Tumor subtype:* Sarcomatoid mesotheliomas, including desmoplastic variants, are associated with a shorter survival than the conventional epithelioid type,[98] whereas the reverse is true for low-grade deciduoid,[38] well-differentiated,[37] and localized variants.[31]

Solitary Fibrous Tumor

Solitary fibrous tumor of pleura (formerly called solitary fibrous mesothelioma) is symptomatic in about half of patients, including most commonly cough, chest pain, dyspnea, and pulmonary osteoarthropathy.[99,100] Hypoglycemia is an uncommon manifestation of solitary fibrous tumor *(Doege-Potter syndrome)* resulting from secretion of insulin-like growth factor II by neoplastic cells and is resolved with complete excision.[101] Solitary fibrous tumor is not associated with asbestos exposure. On rare occasions, it is found together with a microscopically similar tumor in the peritoneum or retroperitoneum.[102]

Grossly, the lesion is well circumscribed, firm, lobulated, gray–white to yellow–white, with frequent whorling and fasciculation. The mean diameter is 6 cm, but some are very large, completely opacifying a hemithorax. The gross appearance is reminiscent of uterine leiomyoma (Fig. 11.12). Cystic degeneration is very unusual, but solitary fibrous tumor can present as a mural nodule within a large pleural-lined cyst. The majority are attached to the visceral (80%) or parietal pleura,[99] within an interlobar fissure, or sometimes within the lung parenchyma without a pleural connection (intrapulmonary solitary fibrous tumor).[103] Lesions with an identical microscopic appearance are now known to occur in a large number of sites, including peritoneum, retroperitoneum (including kidney), mediastinum, nasopharynx, oral cavity, orbit, soft tissues, pancreas, prostate, and breast (see respective chapters).[104]

Microscopically, both benign and malignant forms occur, the former greatly predominating.[99,100,105] The distinction between them can be difficult given the absence of clearly articulated criteria for predicting behavior; malignant tumors are characterized by various combinations of increased cellularity, cytologic atypia that includes nuclear hyperchromasia and pleomorphism, mitoses, and necrosis.[99,100,105] In the typical benign case, there is a tangled network of fibroblast-like cells, squeezed in between abundant collagen fibers, many of which have a keloid-like quality, resulting in what some have referred to as the *patternless pattern of Stout* (Fig. 11.13). The degree of cellularity varies a great deal from area to area.

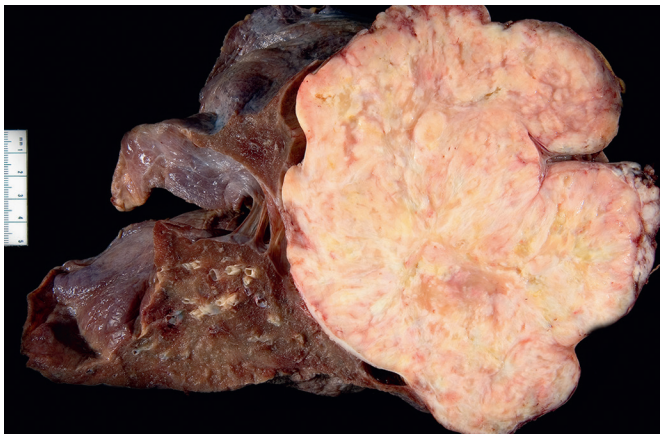

Figure 11.12 Cut surface of solitary fibrous tumor of pleura that measured 17.5 cm in greatest dimension. (Courtesy of Dr. J. Carvalho, Minneapolis, MN.)

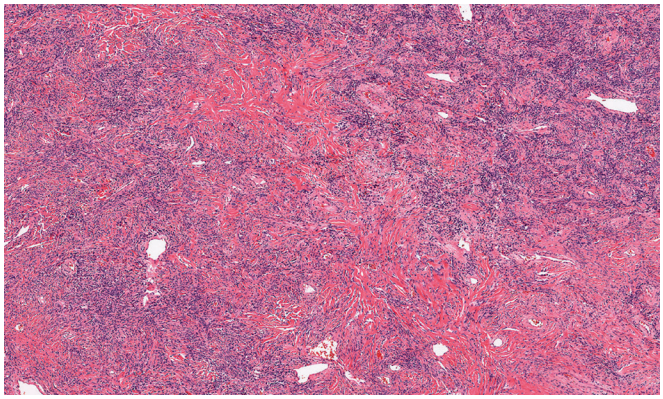

Figure 11.13 Solitary Fibrous Tumor of Pleura. The proliferation of mesenchymal spindle cells separated by thick bands of keloid-type collagen is characteristic of this entity.

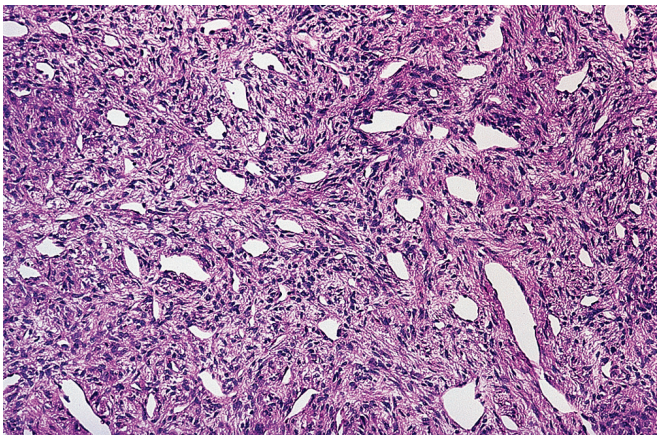

Figure 11.14 Prominent hemangiopericytoma-like pattern in solitary fibrous tumor.

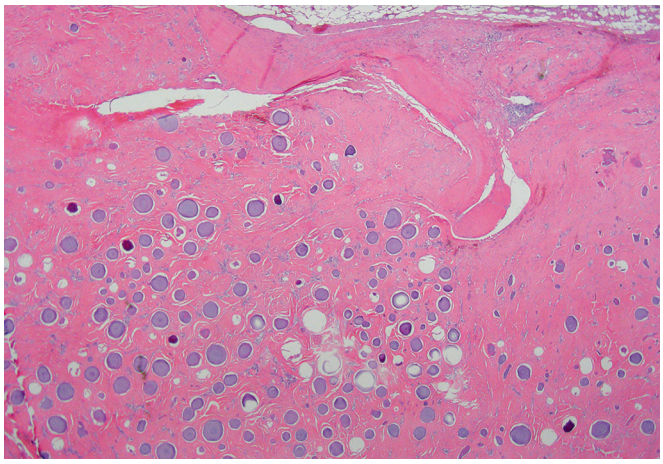

Figure 11.15 Calcifying Fibrous Pseudotumor of Pleura.

Hemangiopericytoma-like changes are frequent in the more cellular zones (Fig. 11.14), and some tumors have prominent myxoid features.[106]

The differential diagnosis of the more sclerotic types of solitary fibrous tumor include fibrous plaque, fibromatosis (desmoid tumor),[107] and calcifying fibrous pseudotumor (Fig. 11.15).[108] Myxoid

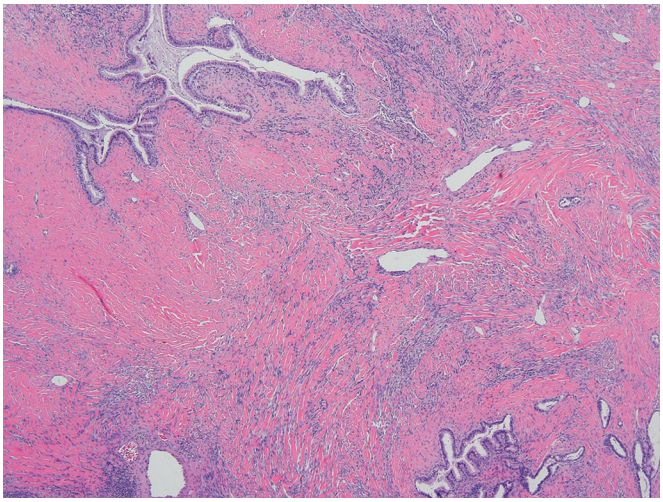

Figure 11.16 Intrapulmonary solitary fibrous tumor with entrapped non-neoplastic respiratory epithelium resulting in a biphasic appearance.

tumors need to be distinguished from low-grade myxofibrosarcoma and low-grade fibromyxoid tumor. The most cellular types may be misdiagnosed as fibrosarcoma or malignant peripheral nerve sheath tumor. If proper attention is paid to the lack of nuclear aberrations and the rarity or absence of mitoses, confusion is unlikely to occur. In some instances, entrapped non-neoplastic epithelial cells are found at the periphery of predominantly fibrous tumors (Fig. 11.16); these represent entrapped mesothelium or respiratory epithelium and should not be misconstrued as evidence of a truly biphasic neoplasm. Malignant solitary fibrous tumors are characterized by increased cellularity, atypia, mitotic activity, and necrosis.

This neoplasm was regarded historically as a form of mesothelioma, largely on the basis of the pattern of growth that the tumor cells exhibit in tissue culture[109]; however, on ultrastructural examination these cells show fibroblast-like rather than mesothelial-like features, and by immunohistochemistry their filament profile includes vimentin and sometimes desmin but not keratin.[110,111] The most likely interpretation of this tumor, therefore, is that it arises from noncommitted mesenchymal cells present in the areolar tissue subjacent to the mesothelial lining. This has led to the proposal of alternative terms, such as submesothelioma or submesothelial fibroma, which, however, are hard to apply to tumors located well away from any mesothelial-lined surfaces.

The tumor cells of this lesion stain strongly and consistently for CD34 and BCL2, a useful finding in the differential diagnosis with some of the entities described previously.

Recurrent intrachromosomal rearrangements resulting in fusion of *NAB2* and *STAT6* on chromosome 12q have been identified as a unique driver mutation in solitary fibrous tumors.[112] The fusion product is overexpressed in nearly all cases and can be detected using a commercially available antibody directed against STAT6 characterized by diffuse nuclear staining (Fig. 11.17). STAT6 staining is a very useful addition to CD34 as a relatively sensitive marker in diagnostically challenging cases, but STAT6 staining can also be seen in other potential mimics, including synovial sarcoma, and therefore should be interpreted with caution.[104]

The vast majority of solitary fibrous tumors of the pleura are cured with complete surgical excision and tumor-free margins.[113] Relapse can present as recurrent intrathoracic (Fig. 11.18) or widely metastatic disease, the latter restricted in large part to cases with

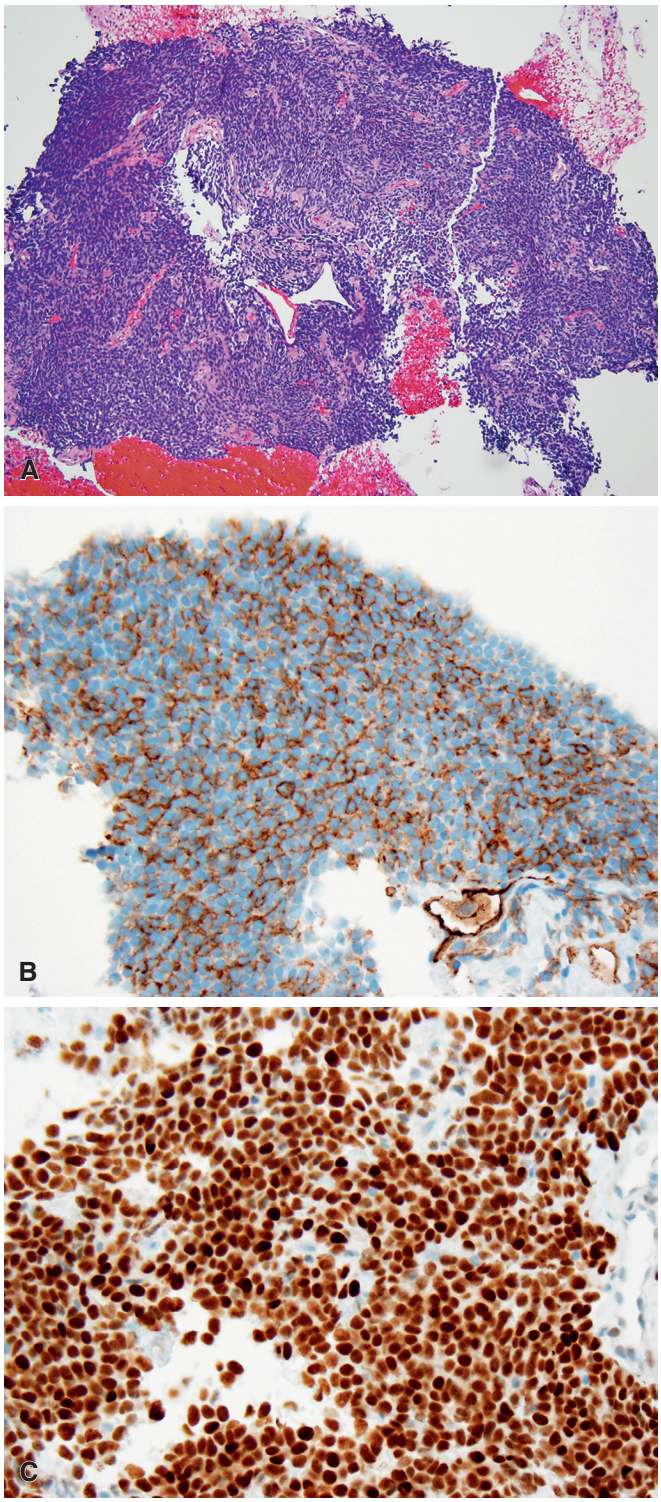

Figure 11.17 Intrathoracic solitary fibrous tumor on core needle biopsy **(A)** showing positive staining for CD34 **(B)** and STAT6 **(C)**. Stains for keratins and TLE-1 were negative, which were helpful in excluding monophasic synovial sarcoma.

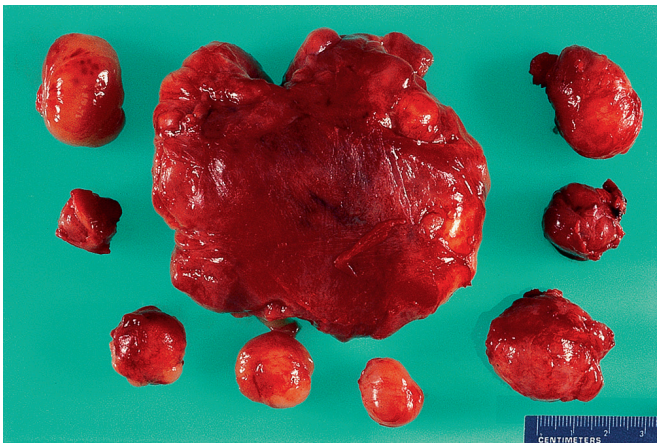

Figure 11.18 Malignant solitary fibrous tumor of pleura resulting in numerous serosal implants.

malignant histologic features.[100,113] In a scoring system intended to predict risk of recurrence, Tapias et al. proposed parietal (vs. visceral) origin, sessile (vs. pedunculated) gross morphology, size (≥10 cm), hypercellularity (i.e. crowded tumor cells with back-to-back and/or overlapping nuclei and minimal/absent matrix), necrosis or hemorrhage, and a high (≥4/10 hpf) mitotic rate as adverse prognostic factors (≥3 = "high risk"); however, high mitotic rate was the only factor significantly associated with recurrence in multivariate analysis.[114]

Other Primary Tumors

Two cases of primary **mucoepidermoid carcinoma** have been reported, each presenting as a localized pleural-based mass.[115]

Soft tissue–type tumors of various types can occur in the pleura.[116] These need to be distinguished from the more common sarcomatoid mesothelioma and the malignant form of solitary fibrous tumor, as described elsewhere in this chapter.

Synovial sarcoma has now been recognized as sometimes arising in the pleura and is the most common of those soft tissue sarcomas that may present as primary intrathoracic neoplasms.[116,117] In the past, most of these cases were diagnosed as malignant mesotheliomas or malignant solitary fibrous tumors. Both biphasic and monophasic forms occur.[118,119] Molecular testing for the *SYT–SSX* gene fusion that characterizes this tumor may be helpful to confirm the diagnosis in some cases. Other soft tissue tumors and tumorlike conditions that have been reported in the pleura are *fibromatosis* (desmoid tumor), *calcifying fibrous pseudotumor*, *liposarcoma*, *chondrosarcoma*, so-called *pleomorphic undifferentiated sarcoma* (formerly termed malignant fibrous histiocytoma), *gastrointestinal stromal tumor (GIST)*, *desmoplastic small round cell tumor*, *primitive neuroectodermal tumor* (Askin tumor), and *liposarcoma*.[116]

Epithelioid hemangioendothelioma and *angiosarcoma* may diffusely infiltrate the pleura in a fashion simulating mesothelioma (Fig. 11.19).[120] Rarely angiosarcomas have occurred against a background of chronic pyothorax.[121]

Malignant lymphoma involving the pleura is usually associated with systemic disease. The most frequent type is diffuse large B-cell lymphoma, followed by follicular lymphoma.[122] Lymphoma centered in the pleural cavity can complicate longstanding pyothorax, a variant referred to as *pyothorax-associated lymphoma*. This is an Epstein–Barr virus (EBV)-related diffuse large B-cell lymphoma distinguished not only by its peculiar presentation but also frequent plasmacytoid features and aberrant expression of T-cell markers.[123,124] Pyothorax-associated lymphoma is unrelated to human herpesvirus 8 (HHV8), a feature that sets it apart from primary effusion lymphoma. *Primary effusion lymphoma* occurs most often in the setting of immunodeficiency and does not result in tumor mass formation as in

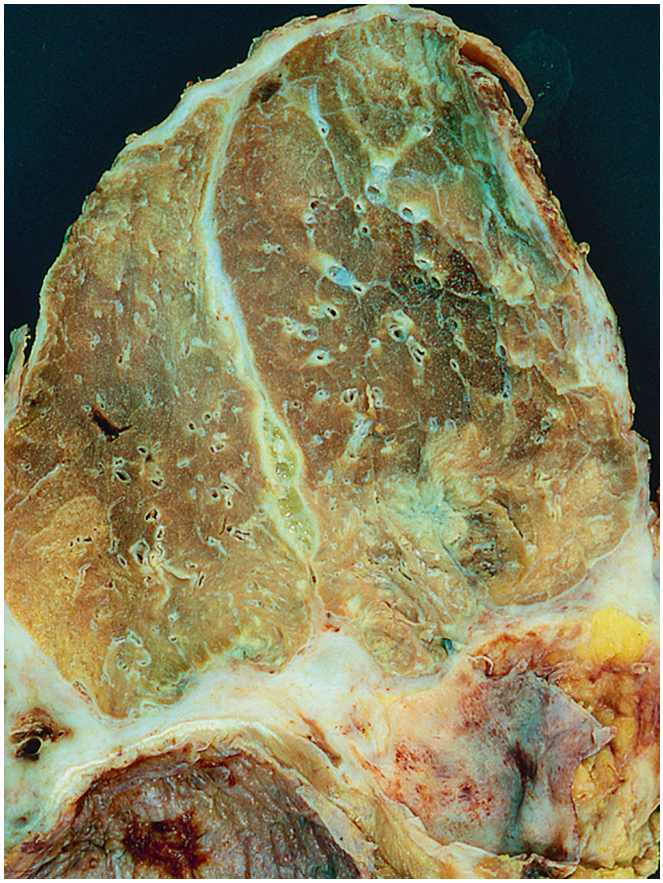

Figure 11.19 Epithelioid Hemangioendothelioma of Pleura. The tumor involves the pleural surface in a fashion indistinguishable from diffuse malignant mesothelioma.

pyothorax-associated lymphoma.[125,126] It is composed of a population of large pleomorphic lymphoid cells that frequently demonstrates a null or ambiguous immunophenotype that may include expression of T-cell associated antigens; despite an ambiguous immunophenotype, molecular studies show rearrangements of immunoglobulin heavy chain genes consistent with a B-cell lineage lymphoma in nearly all cases.[125–127] Primary effusion lymphoma, like pyothorax-associated lymphoma, is EBV related but differs in also being invariably associated with HHV8 virus, an extremely helpful diagnostic feature.[127]

Thymoma can also present as a primary pleural mass, resulting in possible diagnostic confusion with mesothelioma.[128]

Metastatic Tumors

Most malignant tumors involving the pleura are of metastatic nature; of these, about 75% are metastatic carcinomas. They are second only to congestive heart failure as the cause of pleural effusions in patients over 50 years of age.[129] Dyspnea, cough, and chest pain are the most common presenting symptoms. Most malignant pleural effusions are greater than 500 mL. The fluid is most often serous to serosanguineous, but it may be frankly hemorrhagic. The most common sites for the primary lesion are lung (33%), breast (20.9%), and stomach (7.3%).[130] Approximately 90% of the lung, breast, and ovarian malignant effusions are ipsilateral to the primary lesion. A malignant pleural effusion may be the first evidence of the existence of cancer.

Biopsy and Cytology

Needle biopsy of the parietal pleura is very useful for the differential diagnosis between inflammatory and neoplastic processes.[131] Histopathologic examination and culture of pleural biopsies has played an important part in the diagnosis of pleural tuberculosis,[132] but the advent of modern techniques, including polymerase chain reaction (PCR)-based assays, may improve diagnostic sensitivity.[133,134]

If pleural effusion is present, cytologic examination of the fluid has been found to be more effective in detecting malignancy than pleural biopsy.[134–136] The sensitivity and specificity is improved with use of ancillary techniques, including flow cytometry, immunohistochemistry, and molecular techniques, including FISH assays for p16 deletion in the case of mesotheliomas.[51,81,137] In the huge series by Johnston, a cytopathologic diagnosis conclusive for cancer was obtained in the first specimen of fluid in 90.5% of the cases; there were no false-positive diagnoses.[138] Therefore, when the possibility of malignancy is considered in the presence of pleural effusion, a cytologic examination of the pleural fluid should always be performed, regardless of the gross appearance of the fluid.

There is probably no area in diagnostic cytology that is more difficult to interpret than that of effusions in serous cavities. This is mainly because proliferating reactive mesothelial cells can acquire features dangerously similar to those of cells of mesothelioma and even metastatic carcinoma. The cells of mesothelioma can occur singly or in clusters with scalloped borders. The cytoplasm is dense and often has small, regular, centrally located vacuoles.[139] Nuclei are atypical, the nuclear to cytoplasmic ratio is altered, and multinucleated forms may be present. The cytologic features of potential value in separating mesothelioma, benign mesothelial proliferations, and adenocarcinoma are preserved in liquid-based monolayers preparations, such as ThinPrep.[140] Cytologic preparations can also be used for histochemistry, immunohistochemistry, electron microscopy, and molecular testing using the previously described diagnostic tools.

References

1. Lee KF, Olak J. Anatomy and physiology of the pleural space. *Chest Surg Clin N Am*. 1994;4(3):391-403.
2. Sahn SA. State of the art. The pleura. *Am Rev Respir Dis*. 1988;138(1):184-234.
3. English JC, Leslie KO. Pathology of the pleura. *Clin Chest Med*. 2006;27(2):157-180.
4. Bolen JW, Hammar SP, McNutt MA. Reactive and neoplastic serosal tissue. A light-microscopic, ultrastructural, and immunocytochemical study. *Am J Surg Pathol*. 1986;10(1):34-47.
5. Chung-Park M, Tomashefski JF Jr, Cohen AM, et al. Shrinking pleuritis with lobar atelectasis, a morphologic variant of "round atelectasis. *Hum Pathol*. 1989;20(4): 382-387.
6. Menzies R, Fraser R. Round atelectasis. Pathologic and pathogenetic features. *Am J Surg Pathol*. 1987;11(9):674-681.
7. Aru A, Engel U, Francis D. Characteristic and specific histological findings in rheumatoid pleurisy. *Acta Pathol Microbiol Immunol Scand [A]*. 1986;94(1):57-62.
8. Hwang SM, Lee CW, Lee BS, Park JH. Clinical features of thoracic endometriosis: a single center analysis. *Obstet Gynecol Sci*. 2015;58(3):223-231.
9. Channabasavaiah AD, Joseph JV. Thoracic endometriosis: revisiting the association between clinical presentation and thoracic pathology based on thoracoscopic findings in 110 patients. *Medicine (Baltimore)*. 2010;89(3):183-188.
10. Visouli AN, Darwiche K, Mpakas A, et al. Catamenial pneumothorax: a rare entity? Report of 5 cases and review of the literature. *J Thorac Dis*. 2012;4(suppl 1):17-31.
11. Chikkamuniyappa S, Herrick J, Jagirdar JS. Nodular histiocytic/mesothelial hyperplasia: a potential pitfall. *Ann Diagn Pathol*. 2004;8(3):115-120.

12. Churg AM, Warnock ML. Asbestos and other ferruginous bodies: their formation and clinical significance. *Am J Pathol*. 1981;102(3):447-456.
13. Roggli VL, Vollmer RT. Twenty-five years of fiber analysis: what have we learned? *Hum Pathol*. 2008;39(3):307-315.
14. Cauna D, Totten RS, Gross P. Asbestos bodies in human lungs at autopsy. *JAMA*. 1965;192:371-373.
15. Churg A. Asbestos fibers and pleural plaques in a general autopsy population. *Am J Pathol*. 1982;109(1):88-96.
16. Mitchev K, Dumortier P, De Vuyst P. Black Spots' and hyaline pleural plaques on the parietal pleura of 150 urban necropsy cases. *Am J Surg Pathol*. 2002;26(9): 1198-1206.
17. Wagner JC, Sleggs CA, Marchand P. Diffuse pleural mesothelioma and asbestos exposure in the North Western Cape Province. *Br J Ind Med*. 1960;17:260-271.
18. Teta MJ, Mink PJ, Lau E, et al. US mesothelioma patterns 1973-2002: indicators of change and insights into background rates. *Eur J Cancer Prev*. 2008;17(6):525-534.
19. Peterson JT Jr, Greenberg SD, Buffler PA. Non-asbestos-related malignant mesothelioma. A review. *Cancer*. 1984;54(5):951-960.
20. Carbone M, Bedrossian CW. The pathogenesis of mesothelioma. *Semin Diagn Pathol*. 2006;23(1):56-60.
21. Ghio AJ, Roggli VL, Richards JH, et al. Oxalate deposition on asbestos bodies. *Hum Pathol*. 2003;34(8):737-742.
22. Roggli VL, Benning TL. Asbestos bodies in pulmonary hilar lymph nodes. *Mod Pathol*. 1990;3(4):513-517.
23. Goepel JR. Benign papillary mesothelioma of peritoneum: a histological, histochemical and ultrastructural study of six cases. *Histopathology*. 1981;5(1):21-30.
24. Ball NJ, Urbanski SJ, Green FH, Kieser T. Pleural multicystic mesothelial proliferation. The so-called multicystic mesothelioma. *Am J Surg Pathol*. 1990;14(4):375-378.
25. Kaplan MA, Tazelaar HD, Hayashi T, et al. Adenomatoid tumors of the pleura. *Am J Surg Pathol*. 1996;20(10):1219-1223.
26. Kane MJ, Chahinian AP, Holland JF. Malignant mesothelioma in young adults. *Cancer*. 1990;65(6):1449-1455.
27. Dawson A, Gibbs A, Browne K, et al. Familial mesothelioma. Details of 17 cases with histopathologic findings and mineral analysis. *Cancer*. 1992;70(5):1183-1187.
28. Weissmann LB, Corson JM, Neugut AI, Antman KH. Malignant mesothelioma following treatment for Hodgkin's disease. *J Clin Oncol*. 1996;14(7):2098-2100.
29. Churg A, Galateau-Salle F. The separation of benign and malignant mesothelial proliferations. *Arch Pathol Lab Med*. 2012;136(10):1217-1226.
30. Cristaudo A, Bonotti A, Simonini S, et al. Combined serum mesothelin and plasma osteopontin measurements in malignant pleural mesothelioma. *J Thorac Oncol*. 2011;6(9):1587-1593.
31. Allen TC, Cagle PT, Churg AM, et al. Localized malignant mesothelioma. *Am J Surg Pathol*. 2005;29(7):866-873.
32. Crotty TB, Myers JL, Katzenstein AL, et al. Localized malignant mesothelioma. A clinicopathologic and flow cytometric study. *Am J Surg Pathol*. 1994;18(4):357-363.
33. Attanoos RL, Gibbs AR. Pathology of malignant mesothelioma. *Histopathology*. 1997;30(5):403-418.
34. Klebe S, Brownlee NA, Mahar A, et al. Sarcomatoid mesothelioma: a clinical-pathologic correlation of 326 cases. *Mod Pathol*. 2010;23(3):470-479.
35. Klebe S, Mahar A, Henderson DW, Roggli VL. Malignant mesothelioma with heterologous elements: clinicopathological correlation of 27 cases and literature review. *Mod Pathol*. 2008;21(9):1084-1094.
36. Roggli V, Churg A, Chirieac LR, et al. Sarcomatoid, desmoplastic, and biphasic mesothelioma. In: Travis WD, Brambilla E, Burke AP, et al, eds. *WHO Classification of Tumours of the Lung, Pleura, Thymus and Heart*. 4th ed. Lyon: IARC; 2015:165-168.
37. Galateau-Salle F, Vignaud JM, Burke L, et al. Well-differentiated papillary mesothelioma of the pleura: a series of 24 cases. *Am J Surg Pathol*. 2004;28(4):534-540.
38. Ordonez NG. Deciduoid mesothelioma: report of 21 cases with review of the literature. *Mod Pathol*. 2012;25(11):1481-1495.
39. Shanks JH, Harris M, Banerjee SS, et al. Mesotheliomas with deciduoid morphology: a morphologic spectrum and a variant not confined to young females. *Am J Surg Pathol*. 2000;24(2):285-294.
40. Ordonez NG. Mesothelioma with clear cell features: an ultrastructural and immunohistochemical study of 20 cases. *Hum Pathol*. 2005;36(5):465-473.
41. Ordonez NG. Mesothelioma with rhabdoid features: an ultrastructural and immunohistochemical study of 10 cases. *Mod Pathol*. 2006;19(3):373-383.
42. Mayall FG, Gibbs AR. The histology and immunohistochemistry of small cell mesothelioma. *Histopathology*. 1992;20(1):47-51.
43. Ordonez NG. Mesotheliomas with small cell features: report of eight cases. *Mod Pathol*. 2012;25(5):689-698.
44. Galateau-Salle F, Attanoos R, Gibbs AR, et al. Lymphohistiocytoid variant of malignant mesothelioma of the pleura: a series of 22 cases. *Am J Surg Pathol*. 2007;31(5):711-716.
45. Kawai T, Hiroi S, Nakanishi K, et al. Lymphohistiocytoid mesothelioma of the pleura. *Pathol Int*. 2010;60(8):566-574.
46. Kadota K, Suzuki K, Sima CS, et al. Pleomorphic epithelioid diffuse malignant pleural mesothelioma: a clinicopathological review and conceptual proposal to reclassify as biphasic or sarcomatoid mesothelioma. *J Thorac Oncol*. 2011;6(5):896-904.
47. Ordonez NG. Pleomorphic mesothelioma: report of 10 cases. *Mod Pathol*. 2012;25(7):1011-1022.
48. Brcic L, Jakopovic M, Brcic I, et al. Reproducibility of histological subtyping of malignant pleural mesothelioma. *Virchows Arch*. 2014;465(6):679-685.
49. Epstein JI, Budin RE. Keratin and epithelial membrane antigen immunoreactivity in nonneoplastic fibrous pleural lesions: implications for the diagnosis of desmoplastic mesothelioma. *Hum Pathol*. 1986;17(5):514-519.
50. Mangano WE, Cagle PT, Churg A, et al. The diagnosis of desmoplastic malignant mesothelioma and its distinction from fibrous pleurisy: a histologic and immunohistochemical analysis of 31 cases including p53 immunostaining. *Am J Clin Pathol*. 1998;110(2):191-199.
51. Churg A, Sheffield BS, Galateau-Salle F. New markers for separating benign from malignant mesothelial proliferations: are we there yet? *Arch Pathol Lab Med*. 2016;140(4):318-321.
52. Hwang HC, Pyott S, Rodriguez S, et al. BAP1 Immunohistochemistry and p16 FISH in the diagnosis of sarcomatous and desmoplastic mesotheliomas. *Am J Surg Pathol*. 2016;40(5):714-718.
53. Sheffield BS, Hwang HC, Lee AF, et al. BAP1 immunohistochemistry and p16 FISH to separate benign from malignant mesothelial proliferations. *Am J Surg Pathol*. 2015;39(7):977-982.
54. Monaco SE, Shuai Y, Bansal M, et al. The diagnostic utility of p16 FISH and GLUT-1 immunohistochemical analysis in mesothelial proliferations. *Am J Clin Pathol*. 2011;135(4):619-627.
55. Cagle PT, Churg A. Differential diagnosis of benign and malignant mesothelial proliferations on pleural biopsies. *Arch Pathol Lab Med*. 2005;129(11):1421-1427.
56. Attanoos RL, Gibbs AR. 'Pseudomesotheliomatous' carcinomas of the pleura: a 10-year analysis of cases from the environmental lung disease research group, Cardiff. *Histopathology*. 2003;43(5):444-452.
57. Koss M, Travis W, Moran C, Hochholzer L. Pseudomesotheliomatous adenocarcinoma: a reappraisal. *Semin Diagn Pathol*. 1992;9(2):117-123.
58. Kannerstein M, Churg J, Magner D. Histochemistry in the diagnosis of malignant mesothelioma. *Ann Clin Lab Sci*. 1973;3(3):207-211.
59. Hammar SP, Bockus DE, Remington FL, Rohrbach KA. Mucin-positive epithelial mesotheliomas: a histochemical, immunohistochemical, and ultrastructural comparison with mucin-producing pulmonary adenocarcinomas. *Ultrastruct Pathol*. 1996;20(4):293-325.
60. Oury TD, Hammar SP, Roggli VL. Ultrastructural features of diffuse malignant mesotheliomas. *Hum Pathol*. 1998;29(12):1382-1392.
61. Oczypok EA, Oury TD. Electron microscopy remains the gold standard for the diagnosis of epithelial malignant mesothelioma: a case study. *Ultrastruct Pathol*. 2015;39(2):153-158.
62. Hammar SP. Macroscopic, histologic, histochemical, immunohistochemical, and ultrastructural features of mesothelioma. *Ultrastruct Pathol*. 2006;30(1):3-17.
63. Di Muzio M, Spoletini L, Strizzi L, et al. Prognostic significance of presence and reduplication of basal lamina in malignant pleural mesothelioma. *Hum Pathol*. 2000;31(11):1341-1345.
64. Tot T. The value of cytokeratins 20 and 7 in discriminating metastatic adenocarcinomas from pleural mesotheliomas. *Cancer*. 2001;92(10):2727-2732.
65. Ordonez NG. Application of immunohistochemistry in the diagnosis of epithelioid mesothelioma: a review and update. *Hum Pathol*. 2013;44(1):1-19.
66. Ordonez NG. Value of claudin-4 immunostaining in the diagnosis of mesothelioma. *Am J Clin Pathol*. 2013;139(5):611-619.
67. Ordonez NG. What are the current best immunohistochemical markers for the diagnosis of epithelioid mesothelioma? A review and update. *Hum Pathol*. 2007;38(1):1-16.
68. Ordonez NG, Sahin AA. Diagnostic utility of immunohistochemistry in distinguishing between epithelioid pleural mesotheliomas and breast carcinomas: a comparative study. *Hum Pathol*. 2014;45(7):1529-1540.
69. Klebe S, Swalling A, Jonavicius L, Henderson DW. An immunohistochemical comparison of two TTF-1 monoclonal antibodies in atypical squamous lesions and sarcomatoid carcinoma of the lung, and pleural malignant mesothelioma. *J Clin Pathol*. 2016;69(2):136-141.
70. Ordonez NG. The immunohistochemical diagnosis of mesothelioma: a comparative study of epithelioid mesothelioma and lung adenocarcinoma. *Am J Surg Pathol*. 2003;27(8):1031-1051.
71. Mohammad T, Garratt J, Torlakovic E, et al. Utility of a CEA, CD15, calretinin, and CK5/6

panel for distinguishing between mesotheliomas and pulmonary adenocarcinomas in clinical practice. *Am J Surg Pathol*. 2012;36(10):1503-1508.
72. Yaziji H, Battifora H, Barry TS, et al. Evaluation of 12 antibodies for distinguishing epithelioid mesothelioma from adenocarcinoma: identification of a three-antibody immunohistochemical panel with maximal sensitivity and specificity. *Mod Pathol*. 2006;19(4):514-523.
73. Padgett DM, Cathro HP, Wick MR, Mills SE. Podoplanin is a better immunohistochemical marker for sarcomatoid mesothelioma than calretinin. *Am J Surg Pathol*. 2008;32(1):123-127.
74. Guo G, Chmielecki J, Goparaju C, et al. Whole-exome sequencing reveals frequent genetic alterations in BAP1, NF2, CDKN2A, and CUL1 in malignant pleural mesothelioma. *Cancer Res*. 2015;75(2):264-269.
75. Hylebos M, Van Camp G, van Meerbeeck JP, Op de Beeck K. The genetic landscape of malignant pleural mesothelioma: results from massively parallel sequencing. *J Thorac Oncol*. 2016;11:1615-1626.
76. Illei PB, Ladanyi M, Rusch VW, Zakowski MF. The use of CDKN2A deletion as a diagnostic marker for malignant mesothelioma in body cavity effusions. *Cancer*. 2003;99(1):51-56.
77. Chiosea S, Krasinskas A, Cagle PT, et al. Diagnostic importance of 9p21 homozygous deletion in malignant mesotheliomas. *Mod Pathol*. 2008;21(6):742-747.
78. Chung CT, Santos Gda C, Hwang DM, et al. FISH assay development for the detection of p16/CDKN2A deletion in malignant pleural mesothelioma. *J Clin Pathol*. 2010;63(7):630-634.
79. Takeda M, Kasai T, Enomoto Y, et al. 9p21 deletion in the diagnosis of malignant mesothelioma, using fluorescence in situ hybridization analysis. *Pathol Int*. 2010;60(5):395-399.
80. Dacic S, Kothmaier H, Land S, et al. Prognostic significance of p16/cdkn2a loss in pleural malignant mesotheliomas. *Virchows Arch*. 2008;453(6):627-635.
81. Ladanyi M. Implications of P16/CDKN2A deletion in pleural mesotheliomas. *Lung Cancer*. 2005;49(suppl 1):S95-S98.
82. Brenner J, Sordillo PP, Magill GB, Golbey RB. Malignant mesothelioma of the pleura: review of 123 patients. *Cancer*. 1982;49(11):2431-2435.
83. Nind NR, Attanoos RL, Gibbs AR. Unusual intraparenchymal growth patterns of malignant pleural mesothelioma. *Histopathology*. 2003;42(2):150-155.
84. Felner KJ, Wieczorek R, Kline M, et al. Malignant mesothelioma masquerading as a multinodular bronchioloalveolar cell adenocarcinoma with widespread pulmonary nodules. *Int J Surg Pathol*. 2006;14(3):229-233.
85. Rossi G, Cavazza A, Turrini E, et al. Exclusive intrapulmonary lepidic growth of a malignant pleural mesothelioma presenting with pneumothorax and involving the peritoneum. *Int J Surg Pathol*. 2006;14(3):234-237.
86. Adams VI, Unni KK. Diffuse malignant mesothelioma of pleura: diagnostic criteria based on an autopsy study. *Am J Clin Pathol*. 1984;82(1):15-23.
87. Sussman J, Rosai J. Lymph node metastasis as the initial manifestation of malignant mesothelioma. Report of six cases. *Am J Surg Pathol*. 1990;14(9):819-828.
88. Zanconati F, DelConte A, Bonifacio-Gori D, Falconieri G. Metastatic pleural mesothelioma presenting with solitary involvement of the tongue: report of a new case and review of the literature. *Int J Surg Pathol*. 2003;11(1):51-55.
89. Cao C, Tian D, Manganas C, et al. Systematic review of trimodality therapy for patients with malignant pleural mesothelioma. *Ann Cardiothorac Surg*. 2012;1(4):428-437.
90. Cao C, Tian DH, Pataky KA, Yan TD. Systematic review of pleurectomy in the treatment of malignant pleural mesothelioma. *Lung Cancer*. 2013;81(3):319-327.
91. de Perrot M, Feld R, Cho BC, et al. Trimodality therapy with induction chemotherapy followed by extrapleural pneumonectomy and adjuvant high-dose hemithoracic radiation for malignant pleural mesothelioma. *J Clin Oncol*. 2009;27(9):1413-1418.
92. Krug LM, Pass HI, Rusch VW, et al. Multicenter phase II trial of neoadjuvant pemetrexed plus cisplatin followed by extrapleural pneumonectomy and radiation for malignant pleural mesothelioma. *J Clin Oncol*. 2009;27(18):3007-3013.
93. Rea F, Marulli G, Bortolotti L, et al. Induction chemotherapy, extrapleural pneumonectomy (EPP) and adjuvant hemi-thoracic radiation in malignant pleural mesothelioma (MPM): feasibility and results. *Lung Cancer*. 2007;57(1):89-95.
94. Sugarbaker DJ, Flores RM, Jaklitsch MT, et al. Resection margins, extrapleural nodal status, and cell type determine postoperative long-term survival in trimodality therapy of malignant pleural mesothelioma: results in 183 patients. *J Thorac Cardiovasc Surg*. 1999;117(1):54-63, discussion 63-65.
95. Weder W, Stahel RA, Bernhard J, et al. Multicenter trial of neo-adjuvant chemotherapy followed by extrapleural pneumonectomy in malignant pleural mesothelioma. *Ann Oncol*. 2007;18(7):1196-1202.
96. Purek L, Laroumagne S, Dutau H, et al. Miliary mesothelioma: a new clinical and radiological presentation in mesothelioma patients with prolonged survival after trimodality therapy. *J Thorac Oncol*. 2011;6(10):1753-1756.
97. Attanoos RL, Gibbs AR. The pathology associated with therapeutic procedures in malignant mesothelioma. *Histopathology*. 2004;45(4):393-397.
98. Adams VI, Unni KK, Muhm JR, et al. Diffuse malignant mesothelioma of pleura. Diagnosis and survival in 92 cases. *Cancer*. 1986;58(7):1540-1551.
99. England DM, Hochholzer L, McCarthy MJ. Localized benign and malignant fibrous tumors of the pleura. A clinicopathologic review of 223 cases. *Am J Surg Pathol*. 1989;13(8):640-658.
100. Briselli M, Mark EJ, Dickersin GR. Solitary fibrous tumors of the pleura: eight new cases and review of 360 cases in the literature. *Cancer*. 1981;47(11):2678-2689.
101. Ahluwalia N, Attia R, Green A, et al. Doege-Potter syndrome. *Ann R Coll Surg Engl*. 2015;97(7):e105-e107.
102. Ibrahim NB, Briggs JC, Corrin B. Double primary localized fibrous tumours of the pleura and retroperitoneum. *Histopathology*. 1993;22(3):282-284.
103. Rao N, Colby TV, Falconieri G, et al. Intrapulmonary solitary fibrous tumors: clinicopathologic and immunohistochemical study of 24 cases. *Am J Surg Pathol*. 2013;37(2):155-166.
104. Thway K, Ng W, Noujaim J, et al. The current status of solitary fibrous tumor: diagnostic features, variants, and genetics. *Int J Surg Pathol*. 2016;24(4):281-292.
105. Gold JS, Antonescu CR, Hajdu C, et al. Clinicopathologic correlates of solitary fibrous tumors. *Cancer*. 2002;94(4):1057-1068.
106. de Saint Aubain Somerhausen N, Rubin BP, Fletcher CD. Myxoid solitary fibrous tumor: a study of seven cases with emphasis on differential diagnosis. *Mod Pathol*. 1999;12(5):463-471.
107. Wilson RW, Gallateau-Salle F, Moran CA. Desmoid tumors of the pleura: a clinicopathologic mimic of localized fibrous tumor. *Mod Pathol*. 1999;12(1):9-14.
108. Pinkard NB, Wilson RW, Lawless N, et al. Calcifying fibrous pseudotumor of pleura. A report of three cases of a newly described entity involving the pleura. *Am J Clin Pathol*. 1996;105(2):189-194.
109. Stout AP, Murray MR. Localized pleural mesothelioma. Investigation of its characteristics and histogenesis by the method of tissue culture. *Arch Pathol*. 1951;34:50-64.
110. Flint A, Weiss SW. CD-34 and keratin expression distinguishes solitary fibrous tumor (fibrous mesothelioma) of pleura from desmoplastic mesothelioma. *Hum Pathol*. 1995;26(4):428-431.
111. Steinetz C, Clarke R, Jacobs GH, et al. Localized fibrous tumors of the pleura: correlation of histopathological, immunohistochemical and ultrastructural features. *Pathol Res Pract*. 1990;186(3):344-357.
112. Robinson DR, Wu YM, Kalyana-Sundaram S, et al. Identification of recurrent NAB2-STAT6 gene fusions in solitary fibrous tumor by integrative sequencing. *Nat Genet*. 2013;45(2):180-185.
113. Harrison-Phipps KM, Nichols FC, Schleck CD, et al. Solitary fibrous tumors of the pleura: results of surgical treatment and long-term prognosis. *J Thorac Cardiovasc Surg*. 2009;138(1):19-25.
114. Tapias LF, Mercier O, Ghigna MR, et al. Validation of a scoring system to predict recurrence of resected solitary fibrous tumors of the pleura. *Chest*. 2015;147(1):216-223.
115. Moran CA, Suster S. Primary mucoepidermoid carcinoma of the pleura. A clinicopathologic study of two cases. *Am J Clin Pathol*. 2003;120(3):381-385.
116. Guinee DG, Allen TC. Primary pleural neoplasia: entities other than diffuse malignant mesothelioma. *Arch Pathol Lab Med*. 2008;132(7):1149-1170.
117. Essary LR, Vargas SO, Fletcher CD. Primary pleuropulmonary synovial sarcoma: reappraisal of a recently described anatomic subset. *Cancer*. 2002;94(2):459-469.
118. Aubry MC, Bridge JA, Wickert R, Tazelaar HD. Primary monophasic synovial sarcoma of the pleura: five cases confirmed by the presence of SYT-SSX fusion transcript. *Am J Surg Pathol*. 2001;25(6):776-781.
119. Gaertner E, Zeren EH, Fleming MV, et al. Biphasic synovial sarcomas arising in the pleural cavity. A clinicopathologic study of five cases. *Am J Surg Pathol*. 1996;20(1):36-45.
120. Zhang PJ, Livolsi VA, Brooks JJ. Malignant epithelioid vascular tumors of the pleura: report of a series and literature review. *Hum Pathol*. 2000;31(1):29-34.
121. Aozasa K, Naka N, Tomita Y, et al. Angiosarcoma developing from chronic pyothorax. *Mod Pathol*. 1994;7(9):906-911.
122. Vega F, Padula A, Valbuena JR, et al. Lymphomas involving the pleura: a clinicopathologic study of 34 cases diagnosed by pleural biopsy. *Arch Pathol Lab Med*. 2006;130(10):1497-1502.
123. Petitjean B, Jardin F, Joly B, et al. Pyothorax-associated lymphoma: a peculiar clinicopathologic entity derived from B cells at late stage of differentiation and with occasional aberrant dual B- and T-cell phenotype. *Am J Surg Pathol*. 2002;26(6):724-732.
124. Ibuka T, Fukayama M, Hayashi Y, et al. Pyothorax-associated pleural lymphoma. A case evolving from T-cell-rich lymphoid

infiltration to overt B-cell lymphoma in association with Epstein-Barr virus. *Cancer*. 1994;73(3):738-744.
125. Brimo F, Michel RP, Khetani K, Auger M. Primary effusion lymphoma: a series of 4 cases and review of the literature with emphasis on cytomorphologic and immunocytochemical differential diagnosis. *Cancer*. 2007;111(4):224-233.
126. Nador RG, Cesarman E, Chadburn A, et al. Primary effusion lymphoma: a distinct clinicopathologic entity associated with the Kaposi's sarcoma-associated herpes virus. *Blood*. 1996;88(2):645-656.
127. Said J, Cesarman E. Primary effusion lymphoma. In: Swerdlow SH, Campo E, Harris NL, et al, eds. *WHO Classification of Tumours of Haematopoietic and Lymphoid Tissues*. 4th ed. Lyon: IARC; 2008:260-261.
128. Attanoos RL, Galateau-Salle F, Gibbs AR, et al. Primary thymic epithelial tumours of the pleura mimicking malignant mesothelioma. *Histopathology*. 2002;41(1):42-49.
129. Matthay RA, Coppage L, Shaw C, Filderman AE. Malignancies metastatic to the pleura. *Invest Radiol*. 1990;25(5):601-619.
130. Chernow B, Sahn SA. Carcinomatous involvement of the pleura: an analysis of 96 patients. *Am J Med*. 1977;63(5): 695-702.
131. Von Hoff DD, LiVolsi V. Diagnostic reliability of needle biopsy of the parietal pleura. A review of 272 biopsies. *Am J Clin Pathol*. 1975;64(2):200-203.
132. Kirsch CM, Kroe DM, Azzi RL, et al. The optimal number of pleural biopsy specimens for a diagnosis of tuberculous pleurisy. *Chest*. 1997;112(3):702-706.
133. Kumar P, Sen MK, Chauhan DS, et al. Assessment of the N-PCR assay in diagnosis of pleural tuberculosis: detection of M. tuberculosis in pleural fluid and sputum collected in tandem. *PLoS ONE*. 2010;5(4):e10220.
134. Nance KV, Shermer RW, Askin FB. Diagnostic efficacy of pleural biopsy as compared with that of pleural fluid examination. *Mod Pathol*. 1991;4(3):320-324.
135. Frist B, Kahan AV, Koss LG. Comparison of the diagnostic values of biopsies of the pleura and cytologic evaluation of pleural fluids. *Am J Clin Pathol*. 1979;72(1):48-51.
136. Irani DR, Underwood RD, Johnson EH, Greenberg SD. Malignant pleural effusions. A clinical cytopathologic study. *Arch Intern Med*. 1987;147(6):1133-1136.
137. Kundu R, Handa U, Mohan H. Role of DNA flow cytometry and immunocytochemical analysis in diagnosis of malignant effusions. *Diagn Cytopathol*. 2012;40(10): 887-892.
138. Johnston WW. The malignant pleural effusion. A review of cytopathologic diagnoses of 584 specimens from 472 consecutive patients. *Cancer*. 1985;56(4):905-909.
139. Boon ME, Veldhuizen RW, Ruinaard C, et al. Qualitative distinctive differences between the vacuoles of mesothelioma cells and of cells from metastatic carcinoma exfoliated in pleural fluid. *Acta Cytol*. 1984;28(4): 443-449.
140. Ylagan LR, Zhai J. The value of ThinPrep and cytospin preparation in pleural effusion cytological diagnosis of mesothelioma and adenocarcinoma. *Diagn Cytopathol*. 2005;32(3):137-144.

Mediastinum

12

Jeffrey L. Myers

CHAPTER CONTENTS

Generalities, *457*
Inflammatory diseases, *457*
Cysts (other than thymic), *459*
Pericardial (coelomic) cysts, *459*
Foregut cysts, *459*
Other cysts, *460*
Thymus, *460*
Normal anatomy, *460*
Primary immunodeficiencies, *461*
Cysts, *462*
Other non-neoplastic diseases, *462*
Thymoma and thymic carcinoma, *463*
Cervical tumors of thymic or related branchial pouch derivation, *477*
Neuroendocrine tumors, *479*
Stromal and other tumors, *481*
Germ cell tumors, *481*
Malignant lymphoma, *484*
Classical Hodgkin lymphoma, *484*
Lymphoblastic lymphoma, *486*
Primary mediastinal (thymic) large B-cell lymphoma, *486*
Marginal zone B-cell lymphoma, *488*
Other hematolymphoid conditions, *488*
Neurogenic tumors, *489*
Tumors of sympathetic nervous system, *489*
Tumors of peripheral nerves, *490*
Other neurogenic tumors, *490*
Tumors of paraganglia, *490*
Mesenchymal tumors, *491*
Metastatic tumors, *492*

Generalities

The mediastinum is the portion of the thoracic cavity located between the pleural cavities, extending anteroposteriorly from the sternum to the spine and from the thoracic inlet superiorly to the diaphragm inferiorly. The numerous organs and structures it contains make it a veritable Pandora's box, within which congenital cysts, benign tumors, and primary and metastatic neoplasms may develop.

An arbitrary division of the mediastinum into *superior*, *anterior*, *middle*, and *posterior* compartments has proven useful, since most cysts and neoplasms have a predilection for one compartment over the others. The most common mediastinal lesions are noted in Fig. 12.1 according to their frequency and most common site of occurrence in adults.[1] As expected, the relative frequencies of these lesions are considerably different in the pediatric population.[2]

About half of the patients with mediastinal cysts and tumors are asymptomatic, the lesions being discovered incidentally on chest x-rays or CT scans done for other reasons. When symptoms develop, they usually result from compression and/or invasion of adjacent structures, and include chest pain, cough, and dyspnea. Development of the superior vena cava syndrome is usually indicative of malignancy, the two most common causes in adults being metastatic lung carcinoma and malignant lymphoma,[3] and in children malignant lymphoma and acute leukemia.[4] However, it can also occur with benign conditions such as fibrosing mediastinitis.[5] Pulmonary stenosis can also occur with mediastinal tumors as a result of compression of the pulmonary artery or the right ventricular outflow tract.

The location of lesions in the mediastinum, together with their configuration, provides important diagnostic information, but many lesions (both benign and malignant) result in similar radiographic and CT scan appearances. Biopsy and/or exploration are therefore mandatory in most instances. Preoperative irradiation should be avoided when possible because the resulting changes may render the pathologic interpretation difficult or even impossible. Core needle and fine-needle aspiration of mediastinal masses are important diagnostic strategies, particularly in lesions of the anterosuperior compartment.

Inflammatory Diseases

Acute mediastinitis is usually the result of traumatic perforation of the esophagus, or descent of infection from within the neck through the "danger space" anterior to the prevertebral fascia; in both cases, it involves predominantly the posterior portion of the mediastinum. The initial lesion may be a neck abscess resulting from dental infection, Ludwig angina, necrotizing fasciitis, or a pyriform sinus fistula.[6] Abscess formation usually takes place and generally requires surgical drainage. Superior vena cava syndrome is an uncommon complication

Abstract

This chapter reviews diseases of the mediastinum after a brief overview of mediastinal compartments and the importance of gross features and distribution of disease in differential diagnosis. Inflammatory diseases, mediastinal cysts, and lesions arising in thyroid and parathyroid tissue is followed by a more detailed review of the anatomy of the thymus and thymic pathology in various primary immunodeficiencies. Thymic cysts and other non-neoplastic conditions precede a more exhaustive summary of primary thymic epithelial and non-epithelial neoplasms. The chapter concludes with a brief summary of metastases that may involve the mediastinum.

Keywords

Pericardial cysts,
foregut cysts,
thymic cysts,
myasthenia gravis,
thymoma,
thymic carcinoma,
neuroendocrine tumors,
carcinoid,
atypical carcinoid,
spindle epithelial tumor with thymus-like elements (SETTLE),
carcinoma with thymus-like elements (CASTLE),
ectopic thymoma,
ectopic hamartomatous thymoma,
seminoma yolk sac tumor,
embryonal carcinoma,
choriocarcinoma,
mixed germ cell tumors,
classical Hodgkin lymphoma,
lymphoblastic lymphoma,
primary mediastinal (thymic) large B-cell lymphoma,
marginal zone B-cell lymphoma,
anaplastic large cell lymphoma,
myeloid sarcoma,
plasmacytoma,
Castleman disease,
extramedullary hematopoiesis,
myelolipoma,
follicular dendritic cell tumor,
neuroblastoma,
ganglioneuroblastoma,
ganglioneuroma,
malignant peripheral nerve sheath tumor,
paraganglioma,
lipoma,
lymphangioma,
hemangioma,
hemangioendothelioma,
solitary fibrous tumor,
angiosarcoma,
leiomyoma,
rhabdomyoma,
synovial sarcoma

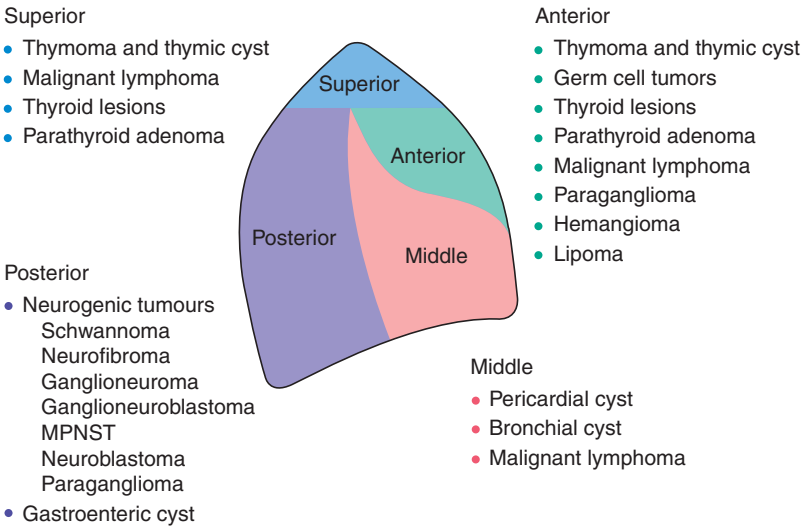

Figure 12.1 Location of most common lesions of mediastinum. *MPNST*, Malignant peripheral nerve sheath tumor.

Figure 12.2 Fibrosing mediastinitis constricting the superior vena cava resulting in superior vena cava syndrome.

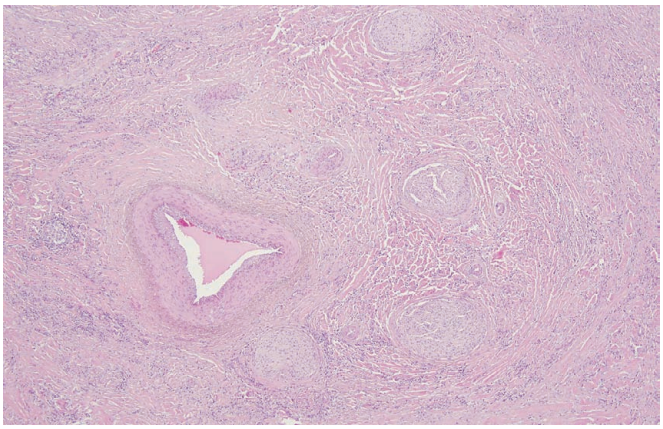

Figure 12.3 Fibrosing Mediastinitis. Dense ropey collagen bundles surround nerves and vessels.

of acute mediastinitis but has been described in cases of *Nocardia* spp. and other types of bacterial lung infections with secondary mediastinal involvement.[7–9]

Other types of mediastinitis are those resulting from spread of infection from the chest wall and those developing after heart surgery.[10]

Chronic mediastinitis can produce compression of mediastinal structures and simulate a malignant process.[11,12] The typical location is the anterior mediastinum, in front of the tracheal bifurcation. Microscopically, one may find necrotizing granulomatous infection *(granulomatous mediastinitis)*, fibrosis *(fibrosing mediastinitis)*, or a combination of both.[13] *Histoplasma capsulatum* (histoplasmosis) is the organism most commonly identified in those cases of fibrosing mediastinitis for which a specific etiology can be determined.[14]

Fibrosing mediastinitis is characterized by coarse, keloid-like, collagen deposition that can invade the superior vena cava, resulting in superior vena cava syndrome, and can also invade the pulmonary hilum, resulting in complete occlusion of hilar vessels (Figs. 12.2 and 12.3). The latter may result in complete obstruction of venous outflow, resulting in a peculiar pattern of microscopic subpleural and paraseptal infarction *("venous infarcts")*.[15] The fibrosis is accompanied by a variable but generally mild, patchy infiltrate of lymphocytes and plasma cells. In selected cases a lymphoplasmacytic infiltrate is accompanied by other changes characteristic of IgG4-related disease (i.e. storiform fibrosis, obliterative phlebitis/arteritis, and an increase in IgG4-positive plasma cells above proposed diagnostic thresholds), a finding that is not yet fully understood.[16] Cases in which there is an associated granulomatous infection show necrotizing granulomas in which there may be relatively few epithelioid or multinucleated histiocytes. Special stains may be helpful in identifying pathogens within the necrotic zones. The differential diagnosis for fibrosing mediastinitis includes primarily neoplastic disorders that may contain extensive areas in which only fibrosis and chronic inflammation predominate; this is particularly true for Hodgkin lymphoma.

In many instances of fibrosing mediastinitis, a specific infectious etiology cannot be demonstrated (*idiopathic* fibrosing mediastinitis). Some of these cases belong to a group of fibrosing (sclerosing) inflammatory conditions, which includes pulmonary hyalinizing granuloma, retroperitoneal fibrosis, sclerosing cholangitis, Riedel struma, and inflammatory pseudotumor of the orbit. As previously mentioned, fibrosing mediastinitis has in common with the other members of this list a link to IgG4-related disease.

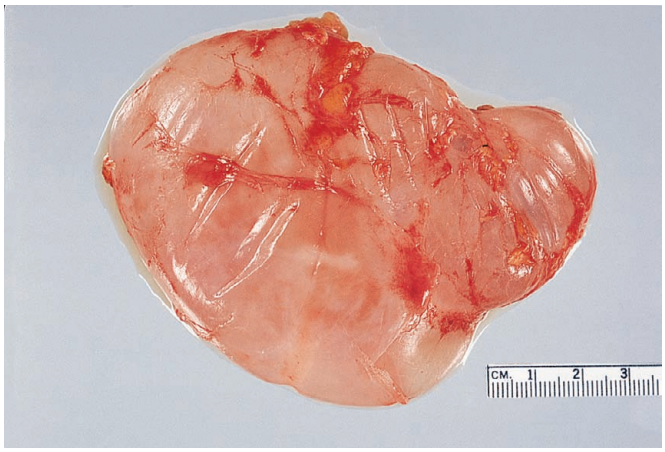

Figure 12.4 Gross Appearance of Pericardial Cyst. Note the thin translucent quality of the wall, which is partially covered by adipose tissue.

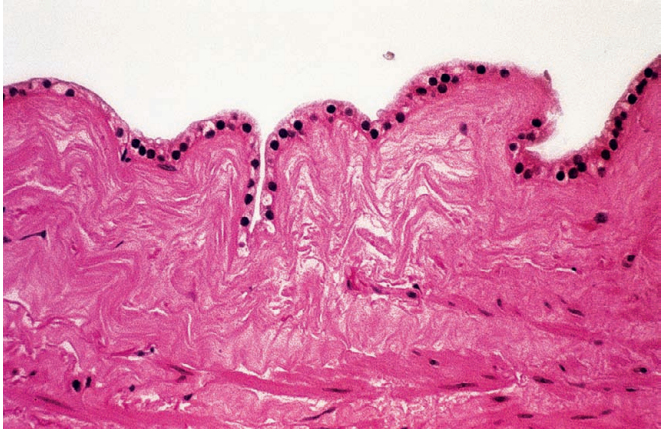

Figure 12.5 Microscopic Appearance of Pericardial Cyst. The lining is composed of a single layer of mesothelial cells.

The tendency for fibrosing mediastinitis to grow in an invasive fashion accounts for the historically high rates of morbidity and mortality attributed to this condition; a more recent report suggests that overall survival may be equivalent to age-matched controls.[14] The treatment of fibrosing mediastinitis includes surgical excision and nonsurgical interventions in those with compression of vital mediastinal structures.[14] Anti-inflammatory and anti-fungal strategies are generally ineffective. A few cases have benefitted from rituximab, a strategy targeting the predominance of B lymphocytes in some examples.[17]

Cysts (Other Than Thymic)

Pericardial (Coelomic) Cysts

The pericardial sac is formed by the fusion of multiple disconnected lacunae. Failure of one of the lacunar cavities to merge with the others results in the development of a pericardial (coelomic) cyst. Such cysts are usually located at the right cardiophrenic angle.[18] They are soft and unilocular, usually loosely adherent to the pericardium and attached to the diaphragm; sometimes they communicate with the pericardial cavity (Fig. 12.4). Less commonly, they are seen in a suprapericardial position. At times, multiple cysts may be present. They contain clear fluid unless infected. The blood supply comes from the pericardium. The inner surface of the cyst wall is covered by a single layer of flat or cuboidal mesothelium, which is strongly immunoreactive for keratin and mesothelial markers (Fig. 12.5).

Foregut Cysts

During embryonic development, fusion of the lateral walls that form the tracheoesophageal septum begins caudally. If a small bud or diverticulum of the foregut is pinched off during this process, it will be carried into the mediastinum by the downward growth of the lungs. This structure contains the endoderm and mesoderm that were destined to become part of the trachea, bronchi, esophagus, stomach, or intestine.

Bronchial cysts occur along the tracheobronchial tree, their most common location being posterior to the carina.[19] Rarely, they are located just above the diaphragm. They can be missed on plain films but are easily detectable on CT scans. These cysts contain clear or gelatinous fluid; they are usually unilocular, thin-walled, and spherical with an average diameter of 3–4 cm (Fig. 12.6). Microscopically, they usually are lined by ciliated columnar epithelium, but focal or extensive squamous metaplasia and/or extreme attenuation of this lining can occur (Fig. 12.7). The wall may contain hyaline cartilage, smooth muscle, bronchial glands, and nerve trunks.

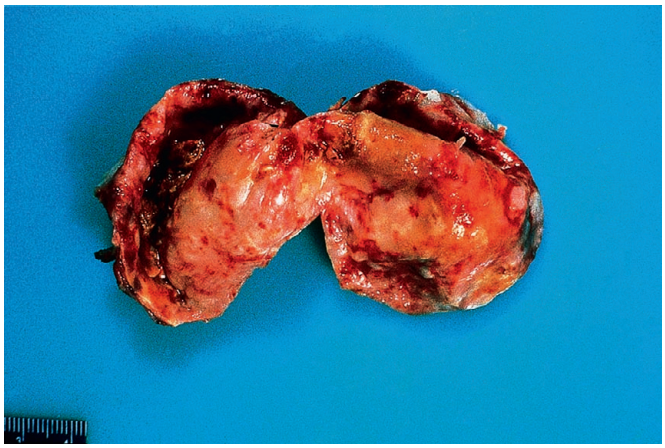

Figure 12.6 Gross Appearance of Bronchial Mediastinal Cyst. The inner lining has a granular quality.

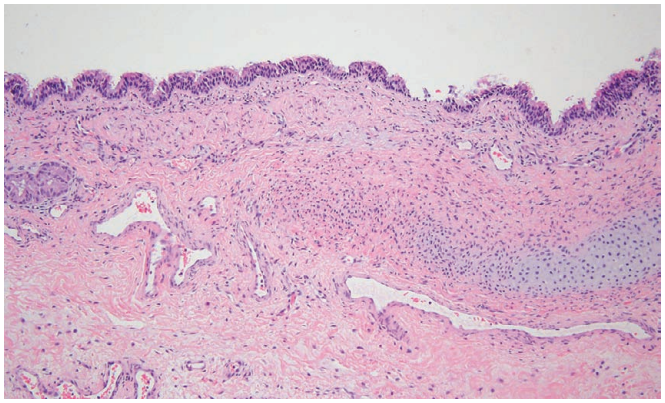

Figure 12.7 Microscopic Appearance of Bronchial Mediastinal Cyst. The lining is composed of pseudostratified ciliated respiratory epithelium; the wall contains hyaline cartilage and submucosal glands.

Esophageal cysts probably arise from a persistence, in the wall of the foregut, of vacuoles that form during the solid tube stage of

development. Most are found embedded in the wall of the lower half of the esophagus. The lining may be squamous, ciliated, columnar, or a mixture of these. Distinction from bronchial cyst may be difficult or even impossible, especially because the latter can be found entirely within the wall of the esophagus. The best evidence that a cyst in this location is of esophageal type is the presence of a definite double layer of smooth muscle in the wall.

Gastric and **enteric cysts** usually are located in the posterior mediastinum in a paravertebral location, attached to the wall of the esophagus or even embedded within the muscle layer of this organ. Nearly all cases are associated with vertebral malformations. The gastric variety is made up of the same coats as the stomach, whereas the enteric type simulates the wall of normal intestine. Combined forms occur and are designated as **gastroenteric cysts**. Nerve fibers and ganglia are often present in them.[18]

Pancreatic cysts and pseudocysts may have a primarily mediastinal presentation.[20] Knowing the tendency of mediastinal germ cell tumors to contain pancreatic tissue (see elsewhere in this chapter), it is logical to assume that some of these pseudocysts have a teratomatous origin.

These congenital cysts only exceptionally communicate with the tracheobronchial tree or the esophagus. Malignant change within them is very unusual, but when it occurs takes the form of adenocarcinoma.[21] Symptoms from these cysts depend on their size and location; they are related to pressure phenomena and consist of cough, dysphagia, recurrent pulmonary infection, dyspnea, pain, and rarely hemoptysis. Most bronchial, esophageal, and enteric cysts are asymptomatic and are found incidentally. In contrast, gastric and gastroenteric cysts are often symptomatic and even life-threatening because of the occurrence of gastric secretion and the hemorrhage, peptic ulcer, or perforation that may supervene as a result.

Other Cysts

Thymic cysts are discussed elsewhere in this chapter and **parathyroid cysts** in the next section.

Cases of mediastinal cysts arising from the **thoracic duct** (the largest lymph vessel in humans) have been reported.[22] Some of these may represent examples of cystic lymphangiomas.

A type of posterior mediastinal cyst occurring in adult women and lined by ER+ PR+ epithelium resembling fallopian tube mucosa and a smooth muscle–containing thin wall are of probable **müllerian origin**.[23]

Another bizarre occurrence is that of an **adenomatoid tumor** presenting as a cystic mass in the anterior mediastinum.[24]

Thyroid and Parathyroid Lesions

Thyroid tumors and tumorlike conditions of several types can present as superior mediastinal masses. The most common pathologic change in mediastinal thyroid glands is nodular hyperplasia, which can reach huge proportions and cause compression symptoms.[25,26] Thyroid nodular hyperplasia in the mediastinum may occur in the form of seemingly independent nodules (so-called parasitic or accessory nodules), a fact that may lead the unwary to regard the lesion as malignant. Actually, malignant change in mediastinal thyroid (except for the clinically inconsequential papillary microcarcinomas) is too unusual to justify excision because of fear of this complication; the main rationale for surgery is the relief of compression symptoms.

From a pathogenetic standpoint, the nodular hyperplasia in most instances probably does not arise from ectopic thyroid tissue but rather from cervical thyroid that has been pulled down either into the anterior prevascular compartment or the retrotracheal compartment (so-called posterior descending goiter) by the nodular enlargement. Support for this interpretation comes from the fact that these masses retain their cervical blood supply through a narrow pedicle. Radioactive iodine scanning yields a positive result in over half of the cases.

Parathyroid tumors and tumorlike conditions can also occur in the mediastinum, a not surprising event in view of the embryologic origin of the parathyroid glands and their intimate relationship with the thymus. About 7% of parathyroid adenomas are found in the superior mediastinum, and most of them can be excised through a suprasternal incision. Most of the others are located in the anterior mediastinum where they can sometimes be excised using a combination of preoperative targeting and either mediastinoscopy or video-assisted thoracoscopy.[27,28] Because of their location, these adenomas can grow to a much larger size than their equivalents in the neck. Like their cervical counterparts, mediastinal parathyroid adenomas can be accompanied by a heavy lymphocytic infiltrate.

Mediastinal parathyroid carcinomas have also been reported, some of them being nonfunctioning.[29]

Parathyroid cysts of the mediastinum are usually located in the anterosuperior compartment, and are often functioning.[30]

Thymus

Normal Anatomy

The thymus is a lobulated organ covered by a capsule and divided into cortical and medullary portions, the cortex being further subdivided into a subcapsular (outer) and a deep region. The cortex stains more deeply basophilic at low magnification in routinely stained sections due to a higher proportion of lymphocytes compared to cortical epithelial cells, while the medullary portions are more pale as a result of fewer lymphocytes compared to medullary epithelial cells including Hassall corpuscles. The two major cell types are endodermally derived epithelial cells (with a possible minor ectodermal contribution) and bone marrow–derived lymphocytes. The epithelial cells have been further divided on the basis of their location, appearance, and phenotypic properties into cortical (dendritic), subcapsular, medullary, and Hassall corpuscle related.[31] These epithelial cells are keratin positive and express HLA-DR antigens, the keratin profile showing differences related to the anatomic compartment and the functional status (growth phase or involution) of the gland.[32] One or more subsets of these cells are responsible for the differentiation of T lymphocytes. It has been assumed for a long time that this process is modulated in the thymic microenvironment through the secretion of thymic hormones; however, the specificity, mechanism of action, and exact role of these substances remain elusive despite decades of work on the subject by several groups.[33] Thymic lymphocytes (traditionally known as thymocytes) have a T-cell phenotype; a whole range of differentiation exists among them, the better defined stages being those of subcapsular thymocyte, cortical thymocyte, medullary thymocyte, and mature (peripheral type) T lymphocyte.[34] Other cells normally present in the thymus include B cells (present both in the thymic medulla and in the perivascular compartment),[35] interdigitating reticulum cells, Langerhans cells,[36] mast cells, eosinophils (particularly in neonates), and the usual nonspecific types of stromal cell. Aggregates of benign nevus cells have also been described within the substance of the thymus.[37] A notable subtype of stromal-type cell found in the thymic medulla and possibly playing a role in the pathogenesis of myasthenia gravis is a skeletal muscle cell known as *myoid cell*, from which a human cell line has been established.[38] The embryologic origin and functional significance of these enigmatic cells remain controversial.

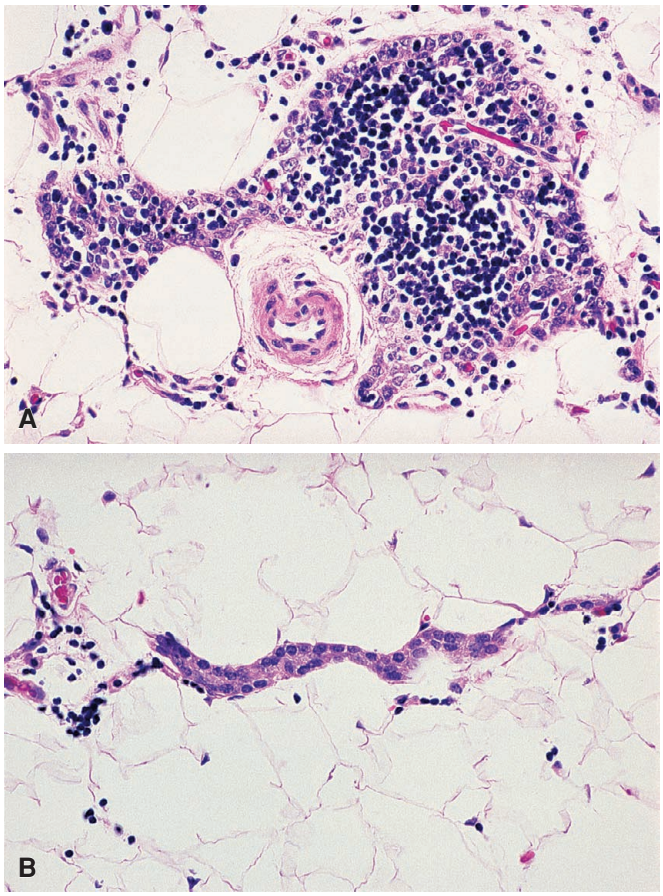

Figure 12.8 Residual Thymic Tissue. A, This island is predominantly composed of small lymphocytes, but a row of epithelial cells is visible at the periphery. **B**, This thin elongated strand is predominantly composed of oval to spindle epithelial cells.

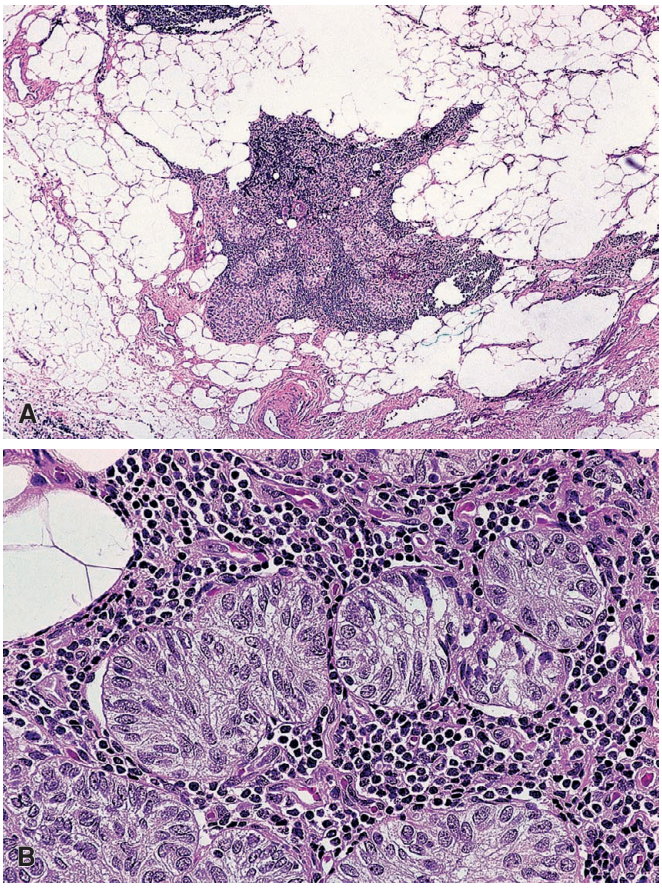

Figure 12.9 A and **B**, Low-power and higher appearance of nodular hyperplasia of thymic epithelium.

The thymus undergoes normal involution after puberty, although it never disappears completely.[39,40] Islands of thymic tissue are consistently found on microscopic examination of the prepericardial fat and sometimes also in the retrocarinal fat.[41] The islands predominantly composed of lymphocytes may be confused with lymph nodes, whereas those mainly made up of epithelial cells show trabecular or rosette-like formations and may be misinterpreted as carcinomatous or neuroendocrine (Fig. 12.8).[42] Occasionally the epithelial component acquires a nodular character. This inconsequential change, which can also be seen in ectopic thymus, probably represents nodular hyperplasia (or a *thymic tumorlet*, so to speak) and should therefore be distinguished from a bona fide small thymoma ("microthymoma") (Fig. 12.9).[43]

Primary Immunodeficiencies

Thymic dysplasia is the generic term that has been proposed for a congenital thymic alteration thought to be the expression of a failure and/or arrest in the development of the organ.[44] The most salient features are very small size (less than 5 g), primitive-appearing epithelium without segregation into cortical and medullary regions, presence of tubules and rosettes, absence of Hassall corpuscles, and almost total absence of lymphocytes. Nezelof[44] has described four morphologic variations on the theme, which probably are more a reflection of the degree of severity of the process than an indicator of the specific type of immunodeficiency. Diseases accompanied by thymic dysplasia include the usual X-linked or autosomal recessive form of *severe combined immunodeficiency*, *ataxia–telangiectasia*, and related *chromosomal instability syndromes*, *Nezelof syndrome*, and the *incomplete form of DiGeorge syndrome*; in the last condition, the thymus is not only dysplastic but is also often located ectopically. In the complete form of DiGeorge syndrome the thymus is by definition absent (i.e. there is *thymic aplasia*).

In most other types of immunodeficiency there is no primary thymic abnormality. These include *congenital agammaglobulinemia* and *adenosine deaminase* (*ADA*) *deficiency* (also known as the ADA-negative form of severe combined immunodeficiency).[45]

The main differential diagnosis of thymic dysplasia is with the *acute thymic involution* resulting from "stress" and superimposed infections, which of course are often present in immunosuppressed populations, particularly at autopsy.[46] Acute thymic involution is characterized by marked lymphocytic depletion accompanied by preservation of the lobular architecture and of Hassall corpuscles. The identification of well-formed Hassall corpuscles in a thymus biopsy is the best evidence against the diagnosis of primary thymic dysplasia. In some instances, these structures become prominent by virtue of their cystic dilation, the cysts containing an admixture of keratin, calcium, and mucinous material.

In acute thymic involution, the size of the vessels is large for the size of the lobules, this being another important feature in the differential diagnosis with thymic dysplasia. A scattering of inflammatory cells is present in the interlobular and perilobular tissue, sometimes with a marked predominance of plasma cells. This acute involution process can proceed at a rapid rate, leading to almost complete lymphocytic depletion of the cortex within 1 week.[45]

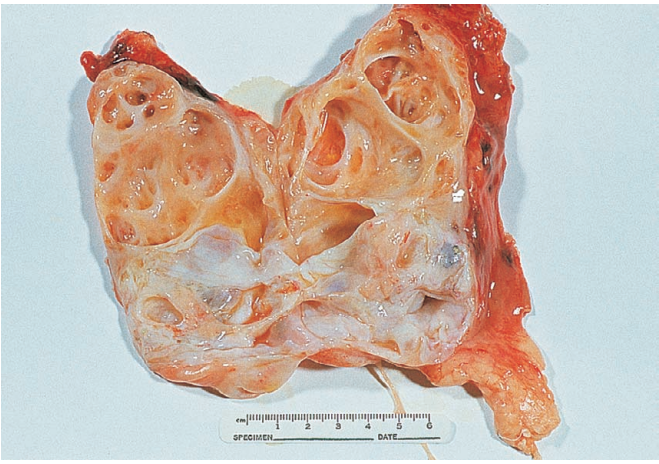

Figure 12.10 Multilocular Thymic Cyst. The fibrous septa separating the individual cysts are rather thick. The content of the cysts varied from cloudy to blood tinged.

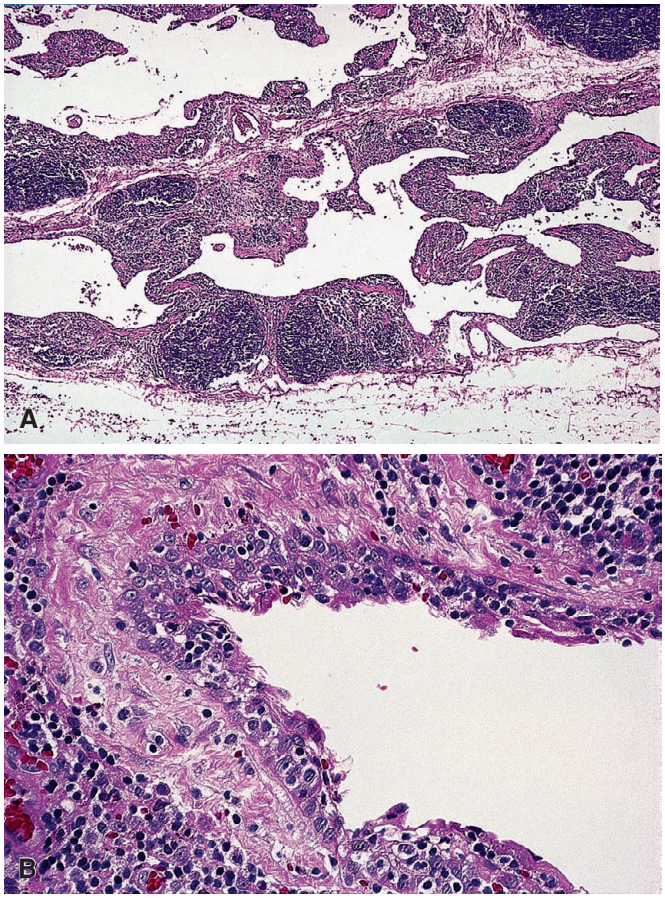

Figure 12.11 **A** and **B**, Microscopic appearance of multilocular thymic cyst. This case was associated with thymic Hodgkin lymphoma, not shown in the photographs. The high-power view shows the stratified squamous lining of the cyst, which is infiltrated by lymphocytes.

Cysts

Thymic cysts can be divided into two distinct types. **Unilocular thymic cysts** are of developmental origin, thought to arise from remnants of the third branchial pouch–derived thymopharyngeal duct. They are generally small and located in the neck more often than in the mediastinum.[47] The cervical cysts tend to be elongated and can be found anywhere along a line extending from the angle of the mandible to the manubrium sternum. The wall is thin and translucent, and inflammation is usually lacking. The epithelial lining is flattened, cuboidal, columnar, or (rarely) squamous. Thymic tissue is present in the wall, some of it connecting with the lining epithelium.

Multilocular thymic cyst is in all likelihood an acquired process of a reactive nature.[48] It is by definition multilocular and always accompanied by inflammation and fibrosis (Fig. 12.10). It can be an incidental microscopic finding or result in a large tumorlike mass adherent to other mediastinal structures, simulating a malignant process at thoracotomy. The lining of the individual cysts may be flat, cuboidal, ciliated columnar, or (often) squamous, either single or stratified (Fig. 12.11). In some areas it may be absent, whereas in others it may have a highly reactive appearance, occasionally acquiring the features of pseudoepitheliomatous hyperplasia.[49] Cholesterol granulomas are common. In some instances the inflammatory infiltrate is very prominent, with formation of numerous lymphoid follicles.[50]

We believe that multilocular thymic cyst is the result of an acquired cystic dilation of medullary duct epithelium–derived structures, induced by an inflammatory reaction of the thymic parenchyma.[48] This inflammation is usually idiopathic, although in some cases a specific etiology (such as HIV infection or an autoimmune disorder) can be documented.[51] The so-called *Dubois abscesses* described in the thymuses of neonates with congenital syphilis probably also belong to this category.[48]

Most importantly, a morphologically similar change can be seen in about half of the thymuses harboring nodular sclerosis Hodgkin lymphoma[52] or seminoma (germinoma).[53] It can also be seen, although with much lesser frequency, in association with other tumors such as thymoma,[54] large cell lymphoma, yolk sac tumor,[55] and mature teratoma.[56] Therefore, in the presence of these cystic changes it is important to determine whether the changes are purely inflammatory or whether an underlying neoplastic process is present. In regard to the pathogenesis of the lesion, it is of interest that the two malignant tumors most commonly associated with it (Hodgkin lymphoma and seminoma) are those in which a non-neoplastic lymphocytic component is particularly prominent.

We have made the proposal that the process of lymphocyte-induced cystic ductular dilation resulting in multilocular thymic cyst is also responsible for the development of the following head and neck lesions: branchial cleft cyst, multiple branchial cleft-like cysts in Hashimoto thyroiditis,[57,58] benign lymphoepithelial cysts, lymphoepithelial cysts in the parotid glands with HIV infection, and possibly even Warthin tumor of parotid.[48]

Multilocular thymic cysts must be distinguished from thymomas undergoing cystic degeneration[59] and from cystic lymphangioma. Exceptionally, squamous cell carcinomas,[60] basaloid carcinomas,[61] and well-differentiated neuroendocrine carcinomas (carcinoid tumors)[62] have been seen in intimate connection with these cysts and possibly arose from them.

Other Non-Neoplastic Diseases

Ectopic thymus with an entirely normal microscopic appearance can present as a mass in the neck or pleural surface.[63] The maldescended thymic tissue in the neck can be unilateral or bilateral. It is often located adjacent to the thyroid gland and usually associated with a parathyroid gland. Ectopic thymic tissue in the skin of the neck can be a clue to the *branchio-oculo-facial syndrome*.[64]

Ectopic tissues sometimes found in a normally located thymus include *parathyroid gland* (not surprising in view of their common embryogenesis) and *sebaceous glands*.[65]

Acute thymic involution is a constant feature of chronic, debilitating diseases. As already stated, these changes are of a secondary nature and should not be misinterpreted as evidence of a primary immune defect. In patients with HIV infection, thymic involution is particularly pronounced and is accompanied by effacement of the corticomedullary junction, marked lymphocytic depletion, variable degrees of plasma cell infiltration and fibrosis, and inconspicuous Hassall corpuscles.[66] Apparently, these late changes are preceded by thymic follicular hyperplasia.

Diffuse thymic fibrosis is occasionally seen in the absence of another primary thymic lesion or features of IgG4-related disease.[67] It is not clear whether it represents a nonspecific pattern of injury or a distinct entity, but the former seems more likely.

True thymic hyperplasia is defined as thymic enlargement beyond the upper limits of normal for the age (as determined by weight using the Hammar table or by volumetric measurement) but accompanied by a microscopically normal gland. It has been most often described in infants and children but has also been found in adults, sometimes after successful chemotherapy for malignant disease.[68,69] In some cases it may simply represent a failure of involution, but in others it is clearly an acquired phenomenon secondary to some therapeutic manipulation.

Thymic follicular hyperplasia (often called simply "thymic hyperplasia", a misleading term) is defined as the presence of more than an occasional lymphoid follicle in the thymus independent of the size of the gland. Actually, the weight of most of the thymuses with lymphoid hyperplasia is within normal limits.[70] These follicles are of secondary type, with germinal center formation (Fig. 12.12), and are largely composed of B lymphocytes. According to some authors, their presence is accompanied by a disorderly arrangement and hypertrophy of medullary epithelial cells.[71]

Follicular hyperplasia is seen in about 65% of patients with myasthenia gravis (see next section). It is also commonly present in patients with hyperthyroidism, Addison disease, lupus erythematosus, and other immune-mediated diseases. It has also been described in the early stage of HIV infection, sometimes associated with multilocular cystic formation.[51,72]

A few germinal centers also may be found in the apparently normal thymus, especially during infancy and childhood; therefore only their presence in a substantial number in adult patients can be viewed as a distinctly abnormal finding.

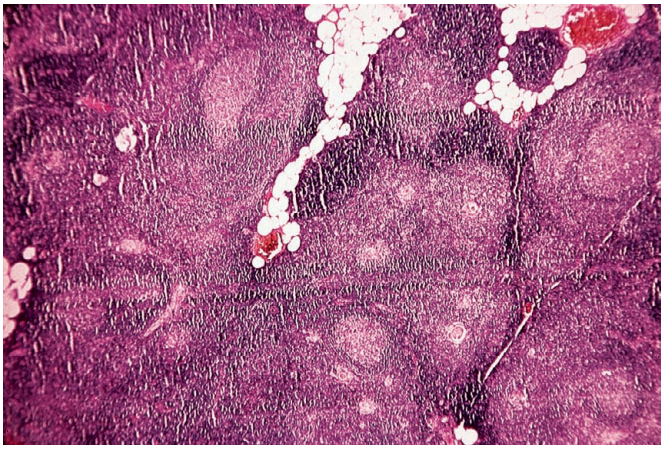

Figure 12.12 Prominent follicular hyperplasia of thymus in a patient with myasthenia gravis. Florid germinal centers are present throughout the organ.

Langerhans cell histiocytosis can present as a thymic mass, either alone or with involvement of other sites.[73,74] The microscopic appearance is characteristic, and the overall prognosis is excellent. Exceptionally, it is seen in association with myasthenia gravis.[75] It may also coexist with multilocular thymic cyst.[76] Granulomas containing numerous eosinophils and simulating Langerhans cell histiocytosis can develop in the thymic capsule as a result of diagnostic pneumomediastinum, a procedure that has been largely abandoned, and is likely equivalent to the reactive eosinophilic pleuritis seen in patients with pneumothorax.[77]

Other inflammatory diseases that can occasionally involve the thymus are **eosinophilic granulomatosis with polyangiitis** (Churg–Strauss disease)[78] and **Castleman disease** (giant lymph node hyperplasia).[79,80]

Thymoma and Thymic Carcinoma

General Features

Thymoma is a term that should be restricted to neoplasms of thymic epithelial cells, independently of the presence or number of lymphocytes.[81] Seminoma, carcinoid tumor, Hodgkin lymphoma, and non-Hodgkin lymphoma can all involve the thymus primarily; thus they can be viewed as thymic tumors but should not be regarded as variants of thymoma.

Nearly all thymomas present in adult life. Thymomas in children are exceptional; most of the cases so diagnosed in the past actually represent lymphoblastic lymphomas of the thymus. However, some well-documented cases exist, most of them occurring near the age of puberty with an appearance and behavior equivalent to that of their adult counterpart, including an occasional association with myasthenia gravis.[82] Some younger children are found to have highly malignant thymic neoplasms with unusual morphologic features, the nature of which has not yet been thoroughly elucidated[83]; it is possible that some cases may represent so-called NUT midline carcinoma (see Chapter 4).[84,85] Familial incidence of thymoma has been recorded only exceptionally.

The usual location of thymoma is the anterosuperior mediastinum; however, this tumor can also occur in other mediastinal compartments (although a posterior location is very rare), in the neck, within the thyroid (see later section), within the pericardial cavity, within a cardiac myxoma, in the pulmonary hilum, within the lung parenchyma, or in the pleura itself, sometimes coating it in a mesothelioma-like fashion.[86]

Radiographically, thymoma usually presents as a lobulated opacity that may be calcified (Fig. 12.13). CT scan and MRI are the methods of choice for preoperative diagnosis and evaluation of extent. Fine-needle aspiration has been used with success, the diagnosis of thymoma being based on the finding of a dual population of epithelial cells and lymphocytes with the appropriate cytologic features.[87]

Myasthenia Gravis

In patients with myasthenia gravis, the thymus shows follicular hyperplasia as the only abnormality in about 65% of cases, a thymoma (with or without follicular hyperplasia in the non-neoplastic portion of the gland) in 10%, and no gross or overt microscopic abnormalities in 25% (see later text).[70] Viewed from another angle, about 30%–45% of patients with thymoma develop myasthenia.[88] The tumor may be diagnosed during the investigation of a myasthenic patient, or—less commonly—the myasthenia may develop months or years after the tumor has been excised. A patient with myasthenia is more likely to have a thymoma if male and/or developing symptoms after the age of 50.[89] The incidence of aggressive behavior in these tumors

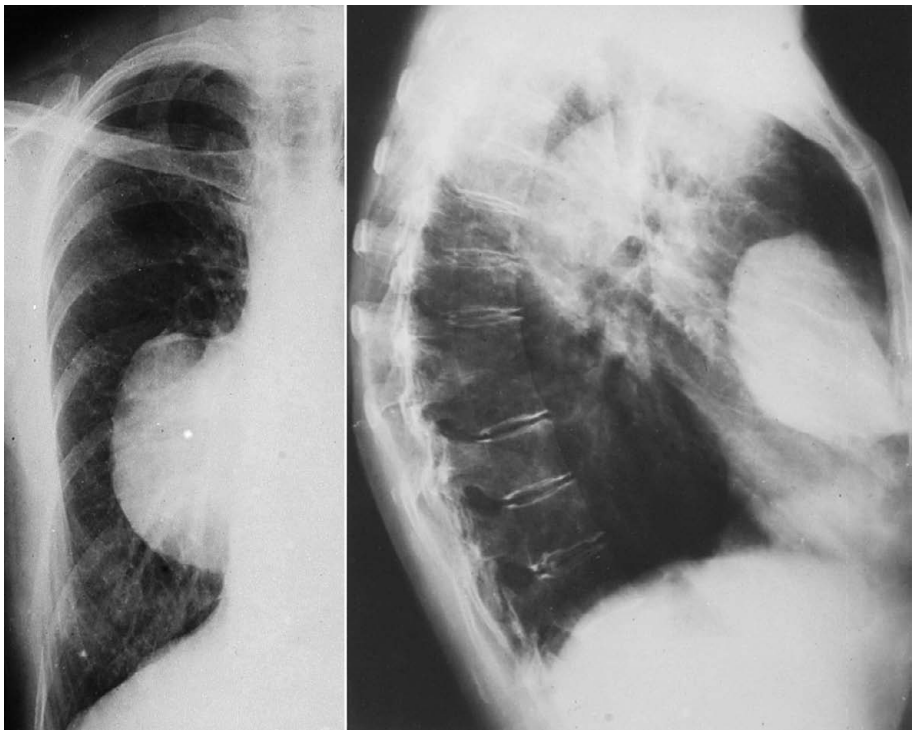

Figure 12.13 Lobulated large benign thymoma located in anterior portion of mediastinum.

seems to be similar to that seen in patients without myasthenia gravis. Thymomas associated with myasthenia almost always have epithelial cells of stellate or cuboidal rather than spindle shape, but only a percentage of the tumors with these morphologic features will be associated with myasthenia.

The relative proportion of epithelial cells and lymphocytes does not seem to correlate with the presence of myasthenia. No consistent ultrastructural or immunohistochemical differences have been found between myasthenic and nonmyasthenic thymomas.[90] Actually, the most accurate way to predict the likelihood of myasthenia in a patient with thymoma is to find lymphoid follicles in the adjacent non-neoplastic thymic tissue or, exceptionally, even in the thymoma itself.[91]

In the past, the presence of myasthenia in a patient with thymoma had a profound influence on survival. In a large series reported by Wilkins et al. in the 1960s, the 10-year cumulative survival rate for patients with thymoma with and without myasthenia was 32% and 67%, respectively.[92] Most of the deaths in the former group resulted from myasthenic crisis. As a consequence of marked improvements in the medical treatment of myasthenia, the picture has changed dramatically.[93] As a matter of fact, subsequently published series of patients with thymomas show that this association is no longer of prognostic significance.[88,94] Similarly, the presence of a thymoma is no longer viewed as a negative prognostic indicator in patients with myasthenia gravis.[95,96]

Myasthenia gravis has been found to be related in nearly all cases to a defect in the nicotinic acetylcholine receptor (AChR) located in the subsynaptic membrane of the neuromuscular junction (motor end plate), as a result of circulating autoantibodies that bind to this molecule.[97–99]

AChR or a related protein has been detected in the normal thymus. Although it has been suggested that this compound might be expressed by thymic epithelial cells, it seems clear that it is mainly localized to a subset of intrathymic cells that exhibit phenotypic features of skeletal muscle cells (such as cross striations and immunoreactivity for myoglobin and desmin) and that are generally designated as *myoid cells*.[97] It has also been found that non-neoplastic thymuses in myasthenic patients (whether exhibiting obvious follicular hyperplasia or appearing microscopically normal) often contain cell clusters composed of myoid cells, infiltrating antigen presenting cells, and CD3+/CD4+ T lymphocytes, that some of these T lymphocytes are AChR specific, that activated AChR-reactive B cells may also be demonstrated, and that there is increased production of interleukins.[99] The theory has thus evolved that the autosensitization process leading to myasthenia is initiated in the thymus through an aberrant interaction between myoid cells with AChR-specific T lymphocytes, followed by emigration of these activated thymic T cells to the peripheral immune system and induction of complementary B lymphocytes to produce myasthenogenic autoantibodies.

The role that thymoma, when present, plays in this pathogenetic scheme remains unclear. Some have suggested that the two events are not directly related and that the mechanism for the myasthenia is independent of the presence or absence of a thymic epithelial neoplasm. Others have postulated that the thymoma is directly responsible for myasthenia in a subset of patients, through the presence of one or more proteins unique to the tumor that share an antigenic determinant with the nicotinic AChR or other structures of the neuromuscular junction and that trigger an autoimmune response.[100]

Myasthenia gravis should be distinguished from the Lambert–Eaton syndrome, a similar condition that is frequently associated with pulmonary small cell carcinoma and that is also autoimmune related[101] (see Chapter 10).

The treatment of myasthenia includes thymectomy, regardless of the presence or absence of thymoma.[93,102] Symptomatic improvement is more likely if the thymus is the site of follicular hyperplasia than if it is normal or involved by thymoma. The long-term results of

the operation may be related to the duration and severity of the myasthenic symptoms and the age of the patient; however, substantial differences in this regard exist among the various published series.[103–105] Persistence of symptoms has been attributed to residual thymic tissue with lymphoid hyperplasia.

Other Associated Diseases

In addition to myasthenia gravis, thymoma has been found to be associated with a large number of systemic disorders, nearly all of which are immune mediated. These include hypogammaglobulinemia (12% of the cases), erythroid hypoplasia/pure red cell aplasia (5%) and, more rarely, white blood cell aplasia, myositis, myocarditis, dermatomyositis, systemic lupus erythematosus, rheumatoid arthritis, scleroderma, Sjögren disease, multiple myeloma, Kaposi sarcoma, subacute motor neuronopathy, inappropriate antidiuretic hormone secretion, bullous dermatoses, hyperglobulinemic purpura, mucocutaneous candidiasis, graft-versus-host-like colitis, autoimmune enteropathy, peripheral T-cell lymphocytosis, T-cell chronic lymphocytic leukemia, and T-cell lymphoblastic lymphoma/leukemia. Most of the thymomas associated with erythroid hypoplasia have been said to be largely composed of spindle cells (type A thymomas), but a critical review of the literature did not show a strong correlation with a particular histologic type.[106]

Pathologic Features; Electron Microscopic, Histochemical, Immunohistochemical, and Molecular Genetic Features

Grossly, the typical thymoma is largely or entirely solid, yellowish gray, and separated into lobules by connective tissue septa (Figs. 12.14 and 12.15).[88,107] In approximately 80% of cases, the tumor is well encapsulated and can be removed with ease. In the remainder, infiltration of surrounding structures is noted at surgery. Most clinically evident tumors are large, but very small thymomas ("microthymomas") may be discovered incidentally in the course of cardiac surgeries or in thymectomy specimens from cases of myasthenia gravis or red cell aplasia.[43] Foci of necrosis and cystic degeneration are common, particularly among larger tumors. Sometimes the entire tumor undergoes prominent cystic, necrotic, and hemorrhagic changes, many sections being needed to identify residual diagnostic areas (Fig. 12.16).[108] This sort of infarct-like necrosis and hemorrhagic degeneration does not by itself convey a poor prognosis in an otherwise well encapsulated thymoma. Predominantly cystic thymomas should be distinguished from multilocular thymic cysts which can coexist with thymoma and other thymic neoplasms prone to undergo cystic changes.

Microscopically, the majority of thymomas are composed of a mixture of neoplastic epithelial cells and non-neoplastic lymphocytes, the proportion among them varying widely from case to case and in different lobules of the same tumor (Figs. 12.17–12.23).[109,110] The epithelial cells may have a round–polygonal ("plump"), stellate, or spindle/oval shape (see Figs. 12.17 and 12.20). The nuclei are vesicular and of smooth contour; the nucleolus may be conspicuous, particularly when the nuclei are round or polygonal. The lymphocytes may appear mature (inactive) or show varying degrees of "activation," manifested by a larger nuclear size, open chromatin pattern, visible nucleolus, identifiable cytoplasmic rim, and mitotic activity; however, they should not appear convoluted or cleaved. Thymomas with a sizable component of epithelial cells often show one or more features suggestive of organoid differentiation, which correlate with the various subtypes. These include *perivascular spaces* containing lymphocytes, proteinaceous fluid, red blood cells, foamy macrophages, or fibrous tissue (see Fig. 12.21); *rosettes without central lumens* (see Fig. 12.18); *glandlike formations* within the tumor or, more often, in the tumor

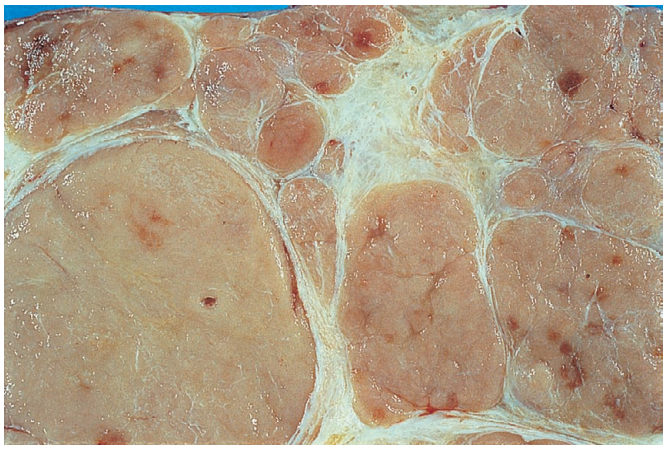

Figure 12.15 Close-up of the Cut Surface of Thymoma. Note the sharp lobulation induced by the fibrous bands. The pointed ends of some of the nodules are particularly typical of this entity.

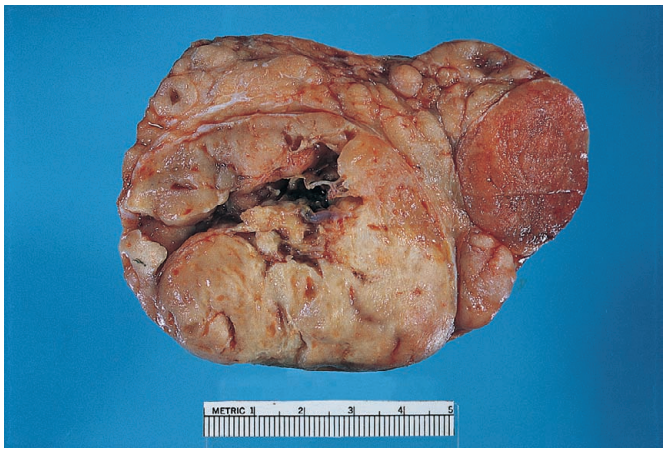

Figure 12.14 Gross appearance of a thymoma showing distinct multinodularity. There is focal cystic change in the larger nodule.

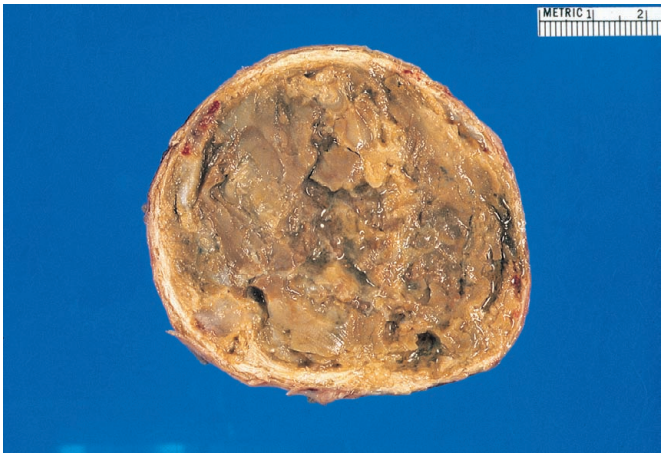

Figure 12.16 Thymoma With Extensive Necrosis and Cystic Degeneration. Only one of many microscopic sections showed residual neoplasm. This lesion is likely to be misdiagnosed as a thymic cyst.

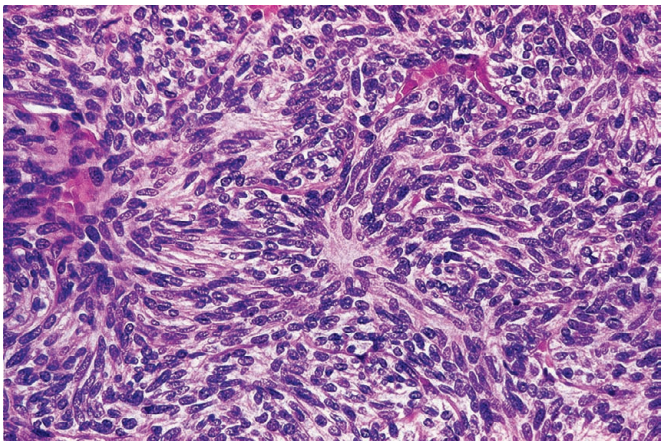

Figure 12.17 Type A (Spindle, Medullary) Thymoma. The pseudo-mesenchymal appearance of the tumor is striking.

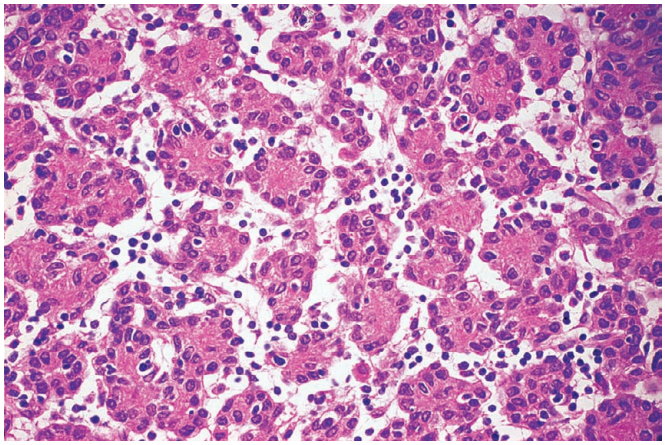

Figure 12.18 Type A Thymoma With Prominent Rosette Formation. Notice the absence of a central lumen in the rosettes. This tumor should not be confused with thymic carcinoid.

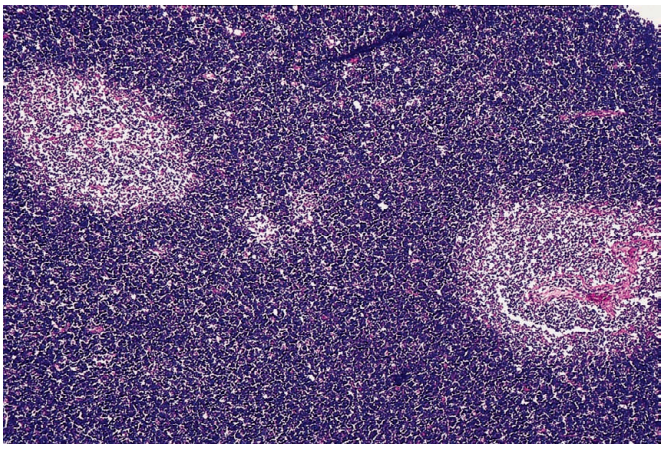

Figure 12.19 Type B1 thymoma with prominent foci of medullary differentiation.

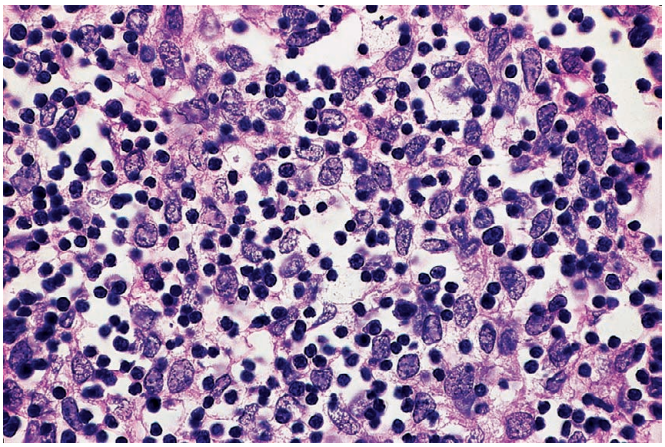

Figure 12.20 Type B2 Thymoma. There is an even proportion of neoplastic epithelial cells and non-neoplastic lymphocytes.

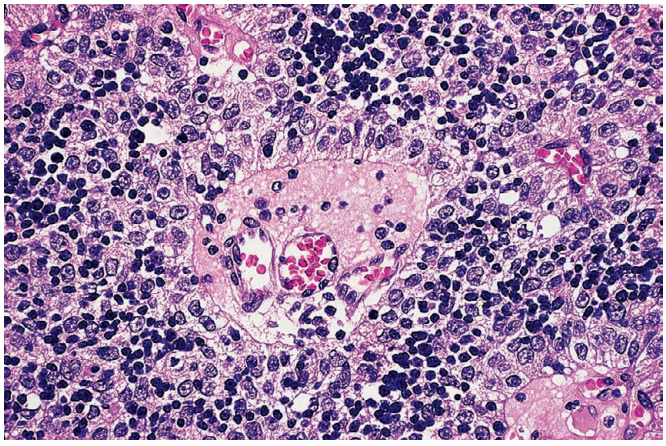

Figure 12.21 Perivascular Space in Type B2 Thymoma. The space is occupied by a proteinaceous fluid and lymphocytes.

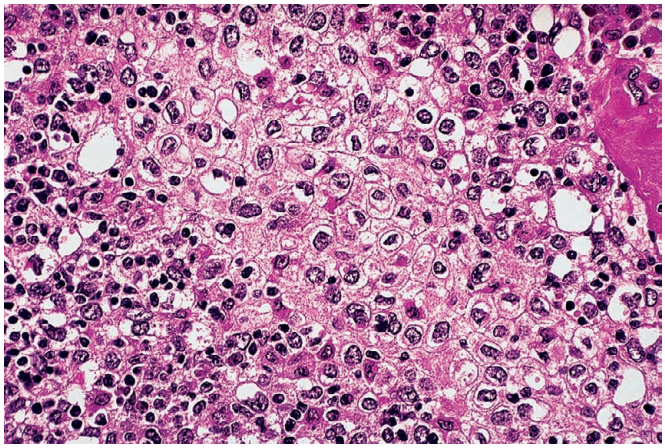

Figure 12.22 Type B3 Thymoma. This tumor, which is predominantly composed of slightly atypical neoplastic thymic epithelial cells, is also known as squamoid thymoma, atypical thymoma, and well-differentiated (organotypic) thymic carcinoma.

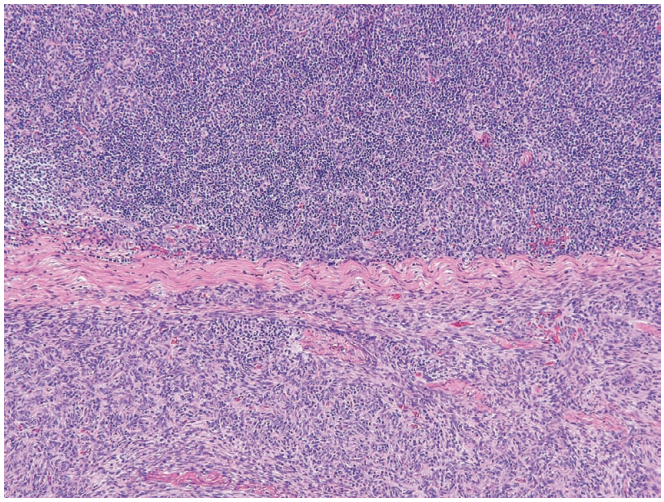

Figure 12.23 Type AB Thymoma. This is one of the most common thymoma subtypes.

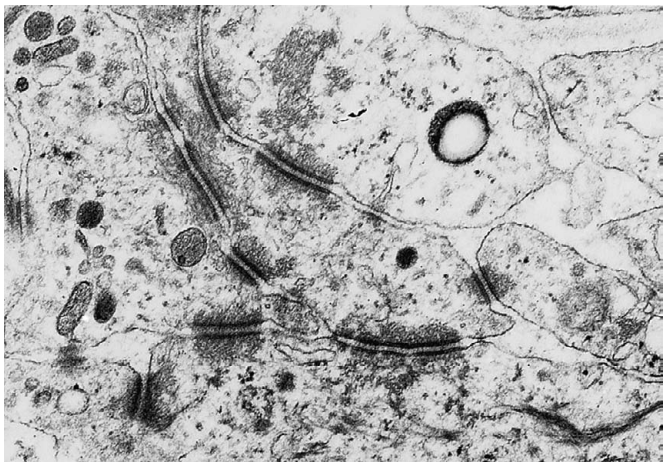

Figure 12.24 Numerous desmosomes and tonofibrils in tumor cells as seen ultrastructurally indicate epithelial origin of a thymoma composed of spindle cells. (Uranyl acetate–lead citrate; ×54,500). (From Levine GD, Bensch KG. Epithelial nature of spindle cell thymoma. An ultrastructural study. *Cancer*. 1972;30:500–511.)

capsule; *true glandular structures* (an exceptional event); and *whorls suggestive of abortive Hassall corpuscle formation*. Well-formed Hassall corpuscles are occasionally found within thymomas, but their presence in large numbers is usually an indication of preexisting structures surrounded by a tumor and is actually more common in other neoplasms (such as malignant lymphoma of the thymus) than in thymoma. Presence of rosette-like structures with *well-defined lumens* should suggest a diagnosis of thymic carcinoid rather than thymoma. In lymphocyte-rich (type B1, see later section) thymomas, it is common to find round, lighter foci of medullary differentiation, an important clue to the diagnosis (see Fig. 12.19). Other helpful diagnostic features of thymoma are the thick, often calcified fibrous capsule, the lobular arrangement induced by these fibrous bands, the sharp interphase between tumor lobules and fibrous tracts, and the angular shape of some of the lobules, resembling arrowheads. Vascularization may be prominent and result in a mistaken diagnosis of hemangiopericytoma. Microcystic and pseudopapillary formations may be focally present. Sclerosis may be very extensive, possibly as a manifestation of tumor regression, and may obscure the neoplastic component.[111] Exceptionally, there is a massive plasma cell infiltrate.[112]

By electron microscopy, the neoplastic epithelial cells exhibit branching tonofilaments, complex desmosomes, elongated cell processes, and basal lamina (Fig. 12.24).[113] These characteristics have proven historically useful in the segregation of thymoma from other anterior mediastinal tumors, such as thymic carcinoid, malignant lymphoma, seminoma, and solitary fibrous tumor but have been largely supplanted in daily practice by immunohistochemical stains (Table 12.1).

The epithelial cells of thymoma are immunoreactive for keratins, including cytokeratin 7, high-molecular cytokeratins (e.g. CK5/6, 34βE12), p63 and p40 (ΔN-p63α), and PAX8 (Fig. 12.25).[114–117] Staining for epithelial membrane antigen (EMA) is usually restricted either to the glandlike formations of spindle thymomas or to the tumors predominantly composed of round or polygonal cells.[118] Thymomas have also been found to express the tissue blood group O (H) and peanut agglutinin receptor antigens,[119] major histocompatibility complex (MHC) class II molecules,[120] epidermal and nerve growth factor receptors,[121] growth hormone,[122] and metallothionein.[123] Two novel thymic epithelial markers—CD205 and Foxn1—are positive in nearly all thymomas and a subset of thymic carcinomas; unfortunately, they are also sometimes expressed in carcinomas of other sites.[124] Stains for basement membrane material, such as laminin or type IV collagen, show abundant deposition around individual tumor cells in spindle-shaped tumors and paucity of this material in those made up of stellate or round or polygonal cells.[125]

Markers that are preferentially expressed in thymic carcinomas (referred to historically as type C thymomas) as opposed to conventional (types A, AB, and B) thymomas are discussed elsewhere.

The lymphocytes of thymoma are of T-cell derivation, except for those located in lymphoid follicles (whether the patients have myasthenia gravis or not).[126] Most of these T lymphocytes are immature thymocytes rather than mature (peripheral) T cells. As such, they are reactive for terminal deoxynucleotidyl transferase (TdT), CD99, and CD1a.[127,128] A close correlation has been found between the morphologic features of the more organoid thymomas and the phenotype of the lymphocytes. In the more lymphocyte-rich areas, the lymphocytes have the features of cortical (very immature) thymocytes; in areas of medullary differentiation they acquire features of medullary (less immature) thymocytes. It should be pointed out that *both* the lymphocytes of thymoma and those of lymphoblastic lymphoma usually exhibit an immature T phenotype, and therefore cell marker studies cannot be used to separate these two disorders. Instead, it has been shown that the lymphocytes of thymoma do not show evidence of clonality at the molecular level, even if this can be simulated by the presence of a polyclonal incomplete rearrangement of the T-cell receptor gene.[129,130] This finding not only provides another criterion for distinguishing the two entities but also offers corroborating evidence for the non-neoplastic nature of the lymphocytes of thymoma. Incidentally, the number of these non-neoplastic lymphocytes will be greatly decreased in patients who have been treated preoperatively with corticosteroids.[131]

In addition to epithelial cells and lymphocytes, thymomas often contain an important population of S-100 protein– and CD1a-positive cells, presumably non-neoplastic *interdigitating reticulum cells*.[132] Kondo et al.[132] found that their number and distribution correlated with the microscopic type of thymoma but not with invasiveness. Interestingly, there is also a population of interdigitating cells (designated as "asteroid cells") located in the medullary portion of the more organoid thymomas that react immunohistochemically for the B-cell marker CD20.[133] Even more peculiar (and potentially misleading

Table 12.1 Differential features of tumors of the anterior mediastinum[a]

FEATURES	THYMOMA[a]	LARGE CELL LYMPHOMA	LYMPHOBLASTIC LYMPHOMA	THYMIC HODGKIN LYMPHOMA	THYMIC SEMINOMA	THYMIC CARCINOID
Patterns (low-power observation)	Sharply defined, angular lobules Fibrous bands and capsule Mottling and trabeculation (caused by epithelial–lymphocyte admixture)	Diffuse growth Variable fibrosis with occasional compartmentalizing sclerotic pattern Residual cystic thymus	Diffuse growth or pseudonodular pattern (both in lymph nodes and in thymus)	Extensive fibrosis with rounded lobules of tumor Prominent cysts seen at low power	Subdivided by fine fibrous trabeculae into variable-sized compartments	Ribbons, festoons, punctate calcified necrosis producing discrete and rounded masses of tumor
Nuclei	Often fine chromatin contrasting with well-defined nuclear membrane Usually inconspicuous nucleoli; great variation, including spindle shape Epithelial mitoses usually rare	Vesicular with prominent nucleoli Marked folding of nuclei ("cloverleaf") Variable chromatin pattern Mitotic figures variable (usually readily found)	Even chromatin ("dusky" at low power) Scant inconspicuous nucleoli Numerous mitotic figures	Cytologic features—those of nodular sclerosing Hodgkin lymphoma complicated by admixture with thymic epithelium and cysts	Coarse chromatin, marked prominence of nucleoli, variable numbers of mitotic figures	Rounded nuclei with sharp stippling chromatin Variable number of mitotic figures (note spindle cell variant)
Cytoplasm	Great variation from scant to squamoid to squamous Intracytoplasmic cysts (emperipolesis) Glandlike spaces	Variable, occasionally abundant and rich in RNA (methyl green–pyronine positive)	Scant	Lacunar cells often prominent	Marked retraction of cytoplasm; often glycogen rich	Polyhedral cells with finely granular eosinophilic cytoplasm True gland formation
Associated features	Germinal centers in surrounding thymus (in cases of myasthenia gravis) Incorporation of non-neoplastic thymus (13%)	Residual lymphocytes often form tight perivascular cuffs Necrosis frequent Markedly invasive	Residual Hassall corpuscles	—	Germinal centers, epithelioid and giant cells	—
Electron microscopy	Well-formed desmosomes	Nuclear blebs Absence of epithelial features	Nuclear blebs Fine chromatin Absence of epithelial features	Absence of epithelial characteristics in Reed–Sternberg cells	Even chromatin Prominent nucleoli Glycogen rich Scant desmosomes Only rare tonofilaments	Dense-core granules Desmosomes inconspicuous or poorly formed Tonofilaments only rarely prominent
Immunohistochemistry	Keratin	B-lymphocyte markers	T-lymphocyte markers	CD15, CD30	PLAP, CD117	Chromogranin, synaptophysin

[a]Nuclear and cytoplasmic features refer only to epithelium.
Modified from Levine GD, Rosai J. Thymic hyperplasia and neoplasia. A review of current concepts. *Hum Pathol*. 1978;9:495–515.

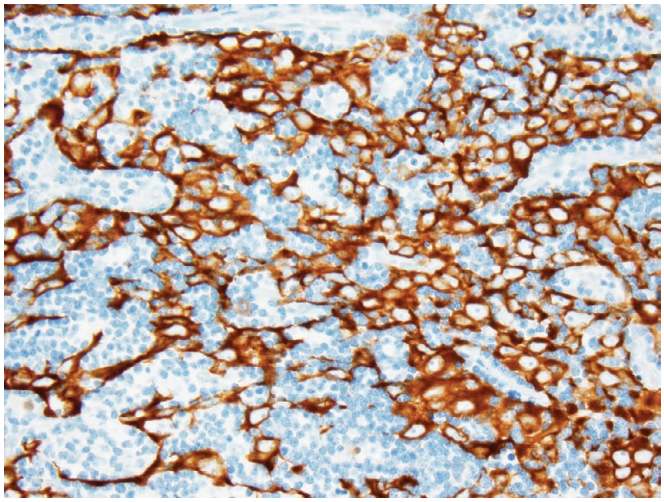

Figure 12.25 Type B1 (lymphocyte-rich) thymoma stained for keratins (AE1/AE3 and CAM5.2 cocktail). The cytoplasm and cell processes of the neoplastic epithelial cells are strongly immunoreactive for this marker.

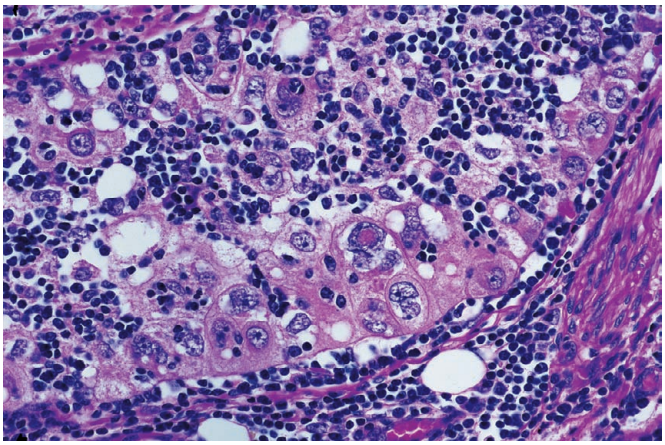

Figure 12.27 Thymic tumor bridging the gap between thymoma and thymic carcinoma. The degree of atypia in the neoplastic cell is such as to justify a diagnosis of thymic carcinoma, but the overall configuration of the tumor and the phenotype of the lymphocytes were those of conventional thymoma.

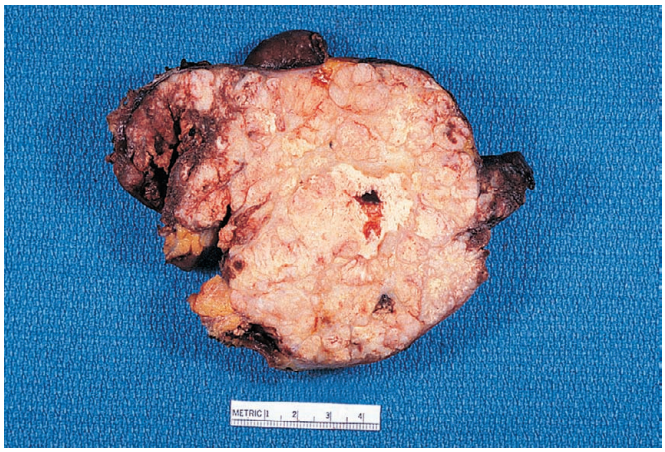

Figure 12.26 Gross Appearance of Thymic Carcinoma. The tumor is invasive and shows foci of necrosis.

from a diagnostic standpoint) is the fact that CD20 sometimes also reacts with some of the neoplastic epithelial cells of the thymoma, as evidenced by the coexpression of keratin by these cells.[134]

Coexpression of bcl-2 and p53 is seen in a subset of thymomas and seems to be stronger in the clinically aggressive and histologically higher-grade tumors.[135] There is also common expression of Fas antigen, another apoptosis-related marker.[136]

Cytogenetically, the most frequent aberrations found in thymoma are located on chromosome 6, half of them occurring in region 6q25.2.[137] The type and frequency of these aberrations vary among the thymoma subtypes, suggesting that these tumors may develop along different pathways.[138] Type A thymoma shows few genetic alterations except chromosome 6p deletion.[139] Type B3 thymoma commonly shows gain of 1q and loss of 6 and 13q.[139]

Thymic carcinoma is defined as a thymic epithelial tumor exhibiting clear-cut cytologic features of malignancy (Fig. 12.26).[140–143] Despite its rarity, it displays a relatively large variety of microscopic patterns, described in the following text. As a group, they differ from other conventional types of thymoma in the following respects[1]: they are very rarely associated with myasthenia gravis or any of the other previously listed immune-mediated systemic diseases[2]; they generally lack all of the ancillary features of thymoma seen with one or another of the other types, such as perivascular spaces, foci of medullary differentiation, abortive Hassall corpuscles, rosettes, or glandlike spaces; and[3] they lack immature T lymphocytes. Lymphocytes may be present and even numerous, but they exhibit the phenotype of mature T or (rarely) B cells. In other words, thymic carcinomas lack all of the morphologic and functional attributes of the other thymoma types, allowing for the rare occurrence of intermediate or hybrid forms (Fig. 12.27). Their appearance is instead similar to and sometimes indistinguishable from that of corresponding carcinoma types in other organs, and their specific identification as thymic neoplasms can therefore be difficult or impossible. The diagnosis is often one of exclusion, in the presence of a malignant epithelial tumor located in the thymic region in the absence of disease in the lung or any other organ.

There are some immunostains that can be of great assistance in the identification of the two major subtypes of thymic carcinoma[1]: CD5 (a receptor molecule that signals cell growth in T cells), which is present in the majority of thymic carcinomas but absent in other types of thymoma and in carcinomas of nonthymic origin[2,144]; CD117 (c-kit), positive in 80% or more of thymic carcinomas, almost always negative in thymomas, and occasionally positive in nonthymic carcinomas[3,145,146]; CD70, a member of the tumor necrosis factor (TNF) family that mediates the interaction between B and T lymphocytes which is present in most thymic carcinomas but not in conventional thymomas[4,147]; CEA, MUC-1, and GLUT-1 (glucose transporter 1) are usually positive in thymic carcinoma and are less commonly positive in B3 thymomas, with MUC-1 and GLUT-1 showing the highest sensitivity for carcinoma and CEA showing greater specificity in separating carcinoma from thymoma[5,148]; TTF-1, which stains a high percentage of lung carcinomas but not thymic carcinomas.[127] Furthermore, thymic carcinomas show higher expression of p53, stronger immunoreactivity for bcl-2, and higher rates of nuclear staining for p16 than thymomas.[135,149] It should also be noted that about half of thymic carcinomas—in striking contrast with the other thymoma types—exhibit immunohistochemical evidence of focal (and sometimes extensive) neuroendocrine differentiation (Fig. 12.28).[150]

On comparative genomic hybridization, common findings in thymic squamous cell carcinoma include loss of 16q, 6, 3p, and 17p and gain of 1q, 17q, and 18.[139] Of note, loss of chromosome

6 and gain of 1q are common in type B3 thymoma, suggesting possible evolution to squamous cell carcinoma or a close histogenetic relationship between the two tumor types. Comprehensive sequencing demonstrates a low mutation burden in thymic carcinomas.[151] *TP53* mutations are the most common recurrent mutations, occurring in about 30% of cases, and correlate imperfectly with p53 overexpression by immunohistochemistry.[151,152] *KIT* mutations are rare and do not correlate with the CD117 staining seen in the majority of cases.[151,153]

The following microscopic types of thymic carcinoma are recognized by the World Health Organization (WHO) Committee for the Histologic Typing of Tumors of the Thymus, and other exceptionally rare types that have been described.[141,154] In terms of relative frequency, the first category accounts for over 70% of the cases.[143,155]

Squamous Cell Carcinoma

Like squamous cell carcinomas in other sites, this form is composed of atypical polygonal epithelial cells arranged in characteristic epidermoid growth patterns often with associated intercellular bridges (Fig. 12.29).[155] The range of appearances is similar to squamous cell carcinomas arising in other locations, including well, moderately and poorly differentiated forms that may or may not demonstrate keratinization.[155] However, a lobular pattern of growth is generally maintained, and the tumor lobules are even more widely separated from each other by fibrous bands than in more conventional thymoma types (Fig. 12.30).[156] Before a diagnosis of primary squamous cell carcinoma of the thymus is made, the alternative possibility of metastatic carcinoma (particularly from the lung) should always be considered.

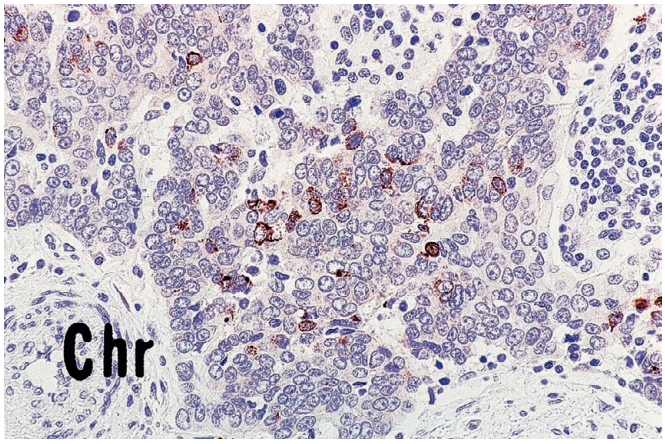

Figure 12.28 Chromogranin Reactivity in Some Tumor Cells of Thymic Carcinoma. This is a common finding in thymic carcinoma, as opposed to conventional thymomas.

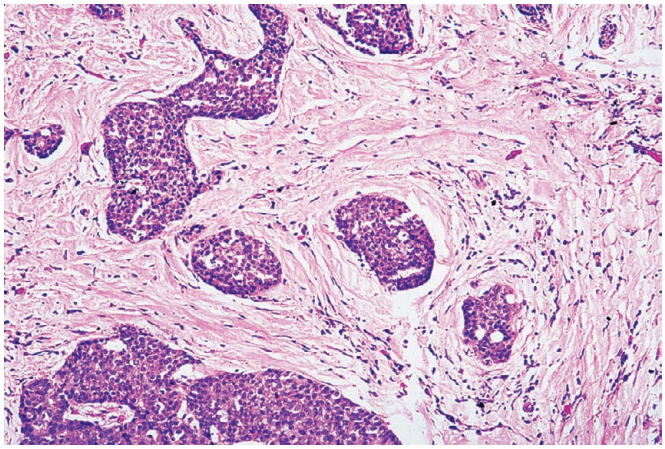

Figure 12.30 Low-Power View of Thymic Carcinoma. The tumor lobules are more widely separated by fibrous tissue that more closely resembles a desmoplastic stromal response than the better organized and smaller fibrous septa characteristic of conventional thymoma.

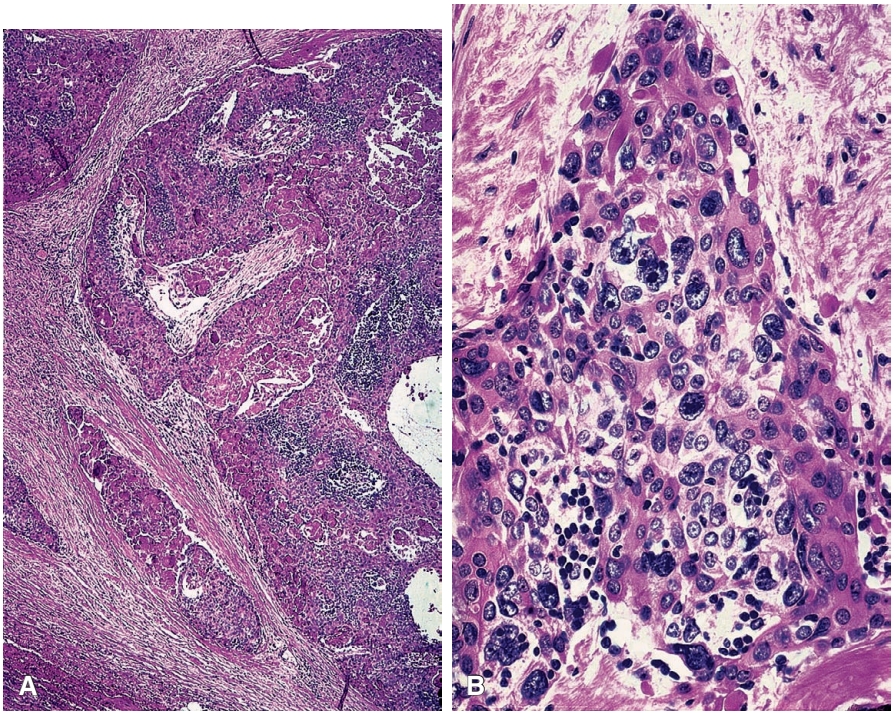

Figure 12.29 A and **B**, Low-power and high-power appearances of thymic squamous cell carcinoma. Note the distinct lobulation in this example.

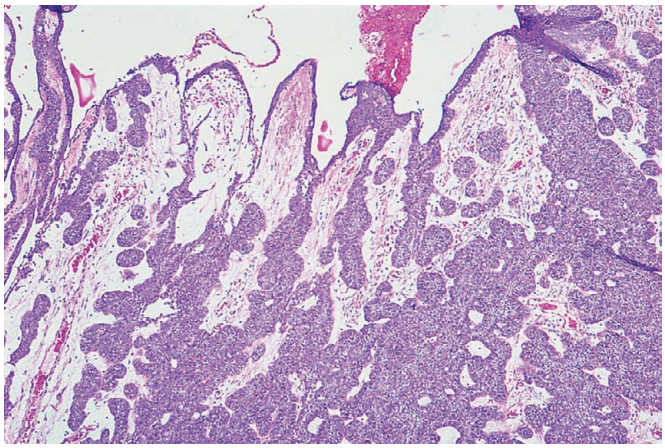

Figure 12.31 Thymic Carcinoma of Basaloid Type. The tumor islands are connected with the epithelium lining a cystic cavity.

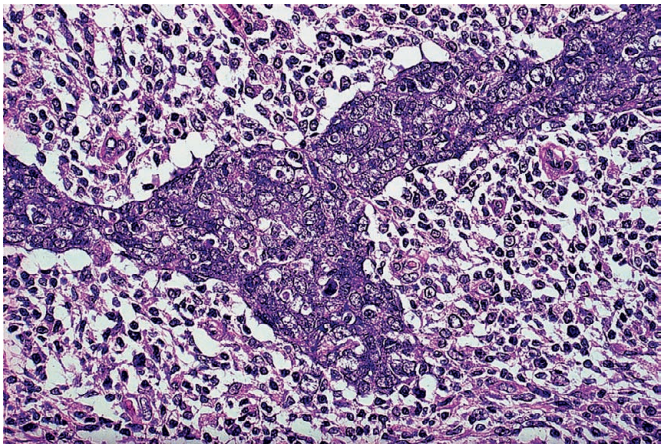

Figure 12.33 Lymphoepithelioma-like variant of thymic carcinoma.

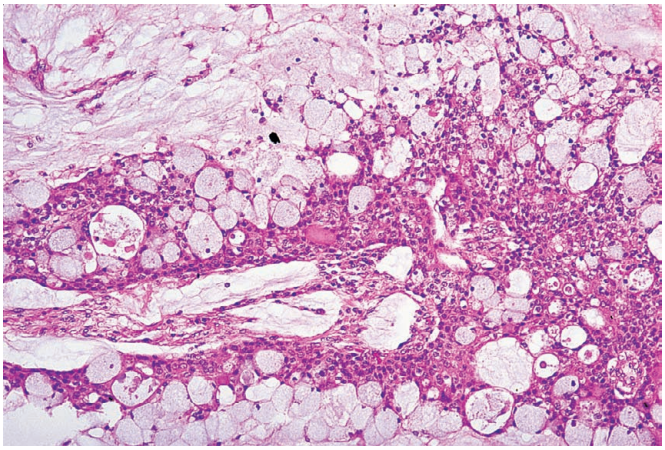

Figure 12.32 Thymic Carcinoma of Mucoepidermoid Type.

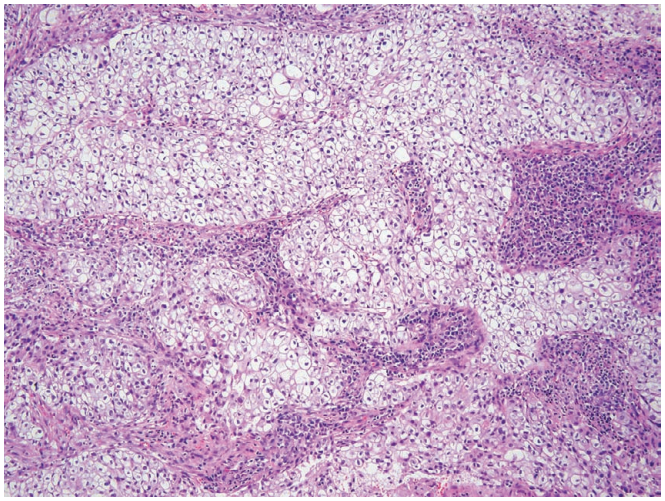

Figure 12.34 Thymic Carcinoma of Clear Cell Type. This tumor needs to be distinguished from metastatic carcinoma, particularly from the kidney.

Basaloid Carcinoma

This tumor is formed by well-defined epithelial islands with prominent peripheral palisading, a combination of features typical of basaloid carcinomas arising in other sites including the lung. Focal squamous differentiation is seen in a minority of cases.[157] It may present as a mural nodule in what otherwise looks like a squamous-lined thymic cyst (Fig. 12.31).[158] The main differential diagnosis is with thymic carcinomas with adenoid cystic carcinoma-like features.

Mucoepidermoid Carcinoma

Areas of squamous and mucin-producing glandular differentiation alternate in this neoplasm. The histologic features are identical to mucoepidermoid carcinomas arising in major salivary glands and lung. Rearrangements of the *MAML2* gene characteristic of these tumors in other sites also occur in primary thymic mucoepidermoid carcinomas.[159] Most examples are low-grade tumors and associated with a good prognosis (Fig. 12.32).[160] High-grade and high-stage cases are uncommon and portend a more aggressive and usually fatal course.

Lymphoepithelioma-Like Carcinoma

The appearance of the tumor approaches, and sometimes becomes indistinguishable from, that of lymphoepithelial carcinoma (so-called lymphoepithelioma) of the tonsil and nasopharynx. Large, deeply acidophilic nucleoli that are sharply outlined and perfectly round are one of the hallmarks of this neoplasm, which is also characterized by a "syncytial" appearance (Fig. 12.33). Keratinization and intercellular bridges are absent; however, the tumor cells are consistently immunoreactive for keratin, including high-molecular-weight cytokeratins such as CK5/6, as well as p63 and p40. The lymphocytes of this tumor, which can be very numerous, have the phenotype of mature peripheral T cells rather than the immature thymocytes seen in ordinary thymoma. The finding of the Epstein–Barr virus (EBV) genome in some cases of this entity suggests that the similarity with nasopharyngeal carcinoma may sometimes extend beyond the morphologic parameters.[161,162] EBV is consistently absent from other thymic epithelial tumors, despite initial reports to the contrary.

Clear cell carcinoma is a rare variant characterized by large amounts of glycogen-rich, clear cytoplasm in the tumor cells, which results in a striking resemblance to renal cell carcinoma (Fig. 12.34).[141,143,158,163]

Sarcomatoid Carcinoma (Carcinosarcoma)

This cytologically malignant tumor simulates a mesenchymal neoplasm by virtue of its diffuse pattern of growth and the prominent spindling of tumor cells.[164,165] The diagnosis is made by finding, somewhere in the tumor, foci with an epithelial appearance or

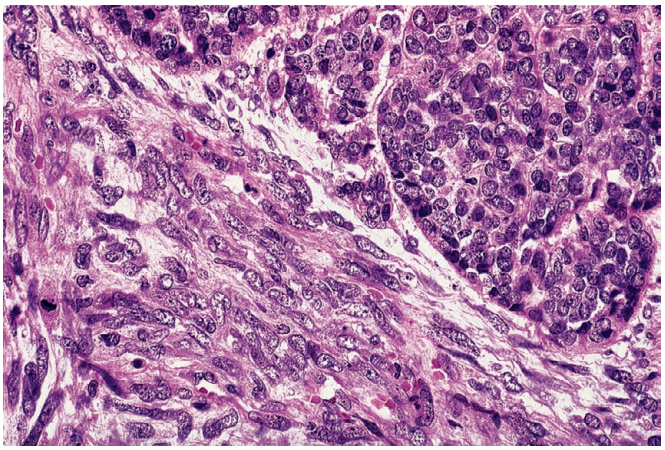

Figure 12.35 Sarcomatoid Carcinoma of Thymus. Because of the sharp segregation of the carcinomatous and the sarcoma-like components, tumors with this appearance are often called *carcinosarcomas*.

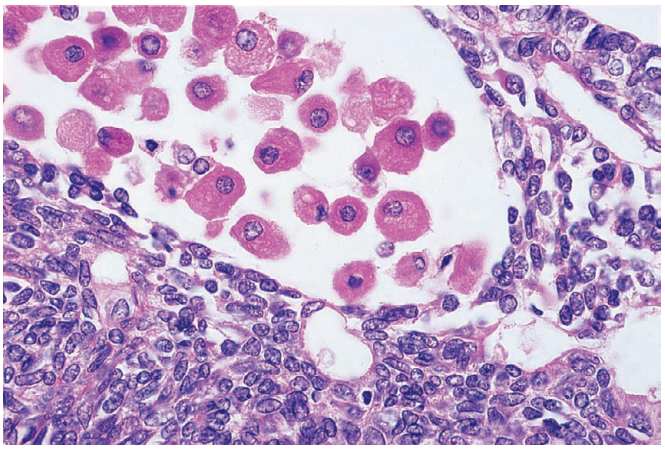

Figure 12.36 Thymoma with clusters of myoid cells showing abundant eosinophilic cytoplasm. These cells were strongly immunoreactive for myoglobin.

evidence of an epithelial phenotype in neoplastic spindle cells (Fig. 12.35). Some authors draw a distinction between sarcomatoid or spindle cell carcinoma on one side and carcinosarcoma on the other, but we regard the exercise just as futile as in other organs, in the sense that both types represent carcinomas in which a component of the tumor has undergone a "phenotypic switch." The sarcoma-like areas may include foci of cartilaginous and skeletal muscle differentiation, the latter having been described as *rhabdomyosarcomatous thymic carcinoma*. Parenthetically, skeletal muscle differentiation in cytologically bland myoid cells has also been described in thymomas and is not by itself diagnostic of carcinoma (Fig. 12.36).

The differential diagnosis of sarcomatoid carcinoma includes germ cell tumors and malignant schwannoma ("triton tumor"). It also includes a low-grade thymic tumor designated as *metaplastic thymoma* in the current WHO classification scheme[166] and previously reported as *thymoma with pseudosarcomatous stroma*[167] and *low-grade metaplastic thymic carcinoma*.[168] It is characterized by a biphasic epithelial and spindle cell morphology, with absence of significant atypia and low proliferation rates in both components.[169] Nearly all of the reported patients have been cured by surgical excision. We agree with the WHO terminology that places these tumors among the thymomas ("metaplastic thymoma") rather than thymic carcinomas while also acknowledging the probable epithelial nature of the spindle cell component. The appearance and interplay of the two components is very reminiscent of that seen in ectopic hamartomatous thymoma, suggesting that this lesion may represent its "orthotopic" counterpart. Further support for this interpretation derives from reports of sarcomatoid carcinomas arising in metaplastic thymomas.[170,171]

Adenocarcinomas are a histologically heterogeneous group, as is true in most other organ sites, and are extremely uncommon. **Papillary adenocarcinoma** resembles papillary thyroid carcinoma by virtue of the complex arborizing structure and the presence of psammoma bodies. However, it lacks optically clear nuclei, it is positive for CD5, and it shows no reactivity for thyroglobulin or TTF-1.[172] Most of the reported cases have arisen from type A (spindle cell, medullary) thymomas. **Mucinous and tubular adenocarcinomas** are a rare variant that includes mucinous adenocarcinoma with enteric differentiation characterized by expression of cytokeratin 20 and CDX2.[173]

NUT (midline) carcinoma is a form of high-grade carcinoma frequently demonstrating squamous differentiation that tends to affect midline structures, most commonly the mediastinum[174,175] (see Chapter 4). This highly aggressive and frequently lethal form of carcinoma tends to affect younger individuals and accounts for fewer than 5% of poorly differentiated thymic carcinomas and undifferentiated thymic neoplasms.[84] Although not pathognomonic, the most common histologic appearance is a highly undifferentiated carcinoma with variably conspicuous foci of abrupt squamous differentiation.[175] Diagnosis hinges on identifying the characteristic rearrangement of the *NUT* gene on chromosome 15q14 which results in fusion with a member of the bromodomain (BRD)-containing protein family, most commonly *BRD4* on chromosome 19.[84,175] The disease-defining genotype can be identified using an immunohistochemical assay for the fusion product, fluorescence in situ hybridization (FISH), or a reverse transcriptase-polymerase chain reaction technique.[176,177]

Undifferentiated (Anaplastic) Carcinoma

This tumor shows no detectable differentiation in any specific direction and tends to exhibit considerable pleomorphism. The more undifferentiated the neoplasm, the more seriously one should consider alternative possibilities, especially large cell or anaplastic lymphoma and germ cell tumors. With regard to the latter, we have seen several cases of upper mediastinal tumors in young adults that we have interpreted as *undifferentiated thymic carcinoma with germ cell–like features*, analogous to those that have been reported in the lung and other organs. We have also observed cases *of undifferentiated large cell carcinomas of the thymus accompanied by a Castleman disease–like reaction* which featured an unexpectedly indolent behavior.[178]

Rare variants of thymic carcinomas include **carcinomas with adenoid cystic carcinoma–like features** resembling its homonymous tumor in the salivary glands. These are among the rarest of thymic carcinomas; the few reported cases tend to present as multicystic lesions.[179] The single example of **hepatoid carcinoma** on record so far presented as a large solid mass that closely resembled hepatocellular carcinoma in nearly all respects except that it was positive for cytokeratin 7 with coexpression of Hep Par-1 and negative staining for alpha-fetoprotein.[180]

Classification

A rich and sometimes contentious history has evolved over the years concerning the classification of thymic epithelial tumors. Historically, two attempts that were perhaps most influential included a descriptive scheme originally proposed by Lattes et al.[181,182] and adopted by Bernatz et al.[183] that divided thymomas into spindle cell, lymphocytic, epithelial, and mixed categories. A second scheme based on

assumptions regarding histogenesis was developed by Marino and Müller-Hermelink and separated thymomas into medullary, mixed, predominantly cortical (organoid), cortical, and well-differentiated thymic carcinoma.[184]

It should be noted that neither of these schemes includes any of the types of thymic carcinoma listed in the preceding section, the potentially misleading terminology used for the fifth tumor type (i.e. well-differentiated thymic carcinoma) in the Müller-Hermelink scheme notwithstanding.[185]

The WHO Committee for the Histologic Typing of Thymic Tumors[186] opted for a new nomenclature, revised in the most current WHO scheme,[110] that acknowledges the malignant potential of all thymic epithelial neoplasms, incorporates the salient points of preexisting classifications, and takes into account two important factors. The first is that the thymus is unique in that it can be viewed as two different organs: the active, functional gland of the fetus and infant, and the inactive, "postmature" structure of adult life. The other is the presence, as an expression of differentiation, of a non-neoplastic lymphocytic component in the tumors composed of functional thymic tissue. For these, the general rules of tumor pathology apply. The better differentiated tumors (lymphocyte-rich or predominantly cortical types) recapitulate the structure of the normal organ almost to perfection, in terms of both cortical *and* medullary regions. Progression in these tumors composed of functional thymic tissue is manifested by an increase in the number of neoplastic epithelial cells, an increasing degree of atypia in these epithelial cells, and a corresponding decrease in the non-neoplastic lymphocytic component.

The WHO scheme consists of a combination of letters and numbers, assigned according to the following general criteria:

1. The thymomas are divided into two major types based on the cytological characteristics of neoplastic epithelial cells and the relative contribution of non-neoplastic immature T lymphocytes typical of normal thymic cortex. Type A thymomas are those in which neoplastic epithelial cells and their nuclei have a spindle/oval shape with few, if any, non-neoplastic T cells. Type B thymomas are those in which neoplastic epithelial cells have a dendritic or plump ("epithelioid") appearance and a variably conspicuous component of non-neoplastic immature T cells. Tumors combining these two morphologies are designated as *type AB*.
2. Type B thymomas are further subdivided on the basis of the proportional increase (in relation to the lymphocytes) and emergence of atypia of the neoplastic epithelial cells into three subtypes, respectively designated as *B1*, *B2*, and *B3*.

Thymic carcinomas are named as such, although they could be viewed as yet another subtype of thymoma (referred to historically as *type C thymoma*), an interpretation supported by the existence of hybrid and combined forms.[187]

Combinations of thymomas other than AB occur. For these cases, a term such as "combined thymoma" can be used, followed by a listing of the various components and their relative amounts, although the clinical value of this exercise is untested.[141] The reader may associate the various letters in the WHO scheme with the various tumor patterns by mnemonically assuming that "A" stands for atrophic (i.e. the effete spindle thymic cell of adult life), and "B" for bioactive (i.e. the biologically active organ of the fetus and infant).

The subtypes of thymomas included in the WHO classification, the corresponding terms in the two preceding schemes, their definition, and a few comments follow.

Type A Thymoma (Spindle Cell; Medullary)

A tumor composed of a population of neoplastic thymic epithelial cells having a spindle/oval shape, lacking nuclear atypia, and accompanied by few or no non-neoplastic lymphocytes (see Figs. 12.17 and 12.18).

The appearance of this tumor can simulate that of a mesenchymal neoplasm, but the immunohistochemical and ultrastructural features are clearly those of an epithelial tissue. A peculiar feature of the neoplastic epithelial cells in type A thymomas is expression of CD20 in about half of them.[134,188] Rosette-like formations (without a central lumen), foci with a storiform pattern of growth, and glandlike formations may be present, the latter often located within or immediately beneath the tumor capsule. Many of the features of the cells of this tumor are reminiscent of the cells seen in the atrophic thymus of adult life, some of which happen to be located in the subcapsular (rather than medullary) region.

There are rare thymomas composed of spindle cells but exhibiting some combination of hypercellularity, nuclear hyperchromasia, pleomorphism, mitotic activity, and/or necrosis. Mitotic activity (≥4/10 high-power fields) and necrosis have been proposed as the most reproducible features for identifying this extremely rare variant for which the term *atypical type A thymoma* has been proposed.[142] Necrosis was the only feature that predicted for higher tumor stage in a large retrospective cohort of type A and AB thymomas.[189] Distinguishing atypical type A thymomas from spindle cell type B3 thymomas may be challenging given the potential presence of nuclear atypia in both. Positive staining for CD20 in type A thymomas is inconsistent but may be helpful; in the absence of CD20 staining separating atypical type A from spindle type B3 thymomas hinges on other histologic findings including rosette-like, glandular, and storiform growth in type A thymoma and perivascular spaces in type B thymomas.[142]

Type AB Thymoma (Mixed)

A tumor in which foci having the features of type A thymoma are admixed with foci rich in lymphocytes including a significant proportion of immature T cells (see Fig. 12.23).[190]

This is a particularly common type of thymoma. The segregation of the two patterns can be sharp or indistinct, and there is a wide range in the relative amount of the two components. In particular, type A areas can be extremely scant, and therefore thorough sampling may be necessary to separate from type B1 thymomas. The presence of Hassall corpuscles strongly favors B1 thymomas; spindled or oval morphology and/or immunoreactivity for CD20 in epithelial tumor cells within lymphocyte-rich areas strongly favor a diagnosis of AB thymoma over a type B thymoma.[142]

Type B1 Thymoma (Lymphocyte-Rich; Lymphocytic; Predominantly Cortical; Organoid)

A tumor that resembles the normal functional thymus in that it combines large expanses having an appearance practically indistinguishable from normal thymic cortex in which cytologically bland thymic epithelial cells are evenly dispersed within a background of immature T cells and accompanied by areas resembling thymic medulla (see Fig. 12.19).[191]

The resemblance between this tumor type and the normal active thymus is such that the distinction between the two may be impossible on high-power examination. Absence of epithelial cell clusters and presence of medullary islands are especially helpful in separating B1 from B2 thymoma (see next).[141]

Type B2 Thymoma (Cortical)

A tumor in which the neoplastic epithelial component appears as scattered plump cell, often including small (≥3 contiguous epithelial cells) clusters, with vesicular nuclei and distinct nucleoli among a heavy population of immature T cells.[192] *Perivascular spaces are common and sometimes very prominent (see Fig. 12.21). A perivascular arrangement of tumor cells resulting in a palisading effect may be seen.* Medullary differentiation and rare Hassall corpuscles may be present but when present are less conspicuous than in B1 thymoma.

The cytoplasm of the tumor cells tends to be abundant and the shape of the cells round or polygonal, this feature having led to the alternative designation (large) polygonal cell thymoma. Like B1 thymoma, type B2 thymoma is lymphocyte rich (albeit to less degree), resulting in a mixed lymphocyte–epithelial pattern (see Fig. 12.20).

Type B3 Thymoma (Epithelial; Atypical; Squamoid; Well-Differentiated Thymic Carcinoma)

A type of thymoma predominantly composed of mildly atypical epithelial cells having a round or polygonal shape admixed with a minor component of immature T cells, resulting in a sheetlike growth of the neoplastic epithelial cells (see Fig. 12.22).[193]

This thymoma type has been traditionally known as epithelial, a term that is accurate but somewhat misleading since it implies that the other types of thymoma are not. Another term that has been suggested for it is atypical, but this is also somewhat inaccurate in view of the fact that the degree of atypia present in it may not be greater than that seen in type B2 thymoma, from which it is distinguished primarily on the basis of the proportionally larger number of epithelial cells compared to non-neoplastic lymphocytes. Another previously proposed term that has been largely discarded is *well-differentiated thymic carcinoma*, which is potentially confusing because of the fact that in most articles on the subject and in most classification schemes this tumor is included with the thymomas rather than with the thymic carcinomas. Yet another proposal is that of squamoid thymoma because of the common presence of squamoid or squamous features in the tumor cells. However, this is neither a constant nor an exclusive feature of this tumor type.

Rare subtypes of thymoma that do not easily fit into the A-B nomenclature include *micronodular thymoma* characterized by a micronodular growth pattern in which epithelial islands are separated by lymphoid stroma that may include florid follicular hyperplasia (Fig. 12.37).[194] The lymphocytes are composed mainly of B cells and mature T cells, and the epithelial cells are generally negative for CD20, two findings that may be helpful in distinguishing micronodular thymoma from type AB thymoma.[188] *Metaplastic thymoma* is another rare subtype that, as previously referenced (see previous section on sarcomatoid carcinomas), is a biphasic tumor in which solid areas of epithelial cells are variably well demarcated from cytologically bland, fibroblast-like spindle cells (Fig. 12.38). *Microscopic thymoma* refers to thymomas measuring less than 0.1 cm in greatest dimension and are usually discovered as multifocal incidental findings in thymectomies from patients with myasthenia gravis.[195] This lesion has also been referred to as *nodular hyperplasia* of thymic epithelium, which may be a more accurate and appealing term.[43] Microscopic thymomas (nodular hyperplasia) are found as frequently in unselected autopsies as they are in patients with myasthenia gravis, leaving the clinical significance of this finding in doubt.[196]

Thymic Carcinoma

A thymic tumor exhibiting clear-cut cytologic atypia and a set of cytoarchitectural features no longer specific to the thymus (as for types A, AB, and B thymomas) but rather analogous to those seen in carcinomas of other organs (see Figs. 12.29–12.35) as discussed in a preceding section.

Cytology

The most important criterion for the cytologic recognition of a thymoma is the identification of a distinct population of epithelial cells admixed with lymphocytes, preferably confirmed by a positive immunostain for keratin. Limitations of the procedure include the difficulty in separating the various subtypes of type B thymoma (not very important clinically) and the inability to detect invasion (a critical prognostic factor).[197]

Staging

Historically, thymomas of any type (other than thymic carcinomas) that appear totally encapsulated have been regarded as benign, whereas those of similar microscopic types but exhibiting evidence of aggressiveness in the form of local invasion, pleural or pericardial implants, or distant metastases have been designated as malignant (Fig. 12.39). The current classification scheme acknowledges that all thymomas have malignant potential that is heavily dependent on disease stage.[142] Because predicting behavior relies so heavily on the presence and, to some extent, on the degree of invasion, the staging system for thymomas first proposed by Masaoka et al.[198] in 1981, modified by Koga et al.[199] in 1994, and refined by Detterbeck et al.[200] in 2011 (Table 12.2) has repeatedly proven superior to histologic classification as an independent prognostic factor.[201] The tenets fundamental to this staging system have been preserved with a few key modifications in the more recently published staging system offered by the American Joint Committee on Cancer (AJCC) for all primary thymic epithelial neoplasms (i.e. thymoma, thymic carcinoma and thymic neuroendocrine neoplasms) in the 8th Edition of their Cancer Staging Manual (Table 12.3).[202] Tumor-related

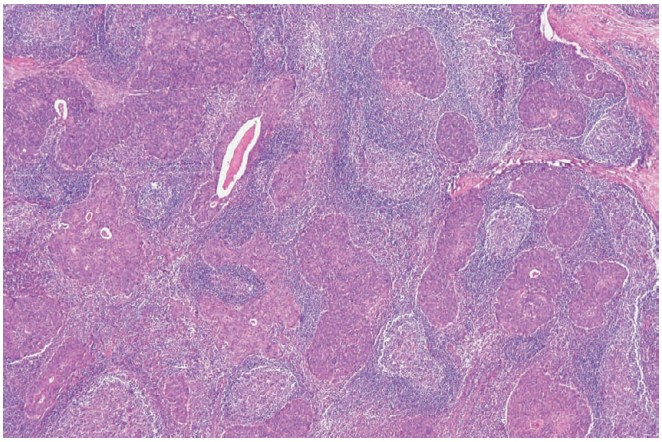

Figure 12.37 Micronodular thymoma with lymphoid stroma in which epithelial islands are separated by an epithelium-free lymphoid stroma.

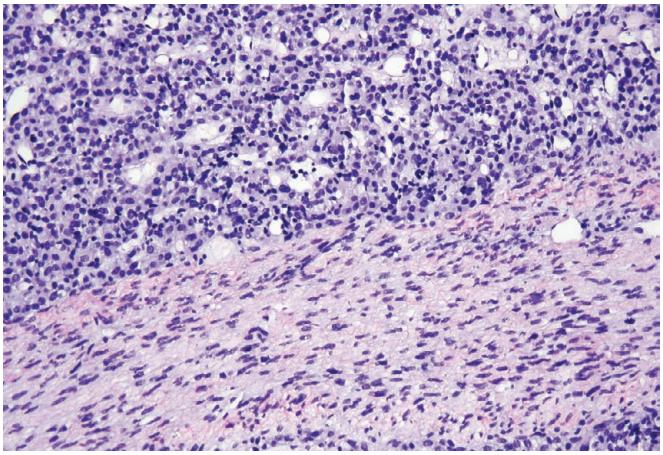

Figure 12.38 Metaplastic thymoma, previously referred to as low-grade metaplastic carcinoma given bland epithelial component juxtaposed with fibroblast-like spindle cells.

Table 12.2 Modified Masaoka–Koga staging system for thymic epithelial neoplasms

STAGE	DEFINITION
I	Grossly and microscopically encapsulated tumor
II	Capsular invasion
a	Limited (≤3 mm) microscopic transcapsular invasion
b	Macroscopic (microscopically confirmed) invasion into thymic or surrounding adipose tissue without pleural or pericardial involvement
III	Macroscopic (microscopically confirmed) invasion into neighboring organs (i.e. mediastinal pleura, pericardium, visceral pleura ± lung parenchyma, phrenic or vagus nerves, major vessels); adherence (i.e. fibrous attachment) to lung or other adjacent organs if (and only if) there is concomitant microscopic invasion of mediastinal pleura and/or pericardium
IV	Metastases
a	Pleural or pericardial metastases (i.e. nodules separate from main mass involving visceral or parietal pleura, or pericardial or epicardial surfaces)
b	Lymphogenous (intrathoracic or extrathoracic lymph nodes) or hematogenous (pulmonary parenchymal or extrathoracic) metastases

Modified from Detterbeck FC, Nicholson AG, Kondo K, et al. The Masaoka-Koga stage classification for thymic malignancies: clarification and definition of terms. *J Thorac Oncol*. 2011;6(7 suppl 3):S1710–S1716.

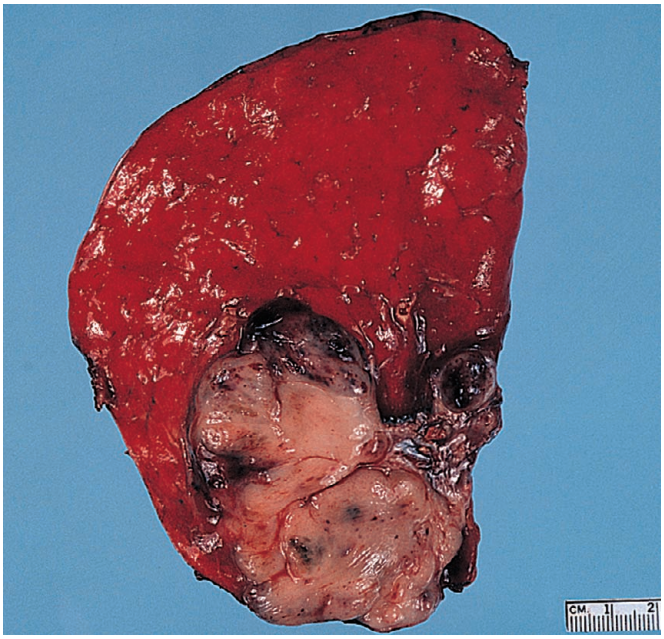

Figure 12.39 Gross appearance of malignant thymoma invading lung.

Table 12.3 American Joint Committee on Cancer staging of primary thymic epithelial neoplasms

Primary Tumor (T)[a,b]	
T CATEGORY	**T CRITERIA**
TX	Primary tumor cannot be assessed
T0	No evidence of primary tumor
T1	Tumor encapsulated or extending into the mediastinal fat; may involve the mediastinal pleura
T1a	Tumor with no mediastinal pleura involvement
T1b	Tumor with direct invasion of mediastinal pleura
T2	Tumor with direct invasion of the pericardium (either partial or full thickness)
T3	Tumor with direct invasion into any of the following: lung, brachiocephalic vein, superior vena cava, phrenic nerve, chest wall, or extrapericardial pulmonary artery or veins
T4	Tumor with invasion into any of the following: aorta (ascending, arch, or descending), arch vessels, intrapericardial pulmonary artery, myocardium, trachea, esophagus
Regional Lymph Node (N)[c]	
N CATEGORY	**N CRITERIA**
NX	Regional lymph nodes cannot be assessed
N0	No regional lymph node metastasis
N1	Metastasis in anterior (perithymic) lymph nodes
N2	Metastasis in deep intrathoracic or cervical lymph nodes
Distant Metastasis (M)	
M CATEGORY	**M CRITERIA**
M0	No pleural, pericardial, or distant metastasis
M1	Pleural, pericardial, or distant metastasis
M1a	Separate pleural or pericardial nodule(s)
M1b	Pulmonary intraparenchymal nodule or distant organ metastasis

[a]Involvement must be microscopically confirmed in pathological staging, if possible.
[b]T categories are defined by "levels" of invasion; they reflect the highest degree of invasion regardless of how many other (lower-level) structures are invaded. T1, level 1 structures: thymus, anterior mediastinal fat, mediastinal pleura; T2, level 2 structures: pericardium; T3, level 3 structures: lung, brachiocephalic vein, superior vena cava, phrenic nerve, chest wall, hilar pulmonary vessels; T4, level 4 structures: aorta (ascending, arch, or descending), arch vessels, intrapericardial pulmonary artery, myocardium, trachea, esophagus.
[c]Involvement must be microscopically confirmed in pathological staging, if possible.
From Detterbeck FC, Marom EM. Thymus. In: Amin MB, Edge SB, Greene FL, et al., eds. *AJCC Cancer Staging Manual*. 8th ed. New York: Springer; 2017:423–429.

categories in this recently proposed staging system disregard the distinction between encapsulated tumors and those that show limited extracapsular invasion into non-neoplastic thymus and thymic fat since this finding alone has little if any prognostic significance.[203] The AJCC staging system instead focuses on contiguous invasion of adjacent structures:

- T1 tumors may (T1b) or may not (T1a) directly invade mediastinal pleura,
- T2 tumors invade the pericardium,
- T3 tumors invade lung, chest wall, phrenic nerve, and/or selected vessels, and
- T4 tumors invade aorta, arch vessels, intrapericardial pulmonary artery, myocardium, trachea or esophagus.

In the absence of metastases the T categories dictate stage groupings (i.e. T1a, T1b = stage I, T2 = stage II, T3 = stage IIIA, T4 = stage IIIB) while stage IV disease is predicated on the presence of nodal metastases (N1 and N2) and/or extranodal metastases (M1a and M1b). The extent to which this model allows for greater precision in predicting prognosis compared to the refined Masaoka–Koga staging system is uncertain[204,205]; regardless, it is likely to become the preferred method for reporting resected thymic epithelial neoplasms.[206]

Overall, about 70%–80% of thymomas are encapsulated or, at most, minimally invasive at the time of diagnosis. Direct local invasion into adjacent structures such as lung or implants into the pleural or pericardial surfaces are considerably more common than extrathoracic metastases. When local invasion is extensive, it is already apparent to the surgeon at the time of thoracotomy. It is therefore important for the pathologist to know the surgical findings while remembering that fibrous adhesions resulting from secondary inflammatory, necrotic, and multilocular cystic changes can give the false impression that the tumor is invasive. The presence of large nerves surrounded by tumor also represents indirect evidence of invasion (sometimes the only such evidence present on the case). Distant metastases, which are exceptional, have been documented in mediastinal and cervical lymph nodes, lung, liver, bone (particularly spine), ovary (we have seen three examples), and other sites. Usually, these distant metastases develop months or years after an invasive thymoma has been detected and treated but sometimes are noted at presentation and exceptionally represent the first clinical manifestation of the disease.

There is a close relationship between the microscopic subtype of thymoma and the likelihood of invasion, and therefore outcome, as follows[205,207]:

A < AB < B1 < B2 < B3

It is, however, important to point out that *any* thymoma type can be associated with the presence of direct extension, pleural or pericardial implants, or distant metastases (Fig. 12.40).

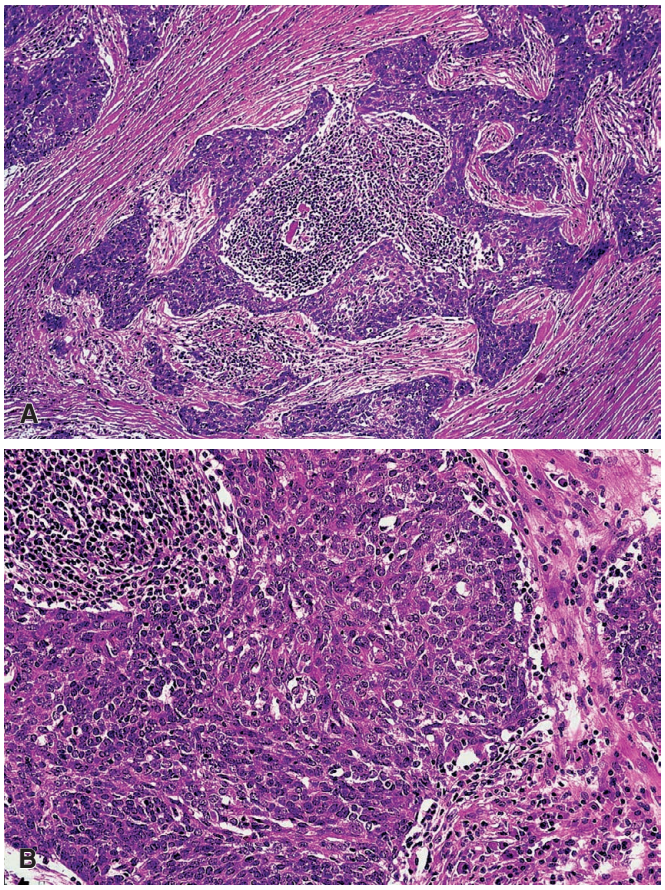

Figure 12.40 **A** and **B**, This tumor had the morphologic features of a type A thymoma, yet it was widely invasive.

Treatment

The primary treatment of thymoma is en-bloc surgical excision and complete thymectomy.[208] For the entirely encapsulated (Masaoka stage I) and minimally invasive (Masaoka stage II) thymomas that have been removed in toto with tumor-free margins, no additional therapy is necessary regardless of their microscopic type. If there is any question about the possibility of residual tumor, postoperative radiation therapy should be considered for tumors other than types A or AB (unless they are extensively invasive, which is very rarely the case).

For thymomas associated with preoperative radiological evidence of gross or suspected invasion and/or intrathoracic implants, multimodality therapy including neoadjuvant chemotherapy followed by adjuvant radiation in selected patients yields improved survivals.[208,209]

Thymic carcinomas are treated with surgery and radiation therapy, with chemotherapy added in selected cases.[210]

Prognosis

Stage remains the single most important prognostic determinant, regardless of the system used, and applies equally to thymomas and thymic carcinomas.[205] The prognosis of fully encapsulated and minimally invasive thymoma after complete surgical excision is excellent. Recurrence has been found in 2%–10% of cases, depending on the series. These local recurrences are still amenable to surgical removal.[211]

In the case of invasive thymomas, the prognosis correlates with the degree of invasion as measured by either the modified Masaoka–Koga or the more recently proposed AJCC staging system. As previously mentioned the prognosis of minimally invasive (modified Masaoka–Koga stage II) thymomas is not significantly different from that of encapsulated (modified Masaoka–Koga stage I) tumors,[203] but it drops markedly for the tumors showing gross invasion or implants and even more for the few cases associated with distant metastases.[204]

There is a definite relationship between the subtype of thymoma (whatever the classification system used) and prognosis. This fact was already very evident in the large series from the Mayo Clinic reported by Lewis et al. in 1987.[88] The reason the usefulness of

Table 12.4 Salient features of tumors in the neck showing thymic or related branchial pouch differentiation

TUMOR	GENDER	MEAN AGE (YEARS)	ANATOMIC LOCATION	MAJOR HISTOLOGIC FEATURES	BEHAVIOR
Ectopic hamartomatous thymoma	M > F	49.9	Supraclavicular or suprasternal soft tissue	Circumscribed; haphazard admixture of bland-looking spindle (epithelial) cells, solid and cystic epithelial islands (commonly squamous and glandular), and mature fat cells	Benign: *No recurrence or metastasis* after excision
Ectopic cervical thymoma	M < F	42.7	Soft tissue of neck, often in a juxtathyroid location, or sometimes inside thyroid	Similar to mediastinal thymomas; encapsulated or invasive; jig-saw puzzle-like lobules; mixture of pale epithelial cells (plump or spindled) and lymphocytes	Most pursue a benign course with *no recurrence*; exceptionally, metastasis can occur
SETTLE	M = F (about the same)	15	Thyroid gland	Encapsulated or infiltrative; highly cellular tumor; merging of compact or reticulated spindle (epithelial) cells with glandular elements; mucous glands often present; component of lymphocytes lacking	Protracted clinical course, with a propensity to develop *delayed distant metastasis*
CASTLE	M < F	48.5	Thyroid gland (usually lower pole) and surrounding soft tissue, or soft tissues of the neck	Lymphoepithelioma-like carcinoma that may show foci of squamous differentiation; lobulation; pushing margins; lymphocytic infiltration often present	Generally indolent tumor that can *recur after long intervals; regional lymph node metastasis* occurs in about half of the cases; occasional cases pursue a more aggressive course

From Chan JK, Rosai J. Tumors of the neck showing thymic or related branchial pouch differentiation. A unifying concept. *Hum Pathol.* 1991;22:349–367.

the microscopic subdivision of thymoma along these lines was minimized by Lewis et al. and other authors is that it is largely superseded by the staging system, which is a more important independent prognostic factor. Three independent studies carried out by Rosai and associates comprise three different series of thymoma patients. One deals with patients treated at the Memorial Sloan Kettering Cancer Center,[212] one with personal consultation cases,[213] and the third with patients seen at the National Cancer Institute of Milan, Italy.[214] The results of these three series, which were notably similar, confirmed the previously referenced relationship between the microscopic type of thymoma and prognosis. When the tumor stage is taken into account, however, the prognostic value of the microscopic type drops considerably. **Completeness of excision** is also an important prognostic parameter, which is directly related to the tumor stage.[212]

Proliferation index (i.e. Ki-67 labeling index) and DNA ploidy correlate with stage and microscopic type but neither has demonstrated consistent value as an independent prognostic biomarker.[215,216]

Cervical Tumors of Thymic or Related Branchial Pouch Derivation

As mentioned previously, *ectopic thymic tissue* and *unilocular thymic cysts* can be found in the lateral aspects of the neck as a result of a malformation related to the third or possibly fourth branchial pouch. In addition, the following neoplasms can develop in a similar location and on a presumably similar histogenetic basis (Table 12.4).

1. **Ectopic (cervical) thymoma.** The microscopic appearance of this tumor is not noticeably different from that of its orthotopic mediastinal counterpart.[86,217] A striking and unexplained predilection for the female gender is present. All of the reported cases have behaved in a benign fashion.[218]
2. **Ectopic hamartomatous thymoma.** The location of this lesion, which shares features of a hamartomatous and a neoplastic process, is the supraclavicular–suprasternal area.[219] Nearly all patients are males, in striking contrast with the previous entity. The bulk of the mass is composed of epithelial cells that are extremely spindle shaped and mesenchymal-like[220]; this finding often results in a misdiagnosis of a Schwannian or fibroblastic neoplasm. However, ultrastructural examination or keratin immunostaining reveals their epithelial nature. Atypia, necrosis, and mitotic figures are absent. The other component (which can be very focal) is represented by solid squamous nests, thin anastomosing cords (sometimes composed of clear cells), and epithelial-lined cysts (Fig. 12.41). Islands of mature fat and clusters of small lymphocytes may also be present. This tumor, which may reach a huge size, does not seem to have a mediastinal counterpart. The behavior is benign,[220] with occasional instances of local recurrence,[221] but exceptional cases with a superimposed carcinoma are on record.[222] Although originally hypothesized to be derived from third branchial arch derivatives,[219] others have suggested origin from

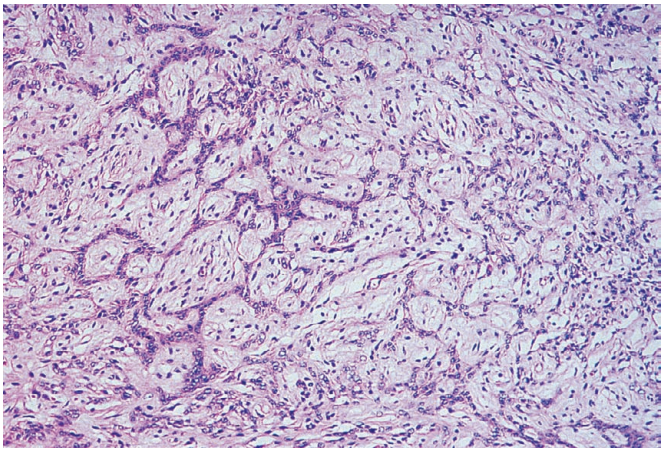

Figure 12.41 Ectopic Hamartomatous Thymoma. Thin anastomosing strands of epithelial cells merge with spindle foci having a mesenchyme-like appearance.

alternative branchial cleft remnants that lack an embryological link to the thymus.[221] Whatever its derivation, ectopic hamartomatous thymoma is a rare clinically and histopathologically distinct entity that should not be confused with other potentially more aggressive lesions.[220]

3. **Spindle epithelial tumor with thymus-like elements (SETTLE).** Most cases of this rare neoplasm have been found in adolescents or young adults and have been located in or around the thyroid.[218] Microscopically, a biphasic pattern resulting from a predominant spindle cell component (more cellular than in the previous type and mitotically active) and a mucin-secreting, occasionally cystic glandular component is present (Fig. 12.42).[223] Immunohistochemically and ultrastructurally, both tumor components have an epithelial phenotype. Prominent mitotic activity and focal necrosis have been reported in a subset of cases.[224] At the molecular level, *KRAS* gene mutation has been detected in a single example of this entity; SETTLE lacks the fusion genes characteristic of synovial sarcoma, a finding of potential value in diagnostically challenging cases.[225,226] The natural history is characterized by a tendency for late (measured in years or decades) distant metastases.[227] The main differential diagnosis for SETTLE is synovial sarcoma, particularly when the spindle cell component predominates ("predominantly monophasic") to the near exclusion of the glandular element (Fig. 12.43).[228] SETTLE should be favored in the presence of stromal hyalinization, lower overall grade, presence of glomeruloid glandular structures, absence of intraglandular necrotic debris, and diffuse expression of high-molecular-weight keratin. If doubts persist, molecular studies for the synovial sarcoma fusion genes can be helpful, as referenced previously.
4. **Carcinoma with thymus-like elements (CASTLE).** This tumor also tends to be located within or around the thyroid,[218] to the point that most of the earliest reported cases were thought to represent squamous cell or undifferentiated carcinomas of this organ.[229] Their microscopic appearance is indistinguishable from that of thymic carcinoma (Fig. 12.44), of which it can be regarded as its ectopic (cervical) equivalent. Support for the thymic rather than thyroidal origin of CASTLE is provided by its immunoreactivity for CD5, CD117, high-molecular-weight keratin, BCL2, p63, and mcl-1 (all of these markers being usually positive in thymic carcinoma) and negativity for thyroglobulin and TTF-1.[230] The tumor has a tendency for late local recurrences, but its behavior is rather indolent, certainly more so than that of undifferentiated thyroid carcinoma.[218]

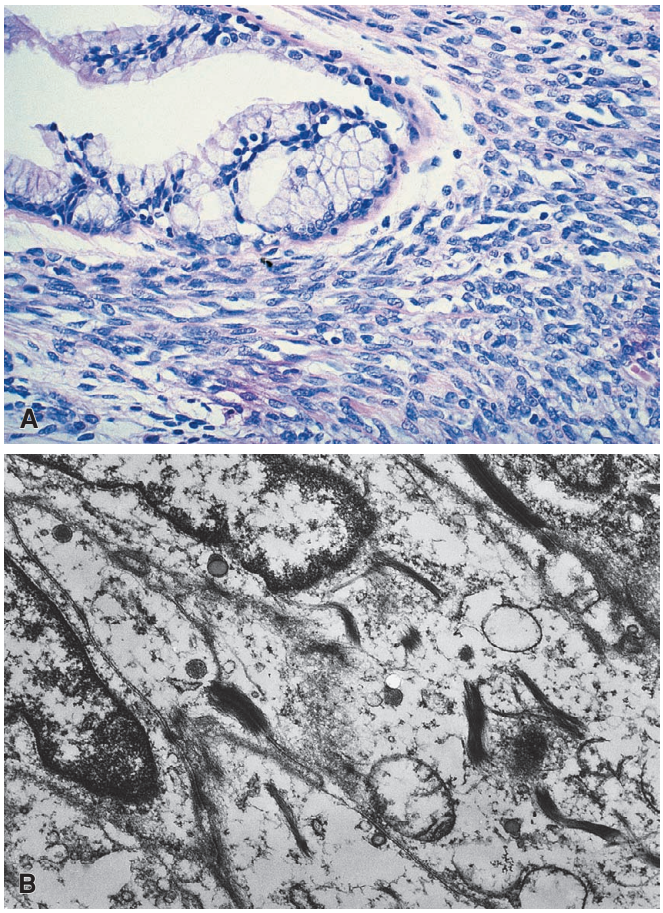

Figure 12.42 A, SETTLE. Spindle epithelial cells of mesenchyme-like appearance surround a well-differentiated gland lined by mucin-producing epithelium. **B**, Electron micrograph of SETTLE. Portion of a cluster of spindle-shaped epithelial cells that are joined by well-formed desmosomes. Note the tonofilament bundles in the cytoplasm. (×26,000; courtesy of Dr Robert A Erlandson, Memorial Sloan Kettering Cancer Center)

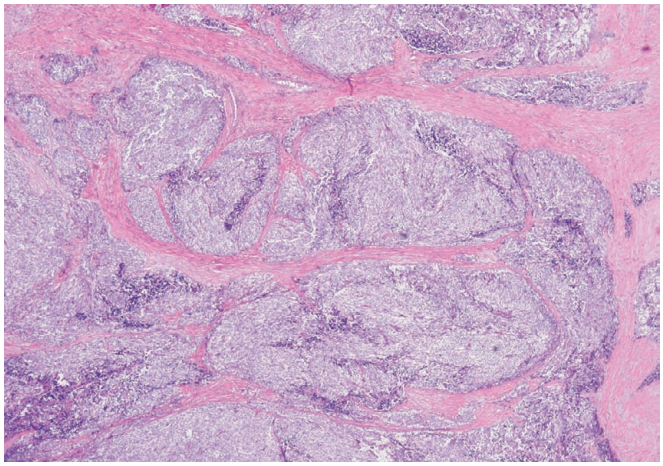

Figure 12.43 "Monophasic" SETTLE in which spindle cells predominate resembling monophasic synovial sarcoma. Stromal hyalinization and location within or immediately adjacent to thyroid are useful clues.

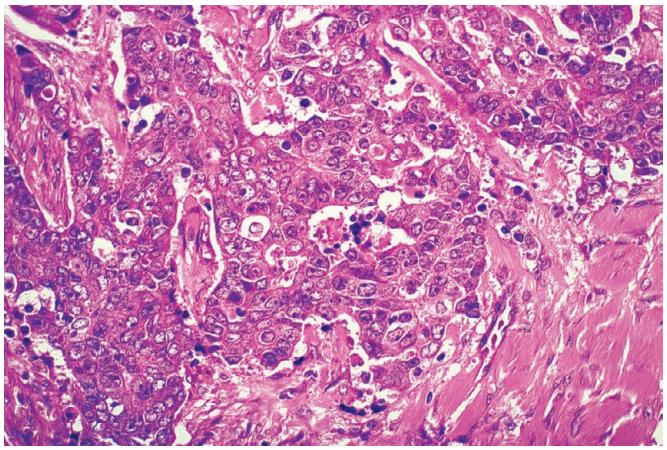

Figure 12.44 Castle. The morphologic appearance is similar to that of thymic carcinoma, of which it probably represents its ectopic counterpart.

Figure 12.45 Gross Appearance of Thymic Carcinoid. Notice the fleshy appearance and the extensive areas of hemorrhage.

Neuroendocrine Tumors

The thymus is the site of several types of neuroendocrine neoplasm, many of which were previously misinterpreted as variants of thymoma.[231] The gamut of neuroendocrine tumors that can develop in the thymus is basically the same as for the lung, the main difference being the relative frequencies of the various types using the same or similar histologic criteria (see Chapter 10).[232,233] Thus, whereas most neuroendocrine tumors of the lung fall into the two extremes (typical carcinoid and small cell carcinoma), those of the thymus tend to fall into an intermediate category (atypical carcinoid), although many publications have lumped typical and atypical carcinoid tumors together.[234] Symptoms and signs of local compression are common at diagnosis. As many as half of cases will have associated endocrinopathies, most commonly Cushing (and only rarely carcinoid) syndrome[235]; it seems apparent that all of the cases of thymomas reported historically to be associated with Cushing syndrome are examples of thymic carcinoids.[236] Thymic neuroendocrine tumors can also occur as a component of multiple endocrine neoplasia (MEN) type 1 or 2a or as *formes frustes* of these syndromes.[235,237] In these patients and in those with Cushing syndrome, the tumor tends to run a more aggressive clinical course. It has also been described in patients with neurofibromatosis type 1.

Typical and atypical carcinoid tumors of the thymus are malignant neoplasms histologically equivalent to their primary pulmonary counterparts that often invade locally and metastasizes distantly.[232,235,238] Histologic grading of thymic neuroendocrine tumors using criteria similar to those applied in the lung has prognostic value,[232] but stage, resectability, and presence of paraneoplastic endocrinopathies at presentation are more significant predictors of outcome.[233,238] Unlike their lung counterparts, thymic neuroendocrine tumors in all categories are more likely to present with more advanced disease and therefore more likely to be affiliated with an aggressive course even if low grade (i.e. typical carcinoid tumors).

Grossly, thymic carcinoid is solid, usually well circumscribed but not encapsulated, and lacks the distinct lobulations of thymoma (Fig. 12.45). Like carcinoid tumors elsewhere it tends to be highly vascularized and may be frankly hemorrhagic, including ectatic blood-filled spaces.[239]

Microscopically, thymic carcinoid tumor exhibits ribbon and festoon formation, rosette-like glands with central lumina, "balls" or nests of cells, and a delicate highly vascular stroma (Figs. 12.46). Lymphocytes, perivascular spaces, and other features of thymoma

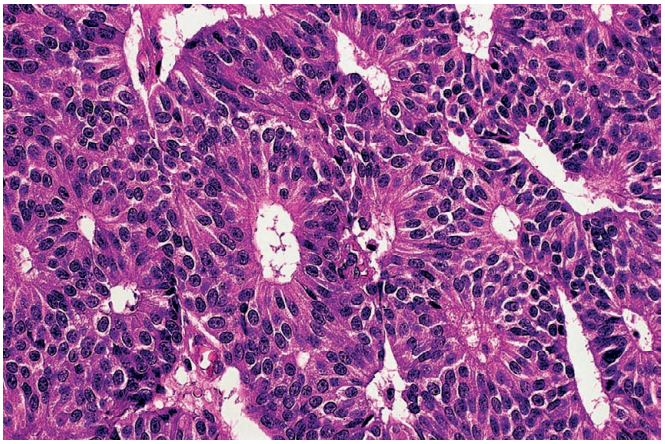

Figure 12.46 Well-differentiated architectural and cytologic appearance of thymic typical carcinoid. Ribbons and rosettes are evident.

are absent. The tumor cells have a more granular cytoplasm than those of thymoma, the nuclear chromatin is slightly coarser, and mitotic activity is frequent. As previously referenced, applying to thymic carcinoids, the criteria currently used for the homonymous bronchial lesion as proposed in the current WHO classification scheme relegates[234] most of them to the category of *atypical* carcinoid tumor (Fig. 12.47).[232,233,238,240] In many tumors the histologic findings are heterogeneous, including areas of low-, intermediate-, and high-grade histology.[241] This probably explains the fact that, as a group, thymic carcinoid is a more aggressive neoplasm than bronchial carcinoid, in which the atypical form represents a minority.[232,235,240]

Special techniques are very useful for confirmation of a diagnosis of thymic carcinoid. Electron microscopy, a technique of historical interest only, shows short interdigitating cell processes, focal basal lamina, scanty junctional processes, and practically no complex desmosomes or tonofilaments. The cytoplasm contains many dense-core granules and sometimes perinuclear whorls of microfilaments[242,243] (Fig. 12.48). Immunohistochemically, there is reactivity for keratin, chromogranin, synaptophysin, neuron-specific enolase, and other general endocrine markers. About a third stain for PAX8, while staining for TTF-1 is rare, a finding sometimes helpful in separating primary thymic neuroendocrine tumors from metastatic pulmonary lesions.[244] In addition, the tumors associated with Cushing

syndrome show positivity for adrenocorticotropic hormone (ACTH).[245,246] Other substances detected in this tumor include serotonin, somatostatin, cholecystokinin, neurotensin, metenkephalin, and growth hormone-releasing hormone (GHRH).[234,245]

Morphologic variants of thymic carcinoid tumor include lesions with a spindle cell pattern[247,248] (Fig. 12.49), a prominent oncocytic component,[249] and melanin pigment.[246] There are also tumors containing amyloid and calcitonin and therefore analogous to medullary thyroid carcinoma.[250] Finally, there are carcinoid tumors accompanied by a high-grade sarcomatoid component.[251]

Small cell neuroendocrine carcinoma of the thymus has an appearance indistinguishable from that of its considerably more common pulmonary counterpart[241,250] (Fig. 12.50). For that reason, a diagnosis of primary small cell carcinoma of the thymus can only be entertained when a mediastinal metastasis from a pulmonary neoplasm has been ruled out. As in the lung, thymic tumors have been described having an admixture of small cell and squamous cell carcinoma[158] and may also be combined with carcinoid tumor.[241]

Large cell neuroendocrine carcinoma, defined according to the criteria applied to pulmonary neoplasms, has been seen in the thymus, albeit only exceptionally.[252]

It is important to point out the difference that exists between all of the previous tumors, generically embraced into the neuroendocrine category, and otherwise conventional thymic carcinomas that show immunohistochemical evidence of neuroendocrine differentiation,[150] a circumstance analogous to use of these terms in the lung (see Chapter 10).

It should also be mentioned that not all thymic tumors showing neural differentiation (e.g. neuroblastoma) are neuroendocrine

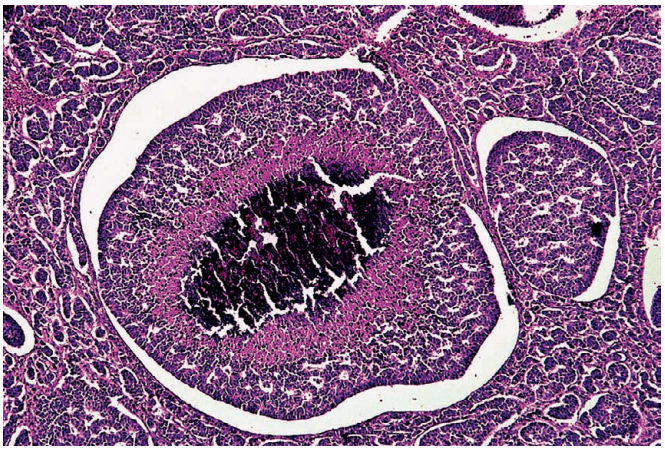

Figure 12.47 Thymic Atypical Carcinoid. The tumor nests show characteristic central necrosis with calcification.

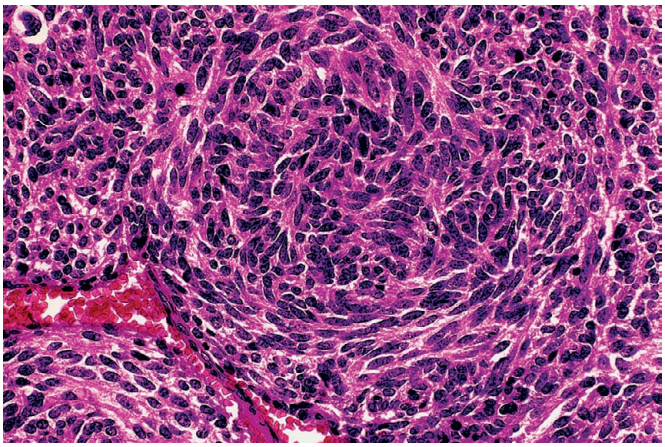

Figure 12.49 Thymic Carcinoid of Spindle Cell Type. This tumor is easily confused with a type A (spindle cell) thymoma.

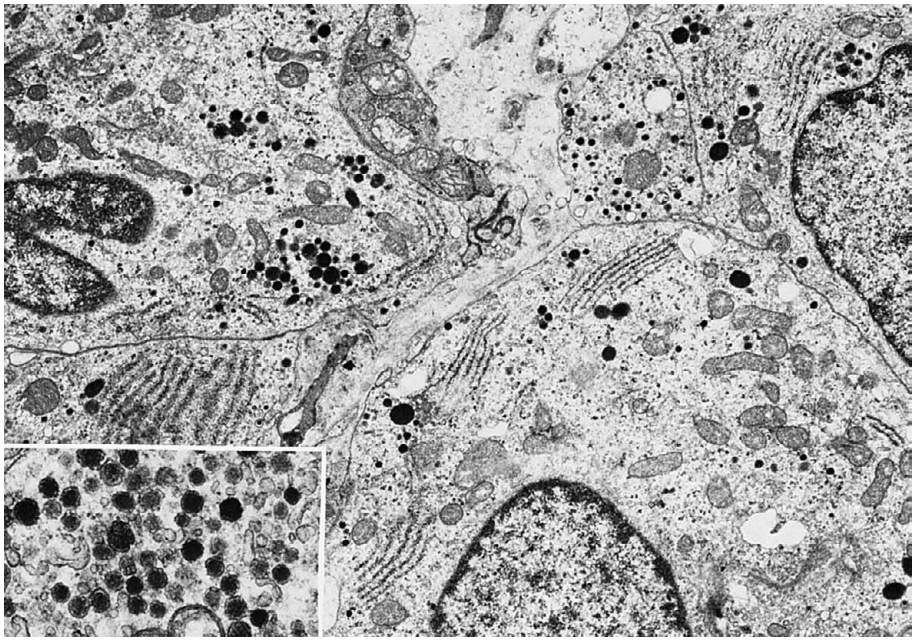

Figure 12.48 Thymic carcinoid tumor characterized ultrastructurally by dense-core secretory granules that separate this neoplasm from other thymic tumors. These cells also have prominent rough endoplasmic reticulum, Golgi apparatus, and scattered mitochondria. *Inset,* Note uniform, membrane-bound, dense-core granules with peripheral halo. (×7450; inset ×25,270.)

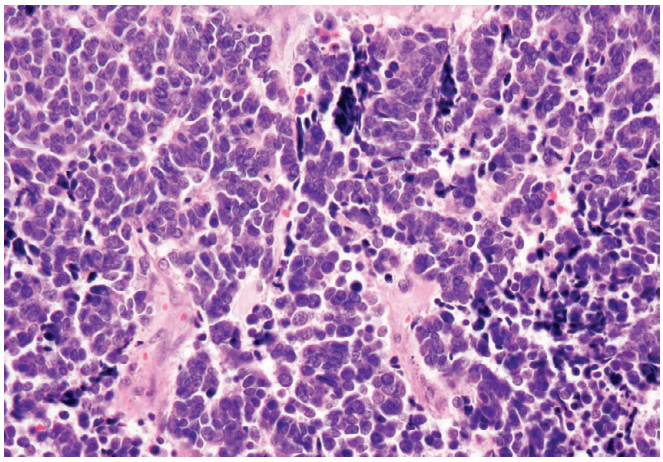

Figure 12.50 Small Cell Carcinoma of the Thymus. The tumor cells have finely dispersed chromatin, inconspicuous nucleoli, and scanty cytoplasm. There is associated necrosis.

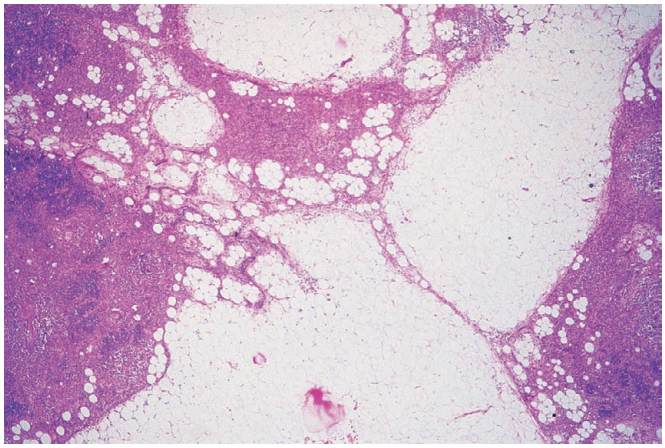

Figure 12.51 Thymolipoma. The lesion is composed of an admixture of mature adipose tissue and microscopically normal thymus.

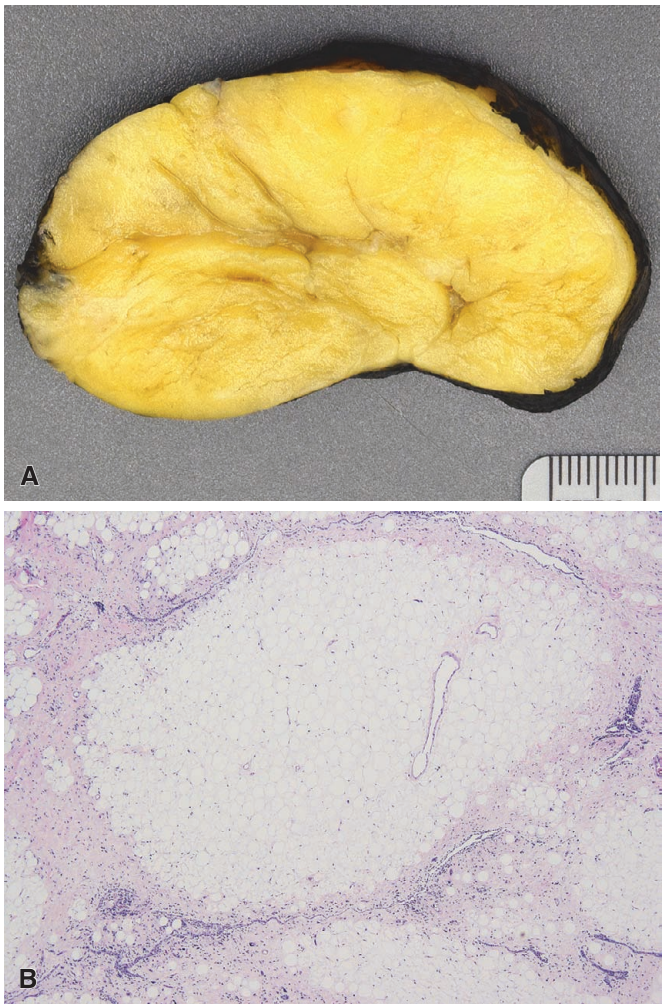

Figure 12.52 A and **B**, Well-differentiated liposarcoma/atypical lipomatous tumor arising within the thymus. A fluorescence in situ hybridization (FISH) assay was positive for *MDM2* amplification.

carcinomas and that rarely posterior mediastinal neuroendocrine carcinomas may arise from structures other than the thymus.[253]

Stromal and Other Tumors

Thymolipoma is an encapsulated benign thymic lesion that can attain a huge size and can simulate radiographically cardiomegaly or pulmonary sequestration.[254] It is questionable whether it represents a true neoplastic process, but the finding in one case of the chromosomal aberration typical of lipoma suggests that it is a neoplasm of thymic fat.[255] The majority of the cases are asymptomatic, but isolated instances of association with myasthenia gravis, aplastic anemia, and Graves disease are on record.[256] Their appearance on CT scan and MRI is characteristic. Grossly, the lesion has the appearance of a lipoma except for the focal presence of whitish solid areas. Microscopically, there is an admixture in various proportions of mature adipose tissue and unremarkable thymic tissue (Fig. 12.51). The amount of the latter is well in excess of that normally expected for the patient's age. Isolated case reports have described associated myoid cells,[257] fibroconnective tissue ("thymofibrolipomas")[258] or vessels ("thymohemangiolipoma"),[259] sebaceous differentiation,[260] and even thymoma and thymic carcinoma.[261]

We and others have seen cases of low-grade malignant mesenchymal tumors seemingly arising from the thymic stroma that we interpreted as **thymic stromal sarcomas**. Their microscopic appearance is variable, but well-differentiated liposarcoma/atypical lipomatous tumor is the predominant component ("thymoliposarcoma") (Fig. 12.52).[262]

Other stromal tumors arising in the thymus are rare, including a single reported case of *kaposiform hemangioendothelioma* in an infant.[263]

Malignant melanoma has been seen presenting as an apparently primary thymic mass.[264] Parenthetically, metastatic tumors to the thymus are exceptional.

Germ Cell Tumors

Germ cell tumors account for approximately 20% of the mediastinal tumors and cysts. Their histogenesis is controversial, but a primary origin from extragonadal germ cells is favored.[265] In this context, it should be pointed out that the mediastinal location of germ cell tumors is specifically related to the thymus gland, even if normal germ cells in this organ have yet to be conclusively demonstrated and their possible function—if indeed they are present—remains

an enigma. The thymic connection of germ cell tumors is also evident by the fact that, when small, they are found totally encased within this organ. However, they seem to have no histogenetic relationship with true thymoma and should not be labeled as such. The possibility of any mediastinal germ cell tumor representing a metastasis from a testicular or ovarian primary lesion should always be investigated, although in the presence of a single upper mediastinal tumor with no evidence of retroperitoneal involvement the chances of this being the case are remote.

Some cases of mediastinal germ cell tumors have occurred in association with Klinefelter syndrome; it has been estimated that the incidence of this syndrome among patients with mediastinal germ cell neoplasms is up to 50 times that seen in the general population.[266]

A definite relationship exists between the patient's sex and the incidence of the various mediastinal germ cell tumors. Seminoma (germinoma), for all practical purposes, affects only males[267]; we have yet to see a convincing case in a female. Embryonal carcinoma, endodermal sinus tumor, teratocarcinoma, and choriocarcinoma show a great male predilection, but unquestionable cases in females have been reported.[268,269]

Seminoma (germinoma) of the mediastinum arises almost always within the thymus but—as already stated—should be regarded as a germ cell tumor rather than a true thymoma (Fig. 12.53). The morphologic appearance is identical to that of its testicular counterpart at the light microscopic, immunohistochemical, and ultrastructural level (Figs. 12.54 and 12.55).[267,270,271] Histologic features common to both is the characteristic cytology of neoplastic cells including prominent nucleoli and clear cytoplasm with distinct cytoplasmic borders, fibrous septa, and a dense inflammatory infiltrate comprising a combination of lymphocytes and granulomatous inflammation that may obscure the underlying neoplasm (Fig. 12.56). Like their testicular counterparts, mediastinal seminomas are frequently positive for various cytokeratins but are more frequently positive for low-molecular-weight cytokeratins (e.g. CAM5.2).[272] Combined with staining for CD117 (c-kit), this is a dangerous diagnostic trap given

Figure 12.53 Seminoma of Thymus. The tumor is solid and homogeneous, with focal necrosis. Residual thymic tissue is seen at the periphery.

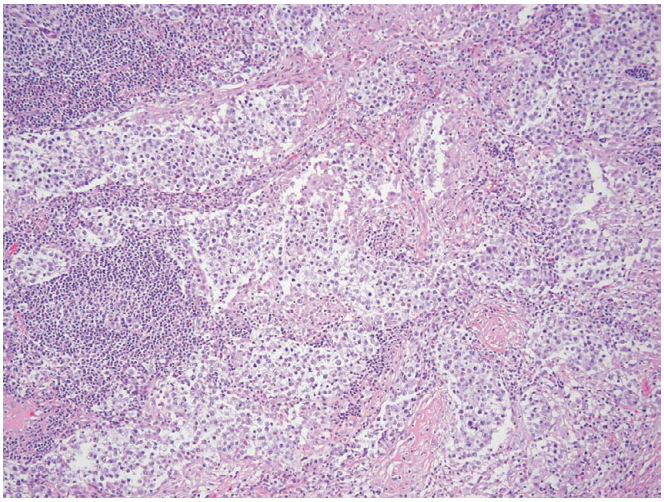

Figure 12.54 Seminoma of thymus showing compact nests of large tumor cells surrounded by lymphocyte-rich fibrous septa.

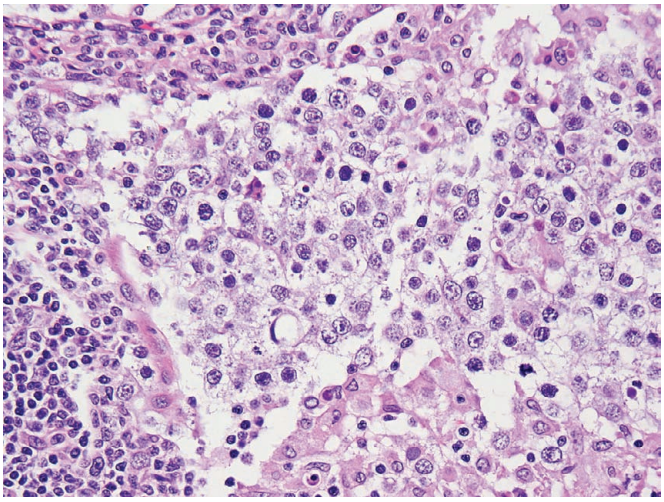

Figure 12.55 This high magnification view shows the multiple prominent and often irregularly shaped nucleoli that are typical of seminoma.

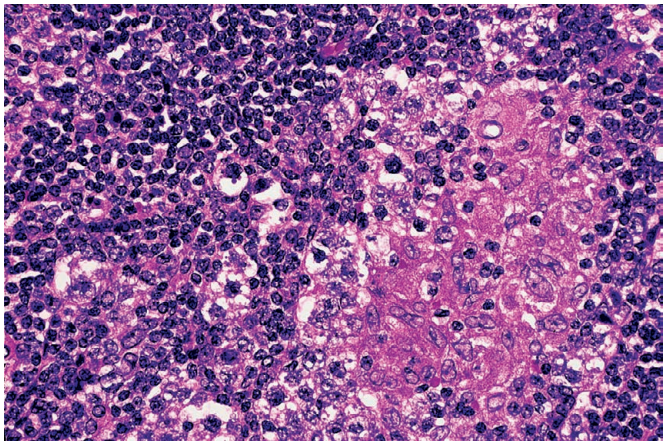

Figure 12.56 Seminoma of Thymus. The associated granulomatous response can obscure the true nature of the lesion.

the immunohistochemical overlap with thymic carcinoma. Staining for OCT3/4 and SALL4 is nearly universal and can be especially helpful in resolving this diagnostic problem.[271,272] Mediastinal seminomas are somewhat different from homologous gonadal tumors in their p53 immunostain profile and specific sites and types of *KRAS* and *KIT* mutations.[273,274]

The differential diagnosis of mediastinal seminoma includes thymoma, thymic carcinoma, and large cell lymphoma. The presence of fibrous septa infiltrated by lymphocytes and plasma cells, epithelioid granulomas, numerous germinal centers, large amounts of cytoplasmic glycogen, and an irregular, skein-like nucleolus favors a diagnosis of seminoma. As summarized previously, immunostains can be especially helpful in this circumstance given the specificity of staining for OCT3/4 and SALL4 in seminoma compared to thymic epithelial tumors and lymphomas. Chromosome 12p abnormalities, most commonly 12p amplification, as detected with a FISH technique are almost always present and offers another potentially useful diagnostic tool.[271] The primary treatment is a combination of chemotherapy and radiation, combined modality therapy resulting in disease-free survivals of nearly 90%.[275,276]

Mature cystic teratoma competes with seminoma as one of the most common types of mediastinal germ cell neoplasms in adults[269] and accounts for the majority of mediastinal germ cell tumors in children.[277] It usually becomes clinically apparent in early adult life. It may grow to a large size and has a distinct, sharply delineated wall that often becomes calcified.[278] The cut surface is predominantly cystic (Fig. 12.57). Adherence to surrounding structures is common. If the sebaceous material within it escapes, a prominent xanthogranulomatous inflammatory reaction follows. Perforation into the tracheobronchial tree may occur, and the patient coughs up sebaceous oily material and hair.

The microscopic appearance resembles that of the more common mature cystic teratoma of ovary. The cysts are lined by stratified squamous epithelium and contain sebaceous glands and hair follicles. Other common components are neural tissue, gastrointestinal tract, cartilage, and respiratory structures. Pancreatic tissue is particularly frequent in this location[279]; it may be accompanied by islet cell elements and result in hypoglycemia. The prognosis for mature teratoma is excellent following complete surgical excision.[280]

Figure 12.57 Mature Cystic Teratoma With Prominent Cystic Component. This tumor contained abundant pancreatic tissue, some of which was heavily inflamed.

Immature teratoma is defined, as in other sites, as a germ cell tumor similar to mature teratoma but also containing immature epithelial, mesenchymal, or neural elements without a component of embryonal carcinoma; the number of cases reported in the mediastinum is too small to know what to expect in terms of behavior, although anecdotal reports suggest more aggressive behavior in older children and young adults.[281] This condition should be distinguished both from teratocarcinoma (see later section) and from malignant ("somatic") transformation of mature cystic teratoma, the latter being a very rare event as summarized elsewhere.

Embryonal carcinoma is an invasive, highly necrotic neoplasm. Its microscopic appearance is, by definition, poorly differentiated. Immunohistochemically, there is reactivity for keratin, PLAP, OCT4, SALL4, CD30, and CD57 (Leu7). It is very important for the pathologist to consider the possibility of germ cell tumor in the presence of a poorly differentiated malignant neoplasm of the mediastinum, especially if the patient is a young male, instead of automatically relegating it to the category of "undifferentiated malignant tumor"; otherwise one might be denying the patient the opportunity of remission or cure with current chemotherapeutic regimens combined with surgery in selected patients.[282,283]

Yolk sac tumor (endodermal sinus tumor) may occur admixed with other germ cell elements or (more rarely) as a pure neoplasm (Fig. 12.58).[268,284] Yolk sac tumor is the second most common mediastinal germ cell tumor in children less than 15 years of age; yolk sac elements are more common in mediastinal than in testicular neoplasms.[285] Mediastinal yolk sac tumors may have prominent spindle cell features,[286] contain a hepatoid component,[287] or be accompanied by secondary multilocular cystic changes in the adjacent non-neoplastic thymus.[55] An OCT4–, SALL4+ immunophenotype is of great help in confirming the diagnosis, especially when combined with staining for alpha-fetoprotein and glypican-3.[288,289] The prognosis of pure yolk sac tumor has improved with combination chemotherapy and surgery.[283]

Teratocarcinoma is an older term used to describe mixed germ cell tumors characterized by a combination of embryonal carcinoma and teratoma (mature and/or immature), and comprises about 5% of all mediastinal germ cell tumors. Grossly, areas of hemorrhage and necrosis are present (Fig. 12.59). Microscopically, areas of embryonal carcinoma alternate with foci of predominantly mature teratoma.

Choriocarcinoma of the mediastinum occurs, for the most part, in the third decade of life.[290] It is often associated with gynecomastia

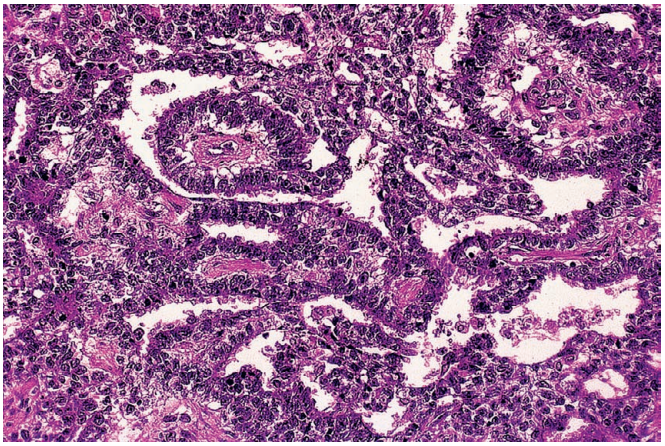

Figure 12.58 Yolk sac tumor of mediastinum, with well-developed Schiller–Duval bodies.

Figure 12.59 Mixed germ cell tumor of the mediastinum comprising a combination of embryonal carcinoma and teratoma *(teratocarcinoma)* that has undergone massive necrosis.

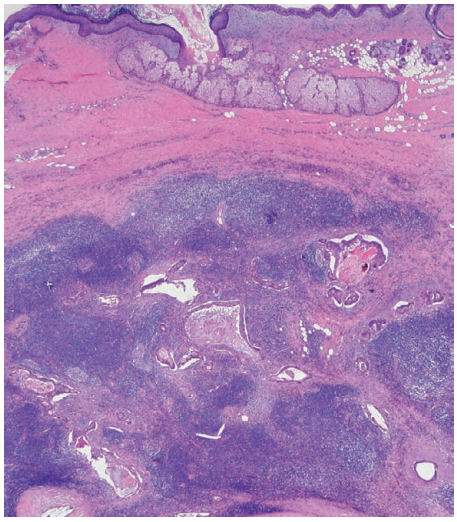

Figure 12.60 Somatic adenocarcinoma arising in a mediastinal teratoma from a 25-year-old man with chest and shoulder pain.

and invariably accompanied by elevated serum levels of human chorionic gonadotropin (hCG). The prognosis is extremely poor. The occurrence of choriocarcinoma as a primary lesion in the mediastinum has been accepted after several classical autopsy studies described cases in which serial sections of both testes showed no abnormalities. It should be emphasized, however, that it is in choriocarcinoma, more than any other germ cell tumor, that the possibility of an occult testicular primary lesion exists because of the tendency for this tumor type to be very small and even regressed ("burnt out") at the time that the metastases develop. The distinction, however, is mainly of academic interest inasmuch as the treatment (systemic chemotherapy) and the prognosis are similar regardless of whether an occult testicular tumor is identified or not. Placental site trophoblastic tumor is the only other type of mediastinal germ cell tumor showing trophoblastic differentiation reported in a 14-year-old boy 2 years after resection of a teratoma.[291]

As in other extragonadal locations and in the gonads, admixtures of various types of germ cell tumor are common.[269] These tumors are collectively referred to as *mixed germ cell tumors*; it is important to accurately report the components present.[292]

A cytogenetic aberration of germ cell tumors that is seen in over 80% of the cases, regardless of microscopic type or whether the tumor is primary or metastatic, is the presence of i(12p), that is, a gain of 12p, usually in the form of an isochromosome.[293] This determination can be of great diagnostic utility in this context and can be performed on formalin-fixed, paraffin-embedded material using a FISH technique.[294]

As a group, nonseminomatous germ cell tumors of the mediastinum respond reasonably well to a combination of chemotherapy and surgery with long-term survivals of around 50%.[282,283] Tumor stage, treatment response, and elevation of serum tumor markers following surgery are important prognostic indicators.[283]

A particularly ominous complication of nonseminomatous germ cell tumors of the mediastinum is the occasional development of a **somatic-type malignant tumor**, such as adenocarcinoma (Fig. 12.60), neuroendocrine tumors, angiosarcoma, malignant peripheral nerve sheath tumor (MPNST) or rhabdomyosarcoma.[295,296] Mediastinal germ cell tumors seem to be more prone to this event than gonadal neoplasms, occurring in adult males usually in association with tumor relapse following chemotherapy.[297] The prognostically unfavorable aspect of this development is that these somatic-type malignancies do not respond to germ cell–type chemotherapeutic protocols the way that conventional germ cell tumors do.[298]

The rare but well-documented development of clonally related hematologic neoplasms in this context can be viewed pathogenetically as another manifestation of this phenomenon.[299,300] It may take the form of acute leukemia or systemic mast cell disease diagnosed concurrently or within a year of the germ cell tumor and is particularly common in tumors with a yolk sac component.[301] The detection in these hematopoietic elements of i(12p) indicates that these cells are clonally related to the germ cell tumor and are not therapy-induced malignancies arising from the host bone marrow.

Malignant Lymphoma

Malignant lymphoma can present as an anterior, superior, or middle mediastinal mass, in this order of frequency. It represents the most common primary neoplasm of the middle portion of the mediastinum. It may appear in this area as a manifestation of a disseminated process, or it may present as a primary mediastinal disease. The diagnosis can be suspected on the basis of clinical and radiological features and can sometimes be confirmed with fine-needle aspiration and or core needle biopsy, including those obtained using an endobronchial ultrasound-guided transbronchial (EBUS) approach.[302] However, in a substantial subset of cases incisional biopsy using a surgical approach is required for diagnosis and classification.[303] The majority of malignant lymphomas presenting as primary mediastinal neoplasms fall into one of the four categories discussed in the following sections. The general features of these lymphomas are discussed in Chapter 37; only comments pertaining specifically to their mediastinal location will be mentioned here.

Classical Hodgkin Lymphoma

Mediastinal Hodgkin lymphoma can involve primarily the thymus, mediastinal lymph nodes, or both.[304] Most patients are young adults, and there is a predilection for females. The disease may present with local pressure symptoms (dyspnea, cough, chest pain) or be found incidentally in a chest x-ray or CT scan examination. Exceptional

cases of thymic Hodgkin lymphoma have been seen in association with myasthenia gravis[305] and with erythroid hypoplasia.[306] Primary Hodgkin lymphoma of the mediastinum is nearly always of the nodular sclerosis subtype. When affecting the nodes, its gross and microscopic appearance is similar to that seen elsewhere. When involving the thymus, it is usually sharply outlined and sometimes surrounded by a thick capsule not too dissimilar from that of a thymoma. The nodules may be multiple (a very rare event in true thymoma), and residual thymic tissue is usually identified. The consistency is hard, and the cut surface is vaguely or distinctly nodular (Fig. 12.61). It is not uncommon to find within the mass variously sized cysts containing clear or grumous fluid. Occasionally, the entire lesion has a gross appearance indistinguishable from that of a benign thymic cyst[307] resulting from the previously described cystic and proliferative reaction of thymic epithelium to form multilocular thymic cysts.[48]

The low-power appearance may resemble that of true thymoma by virtue of the presence of cellular nodules encircled by fibrous bands. In thymoma, however, the interphase between the fibrous strands and the neoplastic nodules is usually sharper, and the contour of the nodules tends to be angular rather than round (Fig. 12.62).

The infiltrate of Hodgkin lymphoma tends to be polymorphic, with lymphocytes, plasma cells, eosinophils, histiocytes, and the elements that provide the diagnosis, that is, Reed–Sternberg cells, their mononuclear variants, and lacunar cells (Fig. 12.63). These are often seen in intimate association with epithelial-lined cysts, Hassall corpuscles, and isolated thymic epithelial cells (Fig. 12.64). This feature has led in the distant past to a misinterpretation of the lesion as a "granulomatous" thymoma.[308] The fact that the thymus is the only extranodal site in which Hodgkin lymphoma occurs frequently and the intimate relationship that the Reed–Sternberg cells and other lymphoid elements have with the thymic epithelium suggest a pathogenetic mechanism that ought to be explored. Immunohistochemical stains for CD15 or CD30 and keratin sharply delineate the lymphoid neoplastic and epithelial reactive components, respectively. Another confusing pattern results from the arrangement of these cells in compact and rather monomorphic clusters, often surrounding foci of necrosis ("syncytial type" of Hodgkin lymphoma, see Chapter 37). These foci may simulate non-Hodgkin lymphoma, germ cell tumor, and carcinoma. Conversely, some foci—especially at the periphery—may show only a nonspecific chronic inflammatory infiltrate and fibrosis and be misdiagnosed as sclerosing mediastinitis. In some instances, the disease is accompanied by the formation of lymphoid follicles with prominent germinal centers, leading to a

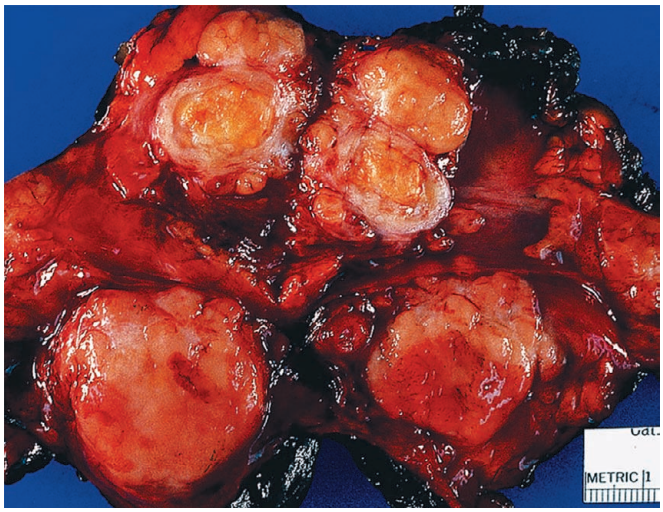

Figure 12.61 Cut surface of nodular sclerosis Hodgkin lymphoma of thymus showing characteristic multinodular involvement of the organ.

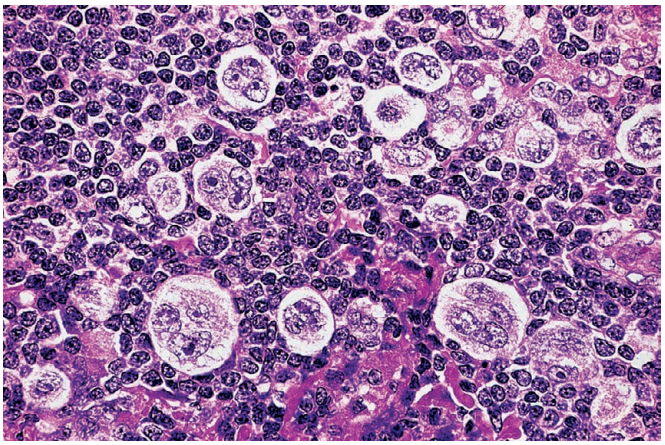

Figure 12.63 High-power view of Hodgkin lymphoma of thymus, showing numerous lacunar cells.

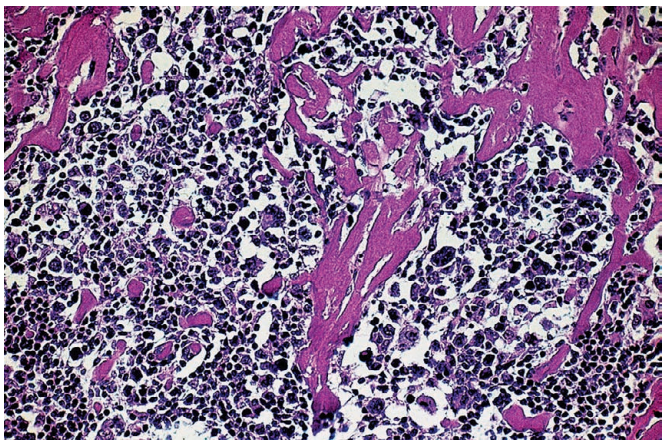

Figure 12.62 Nodular Sclerosis Hodgkin Lymphoma of Thymus. Note the nodular character of the process, the intense intranodular and internodular fibrosis, and the polymorphic nature of the infiltrate.

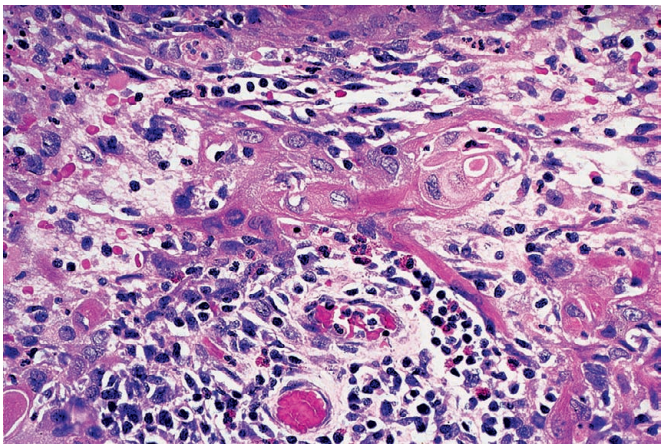

Figure 12.64 Hodgkin lymphoma of thymus accompanied by reactive hyperplasia of the entrapped thymic epithelium, which can simulate a thymic carcinoma of squamous type.

mistaken diagnosis of Castleman disease. In cases of this sort, if there is a strong radiographic suspicion of malignancy, a new biopsy from a more centrally located area should be requested. An important differential diagnostic point about the fibrosis is that, in addition to wide bands, it also manifests itself as a fine network that entraps small groups of cells or even individual cells, this resulting in a blurring of the boundaries of the nodules. This is not a feature of thymoma, although it can also be seen in large cell lymphoma.

The prognosis of mediastinal Hodgkin lymphoma is similar whether the neoplasm involves the thymus, the mediastinal lymph nodes, or both. The disease seldom spreads subdiaphragmatically in the absence of supraclavicular lymph node involvement.

The primary treatment is usually combination chemotherapy and radiotherapy, although irradiation alone or chemotherapy alone is adopted for occasional cases.[309] Sometimes, the aforementioned multilocular thymic cystic formations develop after the therapy and may simulate tumor relapse.[310] Thymic hyperplasia is another complication of treatment that may simulate recurrent disease.[311]

Lymphoblastic Lymphoma

Lymphoblastic lymphoma occurs primarily in children and young adults in whom it has a particular predilection for the thymic region.[312] It is usually of immature (precursor) T-cell type, but a certain degree of phenotypic heterogeneity occurs including cases of precursor B-cell and natural killer cell lineage.[313,314] Its typical presentation includes symptoms resulting from compression of mediastinal structures in an adolescent, sometimes requiring emergency radiation therapy. Males are more commonly affected than females. The disease is usually restricted to the supradiaphragmatic region, with frequent involvement of cervical, supraclavicular, and axillary nodes but sparing of peripheral blood or bone marrow (but see later). Grossly, the tumor is generally solid, soft, and nonencapsulated. Some preservation of the thymic shape can be appreciated in early cases. Microscopically, the infiltrate involves the thymic parenchyma and can be confused with a lymphocyte-rich (type B1) thymoma. However, the lymphocytes are atypical, with a very fine chromatin pattern, frequent nuclear convolutions (hence the older term *convoluted cell lymphoma*), numerous mitotic figures, and equally numerous necrotic cells (Fig. 12.65). Their "blastic" appearance is indistinguishable from that seen in the cells of acute lymphoblastic leukemia, to the point that a distinction between the two processes is arbitrary and mainly based on the sites of involvement. There is usually extension into the perithymic fat, and invasion of blood vessel walls is frequent (Fig. 12.66). Residual thymic lobules and Hassall corpuscles that have been expanded and infiltrated by the lymphoma cells should not be misinterpreted as evidence of thymoma (Fig. 12.67). It also should be remembered that true thymomas in children are exceptional. Fibrosis and formation of multilocular thymic cysts can be seen in thymic lymphoblastic lymphoma, but both phenomena are distinctly less common than in Hodgkin lymphoma. Occasionally, there is a scattering of eosinophils, and we have seen a case accompanied by focal granulomatous reaction. Necrosis can be very extensive, whether spontaneous or induced by radiation or steroid therapy, to the extent that the entire biopsy may show only necrotic lymphoma tissue. Under these circumstances, if the clinical and radiological features are compatible, the possibility of lymphoblastic lymphoma should be suspected, and a new biopsy requested.

A few cases of lymphoblastic lymphoma apparently developing from the lymphocytic component of lymphocyte-rich (type B1) thymomas have been reported.[315]

Primary Mediastinal (Thymic) Large B-Cell Lymphoma

Primary mediastinal (thymic) large B-cell lymphoma is a clinically and biologically distinct form of diffuse large B-cell lymphoma

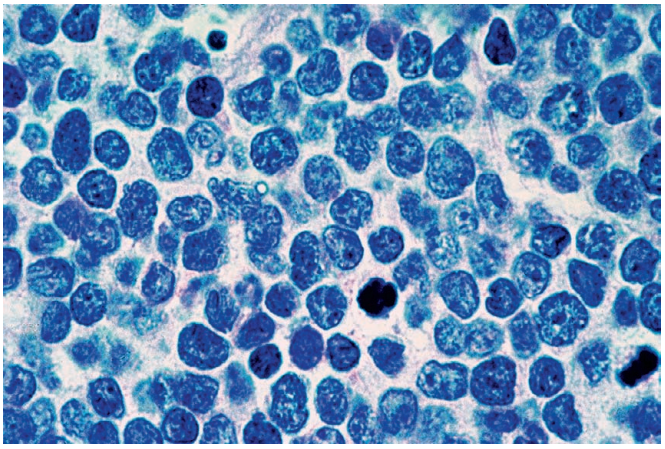

Figure 12.65 High-power view of lymphoblastic lymphoma of thymus, showing delicate convolutions of the nuclear membrane of the tumor cells.

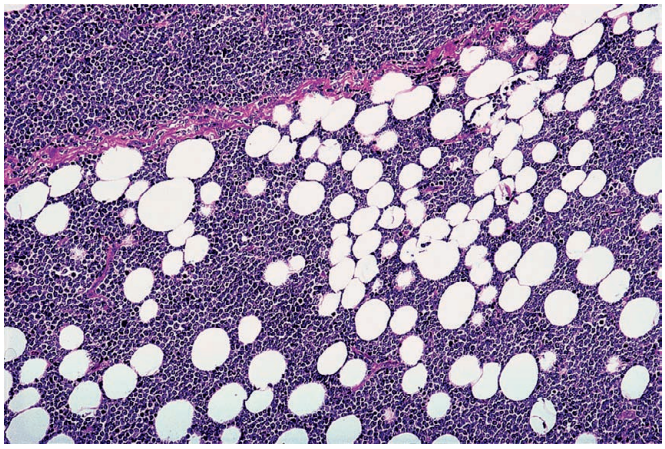

Figure 12.66 Diffuse infiltration of mediastinal fat by lymphoblastic lymphoma.

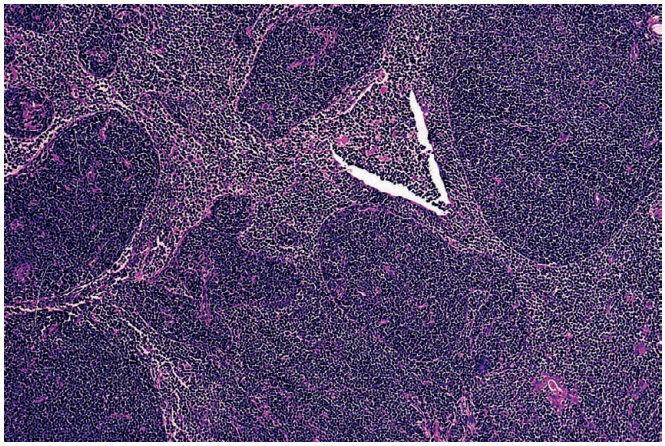

Figure 12.67 Infiltration and expansion of thymic lobules by lymphoblastic lymphoma.

of thymic origin that presents as bulky locally invasive anterior mediastinal disease without bone marrow involvement and nodal disease limited to contiguous cervical and intrathoracic sites. Most patients are young adult females, and presentation with superior vena cava syndrome is frequent.[316] The tumor has grossly invasive features: extension into pericardium, pleura, lung, sternum, and chest wall is common.[317] The consistency is generally firm, and there are frequent foci of necrosis (Fig. 12.68). Microscopically, a sometimes striking feature is the presence of wide bands of fibrosis, which results in compartmentalization of the tumor cells (Fig. 12.69) and a microscopic appearance that simulates an epithelial, germ cell, or neuroendocrine neoplasm. Other reasons for the frequent misdiagnosis of this tumor include the following: perivascular collections of lymphocytes (which may be misinterpreted as the perivascular spaces of thymoma) (Fig. 12.70); artifactual clearing of the cytoplasm induced by formalin fixation (not present in B5 or Zenker's fixed material) simulating seminoma (Fig. 12.71); presence of a large number of reactive T cells; rosette-like formations mimicking thymoma and thymic carcinoma[318]; and entrapment of thymic epithelium.[319]

A diagnosis of large cell lymphoma should be favored in the presence of tumor cells with large, vesicular, irregularly shaped nuclei (indented, kidney-shaped, polylobated); entrapment of intrathymic and perithymic fat; invasion of blood vessel wall, pleura, or lung; and the fact that the fibrosis is manifested not only in the form of wide hyaline bands but also as a fine network that entraps individual cells.[317,320] In some cases, the cellular pleomorphism is extreme.[321] Exceptionally, the tumor cells show tropism for germinal centers. The diagnosis may also be suspected on the basis of fine-needle aspiration material. Immunohistochemical reactivity for CD45 and B-cell antigens such as CD20 is invariably found reflecting the B-cell nature of this tumor. Close to 70% of the cases also express CD30, which is often variable in its intensity and distribution.[322] A

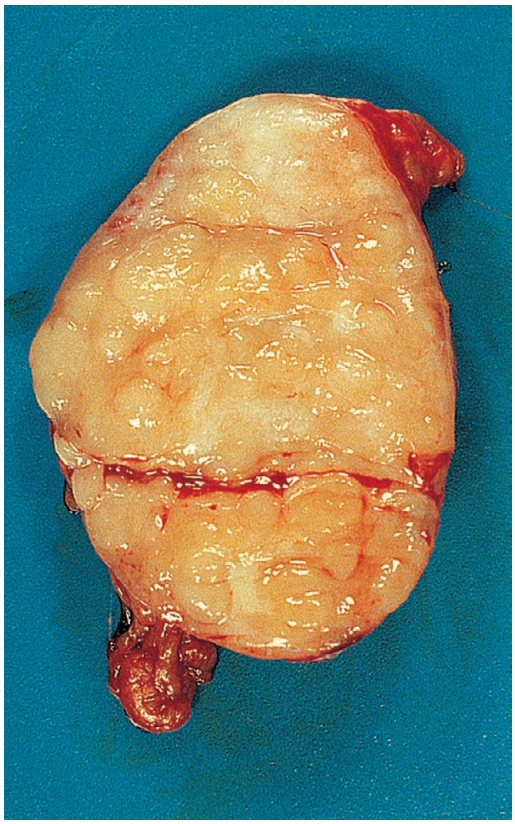

Figure 12.68 Gross Appearance of Large Cell Lymphoma With Sclerosis of the Thymus. There is distinct nodularity induced by the fibrous strands. This appearance is not too dissimilar from that of nodular sclerosis Hodgkin lymphoma.

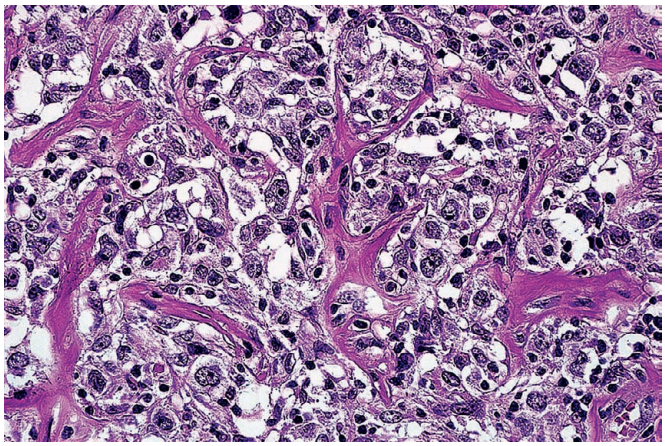

Figure 12.69 Primary mediastinal (thymic) large B-cell lymphoma with extensive fibrosis and nodularity.

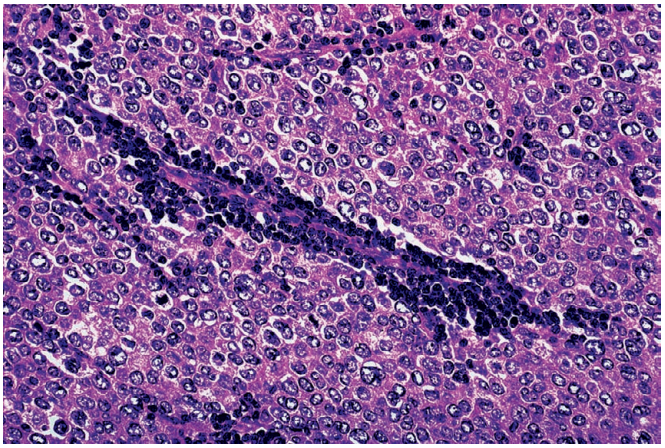

Figure 12.70 Perivascular cuffing by small non-neoplastic lymphocytes in primary mediastinal (thymic) large B-cell lymphoma. These formations should not be confused with the perivascular spaces of thymoma.

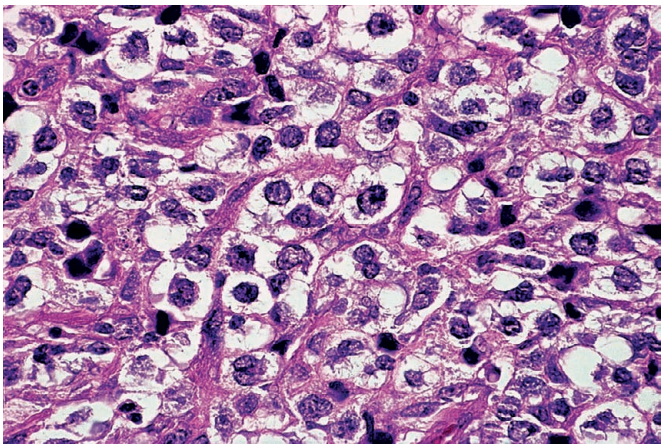

Figure 12.71 Artifactual cytoplasmic clearing in a case of primary mediastinal (thymic) large B-cell lymphoma which has been formalin fixed.

diagnostically helpful marker is CD23, which is expressed in 70% of cases of mediastinal large B-cell lymphoma, but in less than 15% of large B-cell lymphomas of other sites.[323] They also variably express BCL6 and CD10, indicating phenotypic overlap with large B-cell lymphomas derived from germinal center cells.[324] The peculiar morphologic, immunohistochemical, and molecular attributes of primary mediastinal (thymic) large B-cell lymphoma are significantly different from those of large B-cell lymphoma at other sites.[325] It has been postulated that it represents a distinct type of lymphoma, possibly arising from a subset of intrathymic lymphoid cells ("asteroid B-cells"), and that MAL (an integral membrane protein located in glycolipid-enriched membrane microdomains, called lipid rafts) is a distinct molecular marker for this tumor.[326] In contrast to other diffuse large B-cell lymphomas, primary mediastinal (thymic) large B-cell lymphoma rarely exhibits *BCL2* or *BCL6* gene rearrangement.[327] Common genetic changes are gains at 9p24 (including *JAK2*, *PDL1*, and *PDL2* loci) and 2p15 (including *REL* and *BCL11A* loci).[328–330] Inactivating mutations in *SOCS1*, an inhibitor of JAK/STAT signaling, occur in about half of the cases and contribute to activation of STAT.[331] In addition, the nuclear factor kappa B (NFκB) pathway is constitutively activated, but the pathogenetic mechanism remains unclear.[332]

It should be kept in mind that in young females with a clinically and microscopically malignant mediastinal tumor in which the differential diagnosis is among malignant thymoma, seminoma (germinoma), and primary mediastinal (thymic) large B-cell lymphoma, the correct diagnosis will be the latter entity in the large majority of cases.

Primary mediastinal (thymic) large B-cell lymphoma is usually restricted to the intrathoracic region at the time of initial presentation. An excellent response to radiation therapy and combination chemotherapy including rituximab is the rule,[316] but in some instances the tumor recurs within the chest and spreads to other sites, including peripheral lymph nodes and central nervous system.[333] We have been impressed by the high frequency with which the kidneys have been found to be involved in recurrent disease,[317] raising the possibility that some "homing" mechanism analogous to that hypothesized for mucosa-associated lymphoid tissue (MALT) lymphoma is involved.

Marginal Zone B-Cell Lymphoma

In recent years there have been increasingly frequent reports of cases of marginal zone B-cell lymphomas involving the thymus, particularly from Asian countries.[334] A marked predilection for females has been noted, and many of the patients had a history of Sjögren disease[335] or rheumatoid arthritis.[336] Some of the cases have been associated with lymph node[337] or gastric involvement.[338]

Microscopically, the tumors are predominantly composed of small lymphocytes with a variable admixture of monocytoid cells and plasma cells (Fig. 12.72). Prominent lymphoepithelial lesions are present, and there may be cystic formations.[334] Indeed, the presence in otherwise typical thymic lymphoid hyperplasia (of the type seen in association with collagen–vascular diseases) of sheets of centrocyte-like B cells disrupting the cytokeratin-positive medullary epithelial network should suggest the possibility of lymphoma, even if molecular analysis may be necessary to confirm the diagnosis.[339]

Notably, most cases of MALT-type thymic lymphoma express an IgA phenotype (in striking contrast with the IgM phenotype observed with this tumor type at other sites) and lack the *API2–MALT1* gene fusion and IgH-associated abnormalities described in MALT-type lymphomas elsewhere.[334] Instead they frequently demonstrate a pattern of chromosomal abnormalities, including trisomy 3, that is characteristic of autoimmune-associated MALT lymphomas arising in salivary gland and thyroid.[340] The clinical course is usually indolent; however, as with marginal zone B-cell lymphomas at other sites, there may be transformation to a large cell lymphoma.[341]

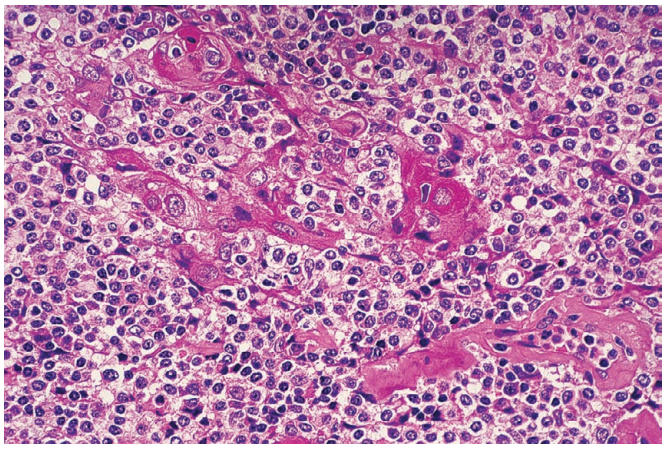

Figure 12.72 Malignant Lymphoma of Marginal Zone Type Involving the Thymus. The tumor cells surround and distort Hassall corpuscles. (Courtesy of Dr John Chan, Hong Kong)

Other Hematolymphoid Conditions

Composite lymphomas of various types have been observed in this location. A type that we have seen with inordinately high frequency is that comprised by large B-cell lymphoma with sclerosis and nodular sclerosis Hodgkin lymphoma, each component exhibiting its distinctive phenotype. The relationship between these two lymphoma types may manifest itself synchronously—either as two distinct zones within the same mass or as a mass having transitional features throughout (so-called mediastinal gray zone lymphoma, now termed *B-cell lymphoma, unclassifiable, with features intermediate between diffuse large B-cell lymphoma and classical Hodgkin lymphoma*)—or sequentially, that is, as a tumor type appearing as a recurrence of the other.[342,343] The frequency of the association, the blending of the two components one sometimes observes, and the several clinicopathologic features they share (predilection for young females, tendency to induce sclerosis) suggest that these two processes are histogenetically and pathogenetically related. Support for this hypothesis comes from a molecular study carried out in one such composite case, in which the results suggested an origin of the tumor from a common precursor in which a secondary molecular event gave rise to two different clonally related lymphomas.[344] Furthermore, the gene expression profile of mediastinal large B-cell lymphoma shows greater similarities with that of classical Hodgkin lymphoma than conventional large B-cell lymphoma, including downregulation of the B-cell receptor signaling pathway and high expression of cytokine pathway components, TNF family members, and extracellular matrix elements.[325,345] These findings can help to explain the development of this form of composite lymphoma.

Anaplastic large cell lymphoma can present as a primary mediastinal mass.[346,347] The main differential diagnostic criteria are the same as for lymph nodes and other sites (see Chapter 37).

Myeloid sarcoma (chloroma, granulocytic sarcoma, extramedullary myeloid tumor) can also present as a mediastinal mass and be mistaken for malignant lymphoma on microscopic grounds.[348,349] As with myeloid sarcomas in other sites (see Chapter 39), it may present as an isolated finding or with associated leukemia.[350]

Plasmacytoma has been reported as a mediastinal mass, preceding the onset of multiple myeloma.[351]

Castleman disease (giant lymph node hyperplasia) has a special predilection for the mediastinum and is discussed in greater detail in Chapter 37. Before its recognition as an entity, it was often confused with thymoma, in part because the hyalinized germinal centers that constitute the hallmark of the hyaline vascular form of this disease were misinterpreted as Hassall corpuscles.[352] It usually involves mediastinal nodes, but exceptionally it may be located within the thymus.[79] Surgical removal of a solitary mass of the hyaline vascular type of this disease (which is by far the most common) is curative.[353]

Extramedullary hematopoiesis may present as a large, solitary mediastinal mass, usually located along the paravertebral column. The primary disease in most patients is hereditary spherocytosis or thalassemia; sickle cell disease has also been reported.[354,355] *Myelolipoma* is a microscopically similar process but it usually lacks evidence of a background hematologic disorder.[356]

Follicular dendritic cell tumor can present as a primary mediastinal mass arising from either lymph nodes or thymus, and may arise in a background of Castleman disease[357] (Fig. 12.73). It is listed in this section because of the functional relationship of the cells of this tumor with the lymphoid system, but its behavior and response to therapy are more in keeping with a sarcoma. Remarkably, a case has been reported associated with myasthenia gravis.[358] The main differential diagnosis because of the location is with type B thymoma. This can be very difficult at the H&E level, but their immunohistochemical profiles are very different.[357]

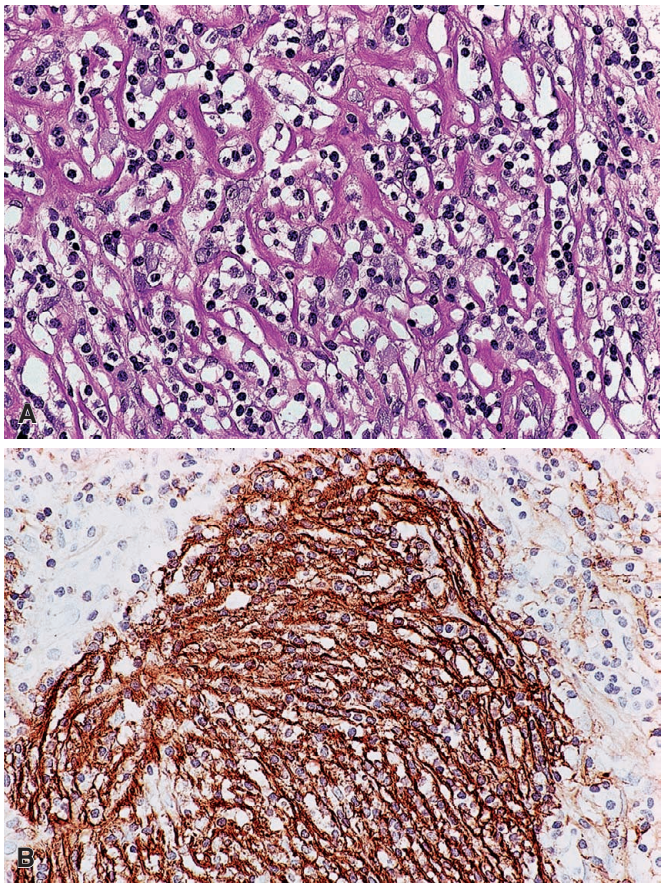

Figure 12.73 **A** and **B**, H&E appearance and CD21 immunoreactivity of dendritic follicular cell tumor of mediastinum. The biphasic pattern resulting from the presence of numerous non-neoplastic lymphocytes can elicit a mistaken diagnosis of thymoma.

Neurogenic Tumors

Neurogenic tumors make up a high proportion of the posterior mediastinal neoplasms, in both adults and children, but they can also occur in other mediastinal compartments. The two major categories are tumors of the *sympathetic nervous system* and tumors of *peripheral nerve sheath*. A definite relationship between age and the relative incidence of these tumors exists.[359] In a series of 160 cases, the majority of the tumors occurring in patients younger than the age of 10 years belonged to the sympathetic nervous system category, and all of those in patients younger than 1 year of age were neuroblastomas or ganglioneuroblastomas.[360] Most ganglioneuromas, paragangliomas, and tumors of nerve sheath origin were seen after the age of 20 years. Radiographically, most tumors of the sympathetic nervous system have an elongated tapered appearance, whereas benign tumors of nerve sheath origin are round and well circumscribed.

Tumors of Sympathetic Nervous System

The general features of these tumors are discussed elsewhere in this text. The main difference between the mediastinal and retroperitoneal (particularly adrenal) tumors is the greater degree of differentiation seen in the former. Thus **neuroblastoma** is rather unusual in this location, appearing as an infiltrative mass with areas of necrosis and calcification, usually high in the posterior mediastinum and seen almost exclusively in children, although notable exceptions occur.[361] Most of the mediastinal tumors of this group in children are examples of **ganglioneuroblastoma**, a tumor that has an intermediate degree of differentiation and that is related to differentiating neuroblastoma and immature ganglioneuroma.[362] Grossly, it tends to be better circumscribed than neuroblastoma and is sometimes surrounded by a well-formed capsule. It should be mentioned that some neuroblastomas and ganglioneuroblastomas are located in the anterosuperior mediastinum (in close relationship with the thymus) rather than in the usual posterior location.[363] Curiously, some of these cases have been associated with inappropriate secretion of antidiuretic hormone (Fig. 12.74).[364] Others have arisen from a mediastinal germ cell tumor[365]; ganglioneuroblastomatous differentiation has also been reported in a thymoma.[366]

Ganglioneuroma occurs in older children and in adults and is the most common of the three tumors.[359] Grossly, it forms a smooth, well-encapsulated mass, usually in the posterior portion of the

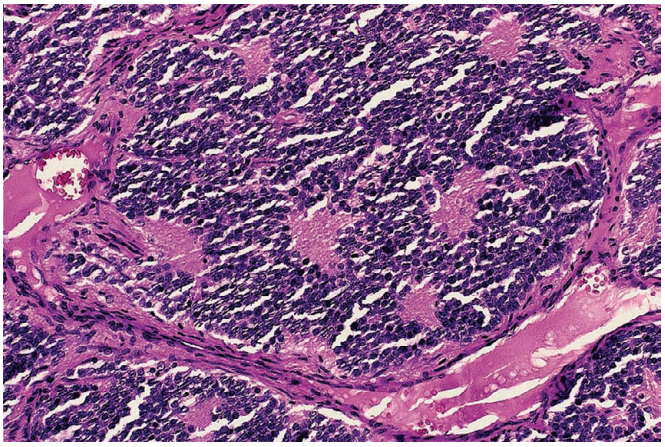

Figure 12.74 Neuroblastoma of mediastinum with prominent rosettes in an adult patient. These tumors can be associated with inadequate secretion of ADH.

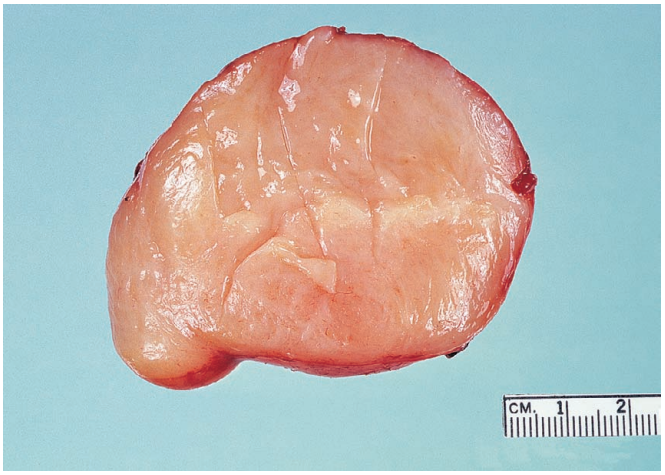

Figure 12.75 Mediastinal Ganglioneuroma. The tumor is solid, yellowish, and homogeneous.

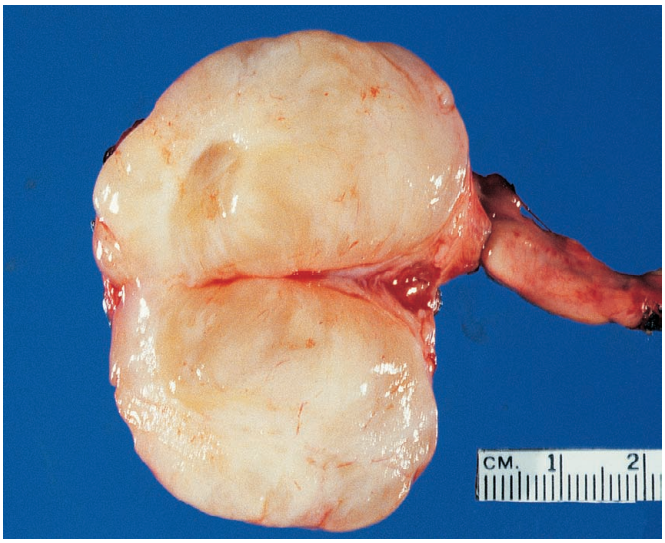

Figure 12.76 Mediastinal Neurofibroma. The tumor is attached to a large nerve trunk.

mediastinum. The consistency is soft, and the cut surface is yellowish gray; it may contain cystic areas and fatty degeneration, but fresh necrosis is generally absent (Fig. 12.75). Microscopically, an admixture of mature ganglion cells and spindle cells, which could be viewed either as Schwann cells or as satellite cells, is present. The ganglion cells may have several nuclei and are often arranged in clusters. Focal collections of lymphocytes are often present; they should not be confused with the immature cells of ganglioneuroblastoma. These tumors can be multiple and can occur in different locations, with various degrees of differentiation.

The survival rate in patients with tumors of the sympathetic nervous system is directly related to the degree of differentiation of the tumor. As already stated, thoracic neoplasms tend to be better differentiated than their retroperitoneal (particularly adrenal) counterparts; this probably explains why as a group they are associated with a better prognosis.[367,368] Relapses in the central nervous system have occurred in some cases of intrathoracic neuroblastoma.[369] Adequate excision effects cure in all patients with ganglioneuromas but may be less impactful in intrathoracic cases.[368] The prognosis in patients with ganglioneuroblastomas that contain both elements is somewhat unpredictable, but cure is achieved in most instances.[362] As expected, the prognosis in neuroblastoma is the least favorable for the entire group.

Tumors of Peripheral Nerves

The three major tumors in this category are schwannoma, neurofibroma, and MPNST (Fig. 12.76).[360,370] The general features of these tumors are discussed in Chapter 41. It is interesting to note that whereas neurofibroma in most other locations is a nonencapsulated tumor, in the mediastinum it is often surrounded by a complete fibrous capsule, perhaps because of the large size that it can reach at this site. Therefore the presence of encapsulation cannot be used as a distinguishing feature between the two types of benign peripheral nerve tumor. Another feature common to these neoplasms, perhaps again the result of their sometimes unduly large size, is the high frequency of regressive change, such as fatty degeneration, hemorrhage, and cystic formation. Some can become completely cystic, and their recognition may be difficult. Schwannomas exhibiting prominent cystic and other regressive changes have been described as "ancient," under the assumption that they have been present for a very long time. Indeed, most benign peripheral nerve sheath tumors are asymptomatic and are discovered incidentally on radiological examinations. Some schwannomas can be very cellular, somewhat pleomorphic, and mitotically active and thus be confused with sarcoma.[371,372] The prognosis for both schwannoma (including its cellular variant) and neurofibroma is excellent, excision being curative in nearly every instance.

MPNST of mediastinum may arise de novo or, more commonly, in the setting of neurofibromatosis type 1.[373] In the initial stages of the malignant transformation of a neurofibroma, the change may be barely perceptible microscopically, the only suggestion being some slight increase in cellularity. With outspoken malignant change, the tumor cells become bizarre, and it may then be impossible to recognize the malignant tumor as originating from a preexisting neurofibroma. In these instances, the presence of neurofibromatosis in a previous biopsy, or the presence of other neurofibromas may suggest the diagnosis.

Some mediastinal MPNSTs have areas of glandular differentiation or rhabdomyoblastic features (so-called "triton tumor"). The prognosis, which is generally poor, seems to be related to resection status, tumor size, and tumor grade.

Other Neurogenic Tumors

Two types of central nervous system-related neoplasm that can exceptionally present as primary (usually posterior) mediastinal neoplasms are **ependymoma**[374] and **meningioma**[375]; the latter, which may have its origin in the stellate ganglion, is closely related to and sometimes indistinguishable from perineurioma.

Tumors of Paraganglia

Most mediastinal paragangliomas occur in association with the aorticopulmonary paraganglia and therefore occur in the anterosuperior mediastinum, close to the base of the heart (Fig. 12.77). Others arise from mediastinal aorticosympathetic paraganglia and occur posteriorly, along the costovertebral sulcus. Their morphologic appearance is identical to paragangliomas in other locations, such as the carotid body (see Chapter 29). A few have been pigmented (melanotic).[376] The majority of these tumors are nonfunctioning. Some, however (particularly when related to the sympathetic system), can result in hypertension and are sometimes referred to as extra-adrenal pheochromocytomas. However, it is now agreed to reserve

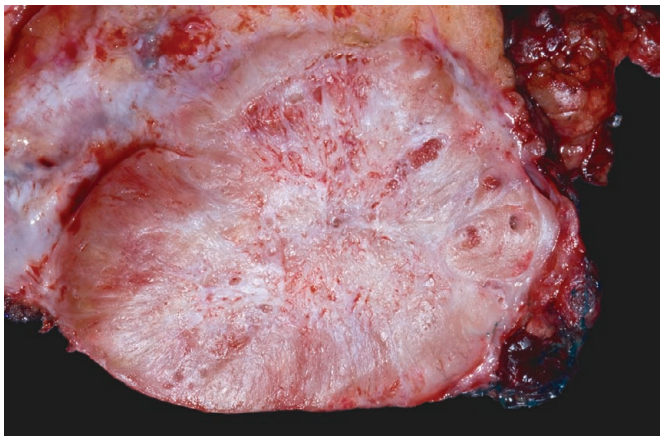

Figure 12.77 Mediastinal Paraganglioma. The well-circumscribed tumor has a characteristic solid, yellow tan cut surface with a vaguely lobular architecture but without the connective tissue septa typical of thymoma. (Courtesy of Dr. J. Carvalho, Minneapolis, MN)



Figure 12.78 Hemangioma of Mediastinum. The tumor is formed of large tortuous vessels.

the designation of pheochromocytomas for paragangliomas located in the adrenal medulla, whether they are functioning or not.

Some mediastinal paragangliomas have occurred as a component of the Carney triad, together with pulmonary hamartomas and malignant gastrointestinal stromal tumors (GISTs).[377]

Traditionally, mediastinal paragangliomas have been regarded as generally benign in nature. However, a critical long-term follow-up study of 35 reported cases revealed that the tumor had behaved in an aggressive fashion in 16 (46%), resulting in significant morbidity and sometimes in death.[378] Subsequent experience with this tumor has confirmed these findings.[379]

Mesenchymal Tumors

The list of microscopic types of neoplasms arising in mediastinal soft tissues outside of the thymus is long despite their rarity.[380]

Lipoma is one of the most common benign mesenchymal neoplasms of the mediastinum. It is often very large and located just above the diaphragm. Occasionally, it extends into both pleural cavities, making complete removal difficult. The absence of thymic tissue separates mediastinal lipoma from thymolipoma. The differential diagnosis also includes *lipomatosis*, a diffuse accumulation of mature adipose tissue that may occur in association with obesity, Cushing disease, or steroid therapy,[381] and which can lead to a "sabre sheath" tracheal deformity radiographically.

Other benign adipose tissue tumors of the mediastinum include *lipoblastoma* and *lipoblastomatosis* of infancy,[382] *hibernoma*,[383] *angiolipoma*,[384] and *angiomyolipoma*.[385]

Lymphangioma is another common mediastinal neoplasm. Most cases are seen in the anterosuperior mediastinum of children, often in continuity with a cervical component.[386] *Lymphangiomyoma* and *lymphangiomyomatosis* occur exclusively in females, the distinction among the two depending on their circumscribed versus infiltrative pattern of growth, respectively; they are included in the family of PEComas and are discussed elsewhere (see Chapters 10 and 41).

Hemangioma in adults is usually of the cavernous variety (Fig. 12.78).[387] Microscopically, it is composed of dilated vessels lined by attenuated endothelium, separated by fine septa. Foci of thrombosis, calcification, and cholesterol granulomas may be present. Excision is usually curative. In children, the hemangiomas may have a very cellular appearance (benign hemangioendotheliomas).[388] **Glomus tumors** have been described in the mediastinum, some of them having atypical features.[389] **Hemangiopericytomas** have been described in this location, but most anterosuperior mediastinal tumors with a hemangiopericytoma-like pattern are either well-vascularized thymomas or cellular solitary fibrous tumors (see following section). Another vascular tumor that can occur in the mediastinum is **epithelioid hemangioendothelioma**[390]; curiously, some of these tumors have been accompanied by osteoclast-like multinucleated giant cells, a feature almost never seen in epithelioid hemangioendotheliomas at other sites. **Angiosarcoma** also occurs[391]; in such cases, the possibility of the lesion having arisen against a background of a germ cell tumor should be investigated by thorough sampling.

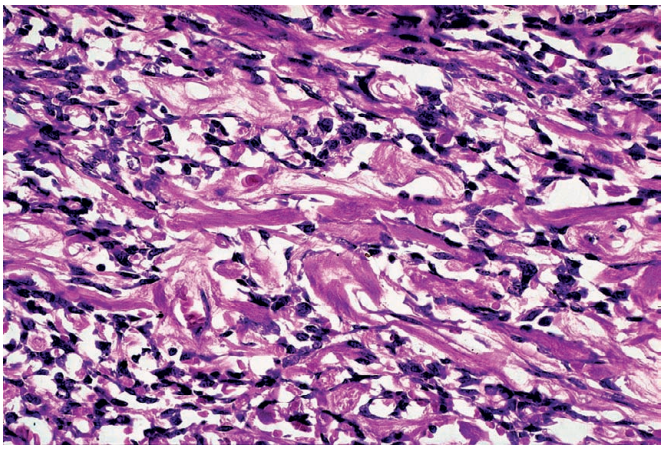

Figure 12.79 Solitary Fibrous Tumor of Mediastinum. The alternation of hypercellular and hypocellular areas is typical of this entity.

Leiomyoma, sometimes arising from vascular trunks, has been sporadically reported.[392]

Rhabdomyoma has been seen not only within the thymus but also independently arising in mediastinal soft tissues.[393]

Solitary fibrous tumor of the mediastinum is the mediastinal equivalent of solitary fibrous tumor of the pleura.[394] It is possible that some of these tumors grow into the mediastinum from the medial pleura, but we think that most originate from the mediastinal (including thymic) stroma. Their microscopic appearance and immunohistochemical profile are similar to those of their pleural counterpart (Fig. 12.79), but a higher proportion of the reported cases have run an aggressive clinical course.

Figure 12.80 Gross appearance of an atypical lipomatous tumor (well-differentiated liposarcoma) of mediastinum.

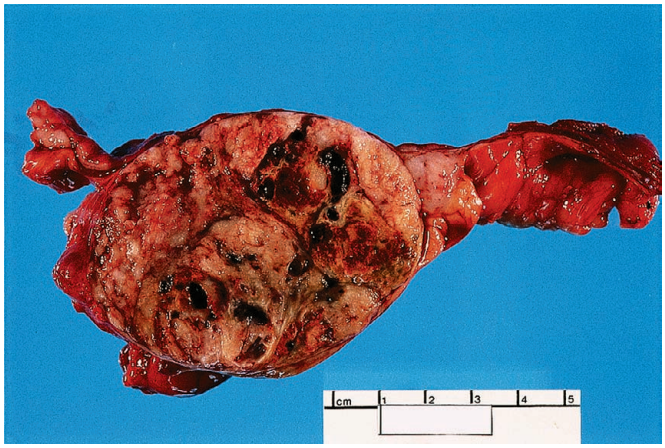

Figure 12.81 Gross appearance of a primary synovial sarcoma of mediastinum.

Liposarcoma predominates among the malignant mesenchymal neoplasms (Fig. 12.80).[262] Sometimes it is seen in conjunction with liposarcoma of thigh or retroperitoneum as a manifestation of multicentric disease. As referenced previously in this chapter, some mediastinal liposarcomas containing thymic tissue can be viewed as thymic stromal sarcomas with a liposarcomatous component and as possible counterparts of thymolipomas (i.e. as thymoliposarcomas). Most mediastinal liposarcomas are well-differentiated tumors, sometimes accompanied by areas of dedifferentiation.

Synovial sarcoma can present as a primary mediastinal neoplasm, its morphologic appearance being the same as that of tumors occurring in the extremities (Fig. 12.81).[395] Biphasic, monophasic, and poorly differentiated types occur. The most important differential diagnosis is with SETTLE (see previous section in this chapter).[227]

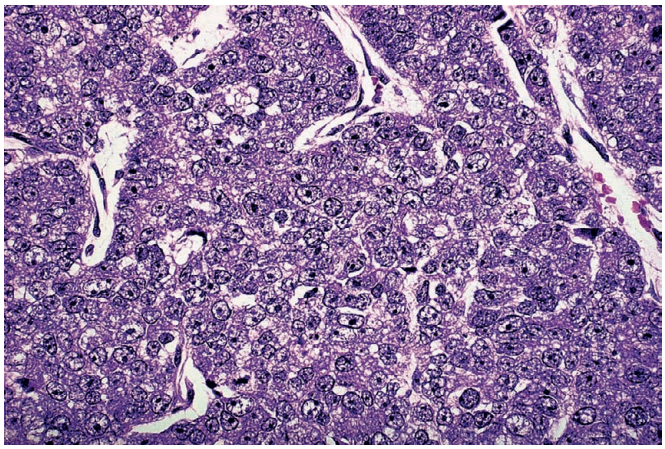

Figure 12.82 **Mediastinal Metastasis of Prostatic Adenocarcinoma.** This tumor was initially misdiagnosed as a thymic carcinoma.

Other malignant mesenchymal tumors that have been observed in the mediastinum include **low-grade fibromyxoid sarcoma**,[396] **leiomyosarcoma**,[397] **rhabdomyosarcoma** (unassociated with germ cell, thymic, or peripheral nerve elements),[398] **chondrosarcoma**[399] (including the mesenchymal variety[400]), **alveolar soft part sarcoma**,[401] **giant cell tumor of soft parts**,[402] **malignant mesenchymoma**, and so-called **malignant fibrous histiocytoma** (undifferentiated pleomorphic sarcoma).[403]

Metastatic Tumors

Some tumors metastatic to the mediastinum can mimic clinically and radiographically a primary mediastinal neoplasm. Small cell undifferentiated carcinoma of the lung is the most notorious example, often appearing as a huge mediastinal mass in the presence of a small, radiographically undetectable bronchial lesion. Other types of lung carcinoma may produce a similar picture, by either direct extension or nodal metastases.

Direct mediastinal extension can also occur with tumors of the esophagus, pleura, chest wall, vertebra, or trachea. Other tumors that can metastasize to the mediastinum and be confused with primary neoplasms—sometimes even at the microscopic level—are carcinomas of the breast, thyroid, nasopharynx, larynx, kidney, prostate, and ovary (which may simulate multilocular thymic cyst[404]); testicular germ cell tumors; and malignant melanoma.[405,406] Two such tumor types that we have seen initially misinterpreted as thymic carcinomas were metastatic prostatic carcinoma and metastatic malignant melanoma (Fig. 12.82). Since most of these tumors are located, at least initially, in mediastinal lymph nodes, they are usually centered in the middle mediastinum (where most mediastinal lymph nodes are situated), and they may exhibit a residual nodal component at their periphery.

References

1. Cohen AJ, Thompson L, Edwards FH, Bellamy RF. Primary cysts and tumors of the mediastinum. *Ann Thorac Surg*. 1991;51(3):378-384, discussion 85-86.
2. Azarow KS, Pearl RH, Zurcher R, et al. Primary mediastinal masses. A comparison of adult and pediatric populations. *J Thorac Cardiovasc Surg*. 1993;106(1):67-72.
3. Wilson LD, Detterbeck FC, Yahalom J. Clinical practice. Superior vena cava syndrome with malignant causes. *N Engl J Med*. 2007;356(18):1862-1869.
4. Ingram L, Rivera GK, Shapiro DN. Superior vena cava syndrome associated with childhood malignancy: analysis of 24 cases. *Med Pediatr Oncol*. 1990;18(6):476-481.
5. Mahajan V, Strimlan V, Ordstrand HS, Loop FD. Benign superior vena cava syndrome. *Chest*. 1975;68(1):32-35.
6. Lalwani AK, Kaplan MJ. Mediastinal and thoracic complications of necrotizing fasciitis of the head and neck. *Head Neck*. 1991;13(6):531-539.

7. Abdelkafi S, Dubail D, Bosschaerts T, et al. Superior vena cava syndrome associated with Nocardia farcinica infection. *Thorax*. 1997;52(5):492-493.
8. Pitchenik AE, Zaunbrecher F. Superior vena cava syndrome caused by Nocardia asteroides. *Am Rev Respir Dis*. 1978;117(4):795-798.
9. Kim JY, Lim CM, Koh Y, et al. A case of superior vena cava syndrome caused by Klebsiella pneumoniae. *Eur Respir J*. 1997;10(12):2902-2903.
10. Combes A, Trouillet JL, Baudot J, et al. Is it possible to cure mediastinitis in patients with major postcardiac surgery complications? *Ann Thorac Surg*. 2001;72(5):1592-1597.
11. Devaraj A, Griffin N, Nicholson AG, Padley SP. Computed tomography findings in fibrosing mediastinitis. *Clin Radiol*. 2007;62(8):781-786.
12. Sherrick AD, Brown LR, Harms GF, Myers JL. The radiographic findings of fibrosing mediastinitis. *Chest*. 1994;106(2):484-489.
13. Dines DE, Payne WS, Bernatz PE, Pairolero PC. Mediastinal granuloma and fibrosing mediastinitis. *Chest*. 1979;75(3):320-324.
14. Peikert T, Colby TV, Midthun DE, et al. Fibrosing mediastinitis: clinical presentation, therapeutic outcomes, and adaptive immune response. *Medicine (Baltimore)*. 2011;90(6):412-423.
15. Katzenstein AL, Mazur MT. Pulmonary infarct: an unusual manifestation of fibrosing mediastinitis. *Chest*. 1980;77(4):521-524.
16. Peikert T, Shrestha B, Aubry MC, et al. Histopathologic Overlap between Fibrosing Mediastinitis and IgG4-Related Disease. *Int J Rheumatol*. 2012;2012:207056.
17. Westerly BD, Johnson GB, Maldonado F, et al. Targeting B lymphocytes in progressive fibrosing mediastinitis. *Am J Respir Crit Care Med*. 2014;190(9):1069-1071.
18. Wick MR. Cystic lesions of the mediastinum. *Semin Diagn Pathol*. 2005;22(3):241-253.
19. St-Georges R, Deslauriers J, Duranceau A, et al. Clinical spectrum of bronchogenic cysts of the mediastinum and lung in the adult. *Ann Thorac Surg*. 1991;52(1):6-13.
20. Rokach A, Izbicki G, Deeb M, et al. Ectopic pancreatic pseudocyst and cyst presenting as a cervical and mediastinal mass: case report and review of the literature. *Diagn Pathol*. 2013;8:176.
21. Suzuki K, Koyama S, Yamada S, Kawabata Y. Adenocarcinoma arising in a mediastinal enteric cyst. *Intern Med*. 2007;46(11):781-784.
22. Electra MM, Evangelia A, Mattheos B, et al. Thoracic duct cyst of posterior mediastinum: a "challenging" differential diagnosis. *Ann Transl Med*. 2016;4(9):166.
23. Simmons M, Duckworth LV, Scherer K, et al. Mullerian cysts of the posterior mediastinum: report of two cases and review of the literature. *J Thorac Dis*. 2013;5(1):E8-E10.
24. Plaza JA, Dominguez F, Suster S. Cystic adenomatoid tumor of the mediastinum. *Am J Surg Pathol*. 2004;28(1):132-138.
25. Katlic MR, Wang CA, Grillo HC. Substernal goiter. *Ann Thorac Surg*. 1985;39(4):391-399.
26. Torre G, Borgonovo G, Amato A, et al. Surgical management of substernal goiter: analysis of 237 patients. *Am Surg*. 1995;61(9):826-831.
27. Sagan D, Gozdziuk K. Surgical treatment of mediastinal parathyroid adenoma: rationale for intraoperative parathyroid hormone monitoring. *Ann Thorac Surg*. 2010;89(6):1750-1755.
28. Wei B, Inabnet W, Lee JA, Sonett JR. Optimizing the minimally invasive approach to mediastinal parathyroid adenomas. *Ann Thorac Surg*. 2011;92(3):1012-1017.
29. Murphy MN, Glennon PG, Diocee MS, et al. Nonsecretory parathyroid carcinoma of the mediastinum. Light microscopic, immunocytochemical, and ultrastructural features of a case, and review of the literature. *Cancer*. 1986;58(11):2468-2476.
30. Shields TW, Immerman SC. Mediastinal parathyroid cysts revisited. *Ann Thorac Surg*. 1999;67(2):581-590.
31. von Gaudecker B. Functional histology of the human thymus. *Anat Embryol (Berl)*. 1991;183(1):1-15.
32. von Gaudecker B, Steinmann GG, Hansmann ML, et al. Immunohistochemical characterization of the thymic microenvironment. A light-microscopic and ultrastructural immunocytochemical study. *Cell Tissue Res*. 1986;244(2):403-412.
33. Anderson G, Jenkinson WE, Jones T, et al. Establishment and functioning of intrathymic microenvironments. *Immunol Rev*. 2006;209:10-27.
34. Janossy G, Bofill M, Trejdosiewicz LK, et al. Cellular differentiation of lymphoid subpopulations and their microenvironments in the human thymus. *Curr Top Pathol*. 1986;75:89-125.
35. Flores KG, Li J, Hale LP. B cells in epithelial and perivascular compartments of human adult thymus. *Hum Pathol*. 2001;32(9):926-934.
36. Landry D, Lafontaine M, Cossette M, et al. Human thymic dendritic cells. Characterization, isolation and functional assays. *Immunology*. 1988;65(1):135-142.
37. Parker JR, Ro JY, Ordonez NG. Benign nevus cell aggregates in the thymus: a case report. *Mod Pathol*. 1999;12(3):329-332.
38. Wakkach A, Poea S, Chastre E, et al. Establishment of a human thymic myoid cell line. Phenotypic and functional characteristics. *Am J Pathol*. 1999;155(4):1229-1240.
39. Smith SM, Ossa-Gomez LJ. A quantitative histologic comparison of the thymus in 100 healthy and diseased adults. *Am J Clin Pathol*. 1981;76(5):657-665.
40. Haynes BF, Sempowski GD, Wells AF, Hale LP. The human thymus during aging. *Immunol Res*. 2000;22(2-3):253-261.
41. Fukai I, Funato Y, Mizuno T, et al. Distribution of thymic tissue in the mediastinal adipose tissue. *J Thorac Cardiovasc Surg*. 1991;101(6):1099-1102.
42. Talmon GA, Lewis JE. Lymphocyte-depleted thymic remnants: a potential diagnostic pitfall in the evaluation of central neck dissections. *Am J Clin Pathol*. 2009;132(5):707-712.
43. Cheuk W, Tsang WY, Chan JK. Microthymoma: definition of the entity and distinction from nodular hyperplasia of the thymic epithelium (so-called microscopic thymoma). *Am J Surg Pathol*. 2005;29(3):415-419.
44. Nezelof C. Thymic pathology in primary and secondary immunodeficiencies. *Histopathology*. 1992;21(6):499-511.
45. Huber J, Zegers BJ, Schuurman HJ. Pathology of congenital immunodeficiencies. *Semin Diagn Pathol*. 1992;9(1):31-62.
46. van Baarlen J, Schuurman HJ, Huber J. Acute thymus involution in infancy and childhood: a reliable marker for duration of acute illness. *Hum Pathol*. 1988;19(10):1155-1160.
47. Strome M, Eraklis A. Thymic cysts in the neck. *Laryngoscope*. 1977;87(10 Pt 1):1645-1649.
48. Suster S, Rosai J. Multilocular thymic cyst: an acquired reactive process. Study of 18 cases. *Am J Surg Pathol*. 1991;15(4):388-398.
49. Suster S, Barbuto D, Carlson G, Rosai J. Multilocular thymic cysts with pseudoepitheliomatous hyperplasia. *Hum Pathol*. 1991;22(5):455-460.
50. Izumi H, Nobukawa B, Takahashi K, et al. Multilocular thymic cyst associated with follicular hyperplasia: clinicopathologic study of 4 resected cases. *Hum Pathol*. 2005;36(7):841-844.
51. Mishalani SH, Lones MA, Said JW. Multilocular thymic cyst. A novel thymic lesion associated with human immunodeficiency virus infection. *Arch Pathol Lab Med*. 1995;119(5):467-470.
52. Lewis CR, Manoharan A. Benign thymic cysts in Hodgkin's disease: report of a case and review of published cases. *Thorax*. 1987;42(8):633-634.
53. Moran CA, Suster S. Mediastinal seminomas with prominent cystic changes. A clinicopathologic study of 10 cases. *Am J Surg Pathol*. 1995;19(9):1047-1053.
54. Nakamura S, Tateyama H, Taniguchi T, et al. Multilocular thymic cyst associated with thymoma: a clinicopathologic study of 20 cases with an emphasis on the pathogenesis of cyst formation. *Am J Surg Pathol*. 2012;36(12):1857-1864.
55. Moran CA, Suster S. Mediastinal yolk sac tumors associated with prominent multilocular cystic changes of thymic epithelium: a clinicopathologic and immunohistochemical study of five cases. *Mod Pathol*. 1997;10(8):800-803.
56. Rakheja D, Weinberg AG. Multilocular thymic cyst associated with mature mediastinal teratoma: a report of 2 cases. *Arch Pathol Lab Med*. 2004;128(2):227-228.
57. Louis DN, Vickery AL Jr, Rosai J, Wang CA. Multiple branchial cleft-like cysts in Hashimoto's thyroiditis. *Am J Surg Pathol*. 1989;13(1):45-49.
58. Miyazaki M, Kiuchi S, Fujioka Y. Branchial cleft-like cysts in Hashimoto's thyroiditis: a case report and literature review. *Pathol Int*. 2016;66(5):297-301.
59. Suster S, Rosai J. Cystic thymomas. A clinicopathologic study of ten cases. *Cancer*. 1992;69(1):92-97.
60. Leong AS, Brown JH. Malignant transformation in a thymic cyst. *Am J Surg Pathol*. 1984;8(6):471-475.
61. Moran CA, Suster S, El-Naggar A, Luna MA. Carcinomas arising in multilocular thymic cysts of the neck: a clinicopathological study of three cases. *Histopathology*. 2004;44(1):64-68.
62. Moran CA, Suster S. Cystic well-differentiated neuroendocrine carcinoma (carcinoid tumor): a clinicopathologic and immunohistochemical study of two cases. *Am J Clin Pathol*. 2006;126(3):377-380.
63. Bale PM, Sotelo-Avila C. Maldescent of the thymus: 34 necropsy and 10 surgical cases, including 7 thymuses medial to the mandible. *Pediatr Pathol*. 1993;13(2):181-190.
64. Drut R, Galliani C. Thymic tissue in the skin: a clue to the diagnosis of the branchio-oculo-facial syndrome: report of two cases. *Int J Surg Pathol*. 2003;11(1):25-28.
65. Wolff M, Rosai J, Wright DH. Sebaceous glands within the thymus: report of three cases. *Hum Pathol*. 1984;15(4): 341-343.
66. Seemayer TA, Laroche AC, Russo P, et al. Precocious thymic involution manifest by epithelial injury in the acquired immune deficiency syndrome. *Hum Pathol*. 1984;15(5):469-474.
67. Shilo K, Mani H, Deshpande C, et al. Diffuse thymic fibrosis: histologic pattern of injury or distinct entity? *Am J Surg Pathol*. 2010;34(2):211-215.
68. Lack EE. Thymic hyperplasia with massive enlargement: report of two cases with review of diagnostic criteria. *J Thorac Cardiovasc Surg*. 1981;81(5):741-746.
69. Carmosino L, DiBenedetto A, Feffer S. Thymic hyperplasia following successful chemotherapy. A report of two cases and review of the literature. *Cancer*. 1985;56(7):1526-1528.
70. Wekerle H, Müller-Hermelink HK. The thymus in myasthenia gravis. *Curr Top Pathol*. 1986;75:179-206.

71. Loning T, Caselitz J, Otto HF. The epithelial framework of the thymus in normal and pathological conditions. Immunohistochemical demonstration of keratin in an autopsy series. *Virchows Arch A Pathol Anat Histol*. 1981;392(1):7-20.
72. Prevot S, Audouin J, Andre-Bougaran J, et al. Thymic pseudotumorous enlargement due to follicular hyperplasia in a human immunodeficiency virus sero-positive patient. Immunohistochemical and molecular biological study of viral infected cells. *Am J Clin Pathol*. 1992;97(3):420-425.
73. Lee BH, George S, Kutok JL. Langerhans cell histiocytosis involving the thymus. A case report and review of the literature. *Arch Pathol Lab Med*. 2003;127(7):e294-e297.
74. Siegal GP, Dehner LP, Rosai J, Histiocytosis X. (Langerhans' cell granulomatosis) of the thymus. A clinicopathologic study of four childhood cases. *Am J Surg Pathol*. 1985;9(2):117-124.
75. Gilcrease MZ, Rajan B, Ostrowski ML, et al. Localized thymic Langerhans' cell histiocytosis and its relationship with myasthenia gravis. Immunohistochemical, ultrastructural, and cytometric studies. *Arch Pathol Lab Med*. 1997;121(2):134-138.
76. Wakely P Jr, Suster S. Langerhans' cell histiocytosis of the thymus associated with multilocular thymic cyst. *Hum Pathol*. 2000;31(12):1532-1535.
77. Halicek F, Rosai J. Histioeosinophilic granulomas in the thymuses of 29 myasthenic patients: a complication of pneumomediastinum. *Hum Pathol*. 1984;15(12):1137-1144.
78. Jessurun J, Azevedo M, Saldana M. Allergic angiitis and granulomatosis (Churg-Strauss syndrome): report of a case with massive thymic involvement in a nonasthmatic patient. *Hum Pathol*. 1986;17(6):637-639.
79. Karcher DS, Pearson CE, Butler WM, et al. Giant lymph node hyperplasia involving the thymus with associated nephrotic syndrome and myelofibrosis. *Am J Clin Pathol*. 1982;77(1):100-104.
80. O'Reilly PE Jr, Joshi VV, Holbrook CT, Weisenburger DD. Multicentric Castleman's disease in a child with prominent thymic involvement: a case report and brief review of the literature. *Mod Pathol*. 1993;6(6):776-780.
81. Hasserjian RP, Strobel P, Marx A. Pathology of thymic tumors. *Semin Thorac Cardiovasc Surg*. 2005;17(1):2-11.
82. Fonseca AL, Ozgediz DE, Christison-Lagay ER, et al. Pediatric thymomas: report of two cases and comprehensive review of the literature. *Pediatr Surg Int*. 2014;30(3):275-286.
83. Ramon y Cajal S, Suster S. Primary thymic epithelial neoplasms in children. *Am J Surg Pathol*. 1991;15(5):466-474.
84. Evans AG, French CA, Cameron MJ, et al. Pathologic characteristics of NUT midline carcinoma arising in the mediastinum. *Am J Surg Pathol*. 2012;36(8):1222-1227.
85. Lee AC, Kwong YI, Fu KH, et al. Disseminated mediastinal carcinoma with chromosomal translocation (15;19). A distinctive clinicopathologic syndrome. *Cancer*. 1993;72(7):2273-2276.
86. Weissferdt A, Moran CA. The spectrum of ectopic thymomas. *Virchows Arch*. 2016;469(3):245-254.
87. Wakely PE Jr. Fine needle aspiration in the diagnosis of thymic epithelial neoplasms. *Hematol Oncol Clin North Am*. 2008;22(3):433-442.
88. Lewis JE, Wick MR, Scheithauer BW, et al. Thymoma. A clinicopathologic review. *Cancer*. 1987;60(11):2727-2743.
89. Monden Y, Nakahara K, Kagotani K, et al. Myasthenia gravis with thymoma: analysis of and postoperative prognosis for 65 patients with thymomatous myasthenia gravis. *Ann Thorac Surg*. 1984;38(1):46-52.
90. Willcox N, Schluep M, Ritter MA, et al. Myasthenic and nonmyasthenic thymoma. An expansion of a minor cortical epithelial cell subset? *Am J Pathol*. 1987;127(3):447-460.
91. Alpert LI, Papatestas A, Kark A, et al. A histologic reappraisal of the thymus in myasthenia gravis. A correlative study of thymic pathology and response to thymectomy. *Arch Pathol*. 1971;91(1):55-61.
92. Wilkins EW Jr, Edmunds LH Jr, Castleman B. Cases of thymoma at the Massachusetts General Hospital. *J Thorac Cardiovasc Surg*. 1966;52(3):322-330.
93. Drachman DB, McIntosh KR, Reim J, Balcer L. Strategies for treatment of myasthenia gravis. *Ann N Y Acad Sci*. 1993;681:515-528.
94. Verley JM, Hollmann KH. Thymoma. A comparative study of clinical stages, histologic features, and survival in 200 cases. *Cancer*. 1985;55(5):1074-1086.
95. de Perrot M, Liu J, Bril V, et al. Prognostic significance of thymomas in patients with myasthenia gravis. *Ann Thorac Surg*. 2002;74(5):1658-1662.
96. Bril V, Kojic J, Dhanani A. The long-term clinical outcome of myasthenia gravis in patients with thymoma. *Neurology*. 1998;51(4):1198-1200.
97. Hohlfeld R, Wekerle H. Reflections on the "intrathymic pathogenesis" of myasthenia gravis. *J Neuroimmunol*. 2008;201-202:21-27.
98. Marx A, Wilisch A, Schultz A, et al. Pathogenesis of myasthenia gravis. *Virchows Arch*. 1997;430(5):355-364.
99. Vincent A. Unravelling the pathogenesis of myasthenia gravis. *Nat Rev Immunol*. 2002;2(10):797-804.
100. Wilisch A, Gutsche S, Hoffacker V, et al. Association of acetylcholine receptor alpha-subunit gene expression in mixed thymoma with myasthenia gravis. *Neurology*. 1999;52(7):1460-1466.
101. Lennon VA, Kryzer TJ, Griesmann GE, et al. Calcium-channel antibodies in the Lambert-Eaton syndrome and other paraneoplastic syndromes. *N Engl J Med*. 1995;332(22):1467-1474.
102. Wolfe GI, Kaminski HJ, Aban IB, et al. Randomized Trial of Thymectomy in Myasthenia Gravis. *N Engl J Med*. 2016;375(6):511-522.
103. Huang CS, Hsu HS, Huang BS, et al. Factors influencing the outcome of transsternal thymectomy for myasthenia gravis. *Acta Neurol Scand*. 2005;112(2):108-114.
104. Masaoka A, Yamakawa Y, Niwa H, et al. Extended thymectomy for myasthenia gravis patients: a 20-year review. *Ann Thorac Surg*. 1996;62(3):853-859.
105. Park IK, Choi SS, Lee JG, et al. Complete stable remission after extended transsternal thymectomy in myasthenia gravis. *Eur J Cardiothorac Surg*. 2006;30(3):525-528.
106. Kuo T, Shih LY. Histologic types of thymoma associated with pure red cell aplasia: a study of five cases including a composite tumor of organoid thymoma associated with an unusual lipofibroadenoma. *Int J Surg Pathol*. 2001;9(1):29-35.
107. Salyer WR, Eggleston JC. Thymoma: a clinical and pathological study of 65 cases. *Cancer*. 1976;37(1):229-249.
108. Moran CA, Suster S. Thymoma with prominent cystic and hemorrhagic changes and areas of necrosis and infarction: a clinicopathologic study of 25 cases. *Am J Surg Pathol*. 2001;25(8):1086-1090.
109. Shimosato Y, Mukai K, Matsuno Y. Thymoma. In: Silverberg S, ed. *Tumors of the Mediastinum. AFIP Atlast of Tumor Pathology*. Vol. 11. 4th ed. Washington, DC: American Registry of Pathology; 2010:19-114.
110. Strobel P, Marx A, Badve S, et al. Thymomas. In: Travis WD, Brambilla E, Burke AP, et al, eds. *WHO Classification of Tumours of the Lung, Pleura, Thymus and Heart. World Health Organization Classification of Tumours*. 4th ed. Lyon: IARC; 2015:187-211.
111. Moran CA, Suster S. "Ancient" (sclerosing) thymomas: a clinicopathologic study of 10 cases. *Am J Clin Pathol*. 2004;121(6):867-871.
112. Moran CA, Suster S, Koss MN. Plasma cell-rich thymoma. *Am J Clin Pathol*. 1994;102(2):199-201.
113. Levine GD, Rosai J, Bearman RM, Polliack A. The fine structure of thymoma, with emphasis on its differential diagnosis. A study of ten cases. *Am J Pathol*. 1975;81(1):49-86.
114. Kuo T. Cytokeratin profiles of the thymus and thymomas: histogenetic correlations and proposal for a histological classification of thymomas. *Histopathology*. 2000;36(5):403-414.
115. Weissferdt A, Hernandez JC, Kalhor N, Moran CA. Spindle cell thymomas: an immunohistochemical study of 30 cases. *Appl Immunohistochem Mol Morphol*. 2011;19(4):329-335.
116. Weissferdt A, Moran CA. Pax8 expression in thymic epithelial neoplasms: an immunohistochemical analysis. *Am J Surg Pathol*. 2011;35(9):1305-1310.
117. Walts AE, Hiroshima K, Marchevsky AM. Desmoglein 3 and p40 immunoreactivity in neoplastic and nonneoplastic thymus: a potential adjunct to help resolve selected diagnostic and staging problems. *Ann Diagn Pathol*. 2015;19(4):216-220.
118. Fukai I, Masaoka A, Hashimoto T, et al. The distribution of epithelial membrane antigen in thymic epithelial neoplasms. *Cancer*. 1992;70(8):2077-2081.
119. Wiley EL, Nosal JM, Freeman RG. Immunohistochemical demonstration of H antigen, peanut agglutinin receptor, and Saphora japonica receptor expression in infant thymuses and thymic neoplasias. *Am J Clin Pathol*. 1990;93(1):44-48.
120. Datta MW, Shahsafaei A, Nadler LM, et al. Expression of MHC class II-associated invariant chain (Ii;CD74) in thymic epithelial neoplasms. *Appl Immunohistochem Mol Morphol*. 2000;8(3):210-215.
121. Pescarmona E, Pisacane A, Pignatelli E, Baroni CD. Expression of epidermal and nerve growth factor receptors in human thymus and thymomas. *Histopathology*. 1993;23(1):39-44.
122. Lauriola L, Maggiano N, Serra FG, et al. Immunohistochemical and in situ hybridization detection of growth-hormone-producing cells in human thymoma. *Am J Pathol*. 1997;151(1):55-61.
123. Kuo T, Lo SK. Immunohistochemical metallothionein expression in thymoma: correlation with histological types and cellular origin. *Histopathology*. 1997;30(3):243-248.
124. Nonaka D, Henley JD, Chiriboga L, Yee H. Diagnostic utility of thymic epithelial markers CD205 (DEC205) and Foxn1 in thymic epithelial neoplasms. *Am J Surg Pathol*. 2007;31(7):1038-1044.
125. Mizuno T, Hashimoto T, Masaoka A. Distribution of fibronectin and laminin in human thymoma. *Cancer*. 1990;65(6):1367-1374.
126. Ichikawa Y, Shimizu H, Yoshida M, Arimori S. Two-color flow cytometric analysis of thymic lymphocytes from patients with myasthenia gravis and/or thymoma. *Clin Immunol Immunopathol*. 1992;62(1 Pt 1):91-96.
127. Pomplun S, Wotherspoon AC, Shah G, et al. Immunohistochemical markers in the differentiation of thymic and pulmonary neoplasms. *Histopathology*. 2002;40(2):152-158.

128. Fukayama M, Maeda Y, Funata N, et al. Pulmonary and pleural thymoma. Diagnostic application of lymphocyte markers to the thymoma of unusual site. *Am J Clin Pathol*. 1988;89(5):617-621.
129. Katzin WE, Fishleder AJ, Linden MD, Tubbs RR. Immunoglobulin and T-cell receptor genes in thymomas: genotypic evidence supporting the nonneoplastic nature of the lymphocytic component. *Hum Pathol*. 1988;19(3):323-328.
130. Pizer ES, McGrath SD, Hruban RH, et al. cell receptor gene rearrangement. A source of pseudo-clonal populations in thymomas and other thymic tissues. *Am J Clin Pathol*. 1996;105(3):262-267.
131. Tateyama H, Takahashi E, Saito Y, et al. Histopathologic changes of thymoma preoperatively treated with corticosteroids. *Virchows Arch*. 2001;438(3):238-247.
132. Kondo K, Mukai K, Sato Y, et al. An immunohistochemical study of thymic epithelial tumors. III. The distribution of interdigitating reticulum cells and S-100 beta-positive small lymphocytes. *Am J Surg Pathol*. 1990;14(12):1139-1147.
133. Taubenberger JK, Jaffe ES, Medeiros LJ. Thymoma with abundant L26-positive 'asteroid' cells. A case report with an analysis of normal thymus and thymoma specimens. *Arch Pathol Lab Med*. 1991;115(12): 1254-1257.
134. Chilosi M, Castelli P, Martignoni G, et al. Neoplastic epithelial cells in a subset of human thymomas express the B cell-associated CD20 antigen. *Am J Surg Pathol*. 1992;16(10):988-997.
135. Pan CC, Chen PC, Wang LS, et al. Expression of apoptosis-related markers and HER-2/neu in thymic epithelial tumours. *Histopathology*. 2003;43(2):165-172.
136. Tateyama H, Eimoto T, Tada T, et al. Apoptosis, bcl-2 protein, and Fas antigen in thymic epithelial tumors. *Mod Pathol*. 1997;10(10):983-991.
137. Inoue M, Marx A, Zettl A, et al. Chromosome 6 suffers frequent and multiple aberrations in thymoma. *Am J Pathol*. 2002;161(4):1507-1513.
138. Inoue M, Starostik P, Zettl A, et al. Correlating genetic aberrations with World Health Organization-defined histology and stage across the spectrum of thymomas. *Cancer Res*. 2003;63(13):3708-3715.
139. Zettl A, Strobel P, Wagner K, et al. Recurrent genetic aberrations in thymoma and thymic carcinoma. *Am J Pathol*. 2000;157(1):257-266.
140. Suster S. Thymic carcinoma: update of current diagnostic criteria and histologic types. *Semin Diagn Pathol*. 2005;22(3):198-212.
141. Marx A, Chan JK, Coindre JM, et al. The 2015 World Health Organization classification of tumors of the thymus: continuity and changes. *J Thorac Oncol*. 2015;10(10):1383-1395.
142. Marx A, Strobel P, Badve SS, et al. ITMIG consensus statement on the use of the WHO histological classification of thymoma and thymic carcinoma: refined definitions, histological criteria, and reporting. *J Thorac Oncol*. 2014;9(5):596-611.
143. Weissferdt A, Moran CA. Thymic carcinoma, part 1: a clinicopathologic and immunohistochemical study of 65 cases. *Am J Clin Pathol*. 2012;138(1):103-114.
144. Kornstein MJ, Rosai J. CD5 labeling of thymic carcinomas and other nonlymphoid neoplasms. *Am J Clin Pathol*. 1998;109(6):722-726.
145. Petrini I, Zucali PA, Lee HS, et al. Expression and mutational status of c-kit in thymic epithelial tumors. *J Thorac Oncol*. 2010;5(9):1447-1453.
146. Nakagawa K, Matsuno Y, Kunitoh H, et al. Immunohistochemical KIT (CD117) expression in thymic epithelial tumors. *Chest*. 2005;128(1):140-144.
147. Hishima T, Fukayama M, Hayashi Y, et al. CD70 expression in thymic carcinoma. *Am J Surg Pathol*. 2000;24(5):742-746.
148. Su XY, Wang WY, Li JN, et al. Immunohistochemical differentiation between type B3 thymomas and thymic squamous cell carcinomas. *Int J Clin Exp Pathol*. 2015;8(5):5354-5362.
149. Omatsu M, Kunimura T, Mikogami T, et al. Cyclin-dependent kinase inhibitors, p16 and p27, demonstrate different expression patterns in thymoma and thymic carcinoma. *Gen Thorac Cardiovasc Surg*. 2014;62(11):678-684.
150. Lauriola L, Erlandson RA, Rosai J. Neuroendocrine differentiation is a common feature of thymic carcinoma. *Am J Surg Pathol*. 1998;22(9):1059-1066.
151. Moreira AL, Won HH, McMillan R, et al. Massively parallel sequencing identifies recurrent mutations in TP53 in thymic carcinoma associated with poor prognosis. *J Thorac Oncol*. 2015;10(2):373-380.
152. Weirich G, Schneider P, Fellbaum C, et al. p53 alterations in thymic epithelial tumours. *Virchows Arch*. 1997;431(1):17-23.
153. Tsuchida M, Umezu H, Hashimoto T, et al. Absence of gene mutations in KIT-positive thymic epithelial tumors. *Lung Cancer*. 2008;62(3):321-325.
154. *WHO Classification of Tumours of the Lung, Pleura, Thymus and Heart*. 4th ed. In: Travis W, Brambilla E, Burke A, Marx A, Nicholson A, eds. Lyon: IARC; 2015.
155. Chan JKC, Strobel P, Marx A, et al. Thymic carcinomas. Squamous cell carcinoma. In: Travis WD, Brambilla E, Burke AP, et al, eds. *WHO Classification of Tumours of the Lung, Pleura, Thymus and Heart. World Health Organization Classification of Tumours*. 4th ed. Lyon: IARC; 2015:212-215.
156. Suster S, Rosai J. Thymic carcinoma. A clinicopathologic study of 60 cases. *Cancer*. 1991;67(4):1025-1032.
157. Brown JG, Familiari U, Papotti M, Rosai J. Thymic basaloid carcinoma: a clinicopathologic study of 12 cases, with a general discussion of basaloid carcinoma and its relationship with adenoid cystic carcinoma. *Am J Surg Pathol*. 2009;33(8):1113-1124.
158. Snover DC, Levine GD, Rosai J. Thymic carcinoma. Five distinctive histological variants. *Am J Surg Pathol*. 1982;6(5): 451-470.
159. Roden AC, Erickson-Johnson MR, Yi ES, Garcia JJ. Analysis of MAML2 rearrangement in mucoepidermoid carcinoma of the thymus. *Hum Pathol*. 2013;44(12):2799-2805.
160. Nonaka D, Klimstra D, Rosai J. Thymic mucoepidermoid carcinomas: a clinicopathologic study of 10 cases and review of the literature. *Am J Surg Pathol*. 2004;28(11):1526-1531.
161. Mann RB, Wu TC, MacMahon EM, et al. In situ localization of Epstein-Barr virus in thymic carcinoma. *Mod Pathol*. 1992;5(4):363-366.
162. Chen PC, Pan CC, Yang AH, et al. Detection of Epstein-Barr virus genome within thymic epithelial tumours in Taiwanese patients by nested PCR, PCR in situ hybridization, and RNA in situ hybridization. *J Pathol*. 2002;197(5):684-688.
163. Hasserjian RP, Klimstra DS, Rosai J. Carcinoma of the thymus with clear-cell features. Report of eight cases and review of the literature. *Am J Surg Pathol*. 1995;19(7):835-841.
164. Suster S, Moran CA. Spindle cell thymic carcinoma: clinicopathologic and immunohistochemical study of a distinctive variant of primary thymic epithelial neoplasm. *Am J Surg Pathol*. 1999;23(6):691-700.
165. Mukai K, Chan JKC, Detterbeck F, et al. Sarcomatoid carcinoma. In: Travis W, Brambilla E, Burke AP, Nicholson AG, eds. *WHO Classification of Tumours of Lung, Pleura, Thymus and Heart. World Health Organization Classification of Tumours*. 4th ed. Lyon: IARC; 2015:224-226.
166. Chen G, Chan JKC, Marchevsky AM, et al. Metaplastic thymoma. In: Travis W, Brambilla E, Burke AP, et al, eds. *WHO Classification of Tumours of the Lung, Pleura, Thymus and Heart. World Health Organization Classification of Tumours*. 4th ed. Lyon: IARC; 2015:207-209.
167. Suster S, Moran CA, Chan JK. Thymoma with pseudosarcomatous stroma: report of an unusual histologic variant of thymic epithelial neoplasm that may simulate carcinosarcoma. *Am J Surg Pathol*. 1997;21(11):1316-1323.
168. Yoneda S, Marx A, Heimann S, et al. Low-grade metaplastic carcinoma of the thymus. *Histopathology*. 1999;35(1):19-30.
169. Liu B, Rao Q, Zhu Y, et al. Metaplastic thymoma of the mediastinum. A clinicopathologic, immunohistochemical, and genetic analysis. *Am J Clin Pathol*. 2012;137(2):261-269.
170. Lu HS, Gan MF, Zhou T, Wang SZ. Sarcomatoid thymic carcinoma arising in metaplastic thymoma: a case report. *Int J Surg Pathol*. 2011;19(5):677-680.
171. Moritani S, Ichihara S, Mukai K, et al. Sarcomatoid carcinoma of the thymus arising in metaplastic thymoma. *Histopathology*. 2008;52(3):409-411.
172. Matsuno Y, Morozumi N, Hirohashi S, et al. Papillary carcinoma of the thymus: report of four cases of a new microscopic type of thymic carcinoma. *Am J Surg Pathol*. 1998;22(7):873-880.
173. Moser B, Schiefer AI, Janik S, et al. Adenocarcinoma of the thymus, enteric type: report of 2 cases, and proposal for a novel subtype of thymic carcinoma. *Am J Surg Pathol*. 2015;39(4):541-548.
174. Bauer DE, Mitchell CM, Strait KM, et al. Clinicopathologic features and long-term outcomes of NUT midline carcinoma. *Clin Cancer Res*. 2012;18(20):5773-5779.
175. French CA. Pathogenesis of NUT midline carcinoma. *Annu Rev Pathol*. 2012;7:247-265.
176. Stelow EB. A review of NUT midline carcinoma. *Head Neck Pathol*. 2011;5(1): 31-35.
177. Haack H, Johnson L, Fry C, et al. Diagnosis of NUT midline carcinoma using a NUT-specific monoclonal antibody. *Am J Surg Pathol*. 2009;33(7):984-991.
178. Nonaka D, Rodriguez J, Rollo JL, Rosai J. Undifferentiated large cell carcinoma of the thymus associated with Castleman disease-like reaction: a distinctive type of thymic neoplasm characterized by an indolent behavior. *Am J Surg Pathol*. 2005;29(4):490-495.
179. Di Tommaso L, Kuhn E, Kurrer M, et al. Thymic tumor with adenoid cystic carcinomalike features: a clinicopathologic study of 4 cases. *Am J Surg Pathol*. 2007;31(8):1161-1167.
180. Franke A, Strobel P, Fackeldey V, et al. Hepatoid thymic carcinoma: report of a case. *Am J Surg Pathol*. 2004;28(2):250-256.
181. Lattes R. Thymoma and other tumors of the thymus. An analysis of 107 cases. *Cancer*. 1962;15:1224-1260.
182. Lattes R, Jonas S. The pathological and clinical features in eighty cases of thymoma. *Bull N Y Acad Med*. 1957;33:145-147.
183. Bernatz PE, Harrison EG, Clagett OT. Thymoma: a clinicopathologic study. *J Thorac Cardiovasc Surg*. 1961;42:424-444.
184. Marino M, Muller-Hermelink HK. Thymoma and thymic carcinoma. Relation of thymoma epithelial cells to the cortical and medullary

differentiation of thymus. *Virchows Arch A Pathol Anat Histol*. 1985;407(2):119-149.
185. Kirchner T, Schalke B, Buchwald J, et al. Well-differentiated thymic carcinoma. An organotypical low-grade carcinoma with relationship to cortical thymoma. *Am J Surg Pathol*. 1992;16(12):1153-1169.
186. Rosai J. *Histological typing of tumours of the thymus. World Health Organization international histological classification of tumours*. Berlin: Springer; 1999.
187. Suster S, Moran CA. Primary thymic epithelial neoplasms showing combined features of thymoma and thymic carcinoma. A clinicopathologic study of 22 cases. *Am J Surg Pathol*. 1996;20(12):1469-1480.
188. Pan CC, Chen WY, Chiang H. Spindle cell and mixed spindle/lymphocytic thymomas: an integrated clinicopathologic and immunohistochemical study of 81 cases. *Am J Surg Pathol*. 2001;25(1):111-120.
189. Green AC, Marx A, Strobel P, et al. Type A and AB thymomas: histological features associated with increased stage. *Histopathology*. 2015;66(6):884-891.
190. Strobel P, Marx A, Badve S, et al. Type AB thymoma. In: Travis W, Brambilla E, Burke AP, et al, eds. *WHO Classification of Tumours of the Lung, Pleura, Thymus and Heart. World Health Organization Classification of Tumours*. 4th ed. Lyon: IARC; 2015:193-195.
191. den Bakker MA, Marx A, Strobel P, et al. Type B1 thymoma. In: Travis WD, Brambilla E, Burke AP, et al, eds. *WHO Classification of Tumours of the Lung, Pleura, Thymus and Heart. World Health Organization Classification of Tumours*. 4th ed. Lyon: IARC; 2015:196-198.
192. Marchevsky AM, Marx A, Strobel P, et al. Type B2 thymoma. In: Travis WD, Brambilla E, Burke AP, et al, eds. *WHO Classification of Tumours of the Lung, Pleura, Thymus and Heart. World Health Organization Classification of Tumours*. 4th ed. Lyon: IARC; 2015:199-201.
193. Marx A, Strobel P, Badve S, et al. Type B3 thymoma. In: Travis WD, Brambilla E, Burke AP, et al, eds. *WHO Classification of Tumours of the Lung, Pleura, Thymus and Heart. World Health Organization Classification of Tumours*. 4th ed. Lyon: IARC; 2015:202-204.
194. Suster S, Moran CA. Micronodular thymoma with lymphoid B-cell hyperplasia: clinicopathologic and immunohistochemical study of eighteen cases of a distinctive morphologic variant of thymic epithelial neoplasm. *Am J Surg Pathol*. 1999;23(8):955-962.
195. Pescarmona E, Rosati S, Pisacane A, et al. Microscopic thymoma: histological evidence of multifocal cortical and medullary origin. *Histopathology*. 1992;20(3):263-266.
196. Puglisi F, Finato N, Mariuzzi L, et al. Microscopic thymoma and myasthenia gravis. *J Clin Pathol*. 1995;48(7):682-683.
197. Wakely PE Jr. Cytopathology of thymic epithelial neoplasms. *Semin Diagn Pathol*. 2005;22(3):213-222.
198. Masaoka A, Monden Y, Nakahara K, Tanioka T. Follow-up study of thymomas with special reference to their clinical stages. *Cancer*. 1981;48(11):2485-2492.
199. Koga K, Matsuno Y, Noguchi M, et al. A review of 79 thymomas: modification of staging system and reappraisal of conventional division into invasive and non-invasive thymoma. *Pathol Int*. 1994;44(5):359-367.
200. Detterbeck FC, Nicholson AG, Kondo K, et al. The Masaoka-Koga stage classification for thymic malignancies: clarification and definition of terms. *J Thorac Oncol*. 2011;6(7 suppl 3):S1710-S1716.
201. Roden AC, Yi ES, Jenkins SM, et al. Modified Masaoka stage and size are independent prognostic predictors in thymoma and modified Masaoka stage is superior to histopathologic classifications. *J Thorac Oncol*. 2015;10(4):691-700.
202. Detterbeck FC, Marom EM. Thymus. In: Amin MB, Edge SB, Greene FL, et al, eds. *AJCC Cancer Staging Manual*. 8th ed. Springer; 2017:423-429.
203. Gupta R, Marchevsky AM, McKenna RJ, et al. Evidence-based pathology and the pathologic evaluation of thymomas: transcapsular invasion is not a significant prognostic feature. *Arch Pathol Lab Med*. 2008;132(6):926-930.
204. Detterbeck FC, Stratton K, Giroux D, et al. The IASLC/ITMIG Thymic Epithelial Tumors Staging Project: proposal for an evidence-based stage classification system for the forthcoming (8th) edition of the TNM classification of malignant tumors. *J Thorac Oncol*. 2014;9(9 suppl 2):S65-S72.
205. Roden AC, Yi ES, Jenkins SM, et al. Reproducibility of 3 histologic classifications and 3 staging systems for thymic epithelial neoplasms and its effect on prognosis. *Am J Surg Pathol*. 2015;39(4):427-441.
206. Nicholson AG, Detterbeck F, Marx A, et al. Dataset for reporting of thymic epithelial tumours: recommendations from the International Collaboration on Cancer Reporting (ICCR). *Histopathology*. 2016;70(4):522-538.
207. Honglin Y, Jun D, Zhenfeng L, et al. The correlation of the World Health Organization histologic classification of thymic epithelial tumors and its prognosis: a clinicopathologic study of 108 patients from China. *Int J Surg Pathol*. 2009;17(3):255-261.
208. Wright CD. Management of thymomas. *Crit Rev Oncol Hematol*. 2008;65(2):109-120.
209. Wright CD, Choi NC, Wain JC, et al. Induction chemoradiotherapy followed by resection for locally advanced Masaoka stage III and IVA thymic tumors. *Ann Thorac Surg*. 2008;85(2):385-389.
210. Ahmad U, Yao X, Detterbeck F, et al. Thymic carcinoma outcomes and prognosis: results of an international analysis. *J Thorac Cardiovasc Surg*. 2015;149(1):95-100, 101.e1-e2.
211. Urgesi A, Monetti U, Rossi G, et al. Aggressive treatment of intrathoracic recurrences of thymoma. *Radiother Oncol*. 1992;24(4):221-225.
212. Blumberg D, Port JL, Weksler B, et al. Thymoma: a multivariate analysis of factors predicting survival. *Ann Thorac Surg*. 1995;60(4):908-913, discussion 914.
213. Begg CB, Cramer LD, Venkatraman ES, Rosai J. Comparing tumour staging and grading systems: a case study and a review of the issues, using thymoma as a model. *Stat Med*. 2000;19(15):1997-2014.
214. Bedini AV, Andreani SM, Tavecchio L, et al. Proposal of a novel system for the staging of thymic epithelial tumors. *Ann Thorac Surg*. 2005;80(6):1994-2000.
215. Pan CC, Ho DM, Chen WY, et al. Ki67 labelling index correlates with stage and histology but not significantly with prognosis in thymoma. *Histopathology*. 1998;33(5):453-458.
216. Gripp S, Hilgers K, Ploem-Zaaijer JJ, et al. Prognostic significance of DNA cytometry in thymoma. *J Cancer Res Clin Oncol*. 2000;126(5):280-284.
217. Weissferdt A, Moran CA. Ectopic primary intrathyroidal thymoma: a clinicopathological and immunohistochemical analysis of 3 cases. *Hum Pathol*. 2016;49:71-76.
218. Chan JK, Rosai J. Tumors of the neck showing thymic or related branchial pouch differentiation: a unifying concept. *Hum Pathol*. 1991;22(4):349-367.
219. Rosai J, Limas C, Husband EM. Ectopic hamartomatous thymoma. A distinctive benign lesion of lower neck. *Am J Surg Pathol*. 1984;8(7):501-513.
220. Weissferdt A, Kalhor N, Petersson F, Moran CA. Ectopic hamartomatous thymoma-new insights into a challenging entity: a clinicopathologic and immunohistochemical study of 9 cases. *Am J Surg Pathol*. 2016.
221. Fetsch JF, Laskin WB, Michal M, et al. Ectopic hamartomatous thymoma: a clinicopathologic and immunohistochemical analysis of 21 cases with data supporting reclassification as a branchial anlage mixed tumor. *Am J Surg Pathol*. 2004;28(10):1360-1370.
222. Michal M, Neubauer L, Fakan F. Carcinoma arising in ectopic hamartomatous thymoma. An ultrastructural study. *Pathol Res Pract*. 1996;192(6):610-618, discussion 619-621.
223. Su L, Beals T, Bernacki EG, Giordano TJ. Spindle epithelial tumor with thymus-like differentiation: a case report with cytologic, histologic, immunohistologic, and ultrastructural findings. *Mod Pathol*. 1997;10(5):510-514.
224. Kirby PA, Ellison WA, Thomas PA. Spindle epithelial tumor with thymus-like differentiation (SETTLE) of the thyroid with prominent mitotic activity and focal necrosis. *Am J Surg Pathol*. 1999;23(6): 712-716.
225. Xu B, Hirokawa M, Yoshimoto K, et al. Spindle epithelial tumor with thymus-like differentiation of the thyroid: a case report with pathological and molecular genetics study. *Hum Pathol*. 2003;34(2):190-193.
226. Folpe AL, Lloyd RV, Bacchi CE, Rosai J. Spindle epithelial tumor with thymus-like differentiation: a morphologic, immunohistochemical, and molecular genetic study of 11 cases. *Am J Surg Pathol*. 2009;33(8):1179-1186.
227. Cheuk W, Jacobson AA, Chan JK. Spindle epithelial tumor with thymus-like differentiation (SETTLE): a distinctive malignant thyroid neoplasm with significant metastatic potential. *Mod Pathol*. 2000;13(10):1150-1155.
228. Chetty R, Goetsch S, Nayler S, Cooper K. Spindle epithelial tumour with thymus-like element (SETTLE): the predominantly monophasic variant. *Histopathology*. 1998;33(1):71-74.
229. Watanabe I, Tezuka F, Yamaguchi M, et al. Thymic carcinoma of the thyroid. *Pathol Int*. 1996;46(6):450-456.
230. Reimann JD, Dorfman DM, Nose V. Carcinoma showing thymus-like differentiation of the thyroid (CASTLE): a comparative study: evidence of thymic differentiation and solid cell nest origin. *Am J Surg Pathol*. 2006;30(8):994-1001.
231. Rosai J, Higa E. Mediastinal endocrine neoplasm, of probable thymic origin, related to carcinoid tumor. Clinicopathologic study of 8 cases. *Cancer*. 1972;29(4):1061-1074.
232. Moran CA, Suster S. Neuroendocrine carcinomas (carcinoid tumor) of the thymus. A clinicopathologic analysis of 80 cases. *Am J Clin Pathol*. 2000;114(1):100-110.
233. Cardillo G, Treggiari S, Paul MA, et al. Primary neuroendocrine tumours of the thymus: a clinicopathologic and prognostic study in 19 patients. *Eur J Cardiothorac Surg*. 2010;37(4):814-818.
234. Strobel P, Marx A, Chan JKC, et al. Thymic neuroendocrine tumors: typical and atypical carcinoid. In: Travis WD, Brambilla E, Burke AP, et al, eds. *WHO Classification of Tumours of the Lung, Pleura, Thymus and Heart. World Health Organization Classification of Tumours*. 4th ed. Lyon: IARC; 2015:234-238.
235. Chaer R, Massad MG, Evans A, et al. Primary neuroendocrine tumors of the thymus. *Ann Thorac Surg*. 2002;74(5):1733-1740.
236. Salyer WR, Salyer DC, Eggleston JC. Carcinoid tumors of the thymus. *Cancer*. 1976;37(2):958-973.

237. Rosai J, Higa E, Davie J. Mediastinal endocrine neoplasm in patients with multiple endocrine adenomatosis. A previously unrecognized association. *Cancer*. 1972;29(4):1075-1083.
238. Gal AA, Kornstein MJ, Cohen C, et al. Neuroendocrine tumors of the thymus: a clinicopathological and prognostic study. *Ann Thorac Surg*. 2001;72(4):1179-1182.
239. Moran CA, Suster S. Angiomatoid neuroendocrine carcinoma of the thymus: report of a distinctive morphological variant of neuroendocrine tumor of the thymus resembling a vascular neoplasm. *Hum Pathol*. 1999;30(6):635-639.
240. Moran CA. Primary neuroendocrine carcinomas of the mediastinum: review of current criteria for histopathologic diagnosis and classification. *Semin Diagn Pathol*. 2005;22(3):223-229.
241. Moran CA, Suster S. Thymic neuroendocrine carcinomas with combined features ranging from well-differentiated (carcinoid) to small cell carcinoma. A clinicopathologic and immunohistochemical study of 11 cases. *Am J Clin Pathol*. 2000;113(3):345-350.
242. Tiffet O, Nicholson AG, Ladas G, et al. A clinicopathologic study of 12 neuroendocrine tumors arising in the thymus. *Chest*. 2003;124(1):141-146.
243. Wick MR, Scheithauer BW. Thymic carcinoid. A histologic, immunohistochemical, and ultrastructural study of 12 cases. *Cancer*. 1984;53(3):475-484.
244. Weissferdt A, Tang X, Wistuba II, Moran CA. Comparative immunohistochemical analysis of pulmonary and thymic neuroendocrine carcinomas using PAX8 and TTF-1. *Mod Pathol*. 2013;26(12):1554-1560.
245. Dixon JL, Borgaonkar SP, Patel AK, et al. Thymic neuroendocrine carcinoma producing ectopic adrenocorticotropic hormone and Cushing's syndrome. *Ann Thorac Surg*. 2013;96(4):e81-e83.
246. Kuo TT. Pigmented spindle cell carcinoid tumour of the thymus with ectopic adrenocorticotropic hormone secretion: report of a rare variant and differential diagnosis of mediastinal spindle cell neoplasms. *Histopathology*. 2002;40(2):159-165.
247. Moran CA, Suster S. Spindle-cell neuroendocrine carcinomas of the thymus (spindle-cell thymic carcinoid): a clinicopathologic and immunohistochemical study of seven cases. *Mod Pathol*. 1999;12(6):587-591.
248. Levine GD, Rosai J. A spindle cell varient of thymic carcinoid tumor. A clinical, histologic, and fine structural study with emphasis on its distinction from spindle cell thymoma. *Arch Pathol Lab Med*. 1976;100(6):293-300.
249. Moran CA, Suster S. Primary neuroendocrine carcinoma (thymic carcinoid) of the thymus with prominent oncocytic features: a clinicopathologic study of 22 cases. *Mod Pathol*. 2000;13(5):489-494.
250. Rosai J, Levine G, Weber WR, Higa E. Carcinoid tumors and oat cell carcinomas of the thymus. *Pathol Ann*. 1976;11:201-226.
251. Kuo TT. Carcinoid tumor of the thymus with divergent sarcomatoid differentiation: report of a case with histogenetic consideration. *Hum Pathol*. 1994;25(3):319-323.
252. Mega S, Oguri M, Kawasaki R, et al. Large-cell neuroendocrine carcinoma in the thymus. *Gen Thorac Cardiovasc Surg*. 2008;56(11):566-569.
253. Horie Y, Kato M. Neuroendocrine carcinoma of the posterior mediastinum: a possible primary lesion. *Arch Pathol Lab Med*. 1999;123(10):933-936.
254. Moran CA, Rosado-de-Christenson M, Suster S. Thymolipoma: clinicopathologic review of 33 cases. *Mod Pathol*. 1995;8(7):741-744.
255. Hudacko R, Aviv H, Langenfeld J, Fyfe B. Thymolipoma: clues to pathogenesis revealed by cytogenetics. *Ann Diagn Pathol*. 2009;13(3):185-188.
256. Huang CS, Li WY, Lee PC, et al. Analysis of outcomes following surgical treatment of thymolipomatous myasthenia gravis: comparison with thymomatous and non-thymomatous myasthenia gravis. *Interact Cardiovasc Thorac Surg*. 2014;18(4):475-481.
257. Iseki M, Tsuda N, Kishikawa M, et al. Thymolipoma with striated myoid cells. Histological, immunohistochemical, and ultrastructural study. *Am J Surg Pathol*. 1990;14(4):395-398.
258. Moran CA, Zeren H, Koss MN. Thymofibrolipoma. A histologic variant of thymolipoma. *Arch Pathol Lab Med*. 1994;118(3):281-282.
259. Ogino S, Franks TJ, Deubner H, Koss MN. Thymohemangiolipoma, a rare histologic variant of thymolipoma: a case report and review of the literature. *Ann Diagn Pathol*. 2000;4(4):236-239.
260. Ajaz B, Tran TA, Truong T, Manoucheri M. Thymolipoma with sebaceous differentiation: a hitherto unreported variant of thymolipoma. *Int J Surg Pathol*. 2013;21(5):526-530.
261. Haddad H, Joudeh A, El-Taani H, et al. Thymoma and thymic carcinoma arising in a thymolipoma: report of a unique case. *Int J Surg Pathol*. 2009;17(1):55-59.
262. Klimstra DS, Moran CA, Perino G, et al. Liposarcoma of the anterior mediastinum and thymus. A clinicopathologic study of 28 cases. *Am J Surg Pathol*. 1995;19(7):782-791.
263. Wilken JJ, Meier FA, Kornstein MJ. Kaposiform hemangioendothelioma of the thymus. *Arch Pathol Lab Med*. 2000;124(10):1542-1544.
264. Fushimi H, Kotoh K, Watanabe D, et al. Malignant melanoma in the thymus. *Am J Surg Pathol*. 2000;24(9):1305-1308.
265. Chaganti RS, Rodriguez E, Mathew S. Origin of adult male mediastinal germ-cell tumours. *Lancet*. 1994;343(8906):1130-1132.
266. Aguirre D, Nieto K, Lazos M, et al. Extragonadal germ cell tumors are often associated with Klinefelter syndrome. *Hum Pathol*. 2006;37(4):477-480.
267. Moran CA, Suster S, Przygodzki RM, Koss MN. Primary germ cell tumors of the mediastinum: II. Mediastinal seminomas—a clinicopathologic and immunohistochemical study of 120 cases. *Cancer*. 1997;80(4):691-698.
268. Moran CA, Suster S, Koss MN. Primary germ cell tumors of the mediastinum: III. Yolk sac tumor, embryonal carcinoma, choriocarcinoma, and combined nonteratomatous germ cell tumors of the mediastinum—a clinicopathologic and immunohistochemical study of 64 cases. *Cancer*. 1997;80(4):699-707.
269. Moran CA, Suster S. Primary germ cell tumors of the mediastinum: I. Analysis of 322 cases with special emphasis on teratomatous lesions and a proposal for histopathologic classification and clinical staging. *Cancer*. 1997;80(4):681-690.
270. Levine GD. Primary thymic seminoma—a neoplasm ultrastructurally similar to testicular seminoma and distinct from epithelial thymoma. *Cancer*. 1973;31(3):729-741.
271. Sung MT, Maclennan GT, Lopez-Beltran A, et al. Primary mediastinal seminoma: a comprehensive assessment integrated with histology, immunohistochemistry, and fluorescence in situ hybridization for chromosome 12p abnormalities in 23 cases. *Am J Surg Pathol*. 2008;32(1):146-155.
272. Weissferdt A, Rodriguez-Canales J, Liu H, et al. Primary mediastinal seminomas: a comprehensive immunohistochemical study with a focus on novel markers. *Hum Pathol*. 2015;46(3):376-383.
273. Przygodzki RM, Hubbs AE, Zhao FQ, O'Leary TJ. Primary mediastinal seminomas: evidence of single and multiple KIT mutations. *Lab Invest*. 2002;82(10):1369-1375.
274. Przygodzki RM, Moran CA, Suster S, et al. Primary mediastinal and testicular seminomas: a comparison of K-ras-2 gene sequence and p53 immunoperoxidase analysis of 26 cases. *Hum Pathol*. 1996;27(9):975-979.
275. Bokemeyer C, Droz JP, Horwich A, et al. Extragonadal seminoma: an international multicenter analysis of prognostic factors and long term treatment outcome. *Cancer*. 2001;91(7):1394-1401.
276. Fizazi K, Culine S, Droz JP, et al. Initial management of primary mediastinal seminoma: radiotherapy or cisplatin-based chemotherapy? *Eur J Cancer*. 1998;34(3):347-352.
277. Yalcin B, Demir HA, Tanyel FC, et al. Mediastinal germ cell tumors in childhood. *Pediatr Hematol Oncol*. 2012;29(7):633-642.
278. Drevelegas A, Palladas P, Scordalaki A. Mediastinal germ cell tumors: a radiologic-pathologic review. *Eur Radiol*. 2001;11(10):1925-1932.
279. Suda K, Mizuguchi K, Hebisawa A, et al. Pancreatic tissue in teratoma. *Arch Pathol Lab Med*. 1984;108(10):835-837.
280. Takeda S, Miyoshi S, Ohta M, et al. Primary germ cell tumors in the mediastinum: a 50-year experience at a single Japanese institution. *Cancer*. 2003;97(2):367-376.
281. Carter D, Bibro MC, Touloukian RJ. Benign clinical behavior of immature mediastinal teratoma in infancy and childhood: report of two cases and review of the literature. *Cancer*. 1982;49(2):398-402.
282. Nichols CR, Saxman S, Williams SD, et al. Primary mediastinal nonseminomatous germ cell tumors. A modern single institution experience. *Cancer*. 1990;65(7):1641-1646.
283. Kesler KA, Rieger KM, Hammoud ZT, et al. A 25-year single institution experience with surgery for primary mediastinal nonseminomatous germ cell tumors. *Ann Thorac Surg*. 2008;85(2):371-378.
284. Truong LD, Harris L, Mattioli C, et al. Endodermal sinus tumor of the mediastinum. A report of seven cases and review of the literature. *Cancer*. 1986;58(3):730-739.
285. Marx A, Moreira AL, Chan JKC, et al. Yok sac tumour. In: Travis WD, Brambilla E, Burke AP, et al, eds. *WHO Classification of Tumours of the Lung, Pleura, Thymus and Heart. World Health Organization Classification of Tumours*. 4th ed. Lyon: IARC; 2015:251-254.
286. Moran CA, Suster S. Yolk sac tumors of the mediastinum with prominent spindle cell features: a clinicopathologic study of three cases. *Am J Surg Pathol*. 1997;21(10):1173-1177.
287. Moran CA, Suster S. Hepatoid yolk sac tumors of the mediastinum: a clinicopathologic and immunohistochemical study of four cases. *Am J Surg Pathol*. 1997;21(10):1210-1214.
288. Wang F, Liu A, Peng Y, et al. Diagnostic utility of SALL4 in extragonadal yolk sac tumors: an immunohistochemical study of 59 cases with comparison to placental-like alkaline phosphatase, alpha-fetoprotein, and glypican-3. *Am J Surg Pathol*. 2009;33(10):1529-1539.
289. Nogales FF, Quinonez E, Lopez-Marin L, et al. A diagnostic immunohistochemical panel for yolk sac (primitive endodermal) tumours based on an immunohistochemical comparison with the human yolk sac. *Histopathology*. 2014;65(1):51-59.
290. Moran CA, Suster S. Primary mediastinal choriocarcinomas: a clinicopathologic and immunohistochemical study of eight cases. *Am J Surg Pathol*. 1997;21(9):1007-1012.

291. Went PT, Dirnhofer S, Stallmach T, et al. Placental site trophoblastic tumor of the mediastinum. *Hum Pathol*. 2005;36(5):581-584.
292. Chan JKC, Looijenga LHJ, Marx A, et al. Mixed germ cell tumors. In: Travis WD, Brambilla E, Burke AP, et al, eds. *WHO Classification of Tumours of the Lung, Pleura, Thymus and Heart. World Health Organization Classification of Tumours*. 4th ed. Lyon: IARC; 2015:260-262.
293. Ilson DH, Bosl GJ, Motzer R, et al. Genetic analysis of germ cell tumors: current progress and future prospects. *Hematol Oncol Clin North Am*. 1991;5(6):1271-1283.
294. Kernek KM, Brunelli M, Ulbright TM, et al. Fluorescence in situ hybridization analysis of chromosome 12p in paraffin-embedded tissue is useful for establishing germ cell origin of metastatic tumors. *Mod Pathol*. 2004;17(11):1309-1313.
295. Malagon HD, Valdez AM, Moran CA, Suster S. Germ cell tumors with sarcomatous components: a clinicopathologic and immunohistochemical study of 46 cases. *Am J Surg Pathol*. 2007;31(9):1356-1362.
296. Ulbright TM, Loehrer PJ, Roth LM, et al. The development of non-germ cell malignancies within germ cell tumors. A clinicopathologic study of 11 cases. *Cancer*. 1984;54(9):1824-1833.
297. Strobel P, Chan JKC, Looijenga LHJ, et al. Germ cell tumours with somatic-type solid malignancy. In: Travis WD, Brambilla E, Burke AP, et al, eds. *WHO Classification of Tumours of the Lung, Pleura, Thymus and Heart. World Health Organization Classification of Tumours*. 4th ed. Lyon: IARC; 2015:263-264.
298. Gonzalez-Vela JL, Savage PD, Manivel JC, et al. Poor prognosis of mediastinal germ cell cancers containing sarcomatous components. *Cancer*. 1990;66(6):1114-1116.
299. Ikdahl T, Josefsen D, Jakobsen E, et al. Concurrent mediastinal germ-cell tumour and haematological malignancy: case report and short review of literature. *Acta Oncol*. 2008;47(3):466-469.
300. Ladanyi M, Samaniego F, Reuter VE, et al. Cytogenetic and immunohistochemical evidence for the germ cell origin of a subset of acute leukemias associated with mediastinal germ cell tumors. *J Natl Cancer Inst*. 1990;82(3):221-227.
301. Orazi A, Neiman RS, Ulbright TM, et al. Hematopoietic precursor cells within the yolk sac tumor component are the source of secondary hematopoietic malignancies in patients with mediastinal germ cell tumors. *Cancer*. 1993;71(12):3873-3881.
302. Ko HM, da Cunha Santos G, Darling G, et al. Diagnosis and subclassification of lymphomas and non-neoplastic lesions involving mediastinal lymph nodes using endobronchial ultrasound-guided transbronchial needle aspiration. *Diagn Cytopathol*. 2013;41(12):1023-1030.
303. Petersdorf SH, Wood DE. Lymphoproliferative disorders presenting as mediastinal neoplasms. *Semin Thorac Cardiovasc Surg*. 2000;12(4):290-300.
304. Keller AR, Castleman B. Hodgkin's disease of the thymus gland. *Cancer*. 1974;33(6):1615-1623.
305. Null JA, Livolsi VA, Glenn WW. Hodgkin's disease of the thymus (granulomatous thymoma) and myasthenia gravis: a unique association. *Am J Clin Pathol*. 1977;67(6):521-525.
306. Remigio PA. Granulomatous thymoma associated with erythroid hypoplasia. *Am J Clin Pathol*. 1971;55(1):68-72.
307. Kaesberg PR, Foley DB, Pellett J, et al. Concurrent development of a thymic cyst and mediastinal Hodgkin's disease. *Med Pediatr Oncol*. 1988;16(4):293-294.
308. Rosai J. Lowenhaupt's embryology-based classification of thymic tumors and the concept of granulomatous thymoma. *Cancer*. 1998;82(7):1209-1216.
309. Mauch PM, Girinsky T, Behringer K, et al. Treatment of favorable-prognosis, stage I–II Hodgkin lymphoma. In: Hoppe RT, Mauch PM, Armitage JO, et al, eds. *Hodgkin Lymphoma*. Philadelphia: Lippincott Williams & Wilkins; 2007:225-252.
310. Kim HC, Nosher J, Haas A, et al. Cystic degeneration of thymic Hodgkin's disease following radiation therapy. *Cancer*. 1985;55(2):354-356.
311. Scheinpflug K, Schmitt J, Jentsch-Ullrich K, et al. Thymic hyperplasia following successful treatment for nodular-sclerosing Hodgkin's disease. *Leuk Lymphoma*. 2003;44(9):1615-1617.
312. Cortelazzo S, Ponzoni M, Ferreri AJ, Hoelzer D. Lymphoblastic lymphoma. *Crit Rev Oncol Hematol*. 2011;79(3):330-343.
313. Soslow RA, Baergen RN, Warnke RA. B-lineage lymphoblastic lymphoma is a clinicopathologic entity distinct from other histologically similar aggressive lymphomas with blastic morphology. *Cancer*. 1999;85(12):2648-2654.
314. Koita H, Suzumiya J, Ohshima K, et al. Lymphoblastic lymphoma expressing natural killer cell phenotype with involvement of the mediastinum and nasal cavity. *Am J Surg Pathol*. 1997;21(2):242-248.
315. Macon WR, Rynalski TH, Swerdlow SH, Cousar JB. T-cell lymphoblastic leukemia/lymphoma presenting in a recurrent thymoma. *Mod Pathol*. 1991;4(4):524-548.
316. Bhatt VR, Mourya R, Shrestha R, Armitage JO. Primary mediastinal large B-cell lymphoma. *Cancer Treat Rev*. 2015;41(6):476-485.
317. Perrone T, Frizzera G, Rosai J. Mediastinal diffuse large-cell lymphoma with sclerosis. A clinicopathologic study of 60 cases. *Am J Surg Pathol*. 1986;10(3):176-191.
318. Tsai HW, Yen YS, Chang KC. Mediastinal large B-cell lymphoma with rosette formation mimicking thymoma and thymic carcinoid. *Histopathology*. 2006;49(1):93-95.
319. Davis RE, Dorfman RF, Warnke RA. Primary large-cell lymphoma of the thymus: a diffuse B-cell neoplasm presenting as primary mediastinal lymphoma. *Hum Pathol*. 1990;21(12):1262-1268.
320. Paulli M, Strater J, Gianelli U, et al. Mediastinal B-cell lymphoma: a study of its histomorphologic spectrum based on 109 cases. *Hum Pathol*. 1999;30(2):178-187.
321. Suster S, Moran CA. Pleomorphic large cell lymphomas of the mediastinum. *Am J Surg Pathol*. 1996;20(2):224-232.
322. Higgins JP, Warnke RA. CD30 expression is common in mediastinal large B-cell lymphoma. *Am J Clin Pathol*. 1999;112(2):241-247.
323. Calaminici M, Piper K, Lee AM, Norton AJ. CD23 expression in mediastinal large B-cell lymphomas. *Histopathology*. 2004;45(6):619-624.
324. de Leval L, Ferry JA, Falini B, et al. Expression of bcl-6 and CD10 in primary mediastinal large B-cell lymphoma: evidence for derivation from germinal center B cells? *Am J Surg Pathol*. 2001;25(10):1277-1282.
325. Rosenwald A, Wright G, Leroy K, et al. Molecular diagnosis of primary mediastinal B cell lymphoma identifies a clinically favorable subgroup of diffuse large B cell lymphoma related to Hodgkin lymphoma. *J Exp Med*. 2003;198(6):851-862.
326. Copie-Bergman C, Plonquet A, Alonso MA, et al. MAL expression in lymphoid cells: further evidence for MAL as a distinct molecular marker of primary mediastinal large B-cell lymphomas. *Mod Pathol*. 2002;15(11):1172-1180.
327. Tsang P, Cesarman E, Chadburn A, et al. Molecular characterization of primary mediastinal B cell lymphoma. *Am J Pathol*. 1996;148(6):2017-2025.
328. Bentz M, Barth TF, Bruderlein S, et al. Gain of chromosome arm 9p is characteristic of primary mediastinal B-cell lymphoma (MBL): comprehensive molecular cytogenetic analysis and presentation of a novel MBL cell line. *Genes Chromosomes Cancer*. 2001;30(4):393-401.
329. Joos S, Otano-Joos MI, Ziegler S, et al. Primary mediastinal (thymic) B-cell lymphoma is characterized by gains of chromosomal material including 9p and amplification of the REL gene. *Blood*. 1996;87(4):1571-1578.
330. Wessendorf S, Barth TF, Viardot A, et al. Further delineation of chromosomal consensus regions in primary mediastinal B-cell lymphomas: an analysis of 37 tumor samples using high-resolution genomic profiling (array-CGH). *Leukemia*. 2007;21(12):2463-2469.
331. Mottok A, Renne C, Seifert M, et al. Inactivating SOCS1 mutations are caused by aberrant somatic hypermutation and restricted to a subset of B-cell lymphoma entities. *Blood*. 2009;114(20):4503-4506.
332. Feuerhake F, Kutok JL, Monti S, et al. NFkappaB activity, function, and target-gene signatures in primary mediastinal large B-cell lymphoma and diffuse large B-cell lymphoma subtypes. *Blood*. 2005;106(4):1392-1399.
333. Lazzarino M, Orlandi E, Paulli M, et al. Treatment outcome and prognostic factors for primary mediastinal (thymic) B-cell lymphoma: a multicenter study of 106 patients. *J Clin Oncol*. 1997;15(4):1646-1653.
334. Inagaki H, Chan JK, Ng JW, et al. Primary thymic extranodal marginal-zone B-cell lymphoma of mucosa-associated lymphoid tissue type exhibits distinctive clinicopathological and molecular features. *Am J Pathol*. 2002;160(4):1435-1443.
335. Kurabayashi A, Iguchi M, Matsumoto M, et al. Thymic mucosa-associated lymphoid tissue lymphoma with immunoglobulin-storing histiocytosis in Sjogren's syndrome. *Pathol Int*. 2010;60(2):125-130.
336. Yokose T, Kodama T, Matsuno Y, et al. Low-grade B cell lymphoma of mucosa-associated lymphoid tissue in the thymus of a patient with rheumatoid arthritis. *Pathol Int*. 1998;48(1):74-81.
337. Isaacson PG, Chan JK, Tang C, Addis BJ. Low-grade B-cell lymphoma of mucosa-associated lymphoid tissue arising in the thymus. A thymic lymphoma mimicking myoepithelial sialadenitis. *Am J Surg Pathol*. 1990;14(4):342-351.
338. Nagasaka T, Lai R, Harada T, et al. Coexisting thymic and gastric lymphomas of mucosa-associated lymphoid tissues in a patient with Sjogren syndrome. *Arch Pathol Lab Med*. 2000;124(5):770-773.
339. Parrens M, Dubus P, Danjoux M, et al. Mucosa-associated lymphoid tissue of the thymus hyperplasia vs lymphoma. *Am J Clin Pathol*. 2002;117(1):51-56.
340. Kominato S, Nakayama T, Sato F, et al. Characterization of chromosomal aberrations in thymic MALT lymphoma. *Pathol Int*. 2012;62(2):93-98.
341. Lorsbach RB, Pinkus GS, Shahsafaei A, Dorfman DM. Primary marginal zone lymphoma of the thymus. *Am J Clin Pathol*. 2000;113(6):784-791.
342. Gualco G, Natkunam Y, Bacchi CE. The spectrum of B-cell lymphoma, unclassifiable, with features intermediate between diffuse large B-cell lymphoma and classical Hodgkin

lymphoma: a description of 10 cases. *Mod Pathol*. 2012;25(5):661-674.
343. Traverse-Glehen A, Pittaluga S, Gaulard P, et al. Mediastinal gray zone lymphoma: the missing link between classic Hodgkin's lymphoma and mediastinal large B-cell lymphoma. *Am J Surg Pathol*. 2005;29(11):1411-1421.
344. Bellan C, Lazzi S, Zazzi M, et al. Immunoglobulin gene rearrangement analysis in composite Hodgkin disease and large B-cell lymphoma: evidence for receptor revision of immunoglobulin heavy chain variable region genes in Hodgkin–Reed–Sternberg cells? *Diagn Mod Pathol*. 2002;11:2-8.
345. Savage KJ, Monti S, Kutok JL, et al. The molecular signature of mediastinal large B-cell lymphoma differs from that of other diffuse large B-cell lymphomas and shares features with classical Hodgkin lymphoma. *Blood*. 2003;102(12):3871-3879.
346. Williams DM, Hobson R, Imeson J, et al. Anaplastic large cell lymphoma in childhood: analysis of 72 patients treated on The United Kingdom Children's Cancer Study Group chemotherapy regimens. *Br J Haematol*. 2002;117(4):812-820.
347. Clavio M, Rossi E, Truini M, et al. Anaplastic large cell lymphoma: a clinicopathologic study of 53 patients. *Leuk Lymphoma*. 1996;22(3-4):319-327.
348. Hishima T, Fukayama M, Hayashi Y, et al. Granulocytic sarcoma of the thymus in a nonleukaemic patient. *Virchows Arch*. 1999;435(4):447-451.
349. McCluggage WG, Boyd HK, Jones FG, et al. Mediastinal granulocytic sarcoma: a report of two cases. *Arch Pathol Lab Med*. 1998;122(6):545-547.
350. Ramasamy K, Lim Z, Pagliuca A, et al. Acute myeloid leukaemia presenting with mediastinal myeloid sarcoma: report of three cases and review of literature. *Leuk Lymphoma*. 2007;48(2):290-294.
351. Moran CA, Suster S, Fishback NF, Koss MN. Extramedullary plasmacytomas presenting as mediastinal masses: clinicopathologic study of two cases preceding the onset of multiple myeloma. *Mod Pathol*. 1995;8(3):257-259.
352. Keller AR, Hochholzer L, Castleman B. Hyaline-vascular and plasma-cell types of giant lymph node hyperplasia of the mediastinum and other locations. *Cancer*. 1972;29(3):670-683.
353. Bowne WB, Lewis JJ, Filippa DA, et al. The management of unicentric and multicentric Castleman's disease: a report of 16 cases and a review of the literature. *Cancer*. 1999;85(3):706-717.
354. Verani R, Olson J, Moake JL. Intrathoracic extramedullary hematopoiesis: report of a case in a patient with sickle-cell disease-beta-thalassemia. *Am J Clin Pathol*. 1980;73(1):133-137.
355. Kouraklis G, Dosios T. Intrathoracic extramedullary hematopoiesis simulating tumor, in a patient with sickle cell anemia. *Eur J Cardiothorac Surg*. 1994;8(4):220-221.
356. Vaziri M, Sadeghipour A, Pazooki A, Shoolami LZ. Primary mediastinal myelolipoma. *Ann Thorac Surg*. 2008;85(5):1805-1806.
357. Viola P, Vroobel KM, Devaraj A, et al. Follicular dendritic cell tumour/sarcoma: a commonly misdiagnosed tumour in the thorax. *Histopathology*. 2016;69(5): 752-761.
358. Hartert M, Strobel P, Dahm M, et al. A follicular dendritic cell sarcoma of the mediastinum with immature T cells and association with myasthenia gravis. *Am J Surg Pathol*. 2010;34(5):742-745.
359. Simpson I, Campbell PE. Mediastinal masses in childhood: a review from a paediatric pathologist's point of view. *Prog Pediatr Surg*. 1991;27:92-126.
360. Reed JC, Hallet KK, Feigin DS. Neural tumors of the thorax: subject review from the AFIP. *Radiology*. 1978;126(1):9-17.
361. Salter JE Jr, Gibson D, Ordonez NG, Mackay B. Neuroblastoma of the anterior mediastinum in an 80-year-old woman. *Ultrastruct Pathol*. 1995;19(4):305-310.
362. Adam A, Hochholzer L. Ganglioneuroblastoma of the posterior mediastinum: a clinicopathologic review of 80 cases. *Cancer*. 1981;47(2):373-381.
363. Nagashima Y, Miyagi Y, Tanaka Y, et al. Adult ganglioneuroblastoma of the anterior mediastinum. *Pathol Res Pract*. 1997;193(10):727-732, discussion 733.
364. Argani P, Erlandson RA, Rosai J. Thymic neuroblastoma in adults: report of three cases with special emphasis on its association with the syndrome of inappropriate secretion of antidiuretic hormone. *Am J Clin Pathol*. 1997;108(5):537-543.
365. Pelosi G, Sonzogni A, Solli P, et al. Differentiating neuroblastoma arising in mediastinal germ cell tumour. *Histopathology*. 2008;53(3):350-352.
366. Kashiwabara K, Ikota H, Tanaka S, et al. Thymoma with ganglioneuroblastomatous component: case report. *Virchows Arch*. 2008;452(3):319-324.
367. Young DG. Thoracic neuroblastoma/ganglioneuroma. *J Pediatr Surg*. 1983;18(1):37-41.
368. Horiuchi A, Muraji T, Tsugawa C, et al. Thoracic neuroblastoma: outcome of incomplete resection. *Pediatr Surg Int*. 2004;20(9):714-748.
369. Kellie SJ, Hayes FA, Bowman L, et al. Primary extracranial neuroblastoma with central nervous system metastases characterization by clinicopathologic findings and neuroimaging. *Cancer*. 1991;68(9):1999-2006.
370. Marchevsky AM. Mediastinal tumors of peripheral nervous system origin. *Semin Diagn Pathol*. 1999;16(1):65-78.
371. Lodding P, Kindblom LG, Angervall L, Stenman G. Cellular schwannoma. A clinicopathologic study of 29 cases. *Virchows Arch A Pathol Anat Histol*. 1990;416(3):237-248.
372. White W, Shiu MH, Rosenblum MK, et al. Cellular schwannoma. A clinicopathologic study of 57 patients and 58 tumors. *Cancer*. 1990;66(6):1266-1275.
373. Kourea HP, Bilsky MH, Leung DH, et al. Subdiaphragmatic and intrathoracic paraspinal malignant peripheral nerve sheath tumors: a clinicopathologic study of 25 patients and 26 tumors. *Cancer*. 1998;82(11):2191-2203.
374. Wilson RW, Moran CA. Primary ependymoma of the mediastinum: a clinicopathologic study of three cases. *Ann Diagn Pathol*. 1998;2(5):293-300.
375. Falleni M, Roz E, Dessy E, et al. Primary intrathoracic meningioma: histopathological, immunohistochemical and ultrastructural study of two cases. *Virchows Arch*. 2001;439(2):196-200.
376. Moran CA, Albores-Saavedra J, Wenig BM, Mena H. Pigmented extraadrenal paragangliomas. A clinicopathologic and immunohistochemical study of five cases. *Cancer*. 1997;79(2):398-402.
377. Carney JA. Gastric stromal sarcoma, pulmonary chondroma, and extra-adrenal paraganglioma (Carney Triad): natural history, adrenocortical component, and possible familial occurrence. *Mayo Clin Proc*. 1999;74(6):543-552.
378. Olson JL, Salyer WR. Mediastinal paragangliomas (aortic body tumor): a report of four cases and a review of the literature. *Cancer*. 1978;41(6):2405-2412.
379. Odze R, Begin LR. Malignant paraganglioma of the posterior mediastinum. A case report and review of the literature. *Cancer*. 1990;65(3):564-569.
380. Swanson PE. Soft tissue neoplasma of the mediastinum. *Semin Diagn Pathol*. 1991;8(1):14-34.
381. Nguyen KQ, Hoeffel C, Le LH, Phan HT. Mediastinal lipomatosis. *South Med J*. 1998;91(12):1169-1172.
382. Dogan R, Kara M, Firat P, Gedikoglu G. An unusual tumor of the neck and mediastinum: lipoblastomatosis resulting in paraparesis. *Eur J Cardiothorac Surg*. 2007;31(2):325-327.
383. Baldi A, Santini M, Mellone P, et al. Mediastinal hibernoma: a case report. *J Clin Pathol*. 2004;57(9):993-994.
384. Kline ME, Patel BU, Agosti SJ. Noninfiltrating angiolipoma of the mediastinum. *Radiology*. 1990;175(3):737-738.
385. Knight CS, Cerfolio RJ, Winokur TS. Angiomyolipoma of the anterior mediastinum. *Ann Diagn Pathol*. 2008;12(4):293-295.
386. Brown LR, Reiman HM, Rosenow EC 3rd, et al. Intrathoracic lymphangioma. *Mayo Clin Proc*. 1986;61(11):882-892.
387. Moran CA, Suster S. Mediastinal hemangiomas: a study of 18 cases with emphasis on the spectrum of morphological features. *Hum Pathol*. 1995;26(4):416-421.
388. Rubinowitz AN, Moreira AL, Naidich DP. Mediastinal hemangioendothelioma: radiologic—pathologic correlation. *J Comput Assist Tomogr*. 2000;24(5):721-723.
389. Gaertner EM, Steinberg DM, Huber M, et al. Pulmonary and mediastinal glomus tumors—report of five cases including a pulmonary glomangiosarcoma: a clinicopathologic study with literature review. *Am J Surg Pathol*. 2000;24(8):1105-1114.
390. Suster S, Moran CA, Koss MN. Epithelioid hemangioendothelioma of the anterior mediastinum. Clinicopathologic, immunohistochemical, and ultrastructural analysis of 12 cases. *Am J Surg Pathol*. 1994;18(9):871-881.
391. Gibbs AR, Johnson NF, Giddings JC, et al. Primary angiosarcoma of the mediastinum: light and electron microscopic demonstration of Factor VIII-related antigen in neoplastic cells. *Hum Pathol*. 1984;15(7):687-691.
392. Shaffer K, Pugatch RD, Sugarbaker DJ. Primary mediastinal leiomyoma. *Ann Thorac Surg*. 1990;50(2):301-302.
393. Zolota V, Tzelepi V, Charoulis N, et al. Mediastinal rhabdomyoma: case report and review of the literature. *Virchows Arch*. 2006;449(1):124-128.
394. Witkin GB, Rosai J. Solitary fibrous tumor of the mediastinum. A report of 14 cases. *Am J Surg Pathol*. 1989;13(7):547-557.
395. Hartel PH, Fanburg-Smith JC, Frazier AA, et al. Primary pulmonary and mediastinal synovial sarcoma: a clinicopathologic study of 60 cases and comparison with five prior series. *Mod Pathol*. 2007;20(7):760-769.
396. Jakowski JD, Wakely PE Jr. Primary intrathoracic low-grade fibromyxoid sarcoma. *Hum Pathol*. 2008;39(4):623-628.
397. Moran CA, Suster S, Perino G, et al. Malignant smooth muscle tumors presenting as mediastinal soft tissue masses. A clinicopathologic study of 10 cases. *Cancer*. 1994;74(8):2251-2260.
398. Suster S, Moran CA, Koss MN. Rhabdomyosarcomas of the anterior mediastinum: report of four cases unassociated with germ cell, teratomatous, or thymic carcinomatous components. *Hum Pathol*. 1994;25(4): 349-356.

399. Suster S, Moran CA. Malignant cartilaginous tumors of the mediastinum: clinicopathological study of six cases presenting as extraskeletal soft tissue masses. *Hum Pathol*. 1997;28(5): 588-594.
400. Chetty R. Extraskeletal mesenchymal chondrosarcoma of the mediastinum. *Histopathology*. 1990;17(3):261-263.
401. Flieder DB, Moran CA, Suster S. Primary alveolar soft-part sarcoma of the mediastinum: a clinicopathological and immunohistochemical study of two cases. *Histopathology*. 1997;31(5):469-473.
402. Fu K, Moran CA, Suster S. Primary mediastinal giant cell tumors: a clinicopathologic and immunohistochemical study of two cases. *Ann Diagn Pathol*. 2002;6(2):100-105.
403. Chen W, Chan CW, Mok C. Malignant fibrous histiocytoma of the mediastinum. *Cancer*. 1982;50(4):797-800.
404. Moran CA, Suster S, Silva EG. Low-grade serous carcinoma of the ovary metastatic to the anterior mediastinum simulating multilocular thymic cysts: a clinicopathologic and immunohistochemical study of 3 cases. *Am J Surg Pathol*. 2005;29(4):496-499.
405. McLoud TC, Kalisher L, Stark P, Greene R. Intrathoracic lymph node metastases from extrathoracic neoplasms. *AJR Am J Roentgenol*. 1978;131(3):403-407.
406. Mahon TG, Libshitz HI. Mediastinal metastases of infradiaphragmatic malignancies. *Eur J Radiol*. 1992;15(2):130-134.

13 Esophagus

John R. Goldblum

CHAPTER CONTENTS

Normal anatomy of the esophagus, *502*
Atresia and related anomalies, *502*
Heterotopia, *503*
Diverticula, *504*
Cysts, *504*
Rings and webs, *504*
Achalasia and related motor disorders, *504*
Lye strictures, *505*
Esophagitis (nonreflux related), *505*
Reflux esophagitis, *506*
Barrett esophagus, *508*
Squamous cell carcinoma, *511*
General and clinical features, *511*
Morphologic features and local spread, *513*
Immunohistochemical and molecular genetic features, *513*
Esophageal squamous dysplasia, *514*
Metastases, *515*
Cytology, *515*
Treatment, *515*
Prognosis, *515*
Other types of carcinoma, *515*
Smooth muscle tumors and gastrointestinal stromal tumors, *519*
Other tumors and tumorlike conditions, *520*

Normal Anatomy of the Esophagus

The esophagus is a muscular tubular structure that measures approximately 25 cm in adult individuals and extends from the cricopharyngeal muscle, which forms the upper esophageal sphincter (at the level of the sixth cervical vertebra, about 15–18 cm from the incisors), to the lower esophageal sphincter, which forms the gastroesophageal junction (GEJ; several centimeters below the diaphragm). The lower esophageal sphincter is usually described as being 40 cm from the incisors, but this is subject to considerable individual variations.[1]

The esophagus is lined by stratified nonkeratinized squamous mucosa. The basal layer is one to four cells thick and does not exceed 15% of the total epithelial thickness except in the most distal esophagus.[2] Melanocytes and neuroendocrine cells may be found in this layer. The lamina propria is composed of loose connective tissue that, in the distal portion of the organ, contains mucous glands, referred to as (esophageal) cardiac glands. The esophageal muscularis mucosae is rather thick compared with other portions of the gastrointestinal tract, especially in the distal portion.

The submucosa contains mucous glands distributed throughout the esophagus; their ducts, which open into the esophageal lumen, sometimes are found to be cystically dilated and surrounded by lymphoid collections. The esophageal muscularis propria consists of an admixture of striated and smooth muscle in the upper quarter and exclusively smooth muscle in the rest of the organ.[3] The esophagus lacks a serosal layer, except for its most distal portion. The autonomic nervous plexuses are represented by the Meissner plexus in the submucosa (very sparse) and the Auerbach (myenteric) plexus between the two layers of muscularis propria.

A perennial area of contention is the site and definition of the *GEJ*. The GEJ is the point at which the tubular esophagus flares to the saccular stomach and is recognized endoscopically by the proximal margin of the gastric folds.[4,5] Thus defined, the GEJ does not necessarily correspond to the squamocolumnar junction (SCJ) or "Z line," which is the irregular meeting point of the squamous and glandular epithelia. On the contrary, in many individuals the SCJ will be found *proximally displaced* above the GEJ.

The upper third of the esophagus drains into the cervical nodes, the middle third into the paraesophageal and paratracheal mediastinal nodes, and the lower third into the nodes around the aorta and celiac axis.[6]

Atresia and Related Anomalies

The esophagus of a 3-week-old embryo is an annular constriction between the pharynx and stomach. With growth of the lung beds and elongation of the neck, it becomes tubular. At first, the cephalad portions of the esophagus and trachea form a single channel. Later, a septum grows in and separates them.

Five major types of tracheoesophageal anomalies have been described as a result of failures in this process (Fig. 13.1). The most common, referred to as *type C*, is esophageal atresia with a fistula

Abstract

The esophagus is one of the most common sites of endoscopic mucosal biopsy in the gastrointestinal tract. Most of these biopsies are performed to exclude esophagitis (usually secondary to gastroesophageal reflux disease) or to document the presence or absence of Barrett esophagus, with or without dysplasia. Other forms of infectious esophagitis include esophagitis secondary to *Candida* spp., cytomegalovirus, or herpes simplex virus. The esophagus is also the site of glandular and squamous dysplastic processes that predispose to adenocarcinoma and squamous cell carcinoma, respectively.

Keywords

Achalasia, esophagitis,
Barrett esophagus,
epithelial dysplasia,
esophageal adenocarcinoma,
squamous dysplasia,
squamous cell carcinoma

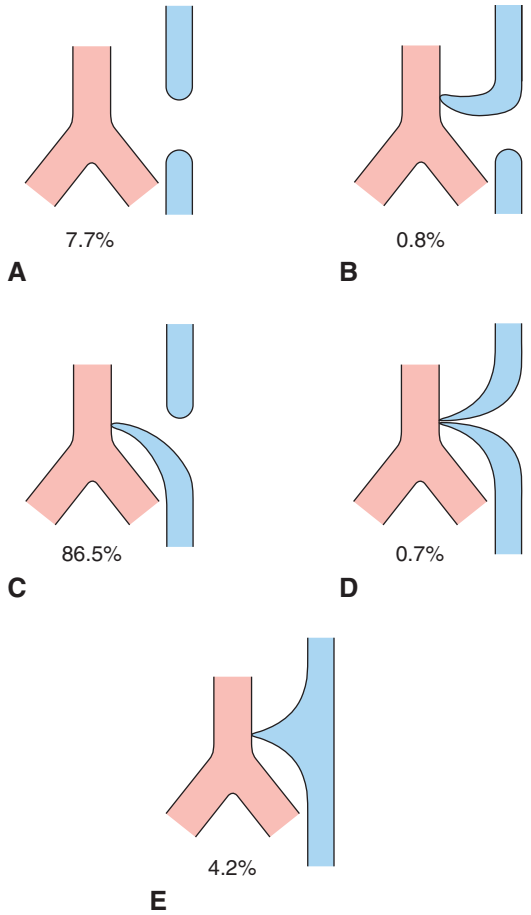

Figure 13.1 Types of tracheoesophageal anomalies and their relative frequencies. (Adapted from Holder TM, Ashcraft KW. Esophageal atresia and tracheoesophageal fistula. *Ann Thorac Surg*. 1970;9:445–467.)

between the lower portion of the esophagus and the respiratory tree.[7] In this type, the hypertrophied and dilated upper portion of the esophagus ends blindly at a variable distance below the larynx, whereas the lower portion communicates with the trachea (usually about 0.5 cm above the bifurcation) or the right mainstem bronchus. Striated muscle is present in the upper portion of the esophagus but not in the lower, which instead may contain cartilaginous rings near its fistulous end. Tracheomalacia, abnormalities of the Auerbach plexus, and cardiovascular anomalies can be seen in association with tracheoesophageal fistula.[8] There also can be defects of the esophagus alone, such as congenital narrowing, stenosis, or an occluding diaphragm of mucous membrane. Successful surgical repair can be accomplished for most of these abnormalities.[9] Survival rates of over 90% can be expected in esophageal atresia with tracheo/esophageal fistula.[10] The treatment of esophageal atresia without fistula remains particularly challenging.[11]

Heterotopia

Heterotopic gastric mucosa can occur at any point in the esophagus but is most common in the postcricoid region, within the first few centimeters of the esophagus.[12] It has been detected in 1%–4% of patients who undergo esophagoscopic examination as a circular, flat, orange to red area, often referred to as the "(*cervical*) *inlet patch*."[13] It is usually asymptomatic but may produce dysphagia and simulate a malignant neoplasm clinically and radiographically.[14]

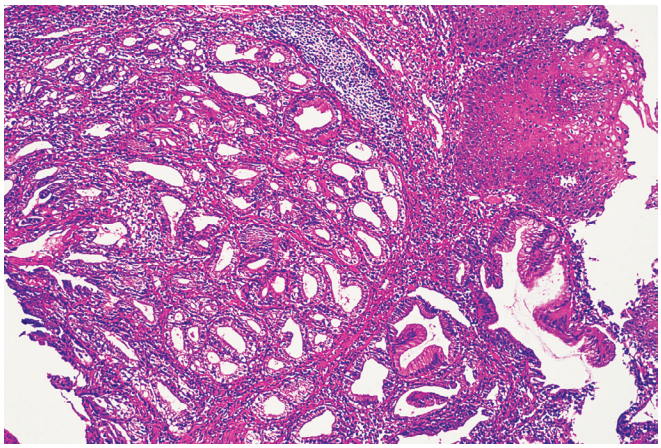

Figure 13.2 Heterotopic gastric mucosa in the esophagus (cervical inlet patch).

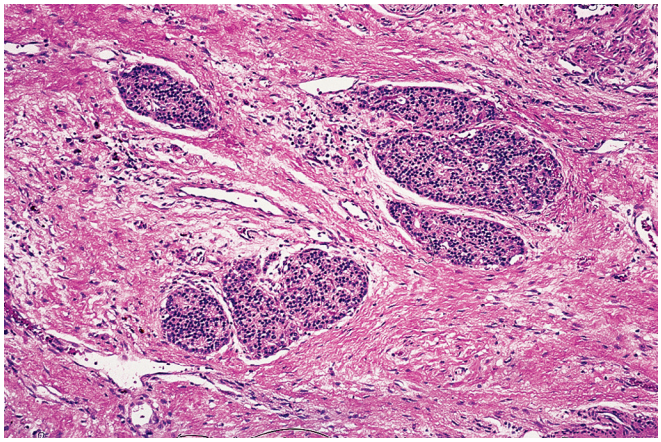

Figure 13.3 Heterotopic pancreas at the gastroesophageal junction, mainly represented by islets of Langerhans.

Grossly, the surface has an appearance similar to that of normal gastric mucosa. It is sharply delineated, and the border with the normal stratified epithelium is apparent. Microscopically, the heterotopic gastric mucosa is usually made up of gastric glands of cardiofundic type, with mucous glands admixed with fundic gland elements (Fig. 13.2). Goblet cells may be present, and it has been reported that up to 20% of patients also have Barrett esophagus.[13] There is often an extensive inflammatory reaction in the heterotopic mucosa that may induce a reactive proliferation and complex glandular architecture, leading to a mistaken diagnosis of malignancy. True instances of adenocarcinoma of the upper esophagus in heterotopic gastric mucosa have been described, in which normal lining squamous epithelium was present both proximal and distal to the lesion.[15]

Heterotopic pancreatic tissue (pancreatic acinar metaplasia) in the form of acinar structures and/or Langerhans islands is commonly seen in the vicinity of the GEJ (Fig. 13.3). Recent studies suggest that this is a congenital rather than an acquired condition.[16] However, other studies have found an association with advancing age, *Helicobacter pylori* infection, female gender, and gastroesophageal reflux disease (GERD).[17]

Heterotopic sebaceous glands may rarely be seen in the midportion or distal portion of the esophagus.[18]

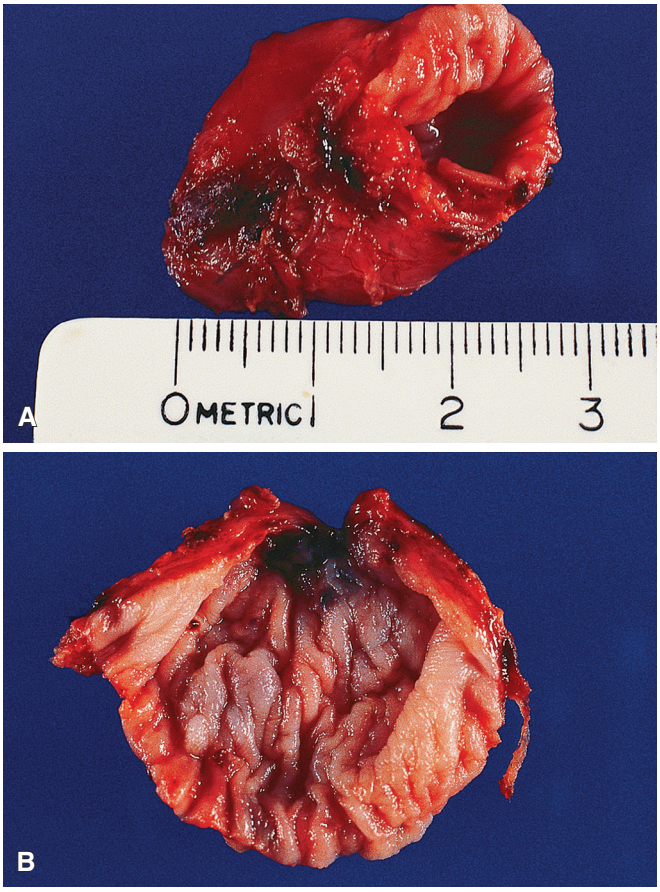

Figure 13.4 **A** and **B,** Outer aspect and inner surface of Zenker diverticulum.

Diverticula

Diverticula located in the upper portion of the esophagus **(Zenker diverticula)** are the most common type of diverticulum in the upper aerodigestive tract.[19] They are the result of outpouching of esophageal mucosa in the wall of the esophagus at the junction with the pharynx (Fig. 13.4). They are therefore more properly designated as pharyngoesophageal and are classified pathogenetically as **pulsion diverticula**. They occur at this point because of the weakness resulting from the relationship between the inferior constrictor muscle and the obliquely passing fibers of the cricopharyngeal muscles as they descend on the posterior wall of the esophagus to become longitudinal.

In the lower third of the esophagus and in the region of the hilum of the lung, inflammatory lymph nodes (usually tuberculous) can become firmly attached to the esophagus and produce **traction diverticula**.[20]

Just above the diaphragm, so-called **epiphrenic diverticula** of the pulsion variety may occur. These outpouchings contain mucosa and submucosa and are lined by inflamed squamous epithelium. Many are associated with achalasia.[21] Complications include obstruction, aspiration pneumonia and lung abscess, infection with perforation and mediastinitis, hemorrhage, and even malignancy (carcinomas). The indications for surgical removal of esophageal diverticula (particularly of the epiphrenic type) remain controversial,[22] but many can be removed by minimally invasive surgery.[23]

An altogether different type of esophageal diverticular process has been designated **diffuse intramural esophageal (pseudo) diverticulosis**.[24] Dysphagia may be the presenting symptom. Endoscopic examination reveals innumerable 1–3 mm flask-shaped diverticula, with a pinpoint mouth, more numerous in the upper third of the organ. The lining is predominantly squamous. A short stricture is usually present in the region. It has been suggested that these formations represent cystically dilated ducts of submucosal glands and, therefore, are not a true diverticular process.[25] The pathogenesis is not completely clear, but underlying esophageal motor abnormalities have been implicated.[26]

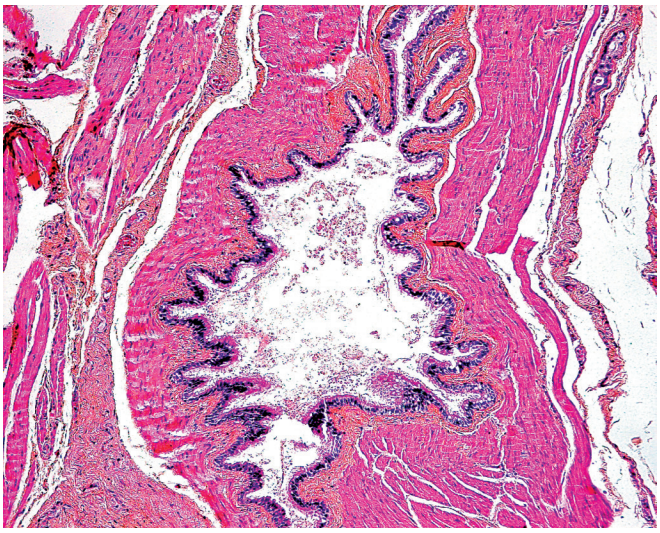

Figure 13.5 Esophageal cyst lined by ciliated columnar epithelium.

Cysts

Esophageal cysts are classified into *inclusion cysts* (lined by squamous or columnar epithelium, sometimes ciliated), *retention cysts* or mucoceles (arising from cystic dilation of submucosal glands), and *developmental cysts* (of esophageal, bronchial, or gastric origin) (Fig. 13.5).[27,28] Their microscopic distinction may be very difficult. Cases of squamous cell carcinoma and adenocarcinoma arising in these cysts have been reported.[29,30]

Rings and Webs

Esophageal shadows with a configuration resembling rings and webs are often described by radiologists in patients complaining of dysphagia. Those located in the upper esophagus of women and associated with iron-deficiency anemia are a component of the Plummer–Vinson or Paterson–Kelly syndrome, in which an increased incidence of carcinoma has been described.[31] Those located in the lower esophagus are commonly referred to as Schatzki, esophagogastric, or lower esophageal rings. Some rings are caused by a transverse circumferential fold of the mucosa, typically located at the SCJ. Others are formed by localized annular thickening of the muscle.[32]

Cervical esophageal (pharyngoesophageal) webs also represent transverse folds of normal mucosa and submucosa.[33] The treatment of esophageal webs includes endoscopic dilation and surgical myomectomy.[34]

Achalasia and Related Motor Disorders

Achalasia (cardiospasm, megaesophagus) is due to a failure of relaxation of the lower esophageal sphincter while peristaltic waves

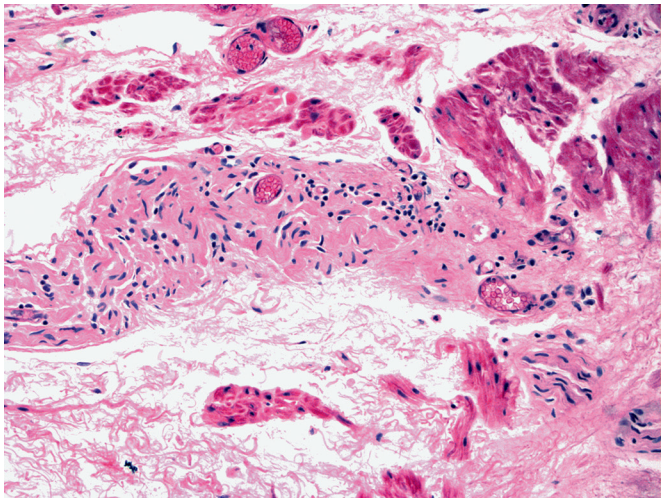

Figure 13.6 Myenteric plexus in achalasia with scattered lymphocytes and no residual ganglion cells.

conveying food through the esophagus reach it. It is usually seen in adults but can also occur in children.[35] Some of the patients are affected by the Allgrove (triple A) syndrome, in which the achalasia is combined with adrenal deficiency or addisonianism and alacrima.[36] A nearly complete loss of myenteric ganglion cells is present in the lower third of the esophagus in almost all cases; this loss extends to the middle third of the esophagus in about 20% of cases.[37] Secondary changes include marked hypertrophy of the muscularis propria and prominent mucosal and submucosal inflammation. The primary abnormality is inflammatory destruction of myenteric ganglion cells, predominantly by CD3+ T cells.[38] Eventually, there is loss of ganglion cells and widespread fibrosis of the myenteric nerves (Fig. 13.6). In longstanding cases, the mucosa shows marked squamous hyperplasia and an increased incidence of P53 immunoreactivity, possibly indicating the preneoplastic nature of this mucosa.[39]

The pathogenesis of achalasia remains unknown. At present, the hypothesis that achalasia is an inflammatory, immune-mediated disease is favored, but the responsible antigen remains unknown.[40,41]

In the early stages, achalasia is reversible. With time, however, chronic inflammation and ulceration supervene, and fibrotic stricture results. Esophagomyotomy and pneumatic dilation remain the major treatment modalities.[42,43] Rarely, carcinoma develops in association with longstanding achalasia,[44] with an estimated 16–33-fold increased risk.[45] Almost all are squamous cell carcinomas, most commonly arising in the middle esophagus.

Cricopharyngeal dysphagia (cricopharyngeal achalasia, cricopharyngeal spasm) is a well-recognized entity with prominent clinical symptoms but only meager microscopic findings, represented by degeneration and regeneration of the fibers of the cricopharyngeal muscle, accompanied by interstitial fibrosis.[46]

Chagas disease, an endemic parasitosis of South America, can be associated with alterations of Auerbach plexus and megaesophagus.[47]

Pseudoachalasia is an esophageal motor disorder usually associated with malignancy; the clinical, radiographic, and manometric features are very similar to those of achalasia.[48,49] The most common microscopic finding, which is in keeping with its presumed pathogenesis, is neoplastic infiltration of the myenteric plexus,[48] although some cases are paraneoplastic.

Giant muscular hypertrophy (diffuse spasm, corkscrew esophagus, diffuse leiomyomatosis) is a motor disorder of the esophagus characterized clinically by dysphagia and pathologically by focal or diffuse hypertrophy of the muscular layer.[50] Some cases have been reported in association with Alport syndrome, a hereditary glomerular nephropathy.[51] Mutations of the *COL4A5* gene have been implicated in this process.[52]

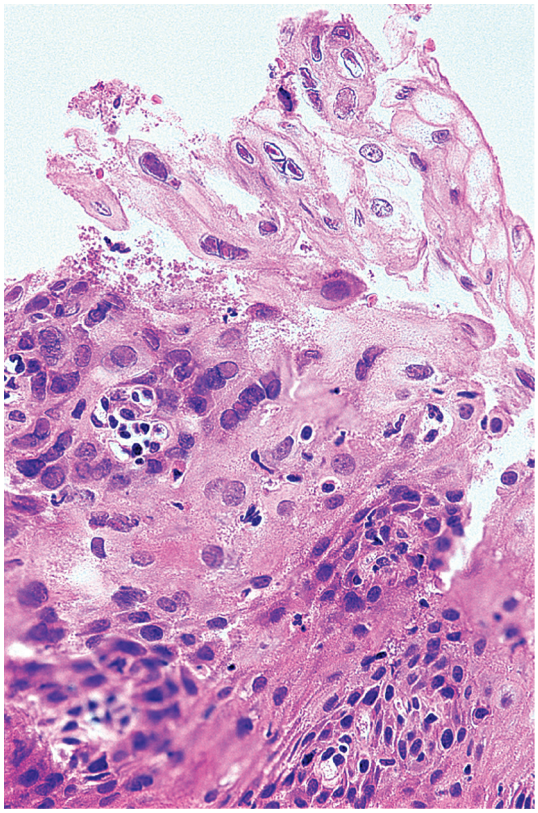

Figure 13.7 **Herpes Simplex Esophagitis.** Several intranuclear eosinophilic inclusions are seen in the squamous mucosa.

Lye Strictures

Lye strictures of the esophagus are most common at the level of bifurcation of the trachea. The mean age of the patients at the time of lye ingestion is about 6 years. Once the lesion is well established, most patients require surgical resection, although, more recently, endoscopic therapies have been attempted.[53] Carcinoma of the esophagus may develop at the site,[54] most often at the level of the tracheal bifurcation. The mean latent time is about 40 years; the later in life the lye is ingested, the shorter the interval.

Esophagitis (Nonreflux Related)

Herpes simplex esophagitis can arise in both immunosuppressed and immunocompetent individuals.[55] It may be asymptomatic or result in odynophagia, retrosternal chest pain, and fever.[56] The diagnosis should be suspected in the presence of "volcano ulcers" at endoscopy and discrete, diffusely scattered, shallow ulcers on double-contrast esophagogram.[57] Microscopically, inflammation, ulcerations, and Cowdry type A inclusions are the hallmarks of the disease, but the latter are not always identifiable (Fig. 13.7).[58] Multinucleated epithelial cells constitute another classic morphologic feature of herpes esophagitis; however, it should be noted that similar multinucleated cells can be seen in esophagitis of other etiologies as a nonspecific regenerative response to injury.[59] Aggregates of large

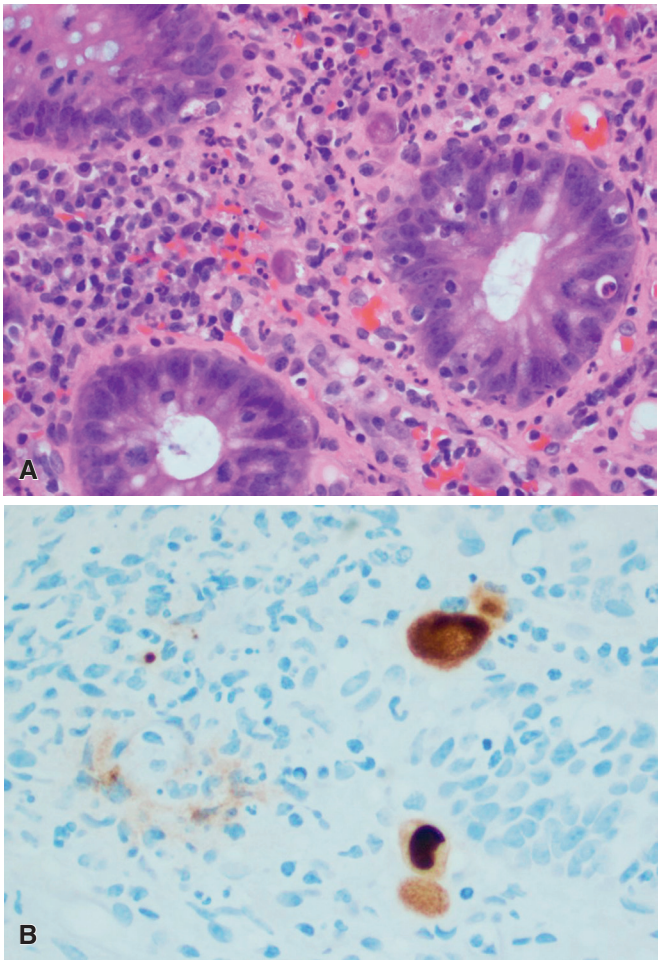

Figure 13.8 A, CMV inclusions in a patient with Barrett esophagus. **B,** CMV immunostain showing rare immunopositive cells.

mononuclear cells with convoluted nuclei (CD68+) adjacent to the inflamed epithelium constitute an important diagnostic clue.[60]

Cytomegalovirus (CMV) esophagitis is also on the rise because of its predilection for immunocompromised patients.[61] Its endoscopic appearance is similar to that of herpes esophagitis. Microscopically, the diagnosis is made by finding the typical large cells with basophilic cytoplasm and large oval, eosinophilic intranuclear inclusions,[62] usually at the base of the ulcer (Fig. 13.8).

Candida esophagitis can complicate the ulcers of herpes or CMV esophagitis or appear in the absence of viral infection, usually in immunosuppressed individuals,[63] but it may be seen in immunocompetent individuals as well. At endoscopy, it typically appears as white plaques that are often easily scraped away. Pseudohyphae can be seen in a background of active esophagitis (Fig. 13.9); in some cases, special stains (periodic acid–Schiff [PAS], silver stain) may be of use.

AIDS-related chronic idiopathic esophageal ulceration is characterized by the presence of large, undermined ulcers with severe acute inflammation.[64–66] No evidence of herpes simplex, CMV, fungi, or tumors has been found, and the startling suggestion has been made that the ulcers are the direct result of the HIV itself.[67]

Crohn disease can involve the esophagus, usually in association with gastric and/or intestinal disease.[68] Some cases clearly show an esophageal mucosal infiltration of lymphocytes (lymphocytic esophagitis), but some have found that patients with Crohn disease were not more likely than controls to show this morphologic finding.[69]

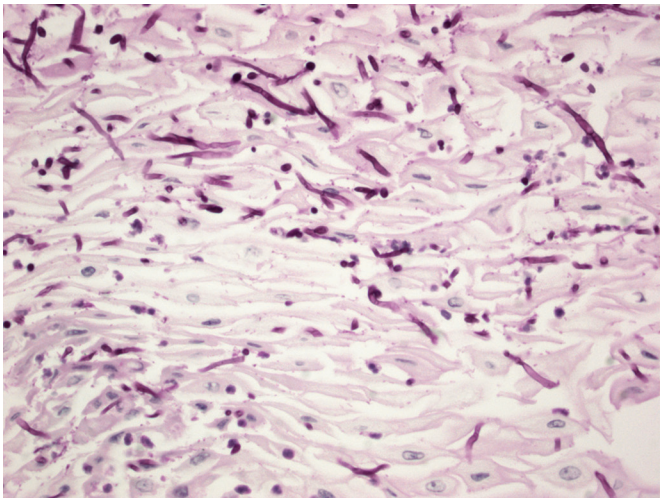

Figure 13.9 Esophageal Candidiasis. Pseudohyphae are seen within the squamous mucosa.

Eosinophilic (allergic) esophagitis is an allergic eosinophilic disorder that seems to be increasing in frequency.[70] The favored interpretation is that it is the result of local hypersensitivity to food- or blood-borne allergens, and that antigen-presenting cells play an important role in its pathogenesis.[71] This condition should be distinguished from the much more common eosinophilic infiltration of esophageal mucosa seen in patients with gastroesophageal reflux, discussed later. Although eosinophilic microabscesses and lamina propria fibrosis favors the diagnosis of eosinophilic esophagitis (Fig. 13.10), no histologic feature is specific for this condition, as diagnosis requires clinical, endoscopic, and pathologic data.[70] Although this condition may result in many endoscopic appearances, the most characteristic is the ringed esophagus.

Esophagitis dissecans superficialis ("sloughing esophagitis") is an endoscopically defined disease characterized by detachment of large fragments of squamous esophageal mucosa. It affects mainly adults, with a female predominance.[72] The etiology is unknown, and the usual evolution is towards total resolution. Microscopically, there is "sloughing" and "flaking" of the superficial squamous epithelium, with occasional bullous separation of the layers, parakeratosis, and nonspecific inflammation (Fig. 13.11).[72,73] Some cases may be medication induced, and psychoactive agents, clindamycin, and acid-suppressive agents have been implicated.[72,74]

Other types of esophagitis include those caused by *tuberculosis*,[75] *blastomycosis*,[76] *Behçet disease*,[77] *drugs* (including iron medication[78]), *irradiation*,[79] and *ingestion of corrosive chemicals*.[80] Dermatologic diseases that can involve the esophagus include *scleroderma*,[81] *pemphigus vulgaris*,[82] *lichen planus*,[83] and *epidermolysis bullosa*.[84] Inflammation and sometimes perforation of the esophagus may result from *instrumentation*, *intubation*, or the *ingestion of foreign bodies*.[85] Recently, Salaria et al. described a form of esophagitis resembling lichen planus (lichenoid esophagitis) characterized by intraepithelial and lamina propria lymphocytosis and apoptosis of squamous cells (so-called Civatte bodies) but showing an association with viral hepatitis and HIV infection.[86]

Reflux Esophagitis

As the name indicates, this form of esophagitis (also known as GERD) is the result of reflux of gastroduodenal contents into the esophagus (Fig. 13.12). It is often associated with a sliding hiatal hernia. Esophageal reflux is accompanied by regurgitation, heartburn,

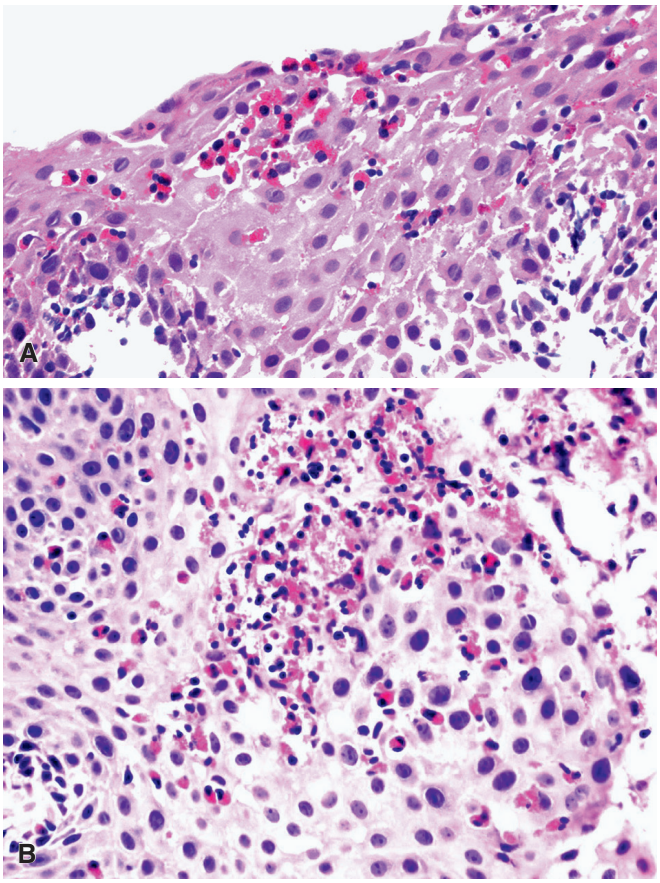

Figure 13.10 Eosinophilic Esophagitis. A, There is a marked increase in the number of intraepithelial eosinophils with a surface-heavy infiltrate. **B,** Eosinophilic microabscesses are characteristic.

Figure 13.12 Gross Appearance of a Severe Case of Reflux Esophagitis. Marked hyperemia with focal hemorrhage is present in the area of reflux.

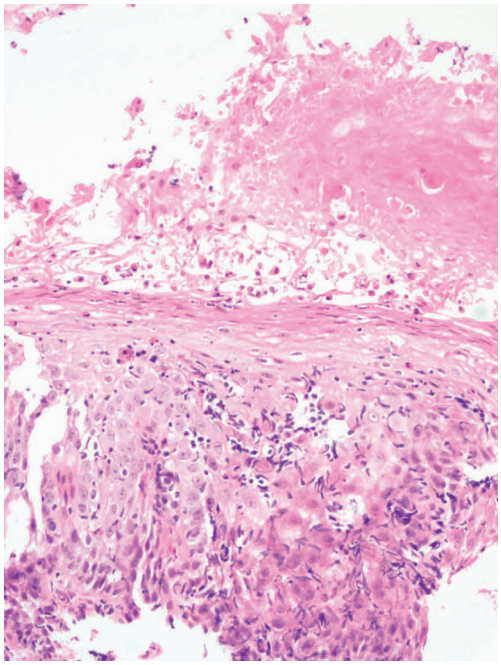

Figure 13.11 Characteristic histologic appearance of so-called sloughing esophagitis.

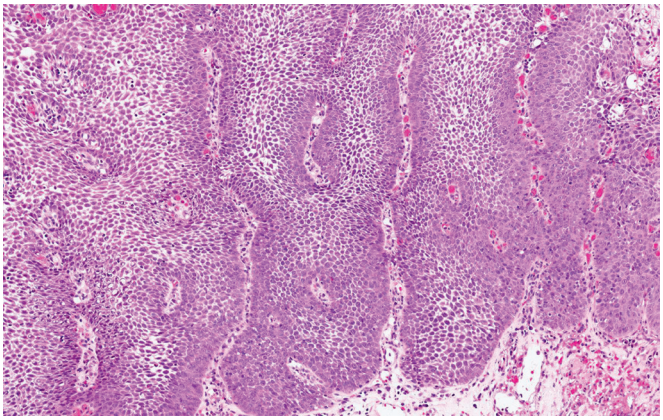

Figure 13.13 Gastroesophageal reflux disease with marked squamous hyperplasia and basal cell hyperplasia. Scattered intraepithelial inflammatory cells are seen.

pain, and dysphagia. The early microscopic lesions consist of epithelial hyperplasia and infiltration by neutrophils and eosinophils, sometimes accompanied by focal epithelial necrosis (Fig. 13.13).[87–89] The papillary height of the lamina propria and the degree of basal cell proliferation are substantially higher than in control subjects, as estimated subjectively and corroborated with morphometric techniques.[90,91] Dilated and congested venules are seen high up in the top of the lengthened papillae between the epithelial layers.[92,93] Intraepithelial eosinophils are among the most common features seen in reflux, but this feature lacks sensitivity (since it is not found in many patients with reflux)

and specificity (as it is found in many other conditions). Cells with irregular nuclear contours can be seen amid the epithelial elements in reflux esophagitis; they represent reactive T-lymphocytes and are a component of the inflammatory response.[94,95] Although this constellation of histologic features is characteristic, no single feature or combination of features is diagnostic of GERD; this is a clinicopathologic and endoscopic diagnosis that cannot be made by the pathologist in isolation.

Reflux esophagitis may progress to superficial ulceration and circumferential fibrosis with stricture formation and fixation to the surrounding structures. Occasionally, the inflammatory reaction associated with the esophagitis may be of such a degree as to result in a pseudolymphomatous appearance.[96]

Depending on the severity of the symptoms, reflux esophagitis can be treated medically (with motility-promoting drugs, H_2-receptor antagonists, or proton pump inhibitors) or surgically.[97] All of the various operations that have been devised for this disorder (such as fundoplication) involve the reduction of the hiatal hernia (often present) coupled with the construction of a valve mechanism to reestablish gastroesophageal competence.

Barrett Esophagus

This condition is defined as replacement of esophageal squamous mucosa by metaplastic columnar epithelium with goblet cells (Fig. 13.14). According to guidelines provided by the American College of Gastroenterology, this condition requires an endoscopic abnormality (columnar-lined esophagus) and the identification of unequivocal goblet cells in a biopsy from the area of the endoscopic abnormality.[98] A large majority of patients are adult white males. However, it has also been reported in children, sometimes in association with cystic fibrosis (a condition known to induce gastroesophageal reflux) and following chemotherapy.[99] A genetic predisposition to develop Barrett esophagus has been detected.[100] Lack of a precise definition on the nature and location of the GEJ and the microscopic variations at this junction have clouded the issue as to whether this condition is congenital or acquired, but most clinical and experimental evidence indicates that this change is acquired and the result of acid-induced ulceration with subsequent reepithelialization by columnar cells.[101] The origin of the columnar cells remains uncertain; theoretically, they could arise from migration of gastric mucosa as a result of a phenotypic switch of undifferentiated elements in the stem cell population or as a repopulation from underlying submucosal glands.[102–104]

Some have suggested that the so-called multilayered epithelium having morphologic and ultrastructural features of both squamous and columnar epithelium could be the precursor epithelium that gives rise to Barrett mucosa.[105]

This columnar epithelial extension may be circumferential or in the form of finger-like projections or islands. At present, only intestinal metaplasia is diagnostic of this condition, although there typically is an admixture of other types of columnar mucosa of cardiac or fundic type.[103] Most cases show incomplete intestinal metaplasia, but many show an admixture of incomplete and complete intestinal metaplasia. Interesting, the non-goblet columnar cells have immunophenotypic[106] and DNA flow cytometric abnormalities similar to those found in intestinal metaplasia.[107] Some have suggested that perhaps the definition of Barrett esophagus is too restrictive and should include this "preintestinalized" non-goblet columnar mucosa.[108]

The topic of intestinal metaplasia at the GEJ is controversial. While some believe that all intestinal metaplasia in this location is indicative of Barrett esophagus,[109,110] others believe this is a multifactorial condition,[111] and, as such, these cases should be diagnosed as intestinal metaplasia of the GEJ, as opposed to Barrett esophagus. Although a number of immunohistochemical markers have been reported to be useful in distinguishing intestinal metaplasia of distal esophagus versus proximal gastric origin (CDX2, Das1, CK7/20), none has been found to be of sufficient sensitivity and specificity to be used clinically.[111] On the other hand, subtle clues may be present in the biopsy to suggest an esophageal origin of intestinal metaplasia, including squamous epithelium overlying intestinalized glands, hybrid glands (a mixture of goblet cells and non-goblet columnar cells) and the identification of esophageal glands/ducts.[112]

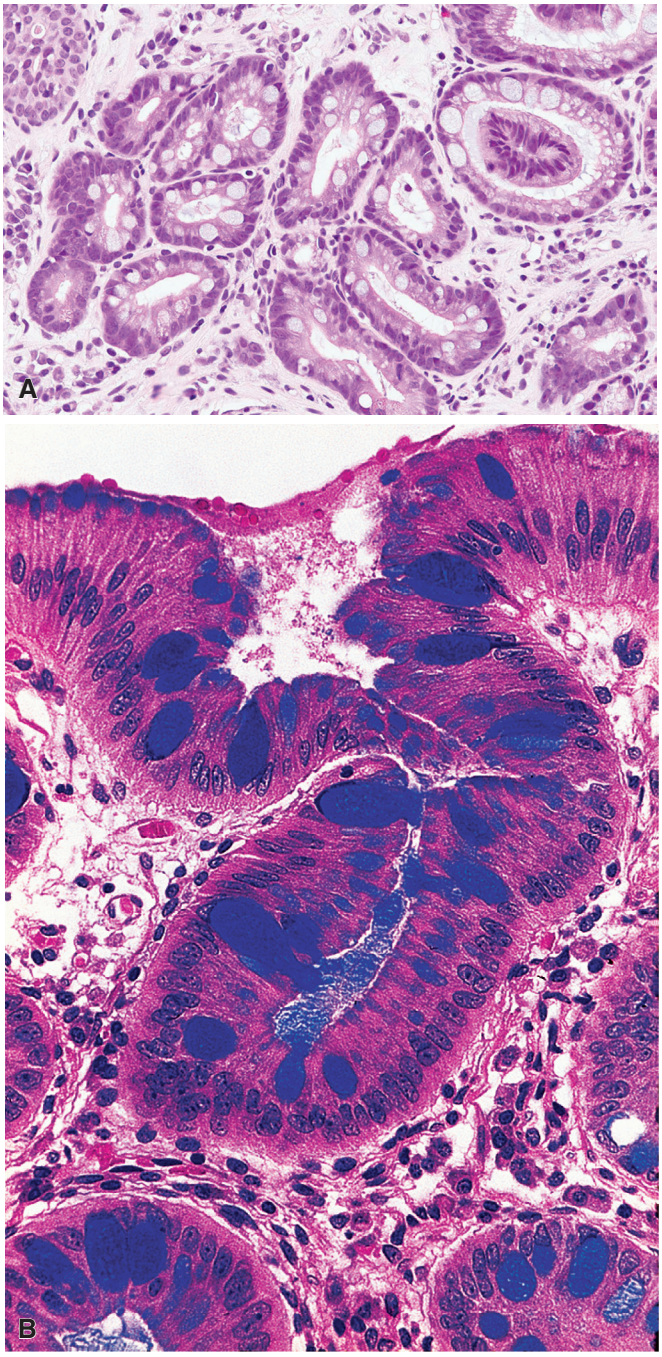

Figure 13.14 **A,** Barrett esophagus with scattered goblet cells. **B,** Alcian blue stain at pH 2.5 highlighting the acid mucin-containing goblet cells.

An interesting feature often seen in Barrett esophagus is the formation of a new, superficially located muscularis mucosae (reduplication), which results in the division of the lamina propria into a superficial and deep compartment.[113,114] This has clinical importance, as it is easy to overstage tumors invading into the native (deeper) muscularis mucosal layer, since this can be misinterpreted as evidence of muscularis propria invasion.

Barrett esophagus has been further subdivided into *long segment* (the classic form, in which the changes involve 3 cm or more of the esophagus) and *short segment* (less than 3 cm). For practical purposes, these two artificially defined types are managed similarly. At the histochemical level, most of the mucin present in specialized columnar epithelium is of neutral type, but in over 70% of the cases there are also sialomucins and sulfomucins.[115] The intestinal type of differentiation is also evidenced by the common presence of the intestinal-type mucin MUC2, in addition to gastric-type mucins (MUC5AC, MUC6), TFF peptides (TFF1 and TFF2)[116,117] and by the presence of the CDX2 protein, as detected immunohistochemically.[118]

The main complications of Barrett esophagus are the same as for reflux esophagitis (i.e. peptic ulcer, stricture, bleeding), plus the development of dysplasia and adenocarcinoma[119]; the latter is discussed in detail in the next section. Once a diagnosis of Barrett esophagus is established, most patients undergo endoscopic surveillance at regular intervals. If biopsies show changes indefinite for dysplasia (IND) or low-grade dysplasia (LGD), anti-reflux medical therapy is maximized, and the patient returns for repeat endoscopy with biopsy in a shorter period of time.[101] If a diagnosis of high-grade dysplasia (HGD) is rendered, patients are now often referred for endoscopic ablative therapy (radiofrequency ablation and cryoablation, among others).[120] In the past, many of these patients would have undergone an esophagectomy, a major operation with not insignificant morbidity and mortality.[121] Endoscopic mucosal resection is commonly used in patients with an endoscopic lesion, which is determined to be either an intramucosal or superficial submucosal adenocarcinoma.[122]

Diagnostic Categories in Barrett Esophagus

The vast majority of biopsies for Barrett esophagus are negative for dysplasia, and most patients never develop dysplasia or adenocarcinoma. The diagnostic categories listed later are those agreed upon at the 1988 consensus conference for grading dysplasia in Barrett esophagus (Fig. 13.15).[123] These criteria were further refined by Montgomery and colleagues in 2001.[124] Unfortunately, a high degree of interobserver variability remains.[125,126]

- **Negative for dysplasia**: The architecture is within normal limits. The nuclei do not vary greatly in size or shape and are located basally. The nucleocytoplasmic ratio is not increased, and the nuclear envelope is generally smooth. Nucleoli are not markedly enlarged. Focal nuclear stratification is acceptable, as are small numbers of "dystrophic" goblet cells, the apical aspect of which does not communicate with the luminal surface. Greater nuclear alterations are acceptable when associated with evidence of inflammation, erosion, or ulceration. Apical cytoplasmic mucus is usually present but may be reduced or absent in inflammation.
- **IND:** The architecture may be moderately distorted. Nuclear abnormalities are less marked than those seen in dysplasia. Other features that may lead to a diagnosis of IND include more numerous dystrophic goblet cells, more extensive nuclear stratification, diminished or absent mucus production, increased cytoplasmic basophilia, and increased mitoses. The diagnosis of IND should be limited to cases in which the changes are too marked for negative but not sufficient for the diagnosis of dysplasia.
- **Positive for LGD or HGD:** The diagnosis of LGD or HGD is based on the severity of both architectural and cytologic alterations. Although either architectural or cytologic abnormalities may predominate, HGD is diagnosed if either one is sufficiently prominent. Architectural abnormalities may include budded, branched, crowded, or irregularly shaped glands; papillary extensions into gland lumina; and villiform configuration of the mucosal surface. Nuclear features may include marked variation in size and shape, nuclear and/or nucleolar enlargement, increased nucleocytoplasmic ratio, hyperchromasia, and increased numbers of abnormal mitoses. Nuclear alterations are especially noteworthy if they involve the mucosal surface. Diagnostic features easily recognizable at low power are cytoplasmic basophilia with loss of mucus, nuclear hyperchromasia, and excessive nuclear stratification, often extending from the epithelial basement membrane to the luminal surface. The significance of crypt dysplasia *with surface maturation* (also known as basal crypt dysplasia) is yet to be defined, but the view has been advanced that it represents dysplasia that has not yet involved the surface.[127]
- **Intramucosal adenocarcinoma:** Intramucosal adenocarcinoma is defined as carcinoma that has penetrated through the basement membrane of the glands into the lamina propria or muscularis mucosae, but not below. Most biopsy specimens are not deep enough to rule out submucosal invasion. Useful features include back-to-back glands with little to no intervening stroma, identification of individual cells, small cell groups, or irregularly shaped glands in the lamina propria and dilated deep glands with intraluminal necrosis.[128]

In some cases of dysplasia, the polypoid architecture of the lesion and the crowding and stratification of the hyperchromatic nuclei are similar to those seen in adenomas of the large bowel.[129]

The risk for the development of invasive carcinoma in patients with Barrett-related dysplasia is certainly increased, but the exact magnitude of this risk remains to be determined.[101,130] Certainly, the risk for progression from HGD to carcinoma is significant; up to 50% progress to carcinoma in 5 years.[131] The risk of progression from LGD is less well established, mostly due to the notorious lack of reproducibility of this diagnosis.[132,133]

A large number of biomarkers have been evaluated in the Barrett–dysplasia–carcinoma sequence, which are too numerous to mention in detail.[134–136] At this point, no biomarker has been found to be superior to the morphologic identification of dysplasia in predicting progression to carcinoma. Since the vast majority of patients with this disease do not progress to carcinoma, the identification of a biomarker in nondysplastic Barrett mucosa that is predictive of progression would be extremely helpful. Studies from the University of Washington have suggested that somatic mutations in *CDKN2A* and *TP53* may be predictive of progression from nondysplastic Barrett mucosa.[137]

Adenocarcinoma Arising in Barrett Esophagus

The large majority of invasive carcinomas developing in Barrett esophagus are adenocarcinomas, although rare cases can show squamous[138,139] or even neuroendocrine differentiation.[140] The majority of patients are elderly white males, but not all patients fit into this demographic group. Some of the reported cases have been in children.[141] The main features used to suggest an origin for an esophageal adenocarcinoma from Barrett mucosa are the identification of goblet cells adjacent to the neoplasm and the epicenter of the tumor being located on the esophageal side of the GEJ. Adenocarcinomas of the GEJ have essentially similar morphologic, immunohistochemical, and epidemiologic features whether an associated Barrett metaplasia can be detected in the specimen or not.[142,143] The tumor may be multicentric and is often far advanced at the time of diagnosis, with extension into the wall and nodal metastases.[144] Microscopically, a wide range of glandular differentiation exists, sometimes in the same tumor.

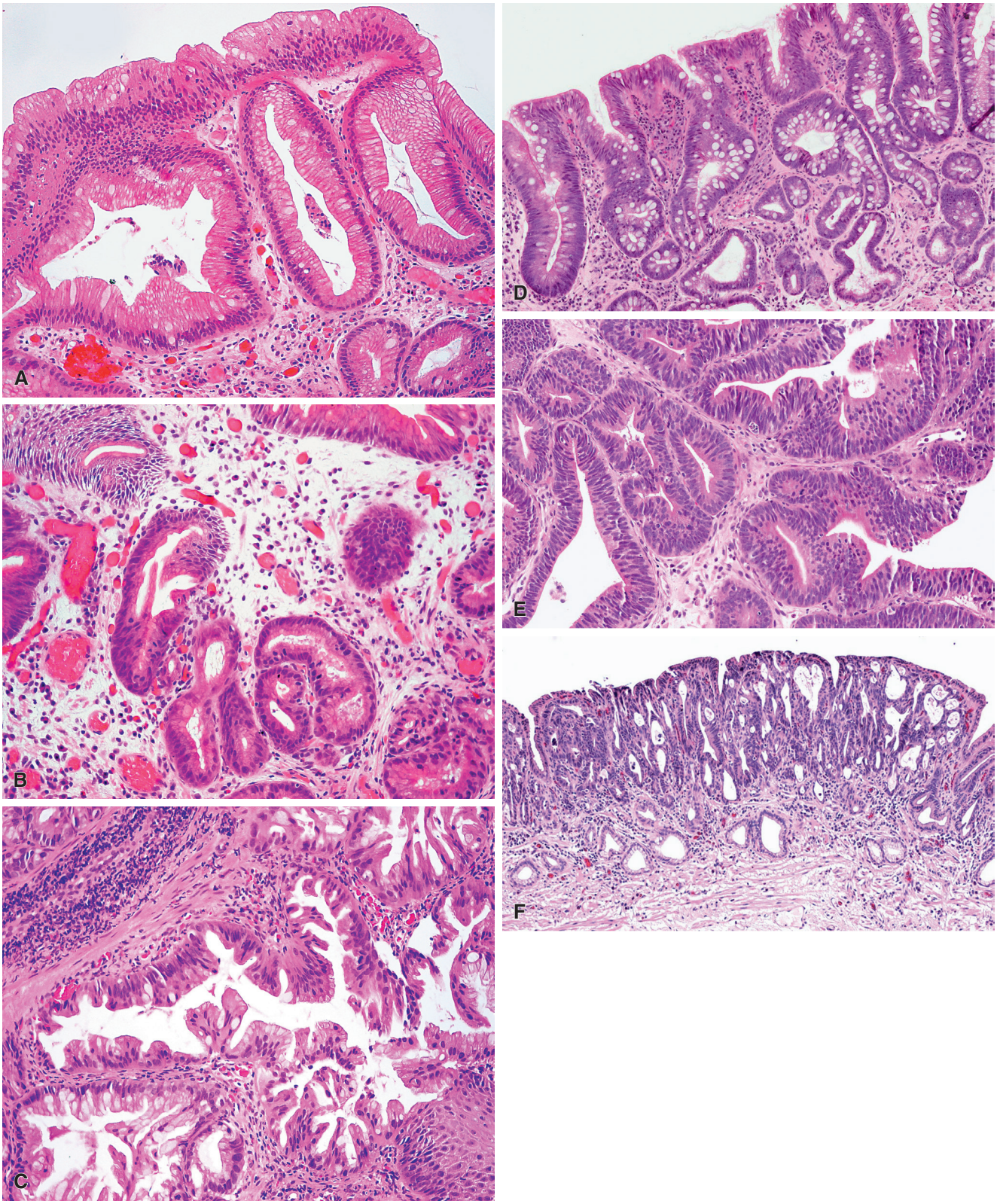

Figure 13.15 **A,** Barrett esophagus negative for dysplasia. **B,** Barrett esophagus with mild chronic inflammation and reactive glandular atypia, negative for dysplasia. **C,** Barrett esophagus with epithelial alterations indefinite for dysplasia. **D,** Barrett esophagus with low-grade dysplasia, intestinal type. **E,** Barrett esophagus with high-grade dysplasia, intestinal type. **F,** Intramucosal adenocarcinoma with infiltration of glands into the lamina propria.

Architecturally and immunohistochemically, most of these tumors resemble their gastric counterparts, while others exhibit an intestinal phenotype. Signet ring carcinomas are much less common than in the stomach but show aggressive clinical behavior.[145] Rare cases of Barrett-related adenocarcinoma become sarcomatoid.[146]

Many molecular alterations have been identified in specimens of Barrett esophagus containing lesions within the dysplasia–adenocarcinoma sequence.[147,148] These include *TP53* mutation and overexpression, altered expression of various apoptosis-related proteins, *MYC* amplification,[149,150] mutations of β-catenin and other alterations of the cadherin/catenin membrane complex,[151] hypermethylation of multiple tumor suppressor genes (such as *APC*, *TERT*, *RUNX3*, *TIMP3*),[152] loss of heterozygosity (including *CDKN2A* at 9p21)[137] and microsatellite instability,[147] alterations of MUC expression,[153] and *HER2* amplification,[154] among many others. It appears that the earliest molecular changes are loss of *CDKN2A* (by deletion or hypermethylation) and *TP53* (by mutation and deletion).[155]

Surgical resection is the primary treatment, sometimes combined with preoperative neoadjuvant chemoradiotherapy.[156,157] In some cases, prominent pools of mucin can be found in the wall of the esophagus after neoadjuvant therapy and should not be misinterpreted as evidence of residual adenocarcinoma unless viable tumor cells are identified.[158]

The prognosis of adenocarcinoma in Barrett esophagus is poor, with a 5-year survival rate of less than 20%.[159] The most important prognostic factors, as in many other sites, is tumor stage (Tables 13.1 and 13.2), particularly in relation to the depth of invasion and the lymph node status.[159–162] Histologic evidence of tumor regression following neoadjuvant chemotherapy seems also to be a strong prognostic indicator.[163] Other potential prognostic factors include lymphatic vessel density,[160] extracapsular lymph node involvement,[164] *HER2* amplification,[165] and β-catenin abnormal expression.[166]

Squamous Cell Carcinoma

General and Clinical Features

Squamous cell carcinoma of the esophagus occurs more frequently in men over 50 years of age. It is relatively common in China and other Asian countries[167] and is the most common tumor of the gastrointestinal tract in the African Bantus.[168] In the United States over the past decades, it has become distinctly less common than

Table 13.1 Definitions of AJCC TNM for squamous cell carcinoma and adenocarcinoma

Primary Tumor (T)

T CATEGORY	T CRITERIA
Tx	Tumor cannot be assessed
T0	No evidence of primary tumor
Tis	High-grade dysplasia, defined as malignant cells confined to the epithelium by the basement membrane
T1	Tumor invades the lamina propria, muscularis mucosae, or submucosa
T1a	Tumor invades the lamina propria or muscularis mucosae
T1b	Tumor invades the submucosa
T2	Tumor invades the muscularis propria
T3	Tumor invades adventitia
T4	Tumor invades adjacent structures
T4a	Tumor invades the pleura, pericardium, azygos vein, diaphragm, or peritoneum
T4b	Tumor invades other adjacent structures, such as the aorta, vertebral body, or airway

Regional Lymph Nodes (N)

N CATEGORY	N CRITERIA
Nx	Regional lymph nodes cannot be assessed
N0	No regional lymph node metastasis
N1	Metastasis in one or two regional lymph nodes
N2	Metastasis in three to six regional lymph nodes
N3	Metastasis in seven or more regional lymph nodes

Distant Metastasis (M)

M CATEGORY	M CRITERIA
M0	No distant metastasis
M1	Distant metastasis

Histologic Grade (G)

G CATEGORY	G CRITERIA
Gx	Grade cannot be assessed
G1	Well differentiated
G2	Moderately differentiated
G3	Poorly differentiated, undifferentiated

Location (L)*

L CATEGORY	L CRITERIA
X	Location unknown
Upper	Cervical esophagus to lower border of azygos vein
Middle	Lower border of azygos vein to lower border of inferior pulmonary vein
Lower	Lower border of inferior pulmonary vein to stomach, including gastroesophageal junction

*Location plays a role in stage grouping of esophageal squamous cancers and is defined by the position of the epicenter of the tumor in the esophagus.
From Amin M, Edge S, Greene F, et al. (eds.). AJCC Cancer Staging Manual. vol 8. New York: Springer; 2017.

Table 13.2 AJCC prognostic stage groups: adenocarcinoma

Clinical (cTNM)

WHEN cT IS...	AND cN IS...	AND M IS...	THEN THE STAGE GROUP IS...
Tis	N0	M0	0
T1	N0	M0	I
T1	N1	M0	IIA
T2	N0	M0	IIB
T2	N1	M0	III
T3	N0-1	M0	III
T4a	N0-1	M0	III
T1-4a	N2	M0	IVA
T4b	N0-2	M0	IVA
Any T	N3	M0	IVA
Any T	Any N	M1	IVB

Pathological (pTNM)

WHEN cT IS...	AND cN IS...	AND M IS...	AND G IS...	THEN THE STAGE GROUP IS...
Tis	N0	M0	N/A	0
T1a	N0	M0	G1	IA
T1a	N0	M0	GX	IA
T1a	N0	M0	G2	IB
T1b	N0	M0	G1-2	IB
T1b	N0	M0	GX	IB
T1	N0	M0	G3	IC
T2	N0	M0	G1-2	IC
T2	N0	M0	G3	IIA
T2	N0	M0	GX	IIA
T1	N1	M0	Any	IIB
T3	N0	M0	Any	IIB
T1	N2	M0	Any	IIIA
T2	N1	M0	Any	IIIA
T2	N2	M0	Any	IIIB
T3	N1-2	M0	Any	IIIB
T4a	N0-1	M0	Any	IIIB
T4a	N2	M0	Any	IVA
T4b	N0-2	M0	Any	IVA
Any T	N3	M0	Any	IVA
Any T	Any N	M1	Any	IVB

Table 13.2 AJCC prognostic stage groups: adenocarcinoma—cont'd

Postneoadjuvant Therapy (ypTNM)			
WHEN yP T IS...	**AND yP N IS...**	**AND M IS...**	**THEN THE STAGE GROUP IS...**
T0-2	N0	M0	I
T3	N0	M0	II
T0-2	N1	M0	IIIA
T3	N1	M0	IIIB
T0-3	N2	M0	IIIB
T4a	N0	M0	IIIB
T4a	N1-2	M0	IVA
T4a	NX	M0	IVA
T4b	N0-2	M0	IVA
Any T	N3	M0	IVA
Any T	Any N	M1	IVB

From Amin M, Edge S, Greene F, et al. (eds.). AJCC Cancer Staging Manual. vol 8. New York: Springer; 2017.

Barrett-related adenocarcinoma.[169] Smoking and alcohol are two important and well-known risk factors.[170] The tumor has also been reported in association with lye strictures,[54] achalasia,[171] Plummer–Vinson syndrome,[172] diverticula,[173] tylosis (an autosomal dominant disorder characterized by hyperkeratosis of palms and soles),[174] and history of previous irradiation.[175]

Another known association is with squamous cell carcinoma in other sites, particularly the oropharynx and larynx,[176] some of whom show clear-cut evidence of high-risk human papillomavirus (HPV) infection.[177] Studies searching for DNA sequences of HPV in esophageal squamous cell carcinomas have given widely divergent results, with a tendency for low prevalence in North American cases.[178–180] Tumor multicentricity in the esophagus is a rare event, but it may occur, either synchronously or metachronously.[181] Most patients present with dysphagia related to the local spread of the tumor and this is usually the expression of advanced disease.

Morphologic Features and Local Spread

Squamous cell carcinoma can occur in any portion of the esophagus but is most common in the middle and lower thirds.[182] Grossly, the tumor usually is circumferential, often ulcerated, with sharply demarcated margins; rare cases have a polypoid appearance (Fig. 13.16).[183] On cut section, a grayish white tumor is seen to invade part or all of the muscular wall, from which it may extend into the surrounding soft tissues and trachea. Intraluminal growth also occurs and may eventually lead to total obstruction. Distally located tumors often invade the stomach. Submucosal spread, not always appreciable grossly, is also common, sometimes up to 5 cm or more beyond the gross margins of the tumor.[184] Intraepithelial spread along the submucosal gland/ducts may also be seen.[185] Vascular invasion is present in the majority of cases. Separate tumor nodules may be seen in the wall of the esophagus or stomach (so-called intramural metastases).[186]

Microscopically, the degree of squamous differentiation is variable, but most tumors are well or moderately differentiated (Fig. 13.17). The main differential diagnosis in a biopsy specimen is with atypical regenerative hyperplasia.[187] Occasionally, lack of cohesiveness of tumor cells results in an acanthotic appearance. True glandular and/or mucus-secreting components are found focally in up to 20% of cases, and, when extensive, the tumors are designated *adenosquamous carcinomas*.[188] The occasional presence of an intraepithelial component with the appearance of *Paget disease* has also been described,[189] although most cases with esophageal Paget cells are associated with an underlying adenocarcinoma.[190]

Immunohistochemical and Molecular Genetic Features

Esophageal squamous cell carcinomas are invariably immunoreactive for cytokeratins, particularly high-molecular-weight cytokeratins (CK5/6).[191] p63 is also a highly sensitive marker of this tumor, and both of these markers are useful in distinguishing squamous cell carcinoma from adenocarcinoma.[191,192] Some poorly differentiated carcinomas react for human chorionic gonadotrophin (hCG), even in the absence of morphologically demonstrable trophoblastic differentiation.[193] Production of basement membrane components, such as laminin and type IV collagen, correlates with the degree of differentiation of the tumor.[194]

DNA studies have shown that two-thirds to three-fourths of the cases have an aneuploid pattern, which correlates with a higher grade and a higher incidence of nodal metastases.[195] Heterogeneity in DNA ploidy, whether comparing the primary tumor with its metastasis or comparing different areas of the primary tumor, is common.[196]

Squamous cell carcinoma of the esophagus develops through accumulation of somatic mutations and epigenetic changes in oncogenes, tumor suppressor genes, and cell adhesion molecules.[197] Mutations and/or overexpression of *TP53* have been found in a high proportion of squamous dysplasia and esophageal squamous cell carcinomas, suggesting an early genetic alteration in this sequence.[198]

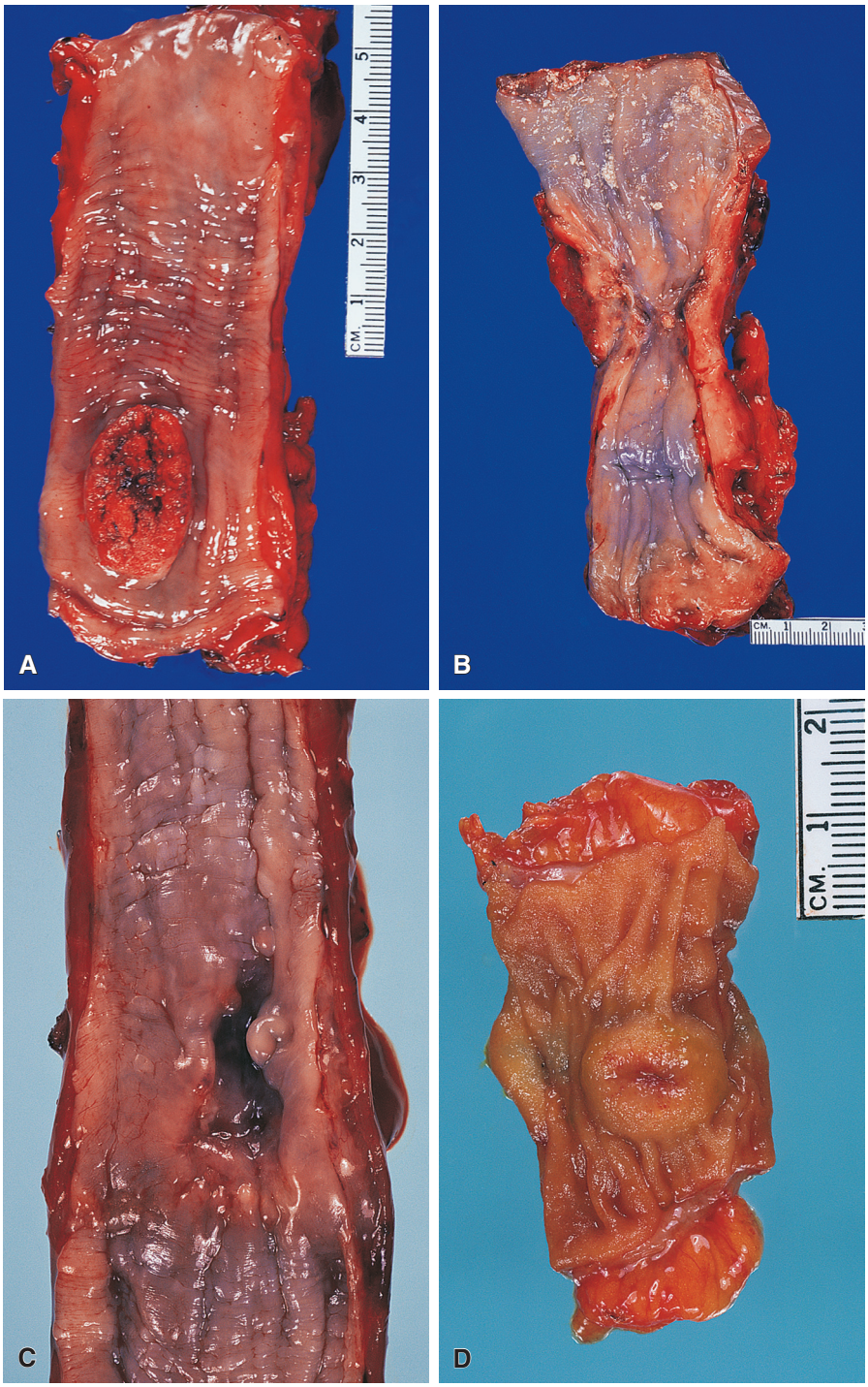

Figure 13.16 Various Gross Appearances of Esophageal Squamous Cell Carcinoma. A, Cakelike exophytic mass. **B,** Circumferential constricting lesion. **C,** Elevated round nodule with central ulceration. **D,** Widely invasive lesion with deep ulceration.

Esophageal Squamous Dysplasia

Squamous dysplasia of the esophagus is being recognized with increasing frequency, particularly in regions of the world with a high incidence of invasive esophageal squamous cell carcinoma.[199,200] Risk factors for esophageal dysplasia are the same as for the invasive tumors.[201] As in other sites, squamous dysplasia may be the only lesion present, or it could represent the peripheral component of an invasive carcinoma, the latter being more common. Squamous dysplasia/carcinoma in situ has been found at the periphery of an invasive tumor in approximately 30% of cases, the incidence being much higher when no preoperative irradiation has been given and when the main lesion is superficial[202]; sometimes the dysplastic lesion is found anatomically separate from the main tumor supporting the concept of a field effect.[203] The dysplastic change can extend into the ducts of the submucosal glands in a fashion analogous to

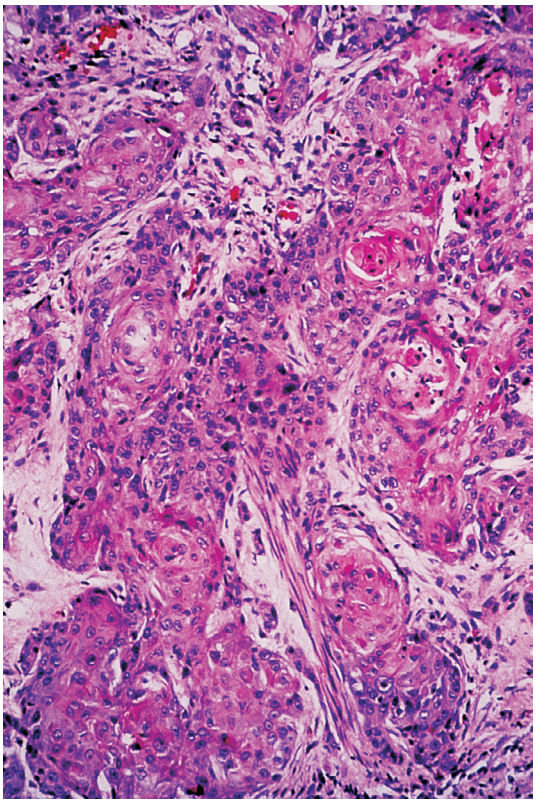

Figure 13.17 Low-power view of an invasive moderately differentiated squamous cell carcinoma of the esophagus.

endocervical gland involvement by cervical carcinoma in situ.[204] Occasionally, the dysplastic or malignant cells exhibit a pagetoid pattern of growth, which can be extensive.[189]

Intramucosal carcinoma is the term used for the carcinomas that do not invade beyond the muscularis mucosae, *superficial* (*or microinvasive*) *carcinoma* for those that do not invade beyond the submucosa, and *superficial*(*ly*) *spreading carcinoma* for those tumors having a lateral intramucosal spread of at least 2 cm beyond the invasive lesion.[205–207] Grossly, superficial carcinomas have been arbitrarily divided into flat, coarse, verrucous, polypoid, and ulcerating infiltrating patterns.[208] The more polypoid the lesion, the more likely that it will be found to invade the submucosa and that it will be associated with lymph node metastases.[209,210] The incidence of nodal metastases is virtually zero for intramucosal carcinomas; it ranges from over 20% to almost 50% in cases with submucosal invasion, depending on the series.[211–213] Depth of tumor invasion and any lymphatic invasion are independent predictors of nodal metastases.[212] Some have found the depth of invasion into the submucosa (divided into inner, middle, and outer thirds) is predictive of nodal metatatic risk.[213]

Metastases

The abundant lymphatic supply of the esophagus is responsible for the high frequency of lymph node metastases in the periesophageal area, below the diaphragm, and upward into the cervical nodes.[214] These nodal metastases occur early in the course of the disease and are the main reason for treatment failure. It should be pointed out that in small carcinomas confined to the esophageal wall, the lymph node metastasis is solitary in almost half of the cases.[215] Metastases to distant organs are also frequent, particularly to liver, lung, and adrenal glands. The tumor may also metastasize to the submucosa of the stomach, probably through the submucosal lymphatic plexus.[216]

Cytology

Exfoliative cytology in experienced hands is an extremely accurate technique for the evaluation of esophageal lesions, particularly those of the lower third.[217] However, since the introduction of the flexible fiberoptic endoscope, the diagnostic accuracy of direct-vision biopsy has surpassed that of cytology.[218] It is clear these are complementary methods which, when used together, provide diagnostic accuracy higher than either technique alone. Diagnostic cytology is particularly rewarding in countries with a high incidence of esophageal carcinoma, such as China or South Africa.[219,220]

Treatment

Traditionally, radiation therapy has been the most common form of treatment for carcinoma of the upper two-thirds of the esophagus, and surgery (in the form of esophagogastrectomy) the usual approach for carcinoma of the lower third. The current approach favors combined modalities consisting of preoperative radiation therapy (intracavitary or external beam) followed by surgery or the combination of chemotherapy and radiation therapy, with or without surgery.[221,222] Unfortunately, the overall results with any of these combination therapies remain disappointingly poor.[223]

Prognosis

The overall prognosis for esophageal squamous cell carcinoma is very poor (Tables 13.1 and 13.3). A recent study reported 3- and 5-year survival rates of 29.8% and 15%, respectively.[224] Factors thought to influence survival include gender (females > males),[225] tumor grade,[226] status of surgical margins,[227] and angiolymphatic invasion.[212] A number of yet to be substantiated biomarkers have also been reported to be of prognostic significance.[228] Histopathologic response following neoadjuvant chemoradiotherapy, as estimated by the percentage of residual tumor cells, is an independent prognostic factor.[229]

Other Types of Carcinoma

Sarcomatoid carcinoma (carcinosarcoma, spindle cell carcinoma, polypoid carcinoma) accounts for approximately 2% of all esophageal carcinomas and usually presents as a large polypoid neoplasm (Fig. 13.18).[230,231] The epithelial-appearing component can be quite inconspicuous and is usually limited to a few areas of in situ or superficially invasive carcinoma. Its appearance is usually that of a squamous cell carcinoma of either conventional or basaloid type. The bulk of the tumor has a pleomorphic sarcoma-like appearance (Figs. 13.19 and 13.20), sometimes exhibiting focal "divergent" differentiation toward cartilage, bone, or skeletal muscle.[232,233] Evidence suggests this component is also of epithelial derivation, and that all of the morphologically diverse tumor components have the same clonal origin.[234] Ultrastructurally, *some* of these sarcoma-like cells in *some* of the tumors retain epithelial markers, such as desmosomes and tonofibrils, but most have the appearance of myofibroblasts or other mesenchymal cells.[235] Immunohistochemically, cytokeratin can be consistently demonstrated in the epithelial-appearing component and, in a variable proportion of cases, also in some of the sarcoma-like cells. For sarcomatoid squamous cell carcinomas, markers such as CK5/6, p63, and p40 can be extremely helpful. The epithelial component may exhibit focal neuroendocrine features as an additional sign of multidirectional differentiation.[236] The sarcoma-like component has a higher proliferative index and higher aneuploidy than

Table 13.3 AJCC prognostic stage groups: squamous cell carcinoma

Clinical (cTNM)

WHEN cT IS...	AND cN IS...	AND M IS...	THEN THE STAGE GROUP IS...
Tis	N0	M0	0
T1	N0-1	M0	I
T2	N0-1	M0	II
T3	N0	M0	II
T3	N1	M0	III
T1-3	N2	M0	III
T4	N0-2	M0	IVA
Any T	N3	M0	IVA
Any T	Any N	M1	IVB

Pathological (pTNM)

WHEN pT IS...	AND pN IS...	AND M IS...	AND G IS...	AND LOCATION IS...	THEN THE STAGE GROUP IS...
Tis	N0	M0	N/A	Any	0
T1a	N0	M0	G1	Any	IA
T1a	N0	M0	G2-3	Any	IB
T1a	N0	M0	GX	Any	IA
T1b	N0	M0	G1-3	Any	IB
T1b	N0	M0	GX	Any	IB
T2	N0	M0	G1	Any	IB
T2	N0	M0	G2-3	Any	IIA
T2	N0	M0	GX	Any	IIA
T3	N0	M0	Any	Lower	IIA
T3	N0	M0	G1	Upper/middle	IIA
T3	N0	M0	G2-3	Upper/middle	IIB
T3	N0	M0	GX	Any	IIB
T3	N0	M0	Any	Location X	IIB
T1	N1	M0	Any	Any	IIB
T1	N2	M0	Any	Any	IIIA
T2	N1	M0	Any	Any	IIIA
T2	N2	M0	Any	Any	IIIB
T3	N1-2	M0	Any	Any	IIIB
T4a	N0-1	M0	Any	Any	IIIB
T4a	N2	M0	Any	Any	IVA
T4b	N0-2	M0	Any	Any	IVA
Any T	N3	M0	Any	Any	IVA
Any T	Any N	M1	Any	Any	IVB

Table 13.3 AJCC prognostic stage groups: squamous cell carcinoma—cont'd

Postneoadjuvant Therapy (ypTNM)			
WHEN yP T IS...	**AND yP N IS...**	**AND M IS...**	**THEN THE STAGE GROUP IS...**
T0-2	N0	M0	I
T3	N0	M0	II
T0-2	N1	M0	IIIA
T3	N1	M0	IIIB
T0-3	N2	M0	IIIB
T4a	N0	M0	IIIB
T4a	N1-2	M0	IVA
T4a	NX	M0	IVA
T4b	N0-2	M0	IVA
Any T	N3	M0	IVA
Any T	Any N	M1	IVB

From Amin M, Edge S, Greene F, et al. (eds.). AJCC Cancer Staging Manual. vol 8. New York: Springer; 2017.

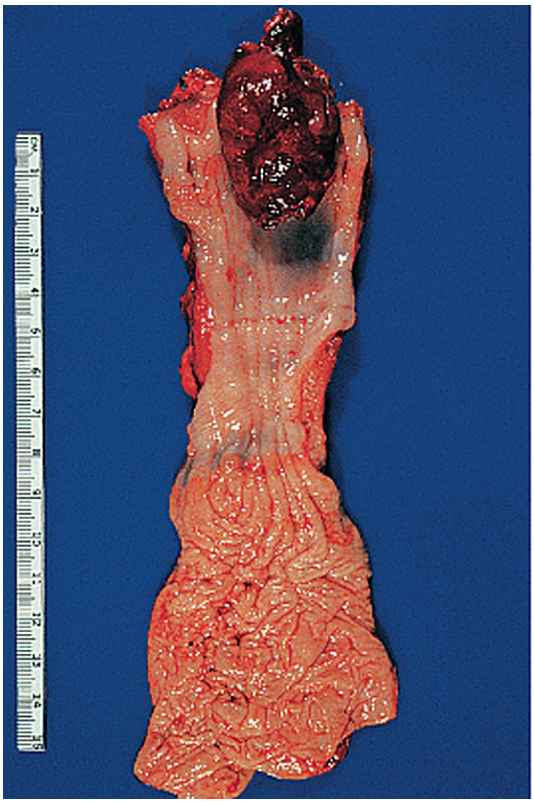

Figure 13.18 Gross appearance of sarcomatoid carcinoma of the esophagus. The tumor has a characteristic large size and polypoid shape.

the morphologically identifiable carcinomatous component, thereby giving it a growth advantage and probably explaining its dominance in most cases.[237] Metastases or recurrences supervene in about 20% of the patients undergoing surgery, and the overall survival rate is in the neighborhood of 50%.[238] The nodal metastases usually contain epithelial elements alone or a mixture of epithelial and spindle elements; occasionally, the entire metastatic focus is made up of the spindle cell element, giving further credence to the interpretation that this component is indeed neoplastic and not a stromal reaction to the tumor.[239]

Verrucous carcinoma, morphologically identical to its more common counterpart in the oral cavity, has been described in the esophagus.[240,241] It is grossly polypoid and well differentiated throughout microscopically, which makes it extremely difficult to diagnose on superficial endoscopic biopsies.[242] Despite these features and its inability to metastasize, the mortality associated with this tumor in this particular location is high.[243]

Basaloid squamous cell carcinoma is the preferred term for a variant of squamous cell carcinoma with prominent peripheral palisading (Fig. 13.21), accounting for approximately 3% of esophageal squamous cell carcinomas.[244] Stage for stage, this variant seems to be more clinically aggressive than conventional squamous cell carcinoma, and, as such, an attempt should be made to distinguish these tumors.[244,245] Immunohistochemically, the cells express CK5/6 as well as keratins 14 and 19 at the periphery of the basaloid nests.[246] Recent studies have not found this variant to be associated with high-risk HPV.[247] The tumor can be difficult to distinguish from **adenoid cystic carcinoma**, an even more rare esophageal neoplasm.[248,249] This tumor presumably arises from the submucosal glands and is morphologically identical to the tumor of the same name which arises in salivary glands.

Adenocarcinoma of the esophagus can arise from Barrett metaplastic mucosa (previously discussed), from a focus of heterotopic gastric mucosa (also mentioned earlier in this chapter) or from esophageal glands.[250] A very small proportion of primary esophageal adenocarcinomas have *signet ring cell* features, which generally portends a poor prognosis and poor response to preoperative chemoradiation.[251,252] In these cases, esophageal extension of a gastric carcinoma should be excluded.

Adenosquamous carcinoma shows evidence of both squamous and glandular differentiation.[188] This tumor generally behaves in an aggressive manner and should be distinguished from both the low-grade **mucoepidermoid carcinoma,** possibly arising in salivary-type submucosal esophageal glands,[253] and the equally rare **collision**

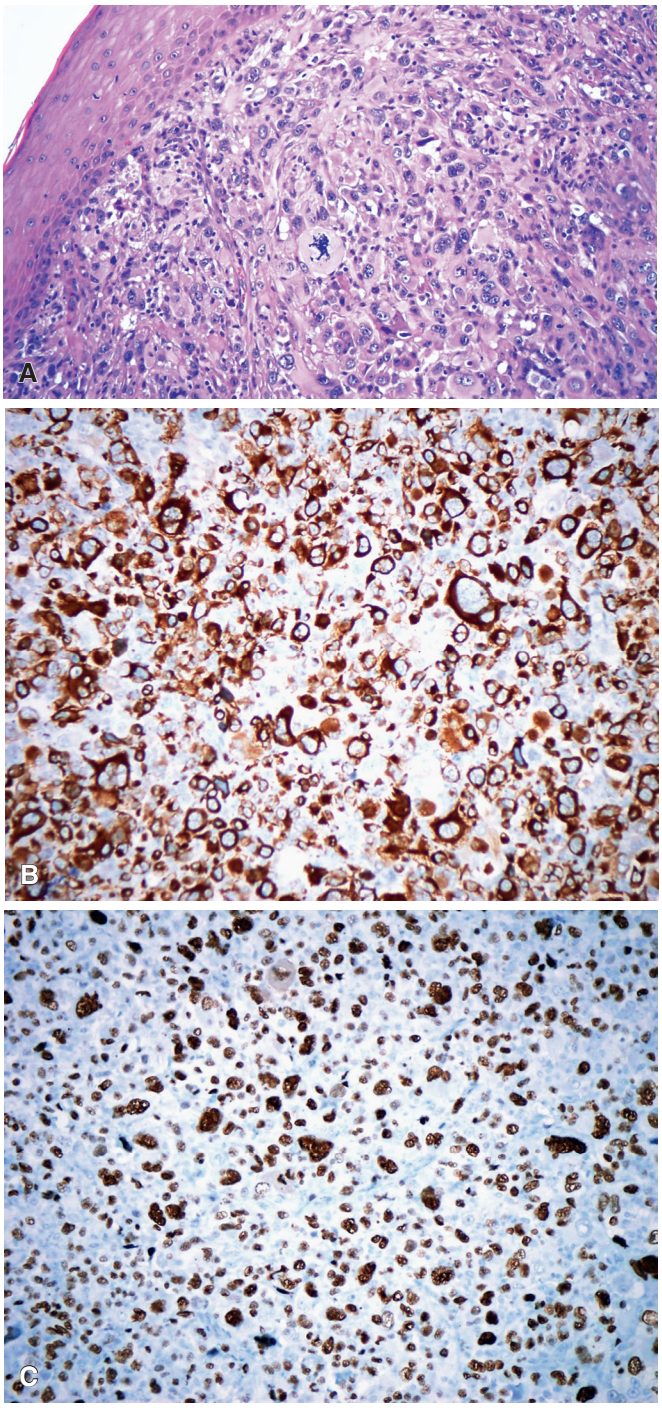

Figure 13.19 **A,** Pleomorphic (sarcomatoid) carcinoma of the esophagus. **B,** Strong cytokeratin 5/6 immunoreactivity is characteristic. **C,** There is also strong nuclear expression of p63.

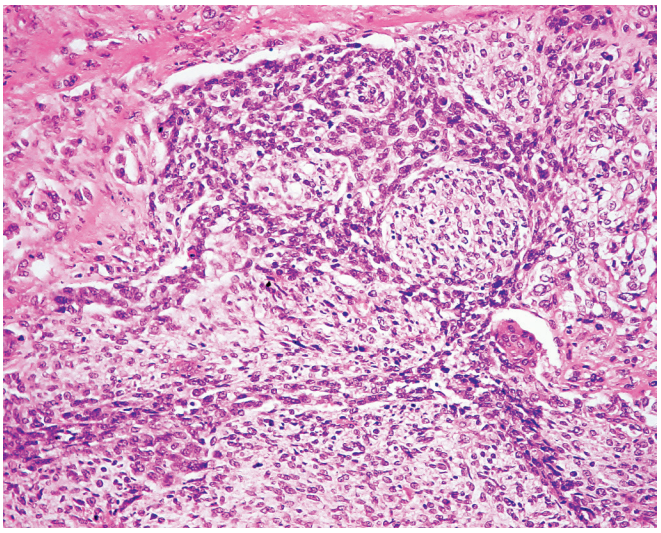

Figure 13.20 Sarcomatoid carcinoma of the esophagus. In this case, the carcinomatous component has a basaloid appearance.

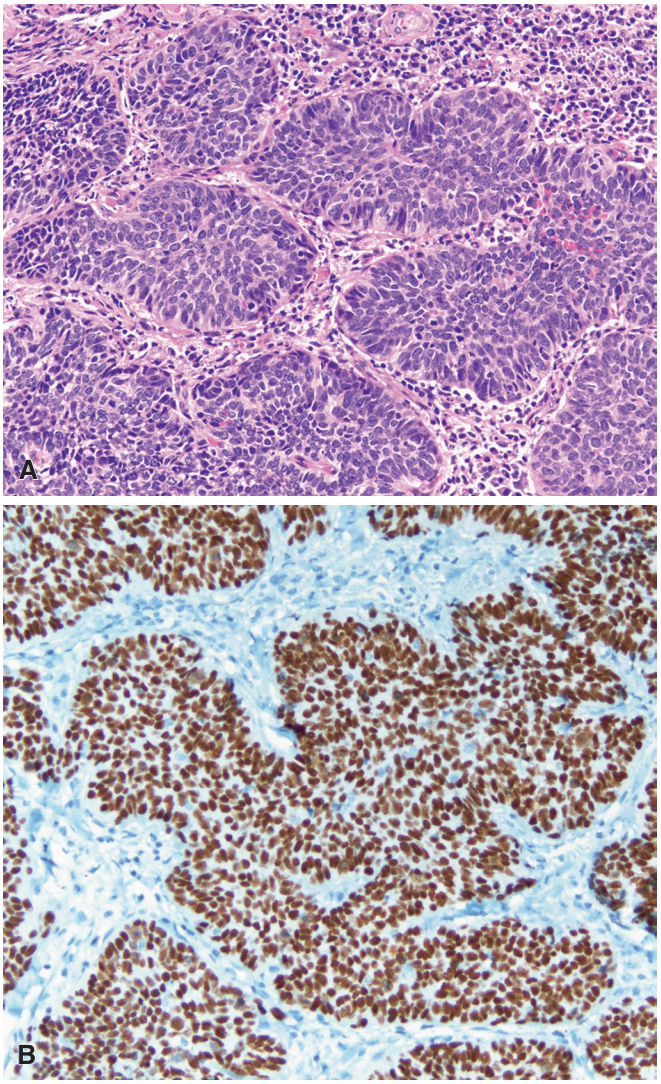

Figure 13.21 **A,** Basaloid squamous cell carcinoma with peripheral nuclear palisading. **B,** Strong p63 nuclear immunoreactivity is expected in this variant of squamous cell carcinoma.

tumor, represented by a merging of two originally separate neoplasms (i.e. squamous cell carcinoma and adenocarcinoma).[254] Molecular studies suggest that most of these tumors are actually derived from a single clone.[255]

Lymphoepithelioma-like carcinoma has been reported in the esophagus; as in other sites, it has been found to contain Epstein–Barr virus DNA.[256]

Small cell (neuroendocrine) carcinoma is a highly malignant esophageal tumor having morphologic features similar to those of its pulmonary counterpart.[257,258] Microscopically, small cells with dark nuclei of round or oval shape and scanty cytoplasm are seen growing in a predominantly diffuse fashion and accompanied by a rich vasculature. As in small cell carcinoma of the lung, there may be rosette formation and focal mucin secretion. Neuroendocrine markers, such as chromogranin and synaptophysin, are usually detectable immunohistochemically. The prognosis is very poor; most patients die within 1 year with generalized metastases.[258,259] This tumor probably arises from the same multipotent epithelial basal cells that give rise to conventional squamous cell carcinoma; interestingly, some cases are associated with squamous dysplasia or invasive squamous cell carcinoma.

Small cell carcinoma should be clearly separated from the much better differentiated **carcinoid tumor (well-differentiated neuroendocrine tumor)**.[260] The latter neoplasm, which is vanishingly rare in this location, probably arises from the endocrine cells ordinarily present in the normal esophageal mucosa. Its gross appearance tends to be polypoid. Some of the cases have been seen as an incidental finding in association with adenocarcinoma arising in the background of Barrett esophagus.[261] **Large cell neuroendocrine carcinoma** of the esophagus has also been described, the diagnostic criteria being the same as for its pulmonary counterpart.[262,263]

Smooth Muscle Tumors and Gastrointestinal Stromal Tumors

Leiomyomas are the most common benign tumors of the esophagus.[264] In a meticulous study by Abraham et al., an astounding 47% of resection specimens for tumors of the esophagogastric junction were found to harbor such lesions, almost always as an incidental microscopic finding.[265] Half of the patients with surgically excised lesions are asymptomatic; dysphagia and vague thoracic pain are the main complaints in the others.[264] The majority arise from the inner circular muscle and two-thirds arise in the middle or distal thirds of the esophagus. Multiple leiomyomas may occur and need to be distinguished from both gastrointestinal stromal tumors (GISTs; see later) and giant muscular hypertrophy. Grossly, leiomyomas form well-defined masses in the esophageal wall and have a solid, grayish white appearance on cross section (Fig. 13.22). When they grow intraluminally, they encroach on the mucosa and appear as sessile or pedunculated polyps. Ulceration of the overlying mucosa is uncommon.

Microscopically, leiomyomas have the usual characteristics of a benign smooth muscle tumor and stain for muscle markers such as desmin and smooth muscle actin (Fig. 13.23). Local resection or enucleation is usually successful.

Leiomyosarcomas are quite uncommon in the esophagus. In a study from the Armed Forces Institute of Pathology, only 3 esophageal leiomyosarcomas were identified out of 68 esophageal mesenchymal neoplasms.[266] Grossly, they may be indistinguishable from leiomyoma, although they tend to be larger and softer and often are associated with areas of hemorrhage and necrosis. The presence of cytologic atypia, mitotic figures, and necrosis are the main microscopic criteria by which they are separated from their more common benign counterpart (Fig. 13.24).

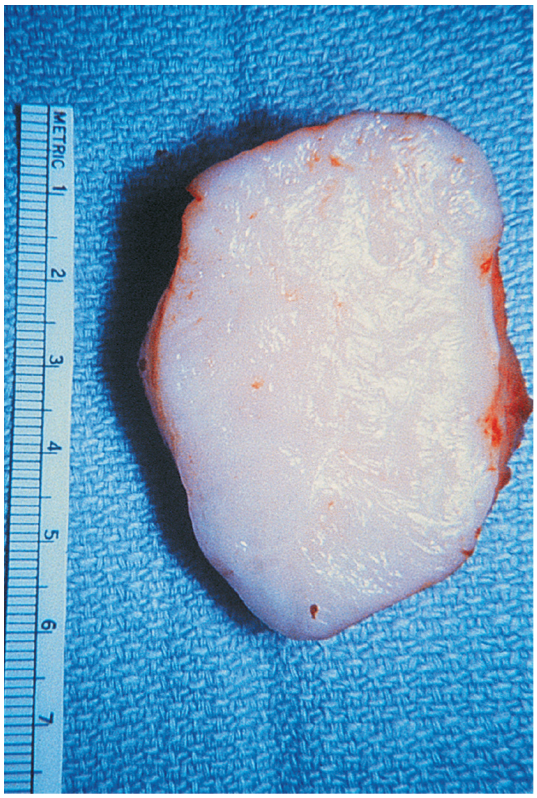

Figure 13.22 Gross Appearance of an Esophageal Leiomyoma. The tumor is sharply circumscribed and has a white color and elastic consistency.

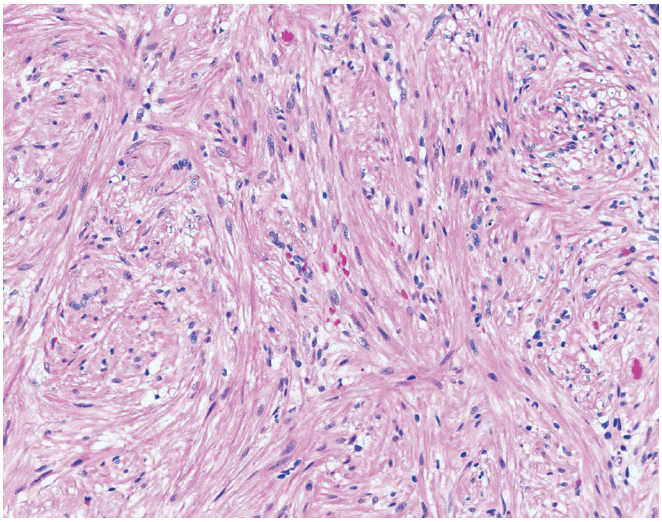

Figure 13.23 Esophageal leiomyoma with bland-appearing, densely eosinophilic spindle cells.

GISTs also occur in the esophagus, although the relative frequency of the clinically significant cases is considerably lower than in the stomach or bowel.[266] As in other locations, they are characteristically positive for DOG1, CD117, and CD34, with occasional immunoreactivity for smooth muscle actin. At the genetic level, they usually show mutations in exon 11 of *KIT*, similar to their counterparts in other parts of the gastrointestinal tract. Microscopically, most have a spindled morphology (Fig. 13.25), but some have epithelioid features. As a group, the behavior of clinically detectable esophageal

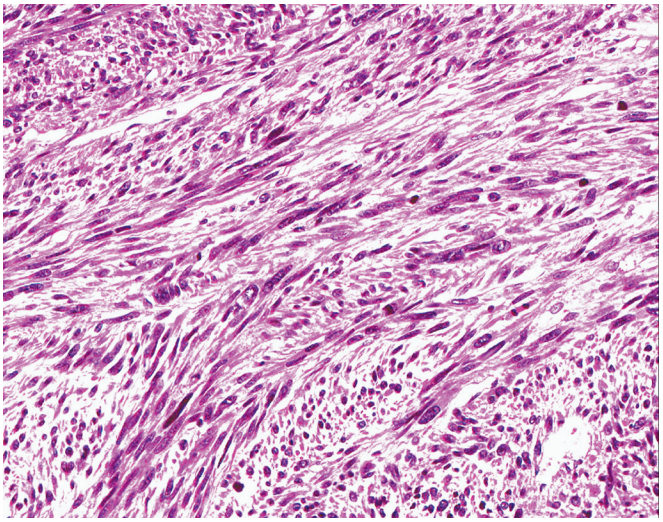

Figure 13.24 Esophageal Leiomyosarcoma. The cells show nuclear hyperchromasia and pleomorphism.

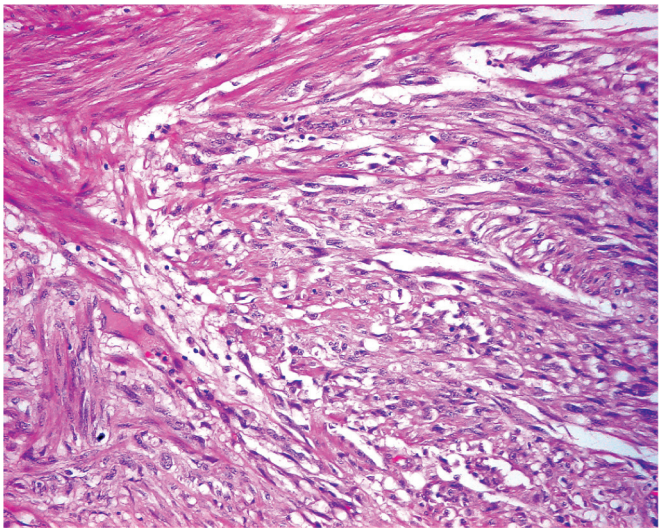

Figure 13.25 Extremely rare gastrointestinal stromal tumor of the esophagus. (Courtesy of Dr. Fabio Facchetti, Brescia, Italy.)

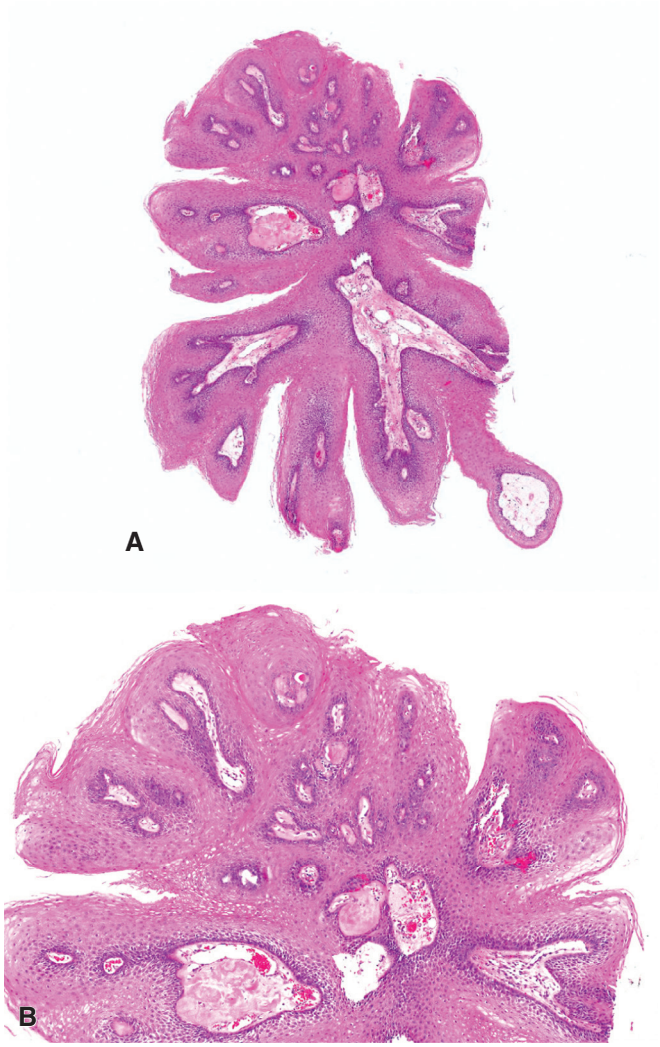

Figure 13.26 Low-power **(A)** and high-power **(B)** views of an esophageal squamous papilloma.

stromal tumors is aggressive, particularly for those which are large and/or mitotically active.[266]

Other Tumors and Tumorlike Conditions

Glycogenic acanthosis appears grossly as multiple, uniformly sized, oval or round white elevations usually measuring less than 1 cm.[267] They represent areas of focal thickening of the epithelium resulting from a marked increase in cytoplasmic glycogen.[268]

Amyloidosis in its localized form (so-called amyloid tumor) can present as an intramural esophageal mass; exceptionally, it may result in perforation and hematemesis.[269]

Squamous papillomas may be found in the esophagus,[270] and there is some evidence that human papillomavirus plays a pathogenetic role,[271] at least in some cases (Fig. 13.26).

Benign fibrovascular polyps of the esophagus usually are pedunculated and solitary and may attain huge dimensions ("giant").[272] Patients present with dysphagia and sometimes with intermittent regurgitation of a fleshy mass in the mouth. Most of the 53 cases reviewed by Jang et al. occurred in adults, and approximately 85% were located in the upper third of the esophagus.[273] Microscopically, they are composed of fibrous tissue and numerous blood vessels, with stromal edema and mild lymphocytic infiltration.[274] If hyperchromatic cells are seen, consideration should be given to a diagnosis of atypical lipomatous tumor (and confirmed using molecular techniques).[275] These polyps most likely represent a non-neoplastic condition and local excision is curative.[276]

Hyperplastic polyps of the esophagus and GEJ are characterized by hyperplastic epithelium of foveolar and/or squamous type accompanied by stromal inflammation. They are usually associated with (and probably the result of) recent esophageal ulcers and erosive esophagitis.[277] Some patients also show evidence of Barrett esophagus, further suggesting a role for reflux.[278]

Granular cell tumors may be found in the esophagus, as either solitary or multiple nodules; sometimes they are associated with similar lesions in other parts of the gastrointestinal tract (Fig. 13.27).[279] As in other sites, they can induce pseudoepitheliomatous hyperplasia of the overlying epithelium, resulting in a mimic of squamous cell carcinoma. Almost all of these act in a clinically benign fashion.

Other benign tumors that have been exceptionally reported in the esophagus include *lobular capillary hemangioma (pyogenic*

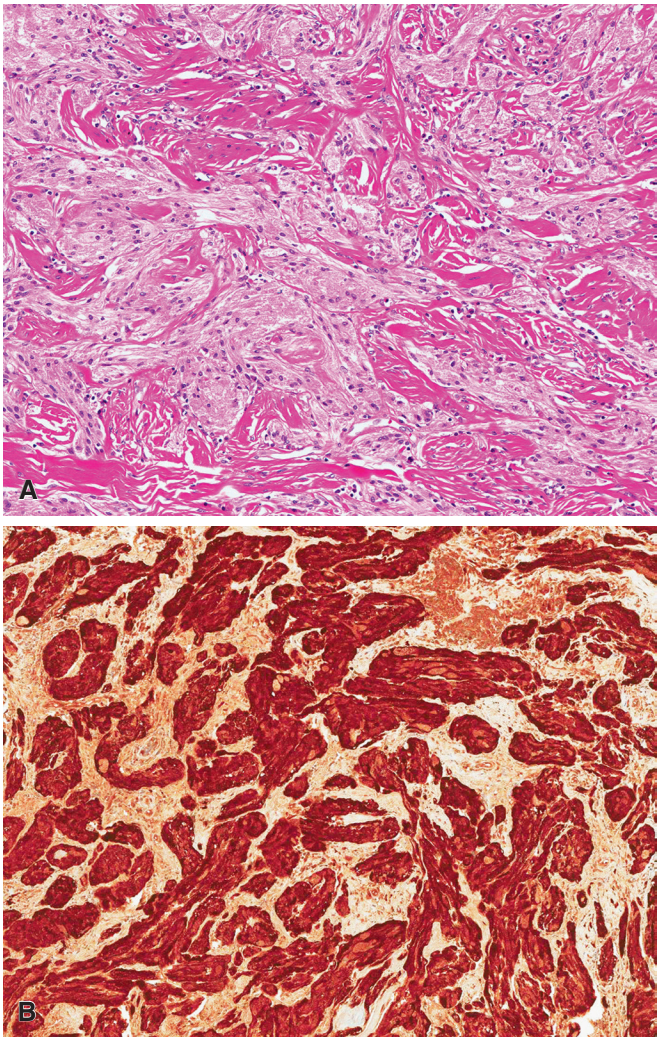

Figure 13.27 **A,** Esophageal granular cell tumor with nests of ovoid cells with granular cytoplasm. **B,** Strong S-100 protein staining in esophageal granular cell tumor.

Figure 13.28 **Malignant Melanoma of Esophagus.** The tumor has a characteristic polypoid appearance and is partially ulcerated. The dark color is the combined result of melanin deposition and hemorrhage within the tumor.

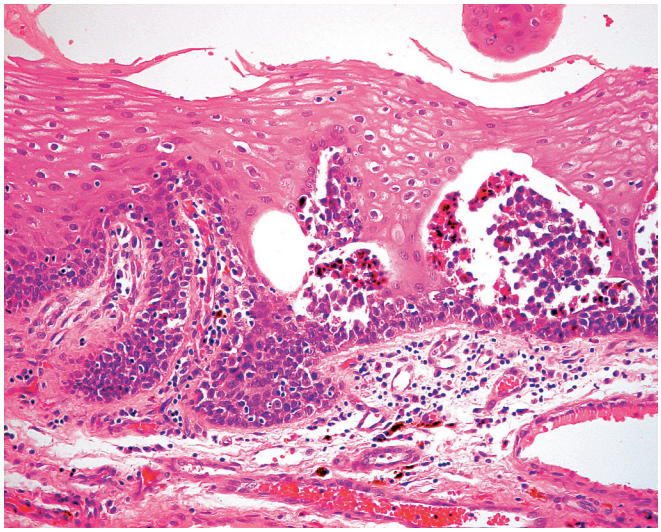

Figure 13.29 **Primary Malignant Melanoma of the Esophagus.** There is a prominent intraepithelial component with the formation of large tumor nests.

granuloma),[280] *neurofibroma,*[281] *schwannoma,*[282] *perineurioma,*[283] and *solitary fibrous tumor.*[284]

Malignant melanoma is an uncommon esophageal neoplasm that can be located at any level in the esophagus but has a predilection for the lower third.[285,286] Grossly, the tumor is usually large and has a prominent polypoid appearance (Fig. 13.28). Microscopically, epithelioid, spindled, and pleomorphic areas may be seen singly or in combination, with variable melanin production (Fig. 13.29). Immunohistochemically, S-100 protein and HMB-45 positivity are the rule. The search for a lateral intraepidermal component ("junctional activity") should be made in order to confirm the primary nature of the tumor.[285] At the molecular level, esophageal melanoma shows differences with other mucosal melanomas with frequent *NRAS* mutations.[286] The prognosis is exceedingly poor.

Non-Hodgkin malignant lymphoma[287] and **plasmacytoma**[288] occasionally present with dysphagia because of diffuse esophageal involvement. Some esophageal lymphomas have occurred in HIV-infected patients.[289] The esophageal wall can also be the site of leukemic infiltration[290] or Hodgkin lymphoma.[291]

Malignant mesenchymal neoplasms other than smooth muscle/stromal tumors are rare, including *osteosarcoma,*[292] *rhabdomyosarcoma,*[293] *synovial sarcoma,*[294] *epithelioid sarcoma,*[295] *Ewing sarcoma/primitive neuroectodermal tumor,*[296] and *malignant peripheral nerve sheath tumor.*[297]

Metastatic carcinoma in the esophagus usually represents extension from pulmonary, laryngeal, gastric, or thyroid tumors, either directly or via periesophageal nodes. Rarely, blood-borne metastases occur from carcinomas of distant sites, such as prostate, endometrium, or breast.

References

1. Naini BV, Chak A, Ali MA, Odze RD. Barrett's oesophagus diagnostic criteria: endoscopy and histology. *Best Pract Res Clin Gastroenterol*. 2015;29(1):77-96.
2. Weinstein WM, Bogoch ER, Bowes KL. The normal human esophageal mucosa: a histological reappraisal. *Gastroenterology*. 1975;68(1):40-44.
3. Meyer GW, Austin RM, Brady CE, Castell DO. Muscle anatomy of the human esophagus. *J Clin Gastroenterol*. 1986;8(2):131-134.
4. Odze RD. Unraveling the mystery of the gastroesophageal junction: a pathologist's perspective. *Am J Gastroenterol*. 2005;100(8):1853-1867.
5. Odze RD. Pathology of the gastroesophageal junction. *Semin Diagn Pathol*. 2005;22(4):256-265.
6. Howard JM, Johnston C. Patterns of lymphatic drainage and lymph node involvement in esophageal cancer. *Abdom Imaging*. 2013;38(2):233-243.
7. Robie DK. Initial experience with thoracoscopic esophageal atresia and tracheoesophageal fistula repair: lessons learned and technical considerations to achieve success. *Am Surg*. 2015;81(3):268-272.
8. Ngerncham M, Lee EY, Zurakowski D, et al. Tracheobronchomalacia in pediatric patients with esophageal atresia: comparison of diagnostic laryngoscopy/bronchoscopy and dynamic airway multidetector computed tomography. *J Pediatr Surg*. 2015;50(3):402-407.
9. Gallo G, Zwaveling S, Van der Zee DC, et al. A two-center comparative study of gastric pull-up and jejunal interposition for long gap esophageal atresia. *J Pediatr Surg*. 2015;50(4):535-539.
10. Houben CH, Curry JI. Current status of prenatal diagnosis, operative management and outcome of esophageal atresia/tracheo-esophageal fistula. *Prenat Diagn*. 2008;28(7):667-675.
11. Holland AJA, Ron O, Pierro A, et al. Surgical outcomes of esophageal atresia without fistula for 24 years at a single institution. *J Pediatr Surg*. 2009;44(10):1928-1932.
12. Cheng C-L, Lin C-H, Liu N-J, et al. Endoscopic diagnosis of cervical esophageal heterotopic gastric mucosa with conventional and narrow-band images. *World J Gastroenterol*. 2014;20(1):242-249.
13. Tang P, McKinley MJ, Sporrer M, Kahn E. Inlet patch: prevalence, histologic type, and association with esophagitis, Barrett esophagus, and antritis. *Arch Pathol Lab Med*. 2004;128(4):444-447.
14. von Rahden BHA, Stein HJ, Becker K, et al. Heterotopic gastric mucosa of the esophagus: literature-review and proposal of a clinicopathologic classification. *Am J Gastroenterol*. 2004;99(3):543-551.
15. Möschler O, Vieth M, Müller MK. Endoscopic resection of an adenocarcinoma occurring in ectopic gastric mucosa within the proximal esophagus. *Endoscopy*. 2014;46(suppl 1 UCTN):E24-E25.
16. Schneider NI, Plieschnegger W, Geppert M, et al. Pancreatic acinar cells—a normal finding at the gastroesophageal junction? Data from a prospective Central European multicenter study. *Virchows Arch*. 2013;463(5):643-650.
17. Johansson J, Håkansson H-O, Mellblom L, et al. Pancreatic acinar metaplasia in the distal oesophagus and the gastric cardia: prevalence, predictors and relation to GORD. *J Gastroenterol*. 2010;45(3):291-299.
18. Nakanishi Y, Ochiai A, Shimoda T, et al. Heterotopic sebaceous glands in the esophagus: histopathological and immunohistochemical study of a resected esophagus. *Pathol Int*. 1999;49(4):364-368.
19. Ferreira LEVVC, Simmons DT, Baron TH. Zenker's diverticula: pathophysiology, clinical presentation, and flexible endoscopic management. *Dis Esophagus*. 2008;21(1):1-8.
20. Rastogi A, Sarda D, Kothari P, Kulkarni B. Mediastinal tuberculosis presenting as traction diverticulum of the esophagus. *Ann Thorac Med*. 2007;2(3):126-127.
21. Fisichella PM, Jalilvand A, Dobrowolsky A. Achalasia and epiphrenic diverticulum. *World J Surg*. 2015;39(7):1614-1619.
22. Altorki NK, Sunagawa M, Skinner DB. Thoracic esophageal diverticula. Why is operation necessary? *J Thorac Cardiovasc Surg*. 1993;105(2):260-264.
23. Rossetti G, Fei L, del Genio G, et al. Epiphrenic diverticula mini-invasive surgery: a challenge for expert surgeons—personal experience and review of the literature. *Scand J Surg*. 2013;102(2):129-135.
24. Graham DY, Goyal RK, Sparkman J, et al. Diffuse intramural esophageal diverticulosis. *Gastroenterology*. 1975;68(4 Pt 1):781-785.
25. Levine MS, Moolten DN, Herlinger H, Laufer I. Esophageal intramural pseudodiverticulosis: a reevaluation. *AJR Am J Roentgenol*. 1986;147(6):1165-1170.
26. Murney RG, Linne JH, Curtis J. High-amplitude peristaltic contractions in a patient with esophageal intramural pseudodiverticulosis. *Dig Dis Sci*. 1983;28(9):843-847.
27. Altieri MS, Zheng R, Pryor AD, et al. Esophageal bronchogenic cyst and review of the literature. *Surg Endosc*. 2015;29(10):3010-3015.
28. Liu R, Adler DG. Duplication cysts: diagnosis, management, and the role of endoscopic ultrasound. *Endosc Ultrasound*. 2014;3(3):152-160.
29. Jacob R, Hawkes ND, Dallimore N, et al. Case report: squamous carcinoma in an oesophageal foregut cyst. *Br J Radiol*. 2003;76(905):343-346.
30. Santacroce CM, Fléjou JF. Early adenocarcinoma of the oesophagus and oesophageal cyst. *Histopathology*. 1997;31(1):87-90.
31. Katsinelos P, Gkagkalis S, Chatzimavroudis G, et al. Recurrent esophageal web in Plummer-Vinson syndrome successfully treated with postdilation intralesional injection of mitomycin C. *Gastrointest Endosc*. 2012;75(5):1124.
32. Hirano I, Gilliam J, Goyal RK. Clinical and manometric features of the lower esophageal muscular ring. *Am J Gastroenterol*. 2000;95(1):43-49.
33. Clements JL, Cox GW, Torres WE, Weens HS. Cervical esophageal webs—a roentgenanatomic correlation. Observations on the pharyngoesophagus. *Am J Roentgenol Radium Ther Nucl Med*. 1974;121(2): 221-231.
34. Enomoto M, Kohmoto M, Arafa UA, et al. Plummer-Vinson syndrome successfully treated by endoscopic dilatation. *J Gastroenterol Hepatol*. 2007;22(12): 2348-2351.
35. Sharp NE, St Peter SD. Treatment of idiopathic achalasia in the pediatric population: a systematic review. *Eur J Pediatr Surg*. 2016;26(2):143-149.
36. Bustanji H, Sahar B, Huebner A, et al. Triple A syndrome with a novel indel mutation in the AAAS gene and delayed puberty. *J Pediatr Endocrinol Metab*. 2015;28(7-8):933-936.
37. Goldblum JR, Whyte RI, Orringer MB, Appelman HD. Achalasia. A morphologic study of 42 resected specimens. *Am J Surg Pathol*. 1994;18(4):327-337.
38. Clark SB, Rice TW, Tubbs RR, et al. The nature of the myenteric infiltrate in achalasia: an immunohistochemical analysis. *Am J Surg Pathol*. 2000;24(8):1153-1158.
39. Lehman MB, Clark SB, Ormsby AH, et al. Squamous mucosal alterations in esophagectomy specimens from patients with end-stage achalasia. *Am J Surg Pathol*. 2001;25(11):1413-1418.
40. Birgisson S, Galinski MS, Goldblum JR, et al. Achalasia is not associated with measles or known herpes and human papilloma viruses. *Dig Dis Sci*. 1997;42(2):300-306.
41. Yasawy MI. Diagnosis and treatment of achalasia patients: a ten-year review of the clinical features. *Hepatogastroenterology*. 2014;61(134):1611-1616.
42. Tolone S, Limongelli P, Del Genio G, et al. Recent trends in endoscopic management of achalasia. *World J Gastrointest Endosc*. 2014;6(9):407-414.
43. Richter JE, Boeckxstaens GE. Management of achalasia: surgery or pneumatic dilation. *Gut*. 2011;60(6):869-876.
44. Boeckxstaens GE, Zaninotto G, Richter JE. Achalasia. *Lancet*. 2014;383(9911):83-93.
45. Ríos-Galvez S, Meixueiro-Daza A, Remes-Troche JM. Achalasia: a risk factor that must not be forgotten for esophageal squamous cell carcinoma. *BMJ Case Rep*. 2015;2015:bcr2014204418.
46. Watanabe T, Shimizu T, Takahashi M, et al. Cricopharyngeal achalasia treated with myectomy and post-operative high-resolution manometry. *Int J Pediatr Otorhinolaryngol*. 2014;78(7):1182-1185.
47. Vicentine FP, Herbella FA, Allaix ME, et al. Comparison of idiopathic achalasia and Chagas' disease esophagopathy at the light of high-resolution manometry. *Dis Esophagus*. 2014;27(2):128-133.
48. Liu W, Fackler W, Rice TW, et al. The pathogenesis of pseudoachalasia: a clinicopathologic study of 13 cases of a rare entity. *Am J Surg Pathol*. 2002;26(6):784-788.
49. Campo SMA, Zullo A, Scandavini CM, et al. Pseudoachalasia: a peculiar case report and review of the literature. *World J Gastrointest Endosc*. 2013;5(9):450-454.
50. Heald J, Moussalli H, Hasleton PS. Diffuse leiomyomatosis of the oesophagus. *Histopathology*. 1986;10(7):755-759.
51. Sousa RG, Figueiredo PC, Pinto-Marques P, et al. An unusual cause of pseudoachalasia: the Alport syndrome-diffuse leiomyomatosis association. *Eur J Gastroenterol Hepatol*. 2013;25(11):1352-1357.
52. Sá MJ, Fieremans N, de Brouwer AP, et al. Deletion of the 5'exons of COL4A6 is not needed for the development of diffuse leiomyomatosis in patients with Alport syndrome. *J Med Genet*. 2013;50(11): 745-753.
53. Kachaamy T, Lott D, Crujido LR, et al. Esophageal luminal restoration for a patient with a long lye-induced stricture via tunnel endoscopic therapy during a rendezvous procedure followed by self-dilation (with video). *Gastrointest Endosc*. 2014;80(1):192-194.
54. Lopes AB, Fagundes RB. Esophageal squamous cell carcinoma—precursor lesions and early diagnosis. *World J Gastrointest Endosc*. 2012;4(1):9-16.
55. Rodrigues F, Brandão N, Duque V, et al. Herpes simplex virus esophagitis in immunocompetent children. *J Pediatr Gastroenterol Nutr*. 2004;39(5):560-563.
56. Galbraith JC, Shafran SD. Herpes simplex esophagitis in the immunocompetent patient:

report of four cases and review. *Clin Infect Dis*. 1992;14(4):894-901.
57. Albuquerque A, Cardoso H, Ribeiro A, et al. Herpes and cytomegalovirus esophagitis. *Endoscopy*. 2012;44(suppl 2 UCTN):E242-E243.
58. McBane RD, Gross JB. Herpes esophagitis: clinical syndrome, endoscopic appearance, and diagnosis in 23 patients. *Gastrointest Endosc*. 1991;37(6):600-603.
59. Singh SP, Odze RD. Multinucleated epithelial giant cell changes in esophagitis: a clinicopathologic study of 14 cases. *Am J Surg Pathol*. 1998;22(1):93-99.
60. Greenson JK, Beschorner WE, Boitnott JK, Yardley JH. Prominent mononuclear cell infiltrate is characteristic of herpes esophagitis. *Hum Pathol*. 1991;22(6):541-549.
61. Lemonovich TL, Watkins RR. Update on cytomegalovirus infections of the gastrointestinal system in solid organ transplant recipients. *Curr Infect Dis Rep*. 2012;14(1):33-40.
62. Baroco AL, Oldfield EC. Gastrointestinal cytomegalovirus disease in the immunocompromised patient. *Curr Gastroenterol Rep*. 2008;10(4):409-416.
63. Rosołowski M, Kierzkiewicz M. Etiology, diagnosis and treatment of infectious esophagitis. *Prz Gastroenterol*. 2013;8(6):333-337.
64. Slavik T. Human immunodeficiency virus-related gastrointestinal pathology: a southern Africa perspective with review of the literature (part 2: neoplasms and noninfectious disorders). *Arch Pathol Lab Med*. 2012;136(3):316-323.
65. Wilcox CM, Schwartz DA, Clark WS. Esophageal ulceration in human immunodeficiency virus infection. Causes, response to therapy, and long-term outcome. *Ann Intern Med*. 1995;123(2):143-149.
66. Wilcox CM, Straub RF, Clark WS. Prospective evaluation of oropharyngeal findings in human immunodeficiency virus-infected patients with esophageal ulceration. *Am J Gastroenterol*. 1995;90(11):1938-1941.
67. Kotler DP, Reka S, Orenstein JM, Fox CH. Chronic idiopathic esophageal ulceration in the acquired immunodeficiency syndrome. Characterization and treatment with corticosteroids. *J Clin Gastroenterol*. 1992;15(4):284-290.
68. Patel KV, Irving PM, Sanderson JD. Oesophageal Crohn's disease: a novel approach to managing iatrogenic perforation of an oesophageal Crohn's stricture. *J Crohns Colitis*. 2014;8(4):332-333.
69. Purdy JK, Appelman HD, Golembeski CP, McKenna BJ. Lymphocytic esophagitis: a chronic or recurring pattern of esophagitis resembling allergic contact dermatitis. *Am J Clin Pathol*. 2008;130(4):508-513.
70. Dellon ES. Diagnostics of eosinophilic esophagitis: clinical, endoscopic, and histologic pitfalls. *Dig Dis*. 2014;32(1-2):48-53.
71. Aceves SS. Eosinophilic esophagitis. *Immunol Allergy Clin North Am*. 2015;35(1):145-159.
72. Hart PA, Romano RC, Moreira RK, et al. Esophagitis dissecans superficialis: clinical, endoscopic, and histologic features. *Dig Dis Sci*. 2015;60(7):2049-2057.
73. Carmack SW, Vemulapalli R, Spechler SJ, Genta RM. Esophagitis dissecans superficialis ("sloughing esophagitis"): a clinicopathologic study of 12 cases. *Am J Surg Pathol*. 2009;33(12):1789-1794.
74. da Silva JR, Pinho R, Ponte A, et al. Esophagitis dissecans superficialis associated with severe clindamycin toxicity. *J Gastrointest Liver Dis*. 2014;23(4):363.
75. Welzel TM, Kawan T, Bohle W, et al. An unusual cause of dysphagia: esophageal tuberculosis. *J Gastrointest Liver Dis*. 2010;19(3):321-324.
76. Sutton FM, Graham DY, Goodgame RW. Infectious esophagitis. *Gastrointest Endosc Clin N Am*. 1994;4(4):713-729.
77. Houman MH, Ben Ghorbel I, Lamloum M, et al. Esophageal involvement in Behcet's disease. *Yonsei Med J*. 2002;43(4):457-460.
78. Seminerio J, McGrath K, Arnold CA, et al. Medication-associated lesions of the GI tract. *Gastrointest Endosc*. 2014;79(1):140-150.
79. Palma DA, Senan S, Oberije C, et al. Predicting esophagitis after chemoradiation therapy for non-small cell lung cancer: an individual patient data meta-analysis. *Int J Radiat Oncol Biol Phys*. 2013;87(4): 690-696.
80. Seo JY, Kang KJ, Kang HS, et al. Corrosive esophagitis caused by ingestion of picosulfate. *Clin Endosc*. 2015;48(1):66-69.
81. Vischio J, Saeed F, Karimeddini M, et al. Progression of esophageal dysmotility in systemic sclerosis. *J Rheumatol*. 2012;39(5):986-991.
82. Mohan P, Srinivas CR, Leelakrishnan V. A rare initial presentation of esophageal involvement in pemphigus. *Dis Esophagus*. 2013;26(3):351.
83. Linton MS, Zhao L, Gui X, et al. Lichen planus is an uncommon cause of nonspecific proximal esophageal inflammation. *Gut Liver*. 2013;7(4):401-405.
84. Djurić Z, Nagorni A, Zivanović D. Esophagitis and almost complete esophageal occlusion in a girl with epidermolysis bullosa. *Turk J Pediatr*. 2012;54(3):301-304.
85. Dray X, Cattan P. Foreign bodies and caustic lesions. *Best Pract Res Clin Gastroenterol*. 2013;27(5):679-689.
86. Salaria SN, Abu Alfa AK, Cruise MW, et al. Lichenoid esophagitis: clinicopathologic overlap with established esophageal lichen planus. *Am J Surg Pathol*. 2013;37(12):1889-1894.
87. Appelman HD, Streutker C, Vieth M, et al. The esophageal mucosa and submucosa: immunohistology in GERD and Barrett's esophagus. *Ann N Y Acad Sci*. 2013;1300:144-165.
88. Brown LF, Goldman H, Antonioli DA. Intraepithelial eosinophils in endoscopic biopsies of adults with reflux esophagitis. *Am J Surg Pathol*. 1984;8(12):899-905.
89. Frierson HF. Histological criteria for the diagnosis of reflux esophagitis. *Pathol Annu*. 1992;27(Pt 1):87-104.
90. Behan M, Gledhill A, Hayes S. Immunohistochemistry for CDX2 expression in non-goblet-cell Barrett's oesophagus. *Br J Biomed Sci*. 2014;71(2):86-92.
91. Collins BJ, Elliott H, Sloan JM, et al. Oesophageal histology in reflux oesophagitis. *J Clin Pathol*. 1985;38(11):1265-1272.
92. Collins JS, Watt PC, Hamilton PW, et al. Assessment of oesophagitis by histology and morphometry. *Histopathology*. 1989;14(4):381-389.
93. Behar J, Sheahan D. Histologic abnormalities in reflux esophagitis. *Arch Pathol*. 1975;99(7):387-391.
94. Esposito S, Valente G, Zavallone A, et al. Histological score for cells with irregular nuclear contours for the diagnosis of reflux esophagitis in children. *Hum Pathol*. 2004;35(1):96-101.
95. Wang HH, Mangano MM, Antonioli DA. Evaluation of T-lymphocytes in esophageal mucosal biopsies. *Mod Pathol*. 1994;7(1):55-58.
96. Sheahan DG, West AB. Focal lymphoid hyperplasia (pseudolymphoma) of the esophagus. *Am J Surg Pathol*. 1985;9(2):141-147.
97. Witteman BPL, Conchillo JM, Rinsma NF, et al. Randomized controlled trial of transoral incisionless fundoplication vs. proton pump inhibitors for treatment of gastroesophageal reflux disease. *Am J Gastroenterol*. 2015;110(4):531-542.
98. Wang KK, Sampliner RE, Practice Parameters Committee of the American College of Gastroenterology. Updated guidelines 2008 for the diagnosis, surveillance and therapy of Barrett's esophagus. *Am J Gastroenterol*. 2008;103(3):788-797.
99. Jeurnink SM, van Herwaarden-Lindeboom MYA, Siersema PD, et al. Barrett's esophagus in children: does it need more attention? *Dig Liver Dis*. 2011;43(9):682-687.
100. Sun X, Chandar AK, Elston R, Chak A. What we know and what we need to know about familial gastroesophageal reflux disease and Barrett's esophagus. *Clin Gastroenterol Hepatol*. 2014;12(10):1664-1666.
101. Spechler SJ, Souza RF. Barrett's esophagus. *N Engl J Med*. 2014;371(9):836-845.
102. Dunbar KB, Spechler SJ. Controversies in Barrett esophagus. *Mayo Clin Proc*. 2014;89(7):973-984.
103. Chandrasoma PT, Der R, Dalton P, et al. Distribution and significance of epithelial types in columnar-lined esophagus. *Am J Surg Pathol*. 2001;25(9):1188-1193.
104. Suo Z, Nesland JM. Barrett's esophagus: intestinal metaplasia or phenotypic shift of undifferentiated elements in the stem cells. *Ultrastruct Pathol*. 2002;26(2):53-54.
105. Glickman JN, Chen YY, Wang HH, et al. Phenotypic characteristics of a distinctive multilayered epithelium suggests that it is a precursor in the development of Barrett's esophagus. *Am J Surg Pathol*. 2001;25(5):569-578.
106. Hahn HP, Blount PL, Ayub K, et al. Intestinal differentiation in metaplastic, nongoblet columnar epithelium in the esophagus. *Am J Surg Pathol*. 2009;33(7):1006-1015.
107. Liu W, Hahn H, Odze RD, Goyal RK. Metaplastic esophageal columnar epithelium without goblet cells shows DNA content abnormalities similar to goblet cell-containing epithelium. *Am J Gastroenterol*. 2009;104(4):816-824.
108. Riddell RH, Odze RD. Definition of Barrett's esophagus: time for a rethink—is intestinal metaplasia dead? *Am J Gastroenterol*. 2009;104(10):2588-2594.
109. Chandrasoma P. Controversies of the cardiac mucosa and Barrett's oesophagus. *Histopathology*. 2005;46(4):361-373.
110. DeMeester SR, Wickramasinghe KS, Lord RVN, et al. Cytokeratin and DAS-1 immunostaining reveal similarities among cardiac mucosa, CIM, and Barrett's esophagus. *Am J Gastroenterol*. 2002;97(10):2514-2523.
111. Goldblum JR. The significance and etiology of intestinal metaplasia of the esophagogastric junction. *Ann Diagn Pathol*. 2002;6(1):67-73.
112. Srivastava A, Odze RD, Lauwers GY, et al. Morphologic features are useful in distinguishing Barrett esophagus from carditis with intestinal metaplasia. *Am J Surg Pathol*. 2007;31(11):1733-1741.
113. Hahn HP, Shahsafaei A, Odze RD. Vascular and lymphatic properties of the superficial and deep lamina propria in Barrett esophagus. *Am J Surg Pathol*. 2008;32(10):1454-1461.
114. Lewis JT, Wang KK, Abraham SC. Muscularis mucosae duplication and the musculo-fibrous anomaly in endoscopic mucosal resections for barrett esophagus: implications for staging of adenocarcinoma. *Am J Surg Pathol*. 2008;32(4):566-571.
115. Lee RG. Mucins in Barrett's esophagus: a histochemical study. *Am J Clin Pathol*. 1984;81(4):500-503.
116. Chinyama CN, Marshall RE, Owen WJ, et al. Expression of MUC1 and MUC2 mucin gene products in Barrett's metaplasia, dysplasia and

adenocarcinoma: an immunopathological study with clinical correlation. *Histopathology*. 1999;35(6):517-524.
117. Warson C, Van De Bovenkamp JHB, Korteland-Van Male AM, et al. Barrett's esophagus is characterized by expression of gastric-type mucins (MUC5AC, MUC6) and TFF peptides (TFF1 and TFF2), but the risk of carcinoma development may be indicated by the intestinal-type mucin, MUC2. *Hum Pathol*. 2002;33(6):660-668.
118. Phillips RW, Frierson HF, Moskaluk CA. Cdx2 as a marker of epithelial intestinal differentiation in the esophagus. *Am J Surg Pathol*. 2003;27(11):1442-1447.
119. Lagergren J, Bergström R, Lindgren A, Nyrén O. Symptomatic gastroesophageal reflux as a risk factor for esophageal adenocarcinoma. *N Engl J Med*. 1999;340(11):825-831.
120. Blevins CH, Iyer PG. Endoscopic therapy for Barrett's oesophagus. *Best Pract Res Clin Gastroenterol*. 2015;29(1):167-177.
121. Rice TW, Goldblum JR. Management of Barrett esophagus with high-grade dysplasia. *Thorac Surg Clin*. 2012;22(1):101-107, vii.
122. Chadwick G, Groene O, Markar SR, et al. Systematic review comparing radiofrequency ablation and complete endoscopic resection in treating dysplastic Barrett's esophagus: a critical assessment of histologic outcomes and adverse events. *Gastrointest Endosc*. 2014;79(5):718.e3-731.e3.
123. Reid BJ, Haggitt RC, Rubin CE, et al. Observer variation in the diagnosis of dysplasia in Barrett's esophagus. *Hum Pathol*. 1988;19(2):166-178.
124. Montgomery E, Bronner MP, Goldblum JR, et al. Reproducibility of the diagnosis of dysplasia in Barrett esophagus: a reaffirmation. *Hum Pathol*. 2001;32(4):368-378.
125. Kerkhof M, van Dekken H, Steyerberg EW, et al. Grading of dysplasia in Barrett's oesophagus: substantial interobserver variation between general and gastrointestinal pathologists. *Histopathology*. 2007;50(7):920-927.
126. Goldblum JR. Current issues in Barrett's esophagus and Barrett's-related dysplasia. *Mod Pathol*. 2015;28(suppl 1):S1-S6.
127. Lomo LC, Blount PL, Sanchez CA, et al. Crypt dysplasia with surface maturation: a clinical, pathologic, and molecular study of a Barrett's esophagus cohort. *Am J Surg Pathol*. 2006;30(4):423-435.
128. Downs-Kelly E, Mendelin JE, Bennett AE, et al. Poor interobserver agreement in the distinction of high-grade dysplasia and adenocarcinoma in pretreatment Barrett's esophagus biopsies. *Am J Gastroenterol*. 2008;103(9):2333-2340, quiz 2341.
129. Goldblum JR. Barrett's esophagus and Barrett's-related dysplasia. *Mod Pathol*. 2003;16(4):316-324.
130. Spechler SJ, Robbins AH, Rubins HB, et al. Adenocarcinoma and Barrett's esophagus. An overrated risk? *Gastroenterology*. 1984;87(4):927-933.
131. Maley CC, Galipeau PC, Finley JC, et al. Genetic clonal diversity predicts progression to esophageal adenocarcinoma. *Nat Genet*. 2006;38(4):468-473.
132. Falk GW. Barrett's oesophagus: frequency and prediction of dysplasia and cancer. *Best Pract Res Clin Gastroenterol*. 2015;29(1): 125-138.
133. Thota PN, Lee H-J, Goldblum JR, et al. Risk stratification of patients with barrett's esophagus and low-grade dysplasia or indefinite for dysplasia. *Clin Gastroenterol Hepatol*. 2015;13(3):459.e1-465.e1.
134. Zeki S, Fitzgerald RC. The use of molecular markers in predicting dysplasia and guiding treatment. *Best Pract Res Clin Gastroenterol*. 2015;29(1):113-124.
135. Fouad YM, Mostafa I, Yehia R, El-Khayat H. Biomarkers of Barrett's esophagus. *World J Gastrointest Pathophysiol*. 2014;5(4):450-456.
136. Jankowski M, Wani S. Diagnostic and management implications of basic science advances in Barrett's esophagus. *Curr Treat Options Gastroenterol*. 2015;13(1):16-29.
137. Buas MF, Levine DM, Makar KW, et al. Integrative post-genome-wide association analysis of CDKN2A and TP53 SNPs and risk of esophageal adenocarcinoma. *Carcinogenesis*. 2014;35(12):2740-2747.
138. Noguchi T, Uchida Y, Fumoto S, et al. Adenosquamous carcinoma arising in Barrett's esophagus. *Jpn J Thorac Cardiovasc Surg*. 2002;50(12):537-540.
139. Streppel MM, Siersema PD, de Leng WW, et al. Squamous cell carcinoma in Barrett's esophagus: field effect versus metastasis. *Dis Esophagus*. 2012;25(7):630-637.
140. Bibeau F, Chateau M-C, Guiu M, et al. Small cell carcinoma with concomitant adenocarcinoma arising in a Barrett's oesophagus: report of a case with a favourable behaviour. *Virchows Arch*. 2008;452(1):103-107.
141. Issaivanan M, Redner A, Weinstein T, et al. Esophageal carcinoma in children and adolescents. *J Pediatr Hematol Oncol*. 2012;34(1):63-67.
142. Thompson JJ, Zinsser KR, Enterline HT. Barrett's metaplasia and adenocarcinoma of the esophagus and gastroesophageal junction. *Hum Pathol*. 1983;14(1):42-61.
143. Al-Haddad S, Chang AC, De Hertogh G, et al. Adenocarcinoma at the gastroesophageal junction. *Ann N Y Acad Sci*. 2014;1325:211-225.
144. Davies AR, Gossage JA, Zylstra J, et al. Tumor stage after neoadjuvant chemotherapy determines survival after surgery for adenocarcinoma of the esophagus and esophagogastric junction. *J Clin Oncol*. 2014;32(27):2983-2990.
145. Nafteux PR, Lerut TE, Villeneuve PJ, et al. Signet ring cells in esophageal and gastroesophageal junction carcinomas have a more aggressive biological behavior. *Ann Surg*. 2014;260(6):1023-1029.
146. Singhi AD, Seethala RR, Nason K, et al. Undifferentiated carcinoma of the esophagus: a clinicopathological study of 16 cases. *Hum Pathol*. 2015;46(3):366-375.
147. Yanagi M, Keller G, Mueller J, et al. Comparison of loss of heterozygosity and microsatellite instability in adenocarcinomas of the distal esophagus and proximal stomach. *Virchows Arch*. 2000;437(6): 605-610.
148. Huang Q, Hardie LJ. Biomarkers in Barrett's oesophagus. *Biochem Soc Trans*. 2010;38(2):343-347.
149. Weaver JMJ, Ross-Innes CS, Shannon N, et al. Ordering of mutations in preinvasive disease stages of esophageal carcinogenesis. *Nat Genet*. 2014;46(8):837-843.
150. Davelaar AL, Calpe S, Lau L, et al. Aberrant TP53 detected by combining immunohistochemistry and DNA-FISH improves Barrett's esophagus progression prediction: a prospective follow-up study. *Genes Chromosomes Cancer*. 2015;54(2): 82-90.
151. Washington K, Chiappori A, Hamilton K, et al. Expression of beta-catenin, alpha-catenin, and E-cadherin in Barrett's esophagus and esophageal adenocarcinomas. *Mod Pathol*. 1998;11(9):805-813.
152. Kailasam A, Mittal SK, Agrawal DK. Epigenetics in the pathogenesis of esophageal adenocarcinoma. *Clin Transl Sci*. 2015;8(4):394-402.
153. Davison JM, Ellis ST, Foxwell TJ, et al. MUC2 expression is an adverse prognostic factor in superficial gastroesophageal adenocarcinomas. *Hum Pathol*. 2014;45(3):540-548.
154. Mokrowiecka A, Wierzchniewska-Lawska A, Smolarz B, et al. Amplification of Her-2/neu oncogene in GERD—Barrett's metaplasia—dysplasia—adenocarcinoma sequence. *Hepatogastroenterology*. 2013;60(125):1063-1066.
155. Maley CC. Multistage carcinogenesis in Barrett's esophagus. *Cancer Lett*. 2007;245(1-2):22-32.
156. Walsh TN, Noonan N, Hollywood D, et al. A comparison of multimodal therapy and surgery for esophageal adenocarcinoma. *N Engl J Med*. 1996;335(7):462-467.
157. Gronnier C, Tréchot B, Duhamel A, et al. Impact of neoadjuvant chemoradiotherapy on postoperative outcomes after esophageal cancer resection: results of a European multicenter study. *Ann Surg*. 2014;260(5):764-770, discussion 770-771.
158. Hornick JL, Farraye FA, Odze RD. Prevalence and significance of prominent mucin pools in the esophagus post neoadjuvant chemoradiotherapy for Barrett's-associated adenocarcinoma. *Am J Surg Pathol*. 2006;30(1):28-35.
159. Hosokawa Y, Kinoshita T, Konishi M, et al. Clinicopathological features and prognostic factors of adenocarcinoma of the esophagogastric junction according to Siewert classification: experiences at a single institution in Japan. *Ann Surg Oncol*. 2012;19(2):677-683.
160. Torres C, Turner JR, Wang HH, et al. Pathologic prognostic factors in Barrett's associated adenocarcinoma: a follow-up study of 96 patients. *Cancer*. 1999;85(3):520-528.
161. Rice TW, Blackstone EH, Adelstein DJ, et al. Role of clinically determined depth of tumor invasion in the treatment of esophageal carcinoma. *J Thorac Cardiovasc Surg*. 2003;125(5):1091-1102.
162. Rice TW, Zuccaro G, Adelstein DJ, et al. Esophageal carcinoma: depth of tumor invasion is predictive of regional lymph node status. *Ann Thorac Surg*. 1998;65(3):787-792.
163. Hölscher AH, Drebber U, Schmidt H, Bollschweiler E. Prognostic classification of histopathologic response to neoadjuvant therapy in esophageal adenocarcinoma. *Ann Surg*. 2014;260(5):779-784, discussion 784-785.
164. Yoon HH, Khan M, Shi Q, et al. The prognostic value of clinical and pathologic factors in esophageal adenocarcinoma: a mayo cohort of 796 patients with extended follow-up after surgical resection. *Mayo Clin Proc*. 2010;85(12):1080-1089.
165. Gordon MA, Gundacker HM, Benedetti J, et al. Assessment of HER2 gene amplification in adenocarcinomas of the stomach or gastroesophageal junction in the INT-0116/SWOG9008 clinical trial. *Ann Oncol*. 2013;24(7):1754-1761.
166. Pozdnyakova O, Hoang MMP, Dresser KA, Mahalingam M. Prognostic value of E-cadherin, beta-catenin, CD44v6, and HER2/neu in metastatic cutaneous adenocarcinoma. *Arch Pathol Lab Med*. 2009;133(8):1285-1290.
167. Yang H-X, Hou X, Liu Q-W, et al. Tumor location does not impact long-term survival in patients with operable thoracic esophageal squamous cell carcinoma in China. *Ann Thorac Surg*. 2012;93(6):1861-1866.
168. Dandara C, Robertson B, Dzobo K, et al. Patient and tumour characteristics as prognostic markers for oesophageal cancer: a retrospective analysis of a cohort of patients at Groote Schuur Hospital. *Eur J Cardiothorac Surg*. 2016;49(2):629-634.
169. Vizcaino AP, Moreno V, Lambert R, Parkin DM. Time trends incidence of both major histologic types of esophageal carcinomas in

selected countries, 1973–1995. *Int J Cancer*. 2002;99(6):860-868.
170. Rustgi AK, El-Serag HB. Esophageal carcinoma. *N Engl J Med*. 2014;371(26):2499-2509.
171. Zendehdel K, Nyrén O, Edberg A, Ye W. Risk of esophageal adenocarcinoma in achalasia patients, a retrospective cohort study in Sweden. *Am J Gastroenterol*. 2011;106(1):57-61.
172. Ribeiro U, Posner MC, Safatle-Ribeiro AV, Reynolds JC. Risk factors for squamous cell carcinoma of the oesophagus. *Br J Surg*. 1996;83(9):1174-1185.
173. Brücher BLDM, Sarbia M, Oestreicher E, et al. Squamous cell carcinoma and Zenker diverticulum. *Dis Esophagus*. 2007;20(1):75-78.
174. Varela AB, Blanco Rodríguez MM, Boullosa PE, Silva JG. Tylosis A with squamous cell carcinoma of the oesophagus in a Spanish family. *Eur J Gastroenterol Hepatol*. 2011;23(3):286-288.
175. Goffman TE, McKeen EA, Curtis RE, Schein PS. Esophageal carcinoma following irradiation for breast cancer. *Cancer*. 1983;52(10):1808-1809.
176. Su Y-Y, Chen W-C, Chuang H-C, et al. Effect of routine esophageal screening in patients with head and neck cancer. *JAMA Otolaryngol Head Neck Surg*. 2013;139(4):350-354.
177. Ludmir EB, Palta M, Zhang X, et al. Incidence and prognostic impact of high-risk HPV tumor infection in cervical esophageal carcinoma. *J Gastrointest Oncol*. 2014;5(6):401-407.
178. Chen B, Yin H, Dhurandhar N. Detection of human papillomavirus DNA in esophageal squamous cell carcinomas by the polymerase chain reaction using general consensus primers. *Hum Pathol*. 1994;25(9):920-923.
179. Lam KY, He D, Ma L, et al. Presence of human papillomavirus in esophageal squamous cell carcinomas of Hong Kong Chinese and its relationship with p53 gene mutation. *Hum Pathol*. 1997;28(6):657-663.
180. Turner JR, Shen LH, Crum CP, et al. Low prevalence of human papillomavirus infection in esophageal squamous cell carcinomas from North America: analysis by a highly sensitive and specific polymerase chain reaction-based approach. *Hum Pathol*. 1997;28(2):174-178.
181. Morita M, Araki K, Saeki H, et al. Risk factors for multicentric occurrence of carcinoma in the upper aerodigestive tract-analysis with a serial histologic evaluation of the whole resected-esophagus including carcinoma. *J Surg Oncol*. 2003;83(4):216-221.
182. Shimizu M, Zaninotto G, Nagata K, et al. Esophageal squamous cell carcinoma with special reference to its early stage. *Best Pract Res Clin Gastroenterol*. 2013;27(2):171-186.
183. Oda I, Abe S, Kusano C, et al. Correlation between endoscopic macroscopic type and invasion depth for early esophagogastric junction adenocarcinomas. *Gastric Cancer*. 2011;14(1):22-27.
184. Amano T, Matsumoto T, Hayashi T, et al. Subepithelial extension of squamous cell carcinoma in the esophagus: histopathological study using D2-40 immunostaining for 108 superficial carcinomas. *Pathol Int*. 2007;57(12):759-764.
185. Takubo K, Takai A, Takayama S, et al. Intraductal spread of esophageal squamous cell carcinoma. *Cancer*. 1987;59(10):1751-1757.
186. Takubo K, Sasajima K, Yamashita K, et al. Prognostic significance of intramural metastasis in patients with esophageal carcinoma. *Cancer*. 1990;65(8): 1816-1819.
187. Arista-Nasr J, Rivera I, Martinez-Benitez B, et al. Atypical regenerative hyperplasia of the esophagus in endoscopic biopsy: a mimicker of squamous esophagic carcinoma. *Arch Pathol Lab Med*. 2005;129(7):899-904.
188. Zhang HD, Chen CG, Gao YY, et al. Primary esophageal adenosquamous carcinoma: a retrospective analysis of 24 cases. *Dis Esophagus*. 2014;27(8):783-789.
189. Chu P, Stagias J, West AB, Traube M. Diffuse pagetoid squamous cell carcinoma in situ of the esophagus: a case report. *Cancer*. 1997;79(10):1865-1870.
190. Abraham SC, Wang H, Wang KK, Wu T-T. Paget cells in the esophagus: assessment of their histopathologic features and near-universal association with underlying esophageal adenocarcinoma. *Am J Surg Pathol*. 2008;32(7):1068-1074.
191. DiMaio MA, Kwok S, Montgomery KD, et al. Immunohistochemical panel for distinguishing esophageal adenocarcinoma from squamous cell carcinoma: a combination of p63, cytokeratin 5/6, MUC5AC, and anterior gradient homolog 2 allows optimal subtyping. *Hum Pathol*. 2012;43(11):1799-1807.
192. Hara T, Kijima H, Yamamoto S, et al. Ubiquitous p63 expression in human esophageal squamous cell carcinoma. *Int J Mol Med*. 2004;14(2):169-173.
193. Li D-M, Li S-S, Zhang Y-H, et al. Expression of human chorionic gonadotropin, CD44v6 and CD44v4/5 in esophageal squamous cell carcinoma. *World J Gastroenterol*. 2005;11(47):7401-7404.
194. Baba Y, Iyama K-I, Ikeda K, et al. The expression of type IV collagen alpha6 chain is related to the prognosis in patients with esophageal squamous cell carcinoma. *Ann Surg Oncol*. 2008;15(2):555-565.
195. Segalin A, Ruol A, Panozzo M, et al. Flow cytometric DNA analysis does not predict the radiochemoresponsiveness of esophageal cancer. *J Surg Oncol*. 1993;54(2):87-90.
196. Tsutsui S, Kuwano H, Mori M, et al. A flow cytometric analysis of DNA content in primary and metastatic lesions of esophageal squamous cell carcinoma. *Cancer*. 1992;70(11):2586-2591.
197. Chen J, Kwong DL, Cao T, et al. Esophageal squamous cell carcinoma (ESCC): advance in genomics and molecular genetics. *Dis Esophagus*. 2015;28(1):84-89.
198. Kandioler D, Schoppmann SF, Zwrtek R, et al. The biomarker TP53 divides patients with neoadjuvantly treated esophageal cancer into 2 subgroups with markedly different outcomes. A p53 Research Group study. *J Thorac Cardiovasc Surg*. 2014;148(5):2280-2286.
199. Appelman HD, Matejcic M, Parker MI, et al. Progression of esophageal dysplasia to cancer. *Ann N Y Acad Sci*. 2014;1325:96-107.
200. Dry SM, Lewin KJ. Esophageal squamous dysplasia. *Semin Diagn Pathol*. 2002;19(1):2-11.
201. Takiyama W, Moriwaki S, Mandai K, Takashima S. Dysplasia in the human esophagus: clinicopathological study on 500 esophagi at autopsy. *Jpn J Clin Oncol*. 1992;22(4):250-255.
202. Taylor PR, Abnet CC, Dawsey SM. Squamous dysplasia—the precursor lesion for esophageal squamous cell carcinoma. *Cancer Epidemiol Biomarkers Prev*. 2013;22(4):540-552.
203. Kuwano H, Morita M, Matsuda H, et al. Histopathologic findings of minute foci of squamous cell carcinoma in the human esophagus. *Cancer*. 1991;68(12):2617-2620.
204. Tajima Y, Nakanishi Y, Tachimori Y, et al. Significance of involvement by squamous cell carcinoma of the ducts of esophageal submucosal glands. Analysis of 201 surgically resected superficial squamous cell carcinomas. *Cancer*. 2000;89(2):248-254.
205. Rubio CA, Liu FS, Zhao HZ. Histological classification of intraepithelial neoplasias and microinvasive squamous carcinoma of the esophagus. *Am J Surg Pathol*. 1989;13(8):685-690.
206. Nozoe T, Saeki H, Ohga T, Sugimachi K. Clinicopathologic characteristics of superficial spreading type squamous cell carcinoma of the esophagus. *Oncol Rep*. 2002;9(2):313-316.
207. Ebi M, Shimura T, Yamada T, et al. Multicenter, prospective trial of white-light imaging alone versus white-light imaging followed by magnifying endoscopy with narrow-band imaging for the real-time imaging and diagnosis of invasion depth in superficial esophageal squamous cell carcinoma. *Gastrointest Endosc*. 2015;81(6):1355.e2-1361.e2.
208. Bogomoletz WV, Molas G, Gayet B, Potet F. Superficial squamous cell carcinoma of the esophagus. A report of 76 cases and review of the literature. *Am J Surg Pathol*. 1989;13(7):535-546.
209. Araki K, Ohno S, Egashira A, et al. Pathologic features of superficial esophageal squamous cell carcinoma with lymph node and distal metastasis. *Cancer*. 2002;94(2):570-575.
210. Tajima Y, Nakanishi Y, Ochiai A, et al. Histopathologic findings predicting lymph node metastasis and prognosis of patients with superficial esophageal carcinoma: analysis of 240 surgically resected tumors. *Cancer*. 2000;88(6):1285-1293.
211. Hsu P-K, Huang C-S, Hsieh C-C, et al. Role of right upper mediastinal lymph node metastasis in patients with esophageal squamous cell carcinoma after tri-incisional esophagectomies. *Surgery*. 2014;156(5):1269-1277.
212. Moon JY, Kim GH, Kim JH, et al. Clinicopathologic factors predicting lymph node metastasis in superficial esophageal squamous cell carcinoma. *Scand J Gastroenterol*. 2014;49(5):589-594.
213. Li B, Chen H, Xiang J, et al. Prevalence of lymph node metastases in superficial esophageal squamous cell carcinoma. *J Thorac Cardiovasc Surg*. 2013;146(5):1198-1203.
214. Mitobe J, Ikegami M, Urashima M, et al. Clinicopathological investigation of lymph node metastasis predictors in superficial esophageal squamous cell carcinoma with a focus on evaluation of lympho-vascular invasion. *Scand J Gastroenterol*. 2013;48(10):1173-1182.
215. Matsubara T, Ueda M, Kaisaki S, et al. Localization of initial lymph node metastasis from carcinoma of the thoracic esophagus. *Cancer*. 2000;89(9):1869-1873.
216. Saito T, Iizuka T, Kato H, Watanabe H. Esophageal carcinoma metastatic to the stomach. A clinicopathologic study of 35 cases. *Cancer*. 1985;56(9):2235-2241.
217. Clayton AC, Bentz JS, Wasserman PG, et al. Comparison of ThinPrep preparations to other preparation types in gastrointestinal cytology: observations from the College of American Pathologists Interlaboratory Comparison Program in Nongynecologic Cytology. *Arch Pathol Lab Med*. 2010;134(8):1116-1120.
218. Goldman H, Antonioli DA. Mucosal biopsy of the esophagus, stomach, and proximal duodenum. *Hum Pathol*. 1982;13(5): 423-448.
219. Lazarus C, Jaskiewicz K, Sumeruk RA, Nainkin J. Brush cytology technique in the detection of oesophageal carcinoma in the asymptomatic, high risk subject; a pilot survey. *Cytopathology*. 1992;3(5):291-296.
220. Shen O, Liu SF, Dawsey SM, et al. Cytologic screening for esophageal cancer: results from 12,877 subjects from a high-risk population in China. *Int J Cancer*. 1993;54(2):185-188.
221. Jang R, Darling G, Wong RKS. Multimodality approaches for the curative treatment of

esophageal cancer. *J Natl Compr Canc Netw*. 2015;13(2):229-238.
222. Little AG, Lerut AE, Harpole DH, et al. The Society of Thoracic Surgeons practice guidelines on the role of multimodality treatment for cancer of the esophagus and gastroesophageal junction. *Ann Thorac Surg*. 2014;98(5):1880-1885.
223. Paul S, Altorki N. Outcomes in the management of esophageal cancer. *J Surg Oncol*. 2014;110(5):599-610.
224. Watanabe M, Mine S, Nishida K, et al. Salvage esophagectomy after definitive chemoradiotherapy for patients with esophageal squamous cell carcinoma: who really benefits from this high-risk surgery? *Ann Surg Oncol*. 2015;22(13):4438-4444.
225. Utsumi Y, Nakamura T, Nagasue N, et al. Role of estrogen receptors in the growth of human esophageal carcinoma. *Cancer*. 1989;64(1):88-93.
226. Situ D, Wang J, Lin P, et al. Do tumor location and grade affect survival in pT2N0M0 esophageal squamous cell carcinoma? *J Thorac Cardiovasc Surg*. 2013;146(1):45-51.
227. Liu C-Y, Wang B-Y, Lee M-Y, et al. The prognostic value of circumferential resection margin in esophageal squamous cell carcinoma after concurrent chemoradiation therapy and surgery. *J Chin Med Assoc*. 2013;76(10):570-575.
228. Okumura H, Uchikado Y, Setoyama T, et al. Biomarkers for predicting the response of esophageal squamous cell carcinoma to neoadjuvant chemoradiation therapy. *Surg Today*. 2014;44(3):421-428.
229. Wu T-T, Chirieac LR, Abraham SC, et al. Excellent interobserver agreement on grading the extent of residual carcinoma after preoperative chemoradiation in esophageal and esophagogastric junction carcinoma: a reliable predictor for patient outcome. *Am J Surg Pathol*. 2007;31(1):58-64.
230. Raza MA, Mazzara PF. Sarcomatoid carcinoma of esophagus. *Arch Pathol Lab Med*. 2011;135(7):945-948.
231. Iezzoni JC, Mills SE. Sarcomatoid carcinomas (carcinosarcomas) of the gastrointestinal tract: a review. *Semin Diagn Pathol*. 1993;10(2):176-187.
232. Amatya VJ, Takeshima Y, Kaneko M, Inai K. Esophageal carcinosarcoma with basaloid squamous carcinoma and rhabdomyosarcoma components with TP53 mutation. *Pathol Int*. 2004;54(10):803-809.
233. Hung J-J, Li AF-Y, Liu J-S, et al. Esophageal carcinosarcoma with basaloid squamous cell carcinoma and osteosarcoma. *Ann Thorac Surg*. 2008;85(3):1102-1104.
234. Handra-Luca A, Terris B, Couvelard A, et al. Spindle cell squamous carcinoma of the oesophagus: an analysis of 17 cases, with new immunohistochemical evidence for a clonal origin. *Histopathology*. 2001;39(2):125-132.
235. Linder J, Stein RB, Roggli VL, et al. Polypoid tumor of the esophagus. *Hum Pathol*. 1987;18(7):692-700.
236. Kanamoto A, Nakanishi Y, Ochiai A, et al. A case of small polypoid esophageal carcinoma with multidirectional differentiation, including neuroendocrine, squamous, ciliated glandular, and sarcomatous components. *Arch Pathol Lab Med*. 2000;124(11):1685-1687.
237. Lauwers GY, Grant LD, Scott GV, et al. Spindle cell squamous carcinoma of the esophagus: analysis of ploidy and tumor proliferative activity in a series of 13 cases. *Hum Pathol*. 1998;29(8):863-868.
238. Osamura RY, Shimamura K, Hata J, et al. Polypoid carcinoma of the esophagus. A unifying term for "carcinosarcoma" and "pseudosarcoma.". *Am J Surg Pathol*. 1978;2(2):201-208.
239. Martin MR, Kahn LB. So-called pseudosarcoma of the esophagus: nodal metastases of the spindle cell element. *Arch Pathol Lab Med*. 1977;101(11):604-609.
240. Ramani C, Shah N, Nathan RS. Verrucous carcinoma of the esophagus: a case report and literature review. *World J Clin Cases*. 2014;2(7):284-288.
241. Osborn NK, Keate RF, Trastek VF, Nguyen CC. Verrucous carcinoma of the esophagus: clinicopathophysiologic features and treatment of a rare entity. *Dig Dis Sci*. 2003;48(3):465-474.
242. Devlin S, Falck V, Urbanski SJ, et al. Verrucous carcinoma of the esophagus eluding multiple sets of endoscopic biopsies and endoscopic ultrasound: a case report and review of the literature. *Can J Gastroenterol*. 2004;18(7):459-462.
243. Garrard CL, Sheih WJ, Cohn RA, Sawyers JL. Verrucous carcinoma of the esophagus: surgical treatment for an often fatal disease. *Am Surg*. 1994;60(8):613-616.
244. Imamhasan A, Mitomi H, Saito T, et al. Immunohistochemical and oncogenetic analyses of the esophageal basaloid squamous cell carcinoma in comparison with conventional squamous cell carcinomas. *Hum Pathol*. 2012;43(11):2012-2023.
245. Chen S-B, Weng H-R, Wang G, et al. Basaloid squamous cell carcinoma of the esophagus. *J Cancer Res Clin Oncol*. 2012;138(7):1165-1171.
246. Abe K, Sasano H, Itakura Y, et al. Basaloid-squamous carcinoma of the esophagus. A clinicopathologic, DNA ploidy, and immunohistochemical study of seven cases. *Am J Surg Pathol*. 1996;20(4):453-461.
247. Bellizzi AM, Woodford RL, Moskaluk CA, et al. Basaloid squamous cell carcinoma of the esophagus: assessment for high-risk human papillomavirus and related molecular markers. *Am J Surg Pathol*. 2009;33(11):1608-1614.
248. Guo X, Mao T, Gu Z, et al. Adenoid cystic carcinoma of the esophagus: report of two cases and review of the Chinese literature. *Diagn Pathol*. 2012;7:179.
249. Na YJ, Shim K-N, Kang M-J, et al. Primary esophageal adenoid cystic carcinoma. *Gut Liver*. 2007;1(2):178-181.
250. Garman KS, Kruger L, Thomas S, et al. Ductal metaplasia in esophageal submucosal glands is associated with inflammation and esophageal adenocarcinoma. *Histopathology*. 2015;67(6):771-782.
251. Patel VR, Hofstetter WL, Correa AM, et al. Signet ring cells in esophageal adenocarcinoma predict poor response to preoperative chemoradiation. *Ann Thorac Surg*. 2014;98(3):1064-1071.
252. Piessen G, Messager M, Lefevre JH, et al. Signet ring cell adenocarcinomas: different clinical-pathological characteristics of oesophageal and gastric locations. *Eur J Surg Oncol*. 2014;40(12):1746-1755.
253. Kiyozaki H, Obitsu T, Ishioka D, et al. A rare case of primary mucoepidermoid carcinoma of the esophagus. *Clin J Gastroenterol*. 2015;8(1):26-28.
254. Wang L, Zhan C, Ma J, et al. Collision tumor of esophagus: report of three cases. *Ann Thorac Surg*. 2014;97(3):1075-1077.
255. Milne ANA, Carvalho R, van Rees BP, et al. Do collision tumors of the gastroesophageal junction exist? A molecular analysis. *Am J Surg Pathol*. 2004;28(11):1492-1498.
256. Terada T. Epstein-Barr virus associated lymphoepithelial carcinoma of the esophagus. *Int J Clin Exp Med*. 2013;6(3):219-226.
257. Xie MR, Xu SB, Sun XH, et al. Role of surgery in the management and prognosis of limited-stage small cell carcinoma of the esophagus. *Dis Esophagus*. 2015;28(5):476-482.
258. Chen W-W, Wang F, Zhang D-S, et al. Primary small cell carcinoma of the esophagus: clinicopathological study of 44 cases. *BMC Cancer*. 2014;14:222.
259. Chen W-W, Wang F, Chen S, et al. Detailed analysis of prognostic factors in primary esophageal small cell carcinoma. *Ann Thorac Surg*. 2014;97(6):1975-1981.
260. Yagi M, Abe Y, Sasaki Y, et al. Esophageal carcinoid tumor treated by endoscopic resection. *Dig Endosc*. 2015;27(4):527-530.
261. Chuah S-K, Hu T-H, Kuo C-M, et al. Upper gastrointestinal carcinoid tumors incidentally found by endoscopic examinations. *World J Gastroenterol*. 2005;11(44):7028-7032.
262. Xiaogang Z, Xingtao J, Huasheng W, Mo W. Atypical carcinoid of the esophagus: report of a case. *Ann Thorac Cardiovasc Surg*. 2002;8(5):302-305.
263. Maru DM, Khurana H, Rashid A, et al. Retrospective study of clinicopathologic features and prognosis of high-grade neuroendocrine carcinoma of the esophagus. *Am J Surg Pathol*. 2008;32(9):1404-1411.
264. Jiang W, Rice TW, Goldblum JR. Esophageal leiomyoma: experience from a single institution. *Dis Esophagus*. 2013;26(2):167-174.
265. Abraham SC, Krasinskas AM, Hofstetter WL, et al. "Seedling" mesenchymal tumors (gastrointestinal stromal tumors and leiomyomas) are common incidental tumors of the esophagogastric junction. *Am J Surg Pathol*. 2007;31(11):1629-1635.
266. Miettinen M, Sarlomo-Rikala M, Sobin LH, Lasota J. Esophageal stromal tumors: a clinicopathologic, immunohistochemical, and molecular genetic study of 17 cases and comparison with esophageal leiomyomas and leiomyosarcomas. *Am J Surg Pathol*. 2000;24(2):211-222.
267. Nazligül Y, Aslan M, Esen R, et al. Benign glycogenic acanthosis lesions of the esophagus. *Turk J Gastroenterol*. 2012;23(3):199-202.
268. Tsai S-J, Lin C-C, Chang C-W, et al. Benign esophageal lesions: endoscopic and pathologic features. *World J Gastroenterol*. 2015;21(4):1091-1098.
269. Kahi CJ, Vakili S, Liepnieks JJ, Benson M. Amyloidoma of the esophagus. *Am J Gastroenterol*. 2007;102(4):910-911.
270. Del Genio G, Del Genio F, Schettino P, et al. Esophageal papilloma: flexible endoscopic ablation by radiofrequency. *World J Gastrointest Endosc*. 2015;7(3):290-294.
271. Takeshita K, Murata S-I, Mitsufuji S, et al. Clinicopathological characteristics of esophageal squamous papillomas in Japanese patients—with comparison of findings from Western countries. *Acta Histochem Cytochem*. 2006;39(1):23-30.
272. Goenka AH, Sharma S, Ramachandran V, et al. Giant fibrovascular polyp of the esophagus: report of a case. *Surg Today*. 2011;41(1):120-124.
273. Jang GC, Clouse ME, Fleischner FG. Fibrovascular polyp—a benign intraluminal tumor of the esophagus. *Radiology*. 1969;92(6):1196-1200.
274. Lewis RB, Mehrotra AK, Rodriguez P, Levine MS. From the radiologic pathology archives: esophageal neoplasms: radiologic-pathologic correlation. *Radiographics*. 2013;33(4):1083-1108.
275. McQueen C, Montgomery E, Dufour B, et al. Giant hypopharyngeal atypical lipomatous tumor. *Adv Anat Pathol*. 2010;17(1):38-41.
276. Peltz M, Estrera AS. Resection of a giant esophageal fibrovascular polyp. *Ann Thorac Surg*. 2010;90(3):1017-1019.
277. Abraham SC, Singh VK, Yardley JH, Wu TT. Hyperplastic polyps of the esophagus and esophagogastric junction: histologic and

clinicopathologic findings. *Am J Surg Pathol*. 2001;25(9):1180-1187.
278. Long KB, Odze RD. Gastroesophageal junction hyperplastic (inflammatory) polyps: a clinical and pathologic study of 46 cases. *Am J Surg Pathol*. 2011;35(7):1038-1044.
279. Goldblum JR, Rice TW, Zuccaro G, Richter JE. Granular cell tumors of the esophagus: a clinical and pathologic study of 13 cases. *Ann Thorac Surg*. 1996;62(3):860-865.
280. Seoung HG, Kim GH, Song GA, et al. Esophageal pyogenic granuloma: endosonographic findings and endoscopic treatments. *Clin Endosc*. 2013;46(1):81-84.
281. Tanaka M, Kataoka H, Joh T. Neurofibroma of the esophagus complicating Von Recklinghausen's neurofibromatosis. *Am J Gastroenterol*. 2013;108(12):1935-1936.
282. Tomono A, Nakamura T, Otowa Y, et al. A case of benign esophageal schwannoma causing life-threatening tracheal obstruction. *Ann Thorac Cardiovasc Surg*. 2015;21(3):289-292.
283. Kelesidis T, Tarbox A, Lopez M, Aish L. Perineurioma of esophagus: a first case report. *Am J Med Sci*. 2009;338(3):230-232.
284. Li H, Hu B, Li T, et al. A rare case of giant solitary fibrous tumor of the esophagus. *Ann Thorac Surg*. 2009;88(6):2019-2021.
285. Sanchez AA, Wu T-T, Prieto VG, et al. Comparison of primary and metastatic malignant melanoma of the esophagus: clinicopathologic review of 10 cases. *Arch Pathol Lab Med*. 2008;132(10):1623-1629.
286. Sekine S, Nakanishi Y, Ogawa R, et al. Esophageal melanomas harbor frequent NRAS mutations unlike melanomas of other mucosal sites. *Virchows Arch*. 2009;454(5):513-517.
287. Peng JC, Zhong L, Ran ZH. Primary lymphomas in the gastrointestinal tract. *J Dig Dis*. 2015;16(4):169-176.
288. Zhou Y, Xu X, Xu L, et al. Treatment of primary isolated extramedullary plasmacytoma of esophagus with endoscopic submucosal dissection. *Clin Gastroenterol Hepatol*. 2012;10(3):e21-e22.
289. Radin DR. Primary esophageal lymphoma in AIDS. *Abdom Imaging*. 1993;18(3): 223-224.
290. Fulp SR, Nestok BR, Powell BL, et al. Leukemic infiltration of the esophagus. *Cancer*. 1993;71(1):112-116.
291. Gelb AB, Medeiros LJ, Chen YY, et al. Hodgkin's disease of the esophagus. *Am J Clin Pathol*. 1997;108(5):593-598.
292. Erra S, Costamagna D, Durando R. A rare case of extraskeletal osteosarcoma of the esophagus: an example of difficult diagnosis. *G Chir*. 2010;31(1-2):24-27.
293. Gandhi JS, Pasricha S, Gupta G, et al. Synchronous embryonal rhabdomyosarcoma (NOS) of the mid-oesophagus and stomach. *J Gastrointest Cancer*. 2012;43(suppl 1):S217-S220.
294. Butori C, Hofman V, Attias R, et al. Diagnosis of primary esophageal synovial sarcoma by demonstration of t(X;18) translocation: a case report. *Virchows Arch*. 2006;449(2): 262-267.
295. Maggiani F, Debiec-Rychter M, Ectors N, et al. Primary epithelioid sarcoma of the oesophagus. *Virchows Arch*. 2007;451(4):835-838.
296. Johnson AD, Pambuccian SE, Andrade RS, et al. Ewing sarcoma and primitive neuroectodermal tumor of the esophagus: report of a case and review of literature. *Int J Surg Pathol*. 2010;18(5):388-393.
297. Wang S, Zheng J, Ruan Z, et al. Long-term survival in a rare case of malignant esophageal schwannoma cured by surgical excision. *Ann Thorac Surg*. 2011;92(1):357-358.

14 Stomach

John R. Goldblum

CHAPTER CONTENTS

Normal anatomy, *528*
Heterotopic tissues, *529*
Hypertrophic pyloric stenosis, *530*
Chronic gastritis, *530*
Other types of gastritis, *532*
Peptic and other benign ulcers, *533*
Other non-neoplastic lesions, *535*
Polyps, *536*
Ménétrier disease and Zollinger–Ellison syndrome, *539*
Regenerative changes and dysplasia, *539*
Carcinoma, *541*
General features, *541*
Morphologic features and classification, *541*
Histochemical and immunohistochemical features, *543*
Molecular genetic features, *543*
Other microscopic tumor types, *544*
Diagnosis—biopsy and cytology, *545*
So-called early carcinoma, *545*
Spread and metastases, *546*
Treatment, *547*
Prognosis, *547*
Well-differentiated neuroendocrine tumors ("carcinoid tumors"), *549*
Stromal tumors (gastrointestinal stromal tumors and related lesions), *550*
Histogenetic considerations: microscopic, immunohistochemical, and molecular genetic features, *550*
General, clinical, and gross features of gastrointestinal stromal tumor, *551*
Microscopic features and differential diagnosis of gastrointestinal stromal tumor, *551*
Tumor multiplicity, *552*
Spread and metastases, *552*
Treatment, *552*
Prognosis, *553*
Lymphoid tumors and tumorlike conditions, *553*
The mucosa-associated lymphoid tissue concept, *554*
Low-grade lymphomas, *554*
Large cell lymphomas, *555*
Other types of lymphoma and related conditions, *556*
Other tumors, *557*

Normal Anatomy

The stomach is divided into the following regions: *cardia*, *fundus*, *corpus* or *body*, *antrum*, and *pylorus*. The superomedial margin is termed the *lesser curvature*, and the inferolateral margin is termed the *greater curvature*. The junction between the corpus and the antrum is marked on the serosal side by a notch in the lesser curvature known as the *incisura*. Internally, the mucosa is thrown into coarse folds called *rugae*.

These anatomic regions show some correspondence to (but should not be equated with) the three traditionally recognized microscopic types of gastric mucosa: *cardiac*, *fundic*, and *pyloric (antral)*, with transitional forms in the boundary areas. The mucosa is composed of two major compartments—the foveolar and glandular compartments. The differences among the various types of gastric mucosa depend on the relative proportions between foveolae and secretory portions and the microscopic composition of the latter. Cardiac and pyloric glands are similar: foveolae occupy the upper half, and branching mucus-secreting glands occupy the lower half. Looser packing of the glands and the presence of occasional cysts in cardiac glands are the only two minor microscopic differences that exist with the pyloric glands. The cytoplasm of the pyloric cells can be bubbly, vacuolated, granular, or glassy.[1] Subnuclear vacuolization of mucous cells sometimes occurs and should not be misinterpreted as an expression of metaplasia.[2] Similarly, pyloric cells with glassy cytoplasm occurring in cohesive clusters should not be confused with signet ring adenocarcinoma.[3] Ciliated cells are sometimes found in the pyloric area; they are more common in the Japanese and are regarded by some as an expression of metaplasia.[4]

The fundic (oxyntic) glands are characterized by foveolae, which occupy only one-fourth of the mucosal thickness, and straight glands of composite cell distribution, which includes chief (zymogenic) cells, parietal (acid-secreting) cells, endocrine cells, and mucous neck cells. Immunohistochemical and in situ hybridization studies have shown production of pepsinogen I in both chief and mucous

Abstract

The stomach is the site of common inflammatory processes including *Helicobacter pylori*–related gastritis and alterations of the mucosa secondary to mucosal injury, generally referred to as reactive gastropathy. Other forms of gastritis including lymphocytic gastritis and other types of infectious gastritis are relatively uncommon. As is true in other organs, the most common neoplastic process is adenocarcinoma, commonly occurring in patients with *H. pylori* infection. Other neoplastic processes include lymphoma (most commonly of MALT type) and mesenchymal neoplasm (most commonly gastrointestinal stromal tumors).

Keywords

Normal anatomy,
heterotopic tissues,
hypertrophic pyloric stenosis,
chronic gastritis,
peptic and other benign ulcers,
non-neoplastic lesions,
polyps,
regenerative hyperplasia and dysplasia,
carcinoma,
lymphoid tumors,
stromal tumors
Helicobacter pylori,
peptic ulcer disease,
reactive gastropathy,
gastric adenocarcinoma,
lymphoma

neck cells (but not in the pyloric region, which features instead production of pepsinogen II).[5]

The provocative suggestion has been made that the only normally occurring epithelia in the gastroesophageal junction are esophageal squamous mucosa and gastric fundic mucosa. According to this concept, the mucosa that has been traditionally regarded as cardiac is actually metaplastic rather than native.[6] However, autopsy studies have suggested a small native and microscopically identifiable gastric cardiac mucosa exists, which of course does not preclude that this can coexist with more proximally located metaplastic cardiac-type mucosa.[7]

The mucin secreted by the gastric mucosa is almost entirely of neutral type and therefore is positive for periodic acid–Schiff (PAS) but negative for alcian blue. At the immunohistochemical level, the foveolar epithelium expresses MUC1 and MUC5AC, and the glands express MUC6[8]; these mucins have also been detected in carcinomas derived from this mucosa.[9]

Many types of endocrine–paracrine cells have been identified in the gastrointestinal mucosa, and many of them occur in the stomach.[10] In the pyloric mucosa, approximately 50% of the endocrine cells are G cells (gastrin producing), 30% are enterochromaffin (EC) cells (5-hydroxytryptamine (serotonin) producing), and 15% are D cells (somatostatin producing). In the fundic mucosa, the predominant endocrine cell is the enterochromaffin-like (ECL) cell (histamine storing); ECL cells are thought to play a key role in the mechanism of gastric acid secretion as controlled by gastrin stimulation.[11]

The other two components of the mucosa are the lamina propria and the muscularis mucosae. The latter is composed of an inner circular and an outer longitudinal layer; it is continuous with thin fascicles of smooth muscle that go up inside the lamina propria to reach beneath the surface epithelium. Under normal conditions the lamina propria contains few or no lymphoid follicles.[12]

The other layers of the stomach are the same as for the rest of the gastrointestinal tract, that is, submucosa, muscularis propria, and serosa. The submucosa consists of loose connective tissue with numerous elastic fibers; it contains plexuses of arteries, veins, lymphatics, and the Meissner nerve plexus. The muscularis propria is composed of three layers: outer longitudinal, inner circular, and innermost oblique. The inner circular layer forms the pyloric sphincter at the gastroduodenal junction. The Auerbach (myenteric) plexus is located between the circular and longitudinal layers of the muscularis propria. The interstitial cells of Cajal are also intimately associated with the nerves of the myenteric plexus and seem to play an important role in the development of gastrointestinal stromal tumors (GISTs; discussed later).

The blood supply of the stomach originates from the celiac axis, hepatic artery, and splenic artery. The lymphatic channels drain into four major areas, according to the following scheme:

1. Cardia and most of lesser curvature: left gastric nodes
2. Pylorus and distal lesser curvature: right gastric and hepatic nodes
3. Proximal portion of the greater curvature: pancreaticosplenic nodes in the splenic hilum
4. Distal portion of greater curvature: right gastroepiploic nodes in greater omentum and pyloric nodes at the head of the pancreas.

Heterotopic Tissues

Heterotopic pancreas can present clinically as a gastric mass or be discovered incidentally at autopsy or at laparotomy.[13] Grossly, it may form a hemispheric mass, a symmetric cone, or a short cylindric nipple-like projection. In the last instance, one or more ducts are usually seen emptying on the gastric lumen; this feature constitutes an important diagnostic sign radiographically (Fig. 14.1).

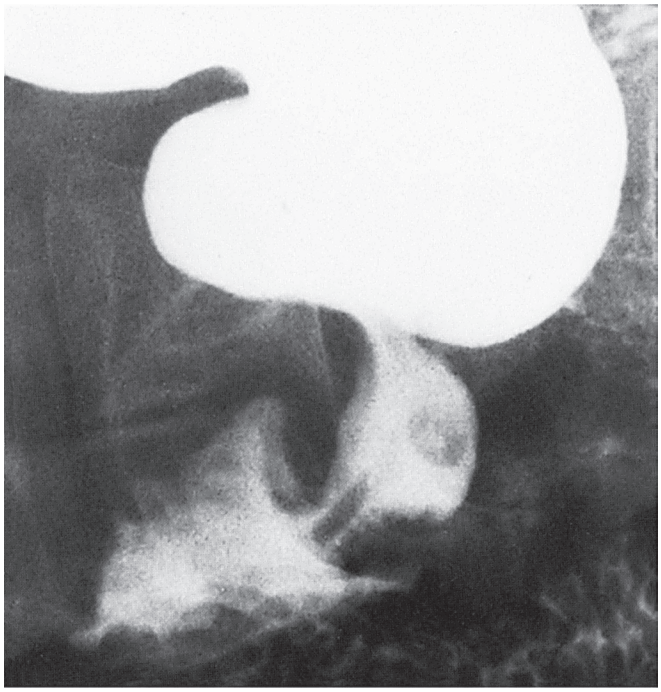

Figure 14.1 Heterotopic pancreatic tissue presenting radiographically as a small, round nodule with central umbilication in the antrum.

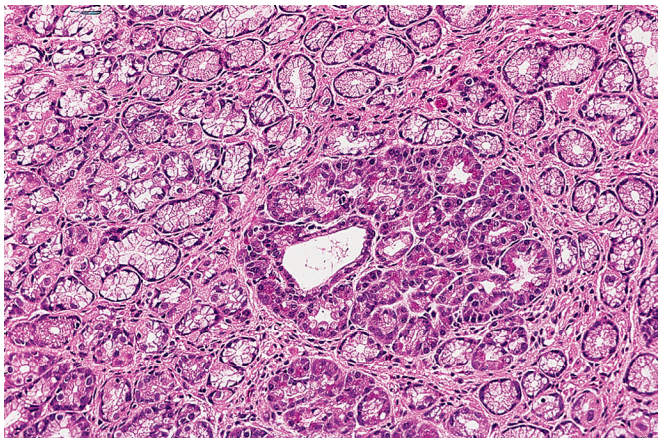

Figure 14.2 Island of exocrine pancreatic tissue composed of acini within the gastric mucosa.

Approximately 85% of these lesions occur in the submucosa and most of the remainder are in the muscular layer. It arises predominantly in the antrum (61%) followed by the pylorus (24%). Grossly, the cut surface looks like normal pancreas except for the occasional occurrence of cystic structures. Microscopically, pancreatic acini and ducts are always present, whereas islets are seen in only one-third of the cases. Mucocele-like changes and calcifications may be present.[14] Rare cases of adenocarcinoma have been reported to arise in these heterotopic tissues.[15]

An altogether different phenomenon is represented by the **pancreatic acinar metaplasia** of gastric mucosa, frequently seen in patients with chronic gastritis (Fig. 14.2).[16] These cells, which can be found in both adults and children, are immunohistochemically reactive for pancreatic lipase and trypsinogen[17]; they also contain amylase but not as frequently or abundantly as the heterotopic glands.

The lesion described as gastric **adenomyoma** is closely related to heterotopic pancreas. It is probably a hamartoma rather than a true neoplasm, the usual components being large ducts, Brunner glands, and prominent smooth muscle bundles.[18] Like conventional heterotopic pancreas, it has occasionally been found to undergo malignant transformation.[19]

Hypertrophic Pyloric Stenosis

Hypertrophic pyloric stenosis is one of the most common congenital anomalies, but its incidence is decreasing, suggesting that environmental factors are of importance in this disorder, although its identification in twins also suggests a genetic component.[20] Most patients are males, and the most common age of onset is between 3 and 12 weeks. The gross appearance is that of a greatly thickened pyloric muscle, which occludes the pyloric channel and partially obstructs the gastric outflow. The etiology and pathogenesis remain obscure, although there is increasing evidence that the smooth muscle cells of the gastric wall are not properly innervated, and that the phasic and tonic contractile activity in the gastroduodenal junction of these patients is not coordinated with the antral contractions.[21,22] The operation of choice for decades has been the Fredet–Ramstedt pyloromyotomy, which basically consists of a linear incision through the hypertrophic muscle, leaving the mucosa intact, a procedure that is usually performed endoscopically.[23] Usually no tissue is resected in this procedure. The few microscopic studies that have been done on this condition have shown no pathologic alterations of note.[24]

The main differential diagnosis of congenital hypertrophic pyloric stenosis is with *pyloric atresia*, a genetically determined disease associated with epidermolysis bullosa.[25] The treatment consists of the surgical removal of the atretic segment (Heineke–Mikulicz technique).

Hypertrophy of the pylorus in the adult is a rare condition, usually arising in males. Clinically and radiographically, a tumor is often suspected and the stomach resected. Grossly and microscopically, all that is found is hypertrophy of the pyloric circular muscle fibers that ends abruptly at the duodenum, sometimes accompanied by a mild degree of fibrosis.[26,27]

Pyloric hypertrophy in an adult in the absence of another gastric abnormality occurs only exceptionally. Although it is possible that some of the cases represent a persistence of the infantile form into adult life, in most instances the process is probably secondary to antral gastritis or peptic ulcer of the pyloric channel, which may have healed by the time of surgery. It is also good to remember that the gross appearance of pyloric hypertrophy can be simulated by the diffuse form of gastric adenocarcinoma (traditionally known as linitis plastica).

Chronic Gastritis

The incidence and natural history of chronic gastritis has been greatly clarified by the systematic use of endoscopic gastric biopsy. The two main features of this disease are infiltration of the lamina propria by inflammatory cells and eventually atrophy of the glandular epithelium. Plasma cells and lymphocytes (with occasional formation of lymphoid follicles) predominate among the inflammatory cells, but eosinophils and neutrophils may also be present. If the inflammatory infiltrate is limited to the foveolar region and unaccompanied by glandular atrophy, the condition is designated as **chronic superficial gastritis** (Fig. 14.3). Subtle epithelial abnormalities seen in this form include a reduced amount of cytoplasmic mucin, nuclear and nucleolar enlargement, and some increase in foveolar mitoses. When the inflammation is more extensive and accompanied by glandular atrophy, the condition is termed **chronic atrophic gastritis**. Glandular atrophy is also manifested by an increase in the distance between the individual

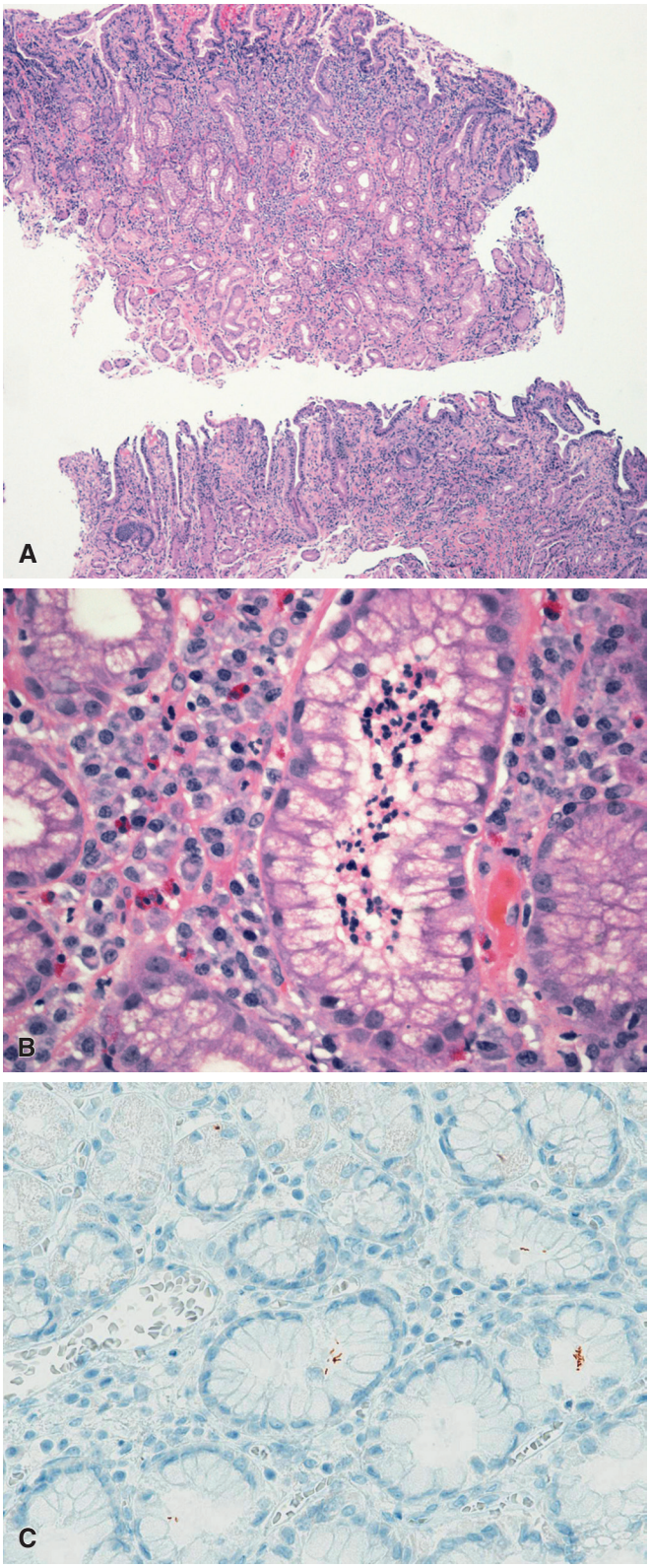

Figure 14.3 Low-Power View of a Gastric Biopsy With *Helicobacter pylori*–Related Gastritis. A, The lamina propria is expanded by lymphocytes and plasma cells. **B,** High-power view showing prominent plasmacytosis of the lamina propria and neutrophil-mediated epithelial injury (activity). **C,** Immunohistochemical stain for *H. pylori* revealing rare organisms within the mucous layer.

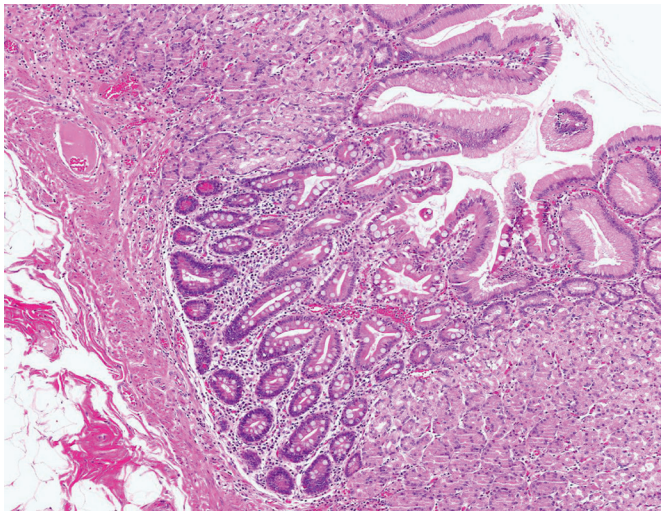

Figure 14.4 Gastric body with atrophic gastritis including intestinal metaplasia.

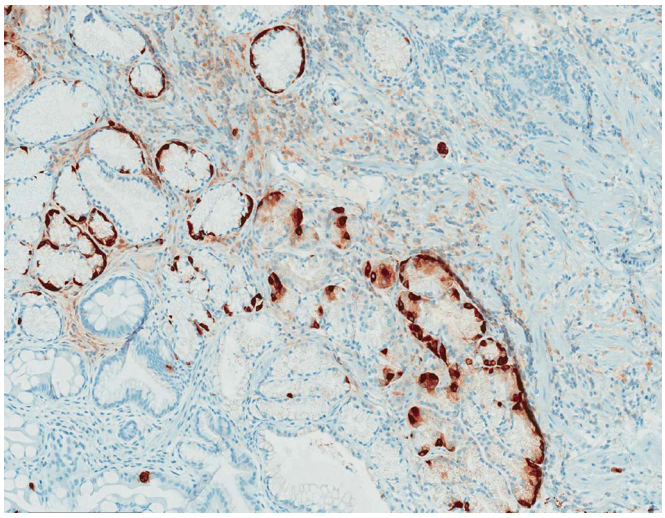

Figure 14.5 Immunohistochemical stain for chromogranin showing linear staining indicative of a neuroendocrine proliferation in the setting of atrophic gastritis.

glands and is virtually always accompanied by intestinal metaplasia. In rare cases of (auto)immune gastritis (see later), the atrophy may have a patchy quality, resulting in a pseudopolypoid appearance of the oxyntic mucosa (Fig. 14.4).[28] Cases of gastritis in which small collections of lymphocytes and histiocytes (sometimes admixed with neutrophils) are seen surrounding a small group of glands have been referred to as *focally enhanced gastritis*; some believe this to be a marker of inflammatory bowel disease, particularly Crohn disease, but this has not been confirmed in other studies.[29]

Two types of **metaplastic change** can occur in chronic gastritis, often in combination: pyloric metaplasia of the fundic mucosa and intestinal metaplasia. In *pyloric metaplasia*, there is a replacement of the fundic-type glands by mucus-secreting glands. This is a gradual process that proceeds as an advancing front along the fundic–pyloric junction and moves proximally toward the cardia. *Intestinal metaplasia* refers to the progressive replacement of the gastric mucosa by epithelium having the light and electron microscopic features of intestinal epithelium of either small or large bowel type, including goblet cells, absorptive (brush border) cells, Paneth cells, and a variety of endocrine cells.[30] Intestinal metaplasia has been further divided into *complete (type I)* and *incomplete (type II)* types. In complete metaplasia, the gastric mucosa changes to a pattern nearly identical to that of small bowel epithelium, with the development of villi and crypts in the most advanced cases. In incomplete metaplasia, absorptive cells are absent, whereas columnar cells with the appearance of gastric foveolar cells are retained. Histochemically, the predominant mucin present in complete intestinal metaplasia is sialomucin, with small amounts of sulfomucins and/or neutral mucins; in the incomplete form, there may be predominance of either neutral mucins (type IIA) or sulfomucins (type IIB).[31] Immunohistochemically, type I intestinal metaplasia is characterized by MUC2 intestinal-type mucin and a correspondingly decreased or absent expression of MUC1, MUC5AC, and MUC6. In type II metaplasia there is, as expected, a coexpression of MUC2 and the mucins normally expressed in the stomach.[8,32]

The relationship between intestinal metaplasia of the stomach and *Helicobacter pylori* is of interest. *H. pylori* is usually absent in foci of type I intestinal metaplasia but may be present in type II foci, that is, those in which some gastric features are retained.[33] Type IIB intestinal metaplasia is said to show a closer association with intestinal-type gastric carcinoma than the other types,[34] but the results in the literature have been conflicting.[35]

Chronic gastritis is a very common disease. Its prevalence in the US population is unknown, but it clearly increases in incidence with advancing age. Most patients with mild forms of chronic gastritis are asymptomatic. Endoscopically, well-developed atrophic gastritis and gastric atrophy produce a thin, smooth mucosa with undue prominence of submucosal vessels. There is an excellent correlation between the degree of gastric atrophy as estimated by endoscopic biopsy and the results of acid secretory tests. Conversely, the correlation of histology with symptomatology, radiology, and gastroscopy is poor.[36]

Chronic gastritis has been divided into two types having similar histologic features (as already described) but a presumed different pathogenesis. The first type, which is less common, is designated as *type A* or *immune*.[37] It usually affects the fundus in a diffuse manner, spares the antrum, shows characteristic neuroendocrine hyperplasia, and is associated with antibodies to parietal cells, hypochlorhydria or achlorhydria, and high serum gastrin levels (Fig. 14.5). The alpha and beta subunits of the gastric proton pump have been identified as the major molecular target of this presumed autoimmune disease, which may evolve into pernicious anemia.[38,39] A variation on the theme is atrophic autoimmune pangastritis, in which there is both antral and fundic involvement but absence of neuroendocrine hyperplasia.[40]

The other type, by far the more frequent and referred to as *type B* or *nonimmune gastritis*, begins in the antrum and progresses proximally.[36] In some classification schemes, this has been further subdivided into a form restricted to the antrum and associated with hyperchlorhydria and often duodenal peptic ulceration *(hypersecretory gastritis)* and a form that involves both antrum and fundus in an initially patchy and eventually diffuse distribution *(environmental gastritis)*.[41,42]

Chronic atrophic gastritis is usually present in cases of gastric carcinoma, and in general its severity is proportional to the extent of the tumor. Most cases of gastric peptic ulcer are associated with antral and fundic gastritis, whereas in duodenal ulcer the gastritis, if present at all, is restricted to the antrum. The incidence and extent of intestinal metaplasia are greatest in stomachs removed for carcinoma, least in those with duodenal ulcer, and intermediate in cases of gastric ulcer.[43]

The pathogenesis of type B chronic gastritis was elucidated by the discovery of the central role of *H. pylori*, formerly known as

Campylobacter pylori. This is a curved spirochete-like bacterium that colonizes the gastric mucosa (particularly the antrum and cardia) in a variety of ways: free in mucus, surface adhesion, and intercellularly.[44] Cases with intracellular colonization show the greatest degree of epithelial damage, which includes loss of apical mucus with formation of epithelial pits and, less frequently, erosions and ulcerations.[45] *H. pylori* can be recognized in routine hematoxylin and eosin stains, especially in cases with neutrophil-mediated epithelial injury (activity). However, if the density of the organism is low, its detection can be greatly facilitated by the performance of special stains, which include Giemsa, Warthin–Starry, Steiner silver stains, the alcian yellow–toluidine blue method, Genta stain, or immunohistochemistry.[46] With the use of these techniques, *H. pylori* has been found in up to 90% of patients with chronic gastritis, 95% with duodenal ulcer disease, 70% with gastric ulcer, and 50% with gastric carcinoma.[47]

In 1991, a system was proposed for the comprehensive microscopic reporting of gastritis, referred to as "the Sydney system"[48] and later modified at Baylor.[49]

Recommendations include:

1. For antral and corpus biopsies to be assessed separately
2. For gastritis to be classified into

   Acute
   Chronic
   Special (e.g. lymphocytic, granulomatous)

3. For the following variables to be graded

   H. pylori
   Chronic inflammation
   Neutrophils (as a sign of activity)
   Atrophy
   Intestinal metaplasia

4. A concluding summary is to be provided, indicating the etiology (if known), topography (antrum, corpus, or pangastritis), and morphology (including all variables).

Other Types of Gastritis

Acute gastritis may result from the ingestion of alcohol, salicylates, and other anti-inflammatory drugs, or by the reflux of bile salts. It is more often referred to as *reactive* or *chemical gastropathy*, as there is typically little inflammation, and as such, there is little gastritis (Fig. 14.6).[50] Endoscopic biopsies often show foveolar hyperplasia, reactive epithelial alterations, subepithelial capillary ectasia, increased lamina propria smooth muscle, and sometimes an erosion. Neutrophilic infiltration of the foveolar and glandular lumina may also be present, but in general the inflammatory component is not significant.

Hemorrhagic gastritis is an acute life-threatening condition usually engrafted on a background of chronic gastritis.[51] Alcoholism, anti-inflammatory drugs, and stress have been implicated as precipitating factors.[52] Some cases have been attributed to cytomegalovirus (CMV) infection.[53] The appearance of the stomach at surgery is characterized by multiple areas of hemorrhage throughout the entire mucosa (Fig. 14.7). The microscopic appearance is not as dramatic as the surgical findings would suggest. In some cases, multiple superficial erosions are found (and the term *erosive gastritis* is therefore used), but in many others the only abnormality seen in the biopsy is a chronic atrophic gastritis, with perhaps some extravasation of blood in the lamina propria. The diffuse gastric condition, often seen as a complication of portal hypertension and sometimes leading to severe hemorrhage, is often reported as a form of hemorrhagic gastritis, but the microscopic changes are more consistent with reactive gastropathy and referred to as *portal hypertensive gastropathy*.[54]

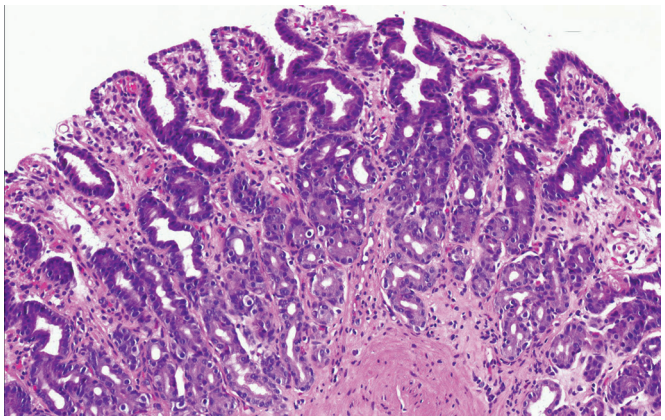

Figure 14.6 Reactive gastropathy with loss of mucin within the epithelium and regenerative nuclear changes.

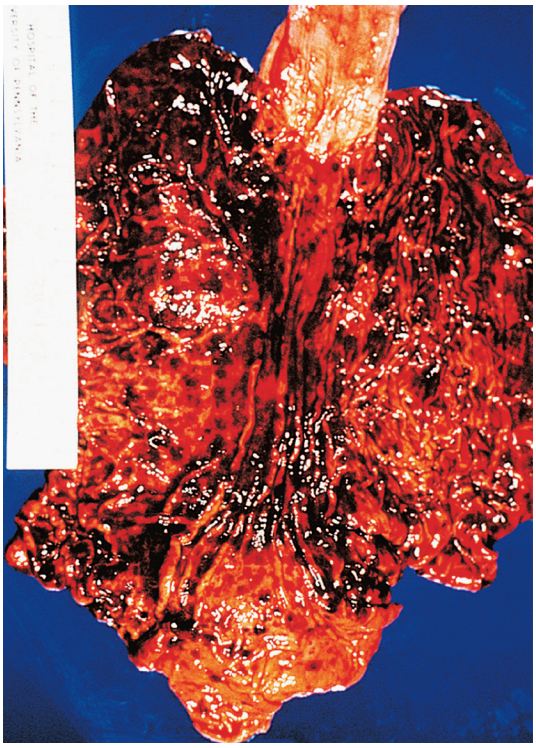

Figure 14.7 Gross appearance of hemorrhagic gastritis as seen at autopsy. The entire gastric mucosa is involved by fresh hemorrhage.

Collagenous gastritis is an exceptionally rare condition which—like its more common colonic counterpart—is characterized by a thick subepithelial collagen band associated with a mucosal inflammatory infiltrate often rich in eosinophils (Fig. 14.8).[55,56] Most pediatric cases have presented with anemia and abdominal pain and have been limited to the stomach, whereas those in adults have been usually associated with involvement of the ileum and colon (but not of the duodenum).[57]

Lymphocytic gastritis is a fairly uncommon form of chronic gastritis that shows some resemblance to celiac disease and lymphocytic colitis.[58] Indeed, most cases are associated with celiac disease, although others may be related to *H. pylori* infection.[59] Microscopically,

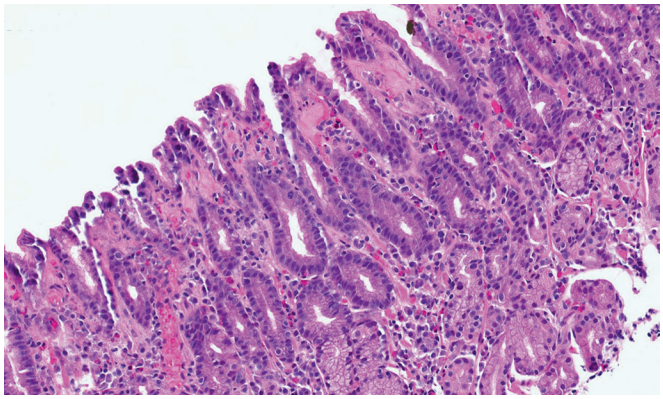

Figure 14.8 Collagenous gastritis with thickening of the subepithelial collagen table.

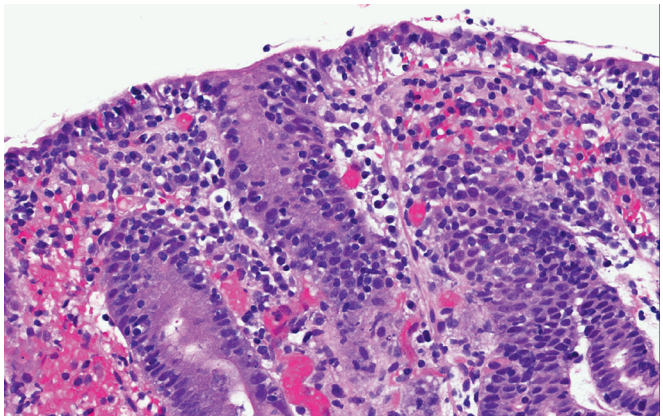

Figure 14.9 Lymphocytic gastritis showing significant surface epithelial lymphocytosis.

the condition is characterized by lymphocytosis of foveolar and surface epithelium (intraepithelial lymphocytosis) with expansion of the lamina propria by plasma cells (Fig. 14.9).[60]

Allergic/eosinophilic gastroenteritis presents in a gastric biopsy as infiltration of the lamina propria by eosinophils, which in severe cases is diffuse and accompanied by degenerative and regenerative changes of the surface and foveolar epithelium.[61] This occurs most commonly in young male patients, often in patients with food allergies. This mucosal disease can result in malabsorptive diarrhea, iron deficiency anemia, protein-losing enteropathy, or failure to thrive. Most patients have a peripheral eosinophilia. This is essentially a diagnosis of exclusion.[62]

There are mural and serosal forms of eosinophilic gastroenteritis which appear to be unrelated to the mucosal form. The mural form predominates in the antrum, resulting in mural thickening and occasionally obstructive symptoms.[62] Some patients respond to *H. pylori* eradication therapy. The rare serosal form typically results in acute abdominal pain and eosinophilic ascites fluid. Patients do not have a history of hypersensitivity, and the exact cause is unknown. Parasitic infection can closely mimic this condition.[63]

Granulomatous gastritis can be caused by tuberculosis,[64] mycosis,[39] sarcoidosis,[65] or Crohn disease[58] or may be part of a diffuse vasculitis syndrome.[66] When the cause of the inflammation remains unknown, the term *idiopathic granulomatous gastritis* is used but with the understanding that this is not a specific entity.[67] Although the relationship is not clear, some patients with this finding also have *H. pylori* infection.

Syphilis of the stomach, now extremely rare but still encountered, begins as an erosive or ulcerative lesion in the pylorus.[68] In later stages, the stomach becomes shrunken and fibrotic, with a leather bottle appearance that simulates radiographically and grossly the "linitis plastica" appearance of diffuse carcinoma.[69] Microscopically, there is ulceration, chronic inflammation rich in plasma cells, and lamina propria fibrosis; endarteritis obliterans may also be present. Other cases may show a heavy lymphoid infiltrate. Treponemal DNA has been isolated from some of these cases by polymerase chain reaction.[70] The organism can also be identified immunohistochemically.[71]

Malakoplakia can present as a focal gastric lesion.[72] As in other sites, the disease is characterized microscopically by a predominantly histiocytic inflammatory infiltrate containing Michaelis–Gutmann bodies.

CMV infection may be identified in gastric biopsies of bone marrow transplant recipients and other immunocompromised patients; the finding is indicative of generalized disease.[73] It may rarely be complicated by perforation and fistula formation.[74] Its diagnosis may require immunohistochemistry, in situ hybridization, or even PCR.[75]

Cryptococcosis is another infectious disease that has been observed in the stomach and other portions of the digestive tract in susceptible individuals, including patients with HIV infection.[76] Similarly, **bacillary angiomatosis** can involve the stomach of HIV-infected individuals and result in severe hematemesis.[77]

Graft-versus-host disease following allogeneic bone marrow transplantation manifests in the stomach with subtle microscopic findings, including apoptosis and gland destruction, sparse inflammatory infiltrate, and granular eosinophilic debris in dilated glands.[78] The latter is a very specific but relatively insensitive marker. In its absence, the distinction from CMV infection may not be possible.[79]

Peptic and Other Benign Ulcers

Peptic ulcer can occur wherever mucosa is bathed by gastric secretion. This includes the stomach, duodenum, lower third of esophagus, margin of a gastrojejunostomy, and Meckel diverticulum with ectopic gastric mucosa. Acid peptic digestion is the ultimate cause for ulceration, but the mechanism(s) that render the mucosa susceptible to this digestion are just as important for the pathogenesis.

Duodenal ulcers (which are more common than gastric ulcers, although their relative incidence seems to be decreasing) are classically associated with acid hypersecretion, whereas most patients with gastric ulcer secrete either low normal or below normal amounts of acid. Thus it would seem that the initial event in gastric ulcer is mucosal injury, which renders it more susceptible to acid peptic damage. This injury may be mediated in some instances by reflux of bile and pancreatic juice and is manifested anatomically by the presence of gastritis, an almost invariable finding in patients with peptic ulcer disease. Considerable evidence has accumulated indicating that *H. pylori* plays a crucial role in the pathogenesis of this disease.[80,81] The risk for the development of a peptic ulcer is approximately 10-fold higher in patients with nonatrophic *H. pylori*–positive gastritis than in those with a normal stomach, and the risk is increased further (twofold to threefold) when there is antral atrophy. Instead, the presence of corpus atrophy decreases the incidence of ulcer (to practically negligible levels when the atrophy is complete).[82]

Acute gastric ulcer is a common finding at autopsy and is usually a terminal event (Fig. 14.10). It may also be seen during life in any debilitating illness, in sepsis, following surgery or trauma *(stress ulcer)*, in patients with central nervous system injury or disease *(Cushing ulcer)*, as a complication of long-term steroid therapy *(steroid ulcer)*, in association with aspirin ingestion, in patients with extensive

Figure 14.10 Multiple acute ulcers of the stomach occurring in a chronically debilitated patient. Microscopically, there was little fibrous reaction in the ulcer bed.

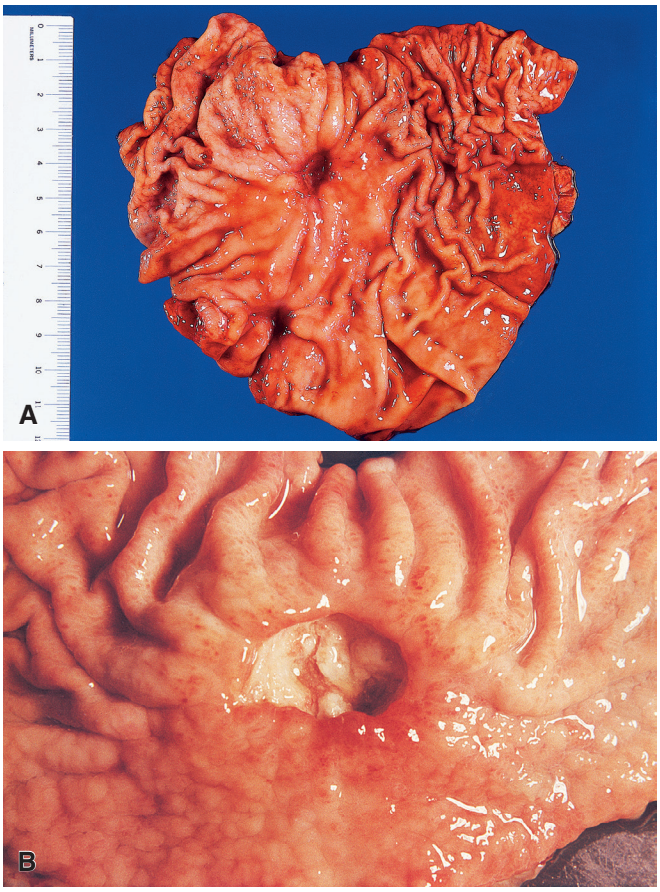

Figure 14.11 **A,** Typical gross appearance of chronic peptic ulcer of the stomach. Sharply delimited chronic peptic ulcer with converging folds of mucosa in the upper half. **B,** The ulcer bed is covered by fibrinopurulent exudate.

burns *(Curling ulcer)*, as a complication of radiation therapy or hepatic arterial chemotherapy, and following the introduction of tubes into the stomach.[83] Marked epithelial atypia may be present in the gastric lesions resulting from hepatic arterial infusion chemotherapy, which can be easily confused with carcinoma.[84,85] If the ulcer involves only the mucosa (erosion), it can heal completely; if part of the muscle is destroyed, it is replaced by fibrotic tissue, leaving a depressed pit. Any of these ulcers, if deep enough, may perforate; this complication is particularly common in ulcers induced by radiation therapy.[86]

Chronic peptic ulcer always occurs in an achlorhydric zone of mucosa (i.e. an area of stomach lined by pyloric-type mucosa). Up to 95% of the ulcers are located on the lesser curvature near the incisura angularis; however, since chronic gastritis is accompanied by antral metaplasia of the fundal mucosa that advances proximally from the pylorus, peptic ulcer can be found anywhere in the stomach, although it is always surrounded by pyloric-type mucosa.

The average age at the time of diagnosis is 50 years, but the disease can occur in any age group, including children. A male predilection exists but seems to be decreasing. Approximately 5% of ulcers are multiple. Although some controversy persists, most authors believe that ulcers larger than 3 cm, or those located in the greater curvature, do not indicate a high likelihood of malignancy as formerly believed. The diagnosis of peptic ulcer has been greatly facilitated by the use of fiberoptic gastroscopy, which allows the endoscopist to have a direct view of the ulcer, to photograph it, and to obtain biopsies from the edges.

Grossly, an active lesion is sharply delineated, usually oval or round but sometimes linear, with converging mucosal folds extending to its margin (Fig. 14.11). The proximal margin tends to have overhanging edges, whereas the distal margin usually has sloping borders. On section, there is undermining of the edges (especially on the proximal side) and complete replacement of the muscle wall by white fibrous tissue. On the serosal side, there may be subserosal fibrosis and inflammatory enlargement of regional lymph nodes. Prominent marginal nodularity about the ulcer suggests the presence of carcinoma; however, it should be remembered that it may be impossible to grossly distinguish a peptic ulcer from an ulcerated carcinoma, as 10%–15% of gastric carcinomas appear, grossly, to be benign ulcers.

Microscopically, chronic peptic ulcer will show four more or less distinct layers: (1) a surface coat of purulent exudate, bacteria, and necrotic debris; (2) fibrinoid necrosis; (3) granulation tissue; and (4) fibrosis, which can replace the muscle wall and even extend into the subserosa (Fig. 14.12). At the edges, the muscularis mucosae is seen to fuse with the muscularis externa. Other common features in the ulcer bed include thickening of vessels (caused by subendothelial fibrous proliferation) and hypertrophy of nerve bundles. The necrotic surface may show superimposed infection by *Candida albicans*. As already stated, the mucosa surrounding the ulcer is of pyloric type. In cases infected with *H. pylori*, a typical constellation of morphologic changes (loss of the apical portion and dropout of epithelial cells, epithelial pits, erosions, and cellular tufts) is seen at the ulcer edge.[87]

In the healing process of a peptic ulcer, regenerating epithelium grows over the surface. This epithelium often exhibits intestinal metaplasia and may contain chief and parietal cells when the ulcer is located in the fundic area. As already stated, the danger of overdiagnosis is particularly great in ulcers caused by arterial infusion chemotherapy because of the marked epithelial atypia that may be present.

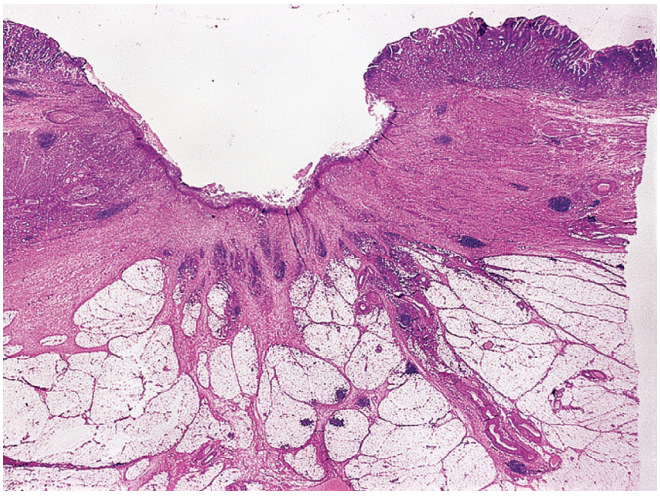

Figure 14.12 Whole-Mount View of Chronic Peptic Ulcer. The external muscle layer has been totally destroyed. Note the overhanging mucosa on one edge and the sloping mucosa on the other.

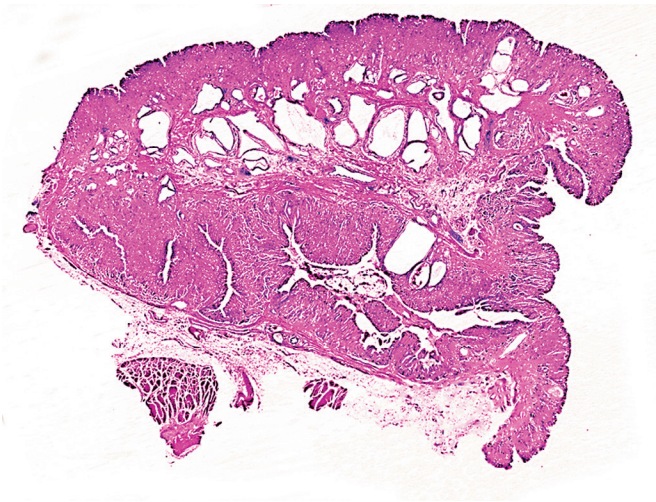

Figure 14.13 Whole-mount view of gastritis cystica profunda.

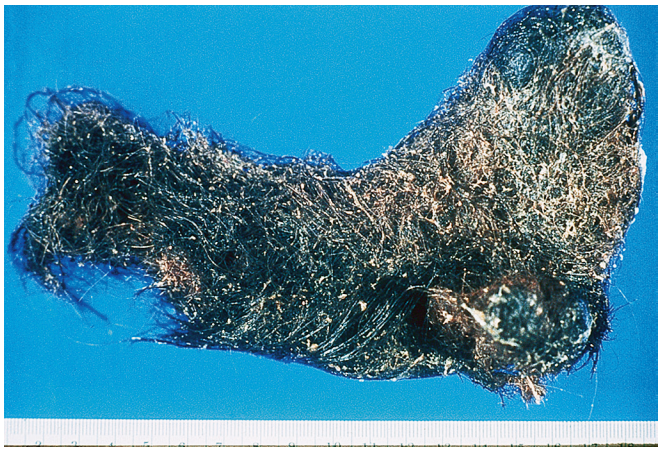

Figure 14.14 Huge Trichobezoar Removed From the Stomach. The tangled mass of hair looks like a mold of the gastric cavity.

The medical treatment of gastric ulcer consists of neutralizers of gastric acid (antacids, proton pump inhibitors, and/or H_2-blockers), and antibiotic eradication of *H. pylori* when present.[88] The development of complications (hemorrhage, perforation, obstruction), and recurrence of the ulcer are indications for surgery, including subtotal gastric resection without vagotomy, truncal vagotomy and drainage (either gastroenterostomy or pyloroplasty), and truncal vagotomy plus antrectomy. When a portion of stomach is removed, continuity is reestablished through a gastroduodenostomy (Billroth I) or gastrojejunostomy (Billroth II). The long-term results of surgery are good to excellent in over 80% of the patients.[89]

Other Non-Neoplastic Lesions

Duplication of the stomach, a very rare anomaly, presents as a unilocular or multilocular cyst lined by gastric mucosa.[90] It may communicate with the lumen of the normal stomach; usually it does not, the result being distention with fluid causing obstruction and a palpable mass. **Diverticula** most often occur in a juxtacardiac position and likely are the result of anatomically weak areas.[91]

Cysts may be found in a mucosal or submucosal location. Intramucosal cysts are the most common and are often associated with intestinal metaplasia.[92] Submucosal cysts have also been designated as *gastritis cystica profunda* (Fig. 14.13).[93] Although some may be an expression of heterotopia, most seem to be acquired.[94]

Bezoars are foreign bodies in the stomach and are occasionally seen as surgical specimens (Fig. 14.14).[95] The great majority fall into two categories: *trichobezoar*, composed of hair, and *phytobezoar*, composed of vegetable matter.[96] More than 85% of the latter are caused by ingestion of unripened persimmons.[97] Factors favoring the development of bezoars include lack of teeth, vagotomy or previous gastric surgery, and obstructing lesions of the gastric outlet.[98]

Aneurysms of gastric vessels (Dieulafoy disease; caliber-persistent artery) are thought to be malformative rather than degenerative in origin.[99,100] They are usually single, located in the submucosa, usually high on the lesser curvature, and characterized by a large tortuous vessel surmounted by a small defect in the overlying mucosa.[101] When the lesion perforates, massive and sometimes fatal hemorrhage may result.

Gastric antral vascular ectasia (GAVE or "watermelon stomach") is an acquired vascular disease of the stomach that may result in blood loss and iron deficiency anemia.[102] Endoscopically, one sees parallel red stripes at the crest of the mucosal folds in the antrum, resembling the stripes of a watermelon. Cases involving the cardia have also been described.[103] The microscopic changes on gastric biopsy are minimal and consist of an increase in the number and caliber of vessels, fibrin thrombi, and fibromuscular hyperplasia.[104,105] The changes resemble those of reactive gastropathy but include the characteristic fibrin thrombi, and correlation with the endoscopic findings is required to render a diagnosis.

Xanthoma (xanthelasma) of the stomach appears as a small yellow intramucosal lesion characterized by the accumulation of neutral fat in foamy histiocytes in the lamina propria. This clinically insignificant lesion should not be confused microscopically with early carcinoma or signet ring carcinoma.[106]

Other rare non-neoplastic gastric disorders, many of them clinically inconsequential, associated with ulcers or inflammatory processes, and possibly beginning as perivascular fibrotic lesions, include **pseudoxanthoma elasticum** (which can result in severe hemorrhage),[107] **elastofibroma**,[108] **mucosal calcinosis** (secondary to the administration of aluminum-containing antacids or sucralfate therapy in organ transplant patients),[109] **siderosis** (diffuse iron deposition in antral and fundic epithelium),[110] **amyloidosis** (diffuse or localized, sometimes complicated by bleeding),[111] **barium granuloma**

(developing in the gastric wall following radiographic examination),[112] isolated **Langerhans cell histiocytosis**,[113] **parasitic infections** (such as strongyloidosis in immunocompromised patients)[114] and Rosai–Dorfman disease.[115]

Polyps

The nomenclature of gastric polyps has been confusing, in part because they have often been regarded as analogous to colorectal polyps in microscopic appearance and natural history, whereas in fact most types of gastric polyp do not have an exact counterpart in the large bowel.[116]

Hyperplastic polyps are a fairly common type of gastric polyp. Use of the term *hamartomatous polyp* for these lesions should be discouraged because it elicits confusion with the different type of polyp seen as a component of the Peutz–Jeghers syndrome. The term hyperplastic polyp is preferable, but it should be emphasized that this lesion is morphologically very different from the lesion so named in the large bowel. Gastric hyperplastic polyps tend to arise in a background of hypochlorhydria, low levels of pepsinogen I, hypergastrinemia, chronic gastritis, and gastric atrophy.[117] Interestingly, they have also been found to be more common in post-transplant patients.[118]

Hyperplastic polyps are randomly distributed in the stomach and are generally small, sessile, and multiple, with a smooth or slightly lobulated contour (Fig. 14.15). Microscopically, they show elongation, tortuosity, and dilation (often cystic) of the gastric foveolae, with a component of pyloric or—less commonly—fundic type of glands in the deeper portion. The stroma, usually prominent, is characterized by edema, patchy fibrosis, inflammatory cells, and scattered smooth muscle bundles from the muscularis mucosae. Exceptionally, collections of foamy macrophages (not to be confused with signet ring cells) are present. Epithelial atypia may be present but is regenerative in nature and limited to the tips of the foveolae. Some authors separate hyperplastic from inflammatory polyps on the basis of relative amounts of glandular and stromal changes, but the presence of a continuous spectrum suggests that these are different stages of the same process.[119] The polypoid lesion sometimes developing on the gastric side of gastroenterostomy stomas may also have a microscopic appearance similar to that of a hyperplastic polyp, except for its more diffuse nature; dysplastic changes can also occur at this site.[120]

Hyperplastic polyps have been found to coexist frequently with carcinoma elsewhere in the stomach,[121] but these figures are biased, since most of the specimens studied had been removed because of carcinoma. The incidence of gastric carcinoma developing after endoscopic removal of hyperplastic polyps is quite low and probably more related to the atrophic gastritis that often accompanies the polyp than to the polyp itself[122]; in a study by Orlowska et al., only 2 of 131 patients with hyperplastic polyps (1.6%) developed carcinoma in follow-up.[123]

As the name indicates, hyperplastic polyps have traditionally been regarded as non-neoplastic; however, they share some molecular alterations with the adenomatous lesions described next. Furthermore, they may undergo progression to dysplasia or carcinoma, although the likelihood of this occurring remains much lower than for their adenomatous counterparts.[124] Malignant transformation is accompanied by increased proliferative activity and overexpression of p53.[125]

Adenomas are usually antral in location, generally single and large, and either sessile or pedunculated (Fig. 14.16). Microscopically, they are composed of dysplastic glands with pseudostratified epithelium showing nuclear abnormalities and prominent mitotic figures.[116] They have been further subdivided into *foveolar-type* and *intestinal-type*, depending on the nature of the glandular epithelium.[126,127] The intestinal-type adenomas, which are the most common, are analogous in appearance and natural history to those in the colorectum and are thought to arise in a background of mucosal atrophy and intestinal metaplasia (Fig. 14.17).[127] Adenomatous polyps appear grossly as elevated lesions with a flat surface. A few of these polyps appear as shallow mucosal depressions rather than elevations; these are referred to as *depressed adenomas*.[128] Many of

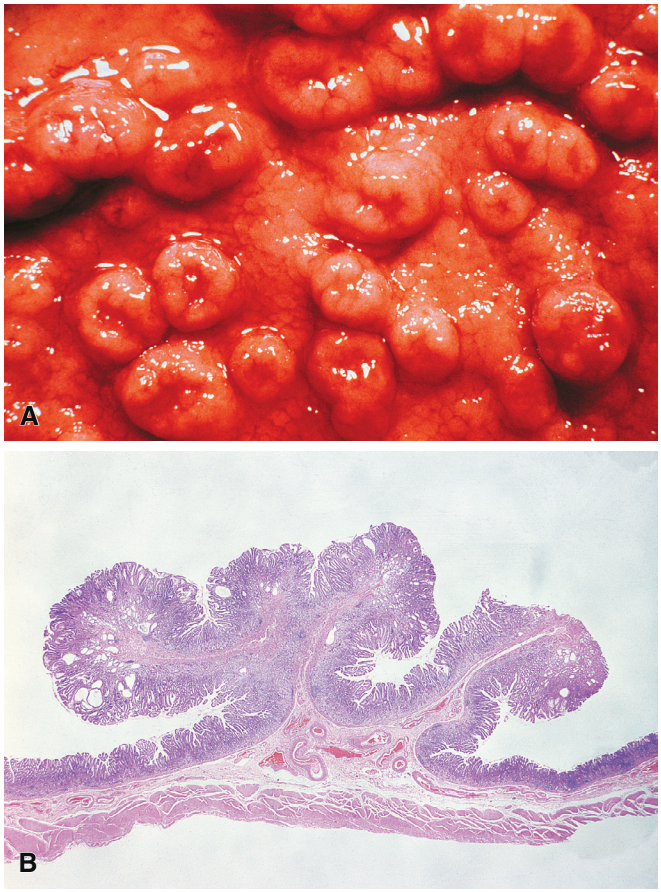

Figure 14.15 **A,** Gross appearance of gastric polyps of hyperplastic type. Many of the lesions show central umbilication. Low-power microscopic view of gastric polyps of hyperplastic type. **B,** The cystic dilation of the glands is more evident on the left side.

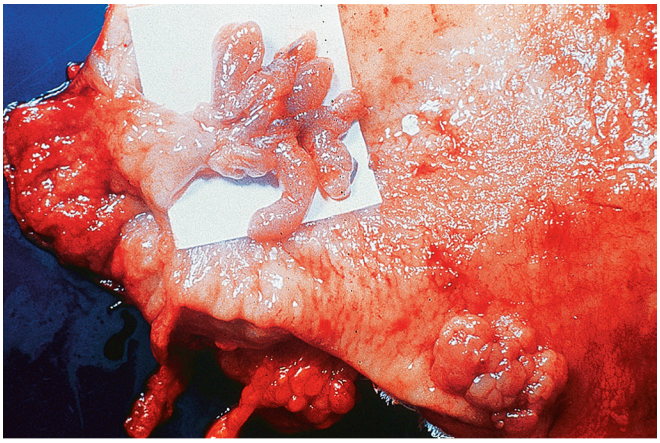

Figure 14.16 Gross appearance of gastric adenomatous polyps. The larger lesion is a tangle of finger-like projections.

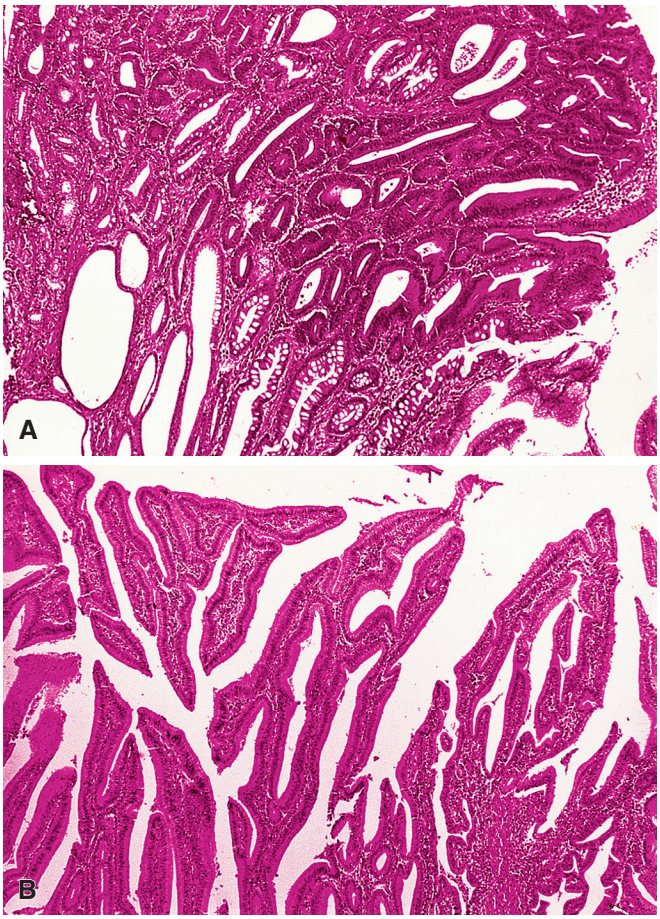

Figure 14.17 **A,** Adenomatous polyp. **B,** Villous adenoma. (From Oota K, Sobin LH. *Histological Typing of Gastric and Oesophageal Tumours*. Geneva: World Health Organization; 1977.)

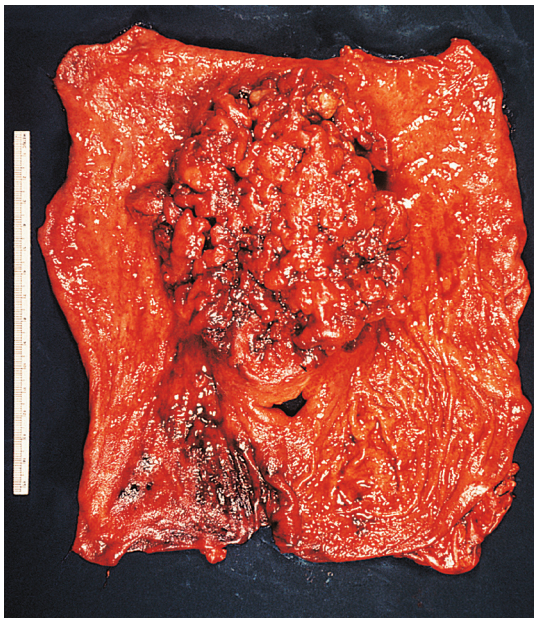

Figure 14.18 Large gastric villous adenoma containing areas of adenocarcinoma. The tumor was located near the cardia.

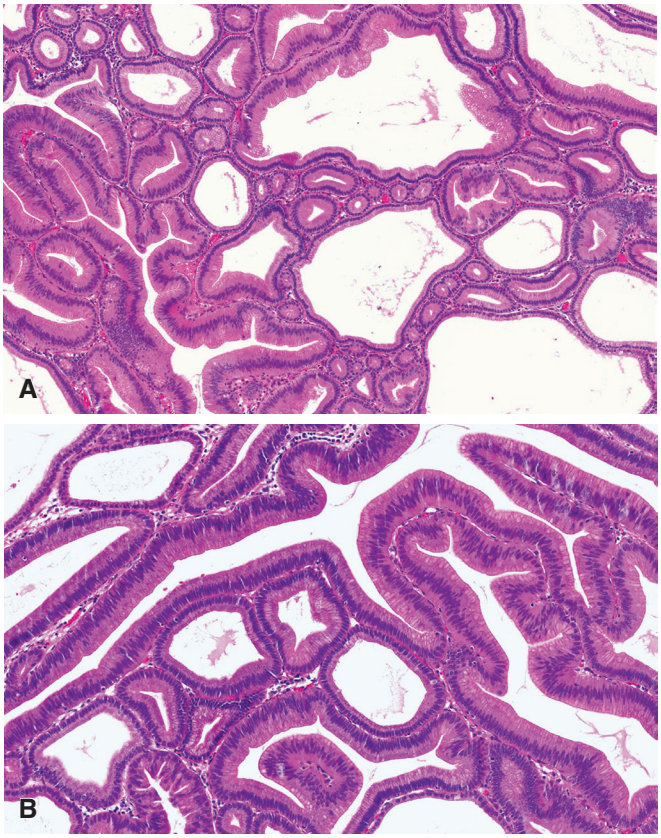

Figure 14.19 Low-power **(A)** and higher-power **(B)** views of a gastric pyloric gland adenoma.

these polyps have been described in stomachs that have been removed because of an independent carcinoma, but a selection bias is obviously operating; however, there is no question that the two processes are related and that the polyps themselves can undergo malignant transformation, similar to their colorectal counterparts (Fig. 14.18).[129] The exact incidence of progression is not known but appears to be relatively low. The tendency for malignant transformation is higher for the intestinal-type than for the foveolar-type adenomas[127] despite the fact that the molecular alterations that have been detected in these two polyp types are similar.[126]

Pyloric gland adenoma is a well-described type of gastric polyp, although they are relatively uncommon. They also frequently develop in the setting of chronic gastritis with intestinal metaplasia and/or atrophy,[130,131] and they are most common in elderly patients, with a slight female predilection.[130,131] They most often arise in the fundus/body and are usually less than 2 cm. Histologically, it is composed of tightly packed tubules comprised of cuboidal or columnar cells with pale to eosinophilic cytoplasm (Fig. 14.19). They lack an apical cap of mucin. These lesions stain with antibodies to MUC5AC and MUC6, the latter marker being typically absent in intestinal and foveolar-type adenomas.[132] Between 10% and 40% show conventional dysplasia, and invasive carcinomas may also arise from these lesions.[130,131] As such, they are ideally treated by complete removal.[133]

Oxyntic gland adenoma may arise in the setting of chronic gastritis or familial adenomatous polyposis (FAP) and is composed of oxyntic glands with parietal and chief cells.[134] It typically arises in the fundus/body, and, although cytologic atypia is often present, they typically behave in a benign fashion. Prior to more recent studies, such lesions were often referred to as "gastric adenocarcinoma with chief cell differentiation."[135]

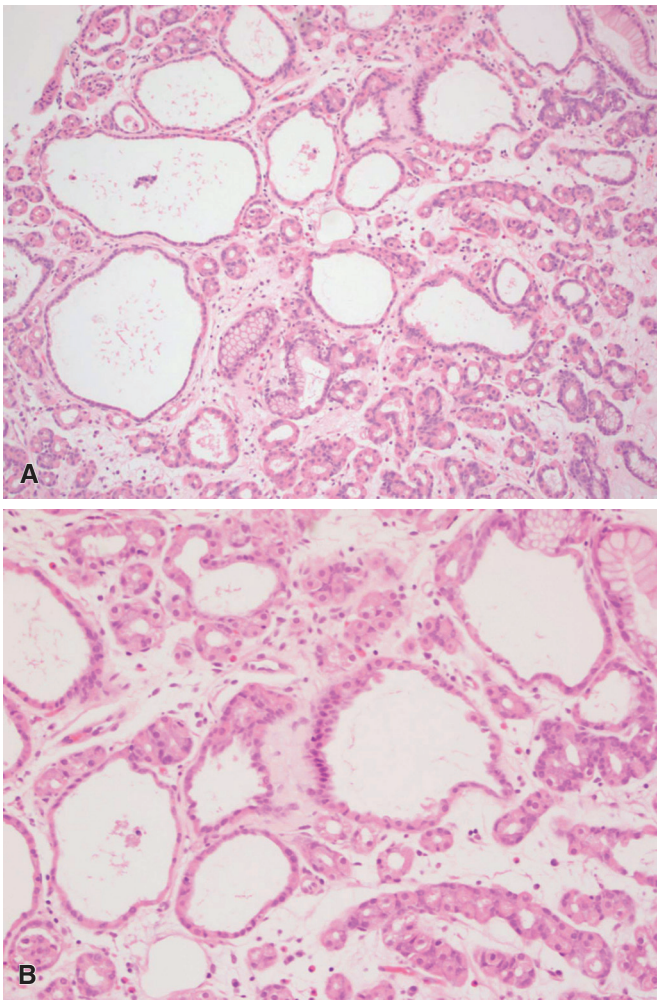

Figure 14.20 Low-power **(A)** and high-power **(B)** views of a fundic gland polyp with cystic dilation of fundic glands.

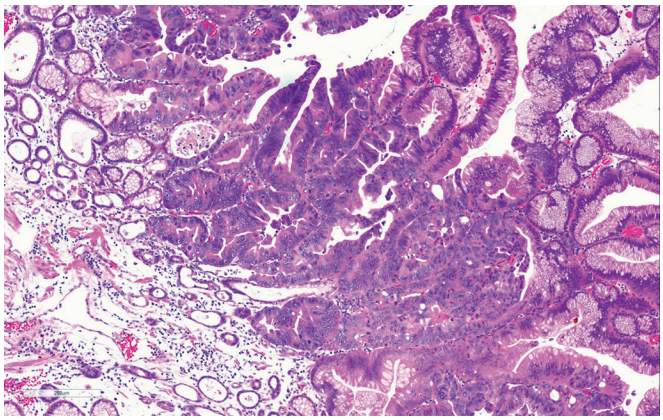

Figure 14.21 Fundic gland polyp with a focus of high-grade dysplasia.

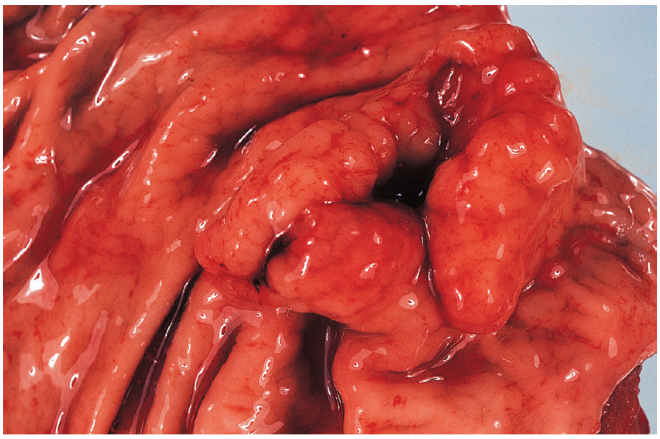

Figure 14.22 Gross appearance of inflammatory fibroid polyp of stomach. The surface has a knobby appearance.

Fundic gland polyps are incredibly common and present as multiple small (average size 2.3 mm) polypoid projections in the gastric fundus or body.[136,137] Their distinguishing microscopic feature is the presence of microcysts lined by fundic epithelium (Fig. 14.20); the overlying foveolae are usually shortened.[138] These polyps can occur in a sporadic form or present in patients with the Zollinger–Ellison syndrome,[139] those on long-term treatment with proton pump inhibitors,[140] and those affected by FAP. In the latter instance, they are more likely to show focal dysplastic changes than otherwise (Fig. 14.21).[141,142] It has been proposed that the key molecular alteration in sporadic fundic gland polyps is an activating mutation of the β-catenin gene,[143] whereas those associated with FAP harbor somatic, second hit alterations in the *APC* gene.[144]

Other types of gastric epithelial polypoid lesions that have been described include *foveolar hyperplasia* (which arises against a background of atrophic gastritis and represents an early stage of hyperplastic polyp)[145] and the *hamartomatous polyps* associated with Peutz–Jeghers syndrome and juvenile polyposis.

It should be stated that polyps of different types can coexist in the same stomach and that occasional lesions cannot be easily placed in a specific category, especially in small biopsy specimens.

Polyposis syndromes of the gastrointestinal tract often involve the stomach. In FAP and the related Gardner syndrome, gastric involvement occurs in over 50% of the cases; the gastric polyps can be adenomatous (including pyloric gland adenomas), hyperplastic, or of the fundic gland type.[141,142,146] As stated above, fundic gland polyps in these patients often show dysplastic features. In Peutz–Jeghers syndrome, hamartomatous gastric polyps have been found in approximately 20% of the cases (sometimes accompanied by an adenomatous component) and occasionally gastric adenocarcinomas.[147–149] In generalized juvenile polyposis and Cronkhite–Canada syndrome, the incidence of gastric retention (juvenile) polyps is very high,[150,151] and there have been occasional cases of associated gastric adenocarcinoma.[152] Cowden syndrome (multiple hamartoma syndrome) can also be accompanied by small sessile gastric polyps, most of which seem to be of the hyperplastic type.[153]

Inflammatory fibroid polyp of the stomach is not uncommon, may be associated with hypochlorhydria or achlorhydria, and is usually located in the antrum.[154] Radiographically, endoscopically and grossly, it presents as a sessile or pedunculated mass (Fig. 14.22). Microscopically, this lesion is centered in the submucosa and is characterized by a vascular and fibroblastic proliferation (often in a whorl-like arrangement around blood vessels) and a polymorphic inflammatory response, usually dominated by eosinophils (Fig. 14.23).[155] Many also show focal staining for $CD34_{156}$, raising the possibility of dendritic cell origin.[156] Local excision (preferably in the form of endoscopic removal) is the treatment of choice, and the evolution is benign. Interestingly, it has been shown that gastric inflammatory fibroid polyps consistently express platelet-derived growth factor receptor alpha *(PDGFRA)*, and activating mutations

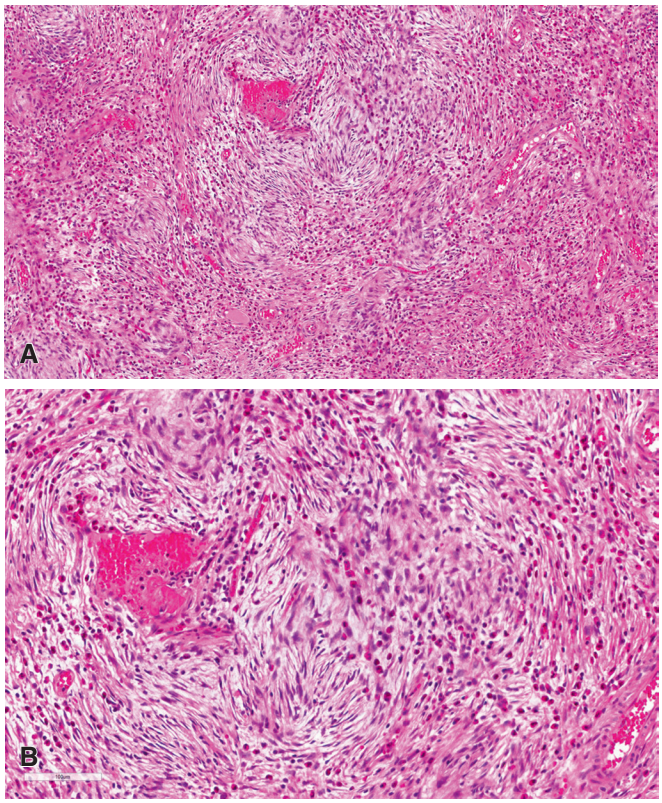

Figure 14.23 Low-grade **(A)** and higher-power **(B)** views of a gastric inflammatory fibroid polyp. Concentric cellularity and fibrosis around blood vessels is a prominent feature, as is a scattering of eosinophils.

Figure 14.24 Gross Appearance of Ménétrier Disease. The entire fundic mucosa is involved by an exuberant proliferative change. Note the sharp edge of the lesion at the junction of the fundus and antrum.

of the encoding gene are found in 70% of cases,[157,158] raising the possibility of a neoplastic process.

Ménétrier Disease and Zollinger–Ellison Syndrome

Ménétrier disease, also known as hypertrophic or hyperplastic gastropathy, giant hypertrophic gastritis, and giant hypertrophy of gastric rugae, is accompanied by hypochlorhydria or achlorhydria and often by impressive hypoproteinemia.[159] Chronicity and severity are the rule in adults, but it is often self-limited in the few reported pediatric cases.[160] Radiographically, endoscopically, and grossly, the condition can be confused with malignant lymphoma and carcinoma. It is often centered along the greater curvature of the stomach and is characterized grossly by markedly hypertrophic rugae resembling cerebral convolutions (Fig. 14.24). The transition between normal and diseased mucosa is always abrupt. In the typical form of the disease, there is diffuse involvement of the fundic portion, with sparing of the antrum. In the localized form, there is a well-circumscribed cerebroid mass either in the fundus or the antrum.[161] Microscopically, there is a striking *foveolar hyperplasia*, accompanied by hypermucinous change, tortuosity, some degree of cystic dilation, and extension into the base of the glands and sometimes even beyond the muscularis mucosae (Fig. 14.25). The glandular component is diminished, and the stroma is edematous and inflamed, with a component of eosinophils.[162] Many cases diagnosed by radiologists and endoscopists as hypertrophic gastritis do not show the diagnostic morphologic features of Ménétrier disease, but rather a chronic gastritis with prominent lymphocytic infiltration and varying degrees of glandular atrophy ("hypertrophic lymphocytic gastritis").[163] The relationship between the latter disorder (sometimes designated as "varioliform gastritis" by endoscopists) and the fully developed Ménétrier disease is not clear.[164] The differential diagnosis also often includes gastric involvement by juvenile polyps. Carcinoma may develop in a stomach affected by Ménétrier disease, but the incidence does not seem higher than that seen in ordinary atrophic gastritis.[165]

Zollinger–Ellison syndrome may be accompanied by gastric changes radiographically and grossly similar to those of Ménétrier disease; however, microscopic examination will reveal hyperplasia primarily affecting the *secretory* rather than the foveolar portion of the fundic gland, even if the latter may also participate (Fig. 14.26). This hyperplasia mainly involves the parietal cells, but there may also be an increase in the number of ECL cells, both resulting from gastrin stimulation.[166] In some of these patients, the Zollinger–Ellison syndrome is part of a multiple endocrine neoplasia syndrome. We have seen several cases of this syndrome associated with multicentric carcinoid tumors, mainly located in the fundus and composed of ECL cells. Other abnormalities of the gastric mucosa that can be seen in patients with Zollinger–Ellison syndrome include fundic gland polyps and intramucosal cysts.[167]

The occurrence of gastric lesions with morphologic features similar to those seen in the Zollinger–Ellison syndrome but without hypergastrinemia (some of them associated with protein loss and others with gastric adenocarcinoma) suggests the existence of clinicopathologic variations among these poorly understood disorders.[161,162]

Regenerative Changes and Dysplasia

Regenerative changes occur most often in areas of mucosal injury, resulting in epithelial cells which are immature, with basophilic cytoplasm, slightly hyperchromatic nuclei, and reduced or absent mucus secretion. These cells are uniform in size and shape, with basally or centrally located nuclei arranged in a row; pseudostratification is slight or absent. Maturation and differentiation toward the surface are present. There is usually an accompanying

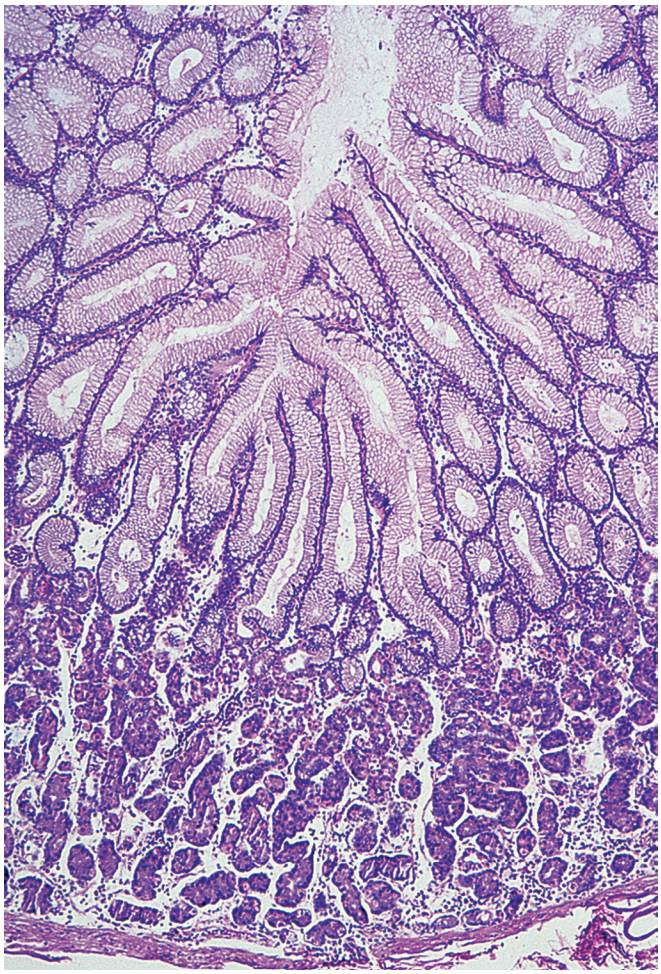

Figure 14.25 Microscopic Appearance of Ménétrier Disease. There is marked hyperplasia of the foveolar epithelium accompanied by atrophy of the underlying secretory mucosa.

inflammatory reaction, sometimes intense, and focal erosive changes are common. A particularly atypical form of reactive change occurs following chemoradiotherapy for esophageal carcinoma.[168]

Dysplasia should be clearly distinguished from regenerative changes, which are far more common. Most carcinomas of the stomach are accompanied and often preceded by dysplasia; therefore, the recognition of this condition in biopsy specimens is of great importance in giving warning of the possibility of a coexisting carcinoma and in indicating that the patient may be at a higher risk for the subsequent development of gastric cancer. Interestingly, this risk seems to be much higher in Asian and European countries than in the United States. In **dysplasia**, there is increased cell proliferation accompanied by abnormalities in cell size, configuration, and orientation (Fig. 14.27). Mucus secretion is reduced or absent, and there is an increase in the nucleocytoplasmic ratio, loss of nuclear polarity, and pseudostratification. Mitoses are numerous, including atypical forms. These cellular abnormalities are accompanied by architectural derangement of the glands, resulting in cellular crowding, intraluminal folding, and glandular budding and branching. There are two forms

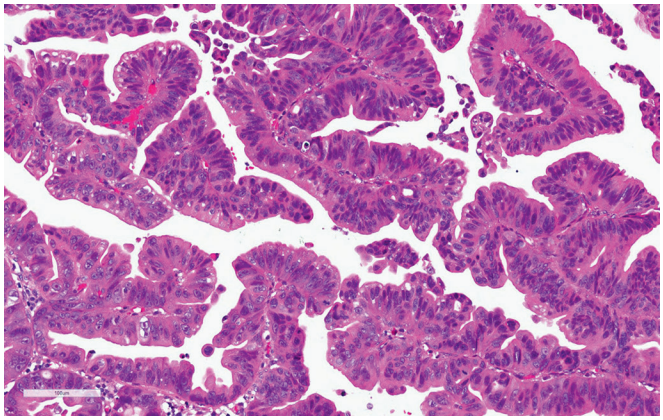

Figure 14.27 High-grade dysplasia of the gastric mucosa showing a prominent villiform architecture.

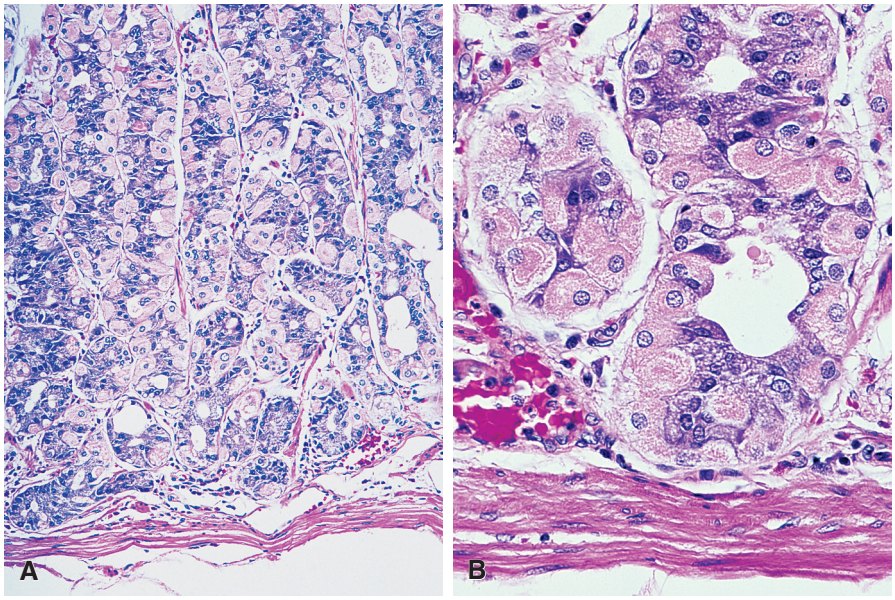

Figure 14.26 Low-power **(A)** and high-power **(B)** views of gastric mucosa in a patient with Zollinger–Ellison syndrome. Note the large increase in the number of parietal cells.

of gastric dysplasia—intestinal type (adenomatous, type 1) and gastric type (foveolar, type 2), as well as combined (hybrid) forms—each having different patterns of mucin expression.[169,170] Gastric dysplasia can be divided into two categories: *low grade* and *high grade*. High-grade dysplasia is regarded as synonymous with carcinoma in situ (CIS) and must be distinguished from intramucosal carcinoma, in which the process has penetrated the basement membrane. As such, gastric biopsies can be grouped for reporting purposes into the following categories:

1. Negative for dysplasia
2. Indefinite for dysplasia
3. Low-grade dysplasia
4. High-grade dysplasia (which incorporates so-called CIS)
5. Intramucosal carcinoma
6. Invasive carcinoma.

The risk for invasive carcinoma is small for low-grade dysplasia and considerable for high-grade dysplasia; surgical excision (including a gastrectomy) should be considered whenever the latter change is found.[171]

Carcinoma

General Features

The pathogenesis of gastric carcinoma is closely related to environmental factors. Its incidence has markedly decreased in some countries, such as the United States and England,[172,173] but it remains inordinately high in others, such as Japan, Chile, and Italy.[174] However, there is increasing evidence that a genetic predisposition plays an important role in at least a subset of patients, as already suggested by the fact that familial aggregation of the disease is seen in about 10% of the cases.[175,176] Although most patients are over 50 years of age, rare cases arise in younger individuals and even children.[177]

Practically all gastric carcinomas arise from the generative (stem/basal) cells of the foveolae, in most instances on a background of chronic atrophic gastritis with intestinal metaplasia and preceded by various stages of dysplasia.[178]

Gastric carcinoma is accompanied by hypochlorhydria in 85%–90% of cases; hypochlorhydria may precede gastric cancer by several years. It has been postulated that high intragastric pH promotes the growth of bacteria that reduce dietary nitrate to nitrite and then convert dietary amines, in the presence of this nitrite, into carcinogenic *N*-nitroso compounds.[179] The coexistence of chronic atrophic gastritis and carcinoma is common, but the etiopathogenic link between the two and the relative risk for malignancy in the former condition remain controversial.[180] The same could be said for pernicious anemia; the rate of carcinoma development, although statistically increased, is not high enough to justify surveillance in asymptomatic patients.[181]

The most important development in the field has been the identification of *H. pylori* as an important etiologic factor in gastric carcinoma through its role in the development of chronic gastritis.[182,183] This is particularly true for the most common subtype, referred to as *intestinal-type adenocarcinoma* by Lauren.[184] The other, designated as the *diffuse type*, does not show as close an association to these environmental factors.

Other factors thought to be involved in the pathogenesis of gastric cancer (albeit in a minor fashion) are gastric polyps, Ménétrier disease, gastric peptic ulcer, and gastric stump (see respective sections in this chapter). Cases of gastric carcinoma in young patients following irradiation and chemotherapy for other malignancies have been reported.[185] Some cases of gastric adenocarcinomas are Epstein–Barr virus (EBV) related, the incidence varying from 6% to 7% in Japan and Europe to 16% in the United States.[186,187] Such tumors often show a lymphoepithelioma-like appearance.[187,188]

Table 14.1 WHO classification of tumors of the stomach

DESCRIPTION	CODE
Epithelial Tumors	
Premalignant Lesions	
Adenoma	8140/0
Intraepithelial neoplasia (dysplasia), low grade	8148/0
Intraepithelial neoplasia (dysplasia), high grade	8148/2
Carcinoma	
Adenocarcinoma	8140/3
Papillary adenocarcinoma	8260/3
Tubular adenocarcinoma	8211/3
Mucinous adenocarcinoma	8480/3
Poorly cohesive carcinoma (including signet ring cell carcinoma and other variants)	8490/3
Mixed adenocarcinoma	8255/3
Adenosquamous carcinoma	8560/3
Carcinoma with lymphoid stroma (medullary carcinoma)	8512/3
Hepatoid adenocarcinoma	8576/3
Squamous cell carcinoma	8070/3
Undifferentiated carcinoma	8020/3
Neuroendocrine Neoplasms	
Neuroendocrine tumor (NET)	
NET G1 (carcinoid)	8240/3
NET G2	8249/3
Neuroendocrine carcinoma (NEC)	8246/3
Large cell NEC	8013/3
Small cell NEC	8041/3
Mixed adenoneuroendocrine carcinoma	8244/3
EC cell, serotonin-producing NET	8241/3
Gastrin-producing NET (gastrinoma)	8153/3

/0, benign tumors; */1*, unspecified, borderline, or uncertain behavior; */2*, carcinoma in situ and grade III intraepithelial neoplasia; */3*, malignant
From Bosman FT, Carniero F, Hruban RH, Theise ND (eds). World Health Organization Classification of Tumours of the Digestive System. Lyon: IARC; 2010.

Morphologic Features and Classification

There is wide variation in the gross appearance of gastric carcinoma (Table 14.1). Many intermediate stages exist between the two extremes, represented by the intraluminal fungating tumor and the flat, ulcerated, and deeply invasive tumor growing through the wall of the stomach (Figs. 14.28 and 14.29). Carcinomas located in the fundic area are more likely to have invaded the submucosa and beyond at the time of surgery than those located in the pyloric area.[189] Depending on the relative amounts of mucin secreted and desmoplastic reaction elicited, the tumors may have a fleshy, fibrous, or gelatinous gross appearance. Any area of the stomach can be affected: anterior and posterior walls, lesser curvature, and greater curvature (in that order of frequency).[190] Multiple tumors are found in approximately 6% of the cases.[191]

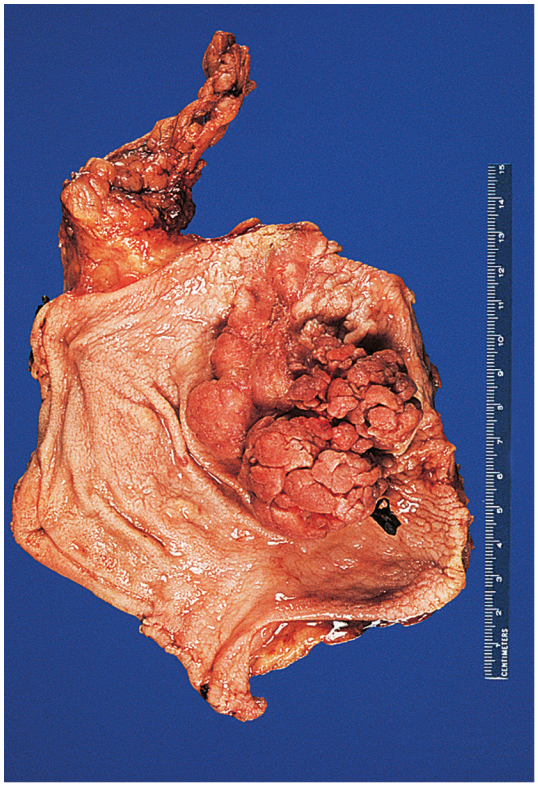

Figure 14.28 Gross appearance of polypoid gastric adenocarcinoma.

Figure 14.29 Gross appearance of gastric adenocarcinoma of ulcerative type showing marked resemblance to chronic peptic ulcer.

The non-neoplastic mucosa adjacent to the carcinoma is often thickened, a feature that may result in false-negative endoscopic biopsies and that has been attributed to production of epidermal growth factor by the tumor.[192] Microscopically, nearly all gastric carcinomas are adenocarcinomas. As already indicated, two major categories exist, which have been designated *intestinal* (53%) and *diffuse* (33%) by Lauren[184]; the remainder are either *mixed* or *unclassifiable*.[193]

Intestinal-type adenocarcinomas show a wide range in the degree of differentiation, which correlates inversely with tumor size.[194] In the better differentiated tumors, most of the cells are columnar and mucin secreting (Fig. 14.30). On occasion, the tumor is so well differentiated as to simulate a complete-type intestinal metaplasia.[195] Poorly differentiated variants have a predominantly solid pattern. Exceptionally, the better differentiated tumor cells are ciliated.[196]

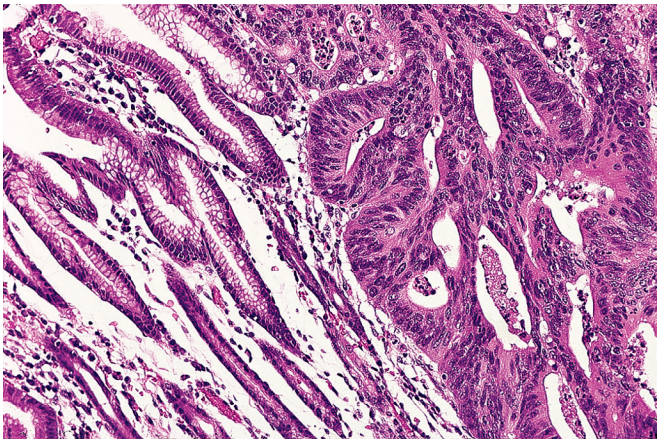

Figure 14.30 Gastric adenocarcinoma of intestinal type.

The amount of mucin production is highly variable; when abundant, it is often accompanied by calcification. Sometimes, metaplastic ossification is present either in the primary tumor or the metastasis. Scattered endocrine cells may be demonstrated with immunohistochemical stains.[197] The occurrence of easily identifiable Paneth cells is less common. On occasion the stroma of the tumor is heavily infiltrated by neutrophils or histiocytes.[198]

Diffuse-type adenocarcinomas are best represented by the tumor type classically known as *linitis plastica* and currently designated as *signet ring (adeno)carcinoma*. It represents a disproportionately high percentage of gastric cancers occurring in the young,[199] and its *relative* incidence seems to be on the rise in the United States.[200] The gross alterations usually begin in the prepyloric area. Pyloric obstruction often develops as the wall of the stomach becomes thickened and rigid (Fig. 14.31). The muscle is hypertrophic and segmented by the presence of thin, parallel, grayish white, longitudinal lines that give it a comblike appearance. These lines are continuous with foci of subserosal thickening.

Microscopically, a diffuse growth of malignant cells is seen, associated with extensive fibrosis and inflammation. Often the entire wall is involved. Although an *intramucosal* type of signet ring carcinoma occurs, in many cases the mucosa is less affected than the deeper layers. Glandular formations are rare, and most tumor cells grow individually or in linear arrays (Fig. 14.32). Most of the mucin produced is intracytoplasmic, resulting in the typical signet ring appearance (Fig. 14.33). Pools of extracellular mucin may also be present, but as long as signet ring cells are evident, this tumor should be categorized as signet ring adenocarcinoma rather than mucinous adenocarcinoma.

There are few malignant tumors in the human body that are more likely to be missed on microscopic examination than this type of gastric cancer. Over the years, we have seen specimens from stomach wall, lymph nodes, omentum, mesentery, pelvic peritoneum, and ovary that were initially misinterpreted as a benign process because of the inconspicuousness of the tumor cells and the marked degree of inflammatory and desmoplastic reaction. The tumor may also closely simulate malignant lymphoma because of its diffuse pattern of growth and the round shape of the cells and their nuclei.

The differential diagnosis of gastric carcinoma in a biopsy specimen includes severe dysplasia and a variety of reactive or otherwise non-neoplastic conditions that may simulate malignancy, including bizarre epithelial atypia associated with chemotherapy or radiochemotherapy,[168] radiation-induced atypia due to extrahepatic localization of yttrium microspheres used for selective internal radiation therapy,[201] degenerative changes associated with erosion and regeneration, plump

Figure 14.31 Typical gross appearance of diffuse carcinoma of the stomach (so-called linitis plastica). Virtually the entire gastric wall is involved by tumor. Note the prominence of rugal folds.

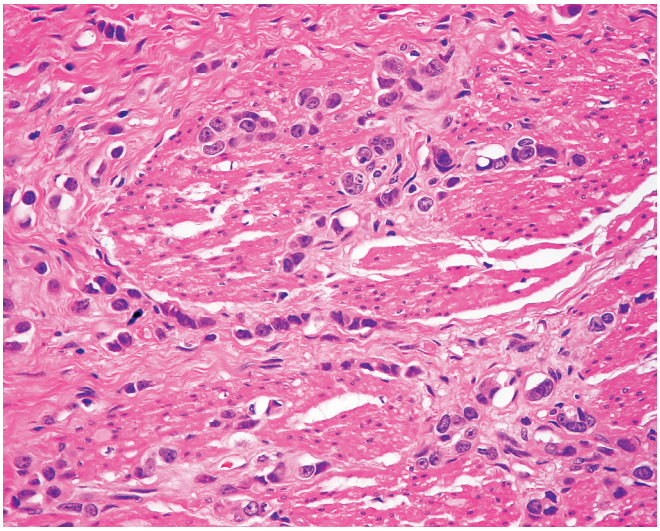

Figure 14.32 Gastric adenocarcinoma of diffuse type showing a single-file pattern of infiltration of the muscularis propria.

reactive mesenchymal cells related to granulation tissue, and gastric xanthoma, just to name a few.

Histochemical and Immunohistochemical Features

The secretory product of most gastric adenocarcinomas (especially those of intestinal type) is an acid mucosubstance, easily detected with Mayer mucicarmine, alcian blue, or colloidal iron stains and

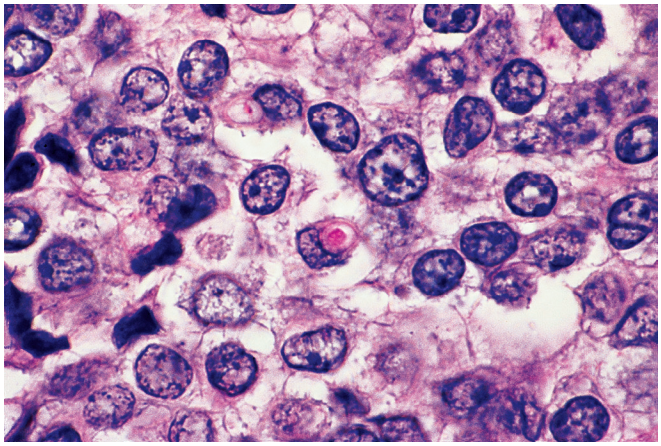

Figure 14.33 Intracytoplasmic mucin droplet in the cell in the very center is seen on this Mayer mucicarmine stain.

having features analogous to those of intestinal-type mucins.[202] The mucin secreted by the diffuse-type carcinoma and present within the cytoplasm of the signet ring cell is of either acidic or neutral type, the latter predominating in some cases.[203]

At the immunohistochemical level, the main mucin types expressed (with many variations and overlaps) are MUC1 for the intestinal type, MUC5AC for the diffuse type, MUC2 for the mucinous type, and MUC5B for the unclassified type (see later).[9,204,205] There is also an interesting relationship between mucin type and tumor location, in the sense that MUC5AC is prevalent in antral tumors whereas MUC2 is preferentially expressed in cardia tumors. CDX2 is present in about 90% of the cases and HepPar-1 in approximately 80%.[206] The former appears very early in tumor development, indicating a switch from a gastric to an intestinal phenotype.[207] The keratins present are usually of the simple epithelial type (low molecular weight), but sometimes those seen in normal squamous epithelia (such as CK13 and 16) are also detected.[208] The CK7/CK20 expression patterns of gastric carcinoma vary considerably; on the whole, approximately 70% of the cases are CK7+ and 20% are CK20+.[209] Immunohistochemical positivity for α1-antitrypsin, α1-antichymotrypsin, and α2-macroglobulin is also common, particularly in advanced tumors.[210] Reactivity to human chorionic gonadotropin (hCG) is found in scattered tumor cells in approximately 10%–50% of the cases[211]; the microscopic appearance of these tumors is usually not different from others, and therefore this phenomenon should not be equated with the rare entity of gastric choriocarcinoma, whether pure or associated with adenocarcinoma.

Molecular Genetic Features

Intestinal-type and diffuse-type gastric carcinoma appear to evolve through different molecular pathways, involving different oncogenes and tumor suppressor genes. Development of the former follows a multistep progression, from chronic gastritis to intestinal metaplasia, dysplasia, and carcinoma. Some have proposed the presence of an in situ component that gives rise to signet ring carcinomas.[178] Gene expression profiling studies show that diffuse-type carcinoma exhibits altered expression of genes related to cell-matrix interaction and extracellular-matrix components, whereas intestinal-type carcinoma exhibits enhancement of cell growth.[212]

Germline truncating mutations of the E-cadherin *(CDH1)* gene have been found in families with hereditary diffuse gastric cancer. The penetrant susceptibility is so high that prophylactic gastrectomy for these individuals is advised.[213,214] In the gastrectomy specimens,

occult intramucosal signet ring adenocarcinoma is commonly found.[213] Female carriers of the *CDH1* mutation also have an increased risk for lobular carcinoma of the breast.[215] Inactivating somatic mutation of *CDH1* or hypermethylation of its promoter is found in up to 50% of sporadic diffuse-type carcinomas but rarely in intestinal-type tumors.[216,217] This molecular alteration, which results in decreased or loss of expression of E-cadherin, a component of the adherens junctions, provides a neat explanation for the observed discohesive growth of diffuse-type gastric carcinoma.

Intestinal-type carcinomas show microsatellite instability in 15%–50% of cases,[218] commonly associated with frameshift mutations in *TGFβRII*, *IGFIIR*, *BAX*, *MSH6*, *MSH3*, and *E2F4*.[219,220] They also commonly exhibit *TP53* mutations and a higher *hTERT* expression level.[125,221] A subset of cases show strong membrane immunostaining for HER2 due to amplification of the *HER2* gene (5%–15% of all gastric carcinomas, almost always of intestinal type).[222] The presence of the latter feature is a predictor of the response to targeted therapy using trastuzumab.[223]

The tumor suppressor gene *RUNX3*, a member of the Runt domain family of transcription factors that are master regulators of gene expression in major developmental pathways, is implicated in gastric carcinogenesis.[224] Hypermethylation of the *RUNX3* promoter occurs in more than 60% of gastric carcinomas, more frequently in intestinal-type than diffuse-type tumors.[225,226]

Somatic mutations of the *APC* gene are present in 4%–21% of gastric adenocarcinomas, in contrast to an incidence of 76% in adenomas or flat dysplasia,[129] suggesting that *APC* mutations do not play a significant role in the progression from adenoma to carcinoma.

Other Microscopic Tumor Types

Neuroendocrine differentiation can be seen in a wide range of gastric neoplasms, which differ greatly in both morphologic and clinical features.[227] Although admixtures and overlaps occur, most gastric tumors with neuroendocrine differentiation can be placed into one of the following categories:

1. Well-differentiated and slow-growing **well-differentiated neuroendocrine tumors** (WDNETs; traditionally known as carcinoid tumors), composed of any of the neuroendocrine cells of the gastric mucosa.
2. Tumors with obvious morphologic features of neuroendocrine differentiation (trabeculae, rosettes, insulae; dense-core secretory granules ultrastructurally; immunoreactivity for neuroendocrine markers) but equally obvious atypical morphologic features (marked invasiveness, necrosis, and mitotic activity). Like their counterparts in the lung, these tumors have been variously called *atypical carcinoid tumors* and *large cell neuroendocrine carcinomas*.[228] This is a heterogeneous group (as it is in the lung), a fact which probably explains the differences in prognosis among different series. When the tumor has features analogous to those of large cell neuroendocrine carcinoma of the lung, the prognosis is poor.[228]
3. **Small cell carcinomas** that are morphologically analogous to their more common pulmonary counterpart and characterized by a very aggressive clinical course.[229,230]
4. Otherwise typical **adenocarcinomas** of either diffuse or intestinal type (particularly the former), having cells that show evidence of neuroendocrine differentiation. Rarely, the neuroendocrine cells can be recognized at the hematoxylin and eosin level because of the fact that their granules are brightly eosinophilic, resembling those of Paneth cells. These tumors do not behave differently from ordinary adenocarcinomas.
5. **Adenosquamous** and **squamous cell carcinomas** comprise less than 1% of all gastric carcinomas.[231,232] Only cases surrounded on all sides by gastric mucosa can be accepted, particularly for the pure squamous cell carcinomas. Those also involving the lower end of the esophagus should be interpreted as primary esophageal carcinomas with gastric extension. The behavior of gastric adenosquamous carcinomas is largely determined by the degree of differentiation of the glandular component, which varies widely.[233] Careful sectioning of tumors originally thought to be squamous cell carcinomas often show a minute glandular component.

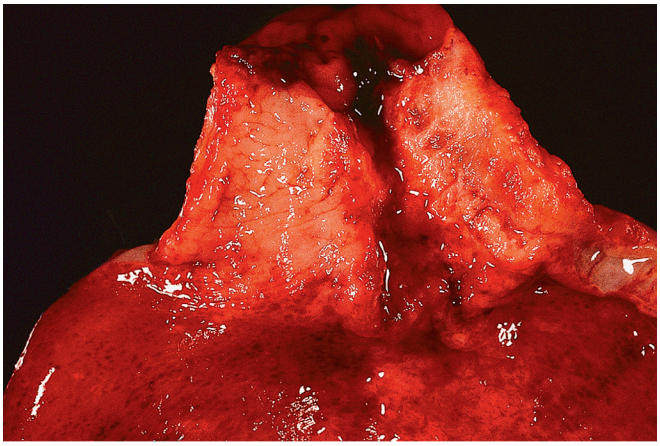

Figure 14.34 Gross appearance of mucinous adenocarcinoma of the stomach. The cut surface has a homogeneous gelatinous appearance.

Mucinous adenocarcinoma is characterized by prominent glandular formations and abundant mucin deposition, nearly all of which is extracellular (Figs. 14.34 and 14.35). The mucin secreted by this tumor is a distinct *O*-acylated form of sialomucin which is immunoreactive for MUC2.[8,234] The prognosis is better than that of signet ring carcinoma but not significantly different from that of ordinary adenocarcinoma.

Hepatoid adenocarcinoma is a type of gastric carcinoma having both glandular and hepatocellular differentiation, with frequent admixtures between the two components.[235] There is also a tubulopapillary pattern with clear cells, which has been interpreted as representing enteroblastic differentiation.[236] As a group, these tumors are characterized by a nodular pattern of growth, presence of abundant cytoplasmic glycogen and hyaline globules, extensive venous invasion, and poor prognosis. Sometimes this venous permeation extends to the omental and mesenteric vessels in a fashion resembling that of hepatocellular carcinoma. Similar to hepatocellular carcinoma, a "canalicular" pattern of staining is seen with polyclonal CEA, and there is often immunoreactivity for HepPar1[237] with alpha-fetoprotein (AFP) expression in about half of the cases.[238] Furthermore, positivity for PLUNC protein (palate, lung, and nasal epithelium carcinoma-associated protein) and the germ cell marker SALL4 have been identified immunohistochemically in hepatoid adenocarcinomas of the stomach but not in hepatocellular carcinomas of the liver.[239,240] Gastric hepatoid carcinomas should be distinguished from otherwise typical gastric adenocarcinomas (without morphologically recognizable hepatoid features) which are immunoreactive for AFP.[238] Glypican 3 (GPC3) is generally present in AFP-producing gastric carcinomas, whether they have hepatoid features or not.[241]

Lymphoepithelioma-like carcinoma (undifferentiated carcinoma with intense lymphoid infiltration) resembles morphologically the homonymous tumor of the upper respiratory tract; the presence of

Figure 14.35 Microscopic appearance of mucinous adenocarcinoma of the stomach. In contrast to diffuse carcinoma, most of the mucin is located extracellularly.

EBV has been documented in most of the cases.[186–188] This tumor is probably identical to gastric medullary carcinoma with lymphocytic infiltration, which also shows a similarly strong relationship with EBV.[242] It should be noted that EBV is also found in a certain percentage of gastric adenocarcinomas of conventional microscopic types.[243] Lymphocyte-rich gastric carcinoma has also been found to be associated with microsatellite instability.[244]

Sarcomatoid carcinoma (carcinosarcoma) is a tumor of dual composition, with epithelial elements (usually glandular) intermingling with a sarcoma-like spindle cell component.[245,246] The sarcomatoid component may contain heterologous elements, such as skeletal muscle and bone,[247] and the epithelial component may contain neuroendocrine cells.[248] This tumor type is much less common in the stomach than in the esophagus. An even rarer occurrence are tumors in which the epithelial component appears benign (so-called adenosarcoma), analogous to the tumors seen in the female genital tract.[249]

(Adeno)carcinoma with rhabdoid features is a very rare form of gastric carcinoma that grows in a solid fashion and is characterized by the presence of rhabdoid cells with paranuclear inclusions filled with intermediate filaments.[250] These neoplasms coexpress cytokeratin and vimentin and show loss of SMARCB1 (INI1). As is true of other tumors with rhabdoid differentiation, they are clinically highly aggressive neoplasms.[251]

Gastric carcinoma with osteoclast-like giant cells has a solid or cribriform pattern of growth and a scattering of multinucleated cells that exhibit histiocytic markers.[252]

Acinar cell carcinoma of pancreatic type has been reported beneath a focus of pancreatic metaplasia of the gastric mucosa, presumably arising from it.[253]

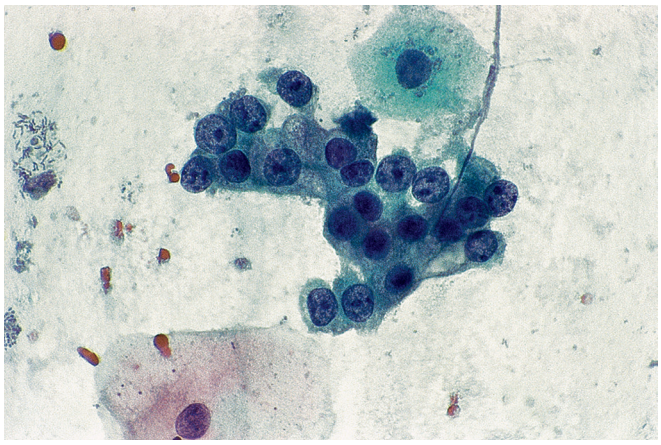

Figure 14.36 Cytologic appearance of reactive (reparative) atypia.

Clear cell (glycogen-rich) adenocarcinoma is vanishingly rare. Most of the few reported cases presented as high-stage disease.[254] Renal metastasis to the stomach should be excluded.

Micropapillary carcinoma morphologically similar to its homonym in breast, bladder, and other sites can exceptionally occur in the stomach.[105] It is associated with prominent lymphovascular invasion, frequent lymph node metastases, and a poor prognosis,[255,256] although one study did not find a significant difference in outcome when compared with conventional adenocarcinoma.[257]

Diagnosis—Biopsy and Cytology

Symptoms from gastric carcinoma usually indicate advanced disease. If the tumor is located in the cardiac or pyloric areas, it may produce obstruction relatively early; otherwise the symptoms are vague and nonspecific, usually consisting of dyspepsia, weight loss, and anemia. Sometimes, the first sign of gastric carcinoma is the detection of a nodal, hepatic, or pulmonary metastasis. Isolated nodal metastasis in the left supraclavicular region is sometimes referred to as *Trousseau sign* or *Virchow node.*

Radiographic examination of the stomach demonstrates the lesion in most cases, but in approximately 10% it will be impossible to determine whether the lesion is benign or malignant.

In countries with a high incidence of gastric carcinoma, particularly Japan, the increased use of mass screening, endoscopy, cytology, and biopsy has resulted in the identification of a large percentage (up to a third) of early cases, with a corresponding increase in survival rates.[258,259]

With the introduction of the flexible fiberoptic gastroscope, the results of direct-vision gastric biopsy and brush cytology have improved dramatically (Figs. 14.36–14.38).[260] False-negative diagnoses with biopsy specimens are most often seen with the ulcerating types and are inversely related to the number of specimens obtained.[261] There is also a greater rate of false-negative results with diffuse compared with intestinal-type carcinomas, a finding not surprising in view of the predominantly submucosal distribution of this tumor.

So-Called Early Carcinoma

"Early" gastric carcinoma is defined by the Japanese authors as a carcinoma confined to the mucosa or to the mucosa and submucosa (not extending into the muscularis externa), regardless of the status of the regional lymph nodes (Fig. 14.39).[262] The name is inaccurate because the concept is not related to the presumed duration of the lesion but exclusively to its depth of penetration. Other terms that

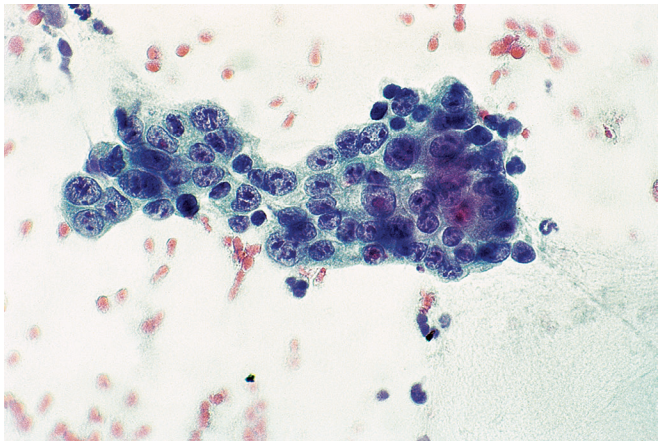

Figure 14.37 Cytologic appearance of intestinal-type gastric adenocarcinoma.

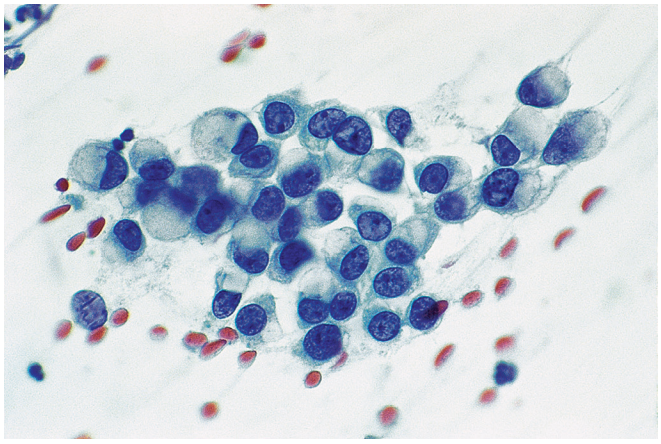

Figure 14.38 Cytologic appearance of diffuse-type gastric adenocarcinoma.

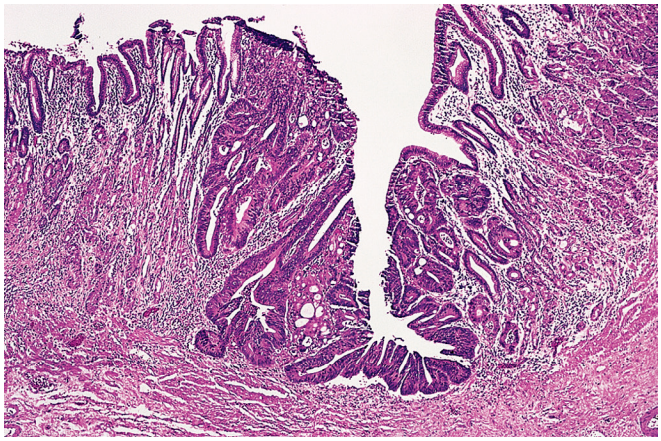

Figure 14.39 Early gastric adenocarcinoma limited to the mucosa.

have been used for the various subsets of this entity include *surface*, *superficial*, *superficial spreading*, and *microinvasive cancer*. The form limited to the mucosa, known as *intramucosal carcinoma*, needs to be separated from high-grade dysplasia, as the former shows evidence of invasion through the glandular basement membrane into the lamina propria or muscularis mucosae, a determination that is admittedly not always easy to make.

Most cases of early carcinoma are of Lauren's intestinal type, but early forms of diffuse carcinoma (composed almost entirely of signet ring cells) and of mucinous carcinoma also exist.[263] The degree of microscopic differentiation varies widely. The better differentiated types show closer association with *H. pylori* than the poorly differentiated tumors. The deep mucosal component underlying the carcinoma often shows cystic dilation of the glands.[264]

The relative incidence of early carcinoma is clearly related to the magnitude of the diagnostic efforts. In Japan, the proportion of early carcinoma cases has risen from 5.7% in the early 1920s to 45% in the late 1990s.[265] Variations in gross appearance of early carcinoma at endoscopy mirror those of its larger counterpart—protruding or type I (polypoid, nodular, or villous), superficial or type II (elevated, flat, or depressed), and excavated or type III. Combinations of the gross appearances are common.[266] Most cases are located in the distal third of the stomach, but they also occur at the gastric cardia; multicentricity is seen in approximately 10%–20% of the cases.[267] Genetic studies suggest that these lesions are truly multicentric, supporting the theory of field cancerization.[268]

On average, lymph node metastases are seen in approximately 6% of intramucosal tumors and in 25%–30% of those invading the submucosa.[269] In intramucosal carcinomas, lymph node metastatic disease correlates with diffuse histology and deep invasion into the muscularis mucosae.[270] For those tumors invading the submucosa, the incidence of nodal metastases is higher in those with angiolymphatic invasion, those invading over half of the submucosa, and those in which the submucosal invasion is expansile, with complete destruction of the muscularis mucosae.[271,272] Most "early" carcinomas are treated at present by minimal surgical procedures, such as endoscopic mucosal or submucosal resection or laparoscopic partial resection.[273,274] The 5-year survival rate following resection is between 80% and 95% and remains remarkably high even when nodal metastases are present.[275] As expected, the prognosis of early gastric carcinomas with focal invasion of the muscle layer is intermediate between that of the truly superficial tumors and the obviously invasive ones.[276]

Spread and Metastases

Distal carcinomas of the stomach invade the duodenum in a high percentage of cases. Similarly, carcinomas of the proximal stomach often involve the esophagus (to the point that a distinction between them and the tumors arising from Barrett esophagus is not always possible) and induce reactive changes in the adjacent esophageal epithelium. Serosal spread is common, its extent being greater in tumors with an infiltrative pattern of growth than in the expanding types.[277] Local extension also occurs to the omentum, colon, pancreas, and spleen. The rich mucosal and submucosal (Borrman) lymphatic plexus of the stomach is often invaded; from here, the tumor can spread to perigastric, periaortic, and celiac axis-related lymph nodes.[278] Tumors of the distal third of the stomach show a high incidence of involvement of hepatoduodenal nodes.[279] The presence of mucosal lymphangiectasia has been found to be statistically associated with the presence of regional lymph node metastases.[280] Invasion of the blood vessel walls by the tumor *("vasculitis carcinomatosa")* can also occur.[281]

The incidence of detectable lymph node metastases is influenced by the method used to search for them; it is significantly higher when a comprehensive fat-clearing method is employed[282,283] or if the microscopic sections are evaluated immunohistochemically for cytokeratin.[284] Tumor cells can also diffusely permeate the lymphatic plexus of the bowel, more often at the level of the upper duodenum

but sometimes down into the distal ileum and even the large bowel; the latter feature is seen almost exclusively in carcinomas of the diffuse type.[285] The most frequent sites of distant metastases are liver (often found unexpectedly at operation), peritoneum, lung, adrenal gland, and ovary. Bilateral ovarian metastases from the diffuse type of gastric carcinoma constitute the majority of cases referred to as *Krukenberg tumor*, but ovarian metastases of intestinal-type tumors can also supervene and be confused with primary ovarian endometrioid or mucinous neoplasms.[286] The diffuse type of gastric carcinoma shows a wider pattern of dissemination than the intestinal type, with more frequent involvement of peritoneum, lungs, and ovary.[287] On the other hand, liver metastases are more common with intestinal-type tumors; occasionally, the liver metastases grow in a diffuse intrasinusoidal pattern and lead to hepatic failure.[288]

Treatment

The standard treatment for gastric carcinoma (excluding "early" carcinoma) is gastrectomy, the extent of surgery being largely dependent on the extent of tumor and status of the rest of the mucosa.[289] In the United States, the resectability rate remains much lower than in Japan.[290] The operations most commonly performed are subtotal gastrectomy, radical subtotal gastrectomy, and total gastrectomy. These are often accompanied by splenectomy, but there is no evidence that this increases survival.[199] There is also no convincing evidence that extended lymph node dissection, as advocated by some Japanese surgeons, significantly increases survival.[291] The operative mortality following total gastrectomy is low, but the morbidity remains high. This operation is most often performed for carcinomas located at the cardia or high on the lesser curvature. For most of the others, subtotal resections are often performed because of the lower morbidity, despite occasional tumor recurrence in the gastric stump.[292] There seems to be relatively little benefit to chemoradiotherapy,[293] but as previously mentioned, *HER2* has been validated as a molecular target for this disease.[294]

Prognosis

The prognosis for gastric carcinoma in the United States remains disappointingly poor. The overall survival rate for all patients is between 4% and 13%. In a series of 10,000 consecutive cases from Fukuoka, Japan, the 5-year survival rates were 46% for advanced carcinoma and 89% for "early" carcinoma.[295] Possible explanations for these strikingly better survival rates when compared with the West include a greater frequency of superficial carcinomas, a more meticulous pathologic examination of the specimens, the performance of extended nodal dissection, and intrinsic differences in the growth patterns of the tumors. Different criteria in the differential diagnosis between high-grade dysplasia and carcinoma between Japanese and Western authors may also account for some of the differences.[296]

Anatomic stage remains the strongest prognostic indicator, and, as such, careful examination of the gastrectomy specimen with procurement of (ideally) at least 15 lymph nodes is critical in this evaluation (Tables 14.2 and 14.3).[297] In fact, lymph node status is the single best predictive indicator of prognosis.[174,298] There are several types of lymphadenectomy which can be performed during gastrectomy, but the more extensive the procedure, the more accurate the pathologic staging can be.[299]

Other prognostic parameters have been reported as well. Japanese ethnicity and female gender has been reported to be favorable prognostic indicators.[300] Some have found tumors in the distal stomach to be associated with a better outcome than those in the proximal stomach.[301] Younger patient age at diagnosis seems to be an adverse prognostic indicator,[302] but this may be related to the

Table 14.2 Definitions of AJCC TNM for squamous cell carcinoma and adenocarcinoma

Primary Tumor (T)	
T CATEGORY	**T CRITERIA**
Tx	Tumor cannot be assessed
T0	No evidence of primary tumor
Tis	High-grade dysplasia, defined as malignant cells confined to the epithelium by the basement membrane
T1	Tumor invades the lamina propria, muscularis mucosae, or submucosa
T1a	Tumor invades the lamina propria or muscularis mucosae
T1b	Tumor invades the submucosa
T2	Tumor invades the muscularis propria[a]
T3	Tumor penetrates the subserosal connective tissue without invasion of the visceral peritoneum or adjacent structures[b,c]
T4	Tumor invades the serosa (visceral peritoneum) or adjacent structures[b,c]
T4a	Tumor invades the serosa (visceral peritoneum)
T4b	Tumor invades adjacent structures/organs
Regional Lymph Nodes (N)	
N CATEGORY	**N CRITERIA**
Nx	Regional lymph nodes cannot be assessed
N0	No regional lymph node metastasis
N1	Metastasis in one or two regional lymph nodes
N2	Metastasis in three to six regional lymph nodes
N3	Metastasis in seven or more regional lymph nodes
N3a	7–15
N3b	16 or more
Distant Metastasis (M)	
M CATEGORY	**M CRITERIA**
M0	No distant metastasis
M1	Distant metastasis

From Amin M, Edge S, Greene F, et al. (eds). AJCC Cancer Staging Manual. 8th ed. New York: Springer; 2017.

[a]A tumor may penetrate the muscularis propria with extension into the gastrocolic or gastrohepatic ligaments, or into the greater or lesser omentum, without perforation of the visceral peritoneum covering these structures. In this case, the tumor is classified as T3. If there is perforation of the visceral peritoneum covering the gastric ligaments or the omentum, the tumor should be classified as T4.

[b]The adjacent structures of the stomach include the spleen, transverse colon, liver, diaphragm, pancreas, abdominal wall, adrenal gland, kidney, small intestine, and retroperitoneum.

[c]Intramural extension to the duodenum or esophagus is not considered invasion of an adjacent structure, but is classified using depth of greatest invasion in any of these sites.

Table 14.3 AJCC prognostic stage groups

Clinical (cTNM)			
WHEN cT IS...	**AND cN IS...**	**AND M IS...**	**THEN THE STAGE GROUP IS...**
Tis	N0	M0	0
T1	N0	M0	I
T2	N0	M0	I
T1	N1, N2, or N3	M0	IIA
T2	N1, N2, or N3	M0	IIA
T3	N0	M0	IIB
T4a	N0	M0	IIB
T3	N1, N2, or N3	M0	III
T4a	N1, N2, or N3	M0	III
T4b	Any N	M0	IVA
Any T	Any N	M1	IVB
Pathological (pTNM)			
WHEN pT IS...	**AND pN IS...**	**AND M IS...**	**THEN THE STAGE GROUP IS...**
Tis	N0	M0	0
T1	N0	M0	IA
T1	N1	M0	IB
T2	N0	M0	IB
T1	N2	M0	IIA
T2	N1	M0	IIA
T3	N0	M0	IIA
T1	N3a	M0	IIB
T2	N2	M0	IIB
T3	N1	M0	IIB
T4a	N0	M0	IIB
T2	N3a	M0	IIIA
T3	N2	M0	IIIA
T4a	N1	M0	IIIA
T4a	N2	M0	IIIA
T4b	N0	M0	IIIA
T1	N3b	M0	IIIB
T2	N3b	M0	IIIB
T3	N3a	M0	IIIB
T4a	N3a	M0	IIIB
T4b	N1	M0	IIIB
T4b	N2	M0	IIIB

Table 14.3 AJCC prognostic stage groups—cont'd

Pathological (pTNM)			
WHEN pT IS...	**AND pN IS...**	**AND M IS...**	**THEN THE STAGE GROUP IS...**
T3	N3b	M0	IIIC
T4a	N3b	M0	IIIC
T4b	N3a	M0	IIIC
T4b	N3b	M0	IIIC
Any T	Any N	M1	IV
Postneoadjuvant Therapy (ypTNM)			
WHEN yP T IS...	**AND yP N IS...**	**AND M IS...**	**THEN THE STAGE GROUP IS...**
T1	N0	M0	I
T2	N0	M0	I
T1	N1	M0	I
T3	N0	M0	II
T2	N1	M0	II
T1	N2	M0	II
T4a	N0	M0	II
T3	N1	M0	II
T2	N2	M0	II
T1	N3	M0	II
T4a	N1	M0	III
T3	N2	M0	III
T2	N3	M0	III
T4b	N0	M0	III
T4b	N1	M0	III
T4a	N2	M0	III
T3	N3	M0	III
T4b	N2	M0	III
T4b	N3	M0	III
T4a	N3	M0	III
Any T	Any N	M1	IV

From Amin M, Edge S, Greene F, et al. (eds). AJCC Cancer Staging Manual. 8th ed. New York: Springer; 2017.

higher percentage of diffuse-type cancers in this age group. Small tumor size is a favorable indicator, but this in turn may be linked to depth of invasion.[295] The presence of a pushing margin is more favorable than those with infiltrating margins.[295]

At the molecular level, it is clear that intestinal and diffuse-type cancers result from different genetic pathways involving a number of tumor suppressor genes, DNA mismatch repair genes, and oncogenes.[303] None of these alterations has been proven to have prognostic significance above that which has been mentioned previously.[304]

Well-Differentiated Neuroendocrine Tumors ("Carcinoid Tumors")

Discussed in this section are all the well-differentiated neoplasms composed of any of the cells of the diffuse (neuro)endocrine system, of which many types are known to occur in the normal stomach of humans. In the past, these WDNETs had been known as *carcinoid tumors*, but the latter term is now discouraged (Fig. 14.40).

Grossly, gastric WDNETs tend to be small, sharply outlined, and covered by a flattened mucosa, although they can cause a polyp.

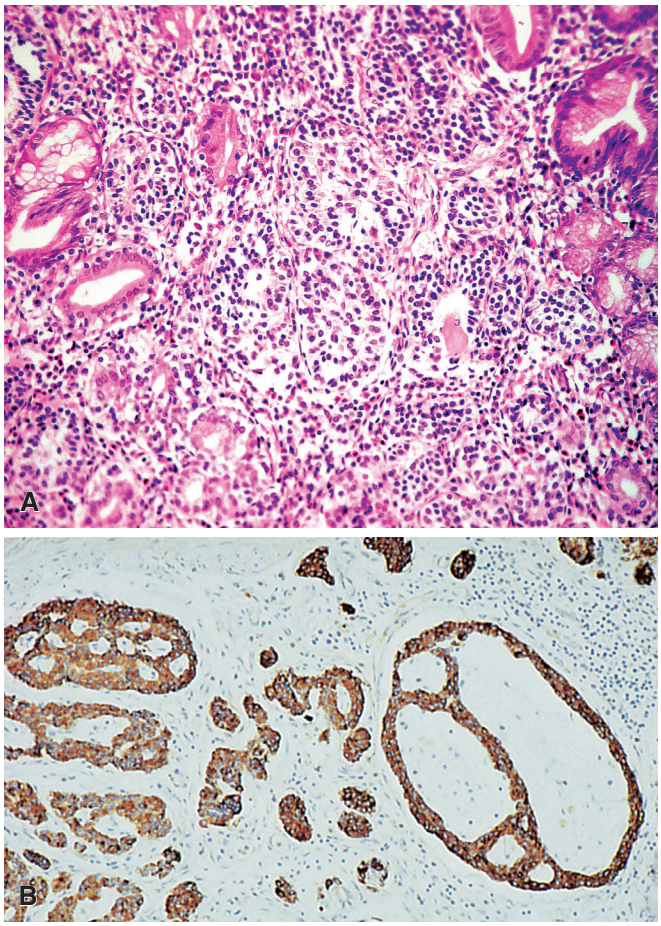

Figure 14.40 **A,** Well-differentiated neuroendocrine tumor of the stomach composed of enterochromaffin-like cells. **B,** Immunohistochemical stain for chromogranin.

Microscopically, the predominant pattern of growth may be microglandular, trabecular, or—rarely—insular. The nuclei are regular and normochromatic, mitoses are scanty, necrosis is usually absent, and vascularization is florid. Exceptionally, the cytoplasm of the tumor cells has a clear appearance.[305] Focal mucin positivity may be present. Immunohistochemically, there is consistent positivity for neuron-specific enolase, chromogranin, synaptophysin, and cytokeratin. Ultrastructurally, dense-core secretory granules are found in the cytoplasm, usually in abundance. The rate of growth of these tumors is very slow.

The histogenetic diversity of WDNETs of the stomach is already indicated by the wide variety of products that these tumors have been found to secrete, such as 5-hydroxytryptophan (serotonin), epinephrine, norepinephrine, somatostatin, VIP, PP, YY peptide, secretogranin, ACTH, β-MSH, and α1-antitrypsin.[306]

A combined morphologic, ultrastructural, and immunohistochemical approach has allowed the identification of at least two definite subtypes of gastric WDNETs.[307] The first is a tumor composed of **G cells** (gastrinoma), analogous to its most common pancreatic or duodenal counterpart; this is usually solitary, located in the antrum, non-argentaffin and non-argyrophilic, immunoreactive for gastrin, and sometimes associated with peptic ulcer. Parenthetically, gastric G-cell tumor should be clearly separated from the disputed entity of *primary G-cell hyperplasia*, in which an increased number of G cells in the antrum is accompanied by hypergastrinemia and an ulcerogenic syndrome resembling the Zollinger–Ellison syndrome.[308]

The second form, which constitutes by far the most common type of gastric WDNET, is composed of **ECL cells**.[309] These lesions are usually multiple, often polypoid, and distributed throughout the fundus. They are non-argentaffin but strongly argyrophilic, nonreactive for any of the standard gastroduodenopancreatic hormones, and accompanied by diffuse hyperplasia of similar cells in the surrounding mucosa. These tumors and associated hyperplasias usually occur on a background of atrophic gastritis with intestinal metaplasia, with or without pernicious anemia.[11,310] The gastritis is usually of type A (immune) with a low incidence of *H. pylori* colonization. The tumors have also been seen in association with the Zollinger–Ellison syndrome, either alone or as a component of multiple endocrine neoplasia type 1 (MEN 1).[311–313] Since the common denominator for these disorders is hypergastrinemia, and since gastrin is known to have a trophic influence on ECL cells, it has been postulated that these tumors are the direct result of the combined continuous stimulation by gastrin and a predisposing genetic background.[314] On the basis of these observations, it has been proposed that ECL cell tumors of the stomach be divided into three types: type I, associated with chronic atrophic gastritis; type II, associated with MEN 1; and type III, sporadic. Loss of heterozygosity of 11q13 (where the *MEN1* gene is located) has been detected in nearly all cases of type II ECL cell tumors; interestingly, a high frequency of this genetic alteration has also been found in type I but not in type III tumors.[315]

Regression of type I and type II lesions has been documented following the performance of antrectomy and normalization of serum gastrin levels,[316,317] suggesting that some of them may represent nodular hyperplasias of ECL cells rather than true neoplasms. Indeed, a spectrum exists between the clearly hyperplastic and the clearly neoplastic proliferations, making the dividing line between the two processes a rather arbitrary one. The figure of 0.5 mm has been suggested as the criterion by which to distinguish WDNETs from their precursors.[318]

In terms of natural history, most WDNETs of the stomach grow very slowly. Metastases, if they occur, are usually restricted to regional lymph nodes and liver, and their presence does not preclude long-term survival.[319] This favorable outcome applies particularly to types I and II ECL cell tumors. Conversely, the rare type III (sporadic) ECL cell tumors tend to run a more aggressive clinical course.[320] In terms of morphologic criteria, the main features that relate to prognosis are direct invasion, metastases, angioinvasion, tumor size, and mitotic activity and/or Ki-67 index.[320,321]

Composite tumors are made up of WDNETs admixed with a glandular (exocrine) component. Composite endocrine–exocrine tumors should be distinguished from the phenomenon of colonization of normal gastric glands by a pure WDNET.[322]

High-grade neuroendocrine tumors and adenocarcinomas with focal endocrine features are discussed in the section on gastric carcinoma.

Stromal Tumors (Gastrointestinal Stromal Tumors and Related Lesions)

Histogenetic Considerations: Microscopic, Immunohistochemical, and Molecular Genetic Features

Stromal tumors constitute the majority of primary nonepithelial neoplasms of the stomach.[323] They are members of a larger family that can also involve any portion of the gastrointestinal tract, omentum, mesentery, retroperitoneum, and other sites, collectively designated as *GISTs*.[324] The general features of this complex group and their peculiarities as they pertain to their gastric location are

discussed here, whereas the features connected with the other sites are dealt with in the respective sections.

For many years, these tumors were regarded as being of smooth muscle nature and designated as leiomyomas and leiomyosarcomas when composed of spindle cells, and as benign or malignant leiomyoblastomas (or epithelioid leiomyomas and leiomyosarcomas, respectively) when composed of epithelioid cells.[325] More recently, it has been suggested that these tumors are derived from (or differentiate towards) interstitial cells of Cajal, given that these "pacemaker cells" are positive for KIT and (as discussed later) almost all GISTs also stain for this antigen. However, this argument is flawed for the reason that KIT (CD117) expression by GIST is due (as indicated later) to an altogether different mechanism, i.e. a gain-of-function mutation of the *KIT* gene. The link between GIST and the interstitial cell of Cajal on the basis of their alleged shared reactivity for CD34 has not fared better following the realization that the normal CD34 positive cells in the gastric wall are not the interstitial cells of Cajal but rather fibroblasts adjacent to them.[326] It is our impression that all attempts to rigidly subdivide GISTs along histogenetic lines (i.e. muscular, neural, Cajal cell, schwannian, fibrous, etc.) are ill conceived, whether based on ultrastructural, immunohistochemical, or combined grounds. Rather, we believe there is a wide range of differentiation among these tumors along several lines.

The most important advance that has occurred in the field has been the discovery that about 90% of GISTs in adults are accompanied by a somatic mutation of *KIT*, and that many of the remainder have mutations of *PDGFRA*, these mutations being mutually exclusive. KIT is a tyrosine kinase receptor normally expressed by the interstitial cells of Cajal, mast cells, and germ cells.[327–329] This mutation (which is usually absent in GISTs in children and in some syndromic conditions, see later) is usually at exon 11, rarely at exons 9 and 13, and occasionally at other sites.[330,331] It results in a ligand-independent activation of the receptor, which in turn leads to its detection at the immunohistochemical level.[332] This has provided a very useful tool for the confirmation of the diagnosis of GIST, although it is clear that KIT-negative GISTs do occur, as discussed later.[333] The most convincing pattern of CD117 (KIT) positivity is one featuring a cell membrane component in addition to a cytoplasmic one. Mesenchymal tumors others that GIST that may stain for CD117 tend to show only cytoplasmic staining with a coarse granular pattern.

DOG1 is a more recently described immunohistochemical marker for GIST which has both high sensitivity and specificity for this tumor.[334–339] In effect, virtually all GISTs are positive for one or both of these markers, although KIT-negative tumors are more likely to have an epithelioid morphology, arise in the omentum, harbor *PDGFRA* mutations, have myxoid stroma and numerous mast cells.[333,340–342] It must be remembered that CD117 staining in a GIST does not necessary indicate that *KIT* mutation is present and, conversely, that a *KIT* mutation may exist in the absence of CD117 staining.

General, Clinical, and Gross Features of Gastrointestinal Stromal Tumor

Clinically, most GISTs occur in adults, but they have also been described in children and even neonates.[343,344] About 60% of GISTs occur in the stomach, the most common symptoms being abdominal pain and melena. Approximately 60% are submucosal and grow toward the lumen, where they make a smooth projection. In time, central ulceration may occur (more commonly with the clinically malignant tumors) and may penetrate deeply into the tumor mass and result in hematemesis. The smooth outline of the tumor and the central niche result in a highly characteristic radiographic appearance. Approximately 30% of the tumors are subserosal, and the other 10% are intramural. Grossly, they tend to be well circumscribed and have a smooth, lobulated, or whorled-silk appearance on cut section. An hourglass defect may occur at the cardia or pylorus if the tumor encircles the stomach.

About 5% of cases of GIST occur in patients with von Recklinghausen disease, most of them being located in the small bowel.[345] They tend to be multiple, their microscopic appearance not being necessarily more neural-like than others, except for the more common presence of skeinoid fibers (collagen globules).[346,347] They consistently lack *KIT* or *PDGFRA* mutations.[345,348] Other cases of GIST develop in the context of the Carney triad, in conjunction with pulmonary chondroma and extra-adrenal paragangliomas.[349] Still others arise in the Carney–Stratakis syndrome (associated with familial paraganglioma).[350] These GISTs tend to arise in the stomach of young patients, especially females, and show a multinodular growth pattern, epithelioid morphology, and often lymph node metastases. Despite the latter, these tumors usually show indolent clinical behavior, as well as mutations in the succinate-dehydrogenase complex of genes (SDH deficient).[351,352] Similar to pediatric GISTs, all of these tumors show loss of staining of SDHB.[352,353] Overall, 8%–10% of "wild-type GISTs" show SDH mutations. A smaller number show mutation of the *BRAF* gene.[351,354,355] Exceptionally, germline mutations of the *KIT* gene are seen in patients with familial GIST.[356,357]

Microscopic Features and Differential Diagnosis of Gastrointestinal Stromal Tumor

Gastric GISTs may be predominantly spindled or epithelioid, although some show an admixture of both cell types. Spindle cell tumors range from those which are characteristically low risk, showing bland spindle cells arranged in packets or whorls with normochromatic nuclei, perinuclear vacuoles, little mitotic activity (fewer than 5 mitotic figures/5 mm^2), sometimes nuclear palisading resembling that seen in schwannoma and collagenous stroma, occasionally with dystrophic calcification (Fig. 14.41), to high-risk lesion composed of atypical spindle cells arranged into fascicles with easily identifiable mitotic figures, necrosis, and mucosal invasion (Fig. 14.42). Similarly, epithelioid tumors range from low-risk lesions composed of epithelioid cells with abundant eosinophilic or clear cytoplasm, multinucleation, rare mitotic figures, abundant stroma, and no necrosis or mucosal invasion (Fig. 14.43), to those which are highly cellular tumors with high-grade nuclei, less cytoplasm, numerous mitotic figures and show evidence of necrosis and/or mucosal invasion (Figs. 14.44 and 14.45).

Knowing the wide morphologic spectrum of gastric GISTs, one is not surprised that the differential diagnosis of this entity is vast.[358] Depending on the tumor location and the microscopic features, it includes solitary fibrous tumor, fibromatosis, inflammatory fibroid polyp, glomus tumor, schwannoma, leiomyoma/leiomyosarcoma, and even malignant lymphoma and carcinoma. Fibromatosis (desmoid tumor) is particularly likely to be misdiagnosed as GIST because it can extensively involve the gastrointestinal wall and, at least in some labs, exhibit CD117 immunoreactivity (although the latter tends to be exclusively cytoplasmic and not on the cell membrane).[359] Solitary fibrous tumor shares CD34 positivity with GIST but is negative for CD117 and DOG1 and consistently expresses STAT6. The differential diagnosis of GIST with leiomyoma/leiomyosarcoma and schwannoma becomes cloudy because of the smooth muscle and/or neural-like features that GIST can exhibit. True smooth muscle tumors exhibit more densely eosinophilic cytoplasm and stain strongly for smooth muscle markers (smooth muscle actin, desmin, h-caldesmon) and do not stain for CD117 or DOG1. Gastric schwannomas show a characteristic peripheral lymphoid infiltrate, stain strongly for S-100 protein, and lack CD117 and DOG1 positivity.

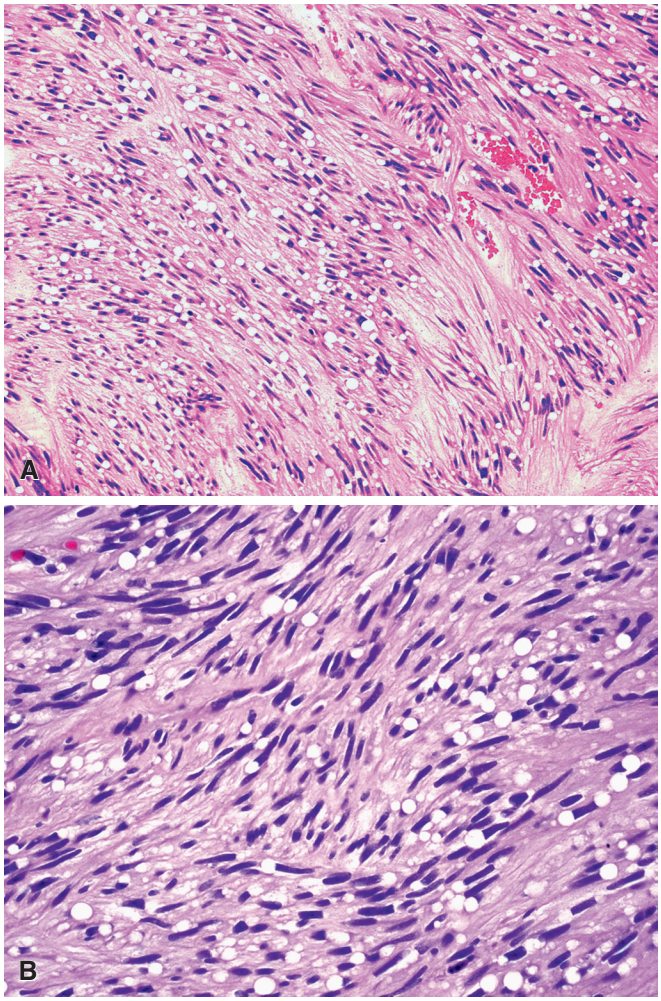

Figure 14.41 Low-power **(A)** and high-power **(B)** views of a low-risk gastrointestinal stromal tumor of the stomach of spindled type. Note the prominent perinuclear vacuoles. The cells are cytologically bland, and mitotic activity is not seen.

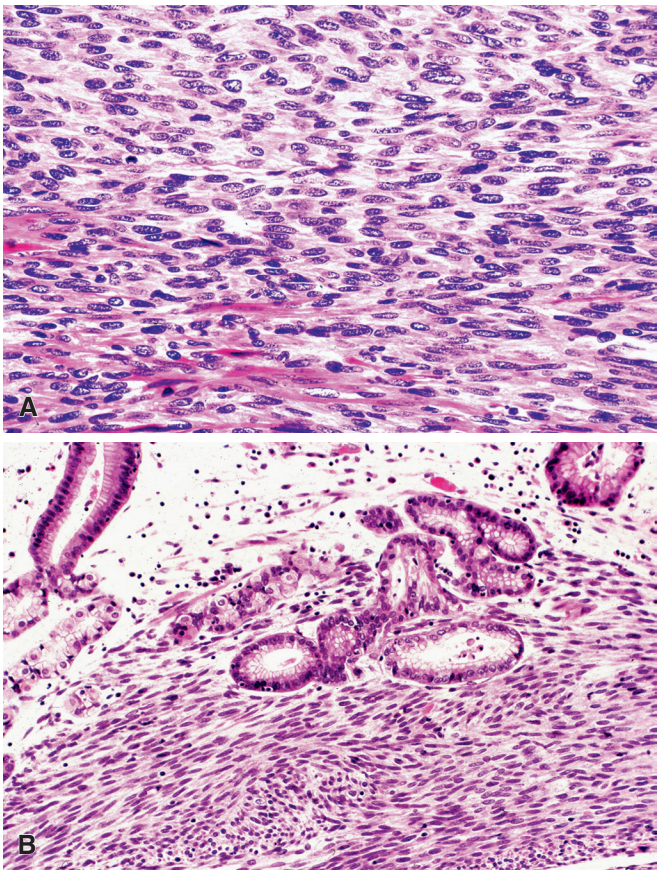

Figure 14.42 High-Risk Spindled Type of Gastrointestinal Stromal Tumor of the Stomach. A, The cells are tightly packed and arranged in sweeping fascicles. Perinuclear vacuoles are not apparent. **B,** Mucosal invasion is often associated with aggressive behavior in these tumors.

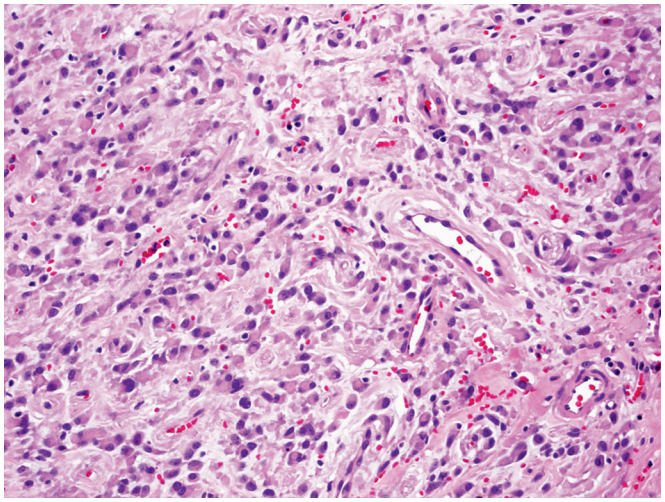

Figure 14.43 Epithelioid type of gastrointestinal stromal tumor of the stomach, low-risk type. The cells have abundant cytoplasm and a somewhat plasmacytoid appearance.

Tumor Multiplicity

As previously indicated, GISTs may present in the form of multiple tumors in the following situations[360]:

1. Neurofibromatosis type 1 (von Recklinghausen disease)
2. Carney triad
3. Associated with paraganglioma but different from Carney triad (Carney–Stratakis syndrome)
4. As a familial syndrome, associated with germline mutations of *KIT* and with small intestinal neuronal dysplasia.

They can also appear as multiple tumors in the absence of any of these conditions. Those of a microscopic size (sometimes called GIST tumorlets, mGISTs, or "seedling" GISTs) are very common and predilect the upper stomach.[361,362] The fact that they have different clonal molecular aberrations is in keeping with an independent origin.[363,364]

Spread and Metastases

The most common sites of metastases of malignant GISTs are the liver (Fig. 14.46), peritoneum, and lungs. Metastases to other sites, such as ovary, can also occur.[365] These metastases can develop as long as 30 years after the removal of the primary tumor.

Treatment

The primary treatment of GIST consists of surgical excision of the tumor with a good margin of normal tissue. Depending on the site and size of the tumor, this may involve a partial, subtotal, or total gastrectomy. Simple enucleation of the tumor should be discouraged.

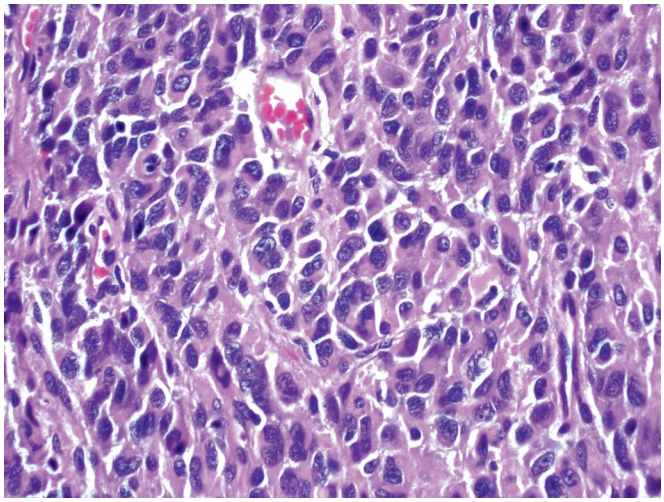

Figure 14.44 Highly cellular high-risk epithelioid gastrointestinal stromal tumor of the stomach.

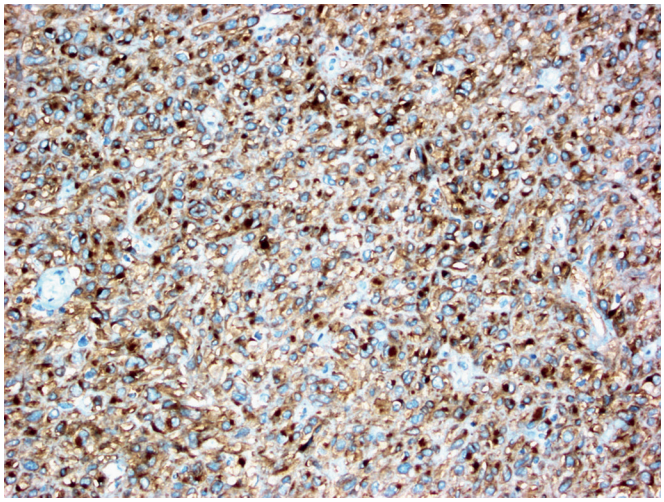

Figure 14.45 Diffuse CD117 (KIT) immunoreactivity in a high-risk epithelioid gastrointestinal stromal tumor of the stomach. Perinuclear globular immunoreactivity can also be seen.

Wide resection of lymph node areas is not indicated because of the extreme rarity of lymph node metastases. The type and extent of the operation are more dependent on the tumor size and location.

A remarkable development in the treatment of GISTs has been the discovery that most of these tumors are exquisitely sensitive to the action of the tyrosine kinase inhibitor imatinib mesylate (STI571; Gleevac; Glivec),[366,367] a response that is dependent upon the presence and type of *KIT* mutation (highest with exon 11 mutations and lowest with a wild-type phenotype).[334] This has led to some of the most spectacular results ever obtained with the medical therapy of solid tumors, even if the initial total regression is often followed by a recurrence in the form of a tumor that has acquired resistance to the drug through an additional mutation.[368]

Response to imatinib therapy is manifested by the loss of tumor cells, resulting in a practically acellular myxohyaline background.[369] Recurrent tumors may show a phenotypic change, such as loss of CD117 immunoreactivity[370] and divergent rhabdomyoblastic differentiation.[371]

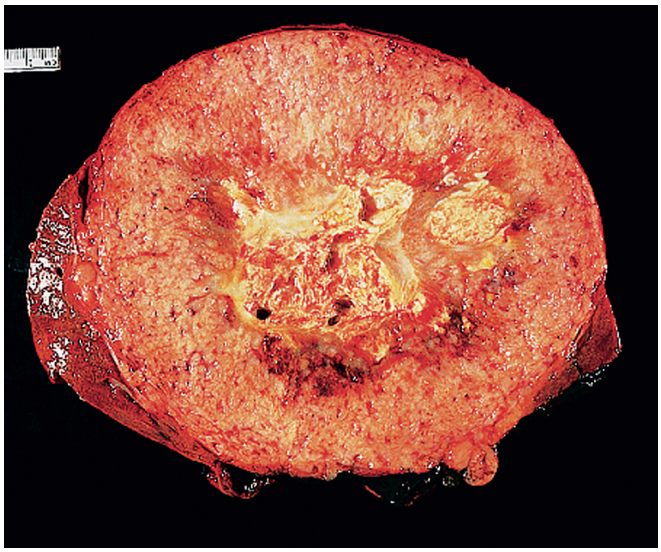

Figure 14.46 Gross appearance of a liver metastasis from a gastric GIST.

Prognosis

Although there are innumerable studies published in the older literature assessing histologic prognostic indicators, current recommendations for assessing prognosis are restricted to three parameters—tumor site, tumor size, and mitotic index (mitoses/5 mm^2).[334] Although the initial risk stratification scheme did not account for tumor site,[372] several large clinicopathologic studies from the Armed Forces Institute of Pathology resulted in separation of these categories by location.[344,345,373] For example, as seen in Table 14.4 gastric GISTs that are less than or equal to 2 cm and have a mitotic index of less than or equal to 5/5 mm^2 have essentially no risk of recurrence or metastasis. In addition to these parameters, tumor rupture (either before or during surgery) has also been found to be an adverse prognostic indicator.[374] As one might expect, incomplete tumor resection is associated with a higher risk of recurrence.[375] Although tumors with *PDGFRA* mutations tend not to respond to imatinib therapy as well as those with *KIT* mutations,[376–378] patients with *PDGFRA* mutations seem to have an overall less aggressive clinical course.[379]

Lymphoid Tumors and Tumorlike Conditions

Primary malignant lymphoma of the stomach makes up only a small percentage (about 10%) of all malignant tumors of this organ, but there is evidence that its incidence is increasing. They are regarded as primary gastric tumors if the bulk of the disease is present in the stomach, with or without regional lymph node involvement. Nearly all of the cases are of non-Hodgkin type and the large majority are of B-cell derivation.[380–382] As such, they show monotypic expression of immunoglobulin and rearrangements of the immunoglobulin genes.[383] For practical purposes, they can be divided into two large categories: (1) low-grade lymphomas, composed of small lymphoid cells; and (2) high-grade lymphomas, composed of large cells. Mixed small cell–large cell lymphomas also occur, but they constitute a distinct minority of the cases.

Occasionally, gastric lymphoma of one type or another is seen adjacent to an adenocarcinoma, as an expression of collision tumor.[384] In other instances, the lymphoma precedes a carcinoma by several years.

Table 14.4 Rates of metastases or tumor-related death in GISTs grouped by tumor location, tumor size, and mitotic rate

TUMOR PARAMETERS			PERCENT OF PATIENTS WITH PROGRESSIVE DISEASE DURING LONG-TERM FOLLOW-UP AND CHARACTERIZATION OF RISK (IN PARENTHESES) FOR METASTASES			
GROUP	TUMOR SIZE	MITOTIC RATE	GASTRIC GISTS	JEJUNAL AND ILEAL GISTS	DUODENAL GISTS	RECTAL GISTS
1	≤2cm	≤5/50-HPFs	0% (none)	0% (none)	0% (none)	0% (none)
2	>2cm to ≤5cm	≤5/50-HPFs	1.9% (very low)	4.3% (low)	8.3% (low)	8.5% (low)
3a 3b	>5cm to ≤10cm >10cm	≤5/50-HPFs ≤5/50-HPFs	3.6% (low) 12% (moderate)	24% (moderate) 52% (high)	34% (high)[b]	57% (high)[b]
4	≤2cm	>5/50-HPFs	0%[a]	50%[a]	——[c]	54% (high)
5	>2cm to ≤5cm	>5/50-HPFs	16% (moderate)	73% (high)	50% (high)	52% (high)
6a 6b	>5cm to ≤10cm >10cm	>5/50-HPFs >5/50-HPFs	55% (high) 86% (high)	85% (high) 90% (high)	86% (high)	71% (high)[b]

Adapted from Miettinen M, Lasota J. Semin Diagn Pathol 2006; 23:70-83.
[a]Tumor categories with very few cases.
[b]Groups 3a and 3b, 6a and 6b are combined in duodenal and rectal GISTs because of the small number of cases.
[c]No tumors in this category were included in the study.
Note: Small intestinal and other intestinal GISTs show a markedly worse prognosis in many mitosis and size categories than gastric GISTs.

The Mucosa-Associated Lymphoid Tissue Concept

Mucosa-associated lymphoid tissue (MALT) is the term originally proposed by Isaacson et al. for the component of the immune system that has evolved to protect the freely permeable surface of the gastrointestinal tract and other mucosal membranes directly exposed to the external environment.[385,386] This comprises lymphoid nodules (which in the ileum form the Peyer patches), lymphocytes and plasma cells in the lamina propria, and intraepithelial lymphocytes. The corollary of this concept is that this immune compartment has distinctive morphofunctional features, and that this is also true of the lymphomas arising from it ("MALTomas" or "MALT-type lymphomas").[387] One such feature is their propensity to involve other mucosal sites when they spread, which has been explained by the normal homing pattern of MALT lymphocytes[388]; as part of this scheme, a particular tendency of lymphoma of Waldeyer ring to develop following gastrointestinal lymphoma has been detected.[389]

Originally the concept was applied primarily to small lymphocytic low-grade lesions, but a significant proportion of cases of intermediate/high-grade (large cell) lymphomas appear to have evolved from MALT lymphomas, on the basis of their occasional coexistence, immunohistochemical and molecular similarities, and clonal link.[390] Another interesting corollary of this concept relates to the pathogenesis of gastric lymphoma, as *H. pylori* infection provides the necessary background in which this tumor develops[391,392]; there is idiotype identity between MALT-type lymphoma and the inflammatory component,[393] the lymphoma cells may be antigen responsive,[387] and the lymphoma may regress following eradication of *H. pylori* infection with antibiotics.[394]

A fascinating point of discussion is whether a well-differentiated lymphocytic population in an *H. pylori*-infected stomach, which has a remarkably indolent clinical course and which may even disappear following eradication of the microorganism, deserves to be regarded as a lymphoma, that is, a malignant tumor, because of the fact that it is clonal, bearing in mind that monoclonality is a common finding in the lymphoid follicles of gastritis.[395,396] Lo et al. showed that these lesions may fluctuate between polyclonality, oligoclonality, and monoclonality, and pointed out that *none of them defines an irreversible stage for progression to MALT lymphoma*.[397] Genta expressed a similar feeling very sharply in his witty and thoughtful editorial entitled *"Le lymphome imaginaire."*[398]

Low-Grade Lymphomas

Low-grade lymphomas comprise about half of all gastric lymphomas. They usually occur in individuals over the age of 50 years. Some arise in immunosuppressed patients.[399] The clinical symptoms often simulate those of gastritis or benign peptic ulcer. Grossly, advanced cases may present as giant convolutions mimicking hypertrophic gastritis or gastric polyps.[400] Microscopically, there may be mucosal–submucosal or transmural involvement. Most cases are located in the distal half of the stomach, but the pylorus is involved only rarely. Multicentricity is common, as supported by molecular studies; with progression, dominant clones appear which disseminate throughout the organ.[401]

Microscopically, the large majority of these low-grade tumors are of the so-called "MALT type" (extranodal marginal zone lymphoma) (Figs. 14.47 and 14.48). There is a dense infiltrate of small lymphoid cells, often accompanied by scattered reactive lymphoid follicles. The lymphoid cells include a variable admixture of small lymphocytes, centrocyte-like cells, and monocytoid cells. It is common for them to exhibit focal or extensive plasmacytoid differentiation. Dutcher bodies (true intranuclear eosinophilic inclusions made up of immunoglobulin), when present, are of great diagnostic significance. Despite the high frequency of plasmacytoid features, it is extremely rare for these tumors to be associated with the presence of an M protein in the serum. An important diagnostic sign is the infiltration of the glandular epithelium by the neoplastic lymphocytes, resulting in so-called lymphoepithelial lesions. Reactive lymphoid follicles may be infiltrated or even replaced by neoplastic cells (follicular colonization). Scattered larger neoplastic cells may also be seen. *H. pylori* may be seen in biopsies of the adjacent non-neoplastic mucosa;

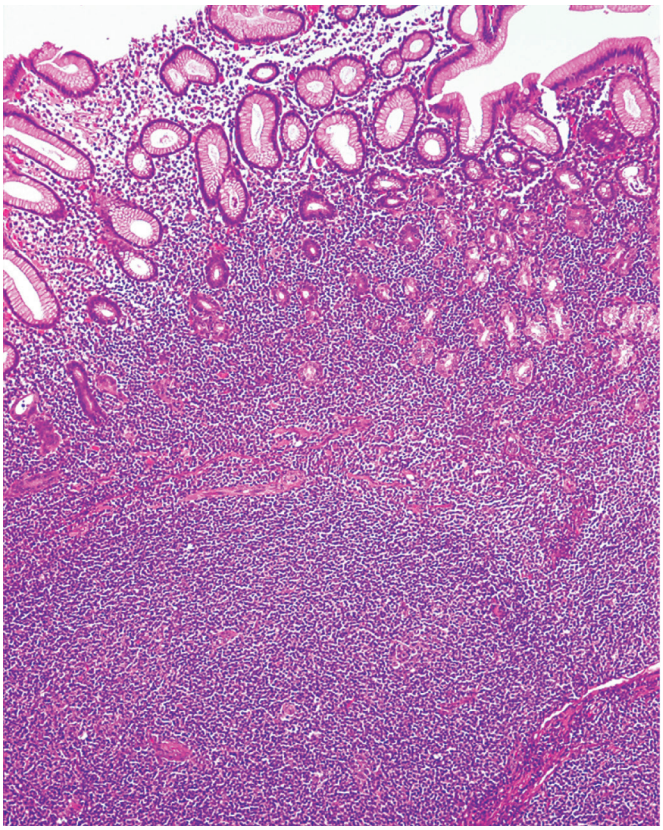

Figure 14.47 MALT-type lymphoma of the stomach involving mucosa and submucosa.

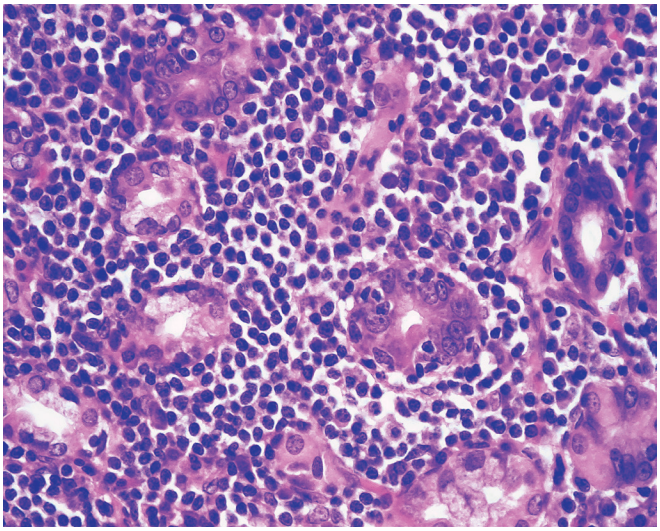

Figure 14.48 High-power view of mucosal involvement by MALT-type lymphoma. A few of the neoplastic lymphocytes are seen within the glandular epithelium (lymphoepithelial lesion).

the ability to find organisms is greatest in superficial lesions and those which are entirely low grade.

By immunohistochemistry, the neoplastic cells stain for CD20 but are negative for CD5, CD10, BCL6, and cyclin D1. They also stain for BCL2. Cytokeratin stains are useful for highlighting the lymphoepithelial lesions. Molecular studies reveal clonal rearrangements of immunoglobulin heavy and light chain genes.

At the molecular level, low-grade MALT-type lymphoma often shows microsatellite instability, allelic imbalance, and trisomies, particularly of chromosome 3; the latter can be detected by fluorescence in situ hybridization (FISH) in paraffin-embedded material.[402] Approximately one-third of the cases have the *API2 (also known as BIRC3)–MALT1* fusion, the result of the t(11;18) translocation, an abnormality that is absent in all other types of gastric lymphoma.[403–405] Gastric MALT lymphomas harboring *API2–MALT1* fusion often comprise a more monotonous cell population than the MALT lymphomas lacking this genetic alteration.[406] This genetic abnormality predicts a lack of response to anti-*Helicobacter* therapy[407] but can apparently protect against transformation to a large B-cell lymphoma.[386] It is also associated with higher-stage disease. Less commonly, these tumors harbor a t(1;14)(t22;q32) involving *BCL10* and *IGH*.[408]

The major diagnostic considerations are distinguishing marginal zone lymphoma from chronic gastritis and other low-grade lymphomas. The presence of cytologic atypia, Dutcher bodies and lymphoepithelial lesions are the most helpful diagnostic clues favoring a lymphoma which can be confirmed by demonstrating monotypic light chain expression as well as a diffuse infiltrate of B cells which coexpress CD43. *Mantle cell lymphoma* is far less common and is composed of a monotonous population of small- to medium-sized B cells that express CD5 and cyclin D1. *Follicular lymphoma* has a more distinct follicular architecture and is composed of more irregular nuclei which express CD10 and BCL6.

Large cell transformation may occur in the background of a marginal zone lymphoma and requires sheets or confluent clusters of large atypical cells (diffuse large B-cell lymphoma).[409] BCL6 highlights the areas of large cell transformation, which portends a worse prognosis.[410]

PCR has been used to demonstrate clonality in paraffin-embedded endoscopic biopsy specimens, but great caution should be exercised in its interpretation, in the sense that the presence of a clonal lymphocytic population does not always imply the existence of a malignant tumor, as indicated previously. It needs to be recognized that, in many instances, it will not be possible to determine with certainty in a gastric biopsy whether one is dealing with a chronic gastritis or a lymphoma.

Low-grade lymphoma is characterized by a very slow clinical evolution, a tendency to remain localized for a long time, and a propensity to involve other mucosal sites when spreading.[411] Regional lymph node involvement is much less frequent than in large cell lymphoma.[412] The treatment is dependent on the stage: antibiotic therapy or extended field radiation therapy for stage I and a combination of radiation therapy and chemotherapy for stages II and III. Approximately 70% of patients with stage I disease are cured.

Large Cell Lymphomas

Large cell lymphomas are usually seen in patients over the age of 50 years, but the age range is wider than for low-grade tumors. Patients may have a large palpable mass and still be in excellent physical condition. Grossly, the tumor usually appears as a large lobulated (sometimes polypoid) mass. Superficial or deep ulceration is common (Fig. 14.49). The gross or radiographic distinction from carcinoma may be very difficult. Like the low-grade form, it has a predilection for the distal half of the stomach, with a tendency to spare the pylorus. Full-thickness invasion of the gastric wall, direct extension to adjacent organs, and involvement of regional and retroperitoneal nodes develop late in the course of the disease. At times, free perforation into the abdominal cavity occurs.

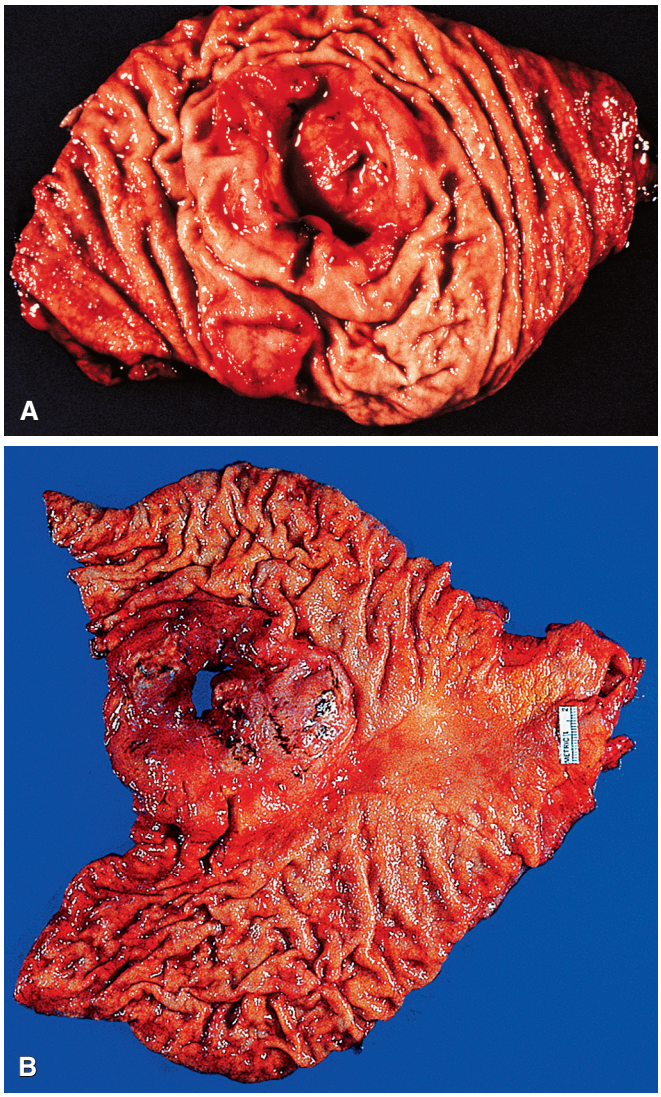

Figure 14.49 **A,** Large cell lymphoma of the stomach presenting as a large ulcerated mass. **B,** Large cell lymphoma of the stomach presenting grossly as a large polypoid mass with central ulceration.

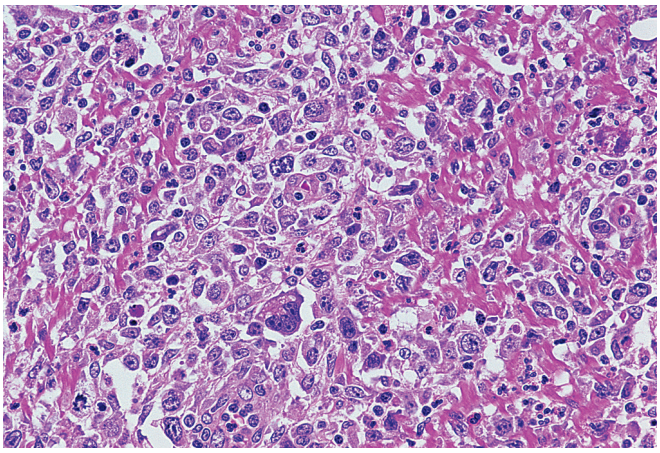

Figure 14.50 High-power view of a large cell lymphoma of the stomach with transmural involvement. The pleomorphism and the presence of multinucleated giant cells may cause confusion with Hodgkin lymphoma.

Large B-cell lymphoma of the stomach constitutes a heterogeneous category.[413] As mentioned previously, many cases represent transformed MALT lymphoma, but the remainder are de novo lymphomas belonging to several different categories.[414–416] A high proportion of large cell lymphomas of the stomach express BCL6 (in contrast to low-grade lymphomas), whether they are thought to be related to MALT lymphoma or not.[417]

Some cases of large B-cell lymphoma of the stomach seen in a setting of immunosuppression (i.e. transplant recipients) and inflammatory bowel disease have been shown to be EBV positive.[418] These tumors seem distinct from conventional gastric large B-cell lymphomas.

Microscopically, most cases of gastric large B-cell lymphoma are composed of cells resembling large noncleaved cells (centroblasts) but with a slightly more abundant cytoplasm, sometimes resulting in a plasmablastic or immunoblastic appearance (Fig. 14.50). Multinucleated cell forms resembling Reed–Sternberg cells may be present. The phenotypic features are those of B cells.

The main microscopic differential diagnosis of large B-cell lymphoma is with undifferentiated carcinoma. Features favoring a diagnosis of lymphoma are the lack of continuity between epithelium and tumor cells, lack of suggestion of an acinar pattern, and preservation of muscularis mucosae fibers. If uncertainties remain, they can be eliminated in nearly every instance with immunohistochemical evaluation using lymphoid and epithelial markers. Another diagnostic consideration is Burkitt lymphoma, which can uncommonly present as a gastric primary.[419]

Following a biopsy diagnosis of large cell lymphoma, exploratory laparotomy with gastric resection and surgical staging is usually indicated.[420] Controversy still exists as to whether postoperative radiation therapy and/or chemotherapy should be given in cases of apparently limited disease, but most authors recommend a combination of radiation therapy and chemotherapy for all stages.[421] The tumor may also be treated with radiation therapy following a biopsy diagnosis, but danger of gastric perforation exists if the tumor involvement is transmural. Distant disease is the most common form of treatment failure.[422]

The prognosis for gastric large B-cell lymphoma is substantially better than for gastric carcinoma. The overall 5-year disease-free survival rate is approximately 65%[423] and is directly related to the stage of the tumor.[424] Favorable prognostic features are small tumor size, superficial mural invasion, presence of low-grade MALT-type areas, and absence of regional lymph node involvement.[424] Some large cell lymphomas run an unusually aggressive course.[425]

Other Types of Lymphoma and Related Conditions

Anaplastic large cell (Ki-1) lymphomas can rarely present as primary gastric neoplasms.[426]

True histiocytic sarcoma is similarly very uncommon.[427]

Plasmacytoma and **multiple myeloma** can involve the stomach,[428] but before making this diagnosis one should rule out the more likely possibility of a malignant lymphoma with plasmacytoid features.

Peripheral T-cell lymphoma has been described, mainly by Japanese authors, sometimes in association with HTLV-1.[429]

Extranodal NK/T-cell lymphoma can involve the stomach as primary disease or part of systemic disease.[430]

Hodgkin lymphoma of the stomach also occurs but is extremely rare[431]; most cases so designated in the past are actually examples of various types of non-Hodgkin lymphoma.

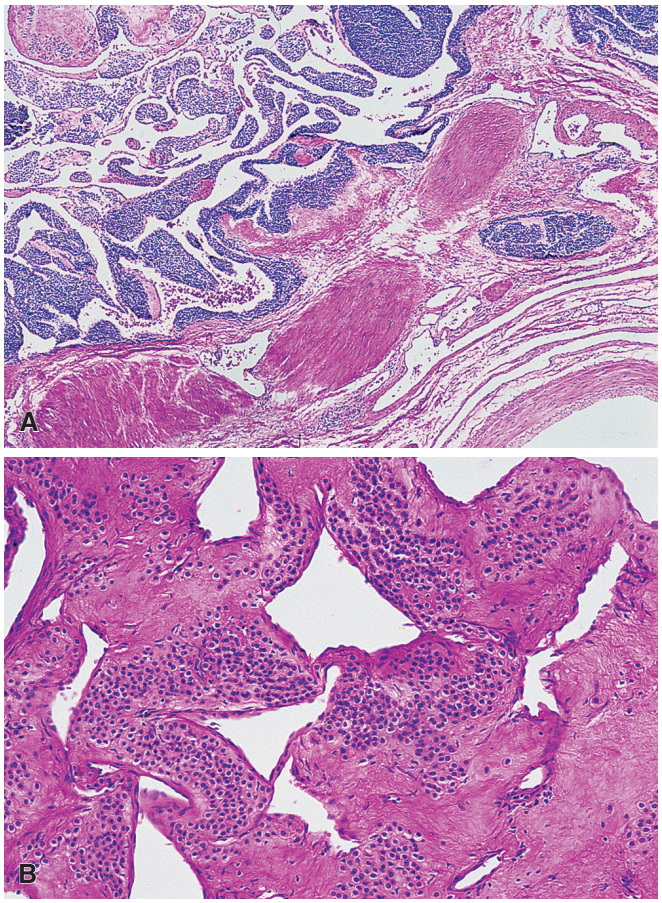

Figure 14.51 **A** and **B,** Two cases of glomus tumor of the stomach. The small size of the round epithelioid cells and the intimate relationship with blood vessels with dilated lumina are characteristic.

Granulocytic sarcoma can occasionally present as a gastric tumor in the absence of bone marrow involvement and be confused with malignant lymphoma or carcinoma.[432]

Langerhans cell histiocytosis may be encountered in the stomach, either as an isolated lesion or in association with disease elsewhere.[113,433] Exceptionally, this infiltrate (which is characteristically immunoreactive for S-100 protein, CD1a, and langerin) has atypical cytologic features.[434]

Other Tumors

Glomus and related tumors (such as **glomangiomyomas**) may arise in the stomach.[435,436] In fact, for some peculiar reason, the stomach is one of the most common extracutaneous sites for this tumor and shows a strong female predominance.[437] Microscopically, the tumors are composed of clear epithelioid cells arranged around dilated vessels (Fig. 14.51). Immunohistochemically, glomus tumors are reactive for actin and calponin and are surrounded by abundant basement membrane material, as demonstrated by type IV collagen and laminin stains. They are negative for desmin, S-100 protein, and CD117.[437] The behavior of this tumor is almost always benign, but one reported case showed multicentricity and extensive intravascular spread,[438] and another resulted in the patient's death from liver metastases.[437]

Lipomas arise within the gastric wall and may protrude into the lumen, resulting in a typical filling defect on radiographic examination.[439] Sometimes they mimic peptic ulcer in their clinical presentation.

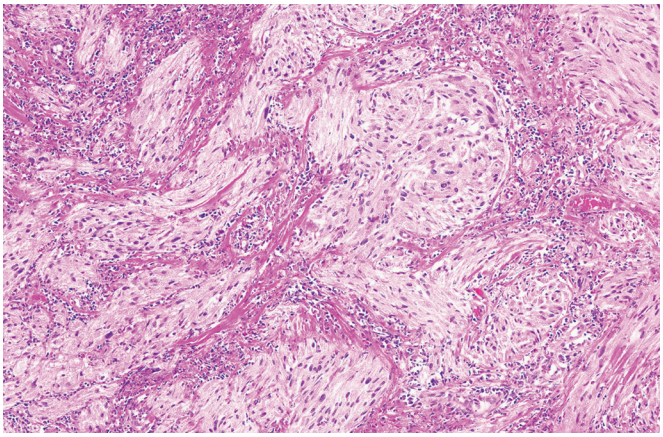

Figure 14.52 Granular cell tumor of the stomach with nests of granular cells.

Granular cell tumors can occur beneath the gastric mucosa (Fig. 14.52): they can be either solitary or multiple and can be associated with similar tumors in other portions of the gastrointestinal tract.[440,441]

Peripheral nerve sheath tumors can occur in the stomach and need to be distinguished from GISTs and other mesenchymal neoplasms. They include *schwannoma*, *neurofibroma*, and *perineurioma*.[439] Some of these tumors have developed in patients with von Recklinghausen disease. As mentioned previously, almost all gastric schwannomas are surrounded by a prominent cuff of lymphocytes, a curious feature rarely if ever seen in their usual soft tissue locations (Fig. 14.53).[442] At the molecular level, gastric schwannomas appear to be different not only from GISTs but also from conventional schwannomas of soft tissues.

Other mesenchymal tumors of the stomach are extremely rare. *Fibromas* and *myxofibromas* have been reported,[443] but most cases so designated are probably examples of other types of mesenchymal neoplasms with secondary regressive changes. Both *inflammatory myofibroblastic tumor*[444] and *calcifying fibrous tumor*[445] can involve the stomach and need to be distinguished from inflammatory fibroid polyp, which is more common.[446] Virtually every other type of sarcoma (e.g. synovial sarcoma, Ewing family of tumors) has been reported in the stomach, but these are described in greater detail elsewhere (see Chapter 41).

Gastroblastoma is the term that has been suggested for a peculiar biphasic epitheliomesenchymal gastric tumor which resembles synovial sarcoma but lacks the classic chromosomal translocation of the latter.[447–450]

Plexiform fibromyxoma is another recently described tumor which is usually located in the antrum and characterized microscopically by a plexiform intramural growth with multiple micronodules containing paucicellular to moderately cellular myxoid, collagenous, and fibromyxoid areas.[451] In contrast with GIST, this tumor is negative for CD117, DOG1, and CD34, showing instead immunoreactivity for smooth muscle actin.[451] This neoplasm had also been described under the designation *plexiform angiomyxoid myofibroblastic tumor.*[452]

Germ cell tumors can arise in the stomach, the two most common forms being *choriocarcinoma* and *yolk sac tumor*. Either can present in a pure form, admixed with each other, or associated with conventional adenocarcinoma (Figs. 14.54 and 14.55).[452,453] The choriocarcinomas show immunohistochemical evidence of hCG production and can be associated with elevated serum levels of this marker.[454] The tumors combined with adenocarcinoma (some of which have arisen in a gastric stump) have been shown to belong to the same clone.[455] Molecular genetic studies in

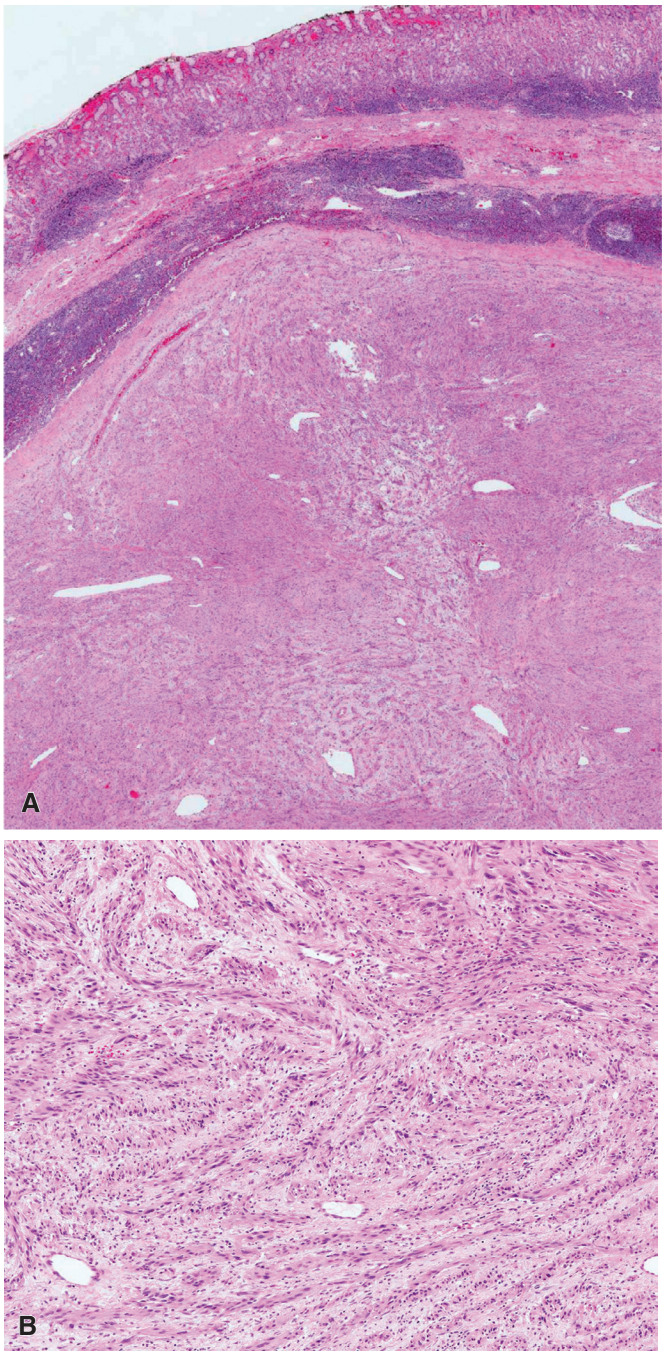

Figure 14.53 **A,** Characteristic low-power view of a gastric schwannoma with a prominent peripheral lymphoid infiltrate. **B,** High-power view showing a trabecular pattern in this gastric schwannoma.

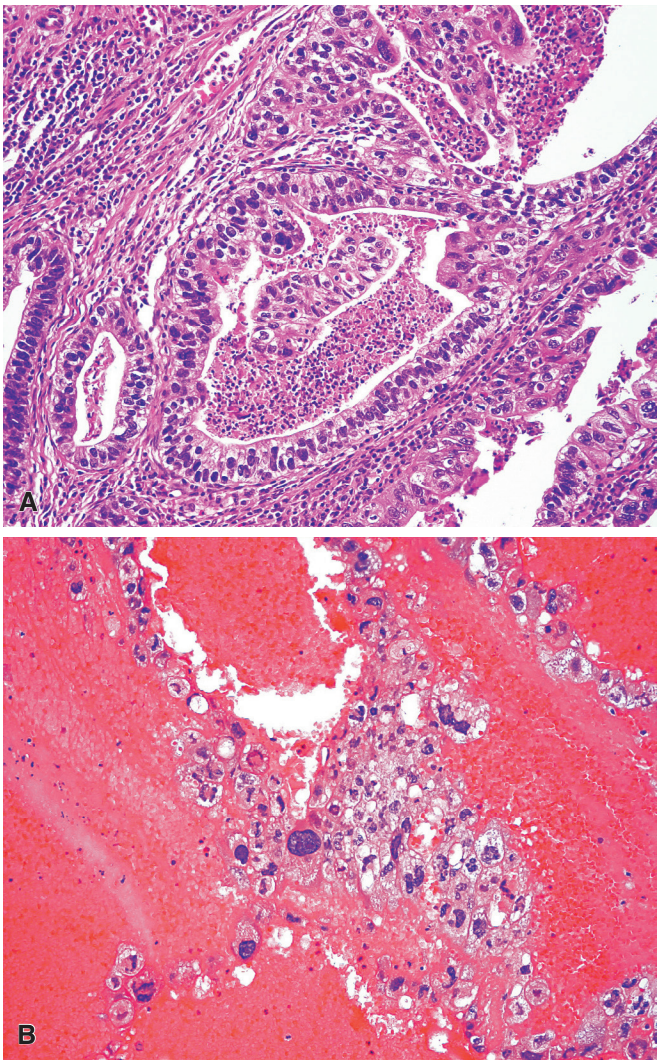

Figure 14.54 **A,** Mixed adenocarcinoma and choriocarcinoma of the stomach, adenocarcinomatous portion. **B,** Choriocarcinomatous portion surrounded by massive hemorrhage.

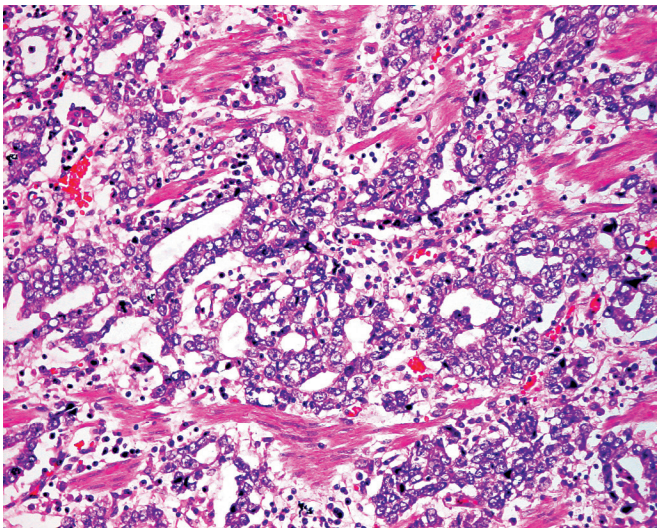

Figure 14.55 Yolk sac tumor of the stomach associated with a high elevation of serum AFP levels.

primary gastric choriocarcinoma have shown aberrations usually associated with gastric adenocarcinomas combined with others commonly seen with gestational choriocarcinoma, suggesting that this tumor represents an alternative differentiation pathway of adenocarcinoma.[456]

Metastatic carcinoma may develop in the stomach from any widely disseminated neoplasm, particularly from the breast and lung.[457,458] Endoscopically, some of these lesions have been described as having a characteristic volcano-like ulcerative appearance.[457] Metastases to the stomach from lobular carcinoma of the breast can

look indistinguishable from primary diffuse carcinoma of this organ ("linitis plastica") (Fig. 14.56). It has been said that, in the United States (considering the high frequency of breast carcinoma and the low frequency of gastric carcinoma), the occurrence of a linitis plastica-type appearance in the stomach is more likely to be due to metastatic mammary lobular carcinoma than to a primary tumor of this organ. The presence of tumor cells with a bull's-eye appearance (indicative of intracellular lumina), immunoreactivity for hormone receptors, GCDFP-15, and GATA3, and loss of E-cadherin favor metastatic breast carcinoma, whereas positivity for cytokeratin 20, DAS-1, MUC2, MUC5AC, MUC6, and CDX2 favors a gastric primary.[459–461]

Another malignant tumor that may metastasize to the stomach as part of its systemic spread is malignant melanoma.[462] As is always the case, it may simulate microscopically a variety of other lesions, including carcinoma, lymphoma and sarcomas.

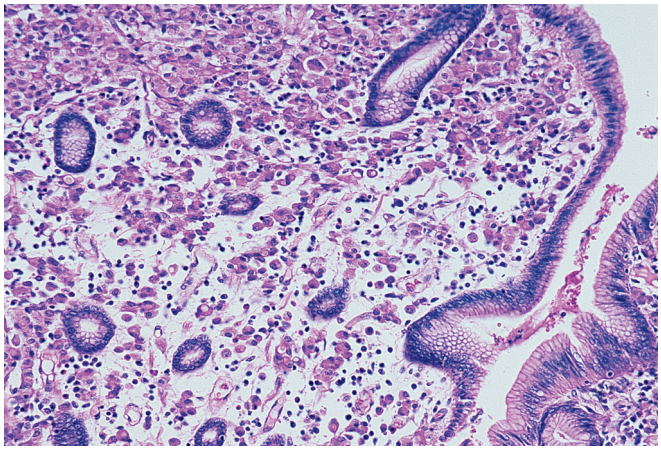

Figure 14.56 Lobular Carcinoma of the Breast Metastatic to Stomach. The tumor cells grow in a diffuse fashion within the lamina propria mimicking the pattern of growth of a primary diffuse-type adenocarcinoma of the stomach. Some of the cells even have a signet ring appearance.

References

1. Rubio CA. Five types of pyloric cells in the antral mucosa of the stomach. *Pathol Res Pract*. 1992;188(1-2):157-161.
2. Thompson IW, Day DW, Wright NA. Subnuclear vacuolated mucous cells: a novel abnormality of simple mucin-secreting cells of non-specialized gastric mucosa and Brunner's glands. *Histopathology*. 1987;11(10):1067-1081.
3. Rubio C, Hirota T, Itabashi M, et al. A possible error in the interpretation of gastric carcinoma. *Jpn J Cancer Res*. 1991;82(12):1354-1355.
4. Rubio CA, Stemmermann GN, Hayashi T. Ciliated gastric cells among Japanese living in Hawaii. *Jpn J Cancer Res*. 1991;82(1):86-89.
5. Sano J, Miki K, Ichinose M, et al. In situ localization of pepsinogens I and II mRNA in human gastric mucosa. *Acta Pathol Jpn*. 1989;39(12):765-771.
6. Chandrasoma P. Controversies of the cardiac mucosa and Barrett's oesophagus. *Histopathology*. 2005;46(4):361-373.
7. Kilgore SP, Ormsby AH, Gramlich TL, et al. The gastric cardia: fact or fiction? *Am J Gastroenterol*. 2000;95(4):921-924.
8. Silva E, Teixeira A, David L, et al. Mucins as key molecules for the classification of intestinal metaplasia of the stomach. *Virchows Arch*. 2002;440(3):311-317.
9. Pinto-de-Sousa J, David L, Reis CA, et al. Mucins MUC1, MUC2, MUC5AC and MUC6 expression in the evaluation of differentiation and clinico-biological behaviour of gastric carcinoma. *Virchows Arch*. 2002;440(3):304-310.
10. Lewin KJ. The endocrine cells of the gastrointestinal tract. The normal endocrine cells and their hyperplasias. Part I. *Pathol Annu*. 1986;21(Pt 1):1-27.
11. Solcia E, Rindi G, Silini E, Villani L. Enterochromaffin-like (ECL) cells and their growths: relationships to gastrin, reduced acid secretion and gastritis. *Baillières Clin Gastroenterol*. 1993;7(1):149-165.
12. Carney JA. Gastric mucosal lymphoid follicles: histology, distribution, frequency, and etiologic features. *Am J Surg Pathol*. 2010;34(7):1019-1024.
13. Filip R, Walczak E, Huk J, et al. Heterotopic pancreatic tissue in the gastric cardia: a case report and literature review. *World J Gastroenterol*. 2014;20(44):16779-16781.
14. Oka R, Okai T, Kitakata H, Ohta T. Heterotopic pancreas with calcification: a lesion mimicking leiomyosarcoma of the stomach. *Gastrointest Endosc*. 2002;56(6):939-942.
15. Lemaire J, Delaunoit T, Molle G. Adenocarcinoma arising in gastric heterotopic pancreas. Case report and review of the literature. *Acta Chir Belg*. 2014;114(1):79-81.
16. Lee H, Tang LH, Veras EF, Klimstra DS. The prevalence of pancreatic acinar differentiation in gastric adenocarcinoma: report of a case and immunohistochemical study of 111 additional cases. *Am J Surg Pathol*. 2012;36(3):402-408.
17. Doglioni C, Laurino L, Dei Tos AP, et al. Pancreatic (acinar) metaplasia of the gastric mucosa. Histology, ultrastructure, immunocytochemistry, and clinicopathologic correlations of 101 cases. *Am J Surg Pathol*. 1993;17(11):1134-1143.
18. Min S-H, Kim H-Y, Kim S-H, et al. Gastric adenomyoma mimicking gastric duplication cyst in a 5-year-old girl. *J Pediatr Surg*. 2012;47(5):1019-1022.
19. Kneafsey PD, Demetrick DJ. Malignant transformation in a pyloric adenomyoma: a case report. *Histopathology*. 1992;20(5):433-435.
20. Gezer HÖ, Oguzkurt P, Temiz A, Hicsonmez A. Hypertrophic pyloric stenosis in twins; genetic or environmental factors. *Clin Genet*. 2015;87(4):388-391.
21. Peters B, Oomen MWN, Bakx R, Benninga MA. Advances in infantile hypertrophic pyloric stenosis. *Expert Rev Gastroenterol Hepatol*. 2014;8(5):533-541.
22. Panteli C. New insights into the pathogenesis of infantile pyloric stenosis. *Pediatr Surg Int*. 2009;25(12):1043-1052.
23. Acker SN, Garcia AJ, Ross JT, Somme S. Current trends in the diagnosis and treatment of pyloric stenosis. *Pediatr Surg Int*. 2015;31(4):363-366.
24. Batcup G, Spitz L. A histopathological study of gastric mucosal biopsies in infantile hypertrophic pyloric stenosis. *J Clin Pathol*. 1979;32(6):625-628.
25. Al-Salem AH, Abdulla MR, Kothari MR, Naga MI. Congenital pyloric atresia, presentation, management, and outcome: a report of 20 cases. *J Pediatr Surg*. 2014;49(7):1078-1082.
26. Gurvits GE, Tan A, Volkov D. Video capsule endoscopy and CT enterography in diagnosing adult hypertrophic pyloric stenosis. *World J Gastroenterol*. 2013;19(37):6292-6295.
27. Zarineh A, Leon ME, Saad RS, Silverman JF. Idiopathic hypertrophic pyloric stenosis in an adult, a potential mimic of gastric carcinoma. *Patholog Res Int*. 2010;2010:614280.
28. Krasinskas AM, Abraham SC, Metz DC, Furth EE. Oxyntic mucosa pseudopolyps: a presentation of atrophic autoimmune gastritis. *Am J Surg Pathol*. 2003;27(2):236-241.
29. Xin W, Greenson JK. The clinical significance of focally enhanced gastritis. *Am J Surg Pathol*. 2004;28(10):1347-1351.
30. Stemmermann GN. Intestinal metaplasia of the stomach. A status report. *Cancer*. 1994;74(2):556-564.
31. Jass JR, Filipe MI. The mucin profiles of normal gastric mucosa, intestinal metaplasia and its variants and gastric carcinoma. *Histochem J*. 1981;13(6):931-939.
32. Vernygorodskyi S. Immunohistochemical evaluation of mucin expression in precancerous tissue of stomach. *Exp Oncol*. 2013;35(2):114-117.
33. Ota H, Katsuyama T, Nakajima S, et al. Intestinal metaplasia with adherent *Helicobacter pylori*: a hybrid epithelium with both gastric and intestinal features. *Hum Pathol*. 1998;29(8):846-850.
34. Segura DI, Montero C. Histochemical characterization of different types of intestinal metaplasia in gastric mucosa. *Cancer*. 1983;52(3):498-503.
35. Matsukura N, Suzuki K, Kawachi T, et al. Distribution of marker enzymes and mucin in intestinal metaplasia in human stomach and relation to complete and incomplete types of intestinal metaplasia to minute gastric carcinomas. *J Natl Cancer Inst*. 1980;65(2):231-240.
36. Owen DA. Gastritis and carditis. *Mod Pathol*. 2003;16(4):325-341.
37. Eidt S, Oberhuber G, Schneider A, Stolte M. The histopathological spectrum of type A gastritis. *Pathol Res Pract*. 1996;192(2):101-106.
38. Park YH, Kim N. Review of atrophic gastritis and intestinal metaplasia as a premalignant lesion of gastric cancer. *J Cancer Prev*. 2015;20(1):25-40.

39. Varbanova M, Frauenschläger K, Malfertheiner P. Chronic gastritis: an update. *Best Pract Res Clin Gastroenterol*. 2014;28(6):1031-1042.
40. Jevremovic D, Torbenson M, Murray JA, et al. Atrophic autoimmune pangastritis: a distinctive form of antral and fundic gastritis associated with systemic autoimmune disease. *Am J Surg Pathol*. 2006;30(11): 1412-1419.
41. Nomura S, Terao S, Adachi K, et al. Endoscopic diagnosis of gastric mucosal activity and inflammation. *Dig Endosc*. 2013;25(2):136-146.
42. Sipponen P, Price AB. The Sydney System for classification of gastritis 20 years ago. *J Gastroenterol Hepatol*. 2011;26(suppl 1):31-34.
43. Quach DT, Le HM, Hiyama T, et al. Relationship between endoscopic and histologic gastric atrophy and intestinal metaplasia. *Helicobacter*. 2013;18(2):151-157.
44. Chan WY, Hui PK, Leung KM, Thomas TM. Modes of Helicobacter colonization and gastric epithelial damage. *Histopathology*. 1992;21(6):521-528.
45. Hui PK, Chan WY, Cheung PS, et al. Pathologic changes of gastric mucosa colonized by *Helicobacter pylori*. *Hum Pathol*. 1992;23(5):548-556.
46. Anim JT, Al-Sobkie N, Prasad A, et al. Assessment of different methods for staining *Helicobacter pylori* in endoscopic gastric biopsies. *Acta Histochem*. 2000;102(2):129-137.
47. Wyatt JI. Gastritis and its relation to gastric carcinogenesis. *Semin Diagn Pathol*. 1991;8(3):137-148.
48. Price AB. The Sydney System: histological division. *J Gastroenterol Hepatol*. 1991;6(3):209-222.
49. Dixon MF, Genta RM, Yardley JH, Correa P. Classification and grading of gastritis. The updated Sydney System. International Workshop on the Histopathology of Gastritis, Houston 1994. *Am J Surg Pathol*. 1996;20(10):1161-1181.
50. Genta RM. Differential diagnosis of reactive gastropathy. *Semin Diagn Pathol*. 2005;22(4):273-283.
51. Winawer SJ, Bejar J, McCray RS, Zamcheck N. Hemorrhagic gastritis. Importance of associated chronic gastritis. *Arch Intern Med*. 1971;127(1):129-131.
52. Ali T, Roberts DN, Tierney WM. Long-term safety concerns with proton pump inhibitors. *Am J Med*. 2009;122(10):896-903.
53. Ruiz AR, Borum ML. Cytomegalovirus hemorrhagic gastritis. *AIDS Patient Care STDS*. 2001;15(1):1-5.
54. Patwardhan VR, Cardenas A. Review article: the management of portal hypertensive gastropathy and gastric antral vascular ectasia in cirrhosis. *Aliment Pharmacol Ther*. 2014;40(4):354-362.
55. Kamimura K, Kobayashi M, Sato Y, et al. Collagenous gastritis: review. *World J Gastrointest Endosc*. 2015;7(3):265-273.
56. Jin X, Koike T, Chiba T, et al. Collagenous gastritis. *Dig Endosc*. 2013;25(5):547-549.
57. Lagorce-Pages C, Fabiani B, Bouvier R, et al. Collagenous gastritis: a report of six cases. *Am J Surg Pathol*. 2001;25(9):1174-1179.
58. Polydorides AD. Pathology and differential diagnosis of chronic, noninfectious gastritis. *Semin Diagn Pathol*. 2014;31(2):114-123.
59. Kim MJ, Eom DW, Park K. *Helicobacter pylori* associated lymphocytic gastritis in a child. *Pediatr Gastroenterol Hepatol Nutr*. 2014;17(3):186-190.
60. Wu TT, Hamilton SR. Lymphocytic gastritis: association with etiology and topology. *Am J Surg Pathol*. 1999;23(2):153-158.
61. Rothenberg ME. Eosinophilic gastrointestinal disorders (EGID). *J Allergy Clin Immunol*. 2004;113(1):11-28, quiz 29.
62. Yantiss RK. Eosinophils in the GI tract: how many is too many and what do they mean? *Mod Pathol*. 2015;28(suppl 1):S7-S21.
63. Walker NI, Croese J, Clouston AD, et al. Eosinophilic enteritis in northeastern Australia. Pathology, association with *Ancylostoma caninum*, and implications. *Am J Surg Pathol*. 1995;19(3):328-337.
64. López Caleya JF, Martín Rodrigo L, Mohammed Mourad F, et al. Gastric tuberculosis. Review apropos of a case. *Gastroenterol Hepatol*. 2007;30(6):334-337.
65. Dulai PS, Rothstein RI. Disseminated sarcoidosis presenting as granulomatous gastritis: a clinical review of the gastrointestinal and hepatic manifestations of sarcoidosis. *J Clin Gastroenterol*. 2012;46(5):367-374.
66. O'Donovan C, Murray J, Staunton H, et al. Granulomatous gastritis: part of a vasculitic syndrome. *Hum Pathol*. 1991;22(10):1057-1059.
67. Shapiro JL, Goldblum JR, Petras RE. A clinicopathologic study of 42 patients with granulomatous gastritis. Is there really an "idiopathic" granulomatous gastritis? *Am J Surg Pathol*. 1996;20(4):462-470.
68. Kim K, Kim EJ, Kim M-J, et al. Clinicopathological features of syphilitic gastritis in Korean patients. *Pathol Int*. 2009;59(12):884-889.
69. Adachi K. Syphilitic gastritis mimicking gastric neoplasms. *Dig Liver Dis*. 2011;43(9):748.
70. Inagaki H, Kawai T, Miyata M, et al. Gastric syphilis: polymerase chain reaction detection of treponemal DNA in pseudolymphomatous lesions. *Hum Pathol*. 1996;27(8):761-765.
71. Cid PM, Cudós ES, Zamora Vargas FX, et al. Pathologically confirmed malignant syphilis using immunohistochemical staining: report of 3 cases and review of the literature. *Sex Transm Dis*. 2014;41(2):94-97.
72. Kim JB, Han DS, Lee HL, et al. Malacoplakia of the stomach: case report and review. *Gastrointest Endosc*. 2003;58(3):441-445.
73. Okubo H, Nagata N, Uemura N. Fulminant gastrointestinal graft-versus-host disease concomitant with cytomegalovirus infection: case report and literature review. *World J Gastroenterol*. 2013;19(4):597-603.
74. Howaizi M, Abboura M, Sbai-Idrissi MS, et al. Cytomegalovirus-associated perforated gastric ulcer healing under antiviral therapy. *Dig Dis Sci*. 2002;47(10):2380-2382.
75. Mills AM, Guo FP, Copland AP, et al. A comparison of CMV detection in gastrointestinal mucosal biopsies using immunohistochemistry and PCR performed on formalin-fixed, paraffin-embedded tissue. *Am J Surg Pathol*. 2013;37(7):995-1000.
76. Sundar R, Rao L, Vasudevan G, et al. Gastric cryptococcal infection as an initial presentation of AIDS: a rare case report. *Asian Pac J Trop Med*. 2011;4(1):79-80.
77. Chetty R, Sabaratnam RM. Upper gastrointestinal bacillary angiomatosis causing hematemesis: a case report. *Int J Surg Pathol*. 2003;11(3):241-244.
78. Velasco-Guardado A, López-Corral L, Alvarez-Delgado A, et al. Endoscopic evaluation and histological findings in graft-versus-host disease. *Rev Esp Enferm Dig*. 2012;104(6):310-314.
79. Washington K, Bentley RC, Green A, et al. Gastric graft-versus-host disease: a blinded histologic study. *Am J Surg Pathol*. 1997;21(9):1037-1046.
80. Testerman TL, Morris J. Beyond the stomach: an updated view of *Helicobacter pylori* pathogenesis, diagnosis, and treatment. *World J Gastroenterol*. 2014;20(36): 12781-12808.
81. Chan FKL, Leung WK. Peptic-ulcer disease. *Lancet*. 2002;360(9337):933-941.
82. Sipponen P, Hyvärinen H. Role of *Helicobacter pylori* in the pathogenesis of gastritis, peptic ulcer and gastric cancer. *Scand J Gastroenterol Suppl*. 1993;196:3-6.
83. Feinman M, Haut ER. Upper gastrointestinal bleeding. *Surg Clin North Am*. 2014;94(1):43-53.
84. Kwee WS, Wils JA, Schlangen J, et al. Gastric epithelial atypia complicating hepatic arterial infusion chemotherapy. *Histopathology*. 1994;24(2):151-154.
85. Petras RE, Hart WR, Bukowski RM. Gastric epithelial atypia associated with hepatic arterial infusion chemotherapy. Its distinction from early gastric carcinoma. *Cancer*. 1985;56(4):745-750.
86. Yang MH, Lee JH, Choi MS, et al. Gastrointestinal complications after radiation therapy in patients with hepatocellular carcinoma. *Hepatogastroenterology*. 2005;52(66):1759-1763.
87. Sipponen P, Maaroos H-I. Chronic gastritis. *Scand J Gastroenterol*. 2015;1-11.
88. Hagymási K, Tulassay Z. *Helicobacter pylori* infection: new pathogenetic and clinical aspects. *World J Gastroenterol*. 2014;20(21):6386-6399.
89. Lundell L. Acid secretion and gastric surgery. *Dig Dis*. 2011;29(5):487-490.
90. Carachi R, Azmy A. Foregut duplications. *Pediatr Surg Int*. 2002;18(5-6):371-374.
91. Hajini FF, Husain M, Bhat A, Bukhari SI. Gastric diverticulum a rare endoscopic finding. *BMJ Case Rep*. 2014;2014.
92. Rubio CA. Intramucosal gastric cysts simulating submucosal cysts. *Pathol Res Pract*. 1989;184(4):418-421.
93. Xu G, Peng C, Li X, et al. Endoscopic resection of gastritis cystica profunda: preliminary experience with 34 patients from a single center in China. *Gastrointest Endosc*. 2015;81(6):1493-1498.
94. Machicado J, Shroff J, Quesada A, et al. Gastritis cystica profunda: endoscopic ultrasound findings and review of the literature. *Endosc Ultrasound*. 2014;3(2):131-134.
95. Iwamuro M, Okada H, Matsueda K, et al. Review of the diagnosis and management of gastrointestinal bezoars. *World J Gastrointest Endosc*. 2015;7(4):336-345.
96. Kim JS, Nam CW. A case of rapunzel syndrome. *Pediatr Gastroenterol Hepatol Nutr*. 2013;16(2):127-130.
97. Ladas SD, Kamberoglou D, Karamanolis G, et al. Systematic review: Coca-Cola can effectively dissolve gastric phytobezoars as a first-line treatment. *Aliment Pharmacol Ther*. 2013;37(2):169-173.
98. Kement M, Ozlem N, Colak E, et al. Synergistic effect of multiple predisposing risk factors on the development of bezoars. *World J Gastroenterol*. 2012;18(9):960-964.
99. Batouli A, Kazemi A, Hartman MS, et al. Dieulafoy lesion: CT diagnosis of this lesser-known cause of gastrointestinal bleeding. *Clin Radiol*. 2015;70(6): 661-666.
100. Senger J-L, Kanthan R. The evolution of Dieulafoy's lesion since 1897: then and now-a journey through the lens of a pediatric lesion with literature review. *Gastroenterol Res Pract*. 2012;2012:432517.
101. Mower GA, Whitehead R. Gastric hemorrhage due to ruptured arteriovenous malformation (Dieulafoy's disease). *Pathology*. 1986;18(1):54-57.
102. Swanson E, Mahgoub A, MacDonald R, Shaukat A. Medical and endoscopic therapies for angiodysplasia and gastric antral vascular ectasia: a systematic review. *Clin Gastroenterol Hepatol*. 2014;12(4):571-582.
103. Stotzer P-O, Willén R, Kilander AF. Watermelon stomach: not only an antral

disease. *Gastrointest Endosc*. 2002;55(7):897-900.
104. Suit PF, Petras RE, Bauer TW, Petrini JL. Gastric antral vascular ectasia. A histologic and morphometric study of "the watermelon stomach.". *Am J Surg Pathol*. 1987;11(10):750-757.
105. Tanaka H, Baba Y, Sase T, et al. Gastric intramucosal adenocarcinoma with an invasive micropapillary carcinoma component. *Clin J Gastroenterol*. 2015;8(1):14-17.
106. Ludvíková M, Michal M, Datková D. Gastric xanthelasma associated with diffuse signet ring carcinoma. A potential diagnostic problem. *Histopathology*. 1994;25(6):581-582.
107. Spinzi G, Strocchi E, Imperiali G, et al. Pseudoxanthoma elasticum: a rare cause of gastrointestinal bleeding. *Am J Gastroenterol*. 1996;91(8):1631-1634.
108. Hobbs CM, Burch DM, Sobin LH. Elastosis and elastofibromatous change in the gastrointestinal tract: a clinicopathologic study of 13 cases and a review of the literature. *Am J Clin Pathol*. 2004;122(2):232-237.
109. Greenson JK, Trinidad SB, Pfeil SA, et al. Gastric mucosal calcinosis. Calcified aluminum phosphate deposits secondary to aluminum-containing antacids or sucralfate therapy in organ transplant patients. *Am J Surg Pathol*. 1993;17(1):45-50.
110. Marginean EC, Bennick M, Cyczk J, et al. Gastric siderosis: patterns and significance. *Am J Surg Pathol*. 2006;30(4):514-520.
111. Jensen K, Raynor S, Rose SG, et al. Amyloid tumors of the gastrointestinal tract: a report of two cases and review of the literature. *Am J Gastroenterol*. 1985;80(10):784-786.
112. Marek J, Jurek K. Comparative light microscopical and X-ray microanalysis study of barium granuloma. *Pathol Res Pract*. 1981;171(3-4):293-302.
113. Lee CK, Lee SH, Cho HD. Localized Langerhans cell histiocytosis of the stomach treated by endoscopic submucosal dissection. *Endoscopy*. 2011;43(suppl 2):E268-E269.
114. Rivasi F, Pampiglione S, Boldorini R, Cardinale L. Histopathology of gastric and duodenal *Strongyloides stercoralis* locations in fifteen immunocompromised subjects. *Arch Pathol Lab Med*. 2006;130(12):1792-1798.
115. Lauwers GY, Perez-Atayde A, Dorfman RF, Rosai J. The digestive system manifestations of Rosai-Dorfman disease (sinus histiocytosis with massive lymphadenopathy): review of 11 cases. *Hum Pathol*. 2000;31(3):380-385.
116. Oberhuber G, Stolte M. Gastric polyps: an update of their pathology and biological significance. *Virchows Arch*. 2000;437(6):581-590.
117. Abraham SC, Singh VK, Yardley JH, Wu TT. Hyperplastic polyps of the stomach: associations with histologic patterns of gastritis and gastric atrophy. *Am J Surg Pathol*. 2001;25(4):500-507.
118. Jewell KD, Toweill DL, Swanson PE, et al. Gastric hyperplastic polyps in post transplant patients: a clinicopathologic study. *Mod Pathol*. 2008;21(9):1108-1112.
119. Laxén F, Sipponen P, Ihamäki T, et al. Gastric polyps: their morphological and endoscopical characteristics and relation to gastric carcinoma. *Acta Pathol Microbiol Immunol Scand [A]*. 1982;90(3):221-228.
120. Stemmermann GN, Hayashi T. Hyperplastic polyps of the gastric mucosa adjacent to gastroenterostomy stomas. *Am J Clin Pathol*. 1979;71(3):341-345.
121. Mizuguchi Y, Takei K, Matsubayashi J, et al. Mucin phenotypes and macroscopic shape of multiple hyperplastic polyps together with two carcinomas in the stomach. *Hepatogastroenterology*. 2012;59(114): 659-663.
122. Dirschmid K, Walser J, Hügel H. Pseudomalignant erosion in hyperplastic gastric polyps. *Cancer*. 1984;54(10):2290-2293.
123. Orlowska J, Jarosz D, Pachlewski J, Butruk E. Malignant transformation of benign epithelial gastric polyps. *Am J Gastroenterol*. 1995;90(12):2152-2159.
124. Murakami K, Mitomi H, Yamashita K, et al. p53, but not c-Ki-ras, mutation and down-regulation of p21WAF1/CIP1 and cyclin D1 are associated with malignant transformation in gastric hyperplastic polyps. *Am J Clin Pathol*. 2001;115(2):224-234.
125. Yao T, Kajiwara M, Kuroiwa S, et al. Malignant transformation of gastric hyperplastic polyps: alteration of phenotypes, proliferative activity, and p53 expression. *Hum Pathol*. 2002;33(10):1016-1022.
126. Abraham SC, Park SJ, Lee J-H, et al. Genetic alterations in gastric adenomas of intestinal and foveolar phenotypes. *Mod Pathol*. 2003;16(8):786-795.
127. Abraham SC, Montgomery EA, Singh VK, et al. Gastric adenomas: intestinal-type and gastric-type adenomas differ in the risk of adenocarcinoma and presence of background mucosal pathology. *Am J Surg Pathol*. 2002;26(10):1276-1285.
128. Ito H, Yasui W, Yoshida K, et al. Depressed tubular adenoma of the stomach: pathological and immunohistochemical features. *Histopathology*. 1990;17(5):419-426.
129. Lee J-H, Abraham SC, Kim H-S, et al. Inverse relationship between APC gene mutation in gastric adenomas and development of adenocarcinoma. *Am J Pathol*. 2002;161(2):611-618.
130. Vieth M, Kushima R, Borchard F, Stolte M. Pyloric gland adenoma: a clinico-pathological analysis of 90 cases. *Virchows Arch*. 2003;442(4):317-321.
131. Chen Z-M, Scudiere JR, Abraham SC, Montgomery E. Pyloric gland adenoma: an entity distinct from gastric foveolar type adenoma. *Am J Surg Pathol*. 2009;33(2):186-193.
132. Vieth M, Kushima R, Mukaisho K, et al. Immunohistochemical analysis of pyloric gland adenomas using a series of Mucin 2, Mucin 5AC, Mucin 6, CD10, Ki67 and p53. *Virchows Arch*. 2010;457(5):529-536.
133. Dumoulin FL, Abel J, Zumfelde P, et al. Endoscopic resection of a rare gastric adenoma (pyloric gland adenoma) with transition into a well-differentiated adenocarcinoma. *Z Für Gastroenterol*. 2012;50(4):393-395.
134. Singhi AD, Lazenby AJ, Montgomery EA. Gastric adenocarcinoma with chief cell differentiation: a proposal for reclassification as oxyntic gland polyp/adenoma. *Am J Surg Pathol*. 2012;36(7):1030-1035.
135. Ueyama H, Yao T, Nakashima Y, et al. Gastric adenocarcinoma of fundic gland type (chief cell predominant type): proposal for a new entity of gastric adenocarcinoma. *Am J Surg Pathol*. 2010;34(5):609-619.
136. Kinoshita Y, Tojo M, Yano T, et al. Incidence of fundic gland polyps in patients without familial adenomatous polyposis. *Gastrointest Endosc*. 1993;39(2):161-163.
137. Torbenson M, Lee J-H, Cruz-Correa M, et al. Sporadic fundic gland polyposis: a clinical, histological, and molecular analysis. *Mod Pathol*. 2002;15(7):718-723.
138. Lee RG, Burt RW. The histopathology of fundic gland polyps of the stomach. *Am J Clin Pathol*. 1986;86(4):498-503.
139. Declich P, Bellone S, Ambrosiani L, et al. Fundic gland polyps: do they arise as a by-product of hypergastrinemia in patients with Zollinger-Ellison syndrome? *Hum Pathol*. 2000;31(7):889-890.
140. Choung RS, Talley NJ. Epidemiology and clinical presentation of stress-related peptic damage and chronic peptic ulcer. *Curr Mol Med*. 2008;8(4):253-257.
141. Arnason T, Liang W-Y, Alfaro E, et al. Morphology and natural history of familial adenomatous polyposis-associated dysplastic fundic gland polyps. *Histopathology*. 2014;65(3):353-362.
142. Bianchi LK, Burke CA, Bennett AE, et al. Fundic gland polyp dysplasia is common in familial adenomatous polyposis. *Clin Gastroenterol Hepatol*. 2008;6(2):180-185.
143. Abraham SC, Nobukawa B, Giardiello FM, et al. Sporadic fundic gland polyps: common gastric polyps arising through activating mutations in the beta-catenin gene. *Am J Pathol*. 2001;158(3):1005-1010.
144. Abraham SC, Nobukawa B, Giardiello FM, et al. Fundic gland polyps in familial adenomatous polyposis: neoplasms with frequent somatic adenomatous polyposis coli gene alterations. *Am J Pathol*. 2000;157(3):747-754.
145. Gonzalez-Obeso E, Fujita H, Deshpande V, et al. Gastric hyperplastic polyps: a heterogeneous clinicopathologic group including a distinct subset best categorized as mucosal prolapse polyp. *Am J Surg Pathol*. 2011;35(5):670-677.
146. Wood LD, Salaria SN, Cruise MW, et al. Upper GI tract lesions in familial adenomatous polyposis (FAP): enrichment of pyloric gland adenomas and other gastric and duodenal neoplasms. *Am J Surg Pathol*. 2014;38(3):389-393.
147. Song SH, Kim KW, Kim WH, et al. Gastrointestinal cancers in a peutz-jeghers syndrome family: a case report. *Clin Endosc*. 2013;46(5):572-575.
148. Lam-Himlin D, Park JY, Cornish TC, et al. Morphologic characterization of syndromic gastric polyps. *Am J Surg Pathol*. 2010;34(11):1656-1662.
149. Hizawa K, Iida M, Matsumoto T, et al. Cancer in Peutz-Jeghers syndrome. *Cancer*. 1993;72(9):2777-2781.
150. Ma C, Giardiello FM, Montgomery EA. Upper tract juvenile polyps in juvenile polyposis patients: dysplasia and malignancy are associated with foveolar, intestinal, and pyloric differentiation. *Am J Surg Pathol*. 2014;38(12):1618-1626.
151. Slavik T, Montgomery EA. Cronkhite–Canada syndrome six decades on: the many faces of an enigmatic disease. *J Clin Pathol*. 2014;67(10):891-897.
152. Aytac E, Sulu B, Heald B, et al. Genotype-defined cancer risk in juvenile polyposis syndrome. *Br J Surg*. 2015;102(1):114-118.
153. Ha M, Chung JW, Hahm KB, et al. A case of Cowden syndrome diagnosed from multiple gastric polyposis. *World J Gastroenterol*. 2012;18(8):861-864.
154. Albuquerque A, Rios E, Carneiro F, Macedo G. Evaluation of clinico-pathological features and *Helicobacter pylori* infection in gastric inflammatory fibroid polyps. *Virchows Arch*. 2014;465(6):643-647.
155. Hasegawa T, Yang P, Kagawa N, et al. CD34 expression by inflammatory fibroid polyps of the stomach. *Mod Pathol*. 1997;10(5): 451-456.
156. Pantanowitz L, Antonioli DA, Pinkus GS, et al. Inflammatory fibroid polyps of the gastrointestinal tract: evidence for a dendritic cell origin. *Am J Surg Pathol*. 2004;28(1):107-114.
157. Schildhaus H-U, Cavlar T, Binot E, et al. Inflammatory fibroid polyps harbour mutations in the platelet-derived growth factor receptor alpha (PDGFRA) gene. *J Pathol*. 2008;216(2):176-182.

158. Huss S, Wardelmann E, Goltz D, et al. Activating PDGFRA mutations in inflammatory fibroid polyps occur in exons 12, 14 and 18 and are associated with tumour localization. *Histopathology*. 2012;61(1):59-68.
159. Lambrecht NWG. Ménétrier's disease of the stomach: a clinical challenge. *Curr Gastroenterol Rep*. 2011;13(6):513-517.
160. Williamson K, Park HK, Schacht R, Kaistha A. A case of Ménétrier disease in a child. *Pediatr Emerg Care*. 2012;28(3):277-279.
161. Stamm B. Localized hyperplastic gastropathy of the mucous cell- and mixed cell-type (localized Ménétrier's disease): a report of 11 patients. *Am J Surg Pathol*. 1997;21(11):1334-1342.
162. Komorowski RA, Caya JG. Hyperplastic gastropathy. Clinicopathologic correlation. *Am J Surg Pathol*. 1991;15(6):577-585.
163. Wolfsen HC, Carpenter HA, Talley NJ. Menetrier's disease: a form of hypertrophic gastropathy or gastritis? *Gastroenterology*. 1993;104(5):1310-1319.
164. Haot J, Bogomoletz WV, Jouret A, Mainguet P. Ménétrier's disease with lymphocytic gastritis: an unusual association with possible pathogenic implications. *Hum Pathol*. 1991;22(4):379-386.
165. Hsu CT, Ito M, Kawase Y, et al. Early gastric cancer arising from localized Ménétrier's disease. *Gastroenterol Jpn*. 1991;26(2):213-217.
166. Delle Fave G, Marignani M, Corleto VD, et al. Progression of gastric enterochromaffin-like cells growth in Zollinger-Ellison syndrome and atrophic body gastritis patients. *Dig Liver Dis*. 2002;34(4):270-278.
167. Aprile MR, Azzoni C, Gibril F, et al. Intramucosal cysts in the gastric body of patients with Zollinger-Ellison syndrome. *Hum Pathol*. 2000;31(2):140-148.
168. Brien TP, Farraye FA, Odze RD. Gastric dysplasia-like epithelial atypia associated with chemoradiotherapy for esophageal cancer: a clinicopathologic and immunohistochemical study of 15 cases. *Mod Pathol*. 2001;14(5):389-396.
169. Khor TS, Alfaro EE, Ooi EMM, et al. Divergent expression of MUC5AC, MUC6, MUC2, CD10, and CDX-2 in dysplasia and intramucosal adenocarcinomas with intestinal and foveolar morphology: is this evidence of distinct gastric and intestinal pathways to carcinogenesis in Barrett Esophagus? *Am J Surg Pathol*. 2012;36(3):331-342.
170. Park DY, Srivastava A, Kim GH, et al. Adenomatous and foveolar gastric dysplasia: distinct patterns of mucin expression and background intestinal metaplasia. *Am J Surg Pathol*. 2008;32(4):524-533.
171. Sakurai U, Lauwers GY, Vieth M, et al. Gastric high-grade dysplasia can be associated with submucosal invasion: evaluation of its prevalence in a series of 121 endoscopically resected specimens. *Am J Surg Pathol*. 2014;38(11):1545-1550.
172. Petrick JL, Steck SE, Bradshaw PT, et al. Dietary intake of flavonoids and oesophageal and gastric cancer: incidence and survival in the United States of America (USA). *Br J Cancer*. 2015;112(suppl):1291-1300.
173. Buckland G, Travier N, Huerta JM, et al. Healthy lifestyle index and risk of gastric adenocarcinoma in the EPIC cohort study. *Int J Cancer*. 2015;137(3):598-606.
174. Noguchi Y, Yoshikawa T, Tsuburaya A, et al. Is gastric carcinoma different between Japan and the United States? *Cancer*. 2000;89(11):2237-2246.
175. Oliveira C, Seruca R, Carneiro F. Genetics, pathology, and clinics of familial gastric cancer. *Int J Surg Pathol*. 2006;14(1):21-33.
176. Vogelaar IP, van der Post RS, Carneiro F, et al. Hereditary diffuse gastric cancer: updated clinical guidelines with an emphasis on germline CDH1 mutation carriers. *J Med Genet*. 2015;52(6):361-374.
177. Brooks-Wilson AR, Kaurah P, Suriano G, et al. Germline E-cadherin mutations in hereditary diffuse gastric cancer: assessment of 42 new families and review of genetic screening criteria. *J Med Genet*. 2004;41(7):508-517.
178. Alfaro EE, Lauwers GY. Early gastric neoplasia: diagnosis and implications. *Adv Anat Pathol*. 2011;18(4):268-280.
179. Hall CN, Darkin D, Brimblecombe R, et al. Evaluation of the nitrosamine hypothesis of gastric carcinogenesis in precancerous conditions. *Gut*. 1986;27(5):491-498.
180. Lahner E, Esposito G, Pilozzi E, et al. Occurrence of gastric cancer and carcinoids in atrophic gastritis during prospective long-term follow up. *Scand J Gastroenterol*. 2015;50(7):856-865.
181. Vannella L, Lahner E, Osborn J, Annibale B. Systematic review: gastric cancer incidence in pernicious anaemia. *Aliment Pharmacol Ther*. 2013;37(4):375-382.
182. Correa P. *Helicobacter pylori* and gastric carcinogenesis. *Am J Surg Pathol*. 1995;19(suppl 1):S37-S43.
183. Graham DY. *Helicobacter pylori* update: gastric cancer, reliable therapy, and possible benefits. *Gastroenterology*. 2015;148(4):719-731, e3.
184. Lauren P. The two histological main types of gastric carcinoma: diffuse and so-called intestinal-type carcinoma. An attempt at a histo-clinical classification. *Acta Pathol Microbiol Scand*. 1965;64:31-49.
185. Brumback RA, Gerber JE, Hicks DG, Strauchen JA. Adenocarcinoma of the stomach following irradiation and chemotherapy for lymphoma in young patients. *Cancer*. 1984;54(6):994-998.
186. Chen X-Z, Chen H, Castro FA, et al. Epstein-Barr virus infection and gastric cancer: a systematic review. *Medicine (Baltimore)*. 2015;94(20):e792.
187. Lim H, Park YS, Lee JH, et al. Features of gastric carcinoma with lymphoid stroma associate with Epstein-Barr virus. *Clin Gastroenterol Hepatol*. 2015;13(10):1738-1744. e2.
188. Park S, Choi M-G, Kim K-M, et al. Lymphoepithelioma-like carcinoma: a distinct type of gastric cancer. *J Surg Res*. 2015;194(2):458-463.
189. Yamada Y, Kato Y. Greater tendency for submucosal invasion in fundic area gastric carcinomas than those arising in the pyloric area. *Cancer*. 1989;63(9):1757-1760.
190. Yamagiwa H, Yoshimura H, Tomiyama H, et al. Clinico-pathological study of gastric cancers in the greater curvature. *Acta Pathol Jpn*. 1984;34(3):519-527.
191. Kosaka T, Miwa K, Yonemura Y, et al. A clinicopathologic study on multiple gastric cancers with special reference to distal gastrectomy. *Cancer*. 1990;65(11): 2602-2605.
192. Lee EY, Wang TC, Clouse RE, DeSchryver-Kecskemeti K. Mucosal thickening adjacent to gastric malignancy: association with epidermal growth factor. *Mod Pathol*. 1989;2(4):397-402.
193. Zheng H, Li X, Hara T, et al. Mixed-type gastric carcinomas exhibit more aggressive features and indicate the histogenesis of carcinomas. *Virchows Arch*. 2008;452(5):525-534.
194. Ikeda H, Kukitsu T, Johmen W, et al. Gastric invasive micropapillary carcinoma with intestinal phenotypes harboring a TP53 R175H mutation. *Case Rep Oncol*. 2014;7(3):611-620.
195. Endoh Y, Tamura G, Motoyama T, et al. Well-differentiated adenocarcinoma mimicking complete-type intestinal metaplasia in the stomach. *Hum Pathol*. 1999;30(7):826-832.
196. Chan WY, Hui PK, Leung KM, et al. Gastric adenocarcinoma with ciliated tumor cells. *Hum Pathol*. 1993;24(10):1107-1113.
197. Fujiyoshi Y, Eimoto T. Chromogranin A expression correlates with tumour cell type and prognosis in signet ring cell carcinoma of the stomach. *Histopathology*. 2008;52(3):305-313.
198. Rice AJ, Griffiths AP, Martin IG, Dixon MF. Gastric carcinoma with prominent neutrophil infiltration. *Histopathology*. 2000;37(3):289-290.
199. Maehara Y, Moriguchi S, Yoshida M, et al. Splenectomy does not correlate with length of survival in patients undergoing curative total gastrectomy for gastric carcinoma. Univariate and multivariate analyses. *Cancer*. 1991;67(12):3006-3009.
200. Henson DE, Dittus C, Younes M, et al. Differential trends in the intestinal and diffuse types of gastric carcinoma in the United States, 1973-2000: increase in the signet ring cell type. *Arch Pathol Lab Med*. 2004;128(7):765-770.
201. Crowder CD, Grabowski C, Inampudi S, et al. Selective internal radiation therapy-induced extrahepatic injury: an emerging cause of iatrogenic organ damage. *Am J Surg Pathol*. 2009;33(7):963-975.
202. Ma J, De Boer WG, Nayman J. Intestinal mucinous substances in gastric intestinal metaplasia and carcinoma studied by immunofluorescence. *Cancer*. 1982;49(8):1664-1667.
203. Cook HC. Neutral mucin content of gastric carcinomas as a diagnostic aid in the identification of secondary deposits. *Histopathology*. 1982;6(5):591-599.
204. Gürbüz Y, Kahlke V, Klöppel G. How do gastric carcinoma classification systems relate to mucin expression patterns? An immunohistochemical analysis in a series of advanced gastric carcinomas. *Virchows Arch*. 2002;440(5):505-511.
205. Lee HS, Lee HK, Kim HS, et al. MUC1, MUC2, MUC5AC, and MUC6 expressions in gastric carcinomas: their roles as prognostic indicators. *Cancer*. 2001;92(6):1427-1434.
206. Chu PG, Weiss LM. Immunohistochemical characterization of signet-ring cell carcinomas of the stomach, breast, and colon. *Am J Clin Pathol*. 2004;121(6):884-892.
207. Kaimaktchiev V, Terracciano L, Tornillo L, et al. The homeobox intestinal differentiation factor CDX2 is selectively expressed in gastrointestinal adenocarcinomas. *Mod Pathol*. 2004;17(11):1392-1399.
208. Levy R, Czernobilsky B, Geiger B. Cytokeratin polypeptide in gastrointestinal adenocarcinomas displaying squamous differentiation. *Hum Pathol*. 1992;23(6):695-702.
209. Park SY, Kim HS, Hong EK, Kim WH. Expression of cytokeratins 7 and 20 in primary carcinomas of the stomach and colorectum and their value in the differential diagnosis of metastatic carcinomas to the ovary. *Hum Pathol*. 2002;33(11):1078-1085.
210. Tahara E, Ito H, Taniyama K, et al. Alpha 1-antitrypsin, alpha 1-antichymotrypsin, and alpha 2-macroglobulin in human gastric carcinomas: a retrospective immunohistochemical study. *Hum Pathol*. 1984;15(10):957-964.
211. Louhimo J, Nordling S, Alfthan H, et al. Specific staining of human chorionic gonadotropin beta in benign and malignant gastrointestinal tissues with monoclonal antibodies. *Histopathology*. 2001;38(5):418-424.
212. Jinawath N, Furukawa Y, Hasegawa S, et al. Comparison of gene-expression profiles between diffuse- and intestinal-type gastric

cancers using a genome-wide cDNA microarray. *Oncogene*. 2004;23(40):6830-6844.
213. Huntsman D, Carneiro F, Lewis F, et al. Prophylactic gastrectomy in patients with deleterious E-cadherin gene mutation. *Gastroentérologie Clin Biol*. 2001;25(10):931-932.
214. Chun YS, Lindor NM, Smyrk TC, et al. Germline E-cadherin gene mutations: is prophylactic total gastrectomy indicated? *Cancer*. 2001;92(1):181-187.
215. Cisco RM, Ford JM, Norton JA. Hereditary diffuse gastric cancer: implications of genetic testing for screening and prophylactic surgery. *Cancer*. 2008;113(7 suppl):1850-1856.
216. Ascaño JJ, Frierson H, Moskaluk CA, et al. Inactivation of the E-cadherin gene in sporadic diffuse-type gastric cancer. *Mod Pathol*. 2001;14(10):942-949.
217. Tamura G, Yin J, Wang S, et al. E-Cadherin gene promoter hypermethylation in primary human gastric carcinomas. *J Natl Cancer Inst*. 2000;92(7):569-573.
218. Theuer CP, Campbell BS, Peel DJ, et al. Microsatellite instability in Japanese vs European American patients with gastric cancer. *Arch Surg*. 2002;137(8):960-965, discussion 965–966.
219. El-Rifai W, Powell SM. Molecular biology of gastric cancer. *Semin Radiat Oncol*. 2002;12(2):128-140.
220. El-Rifai W, Powell SM. Molecular and biologic basis of upper gastrointestinal malignancy. Gastric carcinoma. *Surg Oncol Clin N Am*. 2002;11(2):273-291, viii.
221. Luinetti O, Fiocca R, Villani L, et al. Genetic pattern, histological structure, and cellular phenotype in early and advanced gastric cancers: evidence for structure-related genetic subsets and for loss of glandular structure during progression of some tumors. *Hum Pathol*. 1998;29(7):702-709.
222. Grabsch H, Sivakumar S, Gray S, et al. HER2 expression in gastric cancer: rare, heterogeneous and of no prognostic value—conclusions from 924 cases of two independent series. *Cell Oncol*. 2010;32(1-2):57-65.
223. Jørgensen JT. Targeted HER2 treatment in advanced gastric cancer. *Oncology*. 2010;78(1):26-33.
224. Li QL, Ito K, Sakakura C, et al. Causal relationship between the loss of RUNX3 expression and gastric cancer. *Cell*. 2002;109(1):113-124.
225. Kim TY, Jong H-S, Jung Y, et al. DNA hypermethylation in gastric cancer. *Aliment Pharmacol Ther*. 2004;20(suppl 1): 131-142.
226. Oshimo Y, Oue N, Mitani Y, et al. Frequent loss of RUNX3 expression by promoter hypermethylation in gastric carcinoma. *Pathobiology*. 2004;71(3):137-143.
227. Blumenfeld W, Chandhoke DK, Sagerman P, Turi GK. Neuroendocrine differentiation in gastric adenocarcinomas. An immunohistochemical study. *Arch Pathol Lab Med*. 1996;120(5):478-481.
228. Jiang S-X, Mikami T, Umezawa A, et al. Gastric large cell neuroendocrine carcinomas: a distinct clinicopathologic entity. *Am J Surg Pathol*. 2006;30(8):945-953.
229. Matsui K, Jin XM, Kitagawa M, Miwa A. Clinicopathologic features of neuroendocrine carcinomas of the stomach: appraisal of small cell and large cell variants. *Arch Pathol Lab Med*. 1998;122(11):1010-1017.
230. Frances N, Zeichner SB, Francavilla M, Cusnir M. Gastric small-cell carcinoma found on esophagogastroduodenoscopy: a case report and literature review. *Case Rep Oncol Med*. 2013;2013:475961.
231. Chen Y-Y, Li AF-Y, Huang K-H, et al. Adenosquamous carcinoma of the stomach and review of the literature. *Pathol Oncol Res*. 2015;21(3):547-551.
232. Hwang SH, Lee JH, Kim K, et al. Primary squamous cell carcinoma of the stomach: a case report. *Oncol Lett*. 2014;8(5):2122-2124.
233. Chen H, Shen C, Yin R, et al. Clinicopathological characteristics, diagnosis, treatment, and outcomes of primary gastric adenosquamous carcinoma. *World J Surg Oncol*. 2015;13:136.
234. Sáez C, Japón MA, Poveda MA, Segura DI. Mucinous (colloid) adenocarcinomas secrete distinct O-acylated forms of sialomucins: a histochemical study of gastric, colorectal and breast adenocarcinomas. *Histopathology*. 2001;39(6):554-560.
235. Roberts CC, Colby TV, Batts KP. Carcinoma of the stomach with hepatocyte differentiation (hepatoid adenocarcinoma). *Mayo Clin Proc*. 1997;72(12):1154-1160.
236. Matsunou H, Konishi F, Jalal RE, et al. Alpha-fetoprotein-producing gastric carcinoma with enteroblastic differentiation. *Cancer*. 1994;73(3):534-540.
237. Maitra A, Murakata LA, Albores-Saavedra J. Immunoreactivity for hepatocyte paraffin 1 antibody in hepatoid adenocarcinomas of the gastrointestinal tract. *Am J Clin Pathol*. 2001;115(5):689-694.
238. Nagai E, Ueyama T, Yao T, Tsuneyoshi M. Hepatoid adenocarcinoma of the stomach. A clinicopathologic and immunohistochemical analysis. *Cancer*. 1993;72(6):1827-1835.
239. Sentani K, Oue N, Sakamoto N, et al. Gene expression profiling with microarray and SAGE identifies PLUNC as a marker for hepatoid adenocarcinoma of the stomach. *Mod Pathol*. 2008;21(4):464-475.
240. Ushiku T, Shinozaki A, Shibahara J, et al. SALL4 represents fetal gut differentiation of gastric cancer, and is diagnostically useful in distinguishing hepatoid gastric carcinoma from hepatocellular carcinoma. *Am J Surg Pathol*. 2010;34(4):533-540.
241. Hishinuma M, Ohashi K-I, Yamauchi N, et al. Hepatocellular oncofetal protein, glypican 3 is a sensitive marker for alpha-fetoprotein-producing gastric carcinoma. *Histopathology*. 2006;49(5):479-486.
242. Matsunou H, Konishi F, Hori H, et al. Characteristics of Epstein-Barr virus-associated gastric carcinoma with lymphoid stroma in Japan. *Cancer*. 1996;77(10):1998-2004.
243. Yuen ST, Chung LP, Leung SY, et al. In situ detection of Epstein-Barr virus in gastric and colorectal adenocarcinomas. *Am J Surg Pathol*. 1994;18(11):1158-1163.
244. Grogg KL, Lohse CM, Pankratz VS, et al. Lymphocyte-rich gastric cancer: associations with Epstein-Barr virus, microsatellite instability, histology, and survival. *Mod Pathol*. 2003;16(7):641-651.
245. Choi KW, Lee WY, Hong SW, et al. Carcinosarcoma of the stomach: a case report. *J Gastric Cancer*. 2013;13(1):69-72.
246. Cirocchi R, Trastulli S, Desiderio J, et al. Gastric carcinosarcoma: a case report and review of the literature. *Oncol Lett*. 2012;4(1):53-57.
247. Nakayama Y, Murayama H, Iwasaki H, et al. Gastric carcinosarcoma (sarcomatoid carcinoma) with rhabdomyoblastic and osteoblastic differentiation. *Pathol Int*. 1997;47(8):557-563.
248. Cruz JJ, Paz JI, Cordero M, et al. Carcinosarcoma of the stomach with endocrine differentiation. A case report. *Tumori*. 1991;77(4):355-357.
249. Kallakury BV, Bui HX, delRosario A, et al. Primary gastric adenosarcoma. *Arch Pathol Lab Med*. 1993;117(3):299-301.
250. Agaimy A, Rau TT, Hartmann A, Stoehr R. SMARCB1 (INI1)-negative rhabdoid carcinomas of the gastrointestinal tract: clinicopathologic and molecular study of a highly aggressive variant with literature review. *Am J Surg Pathol*. 2014;38(7):910-920.
251. Geramizadeh B, Nikeghbalian S, Abolghasem-Hosseini S. Primary malignant rhabdoid tumor of the stomach, a rare case report and review of literature. *J Gastrointest Cancer*. 2010;41(4):269-271.
252. Stracca-Pansa V, Menegon A, Donisi PM, et al. Gastric carcinoma with osteoclast-like giant cells. Report of four cases. *Am J Clin Pathol*. 1995;103(4):453-459.
253. Ambrosini-Spaltro A, Potì O, De Palma M, Filotico M. Pancreatic-type acinar cell carcinoma of the stomach beneath a focus of pancreatic metaplasia of the gastric mucosa. *Hum Pathol*. 2009;40(5):746-749.
254. Govender D, Ramdial PK, Clarke B, Chetty R. Clear cell (glycogen-rich) gastric adenocarcinoma. *Ann Diagn Pathol*. 2004;8(2):69-73.
255. Tajima S, Kodama H, Kamiya T, Terasaki M. Gastric carcinoma with an invasive micropapillary carcinoma component showing HER2 gene amplification and CD10 expression: a case report and review of the literature. *Pathol Int*. 2014;64(8):402-408.
256. Ushiku T, Matsusaka K, Iwasaki Y, et al. Gastric carcinoma with invasive micropapillary pattern and its association with lymph node metastasis. *Histopathology*. 2011;59(6):1081-1089.
257. Roh JH, Srivastava A, Lauwers GY, et al. Micropapillary carcinoma of stomach: a clinicopathologic and immunohistochemical study of 11 cases. *Am J Surg Pathol*. 2010;34(8):1139-1146.
258. Choi IJ. Endoscopic gastric cancer screening and surveillance in high-risk groups. *Clin Endosc*. 2014;47(6):497-503.
259. Leja M, You W, Camargo MC, Saito H. Implementation of gastric cancer screening—the global experience. *Best Pract Res Clin Gastroenterol*. 2014;28(6):1093-1106.
260. Tatsuta M, Iishi H, Okuda S, et al. Prospective evaluation of diagnostic accuracy of gastrofiberscopic biopsy in diagnosis of gastric cancer. *Cancer*. 1989;63(7):1415-1420.
261. Jorde R, Ostensen H, Bostad LH, et al. Cancer detection in biopsy specimens taken from different types of gastric lesions. *Cancer*. 1986;58(2):376-382.
262. Xuan ZX, Ueyama T, Yao T, Tsuneyoshi M. Time trends of early gastric carcinoma. A clinicopathologic analysis of 2846 cases. *Cancer*. 1993;72(10):2889-2894.
263. Lee SH, Jee SR, Kim JH, Seol SY. Intramucosal gastric cancer: the rate of lymph node metastasis in signet ring cell carcinoma is as low as that in well-differentiated adenocarcinoma. *Eur J Gastroenterol Hepatol*. 2015;27(2):170-174.
264. Rubio CA, Slezak P, Ohman U, Emås S. The histological classification of early gastric cancer (micro-invasive carcinoma of the stomach). *Acta Pathol Microbiol Immunol Scand [A]*. 1982;90(5):311-316.
265. Kitamura K, Yamaguchi T, Sawai K, et al. Chronologic changes in the clinicopathologic findings and survival of gastric cancer patients. *J Clin Oncol*. 1997;15(12):3471-3480.
266. Mori M, Adachi Y, Kakeji Y, et al. Superficial flat-type early carcinoma of the stomach. *Cancer*. 1992;69(2):306-313.
267. Huguier M, Ferro L, Barrier A. Early gastric carcinoma: spread and multicentricity. *Gastric Cancer*. 2002;5(3):125-128, discussion 128–129.
268. Kang GH, Kim CJ, Kim WH, et al. Genetic evidence for the multicentric origin of synchronous multiple gastric carcinoma. *Lab Invest*. 1997;76(3):407-417.
269. Barreto SG, Windsor JA. Redefining early gastric cancer. *Surg Endosc*. 2016;30(1):24-37.

270. Song SY, Park S, Kim S, et al. Characteristics of intramucosal gastric carcinoma with lymph node metastatic disease. *Histopathology*. 2004;44(5):437-444.
271. Son HJ, Son H, Myung W, et al. Prognostic indicators of gastric carcinoma confined to the muscularis propria. *Histopathology*. 2007;51(1):105-110.
272. Son HJ, Song SY, Kim S, et al. Characteristics of submucosal gastric carcinoma with lymph node metastatic disease. *Histopathology*. 2005;46(2):158-165.
273. Emura F, Mejía J, Donneys A, et al. Therapeutic outcomes of endoscopic submucosal dissection of differentiated early gastric cancer in a Western endoscopy setting (with video). *Gastrointest Endosc*. 2015;82(5):804-811.
274. Peng LJ, Tian SN, Lu L, et al. Outcome of endoscopic submucosal dissection for early gastric cancer of conventional and expanded indications: systematic review and meta-analysis. *J Dig Dis*. 2015;16(2): 67-74.
275. Shin KY, Jeon SW, Cho KB, et al. Clinical outcomes of the endoscopic submucosal dissection of early gastric cancer are comparable between absolute and new expanded criteria. *Gut Liver*. 2015;9(2):181-187.
276. Osterheld MC, Laurini R, Saraga E. Early gastric carcinoma with focal advanced cancer: a particular subtype of gastric carcinoma. *Hum Pathol*. 1998;29(8):815-819.
277. Ludeman L, Shepherd NA. Serosal involvement in gastrointestinal cancer: its assessment and significance. *Histopathology*. 2005;47(2):123-131.
278. Lehnert T, Erlandson RA, Decosse JJ. Lymph and blood capillaries of the human gastric mucosa. A morphologic basis for metastasis in early gastric carcinoma. *Gastroenterology*. 1985;89(5):939-950.
279. Wu CW, Hsieh MJ, Lo SS, et al. Lymph node metastasis from carcinoma of the distal one-third of the stomach. *Cancer*. 1994;73(12):3109-3114.
280. Mak KL, Hui PK, Chan WY, Leung KM. Mucosal lymphangiectasia in gastric adenocarcinoma. *Arch Pathol Lab Med*. 1996;120(1):78-80.
281. Sweeney S, Utzschneider R, Fraire AE. Vasculitis carcinomatosa occurring in association with adenocarcinoma of the stomach. *Ann Diagn Pathol*. 1998;2(4):247-249.
282. Dias AR, Pereira MA, Mello ES, et al. Carnoy's solution increases the number of examined lymph nodes following gastrectomy for adenocarcinoma: a randomized trial. *Gastric Cancer*. 2016;19(1):136-142.
283. Lavy R, Hershkovitz Y, Kapiev A, et al. A comparative study on two different pathological methods to retrieve lymph nodes following gastrectomy. *Int J Surg*. 2014;12(7):725-728.
284. Fukagawa T, Sasako M, Mann GB, et al. Immunohistochemically detected micrometastases of the lymph nodes in patients with gastric carcinoma. *Cancer*. 2001;92(4):753-760.
285. Shin D, Park S-S. Clinical importance and surgical decision-making regarding proximal resection margin for gastric cancer. *World J Gastrointest Oncol*. 2013;5(1):4-11.
286. Lerwill MF, Young RH. Ovarian metastases of intestinal-type gastric carcinoma: a clinicopathologic study of 4 cases with contrasting features to those of the Krukenberg tumor. *Am J Surg Pathol*. 2006;30(11):1382-1388.
287. Esaki Y, Hirayama R, Hirokawa K. A comparison of patterns of metastasis in gastric cancer by histologic type and age. *Cancer*. 1990;65(9):2086-2090.
288. Sawabe M, Kato Y, Ohashi I, Kitagawa T. Diffuse intrasinusoidal metastasis of gastric carcinoma to the liver leading to fulminant hepatic failure. A case report. *Cancer*. 1990;65(1):169-173.
289. Yamamoto M, Rashid OM, Wong J. Surgical management of gastric cancer: the East vs. West perspective. *J Gastrointest Oncol*. 2015;6(1):79-88.
290. Brennan MF, Karpeh MS. Surgery for gastric cancer: the American view. *Semin Oncol*. 1996;23(3):352-359.
291. Bonenkamp JJ, Hermans J, Sasako M, et al. Extended lymph-node dissection for gastric cancer. *N Engl J Med*. 1999;340(12):908-914.
292. Santoro R, Mancini P, Carboni F, et al. Subtotal gastrectomy for gastric cancer: long term outcomes of Billroth I reconstruction at a single European institute. *Hepatogastroenterology*. 2014;61(136):2448-2454.
293. Cohen DJ, Leichman L. Controversies in the treatment of local and locally advanced gastric and esophageal cancers. *J Clin Oncol*. 2015;33(16):1754-1759.
294. Vakiani E. HER2 testing in gastric and gastroesophageal adenocarcinomas. *Adv Anat Pathol*. 2015;22(3):194-201.
295. Nakamura K, Ueyama T, Yao T, et al. Pathology and prognosis of gastric carcinoma. Findings in 10,000 patients who underwent primary gastrectomy. *Cancer*. 1992;70(5):1030-1037.
296. Srivastava A, Lauwers GY. Gastric epithelial dysplasia: the Western perspective. *Dig Liver Dis*. 2008;40(8):641-649.
297. Hermanek P. The superiority of the new International Union Against Cancer and American Joint Committee on Cancer TNM staging of gastric carcinoma. *Cancer*. 2000;88(8):1763-1765.
298. Roder JD, Böttcher K, Busch R, et al. Classification of regional lymph node metastasis from gastric carcinoma. German Gastric Cancer Study Group. *Cancer*. 1998;82(4):621-631.
299. Roukos DH, Kappas AM. Targeting the optimal extent of lymph node dissection for gastric cancer. *J Surg Oncol*. 2002;81(2):59-62, discussion 62.
300. Hundahl SA, Phillips JL, Menck HR. The National Cancer Data Base Report on poor survival of U.S. gastric carcinoma patients treated with gastrectomy: Fifth Edition American Joint Committee on Cancer staging, proximal disease, and the "different disease" hypothesis. *Cancer*. 2000;88(4):921-932.
301. Saito H, Fukumoto Y, Osaki T, et al. Distinct recurrence pattern and outcome of adenocarcinoma of the gastric cardia in comparison with carcinoma of other regions of the stomach. *World J Surg*. 2006;30(10):1864-1869.
302. Grabiec J, Owen DA. Carcinoma of the stomach in young persons. *Cancer*. 1985;56(2):388-396.
303. Murphy A, Kelly RJ. From molecular classification to targeted therapeutics: the changing face of systemic therapy in metastatic gastroesophageal cancer. *Gastroenterol Res Pract*. 2015;2015:896560.
304. Durães C, Almeida GM, Seruca R, et al. Biomarkers for gastric cancer: prognostic, predictive or targets of therapy? *Virchows Arch*. 2014;464(3):367-378.
305. Luk IS, Bhuta S, Lewin KJ. Clear cell carcinoid tumor of stomach. A variant mimicking gastric xanthelasma. *Arch Pathol Lab Med*. 1997;121(10):1100-1103.
306. Modlin IM, Kidd M, Pfragner R, et al. The functional characterization of normal and neoplastic human enterochromaffin cells. *J Clin Endocrinol Metab*. 2006;91(6): 2340-2348.
307. Basuroy R, Srirajaskanthan R, Prachalias A, et al. Review article: the investigation and management of gastric neuroendocrine tumours. *Aliment Pharmacol Ther*. 2014;39(10):1071-1084.
308. Lewin KJ, Yang K, Ulich T, et al. Primary gastrin cell hyperplasia. Report of five cases and a review of the literature. *Am J Surg Pathol*. 1984;8(11):821-832.
309. Rindi G. Clinicopathologic aspects of gastric neuroendocrine tumors. *Am J Surg Pathol*. 1995;19(suppl 1):S20-S29.
310. Klöppel G, Anlauf M, Perren A. Endocrine precursor lesions of gastroenteropancreatic neuroendocrine tumors. *Endocr Pathol*. 2007;18(3):150-155.
311. Solcia E, Capella C, Fiocca R, et al. Gastric argyrophil carcinoidosis in patients with Zollinger-Ellison syndrome due to type 1 multiple endocrine neoplasia. A newly recognized association. *Am J Surg Pathol*. 1990;14(6):503-513.
312. Ito T, Igarashi H, Jensen RT. Zollinger-Ellison syndrome: recent advances and controversies. *Curr Opin Gastroenterol*. 2013;29(6):650-661.
313. von Rosenvinge EC, Wank SA, Lim RM. Gastric masses in multiple endocrine neoplasia type I-associated Zollinger-Ellison syndrome. *Gastroenterology*. 2009;137(4):1222-1537.
314. Bordi C, D'Adda T, Azzoni C, et al. Hypergastrinemia and gastric enterochromaffin-like cells. *Am J Surg Pathol*. 1995;19(suppl 1):S8-S19.
315. D'Adda T, Keller G, Bordi C, Höfler H. Loss of heterozygosity in 11q13-14 regions in gastric neuroendocrine tumors not associated with multiple endocrine neoplasia type 1 syndrome. *Lab Invest*. 1999;79(6):671-677.
316. Kern SE, Yardley JH, Lazenby AJ, et al. Reversal by antrectomy of endocrine cell hyperplasia in the gastric body in pernicious anemia: a morphometric study. *Mod Pathol*. 1990;3(5):561-566.
317. Sato Y, Imamura H, Kaizaki Y, et al. Management and clinical outcomes of type I gastric carcinoid patients: retrospective, multicenter study in Japan. *Dig Endosc*. 2014;26(3):377-384.
318. Capella C, Heitz PU, Höfler H, et al. Revised classification of neuroendocrine tumours of the lung, pancreas and gut. *Virchows Arch*. 1995;425(6):547-560.
319. Kidd M, Gustafsson B, Modlin IM. Gastric carcinoids (neuroendocrine neoplasms). *Gastroenterol Clin North Am*. 2013;42(2):381-397.
320. Rindi G, D'Adda T, Froio E, et al. Prognostic factors in gastrointestinal endocrine tumors. *Endocr Pathol*. 2007;18(3):145-149.
321. Strosberg J, Nasir A, Coppola D, et al. Correlation between grade and prognosis in metastatic gastroenteropancreatic neuroendocrine tumors. *Hum Pathol*. 2009;40(9):1262-1268.
322. Luong TV, Pilozzi E, Bearzi I, Bordi C. Mucosal colonization of gastric endocrine tumors mimicking mixed neoplasms. *Virchows Arch*. 2008;452(2):169-174.
323. Patil DT, Rubin BP. Gastrointestinal stromal tumor: advances in diagnosis and management. *Arch Pathol Lab Med*. 2011;135(10):1298-1310.
324. Liegl-Atzwanger B, Fletcher JA, Fletcher CDM. Gastrointestinal stromal tumors. *Virchows Arch*. 2010;456(2):111-127.
325. Rosai J. GIST: an update. *Int J Surg Pathol*. 2003;11(3):177-186.
326. Vanderwinden JM, Rumessen JJ, De Laet MH, et al. CD34+ cells in human intestine are fibroblasts adjacent to, but distinct from,

interstitial cells of Cajal. *Lab Invest*. 1999;79(1):59-65.
327. Heinrich MC, Rubin BP, Longley BJ, Fletcher JA. Biology and genetic aspects of gastrointestinal stromal tumors: KIT activation and cytogenetic alterations. *Hum Pathol*. 2002;33(5):484-495.
328. Hornick JL, Fletcher CDM. The significance of KIT (CD117) in gastrointestinal stromal tumors. *Int J Surg Pathol*. 2004;12(2):93-97.
329. Hirota S, Isozaki K, Moriyama Y, et al. Gain-of-function mutations of c-kit in human gastrointestinal stromal tumors. *Science*. 1998;279(5350):577-580.
330. Andersson J, Sjögren H, Meis-Kindblom JM, et al. The complexity of KIT gene mutations and chromosome rearrangements and their clinical correlation in gastrointestinal stromal (pacemaker cell) tumors. *Am J Pathol*. 2002;160(1):15-22.
331. Lux ML, Rubin BP, Biase TL, et al. KIT extracellular and kinase domain mutations in gastrointestinal stromal tumors. *Am J Pathol*. 2000;156(3):791-795.
332. Rubin BP, Fletcher JA, Fletcher CDM. Molecular insights into the histogenesis and pathogenesis of gastrointestinal stromal tumors. *Int J Surg Pathol*. 2000;8(1):5-10.
333. Medeiros F, Corless CL, Duensing A, et al. KIT-negative gastrointestinal stromal tumors: proof of concept and therapeutic implications. *Am J Surg Pathol*. 2004;28(7):889-894.
334. Corless CL. Gastrointestinal stromal tumors: what do we know now? *Mod Pathol*. 2014;27(suppl 1):S1-S16.
335. Miettinen M. Immunohistochemistry of soft tissue tumours—review with emphasis on 10 markers. *Histopathology*. 2014;64(1):101-118.
336. Lee C-H, Liang C, Espinosa I. The utility of discovered on gastrointestinal stromal tumor 1 (DOG1) antibody in surgical pathology-the GIST of it. *Adv Anat Pathol*. 2010;17(3):222-232.
337. Espinosa I, Lee C-H, Kim MK, et al. A novel monoclonal antibody against DOG1 is a sensitive and specific marker for gastrointestinal stromal tumors. *Am J Surg Pathol*. 2008;32(2):210-218.
338. West RB, Corless CL, Chen X, et al. The novel marker, DOG1, is expressed ubiquitously in gastrointestinal stromal tumors irrespective of KIT or PDGFRA mutation status. *Am J Pathol*. 2004;165(1):107-113.
339. Liegl B, Hornick JL, Corless CL, Fletcher CDM. Monoclonal antibody DOG1.1 shows higher sensitivity than KIT in the diagnosis of gastrointestinal stromal tumors, including unusual subtypes. *Am J Surg Pathol*. 2009;33(3):437-446.
340. Pauls K, Merkelbach-Bruse S, Thal D, et al. PDGFRalpha- and c-kit-mutated gastrointestinal stromal tumours (GISTs) are characterized by distinctive histological and immunohistochemical features. *Histopathology*. 2005;46(2):166-175.
341. Sakurai S, Hasegawa T, Sakuma Y, et al. Myxoid epithelioid gastrointestinal stromal tumor (GIST) with mast cell infiltrations: a subtype of GIST with mutations of platelet-derived growth factor receptor alpha gene. *Hum Pathol*. 2004;35(10):1223-1230.
342. Daum O, Grossmann P, Vanecek T, et al. Diagnostic morphological features of PDGFRA-mutated gastrointestinal stromal tumors: molecular genetic and histologic analysis of 60 cases of gastric gastrointestinal stromal tumors. *Ann Diagn Pathol*. 2007;11(1):27-33.
343. Bates AW, Feakins RM, Scheimberg I. Congenital gastrointestinal stromal tumour is morphologically indistinguishable from the adult form, but does not express CD117 and carries a favourable prognosis. *Histopathology*. 2000;37(4):316-322.
344. Miettinen M, Lasota J, Sobin LH. Gastrointestinal stromal tumors of the stomach in children and young adults: a clinicopathologic, immunohistochemical, and molecular genetic study of 44 cases with long-term follow-up and review of the literature. *Am J Surg Pathol*. 2005;29(10):1373-1381.
345. Miettinen M, Fetsch JF, Sobin LH, Lasota J. Gastrointestinal stromal tumors in patients with neurofibromatosis 1: a clinicopathologic and molecular genetic study of 45 cases. *Am J Surg Pathol*. 2006;30(1):90-96.
346. Takazawa Y, Sakurai S, Sakuma Y, et al. Gastrointestinal stromal tumors of neurofibromatosis type I (von Recklinghausen's disease). *Am J Surg Pathol*. 2005;29(6):755-763.
347. Yantiss RK, Rosenberg AE, Sarran L, et al. Multiple gastrointestinal stromal tumors in type I neurofibromatosis: a pathologic and molecular study. *Mod Pathol*. 2005;18(4):475-484.
348. Andersson J, Sihto H, Meis-Kindblom JM, et al. NF1-associated gastrointestinal stromal tumors have unique clinical, phenotypic, and genotypic characteristics. *Am J Surg Pathol*. 2005;29(9):1170-1176.
349. Carney JA. Gastric stromal sarcoma, pulmonary chondroma, and extra-adrenal paraganglioma (Carney Triad): natural history, adrenocortical component, and possible familial occurrence. *Mayo Clin Proc*. 1999;74(6):543-552.
350. Carney JA, Stratakis CA. Familial paraganglioma and gastric stromal sarcoma: a new syndrome distinct from the Carney triad. *Am J Med Genet*. 2002;108(2):132-139.
351. Doyle LA, Hornick JL. Gastrointestinal stromal tumours: from KIT to succinate dehydrogenase. *Histopathology*. 2014;64(1):53-67.
352. Doyle LA, Nelson D, Heinrich MC, et al. Loss of succinate dehydrogenase subunit B (SDHB) expression is limited to a distinctive subset of gastric wild-type gastrointestinal stromal tumours: a comprehensive genotype-phenotype correlation study. *Histopathology*. 2012;61(5):801-809.
353. Gill AJ, Chou A, Vilain R, et al. Immunohistochemistry for SDHB divides gastrointestinal stromal tumors (GISTs) into 2 distinct types. *Am J Surg Pathol*. 2010;34(5):636-644.
354. Nannini M, Biasco G, Astolfi A, Pantaleo MA. An overview on molecular biology of KIT/PDGFRA wild type (WT) gastrointestinal stromal tumours (GIST). *J Med Genet*. 2013;50(10):653-661.
355. Falchook GS, Trent JC, Heinrich MC, et al. BRAF mutant gastrointestinal stromal tumor: first report of regression with BRAF inhibitor dabrafenib (GSK2118436) and whole exomic sequencing for analysis of acquired resistance. *Oncotarget*. 2013;4(2):310-315.
356. Hirota S, Okazaki T, Kitamura Y, et al. Cause of familial and multiple gastrointestinal autonomic nerve tumors with hyperplasia of interstitial cells of Cajal is germline mutation of the c-kit gene. *Am J Surg Pathol*. 2000;24(2):326-327.
357. Nishida T, Hirota S, Taniguchi M, et al. Familial gastrointestinal stromal tumours with germline mutation of the KIT gene. *Nat Genet*. 1998;19(4):323-324.
358. Dow N, Giblen G, Sobin LH, Miettinen M. Gastrointestinal stromal tumors: differential diagnosis. *Semin Diagn Pathol*. 2006;23(2):111-119.
359. Yantiss RK, Spiro IJ, Compton CC, Rosenberg AE. Gastrointestinal stromal tumor versus intra-abdominal fibromatosis of the bowel wall: a clinically important differential diagnosis. *Am J Surg Pathol*. 2000;24(7):947-957.
360. Kang DY, Park CK, Choi JS, et al. Multiple gastrointestinal stromal tumors: clinicopathologic and genetic analysis of 12 patients. *Am J Surg Pathol*. 2007;31(2):224-232.
361. Abraham SC, Krasinskas AM, Hofstetter WL, et al. "Seedling" mesenchymal tumors (gastrointestinal stromal tumors and leiomyomas) are common incidental tumors of the esophagogastric junction. *Am J Surg Pathol*. 2007;31(11):1629-1635.
362. Agaimy A, Wünsch PH, Hofstaedter F, et al. Minute gastric sclerosing stromal tumors (GIST tumorlets) are common in adults and frequently show c-KIT mutations. *Am J Surg Pathol*. 2007;31(1):113-120.
363. Agaimy A, Dirnhofer S, Wünsch PH, et al. Multiple sporadic gastrointestinal stromal tumors (GISTs) of the proximal stomach are caused by different somatic KIT mutations suggesting a field effect. *Am J Surg Pathol*. 2008;32(10):1553-1559.
364. Haller F, Schulten H-J, Armbrust T, et al. Multicentric sporadic gastrointestinal stromal tumors (GISTs) of the stomach with distinct clonal origin: differential diagnosis to familial and syndromal GIST variants and peritoneal metastasis. *Am J Surg Pathol*. 2007;31(6):933-937.
365. Irving JA, Lerwill MF, Young RH. Gastrointestinal stromal tumors metastatic to the ovary: a report of five cases. *Am J Surg Pathol*. 2005;29(7):920-926.
366. Dematteo RP, Heinrich MC, El-Rifai WM, Demetri G. Clinical management of gastrointestinal stromal tumors: before and after STI-571. *Hum Pathol*. 2002;33(5):466-477.
367. Demetri GD, von Mehren M, Blanke CD, et al. Efficacy and safety of imatinib mesylate in advanced gastrointestinal stromal tumors. *N Engl J Med*. 2002;347(7):472-480.
368. Antonescu CR. Targeted therapies in gastrointestinal stromal tumors. *Semin Diagn Pathol*. 2008;25(4):295-303.
369. Abdulkader I, Cameselle-Teijeiro J, Forteza J. Pathological changes related to Imatinib treatment in a patient with a metastatic gastrointestinal stromal tumour. *Histopathology*. 2005;46(4):470-472.
370. Pauwels P, Debiec-Rychter M, Stul M, et al. Changing phenotype of gastrointestinal stromal tumours under imatinib mesylate treatment: a potential diagnostic pitfall. *Histopathology*. 2005;47(1):41-47.
371. Liegl B, Hornick JL, Antonescu CR, et al. Rhabdomyosarcomatous differentiation in gastrointestinal stromal tumors after tyrosine kinase inhibitor therapy: a novel form of tumor progression. *Am J Surg Pathol*. 2009;33(2):218-226.
372. Fletcher CDM, Berman JJ, Corless C, et al. Diagnosis of gastrointestinal stromal tumors: a consensus approach. *Hum Pathol*. 2002;33(5):459-465.
373. Miettinen M, Kopczynski J, Makhlouf HR, et al. Gastrointestinal stromal tumors, intramural leiomyomas, and leiomyosarcomas in the duodenum: a clinicopathologic, immunohistochemical, and molecular genetic study of 167 cases. *Am J Surg Pathol*. 2003;27(5):625-641.
374. Misawa S, Takeda M, Sakamoto H, et al. Spontaneous rupture of a giant gastrointestinal stromal tumor of the jejunum: a case report and literature review. *World J Surg Oncol*. 2014;12:153.
375. Agaimy A, Vassos N, Märkl B, et al. Anorectal gastrointestinal stromal tumors: a retrospective multicenter analysis of 15 cases emphasizing their high local recurrence rate and the need for standardized therapeutic

approach. *Int J Colorectal Dis*. 2013;28(8):1057-1064.
376. Heinrich MC, Corless CL, Demetri GD, et al. Kinase mutations and imatinib response in patients with metastatic gastrointestinal stromal tumor. *J Clin Oncol*. 2003;21(23):4342-4349.
377. Heinrich MC, Corless CL, Duensing A, et al. PDGFRA activating mutations in gastrointestinal stromal tumors. *Science*. 2003;299(5607):708-710.
378. Cassier PA, Fumagalli E, Rutkowski P, et al. Outcome of patients with platelet-derived growth factor receptor alpha-mutated gastrointestinal stromal tumors in the tyrosine kinase inhibitor era. *Clin Cancer Res*. 2012;18(16):4458-4464.
379. Lasota J, Dansonka-Mieszkowska A, Sobin LH, Miettinen M. A great majority of GISTs with PDGFRA mutations represent gastric tumors of low or no malignant potential. *Lab Invest*. 2004;84(7):874-883.
380. Peng JC, Zhong L, Ran ZH. Primary lymphomas in the gastrointestinal tract. *J Dig Dis*. 2015;16(4):169-176.
381. Banks PM. Gastrointestinal lymphoproliferative disorders. *Histopathology*. 2007;50(1):42-54.
382. Fischbach W. Gastric MALT lymphoma—update on diagnosis and treatment. *Best Pract Res Clin Gastroenterol*. 2014;28(6):1069-1077.
383. Kossakowska AE, Eyton-Jones S, Urbanski SJ. Immunoglobulin and T-cell receptor gene rearrangements in lesions of mucosa-associated lymphoid tissue. *Diagn Mol Pathol*. 1993;2(4):233-240.
384. Ioachim HL, Hajdu C, Giancotti FR, Dorsett B. Lymphoid proliferations and lymphomas associated with gastric metaplasia, dysplasia, and carcinoma. *Hum Pathol*. 1999;30(7):833-842.
385. Banks PM, Isaacson PG. MALT lymphomas in 1997. Where do we stand? *Am J Clin Pathol*. 1999;111(1 suppl 1):S75-S83.
386. Isaacson PG, Du M-Q. MALT lymphoma: from morphology to molecules. *Nat Rev Cancer*. 2004;4(8):644-653.
387. Hussell T, Isaacson PG, Crabtree JE, Spencer J. The response of cells from low-grade B-cell gastric lymphomas of mucosa-associated lymphoid tissue to *Helicobacter pylori*. *Lancet*. 1993;342(8871):571-574.
388. Krol AD, Hermans J, Kramer MH, et al. Gastric lymphomas compared with lymph node lymphomas in a population-based registry differ in stage distribution and dissemination patterns but not in patient survival. *Cancer*. 1997;79(2):390-397.
389. Ree HJ, Rege VB, Knisley RE, et al. Malignant lymphoma of Waldeyer's ring following gastrointestinal lymphoma. *Cancer*. 1980;46(7):1528-1535.
390. Peng H, Du M, Diss TC, et al. Genetic evidence for a clonal link between low and high-grade components in gastric MALT B-cell lymphoma. *Histopathology*. 1997;30(5):425-429.
391. Parsonnet J, Hansen S, Rodriguez L, et al. *Helicobacter pylori* infection and gastric lymphoma. *N Engl J Med*. 1994;330(18):1267-1271.
392. Wotherspoon AC, Ortiz-Hidalgo C, Falzon MR, Isaacson PG. *Helicobacter pylori*-associated gastritis and primary B-cell gastric lymphoma. *Lancet*. 1991;338(8776):1175-1176.
393. Greiner A, Marx A, Heesemann J, et al. Idiotype identity in a MALT-type lymphoma and B cells in *Helicobacter pylori* associated chronic gastritis. *Lab Invest*. 1994;70(4):572-578.
394. Wotherspoon AC, Doglioni C, de Boni M, et al. Antibiotic treatment for low-grade gastric MALT lymphoma. *Lancet*. 1994;343(8911):1503.
395. Nakamura S, Aoyagi K, Furuse M, et al. B-cell monoclonality precedes the development of gastric MALT lymphoma in *Helicobacter pylori*-associated chronic gastritis. *Am J Pathol*. 1998;152(5):1271-1279.
396. Wündisch T, Neubauer A, Stolte M, et al. B-cell monoclonality is associated with lymphoid follicles in gastritis. *Am J Surg Pathol*. 2003;27(7):882-887.
397. Lo WYF, Li JYW, Chan YK, et al. Instability of clonality in gastric lymphoid infiltrates: a study with emphasis on serial biopsies. *Am J Surg Pathol*. 2005;29(12):1582-1592.
398. Genta RM. Le lymphome imaginaire. *Hum Pathol*. 1998;29(8):769-770.
399. Hsi ED, Singleton TP, Swinnen L, et al. Mucosa-associated lymphoid tissue-type lymphomas occurring in post-transplantation patients. *Am J Surg Pathol*. 2000;24(1):100-106.
400. Yokoi T, Nakamura T, Kasugai K, et al. Primary low-grade gastric mucosa-associated lymphoid tissue (MALT) lymphoma with polypoid appearance. Polypoid gastric MALT lymphoma: a clinicopathologic study of eight cases. *Pathol Int*. 1999;49(8):702-709.
401. Yamauchi A, Tomita Y, Miwa H, et al. Clonal evolution of gastric lymphoma of mucosa-associated lymphoid tissue type. *Mod Pathol*. 2001;14(10):957-962.
402. Blanco R, Lyda M, Davis B, et al. Trisomy 3 in gastric lymphomas of extranodal marginal zone B-cell (mucosa-associated lymphoid tissue) origin demonstrated by FISH in intact paraffin tissue sections. *Hum Pathol*. 1999;30(6):706-711.
403. Baens M, Maes B, Steyls A, et al. The product of the t(11;18), an API2-MLT fusion, marks nearly half of gastric MALT type lymphomas without large cell proliferation. *Am J Pathol*. 2000;156(4):1433-1439.
404. Dierlamm J, Baens M, Stefanova-Ouzounova M, et al. Detection of t(11;18)(q21;q21) by interphase fluorescence in situ hybridization using API2 and MLT specific probes. *Blood*. 2000;96(6):2215-2218.
405. Maes B, Baens M, Marynen P, De Wolf-Peeters C. The product of the t(11;18), an API2-MLT fusion, is an almost exclusive finding in marginal zone cell lymphoma of extranodal MALT-type. *Ann Oncol*. 2000;11(5):521-526.
406. Okabe M, Inagaki H, Ohshima K, et al. API2-MALT1 fusion defines a distinctive clinicopathologic subtype in pulmonary extranodal marginal zone B-cell lymphoma of mucosa-associated lymphoid tissue. *Am J Pathol*. 2003;162(4):1113-1122.
407. Liu H, Ruskon-Fourmestraux A, Lavergne-Slove A, et al. Resistance of t(11;18) positive gastric mucosa-associated lymphoid tissue lymphoma to *Helicobacter pylori* eradication therapy. *Lancet*. 2001;357(9249):39-40.
408. Cavalli F, Isaacson PG, Gascoyne RD, Zucca E. MALT lymphomas. *Hematology Am Soc Hematol Educ Program*. 2001;241-258.
409. Burke JS. Lymphoproliferative disorders of the gastrointestinal tract: a review and pragmatic guide to diagnosis. *Arch Pathol Lab Med*. 2011;135(10):1283-1297.
410. Chen Y-W, Hu X-T, Liang AC, et al. High BCL6 expression predicts better prognosis, independent of BCL6 translocation status, translocation partner, or BCL6-deregulating mutations, in gastric lymphoma. *Blood*. 2006;108(7):2373-2383.
411. Fung CY, Grossbard ML, Linggood RM, et al. Mucosa-associated lymphoid tissue lymphoma of the stomach: long term outcome after local treatment. *Cancer*. 1999;85(1):9-17.
412. Ko YH, Han JJ, Noh JH, Ree HJ. Lymph nodes in gastric B-cell lymphoma: pattern of involvement and early histological changes. *Histopathology*. 2002;40(6):497-504.
413. De Wolf-Peeters C, Achten R. The histogenesis of large-cell gastric lymphomas. *Histopathology*. 1999;34(1):71-75.
414. Connor J, Ashton-Key M. Gastric and intestinal diffuse large B-cell lymphomas are clinically and immunophenotypically different. An immunohistochemical and clinical study. *Histopathology*. 2007;51(5):697-703.
415. Hatano B, Ohshima K, Tsuchiya T, et al. Clinicopathological features of gastric B-cell lymphoma: a series of 317 cases. *Pathol Int*. 2002;52(11):677-682.
416. Kwon MS, Go JH, Choi JS, et al. Critical evaluation of Bcl-6 protein expression in diffuse large B-cell lymphoma of the stomach and small intestine. *Am J Surg Pathol*. 2003;27(6):790-798.
417. Omonishi K, Yoshino T, Sakuma I, et al. bcl-6 protein is identified in high-grade but not low-grade mucosa-associated lymphoid tissue lymphomas of the stomach. *Mod Pathol*. 1998;11(2):181-185.
418. Kumar S, Fend F, Quintanilla-Martinez L, et al. Epstein-Barr virus-positive primary gastrointestinal Hodgkin's disease: association with inflammatory bowel disease and immunosuppression. *Am J Surg Pathol*. 2000;24(1):66-73.
419. Sey MSL, Czader M, DeWitt JM. Burkitt lymphoma presenting as multifocal doughnut-shaped masses in the stomach of a patient with AIDS. *Endoscopy*. 2014;46(suppl 1 UCTN):E322-E323.
420. Paulus EM, Fleming MD, Hendrix AA, et al. The evolving role of surgery for gastric lymphoma: from curative resection to surgical management of complications. *Am Surg*. 2014;80(11):E322-E324.
421. Merchionne F, Iacopino P, Minoia C, et al. Targeted strategies in the treatment of primary gastric lymphomas: from rituximab to recent insights into potential new drugs. *Curr Med Chem*. 2014;21(8):1005-1016.
422. Koch P, Probst A, Berdel WE, et al. Treatment results in localized primary gastric lymphoma: data of patients registered within the German multicenter study (GIT NHL 02/96). *J Clin Oncol*. 2005;23(28):7050-7059.
423. Castro FA, Jansen L, Krilaviciute A, et al. Survival of patients with gastric lymphoma in Germany and the United States. *J Gastroenterol Hepatol*. 2015;30(10):1485-1491.
424. Zhang J, Hu X, Liu X, et al. Prognostic factors in primary gastric non-Hodgkin's lymphoma—a single-center retrospective analysis of 103 cases from China. *Hepatogastroenterology*. 2010;57(101):989-996.
425. Van Krieken JH, Medeiros LJ, Pals ST, et al. Diffuse aggressive B-cell lymphomas of the gastrointestinal tract. An immunophenotypic and gene rearrangement analysis of 22 cases. *Am J Clin Pathol*. 1992;97(2):170-178.
426. Paulli M, Rosso R, Kindl S, et al. Primary gastric CD30 (Ki-1)-positive large cell non-Hodgkin's lymphomas. A clinicopathologic analysis of six cases. *Cancer*. 1994;73(3):541-549.
427. Hanaoka T, Jingu K, Tochigi T, et al. A case of G-CSF-producing histiocytic sarcoma of the stomach. *Int Surg*. 2015;100(3):568-573.
428. Zhao ZH, Yang JF, Wang JD, et al. Imaging findings of primary gastric plasmacytoma: a case report. *World J Gastroenterol*. 2014;20(29):10202-10207.
429. Kawamoto K, Nakamura S, Iwashita A, et al. Clinicopathological characteristics of primary gastric T-cell lymphoma. *Histopathology*. 2009;55(6):641-653.
430. Manley K, Dunning J, Nelson M, Bower M. HIV-associated gastric natural killer/T-cell lymphoma. *Int J STD AIDS*. 2012;23(1):66-67.
431. Mori N, Yatabe Y, Narita M, et al. Primary gastric Hodgkin's disease. Morphologic,

immunohistochemical, and immunogenetic analyses. *Arch Pathol Lab Med*. 1995;119(2):163-166.
432. Huang X-L, Tao J, Li J-Z, et al. Gastric myeloid sarcoma without acute myeloblastic leukemia. *World J Gastroenterol*. 2015;21(7):2242-2248.
433. Sarbia M, Mauerer R, Bettstetter M, Funk A. Langerhans cell histiocytosis of the stomach with BRAF-V600E-mutation: case report and review of the literature. *Z Für Gastroenterol*. 2015;53(4):302-305.
434. Terracciano L, Kocher T, Cathomas G, et al. Langerhans cell histiocytosis of the stomach with atypical morphological features. *Pathol Int*. 1999;49(6):553-556.
435. Chen K-B, Chen L. Glomus tumor in the stomach: a case report and review of the literature. *Oncol Lett*. 2014;7(6):1790-1792.
436. Lo AWI, Chow LTC, To KF, Yu MY. Gastric glomangiomyoma: a pedunculated extramural mass with a florid angiomyomatous pattern. *Histopathology*. 2004;44(3):297-298.
437. Miettinen M, Paal E, Lasota J, Sobin LH. Gastrointestinal glomus tumors: a clinicopathologic, immunohistochemical, and molecular genetic study of 32 cases. *Am J Surg Pathol*. 2002;26(3):301-311.
438. Haque S, Modlin IM, West AB. Multiple glomus tumors of the stomach with intravascular spread. *Am J Surg Pathol*. 1992;16(3):291-299.
439. Kang HC, Menias CO, Gaballah AH, et al. Beyond the GIST: mesenchymal tumors of the stomach. *Radiographics*. 2013;33(6):1673-1690.
440. Johnston J, Helwig EB. Granular cell tumors of the gastrointestinal tract and perianal region: a study of 74 cases. *Dig Dis Sci*. 1981;26(9):807-816.
441. Goldblum JR, Rice TW, Zuccaro G, Richter JE. Granular cell tumors of the esophagus: a clinical and pathologic study of 13 cases. *Ann Thorac Surg*. 1996;62(3):860-865.
442. Hou YY, Tan YS, Xu JF, et al. Schwannoma of the gastrointestinal tract: a clinicopathological, immunohistochemical and ultrastructural study of 33 cases. *Histopathology*. 2006;48(5):536-545.
443. Lasota J, Wasag B, Dansonka-Mieszkowska A, et al. Evaluation of NF2 and NF1 tumor suppressor genes in distinctive gastrointestinal nerve sheath tumors traditionally diagnosed as benign schwannomas: s study of 20 cases. *Lab Invest*. 2003;83(9):1361-1371.
444. Bjelovic M, Micev M, Spica B, et al. Primary inflammatory myofibroblastic tumor of the stomach in an adult woman: a case report and review of the literature. *World J Surg Oncol*. 2013;11:35.
445. Liu Z, Guo J, Ren W, et al. A gastric calcifying fibrous pseudotumor detected by transabdominal ultrasound after oral administration of an echoic cellulose-based gastrointestinal ultrasound contrast agent. *Ultraschall Med*. 2014;35(2):181-183.
446. Han GJ, Kim JH, Lee SS, et al. Inflammatory fibroid polyps of the gastrointestinal tract: a 14-year CT study at a single institution. *Abdom Imaging*. 2015;40(7):2159-2166.
447. Fernandes T, Silva R, Devesa V, et al. AIRP best cases in radiologic-pathologic correlation: gastroblastoma: a rare biphasic gastric tumor. *Radiographics*. 2014;34(7):1929-1933.
448. Wey EA, Britton AJ, Sferra JJ, et al. Gastroblastoma in a 28-year-old man with nodal metastasis: proof of the malignant potential. *Arch Pathol Lab Med*. 2012;136(8):961-964.
449. Shin DH, Lee JH, Kang HJ, et al. Novel epitheliomesenchymal biphasic stomach tumour (gastroblastoma) in a 9-year-old: morphological, ultrastructural and immunohistochemical findings. *J Clin Pathol*. 2010;63(3):270-274.
450. Miettinen M, Dow N, Lasota J, Sobin LH. A distinctive novel epitheliomesenchymal biphasic tumor of the stomach in young adults ("gastroblastoma"): a series of 3 cases. *Am J Surg Pathol*. 2009;33(9):1370-1377.
451. Miettinen M, Makhlouf HR, Sobin LH, Lasota J. Plexiform fibromyxoma: a distinctive benign gastric antral neoplasm not to be confused with a myxoid GIST. *Am J Surg Pathol*. 2009;33(11):1624-1632.
452. Takahashi K, Tsukamoto S, Saito K, et al. Complete response to multidisciplinary therapy in a patient with primary gastric choriocarcinoma. *World J Gastroenterol*. 2013;19(31):5187-5194.
453. Gunduz S, Elpek GO, Uysal M, et al. Coexistence of gastric adenocarcinoma and choriocarcinoma: complete response to trastuzumab and chemotherapy. *Case Rep Oncol*. 2012;5(2):394-399.
454. Jan YJ, Chen JT, Ho WL, et al. Primary coexistent adenocarcinoma and choriocarcinoma of the stomach. A case report and review of the literature. *J Clin Gastroenterol*. 1997;25(3): 550-554.
455. Puglisi F, Damante G, Pizzolitto S, et al. Combined yolk sac tumor and adenocarcinoma in a gastric stump: molecular evidence of clonality. *Cancer*. 1999;85(9):1910-1916.
456. Liu AY, Chan WY, Ng EK, et al. Gastric choriocarcinoma shows characteristics of adenocarcinoma and gestational choriocarcinoma: a comparative genomic hybridization and fluorescence in situ hybridization study. *Diagn Mol Pathol*. 2001;10(3):161-165.
457. Green LK. Hematogenous metastases to the stomach. A review of 67 cases. *Cancer*. 1990;65(7):1596-1600.
458. Huang Q, Su X, Bella AE, et al. Clinicopathological features and outcome of gastric metastases from primary lung cancer: a case report and systematic review. *Oncol Lett*. 2015;9(3):1373-1379.
459. O'Connell FP, Wang HH, Odze RD. Utility of immunohistochemistry in distinguishing primary adenocarcinomas from metastatic breast carcinomas in the gastrointestinal tract. *Arch Pathol Lab Med*. 2005;129(3): 338-347.
460. van Velthuysen M-LF, Taal BG, van der Hoeven JJM, Peterse JL. Expression of oestrogen receptor and loss of E-cadherin are diagnostic for gastric metastasis of breast carcinoma. *Histopathology*. 2005;46(2): 153-157.
461. Liu H, Shi J, Prichard JW, et al. Immunohistochemical evaluation of GATA-3 expression in ER-negative breast carcinomas. *Am J Clin Pathol*. 2014;141(5):648-655.
462. Ozturk O, Basar O, Koklu S, et al. An unusual presentation of malignant melanoma: amelanotic gastric metastasis. *Am J Gastroenterol*. 2015;110(3):476.

15 Small Bowel

Laura W. Lamps

CHAPTER CONTENTS

Normal anatomy, *568*
Congenital defects, *570*
Heterotopias, *570*
Duplication, atresia, stenoses, and related defects, *570*
Congenital diverticula and related vitelline duct abnormalities, *571*
Other congenital defects, *571*
Inflammatory disorders, *572*
Diseases of malabsorption, *572*
Peptic duodenitis/duodenal ulcer, *576*
Vascular diseases, *579*
Inflammatory bowel disease, *579*
Infections, *583*
Drug, chemotherapy, and irradiation-associated enteritis, *584*
Other inflammatory diseases, *587*
Other non-neoplastic diseases, *589*
Polyps and tumors, *590*
Benign epithelial tumors, *590*
Adenocarcinoma, *592*
Neuroendocrine tumors, *594*
Gangliocytic paraganglioma, *597*
Gastrointestinal stromal tumors and other mesenchymal tumors, *598*
Malignant lymphoma and related disorders, *601*
Other tumors and tumorlike conditions, *604*
Metastatic tumors, *605*

Normal Anatomy

The small bowel extends from the pylorus to the ileocecal valve and measures approximately 6–7 m in length in adults. It is divided into three portions: *duodenum*, *jejunum*, and *ileum*. The *ligament of Treitz* is the anatomic landmark for the duodenojejunal junction, at which site the bowel becomes unfixed and wrapped in mesentery.[1,2]

The inner side of the small bowel is characterized by the presence of transverse mucosal folds known as *valvulae conniventes* (a double misnomer) or *Kerckring folds*. They are prominent in the proximal jejunum and flat or absent in the terminal ileum. Another characteristic feature of this region is represented by the *Peyer patches* (Fig. 15.1), which are located in the antimesenteric side of the terminal ileum. Their shape is oval, with the long axis parallel to that of the bowel. They represent lymphoid follicles and are more prominent in young individuals.

The small bowel ends at the *ileocecal valve*, a two-lip structure in which lymphoid tissue—and often adipose tissue (Fig. 15.2)—tends to accumulate.

Microscopically, the small bowel is composed of four layers: mucosa, submucosa, muscularis propria, and serosa. The mucosa is lined by villi, which are short and stubby (sometimes leaf-like) in the duodenum, tall and club-like in the jejunum, and of intermediate height in the ileum. The mucosa is made up of epithelium, lamina propria, and muscularis mucosae. The villous epithelium is composed of an admixture of tall columnar absorptive cells (enterocytes) and goblet cells (more numerous in the ileum).[1,2] Immunohistochemically, normal small bowel enterocytes are typically CK20 positive and CK7 negative.[3]

The *crypts of Lieberkuhn* comprise the lower 20% of the epithelium and represent its proliferative zone. They are surrounded by a pericrypt fibroblast sheath and are composed of multipotential stem cells (often exhibiting mitoses, about 1 or 2 per crypt), Paneth cells (with large cytoplasmic acidophilic granules containing a variety of digestive enzymes and lysozyme), scattered goblet cells, and neuroendocrine cells, of which the *Kulchitsky (argentaffin, basigranular)* cell is the better known representative (Fig. 15.3). The stem cells are the progenitors of all the cell types located in the intestinal mucosa, including those just mentioned. The sum total of the neuroendocrine or enteroendocrine cells (also known at one point as APUD cells) constitutes the so-called diffuse endocrine system, a concept brilliantly developed by Feyrter many decades ago. Functionally speaking, most of these cells are actually paracrine rather than endocrine, in that their action is exerted at a local level. They were thought to be of neural crest origin, but many independent studies (particularly those carried out by LeDouarin with her elegant quail–chick chimera model) have shown that they are endodermally derived,[4] at least in mammals.[5] The qualifier "neuroendocrine" can, however, be retained for them on functional/phenotypic grounds, in addition to the historical considerations.[6]

Abstract

This chapter covers the major congenital, inflammatory, and neoplastic entities that the surgical pathologist will encounter in the small bowel.

Keywords

Duodenum,
ileum,
jejunum,
celiac disease,
malabsorption,
lymphoma,
Crohn disease,
congenital,
inflammatory,
enteropathy,
infection,
adenocarcinoma,
melanoma

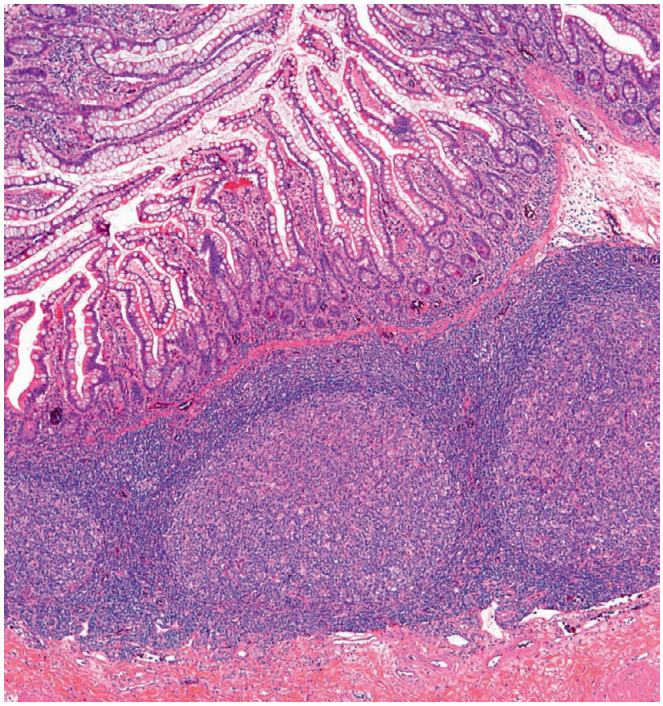

Figure 15.1 Peyer patches are a characteristic feature of the ileum. When large, they may resemble polyps macroscopically and can distort the overlying mucosa.

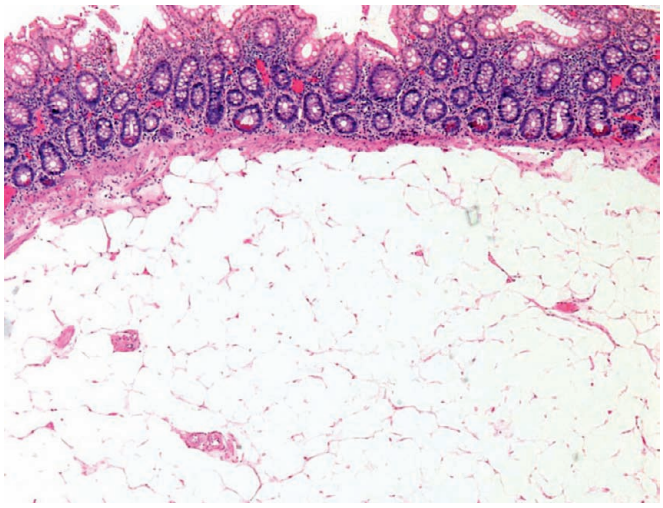

Figure 15.2 The ileocecal valve often contains abundant adipose tissue.

The lamina propria is composed of a loose connective tissue matrix. It contains lymphocytes, plasma cells, and occasionally eosinophils, macrophages, mast cells, and neutrophils. It also has blood vessels, lymph (lacteal) vessels, and numerous nerves. Interestingly, CD38 (a type of transmembrane glycoprotein involved in signaling and adhesion) has been found to stain the human lymph (lacteal) vessels of the bowel but not the lymph vessels of other organs.[7]

The submucosa consists of connective tissue, blood vessels, lymph vessels, and the *submucosal (Meissner) neural plexus*. In the duodenum (particularly the first two portions), it also contains numerous mucus-secreting glands known as *Brunner glands* (Fig. 15.4).

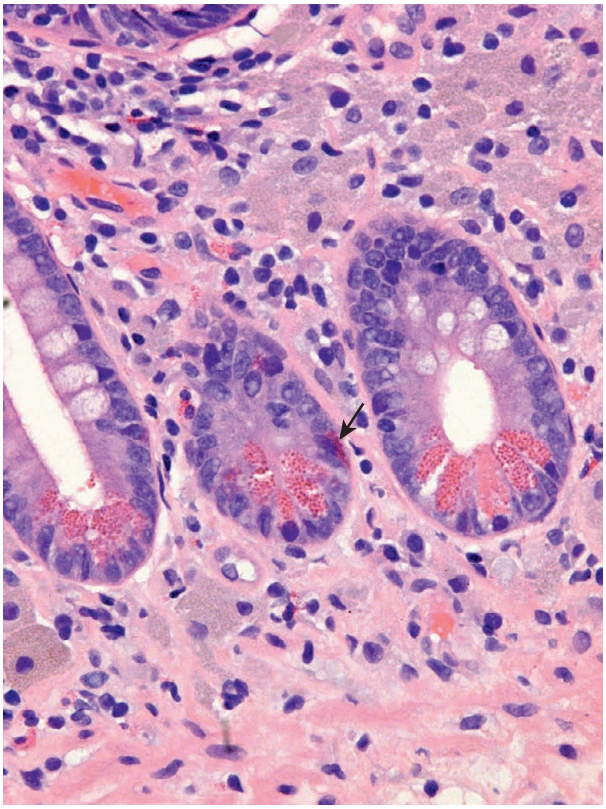

Figure 15.3 Paneth cells have large, red, supranuclear granules. In contrast, neuroendocrine cells in the crypts have smaller granules that are subnuclear and darker red to magenta *(arrow)*. This biopsy also contains pigmented macrophages indicating melanosis duodeni.

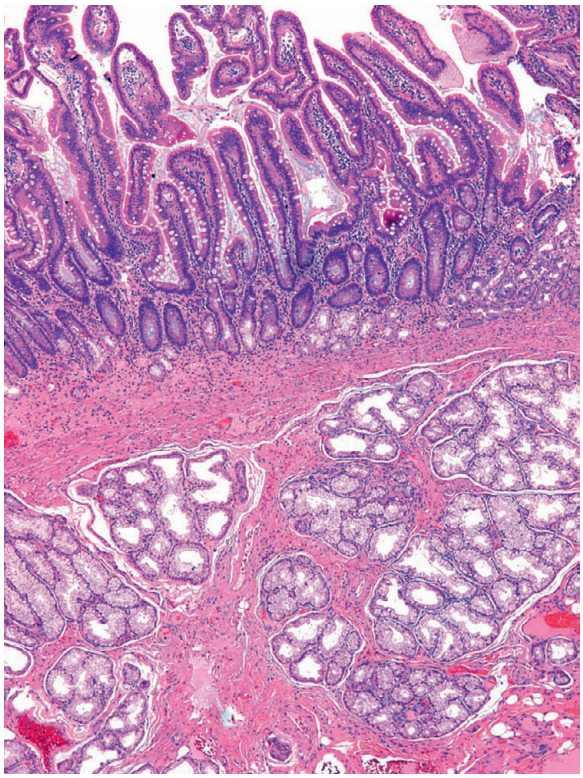

Figure 15.4 This biopsy shows nodular submucosal Brunner glands. When prominent, they may distort the overlying villous architecture.

The muscularis propria is made up of an inner circular and an outer longitudinal layer, with the *myenteric (Auerbach) plexus* located between. This plexus is composed of ganglion cells, satellite cells (similar but not identical to Schwann cells), and perineurial fibroblasts.[2,8,9] In addition, there is the "interstitial cell," described by Cajal in 1893, and interpreted by him as a primitive neural cell featuring several long anastomosing processes. These cells are intercalated between the ganglion cells and the effector smooth muscle cells, and function as the gastroenteric "pacemaker" system.[10,11] Their physiologic development depends upon signaling via the KIT receptor pathway.[12] They are normally immunoreactive for this molecule, as demonstrated with CD117, a fact that has implicated them (perhaps unjustly) in the histogenesis of gastrointestinal stromal tumor (GIST). They are negative for CD34, despite early claims to the contrary.[13] Their ultrastructural appearance is varied, ranging from smooth muscle–like to fibroblast-like; significantly, they lack neural features at this level.[14,15] The interstitial cells of Cajal originate from the same mesodermal precursors that give rise to smooth muscle cells, and not from the neural crest.[16,17] Therefore, these cells should not be regarded as neurally derived, a widespread misconception.

The serosa is covered by a single layer of attenuated mesothelium, separated from the muscularis by a normally thin layer of loose connective tissue. It contains vessels, lymphatics, and nerves.

The duodenum drains its lymph vessels into the portal and pyloric lymph nodes, the jejunum and proximal ileum into the nodes located in the mesentery and around the superior mesenteric artery, and the terminal ileum into the ileocolic nodes.

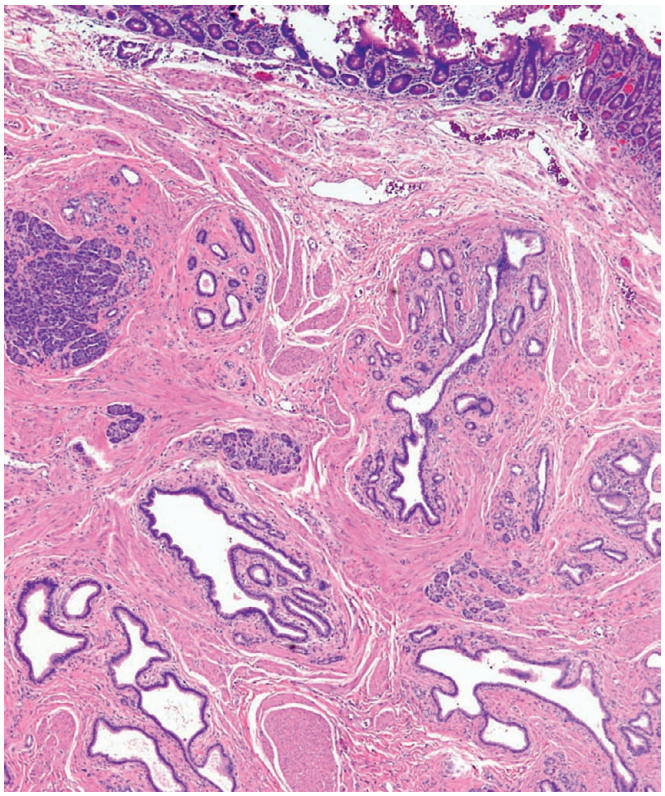

Figure 15.5 Heterotopic pancreas containing a focus of acinar parenchyma. The abundant ductal epithelium invested by smooth muscle creates a lobular appearance.

Congenital Defects

Heterotopias

Heterotopic pancreas consists mainly of ducts and acini, usually without islet tissue. The duodenum is the most common location (particularly in the region of the ampulla of Vater),[18] but it can also occur in the jejunum and (very rarely) in the ileum. Two lesions that are probably pathogenetically related to heterotopic pancreas are the tumorlike processes that have been described as *adenomyoma*[19] and *myoepithelial hamartoma*.[20] They are composed of exocrine-type ducts and bundles of smooth muscle, with or without an acinar cell component (Fig. 15.5). Blockage of the duct can occur where it empties into the intestinal tract, and this blockage can cause cystic dilation, infection, and fat necrosis.[21] Heterotopic pancreas is subject to any of the pathologic changes seen in the orthotopic organ, including acute pancreatitis, neuroendocrine tumors, and adenocarcinoma.[22] It has also been suggested that the rare *duodenal wall cysts* may be derived from the ductal component of ectopic pancreas.[23]

Foci of *heterotopic gastric mucosa* generally present as polyps in the duodenum, or rarely in the jejunum.[24–26] Endoscopically they appear as discrete small nodules or sessile polyps, although occasionally they form large polypoid lesions.[27] Microscopically, the mucosa is of fundic type, composed of chief and parietal cells (Fig. 15.6). Heterotopic gastric mucosa has been rarely associated with pyloric gland adenomas (see later).[28]

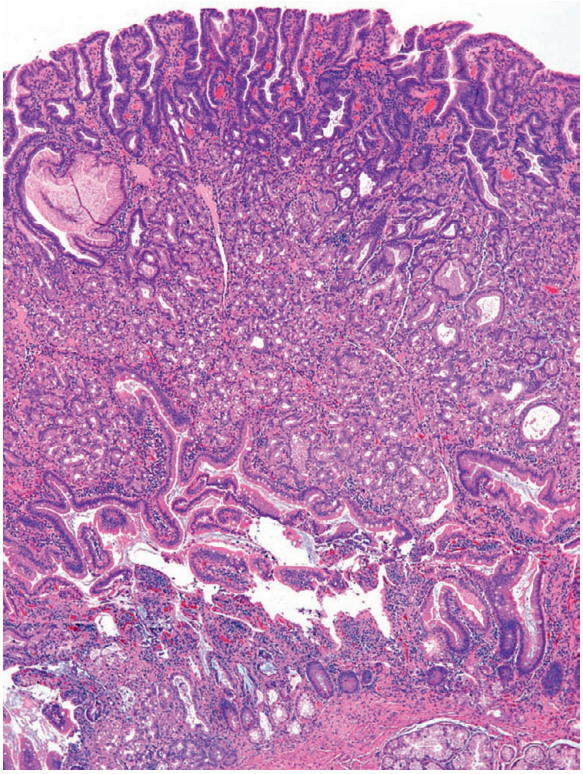

Figure 15.6 Polypoid gastric heterotopia occurring in the first portion of the duodenum. Parietal and chief cells are easily seen.

Duplication, Atresia, Stenoses, and Related Defects

Duplication and atresia of the gastrointestinal (GI) tract occur much more often in the small bowel (particularly ileum) than in the stomach or colon. Duodenal duplication (very rare) needs to be distinguished from the more common choledochocele, which it can mimic radiographically.

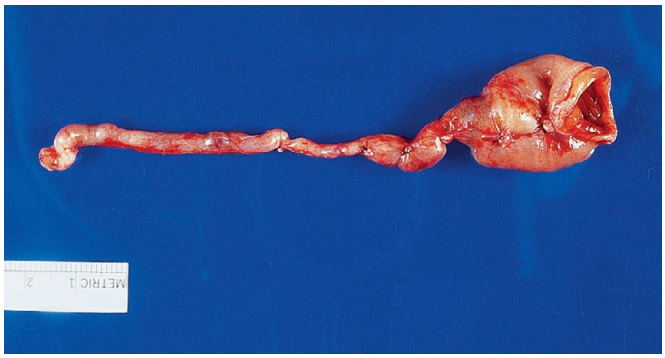

Figure 15.7 Long congenitally atretic segment of small bowel.

Intestinal duplication may be *spherical* (more common) or *tubular* and is usually incomplete, with a common muscular wall between the normal and the duplicate segments. The lumen of the duplicated segment sometimes communicates with the lumen of the bowel, and occasionally with the main pancreatic duct.[29,30] In other instances, the duplicated segment is totally independent and hangs free on its own mesentery. Exceptionally, it may be found within the substance of the liver.[31] Secondary inflammatory changes may supervene, and heterotopic mucosa is common. The treatment is surgical[32]; because the duplication cannot be separated in most cases from the adjacent normal bowel, the treatment usually involves resection of the entire duplication and the segment of normal bowel attached to it, or resection of the wall of the duplication that is not part of the wall of the normal bowel. Rare cases of malignant tumors (both squamous cell carcinoma and adenocarcinoma) developing within the duplicated bowel have been reported.[33,34]

Intestinal atresia can involve any portion of the small bowel and is associated with a wide variety of other congenital anomalies.[35–37] It is characterized by an obliteration of the bowel lumen and its replacement by a fibrous cord that connects the proximal and distal segments (Fig. 15.7). Traditionally, intestinal atresia has been regarded as an embryologic defect. Many believe that the disease is the result of in utero mechanical injury to the vascular system of the bowel, resulting from intussusception, volvulus, or incarceration.[37] A causal relationship between the use of dyes (e.g. methylene blue) during second-trimester amniocentesis and the occurrence of jejunal atresia has been suggested.[38] Complications of intestinal atresia include perforation, meconium peritonitis, and—as a rare late occurrence—brown bowel syndrome (see also Chapter 17).[39]

Infantile hypertrophic pyloric stenosis is an abnormal thickening of the pylorus that causes small bowel obstruction in the neonatal population. The etiology remains unknown. Surgical pyloromyotomy is the treatment of choice.[40] **Congenital absence of intestinal smooth muscle** has also been described, which may lead to obstruction, necrotizing enterocolitis, or spontaneous intestinal perforation.[41,42]

Congenital Diverticula and Related Vitelline Duct Abnormalities

Early in fetal life, the intestine communicates with the yolk sac. By the fourth week, the opening has gradually narrowed to form a tubular structure known as the *vitelline* or *omphalomesenteric duct*. At the 7-mm stage, the vitelline duct normally atrophies and forms a fibrous cord connecting the umbilicus and bowel. This band is subsequently absorbed as well. Failure of all or part of the vitelline duct to become obliterated accounts for the various types of vitelline duct abnormalities.[43] **Persistent fibrous cord** presents as a solid round cord of fibrous appearance, one end of which is attached to the umbilicus. The other end may be attached to the bowel wall, to the tip of a Meckel diverticulum, or to the mesentery. **Enteroumbilical fistula** is the consequence of a persistent patency of the entire vitelline duct.

Meckel diverticulum is the result of persistence of the proximal portion of the vitelline duct. It is found in 2% of the population and is more common in males.[44,45] Approximately 30% of patients have other congenital abnormalities, including tracheoesophageal fistula.[46] The usual location in the adult is approximately 80 cm proximal to the ileocecal valve. It is virtually always located on the outer antimesenteric border—an important diagnostic sign—and it varies in length from less than 1.0 to 8.0 cm. The lining is predominantly of small intestinal type, identical to that of the adjacent bowel; however, gastric, duodenal, or colonic mucosa may also be found, usually near the tip (Fig. 15.8).[47] Pancreatic tissue may also be present.

The complications of Meckel diverticulum include perforation, vesicodiverticular fistula,[48] ulceration, hemorrhage, intussusception, intestinal obstruction from attached bands, and tumors.[44] The ulceration is of peptic type, caused by acid secretion from the ectopic gastric mucosa, and is usually in the adjacent ileum rather than in the Meckel diverticulum itself. It may result in massive hemorrhage, particularly in children. *Helicobacter pylori* does not seem to be involved in the pathogenesis.[49] Among the neoplasms, well-differentiated neuroendocrine (WNET) (carcinoid) tumor predominates (Fig. 15.9),[50] either alone or—rarely—associated with carcinoid tumors of similar histologic appearance in the small bowel.[51] Other tumors include adenocarcinoma, GIST, and malignant melanoma.[52–54] Because of all these potential complications, Meckel diverticula should be removed whenever encountered incidentally at surgery.

Other Small Intestinal Diverticula

Duodenal diverticula occur in 1%–2% of all individuals. Most are solitary and located in the second portion; they can attain a large size and produce obstructive jaundice, pancreatitis, duodenal obstruction, fistulas, hemorrhage, and perforation.[55] Some of them project into the lumen like a polyp,[56] and some penetrate the pancreas along the embryologic fusion line of the ventral and dorsal components of this organ.[57] Microscopically, up to half of them show aggregates of foamy macrophages in the submucosa.[57]

Jejunal diverticula are found in 0.3%–1.4% of postmortem examinations. Most of them affect the upper portion of the jejunum and are characteristically located along the mesenteric border (Fig. 15.10).[58,59] They are often multiple, with thin walls and a decreased number of smooth muscle fibers. They tend to be associated with diverticula elsewhere in the GI tract. Some jejunal diverticula are congenital and may contain ectopic pancreatic tissue at their base; most are thought to be acquired, perhaps resulting from a defect in the muscle wall or myenteric plexus.[60] The majority are asymptomatic, but some may lead to hemorrhage, perforation, abscess formation, intramural gas cyst formation, obstruction caused by enterolith formation, or metabolic disturbances, such as vitamin B12 deficiency and malabsorption.[59,61] Many of these symptoms, which are typically intermittent, are thought to be caused by bacterial overgrowth within the diverticula.

Other Congenital Defects

Malrotation is a congenital anomaly resulting from an error in intestinal development such that (most commonly) the cecum is on the left, the duodenal-jejunal flexure is on the right, and the

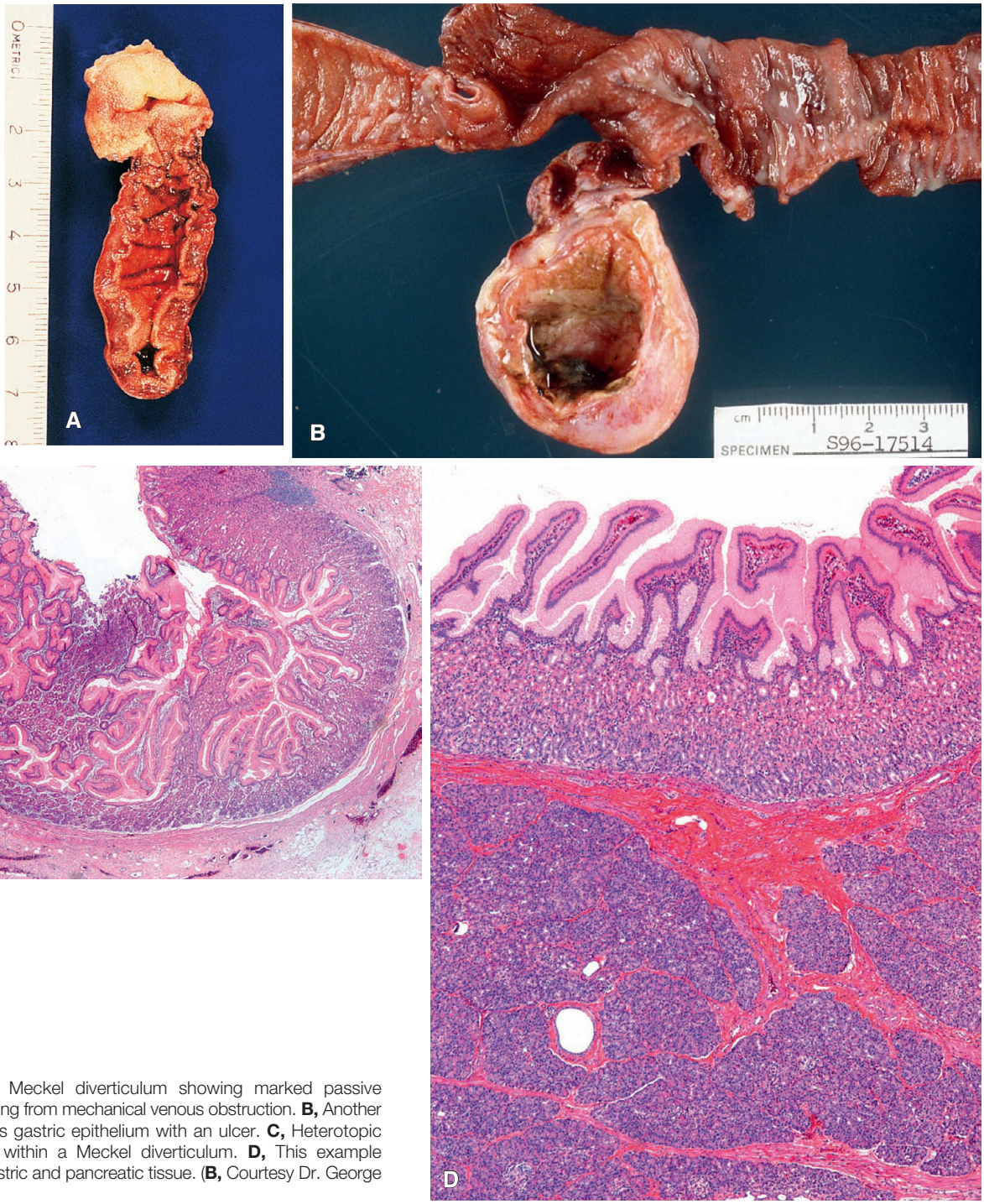

Figure 15.8 **A,** Meckel diverticulum showing marked passive congestion resulting from mechanical venous obstruction. **B,** Another example contains gastric epithelium with an ulcer. **C,** Heterotopic gastric mucosa within a Meckel diverticulum. **D,** This example contains both gastric and pancreatic tissue. (**B,** Courtesy Dr. George F. Gray, Jr.)

mesentery is narrow and unstable in position.[35] This may lead to volvulus with obstruction and ischemia, and affected infants often present with bilious vomiting. *Hirschsprung disease*, when involving the whole colon, may rarely extend to the small intestine, known as *total intestinal aganglionosis* (see also Chapter 17). The form is associated with a high mortality, the most common complication being enterocolitis.[62] *Ehlers–Danlos syndrome*, a congenital defect affecting collagen fibers throughout the body, may result in serious intestinal complications such as spontaneous perforation and massive bleeding.[63]

Inflammatory Disorders

Diseases of Malabsorption

The development of flexible endoscopes has made it possible to biopsy the mucosa of the small intestine with a minimum of discomfort or risk of serious complications, such as bleeding or perforation.[64] Small bowel biopsy is of the utmost importance in the evaluation of malabsorption, a constellation of signs and symptoms that can result from a large variety of disorders, of which

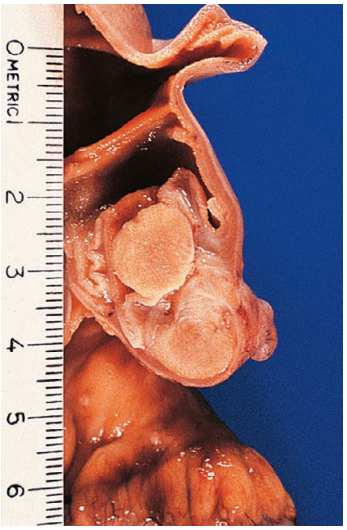

Figure 15.9 Meckel diverticulum complicated by the development of a carcinoid tumor, the cut surface of which has a characteristic yellow color after formalin fixation.

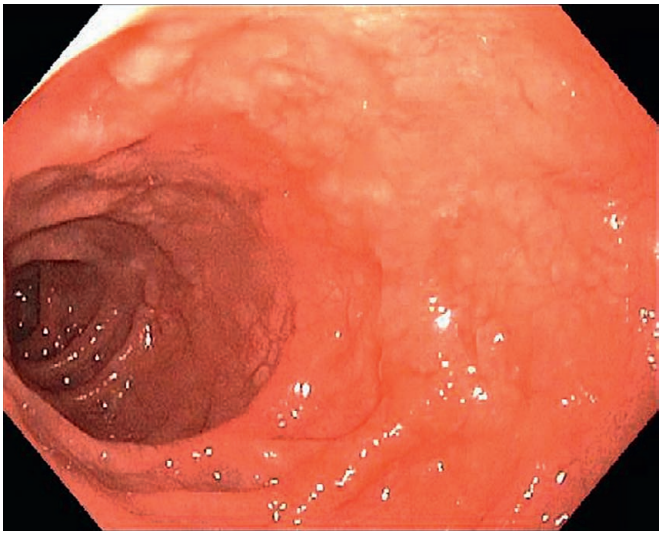

Figure 15.11 This endoscopic photo of the duodenum in celiac disease shows mucosal "mosaicism" and loss of normal folds. (Courtesy Dr. Rhonda Yantiss.)

Figure 15.10 **Multiple Jejunal Diverticula.** They are typically located along the mesenteric border. (Courtesy of Dr RA Cooke, Brisbane, Australia. From Cooke RA, Stewart B. *Colour Atlas of Anatomical Pathology*. Edinburgh: Churchill Livingstone; 2004.)

celiac disease (CD) is the most commonly encountered. Since the morphology of the mucosa shows normal regional variations, it is important that biopsies be taken from approximately the same area in all patients. Separate biopsies should be obtained from the proximal duodenum/duodenal bulb and from the second and/or third portions of the duodenum.[65] Ideally, once biopsies are obtained, they should be placed quickly on a flat surface, mucosal side up, preferably with the aid of a dissecting microscope; filter paper and Gelfoam are commonly used for this purpose.[64] The tissue can be fixed in formalin with the filter paper or Gelfoam attached to it to prevent curling. The filter paper should be removed during any one of the subsequent steps, whereas Gelfoam can be embedded in the paraffin block attached to the tissue. It is imperative that sections be cut at right angles to the mucosal surface.[64,66] Unfortunately, although optimal for orienting the small bowel villi for histologic evaluation, this historical method of orienting, processing, and sectioning small bowel biopsies is no longer widely used in routine practice.

Celiac disease (celiac sprue, nontropical sprue, gluten-sensitive enteropathy) is an immune-mediated disease due to an abnormal response to gluten and related proteins in genetically susceptible people.[65] It is characterized in its fully developed state by totally flat mucosa, a dramatic clinical and morphologic response to the removal of gluten from the diet, and relapse when gluten is reintroduced.[65,67–68] The clinical manifestations can be extremely varied.[69]

Macroscopic findings in CD include scalloping or denting of the duodenal folds, an absence or reduction in the number of folds, a submucosal vascular pattern, and "mosaicism," in which the mucosa has a somewhat nodular appearance (Fig. 15.11). Grooves and fissures have also been described.[70] However, these findings are not specific to CD. Involvement may be patchy and is most prominent in the proximal small bowel with decreasing involvement distally.[67] Microscopically, in fully developed CD, the villi are markedly atrophic or absent, but the overall thickness of the mucosa is essentially normal due to presence of crypt hyperplasia (Fig. 15.12A). There is an increase in lymphocytes and immunoglobulin-containing plasma cells in the lamina propria, and accumulation of fat globules representing partially absorbed lipid in the surface epithelium.[71] Increased intraepithelial T lymphocytes, although far from being pathognomonic, are also a characteristic finding (see Fig. 15.12B).[72–74] It is important to note that in some cases the villous architecture is only mildly atrophic or entirely normal, and increased intraepithelial lymphocytes (IELs) may be the only evidence of disease. Interestingly, IELs have also been detected in the gastric and esophageal mucosa in patients with CD,[75–77] and there is an association with lymphocytic

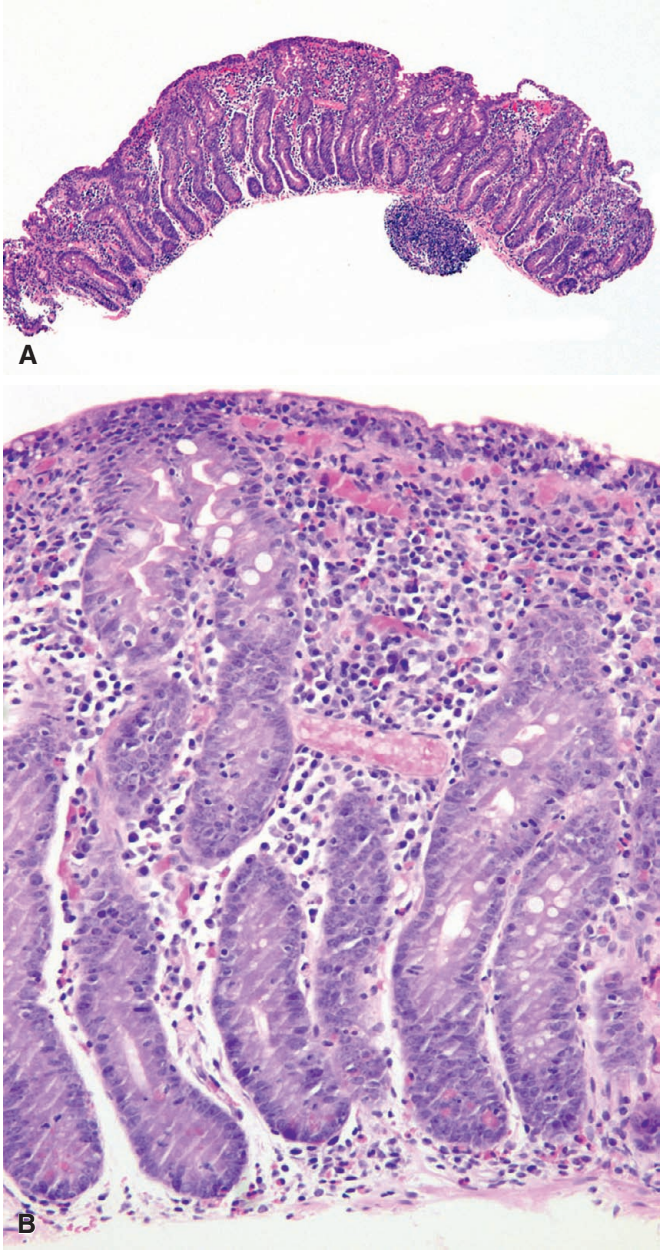

Figure 15.12 **A,** This biopsy from a patient with untreated celiac disease shows total villous atrophy, but concomitant crypt hyperplasia maintains the thickness of the mucosa. There is also a lymphoplasmacytic infiltrate in the lamina propria and a decrease in goblet cells at low power. **B,** Intraepithelial lymphocytes are prominent in both surface and crypt epithelium.

colitis in both children and adults.[78,79] An increase in the number of mitoses (including upwardly displaced mitoses) in the epithelium is a common feature,[80] as is a decrease in goblet cells[67] and hyperplasia of serotonin-containing neuroendocrine cells.[81] The epithelial cells have been shown to have a shortened life span.[82]

The most commonly used grading system for CD in small bowel biopsies is a modification of the Marsh (Marsh–Oberhuber) criteria adopted by the National Institutes of Health[67,74,83]:

Grade 0 = normal
Grade 1 = IELs only

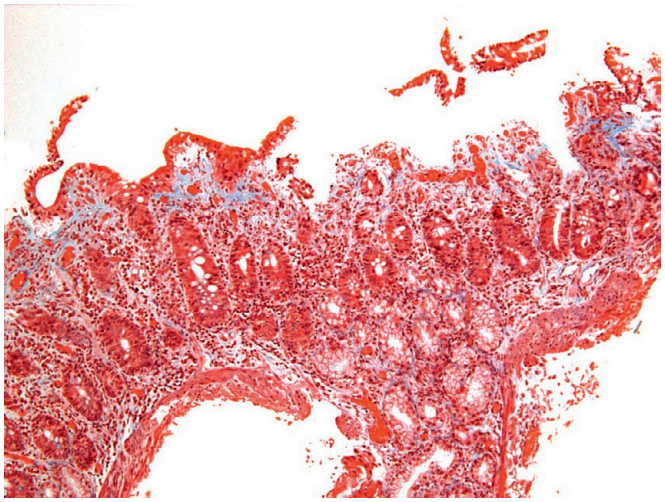

Figure 15.13 Subepithelial collagen deposition, villous atrophy, and increased intraepithelial lymphocytes are seen in this biopsy from a patient with collagenous sprue (Masson trichrome stain).

Grade 2 = IELs plus crypt proliferation
Grades 3 a, b, c = mild, moderate, and severe shortening of villi, respectively.

It is important to note, however, that the Marsh criteria are intended for use in patients with established CD, and it cannot be overemphasized that villous atrophy is not pathognomonic of CD. Therefore, a Marsh 1 lesion in a patient without a known diagnosis of CD could represent a number of conditions, including dermatitis herpetiformis, kwashiorkor, tropical sprue, autoimmune diseases, nonsteroidal anti-inflammatory drug (NSAID) use, and *H. pylori* infection, among others.[67,74,84]

The pathogenesis of CD is related to inappropriate intestinal T-cell activation in HLA-DQ2- or HLA-DQ8-positive individuals, which is triggered by antigenic peptides from wheat gluten or prolamins from barley and rye.[83,85,86] In addition to duodenal biopsy and clinical history, serologic studies are also helpful in diagnosis.[87] In patients above 2 years old, the anti–tissue transglutaminase (TTG) IgA antibody is the preferred serologic test. Anti-endomysial antibodies are more specific, but much more expensive and technically difficult to perform. Deamidated gliadin peptide (DGP) IgA and IgG or an anti-TTG IgG assay may be useful in children who are less than 2 years of age or in adults who are IgA deficient.[87,88]

Weinstein et al.[89] described the entity known as *collagenous sprue* (Fig. 15.13), characterized by increased deposition of eosinophilic hyaline material within the lamina propria, in addition to villous blunting and inflammatory changes. Whether this is a specific entity or merely a morphologic variant of CD is still argued, but the former seems more likely, particularly as many patients lack characteristic serologic findings and do not respond to a gluten-free diet.[90]

Refractory celiac disease (RCD) is a somewhat confusing term with differing definitions depending on the context.[91] Clinically, RCD is defined as persistent or recurrent symptoms and an abnormal biopsy, despite adherence to a gluten-free diet and the exclusion of other entities that could cause malabsorption. From an immunophenotypic standpoint, RCD can be further subdivided into type I, in which the lymphocytes maintain a normal immunophenotype, and type II, in which there is clonal expansion of an aberrant population of T cells that many believe represents an early form of enteropathy-associated lymphoma and have thus designated as "*cryptic intraepithelial lymphoma*."[92]

The development of lymphoma must be suspected in patients with a history of CD who, as discussed earlier, become unresponsive to a gluten-free diet and/or present with fever, weight loss, abdominal pain, rash, or lymphadenopathy.[93] Although CD and *enteropathy-associated T-cell lymphoma* (EATL) may be diagnosed concurrently, lymphoma typically arises within 5–10 years of a prior diagnosis of CD, although the time between initial diagnosis of CD and the development of lymphoma may be decades. The clinical course is aggressive and the prognosis is poor, in part due to the often delayed diagnosis and the poor nutritional status of patients in this situation.[94] Two types of EATL are recognized[95,96]: *type I* or *classical*, which is usually associated with CD and accounts for the majority of cases, and *type II* or *monomorphic epitheliotropic*, which is not typically associated with CD or the CD-associated HLA haplotypes (which has led some to question whether or not it should be regarded as an enteropathy-associated lymphoma at all).

Grossly, cases with full-blown lymphoma tend to involve the small bowel (particularly the jejunum) in a multifocal fashion, causing ulceration, stricture formation, and perforation.[96,97] Microscopically, type I EATLs are very variable,[95] consisting of a mixture of pleomorphic variably sized cells with conspicuous nucleoli and variably present necrosis (Fig. 15.14). Atypical binucleated or multinucleated cells may be present and lead to a mistaken diagnosis of Hodgkin lymphoma. Admixed eosinophils and histiocytes are also common. Morphologic features of CD, ranging from focally increased intra-epithelial lymphocytes to marked villous atrophy, may be present either adjacent to the lymphoma or elsewhere in the small bowel. Type I EATLs typically express CD3, CD7, TIA-1, and the αβ T-cell receptor but lose expression of CD4, CD5, and CD56. CD8 is variably expressed.[95,98,99] These tumors may also express CD30, leading to diagnostic confusion.[98] Type II EATLs, in contrast, are composed of monotonous small to intermediate sized cells with inconspicuous nucleoli. Most are CD8 and CD56 positive, along with CD3 and CD7; CD5 is typically negative, and either the αβ or γδ receptor can be expressed.[95,98,100,101] Increased IELs may be found adjacent to or away from the area of the lymphoma, and villous blunting is variably present.[96,100,101]

Clonal rearrangements of T-cell receptor genes are demonstrable in most cases of EATL.[102,103] Characteristic genetic changes are +9q31–q33 (70% of cases) and −16q12 (23% of cases).[104,105] Furthermore, type I is characterized by +1q32–q41, +5q34–q35, and the CD-associated HLA phenotype HLA-DQB1*02, while type II is characterized by +8q24, which includes the *MYC* gene locus.[104] Epstein–Barr virus (EBV) is usually absent.[106,107]

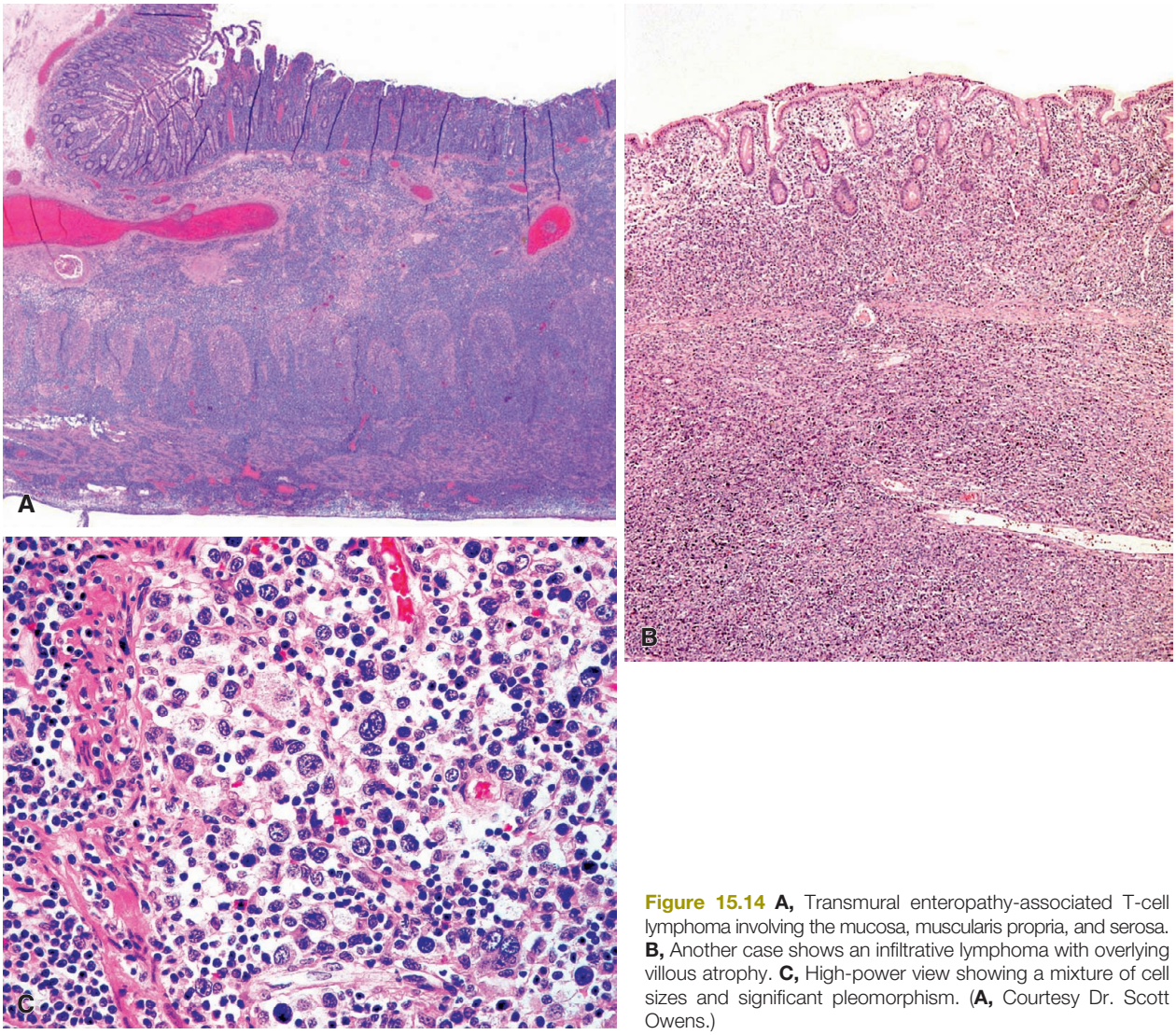

Figure 15.14 **A,** Transmural enteropathy-associated T-cell lymphoma involving the mucosa, muscularis propria, and serosa. **B,** Another case shows an infiltrative lymphoma with overlying villous atrophy. **C,** High-power view showing a mixture of cell sizes and significant pleomorphism. (**A,** Courtesy Dr. Scott Owens.)

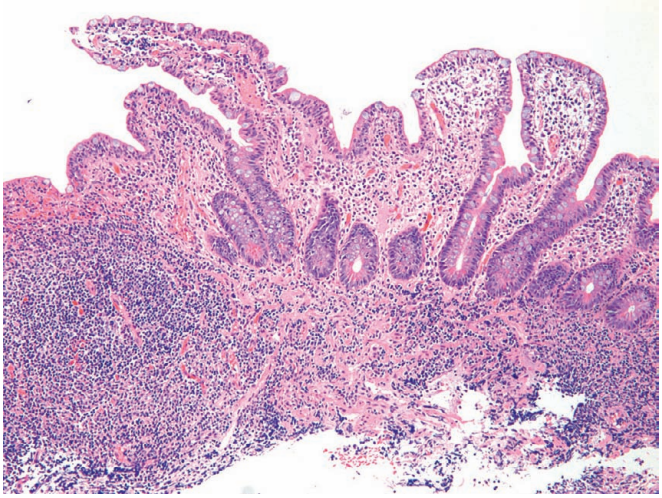

Figure 15.15 A biopsy from a patient with tropical sprue featuring mild villous blunting, a lymphoplasmacytic infiltrate in the lamina propria, and increased intraepithelial lymphocytes.

A complication of CD is *ulcerative duodenojejunoileitis*,[102,108] which is characterized by abdominal pain, fever, and intestinal perforation or obstruction superimposed on a background of a malabsorption syndrome. Most of these cases probably represent the initial stages of EATL, as supported by the fact that the lymphocytic population is clonal and that many patients go on to develop overt lymphoma.[102]

Yet another rare complication of adult CD is the development of *carcinoma*, usually in the small bowel but also in the esophagus.[109,110] Small bowel carcinomas arising in the context of CD are typically solitary adenocarcinomas.

Tropical sprue is an altogether different chronic malabsorptive condition that is unaffected by gluten ingestion.[111,112] It has a definite geographic distribution, affecting both residents and visitors to India, parts of Southeast Asia, Venezuela, Colombia, and parts of Mexico and the Caribbean islands. It is associated with both folate and vitamin B12 deficiencies and responds to vitamin supplementation and tetracycline.[113] The morphologic changes are nonspecific (Fig. 15.15). The large majority of cases show *partial* villous atrophy, with increased lamina propria inflammation and increased IELs. Unlike CD, both the distal and the proximal small bowel are involved.[112] The favored (although unproven) etiology at present is that of persistent bacterial infection or colonization.[111–113] Features in favor of this interpretation are the isolation of enterotoxigenic coliform bacilli, the endemic nature of the disease (and the fact that it may affect visitors to areas where it is endemic), and the well-known response to antibiotics.

Whipple disease (intestinal lipodystrophy) is a systemic disorder with protean manifestations, including arthritis; diarrhea, weight loss, and malabsorption; and neurologic symptoms.[114] Endoscopically, patients may have white plaques representing lipid deposition in the mucosa (Fig. 15.16A and B), although this finding is not always present. The microscopic findings are characteristic, consisting of an infiltrate of histiocytes that fills the lamina propria and distorts the villi (see Fig. 15.16C).[115] Varying numbers of neutrophils may be present, although a mononuclear inflammatory infiltrate is typically absent, and the lamina propria often contains small foci of fat. Epithelioid granulomas are present in a minority of cases.[116] Occasionally, the disease is restricted to the submucosa and can, therefore, be missed in a mucosal biopsy.[117] The cytoplasm of the histiocytes is strongly periodic acid–Schiff (PAS) positive (Fig 15.16D), due to the presence of bacilliform bodies. This organism, which has been named *Tropheryma whipplei*, was identified by sequencing the largest part of a bacterial 16S ribosomal DNA, followed by polymerase chain reaction (PCR) amplification.[118,119] The Whipple bacillus has also been demonstrated by electron microscopy and immunohistochemistry,[120,121] and there have been some allegedly successful attempts at culturing.[122] The response to antibiotic therapy is good, although relapses are common.[123] Of note, PAS-positive macrophages may persist in biopsies for years, even in patients who have been treated with long-term antibiotic therapy.

Macrophages of identical appearance have been identified in the rest of the alimentary tract, as well as in regional and peripheral lymph nodes (see Fig. 15.16E), heart, lung, liver, spleen, adrenal glands, nervous system, and several other sites.[124,125] Mesenteric adenopathy is common, and lymph node biopsy may be useful in diagnosis.[126] Involved lymph nodes may show aggregates of PAS-positive macrophages, as well as small foci of fat, and noncaseating granulomas may be seen there as well. It should be remembered that a similar change (although not accompanied by PAS-positive macrophages) is often seen in intra-abdominal lymph nodes of normal individuals, probably secondary to the ingestion of mineral oil.[127]

Whether Whipple disease represents a specific disease caused by a unique bacterium capable of intracellular survival and replication, or a common organism in a host with impaired immunity, remains to be determined.[123] Macrophages in patients with Whipple disease show several abnormalities, and T-cell abnormalities have also been reported.[123] A few cases of extraintestinal malignant lymphoma have also been reported in patients with Whipple disease.[128]

Important entities in the differential diagnosis include infection with *Mycobacterium avium-intracellulare (MAI)*[129] (see later) and *Rhodococcus equi*.[130] It should also be noted that the evaluation of rectal biopsies for Whipple disease is hampered by the fact that mucin-containing macrophages ("muciphages") present in the lamina propria of many normal individuals have a strong resemblance to the histiocytes of Whipple disease, at least on routine H&E evaluation.[131]

Other diseases associated with malabsorption that may feature increased IELs as well as villous abnormalities, and in which small bowel biopsy may be of value, include *bacterial overgrowth*; *nutritional deficiencies* (such as zinc or B12 deficiency); *allergies to proteins other than gluten*, such as cow's milk, eggs, or soy[67]; *common variable immunodeficiency* (CVID; see later); *autoimmune enteritis* (AIE; see later); *abetalipoproteinemia*, in which the apical villous cytoplasm shows striking vacuolation as a result of inability to synthesize β-lipoprotein[132] (Fig. 15.17); *intestinal lymphangiectasia*, in which a protein-losing enteropathy develops probably as a result of the entrance of protein-rich fluid into the extracellular space of the lamina propria from the dilated lymphatic channels, and subsequent drainage into the gut lumen[133]; *amyloidosis; scleroderma*[134]; and *parasitic infections*, such as giardiasis,[135,136] hookworm infection,[137] strongyloidiasis,[138] and capillariasis.[139]

Peptic Duodenitis/Duodenal Ulcer

Duodenal peptic ulcer remains a very common disease, although its incidence seems to be decreasing. *H. pylori* has been shown to be an important factor in its pathogenesis, but gastric acid hypersecretion (which is the rule in these patients) and reduced duodenal mucosal resistance are also believed to play an important role.[140,141] Thus, a preserved fundic mucosa in the stomach is a prerequisite for the formation of duodenal peptic ulcer.

Grossly, duodenal peptic ulcers are usually single and within 2 cm of the pylorus (Fig. 15.18), although they may also occur

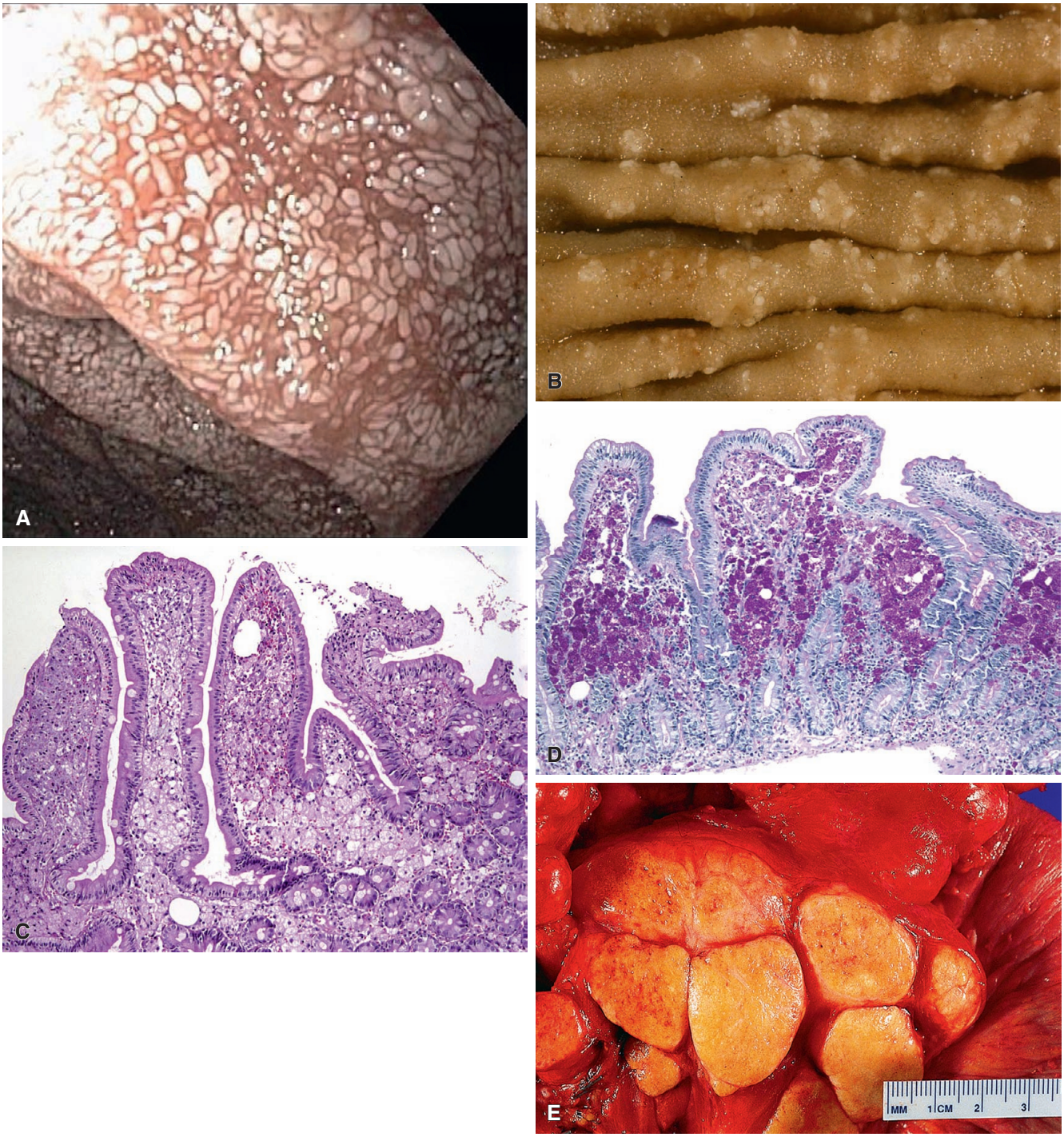

Figure 15.16 Whipple Disease. A, Endoscopic view of the small bowel showing white lipid-filled plaques in the mucosa. **B,** Similar changes are seen in a resection specimen. **C,** On biopsy, the lamina propria is packed with histiocytes and empty round spaces; the latter contained lipid material that has been extracted during tissue processing. **D,** PAS stain highlights the macrophages. **E,** Cut surface of mesenteric lymph nodes massively involved by Whipple disease.

in the second portion of the duodenum. When the ulcer is in the latter position, it may be the source of upper abdominal pain and bleeding, yet not be discernible radiographically. The margins are well defined and sharply demarcated from the surrounding mucosa. At times, a large vessel with an open lumen may be seen at the base of the ulcer. Fibrosis of a healed ulcer may produce secondary diverticula and considerable shortening of the duodenum. When duodenal ulcers are multiple and randomly distributed in the proximal and distal portions of the duodenum, the possibility of Zollinger–Ellison syndrome should be ruled out.

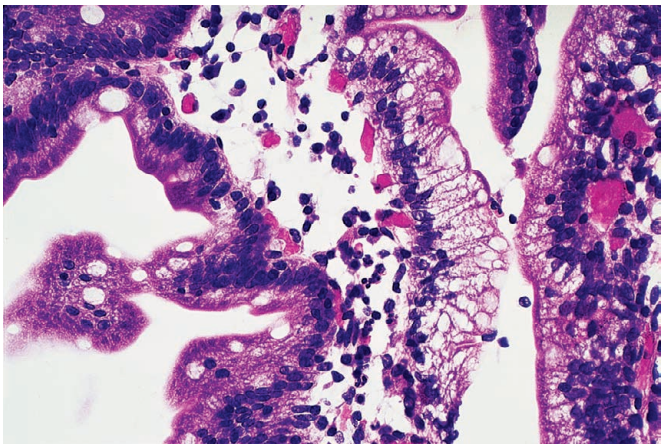

Figure 15.17 Marked cytoplasmic vacuolization of the glandular epithelium of small bowel in abetalipoproteinemia.

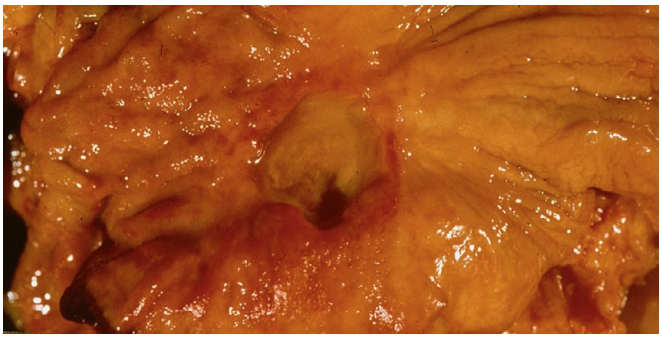

Figure 15.18 Large, deep, well-circumscribed duodenal peptic ulcer in the first portion of the duodenum.

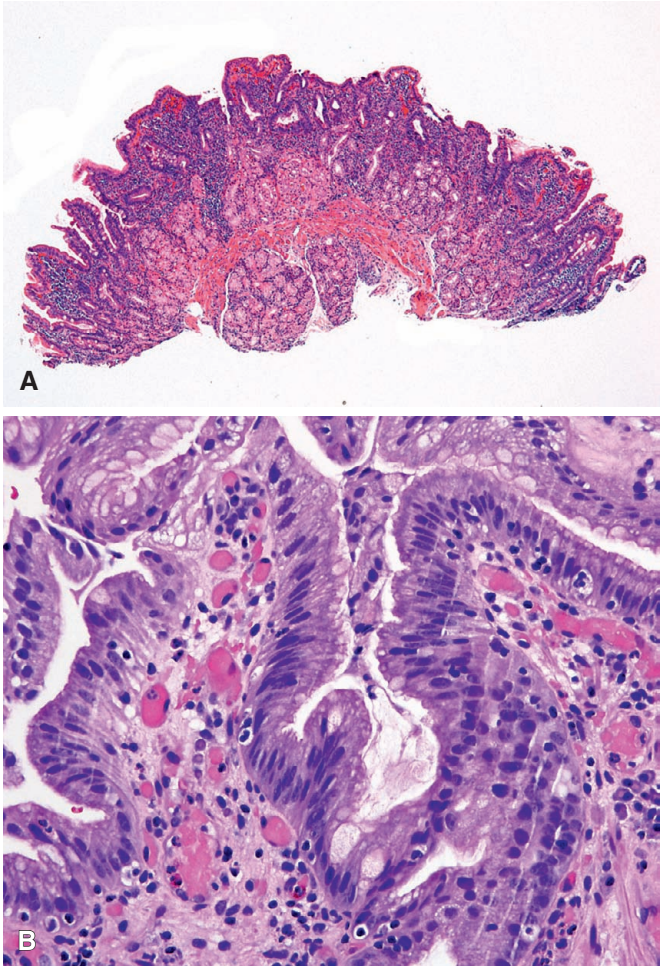

Figure 15.19 **A,** Low-power view of peptic duodenitis showing egress of Brunner glands into the mucosa, a plasmacytic infiltrate in the lamina propria, and mild villous blunting. **B,** Higher-power view shows neutrophils within the epithelium and lamina propria, as well as surface gastric metaplasia. (Courtesy Dr. Wendy Frankel.)

Another important cause of non-*H. pylori*–related duodenal ulcer is NSAID usage.[142]

The microscopic features are analogous to those of its gastric counterpart (see Chapter 14). Gastric metaplasia is common, as is inflammation, loss of goblet cells, variably present villous blunting, and fibrosis in chronic cases.[143] The incidence of malignant change is negligible.

With the widespread use of H_2-receptor antagonists, proton pump inhibitors, and *H. pylori* eradication, the number of cases of duodenal ulcers requiring surgical intervention has markedly decreased. Refractory ulcers tend to occur in younger patients, to be larger, and to be associated with severe duodenitis.[144] Indications for surgery are complications, such as hemorrhage, perforation, and obstruction, and lack of response to medical therapy.[145] Historically, the two standard surgical techniques have been vagotomy with antrectomy and gastroenterostomy, and vagotomy with pyloroplasty. Simple closure is becoming increasingly common, however, as is surgical management via laparoscopy as opposed to laparotomy.[146]

Marginal ulcer is a type of peptic ulcer that appears at the site of a gastrojejunostomy opening. Although the ulcer may be at the stoma itself, in most instances it is located in the jejunum at some distance from the opening. It was a common complication at the time when gastroenterostomy for duodenal peptic ulcer was being done without a concomitant gastric resection. It is still seen, although rarely, following gastroenteroanastomosis with gastric resection (Billroth II operation) for duodenal ulcer, especially if the entire antrum is not removed or if the afferent jejunal loop is of excessive length. Occasionally, marginal ulcer develops following gastric resection for peptic ulcer or carcinoma of the stomach.

Small bowel ulcers that are not related to *H. pylori* infection or NSAID use[147] are uncommon. Many of the cases seen in the early 1960s were due to the ingestion of enteric-coated tablets of potassium chloride.[148] With that medication off the market, most of the "idiopathic" ulcers seen today are secondary to ischemia,[149] radiation, other medications (e.g. iron, colchicine), occult tumors, other infections, or Zollinger–Ellison syndrome.[150] A rare autosomal recessive inherited enteropathy secondary to SLCO2A1 prostaglandin transporter gene mutations has been reported to cause chronic small bowel ulceration,[151] and rare cases have been attributed to extensive gastric metaplasia.[152]

Peptic duodenitis is a common finding in patients with dyspepsia secondary to *H. pylori* infection and NSAID use,[153,154] and the microscopic appearance correlates well with endoscopic findings of duodenitis and/or abnormal mucosa.[155] Cases show increased numbers of plasma cells in the lamina propria, upward expansion of Brunner glands into the mucosa, gastric metaplasia, and a variable degree of neutrophilic infiltration (Fig. 15.19)[153]; more severe cases are accompanied by a more pronounced neutrophilic response. IELs and villous atrophy may also be encountered.[156,157]

Vascular Diseases

The consequences of mesenteric vascular occlusion are discussed elsewhere, but a few points regarding small bowel changes will be made here. Gross pathologic findings range from complete gangrene to foci of mucosal ulceration, accompanied by extensive submucosal edema.[158–160] Perforation may develop, and healing may lead to severe stenosis. Intramucosal signet ring cells may be seen due to mucosal injury, not to be misinterpreted as malignant.[161]

The vascular alterations in the bowel that lead to these complications are usually the result of atherosclerosis, but they can also be secondary to postoperative adhesions from radiation therapy; vasculitis, including rheumatoid arthritis,[162] periarteritis nodosa,[163] giant cell arteritis,[164] thromboangiitis obliterans,[165] and other forms of systemic vasculitis[166]; oral contraceptives[167]; cocaine ingestion[168]; amyloidosis[169]; and infection, typically by viruses[170] or vasotropic fungi.[171] Phlebitis may be seen in the absence of arteritis, in which case systemic involvement is typically absent.[172] Depending on the predominance of a given morphologic alteration, terms such as (*enteric* or *enterocolic*) *lymphocytic*, *granulomatous*, and *necrotizing phlebitis* have been used (Fig. 15.20), but all of these conditions are probably pathogenetically related.[173,174] Cases reported as *myointimal venous hyperplasia* and *veno-occlusive disease of small bowel* may also represent late stages of the same processes.[175] All of these conditions can closely mimic Crohn disease, both histologically, clinically, and radiographically, and can also produce an inflammatory mass that may mimic malignancy. A recently described noninflammatory, nonatherosclerotic entity termed *mesenteric arteriovenous dysplasia/vasculopathy* can also mimic Crohn disease or a mass lesion.[176] Although not an example of vasculitis, anticoagulant therapy can be complicated by the development of massive hemorrhage in the wall of both the small and large bowel.[177,178]

Other vascular diseases that may affect the small bowel include *portal hypertensive enteropathy,* a spectrum of changes in the mucosal microvasculature in patients with portal hypertension that may lead to lower GI bleeding (Fig. 15.21),[179,180] and, rarely, *Dieulafoy lesion* (Fig. 15.22).[181]

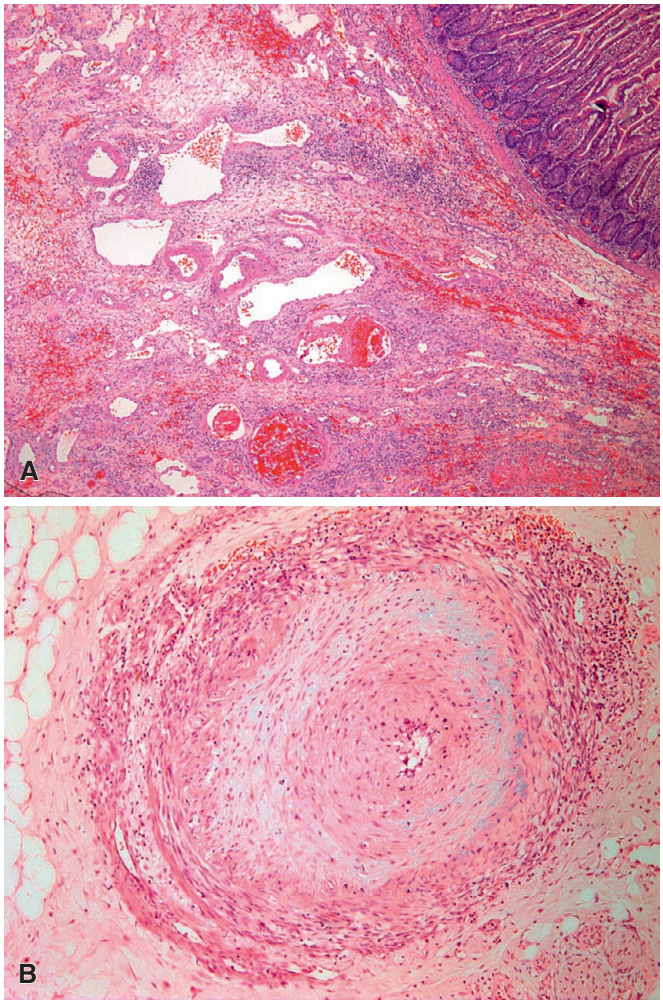

Figure 15.20 **A,** Necrotizing and lymphocytic phlebitis with associated thromboses in the small bowel. **B,** Another case shows a mesenteric vein with marked mural scarring, luminal narrowing, and lymphocytic inflammation.

Inflammatory Bowel Disease

Crohn disease occurs with equal frequency in both sexes.[182] Most patients are in their 20s or 30s,[183] but the disease can first manifest at any age, including childhood and old age. White individuals of Anglo-Saxon extraction are more susceptible to the disease, the incidence of which seems to be increasing.[183] The etiology remains unknown but appears to involve a complex interaction between genetic susceptibility, enteric microflora, and immune-mediated injury.[184] A tendency for familial clustering in Crohn disease has long been noted,[184,185] and a number of different genetic susceptibility loci have been identified.[184,186] Familial concordance studies, however, provide evidence that more than genetic susceptibility is needed for the development of Crohn disease, and the role of the enteric microbiome is now accepted as a major etiologic factor.[186] A number of organisms have been implicated, including several types of mycobacteria (particularly *Mycobacterium paratuberculosis*), *Escherichia*

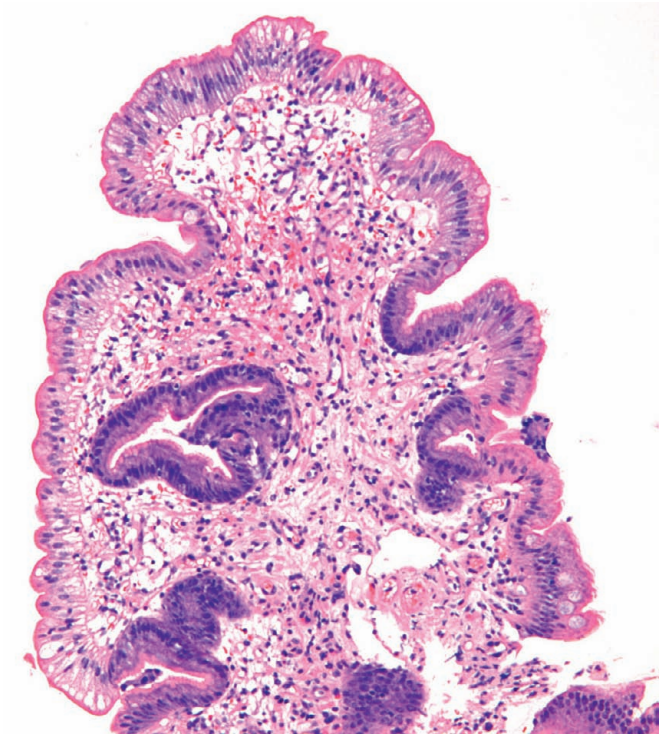

Figure 15.21 A polypoid lesion composed of small, proliferating, granulation tissue–like capillaries in portal enteropathy.

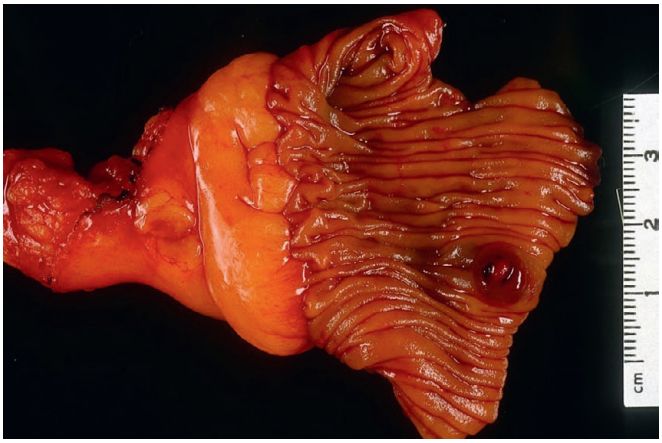

Figure 15.22 Dieulafoy lesion, defined as a solitary ulcer that erodes into a large submucosal artery, is most often found in the stomach but is rarely seen in the small bowel.

Figure 15.23 So-called aphthoid ulcers, an early feature of Crohn disease.

coli, *Yersinia*, *Streptococcus*, and viruses (including measles), but no specific causative agent has been identified.[187–192] The current hypothesis is that Crohn disease results from the interaction between host genetic polymorphisms and the gut microbiome (rather than conventional enteric pathogens), leading to an immune response and chronic inflammatory injury.[193–195]

Grossly, the ileum is the usual site of the disease, although any portion of the small bowel can be involved, and Crohn disease can affect any segment of the digestive tract including the oral cavity, minor salivary glands, esophagus, stomach, duodenum, large bowel, and anus (see also Chapters 14 and 17).[196–201] In a classic series of 297 cases of Crohn disease studied by Morson,[197] 66% of the cases were restricted to the small bowel, 17% were restricted to the large bowel, and 17% had involvement of both segments. In more recent series, lesions were limited to the small bowel in only one third of cases.[202]

Crohn disease can also involve sites outside the alimentary system, such as the skin (particularly around ileostomy or colostomy stomas),[203] vulva,[204] bones and joints,[205] skeletal muscle,[206] larynx, and spleen. The overall incidence of extraintestinal involvement is about 25%.[207] Nonspecific complications of the disease include arthritis, hydronephrosis, osteoporosis, amyloidosis, hidradenitis suppurativa, pyoderma gangrenosum, and various ocular disorders.[208–210]

Grossly, in the early stages of the disease the involved small bowel has a soggy feeling. The mucosa is reddish purple and may show pinpoint erosions known as "aphthoid ulcers" (Fig. 15.23).[211] One of the most distinctive gross features of Crohn disease is the often segmental nature of the process, with sharply outlined foci separated by seemingly normal bowel ("skip areas") (Fig. 15.24A). In later stages, ulceration becomes prominent; these ulcers are linear or serpiginous and often have a longitudinal disposition, arranged in parallel and connected by short transverse ulcerations.[211] As linear ulcerations cross the transverse folds of the bowel, the combination of ulceration and mucosal remnants results in the typical "cobblestone" appearance (see Fig. 15.24B and C). Rarely, the mucosa has a polypoid configuration because of granulation tissue formation or nodular lymphangiectasia (so-called inflammatory pseudopolyps).[212–213] The gross changes in the wall itself evolve from edema to fibrosis, with marked narrowing of the lumen accompanied by dilation and hypertrophy of the proximal segment (Fig. 15.24D and E). At this stage, the impression on palpation has been imaginatively likened to an eel in rigor mortis. The serosa may be focally or diffusely thickened; rarely, it is found to have multiple ("miliary") white nodules composed of either lymphoid aggregates or granulomas.[214] The mesentery becomes fibrotic and shortened, resulting in a corrugated bowel contour and piling up of mesenteric fat. Regional lymph nodes may be moderately enlarged.

Local complications of Crohn disease include the development of intramural abscesses and the formation of fistulas connecting the small bowel with other loops of small bowel or with large bowel, abdominal wall, or bladder.[215] At times, perforation occurs.[216]

The early lesion of Crohn disease is probably a very nonspecific focus of active mucosal inflammation.[211] This may be accompanied by lymphoid hyperplasia in the lamina propria and submucosa and a scattering of chronic inflammatory cells, including plasma cells, lymphocytes, eosinophils, histiocytes (some containing prominent lysosomal inclusions),[217] and mast cells.[218] Small foci of ulceration are often seen to begin at the very top of the lymphoid follicles (the microscopic correlate of the aforementioned aphthoid ulcer) (Fig. 15.25A).

The most typical ulcers in Crohn disease are referred to as *fissures*. These are seen in approximately 30% of the cases and are defined as slitlike formations with sharp edges and narrow lumina, arranged perpendicular to the mucosa, and extending deeply into the submucosa and even the muscularis propria. The nonulcerated mucosa may show cryptitis and crypt abscesses, abnormally shaped villi, architectural distortion, basal plasmacytosis, and regenerative changes. Foci of pyloric metaplasia may also be present (Fig. 15.25B).[211,219] In well-developed Crohn disease, there is nearly always microscopic evidence of transmural involvement (Fig. 15.25C), although the changes may be much more severe in the submucosa and subserosa than in the muscularis propria. Features of transmural involvement include transmural inflammation, often with prominent lymphoid follicles in a linear or "string of beads" array; edema; lymph vessel dilation; thickening of the muscularis mucosae; neural hyperplasia; and fibrosis.[211,220,221] The inflammatory changes can involve the walls of veins and arteries.[222] There is an increase in the number of smooth muscle fibers in the submucosa ("obliterative muscularization") as well, a change that may contribute to the development of obstruction.[223] Along these lines, it has been found that tenascin (an extracellular matrix protein involved in the morphogenesis of muscle tissue and wound healing) is strongly expressed, especially in areas of stricture.[224] Occasionally, following ulceration and reepithelialization, cystically dilated glands are seen in the wall of the bowel, an abnormality known as *enteritis cystica profunda*, which may be confused with invasive adenocarcinoma.[225]

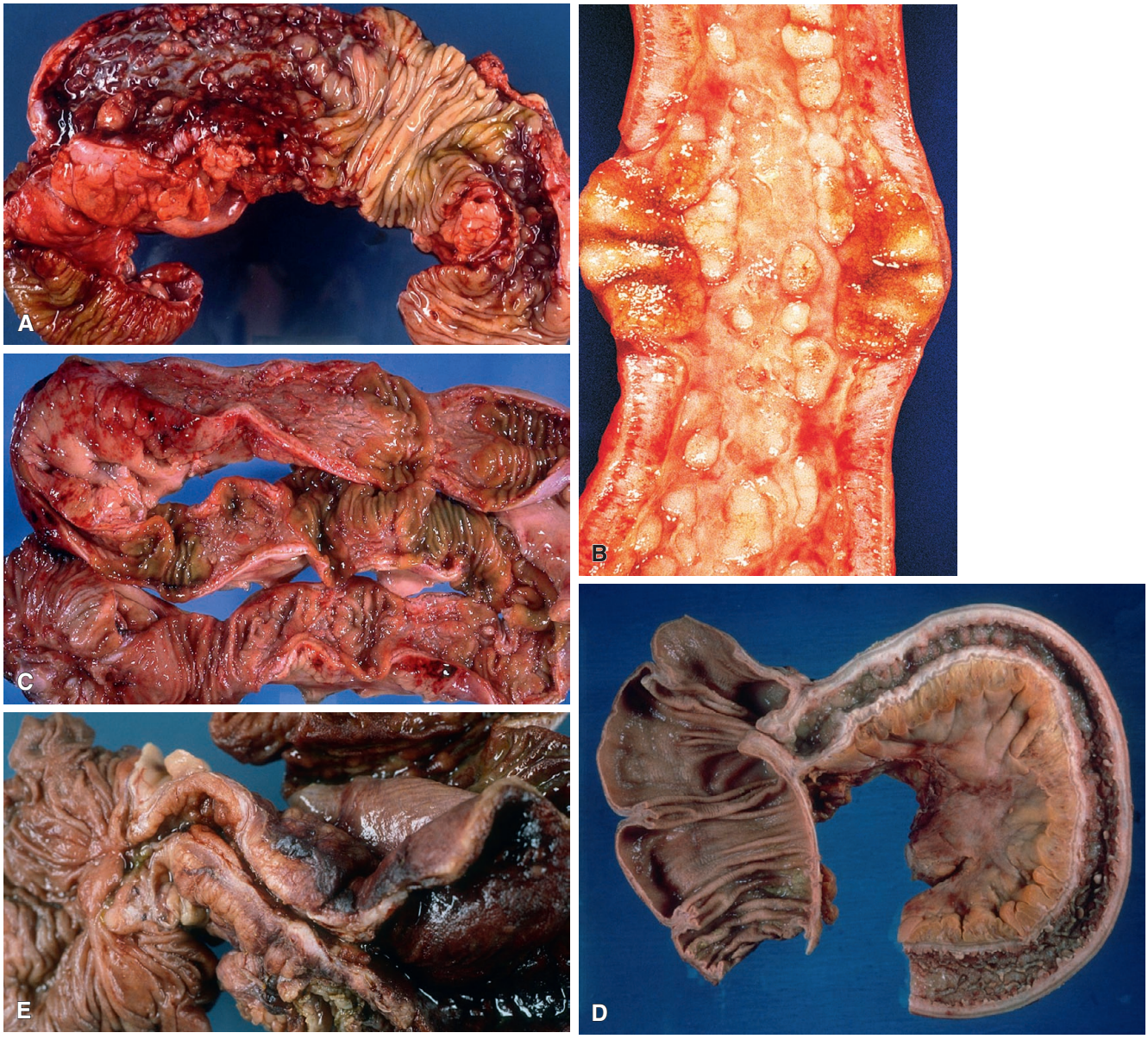

Figure 15.24 Gross Appearance of Crohn Disease. A, Note the segmental nature of the inflammation and the sharp demarcation between involved and uninvolved areas. **B,** The combination of ulceration and elevated remnants of mucosa results in a typical cobblestone appearance. **C,** The rigidity of the wall and the flattening of the mucosa are characteristic; note the linear fissuring ulcers. **D–E,** Fibrotic strictures and stenoses are common. (**A, C–E,** Courtesy Dr. George F. Gray, Jr.)

Another important microscopic change of Crohn disease is the presence of *granulomas* (see Fig. 15.25D), although in the small bowel they are seen only in approximately 50% of cases.[226] They are typically epithelioid and are often seen to arise from within the centers of the lymphoid follicles. Crohn granulomas are largely composed of epithelioid cells and multinucleated giant cells, with necrosis typically absent or limited to a small central area.[226] If necrosis is extensive, the alternative possibility of tuberculosis and other infectious processes should be excluded. The granulomas of Crohn disease may be found anywhere in the wall of the bowel (including serosa), in the regional lymph nodes (which may also show sinusoidal dilation and lymphoid hyperplasia), or at any other site of involvement. Granulomas indistinguishable from those of Crohn disease can be seen in many other conditions, however, particularly tuberculosis, yersiniosis, and (in the large bowel) complicated diverticular disease.[226] A minority of these granulomas are related to vessel walls, a feature that has been regarded by some as evidence of granulomatous vasculitis.[227]

Of all the microscopic features just described, those with greater diagnostic significance are transmural involvement, fissures, and granulomas. However, the first two may not be appreciable on mucosal biopsy. It should also be noted that a superficial variant of the disease exists in which the inflammation is limited to the mucosa and submucosa.[211]

Crohn disease has an undulating, yet progressive course, and complete regression is rare. Occasionally it is complicated by the

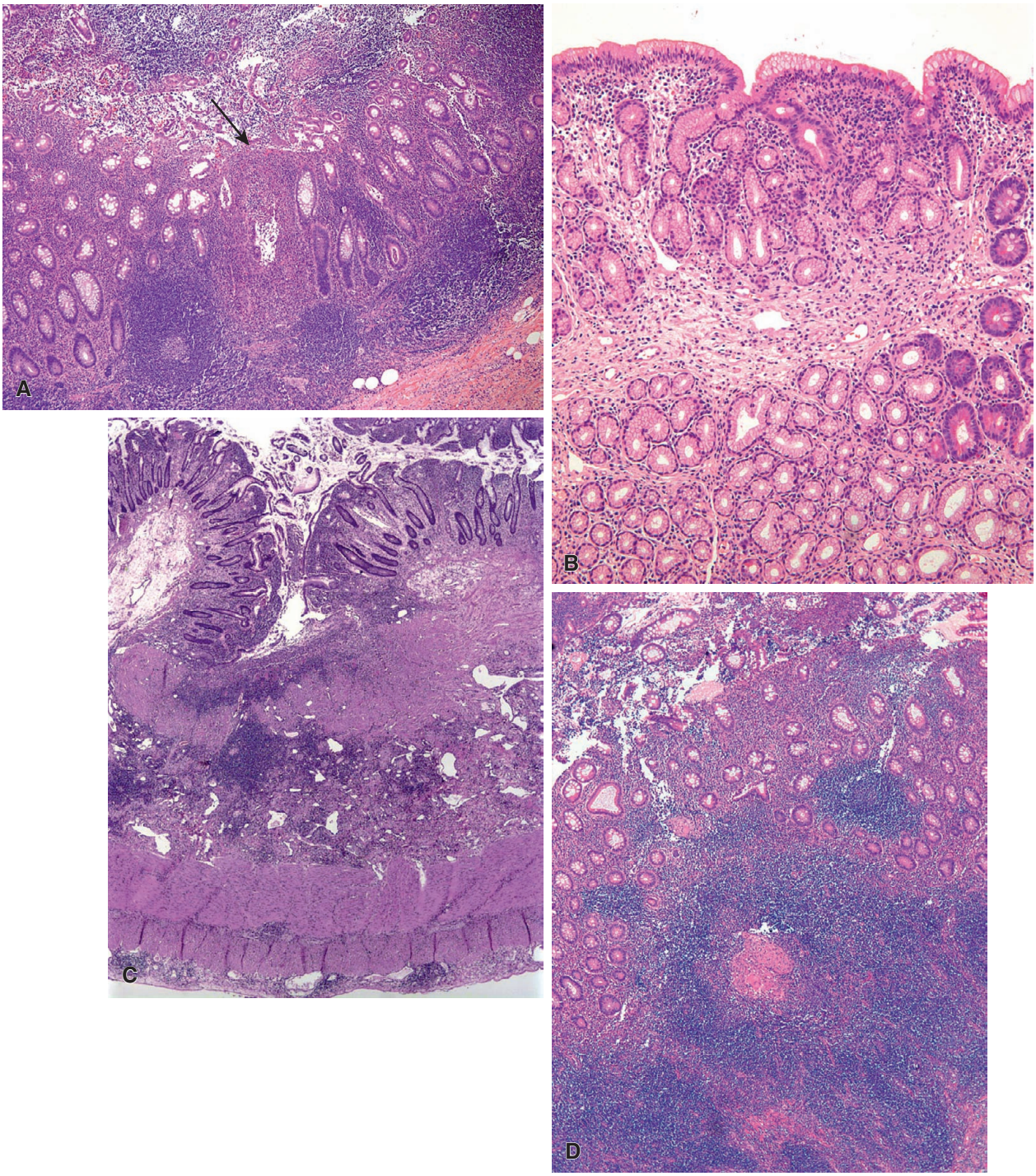

Figure 15.25 Microscopic Appearance of Crohn Disease. A, Superficial mucosal erosion *(arrow)* and active inflammation associated with lymphoid follicles constitutes an early lesion. **B,** Extensive pyloric metaplasia in a case of duodenal Crohn disease. **C,** Ileocecal Crohn disease showing transmural inflammation and fibrosis, along with a fissuring ulcer and markedly thickened muscularis mucosae. **D,** Small epithelioid granulomas in Crohn disease, associated with prominent lymphoid aggregates.

development of small bowel adenocarcinoma, typically located in the ileum.[228,229] Sometimes the tumors are very small and detected only at the time of pathologic examination.[230] The majority are associated with adjacent dysplasia, and some with dysplasia distant from the invasive adenocarcinoma.[231] The carcinomas virtually always develop in inflamed portions of bowel and may arise in a surgically bypassed segment.[232] Mixed adenocarcinoma/neuroendocrine tumors and WNETs (carcinoid tumors) have also been reported in the context of Crohn disease.[233,234] These patients are also at risk for the development of lymphoma, particularly with prolonged immunosuppressive therapy.[235]

The current medical management of Crohn disease includes medications (steroids, antibiotics, immunomodulators, or the newer

biologic agents) and nutritional therapy.[236–238] Despite advances in medical therapy, the vast majority of patients (~80%) require surgical intervention within a decade of diagnosis,[239] particularly in those with partial or complete intestinal obstruction due to strictures, fistulas, perforation, abscess, intractability despite medical management, and noncompliance with medical therapy. The surgical procedures most commonly used in current surgical management include resection and strictureplasty, and both open and laparoscopic approaches are used.[239] Recurrence following surgical remission is common, however, and the risk of recurrence is higher in ileocolonic disease than in pure ileal or colonic disease.[240,241] Other factors associated with recurrence include smoking, perforating disease prior to surgery, and short duration of disease before surgery.[242]

In general, the type and extent of the pathologic features appear to have little relationship with prognosis,[243] and claims have been made that the presence of granulomas portends both a better[244] and a worse[245] prognosis, depending on the study. Furthermore, no statistical relationship has been found between involvement of the surgical margins and recurrence.[246]

Ulcerative colitis usually spares the small bowel entirely, but some patients have ileitis, jejunitis, and even diffuse duodenitis.[247] The ileitis typically associated with ulcerative colitis (seen in about 17% of the cases) is referred to as *"backwash" ileitis* and is further discussed in Chapter 17. The main changes are villous atrophy with crypt regeneration, superficial erosions, neutrophilic and mononuclear inflammation in the lamina propria, and patchy cryptitis and crypt abscesses, although pyloric metaplasia may be present. Although it is usually associated with cecal involvement by ulcerative colitis (hence the term "backwash"), rarely ileitis may be present without involvement of the right colon.[248]

Patients with ulcerative colitis who undergo total proctocolectomy with ileal pouch–anal anastomosis may develop inflammation of the ileal mucosa, comprising the pouch, known as *pouchitis* (Fig. 15.26), the cause of which remains poorly elucidated.[249] Features include neutrophilic cryptitis/crypt abscesses, mucosal ulceration, lymphoplasmacytic inflammation in the lamina propria, and villous blunting in chronic cases.[250] Pyloric metaplasia may also be present.[251] It can be very difficult to distinguish pouchitis from ulcerative colitis involving the rectal cuff mucosa or from Crohn disease.[252] Patients with pouchitis have a small but definite risk of developing dysplasia and adenocarcinoma.[250]

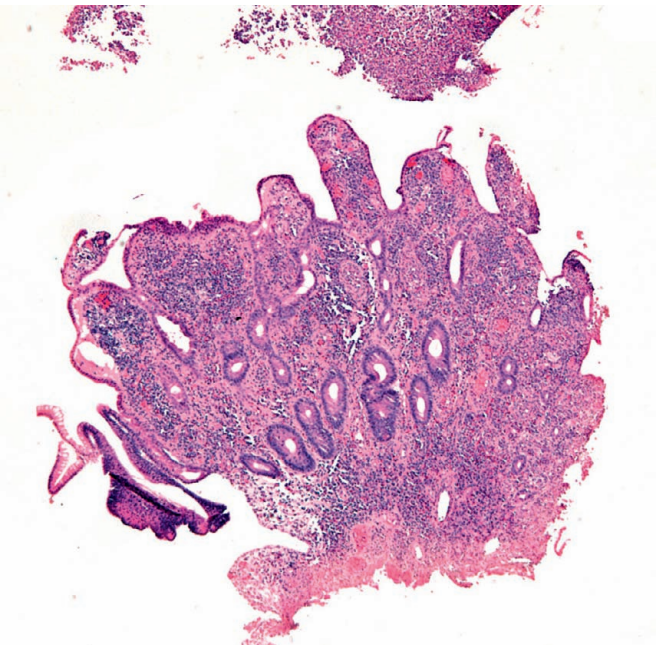

Figure 15.26 A biopsy from an ileal pouch in a patient with ulcerative colitis showing villous blunting, expansion of the lamina propria by a mixed inflammatory infiltrate, and overlying ulcer debris.

Ileal involvement may also be seen associated with lymphocytic and collagenous colitis.[253,254]

Infections

The small bowel may harbor a wide variety of pathogens, some of which are specific to the GI tract and some of which are a manifestation of disseminated disease. Many of the infections discussed here are seen in the context of immune compromise, including patients with AIDS and those who have undergone transplants[255–257]; small bowel biopsy may be very helpful in the diagnostic evaluation.[258] It should be noted, however, that occasionally some of these infections are seen in individuals without evidence of immunodeficiency.

Cytomegalovirus (CMV) infection most commonly presents in immunocompromised patients but occasionally presents in immunocompetent patients. Patients can present with ulcer-type symptoms and bleeding, or diarrhea, fever, and weight loss.[259,260] CMV infection may also cause a vasculitis with associated ischemia, particularly in renal transplant patients (Fig. 15.27).[261]

The term **AIDS enteropathy** has been used by some to describe the nonspecific histologic findings of villous blunting, crypt hyperplasia, and increased apoptotic epithelial cells in AIDS patients with diarrhea in whom no other pathogen can be found. Others believe that "AIDS enteropathy" is not a specific disease entity, and thus the term should not be used.[262–264]

Tuberculosis of the small bowel, still frequent in some parts of the world,[265,266] can be confused with Crohn disease on both clinical, gross, and microscopic grounds.[267,268] In contrast with Crohn disease, tuberculous ulcers are multiple and circumferential rather than linear and serpiginous.[268,269] Destruction of the muscularis externa is common in Crohn disease, and cobblestoning of the mucosa, aphthous ulcers, and skip lesions are not generally seen in tuberculosis. Tuberculosis is also more likely to form mass lesions. Microscopically, the tuberculous granulomas tend to be confluent and often have a caseous center and a peripheral lymphocytic ring. Obviously, special stains for acid-fast bacilli and molecular testing for *Mycobacterium tuberculosis* are in order whenever this differential diagnosis is entertained.

MAI is the most common mycobacterium isolated from the GI tract, and it is frequently found in the small bowel. Patients are typically immunocompromised, and the appearance on biopsy may be similar to Whipple disease (see also earlier). The lamina propria of the bowel and the regional lymph nodes are infiltrated by plump, foamy, macrophages containing a myriad of acid-fast organisms (Fig. 15.28).[270,271]

Yersiniosis results from infection by the gram-negative bacilli *Yersinia enterocolitica* and *Yersinia pseudotuberculosis*. It commonly involves the ileum and may manifest as ulcerative enteritis or enterocolitis (as well as appendicitis) with variably present mesenteric lymphadenitis.[272,273] The ileal changes may closely mimic Crohn disease both grossly and microscopically (Fig. 15.29), and molecular testing, cultures, and serologies may be useful in diagnosis.[274,275] ***Salmonella*** (both typhoid and nontyphoid) also affects the small bowel, particularly the ileum, and can also mimic chronic idiopathic inflammatory bowel disease.[276] Enteroadherent *E. coli* may also affect the ileum in immunocompromised patients in the form of *diarrheogenic bacterial enteritis*, a cause of diarrhea in this patient population.[277,278]

A number of parasites also affect the small bowel. **Cryptosporidiosis** is the result of infection by an intracellular protozoan,

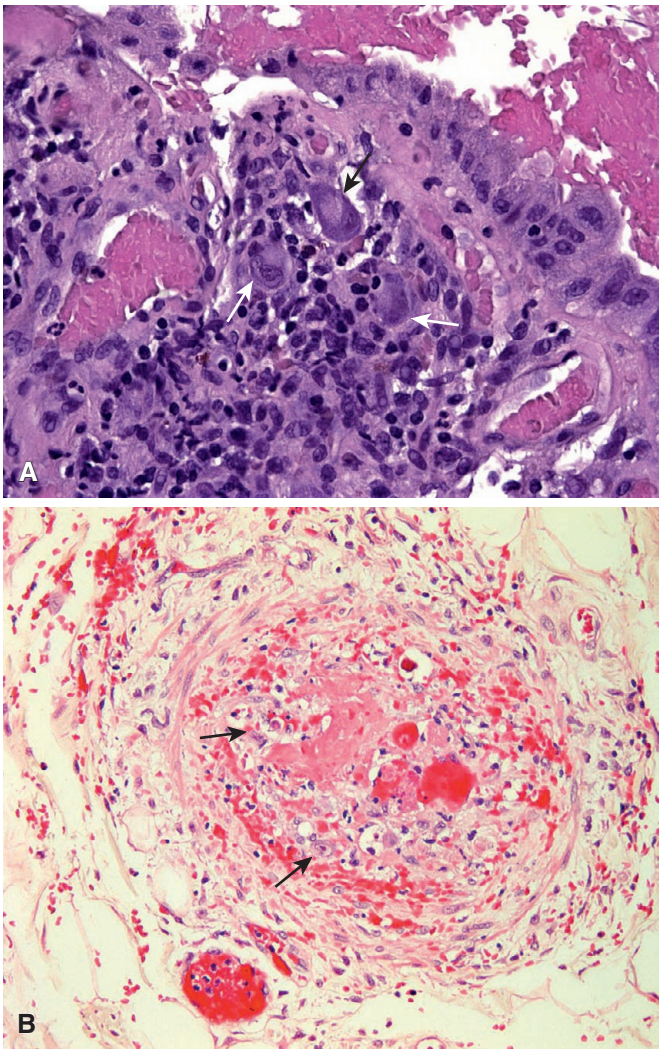

Figure 15.27 **A,** Multiple CMV inclusions *(arrows)* in a small bowel biopsy from a liver transplant patient with diarrhea. **B,** CMV inclusions *(arrows)* within endothelial cells with associated thrombosis and luminal occlusion in a case of CMV vasculitis.

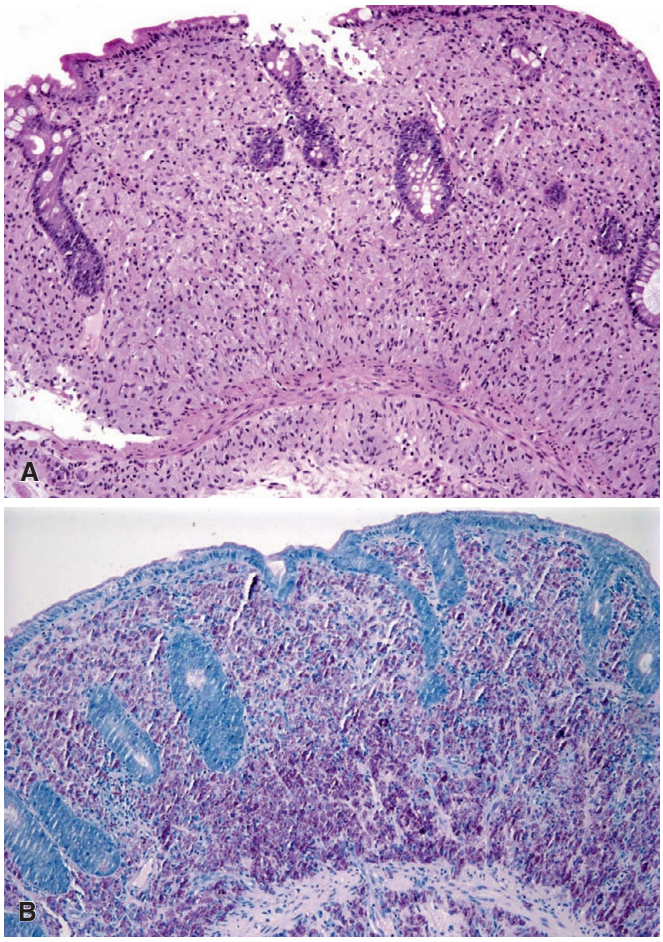

Figure 15.28 **A,** Duodenal biopsy in an AIDS patient with MAI, showing villous distension and blunting by an infiltrate of foamy macrophages. **B,** Ziehl–Neelsen stain highlights numerous organisms within macrophages.

Cryptosporidium parvum. In sections, the organisms appear as 2–5 µm basophilic spherical structures beneath the luminal surface of the epithelium (Fig. 15.30). Their appearance can be simulated by cellular debris or mucin. The organisms stain well with Giemsa, methenamine silver, and PAS but are not acid-fast. They typically do not result in significant light microscopic changes, although increased IELs and surface nuclear disarray may be present[279–281]; changes may be more prominent in cases of massive infection.[282] **Microsporidiosis** is another cause of diarrhea primarily seen in immunocompromised patients; it was originally classified as an obligate intracellular protozoan but is now believed to be closely related to fungi.[283] These organisms are difficult to appreciate by routine light microscopy, but can be detected with tissue Gram and other special stains (Fig. 15.31).[284–286] Exceptionally, systemic dissemination occurs.[287] The coccidians ***Cyclospora cayetanensis***[288,289] and ***Cystoisospora*** (formerly *Isospora*) ***belli***[289] also infect the small bowel, typically (but not always) in immunocompromised patients.

Giardiasis may result in malabsorption and chronic diarrhea[290] and may be associated with CVID (see later). The mucosa is usually intact and inflammatory changes are typically minimal, but there may be blunting of villi and an increased number of inflammatory cells. The organisms have a teardrop or pear shape, with paired nuclei and a central longitudinal axostyle (Fig. 15.32).[291] ***Strongyloides stercoralis***, a nematode with a worldwide distribution, also involves the small bowel (Fig. 15.33). Many patients are asymptomatic, but administration of corticosteroids may result in a life-threatening hyperinfection.[292,293]

A number of fungi affect the small bowel, including *Candida* species, *Aspergillus*, *Mucormycosis*, *Cryptococcus*, and *Histoplasma*[294]; small bowel involvement is usually part of a disseminated disease process in immunocompromised patients. Signs and symptoms of GI fungal infections are in general similar, regardless of fungus, and include diarrhea, vomiting, melena, frank GI bleeding, abdominal pain, and fever. Fungi may be identifiable on H&E sections in heavy infection, but special stains (GMS and PAS) are invaluable diagnostic aids. Fungi can often be correctly classified in tissue sections based on morphology, but culture and molecular testing should be relied upon for definite diagnosis.

Drugs, Chemotherapy, and Irradiation-Associated Enteritis

Mycophenolate mofetil (MMF) is a drug used for maintenance immunosuppression, primarily in solid organ transplant recipients but

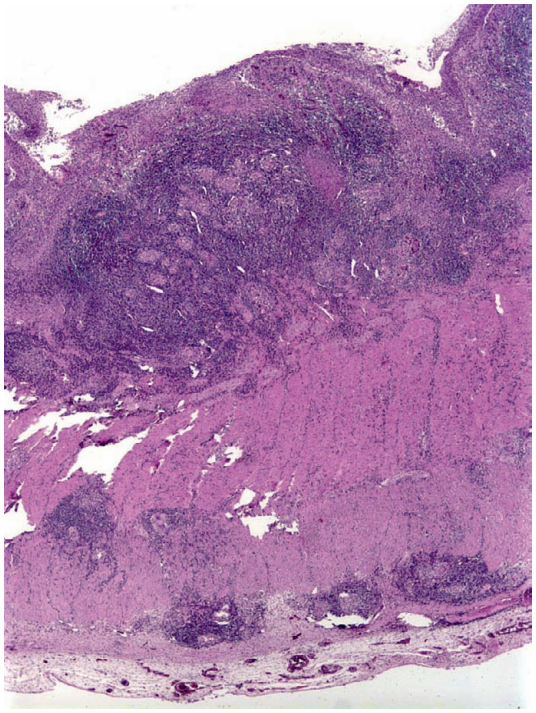

Figure 15.29 *Yersinia enterocolitica* infection featuring ulcerated mucosa, a markedly thickened wall, and numerous small, epithelioid granulomas associated with abundant transmural lymphoid tissue.

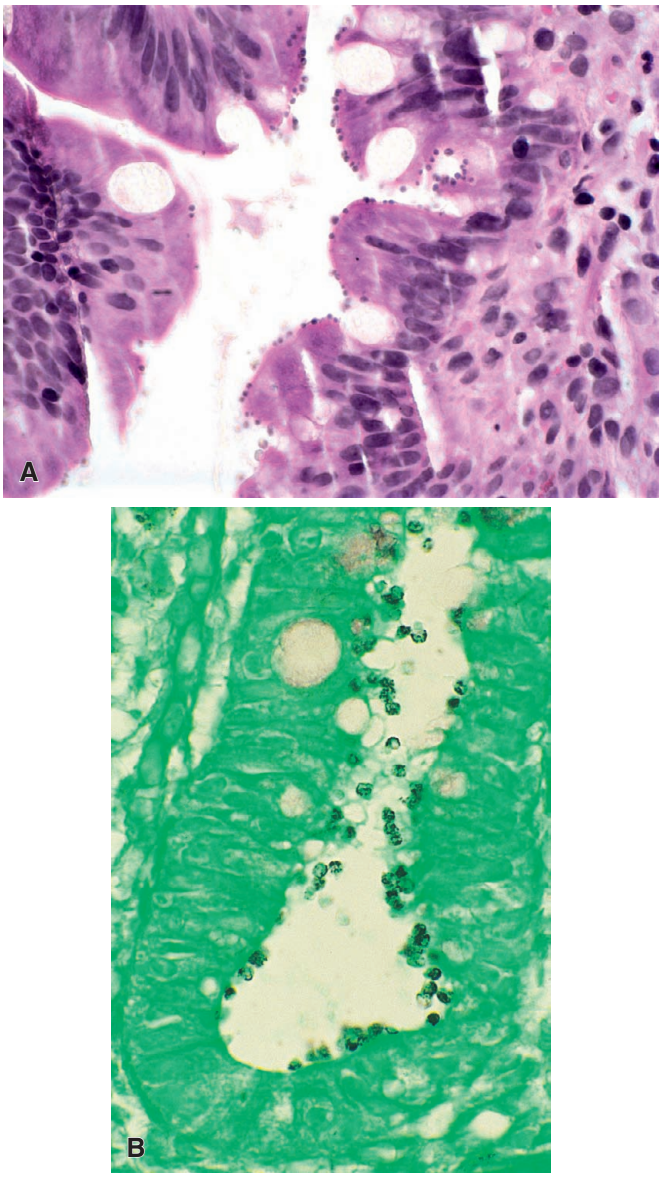

Figure 15.30 **A,** Cryptosporidiosis featuring small basophilic spheres beneath the luminal epithelium in a small bowel biopsy. **B,** The organisms will stain with methenamine silver as well.

also in bone marrow transplant recipients. Its most common side effect is GI toxicity, specifically diarrhea.[295] The colon is most commonly affected, but the small bowel may be affected as well. Histologic features can include increased apoptotic epithelial cells, increased IELs, villous atrophy, active and chronic inflammation, and architectural derangement (Fig. 15.34),[296–298] which can mimic several other entities including graft-versus-host disease (GVHD), chronic idiopathic inflammatory bowel disease, and viral infection. MMF toxicity should be suspected in transplant patients with diarrhea. Infection should be rigorously excluded, although it may certainly coexist with MMF toxicity in this patient population.

Chemotherapy is also well known to cause injury to the small bowel.[299,300] The changes are transient and should resolve within weeks of cessation of treatment; however, injury secondary to chemotherapy can be a significant problem in patients undergoing repeated cycles of treatment over many months. Biopsies often show crypt disorder and atrophy, with more severe mucosal denudation as the injury progresses. If patients are neutropenic, neutrophils will be conspicuously absent. Apoptotic epithelial cells are common, as are marked nuclear atypia and regenerative changes (Fig. 15.35).[301,302] The changes can mimic viral infection (which can coexist with chemotherapy-related injury), GVHD (which may also coexist with chemotherapy-related injury), and, rarely, ischemia.

NSAIDs cause a wide variety of findings in the small bowel, including focal active enteritis, erosions/ulcers, and the peculiar formation of multiple concentric fibrotic membranes known as *diaphragm disease*. NSAIDs are also one of the many drugs that cause increased apoptotic epithelial cells.[303,304]

Other drugs that significantly affect the small bowel include the angiotensin II receptor blocker *olmesartan*, which causes sprue-like changes with variably present subepithelial collagen (Fig. 15.36)[305]; and *ipilimumab*, a monoclonal antibody against the cytotoxic T-lymphocyte antigen-4 (CTLA-4) that is used to treat melanoma, which may cause a severe autoimmune-like enteritis (Fig. 15.37) and colitis.[306,307] *Stevens–Johnson syndrome*, or drug-associated toxic epidermal necrolysis involving skin and mucous membranes, may rarely involve the small bowel.[308]

Radiation therapy of malignant tumors within the peritoneal cavity may cause damage to the intestinal tract, the extent of which depends on many factors.[309] Damage occurs most frequently in patients treated for carcinoma of the cervix, but numerous cases have also been reported in children treated for Wilms tumor, malignant lymphoma, and other malignancies.[310] Symptoms usually appear years after radiation. Grossly, the small bowel appears thickened, and the wall may be partially replaced by fibrous tissue, particularly in the submucosa. This is often accompanied by mucosal ulceration.[311] There is a close correlation between the elapsed time interval between irradiation and the morphologic changes present.[309] Early irradiation effect is manifested by an increased production of mucus and by nuclear

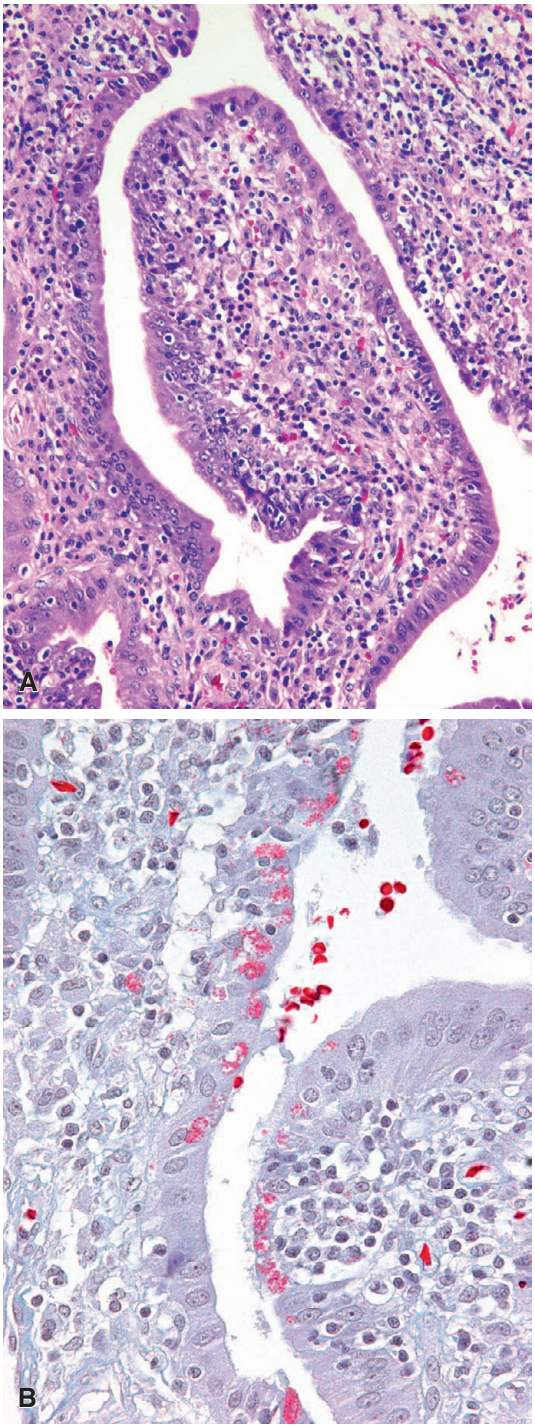

Figure 15.31 **A,** A duodenal biopsy from an AIDS patient with microsporidiosis shows increased intraepithelial lymphocytes and surface epithelial disarray. A subtle vacuolization of the surface epithelium is a clue to the presence of the organisms. **B,** A modified trichrome stain stains the spores a bright red, aiding in identification.

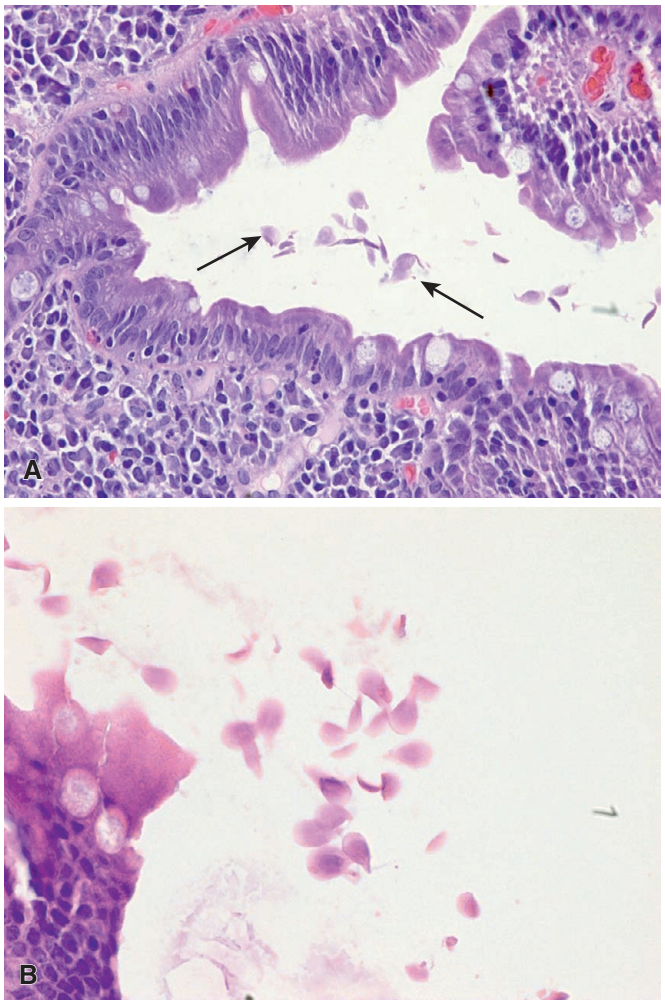

Figure 15.32 **A,** Giardia are typically seen at the surface of the duodenal epithelium *(arrows)*; some have likened their appearance to "falling leaves." Note the minimal associated inflammatory changes. **B,** At higher power the distinctive pearshape can be appreciated.

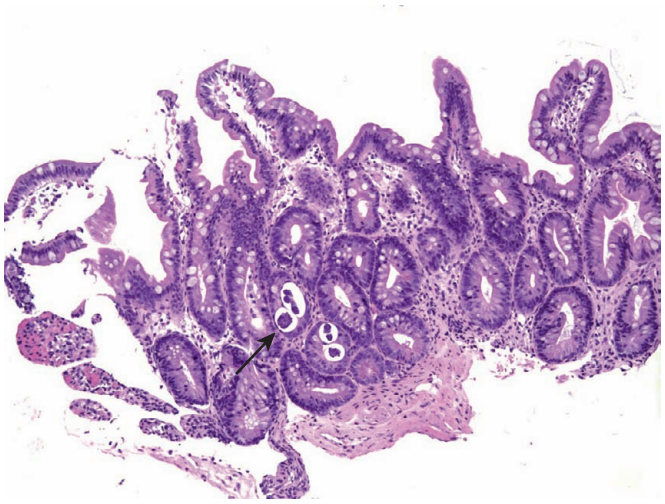

Figure 15.33 Strongyloidiasis larvae *(arrow)* within the crypt epithelial cells in a small bowel biopsy.

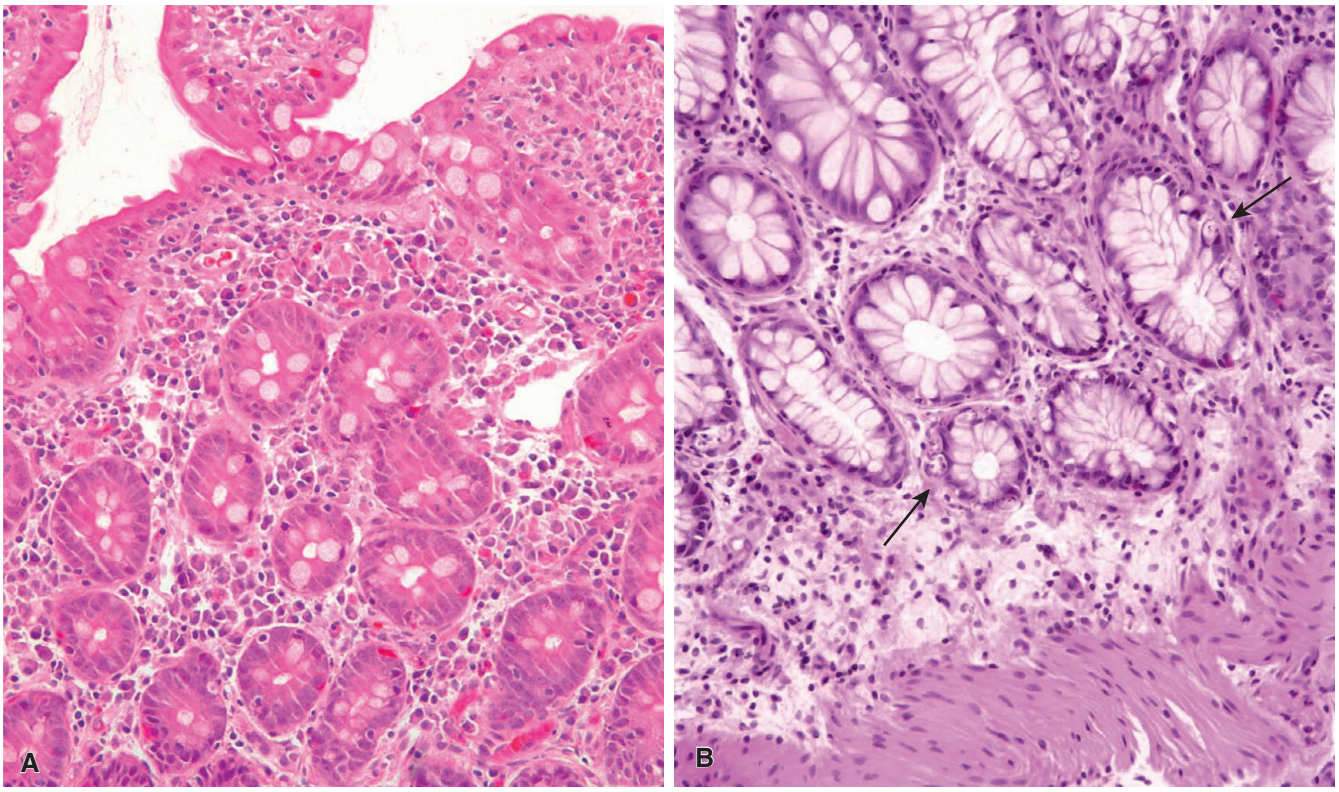

Figure 15.34 **A,** Duodenal biopsy from a case of mycophenolate toxicity shows increased plasma cells and eosinophils in the lamina propria, along with increased intraepithelial lymphocytes. **B,** Another case shows numerous apoptotic epithelial cells at the base of the mucosa *(arrows)*.

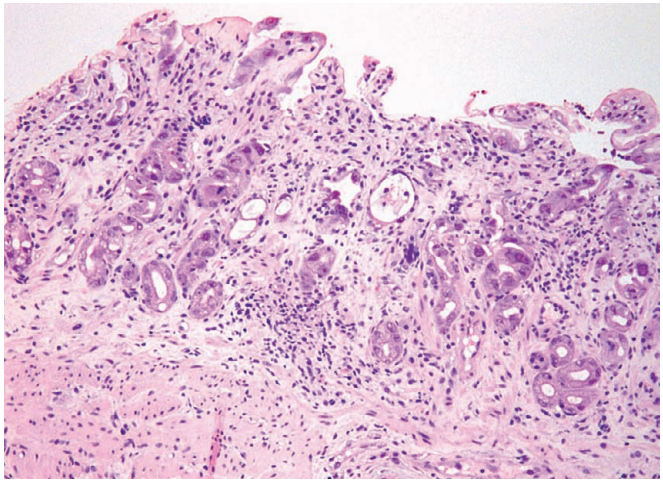

Figure 15.35 Chemotherapy-induced injury featuring crypt atrophy, marked regenerative nuclear atypia, and neutropenia. The nuclear changes should not be mistaken for dysplasia or viral infection.

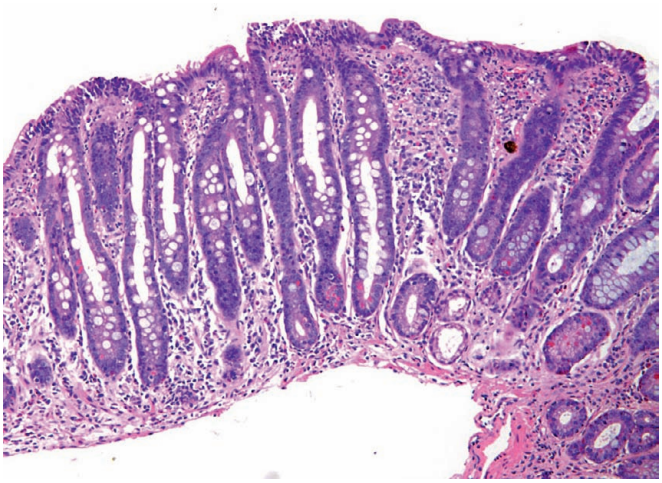

Figure 15.36 Olmesartan-associated enteropathy featuring marked villous atrophy, increased intraepithelial lymphocytes, and increased plasma cells and eosinophils in the lamina propria.

changes in the lining epithelium. Later, submucosal edema that may be completely reversible occurs. If the damage is severe, fibrosis of the muscular wall and ulceration develop (Fig. 15.38). Vascular changes are prominent; they are characterized by subendothelial accumulation of lipid-laden macrophages, calcification, and thrombosis.[312,313] Treatment is multifactorial, including nutritional support, anti-diarrheals, and anti-inflammatory therapy, but approximately a third of cases require surgery for intestinal obstruction, fistula formation, or perforation.[314]

Other Inflammatory Diseases

Acute phlegmonous enteritis is an obscure entity of unknown etiology, although it has been associated with *Bacillus thuringiensis* and *Streptococcus viridans*.[315,316] Grossly, the involved loop of bowel is sharply demarcated. The inflammation is mainly in the mucosa, but there may be pus on the serosal surface. The bowel wall is edematous and slightly distended. Microscopically, there is frequently a widespread lymphangitis and regional lymphadenitis, accompanied by lymph node enlargement. The mesentery has a somewhat glassy appearance. Abscesses between folds of the mesentery have been observed.

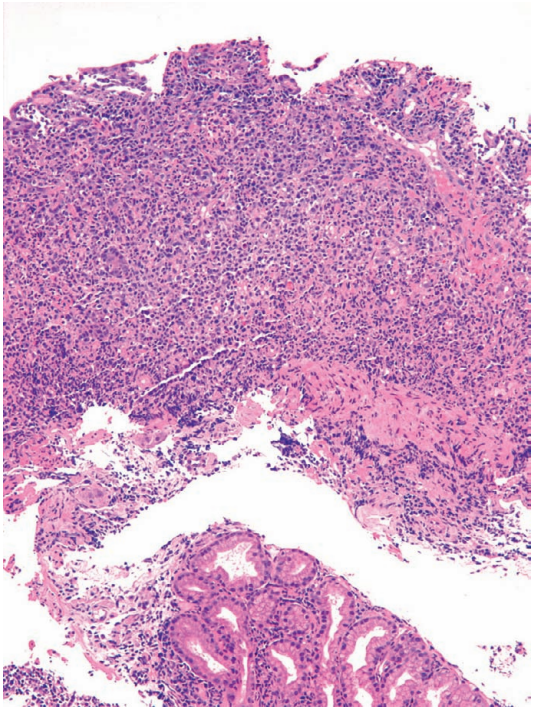

Figure 15.37 Ipilimumab-induced enteritis showing near total destruction of the mucosa secondary to a lymphoplasmacytic infiltrate.

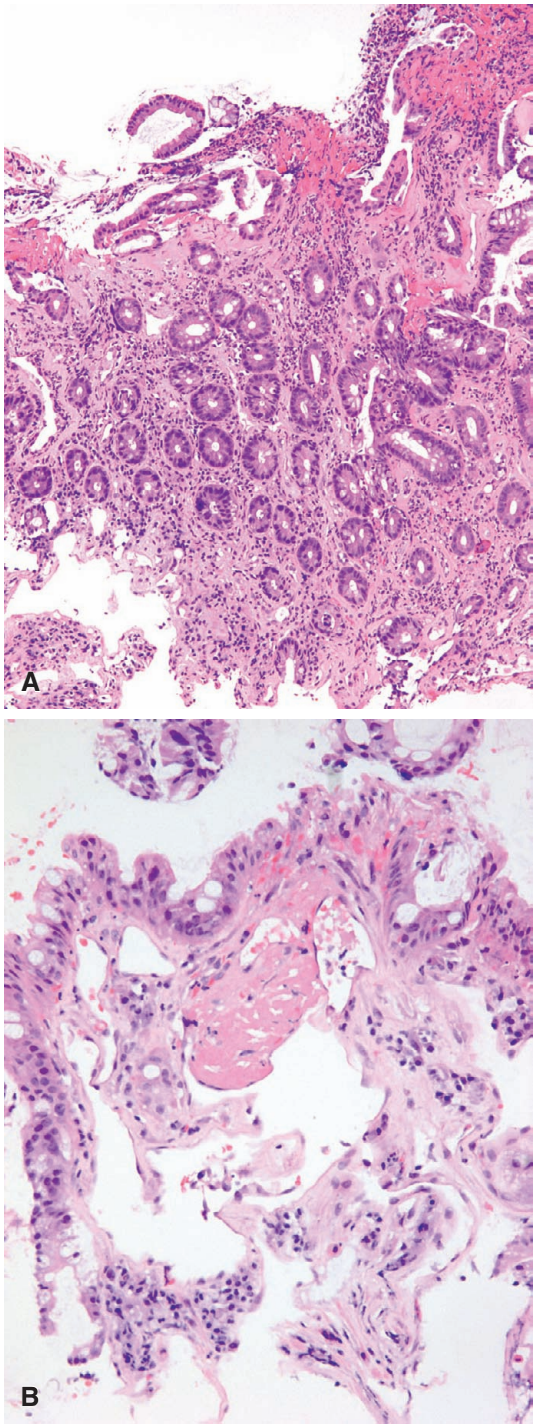

Figure 15.38 **A,** Radiation enteritis with mucosal ulceration, active inflammation, and fibrosis of the lamina propria. **B,** Vessels are ectatic and may contain fibrin thrombi.

Sarcoidosis may involve the small bowel as part of disseminated disease, but it is the least commonly involved organ in the GI tract.[317] There may be associated folate and/or B12 deficiency.

Necrotizing enterocolitis, a disease predominantly affecting premature infants, is discussed in Chapter 17.

Idiopathic eosinophilic enteritis and **gastroenteritis** (EG) connotes a spectrum of diseases characterized by eosinophilic infiltration of one or more segments of the GI tract.[318] Although the pathogenesis remains unclear, many patients have peripheral eosinophilia and/or a history of allergic diseases or asthma. EG most commonly presents in children and adults younger than 50 years. Involvement may be predominantly mucosal, mural, or serosal, or a combination of all three.[319] In the case of serosal involvement, it is often associated with eosinophilic peritonitis and ascites.

The GI manifestations include nausea, vomiting, diarrhea, pain, steatorrhea, and protein-losing enteropathy. Morphologically, the main change is a patchy or diffuse dense eosinophilic infiltration of any layer of the intestinal wall (Fig. 15.39), variably accompanied by other inflammatory cells, eosinophil degranulation, eosinophilic microabscesses, mucosal ulceration, and submucosal edema. Other causes of eosinophilia must be excluded in order to render this diagnosis, including adverse drug reaction, food allergy, parasitic infection, Crohn disease, idiopathic hypereosinophilic syndrome, and vasculitis.[320]

AIE has been best characterized in infants and young children and is likely underdiagnosed in adults, in whom it is frequently mistaken for CD, Crohn disease, or ulcerative colitis.[321,322] Patients typically present with severe diarrhea and weight loss. Unlike CD, both the small and large bowel may be involved. Serum antienterocyte and/or anti-goblet cell antibodies are seen in many (but not all) patients, and many have other autoimmune diseases. Association with thymoma has also been reported.[323,324] Small bowel biopsies show variably severe villous blunting, as well as a striking increase in lamina propria plasma cells, increased apoptotic epithelial cells, and active inflammation (Fig. 15.40). IELs are typically not significantly increased, but a mild increase may be encountered. Patients with anti-goblet cell antibodies may show a dramatic absence of goblet cells.[321]

CVID is the second most common symptomatic primary immunodeficiency after IgA deficiency. It presents at any age, usually with recurrent bacterial upper respiratory tract infections, autoimmune manifestations, and often chronic GI symptoms. Immunologic defects include hypogammaglobulinemia and T-cell abnormalities.

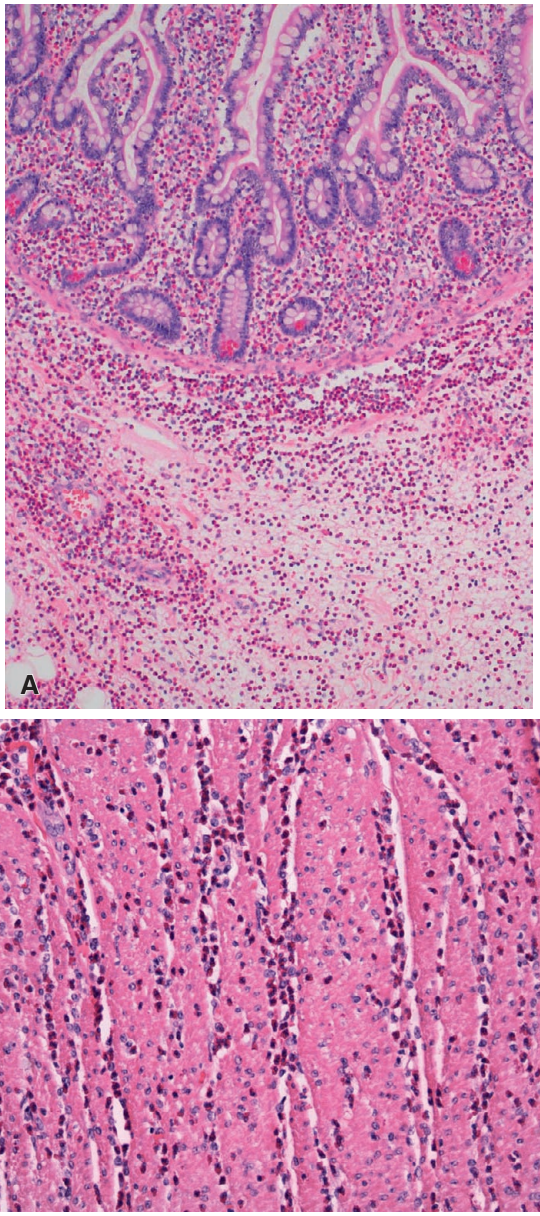

Figure 15.39 **A,** Dense infiltration of the mucosa and submucosa of the jejunum by a virtually pure eosinophilic population. **B,** In this case, the muscle wall was heavily involved.

Any segment of the GI tract can be affected. Increased apoptotic epithelial cells are a common feature as well as, usually but not always, significantly decreased or absent plasma cells (Fig. 15.41). In the small bowel, features may include villous blunting that resemble CD; granulomas; or architectural distortion mimicking chronic idiopathic inflammatory bowel disease. Lymphoid hyperplasia is common, and patients have an increased incidence of both lymphoma and infection, particularly giardiasis.[325]

GVHD following bone marrow transplantation affects primarily the skin, GI tract, and liver. Involvement of the small bowel is manifested clinically by diarrhea and microscopically by a variety of changes, of which single epithelial cell necrosis is the most consistent.[326,327]

Cryptogenic multifocal ulcerating stenosing enteritis is a rare disease resulting in recurrent small bowel ulcerations and stenosis, mimicking those seen with "diaphragm disease" resulting from chronic NSAID use. The etiology is unknown, but some cases have been associated with homozygous deletion mutations in cytosolic phospholipase A2-α.[328]

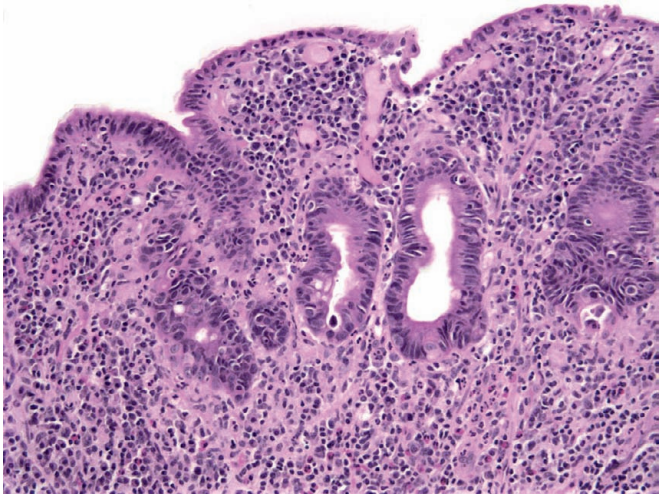

Figure 15.40 Duodenal biopsy in autoimmune enteritis featuring villous blunting, a dense plasmacytic infiltrate, loss of goblet cells, and scattered apoptotic epithelial cells.

Other Non-Neoplastic Diseases

Intussusception

In intussusception, a length of intestine (the *intussuscipiens*) literally swallows part of the bowel just proximal to it. This swallowed portion (the *intussusceptum*) is drawn down within the intussuscipiens until it can go no further because of traction of the mesentery (Fig. 15.42A). The specimen has a curved, sausage-like form, with concavity toward the root of the mesentery. Increasing traction and compression shuts off circulation to the intussusceptum so that it becomes necrotic, with associated mucosal sloughing. The upper ends of the intussuscipiens and the intussusceptum may become firmly united. In exceptional instances, the result has been spontaneous cure in the form of a naturally occurring equivalent of a surgical end-to-end anastomosis.

Most cases of intussusception are seen during the first 5 years of life, with over half occurring during the first year. This is probably related to the fact that the amount of lymphoid tissue in the ileocecal region and the degree of projection of the valve into the cecum are at their maximum during this period but decrease substantially after the second year of life.[329] There is now general agreement that the lymphoid hyperplasia precedes and is often the cause of the intussusception rather than the result, although secondary inflammatory changes certainly occur. The lymphoid hyperplasia is associated with viral infection (particularly adenovirus) in many cases, as indicated by the finding of intranuclear inclusion bodies[330] and the fact that viruses have often been isolated from these children.[331–333] Several cases of intussusception caused by lymphoid hyperplasia in AIDS patients have also been reported.[334]

In early uncomplicated cases, a barium enema may be used to reduce the intussusception, or manual reduction may be performed. Surgery is otherwise needed. Mortality is directly related to the time that elapses between onset and surgery. In children, there is a rapid rise in mortality after the second day. In older children and in adults, intussusception is frequently the result of a pedunculated intraluminal tumor such as lipoma, carcinoma, smooth muscle

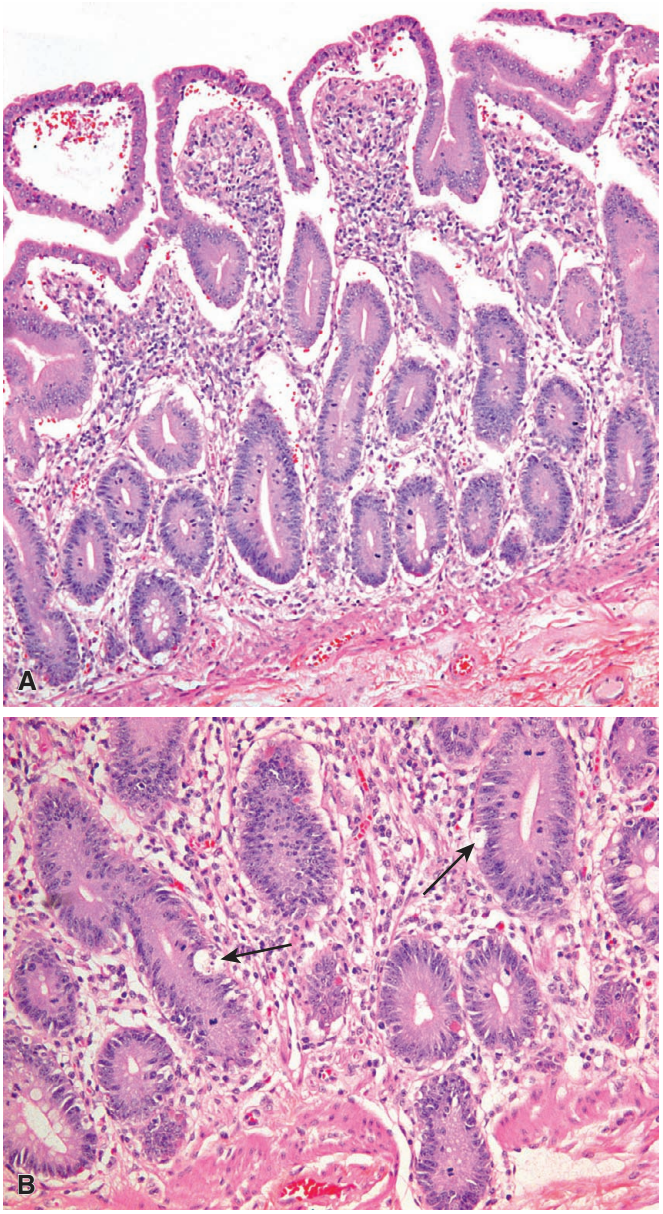

Figure 15.41 **A,** Sections of the small bowel in a case of common variable immunodeficiency show villous blunting with a mild increase in intraepithelial lymphocytes; apoptotic epithelial cells are visible even at low power. **B,** Higher-power view shows increased apoptotic epithelial cells *(arrows)* and an absence of plasma cells.

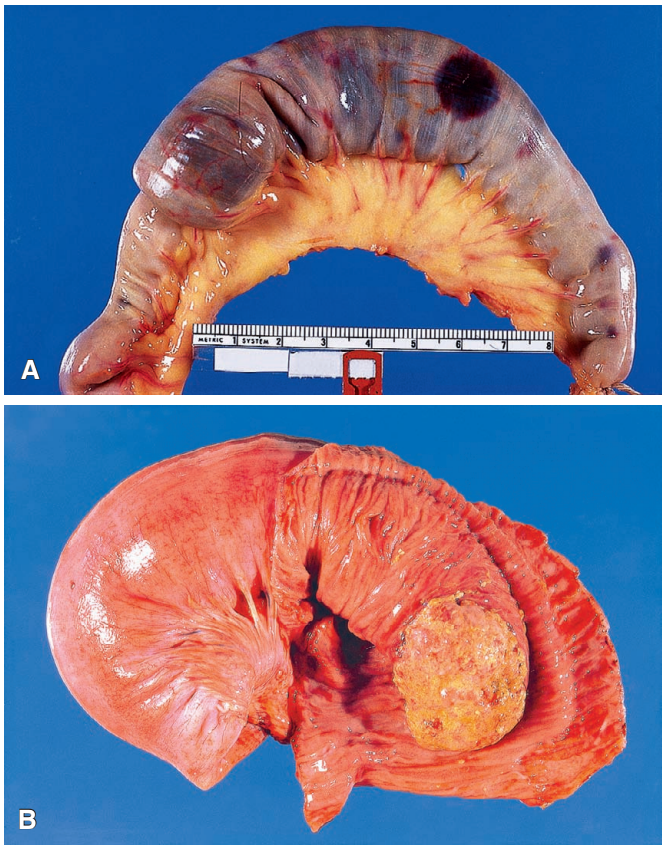

Figure 15.42 **A,** Outer aspect of small bowel in intussusception. **B,** Intussusception of small bowel caused by an adenocarcinoma. The tumor, located at the tip of the intussusceptum, is ulcerated and necrotic.

tumor/GIST, inflammatory fibroid polyp (IFP) or malignant lymphoma (see Fig. 15.42B).[335]

Brown bowel syndrome is characterized by a prominent brown discoloration of the bowel wall, grossly evident from both the serosal side and on cut section, and often associated with chronic malabsorption. Microscopically, large amounts of lipofuscin granules are seen in the cytoplasm of smooth muscle cells. The pathogenesis is unknown, but the suggestion that it may be caused by vitamin E deficiency has been advanced.[336]

The small bowel is the most frequently involved site in GI **amyloidosis,** which may involve the vessels, stroma, or lamina propria as part of generalized disease or—rarely—as a localized finding (Fig. 15.43).[337] In the latter instance, it may lead to intestinal obstruction.[338]

Scleroderma may involve the small bowel as well, presenting as obstruction or malabsorption.[339]

Microvillous inclusion disease (familial microvillous atrophy) is a disorder of the intestinal brush border that results in intractable secretory diarrhea in infants. The diagnosis has been based on the presence of microvillous inclusions at the ultrastructural level. Immunohistochemical staining for CD10 (a membrane-associated neutral peptidase) can aid in the diagnosis by showing a cytoplasmic staining pattern as opposed to the normal linear brush border pattern.[340]

Another congenital cause of intractable diarrhea and failure to thrive is **tufting enteropathy**, which has been associated with mutations in the EpCAM gene on chromosome 2p21 and features epithelial tufts in the intestinal mucosa along with villus alterations, but a normal brush border.[341]

Pneumatosis cystoides intestinalis is characterized by the presence of gas-filled cysts in the intestinal wall; it is associated with a variety of conditions including surgery, colonoscopy, and chronic pulmonary disease.[342] The cysts are macroscopically visible and may be mistaken for polyps or tumors. Histologically, the spaces are often surrounded by foreign body giant cells.

Polyps and Tumors

Benign Epithelial Tumors

Brunner gland nodules (which have also been referred to as Brunner gland hamartoma, Brunner gland adenoma, nodular hyperplasia of

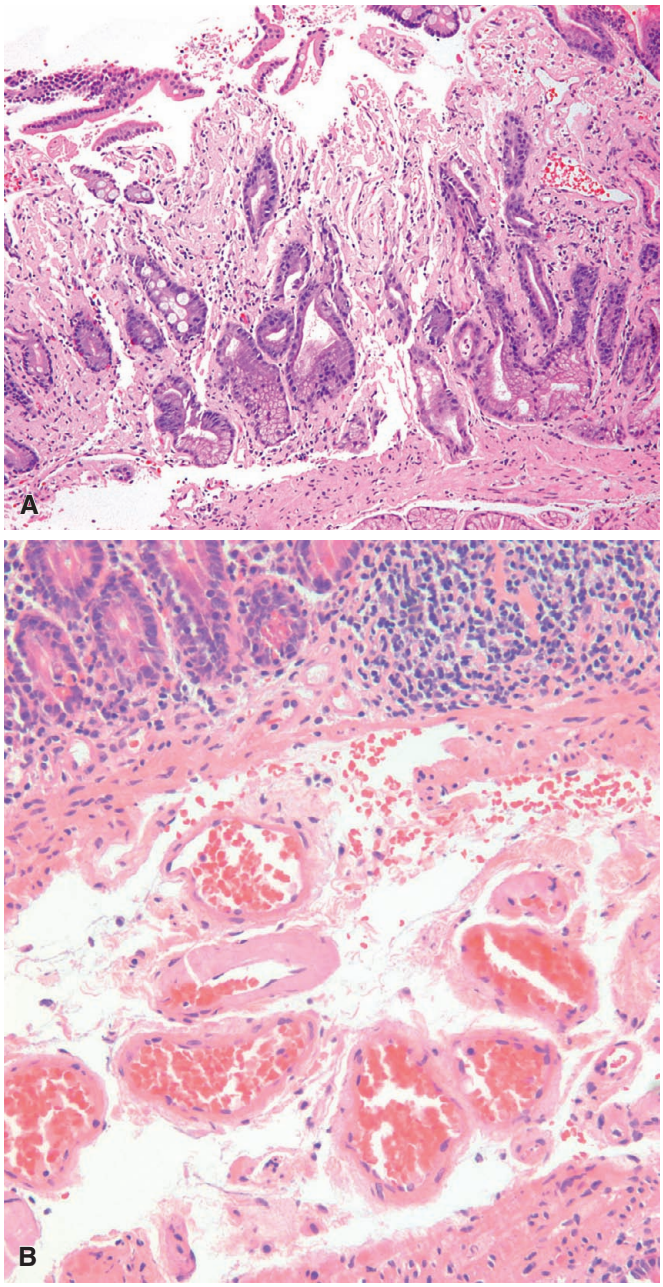

Figure 15.43 Amyloid involving the lamina propria **(A)** and small vessels **(B)** in the duodenum.

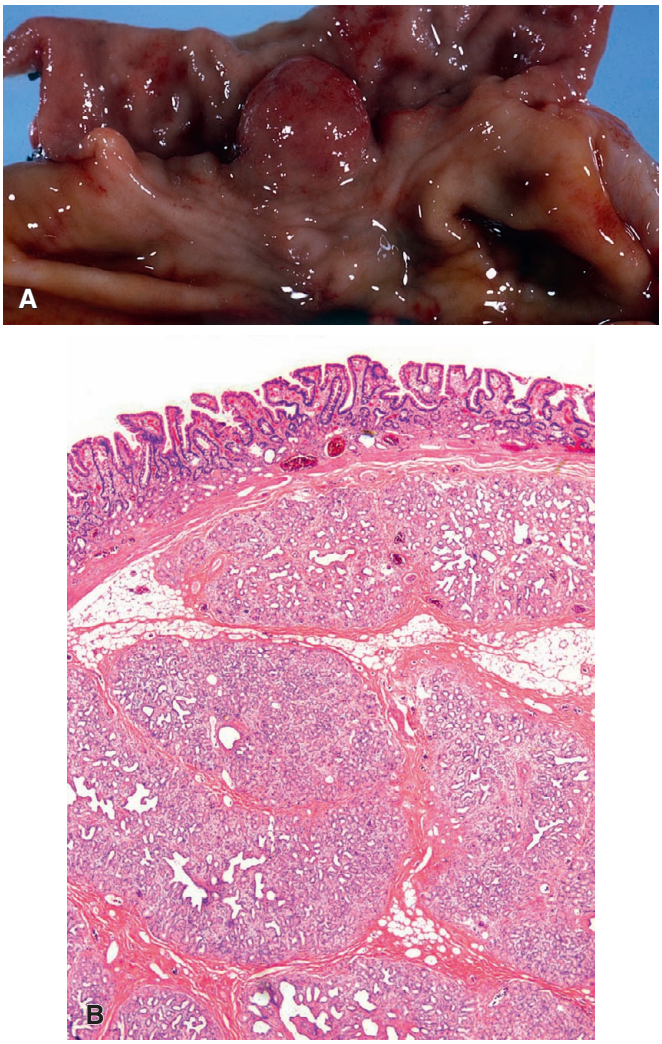

Figure 15.44 **A,** Pedunculated Brunner gland nodule. **B,** Lobules of benign, normal-appearing Brunner glands are separated by fibrous stroma. (**A,** Courtesy Dr. George F. Gray, Jr.)

Brunner glands, or brunneroma) are characterized by a nodular proliferation of Brunner glands, accompanied by ducts and scattered stromal elements, and sometimes associated with ciliated cysts and adipose tissue (Fig. 15.44).[343,344] The process can be focal, multifocal, or diffuse. Microscopically, the Brunner glands are arranged in lobules separated by fibrous bands and have, for the most part, a normal appearance. This entity is probably not a true neoplasm but rather an expression of nodular hyperplasia or a hamartoma; therefore, many avoid the term "Brunner gland adenoma." However, it may exhibit foveolar metaplasia and dysplastic changes have been described.[345] The most common location is the posterior wall of the duodenum at the junction between the first and second portions. It can be seen associated with peptic duodenitis and erosions and may present with GI bleeding or duodenal obstruction.[343,346]

Adenomas similar to those of the large bowel can develop in the small bowel, but their frequency is minuscule.[347] The duodenum and jejunum are involved more often than the ileum. Duodenal adenomas have been reported with increasing frequency in recent years, undoubtedly as a result of the widespread use of endoscopy. Adenomas can be single or multiple, pedunculated, or sessile, and they can have the microscopic appearance of a tubular, tubulovillous, or villous adenoma (Fig. 15.45).[348,349] As with their colorectal counterparts, the incidence of malignancy is greater if the lesions are villous, large, and/or multiple. Villous lesions are often large and sessile, with a tendency to recur and a high incidence of malignant transformation.[349] Thorough sampling at endoscopy is of importance for detection of the latter.[350] Many duodenal adenomas are located at the ampulla of Vater or the periampullary region; these are further discussed in Chapter 22. Small bowel adenomas may also frequently develop in patients with familial adenomatous polyposis, particularly in the duodenum.[351,352] Small bowel adenomas have also been reported in the ileal patch following ileocystoplasty.[353,354]

Pyloric gland adenomas are also found in the small bowel, particularly in the duodenum (Fig. 15.46). These rare lesions are composed of tubular or cystically dilated pyloric-type glands, which

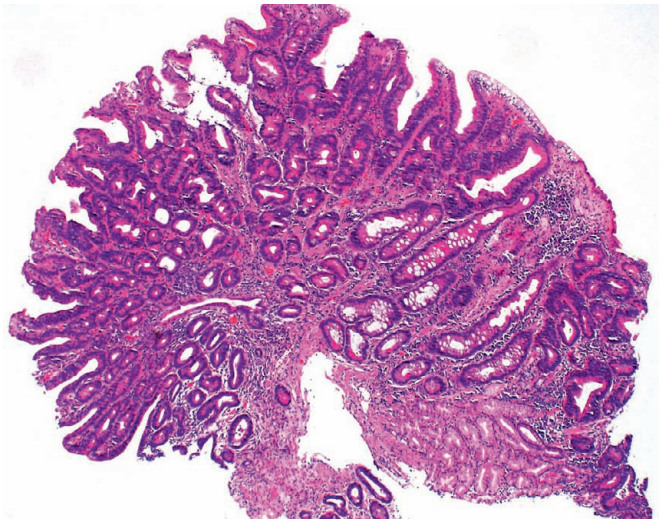

Figure 15.45 Duodenal adenoma, resembling colonic tubular adenoma.

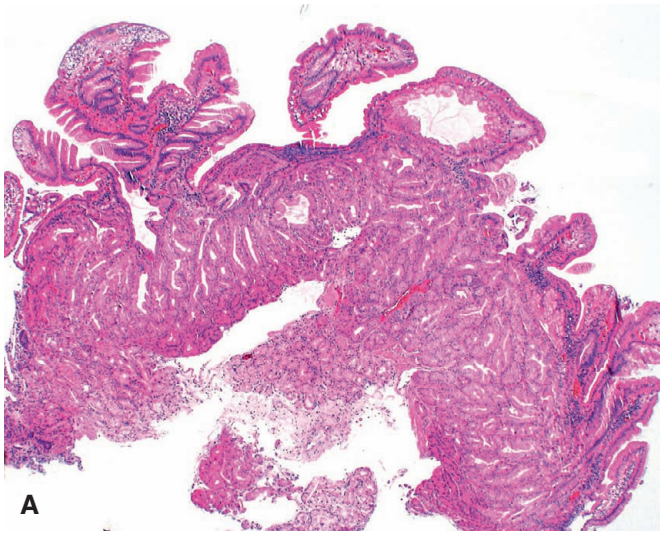

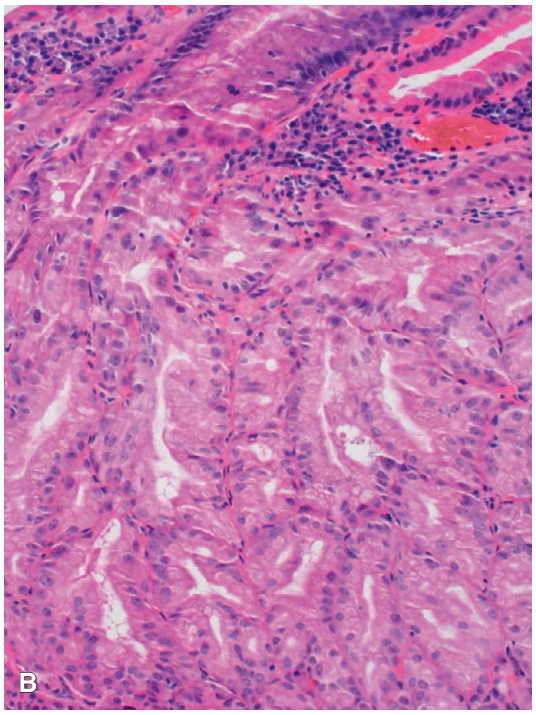

Figure 15.46 **A,** A duodenal pyloric adenoma composed of tightly packed tubules resembling pyloric glands. There is minimal inflammation. **B,** The nuclei are basally located, with small nucleoli.

typically express MUC6 and MUC5AC. These are also found with increased frequency in patients with familial adenomatous polyposis, and they may harbor *APC* mutations.[355] Both sporadic and syndromic pyloric gland adenomas may have *GNAS* and *KRAS* mutations as well.

A number of **hamartomatous polyps** may be encountered in the small bowel. *Peutz–Jeghers syndrome* is an autosomal dominant disorder with variable degrees of penetrance, caused by a germline mutation in the *LKB1* gene located on chromosome 19p13.3, which encodes a serine/threonine kinase.[356] Polyps can be present in the stomach, small bowel, and large bowel, and the patients have a typical pigmentation of the lips, oral mucosa, digits, palms, and soles. The polyps consist of lobules of nondysplastic epithelium and lamina propria, in which glands are supported by broad bands of smooth muscle fibers that are thick in the center of the lesion and thinner on the periphery (Fig. 15.47).[357,358] The architecture is similar for polyps occurring elsewhere in the GI tract, but the cytologic composition depends on the location.[359] Dysplasia may develop but is more common in colorectal Peutz–Jeghers polyps.[360] The intimate intermingling of glands and smooth muscle fibers may simulate the appearance of invasion and lead to a mistaken diagnosis of carcinoma.[361] Although solitary Peutz-Jeghers polyps have been described in the literature,[362] many believe that these patients harbor undetected *STK11* mutations or other features suggestive of the syndrome.[363]

Patients with Peutz–Jeghers syndrome are at significantly increased risk of both GI and extra-intestinal malignancy, including adenocarcinoma of the stomach, small bowel, and colon.[364] Patients with Peutz–Jeghers syndrome may also develop the distinctive ovarian neoplasm known as sex-cord tumor with annular tubules, so-called adenoma malignum of uterine cervix, ovarian mucinous tumors, breast carcinoma (often bilateral), and other types of malignancy.[365–367]

Other hamartomatous polyps encountered in the small bowel include *juvenile polyps* (Fig. 15.48), which in the small bowel are usually part of juvenile polyposis syndrome; and polyps that result from the *PTEN hamartoma tumor syndrome* (which includes *Cowden syndrome*).

Adenocarcinoma

Adenocarcinoma of the small bowel is 40–60 times less common than its counterpart in the large bowel. Most patients are elderly, and there is no sex predilection.[368–370] It can develop in any segment, but approximately half of cases occur in the duodenum.[370] Adenocarcinomas arising from the ampulla and periampullary region are discussed in Chapter 22. Small bowel adenocarcinomas are associated with sporadic small bowel adenomas,[370] familial adenomatous polyposis,[371,372] hereditary nonpolyposis colorectal carcinoma (Lynch) syndrome,[373] Peutz–Jeghers syndrome (see earlier), von Recklinghausen disease,[374] Crohn disease (see earlier), ileostomy sites,[375,376] surgically bypassed duodenum,[377] Roux-en-Y esophagojejunostomy,[378] and ileocystoplasty.[379]

Grossly, tumors may be nodular, polypoid, or infiltrative, with the latter being the most common growth pattern; patients with associated sporadic adenomas were more likely to have polypoid adenocarcinomas (Fig. 15.49).[370] Occasionally these carcinomas

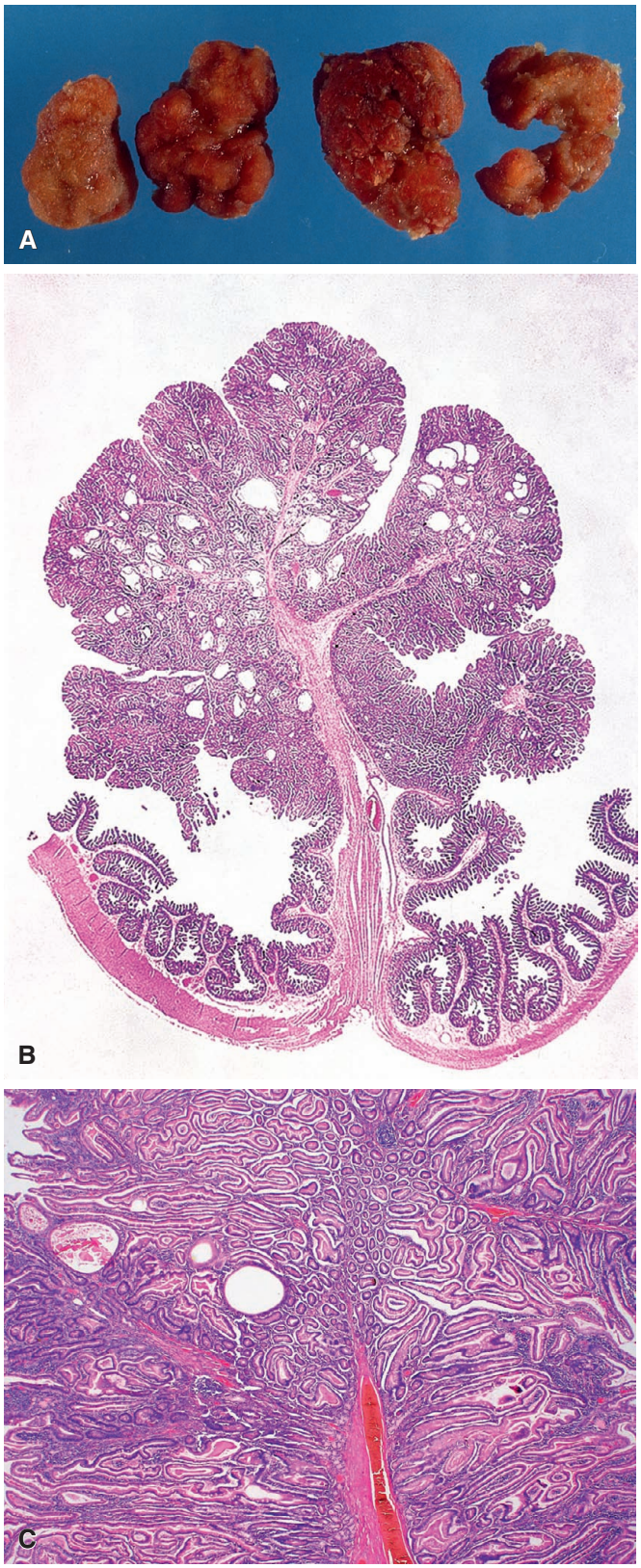

Figure 15.47 **A,** Large lobulated Peutz–Jeghers polyp. **B,** Whole mount view shows lobules of benign epithelium supported by arborizing bands of smooth muscle. **C,** Higher-power view shows benign, focally dilated glands devoid of atypia, separated by bundles of smooth muscle. (**A,** Courtesy Dr. George F. Gray, Jr.)

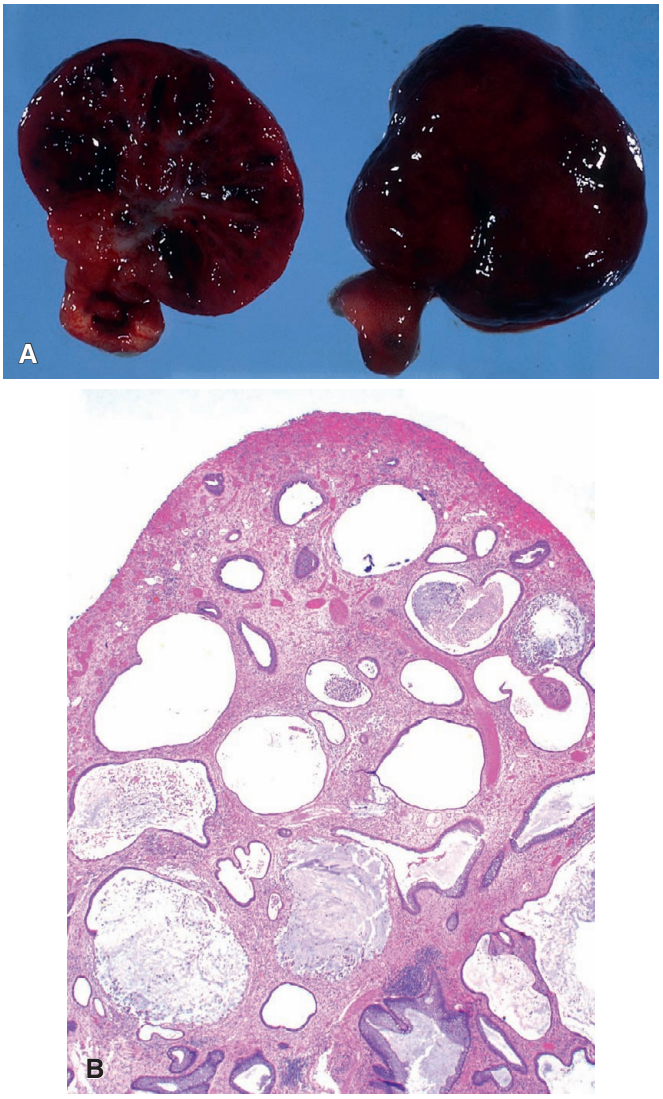

Figure 15.48 **A,** Juvenile polyp in which cystically dilated spaces are grossly apparent. **B,** Histologically the polyp features cystically dilated glands filled with inspissated mucus and inflammatory debris, along with supporting stroma that also contains inflammation. (**A,** Courtesy Dr. George F. Gray, Jr.)

present as multiple tumors[380] or in association with primary malignant neoplasms in other sites.[381,382]

Microscopically, these tumors are usually moderately differentiated adenocarcinomas (Fig. 15.50). CK7 and CK20 expression are variable, whereas immunohistochemical expression of CDX-2 is common.[383] HepPar-1 is also frequently positive in small bowel adenocarcinomas.[384]

At the time of diagnosis, the majority of the tumors have extended deeply into the wall and may have already metastasized to regional lymph nodes or seeded the retroperitoneum.[370] Significant adverse prognostic factors include lymph node involvement, retroperitoneal seeding, lymphovascular invasion and extent of tumor invasion.[370]

Other histologic tumor types include *mucinous* and *signet ring cell* adenocarcinomas.[370] *Adenosquamous* carcinoma has been reported on a few occasions, with either the glandular or the squamous component predominating.[385,386] *Anaplastic (sarcomatoid)* carcinoma is composed of highly bizarre tumor cells, some of them multinucleated, with

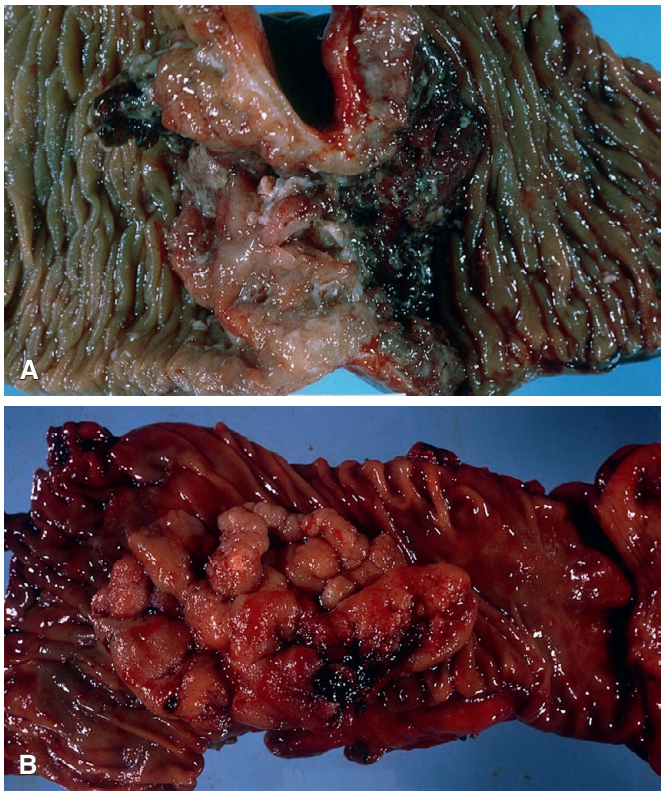

Figure 15.49 Small bowel adenocarcinomas with an infiltrative growth pattern, producing a "napkin-ring"-like lesion **(A)** and a nodular, polypoid growth pattern **(B)**. (Courtesy Dr. George F. Gray, Jr.)

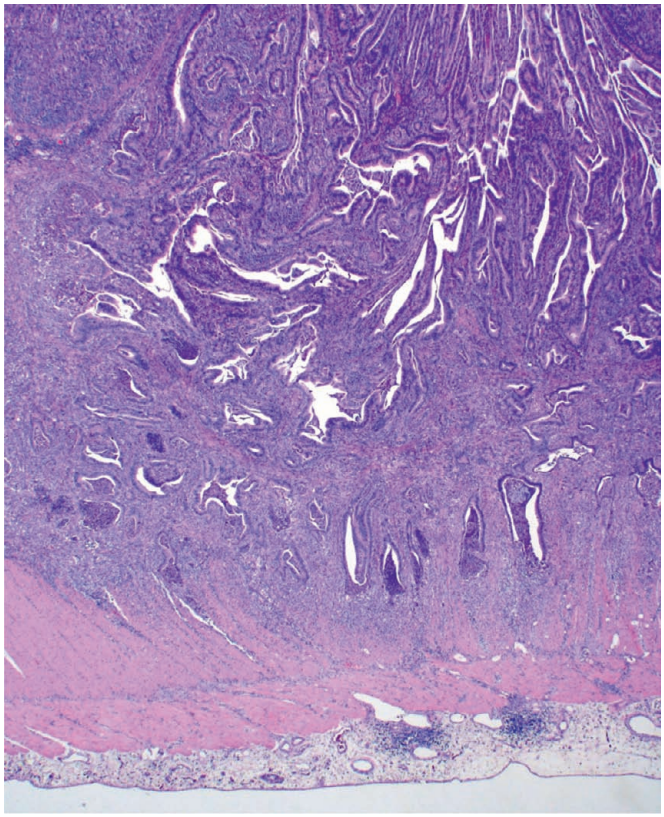

Figure 15.50 Small bowel adenocarcinoma, intestinal type, underlying a large villous adenoma.

abundant cytoplasm and no signs of glandular differentiation. The behavior is extremely aggressive.[387–389] Primary choriocarcinoma of the small bowel has also been reported rarely.[390]

Neuroendocrine Tumors

General and Clinical Features

WNET has replaced *carcinoid tumor* when referring to low-grade malignant neoplasms of the GI tract originating from the diffuse endocrine system.[391,392] The majority of WNET of small bowel occur in adults, but they have also been documented in children.[393] Most are located in the ileum (including Meckel diverticulum), followed in frequency by the jejunum and distal duodenum.[394,395] They have been described in small bowels affected by CD[396] and Crohn disease,[397] in bowel duplication,[398] in association with von Recklinghausen disease[399,400] and with inflammatory polyps.[401] WNETs tumors of the small bowel are multiple in 15%–35% of the cases (Fig. 15.51),[402] and molecular analysis indicates that when multiple, WNETs of the small intestine are derived from the same clone.[403]

Figure 15.51 Multiple carcinoid tumors of small bowel presenting as small sessile polyps. (Courtesy of Dr RA Cooke, Brisbane, Australia. From Cooke RA, Stewart B. Colour atlas of anatomical pathology. Edinburgh, 2004, Churchill Livingstone.)

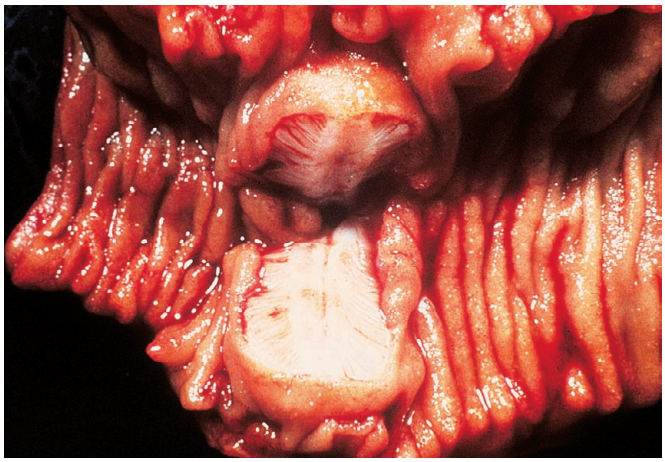

Figure 15.52 Cut surface of carcinoid tumor of the ileum. The tumor is solid, yellow, and accompanied by marked thickening of the muscularis propria.

Pathologic Features

The mucosa is often intact over the tumor. Infiltration of the submucosa is the rule, and extension into the muscularis propria is common (Fig. 15.52). The tumor invasion and the accompanying fibrosis may "buckle" the bowel wall. Following formalin fixation, the tumor acquires a bright yellow color that is not evident in the fresh state.

Microscopically, the most common pattern is that of solid nests of monotonous-appearing cells with small, round nuclei; a moderate amount of finely granular cytoplasm; and indistinct nucleoli (Fig. 15.53A and B). Peripheral palisading is common. Other histologic variations include trabecular and glandular patterns; the latter may contain intraluminal mucin. Multiple patterns are often present within the same tumor. The nesting pattern is often accentuated by artifactual retraction from the stroma. As noted previously, extensive fibrosis is common (see Fig. 15.53C). Lymphovascular invasion is often seen (see Fig. 15.53D), and it is also common to find tumor cells within submucosal nerves. WNETs are graded based on mitotic rate and/or proliferation (Ki-67) index. G1 tumors are characterized by <2 mitotic figures/10 HPF and/or a Ki-67 index of ≤2%. G2 tumors contain 2–20 mitotic figures/10 HPF and/or a proliferation index between 3% and 20%.[391]

In some cases, the mucosa surrounding WNETs may contain highly vascular polypoid formations that can simulate Crohn disease[404]; the change has been attributed by some authors to the secretion of a transforming growth factor by the tumor cells[405] and interpreted by others as a nonspecific reaction secondary to mucosal prolapse.[406] The non-neoplastic mucosa of a small bowel bearing one or more carcinoid tumors may show hyperplasia of endocrine cells, although this is not nearly as common or as prominent as with some types of carcinoid tumors of the stomach.

Histochemical, Immunohistochemical, and Ultrastructural Features

The distinctive phenotypic profile of WNETs can be demonstrated by a variety of special techniques. At the histochemical level, the tumor is argentaffin (and therefore also argyrophilic), positive for the diazo reaction, and generally negative for mucin stains (Fig. 15.54). Ultrastructurally, there are numerous dense-core pleomorphic secretory granules scattered throughout the cytoplasm.[407] Immunohistochemically, there is reactivity indicative of epithelial, intestinal, and neuroendocrine differentiation. Broad-spectrum keratins are usually positive, and—particularly in tumors with a trabecular component—apical or luminal CEA positivity may be seen.[408,409] Among the keratins, CK7 is expressed in almost 10% of the cases and CK20 in approximately 25%.[410] The intestinal lineage is made evident by the consistently strong immunoreactivity for CDX-2, a homeobox gene product necessary for intestinal development and differentiation.[411,412] They are almost universally negative for TTF-1, as opposed to its weak expression in gastric carcinoid tumors and its frequent positivity in pulmonary carcinoid tumors.[412] PAX6 and islet-1 are negative, which is helpful in distinguishing WNET arising in the small bowel from their pancreatic counterparts.[413] The neuroendocrine features are highlighted by chromogranin, synaptophysin, and protein gene product (PGP 9.5).[414–416]

A wide variety of peptide hormones have been found to be expressed in these tumors, but this is of limited clinical usefulness as hormone expression by immunohistochemistry does not correlate with functionality. These include serotonin,[417] substance P (by far the most common), gastrin, somatostatin (and somatostatin receptors[418]), glucagon, glycentin, pancreatic polypeptide (PP), bombesin, secretagogin,[419] gastrin-releasing peptide (GRP), and growth hormone–releasing factor (GRF).[420–427] Peptide YY is found only rarely, in contrast to its consistent presence in rectal carcinoids.[428,429] Neurofilaments are usually absent.[430] Other substances that have been detected in GI carcinoid tumors include calbindin-D28k (a calcium-binding protein expressed by some neural and neuroendocrine cells),[431] villin,[432] and myosin XVA (a member of the myosin superfamily).[433] Staining for S-100 protein is negative, in contrast to the positivity that may be encountered in WNETs of the appendix; this may be related to the alleged difference in the origin of these tumors: endocrine cells from Lieberkuhn crypts for WNETs of small bowel and subepithelial endocrine cells related to nerves for those in the appendix.[434–436] Curiously, prostatic acid phosphatase may also show immunoreactivity in small bowel WNET, although less commonly than rectal WNET.[437,438] Several growth factors and their receptors have been detected in carcinoid tumors of small bowel, and the suggestion has been made that they participate in the autocrine modulation of the tumor growth.[439–441]

Molecular Genetic Features

Loss of all or most of chromosome 18 is the commonest genetic alteration in small bowel WNET, followed by loss of heterozygosity of 9p and 16q.[442] There is also commonly gain on 14q mapped to the locus of the gene encoding the antiapoptotic protein DAD1.[442] Aneuploidy is present in over half of the ileal WNETs.[443] Loss of heterozygosity at the *MEN1* gene locus site on 11q is usually absent in jejunoileal WNETs, suggesting that the gene is not involved in their pathogenesis.[444] Immunoreactivity for P53 is rare[445] but is said to be more frequent in metastasizing lesions.[446]

Spread and Metastases

Many WNETs are low-grade neoplasms that have a slow growth rate, but they may also be highly invasive and have metastasizing properties.[447,448] Metastases occur most commonly in the regional lymph nodes and liver but are also seen in other sites, such as bone, skin, thyroid, and breast.[449,450] The liver metastases are usually multiple and solid but occasionally have a prominent cystic component.[451]

Treatment and Prognosis

Endoscopic resection may be used for tumors less than 1.0 cm that are confined to the submucosa.[452] The primary treatment of intestinal

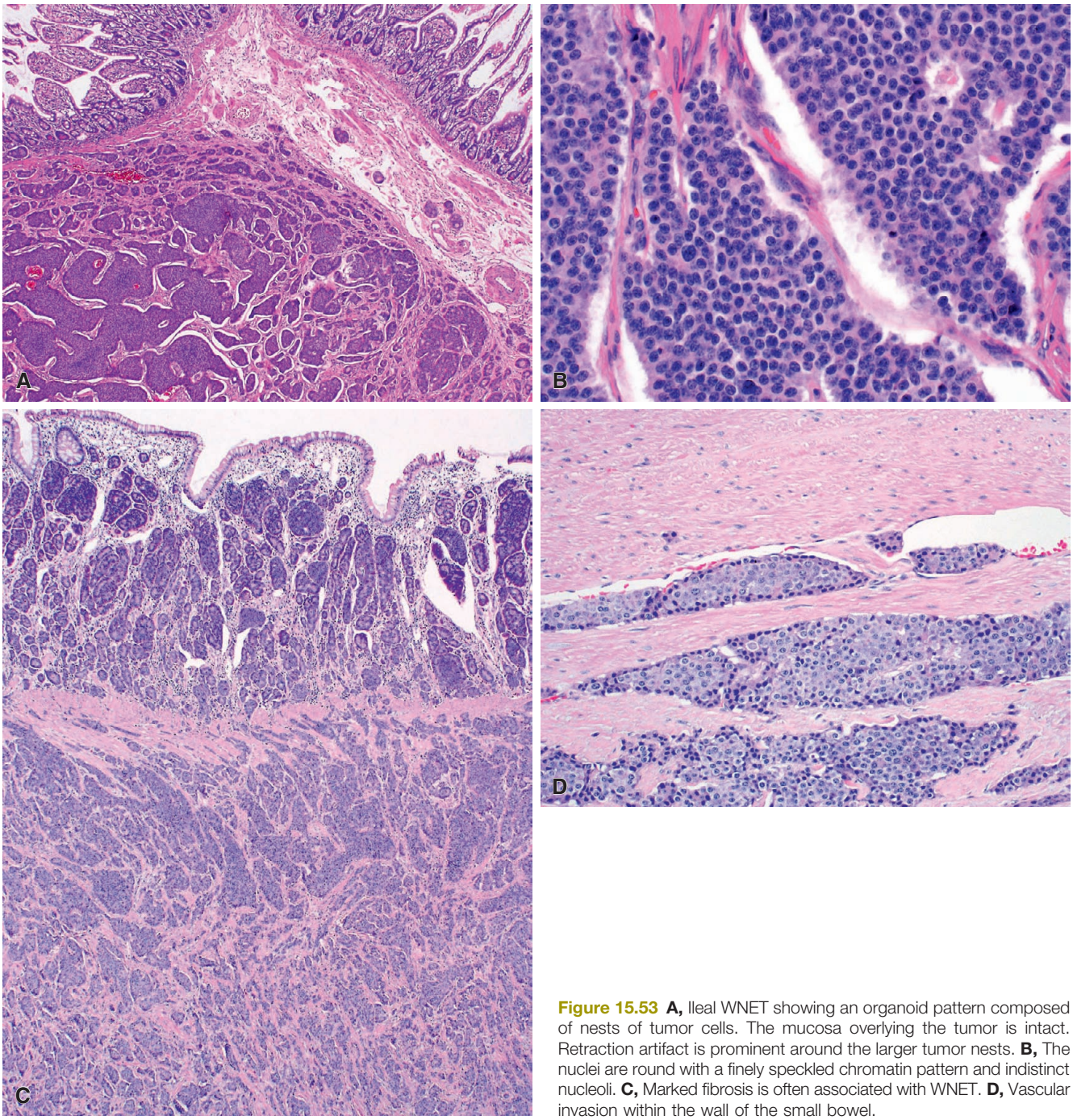

Figure 15.53 **A,** Ileal WNET showing an organoid pattern composed of nests of tumor cells. The mucosa overlying the tumor is intact. Retraction artifact is prominent around the larger tumor nests. **B,** The nuclei are round with a finely speckled chromatin pattern and indistinct nucleoli. **C,** Marked fibrosis is often associated with WNET. **D,** Vascular invasion within the wall of the small bowel.

WNET is wide surgical removal of the primary tumor and lymphadenectomy.[453] Solitary liver metastases are also amenable to surgical excision, and patients with multiple liver metastases may benefit from surgical debulking and have prolonged survival even under these circumstances.[454] Because of the propensity for multiplicity and association with other GI tumors, a thorough exploration of the abdominal cavity is indicated. Somatostatin analogues and similar drugs may be helpful for managing symptoms in patients who are not amenable to surgical therapy.[455] The overall 5-year relative survival rate of small bowel carcinoid is approximately 76%.[456] Prognosis appears to correlate with tumor size, depth of invasion, and node status.[457] TNM staging appears to correlate with prognosis.[458]

Carcinoid Syndrome

WNET tumor may be associated with the *carcinoid syndrome*.[459,460] Nearly all of the reported cases of this syndrome have occurred in tumors that have metastasized to the liver, presumably because of the liver's capacity to inactivate biologically active substances released by the primary tumor into the portal circulation; however, exceptions occur.[461] The syndrome is characterized by cyanosis of the face and anterior part of the chest, intermittent hypertension, palpitation, and frequent watery stools. Traditionally, it has been assumed that the syndrome was due to serotonin, an indolamine regularly secreted by the tumor cells and easily detectable in the urine in the form of

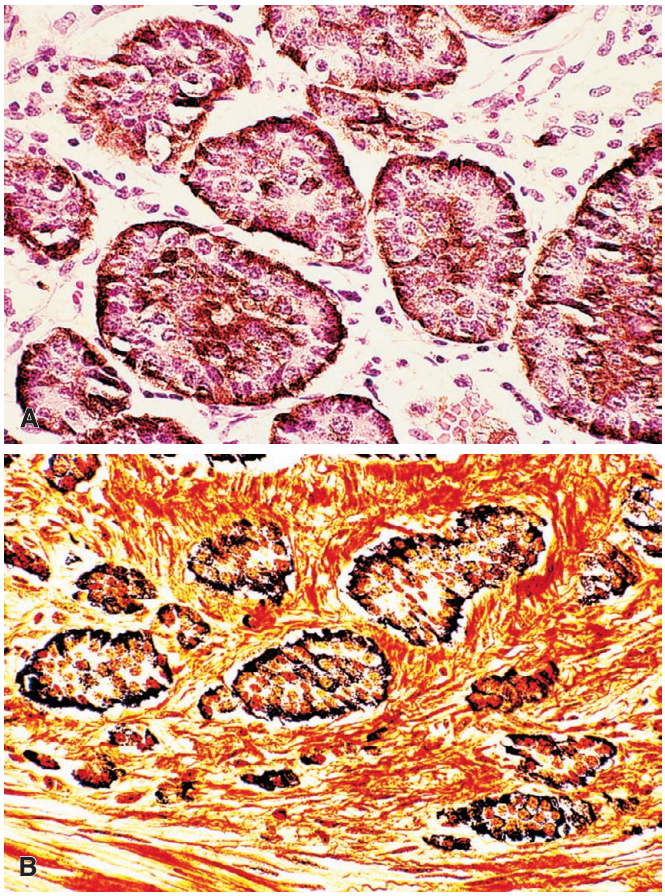

Figure 15.54 **A,** WNET of small bowel. Argentaffin reaction (Fontana–Masson). **B,** Argyrophil reaction (Sevier–Munger).

its catabolite 5-hydroxyindoleacetic acid; however, there is little relation between the serum levels of this marker and the occurrence of the syndrome, especially in regard to its vasodilation component. Other substances known to be secreted by WNETs—such as tachykinins, prostaglandins, and histamine—have been postulated to be responsible as well.[462–464] It is also apparent that the cells of carcinoid tumor must secrete some substance that elicits the deposition of extracellular connective tissue around the tumor and sometimes at a distance. Manifestations of this phenomenon include extensive fibrosclerosis, often seen in the tumor itself (see earlier); fibrosclerosis of the right-sided cardiac valves that results in so-called carcinoid heart disease;[465] obliterative elastic sclerosis of mesenteric blood vessels that may lead to small bowel gangrene[466,467]; and dermal sclerosis that results in scleroderma-like lesions.[468] Furthermore, a few WNETs have resulted in spontaneous hypoglycemia,[469] apparently because of insulin production by the tumor cells.[470]

Duodenal WNET

Endoscopically, duodenal endocrine tumors appear as smooth, round elevations, usually measuring between 5 and 20 mm in diameter but occasionally larger.[471] Gastrin-producing tumors (gastrinomas) may be associated with Zollinger–Ellison syndrome as well as multiple endocrine neoplasia (MEN) type 1.[472–474] They have also been found associated with *H. pylori* gastritis and long-term use of proton pump inhibitors, often against a background of G-cell hyperplasia in the non-neoplastic duodenal mucosa.[475] Somatostatinomas are usually hormonally silent at the clinical level.[476] A high percentage of duodenal

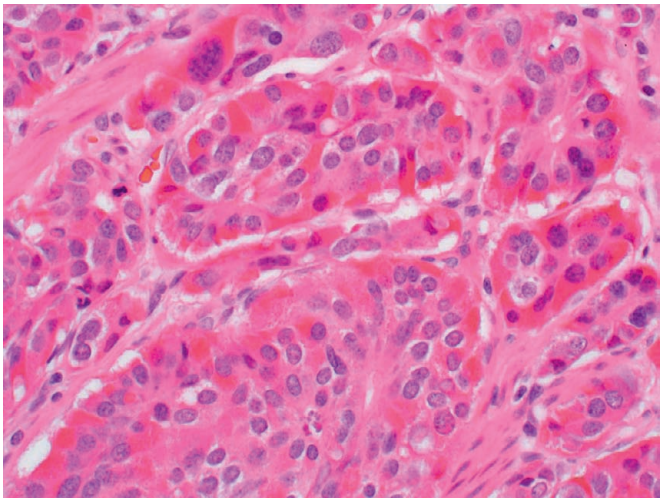

Figure 15.55 Jejunal WNETs often feature prominent eosinophilic cytoplasmic granules that contain serotonin.

somatostatinomas have occurred in patients with von Recklinghausen disease, many of them African-Americans.[477–479] Immunohistochemistry is needed to identify conclusively the specific cell types; however, the nature of these tumors can already be suspected in routinely stained sections by the fact that both of them tend to have a well-developed tubular component and that somatostatinomas have, in addition, numerous psammoma bodies, usually located within glandular lumina.[480–482] It should be noted, however, that psammoma bodies are not specific for somatostatin-secreting tumors; they can also be seen in WNETs of other types in both the bowel and the pancreas.[483] In contrast to their ileal counterparts, duodenal endocrine tumors are positive for PDX-1 and negative for CDX-2.[484]

Jejunal WNET

Jejunal WNETs are much more rare than ileal tumors but are among the most aggressive. Approximately one quarter are multiple.[394] Morphologically, jejunal WNETs often contain prominent eosinophilic cytoplasmic granules that contain serotonin (Fig. 15.55).

Neuroendocrine Carcinoma

Neuroendocrine carcinoma (NEC) includes tumors previously referred to as small cell carcinoma, large cell NEC, and poorly differentiated neuroendocrine neoplasm.[391] This rare type of small bowel malignancy composed of small, round, or oval cells with scant cytoplasm and hyperchromatic nuclei, very similar to that of pulmonary small cell carcinoma. They are typically immunoreactive with neuroendocrine markers as well as keratins. As high-grade (G3) neoplasms, NEC are characterized by >20 mitotic figures/10/HPF and/or a proliferation index of >20%.[391] They are deeply invasive, highly prone to metastasize, and associated with a very poor prognosis.

Mixed adenoneuroendocrine carcinomas (MANECs), by definition, contain at least 30% of a neuroendocrine component, usually NEC, although sometimes WNET is seen in association with an adenocarcinomatous pattern, whether in the primary tumor or in the metastases.[391,485]

Gangliocytic Paraganglioma

Gangliocytic paraganglioma (nonchromaffin paraganglioma, paraganglioneuroma) is a morphologically distinct tumor occurring almost exclusively in the second portion of the duodenum, usually

in proximity to the ampulla of Vater.[486,487] A few morphologically similar cases have been reported at a more distal location, including the jejunoileum[488] and appendix.[489] Occasionally they are multiple[490] or seen in association with von Recklinghausen disease and WNET.[491,492] Most lesions are small, pedunculated, and submucosal, with frequent ulceration of the overlying mucosa and bleeding. The microscopic appearance is distinctive, with few if any exact counterparts elsewhere in the body. Three cell components are present: (1) endocrine cells with a carcinoid-like appearance arranged in compact nests and trabeculae containing dense-core granules ultrastructurally and exhibiting immunoreactivity for a variety of markers, particularly PP; (2) isolated ganglion cells, immunoreactive for neuron-specific enolase and other neural markers; and (3) spindle-shaped Schwann cells and/or sustentacular cells, immunoreactive for S-100 protein (Fig. 15.56).[493–498] Somatostatin may be present in both ganglion cells and endocrine cells, and amyloid may also be present.[499] The peculiar location of this tumor, its highly organoid arrangement, and the striking predominance of PP cells have led to the suggestion that this lesion may represent a hamartomatous process derived from the ventral primordium of the pancreas.[497] Nearly all cases published so far have followed a benign clinical course, but isolated instances associated with lymph node metastases are on record.[500–502]

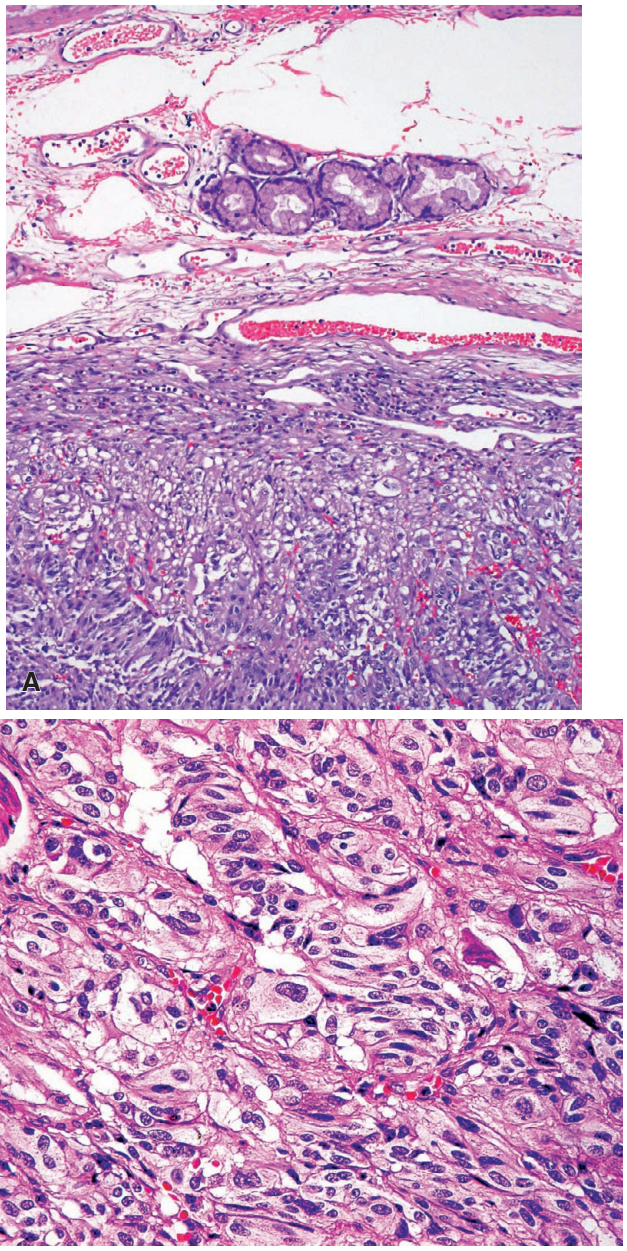

Figure 15.56 **A** and **B,** Gangliocytic paraganglioma of duodenum showing areas of spindle cells, nested epithelioid-appearing cells, and scattered ganglion-like cells (**B,** high power).

Gastrointestinal Stromal Tumors and Other Mesenchymal Tumors

The general considerations concerning GISTs are discussed in Chapter 14. Only features specific to small bowel GISTs will be addressed here.

Approximately 35% of GISTs occur in the small bowel (30% in the jejunum and ileum and 5% in the duodenum), and of these, 40%–50% are clinically malignant.[503] Most small bowel GISTs are spindled lesions, and in particular, GISTs containing so-called skeinoid fibers are characteristically found in this location (Fig. 15.57). Other patterns found in the small bowel include "neuropil"-like areas and epithelioid areas; the latter pattern is less common in the small

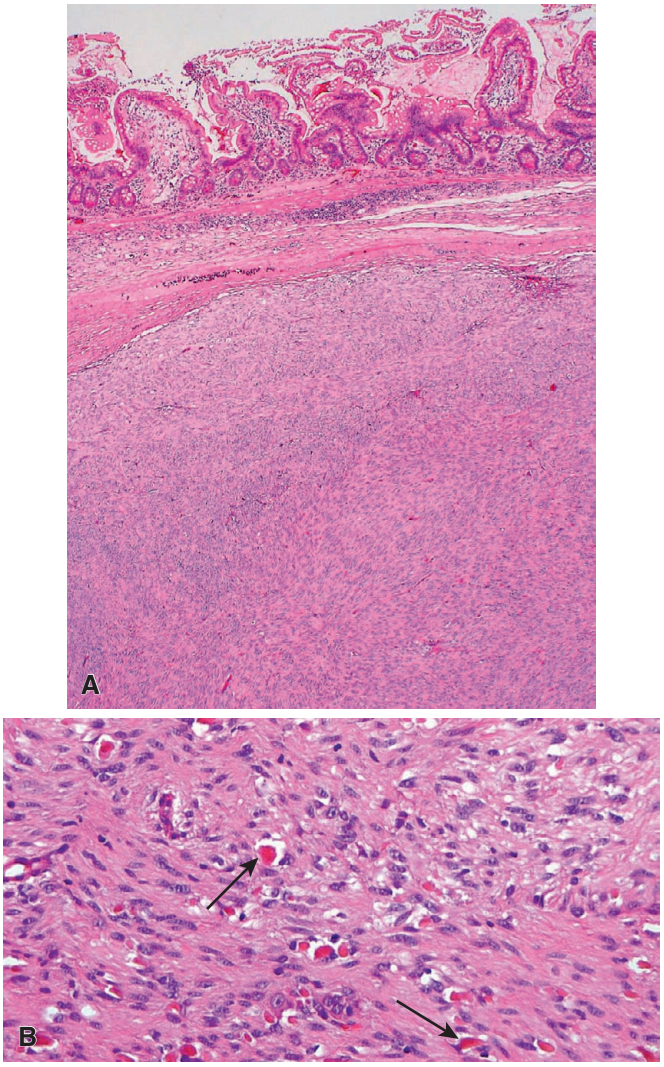

Figure 15.57 **A,** Spindled GIST arising in the wall of the ileum. **B,** Skeinoid fibers are commonly found in small bowel GISTs *(arrows)*.

bowel than in the stomach and is linked with malignant behavior.[503,504] The presence of skeinoid fibers is a sign of good prognosis.[505]

As in other sites in the GI tract, risk stratification of small bowel GISTs is based on site, mitotic count, and size of tumor (Table 15.1). In general, small bowel tumors less than 5 cm with 5 or fewer mitoses/HPF have a low risk of aggressive behavior.[506,507] Lymph node metastases are rarely seen with conventional GISTs, whereas metastases to liver or within the abdomen are much more common.[508] Cases of multiple GISTs of small bowel have been reported in association with von Recklinghausen disease and neuronal intestinal dysplasia.[509–511]

Table 15.1 Risk stratification of primary small bowel GIST

TUMOR CHARACTERISTICS		RISK OF METASTASIS AND/OR DEATH FROM DISEASE	
MITOTIC INDEX	SIZE	DUODENUM	JEJUNUM/ ILEUM
≤5/HPF	≤2 cm	Extremely low	Extremely low
	>2–≤5 cm	Low (8.3%)	Low (4.3%)
	>5–≤10 cm	Not enough data to evaluate	Intermediate (24%)
	>10 cm	High (34%)	High (52%)
>5/HPF	≤2 cm	Not enough data to evaluate	High but few reported cases
	>2–≤5 cm	High (50%)	High (73%)
	>5–≤10 cm	Not enough data to evaluate	High (85%)
	>10 cm	High (86%)	High (90%)

Data from Downs-Kelly E, Rubin BP, Goldblum JR. Mesenchymal tumors of the gastrointestinal tract. In: Odze RD, Goldblum JR, eds. *Surgical Pathology of the GI Tract, Liver, Biliary Tract, and Pancreas*. Philadelphia: Elsevier; 2015; Miettinen M, Lasota J. Gastrointestinal stromal tumors: pathology and prognosis at different sites. *Sem Diag Pathol* 2006;23:70–83; Joensuu H. Risk stratification of patients diagnosed with gastrointestinal stromal tumor. *Hum Pathol*. 2008;39:1411-1419.

Leiomyomas and **leiomyosarcomas** of the small bowel have become a rarity following the description of GISTs, but they do exist (in a proportion of 1 for 36). By definition they exhibit smooth muscle markers, are typically negative for CD117 and DOG1, and show no mutations of *KIT* or *PDGFR*.[512,513] Most of the stromal tumors occurring in the AIDS-affected population belong to the smooth muscle category and are associated with EBV infection.[514] *Leiomyomatosis peritonealis disseminata* is an unusual condition featuring multiple smooth muscle tumors arising beneath the peritoneum throughout the abdomen; it may rarely affect the small bowel.[515]

IFP appears grossly as a localized submucosal sessile polypoid mass, most often occurring in the ileum (and the gastric antrum, see also Chapter 14) (Fig. 15.58).[516,517] The process occasionally extends to involve the entire thickness of the bowel wall, and the overlying mucosa is often ulcerated. The lesion consists of a bland proliferation of spindled myofibroblasts cells with ill-defined borders. There are admixed inflammatory cells, especially eosinophils; stromal hyalinization may be prominent. Vessels are prominent and often (but not always) have surrounding "onion-skin" fibrosis. Ileal IFPs are similar to those found in the stomach, except that the neural-like features commonly seen in the latter are less prominent (Fig. 15.59). Immunohistochemically, there is consistent positivity for CD34, and variable immunoreactivity with smooth muscle actin.[517,518] CD117 is typically negative, as are desmin and S-100.[519] Recently, gain-of-function *PDGFRA* mutations similar to those often encountered in GISTs have been described in over half of the cases of IFPs.[520] The entirely benign IFP should be distinguished from inflammatory myofibroblastic tumor (IMFT) and from inflammatory pseudotumors.[521,522] Multiple and recurrent cases in a familial setting have been described.[523] Obstruction and intussusception are two well-known complications of this entity.[524]

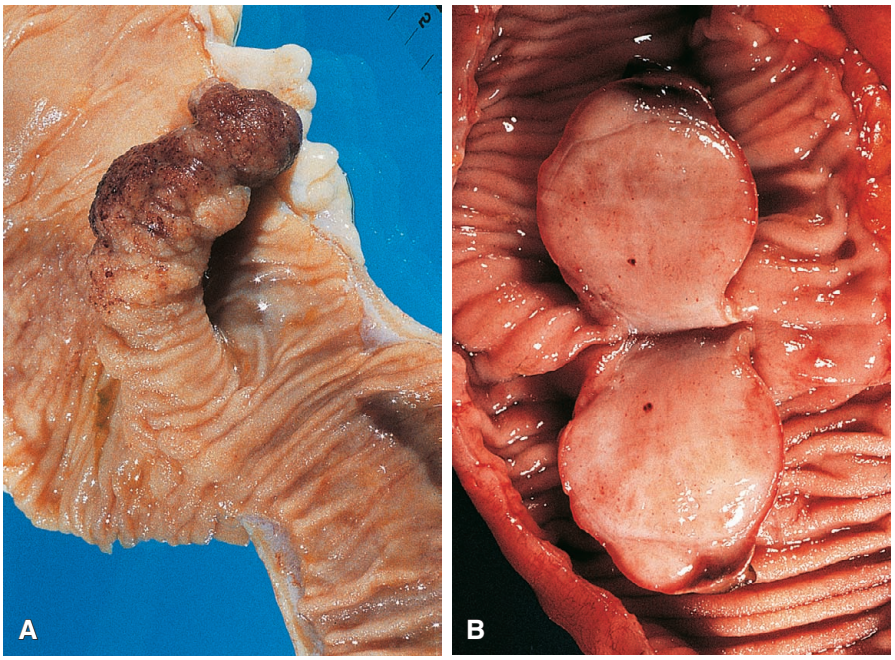

Figure 15.58 **A** and **B,** Gross appearance of inflammatory fibroid polyp.

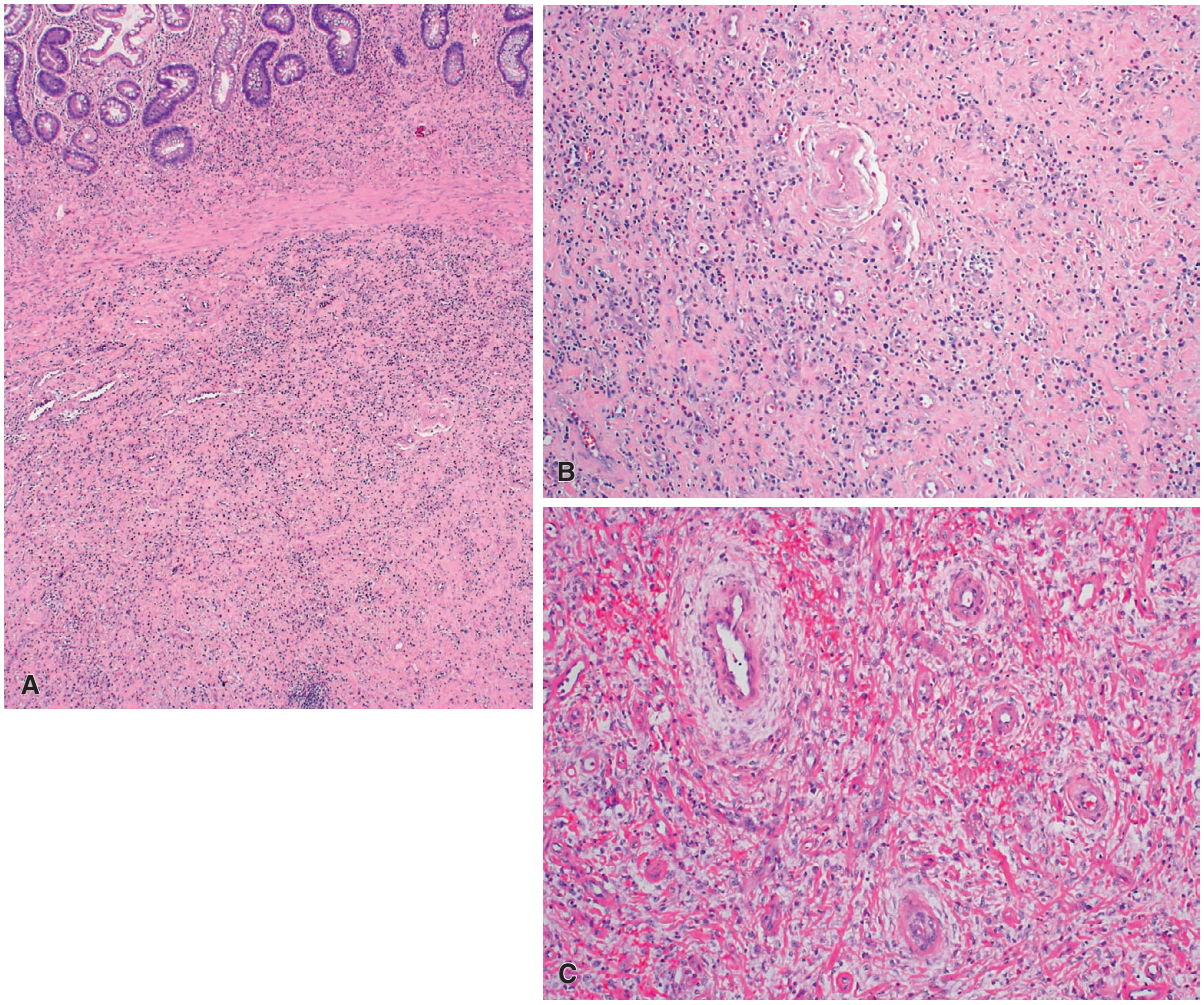

Figure 15.59 **A,** Submucosal-based inflammatory fibroid polyp with spindled stroma, prominent vessels, and a mixed inflammatory infiltrate. **B,** Eosinophils are typically prominent. **C,** Vessels are often surrounded by "onion-skin" fibrosis; this example also has prominent stromal hyalinization.

Lipoma of the small bowel is characteristically centered in the submucosa.[525,526] Grossly, it is a bright yellow, round, encapsulated tumor that bulges upward into the mucosal surface (Fig. 15.60). It has a very characteristic radiographic appearance.[527] The large majority are solitary. Approximately 5% are multiple; these should be distinguished from the rare condition known as *lipomatosis*, in which a segment of bowel (on occasions the entire organ) is infiltrated by mature fat, sometimes in association with diverticulosis or intussusception.[528] Complications of lipoma include ulceration and intussusception.

Benign vascular tumors and tumorlike conditions of various types occur in the small bowel. *Hemangiomas* may be single or multiple and may be associated with similar lesions in other organs.[529,530] They may bleed or perforate. Grossly, the lesions are soft, elevated, reddish, and not well defined. The mid jejunum is the most common location, but they can also occur in other sites. Microscopically, cavernous hemangioma is the most common variety. *Lymphangiomas* often occur in association with similar tumors in other sites, particularly in children (Fig. 15.61).[531] They should be distinguished from the *lymphatic cysts (lacteal cysts)* commonly seen as an incidental finding in the elderly.[532]

In *hereditary telangiectasia* there are vascular lesions of the mucous membrane and skin. These lesions are multiple, and severe GI hemorrhage can occur from them. Smith et al.[533] reported 159 patients, 21 of whom had significant hemorrhage. Demonstration of these lesions at surgery is difficult, and surgical resection is usually not successful.

There are isolated case reports of *intravascular papillary endothelial hyperplasia (Masson hemangioma)*,[534] *glomus tumor*,[535,536] and rare reports of *solitary fibrous tumor*.[537]

Schwannoma, neurofibroma, and **ganglioneuroma** may occur as isolated neoplasms or as components of von Recklinghausen disease or multiple endocrine neoplasia.[538–540] It should be mentioned here that GI involvement in von Recklinghausen disease may manifest in a variety of ways: hyperplasia of the submucosal and myenteric nerve plexuses, mucosal ganglioneuromatosis, GISTs showing varying degrees of neural or smooth muscle differentiation, somatostatin-rich endocrine tumor of the duodenum, adenocarcinoma with (and perhaps without) neuroendocrine features, and gangliocytic paraganglioma.[540]

IMFTs may arise in the mesentery of the small bowel, most often in children and young adults. Historically, these have also been known as *inflammatory pseudotumors of the GI tract* or *plasma cell granulomas*.[522,541,542] They are considered lesions of borderline malignancy, as they have a tendency to recur but metastasize only rarely. They may be spindled, myxoid, or sclerotic; approximately half

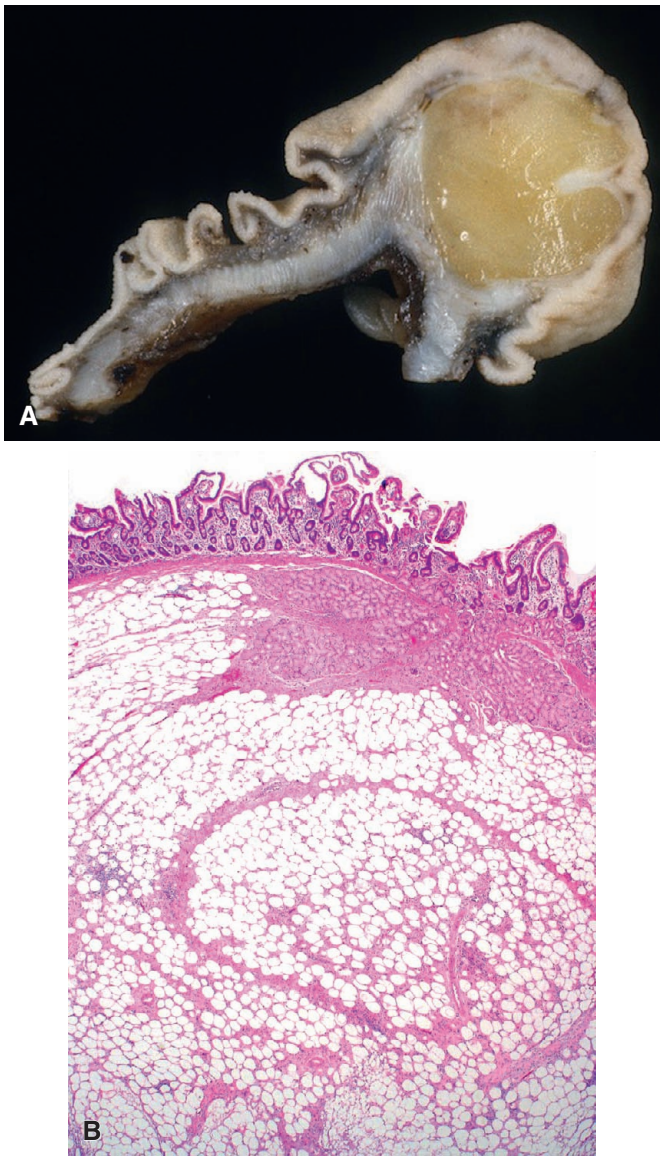

Figure 15.60 **A,** Cut surface of small bowel lipoma. **B,** Duodenal lipoma with overlying nodule of Brunner glands. (**A,** Courtesy Dr. George F. Gray, Jr.)

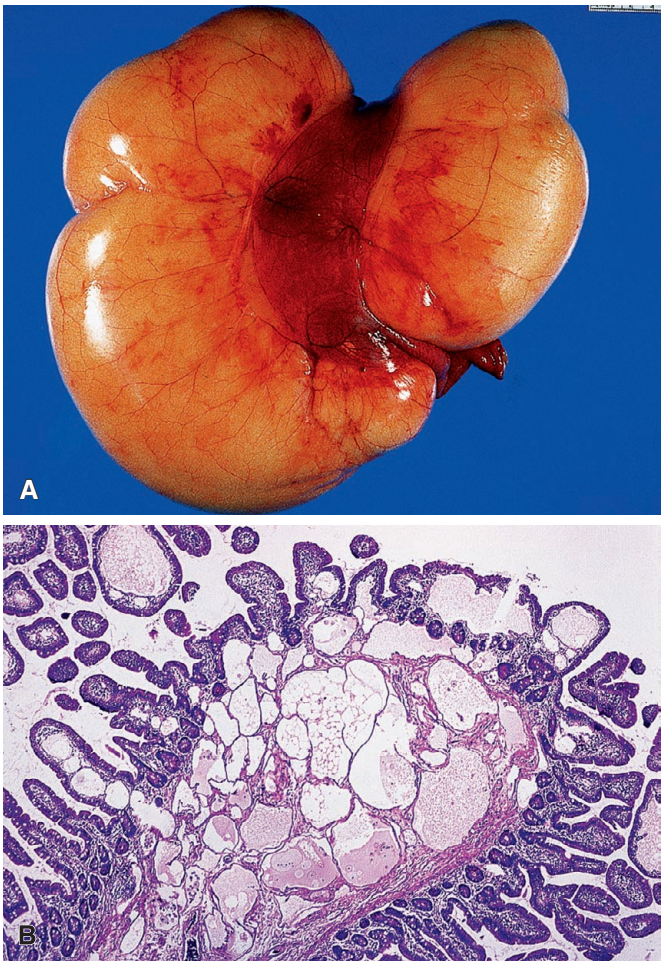

Figure 15.61 **A,** Lymphangioma involving small bowel and adjacent mesentery. **B,** Low-power appearance of lymphangioma showing predominantly submucosal involvement.

contain ganglion-like cells, and a there is often a prominent lymphoplasmacytic inflammatory infiltrate. Some tumors have striking cytologic atypia. IMFT are positive for SMA and variably positive for desmin, and approximately 30% are immunopositive with keratin. Unlike GIST, they are negative for KIT and DOG-1. Approximately half of tumors have an *ALK* gene rearrangement, although there is imperfect correlation between the gene rearrangement and ALK immunohistochemical positivity.[543] It is important to note that ALK staining is not specific to IMFT.[544]

Congenital fibromatosis may result in a solitary intestinal mass, leading to intestinal obstruction in the neonate,[545] whereas **mesenteric fibromatosis** (desmoid tumor) in the adult may involve the bowel wall and be misinterpreted as a GIST.[546] Nuclear β-catenin immunoreactivity is very helpful in diagnosing desmoid tumors.[547]

Malignant GI neurectodermal tumor[548] is a recently coined name that encompasses the exceedingly rare tumors previously described as osteoclast-rich tumors of the GI tract[549,550] or clear cell sarcoma-like tumor of the GI tract.[551] The ultrastructural features and absence of melanocytic differentiation separate these tumors from soft tissue clear cell sarcomas that involve the GI tract. These tumors typically express S-100 and SOX2 but are negative for melanocytic markers and CD117. The majority of cases contain *EWSR1-CREB1* or *EWSR1-ATF1* fusions.

Other mesenchymal and vascular tumors that rarely involve the small bowel include *Kaposi sarcoma* (characteristically multiple lesions)[552]; *angiosarcoma* (also with a tendency for multiplicity and sometimes showing epithelioid features)[553,554]; *synovial sarcoma*[555,556]; *liposarcoma*[557]; *pleomorphic sarcoma*[558]; *Ewing sarcoma/PNET*[559]; *rhabdomyosarcoma*[560,561]; and *PEComa*.[562]

Malignant Lymphoma and Related Disorders

Important concepts to consider when evaluating malignant lymphomas involving the small bowel include: (1) whether or not they are truly primary, versus part of a systemic disease; (2) their cell lineage (B, T or NK cell); and (3) the presence and type of an associated or predisposing condition.[563,564] Although the GI tract is the most common site of primary extranodal lymphoma,[564–566] the possibility of disease being present elsewhere should always be investigated, inasmuch as 10% of patients with non-Hodgkin lymphomas have involvement of some part of the GI tract at the time of initial evaluation.[567,568] The following discussion focuses on

lymphomas that are likely to occur as primary tumors of the small bowel.

T-cell malignant lymphomas represent, in most instances, a complication of longstanding celiac sprue or related malabsorption syndrome and are discussed previously.[95,96] The rare entity known as *extranodal NK/T cell lymphoma (ENKTL), nasal type* is in the differential diagnosis for EATLs, and the most frequent extranasal site of involvement is, in fact, the GI tract. These tumors are positive for CD56, TIA-1, and granzyme B but typically negative for CD4, CD8, and surface CD3. Angiocentric and/or angiodestructive features are characteristic, and these lesions are almost always associated with EBV.[569–572]

B-cell lymphomas are the most common type found in the small bowel. The large majority are thought to arise from mucosa-associated lymphoid tissue, that is, the component of the immune system that is believed to function as a protective mechanism for the freely permeable surface of the GI tract.[573–576]

Low-grade extranodal marginal zone B-cell lymphoma of "MALT type" (other than immunoproliferative small intestinal disease [IPSID], see later) is much less common in the small bowel than in the stomach. Its gross, microscopic, and immunohistochemical features are similar to those of its gastric counterpart, however (see Chapter 14).[563,577] The key features are the predominance of small lymphoid cells (centrocyte-like or monocytoid B cells), the formation of lymphoepithelial lesions, and the presence of reactive follicles (Fig. 15.62). The clinical course is generally very indolent.[578] Low-grade MALT lymphoma may transform to a **large B-cell lymphoma,** however (see next).

IPSID is a distinct type of B-cell lymphoma of small bowel thought to be a special form of MALT lymphoma; it is also known as Mediterranean lymphoma[579,580] and Middle Eastern lymphoma.[570] It is relatively common among non-European Jews, Arabs in the Middle East, and the black population of South Africa.[581] Patients often have a short history of diarrhea and malabsorption, but the mucosa is not completely flat in most cases. Biopsies of the bowel and regional lymph nodes in the low-grade form of this disease (by far the most common) show a heavy lymphoplasmacytic infiltration by cells that appear mature or only slightly immature at both the light and electron microscopic levels.[582,583] This is associated with the presence of monoclonal alpha heavy chains of immunoglobulins in their cytoplasm,[584–586] as well as in the serum and urine—hence the alternative designation "alpha chain disease." Light chains may also be detected.[587] It has been speculated that this lymphoplasmacytic infiltration is originally reactive in nature and that it represents a response to a continuous antigenic stimulus of possible infectious nature. The initially polyclonal nature of the proliferation and the fact that some cases have responded to tetracycline support this contention, and more recent data have demonstrated a connection between IPSID and *Campylobacter jejuni* infection.[588,589]

In the high-grade form of the disease, which is usually preceded and accompanied by the low-grade form, the microscopic appearance of the tumor is that of a highly pleomorphic large cell lymphoma with immunoblastic and plasmacytoid features.[589] Pangalis and Rappaport[590] have shown that the large tumor cells exhibit an immunocytochemical staining for alpha chains similar to that of the small cell lymphoplasmacytic component, suggesting that they represent a clone of highly malignant elements that originate from it. A prominent "starry sky" pattern may be present, as well as intense follicular lymphoid hyperplasia.[591]

The diagnosis of immunoproliferative small intestinal disease can usually be made by endoscopic biopsy, especially if areas with an infiltrating pattern are sampled.[592] The involvement centers in the distal portions of the duodenum and the upper jejunum. Grossly, the presence of diffusely thickened folds with small nodules or discrete tumor growths heralds the emergence of a high-grade malignancy, which proves rapidly fatal in most instances.

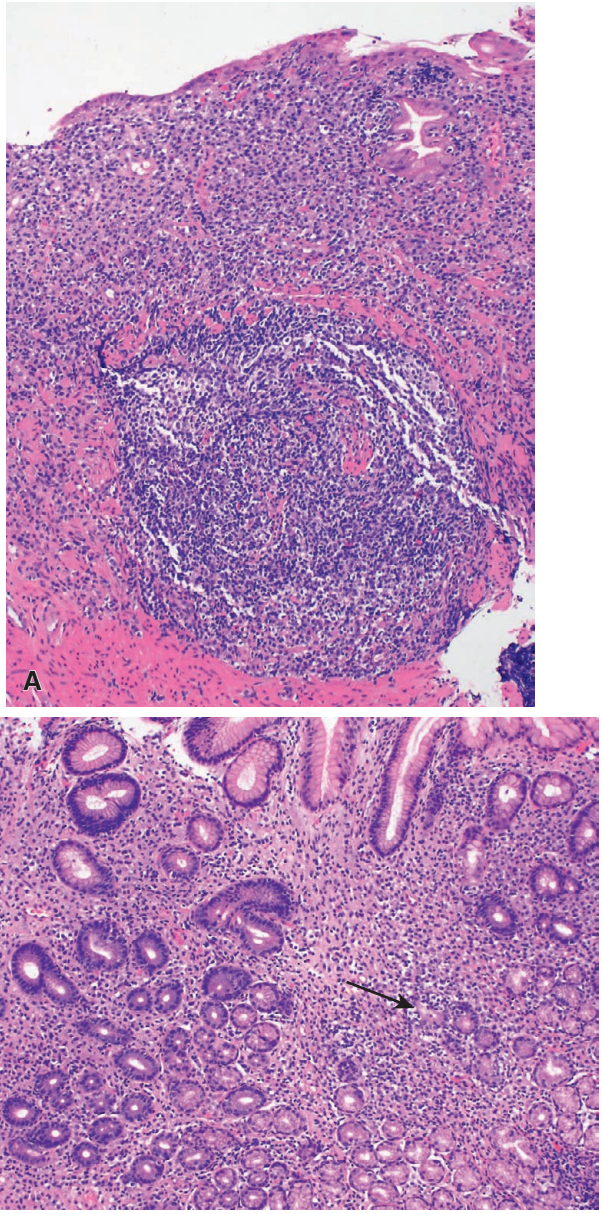

Figure 15.62 Extranodal marginal zone lymphoma of duodenum with plasmacytoid features, showing destruction of the normal mucosal architecture **(A)** and lymphoepithelial lesions (*arrow*, **B**).

Follicular lymphoma can occur anywhere in the GI tract as a primary tumor or secondary to systemic involvement. There is an unusual primary form, however, occurring most often in the duodenum of females, that has a good prognosis despite its morphologic similarity to other follicular lymphomas (Fig. 15.63).[593–595] Some of these cases present grossly as innumerable small polypoid masses throughout the bowel, a condition historically known as *lymphomatoid polyposis;* the lesions may localize around the ampulla of Vater.[596] The 14;18 translocation that is typical of this lymphoma type has been detected in these cases.[593] Curiously, primary follicular lymphoma of the duodenum is usually an unexpected finding on endoscopy performed for various reasons, such as nonspecific abdominal pain.[593,597] Histologically it is usually confined to the

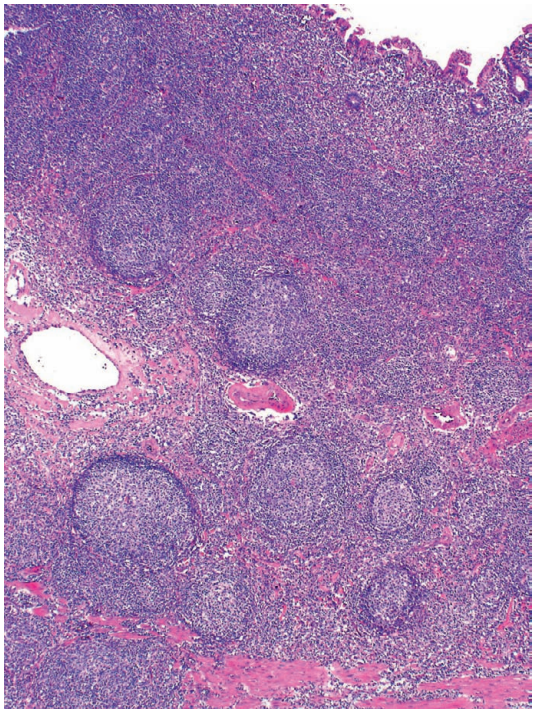

Figure 15.63 Primary follicular lymphoma of the small bowel featuring transmural extension of neoplastic follicles.

mucosa and/or submucosa, and of low histologic grade (grade 1 or 2), with CD10, BCL6, BCL2 expression. These primary small bowel follicular lymphomas are typically detected at an early stage and are associated with an excellent outcome even with conservative management.

Burkitt lymphoma is usually seen in children; the ileum and ileocecal valve are most often involved.[563,598] The endemic form of this tumor is relatively common in the Middle East and Algeria; the other two clinical settings include sporadic and immunodeficiency related. Many patients are in the pediatric age group, and a significant proportion are associated with EBV infection.

Diffuse large B-cell lymphoma of the small bowel is usually solitary. The ileum is more commonly affected, followed by the jejunum and duodenum.[599] Grossly, they can have a diffusely infiltrating mass with a garden hose appearance, a bulky tumor mass with extensive ulceration, or a predominantly polypoid growth pattern (Fig. 15.64). The regional lymph nodes are involved in approximately half of the patients. Most cases have a germinal center phenotype, suggesting an origin from germinal center B cells.[600] A recently described subset of B-cell lymphomas that harbor abnormalities in MYC as well as BCL2 or BCL6 are known as *double-hit lymphomas*. These neoplasms have features intermediate between Burkitt lymphoma and diffuse large B cell lymphoma.[601]

Mantle cell lymphoma uncommonly occurs as a primary tumor of the small intestine, but the intestine is commonly infiltrated as part of systemic involvement. Its morphologic distinction from the other low-grade B-cell lymphomas previously described can be very difficult, and immunophenotyping is crucial (CD20+, CD5+, nuclear cyclin D1+). Its gross presentation may be in the form of multiple lymphoid polyps similar to those seen with follicular lymphoma *(lymphomatous polyposis)*.[602–603]

Hodgkin lymphoma is extremely rare in the small bowel. Only two cases were found by Lewin et al.[568] in a review of 117 lymphomas of the GI tract.

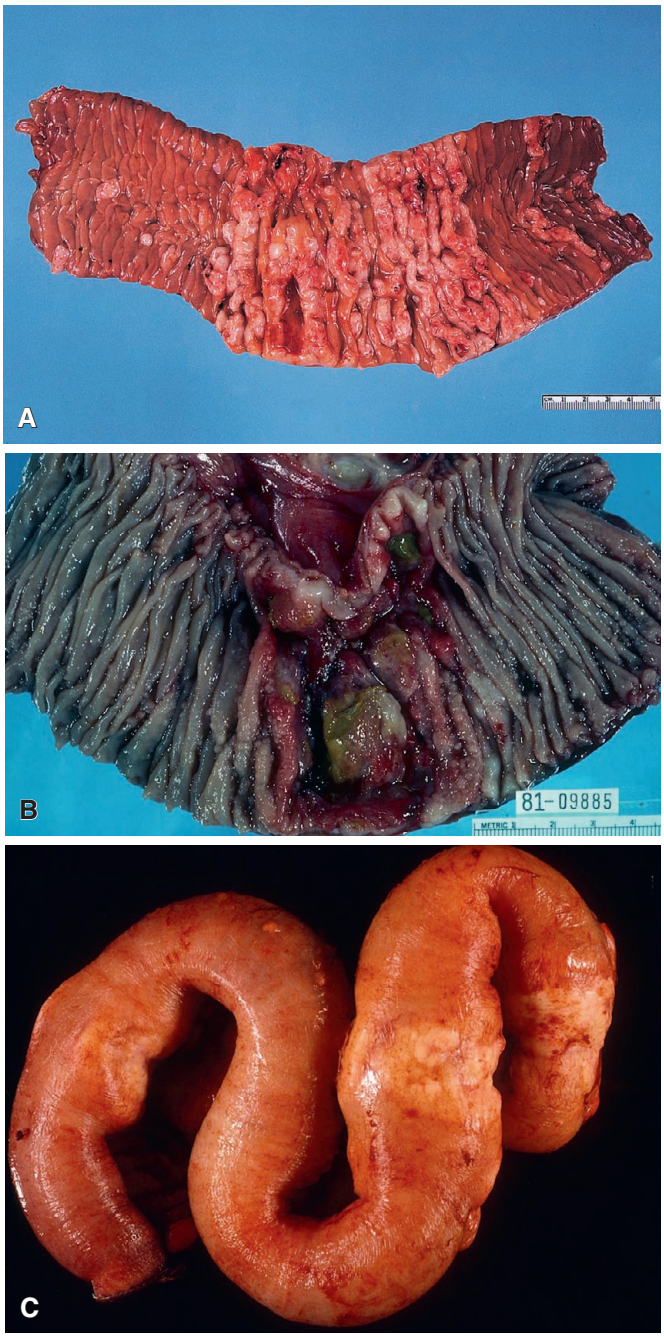

Figure 15.64 **A,** Gross appearance of malignant lymphoma involving the ileum in a diffuse fashion and resulting in polypoid prominence of the transverse mucosal folds. **B,** Malignant lymphoma of small bowel presenting as a circumferential ulcerated lesion that resulted in stenosis. **C,** This diffuse growth pattern in a segment of small bowel resembles a garden hose. (**B** and **C,** Courtesy Dr. George F. Gray, Jr.)

Anaplastic large cell lymphoma can present as a primary lesion of the small bowel; most of the reported cases have been of T-cell lineage.[604]

Multiple myeloma can involve the bowel as a manifestation of systemic extramedullary disease,[605,606] as can Waldenström's macroglobulinemia.[607]

The small bowel is a frequent site of involvement by **post-transplant lymphoproliferative disorders**.[608,609] As in other sites,

the appearance of the neoplastic cells ranges from polymorphic to monomorphic, and the population may be polyclonal or monoclonal.[610,611] The majority of cases are associated with EBV.

True **histiocytic sarcomas** rarely occur in the small bowel, typically showing immunoreactivity for histiocyte markers and lysozyme.[612–615] Curiously, their appearance can be somewhat reminiscent of Rosai–Dorfman disease. *Follicular dendritic cell tumor* (another member of this family) can also rarely present as a primary mass in the small bowel.[613,616] It should be emphasized, however, that most of the large cell tumors that have been regarded in the past as histiocytic on morphologic grounds, and on the basis of their alleged immunohistochemical positivity for lysozyme and α1-antitrypsin, have been shown to be lymphoid neoplasms instead.[617]

Granulocytic sarcoma can present initially as a small bowel mass, preceding the development of acute myelogenous leukemia.[618]

Systemic mastocytosis may also involve the small bowel and present with diarrhea, abdominal pain, nausea, vomiting, and weight loss.[619] The mast cell infiltrates typically expand the lamina propria and are often accompanied by eosinophils (Fig. 15.65).

Lymphoid hyperplasia is a focal reactive process and has historically been known as *pseudolymphoma* (a term that is probably better avoided).[620,621] The ileocecal region is the most common location.[622] Lymphoid hyperplasia associated with viral infection, and leading to intussusception in young children is discussed previously. In other cases (sometimes termed *nodular lymphoid hyperplasia*) the entire small bowel is studded with well-circumscribed nodules of lymphoid tissue, which may be mistaken for other types of polyps. Lymphoid hyperplasia is associated with CVID as well as IgA deficiency.[325,623] In children, it may also be associated with viral infection.[624] The presence of highly reactive germinal centers, numerous cell types, prominent vascularity, and polyclonality (as determined immunohistochemically) are the most important features in the differential diagnosis with malignant lymphoma.[625] It has also become apparent in more recent years that many lesions designated as lymphoid hyperplasia in the past, on purely morphologic grounds, represent instead low-grade lymphomas.[626]

Other Tumors and Tumorlike Conditions

Endometriosis may result in a mass lesion causing intestinal obstruction[627] or mimicking Crohn disease[628] or malignancy (Fig. 15.66). Microscopically, endometrial glands and stroma, foci of fresh and old hemorrhage, and bundles of hypertrophic smooth muscle (which

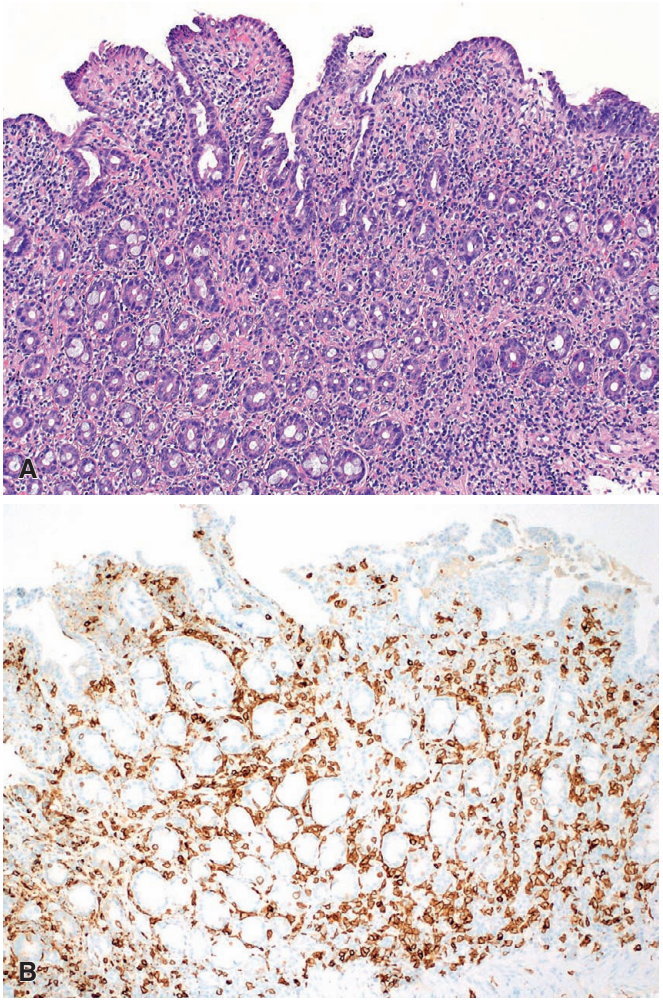

Figure 15.65 **A,** An infiltrate of mast cells expands the lamina propria of the duodenum in this patient with systemic mastocytosis. The mast cells have a "fried egg" appearance and there are scattered admixed eosinophils. **B,** CD117 stain highlights the mast cells.

Figure 15.66 Large blood-filled cystic lesion in the wall of the small bowel due to endometriosis. There is also hyperplasia of smooth muscle, a very common finding. (Courtesy of Dr RA Cooke, Brisbane, Australia. From Cooke RA, Stewart B. *Colour Atlas of Anatomical Pathology*. Edinburgh: Churchill Livingstone; 2004.)

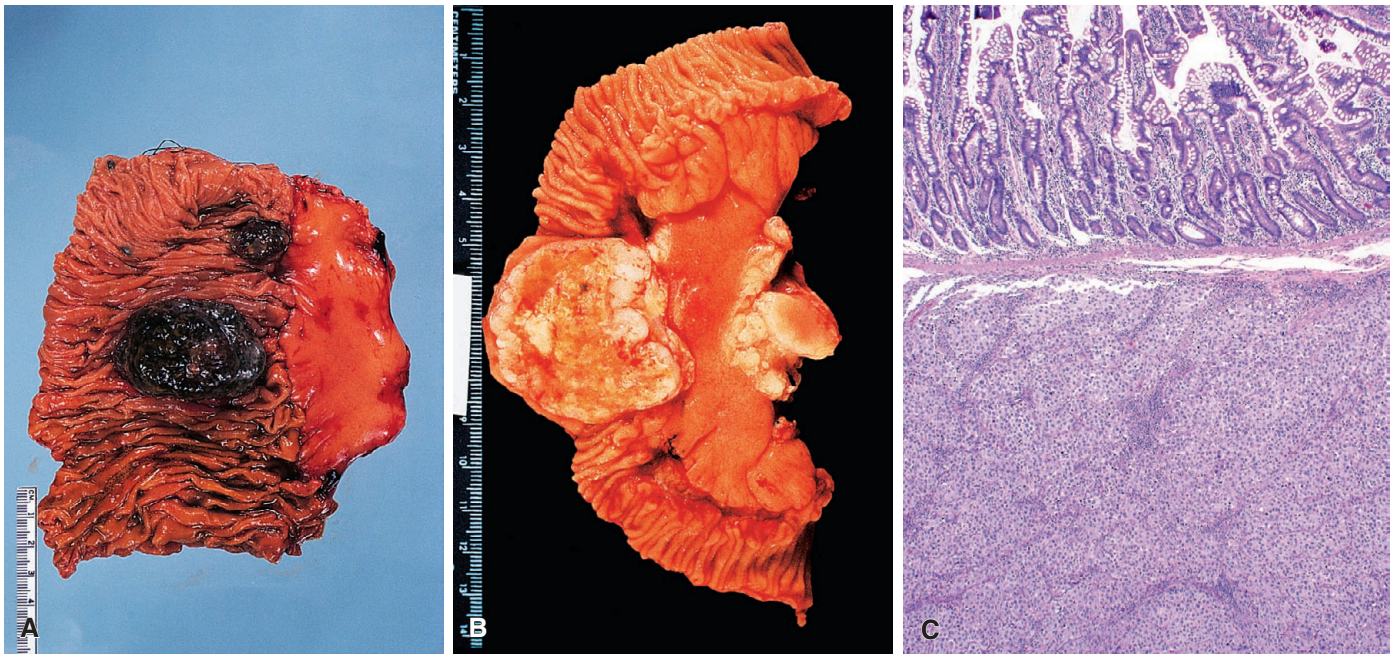

Figure 15.67 Malignant melanoma metastatic to small bowel, which can be deeply pigmented grossly **(A)** or amelanotic **(B)**. **C,** Metastatic melanoma undermining the duodenal mucosa.

may constitute the bulk of the process) are seen. These endometriotic foci may exceptionally undergo malignant transformation in the form of endometrioid carcinoma, müllerian adenosarcoma, or endometrial (endometrioid) stromal sarcoma.[627] *Endocervicosis* is a related müllerian-type process in which the metaplastic mucosa has the appearance of endocervix rather than endometrium.[629]

Neuromuscular and vascular hamartoma of the small bowel is a submucosally based proliferation of mature vessels, nerves, and smooth muscle fibers that can cause obstruction.[630] It has been suggested that this process may be related to so-called *diaphragm disease* and caused by the intake of nonsteroidal anti-inflammatory drugs (see also earlier).[631]

Amyloidosis can exceptionally form globular masses in the bowel wall and grossly evident polypoid lesions.[632]

Metastatic Tumors

Metastases frequently involve the small bowel, often in the form of multiple polypoid masses.[633] The lesions may result in obstruction or perforation, necessitating palliative resection.[634–636] The most common types of tumor metastasizing to the small bowel are malignant melanoma (Fig. 15.67), which must be distinguished from the rare primary melanoma of small bowel,[637] and carcinomas from lung, breast, and ovary, and choriocarcinoma.[634–639] Melanoma can present radiographically as intraluminal masses, ulcerated lesions, diffuse infiltration of the wall, or implants.[637] Patients with multiple metastases from melanoma usually die within 1 year following palliative surgery, but an occasional long-term survivor will be found among those with isolated metastases.[640]

References

1. Gramlich TL, Petras RE. Small intestine. In: Mills SE, ed. *Histology for Pathologists*. 3rd ed. Philadelphia: Lippincott Williams & Wilkins; 2007:603-626.
2. Lamps LW. Small Intestine. In: Lamps LW, ed. *Diagnostic Pathology: Normal Histology*. Salt Lake City: Amirsys; 2013:10:14-10:17.
3. Chen ZM, Wang HL. Alteration of cytokeratin 7 and cytokeratin 20 expression profile is uniquely associated with tumorigenesis of primary adenocarcinoma of the small intestine. *Am J Surg Pathol*. 2004;28(10):1352-1359.
4. Andrew A, Kramer B, Rawdon BB. The origin of gut and pancreatic neuroendocrine (APUD) cells—the last word? *J Pathol*. 1998;186(2):117-118.
5. Rosai J. An evolutionary view of neuroendocrine cells and their tumors. *Int J Surg Pathol*. 2001;9(2):87-92.
6. Skipper M, Lewis J. Getting to the guts of enteroendocrine differentiation. *Nat Genet*. 2000;24(1):3-4.
7. Farstad IN, Malavasi F, Haraldsen G, et al. CD38 is a marker of human lacteals. *Virch Arch*. 2002;441(6):605-613.
8. Dulac C, Le Douarin NM. Phenotypic plasticity of Schwann cells and enteric glial cells in response to the microenvironment. *Proc Natl Acad Sci USA*. 1991;88(14):6358-6362.
9. Goyal RK, Hirano I. The enteric nervous system. *NEJM*. 1996;334(17):1106-1115.
10. Takayama I, Horiguchi K, Daigo Y, et al. The interstitial cells of Cajal and a gastroenteric pacemaker system. *Arch Histol Cytol*. 2002;65(1):1-26.
11. Rumessen JJ, Thuneberg L. Pacemaker cells in the gastrointestinal tract: interstitial cells of Cajal. *Scand J Gastroenterol Suppl*. 1996;216:82-94.
12. Ward SM, Sanders KM. Physiology and pathophysiology of the interstitial cell of Cajal: from bench to bedside. I. Functional development and plasticity of interstitial cells of Cajal networks. *Am J Physiol Gastrointest Liver Physiol*. 2001;281(3):G602-G611.
13. Vanderwinden JM, Rumessen JJ, De Laet MH, et al. CD34 immunoreactivity and interstitial cells of Cajal in the human and mouse gastrointestinal tract. *Cell Tissue Res*. 2000;302(2):145-153.
14. Komuro T, Seki K, Horiguchi K. Ultrastructural characterization of the interstitial cells of Cajal. *Arch Histol Cytol*. 1999;62(4):295-316.
15. Min KW, Sook Seo I. Interstitial cells of Cajal in the human small intestine: immunochemical and ultrastructural study. *Ultrastruct Pathol*. 2003;27(2):67-78.
16. Lecoin L, Gabella G, Le Douarin N. Origin of the c-kit-positive interstitial cells in the avian bowel. *Development*. 1996;122(3):725-733.
17. Young HM. Embryological origin of interstitial cells of Cajal. *Micros Res Tech*. 1999;47(5):303-308.
18. Pang LC. Pancreatic heterotopia: a reappraisal and clinicopathologic analysis of 32 cases. *South Med J*. 1988;81:1264-1275.

19. Park HS, Lee LW, Lee JM, et al. Adenomyoma of the small intestine: report of two cases and review of the literature. *Histopathol*. 2003;53:111-114.
20. Ryan A, Lafnitzegger JR, Lin DH, et al. Myoepithelial hamartoma of the duodenal wall. *Virchows Arch*. 1998;432(2):191-194.
21. Flejou JF, Potet F, Molas G, et al. Cystic dystrophy of the gastric and duodenal wall developing in heterotopic pancreas: an unrecognised entity. *Gut*. 1993;34(3): 343-347.
22. Makhlouf HR, Almeida JL, Sobin LH. Carcinoma in jejunal pancreatic heterotopia. *Arch Pathol Lab Med*. 1999;123(8):707-711.
23. Suda K, Takase M, Shiono S, et al. Duodenal wall cysts may be derived from a ductal component of ectopic pancreatic tissue. *Histopathol*. 2002;41(4):351-356.
24. Franzin G, Musola R, Negri A, et al. Heterotopic gastric (fundic) mucosa in the duodenum. *Endoscopy*. 1982;14(5):166-167.
25. Lessells AM, Martin DF. Heterotopic gastric mucosa in the duodenum. *J Clin Pathol*. 1982;35(6):591-595.
26. Spiller RC, Shousha S, Barrison IG. Heterotopic gastric tissue in the duodenum: a report of eight cases. *Dig Dis Sci*. 1982;27(10):880-883.
27. Nowak M, Deppisch L. Giant heterotopic gastric polyp in the jejunum. *Arch Pathol Lab Med*. 1999;122:90-93.
28. Kushima R, Ruthlein HJ, Stolte M, et al. 'Pyloric gland-type adenoma' arising in heterotopic gastric mucosa of the duodenum, with dysplastic progression of the gastric type. *Virchows Arch*. 1999;435(4):452-457.
29. Stern LE, Warner BW. Gastrointestinal duplications. *Sem Pediatr Surg*. 2000;9(3):135-140.
30. Iyer CP, Mahour GH. Duplications of the alimentary tract in infants and children. *J Pediatri Surg*. 1995;30:1267-1270.
31. Seidman JD, Yale-Loehr AJ, Beaver B, Sun CC. Alimentary duplication presenting as an hepatic cyst in a neonate. *Am J Surg Pathol*. 1991;15(7):695-698.
32. Stringer MD, Spitz L, Abel R, et al. Management of alimentary tract duplication in children. *Br J Surg*. 1995;82(1):74-78.
33. Adair HM, Trowell JE. Squamous cell carcinoma arising in a duplication of the small bowel. *J Pathol*. 1981;133(1):25-31.
34. Blank G, Konigsrainer A, Sipos B, Ladurner R. Adenocarcinoma arising in a cystic duplication of the small bowel: case report and review of the literature. *World J Surg Oncol*. 2012;10:55.
35. Adams SD, Stanton MP. Malrotation and intestinal atresias. *Early Hum Dev*. 2014;90:921-925.
36. Grosfeld JL, Rescorla FJ. Duodenal atresia and stenosis: reassessment of treatment and outcome based on antenatal diagnosis, pathologic variance, and long-term follow-up. *World J Surg*. 1993;17(3):301-309.
37. Dalla Vecchia LK, Grosfeld JL, West KW, et al. Intestinal atresia and stenosis: a 25 year experience with 277 cases. *Arch Surg*. 1998;133:490-496.
38. Gluer S. Intestinal atresia following intraamniotic use of dyes. *Eur J Pediatr Surg*. 1995;5:240-242.
39. Ward HC, Leake J, Milla PJ, Spitz L. Brown bowel syndrome: a late complication of intestinal atresia. *J Pediatr Surg*. 1992;27(12):1593-1595.
40. Taylor ND, Cass DT, Holland AJ. Infantile hypertrophic pyloric stenosis: has anything changed? *J Paediatr Child Health*. 2013;49:33-37.
41. Stephens D, Arensman R, Pillai S, Alagiozian-Angelova V. Congenital absence of intestinal smooth muscle: a case report and review of the literature. *J Pediatr Surg*. 2009;44:2211-2215.
42. Litwin A, Avidor I, Schujman E, et al. Neonatal intestinal perforation caused by congenital defects of the intestinal musculature. *Am J Clin Pathol*. 1984;81(1):77-80.
43. Steck WD, Helwig EB. Cutaneous remnants of the omphalomesenteric duct. *Arch Dermatol*. 1964;90:463-470.
44. Sagar J, Kumar V, Shah DK. Meckel's diverticulum: a systematic review. *J R Soc Med*. 2006;99:501-505.
45. Menezes M, Tareen F, Saeed A, et al. Symptomatic Meckel's diverticulum in children: a 16-year review. *Pediatr Surg Int*. 2008;24:575-577.
46. Ford EG, Woolley MM. Tracheoesophageal fistula associated with perforated Meckel's diverticulum. *J Pediatr Surg*. 1992;27(9):1223-1224.
47. Cserni G. Gastric pathology in Meckel's diverticulum. Review of cases resected between 1965 and 1995. *Am J Clin Pathol*. 1996;106(6):782-785.
48. Hudson HM 2nd, Millham FH, Dennis R. Vesico-diverticular fistula: a rare complication of Meckel's diverticulum. *Am Surg*. 1992;58(12):784-786.
49. Finn LS, Christie DL. *Helicobacter pylori* and Meckel's diverticula. *J Pediatr Gastroenterol Nutr*. 2001;32:150-155.
50. Nies C, Zielke A, Hasse C, et al. Carcinoid tumors of Meckel's diverticula. Report of two cases and review of the literature. *Dis Col Rectum*. 1992;35(6):589-596.
51. Ohmori T, Okada K, Arita N, Tabei R. Multiple ileal carcinoids and appendiceal endocrine carcinoma in association with Meckel's diverticulum. A histochemical and immunohistochemical study. *Arch Pathol Lab Med*. 1994;118(3):283-288.
52. Bloch T, Tejada E, Brodhecker C. Malignant melanoma in Meckel's diverticulum. *Am J Clin Pathol*. 1986;86(2):231-234.
53. Kusumoto H, Yoshitake H, Mochida K, et al. Adenocarcinoma in Meckel's diverticulum: report of a case and review of 30 cases in the English and Japanese literature. *Am J Gastroenterol*. 1992;87(7):910-913.
54. Van Loo S, Van Thielen J, Cools P. Gastroentestinal bleeding caused by a GIST of Meckel's diverticulum—a case report. *Acta Chir Belg*. 2010;110:365-366.
55. Juler GL, List JW, Stemmer EA, Connolly JE. Perforating duodenal diverticulitis. *Arch Surg*. 1969;99(5):572-578.
56. Economides NG, McBurney RP, Hamilton FH 3rd. Intraluminal duodenal diverticulum in the adult. *Ann Surg*. 1977;185:147-152.
57. Matsukuma S, Suda K. Foamy cell aggregation in duodenal diverticula. *Histopathol*. 1996;29(3):271-274.
58. Meagher AP, Porter AJ, Rowland R, et al. Jejunal diverticulosis. *Aust N Z J Surg*. 1993;63(5):360-366.
59. Palder SB, Frey CB. Jejunal diverticulosis. *Arch Surg*. 1988;123(7):889-894.
60. Krishnamurthy S, Kelly MM, Rohrmann CA, Schuffler MD. Jejunal diverticulosis. A heterogenous disorder caused by a variety of abnormalities of smooth muscle or myenteric plexus. *Gastroenterol*. 1983;85(3):538-547.
61. Zakhour HD, Clark RG. Intramural gas cysts in a case of diverticular disease of the jejunum. *Histopathology*. 1982;6(3):363-369.
62. Ieiri S, Suita S, Nakasuji T, et al. Total colonic aganglionosis with or without small bowel involvement: a 30-year retrospective nationwide survey in Japan. *J Pediatr Surg*. 2008;43:2226-2230.
63. Beighton PH, Murdoch JL, Votteler T. Gastrointestinal complications of the Ehlers-Danlos syndrome. *Gut*. 1969;10(12):1004-1008.
64. Perera DR, Weinstein WM, Rubin CE. Symposium on pathology of the gastrointestinal tract-Part II. Small intestinal biopsy. *Hum Pathol*. 1975;6(2):157-217.
65. Husby S, Koletzko S, Korponay-Szabo IR, et al. European Society for Pediatric Gastroenterology, Hepatology, and Nutrition guidelines for the diagnosis of coeliac disease. *J Pediatr Gastroenterol Nutr*. 2012;54:136-160.
66. Drut R, Rua EC. The histopathology of pediatric celiac disease: order must prevail out of chaos. *Int J Surg Pathol*. 2001;9(4):261-264.
67. Dickson BC, Streutker CJ, Chetty R. Coeliac disease: an update for pathologists. *J Clin Pathol*. 2006;59(10):1008-1016.
68. Owens SR, Greenson JK. The pathology of malabsorption: current concepts. *Histopathology*. 2007;50(1):64-82.
69. Fasano A. Celiac disease—how to handle a clinical chameleon. *N Engl J Med*. 2003;348(25):2568-2570.
70. Ianiro G, Gasbarrini A, Cammarota G, et al. Endoscopic tools for the diagnosis and evaluation of celiac disease. *World J Gastroenterol*. 2013;19:8562-8570.
71. Variend S, Placzek M, Raafat F, Walker-Smith JA. Small intestinal mucosal fat in childhood enteropathies. *J Clin Pathol*. 1984;37(4):373-377.
72. Antonioli DA. Celiac disease: a progress report. *Mod Pathol*. 2003;16(4):342-346.
73. Brown I, Mino-Kenudson M, Deshpande V, Lauwers GY. Intraepithelial lymphocytosis in architecturally preserved proximal small intestinal mucosa: an increasing diagnostic problem with a wide differential diagnosis. *Arch Pathol Lab Med*. 2006;130(7):1020-1025.
74. Robert ME. Gluten sensitive enteropathy and other causes of small intestinal lymphocytosis. *Semin Diagn Pathol*. 2005;22(4):284-294.
75. Alsaigh N, Odze R, Goldman H, et al. Gastric and esophageal intraepithelial lymphocytes in pediatric celiac disease. *Am J Surg Pathol*. 1996;20(7):865-870.
76. Bhatti TR, Jatla M, Verma R, et al. Lymphocytic gastritis in pediatric celiac disease. *Pediatr Dev Pathol*. 2011;14:280-283.
77. Lebwohl B, Green PH, Genta RM. The coeliac stomach: gastritis in patients with coeliac disease. *Aliment Pharmacol Ther*. 2015;42:180-187.
78. Matteoni CA, Goldblum JR, Wang N, et al. Celiac disease is highly prevalent in lymphocytic colitis. *J Clin Gastroenterol*. 2001;32:225-227.
79. Najarian RM, Hait EJ, Leichtner AM, et al. Clinical significance of colonic intraepithelial lymphocytosis in a pediatric population. *Mod Pathol*. 2009;22:13-20.
80. Rubio CA, Theorell M, Befrits R, Uribe A. The characteristics of mitotic figures in jejunal mucosa of patients with celiac disease. *Am J Clin Pathol*. 1992;98(6):575-578.
81. Moyana TN, Shukoor S. Gastrointestinal endocrine cell hyperplasia in celiac disease: a selective proliferative process of serotonergic cells. *Mod Pathol*. 1991;4(4):419-423.
82. Trier JS, Browning TH. Epithelial-cell renewal in cultured duodenal biopsies in celiac sprue. *N Engl J Med*. 1970;283(23):1245-1250.
83. Marsh MN. Gluten, major histocompatibility complex, and the small intestine. A molecular and immunobiologic approach to the spectrum of gluten sensitivity ('celiac sprue'). *Gastroenterol*. 1992;102:330-354.
84. Kakar S, Nehra V, Murray JA, et al. Significance of intraepithelial lymphocytosis in small bowel biopsy samples with normal mucosal

architecture. *Am J Gastroenterol*. 2003;98:2027-2033.
85. McManus R, Kelleher D. Celiac disease—the villain unmasked? *N Engl J Med*. 2003;348(25):2573-2574.
86. Shan L, Molberg O, Parrot I, et al. Structural basis for gluten intolerance in celiac sprue. *Science*. 2002;297(5590):2275-2279.
87. Elli L, Branchi F, Tomba C, et al. Diagnosis of gluten-related disorders: celiac disease, wheat allergy and non-celiac gluten sensitivity. *World J Gastroenterol*. 2015;21:7110-7119.
88. Wang N, Truedsson L, Elvin K, et al. Serological assessment for celiac disease in IgA deficient adults. *PLoS ONE*. 2014;9(4):e93180.
89. Weinstein WM, Saunders DR, Tytgat GN, Rubin CE. Collagenous sprue—an unrecognized type of malabsorption. *N Engl J Med*. 1970;283(24):1297-1301.
90. Vakiani E, Arguelles-Grande C, Mansukhani MM, et al. Collagenous sprue is not always associated with dismal outcomes: a clinicopathologic study of 19 patients. *Mod Pathol*. 2010;23:12-26.
91. Ludvigsson JF, Leffler DA, Bai JC, et al. The Oslo definitions for coeliac diseaes and related terms. *Gut*. 2013;62:43-52.
92. Cellier C, Delabesse E, Helmer C, et al. Refractory sprue, coeliac disease, and enteropathy-associated T-cell lymphoma. French Coeliac Disease Study Group. *Lancet*. 2000;356(9225):203-208.
93. Catassi C, Bearzi I, Holmes GKT. Association of celiac disease and intestinal lymphomas and other cancers. *Gastroenterol*. 2005;128(4, suppl 1):S79-S86.
94. Nijeboer P, Malamut G, Mulder CJ, et al. Enteropathy-associated T-cell lymphoma: improving treatment strategies. *Dig Dis*. 2015;33:231-235.
95. Burke JS. Lymphoproliferative disorders of the gastrointestinal tract: a review and pragmatic guide to diagnosis. *Arch Pathol Lab Med*. 2011;135:1283-1297.
96. Ko YH, Karnan S, Kim KM, et al. Enteropathy-associated T-cell lymphoma-a clinicopathologic and array comparative genomic hybridzation study. *Hum Pathol*. 2010;41:1231-1237.
97. Zettl A, deLeeuw R, Haralambieva E, Mueller-Hermlink HK. Enteropathy-type T-cell lymphoma. *Am J Clin Pathol*. 2007;127:701-706.
98. O'Malley DP, Goldstein NS, Banks PM. The recognition and classification of lymphoproliferative disorders of the gut. *Hum Pathol*. 2014;45:899-916.
99. de Bruin PC, Connolly CE, Oudejans JJ, et al. Enteropathy-associated T-cell lymphomas have a cytotoxic T-cell phenotype. *Histopathology*. 1997;31(4):313-317.
100. Chan JKC, Chan ACL, Cheuk W, et al. Type II enteropathy-associated T-cell lymphoma: a distinct aggressive lymphoma with frequent γδ T-cell receptor expression. *Am J Surg Pathol*. 2011;35:1557-1569.
101. Isaacson PGCA, Ott G, Stein H. Enteropathy-associated T-cell lymphoma. In: Swerdlow SH, Campo E, Harris NL, et al, eds. *WHO Classification of Tumours of Haematopoietic and Lymphoid Tissues*. 4th ed. Lyon: IARC; 2008:289-291.
102. Ashton-Key M, Diss TC, Pan L, et al. Molecular analysis of T-cell clonality in ulcerative jejunitis and enteropathy-associated T-cell lymphoma. *Am J Pathol*. 1997;151(2):493-498.
103. Bagdi E, Diss TC, Munson P, Isaacson PG. Mucosal intra-epithelial lymphocytes in enteropathy-associated T-cell lymphoma, ulcerative jejunitis, and refractory celiac disease constitute a neoplastic population. *Blood*. 1999;94(1):260-264.
104. Deleeuw RJ, Zettl A, Klinker E, et al. Whole-genome analysis and HLA genotyping of enteropathy-type T-cell lymphoma reveals 2 distinct lymphoma subtypes. *Gastroenterol*. 2007;132(5):1902-1911.
105. Zettl A, Ott G, Makulik A, et al. Chromosomal gains at 9q characterize enteropathy-type T-cell lymphoma. *Am J Pathol*. 2002;161(5):1635-1645.
106. Pan L, Diss TC, Peng H, et al. Epstein-Barr virus (EBV) in enteropathy-associated T-cell lymphoma (EATL). *J Pathol*. 1993;170(2):137-143.
107. Walsh SV, Egan LJ, Connolly CE, et al. Enteropathy-associated T-cell lymphoma in the West of Ireland: low-frequency of Epstein-Barr virus in these tumors. *Mod Pathol*. 1995;8(7):753-757.
108. Ho-Yen C, Chang F, van der Walt J, et al. Recent advances in refractory coeliac disease: a review. *Histopathol*. 2009;54(7):783-795.
109. Holmes GK, Dunn GI, Cockel R, Brookes VS. Adenocarcinoma of the small bowel complicating coeliac disease. *Gut*. 1980;21:1010-1015.
110. Han Y, Chen W, Li P, Ye J. Association between coeliac disease and risk of any malignancy and gastrointestinal malignancy: a meta-analysis. *Medicine (Baltimore)*. 2015;94:e1612.
111. Glynn J. Tropical sprue-its aetiology and pathogenesis. *J R Soc Med*. 1986;79:599-606.
112. Ramakrishna BS, Venkataraman S, Mukhopadhya A. Tropical malabsorption. *Postgrad Med J*. 2006;82:779-787.
113. Guerra R, Wheby MS, Bayless TM. Long-term antibiotic therapy in tropical sprue. *Ann Int Med*. 1965;63(4):619-634.
114. Afshar P, Redfield DC, Higginbottom PA. Whipple's disease: a rare disease revisited. *Curr Gastroenterol Rep*. 2010;12:263-269.
115. Marth T, Raoult D. Whipple's disease. *Lancet*. 2003;361(9353):239-246.
116. Babaryka I, Thorn L, Langer E. Epithelioid cell granulomata in the mucosa of the small intestine in Whipple's disease. *Virchows Arch A Pathol Anat Histol*. 1979;382:227-235.
117. Kuhajda FP, Belitsos NJ, Keren DF, Hutchins GM. A submucosal variant of Whipple's disease. *Gastroenterology*. 1982;82(1):46-50.
118. Relman DA, Schmidt TM, MAcDermott RP, Falkow S. Identification of the uncultured bacillus of Whipple's disease. *N Engl J Med*. 1992;327:293-301.
119. Dobbins WO 3rd. The diagnosis of Whipple's disease. *N Engl J Med*. 1995;332(6):390-392.
120. Baisden BL, Lepidi H, Raoult D, et al. Diagnosis of Wihipple disease by immunohistochemical analysis: a sensitive and specific method for the detection of Tropheryma whipplei (the Whipple bacillus) in paraffin-embedded tissue. *Am J Clin Pathol*. 2002;118(5):742-748.
121. Lepidi H, Fenollar F, Gerolami R, et al. Whipple's disease: immunospecific and quantitative immunohistochemical study of intestinal biopsy specimens. *Human Pathol*. 2003;34(6):589-596.
122. Raoult D, Birg ML, La Scola B, et al. Cultivation of the bacillus of Whipple's disease. *N Engl J Med*. 2000;342(9):620-625.
123. Dutly F, Altwegg M. Whipple's disease and "*Tropheryma whippelii*.". *Clin Microbiol Rev*. 2001;14:561-583.
124. Enzinger FM, Helwig EB. Whipple's disease. A review of the literature and report of fifteen patients. *Virchows Arch A Pathol Anat Histol*. 1963;336:238-269.
125. Gerard A, Sarrot-Reynauld F, Liozon E, et al. Neurologic presentation of Whipple disease: report of 12 cases and review of the literature. *Medicine (Baltimore)*. 2002;81(6):443-457.
126. Saleh H, Williams TM, Minda JM, Gupta PK. Whipple's disease involving the mesenteric lymph nodes diagnosed by fine-needle aspiration. *Diag Cytopathol*. 1992;8(2):177-180.
127. Boitnott JK, Margolis S. Mineral oil in human tissues. Part II. Oil droplets in lymph nodes of the porta hepatis. *Bull Hopkins Hosp*. 1966;118:414-422.
128. Gillen CD, Coddington R, Monteith PG, Taylor RH. Extraintestinal lymphoma in association with Whipple's disease. *Gut*. 1993;34(11):1627-1629.
129. Maliha GM, Hepps KS, Maia DM, et al. Whipple's disease can mimic chronic AIDS enteropathy. *Am J Gastroenterol*. 1991;86(1):79-81.
130. Hamrock D, Azmi F, O'Donnell E, et al. Infection by *Rhodococcus equi* in a patient with AIDS: histological appearance mimicking Whipple's disease and *MAI* infection. *J Clin Pathol*. 1999;52:68-71.
131. Ekuan JH, Hill RB Jr. Colonic histiocytosis: clinical and pathological evaluation. *Gastroenterology*. 1968;55(5):619-625.
132. Isselbacher KJ, Scheig R, Plotkin GR, Caulfield JB. Congenital beta-lipoprotein deficiency: an hereditary disorder involving a defect in the absorption and transport of lipids. *Medicine (Baltimore)*. 1964;43:347-361.
133. Strober W, Wochner RD, Carbone PP, Waldmann TA. Intestinal lymphangiectasia: a protein-losing enteropathy with hypogammaglobulinemia, lymphocytopenia and impaired homograft rejection. *J Clin Invest*. 1967;46:1643-1656.
134. Levinson JD, Kirsner JB. Infiltrative diseases of the small bowel and malabsorption. *Am J Dig Dis*. 1970;15(8):741-766.
135. Rosekrans PC, Lindeman J, Meijer CJ. Quantitative histological and immunohistochemical findings in jejunal biopsy specimens in giardiasis. *Virchows Arch A Pathol Anat Histol*. 1981;393(2):145-151.
136. Yardleyjhtakano J, Hendrix TR. Epithelial and other mucosal lesions of the jejunum in giardiasis. jejunal biopsy studies. *Bull Johns Hopkins Hospital*. 1964;115:389-406.
137. Sheehy TW, Meroney WH, Cox RS Jr, Soler JE. Hookworm disease and malabsorption. *Gastroenterology*. 1962;42:148-156.
138. Toh CC, Chow KW. Malabsorption syndrome in a patient infected with Strongyloides stercoralis. *Ann Trop Med Parasitol*. 1969;63:493-497.
139. Whalen GE, Rosenberg EB, Strickland GT, et al. Intestinal capillariasis. A new disease in man. *Lancet*. 1969;1(7584):13-16.
140. Graham DY. History of *Helicobacter pylori*, duodenal ulcer, gastric ulcer and gastric cancer. *World J Gastroenterol*. 2014;20:5191-5204.
141. Tovey FI, Hobsley M. Is *Helicobacter pylori* the primary cause of duodenal ulceration? *J Gastroenterol Hepatol*. 1999;14: 1053-1056.
142. Quan C, Talley NJ. Management of peptic ulcer disease not related to *Helicobacter pylori* or NSAIDs. *Am J Gastroenterol*. 2002;97(12):2950-2961.
143. Pugh S, Jayaraj AP, Bardhan KD. Duodenal mucosal histology and histochemistry in active, treated and healed duodenal ulcer: correlation with mucosal prostaglandin E2 production. *J Gastroenterol Hepatol*. 1996;11:120-124.
144. Pounder RE. Duodenal ulcers that will not heal. *Gut*. 1984;25(7):697-702.
145. Rigopoulos A, Ramboiu S, Georgescu I. A critical evaluation of surgical treatment of perforated ulcer. *Curr Health Sci J*. 2011;37:75-78.
146. Agaba EA, Klair T, Ikedilo O, Vemulapalli P. A 10-year review of surgical management of complicated peptic ulcer disease from a single center: is laparoscopic approach the future?

Surg Laparosc Endosc Percutan Tech. 2016;26:385-390.
147. Gisbert JP, Calvet X. Review article: *Helicobacter pylori*-negative duodenal ulcer disease. *Aliment Pharmacol Ther*. 2009;30:791-815.
148. Allen AC, Boley SJ, Schultz L, Schwartz S. Potassium-induced lesions of the small bowel. *JAMA*. 1965;193:85-90.
149. Gomez-Rubio M, Opio V, Acin F, et al. Chronic mesenteric ischemia: a cause of refractory duodenal ulcer. *Am J Med*. 1995;98:308-310.
150. McColl KE. *Helicobacter pylori*-negative nonsteroidal anti-inflammatory drug-negative ulcer. *Gastroenterol Clin North Am*. 2009;38:353-361.
151. Umeno J, Hisamatsu T, Esaki M, et al. A hereditary enteropathy caused by mutations in the SLCO2A1 gene, encoding a prostaglandin transporter. *PLoS Genet*. 2015;11(11):e1005581.
152. Canavese G, Villanacci V, Zambelli C, et al. Gastric metaplasia and small bowel ulcerogenesis in a case of ulcerative jejunitis not related to celiac disease. *Int J Surg Pathol*. 2004;12:415-419.
153. Taha AS, Dahill S, Nakshabendi I, et al. Duodenal histology, ulceration, and *Helicobacter pylori* in the presence or absence of non-steroidal anti-inflammatory drugs. *Gut*. 1993;34:1162-1166.
154. Wyatt JI. Histopathology of gastroduodenal inflammation: the impact of *Helicobacter pylori*. *Histopathol*. 1995;26(1):1-15.
155. Shousha S, Spiller RC, Parkins RA. The endoscopically abnormal duodenum in patients with dyspepsia: biopsy findings in 60 cases. *Histopathology*. 1983;7(1):23-34.
156. Jenkins D, Goodall A, Gillet FR, Scott BB. Defining duodenitis: quantitative histological study of mucosal responses and their correlations. *J Clin Pathol*. 1985;38(10):1119-1126.
157. Chang F, Mahadeva U, Deere H. Pathological and clinical significance of increased intraepithelial lymphocytes (IELs) in small bowel mucosa. *APMIS*. 2005;113:385-399.
158. Feurle GE, Haag B. Acute small bowel ischemia without transmural infarction. *Z Gastroenterology*. 1991;29(7):349-352.
159. Whitehead R. The pathology of ischemia of the intestines. *Pathol Ann*. 1976;11:1-52.
160. Williams LF Jr. Vascular insufficiency of the intestines. *Gastroenterology*. 1971;61(5):757-777.
161. Biedrzycki OJ, Arnaout A, Coppen MJ, Shepherd NA. Isolated intramucosal goblet cells in subacute ischaemic enteritis: mimicry of signet ring cell carcinoma. *Histopathology*. 2005;46(4):460-462.
162. McCurley TL, Collins RD. Intestinal infarction in rheumatoid arthritis. Three cases due to unusual obliterative vascular lesions. *Arch Pathol Lab Med*. 1984;108(2):125-128.
163. Burke AP, Sobin LH, Virmani R. Localized vasculitis of the gastrointestinal tract. *Am J Surg Pathol*. 1995;19(3):338-349.
164. Phelan MJ, Kok K, Burrow C, Thompson RN. Small bowel infarction in association with giant cell arteritis. *Brit J Rheumatol*. 1993;32(1):63-65.
165. Kempczinski RF, Clark SM, Blebea J, et al. Intestinal ischemia secondary to thromboangiitis obliterans. *Ann Vasc Surg*. 1993;7(4):354-358.
166. Ahn E, Luk A, Chetty R, Butany J. Vasculitides of the gastrointestinal tract. *Semin Diagn Pathol*. 2009;26(2):77-88.
167. Ottinger LW. Mesenteric ischemia. *N Engl J Med*. 1982;307(9):535-537.
168. Endress C, Gray DG, Wollschlaeger G. Bowel ischemia and perforation after cocaine use. *Am J Roentgenol*. 1992;159(1):73-75.
169. Oweity T, West AB, Stokes MB. Necrotizing angiitis of the small intestine related to AA-amyloidosis: a novel association. *Int J Surg Pathol*. 2001;9(2):149-154.
170. Shintaku M, Inoue N, Sasaki M, et al. Cytomegalovirus vasculitis accompanied by an exuberant fibroblastic reaction in the intestine of an AIDS patient. *Acta Pathol Jpn*. 1991;41(12):900-904.
171. Cohen R, Heffner JE. Bowel infarction as the initial manifestation of disseminated aspergillosis. *Chest*. 1992;101(3):877-879.
172. Flaherty MJ, Lie JT, Haggitt RC. Mesenteric inflammatory veno-occlusive disease. A seldom recognized cause of intestinal ischemia. *Am J Surg Pathol*. 1994;18(8):779-784.
173. Medlicott SA, Guggisberg KA, DesCoteaux JG, Beck P. Enterocolic lymphocytic phlebitis: statistical analysis of histology features in viable and ischemic bowel. *Int J Surg Pathol*. 2006;14(3):200-205.
174. Ngo N, Chang F. Enterocolic lymphocytic phlebitis: clinicopathologic features and review of the literature. *Arch Pathol Lab Med*. 2007;131:1130-1134.
175. Saraga E, Bouzourenne H. Enterocolic (lymphocytic) phlebitis: a rare cause of intestinal ischemic necrosis: a series of six patients and review of the literature. *Am J Surg Pathol*. 2000;24(6):824-829.
176. Patil DT, Kissiedu J, Rodriguez ER, et al. Mesenteric arteriovenous dysplasia/vasculopathy is distinct from fibromuscular dysplasia. *Am J Surg Pathol*. 2016;40:1316-1325.
177. Gilbert AE, Jorgenson NC. Small bowel obstruction due to hemorrhage secondary to anticoagulant therapy. *Am J Surg*. 1960;99:945-948.
178. Levine S, Whelan TJ Jr. Small-bowel infarction due to intramural hematoma during anticoagulant therapy. *Arch Surg*. 1967;95(2):245-248.
179. Lamps LW, Hunt CM, Green A, et al. Alternations in colonic mucosal vessels in patients with cirrhosis and noncirrhotic portal hypertension. *Hum Pathol*. 1998;29:527-535.
180. Mekaroonkamol P, Cohen R, Chawla S. Portal hypertensive enteropathy. *World J Hepatol*. 2015;7:127-138.
181. Dulic-Lakovic E, Dulic M, Hubner D, et al. Bleeding Dieulafoy lesions of the small bowel: a systematic study on the epidemiology and efficacy of enteroscopic treatment. *Gastrointest Endosc*. 2011;74:573-580.
182. Michelassi F, Balestracci T, Chappell R, Block GE. Primary and recurrent Crohn's disease. Experience with 1379 patients. *Ann Surg*. 1991;214(3):230-238, discussion 238-240.
183. Freeman HJ. Natural history and long-term clinical course of Crohn's disease. *World J Gastroenterol*. 2014;20:31-36.
184. Shanahan F. Crohn's disease. *Lancet*. 2002;359:62-69.
185. Monsen U, Bernell O, Johansson C, Hellers G. Prevalence of inflammatory bowel disease among relatives of patients with Crohn's disease. *Scand J Gastroenterol*. 1991;26(3):302-306.
186. Ponder A, Long MD. A clinical review of recent findings in the epidemiology of inflammatory bowel disease. *Clin Epidemiol*. 2013;5:237-247.
187. Cartun RW, Van Kruiningen HJ, Pedersen CA, Berman MM. An immunocytochemical search for infectious agents in Crohn's disease. *Mod Pathol*. 1993;6(2):212-219.
188. Frank TS, Cook SM. Analysis of paraffin sections of Crohn's disease for Mycobacterium paratuberculosis using polymerase chain reaction. *Mod Pathol*. 1996;9(1):32-35.
189. Lamps LW, Madhusudhan KT, Havens JM, et al. Pathogenic Yersinia DNA is detected in bowel and mesenteric lymph nodes from patients with Crohn's disease. *Am J Surg Pathol*. 2003;27(2):220-227.
190. Mishina D, Katsel P, Brown ST, et al. On the etiology of Crohn disease. *Proc Natl Acad Sci USA*. 1996;93(18):9816-9820.
191. Stainsby KJ, Lowes JR, Allan RN, Ibbotson JP. Antibodies to Mycobacterium paratuberculosis and nine species of environmental mycobacteria in Crohn's disease and control subjects. *Gut*. 1993;34(3):371-374.
192. Wakefield AJ, Pittilo RM, Sim R, et al. Evidence of persistent measles virus infection in Crohn's disease. *J Med Virol*. 1993;39(4):345-353.
193. Sartor RB. Microbial influences in inflammatory bowel diseases. *Gastroenterol*. 2008;134:577-594.
194. Abraham C, Cho JH. Inflammatory bowel disease. *N Engl J Med*. 2009;361(21):2066-2078.
195. Xavier RJ, Podolsky DK. Unravelling the pathogenesis of inflammatory bowel disease. *Nature*. 2007;448(7152):427-434.
196. Fielding JF, Toye DK, Beton DC, Cooke WT. Crohn's disease of the stomach and duodenum. *Gut*. 1970;11(12):1001-1006.
197. Morson BC. Some peculiarities in the histology of intestinal polyps. *Dis Col Rectum*. 1962;5:337-344.
198. Oberhuber G, Hirsch M, Stolte M. High incidence of upper gastrointestinal tract involvement in Crohn's disease. *Virchows Arch*. 1998;432(1):49-52.
199. Plauth M, Jenss H, Meyle J. Oral manifestations of Crohn's disease. An analysis of 79 cases. *J Clin Gastroenterol*. 1991;13(1):29-37.
200. Schnitt SJ, Antonioli DA, Jaffe B, Peppercorn MA. Granulomatous inflammation of minor salivary gland ducts: a new oral manifestation of Crohn's disease. *Hum Pathol*. 1987;18(4):405-407.
201. Wright CL, Riddell RH. Histology of the stomach and duodenum in Crohn's disease. *Am J Surg Pathol*. 1998;22(4):383-390.
202. Triantafillidis JK, Emmanouilidis A, Manousos O, et al. Clinical patterns of Crohn's disease in Greece: a follow-up study of 155 cases. *Digestion*. 2000;61:121-128.
203. Sutphen JL, Cooper PH, Mackel SE, Nelson DL. Metastatic cutaneous Crohn's disease. *Gastroenterology*. 1984;86(5 Pt 1):941-944.
204. Devroede G, Schlaeder G, Sanchez G, Haddad H. Crohn's disease of the vulva. *Am J Clin Pathol*. 1975;63(3):348-358.
205. Nugent FW, Glaser D, Fernandez-Herlihy L. Crohn's colitis associated with granulomatous bone disease. *N Engl J Med*. 1976;294(5):262-263.
206. Menard DB, Haddad H, Blain JG, et al. Granulomatous myositis and myopathy associated with Crohn's colitis. *N Engl J Med*. 1976;295(15):818-819.
207. Rankin GB, Watts HD, Melnyk CS, Kelley ML Jr. National Cooperative Crohn's Disease Study: extraintestinal manifestations and perianal complications. *Gastroenterology*. 1979;77(4 Pt 2):914-920.
208. Attanoos RL, Appleton MA, Hughes LE, et al. Granulomatous hidradenitis suppurativa and cutaneous Crohn's disease. *Histopathol*. 1993;23(2):111-115.
209. Greenstein AJ, Janowitz HD, Sachar DB. The extra-intestinal complications of Crohn's disease and ulcerative colitis: a study of 700 patients. *Medicine (Baltimore)*. 1976;55(5):401-412.
210. Salmon JF, Wright JP, Murray AD. Ocular inflammation in Crohn's disease. *Ophthalmol*. 1991;98(4):480-484.
211. Kleer CG, Appelman HD. Surgical pathology of Crohn's disease. *Surg Clin North Am*. 2001;81:13-30, vii.

212. Kahn E, Daum F. Pseudopolyps of the small intestine in Crohn's disease. *Hum Pathol*. 1984;15(1):84-86.
213. Zalev AH, Gardiner GW. Crohn's disease of the small intestine with polypoid configuration. *Gastrointest Radiol*. 1991;16(1):18-20.
214. Heaton KW, McCarthy CF, Horton RE, et al. Miliary Crohn's disease. *Gut*. 1967;8:4-7.
215. Sokol H, Seksik P, Cosnes J. Complications and surgery in the inflammatory bowel diseases biological era. *Curr Opin Gastroenterol*. 2014;30:378-384.
216. Tonelli F, Ficari F. Pathological features of Crohn's disease determining perforation. *J Clin Gastroenterol*. 1991;13(2):226-230.
217. Thyberg J, Graf W, Klingenstrom P. Intestinal fine structure in Crohn's disease. Lysosomal inclusions in epithelial cells and macrophages. *Virchows Arch A Pathol Anat Histol*. 1981;391(2):141-152.
218. Bischoff SC. Mast cells in gastrointestinal disorders. *Eur J Pharmacol*. 2016;778:139-145.
219. Koukoulis GK, Ke Y, Henley JD, Cummings OW. Detection of pyloric metaplasia may improve the biopsy diagnosis of Crohn's ileitis. *J Clin Gastroenterol*. 2002;34:141-143.
220. Lee EY, Stenson WF, DeSchryver-Kecskemeti K. Thickening of muscularis mucosae in Crohn's disease. *Mod Pathol*. 1991;4(1):87-90.
221. Pedica F, Ligorio C, Tonelli P, et al. Lymphangiogenesis in Crohn's disease: an immunohistochemical study using monoclonal antibody D2-40. *Virchows Arch*. 2008;452(1):57-63.
222. Geller SA, Cohen A. Arterial inflammatory-cell infiltration in Crohn's disease. *Arch Pathol Lab Med*. 1983;107(9):473-475.
223. Koukoulis G, Ke Y, Henley JD, Cummings OW. Obliterative muscularization of the small bowel submucosa in Crohn disease: a possible mechanism of small bowel obstruction. *Arch Pathol Lab Med*. 2001;125(10):1331-1334.
224. Geboes K, El-Zine MY, Dalle I, et al. Tenascin and strictures in inflammatory bowel disease: an immunohistochemical study. *Int J Surg Pathol*. 2001;9(4):281-286.
225. Saul SH, Wong LK, Zinsser KR. Enteritis cystica profunda: association with Crohn's disease. *Hum Pathol*. 1986;17(6):600-603.
226. Shepherd NA. Granulomas in the diagnosis of intestinal Crohn's disease: a myth exploded? *Histopathol*. 2002;41(2):166-168.
227. Matson AP, Van Kruiningen HJ, West AB, et al. The relationship of granulomas to blood vessels in intestinal Crohn's disease. *Mod Pathol*. 1995;8(6):680-685.
228. Collier PE, Turowski P, Diamond DL. Small intestinal adenocarcinoma complicating regional enteritis. *Cancer*. 1985;55(3): 516-521.
229. Solem CA, Harmsen WS, Zzinsmeister AR, Loftus EV Jr. Small intestinal adenocarcinoma in Crohn's disease: a case-control study. *Inflamm Bowel Dis*. 2004;10:32-35.
230. Thompson EM, Clayden G, Price AB. Cancer in Crohn's disease—an "occult" malignancy. *Histopathology*. 1983;7(3):365-376.
231. Sigel JE, Petras RE, Lashner BA, et al. Intestinal adenocarcinoma in Crohn's disease: a report of 30 cases with a focus on co-existing dysplasia. *Am J Surg Pathol*. 1999;23:651-655.
232. Fresko D, Lazarus SS, Dotan J, Reingold M. Early presentation of carcinoma of the small bowel in Crohn's disease ("Crohn's carcinoma"). Case reports and review of the literature. *Gastroenterology*. 1982;82(4):783-789.
233. Hock YL, Scott KW, Grace RH. Mixed adenocarcinoma/carcinoid tumour of large bowel in a patient with Crohn's disease. *J Clin Pathol*. 1993;46(2):183-185.
234. Kortbeek J, Kelly JK, Preshaw RM. Carcinoid tumors and inflammatory bowel disease. *J Surg Oncol*. 1992;49(2):122-126.
235. Afif W, Sandborn WJ, Faubion WA, et al. Risk factors for lymphoma in patients with inflammatory bowel disease: a case-control study. *Inflamm Bowel Dis*. 2013;19:1384-1389.
236. Deepak P, Bruining DH. Update on the medical management of Crohn's disease. *Curr Gastroenterol Rep*. 2015;17(11):41.
237. Buchner AM, Blonski W, Lichtenstein GR. Update on the management of Crohn's disease. *Curr Gastroenterol Rep*. 2011;13:465-474.
238. Day AS, Whitten KE, Sidler M, Lemberg DA. Systematic review: nutritional therapy in paediatric Crohn's disease. *Aliment Pharmacol Ther*. 2008;27:293-307.
239. Schlussel AT, Steele SR, Alavi K. Current challenges in the surgical management of Crohn's disease: a systematic review. *Am J Surg*. 2016;212:345-351.
240. Lock MR, Farmer RG, Fazio VW, et al. Recurrence and reoperation for Crohn's disease: the role of disease location in prognosis. *N Engl J Med*. 1981;304(26):1586-1588.
241. Whelan G, Farmer RG, Fazio VW, Goormastic M. Recurrence after surgery in Crohn's disease. Relationship to location of disease (clinical pattern) and surgical indication. *Gastroenterol*. 1985;88(6):1826-1833.
242. Yamamoto T. Factors affecting recurrence after surgery for Crohn's disease. *World J Gastroenterol*. 2005;11:3971-3979.
243. Gump FE, Sakellariadis P, Wolff M, Broell JR. Clinical-pathological investigation of regional enteritis as a guide to prognosis. *Ann Surg*. 1972;176(2):233-242.
244. Glass RE, Baker WN. Role of the granuloma in recurrent Crohn's disease. *Gut*. 1976;17(1):75-77.
245. Simillis C, Jacovides M, Reese GE, et al. Meta-analysis of the role of granulomas in the recurrence of Crohn disease. *Dis Colon Rectum*. 2010;53:177-185.
246. Fazio VW, Marchetti F, Church M, et al. Effect of resection margins on the recurrence of Crohn's disease in the small bowel. A randomized controlled trial. *Ann Surg*. 1996;224:563-571.
247. Valdez R, Appelman HD, Bronner MP, Greenson JK. Diffuse duodenitis associated with ulcerative colitis. *Am J Surg Pathol*. 2000;24(10):1407-1413.
248. Haskell H, Andrews CW Jr, Reddy SI, et al. Pathologic features and clinical significance of "backwash" ileitis in ulcerative colitis. *Am J Surg Pathol*. 2005;29(11):1472-1481.
249. Yantiss RK, Sapp HL, Farraye FA, et al. Histologic predictors of pouchitis in patients with chronic ulcerative colitis. *Am J Surg Pathol*. 2004;28:999-1006.
250. Mahadevan U, Sandborn WJ. Diagnosis and management of pouchitis. *Gastroenterol*. 2003;124:1636-1650.
251. Agarwal S, Stucchi AF, Dendrinos K, et al. Is pyloric gland metaplasia in ileal pouch biopsies a marker for Crohn's disease? *Dig Dis Sci*. 2013;58:2918-2925.
252. Zezos P, Saibil F. Inflammatory pouch disease: the spectrum of pouchitis. *World J Gastroenterol*. 2015;21:8739-8752.
253. Padmanabhan V, Callas PW, Li SC, Trainer TD. Histopathological features of the terminal ileum in lymphocytic and collagenous colitis: a study of 32 cases and review of literature. *Mod Pathol*. 2003;16(2):115-119.
254. Sapp H, Ithamukkala S, Brien TP, et al. The terminal ileum is affected in patients with lymphocytic or collagenous colitis. *Am J Surg Pathol*. 2002;26(11):1484-1492.
255. Lamps LW. Infective disorders of the gastrointestinal tract. *Histopathology*. 2007;50(1):55-63.
256. Rotterdam H, Tsang P. Gastrointestinal disease in the immunocompromised patient. *Human Pathol*. 1994;25(11):1123-1140.
257. Lai KK, Lamps LW. Enterocolitis in the immunocompromised patient. *Semin Diagn Pathol*. 2014;31:176-191.
258. Cranston RD, Anton PA, McGowan IM. Gastrointestinal mucosal biopsy in HIV disease and AIDS. *Gastrointest Endosc Clin N Am*. 2000;10(4):637-667, vi.
259. Wilcox CM, Schwartz DA. Symptomatic CMV duodenitis. An important clinical problem in AIDS. *J Clin Gastroenterol*. 1992;14(4):293-297.
260. Chetty R, Roskell DE. Cytomegalovirus infection in the gastrointestinal tract. *J Clin Pathol*. 1994;47:968-972.
261. Muldoon J, O'Riordan K, Rao S, Abecassis M. Ischemic colitis secondary to venous thrombosis. A rare presentation of cytomegalovirus vasculitis following renal transplantation. *Transplantation*. 1996;61:1651-1653.
262. Greenson JK, Belitsos PC, Yardley JH, Bartlett JG. AIDS enteropathy: occult enteric infections and duodenal mucosal alterations in chronic diarrhea. *Annals Int Med*. 1991;114(5):366-372.
263. Bartlett JG, Belitsos PC, Sears CL. AIDS enteropathy. *Clin Infect Dis*. 1992;15: 726-735.
264. Cello JP, Day LW. Idiopathic AIDS enteropathy and treatment of gastrointestinal opportunistic pathogens. *Gastroenterol*. 2009;136:1952-1965.
265. Ahmed FB. Tuberculous enteritis. *BMJ*. 1996;313(7051):215-217.
266. Marshall JB. Tuberculosis of the gastrointestinal tract and peritoneum. *Am J Gastroenterology*. 1993;88(7):989-999.
267. Schulze K, Warner HA, Murray D. Intestinal tuberculosis: experience at a Canadian teaching institution. *Am J Med*. 1977;63(5):735-745.
268. Pulimood AB, Amarapurkar DN, Ghoshal U, et al. Differentiation of Crohn's disease from intestinal tuberculosis in India in 2010. *World J Gastroenterol*. 2011;17:433-443.
269. Tandon HD, Prakash A. Pathology of intestinal tuberculosis and its distinction from Crohn's disease. *Gut*. 1972;13(4):260-269.
270. Gillin JS, Urmacher C, West R, Shike M. Disseminated Mycobacterium avium-intracellulare infection in acquired immunodeficiency syndrome mimicking Whipple's disease. *Gastroenterology*. 1983;85(5):1187-1191.
271. Roth RI, Owen RL, Keren DF, Volberding PA. Intestinal infection with *Mycobacterium avium-intracellulare* in acquried immune deficiency syndrome (AIDS): histological and clinical comparison with Whipple disease. *Dig Dis Sci*. 1985;51:497-504.
272. Gleason TH, Patterson SD. The pathology of Yersinia enterocolitica ileocolitis. *Am J Surg Pathol*. 1982;6:347-355.
273. El-Maraghi NRH, Mair N. The histopathology of enteric infection with Yersinia pseudotuberculosis. *Am J Clin Pathol*. 1979;71:631-639.
274. Bradford WD, Noce PS, Gutman LT. Pathologic features of enteric infection with Yersinia enterocolitica. *Arch Pathol*. 1974;98(1):17-22.
275. Lamps LW, Madhusudhan KT, Greenson JK, et al. The role of Y. enterocolitica and Y. pseudotuberculosis in granulomatous appendicitis: a histologic and molecular study. *Am J Surg Pathol*. 2001;25:508-515.
276. Lamps LW. Update on infectious enterocolitidies and the diseases that they mimic. *Histopathology*. 2015;66:3-14.
277. Orenstein JM, Kotler DP. Diarrheogenic bacterial enteritis in acquired immune deficiency syndrome: a light and electron microscopy study of 52 cases. *Hum Pathol*. 1995;26(5):481-492.
278. Hii JH, Guccion JG, Gilbert CL. Enteroadherent eaeA-positive Escherichia coli

associated with chronic AIDS-related diarrhea. *Ann Intern Med*. 1996;125:523.
279. Goodgame R. Understanding intestinal spore-forming protozoa: Cryptosporidia, Microsporidia, Isospora, and Cyclospora. *Ann Intern Med*. 1996;124:429-441.
280. Lefkowitch JH, Krumholz S, Feng-Chen KC, et al. Cryptosporidiosis of the human small intestine: a light and electron microscopic study. *Human Pathol*. 1984;15(8):746-752.
281. Guarda LA, Stein SA, Cleary KA, Ordonez NG. Human cryptosporidiosis in the acquired immune deficiency syndrome. *Arch Pathol Lab Med*. 1983;107(11):562-566.
282. Genta RM, Chappell CL, White AC Jr, et al. Duodenal morphology and intensity of infection in AIDS-related intestinal cryptosporidiosis. *Gastroenterology*. 1993;105(6):1769-1775.
283. Xiang H, Zhang R, De Koeyer D, et al. New evidence on the relationship between Microsporidia and Fungi: a genome-wide analysis by DarkHorse software. *Can J Microbiol*. 2014;60:557-568.
284. Shadduck JA, Orenstein JM. Comparative pathology of microsporidiosis. *Arch Pathol Lab Med*. 1993;117(12):1215-1219.
285. Lamps LW, Bronner MP, Vnencak-Jones CL, et al. Optimal screening and diagnosis of microsporida in tissue sections: a comparison of polarization, special stains, and molecular techniques. *Am J Clin Pathol*. 1998;109:404-410.
286. Peacock CS, Blanshard C, Tovey DG, et al. Histological diagnosis of intestinal microsporidiosis in patients with AIDS. *J Clin Pathol*. 1991;44(7):558-563.
287. Orenstein JM, Dieterich DT, Kotler DP. Systemic dissemination by a newly recognized intestinal microsporidia species in AIDS. *AIDS*. 1992;6(10):1143-1150.
288. Connor BA, Reidy J, Soave R. Cyclosporiasis: clinical and histopathologic correlates. *Clin Infect Dis*. 1999;28:1216-1221.
289. Legua P, Seas C. Cystoisospora and cyclospora. *Curr Opin Infect Dis*. 2013;26:479-483.
290. Sullivan PB, Marsh MN, Phillips MB, et al. Prevalence and treatment of giardiasis in chronic diarrhoea and malnutrition. *Arch Dis Child*. 1991;66(3):304-306.
291. Oberhuber G, Kastner N, Stolte M. Giardiasis: a histologic analysis of 567 cases. *Scand J Gastroenterol*. 1997;32:48-51.
292. Milder JE, Walzer PD, Kilgore GK, et al. Clinical features of Strongyloides stercoralis infection in an endemic area of the United States. *Gastroenterol*. 1981;80:1481-1488.
293. Concha R, Harrington W, Rogers AI. Intestinal strongyloidiasis: recognition, management, and determinants of outcome. *J Clin Gastroenterol*. 2005;39:203-211.
294. Lai KK, Milner DA, Lamps LW. Fungal infections of the gastrointestinal tract in the immunocompromised host-an update. *Adv Anat Pathol*. 2014;21:217-227.
295. Maes BD, Dalle I, Geboes K, et al. Erosive enterocolitis in mycophenolate mofetil-treated renal-transplant recipients with persistent afebrile diarrhea. *Transplantation*. 2003;75:665-672.
296. Ducloux D, Ottignon Y, Semhoun-Ducloux S, et al. Mycophenolate mofetil-induced villous atrophy. *Transplantation*. 1998;66:1115-1116.
297. Berribi C, Loirat C, Jazqz-Aigrain E. Mycophenolate mofetil may induce apoptotis in duodenal villi. *Pediatr Nephrol*. 2000;14:177-178.
298. Nguyen T, Park JY, Scudiere JR, Montgomery E. Mycophenolic acid (cellcept and myofortic) induced injury of the upper GI tract. *Am J Surg Pathol*. 2009;33(9):1355-1363.
299. Lubitz L, Ekert H. Reversible changes in duodenal mucosa associated with intense chemotherapy followed by autologous marrow rescue. *Lancet*. 1979;8:532-533.
300. Slavin RE, Dias MA, Saral R. Cytosine arabinoside induced gastrointestinal toxic alterations in sequential chemotherapeutic protocols: a clinical-pathologic study of 33 patients. *Cancer*. 1978;42:1747-1759.
301. Soldini D, Gaspert A, Montani M, et al. Apoptotic enteropathy caused by antimetabolites and TNF-alpha antagonists. *J Clin Pathol*. 2014;67(7):582-586.
302. Lee FD. Importance of apoptosis in the histopathology of drug related lesions in the large intestine. *J Clin Pathol*. 1993;46(2):118-122.
303. Parfitt JR, Driman DK. Pathological effects of drugs on the gastrointestinal tract: a review. *Hum Pathol*. 2007;38:527-536.
304. Misdraji J. Drug-induced pathology of the upper gastrointestinal tract. *Diagn Histopathol*. 2008;14:411-418.
305. Burbure N, Lebwohl B, Arguelles-Grande C, et al. Olmesartan-associated sprue-like enteropathy: a systematic review with emphasis on histopathology. *Hum Pathol*. 2016;50:127-134.
306. Messmer M, Upreti S, Tarabishy Y, et al. Ipilimumab-induced enteritis without colitis: a new challenge. *Case Rep Oncol*. 2016;9:705-713.
307. Oble DA, Mino-Kenudson M, Goldsmith J, et al. Alpha-CTLA-4 mAb-associated panenteritis: a histologic and immunohistochemical analysis. *Am J Surg Pathol*. 2008;32(8):1130-1137.
308. Fava P, Astrua C, Cavaliere G, et al. Intestinal involvement in toxic epidermal necrolysis. A case report and review of literature. *J Eur Acad Dermatol Venereol*. 2015;29:1843-1845.
309. Oya M, Yao T, Tsuneyoshi M. Chronic irradiation enteritis: its correlation with the elapsed time interval and morphological changes. *Human Pathol*. 1996;27(8): 774-781.
310. Donaldson SS, Jundt S, Ricour C, et al. Radiation enteritis in children. A retrospective review, clinicopathologic correlation, and dietary management. *Cancer*. 1975;35(4):1167-1178.
311. Sugg WL, Lawler WH, Ackerman LV, Butcher HR Jr. Operative therapy for severe irradiational injury in the enteral and urinary tracts. *Ann Surg*. 1963;157:62-70.
312. Hasleton PS, Carr N, Schofield PF. Vascular changes in radiation bowel disease. *Histopathology*. 1985;9(5):517-534.
313. Schofield PF, Holden D, Carr ND. Bowel disease after radiotherapy. *J R Soc Med*. 1983;76:463-466.
314. Theis VS, Sripadam R, Ramani V, Lal S. Chronic radiation enteritis. *Clin Oncol*. 2010;22:70-83.
315. Matsumoto H, Ogura H, Seki M, et al. Fulminant phlegmonitis of the esophagus, stomach, and duodenum due to Bacillus thuringiensis. *World J Gastroenterol*. 2015;21:3741-3745.
316. Svane S. Acute phlegmonous jejunitis and viridans streptococcal peritonitis associated with bronchial carcinoma. *Scand J Infect Dis*. 2000;32:421-422.
317. Ebert EC, Kierson M, Hagspiel KD. Gastrointestinal and hepatic manifestations of sarcoidosis. *Am J Gastroenterol*. 2008;103:3184-3192.
318. Zhang M, Li Y. Eosinophilic gastroenteritis: a state-of-the-art review. *J Gastrenterol Hepatol*. 2017;32:64-72.
319. Talley NJ, Shorter RG, Phillips SF, Zinsmeister AR. Eosinophilic gastroenteritis: a clinicopathologic study of patients with disease of the mucosa, muscle layer, and subserosal tissues. *Gut*. 1990;31:54-58.
320. Rothenberg ME. Eosinophilic gastrointestinal disorders. *J Allergy Clin Immunol*. 2004;113:11-28.
321. Abram S, Murray JA, Pardi DS, et al. Adult autoimmune enteropathy: Mayo Clinic Rochester Experience. *Clin Gastroenterol Hepatol*. 2007;5:1282-1290.
322. Hori K, Fukuda Y, Tomita T, et al. Intestinal goblet cell autoantibody associated enteropathy. *J Clin Pathol*. 2003;56:629-630.
323. Kornacki S, Hansen CH III, Lazenby A. Graft-versus-host-like colitis associated with malignant thymoma. *Am J Surgical Pathol*. 1995;19:224-228.
324. Mais DD, Mulhall BP, Adolphson KR, Yamamoto K. Thymoma-associated autoimmune enteropathy: a report of two cases. *Am J Clin Pathol*. 1999;112:810-815.
325. Daniels JA, Lederman HM, Maitra A, Montgomery EA. Gastrointestinal tract pathology in patients with common variable immunodeficiency (CVID): a clinicopathologic study and review. *Am J Surg Pathol*. 2007;31(12):1800-1812.
326. Snover DC, Weisdorf SA, Vercellotti GM, et al. A histopathologic study of gastric and small intestinal graft-versus-host disease following allogeneic bone marrow transplantation. *Hum Pathol*. 1985;16(4):387-392.
327. Shulman HM, Cardona DM, Greenson JK, et al. NIH Consensus development project on criteria for clinical trials in chronic graft-versus-host disease: II. The 2014 Pathology Working Group Report. *Biol Blood Marrow Transplant*. 2015;21:589-603.
328. Brooke MA, Longhurst HJ, Kirkby NS, et al. Cryptogenic multifocal ulcerating stenosing enteritis associated with homozygous deletion mutations in cytosolic phospholipase A2-α. *Gut*. 2014;63:96-104.
329. Sarason EL, Prior JT, Prowda RL. Recurrent intussusception associated with hypertrophy of Peyer's patches. *N Engl J Med*. 1955;253(21):905-908.
330. Yunis EJ, Atchison RW, Michaels RH, DeCicco FA. Adenovirus and ileocecal intussusception. *Lab Invest*. 1975;33(4):347-351.
331. Bell TM, Steyn JH. Viruses in lymph nodes of children with mesenteric adenitis and intussusception. *BMJ*. 1962;2(5306):700-702.
332. Guarner J, de Leon-Bojorge B, Lopez-Corella E, et al. Intestinal intussusception associated with adenovirus infection in Mexican children. *Am J Clin Pathol*. 2003;120(6):845-850.
333. Montgomery EA, Popek EJ. Intussusception, adenovirus, and children: a brief reaffirmation. *Human Pathol*. 1994;25(2):169-174.
334. Meyerson S, Desai TK, Polidori G, et al. A case of intussusception and lymphoid hyperplasia in a patient with AIDS. *Am J Gastroenterol*. 1993;88(2):303-306.
335. Honjo H, Mike M, Kusanaqi H, Kano N. Adult intussusception: a retrospective review. *World J Surg*. 2015;39:134-138.
336. Albrecht H, Hagel A, de Rossi T, et al. Brown bowel syndrome: a rare complication in diseases associated with longstanding malabsorption. *Digestion*. 2014;89:105-109.
337. Gould M, Zarrin-Khameh N, Sellin J. Small bowel amyloidosis. *Curr Gastroenterol Rep*. 2013;15(10):350.
338. Hamaya K, Kitamura M, Doi K. Primary amyloid tumors of the jejunum producing intestinal obstruction. *Acta Pathol Jn*. 1989;39(3):207-211.
339. Domsic R, Fasanella K, Bielefeldt K. Gastrointestinal manifestations of systemic sclerosis. *Dig Dis Sci*. 2008;53:1163-1174.
340. Groisman GM, Amar M, Livne E. CD10: a valuable tool for the light microscopic diagnosis of microvillous inclusion disease (familial microvillous atrophy). *Am J Surg Pathol*. 2002;26(7):902-907.

341. Ranganathan S, Schmitt LA, Sindhi R. Tufting enteropathy revisited: the utility of MOC31 (EpCAM) immunohistochemistry in diagnosis. *Am J Surg Pathol*. 2014;38:265-272.
342. Azzaroli F, turco L, Ceroni L, et al. Pneumatosis cystoides intestinalis. *World J Gastroenterol*. 2011;17:4932-4936.
343. Levine JA, Burgart LJ, Batts KP, Wang KK. Brunner's gland hamartomas: clinical presentation and pathological features of 27 cases. *Am J Gastroenterol*. 1995;90:290-294.
344. Chatelain D, Maillet E, Boyer L, et al. Brunner gland hamartoma with predominant adipose tissue and ciliated cysts. *Arch Pathol Lab Med*. 2002;126(6):734-735.
345. Sakurai T, Sakashita H, Honjo G, et al. Gastric foveolar metaplasia with dysplastic changes in Brunner gland hyperplasia: possible precursor lesions for Brunner gland adenocarcinoma. *Am J Surg Pathol*. 2005;29(11):1442-1448.
346. Kurella RR, Ancha HR, Hussain S, et al. Evolution of Brunner gland adenoma associated with *Helicobacter pylori* infection. *South Med J*. 2008;101:648-650.
347. Perzin KH, Bridge MF. Adenomas of the small intestine: a clinicopathologic review of 51 cases and a study of their relationship to carcinoma. *Cancer*. 1981;48(3):799-819.
348. Cooperman M, Clausen KP, Hecht C, et al. Villous adenomas of the duodenum. *Gastroenterology*. 1978;74(6):1295-1297.
349. Komorowski RA, Cohen EB. Villous tumors of the duodenum: a clinicopathologic study. *Cancer*. 1981;47(6):1377-1386.
350. Blackman E, Nash SV. Diagnosis of duodenal and ampullary epithelial neoplasms by endoscopic biopsy: a clinicopathologic and immunohistochemical study. *Hum Pathol*. 1985;16(9):901-910.
351. Koornstraa JJ. Small bowel endoscopy in familial adenomatous polyposis and Lynch syndrome. *Best Pract Res Clin Gastroenterol*. 2012;26:359-368.
352. Wagner PL, Chen YT, Yantiss RK. Immunohistochemical and molecular features of sporadic and FAP-associated duodenal adenomas of the ampullary and nonampullary mucosa. *Am J Surg Pathol*. 2008;32(9):1388-1395.
353. Iseki M, Tsuda N, Hayashi T, et al. Multifocal villous adenomas of the anastomotic area following ileocystoplasty: a case report and literature review. *J Urol Pathol*. 2000;12: 29-38.
354. King PH, Osborn DE, Mackay EH. Tubulovillous adenoma arising 30 years after ileocystoplasty. *J Clin Pathol*. 1992;45(10):928-929.
355. Hashimoto T, Ogawa R, Matsubara A, et al. Familial adenomatous polyposis-associated and sporadic pyloric gland adenomas of the upper gastrointestinal tract share common genetic features. *Histopathology*. 2015;67:689-698.
356. Beggs AD, Latchford AR, Vasen HF, et al. Peutz-Jeghers syndrome: a systematic review and recommendations for management. *Gut*. 2010;59:975-986.
357. Haggitt RC, Reid BJ. Hereditary gastrointestinal polyposis syndromes. *Am J Surg Pathol*. 1986;10(12):871-887.
358. Shaco-Levy R, Jasperson KW, Martin K, et al. Morphologic characterization of hamartomatous gastrointestinal polyps in Cowden syndrome, Peutz-Jeghers syndrome, and juvenile polyposis syndrome. *Hum Pathol*. 2016;49:39-48.
359. Fulcheri E, Baracchini P, Pagani A, et al. Significance of the smooth muscle cell component in Peutz-Jeghers and juvenile polyps. *Hum Pathol*. 1991;22(11):1136-1140.
360. Tse JY, Wu S, Shinagare SA, et al. Peutz-Jeghers syndrome: a critical look at colonic Peutz-Jehgers polyps. *Mod Pathol*. 2013;26:1235-1240.
361. Petersen VC, Sheehan AL, Bryan RL, et al. Misplacement of dysplastic epithelium in Peutz-Jeghers Polyps: the ultimate diagnostic pitfall? *Am J Surg Pathol*. 2000;24(1):34-39.
362. Suzuki S, Hirasaki S, Ikeda F, et al. Three cases of solitary Peutz-Jeghers-type hamaromatous polyp in the duodenum. *World J Gastroenterol*. 2008;14:944-947.
363. Sweet K, Willis J, Zhou XP, et al. Molecular classification of patients with unexplained hamartomatous and hyperplastic polyposis syndromes. *JAMA*. 2005;294:2465-2473.
364. Arber N, Moshkowitz M. Small bowel polyposis syndromes. *Curr Gastroenterol Rep*. 2011;13:435-441.
365. Chen KT. Female genital tract tumors in Peutz-Jeghers syndrome. *Hum Pathol*. 1986;17(8):858-861.
366. Trau H, Schewach-Millet M, Fisher BK, Tsur H. Peutz-Jeghers syndrome and bilateral breast carcinoma. *Cancer*. 1982;50(4):788-792.
367. Clements A, Robison K, Granai C, et al. A case of Peutz-Jeghers syndrome with breast cancer, bilateral sex cord tumor with annular tubules, and adenoma malignum caused by STK11 gene mutation. *Int J Gynecol Cancer*. 2009;19:1591-1594.
368. Adler SN, Lyon DT, Sullivan PD. Adenocarcinoma of the small bowel. Clinical features, similarity to regional enteritis, and analysis of 338 documented cases. *Am J Gastroenterol*. 1982;77(5):326-330.
369. Arai T, Murata T, Sawabe M, et al. Primary adenocarcinoma of the duodenum in the elderly: clinicopathological and immunohistochemical study of 17 cases. *Path Int*. 1999;49(1):23-29.
370. Chang HK, Yu E, Kim J, et al. Adenocarcinoma of the small intestine: a multi-institutional study of 197 surgically resected cases. *Hum Pathol*. 2010;41(8):1087-1096.
371. Heiskanen I, Kellokumpu I, Jarvinen H. Management of duodenal adenomas in 98 patients with familial adenomatous polyposis. *Endoscopy*. 1999;31(6):412-416.
372. Ruys AT, Alderlieste YA, Gouma DJ, et al. Jejunal cancer in patients with familial adenomatous polyposis. *Clin Gastroenterol Hepatol*. 2010;8(8):731-733.
373. Rodriguez-Bigas MA, Vasen HF, Lynch HT, et al. Characteristics of small bowel carcinoma in hereditary nonpolyposis colorectal carcinoma. International Collaborative Group on HNPCC. *Cancer*. 1998;83(2):240-244.
374. Benharroch D, Sion-Vardi N, Goldstein J. Neurofibromatosis involving the small bowel associated with adenocarcinoma of the ileum with a neuroendocrine component. *Path Res Pract*. 1992;188(8):959-963.
375. Baciewicz F, Sparberg M, Lawrence JB, Poticha SM. Adenocarcinoma of an ileostomy site with skin invasion: a case report. *Gastroenterology*. 1983;84(1):168-170.
376. Cuesta MA, Donner R. Adenocarcinoma arising at an ileostomy site: report of a case. *Cancer*. 1976;37(2):949-952.
377. Lipper S, Graves GV Jr. Villous adenocarcinoma arising in the bypassed duodenum 18 years after a Billroth II subtotal gastrectomy: report of a case and review of the literature. *Am J Gastroenterol*. 1985;80(3):174-176.
378. Guadagni S, Catarci M, Ventura T, et al. Primary adenocarcinoma arising in the jejunal limb of a Roux-en-Y esophagojejunostomy: a case report. *Jpn J Clin Oncol*. 1993;23(1):59-63.
379. Takahashi A, Tsukamoto T, Kumamoto Y, et al. Adenocarcinoma arising in the ileal segment of a defunctionalized ileocystoplasty. *Hinyokika Kiyo*. 1993;39(8):753-755.
380. Wagner KM, Thompson J, Herlinger H, Caroline D. Thirteen primary adenocarcinomas of the ileum and appendix: a case report. *Cancer*. 1982;49(4):797-801.
381. Barclay TH, Schapira DV. Malignant tumors of the small intestine. *Cancer*. 1983;51(5):878-881.
382. Stemmermann GN, Goodman MT, Nomura AM. Adenocarcinoma of the proximal small intestine. A marker for familial and multicentric cancer? *Cancer*. 1992;70(12):2766-2771.
383. Overman MJ, Pozadzides J, Kopetz S, et al. Immunophenotype and molecular characterization of adenocarcinoma of the small intestine. *Br J Cancer*. 2010;102: 144-150.
384. Lagana S, Hsiao S, Bao F, et al. HepPar-1 and Arginase-1 immunohistochemistry in adenocarcinoma of the small intestine and ampullary region. *Arch Pathol Lab Med*. 2015;139:791-795.
385. Griesser GH, Schumacher U, Elfeldt R, Horny HP. Adenosquamous carcinoma of the ileum. Report of a case and review of the literature. *Virch Archi A Pathol Anat Histopathol*. 1985;406(4):483-487.
386. Ngo N, Villamil C, Macauley W, Cole SR. Adenosquamous carcinoma of the small intestine. Report of a case and review of the literature. *Arch Pathol Lab Med*. 1999;123(8):739-742.
387. Bak M, Teglbjaerg PS. Pleomorphic (giant cell) carcinoma of the intestine. An immunohistochemical and electron microscopic study. *Cancer*. 1989;64(12):2557-2564.
388. Fukuda T, Kamishima T, Ohnishi Y, Suzuki T. Sarcomatoid carcinoma of the small intestine: histologic, immunohistochemical and ultrastructural features of three cases and its differential diagnosis. *Pathol Int*. 1996;46(9):682-688.
389. Robey-Cafferty SS, Silva EG, Cleary KR. Anaplastic and sarcomatoid carcinoma of the small intestine: a clinicopathologic study. *Hum Pathol*. 1989;20(9):858-863.
390. Iyomasa S, Senda Y, Mizuno K, et al. Primary choriocarcinoma of the jejunum: report of a case. *Surg Today*. 2003;33:948-951.
391. Rindi G, Arnold R, Bosman FT, et al. Nomenclature and classification of neuroendocrine neoplams of the digestive system. In: Bosman FT, Carneiro F, Hruban RH, Theise ND, eds. *World Health Organization Classification of Tumours of the Digestive System*. 4th ed. Lyon: IARC; 2010:13-14.
392. Kloppel G. Oberndorfer and his successors: from carcinoid to neuroendocrine carcinoma. *Endocr Pathol*. 2007;18(3):141-144.
393. Chow CW, Sane S, Campbell PE, Carter RF. Malignant carcinoid tumors in children. *Cancer*. 1982;49(4):802-811.
394. Burke AP, Thomas RM, Elsayed AM, Sobin LH. Carcinoids of the jejunum and ileum: an immunohistochemical and clinicopathologic study of 167 cases. *Cancer*. 1997;79(6):1086-1093.
395. Modlin IM, Lye KD, Kidd M. A 5-decade analysis of 13,715 carcinoid tumors. *Cancer*. 2003;97(4):934-959.
396. Gardiner GW, Van Patter T, Murray D. Atypical carcinoid tumor of the small bowel complicating celiac disease. *Cancer*. 1985;56(11):2716-2722.
397. Sigel JE, Goldblum JR. Neuroendocrine neoplasms arising in inflammatory bowel disease: a report of 14 cases. *Mod Pathol*. 1998;11(6):537-542.
398. Smith JH, Hope PG. Carcinoid tumor arising in a cystic duplication of the small bowel. *Arch Pathol Lab Med*. 1985;109(1): 95-96.

399. Anlauf M, Garbrecht N, Bauersfeld J, et al. Hereditary neuroendocrine tumors of the gastroenteropancreatic system. *Virchows Arch*. 2007;451(suppl 1):S29-S38.
400. Hough DR, Chan A, Davidson H. Von Recklinghausen's disease associated with gastrointestinal carcinoid tumors. *Cancer*. 1983;51(12):2206-2208.
401. Allibone RO, Hoffman J, Gosney JR, Helliwell TR. Granulation tissue polyposis associated with carcinoid tumours of the small intestine. *Histopathology*. 1993;22(5):475-480.
402. Yantiss RK, Odze RD, Farraye FA, Rosenberg AE. Solitary versus multiple carcinoid tumors of the ileum: a clinical and pathologic review of 68 cases. *Am J Surg Pathol*. 2003;27(6):811-817.
403. Guo Z, Li Q, Wilander E, Ponten J. Clonality analysis of multifocal carcinoid tumours of the small intestine by X-chromosome inactivation analysis. *J Pathol*. 2000;190(1):76-79.
404. Vesoulis Z, Abrahams N, Becker J, Slezak F. Carcinoid-related angiomatous polyposis simulating Crohn disease. *Arch Pathol Lab Med*. 2000;124:450-454.
405. Cai YC, Barnard G, Hiestand L, et al. Florid angiogenesis in mucosa surrounding an ileal carcinoid tumor expressing transforming growth factor-alpha. *Am J Surg Pathol*. 1997;21(11):1373-1377.
406. Abrahams NA, Vesoulis Z, Petras RE. Angiogenic polypoid proliferation adjacent to ileal carcinoid tumors: a non-specific finding related to mucosal prolapse. *Mod Pathol*. 2001;14:821-827.
407. Hammond EH, Yowell RL, Flinner RL. Neuroendocrine carcinomas: role of immunocytochemistry and electron microscopy. *Hum Pathol*. 1998;29(12):1367-1371.
408. Miettinen M, Lehto VP, Dahl D, Virtanen I. Varying expression of cytokeratin and neurofilaments in neuroendocrine tumors of human gastrointestinal tract. *Lab Invest*. 1985;52(4):429-436.
409. Nash SV, Said JW. Gastroenteropancreatic neuroendocrine tumors. A histochemical and immunohistochemical study of epithelial (keratin proteins, carcinoembryonic antigen) and neuroendocrine (neuron-specific enolase, bombesin and chromogranin) markers in foregut, midgut, and hindgut tumors. *Am J Clin Pathol*. 1986;86(4):415-422.
410. Cai YC, Banner B, Glickman J, Odze RD. Cytokeratin 7 and 20 and thyroid transcription factor 1 can help distinguish pulmonary from gastrointestinal carcinoid and pancreatic endocrine tumors. *Hum Pathol*. 2001;32(10):1087-1093.
411. Jaffee IM, Rahmani M, Singhal MG, Younes M. Expression of the intestinal transcription factor CDX2 in carcinoid tumors is a marker of midgut origin. *Arch Pathol Lab Med*. 2006;130(10):1522-1526.
412. Saqi A, Alexis D, Remotti F, Bhagat G. Usefulness of CDX2 and TTF-1 in differentiating gastrointestinal from pulmonary carcinoids. *Am J Clin Pathol*. 2005;123(3):394-404.
413. Maxwell JE, Sherman SK, Stashek KM, et al. A practical method to determine the site of unknown primary in metastatic neuroendocrine tumors. *Surgery*. 2014;156:1359-1365.
414. Portel-Gomes GM, Grimelius L, Johansson H, et al. Chromogranin A in human neuroendocrine tumors: an immunohistochemical study with region-specific antibodies. *Am J Surg Pathol*. 2001;25(10):1261-1267.
415. Rode J, Dhillon AP, Doran JF, et al. PGP 9.5, a new marker for human neuroendocrine tumours. *Histopathol*. 1985;9(2):147-158.
416. Modlin IM, Kidd M, Latich I, et al. Current status of gastrointestinal carcinoids. *Gastroenterology*. 2005;128:1717-1751.
417. Wilander E, Lundqvist M, el-Salhy M. Serotonin in fore-gut carcinoids. A survey of 60 cases with regard to silver stains, formalin-induced fluorescence and serotonin immunocytochemistry. *J Pathol*. 1985;145(3):251-258.
418. Volante M, Brizzi MP, Faggiano A, et al. Somatostatin receptor type 2A immunohistochemistry in neuroendocrine tumors: a proposal of scoring system correlated with somatostatin receptor scintigraphy. *Mod Pathol*. 2007;20(11):1172-1182.
419. Lai M, Lu B, Xing X, et al. Secretagogin, a novel neuroendocrine marker, has a distinct expression pattern from chromogranin A. *Virchows Arch*. 2006;449(4):402-409.
420. Bostwick DG, Roth KA, Barchas JD, Bensch KG. Gastrin-releasing peptide immunoreactivity in intestinal carcinoids. *Am J Clin Pathol*. 1984;82(4):428-431.
421. Capella C, Heitz PU, Hofler H, et al. Revised classification of neuroendocrine tumours of the lung, pancreas and gut. *Virchows Arch*. 1995;425(6):547-560.
422. Lundqvist M, Wilander E. Somatostatin-like immunoreactivity in mid-gut carcinoids. *Acta Pathol Microbiol Scand [A]*. 1981;89(4):335-337.
423. Mertz H, Vyberg M, Paulsen SM, Teglbjaerg PS. Immunohistochemical detection of neuroendocrine markers in tumors of the lungs and gastrointestinal tract. *Appl Immunohistochem Mol Morphol*. 1998;6:175-180.
424. Papotti M, Bongiovanni M, Volante M, et al. Expression of somatostatin receptor types 1–5 in 81 cases of gastrointestinal and pancreatic endocrine tumors. A correlative immunohistochemical and reverse-transcriptase polymerase chain reaction analysis. *Virchows Arch*. 2002;440(5):461-475.
425. Wick MR. Immunohistology of neuroendocrine and neuroectodermal tumors. *Semin Diagn Pathol*. 2000;17(3):194-203.
426. Wilander E, El-Salhy M. Immuno-cyto-chemical staining of mid-gut carcinoid tumours with sequence-specific gastrin antisera. *Acta Pathol Microbiol Scand [A]*. 1981;89(4):247-250.
427. Yang K, Ulich T, Cheng L, Lewin KJ. The neuroendocrine products of intestinal carcinoids. An immunoperoxidase study of 35 carcinoid tumors stained for serotonin and eight polypeptide hormones. *Cancer*. 1983;51(10):1918-1926.
428. Iwafuchi M, Watanabe H, Ishihara N, et al. Peptide YY immunoreactive cells in gastrointestinal carcinoids: immunohistochemical and ultrastructural studies of 60 tumors. *Hum Pathol*. 1986;17(3):291-296.
429. Takatoh H, Iwamoto H, Ikezu M, et al. Immunohistochemical demonstration of peptide YY in gastrointestinal endocrine tumors. *Acta Pathol Jpn*. 1987;37(5):737-746.
430. Mooney EE, Casey M, Dervan PA. Intermediate filament expression in carcinoid tumours. *Ir J Med Sci*. 1991;160(11):339-341.
431. Katsetos CD, Jami MM, Krishna L, et al. Novel immunohistochemical localization of 28,000 molecular-weight (Mr) calcium binding protein (calbindin-D28k) in enterochromaffin cells of the human appendix and neuroendocrine tumors (carcinoids and small-cell carcinomas) of the midgut and foregut. *Arch Pathol Lab Med*. 1994;118(6):633-639.
432. Zhang PJ, Harris KR, Alobeid B, Brooks JJ. Immunoexpression of villin in neuroendocrine tumors and its diagnostic implications. *Arch Pathol Lab Med*. 1999;123(9):812-816.
433. La Rosa S, Capella C, Lloyd RV. Localization of myosin XVA in endocrine tumors of gut and pancreas. *Endocr Pathol*. 2002;13(1):29-37.
434. Lundqvist M, Wilander E. Subepithelial neuroendocrine cells and carcinoid tumours of the human small intestine and appendix. A comparative immunohistochemical study with regard to serotonin, neuron-specific enolase and S-100 protein reactivity. *J Pathol*. 1986;148(2):141-147.
435. Lundqvist M, Wilander E. A study of the histopathogenesis of carcinoid tumors of the small intestine and appendix. *Cancer*. 1987;60(2):201-206.
436. Moyana TN, Satkunam N. A comparative immunohistochemical study of jejunoileal and appendiceal carcinoids. Implications for histogenesis and pathogenesis. *Cancer*. 1992;70(5):1081-1088.
437. Sobin LH, Hjermstad BM, Sesterhenn IA, Helwig EB. Prostatic acid phosphatase activity in carcinoid tumors. *Cancer*. 1986;58(1):136-138.
438. Azumi N, Traweek ST, Battifora H. Prostatic acid phosphatase in carcinoid tumors. Immunohistochemical and immunoblot studies. *Am J Surg Pathol*. 1991;15(8):785-790.
439. Krishnamurthy S, Dayal Y. Immunohistochemical expression of transforming growth factor alpha and epidermal growth factor receptor in gastrointestinal carcinoids. *Am J Surg Pathol*. 1997;21(3):327-333.
440. La Rosa S, Uccella S, Erba S, et al. Immunohistochemical detection of fibroblast growth factor receptors in normal endocrine cells and related tumors of the digestive system. *Appl Immunohistochem Mol Morphol*. 2001;9(4):319-328.
441. Nilsson O, Wangberg B, McRae A, et al. Growth factors and carcinoid tumours. *Acta Oncol*. 1993;32(2):115-124.
442. Kulke MH, Freed E, Chiang DY, et al. High-resolution analysis of genetic alterations in small bowel carcinoid tumors reveals areas of recurrent amplification and loss. *Genes Chromosomes Cancer*. 2008;47(7):591-603.
443. Goolsby CL, Punyarit P, Mehl PJ, Rao MS. Flow cytometric DNA analysis of carcinoid tumors of the ileum and appendix. *Human Pathol*. 1992;23(12):1340-1343.
444. D'Adda T, Pizzi S, Azzoni C, et al. Different patterns of 11q allelic losses in digestive endocrine tumors. *Hum Pathol*. 2002;33(3):322-329.
445. Weckstrom P, Hedrum A, Makridis C, et al. Midgut Carcinoids and Solid Carcinomas of the Intestine: Differences in Endocrine Markers and p53 Mutations. *Endocr Pathol*. 1996;7(4):273-279.
446. Moyana TN, Xiang J, Senthilselvan A, Kulaga A. The spectrum of neuroendocrine differentiation among gastrointestinal carcinoids: importance of histologic grading, MIB-1, p53, and bcl-2 immunoreactivity. *Arch Pathol Lab Med*. 2000;124(4):570-576.
447. Lechago J. Gastrointestinal neuroendocrine cell proliferations. *Hum Pathol*. 1994;25(11):1114-1122.
448. Modlin IM, Sandor A. An analysis of 8305 cases of carcinoid tumors. *Cancer*. 1997;79(4):813-829.
449. Mosunjac MB, Kochhar R, Mosunjac MI, Lau SK. Primary small bowel carcinoid tumor with bilateral breast metastases: report of 2 cases with different clinical presentations. *Arch Pathol Lab Med*. 2004;128(3):292-297.

450. Rodriguez G, Villamizar R. Carcinoid tumor with skin metastasis. *Am J Dermatopathol*. 1992;14(3):263-269.
451. Dent GA, Feldman JM. Pseudocystic liver metastases in patients with carcinoid tumors: report of three cases. *Am J Clin Pathol*. 1984;82(3):275-279.
452. Kim GH, Kim JI, Jeon SW, et al. Endoscopic resection for duodenal carcinoid tumors: a multicenter, retrospective study. *J Gastrenterol Hepatol*. 2014;29:318-324.
453. Watzka FM, Fottner C, Miederer M, et al. Surgical treatment of NEN of small bowel: a retrospective analysis. *World J Surg*. 2016;40:749-758.
454. Maxwell JE, Sherman SK, O'Dorisio TM, et al. Liver-directed surgery of neuroendocrine metastases: what is the optimal strategy? *Surgery*. 2016;159:320-333.
455. Wolin EM, Jarzab B, Eriksson B, et al. Phase III study of pasireotide long-acting release in patients with metastatic neuroendocrine tumors and carcinoid symptoms refractory to available somatostatin analogyes. *Drug Des Devel Ther*. 2015;9:5075-5086.
456. Maggard MA, O'Connell JB, Ko CY. Updated population-based review of carcinoid tumors. *Ann Surg*. 2004;240:117-122.
457. Soreide JA, van Heerden JA, Thompson GB, et al. Gastrointestinal carcinoid tumors: long term prognosis for surgically treated patients. *World J Surg*. 2000;24:1431-1436.
458. Landry CS, Brock G, Scoggins CR, et al. A proposed staging system for small bowel carcinoid tumors based on an analysis of 6380 patients. *Am J Surg*. 2008;196:896-903.
459. Feldman JM. Carcinoid tumors and syndrome. *Sem Oncol*. 1987;14(3):237-246.
460. Kuwada SK. Carcinoid tumors. *Sem Gastrointestinal Dis*. 2000;11(3):157-161.
461. Feldman JM, Jones RS. Carcinoid syndrome from gastrointestinal carcinoids without liver metastasis. *Ann Surg*. 1982;196(1):33-37.
462. Ganim RB, Norton JA. Recent advances in carcinoid pathogenesis, diagnosis and management. *Surg Oncol*. 2000;9(4): 173-179.
463. Oates JA. The carcinoid syndrome. *N Engl J Med*. 1986;315(11):702-704.
464. Sandler M, Williams ED, Karim SMM. The occurrence of prostaglandins in amine-peptide-secreting tumours. In: Mantegazza P, Horton EW, eds. *Prostaglandins, Peptides and Amines*. London: Academic Press; 1969:3-7.
465. Quaedvlieg PF, Lamers CB, Taal BG. Carcinoid heart disease: an update. *Scand J Gastroenterol Suppl*. 2002;236:66-71.
466. Anthony PP. Gangrene of the small intestine—a complication of argentaffin carcinoma. *Br J Surg*. 1970;57(2):118-122.
467. Qizilbash AH. Carcinoid tumors, vascular elastosis, and ischemic disease of the small intestine. *Dis Colon Rectum*. 1977;20(7): 554-560.
468. Fries JF, Lindgren JA, Bull JM. Scleroderma-like lesions and the carcinoid syndrome. *Arch Int Med*. 1973;131(4):550-553.
469. Modhi G, Nicolis G. Hypoglycemia associated with carcinoid tumors. A case report and review of the literature. *Cancer*. 1984;53(8):1804-1806.
470. Pelletier G, Cortot A, Launay JM, et al. Serotonin-secreting and insulin-secreting ileal carcinoid tumor and the use of in vitro culture of tumoral cells. *Cancer*. 1984;54(2):319-322.
471. Hirakawa K, Iida M, Matsui T, et al. Endoscopic findings in carcinoid tumor of the duodenum. *Am J Gastroenterol*. 1991;86(5):603-605.
472. Kloppel G, Anlauf M, Perren A. Endocrine precursor lesions of gastroenteropancreatic neuroendocrine tumors. *Endocr Pathol*. 2007;18(3):150-155.
473. Pipeleers-Marichal M, Somers G, Willems G, et al. Gastrinomas in the duodenums of patients with multiple endocrine neoplasia type 1 and the Zollinger-Ellison syndrome. *N Engl J Med*. 1990;322(11):723-727.
474. Vesoulis Z, Petras RE. Duodenal microgastrinoma producing the Zollinger-Ellison syndrome. *Arch Pathol Lab Med*. 1985;109(1):40-42.
475. Merchant SH, VanderJagt T, Lathrop S, Amin MB. Sporadic duodenal bulb gastrin-cell tumors: association with *Helicobacter pylori* gastritis and long-term use of proton pump inhibitors. *Am J Surg Pathol*. 2006;30(12):1581-1587.
476. Tanaka S, Yamasaki S, Matsushita H, et al. Duodenal somatostatinoma: a case report and review of 31 cases with special reference to the relationship between tumor size and metastasis. *Pathol Int*. 2000;50(2): 146-152.
477. Burke AP, Sobin LH, Shekitka KM, et al. Somatostatin-producing duodenal carcinoids in patients with von Recklinghausen's neurofibromatosis. A predilection for black patients. *Cancer*. 1990;65(7):1591-1595.
478. Dayal Y, Tallberg KA, Nunnemacher G, et al. Duodenal carcinoids in patients with and without neurofibromatosis. A comparative study. *Am J Surg Pathol*. 1986;10(5): 348-357.
479. Yoshida A, Hatanaka S, Ohi Y, et al. von Recklinghausen's disease associated with somatostatin-rich duodenal carcinoid (somatostatinoma), medullary thyroid carcinoma and diffuse adrenal medullary hyperplasia. *Acta Pathol Jpn*. 1991;41(11):847-856.
480. Dayal Y, Doos WG, O'Brien MJ, et al. Psammomatous somatostatinomas of the duodenum. *Am J Surg Pathol*. 1983;7(7):653-665.
481. Griffiths DF, Jasani B, Newman GR, et al. Glandular duodenal carcinoid—a somatostatin rich tumour with neuroendocrine associations. *J Clin Pathol*. 1984;37(2):163-169.
482. Marcial MA, Pinkus GS, Skarin A, et al. Ampullary somatostatinoma: psammomatous variant of gastrointestinal carcinoid tumor—an immunohistochemical and ultrastructural study. Report of a case and review of the literature. *Am J Clin Pathol*. 1983;80(5):755-761.
483. Greider MH, DeSchryver-Kecskemeti K, Kraus FT. Psammoma bodies in endocrine tumors of the gastroenteropancreatic axis: a rather common occurrence. *Semin Diagn Pathol*. 1984;1(1):19-29.
484. Srivastava A, Hornick JL. Immunohistochemical staining for CDX-2, PDX-1, NESP-55, and TTF-1 can help distinguish gastrointestinal carcinoid tumors from pancreatic endocrine and pulmonary carcinoid tumors. *Am J Surg Pathol*. 2009;33(4):626-632.
485. Volante M, Rindi G, Papotti M. The grey zone between pure (neuro)endocrine and non-(neuro)endocrine tumours: a comment on concepts and classification of mixed exocrine-endocrine neoplasms. *Virchows Arch*. 2006;449(5):499-506.
486. Kepes JJ, Zacharias DL. Gangliocytic paragangliomas of the duodenum. A report of two cases with light and electron microscopic examination. *Cancer*. 1971;27(1):61-67.
487. Taylor HB, Helwig EB. Benign nonchromaffin paragangliomas of the duodenum. *Virchows Arch Pathol Anat Physiol Klin Med*. 1962;335:356-366.
488. Reed RJ, Caroca PJ Jr, Harkin JC. Gangliocytic paraganglioma. *Am J Surg Pathol*. 1977;1(3):207-216.
489. van Eeden S, Offerhaus GJ, Peterse HL, et al. Gangliocytic paraganglioma of the appendix. *Histopathology*. 2000;36(1):47-49.
490. Kawaguchi K, Takizawa T, Koike M, et al. Multiple paraganglioneuromas. *Virchows Arch A Pathol Anat Histopathol*. 1985;406(3):373-380.
491. Kheir SM, Halpern NB. Paraganglioma of the duodenum in association with congenital neurofibromatosis. Possible relationship. *Cancer*. 1984;53(11):2491-2496.
492. Stephens M, Williams GT, Jasani B, Williams ED. Synchronous duodenal neuroendocrine tumours in von Recklinghausen's disease. A case report of coexisting gangliocytic paraganglioma and somatostatin-rich glandular carcinoid. *Histopathol*. 1987;11:1331-1340.
493. Altavilla G, Chiarelli S, Fassina A. Duodenal periampullary gangliocytic paraganglioma: report of two cases with immunohistochemical and ultrastructural study. *Ultrastruct Pathol*. 2001;25(2): 137-145.
494. Collina G, Maiorana A, Trentini GP. Duodenal gangliocytic paraganglioma. Case report with immunohistochemical study on the expression of keratin polypeptides. *Histopathology*. 1991;19(5):476-478.
495. Guarda LA, Ordonez NG, del Junco GW, Luna MA. Gangliocytic paraganglioma of the duodenum: an immunocytochemical study. *Am J Gastroenterol*. 1983;78(12):794-798.
496. Min KW. Gangliocytic paraganglioma of the duodenum: report of a case with immunocytochemical and ultrastructural investigation. *Ultrastruct Pathol*. 1997;21(6):587-595.
497. Perrone T, Sibley RK, Rosai J. Duodenal gangliocytic paraganglioma. An immunohistochemical and ultrastructural study and a hypothesis concerning its origin. *Am J Surg Pathol*. 1985;9(1):31-41.
498. Scheithauer BW, Nora FE, LeChago J, et al. Duodenal gangliocytic paraganglioma. Clinicopathologic and immunocytochemical study of 11 cases. *Am J Clin Pathol*. 1986;86(5):559-565.
499. Hamid QA, Bishop AE, Rode J, et al. Duodenal gangliocytic paragangliomas: a study of 10 cases with immunocytochemical neuroendocrine markers. *Hum Pathol*. 1986;17(11):1151-1157.
500. Dookhan DB, Miettinen M, Finkel G, Gibas Z. Recurrent duodenal gangliocytic paraganglioma with lymph node metastases. *Histopathology*. 1993;22(4):399-401.
501. Hashimoto S, Kawasaki S, Matsuzawa K, et al. Gangliocytic paraganglioma of the papilla of Vater with regional lymph node metastasis. *Am J Gastroenterol*. 1992;87(9):1216-1218.
502. Inai K, Kobuke T, Yonehara S, Tokuoka S. Duodenal gangliocytic paraganglioma with lymph node metastasis in a 17-year-old boy. *Cancer*. 1989;63(12):2540-2545.
503. Miettinen M, Lasota J. Gastrointestinal stromal tumors: review on morphology, molecular pathology, prognosis, and differential diagnosis. *Arch Pathol Lab Med*. 2006;130:1466-1478.
504. Weiss RA, Mackay B. Malignant smooth muscle tumors of the gastrointestinal tract: an ultrastructural study of 20 cases. *Ultrastruct Pathol*. 1981;2(3):231-240.
505. Miettinen M, Makhlouf H, Sobin LH, Lasota J. Gastrointestinal stromal tumors of the jejunum and ileum: a clinicopathologic, immunohistochemical, and molecular genetic study of 906 cases before imatinib with long-term follow-up. *Am J Surg Pathol*. 2006;30(4):477-489.
506. Jojensuu H. Risk stratification of patients diagnosed with gastrointestinal stromal tumor. *Hum Pathol*. 2008;39:1411-1419.

507. Miettinen M, Lasota J. Gastrointetinal stromal tumors: pathology and prognosis at different sites. *Semin Diagn Pathol*. 2006;23:70-83.
508. Brainard JA, Goldblum JR. Stromal tumors of the jejunum and ileum: a clinicopathologic study of 39 cases. *Am J Surg Pathol*. 1997;21(4):407-416.
509. Handra-Luca A, Flejou JF, Molas G, et al. Familial multiple gastrointestinal stromal tumours with associated abnormalities of the myenteric plexus layer and skeinoid fibres. *Histopathology*. 2001;39(4):359-363.
510. Ishida T, Wada I, Horiuchi H, et al. Multiple small intestinal stromal tumors with skeinoid fibers in association with neurofibromatosis 1 (von Recklinghausen's disease). *Pathol Int*. 1996;46(9):689-695.
511. Jeng YM, Mao TL, Hsu WM, et al. Congenital interstitial cell of cajal hyperplasia with neuronal intestinal dysplasia. *Am J Surg Pathol*. 2000;24(11):1568-1572.
512. Miettinen M, Sobin LH, Lasota J. True smooth muscle tumors of the small intestine: a clinicopathologic, immunhistochemical, and molecular genetic study of 25 cases. *Am J Surg Pathol*. 2009;33(3):430-436.
513. Miettinen M, Kopczynski J, Makhlouf HR, et al. Gastrointestinal stromal tumors, intramural leiomyomas, and leiomyosarcomas in the duodenum: a clinicopathologic, immunohistochemical, and molecular genetic study of 167 cases. *Am J Surg Pathol*. 2003;27(5):625-641.
514. McClain KL, Leach CT, Jenson HB, et al. Association of Epstein-Barr virus with leiomyosarcomas in children with AIDS. *N Engl J Med*. 1995;332(1):12-18.
515. Vallaeys JH, Cuvelier CA, Bekaert L, Roels H. Combined leiomyomatosis of the small intestine and colon. *Arch Pathol Lab Med*. 1992;116(3):281-283.
516. Ozolek JA, Sasatomi E, Swalsky PA, et al. Inflammatory fibroid polyps of the gastrointestinal tract: clinical, pathologic, and molecular characteristics. *Appl Immunohistochem Mol Morphol*. 2004;12(1):59-66.
517. Liu TC, Lin MT, Montgomery EA, Singhi AD. Inflamamtory fibroid polyps of the gastrointestinal tract: spectrum of clinical, morphologic, and immunohistochemistry features. *Am J Surg Pathol*. 2013;37: 586-592.
518. Wille P, Borchard F. Fibroid polyps of intestinal tract are inflammatory-reactive proliferations of CD34-positive perivascular cells. *Histopathology*. 1998;32(6):498-502.
519. Pantanowitz L, Antonioli DA, Pinkus GS, et al. Inflammatory fibroid polyps of the gastrointestinal tract: evidence for a dendritic cell origin. *Am J Surg Pathol*. 2004;28:107-114.
520. Lasota J, Wang ZF, Sobin LH, Miettinen M. Gain-of-function PDGFRA mutations, earlier reported in gastrointestinal stromal tumors, are common in small intestinal inflammatory fibroid polyps. A study of 60 cases. *Mod Pathol*. 2009;22(8):1049-1056.
521. Daum O, Vanecek T, Sima R, et al. Reactive nodular fibrous pseudotumors of the gastrointestinal tract: report of 8 cases. *Int J Surg Pathol*. 2004;12(4):365-374.
522. Makhlouf HR, Sobin LH. Inflammatory myofibroblastic tumors (inflammatory pseudotumors) of the gastrointestinal tract: how closely are they related to inflammatory fibroid polyps? *Hum Pathol*. 2002;33(3):307-315.
523. Allibone RO, Nanson JK, Anthony PP. Multiple and recurrent inflammatory fibroid polyps in a Devon family ("Devon polyposis syndrome"): an update. *Gut*. 1992;33(7):1004-1005.
524. Nkanza NK, King M, Hutt MS. Intussusception due to inflammatory fibroid polyps of the ileum: a report of 12 cases from Africa. *Br J Surg*. 1980;67(4):271-274.
525. Mayo CW, Pagtalunan RJ, Brown DJ. Lipoma of the alimentary tract. *Surgery*. 1963;53:598-603.
526. Weinberg T, Feldman M Sr. Lipomas of the gastrointestinal tract. *Am J Clin Pathol*. 1955;25(3):272-281.
527. Hurwitz MM, Redleaf PD, Williams HJ, Edwards JE. Lipomas of the gastrointestinal tract. An analysis of seventy-two tumors. *Am J Roentgenol Radium Ther Nucl Med*. 1967;99(1):84-89.
528. Climie AR, Wylin RF. Small-intestinal lipomatosis. *Arch Pathol Lab Med*. 1981;105(1):40-42.
529. Boyle L, Lack EE. Solitary cavernous hemangioma of small intestine. Case report and literature review. *Arch Pathol Lab Med*. 1993;117(9):939-941.
530. Shepherd JA. Angiomatous conditions of the gastro-intestinal tract. *Br J Surg*. 1953;40(163):409-421.
531. Hanagiri T, Baba M, Shimabukuro T, et al. Lymphangioma in the small intestine: report of a case and review of the Japanese literature. *Surg Today*. 1992;22(4):363-367.
532. Aase S, Gundersen R. Submucous lymphatic cysts of the small intestine. An autopsy study. *Acta Pathol Microbiol Scand [A]*. 1983;91(3):191-194.
533. Smith CR Jr, Bartholomew LG, Cain JC. Hereditary hemorrhagic telangiectasia and gastrointestinal hemorrhage. *Gastroenterol*. 1963;44:1-6.
534. Mestiri S, Karoui M, Charachon A, et al. Intravascular papillary endothelial hyperplasia of the jejunum: an unusual cause of melena. *Int J Surg Pathol*. 2007;15(2):192-195.
535. Hamilton CW, Shelburne JD, Bossen EH, Lowe JE. A glomus tumor of the jejunum masquerading as a carcinoid tumor. *Human Pathol*. 1982;13(9):859-861.
536. Jundi M, Lack EE, Brun EA, et al. Glomus tumor of the duodenum: a case report. *Int J Surg Pathol*. 2004;12(4):411-414.
537. Liu YQ, Yue JQ. Intramural solitary fibrous tumor of the ileum: a case report and review of the literature. *J Cancer Res Ther*. 2013;9:724-726.
538. Hou YY, Tan YS, Xu JF, et al. Schwannoma of the gastrointestinal tract: a clinicopathological, immunohistochemical and ultrastructural study of 33 cases. *Histopathology*. 2006;48(5):536-545.
539. Shekitka KM, Sobin LH. Ganglioneuromas of the gastrointestinal tract. Relation to Von Recklinghausen disease and other multiple tumor syndromes. *Am J Surg Pathol*. 1994;18(3):250-257.
540. Fuller CE, Williams GT. Gastrointestinal manifestations of type 1 neurofibromatosis (von Recklinghausen's disease). *Histopathology*. 1991;19(1):1-11.
541. Coffin CM, Watterson J, Priest JR, Dehner LP. Extrapulmonary inflammatory myofibroblastic tumor (inflammatory pseudotumor). A clinicopathologic and immunohistochemical study of 84 cases. *Am J Surg Pathol*. 1995;19:859-872.
542. Sanders BM, West KW, Gingalewski C, et al. Inflammatory pseudotumor of the alimentary tract: clinical and surgical experience. *J Pediatr Surg*. 2001;36:169-173.
543. Cook JR, Dehner LP, Collins MH, et al. Anaplastic lymphoma kinase (ALK) expression in the inflammatory myofibroblastic tumor: a comparative immunohistochemical study. *Am J Surg Pathol*. 2001;25:1364-1371.
544. Cessna MH, Zhou H, Sanger WG, et al. Expression of ALK1 and p80 in inflammatory myofibroblastic tumor and its mesenchymal mimics: a study of 135 cases. *Mod Pathol*. 2002;15:931-938.
545. Gonzalez-Crussi F, Noronha R. Solitary intestinal fibromatosis in the newborn. Rare cause of neonatal intestinal obstruction. *Arch Pathol Lab Med*. 1985;109(1):97-99.
546. Rodriguez JA, Guarda LA, Rosai J. Mesenteric fibromatosis with involvement of the gastrointestinal tract. A GIST simulator: a study of 25 cases. *Am J Clin Pathol*. 2004;121(1):93-98.
547. Huss S, Nehles J, Binot E, et al. β-catenin (CTNNB1) mutations and clinicopathological features of mesenteric desmoid-type fibromatosis. *Histopathology*. 2013;62:294-304.
548. Stockman DL, Miettinen M, Suster S, et al. Malignant gastrointestinal neurectodermal tumor: clinicopathologic, immunohistochemical, ultrastructural, and molecular analysis of 16 cases with a reappraisal of clear cell sarcoma-like tumors of the gastrointestinal tract. *Am J Surg Pathol*. 2012;36:857-868.
549. Zambrano E, Reyes-Mugica M, Franchi A, Rosai J. An osteoclast-rich tumor of the gastrointestinal tract with features resembling clear cell sarcoma of soft parts: reports of 6 cases of a GIST simulator. *Int J Surg Pathol*. 2003;11:75-81.
550. Huang W, Zhang X, Li D, et al. Osteoclast-rich tumor of the gastrointestinal tract with features resembling those of clear cell sarcoma of soft parts. *Virchows Arch*. 2006;448:200-203.
551. Antonescu CR, Nafa K, SegL NH, et al. EWS-CREB1: a recurrent variant fusion in clear cell sarcoma-association with gastrointestinal location and absence of melanocytic differentiation. *Clin Cancer Res*. 2006;12:5356-5362.
552. Parfitt JR, Rodriguez-Justo M, Feakins R, Novelli MR. Gastrointestinal Kaposi's sarcoma: CD117 expression and the potential for misdiagnosis as gastrointestinal stromal tumour. *Histopathology*. 2008;52(7):816-823.
553. Allison KH, Yoder BJ, Bronner MP, et al. Angiosarcoma involving the gastrointestinal tract: a series of primary and metastatic cases. *Am J Surg Pathol*. 2004;28(3):298-307.
554. Delvaux V, Sciot R, Neuville B, et al. Multifocal epithelioid angiosarcoma of the small intestine. *Virchows Arch*. 2000;437(1):90-94.
555. Chan GS, Yuen ST, Chan KW. Synovial sarcoma presenting as a polypoid jejunal mass. *Histopathology*. 2004;44(2):191-193.
556. Schreiber-Facklam H, Bode-Lesniewska B, Frigerio S, Flury R. Primary monophasic synovial sarcoma of the duodenum with SYT/SSX2 type of translocation. *Hum Pathol*. 2007;38(6):946-949.
557. Papadopoulos T, Kirchner T, Bergmann M, Muller-Hermelink HK. Primary liposarcoma of the jejunum. *Pathol Res Pract*. 1990;186(6):803-806, discussion 7-8.
558. Agaimy A, Gaumann A, Schroeder J, et al. Primary and metastatic high-grade pleomorphic sarcoma/malignant fibrous histiocytoma of the gastrointestinal tract: an approach to the differential diagnosis in a series of five cases with emphasis on myofibroblastic differentiation. *Virchows Arch*. 2007;451(5):949-957.
559. Kie JH, Lee MK, Kim CJ, et al. Primary Ewing's sarcoma of the duodenum: a case report. *Int J Surg Pathol*. 2003;11(4):331-337.
560. Damiani S, Nappi O, Eusebi V. Primary rhabdomyosarcoma of the ileum in an adult. *Arch Pathol Lab Med*. 1991;115(3):235-238.
561. Lee JR, Chamberlain CR, Gerrity RG, et al. Malignant rhabdoid tumor of the duodenum. *Ann Diagn Pathol*. 1998;2(1):25-30.
562. Doyle LA, Hornick JL, Fletcher CD. PEComa of the gastrointestinal tract: clinicopathologic study of 35 cases with evaluation of prognostic parameters. *Am J Surg Pathol*. 2013;37:1769-1782.

563. Banks PM. Gastrointestinal lymphoproliferative disorders. *Histopathology*. 2007;50(1):42-54.
564. Crump M, Gospodarowicz M, Shepherd FA. Lymphoma of the gastrointestinal tract. *Sem Oncol*. 1999;26(3):324-337.
565. Appelman HD, Hirsch SD, Schnitzer B, Coon WW. Clinicopathologic overview of gastrointestinal lymphomas. *Am J Surg Pathol*. 1985;9:71-83.
566. Domizio P, Owen RA, Shepherd NA, et al. Primary lymphoma of the small intestine. A clinicopathological study of 119 cases. *Am J Surg Pathol*. 1993;17(5):429-442.
567. Hall PA, Levison DA. Malignant lymphoma in the gastrointestinal tract. *Semin Diagn Pathol*. 1991;8(3):163-177.
568. Lewin KJ, Ranchod M, Dorfman RF. Lymphomas of the gastrointestinal tract: a study of 117 cases presenting with gastrointestinal disease. *Cancer*. 1978;42(2):693-707.
569. Swerdlow SH, Jaffe Es, Brousset P, et al. Cytotoxic T-cell and NK-cell lymphomas: current questions and controversies. *Am J Surg Pathol*. 2014;38:e60-e71.
570. Chott A, Haedicke W, Mosberger I, et al. Most CD56+ intestinal lymphomas are CD8+CD5-T-cell lymphomas of monomorphic small to medium size histology. *Am J Pathol*. 1998;153(5):1483-1490.
571. Lavergne A, Brocheriou I, Delfau MH, et al. Primary intestinal gamma-delta T-cell lymphoma with evidence of Epstein-Barr virus. *Histopathology*. 1998;32(3):271-276.
572. Weiss RL, Lazarus KH, Macon WR, et al. Natural killer-like T-cell lymphoma in the small intestine of a child without evidence of enteropathy. *Am J Surg Pathol*. 1997;21(8):964-969.
573. Kohno S, Ohshima K, Yoneda S, et al. Clinicopathological analysis of 143 primary malignant lymphomas in the small and large intestines based on the new WHO classification. *Histopathology*. 2003;43(2):135-143.
574. Chan JK. Gastrointestinal lymphomas: an overview with emphasis on new findings and diagnostic problems. *Semin Diagn Pathol*. 1996;13(4):260-296.
575. Isaacson PG. Gastrointestinal lymphoma. *Hum Pathol*. 1994;25(10):1020-1029.
576. Isaacson PG. Gastrointestinal lymphomas of T- and B-cell types. *Mod Pathol*. 1999;12(2):151-158.
577. Nakamura S, Matsumoto T, Takeshita M, et al. A clinicopathologic study of primary small intestine lymphoma: prognostic significance of mucosa-associated lymphoid tissue-derived lymphoma. *Cancer*. 2000;88(2):286-294.
578. Thieblemont C, Bastion Y, Berger F, et al. Mucosa-associated lymphoid tissue gastrointestinal and nongastrointestinal lymphoma behavior: analysis of 108 patients. *J Clin Oncol*. 1997;15(4): 1624-1630.
579. Isaacson PG. Middle Eastern intestinal lymphoma. *Semin Diagn Pathol*. 1985;2(3):210-223.
580. Nassar VH, Salem PA, Shahid MJ, et al. "Mediterranean abdominal lymphoma" or immunoproliferative small intestinal disease. Part II: pathological aspects. *Cancer*. 1978;41(4):1340-1354.
581. Salem P, el-Hashimi L, Anaissie E, et al. Primary small intestinal lymphoma in adults. A comparative study of IPSID versus non-IPSID in the Middle East. *Cancer*. 1987;59(9):1670-1676.
582. Khojasteh A, Haghshenass M, Haghighi P. Current concepts immunoproliferative small intestinal disease. A "Third-World lesion.". *N Engl J Med*. 1983;308(23):1401-1405.
583. Lewin KJ, Kahn LB, Novis BH. Primary intestinal lymphoma of "Western" and "Mediterranean" type, alpha chain disease and massive plasma cell infiltration: a comparative study of 37 cases. *Cancer*. 1976;38(6):2511-2528.
584. Rappaport H, Ramot B, Hulu N, Park JK. The pathology of so-called Mediterranean abdominal lymphoma with malabsorption. *Cancer*. 1972;29(6):1502-1511.
585. Isaacson P. Middle East lymphoma and alpha-chain disease. An immunohistochemical study. *Am J Surg Pathol*. 1979;3(5):431-441.
586. Price SK. Immunoproliferative small intestinal disease: a study of 13 cases with alpha heavy-chain disease. *Histopathology*. 1990;17(1):7-17.
587. Isaacson PG, Price SK. Light chains in Mediterranean lymphoma. *J Clin Pathol*. 1985;38(6):601-607.
588. Asselah F, Slavin G, Sowter G, Asselah H. Immunoproliferative small intestinal disease in Algerians. I. Light microscopic and immunochemical studies. *Cancer*. 1983;52(2):227-237.
589. Al-Saleem T, Al-Mondhiry H. Immunoproliferative small intestinal disease (IPSID): a model for mature B-cell neoplasms. *Blood*. 2005;105:2274-2280.
590. Pangalis GA, Rappaport H. Common clonal origin of lymphoplasmacytic proliferation and immunoblastic lymphoma in intestinal alpha-chain disease. *Lancet*. 1977;2(8043):880.
591. Haghighi P, Kharazmi A, Gerami C, et al. Primary upper small-intestinal lymphoma and alpha-chain disease. Report of 10 cases emphasizing pathological aspects. *Am J Surg Pathol*. 1978;2(2):147-157.
592. Halphen M, Najjar T, Jaafoura H, et al. Diagnostic value of upper intestinal fiber endoscopy in primary small intestinal lymphoma. A prospective study by the Tunisian-French Intestinal Lymphoma Group. *Cancer*. 1986;58(9):2140-2145.
593. Damaj G, Verkarre V, Delmer A, et al. Primary follicular lymphoma of the gastrointestinal tract: a study of 25 cases and a literature review. *Ann Oncol*. 2003;14:623-629.
594. Yoshino T, Miyake K, Ichimura K, et al. Increased incidence of follicular lymphoma in the duodenum. *Am J Surg Pathol*. 2000;24(5):688-693.
595. Shia J, Teruya-Feldstein J, Pan D, et al. Primary follicular lymphoma of the gastrointestinal tract: a clinical and pathologic study of 26 cases. *Am J Surg Pathol*. 2002;26(2): 216-224.
596. Sato Y, Ichimura K, Tanaka T, et al. Duodenal follicular lymphomas share common characteristics with mucosa-associated lymphoid tissue lymphomas. *J Clin Pathol*. 2008;61(3):377-381.
597. Sentani K, Maeshima AM, Nomoto J, et al. Follicular lymphoma of the duodenum: a clinicopathologic analysis of 26 cases. *Jpn J Clin Oncol*. 2008;38(8):547-552.
598. Van Krieken JH, Medeiros LJ, Pals ST, et al. Diffuse aggressive B-cell lymphomas of the gastrointestinal tract. An immunophenotypic and gene rearrangement analysis of 22 cases. *Am J Clin Pathol*. 1992;97(2):170-178.
599. Najem AZ, Porcaro JL, Rush BF Jr. Primary non-Hodgkin's lymphoma of the duodenum. Case report and literature review. *Cancer*. 1984;54(5):895-898.
600. Connor J, Ashton-Key M. Gastric and intestinal diffuse large B-cell lymphomas are clinically and immunophenotypically different. An immunohistochemical and clinical study. *Histopathology*. 2007;51(5):697-703.
601. Petrich AM, Nabhan C, Smith SM. MYC-associated and double-hit lymphomas: a review of pathobiology, prognosis, and therapeutic approaches. *Cancer*. 2014;120:3884-3895.
602. Hashimoto Y, Nakamura N, Kuze T, et al. Multiple lymphomatous polyposis of the gastrointestinal tract is a heterogenous group that includes mantle cell lymphoma and follicular lymphoma: analysis of somatic mutation of immunoglobulin heavy chain gene variable region. *Hum Pathol*. 1999;30(5):581-587.
603. Kodama T, Ohshima K, Nomura K, et al. Lymphomatous polyposis of the gastrointestinal tract, including mantle cell lymphoma, follicular lymphoma and mucosa-associated lymphoid tissue lymphoma. *Histopathology*. 2005;47(5):467-478.
604. Carey MJ, Medeiros LJ, Roepke JE, et al. Primary anaplastic large cell lymphoma of the small intestine. *Am J Clin Pathol*. 1999;112(5):696-701.
605. Griffiths AP, Shepherd NA, Beddall A, Williams JG. Gastrointestinal tumour masses due to multiple myeloma: a pathological mimic of malignant lymphoma. *Histopathology*. 1997;31(4):318-323.
606. Henry K, Farrer-Brown G. Primary lymphomas of the gastrointestinal tract. I. Plasma cell tumours. *Histopathol*. 1977;1(1):53-76.
607. Brandt LJ, Davidoff A, Bernstein LH, et al. Small-intestine involvement in Waldenstrom's macroglobulinemia. Case report and review of the literature. *Dig Dis Sci*. 1981;26:174-180.
608. Guettier C, Hamilton-Dutoit S, Guillemain R, et al. Primary gastrointestinal malignant lymphomas associated with Epstein-Barr virus after heart transplantation. *Histopathology*. 1992;20(1):21-28.
609. Lai YC, Ni YH, Jou ST, et al. Post-transplantation lymphoproliferative disorders localizing to the gastrointestinal tract after liver transplantation: report of five pediatric cases. *Pediatr Transplant*. 2006;10:390-394.
610. Nalesnik MA. Involvement of the gastrointestinal tract by Epstein-Barr virus—associated posttransplant lymphoproliferative disorders. *Am J Surg Pathol*. 1990;14(suppl 1):92-100.
611. Lo RC, Chan SC, Chan KL, et al. Post-transplant lymphoproliferative disorders in liver transplant recipients: a clinicopathologic study. *J Clin Pathol*. 2013;66:392-398.
612. Miettinen M, Fletcher CD, Lasota J. True histiocytic lymphoma of small intestine. Analysis of two S-100 protein-positive cases with features of interdigitating reticulum cell sarcoma. *Am J Clin Pathol*. 1993;100(3):285-292.
613. Pileri SA, Grogan TM, Harris NL, et al. Tumours of histiocytes and accessory dendritic cells: an immunohistochemical approach to classification from the International Lymphoma Study Group based on 61 cases. *Histopathology*. 2002;41:1-29.
614. Milchgrub S, Kamel OW, Wiley E, et al. Malignant histiocytic neoplasms of the small intestine. *Am J Surg Pathol*. 1992;16(1):11-20.
615. Hornick JL, Jaffe ES, Fletcher CD. Extranodal histiocytic sarcoma: clinicopathologic analysis of 14 cases of a rare epithelioid malignancy. *Am J Surg Pathol*. 2004;28(9):1133-1144.
616. Hollowood K, Stamp G, Zouvani I, Fletcher CD. Extranodal follicular dendritic cell sarcoma of the gastrointestinal tract. Morphologic, immunohistochemical and ultrastructural analysis of two cases. *Am J Clin Pathol*. 1995;103(1):90-97.
617. Grody WW, Magidson JG, Weiss LM, et al. Gastrointestinal lymphomas. Immunohistochemical studies on the

cell of origin. *Am J Surg Pathol*. 1985;9(5):328-337.
618. Brugo EA, Larkin E, Molina-Escobar J, Contanzi J. Primary granulocytic sarcoma of the small bowel. *Cancer*. 1975;35(5):1333-1340.
619. Doyle LA, Sepehr GJ, Hamilton MJ, et al. A clinicopathologic study of 24 cases of systemic mastocytosis involving the gastrointestinal tract and assessment of mucosal mast cell density in irritable bowel syndrome and asymptomatic patients. *Am J Surg Pathol*. 2014;38:832-843.
620. Ranchod M, Lewin KJ, Dorfman RF. Lymphoid hyperplasia of the gastrointestinal tract. A study of 26 cases and review of the literature. *Am J Surg Pathol*. 1978;2(4):383-400.
621. Weaver DK, Batsakis JG. Pseudolymphomas of the small intestine. *Am J Gastroenterol*. 1965;44(4):374-381.
622. Rubin A, Isaacson PG. Florid reactive lymphoid hyperplasia of the terminal ileum in adults: a condition bearing a close resemblance to low-grade malignant lymphoma. *Histopathology*. 1990;17(1): 19-26.
623. Joo M, Shim SH, Chang SH, et al. Nodular lymphoid hyperplasia and histologic changes mimicking celiac diasese, collagenous sprue, and lymphocytic colitis in a patient with selective IgA deficiency. *Pathol Res Pract*. 2009;205:876-880.
624. Atwell JD, Burge D, Wright D. Nodular lymphoid hyperplasia of the intestinal tract in infancy and childhood. *J Pediatr Surg*. 1985;20(1):25-29.
625. McDonald GB, Schuffler MD, Kadin ME, Tytgat GN. Intestinal pseudoobstruction caused by diffuse lymphoid infiltration of the small intestine. *Gastroenterol*. 1985;89(4):882-889.
626. Burke JS, Sheibani K, Nathwani BN, et al. Monoclonal small (well-differentiated) lymphocytic proliferations of the gastrointestinal tract resembling lymphoid hyperplasia: a neoplasm of uncertain malignant potential. *Hum Pathol*. 1987;18(12):1238-1245.
627. Yantiss RK, Clement PB, Young RH. Neoplastic and pre-neoplastic changes in gastrointestinal endometriosis: a study of 17 cases. *Am J Surg Pathol*. 2000;24(4):513-524.
628. Cappell MS, Friedman D, Mikhail N. Endometriosis of the terminal ileum simulating the clinical, roentgenographic, and surgical findings in Crohn's disease. *Am J Gastroenterol*. 1991;86(8):1057-1062.
629. Chen KT. Endocervicosis of the small intestine. *Int J Surg Pathol*. 2002;10(1): 65-67.
630. Fernando SS, McGovern VJ. Neuromuscular and vascular hamartoma of small bowel. *Gut*. 1982;23(11):1008-1012.
631. Cortina G, Wren S, Armstrong B, et al. Clinical and pathologic overlap in nonsteroidal anti-inflammatory drug-related small bowel diaphragm disease and the neuromuscular and vascular hamartoma of the small bowel. *Am J Surg Pathol*. 1999;23(11):1414-1417.
632. Hemmer PR, Topazian MD, Gertz MA, Abraham SC. Globular amyloid deposits isolated to the small bowel: a rare association with AL amyloidosis. *Am J Surg Pathol*. 2007;31(1):141-145.
633. De Castro CA, Dockerty MB, Mayo CW. Metastatic tumors of the small intestines. *Surg Gyn Obst*. 1957;105(2):159-165.
634. Washington K, McDonagh D. Secondary tumors of the gastrointestinal tract: surgical pathologic findings and comparison with autopsy survey. *Mod Pathol*. 1995;8(4):427-433.
635. Winchester DP, Merrill JR, Victor TA, Scanlon EF. Small bowel perforation secondary to metastatic carcinoma of the lung. *Cancer*. 1977;40(1):410-415.
636. Adair C, Ro JY, Sahin AA, et al. Malignant melanoma metastatic to gastrointestinal tract. A clinicopathologic study. *Int J Surg Pathol*. 1994;2:3-10.
637. Lens M, Bataille V, Krivokapic Z. Melanoma of the small intestine. *Lancet Oncol*. 2009;10:516-521.
638. Jorge E, Harvey HA, Simmonds MA. Symptomatic malignant melanoma of the gastrointestinal tract. Operative treatment and survival. *Ann Surg*. 1984;199(3):328-331.
639. McNeill PM, Wagman LD, Neifeld JP. Small bowel metastases from primary carcinoma of the lung. *Cancer*. 1987;59(8):1486-1489.
640. Willbanks OL, Fogelmann MJ. Gastrointestinal melanosarcoma. *Am J Surg*. 1970;120(5):602-606.

Appendix

16

Laura W. Lamps

CHAPTER CONTENTS

Normal anatomy of the appendix, *617*
Congenital abnormalities of the appendix, *619*
Acute appendicitis, *619*
Epidemiology and pathogenesis, *619*
Clinical features, *620*
Pathologic features, *620*
Complications, *622*
Treatment, *622*
Periappendicitis, *622*
The negative appendectomy, *623*
Stump appendicitis, *623*
Chronic appendicitis, *623*
Other inflammatory processes, *623*
Diverticular disease, *623*
Chronic idiopathic inflammatory bowel disease, *623*
Parasitic infections, *626*
Bacterial infections, *627*
Viral infections, *627*
Fungal infections, *629*
Tumors, *629*
Nonmucinous tumors, *629*
Mucinous neoplasms, *634*
Neuroendocrine tumors, *639*
Other tumors and tumor-like lesions, *641*
Müllerian lesions, *641*
Mesenchymal tumors, *641*

Normal Anatomy of the Appendix

The vermiform appendix is a tubular structure arising from the medial wall of the cecum; it averages 9 cm in length and 0.7 cm in greatest diameter, although the luminal dimensions may vary along the length of the organ. Despite ongoing speculation and debate, vermiform appendix has no known function in humans and is typically regarded as a vestigial organ. The appendix reaches its maximum diameter by 4 years of age and becomes narrower (particularly after age 40) as lymphoid tissue decreases and fibrosis increases.[1] The position of the appendix varies considerably, due to variation in the position and shape of the cecum that occur during its development and rotation. The appendix most often lies posterior to the cecum or ascending colon, below the ileocecal valve.[2] Other appendiceal locations include retroileal, preileal, pelvic, and in the hepatorenal recess.[1–3] The significance of this variation in anatomic location is that unusual locations may lead to atypical clinical presentations of acute appendicitis.[4]

The layers of the wall of the appendix are similar to that of the large bowel (Fig. 16.1A), except for a greater representation of lymphoid tissue (which is particularly prominent during childhood and adolescence). Irregular distribution of the crypts in the appendix can raise the possibility of chronic idiopathic inflammatory bowel disease, but this is normal physiological variation (Fig. 16.1B).[1,5] Large lymphoid aggregates may have prominent germinal centers and can disrupt the muscularis mucosae (Fig. 16.1C); the epithelium overlying them may be attenuated as well.[5,6] Of note, lymphoid hyperplasia in children (Fig. 16.2), which may be associated with a variety of viral infections, has been associated with intussusception and symptoms mimicking acute nonspecific appendicitis.[7] Microscopically, the epithelium is columnar, similar to the colon, and contains absorptive cells, goblet cells, neuroendocrine cells (mainly of Kulchitsky type and located at the base) and occasional Paneth cells (Fig. 16.3).[6,8] Neuroendocrine cells have also been detected (both ultrastructurally and with chromogranin or related stains) within the lamina propria, unconnected with the crypts but in close association with nerve fibers.[1,9] These complexes, first identified by Masson, have been referred to as *subepithelial neuroendocrine complexes* or *endocrine cell-nerve fiber complexes*, and some have postulated that they are the origin of appendiceal neuroendocrine tumors (NETs). The submucosal, muscular, and serosal layers are qualitatively similar to their counterparts in the rest of the lower intestinal tract. Nerves and ganglion cells are often easily identifiable within the inner and outer layers of the muscularis propria. Grossly, the serosa is smooth, glistening, and transparent, and a thin layer of peritoneum covers the entire appendix. The mesoappendix, which is largely made up of adipose tissue and is contiguous with the mesentery of the bowel, contains the appendiceal vessels. Very infrequently, one or more small lymph nodes are found within it; these drain to the pericolic and superior mesenteric nodes.

Abstract

This chapter covers the major congenital, inflammatory, and neoplastic entities that the surgical pathologist will encounter in the appendix.

Keywords

appendix,
appendicitis,
adenoma,
sessile serrated adenoma/polyp,
adenocarcinoma,
well-differentiated neuroendocrine tumor,
low grade appendiceal mucinous tumor,
goblet cell carcinoid,
endometriosis,
endosalpingiosis,
pinworm,
pseudomyxoma peritonei

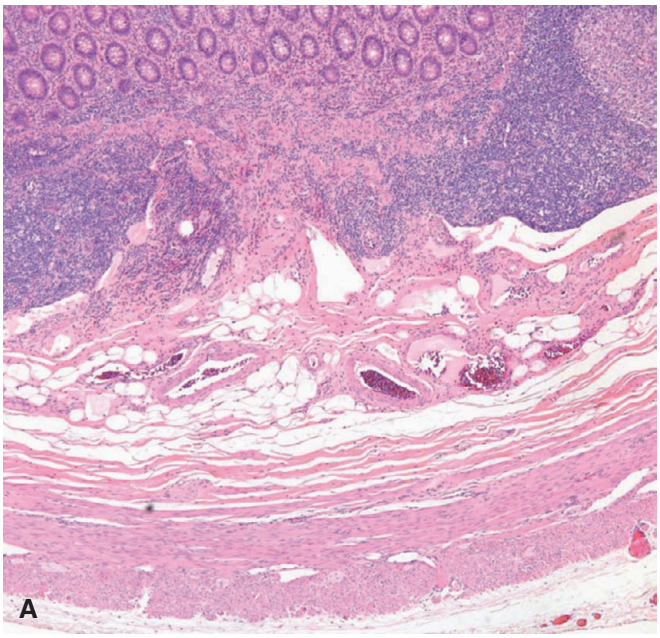

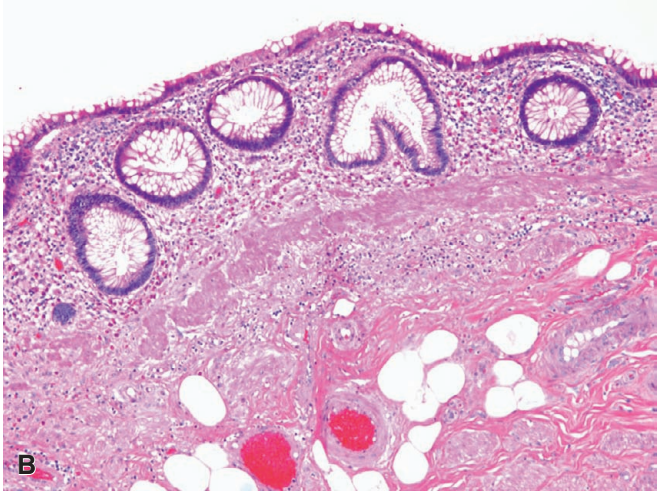

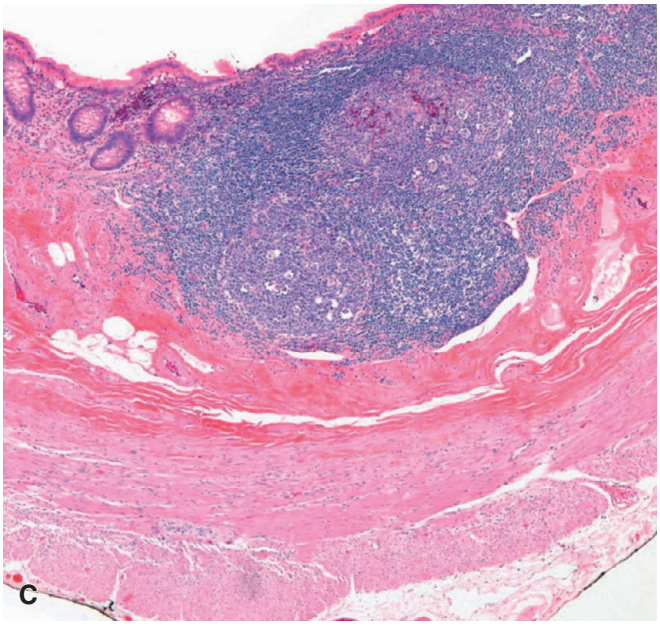

Figure 16.1 **A,** The layers of the walll of the appendix are similar to that of the large bowel. **B,** Irregular distribution of the crypts is a normal physiological variant and should not be misinterpreted as chronic idiopathic inflammatory bowel disease. **C,** Large lymphoid aggregates may disrupt the muscularis mucosae, and the overlying epithelium may be attenuated.

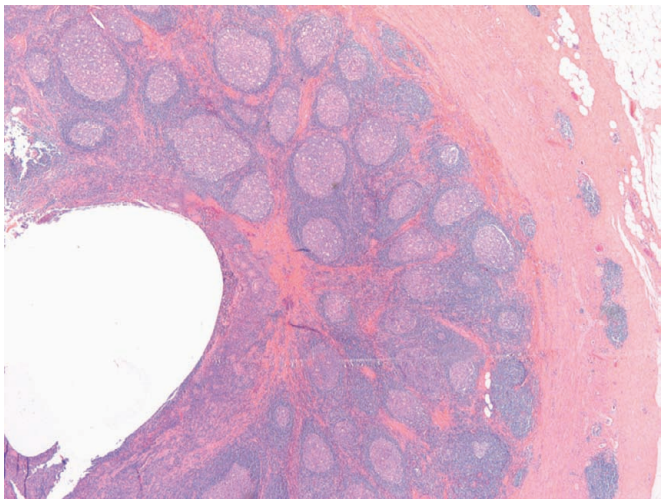

Figure 16.2 Lymphoid hyperplasia in children may be striking and is associated with viral infections as well as intussusception.

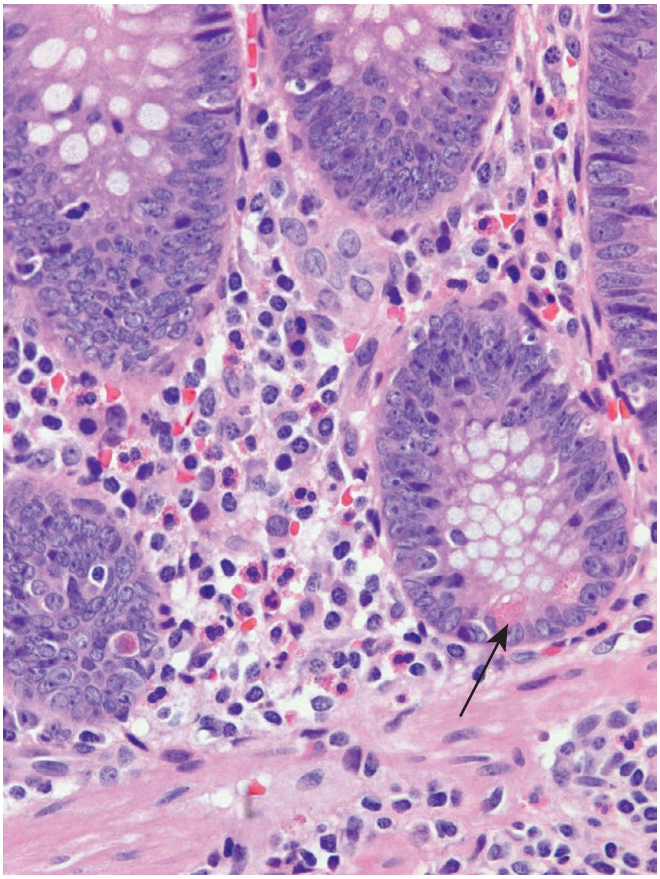

Figure 16.3 Paneth cells may be seen in the appendiceal mucosa *(arrow)*, along with neuroendocrine cells.

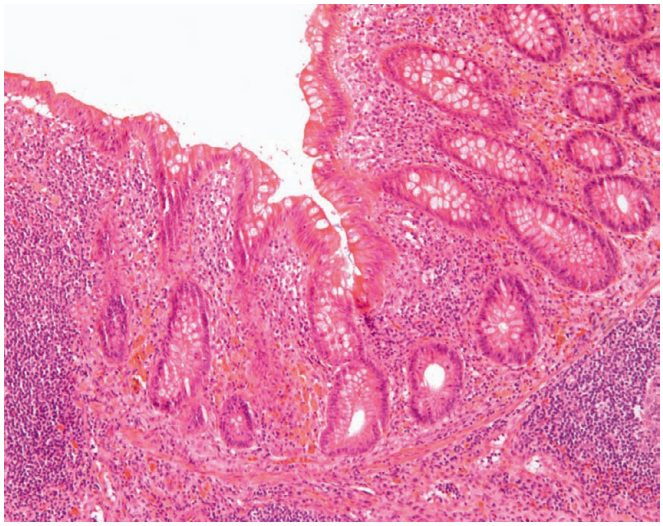

Figure 16.4 Melanosis is common in both adults and children and is analogous to melanosis coli.

Heterotopic gastric and **esophageal** tissue have been rarely described in the appendix.[10] **Melanosis** of the appendix, analogous to the homonymous large bowel condition, refers to the presence of melanin-like pigment in lamina propria macrophages (Fig. 16.4). It is relatively common at the microscopic level in both the pediatric and adult populations.[11,12]

Obliteration of the tip of the appendix is a frequent finding, the nature, significance, and mechanism of which remain controversial. The lesions in question consist of a variable mixture of nerve fibers, Schwann cells, neuroendocrine cells, fibrous tissue, and muscle, hence the variety of names for them including fibrous obliteration, neuroma, neuroappendicopathy, and neurogenic appendicitis (Fig. 16.5).[13–16] Some view this type of lesion as part of the normal aging process, and others as a sequela of a resolved acute appendicitis.[13,16] Regardless, many are incidental findings in patients whose appendices are removed for other reasons, and the incidence does increase with age. Appendiceal neural proliferations are rarely described in the context of neurofibromatosis type 1.[17] Importantly, appendiceal neural proliferations should not be mistaken for true appendiceal gastrointestinal stromal tumors (GISTs). The opposite phenomenon is characterized by a mild to moderate dilation of the lumen, an inconsequential process that may be distal to obstructive lesions such as fibrous obliteration or fecalith; in children, this finding has also been associated with an increase in goblet cells.[18] These lesions are sometimes dignified with the term *appendiceal ectasia*. Appendiceal ectasias should not be referred to as mucoceles or—worse—regarded as mucinous neoplasms (see later for further discussion).

Congenital Abnormalities of the Appendix

Congenital abnormalities of the appendix are fairly rare and include appendiceal agenesis, duplication, and congenital diverticula.[14] Congenital absence of the appendix is very rare and may be accompanied by developmental abnormalities of the cecum.[19,20] Appendiceal agenesis can be mimicked by several conditions, including unknown prior appendectomy, atrophy, autoamputation, and intussception.[19,21] Appendiceal duplication is more common, with an incidence of around 0.004%–0.009%.[22] Appendiceal duplication has been subdivided into multiple types, several of which are associated with multiple severe gastrointestinal and genitourinary anomalies.[14,23]

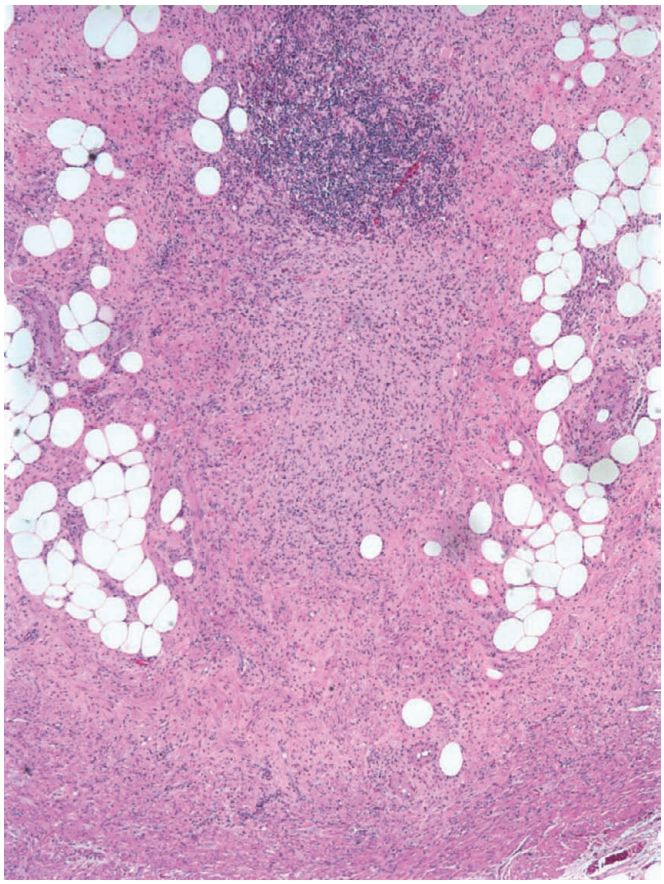

Figure 16.5 Fibrous obliteration of the appendiceal tip consists of a variable mixture of nerve fibers, fibrous tissue, Schwann cells, neuroendocrine cells, and muscle.

Appendiceal diverticula (see section later) can mimic duplications; the presence of a muscular wall virtually excludes acquired diverticulum. Appendiceal septa have also been described, typically in children and young adults, and in association with acute appendicitis.[24]

Acute Appendicitis

Epidemiology and Pathogenesis

Acute appendicitis is the most common abdominal surgical emergency, and it is predominantly a disease of the Western world. It is particularly common in the United States and Great Britain, and less common in Asia and Africa. In the United States, it is more common among whites than among African-Americans or Asians, and there is a male predominance.[25] Peak incidence is during the second and third decades, but acute appendicitis can occur at any time from early infancy to old age.

Historically, the most popular theory regarding the pathogenesis of acute "nonspecific" appendicitis has been that of obstruction of the appendiceal lumen. Advocates of this theory argue that obstruction (by fecalith, adhesions, tumor, lymphoid hyperplasia, etc.) leads to increased intraluminal pressure and that the resulting secretions under pressure impair the resistance of the mucosa to invasion by microorganisms.[26] Controversy persists, however, and detractors from the obstruction theory point out that evidence of obstruction is found in only a minority of appendices resected for acute appendicitis.[27,28] Other theories include compromise of the extramural

vascular supply, mucosal ulceration (possibly secondary to viral infection) with superimposed bacterial infection, and low-fiber diets resulting in retention of stool and resultant susceptibility to infection.[28–30] Rarely, acute appendicitis is caused by foreign bodies, including pins, bones, shotgun pellets, and other foreign objects.[29] It is fair to say that no single theory explains all cases of acute nonspecific appendicitis and that multiple factors may lead to mucosal ulceration and invasion of the wall by enteric bacteria.[28,31]

Clinical Features

The usual presentation of acute appendicitis is colicky periumbilical pain that eventually migrates to the right lower quadrant, accompanied by tenderness to palpation, nausea and vomiting, fever, leukocytosis, and elevated erythrocyte sedimentation rate and C-reactive protein.[32] Fewer than 50% of patients have all of these findings, however. The use of diagnostic imaging, especially the CT scan, is helpful in confirming or excluding a diagnosis of acute appendicitis.[32] If perforation of the appendix occurs, there may be temporary relief of pain followed by signs of acute peritonitis. Acute appendicitis in young children[33] and in the elderly[34,35] is more likely to be mishandled because of failure to consider the diagnosis and because the clinical findings are often atypical. The conditions most likely to mimic appendicitis clinically include gynecologic and urologic disease (e.g. adnexal mass and urinary tract infection), mesenteric lymphadenitis, Meckel diverticulitis, infarction or torsion of the greater omentum, and chemotherapy-induced typhlitis, particularly in children with leukemia and other malignancies.[36–39] False-positive diagnoses are twice as common in females as in males.[36] Of note, cases of acute appendicitis in AIDS patients does not differ significantly from that seen in immunocompetent individuals, except for a lower tendency to have an elevation of the white blood cell count.[40,41]

Pathologic Features

The macroscopic pathology of acute appendicitis is very variable, and the external appearance may not correlate with the extent of inflammation microscopically.[28,31] In addition, the correlation between the gross findings by the surgeon and the microscopic findings by the pathologist is only fair; in one series, one-third of appendices perceived to be normal by the surgeon at appendectomy showed inflammation at the microscopic level.[42] The earliest gross findings often consist of the usually glistening serosal surface becoming dull, with injection of the serosal vessels (Fig. 16.6A). As the inflammatory process progresses, there is increased edema and hyperemia, with variably present fibrinous or purulent exudates covering the serosa (Fig. 16.6B). The mucosal surface is often hyperemic as well, with associated intraluminal pus and narrowing of the lumen. Ultimately, the gangrenous appendix shows green, black, or purple discoloration of the wall, reflecting transmural inflammation and necrosis (Fig. 16.6C). The inflammatory process may involve the entire appendix, or only a part; if only one area is involved, it is most often the tip.[28]

The histologic findings in acute appendicitis are also very variable, ranging from minimal focal inflammation to total necrosis of the appendiceal wall. The degree of abnormality is at least partially dependent on the interval between the onset of symptoms and operation. In early lesions, neutrophils appear at the base of the crypts, often adjacent to a small defect in the epithelium (Fig. 16.7A). After this inflammatory process reaches the submucosa, it spreads quickly to the remaining appendix. Historically, neutrophilic infiltration of the appendiceal wall, often with associated mucosal ulceration, neutrophilic inflammation, and crypt abscesses, has been termed

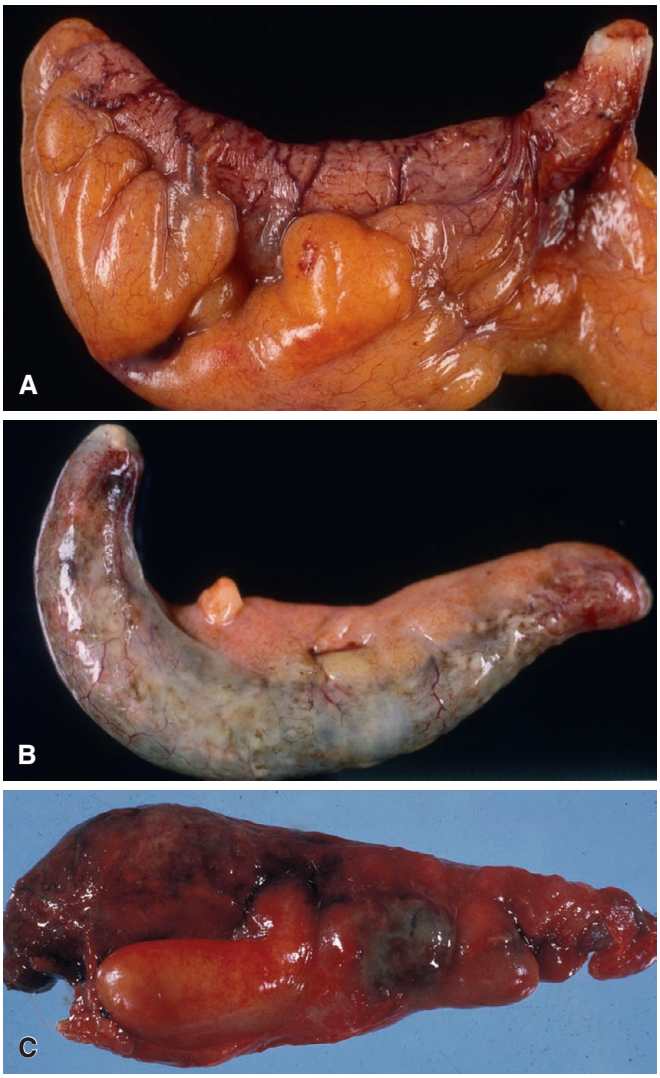

Figure 16.6 **A,** The earliest gross findings in acute appendicitis consist of dullness of the serosal surface, with injection of the serosal vessels. **B,** As the inflammatory process progresses, there is variably present fibrinous or purulent exudates along with hyperemia or hemorrhage. **C,** *Green*, *black*, or *purple* discoloration of the appendiceal wall indicates gangrene. (Photographs courtesy of Dr. George F. Gray, Jr.)

"acute suppurative appendicitis" (Fig. 16.7B and C).[28,31,43,44] Eosinophils may also be present within the exudate, the significance of which is unclear.[28] Thrombosed vessels are seen in approximately one-fourth of cases.[45] Gangrenous appendicitis features transmural inflammation and necrosis (Fig. 16.7D), often involving the mesoappendix as well, and perforation will occur without treatment. Fecaliths are frequently seen in cases of acute appendicitis but are also common in incidentally removed appendices.[46] Serosal vessels may be packed with lymphocytes, a change that may mimic chronic lymphocytic leukemia (Fig. 16.8).[47]

Controversy remains regarding the so-called "minimal diagnostic criteria" for acute nonspecific appendicitis. Some authorities maintain that inflammation limited to the mucosa and submucosa of the appendix alone are not adequate to explain the patient's symptoms and that the diagnosis of acute appendicitis requires the finding of neutrophils within the wall.[28] Others believe that early acute appendicitis does consist of mucosal neutrophilic inflammation and mucosal ulceration and that more impressive inflammation is often found

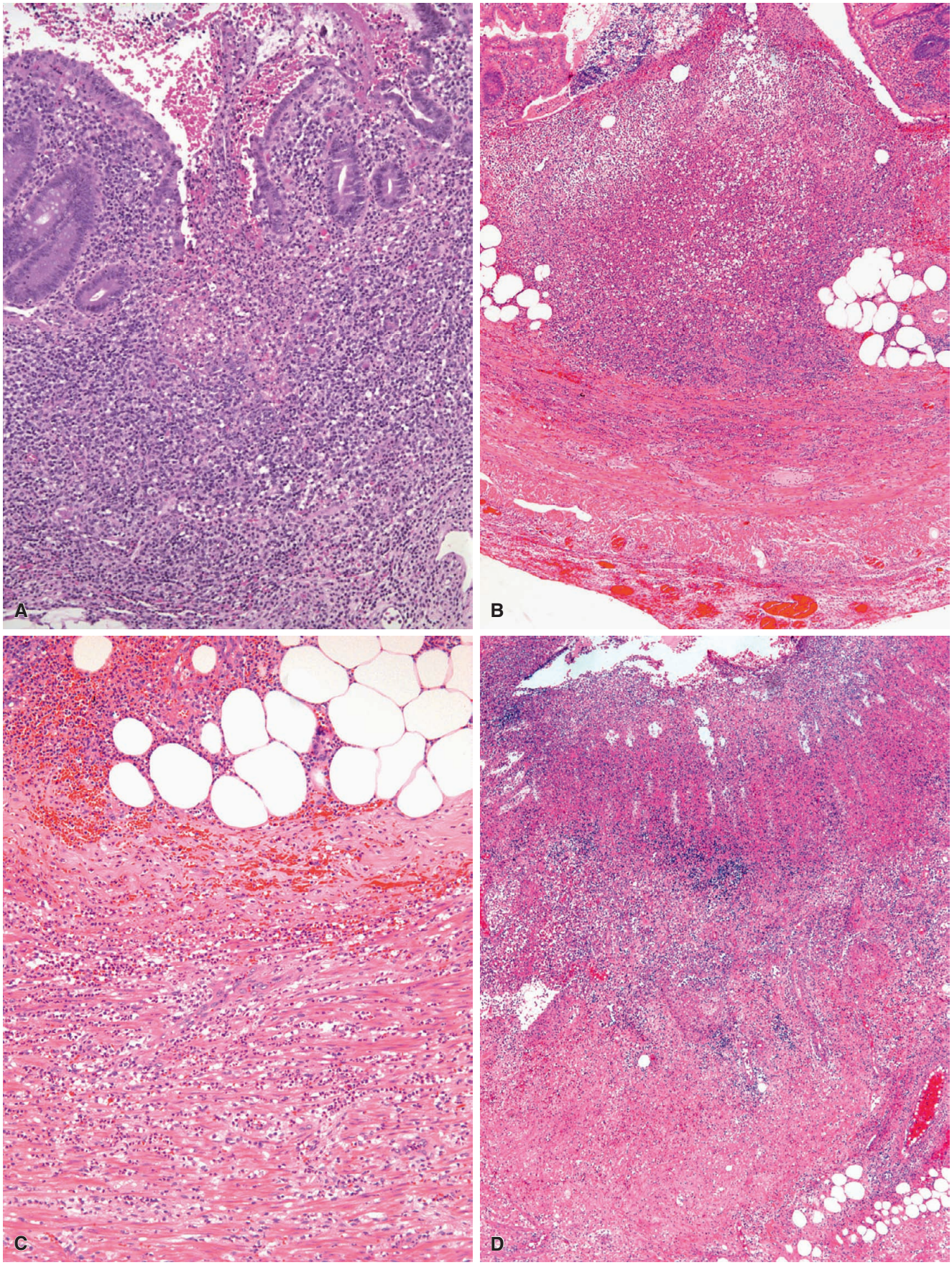

Figure 16.7 **A,** Early acute appendicitis with acute inflammation arising from a small mucosal defect. **B** and **C,** A more advanced case with massive acute inflammation extending into the muscular wall of the appendix, with extensive ulceration; residual mucosa is seen at the edges in **B**. **D,** Transmural inflammation and necrosis in gangrenous appendicitis.

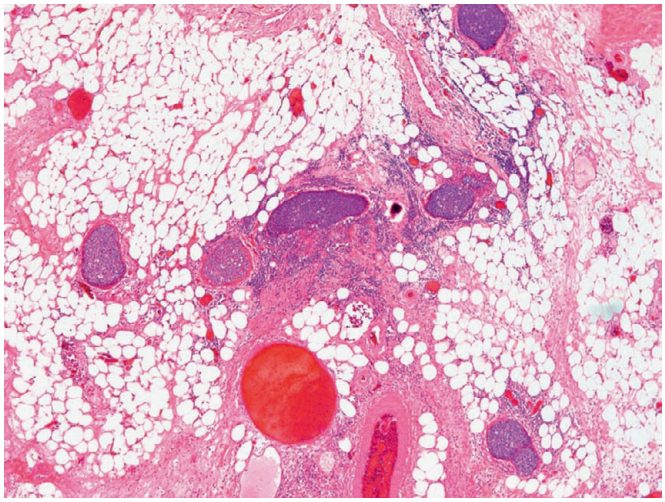

Figure 16.8 Serosal vessels in cases of acute appendicitis are often packed with lymphocytes, mimicking chronic lymphocytic leukemia.

if the specimen is extensively sampled. Although patients with symptoms of acute appendicitis may show only mucosal or submucosal inflammation even after extensive sampling, fecaliths and some enteric infections can also produce such changes. Clusters of neutrophils in the lumen should stimulate a search for evidence of mucosal or mural inflammation, but they are not diagnostic of acute appendicitis by themselves.

Some cases of appendicitis feature a prominent histiocytic component with clusters of xanthoma-like cells, which may be referred to as *xanthogranulomatous appendicitis*.[48] This pattern is regarded as an unusual healing pattern of appendicitis, often in protracted cases. It is associated with delayed or interval appendectomy (Fig. 16.9A), many of which may show granulomatous as well as xanthogranulomatous inflammation, in addition to transmural lymphoid aggregates and fibrosis that may mimic Crohn disease (Fig. 16.9B).[49]

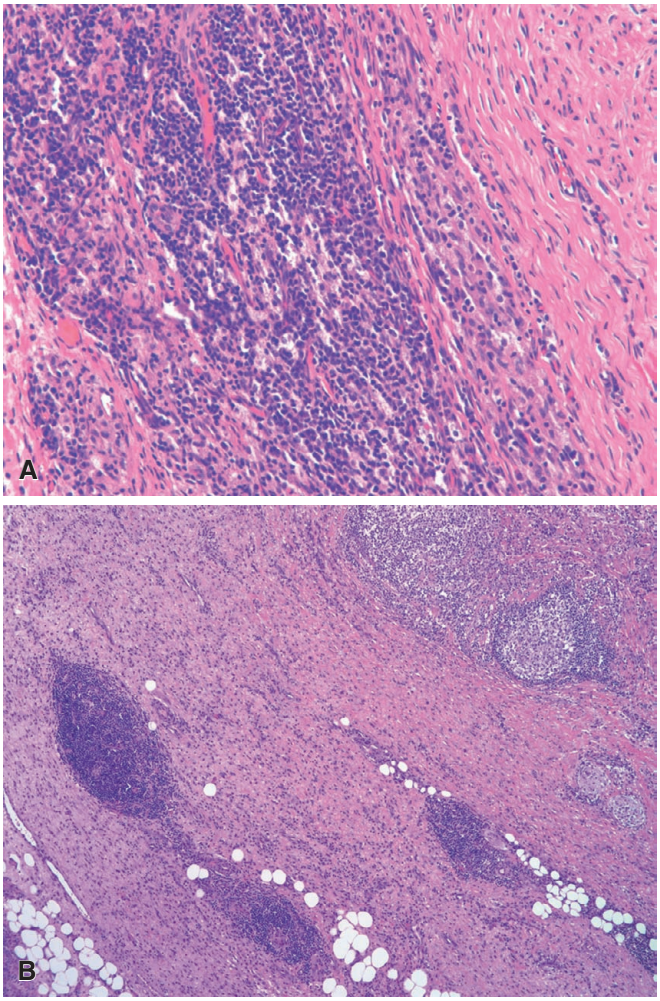

Figure 16.9 **A,** Interval appendectomy specimens often show lymphohistiocytic inflammation and transmural lymphoid aggregates that may mimic Crohn disease **(B)**. (Courtesy of Dr. Joel K. Greenson.)

Complications

The most common complication of acute appendicitis is perforation, which may lead to diffuse peritonitis or to the formation of a periappendiceal abscess or fibrous induration ("ligneous peri-typhlitis").[50,51] This latter condition, which may simulate a neoplasm clinically, is usually located in the right iliac fossa lateral to the cecum, but can occur in other sites depending on the original location of the appendix. Abscesses may perforate into the cecum, ileum, or rectum or even open onto the skin surface and form a fistulous tract. Another serious complication is the spread of the inflammation via the ileocolic, upper mesenteric, and portal veins to the liver, with formation of hepatic abscesses and occasionally complicated by septic thrombophlebitis.[52] Historically, appendicitis with perforation was also believed to be a risk factor for infertility in women because of obstruction of the fallopian tubes[53]; however, more recent studies have not provided substantial evidence that this is the case.[54]

The potential role of enteric bacteria in the development and the complications of acute appendicitis has been extensively debated.[31,55,56] Bacteriologic studies, most often performed using microbiologic cultures, have revealed a wide variety of aerobic and anaerobic bacteria, most commonly *Bacteroides* species,[55,57] but no causative role has ever been proven. It is, however, important to be aware of the variety of bacteria that can be present within an inflamed appendix and to select appropriately broad antibiotics if wound infection or other sequelae occur.[43,55]

Treatment

In 1886, Reginald H. Fitz (arguably the first American surgical pathologist) demonstrated that the appendix was the origin of the mysterious and often fatal inflammation of the right iliac fossa known at the time as *perityphlitis*.[58] Three years later, McBurney emphasized the importance of accurate early diagnosis of acute appendicitis and prompt surgical intervention. By 1900, the mortality rate had already fallen to 35%.[59,60] During the next three decades, it was further reduced to 5% as a result of better awareness on the part of the patient and the physician concerning the symptoms and signs of acute appendicitis, the need for early surgical intervention, and the dangers of catharsis and morphine for undiagnosed abdominal pain.

In the ensuing years, a combination of improved surgical technique, better preoperative and postoperative care, advances in anesthesiology, and the development of effective antibacterial agents have led to further declines in mortality to a fraction of 1%. Laparoscopic appendectomy is now considered the treatment of choice for acute appendicitis, even in complicated cases.[61]

Periappendicitis

Periappendicitis refers to acute or chronic inflammation of the appendiceal serosa.[28,31,43,44,62] It is almost always present in the

advanced stages of appendicitis with transmural inflammation, but it also occurs in the absence of primary appendiceal inflammation, secondary to spread of inflammation from another site (such as the female adnexa). Periappendicitis may be accompanied by a fibrinous exudate and/or adhesions. In the presence of periappendicitis, evidence of acute inflammation elsewhere within the appendix itself or an appendiceal diverticulum should be thoroughly sought, usually by submitting the entire appendix; if none is found, the diagnosis given should be that of periappendicitis rather than appendicitis, suggesting an extra-appendicular inflammatory process. In order not to overdiagnose this condition, however, it should be remembered that surgical manipulation may induce a neutrophilic infiltrate in the serosa.

The Negative Appendectomy

A certain percentage of appendices removed for signs and symptoms of acute appendicitis will be histologically normal. The rate of negative appendectomy specimens has declined significantly in recent years, most likely due to better diagnostic modalities, and is currently approximated at 8%–9%.[63] When initial sections are unremarkable, submission of the remainder of the appendix is recommended so that focal lesions are not overlooked. In many patients with grossly and histologically normal appendices, symptoms still resolve following appendectomy.[43] Some have suggested that these cases can be explained by expression of inflammatory mediators (such as cyclooxygenase 1 and 2, and prostaglandin E)[64] at the molecular level, but this remains a controversial proposition.

Stump Appendicitis

Stump appendicitis is defined as residual or progressive acute inflammation in the postresection appendiceal stump; contributing factors remain poorly elucidated.[65] It is an uncommon complication of appendectomy, and diagnosis is often delayed due to its rarity.[65,66] Patients typically present with nonspecific findings, including abdominal pain, nausea and vomiting, and fever, and imaging studies may reveal a distended appendiceal stump. Complications include stump necrosis and perforation. The histologic findings have not been well studied but appear to be similar to those of acute appendicitis. Stump appendicitis is likely under-reported and should be considered in patients with postappendectomy abdominal pain.

Chronic Appendicitis

The existence of primary chronic appendicitis as a pathologic or clinical entity has been greatly disputed, with putative symptoms and signs that are as vague and shadowy as the pathology. Normally, there may be collections of lymphocytes in the muscular wall of the appendix, as well as rare plasma cells or eosinophils in the mucosa, and these findings should not be diagnosed as chronic appendicitis. Fibrous obliteration of the appendiceal tip, whatever its pathogenesis, should not be regarded as chronic appendicitis either. Some patients may suffer recurrent bouts of acute appendicitis prior to resection, leading to chronic symptoms, and occasionally pathologists are confronted with an appendix containing a destructive mononuclear or plasmacytic infiltrate with associated fibrosis. These changes most likely represent resolving or ongoing acute appendicitis and are also seen in the context of delayed or interval appendectomy (see earlier). Most authorities agree that, although there are numerous chronic inflammatory disorders of the appendix (e.g. infection, involvement by chronic inflammatory bowel disease), "primary chronic appendicitis" is not an entity that should be clinically or pathologically recognized.[28,43]

Other Inflammatory Processes

Diverticular Disease

Diverticula of the appendix may be congenital or acquired. Congenital diverticula are rare, with a reported incidence of 0.014%.[14,67] They are typically solitary and located on the antimesenteric border of the appendix.[14] They can be recognized by the presence of the muscularis propria.

Acquired appendiceal diverticula are more common, with an incidence varying between 0.2% and 1.7%.[14] They are usually multiple (Fig. 16.10A) and arise in a weak area of the appendiceal wall likely as a result of increased intraluminal pressure (similar to their colonic counterparts). Diverticulitis may occur, resulting in a clinical picture indistinguishable from that of acute appendicitis, although patients are often older at presentation.[68] The pathogenesis is likely related to obstruction and increased intraluminal pressure, a theory that is supported by the association of appendiceal diverticula with both neoplasms and cystic fibrosis.[69–72] For this reason, some authorities recommend submission of the entire appendix in specimens with diverticula, so that small neoplasms are not overlooked.

Appendiceal diverticula can occur on the mesenteric or antimesenteric aspect of the appendix and are frequently found at the tip.[14,73] Histologically, they consist of mucosa and submucosa herniating through the muscularis propria (Fig. 16.10B), with associated acute inflammation in cases of diverticulitis. When perforated, the extrusion of mucus can mimic low-grade appendiceal mucinous neoplasms (LAMNs; see Fig. 16.10C), although neoplastic epithelium should be absent in cases of appendiceal diverticula with extruded mucin.[74] Appendiceal diverticula are probably markedly under-reported due to their small size and the fact that they are often obliterated by inflammation at the time of resection.[68]

Chronic Idiopathic Inflammatory Bowel Disease

Ulcerative colitis involves the appendix in many cases, often in the context of contiguous cecal involvement (Fig. 16.11).[75] The concept of the appendiceal "skip lesion" in ulcerative colitis is now well established, however, defined as patchy involvement of the appendix and peri-appendiceal orifice in patients with distal disease that spares the intervening segment of colon.[48,76,77] Clinically, these patients behave similarly to those without appendiceal skip lesions, and thus the presence of skip lesions without contiguous cecal involvement should not be regarded as evidence of Crohn disease (see Chapter 17).

The appendix is involved in approximately 40% of patients who undergo ileocecal resection for *Crohn disease*.[78] Histologic features are similar to Crohn disease elsewhere in the bowel and include transmural inflammation with lymphoid aggregates, crypt architectural distortion, mural fibrosis, neural hyperplasia, and granulomas (Fig. 16.12). However, only a minority of patients with isolated granulomatous appendicitis go on to develop Crohn disease elsewhere; these cases are usually attributable to infection (e.g. *Yersinia*, *Mycobacteria* spp.), interval appendectomy (see earlier), or sarcoidosis.[48,49,79–81] It is often impossible to distinguish between Crohn disease and other causes of granulomatous appendicitis, particularly *Yersinia* and mycobacterial infection, on histologic grounds alone, and correlation with cultures, molecular assays, imaging studies, and ultimately close clinical follow-up for additional manifestations of Crohn disease may be necessary.[48,80,81]

Sarcoidosis can involve virtually any organ of the body but is responsible for only a very small minority of the reported cases of granulomatous inflammation of the appendix. As in other organs,

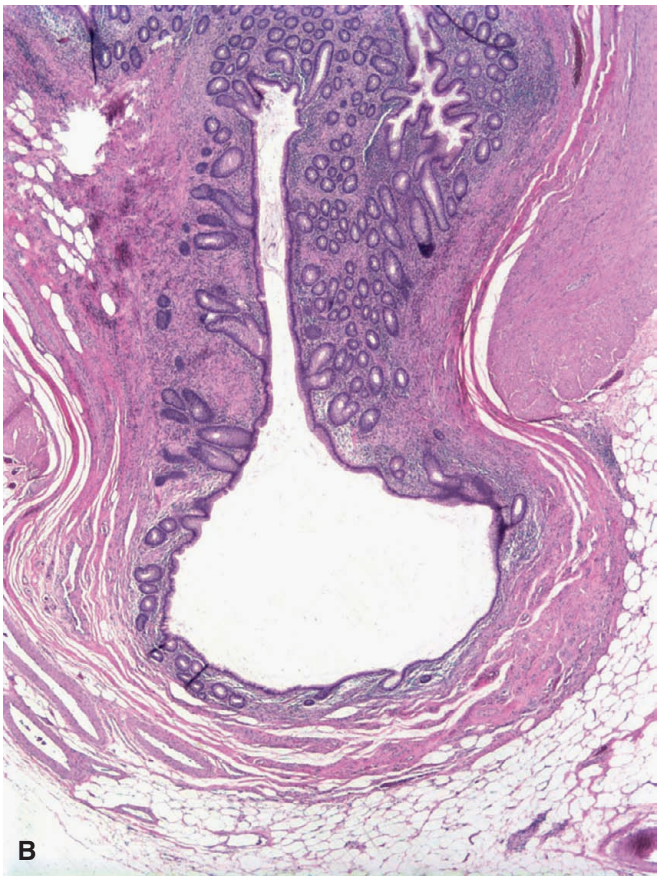

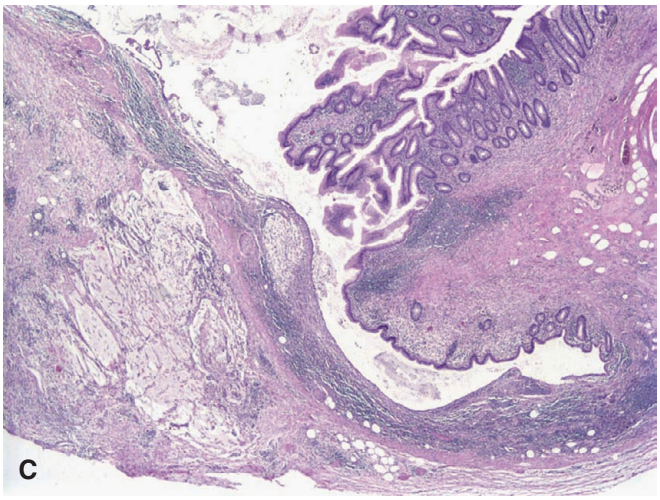

Figure 16.10 **A,** Appendiceal diverticula, at the tip and along the side of an appendectomy specimen. **B,** The mucosa and submucosa herniate through the muscularis propria, similar to colonic diverticula. **C,** Ruptured appendiceal diverticula can mimic low-grade mucinous neoplasms; note the lack of neoplastic epithelium.

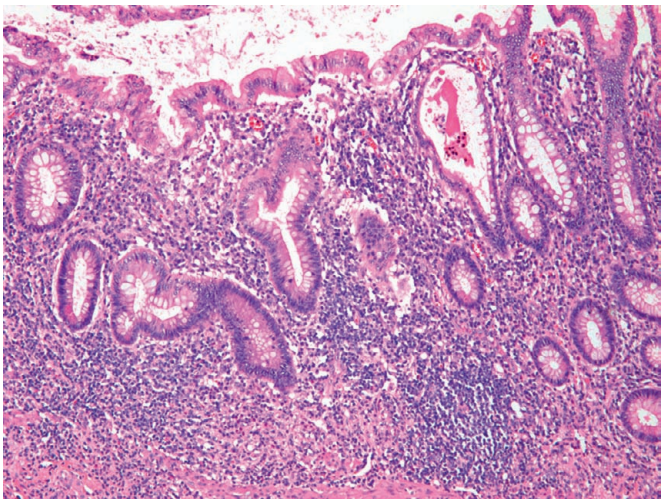

Figure 16.11 Mild architectural distortion and focal active inflammation in an appendix from a patient with ulcerative colitis.

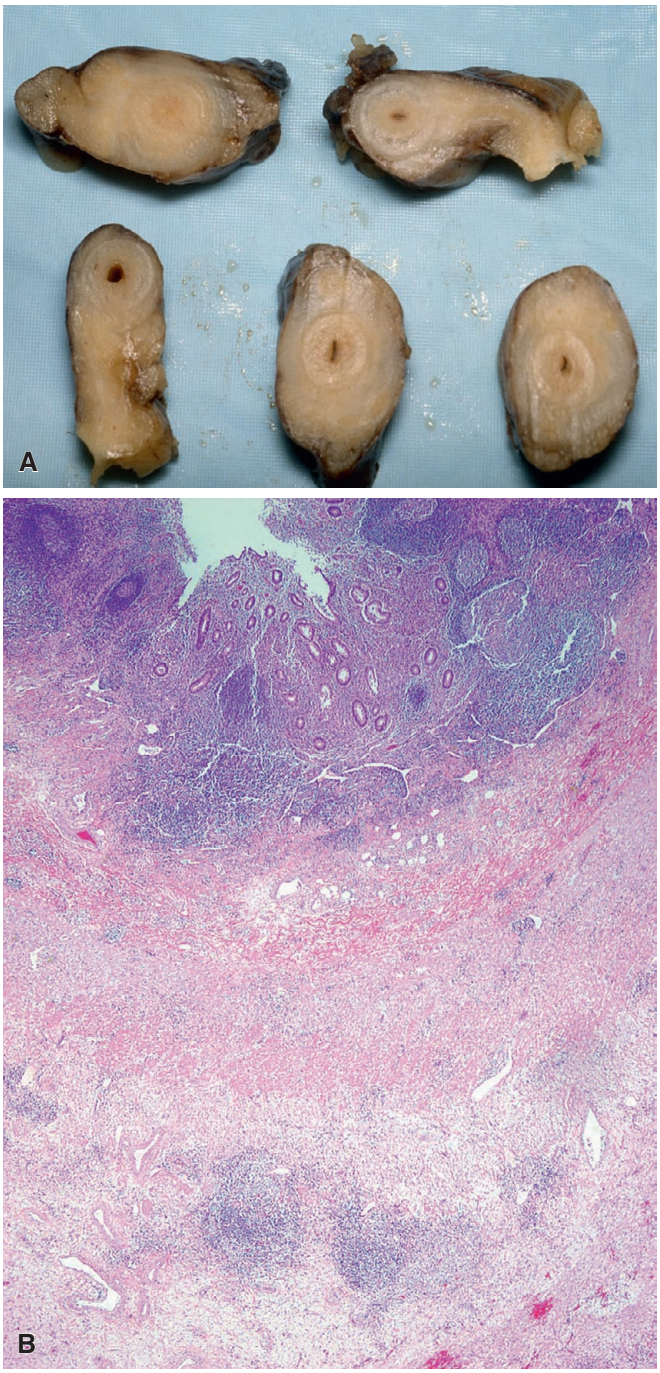

Figure 16.12 Gross Specimen Showing Appendiceal Involvement by Crohn Disease. A, Note the marked wall thickening and extension of the inflammatory process into the periappendiceal fat. **B,** There is mural edema and transmural lymphoid aggregates; the overlying mucosa shows pyloric metaplasia. (Photographs courtesy of Dr. Henry Appelman.)

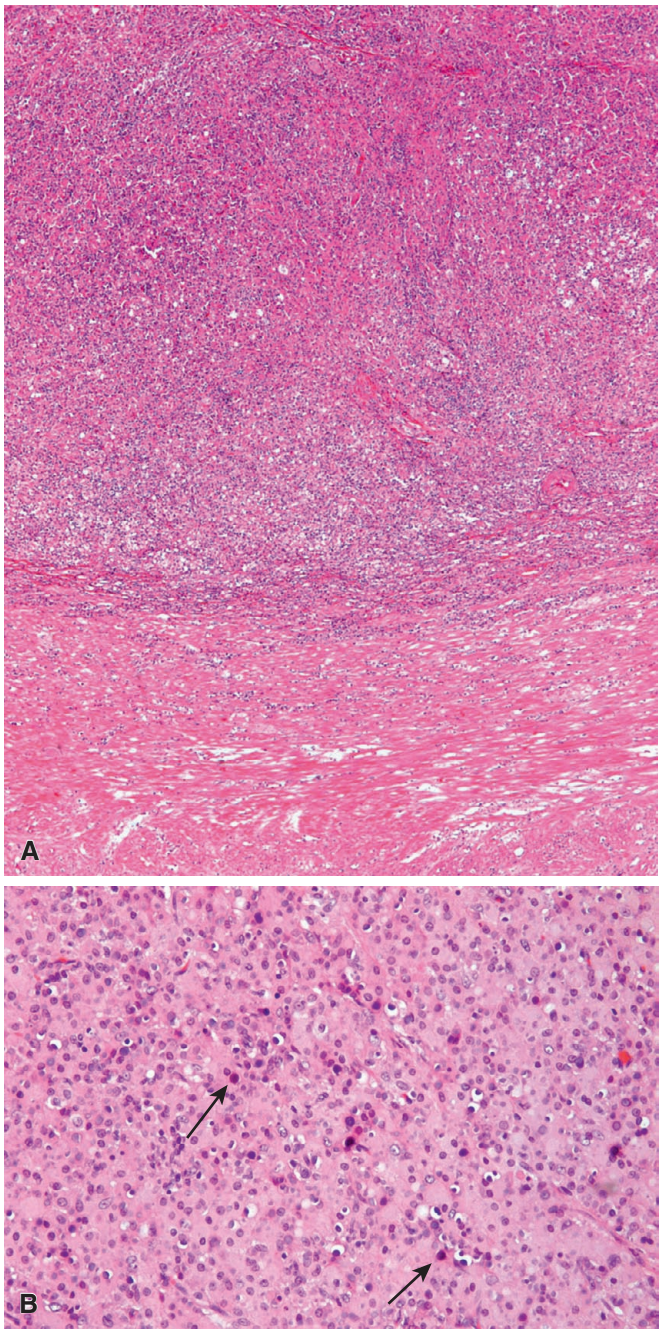

Figure 16.13 A, Malakoplakia is composed of an infiltrate of macrophages that in this case destroys the normal appendiceal architecture. **B,** Michaelis–Gutmann bodies are characteristic *(arrows)*.

sarcoidosis is a diagnosis of exclusion and should be diagnosed only after other causes of granulomatous appendicitis have been excluded. Extra-appendiceal disease is most helpful in confirming the diagnosis.[48,82,83]

Several types of **vasculitis** have been reported in the appendix; although some cases are organ-limited, many are associated with systemic diseases such as rheumatoid arthritis, polyarteritis nodosa, lupus, and Henoch–Schönlein purpura.[84–86] Enterocolic lymphocytic phlebitis has also been reported to involve the appendix.[87]

Although the appendix is a rare site for **malakoplakia**, occurrence there is well documented.[88,89] Malakoplakia in the GI tract is often associated with underlying malignancy or some other form of immunocompromise. As in other sites, this lesion consists of soft yellow-white plaques composed of an infiltrate of macrophages with granular cytoplasm and associated Michaelis–Gutmann bodies, which are virtually diagnostic (Fig. 16.13). These bodies stain positively with iron and calcium stains. There is usually an attendant mixed inflammatory infiltrate, and special stains for microorganisms are

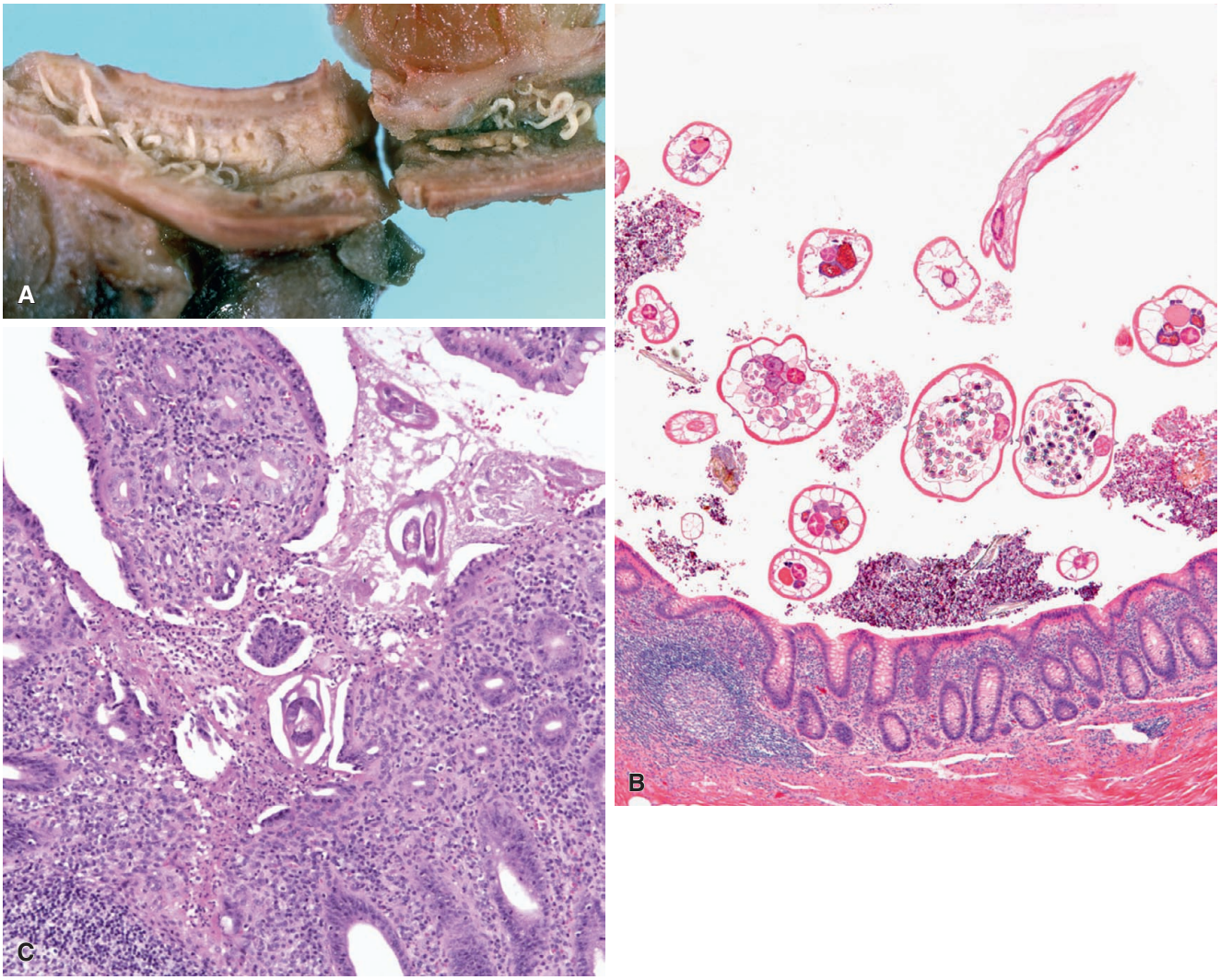

Figure 16.14 **A,** A resected appendix containing numerous pinworms. **B,** Typical appearance of pinworms within the appendiceal lumen, with eosinophilic cuticle and prominent lateral ala. **C,** Rarely, pinworms may invade the appendiceal mucosa. (**A,** Courtesy Dr. George F. Gray, Jr.)

typically negative. Many authorities believe that this unusual lesion represents some type of occult bacterial infection, and it has been postulated that Michaelis–Gutmann bodies represent mineralized portions of bacterial capsule. Several bacterial species have been detected within the lesions of malakoplakia using electron microscopy, microbiologic techniques, and PCR, including *Escherichia coli*, *Yersinia*, *Klebsiella*, *Aeromonas*, and *Rhodococcus* species.

Rosai–Dorfman disease can exceptionally involve the appendix as an isolated event, or in association with involvement of other portions of the gastrointestinal tract.[90]

Intussusception (invagination) of the appendix into the cecal lumen may develop spontaneously; the *intussusceptum* may be composed of the entire appendix or, more commonly, of only the base.[91] The underlying cause is often lymphoid hyperplasia, but intussusception has also been associated with tumors, polyps, infections, and endometriosis of the appendix.[91,92]

Parasitic Infections

Enterobius vermicularis (also known as pinworms or oxyuriasis) is found in 0.6%–13% of resected appendices (Fig. 16.14A and B).[43,93] Children and adolescents have the highest prevalence of infection.[93,94] Pinworms are more commonly seen in otherwise normal appendices, and although invasion of the mucosa has been rarely documented (Fig. 16.14C), the ability of the parasite to cause mucosal damage and appendiceal inflammation remains controversial.[93,95] Both worms and eggs can also fill and obstruct the lumen, causing inflammation similar to that caused by fecaliths.[43,93,94] *Strongyloidiasis stercoralis* in the appendix is often characterized by a diffuse eosinophilic and/or mixed eosinophilic and neutrophilic infiltrate or by the presence of granulomas with necrotic centers and an associated eosinophilic infiltrate.[31,96] The parasites are found only exceptionally within the granulomas, but characteristic larvae and worms with sharply pointed tails may be found within the appendiceal crypts (Fig. 16.15), similar to the remainder of the GI tract. *Schistosomiasis* can involve the appendix, but this is rare even in countries where infection is endemic. Arguments similar to those regarding pinworms and their ability to cause appendicitis have occurred pertaining to schistosomiasis, but it does appear that schistosomiasis causes appendicitis in rare cases, either by a granulomatous response to ova or by marked fibrosis leading to luminal obstruction.[31,97,98] Findings include calcified eggs in the appendix, with associated fibrosis

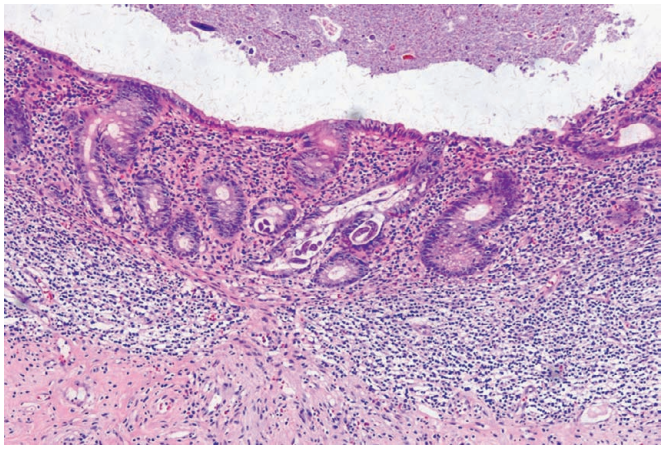

Figure 16.15 Larvae of *Strongyloides stercoralis* within the crypt epithelial cells of the appendix. (Courtesy Dr. Dennis Baroni-Cruz.)

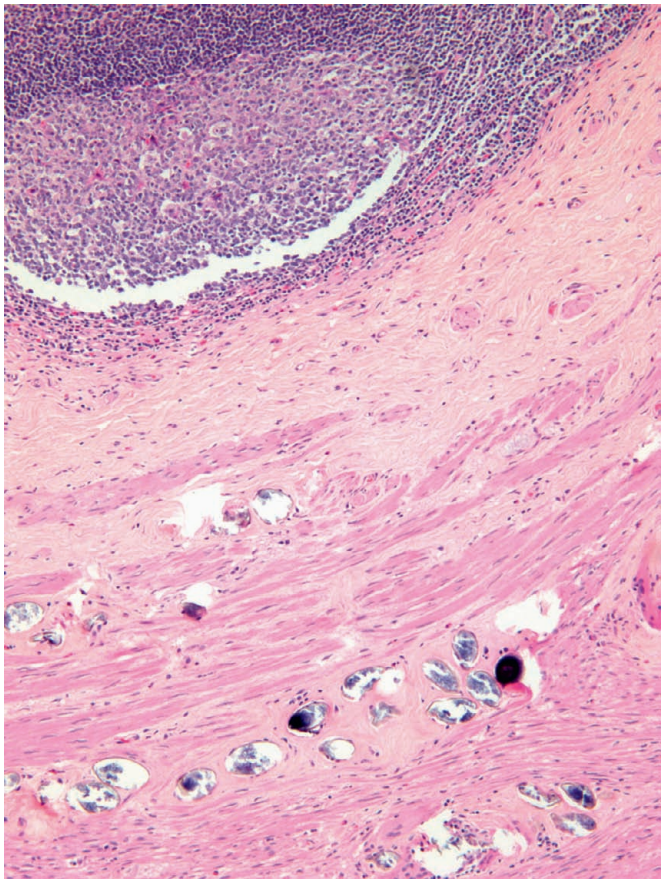

Figure 16.16 Appendiceal schistosomiasis featuring numerous calcified eggs with associated fibrosis within the wall of the appendix. (Courtesy Dr. Joseph Misdraji.)

(Fig. 16.16). Occasionally, appendices contain transmural inflammation that is rich in eosinophils, with granulomatous inflammation in response to the ova. Other parasitic infections that rarely affect that appendix include *Entamoeba histolytica*, which often represents extension from an infection of the right colon and must be distinguished from nonpathogenic amoeba[43,99]; *Cryptosporidium*, most often seen in immunocompromised patients[100]; and nematodes such as *Ascaris lumbricoides* (roundworms)[43,101] and *Trichuris* species (whipworms).[102]

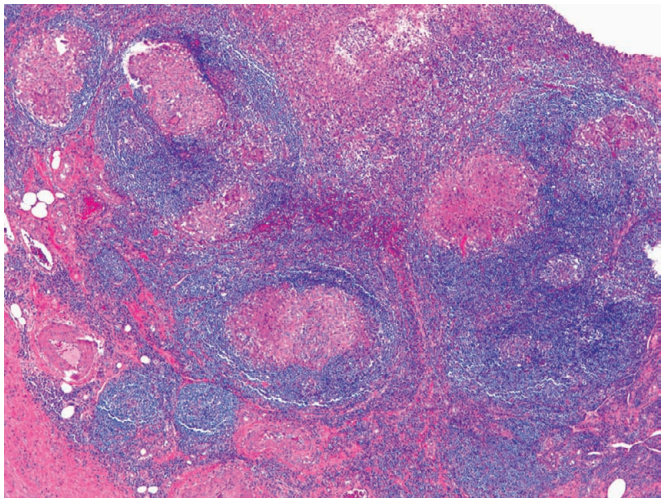

Figure 16.17 *Yersinia* infection of the appendix characteristically features epithelioid granulomas with prominent associated lymphoid tissue.

Bacterial Infections

Yersinia infection (caused by *Y. enterocolitica* or *Y. pseudotuberculosis*) is a well-known cause of granulomatous appendicitis. Characteristic histologic features, including epithelioid granulomas with associated prominent lymphoid tissue (Fig. 16.17), mural fibrosis, and transmural lymphoid aggregates, may be close mimics of Crohn disease. Microbiologic cultures or molecular testing may be necessary to confirm the diagnosis.[81,103,104] *Actinomycosis (Actinomyces israelii)* may involve the appendix and can produce a mixed suppurative and granulomatous inflammatory process (Fig. 16.18) with marked associated fibrosis that may simulate a tumor.[105,106] Because *Actinomyces* are gut commensals that are commonly found in the lumen of the appendix incidentally, it is necessary to identify organisms in the wall of the appendix with an appropriate associated inflammatory response to make the diagnosis, so that long-term antibiotic therapy is not given inappropriately.[43] Although the ileocecum is involved in almost half of cases of intra-abdominal *tuberculosis*, the appendix is affected in only about 1%.[107] Characteristic findings include caseating granulomas with mucosal ulceration.[108] Appendiceal tuberculosis must be differentiated from other granulomatous infections as well as Crohn disease. Atypical mycobacteria rarely cause appendicitis and occurs almost exclusively in immunocompromised patients.[31] Other bacterial infections that rarely involve the appendix include enteric organisms such as *Salmonella*, *Shigella*, and *Campylobacter* species.[31] Appendiceal involvement by *Clostridium difficile* is rare, but the macroscopic and histologic features are identical to those seen in *C. difficile*-associated colitis (Fig. 16.19).[109]

Viral Infections

Adenovirus is one of the more common viruses found in the appendix, causing lymphoid hyperplasia and subsequent intussusception (Fig. 16.20; see also Fig. 16.2).[110,111] *Measles* can be accompanied by appendicitis during its prodromal stage. Microscopic examination typically shows marked lymphoid hyperplasia with the presence of multinucleated giant cells of the Warthin–Finkeldey type, similar to those seen in the tonsil (Fig. 16.21)[112]; as infection progresses, a suppurative component may develop. An astute pathologist could thus tell the patient's physician that the child is about to break out into the characteristic rash of measles. *Infectious mononucleosis* (Epstein–Barr virus) can also be accompanied by changes similar to those seen in lymph nodes, including marked lymphoid hyperplasia and marked expansion of the lamina propria by a mixed proliferation

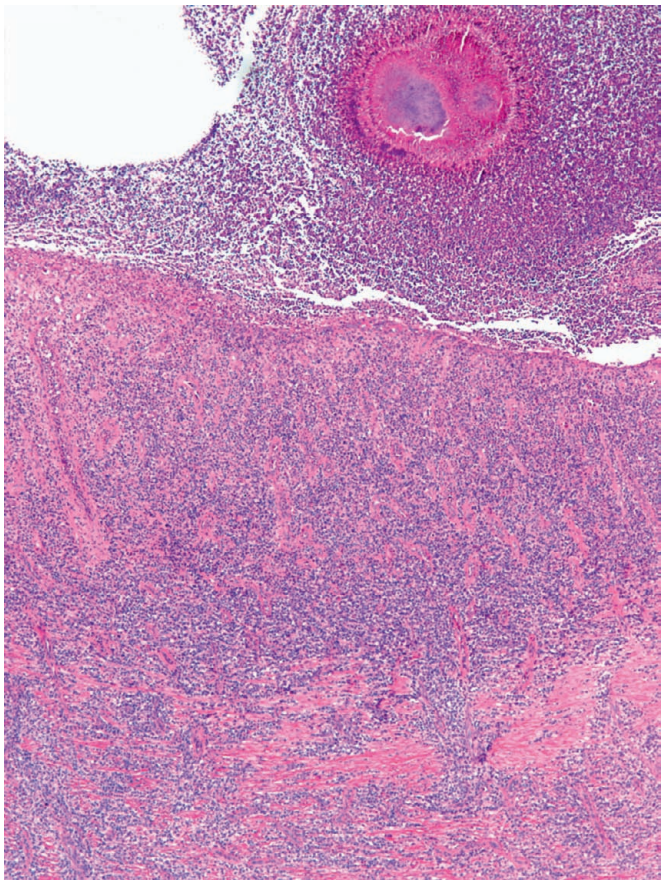

Figure 16.18 Actinomycosis of the appendix, featuring mucosal ulceration and mural fibrosis, with overlying clusters of bacteria with associated acute inflammation and Splendore–Hoeppli protein.

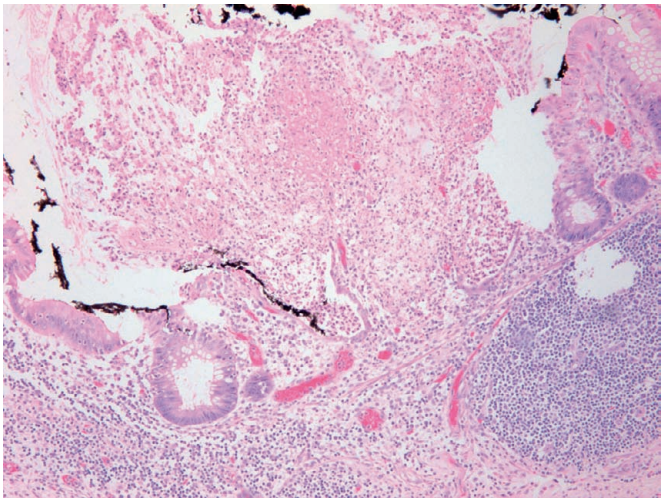

Figure 16.19 Appendix with pseudomembranes and dilated, "exploding" crypts typical of *Clostridium difficile* infection.

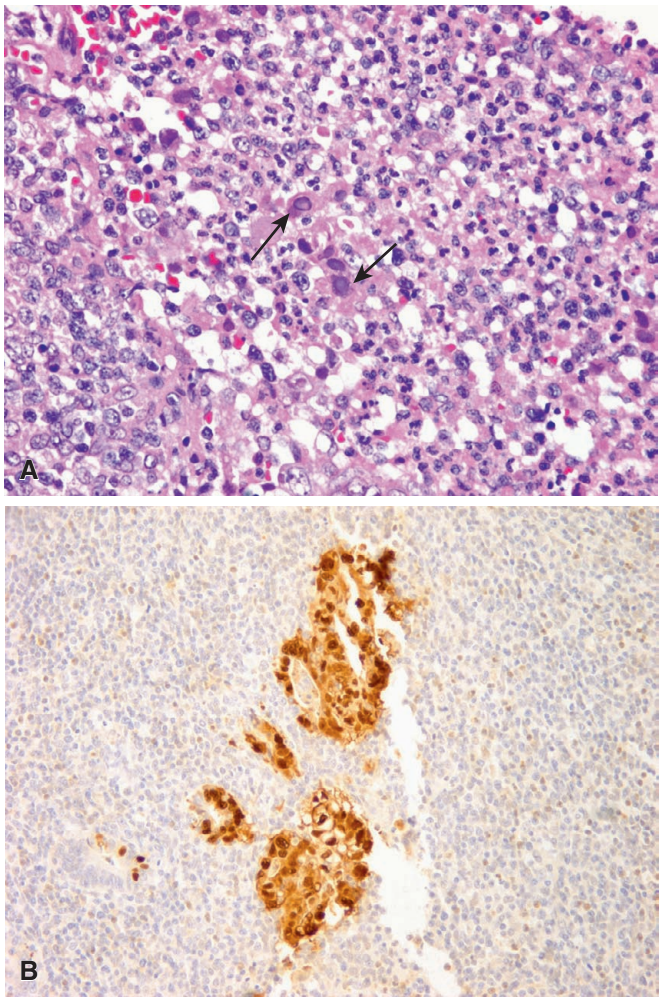

Figure 16.20 **A,** Typical "smudge cell" inclusions within the inflamed mucosa *(arrows)*. **B,** Infected cells are highlighted by adenovirus immunostain.

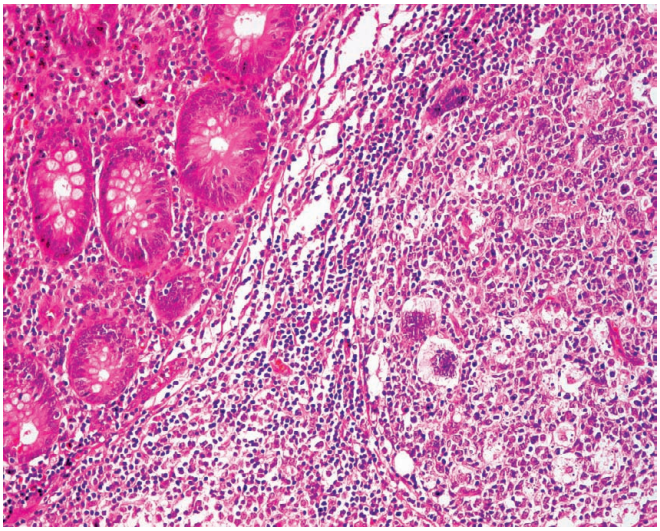

Figure 16.21 Warthin–Finkeldey multinucleated giant cells in the appendix of a child with measles.

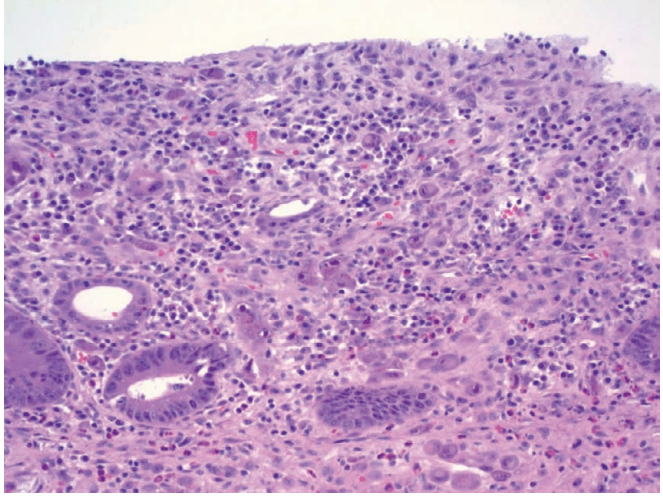

Figure 16.22 Innumerable CMV inclusions in the mucosa of an appendix. (Courtesy of Dr. Joseph Misdraji, MD.)

of small lymphoid cells and immunoblasts, some of the latter resembling Reed–Sternberg cells.[113] *Cytomegalovirus (CMV)* appendicitis (Fig. 16.22) has been reported in immunocompromised patients, including HIV-infected and organ transplant patients.[114,115]

Fungal Infections

Appendiceal fungal infections are very rare and are typically a manifestation of disseminated disease in immunocompromised patients. *Candida* spp., *Aspergillus* spp., *Mucor* spp., and *Histoplasma capsulatum* have been reported (Fig. 16.23).[116–118]

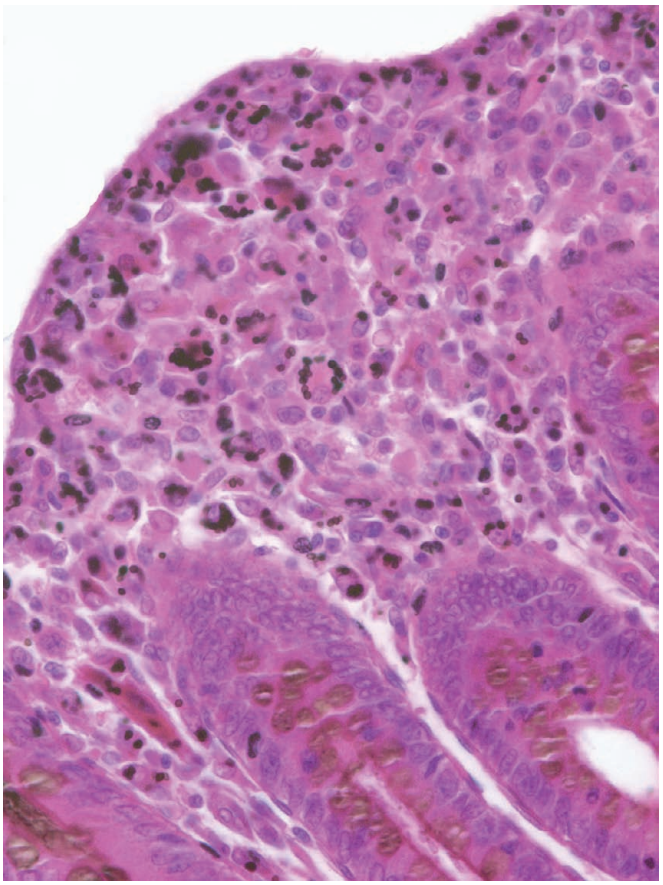

Figure 16.23 H&E/methenamine silver stain highlights *Histoplasma* within macrophages in the appendiceal mucosa. The patient was immunocompromised and died of disseminated histoplasmosis.

Tumors

Nonmucinous Tumors

Serrated Lesions

A variety of serrated lesions occur in the appendix, similar to those seen in the colon. In the appendix, they are often found incidentally in patients who undergo appendectomy for other reasons.

Hyperplastic polyps in the appendix are relatively rare. They are typically localized sessile nodules that do not involve the entire luminal circumference. The glands are elongated and serrated, most notably towards the surface, and are composed of a mixture of goblet cells and non-goblet columnar cells with microvesicles of cytoplasmic mucin, reminiscent of microvesicular hyperplastic polyps in the colorectum (Fig. 16.24).[119–121] A diffuse, nonpolypoid *mucosal hyperplasia* of the appendix has also been described, sometimes in association with inflamed appendices, which can involve a large portion of the surface area of the mucosa. The histologic features are similar to hyperplastic polyps, but the lesion is diffuse rather than localized.[119,121] Because diffuse mucosal hyperplasia was described long before the lesion now known as sessile serrated polyp/adenoma (SSP/A), some authorities do not recognize diffuse mucosal hyperplasia as an entity, and regard these lesions as sessile serrated adenomas/polyps.[120] Proponents of the entity, however, note that the architectural features that distinguish SSP/A (see later) are absent in diffuse mucosal hyperplasia, and thus regard it as an entirely benign lesion that is distinct from SSP/A and analogous to a diffuse form of hyperplastic polyp.[119]

SSPs/As of the appendix are larger than hyperplastic polyps and may appear as sessile polyps but often circumferentially involve the mucosa (Fig. 16.25A). Similar to the colon, they contain elongated

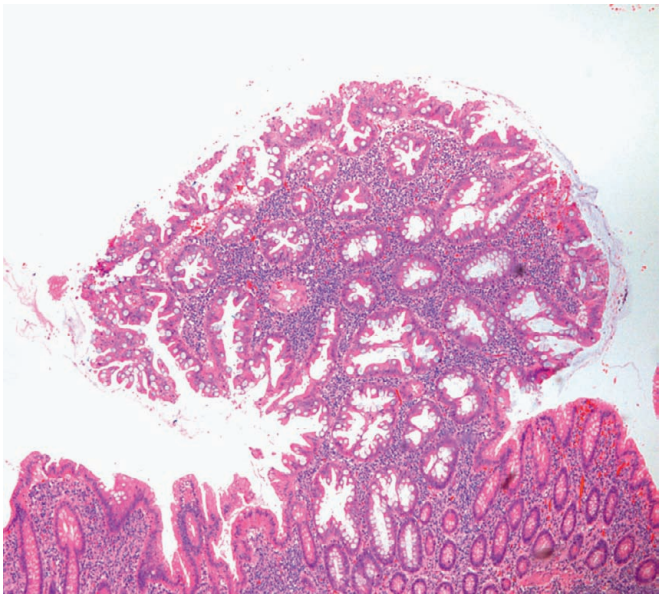

Figure 16.24 Hyperplastic polyp of the appendix, similar to hyperplastic polyps of the colon and rectum.

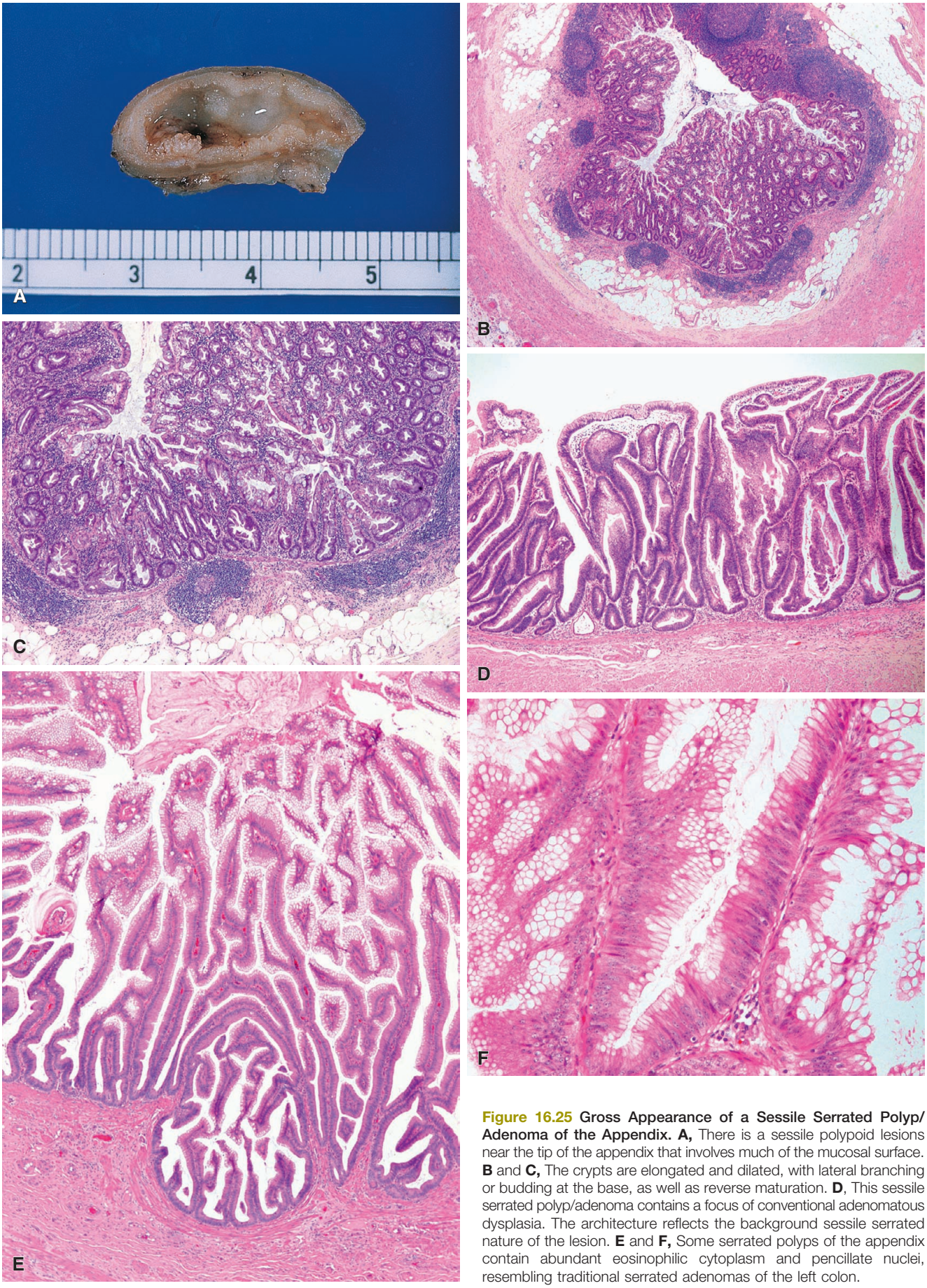

Figure 16.25 Gross Appearance of a Sessile Serrated Polyp/Adenoma of the Appendix. A, There is a sessile polypoid lesions near the tip of the appendix that involves much of the mucosal surface. **B** and **C,** The crypts are elongated and dilated, with lateral branching or budding at the base, as well as reverse maturation. **D**, This sessile serrated polyp/adenoma contains a focus of conventional adenomatous dysplasia. The architecture reflects the background sessile serrated nature of the lesion. **E** and **F,** Some serrated polyps of the appendix contain abundant eosinophilic cytoplasm and pencillate nuclei, resembling traditional serrated adenomas of the left colon.

and/or dilated crypts with a serrated appearance, lateral branching or budding of the glands at the base of the lesion, and goblet or foveolar-type cells at the base ("reverse maturation"; Figs. 16.25B and C).[120,122] Sessile serrated polyps frequently contain conventional-type (adenomatous or intestinal; Fig. 16.25D) or serrated dysplasia (see Chapter 17)[120,122,123]; historically, those that contain adenomatous dysplasia have also been referred to as "mixed hyperplastic/adenomatous" polyps, but the term "SSP/A with dysplasia" is now preferred by many, similar to the terminology used in the colon. Some serrated polyps of the appendix are composed of crypts lined by cells with abundant eosinophilic cytoplasm and pencillate nuclei, resembling traditional serrated adenomas of the left colon (Figs. 16.25E and F)[122,123]; these have also been referred to simply as "serrated adenomas" of the appendix.[122]

MUC 6 is positive in virtually all SSP/A, and Ki-67 immunostaining shows irregular, asymmetrical labeling of crypt epithelial cells, similar to their counterparts in the colon.[120,122] They also display partial loss of DNA repair protein expression, typically in the superficial epithelium, but this reflects the nonproliferative nature of the epithelium and is not associated with microsatellite instability.[122] Staining is preserved at the crypt bases, and the lesions are mismatch proficient by PCR. Mutually exclusive *BRAF* and *KRAS* mutations have been detected in a significant number of appendiceal serrated lesions, although the percentages vary between studies. As *BRAF* mutations are far more common and *KRAS* mutations are less frequent among similar-appearing colonic polyps, this is evidence that the molecular alterations underlying appendiceal serrated lesions are different from their colonic counterparts.[122,123]

Sessile serrated polyps/adenomas are distinguished from hyperplastic polyps by the presence of the previously mentioned features, including dilated crypts, serrations that extend the full length of the gland, lateral branching/budding of glands at the base, and "reverse maturation." However, there may be significant morphologic overlap. For this reason, as well as the challenges in terminology that plague any discussion of serrated neoplasia, and the fact that even nondysplastic serrated appendiceal lesions may harbor *BRAF* or *KRAS* mutations, some authors have suggested simply classifying appendiceal serrated lesions as either nondysplastic serrated polyps or dysplastic serrated polyps.[122,123]

The relationship between serrated lesions of the appendix and colorectal carcinoma remains unclear. Although earlier literature suggested a relationship between serrated appendiceal lesions and colorectal carcinoma, more recent data (also noted previously) show that serrated appendiceal lesions may in fact be unrelated to the "serrated pathway" of neoplasia in the colon.[122,123] Invasive adenocarcinomas of the appendix occasionally arise in association with serrated lesions, and these are discussed further below in the section on nonmucinous adenocarcinoma.

Intestinal-Type Adenoma

Intestinal-type adenomas, although common in the colon, are rare in the appendix, and are usually found after appendectomy is performed for other reasons. They may occur more frequently in patients with familial adenomatous polyposis.[119,121,124] Intestinal-type adenomas form polypoid projections that are sharply demarcated from adjacent normal-appearing mucosa, and in contrast to SSP/A and low-grade mucinous neoplasms, do not show circumferential involvement of the mucosa. They contain crowded, tubular crypts lined by dysplastic epithelial cells with elongated, hyperchromatic nuclei, similar to their colonic counterparts (Fig. 16.26A). Intestinal-type adenomas of the appendix have an apparently low risk of developing adenocarcinoma.[125] Adenomas involving the proximal appendix often represent extension of adenomas of the right colon into the appendiceal orifice (Fig. 16.26B).

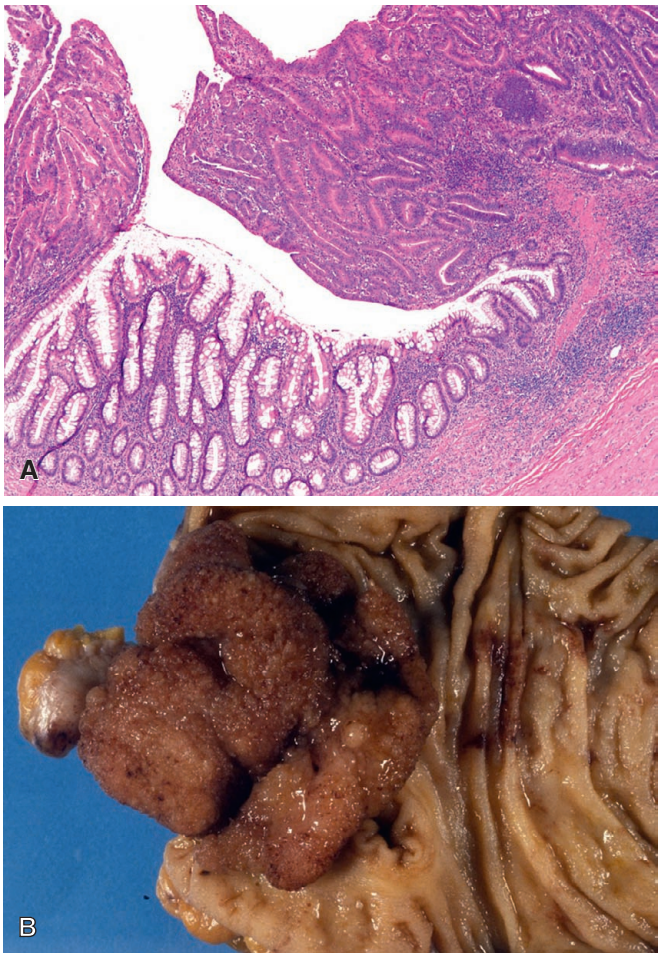

Figure 16.26 A, This tubular adenoma of the appendix is sharply demarcated from the surrounding mucosa and resembles a tubular adenoma of the colorectum. **B,** This large adenomatous polyp from the cecum extends to involve the appendiceal orifice and proximal appendix.

Nonmucinous Adenocarcinoma

Primary nonmucinous adenocarcinoma of the appendix is rare,[119,126] and most arise from either serrated lesions or goblet cell carcinoid (see later). The symptoms often resemble acute appendicitis, and inflammation is frequently found in addition to the carcinoma.[119,127] Most nonmucinous adenocarcinomas are asymptomatic until they penetrate the visceral peritoneum and cause abdominal pain, so they tend to be locally advanced at the time of diagnosis.[125]

These tumors can be located in any part of the appendix, although the proximal third is more commonly involved than the distal appendix.[119,128] Adenocarcinomas at the base of the appendix should be distinguished from cecal adenocarcinomas that extend into the proximal appendix.[119] The microscopic appearance is essentially the same as that of colorectal adenocarcinoma and is indeed referred to as colonic type (Fig. 16.27).[128,129] Adenocarcinomas associated with serrated appendiceal lesions show a destructive growth pattern with infiltrative glands that may have a tubular or serrated appearance.[125] Some tumors contain abundant extracellular mucin, but they are typically more cellular and show high-grade cytologic features with desmoplasia, beyond the spectrum of changes seen in appendiceal mucinous neoplasms with associated pseudomyxoma peritonei. Right hemicolectomy is the treatment of choice for nonmucinous adenocarcinomas. These tumors have a relatively poor prognosis,

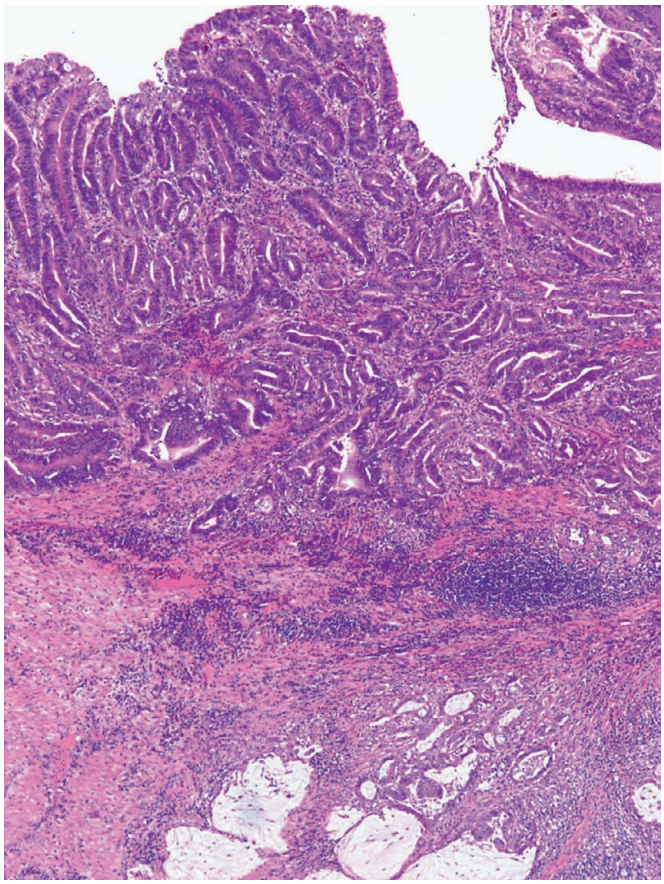

Figure 16.27 Nonmucinous adenocarcinoma of the appendix is histologically similar to intestinal-type colorectal adenocarcinoma. This lesion arises in a background of adenomatous polyp and extends into the wall.

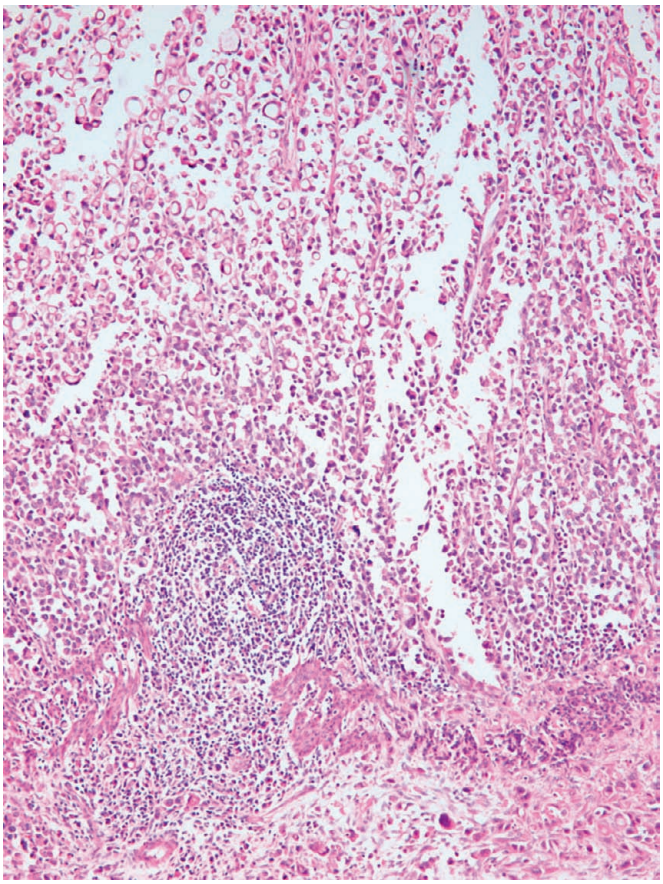

Figure 16.28 Primary signet ring cell carcinoma of the appendix.

with a 5-year survival of approximately 55%.[130] Distinction from mucinous adenocarcinomas of the appendix is important, as nonmucinous carcinomas are unlikely to respond to therapeutic regimens used for mucinous adenocarcinomas, and patients with mucinous adenocarcinoma typically have a better prognosis.[131]

An exceptionally rare type of primary appendiceal tumor is *signet ring cell carcinoma* (Fig. 16.28).[119,129] These tumors are morphologically similar to signet ring cell carcinomas at other sites and must be distinguished from metastases from the stomach or breast, and from goblet cell carcinoid tumors (see the following discussion), although signet ring cell carcinomas may arise from goblet cell carcinoids.[132] Signet ring cell carcinoma has a poor prognosis, due to dissemination within the peritoneal cavity; lymph node metastases and metastases to the ovaries are also common.[129,133]

Goblet cell carcinoid tumors are virtually unique to the appendix and have historically also been called *goblet cell–type adenocarcinoid*,[134] *mucinous carcinoid tumor*,[135] and *crypt cell carcinoma*.[136] Although traditionally classified as neuroendocrine, many have questioned the wisdom of placing into a carcinoid category a tumor in which the neuroendocrine component is only one of several and not necessarily the more conspicuous one. Goblet cell carcinoid tumors are now recognized as a distinct clinicopathologic entity with behavior that is more aggressive than classical appendiceal carcinoid tumors[125,137] and more akin to adenocarcinoma. In addition, they frequently give rise to poorly differentiated adenocarcinomas that behave in a stage-dependent fashion.[132] For this reason, appendices in which goblet cell carcinoid tumors are initially identified should be completely submitted to exclude the possibility of associated carcinoma.

Many goblet cell carcinoid tumors are found in patients with symptoms suggestive of acute appendicitis,[138] and acute appendicitis often coexists with these lesions. The diagnosis is rarely suspected at the time of surgery. Grossly, goblet cell carcinoids may be found in any portion of the appendix[125,139]; unlike classic carcinoid tumors, goblet cell carcinoid are more common in the midportion. They appear as an area of whitish, sometimes mucoid induration without dilation of the lumen, with poorly defined mural thickening that may be difficult to appreciate at the time of gross examination.

Microscopically, goblet cell carcinoids predominantly show deep mucosal and submucosal growth in a circumferential pattern around the lumen of the appendix (Fig. 16.29A) but unassociated with surface epithelial dysplasia. Extension into the muscle and serosa is common. The tumor is composed of small nests, clusters, and cords of goblet cells embedded in dense collagenous stroma (Fig. 16.29B), often arranged in a microglandular fashion and sometimes accompanied by extracellular mucus. Tumor cells are distended by large cytoplasmic mucin vacuoles that compress the nuclei towards the base of the cell. Mitotic activity is generally inconspicuous, and Ki-67 immunolabeling indices are low (<2%).[140] Paneth cells may be present, as well as neuroendocrine cells (Fig. 16.29C).[141] Mucicarmine and carcinoembryonic antigen (CEA) stains are consistently positive, but goblet cell carcinoid tumors show only patchy immunopositivity for neuroendocrine markers.[125,141] They typically express CK20 and occasionally express CK7, usually in a focal fashion.[125,141–143] There is also frequent expression of CK19 and CD99.[144]

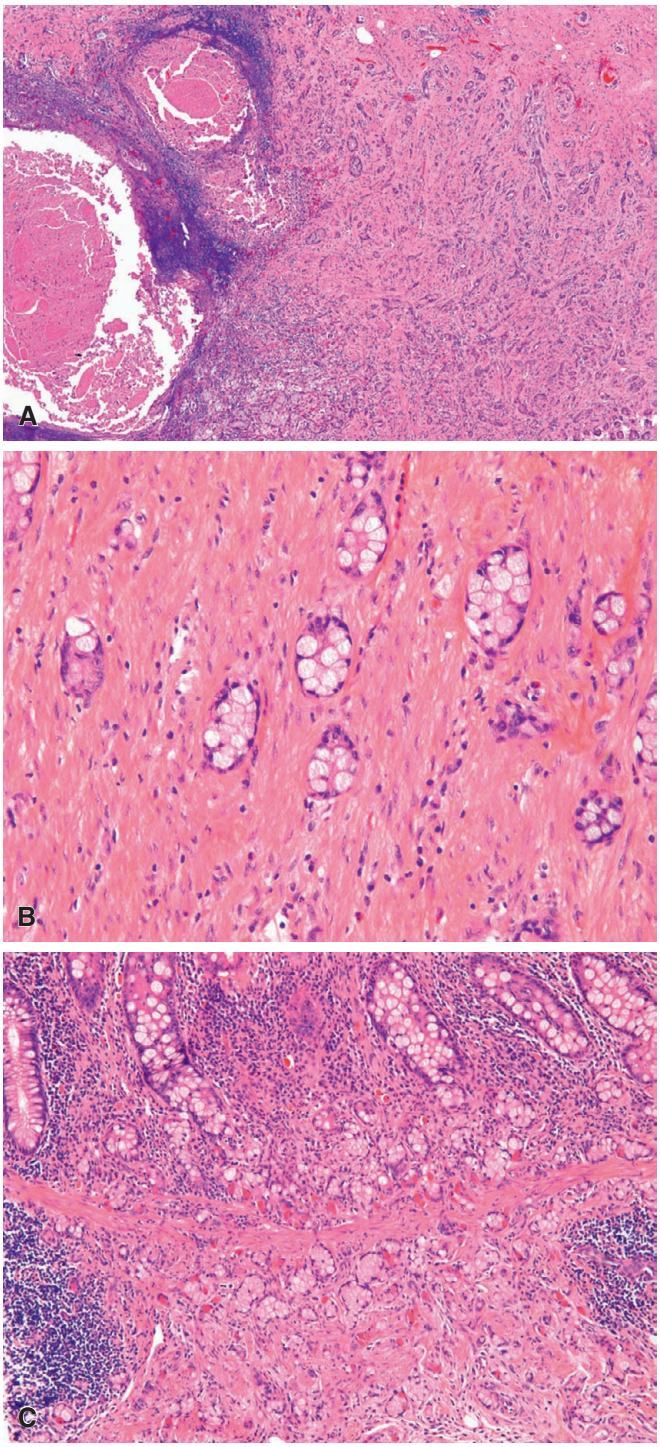

Figure 16.29 **A,** Goblet cell carcinoids have a circumferential growth pattern and typically extend deeply into the muscle and mesoappendix. **B,** The small nests, clusters, and cords of neoplastic cells have large mucin vacuoles and small basally located nuclei. **C,** Paneth cells may be very prominent.

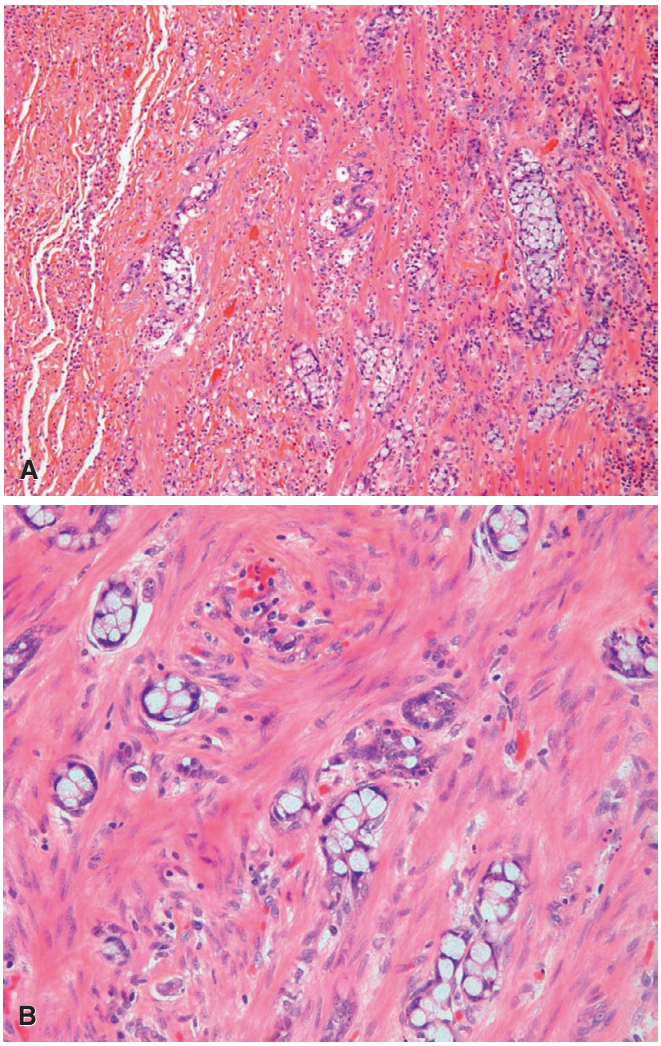

Figure 16.30 **A** and **B,** Poorly differentiated adenocarcinoma ex goblet cell carcinoid; note the nuclear atypia and infiltrating poorly differentiated glands admixed with elements of goblet cell carcinoid.

The matter gets even more complicated by the fact that at least half of goblet cell carcinoid tumors give rise to areas of adenocarcinoma, often signet ring cell type or poorly differentiated (Fig. 16.30), which has been termed "adenocarcinoma ex goblet cell carcinoid."[132] As one might imagine, the development of an overt malignancy in the context of goblet cell carcinoid represents an unfavorable prognostic turn of events. Features indicative of carcinoma include significant nuclear atypia, single infiltrating cells, loss of mucin production, and increased Ki-67 immunolabeling. Unlike other malignancies of the lower gastrointestinal tract, carcinomas derived from goblet cell carcinoid tumors do not show alterations affecting β-catenin, *KRAS*, *DPC4*, or *TP53*.[142]

Most goblet cell carcinoid tumors invade deeply into the appendiceal wall and penetrate the serosa, with frequent involvement of regional lymph nodes, peritoneum, and ovaries.[139,145] Metastases to the ovary are particularly common, where they can acquire the features of a Krukenberg tumor (Fig. 16.31).[146] Both the World Health Organization and American Joint Commission on Cancer classify and stage goblet cell carcinoid tumors as adenocarcinomas.[125] Management of goblet cell carcinoid tumors is not standardized, although appendectomy alone is unlikely to be adequate therapy owing to their high metastatic potential, and thus surgical management generally consists of right colectomy with lymph node dissection.

Classic and goblet cell carcinoid tumors can exceptionally occur together, and this combined form appears to behave more like goblet cell carcinoid tumors than classical carcinoids.[147]

Mucinous Neoplasms

The significance of mucinous appendiceal neoplasms lies in the fact that even low-grade, extremely bland-appearing neoplasms can involve the peritoneal cavity in the form of pseudomyxoma peritonei. Because these tumors with very low-grade features can, in fact, lead to significant morbidity and even death, they have been the subject of much (and ongoing) debate regarding terminology and classification, which continues to evolve.[119,121,148–150] Furthermore, the criteria for invasion in the appendix are not well defined, and the multiple classification schemes that exist reflect the difficulty with neatly labeling them as benign or malignant.

Figure 16.31 Ovarian metastasis of appendiceal adenocarcinoid tumor of goblet cell type. Sometimes this constitutes the initial presentation of this tumor type.

Adenoma/Cystadenoma

By definition, mucinous adenomas are confined to the appendiceal mucosa, and they should not have associated mucin on the serosal surface or in the mesoappendix.[121,148,149] Some are grossly unremarkable, whereas others cause focal or generalized dilatation of the appendix with accumulation of mucin (hence the term cystadenoma; Fig. 16.32A). Many authorities require the presence of an intact muscularis mucosae to make a diagnosis of adenoma.[126,150,151] The mucinous epithelium may be flat or undulating, but villous projections are present in many cases (Fig. 16.32B).[126,148,151] The deeper crypts typically have straight luminal edges similar to those of the non-neoplastic appendix, but some lesions contain crypts with a serrated appearance near the lumen.[151] Overall, adenomas generally lack significant architectural complexity.Most adenomas display low-grade cytologic atypia characterized by nuclear hyperchromasia and pseudostratification with rare mitotic figures (Fig. 16.32C).[148,151] High-grade dysplasia is uncommon and is characterized by architectural abnormalities, including cribriform and micropapillary growth, as well as nuclear pleomorphism with loss of cell polarity and readily identifiable mitotic figures (Fig. 16.33A and B).[150,151] In the past, lesions currently classified as adenomas with high-grade dysplasia have been classified in a number of ways, including noninvasive adenocarcinoma.[119,150] However, regardless of the degree of cytologic dysplasia, appendiceal mucinous adenomas are cured

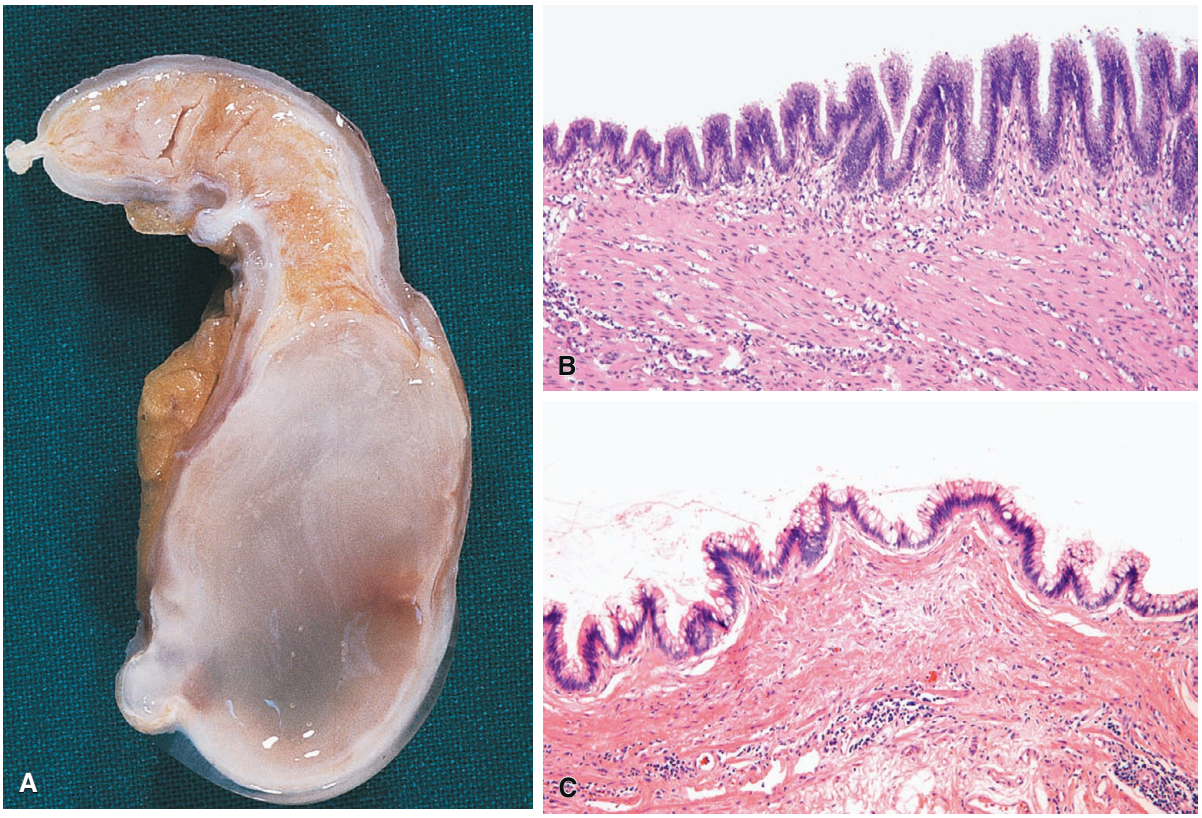

Figure 16.32 **A,** Mucinous cystadenoma involving the proximal half of the appendix and associated with formation of diverticula. Note the lack of mucin on the outside of the appendix. **B,** The epithelium is undulating with an intact muscularis mucosae and lacks architectural complexity. **C,** The cytologic atypia is low grade.

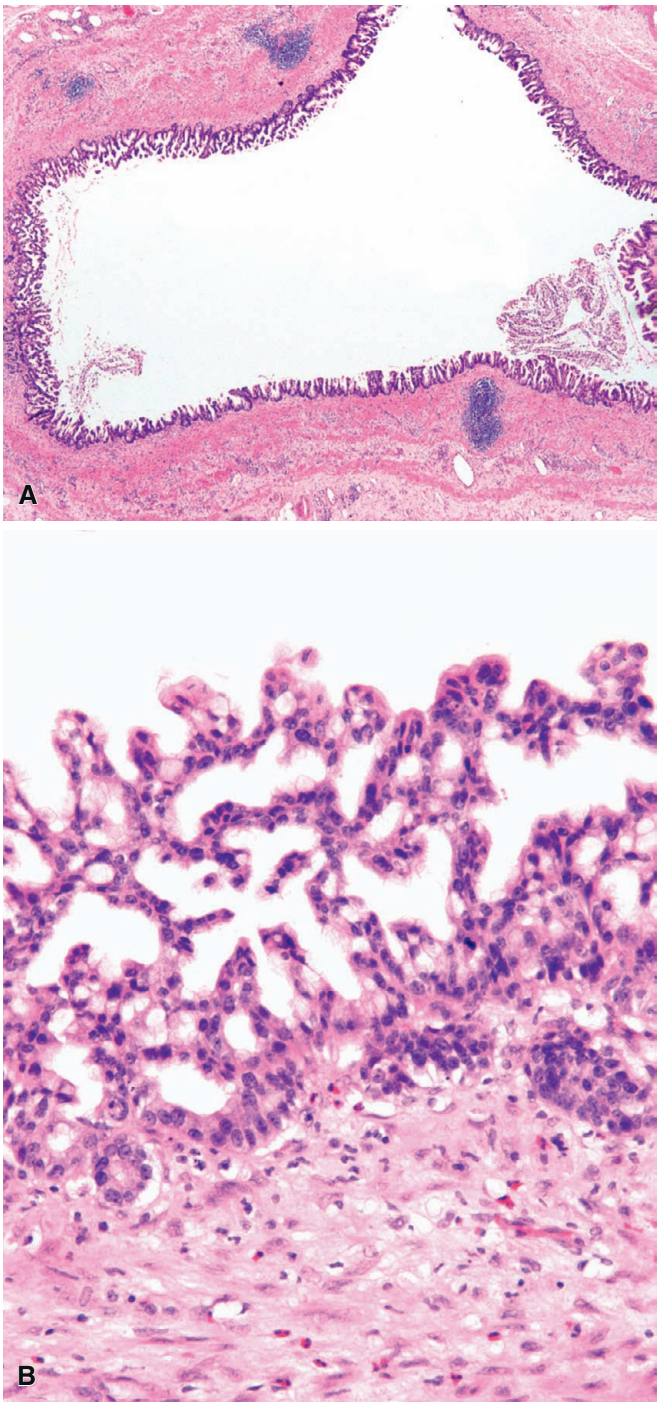

Figure 16.33 Adenoma confined to the appendix **(A)** but containing high-grade dysplasia **(B)**, characterized by architectural complexity, nuclear atypia, and mitoses.

by appendectomy with negative margin.[148,151] However, some authors have proposed that adenoma at the surgical resection margin warrants concern for recurrent disease or metastasis and consider such tumors to have uncertain malignant potential or low risk for recurrence.[148,149,151] For these reasons, the term "high-grade appendiceal mucinous neoplasm" (HAMN) has been proposed for these types of tumors. Submission of the entire appendix is essential in cases of mucinous adenoma, in order to exclude the possibility of extra-appendiceal epithelium and/or mucin, as described later. Low-grade mucinous

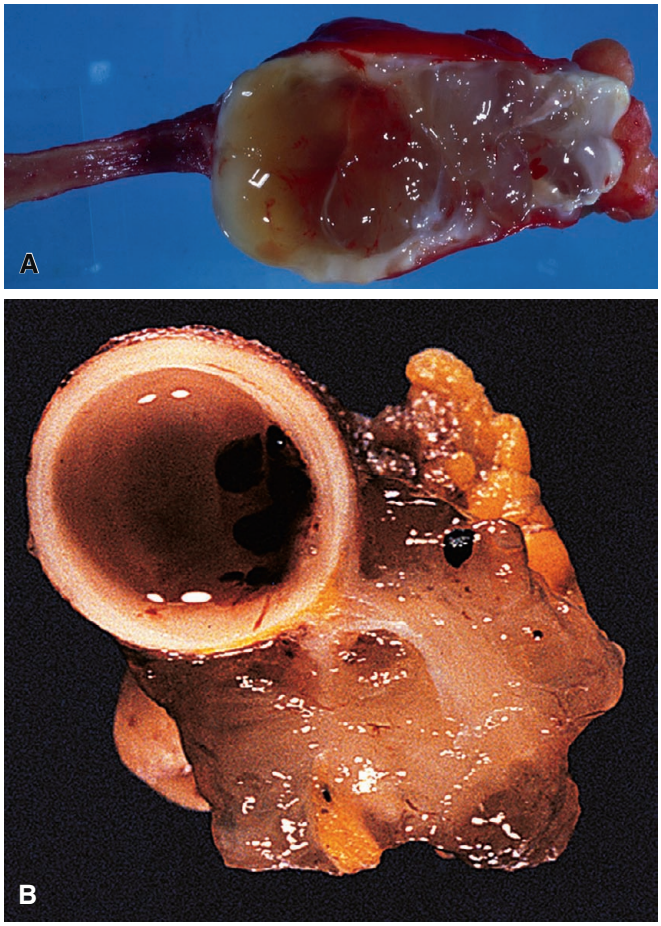

Figure 16.34 **A,** Low-grade appendiceal mucinous tumor featuring a markedly dilated appendiceal lumen and thin wall. **B,** Another case showing a markedly dilated appendix with extension of mucin into the mesoappendix (**A,** Courtesy of Dr. George F. Gray, Jr.)

neoplasms with mural changes such as disruption of the muscularis mucosae, mural atrophy with fibrosis of the mucosa and muscularis mucosae, and/or with extra-appendiceal mucin are best classified as LAMN rather than adenomas.[148,149,151]

Low-Grade Appendiceal Mucinous Neoplasm

Historically, in an attempt to avoid nomenclature confusion as well as correlate histologic features with biologic behavior, some authorities classified the entire spectrum of low-grade mucinous tumors from adenoma to low-grade mucinous tumors with extra-appendiceal mucin as LAMN.[119,150] More recent classification schemes have reinstated the term adenoma/cystadenoma, as previously discussed, recognizing that these lesions are cured by appendectomy as long as the entire appendix is evaluated and no histologic risk factors for recurrence are identified. Currently, most authorities use the term LAMN to indicate those appendiceal mucinous tumors that have features portending at least some increased risk of peritoneal dissemination.[148,149,151]

Similar to adenomas, these lesions may be grossly unremarkable or produce a cystically dilated appendix filled with mucin (Fig. 16.34A). Grossly visible mucin on the serosal surface or in the mesoappendix (Fig. 16.34B) is an important finding and, if present, should be carefully documented and submitted entirely in order to establish the presence or absence of extra-appendiceal neoplastic epithelium.[148–151]

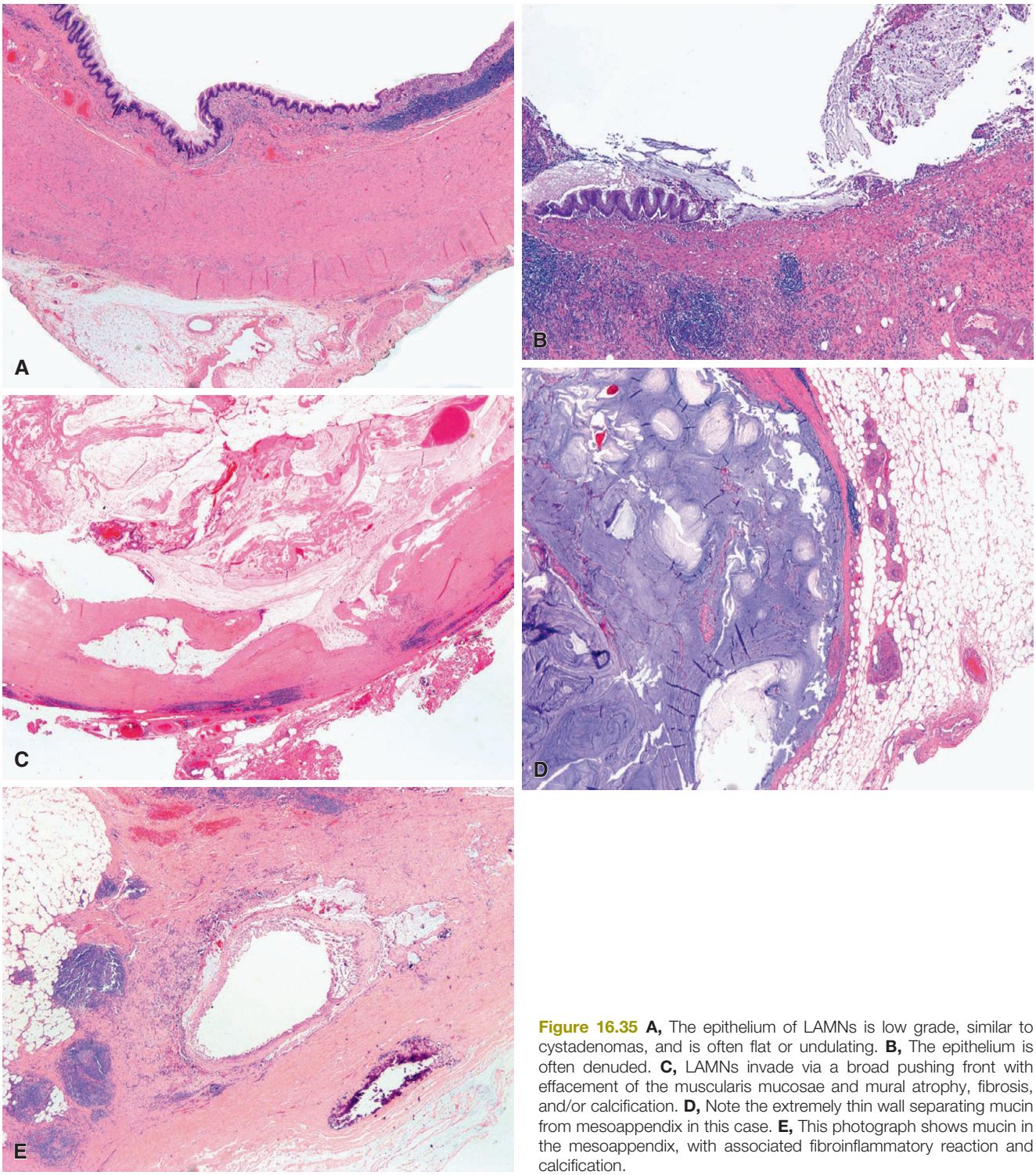

Figure 16.35 **A,** The epithelium of LAMNs is low grade, similar to cystadenomas, and is often flat or undulating. **B,** The epithelium is often denuded. **C,** LAMNs invade via a broad pushing front with effacement of the muscularis mucosae and mural atrophy, fibrosis, and/or calcification. **D,** Note the extremely thin wall separating mucin from mesoappendix in this case. **E,** This photograph shows mucin in the mesoappendix, with associated fibroinflammatory reaction and calcification.

The low-grade epithelium of LAMNs is similar to cystadenomas and is characterized by tall mucinous epithelial cells in a villous or flat configuration (Fig. 16.35A).[148–151] The villi are usually slender with straight edges. The epithelium is almost completely denuded in many cases, and multiple sections may be required to find neoplastic epithelium (Fig. 16.35B).[121,151] LAMN have a distinct manner of invasion of the appendiceal wall, which features a broad pushing front (rather than infiltrative neoplastic glands with desmoplasia) with effacement of the muscularis mucosae and mural atrophy, fibrosis, and/or calcification (Fig. 16.35C and D).[150] These tumors may dissect through the wall to create diverticulum-like outpouchings or even overtly perforate the organ (leading to the historical term 'ruptured adenoma,' which does not reflect the biologic potential of these tumors) (Fig. 16.35E). Mucinous neoplasms with high-grade cytologic features should not be classified as LAMN. If confined to the mucosa, they may be classified as adenomas, as

above; otherwise, they should be classified as mucinous adenocarcinoma (see subsequent section).

LAMN confined to the appendix are virtually always cured by appendectomy,[148] and recent studies have shown that even involvement of the margin by neoplastic epithelium or acellular mucin does not portend recurrence of disease.[152] Tumors with either acellular mucin in the peritoneal cavity, or neoplastic epithelium outside the appendix but confined to the right lower quadrant, have a low risk of progression to widespread pseudomyxoma peritonei, particularly if all of the extra-appendiceal mucin is evaluated histologically to exclude the presence of neoplastic epithelium in the former scenario.[148,153] Even so, approximately one-third of patients with extra-appendiceal neoplastic epithelium confined to the right lower quadrant may progress to disseminated peritoneal disease leading to death,[148,153] and because of this, some authors have previously classified tumors with any extra-appendiceal involvement by cellular mucin as low-grade mucinous adenocarcinomas.[126,151]

Management of patients with extra-appendiceal mucin limited to the periappendiceal region is controversial. Patients should have all grossly visible peritoneal mucin removed for histologic evaluation and then undergo radiographic surveillance to evaluate for development of mucinous ascites.[151,153] There are currently no data to support cytoreductive surgery with intraperitoneal chemotherapy as a preventive measure, and right colectomy offers no survival benefit over appendectomy.[154,155]

A number of benign lesions can mimic LAMN. Retention cysts are rare and usually smaller than 2.0 cm. The mucosa has often sloughed but when retained is atrophic or attenuated, lacking the undulating and/or villous features of LAMN as well as the low-grade cytologic atypia. Although retention cysts can rupture, the mucin is acellular and does not recur following appendectomy.[119,126] Reactive or hyperplastic appendiceal mucosa should not be mistaken for a mucinous neoplasm, particularly when associated with a retention cyst or diverticulum. Appendiceal diverticula, also discussed previously, can occur in association with mucinous adenomas as well as in non-neoplastic appendices.[156] Diverticula that complicate mucinous adenomas can be confused with the "pushing front" of a low-grade appendiceal neoplasm, particularly if the diverticulum is colonized by neoplastic epithelium, and ruptured diverticula may also be confused with LAMN with extra-appendiceal mucin (Fig. 16.10C).[74] Features favoring diverticulum over LAMN include the presence of non-neoplastic epithelium, continuity of mural epithelium with that lining the lumen of the lesion, and an intact, normal-appearing muscularis propria. Another extremely unusual condition associated with mucus production in the appendix is myxoglobulosis, also known as "caviar appendix."[119,157] In this condition, the appendiceal lumen contains numerous ovoid globules composed of mucus (Fig. 16.36), which are occasionally calcified. Histologically, the globules consist of laminated mucin surrounding an eosinophilic, granular core. The pathogenesis is unclear, but it is believed that this change represents organized mucin that has detached from the wall.

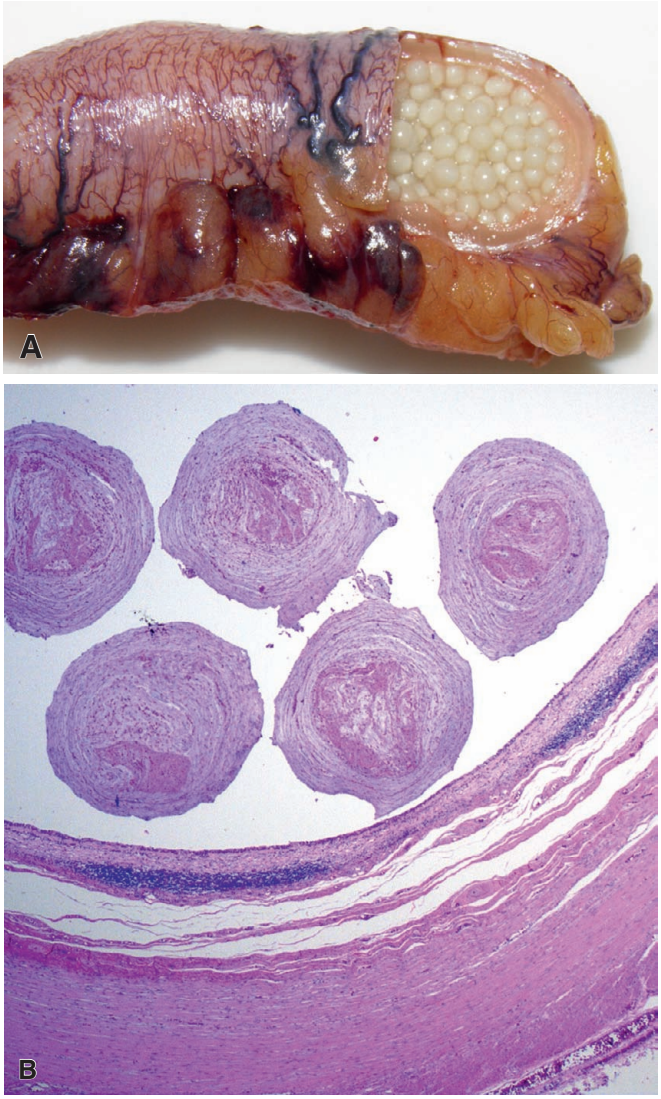

Figure 16.36 **A,** Myxoglobulosis, or "caviar appendix," features numerous ovoid globules composed of mucus within the lumen. **B,** Histologically, the globules are composed of laminated mucin surrounding a granular eosinophilic core. (Photographs courtesy of Dr. Ian Brown.)

Mucinous Adenocarcinoma and Pseudomyxoma Peritonei

Pseudomyxoma peritonei is a descriptive term, characterizing mucin accumulation in the peritoneal cavity due to spread of a mucinous neoplasm.[151,158] Most cases develop secondary to spread of low-grade mucinous tumors of the appendix, although rare cases are associated with origins from other sites (e.g. ovary).[158,159] Widely disseminated pseudomyxoma peritonei results in the formation of innumerable gelatinous nodules and, in time, often causes death through infection, intestinal obstruction, or invasion of the surrounding structures such as the bladder, abdominal wall, and intestine (Fig. 16.37A). It may also involve the outer aspect of the spleen[160] and extend through the diaphragm to produce *pseudomyxoma pleurii*.[161] Finally, it can extend into inguinal and other hernia sacs; as a matter of fact, it is not rare for the disease to be first diagnosed on histologic examination of the contents of a herniorrhaphy operation.[162,163]

The peritoneal tumor deposits are generally morphologically similar to the primary appendiceal neoplasm.[150,164] Low-grade lesions (often associated with LAMN) consist of mucin pools containing scant strips of low-grade mucinous epithelium with rare mitoses, often in a background of hyalinized collagen bands and reactive fibrosis around mucin pools (Fig. 16.37B).[150,164] Peritoneal mucinous tumors with high-grade features, such as solid cell clusters that display nuclear enlargement and hyperchromasia, single cell necrosis, and mitotic activity, are more often associated with a mucinous adenocarcinoma (Fig. 16.37C and D).[150,164] The high-grade epithelium is often more abundant than in low-grade lesions and may be accompanied by destructive tissue invasion and/or a desmoplastic tissue response and lymph node metastases. These high-grade neoplasms

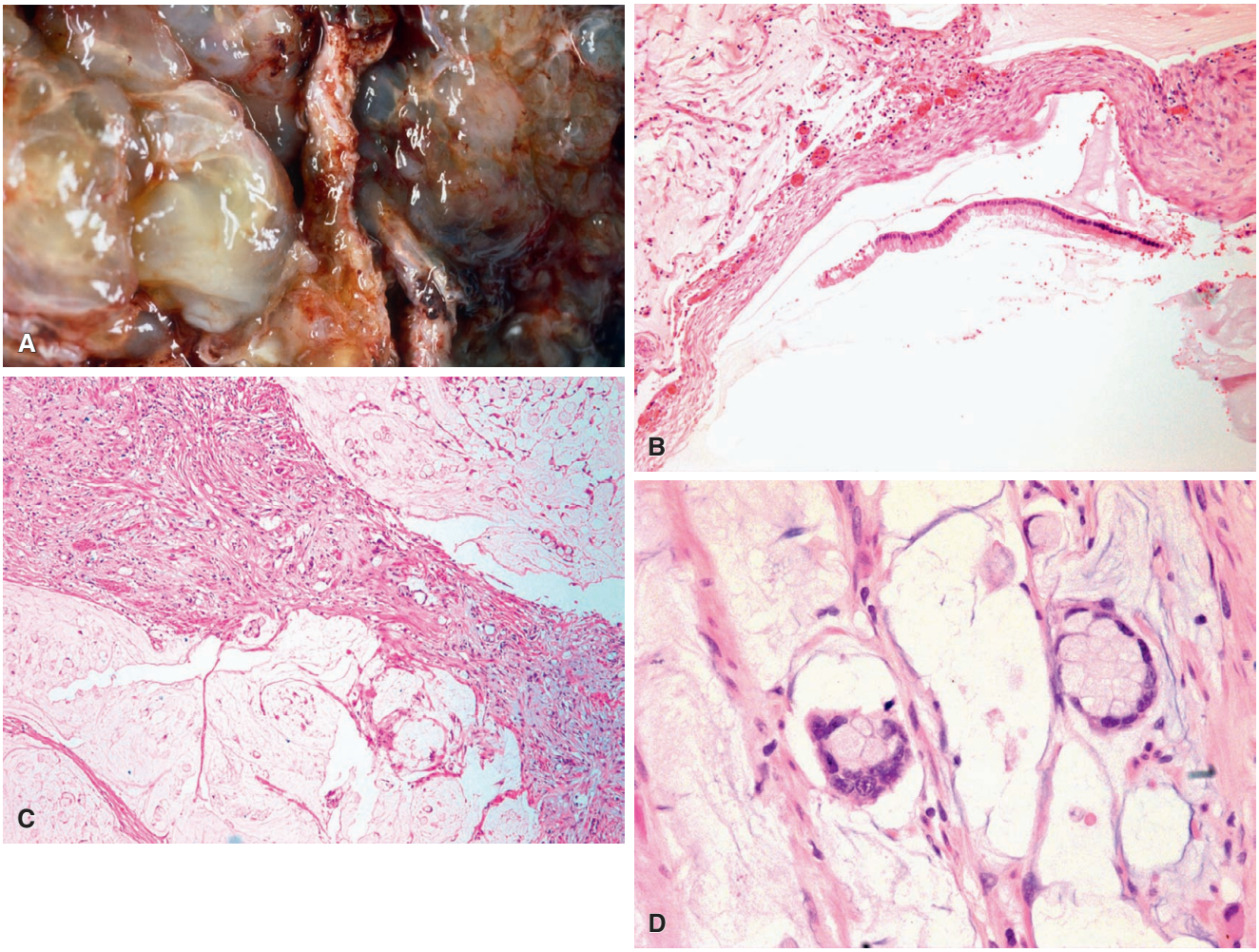

Figure 16.37 **A,** Gross photograph from a debulking procedure for pseudomyxoma peritonei. **B,** In this case, strips of low-grade epithelium float within pools of mucin. **C,** This case of pseudomyxoma peritonei with high-grade features shows invasion of the fibrous bands surrounding the mucin pools, as well as signet ring cells and marked nuclear atypia **(D)**. (**A,** Courtesy Dr. George F. Gray, Jr.)

often represent spread from a small bowel, colon, or pancreatic primary rather than a primary appendiceal tumor.[150,164] Some appendiceal neoplasms do show discordant histologic features in the primary appendiceal lesion and the peritoneal tumor deposits,[148,150] and progression from low-grade to high-grade histology has been seen in patients who fail therapy and/or have multiple tumor recurrences.[165,166]

The term *disseminated peritoneal adenomucinosis* has been proposed for this extremely well-differentiated form of disease, reserving the term *peritoneal mucinous carcinomatosis* for those cases in which the cytoarchitectural atypia is greater.[164,167] Although the distinction is of prognostic significance, it should be realized that these refer to different grades of malignancy and that calling them *adenomucinosis* may lead to an underestimation of their potentially aggressive behavior.[168]

Appendiceal mucinous neoplasms and pseudomyxoma peritonei typically express cytokeratin 20, CDX-2, and MUC2; cytokeratin 7 is variably positive.[169,170] Appendiceal adenomas, LAMN, and mucinous adenocarcinomas frequently show *KRAS* mutations, but they do not typically harbor abnormalities in *BRAF*, or *APC*, or show microsatellite instability.[151,171–173]

Most patients with peritoneal mucinous adenocarcinoma experience multiple tumor recurrences requiring intervention over time, leading to extensive intra-abdominal adhesions that ultimately prohibit further therapy.[174] Aggressive modern therapeutic approaches consist of a combination of surgery, directed towards complete cytoreduction, and hyperthermic intraoperative intraperitoneal chemotherapy (HIPEC) plus additional cycles of early postoperative intraperitoneal chemotherapy. The natural history of disease is dictated by tumor grade and pathologic stage[175]; 5-year survival rates of 86% are achievable among low-grade tumors that are treated with this approach, compared to 50% for high-grade tumors.[151,176,177] Although these aggressive modalities show promise, there is significant morbidity and mortality.

This topic would not be complete without addressing the entity known as *"mucocele."* In the appendiceal disease historically designated as such, the appendix shows either focal or diffuse globular enlargement, and the lumen is dilated and contains large amounts of glairy mucus. In our opinion, the term *mucocele* should not be used, because it is merely descriptive and tells nothing about the underlying cause of the mucin accumulation (which can range from a benign to frankly malignant and aggressive process). What matters is the nature of the underlying lesion, not the fact that abundant mucin is being produced by it. Making a diagnosis of "mucocele" is equivalent to using the term "hematocele" for any blood-containing lesion, regardless of whether the underlying lesion is a hematoma, a cavernous

hemangioma, an angiomatoid malignant fibrous histiocytoma, or an angiosarcoma.

Neuroendocrine Tumors

Well-differentiated NETs (formerly known as carcinoid tumors) are the most common type of appendiceal tumor.[178] They are identified in less than 1% of appendectomy specimens[141] and are more common among adults than children, although they can present at any age.[179] These lesions tend to occur in a slightly younger age group than NETs at other sites in the gastrointestinal tract and show a slight female predominance, although these features may at least in part reflect the frequency of acute appendicitis among young patients and women undergoing gynecologic surgery.[180] In most cases they are incidental findings at appendectomy for another reason, but they may be found associated with acute appendicitis as a result of obstruction of the lumen. Exceptionally, they have been found to secrete ACTH and result in a clinical picture of Cushing syndrome.[181] Carcinoid syndrome secondary to appendiceal carcinoid tumor is extremely rare.[182]

In terms of location within the appendix, the great majority of appendiceal NETs occur at the tip/distal third of the organ. The majority of tumors measure less than 1.0 cm in diameter and only rarely measure 2.0 cm or more.[141,183] Grossly, the tumors are firm, grayish white, and fairly well circumscribed but not encapsulated (Fig. 16.38). They acquire a characteristic yellow color after formalin fixation. When sufficiently large, those located at the tip often result in a typical "bell clapper" configuration of the appendix.

Morphologically, the vast majority of appendiceal NETs are serotonin-producing enterochromaffin (EC) cell tumors, similar to their counterparts in the jejunoileum. Previously, these tumors have been known as "classic" carcinoid tumors. EC cell tumors are composed of unencapsulated, tightly packed solid nests ("insulae") of small monotonous cells with occasional acini (Fig. 16.39),[141] which harbor luminal material that is positive for periodic acid–Schiff stain, but do not contain mucin. Other admixed architectural patterns are occasionally seen.[141] Tumor cells contain abundant amphophilic, often granular, cytoplasm and are both argentaffin and argyrophil positive.[141,184] The nuclei are typically round with coarse "salt and pepper" chromatin and small nucleoli; mitotic figures are rare. Occasional tumors display degenerative-type nuclear atypia with hyperchromasia and multinucleation, which has no bearing on behavior. A retraction of the tumor periphery from the stroma is usually evident and sometimes prominent. Invasion of the appendiceal muscle wall and lymph vessels is the rule, and spread to the peritoneal surface is not rare.

There is little question that the cells of most EC cell (classic carcinoid) tumors have morphologic, immunohistochemical, and ultrastructural features similar to those of the EC cells normally located at the base of Lieberkühn glands, but there is still debate over whether the tumors arise from these cells or from phenotypically similar cells located in the lamina propria and submucosa in close association with nerves, which sometimes form discrete units known as *subepithelial neuroendocrine complexes*, first identified by Masson. Because of this, it has been postulated that tumor cells found within intra-appendiceal nerves may be more closely related to tumor histogenesis than a manifestation of neoplastic perineural spread.[185–187]

EC cells are strongly immunoreactive with chromogranin A, synaptophysin, and serotonin.[141,184] Pankeratin staining tends to be weak, and both CK7 and CK20 are usually negative.[143] The tumors characteristically express CDX2, as a marker of midgut derivation.[188] The tumor cells are intimately associated with a population of S-100 protein–positive Schwann-like cells, probably belonging to the intra-appendiceal nerves mentioned previously.[185] Most EC cell tumors show a very low Ki-67 proliferation index (<1%).[189]

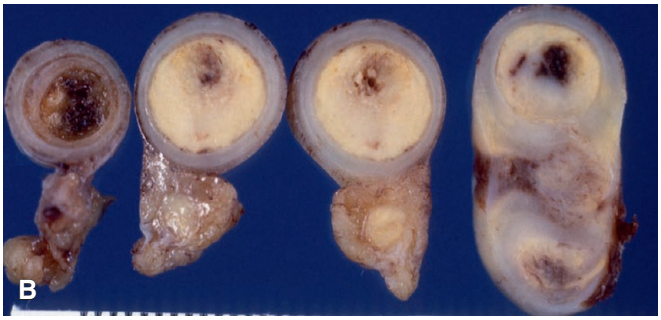

Figure 16.38 Gross Appearance of Well-Differentiated Neuroendocrine Tumor (Formerly Carcinoid Tumor) of the Appendix. These tumors are white-yellow and characteristically located in the tip **(A)**; they are well circumscribed but not encapsulated and may extend into the periappendiceal soft tissues **(B)**. (Courtesy Dr. George F. Gray, Jr.)

Approximately 10%–20% of appendiceal NETs are composed of enteroglucagon (L) cells. These tumors are characterized by glandular structures rather than solid nests[190,191] and have therefore been referred to as tubular carcinoids in the past. These tumors are typically small (2–3 mm) and composed of trabeculae and cords of cytologically bland tumor cells (Fig. 16.40). Some tumors display a predominantly acinar, or tubular, growth pattern,[190] contributing to their previous classification as tubular carcinoids. Although small amounts of inspissated mucin can be seen in the lumens, the cytoplasm is predominantly mucin negative.[141,191] Small red basophilic neuroendocrine granules may be visible; on occasion, these granules are large and acidophilic, simulating those of Paneth cells, but true Paneth cells are not a feature of tubular carcinoids.[141] The tumor cells are argyrophilic but argentaffin negative[184]; they are immunoreactive for chromogranin B, synaptophysin, glucagon,

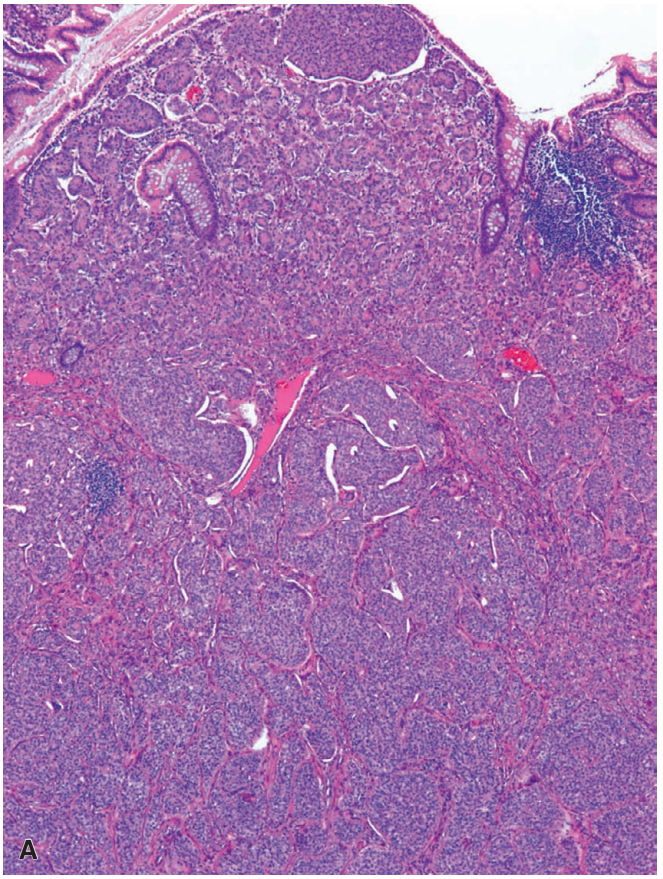

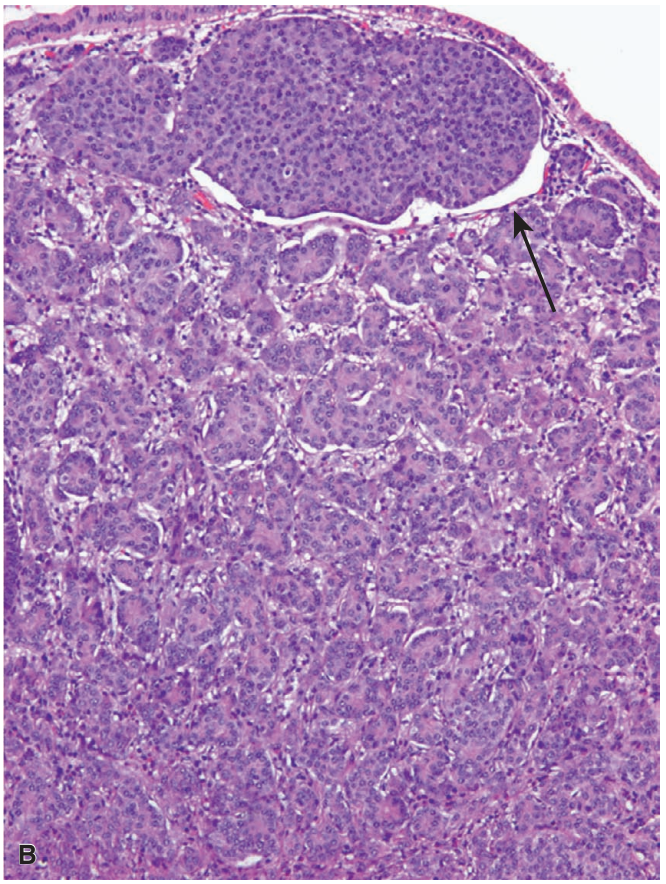

Figure 16.39 **A,** The majority of appendiceal NETs are composed of uncapsulated, tightly packed solid nests (insulae) of small monotonous cells with eosinophilic or amphophilic cytoplasm. **B,** Nuclei are uniform, small, and round, with speckled or "salt and pepper" chromatin. Lymphovascular invasion is typical *(arrow)*.

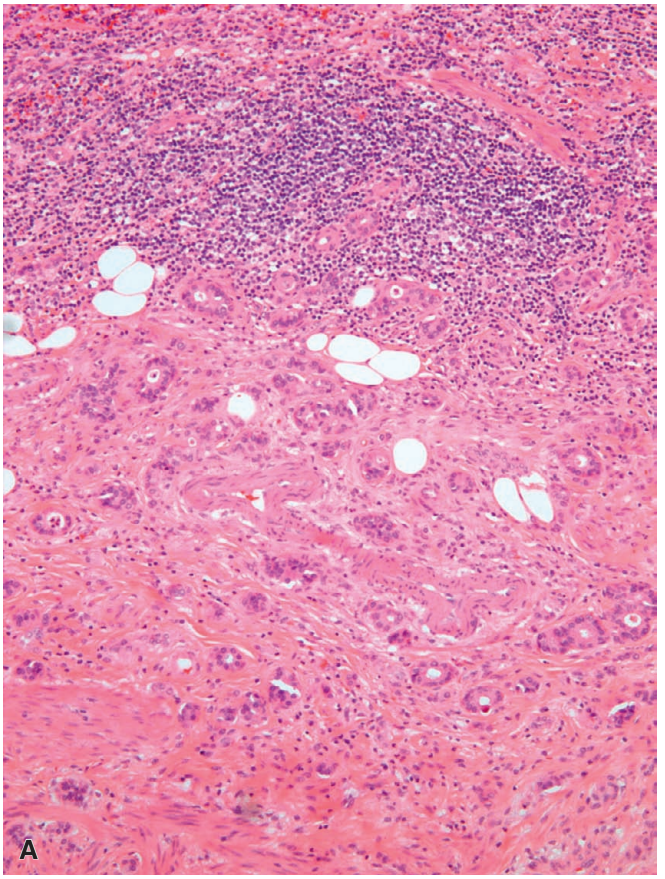

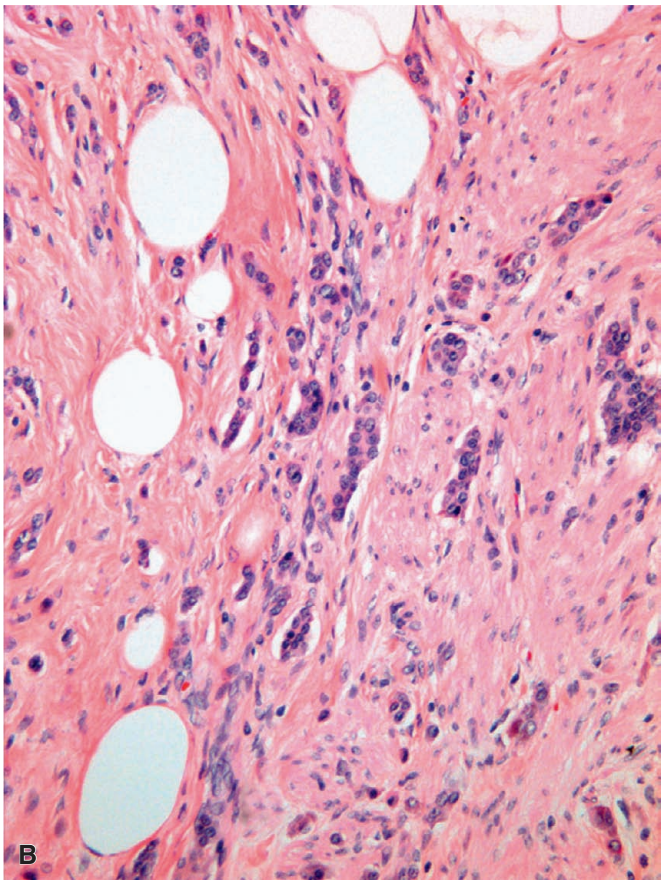

Figure 16.40 **A,** L-cell NETs, formerly known as tubular carcinoids, are composed of trabeculae and cords of neoplastic cells that may be mistaken for a carcinoma. **B,** Small red acidophilic neuroendocrine granules may be present.

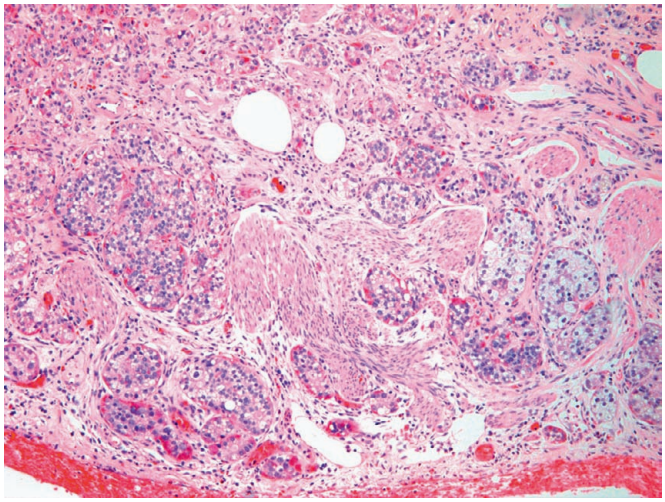

Figure 16.41 This well-differentiated NET has striking clear cytoplasm as well as eosinophilic neuroendocrine cells.

immunoglobulin A, pancreatic polypeptide, peptide YY, and CEA but typically do not stain for chromogranin A.[184,185,190] The Ki-67 proliferation index is also very low. Because of the infiltrative growth pattern and the lack of chromogranin A expression, as well as the fact that they variably express CK7 and CK20,[192] tubular carcinoids may be mistaken for metastatic carcinoma, but the lack of mitoses and nuclear atypia, orderly arrangement, and origin at the base of the glands of otherwise normal mucosa should lead to the correct diagnosis and avoid confusion with a primary or metastatic adenocarcinoma.

Occasional appendiceal NETs exhibit cells with clear cytoplasm and/or cytoplasmic vacuolization (Fig. 16.41). These tumors are referred to as lipid-rich or clear cell NETs, and this appears to represent a degenerative phenomenon in otherwise typical EC cell tumors. Clear cell NETs express general neuroendocrine markers but do not express mucins.[193,194]

Tubular carcinoids are typically minute and pursue a benign clinical course.[141] The behavior of most classic carcinoid tumors of the appendix is very indolent, especially when small, as fewer than 1% of tumors less than 2.0 cm metastasize.[141] Metastatic spread is usually associated with tumors greater than 2 cm in diameter, allowing for the occasional exception,[195] and even then often limited to the regional lymph nodes. Management decisions are largely based on tumor size. Most authors agree that simple appendectomy is adequate therapy for carcinoid tumors measuring less than 1 cm, provided that the margin is negative. Right hemicolectomy with lymph node dissection is generally reserved for tumors measuring more than 2 cm, given the greater likelihood of regional lymph node metastases and vascular invasion.[196,197] The treatment of carcinoid tumors measuring 1–2 cm and/or accompanied by mesoappendiceal invasion remains controversial. Completely resected tumors may be treated with appendectomy and clinical follow-up, although some favor a more radical approach in young patients.[183,196] Features suggestive of aggressive behavior (e.g. positive margin, invasion of the mesoappendix, vascular invasion, mitotic activity, and high Ki-67 labeling) may also prompt right colectomy and lymph node dissection,[197,198] although most studies have failed to show a survival benefit to extensive surgery. Given the importance of the previously mentioned factors in the therapeutic decision-making process, this information should be included in the pathology report. Approximately 18% of appendiceal NETs have associated malignancies elsewhere in the GI tract, so imaging and/or colonoscopy should be considered as well in the evaluation of these patients.[197]

Before leaving the subject of NETs of the appendix, we should mention some vanishingly rare entities that have primarily been documented as individual case reports. True primary small cell neuroendocrine carcinoma of the appendix is extremely rare,[199] as is mixed adenocarcinoma/neuroendocrine carcinoma (MANEC).[200] Rare cases of combined classical carcinoid/goblet cell carcinoid have also been described, as previously discussed.[147] Primary gangliocytic paraganglioma of the appendix has also been reported.[201]

Other Tumors and Tumor-Like Lesions

Müllerian Lesions

Endometriosis (Fig. 16.42A and B) involves the appendix in a significant minority of women with gastrointestinal endometriosis. Patients may present with signs and symptoms of acute appendicitis, although many are asymptomatic.[14,202] Appendiceal endometriosis may result in intussusception,[92] and, exceptionally, appendiceal rupture, particularly during pregnancy.[203,204] Appendiceal endometriosis can also lead to obstruction of the lumen with a mucocele-like distal dilation.[14,205] Rare reports of dysplastic changes arising in the context of appendiceal endometriosis have occurred, raising the possibility that any neoplasm of müllerian origin arising from endometriosis could present as an appendiceal tumor.[14,206] *Endosalpingiosis* (Fig. 16.42C and D) is typically an incidental finding as well,[14] although it can occasionally mimic a well-differentiated adenocarcinoma on frozen section evaluation, and has been reported to cause both a rectosigmoid stricture and a cystic mass.[207,208] The mucinous variant of benign müllerian glandular lesions, endocervicosis, has not been described in the appendix but conceivably could occur.[14] Rare cases of ectopic decidual reaction *("deciduosis")* have been reported in the appendix as well (Fig. 16.42E).[209]

Mesenchymal Tumors

Granular cell tumors,[210,211] *PEComas*,[212] *inflammatory fibroid polyps*,[213] and *schwannomas*[214] rarely involve the appendix and are similar to their counterparts found elsewhere in the GI tract. *GIST* can rarely involve the appendix as a primary site (Fig. 16.43)[214,215]; many of the reported cases have featured skeinoid fibers. There have also been isolated reports of appendiceal *leiomyoma* and *leiomyosarcoma*.[14,214]

Malignant lymphoma can involve the appendix as a primary site, although it is quite rare. Many different types of lymphoma have been reported in the appendix, primarily as case reports, including *Burkitt lymphoma*, *myeloid sarcoma*, and *mantle cell lymphoma*, some of which presented with the clinical picture of acute appendicitis.[14,215–218]

Kaposi sarcoma involving the appendix of HIV-infected individuals and resulting in acute appendicitis has been reported.[219]

Metastases to the appendix are rare and usually originate in carcinomas of the gastrointestinal tract, breast, or female genital tract (Fig. 16.44).[220–222]

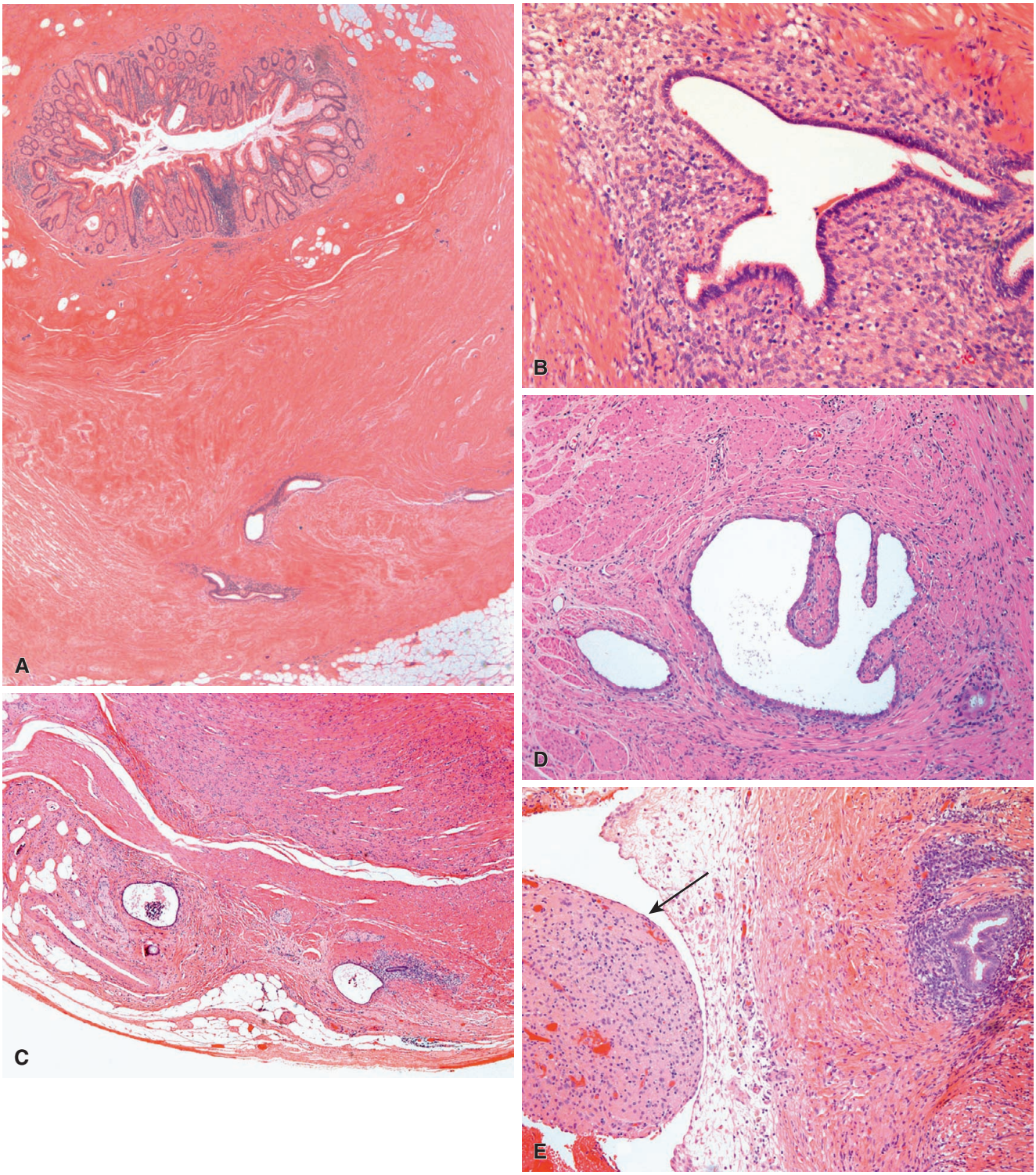

Figure 16.42 **A** and **B,** Endometriosis, characterized by endometrial glands and stroma, in the wall of the appendix. Endosalpingiosis in the outer wall of the appendix **(C)**; cilia are visible at higher power **(D)**. A focus of ectopic decidualization is seen on the left (**E,** *arrow*), while a focus of endometriosis is seen on the right.

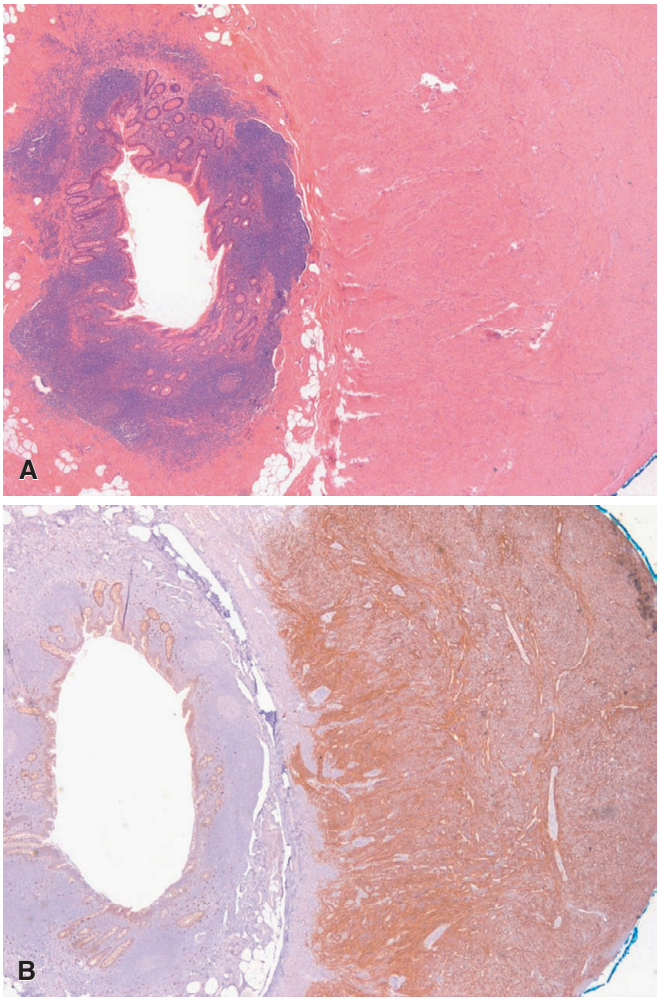

Figure 16.43 A primary GIST arising in the wall of the appendix **(A)**, confirmed by CD117 immunostaining **(B)**.

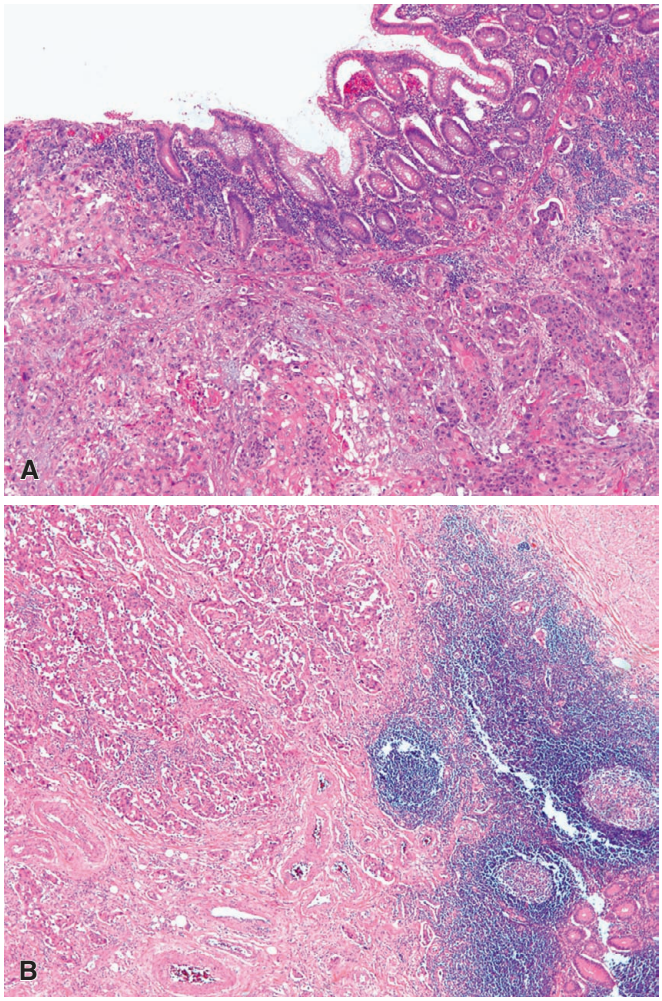

Figure 16.44 **A,** Metastatic squamous cell carcinoma from the cervix. **B,** Metastatic high-grade serous carcinoma from the ovary.

References

1. Williams R. Development, structure, and function of the appendix. In: Williams RA, Myers P, eds. *Pathology of the Appendix and Its Surgical Treatment*. London: Chapman and Hall Medical; 1994:9-30.
2. Wakely CP. The position of the vermiform appendix as ascertained by an analysis of 10,000 cases. *J Anat*. 1933;67:277-283.
3. Deshmukh S, Verde F, Johnson PT, et al. Anatomical variants and pathologies of the vermix. *Emerg Radiol*. 2014;21:543-552.
4. Kim S, Lim HK, Lee JY, et al. Ascending retrocecal appendicitis: clinical and computed tomographic findings. *J Comput Assis Tomogr*. 2006;30:772-776.
5. Lamps LW. Appendix. In: Lamps LW, ed. *Diagnostic Pathology-Normal Histology*. Vol. 10. Park City, UT: Amirsys; 2013:24-27.
6. Gramlich TL, Petras RE. Vermiform appendix. In: Mills SE, ed. *Histology for Pathologists*. 3rd ed. Philadelphia, PA: Lippincott Williams & Wilkins; 2007:649-662.
7. Smith TA. Lymphoid hyperplasia of the appendix in children; its relation to recurrent appendicitis. *Ann Surg*. 1924;79:871-878.
8. Milliken PD. Eosinophilic argentaffin cells in the human appendix. *Arch Pathol*. 1974;98(6):393-395.
9. Aubock L, Hofler H. Extraepithelial intraneural endocrine cells as starting-points for gastrointestinal carcinoids. *Virchows Arch A Pathol Anat Histopathol*. 1983;401:17-33.
10. Droga BW, Levine S, Baber JJ. Heterotopic gastric and esophageal tissue in the vermiform appendix. *Am J Clin Pathol*. 1963;40:190-193.
11. Graf NS, Arbuckle S. Melanosis of the appendix: common in the paediatric age group. *Histopathology*. 2001;39(3):243-249.
12. Rutty GN, Shaw PA. Melanosis of the appendix: prevalence, distribution and review of the pathogenesis of 47 cases. *Histopathology*. 1997;30(4):319-323.
13. Williams R. Neuroma of the appendix. In: Williams RA, Myers P, eds. *Pathology of the Appendix and Its Surgical Treatment*. London: Chapman and Hall Medical; 1994:126-136.
14. Misdraji J, Graeme-Cook FM. Miscellaneous conditions of the appendix. *Semin Diag Pathol*. 2004;21:151-163.
15. Olsen BS, Holck S. Neurogenous hyperplasia leading to appendiceal obliteration: an immunohistochemical study of 237 cases. *Histopathology*. 1987;11:843-849.
16. Stanley MW, Cherwitz D, Hagen K, Snover DC. Neuromas of the appendix. A light-microscopic, immunohistochemical, and electron-microscopic study of 20 cases. *Am J Surg Pathol*. 1986;10:801-815.
17. Guo L, He K, Xu X, et al. Giant appendiceal neurofibroma in von Recklinghausen's disease: a case report and literature review. *Oncol Lett*. 2014;5:1957-1960.
18. de Chadarévian JP, Guzman MA, Pascasio JM, Arthur LG 3rd. Appendiceal goblet cell metaplasia and benign obstructive mucus retention in children: report of eight cases and review of the literature. *Pediatr Dev Pathol*. 2012;15(2):96-100.
19. Rolff M, Jepsen LV, Hoffmann J. The "absent" appendix. *Arch Surg*. 1992; 127:992.
20. Elias EG, Hults R. Congenital absence of the vermiform appendix. *Arch Surg*. 1967;95:257-258.
21. Iuchtman M. Autoamputation of the appendix and the "absent" appendix. *Arch Surg*. 1993;128:600.
22. Varshney M, Shadid M, Maheshwari V, et al. Duplication of appendix: an accidental finding. *BMJ Case Rep*. 2011;doi:10.1136/bcr.01.2011.3679.
23. Khanna AK. Appendix vermiformis duplex. *Postgrad Med J*. 1983;59:69-70.

24. de la Fuente AA. Septa in the appendix: a previously undescribed condition. *Histopathology*. 1985;9:1329-1337.
25. Luckmann R, Davis P. The epidemiology of acute appendicitis in California: racial, gender, and seasonal variation. *Epidemiology*. 1991;2(5):323-330.
26. Wangensteen OH, Dennis C. Experimental proof of the obstructive origin of appendicitis in man. *Ann Surg*. 1939;110(4):629-647.
27. Arnbjornsson E, Bengmark S. Role of obstruction in the pathogenesis of acute appendicitis. *Am J Surg*. 1884;147:390-392.
28. Carr NJ. The pathology of acute appendicitis. *Ann Diag Pathol*. 2000;4(1):46-58.
29. Williams R. Inflammatory disorders of the appendix. In: Williams RA, Myers P, eds. *Pathology of the Appendix and Its Surgical Treatment*. London: Chapman and Hall Medical; 1994:53-89.
30. Arnbjornsson E. Acute appendicitis and dietary fiber. *Arch Surg*. 1983;118:868-870.
31. Lamps LW. Appendicitis and infections of the appendix. *Semin Diag Pathol*. 2004;21(2):86-97.
32. Flum DR. Acute appendicitis-appendectomy or the "antibiotics first" strategy. *N Engl J Med*. 2015;372:1937-1943.
33. Marzuillo P, Germani C, Krauss BS, Barbi E. Appendicitis in children less than five years old: a challenge for the general practitioner. *World J Clin Pediatr*. 2015;8:19-24.
34. Segev L, Keidar A, Schrier I, et al. Acute appendicitis in the elderly in the twenty-first century. *J Gastrointest Surg*. 2015;19:730-735.
35. Williams JS, Hale HW Jr. Acute appendicitis in the elderly: review of 83 cases. *Ann Surg*. 1965;162:208-212.
36. Gilmore OJ, Browett JP, Griffin PH, et al. Appendicitis and mimicking conditions. A prospective study. *Lancet*. 1975;2(7932):421-424.
37. Pooler BD, Lawrence EM, Pickhardt PJ. Alternative diagnoses to suspected appendicitis at CT. *Radiology*. 2012;265:733-742.
38. Sasmal PK, Tantia O, Patle N, Khanna S. Omental torsion and infarction: a diagnostic dilemma and its laparoscopic management. *J Laparoendosc Adv Surg Tech A*. 2010;20:225-229.
39. Angel CA, Rao BN, Wrenn E Jr, et al. Acute appendicitis in children with leukemia and other malignancies: still a diagnostic dilemma. *J Pediatr Surg*. 1992;27:476-479.
40. Binderow SR, Shaked AA. Acute appendicitis in patients with AIDS/HIV infection. *Am J Surg*. 1991;162(1):9-12.
41. Whitney TM, Macho JR, Russell TR, et al. Appendicitis in acquired immunodeficiency syndrome. *Am J Surg*. 1992;164(5):467-470.
42. Roberts JK, Behravesh M, Dmitrewski J. Macroscopic findings at appendicectomy are unreliable: implications for laparoscopy and malignant conditions of the appendix. *Int J Surg Pathol*. 2008;16(4):386-390.
43. Williams RA. Inflammatory disorders of the appendix. In: Williams RA, Myers P, eds. *Pathology of the Appendix and Its Surgical Treatment*. London: Chapman and Hall Medical; 1994:53-89.
44. Gray GF Jr, Wackym PA. Surgical pathology of the vermiform appendix. *Pathol Ann*. 1986;21(Pt 2):111-144.
45. Remington JH, McDonald JR. Vascular thrombosis in acute appendicitis. *Surgery*. 1948;24(5):787-792.
46. Ramdass MJ, Young SQ, Milne D, et al. Association between the appendix and the fecalith in adults. *Can J Surg*. 2015;58:10-14.
47. Lee S, Ogilvie RT, Dupre M, Gao ZH. Intravascular lymphocytosis in acute appendicitis: potential mimicry of chronic lymphocytic leukaemia. *Histopathology*. 2009;55(6):660-664.
48. Bronner MP. Granulomatous appendicitis and the appendix in inflammatory bowel disease. *Semin Diag Pathol*. 2004;21:98-107.
49. Guo G, Greenson JK. Histopathology of interval (delayed) appendectomy specimens: strong association with granulomatous and xanthogranulomatous appendicitis. *Am J Surg Pathol*. 2003;27:1147-1151.
50. Rex JC, Harrison EG Jr, Priestley JT. Appendicitis and ligneous perityphlitis. *Arch Surg*. 1961;82:735-745.
51. Young RH. Howard Atwood Kelly, Elizabeth Hurdon, and their great work: "The vermiform appendix and its diseases." *Semin Diag Pathol*. 2004;21(2):77-85.
52. Nishimori H, Ezoe E, Ura H, et al. Septic thrombophlebitis of the portal and superior mesenteric veins as a complication of appendicitis: report of a case. *Surg Today*. 2004;34:173-176.
53. Mueller BA, Daling JR, Moore DE, et al. Appendectomy and the risk of tubal infertility. *N Engl J Med*. 1986;315(24):1506-1508.
54. Urbach DR, Marrett LD, Kung R, Cohen MM. Association of perforation of the appendix with female tubal infertility. *Am J Epidemiol*. 2001;153:566-571.
55. Jindal N, Kaur GD, Arora S, Rajiv. Bacteriology of acute appendicitis with special reference to anaerobes. *Indian J Pathol Microbiol*. 1994;37:299-305.
56. Roberts JP. Quantitative bacterial flora of acute appendicitis. *Arch Dis Child*. 1988;63:536-540.
57. Pieper R, Kager L, Weintraub A, et al. The role of *Bacteroides fragilis* in the pathogenesis of acute appendicitis. *Acta Chir Scand*. 1982;148:39-44.
58. Scully RE, Vickery AL. Surgical pathology at the hospitals of Harvard Medical School. In: Rosai J, ed. *Guiding the Surgeon's Hand: The History of American Surgical Pathology*. Washington, DC: American Registry of Pathology; 1997:88-89.
59. Berry J Jr, Malt RA. Appendicitis near its centenary. *Ann Surg*. 1984;200(5):567-575.
60. Williams GR. Presidential Address: a history of appendicitis. *Ann Surg*. 1983;197(5):495-506.
61. Cash C, Frazee R. Improvements in laparoscopic treatment for complicated appendicitis. *J Laparoendosc Adv Surg Tech A*. 2012;22:581-583.
62. Mukherjee A, Schlenker E, LaMasters T, et al. Periappendicitis: is it a clinical entity? *Am Surg*. 2002;68(10):913-916.
63. Seetahal SA, Bolorunduro OB, Sookdeo TC, et al. Negative appendectomy: a 10-year review of a nationally representative sample. *Am J Surg*. 2011;201:433-437.
64. Nemeth L, Reen DJ, O'Briain DS, et al. Evidence of an inflammatory pathologic condition in "normal" appendices following emergency appendectomy. *Arch Pathol Lab Med*. 2001;125(6):759-764.
65. Roberts KE, Starker LF, Duffy AJ, et al. Stump appendicitis: a surgeon's dilemma. *JSLS*. 2011;15:373-378.
66. Leff DR, Sait MR, Hanief M, et al. Inflammation of the residual appendix stump: a systematic review. *Colorectal Dis*. 2012;14:282-293.
67. Collins DC. A study of 50,000 specimens of the human vermiform appendix. *Surg Gynecol Obstet*. 1955;101:437-445.
68. Payan HM. Diverticular disease of the appendix. *Dis Col Rectum*. 1977;20:473-476.
69. Rabinovitch J, Arlen M, Barnett T, et al. Diverticulosis and diverticulitis of the vermiform appendix. *Ann Surg*. 1962;155(3):434-440.
70. Dupre MP, Jadavji I, Matshes E, Urbanski SJ. Diverticular disease of the vermiform appendix: a diagnostic clue to underlying appendiceal neoplasm. *Hum Pathol*. 2008;39(12):1823-1826.
71. Kallenbach K, Hjorth SV, Engel U, et al. Significance of acquired diverticular disease of the vermiform appendix: a marker of regional neoplasms? *J Clin Pathol*. 2012;65:638-642.
72. George DH. Diverticulosis of the appendix in patients with cystic fibrosis. *Hum Pathol*. 1987;18:75-79.
73. Chong KC. Diverticiula of the vermiform appendix: a report of nine cases. *Postgrad Med J*. 1976;52:504-510.
74. Hsu M, Young RH, Misdraji M. Ruptured appendiceal diverticula mimcking low-grade appendiceal mucinous neoplasms. *Am J Surg Pathol*. 2009;33:1515-1521.
75. Goldblum JR, Appelman HD. Appendiceal involvement in ulcerative colitis. *Mod Pathol*. 1992;5(6):607-610.
76. Groisman GM, George J, Harpaz N. Ulcerative appendicitis in universal and nonuniversal ulcerative colitis. *Mod Pathol*. 1994;7:322-325.
77. Perry WB, Opelka FG, Smith D, et al. Discontinuous appendiceal involvement in ulcerative colitis; pathology and clinical correlation. *J Gastrointest Surg*. 1999;3:141-144.
78. Stangl PC, Herbst F, Birner P, Oberhuber G. Crohn's disease of the appendix. *Virchows Arch*. 2002;440(4):397-403.
79. Dudley TH Jr, Dean PJ. Idiopathic granulomatous appendicitis, or Crohn's disease of the appendix revisited. *Hum Pathol*. 1993;24(6):595-601.
80. Huang JC, Appelman HD. Another look at chronic appendicitis resembling Crohn's disease. *Mod Pathol*. 1996;9(10):975-981.
81. Lamps LW, Madhusudhan KT, Greenson JK, et al. The role of Yersinia enterocolitica and Yersinia pseudotuberculosis in granulomatous appendicitis: a histologic and molecular study. *Am J Surg Pathol*. 2001;25:508-515.
82. Clarke H, Pollett W, Chittal S, Ra M. Sarcoidosis with involvement of the appendix. *Arch Intern Med*. 1983;143:1603-1604.
83. Cullinane DC, Schultz SC, Zellos L, Holt RW. Sarcoidosis manifesting as acute appendicitis: report of a case. *Dis Colon Rectum*. 1997;40(1):109-111.
84. Fayemi AO, Ali M, Braun EV. Necrotizing vasculitis of the gallbladder and appendix. Similarity in the morphology of rheumatoid arteritis and polyarteritis nodosa. *Am J Gastroenterol*. 1977;67:608-612.
85. Van Laar JM, Smit VT, de Beus WM, et al. Rheumatoid vasculitis presenting as appendicitis. *Clin Exp Rheumatol*. 1998;16:736-738.
86. De Castro SM, Joosse P, Ulu C, Steller EP. Henoch-Schonlein disease localized in the appendix. *Indian J Pediatr*. 2013;80: 1047-1049.
87. Wright CL, Cacala S. Enterocolic lymphocytic phlebitis with lymphocytic colitis, lymphocytic appendicitis, and lymphocytic enteritis. *Am J Surg Pathol*. 2004;28:542-547.
88. McClure J. Malakoplakia of the gastrointestinal tract. *Postgrad Med J*. 1981;57:95-103.
89. Shaktawat SS, Sissons MC. Malakoplakia of the appendix, an uncommon entity at an unusual site: a case report. *J Med Case Rep*. 2008;2:181.
90. Lauwers GY, Perez-Atayde A, Dorfman RF, Rosai J. The digestive system manifestations of Rosai-Dorfman disease (sinus histiocytosis with massive lymphadenopathy): review of 11 cases. *Hum Pathol*. 2000;31(3):380-385.
91. Jevon GP, Daya D, Qizilbash AH. Intussusception of the appendix. A report of four cases and review of the literature. *Arch Pathol Lab Med*. 1992;116(9):960-964.
92. Liang HH, Huang MT, Wei PL, et al. Endometriosis-induced appendiceal intussusception. *Am J Surg*. 2009;197: e66-e68.

93. Wiebe BM. Appendicitis and *Enterobius vermicularis*. *Scand J Gastroenterol*. 1991;26(3):336-338.
94. Sinniah B, Leopairut RC, Neafie RC, et al. Enterobiasis: a histopathological study of 259 patients. *Ann Trop Med Parasitol*. 1991;85:625-635.
95. Moggensen K, Pahle E, Kowalski K. *Enterobius vermicularis* and acute appendicitis. *Acta Chir Scand*. 1985;151:705-707.
96. Noodleman JS. Eosinophilic appendicitis. Demonstration of *Strongyloides stercoralis* as a causative agent. *Arch Pathol Lab Med*. 1981;105(3):148-149.
97. Adebamowo CA, Akang EEU, Ladipo JK, Ajao OG. Schistosomiasis of the appendix. *Br J Surg*. 1991;78:1219-1221.
98. Satti MB, Tamimi DM, Al Sohaibani MO, Al Quorain A. Appendicular schistosomiasis: a cause of clinical acute appendicitis? *J Clin Pathol*. 1987;40(4):424-428.
99. Ramdial PK, Madiba TE, Kharwa S, et al. Isolated amoebic appendicitis. *Virchows Arch*. 2002;441:63-68.
100. Oberhuber G, Lauer E, Stolte M, Borchard F. Cryptosporidiosis of the appendix vermiformis: a case report. *Z Gastroenterol*. 1991;29:606-608.
101. Sinha SN, Sinha B. Appendicular per foration due to *Ascaris lumbricoides*. *J Indian Med Assoc*. 1974;63:396-397.
102. Kenney M, Yermakov V. Infection of man with *Trichuris vulpis*, the whipworm of dogs. *Am J Trop Med Hyg*. 1980;29:1205-1208.
103. Gleason TH, Patterson SD. The pathology of Yersinia enterocolitica ileocolitis. *Am J Surg Pathol*. 1982;6:347-355.
104. El-Maraghi NRH, Mair N. The histopathology of enteric infection with *Yersinia pseudotuberculosis*. *Am J Clin Pathol*. 1979;71:631-639.
105. Ferrari TC, Couto CA, Murta-Oliveira C, et al. Actinomycosis of the colon: a rare form of presentation. *Scand J Gastroenterol*. 2000;35:108-109.
106. Schmidt P, Koltai JL, Weltzien A. Actinomycosis of the appendix in childhood. *Pediatr Surg Int*. 1999;15:63-65.
107. Horvath KD, Whelan RL. Intestinal tuberculosis: return of an old disease. *Am J Gastroenterol*. 1998;93:692-696.
108. Mittal VK, Khanna SK, Gupta M, Aikat M. Isolated tuberculosis of the appendix. *Am Surg*. 1975;41:172-174.
109. Coyne JK, Dervan PA, Haboubi NY. Involvement of the appendix in pseudomembranous colitis. *J Clin Pathol*. 1997;50:70-71.
110. Reif RM. Viral appendicitis. *Hum Pathol*. 1981;12(2):193-196.
111. Grynspan D, Rabah R. Adenoviral appendicitis presenting clinically as acute appendicitis. *Pediatr Dev Pathol*. 2008;11:138-141.
112. Stadlmann S, Lenggenhager DM, Alves VA, et al. Histopathologic characteristics of the transitional stage of measles-associated appendicitis: a case report and review of the literature. *Hum Pathol*. 2011;42:285-290.
113. O'Brien A, O'Briain DS. Infectious mononucleosis. Appendiceal lymphoid tissue involvement parallels characteristic lymph node changes. *Arch Pathol Lab Med*. 1985;109(7):680-682.
114. Neumayer LA, Makar R, Ampel NM, Zukoski CF. Cytomegalovirus appendicitis in a patient with human immunodeficiency virus infection. Case report and review of the literature. *Arch Surg*. 1993;128(4):467-468.
115. McCarty TP, Lee RA, Herfel BM, Pappas PG. Cytomegalovirus appendicitis in solid organ transplant recipients. Two cases and a review. *J Clin Virol*. 2015;66:48-50.
116. Larbcharoensub N, Boonsakan P, Kanoksil W, et al. Fungal appendicitis: a case series and review of the literature. *Southeast Asian J Trop Med Public Health*. 2013;44(4):681-689.
117. Agarwal K, Sharma M, Singh S, Jain M. Antemortem diagnosis of gastrointestinal mucormycosis in neonates: a report of two cases and revew of literature. *Indian J Pathol Microbiol*. 2006;49:430-432.
118. Lamps LW, Molina CP, Haggitt RC, Scott MA. The pathologic spectrum of gastrointestinal and hepatic histoplasmosis. *Am J Clin Pathol*. 2000;113:64-72.
119. Misdraji J, Young RH. Primary epithelial neoplasms and other epithelial lesions of the appendix (excluding carcinoid tumors). *Semin Diag Pathol*. 2004;21:120-133.
120. Bellizzi AM, Rock J, Marsh WL, Frankel WL. Serrated lesions of the appendix: a morphologic and immunohistochemical appraisal. *Am J Clin Pathol*. 2010;133(4):623-632.
121. Carr NJ, Sobin LH. Unusual tumors of the appendix and pseudomyxoma peritonei. *Semin Diagn Pathol*. 1996;13:314-325.
122. Yantiss RK, Panczykowski A, Misdraji J, et al. A comprehensive study of nondysplastic and dysplastic serrated polyps of the vermiform appendix. *Am J Surg Pathol*. 2007;31:1742-1753.
123. Pai RK, Hartman DJ, Gonzalo DH, et al. Serrated lesions of the appendix frequently harbor KRAS mutations and not BRAF mutations, indicating a distinctly different serrated neoplastic pathway in the appendix. *Hum Pathol*. 2014;45:227-235.
124. Mibu R, Itoh H, Iwashita A, et al. Carcinoma in situ of the vermiform appendix associated with adenomatosis of the colon. *Dis Colon Rectum*. 1981;24:482-484.
125. Yantiss RK. Nonmucinous epithelial tumors of the appendix. In: Yantiss RK, ed. *Colorectal Carcinoma and Tumors of the Vermiform Appendix*. Philadelphia, PA: Lippincott Williams & Wilkins; 2014:301-312.
126. Carr NJ, McCarthy WF, Sobin LH. Epithelial noncarcinoid tumors and tumor-like lesions of the appendix. A clinicopathologic study of 184 patients with a multivariate analysis of prognostic factors. *Cancer*. 1995;75(3):757-768.
127. Wolff M, Ahmed N. Epithelial neoplasms of the vermiform appendix (exclusive of carcinoid). I. Adenocarcinoma of the appendix. *Cancer*. 1976;37(5): 2493-2510.
128. Andersson A, Bergdahl L, Boquist L. Primary carcinoma of the appendix. *Ann Surg*. 1976;183(1):53-57.
129. McCusker ME, Cote TR, Clegg LX, Sobin LH. Primary malignant neoplasms of the appendix: a population-based study from the surveillance, epidemiology and end-results program, 1973-1998. *Cancer*. 2002;94(12):3307-3312.
130. Turaga KK, Pappas SG, Gamblin T. Importance of histologic subtype in the staging of appendiceal tumors. *Ann Surg Oncol*. 2012;19:1379-1385.
131. Cortina R, McCormick J, Kolm P, Perry RR. Management and prognosis of adenocarcinoma of the appendix. *Dis Colon Rectum*. 1995;38:848-852.
132. Tang LH, Shia J, Soslow RA, et al. Morphologic classification and clinical behavior of the spectrum of goblet cell carcinoid tumors of the appendix. *Am J Surg Pathol*. 2008;32:1429-1443.
133. Ronnett BM, Kurman RJ, Shmookler BM, et al. The morphologic spectrum of ovarian metastases of appendiceal adenocarcinomas: a clinicopathologic and immunohistochemical analysis of tumors often misinterpreted as primary ovarian tumors or metastatic tumors from other gastrointestinal sites. *Am J Surg Pathol*. 1997;21:1144-1155.
134. Warkel RL, Cooper PH, Helwig EB. Adenocarcinoid, a mucin-producing carcinoid tumor of the appendix: a study of 39 cases. *Cancer*. 1978;42(6):2781-2793.
135. Klein HZ. Mucinous carcinoid tumor of the vermiform appendix. *Cancer*. 1974;33(3):770-777.
136. Isaacson P. Crypt cell carcinoma of the appendix (so-called adenocarcinoid tumor). *Am J Surg Pathol*. 1981;5(3):213-224.
137. Kanthan R, Saxena A, Kanthan SC. Goblet cell carcinoids of the appendix: immunophenotype and ultrastructural study. *Arch Pathol Lab Med*. 2001;125(3):386-390.
138. Lee KS, Tang LH, Shia J, et al. Goblet cell carcinoid neoplasm of the appendix: clinical and CT features. *Eur J Radiol*. 2013;82:85-89.
139. Burke AP, Sobin LH, Federspiel BH, et al. Goblet cell carcinoids and related tumors of the vermiform appendix. *Am J Clin Pathol*. 1990;94:27-35.
140. Li CC, Hirowaka M, Qian ZR, et al. Expression of E-cadherin, b-catenin, and Ki-67 in goblet cell carcinoids of the appendix: an immunohistochemical study with clinical correlation. *Endocr Pathol*. 2002;13:47-58.
141. Carr NJ, Sobin LH. Neuroendocrine tumors of the appendix. *Semin Diag Pathol*. 2004;21:108-119.
142. Stancu M, Wu TT, Wallace C, et al. Genetic alterations in goblet cell carcinoids of the vermiform appendix and comparison with gastrointestinal carcinoid tumors. *Mod Pathol*. 2003;16:1189-1198.
143. Alsaad KO, Serra S, Schmitt A, et al. Cytokeratins 7 and 20 immunoexpression profile in goblet cell and classical carcinoids of appendix. *Endocr Pathol*. 2007;18(1): 16-22.
144. Alsaad KO, Serra S, Perren A, et al. CK19 and CD99 immunoexpression profile in goblet cell (mucin-producing neuroendocrine tumors) and classical carcinoids of the vermiform appendix. *Int J Surg Pathol*. 2007;15(3):252-257.
145. Edmonds P, Merino MJ, LiVolsi VA, Duray PH. Adenocarcinoid (mucinous carcinoid) of the appendix. *Gastroenterology*. 1984;86(2):302-309.
146. Hristov AC, Young RH, Vang R, et al. Ovarian metastases of appendiceal tumors with goblet cell carcinoidlike and signet ring cell patterns: a report of 30 cases. *Am J Surg Pathol*. 2007;31(10):1502-1511.
147. Chetty R, Klimstra DS, Henson DE, Albores-Saavedra J. Combined classical carcinoid and goblet cell carcinoid tumor: a new morphologic variant of carcinoid tumor of the appendix. *Am J Surg Pathol*. 2010;34(8):1163-1167.
148. Pai RK, Beck AH, Norton JA, Longacre TA. Appendiceal mucinous neoplasms: a clinicopathologic study of 116 cases with analysis of factors predicting recurrence. *Am J Surg Pathol*. 2009;33:1425-1439.
149. Pai RK, Longacre TA. Appendiceal mucinous tumors and pseudomyxoma peritonei: histologic features, diagnostic problems, and proposed classification. *Adv Anat Pathol*. 2005;12:291-311.
150. Misdraji J, Yantiss RK, Graeme-Cook FM, et al. Appendiceal mucinous neoplasms: a clinicopathologic analysis of 107 cases. *Am J Surg Pathol*. 2003;27:1089-1103.
151. Misdraji J. Appendiceal mucinous neoplasms and pseudomyxoma peritonei. In: Yantiss RK, ed. *Colorectal Carcinoma and Tumors of the Vermiform Appendix*. Lippincott Williams & Wilkins; 2014:289-300.
152. Arnason T, Kamionek M, Yang M, et al. Significance of proximal margin involvement in low-grade appendiceal mucinous neoplasms. *Arch Pathol Lab Med*. 2015;139:518-521.

153. Yantiss RK, Shia J, Klimstra DS, et al. Prognostic significance of localized extra-appendiceal mucin deposition in appendiceal mucinous neoplasms. *Am J Surg Pathol*. 2009;33:248-255.
154. McDonald JR, O'Dwyer ST, Rout S, et al. Classification of and cytoreductive surgery for low grade appendiceal mucinous neoplasms. *Br J Surg*. 2012;99:987-992.
155. Foster JM, Gupta PK, Carreau JH, et al. Right hemicolectomy is not routinely indicated in pseudomyxoma peritonei. *Am Surg*. 2012;78(2):171-177.
156. Lamps LW, Gray GF Jr, Dilday BR, Washington MK. The coexistence of low-grade mucinous neoplasms of the appendix and appendiceal diverticula: a possible role in the pathogenesis of pseudomyxoma peritonei. *Mod Pathol*. 2000;13(5):495-501.
157. Aroukatos P, Verras D, Vandoros GP, Repanti M. Myxoglobulosis of the appendix: a case associated with ruptured diverticulum. *Case Rep Med*. 2010;2010. doi:10.1155/2010/745021.
158. Young RH. Pseudomyxoma peritonei and selected other aspects of the spread of appendiceal neoplasms. *Semin Diag Pathol*. 2004;21:134-150.
159. Smeenk RM, van Velthuysen ML, Verwaal VJ, Zoetmulder FA. Appendiceal neoplasms and pseudomyxoma peritonei: a population based study. *Eur J Surg Oncol*. 2008;34: 196-201.
160. Du Plessis DG, Louw JA, Wranz PA. Mucinous epithelial cysts of the spleen associated with pseudomyxoma peritonei. *Histopathology*. 1999;35(6):551-557.
161. Mortman KD, Sugarbaker PA, Shmookler BM, et al. Pulmonary metastases in pseudomyxoma peritonei syndrome. *Ann Thorac Surg*. 1997;64(5):1434-1436.
162. Esquivel J, Sugarbaker PH. Pseudomyxoma peritonei in a hernia sac: analysis of 20 patients in whom mucoid fluid was found during a hernia repair. *Eur J Surg Oncol*. 2001;27(1):54-58.
163. Young RH, Rosenberg AE, Clement PB. Mucin deposits within inguinal hernia sacs: a presenting finding of low-grade mucinous cystic tumors of the appendix. A report of two cases and a review of the literature. *Mod Pathol*. 1997;10(12):1228-1232.
164. Ronnett BM, Zahn CM, Kurman RJ, et al. Disseminated peritoneal adenomucinoisis and peritoneal mucinous carcinomatosis. A clinicopathologic analysis of 109 cases with emphasis on distinguishing pathologic features, site of origin, prognosis, and relationship to "pseudomyxoma peritonei.". *Am J Surg Pathol*. 1995;19:1390-1408.
165. Yan H, Pestieau SR, Shmookler BM, Sugarbaker PH. Histopathologic analysis in 46 patients with pseudomyxoma peritonei syndrome: failure versus success with a second-look operation. *Mod Pathol*. 2001;14:164-171.
166. Chua TC, Al-Zahrani A, Saxena A, et al. Secondary cytoreduction and perioperative intraperitoneal chemotherapy after initial debulking of pseudomyxoma peritonei: a study of timing and the impact of malignant dedifferentiation. *J Am Coll Surg*. 2010;211:526-535.
167. Ronnett BM, Yan H, Kurman RJ, et al. Patients with pseudomyxoma peritonei associated with disseminated peritoneal adenomucinosis have a significantly more favorable prognosis than patients with peritoneal mucinous carcinomatosis. *Cancer*. 2001;92(1):85-91.
168. Bradley RF, Stewart JH 4th, Russell GB, et al. Pseudomyxoma peritonei of appendiceal origin: a clinicopathologic analysis of 101 patients uniformly treated at a single institution, with literature review. *Am J Surg Pathol*. 2006;30(5):551-559.
169. Nonaka D, Kusamura S, Baratti D, et al. CDX-2 expression in pseudomyxoma peritonei: a clinicopathological study of 42 cases. *Histopathology*. 2006;49(4):381-387.
170. Yajima N, Wada R, Yamagishi S, et al. Immunohistochemical expressions of cytokeratins, mucin core proteins, p53, and neuroendocrine cell markers in epithelial neoplasm of appendix. *Hum Pathol*. 2005;36:1217-1225.
171. Singhi AD, Davison JM, Choudry HA, et al. GNAS is frequently mutated in both low-grade and high-grade disseminated appendiceal mucinous neoplasms but does not affect survival. *Hum Pathol*. 2014;45(8):1737-1743.
172. Zauber P, Berman E, Marotta S, et al. Ki-ras gene mutations are invariably present in low-grade mucinous tumors of the vermiform appendix. *Scand J Gastroenterol*. 2011;46:869-874.
173. Misdraji J, Burgart LJ, Lauwers GY. Defective mismatch repair in the pathogenesis of low-grade appendiceal mucinous neoplasms and adenocarcinomas. *Mod Pathol*. 2004;17:1447-1454.
174. Chua TC, Moran BJ, Sugarbaker PH, et al. Early- and long-term outcome data of patients with pseudomyxoma peritonei from appendiceal orgin treated by a strategy of cytoreductive surgery and hyperthermic intraperitoneal chemotherapy. *J Clin Oncol*. 2012;30:2449-2456.
175. Carr NJ, Finch J, Ilesley IC, et al. Pathology and prognosis in pseudomyxoma peritonei: a review of 274 cases. *J Clin Pathol*. 2012;65:919-923.
176. Sugarbaker PH, Chang D. Results of treatment of 385 patients with peritoneal surface spread of appendiceal malignancy. *Ann Surg Oncol*. 1999;6:727-731.
177. Elias D, Gilly F, Quenet F, et al. Pseudomyxoma peritonei: a French multicentric study of 301 patients treated with cytoreductive surgery and intraperitoneal chemotherapy. *Eur J Surg Oncol*. 2010;36:456-462.
178. Shapiro R, Eldar S, Sadot E, et al. Appendiceal carcinoid at a large tertiary center: pathologic findings and long term follow-up evaluation. *Am J Surg*. 2011;201:805-808.
179. Alemayehu H, Snyder CL, St Peter SD, Ostlie DJ. Incidence and outcomes of unexpected pathology findings after appendectomy. *J Pediatr Surg*. 2014;49:1390-1393.
180. Hemminki K, Li X. Incidence trends and risk factors of carcinoid tumors: a nationwide epidemiologic study from Sweden. *Cancer*. 2001;92(8):2204-2210.
181. Beddy D, Larson D. Cushing's syndrome cured by resection of an appendiceal carcinoid tumor. *Int J Colorectal Dis*. 2011;26:949-950.
182. Markgraf WH, Dunn TM. Appendiceal Carcinoid with Carcinoid Syndrome. *Am J Surg*. 1964;107:730-732.
183. Roggo AN, Wood WC, Ottinger LW. Carcinoid tumors of the appendix. *Ann Surg*. 1993;217:385-390.
184. Burke AP, Sobin LH, Federspiel BH, Shekitka KM. Appendiceal carcinoids: correlation of histology and immunohistochemistry. *Mod Pathol*. 1989;2(6):630-637.
185. Goddard MJ, Lonsdale RN. The histogenesis of appendiceal carcinoid tumours. *Histopathology*. 1992;20(4):345-349.
186. Lundqvist M, Wilander E. Subepithelial neuroendocrine cells and carcinoid tumours of the human small intestine and appendix. A comparative immunohistochemical study with regard to serotonin, neuron-specific enolase and S-100 protein reactivity. *J Pathol*. 1986;148(2):141-147.
187. Millikin PD. Extraepithelial enterochromaffin cells and Schwann cells in the human appendix. *Arch Pathol Lab Med*. 1983;107:189-194.
188. Jaffee IM, Rahmani M, Singhal MG, Younes M. Expression of the intestinal transcription factor CDX2 in carcinoid tumors is a marker of midgut origin. *Arch Pathol Lab Med*. 2006;130(10):1522-1526.
189. Alexandraki KI, Griniatsos J, Bramis KI, et al. Clinical value of right hemicolectomy for appendiceal carcinoids using pathologic data. *J Endocrinol Invest*. 2011;34:255-259.
190. Williams GT. Endocrine tumors of the gastrointestinal tract-selected topics. *Histopathology*. 2007;50:30-41.
191. Dische FE. Argentaffin and non-argentaffin carcinoid tumors of the appendix. *J Clin Pathol*. 1968;21(1):60-66.
192. Matsukuma KE, Montgomery EA. Tubular carcinoids of the appendix: the CK7/CK20 immunophenotype can be a diagnostic pitfall. *J Clin Pathol*. 2012;65(7):666-668.
193. Chetty R, Serra S. Lipid-rich and clear cell neuroendocrine tumors ("carcinoids") of the appendix: potential confusion with goblet cell carcinoid. *Am J Surg Pathol*. 2010;34(3):401-404.
194. La Rosa S, Finzi G, Puppa G, Capella C. Lipid-rich variant of appendiceal well-differentiated endocrine tumor (carcinoid). *Am J Clin Pathol*. 2010;133(5):809-814.
195. MacGillivray DC, Heaton RB, Rushin JM, Cruess DF. Distant metastasis from a carcinoid tumor of the appendix less than one centimeter in size. *Surgery*. 1992;111(4):466-471.
196. Moertel CG, Weiland LH, Nagorney DM, Dockerty MB. Carcinoid tumor of the appendix: treatment and prognosis. *N Engl J Med*. 1987;317(27):1699-1701.
197. Boudreaux JP, Klimstra DS, Hassan MM, et al. The NANETS consensus guideline for the diagnosis and management of neuroendocrine tumors: well-differentiated neuroendocrine tumors of the jejunum, ileum, appendix, and cecum. *Pancreas*. 2010;39(6):753-766.
198. Deschamps L, Couvelard A. Endocrine tumors of the appendix: a pathologic review. *Arch Pathol Lab Med*. 2010;134:871-875.
199. O'Kane AM, O'Donnell ME, Shah R, et al. Small cell carcinoma of the appendix. *World J Surg Oncol*. 2008;6:4.
200. Rossi G, Bertolini F, Sartori G, et al. Primary mixed adenocarcinoma and small cell carcinoma of the appendix: a clinicopathologic, immunohistochemical, and molecular study of a hitherto unreported tumor. *Am J Surg Pathol*. 2004;28(9):1233-1239.
201. van Eeden S, Offerhaus GJ, Peterse HL, et al. Gangliocytic paraganglioma of the appendix. *Histopathology*. 2000;36(1):47-49.
202. Yantiss RK, Clement PB, Young RH. Endometriosis of the intestinal tract: a study of 44 cases of a disease that may cause diverse challenges in clinical and pathological evaluation. *Am J Surg Pathol*. 2001;25:445-454.
203. Yelon JA, Green JM, Hashmi HF. Endometriosis of the appendix resulting in perforation: a case report. *J Clin Gastroenterol*. 1993;16:355-356.
204. Nakatani Y, Hara M, Misugi K, Korehisa H. Appendiceal endometrosis in pregnancy. Report of a case with perforation and review of the literature. *Acta Pathol Jpn*. 1987;37:1685-1690.
205. Driman DK, Melega DE, Vilos GA, Plewes EA. Mucocele of the appendix secondary to endometriosis. Report of two cases, one with localized pseudomyxoma peritonei. *Am J Clin Pathol*. 2000;113:860-864.
206. Mai KT, Burns BF. Development of dysplastic mucinous epithelium from endometriosis of the appendix. *Histopathology*. 1999;35:368-372.

207. McCluggage WG, Clements WD. Endoalpingiosis of the colon and appendix. *Histopathology*. 2001;39:645-646.
208. Pollheimer MJ, Leibl S, Pollheimer VS, et al. Cystic endosalpingiosis of the appendix. *Virchows Arch*. 2007;450(2): 239-241.
209. Suster S, Moran CA. Deciduosis of the appendix. *Am J Gastroenterol*. 1990;85(7):841-845.
210. Roncati L, Manco G, Italia S, et al. Granular cell tumor of the appendix: a new case and review of the literature. *Springerplus*. 2013;2:649.
211. Johnston J, Helwig EB. Granular cell tumors of the gastrointestinal tract and perianal region: a study of 74 cases. *Dig Dis Sci*. 1981;26(9):807-816.
212. Matkowskyj KA, Rao MS, Raparia K. Transcription factor E3 protein-positive perivascular epithelioid cell tumor of the appendix presenting as acute appendicitis: a case report and review of the literature. *Arch Pathol Lab Med*. 2013;137:434-437.
213. Sánchez-Cifuentes Á, González-Valverde FM, Ruiz-Marín M, et al. Inflammatory fibroid polyp of the appendix or Vanek's tumor. *Rev Esp Enferm Dig*. 2015;107(1):37-38.
214. Miettinen M, Sobin LH. Gastrointestinal stromal tumors in the appendix: a clinicopathologic and immunohistochemical study of four cases. *Am J Surg Pathol*. 2001;25(11):1433-1437.
215. Agaimy A, Pelz AF, Wieacker P, et al. Gastrointestinal stromal tumors of the vermiform appendix: clinicopathologic, immunohistochemical, and molecular study of 2 cases with literature review. *Hum Pathol*. 2008;39(8):1252-1257.
216. Palomino-Portilla EA, Valbuena JR, Quinones-Avila Mdel P, Medeiros LJ. Myeloid sarcoma of appendix mimicking acute appendicitis. *Arch Pathol Lab Med*. 2005;129(8):1027-1031.
217. Sin IC, Ling ET, Prentice RS. Burkitt's lymphoma of the appendix: report of two cases. *Hum Pathol*. 1980;11(5): 465-470.
218. Chae M, Kumar S, Cheema M. Mantle cell lymphoma presenting as acute appendicitis. *Int J Surg Case Rep*. 2015;6C:33-35.
219. Meyer-Rochow GY, Lee KM, Smeeton IW, Shaw JH. Primary Kaposi's sarcoma of the appendix: a rare cause of appendicitis. *ANZ J Surg*. 2007;77:402-403.
220. Maddox PR. Acute appendicitis secondary to metastatic carcinoma of the breast. *Br J Clin Pract*. 1990;44:376-378.
221. Lin CY, Huang JS, Jwo SC, Chen HY. Recurrent gastric adenocarcinoma presenting as acute appendicitis: a case report. *Int J Clin Pract Suppl*. 2005;147:89-91.
222. Yoon WJ, Yoon YB, Kim YJ, et al. Secondary appendiceal tumors: a review of 139 cases. *Gut Liver*. 2010;4:351-356.

17 Large Bowel

John R. Goldblum

CHAPTER CONTENTS

Normal anatomy of the large bowel, *648*
Hirschsprung disease and related disorders, *649*
Diverticulosis, *651*
Colitis, *652*
Ulcerative colitis, *653*
Crohn disease, *657*
Indeterminate colitis, *659*
Ischemic colitis, *659*
Other types of colitis, *660*
Other non-neoplastic lesions, *663*
Tumors, *668*
Epithelial polyps, *668*
Carcinoma, *676*
Well-differentiated neuroendocrine tumor (carcinoid tumor), *685*
Malignant lymphoma and related lesions, *686*
Gastrointestinal stromal and smooth muscle tumors, *686*
Neural tumors and related conditions, *687*
Other tumors and tumorlike conditions, *687*

Normal Anatomy of the Large Bowel

The large bowel comprises the terminal 1–1.5 m of the gastrointestinal tract and is divided into the following regions: cecum, ascending (right) colon, transverse colon, descending (left) colon, sigmoid colon, and rectum. The hepatic flexure is at the junction of the ascending and transverse colon, and the splenic flexure is at the junction of the transverse and descending colon. The rectum forms the distal 8–15 cm of extraperitoneal large bowel that lies within the pelvis and ends at the anal canal.

The large bowel wall is composed of four layers: mucosa, submucosa, muscularis externa (propria), and serosa (or, in the rectum, perimuscular tissues). The mucosa has three components: epithelium, lamina propria, and muscularis mucosae. The mucosal surface is covered by a single layer of low columnar to cuboidal epithelium into which the crypts of Lieberkühn open. This surface epithelium is composed of absorptive cells (with basally located nuclei, mucin-negative acidophilic cytoplasm, and luminally directed apical striated borders) and goblet cells (which synthesize, store, and secrete mucin granules). Lymphocytes and occasional eosinophils may be present between the surface epithelial cells, which rest on a continuous thin basement membrane.[1] The crypts have a tubular, test tube-like shape and are arranged parallel to each other. Branching of these glands occurs very rarely; its presence is usually an indication of chronic disease. It should be distinguished from the cloverleaf-like structure resulting from the opening of several crypts into a single innominate groove.[2]

The crypt epithelium contains mature absorptive cells and goblet cells similar to those in the surface epithelium, but, in addition, it features immature and undifferentiated precursor cells, endocrine cells, and Paneth cells. Both precursor and endocrine cells predominate at the base of the crypts.[3] As in the small intestine, the precursor cells are the progenitors of all other types of epithelial mucosal cells. Paneth cells, identified by their numerous eosinophilic secretory granules (much larger than those of most neuroendocrine cells), contain lysozyme, epidermal growth factor, and other substances. They are normally present only in the cecum and proximal right colon; their occurrence elsewhere in the colon is a sign of metaplasia, usually secondary to chronic mucosal injury.[4] Immunohistochemically, the epithelial cells of the normal colonic mucosa stain for CK8, 18, 19, and 20 but not CK7.[5]

The lamina propria contains a few lymphocytes (both T and B cells), plasma cells, histiocytes, and mast cells scattered in a network of collagen fibers, smooth muscle bundles, vessels, and nerves.[6] Intramucosal ganglion cells can also be seen, isolated or in clusters, but they carry no pathologic significance.[7] In other instances one finds scattered multinucleated stromal giant cells of presumed myofibroblastic nature, similar to those seen more frequently beneath squamous-lined mucosal membranes.[8] *Lymphoglandular complexes* are normal structures formed by deep crypt epithelium surrounded by lymphoid follicles that extend from the mucosa through the muscularis mucosae into the submucosa.[9] The *pericryptal fibroblast sheath* is a collection of fibroblasts or myofibroblasts located around the crypts and at the most superficial portion of the lamina propria.[10]

The macrophages in the lamina propria may contain brown pigment consisting of hemosiderin (usually as the result of prior mucosal hemorrhages) or "pseudomelanin" (as the consequence of ingestion of anthracene-type laxatives).[11] The latter condition, if

Abstract

The colon is one of the most common sites of the gastrointestinal tract biopsied during endoscopic evaluation. The majority of colonic biopsies are performed to exclude either inflammatory or preneoplastic or neoplastic processes. The most common forms of colitis encountered include inflammatory bowel disease (both ulcerative colitis and Crohn disease) and infectious colitis, ischemic colitis, and lymphocytic/collagenous colitis. In addition, a variety of polyps can arise in the colon or rectum, most commonly hyperplastic polyps, adenomatous polyps, and sessile serrated polyps/adenomas. The most common neoplastic process is colonic adenocarcinoma, often arising in patients with previous documented preneoplastic polyps.

Keywords

normal anatomy,
Hirschsprung disease,
diverticulosis,
ulcerative colitis,
Crohn disease,
indeterminate colitis,
ischemic colitis,
polyps,
carcinoma,
carcinoid tumor,
lymphoma,
gastrointestinal stromal tumor,
smooth muscle tumor,
neural tumor,
infectious colitis,
lymphocytic colitis,
collagenous colitis,
colonic adenocarcinoma

extensive enough to be detectable grossly, is referred to as *melanosis coli*.[12] Macrophages containing mucin ("muciphages") are a normal finding and should not be confused with the cells of Whipple disease or with signet ring cancer cells.[13] When grouping in clusters, they have been dignified with the name *colonic histiocytosis*, but they are not the manifestation of a disease entity. Rather, they are probably the expression of a previous unimportant local injury.[14] Histochemically they may contain neutral or acidic mucin, mainly of the sialomucin type.[15]

The lamina propria vessels consist of capillaries (regularly distributed) and lymph vessels (limited to the region immediately above the muscularis mucosae).

The submucosa is composed of loose connective tissue having cell constituents similar to the lamina propria. It also contains the submucosal neural plexus of Meissner. The muscularis externa (propria) includes a circular inner layer and a longitudinal outer layer, with the myenteric neural plexus of Auerbach lying between them. The serosa is composed of a single layer of flattened to cuboidal mesothelial cells and the subjacent fibroelastic tissue.

Interstitial cells of Cajal are scattered throughout the wall, as they are in other portions of the gastrointestinal tract.

The large bowel is supplied by branches of the superior mesenteric artery (from the cecum to the splenic flexure) and the inferior mesenteric artery (distal to the splenic flexure). The lower portion of the rectum is irrigated by the middle and inferior rectal arteries, which are branches of the internal iliac arteries.

The lymphatic drainage of the colon is mainly through the mesentery into the paracolic groups of lymph nodes located along the marginal vascular arcades. Subsequent stations are the intermediate nodal groups (more proximal, at the level of major arterial branches), the central or principal lymph nodes (adjacent to the superior and inferior mesenteric arteries), and the entire para-aortic chain. The lymphatic drainage of the rectum is toward the inferior mesenteric artery nodes, the superior hemorrhoidal chain, and the hypogastric and common iliac nodes.

Hirschsprung Disease and Related Disorders

Hirschsprung disease is a common congenital disorder (1 in 5000 newborns) that results from lack of coordinated propulsive movement of the distal portion of the large bowel due to the loss of intrinsic inhibitory innervation.[16] This is caused by the absence of parasympathetic ganglion cells in the intramural and submucosal plexuses, which in turn may be caused by either failure of migration from the neural crest or by immune-mediated neuronal necrosis (Fig. 17.1).[17] It is diagnosed during the first year of life in most patients, but it may present later, occasionally even in adulthood.[18] Approximately 80% of the patients are male; 10% have Down syndrome, and another 5% have other serious neurologic abnormalities.[19] Cases have also been associated with intestinal atresia[20] and anorectal malformations.[21] Familial cases have also been described.[22] Hirschsprung disease is currently regarded as a genetic disorder with a complex pattern of inheritance. As many as eight genes can be involved, with the *RET* and *EDNRB* genes apparently playing major roles.[22,23] In the total colonic aganglionosis form of Hirschsprung disease, *RET* germline mutation is found in greater than 70% of cases.[23,24]

The symptoms usually begin shortly after birth, with abdominal gaseous distention, delayed meconium passage, and tight anus. With the passage of time, the large bowel proximal to the lesion undergoes dilation of the lumen and hypertrophy of the muscular wall, whereas the diseased segment is narrowed (Fig. 17.2). Mucosal prolapse may be seen at the junction between the ganglionic and aganglionic bowel, particularly in older patients.[25] The most important complications are acute intestinal obstruction and enterocolitis.[26,27]

Microscopically, the hallmark of the disease is the *absence* of ganglion cells (aganglionosis) in *both* plexuses of a segment of bowel.[28] This is associated with the presence of hypertrophied, disorganized, nonmyelinated nerve fibers of both adrenergic and nonadrenergic type in the aganglionic segment, which apparently fail to properly

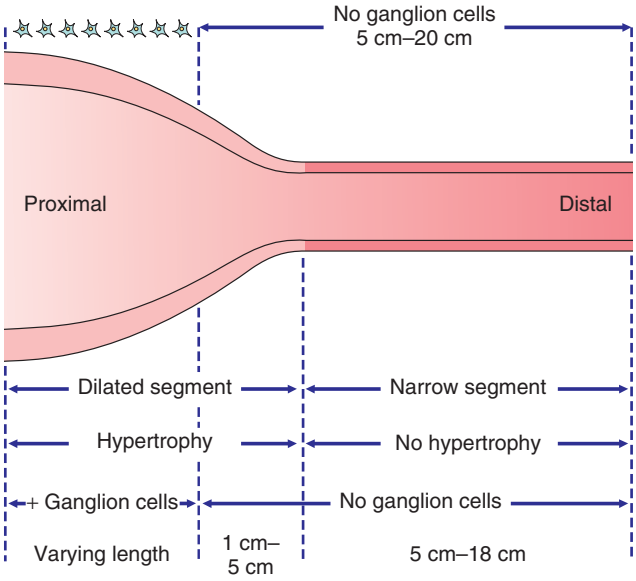

Figure 17.1 Schematic diagram of gross and microscopic changes in 15 cases of Hirschsprung disease.

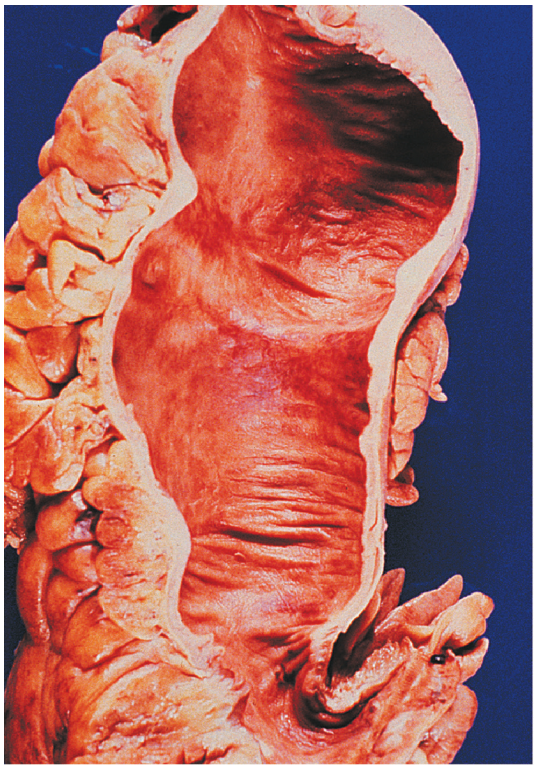

Figure 17.2 Gross Specimen of Hirschsprung Disease. The proximally dilated segment of bowel has been resected.

innervate the muscle layers of the bowel.[29,30] There may also be an altered distribution of the interstitial cells of Cajal,[31] fibromuscular dysplasia in the arteries located in the transitional zone between the aganglionic and the dilated segments,[32] and hyperplasia of lymphoglandular complexes (the latter as an expression of secondary diversion colitis).[33]

Depending on the extent and location of the aganglionic segment, several forms of the disease have been recognized:

1. *Classic form:* The aganglionic segment begins in the distal colorectum and extends for a considerable distance in the adjoining proximal dilated bowel.
2. *Short-segment form:* The aganglionic segment involves the rectum and rectosigmoid for a distance of only a few centimeters.
3. *Ultrashort-segment form:* In this variant, the aganglionic segment is so short that the diagnosis can be missed if the biopsy is taken too high.[34]
4. *Long-segment form (total colonic aganglionosis):* Here the abnormality is more extensive, involving most or all of the large bowel, and occasionally even extending to the small bowel.[35] These patients present with symptoms of intestinal obstruction without megacolon.
5. *Zonal colonic aganglionosis:* Only a short segment of bowel is involved. In contrast to all other forms, ganglion cells are present not only above but also *below* the aganglionic segment.[36,37]

The traditional approach to morphologic documentation of Hirschsprung disease has been the biopsy procedure described by Swenson et al., in which a full-thickness segment of the muscular wall of the rectum is excised and examined for the presence of ganglion cells in the myenteric plexus.[16] Since ganglion cells are normally scanty near the internal anal sphincter, the standard guideline is that the biopsy should be taken at a point 2 cm above the anal valve in infants and 3 cm in older children,[38] even if some authors believe that biopsies taken at 1–1.5 cm from the anal valves may also be adequate.[34] The presence of squamous or transitional epithelium in a specimen indicates that the level of the biopsy is too low. Although this procedure is highly accurate, it requires technical skill, and general anesthesia and may lead to complications. For these reasons, "suction" or mucosal rectal biopsies are now typically done to confirm a diagnosis.[39] These are based on the premise that the limit of aganglionosis in Hirschsprung disease coincides closely in the submucosal and myenteric plexus, as shown by the careful microscopic mapping studies of Gherardi.[40] The ganglion cells of the submucosal plexus are smaller and more irregularly distributed than those located intermuscularly, and their identification requires expertise, patience, and the performance of serial sections in the biopsy obtained. Another abnormality that ought to be looked for is the presence of large (40 µm or greater) submucosal nerve trunks, since they correlate closely with the absence of ganglion cells.[41] Yunis et al. found that, in experienced hands, the mucosal biopsy is a simple and effective method for the exclusion of Hirschsprung disease.[42] These biopsies also can be evaluated with acetylcholinesterase histochemical stain, which highlights a marked increase in thick nerve fibers throughout the lamina propria and muscularis mucosae in patients with this disorder (Fig. 17.3).[43] In problematic cases, it has been shown that the determination of the acetylcholinesterase–butyryl-cholinesterase ratio may be helpful.[44] A number of immunohistochemical techniques have been reported to be useful in the diagnosis of this disease, including neuron-specific enolase, PGP 9.5, neurofilaments, microtubule-associated ("Tau") and MAP-2 proteins, antisynaptic vesicles 171 B.5, Neu N, BMPRIA, ret oncoprotein, cathepsin D (which highlights the presence of hypertrophied nerve fibers and the absence of ganglion cells) and S-100 protein (which shows absence of the normal periganglionic satellite cells and accentuates the enlarged nerve bundles).[45–48] Yet another promising marker is calretinin, whereby loss of calretinin-immunoreactive nerves is characteristic of Hirschsprung disease,[49] a stain we have found to be most useful in our practice.

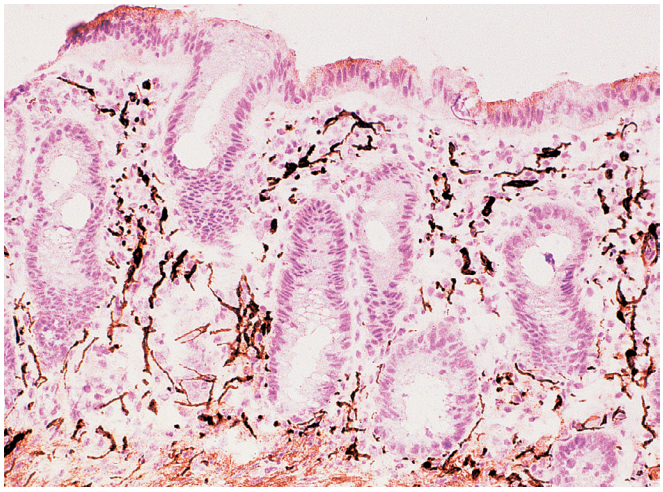

Figure 17.3 Colonic mucosa stained for acetocholinesterase from a patient with Hirschsprung disease. There is a marked increase in the number of nerve fibers in the lamina propria.

The ganglion cells present in the proximal segment, which appear normal by both hematoxylin and eosin (H&E) and the generic neuronal stains listed previously, may still fail to react for colonic neuropeptides such as VIP, GAL, SP, NPY, CGRP, and Met-ENR. It has been suggested that these abnormalities of enteric innervation may be responsible for the unsatisfactory postoperative results seen in approximately 20% of the cases.[50]

Another interesting finding is the marked elevation of class II major histocompatibility antigens in the aganglionic area (not present in patients with chronic constipation resulting from other causes), suggesting an underlying autoimmune mechanism for the disease.[51]

Frozen section is routinely used for documenting the absence of ganglion cells and determining the level of transection of the bowel at surgery. This procedure is facilitated if the surgeon gives the pathologist a rectangular piece of the entire muscular wall, so that the tissue can be properly oriented. For frozen section evaluation to be reliable, the tissue should be at least 4 mm long, and multiple serial sections should be taken. Even under these ideal circumstances it should be understood that the inaccuracy rate is relatively high, significantly more so than for frozen section diagnoses in general.[52]

The most common operations for the treatment of Hirschsprung disease are Swenson proctectomy with pull-through of ganglionic bowel to the anus, the Duhamel side-to-side anastomosis of ganglionic bowel with the aganglionic rectal stump, and the Soave endorectal pull-through, in which the rectal mucosa is stripped away and the ganglionic bowel brought down to the anus.[53,54]

Occasionally, successfully operated patients develop a recurrence of obstructive symptoms and are found to have aganglionosis in pulled-through bowel that had previously been shown to be ganglionated.[55]

Hypoganglionosis is a disputed entity in which there is a deficiency rather than an absence of ganglion cells.[56,57] It should be remembered that a decrease of ganglion cells is usually present at the junction between the dilated and aganglionic bowel in conventional Hirschsprung disease.

Intestinal neuronal dysplasia (neuronal colonic dysplasia, hyperganglionosis) is another controversial entity or entities included

in the vague group of disorders generically designated as pseudo-Hirschsprung disease.[58] Hyperplasia of the myenteric nerves is accompanied by giant ganglia, isolated ganglion cells in the submucosa, and an increase in acetylcholinesterase staining;[59] it has been described in association with von Recklinghausen disease and multiple endocrine neoplasia.[60,61] However, the entity is far from well defined, and its diagnosis should be reserved for the rare florid cases that occur in the absence of associated obstruction or other known entities and should be made only if multiple biopsies, including ample submucosa or transmural sections (preferably the latter), are available.[62]

Chronic idiopathic intestinal pseudo-obstruction is a syndrome in which symptoms of intestinal obstruction are present in the absence of mechanical obstruction. It has been attributed to an abnormal physiology of the bowel propulsive system. Loss of CD117-positive (presumably interstitial cells of Cajal) and CD34-positive cells has been found in a subset of these cases.[63] Staining for BCL2 is said to be a useful means of evaluating the presence of immature enteric ganglion cells that are allegedly present in this and some of the other nebulous conditions listed in this section.[64]

Slow transit constipation is yet another colonic mobility disorder characterized by delayed movement of stools through the colon. The mean number of interstitial cells of Cajal and enteric neurofilaments are said to be considerably reduced in this condition, particularly in the inner circular muscle layer.[65]

Megacolon can also result from **cytomegalovirus (CMV) infection** and **Chagas disease** as the result of acquired abnormalities of the neural plexuses.[66] In the latter condition there is a cytotoxic T cell–rich inflammatory infiltrate of the enteric plexuses accompanied by degeneration of ganglion and glial cells.[67,68]

Diverticulosis

Most cases of diverticulosis are acquired and occur in patients over the age of 40 years. Clinical evidence of diverticulosis is seen in slightly over 10% of the individuals in this age group, but surgical complications develop in only 10% of them.[69] Naturally, the incidence of diverticulosis at autopsy is higher; in a study from Australia, 45% of 200 examined large bowels had diverticula.[70] There have been reports of diverticula occurring in children, in young patients with Marfan, Williams–Beuren, or Ehlers–Danlos syndrome, and in association with polycystic renal disease.[71–73]

Diverticulosis shows a remarkable geographic difference in its frequency. It is common in North America, Europe, and Australia but uncommon in Asia, Africa, and parts of South America.[74] The main protective factor seems to be a high-residue diet, although the evidence is not conclusive.[75] This type of diet is thought to act by diminishing the degree of colonic segmentation, which is the mechanism responsible for mucosal herniation. The disease is characteristically multiple and preferentially involves the left colon. In the previously mentioned autopsy study from Australia, the sigmoid colon was affected in 99% of the specimens.[70] This was the only area of involvement in 41% of the cases; in 30%, the disease involved the descending colon; in 4%, the transverse colon; and in 16%, the entire colon. The rectum is only rarely affected. The distribution of the disease is different in patients from the Far East, in whom there is a greater frequency of right-sided involvement.[76]

As seen radiographically and grossly, the diverticula are located on the mesenteric and lateral aspects of the bowel (Figs. 17.4 and 17.5). They have a flask-like shape and may be filled with feces or mucin. Some extend into the appendices epiploicae and bulge over the serosa, but they may still be difficult to recognize at the time of surgery in obese persons. The muscular wall of the bowel always appears abnormal in the area of diverticulosis. The teniae are prominent, with an almost cartilaginous look. The circular layer is also thickened, with a corrugated appearance corresponding to interdigitating processes of the muscle.[77] Microscopically, the diverticulum lacks a muscle layer except for residual bundles of muscularis mucosae (Fig. 17.6). The adjacent bowel, including the myenteric plexus, shows no appreciable abnormalities. Polypoid prolapsing mucosal folds may occur, probably resulting from a combination of venous congestion and mucosal redundancy caused by the spastic contraction of the muscle coat.[78]

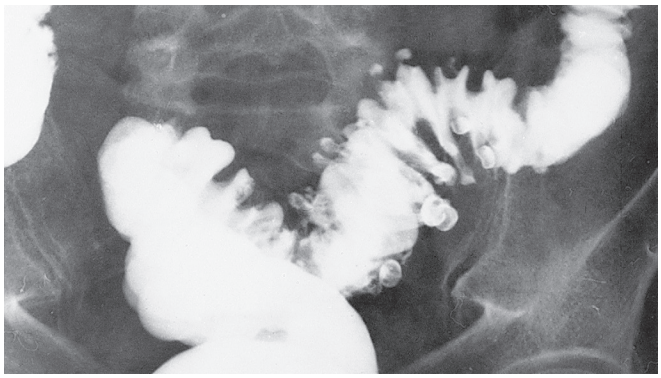

Figure 17.4 Classic radiographic appearance of diverticulosis.

Figure 17.5 Extensive diverticulosis of the sigmoid colon with segmentation and shortening of bowel. Openings of diverticula can be clearly seen. The circular muscle is thick and corrugated.

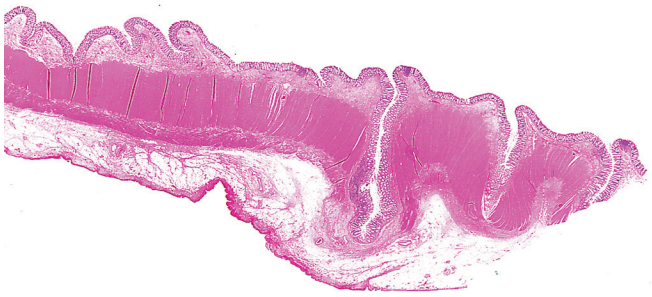

Figure 17.6 Whole-mount section of colonic diverticular disease.

Cecal diverticula may be of two types. One, usually multiple, is similar in all aspects to diverticula of the left colon and is often associated with them. The other, thought to be congenital, is solitary

and unassociated with diverticular disease elsewhere; it is usually located on the medial wall of the cecum near the ileocecal valve and contains an external muscle layer.[79]

The main complications of diverticulosis are hemorrhage, perforation, and diverticulitis. The bleeding, which is right sided in about half of the cases and which may be massive, results from rupture of one of the colonic nutrient vessels that run on the side of the diverticulum.[80] Arteriographic and microangiographic techniques have shown a characteristic asymmetric rupture of the vessel toward the lumen of the diverticulum precisely at its dome or antimesenteric margin.[81]

Perforation of the diverticulum may lead to a pericolic or pericecal abscess, which in later stages evolves into an indurated mass that may be confused with carcinoma clinically and radiographically. The abscess may drain into bladder or adjacent bowel and result in fistula formation (*"dissecting diverticulitis"*), producing a double tracking effect on x-ray studies. Rarely, this fistulous tract may extend into the perineum, scrotum, buttocks, hip, or even lower extremities.[82] Acute free perforation into the abdominal cavity is rare. Sometimes the release of mucin contained within the diverticula results in a pericolic mucocele-like formation. Exceptionally, hyaline rings ("pulse granulomas") similar to those seen more often in the oral cavity are found in the areas of perforation.[83]

Diverticulitis manifests radiographically with sawtoothed serrations and a narrowed lumen. It may resemble carcinoma, but the segment involved is usually longer and the mucosa is intact. Microscopically, there is acute or chronic inflammation in—but mainly around—the base of the diverticulum (Fig. 17.7). Sometimes there is granulomatous inflammation around the diverticulum that can closely simulate Crohn disease. Not uncommonly, there is a chronic colitis limited to the sigmoid colon in areas near diverticula that are indistinguishable from idiopathic inflammatory bowel disease (IBD) in the absence of clinical and endoscopic data (see next section).[84–86] The inflammation can spread into the mesentery and result in panniculitis, not to be confused with sclerosing mesenteritis.

Pain, a common symptom of diverticular disease, may be secondary to these inflammatory changes; however, it may also be present in the absence of diverticulitis and is probably induced by the muscle abnormalities. Parenthetically, chronic corticosteroid therapy may lead to free perforation of the colon and closely simulate the picture of diverticulosis with diverticulitis.[87] Exceptionally, a polyp or carcinoma is found contained within a diverticulum.[88]

Acute uncomplicated diverticulitis can often be treated successfully with antibiotics alone.[89] Surgical resection is often performed in patients with complications of diverticulitis such as hemorrhage, ulceration, perforation, abscess formation, fistulae, strictures, obstruction, and pylephlebitis.[90] Prompt resection for patients with free diverticular perforation and spreading peritonitis may be required. Not surprisingly, morbidity and mortality rates are higher in these instances than when resections are performed for uncomplicated acute diverticulitis.[91] Other indications for surgery are repeated attacks of diverticulitis while on a good medical regimen and the development of urinary symptoms. The latter may be the manifestation of an impending sigmoid–vesical fistula.

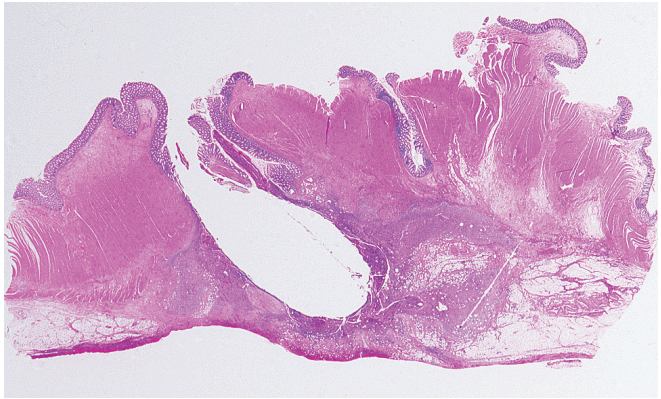

Figure 17.7 Whole-Mount Section of Colonic Diverticulosis. One of the diverticula shows marked chronic peridiverticulitis. Note hypertrophy of the muscular wall.

Colitis

The term *inflammatory bowel disease*—sometimes preceded by the qualifier *idiopathic*—is employed for a group of inflammatory disorders currently thought to be associated with a number of susceptibility genes leading to defects in the epithelial barrier function, and activation of the mucosal immune system driven by the presence of normal luminal flora (commensal bacteria and their products).[92,93] The two main members of this group are ulcerative colitis and Crohn disease. However, as discussed later, distinction between these forms of IBD may be impossible in some cases (Table 17.1).

Table 17.1 Comparison of clinical and pathologic features between ulcerative colitis and Crohn disease

FEATURE	ULCERATIVE COLITIS	CROHN DISEASE
Clinical Features		
Rectal bleeding	Common	Uncommon
Abdominal mass	Very rare	10-15%
Abdominal pain	Usually left-sided	Usually right-sided
Sigmoidoscopy	Abnormal in 95%	Abnormal in <50%
Free perforation	10-15%	<5%
Colon carcinoma	5-10%	Very rare
Anal complications	Very rare	75% (fissures, fistulas)
Pathologic Features		
Distribution	Diffuse, predominantly left-sided Mucosal, some submucosal	Patchy, predominantly right-sided Transmural
Fissures	Absent	Common
Fistulas	Absent	Common
Rectal involvement	Virtually always	<50%
Ileal involvement	Backwash in pancolitis	>50%
Pyloric gland metaplasia	Uncommon	Common
Granulomas	Crypt rupture	True granulomas in >50%

Ulcerative Colitis

Ulcerative colitis occurs with equal frequency in both sexes. It appears most often in patients between 20 and 30 years of age; however, it can occur at any age, including in childhood.[94,95] The etiology remains unknown. There is increasing evidence that susceptibility is inherited, although the genetic contribution does not seem to be as important as for Crohn disease. The duration is usually prolonged, with many remissions and exacerbations; nutritional deficiencies and anemia are common accompanying features.

Ulcerative colitis is characteristically a left-sided disease that begins in the rectosigmoid colon. In some cases, it remains localized to the rectum *(ulcerative proctitis)*, but in most instances it spreads proximally, sometimes to involve the entire colon *(pancolitis)*.

The gross appearance of the lesions varies with the stage of the disease (Fig. 17.8). In the acute form, the mucosal surface of the bowel is wet and glaring from blood and mucus, and petechial hemorrhages are often seen. Various-sized ulcers of irregular configuration then appear. Some of these ulcers undermine the mucosa so that mucosal bridges with an underlying inflammatory infiltrate develop. Extensive longitudinal ulcers, especially if connected by transverse ulcers, are *not* a feature of ulcerative colitis and are more characteristic of Crohn disease. Elevated sessile reddish nodules, known as *pseudopolyps*, are often seen in an otherwise flat surface (Fig. 17.9). They are typically small and multiple. Rarely, they may have a filiform configuration; sometimes they attain a giant size, thus raising the clinical and radiographic suspicion of carcinoma.[96]

In the more advanced stages of the process, the entire bowel becomes fibrotic, narrowed, and shortened. The cicatricial stenosis associated with an inflammatory mass may result in an erroneous clinical and radiographic diagnosis of carcinoma. If the colon has become defunctionalized with an ileostomy or colostomy before the colectomy, it may show extreme narrowing of the lumen, striking atrophy of all the components of the wall, and a marked increase in pericolic fat. In the quiescent stage, ulceration is absent, the mucosa is atrophic, and there may be extensive submucosal fat deposition. In some cases the mucosa may appear grossly normal.

Microscopically, ulcerative colitis is primarily a mucosal and submucosal disease.[97,98] In the acute phase, there is an increase in the number of inflammatory cells in the lamina propria, including basal plasmacytosis. Crypt abscesses (i.e. collections of neutrophils in the glandular lumen) appear; these are preceded by accumulation of these cells at the base of the crypts (Figs. 17.10–17.12). This leads to a progressive destruction of the crypts, which show a marked decrease in cytoplasmic mucus and irregular shapes, resulting from a combination of atrophic and regenerative changes. These regenerative changes are also manifested by nuclear enlargement and increased mitotic activity; the latter is no longer limited to the lower portion of the crypts, as in the normal mucosa. Paneth cells, usually absent

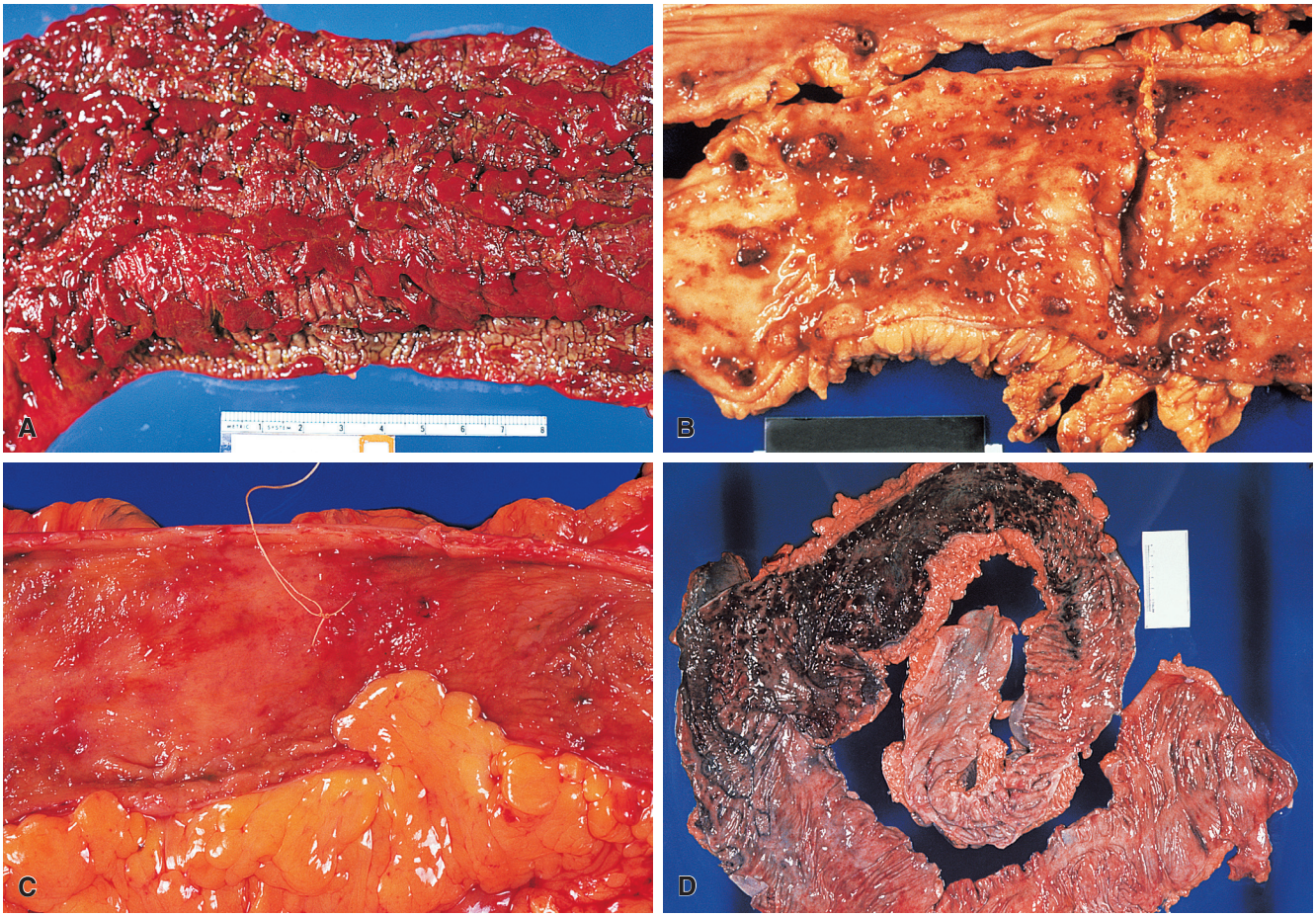

Figure 17.8 Various Gross Appearances of Ulcerative Colitis. A, Acute ulcerative colitis with marked hyperemia. **B,** Ulcerative colitis showing mucosal ulceration with residual foci of elevated and hyperemic mucosa. **C,** Longstanding ulcerative colitis showing total mucosal atrophy. **D,** Fulminant ulcerative colitis with toxic megacolon.

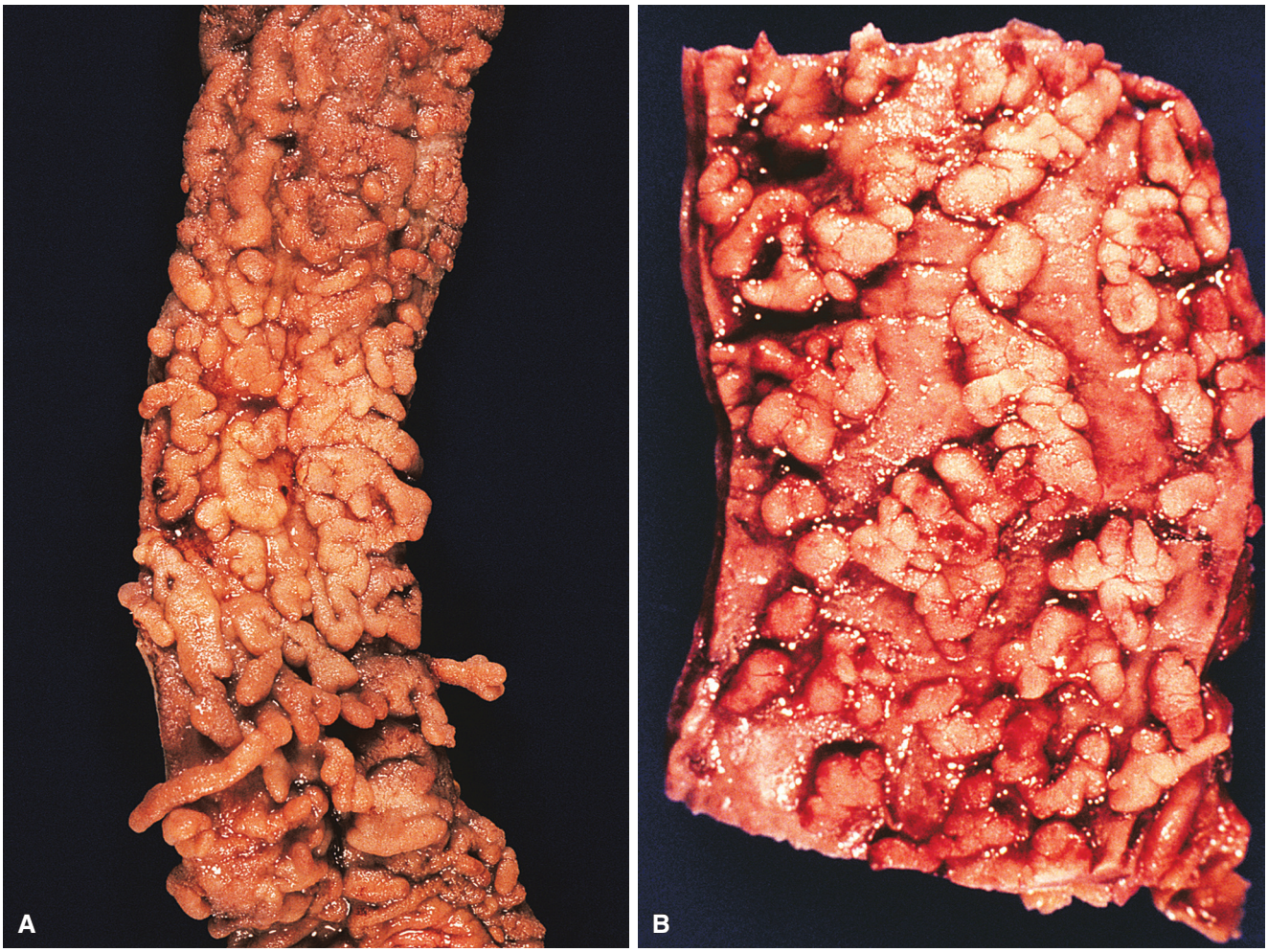

Figure 17.9 **A** and **B,** Pseudopolyps in separate cases of ulcerative colitis.

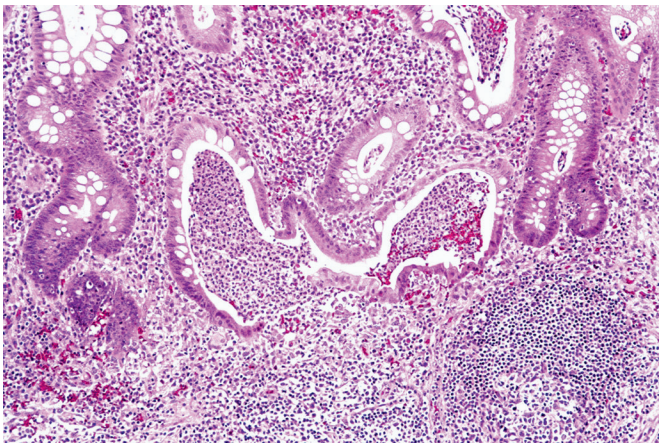

Figure 17.10 Low-power view of ulcerative colitis showing a chronic active colitis pattern of injury.

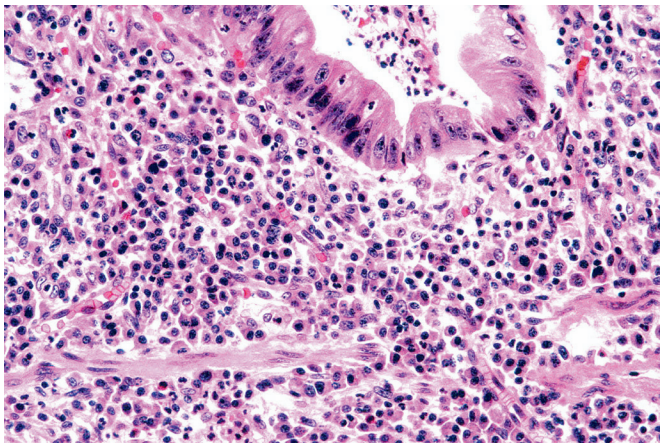

Figure 17.11 Chronic changes in ulcerative colitis with basal plasmacytosis and separation of the base of the crypts from the muscularis mucosae by a sheet of plasma cells.

beyond the right colon in normal individuals, appear as an expression of metaplasia, and are an indicator of chronic colitis.

The stromal inflammatory infiltrate of ulcerative colitis is composed of neutrophils, lymphocytes, plasma cells, a few histiocytes and other "accessory immune" cells, scattered eosinophils, and mast cells.[99,100] As a rule, granulomas containing epithelioid and multinucleated giant cells are absent, this being an important criterion in the differential diagnosis with Crohn disease. However, crypt-associated intramucosal granulomas may supervene in ulcerative colitis as a result of crypt rupture.[101] The infiltrate may be accompanied by numerous lymphoid

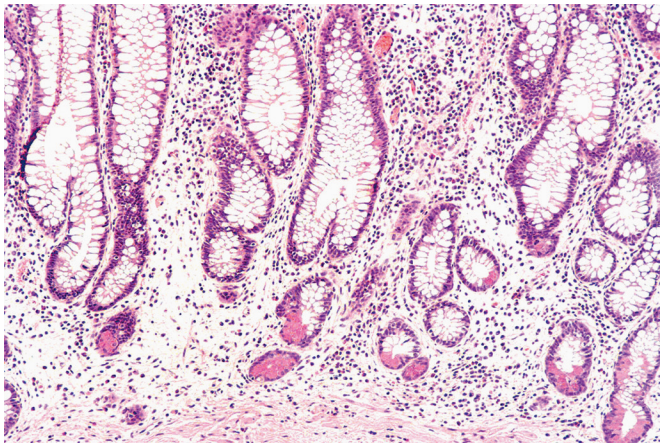

Figure 17.12 Chronic changes in ulcerative colitis characterized by crypt architectural distortion and Paneth cell metaplasia.

follicles, particularly in the rectum, and may lead to marked distortion of the crypts. Blood vessels are dilated, and mucosal capillary thrombi may be seen.[102] The inflammation may remain above the muscularis mucosae or extend into the submucosa. Ulcers and granulation tissue may be prominent and can result in pseudopolyps composed of granulation tissue mixed with inflamed and hyperemic mucosa. In some instances, the mucosal regeneration acquires a villous configuration reminiscent of small bowel mucosa.[103] Depending on the stage of the disease, the submucosa may appear normal or inflamed, hyperemic, infiltrated by fat, or fibrosed; sometimes it contains glands that have herniated through gaps in the muscularis mucosae, which often appears hypertrophic.[104] In approximately 10% of cases, the submucosal arteries show features of endarteritis obliterans, with or without thrombosis. The muscularis mucosae may appear reduplicated, but the muscularis externa is usually normal or slightly hypertrophic.[105]

As already stated, in the quiescent or resolving stage of the disease, the mucosa may appear grossly normal, with nearly total restoration of the mucin content. However, subtle microscopic abnormalities are often detected in the form of branching and irregular glands (rather than parallel, evenly spaced glands), a gap between the base of the crypts and the muscularis mucosae, the appearance of Paneth cells and hyperplasia of neuroendocrine cells. However, there are cases where medical therapy can induce a return to histologically normal mucosa, without any vestiges of prior mucosal injury.[106,107] It should also be noted that pediatric patients may show a near normal or even (very rarely) a completely normal rectum at first diagnosis.[108,109]

Ulcerative colitis can spread to other portions of the gastrointestinal tract. The ileum is involved in approximately one-fifth to one-third of the cases. This involvement (sometimes referred to as *backwash ileitis*) is superficial, mild, of little clinical importance, and typically occurs in continuity with the colonic disease; it rarely spreads more than 10 cm from the ileocecal valve and may be accompanied by dilation of the lumen.[110,111] Rare cases of diffuse *duodenitis* in ulcerative colitis patients have been described.[112]

Interestingly, the ileal stoma of proctocolectomized patients may develop colonic metaplasia and ulcerative colitis-like lesions, including inflammatory polyps.[113] Similar changes have been described in pelvic ileal reservoirs (ileal pouches) constructed in patients with ulcerative colitis *(postcolectomy pouchitis)*.[114] In turn, the defunctioned rectum may show changes that can simulate Crohn disease and are thought to result from a combination of defunctioning and of active ulcerative colitis.[115]

Figure 17.13 Fulminant ulcerative colitis complicated by toxic megacolon.

The vermiform appendix is affected in 20%–60% of cases; this may occur in continuity with adjacent involved cecum or as a skip lesion.[116,117] In the anal canal, there is often involvement of the glandular epithelium, and sometimes there are hyperplastic changes of the transitional mucosa.[118] Anal lesions are seen in 10% of cases; they may consist of midline dorsal fissures, skin excoriations, acute perianal and ischiorectal abscesses, or rectovaginal fistulas.

Some patients with ulcerative colitis have associated liver disease. This may consist of fatty infiltration, abscess, cirrhosis, sclerosing cholangitis, pericholangitis, and—rarely—carcinoma of the biliary tract.[119,120] Patients in whom the latter complication occurs are younger than those developing carcinoma de novo.[120]

Other distant manifestations of ulcerative colitis include arthritis, uveitis, pyoderma gangrenosum, and limited forms of Wegener granulomatosis.[121] These are usually limited to patients with extensive colonic involvement and appear only exceptionally in those with disease limited to the rectum.

Local complications of ulcerative colitis are perforation with peritonitis and abscess, toxic megacolon (Fig. 17.13), venous thrombosis (most often in the iliac vein), and carcinoma (discussed in the next section).

The treatment of ulcerative colitis, depending on its extent, severity, and duration, includes sulfasalazine therapy, local or systemic steroid therapy, and total colectomy.[122–124]

Carcinoma and Dysplasia in Ulcerative Colitis

The incidence of carcinoma of the large bowel is markedly increased in patients with ulcerative colitis.[125,126] The overall incidence of this complication is probably in the vicinity of 2%, which represents only 1% of all cases of colorectal carcinoma in the general population.[127] Risk factors include patients with extensive colitis, those with disease for greater than 7–10 years, young age of colitis onset, and primary sclerosing cholangitis.[128–131]

Studies have emphasized the atypical gross appearance of the carcinoma developing in ulcerative colitis, its more even distribution in the large bowel, its frequent multiplicity (10%–20% of the cases), its tendency to occur in younger persons, and the fact that the site of origin is almost always a flat rather than a polypoid mucosa.[132,133] Carcinoma may also develop in the rectal cuff or pouch following ileoanal pouch anastomosis.[134,135]

The earliest gross change is often represented by a thick mucosa with a finely nodular or velvety surface configuration. Microscopically, most of these tumors are adenocarcinomas of varying degrees of differentiation. The proportion of poorly differentiated and mucinous carcinomas is higher than for tumors arising in uninflamed mucosa, but rare low-grade well-differentiated tubuloglandular forms also exist.[136] It has been traditionally assumed that carcinomas developing in this setting carry an ominous prognosis; however, in several series with control subjects from a population without colitis matched by stage and microscopic grade, no difference in survival between the two groups has been found.[137–139]

The development of adenocarcinoma is always accompanied—and probably always preceded—by dysplastic changes of the colorectal mucosa. These dysplastic changes, which tend to occur in flat atrophic mucosa, should be distinguished from the more common regenerative changes that are often seen in inflamed mucosa.[140] As a rule, the diagnosis of dysplasia should not be made in areas of active inflammation. The evaluation of these changes is difficult and somewhat subjective,[141] but, when properly done, it has been successful in identifying a population at high risk for developing colorectal carcinoma.[142] The presence of dysplastic changes does not necessarily indicate that the patient harbors an invasive carcinoma elsewhere in the bowel. Similarly, the absence of such changes does not guarantee that the patient is free of carcinoma elsewhere. A standardized classification of dysplasia has been recommended,[143] using the following terminology (Figs. 17.14–17.17):

1. Negative for dysplasia
2. Indefinite for dysplasia

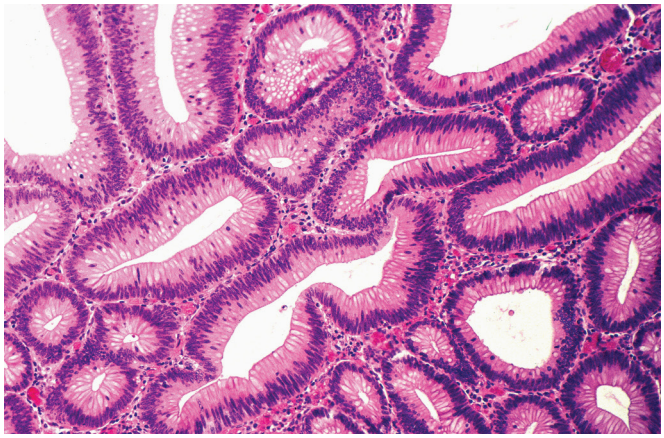

Figure 17.14 Focus of polypoid low-grade dysplasia in ulcerative colitis. The focus is histologically indistinguishable from a sporadic tubular adenoma.

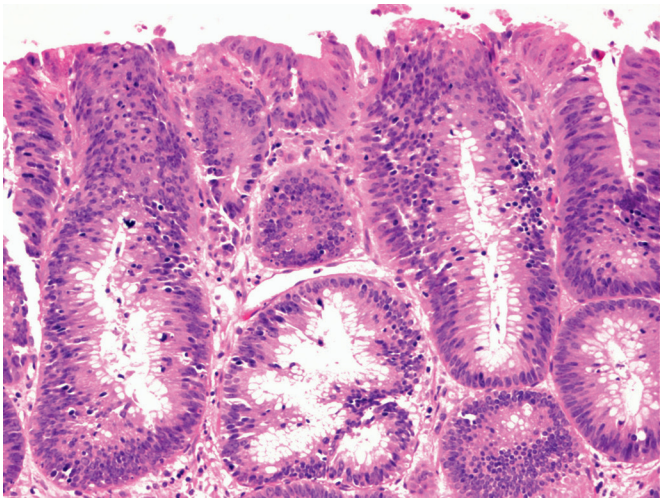

Figure 17.15 Focus of flat low-grade dysplasia in ulcerative colitis.

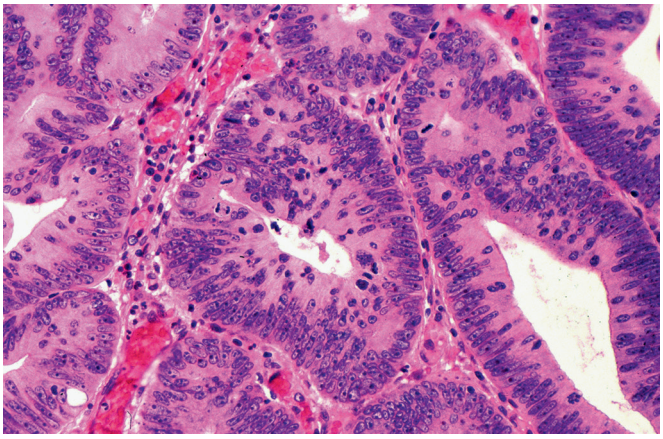

Figure 17.16 Flat high-grade dysplasia in ulcerative colitis characterized by marked cytologic atypia and architectural complexity.

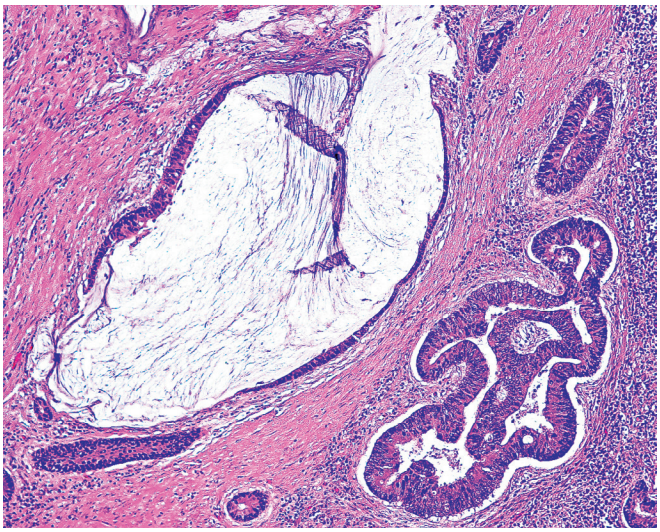

Figure 17.17 Invasive adenocarcinoma with abundant extracellular mucin arising in a colon affected by ulcerative colitis.

3. Positive for dysplasia, low grade
4. Positive for dysplasia, high grade

Pathologic diagnosis directly impacts patient management. Patients with a diagnosis of indefinite for dysplasia are treated with maximal medical therapy to reduce inflammatory changes and are brought back for repeat biopsy in a shorter period of time than those whose biopsies are negative for dysplasia. The implications of biopsies with low-grade or high-grade dysplasia in part depend on the endoscopic appearance of the area in question. For polypoid lesions, most cases can be treated by endoscopic polypectomy, even those with high-grade dysplasia.[144–146] However, most patients with flat high-grade dysplasia, and many with flat low-grade dysplasia (especially if multifocal), opt for colectomy.[145] Histologically, it is not possible to reliably distinguish a sporadic adenoma arising in a field of IBD from IBD-related polypoid dysplasia. By immunohistochemistry, IBD-related dysplasia tends to show strong staining for p53 and absent or weak staining for β-catenin,[147] as well as Ki-67 staining above the basal two-thirds of the crypt.[148] However, there is overlap with the patterns seen in sporadic adenomas, thereby limiting the clinical utility of these markers.

At the molecular level, the aberrations encountered in the dysplastic glands have included *TP53* mutation,[149,150] *KRAS* mutation,[151] and microsatellite instability (MSI).[151] It has also been found that ulcerative colitis patients with dysplasia and/or carcinoma have a much greater degree of genomic instability in both their dysplastic and nondysplastic mucosa than those lacking morphologic features of dysplasia/carcinoma.[152]

An interesting issue is whether the immunohistochemical and molecular alterations of the dysplastic lesions in ulcerative colitis (and therefore the mechanisms leading to its appearance and progression) are the same as or different from those operating in colorectal adenomas (which, of course, can be present in the large bowel affected by ulcerative colitis).[153–155] Although the results from the various groups are not always congruent, a consensus is beginning to emerge that flat dysplastic lesions in ulcerative colitis patients show substantial differences from de novo colorectal adenomas, whereas the polypoid dysplastic lesions in the same patients are very similar if not identical to the de novo lesions.[155–157]

The presence of these immunohistochemical or molecular alterations may be helpful in confirming the presence of dysplasia and eventually contribute to its grading, but at the present time this determination is largely based on the appearance of the epithelium in routinely stained sections. The surveillance protocols that have been devised for patients with ulcerative colitis, recommended to be started after 8–10 years of extensive colitis and after 15 years of left-sided colitis, depend on the skill and experience with endoscopic and microscopic features on the part of the gastroenterologist and pathologist, respectively.[158,159] Whether this close surveillance is actually truly beneficial and cost-effective remains controversial.[160] It needs to be emphasized in this regard that the absence of dysplasia in a colorectal biopsy does not exclude the possibility of the patient developing adenocarcinoma in the future.

Other colorectal malignancies that rarely occur in association with ulcerative colitis are various types of *neuroendocrine neoplasms*[161] and *malignant lymphoma*, particularly in the setting of immunosuppressive therapy.[162,163]

Crohn Disease

Crohn disease, originally described as a small bowel disorder, is now known to involve the large bowel in approximately 40% of all cases, with or without a concomitant ileal component. The etiology remains undetermined. Susceptibility to the disease is inherited, suggesting a genetic contribution to its development.[164] Bacterial infection and the gastrointestinal "microbiome" are also hypothesized to be important in the pathogenesis of this disease.[165]

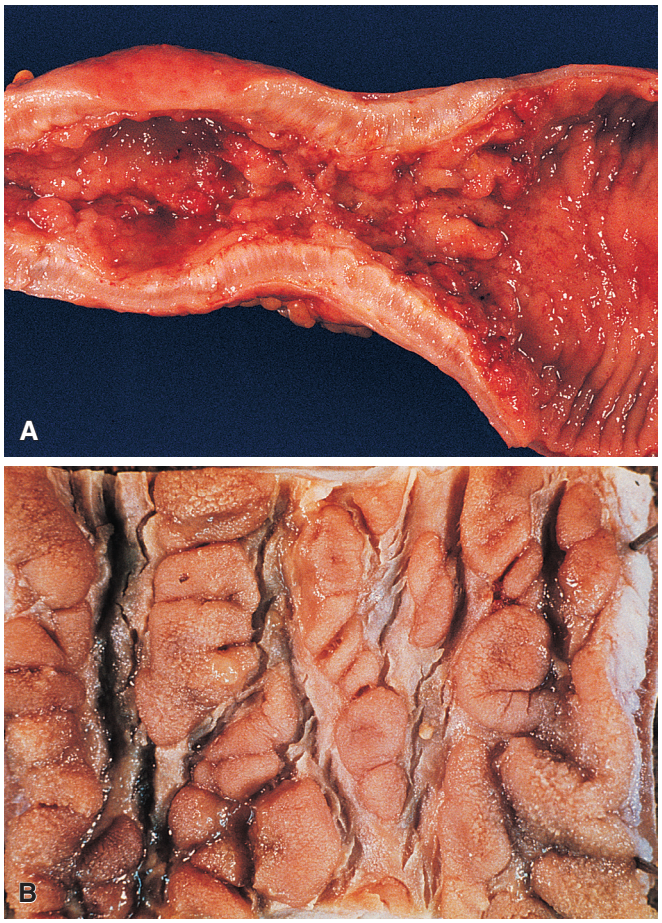

Figure 17.18 Gross Appearance of Crohn Disease of the Large Bowel. **A,** Segmental involvement with transmural inflammation and a stricture. The appearance is similar to that seen in small bowel Crohn disease. **B,** Typical cobblestone appearance.

Grossly, segmental distribution of the lesions (with "skip" areas that can be demonstrated radiographically), and preference for the right side of the colon are two important diagnostic features. Other gross findings of significance include stricture formation, fissuring, a cobblestone appearance, transmural involvement, and fat wrapping (Fig. 17.18). The ulcers (fissures) are linear, serpiginous, and discontinuous, with an intervening normal or edematous (but not markedly abnormal) mucosa. Often, they run longitudinally for long distances and are connected by short transversal ulcers (Fig. 17.19). Healing of this process leads to long rail-track scars. Sometimes, pseudopolyps (of the usual filiform or giant type) and mural bridging lesions develop similar to those seen in ulcerative colitis.[96,166] The microscopic appearance of Crohn disease in the large bowel is not qualitatively different from that seen in the small bowel. Fissures, noncaseating sarcoid-like granulomas (present in 40%–60% of cases), and transmural involvement are the typical triad of colonic Crohn disease. The mucosa has a relatively normal appearance and retains a significant amount of mucus, even in areas immediately adjacent to ulcerations. The presence of a well-defined focus of inflammatory cells surrounded by noninflamed and histologically normal mucosa is particularly suggestive of Crohn disease, as is the predominance of inflammatory infiltrate deep into the mucosa and extending into the submucosa. However,

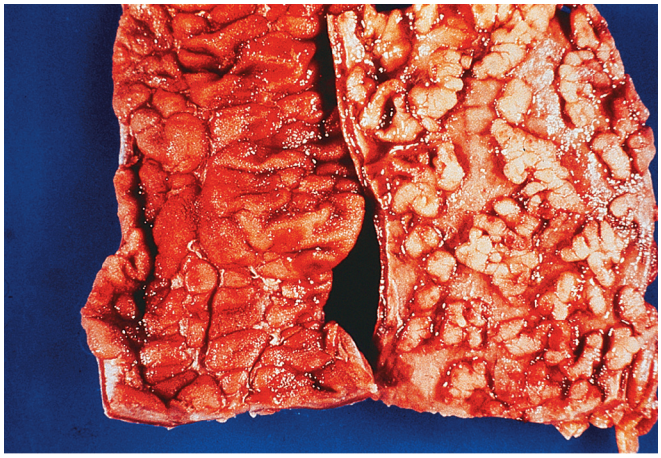

Figure 17.19 Comparison between pseudopolyps in ulcerative colitis *(right)* and the cobblestone pattern of Crohn disease *(left)*.

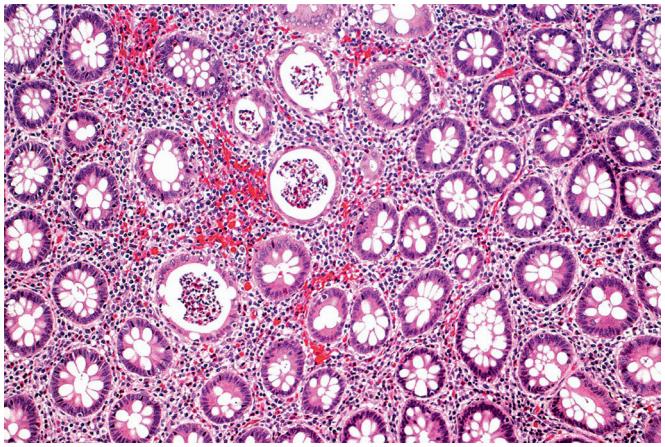

Figure 17.21 Patchy active inflammation in mucosa involved by Crohn disease with crypt abscesses.

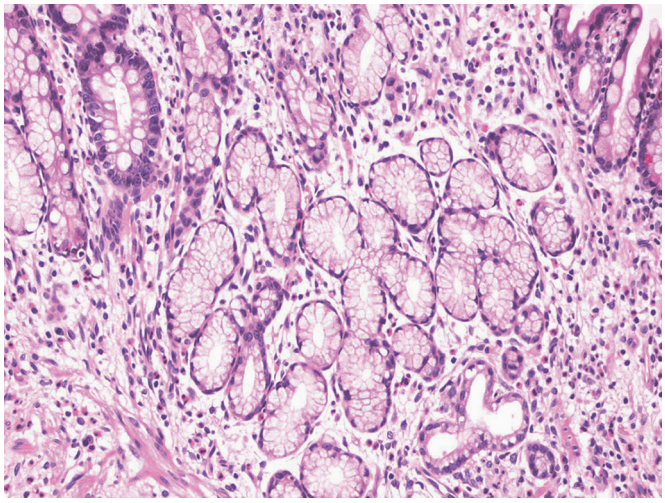

Figure 17.20 Focus of pyloric gland metaplasia in mucosa involved by Crohn disease.

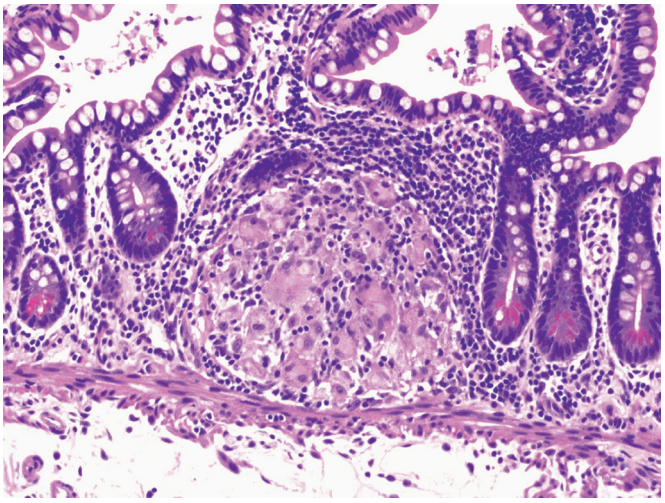

Figure 17.22 Crohn disease with a mucosal granuloma in the ileum.

on occasions the disease is superficial (i.e. limited to the mucosa and submucosa); in these instances, the cobblestone pattern is more diffuse and more finely nodular than is seen in classic Crohn disease.

The main features to look for in an endoscopic biopsy are patchy mucosal inflammation, granulomas, preservation of the goblet cell population, pyloric gland metaplasia, and maintenance of the architecture of the glands (Figs. 17.20–17.23). Serial sections may be necessary to demonstrate granulomas.[167] A rectal biopsy may be normal or show minor nonspecific changes, and a microscopically normal rectal biopsy in a definite case of colitis strongly favors Crohn disease over ulcerative colitis in the untreated setting.[168] If a colon involved by Crohn disease contains diverticula, the inflammatory process often spreads to them, making distinction from diverticulitis very difficult.[169] As previously mentioned, diverticular-associated colitis may have a Crohn-like pattern. Thus, inflammatory changes away from diverticula are the most useful finding in distinguishing these inflammatory conditions.

The ileum is involved in approximately 50% of cases of colonic Crohn disease.[168] Anal lesions are seen in 75% of cases and may present as chronic fissures, fistulas, and ulceration, and they can be

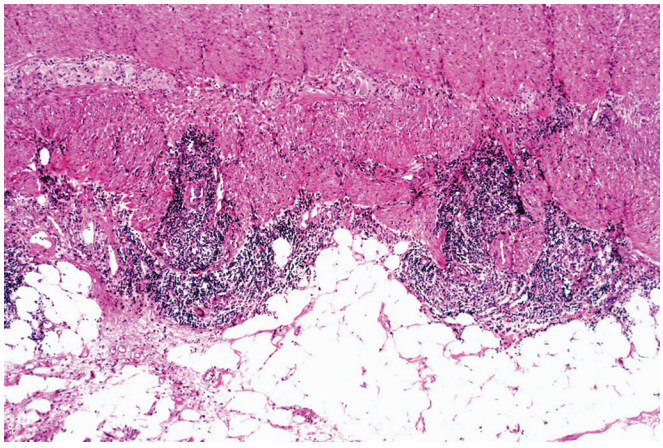

Figure 17.23 Resection specimen of Crohn disease showing transmural lymphoid aggregates.

the first clinical manifestation of Crohn disease.[170] The regional lymph nodes are often enlarged. Microscopically, they do not differ significantly from those in patients with ulcerative colitis, except for the occasional presence of granulomas.

One of the most common complications of Crohn disease is the formation of fistulas, arising on the basis of fissuring. Although perianal fistulas can be seen in both Crohn disease and ulcerative colitis, internal fistulas are virtually pathognomonic of the former.

Other complications of Crohn disease include skin ulceration (of perianal skin, around colostomies and ileostomies, and elsewhere) and toxic megacolon.[171] In a series of 615 patients with Crohn disease studied at the Cleveland Clinic, the overall incidence of toxic megacolon was 4%.[172] No cases were found when the disease was limited to the small bowel, but megacolon developed in 2% of patients with ileocolic disease and in 11% when the disease was limited to the colon. It should be pointed out that if the bowel is removed at the time when a toxic megacolon has developed (fulminant colitis), it may be impossible to determine the nature of the underlying disease.[173] Specifically, the criterion of transmural inflammation as a differential diagnostic point loses its significance in areas that are deeply ulcerated.

The other important complication of Crohn disease is the development of carcinoma, most commonly in the colon or rectum.[174] Although the incidence is much lower than for ulcerative colitis, there is no longer any doubt that the risk is substantially higher than for the normal population.[175] As in ulcerative colitis, the malignancy can be difficult to identify grossly, and it can also be accompanied and/or preceded by dysplastic changes of the colonic mucosa.[176,177] The criteria for the recognition and nomenclature of dysplasia are the same in both conditions.[143] In addition, a peculiar hyperplastic mucosal change is sometimes found in large bowels affected by Crohn disease and may be another form of dysplasia characteristic of this setting.[178]

The majority of patients with Crohn disease of the large bowel eventually require surgical excision of the disease; the decision as to which operation to perform depends on the extent and site of the disease, the presence of perianal involvement, and the age of the patient.[179]

Indeterminate Colitis

The distinction between ulcerative colitis and colorectal Crohn disease can be very difficult. For many years, the presence of a chronic inflammatory disease of the large bowel not attributed to a specific organism was equivalent to a diagnosis of ulcerative colitis. It is now apparent that many of these cases actually represent examples of colonic Crohn disease. The clinical, radiographic, and morphologic differences between these two diseases have now been clearly delineated. Alas, this exercise has rendered apparent the fact that none of the criteria are pathognomonic for either condition and that in approximately 15% of cases (particularly fulminant colitis) features of both conditions are present, so that the differential diagnosis becomes impossible.[180] The term *indeterminate colitis* has been proposed for this hybrid group.[180,181] On long-term follow-up, most cases will behave like ulcerative colitis and very few will later develop features of Crohn disease.[182] The occurrence of these indeterminate cases, the occasional coexistence of typical Crohn disease of the small bowel and ulcerative colitis of the large bowel in the same patient, the development of Crohn disease-like complications in patients with ulcerative colitis after proctocolectomy and ileal pouch-anal anastomosis, and the occurrence of both diseases in the same family[183] suggest that perhaps the distinction between these two entities has been too rigidly drawn. In any event, there are enough clinical and pathologic differences in the majority of cases to justify a separation that has prognostic and therapeutic implications. As a corollary, it is important not to use the term indeterminate colitis as a wastebasket diagnosis in biopsy specimens.

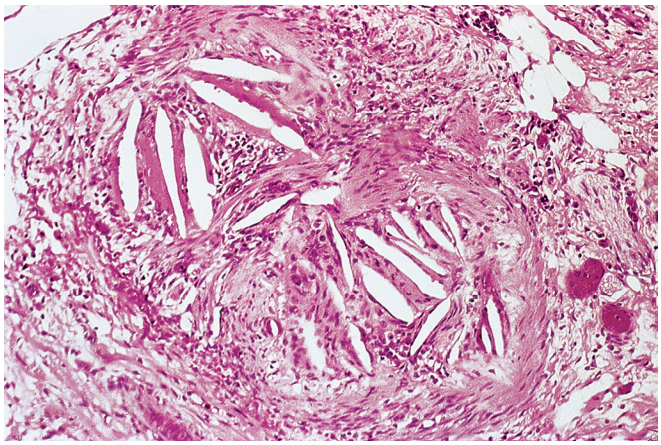

Figure 17.24 Cholesterol emboli in mesenteric vessels which resulted in ischemic colitis.

Ischemic Colitis

Ischemic colitis most often occurs in patients over 50 years of age, and the usual predisposing factors are arteriosclerosis, diabetes, and vascular surgery.[184] It may also be seen in younger patients in association with collagen vascular diseases (i.e. scleroderma and rheumatoid arthritis),[185] polyangitis granulomatosis,[186] idiopathic lymphocytic phlebitis,[187,188] amyloidosis,[189] and as a complication of birth control pill[190] or cocaine use.[191] Arteriosclerosis may lead to ischemic colitis by intrinsic obstruction of colonic vessels or by atheromatous embolism (Fig. 17.24).[192] The process usually manifests itself by sudden onset of bleeding and abdominal pain. It is a segmental disease, the splenic flexure being the classic site of involvement because of its relative paucity of blood supply; however, other sites, including the rectum, can be involved. The typical radiographic signs are gas within the bowel wall and "thumbprinting."[193] Radiographic, endoscopic, and intraoperative confusion with carcinoma may occur. Grossly, pseudopolyps may be present in addition to ulcers and fibrosis. Microscopically, there is ulceration covered by granulation tissue, which may extend into the submucosa and surround individual smooth muscle fibers of the muscularis mucosae. Hemosiderin is abundant. Hyaline thrombi can be seen in the lumen of small vessels. Cholesterol crystals, when present in the vascular lumen, support a diagnosis of atheroembolism. Fissures, lymphoid follicles, and granulomas are absent, but crypt abscesses may be seen. Microscopic features suggestive of ischemic necrosis are full-thickness mucosal necrosis in the acute stage, and hyalinization of the lamina propria, hemorrhage, and atrophic microcrypts in the healed phase (Fig. 17.25).[193] One can encounter bizarre stromal cells,[194] atypical reactive changes in the epithelial cells mimicking dysplasia,[195] and isolated goblet cells simulating neoplastic signet ring cells. One may encounter similar changes with ischemic-type features in the mucosa proximal to an obstructive lesion, usually a neoplasm.[196]

Aggressive management is of crucial importance to minimize the damage to the ischemic colon. Surgical intervention is indicated if there is evidence of peritonitis, transmural infarction, or perforation.[197]

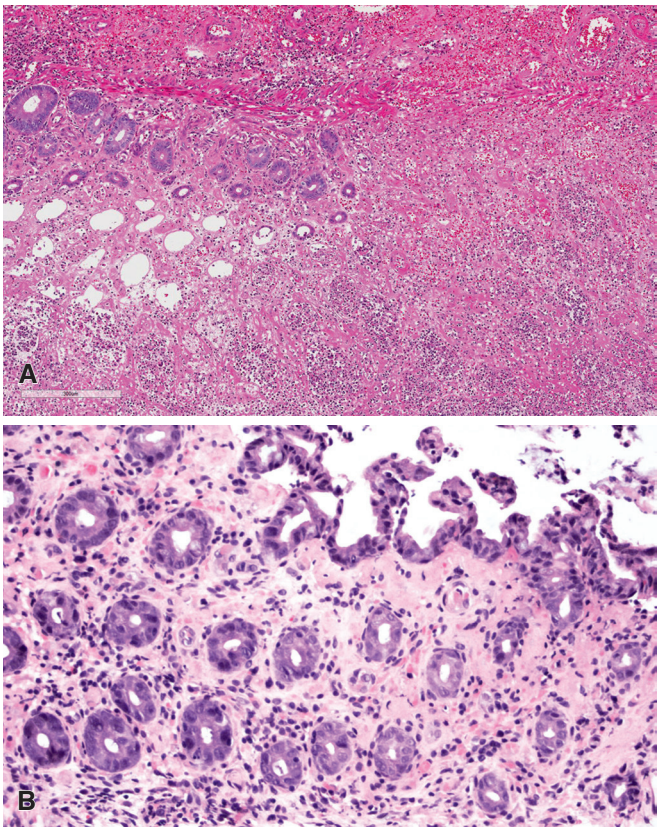

Figure 17.25 Ischemic Colitis. A, Mucosal erosion associated with regenerative epithelial changes and lamina propria hyalinization characteristic of ischemic colitis. **B,** High-power view of lamina propria hyalinization.

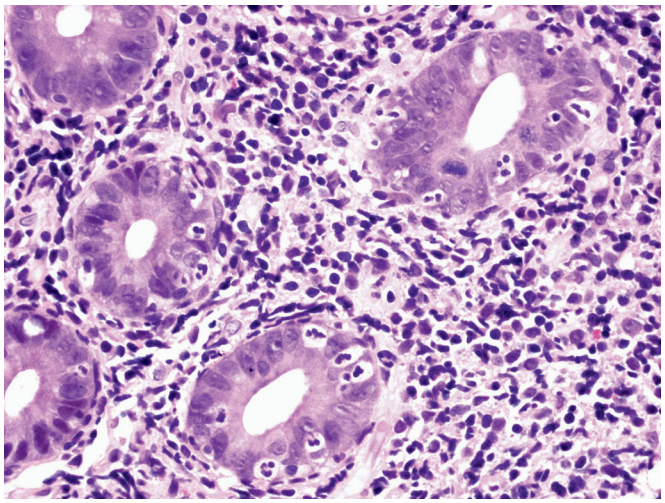

Figure 17.26 Acute self-limited colitis with patchy neutrophil-mediated crypt injury.

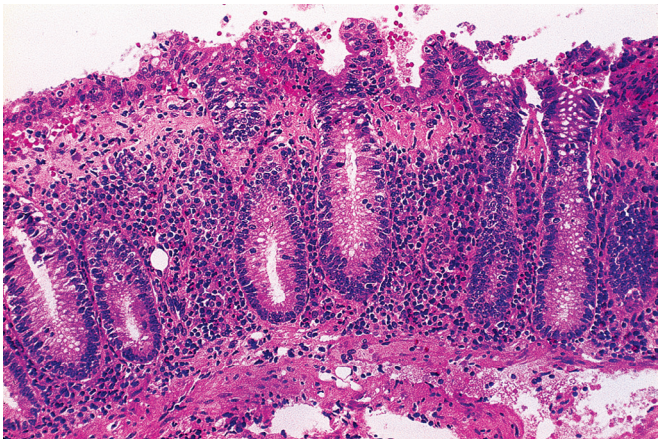

Figure 17.27 Collagenous colitis showing expanded lamina propria, lymphocyte-mediated surface injury, and subepithelial thickening of the collagen table.

Other Types of Colitis

Acute infectious-type colitis (acute self-limited colitis) is a self-limited diarrheal illness thought to be caused by infectious agents, particularly *Campylobacter, Escherichia coli* (especially with 0157:H7), *Salmonella*, and *Shigella*; however, in over half of the cases the etiology remains undetermined.[198] Microscopically, there is inflammatory infiltration of the lamina propria, edema, hyperemia, and hemorrhage with neutrophil-mediated crypt injury (Fig. 17.26). These changes may be difficult to distinguish from an early stage of ulcerative colitis, and a follow-up biopsy may be necessary to separate the two.[199] Infections by *Salmonella* and *Shigella* organisms are particularly well known for their capacity to simulate ulcerative colitis clinically and radiographically.[200] Acute inflammation out of proportion to chronic features should suggest an infectious etiology. Conversely, crypt distortion and plasma cell infiltration in the basal portion of the mucosa favor a diagnosis of ulcerative colitis.[201,202] The distinction between the two conditions is easier if the biopsy is taken within the first 4 days from the onset of symptoms.[198]

Allergic colitis and **proctitis** are related to foods (particularly cows' milk) and are seen more commonly in infants and children.[203,204] They present with rectal bleeding, sometimes accompanied by diarrhea. The main microscopic abnormalities on rectal biopsy are mucosal edema and marked eosinophilic infiltration. The eosinophils tend to aggregate around lymphoid nodules; others are located within crypts resulting in crypt abscesses, and there may be infiltrates within bundles of muscularis mucosae.[205,206] The eosinophilic infiltrates may be patchy, and thus multiple biopsies are recommended for their detection.[204]

Collagenous colitis usually presents clinically in middle-aged women with chronic watery diarrhea.[207] Endoscopic and radiographic studies are often normal. Microscopically, there is apical expansion of the lamina propria by plasma cells, lymphocytes, and eosinophils, usually without crypt distortion (Fig. 17.27), although rarely there may be minor crypt irregularities that can mimic IBD.[208] There is lymphocyte-mediated surface injury associated with thickening of the subepithelial collagen table, typically measuring 10 µm or greater.[209] The collagen thickening is often greatest in the right colon and is typically patchy; therefore, it can be missed on endoscopic biopsy, resulting in a diagnosis of lymphocytic colitis (described later).[210] Lymphocytes and neutrophils may be present in the crypts. A *pseudomembranous* form of collagenous colitis has been described.[211]

An immune pathogenesis and a relationship with celiac disease have been postulated.[212,213] It has been further suggested that non-steroidal anti-inflammatory drugs may play an etiologic role in some of these cases,[214] although other drugs including proton pump inhibitors have also been implicated.[215] The clinical course is benign, and microscopic resolution may occur,[216] but the course tends to be relapsing and remitting.[217,218] Rare cases have been reported in association with colonic carcinoma.[217]

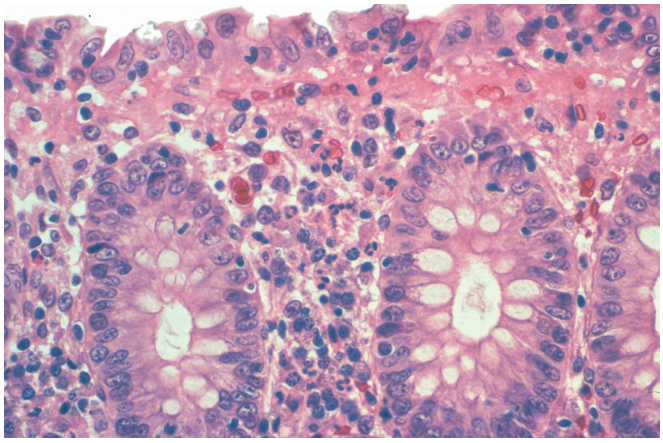

Figure 17.28 High-power view of lymphocyte-mediated surface injury in a case of lymphocytic colitis.

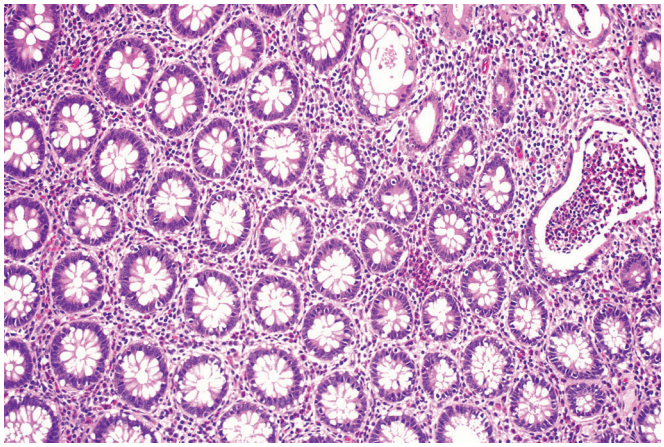

Figure 17.29 Focal active colitis pattern of injury.

Lymphocytic colitis appears to be closely related to collagenous colitis.[210,219,220] There are occasional transitions between these two disorders, which have been grouped by some under the term *watery diarrhea–colitis syndrome.*[221,222] The main microscopic differences between the two conditions are the absence of a thickened collagenous layer and the greater prominence of intraepithelial lymphocytes in lymphocytic colitis (Fig. 17.28).[223,224] Changes morphologically indistinguishable from lymphocytic colitis have been consistently found in large bowel biopsies of patients with celiac disease, further suggesting a pathogenetic relationship between these two disorders.[225,226]

The terminal ileum may be involved in cases of collagenous or lymphocytic colitis.[227] Rare cases of lymphocytic colitis containing scattered multinucleated giant cells in the subepithelial region have been described.[228,229]

It is clear that lymphocytic colitis represents a heterogeneous group of disorders, all of which result in an epithelial lymphocytosis.[230] In some instances, the microscopic features of lymphocytic colitis have been seen in patients later found to have Crohn disease.[231] It should also be mentioned that colonic biopsies taken in patients with *Brainerd diarrhea* (a chronic watery diarrhea of presumed infectious etiology characterized by acute onset and prolonged duration) show a microscopic appearance similar to that of lymphocytic colitis but usually lacking surface degenerative changes.[232] It is also likely that certain drugs (for example anti-seizure medications and nonsteroidal anti-inflammatory drugs) can induce this pattern of injury.[233,234]

Focal active colitis refers to a pattern of injury commonly seen in colorectal biopsy specimens characterized by focal crypt and surface epithelial injury mediated by neutrophils associated with a focal increase of inflammatory cells in the lamina propria (Fig. 17.29). It represents a pattern of injury rather than a specific diagnosis; most cases correlate clinically with infectious-type colitis, but other causes include bowel preparation, medication-induced injury, ischemia, and even Crohn disease, especially when this pattern is seen in children.[235–237]

Pseudomembranous colitis is due, in most instances, to a toxin produced by *Clostridium difficile*.[238,239] A substantial number of cases have been associated with the use of antibiotics, particularly lincomycin and clindamycin.[240] However, it should be kept in mind that not all pseudomembranes are secondary to an infection, as they may be seen in collagenous colitis, IBD, ischemia, and secondary to mucosal prolapse. Florid cases of this condition may be difficult to distinguish from ulcerative colitis and Crohn disease on clinical and radiographic grounds. Acute abdomen may be the presenting manifestation.[241] The thickening of the wall can be appreciated by CT and sonographic techniques.[242] Grossly, discrete yellow–white mucosal plaques are seen (Fig. 17.30). The distinguishing microscopic feature is a "focal explosive mucosal lesion" characterized by the presence of a mushroom-like mass of mucus and neutrophils attached to the surface of the mucosal glands (Fig. 17.31).[243] The mucosa immediately adjacent to these changes is remarkably normal. The wall may show massive edema, probably resulting from vascular

Figure 17.30 Pseudomembranous Colitis. There are multiple discrete white plaques of purulent exudate on the mucosal surface. This patient was taking ampicillin. (Courtesy of Dr. R.A. Cooke, Brisbane, Australia, from Cooke RA, Stuart B. *Colour Atlas of Anatomical Pathology*. Edinburgh: Churchill Livingstone; 2004.)

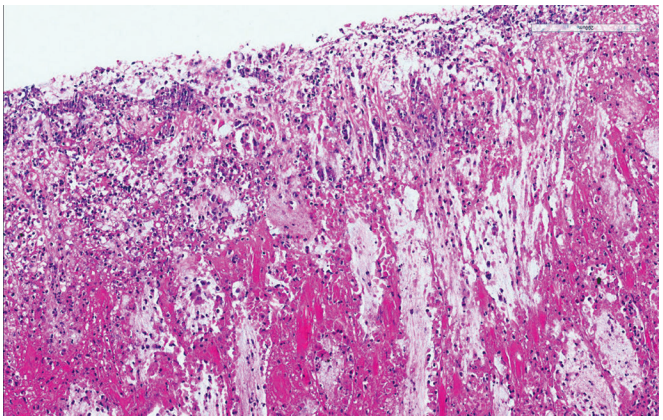

Figure 17.31 High-power view of a pseudomembrane in a case of *C. difficile*-associated pseudomembranous colitis.

injury.[244] Intramucosal signet ring cells may be present and potentially be overinterpreted as evidence of a signet ring carcinoma.[245] Emergency surgery may be needed for complications, including colonic perforation and toxic colitis.[246]

Diversion colitis is an inflammatory bowel disorder resulting from diversion of the fecal stream by ileostomy or colostomy. The pathogenesis is unknown, but the removal of short-chain fatty acids present in the fecal stream is suspected to play an important role.[247,248] The disease occurs in adults as well as in children, and the abnormalities range from minimal mucosal friability to gross ulcerations.[249] Microscopically, the most common changes are mild to moderate lamina propria expansion, predominantly by plasma cells, crypt abscesses, and follicular lymphoid hyperplasia.[250] Aphthous ulcers are present in the most severe cases.[251] Of all these changes, lymphoid follicular hyperplasia is the most common and prominent.[252] These abnormalities quickly revert after reanastomosis.

Neonatal necrotizing enterocolitis is a condition primarily affecting infants who either are premature or have had exchange transfusions.[253] A few cases have followed thrombosis of the abdominal aorta,[254] suggesting that ischemia is an important risk factor. The condition may also be seen as a complication of Hirschsprung disease.[255] Most cases begin in the first week of life and are manifested by abdominal distention, the disappearance of bowel sounds, and the passage of small amounts of blood-stained stool.[256] The area of maximal involvement is usually the terminal ileum and ascending colon. The mucosa becomes necrotic and may partially slough off. Small submucosal gas-filled cysts are often present and can be seen radiographically and represent an important diagnostic sign (Fig. 17.32).[257] Bowel perforation may occur necessitating emergent surgery and resection of the affected segment.[258]

Ecchymotic colitis is the name sometimes given to a rare condition seen in neonates resulting in isolated rectal bleeding. It is characterized endoscopically by ecchymotic mucosal lesions and microscopically by a predominantly neutrophilic inflammation, foci of hemorrhage, and sometimes foci of pneumatosis. The etiology is unknown,[259] but it may be pathogenetically linked to necrotizing enterocolitis.

Amebic colitis can closely simulate ulcerative colitis or Crohn disease on clinical grounds.[260] The classic endoscopic appearance is that of discrete areas of ulceration covered by exudate, with normal intervening mucosa; however, many cases depart from this description. Amebiasis may involve any part of the bowel, but it has a predilection for the cecum and ascending colon (Fig. 17.33). In some cases the entire large bowel is involved, and there may even be extension into the terminal ileum.[261] Perforation occurs in 5%–10% of the cases.

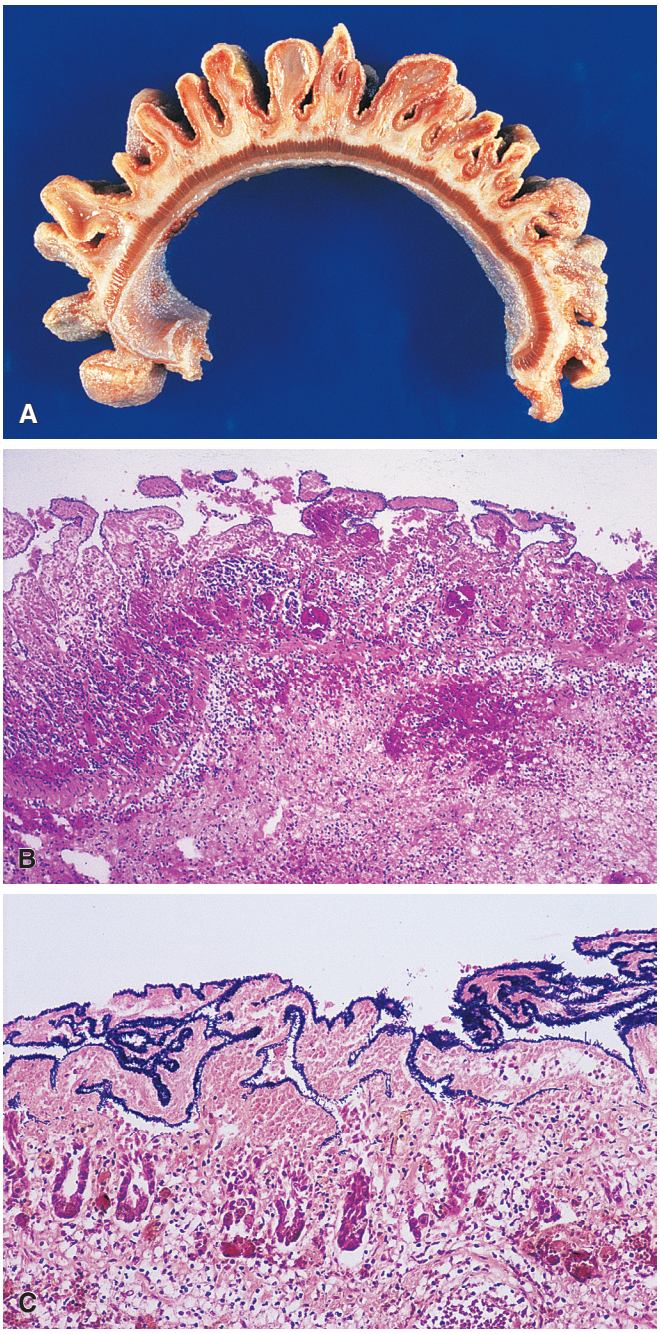

Figure 17.32 Necrotizing Enterocolitis. A, Gross appearance with mucosal necrosis and numerous small gas-filled cysts within the wall. **B,** Low-power microscopic appearance showing extensive ulceration, necrosis, and hemorrhage. **C,** Gram stain showing coating of the ulcerated surface by organisms.

The microscopic appearance of a rectal biopsy is rather nonspecific, although the relative paucity of inflammatory cells beneath the ulcer and the flask shape of the ulcer itself should alert the pathologist to consider this diagnosis. Confirmation rests on the identification of trophozoites of *Entamoeba histolytica*, which can be seen in H&E slides, although the inexperienced observer may confuse them with macrophages (and vice versa). Typically, the parasites are surrounded by an artifactually clear space. They are round or ovoid, measure 6–40 nm in diameter, and contain an abundant cytoplasm with a distinctive vacuolated appearance and relatively small, perfectly round

Figure 17.33 Amebic Colitis. Multiple, undermined ulcers are present in the cecum and ascending colon. (Courtesy of Dr. R.A. Cooke, Brisbane, Australia, from Cooke RA, Stuart B. *Colour Atlas of Anatomical Pathology*. Edinburgh: Churchill Livingstone; 2004.)

nuclei with prominent nuclear borders and a central karyosome. The organisms can also be demonstrated with periodic acid–Schiff (PAS) and immunoperoxidase stains, both in sections and in smears.[262] Erythrophagocytosis by the trophozoites is usually present. Some cases present as a fulminant colitis, which can be difficult to distinguish from fulminant IBD.[263]

Tuberculosis may involve the gastrointestinal tract in the presence of minimal pulmonary disease.[264] The usual location is the ileocecal region, and a mass can be palpated in approximately half of the cases ("tuberculoma").[265] Grossly, there is ulceration with diffuse fibrosis extending through the wall, causing stenosis and obstruction. Coexistent tuberculous peritonitis is seen in rare cases. Microscopically, typical granulomas are usually present, which can be caseating, noncaseating, suppurative, or fibrous (healed).[266] Vasculitis may be present.[267] In some instances, a nonspecific, diffuse, chronic inflammation with fibrosis without granulomas is seen focally or—very rarely—as the sole pattern.[266] Demonstration of acid-fast bacilli, either by stain of the sections or by culture, is needed to establish a diagnosis. It should be remembered that the large majority of cases of granulomatous disease of the ileocecal area seen in the United States and western Europe represent examples of Crohn disease[268]; features favoring tuberculosis over Crohn disease are caseation and coalescence of the granuloma, whereas longitudinal ulcers favor Crohn disease.[269] Most patients with secondary ulcerating tuberculosis of the colon can be treated medically; surgery, sometimes in the form of ileocolectomy, is reserved for the large cecal tuberculomas.

CMV colitis is seen with increased frequency in immunocompromised patients, such as transplant recipients and individuals affected by AIDS.[270,271] It is also significantly associated with steroid-refractory ulcerative colitis.[272,273] The disease has a predilection for the ileocecal region and may be accompanied by extensive ulceration and rarely forms a discrete mass.[274] Inclusion bodies are found mainly in cells located in the wall or lining the lumen of submucosal vessels showing features of vasculitis, but they may also be seen in fibroblasts and epithelial cells. The diagnosis can be confirmed immunohistochemically (Fig. 17.34), which can be complemented by PCR in some cases.[275] Surgical resection may be necessary in cases resulting in massive hemorrhage.

HIV-infected patients may also develop colitis caused by *Pneumocystis*,[276] *Histoplasma*[277] adenovirus,[278] and *Toxoplasma*.[279] In addition, it has been suggested that HIV itself may be responsible for some cases of chronic colitis in this population.[280]

Strongyloides colitis can clinically mimic ulcerative colitis and cause the death of the patient if untreated.[281] Features seen in this form of colitis include skin lesions, distal attenuation of the disease, a predominance of eosinophils, less severe crypt distortion and frequent involvement of the submucosa.[281]

Behçet colitis is characterized by multiple ulcers of various sizes, shapes, and depths involving any portion of the large bowel and is accompanied by lymphocytic vasculitis of the submucosal veins[282]; it may closely resemble the appearance of Crohn disease.[283]

Graft-versus-host disease (GVHD), occurring in patients who have received bone marrow allografts, manifests in the gastrointestinal tract primarily as colitis.[284] Microscopically, there is focal crypt epithelial cell apoptosis, a feature that is thought to signify cell-mediated cytolysis (Fig. 17.35).[285] Crypt abscesses may also be present. Severe disease may lead to loss of crypts, sloughing of the mucosa, and formation of inflammatory polyps.[286] In the chronic phase there is architectural distortion (villiform surface with crypt branching and atrophy) similar to that seen in idiopathic IBD.[287] The histology of acute GVHD can be simulated by cytoreductive agents and viral infections, particularly CMV. In addition, these changes can be closely mimicked by patients taking mycophenolate mofetil, a T-cell inhibitor frequently used in the treatment of acute allograft rejection. However, histologic features favoring mycophenolate-induced injury over GVHD include lack of endocrine aggregates in the lamina propria, lack of apoptotic microabscesses and eosinophils greater than 15 per 10 HPF.[288] Similar changes are also seen in patients with AIDS.

Neutropenic enterocolitis (NEC) is a rare complication of neutropenia that occurs secondary to the administration of chemotherapy, usually for hematologic malignancies.[289] It may also occur in the setting of autologous or bone marrow transplantation for solid organ malignancies.[290] In most cases, chemotherapy has been delivered within 30 days of onset, and most patients have neutrophil counts below 1500 cells/mm^3.[291] Patients may present with gastrointestinal bleeding, fever, diarrhea, right lower quadrant pain, or even a mass. The process most commonly affects the terminal ileum and right colon. *Typhlitis* refers to hemorrhagic necrosis of the cecum.[292] Grossly, the affected areas are dilated, congested, and sometimes hemorrhagic. The mucosa shows hemorrhage and often necrosis without significant acute inflammation. Bacterial infection and ischemic injury likely also play a pathogenetic role.

Other Non-Neoplastic Lesions

Colonic atresia is much less common than atresia of the small bowel.[293,294] Most patients require early surgical intervention, but long-term outlook is excellent.

Heterotopic gastric epithelium, salivary gland tissue, and respiratory mucosa may be rarely found in the rectum.[295–297] The lesions typically present as sessile polypoid masses.

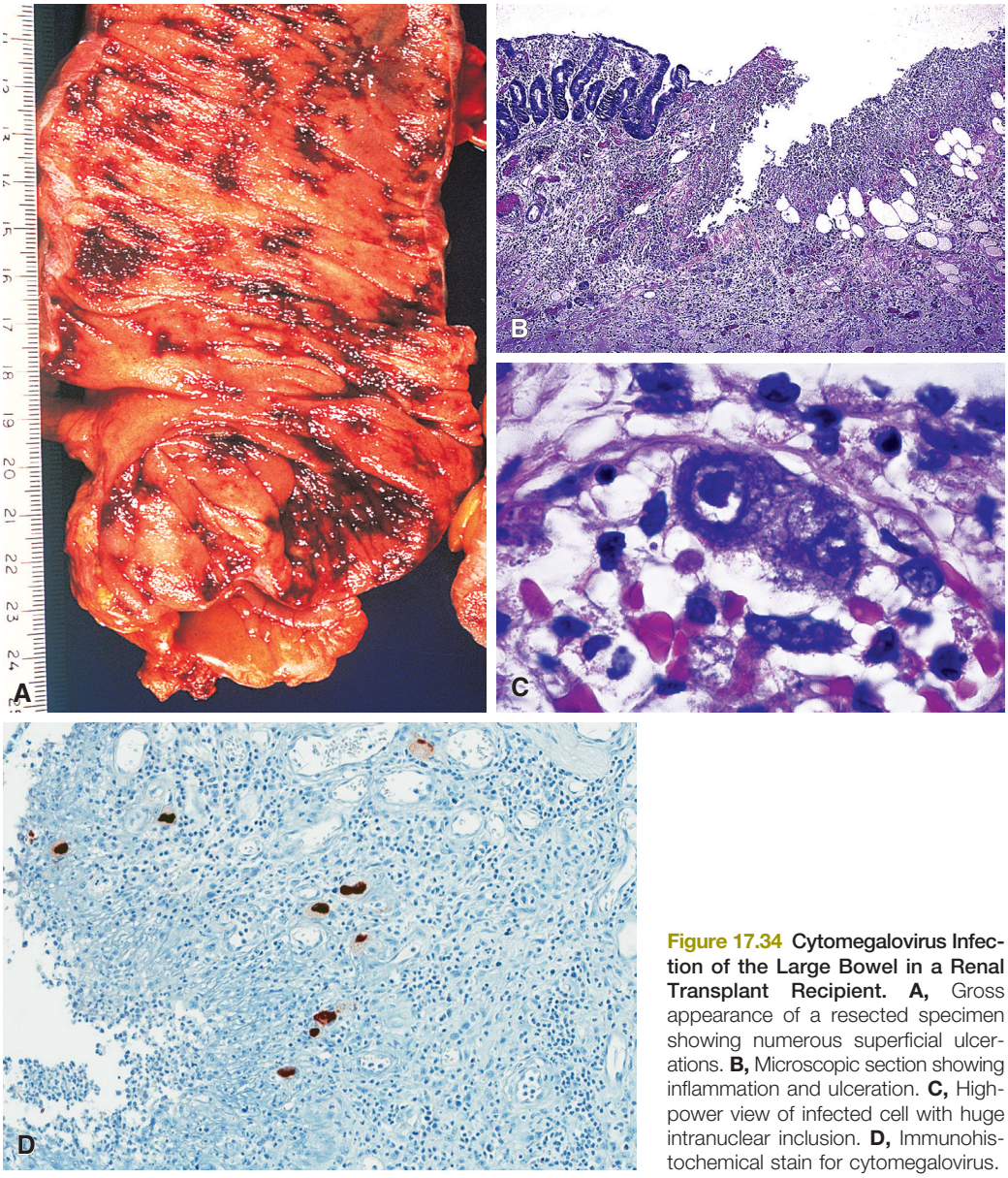

Figure 17.34 Cytomegalovirus Infection of the Large Bowel in a Renal Transplant Recipient. A, Gross appearance of a resected specimen showing numerous superficial ulcerations. **B,** Microscopic section showing inflammation and ulceration. **C,** High-power view of infected cell with huge intranuclear inclusion. **D,** Immunohistochemical stain for cytomegalovirus.

Neuronal storage diseases of various types are accompanied by changes in the ganglion cells of the submucosal and myenteric plexuses, so that the conditions may be diagnosed by rectal biopsy.[298,299]

Melanosis coli is the name given to a condition in which macrophages filled with a lipofuscin-like pigment ("pseudomelanin") are found within the lamina propria.[11] If they are numerous enough, the mucosa acquires a brown-to-black color which can be seen at endoscopy (Figs. 17.36 and 17.37). Interestingly, adenomatous polyps that may be present in such a mucosa may not show any pigmentation. Melanosis coli has been associated with the ingestion of anthracene laxatives,[12] but it can also be seen in patients without this history. Increased apoptosis seems to be the pathogenetic mechanism responsible for the change.[300] It should be mentioned here that other pigments sometimes seen in specimens from this region include India ink and methylene blue used as endoscopic tattoo agents.[301]

Endometriosis may involve the wall of the large bowel, induce secondary smooth muscle hypertrophy, and result in almost complete obstruction of the bowel lumen.[302] Microscopically, endometrial glands and stroma are seen surrounded by proliferated smooth muscle and clusters of hemosiderin-laden macrophages (Figs. 17.38 and 17.39). The overlying epithelium may show various types of inflammatory and ulcerative changes that may simulate IBD or solitary rectal ulcer syndrome in a biopsy specimen.[303,304] Some cases can involve the overlying mucosa and can closely simulate a primary colorectal adenoma.[305]

Neoplastic transformation can supervene in these endometriotic foci, usually in the form of endometrioid adenocarcinoma but also müllerian adenosarcoma and endometrial stromal sarcoma.[306,307] In some cases, immunostains with CDX-2 and PAX-8 can be helpful in distinguishing these tumors from a primary colorectal neoplasm.

Amyloidosis can involve the large bowel and be diagnosed on rectal biopsy.[308] The detection rates are comparable to those obtained by renal biopsy and better than those achieved by liver biopsy. It is important for the specimen to include the submucosa, for this can be the only place of amyloid deposition.[309] If the amyloid deposition is mainly beneath the epithelium, the appearance may

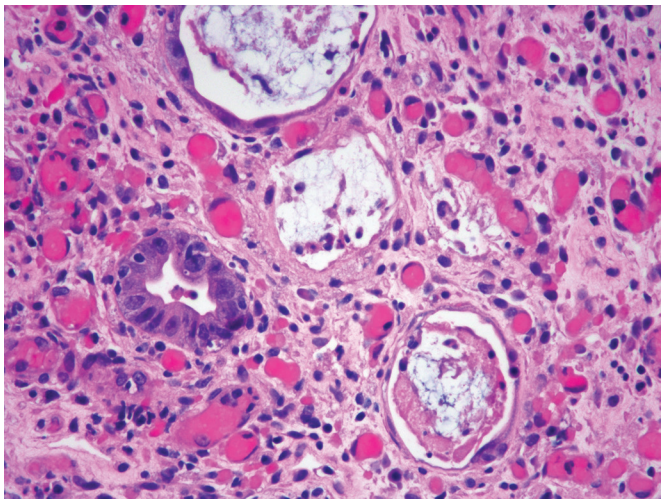

Figure 17.35 High-power view of graft-versus-host disease with characteristic scattered apoptotic cells.

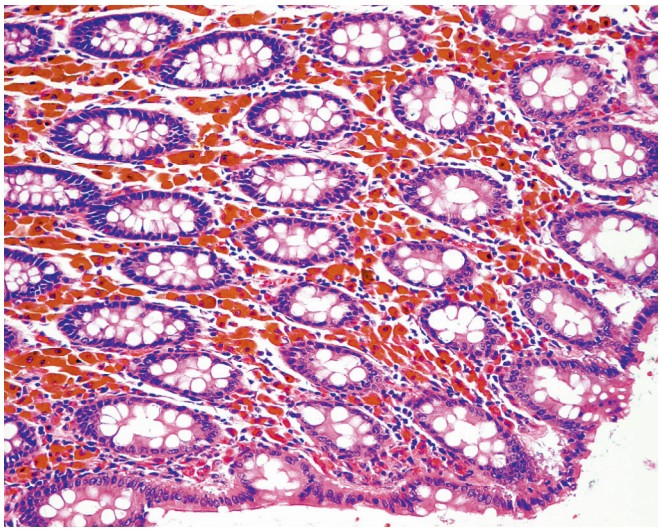

Figure 17.37 Melanosis coli with pigment-containing macrophages within the lamina propria.

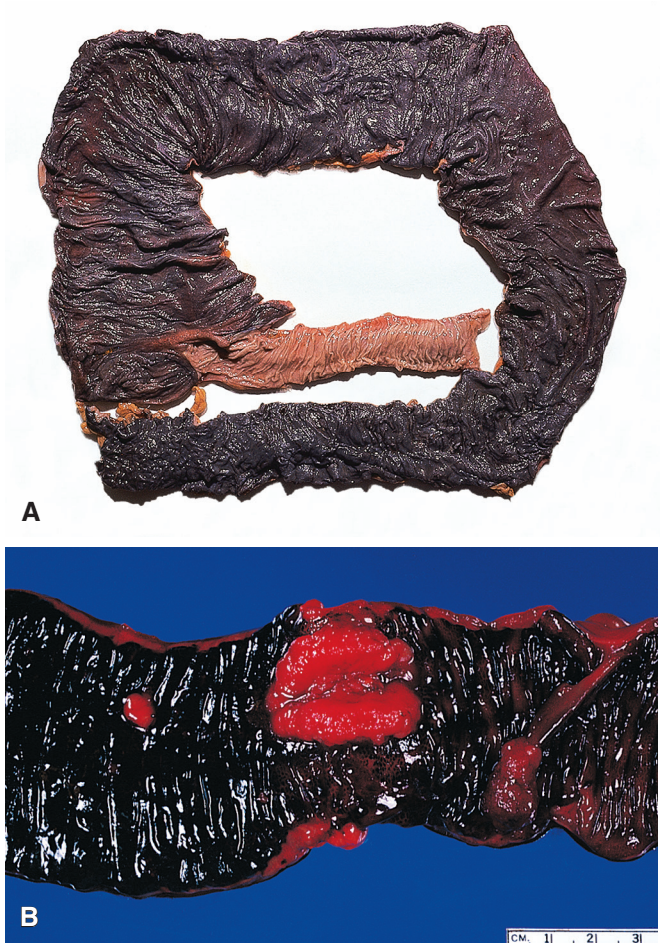

Figure 17.36 **Melanosis Coli. A,** The change begins sharply at the level of the ileocecal valve. **B,** Large bowel diffusely involved by melanosis coli. There is also a carcinoma which is not involved by the melanosis.

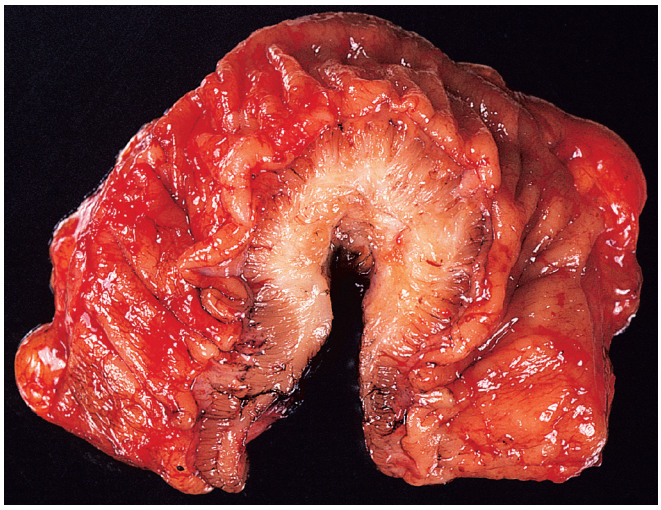

Figure 17.38 Endometriosis of the large bowel showing thickening of the wall associated with muscular hypertrophy resulting in partial obstruction.

simulate that of collagenous colitis.[310] Occasionally, amyloid deposition results in ischemic changes in the colon. Amyloidosis can be simulated by **elastotic and elastofibromatous depositions** in the muscularis mucosae and submucosa, a lesion which is of no clinical significance.[311]

Volvulus of the large bowel is a rare cause of acute abdominal obstruction.[312] Approximately 25%–40% of cases occur in the cecum.[313] Prompt surgical intervention is imperative. Gangrene is found in approximately 25% of cases at the time of exploration and is a definite indication for resection.

Malakoplakia can involve the colon diffusely (Fig. 17.40).[314] Most patients are adults, but cases in infants have been described.[315] Malakoplakia can occur in association with other conditions, including colonic adenocarcinoma,[316] immunodeficiency syndromes,[317] and ulcerative colitis.[318]

Barium granulomas can occur as a consequence of barium enema. The barium may escape through a break in the mucosa produced by infection, tumor, foreign body, or trauma and induce a

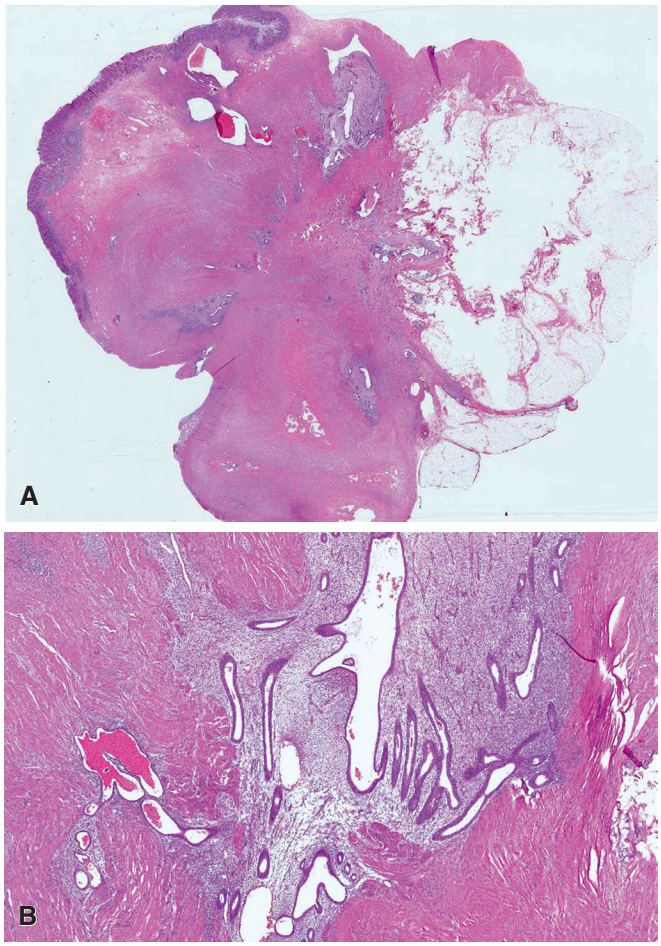

Figure 17.39 Endometriosis. A, Low-power view of endometriosis. **B,** High-power view of endometriosis showing endometrial glands surrounded by endometrial stroma.

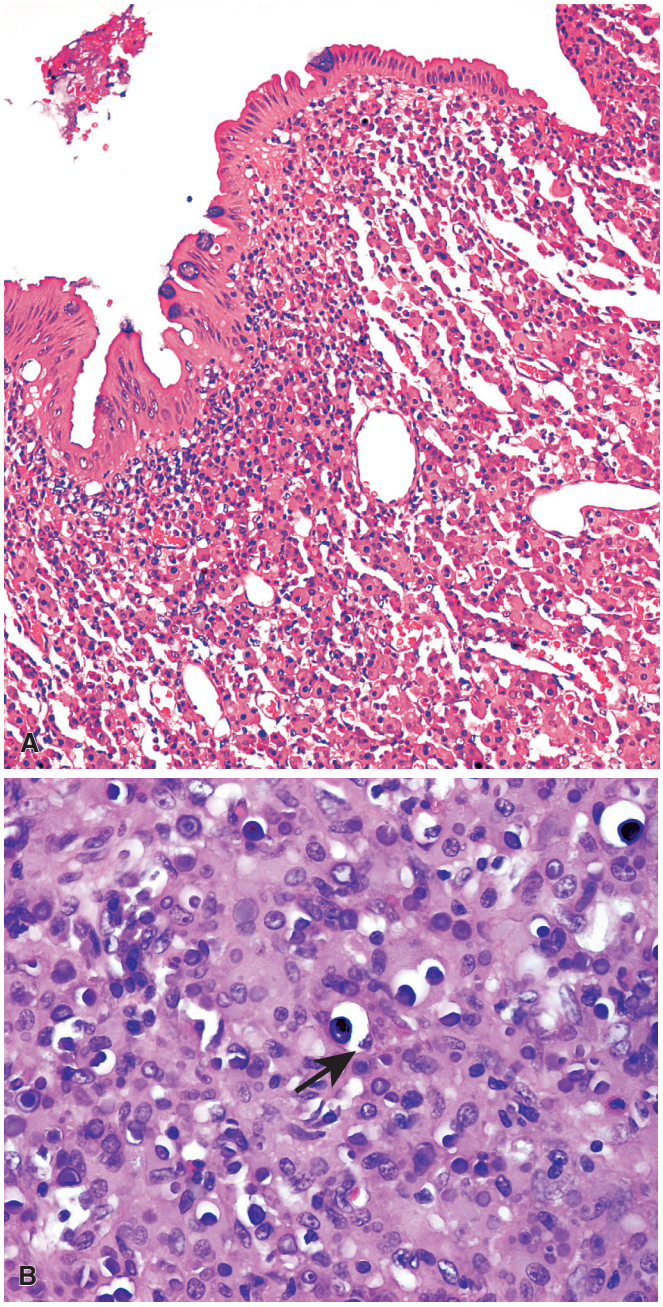

Figure 17.40 Malakoplakia. A, Low-power view showing packing of the lamina propria by a histiocyte-rich infiltrate. **B,** High-power view showing numerous histiocytes and rare Michaelis–Gutmann bodies (arrow).

granulomatous reaction. The crystals, which may remain in the tissues permanently, are easily visible under polarized light.[319]

Radiation changes in the colon and rectum can be accompanied by bizarre cellular changes in the crypt epithelium. Inflammation is also present, sometimes in the form of crypt abscesses; eosinophils may be numerous.[320] These acute changes usually subside within 1–2 months. Late changes include arterial stenosis due to the subendothelial accumulation of macrophages (Fig. 17.41). Severe radiation changes include ulceration, necrosis, hemorrhage, and perforation (Fig. 17.42).[321] In some cases, the degree of radiation-induced atypia may mimic adenocarcinoma.

Solitary cecal ulcers have an unknown etiology, and their microscopic appearance is completely nonspecific.[322,323] Most patients are middle-aged to elderly and present with hematochezia and right-sided abdominal pain.

Pneumatosis cystoides intestinalis occurring in infants is usually seen as a component of necrotizing enterocolitis and often has a fatal outcome.[324] Exceptionally, it occurs in association with cystic fibrosis.[325] In adults it may present as an idiopathic finding or in association with mechanical intestinal obstruction, chronic lung disease, or scleroderma.[326] When not associated with other abnormalities, it follows a chronic and indolent clinical course, although in some instances it may produce signs of intestinal obstruction and lead to an incorrect radiographic diagnosis of carcinoma. Grossly, polypoid grapelike masses formed by submucosal gas-filled cysts protrude through the mucosa (Fig. 17.43). Microscopically, the cysts are lined by foreign body–type multinucleated giant cells (Fig. 17.44). The overlying mucosa may show cryptitis, crypt abscesses, chronic inflammation, and granulomas (i.e. changes that may mimic IBD, particularly Crohn disease).[327] The arrangement of the giant cells around intact, partial, or collapsed cysts is a key diagnostic feature.[328] It is believed that the gas is generated in the lumen or within inflamed crypts, from where it penetrates through the muscularis mucosae to accumulate in the form of submucosal cysts. Some authors have suggested a lymph vessel origin for the cysts, as the pericystic tissue stains for podoplanin.[329]

Mucosal pseudolipomatosis is the name given to the lesion in which small gas-filled cysts are limited to the lamina propria of the

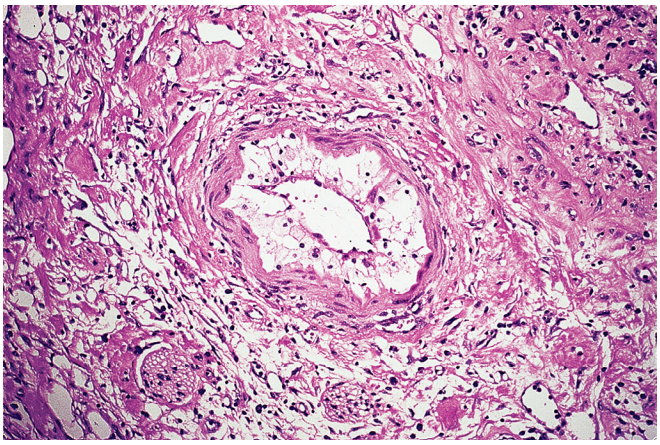

Figure 17.41 Subendothelial accumulation of foamy macrophages within a vessel in radiation colitis.

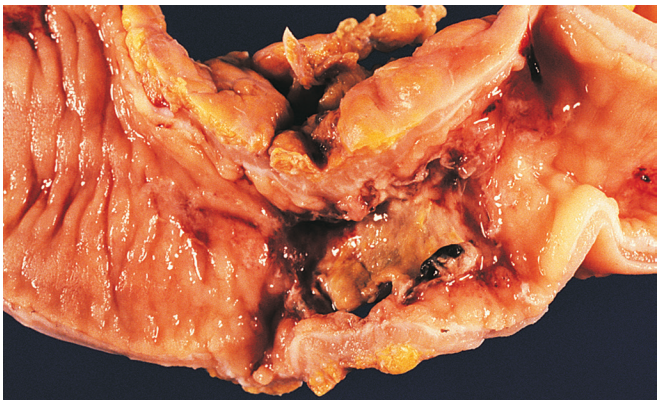

Figure 17.42 Gross appearance of radiation colitis with thickening of the wall, ulceration, and perforation.

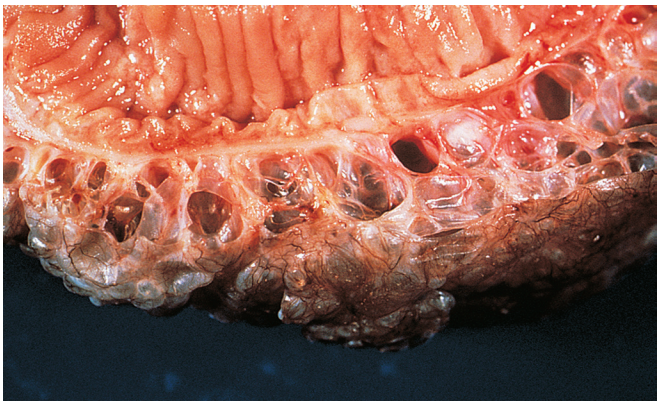

Figure 17.43 Pneumatosis cystoides intestinalis in a patient with scleroderma.

mucosa, resulting in an endoscopic appearance that simulates lipomatosis.[330] This presumably occurs secondary to gas introduced into the mucosa at the time of endoscopy.[331]

Colitis cystica profunda is a non-neoplastic condition characterized by the presence of intramural mucus-containing cysts in the colon and rectum. It may present as a single polypoid mass or involve extensive areas of the bowel.[332] The localized form is typically

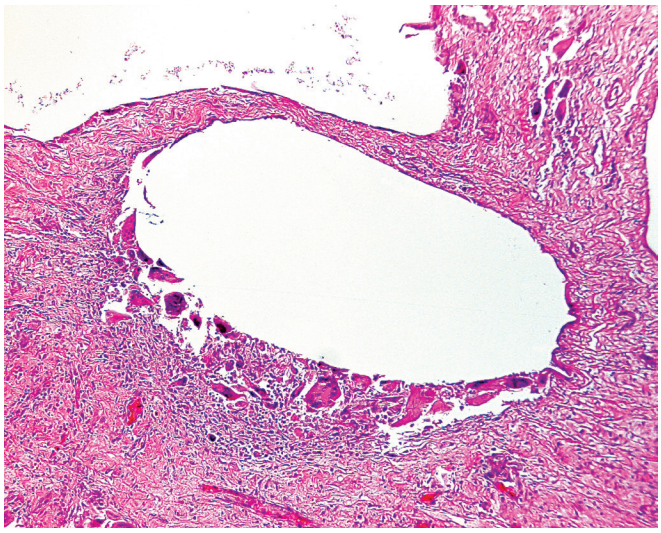

Figure 17.44 Pneumatosis cystoides intestinalis. The cysts are partially lined by multinucleated giant cells.

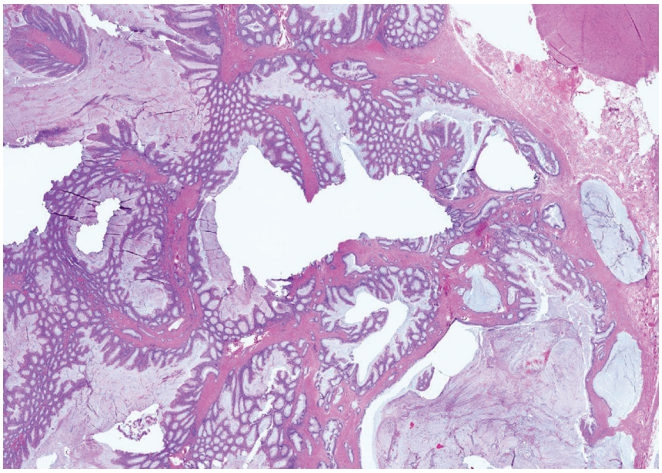

Figure 17.45 Low-power view of colitis cystica profunda.

located in the rectum, 5–12 cm from the anal margin, and presents as a plaque, nodule, or polyp and is associated with chronic proctitis.[333] This form is often associated with mucosal prolapse (solitary rectal ulcer syndrome; see later).

The diffuse form of colitis cystica profunda is in most cases the result of inflammation and ulceration of the bowel, as seen in ulcerative colitis, Crohn disease, or irradiation change[334]; the ulceration provides the means by which mucosa can extend along granulation tracts and thus form lakes of mucus in the submucosa. This disease may be easily mistaken for a mucinous carcinoma; however, the mucin production in colitis cystica profunda is not accompanied by epithelial atypia, tends to be round as opposed to infiltrative, and only rarely extends beyond the submucosa (Fig. 17.45).

Mucosal prolapse, sometimes referred to as "solitary rectal ulcer syndrome," presents as a (usually) solitary ulcerated or polypoid lesion located 4–18 cm from the anal margin.[335–337] The usual symptoms are the passage of blood and mucus via the rectum, an alteration in bowel habits, and pain. Microscopically, there is intercryptal erosion, hyperplasia of the crypts (some of which have a peculiar diamond shape), a tendency toward villous configuration, obliteration of the lamina propria by fibroblasts, elastin, and smooth

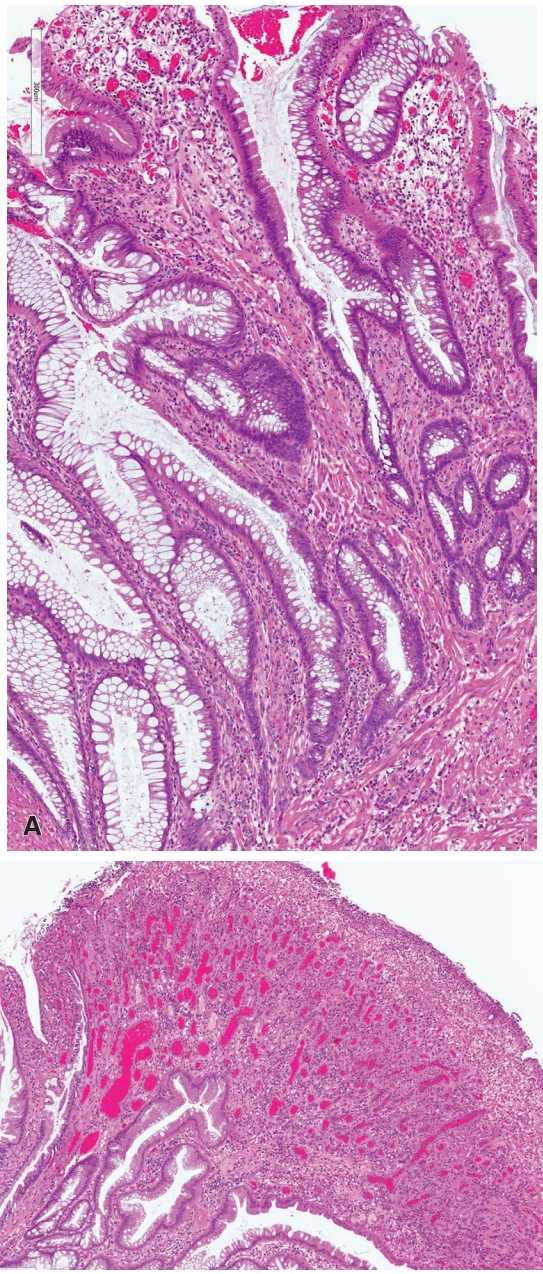

Figure 17.46 Mucosal Prolapse. A, Rectal mucosal prolapse with parallel strands of smooth muscle emanating into the mucosa. **B,** Mucosal prolapse with ulcer and granulation tissue (so-called solitary rectal ulcer syndrome).

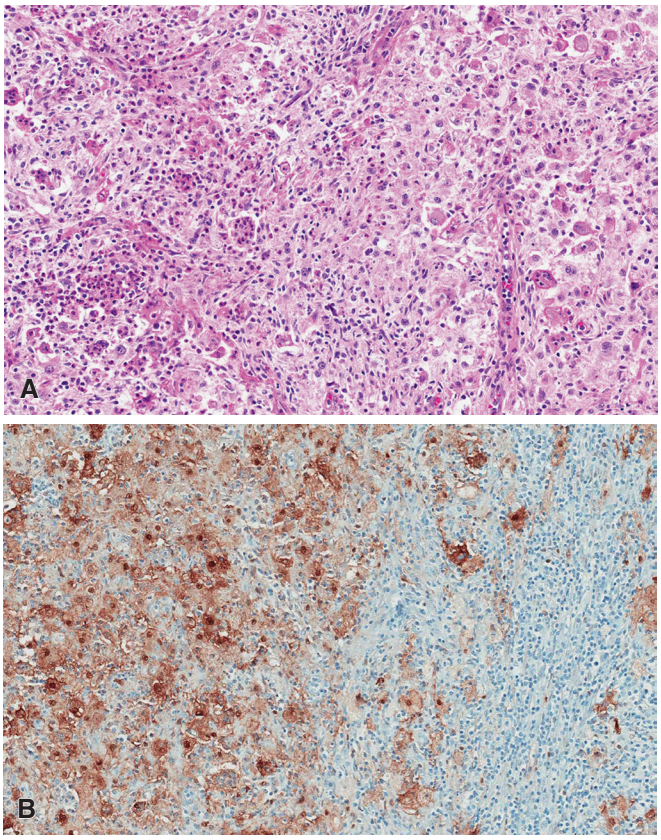

Figure 17.47 Colonic Rosai–Dorfman Disease. A, Rosai–Dorfman disease with enlarged histiocytes admixed with lymphocytes and plasma cells. **B,** Strong S-100 protein immunoreactivity is characteristic of Rosai–Dorfman disease.

muscle cells from the muscularis mucosae, a reduction in the number of lymphocytes and plasma cells, and thickening of the muscularis mucosae with splaying of its fibers (Fig. 17.46).[337,338] Some cases are associated with colitis cystica profunda. The lesion referred to as inflammatory cloacogenic polyp is also a variation on this same theme, and some have grouped all of these changes as components of the *mucosal prolapse syndrome*.[339]

It is important to be aware of the fact that mucosal prolapse may occur secondary to an adjacent or underlying lesion such as endometriosis or primary or metastatic neoplasms.[340]

Enterocolic lymphocytic phlebitis is characterized by a circumferential, predominantly lymphocytic infiltration of small submucosal and/or subserosal veins, with sparing of the arteries. Some have proposed this lesion could be part of the IgG4-related family of diseases.[341,342] It also may be seen in the setting of diversion colitis in patients with IBD.[343]

Rosai–Dorfman disease can exceptionally involve the large bowel, usually associated with other extranodal manifestations of the disease.[344,345] Histologically, it resembles the lesion at other more typical sites (Fig. 17.47).

Fibrosing colonopathy is a rare condition seen in patients with cystic fibrosis who have been treated with high-strength enzyme replacement.[346] Morphologically, the affected colon has a cobblestone appearance, submucosal fibrosis, thickening of the muscularis externa, chronic mucosal inflammation, and mucosal eosinophilia.[347]

Tumors

Epithelial Polyps

The colorectal polyps included in this discussion are those of epithelial origin, which represent the large majority. They can be divided into several broad categories—adenomatous and serrated polyps. The latter category includes the exceedingly common hyperplastic polyp, as well as traditional serrated adenoma (TSA) and sessile serrated polyp (SSP)/sessile serrated adenoma.

Adenomatous polyps (tubular adenomas) are distributed regularly throughout the large bowel,[348] with 40% located in the right colon, 40% in the left colon, and 20% in the rectum, their frequency rising with age.[349] Blacks have a lower prevalence than whites. Most

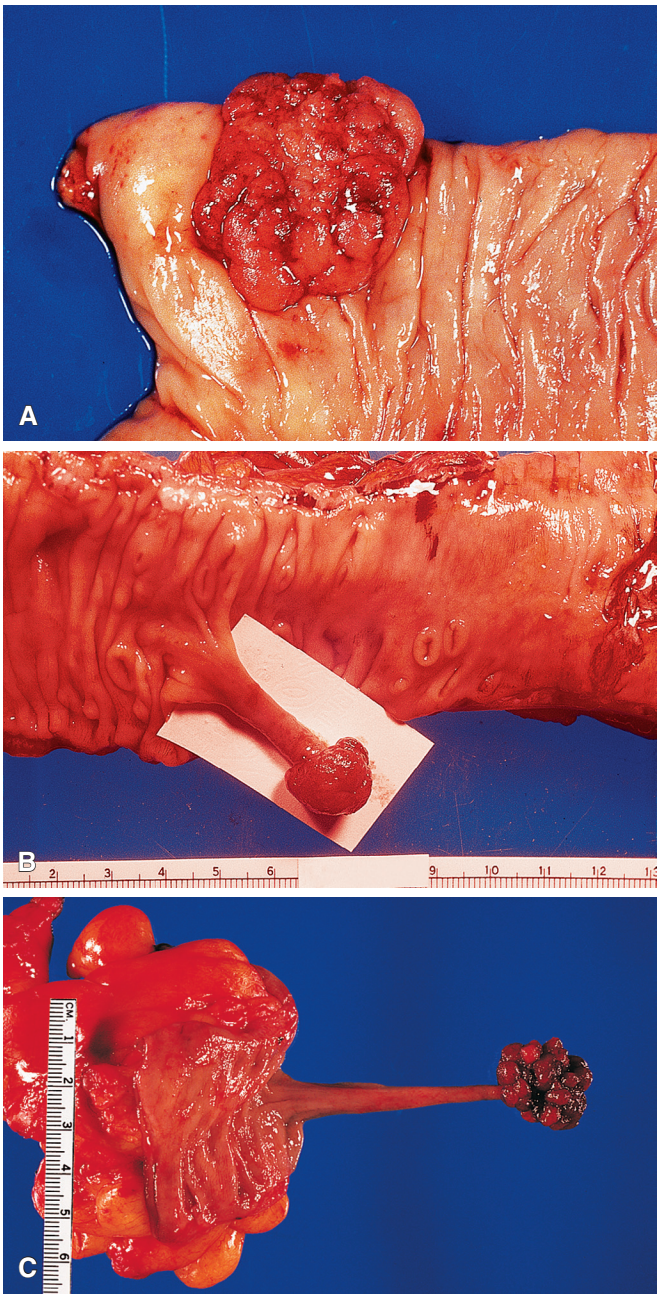

Figure 17.48 **Various Gross Appearances of Colonic Adenomatous Polyps. A,** Polyp with a sessile growth. **B** and **C,** Pedunculated polyps.

polyps are asymptomatic, but they may result in bleeding from twisting or vascular obstruction.[350] If large enough, they may cause changes in bowel habits or rarely intussusception. Grossly, most measure less than 1 cm in diameter. They may be sessile or pedunculated and single or multiple (Fig. 17.48). When multiple, they have a tendency to cluster.[351] When pedunculated, they may have a short or a long stalk attached by a narrow base. When sessile, they may be protruding, flat, or depressed (in which case the term "polyp" is a misnomer).[352] Flat and depressed lesions have been described with increasing frequency, particularly by Japanese authors using advanced microscopic techniques.[353]

Microscopically, there is an increase in the number of glands and cells per unit area compared to the normal mucosa (Fig. 17.49). The cells are crowded, contain enlarged hyperchromatic nuclei, and

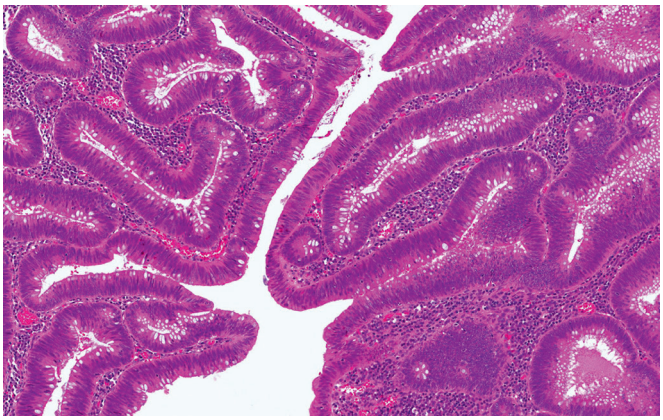

Figure 17.49 Tubular adenoma with characteristic low-grade dysplastic appearance.

have an increased number of mitoses, some of which may be atypical.[354] Mucin production is highly variable but usually decreased. The basement membrane is not thickened.

Focal areas of villous configuration are not infrequent in adenomatous polyps (Fig. 17.50).[355] Those with a villous component comprising 25% or more of the polyp are considered *tubulovillous adenomas*, and those with a villous component comprising 75% or more of the polyp are *villous adenomas*. The larger the polyp, the greater the frequency of a villous component.[356]

The degree of atypia seen in adenomatous polyps is related to increasing age, number of polyps per patient, size of the polyps, and presence of villous changes.[348] All adenomas have at least low-grade dysplasia (by definition), but some have more severe cytologic alterations and should be labeled as having high-grade dysplasia.

The term *carcinoma in situ* is not recommended, as this simply represents the upper end of the high-grade dysplasia spectrum (Fig. 17.51). Although the presence of a villous component and degree of dysplasia are known to be subject to significant interobserver variation,[357] they should still be assessed and reported, as the gastroenterology society guidelines still require their reporting in order to recognize when a patient has an "advanced adenoma," which necessitates closer endoscopic surveillance.[358]

Sometimes clusters of dysplastic glands in an adenomatous polyp are seen beneath the muscularis mucosae and may lead to a mistaken diagnosis of malignant transformation, a process often referred to as "pseudoinvasion" (Fig. 17.52). This is not an uncommon event; as a matter of fact, it may be more prevalent than true malignant transformation. The features that allow its recognition are as follows[359]: (1) the cytologic features of the misplaced glands are similar to those on the surface; (2) the glands are surrounded by inflamed loose stroma (lamina propria) and scattered bundles of muscularis mucosae, rather than the desmoplastic reaction associated with invasive carcinoma; and (3) there are abundant hemosiderin deposits around the dysplastic glands. Some of the glands may become cystic, rupture, and result in the formation of mucin lakes (colitis cystica profunda). This process tends to occur in larger polyps and likely occurs in areas of weakening of the muscularis mucosae where blood vessels penetrate, resulting in prolapse of epithelial elements in the submucosa.

Rarely, adenomatous polyps may exhibit morular formation,[360] focal squamous metaplasia,[361] cytoplasmic clear cell changes,[362] a minor component of Paneth cells,[363] multinucleated epithelial giant cells,[8,364] a population of neuroendocrine cells (Fig. 17.53),[365] malakoplakia in the polyp stroma,[366] osseous metaplasia,[367] or the presence of metastases from another site within the polyp.[368]

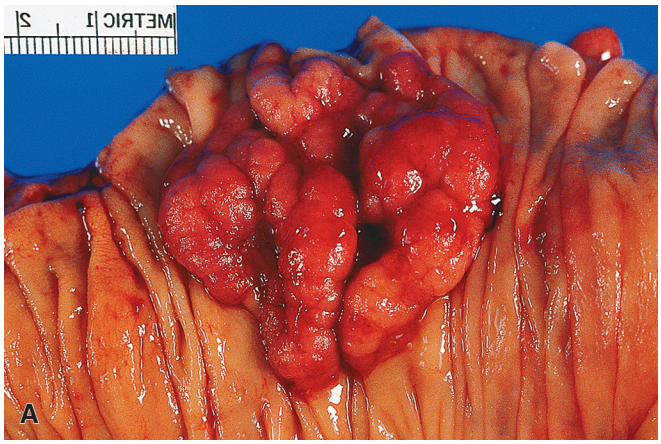

Figure 17.50 Adenomatous Polyp. A, Gross appearance of a polyp with tubulovillous features. **B,** Microscopic appearance of a tubulovillous adenoma.

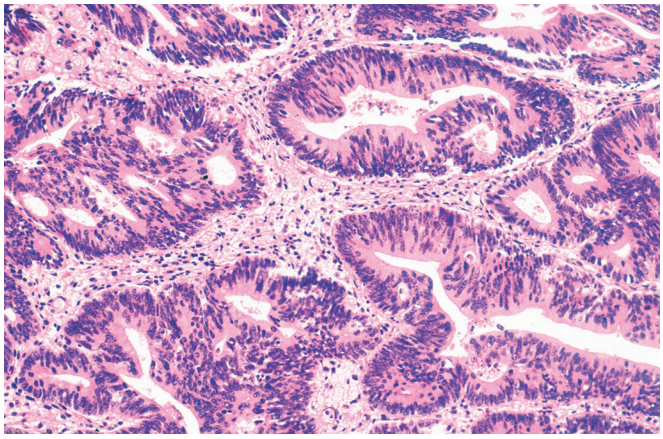

Figure 17.51 Adenoma with high-grade dysplasia showing a complex growth pattern, often formerly referred to as "carcinoma in situ," a term which is discouraged from being used.

"Aberrant crypts" were originally described in experimental animals exposed to colonic carcinogens and were identified by methylene blue stains of whole-mount preparations and probably represent the earliest identifiable "adenomatous" change.[369,370] They seem to be more numerous in colons harboring carcinoma than in those devoid of malignancy.[371,372]

The standard treatment for adenomatous polyps is polypectomy, followed by repeated colonoscopy.[373]

A **serrated (sawtoothed)** architecture is the common morphologic denominator of a group of polypoid colorectal lesions that have gained attention in recent years and which have generated an evolving terminology which at long last seems to be agreed upon by most involved in the field. The paradigmatic member of this group (and by far most common) is the **hyperplastic polyp**. This lesion is characteristically sessile and small, rarely exceeding 5 mm in diameter.[374] If pedunculated and/or large (particularly if located in the right colon), the possibility of it belonging to another member of the group of serrated polyps (SSP; see later) should be strongly considered. If a careful gross examination of the colonic mucosa is made, hyperplastic polyps will be found in 15%–30% of adult individuals.[375] Microscopically, elongated glands with intraluminal infoldings are seen, giving rise to the sawtoothed configuration that constitutes its morphologic signature and which is supposedly due to inhibition of apoptosis (Fig. 17.54).[376] Mitotic activity is increased only at the base, paralleling the pattern of the normal mucosa, and showing a striking contrast with that seen in adenomas. The epithelial cells have an inconspicuous basal nucleus and abundant cytoplasm filled with mucin. The basement membrane beneath the surface epithelium is often thickened, a change that can be easily appreciated on routine-stained sections. The surface epithelium has a micropapillary appearance and is often infiltrated by "nuclear dust."

In recent years, it has become obvious that many lesions diagnosed in the past as hyperplastic polyps are actually **SSPs**, also known has **sessile serrated adenomas**. Although there has been tremendous controversy over which name is most appropriate, the World Health Organization (WHO) recognizes both terms as equivalent.[377] We prefer the term SSP in our practice and, as such, this is the nomenclature that will be used for this discussion.

This polyp was first brought to attention by Longacre and Fenoglio-Preiser in 1990 as "serrated adenoma."[378] The same lesion was later defined in a detailed morphologic study by Torlakovic and Snover in 1996, when they coined the term "sessile serrated adenoma."[379] Subsequent studies clearly identified this lesion as preneoplastic and linked it to the serrated pathway of colorectal cancer,[380–384] which comprises approximately 15% of all colorectal carcinomas, particularly in elderly females and in the right colon.[385] At the molecular level, this pathway is associated with MSI, *BRAF* mutations, and excessive methylation (CIMP:CpG island methylator phenotype).[386,387]

SSPs are more likely to be larger and right sided than are hyperplastic polyps[385]; however, morphologic features should dictate this separation (described later), as there are rare SSPs that are relatively small (less than 5 mm) and/or left sided.[388] As the name implies, these lesions have a sessile endoscopic appearance and do not typically

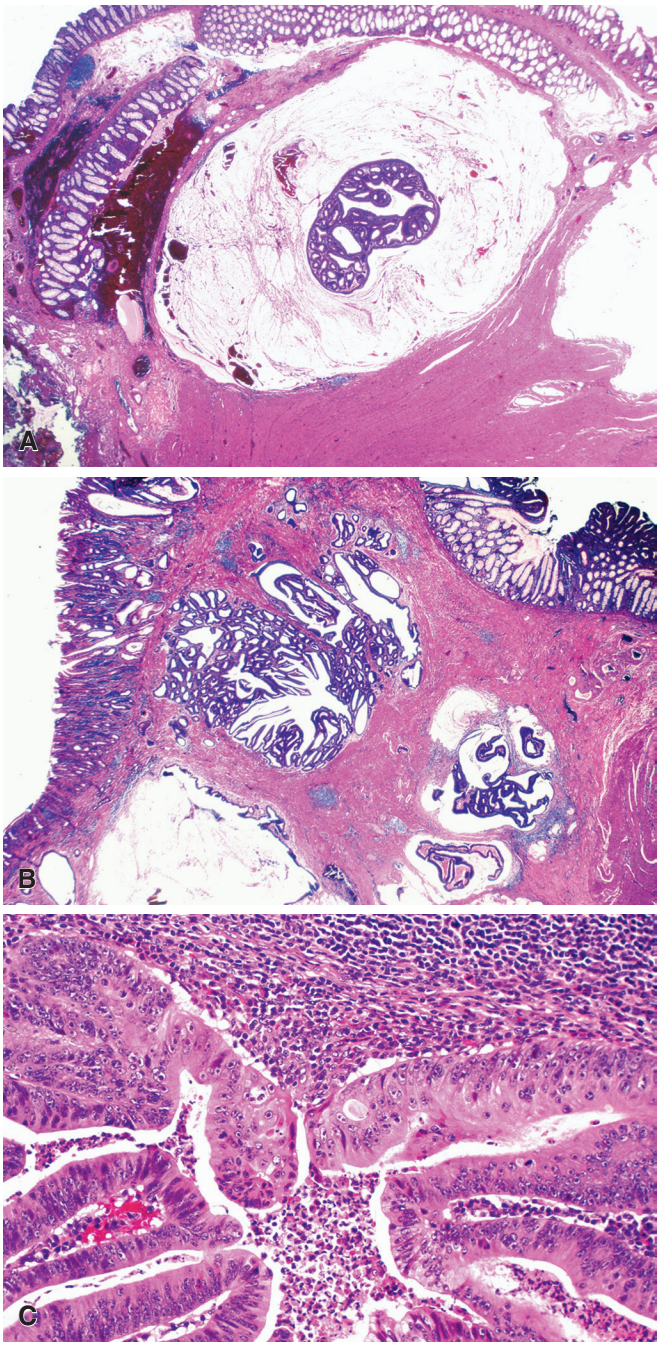

Figure 17.52 Pseudoinvasion in an Adenomatous Polyp. A, Intact adenomatous fragment floating in the center of a pool of well-circumscribed mucin within the submucosa. **B,** Misplaced adenomatous glands viewed at low power with characteristic rounded or lobular architecture. **C,** High-power view of misplaced adenomatous glands surrounded by lamina propria, as opposed to stromal desmoplasia.

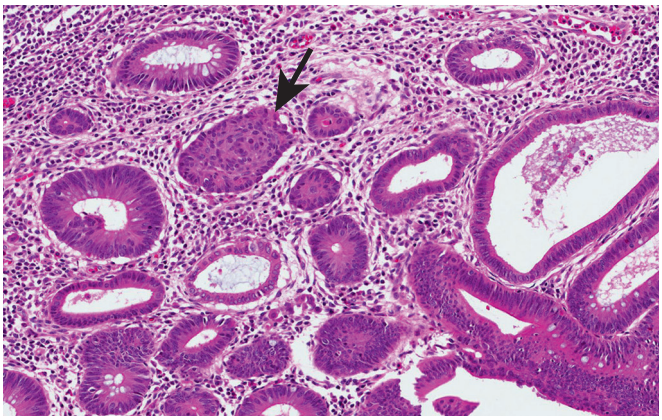

Figure 17.53 Rare case of an adenoma with focal neuroendocrine differentiation (arrow).

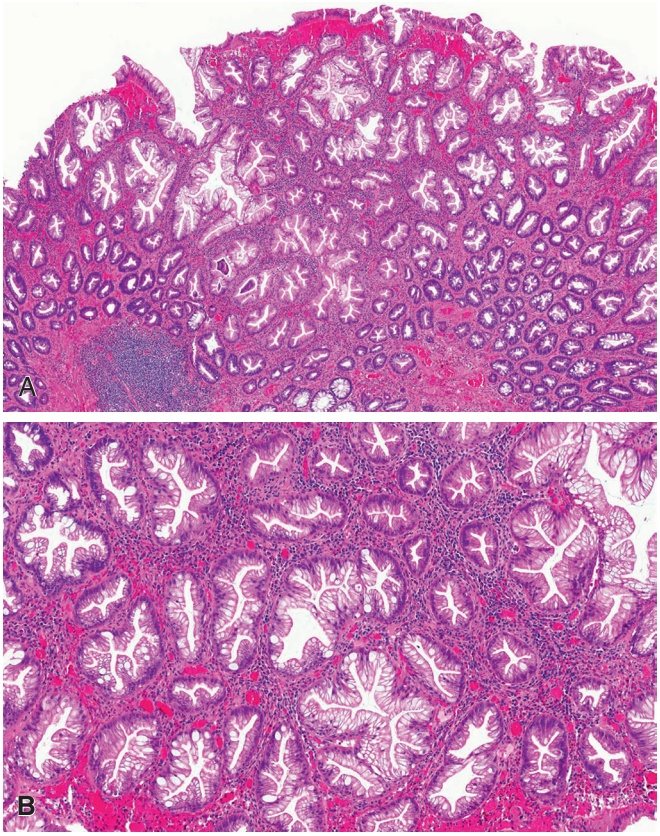

Figure 17.54 Hyperplastic Polyp. A, Characteristic low-power view of a hyperplastic polyp. **B,** Serrated crypts in a hyperplastic polyp.

have a pedunculated growth pattern. In fact, their recognition can be quite subtle and can even be overlooked by the endoscopist.[389]

Morphologically, SSPs can be recognized both by their architectural and cytologic features, although the former are generally more reproducible in arriving at a diagnosis.[390,391] SSPs virtually always show either basal crypt dilatation or lateral spread of crypts at the base of the mucosa, or both (Fig. 17.55).[385] In addition, many show excessive serrations, sometimes all the way to the base of the mucosa, as well as prominent submucosal fat. Some show an inverted (pseudoinvasive) growth pattern with penetration of crypts into the submucosa, although this pattern may also be seen in hyperplastic polyps. Cytologic features are subtle and less reliable in distinguishing SSPs from hyperplastic polyps. SSPs often show an upward migration of the proliferative zone into the middle or upper-third of the crypts, whereas this zone is restricted to the lower one-third of the crypts in hyperplastic polyps.[385]

A small percentage of SSPs progress to true cytologic dysplasia, which commonly resembles a conventional tubular adenoma (Fig. 17.56). These foci are usually sharply demarcated from the underlying

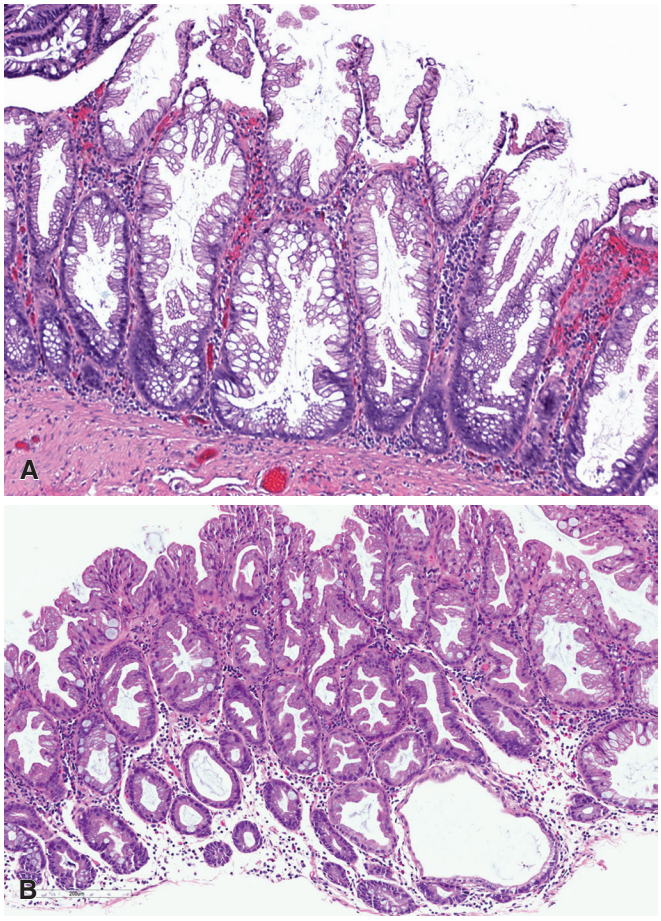

Figure 17.55 Sessile Serrated Polyp. A, Characteristic anchor-shaped crypts at the base of the mucosa in a sessile serrated polyp. **B,** Dilation of crypts at the mucosal base characteristic of sessile serrated polyp.

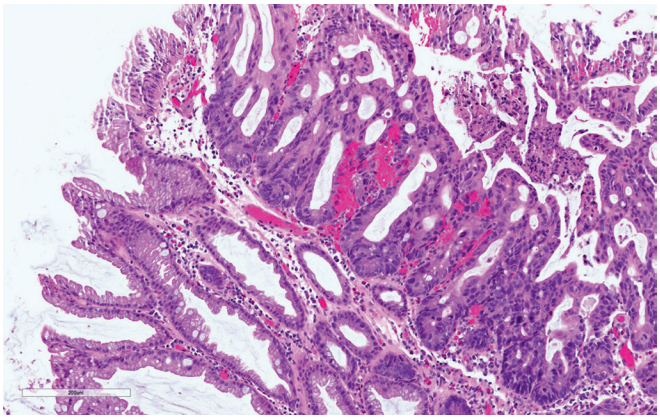

Figure 17.56 Sessile Serrated Polyp With Cytologic Dysplasia. The residual sessile serrated polyp is found on the left side. There is an abrupt transition to the dysplastic component located on the right.

SSP. In years past, such areas were often interpreted as representing a mixed hyperplastic polyp—tubular adenoma, but we now know this represents what the WHO refers to as an SSP with cytologic dysplasia.[377] The dysplastic area can on occasion resemble a TSA, described further later. Although most dysplastic foci are low grade, some develop high-grade dysplasia and a small subset develops invasive adenocarcinoma. Some have even suggested this progression to invasive cancer may occur rapidly following development of cytologic dysplasia and, as such, it is recommended that the endoscopist ensure complete excision of this lesion and consider earlier (1–3 years) follow-up endoscopy[385,392]

Immunohistochemically, there is typically loss of MLH1 staining in the dysplastic foci, a feature that is not typical of sporadic adenomas.[393] In addition, these dysplastic foci retain *BRAF* mutations, which are also found in the adjacent SSPs.[393] **Serrated polyposis syndrome (SPS)** is the name endorsed by the WHO for what was formerly known as "hyperplastic polyposis,"[377] as it is now known these polyps are actually predominantly SSPs rather than hyperplastic polyps. The 2010 WHO criteria for SPS include any of the following features: (1) At least five serrated polyps proximal to the sigmoid colon, with two or more greater than 10 mm in greatest dimension, (2) any number of serrated polyps proximal to the sigmoid colon in an individual with a first-degree relative with SPS, and (3) more than 20 serrated polyps of any size throughout the colon.

Interestingly, studies have found hypermethylation not only in the serrated polyps but also in the nonpolypoid intervening mucosa.[394] Most cases of SPS are sporadic, and germline mutations have not been identified.[385] Patients with this syndrome clearly have an increased risk of colorectal carcinoma, which is often multifocal.[395] As such, these patients are generally followed with close colonoscopic surveillance and consideration for an extended colectomy when polyps become unmanageable endoscopically or cancer intervenes.[392]

TSA has also been a somewhat controversial lesion but clearly is the least common of the colorectal serrated polyps. Despite similarities to SSP in name, TSAs are distinct endoscopically as well as pathologically and at the molecular genetic level.[385] The exact relationship between TSA and the serrated colorectal neoplasia pathway is uncertain, but as of now, it appears to not be a lesion that is central to the pathogenesis of serrated colorectal neoplasia.

TSAs are relatively uncommon, comprising less than 1% of all colorectal polyps.[396] Most are small and left sided, but of course exceptions occur. Patients with TSAs seem to be at higher risk of metachronous polyps than patients with conventional adenomas.[397]

Histologically, these lesions tend to be uniform throughout, often with a villiform ("filiform") appearance.[391,398] The cytoplasm is often distinctly eosinophilic, with centrally or basally located uniform slightly hyperchromatic pencillate nuclei, with infrequent mitoses (Fig. 17.57). A characteristic feature is the "ectopic crypt foci," which are abortive attempts at new crypt base formation high in the polyp.[398] However, this feature can also be in tubulovillous/villous adenomas and is not entirely specific for TSA.[399]

As previously mentioned, TSA-like areas can be identified in the background of an SSP. Additionally, some cases of TSA harbor areas of conventional adenomatous dysplasia.[391] At the molecular level, TSAs are heterogeneous, with some showing evidence of *BRAF* mutations, while others harbor *KRAS* mutations.[391] Interestingly, a large molecular study of TSAs from Australia found that *BRAF*-mutated TSAs were more frequently proximal and were exclusively associated with a precursor polyp when compared to *KRAS*-mutated TSAs.[391] Malignant progression is rare and is associated with *TP53* mutation and activation of the Wnt pathway.[400]

Juvenile (retention) polyp is the most frequent colonic polyp seen in children, but approximately one-third of cases occur in adults.[401] Traditionally, it has been described as single and located in the rectosigmoid area; however, increased use of endoscopy has shown that in many cases more than one polyp is present and that a high proportion of them occur proximal to the sigmoid colon.[402] The lesion usually presents with rectal bleeding;

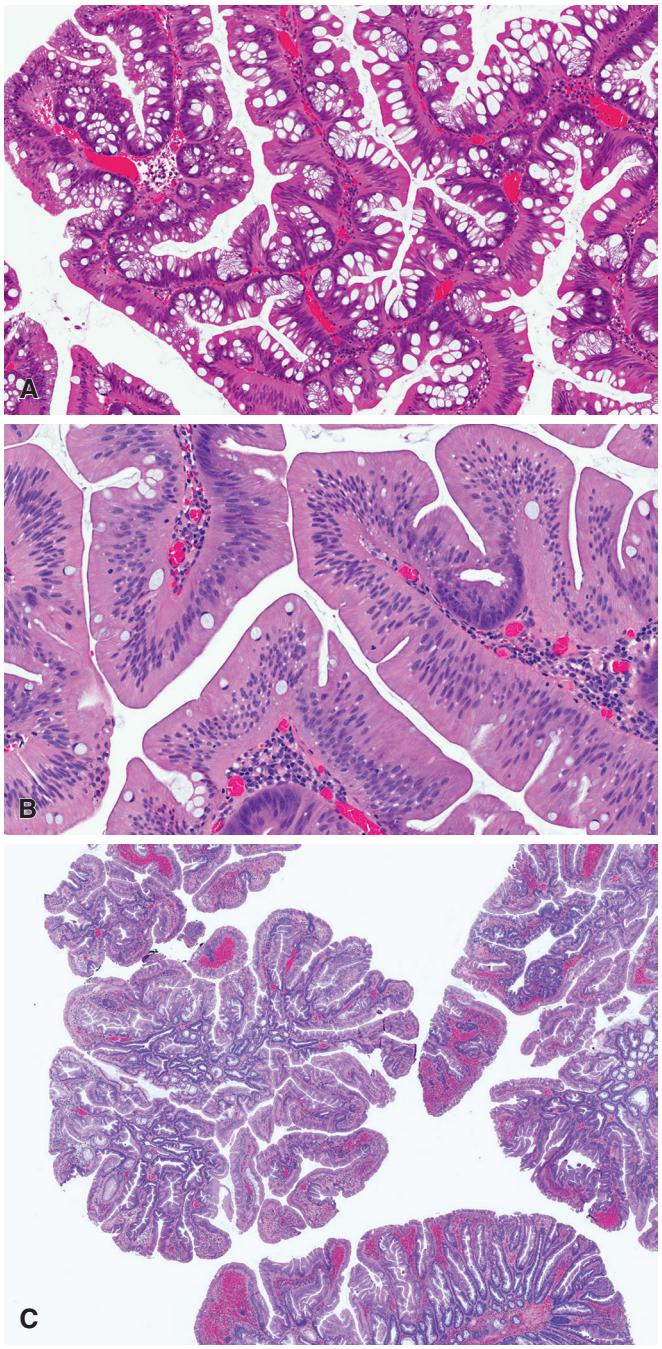

Figure 17.57 Traditional Serrated Adenoma. A, Lateral ectopic crypts in a traditional serrated adenoma. **B,** Apically located cytoplasmic eosinophilia is a characteristic feature. **C,** Most cases of traditional serrated adenoma show villiform architecture which can be mistaken for a tubulovillous adenoma.

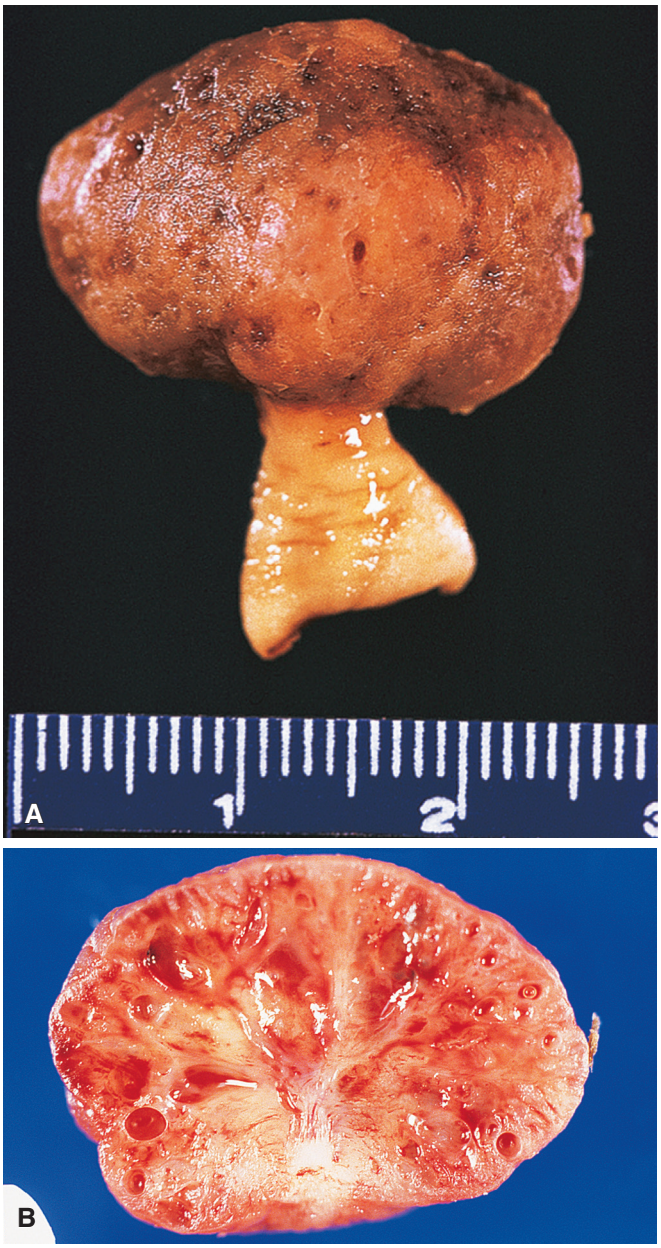

Figure 17.58 Juvenile Polyp. A, Outer aspect of a juvenile polyp. **B,** Cut section showing cystically dilated glands in an edematous stroma. (Courtesy of Dr. R.A. Cooke, Brisbane, Australia, from Cooke RA, Stuart B. *Colour Atlas of Anatomical Pathology*. Edinburgh: Churchill Livingstone; 2004.)

autoamputation is common, the polyp being sloughed off and passed per rectum.

Grossly, juvenile polyp has a granular, red surface and a cystic, lattice-like appearance on cross section (Fig. 17.58). Microscopically, ulceration and granulation tissue are often seen at the surface and are associated with regenerative changes which can be confused with dysplasia. Beneath, there are cystically dilated glands filled with mucus, devoid of atypical features, and separated by an inflamed and edematous stroma (Fig. 17.59). Hyperplastic mucosal changes are present in approximately 20% of cases. As the name indicates, juvenile (retention) polyps have been traditionally regarded as non-neoplastic.[403] However, the occasional presence of foci of low- or high-grade dysplasia and of genetic alterations (such as *KRAS* mutations) raises some questions as to their true nature.[404] As noted later, some arise in the setting of juvenile polyposis syndrome.

Peutz–Jeghers polyps are practically always seen as part of a syndrome[405] (see later) and have microscopic features similar to their more common counterparts in the small bowel. Lack of cellular atypia, disorganization of glands, the occurrence of several cell types (including Paneth cells), and the presence of smooth muscle fibers from the muscularis mucosae (which give the lesion

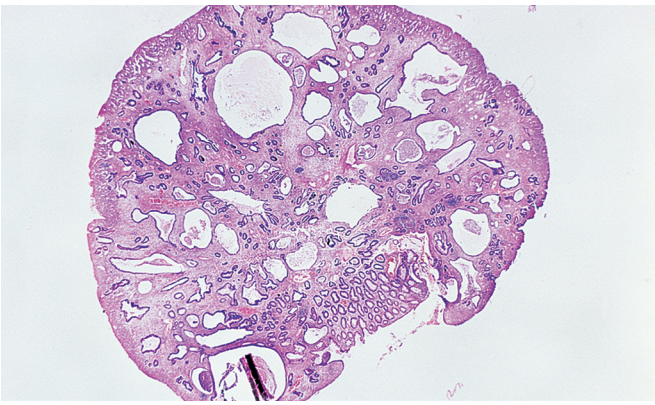

Figure 17.59 Whole-mount view of a juvenile (so-called retention) polyp.

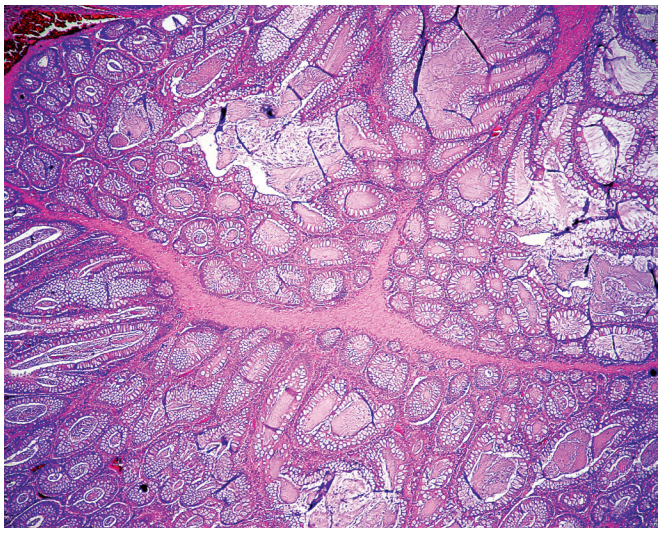

Figure 17.60 Peutz–Jeghers Polyp. There are ramifying bundles of smooth muscle and an absence of dysplasia.

a "hamartomatous" appearance) are the most important features (Fig. 17.60).[406] This pattern of glandular disorganization and epithelial misplacement simulating invasion should not be confused with malignancy.[407]

Polyposis Syndromes

Familial adenomatous polyposis (FAP; also known as polyposis coli) is characterized by the presence of hundreds or thousands of polyps throughout the bowel. The microscopic appearance of most of the individual lesions is indistinguishable from sporadic adenomatous polyps, but some look like "colonic aberrant crypts," flat adenomas, depressed adenomas, or villous adenomas.[408,409] This inherited condition shows autosomal dominant inheritance with a high degree of penetrance.[410] The responsible gene *(APC)* has been localized to chromosome 5q21.[411] A small percentage of cases is caused by germline mutation of the base-excision repair gene *MYH*.[412] The tumors in FAP become manifest much earlier than the usual adenomatous polyp, usually in the second decade of life.[413] Molecular techniques can be used for the presymptomatic diagnosis of this disorder through demonstration of germline mutations in the relevant genes.[414–416]

Radiographically and grossly, the bowel is studded with polyps ranging from very slight elevations of the mucosa to relatively large

Figure 17.61 Radiograph of familial adenomatous polyposis involving the entire bowel.

Figure 17.62 Gross appearance of familial adenomatous polyposis. The entire large bowel is involved by innumerable small polyps.

masses (Figs. 17.61 and 17.62). The presence of several adenomatous polyps in a patient does not necessarily indicate the presence of FAP. A minimum of 100 polyps needs to be present before such a diagnosis can be assumed on morphologic grounds.

KRAS mutations are found in approximately one-fourth of these polyps, the frequency being similar to that seen in sporadic cases.[417]

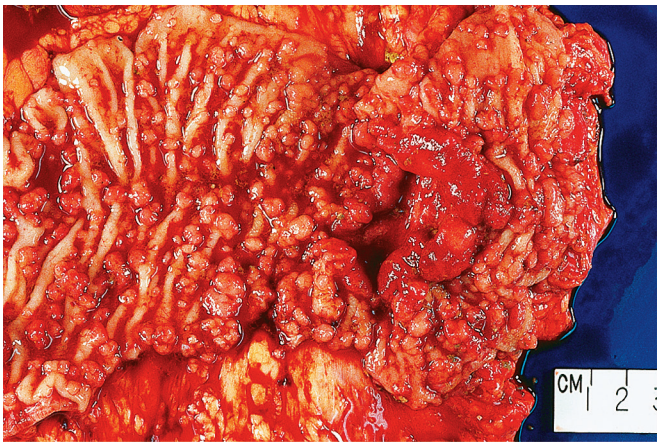

Figure 17.63 Familial adenomatous polyposis complicated by adenocarcinoma.

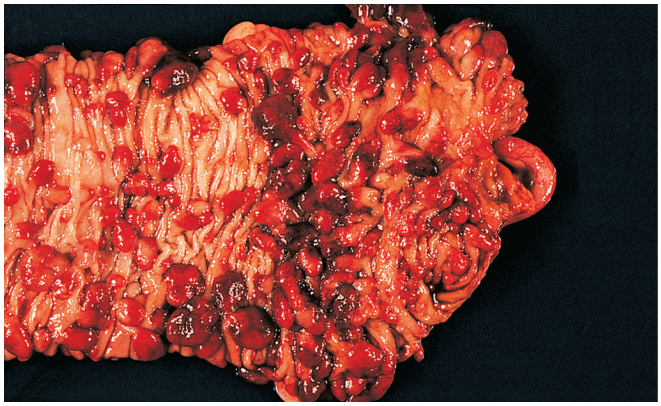

Figure 17.64 Juvenile Polyposis. The marked hyperemic quality is a characteristic feature of these lesions.

These mutations are also increased in the morphologically normal mucosa.[418]

FAP can involve other portions of the gastrointestinal tract, such as stomach and small bowel.[419] It should be remembered, however, that most polypoid lesions of the ileum seen in patients with this disorder represent foci of lymphoid hyperplasia and that many of the gastric lesions in these same patients are fundic gland polyps.[420]

If FAP is left untreated, one or more carcinomas will develop in the large bowel in nearly all patients (Fig. 17.63). Carcinomas arising in a background of FAP occur, on average, 20 years earlier than the ordinary colorectal carcinomas, most of them becoming manifest in the early thirties; therefore, prophylactic colectomy at 20–25 years of age is recommended.[419] If the surgery performed is a total colectomy followed by ileal pouch–anal anastomosis, close monitoring of the rectal cuff and ileal pouch is indicated because of the possibility of development of polyps and carcinoma at these sites.[421]

Carcinomas developing in other organs, such as the gallbladder, pancreas, thyroid, and adrenal gland, have also been reported in this disorder.[422–425] The thyroid carcinomas developing in these patients have a distinct microscopic appearance characterized by cribriform and morular formations.[426] Other described associations with FAP include hepatoblastoma,[427] multiple endocrine neoplasia,[426] nasopharyngeal angiofibroma,[428] and Sertoli cell tumors.[429]

In the variant of FAP known as *hereditary flat adenoma syndrome*, the polyps are flat rather than elevated, usually number less than 100, and exhibit a right-sided predominance.[430] The chromosomal abnormality is in the same gene *(APC)* as in ordinary FAP,[431] and the affected individuals may develop the same types of upper gastrointestinal tract lesions.[432]

Gardner syndrome is a variant of FAP characterized by the presence of numerous large bowel adenomas, multiple osteomas of the skull and mandible, multiple keratinous cysts of the skin, and soft tissue neoplasms, especially fibromatosis.[433] Most of the fibromatoses are intra-abdominal and develop following surgical intervention.[434] These lesions show coexistence of somatic and germline mutations of the *APC* gene, suggesting that inactivation of both alleles of this gene is involved in their development.[435] Because of the variable degree of penetrance, only one of the extracolonic manifestations may be present, such as fibromatosis. Adenomatous polyps may also be present in the small bowel and stomach. The potential for development of large bowel carcinoma is no different from typical FAP. In addition, patients with this syndrome can develop carcinomas of the small bowel, particularly in the periampullary area.[436]

Turcot syndrome, a variant of hereditary nonpolyposis colorectal cancer (HNPCC, also known as Lynch syndrome), is the name given to the odd combination of colorectal adenomatous polyps and brain tumors, usually glioblastomas.[437] This is an entity genetically distinct from FAP, with a recessive pattern of inheritance,[438] resulting from germline mutations in the mismatch repair (MMR) genes.[439,440] Muir–Torre syndrome is also considered to be a variant of HNPCC associated with tumors of sebaceous glands.[440,441]

SPS (mentioned earlier in this chapter) is characterized by the presence of multiple serrated polyps, especially SSP, some of them of large size and sometimes accompanied by adenocarcinoma.[442]

Juvenile polyposis is defined by the presence of multiple juvenile polyps throughout the bowel. This condition, which can be life threatening,[409] is associated with the development of adenomatous polyps and adenocarcinoma of the large bowel, duodenum, stomach, or pancreas (Fig. 17.64).[401] Some of the polyps in this disorder have combined juvenile and adenomatous features.[443] Some cases are associated with ganglioneuromatous proliferation.[444] The genetic defect in juvenile polyposis has been found to be inherited inactivating mutations of the *SMAD4* or *BMPR1A* genes, this inactivation being limited to the stromal cells.[445]

Cronkhite–Canada syndrome is a nonhereditary disorder in which multiple colorectal polyps of the juvenile type are associated with ectodermal changes (alopecia, nail atrophy, and hyperpigmentation).[446,447] The polyps associated with this syndrome are less commonly pedunculated than other juvenile polyps (Fig. 17.65).[448] Adenomatous changes and colorectal carcinoma may also develop in these patients.[449]

Peutz–Jeghers syndrome patients may feature, in addition to the typical Peutz–Jeghers polyps that define the syndrome (see previous discussion), adenomatous polyps with a marked degree of atypia. Some of these patients develop colorectal adenocarcinoma.[450] The syndrome is due to germline mutations of the *LKB1* gene.[451]

Cowden syndrome (multiple hamartoma syndrome) is an autosomal dominant illness characterized by mucocutaneous stigmata (facial trichilemmomas, acral keratoses, and oral mucosal papillomas), colorectal polyps, and an increased incidence of malignancy in various sites (breast, thyroid, renal, and uterine, among others).[452] The polyps have hamartomatous features, with disorganization and proliferation of the muscularis mucosae, but they differ microscopically from the polyps of Peutz–Jeghers syndrome.[409,453] The syndrome is due to germline mutation in the *PTEN* gene.[454]

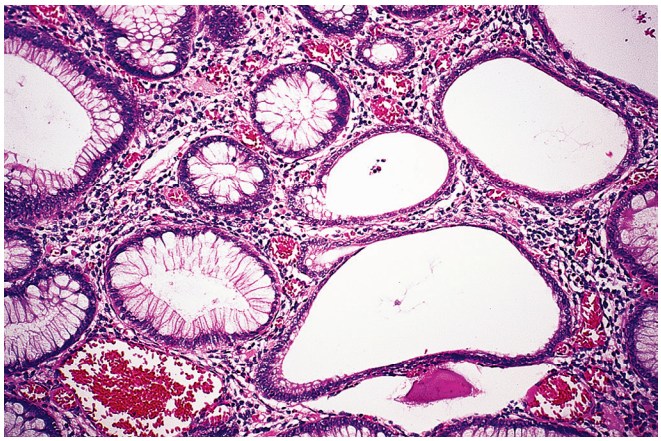

Figure 17.65 Colonic polyps in a patient with Cronkhite–Canada syndrome. The appearance resembles that of a juvenile polyp.

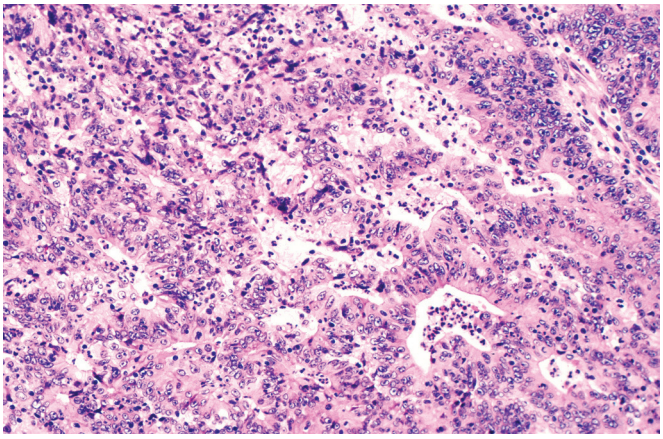

Figure 17.67 Adenomatous polyp with "never-ending" pattern of glands but evidence of stromal desmoplasia (intramucosal adenocarcinoma).

Figure 17.66 Low-power view of a malignant colorectal polyp.

Relationship With Carcinoma and Treatment

Colonoscopic polypectomy results in a lower-than-expected incidence of colorectal carcinoma in the population subjected to that procedure, providing support to the current practice of searching for and removing adenomatous polyps.[455] When possible, adenomas should be removed in toto, preferably in one piece. This allows a proper orientation of the specimen, so that in the presence of focal carcinoma the extent of the tumor and the relationship to the polypectomy margin can be assessed (Fig. 17.66). This determination is of great importance in deciding whether further surgery is indicated or whether endoscopic polypectomy is adequate therapy.

Malignant colorectal polyps should be assessed for the following features:

1. Tumor differentiation
2. Angiolymphatic invasion (lymphovascular invasion [LVI])
3. Adequacy of excision

Endoscopic polypectomy can be performed for those malignant colorectal polyps that are either well or moderately differentiated (i.e. not poorly differentiated), lack angiolymphatic invasion (although this assessment can be exceedingly difficult and subject to significant interobserver variability),[456] and have a free polypectomy margin.[457–459] Again, there is some disagreement as to what constitutes a tumor-free polypectomy margin. While some studies advocate for a 2-mm margin,[460] others require only 1 mm, and still others would consider a lesion as completely excised if the tumor is not seen at the cauterized polypectomy margin.[461]

In reality, the specimens obtained with endoscopic resection are often fragmented and difficult to orient. When a focal carcinoma is present in a polyp, it may be impossible to determine the adequacy of excision. In such circumstances, surgical excision is often indicated.

If a proximally located lesion is very large, a small endoscopic biopsy may fail to detect the area of malignant transformation if present; therefore such a lesion may be best treated by anterior resection of a segment of bowel.

The term **intramucosal adenocarcinoma** is a controversial one when used in the context of colorectal neoplasms. This refers to a neoplasm that has penetrated the basement membrane into the lamina propria or muscularis mucosae but not below (Fig. 17.67). As such, stromal desmoplasia, the best indicator of submucosal invasion, is absent. In the situation of an intact polyp with intramucosal adenocarcinoma that has been completely excised, endoscopic polypectomy is adequate therapy since there is no risk of lymphatic dissemination given the absence of lymphatic channels in the colorectal mucosa.[462] However, if the lesion is fragmented or from a larger incompletely excised lesion, we used the diagnostic term "at least intramucosal adenocarcinoma" with a comment that invasion still could be present in the remainder of the unexamined lesion remaining in the patient. In this situation, bowel resection with removal of regional lymph nodes is often indicated.[463–465]

We believe that following the rather conservative recommendations presented herein will help avoid subjecting patients with colorectal polyps to unnecessarily radical, costly, and potentially dangerous procedures. Obviously, a thorough pathologic evaluation is of paramount importance in this determination.[466]

Carcinoma

General Features

Carcinoma of the large bowel is common in northwest Europe, North America, and other Anglo-Saxon areas, but low in Africa,

Asia, and some parts of South America.[467,468] In the United States, it is the third most common cancer among men and women and the second leading cause of death from cancer. At the same time, it is by far the most curable form of carcinoma of the gastrointestinal tract. Males and females are affected equally, and the mean age at diagnosis is in the sixth to seventh decades of life. Cases occurring in the young (<40 years of age) are usually located in the distal colon and rectum and tend to show features associated with aggressive behavior or are associated with one of the hereditary colorectal cancer syndromes.[469]

The cause and pathogenesis of colorectal carcinoma are related to both environmental and genetic factors. The former are largely dietary, particularly in terms of fats and animal protein; they are related to their influence on the intestinal microflora and ultimately on the chemical composition of the intraluminal content.[470] Specifically, there is a close association between beef consumption, the ingestion of large amounts of animal fat, and the incidence of colorectal carcinoma; however, the issue is complex, and the precise nature of the relationship is far from established.[471]

The genetic factor manifests itself in a variety of ways. The most obvious is the high predisposition for colorectal carcinoma in patients with FAP (nearly 100% by age 50 years see previous discussion), other forms of polyposis (to a much lesser degree; see previous discussion), and in those with the HNPCC syndrome *(Lynch syndrome)* and related nonpolyposis associated hereditary conditions.

The issues of the relationship between epithelial polyps and colorectal carcinoma and the sequence of molecular alterations that have been detected in these lesions have already been discussed. Patients with IBD have a definite predisposition to colorectal carcinoma, but they comprise only a small percentage of the patients with colorectal carcinoma in the general population.[158] Some cases of colorectal carcinoma occur as a late complication of pelvic irradiation, usually for carcinoma of the cervix.[472] A few others have been reported as arising at ureteral implantation sites.[473]

Hereditary Nonpolyposis Colorectal Cancer Syndrome (Lynch Syndrome) and Other Familial Forms of Colorectal Cancer

HNPCC is due to germline mutations in one of the genes responsible for repair of DNA mismatches, most commonly *MLH1*, *MSH2*, *MSH6*, and *PMS2*, resulting in high levels of MSI.[474] There is a 50% risk of developing colorectal carcinoma for a first-degree relative of an affected patient in the direct genetic lineage.[475] The carcinomas most commonly involve the proximal colon. Patients with HNPCC are also at an increased risk for the development of malignant tumors at other sites, such as liver (cholangiocarcinoma), uterine corpus, urinary bladder, renal pelvis, ureter, pancreas, and several other organs.[476]

A variation on the theme of HNPCC is represented by colorectal carcinoma-prone families who have right-sided flat adenomas. The number of polyps is intermediate between that in FAP and that in classic HNPCC; the carcinomas, most of which are also right sided, occur at a later age than in the other two conditions.[477]

In **familial colorectal carcinoma** (defined by the presence of two or more first-degree relatives with this tumor), the risk for first-degree relatives of affected individuals is increased threefold.[430] Mutant alleles of the *HRAS*-1 minisatellite may predispose to this condition.[478]

The colorectal carcinomas that arise in HNPCC tend to show several of the following features, none of which can, however, be regarded as pathognomonic: young patient age, right-sided location, mucinous features, poor differentiation (solid or medullary appearance), tumor-infiltrating lymphocytes, lack of "dirty" necrosis, and presence of a Crohn-like inflammatory reaction.[479,480] Interestingly, the adenomatous polyps occasionally present in the colon of patients with HNPCC also tend to be infiltrated by lymphocytes.[481]

The approach (molecular vs. immunohistochemistry) to assessing tumors for HNPCC has been the topic of innumerable publications and debate. While both techniques are sensitive and specific for MMR deficiency, neither technique is perfect, and they should be viewed as complementary.[474] There are both technique and interpretive issues with immunohistochemical staining for MLH1, MSH2, MSH6, and PMS2, but in general, the recognition of good internal control staining can help to identify these technical issues. A normal staining profile indicates a low likelihood of HNPCC. An abnormal profile (besides loss of MLH1 and PMS2) should result in a germline evaluation for HNPCC. If there is concurrent loss of staining for MLH1 and PMS2, we test for *BRAF* V600E mutations and/or MLH1 methylation, which, if abnormal, indicates a low likelihood of HNPCC.[482]

Which tumors to test has also been the topic of debate. The Revised Bethesda Guidelines (accounting for age, tumor histology, family history) has been estimated to miss up to 30% of Lynch-associated tumors.[483,484] The Jerusalem criteria suggest testing colorectal cancers in all patients less than 70 years of age, although it has been estimated to miss approximately 10% of these tumors.[474,485] Others perform universal screening, usually assessing for MMR deficiency by immunohistochemistry.

Clinical Features

Carcinomas of the large bowel may present with rectal bleeding, changes in bowel habits (such as diarrhea alternating with constipation), anemia resulting from chronic blood loss, and vague abdominal pain. Intestinal obstruction is common when the tumor is situated in the left colon and rare for tumors in the cecum or ascending colon. Perforation may rarely occur, either at the site of the carcinoma or in the cecum as a result of distention caused by an obstructing rectosigmoid carcinoma. The endoscopic appearance is usually characteristic, but some inflammatory lesions may simulate carcinoma, and some undifferentiated carcinomas may have an innocent appearance.

Unfortunately, the previously mentioned symptoms are often indicative of advanced disease; therefore, many attempts have been made over the years to detect tumors at an earlier stage. One such procedure is the performance of appropriately timed endoscopic examinations of both men and women over 40 years of age.[486] Stool examination for occult blood also has proved to be an efficient and inexpensive way of detecting cases of early, asymptomatic carcinoma.[487]

Carcinoembryonic antigen (CEA) is a glycocalyx-related antigen that has been detected in the serum of 72%–97% of patients with colorectal carcinoma.[488] It disappears after resection of the tumor and reappears in the event of recurrence or metastases. Higher values are found in tumors that have spread beyond the bowel wall, in poorly differentiated neoplasms, and in tumors associated with angiolymphatic and perineurial invasion.[489] Elevated circulating levels of CEA also occur in carcinomas of the stomach, pancreas, breast, lung, prostate gland, and thyroid (medullary carcinoma). Serum CEA is practically never elevated in normal individuals, but high values can be found in patients with chronic liver or renal disease.[489] Unfortunately, the test is often negative during the early stages of colorectal carcinoma and is, therefore, not an effective screening tool. Its main utility rests in the monitoring of therapy, in the early detection of metastases, and as an indicator for second-look

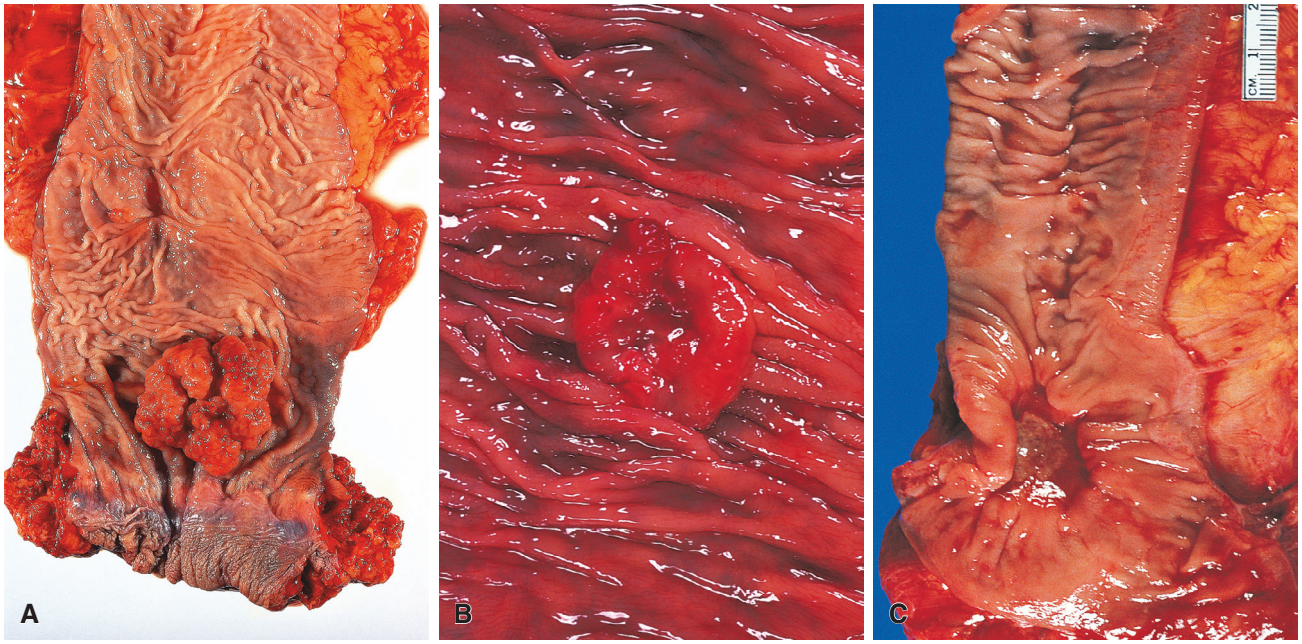

Figure 17.68 Various Gross Appearances of Colonic Adenocarcinoma. A, Polypoid pattern of growth in a rectal lesion. **B,** Cake-like configuration with central ulceration. **C,** Deeply penetrating and ulcerating tumor. (Courtesy of Dr. R.A. Cooke, Brisbane, Australia, from Cooke RA, Stuart B. *Colour Atlas of Anatomical Pathology*. Edinburgh: Churchill Livingstone; 2004.)

surgery.[488,490] Recently, *KRAS* mutation screening by chip-based DNA hybridization has shown promise as a potential tool in this regard.[491]

Site and Gross Features

Approximately 50% of all carcinomas occur in the rectosigmoid area, although their relative incidence seems to be decreasing[492]; a shift in location toward the proximal colon during the past few decades has been noted.[493] Right-sided tumors are associated with older age at presentation.[494] Multicentric carcinomas are found in 3%–6% of the cases.[495]

Grossly, most colorectal carcinomas are either polypoid or ulcerative/infiltrating (Fig. 17.68). The former presents as a bulky mass with well-defined, rolled margins, and a sharp dividing line with the normal bowel. The latter has a less elevated surface and is centrally ulcerated. A particular variant of this tumor type, well documented in the Japanese literature, is referred to as "flat" or "depressed" carcinoma and is thought to arise de novo rather than through malignant transformation of an adenoma.[496] These flat carcinomas have a greater tendency for deep invasion with lymphovascular permeation than the more common polypoid types.[497]

In general, there is good correspondence between the gross and the microscopic margins of the tumor. Extensive lateral superficial spread of the type often seen in the stomach is very rare in colorectal tumors, but it does occur.[498] On cross section, grayish white tissue is seen replacing the bowel wall. The edges may be well demarcated or with finger-like projections extending from the main mass. Highly mucinous tumors have a gelatinous, glaring appearance, and layers of mucus may separate the layers of bowel wall.

Important features to evaluate at the time of gross inspection are whether the tumor is confined to the wall or whether it has extended to the pericolic tissues, whether gross invasion of veins is present, and whether the remainder of the colon shows other carcinomas or polyps of any type.

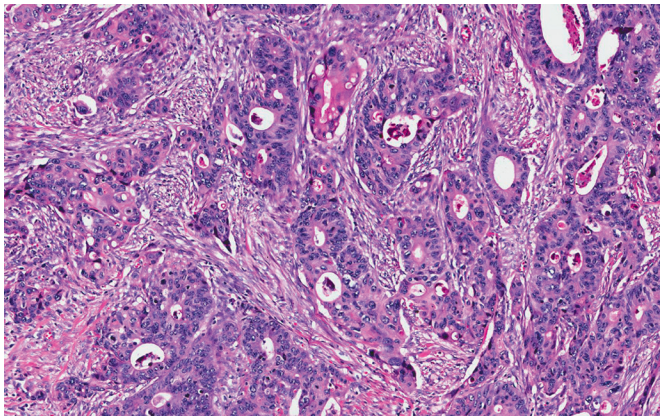

Figure 17.69 Microscopic appearance of an invasive colonic adenocarcinoma characterized by stromal desmoplasia.

Microscopic Features

The usual malignant tumor of the large bowel is a well-to-moderately differentiated adenocarcinoma secreting variable amounts of mucin. The tumor cells represent a combination of columnar and goblet cells, with occasional participation of neuroendocrine cells and the exceptional occurrence of Paneth cells.[499] The carcinoma consistently elicits an inflammatory and desmoplastic reaction, which is particularly prominent at the edge of the tumor (Fig. 17.69). Most of the inflammatory cells are T lymphocytes,[500] but B lymphocytes, plasma cells, histiocytes, and S-100 protein–positive dendritic cells may also be present.[501] Occasionally there are numerous eosinophils, a feature thought to be due to interleukin-5 production.[502]

The tumor surface may have a papillary or villous configuration, to be distinguished from a residual villous adenoma described previously and the micropapillary pattern described later. The tumor

may be seen invading all the layers of the bowel and extending into the pericolic fat, permeating perineurial spaces, and invading veins. The latter feature, which is of prognostic significance, can be better appreciated with stains for elastic fibers (Verhoeff–van Gieson or Movat stain).[503]

The edge of the tumor may show foci of a residual adenoma, but more commonly one identifies a reactive hyperplastic alteration in the glands, which appear taller, more tortuous, and with more goblet cells than the normal mucosa (so-called transitional mucosa).[504]

Histochemical and Immunohistochemical Features

Histochemically, the large majority of colorectal carcinomas are positive for mucin stains. Immunohistochemically, the main mucin protein cores expressed by conventional colorectal adenocarcinoma are MUC1 and MUC3 (as opposed to MUC2 in mucinous carcinoma).[505] There is also expression of MUC13, particularly in poorly differentiated tumors.[506] Recently, the serrated pathway of colon cancer has been found to be associated with increased expression of MUC2, MUC5AC, and MUC6.[507]

Colorectal adenocarcinomas are invariably positive for cytokeratin (CK), with the most common pattern being positivity for CK20 and negativity for CK7.[508] The reverse pattern is extremely rare, which is helpful in distinguishing colorectal adenocarcinoma from adenocarcinomas of other sites, such as lung and ovary.[509] However, aberrant patterns of immunoreactivity (such as positivity for CK7) can be found in some colorectal carcinomas, particularly those that are poorly differentiated.[510,511] Reactivity for CEA is also the rule, and failure to demonstrate CEA in an adenocarcinoma makes a colorectal origin unlikely.[512] The positivity for this marker is equally distributed throughout the cell surface in most cases, as opposed to the polar distribution seen in normal mucosa and in the better differentiated tumors.[513] A variety of monoclonal antibodies to different epitopes of the CEA molecule are available, but those that recognize epitopes of group 1 or 2 have been found to have the greatest degree of sensitivity and specificity.[508]

CDX2 is a caudal-type homeobox gene that encodes a transcription factor that plays an important role in the proliferation and differentiation of intestinal epithelial cells. It is found by immunohistochemistry in the overwhelming majority of colorectal carcinomas,[514] but it can also be expressed in primary mucin-producing carcinomas of ovary, bladder, and lung, as well as pancreaticobiliary adenocarcinomas.[515]

Tumor-associated glycoprotein 72 (TAG-72), recognized by monoclonal antibody B72.3, is present in virtually all invasive colorectal carcinomas but also in the majority of hyperplastic and adenomatous polyps and even in normal mucosa; however, the frequency of reactivity and the pattern of expression vary depending on the condition.[516]

Other markers consistently expressed by colorectal carcinoma regardless of differentiation are villin (a cytoskeletal protein associated with the axial microfilament bundles of brush border microvilli),[517] cathepsin B (a lysosomal cysteine proteinase),[518] neuropilin-1 (a molecule normally present in the developing nervous system), SRCA2 (an ATPase crucial to many cell functions),[519] and cadherin-17 (also known as liver-intestine cadherin).[520] Calretinin can be expressed by a minority of colorectal adenocarcinomas (especially the undifferentiated ones), a fact to be remembered in the differential diagnosis with mesothelioma.[521]

A high percentage of colorectal carcinomas show immunoreactivity for human chorionic gonadotropin (hCG)[522]; this seems particularly common in mucinous and poorly differentiated tumors.[523] Estrogen and progesterone receptors are usually absent or are present in a small minority of tumor cells.[524] Racemase, a marker for prostatic adenocarcinoma, is expressed in over half of colorectal adenocarcinomas, a potential source of misdiagnosis.[525]

Molecular Genetic Features

The identification of several types of familial colorectal carcinoma has led to the discovery of some of the genetic alterations associated with (and presumably pathogenetically responsible for) these tumors.[526] It was subsequently shown that somatic mutations of these genes also occur in sporadic colorectal cancer, such as *APC* and MMR genes.[527,528] The model still standing for colonic carcinogenesis is that proposed by Fearon and Vogelstein in the late 1980s,[529] but it has become increasingly obvious that many variations exist and that not all colorectal cancers follow the same genetic pathway during carcinogenesis. Specifically, DNA MMR deficiencies with resulting MSI has been found to be an important alternate pathway, present in approximately 15% of cases; it operates in HNPCC[530,531] and in sporadic carcinomas that are usually right sided and arising from serrated polyps (serrated pathway).[532,533]

Tumors associated with MSI tend to be mucinous or poorly differentiated, with a prominent host response, a circumscribed growth pattern, and right-sided location. The presence of tumor-infiltrating lymphocytes has been found to be one of the best histologic predictors of MSI.[479,534] It has been further pointed out that differences may exist depending on the specific type of MMR gene involved.[535]

Oncogenes that commonly show somatic mutations in colorectal carcinomas include *KRAS*, *BRAF*, *PIK3*, and *CTNNB1* (β-catenin gene).[536] For example, mutations of the *KRAS* oncogene have been found in about 40% of colorectal carcinomas, particularly metastatic lesions.[537,538] Its presence has been correlated with a lack of response to anti-epidermal growth factor receptor (EGFR) therapy.[539,540]

β-Catenin, which is associated with APC protein, is dysregulated either as a result of *APC* mutation (>70%) or *CTNNB1* (β-catenin gene) mutation (2%–5%), resulting in aberrant nuclear localization of the molecule as demonstrated by immunohistochemistry in a high proportion of cases.[541]

Tumor suppressor genes that are commonly involved in colorectal carcinomas include *TP53*, *APC*, *DPC4/SMAD4*, *DCC*, *CDKN1B*, and *MCC*.[528] Mutations of *TP53* have been detected by molecular techniques in the majority of colorectal carcinomas[542] and have been correlated with the immunohistochemical overexpression of the protein coded by the abnormal gene, albeit imperfectly. Decreased expression of CDKN1B (p27) has been associated with poor outcome.[543,544]

Other Microscopic Types

Mucinous carcinoma is a special type of colorectal carcinoma in which large lakes of extracellular mucin are formed, mixed with collections of tumor cells (Fig. 17.70).[545] According to the WHO, by definition, these mucinous foci should constitute at least half of the tumor mass. They represent up to 10% of all colorectal cancers.[546] At the molecular level, they show a high rate of MSI.[547] These tumors secrete distinct *O*-acylated forms of mucin containing the MUC2 protein core.[548,549] They usually have an exophytic shape and should not be equated to the pure signet ring carcinomas described later. Mucinous carcinomas are also more frequently associated with adenomas elsewhere in the colorectum than are conventional adenocarcinomas[550] and tend to present at a more advanced stage.[551]

The relationship between mucinous subtype and survival is not clear cut, with some studies showing a worse prognosis when compared to conventional colorectal carcinoma and others showing no significant difference.[552–554] This subtype does have a propensity

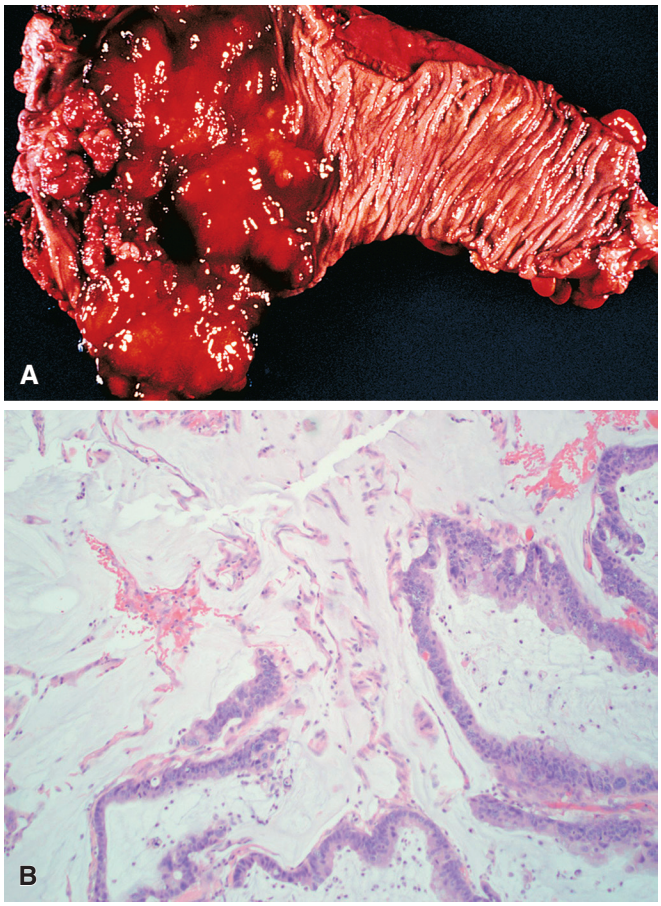

Figure 17.70 Mucinous Adenocarcinoma. A, Gross appearance of a mucinous adenocarcinoma of the rectum. **B,** Microscopic appearance of mucinous adenocarcinoma.

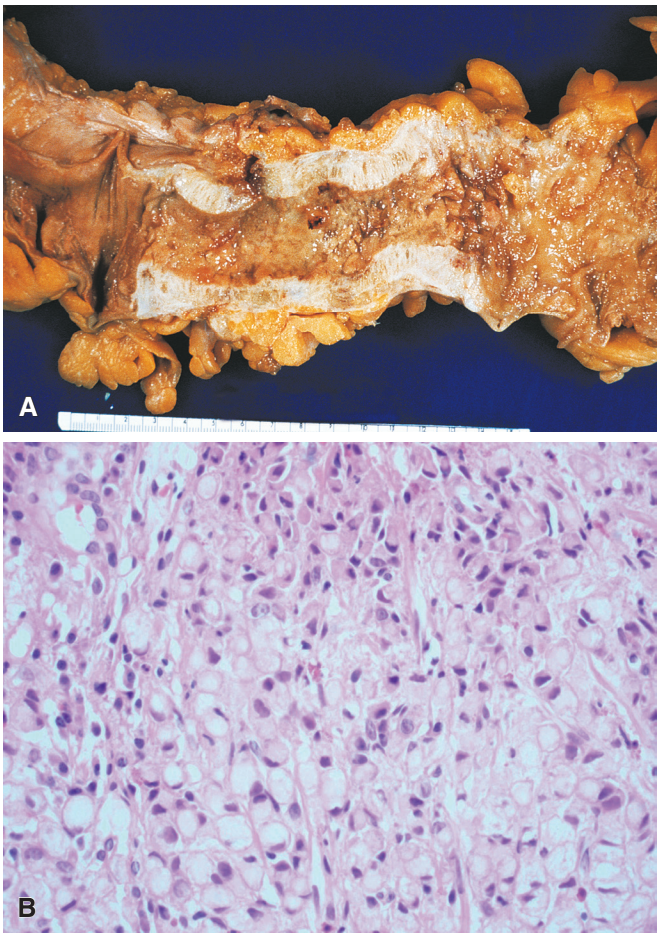

Figure 17.71 Signet Ring Adenocarcinoma. A, Gross appearance of signet ring carcinoma. This tumor type is highly malignant and characteristically results in luminal narrowing. **B,** Microscopic appearance of signet ring carcinoma.

to invade adjacent viscera[555] as well as to develop peritoneal implants.[556] They are also more likely to develop lymph node metastases beyond the pericolonic region.[555] Greenson et al. found that mucinous tumors that are MSI low or stable are more likely to behave in an aggressive manner.[479]

Signet ring carcinoma is a rare form of colorectal carcinoma (up to 1% of all colorectal cancers) that usually affects young patients. Similar to mucinous carcinomas, about one-third of the cases are MSI high.[557] Like its more common gastric counterpart, signet ring carcinoma usually presents grossly as a diffuse infiltration of the wall, although it has also been described arising in an adenomatous polyp (Fig. 17.71).[558] By definition, more than 50% of the tumor should be composed of signet ring cells, regardless of the amount of extracellular mucin. Microscopically, the tumor grows in a diffuse fashion, with little if any glandular formation. Most or all of the mucin is intracellular, in contrast to that seen in mucinous carcinoma. This intracellular accumulation of mucin results in displacement of the nucleus and a typical signet ring configuration of the cells. Metastases tend to develop in lymph nodes, the peritoneal surface, and the ovary rather than the liver. The pattern of spread is mainly in the form of peritoneal dissemination, and the prognosis is extremely poor.[559] The possibility of the colorectal lesion representing a metastasis from a gastric or mammary primary lesion should always be investigated before a diagnosis of primary signet ring carcinoma is made.[560] Immunohistochemically, a CK7−/CK20+ profile favors a colorectal primary, whereas CK7+/CK20− favors a metastasis.[561] Colorectal signet ring carcinoma also expresses MUC2, MUC5AC, and CDX2, its overall profile being different from the homologous tumor in the breast but quite similar to that in the stomach.[562]

As mentioned earlier in this chapter, care should be exercised in distinguishing signet ring carcinoma from the benign signet ring change that may accompany pseudomembranous colitis and other inflammatory conditions.[563]

In some cases of mucin-producing colorectal adenocarcinomas, there is an admixture of extracellular and intracellular mucin formation, resulting in a mixed mucinous–signet ring carcinoma.[553] The greater the signet ring component, the worse the outcome. It is therefore useful to specify the presence and percentage of signet ring cells in mucinous tumors.[564]

A **micropapillary pattern** may be identified in about 20% of colorectal adenocarcinomas, a phenomenon analogous to the more familiar one seen in some carcinomas of breast, bladder, lung, and other organs.[565,566] This finding is associated with a greater frequency of angiolymphatic and perineural invasion and lymph node metastases and therefore of decreased survival (Fig. 17.72).[566,567]

Serrated adenocarcinoma has been recently proposed as a morphologically distinct type of colorectal adenocarcinoma, backed by some molecular findings. As one might expect, it is linked to the serrated pathway and precursor serrated lesions (SSP).[568] It is described

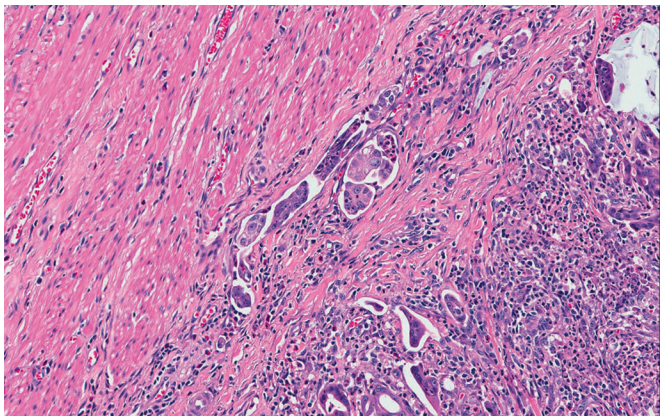

Figure 17.72 Poorly differentiated adenocarcinoma with micropapillary features and prominent angiolymphatic invasion.

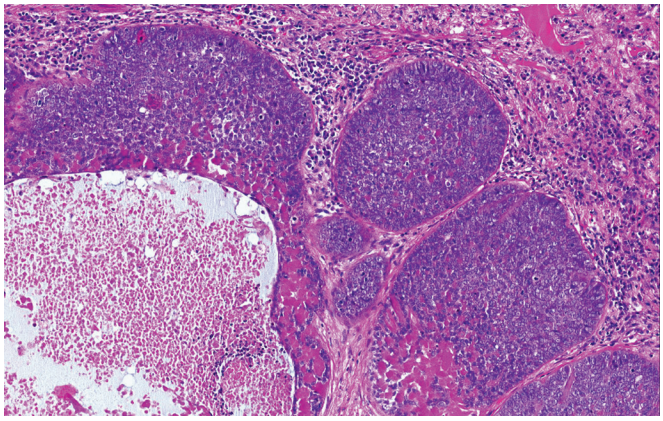

Figure 17.73 Characteristic appearance of basaloid squamous cell carcinoma arising in the anus.

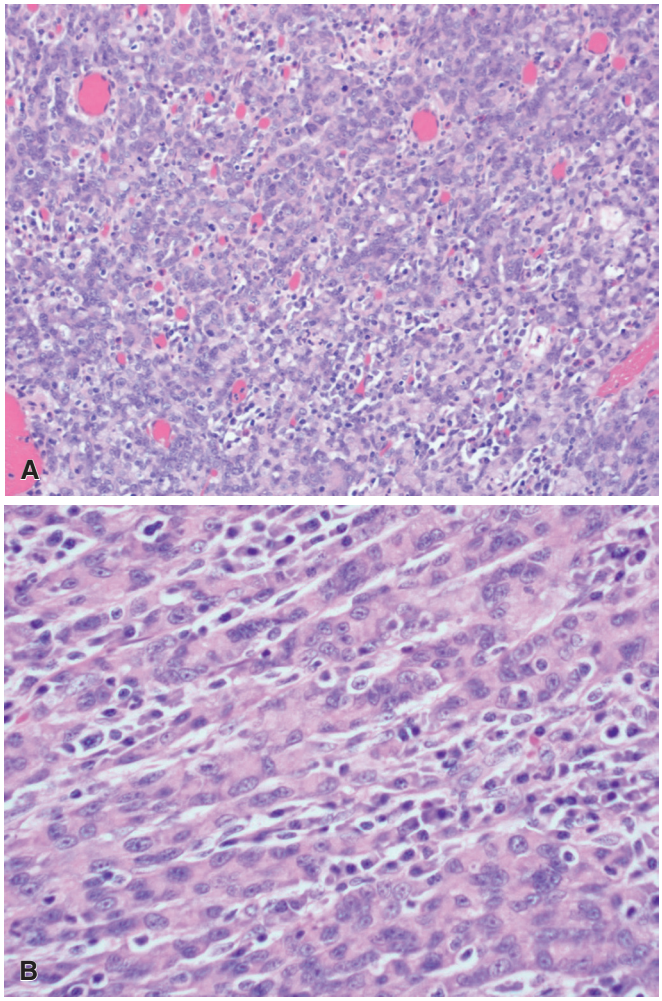

Figure 17.74 Characteristic appearance of so-called medullary carcinoma.

as showing a serrated, mucinous or trabecular pattern of growth, abundant eosinophilic cytoplasm, chromatin condensation, preserved polarity, and no necrosis.[569] It accounts for approximately 7.5% of all colorectal cancers and up to 10%–15% of proximally located tumors.[570,571]

There appear to be two distinct subtypes of serrated carcinomas. The more common are those arising in the proximal colon from SSPs and are MSI high. The less common type arise in the distal colon from TSAs and are MSI low or stable.[570] It should be noted that although it is believed that most proximal MSI-high cancers arise from SSPs, only a minority of these tumors actually show serrated features in the malignant component.[569,571]

Basaloid (cloacogenic) carcinoma, similar to its counterpart in the anal canal, has been reported on a few occasions in the colorectum, as proximally as the splenic flexure (Fig. 17.73).[572]

Clear cell carcinoma is not a specific entity but rather a minor morphologic variant of adenocarcinoma in which the accumulation of glycogen results in a clear appearance of the cytoplasm.[573]

Hepatoid adenocarcinoma can arise in the colon, the appearance being similar to that of its more common gastric counterpart.[574]

Medullary adenocarcinoma usually presents in the cecum or right colon of females.[575] Some cytoarchitectural features suggest neuroendocrine differentiation, but neuroendocrine markers are negative.[576] The tumor is composed of polygonal cells arranged in sheets, trabeculae, or an organoid pattern. The cells have vesicular nuclei, prominent nucleoli, abundant cytoplasm, and numerous tumor-infiltrating lymphocytes (Fig. 17.74).[577] The differential diagnosis includes poorly differentiated adenocarcinoma; in contrast to the latter, medullary carcinoma shows consistent loss of staining for MLH1 and CDX2.[578] Instead, it is usually immunoreactive for MUC1, MUC2, and TF3.[578] It also stains much more frequently for calretinin than poorly differentiated adenocarcinomas.[578] The behavior is not nearly as aggressive as the morphologic appearance might suggest.[577] Genetically, most of these tumors are characterized by MSI.[579,580]

Sarcomatoid (spindle cell) carcinoma is similar in appearance to that of its counterpart in many other organs, and its behavior is, as one would expect, very aggressive.[581,582] These are more common in elderly patients.

Squamous differentiation may be present in colorectal carcinoma. It is more common in cecal neoplasms but may be seen in tumors from any other area of the large bowel.[583] In most instances, the squamous component is associated with glandular elements *(adenosquamous carcinoma)*, but occasionally it is seen in a pure form *(squamous cell carcinoma)*.[584] An association has been noted between squamous changes in colorectal carcinoma and ulcerative colitis.[585] Some are associated with the production of parathyroid hormone-related protein and paraneoplastic hypercalcemia.[586] Several studies have failed to find a pathogenetic role for HPV.[584,587] The possibility of upward extension or submucosal metastasis from a carcinoma of the anal canal should be considered for squamous tumors located

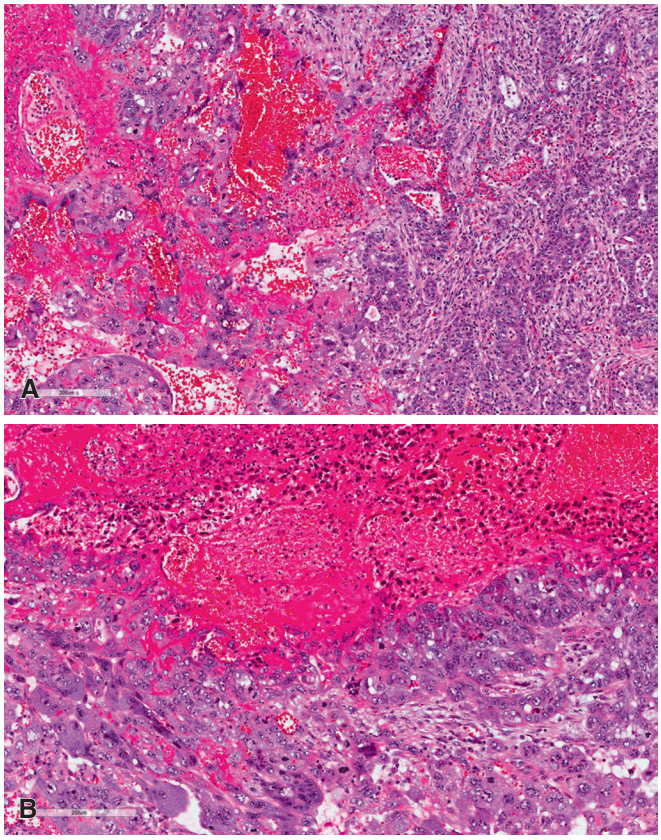

Figure 17.75 Mixed Adenocarcinoma-Choriocarcinoma. A, Low-power view showing an admixture of adenocarcinoma and choriocarcinomatous elements. **B,** High-power view of a focus of choriocarcinoma in a mixed tumor.

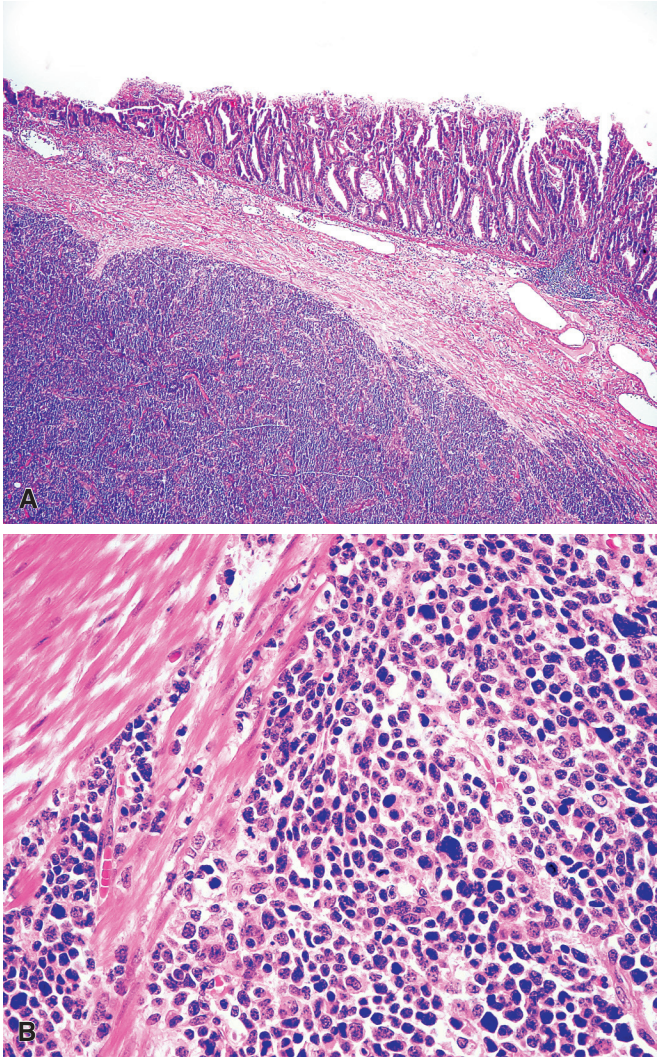

Figure 17.76 Colonic Small Cell Neuroendocrine Carcinoma. A, The small cell carcinoma is seen in association with a tubular adenoma. **B,** High-power view of small cell carcinoma.

in the low rectum. Metastases from another site (especially the lung) should also be excluded, as should the presence of a squamous-lined fistula tract.

Trophoblastic differentiation can occur focally in colorectal adenocarcinoma, as it does in tumors of stomach and gallbladder (Fig. 17.75). hCG can be demonstrated immunohistochemically in the tumor cells.[523] Occasionally the entire tumor has the appearance of a choriocarcinoma.[588] This phenomenon should be distinguished from the more common finding of hCG positivity in morphologically conventional adenocarcinomas.

Glassy cell carcinoma, similar to its homolog in the uterine cervix, has been rarely described in the large bowel.[589]

Neuroendocrine differentiation may manifest itself in a variety of ways, as it does elsewhere in the gastrointestinal tract:

1. As *scattered neuroendocrine cells* in otherwise typical adenocarcinomas (particularly of the mucinous type), a feature that does not seem to independently influence the prognosis or natural history of these tumors.[590,591] This occurs in 15%–50% of all adenocarcinomas, as detected immunohistochemically or by hybridization procedures for neuroendocrine markers such as chromogranin.[592] This phenomenon seems to be more frequent after chemotherapy and radiotherapy, a fact which suggests that it might be induced by these treatment modalities.[593]
2. In the form of tumors with a *mixed composition*, in which typical adenocarcinoma intermingles with a component exhibiting clear-cut neuroendocrine differentiation. By definition, each component should comprise at last 30% of the tumor.[594] The existence of these tumors is explained by assuming an origin from endodermally derived multipotential cells located at the base of the crypts, which during the course of neoplastic transformation undergo differentiation along several different pathways.[595]
3. In the form of tumors showing throughout the appearance of a *neuroendocrine carcinoma* but having a more organoid appearance and being composed of larger cells than the small cell carcinomas *(large cell neuroendocrine carcinoma)*.[596]
4. In the form of *small cell neuroendocrine carcinoma*, a tumor having a microscopic appearance similar to that of its pulmonary homonym (Fig. 17.76).[596,597] Most of the cases are located in the right colon.[598] Electron microscopy usually reveals a few dense-core secretory granules in the cytoplasm, and immunohistochemical techniques show positivity for neuron-specific enolase and other neuroendocrine markers such as synaptophysin, although stains for chromogranin may be negative due to the low density of neurosecretory granules.[599] The entire tumor may have this appearance, or there may be foci of glandular differentiation, with or without mucin production.[596] Squamous differentiation may also be present.[598] Some of these small cell carcinomas arise

in the setting of a precursor adenoma.[596] The prognosis is poor, with early metastases to lymph nodes and liver.[596,598]

5. In the form of typical *carcinoid tumors (well-differentiated neuroendocrine tumor [WDNET])*, discussed later in this chapter.

Rhabdoid features can be seen in adenocarcinoma of the cecum and other portions of the large bowel[600,601]; as in other sites, this pattern is predictive of aggressive clinical behavior.

Oncocytic adenocarcinoma of the rectum has been reported occasionally, sometimes after preoperative chemoradiation or developing from a villous adenoma with oncocytic changes.[343] They should be distinguished from tumor cells with squamous metaplasia and from plain oxyphilic tumor cells.

Biopsy

A positive biopsy should always be obtained before radical surgery for colorectal carcinoma is undertaken. In large lesions, it is advisable to perform several biopsies from diverse areas; those from the center may show only granulation tissue, and those from the very periphery may contain only hyperplastic (so-called transitional) colonic epithelium. A sometimes more difficult (but just as critical) determination once a carcinoma has been recognized is to ascertain its location and extent. Obviously, the significance of the finding is markedly different if the fragment of tissue with adenocarcinoma was taken from the tip of a pedunculated polyp or from the side of a large ulcerated mass. Close communication with the endoscopist and surgeon, intact biopsy of an adequate size and depth, and proper orientation of the specimen are essential requisites for this determination.

Staging, Grading, and Prognostic Factors

In 1937, Dukes proposed his famous staging system for rectal carcinomas that also can be applied to carcinomas of the colon.[602] It is still widely used in one form or another because of its direct relationship with prognosis, as it is clear that the anatomic extent of tumor (pathologic stage) is the single most important predictor of clinical behavior for colorectal carcinoma.

A number of staging systems have been proposed since that time but, at least in North America, the TNM staging system is the most widely used (Tables 17.2 and 17.3). Depth of invasion (T) is critically important in this evaluation. *Tis* encompasses high-grade dysplasia and intramucosal adenocarcinoma (invasion into the lamina propria or muscularis mucosae but not beyond). T1 and T2 refer to invasion into the submucosa and muscularis propria, respectively. Those that invade into the subserosal adipose tissue or the nonperitonealized pericolic or perirectal soft tissue are T3. Some have found subclassification of T3 tumors based upon distance of tumor invasion beyond the muscularis propria to be of prognostic significance (pT3a less than 1 mm; pT3b 1–5 mm, pT3c 5–15 mm, pT3d greater than 15 mm).[603] Finally, invasion of the visceral peritoneum and invasion of adjacent structures constitute T4a and T4b, respectively. Several studies have found penetration of the visceral peritoneum (serosal involvement) to be an important adverse prognostic indicator.[604,605] However, it can be challenging to determine the status of peritoneal involvement in some cases.[606]

Regional lymph node involvement (N) is also a critical prognostic parameter. At least 10 (and ideally 12) lymph nodes should be examined in specimens which have not been subjected to neoadjuvant therapy.[607] Some have found the ratio of involved lymph nodes to the total number of lymph nodes to be an important prognostic factor.[608,609] A difficult problem can be distinguishing a pericolonic tumor deposit (PTD) from an involved lymph node, as the former is associated with an even poorer prognosis.[610,611] PTDs can be recognized by their irregular outline of tumor in the fat (away from the leading edge of the tumor), with no evidence of residual lymph node tissue. Involvement of common iliac and external iliac lymph nodes is considered evidence of distant metastasis (M1).[612]

Isolated tumor cells are defined as single or small clusters of tumor cells in a lymph node measuring ≤0.2 mm. *Micrometastases* are defined as tumor deposits in a lymph nodes greater than 0.2 mm but ≤2 mm. The former are considered N0, and the latter are considered N1(mic) or M1(mic) for regional and nonregional lymph nodes, respectively. The prognostic significance of these two categories is not entirely clear,[613,614] although there are emerging data to suggest the negative prognostic impact of micrometastases.[615–617]

There are a number of other important prognostic variables that will be highlighted here. As mentioned elsewhere in this chapter, *tumor subtype* is prognostically important, as mucinous, signet ring, and undifferentiated carcinomas are more clinically aggressive tumors. *Tumor grading* is important in that high-grade tumors (which have less than 50% gland formation) are more aggressive than low-grade tumors (which have ≥50% gland formation). The latter category encompasses both well- and moderately differentiated tumors.[618]

Vascular invasion, in particular, *extramural venous invasion*, has been found to be an important independent adverse indicator.[619,620] Given the notorious difficulty of recognizing this feature, some have advocated the use of elastin stains to increase sensitivity and specificity.[621] This finding has been estimated to be present in approximately 25% of all colectomy specimens for colorectal carcinoma. The relationship between lymphatic invasion and outcome is far less clear.[622]

The nature of the invasive margin of the tumor also has significance. Tumors with an "expanding" border with smooth rounded contours have a less aggressive clinical course than those with an infiltrative margin.[623] Interestingly, tumors with an expanding border have also been associated with MSI-high phenotype.[624,625] Tumor budding, defined as five tumor cells or less that detach from the tumor at the advancing edge and infiltrate into the desmoplastic stroma, is also a recently identified negative prognostic factor.[626,627] It also seems to correlate with risk of nodal metastasis in malignant colorectal polyps.[628]

Adequacy of surgical excision is also an important prognostic factor. Not only should one document the proximal and distal resection margins, but the radial (circumferential) margin in colorectal cancers is of clinical importance. In a seminal study done in 1986, Quirke et al. found positive radial margins in 27% of rectal resection specimens, and tumor recurrence occurred in almost all of those patients.[629] Subsequent studies confirmed the importance of this margin on recurrence and overall survival.[630] As such, these patients are treated by total mesorectal excision, which removes the mesorectal envelope[631] and potentially also resects unrecognized PTDs in the perirectal adipose tissue.[632]

Other prognostic factors include patient age (poorer prognosis in very young and very old patients)[633]; gender (better prognosis in females)[633]; serum CEA levels greater than 5.0 ng/mL (adverse indicator)[634]; bowel wall perforation (adverse indicator)[635]; prominent lymphoplasmacytic infiltrate at the advancing edge of the tumor, including a Crohn-like lymphoid reaction (favorable indicator)[636,637]; perineural invasion (adverse indicator)[638] and prominent tumor angiogenesis (adverse indicator)[639] Innumerable immunohistochemical, flow cytometric and molecular markers, far too numerous to be reaccounted here (e.g. fascin, HLA-DR, p16, HCG, BCL2, DNA ploidy, cell proliferation index, Claudin1), have been purported to be prognostic indicators, but none of these has reached the point of becoming part of routine clinical practice, aside from some of the previously mentioned molecular markers (e.g. MMR genes and

Table 17.2 Definitions of AJCC TNM

Primary Tumor (T)	
T CATEGORY	**T CRITERIA**
Tx	Primary tumor cannot be assessed
T0	No evidence of primary tumor
Tis	Carcinoma in situ, intramucosal carcinoma (involvement of lamina propria with no extension through muscularis mucosae)
T1	Tumor invades the submucosa (through the muscularis mucosa but not into the muscularis propria)
T2	Tumor invades the muscularis propria
T3	Tumor invades through the muscularis propria into pericolorectal tissues
T4	Tumor invades the visceral peritoneum or invades or adheres to adjacent organ or structure
T4a	Tumor invades through the visceral peritoneum (including gross perforation of the bowel through tumor and continuous invasion of tumor through areas of inflammation to the surface of the visceral peritoneum)
T4b	Tumor directly invades or adheres to adjacent organs or structures
Regional Lymph Nodes (N)	
N CATEGORY	**N CRITERIA**
Nx	Regional lymph nodes cannot be assessed
N0	No regional lymph node metastasis
N1	One to three regional lymph nodes are positive (tumor in lymph nodes measuring ≥0.2mm) or a number of tumor deposits are present and all identifiable lymph nodes are negative
N1a	One regional lymph node is positive
N1b	Two or three regional lymph nodes are positive
N1c	No regional lymph nodes are positive, but there are tumor deposits in the subserosa mesentery or nonperitonealized pericolic or perirectal/mesorectal tissues
N2	Four or more regional nodes are positive
N2a	Four to six regional nodes are positive
N2b	Seven or more regional nodes are positive
Distant Metastasis (M)	
M CATEGORY	**M CRITERIA**
M0	No distant metastasis by imaging; no evidence of tumor in distant sites or organs (This category is not assigned by pathologists.)
M1	Metastasis to one or more distant sites or organs or peritoneal metastasis is identified
M1a	Metastasis to one site or organ is identified without peritoneal metastasis
M1b	Metastasis to two or more sites or organs is identified without peritoneal metastasis
M1c	Metastasis to the peritoneal surface is identified alone or with other site or organ metastasis

From Amin M, Edge S, Greene F, et al. (eds). AJCC Cancer Staging Manual. 8th ed. New York: Springer; 2017.

proteins, *KRAS*). Most studies have found that MMR deficiency is associated with an improved outcome independent of other clinical and pathologic variables.[640–643] This has particular clinical significance for stage 2 and 3 disease, as these patients do not seem to benefit from 5-FU chemotherapy.[644] In fact, studies have also found that 5-FU may have deleterious effects in patients with MMR-deficient tumors.[645] Many studies have also found 18qLOH or *DCC* loss to be adverse prognostic indicators.[646,647]

Spread and Metastases

The most common sites of metastatic involvement of colorectal carcinoma are regional lymph nodes and liver. If there is tumor present in the lymph nodes, it is necessary to examine the tissue in the immediate vicinity of nodes, for tumor frequently extends beyond the lymph node capsule to invade surrounding veins.

Because of the great prognostic significance of lymph node metastases, it is important that the search for lymph nodes is thorough, whether done in the fresh or fixed specimen, with or without clearing of the fat in which the nodes are embedded. Sometimes the metastases will be present only in lymph nodes measuring 1 or 2 mm.[607]

Liver metastases are more common in tumors showing evidence of blood vessel invasion.[648] Other relatively common metastatic sites include peritoneum, lung, and ovaries. The incidence of ovarian metastases is high enough to justify the performance of a prophylactic

Table 17.3 AJCC prognostic stage groups

WHEN cT IS...	AND cN IS...	AND M IS...	THEN THE STAGE GROUP IS...
Tis	N0	M0	0
T1, T2	N0	M0	I
T3	N0	M0	IIA
T4a	N0	M0	IIB
T4b	N0	M0	IIC
T1-T2	N1/N1c	M0	IIIA
T1	N2a	M0	IIIA
T3-T4a	N1/N1c	M0	IIIB
T2-T3	N2a	M0	IIIB
T1-T2	N2b	M0	IIIB
T4a	N2a	M0	IIIC
T3-T4a	N2b	M0	IIIC
T4b	N1-N2	M0	IIIC
Any T	Any N	M1a	IVA
Any T	Any N	M1b	IVB
Any T	Any N	M1c	IVC

From Amin M, Edge S, Greene F, et al. (eds). AJCC Cancer Staging Manual. 8th ed. New York: Springer; 2017.

bilateral oophorectomy in a postmenopausal woman at the time of resection of the colorectal tumor. Rare metastatic sites include central nervous system, bone, testis, uterus, and oral cavity. Some of the metastases from colorectal adenocarcinoma can closely simulate primary tumors of the respective organs. This is particularly true for the ovary, in which the metastasis can be the form of initial presentation and be misdiagnosed as a primary endometrioid (including its secretory variant) or clear cell carcinoma.[649,650] Immunohistochemical and molecular studies can be helpful in this differential, as previously discussed. Secondary invasion of the bladder can simulate a primary tumor of this organ,[651] involvement of the prostate may be misinterpreted as a primary prostatic adenocarcinoma,[652] and intrabiliary growth in the liver may mimic a primary neoplasm of the biliary tract.[653]

Treatment

The standard therapy for colorectal carcinoma is surgical resection, the type of surgery obviously depending on the site of the tumor. For carcinoma of the cecum or ascending colon, ileocolectomy is the treatment of choice. Tumors located below the peritoneal reflection have been traditionally treated by an abdominoperineal resection.[654] Sphincter-preserving procedures are very effective if the cases are carefully selected.[655] Carcinomas located in other areas of the large bowel are treated by anterior resection, the extent of the operation being such as to remove the potentially involved lymph nodes. Local recurrence sometimes develops at the anastomotic line from tumor cells apparently implanted on the raw surface at the time of operation. Regular endoscopic examinations in the first year after surgery are important for the detection of potentially curable recurrences.[656]

Neoadjuvant therapy has become the treatment of choice for T3, T4, or node-positive rectal cancers.[657] Complete pathologic response (no residual tumor) is seen in up to 30% of patients.[658] Pathologic downstaging after therapy is associated with improved survival,[659] so a thorough pathologic evaluation of the tumor, tumor margins, and lymph nodes is essential. Only residual viable tumor cells should be considered as residual neoplasm (as opposed to necrotic tumor), and one often sees prominent ulceration, fibrosis, hemosiderin deposition, foamy macrophages, and mucin pools in these specimens.[660] Acellular mucin pools should not be considered as evidence of residual tumor and do not seem to be associated with a worse outcome.[661]

A significant number of patients with colorectal carcinoma develop liver metastases, a poor prognostic indicator.[662] In selected patients, resection of liver metastases has been found to prolong survival, especially for those in which a greater than 1 cm tumor-free margin can be obtained.[663]

Well-Differentiated Neuroendocrine Tumor (Carcinoid Tumor)

For many years, the term carcinoid tumor was used to describe well-differentiated neuroendocrine neoplasms arising in the tubal gut. In 2010, the WHO endorsed the term WDNET to distinguish these lesions from the more aggressive poorly differentiated neuroendocrine carcinomas, which encompasses small cell and large cell neuroendocrine carcinomas.[664,665] Although the term well-differentiated neuroendocrine carcinoma was used for "carcinoid tumors" that had metastasized, WDNET is a WHO-endorsed name which is independent of tumor stage. Using Ki-67 proliferation index and mitotic index, WDNETs are graded as grade 1 (Ki-67 index <3% and mitotic index <2/10 HPF) or grade 2 (Ki-67 index 3%–20% or 2–20 mitotic figures/10 HPF). Very rarely, WDNETs are grade 3 based upon Ki-67 or mitotic index, but there are insufficient data to understand the clinical behavior of these rare tumors.

The tumors are quite uncommon in the colon and are most common in the cecum.[666] They tend to be larger than 2 cm and behave in a clinically aggressive fashion. Rare examples secrete serotonin, in some cases resulting in the classic carcinoid syndrome.[667]

Rectal WDNETs are far more common (Fig. 17.77). They are often found as incidental polyps at endoscopy done for other reasons[668] and most are less than 0.5 cm at the time of discovery.[669] It is very uncommon for tumors less than 1 cm to metastasize, but the risk of metastasis is substantial for rectal WDNETs greater than 2 cm.[668] Many can be treated by endoscopic polypectomy provided the margin can be assessed. However, those tumors that are ulcerated or show invasion of the muscularis propria often require surgical excision, especially if greater than 1 cm. Rarely, WDNETs may arise in the setting of IBD, and such lesions may be multicentric.[161]

Grossly, it may appear as a flat and slightly depressed plaque or as a polypoid lesion.[670] One of its most distinctive features is the yellow color that it acquires after formalin fixation. Microscopically, invasion of the stroma by small uniform cells growing in a ribbon or festoon fashion is seen. This may be associated with crypt cell proliferative micronests (presumably the precursor lesion).[671] A minor tubular and/or acinar component associated with mucin production may also be present.[672] Immunohistochemically, they stain for the panendocrine markers (neuron-specific enolase, chromogranin, synaptophysin) and for a variety of peptide hormones.[673] Somatostatin, glucagon, substance P, and peptide YY are the ones most commonly represented, but gastrin/cholecystokinin, calcitonin, and pancreatic polypeptide have also been demonstrated in some

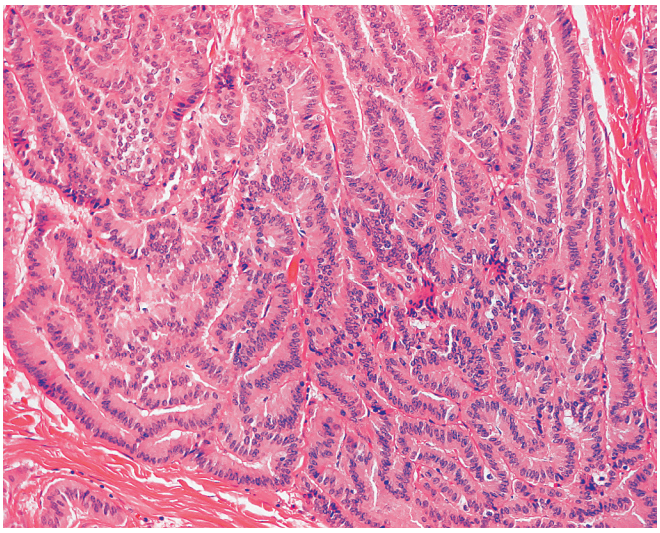

Figure 17.77 Rectal Carcinoid Tumor. The trabecular arrangement is typical of well-differentiated neuroendocrine tumors in this location.

cases.[674,675] Many of the tumors are polyhormonal.[674] Negativity for CDX2 and TTF-1 is the rule.[676] Rectal WDNETs have also often been found to exhibit immunoreactivity for CEA,[673] hCG,[677] and prostate-specific acid phosphatase.[678] The latter, whether real or the result of a cross reaction, is of practical importance because metastatic prostatic carcinoma may enter in the differential diagnosis with WDNET; the distinction is made (among other reasons) because the latter is consistently negative for prostate specific antigen.[678]

Malignant Lymphoma and Related Lesions

Malignant lymphomas are less frequently found in the large bowel than in the small bowel or stomach.[679] Some of the cases of large bowel lymphoma have been seen in immunosuppressed patients (HIV infected or transplant recipients) or in patients with ulcerative colitis.[680,681] These tumors can occur anywhere in the colorectum. They may produce prominent mucosal folds, ulceration, a large mass or a solitary polyp, or multiple small polyps distributed throughout the colorectum that may also extend to the small bowel *("lymphomatous polyposis")*.[682,683] The regional lymph nodes are involved in approximately half of the cases.

Colorectal malignant lymphomas are nearly always of non-Hodgkin type.[679] Most of the low-grade tumors are thought to belong to the mucosa-associated lymphoid tissue (MALT)-type category. They often show evidence of plasmacytic differentiation.

Other types of colorectal lymphoma include mantle cell lymphoma (Fig. 17.78),[684] anaplastic large cell lymphoma,[685] angioimmunoblastic T-cell lymphoma,[686] and Hodgkin lymphoma.[687]

As already stated, some cases of colorectal lymphoma present in the form of innumerable small polyps *("lymphomatous polyposis")*; it was initially thought that this presentation was more common with mantle cell lymphoma,[688] but it has also been documented with follicle center cell lymphoma,[689] MALT-type lymphoma,[690] and large cell lymphoma.[691]

Lymphoid polyps of benign (reactive) nature are sometimes found in the rectal area, sometimes designated as *lymphoid hyperplasia*, *pseudolymphoma*, and "*rectal tonsil.*"[692] They appear as soft, superficial polyps usually covered by an intact, gray, smooth mucosa. The patient may complain of a mass, bleeding, or prolapse. Microscopically, these lesions are located in the lamina propria or submucosa and are made up of lymphoid tissue with follicle formation, a lobular pattern, and germinal centers. They may distort the muscularis mucosae and even extend to the muscularis propria. Nondestructive lymphoepithelial lesions may be present.[692] In a superficial or small biopsy, they can be incorrectly diagnosed as malignant lymphoma. Local excision is curative.

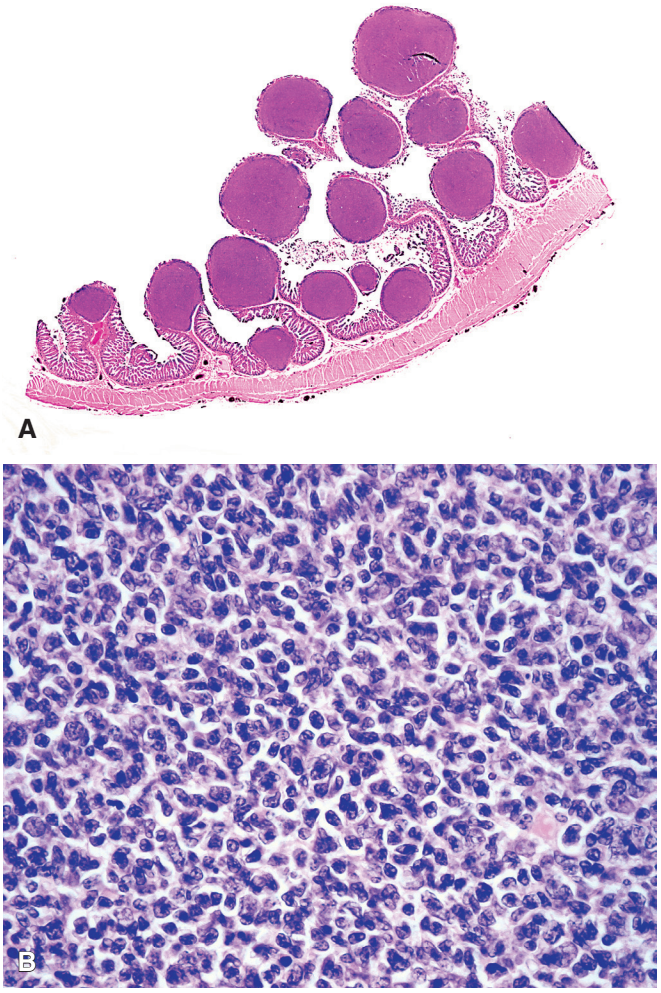

Figure 17.78 Mantle Cell Lymphoma of the Large Bowel. A, Whole-mount view showing characteristic "lymphomatous polyposis" appearance. **B,** High-power view of the neoplastic cells showing irregularity of their nuclear contours.

Langerhans cell histiocytosis can involve the gastrointestinal tract and be diagnosed in an endoscopic biopsy.[693] It can occur in adults or children, and there seems to be a female predominance.[694] Pediatric cases more often show evidence of systemic disease, which imparts a poor prognosis.

Other hematolymphoid disorders that occur in the colorectal region include *true histiocytic sarcoma*,[695] *follicular dendritic cell tumor*,[696] and *mast cell sarcoma*.[697]

Gastrointestinal Stromal and Smooth Muscle Tumors

The general features of gastrointestinal stromal tumors (GISTs) are discussed in the Stomach chapter and will not be repeated here. They are far less common in the colon when compared to the stomach and small bowel, although anorectal GISTs are a bit more common

than those arising in the colon.[698–700] However, compared to other portions of the GI tract, true smooth muscle tumors are relatively more common.

Colonic GISTs tend to occur in adults, and many are overtly histologically malignant (high risk) with marked cytologic atypia, necrosis, prominent mitotic activity, and mucosal invasion.[700] Most are predominantly spindled and stain for CD117, DOG1, and CD34. Anorectal GISTs are also predominantly spindled but appear more cytologically bland when compared to their colonic counterparts. Despite the low-grade appearance, they are deceptively aggressive and tend to recur, sometimes multiple times, emphasizing the need for an aggressive surgical approach.[698]

True smooth muscle tumors, both leiomyomas and leiomyosarcomas, can arise anywhere in the colon or anorectal region. The most common type is the leiomyoma which arises from the muscularis mucosae (leiomyomatous polyp), usually in the rectum or sigmoid colon.[701]

These superficial leiomyomas are small, sharply circumscribed, and lack mitotic activity and necrosis. They also generally lack atypia, although occasional examples containing bizarre hyperchromatic nuclei ("symplastic leiomyomas") do occur.[701] Smooth muscle tumors situated higher up in the colon have a higher incidence of malignancy.[700] Some present as polypoid lesions, and these tend to behave less aggressively than those arising as bulky intramural masses.[700]

Neural Tumors and Related Conditions

Neuromas, neurofibromas, and **(diffuse) ganglioneuromas** can occur in association with von Recklinghausen disease,[702,703] with multiple endocrine neoplasia (MEN) type 2b, or in the absence of either condition (Fig. 17.79). Most of these cases appear to arise from the neural plexuses in the bowel wall (transmural type), but others with a predominantly mucosal distribution *(mucosal type)* have been reported, sometimes in association with juvenile polyps, adenomatous polyps, and/or adenocarcinoma.[704,705]

Schwannomas can also occur in the colon and rectum and appear similar to the schwannomas arising elsewhere in the gastrointestinal tract with a characteristic peripheral lymphoid rim and strong S-100 protein staining (Fig. 17.80).[706] A few are of the *plexiform* or *epithelioid* varieties,[707] with even rarer cases with an EMA-positive perineural component *(hybrid perineurioma-schwannoma)*.[708] A further variant on the theme is the "*mucosal Schwann cell hamartoma,*" which presents as a solitary small sessile polypoid lesion, strongly positive for S-100 protein (Fig. 17.81). In contrast to the above lesions, it is not associated with von Recklinghausen disease.[709]

Benign fibroblastic polyp is the term originally proposed for a small polypoid lesion of the large bowel composed of cytologically bland spindle cells in the lamina propria which displace the normal glands and which were said to have a fibroblastic phenotype.[710,711] A subsequent study found that these lesions are composed of perineurial cells in view of their common immunoreactivity for EMA and claudin-1 and, as such, these lesions are now regarded as **mucosal perineuriomas** (Fig. 17.82).[711] A similar proliferation of perineurial cells is commonly identified in SSPs and is presumably a secondary, reactive proliferation inasmuch as they lack *BRAF* mutations which are typically found in the serrated proliferations.[712]

Other Tumors and Tumorlike Conditions

Tumorlike conditions of large bowel include the *inflammatory myoglandular polyp*, a pedunculated polypoid lesion (usually solitary) of the left (especially sigmoid) colon, characterized by submucosal granulation tissue, proliferation of smooth muscle, and hyperplastic glands with occasional cystic dilation.[713,714]

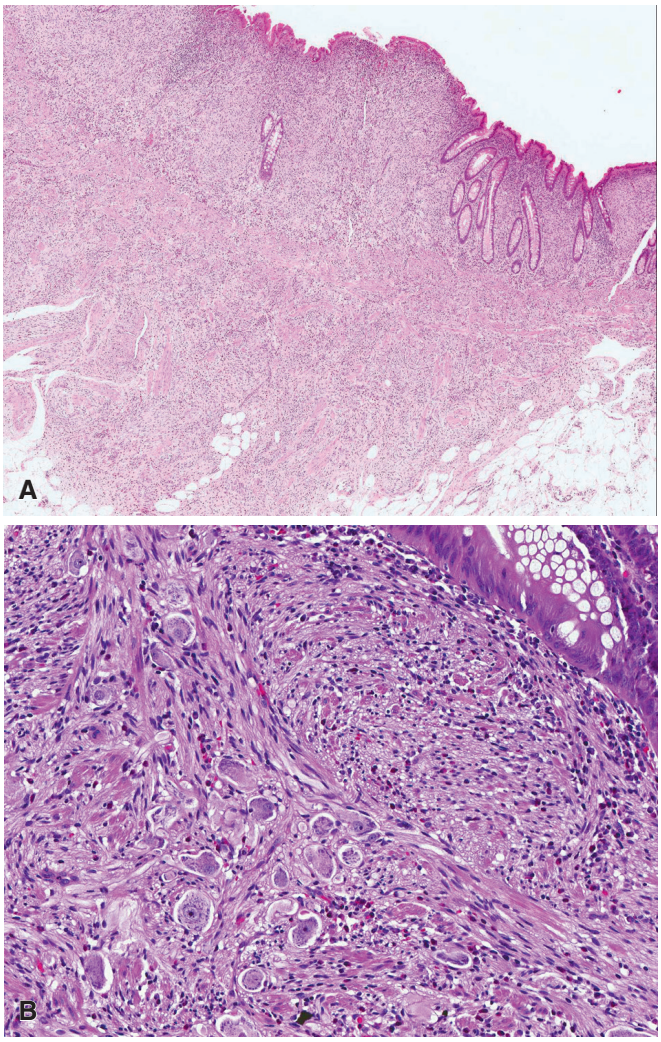

Figure 17.79 Colonic Neural Neoplasms. A, Diffuse-type ganglioneuroma involving the wall of the colon. **B,** High-power view of a polypoid ganglioneuroma.

Another tumorlike condition is represented by the *bizarre stromal cells* sometimes present in polyps and ulcers of the gastrointestinal tract. The bizarre cells are characterized by a pyramidal shape and a strongly basophilic cytoplasm. They probably represent reactive myofibroblastic cells and should not be confused with malignant cells.[715]

Three pseudomalignant vascular conditions are the *florid vascular proliferation* that can develop secondarily to intussusception and muscular prolapse (Fig. 17.83),[716] *pyogenic granuloma (lobular capillary hemangioma)*,[717] and the exceptionally rare *reactive angioendotheliomatosis*.[718] All of these benign processes can be mistaken for an angiosarcoma.

Two other tumorlike processes that can involve this region are *xanthogranuloma*[719] and *reactive nodular fibrous pseudotumor*, a serosal-based proliferation of keratin-positive submesothelial fibroblasts.[720,721]

Vascular ectasias of the right colon are increasingly recognized as an important cause of lower intestinal bleeding in the elderly. They have also been designated as angiomas, angiodysplasias, and arteriovenous malformations, these various names reflecting the

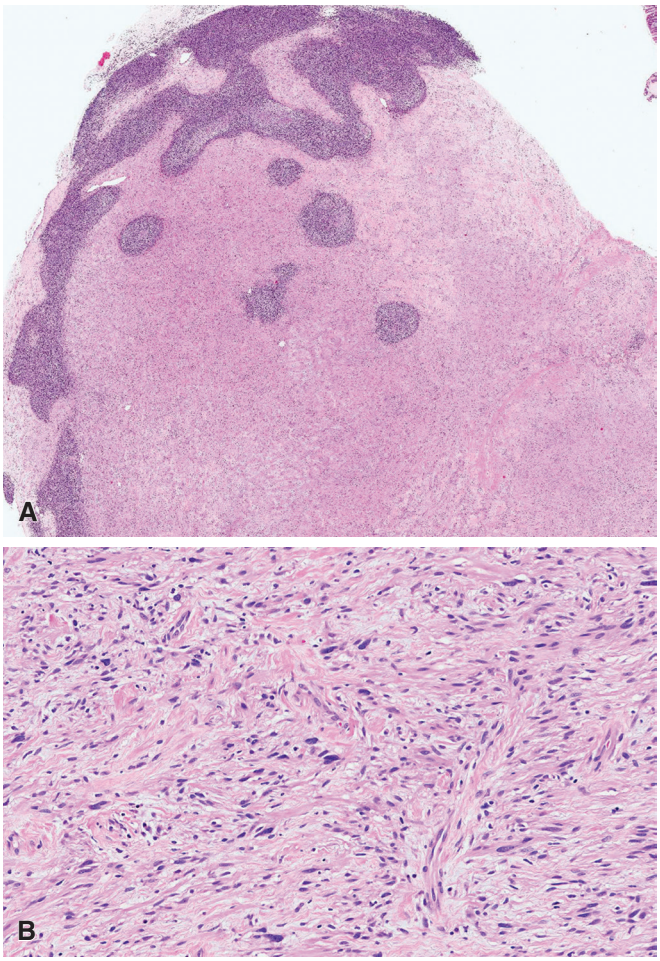

Figure 17.80 **Colonic Schwannoma. A,** Low-power view showing characteristic lymphoid rim surrounding the neoplastic cells. **B,** High-power view of cells with a schwannian appearance. Scattered degenerative atypical cells are characteristic.

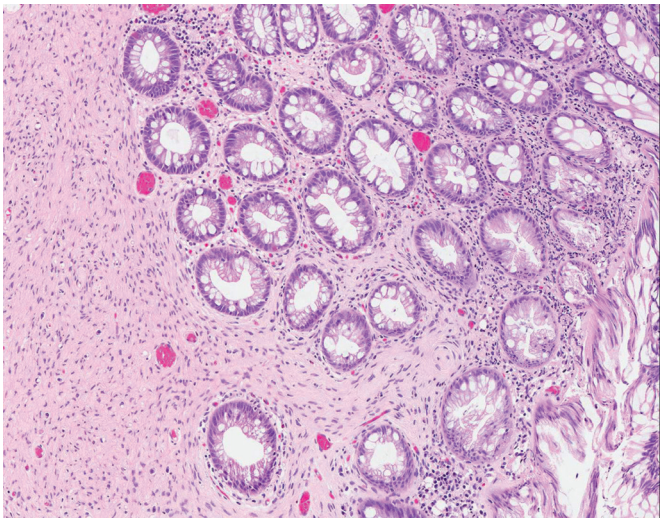

Figure 17.82 High-power view of a mucosal perineurioma with bland spindle-shaped cells surrounding crypts. This lesion has also been referred to as a benign fibroblastic polyp.

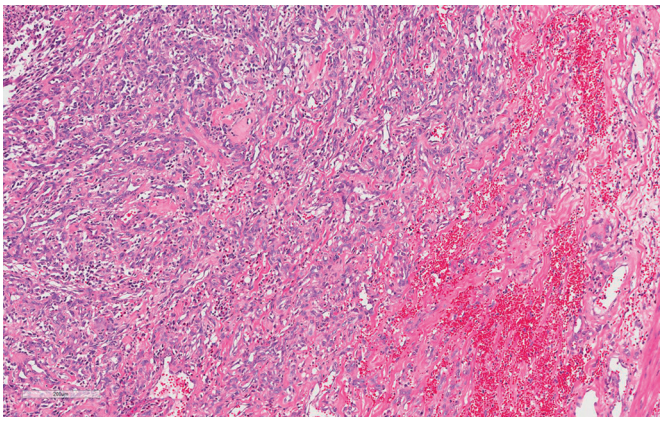

Figure 17.83 Florid reactive vascular proliferation in a colon involved by intussusception. This florid vascular proliferation can be mistaken for a more ominous lesion.

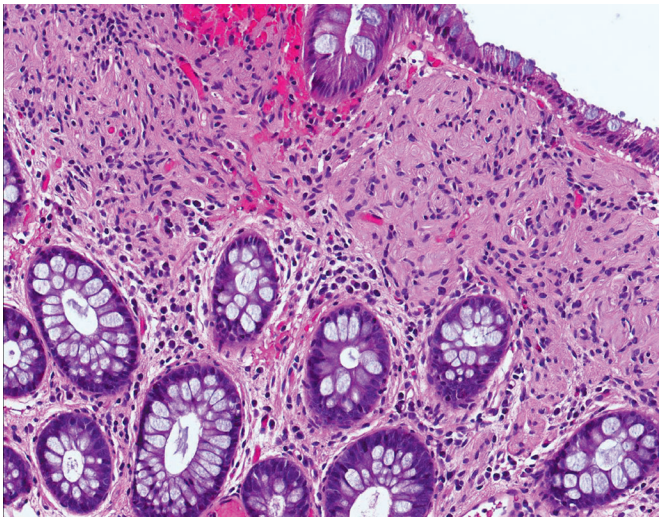

Figure 17.81 Mucosal Schwann cell hamartoma causing a small polyp in the sigmoid colon.

uncertainty about their nature.[722,723] An acquired (degenerative) pathogenesis seems likely for most cases. The lesions are often small, multiple, and easily demonstrated by arteriography but may be difficult to identify in a colonic biopsy or after they have collapsed following colectomy[724]; injection with silicone rubber or other compounds followed by clearing of the specimen shows them dramatically.[725] Associated cholesterol emboli can lead to infarct and bowel perforation. Vascular ectasias should be distinguished from the *colonic varices* that may be seen as a complication of portal hypertension.[726]

Dermoid cysts have been described arising in the colon[727] and have identical histologic features to those arising elsewhere.

Hemangiomas rarely involve the large bowel. Most are of the cavernous type and may be multicentric.[728,729] Others are of cellular type and occur in infants.[730]

Lipomas of the large bowel are rare; they are invariably submucosal and therefore may intussuscept or be associated with mucosal prolapse.[731] Lipomas can also present in the form of multiple polyps in the colon.[732] **Lipomatosis** of the ileocecal valve or other portions of the colon (probably a non-neoplastic condition) may be mistaken radiographically for a tumor.[733]

Lymphangioleiomyomatosis can involve the colon in a diffuse fashion and be confused with leiomyomatosis[734]; HMB-45 immunoreactivity is a key to the diagnosis. **Angiomyolipoma/PEComa** is a tumor of HMB-45–positive smooth muscle cells that can occur in the large bowel, both in its conventional and epithelioid forms.[735] Although most are clinically benign, some are malignant, particularly those with marked nuclear atypia with diffuse pleomorphism and mitotic activity.[735]

Granular cell tumor can involve the colon or rectum, sometimes in association with similar tumors in other portions of the gastrointestinal tract.[736]

Melanoma of the anorectal region most commonly represents an upward extension or metastasis of tumors originating in the anal canal.[737]

Kaposi sarcoma can involve the large bowel; occasionally, the disease may initially present with intestinal symptoms and simulate the appearance of ulcerative colitis, particularly in AIDS patients.[738] As in other locations, these lesions stain for HHV8, allowing for reliable diagnosis.

Angiosarcoma can present as a solitary or multicentric mass and may be spindled or epithelioid.[739] These lesions reliably show strong nuclear staining for ERG and membranous immunoreactivity for CD31.

Metastatic tumors to the large bowel occur as a part of a disseminated process. These tumors form disk-like areas in which there is a central area of ulceration; the normal mucosa extends to the ulcer, giving indirect evidence that the metastatic focus began in the submucosa. This phenomenon is particularly common in malignant melanoma and primary carcinoma of the lung. Prostatic carcinoma can extend into the rectum and simulate a primary rectal neoplasm in a rectal biopsy.[740]

Metastatic malignant mesothelioma can involve the colon and even present as multiple colonic polyps.[741] Of course renal cell carcinoma may also metastasize to the large bowel. The differential diagnosis between primary and metastatic carcinoma involving the bowel is greatly aided by CDX2 immunostaining, which is consistently strongly positive in the former and negative in most of the others, allowing for the usual exceptions.[742]

References

1. Shamsuddin AM, Phelps PC, Trump BF. Human large intestinal epithelium: light microscopy, histochemistry, and ultrastructure. *Hum Pathol*. 1982;13(9):790-803.
2. Levine DS, Haggitt RC. Normal histology of the colon. *Am J Surg Pathol*. 1989;13(11):966-984.
3. Lewin KJ. The endocrine cells of the gastrointestinal tract. The normal endocrine cells and their hyperplasias. Part I. *Pathol Annu*. 1986;21(Pt 1):1-27.
4. Symonds DA. Paneth cell metaplasia in diseases of the colon and rectum. *Arch Pathol*. 1974;97(6):343-347.
5. Osborn M, van Lessen G, Weber K, et al. Differential diagnosis of gastrointestinal carcinomas by using monoclonal antibodies specific for individual keratin polypeptides. *Lab Invest*. 1986;55(4): 497-504.
6. Bartnik W, ReMine SG, Chiba M, et al. Isolation and characterization of colonic intraepithelial and lamina proprial lymphocytes. *Gastroenterology*. 1980;78(5 Pt 1):976-985.
7. Tunru-Dinh V, Wu ML. Intramucosal ganglion cells in normal adult colorectal mucosa. *Int J Surg Pathol*. 2007;15(1):31-37.
8. Wu ML, Zhao X. Multinucleated stromal giant cells in colonic lamina propria. *Histopathology*. 2007;50(5):584-590.
9. O'Leary AD, Sweeney EC. Lymphoglandular complexes of the colon: structure and distribution. *Histopathology*. 1986;10(3):267-283.
10. Kaye GI, Pascal RR, Lane N. The colonic pericryptal fibroblast sheath: replication, migration, and cytodifferentiation of a mesenchymal cell system in adult tissue. 3. Replication and differentiation in human hyperplastic and adenomatous polyps. *Gastroenterology*. 1971;60(4):515-536.
11. Ghadially FN, Walley VM. Pigments of the gastrointestinal tract: a comparison of light microscopic and electron microscopic findings. *Ultrastruct Pathol*. 1995;19(4):213-219.
12. Walker NI, Bennett RE, Axelsen RA. Melanosis coli. A consequence of anthraquinone-induced apoptosis of colonic epithelial cells. *Am J Pathol*. 1988;131(3):465-476.
13. Lou TY, Teplitz C, Thayer WR. Ultrastructural morphogenesis of colonic PAS-positive macrophages ("colonic histiocytosis"). *Hum Pathol*. 1971;2(3):421-439.
14. Salto-Tellez M, Price AB. What is the significance of muciphages in colorectal biopsies? The significance of muciphages in otherwise normal colorectal biopsies. *Histopathology*. 2000;36(6):556-559.
15. Bejarano PA, Aranda-Michel J, Fenoglio-Preiser C. Histochemical and immunohistochemical characterization of foamy histiocytes (muciphages and xanthelasma) of the rectum. *Am J Surg Pathol*. 2000;24(7): 1009-1015.
16. Swenson O. Hirschsprung's disease: a review. *Pediatrics*. 2002;109(5):914-918.
17. Kapur RP. Contemporary approaches toward understanding the pathogenesis of Hirschsprung disease. *Pediatr Pathol*. 1993;13(1):83-100.
18. Crocker NL, Messmer JM. Adult Hirschsprung's disease. *Clin Radiol*. 1991;44(4):257-259.
19. Ryan ET, Ecker JL, Christakis NA, Folkman J. Hirschsprung's disease: associated abnormalities and demography. *J Pediatr Surg*. 1992;27(1):76-81.
20. Lally KP, Chwals WJ, Weitzman JJ, et al. Hirschsprung's disease: a possible cause of anastomotic failure following repair of intestinal atresia. *J Pediatr Surg*. 1992;27(4):469-470.
21. Jiménez-Urueta PS, Alvarado-García R, Gallego-Grijalva JE. Colon aganglionosis in patients with anorectal malformation. Analysis of five cases. *Cir Cir*. 2005;73(4):283-285.
22. Moore SW, Zaahl M. Clinical and genetic correlations of familial Hirschsprung's disease. *J Pediatr Surg*. 2015;50(2):285-288.
23. Moore SW, Zaahl MG. Tissue specific somatic mutations and aganglionosis in Hirschsprung's disease. *J Pediatr Surg*. 2014;49(2):258-261, discussion 261.
24. Tam PKH, Garcia-Barceló M. Genetic basis of Hirschsprung's disease. *Pediatr Surg Int*. 2009;25(7):543-558.
25. Chetty R, Govender D. Mucosal prolapse changes in Hirschsprung's disease. *Histopathology*. 1997;30(4):324-327.
26. Klein MD, Philippart AI. Hirschsprung's disease: three decades' experience at a single institution. *J Pediatr Surg*. 1993;28(10):1291-1293, discussion 1293-1294.
27. Demehri FR, Halaweish IF, Coran AG, Teitelbaum DH. Hirschsprung-associated enterocolitis: pathogenesis, treatment and prevention. *Pediatr Surg Int*. 2013;29(9):873-881.
28. Blisard KS, Kleinman R. Hirschsprung's disease: a clinical and pathologic overview. *Hum Pathol*. 1986;17(12):1189-1191.
29. Yamataka A, Miyano T, Urao M, Nishiye H. Hirschsprung's disease: diagnosis using monoclonal antibody 171B5. *J Pediatr Surg*. 1992;27(7):820-822.
30. Larsson LT, Malmfors G, Ekblad E, et al. NPY hyperinnervation in Hirschsprung's disease: both adrenergic and nonadrenergic fibers contribute. *J Pediatr Surg*. 1991;26(10):1207-1214.
31. Rolle U, Piotrowska AP, Nemeth L, Puri P. Altered distribution of interstitial cells of Cajal in Hirschsprung disease. *Arch Pathol Lab Med*. 2002;126(8):928-933.
32. Taguchi T, Tanaka K, Ikeda K. Fibromuscular dysplasia of arteries in Hirschsprung's disease. *Gastroenterology*. 1985;88(5 Pt 1):1099-1103.
33. Drut R, Drut RM. Hyperplasia of lymphoglandular complexes in colon segments in Hirschsprung's disease: a form of diversion colitis. *Pediatr Pathol*. 1992;12(4):575-581.
34. Venugopal S, Mancer K, Shandling B. The validity of rectal biopsy in relation to morphology and distribution of ganglion cells. *J Pediatr Surg*. 1981;16(4):433-437.
35. Ikeda K, Goto S. Total colonic aganglionosis with or without small bowel involvement: an analysis of 137 patients. *J Pediatr Surg*. 1986;21(4):319-322.
36. MacMahon RA, Moore CC, Cussen LJ. Hirschsprung-like syndromes in patients with normal ganglion cells on suction rectal biopsy. *J Pediatr Surg*. 1981;16(6):835-839.
37. Skelly BL, Ervine E, Bisharat M, et al. Small bowel skip segment Hirschprung's disease presenting with perforated Meckel's diverticulum. *Pediatr Surg Int*. 2012;28(6):645-648.
38. Aldridge RT, Campbell PE. Ganglion cell distribution in the normal rectum and anal canal. A basis for the diagnosis of Hirschsprung's disease by anorectal biopsy. *J Pediatr Surg*. 1968;3(4):475-490.
39. Hirose R, Hirata Y, Yamada T, et al. The simple technique of rectal mucosal biopsy for

the diagnosis of Hirschsprung's disease. *J Pediatr Surg*. 1993;28(7):942-944.
40. Gherardi GJ. Pathology of the ganglionic-aganglionic junction in congenital megacolon. *Arch Pathol*. 1960;69:520-523.
41. Monforte-Muñoz H, Gonzalez-Gomez I, Rowland JM, Landing BH. Increased submucosal nerve trunk caliber in aganglionosis: a "positive" and objective finding in suction biopsies and segmental resections in Hirschsprung's disease. *Arch Pathol Lab Med*. 1998;122(8):721-725.
42. Yunis EJ, Dibbins AW, Sherman FE. Rectal suction biopsy in the diagnosis of Hirschsprung disease in infants. *Arch Pathol Lab Med*. 1976;100(6):329-333.
43. Patrick WJ, Besley GT, Smith II. Histochemical diagnosis of Hirschsprung's disease and a comparison of the histochemical and biochemical activity of acetylcholinesterase in rectal mucosal biopsies. *J Clin Pathol*. 1980;33(4):336-343.
44. Causse E, Vaysse P, Fabre J, et al. The diagnostic value of acetylcholinesterase/butyrylcholinesterase ratio in Hirschsprung's disease. *Am J Clin Pathol*. 1987;88(4):477-480.
45. Yang S, Donner LR. Detection of ganglion cells in the colonic plexuses by immunostaining for neuron-specific marker NeuN: an aid for the diagnosis of Hirschsprung disease. *Appl Immunohistochem Mol Morphol*. 2002;10(3):218-220.
46. Tam PK, Owen G. An immunohistochemical study of neuronal microtubule-associated proteins in Hirschsprung's disease. *Hum Pathol*. 1993;24(4):424-431.
47. Sams VR, Bobrow LG, Happerfield L, Keeling J. Evaluation of PGP9.5 in the diagnosis of Hirschsprung's disease. *J Pathol*. 1992;168(1):55-58.
48. Karim S, Hession C, Marconi S, et al. The identification of ganglion cells in Hirschsprung disease by the immunohistochemical detection of ret oncoprotein. *Am J Clin Pathol*. 2006;126(1):49-54.
49. Guinard-Samuel V, Bonnard A, De Lagausie P, et al. Calretinin immunohistochemistry: a simple and efficient tool to diagnose Hirschsprung disease. *Mod Pathol*. 2009;22(10):1379-1384.
50. Romanska HM, Bishop AE, Brereton RJ, et al. Immunocytochemistry for neuronal markers shows deficiencies in conventional histology in the treatment of Hirschsprung's disease. *J Pediatr Surg*. 1993;28(8):1059-1062.
51. Hirobe S, Doody DP, Ryan DP, et al. Ectopic class II major histocompatibility antigens in Hirschsprung's disease and neuronal intestinal dysplasia. *J Pediatr Surg*. 1992;27(3):357-362, discussion 363.
52. Maia DM. The reliability of frozen-section diagnosis in the pathologic evaluation of Hirschsprung's disease. *Am J Surg Pathol*. 2000;24(12):1675-1677.
53. Sulkowski JP, Cooper JN, Congeni A, et al. Single-stage versus multi-stage pull-through for Hirschsprung's disease: practice trends and outcomes in infants. *J Pediatr Surg*. 2014;49(11):1619-1625.
54. Nasr A, Haricharan RN, Gamarnik J, Langer JC. Transanal pullthrough for Hirschsprung disease: matched case-control comparison of Soave and Swenson techniques. *J Pediatr Surg*. 2014;49(5):774-776.
55. Cohen MC, Moore SW, Neveling U, Kaschula RO. Acquired aganglionosis following surgery for Hirschsprung's disease: a report of five cases during a 33-year experience with pull-through procedures. *Histopathology*. 1993;22(2):163-168.
56. Friedmacher F, Puri P. Classification and diagnostic criteria of variants of Hirschsprung's disease. *Pediatr Surg Int*. 2013;29(9):855-872.
57. Dingemann J, Puri P. Isolated hypoganglionosis: systematic review of a rare intestinal innervation defect. *Pediatr Surg Int*. 2010;26(11):1111-1115.
58. Qualman SJ, Murray R. Aganglionosis and related disorders. *Hum Pathol*. 1994;25(11):1141-1149.
59. Hirayama Y, Iinuma Y, Numano F, et al. Intestinal neuronal dysplasia-like histopathology in infancy. *Pediatr Int*. 2015;57(3):491-493.
60. Bahuau M, Laurendeau I, Pelet A, et al. Tandem duplication within the neurofibromatosis type 1 gene (NF1) and reciprocal t(15;16)(q26.3;q12.1) translocation in familial association of NF1 with intestinal neuronal dysplasia type B (IND B). *J Med Genet*. 2000;37(2):146-150.
61. Schofield DE, Yunis EJ. Intestinal neuronal dysplasia. *J Pediatr Gastroenterol Nutr*. 1991;12(2):182-189.
62. Schofield DE, Yunis EJ. What is intestinal neuronal dysplasia? *Pathol Annu*. 1992;27(Pt 1):249-262.
63. Streutker CJ, Huizinga JD, Campbell F, et al. Loss of CD117 (c-kit)- and CD34-positive ICC and associated CD34-positive fibroblasts defines a subpopulation of chronic intestinal pseudo-obstruction. *Am J Surg Pathol*. 2003;27(2):228-235.
64. Park S-H, Min H, Chi JG, et al. Immunohistochemical studies of pediatric intestinal pseudo-obstruction: bcl2, a valuable biomarker to detect immature enteric ganglion cells. *Am J Surg Pathol*. 2005;29(8):1017-1024.
65. Wang LM, McNally M, Hyland J, Sheahan K. Assessing interstitial cells of Cajal in slow transit constipation using CD117 is a useful diagnostic test. *Am J Surg Pathol*. 2008;32(7):980-985.
66. Dimmick JE, Bove KE. Cytomegalovirus infection of the bowel in infancy: pathogenetic and diagnostic significance. *Pediatr Pathol*. 1984;2(1):95-102.
67. da Silveira ABM, Lemos EM, Adad SJ, et al. Megacolon in Chagas disease: a study of inflammatory cells, enteric nerves, and glial cells. *Hum Pathol*. 2007;38(8):1256-1264.
68. Iantorno G, Bassotti G, Kogan Z, et al. The enteric nervous system in chagasic and idiopathic megacolon. *Am J Surg Pathol*. 2007;31(3):460-468.
69. Martel J, Raskin JB, NDSG. History, incidence, and epidemiology of diverticulosis. *J Clin Gastroenterol*. 2008;42(10):1125-1127.
70. Hughes LE. Postmortem survey of diverticular disease of the colon. I. Diverticulosis and diverticulitis. *Gut*. 1969;10(5):336-344.
71. Almy TP, Howell DA. Medical progress. Diverticular disease of the colon. *N Engl J Med*. 1980;302(6):324-331.
72. Santin BJ, Prasad V, Caniano DA. Colonic diverticulitis in adolescents: an index case and associated syndromes. *Pediatr Surg Int*. 2009;25(10):901-905.
73. Luciano RL, Dahl NK. Extra-renal manifestations of autosomal dominant polycystic kidney disease (ADPKD): considerations for routine screening and management. *Nephrol Dial Transplant*. 2014;29(2):247-254.
74. Heise CP. Epidemiology and pathogenesis of diverticular disease. *J Gastrointest Surg Aliment Tract*. 2008;12(8):1309-1311.
75. Mosadeghi S, Bhuket T, Stollman N. Diverticular disease: evolving concepts in classification, presentation, and management. *Curr Opin Gastroenterol*. 2015;31(1):50-55.
76. Markham NI, Li AK. Diverticulitis of the right colon—experience from Hong Kong. *Gut*. 1992;33(4):547-549.
77. Hellwig I, Böttner M, Barrenschee M, et al. Alterations of the enteric smooth musculature in diverticular disease. *J Gastroenterol*. 2014;49(8):1241-1252.
78. Kelly JK. Polypoid prolapsing mucosal folds in diverticular disease. *Am J Surg Pathol*. 1991;15(9):871-878.
79. Magness LJ, Sanfelippo PM, van Heerden JA, Judd ES. Diverticular disease of the right colon. *Surg Gynecol Obstet*. 1975;140(1):30-32.
80. Bateman AC, Beer TW, Bass PS, et al. Massive arterial haemorrhage from the lower gastrointestinal tract. *Histopathology*. 1996;29(3):225-231.
81. Lewis M, NDSG. Bleeding colonic diverticula. *J Clin Gastroenterol*. 2008;42(10):1156-1158.
82. Ravo B, Khan SA, Ger R, et al. Unusual extraperitoneal presentations of diverticulitis. *Am J Gastroenterol*. 1985;80(5):346-351.
83. Zhai J, Maluf HM. Peridiverticular colonic hyaline rings (pulse granulomas): report of two cases associated with perforated diverticula. *Ann Diagn Pathol*. 2004;8(6):375-379.
84. Goldstein NS, Sanford WW, Bodzin JH. Crohn's-like complications in patients with ulcerative colitis after total proctocolectomy and ileal pouch-anal anastomosis. *Am J Surg Pathol*. 1997;21(11):1343-1353.
85. Mulhall AM, Mahid SS, Petras RE, Galandiuk S. Diverticular disease associated with inflammatory bowel disease-like colitis: a systematic review. *Dis Colon Rectum*. 2009;52(6):1072-1079.
86. Makapugay LM, Dean PJ. Diverticular disease-associated chronic colitis. *Am J Surg Pathol*. 1996;20(1):94-102.
87. Scotti A, Santangelo M, Federico S, et al. Complicated diverticulitis in kidney transplanted patients: analysis of 717 cases. *Transplant Proc*. 2014;46(7):2247-2250.
88. Parsyan A, Cardin M-J, Hassoun H, et al. Challenging diagnosis of intra-diverticular colonic adenocarcinoma with submucosal localization. *Int J Colorectal Dis*. 2013;28(12):1735-1737.
89. Touzios JG, Dozois EJ. Diverticulosis and acute diverticulitis. *Gastroenterol Clin North Am*. 2009;38(3):513-525.
90. Collins D, Winter DC. Modern concepts in diverticular disease. *J Clin Gastroenterol*. 2015;49(5):358-369.
91. Wieghard N, Geltzeiler CB, Tsikitis VL. Trends in the surgical management of diverticulitis. *Ann Gastroenterol*. 2015;28(1):25-30.
92. Abraham C, Cho JH. Inflammatory bowel disease. *N Engl J Med*. 2009;361(21):2066-2078.
93. Xavier RJ, Podolsky DK. Unravelling the pathogenesis of inflammatory bowel disease. *Nature*. 2007;448(7152):427-434.
94. Farmer RG, Easley KA, Rankin GB. Clinical patterns, natural history, and progression of ulcerative colitis. A long-term follow-up of 1116 patients. *Dig Dis Sci*. 1993;38(6):1137-1146.
95. Ananthakrishnan AN. Epidemiology and risk factors for IBD. *Nat Rev Gastroenterol Hepatol*. 2015;12(4):205-217.
96. Kelly JK, Langevin JM, Price LM, et al. Giant and symptomatic inflammatory polyps of the colon in idiopathic inflammatory bowel disease. *Am J Surg Pathol*. 1986;10(6):420-428.
97. Yantiss RK, Farraye FA, O'Brien MJ, et al. Prognostic significance of superficial fissuring ulceration in patients with severe "indeterminate" colitis. *Am J Surg Pathol*. 2006;30(2):165-170.
98. Yantiss RK, Odze RD. Pitfalls in the interpretation of nonneoplastic mucosal biopsies in inflammatory bowel disease. *Am J Gastroenterol*. 2007;102(4):890-904.
99. Bischoff SC, Wedemeyer J, Herrmann A, et al. Quantitative assessment of intestinal

eosinophils and mast cells in inflammatory bowel disease. *Histopathology*. 1996;28(1):1-13.
100. Waraich T, Sarsfield P, Wright DH. The accessory cell populations in ulcerative colitis: a comparison between the colon and appendix in colitis and acute appendicitis. *Hum Pathol*. 1997;28(3):297-303.
101. Mahadeva U, Martin JP, Patel NK, Price AB. Granulomatous ulcerative colitis: a re-appraisal of the mucosal granuloma in the distinction of Crohn's disease from ulcerative colitis. *Histopathology*. 2002;41(1):50-55.
102. Dhillon AP, Anthony A, Sim R, et al. Mucosal capillary thrombi in rectal biopsies. *Histopathology*. 1992;21(2):127-133.
103. Lee RG. Villous regeneration in ulcerative colitis. *Arch Pathol Lab Med*. 1987;111(3):276-278.
104. Allen DC, Biggart JD. Misplaced epithelium in ulcerative colitis and Crohn's disease of the colon and its relationship to malignant mucosal changes. *Histopathology*. 1986;10(1):37-52.
105. Soundy VC, Davies SE, Warren BF. The double muscularis mucosa in ulcerative colitis: is it all new? *Histopathology*. 1998;32(5):484-485.
106. Odze R, Antonioli D, Peppercorn M, Goldman H. Effect of topical 5-aminosalicylic acid (5-ASA) therapy on rectal mucosal biopsy morphology in chronic ulcerative colitis. *Am J Surg Pathol*. 1993;17(9):869-875.
107. Kleer CG, Appelman HD. Ulcerative colitis: patterns of involvement in colorectal biopsies and changes with time. *Am J Surg Pathol*. 1998;22(8):983-989.
108. Robert ME, Skacel M, Ullman T, et al. Patterns of colonic involvement at initial presentation in ulcerative colitis: a retrospective study of 46 newly diagnosed cases. *Am J Clin Pathol*. 2004;122(1):94-99.
109. Glickman JN, Bousvaros A, Farraye FA, et al. Pediatric patients with untreated ulcerative colitis may present initially with unusual morphologic findings. *Am J Surg Pathol*. 2004;28(2):190-197.
110. Goldstein N, Dulai M. Contemporary morphologic definition of backwash ileitis in ulcerative colitis and features that distinguish it from Crohn disease. *Am J Clin Pathol*. 2006;126(3):365-376.
111. Arrossi AV, Kariv Y, Bronner MP, et al. Backwash ileitis does not affect pouch outcome in patients with ulcerative colitis with restorative proctocolectomy. *Clin Gastroenterol Hepatol*. 2011;9(11):981-988.
112. Valdez R, Appelman HD, Bronner MP, Greenson JK. Diffuse duodenitis associated with ulcerative colitis. *Am J Surg Pathol*. 2000;24(10):1407-1413.
113. Berman JJ, Ullah A. Colonic metaplasia of ileostomies. Biological significance for ulcerative colitis patients following total colectomy. *Am J Surg Pathol*. 1989;13(11):955-960.
114. Shepherd NA, Healey CJ, Warren BF, et al. Distribution of mucosal pathology and an assessment of colonic phenotypic change in the pelvic ileal reservoir. *Gut*. 1993;34(1):101-105.
115. Warren BF, Shepherd NA, Bartolo DC, Bradfield JW. Pathology of the defunctioned rectum in ulcerative colitis. *Gut*. 1993;34(4):514-516.
116. Goldblum JR, Appelman HD. Appendiceal involvement in ulcerative colitis. *Mod Pathol*. 1992;5(6):607-610.
117. Scott IS, Sheaff M, Coumbe A, et al. Appendiceal inflammation in ulcerative colitis. *Histopathology*. 1998;33(2):168-173.
118. Ambroze WL, Pemberton JH, Dozois RR, et al. The histological pattern and pathological involvement of the anal transition zone in patients with ulcerative colitis. *Gastroenterology*. 1993;104(2):514-518.
119. Yarur AJ, Czul F, Levy C. Hepatobiliary manifestations of inflammatory bowel disease. *Inflamm Bowel Dis*. 2014;20(9):1655-1667.
120. Liu R, Cox K, Guthery SL, et al. Cholangiocarcinoma and high-grade dysplasia in young patients with primary sclerosing cholangitis. *Dig Dis Sci*. 2014;59(9):2320-2324.
121. Vavricka SR, Rogler G, Gantenbein C, et al. Chronological order of appearance of extraintestinal manifestations relative to the time of IBD diagnosis in the swiss inflammatory bowel disease cohort. *Inflamm Bowel Dis*. 2015;21:1794-1800.
122. Singh S, Al-Darmaki A, Frolkis AD, et al. Post-operative mortality among patients with inflammatory Bowel diseases: a systematic review and meta-analysis of population-based studies. *Gastroenterology*. 2015;149(4):928-937.
123. Cohen RD, Dalal SR. Systematic review: rectal therapies for the treatment of distal forms of ulcerative colitis. *Inflamm Bowel Dis*. 2015;21(7):1719-1736.
124. Amiot A, Peyrin-Biroulet L. Current, new and future biological agents on the horizon for the treatment of inflammatory bowel diseases. *Therap Adv Gastroenterol*. 2015;8(2):66-82.
125. Harpaz N, Talbot IC. Colorectal cancer in idiopathic inflammatory bowel disease. *Semin Diagn Pathol*. 1996;13(4):339-357.
126. Wong NA, Harrison DJ. Colorectal neoplasia in ulcerative colitis-recent advances. *Histopathology*. 2001;39(3):221-234.
127. Morson BC. Precancer and cancer in inflammatory bowel disease. *Pathology*. 1985;17(2):173-180.
128. Nieminen U, Jussila A, Nordling S, et al. Inflammation and disease duration have a cumulative effect on the risk of dysplasia and carcinoma in IBD: a case-control observational study based on registry data. *Int J Cancer*. 2014;134(1):189-196.
129. Navaneethan U, Kochhar G, Venkatesh PGK, et al. Duration and severity of primary sclerosing cholangitis is not associated with risk of neoplastic changes in the colon in patients with ulcerative colitis. *Gastrointest Endosc*. 2012;75(5):1045-1054.e1.
130. Ekbom A, Helmick C, Zack M, Adami HO. Ulcerative colitis and colorectal cancer. A population-based study. *N Engl J Med*. 1990;323(18):1228-1233.
131. Sugita A, Sachar DB, Bodian C, et al. Colorectal cancer in ulcerative colitis. Influence of anatomical extent and age at onset on colitis-cancer interval. *Gut*. 1991;32(2):167-169.
132. Sanduleanu S, Rutter MD. Interval colorectal cancers in inflammatory bowel disease: the grim statistics and true stories. *Gastrointest Endosc Clin N Am*. 2014;24(3):337-348.
133. DeRoche TC, Xiao S-Y, Liu X. Histological evaluation in ulcerative colitis. *Gastroenterol Rep*. 2014;2(3):178-192.
134. Morelli L, Luca M, Palmeri M, et al. Adenocarcinoma on j-pouch after proctocolectomy for ulcerative colitis-case report and review of literature. *Int J Colorectal Dis*. 2014;29(9):1171-1173.
135. Derikx LAAP, Hoentjen F. Cuff and pouch cancer in patients with inflammatory bowel disease: what surveillance strategy should be recommended? *Inflamm Bowel Dis*. 2014;20(8):E20.
136. Levi GS, Harpaz N. Intestinal low-grade tubuloglandular adenocarcinoma in inflammatory bowel disease. *Am J Surg Pathol*. 2006;30(8):1022-1029.
137. Gyde SN, Prior P, Allan RN, et al. Colorectal cancer in ulcerative colitis: a cohort study of primary referrals from three centres. *Gut*. 1988;29(2):206-217.
138. Lavery IC, Chiulli RA, Jagelman DG, et al. Survival with carcinoma arising in mucosal ulcerative colitis. *Ann Surg*. 1982;195(4):508-512.
139. Sugita A, Greenstein AJ, Ribeiro MB, et al. Survival with colorectal cancer in ulcerative colitis. A study of 102 cases. *Ann Surg*. 1993;218(2):189-195.
140. Greenson JK. Dysplasia in inflammatory bowel disease. *Semin Diagn Pathol*. 2002;19(1):31-37.
141. Melville DM, Jass JR, Morson BC, et al. Observer study of the grading of dysplasia in ulcerative colitis: comparison with clinical outcome. *Hum Pathol*. 1989;20(10):1008-1014.
142. Yardley JH, Keren DF. "Precancer" lesions in ulcerative colits. A retrospective study of rectal biopsy and colectomy specimens. *Cancer*. 1974;34(3 suppl):835-844.
143. Riddell RH, Goldman H, Ransohoff DF, et al. Dysplasia in inflammatory bowel disease: standardized classification with provisional clinical applications. *Hum Pathol*. 1983;14(11):931-968.
144. Friedman S, Odze RD, Farraye FA. Management of neoplastic polyps in inflammatory bowel disease. *Inflamm Bowel Dis*. 2003;9(4):260-266.
145. Farraye FA, Odze RD, Eaden J, Itzkowitz SH. AGA technical review on the diagnosis and management of colorectal neoplasia in inflammatory bowel disease. *Gastroenterology*. 2010;138(2):746-774.
146. Engelsgjerd M, Farraye FA, Odze RD. Polypectomy may be adequate treatment for adenoma-like dysplastic lesions in chronic ulcerative colitis. *Gastroenterology*. 1999;117(6):1288-1294.
147. Walsh SV, Loda M, Torres CM, et al. P53 and beta catenin expression in chronic ulcerative colitis—associated polypoid dysplasia and sporadic adenomas: an immunohistochemical study. *Am J Surg Pathol*. 1999;23(8):963-969.
148. Wong NA, Mayer NJ, MacKell S, et al. Immunohistochemical assessment of Ki67 and p53 expression assists the diagnosis and grading of ulcerative colitis-related dysplasia. *Histopathology*. 2000;37(2):108-114.
149. Noffsinger AE, Belli JM, Miller MA, Fenoglio-Preiser CM. A unique basal pattern of p53 expression in ulcerative colitis is associated with mutation in the p53 gene. *Histopathology*. 2001;39(5):482-492.
150. Greenwald BD, Harpaz N, Yin J, et al. Loss of heterozygosity affecting the p53, Rb, and mcc/apc tumor suppressor gene loci in dysplastic and cancerous ulcerative colitis. *Cancer Res*. 1992;52(3):741-745.
151. Lyda MH, Noffsinger A, Belli J, Fenoglio-Preiser CM. Microsatellite instability and K-ras mutations in patients with ulcerative colitis. *Hum Pathol*. 2000;31(6):665-671.
152. Chen R, Rabinovitch PS, Crispin DA, et al. DNA fingerprinting abnormalities can distinguish ulcerative colitis patients with dysplasia and cancer from those who are dysplasia/cancer-free. *Am J Pathol*. 2003;162(2):665-672.
153. Mueller JD, Bethke B, Stolte M. Colorectal de novo carcinoma: a review of its diagnosis, histopathology, molecular biology, and clinical relevance. *Virchows Arch Int J Pathol*. 2002;440(5):453-460.
154. Urbanski SJ, Fogt F. Dysplasia in chronic ulcerative colitis: a molecular approach to its differential diagnosis. *Int J Surg Pathol*. 2000;8(1):11-16.
155. Fogt F, Urbanski SJ, Sanders ME, et al. Distinction between dysplasia-associated lesion or mass (DALM) and adenoma in patients with ulcerative colitis. *Hum Pathol*. 2000;31(3):288-291.

156. Aust DE, Willenbucher RF, Terdiman JP, et al. Chromosomal alterations in ulcerative colitis-related and sporadic colorectal cancers by comparative genomic hybridization. *Hum Pathol*. 2000;31(1):109-114.
157. Odze RD, Brown CA, Hartmann CJ, et al. Genetic alterations in chronic ulcerative colitis-associated adenoma-like DALMs are similar to non-colitic sporadic adenomas. *Am J Surg Pathol*. 2000;24(9):1209-1216.
158. Feuerstein JD, Cheifetz AS. Ulcerative colitis: epidemiology, diagnosis, and management. *Mayo Clin Proc*. 2014;89(11): 1553-1563.
159. Murphy J, Kalkbrenner KA, Pemberton JH, et al. Dysplasia in ulcerative colitis as a predictor of unsuspected synchronous colorectal cancer. *Dis Colon Rectum*. 2014;57(8):993-998.
160. Sachar DB. Clinical and colonoscopic surveillance in ulcerative colitis: are we saving colons or saving lives? *Gastroenterology*. 1993;105(2):588-597.
161. Sigel JE, Goldblum JR. Neuroendocrine neoplasms arising in inflammatory bowel disease: a report of 14 cases. *Mod Pathol*. 1998;11(6):537-542.
162. Sandborn WJ. State-of-the-art: immunosuppression and biologic therapy. *Dig Dis Basel Switz*. 2010;28(3):536-542.
163. Cucchiara S, Escher JC, Hildebrand H, et al. Pediatric inflammatory bowel diseases and the risk of lymphoma: should we revise our treatment strategies? *J Pediatr Gastroenterol Nutr*. 2009;48(3):257-267.
164. Ellinghaus D, Bethune J, Petersen B-S, Franke A. The genetics of Crohn's disease and ulcerative colitis—status quo and beyond. *Scand J Gastroenterol*. 2015;50(1):13-23.
165. Wright EK, Kamm MA, Teo SM, et al. Recent advances in characterizing the gastrointestinal microbiome in Crohn's disease: a systematic review. *Inflamm Bowel Dis*. 2015;21(6):1219-1228.
166. Poller DN, Armitage NC. Mural bridging lesions in colonic Crohn's disease. *Arch Pathol Lab Med*. 1993;117(5):550-552.
167. Surawicz CM, Meisel JL, Ylvisaker T, et al. Rectal biopsy in the diagnosis of Crohn's disease: value of multiple biopsies and serial sectioning. *Gastroenterology*. 1981;80(1):66-71.
168. Price AB, Morson BC. Inflammatory bowel disease: the surgical pathology of Crohn's disease and ulcerative colitis. *Hum Pathol*. 1975;6(1):7-29.
169. Meyers MA, Alonso DR, Morson BC, Bartram C. Pathogenesis of diverticulitis complicating granulomatous colitis. *Gastroenterology*. 1978;74(1):24-31.
170. Lam TJ, van Bodegraven AA, Felt-Bersma RJF. Anorectal complications and function in patients suffering from inflammatory bowel disease: a series of patients with long-term follow-up. *Int J Colorectal Dis*. 2014;29(8):923-929.
171. Autenrieth DM, Baumgart DC. Toxic megacolon. *Inflamm Bowel Dis*. 2012;18(3):584-591.
172. Farmer RG, Hawk WA, Turnbull RB. Clinical patterns in Crohn's disease: a statistical study of 615 cases. *Gastroenterology*. 1975;68(4 Pt 1):627-635.
173. Odze RD. A contemporary and critical appraisal of "indeterminate colitis.". *Mod Pathol*. 2015;28(suppl 1):S30-S46.
174. Svrcek M, Cosnes J, Beaugerie L, et al. Colorectal neoplasia in Crohn's colitis: a retrospective comparative study with ulcerative colitis. *Histopathology*. 2007;50(5):574-583.
175. Sebastian S, Hernández V, Myrelid P, et al. Colorectal cancer in inflammatory bowel disease: results of the 3rd ECCO pathogenesis scientific workshop (I). *J Crohns Colitis*. 2014;8(1):5-18.
176. Sigel JE, Petras RE, Lashner BA, et al. Intestinal adenocarcinoma in Crohn's disease: a report of 30 cases with a focus on coexisting dysplasia. *Am J Surg Pathol*. 1999;23(6):651-655.
177. Sonnenberg A, Genta RM. Epithelial dysplasia and cancer in IBD strictures. *J Crohns Colitis*. 2015;9(9):769-775.
178. Kilgore SP, Sigel JE, Goldblum JR. Hyperplastic-like mucosal change in Crohn's disease: an unusual form of dysplasia? *Mod Pathol*. 2000;13(7):797-801.
179. Hedrick TL, Friel CM. Colonic crohn disease. *Clin Colon Rectal Surg*. 2013;26(2):84-89.
180. Yantiss RK, Odze RD. Diagnostic difficulties in inflammatory bowel disease pathology. *Histopathology*. 2006;48(2): 116-132.
181. Odze R. Diagnostic problems and advances in inflammatory bowel disease. *Mod Pathol*. 2003;16(4):347-358.
182. Martland GT, Shepherd NA. Indeterminate colitis: definition, diagnosis, implications and a plea for nosological sanity. *Histopathology*. 2007;50(1):83-96.
183. Moller FT, Andersen V, Wohlfahrt J, Jess T. Familial risk of inflammatory bowel disease: a population-based cohort study 1977–2011. *Am J Gastroenterol*. 2015;110(4):564-571.
184. FitzGerald JF, Hernandez Iii LO. Ischemic colitis. *Clin Colon Rectal Surg*. 2015;28(2):93-98.
185. Yamanishi Y, Yamana S, Ishioka S, Yamakido M. Development of ischemic colitis and scleroderma renal crisis following methylprednisolone pulse therapy for progressive systemic sclerosis. *Intern Med Tokyo Jpn*. 1996;35(7):583-586.
186. Storesund B, Gran JT, Koldingsnes W. Severe intestinal involvement in Wegener's granulomatosis: report of two cases and review of the literature. *Br J Rheumatol*. 1998;37(4):387-390.
187. Saraga EP, Costa J. Idiopathic entero-colic lymphocytic phlebitis. A cause of ischemic intestinal necrosis. *Am J Surg Pathol*. 1989;13(4):303-308.
188. Tuppy H, Haidenthaler A, Schandalik R, Oberhuber G. Idiopathic enterocolic lymphocytic phlebitis: a rare cause of ischemic colitis. *Mod Pathol*. 2000;13(8):897-899.
189. Borczuk A, Mannion C, Dickson D, Alt E. Intestinal pseudo-obstruction and ischemia secondary to both beta 2-microglobulin and serum A amyloid deposition. *Mod Pathol*. 1995;8(5):577-582.
190. Manickam P, Jaurigue M, Batke M, Cappell MS. Recurrent ischemic colitis associated with oral contraceptive therapy. *J Dig Dis*. 2014;15(6):331-333.
191. Elramah M, Einstein M, Mori N, Vakil N. High mortality of cocaine-related ischemic colitis: a hybrid cohort/case-control study. *Gastrointest Endosc*. 2012;75(6):1226-1232.
192. O'Briain DS, Jeffers M, Kay EW, Hourihane DO. Bleeding due to colorectal atheroembolism. Diagnosis by biopsy of adenomatous polyps or of ischemic ulcer. *Am J Surg Pathol*. 1991;15(11):1078-1082.
193. Dignan CR, Greenson JK. Can ischemic colitis be differentiated from *C. difficile* colitis in biopsy specimens? *Am J Surg Pathol*. 1997;21(6):706-710.
194. Serra S, Chetty R. Bizarre stromal cells in ischemic bowel disease. *Ann Diagn Pathol*. 2005;9(4):193-196.
195. Zhang S, Ashraf M, Schinella R. Ischemic colitis with atypical reactive changes that mimic dysplasia (pseudodysplasia). *Arch Pathol Lab Med*. 2001;125(2):224-227.
196. Toner M, Condell D, O'Briain DS. Obstructive colitis. Ulceroinflammatory lesions occurring proximal to colonic obstruction. *Am J Surg Pathol*. 1990;14(8):719-728.
197. Noh M, Yang SS, Jung SW, et al. Poor prognostic factors in patients who underwent surgery for acute non-occlusive ischemic colitis. *World J Emerg Surg*. 2015;10:12.
198. Nostrant TT, Kumar NB, Appelman HD. Histopathology differentiates acute self-limited colitis from ulcerative colitis. *Gastroenterology*. 1987;92(2):318-328.
199. Dundas SA, Dutton J, Skipworth P. Reliability of rectal biopsy in distinguishing between chronic inflammatory bowel disease and acute self-limiting colitis. *Histopathology*. 1997;31(1):60-66.
200. Anand BS, Malhotra V, Bhattacharya SK, et al. Rectal histology in acute bacillary dysentery. *Gastroenterology*. 1986;90(3):654-660.
201. Lamps LW. Infective disorders of the gastrointestinal tract. *Histopathology*. 2007;50(1):55-63.
202. Surawicz CM, Belic L. Rectal biopsy helps to distinguish acute self-limited colitis from idiopathic inflammatory bowel disease. *Gastroenterology*. 1984;86(1):104-113.
203. Lozinsky AC, Morais MB. Eosinophilic colitis in infants. *J Pediatr (Rio J)*. 2014;90(1):16-21.
204. Odze RD, Bines J, Leichtner AM, et al. Allergic proctocolitis in infants: a prospective clinicopathologic biopsy study. *Hum Pathol*. 1993;24(6):668-674.
205. Goldman H, Proujansky R. Allergic proctitis and gastroenteritis in children. Clinical and mucosal biopsy features in 53 cases. *Am J Surg Pathol*. 1986;10(2):75-86.
206. Winter HS, Antonioli DA, Fukagawa N, et al. Allergy-related proctocolitis in infants: diagnostic usefulness of rectal biopsy. *Mod Pathol*. 1990;3(1):5-10.
207. Wang KK, Perrault J, Carpenter HA, et al. Collagenous colitis: a clinicopathologic correlation. *Mayo Clin Proc*. 1987;62(8):665-671.
208. Ayata G, Ithamukkala S, Sapp H, et al. Prevalence and significance of inflammatory bowel disease-like morphologic features in collagenous and lymphocytic colitis. *Am J Surg Pathol*. 2002;26(11):1414-1423.
209. Tanaka M, Mazzoleni G, Riddell RH. Distribution of collagenous colitis: utility of flexible sigmoidoscopy. *Gut*. 1992;33(1):65-70.
210. Lazenby AJ, Yardley JH, Giardiello FM, Bayless TM. Pitfalls in the diagnosis of collagenous colitis: experience with 75 cases from a registry of collagenous colitis at the Johns Hopkins Hospital. *Hum Pathol*. 1990;21(9):905-910.
211. Khan-Kheil AM, Disney B, Ruban E, Wood G. Pseudomembranous collagenous colitis: an unusual cause of chronic diarrhoea. *BMJ Case Rep*. 2014;2014:pii: bcr2013203148.
212. Armes J, Gee DC, Macrae FA, et al. Collagenous colitis: jejunal and colorectal pathology. *J Clin Pathol*. 1992;45(9): 784-787.
213. Jessurun J, Yardley JH, Giardiello FM, et al. Chronic colitis with thickening of the subepithelial collagen layer (collagenous colitis): histopathologic findings in 15 patients. *Hum Pathol*. 1987;18(8):839-848.
214. Riddell RH, Tanaka M, Mazzoleni G. Non-steroidal anti-inflammatory drugs as a possible cause of collagenous colitis: a case-control study. *Gut*. 1992;33(5): 683-686.
215. Bonderup OK, Fenger-Grøn M, Wigh T, et al. Drug exposure and risk of microscopic colitis: a nationwide Danish case-control study with 5751 cases. *Inflamm Bowel Dis*. 2014;20(10):1702-1707.
216. Carpenter HA, Tremaine WJ, Batts KP, Czaja AJ. Sequential histologic evaluations in collagenous colitis. Correlations with disease behavior and sampling strategy. *Dig Dis Sci*. 1992;37(12):1903-1909.

217. Freeman HJ. Long-term natural history and complications of collagenous colitis. *Can J Gastroenterol*. 2012;26(9):627-630.
218. Gardiner GW, Goldberg R, Currie D, Murray D. Colonic carcinoma associated with an abnormal collagen table. Collagenous colitis. *Cancer*. 1984;54(12):2973-2977.
219. Bogomoletz WV, Flejou JF. Microscopic colitis: a "transatlantic" unifying concept. *Gastroenterology*. 1994;106(6):1727.
220. Bogomoletz WV. Collagenous, microscopic and lymphocytic colitis. An evolving concept. *Virchows Arch Int J Pathol*. 1994;424(6):573-579.
221. Ingle SB, Adgaonkar BD, Ingle CRH. Microscopic colitis: common cause of unexplained nonbloody diarrhea. *World J Gastrointest Pathophysiol*. 2014;5(1):48-53.
222. Sylwestrowicz T, Kelly JK, Hwang WS, Shaffer EA. Collagenous colitis and microscopic colitis: the watery diarrhea-colitis syndrome. *Am J Gastroenterol*. 1989;84(7):763-768.
223. Goldman H. Interpretation of large intestinal mucosal biopsy specimens. *Hum Pathol*. 1994;25(11):1150-1159.
224. Lazenby AJ. Collagenous and lymphocytic colitis. *Semin Diagn Pathol*. 2005;22(4):295-300.
225. Wolber R, Owen D, DelBuono L, et al. Lymphocytic gastritis in patients with celiac sprue or spruelike intestinal disease. *Gastroenterology*. 1990;98(2):310-315.
226. Wolber R, Owen D, Freeman H. Colonic lymphocytosis in patients with celiac sprue. *Hum Pathol*. 1990;21(11):1092-1096.
227. Sapp H, Ithamukkala S, Brien TP, et al. The terminal ileum is affected in patients with lymphocytic or collagenous colitis. *Am J Surg Pathol*. 2002;26(11):1484-1492.
228. Saurine TJ, Brewer JM, Eckstein RP. Microscopic colitis with granulomatous inflammation. *Histopathology*. 2004;45(1):82-86.
229. Libbrecht L, Croes R, Ectors N, et al. Microscopic colitis with giant cells. *Histopathology*. 2002;40(4):335-338.
230. Wang N, Dumot JA, Achkar E, et al. Colonic epithelial lymphocytosis without a thickened subepithelial collagen table: a clinicopathologic study of 40 cases supporting a heterogeneous entity. *Am J Surg Pathol*. 1999;23(9):1068-1074.
231. Goldstein NS, Gyorfi T. Focal lymphocytic colitis and collagenous colitis: patterns of Crohn's colitis? *Am J Surg Pathol*. 1999;23(9):1075-1081.
232. Bryant DA, Mintz ED, Puhr ND, et al. Colonic epithelial lymphocytosis associated with an epidemic of chronic diarrhea. *Am J Surg Pathol*. 1996;20(9):1102-1109.
233. Olesen M, Eriksson S, Bohr J, et al. Lymphocytic colitis: a retrospective clinical study of 199 Swedish patients. *Gut*. 2004;53(4):536-541.
234. Baert F, Wouters K, D'Haens G, et al. Lymphocytic colitis: a distinct clinical entity? A clinicopathological confrontation of lymphocytic and collagenous colitis. *Gut*. 1999;45(3):375-381.
235. Greenson JK, Stern RA, Carpenter SL, Barnett JL. The clinical significance of focal active colitis. *Hum Pathol*. 1997;28(6):729-733.
236. Volk EE, Shapiro BD, Easley KA, Goldblum JR. The clinical significance of a biopsy-based diagnosis of focal active colitis: a clinicopathologic study of 31 cases. *Mod Pathol*. 1998;11(8):789-794.
237. Xin W, Brown PI, Greenson JK. The clinical significance of focal active colitis in pediatric patients. *Am J Surg Pathol*. 2003;27(8):1134-1138.
238. Fekety R, Shah AB. Diagnosis and treatment of *Clostridium difficile* colitis. *JAMA*. 1993;269(1):71-75.
239. George RH, Symonds JM, Dimock F, et al. Identification of *Clostridium difficile* as a cause of pseudomembranous colitis. *Br Med J*. 1978;1(6114):695.
240. Medline A, Shin DH, Medline NM. Pseudomembranous colitis associated with antibiotics. *Hum Pathol*. 1976;7(6):693-703.
241. Triadafilopoulos G, Hallstone AE. Acute abdomen as the first presentation of pseudomembranous colitis. *Gastroenterology*. 1991;101(3):685-691.
242. Kawamoto S, Horton KM, Fishman EK. Pseudomembranous colitis: can CT predict which patients will need surgical intervention? *J Comput Assist Tomogr*. 1999;23(1):79-85.
243. Sumner HW, Tedesco FJ. Rectal biopsy in clindamycin-associated colitis. An analysis of 23 cases. *Arch Pathol*. 1975;99(5):237-241.
244. Schnitt SJ, Antonioli DA, Goldman H. Massive mural edema in severe pseudomembranous colitis. *Arch Pathol Lab Med*. 1983;107(4):211-213.
245. Damiani S, Campidelli C. Pseudomembranous colitis with signet-ring cells. *Histopathology*. 2002;41(2):176-177.
246. Luciano JA, Zuckerbraun BS. *Clostridium difficile* infection: prevention, treatment, and surgical management. *Surg Clin North Am*. 2014;94(6):1335-1349.
247. Edwards CM, George B, Warren B. Diversion colitis—new light through old windows. *Histopathology*. 1999;34(1):1-5.
248. Kabir SI, Kabir SA, Richards R, et al. Pathophysiology, clinical presentation and management of diversion colitis: a review of current literature. *Int J Surg*. 2014;12(10):1088-1092.
249. Feakins RM, British Society of Gastroenterology. Inflammatory bowel disease biopsies: updated British Society of Gastroenterology reporting guidelines. *J Clin Pathol*. 2013;66(12):1005-1026.
250. Geraghty JM, Talbot IC. Diversion colitis: histological features in the colon and rectum after defunctioning colostomy. *Gut*. 1991;32(9):1020-1023.
251. Haque S, Eisen RN, West AB. The morphologic features of diversion colitis: studies of a pediatric population with no other disease of the intestinal mucosa. *Hum Pathol*. 1993;24(2):211-219.
252. Yeong ML, Bethwaite PB, Prasad J, Isbister WH. Lymphoid follicular hyperplasia—a distinctive feature of diversion colitis. *Histopathology*. 1991;19(1):55-61.
253. Kliegman RM, Fanaroff AA. Necrotizing enterocolitis. *N Engl J Med*. 1984;310(17):1093-1103.
254. Miller TA, Minich LL, Lambert LM, et al. Abnormal abdominal aorta hemodynamics are associated with necrotizing enterocolitis in infants with hypoplastic left heart syndrome. *Pediatr Cardiol*. 2014;35(4):616-621.
255. Peres LC, Cohen MC. Sudden unexpected early neonatal death due to undiagnosed Hirschsprung disease enterocolitis: a report of two cases and literature review. *Forensic Sci Med Pathol*. 2013;9(4):558-563.
256. Lambert DK, Christensen RD, Henry E, et al. Necrotizing enterocolitis in term neonates: data from a multihospital health-care system. *J Perinatol*. 2007;27(7):437-443.
257. Rehan VK, Seshia MM, Johnston B, et al. Observer variability in interpretation of abdominal radiographs of infants with suspected necrotizing enterocolitis. *Clin Pediatr (Phila)*. 1999;38(11):637-643.
258. Munaco AJ, Veenstra MA, Brownie E, et al. Timing of optimal surgical intervention for neonates with necrotizing enterocolitis. *Am Surg*. 2015;81(5):438-443.
259. Canioni D, Pauliat S, Gaillard JL, et al. Histopathology and microbiology of isolated rectal bleeding in neonates: the so-called "ecchymotic colitis.". *Histopathology*. 1997;30(5):472-477.
260. Pittman FE, el Hashimi WK, Pittman JC. Studies of human amebiasis. I. Clinical and laboratory findings in eight cases of acute amebic colitis. *Gastroenterology*. 1973;65(4):581-587.
261. Haque R, Huston CD, Hughes M, et al. Amebiasis. *N Engl J Med*. 2003;348(16):1565-1573.
262. Kobayashi TK, Koretoh O, Kamachi M, et al. Cytologic demonstration of Entamoeba histolytica using immunoperoxidase techniques. Report of two cases. *Acta Cytol*. 1985;29(3):414-418.
263. Alvi AR, Jawad A, Fazal F, Sayyed R. Fulminant amoebic colitis: a rare fierce presentation of a common pathology. *Trop Doct*. 2013;43(2):80-82.
264. Palmer KR, Patil DH, Basran GS, et al. Abdominal tuberculosis in urban Britain—a common disease. *Gut*. 1985;26(12):1296-1305.
265. Zhao X-S, Wang Z-T, Wu Z-Y, et al. Differentiation of Crohn's disease from intestinal tuberculosis by clinical and CT enterographic models. *Inflamm Bowel Dis*. 2014;20(5):916-925.
266. Gaffney EF, Condell D, Majmudar B, et al. Modification of caecal lymphoid tissue and relationship to granuloma formation in sporadic ileocaecal tuberculosis. *Histopathology*. 1987;11(7):691-704.
267. Mapstone NP, Dixon MF. Vasculitis in ileocaecal tuberculosis: similarities to Crohn's disease. *Histopathology*. 1992;21(5):477-479.
268. Lee FD, Roy AD. Ileo-caecal granulomata. *Gut*. 1964;5:517-523.
269. Yu H, Liu Y, Wang Y, et al. Clinical, endoscopic and histological differentiations between Crohn's disease and intestinal tuberculosis. *Digestion*. 2012;85(3):202-209.
270. Lemonovich TL, Watkins RR. Update on cytomegalovirus infections of the gastrointestinal system in solid organ transplant recipients. *Curr Infect Dis Rep*. 2012;14(1):33-40.
271. Bini EJ, Gorelick SM, Weinshel EH. Outcome of AIDS-associated cytomegalovirus colitis in the era of potent antiretroviral therapy. *J Clin Gastroenterol*. 2000;30(4):414-419.
272. Kim YS, Kim Y-H, Kim JS, et al. Long-term outcomes of cytomegalovirus reactivation in patients with moderate to severe ulcerative colitis: a multicenter study. *Gut Liver*. 2014;8(6):643-647.
273. Kambham N, Vij R, Cartwright CA, Longacre T. Cytomegalovirus infection in steroid-refractory ulcerative colitis: a case-control study. *Am J Surg Pathol*. 2004;28(3):365-373.
274. Wisser J, Zingman B, Wasik M, et al. Cytomegalovirus pseudotumor presenting as bowel obstruction in a patient with acquired immunodeficiency syndrome. *Am J Gastroenterol*. 1992;87(6):771-774.
275. Mills AM, Guo FP, Copland AP, et al. A comparison of CMV detection in gastrointestinal mucosal biopsies using immunohistochemistry and PCR performed on formalin-fixed, paraffin-embedded tissue. *Am J Surg Pathol*. 2013;37(7):995-1000.
276. Bellomo AR, Perlman DC, Kaminsky DL, et al. Pneumocystis colitis in a patient with the acquired immunodeficiency syndrome. *Am J Gastroenterol*. 1992;87(6):759-761.
277. Fan X, Scott L, Qiu S, et al. Colonic coinfection of histoplasma and cytomegalovirus mimicking carcinoma in a patient with HIV/AIDS. *Gastrointest Endosc*. 2008;67(6):977-978, discussion 978.
278. Thomas PD, Pollok RC, Gazzard BG. Enteric viral infections as a cause of diarrhoea in the

acquired immunodeficiency syndrome. *HIV Med*. 1999;1(1):19-24.
279. Lowe D, Hessler R, Lee J, et al. Toxoplasma colitis in a patient with acquired immune deficiency syndrome. *Gastrointest Endosc*. 2006;63(2):341-342.
280. Fernandes ER, Pagliari C, Tuon FF, et al. Chronic colitis associated with HIV infection can be related to intraepithelial infiltration of the colon by CD8+ T lymphocytes. *Int J STD AIDS*. 2008;19(8):524-528.
281. Qu Z, Kundu UR, Abadeer RA, Wanger A. Strongyloides colitis is a lethal mimic of ulcerative colitis: the key morphologic differential diagnosis. *Hum Pathol*. 2009;40(4):572-577.
282. Chin AB, Kumar AS. Behcet colitis. *Clin Colon Rectal Surg*. 2015;28(2):99-102.
283. Lee RG. The colitis of Behçet's syndrome. *Am J Surg Pathol*. 1986;10(12):888-893.
284. Snover DC. Graft-versus-host disease of the gastrointestinal tract. *Am J Surg Pathol*. 1990;14(suppl 1):101-108.
285. Bombí JA, Nadal A, Carreras E, et al. Assessment of histopathologic changes in the colonic biopsy in acute graft-versus-host disease. *Am J Clin Pathol*. 1995;103(6):690-695.
286. Galati JS, Wisecarver JL, Quigley EM. Inflammatory polyps as a manifestation of intestinal graft versus host disease. *Gastrointest Endosc*. 1993;39(5):719-722.
287. Asplund S, Gramlich TL. Chronic mucosal changes of the colon in graft-versus-host disease. *Mod Pathol*. 1998;11(6):513-515.
288. Star KV, Ho VT, Wang HH, Odze RD. Histologic features in colon biopsies can discriminate mycophenolate from GVHD-induced colitis. *Am J Surg Pathol*. 2013;37(9):1319-1328.
289. Andreyev HJN, Davidson SE, Gillespie C, et al. Practice guidance on the management of acute and chronic gastrointestinal problems arising as a result of treatment for cancer. *Gut*. 2012;61(2):179-192.
290. Gorschlüter M, Mey U, Strehl J, et al. Neutropenic enterocolitis in adults: systematic analysis of evidence quality. *Eur J Haematol*. 2005;75(1):1-13.
291. Katz JA, Wagner ML, Gresik MV, et al. Typhlitis. An 18-year experience and postmortem review. *Cancer*. 1990;65(4):1041-1047.
292. Shafey A, Ethier M-C, Traubici J, et al. Incidence, risk factors, and outcomes of enteritis, typhlitis, and colitis in children with acute leukemia. *J Pediatr Hematol Oncol*. 2013;35(7):514-517.
293. Baglaj M, Carachi R, MacCormack B. Colonic atresia: a clinicopathological insight into its etiology. *Eur J Pediatr*. 2010;20(2):102-105.
294. Cox SG, Numanoglu A, Millar AJW, Rode H. Colonic atresia: spectrum of presentation and pitfalls in management. A review of 14 cases. *Pediatr Surg Int*. 2005;21(10):813-818.
295. Downs-Kelly E, Hoschar AP, Prayson RA. Salivary gland heterotopia in the rectum. *Ann Diagn Pathol*. 2003;7(2):124-126.
296. Kawahara K, Mishima H, Nakamura S. Heterotopic respiratory mucosa in the rectum: a first case report. *Virchows Arch*. 2007;451(5):977-980.
297. Chrysanthos N, Anagnostopoulou E, Daskalaki A, Patsavela S. Image of the month: heterotopic gastric mucosa of the rectum presenting as rectal bleeding. *Am J Gastroenterol*. 2015;110(4):498.
298. Brett EM, Berry CL. Value of rectal biopsy in paediatric neurology: report of 165 biopsies. *Br Med J*. 1967;3(5562):400-403.
299. Rapola J, Santavuori P, Savilahti E. Suction biopsy of rectal mucosa in the diagnosis of infantile and juvenile types of neuronal ceroid lipofuscinoses. *Hum Pathol*. 1984;15(4):352-360.
300. Byers RJ, Marsh P, Parkinson D, Haboubi NY. Melanosis coli is associated with an increase in colonic epithelial apoptosis and not with laxative use. *Histopathology*. 1997;30(2):160-164.
301. Lane KL, Vallera R, Washington K, Gottfried MR. Endoscopic tattoo agents in the colon. Tissue responses and clinical implications. *Am J Surg Pathol*. 1996;20(10):1266-1270.
302. Yantiss RK, Clement PB, Young RH. Endometriosis of the intestinal tract: a study of 44 cases of a disease that may cause diverse challenges in clinical and pathologic evaluation. *Am J Surg Pathol*. 2001;25(4):445-454.
303. Daya D, O'Connell G, DeNardi F. Rectal endometriosis mimicking solitary rectal ulcer syndrome. *Mod Pathol*. 1995;8(6):599-602.
304. Langlois NE, Park KG, Keenan RA. Mucosal changes in the large bowel with endometriosis: a possible cause of misdiagnosis of colitis? *Hum Pathol*. 1994;25(10):1030-1034.
305. Aust DE, Rüschoff J. Polyps of the colorectum: non-neoplastic and non-hamartomatous. *Pathol*. 2011;32(4):297-302.
306. Petersen VC, Underwood JCE, Wells M, Shepherd NA. Primary endometrioid adenocarcinoma of the large intestine arising in colorectal endometriosis. *Histopathology*. 2002;40(2):171-176.
307. Slavin RE, Krum R, Van Dinh T. Endometriosis-associated intestinal tumors: a clinical and pathological study of 6 cases with a review of the literature. *Hum Pathol*. 2000;31(4):456-463.
308. Paccalin M, Hachulla E, Cazalet C, et al. Localized amyloidosis: a survey of 35 French cases. *Amyloid*. 2005;12(4):239-245.
309. Kyle RA, Spencer RJ, Dahlin DC. Value of rectal biopsy in the diagnosis of primary systemic amyloidosis. *Am J Med Sci*. 1966;251(5):501-506.
310. Groisman GM, Lachter J, Vlodavsky E. Amyloid colitis mimicking collagenous colitis. *Histopathology*. 1997;31(2):201-202.
311. Hobbs CM, Burch DM, Sobin LH. Elastosis and elastofibromatous change in the gastrointestinal tract: a clinicopathologic study of 13 cases and a review of the literature. *Am J Clin Pathol*. 2004;122(2):232-237.
312. Lodwick DL, Minneci PC, Deans KJ. Current surgical management of intestinal rotational abnormalities. *Curr Opin Pediatr*. 2015;27(3):383-388.
313. Balraj TA, Mohan MJ, P SR. Cecal volvulus—a diagnostic challenge. *J Clin Diagn Res*. 2015;9(4):PJ01.
314. Sagaert X, Tousseyn T, De Hertogh G, Geboes K. Macrophage-related diseases of the gut: a pathologist's perspective. *Virchows Arch Int J Pathol*. 2012;460(6):555-567.
315. Divya P, Crasta JA. Pediatric malakoplakia of colon: a report of two cases. *Pediatr Surg Int*. 2010;26(3):323-325.
316. Karasavvidou F, Potamianos S-P, Barbanis S, et al. Malakoplakia of the colon associated with colonic adenocarcinoma diagnosed in colonic biopsies. *World J Gastroenterol*. 2007;13(45):6109-6111.
317. Boudny P, Kurrer MO, Stamm B, Laeng RH. Malakoplakia of the colon in an infant with severe combined immunodeficiency (SCID) and charge association. *Pathol Res Pract*. 2000;196(8):577-582.
318. Ng IO, Ng M. Colonic malacoplakia: unusual association with ulcerative colitis. *J Gastroenterol Hepatol*. 1993;8(1):110-115.
319. Mayorga M, Castro F, Fernández F, et al. Radiohistology and histochemistry of barium granuloma of the colon and rectum. *Histol Histopathol*. 1992;7(4):625-628.
320. Leupin N, Curschmann J, Kranzbühler H, et al. Acute radiation colitis in patients treated with short-term preoperative radiotherapy for rectal cancer. *Am J Surg Pathol*. 2002;26(4):498-504.
321. Sarin A, Safar B. Management of radiation proctitis. *Gastroenterol Clin North Am*. 2013;42(4):913-925.
322. Castillo Contreras O, Salazar Muente F, Young Tabusso F. Benign solitary cecal ulcer. *Indian J Gastroenterol*. 2014;33(5):495.
323. Ong J, Lim K-H, Lim J-F, Eu K-W. Solitary caecal ulcer syndrome: our experience with this benign condition. *Colorectal Dis*. 2011;13(7):786-790.
324. George S, Cook JV. Pneumatosis intestinalis. *J Pediatr*. 2014;165(3):637.
325. Hernanz-Schulman M, Kirkpatrick J, Shwachman H, et al. Pneumatosis intestinalis in cystic fibrosis. *Radiology*. 1986;160(2):497-499.
326. Wu L-L, Yang Y-S, Dou Y, Liu Q-S. A systematic analysis of pneumatosis cystoids intestinalis. *World J Gastroenterol*. 2013;19(30):4973-4978.
327. Suarez V, Chesner IM, Price AB, Newman J. Pneumatosis cystoides intestinalis. Histological mucosal changes mimicking inflammatory bowel disease. *Arch Pathol Lab Med*. 1989;113(8):898-901.
328. Koreishi A, Lauwers GY, Misdraji J. Pneumatosis intestinalis: a challenging biopsy diagnosis. *Am J Surg Pathol*. 2007;31(10):1469-1475.
329. Gui X, Zhou Y, Eidus L, et al. Is pneumatosis cystoides intestinalis gas-distended and ruptured lymphatics? Reappraisal by immunohistochemistry. *Arch Pathol Lab Med*. 2014;138(8):1059-1066.
330. Snover DC, Sandstad J, Hutton S. Mucosal pseudolipomatosis of the colon. *Am J Clin Pathol*. 1985;84(5):575-580.
331. Nakasono M, Hirokawa M, Muguruma N, et al. Colonic pseudolipomatosis, microscopically classified into two groups. *J Gastroenterol Hepatol*. 2006;21(1 Pt 1):65-70.
332. Guest CB, Reznick RK. Colitis cystica profunda. Review of the literature. *Dis Colon Rectum*. 1989;32(11):983-988.
333. Sarzo G, Finco C, Parise P, et al. Colitis cystica profunda of the rectum: report of a case and review of the literature. *Chir Ital*. 2005;57(6):789-798.
334. Magidson JG, Lewin KJ. Diffuse colitis cystica profunda. Report of a case. *Am J Surg Pathol*. 1981;5(4):393-399.
335. Ford MJ, Anderson JR, Gilmour HM, et al. Clinical spectrum of "solitary ulcer" of the rectum. *Gastroenterology*. 1983;84(6):1533-1540.
336. Saul SH. Inflammatory cloacogenic polyp: relationship to solitary rectal ulcer syndrome/mucosal prolapse and other bowel disorders. *Hum Pathol*. 1987;18(11):1120-1125.
337. Singh B, Mortensen NJM, Warren BF. Histopathological mimicry in mucosal prolapse. *Histopathology*. 2007;50(1):97-102.
338. Warren BF, Dankwa EK, Davies JD. "Diamond-shaped" crypts and mucosal elastin: helpful diagnostic features in biopsies of rectal prolapse. *Histopathology*. 1990;17(2):129-134.
339. Tendler DA, Aboudola S, Zacks JF, et al. Prolapsing mucosal polyps: an underrecognized form of colonic polyp—a clinicopathological study of 15 cases. *Am J Gastroenterol*. 2002;97(2):370-376.
340. Li SC, Hamilton SR. Malignant tumors in the rectum simulating solitary rectal ulcer syndrome in endoscopic biopsy specimens. *Am J Surg Pathol*. 1998;22(1):106-112.
341. Laco J, Örhalmi J, Bártová J, Zimandlová D. Enterocolic lymphocytic phlebitis as a newly

recognized manifestation of IgG4-related disease. *Int J Surg Pathol*. 2015;23(2):165-169.
342. Comtesse S, Friemel J, Fankhauser R, Weber A. Enterocolic lymphocytic phlebitis of the cecal pole and appendix vermiformis with increase of IgG4-positive plasma cells. *Virchows Arch Int J Pathol*. 2014;464(1):113-116.
343. Chetty R, Serra S, Kennedy E, Govender D. Oncocytic rectal adenocarcinomas. *Hum Pathol*. 2009;40(4):478-483.
344. Anders RA, Keith JN, Hart J. Rosai-Dorfman disease presenting in the gastrointestinal tract. *Arch Pathol Lab Med*. 2003;127(2):E74-E75.
345. Lauwers GY, Perez-Atayde A, Dorfman RF, Rosai J. The digestive system manifestations of Rosai-Dorfman disease (sinus histiocytosis with massive lymphadenopathy): review of 11 cases. *Hum Pathol*. 2000;31(3):380-385.
346. Lloyd-Still JD, Beno DW, Kimura RM. Cystic fibrosis colonopathy. *Curr Gastroenterol Rep*. 1999;1(3):231-237.
347. Pawel BR, de Chadarévian JP, Franco ME. The pathology of fibrosing colonopathy of cystic fibrosis: a study of 12 cases and review of the literature. *Hum Pathol*. 1997;28(4):395-399.
348. Konishi F, Morson BC. Pathology of colorectal adenomas: a colonoscopic survey. *J Clin Pathol*. 1982;35(8):830-841.
349. Williams AR, Balasooriya BA, Day DW. Polyps and cancer of the large bowel: a necropsy study in Liverpool. *Gut*. 1982;23(10):835-842.
350. Sobin LH. The histopathology of bleeding from polyps and carcinomas of the large intestine. *Cancer*. 1985;55(3):577-581.
351. Eide TJ, Schweder T. Clustering of adenomas in the large intestine. *Gut*. 1984;25(11):1262-1267.
352. Kubota O, Kino I. Depressed adenomas of the colon in familial adenomatous polyposis. Histology, immunohistochemical detection of proliferating cell nuclear antigen (PCNA), and analysis of the background mucosa. *Am J Surg Pathol*. 1995;19(3):318-327.
353. Hurlstone DP, Brown S, Cross SS. The role of flat and depressed colorectal lesions in colorectal carcinogenesis: new insights from clinicopathological findings in high-magnification chromoscopic colonoscopy. *Histopathology*. 2003;43(5):413-426.
354. Rubio CA. Atypical mitoses in colorectal adenomas. *Pathol Res Pract*. 1991;187(4):508-513.
355. Fung CH, Goldman H. The incidence and significance of villous change in adenomatous polyps. *Am J Clin Pathol*. 1970;53(1):21-25.
356. Imperiale TF, Juluri R, Sherer EA, et al. A risk index for advanced neoplasia on the second surveillance colonoscopy in patients with previous adenomatous polyps. *Gastrointest Endosc*. 2014;80(3):471-478.
357. Mahajan D, Downs-Kelly E, Liu X, et al. Reproducibility of the villous component and high-grade dysplasia in colorectal adenomas <1 cm: implications for endoscopic surveillance. *Am J Surg Pathol*. 2013;37(3):427-433.
358. Rex DK, Goldblum JR. Pro: Villous elements and high-grade dysplasia help guide post-polypectomy colonoscopic surveillance. *Am J Gastroenterol*. 2008;103(6):1327-1329.
359. Tanizawa T, Seki T, Nakano M, Kamiyama R. Pseudoinvasion of the colorectal polypoid tumors: serial section study of problematic cases. *Pathol Int*. 2003;53(9):584-590.
360. Sarlin JG, Mori K. Morules in epithelial tumors of the colon and rectum. *Am J Surg Pathol*. 1984;8(4):281-285.
361. Almagro UA, Pintar K, Zellmer RB. Squamous metaplasia in colorectal polyps. *Cancer*. 1984;53(12):2679-2682.
362. Domoto H, Terahata S, Senoh A, et al. Clear cell change in colorectal adenomas: its incidence and histological characteristics. *Histopathology*. 1999;34(3):250-256.
363. Pai RK, Rybicki LA, Goldblum JR, et al. Paneth cells in colonic adenomas: association with male sex and adenoma burden. *Am J Surg Pathol*. 2013;37(1):98-103.
364. Kambham N, Troxell M, Longacre TA. Multinucleated epithelial giant cells in colorectal polyps: a potential mimic of viropathic and/or dysplastic changes. *Am J Surg Pathol*. 2005;29(7):912-919.
365. Van den Ingh HF, Van den Broek LJ, Verhofstad AA, Bosman FT. Neuroendocrine cells in colorectal adenomas. *J Pathol*. 1986;148(3):231-237.
366. Rizzo E, Sandmeier D, Hack I, et al. Malakoplakia and colonic adenoma: a rare association. *Ann Diagn Pathol*. 2004;8(6):364-366.
367. Groisman GM, Benkov KJ, Adsay V, Dische MR. Osseous metaplasia in benign colorectal polyps. *Arch Pathol Lab Med*. 1994;118(1):64-65.
368. Wiltz O, O'Toole K, Fenoglio CM. Breast carcinoma metastatic to a solitary adenomatous polyp in the colon. *Arch Pathol Lab Med*. 1984;108(4):318-320.
369. Pretlow TP, Barrow BJ, Ashton WS, et al. Aberrant crypts: putative preneoplastic foci in human colonic mucosa. *Cancer Res*. 1991;51(5):1564-1567.
370. Roncucci L, Stamp D, Medline A, et al. Identification and quantification of aberrant crypt foci and microadenomas in the human colon. *Hum Pathol*. 1991;22(3):287-294.
371. Nascimbeni R, Villanacci V, Mariani PP, et al. Aberrant crypt foci in the human colon: frequency and histologic patterns in patients with colorectal cancer or diverticular disease. *Am J Surg Pathol*. 1999;23(10):1256-1263.
372. Nucci MR, Robinson CR, Longo P, et al. Phenotypic and genotypic characteristics of aberrant crypt foci in human colorectal mucosa. *Hum Pathol*. 1997;28(12):1396-1407.
373. Tanaka S, Saitoh Y, Matsuda T, et al. Evidence-based clinical practice guidelines for management of colorectal polyps. *J Gastroenterol*. 2015;50(3):252-260.
374. Estrada RG, Spjut HJ. Hyperplastic polyps of the large bowel. *Am J Surg Pathol*. 1980;4(2):127-133.
375. Qazi TM, O'Brien MJ, Farraye FA, et al. Epidemiology of goblet cell and microvesicular hyperplastic polyps. *Am J Gastroenterol*. 2014;109(12):1922-1932.
376. Tateyama H, Li W, Takahashi E, et al. Apoptosis index and apoptosis-related antigen expression in serrated adenoma of the colorectum: the saw-toothed structure may be related to inhibition of apoptosis. *Am J Surg Pathol*. 2002;26(2):249-256.
377. Snover D, Ahnen D, Burt R, et al. Serrated polyps of the colon and rectum and serrated polyposis. In: Bosman FT, ed. *WHO Classification of Tumors of the Digestive System*. 4th ed. Lyon: IARC Press; 2010:160-165.
378. Longacre TA, Fenoglio-Preiser CM. Mixed hyperplastic adenomatous polyps/serrated adenomas. A distinct form of colorectal neoplasia. *Am J Surg Pathol*. 1990;14(6):524-537.
379. Torlakovic E, Snover DC. Serrated adenomatous polyposis in humans. *Gastroenterology*. 1996;110(3):748-755.
380. Goldstein NS, Bhanot P, Odish E, Hunter S. Hyperplastic-like colon polyps that preceded microsatellite-unstable adenocarcinomas. *Am J Clin Pathol*. 2003;119(6):778-796.
381. Iino H, Jass JR, Simms LA, et al. DNA microsatellite instability in hyperplastic polyps, serrated adenomas, and mixed polyps: a mild mutator pathway for colorectal cancer? *J Clin Pathol*. 1999;52(1):5-9.
382. Kambara T, Simms LA, Whitehall VLJ, et al. BRAF mutation is associated with DNA methylation in serrated polyps and cancers of the colorectum. *Gut*. 2004;53(8):1137-1144.
383. McGivern A, Wynter CVA, Whitehall VLJ, et al. Promoter hypermethylation frequency and BRAF mutations distinguish hereditary non-polyposis colon cancer from sporadic MSI-H colon cancer. *Fam Cancer*. 2004;3(2):101-107.
384. O'Brien MJ, Yang S, Mack C, et al. Comparison of microsatellite instability, CpG island methylation phenotype, BRAF and KRAS status in serrated polyps and traditional adenomas indicates separate pathways to distinct colorectal carcinoma end points. *Am J Surg Pathol*. 2006;30(12):1491-1501.
385. Batts KP. The pathology of serrated colorectal neoplasia: practical answers for common questions. *Mod Pathol*. 2015;28(suppl 1):S80-S87.
386. Szylberg Ł, Janiczek M, Popiel A, Marszałek A. Serrated polyps and their alternative pathway to the colorectal cancer: a systematic review. *Gastroenterol Res Pract*. 2015;2015:573814.
387. O'Brien MJ, Zhao Q, Yang S. Colorectal serrated pathway cancers and precursors. *Histopathology*. 2015;66(1):49-65.
388. Rosty C, Buchanan DD, Walsh MD, et al. Phenotype and polyp landscape in serrated polyposis syndrome: a series of 100 patients from genetics clinics. *Am J Surg Pathol*. 2012;36(6):876-882.
389. Tinmouth J, Henry P, Hsieh E, et al. Sessile serrated polyps at screening colonoscopy: have they been under diagnosed? *Am J Gastroenterol*. 2014;109(11):1698-1704.
390. Rau TT, Agaimy A, Gehoff A, et al. Defined morphological criteria allow reliable diagnosis of colorectal serrated polyps and predict polyp genetics. *Virchows Arch Int J Pathol*. 2014;464(6):663-672.
391. Bettington M, Walker N, Rosty C, et al. Critical appraisal of the diagnosis of the sessile serrated adenoma. *Am J Surg Pathol*. 2014;38(2):158-166.
392. Rex DK, Ahnen DJ, Baron JA, et al. Serrated lesions of the colorectum: review and recommendations from an expert panel. *Am J Gastroenterol*. 2012;107(9):1315-1329, quiz 1314, 1330.
393. Sheridan TB, Fenton H, Lewin MR, et al. Sessile serrated adenomas with low- and high-grade dysplasia and early carcinomas: an immunohistochemical study of serrated lesions "caught in the act.". *Am J Clin Pathol*. 2006;126(4):564-571.
394. Minoo P, Baker K, Goswami R, et al. Extensive DNA methylation in normal colorectal mucosa in hyperplastic polyposis. *Gut*. 2006;55(10):1467-1474.
395. Rosty C, Walsh MD, Walters RJ, et al. Multiplicity and molecular heterogeneity of colorectal carcinomas in individuals with serrated polyposis. *Am J Surg Pathol*. 2013;37(3):434-442.
396. Bettington ML, Chetty R. Traditional serrated adenoma: an update. *Hum Pathol*. 2015;46(7):933-938.
397. Yoon JY, Kim HT, Hong SP, et al. High-risk metachronous polyps are more frequent in patients with traditional serrated adenomas than in patients with conventional adenomas: a multicenter prospective study. *Gastrointest Endosc*. 2015;82(6):1087-1093, e3.
398. Torlakovic EE, Gomez JD, Driman DK, et al. Sessile serrated adenoma (SSA) vs. traditional serrated adenoma (TSA). *Am J Surg Pathol*. 2008;32(1):21-29.
399. Hafezi-Bakhtiari S, Wang LM, Colling R, et al. Histological overlap between colorectal villous/tubulovillous and traditional serrated adenomas. *Histopathology*. 2015;66(2):308-313.

400. Fu X, Li L, Peng Y. Wnt signalling pathway in the serrated neoplastic pathway of the colorectum: possible roles and epigenetic regulatory mechanisms. *J Clin Pathol*. 2012;65(8):675-679.
401. Latchford AR, Neale K, Phillips RKS, Clark SK. Juvenile polyposis syndrome: a study of genotype, phenotype, and long-term outcome. *Dis Colon Rectum*. 2012;55(10):1038-1043.
402. Mestre JR. The changing pattern of juvenile polyps. *Am J Gastroenterol*. 1986;81(5):312-314.
403. Nugent KP, Talbot IC, Hodgson SV, Phillips RK. Solitary juvenile polyps: not a marker for subsequent malignancy. *Gastroenterology*. 1993;105(3):698-700.
404. Wu TT, Rezai B, Rashid A, et al. Genetic alterations and epithelial dysplasia in juvenile polyposis syndrome and sporadic juvenile polyps. *Am J Pathol*. 1997;150(3): 939-947.
405. Burkart AL, Sheridan T, Lewin M, et al. Do sporadic Peutz-Jeghers polyps exist? Experience of a large teaching hospital. *Am J Surg Pathol*. 2007;31(8):1209-1214.
406. Fulcheri E, Baracchini P, Pagani A, et al. Significance of the smooth muscle cell component in Peutz-Jeghers and juvenile polyps. *Hum Pathol*. 1991;22(11):1136-1140.
407. Bolwell JS, James PD. Peutz—Jeghers syndrome with pseudoinvasion of hamartomatous polyps and multiple epithelial neoplasms. *Histopathology*. 1979;3(1):39-50.
408. Cohen M, Thomson M, Taylor C, et al. Colonic and duodenal flat adenomas in children with classical familial adenomatous polyposis. *Int J Surg Pathol*. 2006;14(2):133-140.
409. Haggitt RC, Reid BJ. Hereditary gastrointestinal polyposis syndromes. *Am J Surg Pathol*. 1986;10(12):871-887.
410. Rustgi AK. Hereditary gastrointestinal polyposis and nonpolyposis syndromes. *N Engl J Med*. 1994;331(25):1694-1702.
411. Bodmer WF, Bailey CJ, Bodmer J, et al. Localization of the gene for familial adenomatous polyposis on chromosome 5. *Nature*. 1987;328(6131):614-616.
412. Sieber OM, Lipton L, Crabtree M, et al. Multiple colorectal adenomas, classic adenomatous polyposis, and germ-line mutations in MYH. *N Engl J Med*. 2003;348(9):791-799.
413. Bronner MP. Gastrointestinal inherited polyposis syndromes. *Mod Pathol*. 2003;16(4):359-365.
414. Ando H, Miyoshi Y, Nagase H, et al. Detection of 12 germ-line mutations in the adenomatous polyposis coli gene by polymerase chain reaction. *Gastroenterology*. 1993;104(4):989-993.
415. Miyoshi Y, Ando H, Nagase H, et al. Germ-line mutations of the APC gene in 53 familial adenomatous polyposis patients. *Proc Natl Acad Sci USA*. 1992;89(10): 4452-4456.
416. Powell SM, Petersen GM, Krush AJ, et al. Molecular diagnosis of familial adenomatous polyposis. *N Engl J Med*. 1993;329(27):1982-1987.
417. Boughdady IS, Kinsella AR, Haboubi NY, Schofield PF. K-ras gene mutation in colorectal adenomas and carcinomas from familial adenomatous polyposis patients. *Surg Oncol*. 1992;1(4):269-274.
418. Campbell F, Geraghty JM, Appleton MA, et al. Increased stem cell somatic mutation in the non-neoplastic colorectal mucosa of patients with familial adenomatous polyposis. *Hum Pathol*. 1998;29(12):1531-1535.
419. Syngal S, Brand RE, Church JM, et al. ACG clinical guideline: genetic testing and management of hereditary gastrointestinal cancer syndromes. *Am J Gastroenterol*. 2015;110(2):223-262, quiz 263.
420. Wu TT, Kornacki S, Rashid A, et al. Dysplasia and dysregulation of proliferation in foveolar and surface epithelia of fundic gland polyps from patients with familial adenomatous polyposis. *Am J Surg Pathol*. 1998;22(3):293-298.
421. Zahid A, Kumar S, Koorey D, Young CJ. Pouch adenomas in Familial Adenomatous Polyposis after restorative proctocolectomy. *Int J Surg*. 2015;13:133-136.
422. Steinhagen E, Guillem JG, Chang G, et al. The prevalence of thyroid cancer and benign thyroid disease in patients with familial adenomatous polyposis may be higher than previously recognized. *Clin Colorectal Cancer*. 2012;11(4):304-308.
423. Hirano H, Okimura A, Nakasho K, et al. Familial adenomatous polyposis associated with colon carcinoma, desmoid tumour, gallbladder carcinoma, and endometrioid carcinoma: a case report. *Histopathology*. 2004;45(6):642-643.
424. Moussata D, Senouci L, Berger F, et al. Familial adenomatous polyposis and pancreatic cancer. *Pancreas*. 2015;44(3):512-513.
425. Rauch LB, Erdman SH, Aldrink JH, et al. Fatal extraintestinal adrenal malignancy in a 12-year-old girl with familial adenomatous polyposis. *J Pediatr Gastroenterol Nutr*. 2014;58(2):e19-e20.
426. Harach HR, Williams GT, Williams ED. Familial adenomatous polyposis associated thyroid carcinoma: a distinct type of follicular cell neoplasm. *Histopathology*. 1994;25(6):549-561.
427. Evers C, Gaspar H, Kloor M, et al. Hepatoblastoma in two siblings and familial adenomatous polyposis: causal nexus or coincidence? *Fam Cancer*. 2012;11(3):529-533.
428. Waterhouse D. Nasopharyngeal angiofibroma: a manifestation of familial adenomatous polyposis. *ANZ J Surg*. 2013;83(5):387-388.
429. Xiao G-Q, Granato RC, Unger PD. Bilateral Sertoli cell tumors of the testis—a likely new extracolonic manifestation of familial adenomatous polyposis. *Virchows Arch Int J Pathol*. 2012;461(6):713-715.
430. Lynch HT, Smyrk TC, Watson P, et al. Hereditary flat adenoma syndrome: a variant of familial adenomatous polyposis? *Dis Colon Rectum*. 1992;35(5):411-421.
431. Lynch HT, Watson P, Smyrk TC, et al. Colon cancer genetics. *Cancer*. 1992;70(5 suppl):1300-1312.
432. Lynch HT, Smyrk TC, Lanspa SJ, et al. Upper gastrointestinal manifestations in families with hereditary flat adenoma syndrome. *Cancer*. 1993;71(9):2709-2714.
433. Gardner EJ. Follow-up study of a family group exhibiting dominant inheritance for a syndrome including intestinal polyps, osteomas, fibromas and epidermal cysts. *Am J Hum Genet*. 1962;14:376-390.
434. Penna C, Tiret E, Parc R, et al. Operation and abdominal desmoid tumors in familial adenomatous polyposis. *Surg Gynecol Obstet*. 1993;177(3):263-268.
435. Miyaki M, Konishi M, Kikuchi-Yanoshita R, et al. Coexistence of somatic and germ-line mutations of APC gene in desmoid tumors from patients with familial adenomatous polyposis. *Cancer Res*. 1993;53(21): 5079-5082.
436. van Stolk R, Sivak MV, Petrini JL, et al. Endoscopic management of upper gastrointestinal polyps and periampullary lesions in familial adenomatous polyposis and Gardner's syndrome. *Endoscopy*. 1987;19(suppl 1):19-22.
437. Cervoni L, Celli P, Tarantino R, Fortuna A. Turcot's syndrome: case report and review of the classification. *J Neurooncol*. 1995;23(1):63-66.
438. Tops CM, Vasen HF, van Berge Henegouwen G, et al. Genetic evidence that Turcot syndrome is not allelic to familial adenomatous polyposis. *Am J Med Genet*. 1992;43(5):888-893.
439. Hamilton SR, Liu B, Parsons RE, et al. The molecular basis of Turcot's syndrome. *N Engl J Med*. 1995;332(13):839-847.
440. Ponti G, Manfredini M, Tomasi A, Pellacani G. Muir-Torre Syndrome and founder mismatch repair gene mutations: a long gone historical genetic challenge. *Gene*. 2016;589(2):127-132.
441. Bhaijee F, Brown AS. Muir-Torre syndrome. *Arch Pathol Lab Med*. 2014;138(12): 1685-1689.
442. Toyoshima N, Sakamoto T, Makazu M, et al. Prevalence of serrated polyposis syndrome and its association with synchronous advanced adenoma and lifestyle. *Mol Clin Oncol*. 2015;3(1):69-72.
443. Patel SG, Ahnen DJ. Familial colon cancer syndromes: an update of a rapidly evolving field. *Curr Gastroenterol Rep*. 2012;14(5):428-438.
444. Pham BN, Villanueva RP. Ganglioneuromatous proliferation associated with juvenile polyposis coli. *Arch Pathol Lab Med*. 1989;113(1):91-94.
445. Aytac E, Sulu B, Heald B, et al. Genotype-defined cancer risk in juvenile polyposis syndrome. *Br J Surg*. 2015;102(1):114-118.
446. Kronborg C, Mahar P, Howard A. Cronkhite-Canada syndrome: a rare disease presenting with dermatological and gastrointestinal manifestations. *Australas J Dermatol*. 2016;57(2):e69-e71.
447. Daniel ES, Ludwig SL, Lewin KJ, et al. The Cronkhite-Canada Syndrome. An analysis of clinical and pathologic features and therapy in 55 patients. *Medicine (Baltimore)*. 1982;61(5):293-309.
448. Burke AP, Sobin LH. The pathology of Cronkhite-Canada polyps. A comparison to juvenile polyposis. *Am J Surg Pathol*. 1989;13(11):940-946.
449. Katayama Y, Kimura M, Konn M. Cronkhite-Canada syndrome associated with a rectal cancer and adenomatous changes in colonic polyps. *Am J Surg Pathol*. 1985;9(1):65-71.
450. Campos FG, Figueiredo MN, Martinez CAR. Colorectal cancer risk in hamartomatous polyposis syndromes. *World J Gastrointest Surg*. 2015;7(3):25-32.
451. Bardeesy N, Sinha M, Hezel AF, et al. Loss of the Lkb1 tumour suppressor provokes intestinal polyposis but resistance to transformation. *Nature*. 2002;419(6903):162-167.
452. Mester J, Eng C. Cowden syndrome: recognizing and managing a not-so-rare hereditary cancer syndrome. *J Surg Oncol*. 2015;111(1):125-130.
453. Carlson GJ, Nivatvongs S, Snover DC. Colorectal polyps in Cowden's disease (multiple hamartoma syndrome). *Am J Surg Pathol*. 1984;8(10):763-770.
454. Ngeow J, Eng C. PTEN hamartoma tumor syndrome: clinical risk assessment and management protocol. *Methods*. 2015;77-78:11-19.
455. Winawer SJ, Zauber AG, Ho MN, et al. Prevention of colorectal cancer by colonoscopic polypectomy. The National Polyp Study Workgroup. *N Engl J Med*. 1993;329(27):1977-1981.
456. Kojima M, Puppa G, Kirsch R, et al. Blood and lymphatic vessel invasion in pT1 colorectal cancer: an international concordance study. *J Clin Pathol*. 2015;68(8):628-632.
457. Gill MD, Rutter MD, Holtham SJ. Management and short-term outcome of

malignant colorectal polyps in the north of England(1). *Colorectal Dis*. 2013;15(2):169-176.
458. Bujanda L, Cosme A, Gil I, Arenas-Mirave JI. Malignant colorectal polyps. *World J Gastroenterol*. 2010;16(25):3103-3111.
459. Cooper HS. Pathologic issues in the treatment of endoscopically removed malignant colorectal polyps. *J Natl Compr Cancer Netw*. 2007;5(9):991-996.
460. Volk EE, Goldblum JR, Petras RE, et al. Management and outcome of patients with invasive carcinoma arising in colorectal polyps. *Gastroenterology*. 1995;109(6):1801-1807.
461. Naqvi S, Burroughs S, Chave HS, Branagan G. Management of colorectal polyp cancers. *Ann R Coll Surg Engl*. 2012;94(8):574-578.
462. Fenoglio CM, Kaye GI, Lane N. Distribution of human colonic lymphatics in normal, hyperplastic, and adenomatous tissue. Its relationship to metastasis from small carcinomas in pedunculated adenomas, with two case reports. *Gastroenterology*. 1973;64(1):51-66.
463. Coverlizza S, Risio M, Ferrari A, et al. Colorectal adenomas containing invasive carcinoma. Pathologic assessment of lymph node metastatic potential. *Cancer*. 1989;64(9):1937-1947.
464. Haggitt RC, Glotzbach RE, Soffer EE, Wruble LD. Prognostic factors in colorectal carcinomas arising in adenomas: implications for lesions removed by endoscopic polypectomy. *Gastroenterology*. 1985;89(2):328-336.
465. Riddell RH. Hands off "cancerous" large bowel polyps. *Gastroenterology*. 1985;89(2):432-435.
466. Euscher ED, Niemann TH, Lucas JG, et al. Large colorectal adenomas. An approach to pathologic evaluation. *Am J Clin Pathol*. 2001;116(3):336-340.
467. Boyle P, Zaridze DG, Smans M. Descriptive epidemiology of colorectal cancer. *Int J Cancer*. 1985;36(1):9-18.
468. Center MM, Jemal A, Ward E. International trends in colorectal cancer incidence rates. *Cancer Epidemiol Biomark*. 2009;18(6):1688-1694.
469. Yantiss RK, Goodarzi M, Zhou XK, et al. Clinical, pathologic, and molecular features of early-onset colorectal carcinoma. *Am J Surg Pathol*. 2009;33(4):572-582.
470. Akin H, Tözün N. Diet, microbiota, and colorectal cancer. *J Clin Gastroenterol*. 2014;48(suppl 1):S67-S69.
471. Hullar MAJ, Fu BC. Diet, the gut microbiome, and epigenetics. *Cancer J*. 2014;20(3): 170-175.
472. Daniel CL, Kohler CL, Stratton KL, et al. Predictors of colorectal cancer surveillance among survivors of childhood cancer treated with radiation: a report from the Childhood Cancer Survivor Study. *Cancer*. 2015;121(11):1856-1863.
473. Berg NO, Fredlund P, Månsson W, Olsson SA. Surveillance colonoscopy and biopsy in patients with ureterosigmoidostomy. *Endoscopy*. 1987;19(2):60-63.
474. Samowitz WS. Evaluation of colorectal cancers for Lynch syndrome: practical molecular diagnostics for surgical pathologists. *Mod Pathol*. 2015;28 (suppl 1):S109-S113.
475. Lynch HT, de la Chapelle A. Hereditary colorectal cancer. *N Engl J Med*. 2003;348(10):919-932.
476. Watson P, Lynch HT. Extracolonic cancer in hereditary nonpolyposis colorectal cancer. *Cancer*. 1993;71(3):677-685.
477. Lynch HT, Smyrk TC, Lanspa SJ, et al. Phenotypic variation in colorectal adenoma/cancer expression in two families. Hereditary flat adenoma syndrome. *Cancer*. 1990;66(5):909-915.
478. Krontiris TG, Devlin B, Karp DD, et al. An association between the risk of cancer and mutations in the HRAS1 minisatellite locus. *N Engl J Med*. 1993;329(8):517-523.
479. Greenson JK, Huang S-C, Herron C, et al. Pathologic predictors of microsatellite instability in colorectal cancer. *Am J Surg Pathol*. 2009;33(1):126-133.
480. Jenkins MA, Hayashi S, O'Shea A-M, et al. Pathology features in Bethesda guidelines predict colorectal cancer microsatellite instability: a population-based study. *Gastroenterology*. 2007;133(1):48-56.
481. Polydorides AD, Mukherjee B, Gruber SB, et al. Adenoma-infiltrating lymphocytes (AILs) are a potential marker of hereditary nonpolyposis colorectal cancer. *Am J Surg Pathol*. 2008;32(11):1661-1666.
482. Geiersbach KB, Samowitz WS. Microsatellite instability and colorectal cancer. *Arch Pathol Lab Med*. 2011;135(10):1269-1277.
483. Umar A, Boland CR, Terdiman JP, et al. Revised Bethesda Guidelines for hereditary nonpolyposis colorectal cancer (Lynch syndrome) and microsatellite instability. *J Natl Cancer Inst*. 2004;96(4):261-268.
484. Hampel H, Frankel WL, Martin E, et al. Feasibility of screening for Lynch syndrome among patients with colorectal cancer. *J Clin Oncol*. 2008;26(35):5783-5788.
485. Boland CR, Shike M. Report from the Jerusalem workshop on Lynch syndrome-hereditary nonpolyposis colorectal cancer. *Gastroenterology*. 2010;138(7):2197.e1-2197.e7.
486. Levin B, Lieberman DA, McFarland B, et al. Screening and surveillance for the early detection of colorectal cancer and adenomatous polyps, 2008: a joint guideline from the American Cancer Society, the US Multi-Society Task Force on Colorectal Cancer, and the American College of Radiology. *CA Cancer J Clin*. 2008;58(3): 130-160.
487. van Ballegooijen M, Habbema JDF, Boer R, et al. *A Comparison of the Cost-Effectiveness of Fecal Occult Blood Tests With Different Test Characteristics in the Context of Annual Screening in the Medicare Population [Internet]*. Rockville (MD): Agency for Healthcare Research and Quality (US); 2003. cited 2015 Jul 15.
488. Thirunavukarasu P, Talati C, Munjal S, et al. Effect of incorporation of pretreatment serum carcinoembryonic antigen levels into AJCC staging for colon cancer on 5-year survival. *JAMA Surg*. 2015;150(8):747-755.
489. Zamcheck N, Doos WG, Prudente R, et al. Prognostic factors in colon carcinoma: correlation of serum carcinoembryonic antigen level and tumor histopathology. *Hum Pathol*. 1975;6(1):31-45.
490. Peng Y, Zhai Z, Li Z, et al. Role of blood tumor markers in predicting metastasis and local recurrence after curative resection of colon cancer. *Int J Clin Exp Med*. 2015;8(1):982-990.
491. Steinbach C, Steinbrücker C, Pollok S, et al. KRAS mutation screening by chip-based DNA hybridization—a further step towards personalized oncology. *Analyst*. 2015;140(8):2747-2754.
492. Pugh SA, Shinkins B, Fuller A, et al. Site and stage of colorectal cancer influence the likelihood and distribution of disease recurrence and postrecurrence survival: data from the FACS randomized controlled trial. *Ann Surg*. 2016;263(6):1143-1147.
493. Cady B, Stone MD, Wayne J. Continuing trends in the prevalence of right-sided lesions among colorectal carcinomas. *Arch Surg*. 1993;128(5):505-509.
494. Powell AGMT, Wallace R, McKee RF, et al. The relationship between tumour site, clinicopathological characteristics and cancer-specific survival in patients undergoing surgery for colorectal cancer. *Colorectal Dis*. 2012;14(12):1493-1499.
495. Greenstein AJ, Slater G, Heimann TM, et al. A comparison of multiple synchronous colorectal cancer in ulcerative colitis, familial polyposis coli, and de novo cancer. *Ann Surg*. 1986;203(2):123-128.
496. Iishi H, Tatsuta M, Tsutsui S, et al. Early depressed adenocarcinomas of the large intestine. *Cancer*. 1992;69(10):2406-2410.
497. Nasir A, Boulware D, Kaiser HE, et al. Flat and polypoid adenocarcinomas of the colorectum: a comparative histomorphologic analysis of 47 cases. *Hum Pathol*. 2004;35(5):604-611.
498. Yasuda K, Ajioka Y, Watanabe H, et al. Morphogenesis and development of superficial spreading tumor of the colon and rectum. *Pathol Int*. 1997;47(11):769-774.
499. Joo M, Shahsafaei A, Odze RD. Paneth cell differentiation in colonic epithelial neoplasms: evidence for the role of the Apc/beta-catenin/Tcf pathway. *Hum Pathol*. 2009;40(6):872-880.
500. De Smedt L, Lemahieu J, Palmans S, et al. Microsatellite instable vs stable colon carcinomas: analysis of tumour heterogeneity, inflammation and angiogenesis. *Br J Cancer*. 2015;113(3):500-509.
501. Legitimo A, Consolini R, Failli A, et al. Dendritic cell defects in the colorectal cancer. *Hum Vaccines Immunother*. 2014;10(11):3224-3235.
502. Tajima K, Yamakawa M, Inaba Y, et al. Cellular localization of interleukin-5 expression in rectal carcinoma with eosinophilia. *Hum Pathol*. 1998;29(9):1024-1028.
503. Abdulkader M, Abdulla K, Rakha E, Kaye P. Routine elastic staining assists detection of vascular invasion in colorectal cancer. *Histopathology*. 2006;49(5):487-492.
504. Zhang H, Ahmadi A, Arbman G, et al. Glutathione S-transferase T1 and M1 genotypes in normal mucosa, transitional mucosa and colorectal adenocarcinoma. *Int J Cancer*. 1999;84(2):135-138.
505. Cao Y, Schlag PM, Karsten U. Immunodetection of epithelial mucin (MUC1, MUC3) and mucin-associated glycotopes (TF, Tn, and sialosyl-Tn) in benign and malignant lesions of colonic epithelium: apolar localization corresponds to malignant transformation. *Virchows Arch Int J Pathol*. 1997;431(3):159-166.
506. Walsh MD, Young JP, Leggett BA, et al. The MUC13 cell surface mucin is highly expressed by human colorectal carcinomas. *Hum Pathol*. 2007;38(6):883-892.
507. Walsh MD, Clendenning M, Williamson E, et al. Expression of MUC2, MUC5AC, MUC5B, and MUC6 mucins in colorectal cancers and their association with the CpG island methylator phenotype. *Mod Pathol*. 2013;26(12):1642-1656.
508. Berezowski K, Stastny JF, Kornstein MJ. Cytokeratins 7 and 20 and carcinoembryonic antigen in ovarian and colonic carcinoma. *Mod Pathol*. 1996;9(4):426-429.
509. Loy TS, Calaluce RD, Keeney GL. Cytokeratin immunostaining in differentiating primary ovarian carcinoma from metastatic colonic adenocarcinoma. *Mod Pathol*. 1996;9(11):1040-1044.
510. Kende AI, Carr NJ, Sobin LH. Expression of cytokeratins 7 and 20 in carcinomas of the gastrointestinal tract. *Histopathology*. 2003;42(2):137-140.
511. Saad RS, Silverman JF, Khalifa MA, Rowsell C. CDX2, cytokeratins 7 and 20 immunoreactivity in rectal adenocarcinoma.

Appl Immunohistochem Mol Morphol. 2009;17(3):196-201.
512. O'Brien MJ, Zamcheck N, Burke B, et al. Immunocytochemical localization of carcinoembryonic antigen in benign and malignant colorectal tissues. Assessment of diagnostic value. *Am J Clin Pathol*. 1981;75(3):283-290.
513. Hamada Y, Yamamura M, Hioki K, et al. Immunohistochemical study of carcinoembryonic antigen in patients with colorectal cancer. Correlation with plasma carcinoembryonic antigen levels. *Cancer*. 1985;55(1):136-141.
514. Kaimaktchiev V, Terracciano L, Tornillo L, et al. The homeobox intestinal differentiation factor CDX2 is selectively expressed in gastrointestinal adenocarcinomas. *Mod Pathol*. 2004;17(11):1392-1399.
515. Werling RW, Yaziji H, Bacchi CE, Gown AM. CDX2, a highly sensitive and specific marker of adenocarcinomas of intestinal origin: an immunohistochemical survey of 476 primary and metastatic carcinomas. *Am J Surg Pathol*. 2003;27(3):303-310.
516. Listrom MB, Little JV, McKinley M, Fenoglio-Preiser CM. Immunoreactivity of tumor-associated glycoprotein (TAG-72) in normal, hyperplastic, and neoplastic colon. *Hum Pathol*. 1989;20(10):994-1000.
517. Bacchi CE, Gown AM. Distribution and pattern of expression of villin, a gastrointestinal-associated cytoskeletal protein, in human carcinomas: a study employing paraffin-embedded tissue. *Lab Investig J Tech Methods Pathol*. 1991;64(3):418-424.
518. Campo E, Muñoz J, Miquel R, et al. Cathepsin B expression in colorectal carcinomas correlates with tumor progression and shortened patient survival. *Am J Pathol*. 1994;145(2):301-309.
519. Hansel DE, Wilentz RE, Yeo CJ, et al. Expression of neuropilin-1 in high-grade dysplasia, invasive cancer, and metastases of the human gastrointestinal tract. *Am J Surg Pathol*. 2004;28(3):347-356.
520. Su M-C, Yuan R-H, Lin C-Y, Jeng Y-M. Cadherin-17 is a useful diagnostic marker for adenocarcinomas of the digestive system. *Mod Pathol*. 2008;21(11):1379-1386.
521. Gotzos V, Wintergerst ES, Musy JP, et al. Selective distribution of calretinin in adenocarcinomas of the human colon and adjacent tissues. *Am J Surg Pathol*. 1999;23(6):701-711.
522. Yamaguchi A, Ishida T, Nishimura G, et al. Human chorionic gonadotropin in colorectal cancer and its relationship to prognosis. *Br J Cancer*. 1989;60(3):382-384.
523. Campo E, Palacin A, Benasco C, et al. Human chorionic gonadotropin in colorectal carcinoma. An immunohistochemical study. *Cancer*. 1987;59(9):1611-1616.
524. Slattery ML, Samowitz WS, Holden JA. Estrogen and progesterone receptors in colon tumors. *Am J Clin Pathol*. 2000;113(3):364-368.
525. Chen Z-ME, Ritter JH, Wang HL. Differential expression of alpha-methylacyl coenzyme A racemase in adenocarcinomas of the small and large intestines. *Am J Surg Pathol*. 2005;29(7):890-896.
526. Kinzler KW, Vogelstein B. Lessons from hereditary colorectal cancer. *Cell*. 1996;87(2):159-170.
527. Bosman FT. Molecular pathology of colorectal cancer. *Cytogenet Cell Genet*. 1999;86(2):112-117.
528. Markowitz SD, Bertagnolli MM. Molecular origins of cancer: molecular basis of colorectal cancer. *N Engl J Med*. 2009;361(25):2449-2460.
529. Fearon ER, Vogelstein B. A genetic model for colorectal tumorigenesis. *Cell*. 1990;61(5):759-767.
530. Edmonston TB, Cuesta KH, Burkholder S, et al. Colorectal carcinomas with high microsatellite instability: defining a distinct immunologic and molecular entity with respect to prognostic markers. *Hum Pathol*. 2000;31(12):1506-1514.
531. Loukola A, Salovaara R, Kristo P, et al. Microsatellite instability in adenomas as a marker for hereditary nonpolyposis colorectal cancer. *Am J Pathol*. 1999;155(6): 1849-1853.
532. Hawkins NJ, Ward RL. Sporadic colorectal cancers with microsatellite instability and their possible origin in hyperplastic polyps and serrated adenomas. *J Natl Cancer Inst*. 2001;93(17):1307-1313.
533. Jass JR. Classification of colorectal cancer based on correlation of clinical, morphological and molecular features. *Histopathology*. 2007;50(1):113-130.
534. Shia J, Ellis NA, Paty PB, et al. Value of histopathology in predicting microsatellite instability in hereditary nonpolyposis colorectal cancer and sporadic colorectal cancer. *Am J Surg Pathol*. 2003;27(11):1407-1417.
535. Wright CL, Stewart ID. Histopathology and mismatch repair status of 458 consecutive colorectal carcinomas. *Am J Surg Pathol*. 2003;27(11):1393-1406.
536. Grady WM, Markowitz SD. The molecular pathogenesis of colorectal cancer and its potential application to colorectal cancer screening. *Dig Dis Sci*. 2015;60(3): 762-772.
537. Finkelstein SD, Sayegh R, Christensen S, Swalsky PA. Genotypic classification of colorectal adenocarcinoma. Biologic behavior correlates with K-ras-2 mutation type. *Cancer*. 1993;71(12):3827-3838.
538. Ren J, Li G, Ge J, et al. Is K-ras gene mutation a prognostic factor for colorectal cancer: a systematic review and meta-analysis. *Dis Colon Rectum*. 2012;55(8):913-923.
539. Khambata-Ford S, Garrett CR, Meropol NJ, et al. Expression of epiregulin and amphiregulin and K-ras mutation status predict disease control in metastatic colorectal cancer patients treated with cetuximab. *J Clin Oncol*. 2007;25(22):3230-3237.
540. Plesec TP, Hunt JL. KRAS mutation testing in colorectal cancer. *Adv Anat Pathol*. 2009;16(4):196-203.
541. Brabletz T, Jung A, Reu S, et al. Variable beta-catenin expression in colorectal cancers indicates tumor progression driven by the tumor environment. *Proc Natl Acad Sci USA*. 2001;98(18):10356-10361.
542. Rodrigues NR, Rowan A, Smith ME, et al. p53 mutations in colorectal cancer. *Proc Natl Acad Sci USA*. 1990;87(19):7555-7559.
543. Loda M, Cukor B, Tam SW, et al. Increased proteasome-dependent degradation of the cyclin-dependent kinase inhibitor p27 in aggressive colorectal carcinomas. *Nat Med*. 1997;3(2):231-234.
544. Bertagnolli MM, Warren RS, Niedzwiecki D, et al. p27Kip1 in stage III colon cancer: implications for outcome following adjuvant chemotherapy in cancer and leukemia group B protocol 89803. *Clin Cancer Res*. 2009;15(6):2116-2122.
545. Sasaki O, Atkin WS, Jass JR. Mucinous carcinoma of the rectum. *Histopathology*. 1987;11(3):259-272.
546. Symonds DA, Vickery AL. Mucinous carcinoma of the colon and rectum. *Cancer*. 1976;37(4):1891-1900.
547. Kazama Y, Watanabe T, Kanazawa T, et al. Mucinous carcinomas of the colon and rectum show higher rates of microsatellite instability and lower rates of chromosomal instability: a study matched for T classification and tumor location. *Cancer*. 2005;103(10):2023-2029.
548. Park ET, Oh HK, Gum JR, et al. HATH1 expression in mucinous cancers of the colorectum and related lesions. *Clin Cancer Res*. 2006;12(18):5403-5410.
549. Sáez C, Japón MA, Poveda MA, Segura DI. Mucinous (colloid) adenocarcinomas secrete distinct O-acylated forms of sialomucins: a histochemical study of gastric, colorectal and breast adenocarcinomas. *Histopathology*. 2001;39(6):554-560.
550. Sundblad AS, Paz RA. Mucinous carcinomas of the colon and rectum and their relation to polyps. *Cancer*. 1982;50(11): 2504-2509.
551. Younes M, Katikaneni PR, Lechago J. The value of the preoperative mucosal biopsy in the diagnosis of colorectal mucinous adenocarcinoma. *Cancer*. 1993;72(12):3588-3592.
552. Consorti F, Lorenzotti A, Midiri G, Di Paola M. Prognostic significance of mucinous carcinoma of colon and rectum: a prospective case-control study. *J Surg Oncol*. 2000;73(2):70-74.
553. Connelly JH, Robey-Cafferty SS, Cleary KR. Mucinous carcinomas of the colon and rectum. An analysis of 62 stage B and C lesions. *Arch Pathol Lab Med*. 1991;115(10):1022-1025.
554. Nascimbeni R, Burgart LJ, Nivatvongs S, Larson DR. Risk of lymph node metastasis in T1 carcinoma of the colon and rectum. *Dis Colon Rectum*. 2002;45(2):200-206.
555. Yamamoto S, Mochizuki H, Hase K, et al. Assessment of clinicopathologic features of colorectal mucinous adenocarcinoma. *Am J Surg*. 1993;166(3):257-261.
556. Umpleby HC, Ranson DL, Williamson RC. Peculiarities of mucinous colorectal carcinoma. *Br J Surg*. 1985;72(9): 715-718.
557. Kakar S, Smyrk TC. Signet ring cell carcinoma of the colorectum: correlations between microsatellite instability, clinicopathologic features and survival. *Mod Pathol*. 2005;18(2):244-249.
558. Lewin MR, Fenton H, Burkart AL, et al. Poorly differentiated colorectal carcinoma with invasion restricted to lamina propria (intramucosal carcinoma): a follow-up study of 15 cases. *Am J Surg Pathol*. 2007;31(12):1882-1886.
559. Psathakis D, Schiedeck TH, Krug F, et al. Ordinary colorectal adenocarcinoma vs. primary colorectal signet-ring cell carcinoma: study matched for age, gender, grade, and stage. *Dis Colon Rectum*. 1999;42(12):1618-1625.
560. Stevens WR, Ruiz P. Primary linitis plastica carcinoma of the colon and rectum. *Mod Pathol*. 1989;2(3):265-269.
561. Goldstein NS, Long A, Kuan SF, Hart J. Colon signet ring cell adenocarcinoma: immunohistochemical characterization and comparison with gastric and typical colon adenocarcinomas. *Appl Immunohistochem Mol Morphol*. 2000;8(3):183-188.
562. Chu PG, Weiss LM. Immunohistochemical characterization of signet-ring cell carcinomas of the stomach, breast, and colon. *Am J Clin Pathol*. 2004;121(6):884-892.
563. Wang K, Weinrach D, Lal A, et al. Signet-ring cell change versus signet-ring cell carcinoma: a comparative analysis. *Am J Surg Pathol*. 2003;27(11):1429-1433.
564. Sung CO, Seo JW, Kim K-M, et al. Clinical significance of signet-ring cells in colorectal mucinous adenocarcinoma. *Mod Pathol*. 2008;21(12):1533-1541.

565. Kim M-J, Hong S-M, Jang SJ, et al. Invasive colorectal micropapillary carcinoma: an aggressive variant of adenocarcinoma. *Hum Pathol*. 2006;37(7):809-815.
566. Xu F, Xu J, Lou Z, et al. Micropapillary component in colorectal carcinoma is associated with lymph node metastasis in T1 and T2 Stages and decreased survival time in TNM stages I and II. *Am J Surg Pathol*. 2009;33(9):1287-1292.
567. Haupt B, Ro JY, Schwartz MR, Shen SS. Colorectal adenocarcinoma with micropapillary pattern and its association with lymph node metastasis. *Mod Pathol*. 2007;20(7):729-733.
568. Laiho P, Kokko A, Vanharanta S, et al. Serrated carcinomas form a subclass of colorectal cancer with distinct molecular basis. *Oncogene*. 2007;26(2):312-320.
569. Tuppurainen K, Mäkinen JM, Junttila O, et al. Morphology and microsatellite instability in sporadic serrated and non-serrated colorectal cancer. *J Pathol*. 2005;207(3): 285-294.
570. Mäkinen MJ. Colorectal serrated adenocarcinoma. *Histopathology*. 2007;50(1):131-150.
571. García-Solano J, Pérez-Guillermo M, Conesa-Zamora P, et al. Clinicopathologic study of 85 colorectal serrated adenocarcinomas: further insights into the full recognition of a new subset of colorectal carcinoma. *Hum Pathol*. 2010;41(10):1359-1368.
572. Gurzu S, Szentirmay Z, Bara T, et al. Molecular and immunohistochemical profile of a basaloid (cloacogenic) carcinoma of the sigmoid colon: possible predictive value for clinical outcomes. *Eur J Gastroenterol Hepatol*. 2014;26(5):570-573.
573. Wang W, Li X, Qu G, et al. Primary clear cell adenocarcinoma of the colon presenting as a huge extracolic mass: a case report. *Oncol Lett*. 2014;8(4):1873-1875.
574. Armaghani A, Hernandez Gonzalo D, Daily K. Hepatoid adenocarcinoma of the colon. *BMJ Case Rep*. 2015;2015:pii: bcr2014206222.
575. Thirunavukarasu P, Sathaiah M, Singla S, et al. Medullary carcinoma of the large intestine: a population based analysis. *Int J Oncol*. 2010;37(4):901-907.
576. Wick MR, Vitsky JL, Ritter JH, et al. Sporadic medullary carcinoma of the colon: a clinicopathologic comparison with nonhereditary poorly differentiated enteric-type adenocarcinoma and neuroendocrine colorectal carcinoma. *Am J Clin Pathol*. 2005;123(1):56-65.
577. Jessurun J, Romero-Guadarrama M, Manivel JC. Medullary adenocarcinoma of the colon: clinicopathologic study of 11 cases. *Hum Pathol*. 1999;30(7):843-848.
578. Winn B, Tavares R, Fanion J, et al. Differentiating the undifferentiated: immunohistochemical profile of medullary carcinoma of the colon with an emphasis on intestinal differentiation. *Hum Pathol*. 2009;40(3):398-404.
579. Lanza G, Gafà R, Matteuzzi M, Santini A. Medullary-type poorly differentiated adenocarcinoma of the large bowel: a distinct clinicopathologic entity characterized by microsatellite instability and improved survival. *J Clin Oncol*. 1999;17(8): 2429-2438.
580. Hinoi T, Tani M, Lucas PC, et al. Loss of CDX2 expression and microsatellite instability are prominent features of large cell minimally differentiated carcinomas of the colon. *Am J Pathol*. 2001;159(6):2239-2248.
581. Reyes CV, Siddiqui MT. Anaplastic carcinoma of the colon: clinicopathologic study of eight cases of a poorly recognized lesion. *Ann Diagn Pathol*. 1997;1(1):19-25.
582. Serio G, Aguzzi A. Spindle and giant cell carcinoma of the colon. *Histopathology*. 1997;30(4):383-385.
583. Nahas CSR, Shia J, Joseph R, et al. Squamous-cell carcinoma of the rectum: a rare but curable tumor. *Dis Colon Rectum*. 2007;50(9):1393-1400.
584. Frizelle FA, Hobday KS, Batts KP, Nelson H. Adenosquamous and squamous carcinoma of the colon and upper rectum: a clinical and histopathologic study. *Dis Colon Rectum*. 2001;44(3):341-346.
585. Petrelli NJ, Valle AA, Weber TK, Rodriguez-Bigas M. Adenosquamous carcinoma of the colon and rectum. *Dis Colon Rectum*. 1996;39(11):1265-1268.
586. Thompson JT, Paschold EH, Levine EA. Paraneoplastic hypercalcemia in a patient with adenosquamous cancer of the colon. *Am Surg*. 2001;67(6):585-588.
587. Audeau A, Han HW, Johnston MJ, et al. Does human papilloma virus have a role in squamous cell carcinoma of the colon and upper rectum? *Eur J Surg Oncol*. 2002;28(6):657-660.
588. Ordóñez NG, Luna MA. Choriocarcinoma of the colon. *Am J Gastroenterol*. 1984;79(1):39-42.
589. Aru A, Rasmussen LA, Federspiel B, Horn T. Glassy cell carcinoma of the colon with human chorionic gonadotropin-production. A case report with immunohistochemical and ultrastructural analysis. *Am J Surg Pathol*. 1996;20(2):187-192.
590. Bosman FT. Neuroendocrine cells in colonic tumors. *Mod Pathol*. 1992;5(3):312-314.
591. de Bruïne AP, Wiggers T, Beek C, et al. Endocrine cells in colorectal adenocarcinomas: incidence, hormone profile and prognostic relevance. *Int J Cancer*. 1993;54(5):765-771.
592. Pagani A, Papotti M, Abbona GC, Bussolati G. Chromogranin gene expressions in colorectal adenocarcinomas. *Mod Pathol*. 1995;8(6):626-632.
593. Shia J, Tickoo SK, Guillem JG, et al. Increased endocrine cells in treated rectal adenocarcinomas: a possible reflection of endocrine differentiation in tumor cells induced by chemotherapy and radiotherapy. *Am J Surg Pathol*. 2002;26(7):863-872.
594. La Rosa S, Marando A, Furlan D, et al. Colorectal poorly differentiated neuroendocrine carcinomas and mixed adenoneuroendocrine carcinomas: insights into the diagnostic immunophenotype, assessment of methylation profile, and search for prognostic markers. *Am J Surg Pathol*. 2012;36(4):601-611.
595. Cox WF, Pierce GB. The endodermal origin of the endocrine cells of an adenocarcinoma of the colon of the rat. *Cancer*. 1982;50(8):1530-1538.
596. Bernick PE, Klimstra DS, Shia J, et al. Neuroendocrine carcinomas of the colon and rectum. *Dis Colon Rectum*. 2004;47(2):163-169.
597. Schwartz AM, Orenstein JM. Small-cell undifferentiated carcinoma of the rectosigmoid colon. *Arch Pathol Lab Med*. 1985;109(7):629-632.
598. Burke AB, Shekitka KM, Sobin LH. Small cell carcinomas of the large intestine. *Am J Clin Pathol*. 1991;95(3):315-321.
599. Grabowski P, Schönfelder J, Ahnert-Hilger G, et al. Expression of neuroendocrine markers: a signature of human undifferentiated carcinoma of the colon and rectum. *Virchows Arch Int J Pathol*. 2002;441(3):256-263.
600. Cho I-J, Kim S-S, Min Y-D, et al. Poorly differentiated cecal adenocarcinoma showing prominent rhabdoid feature combined with appendiceal mucinous cystadenoma: A case report and review of the literature. *Oncol Lett*. 2015;9(4):1527-1530.
601. Kalyan A, Pasricha G, Monga D, et al. Case report of rhabdoid colon cancer and review of literature. *Clin Colorectal Cancer*. 2015;14(1):e5-e8.
602. Dukes C. Histological grading of rectal cancer: (Section of Pathology). *Proc R Soc Med*. 1937;30(4):371-376.
603. Pollheimer MJ, Kornprat P, Pollheimer VS, et al. Clinical significance of pT sub-classification in surgical pathology of colorectal cancer. *Int J Colorectal Dis*. 2010;25(2):187-196.
604. Lennon AM, Mulcahy HE, Hyland JMP, et al. Peritoneal involvement in stage II colon cancer. *Am J Clin Pathol*. 2003;119(1):108-113.
605. Ludeman L, Shepherd NA. Serosal involvement in gastrointestinal cancer: its assessment and significance. *Histopathology*. 2005;47(2):123-131.
606. Stewart C, Hillery S, Havlat M. Serosal involvement in colorectal carcinoma. *Histopathology*. 2006;49(4):435-437.
607. Goldstein NS. Lymph node recoveries from 2427 pT3 colorectal resection specimens spanning 45 years: recommendations for a minimum number of recovered lymph nodes based on predictive probabilities. *Am J Surg Pathol*. 2002;26(2):179-189.
608. Schumacher P, Dineen S, Barnett C, et al. The metastatic lymph node ratio predicts survival in colon cancer. *Am J Surg*. 2007;194(6):827-831, discussion 831-832.
609. Derwinger K, Carlsson G, Gustavsson B. A study of lymph node ratio as a prognostic marker in colon cancer. *Eur J Surg Oncol*. 2008;34(7):771-775.
610. Lo DS, Pollett A, Siu LL, et al. Prognostic significance of mesenteric tumor nodules in patients with stage III colorectal cancer. *Cancer*. 2008;112(1):50-54.
611. Puppa G, Maisonneuve P, Sonzogni A, et al. Pathological assessment of pericolonic tumor deposits in advanced colonic carcinoma: relevance to prognosis and tumor staging. *Mod Pathol*. 2007;20(8):843-855.
612. Edge S, Byrd D, Compton C, et al. *AJCC Cancer Staging Manual*. 7th ed. New York: Springer; 2010.
613. Calaluce R, Miedema BW, Yesus YW. Micrometastasis in colorectal carcinoma: a review. *J Surg Oncol*. 1998;67(3):194-202.
614. Oberg A, Stenling R, Tavelin B, Lindmark G. Are lymph node micrometastases of any clinical significance in Dukes Stages A and B colorectal cancer? *Dis Colon Rectum*. 1998;41(10):1244-1249.
615. Bilchik A, Nissan A, Wainberg Z, et al. Surgical quality and nodal ultrastaging is associated with long-term disease-free survival in early colorectal cancer: an analysis of 2 international multicenter prospective trials. *Ann Surg*. 2010;252(3):467-474, discussion 474-476.
616. Faerden AE, Sjo OH, Bukholm IRK, et al. Lymph node micrometastases and isolated tumor cells influence survival in stage I and II colon cancer. *Dis Colon Rectum*. 2011;54(2):200-206.
617. Koebrugge B, Bosscha K, Liefers G-J, et al. Can micrometastases be used to predict colon cancer prognosis? Hopes for the EnRoute+ study. *Expert Rev Gastroenterol Hepatol*. 2011;5(5):559-561.
618. Compton CC, Fielding LP, Burgart LJ, et al. Prognostic factors in colorectal cancer. College of American Pathologists Consensus Statement 1999. *Arch Pathol Lab Med*. 2000;124(7):979-994.
619. Morris M, Platell C, de Boer B, et al. Population-based study of prognostic factors in stage II colonic cancer. *Br J Surg*. 2006;93(7):866-871.
620. Sato T, Ueno H, Mochizuki H, et al. Objective criteria for the grading of venous invasion in

colorectal cancer. *Am J Surg Pathol*. 2010;34(4):454-462.
621. Howlett CJ, Tweedie EJ, Driman DK. Use of an elastic stain to show venous invasion in colorectal carcinoma: a simple technique for detection of an important prognostic factor. *J Clin Pathol*. 2009;62(11):1021-1025.
622. Michelassi F, Block GE, Vannucci L, et al. A 5- to 21-year follow-up and analysis of 250 patients with rectal adenocarcinoma. *Ann Surg*. 1988;208(3):379-389.
623. Jass JR, Love SB, Northover JM. A new prognostic classification of rectal cancer. *Lancet*. 1987;1(8545):1303-1306.
624. Alexander J, Watanabe T, Wu TT, et al. Histopathological identification of colon cancer with microsatellite instability. *Am J Pathol*. 2001;158(2):527-535.
625. Kim H, Jen J, Vogelstein B, Hamilton SR. Clinical and pathological characteristics of sporadic colorectal carcinomas with DNA replication errors in microsatellite sequences. *Am J Pathol*. 1994;145(1):148-156.
626. Prall F. Tumour budding in colorectal carcinoma. *Histopathology*. 2007;50(1):151-162.
627. Wang LM, Kevans D, Mulcahy H, et al. Tumor budding is a strong and reproducible prognostic marker in T3N0 colorectal cancer. *Am J Surg Pathol*. 2009;33(1):134-141.
628. Beaton C, Twine CP, Williams GL, Radcliffe AG. Systematic review and meta-analysis of histopathological factors influencing the risk of lymph node metastasis in early colorectal cancer. *Colorectal Dis*. 2013;15(7):788-797.
629. Quirke P, Durdey P, Dixon MF, Williams NS. Local recurrence of rectal adenocarcinoma due to inadequate surgical resection. Histopathological study of lateral tumour spread and surgical excision. *Lancet*. 1986;2(8514):996-999.
630. Adam IJ, Mohamdee MO, Martin IG, et al. Role of circumferential margin involvement in the local recurrence of rectal cancer. *Lancet*. 1994;344(8924):707-711.
631. Kapiteijn E, Marijnen CA, Nagtegaal ID, et al. Preoperative radiotherapy combined with total mesorectal excision for resectable rectal cancer. *N Engl J Med*. 2001;345(9):638-646.
632. Reynolds JV, Joyce WP, Dolan J, et al. Pathological evidence in support of total mesorectal excision in the management of rectal cancer. *Br J Surg*. 1996;83(8):1112-1115.
633. Griffin MR, Bergstralh EJ, Coffey RJ, et al. Predictors of survival after curative resection of carcinoma of the colon and rectum. *Cancer*. 1987;60(9):2318-2324.
634. Harrison LE, Guillem JG, Paty P, Cohen AM. Preoperative carcinoembryonic antigen predicts outcomes in node-negative colon cancer patients: a multivariate analysis of 572 patients. *J Am Coll Surg*. 1997;185(1):55-59.
635. Steinberg SM, Barkin JS, Kaplan RS, Stablein DM. Prognostic indicators of colon tumors. The Gastrointestinal Tumor Study Group experience. *Cancer*. 1986 1;57(9): 1866-1870.
636. Graham DM, Appelman HD. Crohn's-like lymphoid reaction and colorectal carcinoma: a potential histologic prognosticator. *Mod Pathol*. 1990;3(3):332-335.
637. Kim JH, Kim K-J, Bae JM, et al. Comparative validation of assessment criteria for Crohn-like lymphoid reaction in colorectal carcinoma. *J Clin Pathol*. 2015;68(1):22-28.
638. Yun J-A, Kim HC, Kim S-H, et al. Prognostic significance of perineural invasion in stage IIA colon cancer. *ANZ J Surg*. 2016;86(12):1007-1013.
639. Takebayashi Y, Aklyama S, Yamada K, et al. Angiogenesis as an unfavorable prognostic factor in human colorectal carcinoma. *Cancer*. 1996;78(2):226-231.
640. Gryfe R, Kim H, Hsieh ET, et al. Tumor microsatellite instability and clinical outcome in young patients with colorectal cancer. *N Engl J Med*. 2000;342(2):69-77.
641. Halling KC, French AJ, McDonnell SK, et al. Microsatellite instability and 8p allelic imbalance in stage B2 and C colorectal cancers. *J Natl Cancer Inst*. 1999;91(15):1295-1303.
642. Kelley RK, Wang G, Venook AP. Biomarker use in colorectal cancer therapy. *J Natl Compr Cancer Netw*. 2011;9(11):1293-1302.
643. Legolvan MP, Taliano RJ, Resnick MB. Application of molecular techniques in the diagnosis, prognosis and management of patients with colorectal cancer: a practical approach. *Hum Pathol*. 2012;43(8):1157-1168.
644. Sargent DJ, Marsoni S, Monges G, et al. Defective mismatch repair as a predictive marker for lack of efficacy of fluorouracil-based adjuvant therapy in colon cancer. *J Clin Oncol*. 2010;28(20): 3219-3226.
645. Ribic CM, Sargent DJ, Moore MJ, et al. Tumor microsatellite-instability status as a predictor of benefit from fluorouracil-based adjuvant chemotherapy for colon cancer. *N Engl J Med*. 2003;349(3):247-257.
646. Shibata D, Reale MA, Lavin P, et al. The DCC protein and prognosis in colorectal cancer. *N Engl J Med*. 1996;335(23):1727-1732.
647. Jen J, Kim H, Piantadosi S, et al. Allelic loss of chromosome 18q and prognosis in colorectal cancer. *N Engl J Med*. 1994;331(4):213-221.
648. Inada K, Shimokawa K, Ikeda T, et al. Development of liver metastasis in colorectal carcinoma. With special reference to venous invasion and basement membrane laminin. *Acta Pathol Jpn*. 1991;41(3):240-245.
649. Judson K, McCormick C, Vang R, et al. Women with undiagnosed colorectal adenocarcinomas presenting with ovarian metastases: clinicopathologic features and comparison with women having known colorectal adenocarcinomas and ovarian involvement. *Int J Gynecol Pathol*. 2008;27(2):182-190.
650. Young RH, Hart WR. Metastatic intestinal carcinomas simulating primary ovarian clear cell carcinoma and secretory endometrioid carcinoma: a clinicopathologic and immunohistochemical study of five cases. *Am J Surg Pathol*. 1998;22(7):805-815.
651. Silver SA, Epstein JI. Adenocarcinoma of the colon simulating primary urinary bladder neoplasia. A report of nine cases. *Am J Surg Pathol*. 1993;17(2):171-178.
652. Osunkoya AO, Netto GJ, Epstein JI. Colorectal adenocarcinoma involving the prostate: report of 9 cases. *Hum Pathol*. 2007;38(12):1836-1841.
653. Riopel MA, Klimstra DS, Godellas CV, et al. Intrabiliary growth of metastatic colonic adenocarcinoma: a pattern of intrahepatic spread easily confused with primary neoplasia of the biliary tract. *Am J Surg Pathol*. 1997;21(9):1030-1036.
654. Enker WE. Designing the optimal surgery for rectal carcinoma. *Cancer*. 1996;78(9):1847-1850.
655. Andreola S, Leo E, Belli F, et al. Adenocarcinoma of the lower third of the rectum surgically treated with a <10-MM distal clearance: preliminary results in 35 N0 patients. *Ann Surg Oncol*. 2001;8(7): 611-615.
656. Rose J, Augestad KM, Cooper GS. Colorectal cancer surveillance: what's new and what's next. *World J Gastroenterol*. 2014;20(8):1887-1897.
657. Fleming FJ, Påhlman L, Monson JRT. Neoadjuvant therapy in rectal cancer. *Dis Colon Rectum*. 2011;54(7):901-912.
658. Capirci C, Valentini V, Cionini L, et al. Prognostic value of pathologic complete response after neoadjuvant therapy in locally advanced rectal cancer: long-term analysis of 566 ypCR patients. *Int J Radiat Oncol Biol Phys*. 2008;72(1):99-107.
659. Rullier A, Laurent C, Vendrely V, et al. Impact of colloid response on survival after preoperative radiotherapy in locally advanced rectal carcinoma. *Am J Surg Pathol*. 2005;29(5):602-606.
660. Compton CC. Updated protocol for the examination of specimens from patients with carcinomas of the colon and rectum, excluding carcinoid tumors, lymphomas, sarcomas, and tumors of the vermiform appendix: a basis for checklists. Cancer Committee. *Arch Pathol Lab Med*. 2000;124(7):1016-1025.
661. de Campos-Lobato LF, Dietz DW, Stocchi L, et al. Clinical implications of acellular mucin pools in resected rectal cancer with pathological complete response to neoadjuvant chemoradiation. *Colorectal Dis*. 2012;14(1):62-67.
662. Stangl R, Altendorf-Hofmann A, Charnley RM, Scheele J. Factors influencing the natural history of colorectal liver metastases. *Lancet*. 1994;343(8910):1405-1410.
663. Ruers T, Bleichrodt RP. Treatment of liver metastases, an update on the possibilities and results. *Eur J Cancer*. 2002;38(7):1023-1033.
664. Klimstra DS, Modlin IR, Adsay NV, et al. Pathology reporting of neuroendocrine tumors: application of the Delphic consensus process to the development of a minimum pathology data set. *Am J Surg Pathol*. 2010;34(3):300-313.
665. Rindi G, Arnold R, Bosman F, World Health Organization; International Agency for Research on Cancer, et al. Nomenclature and classification of neuroendocrine neoplasms of the digestive system. In: Bosman FT, ed. *WHO Classification of Tumours of the Digestive System*. 4th ed. Lyon: IARC Press; 2010.
666. Spread C, Berkel H, Jewell L, et al. Colon carcinoid tumors. A population-based study. *Dis Colon Rectum*. 1994;37(5):482-491.
667. Eggenberger JC. Carcinoid and other neuroendocrine tumors of the colon and rectum. *Clin Colon Rectal Surg*. 2011;24(3):129-134.
668. Jetmore AB, Ray JE, Gathright JB, et al. Rectal carcinoids: the most frequent carcinoid tumor. *Dis Colon Rectum*. 1992;35(8):717-725.
669. Koura AN, Giacco GG, Curley SA, et al. Carcinoid tumors of the rectum: effect of size, histopathology, and surgical treatment on metastasis free survival. *Cancer*. 1997;79(7):1294-1298.
670. Matsui K, Iwase T, Kitagawa M. Small, polypoid-appearing carcinoid tumors of the rectum: clinicopathologic study of 16 cases and effectiveness of endoscopic treatment. *Am J Gastroenterol*. 1993;88(11):1949-1953.
671. Moyana TN, Satkunam N. Crypt cell proliferative micronests in rectal carcinoids. An immunohistochemical study. *Am J Surg Pathol*. 1993;17(4):350-356.
672. Arai T, Kino I. Histochemical and ultrastructural analyses of glandular differentiation in typical carcinoid tumor of the hindgut. *Pathol Int*. 1994;44(1):49-56.
673. Federspiel BH, Burke AP, Sobin LH, Shekitka KM. Rectal and colonic carcinoids. A clinicopathologic study of 84 cases. *Cancer*. 1990;65(1):135-140.
674. O'Briain DS, Dayal Y, DeLellis RA, et al. Rectal carcinoids as tumors of the hindgut endocrine cells: a morphological and immunohistochemical analysis. *Am J Surg Pathol*. 1982;6(2):131-142.
675. Wilander E, El-Salhy M, Lundqvist M, et al. Polypeptide YY (PYY) and pancreatic polypeptide (PP) in rectal carcinoids. An immunocytochemical study. *Virchows*

Arch A Pathol Anat Histopathol. 1983;401(1): 67-72.
676. Srivastava A, Hornick JL. Immunohistochemical staining for CDX-2, PDX-1, NESP-55, and TTF-1 can help distinguish gastrointestinal carcinoid tumors from pancreatic endocrine and pulmonary carcinoid tumors. *Am J Surg Pathol*. 2009;33(4):626-632.
677. Fukayama M, Hayashi Y, Shiozawa Y, et al. Human chorionic gonadotropin alpha-subunit in rectal carcinoids. Its mode of presence and the change of granule morphology. *Am J Pathol*. 1989;135(6):1065-1072.
678. Sobin LH, Hjermstad BM, Sesterhenn IA, Helwig EB. Prostatic acid phosphatase activity in carcinoid tumors. *Cancer*. 1986;58(1):136-138.
679. Kohno S, Ohshima K, Yoneda S, et al. Clinicopathological analysis of 143 primary malignant lymphomas in the small and large intestines based on the new WHO classification. *Histopathology*. 2003;43(2):135-143.
680. Wong MTC, Eu KW. Primary colorectal lymphomas. *Colorectal Dis*. 2006;8(7): 586-591.
681. Hemminki K, Li X, Sundquist J, Sundquist K. Cancer risks in ulcerative colitis patients. *Int J Cancer*. 2008;123(6):1417-1421.
682. Isaacson PG, MacLennan KA, Subbuswamy SG. Multiple lymphomatous polyposis of the gastrointestinal tract. *Histopathology*. 1984;8(4):641-656.
683. Xu XJ, Wu SM. Multiple lymphomatous polyposis of the gastrointestinal tract: report of three cases and literature review. *J Dig Dis*. 2012;13(12):649-653.
684. Vandermeulen L, Trullemans F, Urbain D. A case of mantle cell lymphoma in the colon. *Acta Gastro-Enterol Belg*. 2014;77(4):441-442.
685. Shukla T, Jin J, Marginean EC, Saloojee N. Anaplastic large cell lymphoma of the colon in a patient with colonic Crohn disease treated with infliximab and methotrexate. *Can J Gastroenterol Hepatol*. 2014;28(1):11-12.
686. Mezwa DG, Feczko PJ, Korensky T. Angioimmunoblastic lymphadenopathy of the colon with malignant transformation. *Gastrointest Radiol*. 1991;16(4):348-350.
687. Rasmussen SL, Thomsen C. Rectal Hodgkin lymphoma in a patient with ulcerative colitis: a case study. *Diagn Pathol*. 2015;10:25.
688. Kodama T, Ohshima K, Nomura K, et al. Lymphomatous polyposis of the gastrointestinal tract, including mantle cell lymphoma, follicular lymphoma and mucosa-associated lymphoid tissue lymphoma. *Histopathology*. 2005;47(5):467-478.
689. Moynihan MJ, Bast MA, Chan WC, et al. Lymphomatous polyposis. A neoplasm of either follicular mantle or germinal center cell origin. *Am J Surg Pathol*. 1996;20(4):442-452.
690. Yatabe Y, Nakamura S, Nakamura T, et al. Multiple polypoid lesions of primary mucosa-associated lymphoid-tissue lymphoma of colon. *Histopathology*. 1998;32(2):116-125.
691. Gloeckner K, Leithaeuser F, Lang W, et al. Colonic primary large cell lymphoma with marginal zone growth pattern presenting as multiple polyps. *Am J Surg Pathol*. 1999;23(9):1149-1153.
692. Farris AB, Lauwers GY, Ferry JA, Zukerberg LR. The rectal tonsil: a reactive lymphoid proliferation that may mimic lymphoma. *Am J Surg Pathol*. 2008;32(7):1075-1079.
693. Nanduri VR, Kelly K, Malone M, et al. Colon involvement in Langerhans' cell histiocytosis. *J Pediatr Gastroenterol Nutr*. 1999;29(4): 462-466.
694. Singhi AD, Montgomery EA. Gastrointestinal tract langerhans cell histiocytosis: a clinicopathologic study of 12 patients. *Am J Surg Pathol*. 2011;35(2):305-310.
695. Vos JA, Abbondanzo SL, Barekman CL, et al. Histiocytic sarcoma: a study of five cases including the histiocyte marker CD163. *Mod Pathol*. 2005;18(5):693-704.
696. Chang KC, Jin YT, Chen FF, Su IJ. Follicular dendritic cell sarcoma of the colon mimicking stromal tumour. *Histopathology*. 2001;38(1):25-29.
697. Schwaab J, Horny HP, Jonescheit J, et al. Mast cell sarcoma mimicking metastatic colon carcinoma. *Ann Hematol*. 2014;93(6):1067-1069.
698. Agaimy A, Vassos N, Märkl B, et al. Anorectal gastrointestinal stromal tumors: a retrospective multicenter analysis of 15 cases emphasizing their high local recurrence rate and the need for standardized therapeutic approach. *Int J Colorectal Dis*. 2013;28(8):1057-1064.
699. Miettinen M, Furlong M, Sarlomo-Rikala M, et al. Gastrointestinal stromal tumors, intramural leiomyomas, and leiomyosarcomas in the rectum and anus: a clinicopathologic, immunohistochemical, and molecular genetic study of 144 cases. *Am J Surg Pathol*. 2001;25(9):1121-1133.
700. Miettinen M, Sarlomo-Rikala M, Sobin LH, Lasota J. Gastrointestinal stromal tumors and leiomyosarcomas in the colon: a clinicopathologic, immunohistochemical, and molecular genetic study of 44 cases. *Am J Surg Pathol*. 2000;24(10):1339-1352.
701. Miettinen M, Sarlomo-Rikala M, Sobin LH. Mesenchymal tumors of muscularis mucosae of colon and rectum are benign leiomyomas that should be separated from gastrointestinal stromal tumors—a clinicopathologic and immunohistochemical study of eighty-eight cases. *Mod Pathol*. 2001;14(10):950-956.
702. Fuller CE, Williams GT. Gastrointestinal manifestations of type 1 neurofibromatosis (von Recklinghausen's disease). *Histopathology*. 1991;19(1):1-11.
703. Shekitka KM, Sobin LH. Ganglioneuromas of the gastrointestinal tract. Relation to Von Recklinghausen disease and other multiple tumor syndromes. *Am J Surg Pathol*. 1994;18(3):250-257.
704. d'Amore ES, Manivel JC, Pettinato G, et al. Intestinal ganglioneuromatosis: mucosal and transmural types. A clinicopathologic and immunohistochemical study of six cases. *Hum Pathol*. 1991;22(3):276-286.
705. Weidner N, Flanders DJ, Mitros FA. Mucosal ganglioneuromatosis associated with multiple colonic polyps. *Am J Surg Pathol*. 1984;8(10):779-786.
706. Trivedi A, Ligato S. Microcystic/reticular schwannoma of the proximal sigmoid colon: case report with review of literature. *Arch Pathol Lab Med*. 2013;137(2):284-288.
707. Miettinen M, Shekitka KM, Sobin LH. Schwannomas in the colon and rectum: a clinicopathologic and immunohistochemical study of 20 cases. *Am J Surg Pathol*. 2001;25(7):846-855.
708. Emanuel P, Pertsemlidis DS, Gordon R, Xu R. Benign hybrid perineurioma-schwannoma in the colon. A case report. *Ann Diagn Pathol*. 2006;10(6):367-370.
709. Gibson JA, Hornick JL. Mucosal Schwann cell "hamartoma": clinicopathologic study of 26 neural colorectal polyps distinct from neurofibromas and mucosal neuromas. *Am J Surg Pathol*. 2009;33(5):781-787.
710. Eslami-Varzaneh F, Washington K, Robert ME, et al. Benign fibroblastic polyps of the colon: a histologic, immunohistochemical, and ultrastructural study. *Am J Surg Pathol*. 2004;28(3):374-378.
711. Groisman GM, Polak-Charcon S. Fibroblastic polyp of the colon and colonic perineurioma: 2 names for a single entity? *Am J Surg Pathol*. 2008;32(7):1088-1094.
712. Pai RK, Mojtahed A, Rouse RV, et al. Histologic and molecular analyses of colonic perineurial-like proliferations in serrated polyps: perineurial-like stromal proliferations are seen in sessile serrated adenomas. *Am J Surg Pathol*. 2011;35(9):1373-1380.
713. Nakamura S, Kino I, Akagi T. Inflammatory myoglandular polyps of the colon and rectum. A clinicopathological study of 32 pedunculated polyps, distinct from other types of polyps. *Am J Surg Pathol*. 1992;16(8):772-779.
714. Siow WH, Hawken G, Russell A, et al. Education and imaging. Gastrointestinal: multiple inflammatory myoglandular polyps in a single patient. *J Gastroenterol Hepatol*. 2015;30(2):231.
715. Shekitka KM, Helwig EB. Deceptive bizarre stromal cells in polyps and ulcers of the gastrointestinal tract. *Cancer*. 1991;67(8):2111-2117.
716. Bavikatty NR, Goldblum JR, Abdul-Karim FW, et al. Florid vascular proliferation of the colon related to intussusception and mucosal prolapse: potential diagnostic confusion with angiosarcoma. *Mod Pathol*. 2001;14(11):1114-1118.
717. Yao T, Nagai E, Utsunomiya T, Tsuneyoshi M. An intestinal counterpart of pyogenic granuloma of the skin. A newly proposed entity. *Am J Surg Pathol*. 1995;19(9):1054-1060.
718. Ogawa K, Tada T, Takeuchi Y, et al. Reactive angioendotheliomatosis of the intestine. *Am J Surg Pathol*. 2004;28(2):257-261.
719. Morimatsu M, Shirozu K, Nakashima T, et al. Xanthogranuloma of the rectum. *Acta Pathol Jpn*. 1985;35(1):165-171.
720. Daum O, Vanecek T, Sima R, et al. Reactive nodular fibrous pseudotumors of the gastrointestinal tract: report of 8 cases. *Int J Surg Pathol*. 2004;12(4):365-374.
721. Yantiss RK, Nielsen GP, Lauwers GY, Rosenberg AE. Reactive nodular fibrous pseudotumor of the gastrointestinal tract and mesentery: a clinicopathologic study of five cases. *Am J Surg Pathol*. 2003;27(4):532-540.
722. Boley SJ, Sammartano R, Adams A, et al. On the nature and etiology of vascular ectasias of the colon. Degenerative lesions of aging. *Gastroenterology*. 1977;72(4 Pt 1):650-660.
723. Sami SS, Al-Araji SA, Ragunath K. Review article: gastrointestinal angiodysplasia—pathogenesis, diagnosis and management. *Aliment Pharmacol Ther*. 2014;39(1):15-34.
724. Stamm B, Heer M, Bühler H, Ammann R. Mucosal biopsy of vascular ectasia (angiodysplasia) of the large bowel detected during routine colonoscopic examination. *Histopathology*. 1985;9(6):639-646.
725. Thelmo WL, Vetrano JA, Wibowo A, et al. Angiodysplasia of colon revisited: pathologic demonstration without the use of intravascular injection technique. *Hum Pathol*. 1992;23(1):37-40.
726. Vella-Camilleri FC, Friedrich R, Vento AO. Diffuse colonic varices: an uncommon cause of intestinal bleeding. *Am J Gastroenterol*. 1986;81(6):492-494.
727. Salame G, Sherer DM, Shah T, et al. Mature cystic teratoma of the sigmoid colon. *Ultrasound Obstet Gynecol*. 2011;37(6):739-740.
728. Yoo S. GI-associated hemangiomas and vascular malformations. *Clin Colon Rectal Surg*. 2011;24(3):193-200.
729. Fernandez-Pineda I. Vascular tumors and malformations of the colon. *World J Gastroenterol*. 2009;15(41):5242-5243.
730. Lanjewar DN, Jain P, Shiveshwarkar WS, Kirtane JM. Cellular haemangioma of caecum in a child. *Histopathology*. 1996;29(6):585-586.
731. Ghanem OM, Slater J, Singh P, et al. Pedunculated colonic lipoma prolapsing

through the anus. *World J Clin Cases*. 2015;3(5):457-461.
732. Santos-Briz A, García JP, González C, Colina F. Lipomatous polyposis of the colon. *Histopathology*. 2001;38(1):81-83.
733. Iafrate F, Rengo M, Ferrari R, et al. Spectrum of normal findings, anatomic variants and pathology of ileocecal valve: CT colonography appearances and endoscopic correlation. *Abdom Imaging*. 2007;32(5):589-595.
734. Goh SG, Ho JM, Chuah KL, et al. Leiomyomatosis-like lymphangioleiomyomatosis of the colon in a female with tuberous sclerosis. *Mod Pathol*. 2001;14(11):1141-1146.
735. Doyle LA, Hornick JL, Fletcher CDM. PEComa of the gastrointestinal tract: clinicopathologic study of 35 cases with evaluation of prognostic parameters. *Am J Surg Pathol*. 2013;37(12):1769-1782.
736. Mitomi H, Matsumoto Y, Mori A, et al. Multifocal granular cell tumors of the gastrointestinal tract: immunohistochemical findings compared with those of solitary tumors. *Pathol Int*. 2004;54(1):47-51.
737. Nicholson AG, Cox PM, Marks CG, Cook MG. Primary malignant melanoma of the rectum. *Histopathology*. 1993;22(3): 261-264.
738. Rodríguez-Peláez M, Fernández-García MS, Gutiérrez-Corral N, et al. Kaposi's sarcoma: an opportunistic infection by human herpesvirus-8 in ulcerative colitis. *J Crohns Colitis*. 2010;4(5):586-590.
739. Allison KH, Yoder BJ, Bronner MP, et al. Angiosarcoma involving the gastrointestinal tract: a series of primary and metastatic cases. *Am J Surg Pathol*. 2004;28(3):298-307.
740. Lane Z, Epstein JI, Ayub S, Netto GJ. Prostatic adenocarcinoma in colorectal biopsy: clinical and pathologic features. *Hum Pathol*. 2008;39(4):543-549.
741. Masangkay AV, Susin M, Baker R, et al. Metastatic malignant mesothelioma presenting as colonic polyps. *Hum Pathol*. 1997;28(8):993-995.
742. Groisman GM, Bernheim J, Halpern M, et al. Expression of the intestinal marker Cdx2 in secondary adenocarcinomas of the colorectum. *Arch Pathol Lab Med*. 2005;129(7):920-923.

Anus

18

Laura W. Lamps

CHAPTER CONTENTS

Normal anatomy of the anus, *703*
Embryologic defects of the anus, *704*
Inflammatory and non-neoplastic conditions, *705*
Anal fissures, *705*
Anal fistulae, *705*
Hypertrophic anal papillae, fibroepithelial polyps, and skin tags, *705*
Inflammatory cloacogenic polyps, *706*
Hemorrhoids, *706*
Crohn disease, *707*
Infections involving the anus, *707*
Tumors and precursor lesions of the anus, *709*
Squamous intraepithelial neoplasia (including condyloma acuminatum), *709*
Squamous cell carcinoma, *712*
Anal duct/gland adenocarcinoma, *716*
Paget disease, *716*
Other microscopic types of carcinoma, *718*
Malignant melanoma, *719*
Mammary analogue tumors, *719*
Other tumors and tumorlike conditions, *719*

Normal Anatomy of the Anus

The anus and anal canal comprise a complex anatomic region with historically controversial nomenclature, due to the fact that the extent of the zones from person to person is variable and that the macroscopic and microscopic zones often do not correspond. The anal canal is a tubular structure measuring 3–4 cm in length and includes the squamous zone, the transition zone, and the colorectal zone (Fig. 18.1).[1–4] The most proximal zone of the anal canal is the colorectal zone. The squamous zone is the most distal aspect of the anal canal, and it extends from the perianal skin to the lower end of the rectum and is demarcated by the proximal and distal margins of the internal sphincter muscle. The junction between the anal canal and the perianal skin is known as the anal verge or Hilton's white line. Although no specific structure corresponds to Hilton's line, this transition is identified microscopically by the appearance of cutaneous adnexa and the presence of keratinized squamous epithelium.[1–3] The perianal skin contains a wide variety of adnexal structures, including apocrine glands, eccrine glands, and anogenital sweat glands.[1,2,5] The anal orifice forms a triradiate or Y-shaped opening, with the trunk of the "Y" at the posterior midline. The three folds outlined by the "Y" are known as the anal cushions.[1,2]

The dentate (pectinate) line is located within the anal canal and represents the line formed by the anal valves, anal sinuses, and the bases of the anal columns.[1–4] The anal columns (of Morgagni) are longitudinal folds with depressions between them known as anal sinuses (of Morgagni); homologous structures in the lower rectum are designated rectal columns and sinuses (of Morgagni). The anal columns are connected at the dentate line by the anal or semilunar valves (transverse plicae). These valves form the inner boundary of minute pockets known as anal crypts (of Morgagni). Of note, ganglion cells are normally absent or sparse within 1 cm of the dentate line, which is important to recognize when evaluating patients for Hirschsprung disease.[6]

Anal papillae are tooth-like, raised projections located on top of the anal columns and extending upward into the rectum, representing ridges of squamous mucosa directly joining the rectal mucosa.[1,2] Both anal crypts and papillae show marked individual variation and are occasionally absent. The anal glands discharge into the anal crypts through anal ducts, which can extend upward or, more commonly, downward. They penetrate the sphincters and sometimes extend into the perianal fat (Fig. 18.2).[7,8] The epithelium that lines these ducts is similar to that of the overlying transitional epithelium, including sparse mucin production characterized by scarcity or absence of *O*-acylated sialic acids; goblet cell metaplasia may be present.[9]

Immunohistochemically, the anal glands are strongly positive for CK7 and CK19 but negative for CK20, a pattern similar to that of the overlying mucosa.[10,11]

The anal canal is lined by glandular epithelium in the colorectal zone and by nonkeratinized squamous epithelium in the squamous zone, which is known as pecten.[1–4] The transition zone (also known as the intermediate or cloacogenic zone) lies in between the two, roughly corresponding to the area of the dentate line. This circular zone, 0.3–1.1 cm in width, has a glistening, wrinkled appearance made discontinuous by the presence of the anal papillae.[1–4] The transitional epithelium consists of four to nine cell layers, extending

Abstract

This chapter covers the major inflammatory and neoplastic entities that the surgical pathologist will encounter in the anus.

Keywords

anus,
anal anatomy,
anorectal anomalies,
fistula,
fissure,
Crohn disease,
inflammatory cloacogenic polyp,
hypertrophic papilla,
fibroepithelial polyp,
granuloma inguinale,
lymphogranuloma venereum,
condyloma,
anal intraepithelial neoplasia,
high-grade squamous intraepithelial lesion,
low-grade squamous intraepithelial lesion,
human papillomavirus,
squamous cell carcinoma,
basaloid carcinoma,
anal duct adenocarcinoma,
Paget disease,
melanoma,
mammary analogue tumor,
verrucous carcinoma,
neuroendocrine carcinoma,
mucoepidermoid carcinoma

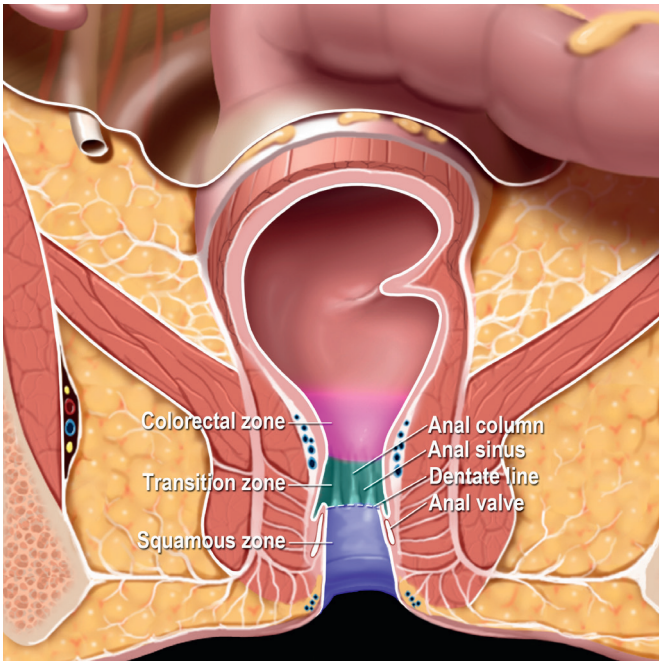

Figure 18.1 Diagrammatic representation of normal anal structures. (From Lamps LW, et al. *Diagnostic Pathology: Normal Histology*. Salt Lake City, UT: Amirsys; 2014).

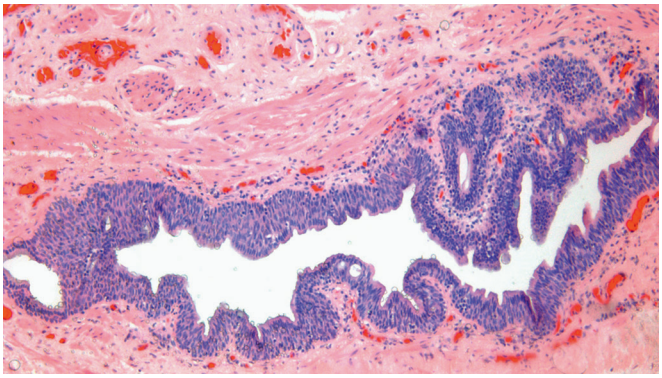

Figure 18.2 Normal anal duct, lined by transitional epithelium, running longitudinally through the muscle wall.

from the small basal cells at the bottom to the surface cells (which can be columnar, cuboidal, or polygonal) at the top, and somewhat resembles bladder epithelium or immature squamous epithelium at the light microscopic level (Fig. 18.3).[1–3] Mature squamous epithelium, glandular epithelium, and simple columnar epithelium may also be present here. Some people lack transitional epithelium altogether and have an abrupt transition from glandular to squamous mucosa. As previously discussed, the transition zone expresses keratins 7 and 19 but not keratin 20.[10,11] Scattered neuroendocrine cells are sometimes identified in the basilar portion of this epithelium.[12] Melanocytes are more common in the anal squamous zone than in the transitional zone and may give rise to nevi in either location.[13]

The vascular supply of the anal canal originates from the superior, middle, and inferior rectal arteries. Individual peculiar vessels characterized by a complex convoluted appearance have been referred to as anal glomeruli, and the network formed by these structures has been designated as corpus cavernosum recti.[1] The two most important components of the anal musculature are the internal anal sphincter (a continuation of the circular muscle coat of the rectum)

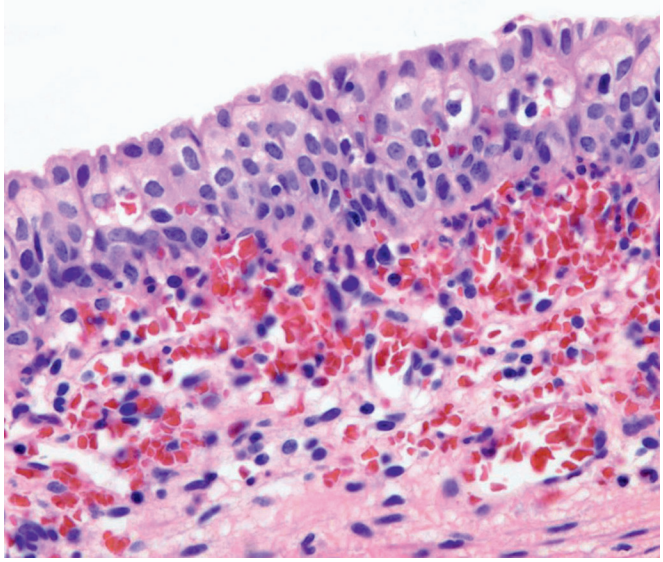

Figure 18.3 Normal transition zone mucosa of anal canal. The stratified epithelium somewhat resembles bladder epithelium or immature squamous epithelium histologically.

and the external anal sphincter (a complex triple-loop structure).[1,2,4] The lower part of the anal canal (below the dentate line) and the anal skin drain to the superficial inguinal nodes; the upper part has a wide draining field, which includes hypogastric, obturator, and internal iliac nodes.

Embryologic Defects of the Anus

Anorectal malformations occur in approximately 1 of every 3000–5000 births and comprise a complex group of congenital anomalies involving the rectum and anus.[14,15] They are often associated with other anomalies, including cardiovascular, musculoskeletal, spinal, and other gastrointestinal defects.[14] There are several classification systems, but most divide anorectal malformations into three major types, depending on the relationship of the rectal pouch to the puborectalis component of the levator ani muscle (puborectal sling).[14–16] **High** or **supralevator anomalies** (40%) include rectal atresia, anorectal agenesis, and cloacal malformations. They have a serious prognosis because of severe obstruction, common association with other congenital anomalies, and defective innervation of the pelvic muscles. A fistulous tract from the rectum to the bladder, urethra, or vagina is often present. **Low** or **translevator anomalies** (40%) include ectopic (perineal, vestibular, or vulvar) anus, anal stenosis, and imperforate (covered) anus. In these forms, obstruction is rarely severe. The pelvic innervation is normal, and associated anomalies are rare. Fistulas may or may not be present. **Intermediate anomalies** are less common (15%) and include anal agenesis, anorectal stenoses, and anorectal membrane. The remaining varieties, which are quite rare (5%), include **perineal groove** and **persistent anal membrane**.

Imaging studies, typically including plain radiographs, ultrasound, MRI, and VCUG (if urogenital anomalies are suspected), are essential for accurate diagnosis and therefore proper treatment. The surgical approach to repairing these defects changed dramatically in 1980 with the introduction of the posterior sagittal approach, allowing the direct visualization and repair of these complex malformations.[5–16] Unsuccessful surgery can lead to incontinence, loss of sexual function, stricture, and colonic obstruction, which may eventually necessitate a permanent colostomy.

Figure 18.4 Anal fissure in the posterior midline. (Courtesy of Dr. Jason Mizell.)

Inflammatory and Non-Neoplastic Conditions

Anal Fissures

Anal fissures are linear tears in the anal mucosa overlying the internal sphincter muscle (Fig. 18.4).[17,18] Approximately 90% of anal fissures are found at the posterior midline overlying the bifurcation of the sphincter as it divides to circle the rectum. Many conditions contribute to the formation of anal fissures, including constipation, chronic diarrhea, childbirth or other trauma, and stress-related clenching of the sphincters. These lesions usually pursue a chronic course or healing and exacerbation over many years. Treatment options include stool softeners, topical agents, and sphincterotomy.[18] The microscopic appearance is nonspecific, featuring acute and chronic inflammation with associated ulceration, granulation tissue, fibrosis, and reactive epithelial changes.

Anal Fistulae

Anal fistulae are abnormal inflammatory tracts having two or more internal openings within the anal canal.[19,20] The fistulous tract may lead to the skin, or it may end blindly in the perianal soft tissues and/or musculature (Fig. 18.5). A classification of anal fistulas into five categories on the basis of their anatomic relationships has been proposed.[21] The lining of the fistula is made of acute and chronic inflammation and granulation tissue, although epithelium (sometimes hyperplastic and with reactive epithelial changes) may eventually grow at either end of the tract. Fibrosis, foreign body giant cell reaction, and abscess formation may also be present.[19] Although some small fistulae heal on their own, many require surgery, and there are several operative approaches that ideally balance healing of the fistula with preservation of continence.[20,22]

Most anal fistulae are caused by an intersphincteric infection/abscess originating in a traumatized or infected anal crypt[19,20] and as previously discussed have a nonspecific microscopic appearance. Fistulae are also associated with numerous conditions including trauma, radiation, tumors, and Crohn disease[23]; it is important, therefore, that tissue obtained from an anal fistula be examined microscopically. Fistulae caused by Crohn disease are often complex and painless, with irregular edges and little induration. The diagnosis may be suggested by the presence of noncaseating granulomas, but it is important not to confuse them with the foci of foreign body reaction that can be seen in nonspecific fistulas. Anal fistulae may also be a manifestation of infections, such as tuberculosis[24,25] and actinomycosis.[26] The incidence of tuberculosis as a cause of anal fistulas dropped from 16% to less than 1% at St. Mark's Hospital (London) in a 50-year period.[24] Because these patients almost invariably show radiological evidence of pulmonary tuberculosis, this may well reflect a decline in tuberculosis in industrialized nations overall.

Figure 18.5 Multiple fistulous tracts *(arrows)* in a patient with Crohn disease. (Courtesy of Dr. Jason Mizell).

Hypertrophic Anal Papillae, Fibroepithelial Polyps, and Skin Tags

Anal papillae can enlarge as a result of edema, inflammation, and fibrosis and protrude into the anal canal in a polypoid fashion. Their appearance is similar to that of cutaneous fibroepithelial polyps, skin tags, and acrochordons, and many consider these lesions of the anus to be essentially identical. They are often confused with hemorrhoids on clinical examination.

Microscopically, these benign lesions are covered by squamous epithelium and contain a central core of edematous and inflamed, sometimes hyalinized fibrovascular stroma (Fig. 18.6).[27–29] Occasionally, atypical stromal cells with large and/or multiple nuclei and stellate cytoplasmic outlines occur in them.[30,31] These cells are immunoreactive for CD34.[29] Hyalinized vessels are a frequent

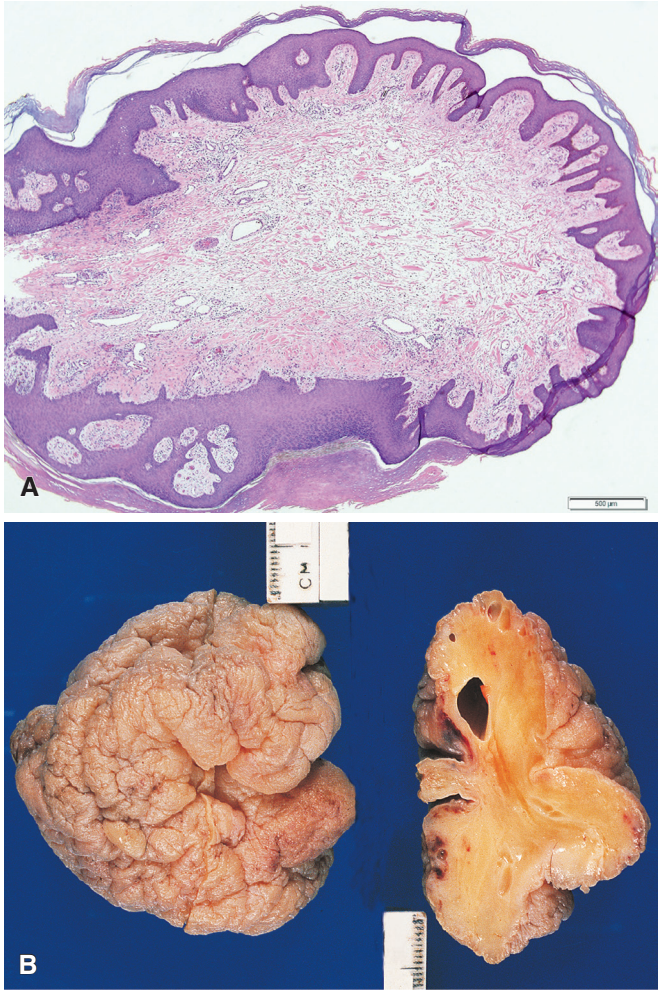

Figure 18.6 **A,** Fibroepithelial polyps, anal skin tags, and hypertrophic papillae are essentially identical and consist of a central core of edematous and inflamed fibrovascular stroma covered by squamous epithelium. (Courtesy of Dr. Sara Shalin.) **B,** These lesions can grow to an impressive size.

accompanying change, but the characteristic dilated submucosal vessels of hemorrhoids are absent.[29] Hypertrophied papillae may be associated with chronic anal ulcers, which are usually of oval shape and extends into the muscular layer. Typically the hypertrophied papilla is above the ulcer, and behind the papilla is an infected crypt. Anal ulcers have a nonspecific microscopic appearance and are surrounded by chronic edema and fibrosis.

Inflammatory Cloacogenic Polyps

Inflammatory cloacogenic polyps are within the spectrum of mucosal prolapse polyps that occur throughout the large bowel.[32–34] Patients typically present with anorectal bleeding, and these lesions are often clinically mistaken for hemorrhoids.[33–35] Although most often recognized in adults, these lesions also occur in children and should not be confused with hamartomatous polyps that are also seen in the pediatric population.[36]

Inflammatory cloacogenic polyps typically present as a single 1–2 cm polypoid mass in the anterior wall of the anorectum. Histologically, due to the location, these polyps may contain glandular colorectal mucosa, anal stratified squamous epithelium, transition zone epithelium, or a combination. Inflammatory cloacogenic polyps

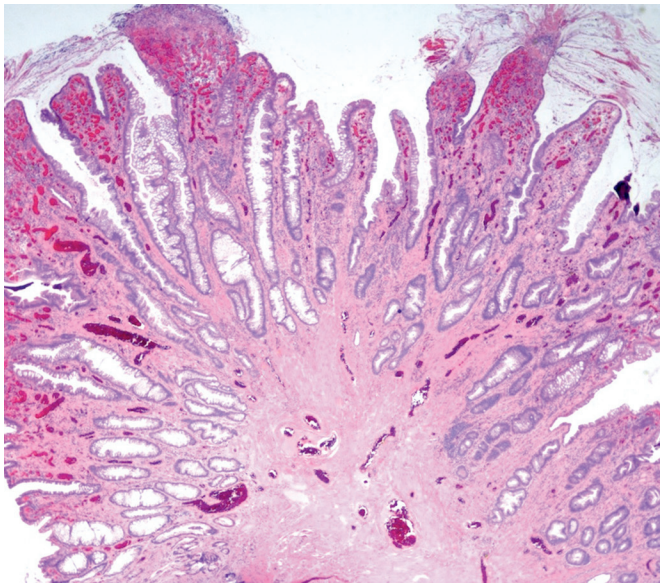

Figure 18.7 Inflammatory cloacogenic polyp featuring perpendicular fibromuscular hyperplasia, prominent lamina propria capillaries, and a villiform appearance to the surface mucosa with overlying erosion and fibrinopurulent exudate. (Courtesy of Dr. Rhonda Yantiss).

often have a striking villiform morphology of the surface epithelium (Fig. 18.7), which can mimic a villous adenoma at low power[33,35]; however, inflammatory cloacogenic polyps lack cytologic dysplasia. Similar to other prolapse type polyps, there may be stromal hyalinization with prominent capillaries; thickened and disorganized muscularis mucosa with perpendicular extension into the lamina propria; elongated irregular crypts that occasionally extend into the submucosa; and surface erosion.[35]

Hemorrhoids

Hemorrhoids (Fig. 18.8) are the result of ectasia of the hemorrhoidal vascular plexus. They are divided into external (derived from the external/inferior hemorrhoidal plexus below the dentate line, and covered by skin or squamous mucosa) and internal (derived from the superior hemorrhoidal plexus above the dentate line, and covered by rectal or transitional mucosa).[37–39] Patients typically present with hematochezia, itching, and anorectal pain.

Stasis of blood in the veins of the hemorrhoidal plexus is usually caused simply by dependency, and the formation of hemorrhoids is then furthered by deterioration of the surrounding connective tissues due to age and downward displacement of the anal cushions.[38] However, increased intravascular pressure due to pathologic processes may cause engorgement of the hemorrhoidal veins, and thus the presence of hemorrhoids may be an indication of some other condition, such as chronic constipation, pregnancy, or tumors. It is important to distinguish between hemorrhoids in patients with portal hypertension and actual anorectal varices, as treatment may be very different.[40] Indeed, patients with portal hypertension and varices actually do not have an increased incidence of hemorrhoids.[39] Treatment options include conservative measures such as dietary modification and topical analgesics/anti-inflammatory agents. Some cases require more aggressive measures such as sclerotherapy, rubber band ligation, or surgical excision.[39]

Histologically, hemorrhoids feature dilated submucosal vessels with thick or thin walls and variably present thrombosis with hemorrhage and recanalization (Fig. 18.9). Thrombosis of external hemorrhoids is frequent, and the organization and recanalization of these

Figure 18.8 Large external hemorrhoid protruding through the anal orifice. (Courtesy of Dr. Jason Mizell.) Engorged vessels are clearly visible.

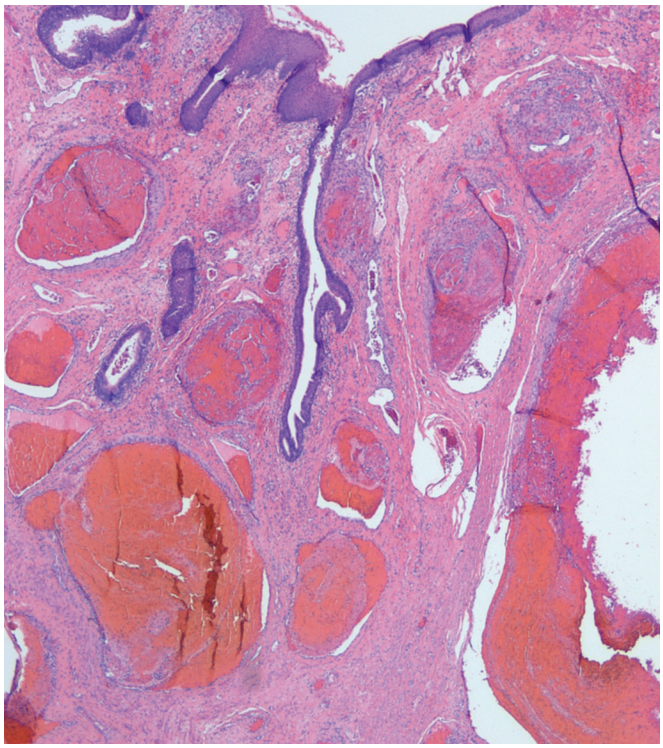

Figure 18.9 Hemorrhoid with markedly dilated submucosal vessels containing numerous thrombi. The overlying epithelium is both squamous and transitional.

thrombi can lead to florid papillary endothelial hyperplasia, a process that can be overinterpreted as angiosarcoma.[41] As a matter of fact, the original description of this process by Pierre Masson was in a hemorrhoidal vessel. Inflammatory changes, surface ulceration, and associated prolapse changes are also frequent findings in hemorrhoids.[37,42]

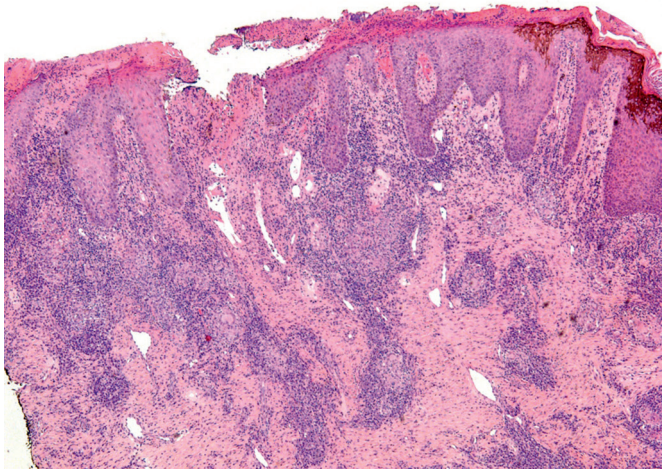

Figure 18.10 Perianal Crohn disease featuring noncaseating epithelioid granulomas with scattered multinucleated giant cells and associated chronic inflammation, fibrosis, and ulceration of the squamous epithelium.

Microscopic examination of tissue submitted with the clinical diagnosis of hemorrhoids rarely shows unsuspected findings such as infections, anal squamous intraepithelial lesions (SILs) and squamous cell carcinoma (SCC), or even nevi and malignant melanoma.[43–45] The latter is sometimes interpreted clinically as a thrombosed hemorrhoid because of its polypoid shape and dark brown color. The practice of histologically evaluating all hemorrhoidectomy specimens remains controversial (although this author is an advocate of it). However, most authors at least agree that hemorrhoids from patients at risk for, or with a history of, anorectal infection or malignancy should be submitted for histologic evaluation, as should any hemorrhoid with a macroscopic abnormality.[43–45]

Crohn Disease

Reportedly 10%–80% of patients with Crohn disease have perianal involvement; the variability in reporting is believed to be due to differing definitions of "perianal disease," duration of follow-up, and composition of patient population.[23] The anal manifestations of Crohn disease are also quite variable and include strictures, fissures, fistulae, ulcers, abscesses, and skin tags. Patients with lower tract disease are more likely to have perianal manifestations than those with upper tract disease.[46] The risk of anal carcinoma in Crohn disease remains controversial, but there may be a slight increased risk in patients with longstanding and/or severe perianal disease.[47,48] Histologic findings are nonspecific and include noncaseating epithelioid granulomas (Fig. 18.10) with associated chronic inflammation, fibrosis, and multinucleated giant cells.[49,50] Overlying ulceration of the skin or mucosa is common. The differential diagnosis is broad, and granulomatous infections such as tuberculosis, as well as entities such as hidradenitis suppurativa and sarcoidosis, must be considered. Diagnosis may be particularly challenging if the patient does not have a known history of Crohn disease.

Infections Involving the Anus

A number of infections may involve the anus, many of which are sexually transmitted. **Granuloma inguinale (donovanosis)** is caused by the coccobacillus *Calymmatobacterium granulomatis*. It is primarily a disease of tropical regions, and although many cases are sexually

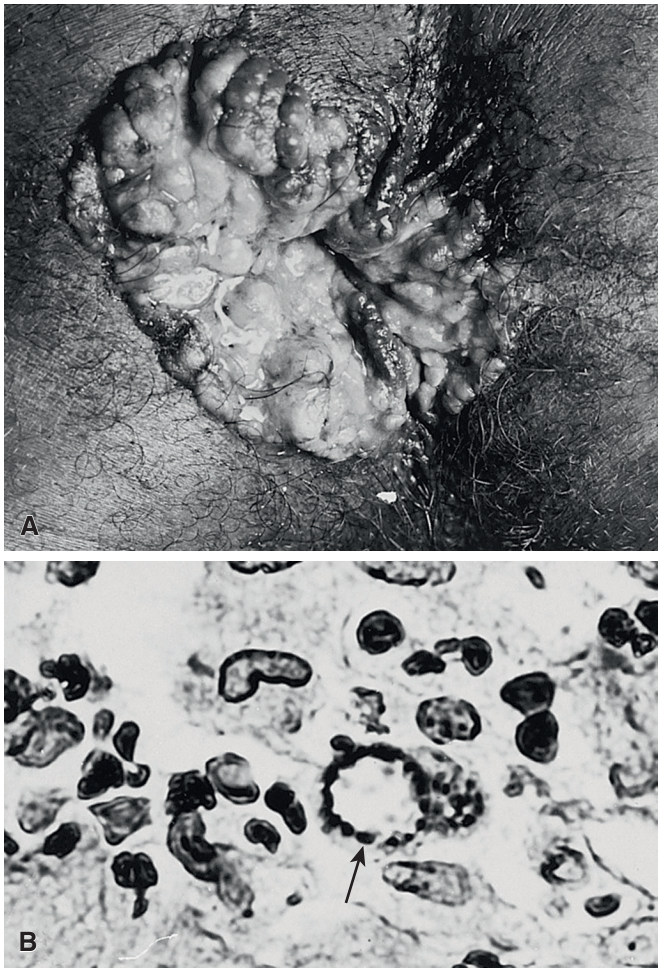

Figure 18.11 **A,** Granuloma inguinale clinically simulating carcinoma. **B,** Donovan bodies *(arrow)* within cyst in cytoplasm of macrophage in a patient with granuloma inguinale (Warthin–Starry stain).

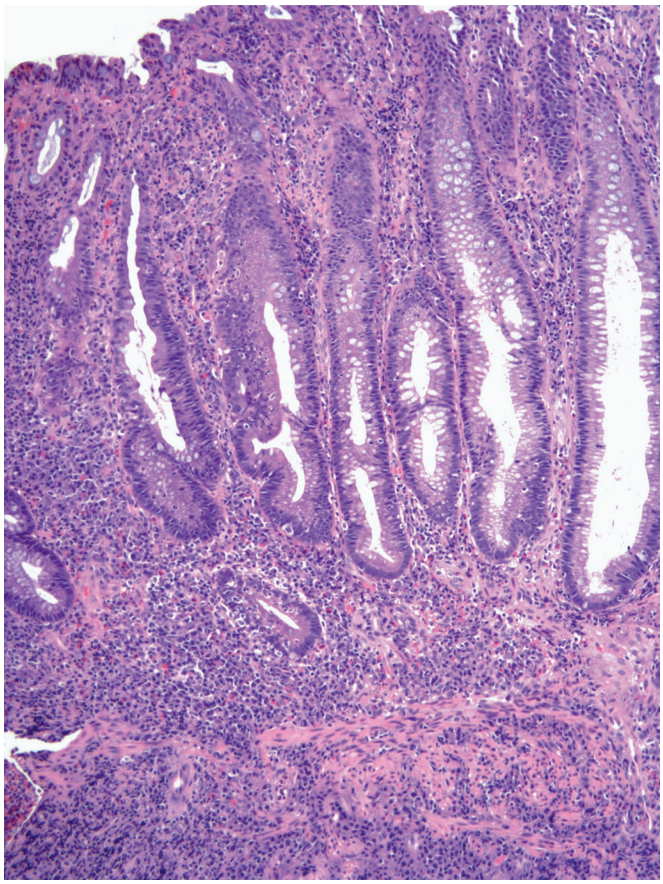

Figure 18.12 Anorectal lymphogranuloma venereum featuring a dense lymphohistiocytic infiltrate with prominent plasma cells, mimicking chronic idiopathic inflammatory bowel disease (Courtesy of Dr. Rhonda Yantiss).

Figure 18.13 Lymphogranuloma venereum complicated by squamous cell carcinoma.

transmitted, transmission is not exclusively venereal. The genitalia and inguinal areas are most commonly involved, but the anus is involved in approximately 7% of cases (Fig. 18.11).[51] Patients present with necrotizing ulcers that progressively enlarge and that may be confused clinically with SCC.[51,52] In addition, SCC may rarely complicate cases of longstanding granuloma inguinale.[53] Biopsy will allow a definite diagnosis if Donovan bodies are found using Warthin–Starry or Giemsa preparations. Otherwise, the histologic features are nonspecific and include a mixed inflammatory infiltrate composed primarily of macrophages (which contain the Donovan bodies), with variably present numbers of admixed neutrophils and mononuclear cells.[52] Older lesions may consist predominantly of granulation tissue.

Lymphogranuloma venereum (LGV) is a sexually transmitted disease caused by *Chlamydia trachomatis*, the incidence of which is rising, particularly in patients who engage in anal intercourse.[54] Clinically, anorectal LGV presents with ulcers, often accompanied by lymphadenopathy, fever, bleeding, and anal pain.[55] Microscopically, the main changes are a dense lymphohistiocytic infiltrate with prominent plasma cells (Fig. 18.12) and associated lymphoid aggregates, which may be associated with neuromatous hyperplasia, extensive transmural fibrosis, and occasionally granulomas.[55,56] These histologic changes may be easily confused with chronic idiopathic inflammatory bowel disease. In contrast to Crohn disease and ulcerative colitis, however, LGV typically has only mild to moderate acute inflammation, and well-developed changes of chronicity (basal plasmacytosis, architectural distortion, and Paneth cell metaplasia) may be absent (this is discussed in greater detail in Chapter 17).[55] Longstanding cases may lead to the formation of abscesses, strictures, and fistulae. Occasionally, SCC develops in association with these lesions (Fig. 18.13), although it is not known if LGV itself is a risk factor, especially as there are confounding risk factors in many patients with LGV.

Cultures, nucleic acid probes, and serologic studies may be very useful in confirming the diagnosis.

In addition to those already discussed in this section, immunocompromised patients (particularly HIV-infected patients) may develop a variety of inflammatory diseases of the anal region. In addition to some of those already listed in this section, these include gonorrhea, syphilis, herpes simplex virus, and cytomegalovirus.[57–59] Human papillomavirus (HPV)-related processes are discussed next.

Tumors and Precursor Lesions of the Anus

Squamous Intraepithelial Neoplasia (Including Condyloma Acuminatum)

Anal squamous intraepithelial neoplasia is relatively uncommon compared to the incidence in the female genital tract, but its incidence is rising, particularly in homosexual men who practice anal receptive intercourse and/or are HIV positive.[60,61] An overall slight female predominance remains, however, as patients with genital HPV-related disease are at high risk for anal neoplasia as well.[62] Many institutions are developing screening programs utilizing high-resolution anoscopy in combination with anal Pap smear for use in high-risk populations.[63] A detailed discussion of HPV and its relation with dysplastic and malignant conditions of squamous epithelia is to be found in Chapter 32, Cervix.

The terminology of HPV-associated anal squamous lesions has historically been confusing and nonstandardized, including terms originally used in cervical (Pap smear) cytology and later extended to cervical biopsy pathology, as well as terms adapted from cutaneous SCC that were applied to anogenital mucosae. In 2012, a project undertaken by the College of American Pathologists (CAP) and the American Society for Colposcopy and Cervical Pathology (ASCCP) recommended standardized terminology for anogenital squamous lesions.[64,65] The CAP-ASCCP Lower Anogenital Squamous Terminology (LAST) project recommends dividing anal squamous dysplasias into two tiers, based on the presence of low-grade or high-grade dysplasia.

Low-grade squamous intraepithelial lesion (LGSIL) is usually (but not always) associated with low-risk HPV genotypes such as 6 and 11, which have a lower risk of progression to malignancy than high-risk genotypes. High-grade squamous intraepithelial lesion (HGSIL) and invasive squamous carcinoma are typically associated with high-risk HPV genotypes such as 16 and 18.[66,67] Although these genotype associations are typical, some LGSIL are associated with high-risk HPV genotypes, and conversely HGSIL may harbor low-risk genotypes.[68] In addition, many HIV+ patients are infected by multiple HPV genotypes.[67] Although recurrence is common, actual progression rates of HGSIL to anal SCC remain controversial, primarily due to the fact that high-grade lesions are typically removed or ablated. However, immunosuppressed patients with multifocal disease appear to be at the highest risk of progression.[69] It is also believed that LGSIL can progress to HGSIL, particularly in HIV+ patients.[70]

Despite their overall recommendations, the older terminology of "anal intraepithelial neoplasia" (AIN) and "perianal intraepithelial neoplasia" (PAIN) remain in the LAST project nomenclature.[64] AIN is used for lesions in squamous mucosa of the anal canal itself, whereas PAIN refers to lesions affecting the perianal skin within 5 cm of the anal verge. These older terms reflect the division of squamous dysplasia into three grades (AIN 1, 2, and 3). Using current criteria, LGSIL encompasses AIN 1, and HGSIL includes AIN grades 2 and 3. Anal squamous lesions should be reported using the LGSIL/HGSIL nomenclature but can be further classified with the P/AIN grade in parenthesis (e.g. "LGSIL (AIN 1)"). HGSIL (AIN3) includes the term "Bowen disease of the anus," which should no longer be used.

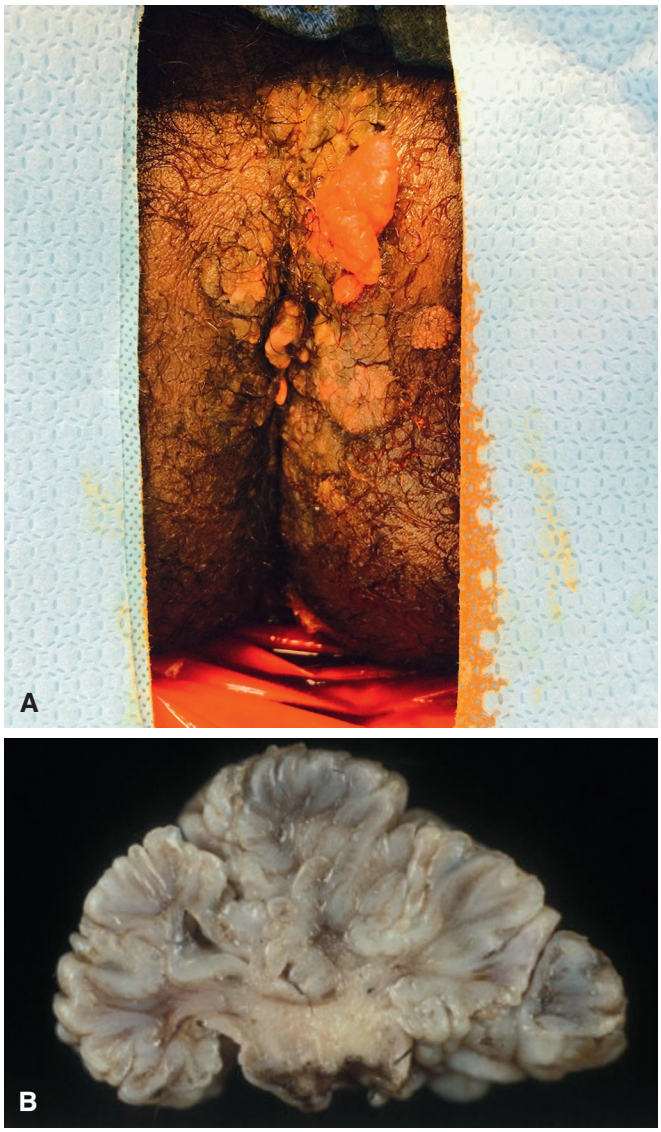

Figure 18.14 **A,** This HIV+ patient has multiple condylomata complicated by SCC. **B,** The cut surface of this anal condyloma shows the typical papillary, cauliflower-like appearance. (**A,** Courtesy of Dr. Rhonda Yantiss; **B,** Courtesy of Dr. George F. Gray, Jr.)

Grossly visible lesions featuring koilocytes and squamous hyperplasia or acanthosis have historically been known as "condyloma acuminatum," and this is perhaps the most common and best known HPV-associated anorectal lesion. This term is commonly used clinically and is considered synonymous with anogenital wart. According to the LAST criteria, these lesions generally harbor low-grade dysplasia and are therefore included in the category of LGSIL. Patients typically present with anal bleeding, pain, and itching. Condylomata typically appear as fleshy, pink/white papillary or "cauliflower-like" masses (Fig. 18.14) that may be single or multiple.[71] They often occur in clusters and may cover large areas of skin or mucosa. In addition to condylomata, squamous lesions of the anus may present clinically as white, pigmented or erythematous areas, as well as papules or scaly plaques; multicentricity is common here as well. Although the anal canal is the usual location of SIL, lesions can also be encountered in the perianal skin. Similar to the cervix, acetic acid may be used to highlight the lesions.

The morphologic changes of HPV infection and AIN can occur within the context of (and be confined to) a condyloma, or occur in flat mucosa.[71] LGSIL/(P)AIN 1 is characterized by squamous atypia and dysmaturation restricted to the basal third of the epithelium, whereas in HGSIL these abnormalities involve roughly the lower two thirds (P/AIN 2) or full-thickness atypia/dysplasia (P/AIN 3 or effectively "carcinoma in situ").[64,65] The histologic feature most often associated with HPV infection, particularly in examples of LGSIL, is koilocytic change (Fig. 18.15). The characteristic features of koilocytes include wrinkled nuclear contours or "raisinoid"

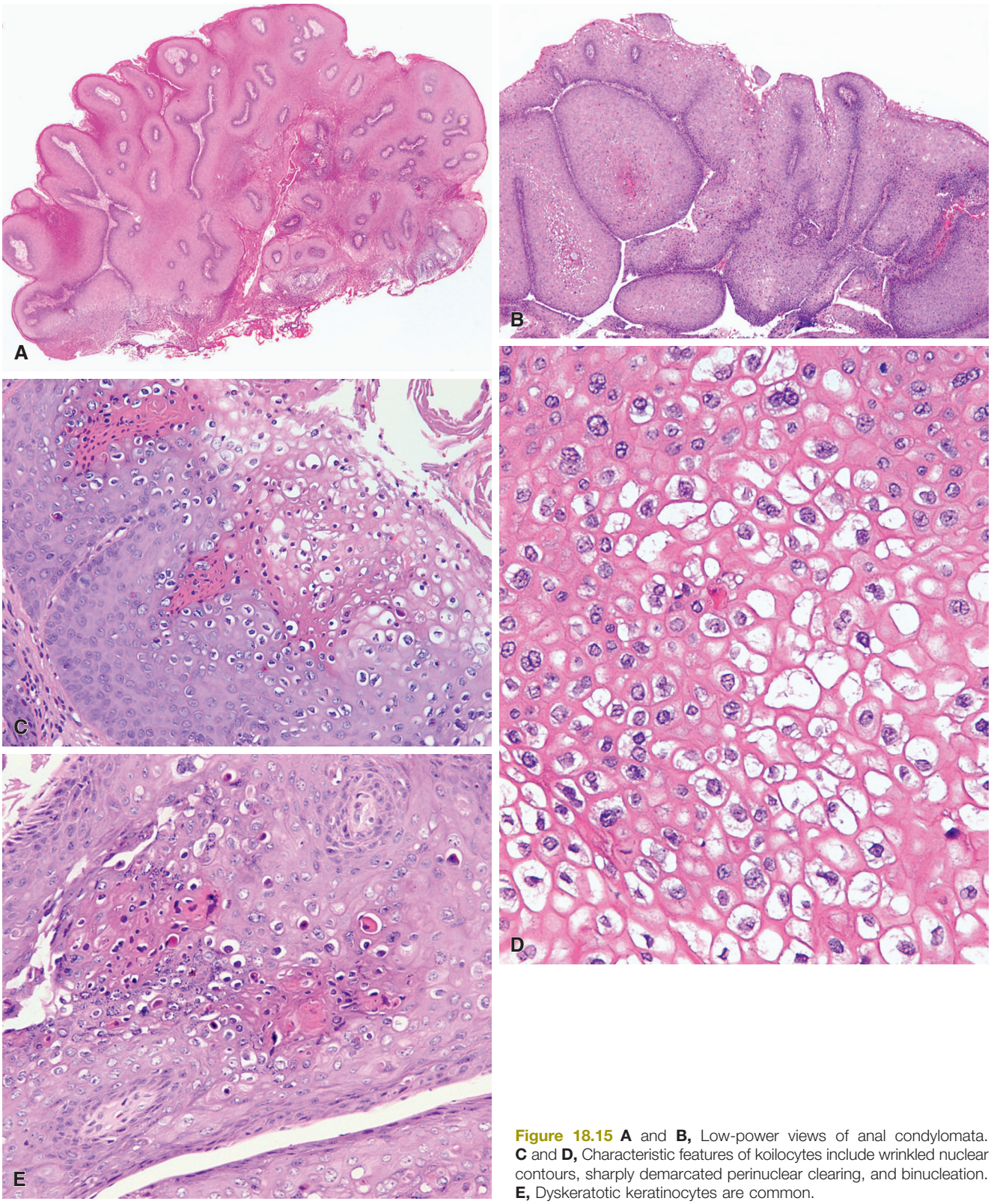

Figure 18.15 **A** and **B,** Low-power views of anal condylomata. **C** and **D,** Characteristic features of koilocytes include wrinkled nuclear contours, sharply demarcated perinuclear clearing, and binucleation. **E,** Dyskeratotic keratinocytes are common.

appearance; sharply demarcated perinuclear clearing or halo; and variably present binucleation. Dyskeratotic keratinocytes are frequently seen as well. Koilocytic changes are not invariably present in HPV-associated lesions, however.[71] Features of the dysplastic cells in HGSIL include nuclear membrane irregularity, hyperchromasia, enlargement, and pleomorphism (Fig. 18.16). Overlying atypical parakeratosis and mitoses in the upper third of the mucosa are often present as well.

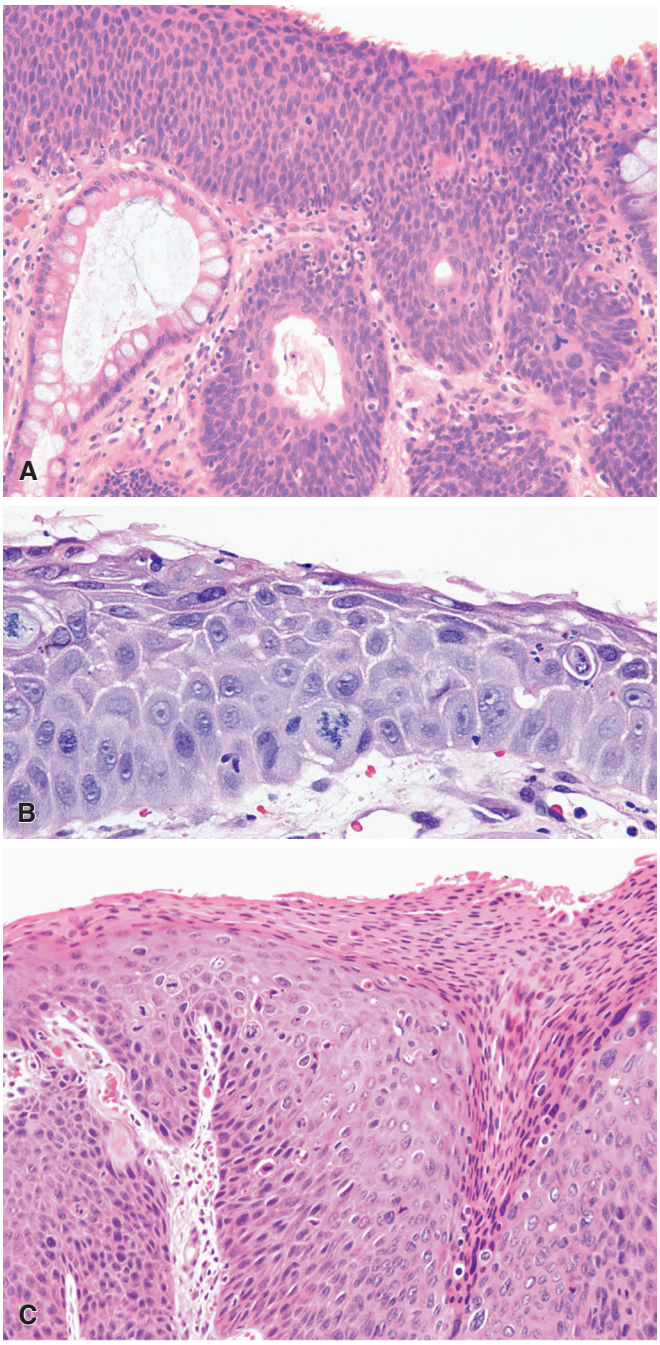

Figure 18.16 High-Grade SIL (AIN2/3) Features Full Thickness Nuclear Atypia. A, Increased nuclear density and loss of maturation are apparent, as seen here at the transition zone. **B,** Dysplastic cells are characterized by nuclear membrane irregularity, hyperchromasia, enlargement, and pleomorphism; increased mitoses are obvious as well, including atypical mitoses mitotic figures present well above the basal zone. **C,** Overlying atypical parakeratosis is common. (Courtesy of Dr. Keith Lai.)

Infection with high-risk HPV genotypes upregulates p16 (a tumor suppressor gene product that is a surrogate marker of HPV infection) and is associated with increased cellular proliferation. HGSIL typically shows diffuse, block-like overexpression of p16 (Fig. 18.17), whereas LGSIL and reactive processes usually show absent or weak, patchy staining.[72–74] Both LGSIL and HGSIL typically show abnormal Ki-67 staining, defined as nuclear positivity in the upper two thirds of the epithelium.

Some workers have subclassified SIL into a bowenoid type (more common, and synonymous with conventional-type SIL as discussed previously) and a differentiated (or simplex) type (Fig. 18.18) using criteria similar to those used for vulvar intraepithelial neoplasia (marked basal atypia with eosinophilic cytoplasm and preservation of squamous maturation).[75] While both types of SIL express 14-3-3σ (a p53-regulated G2/M inhibitor), the conventional type exhibits strong and diffuse p16 immunoreactivity but negative p53 staining, whereas the differentiated type exhibits increased basal p53 immunostaining but is typically negative for p16. These data are interesting both from a diagnostic standpoint and because they suggest the possibility of different pathogenetic mechanisms for the differentiated type of SIL.

A number of reactive conditions of the anus can mimic SIL. Glycogenated squamous cells can mimic koilocytes, and inflamed

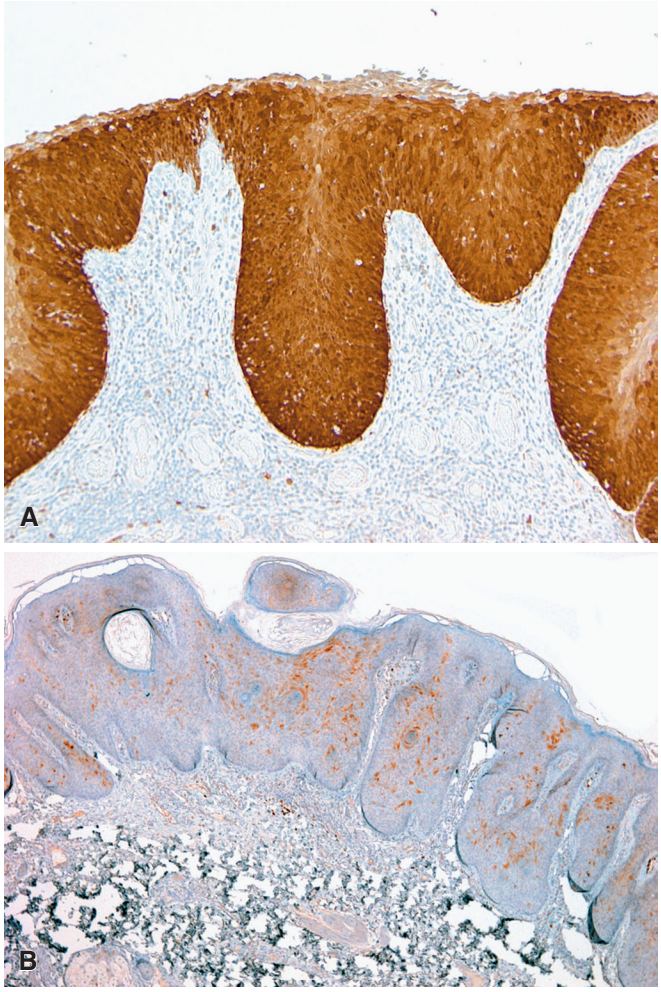

Figure 18.17 A, Diffuse, 'block-like' staining with p16 in a case of anal HGSIL. **B,** In contrast, LGSIL and reactive processes usually show absent or weak, patchy staining. (**A,** Courtesy of Dr. Keith Lai.)

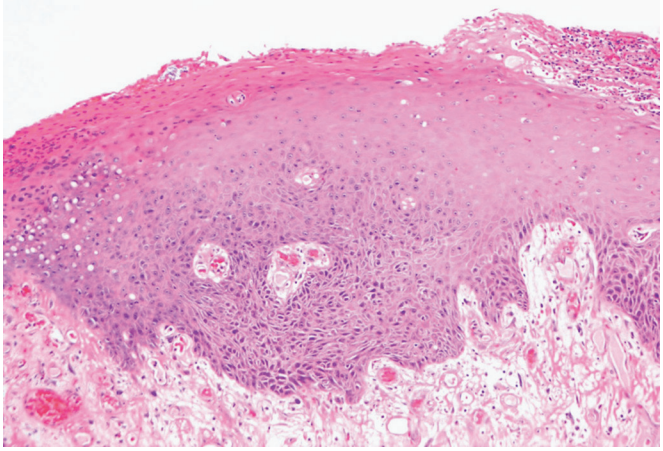

Figure 18.18 The differentiated (or simplex) type of SIL shows marked basal atypia with eosinophilic cytoplasm and preservation of squamous maturation, similar to vulvar SIL. (Courtesy of Drs. Keith Lai and Brad Fogel.)

squamous mucosa and skin may have reactive atypia that mimics dysplasia as well. Finally, as mentioned previously, the anal transition zone is lined by multilayered transitional epithelium that can also undergo squamous metaplasia. These changes can closely mimic HGSIL, particularly when reactive changes are present. As discussed previously, p16 and Ki-67 immunohistochemistry can aid in making the distinction between true squamous dysplasia and reactive atypia. Furthermore, CK7 positivity is characteristically seen in transition zone mucosa but is absent in HGSIL.

Squamous Cell Carcinoma

General and Clinical Features

SCC is the most common primary neoplasm of the anus, although it accounts for less than 5% of large bowel malignancies. The incidence of anal carcinoma is increasing in both males and females.[76] Although historically females outnumbered males with this disease, the male to female ratio has begun to equalize in recent years and is now approximately equal.[77] Clinically, the disease presents with bleeding, anal pain (much more commonly than in colorectal cancer), mass, and pruritus. Unfortunately, diagnosis is often delayed because presenting signs and symptoms are attributed to benign disease such as hemorrhoids. A significant minority of patients is asymptomatic.

There is strong evidence that sexually transmitted HPV infection is an important cause of anal cancer (see also the previous section), and approximately 80%–90% of anal SCC are associated with HPV infection.[78,79] HPV 16 is the specific genotype in the majority of cases, followed by HPV 18.[79] In particular, a strong association has been found between anal SCC and receptive anal intercourse, as well as multiple lifetime sexual partners. There is also a statistical association between anal carcinoma and smoking.[60]

There is no significant difference in HPV positivity among the major morphologic types of anal SCC.[78,80] Instead, the presence of HPV in tumor cells is significantly associated with an increased proliferative rate and aneuploid status.[81] In some instances, anal SCC develop in association with other diseases such as Crohn disease[82] or other immunosuppressive conditions.[83] Patients with HPV-negative SCC appear to have a worse prognosis (shorter disease-free survival) than patients with HPV-positive tumors.[84]

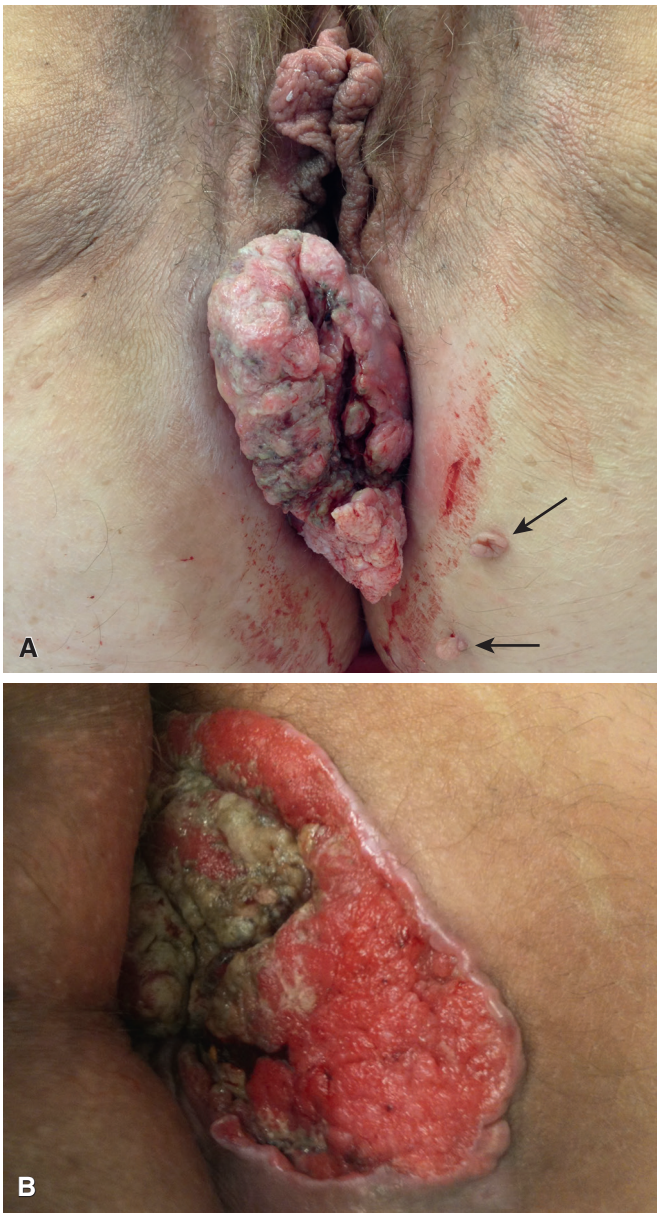

Figure 18.19 **A,** This squamous cell carcinoma (SCC) of the anal canal has a verrucoid appearance and protrudes out through the anal orifice. Note the small adjacent condylomata *(arrows)*. **B,** This ulcerated SCC with rolled edges extends out to involve the perianal skin. (**A,** Courtesy of Dr. Jason Mizell; **B,** Courtesy of Dr. Jason Mizell.)

Pathologic Features

Conventional SCC of the anal canal most often arise distal to the dentate line. Grossly, early lesions are often small and mobile, sometimes with a verrucoid appearance (Fig. 18.19). They may grow either upward into the rectum, in which case the gross appearance may be indistinguishable from that of an adenocarcinoma of the rectum, or outward to the perianal tissues.[85,86] Involvement of the perianal skin may be superficial, with only surface ulceration and slightly elevated margins. Such lesions can be mistaken for an inflammatory process. In other instances, a deeply ulcerated neoplasm with rolled edges can be seen, or a large fungating mass (which occasionally may protrude from the anal orifice). Tumors with upward local extension may burrow beneath the overlying

epithelium to ulcerate at a higher level in the rectum. It is important to remember that tumors above the dentate line may not be visible on external physical examination, and that the basaloid variant of SCC often arises proximal to the dentate line. Lymphadenopathy may be present at initial presentation, indicating spread to regional nodes.

Anal SCC have a variety of morphologic patterns, and the terminology has changed considerably in the course of the years. Traditionally, these tumors were regarded and classified as squamous cell (epidermoid) carcinomas.[87,88] It was then proposed that there were two distinct types of carcinoma in this area: (1) SCC, analogous to its counterpart elsewhere in the skin; and (2) cloacogenic (also known as transitional or basaloid) carcinoma, supposedly originating from the transitional epithelium of the region and recapitulating the features of this zone at both a light and electron microscopic level.[89,90] It is now recognized that both of these (as well as the vast majority of the other subtypes, discussed later) are variants of SCC and that distinguishing these two tumor types is not only difficult in practice but also unwarranted from a therapeutic and prognostic standpoint.[91]

Conventional keratinizing SCC (Fig. 18.20) features invasive nests of malignant squamous cells, similar to its counterparts elsewhere in the body. Keratin whorls or "pearls" may be present, along with intercellular bridges and variably present necrosis. This form of SCC is often found in a background of squamous dysplasia. As with other conventional SCC, it may vary from well to poorly differentiated.

Nonkeratinizing SCC (also known as basaloid or cloacogenic carcinoma in the past, as previously discussed) consists of irregular, angulated, or trabecular nests of basophilic cells with relatively scant cytoplasm and peripheral palisading (Fig. 18.21). Squamous nests may be present but lack keratinization.[86,91] This type of carcinoma can mimic basal cell carcinoma arising in the perianal skin, as well as neuroendocrine carcinomas that rarely occur in this area (see section later). Compared to true cutaneous basal cell carcinomas, nonkeratinizing (basaloid) SCC have more cytologic pleomorphism and often have areas with more recognizable squamous differentiation.

Some anal SCC contain mucinous microcysts; these have also been referred to as mucoepidermoid, adenoid cystic pattern, or microcystic SCC (Fig. 18.22).[91,92] Some have suggested that this morphologic variant is associated with a worse prognosis, but this assertion is based on a limited number of cases.[93] This variant should be distinguished from true adenoid cystic carcinoma of salivary gland type, from which it differs at the immunohistochemical level.[92]

Other Variants of Anal Squamous Cell Carcinoma

Verrucous SCC are polypoid tumors that grossly resemble condylomas and typically are very impressive clinically. Indeed, this lesion was formerly known as the giant condyloma acuminatum of Buschke–Löwenstein, which reflects the difficulty in distinguishing between a large condyloma and verrucous carcinoma. Although they are also HPV-related, morphologic features of both viral infection and dysplasia are typically difficult to find histologically, which adds to the difficulty in diagnosing this type of malignancy.[91] Verrucous SCC are well differentiated and often have extensive and well-developed surface maturation; for these reasons, superficial biopsies may only sample benign-appearing, hyperparakeratotic epithelium, leading to a benign diagnosis (particularly on superficial biopsy) that is at odds with the clinically impressive and worrisome appearance. These tumors have a pushing (Fig. 18.23), rather than infiltrative, pattern of invasion, but verrucous SCC are aggressive neoplasms, invading local structures and sometimes involving the deep soft tissues of the pelvis. There is some evidence that these deceptively well-differentiated carcinomas are more closely associated with low-risk HPV genotypes, in contrast to conventional SCC.[91] These lesions are morphologically identical to those seen in the lower female genital tract and other sites (see Chapter 32, Cervix). Most verrucous SCC are locally destructive but do not metastasize.

Spindle cell (sarcomatoid) carcinoma is much more rare here than in the upper digestive tract, but it does occur.[94] A spectacular case showing neuroendocrine and rhabdomyoblastic features has been described.[95] Others SCC are accompanied by a massive infiltration of eosinophils,[96] a feature again analogous to that seen in carcinomas of other mucosal sites, particularly squamous cell type.

Immunohistochemical and Molecular Genetic Features

Immunohistochemically, most anal squamous carcinomas exhibit reactivity for keratins 4, 5/6, 13, 17, 18, and 19, with a minority expressing keratins 1, 7, and 10.[97,98] p63 and SOX2 (an HMG-box embryonic stem cell transcription factor) are also expressed by the vast majority of anal SCC.[99,100]

HPV infection is an initiating event in most cases, but HPV infection alone is not sufficient to promote progression to malignancy. HPV DNA integration into host cell chromosomes (with subsequent expression of several oncoproteins) appears to be a significant step in the transition from SIL to malignancy.[100] Loss of heterozygosity at 11q appears to be a common event in anal carcinogenesis, similar to cervical cancer carcinogenesis, although the number of cases that have been studied in detail is limited.[100] Loss of heterozygosity involving several other chromosomes has also been reported,[100] and it is likely that progression towards invasive carcinoma requires additional molecular alterations, such as allelic losses at 5q *(APC)*, 17p *(TP53)*, and 18q *(DCC)*.[100] HIV-positive patients progress more rapidly from AIN to invasive carcinoma, and HPV-induced genomic instability (such as microsatellite instability) may play a more significant role. Chromosomal instability (e.g. loss of heterozygosity as described previously) is much less common in anal SCC in HIV-positive patients.[100] Aberrant DNA methylation is also frequent (>70%) in HGSIL and anal carcinoma, while methylation is not seen in LGSIL and normal mucosa.[101]

Spread and Metastases

As far as lymph node metastases are concerned, carcinomas arising above the dentate line typically metastasize to pelvic, perirectal, and para-aortic/paravertebral nodes, whereas those distal to the dentate line typically metastasize to inguinal nodes. Metastatic disease in perirectal lymph nodes is classified as N1 (AJCC 7th edition), whereas metastasis to unilateral internal iliac and/or inguinal lymph nodes is classified as N2. Metastases in perirectal and inguinal nodes and/or bilateral internal iliac and/or inguinal nodes are classified as N3. Lymph node involvement is present in 30%–40% of cases at presentations, while systemic spread is much less common (5%–8% of patients).[102]

Therapy

The primary goals of management are to achieve a cure via locoregional control, while ideally preserving anal function. Until the mid-1980s, the traditional therapy for anal carcinomas was abdominoperineal resection, sometimes combined with hypogastric lymph node dissection and with posterior vaginectomy in women. Surgery is no longer regarded as the primary therapeutic intervention, however, although its role as a salvage therapy is accepted.[102,103] Currently,

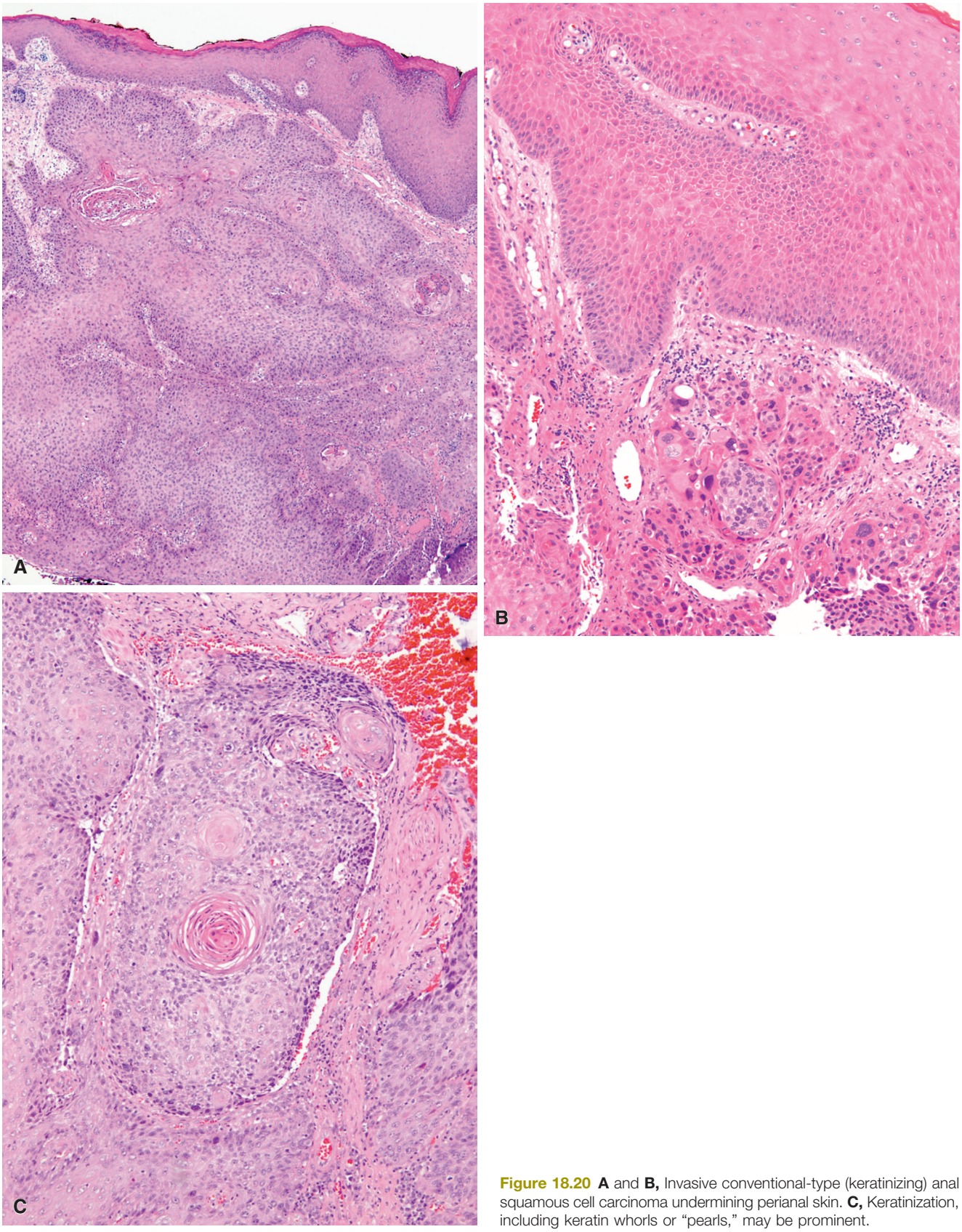

Figure 18.20 **A** and **B,** Invasive conventional-type (keratinizing) anal squamous cell carcinoma undermining perianal skin. **C,** Keratinization, including keratin whorls or "pearls," may be prominent.

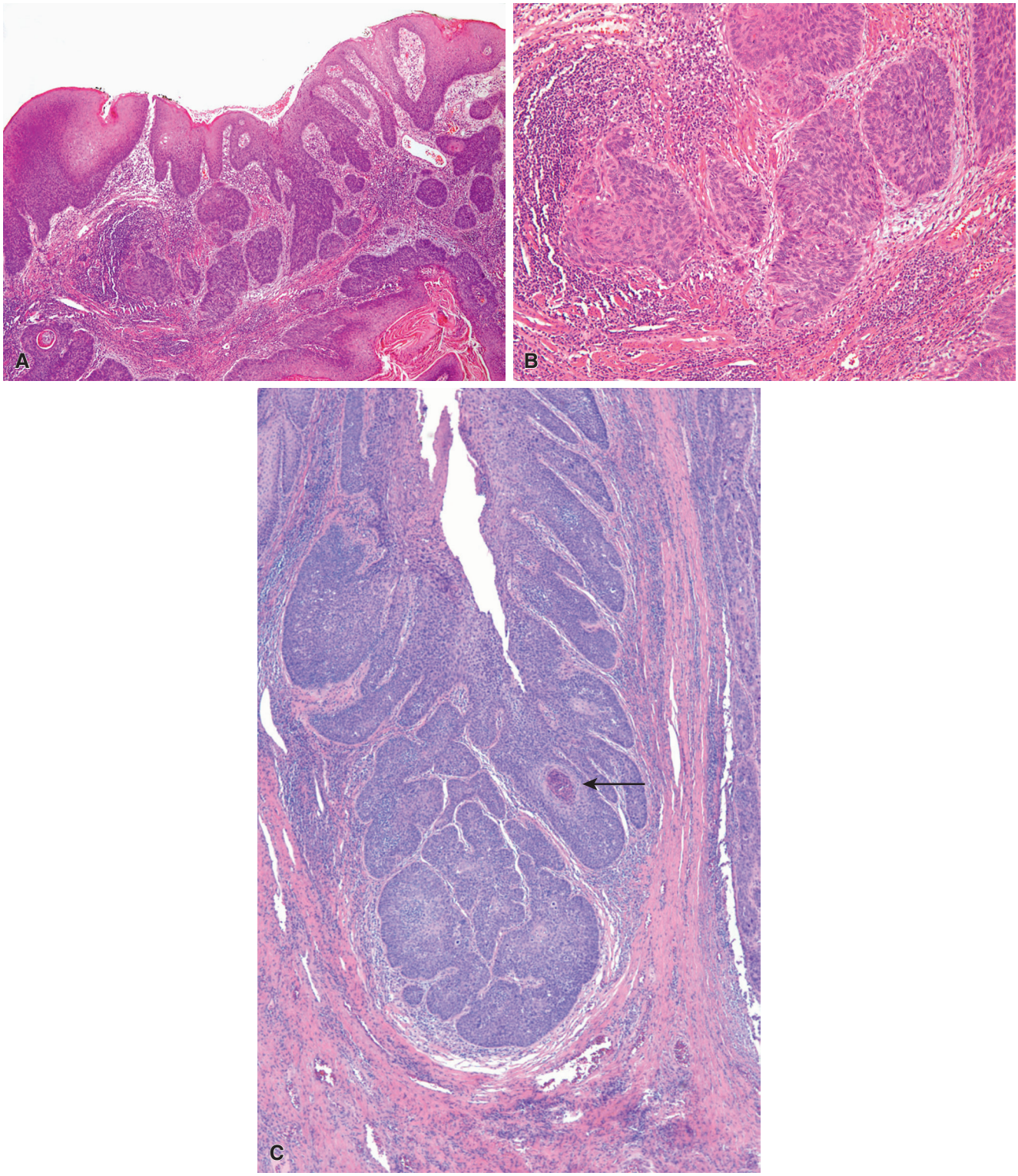

Figure 18.21 **A** and **B,** Basaloid (nonkeratinizing) SCC features irregular nests of basophilic cells that may have peripheral palisading of nuclei. **C,** Some have focal keratinization *(arrow)*.

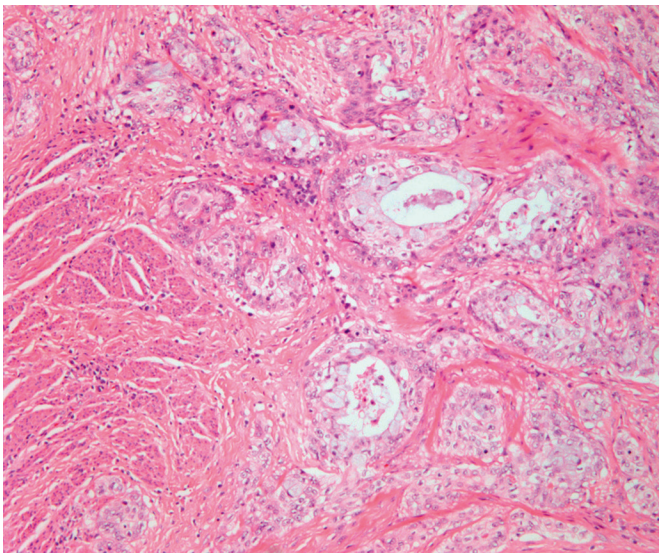

Figure 18.22 Squamous cell carcinoma (SCC) with mucinous microcysts has also been referred to as microcystic SCC or mucoepidermoid carcinoma of the anus.

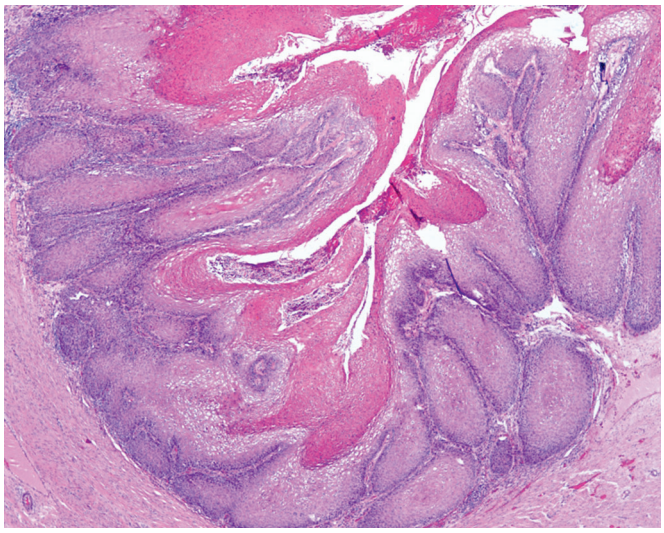

Figure 18.23 Verrucous carcinoma of the anus has a pushing, rather than an infiltrative, border. Note the juxtaposition of the tumor with the muscle of the anal canal wall.

standard of care is a combined approach of chemotherapy and radiation therapy, which achieves complete tumor regression in 80%–90% of patients, with a local treatment failure rate of about 15%.[102,103] Overall, the 5-year disease-free survival rate using a combination chemoradiation protocol is 68%, while the overall survival rate is 58%–67% and the colostomy free survival rate is 85%.[104] Local excision is sometimes used for small (< 2.0 cm) tumors of the anal margin and can be adequate if margins are clear by more than 0.5 cm.[102]

Prognosis

The prognosis of carcinoma of the anal canal is related to several parameters.

1. Patient age, gender, and race. It is worse in older (≥65 years) individuals, men, and African-American patients.[105]
2. Tumor location. Although the literature has shown conflicting results over time, current studies indicate that tumors above the dentate line have a better overall prognosis than those below the dentate line.[106]
3. Tumor size and stage. The prognosis depends largely on the stage of the disease, as determined by depth of invasion, nodal involvement, and presence of distant metastases.[105]
4. Microscopic grade. As discussed previously, histologic subtype does not affect prognosis. Poorly differentiated tumors are associated with shorter survival.[105]
5. Presence of HPV. Patients with HPV-negative SCC appear to have a worse prognosis (shorter disease-free survival) in some studies than patients with HPV-positive tumors.[84]

Anal Duct/Gland Adenocarcinoma

Adenocarcinoma involving the anal canal usually represents a downgrowth of a rectal tumor, and this is the main entity in the differential diagnosis of **primary anal adenocarcinoma**. These rare tumors are thought to arise from the mucus-producing epithelial cells of the anal transition zone, as well as the glandular epithelium of the perianal glands/ducts. Association with HPV remains controversial. These tumors generally present in older adults (60–70 years of age), and there is a male predominance.[107–109] Patients often have a painful buttock mass and/or a mucinous anal discharge, and many also present with bleeding.[107,109] These tumors are aggressive, with high risk of both local and distant recurrences. The overall 5-year survival rate is 30% or less;[108] prognosis is stage dependent, however, and staging is similar to anal SCC.

Macroscopically, anal adenocarcinomas arise within the deep soft tissues of the anal region (Fig. 18.24A), and intraluminal anal canal growth is rare. Tumors may protrude from the anal orifice or form an ulcerated mass that involves the squamous mucosa and therefore causes confusion. Primary anal gland/duct carcinomas typically have one of two patterns.[109,110] The first is a relatively well-differentiated infiltrative process composed of tubules or glands with minimal luminal material. The second is a mucinous or "colloid" pattern, with clusters of malignant cells associated with large pools of paucicellular mucin (see Fig. 18.24B–D). The latter type can present with multiple fistulous tracts and, on rare occasions, as vaginal cysts.[111] Pagetoid spread of tumor cells is frequently seen.[109] Poorly differentiated tumors with signet ring cell features have also been reported, although some of these may represent distal rectal adenocarcinomas.[112] Rare anal carcinomas have clear cell features,[113] which must be distinguished from the equally rare metastases of clear cell tumors (such as renal cell carcinoma) to the anus.[114] Anal duct/gland adenocarcinomas are typically CK7 positive and CK20 negative, which is in contrast to colorectal adenocarcinomas that are frequently CK20 positive and CK7 negative. Rare mucinous anal adenocarcinomas are also CK20 positive, however.[109,110] Patients are generally treated by surgical excision, which may be extensive; surgical therapy may also be combined with chemotherapy and radiation.

Paget Disease

Paget disease of the anal region is a malignant glandular neoplasm having a predominantly or exclusively intraepithelial location and characterized by infiltration of the epithelium by malignant mucin-containing cells. It affects both women and men, although women are more commonly affected, and typically presents in middle-aged to older patients.[115] Clinically, it presents as erythematous, scaly, or ulcerated lesion of eczematoid appearance located anywhere between the dentate line and perianal skin (Fig. 18.25A). Patients typically present with bleeding and/or itching.

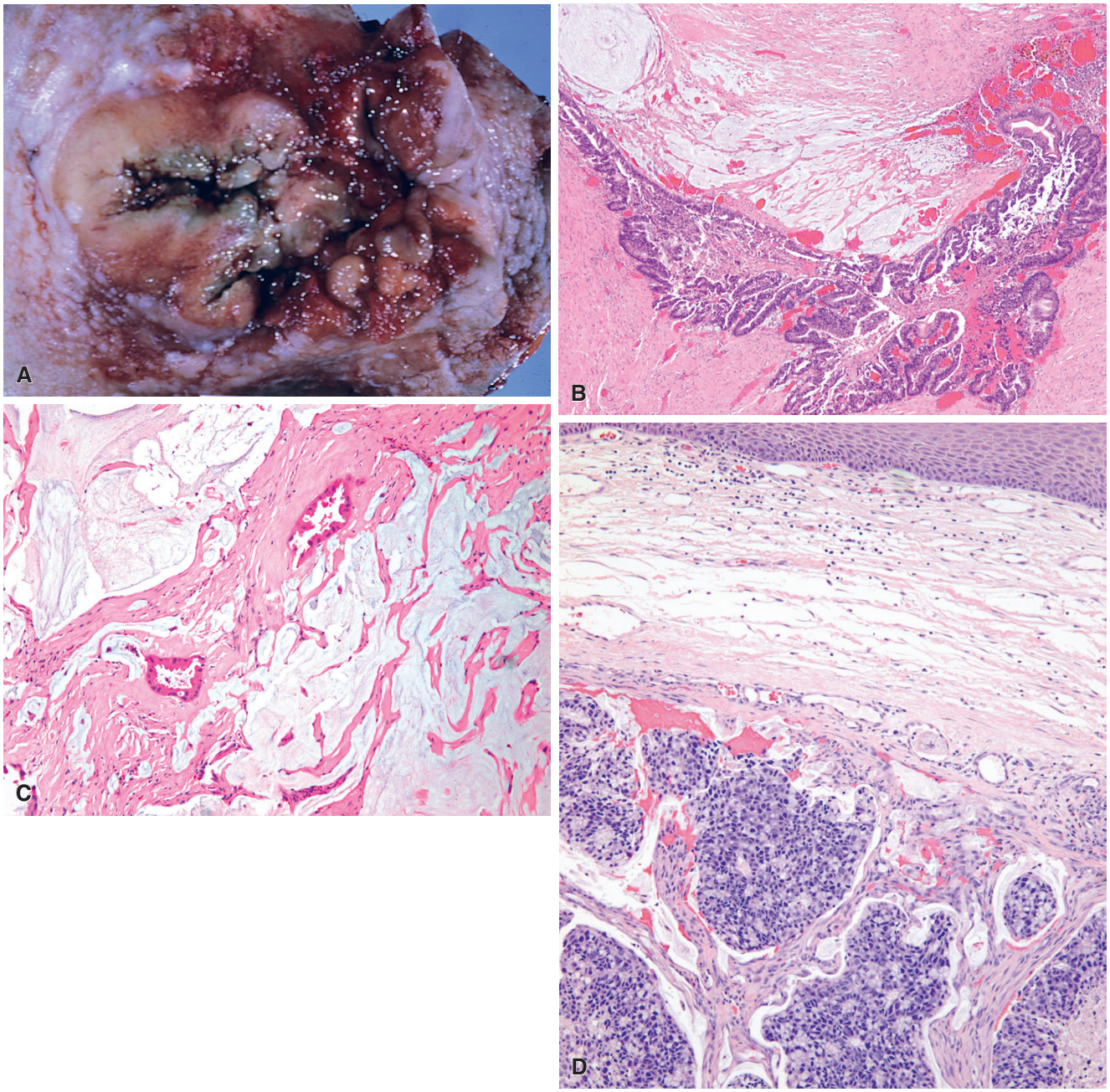

Figure 18.24 **A,** This anal duct adenocarcinoma infiltrates the perianal soft tissues and forms a large mass that undermines the overlying epithelium. **B** and **C,** This anal duct adenocarcinoma features deeply infiltrating well differentiated glands associated with large pools of dissecting mucin. The glands are present deep within the anal musculature. This example **(D)** shows clusters of poorly differentiated cells (including signet ring cells) in pools of mucin. This tumor was CK7+ and CK20–, consistent with an anal primary.

Paget disease of this region can be subdivided into two types.[116] Primary anal/perianal Paget disease is histologically similar to that seen in the vulva and perineum, though it can occur in both sexes. Primary Paget disease is believed to arise from neoplastic cells of either apocrine or eccrine origin.[117] Secondary anal/perianal Paget disease arises from neoplasms that are centered in the rectum, with individually infiltrating cells extending distally to involve the anal mucosa. Primary Paget disease is much less common than the secondary form, reflecting the more frequent occurrence of colorectal adenocarcinoma in general.

In either form of Paget disease, the Paget cells are predominantly located along the epithelial basal layer, infiltrating the squamous mucosa or perianal skin in a pattern known as "pagetoid spread" (see Fig. 18.25B). Most of them are arranged individually, but occasionally there are nests and gland-like formations; neoplastic cells may spread down pilosebaceous units and adnexal structures. The cells are large and have abundant pale cytoplasm, and often contain recognizable mucin vacuoles. Occasionally they have a signet ring appearance.[116] Mucin-containing Paget cells can be highlighted using cytochemical stains, such as mucicarmine, and/or immunohistochemical

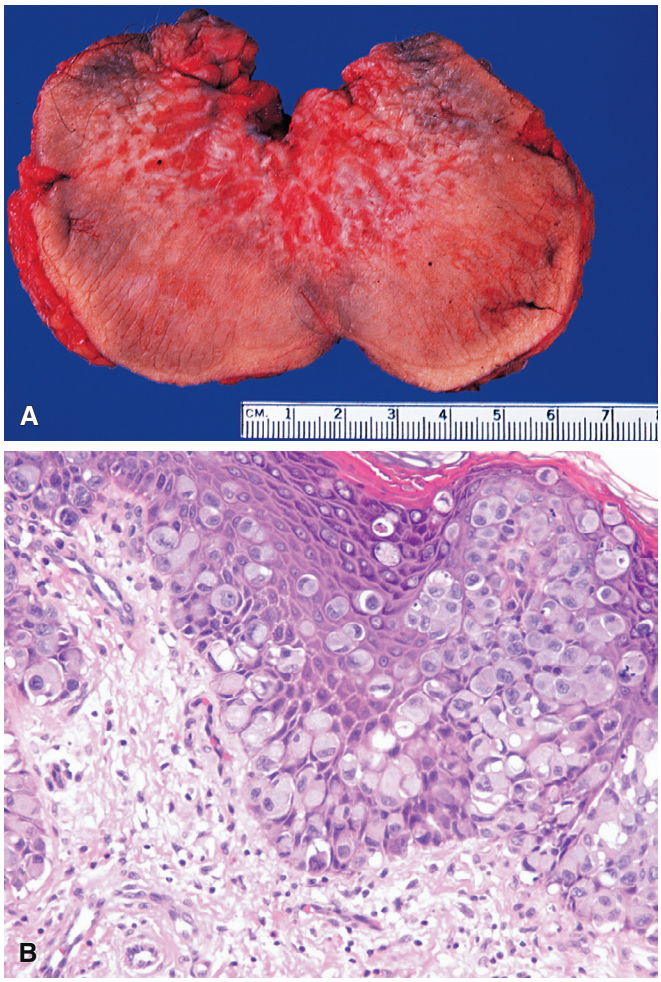

Figure 18.25 Gross Appearance of Paget Disease of the Anus. A, The lesion is erosive and hyperemic and has ill-defined borders. **B,** Paget cells are predominantly located along the basal layer, infiltrating the epithelium as individual cells or nests. The cells are large with atypical nuclei, abundant pale cytoplasm, and occasional mucin vacuoles.

markers of mucin production, an important feature (more in the past than now) in the differential diagnosis with melanoma and Bowen disease.[118,119] The infiltrative nature of the process often causes reactive changes in the adjacent squamous epithelium, including hyperparakeratosis, acanthosis, and basal atypia. Cases of coexistent Paget disease and squamous neoplasia have also been reported at this site.[120]

Immunohistochemistry can aid in both the diagnosis of anorectal Paget disease and in distinguishing between the two forms.[116,121] Distinction between the two types of Paget disease is important because secondary Paget disease may be the presenting sign of a rectal neoplasm. Paget cells are reactive for keratin, CEA, and EMA.[119] As expected, secondary PD has an immunophenotype consistent with colonic adenocarcinoma, expressing CK20, CDX-2, and MUC2; as with other colorectal adenocarcinomas, there may be CK7 positivity as well. In contrast, primary Paget disease of the anus has a phenotype identical to vulvar disease and much more analogous to mammary carcinoma. Specifically, CK7, MUC5AC, and GCDFP-15 are positive, while CK20 and CDX-2 are negative. GCDFP-15 ("gross cystic disease fluid protein") is a marker of apocrine differentiation expressed by many breast carcinomas and may suggest an apocrine origin for primary anal Paget disease as well.[116] Interestingly, the cells of extramammary (including anal) Paget disease consistently lack estrogen and progesterone receptors but frequently express androgen receptor.[122]

The therapy and prognosis of anorectal Paget disease depends on the specific type. For primary cases, wide local excision is the mainstay of treatment,[123] although local recrudescence is very common because of the ill-defined nature of the process, its sometimes multifocal nature, and the difficulties in delimiting it grossly and surgically. Topical and/or noninvasive modalities are effective in some cases. Secondary cases with associated underlying rectal cancer should be treated accordingly, and prognosis in these latter cases depends on the stage of the underlying adenocarcinoma but is usually poor.

Anorectal Paget disease must be distinguished from other tumors of this region that can have pagetoid spread, including primary anal gland/duct adenocarcinoma, melanoma, and SCC. The pagetoid cells of melanoma are keratin negative and express melanoma markers, such as S-100, HMB-45, and/or melan-A. SCCs with pagetoid growth express squamous markers, such as p63 and CK5/6, are mucin negative, and often have evidence of HPV infection. The immunophenotype of anal gland/duct carcinoma generally overlaps with that of primary anorectal Paget disease, so correlation with clinical findings is often necessary to differentiate between these diagnoses. Reactive vacuolated squamous cells may also mimic Paget disease, but these cells should not have significant cytologic atypia and should not contain mucin. It is also interesting that cells identical to those described by Toker in the nipple have been detected in the anal region (V Eusebi, personal communication, 2003), which may also enter into the differential diagnosis.

Other Microscopic Types of Carcinoma

Neuroendocrine carcinoma is exceedingly rare in this location. The histologic and immunophenotypic appearance is reminiscent of the pulmonary homonymous tumors, and they may have either a small cell or large cell phenotype.[124] These tumors should express at least one neuroendocrine marker (synaptophysin, chromogranin, CD56) and are variably keratin positive.[124] Their behavior is extremely aggressive.[93] Some cases have been associated with HPV infection and intraepithelial neoplasia,[125] and some have been reported in HIV-infected patients.[126] There are also very rare reports of Merkel cell carcinoma of the anal canal, with characteristic dot-like keratin positivity.[127] Well-differentiated neuroendocrine (carcinoid) tumors of the "anorectum" have been occasionally reported, but it is unclear in many cases if these tumors are truly arising in the anus, or represent extension from a low rectal tumor.

Basal cell carcinoma is occasionally encountered in perianal skin. Before making this diagnosis, the more likely probability of basaloid SCC should be considered, especially when the tumor encroaches on the anal canal. Some patients develop perianal basal cell carcinomas in association with genetic syndromes, such as the basal cell nevus (Gorlin) syndrome; therefore, patients with these conditions should be carefully examined for perianal lesions.[128]

Perianal basal cell carcinomas develop at or below the anal verge, in hair-bearing skin, in contrast to basaloid SCC that involve the anal canal itself. As in other sites, perianal basal cell carcinomas have a nodular, pearly appearance with variably present ulceration[129,130] and are occasionally mistaken for benign lesions such as anal tags or hemorrhoids. Histologically, analogous to their counterparts elsewhere, they are composed of nodules of basaloid cells with prominent peripheral palisading, and they can sometimes be seen "budding" from the basal surface of the epidermis (Fig. 18.26).

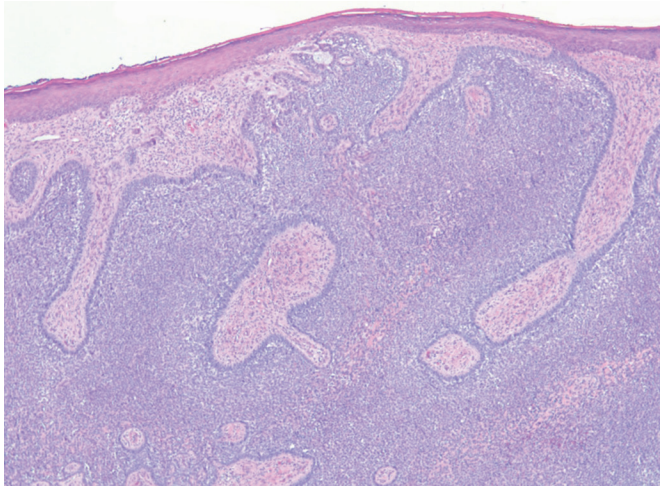

Figure 18.26 This basal cell carcinoma "buds" from the overlying perianal skin and shows a nodular tumor composed of basaloid cells with prominent peripheral palisading.

Retraction artifact may be prominent around the tumor nests, and microcystic spaces filled with mucoid material or foci of abrupt keratinization are sometimes present as well.[129,130] In contrast to basaloid SCC, true cutaneous perianal basal cell carcinomas usually have less nuclear pleomorphism and less mitotic activity. Immunohistochemistry for EpCAM/Ber-EP4 can aid in distinguishing the two, as it tends to be positive in perianal basal cell carcinoma and negative in basaloid SCC.[131] Conversely, basaloid SCC are typically positive for markers of squamous differentiation such as SOX2. Of note, p63 and CK5/6 can mark either tumor.[131] The distinction is of great importance because of the vast difference in therapy and behavior between the two tumors.[130] Wide local excision is the therapy of choice for cutaneous perianal basal cell carcinoma, which is usually curative.[129,130] As previously mentioned, chemoradiation is the standard of care for basaloid SCC of the anal canal. These tumors typically have a more aggressive course than cutaneous perianal basal cell carcinomas.

Malignant Melanoma

Malignant melanoma of the anus is rare, accounting for less than 0.01% of all mucocutaneous melanomas.[132,133] These tumors are believed to arise from normal melanocytes that exist in the anal squamous mucosa and the anal transition zone. Most cases occur in adults, but they can also affect children and adolescents.[134] The typical gross appearance is that of a polypoid, variably pigmented mass with a smooth overlying surface that is often ulcerated (Fig. 18.27A). These lesions are often quite large at presentation (2–5 cm).[132,135] In the early stages, anal melanoma can simulate hemorrhoids or a prolapse polyp, which unfortunately may lead to a delay in diagnosis.[136] The tumor is usually close to the dentate line but can also lie at the anal verge. Sometimes these lesions extend proximally along the submucosa and emerge through the mucosa at a high point, thus simulating a primary rectal tumor.[132] Rectal bleeding, palpable mass, and pain are the most common complaints.[132]

Microscopically, anal melanoma is composed of large, epithelioid, pleomorphic tumor cells with variably present pigment (see Fig. 18.27B and C). Two-thirds show a "junctional" component with a lentiginous appearance in the adjacent mucosa.[137] The appearance and histologic variability are similar to those of melanomas of skin and other mucosal membranes, including the desmoplastic variety featuring spindle cells in an abundant collagenous matrix, and often lacking pigment (see Fig. 18.27D).[138,139] The immunohistochemical profile is also similar to that of cutaneous melanoma,[139] with the caveats that many desmoplastic melanomas lack HMB-45 immunoreactivity (but S-100 protein expression remains fairly sensitive), and that many melanomas are CD117 positive.[140]

Prognosis, which in general is extremely poor, is directly related to tumor stage;[133] the overall 5-year survival rate is 27.3% for localized disease, and 14.5% for regional disease. Surgery is the mainstay of therapy, and options include both wide local excision and abdominoperineal resection.[133] No other morphologic or immunohistochemical features seem to correlate with prognosis.[139]

Malignant melanoma should be distinguished from other epithelioid malignancies of the anus, as well as the exceptionally rare adenocarcinoma of this region which contains abundant melanin in the tumor cells, perhaps through a colonization mechanism similar to that sometimes seen in breast carcinoma.[141]

Mammary Analogue Tumors

Historically, anogenital mammary-like glands were believed to represent ectopic breast tissue along the milk line. Currently, however, these glands are considered to be normal in this location. These glands give rise to a wide variety of lesions that bear a resemblance to their counterparts in the breast (Fig. 18.28), including fibroadenomas, hidradenoma papilliferum, phyllodes tumor, and mammary-type carcinomas.[142,143]

Other Tumors and Tumorlike Conditions

Ectopic prostatic and gastric tissue have been reported in the anal canal.[144,145]

Langerhans cell histiocytosis can involve the perianal skin.[146]

Endometriosis may involve the anus and perineum, typically secondary to an episiotomy scar.[147]

Keratinous cysts of epidermal type located in the anal canal are probably of the so-called epidermal inclusion cyst type.[148]

Benign mesenchymal tumors are very rare in this location, if one avoids labeling hypertrophied anal papillae as 'fibromas.' True **leiomyomas** as well as gastrointestinal stromal tumors (GISTs) are occasionally seen in this location.[149,150] **Granular cell tumors** may grow to a relatively large size and ulcerate, thus simulating clinically the appearance of a malignant tumor.[151] These benign tumors are generally cured by excision, and occur more commonly in African Americans.[152] **Perianal spindle cell lipoma**[153] has been rarely reported. **Leiomyosarcoma** is the most common primary malignant stromal tumor in the region.[150] Sometimes it is difficult to decide whether to classify these tumors as anal or rectal. The differential diagnosis includes GIST and spindle cell/desmoplastic melanoma.

Rhabdomyosarcoma can occur in the perianal region of infants and children and may present as a perirectal abscess. Both alveolar and embryonal patterns have been reported (Fig. 18.29).[154] Kaposi sarcoma can also involve the anus.[155]

Malignant lymphoma of the anorectal region has been observed, most often in HIV-infected patients.[156,157] Some of these tumors have been found to be EBV-related.[158]

Metastases to the anal region often arise from rectal carcinomas (Fig. 18.30). Sometimes these have been seen to develop at the site of a recently performed hemorrhoidectomy.[159] Metastases have also been reported from distant sites such as the kidney, breast (Fig. 18.31), and pancreaticobiliary tree, which can mimic primary anal adenocarcinoma or extension from a low rectal adenocarcinoma.[114–161]

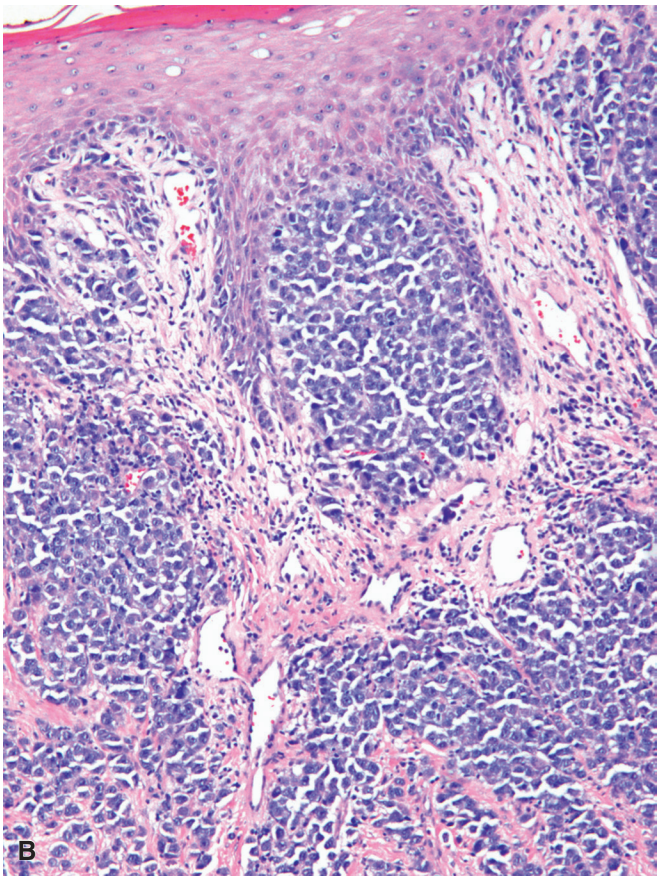

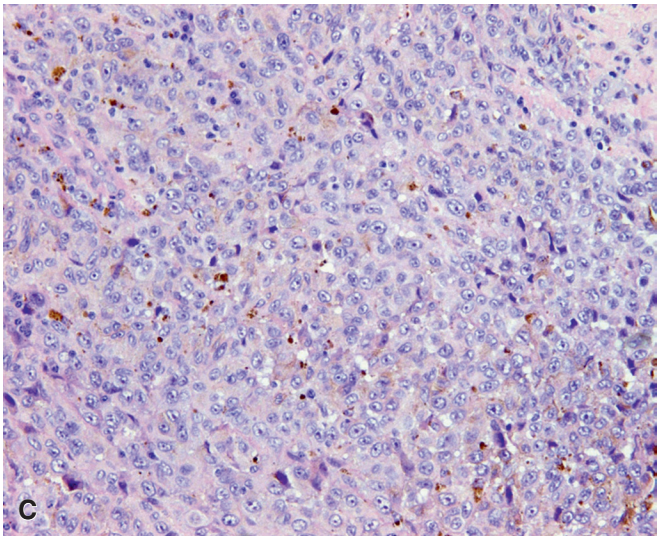

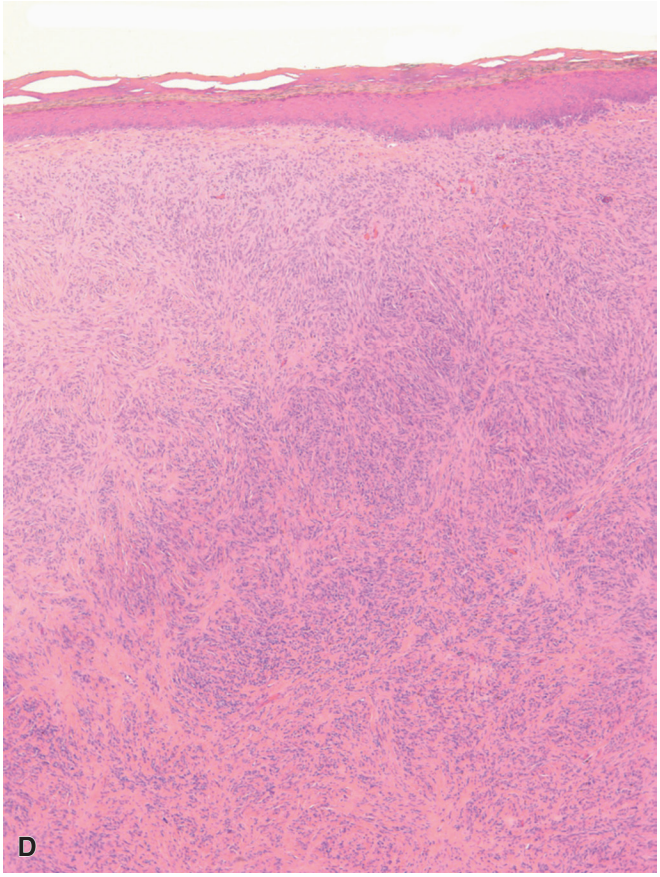

Figure 18.27 **A,** Cross section from excision specimen of an anal melanoma demonstrates the polypoid configuration of the tumor as well as the pigmentation. Note the extension into the surrounding mucosa. **B,** This biopsy from an anal melanoma demonstrates involvement at the dermal/epidermal junction. **C,** High-power view shows large, epithelioid tumor cells with abundant pigment. **D,** This desmoplastic anal melanoma features a spindle cell proliferation with a prominent collagenous matrix and no pigment.

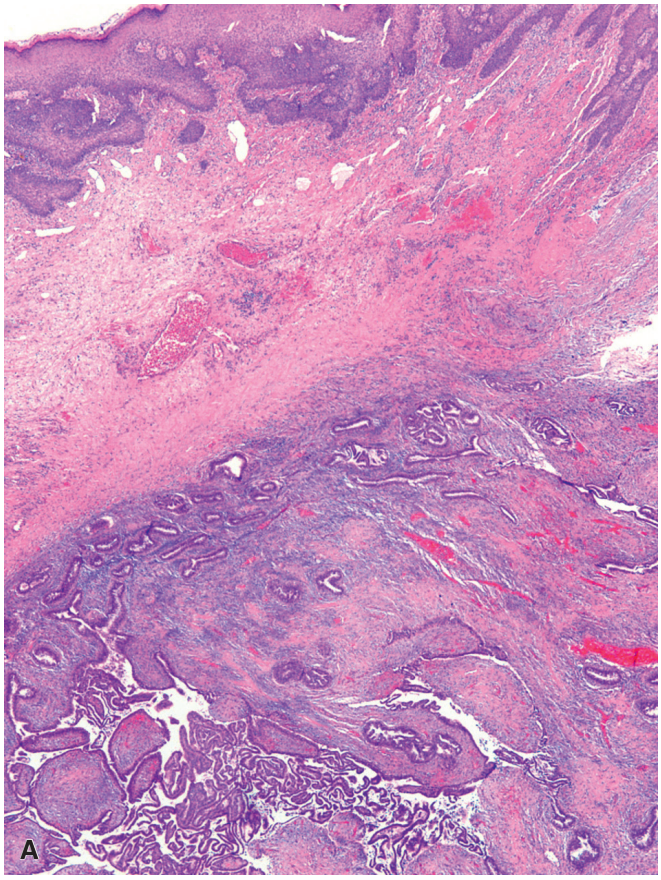

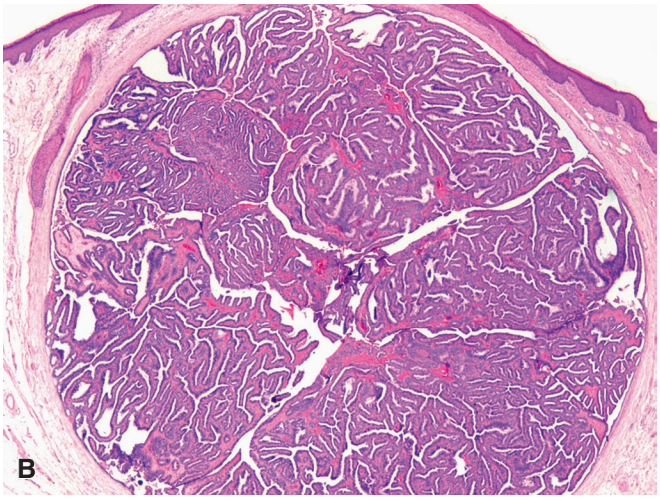

Figure 18.28 Anogenital mammary analog glands give rise to a variety of tumors that resemble their breast counterparts, including fibroadenoma **(A)** and hidradenoma papilliferum **(B)**.

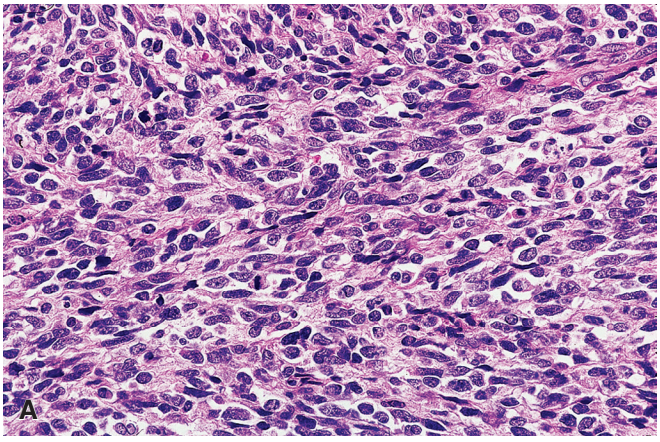

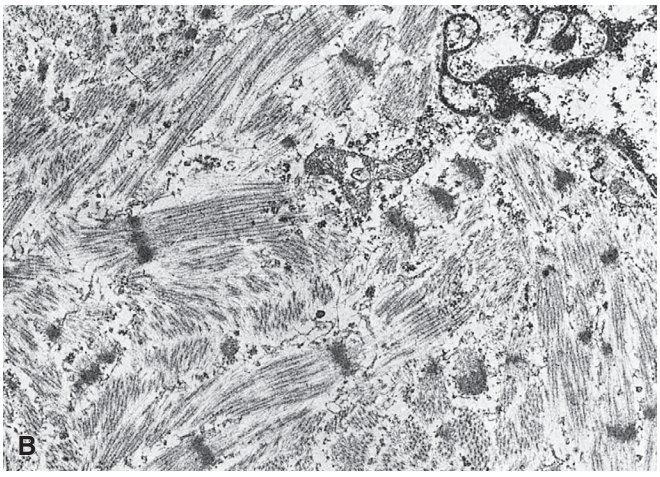

Figure 18.29 **A,** Embryonal rhabdomyosarcoma of perianal region. **B,** Electron microscopic appearance of embryonal rhabdomyosarcoma arising in perianal region. There is clear-cut evidence of skeletal muscle differentiation, including the formation of Z lines. (Courtesy of Dr. J. Magidson, Brookhaven, NY.)

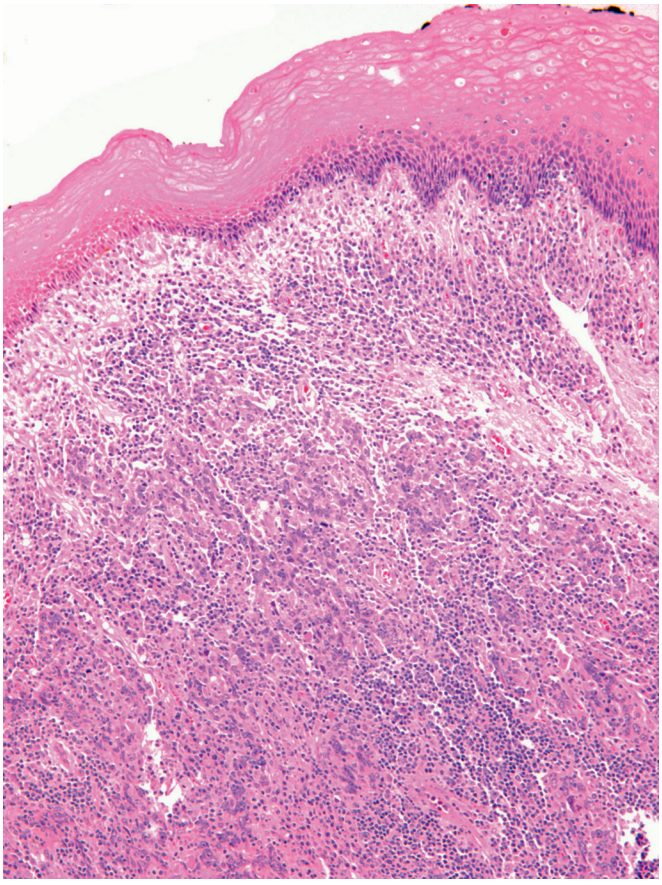

Figure 18.30 A low rectal medullary carcinoma involving the anal canal.

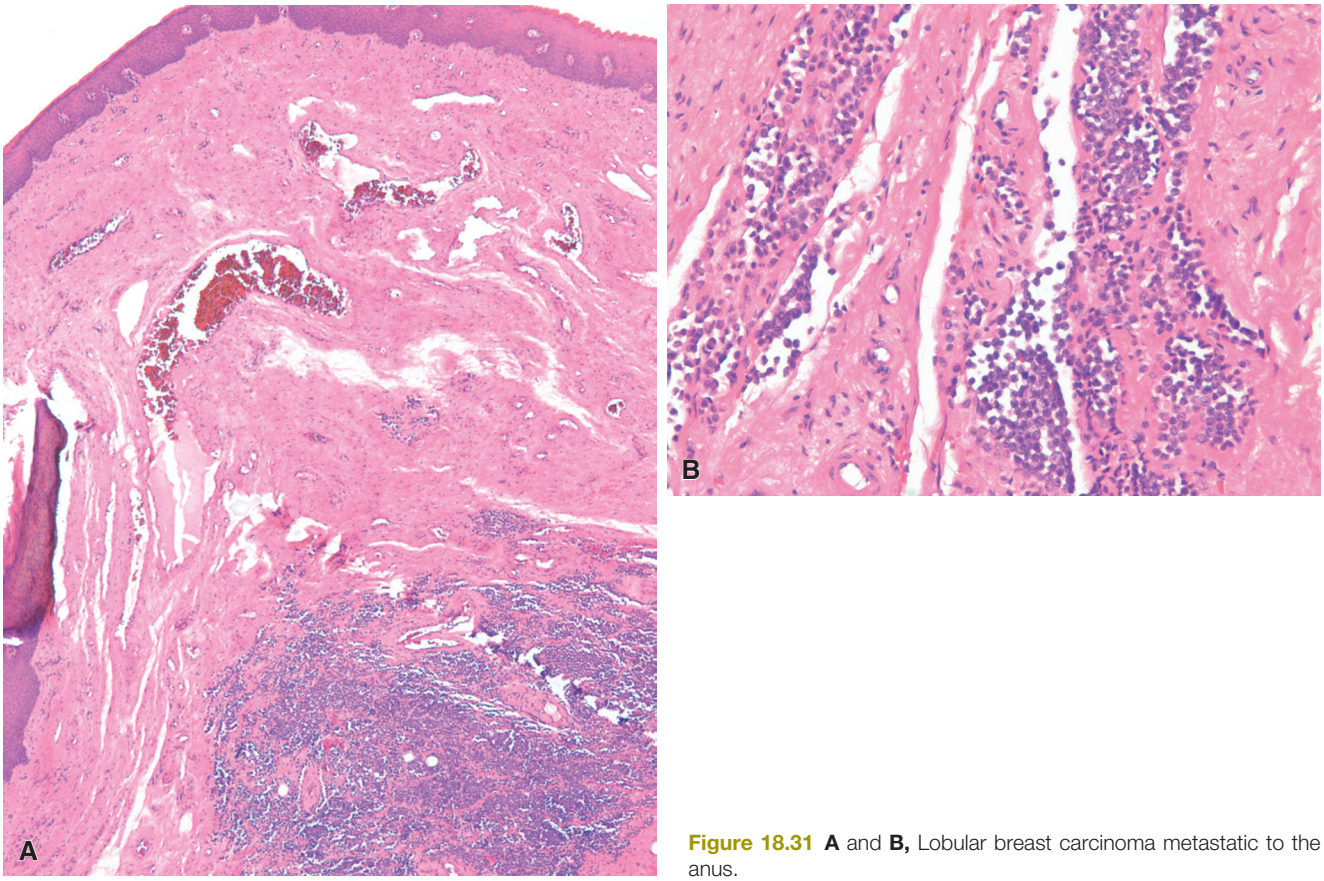

Figure 18.31 **A** and **B,** Lobular breast carcinoma metastatic to the anus.

References

1. Fenger C. Anal canal. In: Mills SE, ed. *Histology for Pathologists*. 3rd ed. Philadelphia, PA: Lippincott Williams & Wilkins; 2007:663-684.
2. Lamps LW. Anus and anal canal. In: Lamps LW, ed. *Diagnostic Pathology: Normal Histology*. 1st ed. Salt Lake City, UT: Amirsys; 2013:10:28-31.
3. Parks AG. Modern concepts of the anatomy of the ano-rectal region. *Postgrad Med J*. 1958;34(393):360-366.
4. Fenger C, Nielsen K. Stereomicroscopic investigation of the anal canal epithelium. *Scand J Gastroenterol*. 1982;17:571-575.
5. van der Putte SC. Anogenital "sweat" glands: histology and pathology of a gland that may mimic mammary glands. *Am J Dermatopathol*. 1991;13(6):557-567.
6. Aldridge RT, Campbell PE. Ganglion cell distribution in the normal rectum and anal canal. A basis for the diagnosis of Hirschsprung's disease by anorectal biopsy. *J Pediatr Surg*. 1968;3(4):475-490.
7. Grinvalsky HT, Helwig EB. Carcinoma of the anorectal junction. I. Histological considerations. *Cancer*. 1956;9(3): 480-488.
8. Klotz RG Jr, Pamukcoglu T, Souilliard DH. Transitional cloacogenic carcinoma of the anal canal. Clinicopathologic study of three hundred seventy-three cases. *Cancer*. 1967;20(10):1727-1745.
9. Seow-Choen F, Ho JM. Histoanatomy of anal glands. *Dis Colon Rectum*. 1994;37(12):1215-1218.
10. Ramalingam P, Hart WR, Goldblum JR. Cytokeratin subset immunostaining in rectal adenocarcinoma and normal anal glands. *Arch Pathol Lab Med*. 2001;125(8):1074-1077.
11. Williams GR, Talbot IC, Northover JM, Leigh IM. Keratin expression in the normal anal canal. *Histopathology*. 1995;26(1):39-44.
12. Fetissof F, Dubois MP, Assan R, et al. Endocrine cells in the anal canal. *Virchows Arch A Pathol Anat Histopathol*. 1984;404(1):39-47.
13. Clemmensen OJ, Fenger C. Melanocytes in the anal canal epithelium. *Histopathology*. 1991;18(3):237-241.
14. Cuschieri A. Anorectal anomalies associated with or as part of other anomalies. *Am J Med Genet*. 2002;110(2):122-130.
15. Levitt MA, Pena A. Anorectal malformations. *Orphanet J Rare Dis*. 2007;2:33.
16. Alamo L, Meyrat BJ, Meuwly JY, et al. Anorectal malformations: finding the pathway out of the labyrinth. *Radiographics*. 2013;33:491-512.
17. Lubowski DZ. Anal fissures. *Aust Fam Physician*. 2000;29:839-844.
18. Madoff RD, Fleshman JW. AGA technical review on the diagnosis and care of patients with anal fissure. *Gastroenterology*. 2003;124(1):235-245.
19. Lamps LW. Anal fistulae. In: Yantiss RK, ed. *Diagnostic Pathology: GI Endoscopic Correlation*. 1st ed. Salt Lake City, UT: Amirsys; 2015:5:8-5:9.
20. Simpson JA, Banerjea A, Scholefield JH. Management of anal fistula. *Br Med J*. 2012;345:e6705.
21. Marks CG, Ritchie JK. Anal fistulas at St Mark's Hospital. *Br J Surg*. 1977;64(2): 84-91.
22. Tabry H, Farrands PA. Update on anal fistulae: surgical perspectives for the gastroenterologist. *Can J Gastroenterol*. 2011;25(12):675-680.
23. Eglinton TW, Barclay ML, Gearry RB, Frizelle FA. The spectrum of perianal Crohn's disease in a population-based cohort. *Dis Colon Rectum*. 2012;55(7):773-777.
24. Logan VS. Anorectal tuberculosis. *Proc R Soc Med*. 1969;62(12):1227-1230.
25. Chourak M, Bentama K, Chamlal I, et al. Anal fistula with a tuberculous origin. *Int J Colorectal Dis*. 2010;25:1035-1036.
26. Coremans G, Margaritis V, Van Poppel HP, et al. Actinomycosis, a rare and unsuspected cause of anal fistulous abscess: report of three cases and review of the literature. *Dis Colon Rectum*. 2005;48:575-581.
27. Beer TW, Carr NJ. Fibroepithelial polyps of the anus with epithelial vacuolation. *Am J Surg Pathol*. 1999;23:488-489.
28. Groisman GM, Polak-Charcon S. Fibroepithelial polyps of the anus: a histologic, immunohistochemical, and ultrastructural study, including comparison with the normal anal subepithelial layer. *Am J Surg Pathol*. 1998;22(1):70-76.
29. Sakai Y, Matsukuma S. CD34+ stromal cells and hyalinized vascular changes in the anal fibroepithelial polyps. *Histopathology*. 2002;41(3):230-235.
30. Groisman GM, Amar M, Polak-Charcon S. Multinucleated stromal cells of the anal mucosa: a common finding. *Histopathology*. 2000;36(3):224-228.
31. Schinella RA. Stromal atypia in anal papillae. *Dis Colon Rectum*. 1976;19(7):611-613.
32. Abid S, Khawaja A, Bhimani SA, et al. The clinical, endoscopic, and histological spectrum of the solitary rectal ulcer syndrome: a single-center experience of 116 cases. *BMC Gastroenterol*. 2012;12:72.

33. Chetty R, Bhathal PS, Slavin JL. Prolapse-induced inflammatory polyps of the colorectum and anal transitional zone. *Histopathology*. 1993;23:63-67.
34. Saul SH. Inflammatory cloacogenic polyp: relationship to solitary rectal ulcer syndrome / mucosal prolapse and other bowel disorders. *Hum Pathol*. 1987;18:1220-1225.
35. Lobert PF, Appelman HD. Inflammatory cloacogenic polyp: a unique inflammatory lesion of the anal transition zone. *Am J Surg Pathol*. 1981;5:761-766.
36. Bass J, Soucy P, Walton M, Nizalik E. Inflammatory cloacogenic polyps in children. *J Pediatr Surg*. 1995;30:585-588.
37. Lamps LW. Hemorrhoids. In: Yantiss RK, ed. *Diagnostic Pathology: GI Endoscopic Correlation*. 1st ed. Salt Lake City, UT: Amirsys; 2015:5:2-5:3.
38. Lohsiriwat V. Hemorrhoids: from basic pathophysiology to clinical management. *World J Gastroenterol*. 2012;18(17):2009-2017.
39. Madoff RD, Fleshman JW. American gastroenterological association technical review on the diagnosis and treatment of hemorrhoids. *Gastroenterology*. 2004;126:1463-1473.
40. Maslekar S, Toh EW, Adair R, et al. Systematic review of anorectal varices. *Colorectal Dis*. 2013;15(12):e702-e710.
41. Kuo T, Sayers CP, Rosai J. Masson's "vegetant intravascular hemangioendothelioma:" a lesion often mistaken for angiosarcoma: study of seventeen cases located in the skin and soft tissues. *Cancer*. 1976;38(3):1227-1236.
42. Laurence AE, Murray AJ. Histopathology of prolapsed and thrombosed hemorrhoids. *Dis Colon Rectum*. 1962;5:56-61.
43. Lemarchand N, Tanne F, Aubert M, et al. Is routine pathologic evaluation of hemorrhoidectomy specimens necessary? *Gastroenterol Clin Biol*. 2004;28(8-9):659-661.
44. Lohsiriwat V, Akkarash V, Lohsiriwat D. Value of routine histopathologic examination of three common surgical specimens: appendix, gallbladder, and hemorrhoid. *World J Surg*. 2009;33:2189-2193.
45. Meguerditchian AN, Meterissian SH, Dunn KB. Anorectal melanoma: diagnosis and treatment. *Dis Colon Rectum*. 2011;54(5):638-644.
46. Kanaan Z, Ahmad S, Bilchuk N, et al. Perianal Crohn's disease: predictive factors and genotype-phenotype correlations. *Dig Surg*. 2012;29(2):107-114.
47. Sjödahl RI, Myrelid P, Söderholm JD. Anal and rectal cancer in Crohn's disease. *Colorectal Dis*. 2003;5(5):490-495.
48. Frisch M, Johansen C. Anal carcinoma in inflammatory bowel disease. *Br J Cancer*. 2000;83:89-90.
49. Taylor BA, Williams GT, Hughes LE, Rhodes J. The histology of anal skin tags in Crohn's disease: an aid to confirmation of the diagnosis. *Int J Colorectal Dis*. 1989;4(3):197-199.
50. Hernandez Z, Almeida P, Borrego L, Hernandez J. Infiltrated perianal plaques. *Int J Dermatol*. 2013;52:23-24.
51. Lal S, Nicholas C. Epidemiological and clinical features in 165 cases of granuloma inguinale. *Br J Vener Dis*. 1970;46(6):461-463.
52. Sehgal VN, Shyamprasad AL, Beohar PC. The histopathological diagnosis of donovanosis. *Br J Vener Dis*. 1984;60:45-47.
53. Sethi S, Sarkar R, Garg V, Agarwal S. Squamous cell carcinoma complicating donovanosis not a thing of the past! *Int J STD AIDS*. 2014;25:894-897.
54. Hesselina N, de Vrieze N, van Rooijen M, et al. Anorectal and inguinal lymphogranuloma venereum among men who have sex with men in Amsterdam, the Netherlands: trends over time, symptomatology and concurrent infections. *Sex Transm Infect*. 2013;89:548-552.
55. Arnold CA, Limketkai BN, Illei PB, et al. Syphilitic and lymphogranuloma venereum (LGV) proctocolitis: clues to a frequently missed diagnosis. *Am J Surg Pathol*. 2013;37(1):38-46.
56. de la Monte SM, Hutchins GM. Follicular proctocolitis and neuromatous hyperplasia with lymphogranuloma venereum. *Hum Pathol*. 1985;16(10):1025-1032.
57. De Vries HJC, Zingoni A, White JA, et al. 2013 European guideline on the management of proctitis, proctocolitis, and enteritis caused by sexually transmissible pathogens. *Int J STD AIDS*. 2014;25:465-474.
58. Puy-Montbrun T, Denis J, Ganansia R, et al. Anorectal lesions in human immunodeficiency virus-infected patients. *Int J Colorectal Dis*. 1992;7(1):26-30.
59. Francis ND, Boylston AW, Roberts AH, et al. Cytomegalovirus infection in gastrointestinal tracts of patients infected with HIV-1 or AIDS. *J Clin Pathol*. 1989;42:1055-1064.
60. Daling JR, Madeleine MM, Johnson LG, et al. Human papillomavirus, smoking, and sexual practices in the etiology of anal cancer. *Cancer*. 2004;101:270-280.
61. Nelson RA, Levine AM, Bernstein L, et al. Changing patterns of anal canal carcinoma in the United States. *J Clin Oncol*. 2013;31:1569-1575.
62. Stier EA, Sebring MC, Mendez AE, et al. Prevalence of anal human papillomavirus infection and anal HPV-related disorders in women: a systematic review. *Am J Obstet Gynecol*. 2015;213(3):278-309.
63. Smyczek P, Singh AE, Romanowski B. Anal intraepithelial neoplasia: a review and recommendations for screening and management. *Int J STD AIDS*. 2013;24:843-851.
64. Darragh TM, Colgan TJ, Cox JT, et al. The lower anogenital squamous terminology standardization project for HPV-associated lesions: background and consensus recommendations from the College of American Pathologists and the American Society for Colposcopy and Cervical Pathology. *Arch Pathol Lab Med*. 2012;136(10):1266-1297.
65. Maniar KP, Nayar R. HPV-related squamous neoplasia of the lower anogenital tract: an update and review of recent guidelines. *Adv Anat Pathol*. 2014;21(5):341-358.
66. Wong AK, Chan RC, Aggarwal N, et al. Human papillomavirus genotypes in anal intraepithelial neoplasia and anal carcinoma as detected in tissue biopsies. *Mod Pathol*. 2010;23:144-150.
67. Tamalet C, Obry-Roguet V, Ressiot E, et al. Distribution of human papillomavirus genotypes, assessment of HPV 16 and 18 viral load and anal related lesions in HIV positive patients: a cross sectional analysis. *J Med Virol*. 2014;86:419-425.
68. Pimenoff VN, Felez-sanchez M, Tous S, et al. Disagreement in high-grade/low-grade intraepithelial neoplasia and high-risk/low-risk HPV infection: clinical implications for anal cancer precursors lesions in HIV-positive and HIV-negative MSM. *Clin Microbiol Infect*. 2015;21(6):605.e11-605.e19.
69. Scholefield JH, Castle MT, Watson NF. Malignant transformation of high-grade anal intraepithelial neoplasia. *Br J Surg*. 2005;92:1133-1136.
70. Palefsky JM, Holly EA, Hogeboom CJ, et al. Virologic, immunologic, and clinical parameters in the incidence and progression of anal squamous intraepithelial lesions in HIV-positive and HIV-negative homosexual men. *J Acquir Immune Defic Syndr Hum Retrovirol*. 1998;17:314-319.
71. Lamps LW. HPV, condyloma, and anal intraepithelial neoplasia. In: Yantiss RK, ed. *Diagnostic Pathology: GI Endoscopic Correlation*. 1st ed. Salt Lake City, UT: Amirsys; 2015:5:10-5:15.
72. Pirog EC, Quint KD, Yantiss RY. p16.CDKN2A and Ki-67 enhance the detection of anal intraepithelial neoplasia and condyloma and correlate with human papillomavirus detection by polymerase chain reaction. *Am J Surg Pathol*. 2010;34:1449-1455.
73. Samama B, Lipsker D, Boehm N. p16 expression in relation to human papillomavirus in anogenital lesions. *Hum Pathol*. 2006;37(5):513-519.
74. Bean SM, Eltoum I, Horton DK, et al. Immunohistochemical expression of p16 and Ki-67 correlates with degree of anal intraepithelial neoplasia. *Am J Surg Pathol*. 2007;31(4):555-561.
75. Roma AA, Goldblum JR, Fazio V, Yang B. Expression of 14-3-3sigma, p16 and p53 proteins in anal squamous intraepithelial neoplasm and squamous cell carcinoma. *Int J Clin Exp Pathol*. 2008;1(5):419-425.
76. Wilkinson JR, Morris EJA, Downing A, et al. The rising incidence of anal cancer in England 1990–2010: a population based study. *Colorectal Dis*. 2014;16:O234-O239.
77. Johnson LG, Madeleine NM, Newcomer LM, et al. Anal cancer incidence and survival: the surveillance, epidemiology, and end results experience, 1973-2000. *Cancer*. 2004;101:281-288.
78. Vincent-Salomon A, de la Rochefordière A, Salmon R, et al. Frequent association of human papillomavirus 16 and 18 DNA with anal squamous cell and basaloid carcinoma. *Mod Pathol*. 1996;9(6):614-620.
79. Alemany L, Saunier M, Alvarado-Cabrero I, et al. Human papillomavirus DNA prevalence and type distribution in anal carcinomas worldwide. *Int J Cancer*. 2015;136:98-107.
80. Shroyer KR, Brookes CG, Markham NE, Shroyer AL. Detection of human papillomavirus in anorectal squamous cell carcinoma. Correlation with basaloid pattern of differentiation. *Am J Clin Pathol*. 1995;104(3):299-305.
81. Noffsinger AE, Hui YZ, Suzuk L, et al. The relationship of human papillomavirus to proliferation and ploidy in carcinoma of the anus. *Cancer*. 1995;75(4):958-967.
82. Slesser AA, Bhangu A, Bower M, et al. A systematic review of anal squamous cell carcinoma in inflammatory bowel disease. *Surg Oncol*. 2013;22:230-237.
83. Sunesen KG, Nørgaard M, Thorlacius-Ussing O, Laurberg S. Immunosuppressive disorders and risk of anal squamous cell carcinoma: a nationwide cohort study in Denmark. *Int J Cancer*. 2010;127:675-684.
84. Ravenda PS, Magni E, Botteri E, et al. Prognostic value of human papillomavirus in anal squamous cell carcinoma. *Cancer Chemother Pharmacol*. 2014;74:1033-1038.
85. Fenger C. Anal canal tumors and their precursors. *Pathol Annu*. 1988;23(Pt 1):45-66.
86. Lamps LW. Anal squamous cell carcinoma. In: Yantiss RK, ed. *Diagnostic Pathology: GI Endoscopic Correlation*. 1st ed. Salt Lake City, UT: Amirsys; 2015:5:16-5:19.
87. Morson BC, Pang LS. Pathology of anal cancer. *Proc R Soc Med*. 1968;61(6):623-624.
88. Dougherty BG, Evans HL. Carcinoma of the anal canal: a study of 79 cases. *Am J Clin Pathol*. 1985;83(2):159-164.
89. Pang LS, Morson BC. Basaloid carcinoma of the anal canal. *J Clin Pathol*. 1967;20(2):128-135.
90. Gillespie JJ, MacKay B. Histogenesis of cloacogenic carcinoma. Fine structure of anal transitional epithelium and cloacogenic carcinoma. *Hum Pathol*. 1978;9(5):579-587.

91. Longacre TA, Kong CS, Welton ML. Diagnostic problems in anal pathology. *Adv Anat Pathol*. 2008;15:263-278.
92. Chetty R, Serra S, Hsieh E. Basaloid squamous carcinoma of the anal canal with an adenoid cystic pattern: histologic and immunohistochemical reappraisal of an unusual variant. *Am J Surg Pathol*. 2005;29(12):1668-1672.
93. Shepherd NA, Scholefield JH, Love SB, et al. Prognostic factors in anal squamous cell carcinoma: a multivariant analysis of clinical, pathological, and flow cytometric parameters in 235 cases. *Histopathology*. 1990;16:545-555.
94. Kalogeropoulos NK, Antonakopoulos GN, Agapitos MB, Papacharalampous NX. Spindle cell carcinoma (pseudosarcoma) of the anus: a light, electron microscopic and immunocytochemical study of a case. *Histopathology*. 1985;9(9):987-994.
95. Roncaroli F, Montironi R, Feliciotti F, et al. Sarcomatoid carcinoma of the anorectal junction with neuroendocrine and rhabdomyoblastic features. *Am J Surg Pathol*. 1995;19(2):217-223.
96. Lowe D, Fletcher CD. Eosinophilia in squamous cell carcinoma of the oral cavity, external genitalia and anus—clinical correlations. *Histopathology*. 1984;8(4):627-632.
97. Williams GR, Talbot IC, Leigh IM. Keratin expression in anal carcinoma: an immunohistochemical study. *Histopathology*. 1997;30(5):443-450.
98. Kaufmann O, Fietze E, Mengs J, Dietel M. Value of p63 and cytokeratin 5/6 as immunohistochemical markers for the differential diagnosis of poorly differentiated and undifferentiated carcinomas. *Am J Clin Pathol*. 2001;116:823-830.
99. Long KB, Hornick JL. SOX2 is highly expressed in squamous cell carcinomas of the gastrointestinal tract. *Hum Pathol*. 2009;40:1768-1773.
100. Gervaz P, Hirschel B, Morel P. Molecular biology of squamous cell carcinoma of the anus. *Br J Surg*. 2006;93:531-538.
101. Zhang J, Martins CR, Fansler ZB, et al. DNA methylation in anal intraepithelial lesions and anal squamous cell carcinoma. *Clin Cancer Res*. 2005;11:6544-6549.
102. Glynne-Jones R, Nilsson PJ, Aschele C, et al. Anal cancer: ESMO-ESSO-ESTRO clinical practice guidelines for diagnosis, treatment, and follow-up. *Eur J Surg Oncol*. 2014;40:1165-1176.
103. Osborne MC, Maykel J, Johnson EK, Steele SR. Anal squamous cell carcinoma: an evolution in disease and management. *World J Gastroenterol*. 2014;20:13052-13059.
104. Oblak I, Petric P, Anderluh F, et al. Long term outcome after combined modality treatment for anal cancer. *Radiol Oncol*. 2012;46: 145-152.
105. Bilimoria KY, Bentrem DJ, Rock CE, et al. Outcomes and prognostic factors for squamous-cell carcinoma of the anal canal: analysis of patients from the National Cancer Data Base. *Dis Colon Rectum*. 2009;52: 624-631.
106. Grabenbauer GG, Kessler H, Matzel KE, et al. Tumor site predicts outcome after radiochemotherapy in squamous cell carcinoma of the anal region: long term results of 101 patients. *Dis Colon Rectum*. 2005;48:1742-1751.
107. Abel ME, Chiu YS, Russell TR, Volpe PA. Adenocarcinoma of the anal glands. Results of a survey. *Dis Colon Rectum*. 1993;36(4):383-387.
108. Basik M, Rodriguez-Bigas MA, Penetrante R, Petrelli NJ. Prognosis and recurrence patterns of anal adenocarcinoma. *Am J Surg*. 1995;169:233-237.
109. Meriden Z, Montgomery EA. Anal duct carcinoma: a report of 5 cases. *Hum Pathol*. 2012;43:216-220.
110. Hobbs CM, Lowry MA, Owen D, Sobin LH. Anal gland carcinoma. *Cancer*. 2001;92:2045-2049.
111. Askin FB, Muhlendorf K, Walz BJ. Mucinous carcinoma of anal duct origin presenting clinically as a vaginal cyst. *Cancer*. 1978;42(2):566-569.
112. Ikeuchi H, Nakano H, Uchino M, et al. Intestinal cancer in Crohn's disease. *Hepatogastroenterology*. 2008;55:2121-2124.
113. Watson PH. Clear-cell carcinoma of the anal canal: a variant of anal transitional zone carcinoma. *Hum Pathol*. 1990;21(3):350-352.
114. Sawh RN, Borkowski J, Broaddus R. Metastatic renal cell carcinoma presenting as a hemorrhoid. *Arch Pathol Lab Med*. 2002;126:856-858.
115. Tulchinsky H, Zmora O, Brazowski E, et al. Extramammary Paget's disease of the perianal region. *Colorectal Dis*. 2004;6:206-209.
116. Goldblum JR, Hart WR. Perianal Paget's disease: a histologic and immunohistochemical study of 11 cases with and without associated rectal adenocarcinoma. *Am J Surg Pathol*. 1998;22(2):170-179.
117. Regauer S. Extramammary Paget's disease—a proliferation of adnexal origin? *Histopathology*. 2006;48:723-729.
118. Yoshii N, Kitajima S, Yonezawa S, et al. Expression of mucin core proteins in extramammary Paget's disease. *Pathol Int*. 2002;52(5-6):390-399.
119. Helm KF, Goellner JR, Peters MS. Immunohistochemical stains in extramammary Paget's disease. *Am J Dermatopathol*. 1992;14(5):402-407.
120. Brainard JA, Hart WR. Proliferative epidermal lesions associated with anogenital Paget's disease. *Am J Surg Pathol*. 2000;24(4):543-552.
121. De Nisi MC, D'Amuri A, Toscano M, et al. Usefulness of CDX2 in the diagnosis of extramammary Paget disease associated with malignancies of the intestinal type. *Br J Dermatol*. 2005;153:677-679.
122. Liegl B, Horn LC, Moinfar F. Androgen receptors are frequently expressed in mammary and extramammary Paget's disease. *Mod Pathol*. 2005;18:1283-1288.
123. Mengjun B, Zheng Qiang W, Tasleem MM. Extramammary Paget's disease of the perianal region: a review of the literature emphasizing management. *Dermatol Surg*. 2013;39(1 Pt 1):69-75.
124. Balachandra B, Marcus V, Jass JR. Poorly differentiated tumours of the anal canal: a diagnostic strategy for the surgical pathologist. *Histopathology*. 2007;50(1):163-174.
125. Ohtomo R, Sekine S, Taniguchi H, et al. Anal canal neuroendocrine carcinoma associated with squamous intraepithelial neoplasia: a human papillomavirus 18-related lesion. *Pathol Int*. 2012;62:356-359.
126. Nakahara H, Moriya Y, Shinkai T, Hirota T. Small cell carcinoma of the anus in a human HIV carrier: report of a case. *Surg Today*. 1993;23(1):85-88.
127. Paterson C, Musselman L, Chorneyko K, et al. Merkel cell (neuroendocrine) carcinoma of the anal canal: report of a case. *Dis Colon Rectum*. 2003;46:676-678.
128. Wang SQ, Goldberg LH. Multiple polypoid basal cell carcinomas on the perineum of a patient with basal cell nevus syndrome. *J Am Acad Dermatol*. 2007;57(2 suppl):S36-S37.
129. Nagendra Naidu DV, Rajakumar V. Perianal basal cell carcinoma-an unusual site of occurrence. *Indian J Dermatol*. 2010;55:178-180.
130. Alvarez-Canas MC, Fernandez FA, Rodilla IG, Val-Bernal JF. Perianal basal cell carcinoma: a comparative histologic, immunohistochemical, and flow cytometric study with basaloid carcinoma of the anus. *Am J Dermatopathol*. 1996;18:371-379.
131. Patil DT, Goldblum JR, Billings SD. Clinicopathologic analysis of basal cell carcinoma of the anal region and its distinction from basaloid squamous cell carcinoma. *Mod Pathol*. 2013;26:1382-1389.
132. Morson BC, Volkstadt H. Malignant melanoma of the anal canal. *J Clin Pathol*. 1963;16(2):126-132.
133. Kiran RP, Rottoli M, Pokala N, Fazio VW. Long-term outcomes after local excision and radical surgery for anal melanoma: data from a population database. *Dis Colon Rectum*. 2010;53:402-408.
134. Ellis ZM, Jassim AD, Wick MR. Anorectal melanoma in childhood and adolescence. *Ann Diagn Pathol*. 2010;14(2):69-73.
135. Cooper PH, Mills SE, Allen MS Jr. Malignant melanoma of the anus: report of 12 patients and analysis of 255 additional cases. *Dis Colon Rectum*. 1982;25:693-703.
136. Felz MW, Winburn GB, Kallab AM, Lee JR. Anal melanoma: an aggressive malignancy masquerading as hemorrhoids. *South Med J*. 2001;94(9):880-885.
137. Wanebo HJ, Woodruff JM, Farr GH, Quan SH. Anorectal melanoma. *Cancer*. 1981;47(7):1891-1900.
138. Ackermann DM, Polk HC Jr, Schrodt GR. Desmoplastic melanoma of the anus. *Hum Pathol*. 1985;16(12):1277-1279.
139. Chute DJ, Cousar JB, Mills SE. Anorectal malignant melanoma: morphologic and immunohistochemical features. *Am J Clin Pathol*. 2006;126:93-100.
140. Santi R, Simi L, Fucci R, et al. KIT genetic alterations in anorectal melanomas. *J Clin Pathol*. 2015;68:130-134.
141. Chumas JC, Lorelle CA. Melanotic adenocarcinoma of the anorectum. *Am J Surg Pathol*. 1981;5(7):711-717.
142. Kazakov KV, Spagnolo DV, Kacerovska D, Michal M. Lesions of anogenital mammary-like glands: an update. *Adv Anat Pathol*. 2011;18:1-28.
143. Kazakov DV, Spagnolo DV, Stewart CJ, et al. Fibroadenoma and phyllodes tumors of anogenital mammary-like glands: a series of 13 neoplasms in 12 cases, including mammary-type juvenile fibroadenoma, fibroadenoma with lactation changes, and neurofibromatosis-associated pseudoangiomatous stromal hyperplasia with multinucleated giant cells. *Am J Surg Pathol*. 2010;34:95-103.
144. Morgan MB. Ectopic prostatic tissue of the anal canal. *J Urol*. 1992;147(1):165-166.
145. Steele SR, Mullenix PS, Martin MJ, et al. Heterotopic gastric mucosa of the anus: a case report and review of the literature. *Am Surg*. 2004;70:715-719.
146. Foster A, Epanoimeritakis M, Moorehead J. Langerhans cell histiocytosis of the perianal region. *Ulster Med J*. 2003;72:50-51.
147. Chen N, Zhu L, Lang J, et al. The clinical features and management of perineal endometriosis with anal sphincter involvement: a clinical analysis of 31 cases. *Hum Reprod*. 2012;27:1624-1627.
148. Bonser GM, Raper FP, Shucksmith HS. Epidermoid cysts in the region of the rectum and anus; a report of four cases. *Br J Surg*. 1950;37(147):303-306.
149. Canda AE, Sarioglu S, Sokmen S. Anal leiomyoma. *Surgery*. 2010;148:160-161.
150. Miettinen M, Furlong M, Sarloma-Rikala M, et al. Gastrointestinal stromal tumors, intramural leiomyomas, and leiomyosarcomas in the rectum and anus: a clinicopathologic, immunohistochemical, and molecular genetic study of 144 cases. *Am J Surg Pathol*. 2001;25:1121-1133.

151. Johnston J, Helwig EB. Granular cell tumors of the gastrointestinal tract and perianal region: a study of 74 cases. *Dig Dis Sci*. 1981;26(9):807-816.
152. Lack EE, Worsham GF, Callihan MD, et al. Granular cell tumor: a clinicopathologic study of 110 patients. *J Surg Oncol*. 1980;13:301-316.
153. Robb JA, Jones RA. Spindle cell lipoma in a perianal location. *Hum Pathol*. 1982;13(11):1052.
154. Hill DA, Dehner LP, Gow KW, et al. Perianal rhabdomyosarcoma presenting as a perirectal abscess: a report of 11 cases. *J Pediatr Surg*. 2002;37:576-581.
155. Rivero Fernandez M, Garcia Martos M, Sanz Moya P, et al. Kaposi's sarcoma with colorectal and anal canal involvement. *Gastroenterol Hepatol*. 2010;33:508-511.
156. Peralta EA. Rare anorectal neoplasms: gastrointestinal stromal tumor, carcinoid, and lymphoma. *Clin Colon Rectal Surg*. 2009;22:107-114.
157. Ioachim HL, Weinstein MA, Robbins RD, et al. Primary anorectal lymphoma. A new manifestation of the acquired immune deficiency syndrome (AIDS). *Cancer*. 1987;60(7):1449-1453.
158. Ioachim HL, Antonescu C, Giancotti F, et al. EBV-associated anorectal lymphomas in patients with acquired immune deficiency syndrome. *Am J Surg Pathol*. 1997;21(9):997-1006.
159. Isbister WH. Unusual "recurrence" sites for colorectal cancer. *Dig Surg*. 2000;17(1):81-83.
160. Ejtehadi F, Chatzizacharias NA, Brais RJ, et al. Colonic and anal metastases from pancreato-biliary malignancies. *World J Gastroenterol*. 2014;20(13):3693-3697.
161. Bochicchio A, Tartarone A, Ignomirelli O, et al. Anal metastasis from breast cancer: a case report and review of the literature. *Future Oncol*. 2012;8:333-336.

19 Liver: Non-Neoplastic Diseases

Laura W. Lamps

CHAPTER CONTENTS

Normal anatomy, *726*
Biopsy, *727*
Viral hepatitis, *728*
Viral hepatitis caused by hepatotropic viruses, *728*
Hepatitis caused by nonhepatotropic viruses, *738*
Drug-induced and toxic liver injury, *739*
Histologic features, *740*
Histologic patterns of injury, *741*
Steatosis and steatohepatitis, *744*
Steatosis, *744*
Grading and staging of steatohepatitis, *745*
Alcoholic steatohepatitis, *745*
Non-alcoholic steatohepatitis and non-alcoholic fatty liver disease, *747*
Glycogenic hepatopathy and other features of diabetes mellitus in the liver, *750*
Cholestasis, biliary diseases, and autoimmune hepatitis, *750*
Cholestatic liver disease, *750*
Autoimmune hepatitis, *759*
Cirrhosis, *761*
Childhood disorders and disorders of metabolism, *762*
Cholestatic disorders, *762*
Inherited metabolic disorders, *768*
Disorders of copper and iron metabolism, *769*
Indian childhood cirrhosis, *769*
Wilson disease (hepatolenticular degeneration), *769*
Iron overload, *770*
Fibropolycystic diseases (ductal plate malformation), *772*
Autosomal recessive polycystic kidney disease (infantile-type polycystic disease), *773*
Congenital hepatic fibrosis, *773*
Caroli disease (congenital dilation of the intrahepatic bile ducts), *773*
Von Meyenburg complex (microhamartoma), *774*
Autosomal dominant polycystic kidney disease (adult-type polycystic disease), *774*
Vascular disorders, *775*
Diseases of the portal venous system, *775*
Hepatic venous outflow obstruction, *775*
Sinusoidal obstruction syndrome, *776*
Miscellaneous other vascular lesions, *776*
Liver disease in pregnancy, *777*
Acute fatty liver of pregnancy, *777*
Toxemia of pregnancy (preeclampsia/eclampsia), *777*
HELLP syndrome, *777*
Intrahepatic cholestasis of pregnancy, *777*
Liver involvement in systemic diseases, *777*
Granulomatous liver diseases, *777*
Malaria, *779*
Hepatic abscess, *779*
Amyloidosis and light chain deposition disease, *780*
Nonspecific reactive changes, *780*
Liver pathology in organ transplantation, *781*
Bone marrow transplantation: graft-versus-host disease, *785*

Normal Anatomy

Several structural and functional units have been proposed in the microanatomy of the liver. Of these, the most relevant for the diagnostic histopathologist are the liver lobule and the liver acinus. For several years the liver acinus[1] was the preferred concept in textbooks of pathology and hepatology, as it appeared to better explain the "bridging" type of lesions connecting afferent and efferent vascular landmarks, that is, portal–central bridging necrosis and fibrosis. The simple liver acinus corresponds to the small area of parenchyma vascularized by a single terminal branch of the portal vein (portal venule) and hepatic artery, and drained by the neighboring terminal hepatic venules. In spite of its popularity in recent years, the liver acinus did not withstand the scrutiny of further detailed angioarchitectural, morphologic, and histochemical investigations, and virtually all later studies support the lobular concept of liver architecture, albeit with several types of subunits.

The classical hexagonal liver lobule[2] is centered on a terminal twig of the hepatic vein (centrilobular or central vein), and surrounded by (on average) six portal tracts. The portal vein ramifications in

Abstract

This chapter covers the major entities and differential diagnoses in non-neoplastic liver pathology, including viral hepatitis, drug-induced liver disease, steatohepatitis, cholestatic liver disease, autoimmune hepatitis, storage and metabolic diseases, vascular diseases, infections, and transplant pathology.

Keywords

Viral hepatitis
hepatitis A
hepatitis B
hepatitis C
drug-induced liver injury
steatosis
steatohepatitis
alcoholic liver disease
NASH
NAFLD
cholestasis
autoimmune hepatitis
cholestatic liver disease
cirrhosis
metabolic disease
iron overload
hemochromatosis
granuloma
sarcoidosis
rejection
fibropolycystic liver disease
storage disease
abscess

the portal tracts give off a series of branches in the plane between adjacent portal tracts; these in turn give rise to sinusoids that drain the blood toward the center of the lobule. The lobular equivalents of the acinar zones 1, 2, and 3 are the periportal zone, midzonal or midlobular zone, and centrilobular area.

The liver parenchymal cell or hepatocyte is a polygonal cell with a characteristically central, single nucleus. Hepatocytes are arranged in plates one to two cells thick with a sinusoid on either side, thus exposing each hepatocyte to portal blood on two surfaces. Within the cell plate each hepatocyte adjoins adjacent parenchymal cells at its intercellular surface. This intercellular domain of the cell membrane forms a groove (hemicanaliculus) as a girdle around the cell. The hemicanaliculi of two adjacent hepatocytes form the intercellular bile canaliculus, which is separated from the rest of the intercellular space and the blood compartment by tight junctions.

The virtual cleft between the sinusoidal lining cells and the sinusoidal domain of the hepatocyte surface is the space of Disse. It is not typically visible in biopsy material but appears dilated in autopsy specimens. The hepatic sinusoids are lined by different cell types. The sinusoidal endothelial cells are of the fenestrated type. Kupffer cells, which are resident members of the mononuclear phagocyte system that undergo enlargement and proliferation in response to a wide variety of stimuli, bulge out on the luminal side of the sinusoids. Hepatic stellate cells (previously known as Ito cells, fat-storing cells or lipocytes) are contractile perisinusoidal "pericytes" located in the space of Disse. They store vitamin A in their cytoplasmic lipid droplets and are able to switch their phenotype to myofibroblast-like cells under appropriate stimulation. Stellate cells are matrix producers in both normal liver and in pathologic intralobular fibrosis. Hepatic stellate cells are only identified with difficulty in routinely stained preparations; immunostaining for synaptophysin marks both resting and activated cells, and immunostaining for alpha-smooth muscle actin reveals activated stellate cells.[3] Located on the inside of sinusoidal endothelial cells are some scattered "pit cells," which are resident intrahepatic lymphocytes, primarily natural killer phenotype.

The portal tracts at the lobular periphery are composed of connective tissue, ensheathing branches of the hepatic artery, portal vein, bile duct, and lymphatics. The caliber of portal tracts and their composing structures decreases from the hilum of the liver toward its periphery; this explains why surgical liver biopsies and autopsy specimens usually contain larger portal areas than needle biopsy specimens. The microarchitectural variability is also greater in the peripheral liver. On average, one may expect two interlobular bile ducts, two hepatic arteries, and one portal vein per portal tract, but in peripheral liver, portal dyads (containing only two of the three artery, vein, or bile duct profiles) are almost as common as portal triads.[4]

Interlobular bile ducts, usually located in the center of the portal tract, are connected with the lobular canaliculi by ductules (or cholangioles) and canals of Hering, the latter being short stretches lined by both hepatocytes and cholangiocytes.[5] These finer structures are hardly visible on hematoxylin–eosin (H&E) staining but clearly revealed by cytokeratin immunostains.[6]

Liver cell plates and sinusoids have a more regular radial arrangement in the center of the lobule, whereas the periportal zone is characterized by a less regular, anastomosing network pattern of these structures.

Hepatocytes are polygonal in shape, with clearly outlined cell membranes in H&E preparations. The cytoplasm is granular and eosinophilic, with basophilic aggregates of rough endoplasmic reticulum in a perinuclear distribution. The nucleus is centrally placed and carries one or more easily identifiable nucleoli. Mitotic figures are very rare. Hepatocytes are rich in glycogen, with diurnal and diet-related variations in amount and distribution. Glycogen accumulation in nuclei occurs as clear vacuoles, predominantly in periportal hepatocytes. This is common in childhood and may be conspicuous in some adult diseases (e.g., diabetes and Wilson disease) but is not by itself of diagnostic significance. Lipofuscin occurs as fine, light brown, periodic acid–Schiff (PAS)-positive and acid-fast granules in the pericanalicular region of centrilobular hepatocytes (Fig. 19.1); it should not be mistaken for bile. Stainable iron is absent or demonstrable in only scant amounts in the adult liver. An occasional hepatocyte in normal liver may contain fat.

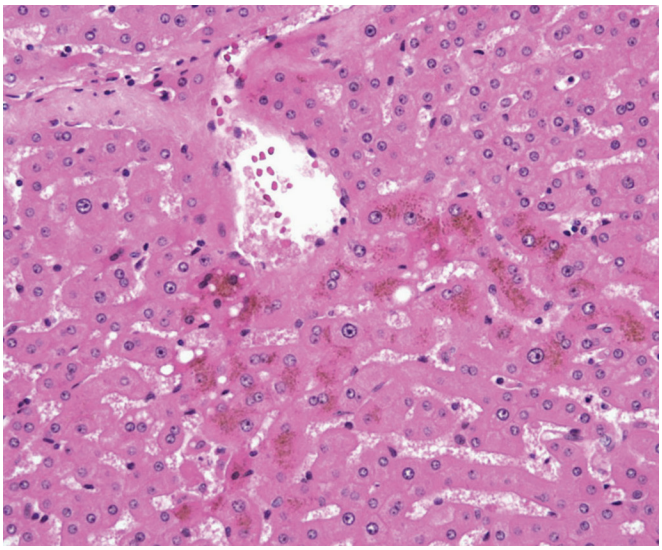

Figure 19.1 Lipofuscin appears as a finely granular brown pigment within hepatocytes, most prominent in zone 3.

There is some variation in hepatic microscopic appearance with age. In neonates, extramedullary hematopoiesis may persist during the first weeks of life. With increasing age, there is more variation in nuclear size (anisokaryosis), somewhat more pronounced centrilobular lipofuscinosis ("wear and tear pigment"), some atrophy of centrilobular hepatocytes and correspondingly broader appearance of perivenular sinusoids, occasional hyalinization of the wall of hepatic artery branches, and thickening of the liver capsule with some fibrous extensions reaching for 1–2 mm into the underlying parenchyma.

Physiologic postnatal liver development comprises three structural components: enlargement of the hepatocytes and expansion and proliferation of the liver lobules. Enlargement of the lobules is exclusively responsible for the regenerative liver growth following partial hepatectomy; the number of hepatic lobules does not change during this latter reaction, but they gain a more complex, irregular structure.[7]

Biopsy

Light microscopic examination of liver tissue remains an essential part of the diagnostic procedure and of the follow-up of the majority of liver diseases. Biopsies obtained during surgical procedures may show "surgical hepatitis," appearing as a neutrophilic infiltrate that may be accompanied by coagulative necrosis of single or small groups of hepatocytes (Fig. 19.2). The lesion is usually centrilobular, but its extent depends on the duration of the operation and the degree of manipulation of the liver.[8] For this reason, biopsies obtained during surgery should be performed immediately on entering the peritoneal cavity. It is also important to note that the

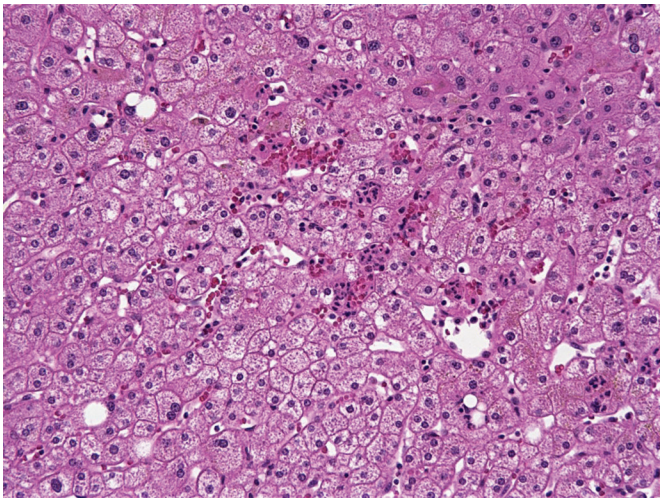

Figure 19.2 "Surgical hepatitis" features a neutrophilic infiltrate associated with necrosis of single hepatocytes or small groups of hepatocytes.

subcapsular area is not representative of the entire organ; marked subcapsular fibrosis may coexist with minimal changes deeper in the liver, and contraction of the elastic fibers in the capsule after wedge biopsy may mimic cirrhosis.[9,10] Therefore, the surgeon should perform not only an incisional biopsy but also a deeper needle biopsy.

The indications for and diagnostic usefulness of liver biopsy change over time. The availability of serologic tests for the etiologic diagnosis of acute viral hepatitis has reduced the need for liver biopsy in this condition, and transient elastography (FibroScan) is replacing biopsy for extent of fibrosis in chronic viral hepatitis in some settings.[11] The refinement of liver imaging techniques and of endoscopic retrograde cholangiopancreatography (ERCP) has also rendered the use of liver biopsy for the diagnosis of large bile duct obstruction largely obsolete. However, liver histopathology remains a mainstay in the diagnostic work-up of most liver diseases, and several studies over the years have emphasized its diagnostic usefulness and importance to therapy.[12–15] With the advent of liver transplantation, liver biopsy remains the gold standard for the diagnosis of cellular rejection[16] and for diagnosis of infection, vascular complications, and recurrence of disease in the transplant setting.[17] In an appreciable number of cases, the pathologist may discover the presence of an unsuspected diagnosis in addition to the clinically presumed diagnosis, for example, α1-antitrypsin (α1-AT) deficiency or non-alcoholic fatty liver disease (NAFLD) in a patient with known chronic viral hepatitis B or C. In a recent Canadian study, such findings amounted to 20% of hepatitis biopsies.[18]

As in all of diagnostic histopathology, the H&E stain is the mainstay in liver pathology. Special stains are useful for visualizing inapparent or easily overlooked features, but the number and type performed routinely is a matter of personal preference, and varies from one laboratory to the next. The strict minimum is an H&E and a connective tissue stain. Many pathologists also routinely employ an iron stain for assessing iron deposition; PAS–diastase stain for ceroid macrophages, α1-AT inclusions, fungi, and thickened basement membranes of interlobular bile ducts; the rhodanine stain for copper (in Wilson disease, chronic cholestasis, and copper toxicosis); and a reticulin stain for examining the reticulin framework and revealing parenchymal collapse. Immunohistochemical staining for "bile duct type keratins" (keratins 7 and 19) may be extremely useful in cholestatic liver diseases, for recognizing early stages of cholate stasis, cholestatic liver cell rosettes, ductular reaction, and ductopenia.[15,19] Over the years, the accuracy and diagnostic yield of liver histopathology have been steadily increasing through expanding availability of immunohistochemistry.[20]

The diagnostic accuracy of liver histopathology depends on numerous factors, which are not always optimal in every instance and which hardly lend themselves to quantitative evaluation. Several factors relate to the biopsy specimen. Size is important, although not in an absolute way; because the average needle biopsy represents 100 thousandth to 150 thousandth (0.00001–0.000006666) of the liver organ, sampling variability and error is an obvious possibility. A reliable diagnosis of a disease with unequal involvement of portal tracts (such as chronic hepatitis or primary biliary cirrhosis [PBC]) often requires a larger sample than a condition with diffuse involvement (such as classic acute hepatitis). The minimum size requirements for a diagnostic biopsy and the minimum number of portal tracts remain controversial. One study evaluating grading and staging in chronic hepatitis indicated that smaller specimens result in both undergrading and understaging disease, and that a minimum biopsy sample should be 15 mm or a core comprising at least 11 complete portal tracts.[21] Another study suggested that a length of at least 25 mm is necessary to evaluate fibrosis accurately with a semiquantitative score.[22] In NAFLD, a significant relationship was also found between diagnostic yield and sample length.[23] On the other hand, there are studies that show that the level of experience in evaluating liver biopsies is more important than the length of the core.[24] Regardless, the pathologist should carefully examine even inadequately sized specimens in order to ensure maximum yield of information from an invasive procedure. The diagnostic accuracy of focal lesions (e.g., granulomas, cytomegalovirus [CMV] inclusions) is also improved by examining multiple sections. Other factors affecting diagnostic yield include experience of the pathologist, availability of clinical information, and knowledge of clinical implications. Even under optimal circumstances, however, an adequate biopsy may not provide a complete diagnosis, or may even fail to give helpful information.

Although a reliable final diagnosis definitely requires knowledge of laboratory information and the clinical background of the patient, it is equally true that objectivity in analysis and conclusion is best served by examination of the slides without any other clinical or laboratory information. Several reviews on how to systematically examine a liver biopsy are available,[25–28] including a position paper from the American Association for the Study of Liver Diseases (AASLD) addressing pathologic considerations of specimen size and quality, tissue allocation, tissue processing, specimen interpretation, and sampling error.[29]

Viral Hepatitis

Viral hepatitis, or liver inflammation due to viral infection, may be caused by specific hepatotropic viruses (the "hepatitis viruses") and by several other viruses that primarily cause generalized infection that may involve the liver (e.g., CMV, Epstein–Barr virus [EBV]).

Viral Hepatitis Caused by Hepatotropic Viruses

Historically, when adequate diagnostic tests for hepatitis A virus (HAV) and hepatitis B virus (HBV) became available in transfusion centers for screening of donor blood, it became evident that a fraction of post-transfusion viral hepatitis was not due to HAV or HBV, and thus designated by the term non-A, non-B hepatitis.[30] After more than a decade of intensive research, hepatitis C virus (HCV) was discovered and found to be responsible for the majority of non-A, non-B hepatitis.[31–33]

Table 19.1 Major hepatitis viruses

VIRUS	TYPE AND FAMILY	INFECTION ROUTE	DISEASE
Hepatitis A (HAV)	Single-stranded RNA virus Picornaviridae family	Fecal–oral, oral	Acute
Hepatitis B (HBV)	Partially double-stranded DNA virus Hepadnaviridae family	Parenteral, sexual, perinatal	Acute, chronic
Hepatitis C (HCV)	RNA virus Flaviviridae family	Parenteral, sexual, perinatal	Acute, chronic
Hepatitis D (HDV, Delta agent)	Defective RNA virus	Parenteral, sexual Requires coinfection with or superinfection of HBV	Acute, chronic
Hepatitis E (HEV)	Single-stranded, nonenveloped RNA virus Caliciviridae family	Vertical, oral, parenteral	Acute

Now there are at least five distinct hepatotropic viruses, belonging to entirely different families (Table 19.1). They have very little in common except that they affect the liver as a target organ, and some degree of shared epidemiology.[34] All have a worldwide distribution. Two of these viruses (HAV and HEV) are spread principally by the fecal–oral route, and three (HBV, HCV, HDV) are spread mainly by exposure to blood, although HBV and HCV may also be spread by unprotected sex. HEV causes a self-limited and often anicteric hepatitis in the West,[35] where it is likely underdiagnosed.[36] It is a major health problem in developing countries, however, causing high morbidity and often fulminant hepatitis in pregnant women in certain geographic areas (e.g., India).[37]

More recently identified hepatitis viruses (non-A-E viruses) include hepatitis G virus (HGV or GBV-C, family Flaviviridae)[38]; Torque teno virus (TTV), a DNA virus of the family Circoviridae[39]; and SEN virus, a transfusion-transmitted DNA virus.[40] The clinical significance of HGV, particularly in the context of patients with chronic liver disease due to HBV or HCV, remains controversial. There is some evidence that although coinfection of HGV in patients with chronic hepatitis B or C does not affect disease severity, it may accelerate the progression of chronic liver disease and the development of hepatocellular carcinoma.[41] TTV and SEN viruses appear to be extraordinarily diverse and to be ubiquitous in >90% of adults worldwide, but no human pathogenicity has been fully established.

Acute Viral Hepatitis

The introduction of serologic and molecular tests for hepatitis viruses has decreased the indication for liver biopsy in acute hepatitis. However, biopsy may still be used to confirm a diagnosis, to assess severity and evolution of the disease, and to exclude concomitant disease (e.g., alcoholic liver disease superimposed on viral hepatitis).

The morphologic features of viral hepatitis have been extensively described.[34,42,43] The histologic picture of acute hepatitis due to different hepatitis viruses may be sufficiently similar to cause problems in differentiation. The general changes of hepatitis are described later, followed by some characteristics specific to individual viruses.

Typical acute viral hepatitis is a panlobular disease, although the changes may predominate in the centrilobular region in HBV and HCV, and in the periportal zone in HAV. Hepatocellular alterations are variable and include a predominantly mononuclear lobular inflammation and spotty hepatocyte necrosis. Some parenchymal cells show swelling, with increased cell volume and pale-staining, granular cytoplasm (so-called hydropic change). The heterogeneous appearance of the parenchymal cells (due to hepatocyte swelling and necrosis), together with cell dropout and regeneration of surviving hepatocytes, leads to a loss of the normal regular liver cell plate pattern; this "lobular disarray" is also a very diagnostically helpful feature (Fig. 19.3). Reactive hepatocellular changes may be prominent, including hepatocytes undergoing mitosis. Syncytial, multinucleated giant hepatocytes, which are typical of neonatal hepatitis, may sometimes be found in adults as well, but this does not indicate a specific etiology.

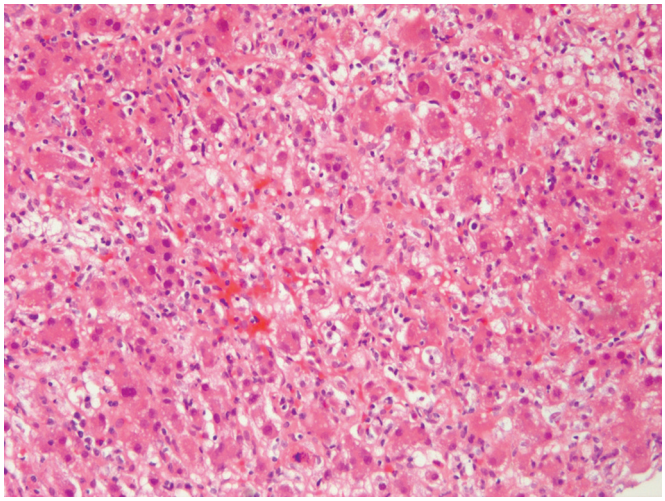

Figure 19.3 Acute hepatitis B infection characterized by ballooning of hepatocytes, lobular disarray, and mononuclear (mainly lymphocytic) inflammatory infiltration.

There is a predominance of mononuclear and lymphocytic cell types. The majority of lymphocytes are activated memory T cells.[44,45] Also, plasma cells may be found in the early stage.[46] Small clusters of lymphocytes, whether or not in close proximity to apoptotic bodies, represent foci of cytotoxic lymphocyte–mediated target cell attack and represent the lesion indicated by the terms "focal inflammation," "focal necrosis," and "spotty necrosis."

Kupffer cells enlarge and become more prominent; they phagocytose cell debris from dying hepatocytes, which results in the intracellular accumulation of clumps of golden brown, lipid-rich "ceroid" pigment, which is best revealed in PAS–diastase stains. In the earlier stages, these "ceroid macrophages" are small and scattered as single cells; later on, they may be larger and form

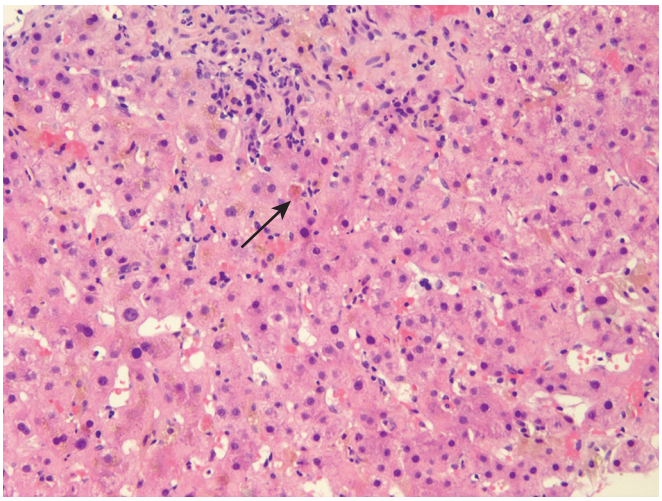

Figure 19.4 Acute viral hepatitis with scattered apoptotic hepatocytes *(arrow)* and cholestasis.

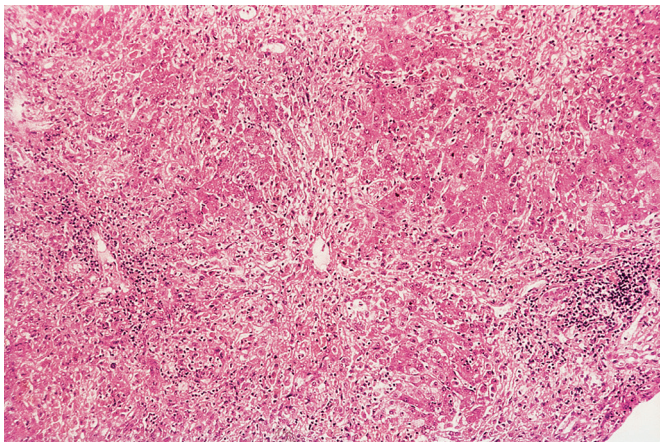

Figure 19.5 Severe Necrotizing Acute Viral Hepatitis B. There is mild to moderate mononuclear cell infiltration in portal tracts, as well as bridging portal–central confluent lytic necrosis with parenchymal loss.

clusters that predominate in centrilobular and midzonal areas. In still later stages, they are found migrated into the portal connective tissue. Ceroid macrophages in acute viral hepatitis may stain for iron in some cases. Some degree of cholestasis is common as well (Fig. 19.4).

Although the lobular pattern predominates in acute viral hepatitis, the portal tracts often also become involved by a mononuclear cell infiltrate, sometimes admixed with neutrophils, eosinophils, and—especially in the later stages—pigment-laden macrophages. The infiltrate may remain confined within the portal connective tissue, or may spill out into the adjacent periportal parenchyma. An increase in ductular profiles at the portal–parenchymal interface ("ductular reaction") also occurs in acute hepatitis; this is typically very mild in classic acute lobular hepatitis, and better revealed by keratin 7 immunostains. The extent of ductular reaction increases with the severity of the necrotizing parenchymal lesions. Lymphocytic infiltration between and inside bile duct lining cells, and some degree of bile duct epithelial damage may rarely occur, particularly in HCV,[47] although acute HCV is rarely seen on liver biopsy.

In the later stages of acute self-limited hepatitis, most of the parenchymal and portal changes gradually disappear. Residual changes such as mild portal inflammation, focal lobular inflammation, pigmented macrophages, and reactive hepatocellular changes may persist for several months.

In severe disease, the death of larger groups of hepatocytes with more extensive parenchymal damage leads to "confluent necrosis." This may initially involve zone 3, but with increasing severity, there may be dropout of parenchyma between portal tracts and central veins (bridging hepatic necrosis[48]; Fig. 19.5). A still higher degree of severity results in necrosis of all acinar zones, resulting in panlobular necrosis. For unexplained reasons, this necrosis usually has an irregular distribution throughout the liver, rendering needle biopsy less reliable for estimating the extent of necrosis in fulminant hepatitis.[49]

Necrotic bridges change in appearance over time. Freshly necrotizing bridges reveal lobular areas where the parenchyma has disappeared, with no or minimal collapse of the reticulin framework. Resolving necrotizing areas are infiltrated by mononuclear cells and some small ceroid macrophages. Later stages are characterized by collapse of the reticulin fibers, proliferation of mesenchymal cells and collagen deposition, possibly bulging of the regenerating remaining parenchyma, and larger numbers of ceroid macrophages. Older necrotic bridges heal with fibrous scars, resulting in portal–central bridging fibrosis ("post-necrotic cirrhosis").

Obvious fibrosis is a characteristic of chronic rather than of acute hepatitis, and thus the distinction between post-necrotic cirrhosis and cirrhosis in the context of chronic liver disease is critical. Fibrous bridges in the context of chronic hepatitis can be recognized by the fact that gradual deposition of elastic fibers takes place. Thus, bridging fibrosis in chronic hepatitis stains with an elastin stain, whereas bridges in acute hepatitis do not contain elastin.[50] Severe necrotizing hepatitis is also characterized by a higher degree of periportal ductular reaction. The areas of surviving parenchyma reveal the changes of acute hepatitis described previously for classical lobular hepatitis but usually with more marked spotty necrosis and cholestasis.

Submassive hepatic necrosis. Progressive severe necrotizing hepatitis, which occurs in a minority of patients, may correspond clinically to fulminant hepatitis with acute liver failure and coma. In such patients, lytic confluent necrosis of the parenchyma typically involves the entire liver lobule (panlobular necrosis) and often affects several adjacent lobules (multilobular necrosis). Extensive confluent necrosis is usually distributed in a heterogeneous way throughout the liver organ, thus needle biopsies may not be representative.[49] In surviving patients, multilobular (or submassive) necrosis results in collapse and fibrous scarring of necrotic zones, alternating with nodular regeneration of surviving parenchymal territories.

Ductular reaction is prominent in multilobular necrosis and represents an attempt at regeneration by liver progenitor cells. The epithelial proliferation comprises not only bile ductular cells but also elements with a phenotype intermediate between that of cholangiocytes and hepatocytes—so-called transitional cells.[51] Some of the ductules may contain inspissated bilirubin-stained concrements in cases with severe necrosis or with sepsis[52]; this lesion should not be mistaken as a sign of biliary obstruction.

Severe necrotizing hepatitis may have causes other than infection by hepatitis viruses, such as autoimmune hepatitis, adverse drug reactions, toxic insults, and Wilson disease. As all or most of the parenchymal cells have disappeared due to necrosis by the time of histologic evaluation, there are few markers pointing to a particular etiology, thus it is often impossible to pinpoint the etiology on histologic grounds alone.

Causative viruses. It is usually not possible to histologically diagnose with certainty the etiology of acute viral hepatitis, since the main histopathologic traits are quite similar; correct diagnosis

typically requires serologic and/or molecular testing. Nevertheless, there are suggestive trends and patterns. One has to keep in mind, however, that the histopathologic picture may be confused by coinfection with more than one virus, or by the presence of another form of liver disease (such as fatty liver disease, for example).

Acute hepatitis A[53–56] may reveal a picture dominated by centrilobular bilirubinostasis with only minimal liver cell damage and inflammation; this may be mistaken for other causes of cholestasis (e.g., drug-induced cholestasis). Particularly in adults, HAV infection may cause cholestatic hepatitis, even occasionally showing bile duct damage.[57] The inflammatory changes often show a periportal predominance, with dense, plasma cell–rich portal infiltrates that may mimic autoimmune hepatitis.[58] Periportal parenchymal necrosis with interruptions of canals of Hering may contribute to the cholestatic features.[55] Fulminant hepatic failure is rare in HAV infection but has been described.[59] Fibrin ring granulomas have also been reported.[60–61] HAV may occasionally present with a prolonged and polyphasic clinical course characterized by two or more relapses with concomitant rise in transaminases.[62]

Acute hepatitis B. The histopathology is roughly similar to that of other forms of acute viral hepatitis,[58,63–65] with centrilobular predominance of liver cell damage and inflammation (see above). Lymphocytes may lie in close contact with hepatocytes (peripolesis) and even inside them (emperipolesis). In fully developed acute HBV, immunostains for hepatitis B surface antigen (HBsAg) and hepatitis B core antigen (HBcAg) are often negative; this correlates with loss of HBsAg serologically and may indicate early efficient elimination of viral antigens.[66] Whether or not a chronic course of disease can be predicted based on liver biopsy findings during the acute phase of HBV has caused controversy for years; a tentative conclusion is that no single lesion has predictive value in the early stage of infection. Ground-glass hepatocytes are not seen in the acute form, and their presence indicates chronicity. As in other parenterally transmitted hepatitides, such as hepatitis D and C, intravenous drug abuse may be recognized by the presence of birefringent spicules of talc in portal tracts.[67,68]

A particular clinicopathologic variant of HBV is so-called *fibrosing cholestatic hepatitis*, which may occur after liver transplantation and in other conditions associated with immune compromise (status post transplantation, HIV infection). It typically has a poor prognosis with a rapidly progressive course. The histopathology of this variant is characterized by a relatively mild portal infiltrate, periportal and pericellular fibrosis, hepatocyte ballooning, marked ductular reaction, prominent parenchymal and sometimes ductular bilirubinostasis, and very high viral load (strongly positive immunostains for HBcAg).[69,70]

Acute hepatitis C. Because acute hepatitis C is often asymptomatic, detection and diagnosis are usually difficult, and it is rarely seen on biopsy. An average of 26% of patients experience spontaneous clearance of the virus, primarily during the first 3 months.[71] The pathologic features of acute HCV are essentially those described in previous years for non-A, non-B hepatitis,[64,72,73] including hepatocyte swelling, apoptosis, cholestasis, and lobular lymphocytic infiltration. Bile duct damage and development of portal lymphoid aggregates and lymphoid follicles, the most characteristic features of hepatitis C in the chronic stage, may also occur in the acute phase.

Lymphocytic infiltration may be prominent in the sinusoids ("Indian file" appearance) in the absence of noticeable parenchymal damage, resembling EBV hepatitis. Steatosis is fairly common. Fulminant hepatitis with multilobular necrosis does occur but is rare in the Western world. Immunohistochemical demonstration of viral antigens with different antibodies has been repeatedly reported, but the overall results appeared to lack specificity. The same criticism applies to in situ hybridization (ISH) for HCV RNA.[74,75] As in viral HBV, a severe, progressive variant of "fibrosing cholestatic hepatitis" may occur in immune deficient conditions (Fig. 19.6A and B).[76,77]

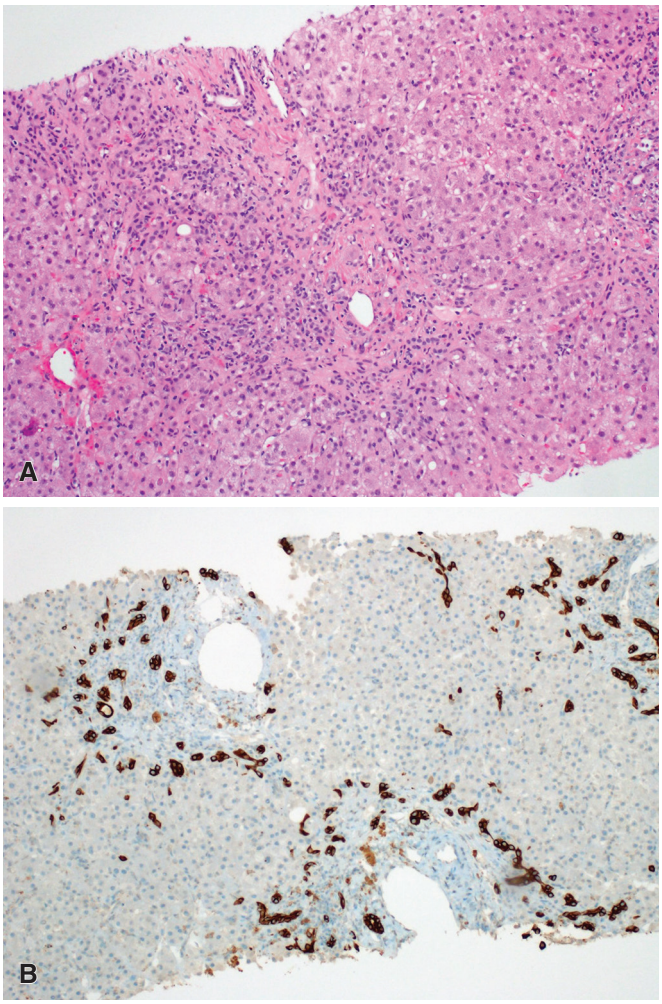

Figure 19.6 Fibrosing Cholestatic Hepatitis C. A, Fibrous expansion of portal areas with marked ductular reaction. There is mild hepatocyte ballooning and hepatocellular cholestasis. **B,** Cytokeratin 7 immunostain highlights the ductular reaction.

Acute hepatitis D can occur in the setting of acute co-infection with HBV or can be superimposed on chronic HBV.[78] The histologic picture of HDV hepatitis is similar to that of other forms of hepatitis, and although it tends to be more severe, it cannot be reliably distinguished histologically from hepatitis B or C.[79–81] In parts of South America and Africa, acute HDV infection has been associated with microvesicular change in hepatocytes[82]; this "spongiocytic change" or "morula cell degeneration" was attributed to accumulation of small lipid droplets in damaged hepatocytes.

Acute hepatitis E. Outbreaks of hepatitis E occur throughout the developing world, primarily transmitted by contaminated water. The epidemiology in industrialized countries is less well understood, although some cases appear to be zoonotic.[83,84] Hepatitis E typically causes self-limited acute infection. Histologically it is characterized by a cholestatic type of hepatitis, with mixed portal infiltrate, ductular reaction, prominent bilirubinostasis, cholestatic rosettes, and marked apoptosis, bearing some resemblance to acute HAV.[85]

Differential diagnosis. Acute viral hepatitis with marked cholestasis can be differentiated from obstructive forms of cholestasis by the lobular necroinflammatory lesions that are typical of acute viral

hepatitis. Drug-induced hepatitis may be indistinguishable histologically from viral hepatitis; hence it follows that drug-induced liver disease should always be kept in mind when facing a case of acute hepatitis that is of questionable etiology. Features suggestive of a drug-induced lesion include sharply delineated centrilobular necrosis, abundant eosinophils, and granulomas (particularly microgranulomas); however, the absence of these features does not exclude drug-associated hepatitis. Autoimmune hepatitis can have an acute onset, histologically similar to viral hepatitis, but typically autoimmune hepatitis has more fibrosis and a more plasma cell-rich infiltrate than that seen in most cases of acute viral hepatitis.

Differentiation of acute from chronic viral hepatitis is generally based on the predominance of portal and periportal changes and fibrosis in the latter, whereas lobular lesions prevail in acute hepatitis, and fibrosis is typically not increased. However, the distinction may be very difficult, if not impossible, in the absence of clinical and laboratory data.

Chronic Viral Hepatitis

History and classification. The introduction of needle aspiration biopsy of the liver[86] greatly contributed to the recognition of noncirrhotic forms of chronic inflammatory liver disease. In the 1960s, chronic hepatitis was presumed to be a sequel of viral hepatitis, although a causative agent had not been identified. Autoimmune hepatitis was considered to be the "classic" form of chronic active hepatitis at that time. Because of marked semantic confusion, a simple classification of chronic hepatitis, based on histology, was proposed by a group of hepatologists and pathologists in 1968.[87,88] Because immunosuppression was the standard treatment, reserved for the more "active" forms of the disease, the classification distinguished between a milder form (chronic persistent hepatitis [CPH]) with a low degree of necroinflammatory activity, and more severe variants (chronic aggressive or active hepatitis [CAH]) featuring higher degrees of necroinflammatory activity. This classification of chronic hepatitis became widely accepted and was used worldwide for nearly 40 years. Although it was emphasized that CPH and CAH were not to be considered distinct disease entities, but as variations in the degree of disease activity, this message was frequently, and with the passage of time, increasingly, ignored.

Remarkable progress has been achieved in the elucidation of the multiple etiologies of chronic hepatitis since 1968, particularly with the discoveries of HBV, HCV, and HDV.[89] A drug-induced form of chronic hepatitis was recognized in 1971[90] and is now established as a classic cause of the disease.[91] Chronic autoimmune hepatitis remained a diagnostic category, with gradual refinements in clinical and serologic diagnosis.[92] Wilson disease was also shown to resemble chronic hepatitis clinically and histologically in some cases[93,94]; the same appeared to apply to another metabolic disease, α1-AT deficiency.[95] Furthermore, piecemeal necrosis, a very important diagnostic criterion in CAH, but (incorrectly) thought by some to be pathognomonic of and synonymous with chronic hepatitis, was also observed in chronic biliary diseases such as PBC and primary sclerosing cholangitis (PSC).

Investigations into the natural course of disease in chronic HBV infection revealed successive phases of viral replication, elimination, and integration, associated successively with less, higher, and again decreasing degrees of necroinflammatory disease activity.[96,97] This implied the successive occurrence of CPH and CAH variants in individual patients over the course of their disease, confusing those who considered CPH and CAH to be distinct disease entities. This precipitated a change of view on chronic hepatitis.[98] Most importantly, the development of more efficient treatment for chronic viral hepatitis (interferons and antiviral agents) urgently necessitated a revision of chronic hepatitis classification.[99–102] In 1994, two proposals for a new classification of chronic hepatitis (both viral and other etiologies) were published.[103,104] Both are largely parallel, although the latter includes chronic biliary and metabolic diseases (which may mimic chronic hepatitis) under that heading. There appears to be general agreement to restrict the term "chronic hepatitis" to its original meaning: a clinical and pathologic syndrome with several causes, characterized by varying degrees of hepatocellular necrosis and inflammation. For lack of a better definition of chronicity, chronic hepatitis is still defined (as in 1968) as a continuing disease (indicated by elevated liver tests) without improvement for at least 6 months.[104]

In order to be comprehensive and clinically useful, these classifications consider: (1) the etiology; (2) the grade of disease activity; and (3) the stage of progression of the disease. The first question to be asked by the pathologist when classifying chronic hepatitis remains: "Is this chronic hepatitis, or another liver disease?" Several liver diseases may have clinical and histologic features resembling those of chronic hepatitis, as mentioned previously, and need to be considered in the differential diagnosis, but do not correspond to "chronic hepatitis" in its strictest sense. The second step concerns determination of the etiology, which cannot be based on histology alone and requires consideration of clinical and serologic data. Histopathologic study of the liver biopsy, however, may be useful in establishing, confirming, or refining an etiologic diagnosis. The next step corresponds to grading of disease activity, which is evaluated by clinical symptoms, by aminotransferase levels, and by histopathology of the liver biopsy. Histologically, the degree of disease activity is evaluated by considering the main components in the histopathologic picture: portal inflammation, interface hepatitis, lobular damage and inflammation, and confluent necrosis. Several systems can be utilized to express the degree of disease activity in the liver biopsy. In daily practice, an adequate report consists of an accurate estimate of the various lesions, described as minimal, mild, moderate, or severe. For specific purposes, such as comparison of pre- and post-treatment biopsy specimens and for evaluation of therapeutic trials, semiquantitative scoring systems may be indicated (see Grading and staging, later).

Staging of the disease is an attempt to place the patient's disease at a specific point in time along an assumed course or time of progression. The histologic evaluation of disease stage is based on the extent of fibrosis and the development of cirrhosis, which has significant prognostic and therapeutic implications. Connective tissue stains are essential for staging. As is the case for histologic grading, staging can also be expressed descriptively, which is an appropriate method for daily reporting of biopsies. Again, however, for specific purposes, semiquantitative scoring systems can be used (see later).

Histopathology. The basic lesions that compose the histopathologic picture of chronic hepatitis (viral and otherwise) include "spotty necrosis," portal inflammation, interface hepatitis, and fibrosis. Occasionally confluent necrosis may be seen and, if disease progresses, parenchymal regeneration and cirrhosis.[65] "Spotty necrosis" is an older term, loosely applied to apoptosis and genuine necrosis of single hepatocytes; this finding may also be seen in acute hepatitis (see earlier). A more appropriate morphologic term would be "focal necroinflammation," recognizable as a small cluster of mononuclear cells (lymphocytes, possibly with histiocytes) with or without an adjacent identifiable apoptotic body or bodies. Spotty necrosis in chronic hepatitis looks the same as in acute hepatitis. Confluent parenchymal necrosis of the lytic type, or dropout of contiguous groups of hepatocytes with collapse of the reticulin framework, occurs in more severe forms of chronic hepatitis, and often coincides with clinical episodes of disease exacerbation.[105] As in acute hepatitis, the extent of confluent necrosis may range from focal to zonal confluent necrosis to "bridging" confluent necrosis (Fig. 19.7), and then to

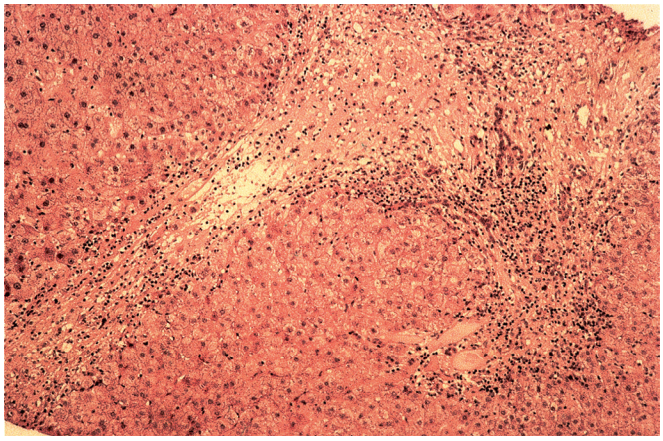

Figure 19.7 Bridging confluent lytic necrosis in severe chronic viral hepatitis B, connecting an inflamed portal tract with a centrilobular area *(lower left)*. The upper right part corresponds to an area of extensive lytic necrosis and postnecrotic collapse of the reticulin framework.

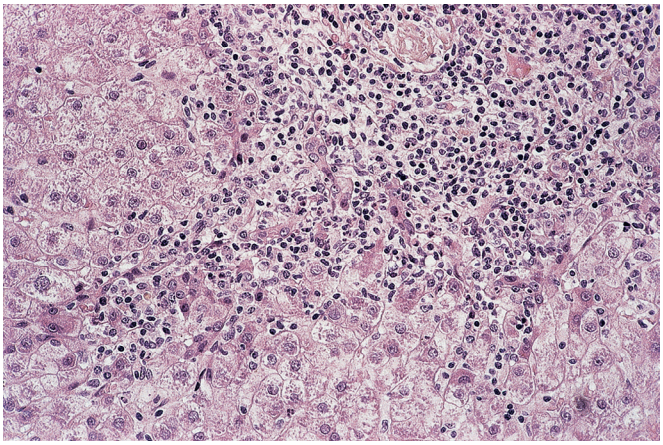

Figure 19.9 Marked interface hepatitis ("piecemeal necrosis") in chronic viral hepatitis B. Note the inflamed portal tract *(upper right)* with an irregular interface between the portal periphery and adjacent parenchyma.

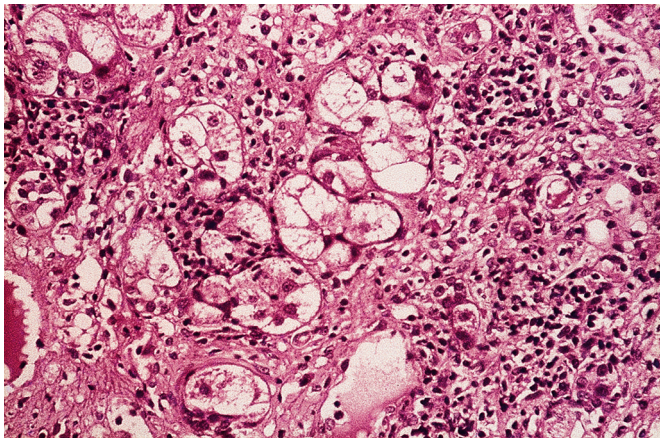

Figure 19.8 Severe Chronic Viral Hepatitis B. Several small islands of surviving hepatocytes, appearing swollen and pale, and sometimes arranged in tubular fashion ("hepatitic-type liver cell rosettes"), are present within an area of postnecrotic collapse and early fibrosis.

the more extensive panlobular and multilobular extent. Severe parenchymal necrosis is often accompanied by the development of small, glandlike clusters of surviving hepatocytes within the inflamed tissue (Fig. 19.8). These "hepatitic rosettes" are usually surrounded by connective tissue, and presumably represent attempts at regeneration from surviving hepatocytes in an unfavorable environment.

Portal inflammation in chronic hepatitis may be mild, moderate, or dense. It is predominantly composed of mononuclear cells, mainly lymphocytes, with variable numbers of plasma cells and histiocytes. Lymphoid aggregates and true lymphoid follicles may develop. Interface hepatitis was originally termed "piecemeal necrosis."[106] This term refers to the extension of the lymphocytic portal infiltrate beyond the limits of the portal tract, along with the death and "piecemeal" dropout of hepatocytes. Surviving hepatocytes are ultimately trapped within the inflammatory infiltrate, neoangiogenesis, and fibrosis, leading to an irregular portal/periportal interface (Fig. 19.9). Interface hepatitis is thus a better term, particularly as the mode of liver cell death is apoptosis and not necrosis,[107–109] and the lesion is located at the interface between mesenchyme (portal tract or septum) and parenchyma. Interface hepatitis may be mild (one or a few foci around the portal perimeter without noticeable fibrous extension), or severe (with wedge-shaped extension of the necroinflammatory lesion and obvious fibrosis deep into the lobule).

Interface hepatitis is responsible for the enlargement of portal tracts with irregular outlines in chronic hepatitis. The distinction should be made between true "lymphocytic piecemeal necrosis" as described previously, and "biliary piecemeal necrosis," which occurs in chronic biliary disease. In the latter variety, the irregular outline of the enlarging portal tract is not due to "invading" lymphocytes but to ductular reaction with associated neutrophil infiltration and cholate stasis of periportal hepatocytes[110] (see later).

Fibrosis may develop with ongoing inflammation.[111] Septal fibrosis may occur as periportal, portal–portal and portal–central septa. Periportal and portal–portal septa presumably result from interface hepatitis, whereas portal–central septa seem to be sequels of portal–central (bridging) confluent necrosis. Ongoing necroinflammation, associated with progressive fibrosis and parenchymal regeneration, eventually leads to cirrhosis. Parenchymal regeneration results from multiplication of mature hepatocytes, and to a variable extent proliferation of hepatic progenitor cells.[112] In the cirrhotic stage, the necroinflammatory changes may have subsided (inactive cirrhosis) or may continue unabated (active cirrhosis).

Grading and staging. Several systems for semiquantitative scoring have been proposed for evaluation of liver biopsies in chronic hepatitis (Tables 19.2 and 19.3).[113-120] Originally, the most widely used was the Histological Activity Index (the HAI or Knodell index) published in 1981.[120] A simple scoring system was proposed by Scheuer[102] and found to be easily applicable and reproducible.[117] A "modified HAI" was published as an extension of the original Knodell system, with a series of modifications attempting to overcome some of the problems that had emerged in its use.[118] This modified HAI has been validated for intra- and interobserver variability.[121] For the evaluation of chronic hepatitis C, the system proposed by the French METAVIR Cooperative Study Group[115,122,123] has been applied to very large numbers of biopsies, especially for staging purposes.[124]

Several papers have commented on the different scoring systems, with discussions of their advantages and disadvantages.[125–127] One review considers all scoring systems for chronic hepatitis as well as for other liver diseases.[128] The conclusion is that each of the systems currently in use has strengths and weaknesses, and all suffer from the problems that apply to any form of histologic scoring of liver biopsies in chronic hepatitis, including lack of scientific validation, observer variation, sample variation, and etiologic differences.[126] In

this era of evidence-based medicine,[129] numerical scoring of liver biopsies continues to have a place, and the pathologist engaged in semiquantitative scoring of liver biopsies has plenty of published advice available in the literature.[123,125,126,130] Numerical staging and grading is particularly useful for comparing pre- and post-treatment biopsies for a single patient; as a research method for studying the course of a disease; and for use in clinical therapeutic trials.[103]

Table 19.2 Modified histological activity index—staging: architectural changes, fibrosis and cirrhosis

CHANGE	SCORE
No fibrosis	0
Fibrous expansion of some portal areas, with or without short fibrous septa	1
Fibrous expansion of most portal areas, with or without short fibrous septa	2
Fibrous expansion of most portal areas with occasional portal–portal (P-P) bridging	3
Fibrous expansion of portal areas with marked bridging (portal–portal (P-P) as well as portal–central (P-C))	4
Marked bridging (P-P and/or P-C) with occasional nodules (incomplete cirrhosis)	5
Cirrhosis, probable or definite	6
Maximum possible score in staging	**6**

Additional features which should be noted but not scored:
Intralobular fibrosis, perivenular ("chicken-wire" fibrosis).
Phlebosclerosis of terminal hepatic venules (central veins).
Data (adapted to new terminologies) from Ishak K, Baptista A, Bianchi L, et al. Histological grading and staging of chronic hepatitis. *J Hepatol*. 1995;22(6):696–699; Westin J, Lagging LM, Wejstal R, Norkrans G, Dhillon AP. Interobserver study of liver histopathology using the Ishak score in patients with chronic hepatitis C virus infection. *Liver*. 1999;19(3):183–187, with permission from authors and publisher.

The need for estimating the degree of liver fibrosis in chronic viral hepatitis C in order to support treatment decisions has stimulated the search for noninvasive markers of liver fibrosis[131] because of sampling variability in needle biopsies.[29,132] A noninvasive technique that is being used with increasing frequency is transient elastography.[11,133,134] Noninvasive methods have even been proposed as substitutes for liver biopsy; however, biopsy and noninvasive alternatives are not mutually exclusive options, and a clear understanding of the significance and limitations of each tool is required.[135] The strengths and weaknesses of liver biopsy and of noninvasive markers were reviewed and their respective roles in management of patients with chronic hepatitis C discussed in a paper by P. Bedossa.[136]

Chronic hepatitis B. During some stages of chronic infection with HBV, overload of some cellular compartments with viral antigens may be so extensive as to be recognizable by light microscopy, creating helpful diagnostic markers of disease. Two such markers are "ground-glass hepatocytes" and "sanded nuclei." *"Ground-glass hepatocytes"*[137] are parenchymal liver cells with a pale, homogeneous, more finely granular appearance in part or all of their cytoplasm; the "ground-glass" area is often separated from the cell membrane by a clear halo, which is an artifact, albeit a helpful one (Fig. 19.10A and B). The ground glass appearance is due to marked hypertrophy of the smooth endoplasmic reticulum, which displaces the cytoplasmic organelles to the periphery of the cell, and which contains excess filamentous structures of HBsAg in its cisternae.[138,139] This ground-glass appearance of hepatocytes is, however, not entirely specific, and also occurs in other liver diseases, including drug-induced hypertrophy of the smooth endoplasmic reticulum (which predominates in centrilobular hepatocytes)[140,141]; fibrinogen storage disease, in which fibrinogen inclusions in parenchymal cells in patients with hypofibrinogenemia resemble ground-glass hepatocytes[142]; Lafora disease (myoclonus epilepsy)[143]; glycogenosis type IV (amylopectinosis or Andersen disease)[144]; and abnormal glycogen metabolism in polypharmacotherapy or following liver transplantation.[145,146] Ground-glass hepatocytes from several causes may, in fact, coexist in the same biopsy.[147]

Table 19.3 Batts–Ludwig grading and staging of chronic hepatitis

GRADE		STAGE	
0	No activity Portal inflammation only No interface activity No lobular activity	0	No fibrosis
1	Minimal activity Portal inflammation Minimal interface activity Occasional lobular apoptotic hepatocytes	1	Portal fibrosis (fibrous portal expansion)
2	Mild activity Interface activity involving some or all portal tracts Mild lobular activity with little hepatocyte damage	2	Periportal fibrosis (portal expansion plus periportal irregularity; rare portal/portal septa)
3	Moderate activity Interface activity involving all portal tracts Moderate lobular activity with obvious hepatocyte damage	3	Septal fibrosis (bridging fibrous septa with architectural distortion; no obvious nodularity)
4	Severe activity ± bridging necrosis Prominent diffuse hepatocyte damage	4	Cirrhosis

Batts KP, Ludwig J. Chronic hepatitis. An update on terminology and reporting. *Am J Surg Pathol*. 1995;19(12):1409–1417.

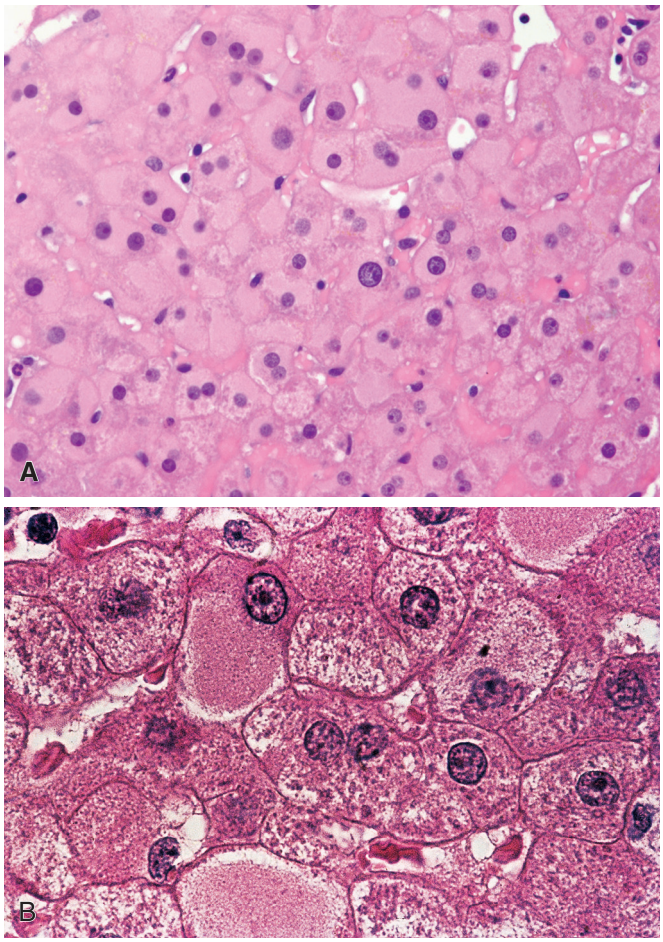

Figure 19.10 **A,** Ground-glass hepatocytes, characterized by eosinophilic, homogeneous and paler cytoplasm than surrounding normal hepatocytes. **B,** Note the artifactual cleft between the "ground-glass" cytoplasm and the hepatocellular cell membrane.

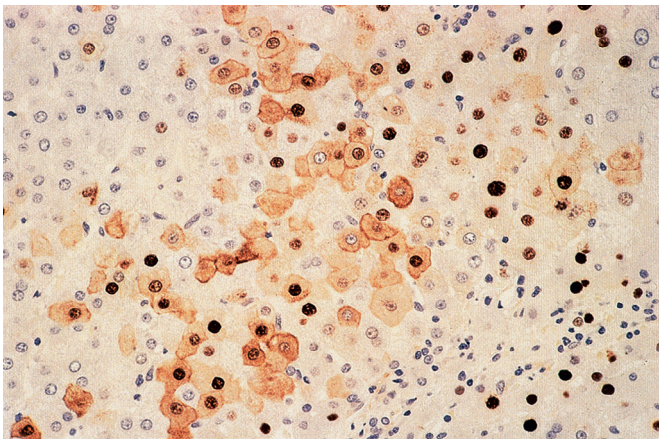

Figure 19.11 **Chronic Viral Hepatitis B, Viral Replicative Phase.** Hepatitis B core antigen is localized in hepatocellular nuclei and, in several hepatocytes, also in the cytoplasm and cell membrane. (Immunoperoxidase stain for HBcAg.)

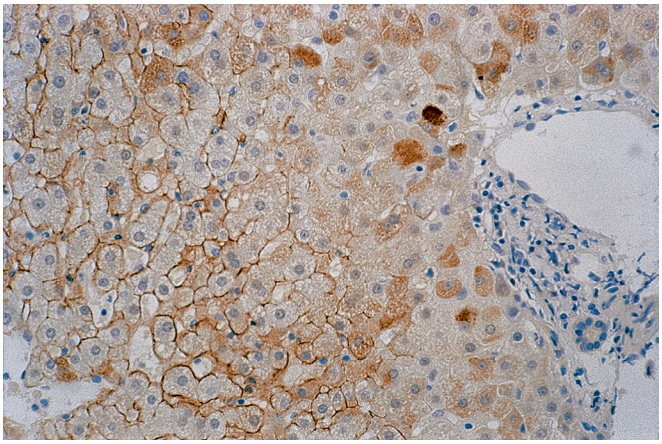

Figure 19.12 **Chronic Viral Hepatitis B, Viral Replicative Phase.** Hepatitis B surface antigen is localized in variable quantities in the cytoplasm and in the cell membrane of several hepatocytes. Note there is only a mild lymphocytic infiltrate in the portal tract and lobule. (Immunoperoxidase stain for HBsAg.)

Special stains such as Shikata orcein stain,[148] Victoria blue,[149] and aldehyde fuchsin[150] confirm the HBsAg relationship of the ground-glass appearance, and even more convincing is immunohistochemical staining with specific anti-HBsAg antibody. *Sanded nuclei*[151] are hepatocellular nuclei with a finely granular, pale eosinophilic appearance in the larger central part of the nucleus, due to massive accumulation of HBcAg. They are not easily recognized, and specific immunohistochemistry is far more helpful in identifying HBcAg.

The clinical, histopathologic, and immunohistochemical findings in chronic HBV have been summarized in several overviews[152,153]; they vary over the course of the disease depending on viral load, quality of immune response, and possibly associated comorbidity.[154] Under most circumstances, HBV is not cytopathic, and it is the immune response of the host that determines the outcome of infection. The most complete immune response is associated with the most severe liver injury and the greatest likelihood of viral clearance, whereas an immature immune response leads to chronic hepatitis. The natural history of chronic HBV has been viewed in four stages by some authors,[155–158] and three stages by other, earlier workers.[157,159,160]

The first stage is characterized by high viral loads and immune tolerance. In acute infection, this corresponds to the incubation period, but with neonatal chronic infection, this period often lasts for decades. During the early viral replication and immune tolerance phase in chronic hepatitis, liver biopsy reveals only minimal hepatocellular damage and inflammation. Immunohistochemically, this viral replicative phase is characterized by nuclear and cytoplasmic localization of HBcAg[161] and HBeAg,[162,163] which also localize in the liver cell membranes (Fig. 19.11). HBsAg is found in the cytoplasm of some scattered hepatocytes and in the membrane of numerous parenchymal cells, revealing a honeycomb-like pattern (Fig. 19.12).[164,165] The second stage, or viral elimination phase, is characterized by immune clearance of hepatocytes, histologically correlating to hepatocyte necrosis. Liver biopsy reveals necroinflammatory lesions, including confluent lytic necrosis of variable extent in more severe cases.[166,167] Immunostaining reveals nuclear, cytoplasmic, and membranous staining for HBcAg; HBsAg appears as weak positivity in the cytoplasm of some hepatocytes, associated with a membranous staining pattern.[96,165] HBeAg staining reveals nuclear and cytoplasmic localization.[168] In patients with chronic infection, stage 2 may persist for 10–20 years and lead to cirrhosis and its complications.

When the immune response decreases the number of infected cells, a third stage featuring low viral replication begins, referred to as the "inactive carrier" state. In this stage, HBeAg is no longer detectable and antibody to HBeAg becomes detectable. A marked

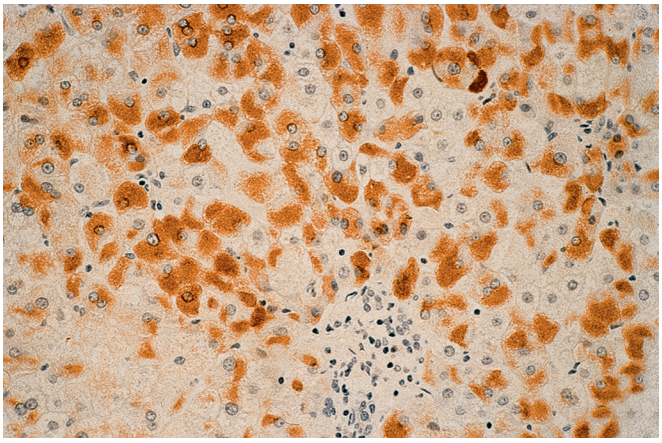

Figure 19.13 Chronic Viral Hepatitis B, Viral Nonreplicative (Integration) Phase. Hepatitis B surface antigen is localized in considerable quantity in the cytoplasm of a contiguous group ("clone") of hepatocytes. Note the relatively mild lymphocytic infiltrate in the portal tract and lobule. The more intensely staining cells appear as "ground-glass hepatocytes" on H&E staining. (Immunoperoxidase stain for HBsAg.)

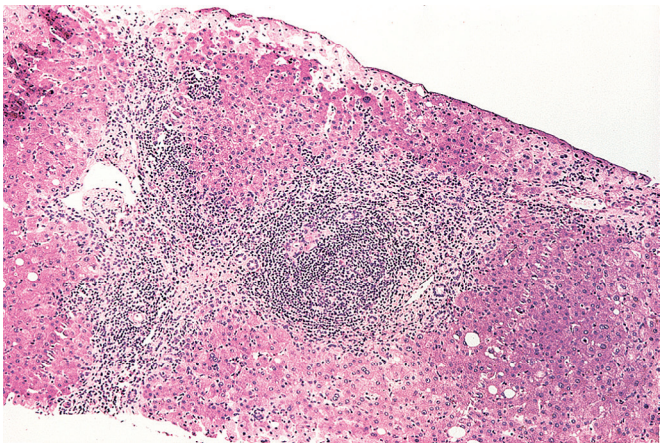

Figure 19.14 Chronic Viral Hepatitis C. Low-power view of two portal tracts connected by bridging fibrosis, with dense mononuclear cell infiltration and a prominent lymphoid aggregate. The portal–parenchymal interface is irregular due to interface hepatitis. Minimal steatosis is also present.

decrease in HBV viral load is observed, and although many patients remain positive for HBV DNA, it is only detectable by polymerase chain reaction (PCR) and aminotransferase levels become normal. Active replication of HBV has ceased, but HBsAg is continuously produced by liver cells that contain integrated HBV genome[169] and the patient becomes an HBsAg carrier (viral integration phase). HBsAg accumulates in clusters of hepatocytes, appearing as ground-glass cells or staining in the periphery of parenchymal cells (Fig. 19.13). HBcAg is usually absent. Mild inflammation may persist for some time after loss of HBsAg in the serum,[170] but substantial necroinflammation at this stage should raise the possibility of superinfection with another virus. The annual negativation (i.e., spontaneous return to seronegativity) rate for HBV surface antigen is approximately 1%.[171]

Some patients continue to have high levels of serum HBV DNA and aminotransferases[172] (stage 4, referred to as HBeAg-negative chronic hepatitis), due to precore mutant HBV variants characterized by deficient synthesis of the immune tolerogen HBeAg.[173,174] Immunostaining then reveals cytoplasmic HBcAg.[175]

If the patient's immune system succeeds in eliminating the virus, the fibrogenesis/fibrolysis balance may change in the direction of the latter, resulting in regression of fibrosis to considerable extent due to the action of metalloproteinases from hepatic stellate cells and hepatocytes.[176] During stage 4, some patients can reactivate their HBV when given chemotherapy or immunosuppressive treatment. Patients with active HBV replication are at increased risk for cirrhosis, hepatic decompensation, and hepatocellular carcinoma compared to inactive carriers. Available evidence indicates that control of HBV replication with antiviral agents decreases the incidence of these complications.

Cirrhosis developing in the viral integration phase of HBV will progress slowly over 20–30 years, eventually with decompensation and other complications. Initially micronodular, the cirrhosis becomes more macronodular,[96] and hepatocellular carcinoma may develop as a further consequence (see also Chapter 20). Even in patients without cirrhosis in the integration phase (so-called healthy HBsAg carriers), the risk for developing hepatocellular carcinoma is higher than in noncarriers.

Chronic hepatitis B + D. Chronic hepatitis D is in decline in Italy, but not in the rest of Europe,[177] and it remains a major health problem in the many underdeveloped areas of the world where HBV is uncontrolled.[178] Chronic hepatitis D tends to be more severe, with higher activity and risk of progression, than chronic HBV alone.[160,179] Rapid progression to cirrhosis is the fate in a minority of patients; more commonly, the disease evolution is slow and insidious, evolving into cirrhosis over many years.[180,181] HDV selectively suppresses HBcAg and HBeAg, but not HBsAg,[182] although it depends on low-grade HBV multiplication and release.[183] Immunohistochemically, HDAg is found mainly in liver cell nuclei,[184] which may show a sanded appearance[185] due to excess HDAg, and in the cytoplasm and membranes of hepatocytes.[186] Double immunostaining for HBV and HDV antigens often shows separate expression of HDAg versus HBsAg or HBcAg, but coexpression does occur.[187]

Chronic hepatitis C. HCV infection is characterized by a silent onset in most infected individuals, a high rate of viral persistence, and the potential for development of chronic liver disease, ranging from chronic hepatitis to cirrhosis and occasionally to hepatocellular carcinoma.[188] The sheer magnitude of the infected population will result in a large number with severe, life-threatening disease, thus rendering chronic HCV infection, with 170 million chronically infected people, a staggering worldwide problem.[189,190]

Histologically, chronic HCV is often mild initially, with little parenchymal damage other than focal inflammation and hepatocellular apoptosis.[190,192] A carrier state with normal liver biopsy has been reported,[193] and conversely abnormal liver histology has been recorded in HCV RNA-positive patients with normal serum alanine aminotransferase.[194,195] The histopathology of chronic HCV, although not pathognomonic, is highly characteristic, and several reviews are available.[192,196–198]

The portal infiltrate is rich in lymphocytes, often forming lymphoid aggregates (Fig. 19.14) and even follicles with prominent germinal centers.[199–203] Lymphoid follicles are not specific for chronic HCV, however, and are also found in HBV,[199,201] autoimmune hepatitis,[199] and PBC. Nevertheless, they are particularly prominent in hepatitis C. Lesions of interlobular bile ducts are not uncommon (Fig. 19.15), with frequencies ranging from 15%–91% of biopsies.[198,199] This broad variation likely indicates a poor consensus on the definition of "bile duct lesion." The most frequently observed bile duct lesions consist of infiltration of the bile duct epithelium by lymphocytes, with variable degrees of cytoplasmic vacuolization, nuclear stratification,

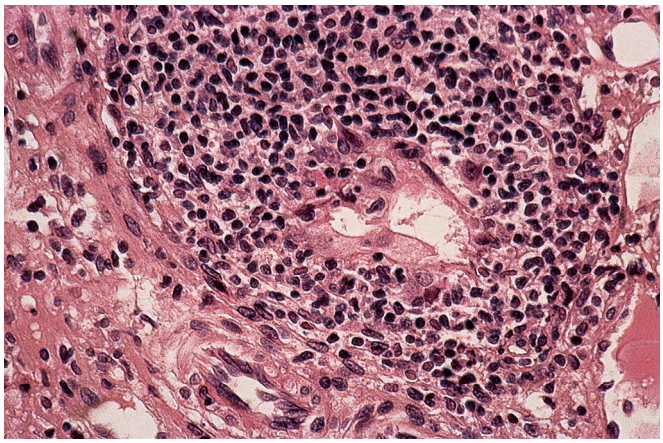

Figure 19.15 Chronic Viral Hepatitis C. Detail of a portal tract showing a lymphoid follicle containing an irregular and damaged bile duct near its center. Note the biliary epithelial irregularity and intramural lymphocytic infiltrate.

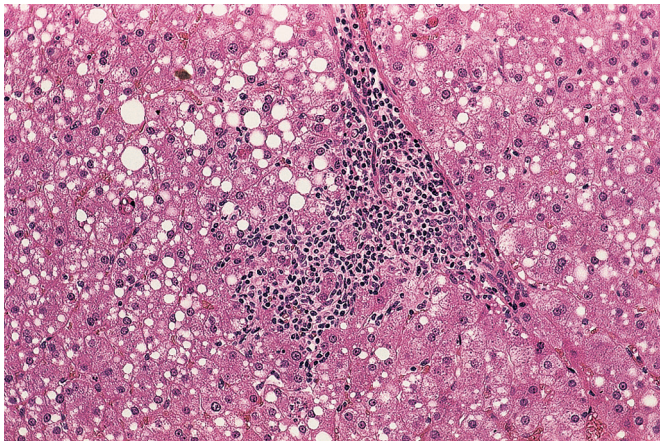

Figure 19.16 Chronic viral hepatitis C showing moderate to marked steatosis in addition to portal inflammation and mild interface hepatitis.

and crowding of the biliary ductal epithelial cells. The most pronounced bile duct lesion, originally described before HCV was even discovered,[204] is characterized by swelling and stratification of bile duct lining cells and infiltration by lymphocytes, yet preservation of the basement membrane of the bile duct.[205] This type of bile duct lesion must be differentiated from that occurring in PBC, which tends to be more destructive, but on occasion the distinction may be difficult.

The lobule in chronic HCV may contain a striking number of acidophil bodies. Oxyphil granular hepatocytes (or oncocytes, cells rich in mitochondria) have been reported in more than a third of biopsies.[206] There is typically patchy lymphocytic infiltration with spotty necrosis; the lymphocytic infiltrate may form rows along the sinusoids (so-called Indian file) resembling hepatic mononucleosis. Mild to moderate steatosis, usually of the macrovesicular type, has been described in frequencies ranging from 40% to 80% (Fig. 19.16), depending on the features of the population studied in terms of alcohol consumption and prevalence of other risk factors for fatty liver including obesity and diabetes. Steatosis is more frequent and more severe in patients with genotype 3.[207] HCV interferes with lipid metabolism via at least three ways, which are not mutually exclusive: impaired secretion of lipid, impaired degradation, and increased synthesis.[208] Steatosis favors viral replication, since the lipid droplet represents an organelle that functions as an assembly platform for the different viral components (HCV core, functional replication complexes, viral RNA, envelope proteins).[209,210] Steatosis is believed secondary to direct viral effect in patients with genotype 3, but is likely secondary to insulin resistance and/or alcohol use in patients infected with other genotypes.[207,211,212] Steatosis and steatohepatitis in chronic hepatitis C are also associated with more inflammatory activity and faster fibrosis progression.[211,213] Insulin resistance appears to be a specific feature of chronic HCV (much less so than in chronic HBV) and is particularly associated with genotypes 1 and 4 and high HCV RNA levels.[214] Thus, it appears that chronic HCV, non-alcoholic steatohepatitis (NASH) and NAFLD may have mutual reinforcing effects: HCV genotype 3 infection may potentiate NAFLD/NASH by providing the "first hit" (steatosis)[215] and by inducing insulin resistance,[216–218] whereas on the other hand, NAFLD/NASH may potentiate HCV replication by providing fat droplets as scaffold for viral assembly.[209,210] Bedossa et al. also found that in patients with NASH and chronic HCV of genotype 3 there was no associated metabolic syndrome, suggesting that NASH may complicate steatosis in chronic HCV irrespective of the etiology of the steatosis.[215]

A number of other histologic alterations in chronic HCV infection have been described. Periportal hepatocytes may contain coarse clumps of eosinophilic cytoplasm, resembling Mallory–Denk bodies (MDBs).[201,219] Venous lesions resembling the endotheliitis observed in acute cellular liver allograft rejection have also been reported and may further confuse the already difficult distinction between those two conditions.[220] Increased amounts of hepatic iron have been reported in patients with chronic hepatitis C, even in the absence of a history of blood transfusion or alcohol abuse,[221] and iron overload has been shown to impair response to interferon therapy.[180,222,223] Increased hepatic iron in the context of chronic hepatitis C, however, may also be due to associated hemochromatosis, porphyria cutanea tarda (PCT), alcohol abuse, oral iron intake, and previous treatment with ribavirin.[224,225]

Another confusing lesion is the occurrence of epithelioid granulomas in a small minority (5%) of cases,[226,227] sometimes as a transient feature.[228] The development of granulomas has been correlated with interferon-α therapy[229] and has been associated with both favorable[230] and adverse responses to therapy.[231] In the post-transplant setting, granulomas have been observed in association with pegylated interferon-treated recurrent viral hepatitis C.[232] Of course, other causes of granulomas must be excluded before the etiology of the granulomas is attributed to hepatitis C. The presence of epithelioid granulomas may also render the distinction of chronic HCV from PBC more difficult, particularly if lymphocytic cholangitis and mild epithelial damage is present (see earlier).[233] A rare case of fibrin-ring granuloma has also been reported.[234]

Syncytial giant cell hepatitis is a rare histologic finding among HIV-infected patients with chronic hepatitis C; specific treatment with pegylated interferon and ribavirin can lead to its histologic resolution.[235]

The natural history of chronic hepatitis C is one of progressive fibrosis, even in cases with mild disease.[236] Adverse risk factors for progression include young age at infection, infection acquired via intravenous drug abuse, and HCV genotype 3.[237] It has also been noted that in HCV-infected children, inflammation, fibrosis, and steatosis were milder than in treatment-naive HCV-infected adults, but there were still several cases with bridging fibrosis or cirrhosis. The positive correlation of inflammation with duration of infection and fibrosis, as well as the correlation between obesity/metabolic syndrome and fibrosis, suggests that children with chronic hepatitis C will be at risk for progressive liver disease as they age and possibly acquire other comorbid risk factors.[238,239]

A strong correlation has also been noted between portal fibrosis and periportal ductular reaction (hepatic progenitor cell expansion), exacerbated by steatosis and associated with impaired hepatocyte replication, suggesting that an altered regeneration pathway may drive ductular reaction, which in turn triggers fibrosis at the portal tract interface.[240] Portal and periductal macrophages expressing matrix metalloproteinase-9 have also been associated with increased ductular reaction and progression of fibrosis.[241] Greater inflammatory activity has also been associated with disease progression.[242]

As noted previously, demonstration of viral antigens by immunohistochemistry has been reported in multiple studies, but reproducible and clinically useful results in paraffin-embedded material have been lacking. The same criticism regarding specificity applies to ISH for HCV RNA.[74,75]

Combined pathology in chronic viral hepatitis. Combined infection with HBV and HCV increases the severity of the histologic liver lesions.[243,244] Triple infection with HBV, HDV, and HCV results in severe disease in the acute superinfection stage; however, the overall course is relatively benign, slowly progressive, and usually dominated by HCV.[244,245] HIV infection may result in reactivation of HBV, with higher levels of HBV replication and more immunocytochemically demonstrable HBcAg and HBeAg, but typically without an increase in necroinflammation.[246] Necroinflammatory activity is also higher in HIV-positive patients with chronic hepatitis C, and cirrhosis is more frequent.[247] The combination of steatosis, steatohepatitis, HIV, and HCV infection is associated with a more advanced degree of fibrosis as well.[248] Infection with multiple hepatitis viruses is quite common and may be difficult to histologically diagnose without knowledge of pertinent clinical and laboratory data.

Foci of hepatocellular hemosiderosis (iron-rich foci) have been described in both chronic HCV and HBV, highlighting the potential for irregular iron storage in chronic viral liver disease and potential confusion with genetic hemochromatosis.[249] Heterozygosity for hereditary hemochromatosis[250] and hepatic iron overload[251] in the context of chronic viral hepatitis may also influence progression toward liver fibrosis.

Some patients with chronic HCV have autoimmune features, including a greater degree of inflammatory activity (often with prominent plasma cells), positive autoimmune serological markers, higher levels of immunoglobulins, and an association with HLA-DR3. These patients have a greater frequency of cirrhosis.[252]

Chronic infection with HBV and HCV can certainly occur in patients with many other unrelated liver diseases, such as PBC, PSC, and alcohol-related liver injury.

Hepatitis Caused by Nonhepatotropic Viruses

Several viruses not belonging to the group of specific "hepatitis" viruses discussed earlier may also induce liver inflammation, as either a primary disease or, more often, as part of systemic infection.

CMV infection. CMV is an important cause of opportunistic hepatitis in immunodeficient patients, particularly transplant patients[253] and HIV-positive patients, and it also causes neonatal hepatitis.[254] CMV inclusions may occur in any type of hepatic cell, including hepatocytes, bile duct cells, endothelial cells, and portal fibroblasts[255]; nuclear inclusions may have the typical "owl's eye" morphology, whereas cytoplasmic inclusions are often basophilic and granular (Fig. 19.17A and B). CMV immunohistochemistry may be very helpful in identifying inclusions, particularly when inclusions are not well formed.[256,257] Neutrophilic microabscesses or aggregation of neutrophils in sinusoids[256] is a useful diagnostic feature that should prompt a diligent search for viral inclusions or antigens. In immunocompetent patients a picture resembling EBV-associated hepatitis may occur (see later).[258,259]

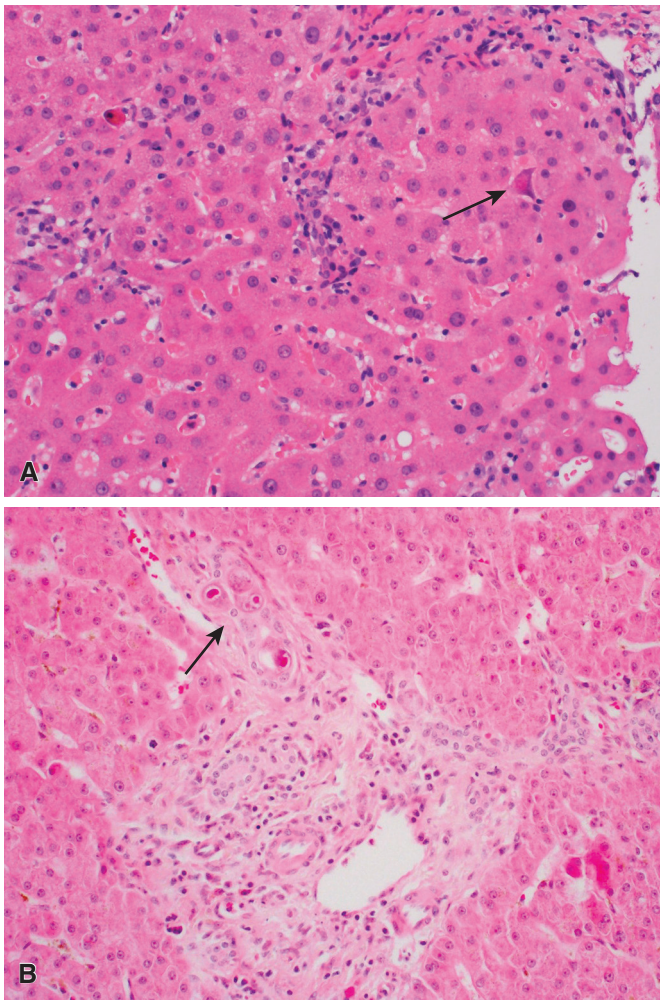

Figure 19.17 **A,** A poorly formed basophilic, granular CMV inclusion is present within an endothelial cell *(arrow)* in the sinusoids. There is surrounding patchy inflammation and scattered apoptotic hepatocytes. **B,** Several "owl's-eye" inclusions are seen within biliary epithelial cells *(arrow)*.

Infectious mononucleosis. EBV infection deserves consideration in the differential diagnosis in all age groups. The liver is affected in over 90% of patients with infectious mononucleosis, although this is often subclinical. Symptomatic liver involvement develops in only 5%–10% of patients. ISH is a useful ancillary tool in confirming the diagnosis of EBV hepatitis in equivocal cases; however, EBER-positive cells can be sparse and easily overlooked.[260] Histologically, dense mononuclear infiltrates, often containing large atypical lymphocytes, are found in portal tracts and sinusoids. In the latter, they spread in a distinctive single-file, "string-of-beads" or "Indian-file" array (Fig. 19.18). Kupffer cells are hypertrophic, and epithelioid and fibrin-ring granulomas are occasionally found. Small foci of hepatocellular necrosis and acidophil bodies may be seen, but generally the parenchymal damage is not in proportion with the density of the infiltrate.[261] Cholestatic hepatitis may also be encountered, albeit rarely.[262] Occasionally EBV-associated hepatitis must be distinguished from hepatic involvement by leukemia or lymphoma.

Acquired immunodeficiency syndrome (AIDS). A wide spectrum of liver abnormalities may be observed in AIDS and HIV infection.[263,264] Although Kupffer cells can serve as a reservoir for HIV,[265] the liver is not a primary target of HIV infection, and most of the

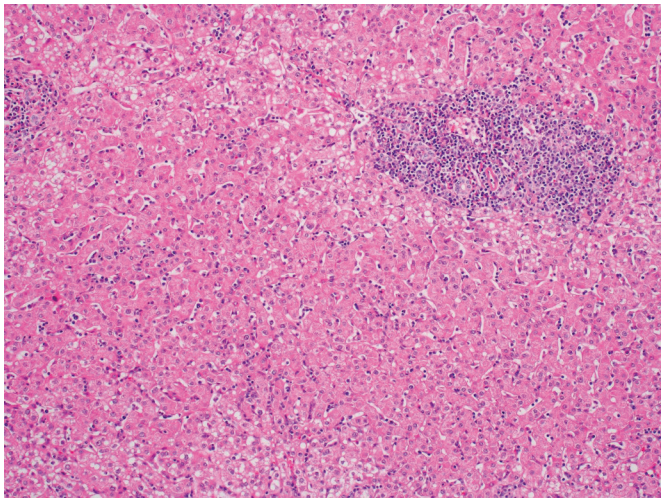

Figure 19.18 EBV hepatitis showing dense lymphocytic portal infiltrates, and a sinusoidal lymphocytosis in a "string of beads" configuration.

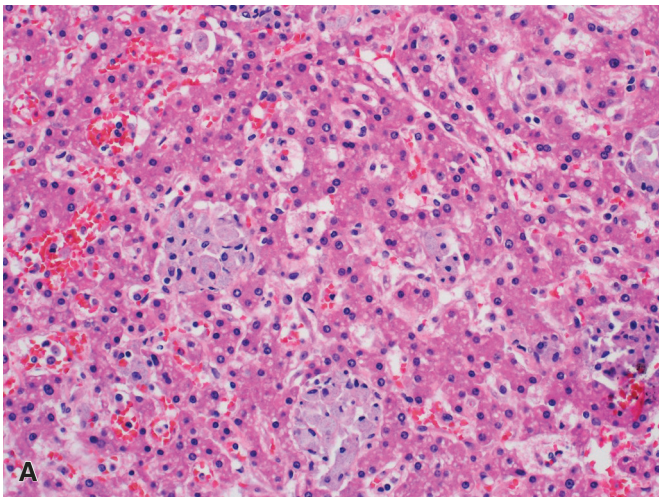

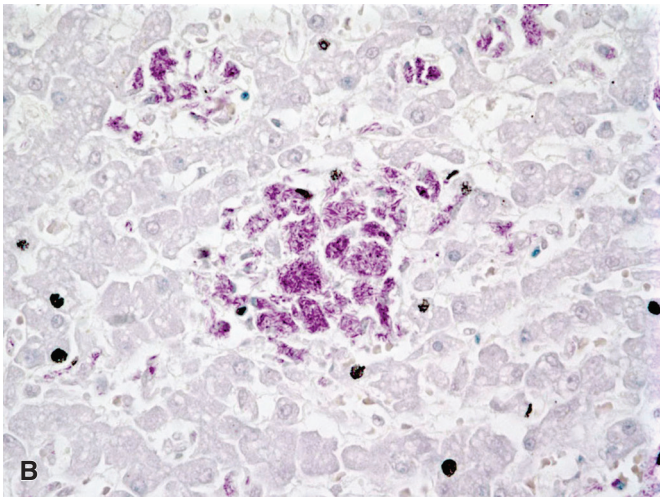

Figure 19.19 Mycobacterium Avium-Intracellulare Complex in the Liver. A, A foamy macrophage infiltrate with virtually no other attendant inflammation. **B,** Ziehl–Neelsen stain highlights organisms within macrophages.

hepatic manifestations reflect opportunistic infections, lymphoma, and Kaposi sarcoma.[266] The patterns of opportunistic infection vary significantly in different parts of the world, depending on the local prevalence of infection, as well as on the availability of treatment and thus the survival of HIV-infected patients. It is also important to recognize that the pathologist may encounter an opportunistic infection well outside its usual geographic distribution, due to travel or immigration. Hepatic involvement by CMV is quite common (see earlier)[266]; other opportunistic infections involving the liver and bile ducts in AIDS patients include *Mycobacterium avium intracellulare*, *Mycobacterium tuberculosis*, *Cryptococcus* species, *Candida* species, *Histoplasma*, and malaria.[266,267] A frequently encountered hepatic lesion is the occurrence of multiple granulomas containing *Mycobacterium avium-intracellulare*, visualized to better advantage by PAS–diastase, Ziehl–Neelsen, or Gomori methenamine silver stains.[268] The mycobacteria are packed in the foamy histiocytes that constitute the granulomas and often show a striated appearance (Fig. 19.19A and B). Small numbers or even single mycobacteria may also be present in scattered Kupffer cells. *Pneumocystis carinii* may cause multiple foci of eosinophilic foamy exudate, similar to that seen in pulmonary infection.[269] *Bartonella henselae*-associated bacillary angiomatosis may also be seen.[270]

Nonspecific histologic changes can also be found in the livers of patients with HIV, including mild mononuclear portal inflammation, scattered lobular lymphocytes and apoptotic bodies, fibrosis, ductular reaction, steatosis, and Kupffer cell siderosis. Lipid-laden perisinusoidal hepatic stellate cells have also been reported in AIDS.[271]

AIDS-associated cholangiopathy is an important biliary disorder caused by opportunistic infection of the biliary epithelium, which resembles sclerosing cholangitis.[272] *Microsporidia*[273] and *Cryptosporidia*[274] are two such biliary pathogens. CMV-associated ductopenia has also been reported as a cause of vanishing bile duct syndrome in an AIDS patient with signs and symptoms of obstructive jaundice and cholestasis.[275]

A number of noninfectious lesions occur in this patient population as well. ***Hepatoportal sclerosis (HPS)***, characterized by varying degrees of portal fibrosis, sclerosis of portal vein branches and dilation of sinusoidal spaces (see also later), has been identified as a cause of noncirrhotic portal hypertension in patients with HIV.[276] ***Highly active antiretroviral therapy (HAART)*** is also a cause of hepatotoxicity and may cause fatty liver disease as well as other patterns of liver injury.[277,278] From a neoplastic standpoint, ***non-Hodgkin lymphomas***, especially of the Burkitt and immunoblastic types, may involve the liver, occurring as portal infiltrates or as nodular masses.[279] Hepatic involvement by ***Kaposi sarcoma*** also occurs.[280]

Drug-Induced and Toxic Liver Injury

The frequent occurrence of adverse drug reactions and toxic damage to the liver is not surprising, as this organ is the main site of biotransformation of endo- and xenobiotics. The incidence is high, with an estimated incidence of up to 14 cases per 100,000 inhabitants in France[281]; drug-induced liver injury (DILI) is also the leading cause of acute liver failure in the United States.[282]

Recognition of DILI is challenging for several reasons. It can mimic virtually any other type of liver disease, and clinical signs of a hypersensitivity reaction may not occur in all cases. DILI can occur with drugs from all classes,[282,283] and the same drug may cause different patterns of liver damage in different patients[91]; for example, mitochondrial dysfunction, a major mechanism of liver injury, may cause fulminant hepatitis, micro- and macrovesicular steatosis, or steatohepatitis.[284] It is often impossible to pinpoint the causative agent

in patients on multiple drug therapy, which usually is the case in elderly patients, and a patient's drug history is often far from reliable. DILI may also be potentiated by the concomitant administration of other pharmacologic agents. Furthermore, hepatotoxicity may not yet have been reported for the drug in question, even when it has been on the market for a long time. Besides medicinal drugs, one also has to consider hepatotoxicity from herbs and dietary supplements.[285,286]

The pathologist should be aware of the types of lesion most likely to be induced by drugs, and how to try to differentiate these from features less likely to be caused by drugs. Although it is useful to be aware of specific sources of information such as books[287–290] and comprehensive reviews on this subject,[282,291–295] because of the growing diversity of drugs, current information is often more accessible on PubMed and other internet sources.

A distinction has been made between predictable (or intrinsic, or drug-dependent) toxicity effects on the one hand, and unpredictable (or hypersensitive, or idiosyncratic, or host-dependent) reactions on the other hand.[282] Predictable reactions are due to the intrinsic hepatotoxicity of the molecule, are typically dose dependent and occur in all exposed individuals, occur with a relatively short (though variable) latent period, and are reproducible in experimental animals. Acetaminophen overdose is an example of this type of toxicity. Of far more concern is the more frequent, unpredictable type of DILI. It occurs in only a small fraction of the population exposed, there is no clear dose relationship, the latent period may be quite long (weeks or months), and it is not reproducible in experimental animals. Exceptional sensitivity to a particular drug may be based on genetically determined differences in drug metabolism ("metabolic idiosyncrasy") or to immunologically based reactions to neoantigens formed by interaction between a drug metabolite and some tissue or cell membrane component ("immunoallergic idiosyncrasy").[282,296,297] The latter mechanism is believed to be the most frequent type of idiosyncratic DILI.[298]

Conclusive proof that a particular drug or combination of drugs is responsible for DILI in an individual case is often impossible to obtain; rechallenge would be an obvious effective test but is clearly unethical. Inadvertent rechallenge may provide strong circumstantial evidence, even many years after a first episode.[299]

Drug-induced adverse reactions in the liver may cause structural and functional changes in all cellular components of the organ, which then coalesce to produce various patterns of injury. Individual histologic features, as well as patterns of drug-induced injury, are briefly summarized next.

Histologic Features

Hepatocytes. In view of the parenchymal heterogeneity in the liver lobule, with predominance of microsomal biotransformation enzymes in the centrilobular zone, it is not surprising that drug-induced effects may show a zonal distribution or predominance.

A ground-glass appearance of hepatocytes in the centrilobular area, due to hypertrophy of the smooth endoplasmic reticulum (similar to that seen in chronic HBV infection, see earlier) with associated enzyme induction, can be caused by a number of drugs such as phenobarbital, rifampin, dioxin, and cyanamide.[141,300]

Lipofuscinosis, or increased accumulation of lipofuscin (wear and tear pigment) in centrilobular hepatocytes is induced by prolonged intake of some drugs such as phenacetin, aminopyrine (aminophenazone), chlorpromazine, Cascara sagrada,[301] and by anticonvulsant therapy.[140] It must be differentiated from the pigment accumulation in Dubin–Johnson syndrome.

Steatosis (see also later) is a frequently occurring effect of xenobiotics. Macrovesicular steatosis can be seen with drugs such as tamoxifen, estrogens, methotrexate, and ethanol.[302] Microvesicular steatosis may be associated with clinical manifestations of severe liver injury, even in the absence of overt hepatocellular necrosis. It is apparently due to inhibition of mitochondrial fatty acid β-oxidation and mitochondrial dysfunction.[284,303] It has been associated with intravenous tetracycline, amiodarone, valproate, and acetyl salicylate in children (Reye syndrome).[302] Microvesicular steatosis has also been reported with several antiviral nucleoside analogs (e.g., fialuridine).[304] A similar alteration is observed in mitochondriopathies[305] and in acute fatty liver of pregnancy (AFLP).[306]

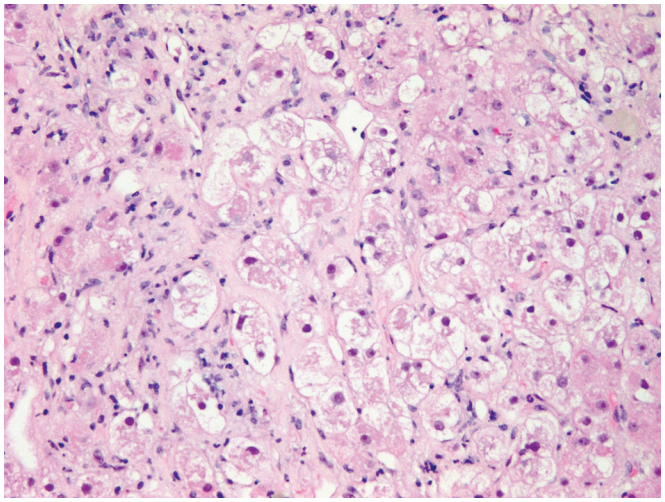

Figure 19.20 Foamy cytoplasmic vacuoles, ballooning, and numerous Mallory–Denk bodies characterize amiodarone toxicity.

Phospholipidosis is characterized by foamy cytoplasmic vacuoles and enlargement of hepatocytes and Kupffer cells due to phospholipid accumulation. Electron microscopy reveals lamellated myeloid bodies (fingerprints) in enlarged lysosomes. Associated drugs include gentamycin, perhexiline maleate, fluoxetine, and amiodarone (Fig. 19.20)[307]; drug toxicity from the latter may even lead to cirrhosis.[308]

Reactive hepatocellular changes. Binucleated hepatocytes increase in number with sulindac, and multinucleated hepatocytes have been reported in several instances of acute and chronic drug-induced hepatitis (e.g., clometacin).[309]

Hepatocellular death: apoptosis and necrosis. Both modes of hepatocellular death may be induced by toxic drug metabolites and immunoallergic hypersensitivity reactions. Hepatocellular necrosis may be variable in appearance (coagulative or lytic), in topography (centrilobular or periportal), and in extent (focal, zonal, bridging, lobular, or multilobular). With larger doses, many hepatotoxic drugs (e.g., chloroform, acetaminophen) and hepatic poisons (e.g., the mushroom *Amanita phalloides*, carbon tetrachloride) produce centrilobular necrosis, often associated with ballooning and steatosis in adjacent non-necrotic parenchymal cells, and with minimal or no inflammation.[283] Other chemicals (e.g., ferrous sulfate, the yellow form of inorganic phosphorus) may cause periportal necrosis. Many of these agents cause fatal massive necrosis when administered in sufficient doses; in smaller doses, apoptosis of liver cells occurs, which, with time, may result in fibrosis and cirrhosis.[310]

Kupffer cells are involved in storage of foreign materials and in granuloma development. Materials stored in Kupffer cells include talc and cellulose in drug addicts, silica and anthracotic pigment in coal miners, polyvinyl pyrrolidone and hydroxyethyl starch[311] from infusion of plasma expanders, and silicone from prosthetic heart valve devices.

Numerous drugs—amongst them sulfonamides, methyldopa, and phenylbutazone—have been incriminated in the production of *hepatic granulomas*.[312] A special variant, the *fibrin ring granuloma*, can be seen in hypersensitivity to allopurinol.[313,314] *Mineral oil granulomas* are composed of lipophages and occur in portal tracts and near central veins. They have been attributed to the absorption and deposition of mineral oil taken as a medicinal agent (laxative) or ingested as a food additive or food contaminant from food packaging.[315] Gold has been identified in lipophages and granulomas in patients who received gold therapy for rheumatoid arthritis.[316]

Vascular changes. *Periportal sinusoidal dilation* has been related to oral contraceptive use.[317] *Peliosis hepatis* (see also later) has been associated with the administration of anabolic–androgenic steroids, contraceptive steroids, and azathioprine.[318] *Sinusoidal obstruction syndrome* (SOS; formerly known as *veno-occlusive disease*),[317] characterized by nonthrombotic narrowing of central vein lumina by loose connective tissue, is associated with pyrrolizidine alkaloids, radiation, conditioning for bone marrow transplantation, and chemotherapeutic agents, (e.g., irinotecan and oxaliplatin).[319–321] *Thrombosis of hepatic veins* (Budd–Chiari syndrome [BCS]) and of portal vein branches is a rare complication of contraceptive steroids. *Phlebosclerosis of portal vein branches (HPS)* has been associated with long-term use of inorganic arsenicals (Fowler solution), Thorotrast, vinyl chloride, vitamin A, and methotrexate.[317] *Arteritis* due to drug hypersensitivity may affect intrahepatic branches of the hepatic artery, resulting in multifocal hemorrhagic necrosis and exceptionally rupture of the liver.[317] *Angiosarcoma* has been associated with inorganic arsenicals, Thorotrast, anabolic–androgenic steroids, cyclophosphamide, oral contraceptives, vinyl chloride, and radium therapy.[317,322]

Hepatic stellate cell (Ito cell) hyperplasia, corresponding to an increased number of hepatic stellate cells (Fig. 19.21), has been associated with a number of drugs including hypervitaminosis A,[323] niacin,[324] and in patients undergoing methotrexate therapy, although to less extent than once thought.[325] Hepatic stellate cell hyperplasia may lead to increased fibrosis.[326]

Cholestatic reactions are the most frequent side effects of drugs overall. Simple *drug-induced cholestasis* is histologically characterized by bland bilirubinostasis without accompanying inflammation (Fig. 19.22). Such "simple" or "pure" cholestasis is seen with many drugs, the prototypes being anabolic and contraceptive steroids.[327,328]

Bile duct damage and ductopenia may be due to the effects of many drugs.[295,329,330] Because of the ductopenia, cholestasis of this type is usually prolonged, and may last for months and even years.[331] The mechanism may be direct toxicity to bile duct cells or immunoallergic injury.[297] Ductopenia has been reported in association with a large number of drugs, including chlorpromazine, haloperidol, ajmaline, glycyrrhizin, and several antibiotics.[329]

Histologic Patterns of Injury

Drug-induced acute hepatitis typically features hepatocellular damage and apoptosis/necrosis (variable in degree) with varying degrees of portal and lobular inflammation (Fig. 19.23A and B). Reactive hepatocellular changes and prominent Kupffer cells are also frequently seen, and cholestasis may be present as well.[295] Eosinophils may or may not be prominent in the inflammatory infiltrate. Fibrosis is absent. Numerous drugs of diverse classes can cause this reaction; classic examples include isoniazid (a tuberculostatic agent), ibuprofen, halothane (an anesthetic), phenytoin, and sulfonamides.[295] The histopathology is virtually indistinguishable from that of other forms of acute hepatitis, including acute viral hepatitis.

Drug-induced chronic hepatitis occurs in a minority (5%–10%) of patients.[295,332] The histologic features can mimic several other types of chronic liver disease, including autoimmune hepatitis (e.g., minocycline and nitrofurantoin) and chronic viral hepatitis (phenytoin).[295,333,334] Serologically, the presence of autoantibodies in cases of drug-induced autoimmune hepatitis may cause further confusion with de novo autoimmune hepatitis.[335] The diagnosis relies on a high degree of suspicion of a possible drug etiology in the absence of viral markers, and close cooperation with clinician and patient. Recognition of this pattern of DILI is important, as withdrawal of the drug is often essential to treatment and prognosis.

Drug-induced steatohepatitis is rarely caused directly by the offending pharmaceutical; more often, the drug exacerbates or initiates steatohepatitis in the context of other risk factors for fatty liver disease.[295] Associated drugs include amiodarone,[336] antiretroviral therapy,[337,338] irinotecan, and parenteral nutrition (total parenteral nutrition [TPN]; Fig. 19.24A and B).[339]

Drug-induced cholestatic hepatitis combines features of acute drug-induced hepatitis with cholestasis and variably present ductular reaction.[294,295] Differentiation from large bile duct obstruction can

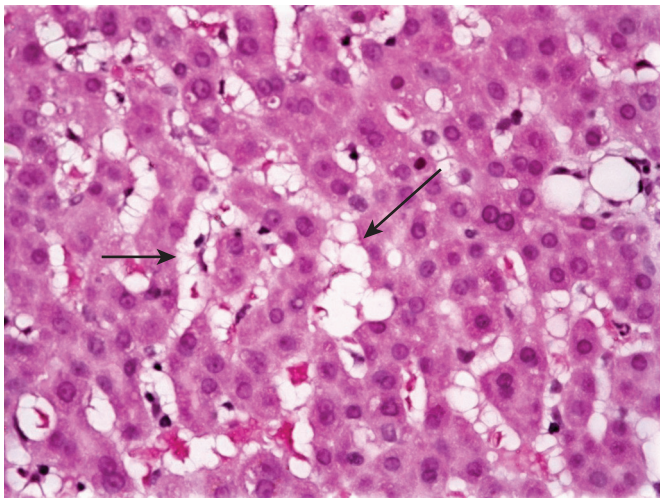

Figure 19.21 Hypervitaminosis A. Increased numbers of enlarged hepatic stellate cells *(arrows)* with clear cytoplasm and delicate cytoplasmic processes.

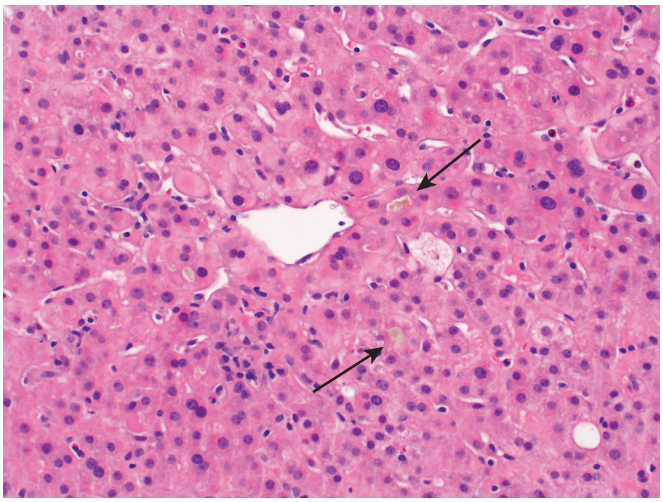

Figure 19.22 Canalicular cholestasis with bile plugs *(arrows)* and minimal associated inflammation in this cholestatic drug reaction secondary to antibiotics.

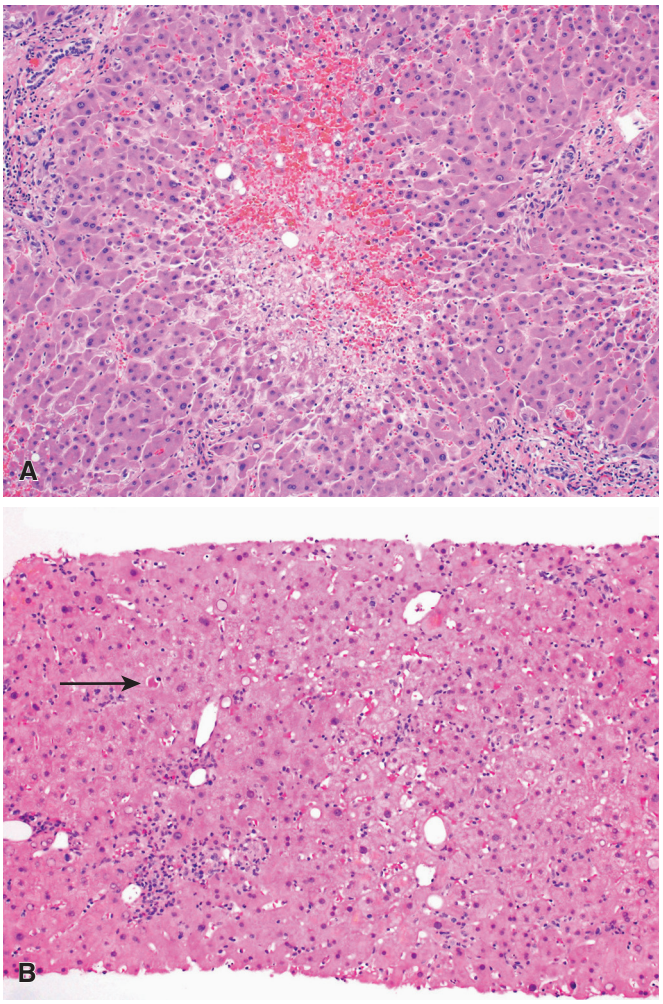

Figure 19.23 **A,** Centrilobular necrosis with minimal attendant inflammation in acetaminophen toxicity. Reactive binucleated hepatocytes are also present. **B,** Acute drug-induced liver injury featuring lobular inflammation, prominent Kupffer cells forming small clusters, and apoptotic hepatocytes *(arrow)*. Fibrosis is absent by definition.

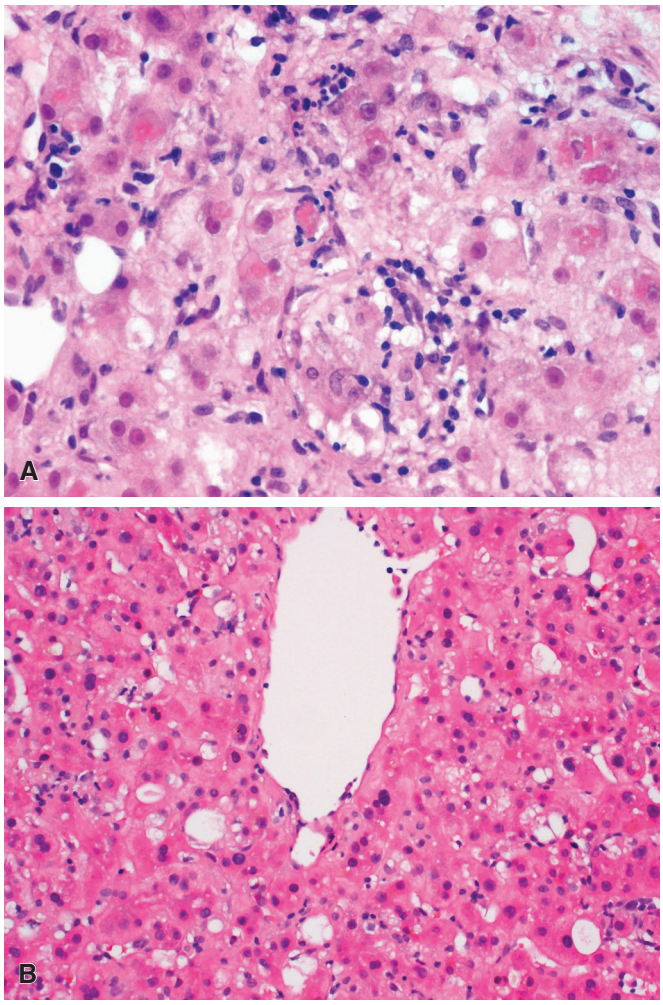

Figure 19.24 **A,** Fat and abundant Mallory-Denk bodies in amiodarone toxicity. **B,** Steatosis, reactive hepatocellular changes, and stellate cell hyperplasia secondary to HAART therapy.

be very difficult. Portal edema and neutrophilic cholangitis favor large bile duct obstruction but are not always present, and correlation with medication history is often essential. Although most cholestatic drug reactions resolve when the offending agent is discontinued, some cases become chronic, with associated interlobular bile duct damage and occasionally ductopenia (Fig. 19.25A–C). A number of antibiotics as well as antifungals and ACE-inhibitors have been associated with cholestatic drug reactions.[295,297,340]

Drug-induced granulomatous hepatitis typically features noncaseating granulomas that can be present in portal tracts, lobules, or both (Fig. 19.26A). Cholestasis and an eosinophilic infiltrate may be helpful clues indicating DILI in addition to the granulomas (Fig. 19.26B). As mentioned previously, fibrin ring granulomas may also represent DILI.[295,312]

TPN-associated liver disease is worthy of additional mention given the frequency of occurrence, particularly in the pediatric population.[341] TPN-associated liver disease develops in 40%–60% of infants and 15%–40% of adults who require long-term TPN. The spectrum of injury includes hepatic steatosis, cholestasis (which occurs more frequently in children than adults), cholelithiasis, and hepatic fibrosis. Progression to biliary cirrhosis and the development of portal hypertension and liver failure occur in a minority but are also more common in infants and neonates than in adults.[342] In infants, histologic features include canalicular cholestasis, cholestatic liver cell rosettes, and ductular cholestasis (Fig. 19.27). Giant hepatocytes and ductular reaction may also occur. The portal tracts variably contain a mixed inflammatory infiltrate, and with longer duration of TPN, periportal fibrosis develops.[342,343] In adults, TPN may lead to steatosis, cholestasis, and periportal fibrosis as well, with periportal copper accumulation (sometimes marked) that is independent of the total duration of TPN.[344] In infants requiring TPN, the liver histology may mimic other cholestatic diseases of infancy, including neonatal hepatitis and biliary atresia (BA).

Diagnostic hints for the histopathologist. One should always maintain a high degree of suspicion for a drug-induced etiology, especially in elderly patients. A histologic picture resembling viral hepatitis, but with a disproportionately severe degree of parenchymal necrosis in relation to the patient's clinical condition, or with associated steatosis, granulomas, an eosinophilic infiltrate, or associated bile duct damage, should arouse suspicion for drug-induced disease.[283] The same applies for centrilobular necrosis sharply delineated from non-necrotic parenchyma, especially if associated with steatosis, with only mild or minimal inflammation, and with numerous ceroid macrophages. Parenchymal giant cell hepatitis in adult patients, and

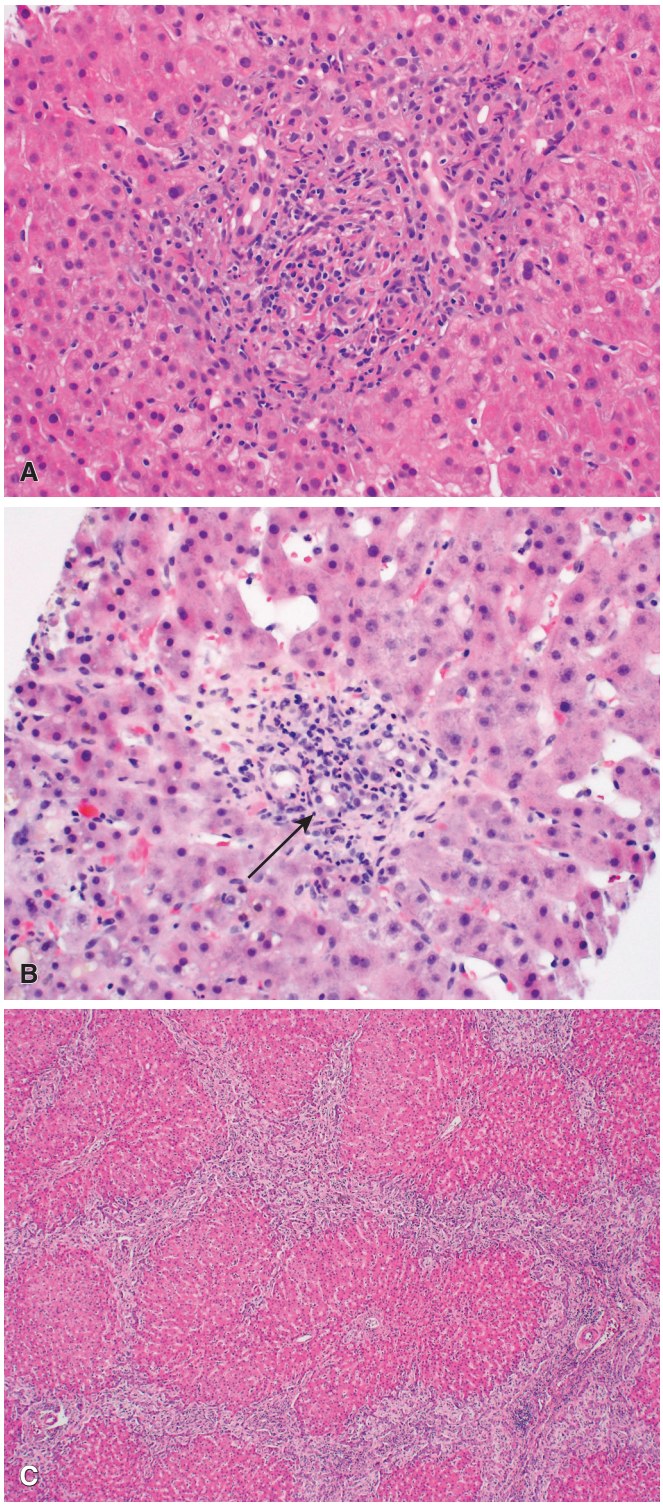

Figure 19.25 **A,** Lymphocytic cholangitis and interlobular bile duct damage associated with Bactrim use. **B,** Neutrophilic cholangitis and interlobular bile duct damage *(arrow)* secondary to the anti-hypertensive lisinopril. This would be difficult to distinguish from large bile duct obstruction. **C,** Vanishing bile duct syndrome leading to biliary cirrhosis and liver transplant secondary to antibiotic administration.

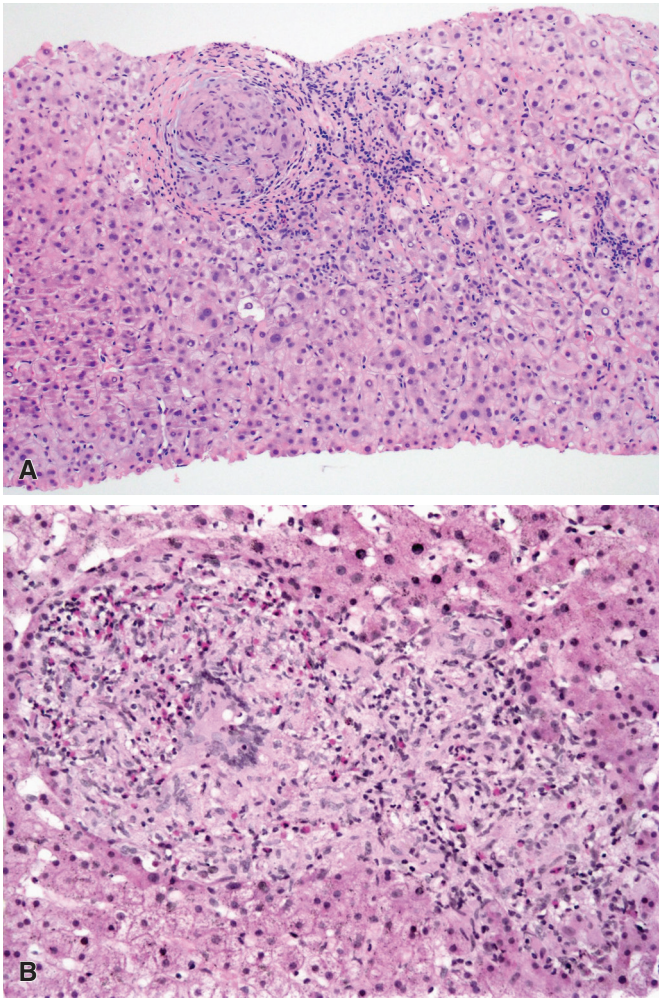

Figure 19.26 **A,** Noncaseating epithelioid granuloma in a portal tract, secondary to allopurinol. **B,** Loosely formed granuloma with numerous associated eosinophils from an adverse reaction to echinacea tea.

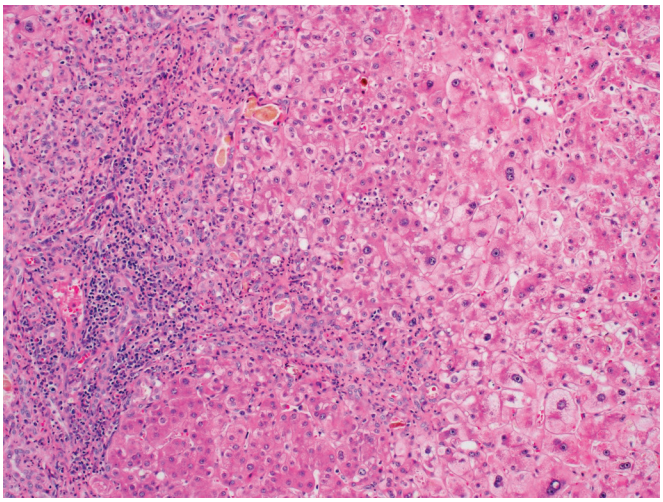

Figure 19.27 TPN-associated injury in an infant featuring ductular and canalicular cholestasis, marked ductular reaction, portal inflammation, and reactive hepatocellular changes.

the association of hepatocyte necrosis with SOS, should also act as an alert for a drug-induced etiology.[297] The final conclusion concerning the diagnosis of drug-induced and toxic liver damage is that it can mimic a wide variety of other liver diseases and thus requires a sustained high degree of suspicion and alertness on the part of both the clinician and the pathologist. An impressive example is the detective story of the Epping jaundice, caused by chemically contaminated daily bread.[345]

Steatosis and Steatohepatitis

Steatosis

Steatosis (fatty liver, fatty change) corresponds to accumulation of triglycerides in the cytoplasm of hepatocytes. It is a frequent finding and represents a manifestation of reversible cell injury.[346,347] Steatosis is a nonspecific lesion induced by a variety of causes. The degree of lipid accumulation is variable, ranging from occasional fat droplets to diffuse deposition involving most parenchymal cells. Histologically, in routinely fixed tissue, steatosis is represented by cytoplasmic vacuoles left behind when lipid is dissolved during processing. Very small droplet steatosis may be difficult to recognize, and thus histochemical staining may be helpful. Lipid can be demonstrated in frozen sections using oil red O or Sudan black, or in tissue that has been postfixed in osmium tetroxide.[348] The clinical presentation of steatosis can include hepatomegaly and elevated levels of serum aminotransferases, alkaline phosphatase, and/or γ-glutamyl transferase (γ-GT).

For a long time, fat droplets in the cytoplasm were considered inert deposits. However, lipid droplets are now regarded as dynamic organelles with neutral lipids as the core, surrounded by a monolayer of amphipathic lipids (phospholipids and cholesterol) and specific proteins (perilipin/ADRP/TIP47 [PAT] proteins and proteins involved in the turnover of lipids and in the formation and trafficking of the droplets). Lipid droplets are formed at microsomal membranes as primordial droplets with a diameter of 0.1–0.4 micron and increase in size by fusion.[349] In mammals, the PAT family of lipid droplet proteins includes perilipin, adipose differentiation–related protein (ADRP), tail-interacting protein of 47 kDa (TIP47), S3–12, and OXPAT. Positioned at the lipid droplet surface, PAT proteins manage access of other proteins (lipases) to the lipid esters within the lipid droplet core and can interact with cellular machinery important for lipid droplet biogenesis. Thus, rather than inert cytoplasmic inclusions, lipid droplets are dynamic organelles that are critical for management of cellular lipid stores.[350,351] The pathogenesis of steatosis is complex, and alterations at many points of the complicated pathway of lipid metabolism can lead to accumulation of neutral fat within hepatocytes. The reader is referred to reviews on this topic.[352–354]

Patterns and distribution. Two morphologic patterns are recognized: macrovesicular and microvesicular steatosis. Both may occur together to some extent in the same biopsy specimen. *Macrovesicular steatosis* (large droplet fatty change, Fig. 19.28) is the most common pattern, in which a single large vacuole distends the hepatocyte and displaces the nucleus to one side. Uncomplicated macrovesicular steatosis used to be regarded as a benign and potentially fully reversible lesion, but this notion has been challenged.[355] Its zonal distribution is variable. It is most often centrilobular but may extend into the mid-zonal areas and eventually the steatosis may become panlobular. Steatosis in periportal zones is more commonly seen in cachexia and protein–energy malnutrition (kwashiorkor), AIDS, after TPN administration, with phosphorus poisoning, and in steroid therapy. There are exceptions to the rule, however, and it is not possible to define the etiology solely on the pattern of lipid distribution in the individual case; identification of the cause requires close clinicopathologic correlation.

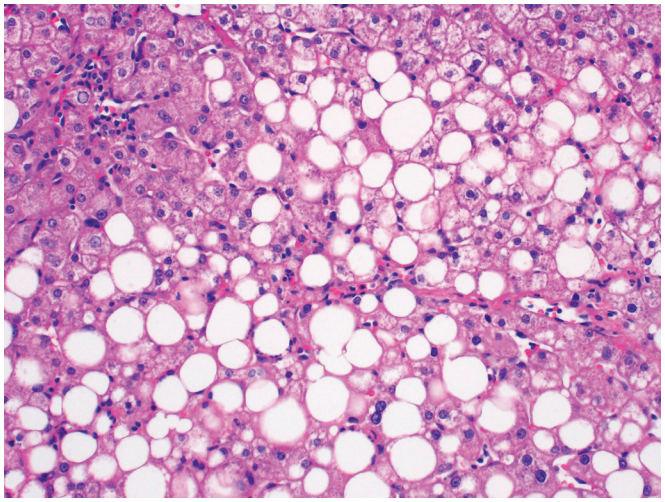

Figure 19.28 Macrovesicular steatosis featuring large droplets of fat.

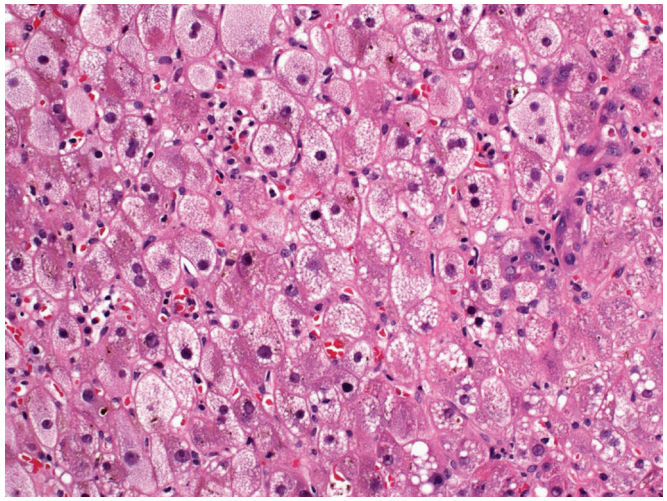

Figure 19.29 **Accumulation of Tiny Lipid Droplets in Microvesicular Steatosis.**

The pathologist should provide information on severity by indicating the approximate amount of parenchyma involved (mild: less than one-third; moderate: one-third to two-thirds; severe: more than two-thirds).[356] Further useful information for the clinician is the finding of a mixed pattern of macro- and microvesicular steatosis because this may be of prognostic importance in relation to alcoholic liver disease.[355] Of note, foci of steatosis may mimic metastatic liver disease radiographically.[357]

Microvesicular steatosis (Fig. 19.29) is often more difficult to recognize, and its demonstration may require histochemistry. Hepatocytes contain many tiny droplets of fat that may even be difficult to identify as such.[347] It is generally a serious lesion associated with impairment of β-oxidation of lipids and frequently accompanied by disturbed liver function and coma.[306] The causes are multiple. The first to be recognized, more than half a century ago, was *AFLP* (see later). *Reye syndrome* (see also earlier) occurs principally, but not exclusively, in young children; it presents clinically with an initial acute, mild viral illness, followed by vomiting, lethargy, and coma, resulting in death in about one-third of patients. The steatosis

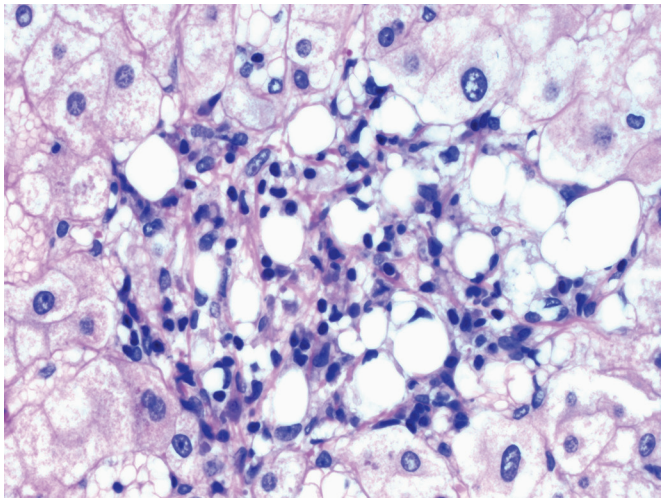

Figure 19.30 Lipogranuloma featuring adipocytes mixed with lymphocytes and macrophages. (Courtesy Dr. Joe Misdraji.)

is usually panlobular, with smaller droplets in centrilobular areas and somewhat larger fat vacuoles in periportal regions. There may be necrosis of periportal hepatocytes. A number of Reye syndrome cases may be attributable to salicylate use.[358] Many patients once thought to have Reye syndrome have been found subsequently to have defects in fatty acid oxidation, a form of *primary mitochondrial hepatopathy*.[359–361] A number of inborn errors of mitochondrial fatty acid β-oxidation and inherited urea cycle disorders have been found to cause microvesicular steatosis.[305,346] Conditions associated with microvesicular steatosis are potentially life threatening, with impairment of liver function and effects on other tissues as well. In the event that the patient survives, there are no long-term effects on the liver.

A number of therapeutic drugs have also been associated with the development of microvesicular steatosis (see earlier). Other causes include alcohol, fulminant hepatitis D in the Amazon basin,[82] and multiple hornet stings.[362]

Lipogranuloma (or fat granuloma) represents a focal response to rupture of lipid-laden hepatocytes. It contains macrophages, occasional lymphocytes, eosinophils, and sometimes giant cells (Fig. 19.30), in addition to adipocytes. Serial sections may be required to identify a central fat globule and to differentiate the lesion from other forms of granuloma.[363] They can be abundant, especially in fatty liver disease and hepatitis C. Lipogranulomas may lead to focal fibrosis without great clinical significance.[364]

Grading and Staging of Steatohepatitis

The understanding of hepatic steatosis has progressed considerably in recent years. Several studies have challenged previous assertions that macrovesicular steatosis is entirely benign,[355] and indicate that fatty liver of either alcoholic or non-alcoholic etiologies can coincide with or lead to necroinflammation and fibrosis. The mere presence of oxidizable fat within the liver appears to be enough to trigger lipid peroxidation in animal studies.[365] Nevertheless, many patients with steatosis never progress to necroinflammation or fibrosis.[355] These observations have led to the "two-hit" hypothesis, which proposes that in addition to steatosis (the first "hit"), the development of steatohepatitis requires the presence of some other factor(s) (second "hit").[366] It is likely that multiple factors together result in accumulation of fat in the liver and cause tissue injury, including insulin resistance, oxidative stress, mitochondrial dysfunction,[367] bacterial (+ endo) toxins, tumor necrosis factor alpha (TNF-α), interleukin (IL)-β, IL-6, low adiponectin levels, high leptin, high resistin, genetic predisposition, and of course factors that are still unknown.[368]

The two most common types of steatohepatitis in the world, by far, are alcoholic steatohepatitis (ASH) and NASH.[347] The pathogenesis and progression of hepatic disease appears to be driven by similar mechanisms in both conditions, although with superimposed toxicities of alcohol and its metabolite acetaldehyde in ASH, in part explaining why a greater proportion of patients with ASH develop cirrhosis and liver-related mortality.[369]

Alcoholic Steatohepatitis

In its early stages, ASH affects predominantly the centrilobular zone and includes a constellation of changes that need not all be present in any individual case. The most essential features are: (1) liver cell injury reflected in ballooning of hepatocytes with or without MDBs and liver cell death by necrosis and/or apoptosis[370]; (2) inflammatory infiltrates composed predominantly, though not exclusively, of neutrophils; and (3) pericellular fibrosis (so-called chicken-wire fibrosis), sometimes accompanied by perivenular fibrosis and phlebosclerosis. The severity of the changes and the extent of lobular involvement may vary considerably and do not necessarily correlate directly with clinical and biochemical data. There have been numerous reviews of the histopathology of ASH over the years, in which it has also been referred to as acute alcoholic hepatitis, acute hepatitis of the alcoholic type, alcoholic steatonecrosis, and fatty liver hepatitis.[371–374]

Ballooning degeneration (Fig. 19.31A and B) is considered a hallmark of steatohepatitis, but enlarged hepatocytes may also be observed in a variety of other acute and chronic liver diseases. It has been reported that keratin 8/18 immunostaining is drastically reduced or lost in the cytoplasm of ballooned hepatocytes in alcoholic and NASH, chronic cholestatic conditions, ischemia/reperfusion injury, and in ballooned hepatocytes in chronic hepatitis C cases with concurrent steatohepatitis. In contrast, substantial decrease or loss of keratin 8/18 immunostaining is not noted in cases of acute hepatitis, giant cell hepatitis, chronic HBV, or autoimmune hepatitis. Therefore, keratin 8/18 immunostaining may serve as an objective marker of a specific type of ballooning degeneration of hepatocytes.[375] Ballooned hepatocytes may contain so-called Mallory bodies (recently renamed "Mallory–Denk bodies"),[376] which are homogeneous, eosinophilic, perinuclear inclusions of variable size and shape (Fig. 19.31C). MDBs are protein aggregates consisting of ubiquitinated K8/K18, chaperones, and sequestosome 1/p62 (p62) as their major constituents. The constant presence of p62 in MDBs suggests that binding of p62 to abnormal keratins may allow hepatocytes to dispose potentially harmful proteins in a biologically inert manner.[377] Genetic contributions help explain why some patients develop MDBs, whereas others are less likely to do so.[378] The pathobiology of these intriguing cell inclusions has been periodically reviewed.[379,380] In florid cases, MDBs are easily discernible in routinely stained sections. In mild disease, they may be small and difficult to identify. Immunostaining of keratins or ubiquitin is helpful. Neutrophil granulocytes often surround and even invade hepatocytes containing MDBs (so-called satellitosis). Macrophages, and lymphocytes may also be found, and cholestasis is variably present.

Steatosis is frequently a feature, although not always, and is usually macrovesicular. As mentioned, a mixed macro- and microvesicular pattern carries a worse prognosis (Fig. 19.32).[355] Still worse is an almost panlobular, predominantly microvesicular steatosis with canalicular bilirubinostasis (so-called alcoholic foamy degeneration).[381] Megamitochondria appear as eosinophilic, PAS–diastase-negative, round, oval, or cigar-shaped inclusions of variable size.

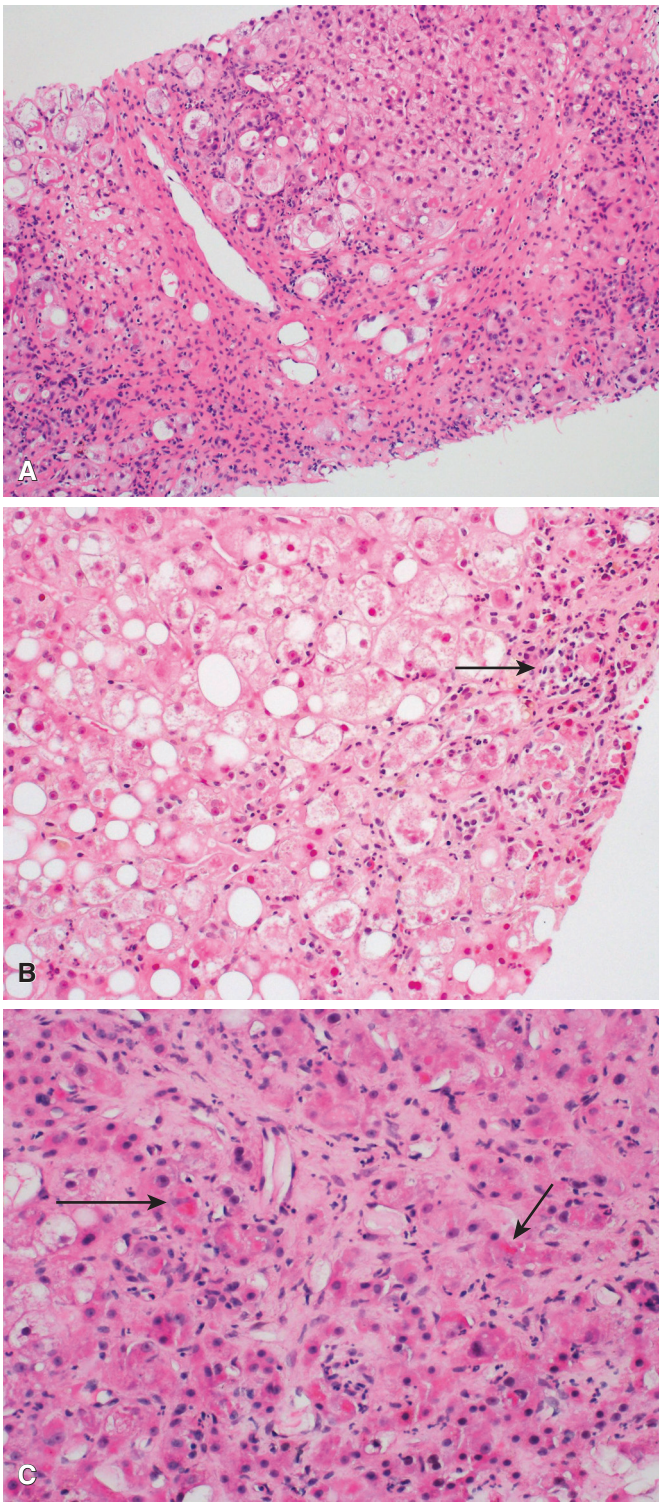

Figure 19.31 **A,** Alcoholic liver disease featuring marked hepatocyte ballooning, a neutrophilic infiltrate, and Mallory–Denk bodies. Steatosis is minimal in this case. **B,** Steatosis with well-developed ballooning and "satellitosis" of neutrophils around apoptotic hepatocytes *(arrow)*. **C,** Higher power view of Mallory–Denk bodies *(arrows)*.

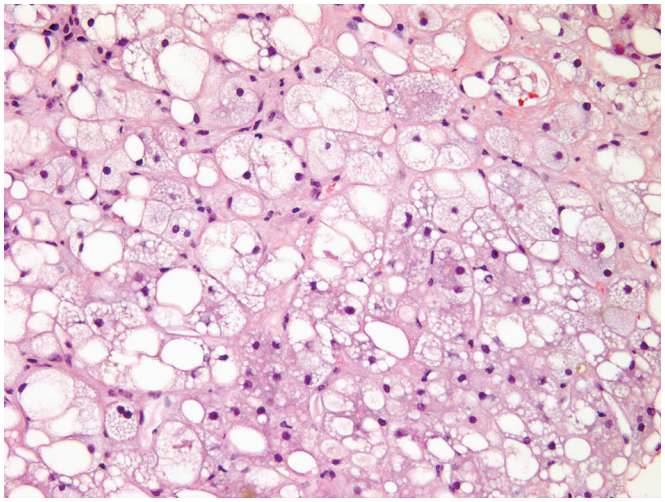

Figure 19.32 **Mixed Macrovesicular and Microvesicular Steatosis.**

They can be better visualized with chromotrope–aniline blue (CAB) stain and immunohistochemistry.[382] They are not specific for alcohol-induced liver disease, but several authors found them more frequently in liver with alcohol-related fibrosis.[383] Oxyphilic granular hepatocytes[384] or oncocytes are another common, though not pathognomonic, cellular component in acute and chronic alcoholic liver disease. Ultrastructurally, they are characterized by an extraordinary number of mitochondria (mitochondriosis).

Fibrosis is a constant feature in ASH, although it appears in different patterns. The most characteristic is pericellular (or perisinusoidal) "chicken-wire" fibrosis, ensheathing hepatocytes (Fig. 19.33A).[385] Its adequate identification usually requires collagen stains. Fibrosis may also involve the central vein, resulting in thickening of its wall (perivenular fibrosis). It has been suggested that this lesion is a marker of future cirrhosis, but others give more prognostic importance to pericellular fibrosis.[386] When pericellular fibrosis is severe and associated with perivenular liver cell necrosis, this pattern is known as sclerosing hyaline necrosis (Fig. 19.33B),[387] and the fibrosis may result in portal hypertension even in the absence of true nodular cirrhosis.[371] In chronic alcoholic liver disease there may also be significant portal tract/septal fibrosis, and in later stages, necrotic bridges and fibrous septa start to link central veins with portal tracts, obscuring lobular topography, which together with parenchymal regeneration, lead to cirrhosis.[388] A semiquantitative scoring system suitable for alcoholic fibrosis has been published.[389]

Cirrhosis of alcoholic origin is typically of the micronodular type (Fig. 19.34). Ongoing superimposed lesions of steatohepatitis worsen the prognosis[390] and suggest the etiology. In their absence, an alcoholic etiology can be suspected (but not proved) on account of the micronodular pattern, pericellular fibrosis, steatosis, and central vein occlusions. When the patient stops alcohol intake, parenchymal regeneration improves, nodules increase in size, and all features of alcoholic etiology may disappear. Patients with established alcoholic cirrhosis have a 5-year cumulative risk of developing hepatocellular carcinoma of approximately 8%.[391]

Several authors have drawn attention to other histologic features in the spectrum of alcoholic liver disease, including veno-occlusive lesions, portal tract inflammation and fibrosis, cholestasis, ductular reaction, and iron overload. Hepatocellular siderosis occurs in some alcoholics and may be confused with genetic hemochromatosis. Difficult cases may be solved by quantitative tissue iron determination

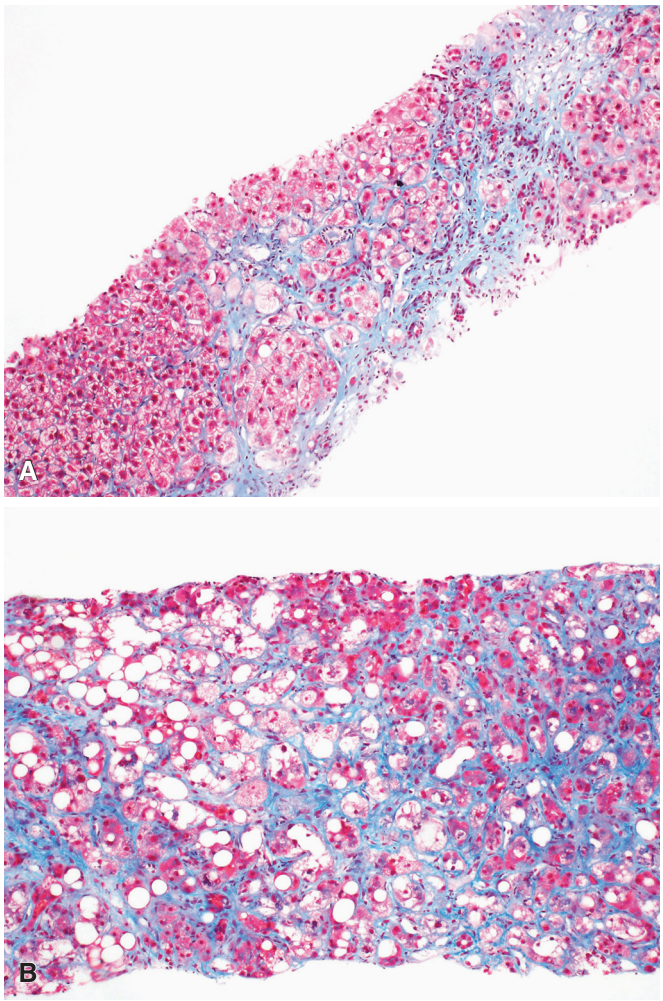

Figure 19.33 **A,** Pericellular or "chicken-wire" fibrosis ensheaths individual hepatocytes and small groups of hepatocytes, many of which show ballooning (Trichrome stain). **B,** Severe pericellular fibrosis in a case of sclerosing hyaline necrosis.

Figure 19.34 A markedly enlarged, pale yellow liver with micronodular cirrhosis from the autopsy of a patient with alcoholic liver disease. (Courtesy Dr. George F. Gray, Jr.)

and calculation of the hepatic iron index (HII).[392] The morphology of alcoholic liver disease can also be significantly affected by abstinence; furthermore, the clinical and morphologic phenotype can be influenced by the presence of comorbid conditions such as NAFLD, viral hepatitis, or hemochromatosis.[371]

Differential diagnosis of ASH. The primary entity in the differential diagnosis is NASH (see later), and this dilemma cannot be solved by histology alone because of the essentially identical histopathology.[393] An incomplete picture of ASH, with only perivenular and pericellular centrilobular fibrosis, may be confused with chronic venous congestion. MDBs, neutrophils, and fibrosis can be seen in diseases unrelated to alcohol, such as amiodarone toxicity and Wilson disease; the latter is a differential diagnosis that should always be considered with alcoholic liver disease, especially in younger patients. MDBs and hepatocyte ballooning are occasionally seen in chronic cholestatic disease, but there is typically a periportal predominance of these changes (rather than a centrilobular distribution). Viral hepatitis is usually suspected clinically, and the liver histopathology is quite different from ASH. Hypervitaminosis A (see earlier) may cause pericellular fibrosis progressing to cirrhosis,[323] and the pathologist should be alert for hepatic stellate cell hyperplasia.

Non-alcoholic liver disease in the alcoholic patient. Patients with a heavy alcohol intake may also suffer from a variety of non-alcoholic liver diseases, such as others cholangitis, viral hepatitis, and passive venous congestion.[394] Alcohol intake may hasten the onset of hepatic and cutaneous manifestations of *PCT*.[395] The hepatocytes contain birefringent acicular cytoplasmic inclusions[396] and usually some degree of siderosis. Chronic alcohol ingestion may also increase the risk of acute DILI, such as acetaminophen-induced centrilobular necrosis.[397] Alcoholic patients undergoing aversion therapy with cyanamide (see earlier) may develop a dramatic form of ground-glass change in periportal hepatocytes, which may lead to cirrhosis.[398] Severe siderosis in the alcoholic patient may be the result of genuine genetic hemochromatosis, which can be confirmed by quantitative iron determination and genotyping. Chronic venous congestion resulting in centrilobular fibrosis can be seen in patients with alcoholic cardiomyopathy.[399]

Chronic alcoholic pancreatitis may lead to stricturing of the common bile duct and cause lesions of extrahepatic bile duct obstruction with or without cholangitis,[400] and some of these patients may develop biliary cirrhosis.[401] An exclusively or predominantly periportal pattern of fibrosis in alcoholic patients should arouse suspicion for some other cause, particularly in the absence of other histologic features of alcoholic liver disease.[402] It should also be remembered that alcoholic hepatitis often coexists with chronic HBV and/or HCV infection.

Non-Alcoholic Steatohepatitis and Non-Alcoholic Fatty Liver Disease

The known causes of NASH are numerous and include jejunoileal bypass surgery, gastroplasty, and other causes of rapid and profound weight loss in obese subjects; TPN; drugs (amiodarone, perhexiline maleate, estrogens and estrogen receptor ligands, methotrexate, retroviral therapy); occupational hepatotoxicity as reported from a petrochemical plant in Brazil[403]; vinyl chloride exposure[404]; copper toxicity; and disorders characterized by insulin resistance. In most cases, the etiopathogenesis of NASH appears multifactorial (obesity, type 2 diabetes, and hypertriglyceridemia) and can be regarded as the hepatic consequence of the metabolic syndrome (also known as cardiovascular dysmetabolic syndrome or syndrome X).[405] The liver pathology was first recognized by H. Thaler in 1962[406–407] and later extensively described (including the histologic components of fatty change, lobular inflammation, and pericellular fibrosis) and termed NASH by Ludwig et al.[408] This study also proposed a subclassification differentiating primary NASH (related to obesity and insulin resistance) from secondary NASH (post bypass surgery, drugs, and toxins).[408] Very soon, however, the term NASH became reserved for the disease associated with the "metabolic syndrome" or "insulin

resistance syndrome," an aggregate of disorders related to obesity, insulin resistance, type 2 diabetes, hypertension, and hyperlipidemia, and related to the emerging epidemic of obesity in the West and in other parts of the world.[409–410] It is estimated that in the United States, NAFLD affects about 20%–30% of adults and 10% of children.[411]

Visceral fat accumulation is more important in the pathogenesis of the metabolic syndrome than general obesity.[412] In human visceral obesity, white adipose tissue is enriched in macrophages. The presence of macrophages in omental white adipose tissue participates in the cellular mechanisms favoring hepatic fibroinflammatory lesions in obese patients.[413] Mildly inflamed adipose tissue functions as an endocrine organ with the capacity to release protein signals, including the adipokines involved in energy and glucose metabolism: leptin, adiponectin, resistin, and visfatin.[414] Visceral fat appears to be directly associated with liver inflammation and fibrosis by itself, independent of insulin resistance and hepatic steatosis.[415] Pessayre and Fromenty suggested that NASH can be considered to some extent to be a mitochondrial disease, since mitochondrial dysfunction is involved at each successive step leading to NASH.[416] Chemokines, cytokines,[417] and innate immune processes, occurring both within and outside the liver, are also involved in insulin resistance and end-organ damage in the form of NAFLD.[418]

The histologic criteria put forth by Ludwig et al.[408] included patterns of injury that are similar to those of ASH. However, the minimal criteria for the diagnosis of NASH were originally controversial.[419–421] The term NAFLD has been proposed as a more inclusive term that incorporates the various grades of severity in the entire spectrum of non-alcoholic steatotic syndromes.[420] The topic was discussed in a review by Brunt, who observed that not all of the lesions of alcoholic liver disease are present in NASH, and conversely, that not all of the lesions of NASH are seen in alcoholic liver disease.[422] Lesions in alcoholic liver disease that have not been seen in NASH include sclerosing hyaline necrosis, veno-occlusive lesions, ductular reaction and cholangiolitis, and acute cholestasis.[410] Further discussion of criteria and terminology resulted in accepted criteria for both mild and more severe NAFLD. The presence of steatosis alone has been considered a rather mild alteration (simple steatosis or non-alcoholic fatty liver [NAFL]); this concept, on second thought, might deserve reconsideration (see also earlier).[423] The condition is less benign when steatosis is associated with portal and/or lobular inflammation and fibrosis, known as NAFLD (Fig. 19.35A and B). The addition of hepatocellular ballooning and Mallory–Denk inclusions results in NASH[410,420,424]; at this point the disease becomes potentially more serious and progressive, even resulting in cirrhosis and/or hepatocellular carcinoma (Fig. 19.36). There appears to be a relationship between the severity and zonal location of steatosis and the presence of the histologic features of NASH; that is, as compared to centrilobular steatosis, panlobular steatosis is more often associated with ballooning, MDBs, and advanced fibrosis.[425]

As in alcoholic liver disease, MDBs can be better visualized by ubiquitin and p62 immunostaining.[426]

Further alterations include microvesicular steatosis, glycogenated nuclei, megamitochondria, and glycogen-rich hepatocytes[410]; the latter resembles the hepatocellular changes described in diabetes-associated glycogenic hepatopathy and must be differentiated from hepatocellular ballooning.[427] It is important to realize that no qualitative histologic differences exist between ASH and NASH that would allow classification of any *individual case* as alcoholic or non-alcoholic in etiology, on the basis of morphology alone.[422] However, when larger groups of patients are compared, NASH is usually associated with more fat and nuclear glycogen, but less hepatocellular damage, inflammation, and fibrosis, and fewer MDBs

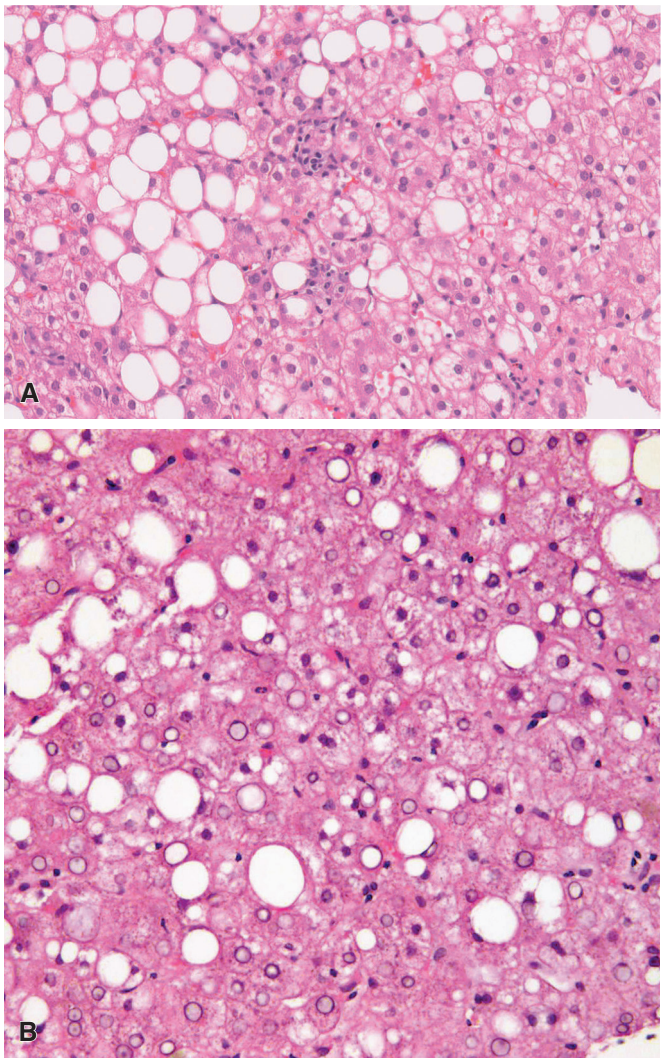

Figure 19.35 Non-alcoholic Fatty Liver Disease. A, Centrilobular area with predominantly macrovesicular steatosis and foci of inflammation. **B,** Higher power view shows numerous glycogenated nuclei, a common finding. (**A,** Courtesy International Liver Pathology Study Group [Gnomes].)

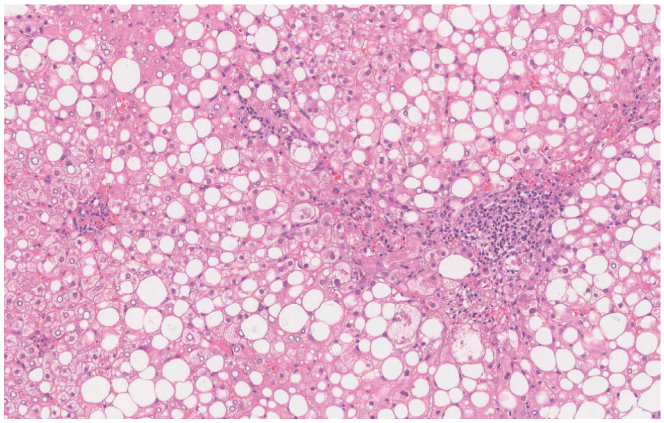

Figure 19.36 Non-Alcoholic Steatohepatitis. Centrilobular parenchyma with steatosis, hepatocellular ballooning, Mallory–Denk bodies, and inflammation. (Courtesy International Liver Pathology Study Group [Gnomes].)

than ASH. However, progression to cirrhosis is definitely possible in patients with NASH.[428,429] Ethnicity also influences metabolic derangements, as well as histology, in NAFLD.[430] One study found that African Americans showed a lower degree of steatosis than whites, but that, in contrast, Asians and Hispanics showed more ballooning and MDBs, respectively, than whites and other ethnicities combined, thus highlighting the need for prospective studies to evaluate ethnic differences in NAFLD.[431]

The diagnosis of NASH is not dependent on a single histopathologic feature but involves assessment of multiple elements. A semiquantitative scoring system for grading and staging the histologic lesions in NASH has been published by Brunt et al.[422,432] The Pathology Committee of the NASH Clinical Research Network designed and validated a histologic scoring system that addresses the full spectrum of lesions of NAFLD and proposed a NAFLD activity score (NAS) for use in clinical trials. The proposed NAS is the unweighted sum of steatosis, lobular inflammation, and hepatocellular ballooning scores. This represents a scoring system and activity index for NAFLD and NASH with reasonable interrater reproducibility that should be useful for studies of both adults and children with any degree of NAFLD. A value of NAS of ≥5 correlates with a diagnosis of NASH.[356] Note that this system is intended for use in clinical trials and not as a tool for diagnosing NASH in routine clinical practice. It always has to be kept in mind that parenchymal injury and fibrosis may vary in different regions of the liver, thus creating the possibility of sampling variability in needle biopsy specimens.[433]

Brunt et al. noted that significant portal mononuclear inflammation is associated with many clinical and pathologic features of progressive NAFLD in both adults and children, and that such infiltrate in liver biopsies of untreated NAFLD may be considered a marker of advanced disease.[434] However, significant portal inflammation may also be a sign of co-existent disease, such as hepatitis C or autoimmune hepatitis.

Portal fibrosis in the absence of other features of NASH, termed isolated portal fibrosis (IPF), has received less attention and has not been classified as a feature of NAFLD. Nevertheless, a significant subset of morbidly obese individuals has portal fibrosis in the absence of features of NASH associated with glycemic dysregulation. It resembles the pattern of NAFLD in the majority of affected children (see later). Therefore, IPF could be considered a part of the spectrum of NAFLD that may precede NASH in morbid obesity.[435]

Periportal and septal fibrosis is a key feature of progressive disease in NASH. Fatty liver impairs hepatocellular regeneration, which triggers a reserve replicative pathway using the bipotential, periportal, hepatic progenitor cells. Activation of this pathway by cell injury in NASH induces a periportal ductular reaction that plays a promoting role in periportal fibrogenesis.[436] When cirrhosis develops, the other histologic features of NASH activity may persist or disappear. In the latter instance, the underlying diagnosis of NASH is often no longer recognizable, and the case falls in the category of cryptogenic cirrhosis. How often this occurs has not been established, but it has been suggested on reasonable grounds that many cases of cryptogenic cirrhosis derive from NASH.[437] When appropriate criteria are used, NAFLD appears to account for close to two-thirds of cases currently labeled as cryptogenic cirrhosis;[438] however, it would be erroneous to assume that all cryptogenic cirrhoses derive from NASH, since cirrhoses from various other etiologies may "burn out" as well.[410] Recurrent fatty liver disease is common following liver transplantation for NASH cirrhosis but does not typically lead to early allograft failure.

Recurrent NASH can occur despite normal liver enzymes, and features of metabolic syndrome are associated with disease recurrence.[439] NASH-related cirrhosis carries a substantial risk for early HCC development. Given the epidemic of obesity and diabetes, the incidence of NASH-related HCC is expected to increase (see also Chapter 20).[440,441]

Histologic evaluation was fundamental to the initial studies that introduced and defined the concept of fatty liver disease, and liver biopsy remains essential in the diagnosis and evaluation of NAFLD and NASH. Currently, liver biopsy in NAFLD serves multiple roles: confirmation (or exclusion) of the diagnosis; distinction of steatohepatitis from "simple steatosis"; assessment of extent of necroinflammatory activity, fibrosis, and architectural alterations[442,443]; and excluding other causes of liver disease, such as viral hepatitis.[444] The histologic severity of liver injury and inflammation is strongly associated with an increased cardiovascular risk and an atherogenic lipid profile.[445] With early biopsy, and early intervention, the ability to prevent advanced liver disease was found to be high,[446] and biopsy may be indicated even in patients with normal alanine transaminase who are suspected to have NAFLD.[447] In view of the huge numbers of patients involved, and the risk, cost, and limitations of liver biopsy, intensive efforts are underway for establishing valuable noninvasive methods for diagnosis in this context.[448]

Given the current worldwide epidemic of pediatric obesity, NAFLD is increasingly diagnosed in children, and NAFLD is now the most common cause of chronic liver disease in children.[449] The rising incidence in children is not restricted to Western populations; epidemiologically, there is a male predominance and frequent Asian and Hispanic ethnicity.[409] It is not exactly identical to NAFLD in adults, perhaps in part because the metabolic derangements of the disease occur during periods of active growth (infancy, mid-childhood, and puberty).[450] The histopathology of pediatric NAFLD and NASH is also reported to be somewhat different from that in adults. Studies noted a minority of what was termed type 1 (similar to classic or adult NAFLD), and predominance of type 2, characterized by more severe steatosis, little or no ballooning degeneration, less lobular inflammation, few or no polymorphonuclear leukocytes, more portal tract inflammation, less zone 3 chicken-wire fibrosis, and more periportal fibrosis, thus making childhood NASH look a bit more like a "chronic hepatitis."[356,451–453] However, a recent multicenter study reported that in the vast majority of the studied patients, overlapping features of both type 1 adult NASH and type 2 pediatric NASH were found and that although portal-based injury is frequently found in children, it is almost universally associated with some elements of the centrilobular pattern identified in adults.[454] Liver biopsy is also required for an adequate evaluation of the severity and pattern of pediatric NAFLD and NASH in children.[455]

It is important to note that the coexistence of NASH and chronic viral hepatitis C causes a mutual synergistic effect in fibrosis progression and evolution to cirrhosis, as discussed earlier. This association may also affect the response to antiviral therapy; patients chronically infected with HCV genotypes 2 and 3, and with insulin resistance, were six times more likely to achieve sustained viral response if their insulin resistance was mild (Homeostasis Model Assessment of Insulin Resistance [HOMA-IR] <2) than those with more severe insulin resistance (HOMA-IR >2).[456]

It has been suggested that,[215] given that NASH is a negative term (*non*-alcoholic) for a condition that is caused by many different etiologies (viruses, metabolic syndrome and/or obesity, drugs, rapid weight loss, inherited metabolic disease), that a positive nomenclature would be more informative. Some have advocated discarding the acronym NASH, and making diagnoses according to etiology, such as viral-associated steatohepatitis (VASH, e.g., in HCV genotype 3), drug-associated steatohepatitis (DASH), alcohol-associated steatohepatitis (AASH), metabolic-associated steatohepatitis (MASH), and perhaps—why not?—CASH (cryptogenic-associated steatohepatitis).[457] But nomenclature is tough to change!

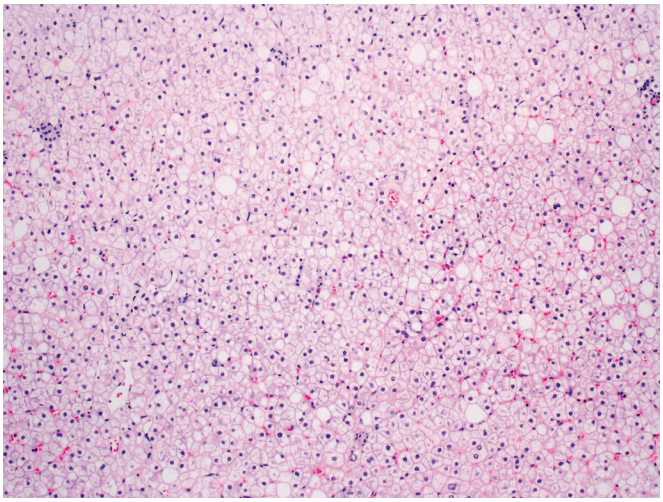

Figure 19.37 Glycogenic hepatopathy featuring enlarged, markedly pale, swollen hepatocytes due to glycogen accumulation.

Fatty liver disease may also act synergistically with other chronic liver diseases to aggravate parenchymal injury. There is evidence that steatosis and its metabolic abnormalities also exacerbate alcoholic liver disease, hemochromatosis, and, possibly, drug-induced liver disease.[458]

Glycogenic Hepatopathy and Other Features of Diabetes Mellitus in the Liver

As discussed previously, a major cause of hepatomegaly in patients with diabetes is steatosis. In both adults and children with type 1 diabetes mellitus, hepatomegaly and abnormalities of liver enzymes also occur as a consequence of hepatocellular glycogen accumulation. This is believed to be a function of the body habitus and state of insulin resistance rather than glycemic control. The livers of affected patients are characterized by marked glycogenosis, a pathologic overloading of hepatocytes with glycogen, known as *glycogenic* or *diabetic hepatopathy*.[427] Liver biopsy shows diffusely pale staining hepatocytes on H&E stains (Fig. 19.37), with excessive glycogen accumulation demonstrated by PAS stains. Ultrastructural examination reveals marked glycogen accumulation in the cytoplasm and nuclei.[427] If accompanied by cushingoid features, growth retardation, and delayed puberty, a diagnosis of Mauriac syndrome can be made.[459] The distinction between steatosis and glycogenosis is important: whereas steatosis may progress to fibrosis and cirrhosis, glycogenosis does not, but reflects the need for better diabetic control. Glycogenosis and steatosis cannot be distinguished reliably on ultrasound examination; the histology, however, is definitive.[460] Patients undergoing dietary management of urea cycle defects with diets containing essential amino acids may have similar focal or diffuse glycogen accumulation in hepatocytes which—except for the focality in deposition—resembles that in glycogen storage disease.[461] Glycogenosis was also described in a patient with anorexia nervosa where it was interpreted as an adaptive response to starvation.[462]

Sinusoidal lesions may also be part of the changes seen in the liver in diabetes. Marked sinusoidal fibrosis has been reported secondary to longstanding diabetes mellitus, in the absence of NASH. The patients have evidence of microvascular complications, including retinopathy, nephropathy, and peripheral and autonomic neuropathy. Liver biopsy shows extensive dense perisinusoidal fibrosis, and immunostaining reveals basement membrane components in a perisinusoidal distribution. The term diabetic hepatosclerosis (DHS) has been suggested for this entity, indicating a form of diabetic microangiopathy affecting the liver.[463] Electron microscopy of sinusoids and sinusoidal cells reveals numerous thick collagen bundles in the space of Disse, and increased basement membrane–like material underlying the sinusoidal cell population. Perisinusoidal cells appear active with abundant rough endoplasmic reticulum and thick cellular processes.[464] The prevalence of DHS was 12% in an autopsy series, suggesting that it is not uncommon, but in the majority of patients it was clinically silent[465]; another more restricted study of autopsied diabetic patients revealed DHS in only one case out of 57, associated with nodular glomerulosclerosis and hepatic hyaline arteriolosclerosis.[466]

Cholestasis, Biliary Diseases, and Autoimmune Hepatitis

Cholestatic Liver Disease

The histologic changes in the liver in cholestatic liver diseases can be conceptualized in two ways: (1) features of cholestatic liver diseases in general; and (2) features characteristic of individual cholestatic liver diseases. The former allows the diagnostic histopathologist to distinguish between cholestatic and noncholestatic disorders, whereas the latter serves to differentiate between diseases *within* the group of cholestatic disorders.

The term *cholestasis* refers to an arrest, or at least a marked reduction, in bile secretion and bile flow. It may be caused by a functional secretory disturbance of the hepatic parenchymal cells, and/or by obstruction at any level in the excretory pathways of bile, from the canaliculi to the papilla of Vater.[467] *Intrahepatic cholestasis* refers to those conditions in which the primary lesions are located inside the liver itself; this term thus encompasses diseases of the parenchymal cells and of the intrahepatic bile ducts. Some conditions combine both; for instance, progressive familial intrahepatic cholestasis (PFIC) type 3 involves both a deficit of canalicular phospholipid transport and damage to interlobular ducts.[468] *Extrahepatic cholestasis* occurs when the bile excretory block is located in larger ducts: outside the liver along the extrahepatic bile ducts (e.g., gallstones, bile duct tumors, bile duct strictures) but also in larger hilar intrahepatic ducts. Some cholestatic disorders affect both the intra- and extrahepatic segments of the biliary tree, and hence qualify as combined intra- and extrahepatic cholestatic diseases. Examples are neonatal extrahepatic bile duct atresia and PSC.

The block in bile secretion may be complete or variably incomplete. Complete cholestasis denotes a total arrest of bile secretion, with retention of bile salts and bilirubin, be it functional or obstructive. Incomplete cholestasis usually indicates an incomplete or partial obstruction of the intrahepatic and/or extrahepatic bile ducts, with retention of bile salts but not of bilirubin.

Incomplete intrahepatic cholestasis is mostly due to destructive diseases of intrahepatic bile ducts such as PBC and PSC. Incomplete extrahepatic cholestasis corresponds to incomplete obstruction (narrowing or strictures) of segments of larger bile ducts.

Cholestasis may be acute or chronic. Acute cholestasis is usually complete cholestasis, corresponding to either total functional exocrine secretory failure of the hepatocytes (e.g., drug-induced cholestasis), or complete obstruction of the extrahepatic bile ducts (e.g., impacted gallstone). Chronic cholestasis indicates a cholestatic condition of longer duration (weeks, months, years), which may be complete (e.g., chronic total extrahepatic bile duct obstruction by a carcinoma of the pancreas) or variably incomplete (e.g., PBC, PSC).

Cholestasis and icterus (or jaundice) are not synonymous terms: the distinction must be made between icteric and anicteric conditions of cholestasis. Patients with incomplete cholestasis may remain

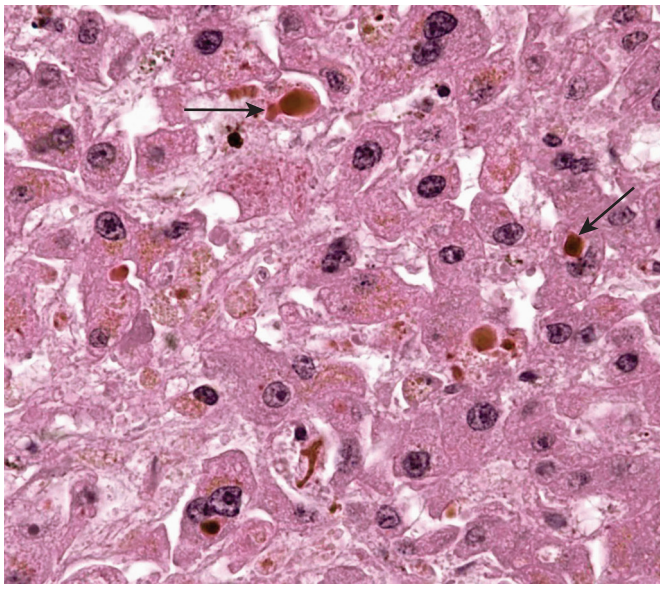

Figure 19.38 Marked bilirubinostasis in hepatocytes and bile canaliculi, leading to bile plugs in the latter *(arrows)*.

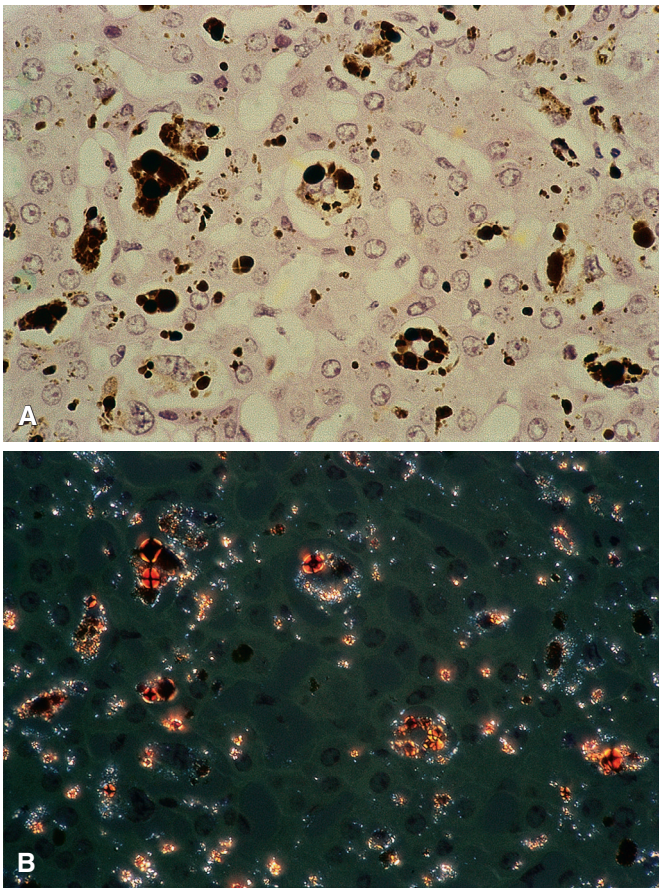

Figure 19.39 Erythropoietic Protoporphyria. A, Dark brownish-black deposits of protoporphyrin in hepatocytes, canaliculi, Kupffer cells, and ductules. **B,** The deposits are birefringent under polarized light, and show a Maltese cross configuration of red birefringence in the larger deposits.

anicteric for long periods. In parallel, histologic cholestasis is not necessarily characterized by the microscopically visible accumulation of the bile pigment bilirubin in liver tissue sections. This underscores the usefulness of distinguishing between *bilirubinostasis* (which many pathologists do, in fact, use interchangeably with the term cholestasis) and *cholate stasis*, or accumulation of bile salts with accompanying characteristic histologic changes. These features may be seen in cholestatic liver diseases either separately or in combination. A comprehensive overview of the pathology of cholestasis was published by Li and Crawford.[469]

Acute complete cholestasis. An acute cholestatic liver disease associated with complete cholestasis is characterized by microscopically demonstrable bilirubin accumulation (Fig. 19.38) which starts in the centrilobular zone; it features pigment granules in parenchymal cells (hepatocellular bilirubinostasis) and inspissated bilirubin-stained bile plugs in dilated intercellular canaliculi (canalicular bilirubinostasis). Retention of detergent bile acids results in hepatocellular damage and even death (necrotic or apoptotic), leading to Kupffer cell activation. The hypertrophic Kupffer cells phagocytose the debris from dying parenchymal cells and the liberated canalicular bile plugs, resulting in Kupffer cell bilirubinostasis. The latter feature indicates a cholestatic condition of at least several days' duration.[470] Acute complete cholestasis, especially in cases of extrahepatic obstructive origin, is further characterized by edema of the portal tract connective tissue, causing some rounding of portal contours, and an incipient ductular reaction (described later).

Bilirubinostasis in its various locations should not be confused with lipofuscin (see earlier), or with the dark brown to black deposits (in hepatocytes, canaliculi, Kupffer cells, and ductules) in liver biopsies from patients with erythropoietic protoporphyria. The latter deposits are darker brown or black and easily identified by the use of polarized light; protoporphyrin deposits have a red to yellow birefringence with a Maltese cross configuration in coarser (ductular) deposits (Fig. 19.39A and B).[471]

Chronic complete cholestasis. The parenchymal changes in complete cholestasis of longer duration include a number of lesions appearing over time and superimposed on the early bilirubinostasis, which gradually extends toward the periportal parenchyma. In most forms of chronic cholestasis lasting for weeks, some lymphocytic inflammatory infiltrate occurs in the areas with bilirubinostasis, apparently secondary to cholestatic changes. Unlike the inflammation in acute hepatitis, this infiltrate is mild and restricted to the area with bilirubinostasis. The parenchymal, portal, and periportal alterations observed in chronic complete cholestasis also occur in chronic incomplete cholestasis, as described in the following section. The basic difference between chronic complete cholestasis and the incomplete variety consists in the absence of bilirubinostasis in the incomplete category and the occasionally more pronounced expression of some of the other lesions in the complete variety.

Chronic incomplete cholestasis. As mentioned previously, bilirubinostasis (as well as clinical jaundice) is not a feature of liver diseases associated with incomplete cholestasis, except in the terminal decompensating phase of the disease or in the case of superimposed pathologic changes (e.g., drug-induced liver damage). Thus, the histopathologist may be required to identify the presence of a chronic cholestatic liver disease in the absence of what used is often regarded as a characteristic feature of cholestasis (bilirubinostasis). The histopathologic diagnosis of chronic (complete as well as incomplete) cholestasis relies on several parenchymal, portal, and periportal alterations. The parenchymal changes include cholate stasis, cholestatic liver cell rosettes, feathery degeneration, xanthomatous cells, and bile infarcts.[110] These alterations occur despite the activation of a series of defense mechanisms on behalf of the parenchymal cells, including repression of bile acid synthesis and induction of basolateral

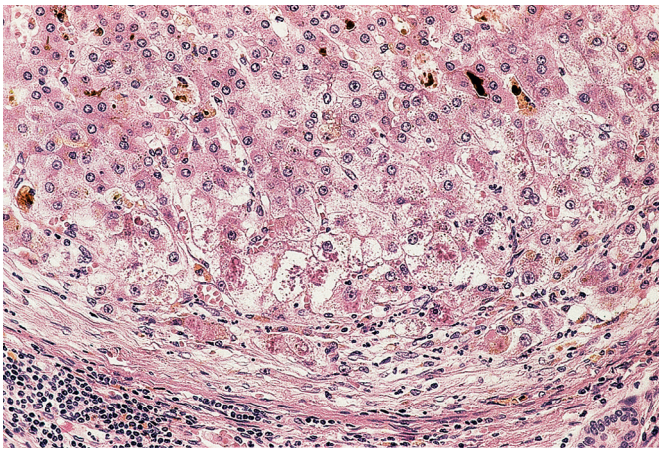

Figure 19.40 Cholate stasis in periphery of parenchymal nodule in cirrhotic liver of patient with end-stage primary sclerosing cholangitis. The hepatocytes near the fibrous septum *(lower part)* show hydropic swelling, clumping of the cytoplasm, and Mallory bodies.

bile acid export by the alternative bile acid efflux pump MRP4 as adaptive mechanisms to limit the bile acid burden in chronic cholestasis. These mechanisms, however, do not sufficiently counteract cholestatic liver damage.[472]

Cholate stasis is thought to be due to the membrane-damaging effect of retained bile acids, and primarily affects periportal hepatocytes.[110] The affected hepatocytes appear swollen, pale, and coarsely granular (Fig. 19.40); they contain granules of lysosomal copper, complexed with copper-binding protein (metallothionein), which are stainable with orcein (metallothionein) and rhodanine (copper) stains (Fig. 19.41A and B). With time, MDBs develop in these cells, and bilirubin inclusions also may appear in the very late stages. The earliest stages of cholate stasis may be revealed by immunostaining for keratin 7, revealing a phenotypic switch to a biliary type of intermediate filament cytoskeleton in periportal hepatocytes (Fig. 19.42). With time, keratin 7 expression extends with a decreasing gradient from the limiting plate toward the center of the lobule, over a distance of several cells.[6]

Cholestatic liver cell rosettes[473] represent a very useful diagnostic feature in any chronic cholestatic condition. They correspond to a tubular rearrangement of the liver cell plates that are normally one cell thick. Under the light microscope, they appear as glandular or tubular structures lined by four or more hepatocytes around a central lumen (Fig. 19.43A and B). The lumen may vary greatly in diameter; it may appear empty, or filled with eosinophilic or bilirubin-stained material in variable degrees of inspissation. Some or all of the lining hepatocytes may show feathery degeneration (see later) and express bile duct–type keratins (keratin 7 and tissue polypeptide antigen [TPA]), indicating a partial shift toward a bile duct cell phenotype.[6,19,474] This should not be misinterpreted as expression of hepatocellular regeneration.

Feathery degeneration is another lesion observed in chronic (incomplete and complete) cholestasis. It affects single cells or groups of parenchymal cells characterized by hydropic swelling. There may be some bilirubin impregnation of the remaining visible cytoplasm in cases of chronic complete cholestasis. *Xanthomatous cells* are a feature of longstanding incomplete and complete cholestasis as well. They are lipid-laden histiocytes with foamy cytoplasm, accumulating in the parenchyma but also in portal tracts, appearing singly or in clusters. They are believed to represent the expression of the hyperlipidemia that accompanies chronic cholestasis.

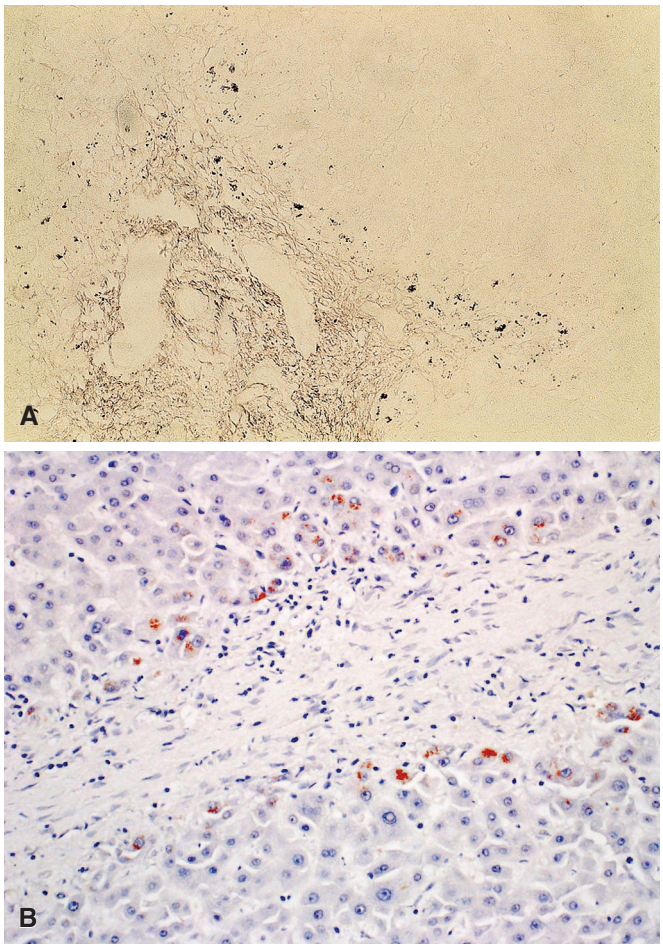

Figure 19.41 **A,** Cholate stasis in chronic cholestatic liver disease. The picture shows orcein-positive granules in periportal hepatocytes, representing lysosomal localization of copper binding protein (metallothionein). **B,** Lysosomal copper–metallothionein complexes appear as red-stained granules in the copper-specific rhodanine stain.

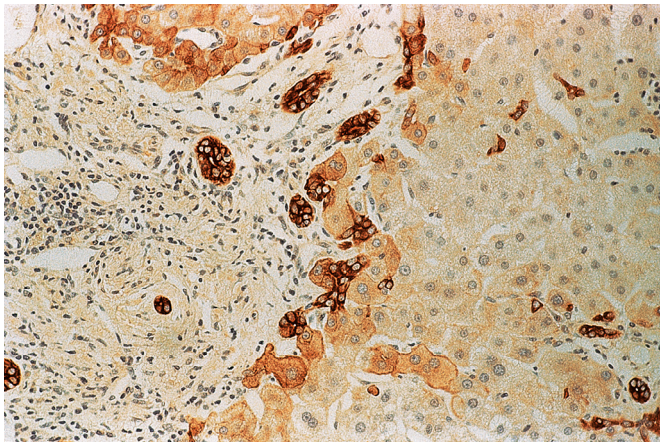

Figure 19.42 Keratin 7 immunostain highlights an increase in the number of ductular structures at the portal tract periphery; expression of keratin 7 in periportal hepatocytes is an indicator of early cholate stasis. A few scattered, small keratin 7 positive cells at some distance from the portal tract are presumed hepatic progenitor cells.

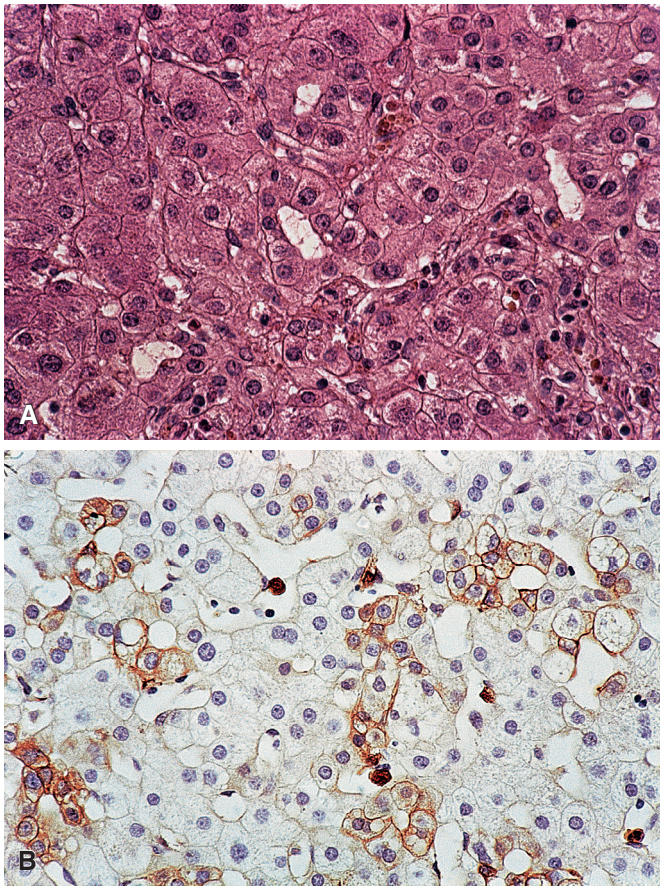

Figure 19.43 Cholestatic Liver Cell Rosettes. A, Liver biopsy of patient with primary sclerosing cholangitis. The involved hepatocytes form small tubules or rosettes. **B,** Immunostaining for keratin 7. Normal hepatocytes do not express keratin 7, whereas cells in cholestatic rosettes express this intermediate filament to variable extent.

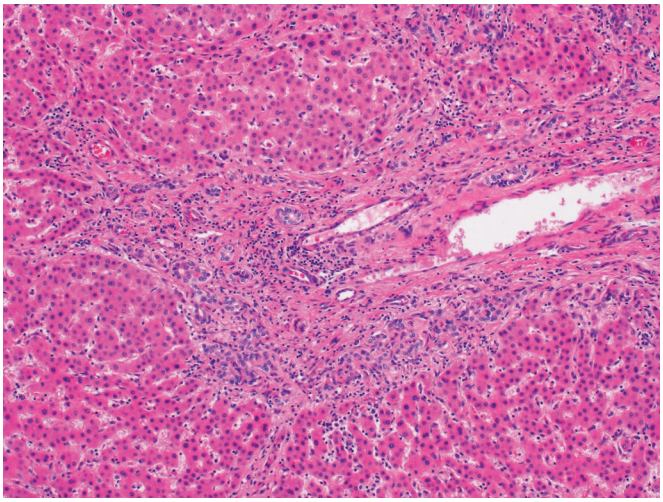

Figure 19.44 Ductular Reaction in Chronic Cholestasis. Liver biopsy from a patient with primary sclerosing cholangitis. The picture shows a mildly inflamed portal tract with ductular reaction at the periphery.

So-called *Charcot–Gombault infarcts* are a late parenchymal lesion in severe cholestasis of long duration, mainly (but not exclusively) seen in large duct obstruction. The lesions consist of necrotic hepatocytes, mostly in a periportal location, sometimes showing bilirubin impregnation of the central necrotic area. Bile infarcts are gradually replaced by organizing mesenchymal tissue, finally resulting in fibrous scars.

Ductular reaction is recognized as an increased number of ductular profiles at the periphery of the portal tract, gradually extending into the periportal parenchyma toward the neighboring portal tracts, and often accompanied by edema and neutrophils (Fig. 19.44).[475] It can be visualized to better extent by keratin 7 or 19 immunostaining.[6] The origin of the increased number of ductules is debated; it is apparently multiple. Ductular reaction in diseases with extrahepatic bile duct obstruction is mainly due to increased bile pressure,[476,477] and involves elongation rather than sprouting of preexisting bile ductules.[477] In other cholestatic diseases, not necessarily obstructive in origin, proinflammatory cytokines may be the predominant triggers.[478] In chronic cholestatic diseases, ductular metaplasia of periportal hepatocytes also plays a role,[474,475] as does activation and proliferation of hepatic progenitor cells.[479] The cholangiocytes lining the ductules may show signs of reabsorption, reflected in vacuolization of their cytoplasm and accumulation of bilirubin and lipofuscin. The wedge-shaped periportal extension of ductular reaction with accompanying inflammation into the periportal parenchyma, which may show features of cholate stasis, results in an irregular portal–parenchymal interface, termed "biliary piecemeal necrosis"[480] or biliary interface activity.[481] For reasons that have not been finally elucidated, chronic states of cholestasis in some patients lack an obvious ductular reaction; this may be the case in Alagille syndrome (AGS), some cases of PSC, and chronic liver allograft rejection.

Ductular reaction may be accompanied by periductular fibrosis, with a significant correlation between the progression rates of fibrosis and of the ductular reaction. The fibrosis is produced by myofibroblasts that derive from portal/periportal mesenchymal cells.[482] However, several recent studies equally emphasize contributions from cholangiocyte–mesenchymal transition.[483,484] Relief of bile duct obstruction or cessation of the cause of cholestasis results in the disappearance of bile duct hyperplasia by apoptosis of cholangiocytes accompanied by a similarly rapid loss of the mesenchymal cells.[485,486] Ductular reaction may be the only histologic change in some biopsies (termed isolated ductular hyperplasia). This has been found in 10% of adults biopsied for persistent mild liver function test abnormalities unrelated to viral hepatitis. The picture consists of well-differentiated hyperplastic ductules in the absence of significant inflammation. It is thought to represent a nonspecific reaction pattern to mild liver damage.[487]

When progressive, ductular reaction with periductular fibrosis eventually results in fibrous linkage of adjacent portal tracts. This stage of *biliary fibrosis* (portal–portal septal fibrosis) is a potentially reversible lesion[488] since the basic angioarchitectural pattern of the liver is preserved.[489] Biliary fibrosis may progress to true *biliary cirrhosis*, which represents the final stage in disturbance of the lobular architecture, characterized—like any cirrhosis—by additional portal–central fibrous septa and nodular parenchymal regeneration. Persistent disease at the point of biliary cirrhosis is characterized by persistence of ductular reaction with accompanying edema and periductular inflammation and fibrosis. Together with lesions of cholate stasis in the nodular periphery, this creates at low magnification the impression of a clear "halo" between the cirrhotic nodules and the fibrous septa. Several staging schemes exist for chronic biliary disease, based on histologic features including interlobular bile duct damage, ductular reaction, and progressive biliary fibrosis. Historically, the stages have been defined as portal (stage 1), periportal (stage 2), septal (stage 3), and cirrhotic (stage 4).[490,491] New staging systems

have been proposed more recently, which take inflammatory activity into consideration as well as fibrosis and other features of chronic cholestasis.[492]

In addition to the general features of cholestasis discussed previously, two other changes that often characterize the histologic picture in neonatal cholestatic liver diseases should be mentioned. *Multinucleated giant cells* result from syncytial fusion of several mononucleated hepatocytes. The number of nuclei and their location are variable. Giant cells often contain pigment granules corresponding to bilirubin, lipofuscin, hemosiderin, or a combination thereof. They may appear necrotic and be surrounded by neutrophils. Giant cell transformation of parenchymal cells occurs in a variety of conditions; they are considered a nonspecific reaction of the infant's hepatocytes to various types of injury and appear to be more specific for age than disease. They are occasionally observed in adult liver as well.[493] Foci of *extramedullary hematopoiesis*, consisting of clusters of erythrocyte precursor cells, myeloid precursor cells, and megakaryocytes, or a combination of these, are often observed in cholestatic liver specimens of young infants as well.[493] They are not a reliable criterion for differentiation between various cholestatic diseases such as BA and neonatal hepatitis.

Individual cholestatic liver diseases. Cholestatic liver diseases can be subdivided in several different ways: intrahepatic versus extrahepatic; medical versus surgical; neonatal versus adult, etc. In the following section, an attempt is made to classify the disorders according to the primary focus of the disease along the pathways through which bile has to travel from its source in the hepatocytes to its destination in the gut.

It is realized that such a categorization is imperfect: first, because the etiology and pathogenesis of several major cholestatic liver diseases remain incompletely clarified; and second, because some disorders involve two or more sites simultaneously.

Hepatocellular (parenchymal) diseases. For this group of disorders, it is useful to consider the serum levels and hepatic expression of the enzyme γ-GT. In most cholestatic conditions, serum γ-GT is increased. This is due to the fact that γ-GT, an enzyme normally inserted in the canalicular membrane of hepatocytes, is eluted from this membrane by the detergent action of bile salts after their export in the canaliculi, explaining the presence of γ-GT in bile. In cholestasis, bile (along with γ-GT) regurgitates through the canalicular tight junctions that have become leaky in these conditions. Thus, increased serum levels of γ-GT in cholestatic liver disease requires the presence of canalicular expression of γ-GT, its elution by bile salts, and regurgitation through leaky tight junctions.

Some cholestatic diseases, however, are characterized by a normal serum level of γ-GT or a serum activity of the enzyme that is unusually low for the degree of cholestasis ("low γ-GT cholestasis"). Cholestasis with (near-) normal serum γ-GT occurs in these circumstances[494–496]:

1. When γ-GT cannot insert in the membrane due to inadequate phospholipid asymmetry in the membrane caused by *ATP8B1* (previously *FIC-1*) mutation, and hence cannot be eluted from the membrane (e.g., progressive familial intrahepatic cholestasis [PFIC] type 1; benign recurrent intrahepatic cholestasis [BRIC] type 1).
2. When the bile salt export pump (BSEP) is absent from the membrane, due to *BSEP* mutation, and hence no bile salts are secreted (e.g., PFIC type 2; BRIC type 2).
3. When no appropriate normal bile salts are synthesized, and hence no bile salt secretion occurs through canalicular membranes (metabolic disorders of bile salt synthesis defects).

These primarily pediatric disorders are discussed in detail later. Several *acquired* cholestatic disorders are also characterized by predominantly parenchymal/hepatocellular features, including intrahepatic cholestasis of pregnancy (ICP; see later) and some forms of postoperative cholestasis,[497] as well as acute viral hepatitis, ASH, and drug-induced liver disease (see earlier).

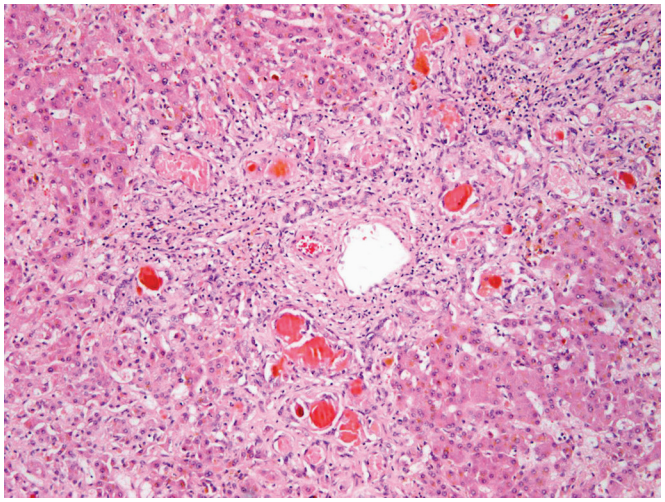

Figure 19.45 Ductular bilirubinostasis featuring markedly dilated ductules filled with bile concrements.

Ductular pathology. In some cholestatic disorders, the disease appears to focus on the ductules and canals of Hering. Most of these conditions are characterized by ductular reaction and ductular bilirubinostasis; the latter is represented by smaller or larger bilirubin-impregnated deposits or concrements in more or less dilated ductular segments (Fig. 19.45). Ductular bilirubinostasis occurs in diverse situations and is thought to result from damage to ductular cells with total paralysis or partial impairment of their normal secretion of bicarbonate-rich fluid. Ductular bilirubinostasis is observed in patients with massive liver cell necrosis[52]; in septicemia and endotoxic shock (see also later) [498,499]; in extrahepatic BA[500]; in TPN[343]; and in some patients with mucoviscidosis (cystic fibrosis [CF]).[501] In extrahepatic bile duct atresia, the ductular bilirubin deposits often appear as a string of pearls in a series of ductular dilations. TPN-associated liver injury is discussed in detail earlier; CF and extrahepatic BA are discussed later with pediatric liver diseases.

Ductal pathology and vanishing bile duct diseases. A number of cholestatic liver diseases are associated with progressive inflammatory destruction of intrahepatic bile ducts of a particular caliber. These may be classified as ductopenic or vanishing bile duct disorders and represent a vast and intriguing chapter in liver pathology (Box 19.1). They all result in reduction of the number of interlobular bile ducts, also termed paucity of ducts or ductopenia.[502] Vanishing bile duct diseases in the neonatal period and childhood include paucity of interlobular bile ducts (PILBD), both syndromic and nonsyndromic, and/or BA, which are discussed in detail in the section on pediatric liver disease.

A sound morphologic diagnosis of ductopenia requires a sufficiently large biopsy specimen to allow quantitative evaluation of interlobular ducts. Although historically a surgical biopsy was recommended,[503] a needle biopsy may certainly suffice provided that the specimen contains at least five portal tracts.[4,504] Recognition of a missing duct is facilitated by comparing with branches of the hepatic artery. As 70%–80% of arterial branches are normally accompanied by a duct of approximately similar size near the center of the portal tract, a "widowed" or unpaired artery signals a missing duct.[504,505] Immunostains for keratin 7 (or 19) or TPA are helpful for better visualization of interlobular ducts,[6] especially in very young children.[506]

Paucity of interlobular ducts (or ductopenia) was originally defined as a ratio of the number of interlobular ducts to the number of portal tracts of less than 0.5. In normal children and adults this

Box 19.1 Vanishing bile duct diseases

Neonatal

Extrahepatic bile duct atresia or BA
Paucity of interlobular bile ducts
Syndromic (AGS)
Nonsyndromic

Adult

PBC
Overlap syndrome autoimmune hepatitis—PBC
PSC and variants
Overlap syndrome autoimmune hepatitis—PSC
Sarcoidosis with intrahepatic cholestasis
Idiopathic adulthood ductopenia
Chronic liver allograft rejection
Chronic graft-versus-host disease
Drug-induced ductopenia
Histiocytosis X
Hodgkin lymphoma
Mucoviscidosis

AGS, Alagille syndrome; *BA*, biliary atresia; *PBC*, primary biliary cirrhosis; *PSC*, primary sclerosing cholangitis.

ratio lies between 0.9 and 1.8.[503] This definition of ductopenia as a ratio of 0.5 or less was valid at the time of its definition in neonatal disease, but since 1975 evidence has accumulated that ductopenia in general is not a static condition but reflects a progressive destruction of interlobular ducts. It follows that a reduced bile duct to portal tract ratio higher than 0.5 (i.e., a less pronounced degree of ductopenia) can still be considered "ductopenia," especially when damaged or inflamed ducts are also observed.[507]

The histopathology in ductopenic diseases is mainly that of chronic incomplete cholestasis, with variably present features specific for an individual disease. One has to keep in mind, however, that such features are not consistently present in every biopsy specimen and may not persist throughout the entire course of the disease; in addition, the specificity of the histopathology may decrease with advancing disease and progression toward cirrhosis.

Primary Biliary Cirrhosis

PBC is considered an autoimmune disease, often associated with other autoimmune disorders.[508,509] The pathogenesis is complex, involving genetic predisposition as well as environmental factors, which remain incompletely understood.[510] The basic lesion is a chronic, nonsuppurative, destructive cholangitis, eventually ending in cirrhosis.[511] The disease is nearly 10 times more frequent in females than in males and usually has an insidious onset starting with pruritus. Characteristic of PBC is the presence of antimitochondrial antibodies (AMAs), the most specific being directed against the M2 component of the pyruvate dehydrogenase complex, detectable in over 90% of patients.[512] Liver biopsy plays an important role in the diagnosis and staging of PBC.[513,514]

The bile duct lesion in the early stage of PBC initially affects ducts ranging from less than 40 to more than 80 μm in external diameter, destroying the smaller ducts first.[515] Septal ducts are affected to a lesser degree.[505] Canals of Hering are also destroyed in PBC in concert with the destruction of small bile ducts; this destruction appears to be an early event.[516] The actual size of the ducts may on occasion be difficult to estimate since some of them tend to enlarge, apparently through damage to the basement membrane and reactive hyperplasia of the lining epithelium.[517] The early lesions are focal in the liver and segmental within the duct system. The affected duct

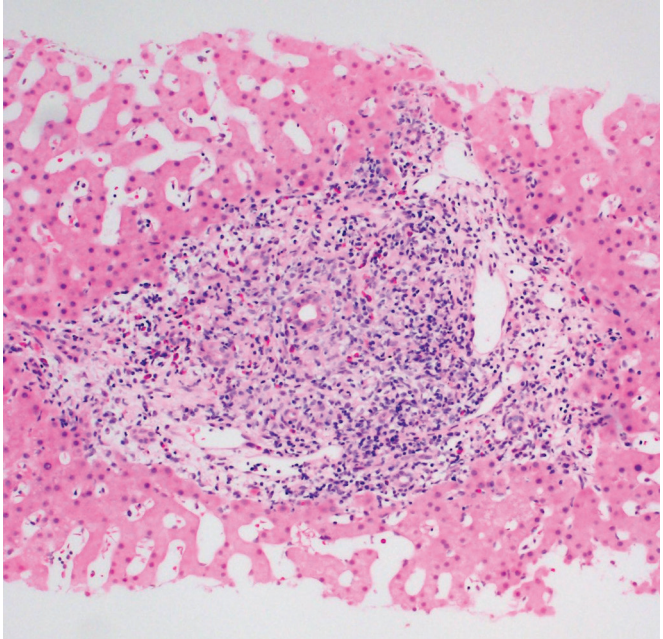

Figure 19.46 A portal tract in primary biliary cirrhosis contains a nodular mixed inflammatory infiltrate consisting of lymphocytes, plasma cells, numerous eosinophils, and histiocytes. There is a damaged bile duct in the center of the portal tract.

segments show epithelial swelling and cytoplasmic vacuolization, nuclear disarray, and infiltration by lymphocytes and plasma cells, which may accumulate beside or around the duct. The inflammatory infiltrate is predominantly lymphocytic and sometimes forms lymphoid follicles with a germinal center. Plasma cells may be abundant, eosinophils quite prominent, and neutrophils may also be present (Fig. 19.46). Plasma cells in the portal tracts are predominantly IgM+, whereas in autoimmune hepatitis, plasma cells are predominately IgG+; therefore, immunostaining for IgM and IgG can be helpful in differentiating PBC from AIH.[518,519] An Italian study reported that the mean counts of IgM plasma cells in portal tracts correlated significantly with female gender; serum alkaline phosphatase, γ-GT and IgM values; positivity for AMA M2, and, on liver biopsy, with bile duct changes, orcein-positive granules, and granulomas. In contrast, IgG plasma cell mean counts correlated more with alanine aminotransferase levels. IgG/IgM ratios lower than 1 were found not only in PBC but also in all cases of autoimmune cholangitis. In contrast, all patients with overlap syndrome showed IgG/IgM ratios higher than 1.[520]

Single or small clusters of epithelioid cells may be present, and in some cases epithelioid granulomas develop close to or surrounding the bile duct. The florid bile duct lesion in PBC can thus be categorized as lymphocytic, pleomorphic, or granulomatous cholangitis (Fig. 19.47), the latter being the most diagnostic.[480] Smaller ducts may be surrounded by edema or fibrosis, presumably as a result of more distal obstruction, and damage of the basement membrane (often most visible with PAS/diastase stain) may lead to rupture of the duct. Parenchymal lesions of chronic cholestasis are absent or minimal at the early stage.

Sampling variability means that not every liver biopsy from a patient with PBC in this stage reveals the characteristic bile duct lesions, making a firm histologic diagnosis challenging. The presence of periportal copper deposition may be extremely helpful.[521]

The majority of patients show histologic progression within 2 years; a minority (20%) remain histologically stable, whereas sustained

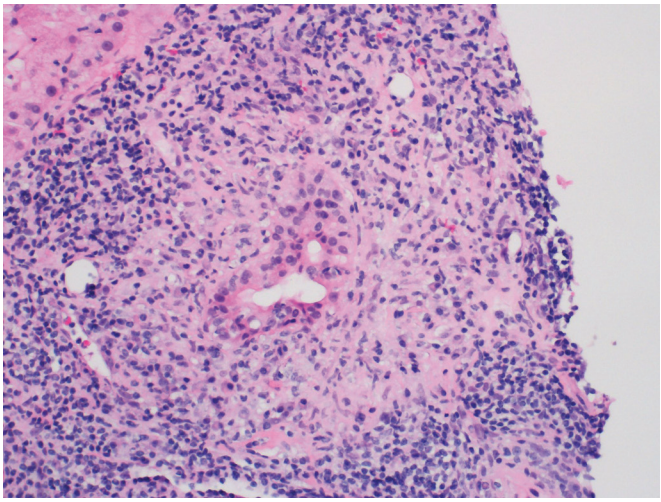

Figure 19.47 Florid Duct Lesion in Primary Biliary Cirrhosis. A loose portal granuloma with admixed lymphocytes and plasma cells is centered on a damaged duct that is infiltrated by lymphocytes and shows marked epithelial disarray.

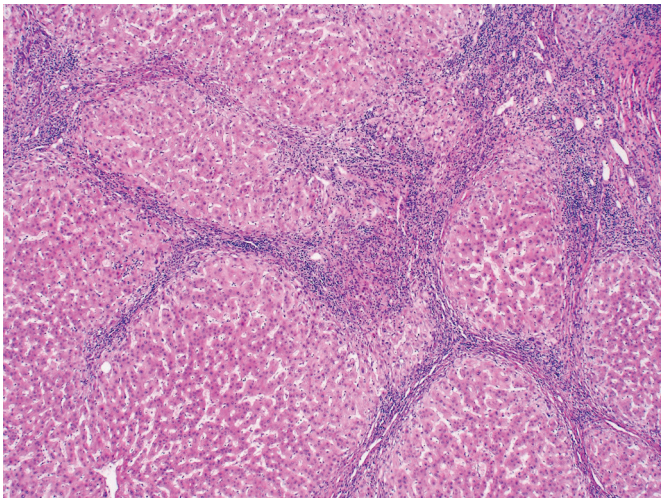

Figure 19.48 Biliary-type cirrhosis in primary biliary cirrhosis, featuring irregular cirrhotic nodules, lymphocytic interface hepatitis, and ductopenia.

regression is rare (2%).[522] Basically, two processes appear to drive histologic progression: the periportal and architectural changes associated with chronic cholestasis (see earlier), and lymphocytic interface hepatitis (piecemeal necrosis).[492,523] As in chronic hepatitis, the intralobular "invading" lymphocytes of interface hepatitis play a role in the development of septal fibrosis,[524] and some degree of lobular necroinflammatory activity may be present as well.[525] However, prominent interface activity and lobular inflammation should raise the question of an overlap syndrome (see later). Histologic stage and severity of lymphocytic interface hepatitis are independent predictive factors for the development of cirrhosis in ursodeoxycholic acid (UDCA)-treated patients with PBC, which suggests that liver biopsy may be necessary to follow UDCA-treated patients who might require additional therapy.[526,527]

Ultimately, progressive ductopenia develops, and in advanced cases, portal lymphoid aggregates mark the former site of bile ducts that have disappeared. Telomere shortening and accumulation of DNA damage coincide with increased expression of p16(INK4a) and p21(WAF1/Cip1) in the damaged bile ducts, reflecting ongoing biliary cellular senescence, and play a role in subsequent progressive bile duct loss in PBC.[528]

The combination of cholestatic and hepatitic features results in progressive fibrosis with portal–portal septum formation, followed by additional portal–central septa.[524] When cholestatic features predominate, the eventual resulting cirrhosis is of the biliary type (Fig. 19.48), whereas in cases with predominance of hepatitic features, the cirrhosis may be macronodular; any combination of the two patterns can also occur. The hepatitic-type lesions appear to be the most important for the progression of fibrosis.[492,529] One study suggested that aberrant expression of keratin 7 in hepatocytes (see earlier) may be a marker for the degree of cholestasis and for progression in PBC,[530] expressing the failure of adaptive mechanisms against bile acid overload.[472]

Several staging systems have been proposed for PBC.[490,491] The most popular staging system, which is applicable to any vanishing bile duct disease, is that of Ludwig et al.,[490] which distinguishes four stages: portal (stage 1); periportal (stage 2); septal fibrosis (stage 3); and cirrhosis (stage 4). Staging of PBC in small needle biopsy specimens is valuable as long as it is interpreted with caution, bearing in mind that there is considerable variability in the degree of fibrosis in different parts of the liver.[531] As mentioned previously, new staging systems have been proposed more recently, some of which aim to provide more correlation with clinical laboratory data,[532] and some of which take inflammatory activity into consideration as well as fibrosis and other features of chronic cholestasis.[492,532]

Liver cell dysplasia of the large and small cell type may be present,[533] and the risk for development of hepatocellular carcinoma is also increased in PBC, particularly in patients with cirrhosis.[534–536] Nodular regenerative hyperplasia has also been described in association with PBC[537]; together with narrowing of portal vein branches,[538] this may explain the development of portal hypertension in some patients even before the development of fibrosis and cirrhosis.

The differential diagnosis of PBC requires consideration of two groups of diseases. Early-stage PBC must be distinguished from other diseases characterized by portal inflammation and bile duct damage, such as chronic hepatitis C, and later stage PBC must be differentiated from other chronic ductopenic diseases.

In the bile duct lesion in viral hepatitis C, the affected duct segment shows vacuolization and stratification of cholangiocytes, with less marked duct damage and preservation of the basement membrane.[204] Cholestatic features are absent as well. Although focal lymphocytic cholangitis and mild bile duct damage is occasionally seen in autoimmune hepatitis, significant duct damage and copper deposition are not, and the degree of inflammatory activity is typically much less in PBC than autoimmune hepatitis. As mentioned previously, immunohistochemistry for IgM and IgG may also be helpful. Drug-induced bile duct damage is also in the differential diagnosis, and clinical history and a positive AMA may be invaluable in this circumstance. Other conditions characterized by bile duct damage and granulomas include sarcoidosis and granulomatous infections. The latter may cause real problems of differentiation, as it also may lead to ductopenia and chronic cholestatic liver disease (see later); the final diagnosis requires consideration of the clinical context and laboratory data.

Autoimmune cholangitis[539] or *autoimmune cholangiopathy*[540] is clinically, biochemically, and histologically very similar to PBC, but AMAs are negative, hence the alternative term AMA-negative PBC.[541,542] Clinically and histologically there are no discernable differences, although the diagnostic threshold tends to be higher, and the treatment and prognosis mirror that of classic PBC.

Primary Sclerosing Cholangitis

PSC is a rare but important liver disease that leads to cirrhosis and the need for liver transplantation in a high proportion of cases.[543] The disease occurs in approximately 1 per 100,000 people per year and usually presents in adulthood but does occur—albeit rarely—in children; men are affected more often than women. The natural history of PSC is variable, the average survival being 12–17 years. The cause remains unknown, although a number of genetic associations have been identified, many of which overlap with those found in other autoimmune diseases.[543] Other hypotheses include ischemic injury ("arteriosclerosis of the bile duct") initiated by toxic biliary lipids,[544] and alterations in the gut microbial composition.[543] Many patients (approximately 70%) with PSC suffer from inflammatory bowel disease as well, often a distinct phenotype that most resembles ulcerative colitis but has a higher incidence of pancolitis, backwash ileitis, and rectal sparing.[545] It has also been hypothesized that aberrant expression of endothelial adhesion molecules, cytokines, and chemokines secondary to colitis may contribute to the development of PSC.[543]

PSC is characterized by inflammation, strictures, and saccular dilations in the biliary system; any part of the biliary tree may be involved. The majority of PSC patients have involvement of both large and small ducts. "Small duct PSC" corresponds to involvement of only the microscopically identifiable (septal and interlobular) intrahepatic bile ducts, previously classified by the now obsolete term "pericholangitis."[546] A high prevalence of small duct PSC is found among patients with overlapping features of AIH and PSC.[547] Cholangiography and microscopic examination of a liver biopsy are complementary investigations in PSC, with primary importance given to cholangiography.

The histopathologic changes in the liver biopsy of patients with PSC depend on the stage of the disease and on the site of the biopsy in relation to the duct lesions caused by the disease. In portal tracts proximal to strictures, only features of obstruction and cholangitis may be seen.

Portal tracts affected by the primary disease may show pleomorphic and fibro-obliterative cholangitis,[480] the characteristic lesion of PSC, occasionally characterized by onion-skin type periductal fibrosis (Fig. 19.49A and B) with degeneration and atrophy of the epithelial lining. Chronic portal inflammation is variably present. This results in disappearance of the duct and its eventual replacement by a fibrous scar. Occasionally, however, biopsies show only duct atrophy with associated ductular reaction (Fig. 19.50). Loss of ducts is more frequent in smaller portal tracts, whereas periductal fibrosis is more often seen in medium-sized tracts.[548] Periductal fibrosis is not a pathognomonic lesion, as it can also be observed in other types of biliary disease, but it is a very suggestive and helpful finding. It is important to recognize, however, that it is not present in every stage of the disease or in all cases and is found in fewer than 40% of biopsy specimens.[480] PAS–diastase staining may reveal thickening of the basement membrane around damaged ducts (Fig. 19.51), or wrinkled empty basement membranes.[549] In some patients, the scars of the vanished bile ducts are unusually prominent, resembling keloid scars.[550,551] The parenchymal changes in PSC are less striking than the portal ones, and correspond to features of chronic cholestasis when present, including periportal copper deposition.

In patients with longstanding and more severe disease, portal fibrosis is more marked, fibrous septa develop, and biliary cirrhosis ensues. More progressive disease is characterized by moderate to severe lymphocytic interface hepatitis.[552]

The most dreaded complication of PSC is cholangiocarcinoma.[553] Patients with PSC and inflammatory bowel disease also have a high long-term risk of developing colorectal carcinoma, however, and

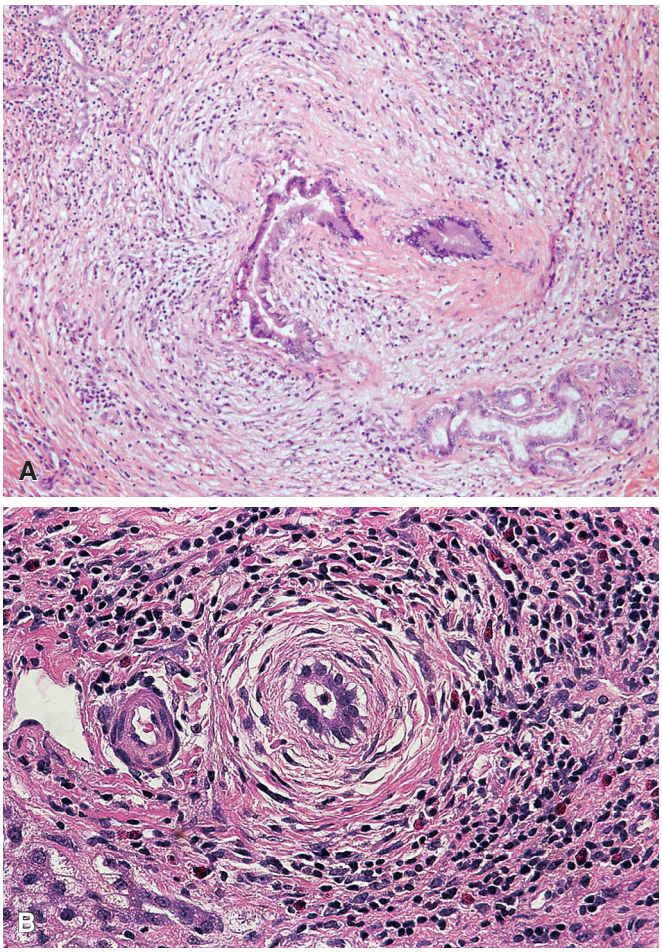

Figure 19.49 **A,** Primary sclerosing cholangitis showing a damaged bile duct with surrounding edema, concentric fibrosis, and lymphoplasmacytic inflammation. **B,** Detail of portal tract with moderately dense inflammatory infiltrate (mainly lymphocytes, some eosinophils) and concentric, lamellated, periductal fibrosis ("onion skin" fibrosis) around the interlobular bile duct.

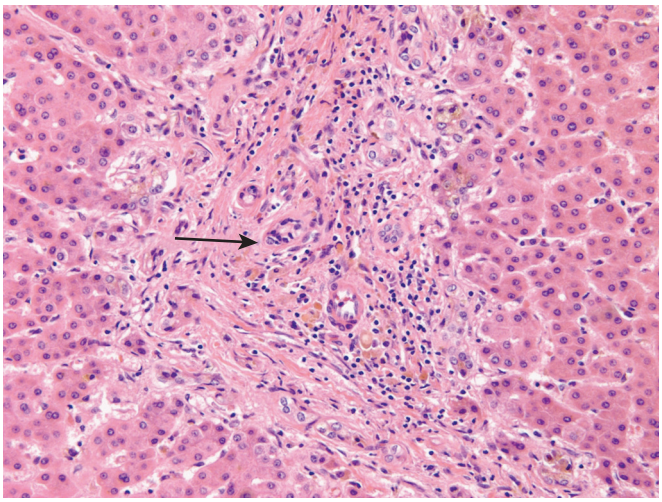

Figure 19.50 Primary sclerosing cholangitis featuring nonspecific ductular reaction, changes of chronic cholestasis, and a markedly atrophic duct *(arrow)*. Inflammation is minimal.

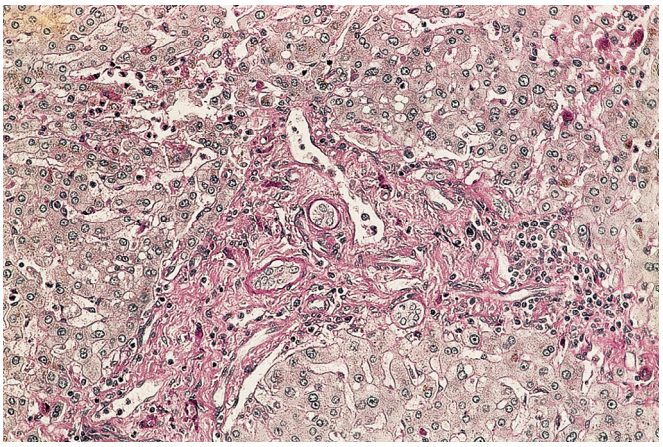

Figure 19.51 Primary Sclerosing Cholangitis. Overview of portal tract and periportal parenchyma. This portal tract shows only mild inflammation; two interlobular bile ducts show clear-cut thickening of their basement membrane on PAS/diastase, a helpful diagnostic feature.

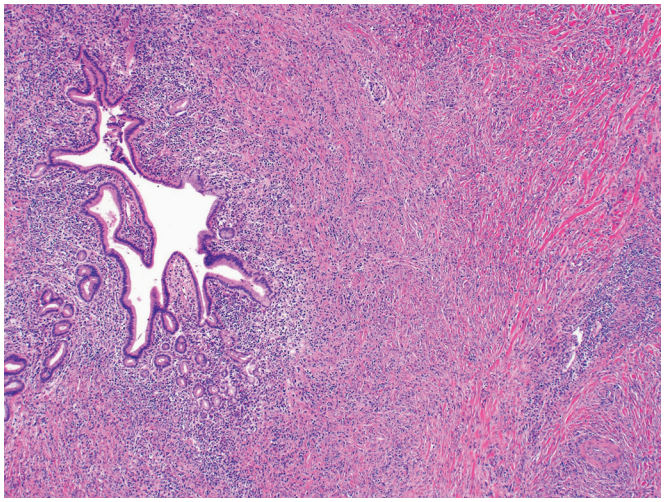

Figure 19.52 IgG4-associated sclerosing cholangitis featuring marked periductal lymphoplasmacytic inflammation and surrounding storiform fibrosis in a large intrahepatic bile duct.

this risk is about threefold higher than the risk for cholangiocarcinoma.[554] A strong association has been found between dysplasia of bile duct epithelium and cholangiocarcinoma in PSC, suggesting that biliary dysplasia might be used as a marker for current or developing malignancy (see also Chapters 20 and 21).[555] The results of a review of 100 consecutive formalin-fixed PSC liver explants (including 30 with cholangiocarcinoma) strongly supported a metaplasia–low-grade dysplasia–high-grade dysplasia–carcinoma sequence in PSC-associated cholangiocarcinoma, and underscored the lack of correlation between patient age, duration of PSC, and the development of cholangiocarcinoma. Dysplasia is generally confined to large and septal-size bile ducts, and its presence may not be recognized unless multiple sections of this caliber duct are examined.[556]

The main differential diagnoses for PSC are chronic hepatitis and other ductopenic diseases, particularly PBC and IgG4-associated sclerosing cholangitis (see later). Chronic hepatitis lacks periductal fibrosis, ductopenia, and other cholestatic features; in addition, PBC may be difficult to differentiate from PSC in the later stages, but in earlier stages PBC typically features more prominent inflammation, florid duct lesions, and granulomas. Of note, however, epithelioid granulomas can also be found in about 4% of PSC cases but not as part of granulomatous cholangitis.[557] Female gender and positive AMA also strongly favor PBC. An overlap syndrome between autoimmune hepatitis and PSC has been described (see later).

IgG4-Related Sclerosing Cholangitis (IgG4-SC; IgG4-Related Hepatopathy; Autoimmune Pancreatocholangitis)

Although first described in 1961, autoimmune pancreatitis was not widely recognized as an autoimmune condition until 1995. It has now become apparent that this form of pancreatitis is part of a clinical syndrome that commonly affects multiple organs (see also Chapters 21 and 22).[558] Many terms have been proposed to describe the condition, but "IgG4-related systemic sclerosing disease" appears most appropriate. Affected extrapancreatic tissues include the biliary tract, liver, kidneys, and lung, but a wide range of other sites may be involved.[559]

Grossly, IgG4-SC may produce fleshy lesions along the biliary tree, and imaging studies may mimic either PSC or cholangiocarcinoma.[558] One of the most common histopathologic features is the presence of numerous IgG4+ plasma cells within involved tissues, as well as lymphoplasmacytic infiltration of the duct with extensive storiform fibrosis, and obliterative phlebitis, similar to IgG4-associated sclerosing pancreatitis (Fig. 19.52). Peribiliary glands are also severely affected. Bile duct epithelia are relatively spared in IgG4-SC in comparison with those of PSC. In some cases numerous IgG4+ plasma cells are also found in small portal tracts. The distinction from PSC may be very difficult, but the finding of more than 10 IgG4-positive plasma cells per high-power field and an IgG4/IgG ratio of more than 40% favor IgG4-SC, as does the presence of storiform fibrosis, elevation of serum IgG4, and involvement of other organs.[558,560,561] However, these histologic changes are often lacking on needle biopsy.[558] Although cases of PSC may show increased numbers of IgG4+ plasma cells, they are typically not as numerous as IgG4-SC, and IgG4-SC does not typically have "onion-skin" fibrosis or significant ductopenia affecting small ducts; however, we have seen rare cases of IgG4 disease with these features. Interestingly, hepatic inflammatory pseudotumor (HIP) has also been associated with IgG4-SC and is considered a local exaggeration of IgG4-SC.[562] Therapeutically, IgG4-SC responds very well to steroid therapy, and thus the distinction from PSC has considerable clinical importance.[563,564]

Secondary Sclerosing Cholangitis

Progressive sclerosing cholangitis after septic shock and trauma represents a more recently described variant of vanishing bile duct disorders in which the liver may progress rapidly to cirrhosis.[565–568] It is probably caused by ischemia of the intrahepatic bile ducts via the peribiliary capillary plexus due to arterial hypotension.[569] A similar variant of secondary sclerosing cholangitis occurring after long-term treatment in intensive care units (ICU-SSC) has also been described.[570] *Ischemic cholangitis* (or cholangiopathy) is a result of impaired blood supply to the biliary tree, often due to injury during surgery, infusion of hepatic arterial chemotherapy, or radiation.[571]

Although PSC certainly occurs in the pediatric population (see earlier), several other forms of sclerosing cholangitis in childhood are worthy of mention.[568] Sclerosing cholangitis may occur in the context of common variable immunodeficiency and other immune deficiency disorders, CF, and Langerhans cell histiocytosis.[572,573] *Neonatal sclerosing cholangitis* is a poorly understood entity that presents

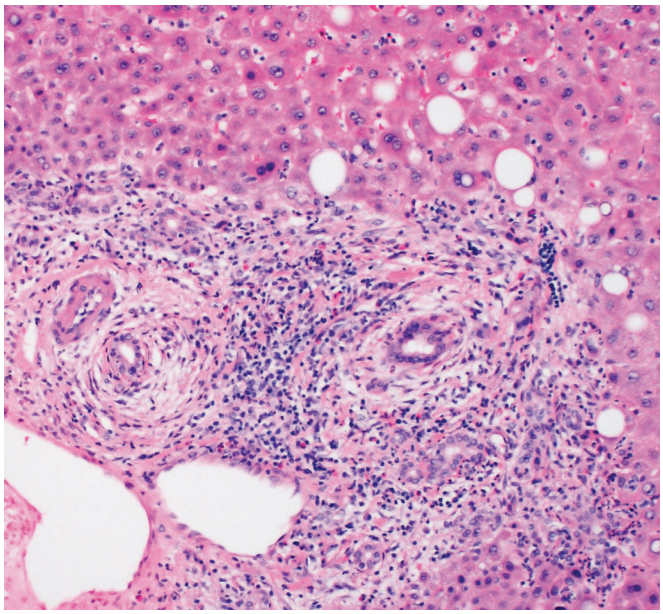

Figure 19.53 Extrahepatic large bile duct obstruction featuring portal edema, a mixed portal inflammatory infiltrate, and ductular reaction with admixed neutrophils.

within the first 2 weeks of life and is associated with parental consanguinity and extrahepatic manifestations. The pathology on liver biopsy resembles BA.[573]

Large Duct Obstruction (Hilar and Extrahepatic)

A very large number of entities, such as gallstones, bile duct strictures, and tumors, may cause complete or incomplete obstruction of the larger bile ducts. Acute complete obstruction induces the full clinical picture of obstructive jaundice, and histopathologically the sequence of changes described previously under acute complete cholestasis (Fig. 19.53). Chronic complete obstruction shows all the components of chronic cholestasis also described previously and eventually results in secondary biliary cirrhosis. An additional rarely seen lesion, which is near-pathognomonic for longstanding large duct obstruction, is rupture of an interlobular duct with escape of bile into the portal connective tissue, giving rise to a *bile extravasate*, which in turn induces a foreign body giant cell reaction. Chronic incomplete obstruction presents clinically as an anicteric cholestasis, with elevated serum levels of alkaline phosphatase, 5′-nucleotidase, and γ-GT, but no increase in serum levels of conjugated bilirubin. In parallel, histologic bilirubinostasis remains absent for long periods of time, and liver biopsy shows parenchymal and periportal features of chronic cholestasis. Chronic incomplete obstruction may arise in the context of postoperative strictures of the common bile duct, large duct sclerosing cholangitis, and annular pancreas, among others.[574]

Miscellaneous Ductopenic Diseases

Ascending cholangitis. Incomplete bile duct obstruction predisposes to bacterial infection. In bacterial ascending cholangitis, the number of neutrophils infiltrating the portal tracts is higher than in aseptic bile duct obstruction, and numerous neutrophils are typically found in the wall and inside the lumen of portal ducts as well. Interlobular ducts are often more affected than larger ducts.[575] The inflamed duct may rupture, resulting in portal abscess formation. Associated lesions include lobular abscesses and sinusoidal neutrophil infiltration, and thrombosis and thrombophlebitis of portal vein branches with the sequel of parenchymal necrosis. Bilirubinostasis is not an obligate feature.[576,577] Ascending cholangitis may be caused by choledocholithiasis, cholecystitis, strictures of any cause, biliary parasites, cholangiocarcinoma, and Caroli disease. In immunodeficient patients (e.g., AIDS), cholangitis is often due to *Cryptosporidium*, CMV, or species of *Microsporidia*.[274,578] Cholangitis easily gives rise to septicemia, in which the lesion of ductular bilirubinostasis is an important diagnostic feature (cholangitis lenta; see earlier). Persistent cholangitis may result in biliary-type cirrhosis.

PILBD is subdivided according to associated clinical features into a syndromic (e.g., AGS) and a nonsyndromic variety. The paucity of ducts is determined by calculating the bile duct to portal tract ratio as mentioned previously. However, in premature infants, a ratio of less than 0.9 may be normal due to the incompleteness of bile duct development at the time of birth.[579] Full development of the finest ramifications of the intrahepatic bile duct system takes an additional 4 weeks.[580] Both categories are characterized by a nonspecific, inflammatory destruction of interlobular ducts, resulting in progressive ductopenia. Both syndromic and nonsyndromic forms typically occur in the pediatric population and are characterized by histopathologic changes of neonatal cholestasis (see earlier) in addition to duct loss. These entities are discussed in detail later. Vanishing bile duct diseases in adulthood comprise a number of different disorders, listed in Box 19.1.

Idiopathic adulthood ductopenia is a term proposed for chronic cholestasis and ductopenia in adults in whom all other possible causes of ductopenia has been excluded.[581,582] Familial cases have been described.[583] Studies of biliary transporter proteins have identified a subgroup of patients with *MDR3-related sclerosing cholangitis*, in which a missense mutation in the phospholipid translocase *MDR3* was found to be responsible for ductopenic chronic liver disease in adulthood in a family from an isolated population in Transylvania. Allelic status correlated with severity of liver disease, ranging from ICP through fibrosis, cirrhosis, and death in both childhood and adulthood, leading to the recommendation that mutational analysis of *ABCB4* should be considered in all patients with cholestatic liver disease of unknown etiology regardless of age at onset of disease.[584] Another study detected heterozygous *MDR3* mutations in 34% of adults with unexplained cholestasis, mostly without biliary symptoms but sometimes resulting in significant liver fibrosis.[585] These findings resemble the bile duct injury in the ortholog of human *MDR3* (Mdr2) (abcb4) knockout mice (Mdr2(−/−)) as a novel model of sclerosing cholangitis.[586,587] Interestingly, patients with idiopathic adulthood ductopenia may be entirely asymptomatic.[588] Some of these cases may be drug related, which is discussed earlier.

Chronic liver allograft rejection is characterized by ductopenia ("ductopenic rejection"), as is **chronic graft-versus-host disease** (see later). Finally, ductopenia is a possible sequel of sarcoidosis, histiocytosis X, Hodgkin lymphoma, mucoviscidosis, and hemophagocytic lymphohistiocytosis.[589]

Autoimmune Hepatitis

Autoimmune hepatitis is a chronic disease, typically affecting women, which is divided into two main types depending on the autoantibody profile: Type 1, associated with positive ANA and/or anti-smooth muscle antibodies, and Type 2, associated with anti-liver kidney microscomal type 1 or type 3 antibodies, or anti-liver cytosol type 1 antibody.[590,591] Correct diagnosis is important, as patients often benefit from immunosuppressive therapy.

The histopathology may overlap with chronic hepatitis of other etiologies, but there are some suggestive features.[590,592,593] Necroinflammatory activity tends to be marked in untreated patients and may

include confluent bridging necrosis, marked interface hepatitis, and hepatocyte rosettes (Fig. 19.54A–C).[119] Multinucleated giant hepatocytes may be found,[594,595] although they also occur in other types of hepatitis.[119] The inflammatory infiltrate is mainly composed of lymphocytes, but plasma cells are a prominent component, often in clusters.[199] Lymphoid aggregates and follicles may be present but less often than in viral hepatitis C.

Immunosuppressive treatment reduces the severity of necroinflammation and fibrosis.[596] "Overlap" syndromes with features of both autoimmune hepatitis and biliary disease have been reported (see later); this issue is confounded by the fact that bile duct lesions, even destructive ones, may occur in genuine autoimmune hepatitis, particularly in severe cases.[597] Centrilobular necrosis with a relatively mild portal infiltrate has been described in some patients with steroid-sensitive AIH, making differentiation from toxic hepatitis difficult.[598] AIH may also occur in childhood, in which case multinucleated hepatocytes are more frequent.

AIH is considered a chronic disease, but it may have an acute onset.[599] Acute AIH and acute exacerbations in chronic AIH may show features of severe acute hepatitis, including interface or lobular hepatitis with lymphoplasmacytic infiltration, hepatocyte rosettes, centrilobular necrosis with plasmacytic infiltration, and giant cell hepatitis. CK19-positive cholangiolar cell proliferation can occur in the periportal areas in cases of massive necrosis, and bile duct injury may be seen more frequently than in classic chronic AIH.[600]

AIH is mainly a clinical and serologic diagnosis, with histopathology serving as supporting or suggestive evidence, but biopsy findings are an important source of information on degree and stage of liver damage, and possibly superimposed disease. For clinical diagnosis, diagnostic scores based on several parameters are used.[590,601–602]

Differentiation from PBC may be difficult. AIH typically lacks the florid duct lesions, bile duct loss, copper deposition, and granulomas often seen in PBC; in addition, AIH typically features markedly elevated transaminases, whereas PBC patients more often have normal or near-normal transaminases in the face of an elevated alkaline phosphatase. Immunostaining for IgG and IgM may be helpful, since plasmacytic infiltrates expressing predominantly IgM are characteristic of PBC, while other forms of liver disease, including AIH, typically show an IgG-predominant plasma cell infiltrate.[518,519] However, this is not always the case. Some studies have also reported increased numbers of IgG4+ plasma cells in a subset of patients with AIH, but the significance of this remains to be elucidated.[603]

Overlap syndromes have been described in which patients present with clinical, serologic, and histologic features of both PBC and AIH, or of AIH and PSC, either simultaneously or sequentially. The AIH–PBC overlap syndrome is the most common form, affecting almost 10% of adults with AIH or PBC. Such cases are histologically characterized by higher serum transaminases and more prominent interface and lobular necroinflammatory activity than typically seen in PBC, and these cases may require immunosuppressive therapy in addition to UDCA.[604]

The AIH–PSC overlap syndrome is predominantly found in children,[605,606] adolescents, and young adults with AIH or PSC (up to 25% of cases with PSC), in which it is often termed *autoimmune sclerosing cholangitis*.[607] The histologic changes of PSC may be absent in one-fourth of pediatric patients with abnormal cholangiograms, however, in which case this overlap syndrome can only be diagnosed by cholangiographic studies.[608] A French study of a cohort of adult patients with AIH noted that the prevalence of sclerosing cholangitis was only 1.7%, with only mild abnormalities of the intrahepatic bile ducts on imaging in one-fourth of patients.[609,610]

A significant reduction in survival has been reported in patients with PSC–AIH overlap syndrome versus those without. Patients with PSC–AIH also have a significantly worse prognosis than patients

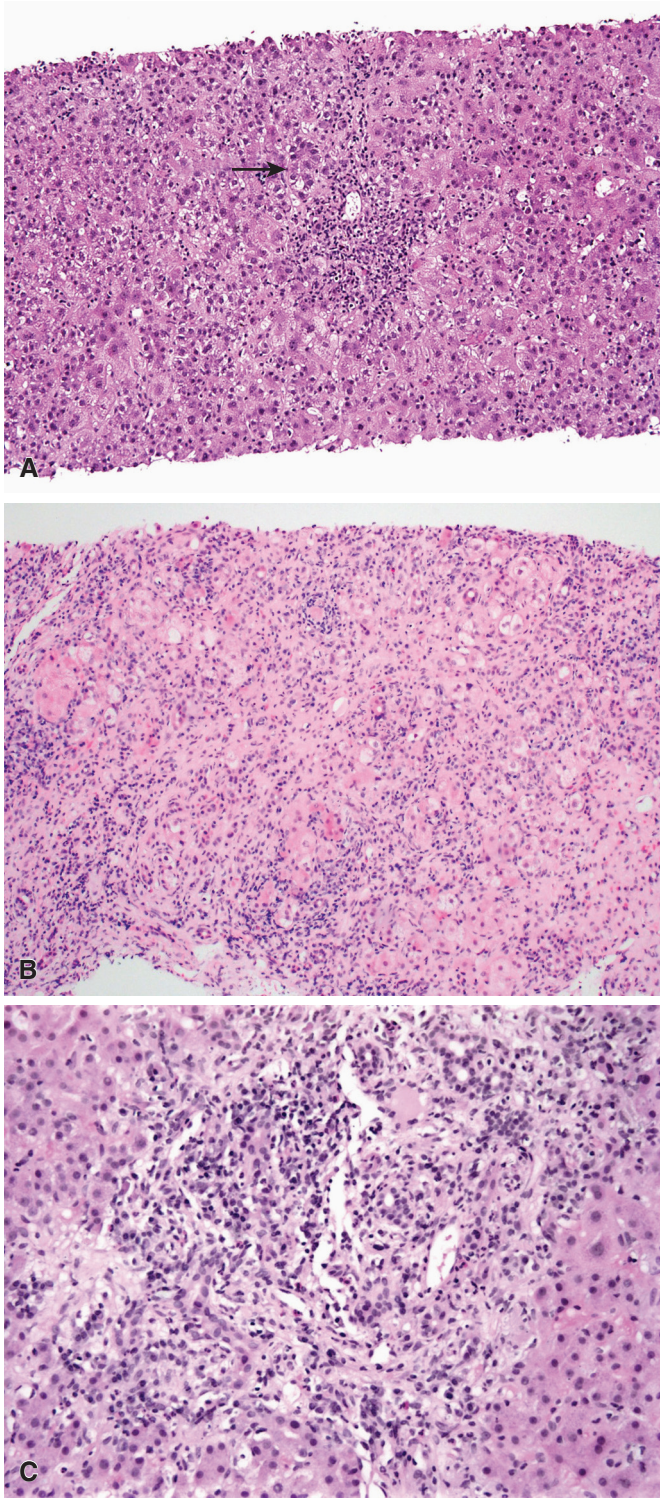

Figure 19.54 Autoimmune Hepatitis. A, Needle biopsy showing lobular disarray, feathery cytoplasmic degeneration, and a hepatocyte rosette *(arrow)*. **B,** Broad zones of bridging necrosis with parenchymal collapse. Note the prominent plasma cells. **C,** Portal tract with lymphoplasmacytic inflammation and interface activity. Bile ducts show reactive changes and are focally infiltrated by inflammatory cells.

with AIH or PBC–AIH overlap. Without treatment, there is progressive course towards liver cirrhosis and liver failure.[611,612]

Cirrhosis

Cirrhosis is the end stage of many chronic liver diseases. This term refers to diffuse hepatic fibrosis with replacement of normal lobular architecture by parenchymal nodules separated by bands of fibrous tissue.[613] Portal–central fibrous septa linking portal tracts and central veins are an important component of cirrhosis, as they create portohepatic vascular shunts. Cirrhosis may be strongly suspected on clinical, laboratory, and imaging parameters, but the final diagnosis mostly requires morphologic confirmation by liver biopsy. Architectural changes are histologically best appreciated on a trichrome or reticulin stain.[614]

Biologically, cirrhosis is the final result of the interplay between ongoing inflammation, parenchymal damage, fibrogenesis and fibrolysis, and hepatocellular regeneration. Chronic or repetitive liver damage incites an inflammatory response and activation and proliferation of mesenchymal cell populations within the liver, which remodel the extracellular matrix similar to that which occurs in a wound-healing response. Progressive scarring (fibrosis) takes place, which eventually alters organ structure and function, resulting in cirrhosis and ultimately liver failure. The mesenchymal cells (fibroblasts) are derived from sources both within and outside the liver. Within the liver, fibroblasts expressing alpha-smooth muscle actin (myofibroblasts) are derived from the trans-differentiation of quiescent hepatic stellate cells; others emerge from the portal tracts. In chronic liver disease, at least a proportion of the fibroblasts originate from the bone marrow. In addition, fibrogenic fibroblasts may be generated through liver epithelial (hepatocyte and biliary epithelial cell)–mesenchymal transition. Regardless of origin, the fibrogenic fibroblast is sensitive to the cytokines and chemokines coming from the resident liver macrophages and infiltrating inflammatory cells. Insight into the complexity of hepatic fibrogenesis has markedly increased in recent years, with growing evidence for the participation of epithelial–mesenchymal transition in chronic liver disease. Several comprehensive reviews of the topic are available.[483,615–619]

Mesenchymal tissue in the liver is not static, and homeostasis of connective tissue is ensured by a correct balance between fibrogenesis and fibrolysis. Fibrosis results from an imbalance that favors fibrogenetic mechanisms. When the trigger(s) causing the imbalance disappear(s), either spontaneously or as result of therapy, the normal equilibrium may be restored and fibrosis regresses either completely or partially, depending on a number of variables, including the amount, the composition, and the structure of the excess connective tissue. The implication of this is that fibrosis in chronic liver diseases is reversible (to variable extent), on the condition that the underlying necroinflammatory processes cease, and as long as the fibrosis is not yet associated with complications such as vascular thromboses,[620] neovascularization of fibrotic areas,[621] portovenous shunts in collapsed zones of parenchymal confluent necrosis, and nodular parenchymal regeneration. Therefore, for prognostic reasons, it is important to distinguish lesser degrees of fibrosis from established cirrhosis.[622,623]

Historically, the morphologic classification of cirrhosis is based on the size of the nodules.[613] Cirrhosis is *micronodular* if nearly all of the nodules are less than 3 mm in diameter (Fig. 19.55), and *macronodular* if greater than 3 mm in diameter (Fig. 19.56). A mixed pattern consists of approximately equal numbers of nodules greater than and less than 3 mm in diameter. The size of the nodules has some use in defining the etiology of the process, but this is relative since many cases of cirrhosis have a mixed pattern, as well as the fact that micronodular cirrhosis may convert into a macronodular type under circumstances more favorable for parenchymal regeneration.[624]

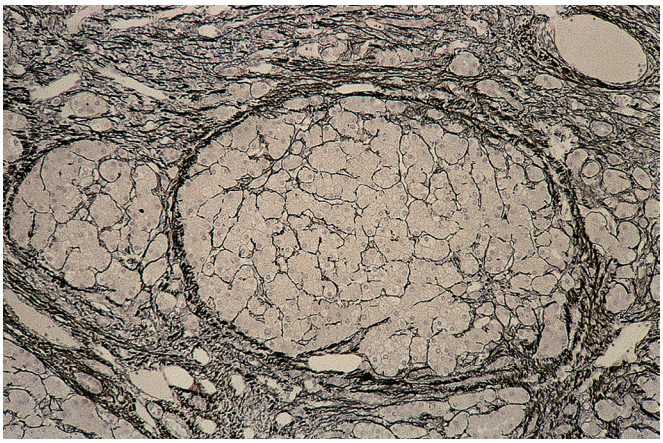

Figure 19.55 Detail from micronodular cirrhosis, reticulin stain.

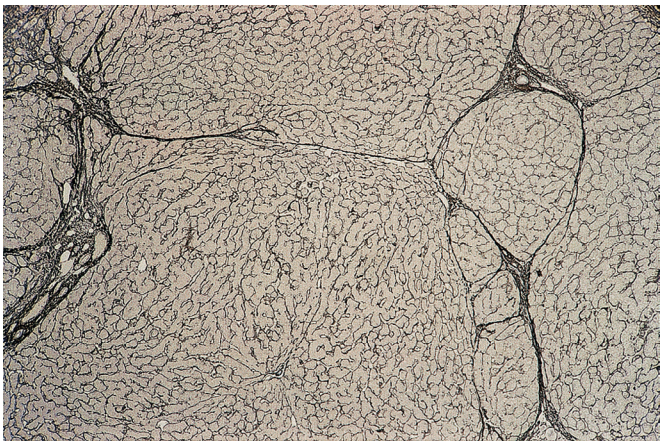

Figure 19.56 Detail from macronodular cirrhosis, reticulin stain. Note larger nodules, thin, fibrous septa, and irregular orientation of liver cell plates.

Nodular size is more important in determining the ease with which the diagnosis of cirrhosis can be made in needle biopsy specimens. Nodularity and septa may be readily evident in specimens from micronodular cirrhosis, whereas morphologic clues may be more subtle in macronodular cirrhosis. Helpful criteria in this latter situation include fragmentation of the biopsy specimen (especially with slender tissue cylinders provided by thin aspiration type needles such as the Menghini needle); thin layers of connective tissue adhering to rounded edges of nodular biopsy fragments; abnormal orientation of reticulin fibers resulting from different rates of parenchymal growth in different areas; abnormal spacing of portal tracts and central veins, and excess numbers of draining veins in relation to the number of portal tracts; presence of minute and poorly formed portal tracts ("mini-portal tracts"); hepatocellular features of regeneration—double-cell plates over widespread areas, different appearance of hepatocytes in adjacent areas; and liver cell dysplasia of the large cell and small cell type (see also Chapter 20).[625]

The most difficult anatomic type to recognize is *incomplete septal cirrhosis* (Fig. 19.57). This is characterized by vague nodularity; slender septa, some of which end blindly; mini-portal tracts; excess efferent veins; and sinusoidal dilation. There is evidence of parenchymal hyperplasia with corresponding compression of reticulin fibers in

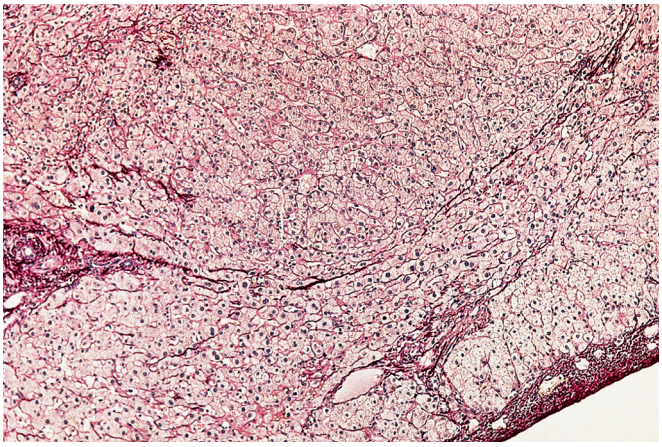

Figure 19.57 "Incomplete septal–type" cirrhosis can be considered a macronodular variety of cirrhosis with large multilobular nodules, thin, incomplete septa, and little inflammatory activity (Sirius red stain).

adjacent areas. Inflammation and necrosis are generally absent or minimal.[626] Many consider this to be a part of the spectrum of macronodular cirrhosis and, furthermore, that it may represent actual regression of cirrhosis (see later).[627] The ease with which cirrhosis is diagnosed further depends on the type of specimen (resection or needle biopsy), the type of needle used (aspiration type, Tru-cut, or transjugular), and the quality of the histologic preparation. In some instances, particularly on needle biopsy, the pathologist can only hint at the possibility of cirrhosis.

Besides confirming the presence or absence of cirrhosis and the size of the nodules, liver biopsy may further permit assessment of the underlying etiology of the liver disease. In many instances this may require additional stains, as well as knowledge of clinical and laboratory data. Unfortunately, in many cases of fully developed cirrhosis, the original etiology of the liver disease is not apparent.

The pattern of nodules and fibrosis may be helpful. Biliary cirrhosis is characterized by garland-shaped nodules, and clues to a biliary etiology include a clear halo in the nodular periphery due to edema, cholate stasis, and ductular reaction. Ductopenia may be a further indicator of chronic biliary disease. Chronic venous outflow obstruction leads to central–central fibrous septa, and may result in "cardiac-type cirrhosis" or cardiac sclerosis with normal-looking portal tracts centered within the parenchymal nodules.[628] Although the degree of steatosis may significantly regress in both NASH patients who have had the underlying causes of their disease treated, and patients with alcoholic liver disease who have stopped drinking, pericellular fibrosis may be a residual clue to the original disease. In fact, many patients with cirrhosis who lack any other etiologic markers ("cryptogenic" cirrhosis) are believed to have "burned-out" NASH.[629]

Ground-glass hepatocytes may help in recognizing HBV infection, and HCV is suggested by lymphoid aggregates and lymph follicles. Numerous plasma cells are suggestive (but not proof) of autoimmune hepatitis. Genetic hemochromatosis is indicated by severe parenchymal siderosis.[630] Perinodular copper suggests biliary disease; however, copper deposition (rhodanine stain) and metallothionein (orcein stain) are found in cirrhosis of many causes,[631] so this finding is not specific. Positive staining of entire nodules may be seen in Wilson disease, although other nodules may be entirely negative. Abundant copper deposition is also noted in Indian childhood cirrhosis (ICC).[632] α1-AT deficiency is recognized by hepatocellular inclusions of this glycoprotein; they are eosinophilic, PAS positive, and diastase resistant and may be highlighted by immunostaining.[633] Of note, a characteristic of cirrhotic nodular parenchyma is the variability between individual nodules; that is, features such as steatosis, siderosis, and ground-glass hepatocytes may be abundant in one nodule but absent in the next, making needle biopsy evaluation even more difficult.

The histologic activity of a cirrhotic liver should be noted, as it may reflect ongoing disease even in the face of established cirrhosis. Activity consists of the various forms of liver cell damage and inflammation seen in the precirrhotic stage of the disease, for example, interface hepatitis or features of ongoing steatohepatitis. Inactive cirrhosis is characterized by the near absence of necroinflammatory lesions, and a sharp delineation between the paucicellular septa and nodules. Further useful information for the clinician that can be recognized in cirrhotic liver include some of the complications of cirrhosis. Coagulative necrosis of entire nodules or of their centers *("nodular infarction")* is seen in hypoperfusion (caused by hypotension due, for instance, to bleeding from esophageal varices).[634] The decompensation phase of a cirrhotic liver often shows severe bilirubinostasis in a background of nonbiliary cirrhosis.[614] *Hepatocellular carcinoma* may arise in the cirrhotic liver, and its putative precursor lesions (dysplastic foci, large cell and small cell change) should be reported (see also Chapter 20).

As mentioned previously, there are ongoing investigations regarding the reversibility of cirrhosis. Reversibility of cirrhosis is rarely complete, due to the advanced stage of fibrosis and the vascular complications that are often present in end-stage liver disease. The reversibility appears to depend on several variables; early fibrosis is more reversible than older, more established fibrous tissue; thin septa resorb more easily than broad fibrous scars; acellular septa are more resistant to degradation than cellular ones; and perisinusoidal fibrosis disappears more easily than septa. Portal–portal and central–central septa may ultimately disappear to a large extent, whereas portal–central septa and areas of multilobular collapse are virtually irreversible due to the development of portohepatic venous shunts.[622,623] A decrease in necroinflammation is also associated with improved hepatocellular regeneration and increased size of parenchymal nodules. As noted previously, incomplete septal cirrhosis appears to correspond either to not yet fully developed macronodular cirrhosis or an intermediate regressive stage of cirrhosis.[627,635] Morphologic correlates to reversal of cirrhosis include delicate perforated septa, isolated thick collagen fibers, delicate periportal fibrous spikes, portal tract remnants, hepatic vein remnants with prolapsed hepatocytes, minute regenerative nodules, and aberrant parenchymal veins.[627]

Cirrhosis has to be distinguished from other nodular and fibrotic conditions of the liver. The differential diagnosis comprises nodular regenerative hyperplasia, congenital hepatic fibrosis (CHF), and focal nodular hyperplasia. Confusion with the latter is easily avoided if information is provided of a focal lesion in the liver rather than a diffuse process.

Childhood Disorders and Disorders of Metabolism

The histologic diagnosis of liver disease in neonates and young children requires knowledge of the particular lesions and diseases that are of diagnostic importance in this age group. Useful recommendations to general pathologists for handling of special pediatric liver biopsy specimens have been provided by subspecialty experts.[636]

Cholestatic Disorders

Several neonatal liver diseases are associated with cholestasis, rendering "neonatal cholestasis" a particular challenge for the pathologist.

The differential diagnosis involves BA, PILBD, biliary transporter deficiencies, disorders of bile acid metabolism, metabolic disorders, and viral infections, and the clinical and prognostic implications are significant.

Transporter deficiencies. This group includes PFIC types 1, 2, and 3, mentioned briefly previously; Greenland familial cholestasis; benign recurrent intrahepatic cholestasis (BRIC); and CF (mucoviscidosis).

PFIC-1 and *BRIC-1* are clinically distinct hereditary disorders. PFIC-1 patients suffer from chronic cholestasis and develop liver fibrosis. BRIC-1 patients experience intermittent attacks of cholestasis that resolve spontaneously. Mutations in *ATP8B1* (previously *FIC-1*, encoding adenosine triphosphatase (ATPase) class I, type 8B, member 1/phospholipid transporting ATPase IC) may result in either PFIC-1 or BRIC-1. *ATP8B1* is expressed in the canalicular membrane of normal hepatocytes and the apical membrane of ileal enterocytes, suggesting a role in the enterohepatic circulation of bile constituents. It functions as an aminophospholipid translocase (flippase), which flips phosphatidylserine and phosphatidylethanolamine from the outer into the inner leaflet of the cell membrane, ensuring membrane asymmetry, which is essential for maintaining the normal functional capacity of integral membrane proteins.[637–641] Mutation analyses of 180 families with PFIC or BRIC identified 54 distinct disease mutations, and the mutation type or location correlates overall with clinical severity, that is, the development of PFIC or BRIC. Mutations causing the complete absence of canalicular expression result in PFIC-1, whereas in BRIC-1 and ICP, residual protein is expressed in the canalicular membrane.[642]

PFIC-1 is a hereditary autosomal recessive syndrome, initially known as *Byler disease*. Clinically, it is characterized by severe low γ-GT cholestasis in infants and children and extrahepatic symptoms of diarrhea and pancreatitis. Histologic features include bland bilirubinostasis, minimal ballooning of hepatocytes, little or no ductular reaction, and slowly progressive fibrosis, ultimately ending in cirrhosis. Electron microscopy reveals a coarsely granular aspect of the canalicular bile deposits (Tables 19.4 and 19.5).[495,496,640] A severe variant of the disease is *Greenland familial cholestasis*,[643] a syndrome of intrahepatic cholestasis leading to death in early childhood, which was described among indigenous Inuit families in Greenland (Nielsen syndrome).[644]

Table 19.4 Morphologic distinction between progressive familial intrahepatic cholestasis-1 and progressive familial intrahepatic cholestasis-2

PFIC TYPE 1	PFIC TYPE 2
Bland bilirubinostasis is the most consistent feature	Severe neonatal hepatitis
Positive immunostaining for BSEP	Negative immunostaining for BSEP
EM: coarsely granular bile	EM: amorphous bile
Portal fibrosis with eventual progression to cirrhosis	Portal fibrosis with eventual progression to cirrhosis
Variably present bile duct injury and ductular reaction	Variably present bile duct injury and ductular reaction
Negative or decreased immunohistochemical staining for canalicular GGT	Intact immunohistochemical staining for canalicular GGT

From Knisely AS. Progressive familial intrahepatic cholestasis: a personal perspective. *Pediatr Dev Pathol*. 2000;3(2):113–125; Knisely AS. Progressive familial intrahepatic cholestasis: an update. *Pediatr Dev Pathol*. 2004;7(4):309–314. *BSEP*, Bile salt export pump; *EM*, electron microscopy; *GGT*, gamma-glutamyltranspeptidase; *PFIC*, progressive familial intrahepatic cholestasis.

PFIC-2 is a disease of low γ-GT cholestasis caused by mutations in the *ABCB11* gene on chromosome 2q24, which encodes the canalicular BSEP.[645] Human BSEP mutations are the molecular basis for at least three clinical forms of liver disease: PFIC-2, BRIC-2, and ICP. Mutations are associated with protein instability and ubiquitin-dependent degradation. The clinical phenotypes of PFIC-2, BRIC-2, and ICP may directly correlate with the amount of mature protein that is expressed at the canalicular cell surface.[646] The histopathology corresponds to that of severe so-called neonatal giant cell hepatitis, characterized by prominent centrilobular bilirubinostasis, clusters of ballooned hepatocytes, multinucleated parenchymal giant cells, increasing perivenular, pericellular, and periportal fibrosis that eventually evolves into cirrhosis, and mild ductular reaction. The canalicular bile plugs appear on electron microscopy as delicate wispy, amorphous material, contrasting with the coarsely granular appearance in PFIC-1. Phenotypic severity appears to correlate with BSEP immunohistochemistry and clinical outcome, in that BSEP as detected by immunohistochemistry is typically absent, or much reduced, in severe disease (see Tables 19.4 and 19.5).[495,496,647] BSEP deficiency in PFIC-2 also represents a previously unrecognized risk for hepatocellular carcinoma in young children.[648] In addition, development of intrahepatic cholangiocarcinoma has been reported in PFIC-2.[649] These observations suggest the need for surveillance for the development of hepatobiliary malignancy, and early consideration for liver transplantation. Interestingly, a subset of patients who undergo liver transplant for PFIC-2 develop post-transplant autoantibodies to BSEP, effectively resulting in disease recurrence.[650]

PFIC-3 is caused by mutations of the *MDR3* gene, encoding the canalicular phospholipid export pump MDR3.[651] This is a phospholipid translocase that flips phosphatidylcholine from the inner to the outer leaflet of the canalicular membrane, ensuring phospholipid–cholesterol–bile acid micelle formation in bile. Mutations lead to the formation of phosphatidylcholine-poor bile with a normal bile acid concentration. The high concentration of bile acids, in the absence of phospholipid–cholesterol–bile acid micelles, renders this bile toxic to the hepatocytes and to the bile duct epithelium, thus explaining the hepatocellular and cholangiocytic damage. Defects of *MDR3* result in impaired biliary excretion of phosphatidylcholine and a variety of cholestatic syndromes, ranging from PFIC-3 in neonates to biliary cirrhosis in adults. Moreover, *MDR3* mutations also predispose to ICP and drug-induced cholestasis.[652] Recent investigations in adult patients with unclarified chronic cholestasis revealed that *MDR3* mutations may also be involved in cholestatic liver disease of unknown etiology[585] or mysterious sclerosing cholangitis resulting in ductopenia.[584] In short, there is evidence that a biallelic or monoallelic *MDR3* defect causes or predisposes patients to six human liver diseases (PFIC-3, adult biliary cirrhosis, low phospholipid-associated cholelithiasis syndrome, transient neonatal cholestasis, ICP, and drug-induced cholestasis).[653]

PFIC-3 is characterized by elevated serum levels of γ-glutamyl transferase (γ-GT). Its histology, in contrast to most cases of PFIC-1 and PFIC-2, is characterized by inflammatory infiltration in portal tracts, damage to interlobular bile ducts, and ductular proliferation (see Table 19.5).[640] PFIC-3 corresponds to the previously recognized subgroup of patients with Byler syndrome characterized by elevated γ-GT in the serum, and ductular reaction morphologically.[654]

BRIC, as mentioned previously, is a recurrent cholestatic disorder in children and adults, caused, like PFIC-1 and PFIC-2, by mutations of the *ATP8B1* gene[655,656] and the *ABCB11* gene.[646] Contrasting with

Table 19.5 Histopathology of transporter deficiencies

	BILIRUBINOSTASIS	MGCT	CELL DAMAGE	BALLOONING	INFLAMMATION	DUCTULAR REACTION	DUCT DAMAGE	FIBROSIS	CIRRHOSIS
PFIC-1	+	—	—	—	—	±	±	+	+
BRIC	+	—	—	—	—	—	—	—	—
Greenland familial cholestasis	+	—	—	—	—	—	—	+	+
PFIC-2	+	+	+	+	+	±	±	+	+ HCC
PFIC-3	+	+	+	+	+	+	+	+	+
MRP2 deficiency	+	—	Pigment	—	—	—	—	—	—
CFTR deficiency 5%–10% liver disease	+	—	—	—	—	+ Concrements	—	+	+ Focal

Vertical columns: histopathologic lesions; horizontal rows: liver diseases due to deficiencies of transporters.
BRIC, Benign recurrent intrahepatic cholestasis; *CFTR*, cystic fibrosis transmembrane conductance regulator; *HCC*, hepatocellular carcinoma; *MGCT*, multinucleated parenchymal giant cell transformation; *MRP2*, multidrug resistance associated protein 2 (canalicular multispecific organic anion transporter or cMOAT); *PFIC-1*, progressive familial intrahepatic cholestasis type 1; *PFIC-2*, progressive familial intrahepatic cholestasis type 2; *PFIC-3*: progressive familial intrahepatic cholestasis type 3.

PFIC-1, BRIC-1 is characterized by recurrent episodes of cholestasis that do not progress to cirrhosis. Nevertheless, considerable overlap may exist between the clinical presentations of PFIC-1 and BRIC-1, and both conditions may represent the extremes of a broad spectrum of cholestatic syndromes.[656] Analogously, PFIC-2 and BRIC-2 are both caused by mutations in the *ABCB11* gene, and phenotypic differences appear to correlate with the degree of mutation-dependent BSEP degradation.[646,657] Histologically, BRIC is characterized by simple or bland bilirubinostasis, with bilirubin deposits in hepatocytes, canaliculi, and Kupffer cells only during the episodes of clinical cholestasis. BRIC was previously also known as Summerskill–Tygstrup–De Groote disease.

Bile acid synthetic defects (BASDs) are uncommon genetic disorders that are responsible for approximately 2% of persistent cholestasis in infants.[658] These defects appear as familial and progressive infantile or late-onset "low γ-GT" cholestasis. Inborn errors have been demonstrated for four single enzymes involved in modification of the sterol nucleus and in five steps in modification of the side chain to form cholic and chenodeoxycholic acids, the primary bile acids. The degree of liver disease varies from mild to severe, depending on the defect. Although they may be life threatening, the disease is treatable, usually by replacement of deficient primary bile acids. Pathologic findings may include intralobular bilirubinostasis with multinucleated giant cell transformation, prevalence of necrotic hepatocytes including giant cell forms, and hepatitic injury confined to the portal limiting plate where the smallest bile ductules may be injured and where fibrosis typically develops. Interlobular bile ducts are usually spared. The ultrastructure of the liver reveals nonspecific changes with the possible exception of unusual canalicular morphology in some defects. The histopathology as such is not really diagnostic, falling into the category of "neonatal giant cell hepatitis" or "cryptogenic neonatal cholestasis" but may have a remarkable degree of multinucleated giant cell transformation.[659] Diagnosis rests on screening of biologic fluids (bile, blood, and urine) for abnormal bile acids by mass spectrometry.[660]

In *syndromic PILBD* (also known as AGS or *arteriohepatic dysplasia*), the absence of small interlobular bile ducts is associated with a set of clinical features (abnormal facies, vertebral, cardiac, ocular, and renal abnormalities) which, according to their presence or absence, result in a complete or incomplete syndrome.[661] The majority of patients have mutations of the *JAG1* gene.[662] Most patients have pruritus, elevated serum bile acids, and variable hyperlipidemia, which may be severe with formation of xanthomas.

Liver biopsy in early infancy shows variable bilirubinostasis and multinucleated giant cell transformation; later on, there may be clusters of xanthomatous cells and mild periportal fibrosis. Controversy exists about the initial presence of and ultimate disappearance of interlobular ducts, which is surprising since ductopenia is actually the hallmark of the disease. Interlobular bile duct proliferation and damage may be seen in newborns, but the ductopenia appears to be progressive and may be more easily seen in late infancy and early childhood as compared to newborns.[662] Approximately 15% of patients progress to cirrhosis requiring transplantation, but it is difficult to predict progression based on histologic or clinical features.[662] Lack of hepatocellular CD10 expression along bile canaliculi is physiologic in early childhood and persistent in AGS, which may help distinguish AGS from BA.[663]

The exact mechanism(s) leading to paucity of ducts in AGS remains unclear, but it does not appear to be due to an initial failure of interlobular bile duct development. The duct abnormalities may, in fact, result from defects in hepatic angiogenesis related to the underlying genetic mutations.[662]

Nonsyndromic paucity of interlobular ducts is a common diagnosis in patients with conjugated hyperbilirubinemia in the first month of life.[664] It may be an isolated hepatic abnormality (idiopathic) or one component of a more complex systemic process with or without a known cause. It is associated with many diseases including α1-AT deficiency, rubella, trisomy 21, Turner syndrome, and Byler disease. The destruction of interlobular ducts starts early (typically before 3 months of age), and the progression has been described as faster than in syndromic paucity.[664,665]

Extrahepatic bile duct atresia or BA. Despite the terminology "extrahepatic," BA is not restricted to the extrahepatic segments of the biliary system but also affects the intrahepatic ducts. It is a panbiliary disease characterized by progressive necroinflammatory destruction of the bile ducts with involvement of part or all of the extrahepatic duct system (see also Chapter 21). Two clinical patterns of BA have been described: a perinatal (or acquired) form, accounting for approximately 80% of affected infants, and an embryonic form, the latter often associated with congenital anomalies, including preduodenal portal vein, midline symmetric liver, intestinal malrotation, situs inversus, asplenia, and polysplenia. The former group is asymptomatic and anicteric at birth and develop jaundice during the first postnatal weeks, whereas the infants with the second pattern are jaundiced at birth.[666] Primary treatment consists of hepatic portoenterostomy or Kasai operation with resection of the obliterated extrahepatic ducts. The histopathology of these fibrous remnants reveals variable degrees of nonspecific inflammation, duct epithelial desquamation and necrosis, ulceration, and fibrosis.[667,668]

Attempts to correlate the number and size of the patent ducts in the porta hepatis at the time of portoenterostomy with the success of the procedure and future prognosis has yielded controversial results. Historically, pediatric surgeons insisted on assessment of bile duct luminal size in frozen sections of the proximal resection margin during a Kasai procedure, as some consider the total diameter of all the prehilar structures an important prognostic parameter, with a total diameter of more than 400 μm indicating a favorable prognosis for adequate bile drainage.[669] A later study showed no correlation between duration of patient survival and size of the bile ducts at the resection margins, however.[670]

Liver biopsy remains the cornerstone of diagnosis. The histopathology evolves over time, as in any case of extrahepatic bile duct obstruction. In the perinatal form of BA, the detrimental cholestatic liver injury, later characteristic, only begins at the time of birth despite a prenatal occlusive biliary pathology, presumably due to the onset of the perinatal bile surge.[671] During the first two or so weeks of life, biopsy mostly reveals nonspecific bilirubinostasis, occasional multinucleated parenchymal giant cell transformation, and foci of extramedullary hematopoiesis (Fig. 19.58). Gradually, portal edema and ductular reaction set in. The latter is considered the most reliable feature, although it is not pathognomonic;[672–673] it was recently reconfirmed in a study of the diagnostic accuracy for BA of prelaparotomy biopsies in developing countries.[674] The extent of ductular reaction at the time of portoenterostomy also correlates with poor prognosis.[675] Patients with conjugated hyperbilirubinemia have been reported, however, in whom the initial liver biopsy findings showed a lack of ductular proliferation, despite subsequent development of BA. In some instances, sequential liver biopsies may be indicated until clinical improvement occurs or until BA can be excluded from the differential diagnosis.[676] The ductules often contain inspissated bile concrements (ductular bilirubinostasis; Fig. 19.59).

In later stages, periportal fibrosis develops, ultimately resulting in biliary cirrhosis. Important for the differentiation from other causes of obstruction (mainly choledochal cyst in this neonatal period) are the degenerative lesions of the intrahepatic ducts, which are part of the basic necroinflammatory and fibrotic process in BA. The ducts show irregularity of their lining cholangiocytes, which feature vacuolization, nuclear pyknosis, atrophy, and infiltration by

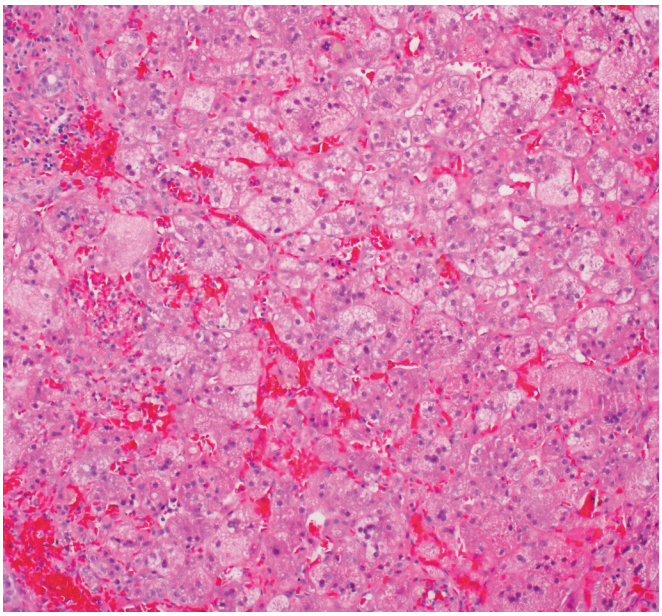

Figure 19.58 Biliary Atresia. Early disease featuring cholestasis and neonatal giant cell transformation.

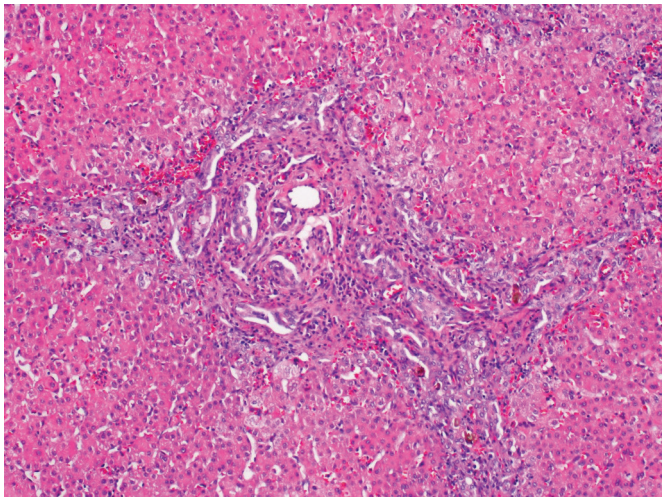

Figure 19.59 Biliary Atresia. Expanded portal tract with marked ductular reaction and ductular cholestasis.

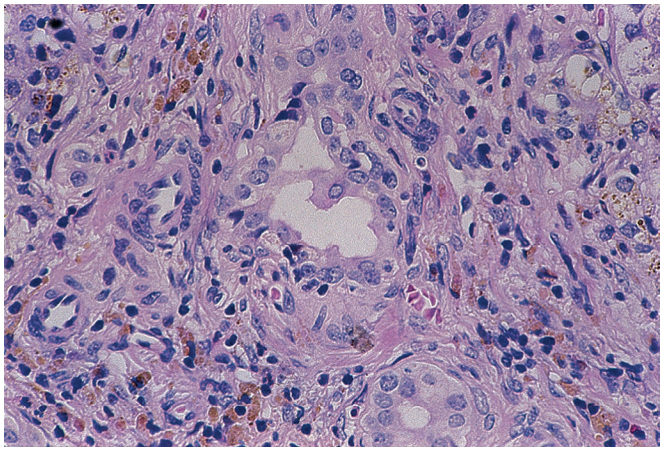

Figure 19.60 Detail of a bile duct from a neonate with biliary atresia, showing an irregular outline and epithelial damage including vacuolization of some cholangiocytes, apoptosis in others, and some inflammatory cells inside the basement membrane.

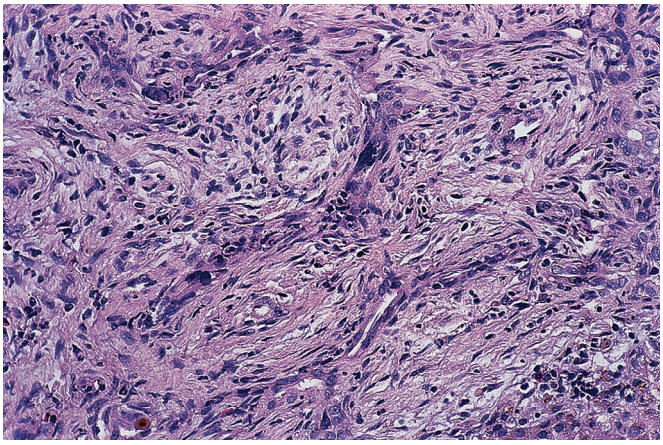

Figure 19.61 Biliary atresia, "early severe" type with advanced fibrosis. The picture shows part of a large, fibrous portal area, with recognizable hepatic artery branches, barely visible or no portal vein branches, and bile duct structures in ductal plate configuration ("ductal plate malformation"). The lining cholangiocytes show involutional changes such as flattening, shrinkage, and nuclear pyknosis.

inflammatory cells (Fig. 19.60). Thickening of the basement membrane occurs, associated with progressing atrophy and disappearance of the ducts. Progressive ductopenia of intrahepatic ducts develops, constituting an ominous sign for the success of hepatic portoenterostomy.[669] A bile duct to portal tract ratio equal to 0 or between 0.1 and 0.5 is frequently observed in BA.[677]

In about a fourth[678] or more[679] of patients, the interlobular bile ducts have been interpreted as retaining their early embryologic shape (so-called ductal plate malformation [DPM]; Fig. 19.61), suggesting an antenatal start of the disease associated with arrest of remodeling of the embryonic ductal plates.[680] In such patients, histology reveals an advanced degree of fibrosis at only a few weeks of age, justifying the term "early, severe" variant of BA. In an independent follow-up study, DPM occurred in 38% of cases, and its presence was predictive of poor clinical outcome.[681] A further study reported that the presence of DPM in the liver predicts poor bile flow after hepatoportoenterostomy in infants with BA,[682] while in another investigation the degree of fibrosis and DPM turned out to be markers of poor prognosis.[683] The broad variation in the few reports (involving relatively small numbers of patients) about the percentage of DPM in BA may relate to variable interpretation of unusual bile duct structures in diagnostic needle and surgical liver biopsies, which in neonates are mostly derived from the liver organ periphery and often of small size. This problem was addressed in a study that addressed DPM in early explants after failed Kasai procedures, and compared the percentage of affected portal tracts in classical perinatal BA patients with that found in patients with the embryonic form of BA, the latter defined as BA associated with splenic malformation syndrome (heterotaxy) or BASM. DPM-like arrays considered "definite" were typically found in larger portal areas of 300 µm diameter or more, and observed in the explanted livers from both BA and BASM patients, with a frequency of about 10% in each group, indicating that DPM does not identify the classical embryonic form of BA defined as BASM, but occurs with equal frequency in both BA and BASM patients. Furthermore, no correlation appeared to exist between the degree of fibrosis and the intensity of portal inflammation with

the number of DPM-like arrays.[684] However, more recent studies have indicated that DPMs in BA are correlated with an adverse prognosis.[685]

Marked fibrosis is already present in many cases of BA at the time of portoenterostomy. Computerized fibrosis scores[686] and intensity of alpha-smooth muscle actin expression may be predictors of outcome after operation.[687]

The differential diagnosis of BA includes bile duct obstruction by choledochal cyst, and differentiation from causes of intrahepatic cholestasis, including so-called neonatal giant cell hepatitis (no or much less ductular reaction, more intralobular than perilobular fibrosis, more hepatocyte swelling and multinucleation), chronic liver injury by parenteral nutrition, paucity of intrahepatic bile ducts, and several inborn errors of metabolism. Differentiation of BA from nonobstructive causes of neonatal cholestasis is crucial in order to avoid unnecessary surgery in patients with nonobstructive disease. Histologic scoring systems have been proposed with the purpose of improving diagnostic accuracy.[673,688]

The etiology of BA remains unknown. One hypothesis is that of viral infection (CMV, reovirus, and rotavirus) with resulting autoimmune-mediated bile duct injury.[689] Laterality genes (transcription factors *ZIC3* and *CFC*) may contribute to the phenotype of BA in patients with polysplenia syndrome.[690] Most likely, BA is a heterogeneous condition representing the common phenotype of several underlying disorders.[666,691]

Other cholestatic disorders (primarily intrahepatic) affecting the pediatric population include the metabolic disorders *galactosemia* and *hereditary fructose intolerance*, which show a histologic picture of severe bilirubinostasis with bile deposits in pseudoglandular tubules of hepatocytes and steatosis; the early stage is characterized by a periportal ductular reaction.[500] *Tyrosinemia* shows a similar histopathology, along with parenchymal siderosis, extramedullary hematopoiesis, and foci of nodular parenchymal regeneration.[692] *α1-AT deficiency* is discussed later.

The term *cryptogenic neonatal cholestasis* (also referred to as *neonatal giant cell hepatitis*) is histologically characterized by cholestasis, variably present multinucleated giant cell transformation, and extramedullary hematopoiesis, with occasional parenchymal siderosis and intralobular fibrosis, in which no cause is elucidated. Many patients previously termed cryptogenic are now known to have PFIC or another inherited disorder. More recently, other entities have been that were previously considered idiopathic have been identified, including *familial hypercholanemia*;[693] *neonatal ichthyosis sclerosing cholangitis* (NISCH) *syndrome*;[694] *North American ICC*[695]; *arthrogryposis, renal dysfunction, cholestasis (ARC) syndrome*[696]; and *neonatal intrahepatic cholestasis caused by citrin deficiency* (NICCD).[697] A rare disease (of older date) is the lymphedema–cholestasis syndrome (Aagenaes syndrome).[698]

CF or *mucoviscidosis* is one of the most common inherited diseases in the white population, caused by mutations in the CF transmembrane conductance regulator *(CFTR)*. *CFTR* is a cAMP-dependent chloride channel but also a "regulator" of other membrane proteins and channels,[699] thus governing the fluid balance across epithelial cells.[700] The most common mutation of *CFTR* amongst the 1400 reported in CF is ΔF508 (66%), resulting in misfolding of the protein and proteasomal degradation. Clinically, the abnormal electrolyte transport results in thick secretions and blockage of glandular ducts. In the liver, CFTR is located in the apical membrane of bile duct epithelial cells contributing to bile formation.[701] Bile duct epithelial cells in patients carrying the ΔF508 mutation display aberrant cytoplasmic immunolocalization of CFTR, as determined with confocal laser scanning microscopy, in contrast to the distinct CFTR expression at the luminal surface seen in controls.[702]

Significant liver disease is seen in 4%–6% of patients, but biochemical evidence of liver involvement occurs in 20%–50%, mainly in the first decade of life.[703] The most common pathologic change in the liver is steatosis; ductular reaction with concrements may also be seen. Increasing periportal fibrosis may ultimately end in cirrhosis, typically a focal pattern known as "focal biliary fibrosis" or "multilobular biliary cirrhosis."[704] The concrements in the dilated ductular lumina (Fig. 19.62), a pathognomonic lesion for CF, are PAS positive and diastase resistant with variable degrees of bilirubin impregnation.[501,700] The diagnosis of CF should be kept in mind in children who present with unexplained liver disease, since in some cases the diagnosis of CF has only been made after histologic examination of a liver specimen.[705]

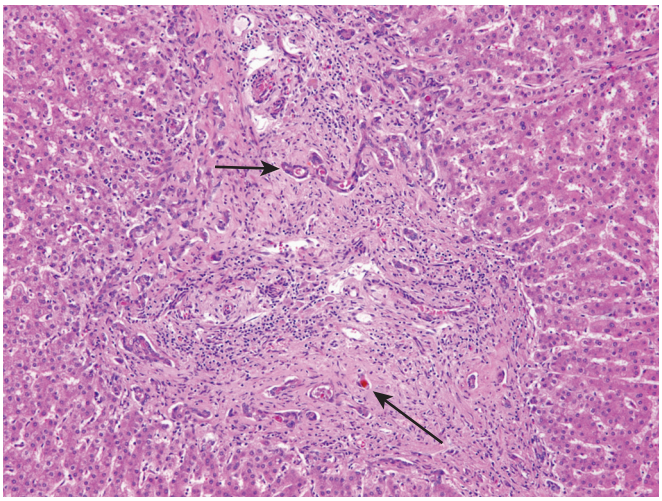

Figure 19.62 Cystic Fibrosis. An expanded portal tract has associated ductular reaction and inspissated pink-brown concretions *(arrows)*.

Hyperbilirubinemias. *Gilbert syndrome* is a common form of familial unconjugated hyperbilirubinemia, caused by a decreased conjugation rate of bilirubin associated with decreased transcription of *UGT1A1*, the gene of the bilirubin conjugating enzyme UDP-glucuronosyltransferase. Liver biopsies may show increased zone 3 lipofuscin. *Crigler–Najjar syndrome* (CNS) type 1 results from a mutation in one of the five exons of the gene coding for UDP-glucuronosyltransferase, resulting in complete absence of enzyme activity with very high levels of unconjugated bilirubin in the blood. CNS type 2 is caused by a single base pair mutation leading to a decreased but not totally absent enzyme activity.[706] The liver histology is normal except for an occasional slight degree of parenchymal siderosis. *Dubin–Johnson syndrome* is a deficiency of the canalicular multispecific organic anion transporter multidrug resistance associated protein 2 (MRP2, coded by the gene *ABCC2*), a member of the multidrug resistance protein subfamily localized exclusively to the apical membrane domain of polarized cells, such as hepatocytes, renal proximal tubule epithelia, and intestinal epithelia. This localization supports the function of MRP2 in the terminal excretion and detoxification of endogenous and xenobiotic organic anions, particularly in the unidirectional efflux of substances conjugated with glutathione, glucuronate, or sulfate, as exemplified by bilirubin, leukotriene C(4), glucuronosides, and some steroid sulfates.[707] Dubin–Johnson syndrome is characterized mainly by hyperbilirubinemia of the conjugated type and absence of cholestasis. Liver biopsy reveals the presence of coarsely granular, dark brown pigment in a pericanalicular location, primarily in the centrilobular zone (see Table 19.5).[708] The pigment resembles lipofuscin and melanin histologically and histochemically (variably PAS positive and acid fast, oil red O positive on frozen sections, and positive Fontana stain). Electron microscopy may allow differentiation.[709] A case of

digenic mixed hyperbilirubinemia, a distinct type of constitutive jaundice resulting from coinherited defects in *ABCC2/MRP2* and *UGT1A1* genes causing *combined Gilbert and Dubin–Johnson syndrome*, has been reported. Although the brown granular lipopigment reported in Dubin–Johnson syndrome was present in hepatocytes, liver histology was otherwise normal.[710] *Rotor syndrome* is a rare familial conjugated hyperbilirubinemia without hepatocellular pigment, and normal liver histology. The cause is unclear. It is not an allelic variant of MRP2 deficiency.[711]

Inherited Metabolic Disorders

Inherited metabolic defects leading to hepatic abnormalities are many and involve disorders of porphyrin, carbohydrate, protein and glycoprotein, amino acid, lipoprotein, lipid, and metal metabolism. Comprehensive reviews and texts should be consulted for a full description of morphologic changes and differential diagnoses.

The **endoplasmic reticulum storage diseases** are a group of inborn errors of metabolism affecting secretory proteins, resulting in retention of the protein in the endoplasmic reticulum and deficiency of the corresponding protein in the plasma.[712] The most important is α1-AT deficiency. Others include α1-antichymotrypsin (α1-ACT) deficiency and fibrinogen storage disease. The storage results from a molecular abnormality of the protein, thus hindering its transfer through the endoplasmic reticulum.

α1-Antitrypsin deficiency. α1-AT is a serum glycoprotein and protease inhibitor (Pi). As an acute phase reactant, serum levels are increased by hormonal influences, inflammatory stimuli, and most liver diseases. More than 70 allelic variants of α1-AT have been described.[713,714] The usual phenotype of the Pi system is PiM, and the most common deficiency alleles are PiZ and PiS. Liver abnormalities are mainly found in individuals carrying the Z allele. An amino acid substitution (lysine for glutamic acid at position 342) causes abnormal folding and retention of α1-AT in the rough endoplasmic reticulum, resulting in failure of secretion and plasma deficiency.[715]

α1-AT deficiency may be associated with cholestasis in neonates and may also present with liver disease in adults, including older people.[716,717] Periportal hepatocytes contain eosinophilic, PAS-positive, diastase resistant globular inclusions ranging in diameter from 1 to 10 μm (Fig. 19.63A and B). The inclusions are difficult to detect in infants less than 3 months of age. Immunostaining with polyclonal anti-α1-AT antibody may be useful, but there is often high background staining. Use of a specific monoclonal antibody allows identification of the PiZ gene products.[633] The abnormal globules can be seen within the endoplasmic reticulum on electron microscopy as well.[718] Immunoreactive globules may be found in several other liver diseases,[719] thus necessitating α1-AT phenotyping in plasma by immunodiffusion or electrophoresis for final diagnosis.

In children, the most common presentation is neonatal cholestasis, which is seen in 11% of infants and usually resolves without therapy by 6 months of age. The histologic changes may include parenchymal giant cells, ductular reaction, and fibrosis, and in some cases also PILBD.[720] The disease in this instance may resemble BA, hence the need to screen for α1-AT deficiency prior to a Kasai procedure. Persistence of hyperbilirubinemia beyond 1 year of age heralds a poor prognosis.[721,722]

The course is highly variable, however, and many children with abnormal transaminases and jaundice normalize spontaneously.[723]

α1-AT–deficient adults usually present with pulmonary emphysema.[724] The incidence of liver disease increases with age[725]; about one-third of genetically susceptible adult patients with the most severe phenotype, PiZZ, develop clinically significant liver injury.[714] An increased prevalence of HBV and HCV has been found in α1-AT deficiency patients and may contribute to the development of liver disease.[726,727] An increased incidence of hepatocellular carcinoma has been documented in adult homozygous PiZ patients with or without cirrhosis.[728] Heterozygosity for α1-AT Pi types does not appear to be associated with an increased risk for hepatocellular or bile duct carcinoma[729]; however, heterozygosity for PiZ type confers an increased risk for chronic liver disease in middle-aged or elderly adults.[730]

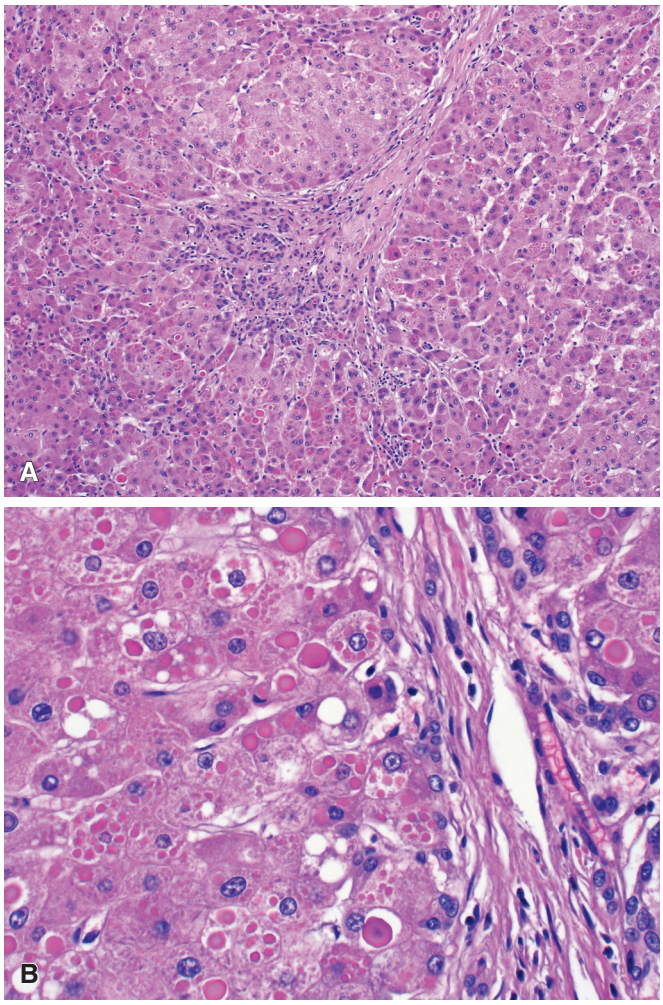

Figure 19.63 Alpha1-Antitrypsin Deficiency. A, Cirrhosis with numerous globules present on H&E stain. **B,** High-power view of globules of various sizes in periportal hepatocytes.

α1-ACT deficiency has also been described in a few cases with granular *α1*-ACT inclusions in periportal/periseptal hepatocytes.[728] Eosinophilic, PAS-positive, diastase-resistant globules have also been described in *antithrombin deficiency*.[712,731]

Fibrinogen storage disease (afibrinogenemia and hypofibrinogenemia) is associated with hepatocellular inclusions which are small and irregular or large and spherical. They are weakly PAS–diastase positive, stain with phosphotungstic acid–hematoxylin (PTAH), and are immunoreactive with antifibrinogen antibodies. In some patients, cirrhosis may develop.[142] The ground-glass cells of fibrinogen storage disease need to be differentiated from those caused by other etiologies (see earlier). Fibrinogen storage disease may occur without hypofibrinogenemia and manifest as minimal hepatitis without coagulopathy.[732] On rare occasions, fibrinogen storage disease without hypofibrinogenemia has been observed in association with acute infection.[733]

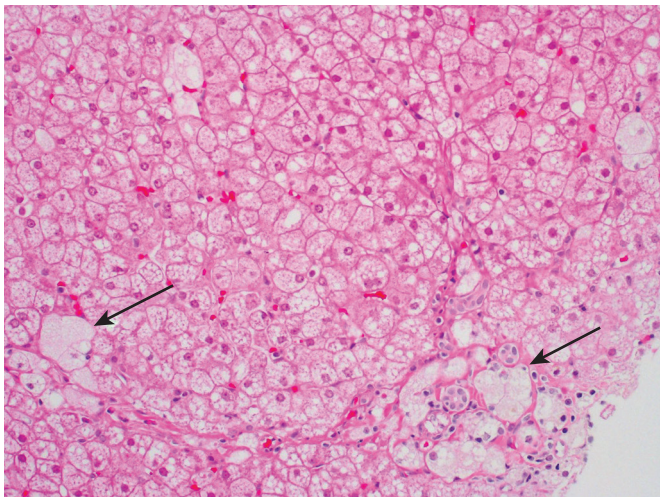

Figure 19.64 Niemann–Pick cells are pale, enlarged histiocytes with amphophilic foamy cytoplasm *(arrows)*, which are clearly seen amidst the hepatocytes. Vacuolated pale inclusions are present within the cytoplasm.

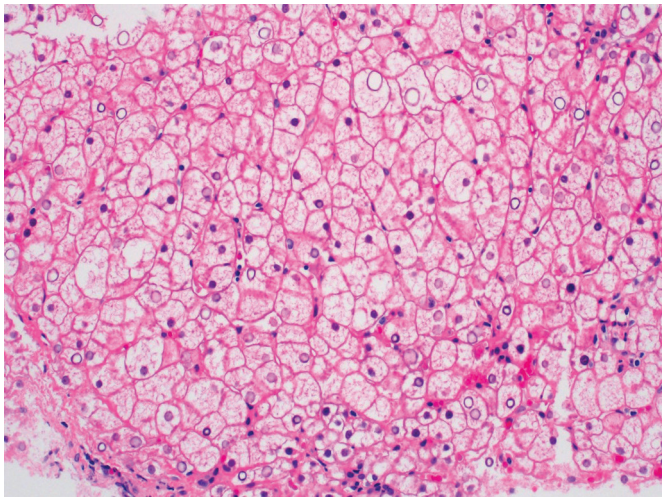

Figure 19.65 Glycogen storage disease type 1 featuring the characteristic "mosaic" pattern, featuring swollen hepatocytes with prominent cell membranes that compress sinusoids. Glycogenated nuclei are also easily visible.

Other storage diseases that may affect the liver include *Gaucher disease*,[734] an autosomal recessive sphingolipid storage disease resulting in the accumulation of glucosylceramide; *Niemann–Pick disease*,[735] a similarly autosomal recessive storage disease resulting in the accumulation of sphingomyelin (Fig. 19.64); and the *glycogen storage diseases*, due to inborn errors of carbohydrate metabolism due to mutations in the genes involved in glycogen metabolism (Fig. 19.65).[736] All of these may result in cirrhosis, and some subtypes of glycogen storage disease are associated with an increased risk of developing hepatic adenoma and hepatocellular carcinoma.

Disorders of Copper and Iron Metabolism

Indian Childhood Cirrhosis

ICC, originally thought to be specific to the Indian subcontinent, has also been reported elsewhere, even in whites.[737–739] This copper overload disease carries a high mortality and sometimes appears familial. The pathogenesis was originally believed to involve both genetic factors and increased exogenous copper intake (tap water, cooking utensils), but the importance of exogenous copper exposure has been questioned in more recent studies.[740]

Histopathology reveals hepatocellular swelling and ballooning in the early stages, with MDBs and necrosis. Accumulations of neutrophils (satellitosis) may be seen as well as pericellular fibrosis, similar to steatohepatitis, but fatty change is virtually absent. Huge amounts of copper and copper-binding protein can be demonstrated in the hepatocytes by rhodanine and orcein stains, respectively.[741,742] Ultimately patients develop a type of cirrhosis characterized by very small parenchymal nodules.

Endemic Tyrolean infantile cirrhosis, clinically and pathologically indistinguishable from ICC and hepatic copper toxicosis, has similarly been attributed to the synergy of an autosomal-recessive inherited defect in copper metabolism and excess dietary copper, although like ICC the role of exogenous copper has come into question.[740] Replacement of untinned copper cooking utensils by modern industrial vessels has apparently eradicated the disease, however, strongly suggesting that the endemic Tyrolean childhood cirrhosis—and by analogy non-Wilsonian hepatic copper toxicosis occurring elsewhere—is an ecogenetic disorder requiring the involvement of both genetic and environmental factors for the disease to become manifest.[743]

Wilson Disease (Hepatolenticular Degeneration)

Wilson disease results from tissue injury by copper overload in the liver and other organs (brain, cornea, and kidneys). It is a rare autosomal recessive disorder, the gene mutation of which is localized on chromosome 13q14–21. The implicated gene is a P type ATPase that transports copper.[744] Copper deposition in the hepatocytes is complex, with several factors involved besides the Wilson ATPase, including copper transporters, metallochaperones, and metallothionein.[745]

Homozygous subjects have increased copper levels in the liver at a very young age, but symptoms of liver disease do not typically develop before the age of 5 years.[746] The disease may manifest itself as acute hepatitis or as chronic hepatitis. In untreated patients, the disease progresses to cirrhosis. Fulminant hepatic failure may be the first manifestation of Wilson disease, associated with extensive parenchymal necrosis, collapse of the reticulin framework, nodular parenchymal regeneration, and postnecrotic cirrhosis.[747]

Histologic liver abnormalities precede the clinical appearance of disease. In the early stage there is usually steatosis and sometimes lipogranulomas. Lipofuscin may be strikingly abundant in periportal hepatocytes, as may glycogen vacuoles in their nuclei.[748] Kupffer cells may be laden with iron as a result of the acute hemolytic crises that frequently complicate the disease. Electron microscopy may reveal characteristic mitochondrial and lysosomal changes.[749] Progressive fibrosis develops with fine septa extending from portal tracts. In some patients portal tracts become infiltrated with mononuclear inflammatory cells, creating a picture indistinguishable from chronic hepatitis due to other causes.[93,94,748] Helpful diagnostic clues include steatosis, ballooned hepatocytes, glycogenated nuclei, moderate to marked copper deposition, presence of MDBs in periportal hepatocytes, lymphocytic portal and interface inflammation, and occasionally occlusive venous lesions (Fig. 19.66A).[748] The MDBs associated with copper intoxication resemble those present in fatty liver disease. Accumulation of p62 in Wilson disease, ICC, and idiopathic copper toxicosis and deposition in MDBs indicates a central role of protein misfolding induced by oxidative stress in copper-induced liver toxicity.

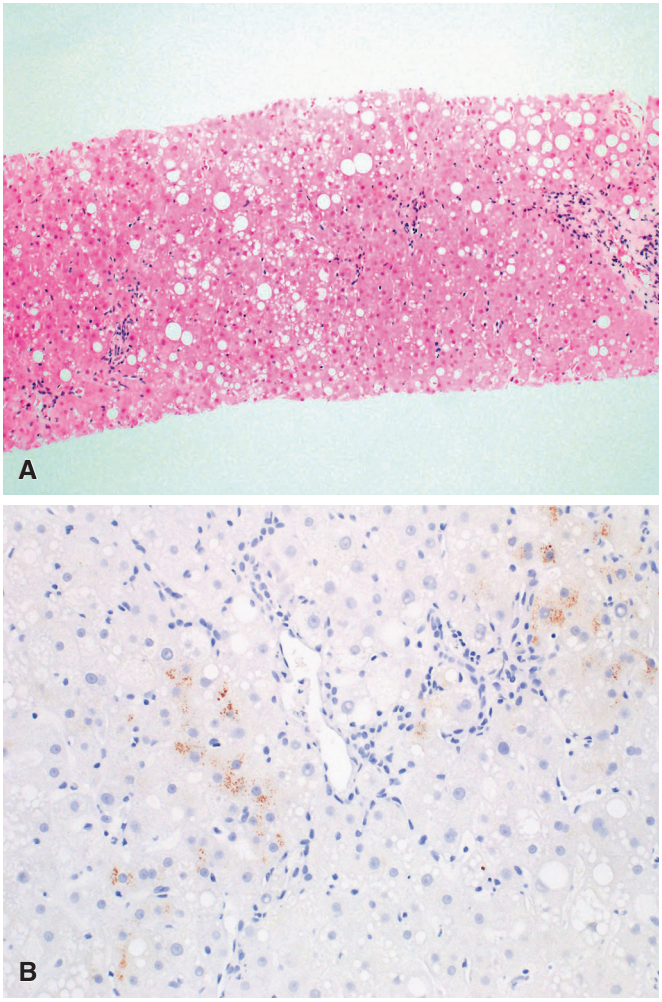

Figure 19.66 **A,** Biopsy from a patient with Wilson disease shows features of steatohepatitis. **B,** Patchy copper staining is a clue to the diagnosis (rhodanine stain).

By sequestering potentially harmful misfolded ubiquitinated proteins as inert cytoplasmic inclusion bodies (e.g., as MDBs), p62 may be a major player in an important cellular rescue mechanism in oxidative hepatocyte injury.[750]

Cytochemical staining for copper and copper-binding protein may be useful in establishing the diagnosis (Fig. 19.66B). However, stains may be negative in some stages of the disease, thus it is important to remember that a negative copper stain does not exclude the diagnosis. In young asymptomatic patients with Wilson disease, hepatic copper levels are often high, but staining may be difficult to demonstrate histochemically because of diffuse distribution in the cytoplasm of hepatocytes; copper stains may reveal at most a faint cytoplasmic staining. In older patients with signs of disease, the metal is both diffusely distributed and intralysosomal, while in patients with advanced disease all the copper is confined to lysosomes,[751] resulting in a granular pattern that is more easily recognized. In the cirrhotic stage, parenchymal nodules may vary strikingly in copper content. On the other hand, copper and metallothionein may accumulate in other diseases (e.g., chronic cholestatic liver disease, ICC) and, furthermore, neonatal liver usually contains high levels of copper.[752] Quantitative determination of hepatic copper may be necessary for final diagnosis; this can be performed on routinely processed paraffin-embedded tissue.[753] Timm silver stain appears to be the most sensitive technique,[754] but the sensitivity of this method in revealing copper deposits in liver cells appears to be dependent on the dewaxing time in xylene; rinsing sections in xylene for 24 hours give the best results.[755] Copper–metallothionein complexes show autofluorescence (which is quenched by paraffin embedding) in frozen sections from snap frozen specimens.[756] Staining results for copper and copper-binding protein are usually equal but may on occasion give divergent results.[757]

The great variety of possible lesions in Wilson disease creates difficult problems for the histopathologist. It must become a habit to consider Wilson disease in the differential diagnosis of hepatocellular disease at all ages but especially in the young. This may save lives. Treatment (penicillamine or zinc acetate) may arrest the disease in patients and prevent its development in siblings.

Iron Overload

The terms siderosis and hemosiderosis refer to the presence of demonstrable iron in tissues. The causes of iron overload are many, including but not limited to genetic hemochromatosis, siderosis secondary to chronic anemia, neonatal iron overload, blood transfusion, hemolysis, chronic renal failure, and PCT. It is preferable not to use the terms hemosiderosis and hemochromatosis as synonyms for iron overload and to reserve the term hemochromatosis specifically to indicate genetic (or hereditary) iron overload. Faced with hepatic siderosis, the pathologist should always consider the possibility of genetic hemochromatosis.

Siderosis is usually demonstrated by the Perls stain (using acid ferrocyanide), which gives the Prussian blue reaction with the ferric compounds ferritin and hemosiderin. Ferritin dispersed in the hyaloplasm gives a diffuse bluish tint to the cell's cytoplasm, whereas intense blue granules correspond to ferritin and hemosiderin packed together within siderosomes (or iron-laden lysosomes).[758] Evaluation of the Perls stain requires attention to both the extent (grade or amount) of stainable iron and its distribution in all the different cell types of portal tract and lobule. Because of the sensitivity of the iron stain, and in view of the numerous conditions in which iron deposition of more or less diagnostic importance may be identified, many recommend that a Perls stain be routinely performed in all liver biopsies.

Iron distribution may vary according to the cause of siderosis. It is predominantly parenchymal in hemochromatosis and neonatal iron overload. Secondary siderosis may preferentially affect Kupffer cells, but both hepatocytes and Kupffer cells store iron in thalassemia. Dense Perls-positive granules are found in endothelial cells in various liver diseases, including acute hepatitis and alcoholic liver disease.

Semiquantitative assessment of stored tissue iron can be achieved in different ways. The simplest system grades from 1 (minimal) to 4 (massive deposits), with grades 2 and 3 indicating intermediate amounts. Basset and colleagues[759] introduced the HII, representing the chemically measured hepatic iron concentration (HIC; μmol/g dry weight) divided by the patient's age in years. It enables the distinction of genetic hemochromatosis (HII of 1.9 or more) from heterozygous individuals and patients with siderosis from other causes. The HII is based on the principle that progressively increasing HIC is found in homozygotes for genetic hemochromatosis, unlike what happens in heterozygotes or in patients with alcoholic siderosis. Chemical determination of tissue iron can be performed on a separate piece of liver tissue obtained when the biopsy is performed, or on the deparaffinized block after histopathologic study is completed. The latter procedure ensures that the adequacy of the sample is known.[392]

The semiquantitative and quantitative procedures mentioned previously have lost a considerable part of their importance since

the genetic diagnosis of hemochromatosis became possible.[760] As it often happens with the development of noninvasive diagnostic techniques for liver diseases, genetic screening has changed the need for liver biopsy. The latter is no longer considered necessary for diagnosis or for simple visualization or semiquantitation of excess hemosiderin deposition, and modern MRI obviates the necessity of tissue procurement for biochemical quantification.[761] However, liver biopsy remains of interest in the assessment of fibrosis and for determining the possible existence of other concurrent liver diseases.[762] Furthermore, only liver biopsy evaluation allows determination of the cellular and zonal deposition of hemosiderin.[763]

Hereditary Hemochromatosis

Hereditary hemochromatosis is an autosomal recessive disease and the most common inherited disorder in whites.[764] Classic hemochromatosis is caused by a missense mutation in the *HFE* gene located on the short arm of chromosome 6. In Northern Europe, more than 90% of *HFE*-linked hemochromatosis patients are homozygous for the C282Y mutation.[760] A less common missense mutation is a substitution at amino acid 63 (H63D), with fewer clinical effects. However, a compound heterozygosity for C282Y and H63D may also cause disease expression.[760]

The pathogenetic mechanism leading to the gradual accumulation of iron stores in the body consists of a persisting minor increase in dietary iron absorption that overrides the dietary regulator during the lifetime of a patient. The precise details of the mechanism of iron overload still need further elucidation, but since the discovery of the *HFE* gene in 1996, a better insight has been reached regarding the players involved. In addition to previously known molecules (transferrin and transferrin receptors [TfR1 and 2], ferritin), these include a number of newcomers: the duodenal enterocytic divalent metal transporter (DMT1), iron regulatory proteins (IRPI and IRPII), ferroportin (a transmembrane protein exporting iron from inside to outside the cell), hephaestin (a ferroxidase and ceruloplasmin homolog), the regulatory peptide hormone hepcidin (encoded by the evolutionary conserved *HAM* gene), and hemojuvelin (a regulator of hepcidin expression, encoded by the *HJV* gene).[765–767]

In brief, hereditary hemochromatosis includes both *HFE*-linked and non-*HFE*-linked hemochromatosis. Non-*HFE*-linked disease with iron overload can be caused by deficiencies of various molecules involved in iron transport, and are categorized as juvenile hemochromatosis (or hemochromatosis type 2; this category is subdivided into the more frequent juvenile hemochromatosis type 2A with *HJV* mutation, and the less frequent juvenile hemochromatosis type 2B, caused by *HAMP* mutation); TfR2-linked hemochromatosis (or the rare hemochromatosis type 3, with mutations in TfR2, mostly in Japanese patients), and ferroportin-linked iron overload (or hemochromatosis type 4 or ferroportin disease, with mutation in the ferroportin gene *SLC40A1*).[765–767] The classic *HFE*-linked variant remains the standard against which other forms of iron overload are compared.[763]

Classic *HFE*-linked hemochromatosis (hemochromatosis type 1). The standard histopathology corresponds to the original descriptions of Scheuer et al.[768] and consists of an intrahepatocellular accumulation of hemosiderin granules in a lysosomal (pericanalicular) location (Fig. 19.67), occurring in a decreasing zonal gradient of hepatocellular iron storage from portal to central zones that persists even in stages of heavy iron overload. However, this pattern is neither specific nor exclusive to C282Y homozygosity, since it is also observed in varying combinations of heterozygosity for C282Y and/or H63D, and with other forms of chronic liver disease.[763,769] It has otherwise been established that not all subjects with *HFE* mutations have complete phenotypic expression of the classical clinicopathologic manifestations of hereditary hemochromatosis.[770]

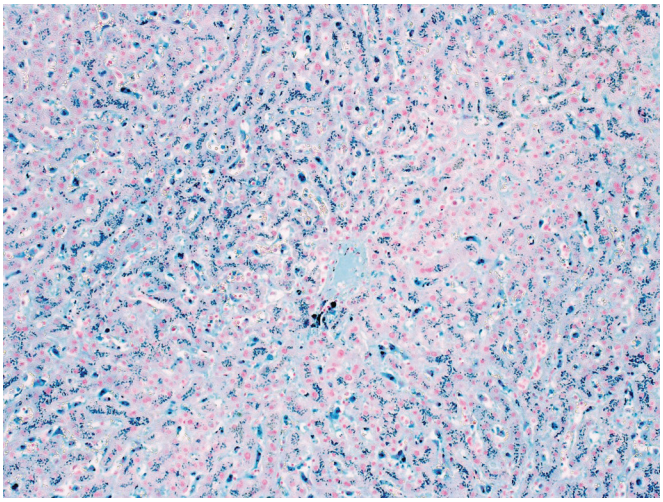

Figure 19.67 Siderosis in Hepatocytes and Macrophages in Genetic Hemochromatosis. There is a decreasing portal–central gradient that can be appreciated even in advanced disease. (Perls iron stain.)

In young homozygotes, the first abnormality is the appearance of stainable iron in periportal hepatocytes, with positivity in males generally being greater than in females of the same age. Unexplained small amounts of iron in hepatocytes should always raise suspicion about a possible early stage of genetic hemochromatosis. This is highly important because cirrhosis can be prevented by appropriate treatment in both the patient and homozygous relatives, with return of life expectancy to normal.[771] With advancing age, the deposition of hemosiderin progresses toward the centrilobular area but usually maintains a portal—central gradient. Biliary epithelium, Kupffer cells, sinusoidal and vascular endothelial cells, and macrophages in portal tracts and septa may also accumulate iron. Some authors report the occurrence of foci of eosinophilic or lytic hepatocellular necrosis of iron-laden hepatocytes, often in close association with clusters of macrophages (so-called sideronecrosis). This provides a dynamic view of the iron overload process and suggests that sideronecrosis and progressive sinusoidal iron overload play a role in the development of fibrosis in human genetic hemochromatosis.[772] Later studies confirmed a correlation between inflammatory cell markers, proinflammatory and profibrotic cytokines, and iron deposition in hemochromatosis.[773] With progressing siderosis, fibrosis indeed develops with expansion of portal tracts and appearance of small fibrous spurs conferring a spiked contour to portal tracts (holly leaf–like). The enlarged portal tracts carry iron-laden macrophages, and there is some increase in ductular profiles, often with only mild inflammation. The cholangiocytes of ductules and interlobular ducts begin to accumulate granules of stainable iron. The proportion of iron located outside hepatocytes versus hepatocellular iron rises progressively.

Periportal fibrosis proceeds with slender periportal septa that join portal tracts and progressively envelop the lobules, resulting in a combination of discrete parenchymal nodules and partially preserved lobules, a pattern characteristic of hemochromatosis.[774] Still further advancement of disease results in a diffuse micronodular cirrhotic pattern with portal-based septal fibrosis.

Excessive alcohol consumption induces a shift of hemosiderin from parenchymal to Kupffer cells and macrophages in the fibrous septa.[774] In later stages of heavy iron overload, occasional small areas can be found with or without very little parenchymal siderosis

and with only some Kupffer cell iron deposition. Such parenchymal iron-free areas are most often seen in established cirrhosis and may indicate a preneoplastic or neoplastic lesion.[775] Hepatocellular carcinoma occurs with an incidence of approximately 15%, predominantly in males. Tumor development is not prevented by removal of iron.[771]

Effective treatment with therapeutic phlebotomies results in a steady disappearance of stainable iron; the pattern of iron removal is the reverse of its accumulation, with periportal hepatocytes remaining iron positive for longer. Iron encrusted in portal collagen is most resistant to removal. Iron removal unmasks a brown lipofuscin-resembling pigment in hepatocytes and portal mesenchyme.

The range of hepatic pathology in C282Y/H63D compound heterozygous patients with and without known underlying liver disease has been studied, and considerable histologic fibrosis can be found in compound heterozygous patients without known underlying liver disease.[776] However, heterozygosity for the hemochromatosis defect is rarely associated with liver damage due to iron alone.[777] One study compared the hepatic histopathologic features and HIC among patients with phenotypic hemochromatosis and different HFE genotypes. C282Y/H63D compound heterozygotes and other non-C282Y homozygotes who expressed the hepatic hemochromatosis phenotype frequently had evidence of steatosis or chronic hepatitis and lower body iron stores than C282Y homozygotes, suggesting that concomitant liver disease may explain the expression of the hemochromatosis phenotype among non-C282Y homozygotes.[778] There are marked differences in the prevalence of the C282Y mutation of the *HFE* gene in patients with different liver diseases, with the highest prevalence rates in AIH and PBC. The C282Y mutation alone leads to only a mild increase in iron accumulation in the majority of the patients, with the exception of H63D/C282Y compound heterozygotes.[779]

Non-HFE-linked hemochromatosis. In this group of disorders, the histopathologic changes may or may not be indicative of a particular mutation.[763,765,766] The entities C282Y *HFE*, TfR2 and hepcidin *(HAM)*-linked mutations result mostly, although not exclusively, in predominantly hepatocellular pericanalicular hemosiderin deposition, with higher periportal iron load, and therefore cannot be distinguished by histopathologic examination. In contrast, the disease(s) caused by ferroportin mutation are characterized initially and predominantly by Kupffer cell iron load, also in the periportal zone. Of interest is the observation that the liver is one of the primary damaged organs in all forms of hemochromatosis with the exception of hepcidin *(HAM)*-linked hemochromatosis, in which endocrine and cardiac manifestations prevail.[763,765,766]

Neonatal Hemochromatosis

Neonatal hemochromatosis (NH) is a rare and enigmatic disease that has been clinically defined as severe neonatal liver disease in association with extrahepatic siderosis.[780] Liver histopathology is characterized by marked hepatocellular necrosis, parenchymal giant cell transformation, siderosis of hepatocytes and cholangiocytes, fibrosis, and parenchymal nodule development during fetal life and in the perinatal period (Fig. 19.68).[781] The etiology is unknown; there is no relationship with genetic hemochromatosis. Putative environmental agents have been suspected to interact with one or more factors intrinsic to the developing fetal liver.[782] An alloimmune mechanism is also considered for the pathogenesis of this disorder.[780]

Hepatic Siderosis of Varied Etiology and Secondary Hemosiderosis

The human fetal and neonatal liver often shows prominent hepatocellular siderosis, mostly in periportal hepatocytes[782]; the iron content shows a striking interindividual variability and uneven distribution throughout the liver.[783] Hepatic iron overload associated with fibrosis and cirrhosis occurs in patients with thalassemia and other forms of chronic anemia (often termed "secondary hemochromatosis"); in these cases, Kupffer cell and macrophage siderosis is present from the early stages. In contrast with genetic hemochromatosis, there is often more portal and lobular lymphocytic infiltration, which in the past has often been due to transfusion-related viral hepatitis C.[784]

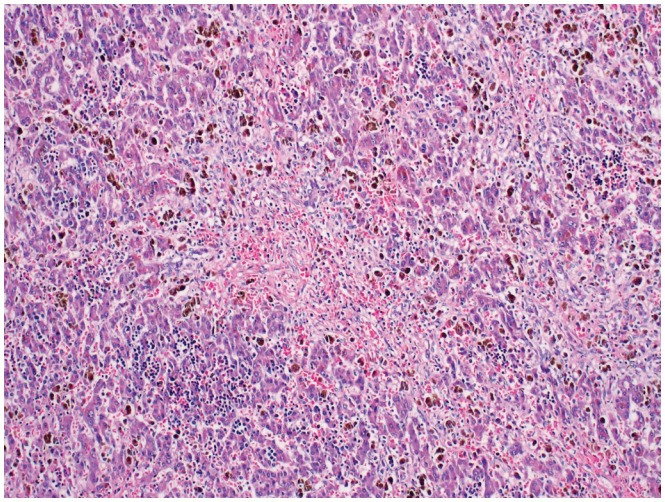

Figure 19.68 Neonatal hemosiderosis is characterized by iron deposition in hepatocytes and Kupffer cells, giant cell transformation, and increased fibrosis. Extramedullary hematopoiesis is also prominent in this case from a neonatal autopsy.

African iron overload (AIO), previously termed Bantu siderosis, has been thought to be due to ingestion of excessive amounts of iron (among others self-medication with iron compounds and use of iron containers by native South Africans for brewing traditional beers). It is now postulated that AIO may have both dietary and genetic components.[785] Histopathology reveals combined reticuloendothelial and hepatocellular siderosis.

Some degree of hepatic siderosis is common in chronic liver disease and cirrhosis in general,[786] including iron accumulation of varying degree secondary to chronic HCV infection, alcoholic liver disease, NAFLD, hepatocellular carcinoma, and PCT.[787] Patients with NAFLD and hepatic iron overload (dysmetabolic hepatic iron overload [DHIO]) show appropriate regulation of mRNAs encoding proteins involved in iron uptake and efflux but dysregulation of hepcidin production.[788] A significant association exists between *PCT* and these liver disorders (including chronic HCV infection, alcohol abuse, iron overload, and hereditary hemochromatosis). Siderosis is present in a majority of these patients.[789]

Fibropolycystic Diseases (Ductal Plate Malformation)

Hepatobiliary fibropolycystic diseases[790] comprise a series of congenital abnormalities involving the intrahepatic bile ducts, most of them related to an abnormal remodeling of the embryonic ductal plate.[791–794] The primitive embryonic form of the developing intrahepatic bile ducts corresponds to a double, perforated epithelial cylinder that surrounds the future portal tracts and is termed the ductal plate.[791] Progressive remodeling of the ductal plate results in the formation of mature tubular ducts located in the portal mesenchyme. Lack of such remodeling results in the persistence of the primitive embryonic

pattern,[794] termed DPM.[795] According to the plane of section and the degree of remodeling, DPM appears in cross sections as a circular lumen containing a fibrovascular axis in its center, as rings of interrupted curved lamina around a central fibrovascular axis, or as a grossly dilated duct containing a polypoid projection.[791,794]

Modern imaging techniques of the liver allow visualization of the macroscopic abnormalities of DPM in larger branches of the intrahepatic bile duct.[796] DPM is usually associated with abnormalities in the ramification pattern of the developing portal vein, resulting in too many, too small, and too closely spaced branches ("pollard willow" pattern).[791] Two main groups of congenital diseases of intrahepatic bile ducts are characterized by DPM: a subgroup of cases with extrahepatic bile duct atresia (so-called early severe form; see earlier); and diseases characterized by a variable degree of ectasia of intrahepatic bile ducts associated with more or less fibrosis—the "fibrocystic" diseases.[792,794]

Most congenital fibrocystic liver disorders are associated with variants of renal cystic disease. The mechanism of cyst formation is quite similar in renal and biliary cystogenesis in the combined renal–hepatic cystic diseases, with a remarkable role played by the primary cilia on the apical pole of renal tubular and bile duct epithelial cells. The gene products involved in the respective mutations (fibrocystin, polycystin 1 and 2) are components of the primary cilium, which plays the role of a sensory antenna in maintaining normal polarity of tubular epithelia.[797,798] The cystogenetic mechanism in isolated polycystic liver disease (PCLD) appears to be different from renal cystogenesis. Moreover, the differential findings for PRKCSH- and SEC63-associated PCLD suggest a divergent mechanism for cystogenesis in these two genetic groups of isolated PCLD.[799]

Autosomal Recessive Polycystic Kidney Disease (Infantile-Type Polycystic Disease)

The gene of autosomal recessive polycystic kidney disease (ARPKD) has been localized to chromosome 6p21–p12. It is termed polycystic and hepatic disease 1 *(PKHD1)* and encodes a receptor-like protein named fibrocystin/polyductin that is localized in the primary cilium of renal tubular cells and cholangiocytes lining the intrahepatic bile ducts.[800] Mutations of *PKHD1* result in bile duct abnormalities of the DPM type and fusiform dilation of renal collecting tubules. The hepatic lesions are fairly uniform and seldom give rise to macroscopically visible cysts. Microscopically, the portal tracts may be enlarged and contain numerous, somewhat dilated bile duct profiles corresponding to incompletely remodeled ductal plates, which sometimes are irregular in shape and extend into the periportal parenchyma. During portal tract maturation, myofibroblastic cells disappear in normal development but persist in fibrosis following DPM.[801] In surviving children, the liver and kidney lesions seem to progress, with a decrease in epithelial (hepatic and renal) tubular profiles and an increase in interstitial (hepatic and renal) fibrosis.[792,802]

Congenital Hepatic Fibrosis

CHF has been considered by several authors as the "juvenile" form of ARPKD.[803] This recessively inherited disorder classically presents with signs of portal hypertension in childhood, more rarely in adults.[804] Besides the classical portal hypertensive CHF, clinical variants include cholangitic CHF, combined portal hypertensive and cholangitic CHF, and latent CHF.

Grossly, the liver is enlarged and very hard, showing a fine reticular pattern of fibrosis. The histopathologic picture varies; some cases only reveal enlarged portal tracts with bile ducts in ductal plate configuration, whereas others show bands of connective tissue of variable thickness that link adjacent portal tracts and contain ductal plate vestigia (Fig. 19.69). The bile duct lumina may contain inspissated bile. Degradation of matrix proteins in the ductal basement membranes plays a role in cystic dilation of the ductal structures.[805] The portal vein branches are usually hypoplastic ("pollard willow" pattern); the hepatic artery branches instead may be numerous and conspicuous. In some cases, mild features of cholate stasis can be found.[803] There is usually no or only minimal inflammation, no necrosis, and no parenchymal regeneration.

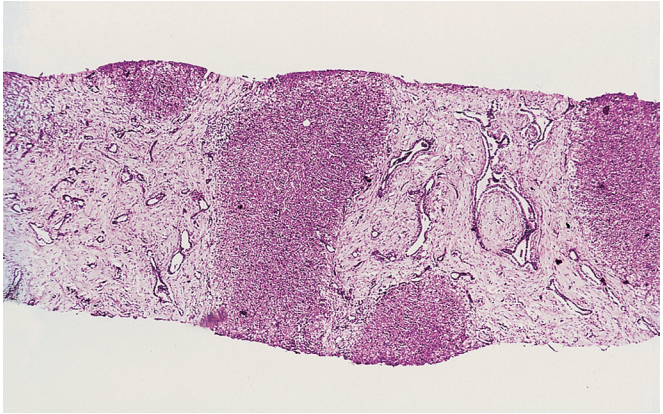

Figure 19.69 Congenital Hepatic Fibrosis. Low-power view of needle biopsy specimen. Portal tracts are enlarged and joined by portal–portal fibrous connections. Bile ducts appear in their immature, embryonic shape (ductal plate malformation). Note the mature aspects of fibrous tissue and virtual absence of inflammation.

The more fibrotic forms of CHF might be confused with biliary fibrosis and secondary biliary cirrhosis, in which the overall pattern of fibrosis may be similar; however, in the latter case the septa are inflamed, with ductular reaction at the septal–parenchymal interface, usually more marked signs of cholate stasis and bilirubinostasis, absence of ductal plate structures, and normal size of portal vein branches.

Hepatic lesions of CHF are present in a number of malformation syndromes, including medullary cystic kidney disease 1 (MCKD1); MCKD2; mutation of *UMOD2*, the gene of uromodulin; nephronophthisis–CHF (mutation in gene *NPHP1*); Meckel–Gruber syndrome (*MKS* genes); renal–hepatic–pancreatic dysplasia or Ivemark syndrome; chondroectodermal dysplasia or Ellis–van Creveld syndrome; asphyxiating thoracic syndrome or Jeune syndrome; Sensenbrenner syndrome,[806] phosphomannose isomerase deficiency or congenital disorder of glycosylation type 1b[807,808]; Joubert syndrome; vaginal atresia syndrome; and tuberous sclerosis.[792]

Caroli Disease (Congenital Dilation of the Intrahepatic Bile Ducts)

Caroli disease corresponds to a congenital dilation of the larger intrahepatic bile ducts. Two variants are recognized: a pure type characterized by only ectasia of larger intrahepatic bile ducts (Caroli disease); and a combined type in which Caroli disease is associated with lesions of CHF (Caroli syndrome).[794]

Caroli disease consists of moniliform or saccular dilations of the larger intrahepatic bile ducts, predominantly segmental ducts. The ectasias predispose to repeated attacks of cholangitis, and complications such as intrahepatic lithiasis, amyloidosis, and cholangiocarcinoma.[809] The polypoid projections or cross bridges often seen in the dilated bile duct lumina attest to the DPM nature of the lesions.[792,794] Also their appearance on liver imaging techniques as dilated ducts with a central dot is most compatible with a DPM

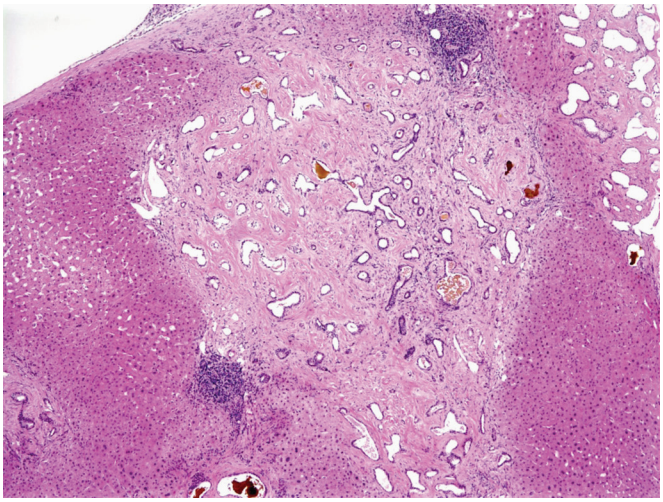

Figure 19.70 Von Meyenburg complex featuring dilated bile ductules containing inspissated bile, embedded in dense fibrous stroma. The lesion is located directly under the capsule.

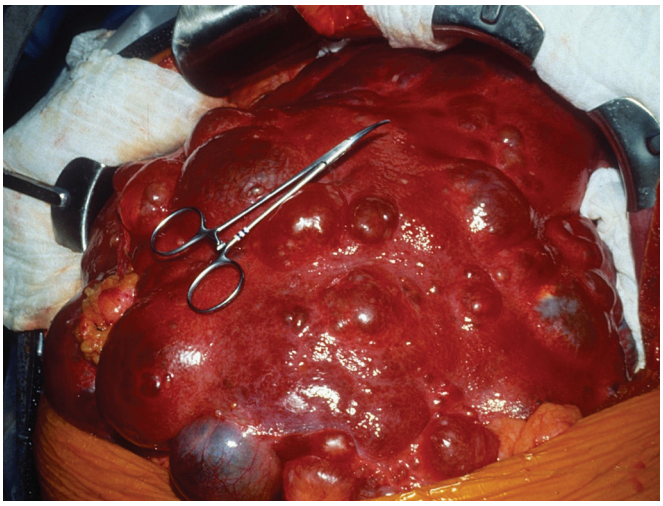

Figure 19.71 Intraoperative Photograph of Adult-Type Fibropolycystic Liver Disease. The liver is markedly enlarged and distorted by numerous cysts. (Courtesy Dr. George F. Gray, Jr.)

pattern.[810,811] Monolobar involvement in Caroli disease has been described in about 35 cases.[812] Microscopically the ducts show lesions of acute purulent cholangitis, usually superimposed on chronic sclerosing changes. Patients with *Caroli syndrome* have additional lesions of CHF.

Von Meyenburg Complex (Microhamartoma)

Von Meyenburg complexes (VMCs) are small, often multiple nodules occurring close to portal tracts throughout the liver. They may be visible as 1–2 mm white nodules on the liver surface. They may occur in an otherwise normal liver, or in association with CHF, Caroli syndrome, or adult polycystic disease.[813]

The lesion features a variable number of dilated bile ducts embedded in a fibrous, sometimes hyalinizing stroma (Fig. 19.70). Some profiles may contain inspissated bile, and some may reveal DPM configurations. VMCs do not normally cause symptoms and are often incidental findings, sometimes mistaken for hepatic metastases at surgery. The lesion apparently represents DPMs of smaller, more peripheral interlobular bile ducts in portal tracts with a "pollard willow" branching pattern.[794] Through luminal dilation and fluid filling, VMCs may be the origin of liver cyst development in subjects carrying the mutations for autosomal dominant polycystic kidney disease (ADPKD).[814] VMCs may give rise to cholangiocarcinoma[815] and have been rarely associated with hepatocellular carcinoma.[816]

Autosomal Dominant Polycystic Kidney Disease (Adult-Type Polycystic Disease)

ADPKD affects 1 in 400 to 1 in 1000 persons, representing the most common hereditary kidney abnormality. ADPKD is caused by mutations in the genes *PKD1* and *PKD2*, encoding the proteins polycystin 1 and 2, respectively.[817] Liver cysts are found in most patients with ADPKD, and their prevalence increases with age. Grossly, the liver contains multiple cysts of variable diameter (Fig. 19.71) that are disseminated throughout the organ or—more rarely—restricted to one lobe. The cavities are lined by biliary-type epithelium, surrounded by a fibrous capsule, and located in or close to portal tracts (Fig. 19.72). The cysts contain a colorless fluid with a composition close to that of the bile salt–independent fraction of bile. They may collapse,

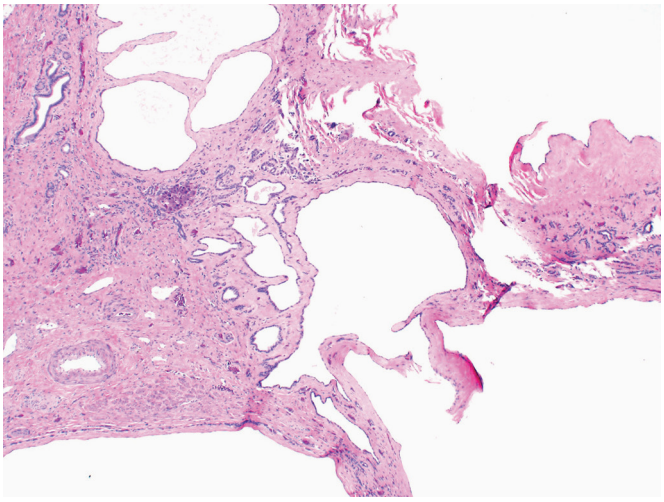

Figure 19.72 Adult-type polycystic liver/kidney disease featuring multiple cysts lined by a thin biliary epithelial lining, with a thick fibrous wall. Cysts are often associated with von Meyenburg complexes or congenital hepatic fibrosis.

resulting in structures resembling corpora atretica in the ovary. The cysts are usually associated with VMCs or with CHF. Complications are infection or rupture of the cysts. In addition to genetic factors, cyst development is further modulated by age, pregnancy, female gender, and severity of the kidney lesions.[818]

Isolated Autosomal Dominant Polycystic Liver Disease (Isolated Autosomal Dominant Polycystic Hepatic Disease or Isolated Polycystic Liver Disease)

Isolated PCLD represents a more recently discovered entity that is genetically heterogeneous. One gene for PCLD is *PRKCSH* located on chromosome 19p13.2–13.1 which codes for the "β-subunit of glucosidase II" or "protein kinase substrate 80K-H" (PRKCSH) or hepatocystin. A second gene associated with PCLD is *SEC63*, encoding an integral membrane protein of the endoplasmic reticulum, which

is part of the multicomponent translocon comprising the translocation machinery for integral and secretory proteins.[819]

The gross pathology is similar to that of ADPKD. Similar to ADPKD, the liver contains—besides the cysts—variable numbers of VMCs, the dilation of which contributes to cyst formation together with dilation of peribiliary glands of the larger bile ducts.[820] Although PCLD is characterized by larger and greater numbers of hepatic cysts than in patients with ADPKD, the clinical course is relatively benign compared with ADPKD.[821] Carbohydrate antigen 19-9 (CA 19-9), used as a biomarker to differentiate benign from malignant gastrointestinal disorders, shows high values in the cyst fluid and serum of PCLD patients due to production and secretion by cyst epithelia. These do not reflect malignancy in these patients and may be of value as a biomarker for intervention efficiency assessment.[822]

Vascular Disorders

Several comprehensive reviews of vascular disorders of the liver, including clinical guidelines, are available.[823,824] In general, hepatic vascular lesions can be subdivided functionally into those that obstruct hepatic vascular inflow (portal vein thrombosis, hepatic artery thrombosis, presinusoidal vascular obstruction); those that obstruct blood flow through the liver (intrasinusoidal malignancy, amyloid, sickle cell disease, etc.); and those that obstruct hepatic vascular outflow (hepatic venous outflow obstruction [HVOO]).[824] They can also be divided anatomically (portal venous system, hepatic venous system, sinusoids).

Diseases of the Portal Venous System

Portal hypertension is most often caused by cirrhosis of the liver but is occasionally a result of noncirrhotic etiologies including (but certainly not limited to) sarcoidosis, schistosomiasis, portal vein disorders, venous outflow obstruction, and massive liver infiltration by malignancy or amyloidosis.[825] Knowledge of the causes of noncirrhotic portal hypertension is important, as liver biopsies are often done to determine the cause of portal hypertension in patients who are not known to have cirrhosis.

HPS is a term referring to fibrous intimal thickening of the portal vein or its branches, resulting in noncirrhotic portal hypertension.[826] In the majority of patients, HPS is of unknown cause. In a small number of cases, the cause is identified as a toxin, such as arsenic,[827] vinyl chloride,[828] or cytotoxic drugs.[829] Recently, as noted previously, HPS has been identified in patients with HIV, postulated to be due to intrahepatic microthrombosis or altered hepatic fibrogenesis related to HAART or due to HIV itself.[276] Endothelial to mesenchymal transition of the portal venous endothelium via TGF-β1/Smad activation is associated with portal venous stenosis in idiopathic portal hypertension and has been suggested to be the mechanism of the portal venous obliteration.[830] What is described as "intrahepatic portal venopathy" of unknown etiology is reported as a major cause of portal hypertension in India (termed noncirrhotic portal fibrosis) and in Japan (termed idiopathic portal hypertension).[831]

Needle biopsies are not always diagnostic. The lesions are heterogeneous within the liver, and not all abnormalities are found in the same case. The hallmarks of the disease are thrombosis/sclerosis of portal vein branches and the presence of aberrant intrahepatic vessels.[832] In disease of the portal vein itself, eccentric intimal thickening suggests organized thrombosis, and smooth muscle hyperplasia of the venous media suggests arterialization of the vessel.[833] The hepatic lesions are often patchy in distribution. Microvascular portal vein disease results in a more homogeneous phlebosclerosis of smaller portal tracts.[826] Recent and old thromboemboli, with or without recanalization, may be superimposed, which characterizes the "obliterative portal venopathy" noted by Indian authors. The vein may have completely disappeared, leaving only a fibrous scar surrounded by several thin-walled vascular spaces presumably resulting from proliferating or recanalized venules ("cavernous transformation").[834] The vascular changes are accompanied by portal and periportal fibrosis of varying extent. In areas without phlebosclerotic lesions, this fibrosis may be the only histologic abnormality. Abnormal vessels occur in the periportal area, termed megasinusoids,[834] periportal angiomatosis,[626] or aberrant intrahepatic vessels,[835] which correspond to dilated terminal portal vein branches or inlet venules.[832] Similar thin-walled vessels occur randomly in the lobules; efferent veins may show sclerosis or dilation.[834]

According to some, nodular regenerative hyperplasia is always present to some degree in patients with HPS—not surprisingly so, since the pathogenesis of the two entities is similar.[832] The mild to moderate incomplete septation and development of parenchymal nodules seen in HPS is similar to that of incomplete septal cirrhosis in the nosologic spectrum of noncirrhotic portal hypertension. Furthermore, the progression from HPS to incomplete septal cirrhosis has occasionally been noted.[836] HPS, nodular regenerative hyperplasia, and incomplete septal cirrhosis are characterized by portal hypertension with only mild liver function abnormalities,[626] supporting the suspicion that these entities represent a spectrum of diseases in which nonuniformity of blood supply to the parenchyma plays a pathogenetic role. In some rare instances the cause of the portal hypertension is obscure: the liver histology is normal and no occlusion of portal or splenic veins can be identified (truly idiopathic portal hypertension).[837] A review describing practical guidelines for the histopathologic study of liver biopsies from patients with noncirrhotic portal hypertension has been published.[826]

Hepatic Venous Outflow Obstruction

HVOO, which may be caused by a number of things, should be specifically characterized by the location, cause, and nature of the occlusive lesion, in order to avoid the inappropriate and confusing use of the term *Budd–Chiari syndrome*.[838]

The histopathology of HVOO varies according to its severity and duration (acute or chronic), independent of its cause. *Acute HVOO* is characterized by dilation and congestion of sinusoids, predominantly in the centrilobular area. In mild cases, the liver cell plates may be thinned, but in severe cases, the hepatocytes become atrophic and may disappear, leaving a denuded framework of lining cells and perisinusoidal fibers. Severe disease creates a hemorrhagic, blood lake-like appearance. Erythrocytes may extravasate into the space of Disse and permeate the liver cell plates, supplanting the hepatocytes (Fig. 19.73),[839] a pattern most visible when sinusoidal red blood cells have drained out during tissue processing. *Chronic HVOO* results in centrilobular fibrosis of variable extent. The fibrotic areas eventually join, resulting in central–central bridging fibrosis that encircles normal portal tracts and their surrounding parenchyma (so-called reversed lobulation). A cirrhosis-like nodularity can evolve in advanced cases (termed cardiac cirrhosis, Fig. 19.74).

BCS is the eponym for hepatic venous outflow tract obstruction, whatever the level or the mechanism of obstruction, although it is often equated with hepatic vein thrombosis. A collaborative study involving several European centers, designed to characterize the causes and treatment of incident BCS, found that most patients with BCS have at least one thrombotic risk factor, and many have more than one; myeloproliferative disorders are most common.[840] BCS is primary when due to a primarily venous disease (thrombosis or phlebitis, Fig. 19.75) and secondary when related to compression or invasion by a lesion originating outside the veins (benign or

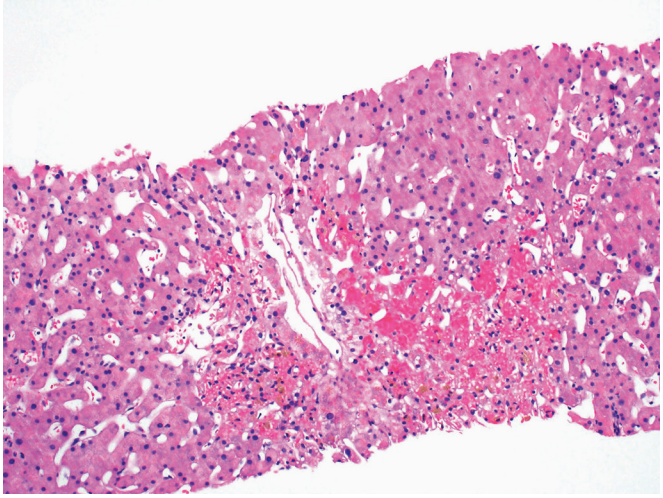

Figure 19.73 Acute hepatic venous outflow obstruction featuring sinusoidal dilatation in zone 3, with atrophy of the cell plates and extravasation of red blood cells.

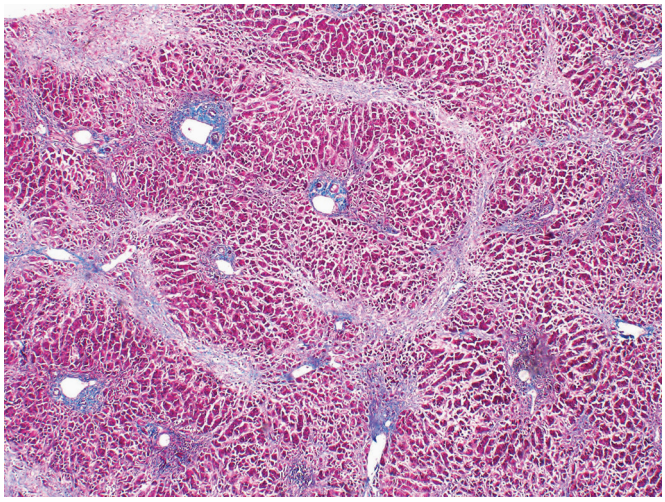

Figure 19.74 So-called cardiac cirrhosis, in which central vein to central vein fibrous bridges form nodules that encircle portal tracts. This patient had chronic congestive heart failure.

Figure 19.75 Massive hepatic vein thrombosis in Budd–Chiari syndrome; note the marked congestion of the liver parenchyma ("nutmeg liver"). (Courtesy Dr. George F. Gray, Jr.)

malignant tumor, abscess, cyst, etc.).[841] Late consequences of thromboses may take the form of fibrous webs.[842] The microscopic lesions are those of venous outflow obstruction. The centrilobular and lobular veins may contain recent or organized thrombi, presumably extensions of thrombus in the larger veins. With time, the fibrous lesions of chronic venous outflow obstruction develop. The surviving periportal parenchyma often shows evidence of regeneration; nodular hyperplasia and even cirrhosis-like nodularity may develop.[843] The liver is often unevenly affected.

Sinusoidal Obstruction Syndrome

The term *veno-occlusive disease* indicates the fibrous occlusion of the small branches of the hepatic vein less than 1 mm in diameter, without large hepatic vein occlusion. This initial lesion is followed by a cascade of events that leads to circulatory compromise of centrilobular hepatocytes, fibrosis, and venular narrowing, with obstruction of liver blood flow; hence this form of liver injury is now termed SOS.[844] This lesion can often be detected in needle biopsies. Several studies have suggested that SOS is a result of toxin-mediated injury to the sinusoidal endothelial cells. The historical cause of SOS is ingestion of pyrrolizidine alkaloids,[845] which remains a hazard.[846] It has also been described in patients who have undergone bone marrow, kidney, or liver transplantation, liver irradiation, or chemotherapy, and in those who suffer from arsenic poisoning, and heroin addiction.[847,848] Veno-occlusive lesions are further observed in alcoholic liver disease.[849] The histologic lesions include occluded hepatic venules, luminal narrowing of hepatic venules, phlebosclerosis, and centrilobular sinusoidal fibrosis and necrosis.[850]

Sinusoidal dilation is an integral feature of HVOO, but it is further observed in some drug-induced lesions (including azathioprine, long-term contraceptive use, and vitamin A toxicity), in rheumatoid arthritis, in malignant or granulomatous diseases,[851,852] and in preeclampsia and eclampsia, associated with sinusoidal fibrin thrombi and periportal ischemic hepatocellular necrosis.[853] The distribution is often zonal, and centrilobular sinusoidal dilation is the most common variety, with prominent involvement of the perivenous region extending to the midzonal region in more severe forms. Periportal dilation affects the periportal sinusoids, eventually extending more centrally. Irregular or nonzonal sinusoidal dilation is noted in many settings and is often of unknown causation; it may also be an artifact of tissue extrusion from the biopsy needle. Of diagnostic importance is its occurrence in the vicinity of intrahepatic space-occupying lesions (granulomas, tumors, and abscesses), sometimes combined with obstructive-type periportal ductular reaction. This finding in a biopsy specimen may provide evidence of a missed mass lesion and prompt additional investigation.[854]

Miscellaneous Other Vascular Lesions

Peliosis hepatis consists of the presence of cystic blood-filled spaces in the liver parenchyma.[855] The lesions may be macro- or microscopic, ranging in size from less than one to several millimeters in diameter. Lesions are randomly distributed without zonal preference. The endothelial lining is often incomplete. Classification on the basis of the presence or absence of endothelium is not warranted.[856] Peliosis occurs in association with numerous conditions including malignancy, organ transplantation, treatment with steroid hormones, and chemotherapy.[857] The lesions may be incidental findings, but occasional cases have ruptured resulting in fatal hemoperitoneum.[858] Peliotic lesions in immunosuppressed patients (e.g., AIDS), known as *"bacillary peliosis hepatis"* or *"bacillary angiomatosis,"* are caused by rickettsial organisms *(Bartonella)*, and are characterized by a myxoid stroma and clumps of microorganisms demonstrable with the Warthin–Starry

stain or molecular assays.[270] A number of vasculitides involve the liver, including *polyarteritis nodosa*,[859] which may be associated with HBV, and *Churg–Strauss syndrome*.[860] The liver may also be involved in *hereditary hemorrhagic telangiectasia*.[861]

Liver Disease in Pregnancy

Normal pregnancy does not entail specific light microscopic hepatic changes. Diseases affecting the liver in pregnancy can be subdivided into those which occur exclusively during pregnancy and those which occur simultaneously but not exclusive to gestation.[862–865]

Acute Fatty Liver of Pregnancy

AFLP is a rare but grave complication that develops in the last 10 weeks of gestation and affects predominantly primigravidae. It is the most serious of the pregnancy-associated diseases, but over the last couple of decades the prognosis has improved dramatically.[866] It is caused by a fatty acid transport and mitochondrial oxidation (FATMO) disorder of the fetus.[360] Affected livers are grossly yellow and frequently small, a reflection of substantial loss of parenchyma. The most characteristic microscopic feature is microvesicular steatosis, usually involving the entire liver lobule but sometimes sparing a narrow periportal rim of hepatocytes (Fig. 19.76). Hepatocytes containing very fine fat droplets of less than 1 µm diameter may not be recognized as steatotic, but rather appear as ballooned hepatocytes on routinely stained sections. This mimics the hydropic swelling of liver cells in acute viral hepatitis and may cause problems with diagnosis in the 10%–20% of cases in which a lymphoplasmacytic infiltrate and acidophil bodies occur.[866,867] Histochemical fat stains on frozen sections may be extremely helpful; therefore, in patients with unexplained jaundice in late pregnancy, it is wise to reserve part of the biopsy specimen for frozen sectioning and oil red O staining.[865] Fibrin thrombi are occasionally demonstrable in the hepatic sinusoids, and some patients show cholestasis, hepatocellular necrosis, extramedullary hematopoiesis, and giant mitochondria.[866,867] Termination of pregnancy and supportive care for hepatic encephalopathy and extrahepatic complications may be necessary for patient survival. AFLP rarely recurs in subsequent pregnancies; exceptions are very rare.[868]

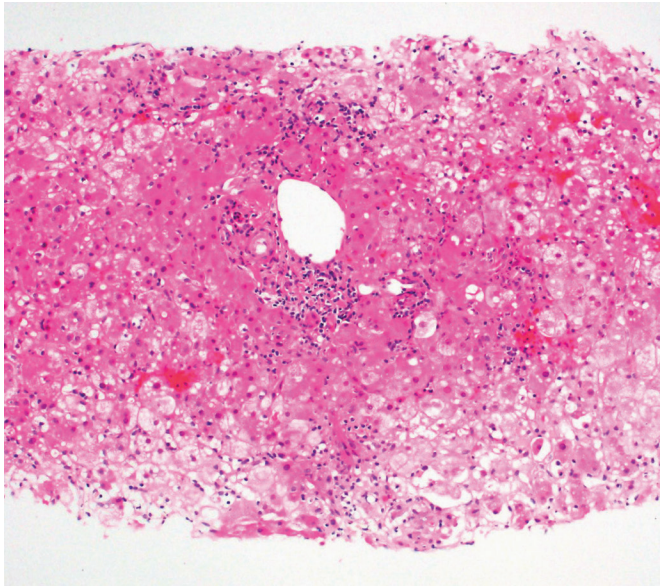

Figure 19.76 Acute Fatty Liver of Pregnancy. Ballooned hepatocytes with microvesicular steatosis are present, with a small zone of spared parenchyma around the portal tract.

Toxemia of Pregnancy (Preeclampsia/Eclampsia)

Preeclampsia is characterized by hypertension that is either induced or aggravated by pregnancy, in association with proteinuria, peripheral edema, and occasional coagulation abnormalities.[869] Convulsions and coma may follow, corresponding to eclampsia.[853,865] Preeclampsia develops in 5% of pregnancies, generally during the third trimester, and especially in primigravidae. The incidence is increased in patients with AFLP.[867] Severe preeclampsia and eclampsia cause hepatocellular dysfunction reflected by elevation of serum transaminases and/or alkaline phosphatase. Macroscopically, the liver shows diffuse, fine or blotchy hemorrhages over the capsule and on the cut surface.[853,865] Endothelial injury and disruption cause intravascular coagulation. Histologically, fibrin thrombi are found in portal vessels and periportal sinusoids, in variable combination with hemorrhage and hepatocellular necrosis. Fibrin can be identified by PTAH staining or immunohistochemistry. Extensive liver damage may lead to liver failure, and two rare complications—rupture preceded by subcapsular hematoma and infarction of the liver—often prove fatal.[853]

HELLP Syndrome

The acronym HELLP stands for hemolysis, elevated levels of liver enzymes, and low platelet count. The syndrome is exceedingly rare and occurs in preeclamptic women.[870] The characteristic features are periportal hemorrhage, hepatocellular necrosis, and fibrin exudate.

Intrahepatic Cholestasis of Pregnancy

ICP is a reversible form of cholestasis, usually occurring in late pregnancy and persisting until delivery.[871] The incidence of ICP in Europe is approximately 10–150 per 10,000 pregnancies. Quality of life can be impaired by pruritus, jaundice, and fat malabsorption; the prognosis for the mother is good, but ICP may be a condition with lethal outcome for the unborn child. Heterozygote mutations of hepatobiliary transport proteins (*MDR3* and *BSEP*)[646,651] predispose to ICP. However, overall ICP is a syndrome with a heterogeneous pathogenesis, including genetic, hormonal, and environmental factors.[872] In general, liver biopsy is unnecessary for diagnosis. Histopathology reveals canalicular and hepatocellular bilirubinostasis, especially in the centrilobular area.[651,873]

Coincident liver diseases that may be encountered during pregnancy include viral hepatitis, cholelithiasis, and preexisting liver disease.

Liver Involvement in Systemic Diseases

This section is restricted to some more frequently observed lesions. For full coverage of the topics, the reader is referred to comprehensive textbooks of hepatic pathology.

Granulomatous Liver Disease

Epithelioid granulomas are present in 3%–10% of liver biopsies,[264] the incidence varying according to geographic location and method of selection of patients for biopsy. An adequate evaluation of hepatic granulomatous lesions requires careful histologic evaluation of the granulomas themselves and of the associated changes (e.g., hepatitis, bilirubinostasis, bile duct damage), as well as correlation with clinical history and laboratory information. Special techniques may be helpful,

for example special histochemical stains (Ziehl–Neelsen, silver methenamine), immunohistochemistry, or molecular assays for organisms; polarizing microscopy for inclusions; and x-ray microanalysis (e.g., for gold, barium, silicon).[264,874] According to one study, a combined histologic, clinical, serologic, and molecular approach can clarify the etiology in up to 64% of cases.[875]

Sarcoidosis

Hepatic sarcoidosis covers a broad spectrum from asymptomatic hepatic granuloma formation and slightly deranged liver function tests to clinically evident disease with cholestasis or, in advanced cases, cirrhosis and portal hypertension.[876] The incidence of granulomas in livers of patients with established sarcoid varies in the literature from 21% to 79%. In liver biopsies from patients with sarcoidosis and clinical evidence of hepatic disease (a discrete subset of all patients suffering from sarcoidosis), granulomatous inflammation was found in 100% in a series of biopsies referred to the Armed Forces Institute of Pathology.[877] In this study, three broad categories of abnormalities were noted besides the granulomatous inflammation: cholestatic (58%), necroinflammatory (41%), and vascular (20%). Histologic mimics of several other disorders, including PBC, PSC, drug-induced liver disease, bile duct obstruction, and viral hepatitis were noted. Hepatic fibrosis was found in 21% of biopsies, including 6% with cirrhosis. Although these numbers may reflect referral bias, they do suggest that some patients with hepatic sarcoidosis have progressive liver disease. The epithelioid granulomas of sarcoidosis typically occur with greatest frequency in the portal and periportal areas, often in clusters (Fig. 19.77A). The granulomas may be of differing "ages" and typically heal with fibrosis, so that varying numbers and degrees of epithelioid cells, inflammation, giant cells, and scarring are often seen in the same biopsy. In a few cases, masses of granulomas and fibrosis may develop (sarcoidoma), raising clinical suspicion of a neoplasm.[877]

PBC can at times be particularly difficult to differentiate from sarcoidosis since both conditions may lead to portal granulomas, lymphocytic cholangitis, bile duct injury and destruction, ductopenia, and chronic cholestasis (Fig. 19.77B).[878,879] It is also possible that both conditions might even coexist.[880] Some sarcoidosis patients initially present with portal hypertension due to portal granulomas and fibrosis.[881] It is important to note that a final diagnosis of sarcoidosis cannot be made by histopathologic study of a liver biopsy alone, due to the multiplicity of histologically similar granulomatous diseases.

Fibrin-ring (or doughnut) granulomas show a distinctive ring pattern in which fibrin is deposited circumferentially within or at the margin of the granuloma, which is composed of epithelioid cells, giant cells, and neutrophils, and a central fat vacuole (Fig. 19.78). Serial sectioning may be required to detect the typical "fibrin-ring" configuration.[882] Originally described in Q fever, it has also been reported in allopurinol hypersensitivity, CMV and EBV infection, leishmaniasis, toxoplasmosis, HAV, Hodgkin lymphoma, giant cell arteritis, and systemic lupus. It has been suggested that it may represent a nonspecific reaction to liver injury.[313]

Echinococcus (Hydatid Cyst)

Since leakage of antigen-containing cyst fluid into the circulation may result in possibly fatal anaphylactic shock, liver biopsy is not recommended, but fine-needle aspiration is a safe diagnostic procedure.[883] The diagnosis rests on liver imaging and positive serology.

Hydatid disease is caused by the larval or cystic stage of echinococcus tapeworms, of which *Echinococcus granulosus* is the most frequent;

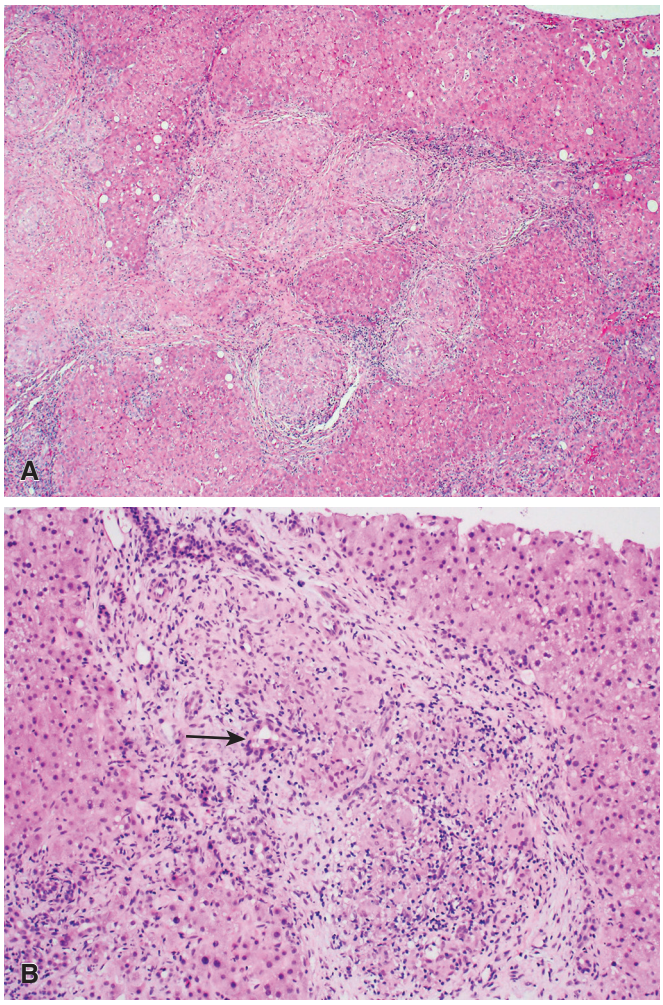

Figure 19.77 Sarcoidosis. A, Multiple confluent, noncaseating, epithelioid granulomas with associated fibrosis. **B,** Cholestatic sarcoidosis mimicking primary biliary cirrhosis. Note bile duct damage *(arrow).*

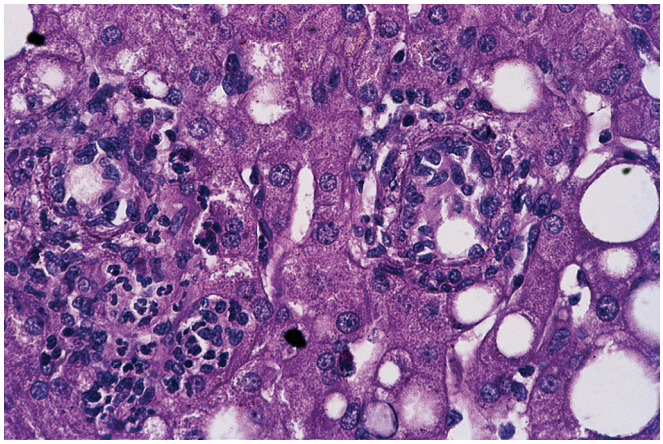

Figure 19.78 Q Fever. Detail of lobular parenchyma with some steatosis and two fibrin ring granulomas. The granuloma is composed of a central fat vacuole, a layer of histiocytes and lymphocytes, a fibrin ring, and additional accumulation of inflammatory cells.

Figure 19.79 Echinococcosis of the liver featuring multiple cysts in a resection specimen.

the adult parasites are found in dogs and jackals in all continents.[884] After ingestion of eggs of *E. granulosus*, the eggs hatch and the larval oncospheres pass to the liver by the portal vein. Three-fourths of infected individuals develop one or more hepatic cysts, which grow slowly. The typical hydatid cyst is spherical and may measure up to more than 30 cm in diameter. The majority occur in the right lobe, but they may be multiple, involving all lobes (Fig. 19.79).[885,886]

Histologic examination of the cyst wall shows an outer chitinous (or fibrous laminar) layer and an inner germinal layer. The cyst wall may be surrounded by either granulation tissue or a fibrous capsule (so-called pericyst layer). Calcification in the latter layer signifies that the cyst is dead. The adjacent liver parenchyma often shows pressure atrophy and a portal infiltrate in which eosinophils may be prominent. The viable cyst is filled with colorless fluid, which contains daughter cysts and brood capsules with scolices. In some patients, daughter cysts are found outside the chitinous layer of the cyst; these are referred to as extracapsular or satellite cysts.[887] The scolices can be easily identified after macerating a portion of the germinal layer in saline solution. They have characteristic hooklets of 20–40 µm length.

Communication with the biliary tract and superimposed infection are frequent in echinococcosis of the liver.[888] Rupture of the cysts into the peritoneal cavity may result in a fatal anaphylactic reaction or in the formation of innumerable small granulomas grossly resembling peritoneal tuberculosis. Identification of fragments of germinal membrane or scolices in the center of a granuloma points to the diagnosis. Hepatic echinococcus cysts can also rupture inside the gallbladder or through the diaphragm into the pleural space and lung. Hydatid cysts occasionally rupture into the bile ducts and cause severe eosinophilic cholangitis with extensive parenchymal destruction, apparently resulting from a hypersensitivity reaction to parasitic antigens.[889]

Echinococcus multilocularis is less common but causes a more aggressive clinical disease. The liver lesions appear as multilocular, necrotic, cystic cavities containing thick pasty material, not surrounded by a fibrous wall. Histologically, the irregular cysts have a laminated membrane, but no nucleated germinal membrane or protoscolices. The laminated membrane is clearly visualized by the PAS stain; it is often fragmented. The lesion may be surrounded by a granulomatous reaction containing neutrophils and eosinophils, or a peripheral rim of necrosis, fibrosis, and focal calcification.[890]

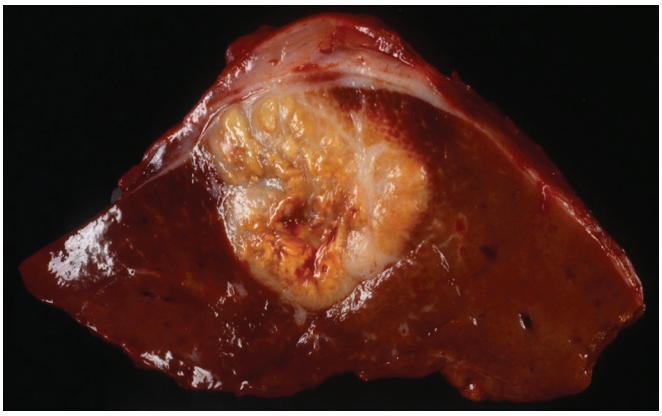

Figure 19.80 Liver Abscess With Necrotic Center and Associated Fibrosis. (Courtesy Dr. George F. Gray, Jr.)

A number of other infections cause granulomas, the majority as part of systemic disease, including *M. tuberculosis*, atypical mycobacteria, cat-scratch disease *(B. henselae)*, and fungal infections (*Histoplasma capsulatum*, *Cryptococcus* species).[264]

Malaria

The most distinctive feature is the presence of finely granular, dark brown or black pigment (hemozoin), initially in Kupffer cells and later in portal macrophages. It is birefringent and negative with PAS and iron stains. It resembles the artifactual formalin pigment and is likewise soluble in saturated alcoholic picric acid. It strongly resembles schistosomal pigment, although it differs biochemically. Anthracotic pigment, which resembles malarial pigment, is not birefringent.[891] Additional histologic changes may include focal necrosis, steatosis, and a mild mononuclear portal infiltrate.

Hepatic Abscess

The incidence of hepatic abscess had been fairly stable over the past five or six decades. However, the character of the disease has changed drastically during that time. In the past, hepatic abscesses often affected young adults; most were amebic (see later) or secondary to pylephlebitis. Today, pyogenic hepatic abscesses in the United States are often due to enteric bacteria and seen in older patients (often with diverticulosis)[892] or in HIV-infected or other immunocompromised young individuals. In the latter population, an increasing number of tuberculous "abscesses" of the liver have been detected.[893] The mortality rate for pyogenic abscess, which ranged from 30% to 80% in the past, has dropped to 10%–20% in more recent studies on the subject.[894] Important predisposing factors include liver transplantation, diabetes, alcoholism, and history of malignancy.[895] Historically *Escherichia coli* has been the primary causative pathogen, but the incidence of abscesses due to *Klebsiella* is increasing and has surpassed *E. coli* in several countries.[896] Neonatal hepatic abscesses are rare but should be considered in a neonate with ongoing sepsis.[897] They may occur in association with misplaced central (umbilical) catheters.

Hepatic abscesses vary considerably in size and may mimic tumors grossly and radiographically (Fig. 19.80). Multiplicity of lesions is seen in about half of pyogenic abscesses and 25% of amebic abscesses.[898] In slightly less than half of cases, there is communication

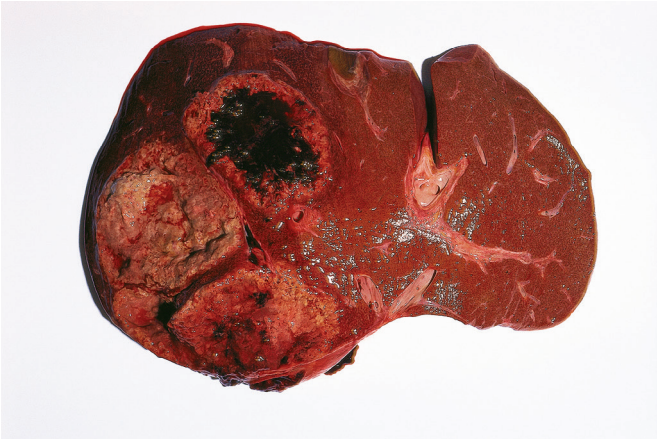

Figure 19.81 Amebic Abscesses Occupying Most of the Right Lobe of the Liver. Three distinct lesions are seen. (Courtesy Dr. RA Cooke, Brisbane, Australia; from Cooke RA, Stewart B. *Colour Atlas of Anatomical Pathology*. Edinburgh: Churchill Livingstone; 2004.)

between the abscess and the intrahepatic biliary system.[899] Treatment of hepatic abscess includes antibiotic therapy and drainage or excision.[900]

Amebic abscess is usually single, most frequently right sided, and close to the liver dome[901] (Fig. 19.81). In immunocompromised patients, it has a greater tendency for multicentricity. Most cases occur in adults, but they can also develop in infants and children.[902] The necrotic center usually contains an odorless, pasty, chocolate brown fluid. Microscopically, the bulk of the lesion consists of necrotic material with few if any neutrophils, surrounded by a layer of fibrin, macrophages, lymphocytes, and a few fibroblasts. The abscess wall is thinner than that of a bacterial liver abscess. Clusters of ameba are usually found, but extensive search may be necessary for their detection. Superinfection by bacteria may supervene, as well as extension and perforation into pleuropulmonary structures, subphrenic space, peritoneal cavity, and—less commonly—pericardial sac, bile ducts, kidney, mediastinum, chest wall, abdominal wall, and flank.[903]

Amyloidosis and Light Chain Deposition Disease

Although systemic amyloidosis commonly involves the liver, it rarely gives rise to clinically evident hepatic disease. Amyloid is recognized as a homogeneous eosinophilic or amphophilic extracellular material (Fig. 19.82A and B) displaying apple green birefringence after positive Congo red staining. Primary myeloma-associated (AL) amyloidosis and reactive (AA) amyloidosis cannot reliably be distinguished by the topographic distribution pattern of the deposits. Immunohistochemistry and mass spectrometry are typically used for amyloid subtyping.[904]

Amyloid is usually deposited in the hepatic artery branches or along the sinusoids in the space of Disse, and often occurs in both locations. Perisinusoidal deposition leads to atrophy of liver cell plates and narrowing of sinusoids, occasionally resulting in intrahepatic cholestasis and portal hypertension.[905,906] Much more rarely, amyloid is deposited in globular form. Intracellular amyloid globules and transitional forms of globular to linear deposits suggest that this is an early form of hepatic involvement by systemic amyloidosis.[907]

Homogeneous perisinusoidal and portal depositions closely resembling amyloid are seen in hepatic involvement in *light chain deposition disease*, which usually causes renal symptoms but rarely

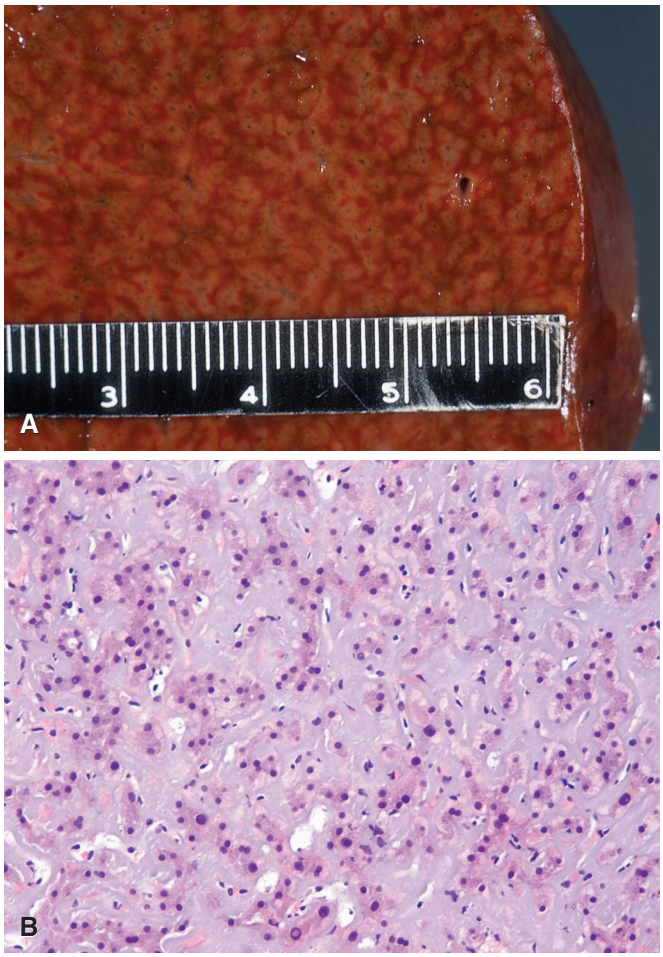

Figure 19.82 Amyloidosis. A, Gross specimen showing sinusoidal amyloid deposition. **B,** Lobular parenchyma with massive amyloid deposition in the space of Disse and corresponding marked atrophy of liver cell plates. (**A,** Courtesy Dr. George F. Gray, Jr.)

affects the liver. Immunohistochemical staining for kappa and lambda light chains permits identification of the deposits, which usually mark as kappa (Fig. 19.83). Light chain deposits are Congo red negative and show no green birefringence with polarized light. In exceptional cases, light chain deposition and amyloid are found in the same patient, even more rarely associated with intrahepatic cholestasis.[908]

Nonspecific Reactive Changes

Several primarily extrahepatic diseases, including febrile, inflammatory, and neoplastic conditions, especially in older patients, are associated with nonspecific reactive changes in the liver. One may find portal and lobular inflammation, steatosis, Kupffer cell hypertrophy, reactive hepatocellular changes, and even focal necrosis of hepatocytes. Clinical information is required for adequate distinction from mild chronic or residual hepatitis.[9,909]

In endotoxic shock and sepsis, there may be marked ductular cholestasis; the ductules may appear broadly dilated, and the bilirubin concrements may show variable degrees of inspissation and admixture of PAS-positive material. Part or all of the lining ductular cells may appear flattened, desquamating, or necrotizing, and infiltrated with neutrophil polymorphs. The dilated ductules may appear all around the perimeter of some portal tracts (see earlier, Fig. 19.45). This lesion is highly suggestive of septicemia and constitutes a

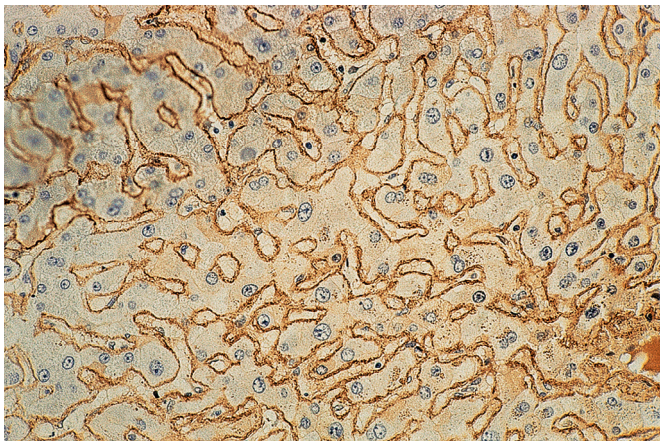

Figure 19.83 Light Chain Deposition Disease. Detail of lobular parenchyma with kappa chain deposition in the space of Disse. (Immunostain for kappa light chain.)

prognostically ominous sign ("cholangitis lenta").[499] Experimental evidence suggests that proinflammatory cytokines and nitric oxide have crucial roles as Kupffer cell–derived mediators of cholestasis. Sepsis-associated cholestasis (in its truest meaning) is caused by reduced expression and function of hepatocellular transport systems. Periductal inflammatory infiltrates, as seen in cholangitis lenta, reflect the ability of the bile-duct epithelium (i.e., cholangiocytes) to actively secrete cytokines and recruit inflammatory cells, which results in impaired ductular bile secretion. In view of its sinister prognosis, the finding of cholangitis lenta necessitates urgent reporting to the clinician.[910]

Liver Pathology in Organ Transplantation

Hepatic abnormalities may be associated with transplantation of the liver and of other organs.

If close clinicopathologic collaboration is essential in modern medicine in general, it is a necessity par excellence in the field of organ transplantation. In transplantation centers, the pathologist is part of the clinical care team, involved in evaluation of the patient's primary disease before transplantation, in identification of underlying donor liver disease (e.g., steatosis, cancer) at the time of allograft procurement, and in recognition of a wide variety of complications following transplantation.[911–913] As liver transplantation centers become established all over the world, pathologists in local hospitals who do not routinely encounter specimens from liver transplant patients may be confronted with them during patients' post-transplant medical care and follow-up, and thus need some familiarity with hepatic transplant pathology.

Most centers obtain percutaneous liver biopsies when the clinician is warned by symptoms or signs of deterioration of liver function. Some centers, however, perform biopsies, often referred to as "protocol biopsies," on a planned schedule irrespective of liver chemistry.[914,915]

Preexisting Donor Lesions

The pathologist may be requested to exclude preexisting disease in a potential donor liver by frozen section, as marked macrovesicular steatosis carries the risk of primary graft dysfunction.[916] Parenchymal involvement should be semiquantitated as absent, mild (<30%), moderate (30%–60%), or marked (>60%),[917] since the latter category is considered unsuitable for use because of the high risk of primary dysfunction of the allograft.[917,918] Although livers with lesser degrees of steatosis (<30%) can usually be transplanted safely, a period of liver dysfunction (rise in transaminases, prolonged prothrombin time) may occur in the early post-transplant period and even lead to reduced graft survival. A retrospective study comparing frozen-section analysis with routine histologic permanent slides and the outcomes of grafts in liver biopsies from 294 candidate donors led to the conclusion that intraoperative histologic evaluation of biopsies from cadaveric liver donors by frozen section is an accurate, time-effective, and predictive method for the assessment of graft suitability.[919] One study does recommend biopsies of two sites to evaluate donor livers.[920] Most fat appears to be cleared during the first post-transplant week.[921]

Due to the urgent need for liver grafts, some centers—noting that the majority of the European centers currently reject liver grafts with severe steatosis—have tested the use of severely steatotic livers with good results, though emphasizing that maximal effort must be expended when dealing with these high-risk organs.[922] A trans-Atlantic survey in 2002 between centers in the USA and the UK noted that current practice policies differed not only between nations, but also among centers in each country, concluding that lack of scientific evidence necessitated more research in the field to allow the safe use of all viable livers.[923] Microvesicular steatosis is not a contraindication.[924,925] Demonstration of a primary or metastatic malignant tumor is a contraindication to liver transplantation.

A study with the primary goal of determining the contribution of biopsy findings to potential living donor evaluation found that a minority (42%) of biopsies from a potential donor population were completely normal; the remainder showed steatosis (37%), steatohepatitis (15%), or unexplained low-grade/early stage chronic hepatitis, PBC, or nodular regenerative hyperplasia (6%). Biopsy findings disqualified 29 out of 56 donors, leading to the conclusion that liver biopsies provide valuable information about otherwise undetectable liver disease in potential liver donors.[926]

Diseases of the Transplanted Liver

The liver graft is subject to many of the same diseases that affect native livers, and, in addition, to a multitude of other abnormalities, including preservation/reperfusion injury (PRI), allograft rejection, various post-transplant complications (e.g., surgical mishaps, hepatic artery and portal vein thrombosis, bile duct problems such as dehiscence, leaks, necrosis, strictures, concrement formation, infection), drug reactions, opportunistic infections, recurrence of the original disease, and post-transplant lymphoproliferative disorders.

Preservation Reperfusion Injury

PRI is nonimmunologic graft damage resulting from the harvesting, ischemic preservation, transportation, and reperfusion of the donor liver.[927,928] This injury appears early (first 2 weeks post-transplant) and regresses spontaneously over several weeks.[929] For evaluation of possible PRI, specimens are obtained at the time of transplantation directly after revascularization of the graft (time zero biopsies).[930] Surgical hepatitis is quite common, as in any surgical specimen,[8] consisting of clusters of neutrophils and scattered acidophil bodies (see earlier, Fig. 19.2). Another preservation injury is so-called functional cholestasis, with bilirubinostasis in hepatocytes and canaliculi.[931,932] This should be distinguished from cholestasis associated with acute rejection, drug toxicity, hepatitis, bile duct obstruction, or sepsis.

Another lesion due to PRI is hepatocellular ballooning of variable degree, centrilobular or panlobular, often associated with bilirubinostasis and some hepatocyte dropout; the presence of all three features represents serious PRI associated with a poor graft outcome.[933]

However, centrilobular hepatocyte loss in early post-transplant biopsies may also represent a rejection-related phenomenon, even if typical portal tract changes are not prominent, and augmentation of immunosuppression should be considered.[934]

Allograft rejection. Hepatic allograft rejection is defined as injury to the transplanted liver caused by the immunologic reaction of the host. Rejection has been classified as humoral, acute (cellular), or chronic (ductopenic).[935] The histopathologic lesions have been well characterized and described in the literature.[936–939]

Humoral rejection (hyperacute or *antibody-mediated rejection)* is rare; it develops in patients with preformed or subsequently formed antibodies to an ABO blood group–incompatible donor.[940] The antibodies react with the graft vasculature and cause endothelial damage and thrombosis within the first few hours, ultimately resulting in coagulative and hemorrhagic necrosis in a few days. Immunohistochemistry for vascular C4d staining may be helpful in making the diagnosis.[941]

Acute (cellular) rejection is the most common form of rejection. Historically, clinically significant rejection has been reported to occur in 20%–40% of patients, whereas histologic abnormalities are seen in up to 80% of protocol biopsies obtained around the first week after transplantation. The incidence of clinically significant rejection appears to be declining, however, presumably related to improved immunosuppression.[942] It generally develops within the first 3 weeks after transplantation, and its median onset ranges between 7 and 10 days (with exceptions, of course).[943] It results from a cell-mediated immune reaction directed at bile duct epithelium and the endothelium of portal and centrilobular veins.[944] Histologically, cellular rejection is characterized by the triad of portal infiltration, bile duct damage, and endotheliitis (also termed endothelitis or endothelialitis; Fig. 19.84). None of these features is, by itself, entirely specific for rejection, and at least two of these three features should be required for diagnosis.[935] The portal infiltrate consists of a mixture of inflammatory cells; small lymphocytes predominate, intermixed with larger lymphoid type cells, immunoblasts, macrophages, plasma cells, neutrophils, and eosinophils. In some cases eosinophils are abundant and represent a helpful diagnostic feature of rejection.[945] The infiltrate typically expands the portal tract but may be focally and unevenly distributed; for this reason, it is recommended that sections at several levels of the specimen be examined, including a minimum of five portal tracts.[946] Occasionally, the infiltrate extends beyond the limits of the portal tract and even leads to portal–portal bridging.[946]

Endotheliitis can be present in either portal or central veins, consisting of supraendothelial and subendothelial lymphocytes, endothelial damage, and lifting off of endothelium from the underlying layers. Endotheliitis of centrilobular veins, accompanied by necrosis of centrilobular hepatocytes and periportal extension of the portal inflammatory infiltrate, is indicative of severe cellular rejection.[946] A less frequent form of cellular rejection with endothelial predominance appears as isolated central venulitis (without typical portal changes) in adult and pediatric liver allograft recipients[947,948] and may result in perivenular fibrosis and a veno-occlusive syndrome.[949] Endotheliitis is not a constant feature and may be absent, especially in cases of acute rejection occurring beyond the early post-transplant period.[950]

Bile ducts are infiltrated by lymphocytes and lymphoid-type cells (lymphocytic cholangitis); bile duct epithelial damage is indicated by anisonucleosis, cytoplasmic vacuolization, areas of cell stratification or occasional dropout, and irregularities in duct outlines. Immunostaining for keratin 7 may be helpful in demonstrating presence and lesions of bile ducts.[951]

In differentiating cellular rejection from cholangitic lesions, portal eosinophilia, endotheliitis, and necroinflammation favor rejection, whereas bilirubinostasis, neutrophilic infiltration, ductular proliferation, and periductal fibrosis/edema favor cholangitis.[952]

Several grading systems of cellular (acute) rejection have been proposed. A review of grading systems was updated by Batts.[936] A consensus document,[946] published by an international panel that met in Banff, Canada, recommends the grading scheme given in Table 19.6.

Additional features that are less consistently present include bilirubinostasis, some lobular inflammatory mononuclear infiltrate, and, in cases of severe rejection, centrilobular confluent parenchymal necrosis.

Chronic rejection. Chronic liver allograft rejection can be defined as an immunologic injury to the allograft that usually evolves from severe or persistent acute cellular rejection and results in potentially irreversible damage to the bile ducts, arteries, and terminal hepatic

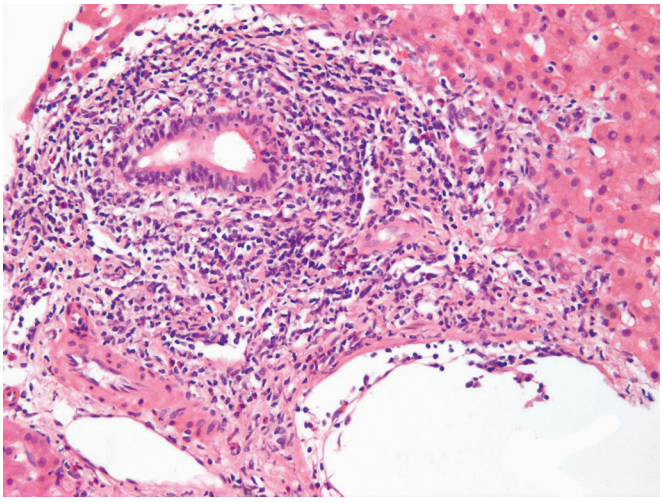

Figure 19.84 Acute cellular rejection of liver allograft, characterized by a dense mixed portal infiltrate (including eosinophils), endotheliitis, and lymphocytic cholangitis.

Table 19.6 Grading of acute cellular rejection

GLOBAL ASSESSMENT[a]	CRITERIA
Indeterminate	Portal inflammatory infiltrate that fails to meet the criteria for the diagnosis of acute rejection
Mild	Rejection infiltrate in a minority of the triads, generally mild, and confined within the portal spaces
Moderate	Rejection infiltrate, expanding most or all of the triads
Severe	As above for moderate, with spillover into periportal areas and moderate to severe perivenular inflammation that extends into the hepatic parenchyma and is associated with centrilobular hepatocyte necrosis

[a]Verbal description of mild, moderate, or severe acute rejection could also be labeled grades I, II, and III respectively.
Data from International Panel. Banff schema for grading liver allograft rejection: an international consensus document. *Hepatology*. 1997;25(3):658–663, with permission from authors and publisher.

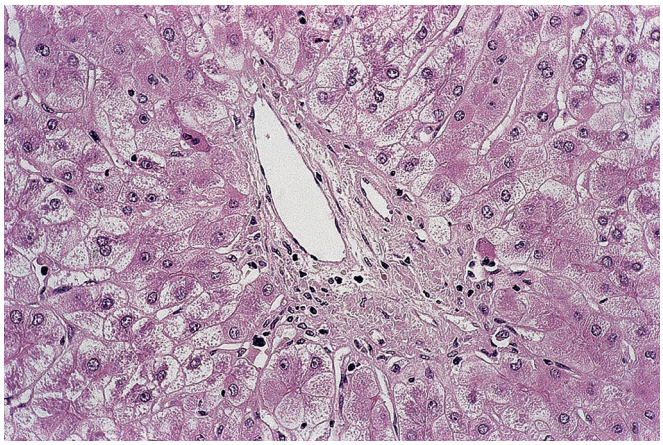

Figure 19.85 Chronic "Ductopenic" Rejection of Liver Allograft. Portal tract without a bile duct and with very sparse lymphocytic infiltration.

veins and surrounding parenchyma.[953] Terms such as "vanishing bile duct syndrome" and "ductopenic rejection" are no longer recommended, because bile duct loss is just one aspect of chronic liver allograft rejection.[935] Nevertheless, "ductopenic rejection" remains a frequently used synonym for chronic rejection.

The clinical diagnosis of chronic rejection is suspected in patients with a history of acute cellular rejection who develop progressive cholestasis, and ultimately should be based on a combination of the clinical, radiologic, laboratory, and histopathologic findings. Histologically, the minimal diagnostic criteria are: (1) the presence of bile duct atrophy/pyknosis, affecting a majority of the bile ducts, with or without bile duct loss; (2) convincing foam cell obliterative arteriopathy; or (3) bile duct loss affecting more than 50% of portal tracts. Since arteries with pathognomonic changes predominate in the hilar region and are rarely present in needle biopsy specimens, considerable significance is placed on damage and loss of small bile ducts. Obviously, other causes of ductal injury and loss should be reasonably excluded; these include biliary tract obstruction and bile duct ischemia due to hepatic artery thrombosis.[946]

The histopathologic changes of the liver in chronic rejection mainly affect the portal tracts and centrilobular areas. Within the portal tracts, chronic rejection reveals itself initially by bile duct damage, followed by loss of small bile ducts and small branches of the hepatic artery (Fig. 19.85). Early bile duct changes include uneven nuclear spacing, nuclear enlargement and hyperchromasia, loss of polarity, and interrupted epithelial lining of the ducts, giving a "dysplastic" or atrophic appearance. Expression of the senescence-related p21(WAF1/Cip1) protein is increased in cholangiocytes during early chronic rejection and decreases with successful recovery. Replicative senescence accounts for the characteristic bile duct cell cytologic alterations used for the diagnosis of early chronic rejection.[954] As the process advances, bile duct loss starts in the smaller interlobular ducts, associated with decreasing portal cellular infiltrate, resulting in a "burned out" appearance of the portal areas. Bile duct loss should be present in at least 50% of portal tracts in order to ensure a firm diagnosis of chronic rejection. Reliable counting of missing ducts requires adequate biopsy specimens, containing at least 20 portal tracts and/or the demonstration of ductopenia in several sequential biopsies.[955] A remarkable feature is the absence of ductular reaction and of periportal fibrosis, except in the presence of associated distal biliary obstruction. Possible causes are the absence of vagal innervation in the transplanted liver, which is important for hepatic progenitor cell activation,[956] and increased cholangiocytic apoptosis.[957]

Early arterial lesions consist of accumulation of subintimal, medial, and adventitial foamy macrophages, but, as mentioned, these lesions are not routinely sampled in peripheral needle biopsies. The macrophages and mesenchymal cells in arterial lesions are of recipient origin.[958] In some cases of chronic rejection inflammatory and/or foam cell lesions may also be observed in portal and hepatic venules, particularly in those cases with a more acute presentation, suggesting an overlap with acute cellular rejection.[959] Late arterial damage is mainly evaluated by the extent of loss of these structures; arterial loss is considered present when less than 77% of the portal tracts contain hepatic artery branches.[946]

In the centrilobular area, the early lesions of chronic rejection are characterized by bilirubinostasis, sinusoidal foam cells (presumably related to chronic cholestasis), and subendothelial and perivenular mononuclear inflammation of the centrilobular vein, accompanied by zone 3 hepatocyte dropout, pigment-laden macrophages, and mild perivenular fibrosis. A "transitional hepatitis," sometimes difficult to distinguish from viral hepatitis, may occur during the evolution to later stages of chronic rejection.[960] Late chronic rejection may also feature severe (bridging) perivenular fibrosis, with at least focal central–central or central–portal bridging and occasional obliteration of terminal hepatic venules.

The features used to define chronic rejection are not uniformly present in all cases. Bile duct loss can occur without arteriopathy, and vice versa, and severe (bridging) centrilobular fibrosis may be present without significant bile duct loss or obliterative arteriopathy. An individual patient may have late features of one component (e.g., bile duct loss), but early features of another component (e.g., perivenular necrosis).[946,953] Besides the two main patterns of chronic rejection (ductopenic and arteriopathic), the possibility of a "chronic hepatitis–like" pattern of chronic rejection has been postulated. It is discussed later, under "Late changes in liver allografts."

A working formulation for histopathologic staging and reporting of chronic liver allograft rejection has been proposed. Early chronic rejection is diagnosed if only one of the target structures shows late changes. An overall diagnosis of late chronic rejection requires that at least two or more of the target structures show late changes.[953]

A set of consensus criteria for the most common and problematic causes of late liver allograft dysfunction, including late-onset acute and chronic rejection, recurrent and new-onset viral and autoimmune hepatitis, biliary strictures, and recurrent PBC and PSC, including a discussion of differential diagnosis, has been published by the Banff Working Group on Liver Allograft Pathology.[962]

Other Complications

Fatty liver disease is a frequent late complication of liver transplantation. Post-transplant obesity, tacrolimus-based regimens, diabetes mellitus, hyperlipidemia, arterial hypertension, alcoholic cirrhosis as the primary indication for transplantation, and pre-transplant graft steatosis are risk factors for post-transplant steatosis.[963] The release of fat globules from dying hepatocytes may also result in the formation of cystic lesions (fat microcysts surrounded by macrophages) which resemble peliosis hepatis (so-called *lipopeliosis*).[964]

Bile duct strictures at the site of anastomosis or elsewhere (due to ischemic cholangitis) can be a cause of graft dysfunction. The classical histopathology of biliary tract obstruction in native livers is also applicable to the diagnosis of biliary complications in transplants.[965]

Hepatic artery thrombosis, alone or in combination with *portal vein thrombosis*, occurs more commonly in children. The consequences are ischemic injury (infarction) of varying extent, distribution, and age, including ischemia of the biliary tree.

Infections are frequent complications, given that hepatic allograft recipients, like other immunocompromised individuals, are susceptible to a wide range of pathogens. These include CMV, EBV, adenovirus and herpes virus infections, and sepsis due to gram-negative bacilli.

Drug-induced injury. Several of the drugs in the therapeutic regimen for immunosuppression are capable of causing hepatic damage, and because of the numerous confounding features, it may be difficult to incriminate a specific drug. Of note, *azathioprine* may cause hepatitis,[966] and *cyclosporine* (cyclosporin) may cause canalicular bilirubinostasis, hepatocyte ballooning, and vacuolization of bile duct epithelial cells.[967]

Recurrent Disease

The diagnosis of recurrent disease can be controversial on liver biopsy because some of these pretransplant disorders have histopathologic features that overlap with those seen in rejection or post-transplant biliary stricture. The risk of recurrent disease increases with time but does not directly correlate with the rate of graft loss.[968] The risk of graft loss from recurrent disease was greatest, when compared to PBC, in those transplanted for HCV, PSC, and AIH, and the overall risk of graft loss was also significantly greater in HCV, PSC, and AIH than in PBC.[969]

Recurrent HBV may cause typical features of acute and chronic hepatitis, cirrhosis, and minimal histologic changes (carrier state). In a minority of cases, atypical features of disease develop in the form of so-called *fibrosing cholestatic hepatitis*, as described previously.[69] The latter typically occurs early (before 150 days),[970] is associated with rapidly progressive graft dysfunction, and is histologically characterized by ductular reaction with associated fibrosis, prominent bilirubinostasis, hepatocellular ballooning with cell loss, and a mild mixed inflammatory reaction.[69] Fibrosing cholestatic hepatitis is associated with high viral load and occurs in other types of immunodeficiency states such as HIV infection and in renal transplant patients.[70] Recurrence of HBV in the graft has significantly decreased with the use of passive immunoprophylaxis with HBV immunoglobulin and lamivudine.[971]

HCV recurrence as defined by histologic injury is almost universal.[972–973] HCV antigens can be detected in liver biopsies within a few days after transplantation.[974] In a small group of patients graft injury is severe, and may result in graft loss.[974,975] The development of direct acting antivirals (such as sofosbuvir) has dramatically changed the treatment options for recurrent hepatitis C after liver transplantation, as they yield a sustained virological response in the great majority of patients and are typically well tolerated.[976,977]

Differentiation from acute cellular rejection is one of the most common and difficult problems in the assessment of post-transplant biopsies,[978] since morphologic features similar to those seen in rejection, such as bile duct damage, and, less generally acknowledged, endotheliitis, portal eosinophils, and pericentral fibrosis may also be due to hepatitis C.[979] It may require sequential biopsies and grading of lesions to document the progressive appearance of hepatitis C features.[980] The portal infiltrate in recurrent hepatitis C is more prominently lymphocytic and less mixed, bile duct infiltration by lymphocytes is milder, endotheliitis is absent or minimal, bile duct loss is absent, and fibrosis is more likely. In addition, the lobular parenchyma may show mild panlobular apoptotic changes (contrasting with perivenular necrosis in rejection), macrovesicular steatosis (missing in rejection) and—except in fibrosing cholestatic forms—cholestasis is rare. Recurrence of HCV often coexists with other causes of liver allograft dysfunction, such as residual PRI, biliary sludging, acute cellular and chronic rejection, and autoimmune hepatitis. The determination of the most important cause of injury is important, but may be extremely challenging.[981] A granulomatous response to HCV infection occurs in a subset of patients after transplantation without portending a worse clinical outcome.[982] Treatment with pegylated-interferon alpha-2a and ribavirin has been reported to trigger rapidly progressive chronic ductopenic rejection with or without first inducing acute cellular rejection,[983] but this is not an issue with the newer direct-acting antivirals (see earlier).

As noted previously, a severe progressive cholestatic syndrome, reminiscent of *fibrosing cholestatic hepatitis* in recurrent HBV infection, has been reported with an incidence of 2%–10%, apparently due to direct viral cytopathic effect in the context of a high viral load.[984] When studying the evolution of these cases, the first abnormality to appear is recurrent hepatitis C and cholestasis, fibrosis develops soon after, and both continue to worsen until the point of allograft failure or patient death.[985]

Recurrent PBC. In most patients, AMA persists after transplant and do not correlate with disease recurrence. Diagnosis of recurrent PBC is defined by histology, thus liver biopsy remains the gold standard.[968] Florid bile duct lesions and epithelioid granulomas are the most helpful features, although granulomatous cholangitis has also been observed in chronic viral hepatitis C.[982] Portal lymphoid aggregates and ductopenia are less helpful, as they may also occur in chronic hepatitis C and in allograft rejection. Ductular reaction and progressive cholate stasis (including the presence of copper deposition) are useful for diagnosis of PBC recurrence, as those features are unusual in hepatitis C and rejection. The presence of plasma cells in the portal infiltrate has been suggested as an early marker of recurrent PBC.[986] A definite diagnosis of recurrent PBC rests on a combination of all clinical, biochemical, and histologic criteria; ultimately, however, recurrence in the graft does not appear to affect either graft survival or patient outcome.[987,988]

Recurrent PSC. This diagnosis is extremely difficult, if not impossible, to distinguish from other causes of biliary strictures or sclerosing cholangitis in allografts using needle biopsy evaluation alone.[989] It is diagnosed by histology and/or imaging of the biliary tree and exclusion of other causes of nonanastomotic biliary strictures.[936,968]

Recurrent fatty liver disease is common following liver transplantation for NASH. In one study, recurrent fatty liver disease was seen in 70% of patients, of whom 25% had recurrent NASH, and 18% had stage II/IV or greater fibrosis at a mean of 18 months. Histologic features may be present despite normal liver enzymes.[439] The development of NAFLD even after liver transplantation for non-NAFLD cirrhosis is also being increasingly recognized. The pretransplant risk factors include immunosuppression, a higher age at transplant, male gender, a history of smoking, the patient's and the donor's pretransplant body mass index, pretransplant diabetes, type of underlying liver disease that resulted in transplantation (hepatitis C, cryptogenic cirrhosis, or alcohol), and marital status.[990]

The diagnosis of recurrent *autoimmune hepatitis* is based on a combination of clinical, biochemical, serologic, and histologic criteria.[968] Portal and periportal inflammation (interface hepatitis) containing plasma cells, although nonspecific, is consistent with recurrent disease.[988]

De novo autoimmune hepatitis, also termed post-transplant plasma cell hepatitis, is defined as clinical and histologic features of AIH in patients who were not transplanted for that disease.[991] This may be a particular diagnostic problem in hepatitis C patients, who may develop a plasma cell-rich hepatitis in the presence of HCV RNA.[992] Some also consider this a histologic variant of rejection,[993] although this remains controversial, and separating rejection from autoimmunity in the liver allograft long after transplantation may be an exercise in semantics given that epitope spreading occurs with all immune responses.[993,994]

Late Changes in Liver Allografts

Besides changes due to recurrence of primary diseases, other abnormalities are also observed in liver biopsies obtained more than a few months after transplantation, including fibrosis and inflammatory changes. Importantly, these lesions are usually not recognized by alterations in liver function tests but detected by the use of "protocol" biopsies performed as part of the systematic follow-up of the condition of the liver allograft (see earlier). It has been reported that only 20% of liver grafts show normal histology at 5 and 10 years post-transplant,[995] decreasing to only 7.4% at 5 years and 1.6% at 10 years.[996]

In long-term pediatric liver transplant survivors, liver fibrosis is a common finding,[995,997] as is the case in adult patients.[914] One study has shown that fewer than 5% of liver grafts at 3 years post-transplant have no fibrosis,[997] and in another,[998] the prevalence of fibrosis increased from 31% to 65% from 1 year to 5 years after transplantation but remained stable for several years thereafter. At 10 years, however, the percentage of patients with "severe" fibrosis had increased from 10% (at 5 years) to 29%. Of the children without fibrosis at 1 year post-transplantation, 64% had developed some degree of fibrosis at 10 years. Fibrosis was strongly related to transplant-related factors such as prolonged cold ischemia time, young age at the time of transplantation, high donor/recipient age ratio, and the use of partial grafts.[998]

Inflammatory lesions in long-term liver grafts include so-called central perivenulitis, corresponding to centrilobular necroinflammation, sometimes not associated with portal inflammation ("isolated" central perivenulitis),[999,1000] and a nonspecific chronic hepatitis termed idiopathic post-transplant chronic hepatitis (IPCH).[996,1001,1002]

Isolated central perivenulitis requires differentiation from all other causes of centrilobular necroinflammation, including ischemia, acute and chronic rejection, recurrent or acquired viral hepatitis B and C, recurrent or acquired autoimmune hepatitis, and IPCH, discussed in an editorial by Hübscher.[999] It appears that isolated central perivenulitis most probably represents a form of late-onset acute rejection, associated with a worse outcome than purely portal-based (classical acute cellular) rejection.[999]

IPCH is probably also best interpreted as a form of late cellular rejection.[1002] Studies from the Birmingham group suggest that IPCH is associated with progressive fibrosis, even leading to bridging fibrosis and cirrhosis in up to 50% of patients at 10 years post-transplant,[1002] but important clinical problems have not been reported to the same extent in other studies.[1003]

Ultimately, difficult diagnostic problems must be resolved by close clinicopathologic collaboration. It must be kept in mind that several pathologic conditions may coexist in the liver allograft concurrently, including drug toxicity, viral hepatitis, disease recurrence, and rejection.

Neoplastic disease. Malignancies occurring after liver transplantation primarily include hepatocellular carcinoma[1004] and post-transplant lymphoproliferative disease. The primary risk factor for de novo hepatocellular carcinoma is cirrhosis developing after transplant.[1005,1006] Post-transplant lymphoproliferative disease is mostly a nodal and extranodal B-cell lymphoma that is a complication of immunosuppressive treatment in transplanted patients. Some other types of neoplasia (skin, lung, head and neck, colon, and rectum) are also more frequent in liver transplant recipients than in age- and sex-matched controls.[1006]

Bone Marrow Transplantation: Graft-Versus-Host Disease

Bone marrow transplantation may cause several hepatic complications. The injury can be due to pretransplant conditioning regimens, to immunosuppression-related infections, and to graft-versus-host disease (GVHD).[1007,1008] The histopathology of hepatic GVHD depends on the timing post-transplant. *Acute hepatic GVHD*, occurring within 90 days after transplantation, is characterized by cholestasis and bile duct damage. Affected ducts show an irregular profile, epithelial atypia with nuclear pleomorphism, cytoplasmic vacuolation, cell necrosis, and possible duct destruction. Lymphocytes infiltrate the duct epithelium, although portal inflammation is typically mild. Early biopsies (<35 days) reveal less bile duct damage and marked hepatocellular apoptosis,[1009] a picture easily confused with viral hepatitis C. Other lesions include endotheliitis, siderosis, and veno-occlusive disease.[1010]

Chronic GVHD, although usually preceded by acute GVHD, occurs de novo in about 25% of cases, and develops more than 3 months after transplantation. Hepatic involvement shows similar lesions to acute GVHD, but with the development of ductopenia, cholate stasis, progressive periportal fibrosis, and occasionally even cirrhosis in advanced disease.[1011–1013] Portal infiltration is dense, and in some cases associated with periportal extension and interface hepatitis. The lymphocytic infiltrates in the liver (and also in other involved tissues of the gastrointestinal tract and skin) are almost exclusively derived from the alpha/beta expressing T-cell subset, and are of the memory cell subset of T cells (CD45RO).[1014] Lobular changes include bilirubinostasis and apoptotic bodies.

References

1. Rappaport AM, Borowy ZJ, Lougheed WM, et al. Subdivision of hexagonal liver lobules into a structural and functional unit; role in hepatic physiology and pathology. *Anat Rec*. 1954;119(1):11-33.
2. Matsumoto T, Kawakami M. The unit-concept of hepatic parenchyma—a re-examination based on angioarchitectural studies. *Acta Pathol Jpn*. 1982;32(suppl 2):285-314.
3. Cassiman D, Libbrecht L, Desmet V, et al. Hepatic stellate cell/myofibroblast subpopulation in fibrotic human and rat livers. *J Hepatol*. 2002;36:200-209.
4. Crawford AR, Lin XZ, Crawford JM. The normal adult human liver biopsy: a quantitative reference standard. *Hepatology*. 1998;28(2):323-331.
5. Roskams TA, Theise ND, Balabaud C, et al. Nomenclature of the finer branches of the biliary tree: canals, ductules, and ductular reactions in human livers. *Hepatology*. 2004;39(6):1739-1745.
6. Van Eyken P, Desmet VJ. Cytokeratins and the liver. *Liver*. 1993;13(3):113-122.
7. Papp V, Dezso K, Laszlo V, et al. Architectural changes during regenerative and ontogenic liver growth in the rat. *Liver Transpl*. 2009;15(2):177-183.
8. Christoffersen P, Poulsen H, Skeie E. Focal liver cell necroses accompanied by infiltration of granulocytes arising during operation. *Acta Hepatosplenol*. 1970;17(4):240-245.
9. Gerber MA, Thung SN. Histology of the liver. *Am J Surg Pathol*. 1987;11(9):709-722.
10. Petrelli M, Scheuer PJ. Variation in subcapsular liver structure and its significance in the interpretation of wedge biopsies. *J Clin Pathol*. 1967;20(5):743-748.
11. Kim JH, Kim MN, Han KH, Kim SU. Clinical application of transient elastography in patients with chronic viral hepatitis receiving antiviral treatment. *Liver Int*. 2015;35:1103-1115.
12. Hay JE, Czaja AJ, Rakela J, Ludwig J. The nature of unexplained chronic aminotransferase elevations of a mild to moderate degree in asymptomatic patients. *Hepatology*. 1989;9(2):193-197.
13. Van Ness MM, Diehl AM. Is liver biopsy useful in the evaluation of patients with chronically elevated liver enzymes? *Ann Intern Med*. 1989;111(6):473-478.

14. Ferrell L. Liver pathology: cirrhosis, hepatitis, and primary liver tumors. Update and diagnostic problems. *Mod Pathol*. 2000;13(6):679-704.
15. Strassburg CP, Manns MP. Approaches to liver biopsy techniques-revisited. *Semin Liver Dis*. 2006;26:318-327.
16. Demetris AJ, Seaberg EC, Batts KP, et al. Reliability and predictive value of the National Institute of Diabetes and Digestive and Kidney Diseases Liver Transplantation Database nomenclature and grading system for cellular rejection of liver allografts. *Hepatology*. 1995;21(2):408-416.
17. Lucey MR. Serial liver biopsies: a gateway into understanding the long-term health of the liver allograft. *J Hepatol*. 2001;34(5):762-763.
18. Nair V, Fischer SE, Adeyi OA. Non-viral-related pathologic findings in liver needle biopsy specimens from patients with chronic viral hepatitis. *Am J Clin Pathol*. 2010;133(1):127-132.
19. Van Eyken P. Cytokeratin immunohistochemistry in liver histopatology. *Adv Clin Path*. 2000;4(4):201-211.
20. Clark I, Torbenson MS. Immunohistochemistry and special stains in medical liver pathology. *Adv Anat Pathol*. 2017;24:99-109.
21. Colloredo G, Guido M, Sonzogni A, Leandro G. Impact of liver biopsy size on histological evaluation of chronic viral hepatitis: the smaller the sample, the milder the disease. *J Hepatol*. 2003;39(2):239-244.
22. Bedossa P, Dargere D, Paradis V. Sampling variability of liver fibrosis in chronic hepatitis C. *Hepatology*. 2003;38(6):1449-1457.
23. Vuppalanchi R, Unalp A, Van Natta ML, et al. Effects of liver biopsy sample length and number of readings on sampling variability in nonalcoholic Fatty liver disease. *Clin Gastroenterol Hepatol*. 2009;7(4):481-486.
24. Rousselet MC, Michalak S, Dupre F, et al. Sources of variability in histological scoring of chronic viral hepatitis. *Hepatology*. 2005;41(2):257-264.
25. Bateman AC. Patterns of histological change in liver disease: my approach to 'medical' liver biopsy reporting. *Histopathology*. 2007;51(5):585-596.
26. Czaja AJ, Carpenter HA. Optimizing diagnosis from the medical liver biopsy. *Clin Gastroenterol Hepatol*. 2007;5(8):898-907.
27. Suriawinata AA, Thung SN. Acute and chronic hepatitis. *Semin Diagn Pathol*. 2006;23(3-4):132-148.
28. Theise ND. Liver biopsy assessment in chronic viral hepatitis: a personal, practical approach. *Mod Pathol*. 2007;20(suppl 1):S3-S14.
29. Rockey DC, Caldwell SH, Goodman ZD, et al. Liver biopsy. *Hepatology*. 2009;49(3):1017-1044.
30. Feinstone SM, Kapikian AZ, Purcell RH, et al. Transfusion-associated hepatitis not due to viral hepatitis type A or B. *N Engl J Med*. 1975;292(15):767-770.
31. Choo Q-L, Kuo G, Weiner AJ, et al. Isolation of cDNA clone derived from blood-borne non-A, non-B viral hepatitis genome. *Science*. 1989;244:359-362.
32. Alter HJ, Seeff LB. Recovery, persistence, and sequelae in hepatitis C virus infection: a perspective on long-term outcome. *Semin Liver Dis*. 2000;20(1):17-35.
33. Purcell R. The hepatitis C virus: overview. *Hepatology*. 1997;26(3 suppl 1):11s-14s.
34. Yerian L. Acute viral hepatitis. In: Lamps LW, Kakar S, eds. *Diagnostic Pathology: Hepatobiliary and Pancreas*. 2nd ed. Philadelphia: Elsevier; 2017:56-59.
35. Dalton HR, Stableforth W, Thurairajah P, et al. Autochthonous hepatitis E in Southwest England: natural history, complications and seasonal variation, and hepatitis E virus IgG seroprevalence in blood donors, the elderly and patients with chronic liver disease. *Eur J Gastroenterol Hepatol*. 2008;20(8):784-790.
36. Purcell RH, Emerson SU. Hepatitis E: an emerging awareness of an old disease. *J Hepatol*. 2008;48(3):494-503.
37. Kar P, Jilani N, Husain SA, et al. Does hepatitis E viral load and genotypes influence the final outcome of acute liver failure during pregnancy? *Am J Gastroenterol*. 2008;103(10):2495-2501.
38. Stapleton JT, Foung S, Muerhoff AS, et al. The GB viruses: a review and proposed classification of GBV-A, GBV-C (HGV), and GBV-D in genus Pegivirus within the family Flaviviridae. *J Gen Virol*. 2011;92(Pt 2):233-246.
39. Hino S, Miyata H. Torque teno virus (TTV): current status. *Rev Med Virol*. 2007;17:45-57.
40. Akiba J, Umemura T, Alter HJ, et al. SEN virus: epidemiology and characteristics of a transfusion-transmitted virus. *Transfusion*. 2005;45(7):1084-1088.
41. Yang JF, Dai CY, Chuang WL, et al. Prevalence and clinical significance of HGV/GBV-C infection in patients with chronic hepatitis B or C. *Jpn J Infect Dis*. 2006;59:25-30.
42. Bianchi L. Liver biopsy interpretation in hepatitis. Part II: Histopathology and classification of acute and chronic viral hepatitis/differential diagnosis. *Pathol Res Pract*. 1983;178(2):180-213.
43. Ishak KG. Light microscopic morphology of viral hepatitis. *Am J Clin Pathol*. 1976;65(5 suppl):787-827.
44. Hashimoti E, Kojimahara N, Noguchi S, et al. Immunohistochemical characterization of hepatic lymphocytes in acute hepatitis A, B, and C. *J Clin Gastroenterol*. 1996;23(3):199-202.
45. Volpes R, van den Oord JJ, Desmet VJ. Memory T cells represent the predominant lymphocyte subset in acute and chronic liver inflammation. *Hepatology*. 1991;13(5):826-829.
46. Mietkiewski JM, Scheuer PJ. Immunoglobulin-containing plasma cells in acute hepatitis. *Liver*. 1985;5(2):84-88.
47. Schmid M, Pirovino M, Altorfer J, et al. Acute hepatitis non-A, non-B; are there any specific light microscopic features? *Liver*. 1982;2(1):61-67.
48. Boyer JL, Klatskin G. Pattern of necrosis in acute viral hepatitis. Prognostic value of bridging (subacute hepatic necrosis). *N Engl J Med*. 1970;283(20):1063-1071.
49. Hanau C, Munoz SJ, Rubin R. Histopathological heterogeneity in fulminant hepatic failure. *Hepatology*. 1995;21(2):345-351.
50. Scheuer PJ, Maggi G. Hepatic fibrosis and collapse: histological distinction by orecin staining. *Histopathology*. 1980;4(5):487-490.
51. Desmet VJ. Ductal plates in hepatic ductular reactions. Hypothesis and implications. I. Types of ductular reaction reconsidered. *Virchows Arch*. 2011;458:251-259.
52. Schmid M, Cueni B. Portal lesions in viral hepatitis with submassive hepatic necrosis. *Hum Pathol*. 1972;3(2):209-216.
53. Abe H, Beninger PR, Ikejiri N, et al. Light microscopic findings of liver biopsy specimens from patients with hepatitis type A and comparison with type B. *Gastroenterology*. 1982;82(5 Pt 1): 938-947.
54. Okuno T, Sano A, Deguchi T, et al. Pathology of acute hepatitis A in humans. Comparison with acute hepatitis B. *Am J Clin Pathol*. 1984;81(2):162-169.
55. Sciot R, Van Damme B, Desmet VJ. Cholestatic features in hepatitis A. *J Hepatol*. 1986;3(2):172-181.
56. Teixeira MR Jr, Weller IV, Murray A, et al. The pathology of hepatitis A in man. *Liver*. 1982;2(1):53-60.
57. Corpechot C, Cadranel JF, Hoang C, et al. [Cholestatic viral hepatitis A in adults. Clinical, biological and histopathological study of 9 cases]. *Gastroenterol Clin Biol*. 1994;18(8-9):743-750.
58. Scheuer PJ, Davies SE, Dhillon AP. Histopathologic aspects of viral hepatitis. *J Viral Hepat*. 1996;3:277-283.
59. Chi H, Haagsma EB, Riezebos-Brilman A, et al. Hepatitis A related acute liver failure by consumption of contaminated food. *J Clin Virol*. 2014;61:456-458.
60. Ruel M, Sevestre H, Henry-Biabaud E, et al. Fibrin ring granulomas in hepatitis A. *Dig Dis Sci*. 1992;37(12):1915-1917.
61. Yamamoto T, Ishii M, Nagura H, et al. Transient hepatic fibrin-ring granulomas in a patient with acute hepatitis A. *Liver*. 1995;15(5):276-279.
62. Villari D, Raimondo G, Attard L, et al. Polyphasic type A hepatitis: histological features. *Infection*. 1993;21(1):46-48.
63. Kryger P, Christoffersen P. Liver histopathology of the hepatitis A virus infection: a comparison with hepatitis type B and non-a, non-b. *J Clin Pathol*. 1983;36(6):650-654.
64. Rugge M, Vanstapel MJ, Ninfo V, et al. Comparative histology of acute hepatitis B and non-A, non-B in Leuven and Padova. *Virchows Arch A Pathol Anat Histopathol*. 1983;401(3):275-288.
65. Desmet VJ. Liver lesions in hepatitis B viral infection. *Yale J Biol Med*. 1988;61(1):61-83.
66. Delladetsima I, Papatheodoridis GV, Tiniakos DG, et al. Significance of liver histology in HBsAg-positive, IgM anti-GHc-negative acute hepatitis B virus-related hepatitis. *Histopathology*. 2012;61:881-888.
67. Min KW, Gyorkey F, Cain GD. Talc granulomata in liver disease in narcotic addicts. *Arch Pathol*. 1974;98(5):331-335.
68. Molos MA, Litton N, Schubert TT. Talc liver. *J Clin Gastroenterol*. 1987;9(2):198-203.
69. Davies SE, Portmann BC, O'Grady JG, et al. Hepatic histological findings after transplantation for chronic hepatitis B virus infection, including a unique pattern of fibrosing cholestatic hepatitis. *Hepatology*. 1991;13(1):150-157.
70. Xiao SY, Lu L, Wang HL. Fibrosing cholestatic hepatitis: clinicopathologic spectrum, diagnosis and pathogenesis. *Int J Clin Exp Pathol*. 2008;1(5):396-402.
71. Santantonio T, Wiegand J, Gerlach JT. Acute hepatitis C: current status and remaining challenges. *J Hepatol*. 2008;49(4):625-633.
72. Dienes HP, Popper H, Arnold W, Lobeck H. Histologic observations in human hepatitis non-A, non-B. *Hepatology*. 1982;2(5): 562-571.
73. Lefkowitch JH, Apfelbaum TF. Non-A, non-B hepatitis: characterization of liver biopsy pathology. *J Clin Gastroenterol*. 1989;11(2):225-232.
74. Negro F. Detection of hepatitis C virus RNA in liver tissue: an overview. *Ital J Gastroenterol Hepatol*. 1998;30(2):205-210.
75. Komminoth P, Adams V, Long AA, et al. Evaluation of methods for hepatitis C virus detection in archival liver biopsies. Comparison of histology, immunohistochemistry, in-situ hybridization, reverse transcriptase polymerase chain reaction (RT-PCR) and in-situ RT-PCR. *Pathol Res Pract*. 1994;190:1017-1025.

76. Evans AT, Loeb KR, Shulman HM, et al. Fibrosing cholestatic hepatitis C after hematopoietic cell transplantation: report of 3 fatal cases. *Am J Surg Pathol*. 2015;39:212-220.
77. Rosenberg PM, Farrell JJ, Abraczinskas DR, et al. Rapidly progressive fibrosing cholestatic hepatitis—hepatitis C virus in HIV coinfection. *Am J Gastroenterol*. 2002;97(2):478-483.
78. Negro F. Hepatitis D virus co-infection and superinfection. *Cold Spring Harb Perspect Med*. 2014;4(11):a021550. doi:10.1101/cshperspect.a021550.
79. Craig JR, Govindarajan S, DeCock KM. Delta viral hepatitis. Histopathology and course. *Pathol Annu*. 1986;21(pt 2):1-21.
80. Lok AS, Lindsay I, Scheuer PJ, Thomas HC. Clinical and histological features of delta infection in chronic hepatitis B virus carriers. *J Clin Pathol*. 1985;38(5):530-533.
81. Verme G, Amoroso P, Lettieri G, et al. A histological study of hepatitis delta virus liver disease. *Hepatology*. 1986;6(6):1303-1307.
82. Popper H, Thung SN, Gerber MA, et al. Histologic studies of severe delta agent infection in Venezuelan Indians. *Hepatology*. 1983;3(6):906-912.
83. Khuroo MS, Khuroo MS. Hepatitis E virus. *Curr Opin Infect Dis*. 2008;21(5):539-543.
84. Kamar N, Bendall R, Legrand-Abravanel F, et al. Hepatitis E. *Lancet*. 2012;379(9835):2477-2488.
85. Malcolm P, Dalton H, Hussaini HS, Mathew J. The histology of acute autochthonous hepatitis E virus infection. *Histopathology*. 2007;51(2):190-194.
86. Iversen P, Roholm K. On aspiration biopsy of the liver, with remarks on its diagnostic significance. *Acta Med Scand*. 1939;102:1-16.
87. De Groote J, Desmet VJ, Gedigk P, et al. A classification of chronic hepatitis. *Lancet*. 1968;2(7568):626-628.
88. Desmet VJ. Histological classification of chronic hepatitis. *Acta Gastroenterol Belg*. 1997;60(4):259-267.
89. Purcell RH. Hepatitis viruses: changing patterns of human disease. *Proc Natl Acad Sci USA*. 1994;91(7):2401-2406.
90. Reynolds TB, Peters RL, Yamada S. Chronic active and lupoid hepatitis caused by a laxative, oxyphenisatin. *N Engl J Med*. 1971;285(15):813-820.
91. Pessayre D, Larrey D. Acute and chronic drug-induced hepatitis. *Baillieres Clin Gastroenterol*. 1988;2(2):385-422.
92. Johnson PJ, McFarlane IG. Meeting report: International Autoimmune Hepatitis Group. *Hepatology*. 1993;18(4):998-1005.
93. Scott J, Gollan JL, Samourian S, Sherlock S. Wilson's disease, presenting as chronic active hepatitis. *Gastroenterology*. 1978;74(4):645-651.
94. Sternlieb I, Scheinberg IH. Chronic hepatitis as a first manifestation of Wilson's disease. *Ann Intern Med*. 1972;76(1):59-64.
95. Hodges JR, Millward-Sadler GH, Wright R. Chronic active hepatitis: the spectrum of disease. *Lancet*. 1982;1(8271):550-552.
96. Chen DS. Natural history of chronic hepatitis B virus infection: new light on an old story. *J Gastroenterol Hepatol*. 1993;8(5):470-475.
97. Chu CM, Karayiannis P, Fowler MJ, et al. Natural history of chronic hepatitis B virus infection in Taiwan: studies of hepatitis B virus DNA in serum. *Hepatology*. 1985;5(3):431-434.
98. Scheuer PJ. Changing views on chronic hepatitis. *Histopathology*. 1986;10(1):1-4.
99. Gerber MA. Chronic hepatitis C: the beginning of the end of a time-honored nomenclature? *Hepatology*. 1992;15(4):733-734.
100. Ishak KG. Chronic hepatitis: morphology and nomenclature. *Mod Pathol*. 1994;7(6):690-713.
101. Ludwig J. The nomenclature of chronic active hepatitis: an obituary. *Gastroenterology*. 1993;105(1):274-278.
102. Scheuer PJ. Classification of chronic viral hepatitis: a need for reassessment. *J Hepatol*. 1991;13(3):372-374.
103. Desmet VJ, Gerber M, Hoofnagle JH, et al. Classification of chronic hepatitis: diagnosis, grading and staging. *Hepatology*. 1994;19(6):1513-1520.
104. Terminology of chronic hepatitis, hepatic allograft rejection, and nodular lesions of the liver: summary of recommendations developed by an international working party, supported by the World Congresses of Gastroenterology, Los Angeles, 1994. *Am J Gastroenterol*. 1994;89(8 suppl):S177-S181.
105. Villari D, Raimondo G, Brancatelli S, et al. Histological features in liver biopsy specimens of patients with acute reactivation of chronic type B hepatitis. *Histopathology*. 1991;18(1):73-77.
106. Popper H, Paronetto F, Schaffner F. Immune processes in the pathogenesis of liver disease. *Ann N Y Acad Sci*. 1965;124(2):781-799.
107. Galle PR. Apoptosis in liver disease. *J Hepatol*. 1997;27(2):405-412.
108. Powell LW. The nature of cell death in piecemeal necrosis: is order emerging from chaos? *Hepatology*. 1987;7:794-796.
109. Searle J, Harmon BV, Bishop CJ, Kerr JFR. The significance of cell death by apoptosis in hepatobiliary disease. *J Gastroenterol Hepatol*. 1987;2:77-96.
110. Desmet VJ. Current problems in diagnosis of biliary disease and cholestasis. *Semin Liver Dis*. 1986;6(3):233-245.
111. Paradis V, Mathurin P, Laurent A, et al. Histological features predictive of liver fibrosis in chronic hepatitis C infection. *J Clin Pathol*. 1996;49(12):998-1004.
112. Roskams TA, Libbrecht L, Desmet VJ. Progenitor cells in diseased human liver. *Semin Liver Dis*. 2003;23(4):385-396.
113. Cross SS. Grading and scoring in histopathology. *Histopathology*. 1998;33(2):99-106.
114. Batts KP, Ludwig J. Chronic hepatitis. An update on terminology and reporting. *Am J Surg Pathol*. 1995;19(12):1409-1417.
115. Bedossa P, Poynard T. An algorithm for the grading of activity in chronic hepatitis C. The METAVIR Cooperative Study Group. *Hepatology*. 1996;24(2):289-293.
116. Duchatelle V, Marcellin P, Giostra E, et al. Changes in liver fibrosis at the end of alpha interferon therapy and 6 to 18 months later in patients with chronic hepatitis C: quantitative assessment by a morphometric method. *J Hepatol*. 1998;29(1):20-28.
117. Goldin RD, Goldin JG, Burt AD, et al. Intra-observer and inter-observer variation in the histopathological assessment of chronic viral hepatitis. *J Hepatol*. 1996;25(5):649-654.
118. Ishak K, Baptista A, Bianchi L, et al. Histological grading and staging of chronic hepatitis. *J Hepatol*. 1995;22(6):696-699.
119. Ishak KG. Pathologic features of chronic hepatitis. A review and update. *Am J Clin Pathol*. 2000;113(1):40-55.
120. Knodell RG, Ishak KG, Black WC, et al. Formulation and application of a numerical scoring system for assessing histological activity in asymptomatic chronic active hepatitis. *Hepatology*. 1981;1(5):431-435.
121. Westin J, Lagging LM, Wejstal R, et al. Interobserver study of liver histopathology using the Ishak score in patients with chronic hepatitis C virus infection. *Liver*. 1999;19(3):183-187.
122. Bedossa P. [Presentation of a grid for computer analysis for compilation of histopathologic lesions in chronic viral hepatitis C. Cooperative study of the METAVIR group]. *Ann Pathol*. 1993;13(4):260-265.
123. Bedossa P, Bioulac-Sage P, Callard P, et al. Intraobserver and interobserver variations in liver biopsy interpretation in patients with chronic hepatitis C. The French METAVIR Cooperative Study Group. *Hepatology*. 1994;20(1 Pt 1):15-20.
124. Poynard T, Ratziu V, Charlotte F, et al. Rates and risk factors of liver fibrosis progression in patients with chronic hepatitis C. *J Hepatol*. 2001;34(5):730-739.
125. Brunt EM. Grading and staging the histopathological lesions of chronic hepatitis: the Knodell histology activity index and beyond. *Hepatology*. 2000;31(1):241-246.
126. Hubscher SG. Histological grading and staging in chronic hepatitis: clinical applications and problems. *J Hepatol*. 1998;29(6):1015-1022.
127. Kleiner DE. The liver biopsy in chronic hepatitis C: a view from the other side of the microscope. *Semin Liver Dis*. 2005;25(1):52-64.
128. Goodman ZD. Grading and staging systems for inflammation and fibrosis in chronic liver diseases. *J Hepatol*. 2007;47(4):598-607.
129. Fleming KA. Evidence-based pathology. *J Pathol*. 1996;179(2):127-128.
130. Scheuer PJ, Standish RA, Dhillon AP. Scoring of chronic hepatitis. *Clin Liver Dis*. 2002;6(2):335-347, v-vi.
131. Cross T, Antoniades C, Harrison P. Non-invasive markers for the prediction of fibrosis in chronic hepatitis C infection. *Hepatol Res*. 2008;38(8):762-769.
132. Ratziu V, Charlotte F, Heurtier A, et al. Sampling variability of liver biopsy in nonalcoholic fatty liver disease. *Gastroenterology*. 2005;128(7):1898-1906.
133. Castera L, Forns X, Alberti A. Non-invasive evaluation of liver fibrosis using transient elastography. *J Hepatol*. 2008;48(5):835-847.
134. Kettaneh A, Marcellin P, Douvin C, et al. Features associated with success rate and performance of FibroScan measurements for the diagnosis of cirrhosis in HCV patients: a prospective study of 935 patients. *J Hepatol*. 2007;46(4):628-634.
135. Van Leeuwen DJ, Balabaud C, Crawford JM, et al. A clinical and histopathologic perspective on evolving noninvasive and invasive alternatives for liver biopsy. *Clin Gastroenterol Hepatol*. 2008;6(5):491-496.
136. Bedossa P. Assessment of hepatitis C: non-invasive fibrosis markers and/or liver biopsy. *Liver Int*. 2009;29(suppl 1):19-22.
137. Hadziyannis S, Gerber MA, Vissoulis C, Popper H. Cytoplasmic hepatitis B antigen in "ground-glass" hepatocytes of carriers. *Arch Pathol*. 1973;96(5):327-330.
138. Gerber MA, Hadziyannis S, Vissoulis C, et al. Electron microscopy and immunoelectronmicroscopy of cytoplasmic hepatitis B antigen in hepatocytes. *Am J Pathol*. 1974;75(3):489-502.
139. Yamada G, Nakane PK. Hepatitis B core and surface antigens in liver tissue. Light and electron microscopic localization by the peroxidase-labeled antibody method. *Lab Invest*. 1977;36(6):649-659.
140. Jezequel AM, Librari ML, Mosca P, et al. Changes induced in human liver by long-term anticonvulsant therapy. Functional and ultrastructural data. *Liver*. 1984;4(5):307-317.
141. Klinge O, Bannasch P. [The increase of smooth endoplasmatic reticulum in hepatocytes of human liver punctates]. *Verh Dtsch Ges Pathol*. 1968;52:568-573.

142. Callea F, de Vos R, Togni R, et al. Fibrinogen inclusions in liver cells: a new type of ground-glass hepatocyte. Immune light and electron microscopic characterization. *Histopathology*. 1986;10(1):65-73.
143. Nishimura RN, Ishak KG, Reddick R, et al. Lafora disease: diagnosis by liver biopsy. *Ann Neurol*. 1980;8(4):409-415.
144. Bannayan GA, Dean WJ, Howell RR. Type IV glycogen-storage disease. Light-microscopic, electron-microscopic, and enzymatic study. *Am J Clin Pathol*. 1976;66(4):702-709.
145. Lefkowitch JH, Lobritto SJ, Brown RS Jr, et al. Ground-glass, polyglucosan-like hepatocellular inclusions: A "new" diagnostic entity. *Gastroenterology*. 2006;131(3):713-718.
146. Bejarano PA, Garcia MT, Rodriguez MM, et al. Liver glycogen bodies: ground-glass hepatocytes in transplanted patients. *Virchows Arch*. 2006;449:539-545.
147. Alonso-Marti C, Moreno A, Barat A, et al. Co-existence of hepatocyte ground-glass inclusions from several causes. *Histopathology*. 1990;16(3):304-307.
148. Shikata T, Uzawa T, Yoshiwara N, et al. Staining methods of Australia antigen in paraffin section—detection of cytoplasmic inclusion bodies. *Jpn J Exp Med*. 1974;44(1):25-36.
149. Tanaka K, Mori W, Suwa K. Victoria blue-nuclear fast red stain for HBs antigen detection in paraffin section. *Acta Pathol Jpn*. 1981;31(1):93-98.
150. Senba M. Staining method for hepatitis B surface antigen (HBs Ag) and its mechanism. *Am J Clin Pathol*. 1982;77(3):312-315.
151. Bianchi L, Gudat F. Sanded nuclei in hepatitis B: eosinophilic inclusions in liver cell nuclei due to excess in hepatitis B core antigen formation. *Lab Invest*. 1976;35(1):1-5.
152. Lai CL, Ratziu V, Yuen MF, Poynard T. Viral hepatitis B. *Lancet*. 2003;362(9401):2089-2094.
153. Mani H, Kleiner DE. Liver biopsy findings in chronic hepatitis B. *Hepatology*. 2009;49(5 suppl):S61-S71.
154. Liang TJ. Hepatitis B: the virus and disease. *Hepatology*. 2009;49(5 suppl):S13-S21.
155. Hadziyannis SJ, Papatheodoridis GV. Hepatitis B e antigen-negative chronic hepatitis B: natural history and treatment. *Semin Liver Dis*. 2006;26(2):130-141.
156. Lee WM. Hepatitis B virus infection. *N Engl J Med*. 1997;337(24):1733-1745.
157. McMahon BJ. The natural history of chronic hepatitis B virus infection. *Hepatology*. 2009;49(5 suppl):S45-S55.
158. Villeneuve JP. The natural history of chronic hepatitis B virus infection. *J Clin Virol*. 2005;34(suppl 1):S139-S142.
159. Chu CM, Liaw YF. Chronic hepatitis B virus infection acquired in childhood: special emphasis on prognostic and therapeutic implication of delayed HBeAg seroconversion. *J Viral Hepat*. 2007;14(3):147-152.
160. Fattovich G. Natural history of hepatitis B. *J Hepatol*. 2003;39(suppl 1):S50-S58.
161. Hsu HC, Su IJ, Lai MY, et al. Biologic and prognostic significance of hepatocyte hepatitis B core antigen expressions in the natural course of chronic hepatitis B virus infection. *J Hepatol*. 1987;5(1):45-50.
162. Chu CM, Liaw YF. Immunohistological study of intrahepatic expression of hepatitis B core and E antigens in chronic type B hepatitis. *J Clin Pathol*. 1992;45(9):791-795.
163. Yamada G, Takaguchi K, Matsueda K, et al. Immunoelectron microscopic observation of intrahepatic HBeAg in patients with chronic hepatitis B. *Hepatology*. 1990;12(1):133-140.
164. Chu CM, Liaw YF. Membrane staining for hepatitis B surface antigen on hepatocytes: a sensitive and specific marker of active viral replication in hepatitis B. *J Clin Pathol*. 1995;48(5):470-473.
165. Hsu HC, Lai MY, Su IJ, et al. Correlation of hepatocyte HBsAg expression with virus replication and liver pathology. *Hepatology*. 1988;8(4):749-754.
166. Davis GL, Hoofnagle JH. Reactivation of chronic type B hepatitis presenting as acute viral hepatitis. *Ann Intern Med*. 1985;102(6):762-765.
167. Liaw YF, Yang SS, Chen TJ, Chu CM. Acute exacerbation in hepatitis B e antigen positive chronic type B hepatitis. A clinicopathological study. *J Hepatol*. 1985;1(3):227-233.
168. Lindh M, Savage K, Rees J, et al. HBeAg immunostaining of liver tissue in various stages of chronic hepatitis B. *Liver*. 1999;19(4):294-298.
169. Chen DS, Sung JL. Hepatitis Be antigen and its antibody in chronic type B hepatitis. *J Gastroenterol Hepatol*. 1987;2:255-270.
170. Perrillo RP, Brunt EM. Hepatic histologic and immunohistochemical changes in chronic hepatitis B after prolonged clearance of hepatitis B e antigen and hepatitis B surface antigen. *Ann Intern Med*. 1991;115(2):113-115.
171. Villeneuve JP, Desrochers M, Infante-Rivard C, et al. A long-term follow-up study of asymptomatic hepatitis B surface antigen-positive carriers in Montreal. *Gastroenterology*. 1994;106(4):1000-1005.
172. Su IJ, Lai MY, Hsu HC, et al. Diverse virological, histopathological and prognostic implications of seroconversion from hepatitis B e antigen to anti-HBe in chronic hepatitis B virus infection. *J Hepatol*. 1986;3(2):182-189.
173. Brunetto MR, Stemler M, Schödel F, et al. Identification of HBV variants which cannot produce precore derived HBeAg and may be responsible for severe hepatitis. *Ital J Gastroenterol*. 1989;21:151-154.
174. Naoumov NV, Schneider R, Grotzinger T, et al. Precore mutant hepatitis B virus infection and liver disease. *Gastroenterology*. 1992;102(2):538-543.
175. Park YN, Han KH, Kim KS, et al. Cytoplasmic expression of hepatitis B core antigen in chronic hepatitis B virus infection: role of precore stop mutants. *Liver*. 1999;19(3):199-205.
176. Issa R, Zhou X, Constandinou CM, et al. Spontaneous recovery from micronodular cirrhosis: evidence for incomplete resolution associated with matrix cross-linking. *Gastroenterology*. 2004;126(7):1795-1808.
177. Farci P. Treatment of chronic hepatitis D: New advances, old challenges. *Hepatology*. 2006;44(3):536-539.
178. Rizzetto M. Hepatitis D: thirty years after. *J Hepatol*. 2009;50(5):1043-1050.
179. Fattovich G, Boscaro S, Noventa F, et al. Influence of hepatitis delta virus infection on progression to cirrhosis in chronic hepatitis type B. *J Infect Dis*. 1987;155(5):931-935.
180. Bonino F, Negro F, Baldi M, et al. The natural history of chronic delta hepatitis. *Prog Clin Biol Res*. 1987;234:145-152.
181. Rizzetto M, Durazzo M. Hepatitis delta virus (HDV) infections. Epidemiological and clinical heterogeneity. *J Hepatol*. 1991;13(suppl 4):S116-S118.
182. Lau JY, Portmann BC, Alexander GJ, Williams R. Differential effect of chronic hepatitis D virus infection on intrahepatic expression of hepatitis B viral antigen. *J Clin Pathol*. 1992;45(4):314-318.
183. Negro F, Rizzetto M. Pathobiology of hepatitis delta virus. *J Hepatol*. 1993;17(suppl 3):S149-S153.
184. Negro F, Pacchioni D, Bussolati G, Bonino F. Hepatitis delta virus heterogeneity: a study by immunofluorescence. *J Hepatol*. 1991;13(suppl 4):S125-S129.
185. Moreno A, Ramon y Cajal S, Marazuela M, et al. Sanded nuclei in delta patients. *Liver*. 1989;9(6):367-371.
186. Stocklin E, Gudat F, Spichtin HP, et al. [Delta superinfection of hepatitis B in Switzerland: histology and serology of 28 patients]. *Schweiz Med Wochenschr*. 1984;114(30):1047-1052.
187. Kojima T, Callea F, Desmyter J, et al. Immuno-light and electron microscopic features of chronic hepatitis D. *Liver*. 1990;10(1):17-27.
188. Thomas DL, Seeff LB. Natural history of hepatitis C. *Clin Liver Dis*. 2005;9(3):383-398, vi.
189. Boyer N, Marcellin P. Pathogenesis, diagnosis and management of hepatitis C. *J Heaptol*. 2000;32(suppl 1):98-112.
190. Wise M, Bialek S, Finelli L, et al. Changing trends in hepatitis C-related mortality in the United States, 1995-2004. *Hepatology*. 2008;47(4):1128-1135.
191. Reference deleted in proofs.
192. Dhingra S, Ward SC, Thung SN. Liver pathology of hepatitis C, beyond grading and staging of the disease. *World J Gastroenterol*. 2016;22:1357-1366.
193. Brillanti S, Foli M, Gaiani S, et al. Persistent hepatitis C viraemia without liver disease. *Lancet*. 1993;341(8843): 464-465.
194. Kyrlagkitsis I, Portmann B, Smith H, et al. Liver histology and progression of fibrosis in individuals with chronic hepatitis C and persistently normal ALT. *Am J Gastroenterol*. 2003;98(7):1588-1593.
195. Persico M, Perrotta S, Persico E, et al. Hepatitis C virus carriers with persistently normal ALT levels: biological peculiarities and update of the natural history of liver disease at 10 years. *J Viral Hepat*. 2006;13(5):290-296.
196. Dhillon AP, Dusheiko GM. Pathology of hepatitis C virus infection. *Histopathology*. 1995;26(4):297-309.
197. Dienes HP, Drebber U, von Both I. Liver biopsy in hepatitis C. *J Hepatol*. 1999;31(suppl 1):43-46.
198. Goodman ZD, Ishak KG. Histopathology of hepatitis C virus infection. *Semin Liver Dis*. 1995;15(1):70-81.
199. Bach N, Thung SN, Schaffner F. The histological features of chronic hepatitis C and autoimmune chronic hepatitis: a comparative analysis. *Hepatology*. 1992;15(4):572-577.
200. Gerber MA, Krawczynski K, Alter MJ, et al. Histopathology of community acquired chronic hepatitis C. The Sentinel Counties Chronic Non-A, Non-B Hepatitis Study Team. *Mod Pathol*. 1992;5(5):483-486.
201. Lefkowitch JH, Schiff ER, Davis GL, et al. Pathological diagnosis of chronic hepatitis C: a multicenter comparative study with chronic hepatitis B. The Hepatitis Interventional Therapy Group. *Gastroenterology*. 1993;104(2):595-603.
202. Mosnier JF, Degott C, Marcellin P, et al. The intraportal lymphoid nodule and its environment in chronic active hepatitis C: an immunohistochemical study. *Hepatology*. 1993;17(3):366-371.
203. Scheuer PJ, Ashrafzadeh P, Sherlock S, et al. The pathology of hepatitis C. *Hepatology*. 1992;15(4):567-571.
204. Christoffersen P, Poulsen H, Scheuer PJ. Abnormal bile duct epithelium in chronic aggressive hepatitis and primary biliary cirrhosis. *Hum Pathol*. 1972;3(2):227-235.

205. Vyberg M. The hepatitis-associated bile duct lesion. *Liver*. 1993;13(6):289-301.
206. Tanikawa K, Kage M, Komuta M, et al. Pathological analysis of oxyphilic granular hepatocytes and hepatocellular mitochondria in chronic hepatitis C. *Hepatol Res*. 2007;37(6):425-432.
207. Abenavoli L, Masarone M, Peta V, et al. Insulin resistance and liver steatosis in chronic hepatitis C infection genotype 3. *World J Gastroenterol*. 2014;20:15233-15240.
208. Clement S, Negro F. Hepatitis C virus: the viral way to fatty liver. *J Hepatol*. 2007;46(6):985-987.
209. Miyanari Y, Atsuzawa K, Usuda N, et al. The lipid droplet is an important organelle for hepatitis C virus production. *Nat Cell Biol*. 2007;9(9):1089-1097.
210. Wolk B, Wedemeyer H. Hepatitis C virus living off the fat of the land. *Hepatology*. 2008;47(1):343-345.
211. Rubbia-Brandt L, Fabris P, Paganin S, et al. Steatosis affects chronic hepatitis C progression in a genotype specific way. *Gut*. 2004;53:406-412.
212. Negro F. Mechanisms and significance of liver steatosis in hepatitis C virus infection. *World J Gastroenterol*. 2006;12(42):6756-6765.
213. Jonsson JR, Barrie HD, O'Rourke P, et al. Obesity and steatosis influence serum and hepatic inflammatory markers in chronic hepatitis C. *Hepatology*. 2008;48(1):80-87.
214. Moucari R, Asselah T, Cazals-Hatem D, et al. Insulin resistance in chronic hepatitis C: association with genotypes 1 and 4, serum HCV RNA level, and liver fibrosis. *Gastroenterology*. 2008;134(2):416-423.
215. Bedossa P, Moucari R, Chelbi E, et al. Evidence for a role of nonalcoholic steatohepatitis in hepatitis C: a prospective study. *Hepatology*. 2007;46(2):380-387.
216. Delgado-Borrego A, Liu YS, Jordan SH, et al. Prospective study of liver transplant recipients with HCV infection: evidence for a causal relationship between HCV and insulin resistance. *Liver Transpl*. 2008;14(2):193-201.
217. Negro F. Insulin resistance and HCV: will new knowledge modify clinical management? *J Hepatol*. 2006;45(4):514-519.
218. Sheikh MY, Choi J, Qadri I, et al. Hepatitis C virus infection: molecular pathways to metabolic syndrome. *Hepatology*. 2008;47(6):2127-2133.
219. Hu B, French SW. Mallory body and empty cell in hepatitis C. *Hepatol Res*. 1997;8:13-20.
220. Lory J, Zimmermann A. Endotheliitis-like changes in chronic hepatitis C. *Histol Histopathol*. 1997;12(2):359-366.
221. Haque S, Chandra B, Gerber MA, Lok AS. Iron overload in patients with chronic hepatitis C: a clinicopathologic study. *Hum Pathol*. 1996;27(12):1277-1281.
222. Bonkovsky HL, Poh-Fitzpatrick M, Pimstone N, et al. Porphyria cutanea tarda, hepatitis C, and HFE gene mutations in North America. *Hepatology*. 1998;27(6):1661-1669.
223. Bonkovsky HL, Banner BF, Rothman AL. Iron and chronic viral hepatitis. *Hepatology*. 1997;25(3):759-768.
224. Chiaverini C, Halimi G, Ouzan D, et al. Porphyria cutanea tarda, C282Y, H63D and S65C HFE gene mutations and hepatitis C infection: a study from southern France. *Dermatology*. 2003;206(3):212-216.
225. Fiel MI, Schiano TD, Guido M, et al. Increased hepatic iron deposition resulting from treatment of chronic hepatitis C with ribavirin. *Am J Clin Pathol*. 2000;113(1):35-39.
226. Emile JF, Sebagh M, Feray C, et al. The presence of epithelioid granulomas in hepatitis C virus-related cirrhosis. *Hum Pathol*. 1993;24(10):1095-1097.
227. Goldin RD, Levine TS, Foster GR, Thomas HC. Granulomas and hepatitis C. *Histopathology*. 1996;28(3):265-267.
228. Okuno T, Arai K, Matsumoto M, Shindo M. Epithelioid granulomas in chronic hepatitis C: a transient pathological feature. *J Gastroenterol Hepatol*. 1995;10:532-537.
229. Hoffmann RM, Jung MC, Motz R, et al. Sarcoidosis associated with interferon-alpha therapy for chronic hepatitis C. *J Hepatol*. 1998;28(6):1058-1063.
230. Harada K, Minato H, Hiramatsu K, Nakanuma Y. Epithelioid cell granulomas in chronic hepatitis C: immunohistochemical character and histological marker of favourable response to interferon-alpha therapy. *Histopathology*. 1998;33(3):216-221.
231. Ryan BM, McDonald GS, Pilkington R, Kelleher D. The development of hepatic granulomas following interferon-alpha2b therapy for chronic hepatitis C infection. *Eur J Gastroenterol Hepatol*. 1998;10(4):349-351.
232. Fiel MI, Shukla D, Saraf N, et al. Development of hepatic granulomas in patients receiving pegylated interferon therapy for recurrent hepatitis C virus post liver transplantation. *Transpl Infect Dis*. 2008;10(3):184-189.
233. Goldin RD, Patel NK, Thomas HC. Hepatitis C and bile duct loss. *J Clin Pathol*. 1996;49(10):836-838.
234. Glazer E, Ejaz A, Coley CJ 2nd, et al. Fibrin ring granuloma in chronic hepatitis C: virus-related vasculitis and/or immune complex disease? *Semin Liver Dis*. 2007;27(2):227-230.
235. Moreno A, Moreno A, Perez-Elias MJ, et al. Syncytial giant cell hepatitis in human immunodeficiency virus-infected patients with chronic hepatitis C: 2 cases and review of the literature. *Hum Pathol*. 2006;37(10):1344-1349.
236. Ryder SD, Irving WL, Jones DA, et al. Progression of hepatic fibrosis in patients with hepatitis C: a prospective repeat liver biopsy study. *Gut*. 2004;53(3):451-455.
237. Rueger S, Bochud PY, Dufour JF, et al. Impact of common risk factors of fibrosis progression in chronic hepatitis C. *Gut*. 2015;64:1605-1615.
238. Goodman ZD, Makhlouf HR, Liu L, et al. Pathology of chronic hepatitis C in children: liver biopsy findings in the Peds-C Trial. *Hepatology*. 2008;47(3):836-843.
239. Iorio R, Giannattasio A, Sepe A, et al. Chronic hepatitis C in childhood: an 18-year experience. *Clin Infect Dis*. 2005;41(10):1431-1437.
240. Clouston AD, Powell EE, Walsh MJ, et al. Fibrosis correlates with a ductular reaction in hepatitis C: roles of impaired replication, progenitor cells and steatosis. *Hepatology*. 2005;41(4):809-818.
241. Gadd VL, Melino M, Roy S, et al. Portal, but not lobular, macropahges express matric metalloproteinase-9: association with the ductular reaction and fibrosis in chronic hepatitis C. *Liver Int*. 2013;33:569-579.
242. Fontaine H, Nalpas B, Poulet B, et al. Hepatitis activity index is a key fctor in determining the natural history of chronic hepatitis C. *Hum Pathol*. 2001;32:904-909.
243. Zarski JP, Bohn B, Bastie A, et al. Characteristics of patients with dual infection by hepatitis B and C viruses. *J Hepatol*. 1998;28(1):27-33.
244. Liaw YF. Role of hepatitis C virus in dual and triple hepatitis virus infection. *Hepatology*. 1995;22(4 Pt 1):1101-1108.
245. Liaw YF, Tsai SL, Sheen IS, et al. Clinical and virological course of chronic hepatitis B virus infection with hepatitis C and D virus markers. *Am J Gastroenterol*. 1998;93(3):354-359.
246. Colin JF, Cazals-Hatem D, Loriot MA, et al. Influence of human immunodeficiency virus infection on chronic hepatitis B in homosexual men. *Hepatology*. 1999;29(4):1306-1310.
247. Allory Y, Charlotte F, Benhamou Y, et al. Impact of human immunodeficiency virus infection on the histological features of chronic hepatitis C: a case-control study. The MULTIVIRC group. *Hum Pathol*. 2000;31(1):69-74.
248. Sterling RK, Contos MJ, Smith PG, et al. Steatohepatitis: Risk factors and impact on disease severity in human immunodeficiency virus/hepatitis C virus coinfection. *Hepatology*. 2008;47(4):1118-1127.
249. Lefkowitch JH, Yee HT, Sweeting J, et al. Iron-rich foci in chronic viral hepatitis. *Hum Pathol*. 1998;29(2):116-118.
250. Smith BC, Gorve J, Guzail MA, et al. Heterozygosity for hereditary hemochromatosis is associated with more fibrosis in chronic hepatitis C. *Hepatology*. 1998;27(6):1695-1699.
251. Piperno A, Vergani A, Malosio I, et al. Hepatic iron overload in patients with chronic viral hepatitis: role of HFE gene mutations. *Hepatology*. 1998;28(4):1105-1109.
252. Czaja AJ, Carpenter HA. Histological findings in chronic hepatitis C with autoimmune features. *Hepatology*. 1997;26:459-466.
253. Lautenschlager I. CMV infection, diagnosis, and antivral strategies after liver transplantation. *Transpl Int*. 2009;22:1031-1040.
254. Chang MH, Huang HH, Huang ES, et al. Polymerase chain reaction to detect human cytomegalovirus in livers of infants with neonatal hepatitis. *Gastroenterology*. 1992;103(3):1022-1025.
255. Theise ND, Conn M, Thung SN. Localization of cytomegalovirus antigens in liver allografts over time. *Hum Pathol*. 1993;24(1):103-108.
256. Vanstapel MJ, Desmet VJ. Cytomegalovirus hepatitis: a histological and immunohistochemical study. *Appl Pathol*. 1983;1(1):41-49.
257. Strickler JG, Manivel JC, Copenhaver CM, Kubic VL. Comparison of in situ hybridization and immunohistochemistry for detection of cytomegalovirus and herpes simplex virus. *Hum Pathol*. 1990;21(4):443-448.
258. Snover DC, Horwitz CA. Liver disease in cytomegalovirus mononucleosis: a light microscopical and immunoperoxidase study of six cases. *Hepatology*. 1984;4(3):408-412.
259. Clarke J, Craig RM, Saffro R, et al. Cytomegalovirus granulomatous hepatitis. *Am J Med*. 1979;66(2):264-269.
260. Suh N, Liapis H, Misdraji J, et al. Epstein-Barr virus hepatitis: diagnostic value of in situ hybridization, polymerase chain reaction, and immunohistochemistry on liver biopsy from immunocompetent patients. *Am J Surg Pathol*. 2007;31(9): 1403-1409.
261. White NJ, Juel-Jensen BE. Infectious mononucleosis hepatitis. *Semin Liver Dis*. 1984;4(4):301-306.
262. Shaukat A, Tsai HT, Rutherford R, Anania FA. Epstein-Barr virus induced hepatitis: An important cause of cholestasis. *Hepatol Res*. 2005;33(1):24-26.
263. Bonacini M. Hepatobiliary complications in patients with human immunodeficiency virus infection. *Am J Med*. 1992;92(4):404-411.
264. Lamps LW. Hepatic granulomas, with an emphasis on infectious causes. *Adv Anat Pathol*. 2008;15(6):309-318.
265. Lafon ME, Kirn A. Human immunodeficiency virus infection of the liver. *Semin Liver Dis*. 1992;12(2):197-204.

266. Lefkowitch JH. The liver in AIDS. *Semin Liver Dis*. 1997;17(4):335-344.
267. Kennedy M, O'Reilly M, Bergin CJ, McDonald GS. Liver biopsy pathology in human immunodeficiency virus infection. *Eur J Gastroenterol Hepatol*. 1998;10(3):255-258.
268. Nakanuma Y, Liew CT, Peters RL, Govindarajan S. Pathologic features of the liver in acquired immune deficiency syndrome (AIDS). *Liver*. 1986;6(3):158-166.
269. Coker RJ, Clark D, Claydon EL, et al. Disseminated pneumocystis carinii infection in AIDS. *J Clin Pathol*. 1991;44(10):820-823.
270. Perkocha LA, Geaghan SM, Yen TS, et al. Clinical and pathological features of bacillary peliosis hepatis in association with human immunodeficiency virus infection. *N Engl J Med*. 1990;323(23):1581-1586.
271. Dupon M, Kosaifi T, Le Bail B, et al. Lipid-laden perisinusoidal cells in patients with acquired immunodeficiency syndrome. *Liver*. 1991;11(4):211-219.
272. Cello JP. Human immunodeficiency virus-associated biliary tract disease. *Semin Liver Dis*. 1992;12(2):213-218.
273. Orenstein JM, Dieterich DT, Kotler DP. Systemic dissemination by a newly recognized intestinal microsporidia species in AIDS. *AIDS*. 1992;6(10):1143-1150.
274. Chen XM, LaRusso NF. Cryptosporidiosis and the pathogenesis of AIDS-cholangiopathy. *Semin Liver Dis*. 2002;22(3):277-289.
275. Aldeen T, Davies S. Vanishing bile duct syndrome in a patient with advanced AIDS. *HIV Med*. 2007;8(8):573-574.
276. Schiano TD, Kotler DP, Ferran E, Fiel MI. Hepatoportal sclerosis as a cause of noncirrhotic portal hypertension in patients with HIV. *Am J Gastroenterol*. 2007;102(11):2536-2540.
277. Vallet-Pichard A, Mallet V, Pol S. Nonalcoholic fatty liver disease and HIV infection. *Semin Liver Dis*. 2012;32:158-166.
278. Bruno R, Sacchi P, Maiocchi L, et al. Hepatoxicity and antiretroviral therapy with protease inhibitors: a review. *Dig Liver Dis*. 2006;38:363-373.
279. Beral V, Peterman T, Berkelman R, Jaffe H. AIDS-associated non-Hodgkin lymphoma. *Lancet*. 1991;337(8745):805-809.
280. Hasan FA, Jeffers LJ, Welsh SW, et al. Hepatic involvement as the primary manifestation of Kaposi's sarcoma in the acquired immune deficiency syndrome. *Am J Gastroenterol*. 1989;84(11):1449-1451.
281. Sgro C, Clinard F, Ouazir K, et al. Incidence of drug-induced hepatic injuries: a French population-based study. *Hepatology*. 2002;36(2):451-455.
282. Fisher K, Vuppalanchi R, Saxena R. Drug-induced liver injury. *Arch Pathol Lab Med*. 2015;139:876-887.
283. Bianchi L, De Groote J, Desmet V, et al. Guidelines for diagnosis of therapeutic drug-induced liver injury in liver biopsies. *Lancet*. 1974;1(7862):854-857.
284. Pessayre D, Mansouri A, Berson A, Fromenty B. Mitochondrial involvement in drug-induced liver injury. *Handb Exp Pharmacol*. 2010;196:311-365.
285. Navarro VJ. Herbal and dietary supplement hepatotoxicity. *Semin Liver Dis*. 2009;29(4):373-382.
286. Suk KT, Kim DJ. Drug-induced liver injury: present and future. *Clin Mol Hepatol*. 2012;18:249-257.
287. Farrell GC. *Drug-induced liver disease*. Edinburgh; New York: Churchill Livingstone; 1994.
288. Kaplowitz N, DeLeve LD. *Drug-induced liver disease*. New York: Marcel Dekker; 2003.
289. Stricker BHC. *Drug-induced hepatic injury*. Amsterdam; New York: Elsevier; 1992.
290. Zimmerman HJ. *Hepatotoxicity: the adverse effects of drugs and other chemicals on the liver*. Philadelphia: Lippincott Williams & Wilkins; 1999.
291. Benichou C. Criteria of drug-induced liver disorders. Report of an international consensus meeting. *J Hepatol*. 1990;11(2):272-276.
292. Kleiner DE. The pathology of drug-induced liver injury. *Semin Liver Dis*. 2009;29(4):364-372.
293. Lewis JH. Drug-induced liver disease. *Med Clin North Am*. 2000;84(5):1275-1311, x.
294. Lewis JH, Zimmerman HJ. Drug- and chemical-induced cholestasis. *Clin Liver Dis*. 1999;3(3):433-464, vii.
295. Ramachandran R, Kakar S. Histological patterns in drug-induced liver disease. *J Clin Pathol*. 2009;62(6):481-492.
296. Bissell DM, Gores GJ, Laskin DL, Hoofnagle JH. Drug-induced liver injury: mechanisms and test systems. *Hepatology*. 2001;33(4):1009-1013.
297. Desmet VJ. Drug-induced liver disease: pathogenetic mechanisms and histopathological lesions. *Eur J Med*. 1993;2:36-47.
298. Uetrecht J. Immunoallergic drug-induced liver injury in humans. *Semin Liver Dis*. 2009;29(4):383-392.
299. Paiva LA, Wright PJ, Koff RS. Long-term hepatic memory for hypersensitivity to nitrofurantoin. *Am J Gastroenterol*. 1992;87(7):891-893.
300. Vazquez JJ, Guillen FJ, Zozaya J, Lahoz M. Cyanamide-induced liver injury. A predictable lesion. *Liver*. 1983;3(4):225-230.
301. Abrahams C, Wheatley A, Rubenstein AH, Stables D. Hepatocellular lipofuscin after excessive ingestion of analgesics. *Lancet*. 1964;2(7360):621-622.
302. Amacher DE, Chalasani N. Drug-induced hepatic steatosis. *Semin Liver Dis*. 2014;34:205-214.
303. Labbe G, Pessayre D, Fromenty B. Drug-induced liver injury through mitochondrial dysfunction: mechanisms and detection during preclinical safety studies. *Fundam Clin Pharmacol*. 2008;22(4):335-353.
304. McKenzie R, Fried MW, Sallie R, et al. Hepatic failure and lactic acidosis due to fialuridine (FIAU), an investigational nucleoside analogue for chronic hepatitis B. *N Engl J Med*. 1995;333(17):1099-1105.
305. Lee WS, Sokol RJ. Liver disease in mitochondrial disorders. *Semin Liver Dis*. 2007;27(3):259-273.
306. Sherlock S. Acute fatty liver of pregnancy and the microvesicular fat diseases. *Gut*. 1983;24(4):265-269.
307. Anderson N, Borlak J. Drug-induced phospholipidosis. *FEBS Lett*. 2006;580:5533-5540.
308. Atiq M, Davis JC, Lamps LW, et al. Amiodarone induced liver cirrhosis. Report of two cases. *J Gastrointestin Liver Dis*. 2009;18(2):233-235.
309. Pessayre D, Degos F, Feldmann G, et al. Chronic active hepatitis and giant multinucleated hepatocytes in adults treated with clometacin. *Digestion*. 1981;22(2):66-72.
310. Bursch W, Oberhammer F, Schulte-Hermann R. Cell death by apoptosis and its protective role against disease. *Trends Pharmacol Sci*. 1992;13(6):245-251.
311. Christidis C, Mal F, Ramos J, et al. Worsening of hepatic dysfunction as a consequence of repeated hydroxyethylstarch infusions. *J Hepatol*. 2001;35(6):726-732.
312. Ishak KG, Zimmerman HJ. Drug-induced and toxic granulomatous hepatitis. *Baillieres Clin Gastroenterol*. 1988;2(2):463-480.
313. Murphy E, Griffiths MR, Hunter JA, Burt AD. Fibrin-ring granulomas: a non-specific reaction to liver injury? *Histopathology*. 1991;19(1):91-93.
314. Roberts IS, Armstrong GR. Hepatic fibrin-ring granulomas. *Histopathology*. 1992;20(6):549.
315. Cruickshank B, Thomas MJ. Mineral oil (follicular) lipidosis: II. Histologic studies of spleen, liver, lymph nodes, and bone marrow. *Hum Pathol*. 1984;15(8):731-737.
316. Mitros F, Landas S, Furst D, Labrecque D. Lipogranulomas and gold in liver in rheumatoid arthritis. *Lab Invest*. 1986;54:44A.
317. Valla D, Benhamou JP. Drug-induced vascular and sinusoidal lesions of the liver. *Baillieres Clin Gastroenterol*. 1988;2(2):481-500.
318. Zafrani ES, von Pinaudeau Y, Dhumeaux D. Drug-induced vascular lesions of the liver. *Arch Intern Med*. 1983;143(3):495-502.
319. Chojkier M. Hepatic sinusoidal-obstruction syndrome: toxicity of pyrrolizidine alkaloids. *J Hepatol*. 2003;39(3):437-446.
320. Morris-Stiff G, Tan YM, Vauthey JN. Hepatic complications following preoperative chemotherapy with oxaliplatin or irinotecan for hepatic colorectal metastases. *Eur J Surg Oncol*. 2008;34:609-614.
321. Beltinger J, Haschke M, Kaufmann P, et al. Hepatic veno-occlusive disease associated with immunosuppressive cyclophosphamide dosing and roxithromycin. *Ann Pharmacother*. 2006;40(4):767-770.
322. Rosenthal AK, Klausmeier M, Cronin ME, McLaughlin JK. Hepatic angiosarcoma occurring after cyclophosphamide therapy: case report and review of the literature. *Am J Clin Oncol*. 2000;23:581-583.
323. Jorens PG, Michielsen PP, Pelckmans PA, et al. Vitamin A abuse: development of cirrhosis despite cessation of vitamin A. A six-year clinical and histopathologic follow-up. *Liver*. 1992;12(6):381-386.
324. Mounajjed T, Graham RP, Sanderson SO, Smyrk TC. Clinical associations of hepatic stellate cell hyperplasia. *Virchows Arch*. 2014;465:57-65.
325. Kaplan MM. Methotrexate hepatotoxicity and the premature reporting of Mark Twain's death: both greatly exaggerated. *Hepatology*. 1990;12(4 Pt 1):784-786.
326. Nollevaux MC, Guiot Y, Horsmans Y, et al. Hypervitaminosis A-induced liver fibrosis: stellate cell activation and daily dose consumption. *Liver Int*. 2006;26:182-186.
327. Pauli-Magnus C, Meier PJ. Hepatobiliary transporters and drug-induced cholestasis. *Hepatology*. 2006;44(4):778-787.
328. Mohi-ud-din R, Lewis JH. Drug- and chemical-induced cholestasis. *Clin Liver Dis*. 2004;8:95-132, vii.
329. Desmet VJ. Vanishing bile duct syndrome in drug-induced liver disease. *J Hepatol*. 1997;26(suppl 1):31-35.
330. Geubel AP, Sempoux CL. Drug and toxin-induced bile duct disorders. *J Gastroenterol Hepatol*. 2000;15:1232-1238.
331. Degott C, Feldmann G, Larrey D, et al. Drug-induced prolonged cholestasis in adults: a histological semiquantitative study demonstrating progressive ductopenia. *Hepatology*. 1992;15(2):244-251.
332. Benichou C. Criteria of drug-induced liver disorders. Report of an international consensus meeting. *J Hepatol*. 1990;11:272-276.
333. Roy AK, Mahoney HC, Levine RA. Phenytoin-induced chronic hepatitis. *Dig Dis Sci*. 1993;38(4):740-743.
334. Stricker BH, Blok AP, Claas FH, et al. Hepatic injury associated with the use of nitrofurans:

a clinicopathological study of 52 reported cases. *Hepatology*. 1988;8(3):599-606.
335. Scully LJ, Clarke D, Barr RJ. Diclofenac induced hepatitis. 3 cases with features of autoimmune chronic active hepatitis. *Dig Dis Sci*. 1993;38(4):744-751.
336. Lewis JH, Mullick F, Ishak KG, et al. Histopathologic analysis of suspected amiodarone hepatotoxicity. *Hum Pathol*. 1990;21(1):59-67.
337. Akhtar MA, Mathieson K, Arey B, et al. Hepatic histopathology and clinical characteristics associated with antiretroviral therapy in HIV patients without viral hepatitis. *Eur J Gastroenterol Hepatol*. 2008;20(12):1194-1204.
338. Ingiliz P, Valantin MA, Duvivier C, et al. Liver damage underlying unexplained transaminase elevation in human immunodeficiency virus-1 mono-infected patients on antiretroviral therapy. *Hepatology*. 2009;49(2):436-442.
339. Briones ER, Iber FL. Liver and biliary tract changes and injury associated with total parenteral nutrition: pathogenesis and prevention. *J Am Coll Nutr*. 1995;14:219-228.
340. Rahier JF, Rahier J, Leclercq I, Geubel AP. Severe acute cholestatic hepatitis with prolonged cholestasis and bile-duct injury following atorvastatin therapy: a case report. *Acta Gastroenterol Belg*. 2008;71(3):318-320.
341. Mullick FG, Moran CA, Ishak KG. Total parenteral nutrition: a histopathologic analysis of the liver changes in 20 children. *Mod Pathol*. 1994;7(2):190-194.
342. Kelly DA. Intestinal failure-associated liver disease: what do we know today? *Gastroenterology*. 2006;130(2 suppl 1):S70-S77.
343. Chung C, Buchman AL. Postoperative jaundice and total parenteral nutrition-associated hepatic dysfunction. *Clin Liver Dis*. 2002;6(4):1067-1084.
344. Blaszyk H, Wild PJ, Oliveira A, et al. Hepatic copper in patients receiving long-term total parenteral nutrition. *J Clin Gastroenterol*. 2005;39(4):318-320.
345. Kopelman H, Robertson MH, Sanders PG, Ash I. The Epping jaundice. *Br Med J*. 1966;1(5486):514-516.
346. Burt AD, Mutton A, Day CP. Diagnosis and interpretation of steatosis and steatohepatitis. *Semin Diagn Pathol*. 1998;15(4):246-258.
347. Yeh MM, Brunt EM. Pathological features of fatty liver disease. *Gastroenterology*. 2014;147:754-764.
348. Hall P, Gormley BM, Jarvis LR, Smith RD. A staining method for the detection and measurement of fat droplets in hepatic tissue. *Pathology*. 1980;12(4):605-608.
349. Olofsson SO, Bostrom P, Andersson L, et al. Lipid droplets as dynamic organelles connecting storage and efflux of lipids. *Biochim Biophys Acta*. 2009;1791(6):448-458.
350. Bickel PE, Tansey JT, Welte MA. PAT proteins, an ancient family of lipid droplet proteins that regulate cellular lipid stores. *Biochim Biophys Acta*. 2009;1791(6):419-440.
351. Ducharme NA, Bickel PE. Lipid droplets in lipogenesis and lipolysis. *Endocrinology*. 2008;149(3):942-949.
352. Eaton S, Record CO, Bartlett K. Multiple biochemical effects in the pathogenesis of alcoholic fatty liver. *Eur J Clin Invest*. 1997;27(9):719-722.
353. Purohit V, Gao B, Song BJ. Molecular mechanisms of alcoholic fatty liver. *Alcohol Clin Exp Res*. 2009;33(2):191-205.
354. Wilfred de Alwis NM, Day CP. Genetics of alcoholic liver disease and nonalcoholic fatty liver disease. *Semin Liver Dis*. 2007;27(1):44-54.
355. Teli MR, Day CP, Burt AD, et al. Determinants of progression to cirrhosis or fibrosis in pure alcoholic fatty liver. *Lancet*. 1995;346(8981):987-990.
356. Kleiner DE, Brunt EM, Van Natta M, et al. Design and validation of a histological scoring system for nonalcoholic fatty liver disease. *Hepatology*. 2005;41(6):1313-1321.
357. Layfield LJ. Focal fatty change of the liver: cytologic findings in a radiographic mimic of metastases. *Diagn Cytopathol*. 1994;11:385-387.
358. Hurwitz ES, Barrett MJ, Bregman D, et al. Public Health Service study of Reye's syndrome and medications. Report of the main study. *JAMA*. 1987;257(14):1905-1911.
359. Glasgow JF, Middleton B, Moore R, et al. The mechanism of inhibition of beta-oxidation by aspirin metabolites in skin fibroblasts from Reye's syndrome patients and controls. *Biochim Biophys Acta*. 1999;1454(1):115-125.
360. Rinaldo P. Fatty acid transport and mitochondrial oxidation disorders. *Semin Liver Dis*. 2001;21(4):489-500.
361. Schror K. Aspirin and Reye syndrome: a review of the evidence. *Paediatr Drugs*. 2007;9(3):195-204.
362. Weizman Z, Mussafi H, Ishay JS, et al. Multiple hornet stings with features of Reye's syndrome. *Gastroenterology*. 1985;89(6):1407-1410.
363. Christoffersen P, Braendstrup O, Juhl E, Poulsen H. Lipogranulomas in human liver biopsies with fatty change. A morphological, biochemical and clinical investigation. *Acta Pathol Microbiol Scand [A]*. 1971;79(2):150-158.
364. Zhu H, Bodenheimer HC Jr, Clain DJ, Theise ND. Hepatic lipogranulomas in patients with chronic liver disease: association with hepatitis C and fatty liver disease. *World J Gastroenterol*. 2010;16:5065-5069.
365. Letteron P, Fromenty B, Terris B, et al. Acute and chronic hepatic steatosis lead to in vivo lipid peroxidation in mice. *J Hepatol*. 1996;24(2):200-208.
366. Day CP, James OFW. Steatohepatitis: a tale of two 'hits'? *Gastroenterology*. 1998;114:842-845.
367. Pessayre D, Berson A, Fromenty B, Mansouri A. Mitochondria in steatohepatitis. *Semin Liver Dis*. 2001;21(1):57-69.
368. Farrell GC, Larter CZ. Nonalcoholic fatty liver disease: from steatosis to cirrhosis. *Hepatology*. 2006;43(2 suppl 1):S99-S112.
369. Syn WK, Teaberry V, Choi SS, Diehl AM. Similarities and differences in the pathogenesis of alcoholic and nonalcoholic steatohepatitis. *Semin Liver Dis*. 2009;29(2):200-210.
370. Ziol M, Tepper M, Lohez M, et al. Clinical and biological relevance of hepatocyte apoptosis in alcoholic hepatitis. *J Hepatol*. 2001;34(2):254-260.
371. Yip WW, Burt AD. Alcoholic liver disease. *Semin Diagn Pathol*. 2006;23(3-4):149-160.
372. Michalak S, Rousselet MC, Bedossa P, et al. Respective roles of porto-septal fibrosis and centrilobular fibrosis in alcoholic liver disease. *J Pathol*. 2003;201(1):55-62.
373. Baptista A, Bianchi L, De Groote J, et al. Alcoholic liver disease: morphological manifestations. Review by an international group. *Lancet*. 1981;1(8222):707-711.
374. MacSween RN, Burt AD. Histologic spectrum of alcoholic liver disease. *Semin Liver Dis*. 1986;6(3):221-232.
375. Lackner C, Gogg-Kamerer M, Zatloukal K, et al. Ballooned hepatocytes in steatohepatitis: the value of keratin immunohistochemistry for diagnosis. *J Hepatol*. 2008;48(5):821-828.
376. Zatloukal K, French SW, Stumptner C, et al. From Mallory to Mallory-Denk bodies: what, how and why? *Exp Cell Res*. 2007;313(10):2033-2049.
377. Stumptner C, Fuchsbichler A, Heid H, et al. Mallory body—a disease-associated type of sequestosome. *Hepatology*. 2002;35(5):1053-1062.
378. Hanada S, Strnad P, Brunt EM, Omary MB. The genetic background modulates susceptibility to mouse liver Mallory-Denk body formation and liver injury. *Hepatology*. 2008;48(3):943-952.
379. Aigelsreiter A, Janig E, Stumptner C, et al. How a cell deals with abnormal proteins. Pathogenetic mechanisms in protein aggregation diseases. *Pathobiology*. 2007;74(3):145-158.
380. Denk H, Stumptner C, Zatloukal K. Mallory bodies revisited. *J Hepatol*. 2000;32(4):689-702.
381. Uchida T, Kao H, Quispe-Sjogren M, Peters RL. Alcoholic foamy degeneration—a pattern of acute alcoholic injury of the liver. *Gastroenterology*. 1983;84(4):683-692.
382. Foschini MP, Macchia S, Losi L, et al. Identification of mitochondria in liver biopsies. A study by immunohistochemistry, immunogold and Western blot analysis. *Virchows Arch*. 1998;433(3):267-273.
383. Junge J, Horn T, Christoffersen P. Megamitochondria as a diagnostic marker for alcohol induced centrilobular and periportal fibrosis in the liver. *Virchows Arch*. 1987;410(6):553-558.
384. Lefkowitch JH, Arborgh BA, Scheuer PJ. Oxyphilic granular hepatocytes. Mitochondrion-rich liver cells in hepatic disease. *Am J Clin Pathol*. 1980;74(4):432-441.
385. Dinges HP, Zatloukal K, Denk H, et al. Alcoholic liver disease. Parenchyma to stroma relationship in fibrosis and cirrhosis as revealed by three-dimensional reconstruction and immunohistochemistry. *Am J Pathol*. 1992;141(1):69-83.
386. Nasrallah SM, Nassar VH, Galambos JT. Importance of terminal hepatic venule thickening. *Arch Pathol Lab Med*. 1980;104(2):84-86.
387. Edmondson HA, Peters RL, Reynolds TB, Kuzma OT. Sclerosing hyaline necrosis of the liver in the chronic alcoholic. A recognizable clinical syndrome. *Ann Intern Med*. 1963;59:646-673.
388. Gerber MA, Popper H. Relation between central canals and portal tracts in alcoholic hepatitis. A contribution to the pathogenesis of cirrhosis in alcoholics. *Hum Pathol*. 1972;3(2):199-207.
389. Chevallier M, Guerret S, Chossegros P, et al. A histological semiquantitative scoring system for evaluation of hepatic fibrosis in needle liver biopsy specimens: comparison with morphometric studies. *Hepatology*. 1994;20(2):349-355.
390. Orrego H, Blake JE, Blendis LM, Medline A. Prognosis of alcoholic cirrhosis in the presence and absence of alcoholic hepatitis. *Gastroenterology*. 1987;92(1):208-214.
391. Fattovich G, Stroffolini T, Zagni I, Donato F. Hepatocellular carcinoma in cirrhosis: incidence and risk factors. *Gastroenterology*. 2004;127(5 suppl 1):S35-S50.
392. Ludwig J, Batts KP, Moyer TP, et al. Liver biopsy diagnosis of homozygous hemochromatosis: a diagnostic algorithm. *Mayo Clin Proc*. 1993;68(3):263-267.
393. Tiniakos DG. Liver biopsy in alcoholic and non-alcoholic steatohepatitis patients. *Gastroenterol Clin Biol*. 2009;33(10-11):930-939.
394. Levin DM, Baker AL, Riddel RH, et al. Non-alcoholic liver disease: overlooked causes of liver injury in patients with heavy alcohol consumption. *Am J Med*. 1979;66:429-434.

395. Bloomer JR. The hepatic porphyrias: pathogenesis, manifestations, and management. *Gastroenterology*. 1976;71(4):689-701.
396. Cortes JM, Oliva H, Paradinas FJ, Hernandez-Guio C. The pathology of the liver in porphyria cutanea tarda. *Histopathology*. 1980;4(5):471-485.
397. Maddrey WC. Hepatic effects of acetaminophen. Enhanced toxicity in alcoholics. *J Clin Gastroenterol*. 1987;9(2):180-185.
398. Vazquez JJ. Ground-glass hepatocytes: light and electron microscopy. Characterization of the different types. *Histol Histopathol*. 1990;5(3):379-386.
399. Lefkowitch JH, Fenoglio JJ Jr. Liver disease in alcoholic cardiomyopathy: evidence against cirrhosis. *Hum Pathol*. 1983;14(5):457-463.
400. Lesur G, Levy P, Flejou JF, et al. Factors predictive of liver histopathological appearance in chronic alcoholic pancreatitis with common bile duct stenosis and increased serum alkaline phosphatase. *Hepatology*. 1993;18(5):1078-1081.
401. Afroudakis A, Kaplowitz N. Liver histopathology in chronic common bile duct stenosis due to chronic alcoholic pancreatitis. *Hepatology*. 1981;1(1):65-72.
402. Morgan MY, Sherlock S, Scheuer PJ. Portal fibrosis in the livers of alcoholic patients. *Gut*. 1978;19(11):1015-1021.
403. Cotrim HP, Andrade ZA, Parana R, et al. Nonalcoholic steatohepatitis: a toxic liver disease in industrial workers. *Liver*. 1999;19(4):299-304.
404. Cave M, Falkner KC, Ray M, et al. Toxicant-associated steatohepatitis in vinyl chloride workers. *Hepatology*. 2010;51(2):474-481.
405. Chitturi S, Farrell GC. Etiopathogenesis of nonalcoholic steatohepatitis. *Semin Liver Dis*. 2001;21(1):27-41.
406. Schaffner F, Thaler H. Non-alcoholic fatty liver disease. In: Popper H, Schaffner F, eds. *Progress in liver disease*. Orlando: Grune and Stratton; 1986:283-298.
407. Thaler H. [The fatty liver and its pathogenetic relation to liver cirrhosis]. *Virchows Arch Pathol Anat Physiol Klin Med*. 1962;335:180-210.
408. Ludwig J, Viggiano TR, McGill DB, Oh BJ. Nonalcoholic steatohepatitis: Mayo Clinic experiences with a hitherto unnamed disease. *Mayo Clin Proc*. 1980;55(7):434-438.
409. Lazo M, Clark JM. The epidemiology of nonalcoholic fatty liver disease: a global perspective. *Semin Liver Dis*. 2008;28(4):339-350.
410. Yeh MM, Brunt EM. Pathology of nonalcoholic fatty liver disease. *Am J Clin Pathol*. 2007;128(5):837-847.
411. Schwimmer JB, Deutsch R, Kahen T, et al. Prevalence of fatty liver in children and adolescents. *Pediatrics*. 2006;118(4):1388-1393.
412. Koda M, Kawakami M, Murawaki Y, Senda M. The impact of visceral fat in nonalcoholic fatty liver disease: cross-sectional and longitudinal studies. *J Gastroenterol*. 2007;42(11):897-903.
413. Cancello R, Tordjman J, Poitou C, et al. Increased infiltration of macrophages in omental adipose tissue is associated with marked hepatic lesions in morbid human obesity. *Diabetes*. 2006;55(6): 1554-1561.
414. Qureshi K, Abrams GA. Metabolic liver disease of obesity and role of adipose tissue in the pathogenesis of nonalcoholic fatty liver disease. *World J Gastroenterol*. 2007;13(26):3540-3553.
415. van der Poorten D, Milner KL, Hui J, et al. Visceral fat: a key mediator of steatohepatitis in metabolic liver disease. *Hepatology*. 2008;48(2):449-457.
416. Pessayre D, Fromenty B. NASH: a mitochondrial disease. *J Hepatol*. 2005;42(6):928-940.
417. Lalor PF, Faint J, Aarbodem Y, et al. The role of cytokines and chemokines in the development of steatohepatitis. *Semin Liver Dis*. 2007;27(2):173-193.
418. Maher JJ, Leon P, Ryan JC. Beyond insulin resistance: Innate immunity in nonalcoholic steatohepatitis. *Hepatology*. 2008;48(2):670-678.
419. James OF, Day CP. Non-alcoholic steatohepatitis (NASH): a disease of emerging identity and importance. *J Hepatol*. 1998;29(3):495-501.
420. Matteoni CA, Younossi ZM, Gramlich T, et al. Nonalcoholic fatty liver disease: a spectrum of clinical and pathological severity. *Gastroenterology*. 1999;116(6):1413-1419.
421. Younossi ZM, Gramlich T, Liu YC, et al. Nonalcoholic fatty liver disease: assessment of variability in pathologic interpretations. *Mod Pathol*. 1998;11(6):560-565.
422. Brunt EM. Nonalcoholic steatohepatitis: definition and pathology. *Semin Liver Dis*. 2001;21(1):3-16.
423. Brunt EM. What's in a NAme? *Hepatology*. 2009;50(3):663-667.
424. Brunt EM. Histopathology of non-alcoholic fatty liver disease. *Clin Liver Dis*. 2009;13(4):533-544.
425. Chalasani N, Wilson L, Kleiner DE, et al. Relationship of steatosis grade and zonal location to histological features of steatohepatitis in adult patients with non-alcoholic fatty liver disease. *J Hepatol*. 2008;48(5):829-834.
426. Banner BF, Savas L, Zivny J, et al. Ubiquitin as a marker of cell injury in nonalcoholic steatohepatitis. *Am J Clin Pathol*. 2000;114(6):860-866.
427. Torbenson M, Chen YY, Brunt E, et al. Glycogenic hepatopathy: an underrecognized hepatic complication of diabetes mellitus. *Am J Surg Pathol*. 2006;30(4):508-513.
428. Diehl AM, Goodman Z, Ishak KG. Alcohollike liver disease in nonalcoholics. A clinical and histologic comparison with alcohol-induced liver injury. *Gastroenterology*. 1988;95(4):1056-1062.
429. Pinto HC, Baptista A, Camilo ME, et al. Nonalcoholic steatohepatitis. Clinicopathological comparison with alcoholic hepatitis in ambulatory and hospitalized patients. *Dig Dis Sci*. 1996;41(1):172-179.
430. Bambha K, Belt P, Abraham M, et al. Ethnicity and nonalcoholic fatty liver disease. *Hepatology*. 2012;55:769-780.
431. Mohanty SR, Troy TN, Huo D, et al. Influence of ethnicity on histological differences in non-alcoholic fatty liver disease. *J Hepatol*. 2009;50(4):797-804.
432. Brunt EM, Janney CG, Di Bisceglie AM, et al. Nonalcoholic steatohepatitis: a proposal for grading and staging the histological lesions. *Am J Gastroenterol*. 1999;94(9):2467-2474.
433. Goldstein NS, Hastah F, Galan MV, Gordon SC. Fibrosis heterogeneity in nonalcoholic steatohepatitis and hepatitis C virus needle core biopsy specimens. *Am J Clin Pathol*. 2005;123(3):382-387.
434. Brunt EM, Kleiner DE, Wilson LA, et al. Portal chronic inflammation in nonalcoholic fatty liver disease (NAFLD): a histologic marker of advanced NAFLD-Clinicopathologic correlations from the nonalcoholic steatohepatitis clinical research network. *Hepatology*. 2009;49(3):809-820.
435. Abrams GA, Kunde SS, Lazenby AJ, Clements RH. Portal fibrosis and hepatic steatosis in morbidly obese subjects: A spectrum of nonalcoholic fatty liver disease. *Hepatology*. 2004;40(2):475-483.
436. Richardson MM, Jonsson JR, Powell EE, et al. Progressive fibrosis in nonalcoholic steatohepatitis: association with altered regeneration and a ductular reaction. *Gastroenterology*. 2007;133(1):80-90.
437. Poonawala A, Nair SP, Thuluvath PJ. Prevalence of obesity and diabetes in patients with cryptogenic cirrhosis: a case-control study. *Hepatology*. 2000;32(4 Pt 1):689-692.
438. Nayak NC, Vasdev N, Saigal S, Soin AS. End-stage nonalcoholic fatty liver disease: evaluation of pathomorphologic features and relationship to cryptogenic cirrhosis from study of explant livers in a living donor liver transplant program. *Hum Pathol*. 2010;41(3):425-430.
439. Malik SM, Devera ME, Fontes P, et al. Recurrent disease following liver transplantation for nonalcoholic steatohepatitis cirrhosis. *Liver Transpl*. 2009;15(12):1843-1851.
440. Bugianesi E. Non-alcoholic steatohepatitis and cancer. *Clin Liver Dis*. 2007;11(1):191-207, x-xi.
441. Page JM, Harrison SA. NASH and HCC. *Clin Liver Dis*. 2009;13(4):631-647.
442. Brunt EM. Pathology of nonalcoholic steatohepatitis. *Hepatol Res*. 2005;33(2):68-71.
443. Brunt EM. Pathology of fatty liver disease. *Mod Pathol*. 2007;20(suppl 1):S40-S48.
444. Pais R, Rusu E, Zilisteanu D, et al. Prevalence of steatosis and insulin resistance in patients with chronic hepatitis B compared with chronic hepatitis C and non-alcoholic fatty liver disease. *Eur J Intern Med*. 2015;26:30-36.
445. Alkhouri N, Tamimi TA, Yerian L, et al. The inflamed liver and atherosclerosis: a link between histologic severity of nonalcoholic fatty liver disease and increased cardiovascular risk. *Dig Dis Sci*. 2010;55(9):2644-2650.
446. Gaidos JK, Hillner BE, Sanyal AJ. A decision analysis study of the value of a liver biopsy in nonalcoholic steatohepatitis. *Liver Int*. 2008;28(5):650-658.
447. Fracanzani AL, Valenti L, Bugianesi E, et al. Risk of severe liver disease in nonalcoholic fatty liver disease with normal aminotransferase levels: a role for insulin resistance and diabetes. *Hepatology*. 2008;48(3):792-798.
448. Wieckowska A, Feldstein AE. Diagnosis of nonalcoholic fatty liver disease: invasive versus noninvasive. *Semin Liver Dis*. 2008;28(4):386-395.
449. Loomba R, Sirlin CB, Schwimmer JB, Lavine JE. Advances in pediatric nonalcoholic fatty liver disease. *Hepatology*. 2009;50(4):1282-1293.
450. Roberts EA. Pediatric nonalcoholic fatty liver disease (NAFLD): a "growing" problem? *J Hepatol*. 2007;46(6):1133-1142.
451. Roberts EA. Non-alcoholic steatohepatitis in children. *Clin Liver Dis*. 2007;11(1):155-172, x.
452. Rubinstein E, Lavine JE, Schwimmer JB. Hepatic, cardiovascular, and endocrine outcomes of the histological subphenotypes of nonalcoholic fatty liver disease. *Semin Liver Dis*. 2008;28(4):380-385.
453. Xanthakos S, Miles L, Bucuvalas J, et al. Histologic spectrum of nonalcoholic fatty liver disease in morbidly obese adolescents. *Clin Gastroenterol Hepatol*. 2006;4(2): 226-232.
454. Carter-Kent C, Yerian LM, Brunt EM, et al. Nonalcoholic steatohepatitis in children: a

multicenter clinicopathological study. *Hepatology*. 2009;50(4):1113-1120.
455. Patton HM, Lavine JE, Van Natta ML, et al. Clinical correlates of histopathology in pediatric nonalcoholic steatohepatitis. *Gastroenterology*. 2008;135(6):1961-1971.e2.
456. Poustchi H, Negro F, Hui J, et al. Insulin resistance and response to therapy in patients infected with chronic hepatitis C virus genotypes 2 and 3. *J Hepatol*. 2008;48(1):28-34.
457. Chavez-Tapia NC, Tellez-Avila FI. Nonalcoholic steatohepatitis in chronic hepatitis C: A new classification? *Hepatology*. 2008;47(2):759, author reply -60.
458. Clouston AD, Jonsson JR, Powell EE. Steatosis as a cofactor in other liver diseases: hepatitis C virus, alcohol, hemochromatosis, and others. *Clin Liver Dis*. 2007;11(1):173-189, x.
459. Kim MS, Quintos JB. Mauriac syndrome: growth failure and type 1 diabetes mellitus. *Pediatr Endocrinol Rev*. 2008;5(suppl 4):989-993.
460. Chatila R, West AB. Hepatomegaly and abnormal liver tests due to glycogenosis in adults with diabetes. *Medicine (Baltimore)*. 1996;75(6):327-333.
461. Miles L, Heubi JE, Bove KE. Hepatocyte glycogen accumulation in patients undergoing dietary management of urea cycle defects mimics storage disease. *J Pediatr Gastroenterol Nutr*. 2005;40(4):471-476.
462. Komuta M, Harada M, Ueno T, et al. Unusual accumulation of glycogen in liver parenchymal cells in a patient with anorexia nervosa. *Intern Med*. 1998;37(8):678-682.
463. Harrison SA, Brunt EM, Goodman ZD, Di Bisceglie AM. Diabetic hepatosclerosis: diabetic microangiopathy of the liver. *Arch Pathol Lab Med*. 2006;130(1):27-32.
464. Latry P, Bioulac-Sage P, Echinard E, et al. Perisinusoidal fibrosis and basement membrane-like material in the livers of diabetic patients. *Hum Pathol*. 1987;18(8):775-780.
465. Chen G, Brunt EM. Diabetic hepatosclerosis: a 10-year autopsy series. *Liver Int*. 2009;29(7):1044-1050.
466. Hudacko RM, Sciancalepore JP, Fyfe BS. Diabetic microangiopathy in the liver: an autopsy study of incidence and association with other diabetic complications. *Am J Clin Pathol*. 2009;132(4):494-499.
467. Jungst C, Lammert F. Cholestatic liver disease. *Dig Dis*. 2013;31:152-154.
468. Jansen PL, Sturm E. Genetic cholestasis, causes and consequences for hepatobiliary transport. *Liv Int*. 2003;23(5):315-322.
469. Li MK, Crawford JM. The pathology of cholestasis. *Semin Liver Dis*. 2004;24(1):21-42.
470. Desmet VJ, Roskams T. Histological features. In: Bircher J, Benhamou JP, McIntyre N, et al, eds. *Oxford Textbook of Clinical Hepatology*. Vol. 1. 2nd ed. Oxford: Oxford University Press; 1999:463-470.
471. Bloomer JR. The liver in protoporphyria. *Hepatology*. 1988;8(2):402-407.
472. Zollner G, Wagner M, Fickert P, et al. Expression of bile acid synthesis and detoxification enzymes and the alternative bile acid efflux pump MRP4 in patients with primary biliary cirrhosis. *Liv Int*. 2007;27(7):920-929.
473. Nagore N, Howe S, Boxer L, Scheuer PJ. Liver cell rosettes: structural differences in cholestasis and hepatitis. *Liver*. 1989;9:43-51.
474. Van Eyken P, Sciot R, Desmet VJ. A cytokeratin immunohistochemical study of cholestatic liver disease: evidence that hepatocytes can express 'bile duct-type' cytokeratins. *Histopathology*. 1989;15(2):125-135.
475. Desmet V, Roskams T, Van Eyken P. Ductular reaction in the liver. *Pathol Res Pract*. 1995;191:513-524.
476. James J, Lygidakis NJ, van Eyken P, et al. Application of keratin immunocytochemistry and sirius red staining in evaluating intrahepatic changes with acute extrahepatic cholestasis due to hepatic duct carcinoma. *Hepatogastroenterology*. 1989;36(3):151-155.
477. Slott PA, Liu MH, Tavoloni N. Origin, pattern, and mechanism of bile duct proliferation following biliary obstruction in the rat. *Gastroenterology*. 1990;99(2):466-477.
478. Matsumoto K, Fujii H, Michalopoulos G, et al. Human biliary epithelial cells secrete and respond to cytokines and hepatocyte growth factors in vitro: interleukin-6, hepatocyte growth factor and epidermal growth factor promote DNA synthesis in vitro. *Hepatology*. 1994;20(2):376-382.
479. Roskams T, Desmet V. Ductular reaction and its diagnostic significance. *Semin Diagn Pathol*. 1998;15:259-269.
480. Ludwig J. New concepts in biliary cirrhosis. *Semin Liver Dis*. 1987;7(4):293-301.
481. Portmann B, Popper H, Neuberger J, Williams R. Sequential and diagnostic features in primary biliary cirrhosis based on serial histologic study in 209 patients. *Gastroenterology*. 1985;88(6):1777-1790.
482. Kinnman N, Housset C. Peribiliary myofibroblasts in biliary type liver fibrosis. *Front Biosci*. 2002;7:d496-d503.
483. Rygiel KA, Robertson H, Marshall HL, et al. Epithelial-mesenchymal transition contributes to portal tract fibrogenesis during human chronic liver disease. *Lab Invest*. 2008;88(2):112-123.
484. Schulze F, Schardt K, Wedemeyer I, et al. [Epithelial-mesenchymal transition of biliary epithelial cells in advanced liver fibrosis]. *Verh Dtsch Ges Pathol*. 2007;91:250-256.
485. Costa AM, Tuchweber B, Lamireau T, et al. Role of apoptosis in the remodeling of cholestatic liver injury following release of the mechanical stress. *Virchows Arch*. 2003;442(4):372-380.
486. Ramm GA, Carr SC, Bridle KR, et al. Morphology of liver repair following cholestatic liver injury: resolution of ductal hyperplasia, matrix deposition and regression of myofibroblasts. *Liver*. 2000;20(5):387-396.
487. Sonzogni A, Colloredo G, Fabris L, et al. Isolated idiopathic bile ductular hyperplasia in patients with persistently abnormal liver function tests. *J Hepatol*. 2004;40(4):592-598.
488. Hammel P, Couvelard A, O'Toole D, et al. Regression of liver fibrosis after biliary drainage in patients with chronic pancreatitis and stenosis of the common bile duct. *N Engl J Med*. 2001;344(6):418-423.
489. Desmet VJ. Cirrhosis: aetiology and pathogenesis: cholestasis. In: Boyer JL, Bianchi L, eds. *Liver cirrhosis Falk Symposium 44*. Lancaster: MTP Press; 1987:101-118.
490. Ludwig J, Dickson ER, McDonald GS. Staging of chronic nonsuppurative destructive cholangitis (syndrome of primary biliary cirrhosis). *Virchows Arch*. 1978;379:103-112.
491. Scheuer PJ. Primary biliary cirrhosis. *Proc R Soc Med*. 1967;60:1257-1260.
492. Kakuda Y, Harada K, Sawada-Kitamura S, et al. Evaluation of a new histologic staging and grading system for primary biliary cirrhosis in comparison with classical systems. *Hum Pathol*. 2013;44:1107-1117.
493. Torbenson M, Hart J, Westerhoff M, et al. Neonatal giant cell hepatitis: histological and etiological findings. *Am J Surg Pathol*. 2010;34:1498-1503.
494. Harris MJ, Le Couteur DG, Arias IM. Progressive familial intrahepatic cholestasis: genetic disorders of biliary transporters. *J Gastroenterol Hepatol*. 2005;20(6):807-817.
495. Knisely AS. Progressive familial intrahepatic cholestasis: a personal perspective. *Pediatr Dev Pathol*. 2000;3(2):113-125.
496. Knisely AS. Progressive familial intrahepatic cholestasis: an update. *Pediatr Dev Pathol*. 2004;7(4):309-314.
497. Molina EG, Reddy KR. Postoperative jaundice. *Clin Liver Dis*. 1999;3(3):477-488.
498. Banks JG, Foulis AK, Ledingham IM, Macsween RN. Liver function in septic shock. *J Clin Pathol*. 1982;35(11):1249-1252.
499. Lefkowitch JH. Bile ductular cholestasis: an ominous histopathologic sign related to sepsis and "cholangitis lenta". *Hum Pathol*. 1982;13(1):19-24.
500. Desmet VJ, Callea F. Cholestatic syndromes of infancy and childhood. In: Zakim D, Boyer TD, eds. *Hepatology: a Textbook of Liver Disease*. Vol. 2. 3rd ed. Philadelphia: W.B. Saunders; 1996:1649-1698.
501. Flora KD, Benner KG. Liver disease in cystic fibrosis. *Clin Liver Dis*. 1998;2(1):51-61.
502. West AB, Chatila R. Differential diagnosis of bile duct injury and ductopenia. *Semin Diagn Pathol*. 1998;15(4):270-284.
503. Alagille D, Odievre M, Gautier M, Dommergues JP. Hepatic ductular hypoplasia associated with characteristic facies, vertebral malformations, retarded physical, mental, and sexual development, and cardiac murmur. *J Pediatr*. 1975;86(1):63-71.
504. Moreira RK, Chopp W, Washington MK. The concept of hepatic artery-bile duct parallelism in the diagnosis of ductopenia in liver biopsy samples. *Am J Surg Pathol*. 2011;35:392-403.
505. Nakanuma Y, Ohta G. Histometric and serial section observations of the intrahepatic bile ducts in primary biliary cirrhosis. *Gastroenterology*. 1979;76(6):1326-1332.
506. Treem WR, Krzymowski GA, Cartun RW, et al. Cytokeratin immunohistochemical examination of liver biopsies in infants with Alagille syndrome and biliary atresia. *J Pediatr Gastroenterol Nutr*. 1992;15(1):73-80.
507. Faa G, Van Eyken P, Demelia L, et al. Idiopathic adulthood ductopenia presenting with chronic recurrent cholestasis. A case report. *J Hepatol*. 1991;12(1):14-20.
508. Kaplan MM, Gershwin ME. Primary biliary cirrhosis. *N Engl J Med*. 2005;353(12):1261-1273.
509. Lindor KD, Gershwin ME, Poupon R, et al. Primary biliary cirrhosis. *Hepatology*. 2009;50(1):291-308.
510. Selmi C, Zuin M, Gershwin ME. The unfinished business of primary biliary cirrhosis. *J Hepatol*. 2008;49(3):451-460.
511. Rubin E, Schaffner F, Popper H. Primary biliary cirrhosis. Chronic non-suppurative destructive cholangitis. *Am J Pathol*. 1965;46:387-407.
512. Gershwin ME, Ansari AA, Mackay IR, et al. Primary biliary cirrhosis: an orchestrated immune response against epithelial cells. *Immunol Rev*. 2000;174:210-225.
513. Roll J, Boyer JL, Barry D, Klatskin G. The prognostic importance of clinical and histologic features in asymptomatic and symptomatic primary biliary cirrhosis. *N Engl J Med*. 1983;308:1-7.
514. Drebber U, Mueller JJ, Klein E, et al. Liver biopsy in primary biliary cirrhosis: clinicopathological data and stage. *Pathol Int*. 2009;59(8):546-554.
515. Yamada S, Howe S, Scheuer PJ. Three-dimensional reconstruction of biliary pathways in primary biliary cirrhosis: a computer-assisted study. *J Pathol*. 1987;152(4):317-323.
516. Saxena R, Hytiroglou P, Thung SN, Theise ND. Destruction of canals of Hering in primary biliary cirrhosis. *Hum Pathol*. 2002;33(10):983-988.

517. Nakanuma Y, Tsuneyama K, Gershwin ME, Yasoshima M. Pathology and immunopathology of primary biliary cirrhosis with emphasis on bile duct lesions: recent progress. *Semin Liver Dis*. 1995;15(4):313-328.
518. Moreira RK, Revetta F, Koehler E, Washington MK. Diagnostic utility of IgG and IgM immunohistochemistry in autoimmune liver disease. *World J Gastroenterol*. 2010;16(4):453-457.
519. Daniels JA, Torbenson M, Anders RA, Boitnott JK. Immunostaining of plasma cells in primary biliary cirrhosis. *Am J Clin Pathol*. 2009;131(2):243-249.
520. Cabibi D, Tarantino G, Barbaria F, et al. Intrahepatic IgG/IgM plasma cells ratio helps in classifying autoimmune liver diseases. *Dig Liver Dis*. 2010;42(8):585-592.
521. Guarascio P, Yentis F, Cevikbas U, et al. Value of copper-associated protein in diagnostic assessment of liver biopsy. *J Clin Pathol*. 1983;36:18-23.
522. Locke GR 3rd, Therneau TM, Ludwig J, et al. Time course of histological progression in primary biliary cirrhosis. *Hepatology*. 1996;23(1):52-56.
523. Nakanuma Y, Saito K, Unoura M. Semiquantitative assessment of cholestasis and lymphocytic piecemeal necrosis in primary biliary cirrhosis: a histologic and immunohistochemical study. *J Clin Gastroenterol*. 1990;12(3):357-362.
524. Nakanuma Y. Pathology of septum formation in primary biliary cirrhosis: a histological study in the non-cirrhotic stage. *Virchows Arch A Pathol Anat Histopathol*. 1991;419(5):381-387.
525. Nakanuma Y. Necroinflammatory changes in hepatic lobules in primary biliary cirrhosis with less well-defined cholestatic changes. *Hum Pathol*. 1993;24(4):378-383.
526. Corpechot C, Poujol-Robert A, Wendum D, et al. Biochemical markers of liver fibrosis and lymphocytic piecemeal necrosis in UDCA-treated patients with primary biliary cirrhosis. *Liver Int*. 2004;24(3):187-193.
527. Corpechot C, Abenavoli L, Rabahi N, et al. Biochemical response to ursodeoxycholic acid and long-term prognosis in primary biliary cirrhosis. *Hepatology*. 2008;48(3):871-877.
528. Sasaki M, Ikeda H, Yamaguchi J, et al. Telomere shortening in the damaged small bile ducts in primary biliary cirrhosis reflects ongoing cellular senescence. *Hepatology*. 2008;48(1):186-195.
529. Degott C, Zafrani ES, Callard P, et al. Histopathological study of primary biliary cirrhosis and the effect of ursodeoxycholic acid treatment on histology progression. *Hepatology*. 1999;29(4):1007-1012.
530. Yabushita K, Yamamoto K, Ibuki N, et al. Aberrant expression of cytokeratin 7 as a histological marker of progression in primary biliary cirrhosis. *Liver*. 2001;21(1):50-55.
531. Garrido MC, Hubscher SG. Accuracy of staging in primary biliary cirrhosis. *J Clin Pathol*. 1996;49(7):556-559.
532. Hiramatsu K, Aoyama H, Zen Y, et al. Proposal of a new staging and grading system of the liver for primary biliary cirrhosis. *Histopathology*. 2006;49(5): 466-478.
533. Nakanuma Y, Hirata K. Unusual hepatocellular lesions in primary biliary cirrhosis resembling but unrelated to hepatocellular neoplasms. *Virchows Arch A Pathol Anat Histopathol*. 1993;422(1):17-23.
534. Deutsch M, Papatheodoridis GV, Tzakou A, Hadziyannis SJ. Risk of hepatocellular carcinoma and extrahepatic malignancies in primary biliary cirrhosis. *Eur J Gastroenterol Hepatol*. 2008;20(1):5-9.
535. Piscaglia F, Sagrini E. Malignancies in primary biliary cirrhosis. *Eur J Gastroenterol Hepatol*. 2008;20(1):1-4.
536. Silveira MG, Suzuki A, Lindor KD. Surveillance for hepatocellular carcinoma in patients with primary biliary cirrhosis. *Hepatology*. 2008;48(4):1149-1156.
537. Colina F, Pinedo F, Solis JA, et al. Nodular regenerative hyperplasia of the liver in early histological stages of primary biliary cirrhosis. *Gastroenterology*. 1992;102(4 Pt 1):1319-1324.
538. Nakanuma Y, Ohta G, Kobayashi K, Kato Y. Histological and histometric examination of the intrahepatic portal vein branches in primary biliary cirrhosis without regenerative nodules. *Am J Gastroenterol*. 1982;77(6):405-413.
539. Brunner G, Klinge O. [A chronic destructive non-suppurative cholangitis-like disease picture with antinuclear antibodies (immunocholangitis)]. *Dtsch Med Wochenschr*. 1987;112(38):1454-1458.
540. Ben-Ari Z, Dhillon AP, Sherlock S. Autoimmune cholangiopathy: part of the spectrum of autoimmune chronic active hepatitis. *Hepatology*. 1993;18(1):10-15.
541. Hirschfield GM, Heathcote EJ. Antimitochondrial antibody-negative primary biliary cirrhosis. *Clin Liver Dis*. 2008;12(2):323-331, viii-ix.
542. Mendes F, Lindor KD. Antimitochondrial antibody-negative primary biliary cirrhosis. *Gastroenterol Clin North Am*. 2008;37(2):479-484, viii.
543. Hirschfield GM, Karlsen TH, Lindor KD, et al. Primary sclerosing cholangitis. *Lancet*. 2013;382(9904):1587-1599.
544. Fickert P, Moustafa T, Trauner M. Primary sclerosing cholangitis—the arteriosclerosis of the bile duct? *Lipids Health Dis*. 2007;6:3.
545. Palmela C, Peerani F, Castaneda D, et al. Inflammatory bowel disease and primary sclerosing cholangitis: a review of the phenotype and associated specific features. *Gut Liver*. 2017. doi:10.5009/gnl16510.
546. Ludwig J. Small-duct primary sclerosing cholangitis. *Semin Liver Dis*. 1991;11(1):11-17.
547. Olsson R, Glaumann H, Almer S, et al. High prevalence of small duct primary sclerosing cholangitis among patients with overlapping autoimmune hepatitis and primary sclerosing cholangitis. *Eur J Intern Med*. 2009;20(2):190-196.
548. Harrison RF, Hubscher SG. The spectrum of bile duct lesions in end-stage primary sclerosing cholangitis. *Histopathology*. 1991;19(4):321-327.
549. Colling R, Verrill C, Fryer E, et al. Bile duct basement membrane thickening in primary sclerosing cholangitis. *Histopathology*. 2016;68:819-824.
550. MacSween RN, Burt AD, Haboubi NY. Unusual variant of primary sclerosing cholangitis. *J Clin Pathol*. 1987;40(5):541-545.
551. Harrison RJ, Hubscher SG. The spectrum of bile duct lesions in end-stage primary sclerosing cholangitis. *Histopathology*. 1991;19:321-327.
552. Aadland E, Schrumpf E, Fausa O, et al. Primary sclerosing cholangitis: a long-term follow-up study. *Scand J Gastroenterol*. 1987;22(6):655-664.
553. Ehlken H, Schramm C. Primary sclerosing cholangitis and cholangiocarcinoma: pathogenesis and modes of diagnostics. *Dig Dis*. 2013;31:118-125.
554. Claessen MM, Vleggaar FP, Tytgat KM, et al. High lifetime risk of cancer in primary sclerosing cholangitis. *J Hepatol*. 2009;50(1):158-164.
555. Fleming KA, Boberg KM, Glaumann H, et al. Biliary dysplasia as a marker of cholangiocarcinoma in primary sclerosing cholangitis. *J Hepatol*. 2001;34(3):360-365.
556. Lewis JT, Talwalkar JA, Rosen CB, et al. Precancerous bile duct pathology in end-stage primary sclerosing cholangitis, with and without cholangiocarcinoma. *Am J Surg Pathol*. 2010;34(1):27-34.
557. Ludwig J, Colina F, Poterucha JJ. Granulomas in primary sclerosing cholangitis. *Liver*. 1995;15(6):307-312.
558. Deshpande V. IgG4-related disease of the gastrointestinal tract: a 21st century chameleon. *Arch Pathol Lab Med*. 2015;139:742-749.
559. Bateman AC, Deheragoda MG. IgG4-related systemic sclerosing disease - an emerging and under-diagnosed condition. *Histopathology*. 2009;55(4):373-383.
560. Deshpande V, Sainani NI, Chung RT, et al. IgG4-associated cholangitis: a comparative histological and immunophenotypic study with primary sclerosing cholangitis on liver biopsy material. *Mod Pathol*. 2009;22(10):1287-1295.
561. Koyabu M, Uchida K, Miyoshi H, et al. Analysis of regulatory T cells and IgG4-positive plasma cells among patients of IgG4-related sclerosing cholangitis and autoimmune liver diseases. *J Gastroenterol*. 2010;45(7):732-741.
562. Zen Y, Fujii T, Sato Y, et al. Pathological classification of hepatic inflammatory pseudotumor with respect to IgG4-related disease. *Mod Pathol*. 2007;20(8):884-894.
563. Nakanuma Y, Zen Y. Pathology and immunopathology of immunoglobulin G4-related sclerosing cholangitis: The latest addition to the sclerosing cholangitis family. *Hepatol Res*. 2007;37(suppl 3):S478-S486.
564. Nishino T, Oyama H, Hashimoto E, et al. Clinicopathological differentiation between sclerosing cholangitis with autoimmune pancreatitis and primary sclerosing cholangitis. *J Gastroenterol*. 2007;42(7):550-559.
565. Engler S, Elsing C, Flechtenmacher C, et al. Progressive sclerosing cholangitis after septic shock: a new variant of vanishing bile duct disorders. *Gut*. 2003;52(5):688-693.
566. Geier A, Fickert P, Trauner M. Mechanisms of disease: mechanisms and clinical implications of cholestasis in sepsis. *Nat Clin Pract Gastroenterol Hepatol*. 2006;3(10):574-585.
567. Ruemmele P, Hofstaedter F, Gelbmann CM. Secondary sclerosing cholangitis. *Nat Rev Gastroenterol Hepatol*. 2009;6(5):287-295.
568. Kulaksiz H, Heuberger D, Engler S, Stiehl A. Poor outcome in progressive sclerosing cholangitis after septic shock. *Endoscopy*. 2008;40:214-218.
569. Benninger J, Grobholz R, Oeztuerk Y, et al. Sclerosing cholangitis following severe trauma: description of a remarkable disease entity with emphasis on possible pathophysiologic mechanisms. *World J Gastroenterol*. 2005;11(27):4199-4205.
570. Esposito I, Kubisova A, Stiehl A, et al. Secondary sclerosing cholangitis after intensive care unit treatment: clues to the histopathological differential diagnosis. *Virchows Arch*. 2008;453(4):339-345.
571. Deltenre P, Valla DC. Ischemic cholangiopathy. *J Hepatol*. 2006;44:806-817.
572. Mieli-Vergani G, Vergani D. Sclerosing cholangitis in the paediatric patient. *Best Pract Res Clin Gastroenterol*. 2001;15: 681-690.
573. Girard M, Franchi-Abella S, Lacaille F, Debray D. Specificities of sclerosing cholangitis in childhood. *Clin Res Hepatol Gastroenterol*. 2012;36:530-535.

574. Benger JR, Thompson MH. Annular pancreas and obstructive jaundice. *Am J Gastroenterol*. 1997;92(4):713-714.
575. Desmet VJ. Histopathology of the intrahepatic biliary tree. *Liver*. 1983;3(3):161-175.
576. Carpenter HA. Bacterial and parasitic cholangitis. *Mayo Clin Proc*. 1998;73(5):473-478.
577. Shimada H, Nihmoto S, Matsuba A, Nakagawara G. Acute cholangitis: a histopathologic study. *J Clin Gastroenterol*. 1988;10(2):197-200.
578. Abdalian R, Heathcote EJ. Sclerosing cholangitis: a focus on secondary causes. *Hepatology*. 2006;44(5):1063-1074.
579. Kahn E, Markowitz J, Aiges H, Daum F. Human ontogeny of the bile duct to portal space ratio. *Hepatology*. 1989;10(1):21-23.
580. Van Eyken P, Sciot R, Callea F, et al. The development of the intrahepatic bile ducts in man: a keratin-immunohistochemical study. *Hepatology*. 1988;8(6):1586-1595.
581. Ludwig J. Idiopathic adulthood ductopenia: an update. *Mayo Clin Proc*. 1998;73(3):285-291.
582. Ludwig J, Wiesner RH, LaRusso NF. Idiopathic adulthood ductopenia. A cause of chronic cholestatic liver disease and biliary cirrhosis. *J Hepatol*. 1988;7(2):193-199.
583. Burak KW, Pearson DC, Swain MG, et al. Familial idiopathic adulthood ductopenia: a report of five cases in three generations. *J Hepatol*. 2000;32(1):159-163.
584. Gotthardt D, Runz H, Keitel V, et al. A mutation in the canalicular phospholipid transporter gene, ABCB4, is associated with cholestasis, ductopenia, and cirrhosis in adults. *Hepatology*. 2008;48(4):1157-1166.
585. Ziol M, Barbu V, Rosmorduc O, et al. ABCB4 heterozygous gene mutations associated with fibrosing cholestatic liver disease in adults. *Gastroenterology*. 2008;135(1):131-141.
586. Fickert P, Fuchsbichler A, Wagner M, et al. Regurgitation of bile acids from leaky bile ducts causes sclerosing cholangitis in Mdr2 (Abcb4) knockout mice. *Gastroenterology*. 2004;127(1):261-274.
587. Nakken KE, Nygard S, Haaland TK, et al. Gene expression profiles reflect sclerosing cholangitis activity in abcb4 (-/-) mice. *Scand J Gastroenterol*. 2009;44(2):211-218.
588. Moreno A, Carreno V, Cano A, Gonzalez C. Idiopathic biliary ductopenia in adults without symptoms of liver disease. *N Engl J Med*. 1997;336(12):835-838.
589. Kapelari K, Fruehwirth M, Heitger A, et al. Loss of intrahepatic bile ducts: an important feature of familial hemophagocytic lymphohistiocytosis. *Virchows Arch*. 2005;446(6):619-625.
590. Manns MP, Lohse AW, Vergani D. Autoimmune hepatitis-update 2015. *J Hepatol*. 2015;62(1 suppl):S100-S111.
591. McFarlane IG. Definition and classification of autoimmune hepatitis. *Semin Liver Dis*. 2002;22(4):317-324.
592. Czaja AJ, Carpenter HA. Sensitivity, specificity, and predictability of biopsy interpretations in chronic hepatitis. *Gastroenterology*. 1993;105(6):1824-1832.
593. Meyer zum Buschenfelde KH, Dienes HP. Autoimmune hepatitis. Definition—classification—histopathology—immunopathogenesis. *Virchows Arch*. 1996;429(1):1-12.
594. Devaney K, Goodman ZD, Ishak KG. Postinfantile giant-cell transformation in hepatitis. *Hepatology*. 1992;16(2): 327-333.
595. Lau JY, Koukoulis G, Mieli-Vergani G, et al. Syncytial giant-cell hepatitis—a specific disease entity? *J Hepatol*. 1992;15(1-2):216-219.
596. Schvarcz R, Glaumann H, Weiland O. Survival and histological resolution of fibrosis in patients with autoimmune chronic active hepatitis. *J Hepatol*. 1993;18(1):15-23.
597. Czaja AJ, Carpenter HA. Autoimmune hepatitis with incidental histologic features of bile duct injury. *Hepatology*. 2001;34(4 Pt 1):659-665.
598. Misdraji J, Thiim M, Graeme-Cook FM. Autoimmune hepatitis with centrilobular necrosis. *Am J Surg Pathol*. 2004;28(4):471-478.
599. Miyake Y, Iwasaki Y, Kobashi H, et al. Autoimmune hepatitis with acute presentation in Japan. *Dig Liver Dis*. 2010;42(1):51-54.
600. Iwai M, Jo M, Ishii M, et al. Comparison of clinical features and liver histology in acute and chronic autoimmune hepatitis. *Hepatol Res*. 2008;38(8):784-789.
601. Hennes EM, Zeniya M, Czaja AJ, et al. Simplified criteria for the diagnosis of autoimmune hepatitis. *Hepatology*. 2008;48(1):169-176.
602. Wiegard C, Schramm C, Lohse AW. Scoring systems for the diagnosis of autoimmune hepatitis: past, present, and future. *Semin Liver Dis*. 2009;29(3):254-261.
603. Yada N, Kudo M, Chung H, Watanabe T. Autoimmune hepatitis and immunoglobulin G4-associated autoimmune hepatitis. *Dig Dis*. 2013;31:415-420.
604. Chazouilleres O. Overlap Syndromes. *Dig Dis*. 2015;33(suppl 2):181-187.
605. Miloh T, Arnon R, Shneider B, et al. A retrospective single-center review of primary sclerosing cholangitis in children. *Clin Gastroenterol Hepatol*. 2009;7(2):239-245.
606. Vergani D, Mieli-Vergani G. Autoimmune Hepatitis and PSC Connection. *Clin Liver Dis*. 2008;12(1):187-202, x.
607. Deneau M, Jensen MK, Holmen J, et al. Primary sclerosing cholangitis, autoimmune hepatitis, and overlap in Utah children: epidemiology and natural history. *Hepatology*. 2013;58:1392-1400.
608. Mieli-Vergani G, Vergani D. Autoimmune hepatitis in children: what is different from adult AIH? *Semin Liver Dis*. 2009;29(3):297-306.
609. Lewin M, Vilgrain V, Ozenne V, et al. Prevalence of sclerosing cholangitis in adults with autoimmune hepatitis: a prospective magnetic resonance imaging and histological study. *Hepatology*. 2009;50(2):528-537.
610. Kaya M, Angulo P, Lindor KD. Overlap of autoimmune hepatitis and primary sclerosing cholangitis: an evaluation of a modified scoring system. *J Hepatol*. 2000;33(4):537-542.
611. Al-Chalabi T, Portmann BC, Bernal W, et al. Autoimmune hepatitis overlap syndromes: an evaluation of treatment response, long-term outcome and survival. *Aliment Pharmacol Ther*. 2008;28(2):209-220.
612. Rust C, Beuers U. Overlap syndromes among autoimmune liver diseases. *World J Gastroenterol*. 2008;14(21):3368-3373.
613. Anthony PP, Ishak KG, Nayak NC, et al. The morphology of cirrhosis. Recommendations on definition, nomenclature, and classification by a working group sponsored by the World Health Organization. *J Clin Pathol*. 1978;31(5):395-414.
614. Desmet VJ, Sciot R, Van Eyken P. Differential diagnosis and prognosis of cirrhosis: role of liver biopsy. *Acta Gastroenterol Belg*. 1990;53(2):198-208.
615. Friedman SL. Mechanisms of hepatic fibrogenesis. *Gastroenterology*. 2008;134(6):1655-1669.
616. Gorrell MD. Liver fibrosis: the hepatocyte revisited. *Hepatology*. 2007;46(5):1659-1661.
617. Guyot C, Lepreux S, Combe C, et al. Hepatic fibrosis and cirrhosis: the (myo)fibroblastic cell subpopulations involved. *Int J Biochem Cell Biol*. 2006;38(2):135-151.
618. Wallace K, Burt AD, Wright MC. Liver fibrosis. *Biochem J*. 2008;411(1):1-18.
619. Wynn TA. Cellular and molecular mechanisms of fibrosis. *J Pathol*. 2008;214(2):199-210.
620. Wanless IR, Wong F, Blendis LM, et al. Hepatic and portal vein thrombosis in cirrhosis: possible role in development of parenchymal extinction and portal hypertension. *Hepatology*. 1995;21(5):1238-1247.
621. Chaparro M, Sanz-Cameno P, Trapero-Marugan M, et al. Mechanisms of angiogenesis in chronic inflammatory liver disease. *Ann Hepatol*. 2007;6(4):208-213.
622. Desmet VJ. Comments on cirrhosis reversal. *Dig Liver Dis*. 2005;37(12):909-916.
623. Desmet VJ, Roskams T. Cirrhosis reversal: a duel between dogma and myth. *J Hepatol*. 2004;40(5):860-867.
624. Fauerholdt L, Schlichting P, Christensen E, et al. Conversion of micronodular cirrhosis into macronodular cirrhosis. *Hepatology*. 1983;3(6):928-931.
625. Scheuer PJ. Liver biopsy in the diagnosis of cirrhosis. *Gut*. 1970;11(3):275-278.
626. Sciot R, Staessen D, Van Damme B, et al. Incomplete septal cirrhosis: histopathological aspects. *Histopathology*. 1988;13:593-603.
627. Wanless IR, Nakashima E, Sherman M. Regression of human cirrhosis. Morphologic features and the genesis of incomplete septal cirrhosis. *Arch Pathol Lab Med*. 2000;124:1599-1607.
628. Lefkowitch JH, Mendez L. Morphologic features of hepatic injury in cardiac disease and shock. *J Hepatol*. 1986;2(3):313-327.
629. Caldwell SH, Crespo DM. The spectrum expanded: cryptogenic cirrhosis and the natural history of non-alcoholic fatty liver disease. *J Hepatol*. 2004;40(4):578-584.
630. Deugnier Y, Turlin B, le Quilleuc D, et al. A reappraisal of hepatic siderosis in patients with end-stage cirrhosis: practical implications for the diagnosis of hemochromatosis. *Am J Surg Pathol*. 1997;21(6):669-675.
631. Guarascio P, Yentis F, Cevikbas U, et al. Value of copper-associated protein in diagnostic assessment of liver biopsy. *J Clin Pathol*. 1983;36(1):18-23.
632. Mehrotra R, Pandey RK, Nath P. Hepatic copper in Indian childhood cirrhosis. *Histopathology*. 1981;5(6):659-665.
633. Callea F, Brisigotti M, Faa G, et al. Identification of PiZ gene products in liver tissue by a monoclonal antibody specific for the Z mutant of alpha 1-antitrypsin. *J Hepatol*. 1991;12(3):372-376.
634. Henrion J, Colin L, Schmitz A, et al. Ischemic hepatitis in cirrhosis. Rare but lethal. *J Clin Gastroenterol*. 1993;16(1): 35-39.
635. Schinoni MI, Andrade Z, de Freitas LA, et al. Incomplete septal cirrhosis: an enigmatic disease. *Liver Int*. 2004;24(5):452-456.
636. Finn LS, Knisely AS. Recommendations for handling of pediatric liver biopsy specimens. *Semin Diagn Pathol*. 1998;15(4):300-305.
637. Alissa FT, Jaffe R, Shneider BL. Update on progressive familial intrahepatic cholestasis. *J Pediatr Gastroenterol Nutr*. 2008;46(3):241-252.
638. Davit-Spraul A, Fabre M, Brancheraeu S, et al. ATP8B1 and ABCB11 analysis in 62 children with normal gamma-glutamyl transferase progressive familial intrahepatic cholestasis (PFIC): phenotypic differences between PFIC1 and PFIC2 and natural history. *Hepatology*. 2010;51:1645-1655.

639. Wagner M, Zollner G, Trauner M. New molecular insights into the mechanisms of cholestasis. *J Hepatol*. 2009;51(3):565-580.
640. Balistreri WF, Bezerra JA, Jansen P, et al. Intrahepatic cholestasis: summary of an American Association for the Study of Liver Diseases single-topic conference. *Hepatology*. 2005;42(1):222-235.
641. Klomp LW, Vargas JC, van Mil SW, et al. Characterization of mutations in ATP8B1 associated with hereditary cholestasis. *Hepatology*. 2004;40(1):27-38.
642. Folmer DE, van der Mark VA, Ho-Mok KS, et al. Differential effects of progressive familial intrahepatic cholestasis type 1 and benign recurrent intrahepatic cholestasis type 1 mutations on canalicular localization of ATP8B1. *Hepatology*. 2009;50(5):1597-1605.
643. Klomp LW, Bull LN, Knisely AS, et al. A missense mutation in FIC1 is associated with Greenland familial cholestasis. *Hepatology*. 2000;32(6):1337-1341.
644. Nielsen IM, Ornvold K, Jacobsen BB, Ranek L. Fatal familial cholestatic syndrome in Greenland Eskimo children. *Acta Paediatr Scand*. 1986;75(6):1010-1016.
645. Suchy FJ, Ananthanarayanan M. Bile salt excretory pump: biology and pathobiology. *J Pediatr Gastroenterol Nutr*. 2006;43(suppl 1):S10-S16.
646. Lam P, Pearson CL, Soroka CJ, et al. Levels of plasma membrane expression in progressive and benign mutations of the bile salt export pump (Bsep/Abcb11) correlate with severity of cholestatic diseases. *Am J Physiol Cell Physiol*. 2007;293(5):C1709-C1716.
647. Strautnieks SS, Byrne JA, Pawlikowska L, et al. Severe bile salt export pump deficiency: 82 different ABCB11 mutations in 109 families. *Gastroenterology*. 2008;134(4):1203-1214.
648. Knisely AS, Strautnieks SS, Meier Y, et al. Hepatocellular carcinoma in ten children under five years of age with bile salt export pump deficiency. *Hepatology*. 2006;44(2):478-486.
649. Scheimann AO, Strautnieks SS, Knisely AS, et al. Mutations in bile salt export pump (ABCB11) in two children with progressive familial intrahepatic cholestasis and cholangiocarcinoma. *J Pediatr*. 2007;150(5):556-559.
650. Kubitz R, Droge C, Kluge S, et al. Autoimmune BSEP disease: disease recurrence after liver transplantation for progressive familial intrahepatic cholestasis. *Clin Rev Allergy Immunol*. 2015;48:273-284.
651. Jacquemin E. Role of multidrug resistance 3 deficiency in pediatric and adult liver disease: one gene for three diseases. *Semin Liver Dis*. 2001;21(4):551-562.
652. Trauner M, Fickert P, Wagner M. MDR3 (ABCB4) defects: a paradigm for the genetics of adult cholestatic syndromes. *Semin Liver Dis*. 2007;27(1):77-98.
653. Gonzales E, Davit-Spraul A, Baussan C. Liver diseases related to MDR3 (ABCB4) gene deficiency. *Front Biosci (Landmark Ed)*. 2009;14:4242-4256.
654. de Vree JM, Jacquemin E, Sturm E, et al. Mutations in the MDR3 gene cause progressive familial intrahepatic cholestasis. *Proc Natl Acad Sci USA*. 1998;95(1):282-287.
655. Bull LN, van Eijk MJ, Pawlikowska L, et al. A gene encoding a P-type ATPase mutated in two forms of hereditary cholestasis. *Nat Genet*. 1998;18(3):219-224.
656. van Mil SW, Klomp LW, Bull LN, Houwen RH. FIC1 disease: a spectrum of intrahepatic cholestatic disorders. *Semin Liver Dis*. 2001;21(4):535-544.
657. Kagawa T, Watanabe N, Mochizuki K, et al. Phenotypic differences in PFIC2 and BRIC2 correlate with protein stability of mutant Bsep and impaired taurocholate secretion in MDCK II cells. *Am J Physiol Gastrointest Liver Physiol*. 2008;294(1):G58-G67.
658. Heubi JE, Setchell KD, Bove KE. Inborn errors of bile acid metabolism. *Semin Liver Dis*. 2007;27(3):282-294.
659. Bove KE, Heubi JE, Balistreri WF, Setchell KD. Bile acid synthetic defects and liver disease: a comprehensive review. *Pediatr Dev Pathol*. 2004;7(4):315-334.
660. Clayton PT. Disorders of bile acid synthesis. *J Inherit Metab Dis*. 2011;34:593-604.
661. Piccoli DA, Spinner NB. Alagille syndrome and the Jagged1 gene. *Semin Liver Dis*. 2001;21(4):525-534.
662. Turnpenny PD, Ellard S. Alagille syndrome: pathogenesis, diagnosis, and management. *Eur J Hum Genet*. 2012;20:251-257.
663. Byrne JA, Meara NJ, Rayner AC, et al. Lack of hepatocellular CD10 along bile canaliculi is physiologic in early childhood and persistent in Alagille syndrome. *Lab Invest*. 2007;87(11):1138-1148.
664. Kahn E, Daum F, Markowitz J, et al. Nonsyndromic paucity of interlobular bile ducts: light and electron microscopic evaluation of sequential liver biopsies in early childhood. *Hepatology*. 1986;6:890-901.
665. Hashida Y, Yunis EJ. Syndromatic paucity of interlobular bile ducts: hepatic histopathology of the early and endstage liver. *Pediatr Pathol*. 1988;8(1):1-15.
666. Sokol RJ, Mack C. Etiopathogenesis of biliary atresia. *Semin Liver Dis*. 2001;21(4):517-524.
667. Gautier M, Eliot N. Extrahepatic biliary atresia. Morphological study of 98 biliary remnants. *Arch Pathol Lab Med*. 1981;105(8):397-402.
668. Gautier M, Jehan P, Odievre M. Histologic study of biliary fibrous remnants in 48 cases of extrahepatic biliary atresia: correlation with postoperative bile flow restoration. *J Pediatr*. 1976;89(5):704-709.
669. Schweizer P. [Extrahepatic bile duct atresia—an analytic assessment of prognostic factors. Contribution to a rational therapeutic approach]. *Z Kinderchir*. 1990;45(6):365-370.
670. Tan CE, Davenport M, Driver M, Howard ER. Does the morphology of the extrahepatic biliary remnants in biliary atresia influence survival? A review of 205 cases. *J Pediatr Surg*. 1994;29(11):1459-1464.
671. Makin E, Quaglia A, Kvist N, et al. Congenital biliary atresia: liver injury begins at birth. *J Pediatr Surg*. 2009;44(3):630-633.
672. Lefkowitch JH. Biliary atresia. *Mayo Clin Proc*. 1998;73(1):90-95.
673. Zerbini MC, Gallucci SD, Maezono R, et al. Liver biopsy in neonatal cholestasis: a review on statistical grounds. *Mod Pathol*. 1997;10(8):793-799.
674. Rastogi A, Krishnani N, Yachha SK, et al. Histopathological features and accuracy for diagnosing biliary atresia by prelaparotomy liver biopsy in developing countries. *J Gastroenterol Hepatol*. 2009;24(1):97-102.
675. Santos JL, Kieling CO, Meurer L, et al. The extent of biliary proliferation in liver biopsies from patients with biliary atresia at portoenterostomy is associated with the postoperative prognosis. *J Pediatr Surg*. 2009;44(4):695-701.
676. Azar G, Beneck D, Lane B, et al. Atypical morphologic presentation of biliary atresia and value of serial liver biopsies. *J Pediatr Gastroenterol Nutr*. 2002;34(2):212-215.
677. Sergi C, Benstz J, Feist D, et al. Bile duct to portal space ratio and ductal plate remnants in liver disease of infants aged less than 1 year. *Pathology*. 2008;40(3):260-267.
678. Raweily EA, Gibson AA, Burt AD. Abnormalities of intrahepatic bile ducts in extrahepatic biliary atresia. *Histopathology*. 1990;17(6):521-527.
679. Terracciano LM, Cathomas G, Vecchione R, et al. Extrahepatic bile duct atresia associated with hyperplasia of the intrahepatic bile ducts ('early severe form'): high incidence in a south-Italian population. *Pathol Res Pract*. 1995;191.
680. Desmet VJ. Ludwig symposium on biliary disorders—part I. Pathogenesis of ductal plate abnormalities. *Mayo Clin Proc*. 1998;73(1):80-89.
681. Low Y, Vijayan V, Tan CE. The prognostic value of ductal plate malformation and other histologic parameters in biliary atresia: an immunohistochemical study. *J Pediatr*. 2001;139(2):320-322.
682. Shimadera S, Iwai N, Deguchi E, et al. Significance of ductal plate malformation in the postoperative clinical course of biliary atresia. *J Pediatr Surg*. 2008;43(2):304-307.
683. Roy P, Chatterjee U, Ganguli M, et al. A histopathological study of liver and biliary remnants with clinical outcome in cases of extrahepatic biliary atresia. *Indian J Pathol Microbiol*. 2010;53(1):101-105.
684. Pacheco MC, Campbell KM, Bove KE. Ductal plate malformation-like arrays in early explants after a Kasai procedure are independent of splenic malformation complex (heterotaxy). *Pediatr Dev Pathol*. 2009;12(5):355-360.
685. Safwan M, Ramachandran P, Vij M, et al. Impact of ductal plate malformation on survival with native liver in children with biliary atresia. *Pediatr Surg Int*. 2015;31:837-843.
686. Pape L, Olsson K, Petersen C, et al. Prognostic value of computerized quantification of liver fibrosis in children with biliary atresia. *Liver Transpl*. 2009;15(8):876-882.
687. Shteyer E, Ramm GA, Xu C, et al. Outcome after portoenterostomy in biliary atresia: pivotal role of degree of liver fibrosis and intensity of stellate cell activation. *J Pediatr Gastroenterol Nutr*. 2006;42(1):93-99.
688. Lee WS, Looi LM. Usefulness of a scoring system in the interpretation of histology in neonatal cholestasis. *World J Gastroenterol*. 2009;15(42):5326-5333.
689. Mack CL. The pathogenesis of biliary atresia: evidence for a virus-induced autoimmune disease. *Semin Liver Dis*. 2007;27(3): 233-242.
690. Davit-Spraul A, Baussan C, Hermeziu B, et al. CFC1 gene involvement in biliary atresia with polysplenia syndrome. *J Pediatr Gastroenterol Nutr*. 2008;46(1):111-112.
691. Sokol RJ, Shepherd RW, Superina R, et al. Screening and outcomes in biliary atresia: summary of a National Institutes of Health workshop. *Hepatology*. 2007;46(2):566-581.
692. Russo PA, Mitchell GA, Tanguay RM. Tyrosinemia: a review. *Pediatr Dev Pathol*. 2001;4:212-221.
693. Carlton VE, Harris BZ, Puffenberger EG, et al. Complex inheritance of familial hypercholanemia with associated mutations in TJP2 and BAAT. *Nat Genet*. 2003;34(1):91-96.
694. Hadj-Rabia S, Baala L, Vabres P, et al. Claudin-1 gene mutations in neonatal sclerosing cholangitis associated with ichthyosis: a tight junction disease. *Gastroenterology*. 2004;127(5):1386-1390.
695. Richter A, Mitchell GA, Rasquin A. [North American Indian childhood cirrhosis (NAIC)]. *Med Sci*. 2007;23(11):1002-1007.
696. Cullinane AR, Straatman-Iwanowska A, Seo JK, et al. Molecular investigations to improve diagnostic accuracy in patients with ARC syndrome. *Hum Mutat*. 2009;30(2):E330-E337.

697. Hutchin T, Preece MA, Hendriksz C, et al. Neonatal intrahepatic cholestasis caused by citrin deficiency (NICCD) as a cause of liver disease in infants in the UK. *J Inherit Metab Dis*. 2009;32(suppl 1):S151-S155.
698. Drivdal M, Trydal T, Hagve TA, et al. Prognosis, with evaluation of general biochemistry, of liver disease in lymphoedema cholestasis syndrome 1 (LCS1/Aagenaes syndrome). *Scand J Gastroenterol*. 2006;41(4):465-471.
699. Schwiebert EM, Benos DJ, Egan ME, et al. CFTR is a conductance regulator as well as a chloride channel. *Physiol Rev*. 1999;79(1 sup pl):S145-S166.
700. Feranchak AP, Sokol RJ. Cholangiocyte biology and cystic fibrosis liver disease. *Semin Liver Dis*. 2001;21(4):471-488.
701. Cohn JA, Strong TV, Picciotto MR, et al. Localization of the cystic fibrosis transmembrane conductance regulator in human bile duct epithelial cells. *Gastroenterology*. 1993;105(6):1857-1864.
702. Kinnman N, Lindblad A, Housset C, et al. Expression of cystic fibrosis transmembrane conductance regulator in liver tissue from patients with cystic fibrosis. *Hepatology*. 2000;32(2):334-340.
703. Lamireau T, Monnereau S, Martin S, et al. Epidemiology of liver disease in cystic fibrosis: a longitudinal study. *J Hepatol*. 2004;41(6):920-925.
704. Leeuwen L, Fitzgerald DA, Gaskin KJ. Liver disease in cystic fibrosis. *Paediatr Respir Rev*. 2014;15:69-74.
705. Collardeau-Frachon S, Bouvier R, Le Gall C, et al. Unexpected diagnosis of cystic fibrosis at liver biopsy: a report of four pediatric cases. *Virchows Arch*. 2007;451(1):57-64.
706. Fevery J. Bilirubin in clinical practice: a review. *Liver Int*. 2008;28(5):592-605.
707. Nies AT, Keppler D. The apical conjugate efflux pump ABCC2 (MRP2). *Pflugers Arch*. 2007;453(5):643-659.
708. Dubin IN, Johnson FB. Chronic idiopathic jaundice with unidentified pigment in liver cells; a new clinicopathologic entity with a report of 12 cases. *Medicine (Baltimore)*. 1954;33(3):155-197.
709. Toker C, Trevino N. Hepatic ultrastructure in chronic idiopathic jaundice. *Arch Pathol*. 1965;80(5):453-460.
710. Cebecauerova D, Jirasek T, Budisova L, et al. Dual hereditary jaundice: simultaneous occurrence of mutations causing Gilbert's and Dubin-Johnson syndrome. *Gastroenterology*. 2005;129(1):315-320.
711. Hrebicek M, Jirasek T, Hartmannova H, et al. Rotor-type hyperbilirubinaemia has no defect in the canalicular bilirubin export pump. *Liver Int*. 2007;27(4):485-491.
712. Callea F, Brisigotti M, Fabbretti G, et al. Hepatic endoplasmic reticulum storage diseases. *Liver*. 1992;12(6):357-362.
713. Brantly M, Nukiwa T, Crystal RG. Molecular basis of alpha-1-antitrypsin deficiency. *Am J Med*. 1988;84(6a):13-31.
714. Fairbanks KD, Tavill AS. Liver disease in alpha 1-antitrypsin deficiency: a review. *Am J Gastroenterol*. 2008;103(8):2136-2141, quiz 42.
715. Perlmutter DH. Alpha-1-antitrypsin deficiency. *Semin Liver Dis*. 1998;18(3):217-225.
716. Jack CI, Evans CC. Three cases of alpha-1-antitrypsin deficiency in the elderly. *Postgrad Med J*. 1991;67(791):840-842.
717. Silverman EK, Sandhaus RA. Clinical practice. Alpha1-antitrypsin deficiency. *N Engl J Med*. 2009;360(26):2749-2757.
718. Feldmann G, Bignon J, Chahinian P, et al. Hepatocyte ultrastructural changes in alpha1-antitrypsin deficiency. *Gastroenterology*. 1974;67(6):1214-1224.
719. Brind AM, Bassendine MF, Bennett MK, James OF. Alpha 1-antitrypsin granules in the liver—always important? *Q J Med*. 1990;76(279):699-709.
720. Odievre M, Martin JP, Hadchouel M, Alagille D. Alpha1-antitrypsin deficiency and liver disease in children: phenotypes, manifestations, and prognosis. *Pediatrics*. 1976;57:226-231.
721. Ibarguen E, Gross CR, Savik SK, Sharp HL. Liver disease in alpha-1-antitrypsin deficiency: prognostic indicators. *J Pediatr*. 1990;117(6):864-870.
722. Odievre M, Martin JP, Hadchouel M, Alagille D. Alpha1-antitrypsin deficiency and liver disease in children: phenotypes, manifestations, and prognosis. *Pediatrics*. 1976;57(2):226-231.
723. Teckman JH, Rosenthal P, Abel R, et al. Baseline analysis of a young α-1-antitrypsin deficiency liver disease cohort reveals frequent portal hypertension. *J Pediatr Gastroenterol Nutr*. 2015;61:94-101.
724. Laurell CB, Eriksson S. The electrophoretic alpha-1-globulin pattern of serum alpha-1-antitrypsin deficiency. *Scand J Clin Lab Invest*. 1963;15:132-140.
725. Larsson C. Natural history and life expectancy in severe alpha1-antitrypsin deficiency, Pi Z. *Acta Med Scand*. 1978;204(5):345-351.
726. Propst T, Propst A, Dietze O, et al. High prevalence of viral infection in adults with homozygous and heterozygous alpha 1-antitrypsin deficiency and chronic liver disease. *Ann Intern Med*. 1992;117(8):641-645.
727. Vogel W, Propst T, Propst A, et al. Causes of liver disease in an adult population with heterozygous and homozygous alpha 1-antitrypsin deficiency. *Acta Paediatr Suppl*. 1994;393:24-26.
728. Eriksson S, Carlson J, Velez R. Risk of cirrhosis and primary liver cancer in alpha 1-antitrypsin deficiency. *N Engl J Med*. 1986;314(12):736-739.
729. Rabinovitz M, Gavaler JS, Kelly RH, et al. Lack of increase in heterozygous alpha 1-antitrypsin deficiency phenotypes among patients with hepatocellular and bile duct carcinoma. *Hepatology*. 1992;15(3):407-410.
730. Fischer HP, Ortiz-Pallardo ME, Ko Y, et al. Chronic liver disease in heterozygous alpha1-antitrypsin deficiency PiZ. *J Hepatol*. 2000;33(6):883-892.
731. Mendelsohn G, Gomperts ED, Gurwitz D. Severe antithrombin III deficiency in an infant associated with multiple arterial and venous thromboses. *Thromb Haemost*. 1976;36(3):495-502.
732. Abukawa D, Tazawa Y, Noro T, et al. Cytoplasmic inclusion bodies and minimal hepatitis: fibrinogen storage without hypofibrinogenemia. *Pediatr Dev Pathol*. 2001;4(3):304-309.
733. Marucci G, Morandi L, Macchia S, et al. Fibrinogen storage disease without hypofibrinogenaemia associated with acute infection. *Histopathology*. 2003;42(1):22-25.
734. Adar T, Ilan Y, Elstein D, Zimran A. Liver involvement in Gaucher disease-review and clinical approach. *Blood Cells Mol Dis*. 2016. pii:S1079-9796(16)30121-8. doi:10.1016/j.bcmd.2016.10.001.
735. Thurberg BL, Wasserstein MP, Schiano T, et al. Liver and skin histopathology in adults with acid sphingomyelinase deficiency (Niemann-Pick disease type B). *Am J Surg Pathol*. 2012;36:1234-1236.
736. Ozen H. Glycogen storage diseases: new perspectives. *World J Gastroenterol*. 2007;13:2541-2553.
737. Adamson M, Reiner B, Olson JL, et al. Indian childhood cirrhosis in an American child. *Gastroenterology*. 1992;102(5):1771-1777.
738. Lefkowitch JH, Honig CL, King ME, Hagstrom JW. Hepatic copper overload and features of Indian childhood cirrhosis in an American sibship. *N Engl J Med*. 1982;307(5):271-277.
739. Muller-Hocker J, Meyer U, Wiebecke B, et al. Copper storage disease of the liver and chronic dietary copper intoxication in two further German infants mimicking Indian childhood cirrhosis. *Pathol Res Pract*. 1988;183(1):39-45.
740. Nayak NC, Chitale AR. Indian childhood cirrhosis (ICC) and ICC-like diseases: the changing scenario of facts versus notions. *Indian J Med Res*. 2013;137:1029-1042.
741. Popper H, Goldfischer S, Sternlieb I, et al. Cytoplasmic copper and its toxic effects. Studies in Indian childhood cirrhosis. *Lancet*. 1979;1(8128):1205-1208.
742. Tanner MS, Portmann B, Mowat AP, et al. Increased hepatic copper concentration in Indian childhood cirrhosis. *Lancet*. 1979;1(8128):1203-1205.
743. Muller T, Feichtinger H, Berger H, Muller W. Endemic Tyrolean infantile cirrhosis: an ecogenetic disorder. *Lancet*. 1996;347(9005):877-880.
744. Roberts EA, Cox DW. Wilson disease. *Baillieres Clin Gastroenterol*. 1998;12(2):237-256.
745. Pietrangelo A. Inherited metabolic disease of the liver. *Curr Opin Gastroenterol*. 2009;25(3):209-214.
746. Gollan JL, Gollan TJ. Wilson disease in 1998: genetic, diagnostic and therapeutic aspects. *J Hepatol*. 1998;28(suppl 1):28-36.
747. Davies SE, Williams R, Portmann B. Hepatic morphology and histochemistry of Wilson's disease presenting as fulminant hepatic failure: a study of 11 cases. *Histopathology*. 1989;15(4):385-394.
748. Stromeyer FW, Ishak KG. Histology of the liver in Wilson's disease: a study of 34 cases. *Am J Clin Pathol*. 1980;73(1):12-24.
749. Sternlieb I. Fraternal concordance of types of abnormal hepatocellular mitochondria in Wilson's disease. *Hepatology*. 1992;16(3):728-732.
750. Muller T, Langner C, Fuchsbichler A, et al. Immunohistochemical analysis of Mallory bodies in Wilsonian and non-Wilsonian hepatic copper toxicosis. *Hepatology*. 2004;39(4):963-969.
751. Goldfischer S, Sternlieb I. Changes in the distribution of hepatic copper in relation to the progression of Wilson's disease (hepatolenticular degeneration. *Am J Pathol*. 1968;53(6):883-901.
752. Faa G, Liguori C, Columbano A, Diaz G. Uneven copper distribution in the human newborn liver. *Hepatology*. 1987;7(5):838-842.
753. Ludwig J, Moyer TP, Rakela J. The liver biopsy diagnosis of Wilson's disease. Methods in pathology. *Am J Clin Pathol*. 1994;102(4):443-446.
754. Pilloni L, Lecca S, Van Eyken P, et al. Value of histochemical stains for copper in the diagnosis of Wilson's disease. *Histopathology*. 1998;33(1):28-33.
755. Nemolato S, Serra S, Saccani S, Faa G. Deparaffination time: a crucial point in histochemical detection of tissue copper. *Eur J Histochem*. 2008;52(3):175-178.
756. Quaglia A, Mustafa A, Mitry RR, Portmann B. Image of the month. Copper-metallothionein autofluorescence. *Hepatology*. 2009;50(4):1312-1313.
757. Mulder TP, Janssens AR, Verspaget HW, et al. Metallothionein concentration in the liver of patients with Wilson's disease, primary

biliary cirrhosis, and liver metastasis of colorectal cancer. *J Hepatol*. 1992;16(3):346-350.
758. Richter GW. The iron-loaded cell—the cytopathology of iron storage. A review. *Am J Pathol*. 1978;91(2):362-404.
759. Bassett ML, Halliday JW, Powell LW. Value of hepatic iron measurements in early hemochromatosis and determination of the critical iron level associated with fibrosis. *Hepatology*. 1986;6(1):24-29.
760. Feder JN, Gnirke A, Thomas W, et al. A novel MHC class I-like gene is mutated in patients with hereditary haemochromatosis. *Nat Genet*. 1996;13(4):399-408.
761. Pietrangelo A. Non-invasive assessment of hepatic iron overload: are we finally there? *J Hepatol*. 2005;42(1):153-154.
762. Adams P, Brissot P, Powell LW. EASL International Consensus Conference on Haemochromatosis. *J Hepatol*. 2000;33(3):485-504.
763. Brunt EM. Pathology of hepatic iron overload. *Semin Liver Dis*. 2005;25(4):392-401.
764. Bacon BR, Powell LW, Adams PC, et al. Molecular medicine and hemochromatosis: at the crossroads. *Gastroenterology*. 1999;116(1):193-207.
765. Pietrangelo A. Non-HFE hemochromatosis. *Semin Liver Dis*. 2005;25(4):450-460.
766. Pietrangelo A. Hemochromatosis: an endocrine liver disease. *Hepatology*. 2007;46(4):1291-1301.
767. Liu J, Pu C, Lang L, et al. Molecular pathogenesis of hereditary hemochromatosis. *Histol Histopathol*. 2016;31:833-840.
768. Scheuer PJ, Williams R, Muir AR. Hepatic pathology in relatives of patients with haemochromatosis. *J Pathol Bacteriol*. 1962;84:53-64.
769. Brunt EM, Olynyk JK, Britton RS, et al. Histological evaluation of iron in liver biopsies: relationship to HFE mutations. *Am J Gastroenterol*. 2000;95:1788-1793.
770. Olynyk JK, Cullen DJ, Aquilia S, et al. A population-based study of the clinical expression of the hemochromatosis gene. *N Engl J Med*. 1999;341(10):718-724.
771. Niederau C, Fischer R, Sonnenberg A, et al. Survival and causes of death in cirrhotic and in noncirrhotic patients with primary hemochromatosis. *N Engl J Med*. 1985;313(20):1256-1262.
772. Deugnier YM, Loreal O, Turlin B, et al. Liver pathology in genetic hemochromatosis: a review of 135 cases and their bioclinical correlations. *Gastroenterology*. 1992;102:2050-2059.
773. Hubscher SG. Iron overload, inflammation and fibrosis in genetic haemochromatosis. *J Hepatol*. 2003;38(4):521-525.
774. Powell LW, Kerr JF. The pathology of the liver in hemochromatosis. *Pathobiol Annu*. 1975;5:317-337.
775. Deugnier YM, Turlin B, Powell LW, et al. Differentiation betewen heterozygotes and homozygotes in genetic hemochromatosis by means of a histological hepatic iron indiex: a study of 192 cases. *Hepatology*. 1993;17:30-34.
776. Schoniger-Hekele M, Muller C, Polli C, et al. Liver pathology in compound heterozygous patients for hemochromatosis mutations. *Liver*. 2002;22(4):295-301.
777. Bulaj ZJ, Griffen LM, Jorde LB, et al. Clinical and biochemical abnormalities in people heterozygous for hemochromatosis. *N Engl J Med*. 1996;335(24):1799-1805.
778. Cheng R, Barton JC, Morrison ED, et al. Differences in hepatic phenotype between hemochromatosis patients with HFE C282Y homozygosity and other HFE genotypes. *J Clin Gastroenterol*. 2009;43(6):569-573.
779. Hohler T, Leininger S, Kohler HH, et al. Heterozygosity for the hemochromatosis gene in liver diseases—prevalence and effects on liver histology. *Liver*. 2000;20(6):482-486.
780. Whitington PF. Neonatal hemochromatosis: a congenital alloimmune hepatitis. *Semin Liver Dis*. 2007;27(3):243-250.
781. Moerman P, Pauwels P, Vandenberghe K, et al. Neonatal haemochromatosis. *Histopathology*. 1990;17(4):345-351.
782. Silver MM, Valberg LS, Cutz E, et al. Hepatic morphology and iron quantitation in perinatal hemochromatosis. Comparison with a large perinatal control population, including cases with chronic liver disease. *Am J Pathol*. 1993;143(5):1312-1325.
783. Faa G, Sciot R, Farci AM, et al. Iron concentration and distribution in the newborn liver. *Liver*. 1994;14(4):193-199.
784. Wonke B, Hoffbrand AV, Brown D, Dusheiko G. Antibody to hepatitis C virus in multiply transfused patients with thalassaemia major. *J Clin Pathol*. 1990;43(8):638-640.
785. Moyo VM, Mandishona E, Hasstedt SJ, et al. Evidence of genetic transmission in African iron overload. *Blood*. 1998;91(3):1076-1082.
786. Ludwig J, Hashimoto E, Porayko MK, et al. Hemosiderosis in cirrhosis: a study of 447 native livers. *Gastroenterology*. 1997;112(3):882-888.
787. Wallace DF, Subramaniam VN. Co-factors in liver disease: the role of HFE-related hereditary hemochromatosis and iron. *Biochim Biophys Acta*. 2009;1790(7):663-670.
788. Barisani D, Pelucchi S, Mariani R, et al. Hepcidin and iron-related gene expression in subjects with dysmetabolic hepatic iron overload. *J Hepatol*. 2008;49(1):123-133.
789. Cassiman D, Vannoote J, Roelandts R, et al. Porphyria cutanea tarda and liver disease. A retrospective analysis of 17 cases from a single centre and review of the literature. *Acta Gastroenterol Belg*. 2008;71(2):237-242.
790. Summerfield JA, Nagafuchi Y, Sherlock S, et al. Hepatobiliary fibropolycystic disease: a clinical and histological review of 51 patients. *J Hepatol*. 1986;2:141-156.
791. Desmet VJ. Congenital diseases of intrahepatic bile ducts: variations on the theme "ductal plate malformation". *Hepatology*. 1992;16(4):1069-1083.
792. Desmet VJ, Roskams TAD. The cholangiopathies. In: Suchy FJ, Sokol RJ, Balistreri WF, eds. *Liver disease in children*. *3*. Cambridge: Cambridge University Press; 2007:35-70.
793. Veigel MC, Prescott-Focht J, Rodriguez MG, et al. Fibropolycystic liver disease in children. *Pediatr Radiol*. 2009;39(4):317-327.
794. Desmet VJ. Pathogenesis of ductal plate abnormalities. *Mayo Clin Proc*. 1998;73:80-89.
795. Jørgensen MJ. The ductal plate malformation. A study of the intrahepatic bile duct lesion in infantile polycystic disease and congenital hepatic fibrosis. *Acta Pathol Microbiol Scand [A]*. 1977;257(suppl):1-88.
796. Inui A, Fujisawa T, Suemitsu T, et al. A case of Caroli's disease with special reference to hepatic CT and US findings. *J Pediatr Gastroenterol Nutr*. 1992;14(4):463-466.
797. Gunay-Aygun M. Liver and kidney disease in ciliopathies. *Am J Med Genet C Semin Med Genet*. 2009;151c(4):296-306.
798. Ong AC, Wheatley DN. Polycystic kidney disease—the ciliary connection. *Lancet*. 2003;361(9359):774-776.
799. Waanders E, Van Krieken JH, Lameris AL, Drenth JP. Disrupted cell adhesion but not proliferation mediates cyst formation in polycystic liver disease. *Mod Pathol*. 2008;21(11):1293-1302.
800. Masyuk TV, Huang BQ, Ward CJ, et al. Defects in cholangiocyte fibrocystin expression and ciliary structure in the PCK rat. *Gastroenterology*. 2003;125(5):1303-1310.
801. Villeneuve J, Pelluard-Nehme F, Combe C, et al. Immunohistochemical study of the phenotypic change of the mesenchymal cells during portal tract maturation in normal and fibrous (ductal plate malformation) fetal liver. *Comp Hepatol*. 2009;8:5.
802. Premkumar A, Berdon WE, Levy J, et al. The emergence of hepatic fibrosis and portal hypertension in infants and children with autosomal recessive polycystic kidney disease. Initial and follow-up sonographic and radiographic findings. *Pediatr Radiol*. 1988;18(2):123-129.
803. Desmet VJ. What is congenital hepatic fibrosis? *Histopathology*. 1992;20(6): 465-477.
804. Giouleme O, Nikolaidis N, Tziomalos K, et al. Ductal plate malformation and congenital hepatic fibrosis: Clinical and histological findings in four patients. *Hepatol Res*. 2006;35(2):147-150.
805. Yasoshima M, Sato Y, Furubo S, et al. Matrix proteins of basement membrane of intrahepatic bile ducts are degraded in congenital hepatic fibrosis and Caroli's disease. *J Pathol*. 2009;217(3):442-451.
806. Zaffanello M, Diomedi-Camassei F, Melzi ML, et al. Sensenbrenner syndrome: a new member of the hepatorenal fibrocystic family. *Am J Med Genet A*. 2006;140(21):2336-2340.
807. de Koning TJ, Dorland L, van Diggelen OP, et al. A novel disorder of N-glycosylation due to phosphomannose isomerase deficiency. *Biochem Biophys Res Commun*. 1998;245(1):38-42.
808. Freeze HH. Congenital disorders of glycosylation and the pediatric liver. *Semin Liver Dis*. 2001;21(4):501-515.
809. Want ZX, Li YG, Wang RL, et al. Clinical classification of Caroli's disease: an analysis of 30 patients. *HPB (Oxford)*. 2015;17:278-283.
810. Choi BI, Yeon KM, Kim SH, Han MC. Caroli disease: central dot sign in CT. *Radiology*. 1990;174(1):161-163.
811. Marchal GJ, Desmet VJ, Proesmans WC, et al. Caroli disease: high-frequency US and pathologic findings. *Radiology*. 1986;158(2):507-511.
812. Boyle MJ, Doyle GD, McNulty JG. Monolobar Caroli's disease. *Am J Gastroenterol*. 1989;84(11):1437-1444.
813. Chung EB. Multiple bile duct hamartomas. *Cancer Lett*. 1970;26:287-296.
814. Karhunen PJ. Adult polycystic liver disease and biliary microhamartomas (von Meyenburg's complexes). *Acta Pathol Microbiol Immunol Scand [A]*. 1986;94(6):397-400.
815. Song JS, Lee YJ, Kim KW, et al. Cholangiocarcinoma arising in von Meyenburg complexes: report of four cases. *Pathol Int*. 2008;58(8):503-512.
816. Heinke T, Pellacani LB, Costa Hde O, et al. Hepatocellular carcinoma in association with bile duct hamartomas: report on 2 cases and review of the literature. *Ann Diagn Pathol*. 2008;12(3):208-211.
817. Sutters M, Germino GG. Autosomal dominant polycystic kidney disease: molecular genetics and pathophysiology. *J Lab Clin Med*. 2003;141(2):91-101.
818. Gabow PA, Johnson AM, Kaehny WD, et al. Risk factors for the development of hepatic cysts in autosomal dominant polycystic kidney disease. *Hepatology*. 1990;11(6):1033-1037.
819. Davila S, Furu L, Gharavi AG, et al. Mutations in SEC63 cause autosomal dominant polycystic liver disease. *Nat Genet*. 2004;36(6):575-577.

820. Qian Q, Li A, King BF, et al. Clinical profile of autosomal dominant polycystic liver disease. *Hepatology*. 2003;37(1): 164-171.
821. Hoevenaren IA, Wester R, Schrier RW, et al. Polycystic liver: clinical characteristics of patients with isolated polycystic liver disease compared with patients with polycystic liver and autosomal dominant polycystic kidney disease. *Liver Int*. 2008;28(2):264-270.
822. Waanders E, van Keimpema L, Brouwer JT, et al. Carbohydrate antigen 19-9 is extremely elevated in polycystic liver disease. *Liver Int*. 2009;29(9):1389-1395.
823. DeLeve LD, Valla DC, Garcia-Tsao G. Vascular disorders of the liver. *Hepatology*. 2009;49(5):1729-1764.
824. Crawford JM. Vascular disorders of the liver. *Clin Liver Dis*. 2010;14:635-650.
825. Wanless IR. Noncirrhotic portal hypertension: recent concepts. *Prog Liver Dis*. 1996;14:265-278.
826. Roskams T, Baptista A, Bianchi L, et al. Histopathology of portal hypertension. A practical guideline. *Histopathology*. 2002;42:2-13.
827. Nevens F, Fevery J, Van Steenbergen W, et al. Arsenic and non-cirrhotic portal hypertension. A report of eight cases. *J Hepatol*. 1990;11(1):80-85.
828. Thomas LB, Popper H, Berk PD, et al. Vinyl-chloride-induced liver disease. From idiopathic portal hypertension (Banti's syndrome) to Angiosarcomas. *N Engl J Med*. 1975;292(1):17-22.
829. Shepherd P, Harrison DJ. Idiopathic portal hypertension associated with cytotoxic drugs. *J Clin Pathol*. 1990;43(3):206-210.
830. Kitao A, Sato Y, Sawada-Kitamura S, et al. Endothelial to mesenchymal transition via transforming growth factor-beta1/Smad activation is associated with portal venous stenosis in idiopathic portal hypertension. *Am J Pathol*. 2009;175(2):616-626.
831. Chawla Y, Dhiman RK. Intrahepatic portal venopathy and related disorders of the liver. *Semin Liver Dis*. 2008;28(3):270-281.
832. Bioulac-Sage P, Le Bail B, Bernard PH, Balabaud C. Hepatoportal sclerosis. *Semin Liver Dis*. 1995;15(4):329-339.
833. Nakanuma Y, Hoso M, Sasaki M, et al. Histopathology of the liver in non-cirrhotic portal hypertension of unknown aetiology. *Histopathology*. 1996;28(3):195-204.
834. Ludwig J, Hashimoto E, Obata H, Baldus WP. Idiopathic portal hypertension; a histopathological study of 26 Japanese cases. *Histopathology*. 1993;22(3):227-234.
835. Ohbu M, Okudaira M, Watanabe K, et al. Histopathological study of intrahepatic aberrant vessels in cases of noncirrhotic portal hypertension. *Hepatology*. 1994;20(2):302-308.
836. Bernard PH, Le Bail B, Cransac M, et al. Progression from idiopathic portal hypertension to incomplete septal cirrhosis with liver failure requiring liver transplantation. *J Hepatol*. 1995;22(4):495-499.
837. Villeneuve JP, Huet PM, Joly JG, et al. Idiopathic portal hypertension. *Am J Med*. 1976;61(4):459-464.
838. Ludwig J, Hashimoto E, McGill DB, van Heerden JA. Classification of hepatic venous outflow obstruction: ambiguous terminology of the Budd-Chiari syndrome. *Mayo Clin Proc*. 1990;65(1):51-55.
839. Kanel GC, Ucci AA, Kaplan MM, Wolfe HJ. A distinctive perivenular hepatic lesion associated with heart failure. *Am J Clin Pathol*. 1980;73(2):235-239.
840. Darwish Murad S, Plessier A, Hernandez-Guerra M, et al. Etiology, management, and outcome of the Budd-Chiari syndrome. *Ann Intern Med*. 2009;151(3):167-175.
841. Plessier A, Valla DC. Budd-Chiari syndrome. *Semin Liver Dis*. 2008;28(3):259-269.
842. Vickers CR, West RJ, Hubscher SG, Elias E. Hepatic vein webs and resistant ascites. Diagnosis, management and implications. *J Hepatol*. 1989;8(3):287-293.
843. Tanaka M, Wanless IR. Pathology of the liver in Budd-Chiari syndrome: portal vein thrombosis and the histogenesis of veno-centric cirrhosis, veno-portal cirrhosis, and large regenerative nodules. *Hepatology*. 1998;27(2):488-496.
844. DeLeve LD, Shulman HM, McDonald GB. Toxic injury to hepatic sinusoids: sinusoidal obstruction syndrome (veno-occlusive disease). *Semin Liver Dis*. 2002;22(1):27-42.
845. Stuart KL, Bras G. Veno-occlusive disease of the liver. *Q J Med*. 1957;26(103):291-315.
846. Bach N, Thung SN, Schaffner F. Comfrey herb tea-induced hepatic veno-occlusive disease. *Am J Med*. 1989;87(1):97-99.
847. DeLeve LD. Hepatic microvasculature in liver injury. *Semin Liver Dis*. 2007;27(4):390-400.
848. McDonald GB, Hinds MS, Fisher LD, et al. Veno-occlusive disease of the liver and multiorgan failure after bone marrow transplantation: a cohort study of 355 patients. *Ann Intern Med*. 1993;118(4):255-267.
849. Burt AD, MacSween RN. Hepatic vein lesions in alcoholic liver disease: retrospective biopsy and necropsy study. *J Clin Pathol*. 1986;39(1):63-67.
850. Shulman HM, Fisher LB, Schoch HG, et al. Veno-occlusive disease of the liver after marrow transplantation: histological correlates of clinical signs and symptoms. *Hepatology*. 1994;19:1171-1181.
851. Bruguera M, Aranguibel F, Ros E, Rodes J. Incidence and clinical significance of sinusoidal dilatation in liver biopsies. *Gastroenterology*. 1978;75(3):474-478.
852. Winkler K, Christoffersen P. A reappraisal of Poulsen's disease (hepatic zone 1 sinusoidal dilatation). *APMIS Suppl*. 1991;23:86-90.
853. Rolfes DB, Ishak KG. Liver disease in toxemia of pregnancy. *Am J Gastroenterol*. 1986;81(12):1138-1144.
854. Gerber MA, Thung SN, Bodenheimer HC Jr, et al. Characteristic histologic triad in liver adjacent to metastatic neoplasm. *Liver*. 1986;6(2):85-88.
855. Tsokos M, Erbersdobler A. Pathology of peliosis. *Forensic Sci Int*. 2005;149(1):25-33.
856. Wold LE, Ludwig J. Peliosis hepatis: two morphologic variants? *Hum Pathol*. 1981;12:388-389.
857. Crocetti D, Palmieri A, Pedulla G, et al. Peliosis hepatis: personal experience and literature review. *World J Gastroenterol*. 2015;21:13188-13194.
858. Takiff H, Brems JJ, Pockros PJ, Elliott ML. Focal hemorrhagic necrosis of the liver. A rare cause of hemoperitoneum. *Dig Dis Sci*. 1992;37(12):1910-1914.
859. Ebert EC, Hagspiel KD, Nagar M, Schlesinger N. Gastrointestinal involvement in polyarteritis nodosa. *Clin Gastroenterol Hepatol*. 2008;6:960-966.
860. Harada M, Oe S, Shibata M, et al. Churg-Strauss syndrome manifesting as cholestsis and diagnosed by liver biopsy. *Hepatol Res*. 2012;42:940-944.
861. Singh S, Swanson KL, Hathcock MA, et al. Identifying the presence of clinically significant hepatic involvement in hereditary haemorrhagic telangiectasia using a simple clinical scoring index. *J Hepatol*. 2014;61:124-131.
862. Hay JE. Liver disease in pregnancy. *Hepatology*. 2008;47(3):1067-1076.
863. Joshi D, James A, Quaglia A, et al. Liver disease in pregnancy. *Lancet*. 2010;375(9714):594-605.
864. Lee NM, Brady CW. Liver disease in pregnancy. *World J Gastroenterol*. 2009;15(8):897-906.
865. Rolfes DB, Ishak KG. Liver disease in pregnancy. *Histopathology*. 1986;10(6):555-570.
866. Rolfes DB, Ishak KG. Acute fatty liver of pregnancy: a clinicopathologic study of 35 cases. *Hepatology*. 1985;5(6):1149-1158.
867. Riely CA. Acute fatty liver of pregnancy. *Semin Liver Dis*. 1987;7(1):47-54.
868. Schoeman MN, Batey RG, Wilcken B. Recurrent acute fatty liver of pregnancy associated with a fatty-acid oxidation defect in the offspring. *Gastroenterology*. 1991;100(2):544-548.
869. Chandiramani M, Shennan A. Hypertensive disorders of pregnancy: a UK-based perspective. *Curr Opin Obstet Gynecol*. 2008;20(2):96-101.
870. Vinnars MT, Wijnaendts LC, Westgren M, et al. Severe preeclampsia with and without HELLP differ with regard to placental pathology. *Hypertension*. 2008;51(5):1295-1299.
871. Geenes V, Williamson C. Intrahepatic cholestasis of pregnancy. *World J Gastroenterol*. 2009;15(17):2049-2066.
872. Beuers U, Pusl T. Intrahepatic cholestasis of pregnancy—a heterogeneous group of pregnancy-related disorders? *Hepatology*. 2006;43(4):647-649.
873. Lammert F, Marschall HU, Glantz A, Matern S. Intrahepatic cholestasis of pregnancy: molecular pathogenesis, diagnosis and management. *J Hepatol*. 2000;33(6):1012-1021.
874. Denk H, Scheuer PJ, Baptista A, et al. Guidelines for the diagnosis and interpretation of hepatic granulomas. *Histopathology*. 1994;25:209-218.
875. Drebber U, Kasper HU, Ratering J, et al. Hepatic granulomas: histological and molecular pathological approach to differential diagnosis—a study of 442 cases. *Liver Int*. 2008;28(6):828-834.
876. Karagiannidis A, Karavalaki M, Koulaouzidis A. Hepatic sarcoidosis. *Ann Hepatol*. 2006;5(4):251-256.
877. Devaney K, Goodman ZD, Epstein MS, et al. Hepatic sarcoidosis. Clinicopathologic features in 100 patients. *Am J Surg Pathol*. 1993;17(12):1272-1280.
878. Murphy JR, Sjogren MH, Kikendall JW, et al. Small bile duct abnormalities in sarcoidosis. *J Clin Gastroenterol*. 1990;12(5):555-561.
879. Rudzki C, Ishak KG, Zimmerman HJ. Chronic intrahepatic cholestasis of sarcoidosis. *Am J Med*. 1975;59(3):373-387.
880. Maddrey WC. Sarcoidosis and primary biliary cirrhosis. Associated disorders? *N Engl J Med*. 1983;308(10):588-590.
881. Valla D, Pessegueiro-Miranda H, Degott C, et al. Hepatic sarcoidosis with portal hypertension. A report of seven cases with a review of the literature. *Q J Med*. 1987;63(242):531-544.
882. Pellegrin M, Delsol G, Auvergnat JC, et al. Granulomatous hepatitis in Q fever. *Hum Pathol*. 1980;11(1):51-57.
883. Hira PR, Shweiki H, Lindberg LG, et al. Diagnosis of cystic hydatid disease: role of aspiration cytology. *Lancet*. 1988;2(8612):655-657.
884. Williams JF, Lopez Adaros H, Trejos A. Current prevalence and distribution of hydatidosis with special reference to the Americas. *Am J Trop Med Hyg*. 1971;20(2):224-236.
885. Magistrelli P, Masetti R, Coppola R, et al. Surgical treatment of hydatid disease of the

liver. A 20-year experience. *Arch Surg*. 1991;126(4):518-522, discussion 523.
886. Munzer D. New perspectives in the diagnosis of Echinococcus disease. *J Clin Gastroenterol*. 1991;13(4):415-423.
887. Kalovidouris A, Voros D, Gouliamos A, et al. Extracapsular (satellite) hydatid cysts. *Gastrointest Radiol*. 1992;17(4):353-356.
888. Langer JC, Rose DB, Keystone JS, et al. Diagnosis and management of hydatid disease of the liver. A 15-year North American experience. *Ann Surg*. 1984;199(4):412-417.
889. Raptou G, Pliakos I, Hytiroglou P, et al. Severe eosinophilic cholangitis with parenchymal destruction of the left hepatic lobe due to hydatid disease. *Pathol Int*. 2009;59(6):395-398.
890. Akinoglu A, Demiryurek H, Guzel C. Alveolar hydatid disease of the liver: a report on thirty-nine surgical cases in eastern Anatolia, Turkey. *Am J Trop Med Hyg*. 1991;45(2):182-189.
891. Pounder DJ. Malarial pigment and hepatic anthracosis. *Am J Surg Pathol*. 1983;7(5):501-502.
892. Tsai MS, Lee HM, Hsin MC, et al. Increased risk of pyogenic liver abscess among patients with colonic diverticular diseases: a nationwide cohort study. *Medicine (Baltimore)*. 2015;94(49):e2210.
893. Lupatkin H, Brau N, Flomenberg P, Simberkoff MS. Tuberculous abscesses in patients with AIDS. *Clin Infect Dis*. 1992;14(5):1040-1044.
894. Kuo SH, Lee YT, Tseng CJ, et al. Mortality in emergency department sepsis score as a prognostic indicator in patients with pyogenic liver abscess. *Am J Emerg Med*. 2013;31:916-921.
895. Kaplan GG, Gregson DB, Laupland KB. Population-based study of the epidemiology and risk factors for pyogenic liver abscess. *Clin Gastroenterol Hepatol*. 2004;2:1032-1038.
896. Lederman ER, Crum NF. Pyogenic liver abscess with a focus on Klebsiella pneumoniae as a primary pathogen: an emerging disease with unique clinical characteristics. *Am J Gastroenterol*. 2005;100:322-331.
897. Simeunovic E, Arnold M, Sidler D, Moore SW. Liver abscess in neonates. *Pediatr Surg Int*. 2009;25(2):153-156.
898. Greenstein AJ, Barth J, Dicker A, et al. Amebic liver abscess: a study of 11 cases compared with a series of 38 patients with pyogenic liver abscess. *Am J Gastroenterol*. 1985;80(6):472-478.
899. Do H, Lambiase RE, Deyoe L, et al. Percutaneous drainage of hepatic abscesses: comparison of results in abscesses with and without intrahepatic biliary communication. *AJR Am J Roentgenol*. 1991;157(6):1209-1212.
900. Lo JZ, Leow JJ, Ng PL, et al. Predictors of therapy failure in a series of 741 adult pyogenic liver abscesses. *J Hepatobiliary Pancreat Sci*. 2015;22:156-165.
901. Stanley SL Jr. Amoebiasis. *Lancet*. 2003;361(9362):1025-1034.
902. Hughes MA, Petri WA Jr. Amebic liver abscess. *Infect Dis Clin North Am*. 2000;14(3):565-582, viii.
903. Meng XY, Wu JX. Perforated amebic liver abscess. Clinical analysis of 110 cases. *South Med*. 1994;87:985-990.
904. Payto D, Heideloff C, Wang S. Sensitive, simple, and robust nano-liquid chromatography-mass spectrometry for amyloid protein subtyping. *Methods Mol Biol*. 2016;1378:55-60.
905. Finkelstein SD, Fornasier VL, Pruzanski W. Intrahepatic cholestasis with predominant pericentral deposition in systemic amyloidosis. *Hum Pathol*. 1981;12(5):470-472.
906. Hoffman MS, Stein BE, Davidian MM, Rosenthal WS. Hepatic amyloidosis presenting as severe intrahepatic cholestasis: a case report and review of the literature. *Am J Gastroenterol*. 1988;83(7):783-785.
907. Makhlouf HR, Goodman ZD. Globular hepatic amyloid: an early stage in the pathway of amyloid formation: a study of 20 new cases. *Am J Surg Pathol*. 2007;31(10):1615-1621.
908. Faa G, Van Eyken P, De Vos R, et al. Light chain deposition disease of the liver associated with AL-type amyloidosis and severe cholestasis. *J Hepatol*. 1991;12(1):75-82.
909. Schaffner F, Popper H. Nonspecific reactive hepatitis in aged and infirm people. *Am J Dig Dis*. 1959;4(5):389-399.
910. Lin CC, Sundaram SS, Hart J, Whitington PF. Subacute nonsuppurative cholangitis (cholangitis lenta) in pediatric liver transplant patients. *J Pediatr Gastroenterol Nutr*. 2007;45(2):228-233.
911. Adeyi O, Fischer SE, Guindi M. Liver allograft pathology: approach to interpretation of needle biopsies with clinicopathological correlation. *J Clin Pathol*. 2010;63(1):47-74.
912. Hubscher SG. Transplantation pathology. *Semin Diagn Pathol*. 2006;23(3-4):170-181.
913. Hubscher SG. Transplantation pathology. *Semin Liver Dis*. 2009;29(1):74-90.
914. Abraham SC, Poterucha JJ, Rosen CB. Histologic abnormalities are common in protocol liver allograft biopsies from patients with normal liver function tests. *Am J Surg Pathol*. 2008;32(7):965-973.
915. Firpi RJ, Abdelmalek MF, Soldevila-Pico C, et al. One-year protocol liver biopsy can stratify fibrosis progression in liver transplant recipients with recurrent hepatitis C infection. *Liver Transpl*. 2004;10(10):1240-1247.
916. Verran D, Kusyk T, Painter D, et al. Clinical experience gained from the use of 120 steatotic donor livers for orthotopic liver transplantation. *Liver Transpl*. 2003;9(5):500-505.
917. Trevisani F, Colantoni A, Caraceni P, Van Thiel DH. The use of donor fatty liver for liver transplantation: a challenge or a quagmire? *J Hepatol*. 1996;24(1):114-121.
918. Selzner M, Clavien PA. Fatty liver in liver transplantation and surgery. *Semin Liver Dis*. 2001;21(1):105-113.
919. Fiorentino M, Vasuri F, Ravaioli M, et al. Predictive value of frozen-section analysis in the histological assessment of steatosis before liver transplantation. *Liver Transpl*. 2009;15(12):1821-1825.
920. Frankel WL, Tranovich JG, Salter L, et al. The optimal number of donor biopsy sites to evaluate liver histology for transplantation. *Liver Transpl*. 2002;8(11):1044-1050.
921. Koneru B, Dikdan G. Hepatic steatosis and liver transplantation current clinical and experimental perspectives. *Transplantation*. 2002;73(3):325-330.
922. McCormack L, Petrowsky H, Jochum W, et al. Use of severely steatotic grafts in liver transplantation: a matched case-control study. *Ann Surg*. 2007;246(6):940-946, discussion 946-948.
923. Imber CJ, St Peter SD, Lopez I, et al. Current practice regarding the use of fatty livers: a trans-Atlantic survey. *Liver Transpl*. 2002;8(6):545-549.
924. Crowley H, Lewis WD, Gordon F, et al. Steatosis in donor and transplant liver biopsies. *Hum Pathol*. 2000;31(10):1209-1213.
925. Imber CJ, St Peter SD, Handa A, Friend PJ. Hepatic steatosis and its relationship to transplantation. *Liver Transpl*. 2002;8(5):415-423.
926. Minervini MI, Ruppert K, Fontes P, et al. Liver biopsy findings from healthy potential living liver donors: reasons for disqualification, silent diseases and correlation with liver injury tests. *J Hepatol*. 2009;50(3):501-510.
927. Abraham S, Furth EE. Quantitative evaluation of histological features in "time-zero" liver allograft biopsies as predictors of rejection or graft failure: receiver-operating characteristic analysis application. *Hum Pathol*. 1996;27(10):1077-1084.
928. Bilzer M, Gerbes AL. Preservation injury of the liver: mechanisms and novel therapeutic strategies. *J Hepatol*. 2000;32(3):508-515.
929. Tillery W, Demetris J, Watkins D, et al. Pathologic recognition of preservation injury in hepatic allografts with six months follow-up. *Transplant Proc*. 1989;21(1 Pt 2):1330-1331.
930. Gaffey MJ, Boyd JC, Traweek ST, et al. Predictive value of intraoperative biopsies and liver function tests for preservation injury in orthotopic liver transplantation. *Hepatology*. 1997;25(1):184-189.
931. Ben-Ari Z, Pappo O, Mor E. Intrahepatic cholestasis after liver transplantation. *Liver Transpl*. 2003;9(10):1005-1018.
932. Williams JW, Vera S, Peters TG, et al. Cholestatic jaundice after hepatic transplantation. A nonimmunologically mediated event. *Am J Surg*. 1986;151(1):65-70.
933. Khettry U, Backer A, Ayata G, et al. Centrilobular histopathologic changes in liver transplant biopsies. *Hum Pathol*. 2002;33(3):270-276.
934. Neil DA, Hubscher SG. Are parenchymal changes in early post-transplant biopsies related to preservation-reperfusion injury or rejection? *Transplantation*. 2001;71(11):1566-1572.
935. International Working Party. Terminology for hepatic allograft rejection. International Working Party. *Hepatology*. 1995;22(2):648-654.
936. Batts KP. Acute and chronic hepatic allograft rejection: pathology and classification. *Liver Transpl*. 1999;5(4 suppl 1):S21-S29.
937. Demetris AJ, Lasky S, Van Thiel DH, et al. Pathology of hepatic transplantation: A review of 62 adult allograft recipients immunosuppressed with a cyclosporine/steroid regimen. *Am J Pathol*. 1985;118(1):151-161.
938. Hubscher SG. Histological findings in liver allograft rejection—new insights into the pathogenesis of hepatocellular damage in liver allografts. *Histopathology*. 1991;18(4):377-383.
939. Jones KD, Ferrell LD. Interpretation of biopsy findings in the transplant liver. *Semin Diagn Pathol*. 1998;15(4):306-317.
940. Demetris AJ, Jaffe R, Tzakis A, et al. Antibody-mediated rejection of human orthotopic liver allografts. A study of liver transplantation across ABO blood group barriers. *Am J Pathol*. 1988;132(3):489-502.
941. Kozlowski T, Andreoni K, Schmitz J, et al. Sinusoidal C4d deposits in liver allografts indicate an antibody-mediated response: diagnostic considerations in the evaluation of liver allografts. *Liver Transpl*. 2012;18:641-658.
942. Shetty S, Adams DH, Hubscher SG. Post-transplant liver biopsy and the immune response: lessons for the clinician. *Expert Rev Clin Immunol*. 2012;8:645-661.
943. Wiesner RH, Demetris AJ, Belle SH, et al. Acute hepatic allograft rejection: incidence,

risk factors, and impact on outcome. *Hepatology*. 1998;28(3):638-645.
944. Martinez OM, Rosen HR. Basic concepts in transplant immunology. *Liver Transpl*. 2005;11(4):370-381.
945. Nagral A, Ben-Ari Z, Dhillon AP, Burroughs AK. Eosinophils in acute cellular rejection in liver allografts. *Liver Transpl*. 1998;4(5):355-362.
946. International Panel. Banff schema for grading liver allograft rejection: an international consensus document. *Hepatology*. 1997;25(3):658-663.
947. Demetris AJ. Central venulitis in liver allografts: considerations of differential diagnosis. *Hepatology*. 2001;33(5): 1329-1330.
948. Krasinskas AM, Ruchelli ED, Rand EB, et al. Central venulitis in pediatric liver allografts. *Hepatology*. 2001;33(5):1141-1147.
949. Sebagh M, Debette M, Samuel D, et al. "Silent" presentation of veno-occlusive disease after liver transplantation as part of the process of cellular rejection with endothelial predilection. *Hepatology*. 1999;30(5):1144-1150.
950. Pappo O, Ramos H, Starzl TE, et al. Structural integrity and identification of causes of liver allograft dysfunction occurring more than 5 years after transplantation. *Am J Surg Pathol*. 1995;19(2):192-206.
951. Harrison RF, Patsiaoura K, Hubscher SG. Cytokeratin immunostaining for detection of biliary epithelium: its use in counting bile ducts in cases of liver allograft rejection. *J Clin Pathol*. 1994;47(4):303-308.
952. Bilezikci B, Demirhan B, Kocbiyik A, et al. Relevant histopathologic findings that distinguish acute cellular rejection from cholangitis in hepatic allograft biopsy specimens. *Transplant Proc*. 2008;40(1):248-250.
953. Demetris A, Adams D, Bellamy C, et al. Update of the International Banff Schema for Liver Allograft Rejection: working recommendations for the histopathologic staging and reporting of chronic rejection. An International Panel. *Hepatology*. 2000;31(3):792-799.
954. Lunz JG 3rd, Contrucci S, Ruppert K, et al. Replicative senescence of biliary epithelial cells precedes bile duct loss in chronic liver allograft rejection: increased expression of p21(WAF1/Cip1) as a disease marker and the influence of immunosuppressive drugs. *Am J Pathol*. 2001;158(4):1379-1390.
955. Ludwig J, Wiesner RH, Batts KP, et al. The acute vanishing bile duct syndrome (acute irreversible rejection) after orthotopic liver transplantation. *Hepatology*. 1987;7(3):476-483.
956. Cassiman D, Libbrecht L, Sinelli N, et al. The vagal nerve stimulates activation of the hepatic progenitor cell compartment via muscarinic acetylcholine receptor type 3. *Am J Pathol*. 2002;161(2):521-530.
957. Koukoulis GK, Shen J, Karademir S, et al. Cholangiocytic apoptosis in chronic ductopenic rejection. *Hum Pathol*. 2001;32(8):823-827.
958. Miyagawa-Hayashino A, Tsuruyama T, Haga H, et al. Arteriopathy in chronic allograft rejection in liver transplantation. *Liver Transpl*. 2004;10(4):513-519.
959. Jain D, Robert ME, Navarro V, et al. Total fibrous obliteration of main portal vein and portal foam cell venopathy in chronic hepatic allograft rejection. *Arch Pathol Lab Med*. 2004;128(1):64-67.
960. Quaglia AF, Del Vecchio Blanco G, Greaves R, et al. Development of ductopaenic liver allograft rejection includes a "hepatitic" phase prior to duct loss. *J Hepatol*. 2000;33(5):773-780.
961. Reference deleted in proofs.
962. Demetris AJ, Adeyi O, Bellamy CO, et al. Liver biopsy interpretation for causes of late liver allograft dysfunction. *Hepatology*. 2006;44(2):489-501.
963. Dumortier J, Giostra E, Belbouab S, et al. Non-alcoholic fatty liver disease in liver transplant recipients: another story of "seed and soil". *Am J Gastroenterol*. 2010;105(3):613-620.
964. Ferrell L, Bass N, Roberts J, Ascher N. Lipopeliosis: fat induced sinusoidal dilatation in transplanted liver mimicking peliosis hepatis. *J Clin Pathol*. 1992;45(12):1109-1110.
965. Sebagh M, Yilmaz F, Karam V, et al. The histologic pattern of "biliary tract pathology" is accurate for the diagnosis of biliary complications. *Am J Surg Pathol*. 2005;29(3):318-323.
966. Pol S, Cavalcanti R, Carnot F, et al. Azathioprine hepatitis in kidney transplant recipients. A predisposing role of chronic viral hepatitis. *Transplantation*. 1996;61:1774-1776.
967. Wisecarver JL, Earl RA, Haven MC, et al. Histologic changes in liver allograft biopsies associated with elevated whole blood and tissue cyclosporine concentrations. *Mod Pathol*. 1992;5(6):611-616.
968. Schreuder TC, Hubscher SG, Neuberger J. Autoimmune liver diseases and recurrence after orthotopic liver transplantation: what have we learned so far? *Transpl Int*. 2009;22(2):144-152.
969. Rowe IA, Webb K, Gunson BK, et al. The impact of disease recurrence on graft survival following liver transplantation: a single centre experience. *Transpl Int*. 2008;21(5):459-465.
970. Khettry U, Anand N, Gordon FD, et al. Recurrent hepatitis B, hepatitis C, and combined hepatitis B and C in liver allografts: a comparative pathological study. *Hum Pathol*. 2000;31(1):101-108.
971. Honaker MR, Shokouh-Amiri MH, Vera SR, et al. Evolving experience of hepatitis B virus prophylaxis in liver transplantation. *Transpl Infect Dis*. 2002;4:137-143.
972. Gane EJ. The natural history of recurrent hepatitis C and what influences this. *Liver Transpl*. 2008;14(suppl 2): S36-S44.
973. Ramirez S, Perez-Del-Pulgar S, Forns X. Virology and pathogenesis of hepatitis C virus recurrence. *Liver Transpl*. 2008;14(suppl 2):S27-S35.
974. Berenguer M, Lopez-Labrador FX, Wright TL. Hepatitis C and liver transplantation. *J Hepatol*. 2001;35(5):666-678.
975. Sheiner PA. Hepatitis C after liver transplantation. *Semin Liver Dis*. 2000;20(2):201-209.
976. Ueda Y, Uemoto S. Interferon-free therapy for hepatitis C in liver transplant recipients. *Transplantation*. 2016;100:54-60.
977. Noell BC, Besur SV, deLemos AS. Changing the face of hepatitis C management-the design and development of sofosbuvir. *Drug Des Devel Ther*. 2015;9:2367-2374.
978. Regev A, Molina E, Moura R, et al. Reliability of histopathologic assessment for the differentiation of recurrent hepatitis C from acute rejection after liver transplantation. *Liver Transpl*. 2004;10(10):1233-1239.
979. Souza P, Prihoda TJ, Hoyumpa AM, Sharkey FE. Morphologic features resembling transplant rejection in core biopsies of native livers from patients with Hepatitis C. *Hum Pathol*. 2009;40(1):92-97.
980. Petrovic LM, Villamil FG, Vierling JM, et al. Comparison of histopathology in acute allograft rejection and recurrent hepatitis C infection after liver transplantation. *Liver Transpl Surg*. 1997;3(4):398-406.
981. Demetris AJ. Evolution of hepatitis C virus in liver allografts. *Liver Transpl*. 2009;15(suppl 2):S35-S41.
982. Vakiani E, Hunt KK, Mazziotta RM, et al. Hepatitis C-associated granulomas after liver transplantation: morphologic spectrum and clinical implications. *Am J Clin Pathol*. 2007;127(1):128-134.
983. Stanca CM, Fiel MI, Kontorinis N, et al. Chronic ductopenic rejection in patients with recurrent hepatitis C virus treated with pegylated interferon alfa-2a and ribavirin. *Transplantation*. 2007;84(2):180-186.
984. Bernard PH, Le Bail B, Rullier A, et al. Recurrence and accelerated progression of hepatitis C following liver transplantation. *Semin Liver Dis*. 2000;20(4):533-538.
985. Dixon LR, Crawford JM. Early histologic changes in fibrosing cholestatic hepatitis C. *Liver Transpl*. 2007;13(2):219-226.
986. Sebagh M, Farges O, Dubel L, et al. Histological features predictive of recurrence of primary biliary cirrhosis after liver transplantation. *Transplantation*. 1998;65(10):1328-1333.
987. Duclos-Vallee JC, Sebagh M. Recurrence of autoimmune disease, primary sclerosing cholangitis, primary biliary cirrhosis, and autoimmune hepatitis after liver transplantation. *Liver Transpl*. 2009;15(suppl 2):S25-S34.
988. Mendes F, Couto CA, Levy C. Recurrent and de novo autoimmune liver diseases. *Clin Liver Dis*. 2011;15:859-878.
989. Demetris AJ. Distinguishing between recurrent primary sclerosing cholangitis and chronic rejection. *Liver Transpl*. 2006;12(11 suppl 2):S68-S72.
990. Pagadala M, Dasarathy S, Eghtesad B, McCullough AJ. Posttransplant metabolic syndrome: an epidemic waiting to happen. *Liver Transpl*. 2009;15(12):1662-1670.
991. Kerkar N, Yanni G. "De novo" and "recurrent" autoimmune hepatitis after liver transplantation: a comprehensive review. *J Autoimmun*. 2016;66:17-24.
992. Ward SC, Schiano TD, Thung SN, Fiel MI. Plasma cell hepatitis in hepatitis C virus patients post-liver transplantation: case-control study showing poor outcome and predictive features in the liver explant. *Liver Transpl*. 2009;15(12):1826-1833.
993. Fiel MI, Agarwal K, Stanca C, et al. Posttransplant plasma cell hepatitis (de novo autoimmune hepatitis) is a variant of rejection and may lead to a negative outcome in patients with hepatitis C virus. *Liver Transpl*. 2008;14(6):861-871.
994. Demetris AJ, Sebagh M. Plasma cell hepatitis in liver allografts: variant of rejection or autoimmune hepatitis? *Liver Transpl*. 2008;14(6):750-755.
995. Sebagh M, Rifai K, Feray C, et al. All liver recipients benefit from the protocol 10-year liver biopsies. *Hepatology*. 2003;37(6):1293-1301.
996. Evans HM, Kelly DA, McKiernan PJ, Hubscher S. Progressive histological damage in liver allografts following pediatric liver transplantation. *Hepatology*. 2006;43(5):1109-1117.
997. Ekong UD, Melin-Aldana H, Seshadri R, et al. Graft histology characteristics in long-term survivors of pediatric liver transplantation. *Liver Transpl*. 2008;14(11):1582-1587.
998. Scheenstra R, Peeters PM, Verkade HJ, Gouw AS. Graft fibrosis after pediatric liver transplantation: ten years of follow-up. *Hepatology*. 2009;49(3):880-886.

999. Hubscher SG. Central perivenulitis: a common and potentially important finding in late posttransplant liver biopsies. *Liver Transpl*. 2008;14(5):596-600.
1000. Krasinskas AM, Demetris AJ, Poterucha JJ, Abraham SC. The prevalence and natural history of untreated isolated central perivenulitis in adult allograft livers. *Liver Transpl*. 2008;14(5):625-632.
1001. Hubscher S. What does the long-term liver allograft look like for the pediatric recipient? *Liver Transpl*. 2009;15(suppl 2):S19-S24.
1002. Syn WK, Nightingale P, Gunson B, et al. Natural history of unexplained chronic hepatitis after liver transplantation. *Liver Transpl*. 2007;13(7):984-989.
1003. Shaikh OS, Demetris AJ. Idiopathic posttransplantation hepatitis? *Liver Transpl*. 2007;13(7):943-946.
1004. McPeake JR, O'Grady JG, Zaman S, et al. Liver transplantation for primary hepatocellular carcinoma: tumor size and number determine outcome. *J Hepatol*. 1993;18(2):226-234.
1005. Trevisani F, Garuti F, Cucchetti A, et al. De novo hepatocellular carcinoma of liver allograft: a neglected issue. *Cancer Lett*. 2015;357:47-54.
1006. Herrero JI. De novo malignancies following liver transplantation: impact and recommendations. *Liver Transpl*. 2009;15(suppl 2):S90-S94.
1007. McDonald GB, Shulman HM, Sullivan KM, Spencer GD. Intestinal and hepatic complications of human bone marrow transplantation. Part I. *Gastroenterology*. 1986;90(2):460-477.
1008. Sloane JP, Norton J. The pathology of bone marrow transplantation. *Histopathology*. 1993;22(3):201-209.
1009. Shulman HM, Sharma P, Amos D, et al. A coded histologic study of hepatic graft-versus-host disease after human bone marrow transplantation. *Hepatology*. 1988;8(3):463-470.
1010. Shulman HM, Fisher LB, Schoch HG, et al. Venoocclusive disease of the liver after marrow transplantation: histological correlates of clinical signs and symptoms. *Hepatology*. 1994;19:1171-1180.
1011. Snover DC. Biopsy interpretation in bone marrow transplantation. *Pathol Annu*. 1989;24(pt 2):63-101.
1012. Geubel AP, Cnudde A, Ferrant A, et al. Diffuse biliary tract involvement mimicking primary sclerosing cholangitis after bone marrow transplantation. *J Hepatol*. 1990;10(1):23-28.
1013. Stechschulte DJ Jr, Fishback JL, Emami A, Bhatia P. Secondary biliary cirrhosis as a consequence of graft-versus-host disease. *Gastroenterology*. 1990;98(1):223-225.
1014. Diamond DJ, Chang KL, Jenkins KA, Forman SJ. Immunohistochemical analysis of T cell phenotypes in patients with graft-versus-host disease following allogeneic bone marrow transplantation. *Transplantation*. 1995;59(10):1436-1444.

Liver: Tumors and Tumorlike Conditions

20

Laura W. Lamps

CHAPTER CONTENTS

Hepatic tumors and tumorlike conditions, *803*
Nodular regenerative hyperplasia, *803*
Focal nodular hyperplasia, *804*
Hepatocellular adenoma, *805*
Regenerative and dysplastic nodules, *808*
Hepatocellular carcinoma, *808*
Hepatoblastoma, *818*
Bile duct tumors and tumorlike conditions, *819*
Simple cyst, *819*
Biliary microhamartoma, *819*
Peribiliary gland hamartoma (bile duct adenoma), *820*
Biliary cystadenoma and cystadenocarcinoma, *821*
Intraductal papillary neoplasms of the bile duct, *822*
Bile duct carcinoma (cholangiocarcinoma), *822*
Mesenchymal tumors and tumorlike conditions, *824*
Vascular tumors, *824*
Other mesenchymal tumors, *826*
Malignant lymphoma and related lesions, *829*
Other primary tumors and tumorlike conditions, *831*
Metastatic tumors, *831*

Hepatic Tumors and Tumorlike Conditions

Surgical pathologists encounter a wide variety of nodules and tumors of hepatic origin, including both neoplastic and non-neoplastic lesions. Distinguishing between them can be challenging, but the distinction is critically important given the differing prognostic and therapeutic implications. Therefore, pathologists must understand the diagnostic criteria of these entities as well as the pitfalls inherent in interpreting small samples, such as core needle biopsies or fine needle aspirate (FNA) specimens. Furthermore, it is necessary to be aware of how the differential diagnosis varies in a cirrhotic versus a noncirrhotic liver, and to be aware of the context of the background liver, ideally from the tissue but at least from radiographic studies.

Nodular Regenerative Hyperplasia

Nodular regenerative hyperplasia (NRH) is a rare condition characterized by transformation of the liver parenchyma into regenerative, non-neoplastic nodules that are not delimited by fibrous septa.[1,2] It is an important cause of noncirrhotic portal hypertension (see also Chapter 19) and is associated with a wide range of conditions, including autoimmune diseases,[1,2] common variable immunodeficiency,[3] hematological disorders,[1,4] and numerous drugs, including azathioprine, didanosine, and oxaliplatin.[1,2,5,6] NRH may also occur in livers containing metastatic or primary tumor.[7,8] Wanless originally postulated that the pathogenesis appears to be related to abnormalities of portal hepatic blood flow (particularly portal venous thrombosis), leading to localized areas of hypo- and hyper-perfusion.[2] Patients may have elevated alkaline phosphatase, GGT, and/or transaminases.[9]

Macroscopically, the surface of the liver may be nodular and resemble micronodular cirrhosis.[1] The histopathologic diagnosis of NRH is easier on wedge biopsies or surgical specimens than on needle biopsies, as the features can be difficult to appreciate in small specimens. Microscopically, NRH is characterized by nodules of hyperplastic hepatocytes arranged in plates more than one cell thick, whereas the parenchymal cells adjacent to the nodules (usually centrilobular areas, but not always) are compressed and atrophic (Fig. 20.1A). Fibrous septa must be absent, which differentiates the lesion from cirrhosis[10]; however, in some cases, the compressed parenchyma between the nodules shows perisinusoidal fibrosis. In general, there is no or only minimal inflammation and no evidence of liver cell damage, although sinusoidal lymphocytosis has been reported in association with NRH.[9] The nodularity is better revealed on a reticulin stain (see Fig. 20.1B).[1,2,10] Vascular changes may be subtle and inconspicuous in needle biopsies and may include periportal angiomatosis as well as obliteration of portal vein branches; the latter is strongly associated with clinically evident portal hypertension.[9]

Partial nodular transformation is a rare entity in which the nodules may be larger than in NRH and are often restricted to the perihilar region, mimicking a neoplasm. Again, portal venous thrombosis is invoked in the pathogenesis of the lesions but in this instance situated near the porta hepatis in the larger portal vein branches.[11–13]

Abstract

This chapter covers neoplastic and non-neoplastic but tumorlike lesions of the liver.

Keywords

nodular regenerative hyperplasia,
cirrhosis,
focal nodular hyperplasia,
hepatocellular carcinoma,
adenoma,
cholangiocarcinoma,
hepatoblastoma,
microhamartoma,
von Meyenburg complex,
bile duct adenoma,
peribiliary gland adenoma,
cystadenoma,
cystadenocarcinoma,
hemangioma,
angiosarcoma,
mesenchymal hamartoma,
hemangioendothelioma,
embryonal sarcoma,
metastatic carcinoma

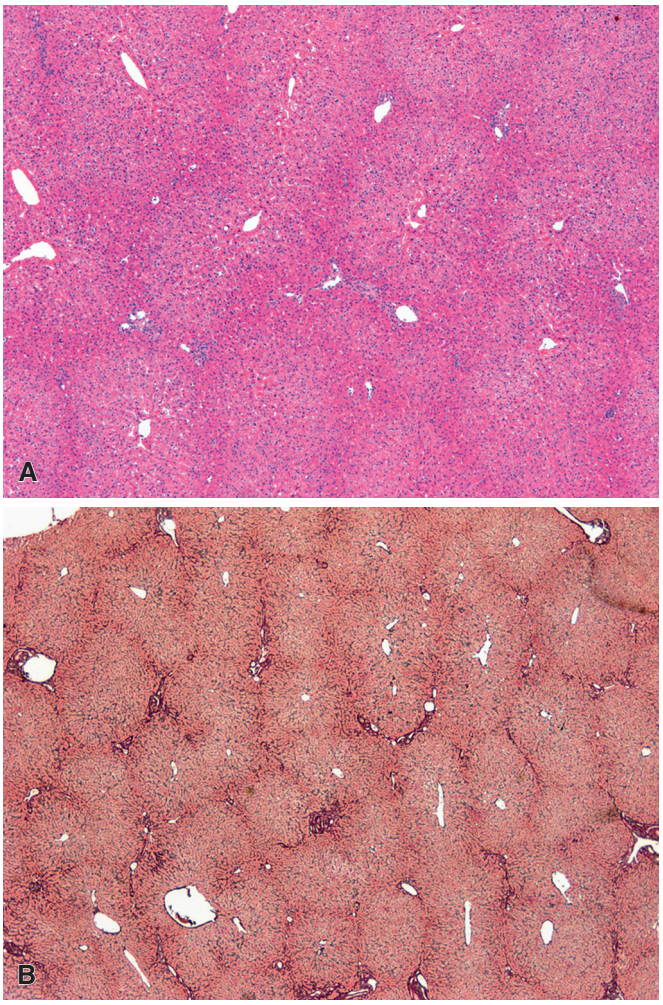

Figure 20.1 **A,** Nodular regenerative hyperplasia features diffuse nodular transformation without fibrous septa. **B,** Reticulin stain highlights the nodularity, with intervening areas of atrophic parenchyma.

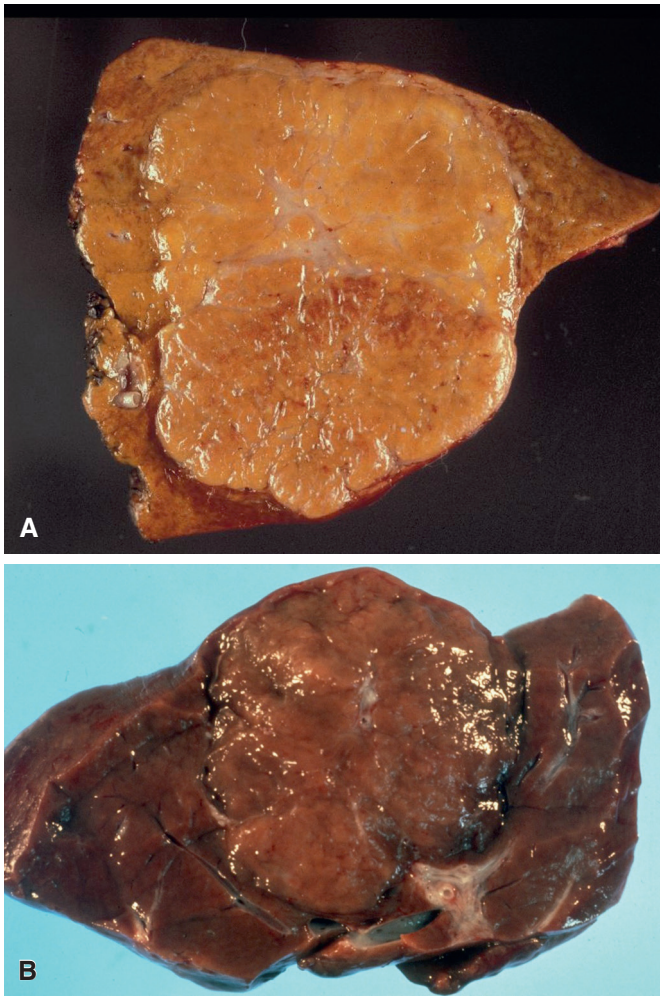

Figure 20.2 **A,** Focal nodular hyperplasia with typical stellate central scar in the center of the nodular lesion. **B,** This example is clearly nodular on cut surface but has a less prominent fibrous scar. (**B,** Courtesy of Dr. George F. Gray Jr.)

Focal Nodular Hyperplasia

Focal nodular hyperplasia (FNH) can occur in any age group, including childhood; most cases, however, are seen during the third to fifth decades of life. The female to male ratio has ranged from 2 : 1 to 8 : 1 in the various adult and pediatric series.[14,15] In approximately 80% of cases, the lesion is asymptomatic.[14] In contrast to hepatocellular adenoma, hemoperitoneum as a complication is extremely rare, although it has been described.[16] FNH is usually solitary; multicentricity has been described in 20% of adult cases, however, and in an even higher percentage of pediatric cases.[15] Multicentric cases may be associated with other lesions (particularly vascular), including hemangiomas of the liver, telangiectasias of the brain, berry aneurysm, and portal vein atresia, as well as neoplasms of the brain including astrocytoma and meningioma.[17]

Overall, the pathogenesis of FNH remains controversial. A possible relationship to oral contraceptives has been postulated,[18] but it is not as clear-cut as for liver cell adenoma.[19] There is no question that this disease occurred prior to the widespread use of oral contraceptives and that it can occur in males, particularly in association with chronic alcohol abuse.[20] It has also been associated (together with hepatocellular adenomas and large regenerative nodules) in patients with hepatic venous outflow obstruction[21] and following orthotopic liver transplantation,[22] suggesting that vascular anomalies or a hyperplastic/regenerative response to a localized insult to the liver parenchyma may also play a role in pathogenesis. This hypothesis is also supported by the fact that lesions indistinguishable from nodular hyperplasia have been reported in cirrhotic livers.[23] Clonality studies of FNH have shown mixed results.[24,25]

Grossly, FNH usually presents as a subcapsular, gray-white, solid mass that is sometimes pedunculated. On cut section, a white depressed area of fibrosis is often seen in the center, with broad strands radiating from it to the periphery in a stellate configuration (Fig. 20.2A and B). This can be detected in more than half of cases by MRI techniques.[26–28] Microscopically, FNH has a nodular appearance with a central stellate scar (Fig. 20.3A), although it is important to note that the scar (at least a well-formed one) is not invariably present. Large, often thick-walled vessels are present in the fibrous bands (see Fig. 20.3B), but they do not have accompanying bile ducts. Patchy areas of ductular reaction are characteristically present at the junction of the fibrous septa with the hepatocellular component (see Fig. 20.3C), and this may be an important clue to the diagnosis, particularly in needle biopsies.[29] Acute or chronic inflammation is common. The hepatocytes may contain increased amounts of glycogen and fat.

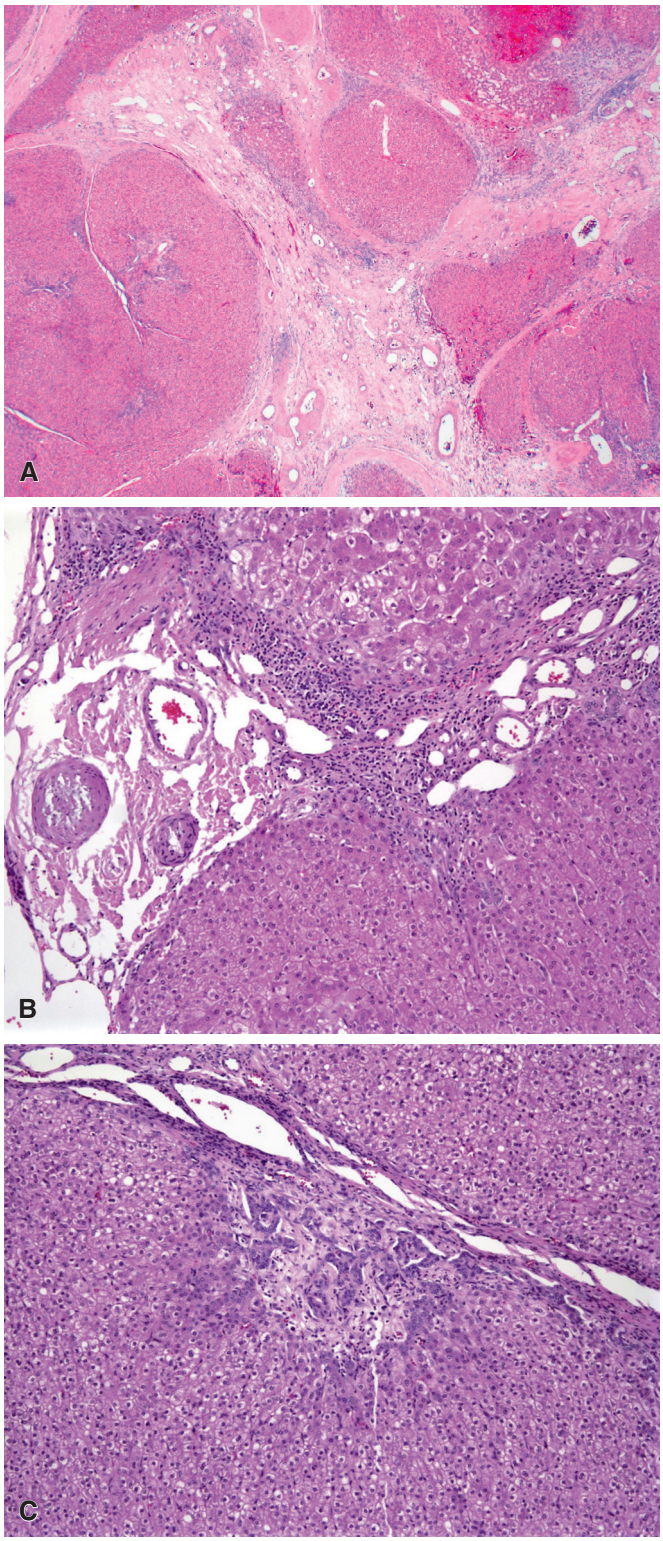

Figure 20.3 **A,** Central portion of focal nodular hyperplasia showing the interface between the fibrous scar and the nodules. Vessels within the scar are often prominent **(B)**, and may be thick-walled. **C,** Patchy ductular reaction is common, particularly at the interface between fibrous septa and liver parenchyma.

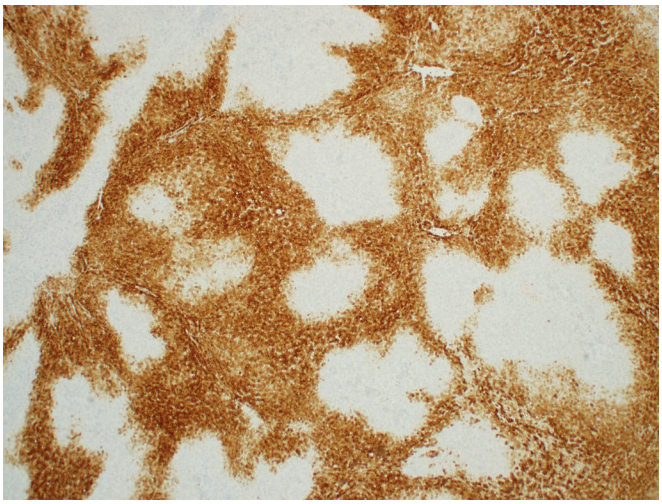

Figure 20.4 Map-like pattern of immunoreactivity with glutamine synthetase in focal nodular hyperplasia. (Courtesy of Dr. Sanjay Kakar.)

FNH typically shows a map-like staining pattern with glutamine synthetase (GS) (Fig. 20.4), which may help to distinguish them from hepatocellular adenoma. CK7, CK19, and neuronal cell adhesion molecule may be used to highlight the ductular reaction.[30] Immunostains for estrogen hormone receptors have yielded mixed results.[31–32]

The differential diagnosis of FNH includes—at both the clinical, radiographic, and histologic level—hepatocellular adenoma, well-differentiated hepatocellular carcinoma (HCC), and cirrhosis; the latter is a particular problem on needle biopsy, and knowledge of the state of the background liver (cirrhotic vs. noncirrhotic) is invaluable in this instance. The lack of a fibrous scar may also be challenging, although often the presence of nodularity, ductular reaction, dysmorphic vessels, and/or a poorly formed fibrous scar may aid in diagnosis.[33] Reticulin stain is useful in distinguishing between FNH and HCC, in that FNH has no loss of reticulin, and immunohistochemistry may aid in distinguishing FNH from hepatocellular adenomas. A summary of the histologic and immunohistochemical differences between FNH and liver cell adenoma is given in Table 20.1. This distinction is clinically important, as asymptomatic FNH may be followed, but hepatocellular adenomas (particularly those with β-catenin mutations, as discussed later) are more likely to be resected or ablated.

Hepatocellular Adenoma

True adenomas of the liver are rare. They have a striking predilection for females and are pathogenetically related to the use of oral contraceptives,[34,35] a fact supported by their occasional total regression following discontinuation of the hormones.[36] These neoplasms have also been reported following anabolic–androgenic steroid therapy,[37] following long-term carbamazepine therapy,[38] in association with glycogen storage diseases and other genetically determined diseases,[39–42] and in children with sex hormone disturbances.[43] When compared with FNH, the adenomas are more often symptomatic and can lead to severe and even fatal intraperitoneal hemorrhage.[44] Most of the patients are in the third to fifth decades of life, but cases have also been reported in children.[45–46]

Hepatocellular adenomas (HA) arise in noncirrhotic livers, and approximately 70% of the lesions are solitary.[47] They can occur anywhere in the liver but are usually located in the right lobe. Adenomas are usually visualized as defects on ^{99m}technetium–sulfur colloid liver scans and may also have characteristic CT and MRI findings;

Table 20.1 Summary of histologic and immunohistochemical features of focal nodular hyperplasia and hepatic adenomas

FEATURE	FOCAL NODULAR HYPERPLASIA	LIVER CELL ADENOMA
Capsule	No capsule	Well demarcated but unencapsulated
Stellate scar	Typically present	Absent
Parenchyma	Nodular	Homogeneous
Hemorrhage, necrosis	Rare	Common
Ductular reaction	Present	Absent
Vascularity	Large thick-walled vessels	Thin-walled sinusoids Telangiectasia, dysmorphic vessels (inflammatory HA)
Background liver	Noncirrhotic	Noncirrhotic
Cytologic atypia	Rare	Can be present
Acinar change	Typically absent	May be focally present
Reticulin framework	Intact	Intact overall
Glutamine synthetase	Positive, map-like pattern	Positive in β-catenin activated HA only
β-Catenin	Negative	Positive in β-catenin activated HA
LFABP	Positive	Negative in HNF1α inactivated HA
Glypican 3	Negative	Negative
SAA/CRP	Negative	Positive in inflammatory HA

LFABP, Liver fatty acid–binding protein.
Adapted from Bioulac-Sage P, Cubel G, Balabaud C, Zucman-Rossi J. Revisiting the pathology of resected benign hepatocellular nodules using new immunohistochemical markers. *Sem Liv Dis*. 2011;31(1):91–103.

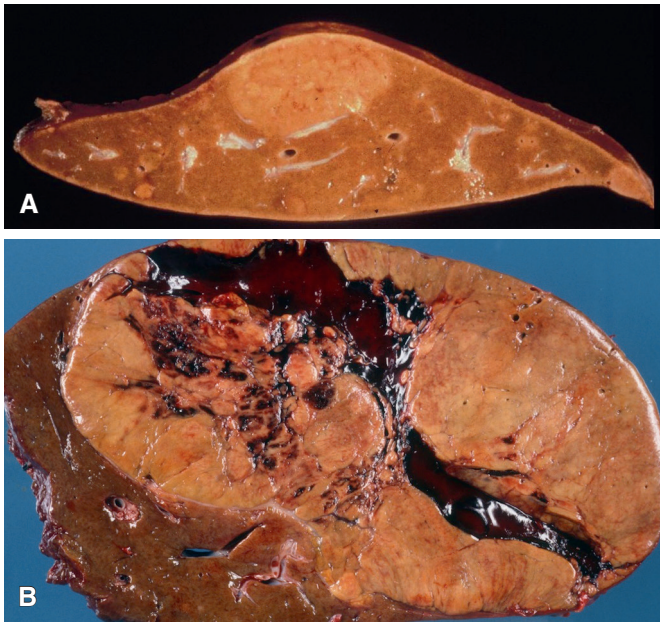

Figure 20.5 **A,** Well-demarcated hepatocellular adenoma but without a well-defined capsule. It is paler than the surrounding liver. **B,** This case has a large central area of recent rupture and hemorrhage. (Courtesy of Dr. George F. Gray Jr.)

however, many adenomas do exhibit typical radiographic features, and thus biopsy may be required for diagnosis.[47] Grossly, they are well demarcated but usually unencapsulated and are more pale and yellow than the surrounding liver. The typical central scar of FNH is absent (Fig. 20.5A and B).

Advances in molecular biology have resulted in the classification of hepatic adenomas into four major groups, based on both genotypic and phenotypic characteristics.[48,49] Adenomas with hepatocyte nuclear factor 1α *(HNF1α)* mutations account for 30%–50% of cases and are characterized by biallelic inactivating mutations of the *HNF1α* gene (both somatic, or one germline and one somatic).[50] These tumors are associated with steatosis, insulin resistance, and absence of liver fatty acid–binding protein (LFABP) expression by immunohistochemistry (as compared with positive staining in normal liver); they may be single or multiple.[47,48,51] Microscopically, adenomas with *HNF1α* mutations are diffusely steatotic, with numerous thin-walled vessels (Fig. 20.6A). The reticulin framework should be intact, and inflammation and nuclear atypia are absent.

The second group are those with *CTNNB1* mutations, accounting for 10%–15% of cases.[49,52] These are the most highly correlated with malignant transformation, and they are associated with male gender, androgen use, and glycogenesis. Immunohistochemically, they overexpress GS, and show nuclear positivity with β-catenin staining (see Fig. 20.6B), although it may be very focal. Microscopically, the features are nonspecific (see Fig. 20.6C), but mild cellular atypia and focal rosette formation can be seen. They typically do not have steatosis.[51]

The third group is known as inflammatory or telangiectatic adenomas, which were previously thought to represent a variant of FNH.[53] They are the most common, comprising 40%–50% of adenomas. These tumors are associated with increased BMI and occasionally present with fever and clinical signs of inflammation; these are also the type most commonly seen in men.[51] Histologically, they have characteristic inflammation, sinusoidal dilatation, and dystrophic vessels (see Fig. 20.6D and E), and they express serum amyloid A and C-reactive protein by immunohistochemistry. LFABP is normally expressed. From a molecular standpoint, they lack *HNF1α* mutations, but 10% harbor *CTNNB1* mutations, and thus are at risk for malignant transformation. The fourth group (<10%), known as unclassified adenomas, lacks specific molecular and phenotypic features.

Other features occasionally seen in hepatocellular adenomas include oncocytic changes,[54] presence of Mallory hyaline,[55] and pigmentation.[56] An associated granulomatous reaction can also be seen with hepatic adenoma, and the granulomas may be within or outside of the tumor.[57] In addition to the immunohistochemical features discussed previously, estrogen and progesterone receptors are present in about 75% of hepatic adenomas, whereas androgen receptors are expressed in only 20% of cases.[58]

The risk of malignant transformation in adenomas is approximately 5%, and risk factors include male gender, size, and adenoma subtype (see earlier).[36] Multiple sections and reticulin stains should

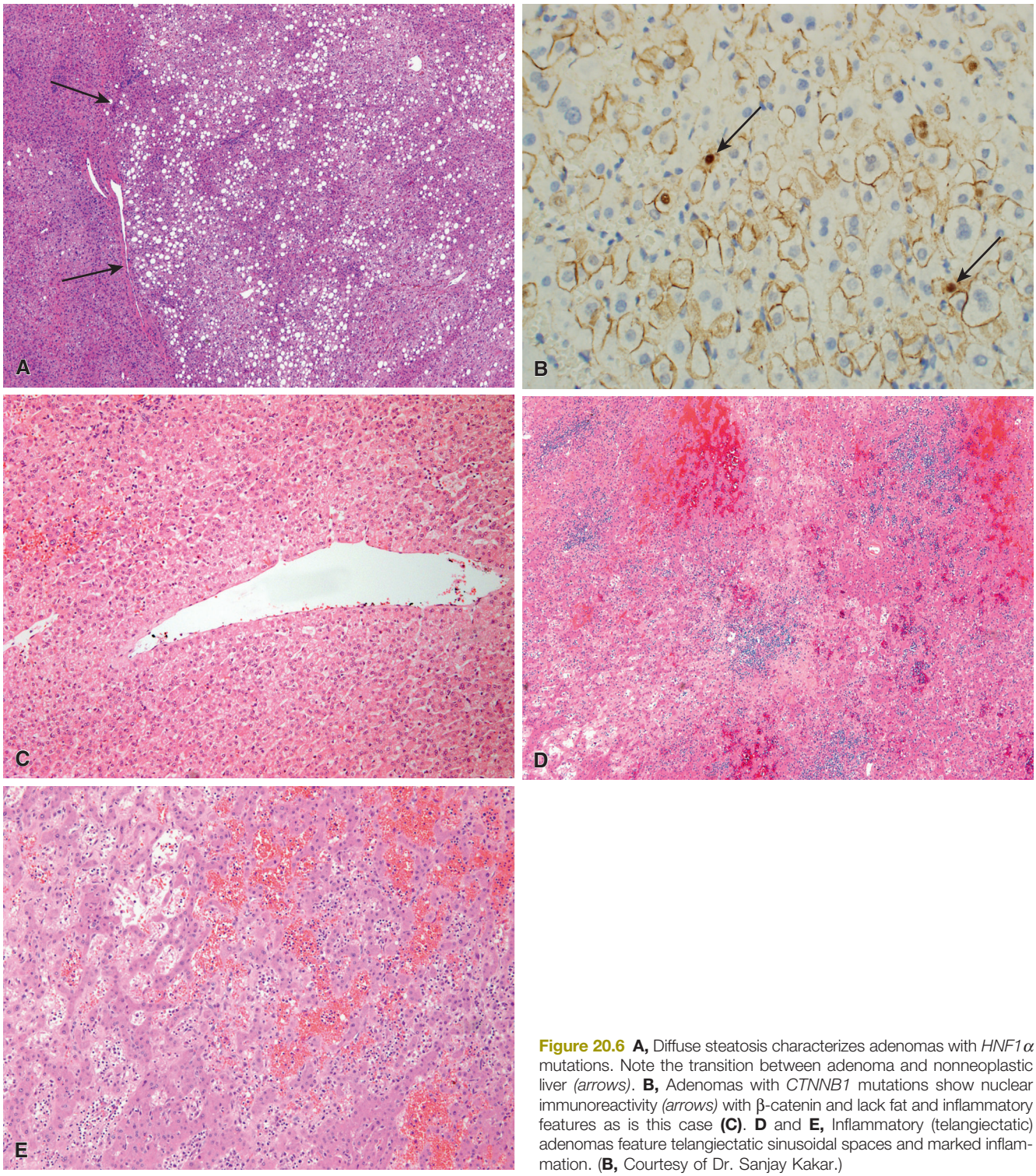

Figure 20.6 **A,** Diffuse steatosis characterizes adenomas with *HNF1α* mutations. Note the transition between adenoma and nonneoplastic liver *(arrows)*. **B,** Adenomas with *CTNNB1* mutations show nuclear immunoreactivity *(arrows)* with β-catenin and lack fat and inflammatory features as is this case **(C)**. **D** and **E,** Inflammatory (telangiectatic) adenomas feature telangiectatic sinusoidal spaces and marked inflammation. (**B,** Courtesy of Dr. Sanjay Kakar.)

be carefully evaluated in these tumors in order to rule out a well-differentiated HCC. The distinction between hepatocellular adenoma and well-differentiated carcinoma may be extremely difficult, however. Recent studies have suggested that GS and heat-shock protein 70 (HSP70) may be useful in this scenario, as these markers are more likely to be positive in cases of well-differentiated malignancy,[59] but the usefulness of this remains controversial.[60] Occasionally, an unequivocal and distinct focus of hepatocellular carcinoma is seen arising within an hepatic adenoma, indicating that these tumors do have a potential for malignant transformation.[61,62] In rare instances, coexistence of adenoma and carcinoma in the same liver have been described.[63]

Reportedly one third of patients with hepatic adenomas have multiple tumors, most commonly associated with the HNF1α subtype.[36] When 10 or more tumors are present, this condition is referred to as *liver cell adenomatosis*. A proportion of cases are familial, due to germline mutations in the *(TCF1/HNF1α)* gene, which also causes maturity-onset diabetes of the young type 3 (MODY3).[64,65]

Regenerative and Dysplastic Nodules

Advances in imaging have made it possible to detect increasingly smaller lesions in cirrhotic patients, which are often biopsied to exclude HCC. The terminology used for these lesions has historically been inconsistent and confusing and has included terms such as ordinary and atypical adenomatous hyperplasia, minimal deviation hepatoma, paraplasia, large regenerative nodule, types I and II macroregenerative nodule, adenomatous hyperplasia, and low-grade dysplastic nodule. In a laudable attempt to standardize the diagnostic criteria and terminology for these lesions, a multinational panel of liver pathologists has proposed the following classification, which has been generally accepted by experienced hepatopathologists.[66]

Regenerative nodules (also known as large regenerative nodules, macroregenerative nodules, adenomatous hyperplasia, and low-grade dysplastic nodules) are greater than 1.0 cm, with normal architecture and intact reticulin framework (Fig. 20.7). The majority of regenerative nodules are probably not premalignant, and, like the rest of a cirrhotic liver, they may contain iron, fat, bile, Mallory hyaline, or large cell change but should not feature small cell change (see later). There are no histologic criteria to distinguish a non-clonal regenerative nodule from a nodule with low-grade dysplasia, as clonality is assessed via molecular means and the likelihood of progression to malignancy is unclear. For these reasons, most pathologists avoid this term.

High-grade dysplastic nodules (HGDNs, also known as borderline nodules or atypical adenomatous hyperplasia) have both architectural and cytologic atypia, and are believed to be precursors of HCC. They may contain a number of abnormalities, including thickening of cell plates up to three cells thick, focal acinar formation, and occasional unpaired arterioles (Fig. 20.8). Small cell change is often present as well (see later). HGDN may contain fat, bile, and Mallory hyaline, as in regenerative nodules, but iron is often absent. Reticulin should be intact or only focally decreased. Both regenerative nodules and HGDNs may differ in color from the surrounding liver and may protrude out from the cut surface.

There are two types of liver cell dysplasia. *Large cell change* is defined by both nuclear and cytoplasmic enlargement (i.e. preserved N:C ratio), nuclear pleomorphism, nuclear hyperchromasia, and occasional multinucleated hepatocytes (Fig. 20.9).[67] Large cell change can be seen throughout a cirrhotic liver, including within regenerative nodules and HGDNs, and the biologic significance remains unelucidated.[68] However, the presence of large cell change in cirrhotic livers due to hepatitis B has been reported as an independent risk factor for the development of HCC.[69,70] *Small cell change* is characterized by a decreased volume of hepatocytic cytoplasm associated with moderately enlarged nuclear size, resulting in an increased nucleocytoplasmic ratio and low-power appearance of increased nuclear density (Fig. 20.10).[67] Small cell change is considered to be a premalignant lesion, based on its proliferative activity, molecular characteristics, and presence within both HGDN and HCCs.[71] Both large cell change and small cell change should be noted in the pathology report.

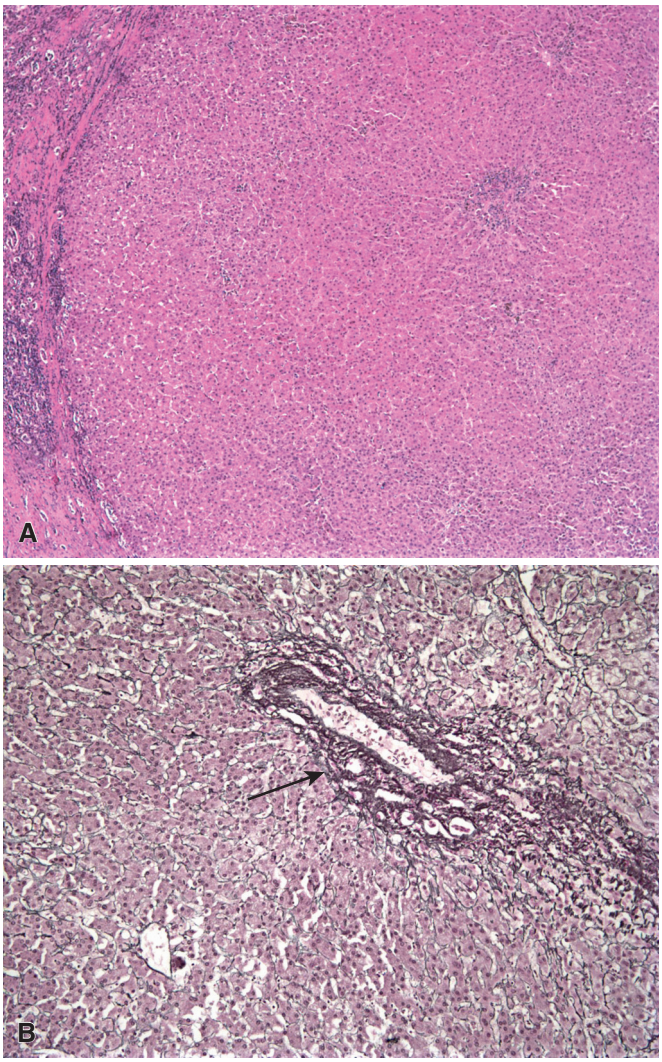

Figure 20.7 **A,** Regenerative nodule within a cirrhotic liver. **B,** The reticulin framework is intact, and there is a portal tract within the nodule *(arrow)*.

Hepatocellular Carcinoma

General and Clinical Features

HCC (also known as liver cell carcinoma, and previously termed hepatocarcinoma or hepatoma) is the sixth most common malignancy worldwide and the second most common cause of cancer-associated death.[72] Historically, it has been relatively rare in the United States,

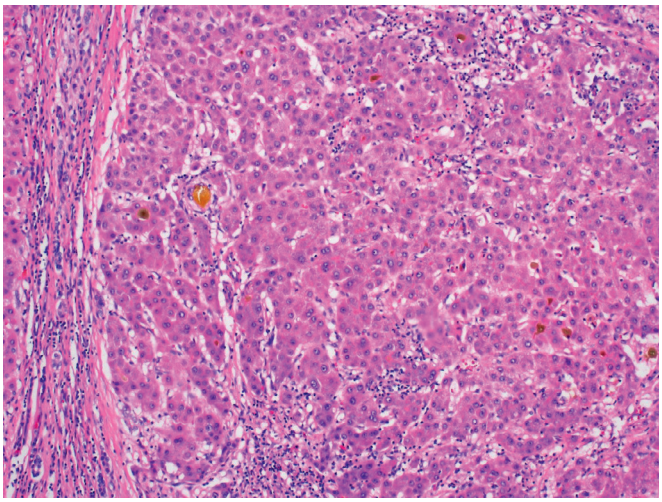

Figure 20.8 High-grade dysplastic nodule showing focal thickening of cell paltes, bile, and focal acinar architecture. Reticulin stain was intact.

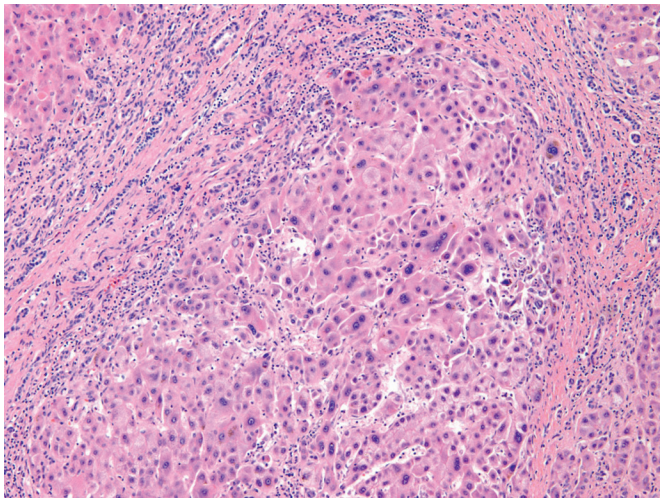

Figure 20.9 Large cell change within a cirrhotic liver, featuring nuclear and cytoplasmic enlargement, nuclear pleomorphism and hyperchromasia, and multinucleated hepatocytes.

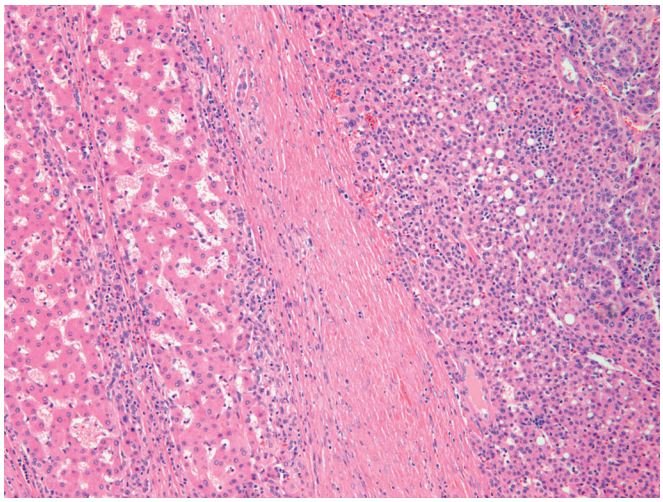

Figure 20.10 Small cell change, indicated by increased nuclear density, is seen in the right half of the picture; cirrhotic liver with hepatocytes of normal size is seen on the left.

but during the past two decades the incidence has tripled secondary to the hepatitis C epidemic.[73] The highest incidence is still in regions with endemic hepatitis B infection, such as Southeast Asia and Subsaharan Africa[73]; China alone accounts for over half of the world's cases of HCC.[74] Most cases are seen in patients older than 40 years, with a peak at 70 years of age,[73] but this tumor can also occur in younger individuals and even in children.[75–78] Some cases have even occurred as second malignancies in successfully treated Wilms tumor patients.[79] Currently, the greatest increase in HCC is among Caucasians and Hispanics between 45 and 60 years of age.[73]

HCC is 2–4 times more common in males than in females.[73] It usually presents with anorexia, malaise, abdominal pain, ascites, and liver enlargement.[80] Obstructive jaundice may result from tumor invasion into the common bile duct.[81] HCC has also been associated with numerous systemic manifestations such as hypoglycemia, hypercholesterolemia, erythrocytosis, hypercalcemia, carcinoid syndrome, ectopic production of chorionic gonadotropin and prostaglandin, and dysfibrinogenemia, and several others.[82–86]

Serum elevation of alpha-fetoprotein (AFP) occurs in a majority of patients with HCC, but up to 40% of HCC patients have normal AFP levels, particularly when tumors are small.[87] Elevated serum AFP can also be seen with malignant germ cell tumors, liver metastases, liver trauma, cirrhosis, chronic hepatitis, and cholangiocarcinoma. For these reasons, recent studies have argued that AFP is not an effective screening or surveillance tool for HCC.[87]

Predisposing and Associated Factors

The major risk factors for HCC include the hepatotropic viruses hepatitis B virus (HBV) and hepatitis C virus (HCV), alcoholic liver disease, and probably non-alcoholic fatty liver disease (NAFLD).[72–74,88]

The majority of the risk factors for HCC result in cirrhosis, which is present in over 80% of patients with HCC.[73] Patients with cirrhosis have an estimated 5-year cumulative risk of developing HCC of 5%–30%, depending on the underlying risk factor, geographic area, and ethnicity of the patient.[73]

Hepatotropic Viruses

Hepatitis B infection is associated with approximately half of the cases of HCC in the world and virtually all childhood cases.[73] Although both hepatitis B and hepatitis C can cause HCC in the absence of cirrhosis, the vast majority of patients with hepatotropic virus-related HCC have cirrhosis.[73] Patients with chronic HBV have a 5–15-fold increased risk of developing HCC, whereas the increased risk for patients with HCV is 15–20 times that of the general population.[73,74] The risk of developing HCC in patients with chronic HBV is further increased in men, elderly patients, and those of Asian or African race; with exposure to aflatoxin; with alcohol and tobacco use; if there is coinfection with HCV or the delta virus; with high levels of HBV DNA, positivity for hepatitis B e antigen (HBeAg), or infection with HBV genotype C; and with increasing length of time of infection.[73,74,89] Similar factors are associated with increased risk of HCC in patients with chronic HCV infection, including older age, male gender, metabolic syndrome, and alcohol use.[73,74]

Integration of hepatitis virus DNA into host genomic DNA is believed to be an early event in the development of HBV-associated HCC.[90] HBV DNA integration induces both genomic instability and mutagenesis of several cancer-related genes. A major role is also played by the HBV-associated protein HBx, which stimulates virus gene expression and replication, and also activates a number of cell cycle pathways that are critical to hepatocyte growth and survival.[90,91] HBV DNA is detectable in patients who are HBsAg negative, but the risk of progression to HCC is unclear in these individuals.[92] The role of the hepatitis C virus in the development of HCC remains less well elucidated, but animal studies have indicated that the core protein of HCV appears to have oncogenic potential.[93]

Alcohol Use

Heavy alcohol intake is a well-established risk factor for the development of HCC, although the direct carcinogenic effect of alcohol remains unproven and there is also evidence of a synergistic effect of heavy alcohol use and HBV or HCV infection.[74,88] The overall risk of developing HCC in the context of alcoholic cirrhosis is estimated at 15%.[88]

Non-Alcoholic Fatty Liver Disease

There is a growing body of evidence that NAFLD is associated with the development of HCC, even in the absence of cirrhosis,[94] and that the annual incidence of NAFLD-associated HCC in the United States increased by almost 10% between 2004 and 2009.[95] The prevalence of HCC in the context of NAFLD is expected to rise as more and more adults develop this disease worldwide, given the

increasing rates of obesity, diabetes, and dyslipidemia. HCC in this context is also associated with a higher mortality rate.[95]

A number of drugs and toxins are associated with the development of HCC. *Thorium dioxide* suspension (Thorotrast), a radiographic contrast medium, has resulted in the development of many liver cell carcinomas, the average latent period being 20 years.[96] The geographic distribution of HCC has also suggested a relationship with the ingestion of aflatoxins, which are metabolic products of the ubiquitous fungus *Aspergillus flavus*[97]; contamination of food with aflatoxins remains a serious problem in parts of the world where the incidence of HCC is highest. Although the exact mechanism remains to be elucidated, it is known that aflatoxin B1 induces p53 mutations and may act synergistically with HBV to contribute to carcinogenesis.[98] Rare cases of HCC have been reported in males in association with long-term administration of androgenic–anabolic steroids.[88,99,100] Data on a potential association between oral contraceptive pills and HCC remain controversial. Although some studies have shown an increased risk of HCC in women with long-term oral contraceptive use (>5 years),[101] the studies are generally small, and more recent studies have shown no definite evidence of an increased risk.[102] There is also little information regarding the risk in patients who are taking newer generation, low-dose contraceptive pills.[74]

A number of metabolic disorders are risk factors for HCC as well.[88] *Tyrosinemia* type 1 is associated with a high incidence of liver cell carcinoma, usually in a background of cirrhosis.[103] In one series, 37% of patients surviving beyond 2 years of age developed this malignancy in childhood.[104,105] Cases of HCC associated with *α1-antitrypsin deficiency* have also been reported.[105,106,107] Patients with the PiZ variant of antitrypsin deficiency seem to be particularly prone to this complication and also to the development of cholangiocarcinoma.[108]

Other hereditary disorders associated with HCC include *ataxia–telangiectasia*;[109] *glycogen storage disease*, particularly type 1a;[105,110] *hereditary hemochromatosis*, in which the risk of HCC is approximately 20 times higher than in the general population[105,111]; and porphyria.[105] Cases of HCC have also been reported following the Kasai procedure in patients with biliary atresia,[112] in association with familial cholestatic cirrhosis of childhood,[113,114] and with congenital hepatic fibrosis associated with adult polycystic kidneys.[115]

Gross Features

Grossly, HCC may present as a single mass, multiple nodules, or as diffuse liver involvement, simulating cirrhosis (Fig. 20.11A–C).[116,117] Some lesions are poorly circumscribed, whereas others are surrounded by a grossly distinct capsule.[118,119] In rare cases, the tumor is pedunculated, presumably because it arises in an accessory lobe.[120,121] Tumor size varies a great deal from case to case. In recent years, progress in radiographic procedures has led to the detection of an increased number of small (<2.0 cm) HCC; however, it can be difficult to distinguish these small HCC from regenerative or HGDNs on imaging studies. Portal vein thrombosis (including thrombosis with tumor) is found in a high proportion of advanced cases and may be the presenting sign of an otherwise undetected HCC.[122]

Figure 20.11 **A,** Poorly encapsulated hepatocellular carcinoma consisting of two dominant nodules with multiple smaller satellite nodules, arising in a background of cirrhosis. **B,** Well-circumscribed, solitary mass with foci of hemorrhage and necrosis. **C,** Hepatocellular carcinoma with central necrosis and bile staining, arising in a patient with hereditary hemochromatosis. A satellite nodule is present some distance from the main tumor mass *(arrow)*. (**A** and **C,** Courtesy of Dr. George F. Gray Jr.)

Microscopic Features

Microscopically, the pattern of growth of HCC may be trabecular, solid, or pseudoglandular[123] (Fig. 20.12A–C), and multiple growth patterns are often present within the same tumor. The latter, which has also been referred to as acinar, may result in glands and papillary-like formations that can lead to diagnostic confusion with bile duct carcinoma.[124] Unpaired arteries may be prominent, and endothelial cells may peripherally "wrap" nests of tumor cells.[125] A feature of great diagnostic significance is the thickness of the trabeculae, as estimated in the H&E sections but better evaluated on reticulin stain; the hepatocytic plates are typically more than three cells wide in HCC.[123] The stroma is usually scant, in contrast to that of cholangiocarcinoma, with the exception of the sclerosing or "scirrhous" form (see later). Invasion of portal venules is a frequent finding. Cytologically, there is a wide range of differentiation (Fig. 20.13A–B).

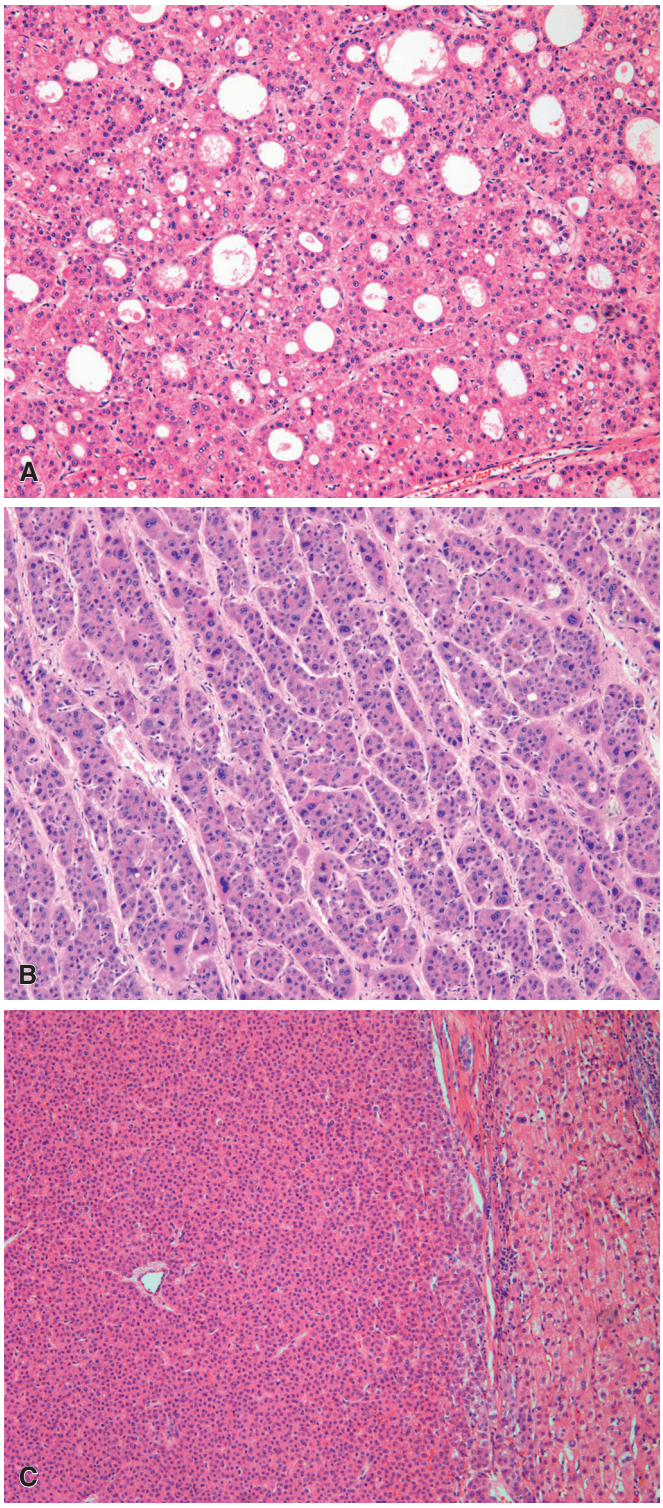

Figure 20.12 Typical growth patterns in hepatocellular carcinoma include pseudoglandular **(A),** trabecular **(B),** and solid **(C)**. Note the diffuse small cell change in **(C),** as compared with the cirrhotic liver on the right.

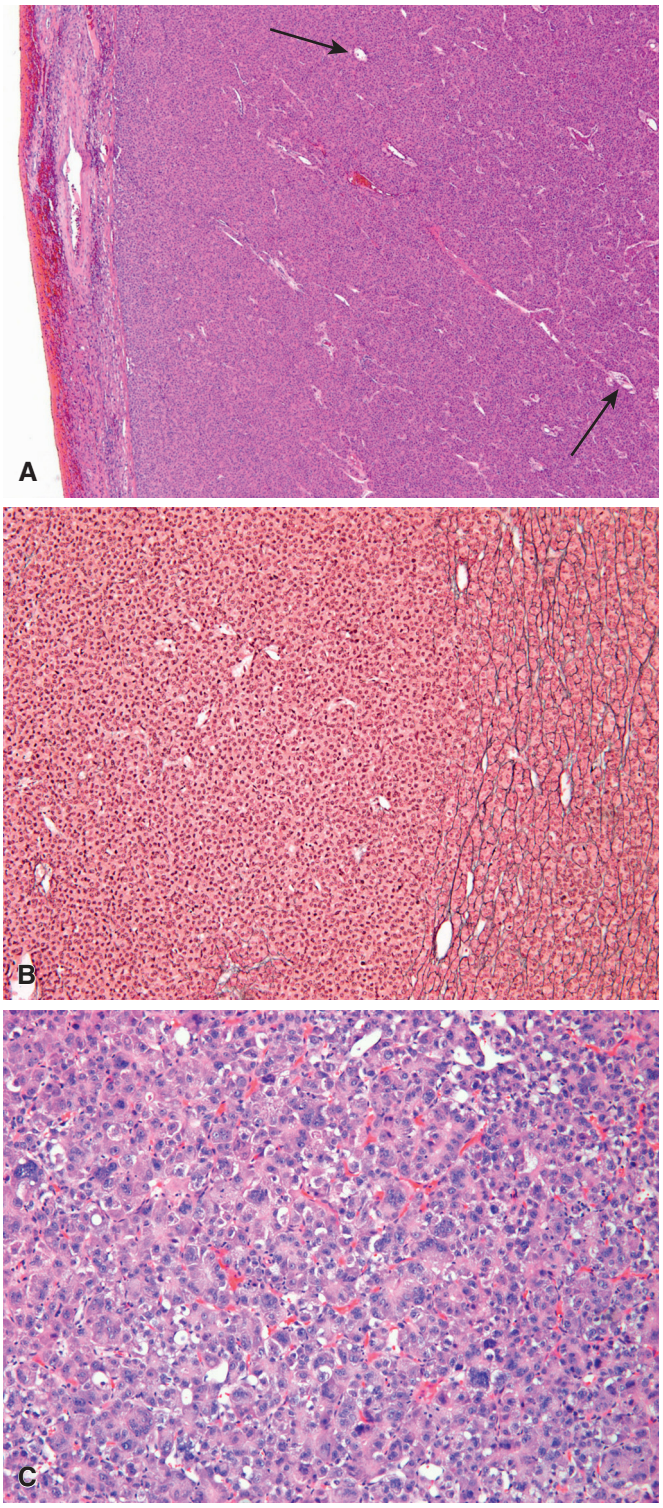

Figure 20.13 **A,** Very well-differentiated HCC with numerous unpaired vessels *(arrows)*. Note the lack of portal tracts within the tumor. **B,** Loss of the normal reticulin framework helps to make the diagnosis; compare with the cirrhotic liver with intact reticulin framework on the right. **C,** Poorly differentiated hepatocellular carcinoma that is difficult to recognize as such without stains.

More poorly differentiated cases may show great pleomorphism, bizarre mitotic figures, and tumor giant cells; nuclei and nucleoli are often prominent (Fig. 20.13C).[123] It may be difficult to identify these tumors with certainty as HCC without immunostains. Conversely, well-differentiated tumors are easily recognized as being composed of hepatocytes but may be difficult to categorize as malignant. Reticulin stain may be particularly helpful in this circumstance, as either loss of normal reticulin framework or reticulin highlighting of abnormal architecture may help to make the diagnosis of well-differentiated HCC (see Fig. 20.13B).[123,126] Tumor cells may exhibit intranuclear pseudoinclusions caused by cytoplasmic invaginations.[127]

The cytoplasm of the tumor cells may contain Mallory hyaline similar to that seen in alcoholic liver disease,[123] round hyaline globules (Fig. 20.14A),[128] copper,[129] "pale bodies" (seen ultrastructurally as a membrane-bound mass of granular or fibrillary material that is immunoreactive for fibrinogen),[130] ground-glass cells,[131] or bile (see Fig. 20.14B)[123]; the latter is an important diagnostic feature. The hyaline globules have been said to contain AFP and α1-antitrypsin,[128] but the interesting observation has been made that their major constituent is p62, a phosphotyrosine-independent ligand of p561ck kinase.[132] In one remarkable case, the tumor was black because of the accumulation of a Dubin–Johnson-like pigment.[133] Steatosis has long been recognized as a feature of HCC, and recently the steatotic variant of HCC has been described (Fig. 20.15), which is associated with underlying fatty liver disease, metabolic syndrome, and late tumor relapse.[134]

The concepts of "small" and "early" HCCs have received a great deal of attention in the recent literature because of the difficulty in distinguishing these lesions from a HGDN, particularly on needle biopsy. "Small HCC" is defined as a tumor measuring less than 2.0 cm. Small HCC can be further subdivided into early HCC, as described later, and progressed HCC, which are distinctly nodular, often encapsulated, and have thickened hepatic plates, and thus are typically easier to diagnose.[135-137] "Early HCC" (also known as vaguely nodular HCC or very well-differentiated HCC) is defined as a nodule with poorly defined margins, and a combination of histologic features including small cell change, intratumoral portal tracts, pseudoglandular architecture, diffuse steatosis, and/or unpaired arteries.[135-137] Stromal invasion (invasion of abnormal hepatocytes into portal tracts, fibrous septa, or adjacent non-neoplastic parenchyma) is the most reliable criterion of malignancy in this circumstance but may be difficult to appreciate on a needle biopsy (Fig. 20.16). The lack of a CK7+ ductular reaction at the periphery of a nodule can also

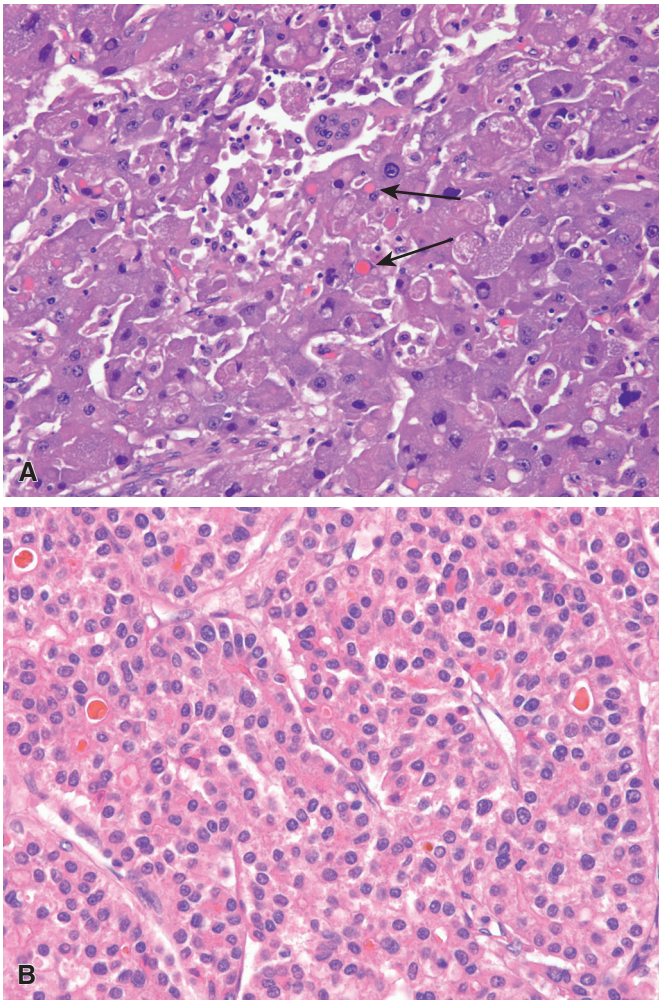

Figure 20.14 The tumor cells of hepatocellular carcinoma may contain hyaline globules (**A,** *arrows*) or bile **(B)**.

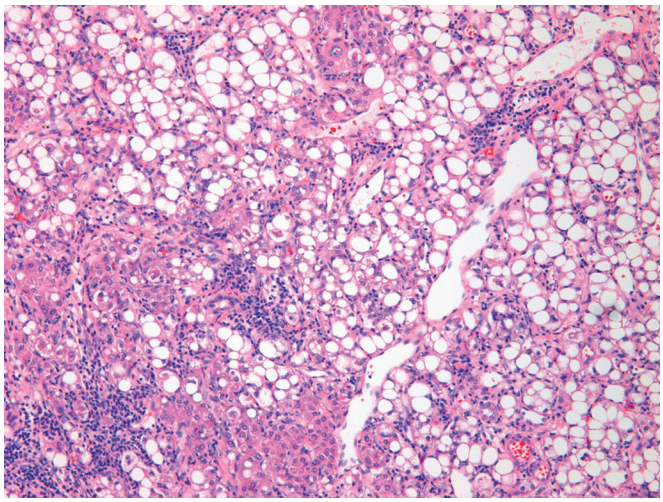

Figure 20.15 Steatotic hepatocellular carcinoma with hepatocyte ballooning, Mallory hyaline, and abundant fat.

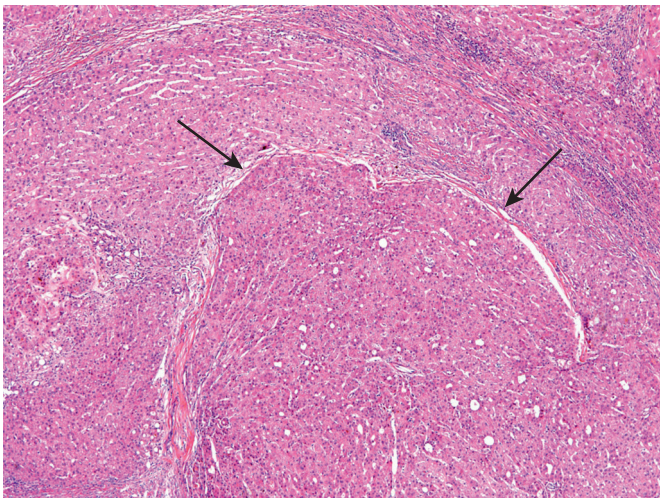

Figure 20.16 Focal parenchymal invasion *(arrows)* of an adjacent regenerative nodule by an early well-differentiated hepatocellular carcinoma.

help to make the diagnosis of malignancy.[136,138] GS, HSP70, and glypican-3 are also more likely to be positive in early HCC, and it is especially helpful if two of the three are positive.[135,136,139]

Immunohistochemical Features

Hep Par-1 (also known as hepatocyte-specific antibody, or HSA) is a monoclonal antibody that is believed to react with urea cycle enzyme carbamoyl phosphate synthetase 1 (CPS1), a rate-limiting enzyme in the urea cycle that is present in hepatocyte mitochondria.[140,141] Because of its good (although not absolute) specificity, it has become one of the most reliable markers of hepatocytic differentiation (Fig. 20.17A).[142–144] Unfortunately, it does not stain most poorly differentiated or sclerosing HCC; in addition, staining may be patchy within the tumor and thus not present on a small needle biopsy sample.[145] Adenocarcinomas of the lung, stomach, and esophagus may also have strong positive reactions, and as expected, it also stains hepatoid adenocarcinomas of the gastrointestinal tract and pancreatobiliary tract.[146,147]

Another more recently available marker that shows a high sensitivity and specificity for benign and malignant hepatocytes is arginase-1, a metalloprotein that catalyzes the hydrolysis of arginine to ornithine and urea.[148] The overall sensitivity of arginase-1 is 96% (compared with 84% for Hep Par-1) and is particularly better in poorly differentiated HCC (86% as compared with 47%). Furthermore, the specificity is extremely high, with only rare cases of non-HCC reportedly showing immunoreactivity.[149]

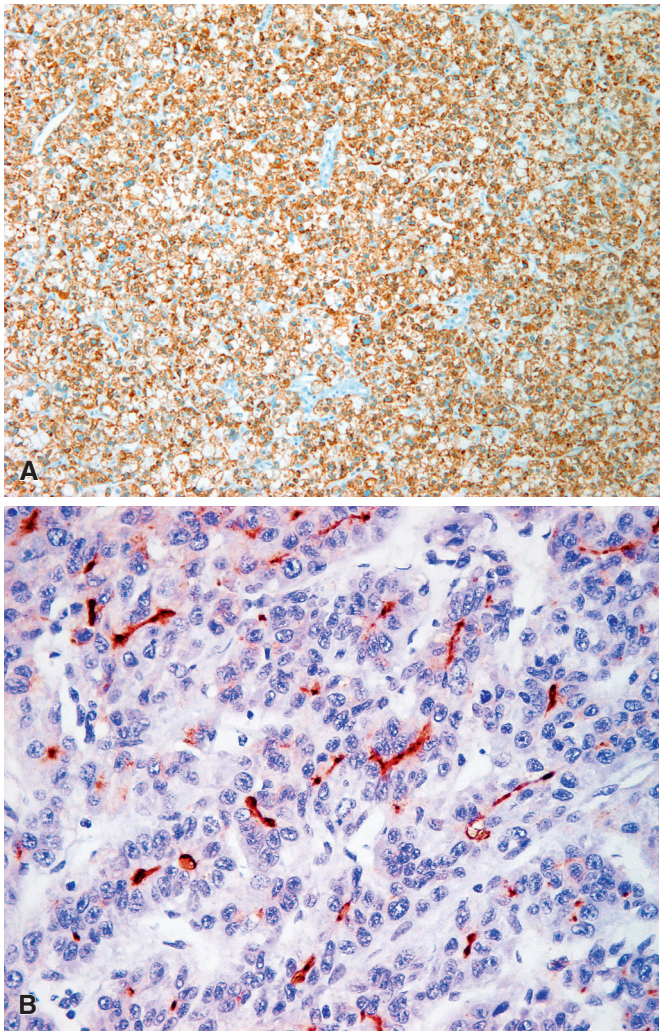

Figure 20.17 **A,** Diffuse cytoplasmic granular positivity with Hep Par-1 in hepatocellular carcinoma. This particular case had clear cell features, and the Hep Par-1 helped to confirm the diagnosis. **B,** Polyclonal CEA (pCEA) canalicular staining in a hepatocellular carcinoma.

Glypican-3 is another more recent marker that has been added to the hepatocellular phenotype armamentarium. It is a member of the heparin sulfate proteoglycans family and plays a role in cell growth, differentiation, and migration.[150,151] Its positivity is cytoplasmic, membranous, and canalicular. It stains most (~80%–90%) of HCCs and is more likely to be positive in HCC arising in cirrhotic livers.[152] It also stains HGDN and occasionally cirrhotic nodules but not normal liver, FNH, or hepatic adenoma.[152,153] In addition, the sensitivity is lower in the fibrolamellar variant of HCC.[152] Unfortunately, it also stains yolk sac tumor, Wilms tumor, rhabdomyosarcoma, undifferentiated embryonal sarcoma, mesenchymal hamartoma, and a subset of hepatoblastomas,[154–156] as well as a number of metastatic tumors that can be encountered in the liver, such as melanoma, squamous cell carcinoma of the lung, and adrenal cortical carcinoma.[157]

Glutamine synthetase (GS) is an enzyme that plays a key role in nitrogen metabolism and is expressed in a number of hepatocellular lesions as well as focally in normal liver (see previous sections on FNH and hepatic adenoma). As noted previously, GS also stains a significant number (13%–70%) of early HCC, as well as a subset (10%–15%) of HGDNs, although the immunoreactivity in the latter is typically focal.[136]

An important diagnostic feature of HCC is the production of bile canalicular structures between the tumor cells. These can be demonstrated in cytologic or histologic preparations of normal and neoplastic liver with a polyclonal antibody for CEA (pCEA),[158,159] which cross reacts with biliary glycoprotein (see Fig. 20.17B). A similar staining pattern may be seen with CD10 (albeit with much lower sensitivity that pCEA) and bile salt export pump.[145,160,161] pCEA may also show cytoplasmic staining in both HCC and adenocarcinomas and may not show well-defined canalicular staining in poorly differentiated HCC.[145]

In contrast to the antibodies discussed previously, MOC-31, a recently described antibody directed against a cell surface glycoprotein, is regularly expressed in cholangiocarcinoma and metastatic adenocarcinoma but only extremely rarely in HCCs.[162,163] A panel consisting of MOC-31 and Hep Par-1 or arginase-1 is sufficient to distinguish the majority of HCC from cholangiocarcinoma and metastatic adenocarcinoma.

Less useful antibodies for the diagnosis of HCC are discussed here briefly. TTF-1, a transcription factor present in the nuclei of thyroid and lung epithelial cells, is often (~70%) expressed in the cytoplasm of the cells of HCC, a curious and unexplained result that seems to be dependent on the clone and antigen retrieval technique used, and which needs further evaluation.[145,164,165] AFP is a relatively specific but rather insensitive (~30%–50%) marker for hepatocellular differentiation.[145] The low sensitivity and the availability of much more sensitive and specific antibodies have rendered AFP much less useful in the diagnosis of HCC. Detection of albumin mRNA by in situ hybridization has proved diagnostically useful, both for HCCs and for extrahepatic hepatoid carcinomas, but is not as widely available as immunohistochemistry for Hep Par-1 and arginase-1.[166,167] On theoretical grounds, albumin itself ought to be an excellent marker of hepatocytic differentiation, as this molecule is selectively produced by liver cells. However, it is present in large amounts in the plasma, thus resulting in a high degree of diffuse tissue staining. Carcinoembryonic antigen (monoclonal CEA) is usually negative or only focally positive (in contrast to pCEA, discussed earlier), an important factor in the differential diagnosis with bile

duct carcinoma and metastatic carcinoma; however, MOC31 is a more sensitive antibody in this circumstance.[168]

CD34 marks the sinusoid-like vasculature in HCC, but similar staining may be encountered in FNH and hepatic adenomas, and better stains are now available for the distinction between HCC and adenocarcinomas.[145]

In regard to the keratins, both normal and neoplastic hepatocytes are typically positive for CK8 and CK18 and negative for CK7, CK20, and CK19. Therefore, most liver cell carcinomas are immunoreactive for CAM 5.2 and 35βH11 (which recognize keratin 8) but not for monoclonal antibody AE1 (which recognizes keratins 10, 14, 15, 16, and 19).[145,169] However, small foci of AE1/AE3-positive cells can be seen in poorly differentiated HCC.[145] This keratin pattern, which recapitulates that of normal hepatocytes,[170,171] is maintained in most HCCs. However, just as reactive or metaplastic hepatocytes can express "bile duct-type" keratins (e.g. CK7),[172] HCC may also show aberrant keratin expression. CK7 is present in a minority (~20%) of cases of HCC, and CK20 may be positive in an even smaller subset (~5%). CK19 may show patchy positivity as well.[145,171,173] We and others have seen several cases of primary neoplasms of the liver otherwise fulfilling all the criteria for this tumor type, in which a wide range of keratin immunoreactivity (including CK7 and/or CK19) was displayed.[174]

HCCs have been found to be immunoreactive for a seemingly endless array of other antibodies, many of which have questionable clinical utility, including epithelial membrane antigen (EMA), α1-antitrypsin,[175] transferrin receptor,[176] ferritin,[177] aromatase (an enzyme that converts androgen into estrogen),[178] integrins VLA-α_1 and VLA-β_1 (as in normal liver tissue),[179] CD15 (an adhesion molecule),[180] insulin-like growth factor II (more so than normal liver),[181] epidermal growth factor receptor,[182] and C-reactive protein.[183] The apparent expression of inhibin by HCC has been shown to be a spurious result due to the presence of endogenous biotin.[184] The cells of liver cell carcinoma have also been found to possess both estrogen and androgen receptors.[185,186]

Molecular Genetic Features

The molecular pathogenesis of HCC is extremely complex and remains incompletely understood. An increasing number of genetic and epigenetic changes are being reported, particularly given recent advances in whole genome sequencing and other techniques. The final common pathway for hepatocarcinogenesis, regardless of underlying etiology, appears to involve chronic hepatocyte damage resulting in cell death and regeneration, which ultimately leads to genetic instability and the initiation of carcinogenesis.

A large number of mutations have been reported in association with HCC, which appear to be further influenced by the underlying etiology.[72,187] Alterations of the *Wnt/β-catenin* pathway are some of the most common in HCC, but the particular mutations vary with HBV or HCV infection status.[72] For example, activating mutations in *CTNNB1* are more common in patients with HCV-associated HCC (30% vs. 10%–15% in patients with chronic HBV infection).[72] Other genes in this pathway, including *APC* and *AXIN1*, may also harbor mutations.[187,188]

TP53 mutations are common in HCC (up to 60% of cases) and are associated with aflatoxin exposure as well as HBV infection.[72,187,189] HCCs associated with HCV are more likely to harbor mutations in the *ARID1A* and *ARID2* genes, which affect chromatin remodeling.[72] Other commonly mutated genes in the pathogenesis of HCC include the *MLL* family of histone methylation writer genes, which may harbor mutations or HBV DNA insertions; genes in the *NFE2L2* oxidative stress pathway; genes involved in activation of the *P13K/AKT/MTOR* and *RAS/RAF* mitogen-activated protein kinase pathways; *JAK1*; and *SALL-4*, which is more strongly associated with Asian patients who have HBV infection.[72,187] Telomerase *(TERT)* promotor mutations, one of the most frequently encountered in HCC (~50%–60%), are found in preneoplastic cirrhotic nodules as well.[187] Gene amplifications, deletions, and translocations are also common in HCC,[188] including the fusion translocation of *DNAJB1* and *PRKACA* that is highly specific for fibrolamellar carcinoma.[190]

A number of epigenetic factors have also been implicated in hepatocellular carcinogenesis. Dysregulated DNA methylation targets multiple genes in HCC, and the genes targeted appear to vary with chronic HBV versus HCV infection.[191] In addition, *CDKN2A* promotor hypermethylation, leading to p16 suppression, is common in HCC.[192] Aberrant expression of microRNAs, groups of tiny RNAs with fundamental roles in the regulation of gene expression, has also been associated with hepatocarcinogenesis.[193]

Based on genetic profiling, a number of molecular classifications of HCC have been proposed in the past.[194,195] Recently, a molecular classification has been proposed that divides HCC into two major groups, termed the "proliferation subclass" and the "nonproliferation subclass."[187,196]

The proliferation subclass comprises about 50% of HCC and has heterogeneous molecular features related to cell proliferation and progression in the cell cycle. Clinically, this subclass is associated with more aggressive behavior, higher serum AFP levels, vascular invasion, and moderately or poor histologic differentiation. The nonproliferation class has molecular features generally resembling normal liver and is dominated by genetic alterations that activate the Wnt/β-catenin pathway. Clinically, tumors in this group are better differentiated histologically, have lower serum AFP levels, and less aggressive behavior. HCV-associated and alcoholic liver disease associated HCC are more common in this class.[187] Unfortunately, the majority of this genetic information has yet to result in targeted therapeutic strategies for treating HCC.

Other Microscopic Types

A number of variant histologic types of HCC have been described, the majority of which have no clinical implications. *Clear cell* HCC comprises about 9% of all malignant hepatocellular neoplasms.[197] The cytoplasmic clearing, which is due to the accumulation of glycogen and/or fat, may result in an appearance closely resembling that of clear cell renal cell carcinoma or adrenal cortical carcinoma (Fig. 20.18).[198-200] The differential diagnosis is facilitated by the performance of special techniques such as immunostaining for Hep Par-1 or arginase-1, PAX-8 (for renal cell carcinoma), and inhibin, MART-1, or SF-1 (for adrenal cortical carcinoma). Of note, ectopic adrenal tissue in the liver, or tumors arising from them, can mimic clear cell HCC as well.[201] As in most other organs (such as lung, thyroid, and breast), clear cell carcinoma is not a distinct entity but rather a clinically inconsequential morphologic variant of one of the major tumor types.[202] The clear cell variant of HCC should not be confused with the more recently described steatotic variant, as described previously, which is associated with fatty liver disease and metabolic syndrome.

Sclerosing or *scirrhous* HCCs comprise less than 5% of HCC and are characterized by marked fibrous stroma, lack of a fibrous capsule, preserved intratumoral portal tracts, and contiguous multinodularity (Fig. 20.19).[203,204] They are much less likely to express Hep Par-1, and more likely to express markers of adenocarcinoma, such as EpCAM, CK19, and CK7, leading to diagnostic confusion. The vast majority do mark with arginase-1 and glypican-3, however. A case has been documented associated with secretion of a parathyroid hormone (PTH)-like protein.[205]

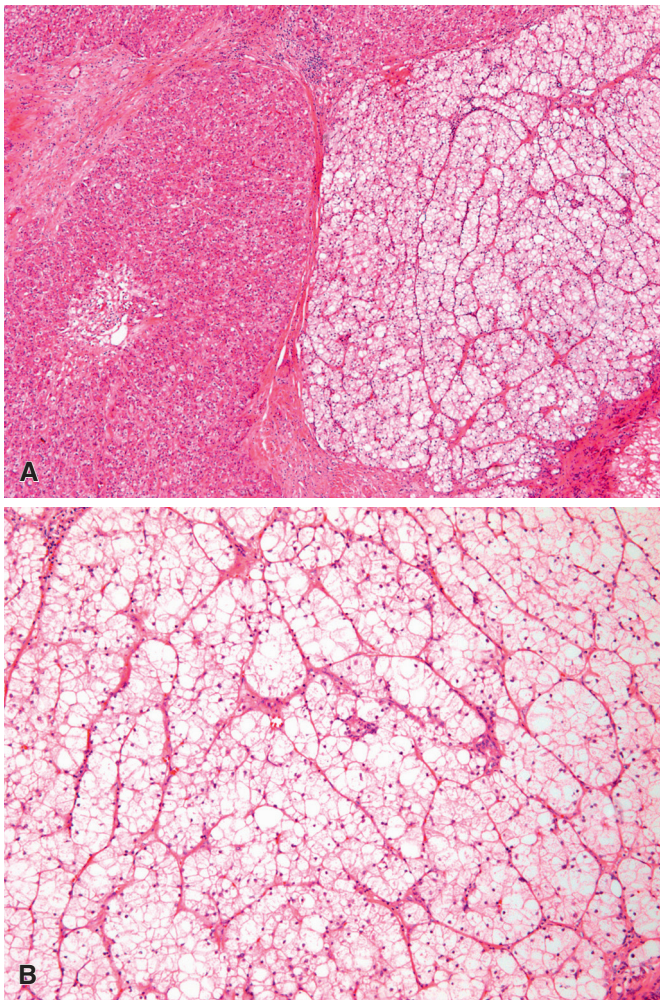

Figure 20.18 **A,** A focus of clear cell hepatocellular carcinoma (HCC) adjacent to conventional-type HCC. **B,** Another case at higher power shows how closely clear cell HCC can mimic metastatic clear cell renal cell carcinoma.

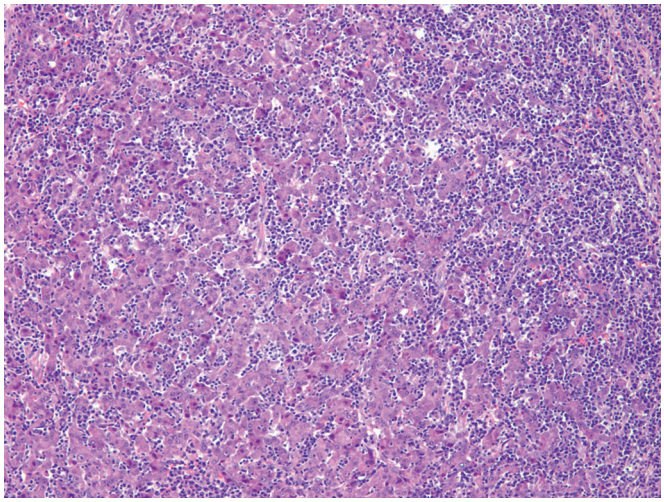

Figure 20.20 Large numbers of tumor-infiltrating lymphocytes are present in lymphoepithelioma-like hepatocellular carcinoma.

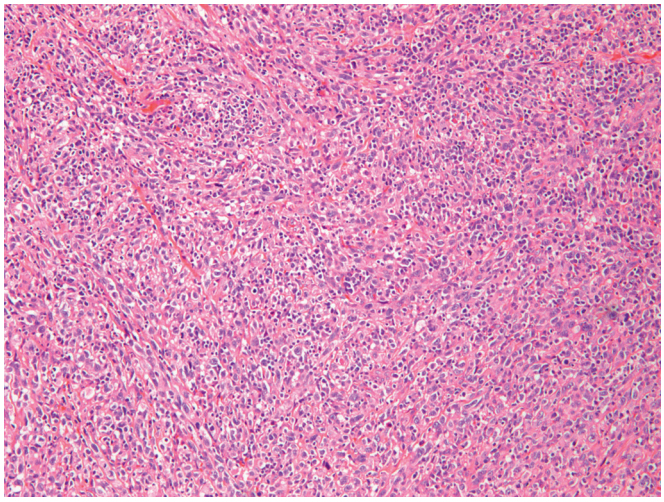

Figure 20.21 Sarcomatoid hepatocellular carcinoma comprised of sheets of neoplastic mesenchymal-type spindled cells and no features reminiscent of hepatocytes.

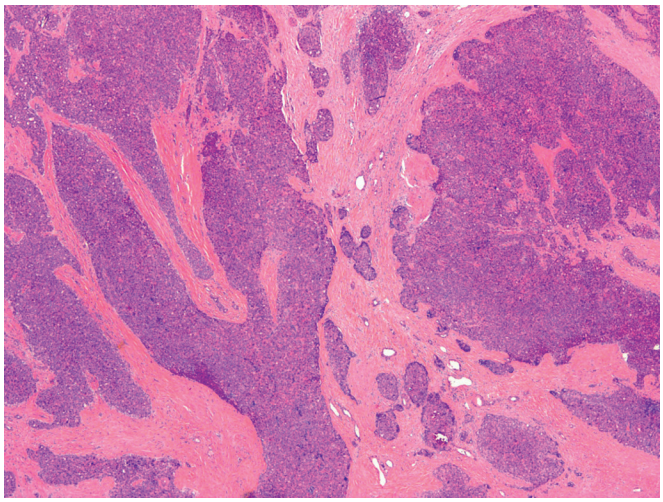

Figure 20.19 Abundant dense fibrous stroma characterizes the scirrhous variant of hepatocellular carcinoma.

Lymphoepithelioma-like HCC resembles its counterparts in the nasopharyngeal region, featuring large numbers of tumor-infiltrating lymphocytes (Fig. 20.20).[206,207] Although some cases have been associated with Epstein–Barr virus (EBV),[208] many are not. This tumor type is probably identical to the neoplasm that has been reported as HCC with lymphoid stroma.[209]

Sarcomatoid (spindle) cell HCC contains spindled and/or multinucleated cells of mesenchymal appearance (Fig. 20.21).[210–212] There may be areas of conventional HCC as well. Variable immunoreactivity with Hep Par-1 and keratins has been reported.[210–214] Osteoclast-like giant cells,[215–216] bone and cartilage, and skeletal muscle may also be present.[217] As in other organs, the term *carcinosarcoma* has been used when the carcinomatous and the sarcoma-like areas are sharply segregated.[218–219] Although some cases of sarcomatoid HCC have been associated with prior aggressive non-surgical therapies such as chemoembolization, radiofrequency ablation, and percutaneous ethanol injection, others have not.[214]

Fibrolamellar carcinoma (FLC, which has also historically been termed polygonal cell type HCC with fibrous stroma and oncocytic hepatocellular tumor) is a distinctive variant of liver cell carcinoma

seen predominantly in young patients without cirrhosis.[220,221] This type of HCC has been associated with a generally favorable prognosis, but more recent studies have indicated that the more favorable outcomes are associated with the absence of cirrhosis rather than the actual tumor type.[222] A case has been reported associated with Fanconi anemia.[223]

The most characteristic microscopic feature is nests and cords of neoplastic cells surrounded by variably dense lamellar bands of fibrosis (Fig. 20.22).[224] The tumor cells are polygonal with abundant deeply eosinophilic (oncocytic) cytoplasm, due to an increase in the number of mitochondria[225]; nucleoli are typically prominent. The collagen deposited around the tumor cells is predominantly composed of types I, III, and V.[226]

Immunohistochemically, fibrolamellar HCC expresses Hep Par-1, similar to conventional HCC, as well as cytokeratins 8 and 18.[224,227] Many cases also express glypican-3, but to less extent than conventional HCC.[152,224] FLC may also express CK7 and (to a lesser extent) CK19.[224,227] Recently, it has been demonstrated that CD68 is strongly expressed by fibrolamellar carcinomas (sensitivity of 96%, specificity of 80%) in a dot-like or stippled pattern[228]; this feature may be useful in distinguishing fibrolamellar HCC from the scirrhous variant. In addition, as noted previously, the fusion translocation of *DNAJB1* and *PRKACA* is highly specific for fibrolamellar carcinoma.[189] The distinction of the fibrolamellar variant is clinically important, given its better prognosis, even if patients present with larger tumors and nodal metastases.[229]

Another rare variant of HCC is the granulocyte colony-stimulating factor (G-CSF)-producing HCC, which may be associated with peripheral granulocytosis and elevated serum G-CSF and interleukin-6.[230]

Mixed HCC–cholangiocarcinoma are exceedingly rare tumors that exhibit dual differentiation into liver cell and bile duct lines, both at the morphologic and the immunohistochemical level; these tumors are less likely to be associated with chronic liver disease and cirrhosis.[231–233] To be classified as a combined HCC/cholangiocarcinoma, tumors should have areas of both unequivocal HCC and cholangiocarcinoma, although some have transitional areas that are intermediate between the two phenotypes (Fig. 20.23A). The areas of biliary differentiation are often accompanied by a chronic inflammatory infiltrate and a desmoplastic stroma, and the epithelium may show positivity for MOC31, CK7, CK19, and/or mucin; areas of hepatocellular growth may be confirmed using any of the markers discussed previously.[233–235] This is a somewhat different phenomenon from the presence of concomitant separate HCC and cholangiocarcinoma in the same liver or even in the same mass, which have been referred to as "collision tumors" (see Fig. 20.23B).[236,237] Recent studies have suggested that mixed (combined) HCC/cholangiocarcinoma arise from hepatocyte progenitor (stem) cells.[235,238,239] Mixed HCC/neuroendocrine carcinoma has also been rarely reported.[240,241]

Biopsy and Cytology

The diagnosis of HCC is often made by core or fine needle biopsy[242–244] or a combination of both.[245–246] The better differentiated the tumor, the more difficult the diagnosis of malignancy. In fine-needle material, the most useful diagnostic criteria are similarity of tumor cells to liver cells, prominence of nucleoli, trabecular pattern of growth, and presence of a sinusoidal stroma (Fig. 20.24A–C).[246–247] Reticulin stain on a core needle biopsy or cell block may be invaluable in establishing a diagnosis of malignancy (see Fig. 20.24D).[248]

At the cytologic level, features favoring the diagnosis of liver cell carcinoma over cirrhosis are absence of bile duct epithelial cells and chronic inflammatory cells, increased nucleocytoplasmic ratio, trabecular pattern, and atypical naked hepatocytic nuclei.[249]

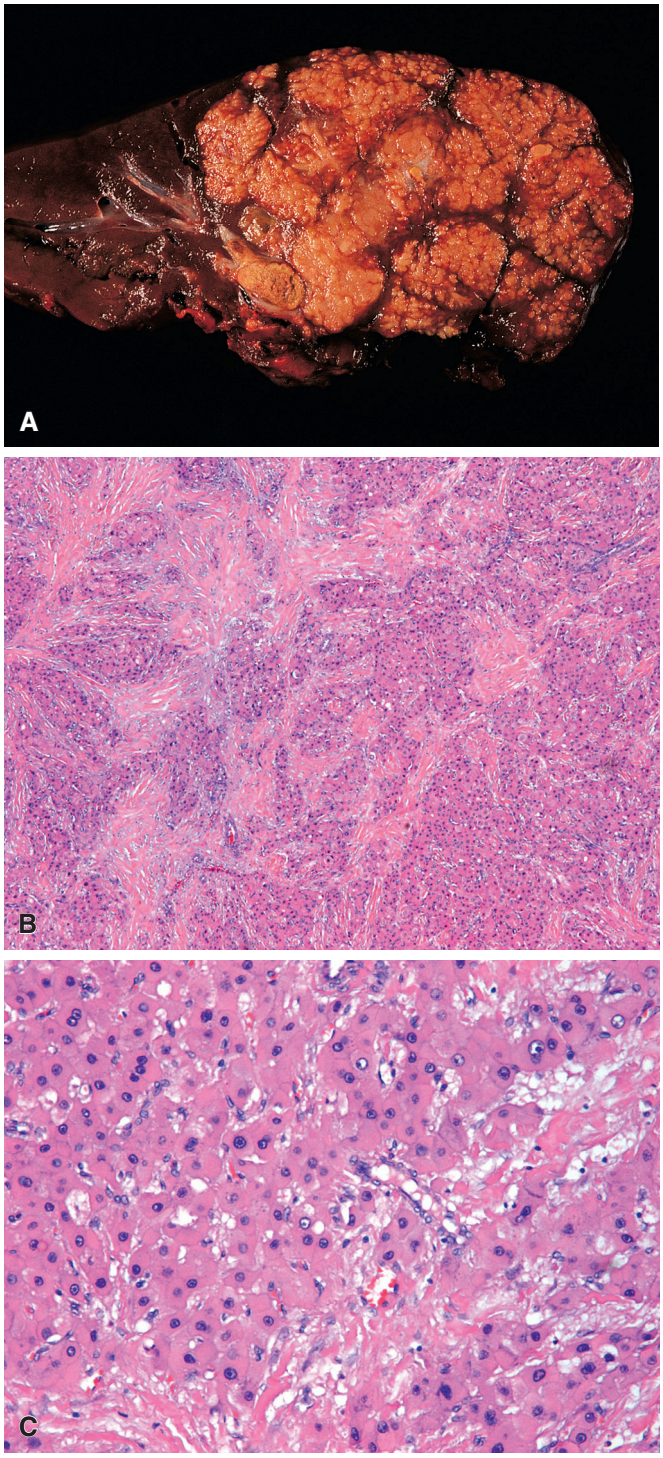

Figure 20.22 **A,** Grossly, fibrolamellar carcinoma is large, well circumscribed, multinodular, and yellow. The adjacent nonneoplastic liver is noncirrhotic. **B,** Fibrolamellar HCC features nests of eosinophilic tumor cells surrounded by dense lamellar fibrosis. **C,** The tumor cells have abundant cytoplasm and prominent nucleoli.

Features favoring liver cell carcinoma over metastatic carcinoma include polygonal cells with centrally placed nuclei, cells separated by sinusoidal stroma, nuclear pseudoinclusions, eosinophilic cytoplasmic globules, and bile secretion.[246,249] As with histologic preparations, the diagnosis can be aided by performing immunostains

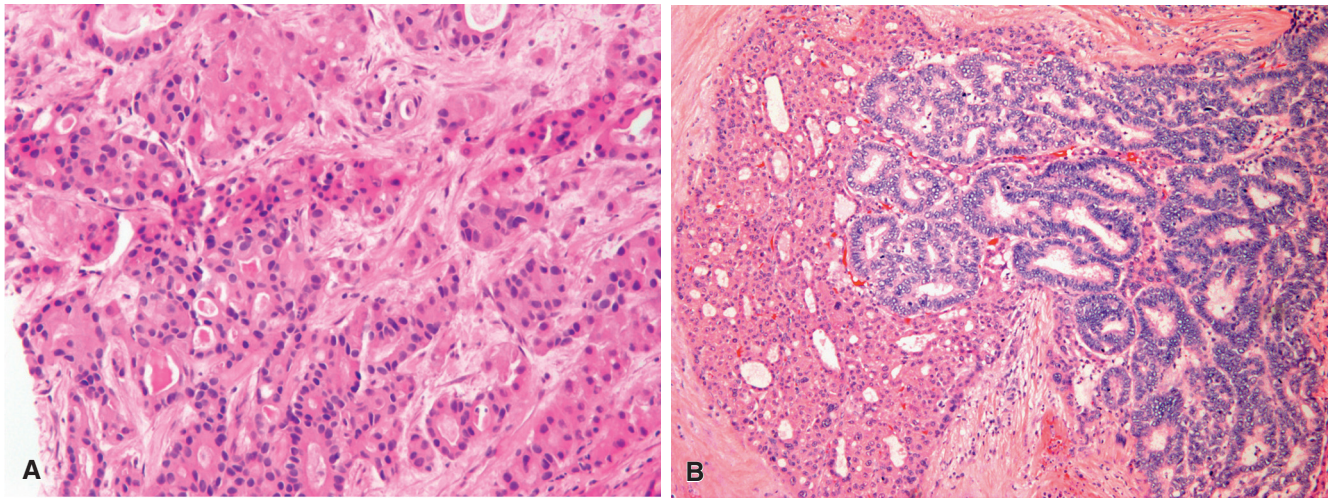

Figure 20.23 **A,** This combined (mixed) hepatocellular carcinoma (HCC)/cholangiocarcinoma has areas with a phenotype intermediate between HCC and cholangiocarcinoma. **B,** This "collision tumor" had separate areas of cholangiocarcinoma and HCC within the same liver.

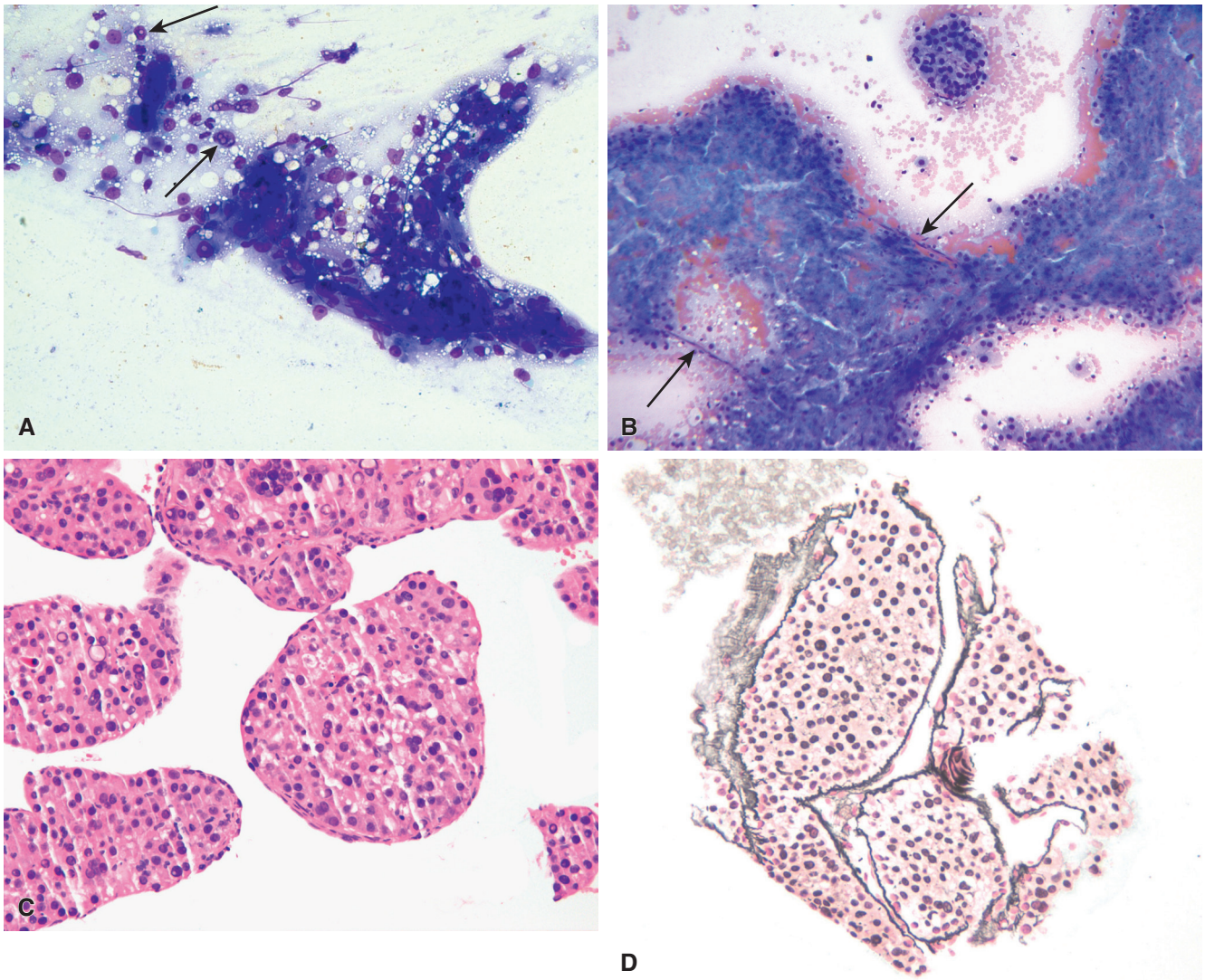

Figure 20.24 **A,** This Diff-Quik smear of an FNA of a hepatocellular carcinoma (HCC) shows a cellular lesion with golden-brown bile and nuclear pseudoinclusions *(arrows)*. **B,** Another example shows thickened trabeculae of neoplastic hepatocytes with endothelial wrapping and capillaries traversing the cellular fragments. **C,** A cell block shows endothelial wrapping of neoplastic cell clusters, as well as nuclear pseudoinclusions. **D,** Reticulin stain can be useful even on small cell block specimens. (**A,** Courtesy of Dr. Asangi Kumarapeli; **B,** Courtesy of Dr. Susi Jeffus).

on the cell block. Two rare but well-documented complications of needle biopsy are implantation along the tract and intra-abdominal hemorrhage.[250]

Grading, Spread, and Metastases

Although the most widely used grading system historically has been the Edmondson and Steiner four-tiered system,[251] many pathologists use a three-tiered system of well (G1), moderately (G2), and poorly (G3) differentiated HCC, ranging from a very close resemblance to normal liver in G1 tumors to pleomorphic tumors that may not resemble liver at all in G3 neoplasms. Higher grade does appear to correlate with worse prognosis; however, when assessing grade on a needle biopsy or FNA specimen, it is important to remember that grade may be heterogeneous within the same tumor, and thus a single small sample may not be representative of the overall grade.[252]

The portal venous system is involved in ~80% of HCC.[253] Tumor cells may also grow into the hepatic vein and from there reach the inferior vena cava and the right atrium.[254] Tumor invasion of the biliary tree is less common but it does occur.[255] The most common sites of extrahepatic spread are lungs, abdominal lymph nodes, and bone[256]; in some cases, a pathologic fracture or some other sign attributable to bone metastasis is the first sign of disease.[257] Unusual sites of metastasis include brain, adrenal, and head and neck.[258,259] Metastases to the ovary need to be distinguished from primary hepatoid tumors of this organ.[260]

Treatment and Prognosis

Resection remains the first line therapy for HCC, but liver reserve and tumor spread must be carefully assessed prior to surgery (the former is particularly important in cirrhotic patients). Unfortunately, recurrence is common, and postsurgical survival rates are approximately 80%–90% at 1 year, 60%–85% at 3 years, and 40%–75% at 5 years.[261,262]

Orthotopic liver transplantation is an option for patients with early stage disease, with 1-year survival rates of approximately 85%, and 5-year survival rates of approximately 70%.[261] The Milan criteria are widely used as the selection criteria for patients with HCC who are being considered for transplant (single tumor ≤5 cm, two to three nodules all <3 cm and without gross vascular invasion or extrahepatic spread).[263]

Patients with single small tumors who are not good surgical candidates may undergo ablative therapy, including radiofrequency ablation, microwave ablation, chemical ablation, or chemoembolization via selective injection of chemotherapeutic agents into tumor-feeding vessels.[261] The only first line systemic therapy with proven efficacy in HCC is sorafenib, an oral tyrosine kinase inhibitor, which can add months to the overall survival of patients with advanced disease.[264] Under exceptional circumstances, HCCs have been found to undergo spontaneous regression.[265]

The 1-year survival of untreated HCC patients is about 17.5% and approximately 7% at 2 years.[266] Clinicopathologic stage is the most important prognostic determinant, although staging of HCC is somewhat different from other cancers, as it must take into account hepatic function as well as tumor-related data. Many HCC staging schemes have been proposed, but the Barcelona Clinic Liver Cancer staging system is the most widely used; it incorporates variables including tumor stage, hepatic functional status, overall performance status, and linkage of clinical stage with treatment modalities.[261] The TNM staging system is widely used by pathologists but is limited as it does not take into account important clinical factors.[267]

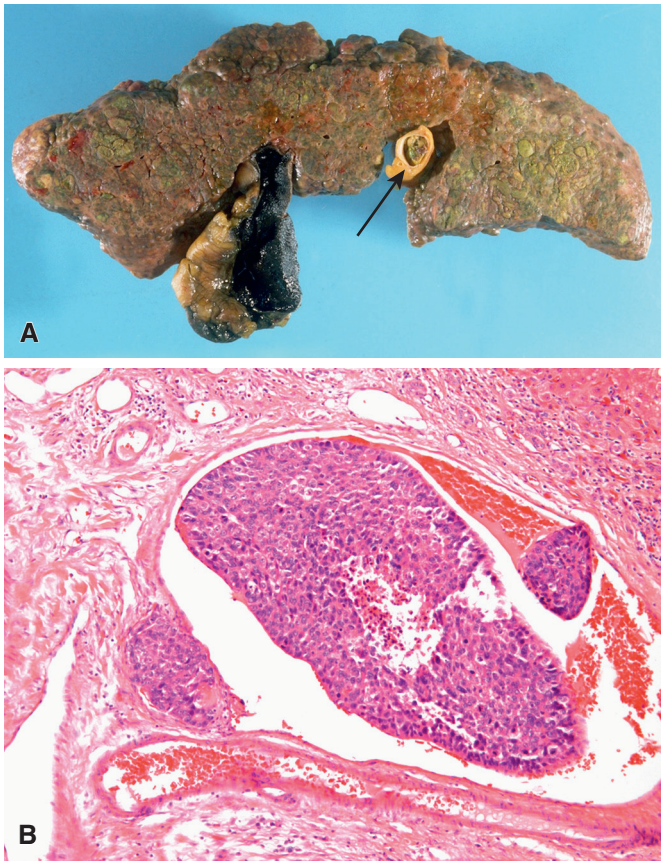

Figure 20.25 **A,** Grossly evident (macroscopic) portal vein involvement in a hepatocellular carcinoma (HCC) with a diffuse pattern of growth *(arrow)*. **B,** Microscopic involvement of a small vein.

A number of independent adverse prognostic factors have been reported, including presence of cirrhosis, poor performance status, presence of multiple tumors, significantly elevated preoperative serum AFP (typically 200 ng/mL or greater), vascular invasion, poorly differentiated histologic grade, and tumor size.[268,269,270] In many series, patients with tumors less than 2–3 cm have a significantly better prognosis.[268,269] Some authors, however, have not found size to be an important prognostic determinator.[271] Although some studies have shown that chronic viral infection had no effect on prognosis, others have shown that HBV and HCV infection are associated with worse outcomes.[272,273] In most series, age and gender have not been found to correlate with prognosis.

A number of other pathologic factors also have significant prognostic implications. Vascular invasion is one of the best predictors of recurrence following resection and is classified as macroscopic (identified grossly or on imaging, Fig. 20.25A) or microscopic (identifiable only by microscopy, see Fig. 20.25B), and both are predictors of recurrence.[274] Microvascular invasion has also been associated with decreased disease-free survival.[275,276] HCCs that are completely encapsulated also behave in a less aggressive fashion than those lacking this feature.[277] Other histologic factors that are independent predictors of poor prognosis are high nuclear grade and increased mitotic activity.[278]

Hepatoblastoma

Hepatoblastoma is the most common primary pediatric liver tumor, typically diagnosed within the first 3 years of life, and the incidence

appears to be slowly increasing.[279] Isolated instances in older children and adults have been reported, which have an overall poorer prognosis than hepatoblastoma occurring in young children.[280,281] The majority of cases are sporadic, but the tumor is associated with a variety of congenital abnormalities (particularly in the genitourinary tract), Beckwith–Wiedemann syndrome, trisomy 18, and familial colonic polyposis.[279,282–283] Some patients present with virilization as a result of ectopic sex hormone production.[284] Serum levels of AFP are often markedly elevated.[285] MRI and CT scans provide the most valuable preoperative assessment of the tumor location and extent.[286]

Grossly, hepatoblastoma is solid, well circumscribed, and more often solitary than multiple (Fig. 20.26A).[287] Microscopically, most (67%) of the tumors are composed exclusively of immature hepatocytic elements (embryonal and fetal) and are referred to as *pure* or *epithelial*.[279,288] Fetal elements consist of hepatocytes arranged in irregular laminae two cells thick, recapitulating those of the fetal liver (see Fig. 20.26B). Patients with tumors that are entirely of the well-differentiated fetal type and a low mitotic rate have a better prognosis.[279] Unfortunately, this is a small minority of cases. Embryonal elements have a more immature appearance and a pattern of growth that is predominantly solid, but that may also exhibit ribbons, rosettes, and papillary formations (see Fig. 20.26C).[289] Foci of extramedullary hematopoiesis are often seen, and multinucleated giant cells may be present, particularly in the tumors associated with hormone production.[289,290] Approximately 20%–30% of tumors (referred to as *mixed*) contain a mesenchymal component as well, which may consist of spindled cells, osteoid, skeletal muscle, or cartilage (see Fig. 20.26D); teratoid features (presence of squamous epithelium, neuroglial tissue, etc.) may also be seen.[291]

Some tumors contain a component of, or are largely made up of, small undifferentiated cells; this pattern may be associated with low AFP levels and a poor prognosis.[279,291,292] These cases may closely resemble malignant rhabdoid tumors, an important diagnostic and therapeutic distinction.[291] Another subset of hepatoblastoma is the cholangioblastic type, which contains a tubular component with cholangiolar features.[291,293] A *macrotrabecular type* of hepatoblastoma resembling liver cell carcinoma has been described, which can mimic HCC (see Fig. 20.26E).[291,294] Primary malignant hepatocellular tumors developing in older children and adolescents may have an appearance intermediate between those of hepatoblastomas and HCCs; these have previously been referred to as *transitional liver cell tumors* and more recently as *hepatocellular malignant tumor not otherwise specified*.[291,295]

Immunohistochemically, AFP is typically expressed by fetal and embryonal elements but negative in mesenchymal and undifferentiated components.[291] CPS1, Hep Par-1, and pCEA are predominantly expressed in fetal components as well.[291,296] Glypican-3 is expressed in the epithelial components of almost all cases of hepatoblastoma (but not in poorly differentiated small cell areas or mesenchymal elements) and not in normal liver tissue.[291,297] Aberrant nuclear immunostaining for β-catenin is a highly characteristic feature in epithelial, mesenchymal, cholangioblastic, and occasionally small cell undifferentiated areas, which is related to the mutation of the encoding gene.[291,298] Nuclear INI1 staining is also characteristic of hepatoblastoma, except for some cases of small cell undifferentiated type.[291,299] Pankeratin and low-molecular-weight keratin expression is variable; cytokeratins 7 and 19 are occasionally expressed by the cholangioblastic type.[291] Delta-like protein (DLK) has been reported to be useful in distinguishing hepatoblastoma from HCC,[300] but the utility of this is still under investigation.

Hepatoblastomas with focal neuroendocrine staining have been reported,[301,302] although the significance of this in hepatoblastomas remains unclear. Rare tumors have also been found to contain melanin and to express immunoreactivity for HMB-45.[303]

A high proportion of cases (>80%) exhibit abnormalities in the *Wnt* signaling pathway, including mutations in the *CTNNB1* (β-catenin) gene, which explains the abnormal nuclear translocation of the protein as detected by immunohistochemistry.[298,304–306] Activation of *TERT* and *MYC*, which play a role in *Wnt* signal activation, appear to play a role in more aggressive hepatoblastomas as well.[279,304]

The treatment of choice of hepatoblastoma is surgical excision. However, 60% of patients are unresectable at diagnosis and may require preoperative chemotherapy.[286,307,308] Liver transplantation is being increasingly used for patients whose tumors remain unresectable.[286,309,310] Over the past four decades, overall survival in hepatoblastoma has increased from approximately 30% to over 80%, primarily due to advances in chemotherapy and the ability to achieve complete resection.[286,308] The survival rate is substantially better than for HCC.

It is important to recognize the morphologic effects of presurgical chemotherapy, which include tumor necrosis, fibrohistiocytic response, an apparent increase in the presence and amount of osteoid, cytoarchitectural differentiation mimicking non-neoplastic liver (but can be distinguished from the latter by nuclear expression of β-catenin), and alterations reminiscent of HCC (e.g. nuclear atypia and thick trabeculae of neoplastic cells).[311,312]

Bile Duct Tumors and Tumorlike Conditions

Simple Cyst

Simple (also known as solitary or unilocular) biliary cysts are lined by a single layer of biliary epithelium overlying a fibrous wall (Fig. 20.27). They occur most commonly in adult women, and are often asymptomatic.[313] Rare cases of carcinoma, particularly squamous cell carcinoma, have been reported arising within simple cysts.[314] They can be distinguished from biliary cystadenomas by their unilocular configuration and lack of ovarian-type stroma.

Biliary Microhamartoma

Biliary microhamartoma (also known as bile duct hamartoma, von Meyenburg complex, or Moschcowitz complex), presents as multiple, small, white subcapsular nodules scattered throughout the liver, which may be mistaken for metastatic carcinoma during surgery or radiographic evaluation.[315,316] Microscopically, these nodules appear as a circumscribed but disorderly collection of dilated, angular biliary channels surrounded by abundant fibrous stroma, located within or at the edge of portal tracts (Fig. 20.28).[317,318] Although the pattern of growth of the individual glands may be irregular, the outline of the lesion as seen on low-power view is sharp, and cellular atypia is nil.

Biliary microhamartomas are believed to be secondary to congenital ductal plate malformations affecting the smallest intrahepatic bile ducts.[319] Although they can be sporadic, they are associated with fibropolycystic liver/kidney disease, congenital hepatic fibrosis, and Caroli disease.[317,319] Virtually 100% of individuals with adult type fibropolycystic liver/kidney disease have biliary microhamartomas in the liver, and approximately 17% of patients with biliary microhamartomas have biliary cysts.[320] Isolated instances of malignant transformation in the form of bile duct carcinomas have been reported.[321–323] A variant characterized by enlargement and cystic dilation of the biliary channels has been called *cystic* or *multicystic biliary hamartoma*.[324,325]

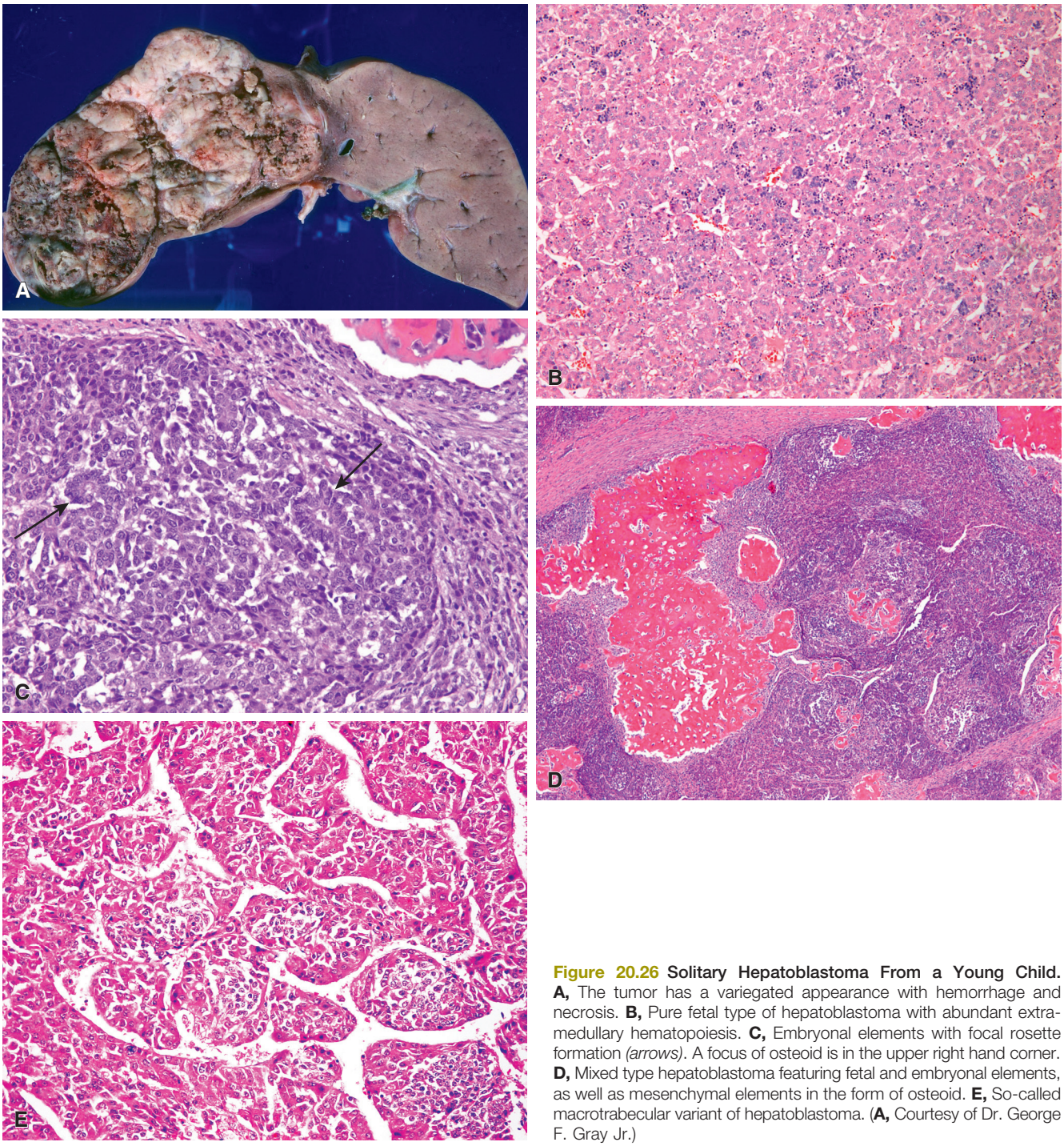

Figure 20.26 Solitary Hepatoblastoma From a Young Child. **A,** The tumor has a variegated appearance with hemorrhage and necrosis. **B,** Pure fetal type of hepatoblastoma with abundant extramedullary hematopoiesis. **C,** Embryonal elements with focal rosette formation *(arrows)*. A focus of osteoid is in the upper right hand corner. **D,** Mixed type hepatoblastoma featuring fetal and embryonal elements, as well as mesenchymal elements in the form of osteoid. **E,** So-called macrotrabecular variant of hepatoblastoma. (**A,** Courtesy of Dr. George F. Gray Jr.)

Peribiliary Gland Hamartoma (Bile Duct Adenoma)

Peribiliary gland hamartomas (bile duct adenomas) are solitary in over 80% of the cases. Macroscopically, they appear as well-circumscribed, wedge-like white masses, sometimes with a central depression, closely resembling metastatic carcinoma. Most of the lesions are less than 1 cm in diameter and are located subcapsularly.[326,327] Microscopically, they are made up of small tubular structures with little or no lumen, often embedded in fibrous stroma (Fig. 20.29). Inflammation is often present. A variant composed of clear cells and simulating metastatic renal cell carcinoma has been described.[328] Immunohistochemically, these lesions are reactive for CK7 and CK19, and have a mucin phenotype similar to that of pyloric gland metaplasia (expressing MUC6, MUC5AC, TFF2, D10, and IF6).[329] Occasionally, a neuroendocrine component resembling pulmonary tumorlet may be seen.[330] Interestingly, a small percentage of these lesions (about 7%) harbor *KRAS* mutations.[331] The behavior of these lesions is benign. The neoplastic versus hamartomatous nature of this process is disputed, and the distinction with von Meyenburg complexes is anything but sharp,[332] except that the latter are more often multiple and associated with fibropolycystic liver/kidney disease.

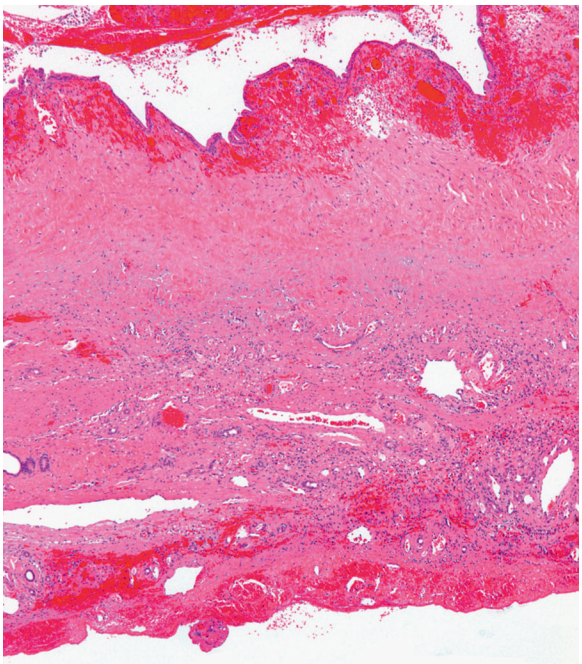

Figure 20.27 Simple biliary cyst with fibrous wall and overlying benign biliary epithelial lining.

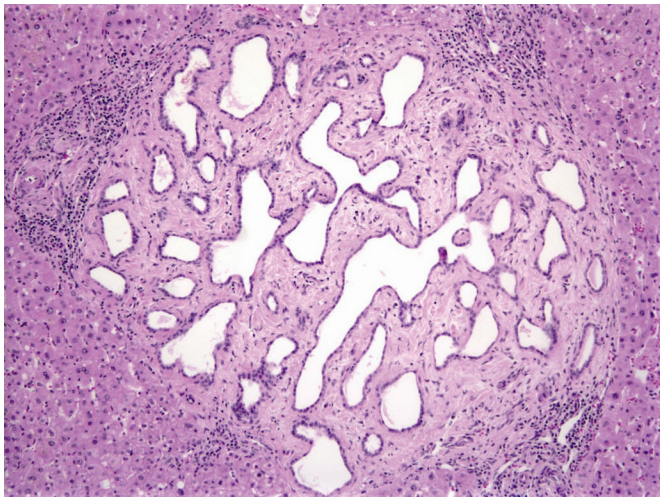

Figure 20.28 Biliary microhamartoma consisting of fibrous stroma with ectatic, angular biliary channels lined by flattened cuboidal epithelium.

Biliary Cystadenoma and Cystadenocarcinoma

Benign and malignant cystic tumors of biliary origin can arise in the liver or, less frequently, in the extrahepatic biliary system (see Chapter 21). Practically all patients are adults, and there is a great predominance of females.[333,334] Grossly, the neoplasms are multilocular and contain mucinous or clear fluid. The benign tumors are lined by a single layer of cuboidal to tall columnar mucin-producing epithelium (similar to that of the intrahepatic bile ducts) (Fig. 20.30A). In the malignant variety the lining may be of intestinal type (including goblet and Paneth cells) or biliary type; there may be areas of frank stromal invasion as well as nuclear atypia and increased mitoses (see Fig. 20.30B).[333,335] In some cases (both cystadenoma and cystadenocarcinoma), occurring almost

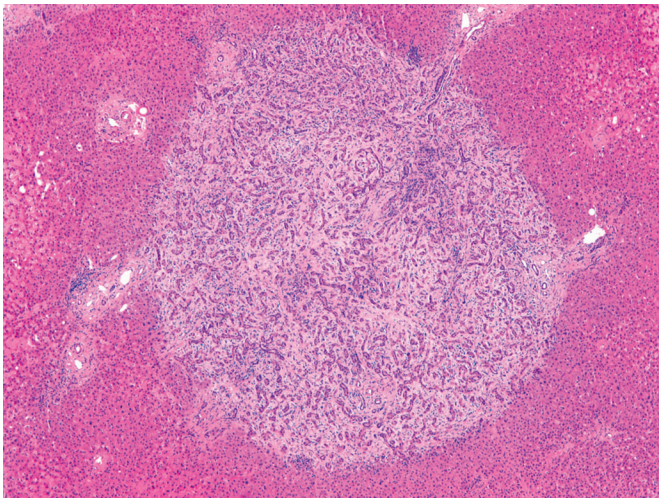

Figure 20.29 Peribiliary gland hamartoma (bile duct adenoma) consisting of small tubular structures with little or no lumen embedded in dense fibrous stroma.

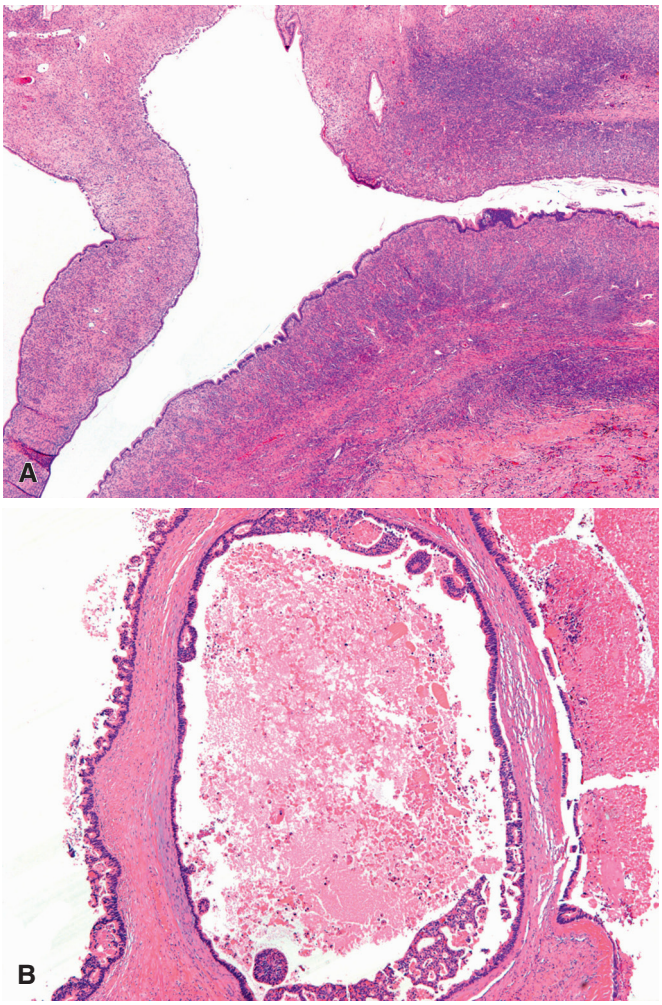

Figure 20.30 **A,** Biliary cystadenoma from a female patient, featuring multilocular cysts lined by a single layer of biliary-type epithelium with underlying cellular ovarian-type stroma. **B,** Cystadenocarcinoma consisting of multilocular cysts lined by markedly atypical neoplastic epithelium. There is necrotic debris within the cyst lumens. Note the absence of ovarian-type stroma.

exclusively in females, the underlying layer of connective tissue is very cellular and closely resembles ovarian stroma.[333,334] These cells are immunoreactive for vimentin, smooth muscle actin, hormone receptors, and inhibin.[336,337]An endocrine cell component may be seen both in the benign and in the malignant types,[338] and oncocytic differentiation has also been described.[339] Rare cases have also been reported that resemble serous cystadenoma of the pancreas.[333] Benign and malignant areas may coexist, emphasizing the need for thorough sampling, but also suggesting that cystadenocarcinomas may arise from their benign counterparts, at least in some cases. In rare cases, the malignant epithelial cells of cystadenocarcinoma acquire a spindle-shaped pseudosarcomatous appearance, as it occurs in the analogous tumor of the pancreas.[340] Immunohistochemically, biliary cystadenomas and cystadenocarcinomas with a biliary phenotype exhibit reactivity for CK7 and CK19.[341] Biliary cystadenocarcinomas with an intestinal phenotype may express CDX2, MUC2, and CK20.

It is difficult to make strong statements about prognosis regarding cystadenocarcinomas, given the rarity of these tumors. However, it has been reported that cystadenocarcinomas with ovarian-like stroma in females follow an indolent course, whereas those lacking this distinctive stroma (more often seen in males) follow a more aggressive course.[333,342] However, there are rare reports of high-grade cystadenocarcinomas with a very poor prognosis despite the presence of ovarian-type stroma.[342] The primary treatment of these tumors consists of complete surgical excision.[342]

Biliary cystadenocarcinomas may be distinguished from intraductal tubulopapillary neoplasms of the liver (see later) by the lack of ovarian-type stroma in the latter, as well as their communication with dilated bile ducts and prominent papillary architecture. Recently, a rare lesion with cystically dilated ducts and prominent fibrous stroma, known as *biliary adenofibroma*, has been described, but these also lack ovarian-type stroma and display an immunophenotype more closely analogous to von Meyenburg complexes.[343]

Intraductal Papillary Neoplasms of the Bile Duct

Intraductal papillary neoplasms of the bile duct, previously termed biliary intraductal papillary–mucinous neoplasms, are regarded as the biliary tract counterparts of the better known intraductal papillary mucinous neoplasms of the pancreas (Fig. 20.31).[344,345] As in the latter, there is a range of phenotypes (including biliary, gastric, intestinal, and oncocytic), as well as a range of dysplasia from low-grade to high-grade to invasive adenocarcinoma. These tumors lack ovarian-type stroma.[345] They can be associated with hepatolithiasis and, exceptionally, with cirrhosis.[346,347] Cases historically described as biliary papillomatosis[348] are now included in this category, similar to the extrahepatic biliary tree (see Chapter 21).

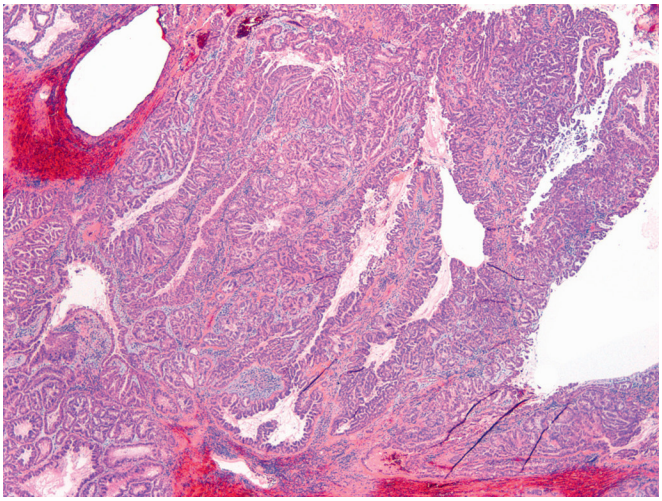

Figure 20.31 Tubular and papillary neoplasm arising within the dilated lumen of an intrahepatic bile duct.

Bile Duct Carcinoma (Cholangiocarcinoma)

Intrahepatic cholangiocarcinomas comprise approximately 10%–20% of all malignant primary liver tumors.[349] Although most cases seen in Western and African countries are unaccompanied by cirrhosis, some series have suggested that HCV-related cirrhosis is a major risk factor for cholangiocarcinoma.[350] Other risk factors include choledochal cysts, Caroli disease,[351] congenital hepatic fibrosis,[352] multiple bile duct hamartomas[353] (von Meyenburg complexes, see earlier), primary sclerosing cholangitis,[349] fluke infection (*Clonorchis sinensis* or *Opisthorchis viverrini*),[354] Thorotrast administration,[355] and intrahepatic lithiasis (hepatolithiasis).[356] Dysplasia of the biliary tree has been identified in association with several of these diseases, including primary sclerosing cholangitis, hepatolithiasis, and choledochal cysts.[357]

Most cases of bile duct carcinoma occur after the age of 60 years in Western countries.[358] The incidence is highest in Asians and Hispanics; there is a slight male predominance, with the exception of the Hispanic population, in which case the incidence is higher in women.[359] Clinically, intrahepatic cholangiocarcinomas are often asymptomatic, and thus large when finally discovered; when they are symptomatic, patients usually present with abdominal pain and weight loss (as opposed to obstructive jaundice, which is the usual form of presentation for their extrahepatic counterpart).[358] Grossly, these tumors tend to be firmer and whiter than liver cell carcinomas because of their greater amount of fibrous stroma (Fig. 20.32A). Multicentricity and perineural invasion are common.[360] Vascular invasion is not as common as in HCC, but it can certainly occur.[360]

Microscopically, tumor cells typically form tubules and glands (see Fig. 20.32B); a cribriform pattern may also be present.[349] Stroma is usually abundant. A common feature is the heterogeneity of the neoplastic epithelial cells within the same gland (see Fig. 20.32C).[361] This peculiarity, which is of great diagnostic significance, is shared by adenocarcinomas of the entire pancreatobiliary system. The tumor has a tendency to spread between hepatocyte plates, along duct walls, and in relation to nerves. In one series, perineurial invasion was found in 81% of the cases (see Fig. 20.32D).[362] The prominent vascularity of HCC is absent. Mucin stains are frequently positive,[361] their profile resembling in some cases those of the gastric foveolae and in others those of pyloric glands.[363] Morphologic variations of cholangiocarcinoma include mucinous,[349] signet ring cell,[364] adenosquamous (see Fig. 20.32E),[365,366] clear cell,[367] spindled/sarcomatoid,[368] with an osteoclast-like giant cell component,[369] with a lymphoepithelioma-like appearance[370,371] (some associated with EBV), and, rarely, with the appearance of a thyroid follicular neoplasm.[372]

Immunohistochemically, there are no specific markers for intrahepatic cholangiocarcinoma, similar to other neoplasms of the biliary tree. There is consistent reactivity for MOC31 (see earlier),[162,163] EMA, and monoclonal CEA, features of importance in the differential diagnosis with liver cell carcinoma.[373,374] Polyclonal CEA will also mark intrahepatic cholangiocarcinomas in a diffuse cytoplasmic, not canalicular, pattern.[374] Keratin immunoreactivity is seen not only with monoclonal antibody CAM 5.2 (as in HCC, indicating the presence of CK8 and CK18), but also with CK7 and CK19.[374] There is a reported difference in the keratin immunoprofile between

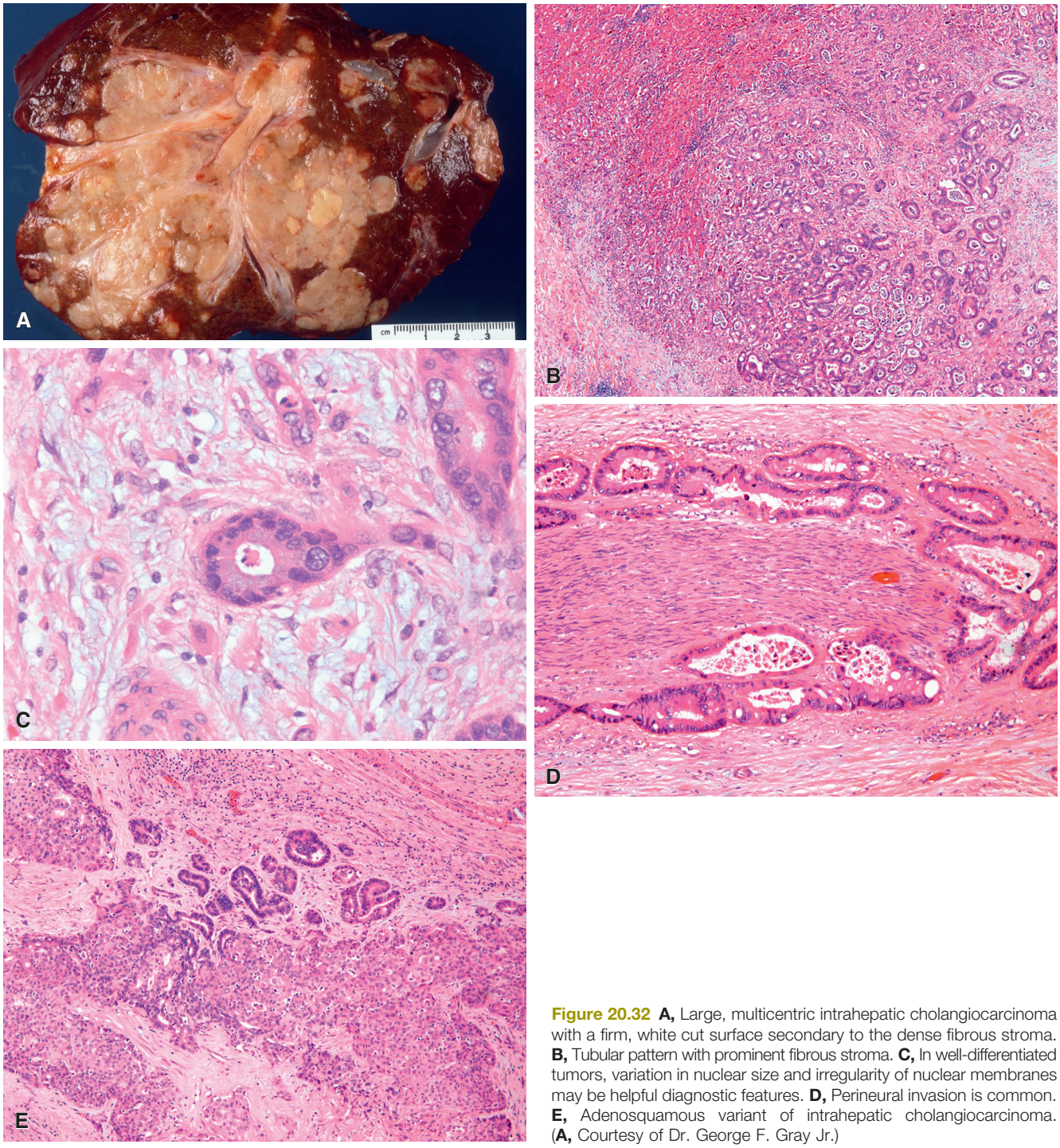

Figure 20.32 **A,** Large, multicentric intrahepatic cholangiocarcinoma with a firm, white cut surface secondary to the dense fibrous stroma. **B,** Tubular pattern with prominent fibrous stroma. **C,** In well-differentiated tumors, variation in nuclear size and irregularity of nuclear membranes may be helpful diagnostic features. **D,** Perineural invasion is common. **E,** Adenosquamous variant of intrahepatic cholangiocarcinoma. (**A,** Courtesy of Dr. George F. Gray Jr.)

intrahepatic and extrahepatic cholangiocarcinoma, in the sense that the former is usually CK7+/CK20–, whereas the latter is frequently CK7+/CK20+.[375,376] Claudin-4 (a component of tight junctions) has been found to be expressed in nearly all bile duct carcinomas but not in normal hepatocytes or in liver cell carcinoma.[377] In contrast to liver cell carcinoma, Hep Par-1 and arginase are typically negative.

A high incidence of *KRAS* gene mutations has been detected, the incidence and spectrum being similar to those reported in large bowel carcinoma.[378,379] Other common molecular changes in cholangiocarcinoma include increased expression of *EGFR* and *MET*, activation of *mTOR*, overexpression of cyclin D1, overexpression of P21, inactivating mutations of *DPC4* (13%–15% of hilar/intrahepatic and 55% of extrahepatic cholangiocarcinomas), and *TP53* mutations (one-third of cases).[380]

Intrahepatic, perihilar, and distal cholangiocarcinomas are staged differently per the seventh edition of the AJCC staging manual.[381] Intrahepatic cholangiocarcinomas may spread extensively within the liver, involving the portal areas, lymphatics, and liver capsule.[382] Perineural, lymphatic, and vascular involvement are also common, as discussed previously, as well as metastases to lymph nodes (in up to one-third of patients at time of diagnosis)[359] and to distant

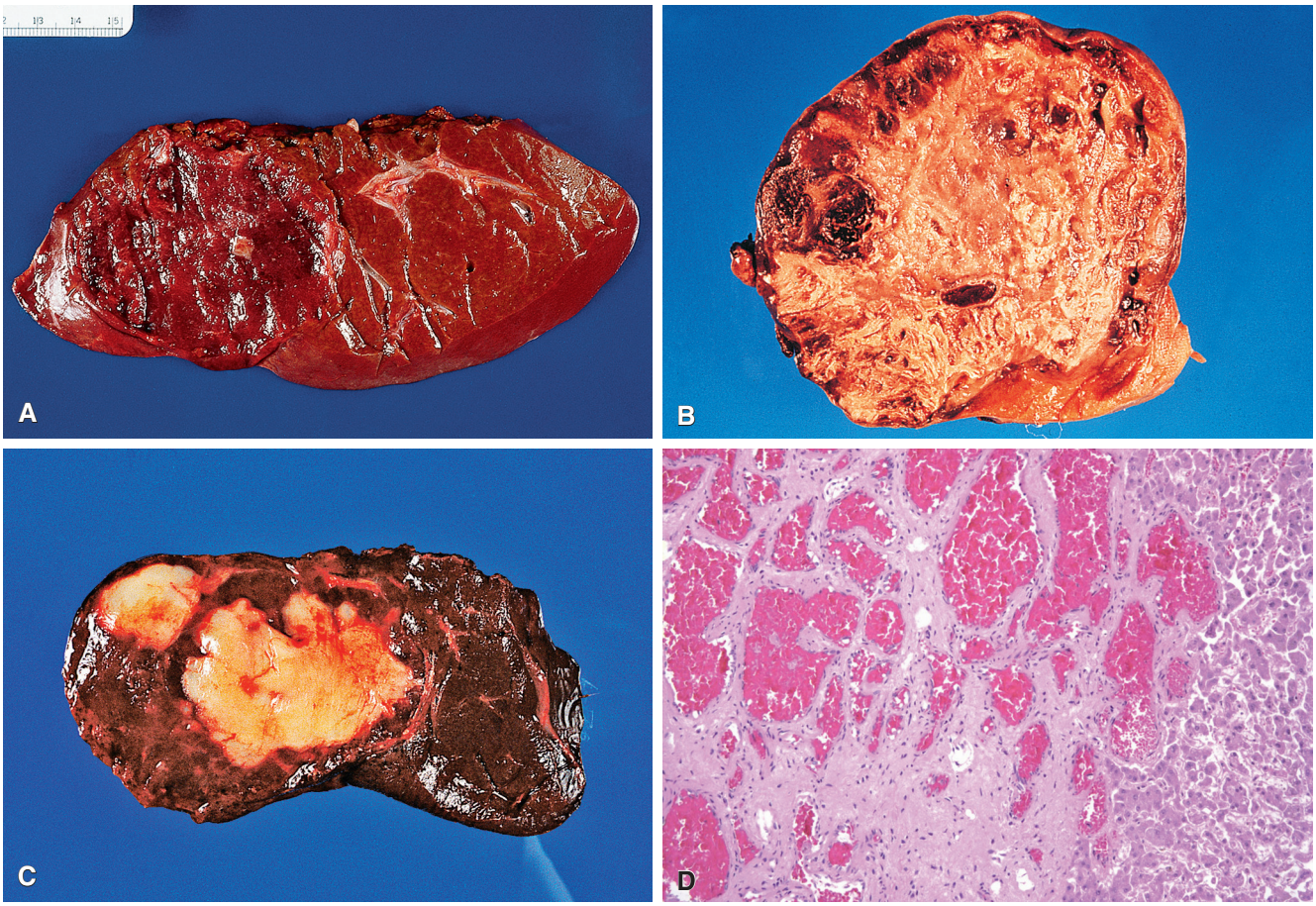

Figure 20.33 **A,** Typical spongy deep red cut surface in hemangioma of the liver. **B,** Tumor accompanied by large fibrin deposits secondary to thrombosis. **C,** An example with marked secondary fibrosis. **D,** Microscopically, there are dilated vascular spaces lined by flat endothelial cells, within dense fibrous stroma.

organs. Ovarian metastases can closely mimic primary ovarian mucinous neoplasms.[383] In rare cases, metastases to distant sites can occur many years following the original diagnosis.[384]

The treatment of bile duct carcinoma is surgical, in the form of partial or total hepatic resection, although curative resection is achieved in less than one-third of patients. Liver transplantation is not recommended for intrahepatic cholangiocarcinoma (unlike perihilar tumors) given the high risk of recurrence following transplantation.[360] The prognosis is poor, with 5-year survival rates of 22%–36%.[359]

Mesenchymal Tumors and Tumorlike Conditions

Vascular Tumors

Hemangioma is the most common benign tumor of the liver. In most cases, it is found incidentally at laparotomy or autopsy. Occasionally, it grows large enough to form a clinically apparent mass. When this is the case, complications such as spontaneous bleeding with rupture and sequestration of platelets resulting in thrombocytopenic purpura may develop.[385] The mass usually projects only slightly above the cut surface, but on occasion it may be pedunculated. On section, it has a characteristic spongy appearance and dark red color. Thrombi in different stages of organization are often encountered (Fig. 20.33A–C). Microscopically, most liver hemangiomas are composed of dilated vascular spaces lined by flat endothelial cells and supported by fibrous tissue (see Fig. 20.33D). Long standing lesions can show extensive hyalinization or calcification[386]; in fact, some authors hypothesize that the so-called *solitary necrotic nodule of the liver* is merely a thrombosed and necrotic hemangioma in many cases.[387] Large and/or symptomatic hemangiomas need to be surgically excised, although there are no agreed-upon criteria for the size at which resection should occur. Observation is justified in small and/or asymptomatic lesions.[385]

Benign (infantile) hemangioendothelioma is a highly cellular variant of hemangioma occurring almost exclusively in children and sometimes in neonates.[388,389] In the classic series reported by Dehner and Ishak,[390] 87% of the cases were diagnosed prior to 6 months of age. The tumors can be solitary or multiple. The latter are not infrequently associated with hemangiomas in other sites, particularly the skin.[391] They can also be seen as part of the Beckwith–Wiedemann syndrome.[392] There may be a serum elevation of AFP.[393] These tumors may be associated with hepatic failure, congestive heart failure, or hyperconsumptive coagulopathy (Kasabach–Merritt syndrome), although with modern surgical and medical therapeutic options, the mortality rate is much lower than in the past.[394] Some tumors

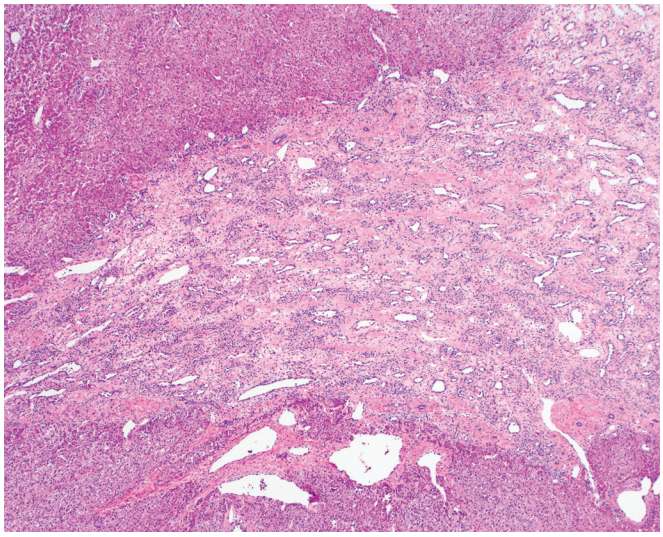

Figure 20.34 Infantile hemangioendothelioma featuring small thin-walled vascular channels within fibrous stroma. (Courtesy of Dr. Grace Kim.)

regress spontaneously.[395] Microscopically and ultrastructurally, the blood vessels of hemangioendothelioma are lined by one or more layers of plump endothelial cells and surrounded by equally prominent perithelial cells (Fig. 20.34).[396] The lumen is small or collapsed in most vessels, but cavernous foci can sometimes be identified. A lobular configuration is focally apparent, and anastomosing channels are not a feature. Immunohistochemically, they show reactivity for GLUT-1, like their cutaneous counterparts, and in contrast to congenital hepatic vascular transformation.[397]

Epithelioid hemangioendothelioma is a rare, distinctive type of endothelial vascular neoplasm.[398–400] Most patients are adult females, and there may be a relationship with oral contraceptive use.[401] Clinically, the tumor may simulate the Budd–Chiari syndrome due to involvement of hepatic veins by tumor.[402] Grossly, the tumors are often multiple and involve both hepatic lobes (Fig. 20.35A). Microscopically, the tumor consists of spindled and epithelioid cells within abundant fibrous stroma, which may have myxoid, sclerotic, or calcifying features. The neoplastic cells infiltrate sinusoids and veins, both as tuft-like intravascular proliferations and as fibrothrombotic occlusions.[403,404] The tumor cells frequently contain intracytoplasmic lumina (see Fig. 20.35B), which may contain red blood cells. Mitoses are typically rare or absent. Immunohistochemically, they are positive for vascular markers (such as CD31, CD34, and ERG) and may also exhibit positivity for D2-40 and CD10.[404,405] Keratins, including pankeratin, CAM5.2, and CK7, may also be positive, leading to diagnostic confusion, particularly in small biopsies.[404,405] Weibel–Palade bodies may be seen ultrastructurally.[406,407] The prognosis is much more favorable than for angiosarcoma, although extrahepatic metastases occurred in 27% of the 137 patients reported by Makhlouf et al.[400] The lung metastases closely simulate the appearance of primary epithelioid hemangioendothelioma of the lung, that is, the lesion formerly known as intravascular bronchioloalveolar tumor (IV-BAT). Historically the treatment has been surgical or ablative, but liver transplant is now more frequently employed due to the fact that many patients have unresectable multifocal disease.[408,409] Exceptionally, the tumor will be seen recurring in the allograft.[410]

Angiosarcoma is characterized by malignant endothelial cells that infiltrate preexisting vascular structures. In the liver, this leads to progressive sinusoidal dilatation and consequent atrophy and

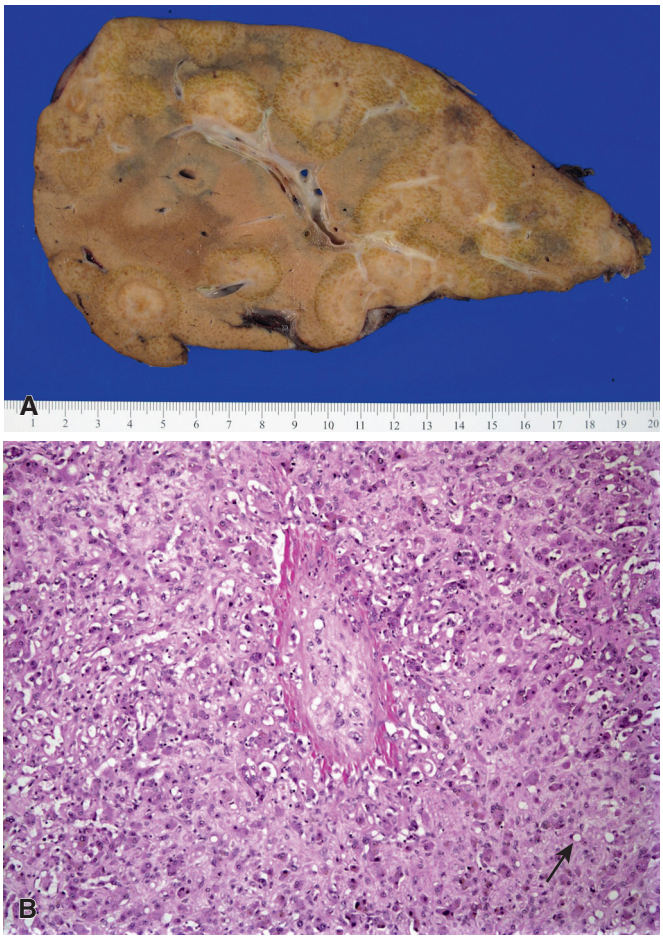

Figure 20.35 **A,** Hepatic epithelioid hemangioendothelioma with multifocal growth pattern and marked parenchymal congestion due to involvement of the hepatic venous system by tumor. **B,** Epithelioid tumor cells with occasional intracytoplasmic lumens *(arrow)* are present within abundant stroma. Note involvement of the central vein in the middle of the photograph.

disappearance of the liver parenchyma (Fig. 20.36).[411,412] The degree of differentiation varies a great deal from case to case and from region to region in the same case, with the better differentiated examples simulating peliosis hepatis or other benign conditions,[411] and the poorly differentiated types being difficult to distinguish from primary or metastatic epithelial neoplasms. Some of the tumors have an epithelioid appearance; they are distinguished from epithelioid hemangioendotheliomas on the basis of their greater degree of atypia, mitotic activity, and necrosis. Vascular markers (CD31, ERG) can be detected immunohistochemically in all but the most undifferentiated neoplasms. Of note, keratin expression can be seen, especially in epithelioid variants.[413]

Most cases occur in adults, but well-documented cases in infants also are on record.[414,415]

The prognosis is extremely poor. An increased risk for the development of angiosarcoma of the liver in adults has been documented in the following conditions:

1. *Cirrhosis:* Fibrosis or cirrhosis is present in approximately 30%–40% of the adult cases, although no causal relationship between chronic liver disease and angiosarcoma has been established.[416]
2. *Vinyl chloride exposure:* It has been shown that hepatic angiosarcoma occurs with undue frequency in workers at chemical plants that produce polyvinyl chloride (PVC), a component of most plastic

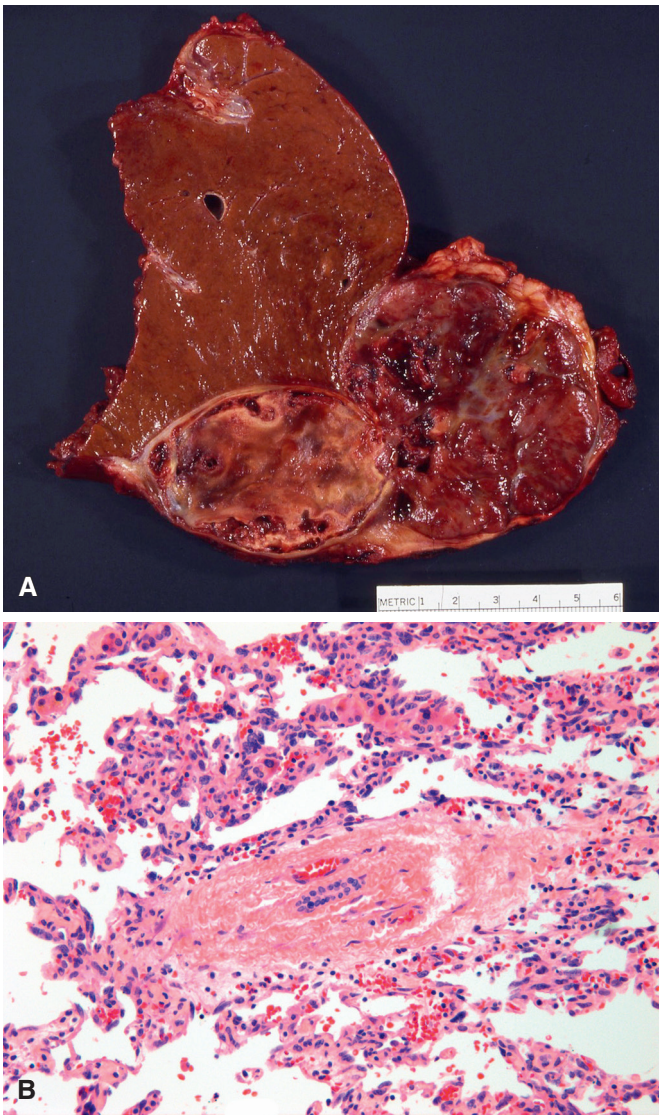

Figure 20.36 **A,** Hepatic angiosarcoma with areas of necrosis and hemorrhage. **B,** The sinusoids are dilated, and the liver parenchyma has essentially been replaced by malignant endothelial cells. A residual portal tract is in the center of the field.

products such as water pipes, wrapping materials, and building materials.[417] In the series of Makk et al.[418] the average time of exposure was 16.9 years. Grossly, most tumors are multicentric, hemorrhagic, and necrotic, with areas of cystic degeneration and fibrosis. The non-neoplastic liver often exhibits subcapsular and portal fibrosis, sinusoidal dilation, and endothelial hyperplasia.[419] The disease is invariably fatal; at autopsy, most of the cases are restricted to the liver or invade the local structures by direct extension. In contrast to the non-PVC-related hepatic angiosarcoma, distant metastases are rare.[418]

3. *Thorium dioxide exposure:* The administration of a suspension of thorium dioxide (Thorotrast) for radiographic purposes has been linked with the late development of hepatic angiosarcoma, the latent period ranging from 20 to 40 years.[420,421] As in the previous group, these tumors are often associated with sinusoidal dilation and endothelial hyperplasia in the non-neoplastic areas.[420] In some of these patients, the angiosarcoma may be combined with liver cell carcinoma and/or cholangiocarcinoma.[420]
4. *Arsenic exposure:* Some cases of hepatic angiosarcomas have followed prolonged therapeutic administration of arsenic in the form of Fowler solution.

Hemangioblastoma rarely occurs in the liver and has been reported in a patient with von Hippel–Lindau syndrome. Its appearance is identical to that of the homonymous cerebellar tumor.[422] *Kaposi's sarcoma* rarely develops in liver transplant patients, and is typically preceded by HHV-8 viremia.[423] *Lymphangioma* is usually seen in infants or children; in most reported cases, the liver involvement is part of a multicentric process affecting other organs, particularly spleen (lymphangiomatosis).[424–426]

Other Mesenchymal Tumors

Mesenchymal hamartoma is a rare benign lesion with a predilection for infants, in whom it appears as a solitary, spherical, reddish nodule, typically in the right lobe (Fig. 20.37).[427] Most patients present during the first 2 years of life with abdominal swelling and a palpable abdominal mass.[428] It has also been reported in adults,[429,430] in whom it may be associated with abdominal pain.[431] Some are solid, and others have a prominent cystic component[432] (see Fig. 20.37A–B); sometimes the lesion grows to a huge size. Microscopically, the main component is well-vascularized mature connective tissue intermixed with elongated branching bile ducts, hepatocytes, and cystic spaces. Some have likened the low-power appearance to fibroadenoma of the breast (see Fig. 20.37C).[433] Some have postulated that this lesion arises from the connective tissue of the portal tracts,[434] but others believe its origin is from hepatic stellate cells.[435] Its vascular pattern is similar to that seen in torsion of an accessory lobe of liver, which has suggested to some authors a related ischemic pathogenesis.[436] However, the detection of specific translocations involving chromosome 19q13.4[437,438] and the occasional occurrence of aneuploid lesions[439] speak in favor of a neoplastic nature. Exceptionally, it may undergo malignant transformation into an undifferentiated (embryonal) sarcoma (see next section).

Angiomyolipoma of liver is similar to its more common renal counterpart, being composed of tortuous blood vessels, smooth muscle, and fat.[440] As in other sites, it is believed that this tumor is a member of perivascular epithelioid cell tumor (PEComa) spectrum.[440–442] Histologically, these tumors consist of a mixture of smooth muscle cells, fat, and vessels (Fig. 20.38); the smooth muscle cells can be spindled or epithelioid, which may lead to diagnostic confusion with other tumors. Immunoreactivity for actin, desmin, S-100 protein (in the adipose component), and—most importantly—HMB-45, is the rule.[443–445] In contrast to the renal tumors, the reported hepatic angiomyolipomas have not been associated with tuberous sclerosis. A variant of this tumor involves the ligamentum teres and has a prominent clear cell component, thus resembling clear cell ("sugar") tumor of the lung.[446,447] The behavior of hepatic angiomyolipoma is generally benign, despite its sometimes invasive growth into the surrounding hepatic parenchyma.[448] However, exceptional instances of clinical malignancy are on record.[449,450]

Inflammatory myofibroblastic tumor was originally described as inflammatory pseudotumor but is now thought to be in most instances neoplastic in nature, although this is still debated.[451] It presents in both adults and children with fever and upper abdominal pain. Grossly, the lesions have a variegated appearance, accompanied by areas of necrosis and hemorrhage. Microscopically, they are composed of an inflammatory mononuclear component rich in mature plasma cells and abundant plump spindle cells (Fig. 20.39).[452,453] The latter have generally been identified as myofibroblasts, but the possibility of them being members of the accessory immune system (i.e. reticulum/dendritic cells) has been raised (see section below on follicular dendritic cell tumors of the liver).[454] Nuclear atypia

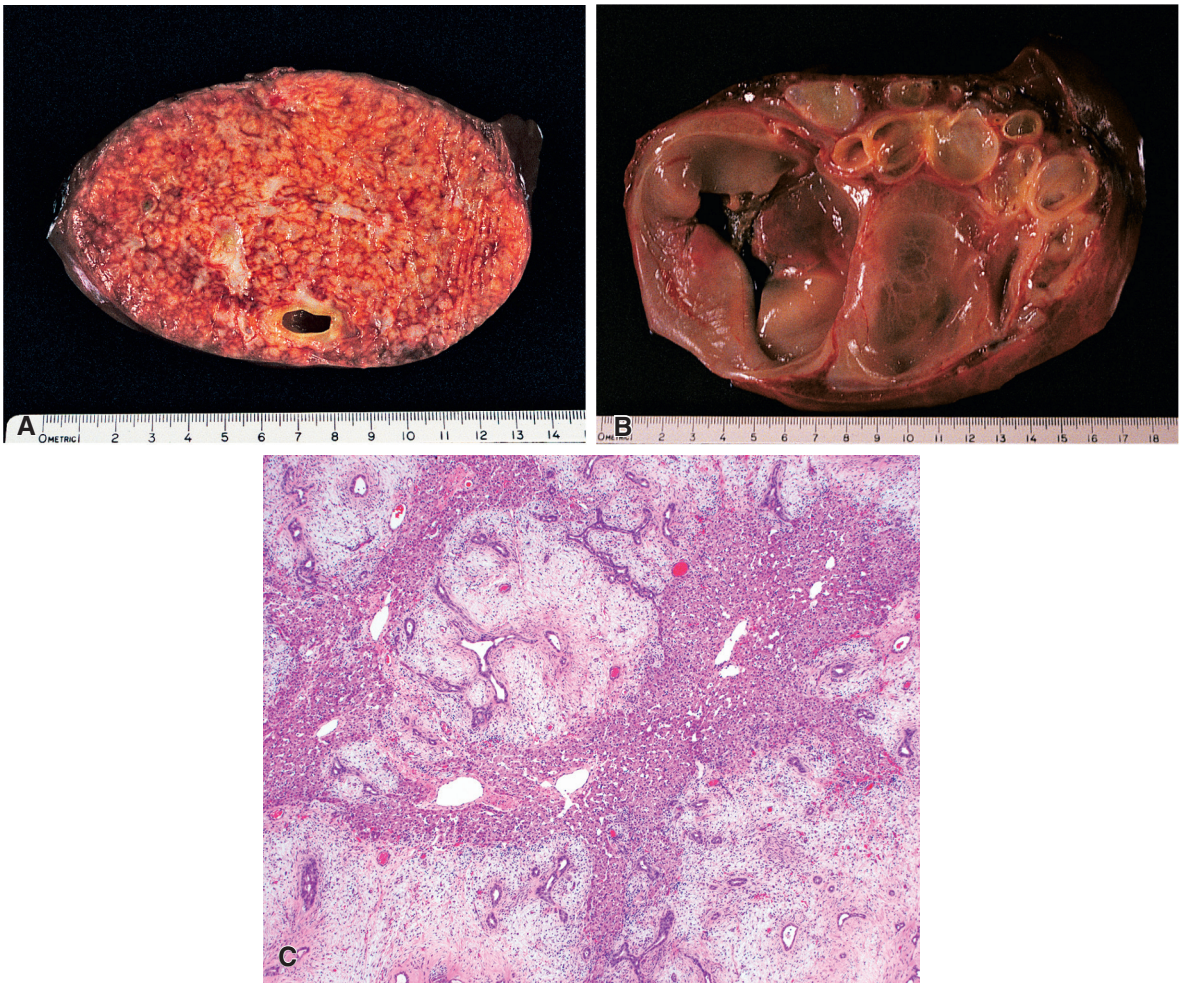

Figure 20.37 Mesenchymal hamartoma of liver, which grossly may have a solid micronodular **(A)** or multicystic appearance **(B)**. **C,** The microscopic appearance consists of abundant mesenchymal tissue with admixed blood vessels, bile ducts, and hepatocytes. (**C,** Courtesy of Dr. Grace Kim.)

may be prominent in some cases. As with inflammatory myofibroblastic tumors of other sites, ALK-1 immunohistochemistry can be helpful in the diagnosis.[455] It is probable that several different conditions are currently included under the terms inflammatory myofibroblastic tumor and inflammatory pseudotumor. Some may be reactive, particularly those associated with occlusive phlebitis and chronic cholangitis,[453,456] as well as those exhibiting spontaneous regression.[457] Others, probably the majority, are or become a true neoplastic process. For these, surgical removal is the treatment of choice.

Leiomyoma can rarely present as a solitary hepatic nodule, the main differential diagnosis being a metastasis from a well-differentiated leiomyosarcoma from the uterus or the gastrointestinal tract, or a metastatic gastrointestinal stromal tumor.[458,459] Some hepatic smooth muscle neoplasms have occurred in HIV-infected patients or following organ transplantation, and have been found to contain EBV by in situ hybridization.[460–462] These tumors can be multicentric,[463] and microscopically they often contain an abundance of intratumoral T lymphocytes.[463]

Myelolipoma is rarely encountered in the liver. It has an appearance similar to that of its more common adrenal counterpart, being composed of an admixture of fat and bone marrow–derived hematopoietic cells.[464,465] Hepatic *lipoma* presents as a single round intraparenchymal mass[466]; it should be distinguished from so-called *hepatic pseudolipoma*, which is a round nodule of fat attached to the Glisson capsule, probably representing entrapped, detached appendix epiploica.[467] *Solitary fibrous tumor* (previously known as localized fibrous mesothelioma or hemangiopericytoma) may arise from beneath the liver capsule or the parenchyma[468] (Fig. 20.40); as in other sites, this tumor is immunoreactive for vimentin, CD34, and BCL2.[469] *Schwannoma* and *malignant peripheral nerve sheath tumor* have been rarely reported in the liver, some of them developing in patients with von Recklinghausen disease.[470–472]

Sarcomas primary in the liver are exceptional. Their differential diagnosis includes metastases from sarcomas of other sites, and sarcomatoid liver cell carcinomas. Types of reported primary sarcoma of liver in adults are numerous, and include *fibrosarcoma*,[473,474] liposarcoma,[475] *leiomyosarcoma*[476–478] (some of them occurring in HIV-infected patients, see also earlier discussion),[479] *rhabdomyosarcoma*[480] (one of them associated with long-term oral contraceptive use),[481] so-called *malignant fibrous histiocytoma* (pleomorphic undifferentiated sarcoma),[482] *osteosarcoma*,[483,484] and *osteoclast-like giant cell tumor*.[485,486] In infants and children, there have been isolated reports of *embryonal rhabdomyosarcoma* and *rhabdoid tumor*.[487–490] As in other sites (except perhaps the kidney), rhabdoid tumor of the liver is probably not a distinct entity but rather a

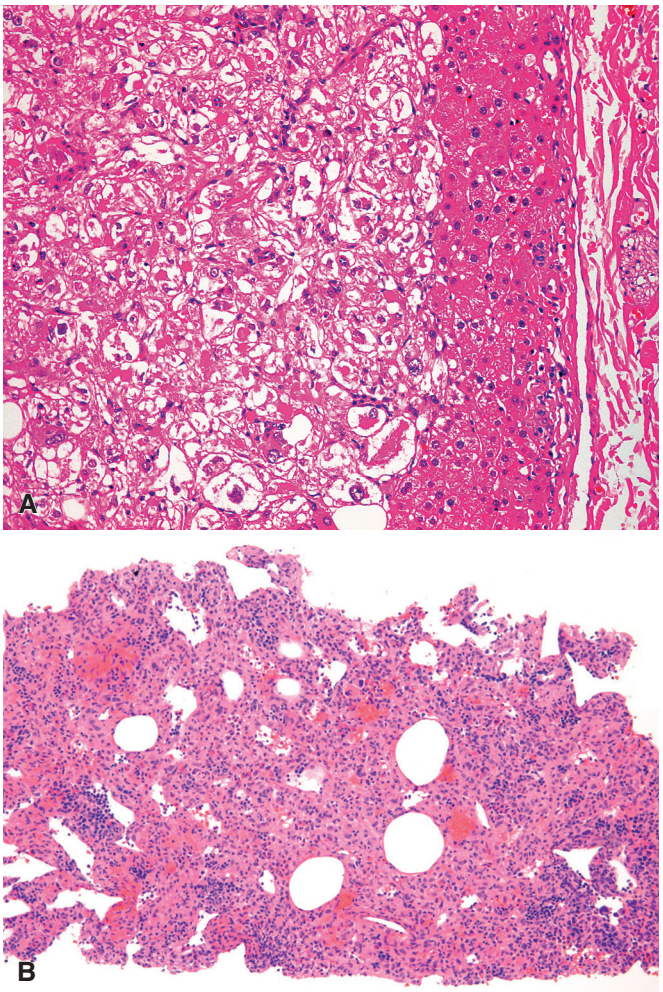

Figure 20.38 **A,** The solid pattern of growth and the epithelioid appearance of the tumor cells in angiomyolipoma, along with ballooned cytoplasm, may lead to a mistaken diagnosis of a hepatocellular neoplasm. **B,** Needle biopsy of another case with epithelioid smooth muscle cells, fat, and thin-walled vessels. Extramedullary hematopoiesis is also present.

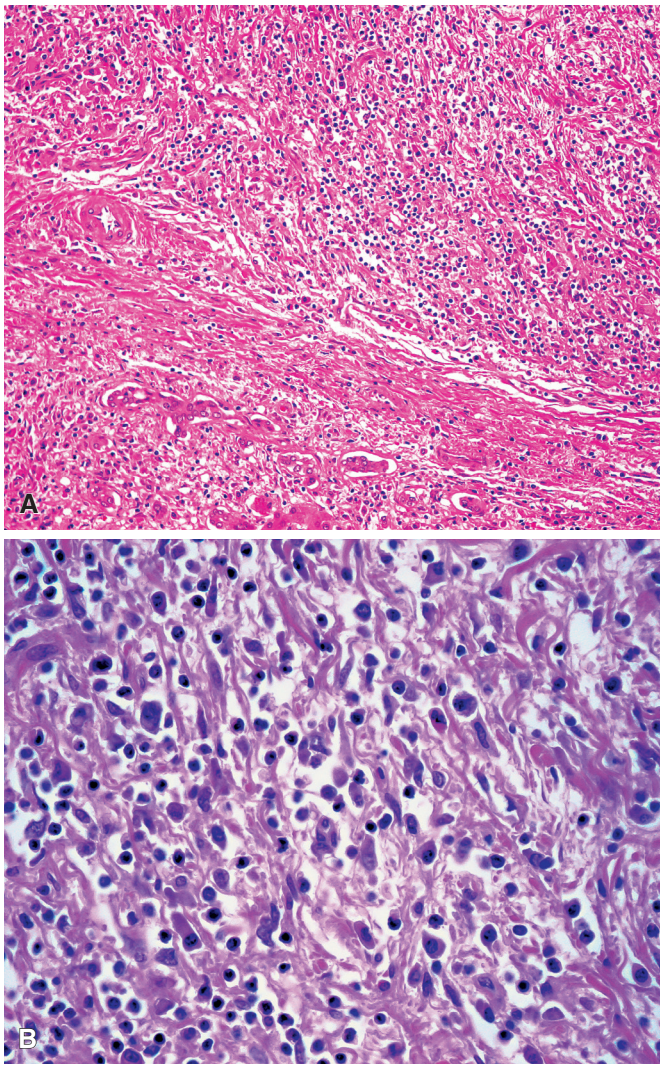

Figure 20.39 **A,** Inflammatory myofibroblastic tumor showing a well-circumscribed nodule with admixed plasma cells, histiocytes, and spindled fibroblasts. **B,** High-power view showing spindle cells admixed with lymphocytes, plasma cells, histiocytes, myofibroblasts.

morphologic and phenotypic pattern that can accompany a variety of cell types.

Undifferentiated (embryonal) sarcoma, also known as malignant mesenchymoma, occurs predominantly in children but has also been seen in adults.[491,492] Several cases are on record arising in conjunction with a mesenchymal hamartoma (see previous discussion).[493–495]

Grossly, these tumors are usually large, solitary, and well circumscribed, with multiple areas of necrosis, hemorrhage, and cystic degeneration (Fig. 20.41A). Microscopically, they are composed of a mixture of anaplastic spindle and giant cells, most of them having a sarcoma-like appearance (see Fig. 20.41B). The larger cells often contain numerous intracytoplasmic hyaline globules that are strongly periodic acid–Schiff (PAS) positive (see Fig. 21.41C). Scattered hyperplastic or degenerating bile duct-like structures surrounded by tumor cells are seen in most cases; since they show no clear-cut neoplastic features and are more numerous at the periphery of the tumor, they have been generally interpreted as entrapped elements.

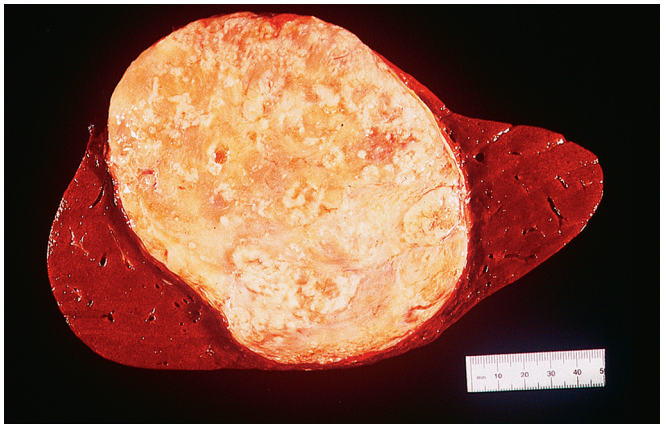

Figure 20.40 Large solitary fibrous tumor of the liver. Microscopically, the tumor had malignant features.

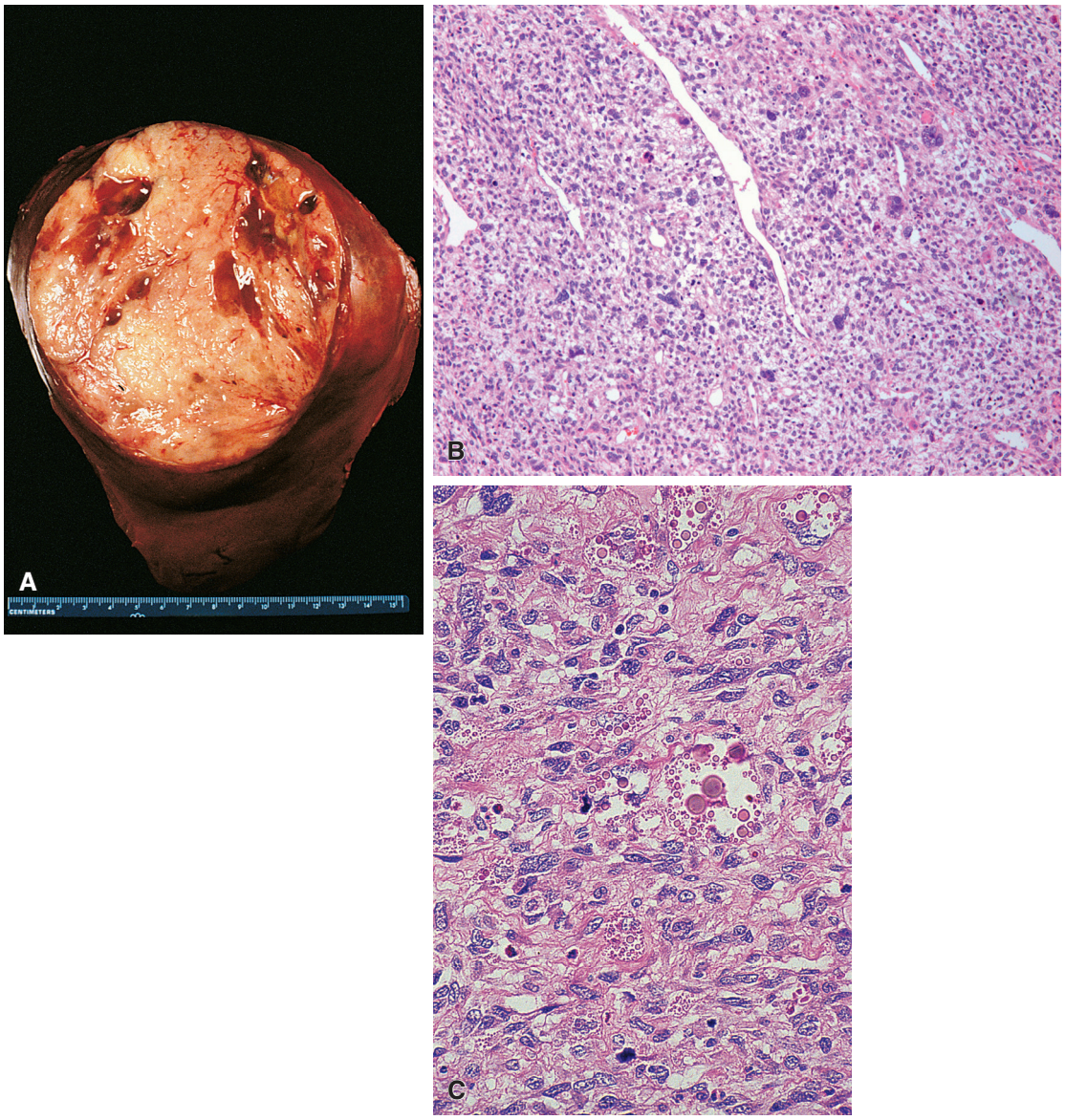

Figure 20.41 **A,** Grossly embryonal sarcoma is well circumscribed, largely solid, and has areas of cystic degeneration. **B,** Low power view shows undifferentiated spindle cells and giant cells, with prominent thin-walled vessels. **C,** Large eosinophilic hyaline globules are present within and between the tumor cells.

Ultrastructurally and immunohistochemically, most of the cells have features of undifferentiated mesenchymal cells, fibroblasts, and myofibroblasts, but others may show differentiation toward smooth and skeletal muscle elements on the one hand and toward epithelial cells on the other.[496] Thus, immunoreactivity has been described with α1-antitrypsin, α1-antichymotrypsin, lysozyme, CD10, glypican-3 (a feature it shares with mesenchymal hamartoma),[156] smooth muscle actin, desmin, and keratin.[496,497,498] This peculiar combination of phenotypic features has led some authors to postulate a histogenetic relationship with primary hepatic embryonal rhabdomyosarcoma and others to suggest that the tumor represents an anaplastic (sarcomatoid) variant of liver cell carcinoma.[499] Both of these seem unlikely prospects, particularly in view of the lack of immunoreactivity of these tumors for myogenin and Hep Par-1.[497,500]

Treatment consists of multiagent chemotherapy along with resection or, in some cases, liver transplantation. Historically the prognosis has been generally poor, with overall survival between 20% and 55%. However, more recent studies have shown overall survival of over 80%.[491]

Malignant Lymphoma and Related Lesions

Malignant lymphoma confined to the liver is a very rare occurrence, although secondary involvement in advanced stages of extrahepatic lymphoma is common.[501–503] In terms of relative frequency, the most common types of lymphoma involving the liver *are diffuse large B-cell lymphoma, Hodgkin lymphoma, peripheral T-cell lymphoma, follicular center cell lymphoma, mucosa-associated lymphoid tissue (MALT)-type marginal zone B-cell lymphoma*, and *anaplastic large cell lymphoma*.[504–509] Patterns of involvement include tumor nodules, infiltration of portal tracts, lymphoepithelial lesions of bile ducts, and infiltration of

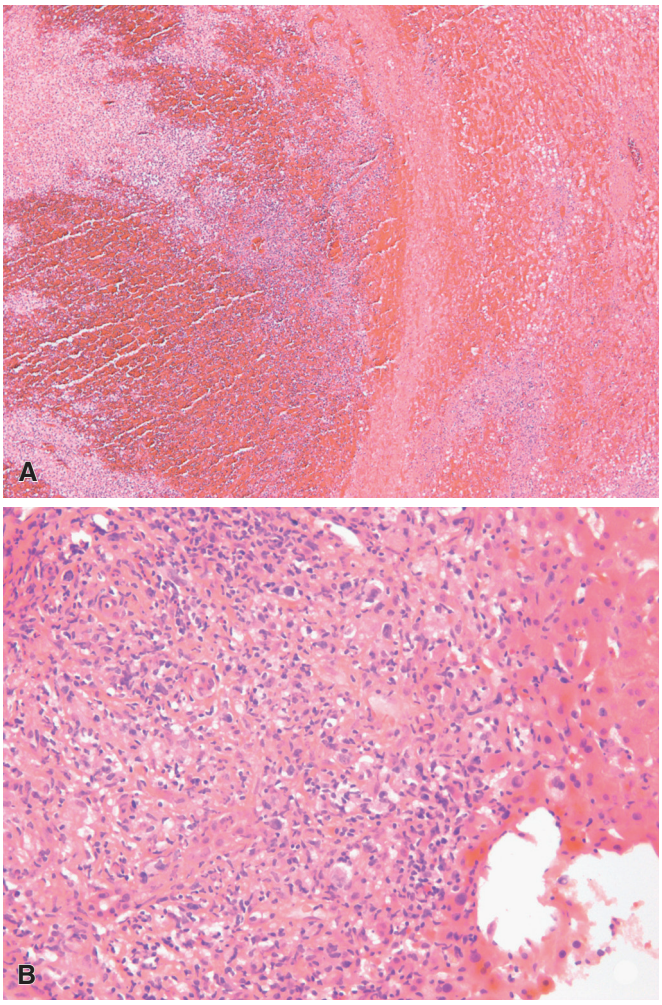

Figure 20.42 **A,** An anaplastic large cell lymphoma forms a large abscess-like mass that effaces the normal liver architecture. Portal involvement by Hodgkin disease. **B,** Note the mixed cellularity of the infiltrate, which has a vaguely granulomatous look and scattered large tumor cells.

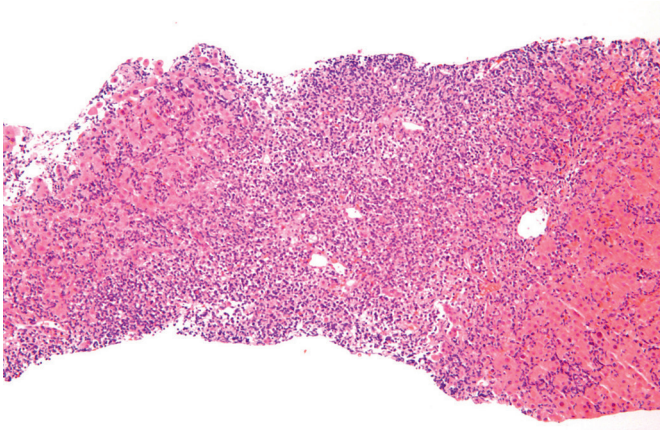

Figure 20.43 Both portal and sinusoidal involvement are seen in this case of chronic lymphocytic leukemia.

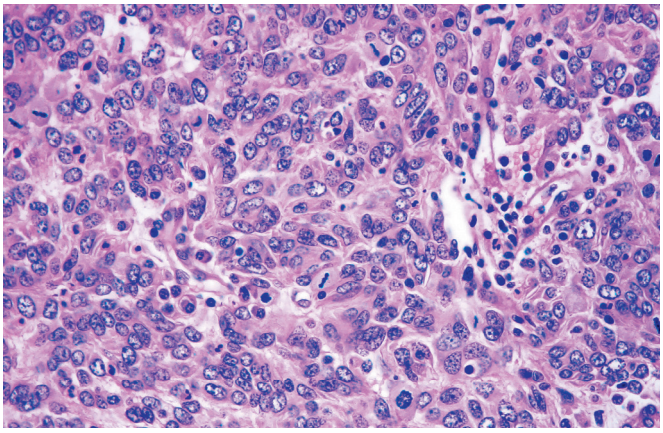

Figure 20.44 Follicular dendritic cell tumor of the liver featuring spindled and epithelioid cells with ovoid nuclei and a sprinkling of lymphocytes.

sinusoids (Fig. 20.42).[504,505,510] Some of the primary hepatic lymphomas have occurred in association with HCV infection.[511,512] Most cases occur in adults, but primary hepatic lymphomas may also affect children.[513–515]

Hepatosplenic (gamma-delta) T-cell lymphoma is a distinct entity characterized by occurrence in young adult males with hepatomegaly, B symptoms, peripheral blood cytopenias, absence of peripheral lymphadenopathy, presence of lymphoid infiltrates in the splenic red pulp, hepatic sinusoids and bone marrow sinuses, and an aggressive clinical course.[515,516] The *alpha-beta* variant of this tumor shows a female preponderance, and the liver infiltrates tend to be periportal. An isochromosome 7q or trisomy 8 are often present; the majority of tumors express gamma-delta T-cell receptors by molecular studies, and a minority express alpha-beta T-cell receptors or neither receptor.[517] Cases have been reported in immunocompromised patients.[518,519] Prognosis is poor overall. This disease is further discussed in Chapter 37.

Leukemic involvement of the liver can occur in both acute and chronic leukemia and may involve the periportal or sinusoidal regions.[504,520] In chronic lymphocytic leukemia, the infiltrate is predominantly periportal, and in chronic myelocytic leukemia predominantly sinusoidal, but many exceptions to this rule exist (Fig. 20.43). Specifically, myelocytic leukemia can present as a mass-like lesion (so-called myeloid or myelocytic sarcoma).[521]

Follicular dendritic cell tumor of the liver is extremely rare and shares several morphologic features with inflammatory myofibroblastic tumor (inflammatory pseudotumor) and may be pathogenetically related to it (Fig. 20.44). It is characterized by the presence of a neoplastic component of cells bearing the markers of dendritic follicular cells, such as CD21 and CD35.[522] In contrast to follicular dendritic cell tumors at other sites, there is evidence of EBV clonal proliferation in many of these tumors in the liver.[523–525] However, this is not always the case.[526]

Reactive lymphoid hyperplasia and *nodular lymphoid lesion* refer to benign reactive lymphoid processes that can mimic follicle center cell lymphoma and MALT lymphoma, respectively.[527,528] Some of these lesions have been referred to as *hepatic pseudolymphomas.*[529]

Post-transplant lymphoproliferative disease, which is typically of B-cell type and associated with EBV, may also involve the liver. It usually presents between 6 and 17 months after transplantation as a systemic illness.[530] *Multiple myeloma* can present as a space-occupying mass in the liver (plasmacytoma) or with sinusoidal involvement (Fig. 20.45).[531–532] *Langerhans cell histiocytosis* can involve the liver as an isolated event or as an expression of multisystem disease.[533]

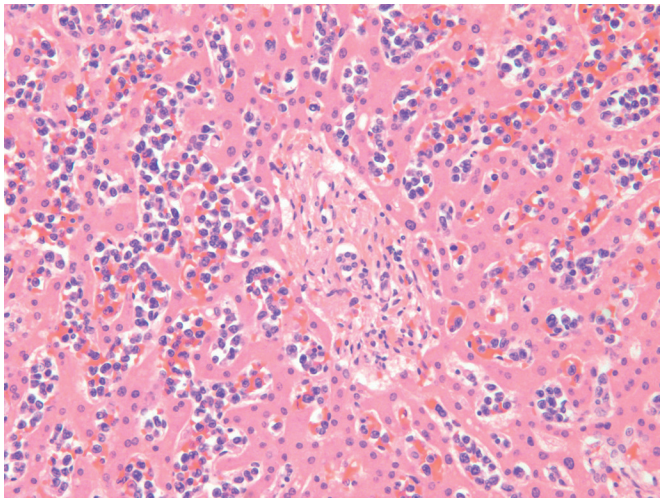

Figure 20.45 Diffuse sinusoidal involvement by neoplastic plasma cells in a case of liver involvement by myeloma.

Other Primary Tumors and Tumorlike Conditions

Squamous cell carcinoma of the liver has been reported as arising from congenital cysts, as a component of teratoma, and in association with intrahepatic lithiasis (hepatolithiasis).[534,535] Most of the latter cases probably represent the squamous component of the adenosquamous variant of cholangiocarcinoma.

Well-differentiated neuroendocrine tumor (carcinoid tumor) in the liver, whether solitary or multiple, is in the overwhelming majority of cases the result of metastatic involvement from a primary tumor, usually located in the gastrointestinal tract. However, on rare occasions, a typical carcinoid tumor has been seen in the liver in the absence of a neoplasm in any other site after prolonged clinical search or at autopsy.[536,537] That being said, primary neuroendocrine tumors (NETs) of the small bowel can be extremely small, and it is difficult to dismiss entirely the possibility of their having been missed during surgery or pathologic dissection. Yet, under these circumstances, it is appropriate to regard the NET as probably originating within the liver. Actually, this occurrence should not be unexpected, in view of the presence of neuroendocrine cells in the normal bile tract and the well-documented occurrence of NETs in the gallbladder and extrahepatic biliary system. As a matter of fact, one of the reported cases of NET of the liver was located within an intrahepatic bile duct.[538] Some of the tumors have been immunoreactive for gastrin and have been accompanied by the Zollinger–Ellison syndrome.[539,540] Others have resulted in symptoms resulting from VIP hyperproduction.[541] Primary hepatic neuroendocrine carcinomas have also been rarely described.[542,543] The occasional occurrence of neuroendocrine differentiation in liver cell carcinoma was discussed previously.

Desmoplastic nested spindle cell tumor (calcifying nested stromal–epithelial tumor) is a recently described primary liver tumor occurring in children and adolescents.[544–546] Grossly, they appear as well-circumscribed lobular white masses measuring up to 30 cm in diameter. Microscopically, they are characterized by the formation of nests and fascicles of bland-looking spindle and epithelioid cells, surrounded by an abundant desmoplastic stroma. Calcification (with psammoma body formation) and ossification are common. Immunohistochemically, the tumor cells react for pankeratin, vimentin, CD57, and WT1, but not neuroendocrine markers (other than NSE). Two of the reported cases were associated with ectopic ACTH production and Cushing syndrome. Most patients do well following tumor excision, but occasional patients can develop recurrence.

Benign and malignant teratomas of the liver are exceptionally rare neoplasms seen predominantly in children but also described in adults.[547] The malignant ones should be distinguished from the mixed type of hepatoblastoma, which is a much more common occurrence (see earlier).[548] Cases of apparently primary *yolk sac tumor* of the liver have been reported as well,[549–551] sometimes combined with hepatoblastoma[552] or with HCC.[553] Primary pure *choriocarcinomas* and *malignant mixed germ cell tumors* have also been described.[554–557]

Other tumors exceptionally involving the liver are *paraganglioma*,[558] pancreatic-type *acinar cell carcinoma*,[559] *glomus tumor*,[560] *benign multicystic mesothelioma*,[561,562] and solid-pseudopapillary (papillary-cystic) tumor of pancreatic type.[563] *Epithelial–myoepithelial carcinoma*, exceptionally reported in the liver, may also be related to the bile duct system.[564]

Tumorlike masses in the liver may result from abscesses, congenital hepatic fibrosis,[565] *ciliated foregut cyst*,[566] and *malakoplakia*.[567]

Metastatic Tumors

Primary malignant tumors of the gallbladder, extrahepatic bile ducts, pancreas, and stomach frequently involve the liver by direct extension. Those from the gallbladder tend to follow the portal tracts.[568] Carcinomas of the large bowel, lung, breast, pancreas, kidney, stomach, and other organs metastasize to the liver with appalling regularity. Sarcomas of soft tissues or internal organs and malignant melanomas also frequently metastasize to this organ. Within the highly receptive liver parenchyma, these metastases often grow to huge dimensions (Fig. 20.46A–D).

In a series of 8455 autopsies of adult patients with malignant tumors, 39% had liver metastases.[569] Only 6% of these were solitary. In 81 patients (2.5%), the metastases were confined to this organ; this phenomenon was seven times more frequent for tumors drained by the portal venous system than for the others.

Grossly, most metastatic tumors in the liver form discrete masses that may locally elevate the capsule. Central necrosis with umbilication occurs in the larger lesions. The absence of visible nodules on the external surface of the liver does not rule out the possibility of metastatic involvement. Sometimes large metastases are completely hidden within the parenchyma.[570] In some instances (particularly with colorectal carcinomas), the metastatic nodules are surrounded by a fibrous pseudocapsule.[571]

A certain correlation exists between the site of the primary tumor and the gross appearance of the liver metastases. Metastases from carcinoma of the large bowel often result in a few large nodules with marked central umbilication; when mucin production is abundant, they tend to undergo marked calcification that may be apparent radiographically. Well-differentiated squamous cell carcinomas result in very soft nodules because of necrosis and keratinization. The nodules from lung or breast carcinoma are usually medium sized, without extensive necrosis or hemorrhage and with early central umbilication. The metastases from gallbladder carcinoma cluster around the gallbladder bed and progressively diminish in size as they move farther into the hepatic parenchyma. Occasionally, extremely small, almost miliary metastatic lesions are seen spreading throughout the liver and even simulating cirrhosis[572]; they are usually the result of tumors from the breast, prostate, or stomach.[573]

It is often said that liver metastases from carcinomas of the right colon tend to be located in the right lobe and those from the left

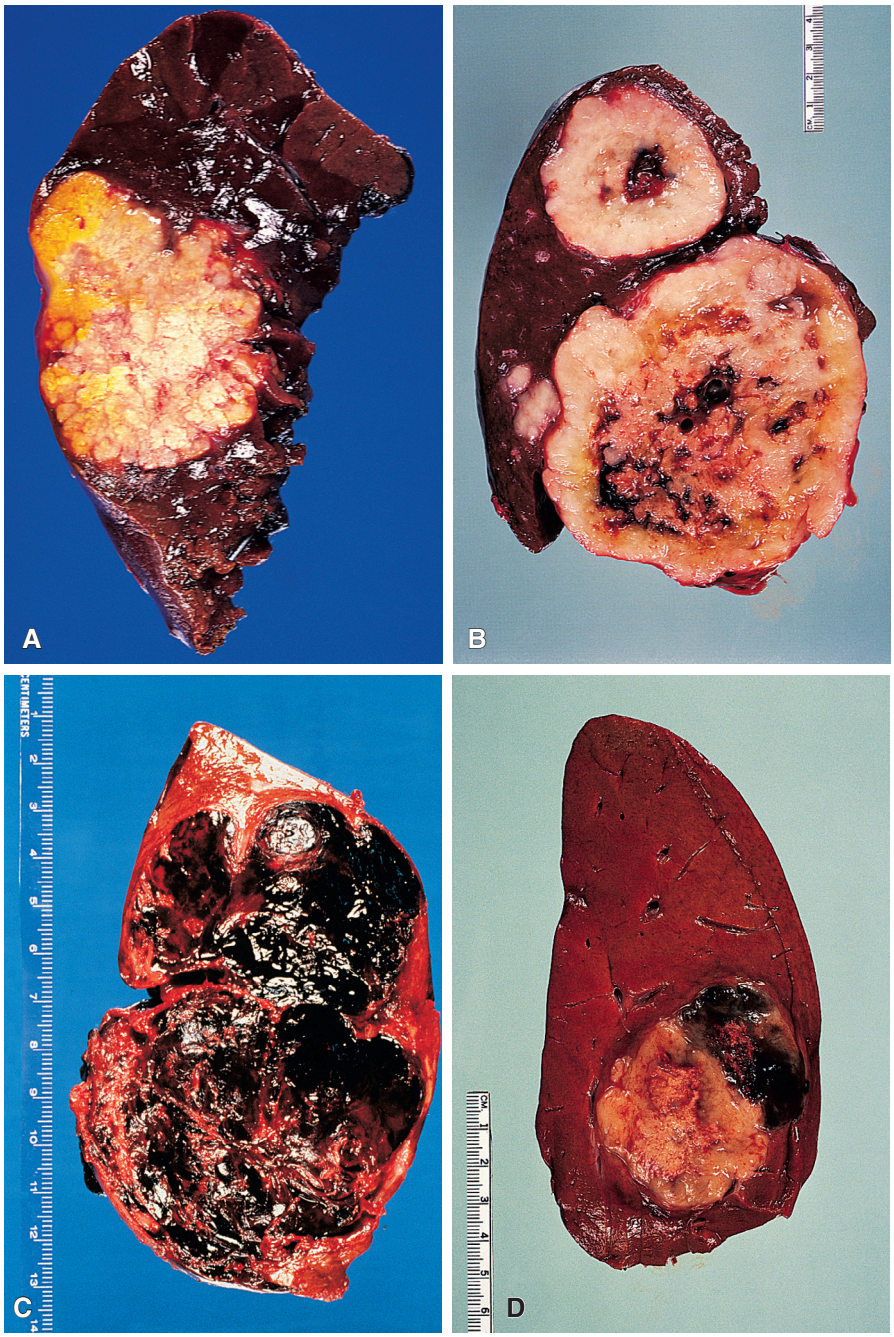

Figure 20.46 **A,** Large bowel carcinoma metastatic to liver. **B,** Leiomyosarcoma metastatic to liver. The primary tumor was located in the stomach. **C,** Choriocarcinoma metastatic to liver. The tumor has the highly hemorrhagic appearance that is characteristic of this entity. **D,** Malignant melanoma metastatic to liver. A portion of the tumor shows black melanin pigmentation.

colon and rectum in the left lobe,[574] but in some series the difference has not reached statistical significance.[575,576] Metastatic breast carcinoma treated with chemotherapy can result in the coarsely lobulated liver appearance known as *hepar lobatum*, traditionally associated with syphilis.[577]

A review of over 10,000 autopsies from Trieste, Italy, and Tokyo-Chiba, Japan, confirmed the often quoted anecdotal observation that metastases are very rare in cirrhotic livers; whatever the reason for this may be (nonreceptive soil for the metastatic growth or simply the fact that most cirrhotic patients do not live long enough to develop them), the conclusion can be drawn that the large majority of malignant tumors occurring in cirrhotic livers are primary.[578]

Many benign lesions may have a gross appearance similar to that of metastatic carcinoma. This is true of fibrous scars, healed granulomas, bile duct hamartoma and adenoma, and nodular hyperplasia. Therefore *it is imperative that a microscopic confirmation be obtained in every patient in whom lesions suggestive of liver metastases are detected*

during surgery, regardless of how typical they might seem grossly to the surgeon or the pathologist. As discussed previously, the microscopic differential diagnosis with primary liver tumors can be difficult. A particularly treacherous but fortunately very rare situation is that of the hepatoid carcinoma of stomach or other sites that metastasizes to the liver.[579]

Resection of hepatic metastases is particularly worthwhile in patients with metastatic carcinoid tumor because of the dramatic amelioration of the symptoms of the carcinoid syndrome that is often achieved.[580] It is also done frequently for metastases of colorectal carcinoma, as surgical resection offers the only long-term cure; recent studies indicate 5-year survival rates of up to 58%.[581,582]

References

1. Hartleb M, Gutkowski K, Milkiewicz P. Nodular regenerative hyperplasia: evolving concepts on underdiagnosed cause of portal hypertension. *World J Gastroenterol*. 2011;17:1400-1409.
2. Wanless IR. Micronodular transformation (nodular regenerative hyperplasia) of the liver: a report of 64 cases among 2500 autopsies and a new classification of bengin hepatocellular nodules. *Hepatology*. 1990;11:787-797.
3. Fuss IJ, Friend J, Yang Z, et al. Nodular regenerative hyperplasia in common variable immunodeficiency. *J Clin Immunol*. 2013;33:748-758.
4. Al-Mukhaizeem KA, Rosenberg A, Sherker AH. Nodular regenerative hyperplasia of the liver: an under-recognized cause of portal hypertension in hematological disorders. *Am J Hematol*. 2004;75:225-230.
5. Ghabril M, Vuppalanchi R. Drug-induced nodular regenerative hyperplasia. *Semin Liver Dis*. 2014;34:240-245.
6. Wicherts DA, de Haas RJ, Sebagh M, et al. Regenerative nodular hyperplasia of the liver related to chemotherapy: impact on outcome of liver surgery for colorectal metastatses. *Ann Surg Oncol*. 2011;18:659-669.
7. Al-Hamoudi WK, Pasieka JL, Urbanski SJ, Lee SS. Hepatic nodular regenerative hyperplasia in a patient with advanced carcinoid tumor. *Eur J Gastroenterol Hepatol*. 2009;21:1083-1085.
8. Kobayashi S, Saito K, Nakanuma Y. Nodular regenerative hyperplasia of the liver in hepatocellular carcinoma. An autopsy study. *J Clin Gastroenterol*. 1993;16:155-159.
9. Barge S, Grando V, Mault JC, et al. Prevalence and clinical significance of nodular regenerative hyperplasia in liver biopsies. *Liver Int*. 2016;36:1059-1066.
10. Jharap B, van Asseldonk DP, de Boer NKH, et al. Diagnosing nodular regenerative hyperplasia of the liver is thwarted by low interobserver agreement. *PLoS ONE*. 2015;10:e0120299.
11. Wanless IR, Lentz JS, Roberts EA. Partial nodular transformation of liver in an adult with persistent ductus venosus. Review with hypothesis on pathogenesis. *Arch Pathol Lab Med*. 1985;109:427-432.
12. Ibarrola C, Colina F. Clinicopathologic features of nine cases of noncirrhotic portal hypertension: current definitions and criteria are inadequate. *Histopathology*. 2003;42:251-264.
13. Hoso M, Terada T, Nakanuma Y. Partial nodular transformation of liver developing around intrahepatic portal venous emboli of hepatocellular carcinoma. *Histopathology*. 1996;29:580-582.
14. Nguyen BN, Flejou JF, Terris B, et al. Focal nodular hyperplasia of the liver: a comprehensive pathologic study of 305 lesions and recognition of new histologic forms. *Am J Surg Pathol*. 1999;23(12):1441-1454.
15. Stocker JT, Ishak KG. Focal nodular hyperplasia of the liver: a study of 21 pediatric cases. *Cancer*. 1981;48(2):336-345.
16. Rahili A, Cai J, Trastour C, et al. Spontaneous rupture and hemorrhage of hepatic focal nodular hyperplasia in lobus caudatus. *J Hepatobiliary Pancreat Surg*. 2005;12:138-142.
17. Wanless IR, Albrecht S, Bilbao J, et al. Multiple focal nodular hyperplasia of the liver associated with vascular malformations of various organs and neoplasia of the brain: a new syndrome. *Mod Pathol*. 1989;2(5):456-462.
18. Scalori A, Tavani A, Gallus S, et al. Oral contraceptives and the risk of focal nodular hyperplasia of the liver: a case control study. *Am J Obstet Gynecol*. 2002;186:195-197.
19. Mathieu D, Kobeiter H, Maison P, et al. Oral contraceptive use and focal nodular hyperplasia of the liver. *Gastroenterology*. 2000;118:560-564.
20. Karhunen PJ, Penttila A, Liesto K, et al. Occurrence of benign hepatocellular tumors in alcoholic men. *Acta Pathol Microbiol Immunol Scand [A]*. 1986;94(2):141-147.
21. Ibarrola C, Castellano VM, Colina F. Focal hyperplastic hepatocellular nodules in hepatic venous outflow obstruction: a clinicopathological study of four patients and 24 nodules. *Histopathology*. 2004;44(2):172-179.
22. Ra SH, Kaplan JB, Lassman CR. Focal nodular hyperplasia after orthotopic liver transplantation. *Liver Transpl*. 2010;16(1):98-103.
23. Quaglia A, Tibballs J, Grasso A, et al. Focal nodular hyperplasia-like areas in cirrhosis. *Histopathology*. 2003;42(1):14-21.
24. Cai YR, Gong L, Teng XY, et al. Clonality and allelotype analyses of focal nodular hyperplasia compared with hepatocellular adenoma and carcinoma. *World J Gastroenterol*. 2009;15:4695-4708.
25. Zheng S, Cummings OW, Saxena R, et al. Clonality and TP53 mutation analysis of focal nodular hyperplasia of the liver. *Am J Clin Pathol*. 2010;134:65-70.
26. Khanna M, Ramanathan S, Fasih N, et al. Current updates on the molecular genetics and magnetic resonance imaging of focal nodular hyperplasia and hepatocellular adenoma. *Insights Imaging*. 2015;6:347-362.
27. Mahfouz AE, Hamm B, Taupitz M, Wolf KJ. Hypervascular liver lesions: differentiation of focal nodular hyperplasia from malignant tumors with dynamic gadolinium-enhanced MR imaging. *Radiology*. 1993;186(1):133-138.
28. Vilgrain V, Flejou JF, Arrive L, et al. Focal nodular hyperplasia of the liver: MR imaging and pathologic correlation in 37 patients. *Radiology*. 1992;184(3):699-703.
29. Makhlouf HR, Abdul-Al HM, Goodman ZD. Diagnosis of focal nodular hyperplasia of the liver by needle biopsy. *Hum Pathol*. 2005;36(11):1210-1216.
30. Ahmad I, Iyer A, Marginean CE, et al. Diagnostic use of cytokeratins, CD34, and neuronal cell adhesion molecule staining in focal nodular hyperplasia and hepatic adenoma. *Hum Pathol*. 2009;40(5):726-734.
31. Masood S, West AB, Barwick KW. Expression of steroid hormone receptors in benign hepatic tumors. An immunocytochemical study. *Arch Pathol Lab Med*. 1992;116(12):1355-1359.
32. Chandrasegaram MD, Shah A, Chen JW, et al. Oestrogen hormone receptors in focal nodular hyperplasia. *HPB (Oxford)*. 2015;17:502-507.
33. Bioulac-Sage P, Balabaud C, Wanless IR. Diagnosis of focal nodular hyperplasia: not so easy. *Am J Surg Pathol*. 2001;25(10):1322-1325.
34. Edmondson HA, Henderson B, Benton B. Liver-cell adenomas associated with use of oral contraceptives. *N Engl J Med*. 1976;294(9):470-472.
35. Barthelmes L, Tait IS. Liver cell adenoma and liver cell adenomatosis. *HPB (Oxford)*. 2005;7:186-196.
36. Agrawal S, Agarwal S, Arnason T, et al. Management of hepatocellular adenomas; recent advances. *Clin Gastroenterol Hepatol*. 2015;13:1221-1230.
37. Velazquez I, Alter BP. Androgens and liver tumors: Fanconi's anemia and non-Fanconi's conditions. *Am J Hematol*. 2004;77:257-267.
38. Tazawa K, Yasuda M, Ohtani Y, et al. Multiple hepatocellular adenomas associated with long-term carbamazepine. *Histopathology*. 1999;35:92-94.
39. Sakellariou S, Al-Hussaini H, Scalori A, et al. Hepatocellular adenoma in glycogen storage disorder type I: a clinicopathologic and molecular study. *Histopathology*. 2012;60(6B):E58-E65.
40. Alshak NS, Cocjin J, Podesta L, et al. Hepatocellular adenoma in glycogen storage disease type IV. *Arch Pathol Lab Med*. 1994;118(1):88-91.
41. Coire CI, Qizilbash AH, Castelli MF. Hepatic adenomata in type Ia glycogen storage disease. *Arch Pathol Lab Med*. 1987;111(2):166-169.
42. Resnick MB, Kozakewich HP, Perez-Atayde AR. Hepatic adenoma in the pediatric age group. Clinicopathological observations and assessment of cell proliferative activity. *Am J Surg Pathol*. 1995;19(10):1181-1190.
43. Khoo US, Nicholls JM, Lee JS, et al. Cholestatic liver cell adenoma in a child with hirsutism and elevated serum levels of cortisol and ACTH. *Histopathology*. 1994;25(6):586-588.
44. Ameriks JA, Thompson NW, Frey CF, et al. Hepatic cell adenomas, spontaneous liver rupture, and oral contraceptives. *Arch Surg*. 1975;110(5):548-557.
45. Wheeler DA, Edmondson HA, Reynolds TB. Spontaneous liver cell adenoma in children. *Am J Clin Pathol*. 1986;85(1):6-12.
46. Chiorean L, Cui XW, Tannapfel A, et al. Benign liver tumors in pediatric patients-review with emphasis on imaging features. *World J Gastroenterol*. 2015;21:8541-8561.
47. Vijay A, Elaffandi A, Khalaf H. Hepatocellular adenoma: an update. *World J Hepatol*. 2015;25:2603-2609.
48. Bioulac-Sage P, Rebouissou S, Thomas C, et al. Hepatocellular adenoma subtype classification using molecular markers and immunohistochemistry. *Hepatology*. 2007;46:740-748.
49. Zucman-Rossi J, Jeannot E, Nhieu JT, et al. Genotype-phenotype correlation in hepatocellular adenoma: new classification

and relationship with HCC. *Hepatology*. 2006;43(3):515-524.
50. Jeannot E, Mellottee L, Bioulac-Sage P, et al. Spectrum of HNF1A somatic mutations in hepatocellular adenoma differs from that in patients with MODY3 and suggests genotoxic damage. *Diabetes*. 2010;59(7):1836-1844.
51. Bioulac-Sage P, Cubel G, Balabaud C, Zucman-Rossi J. Revisiting the pathology of resected benign hepatocellular nodules using new immunohistochemical markers. *Semin Liver Dis*. 2011;31:91-103.
52. Chen YW, Jeng YM, Yeh SH, Chen PJ. P53 gene and Wnt signaling in benign neoplasms: beta-catenin mutations in hepatic adenoma but not in focal nodular hyperplasia. *Hepatology*. 2002;36(4 Pt 1):927-935.
53. Paradis V, Benzekri A, Dargere D, et al. Telangiectatic focal nodular hyperplasia: a variant of hepatocellular adenoma. *Gastroenterology*. 2004;126(5):1323-1329.
54. Salisbury JR, Portmann BC. Oncocytic liver cell adenoma. *Histopathology*. 1987;11(5):533-539.
55. Heffelfinger S, Irani DR, Finegold MJ. "Alcoholic hepatitis" in a hepatic adenoma. *Hum Pathol*. 1987;18(7):751-754.
56. Hasan N, Coutts M, Portmann B. Pigmented liver cell adenoma in two male patients. *Am J Surg Pathol*. 2000;24(10):1429-1432.
57. Bieze M, Bioulac-Sage P, Verheij J, et al. Hepatocellular adenomas associated with hepatic granulomas: experience in five cases. *Case Rep Gastroenterol*. 2012;6:677-683.
58. Torbenson M, Lee JH, Choti M, et al. Hepatic adenomas: analysis of sex steroid receptor status and the Wnt signaling pathway. *Mod Pathol*. 2002;15(3):189-196.
59. Nguyen TB, Roncalli M, Di Tommaso L, Kakar S. Combined use of heat-shock protein 70 and glutamine synthetase is useful in the distinction of typical hepatocellular adenoma from atypical hepatocellular neoplasms and well-differentiated hepatocellular carcinoma. *Mod Pathol*. 2016;29:283-292.
60. Liu L, Shah SS, Naini BV, et al. Immunostains used to subtype hepatic adenomas do not distinguish hepatic adenomas from hepatocellular carcinomas. *Am J Surg Pathol*. 2016;40:1062-1069.
61. Ferrell LD. Hepatocellular carcinoma arising in a focus of multilobular adenoma. A case report. *Am J Surg Pathol*. 1993;17(5):525-529.
62. Micchelli ST, Vivekanandan P, Boitnott JK, et al. Malignant transformation of hepatic adenomas. *Mod Pathol*. 2008;21(4):491-497.
63. Graham RP, Terraccianao LM, Meves A, et al. Hepatic adenomas with synchronous or metachronous fibrolamellar carcinomas: both are characterized by LFABP loss. *Mod Pathol*. 2016;29:607-615.
64. Reznik Y, Dao T, Coutant R, et al. Hepatocyte nuclear factor-1 alpha gene inactivation: cosegregation between liver adenomatosis and diabetes phenotypes in two maturity-onset diabetes of the young (MODY)3 families. *J Clin Endocrinol Metab*. 2004;89:1476-1480.
65. Bacq Y, Jacquemin E, Balabaud C, et al. Familial liver adenomatosis associated with hepatocyte nuclear factor 1alpha inactivation. *Gastroenterology*. 2003;125(5):1470-1475.
66. Ferrell LD, Crawford JM, Dhillon AP, et al. Proposal for standardized criteria for the diagnosis of benign, borderline, and malignant hepatocellular lesions arising in chronic advanced liver disease. *Am J Surg Pathol*. 1993;17(11):1113-1123.
67. Park YN. Update on precursor and early lesions of hepatocellular carcinoma. *Arch Pathol Lab Med*. 2011;135:704-715.
68. Park YN, Roncalli M. Large liver cell dysplasia: a controversial entity. *J Hepatol*. 2006;45:734-743.
69. Ganne-Carrie N, Chastang C, Chapel F, et al. Predictive score for the development of hepatocellular carcinoma and additional value of liver large cell dysplasia in western patients with cirrhosis. *Hepatology*. 1996;23:1112-1118.
70. Koo JS, Kim H, Park BK, et al. Predictive value of liver cell dysplasia for development of hepatocellular carcinoma in patients with chronic hepatitis B. *J Clin Gastroenterol*. 2008;42:738-743.
71. Niu ZS, Niu XJ, Wang WH, Zhao J. Latest developments in precancerous lesions of hepatocellular carcinoma. *World J Gastroenterol*. 2016;22:3305-3314.
72. Choo SP, Tan WL, Goh BK, et al. Comparison of hepatocellular carcinoma in eastern versus western populations. *Cancer*. 2016;122:3430-3446. doi:10.1002/cncr.30327.
73. El-Serag HB. Hepatocellular carcinoma. *N Engl J Med*. 2011;365:1118-1127.
74. El-Serag H, Rudolph KL. Hepatocellular carcinoma: epidemiology and molecular carcinogenesis. *Gastroenterology*. 2007;132:2557-2576.
75. Farhi DC, Shikes RH, Murari PJ, Silverberg SG. Hepatocellular carcinoma in young people. *Cancer*. 1983;52(8):1516-1525.
76. Klein WM, Molmenti EP, Colombani PM, et al. Primary liver carcinoma arising in people younger than 30 years. *Am J Clin Pathol*. 2005;124(4):512-518.
77. Lack EE, Neave C, Vawter GF. Hepatocellular carcinoma. Review of 32 cases in childhood and adolescence. *Cancer*. 1983;52(8):1510-1515.
78. Ni YH, Chang MH, Hsu HY, et al. Hepatocellular carcinoma in childhood. Clinical manifestations and prognosis. *Cancer*. 1991;68(8):1737-1741.
79. Kovalic JJ, Thomas PR, Beckwith JB, et al. Hepatocellular carcinoma as second malignant neoplasms in successfully treated Wilms' tumor patients. A National Wilms' Tumor Study report. *Cancer*. 1991;67(2):342-344.
80. Lai CL, Lam KC, Wong KP, et al. Clinical features of hepatocellular carcinoma: review of 211 patients in Hong Kong. *Cancer*. 1981;47:2746-2755.
81. Chen MF, Jan YY, Jeng LB, et al. Obstructive jaundice secondary to ruptured hepatocellular carcinoma into the common bile duct. Surgical experiences of 20 cases. *Cancer*. 1994;73(5):1335-1340.
82. Chu CW, Hwang SJ, Luo JC, et al. Manifestations of hypercholesterolaemia, hypoglycaemia, erythrocytosis, and hypercalcaemia in patients with hepatocellular carcinoma: a report of two cases. *J Gastroenterol Hepatol*. 1999;14:807-810.
83. Ikeda T, Tozuka S, Hasumura Y, Takeuchi J. Prostaglandin-E-producing hepatocellular carcinoma with hypercalcemia. *Cancer*. 1988;61(9):1813-1814.
84. Dahan MH, Kastell P. Fibrolamellar hepatic carcinoma with a presentation similar to that of septic pregnancy. A case report. *J Reprod Med*. 2002;47:47-49.
85. Primack A, Wilson J, O'Connor GT, et al. Hepatocellular carcinoma with the carcinoid syndrome. *Cancer*. 1971;27(5):1182-1189.
86. Gralnick HR, Givelber H, Abrams E. Dysfibrinogenemia associated with hepatoma. Incresaed carbohydrate content of the fibrinogen molecule. *N Engl J Med*. 1978;299:221-226.
87. Song PP, Xia JF, Inagaki Y, et al. Controversies regarding and persepctives on clinical utility of biomarkers in hepatocellular carcinoma. *World J Gastroenterol*. 2016;22:262-274.
88. Anthony PP. Hepatocellular carcinoma: an overview. *Histopathology*. 2001;39:109-118.
89. Yang HI, Lu SN, Liaw YF, et al. Hepatitis B e antigen and the risk of hepatocellular carcinoma. *N Engl J Med*. 2002;347(3):168-174.
90. Levrero M, Zucman-Rossi J. Mechanisms of HBV-induced hepatocellular carcinoma. *J Hepatol*. 2016;64(1 suppl):S84-S101.
91. Feitelson MA, Reis HM, Liu J, et al. Hepatitis B virus X antigen (HBxAg) and cell cycle control in chronic infection and hepatocarcinogenesis. *Front Biosci*. 2005;10:1559-1572.
92. Paterlini P, Gerken G, Nakajima E, et al. Polymerase chain reaction to detect hepatitis B virus DNA and RNA sequences in primary liver cancers from patients negative for hepatitis B surface antigen. *N Engl J Med*. 1990;323(2):80-85.
93. Koike K. Molecular bass of hepatitis C virus-associated hepatocarcinogenesis: lessons from animal model studies. *Clin Gastroenterol Hepatol*. 2005;3(10 suppl 2):S132-S135.
94. Wong CR, Nguyen MH, Lim JK. Hepatocellular carcinoma in patients with non-alcoholic fatty liver disease. *World J Gastroenterol*. 2016;22:8294-8303.
95. Younossi ZM, Otgonsuren M, Henry L, et al. Association of nonalcoholic fatty liver disease (NAFLD) with hepatocellular carcinoma (HCC) in the United States from 2004 to 2009. *Hepatology*. 2015;62:1723-1730.
96. Smoron GL, Battifora HA. Thorotrast-induced hepatoma. *Cancer*. 1972;30(5):1252-1259.
97. Alpert ME, Davidson CS. Mycotoxins. A possible cause of primary carcinoma of the liver. *Am J Med*. 1969;46(3):325-329.
98. Kew MC. Aflatoxins as a cause of hepatocellular carcinoma. *J Gastrointestin Liver Dis*. 2013;22:305-310.
99. Kesler T, Sandhu RS, Krishnamoorthy S. Hepatology: hepatocellular carcinoma in a young man secondary to androgenic anabolic steroid abuse. *J Gastroenterol Hepatol*. 2014;29:1852.
100. Hardt A, Stippel D, Odenthal M, et al. Development of hepatocellular carcinoma associated with anabolic androgenic steroid abuse in a young bodybuilder: a case report. *Case Rep Pathol*. 2012;2012:195607. doi:10.1155/2012/195607.
101. Fiel MI, Min A, Gerber MA, et al. Hepatocellular carcinoma in long-term oral contraceptive use. *Liver*. 1996;16: 372-376.
102. An N. Oral contraceptives use and liver cancer risk: a dose-response meta-analysis of observational studies. *Medicine (Baltimore)*. 2015;94(43):e1619. doi:10.1097/MD.000000000001619.
103. Seda Neto J, Leite KM, Porta A, et al. HCC prevalence and histopathological findings in liver explants of paitents with hereditary tyrosinemia type 1. *Pediatr Blood Cancer*. 2014;61:1584-1589.
104. Weinberg AG, Mize CE, Worthen HG. The occurrence of hepatoma in the chronic form of hereditary tyrosinemia. *J Pediatr*. 1976;88(3):434-438.
105. Dragani TA. Risk of HCC: genetic heterogeneity and complex genetics. *J Hepatol*. 2010;52:252-257.
106. Lieberman J, Silton RM, Agliozzo CM, McMahon J. Hepatocellular carcinoma and intermediate alpha1-antitrypsin deficiency (MZ phenotype). *Am J Clin Pathol*. 1975;64(3):304-310.
107. Eriksson S, Carlson J, Velez R. Risk of cirrhosis and primary liver cancer in alpha 1-antitrypsin deficiency. *N Engl J Med*. 1986;314(12):736-739.
108. Zhou H, Fischer HP. Liver carcinoma in PiZ alpha-1-antitrypsin deficiency. *Am J Surg Pathol*. 1998;22(6):742-748.
109. Weinstein S, Scottolini AG, Loo SY, et al. Ataxia telangiectasia with hepatocellular carcinoma in a 15-year-old girl and studies of

her kindred. *Arch Pathol Lab Med*. 1985;109(11):1000-1004.
110. Franco LM, Krishnamurthy V, Bali D, et al. Hepatocellular carcinoma in glycogen storage disease type 1a: a case series. *J Inherit Metab Dis*. 2005;28:153-162.
111. Ye Q, Qian BX, Yin WL, et al. Association bewteen the HFE C282Y, H63D polymorphisms and the risks of non-alcoholic fatty liver disease, liver cirrhosis and hepatocellular carcinoma: an updated systematic review and meta-analysis of 5758 cases and 14,741 controls. *PLoS ONE*. 2016;11(9):e0163423.
112. Hirzel AC, Madrazo B, Rojas CP. Two rare cases of hepatocellular carcinoma after Kasai procedure for biliary atresia: a recommendation for close follow-up. *Case Rep Pathol*. 2015;2015:982679.
113. Dahms BB. Hepatoma in familial cholestatic cirrhosis of childhood: its occurrence in twin brothers. *Arch Pathol Lab Med*. 1979;103(1):30-33.
114. Ugarte N, Gonzalez-Crussi F. Hepatoma in siblings with progressive familial cholestatic cirrhosis of childhood. *Am J Clin Pathol*. 1981;76(2):172-177.
115. Kinugasa H, Nouso K, Kobayashi Y, et al. Hepatocellular carcinoma occurring in hepatobiliary fibropolycystic disease. *Hepatol Res*. 2011;41:277-281.
116. Nagasue N, Yukaya H, Hamada T, et al. The natural history of hepatocellular carcinoma. A study of 100 untreated cases. *Cancer*. 1984;54(7):1461-1465.
117. Jakate S, Yabes A, Giusto D, et al. Diffuse cirrhosis-like hepatocellular carcinoma: a clinically and radiographically undetected variant mimicking cirrhosis. *Am J Surg Pathol*. 2010;34(7):935-941.
118. Okuda K, Musha H, Nakajima Y, et al. Clinicopathologic features of encapsulated hepatocellular carcinoma: a study of 26 cases. *Cancer*. 1977;40(3):1240-1245.
119. Ishizake M, Ashida K, Higashi T, et al. The eformation of capsule and septum in human hepatocellular carcinoma. *Virchows Arch*. 2001;438:574-580.
120. Anthony PP, James K. Pedunculated hepatocellular carcinoma. Is it an entity? *Histopathology*. 1987;11(4):403-414.
121. Horie Y, Katoh S, Yoshida H, et al. Pedunculated hepatocellular carcinoma. Report of three cases and review of literature. *Cancer*. 1983;51(4):746-751.
122. Tarantino L, Francica G, Sordelli I, et al. Diagnosis of benign and malignant portal vein thrombosis in cirrhotic patients with hepatocellular carcinoma: color Doppler US, contrast-enhanced US, and fine-needle biopsy. *Abdom Imaging*. 2006;31:537-544.
123. Schlageter M, Terracciano LM, D'angelo S, Sorrentino P. Histopathology of hepatocellular carcinoma. *World J Gastroenterol*. 2014;20:15955-15964.
124. Kondo Y, Nakajima T. Pseudoglandular hepatocellular carcinoma. A morphogenetic study. *Cancer*. 1987;60(5):1032-1037.
125. Quaglia A, Etessami N, Sim R, et al. Vascular invasion and herniation by hepatocellular carcinoma in cirrhosis: a wolf in sheep's clothing? *Arch Pathol Lab Med*. 2005;129(5):639-644.
126. Swanson BJ, Yearsley MM, Marsh W, Frankel WL. A triple stain of reticulin, glypican-3, and glutamine synthetase: a useful aid in the diagnosis of liver lesions. *Arch Pathol Lab Med*. 2015;139:537-542.
127. Dekemezian R, Sneige N, Popok S, Ordonez NG. Fine needle aspiration cytology of pediatric patients with primary hepatic tumors: a compariative study of two hepatoblastomas and a liver cell carcinoma. *Diagn Cytopathol*. 1988;4:162-168.
128. Nayar R, Bourtsos E, DeFrias DV. Hyaline globules in renal cell carcinoma and hepatocellular carcinoma. A clue or a diagnostic pitfall on fine-needle aspiration? *Am J Clin Pathol*. 2000;114:576-582.
129. Haratake J, Horie A, Takeda S, et al. Tissue copper content in primary and metastatic liver cancers. *Acta Pathol Jpn*. 1987;37(2):231-238.
130. Moon WS, Yu HC, Chung MJ, et al. Pale bodies in hepatocellular carcinoma. *J Korean Med Sci*. 2000;15:516-520.
131. Stromeyer FW, Ishak KG, Gerber MA, Mathew T. Ground-glass cells in hepatocellular carcinoma. *Am J Clin Pathol*. 1980;74(3):254-258.
132. Stumptner C, Heid H, Fuchsbichler A, et al. Analysis of intracytoplasmic hyaline bodies in a hepatocellular carcinoma. Demonstration of p62 as major constituent. *Am J Pathol*. 1999;154(6):1701-1710.
133. Roth JA, Berman E, Befeler D, Johnson FB. A black hepatocellular carcinoma with Dubin-Johnson-like pigment and Mallory bodies: a histochemical and ultrastructural study. *Am J Surg Pathol*. 1982;6(4):375-382.
134. Chan AWH, Yu S, Yu YH, et al. Steatotic hepatocellular carcinoma: a variant associated with metabolic factors and late tumour relapse. *Histopathology*. 2016;69(6):971-984. doi:10.1111/his.13029.
135. The International Consensus Group for Hepatocellular Neoplasia. Pathologic diagnosis of early hepatocellular carcinoma: a report of the international consensus group for hepatocellular neoplsia. *Hepatology*. 2009;49:658-664.
136. Shafizadeh N, Kakar S. Diagnosis of well-differentiated hepatocellular lesions: role of immunohistochemistry and other ancillary techniques. *Adv Anat Pathol*. 2011;18:438-445.
137. Roskams T, Kojiro M. Pathology of early hepatocellular carcinoma: conventional and molecular diagnosis. *Semin Liver Dis*. 2010;30:17-25.
138. Park YN, Kojiro M, Di Tommaso L, et al. Ductular reaction is helpful in defining early stromal invasion, small hepatocellular caricnomas, and dysplastic nodules. *Cancer*. 2007;109:915-923.
139. Di Tommaso L, Franchi G, Park YN, et al. Diagnostic value of HSP70, glypican 3, and glutamine synthetase in hepatocellular nodules in cirrhosis. *Hepatology*. 2007;45:725-734.
140. Butler SL, Dong H, Cardona D, et al. The antigen for Hep par 1 antibody is the urea cycle enzyme carbamoyl phosphate synthetase 1. *Lab Invest*. 2008;88:78-88.
141. Wennerberg AE, Nalesnik MA, Coleman WB. Hepatocyte paraffin 1: a monoclonal antibody that reacts with hepatocytes and can be used for differential diagnosis of hepatic tumors. *Am J Pathol*. 1993;143(4):1050-1054.
142. Fan Z, van de Rijn M, Montgomery K, Rouse RV. Hep par 1 antibody stain for the differential diagnosis of hepatocellular carcinoma: 676 tumors tested using tissue microarrays and conventional tissue sections. *Mod Pathol*. 2003;16(2):137-144.
143. Minervini MI, Demetris AJ, Lee RG, et al. Utilization of hepatocyte-specific antibody in the immunocytochemical evaluation of liver tumors. *Mod Pathol*. 1997;10(7):686-692.
144. Lugli A, Tornillo L, Mirlacher M, et al. Hepatocyte paraffin 1 expression in human normal and neoplastic tissues: tissue microarray analysis on 3,940 tissue samples. *Am J Clin Pathol*. 2004;122(5):721-727.
145. Kakar S, Gown AM, Goodman ZD, Ferrell LD. Best practices in diagnostic immunohistochemistry: hepatocellular carcinoma versus metastatic neoplasms. *Arch Pathol Lab Med*. 2007;131(11): 1648-1654.
146. Maitra A, Murakata LA, Albores-Saavedra J. Immunoreactivity for hepatocyte paraffin 1 antibody in hepatoid adenocarcinomas of the gastrointestinal tract. *Am J Clin Pathol*. 2001;115(5):689-694.
147. Steen S, Wolin E, Geller SA, Colquhoun S. Primary hepatocellular carcinoma ("hepatoid" carcinoma) of the pancreas: a case report and review of the literature. *Clin Case Rep*. 2013;1:66-71.
148. Yan BC, Gong C, Song J, et al. Arginase-1: a new immunohistochemical marker of hepatocytes and hepatocellular neoplasms. *Am J Surg Pathol*. 2010;34(8):1147-1154.
149. Geramizadeh B, Seirfar N. Diagnostic value of argainse-1 and glypican-3 in differential diagnosis of hepatocellular carcinoma, cholangiocarcinoma, and metastatic carcinoma of liver. *Hepat Mon*. 2015;15(7):e30336.
150. Wang HL, Anatelli F, Zhai QJ, et al. Glypican-3 as a useful diagnostic marker that distinguishes hepatocellular carcinoma from benign hepatocellular mass lesions. *Arch Pathol Lab Med*. 2008;132(11):1723-1728.
151. Wang XY, Degos F, Dubois S, et al. Glypican-3 expression in hepatocellular tumors: diagnostic value for preneoplastic lesions and hepatocellular carcinomas. *Hum Pathol*. 2006;37(11):1435-1441.
152. Shafizadeh N, Ferrell LD, Kakar S. Utility and limitations of glypican-3 expression for the diagnosis of hepatpocellular carcinoma at both ends of the differentiation spectrum. *Mod Pathol*. 2008;21:1011-1018.
153. Coston WM, Loera S, Lau SK, et al. Distinction of hepatocellular carcinoma from benign hepatic mimickers using Glypican-3 and CD34 immunohistochemistry. *Am J Surg Pathol*. 2008;32(3):433-444.
154. Libbrecht L, Severi T, Cassiman D, et al. Glypican-3 expression distinguishes small hepatocellular carcinomas from cirrhosis, dysplastic nodules, and focal nodular hyperplasia-like nodules. *Am J Surg Pathol*. 2006;30(11):1405-1411.
155. Kinoshita Y, Tanaka S, Souzaki R, et al. Glypican 3 expression on pediatric malignant solid tumors. *Eur J Pediatr Surg*. 2015;25:138-144.
156. Levy M, Trivedi A, Zhang J, et al. Expression of glypican-3 in undifferentiated embryonal sarcoma and mesenchymal hamartoma of the liver. *Hum Pathol*. 2012;43:695-701.
157. Baumhoer D, Tornillo L, Stadlmann S, et al. Glypican 3 expression in human nonnoeplastic, preneoplastic, and neoplastic tissues. A tissue microarray analysis of 4387 tissue samples. *Am J Clin Pathol*. 2008;129:899-906.
158. Wee A. Diagnostic utility of immunohistochemistry in hepatocellular carcinoma, its variants and their mimics. *Appl Immunohistochem Mol Morpholol*. 2006;14(3):266-272.
159. Ma CK, Zarbo RJ, Frierson HF Jr, Lee MW. Comparative immunohistochemical study of primary and metastatic carcinomas of the liver. *Am J Clin Pathol*. 1993;99(5):551-557.
160. Borscheri N, Roessner A, Rocken C. Canalicular immunostaining of neprilysin (CD10) as a diagnostic marker for hepatocellular carcinomas. *Am J Surg Pathol*. 2001;25(10):1297-1303.
161. Lagana SM, Salamao M, Remotti HE, et al. Bile salt export pump: a sensitive and specific immunohistochemical marker of hepatocellular carcinoma. *Histopathology*. 2015;66:598-602.
162. Morrison C, Marsh W Jr, Frankel WL. A comparison of CD10 to pCEA, MOC-31, and hepatocyte for the distinction of malignant tumors in the liver. *Mod Pathol*. 2002;15(12):1279-1298.

163. Porcell AI, De Young BR, Proca DM, Frankel WL. Immunohistochemical analysis of hepatocellular and adenocarcinoma in the liver: MOC31 compares favorably with other putative markers. *Mod Pathol*. 2000;13(7):773-778.
164. Pan CC, Chen PC, Tsay SH, Chiang H. Cytoplasmic immunoreactivity for thyroid transcription factor-1 in hepatocellular carcinoma: a comparative immunohistochemical analysis of four commercial antibodies using a tissue array technique. *Am J Clin Pathol*. 2004;121(3):343-349.
165. Wieczorek TJ, Pinkus JL, Glickman JN, Pinkus GS. Comparison of thyroid transcription factor-1 and hepatocyte antigen immunohistochemical analysis in the differential diagnosis of hepatocellular carcinoma, metastatic adenocarcinoma, renal cell carcinoma, and adrenal cortical carcinoma. *Am J Clin Pathol*. 2002;118(6):911-921.
166. Kakar S, Muir T, Murphy LM, et al. Immunoreactivity of Hep Par 1 in hepatic and extrahepatic tumors and its correlation with albumin in situ hybridization in hepatocellular carcinoma. *Am J Clin Pathol*. 2003;119(3):361-366.
167. Krishna M, Lloyd RV, Batts KP. Detection of albumin messenger RNA in hepatic and extrahepatic neoplasms. A marker of hepatocellular differentiation. *Am J Surg Pathol*. 1997;21(2):147-152.
168. Wang L, Vuolo M, Suhrland MJ, Schlesinger K. HepPar1, Moc-31, pCEA, mCEA, and CD10 for distinguishing hepatocellular carcinoma vs. metastatic adenocarcinoma in liver fine needle aspirates. *Acta Cytol*. 2006;50:257-262.
169. Johnson DE, Herndier BG, Medeiros LJ, et al. The diagnostic utility of the keratin profiles of hepatocellular carcinoma and cholangiocarcinoma. *Am J Surg Pathol*. 1988;12(3):187-197.
170. Vlasoff DM, Baschinsky DY, Frankel WL. Cytokeratin 5/6 immunostaining in hepatobiliary and pancreatic neoplasms. *Appl Immunohistochem Mol Morphol*. 2002;10(2):147-151.
171. Maeda T, Kajiyama K, Adachi E, et al. The expression of cytokeratins 7, 19, and 20 in primary and metastatic carcinomas of the liver. *Mod Pathol*. 1996;9(9):901-909.
172. Van Eyken P, Sciot R, Desmet VJ. A cytokeratin immunohistochemical study of cholestatic liver disease: evidence that hepatocytes can express 'bile duct-type' cytokeratins. *Histopathology*. 1989;15(2):125-135.
173. Lai YS, Thung SN, Gerber MA, et al. Expression of cytokeratins in normal and diseased livers and in primary liver carcinomas. *Arch Pathol Lab Med*. 1989;113(2):134-138.
174. Durnez A, Verslype C, Nevens F, et al. The clinicopathological and prognostic relevance of cytokeratin 7 and 19 expression in hepatocellular carcinoma. A possible progenitor cell origin. *Histopathology*. 2006;49(2):138-151.
175. Fucich LF, Cheles MK, Thung SN, et al. Primary vs metastatic hepatic carcinoma. An immunohistochemical study of 34 cases. *Arch Pathol Lab Med*. 1994;118(9):927-930.
176. Sciot R, Paterson AC, van Eyken P, et al. Transferrin receptor expression in human hepatocellular carcinoma: an immunohistochemical study of 34 cases. *Histopathology*. 1988;12(1):53-63.
177. Cohen C, Berson SD, Shulman G, Budgeon LR. Immunohistochemical ferritin in hepatocellular carcinoma. *Cancer*. 1984;53(9):1931-1935.
178. Yabuuchi I, Kawata S, Tamura S, et al. Aromatase activity in human hepatocellular carcinoma. Relationship with the degree of histologic differentiation. *Cancer*. 1993;71(1):56-61.
179. Volpes R, van den Oord JJ, Desmet VJ. Integrins as differential cell lineage markers of primary liver tumors. *Am J Pathol*. 1993;142(5):1483-1492.
180. Torii A, Nakayama A, Harada A, et al. Expression of the CD15 antigen in hepatocellular carcinoma. *Cancer*. 1993;71(12):3864-3867.
181. Lamas E, Le Bail B, Housset C, et al. Localization of insulin-like growth factor-II and hepatitis B virus mRNAs and proteins in human hepatocellular carcinomas. *Lab Invest*. 1991;64(1):98-104.
182. Fukusato T, Mori S, Kawamoto T, et al. Immunohistochemical and ultrastructural localization of epidermal growth factor receptor in human liver and hepatocellular carcinoma tissues. *Acta Pathol Jpn*. 1990;40(1):22-29.
183. Shin JH, Kim CJ, Jeon EJ, et al. Overexpression of C-reactive protein as a poor prognostic marker of resectable hepatocellular carcinoma. *J Pathol Transl Med*. 2015;49:105-111.
184. Iezzoni JC, Mills SE, Pelkey TJ, Stoler MH. Inhibin is not immunohistochemical marker for hepatocellular carcinoma, an example of the potential pitfall in diagnostic immunohistochemistry caused by endogenous biotin. *Am J Clin Pathol*. 1999;111:229-234.
185. Nagasue N, Kohno H, Yamanoi A, et al. Progesterone receptor in hepatocellular carcinoma. Correlation with androgen and estrogen receptors. *Cancer*. 1991;67(10):2501-2505.
186. Nagasue N, Yukaya H, Chang YC, et al. Active uptake of testosterone by androgen receptors of hepatocellular carcinoma in humans. *Cancer*. 1986;57(11):2162-2167.
187. Zucman-Rossi J, Villanueva A, Nault JC, Llovet JM. Genetic landscape and biomarkers of hepatocellular carcinoma. *Gastroenterology*. 2015;149:1226-1263.
188. Wong CM, Ng IO. Molecular pathogenesis of hepatocellular carcinoma. *Liver Int*. 2008;28(2):160-174.
189. Kirk GD, Lesi OA, Mendy M, et al. 249 (ser) TP53 mutation in plasma DNA, hepatitis B viral infection, and risk of hepatocellular carcinoma. *Oncogene*. 2005;24:5858-5886.
190. Graham RP, Jin L, Knutson DL, et al. DNAJB1-PRKACA is specific for fibrolamellar carcinoma. *Mod Pathol*. 2015;28:822-829.
191. Song MA, Kwee SA, Tiirikainen M, et al. Comparison of genome-scale DNA methylation profiels in hepatocellular carcinoma by viral status. *Epigenetics*. 2016;11:464-474.
192. Csepregi A, Ebert MP, Rocken C, et al. Promoter methylation of CDKN2A and lack of p16 expression characterize patietns with heaptocellular carcionma. *BMC Cancer*. 2010;10:317.
193. Gramantieri L, Fornari F, Callegari E, et al. MicroRNA involvement in hepatocellular carcinoma. *J Cell Mol Med*. 2008;12(6A):2189-2204.
194. Zucman-Rossi J. Molecular classification of hepatocellular carcinoma. *Dig Liver Dis*. 2010;42(suppl 3):S235-S241.
195. Hoshida Y, Toffanin S, Lachenmayer A, et al. Molecular classification and novel targets in hepatocellular carcinoma: recent advancements. *Semin Liver Dis*. 2010;30(1):35-51.
196. Hoshida Y, Nijman SM, Kobayashi M, et al. Integrative transcriptome analysis reveals common molecular subclasses of human hepatocellular carcinoma. *Cancer Res*. 2009;69:7385-7392.
197. Wu PC, Lai CL, Lam KC, et al. Clear cell carcinoma of liver. An ultrastructural study. *Cancer*. 1983;52(3):504-507.
198. Yang SH, Watanabe J, Nakashima O, Kojiro M. Clinicopathologic study on clear cell hepatocellular carcinoma. *Pathol Int*. 1996;46(7):503-509.
199. Buchanan TF Jr, Huvos AG. Clear-cell carcinoma of the liver. A clinicopathologic study of 13 patients. *Am J Clin Pathol*. 1974;61(4):529-539.
200. Murakata LA, Ishak KG, Nzeako UC. Clear cell carcinoma of the liver: a comparative immunohistochemical study with renal clear cell carcinoma. *Mod Pathol*. 2000;13(8):874-881.
201. Sugiyama T, Tajiri T, Hiraiwa S, et al. Hepatic adrenal rest tumor: diagnostic pitfall and proposed algorithms to prevent misdiagnosis as lipid-rich hepatocellular carcinoma. *Pathol Int*. 2015;65:95-99.
202. Emile JF, Lemoine A, Azoulay D, et al. Histological, genomic and clinical heterogeneity of clear cell hepatocellular carcinoma. *Histopathology*. 2001;38(3):225-231.
203. Krings G, Ramachandran R, Jain D, et al. Immunohistochemical pitfalls and the importance of glypican 3 and arginase in the diagnosis of scirrhous hepatocellular carcinoma. *Mod Pathol*. 2013;26:782-791.
204. Matsuura S, Aishima S, Taguchi K, et al. 'Scirrhous' type hepatocellular carcinomas: a special reference to expression of cytokeratin 7 and hepatocyte paraffin 1. *Histopathology*. 2005;47(4):382-390.
205. Albar JP, De Miguel F, Esbrit P, et al. Immunohistochemical detection of parathyroid hormone-related protein in a rare variant of hepatic neoplasm (sclerosing hepatic carcinoma). *Hum Pathol*. 1996;27(7):728-731.
206. Chan AW, Tong JH, Pan Y, et al. Lymphoepithelioma-like hepatocellular carcinoma: an uncommon variant of hepatocellular carcinoma with a favorable outcome. *Am J Surg Pathol*. 2015;39:304-312.
207. Patel KR, Liu TC, Vaccharajani N, et al. Characterization of inflammatory (lymphoepithelioma-like) hepatocellular carcinoma. *Arch Pathol Lab Med*. 2014;138:1193-1202.
208. Si MW, Thorson JA, Lauwers GY, et al. Hepatocellular lymphoepithelioma-like carcinoma associated with Epstein barr virus: a hitherto unrecognized entity. *Diagn Mol Pathol*. 2004;13:183-189.
209. Emile JF, Adam R, Sebagh M, et al. Hepatocellular carcinoma with lymphoid stroma: a tumour with good prognosis after liver transplantation. *Histopathology*. 2000;37:523-529.
210. Haratake J, Horie A. An immunohistochemical study of sarcomatoid liver carcinomas. *Cancer*. 1991;68(1):93-97.
211. Kakizoe S, Kojiro M, Nakashima T. Hepatocellular carcinoma with sarcomatous change. Clinicopathologic and immunohistochemical studies of 14 autopsy cases. *Cancer*. 1987;59(2):310-316.
212. Maeda T, Adachi E, Kajiyama K, et al. Spindle cell hepatocellular carcinoma. A clinicopathologic and immunohistochemical analysis of 15 cases. *Cancer*. 1996;77(1): 51-57.
213. Dahm HH. Immunohistochemical evaluation of a sarcomatoid hepatocellular carcinoma with osteoclastlike giant cells. *Diagn Pathol*. 2015;10:40.
214. Yoshida N, Midorikawa Y, Kajiwara T, et al. Hepatocellular carcinoma with sarcomatoid change without anticancer therapies. *Case Rep Gastroenterol*. 2013;7:169-174.
215. Hood DL, Bauer TW, Leibel SA, McMahon JT. Hepatic giant cell carcinoma. An

ultrastructural and immunohistochemical study. *Am J Clin Pathol*. 1990;93(1): 111-116.
216. Kuwano H, Sonoda T, Hashimoto H, Enjoji M. Hepatocellular carcinoma with osteoclast-like giant cells. *Cancer*. 1984;54(5):837-842.
217. Akasofu M, Kawahara E, Kaji K, Nakanishi I. Sarcomatoid hepatocellular-carcinoma showing rhabdomyoblastic differentiation in the adult cirrhotic liver. *Virchows Arch*. 1999;434(6):511-515.
218. Fayyazi A, Nolte W, Oestmann JW, et al. Carcinosarcoma of the liver. *Histopathology*. 1998;32(4):385-387.
219. Lao XM, Chen DY, Zhang YQ, et al. Primary carcinosarcoma of the liver: clinicopathologic features of 5 cases and a review of the literature. *Am J Surg Pathol*. 2007;31(6):817-826.
220. Berman MM, Libbey NP, Foster JH. Hepatocellular carcinoma. Polygonal cell type with fibrous stroma—an atypical variant with a favorable prognosis. *Cancer*. 1980;46(6):1448-1455.
221. Craig JR, Peters RL, Edmondson HA, Omata M. Fibrolamellar carcinoma of the liver: a tumor of adolescents and young adults with distinctive clinico-pathologic features. *Cancer*. 1980;46(2):372-379.
222. Kakar S, Burgart LJ, Batts KP, et al. Clinicopathologic features and survival in fibrolamellar carcinoma: comparison with conventional hepatocellular carcinoma with and without cirrhosis. *Mod Pathol*. 2005;18:1417-1423.
223. LeBrun DP, Silver MM, Freedman MH, Phillips MJ. Fibrolamellar carcinoma of the liver in a patient with Fanconi anemia. *Hum Pathol*. 1991;22(4):396-398.
224. Ward SC, Huang J, Tickoo SK, et al. Fibrolamellar carcinoma of the liver exhibits immunohistochemical evidence of both hepatocyte and bile duct differentation. *Mod Pathol*. 2010;23:1180-1190.
225. Farhi DC, Shikes RH, Silverberg SG. Ultrastructure of fibrolamellar oncocytic hepatoma. *Cancer*. 1982;50:702-709.
226. Nerlich AG, Majewski S, Hunzelmann N, et al. Excessive collagen formation in fibrolamellar carcinoma of the liver: a morphological and biochemical study. *Mod Pathol*. 1992;5(5):580-585.
227. Van Eyken P, Sciot R, Brock P, et al. Abundant expression of cytokeratin 7 in fibrolamellar carcinoma of the liver. *Histopathology*. 1990;17(2):101-107.
228. Ross HM, Daniel HDJ, Vivekanandan P, et al. Fibrolamellar carcinomas are positive for CD68. *Mod Pathol*. 2011;24:390-395.
229. Jernigan PL, Wima K, Hanseman DJ, et al. Natural history and treatment trends in hepatocellular carcinoma subtypes: insights from a national cancer registry. *J Surg Oncol*. 2015;112:872-876.
230. Araki K, Kishihara F, Takahashi K, et al. Hepatocellular carcinoma producing a granulocyte colony-stimulating factor: report of a resected case with a literature review. *Liver Int*. 2007;27:716-721.
231. Goodman ZD, Ishak KG, Langloss JM, et al. Combined hepatocellula r-cholangiocarcinoma. A histologic and immunohistochemical study. *Cancer*. 1985;55(1):124-135.
232. Jarnagin WR, Weber S, Tickoo SK, et al. Combined hepatocellular and cholangiocarcinoma: demographic, clinical, and prognostic factors. *Cancer*. 2002;94(7):2040-2046.
233. Tickoo SK, Zee SY, Obiekwe S, et al. Combined hepatocellula r-cholangiocarcinoma: a histopathologic, immunohistochemical, and in situ hybridization study. *Am J Surg Pathol*. 2002;26(8):989-997.
234. Akiba J, Nakashima O, Hattori S, et al. The expression of arginase-1, keratin (K) 8, and K18 in combined hepatocellula r-cholangiocarcinoma, subtypes with stem-cell features, intermediate-cell type. *J Clin Pathol*. 2016;69:846-851.
235. Akiba J, Nakashina O, Hattori S, et al. Clinicopathologic analysis of combined hepatocellular-cholangiocarcinoma according to the latest WHO classification. *Am J Surg Pathol*. 2013;37:496-505.
236. Kwon Y, Lee SK, Kim JS, et al. Synchronous hepatocellular carcinoma and cholangiocarcinoma arising in two different dysplastic nodules. *Mod Pathol*. 2002;15(10):1096-1101.
237. Al Hamoudi W, Khalaf H, Allam N, Al Sebayel M. Coincidental occurrence of hepatocellular carcinoma and cholangiocarcinoma (collision tumors) after liver transplantation: a case report. *Hepat Mon*. 2012;12(10 HCC):e5871.
238. Theise ND, Yao JL, Harada K, et al. Hepatic "stem cell" malignancies in adults: four cases. *Histopathology*. 2003;43:263-271.
239. Kim H, Park C, Han KH, et al. Primary liver carcinoma of intermediate (hepatocyte-cholangiocyte) phenotype. *J Hepatol*. 2004;40:298-304.
240. Nishino H, Hatano E, Shibuya S, et al. Histological features of mied neuroendocrine carcinoma and hepatocellular carcinoma in the liver: a case report and literature review. *Clin J Gastroenterol*. 2016;9:272-279.
241. Nakanishi C, Sato K, Ito Y, et al. Combined hepatocellular carcinoma and neuroendocrine carcinoma with sarcomatous change of the liver after transarterial chemoembolization. *Hepatol Res*. 2012;42:1141-1145.
242. Glenthoj A, Sehested M, Torp-Pedersen S. Diagnostic reliability of histological and cytological fine needle biopsies from focal liver lesions. *Histopathology*. 1989;15(4):375-383.
243. Noguchi S, Yamamoto R, Tatsuta M, et al. Cell features and patterns in fine-needle aspirates of hepatocellular carcinoma. *Cancer*. 1986;58(2):321-328.
244. Tao LC, Ho CS, McLoughlin MJ, et al. Cytologic diagnosis of hepatocellular carcinoma by fine-needle aspiration biopsy. *Cancer*. 1984;53(3):547-552.
245. Kung IT, Chan SK, Fung KH. Fine-needle aspiration in hepatocellular carcinoma. Combined cytologic and histologic approach. *Cancer*. 1991;67(3):673-680.
246. Zainol H, Sumithran E. Combined cytological and histological diagnosis of hepatocellular carcinoma in ultrasonically guided fine needle biopsy specimens. *Histopathology*. 1993;22(6):581-586.
247. Greene CA, Suen KC. Some cytologic features of hepatocellular carcinoma as seen in fine needle aspirates. *Acta Cytol*. 1984;28(6):713-718.
248. Yang GC, Yang GY, Tao LC. Cytologic features and histologic correlations of microacinar and microtrabecular types of well-differentiated hepatocellular carcinoma in fine-needle aspiration biopsy. *Cancer*. 2004;102:27-33.
249. Bottles K, Cohen MB. An approach to fine-needle aspiration biopsy diagnosis of hepatic masses. *Diagn Cytopathol*. 1991;7(2):204-210.
250. Sakurai M, Okamura J, Seki K, Kuroda C. Needle tract implantation of hepatocellular carcinoma after percutaneous liver biopsy. *Am J Surg Pathol*. 1983;7(2):191-195.
251. Edmondson HA, Steiner PE. Primary carcinoma of the liver: a study of 100 cases among 48900 necropsies. *Cancer*. 1954;7:462-503.
252. Pawlik TM, Gleisner AL, Anders RA, et al. Preoperative assessment of hepatocellular carcionma tumor grade using needle biopsy. *Ann Surg*. 2007;145:435-442.
253. Sawabe M, Nakamura T, Kanno J, Kasuga T. Analysis of morphoogical factors of hepatocellular carcinoma in 98 autopsy cases with respect to pulmonary metastases. *Acta Pathol Jpn*. 1987;37:1389-1404.
254. Kojiro M, Nakahara H, Sugihara S, et al. Hepatocellular carcinoma with intra-atrial tumor growth. A clinicopathologic study of 18 autopsy cases. *Arch Pathol Lab Med*. 1984;108(12):989-992.
255. Kojiro M, Kawabata K, Kawano Y, et al. Hepatocellular carcinoma presenting as intrabile duct tumor growth: a clinicopathologic study of 24 cases. *Cancer*. 1982;49(10):2144-2147.
256. Duseja A. Staging of hepatocellular carcinoma. *J Clin Exp Hepatol*. 2014;4(suppl 3):S74-S79.
257. Liaw CC, Ng KT, Chen TJ, Liaw YF. Hepatocellular carcinoma presenting as bone metastasis. *Cancer*. 1989;64(8):1753-1757.
258. Pan Z, Yang G, Yuan T, et al. Leptomeningeal metastasis from hepatocellular carcinoma with other unusual metastases: a case report. *BMC Cancer*. 2014;14:399.
259. Mohammed H, Sheikh R, Rahman W, et al. Undiagnosed hepatocellular carcinoma presenting as nasal metastases. *Case Rep Otolaryngol*. 2015;2015:856134.
260. Young RH, Gersell DJ, Clement PB, Scully RE. Hepatocellular carcinoma metastatic to the ovary: a report of three cases discovered during life with discussion of the differential diagnosis of hepatoid tumors of the ovary. *Hum Pathol*. 1992;23(5):574-580.
261. Tabrizian P, Roayaie S, Schwartz ME. Current management of hepatocellular carcinoma. *World J Gastroenterol*. 2014;20:10223-10237.
262. Duffy JP, Hiatt JR, Busuttil RW. Surgical resection of hepatocellular carcinoma. *Cancer J*. 2008;14:100-110.
263. Mazzaferro V, Regalia E, Doci R, et al. Liver transplantation for the treatment of small hepatocellular carcinomas in patients with cirrhosis. *N Engl J Med*. 1996;334:693-699.
264. Llovet JM, Ricci S, Mazzaferro V, et al. Sorafenib in advanced hepatocellular carcinoma. *N Engl J Med*. 2008;359: 378-390.
265. Kaczynski J, Hansson G, Remotti H, Wallerstedt S. Spontaneous regression of hepatocellular carcinoma. *Histopathology*. 1998;32(2):147-150.
266. Tejeda-Maldonado J, Garcia-Juarez I, Aguirre-Valadez J, et al. Diagnosis and treatment of hepatocellular carcinoma: an update. *World J Hepatol*. 2015;7:362-376.
267. Befeler AS, Di Bisceglie AM. Hepatocellular carcinoma: diagnosis and treatment. *Gastroenterology*. 2002;122:1609-1619.
268. Han DH, Choi GH, Park JY, et al. Lesson from 610 liver resections of hepatocellular carcinoma in a single center over 10 years. *World J Surg Oncol*. 2014;12:192.
269. Haratake J, Takeda S, Kasai T, et al. Predictable factors for estimating prognosis of patients after resection of hepatocellular carcinoma. *Cancer*. 1993;72(4):1178-1183.
270. Liu PH, Hsu CY, Hsia CY, et al. Prognosis of hepatocellular carcinoma: assessment of eleven staging systems. *J Hepatol*. 2016;64:601-608.
271. Thng Y, Tan JK, Shridhar IG, et al. Outcomes of resection of giant hepatocellular carcinoma in a tertiary institution: does size matter? *HPB (Oxford)*. 2015;17:988-993.
272. Li Z, Zhao X, Jiang P, et al. HBV is a risk factor for poor patient prognosis after curative resection of hepatocellular carcinoma: a retrospective case control study. *Medicine (Baltimore)*. 2016;95:e4224.

273. Utsunomiya T, Shimada M, Kudo M, et al. A comparison of the surgical outcomes among patients with HBV-positive, HCV-positive, and non-B non-C hepatocellular carcinoma: a nationwide study of 11,950 patients. *Ann Surg*. 2015;261:513-520.
274. Colecchia A, Schiumerini R, Cucchetti A, et al. Prognostic factors for hepatocellular carcinoma recurrence. *World J Gastroenterol*. 2014;20:5935-5950.
275. Rodriguez-Peralvarez M, Luong TV, Andreana L, et al. A systematic review of microvascular invasion in hepatocellular carcinoma: diagnostic and prognostic variability. *Ann Surg Oncol*. 2013;20:325-339.
276. Du M, Chen L, Zhao J, et al. Microvascular invasion (MVI) is a poorer prognostic predictor for small hepatocellular carcinoma. *BMC Cancer*. 2014;14:38.
277. Ng IO, Lai EC, Ng MM, Fan ST. Tumor encapsulation in hepatocellular carcinoma. A pathologic study of 189 cases. *Cancer*. 1992;70(1):45-49.
278. Lauwers GY, Terris B, Balis UJ, et al. Prognostic histologic indicators of curatively resected hepatocellular carcinomas: a multi-institutional analysis of 425 patients with definition of a histologic prognostic index. *Am J Surg Pathol*. 2002;26(1):25-34.
279. Czauderna P, Lopez-Terrada D, Hiyama E, et al. Hepatoblastoma state of the art: pathology, genetics, risk stratification, and chemotherapy. *Curr Opin Pediatr*. 2014;26:19-28.
280. Green LK, Silva EG. Hepatoblastoma in an adult with metastasis to the ovaries. *Am J Clin Pathol*. 1989;92(1):110-115.
281. Rougemont AL, McLin VA, Toso C, Wildhaber BE. Adult hepatoblastoma: learning from children. *J Hepatol*. 2012;56:1392-1403.
282. Venkatramani R, Spector LG, Georgieff M, et al. Congenital Abnormalities and hepatoblastoma: a report from the Children's Oncology Group (COG) and the Utah Population Database (UPDB). *Am J Med Genet A*. 2014;164:2250-2255.
283. Giardiello FM, Offerhaus GJ, Krush AJ, et al. Risk of hepatoblastoma in familial adenomatous polyposis. *J Pediatr*. 1991;119(5):766-768.
284. Lack EE, Neave C, Vawter GF. Hepatoblastoma. A clinical and pathologic study of 54 cases. *Am J Surg Pathol*. 1982;6:693-705.
285. Rojas Y, Guillerman RP, Zhang W, et al. Relapse surveillance in AFP-positive hepatoblastoma: re-evaluating the role of imaging. *Pediatr Radiol*. 2014;44:1275-1280.
286. Meyers R, Tiao G, de Ville de Goyet J, et al. Hepatoblastoma state of the art: pretreatment extent of disease, surgical resection guidelines and the role of liver transplantation. *Curr Opin Pediatr*. 2014;26:29-36.
287. Ishak KG, Glunz PR. Hepatoblastoma and hepatocarcinoma in infancy and childhood. Report of 47 cases. *Cancer*. 1967;20(3): 396-422.
288. Stocker JT. Hepatoblastoma. *Semin Diagn Pathol*. 1994;11(2):136-143.
289. Morinaga S, Yamaguchi M, Watanabe I, et al. An immunohistochemical study of hepatoblastoma producing human chorionic gonadotropin. *Cancer*. 1983;51(9):1647-1652.
290. Nakagawara A, Ikeda K, Tsuneyoshi M, et al. Hepatoblastoma producing both alpha-fetoprotein and human chorionic gonadotropin. Clinicopathologic analysis of four cases and a review of the literature. *Cancer*. 1985;56(7):1636-1642.
291. Tanaka Y, Inoue T, Horie H. International pediatric liver cancer pathological classification: current trend. *Int J Clin Oncol*. 2013;18:946-954.
292. Gonzalez-Crussi F. Undifferentiated small cell ("anaplastic") hepatoblastoma. *Pediatr Pathol*. 1991;11(1):155-161.
293. Zimmermann A. Hepatoblastoma with cholangioblastic features ('cholangioblastic hepatoblastoma') and other liver tumors with bimodal differentiation in young patients. *Med Pediatr Oncol*. 2002;39(5):487-491.
294. Gonzalez-Crussi F, Upton MP, Maurer HS. Hepatoblastoma. Attempt at characterization of histologic subtypes. *Am J Surg Pathol*. 1982;6(7):599-612.
295. Prokurat A, Kluge P, Kosciesza A, et al. Transitional liver cell tumors (TLCT) in older children and adolescents: a novel group of aggressive hepatic tumors expressing beta-catenin. *Med Pediatr Oncol*. 2002;39(5):510-518.
296. Fasano M, Theise ND, Nalesnik M, et al. Immunohistochemical evaluation of hepatoblastomas with use of the hepatocyte-specific marker, hepatocyte paraffin 1, and the polyclonal anti-carcinoembryonic antigen. *Mod Pathol*. 1998;11(10):934-938.
297. Zynger DL, Gupta A, Luan C, et al. Expression of glypican 3 in hepatoblastoma: an immunohistochemical study of 65 cases. *Hum Pathol*. 2008;39(2):224-230.
298. Blaker H, Hofmann WJ, Rieker RJ, et al. Beta-catenin accumulation and mutation of the CTNNB1 gene in hepatoblastoma. *Genes Chromosomes Cancer*. 1999;25(4):399-402.
299. Trobaugh-Lotrario AD, Tomlinson GE, Finegold MJ, et al. Small cell undifferentiated variant of hepatoblastoma: adverse clinical and molecular features similar to rhabdoid tumors. *Pediatr Blood Cancer*. 2009;52:328-334.
300. Dezso K, Halasz J, Bisgaard HC, et al. Delta-like protein (DLK) is a novel immunohistochemical marker for human hepatoblastomas. *Virchows Arch*. 2008;452:443-448.
301. Ruck P, Harms D, Kaiserling E. Neuroendocrine differentiation in hepatoblastoma. An immunohistochemical investigation. *Am J Surg Pathol*. 1990;14(9):847-855.
302. Warfel KA, Hull MT. Hepatoblastomas: an ultrastructural and immunohistochemical study. *Ultrastruct Pathol*. 1992;16(4):451-461.
303. Ruck P, Kaiserling E. Melanin-containing hepatoblastoma with endocrine differentiation. An immunohistochemical and ultrastructural study. *Cancer*. 1993;72(2):361-368.
304. Armengol C, Cairo S, Fabre M, Buendia MA. Wnt signaling and hepatocarcinogenesis: the hepatoblastoma model. *Int J Biochem Cell Biol*. 2011;43(2):265-270.
305. Jeng YM, Wu MZ, Mao TL, et al. Somatic mutations of beta-catenin play a crucial role in the tumorigenesis of sporadic hepatoblastoma. *Cancer Lett*. 2000;152(1):45-51.
306. Lopez-Terrada D, Gunaratne PH, Adesina AM, et al. Histologic subtypes of hepatoblastoma are characterized by differential canonical Wnt and Notch pathway activation in DLK+ precursors. *Hum Pathol*. 2009;40(6): 783-794.
307. Fuchs J, Rydzynski J, Hecker H, et al. The influence of preoperative chemotherapy and surgical technique in the treatment of hepatoblastoma—a report from the German Cooperative Liver Tumour Studies HB 89 and HB 94. *Eur J Pediatr Surg*. 2002;12(4):255-261.
308. Kremer N, Walther AE, Tiao GM. Management of hepatoblastoma: an update. *Curr Opin Pediatr*. 2014;26:362-369.
309. Molmenti EP, Wilkinson K, Molmenti H, et al. Treatment of unresectable hepatoblastoma with liver transplantation in the pediatric population. *Am J Transplant*. 2002;2(6):535-538.
310. Srinivasan P, McCall J, Pritchard J, et al. Orthotopic liver transplantation for unresectable hepatoblastoma. *Transplantation*. 2002;74(5):652-655.
311. Saxena R, Leake JL, Shafford EA, et al. Chemotherapy effects on hepatoblastoma. A histological study. *Am J Surg Pathol*. 1993;17(12):1266-1271.
312. Wang LL, Filippi RZ, Zurakowski D, et al. Effects of neoadjuvant chemotherapy on hepatoblastoma: a morphologic and immunohistochemical study. *Am J Surg Pathol*. 2010;34(3):287-299.
313. Scheuerlein H, Rauchfuss F, Franke J, et al. Clinical symptoms and sonographic follow-up after surgical treatment of nonparasitic liver cysts. *BMC Surg*. 2013;13:42.
314. Nieweg O, Slooff MJ, Grond J. A case of primary squamous cell carcinoma of the liver arising in a solitary cyst. *HPB Surg*. 1992;5:203-208.
315. van Baardewijk LJ, Idenburg FJ, Clahsen PC, Mollers MJ. [Von Meyenburg complexes in the liver: not metastases]. *Ned Tijdschr Geneeskd*. 2010;154:A1674.
316. Salo J, Bru C, Vilella A, et al. Bile-duct hamartomas presenting as multiple focal lesions on hepatic ultrasonography. *Am J Gastroenterol*. 1992;87(2):221-223.
317. Tsui WM. How many types of biliary hamartomas and adenomas are there? *Adv Anat Pathol*. 1998;5(1):16-20.
318. Chung EB. Multiple bile-duct hamartomas. *Cancer*. 1970;26(2):287-296.
319. Dhumeaux D. Congenital cystic diseases of the intra and extrahepatic bile ducts. *Gastroenterol Clin Biol*. 2005;29:878-882.
320. Redston MS, Wanless IR. The hepatic von Meyenburg complex: prevalence and association with hepatic and renal cysts among 2843 autopsies. *Mod Pathol*. 1996;9(3):233-237.
321. Honda N, Cobb C, Lechago J. Bile duct carcinoma associated with multiple von Meyenburg complexes in the liver. *Hum Pathol*. 1986;17(12):1287-1290.
322. Jain D, Sarode VR, Abdul-Karim FW, et al. Evidence for the neoplastic transformation of Von-Meyenburg complexes. *Am J Surg Pathol*. 2000;24(8):1131-1139.
323. Song JS, Lee YJ, Kim KW, et al. Cholangiocarcinoma arising in von Meyenburg complexes: report of four cases. *Pathol Int*. 2008;58(8):503-512.
324. Zen Y, Terahata S, Miyayama S, et al. Multicystic biliary hamartoma: a hitherto undescribed lesion. *Hum Pathol*. 2006;37(3):339-344.
325. Martin DR, Kalb B, Sarmiento JM, et al. Giant and complicated variants of cystic bile duct hamartomas of the liver: MRI findings and pathological correlations. *J Magn Reson Imaging*. 2010;31:903-911.
326. Allaire GS, Rabin L, Ishak KG, Sesterhenn IA. Bile duct adenoma. A study of 152 cases. *Am J Surg Pathol*. 1988;12:708-715.
327. Govindarajan S, Peters RL. The bile duct adenoma. A lesion distinct from Meyenburg complex. *Arch Pathol Lab Med*. 1984;108(11):922-924.
328. Albores-Saavedra J, Hoang MP, Murakata LA, et al. Atypical bile duct adenoma, clear cell type: a previously undescribed tumor of the liver. *Am J Surg Pathol*. 2001;25(7):956-960.
329. Hughes NR, Goodman ZD, Bhathal PS. An immunohistochemical profile of the so-called bile duct adenoma: clues to pathogenesis. *Am J Surg Pathol*. 2010;34(9):1312-1318.
330. O'Hara BJ, McCue PA, Miettinen M. Bile duct adenomas with endocrine component. Immunohistochemical study and comparison

with conventional bile duct adenomas. *Am J Surg Pathol*. 1992;16(1):21-25.
331. Hruban RH, Sturm PD, Slebos RJ, et al. Can K-ras codon 12 mutations be used to distinguish benign bile duct proliferations from metastases in the liver? A molecular analysis of 101 liver lesions from 93 patients. *Am J Pathol*. 1997;151(4):943-949.
332. Bhathal PS, Hughes NR, Goodman ZD. The so-called bile duct adenoma is a peribiliary gland hamartoma. *Am J Surg Pathol*. 1996;20(7):858-864.
333. Devaney K, Goodman ZD, Ishak KG. Hepatobiliary cystadenoma and cystadenocarcinoma. A light microscopic and immunohistochemical study of 70 patients. *Am J Surg Pathol*. 1994;18(11):1078-1091.
334. Wheeler DA, Edmondson HA. Cystadenoma with mesenchymal stroma (CMS) in the liver and bile ducts. A clinicopathologic study of 17 cases, 4 with malignant change. *Cancer*. 1985;56:1434-1445.
335. Gourley WK, Kumar D, Bouton MS, et al. Cystadenoma and cystadenocarcinoma with mesenchymal stroma of the liver. Immunohistochemical analysis. *Arch Pathol Lab Med*. 1992;116(10):1047-1050.
336. Grayson W, Teare J, Myburgh JA, Paterson AC. Immunohistochemical demonstration of progesterone receptor in hepatobiliary cystadenoma with mesenchymal stroma. *Histopathology*. 1996;29(5):461-463.
337. Subramony C, Herrera GA, Turbat-Herrera EA. Hepatobiliary cystadenoma. A study of five cases with reference to histogenesis. *Arch Pathol Lab Med*. 1993;117(10):1036-1042.
338. Terada T, Kitamura Y, Ohta T, Nakanuma Y. Endocrine cells in hepatobiliary cystadenomas and cystadenocarcinomas. *Virchows Arch*. 1997;430(1):37-40.
339. Wolf HK, Garcia JA, Bossen EH. Oncocytic differentiation in intrahepatic biliary cystadenocarcinoma. *Mod Pathol*. 1992;5(6):665-668.
340. Unger PD, Thung SN, Kaneko M. Pseudosarcomatous cystadenocarcinoma of the liver. *Hum Pathol*. 1987;18(5):521-523.
341. Albores-Saavedra J, Cordova-Ramon JC, Chable-Montero F, et al. Cystadenomas of the liver and extrahepatic bile ducts: morphologic and immunohistochemical characterization of the biliary and intestinal variants. *Ann Diagn Pathol*. 2015;19:124-129.
342. Vogt DP, Henderson JM, Chmielewski E. Cystadenoma and cystadenocarcinoma of the liver: a single center experience. *J Am Coll Surg*. 2005;200:727-733.
343. Varnholt H, Vauthey JN, Dal Cin P, et al. Biliary adenofibroma: a rare neoplasm of bile duct origin with an indolent behavior. *Am J Surg Pathol*. 2003;27(5):693-698.
344. Shibahara H, Tamada S, Goto M, et al. Pathologic features of mucin-producing bile duct tumors: two histopathologic categories as counterparts of pancreatic intraductal papillary-mucinous neoplasms. *Am J Surg Pathol*. 2004;28(3):327-338.
345. Zen Y, Pedica F, Patcha VR, et al. Mucinous cystic neoplasms of the liver: a clinicopathologic study and comparison with intraductal papillary neoplasms of the bile duct. *Mod Pathol*. 2011;24:1079-1089.
346. Aishima S, Nishihara Y, Tsujita E, et al. Biliary neoplasia with extensive intraductal spread associated with liver cirrhosis: a hitherto unreported variant of biliary intraepithelial neoplasia. *Hum Pathol*. 2008;39(6): 939-947.
347. Ishikawa A, Sasaki M, Ohira S, et al. Aberrant expression of CDX2 is closely related to the intestinal metaplasia and MUC2 expression in intraductal papillary neoplasm of the liver in hepatolithiasis. *Lab Invest*. 2004;84(5):629-638.
348. Lee SS, Kim MH, Lee SK, et al. Clinicopathologic review of 58 patients with biliary papillomatosis. *Cancer*. 2004;100(4):783-793.
349. Goodman ZD. Neoplasms of the liver. *Mod Pathol*. 2007;20(suppl 1):S49-S60.
350. Kobayashi M, Ikeda K, Saitoh S, et al. Incidence of primary cholangiocellular carcinoma of the liver in japanese patients with hepatitis C virus-related cirrhosis. *Cancer*. 2000;88(11):2471-2477.
351. Alvaro D, Cannizzaro R, Labiance R, et al. Cholangiocarcinoma: a position paper by the Italian Society of Gastroenterology (SIGE), the Italian Association of Hospital Gastroenterology (AIG), the Italian Association of Medical Oncology (AIOM), and the Italian Association of ONcological Radiotherapy (AIRO). *Dig Liver Dis*. 2010;42:831-838.
352. Srinath A, Shneider BL. Congenial hepatic fibrosis and autosomal recessive polycystic kidney disease. *J Pediatr Gastroenterol Nutr*. 2012;54:580-587.
353. Rocken C, Pross M, Brucks U, et al. Cholangiocarcinoma occurring in a liver with multiple bile duct hamartomas (von Meyenburg complexes). *Arch Pathol Lab Med*. 2000;124(11):1704-1706.
354. Sithithaworn P, Yongvanit P, Duenngai K, et al. Roles of liver fluke infection as risk factor for cholangiocarcinoma. *J Hepatobiliary Pancreat Sci*. 2014;21:301-308.
355. Rubel LR, Ishak KG. Thorotrast-associated cholangiocarcinoma: an epidemiologic and clinicopathologic study. *Cancer*. 1982;50(7):1408-1415.
356. Kim HJ, Kim JS, Joo MK, et al. Hepatolithiasis and intrahepatic cholangiocarcinoma: a review. *World J Gastroenterol*. 2015;21:13418-13431.
357. Sibulesky L, Nguyen J, Patel T. Preneoplastic conditions underlying bile duct cancer. *Langenbecks Arch Surg*. 2012;397:861-867.
358. Esnaola NF, Meyer JE, Karachristos A, et al. Evaluation and management of intrahepatic and extrahepatic cholangiocarcinoma. *Cancer*. 2016;122:1349-1369.
359. Razumilava N, Gores GJ. Cholangiocarcinoma. *Lancet*. 2014;383(9935):2168-2179.
360. Doussot A, Gonen M, Wiggers JK, et al. Recurrence patterns and disease-free survival after resection of intrahepatic cholangiocarcinoma: preoperative and postoperative prognostic models. *J Am Coll Surg*. 2016;223:493-505.
361. Weinbren K, Mutum SS. Pathological aspects of cholangiocarcinoma. *J Pathol*. 1983;139(2):217-238.
362. Bhuiya MR, Nimura Y, Kamiya J, et al. Clinicopathologic studies on perineural invasion of bile duct carcinoma. *Ann Surg*. 1992;215(4):344-349.
363. Aishima S, Kuroda Y, Nishihara Y, et al. Gastric mucin phenotype defines tumour progression and prognosis of intrahepatic cholangiocarcinoma: gastric foveolar type is associated with aggressive tumour behaviour. *Histopathology*. 2006;49(1):35-44.
364. Sasaki M, Nakanuma Y, Shimizu K, Izumi R. Pathological and immunohistochemical findings in a case of mucinous cholangiocarcinoma. *Pathol Int*. 1995;45:781-786.
365. Maeda T, Takenaka K, Taguchi K, et al. Adenosquamous carcinoma of the liver: clinicopathologic characteristics and cytokeratin profile. *Cancer*. 1997;80(3):364-371.
366. Nakajima T, Kondo Y. A clinicopathologic study of intrahepatic cholangiocarcinoma containing a component of squamous cell carcinoma. *Cancer*. 1990;65(6):1401-1404.
367. Haas S, Gutgemann I, Wolff M, Fischer HP. Intrahepatic clear cell cholangiocarcinoma: immunohistochemical aspects in a very rare type of cholangiocarcinoma. *Am J Surg Pathol*. 2007;31(6):902-906.
368. Nakajima T, Tajima Y, Sugano I, et al. Intrahepatic cholangiocarcinoma with sarcomatous change. Clinicopathologic and immunohistochemical evaluation of seven cases. *Cancer*. 1993;72(6):1872-1877.
369. Haratake J, Yamada H, Horie A, Inokuma T. Giant cell tumor-like cholangiocarcinoma associated with systemic cholelithiasis. *Cancer*. 1992;69(10):2444-2448.
370. Chen TC, Ng KF, Kuo T. Intrahepatic cholangiocarcinoma with lymphoepithelioma-like component. *Mod Pathol*. 2001;14(5):527-532.
371. Ortiz MR, Garijo G, Adrados M, et al. Epstein-Barr virus-associated cholangiocarcinoma with lymphoepithelioma-like component. *Int J Surg Pathol*. 2000;8(4):347-351.
372. Fornelli A, Bondi A, Jovine E, Eusebi V. Intrahepatic cholangiocarcinoma resembling a thyroid follicular neoplasm. *Virchows Arch*. 2010;456(3):339-342.
373. Bonetti F, Chilosi M, Pisa R, et al. Epithelial membrane antigen expression in cholangiocarcinoma. An useful immunohistochemical tool for differential diagnosis with hepatocarcinoma. *Virchows Arch A Pathol Anat Histopathol*. 1983;401(3):307-313.
374. Sempoux C, Jibara G, Ward SC, et al. Intrahepatic cholangiocarcinoma: new insights in pathology. *Semin Liver Dis*. 2011;31:49-60.
375. Rullier A, Le Bail B, Fawaz R, et al. Cytokeratin 7 and 20 expression in cholangiocarcinomas varies along the biliary tract but still differs from that in colorectal carcinoma metastasis. *Am J Surg Pathol*. 2000;24(6):870-876.
376. Shimonishi T, Miyazaki K, Nakanuma Y. Cytokeratin profile relates to histological subtypes and intrahepatic location of intrahepatic cholangiocarcinoma and primary sites of metastatic adenocarcinoma of liver. *Histopathology*. 2000;37(1):55-63.
377. Lodi C, Szabo E, Holczbauer A, et al. Claudin-4 differentiates biliary tract cancers from hepatocellular carcinomas. *Mod Pathol*. 2006;19(3):460-469.
378. Tada M, Omata M, Ohto M. High incidence of ras gene mutation in intrahepatic cholangiocarcinoma. *Cancer*. 1992;69(5):1115-1118.
379. Marks EI, Yee NS. Molecular genetics and targeted therapeutics in biliary tract carcinoma. *World J Gastroenterol*. 2016;22:1335-1347.
380. Bickenbach K, Galka E, Roggin KK. Molecular mechanisms of cholangiocarcinogenesis: are biliary intraepithelial neoplasia and intraductal papillary neoplasms of the bile duct precursors to cholangiocarcinoma? *Surg Oncol Clin N Am*. 2009;18(2):215-224.
381. Edge S, Byrd DR, Compton CC, et al. *AJCC Staging Manual*. 7th ed. New York: Springer-Verlag; 2010.
382. Yang J, Yan LN. Current status of intrahepatic cholangiocarcinoma. *World J Gastroenterol*. 2008;14:6289-6297.
383. Khunamornpong S, Siriaunkgul S, Suprasert P, et al. Intrahepatic cholangiocarcinoma metastatic to the ovary: a report of 16 cases of an underemphasized form of secondary tumor in the ovary that may mimic primary neoplasia. *Am J Surg Pathol*. 2007;31(12):1788-1799.
384. Kondo NI, Shirabe K, Mano Y, et al. Late recurrence after resection of mass-forming intrahepatic cholangiocarcinoma: report of a case. *Surg Today*. 2012;42:1210-1214.

385. Miura JT, Amini A, Schmocker R, et al. Surgical management of hepatic hemangiomas: a multi-institutional experience. *HPB (Oxford)*. 2014;16: 924-928.
386. Haratake J, Horie A, Nagafuchi Y. Hyalinized hemangioma of the liver. *Am J Gastroenterol*. 1992;87(2):234-236.
387. Sundaresan M, Lyons B, Akosa AB. "Solitary" necrotic nodules of the liver: an aetiology reaffirmed. *Gut*. 1991;32:1378-1380.
388. Cerar A, Dolenc-Strazar ZD, Bartenjev D. Infantile hemangioendothelioma of the liver in a neonate. Immunohistochemical observations. *Am J Surg Pathol*. 1996;20(7):871-876.
389. Luks FI, Yazbeck S, Brandt ML, et al. Benign liver tumors in children: a 25-year experience. *J Pediatr Surg*. 1991;26(11):1326-1363.
390. Dehner LP, Ishak KG. Vascular tumors of the liver in infants and children. A study of 30 cases and review of the literature. *Arch Pathol*. 1971;92(2):101-111.
391. McLean RH, Moller JH, Warwick WJ, et al. Multinodular hemangiomatosis of the liver in infancy. *Pediatrics*. 1972;49(4):563-573.
392. Drut R, Drut RM, Toulouse JC. Hepatic hemangioendotheliomas, placental chorioangiomas, and dysmorphic kidneys in Beckwith-Wiedemann syndrome. *Pediatr Pathol*. 1992;12(2):197-203.
393. Itinteang T, Chibnall AM, Marsh R, et al. Elevated serum levels of alpha-fetoprotein in patients with infantile hemangioma are not derived from within the tumor. *Front Surg*. 2016;3:5.
394. Sevinir B, Ozkan TB. Infantile hepatic hemangioendothelioma: clinical presentation and treatment. *Turk J Gastroenterol*. 2007;18:182-187.
395. Pardes JG, Bryan PJ, Gauderer MW. Spontaneous regression of infantile hemagioendotheliomatosis of the liver: demonstration by ultrasound. *J Ultrasound Med*. 1982;1:349-353.
396. Selby DM, STocker JT, Waclawiw MA, et al. Infantile hemangioendothelioma of the liver. *Hepatology*. 1994;20(1 Pt 1):39-45.
397. Mo JQ, Dimashkieh HH, Bove KE. GLUT1 endothelial reactivity distinguishes hepatic infantile hemangioma from congenital hepatic vascular malformation with associated capillary proliferation. *Hum Pathol*. 2004;35(2):200-209.
398. Ishak KG, Sesterhenn IA, Goodman ZD, et al. Epithelioid hemangioendothelioma of the liver: a clinicopathologic and follow-up study of 32 cases. *Hum Pathol*. 1984;15(9):839-852.
399. Lauffer JM, Zimmermann A, Krahenbuhl L, et al. Epithelioid hemangioendothelioma of the liver. A rare hepatic tumor. *Cancer*. 1996;78(11):2318-2327.
400. Makhlouf HR, Ishak KG, Goodman ZD. Epithelioid hemangioendothelioma of the liver: a clinicopathologic study of 137 cases. *Cancer*. 1999;85:562-582.
401. Dean PJ, Haggitt RC, O'Hara CJ. Malignant epithelioid hemangioendothelioma of the liver in young women. Relationship to oral contraceptive use. *Am J Surg Pathol*. 1985;9(10):695-704.
402. Walsh MM, Hytiroglou P, Thung SN, et al. Epithelioid hemangioendothelioma of the liver mimicking Budd-Chiari syndrome. *Arch Pathol Lab Med*. 1998;122(9):846-848.
403. Dietze O, Davies SE, Williams R, Portmann B. Malignant epithelioid haemangioendothelioma of the liver: a clinicopathological and histochemical study of 12 cases. *Histopathology*. 1989;15(3):225-237.
404. Jurczyk M, Zhu B, Laskin W, Lin X. Pitfalls in the diagnosis of hepatic epithelioid hemangioendothelioma by FNA and needle core biopsy. *Diagn Cytopathol*. 2014;42:516-520.
405. Flucke U, Vogels RJ, de Saint Aubain Somerhausen N, et al. Epithelioid hemangioendothelioma: clinicopathologic, immunohistochemical, and molecular genetic analysis of 39 cases. *Diagn Pathol*. 2014;9:131.
406. Ruebner BH, Eggleston JC. What is new in epithelioid hemangioendothelioma of the liver? *Pathol Res Pract*. 1987;182(1):110-112.
407. Scoazec JY, Degott C, Reynes M, et al. Epithelioid hemangioendothelioma of the liver: an ultrastructural study. *Hum Pathol*. 1989;20(7):673-681.
408. Nudo CG, Yoshida EM, Bain VG, et al. Liver transplantation for hepatic epithelioid hemangioendothelioma: the Canadian multicentre experience. *Can J Gastroenterol*. 2008;22:821-824.
409. Mehrabi A, Kashfi A, Fonouni H, et al. Primary malignant hepatic epithelioid hemangioendoendothelioma: a comprehensive review of the literature with emphasis on the surgical therapy. *Cancer*. 2006;107:2108-2121.
410. Demetris AJ, Minervini M, Raikow RB, Lee RG. Hepatic epithelioid hemangioendothelioma: biological questions based on pattern of recurrence in an allograft and tumor immunophenotype. *Am J Surg Pathol*. 1997;21(3):263-270.
411. Ludwig J, Hoffman HN. Hemangiosarcoma of the liver. Spectrum of morphologic changes and clinical findings. *Mayo Clin Proc*. 1975;50(5):255-263.
412. Popper H, Thomas LB, Telles NC, et al. Development of hepatic angiosarcoma in man induced by vinyl chloride, thorotrast, and arsenic. Comparison with cases of unknown etiology. *Am J Pathol*. 1978;92:349-376.
413. Rao P, Lahat G, Arnold C, et al. Angiosarcoma: a tissue microarray study with diagnostic implications. *Am J Dermatopathol*. 2013;35:432-437.
414. Falk H, Herbert JT, Edmonds L, et al. Review of four cases of childhood hepatic angiosarcoma—elevated environmental arsenic exposure in one case. *Cancer*. 1981;47(2):382-391.
415. Selby DM, Stocker JT, Ishak KG. Angiosarcoma of the liver in childhood: a clinicopathologic and follow-up study of 10 cases. *Pediatr Pathol*. 1992;12(4):485-498.
416. Locker GY, Doroshow JH, Swelling LA, Chabner BA. The clinical features of hepatic angiosarcoma: a report of four cases and review of the literature. *Medicine (Baltimore)*. 1979;58:48-64.
417. Dannaher CL, Tamburro CH, Yam LT. Occupational carcinogenesis: the Louisville experience with vinyl chloride-associated hepatic angiosarcoma. *Am J Med*. 1981;70(2):279-287.
418. Makk L, Delmore F, Creech JL Jr, et al. Clinical and morphologic features of hepatic angiosarcoma in vinyl chloride workers. *Cancer*. 1976;37(1):149-163.
419. Thomas LB, Popper H, Berk PD, et al. Vinyl-chloride-induced liver disease. From idiopathic portal hypertension (Banti's syndrome) to Angiosarcomas. *N Engl J Med*. 1975;292(1):17-22.
420. Ito Y, Kojiro M, Nakashima T, Mori T. Pathomorphologic characteristics of 102 cases of thorotrast-related hepatocellular carcinoma, cholangiocarcinoma, and hepatic angiosarcoma. *Cancer*. 1988;62(6): 1153-1162.
421. Kojiro M, Nakashima T, Ito Y, et al. Thorium dioxide-related angiosarcoma of the liver. Pathomorphologic study of 29 autopsy cases. *Arch Pathol Lab Med*. 1985;109(9):853-857.
422. Rojiani AM, Owen DA, Berry K, et al. Hepatic hemangioblastoma. An unusual presentation in a patient with von Hippel-Lindau disease. *Am J Surg Pathol*. 1991;15(1):81-86.
423. Garcia-Astudillo LA, Leyva-Cobian F. Human herpesvirus-8 infection and Kaposi's sarcoma after liver and kidney transplantation in different geographical areas of Spain. *Transpl Immunol*. 2006;17:65-69.
424. Haratake J, Koide O, Takeshita H. Hepatic lymphangiomatosis: report of two cases, with an immunohistochemical study. *Am J Gastroenterol*. 1992;87(7):906-909.
425. Schmid C, Beham A, Uranus S, et al. Non-systemic diffuse lymphangiomatosis of spleen and liver. *Histopathology*. 1991;18(5):478-480.
426. Van Steenbergen W, Joosten E, Marchal G, et al. Hepatic lymphangiomatosis. Report of a case and review of the literature. *Gastroenterology*. 1985;88(6):1968-1972.
427. Lack EE. Mesenchymal hamartoma of the liver. A clinical and pathologic study of nine cases. *Am J Pediatr Hematol Oncol*. 1986;8(2):91-98.
428. Srouji MN, Chatten J, Schulman WM, et al. Mesenchymal hamartoma of the liver in infants. *Cancer*. 1978;42(5):2483-2489.
429. Drachenberg CB, Papadimitriou JC, Rivero MA, Wood C. Distinctive case. Adult mesenchymal hamartoma of the liver: report of a case with light microscopic, FNA cytology, immunohistochemistry, and ultrastructural studies and review of the literature. *Mod Pathol*. 1991;4(3):392-395.
430. Wada M, Ohashi E, Jin H, et al. Mesenchymal hamartoma of the liver: report of an adult case and review of the literature. *Intern Med*. 1992;31(12):1370-1375.
431. Cook JR, Pfeifer JD, Dehner LP. Mesenchymal hamartoma of the liver in the adult: association with distinct clinical features and histological changes. *Hum Pathol*. 2002;33(9):893-898.
432. Stringer MD, Alizai NK. Mesenchymal hamartoma of the liver: a systematic review. *J Pediatr Surg*. 2005;40:1681-1690.
433. Sutton CA, Eller JL. Mesenchymal hamartoma of the liver. *Cancer*. 1968;22(1):29-34.
434. Dehner LP, Ewing SL, Sumner HW. Infantile mesenchymal hamartoma of the liver. Histologic and ultrastructural observations. *Arch Pathol*. 1975;99(7):379-382.
435. Shintaku M, Watanabe K. Mesenchymal hamartoma of the liver: a proliferative lesion of possible heaptic stellate cell (Ito cell) origin. *Pathol Res Pract*. 2010;206:532-536.
436. Lennington WJ, Gray GF Jr, Page DL. Mesenchymal hamartoma of liver. A regional ischemic lesion of a sequestered lobe. *Am J Dis Child*. 1993;147(2):193-196.
437. Rajaram V, Knezevich S, Bove KE, et al. DNA sequence of the translocation breakpoints in undifferentiated embryonal sarcoma arising in mesenchymal hamartoma of the liver harboring the t(11;19)(q11;q13.4) translocation. *Genes Chromosomes Cancer*. 2007;46(5):508-513.
438. Rakheja D, Margraf LR, Tomlinson GE, Schneider NR. Hepatic mesenchymal hamartoma with translocation involving chromosome band 19q13.4: a recurrent abnormality. *Cancer Genet Cytogenet*. 2004;153(1):60-63.
439. Otal TM, Hendricks JB, Pharis P, Donnelly WH. Mesenchymal hamartoma of the liver. DNA flow cytometric analysis of eight cases. *Cancer*. 1994;74(4):1237-1242.
440. Petrolla AA, Xin W. Hepatic angiomyolipoma. *Arch Pathol Lab Med*. 2008;132:1679-1682.
441. Yamasaki S, Tanaka S, Fujii H, et al. Monotypic epithelioid angiomyolipoma of the liver. *Histopathology*. 2000;36(5):451-456.
442. Tsui WM, Colombari R, Portmann BC, et al. Hepatic angiomyolipoma: a clinicopathologic

study of 30 cases and delineation of unusual morphologic variants. *Am J Surg Pathol*. 1999;23(1):34-48.
443. Tsui WM, Yuen AK, Ma KF, Tse CC. Hepatic angiomyolipomas with a deceptive trabecular pattern and HMB-45 reactivity. *Histopathology*. 1992;21(6):569-573.
444. Weeks DA, Malott RL, Arnesen M, et al. Hepatic angiomyolipoma with striated granules and positivity with melanoma—specific antibody (HMB-45): a report of two cases. *Ultrastruct Pathol*. 1991;15(4-5):563-571.
445. Xu AM, Zhang SH, Zheng JM, et al. Pathological and molecular analysis of sporadic hepatic angiomyolipoma. *Hum Pathol*. 2006;37(6):735-741.
446. Folpe AL, Goodman ZD, Ishak KG, et al. Clear cell myomelanocytic tumor of the falciform ligament/ligamentum teres: a novel member of the perivascular epithelioid clear cell family of tumors with a predilection for children and young adults. *Am J Surg Pathol*. 2000;24(9):1239-1246.
447. Tanaka Y, Ijiri R, Kato K, et al. HMB-45/melan-A and smooth muscle actin-positive clear-cell epithelioid tumor arising in the ligamentum teres hepatis: additional example of clear cell 'sugar' tumors. *Am J Surg Pathol*. 2000;24(9):1295-1299.
448. Nonomura A, Enomoto Y, Takeda M, et al. Angiomyolipoma of the liver: a reappraisal of morphologic features and delineation of new characteristic histological features from the clinicopathologic findings of 55 tumours in 47 patients. *Histopathology*. 2012;61:863-880.
449. Dalle I, Sciot R, de Vos R, et al. Malignant angiomyolipoma of the liver: a hitherto unreported variant. *Histopathology*. 2000;36(5):443-450.
450. Parfitt JR, Bella AJ, Izawa JI, Wehrli BM. Malignant neoplasm of perivascular epithelioid cells of the liver. *Arch Pathol Lab Med*. 2006;130(8):1219-1222.
451. Yang X, Miao R, Yang H, et al. Retrospective and comparative study of inflammatory myofibroblastic tumor of the liver. *J Gastroenterol Hepatol*. 2015;30:885-890.
452. Shek TW, Ng IO, Chan KW. Inflammatory pseudotumor of the liver. Report of four cases and review of the literature. *Am J Surg Pathol*. 1993;17(3):231-238.
453. Horiuchi R, Uchida T, Kojima T, Shikata T. Inflammatory pseudotumor of the liver. Clinicopathologic study and review of the literature. *Cancer*. 1990;65:1583-1590.
454. Nonaka D, Birbe R, Rosai J. So-called inflammatory myofibroblastic tumour: a proliferative lesion of fibroblastic reticulum cells? *Histopathology*. 2005;46(6):604-613.
455. Elpek GO. Inflammatory myofibroblastic tumor of the liver: a diagnostic challenge. *J Clin Transl Hepatol*. 2014;2:53-57.
456. Nakanuma Y, Tsuneyama K, Masuda S, Tomioka T. Hepatic inflammatory pseudotumor associated with chronic cholangitis: report of three cases. *Hum Pathol*. 1994;25(1):86-91.
457. Gollapudi P, Chejfec G, Zarling EJ. Spontaneous regression of hepatic pseudotumor. *Am J Gastroenterol*. 1992;87(2):214-217.
458. Hawkins EP, Jordan GL, McGavran MH. Primary leiomyoma of the liver. Successful treatment by lobectomy and presentation of criteria for diagnosis. *Am J Surg Pathol*. 1980;4(3):301-304.
459. Reinertson TE, Fortune JB, Peters JC, et al. Primary leiomyoma of the liver. A case report and review of the literature. *Dig Dis Sci*. 1992;37(4):622-627.
460. Le Bail B, Morel D, Merel P, et al. Cystic smooth-muscle tumor of the liver and spleen associated with Epstein-Barr virus after renal transplantation. *Am J Surg Pathol*. 1996;20(11):1418-1425.
461. Lee ES, Locker J, Nalesnik M, et al. The association of Epstein-Barr virus with smooth-muscle tumors occurring after organ transplantation. *N Engl J Med*. 1995;332(1):19-25.
462. Prevot S, Neris J, de Saint Maur PP. Detection of Epstein Barr virus in an hepatic leiomyomatous neoplasm in an adult human immunodeficiency virus 1-infected patient. *Virchows Arch*. 1994;425(3):321-325.
463. Deyrup AT, Lee VK, Hill CE, et al. Epstein-Barr virus-associated smooth muscle tumors are distinctive mesenchymal tumors reflecting multiple infection events: a clinicopathologic and molecular analysis of 29 tumors from 19 patients. *Am J Surg Pathol*. 2006;30(1):75-82.
464. Nishizaki T, Kanematsu T, Matsumata T, et al. Myelolipoma of the liver. A case report. *Cancer*. 1989;63(5):930-934.
465. Rubin E, Russinovich NA, Luna RF, et al. Myelolipoma of the liver. *Cancer*. 1984;54(9):2043-2046.
466. Bornstein-Quevedo L, Aviles-Salas A, Laguna M, et al. [Primary lipoma of the liver]. *Rev Gastroenterol Mex*. 2000;65:175-178.
467. Karhunen PJ. Hepatic pseudolipoma. *J Clin Pathol*. 1985;38(8):877-879.
468. Moran CA, Ishak KG, Goodman ZD. Solitary fibrous tumor of the liver: a clinicopathologic and immunohistochemical study of nine cases. *Ann Diagn Pathol*. 1998;2(1):19-24.
469. Dey B, Gochhait D, Kaushal G, et al. Solitary fibrous tumor of the liver: a rare tumor in a rarer location. *Rare Tumors*. 2016;8:6403.
470. Fiel MI, Schwartz M, Min AD, et al. Malignant schwannoma of the liver in a patient without neurofibromatosis: a case report and review of the literature. *Arch Pathol Lab Med*. 1996;120(12):1145-1147.
471. Hytiroglou P, Linton P, Klion F, et al. Benign schwannoma of the liver. *Arch Pathol Lab Med*. 1993;117(2):216-218.
472. Wada Y, Jimi A, Nakashima O, et al. Schwannoma of the liver: report of two surgical cases. *Pathol Int*. 1998;48(8):611-617.
473. Alrenga DP. Primary fibrosarcoma of the liver. Case report and review of the literature. *Cancer*. 1975;36(2):446-449.
474. Nakahama M, Takanashi R, Yamazaki I, Machinami R. Primary fibrosarcoma of the liver. Immunohistochemical and electron microscopic studies. *Acta Pathol Jpn*. 1989;39(12):814-820.
475. Naik PR, Kumar P, Kumar PV. Primary pleomorphic liposarcoma of liver: a case report and review of the literature. *Case Reports Hepatol*. 2013;2013:398910.
476. Bloustein PA. Hepatic leiomyosarcoma: ultrastructural study and review of the differential diagnosis. *Hum Pathol*. 1978;9(6):713-715.
477. O'Leary MR, Hill RB, Levine RA. Peritoneoscopic diagnosis of primary leiomyosarcoma of liver. *Hum Pathol*. 1982;13(1):76-78.
478. Watanabe K, Saito A, Wakabayashi H, et al. Two autopsy cases of primary leiomyosarcoma of the liver. Superiority of muscle-specific actin immunoreactivity in diagnosis. *Acta Pathol Jpn*. 1991;41(6):461-465.
479. Ross JS, Del Rosario A, Bui HX, et al. Primary hepatic leiomyosarcoma in a child with the acquired immunodeficiency syndrome. *Hum Pathol*. 1992;23(1):69-72.
480. McArdle JP, Hawley I, Shevland J, Brain T. Primary rhabdomyosarcoma of the adult liver. *Am J Surg Pathol*. 1989;13(11):961-965.
481. Cote RJ, Urmacher C. Rhabdomyosarcoma of the liver associated with long-term oral contraceptive use. Possible role of estrogens in the genesis of embryologically distinct liver tumors. *Am J Surg Pathol*. 1990;14(8):784-790.
482. Li YR, Akbari E, Tretiakova MS, et al. Primary hepatic malignant fibrous histiocytoma: clinicopathologic characteristics and prognostic value of ezrin expression. *Am J Surg Pathol*. 2008;32(8):1144-1145.
483. Sumiyoshi A, Niho Y. Primary osteogenic sarcoma of the liver—report of an autopsy case. *Acta Pathol Jpn*. 1971;21(2):305-312.
484. von Hochstetter AR, Hattenschwiler J, Vogt M. Primary osteosarcoma of the liver. *Cancer*. 1987;60(9):2312-2317.
485. Horie Y, Hori T, Hirayama C, et al. Osteoclast-like giant cell tumor of the liver. *Acta Pathol Jpn*. 1987;37(8):1327-1335.
486. Munoz PA, Rao MS, Reddy JK. Osteoclastoma-like giant cell tumor of the liver. *Cancer*. 1980;46(4):771-779.
487. Foschini MP, Van Eyken P, Brock PR, et al. Malignant rhabdoid tumour of the liver. A case report. *Histopathology*. 1992;20(2):157-165.
488. Ohyama M, Ijiri R, Tanaka Y, et al. Congenital primitive epithelial tumor of the liver showing focal rhabdoid features, placental involvement, and clinical features mimicking multifocal hemangioma or stage 4S neuroblastoma. *Hum Pathol*. 2000;31(2):259-263.
489. Parham DM, Peiper SC, Robicheaux G, et al. Malignant rhabdoid tumor of the liver. Evidence for epithelial differentiation. *Arch Pathol Lab Med*. 1988;112(1):61-64.
490. Scheimberg I, Cullinane C, Kelsey A, Malone M. Primary hepatic malignant tumor with rhabdoid features. A histological, immunocytochemical, and electron microscopic study of four cases and a review of the literature. *Am J Surg Pathol*. 1996;20(11):1394-1400.
491. Techavichit P, Masand PM, Himes RW, et al. Undifferentiated embryonal sarcoma of the liver (UESL): a single-center experience and review of the literature. *J Pediatr Hematol Oncol*. 2016;38:261-268.
492. Nishio J, Iwasaki H, Sakashita N, et al. Undifferentiated (embryonal) sarcoma of the liver in middle-aged adults: smooth muscle differentiation determined by immunohistochemistry and electron microscopy. *Hum Pathol*. 2003;34(3):246-252.
493. de Chadarevian JP, Pawel BR, Faerber EN, Weintraub WH. Undifferentiated (embryonal) sarcoma arising in conjunction with mesenchymal hamartoma of the liver. *Mod Pathol*. 1994;7(4):490-493.
494. Lauwers GY, Grant LD, Donnelly WH, et al. Hepatic undifferentiated (embryonal) sarcoma arising in a mesenchymal hamartoma. *Am J Surg Pathol*. 1997;21(10):1248-1254.
495. O'Sullivan MJ, Swanson PE, Knoll J, et al. Undifferentiated embryonal sarcoma with unusual features arising within mesenchymal hamartoma of the liver: report of a case and review of the literature. *Pediatr Dev Pathol*. 2001;4(5):482-489.
496. Aoyama C, Hachitanda Y, Sato JK, et al. Undifferentiated (embryonal) sarcoma of the liver. A tumor of uncertain histogenesis showing divergent differentiation. *Am J Surg Pathol*. 1991;15(7):615-624.
497. Kiani B, Ferrell LD, Qualman S, Frankel WL. Immunohistochemical analysis of embryonal sarcoma of the liver. *Appl Immunohistochem Mol Morphol*. 2006;14(2):193-197.
498. Miettinen M, Kahlos T. Undifferentiated (embryonal) sarcoma of the liver. Epithelial features as shown by immunohistochemical analysis and electron microscopic examination. *Cancer*. 1989;64(10):2096-2103.
499. Parham DM, Kelly DR, Donnelly WH, Douglass EC. Immunohistochemical and ultrastructural spectrum of hepatic sarcomas of childhood: evidence for a common histogenesis. *Mod Pathol*. 1991;4(5):648-653.

500. Nicol K, Savell V, Moore J, et al. Distinguishing undifferentiated embryonal sarcoma of the liver from biliary tract rhabdomyosarcoma: a Children's Oncology Group study. *Pediatr Dev Pathol*. 2007;10(2):89-97.
501. Bagley CM Jr, Thomas LB, Johnson RE, et al. Diagnosis of liver involvement by lymphoma: results in 96 consecutive peritoneoscopies. *Cancer*. 1973;31(4):840-847.
502. Ryan J, Straus DJ, Lange C, et al. Primary lymphoma of the liver. *Cancer*. 1988;61(2):370-375.
503. Ugurluer G, Miller RC, Li Y, et al. Primary hepatic lymphoma: a retrospective, multicenter rare cancer network study. *Rare Tumors*. 2016;8:6502.
504. Baumhoer D, Tzankov A, Dirnhofer S, et al. Patterns of liver infiltration in lymphoproliferative disease. *Histopathology*. 2008;53(1):81-90.
505. Dargent JL, De Wolf-Peeters C. Liver involvement by lymphoma: identification of a distinctive pattern of infiltration related to T-cell/histiocyte-rich B-cell lymphoma. *Ann Diagn Pathol*. 1998;2(6):363-369.
506. DeMent SH, Mann RB, Staal SP, et al. Primary lymphomas of the liver. Report of six cases and review of the literature. *Am J Clin Pathol*. 1987;88(3):255-263.
507. Isaacson PG, Banks PM, Best PV, et al. Primary low-grade hepatic B-cell lymphoma of mucosa-associated lymphoid tissue (MALT)-type. *Am J Surg Pathol*. 1995;19(5):571-575.
508. Loddenkemper C, Longerich T, Hummel M, et al. Frequency and diagnostic patterns of lymphomas in liver biopsies with respect to the WHO classification. *Virchows Arch*. 2007;450(5):493-502.
509. Strayer DS, Reppun TS, Levin M, Deschryver-Kecskemeti K. Primary lymphoma of the liver. *Gastroenterology*. 1980;78(6):1571-1576.
510. Trudel M, Aramendi T, Caplan S. Large-cell lymphoma presenting with hepatic sinusoidal infiltration. *Arch Pathol Lab Med*. 1991;115(8):821-824.
511. Ascoli V, Lo Coco F, Artini M, et al. Extranodal lymphomas associated with hepatitis C virus infection. *Am J Clin Pathol*. 1998;109(5):600-609.
512. Rubbia-Brandt L, Brundler MA, Kerl K, et al. Primary hepatic diffuse large B-cell lymphoma in a patient with chronic hepatitis C. *Am J Surg Pathol*. 1999;23(9):1124-1130.
513. Miller ST, Wollner N, Meyers PA, et al. Primary hepatic or hepatosplenic non-Hodgkin's lymphoma in children. *Cancer*. 1983;52(12):2285-2288.
514. Mantadakis E, Raissaki M, Tzardi M, et al. Primary hepatic Burkitt lymphoma. *Pediatr Hematol Oncol*. 2008;25:331-338.
515. Chang KL, Arber DA. Hepatosplenic gamma delta T-cell lymphoma—not just alphabet soup. *Adv Anat Pathol*. 1998;5(1):21-29.
516. Macon WR, Levy NB, Kurtin PJ, et al. Hepatosplenic alphabeta T-cell lymphomas: a report of 14 cases and comparison with hepatosplenic gammadelta T-cell lymphomas. *Am J Surg Pathol*. 2001;25(3):285-296.
517. Yabe M, Medeiros LJ, Tang G, et al. Prognostic factors of hepatosplenic T-cell lymphoma: clinicopathologic study of 28 cases. *Am J Surg Pathol*. 2016;40:676-688.
518. Francois A, Lesesve JF, Stamatoullas A, et al. Hepatosplenic gamma/delta T-cell lymphoma: a report of two cases in immunocompromised patients, associated with isochromosome 7q. *Am J Surg Pathol*. 1997;21(7):781-790.
519. Wu H, Wasik MA, Przybylski G, et al. Hepatosplenic gamma-delta T-cell lymphoma as a late-onset posttransplant lymphoproliferative disorder in renal transplant recipients. *Am J Clin Pathol*. 2000;113(4):487-496.
520. Scheimberg IB, Pollock DJ, Collins PW, et al. Pathology of the liver in leukaemia and lymphoma. A study of 110 autopsies. *Histopathology*. 1995;26(4):311-321.
521. Piccaluga PP, Ascani S, Agostinelli C, et al. Myeloid sarcoma of liver: an unusual cause of jaundice. Report of three cases and review of literature. *Histopathology*. 2007;50(6):802-805.
522. Martins PN, Reddy S, Martins AB, Facciuto M. Follicular dendritic cell sarcomas of the liver: unusual presentation of a rare tumor and literature review. *HBPD INT*. 2011;10: 443-445.
523. Chen TC, Kuo TT, Ng KF. Follicular dendritic cell tumor of the liver: a clinicopathologic and Epstein-Barr virus study of two cases. *Mod Pathol*. 2001;14(4):354-360.
524. Shek TW, Ho FC, Ng IO, et al. Follicular dendritic cell tumor of the liver. Evidence for an Epstein-Barr virus-related clonal proliferation of follicular dendritic cells. *Am J Surg Pathol*. 1996;20(3):313-324.
525. Cheuk W, Chan JK, Shek TW, et al. Inflammatory pseudotumor-like follicular dendritic cell tumor: a distinctive low-grade malignant intra-abdominal neoplasm with consistent Epstein-Barr virus association. *Am J Surg Pathol*. 2001;25(6):721-731.
526. Torres U, Hawkins WG, Antonescu CR, DeMatteo RP. Hepatic follicular dendritic cell sarcoma without Epstein-Barr virus expression. *Arch Pathol Lab Med*. 2005;129(11):1480-1483.
527. Nonomura A, Minato H, Shimizu K, et al. Pseudolymphoma (reactive lymphoid hyperplasia) of the liver containing epithelioid cell granulomas and Schaumann's bodies in giant cells: a case report. *Int J Surg Pathol*. 1998;6:101-108.
528. Sharifi S, Murphy M, Loda M, et al. Nodular lymphoid lesion of the liver: an immune-mediated disorder mimicking low-grade malignant lymphoma. *Am J Surg Pathol*. 1999;23(3):302-308.
529. Zen Y, Fujii T, Nakanuma Y. Hepatic pseudolymphoma: a clinicopathological study of five cases and review of the literature. *Mod Pathol*. 2010;23(2):244-250.
530. Nuckols JD, Baron PW, Stenzel TT, et al. The pathology of liver-localized post-transplant lymphoproliferative disease: a report of three cases and a review of the literature. *Am J Surg Pathol*. 2000;24(5):733-741.
531. Thiruvengadam R, Penetrante RB, Goolsby HJ, et al. Multiple myeloma presenting as space-occupying lesions of the liver. *Cancer*. 1990;65(12):2784-2786.
532. Weichhold W, Labouyrie E, Merlio JP, et al. Primary extramedullary plasmacytoma of the liver. A case report. *Am J Surg Pathol*. 1995;19(10):1197-1202.
533. Kaplan KJ, Goodman ZD, Ishak KG. Liver involvement in Langerhans' cell histiocytosis: a study of nine cases. *Mod Pathol*. 1999;12(4):370-378.
534. Gresham GA, Rue LW 3rd. Squamous cell carcinoma of the liver. *Hum Pathol*. 1985;16(4):413-416.
535. Song E, Kew MC, Grieve T, et al. Primary squamous cell carcinoma of the liver occurring in association with hepatolithiasis. *Cancer*. 1984;53(3):542-546.
536. Andreola S, Lombardi L, Audisio RA, et al. A clinicopathologic study of primary hepatic carcinoid tumors. *Cancer*. 1990;65(5):1211-1218.
537. Miura K, Shirasawa H. Primary carcinoid tumor of the liver. *Am J Clin Pathol*. 1988;89(4):561-564.
538. Gembala RB, Arsuaga JE, Friedman AC, et al. Carcinoid of the intrahepatic ducts. *Abdom Imaging*. 1993;18(3):242-244.
539. Larriva-Sahd J, Angeles-Angeles A, Hernandez-Pando R, et al. Ultrastructural and immunocytochemical study of a primary gastrinoma of the liver. *Ultrastruct Pathol*. 1992;16(6):667-672.
540. Moriura S, Ikeda S, Hirai M, et al. Hepatic gastrinoma. *Cancer*. 1993;72(5):1547-1550.
541. Ayub A, Zafar M, Abdulkareem A, et al. Primary hepatic vipoma. *Am J Gastroenterol*. 1993;88(6):958-961.
542. Hsueh C, Tan XD, Gonzalez-Crussi F. Primary hepatic neuroendocrine carcinoma in a child. Morphologic, immunocytochemical, and molecular biologic studies. *Cancer*. 1993;71(8):2660-2665.
543. Pilichowska M, Kimura N, Ouchi A, et al. Primary hepatic carcinoid and neuroendocrine carcinoma: clinicopathological and immunohistochemical study of five cases. *Pathol Int*. 1999;49(4):318-324.
544. Heerema-McKenney A, Leuschner I, Smith N, et al. Nested stromal epithelial tumor of the liver: six cases of a distinctive pediatric neoplasm with frequent calcifications and association with Cushing syndrome. *Am J Surg Pathol*. 2005;29(1):10-20.
545. Hill DA, Swanson PE, Anderson K, et al. Desmoplastic nested spindle cell tumor of liver: report of four cases of a proposed new entity. *Am J Surg Pathol*. 2005;29(1): 1-9.
546. Makhlouf HR, Abdul-Al HM, Wang G, Goodman ZD. Calcifying nested stromal-epithelial tumors of the liver: a clinicopathologic, immunohistochemical, and molecular genetic study of 9 cases with a long-term follow-up. *Am J Surg Pathol*. 2009;33(7):976-983.
547. Robinson RA, Nelson L. Hepatic teratoma in an anencephalic fetus. *Arch Pathol Lab Med*. 1986;110(7):655-657.
548. Misugi K, Reiner CB. A malignant true teratoma of liver in childhood. *Arch Pathol*. 1965;80(4):409-412.
549. Hart WR. Primary endodermal sinus (yolk sac) tumor of the liver. First reported case. *Cancer*. 1975;35(5):1453-1458.
550. Villaschi S, Balistreri P. Endodermal sinus tumour of the liver. *Histopathology*. 1991;18(1):86-88.
551. Wakely PE Jr, Krummel TM, Johnson DE. Yolk sac tumor of the liver. *Mod Pathol*. 1991;4(1):121-125.
552. Cross SS, Variend S. Combined hepatoblastoma and yolk sac tumor of the liver. *Cancer*. 1992;69(6):1323-1326.
553. Morinaga S, Nishiya H, Inafuku T. Yolk sac tumor of the liver combined with hepatocellular carcinoma. *Arch Pathol Lab Med*. 1996;120(7):687-690.
554. Fernandez Alonso J, Saez C, Perez P, et al. Primary pure choriocarcinoma of the liver. *Pathol Res Pract*. 1992;188(3):375-377, discussion 378-379.
555. Heaton GE, Matthews TH, Christopherson WM. Malignant trophoblastic tumors with massive hemorrhage presenting as liver primary. A report of two cases. *Am J Surg Pathol*. 1986;10(5):342-347.
556. Shi H, Cao D, Wei L, et al. Primary choriocarcinoma of the liver: a clinicopathological study of five cases in males. *Virchows Arch*. 2010;456(1):65-70.
557. Theegarten D, Reinacher A, Graeven U, Philippou S. Mixed malignant germ cell tumour of the liver. *Virchows Arch*. 1998;433(1):93-96.
558. Corti B, D'Errico A, Pierangeli F, et al. Primary paraganglioma strictly confined to the liver and mimicking hepatocellular carcinoma: an immunohistochemical and in situ hybridization study. *Am J Surg Pathol*. 2002;26:945-949.

559. Hervieu V, Lombard-Bohas C, Dumortier J, et al. Primary acinar cell carcinoma of the liver. *Virchows Arch*. 2008;452(3): 337-341.
560. Jaiswal VR, Champine JG, Sharma S, Molberg KH. Primary glomangioma of the liver: a case report and review of the literature. *Arch Pathol Lab Med*. 2004;128(3):e46-e49.
561. Di Blasi A, Boscaino A, De Dominicis G, et al. Multicystic mesothelioma of the liver with secondary involvement of peritoneum and inguinal region. *Int J Surg Pathol*. 2004;12(1):87-91.
562. Flemming P, Becker T, Klempnauer J, et al. Benign cystic mesothelioma of the liver. *Am J Surg Pathol*. 2002;26(11):1523-1527.
563. Kim YI, Kim ST, Lee GK, Choi BI. Papillary cystic tumor of the liver. A case report with ultrastructural observation. *Cancer*. 1990;65(12):2740-2746.
564. Tsuneyama K, Hoso M, Kono N, et al. An unusual case of epithelial-myoepithelial carcinoma of the liver. *Am J Surg Pathol*. 1999;23(3):349-353.
565. Hausner RJ, Alexander RW. Localized congenital hepatic fibrosis presenting as an abdominal mass. *Hum Pathol*. 1978;9(4):473-476.
566. Bishop KC, Perrino CM, Ruzinova MB, Brunt EM. Ciliated hepatic foregut cyst: a report of 6 cases and a review of the English literature. *Diagn Pathol*. 2015;10:81.
567. Robertson SJ, Higgins RB, Powell C. Malacoplakia of liver: a case report. *Hum Pathol*. 1991;22(12):1294-1295.
568. Ohtsuka M, Miyazaki M, Itoh H, et al. Routes of hepatic metastasis of gallbladder carcinoma. *Am J Clin Pathol*. 1998;109(1):62-68.
569. Pikren JW, Tsukada Y, Lane WW. Liver metastases. Analysis of autopsy data. In: Weiss L, Gilber HA, eds. *Liver Metastases*. Boston: GK Hall.; 1982.
570. Schulz W, Hort W. The distribution of metastases in the liver. A quantitative postmortem study. *Virchows Arch A Pathol Anat Histol*. 1981;394(1-2):89-96.
571. Okano K, Yamamoto J, Kosuge T, et al. Fibrous pseudocapsule of metastatic liver tumors from colorectal carcinoma. Clinicopathologic study of 152 first resection cases. *Cancer*. 2000;89(2):267-275.
572. Borja ER, Hori JM, Pugh RP. Metastatic carcinomatosis of the liver mimicking cirrhosis: case report and review of the literature. *Cancer*. 1975;35(2):445-449.
573. Sawabe M, Kato Y, Ohashi I, Kitagawa T. Diffuse intrasinusoidal metastasis of gastric carcinoma to the liver leading to fulminant hepatic failure. A case report. *Cancer*. 1990;65(1):169-173.
574. Shirai Y, Wakai T, Ohtani T, et al. Colorectal carcinoma metastases to the liver. Does primary tumor location affect its lobar distribution? *Cancer*. 1996;77(11): 2213-2216.
575. Schulz W, Hagen CH, Hort W. The distribution of liver metastases from colonic cancer. A quantitative postmortem study. *Virchows Arch*. 1985;406:279-284.
576. Wigmore SJ, Madhavan K, Redhead DN, et al. Distribution of colorectal liver metastases in patients referred for hepatic resection. *Cancer*. 2000;89(2):285-287.
577. Qizilbash A, Kontozoglou T, Sianos J, Scully K. Hepar lobatum associated with chemotherapy and metastatic breast cancer. *Arch Pathol Lab Med*. 1987;111(1):58-61.
578. Melato M, Laurino L, Mucli E, et al. Relationship between cirrhosis, liver cancer, and hepatic metastases. An autopsy study. *Cancer*. 1989;64(2):455-459.
579. Terracciano LM, Glatz K, Mhawech P, et al. Hepatoid adenocarcinoma with liver metastasis mimicking hepatocellular carcinoma: an immunohistochemical and molecular study of eight cases. *Am J Surg Pathol*. 2003;27(10):1302-1312.
580. Bendelow J, Apps E, Jones LE, Poston GJ. Carcinoid syndrome. *Eur J Surg Oncol*. 2008;34:289-296.
581. Frankel TL, D'Angelica MI. Hepatic resection for colorectal metastatses. *J Surg Oncol*. 2014;109:207.
582. McNally SJ, Parks RW. Surgery for colorectal liver metastases. *Dig Surg*. 2013;30:337-347.

21 Gallbladder and Extrahepatic Bile Ducts

Laura W. Lamps

CHAPTER CONTENTS

Normal anatomy, *844*
Congenital abnormalities, *845*
Gallbladder, *845*
Extrahepatic biliary tree, *847*
Cholesterosis, *848*
Cholelithiasis, *849*
Acute cholecystitis, *851*
Chronic cholecystitis, *851*
Other inflammatory processes involving the gallbladder, *855*
Inflammatory disorders of the extrahepatic bile ducts, *856*
Infections of the gallbladder and extrahepatic bile ducts, *857*
Tumors and tumorlike conditions of the gallbladder, *858*
Benign tumors and tumorlike conditions, *858*
Tumoral intraepithelial neoplasia, *860*
Flat/nontumoral preinvasive lesions (dysplasia/carcinoma in situ), *861*
Carcinoma of the gallbladder, *863*
Tumors of the extrahepatic bile ducts, *871*
Benign tumors of the extrahepatic bile ducts, *871*
Tumoral intraepithelial neoplasms, *871*
Nontumoral (flat) dysplasia, *872*
Adenocarcinoma of the extrahepatic bile ducts, *874*
Miscellaneous tumors of the gallbladder and extrahepatic bile ducts, *877*

Normal Anatomy

The gallbladder is a pear-shaped sac that lies in a shallow depression on the inferior surface of the right hepatic lobe. In the adult, it measures up to 10 cm in length and 3–4 cm in width, and the normal wall thickness is 1–2 mm.[1] The free surface is covered by serosa that is continuous with that on the hepatic surface, and the subserosal connective tissue of the gallbladder merges into the hepatic interlobular connective tissue at the hepatic surface. The gallbladder is divided into the *fundus*, *body*, and *neck* (Fig. 21.1). The portion of the body that joins the neck is referred to as the *infundibulum*; sometimes there is a small bulge in this portion, known as *Hartmann pouch*.

The blood supply of the gallbladder is via the cystic artery, which is usually a branch of the right hepatic artery (see later). Lymph drains to the node(s) at the gallbladder neck or cystic duct, from which it flows to nodes near the hepatic hilum and in the inferior portion of the hepatoduodenal ligament, the latter reaching nodes on the celiac axis.

The wall of the gallbladder is composed of three layers: mucosa, muscularis propria, and serosa (the latter only on the free surface) (Fig. 21.2). There is no muscularis mucosae or submucosa, and thus the lamina propria abuts directly onto the muscularis propria.[1,2] The mucosa is made up of variably sized branching folds consisting of a core of lamina propria lined by a single layer of columnar epithelium. The epithelial cells have eosinophilic cytoplasm with occasional small apical vacuoles, and basally located nuclei.[1,2] Smaller, darkly staining columnar cells known as *penciloid cells* are interspersed within the epithelium (Fig. 21.3), along with basal cells that are often inconspicuous. Scattered lymphocytes, plasma cells, mast cells, and histiocytes are normal and should not be interpreted as evidence of chronic cholecystitis. The muscular wall consists of loosely arranged bundles of longitudinal, circular, and oblique muscle fibers, but the gallbladder lacks the well-formed layers seen in the tubular gut.[1] Ganglion cells may be found anywhere in the wall of the gallbladder. Minute paraganglia are present in the subserosal region and are occasionally detected in random sections of the organ.[3]

In the gallbladder, true mucous glands are present only in the neck. They consist of cuboidal or low columnar epithelium with clear to lightly basophilic cytoplasm,[1] and scattered neuroendocrine cells may be found within them. The ducts of Luschka (Fig. 21.4) are small accessory bile ducts located in the perimuscular connective tissue, typically on the hepatic surface of the gallbladder. The epithelium is very similar to biliary epithelium, and there is a distinctive ring of surrounding connective tissue. These ducts may be mistaken for carcinoma on frozen section,[4] particularly when inflamed, and the lobular architecture may be a helpful distinguishing feature for these normal accessory ducts. Occasionally, accessory bile ducts are located in the gallbladder bed itself and may leak after cholecystectomy.[5]

The neck of the gallbladder connects with the cystic duct, joining the gallbladder to the biliary tree; the lining of the cystic duct is pleated, with large oblique folds containing smooth muscle

Abstract

This chapter covers the pathologic features of the major neoplastic and non-neoplastic entities that the surgical pathologist will encounter in the gallbladder and extrahepatic bile ducts, including congenital anomalies, inflammatory processes, and tumors and tumor-like conditions.

Keywords

gallbladder,
extrahepatic bile ducts,
cholangiocarcinoma,
choledochal cyst,
biliary atresia,
biliary intraepithelial neoplasia,
tumoral intraepithelial neoplasms,
intracholecystic papillary-tubular neoplasms

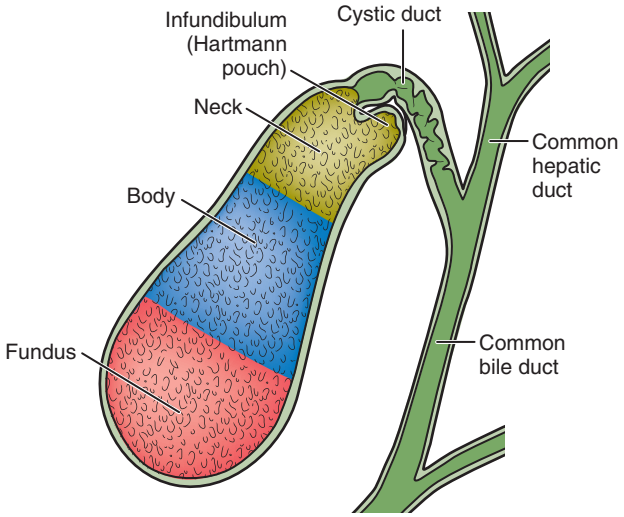

Figure 21.1 The gallbladder is divided into the fundus, body, and neck; the portion of the body adjoining the neck is referred to as the infundibulum. A small bulge in this portion is known as Hartmann pouch, notable because gallstones may become lodged here.

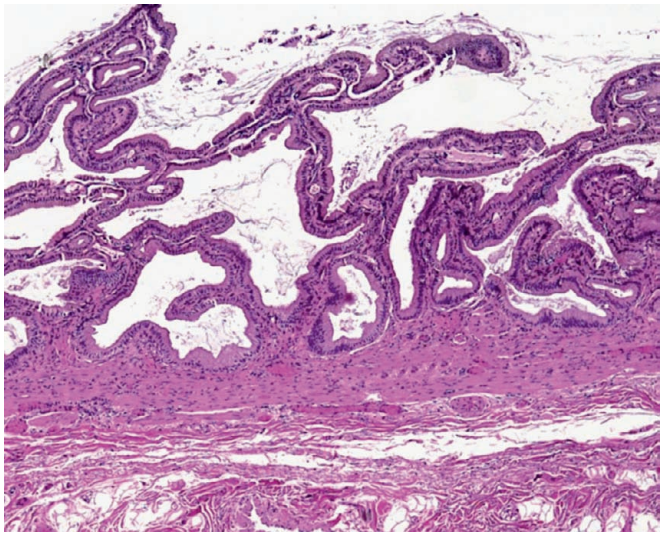

Figure 21.2 The gallbladder wall contains three layers: mucosa, muscularis propria, and serosa on the free surface. There is no muscularis mucosae or submucosa, thus the lamina propria abuts directly onto the muscularis propria. The mucosa is composed of variably sized branching folds consisting of a core of lamina propria lined by a single layer of columnar epithelium.

(spiral valves of Heister), in order to prevent collapse. The other components of the extrahepatic biliary system are the *hepatic* (*right*, *left*, and *common*) *ducts* and *common bile duct*. Numerous variations in the anatomy of these ducts and their blood supply occur (Fig. 21.5).[6] The lymph drainage from the common bile duct is to nodes located along the duct, near the porta hepatis, around the pancreas, and ultimately into the celiac axis group.

Microscopically, the epithelium of all of the extrahepatic bile ducts is made up of a single layer of columnar cells resting on dense connective tissue (Fig. 21.6). Different patterns of smooth muscle distribution are seen in different portions of the extrahepatic biliary system, which may influence the estimation of depth of invasion of tumors. The upper portion of the common bile duct contains thin strands of

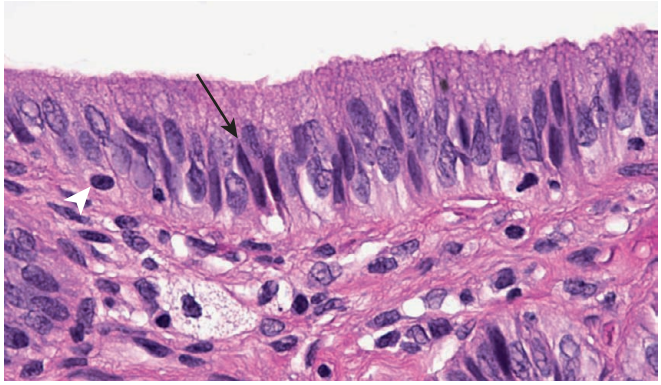

Figure 21.3 Gallbladder epithelial cells have eosinophilic cytoplasm with basally located nuclei. Smaller, darkly staining columnar cells known as *penciloid cells* are interspersed within the epithelium *(arrow)*, as well as basal cells that are often inconspicuous *(arrowhead)*.

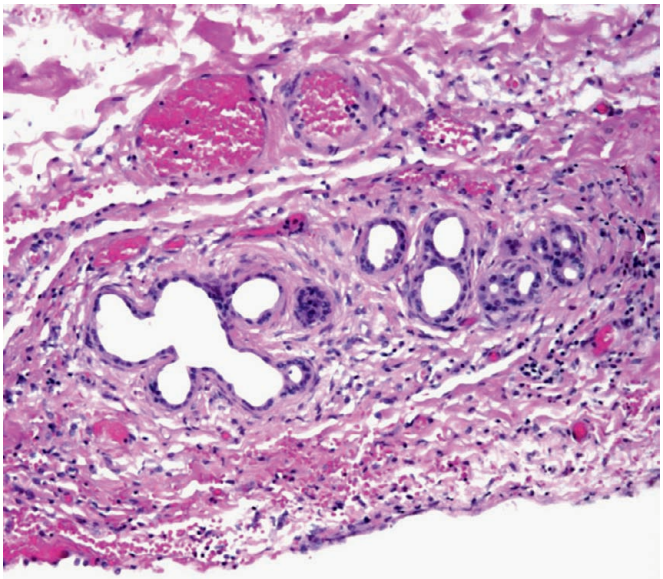

Figure 21.4 The ducts of Luschka are normal small accessory bile ducts typically located in the perimuscular connective tissue on the hepatic surface of the gallbladder. There is a distinctive ring of surrounding connective tissue, which helps distinguish them from carcinoma, particularly on frozen section evaluation.

muscle, whereas the lower third is invested by thick smooth muscle. Muscle is also present at the junction of the gallbladder and the cystic duct. The muscle coat is inconspicuous or absent in the upper third of the tract.[1,7] This epithelium penetrates into the stroma to form pits known as the *sacculi of Beale*, the larger of which can be seen grossly. Surrounding these saccules are small lobular mucous glands that are surrounded by dense stroma, known as peribiliary glands, biliary glands, or periductal glands; these may mimic well-differentiated carcinoma, and their lobular architecture seen on low-power microscopy is the most important identifying feature.[1,2]

Congenital Abnormalities

Gallbladder

Congenital abnormalities of the gallbladder are rare, and include *duplication*, *diverticula*, *absence (agenesis)*, *septation*, *phrygian cap*,

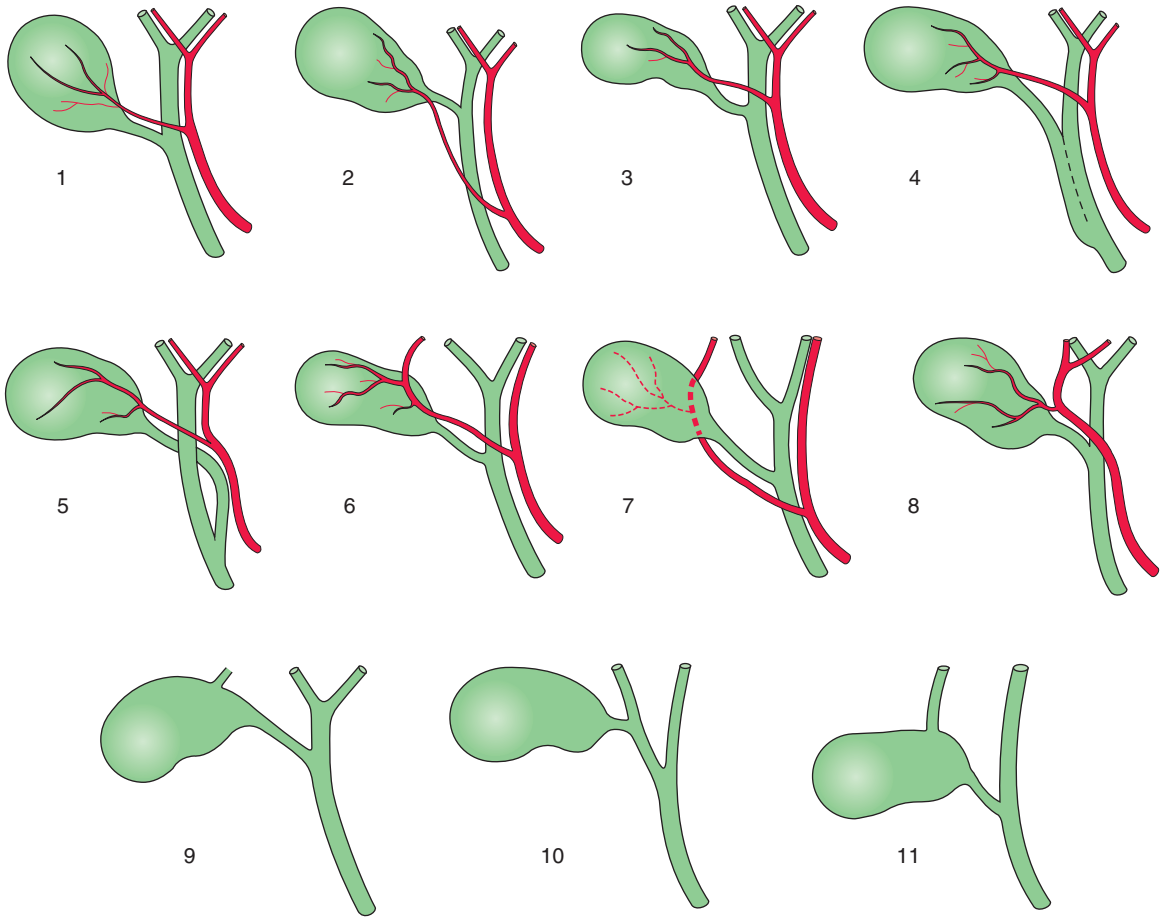

Figure 21.5 Normal and Anomalous Arrangements of Extrahepatic Bile Ducts and Their Adjoining Arteries. ***1,*** Normal arrangement. ***2,*** Caudad origin of cystic artery (frequent variation). ***3,*** Placement of cystic artery posterior to common hepatic duct. ***4,*** Long cystic duct attached to common hepatic duct for some distance before confluence to form common bile duct. ***5,*** Long cystic duct passing behind common hepatic duct and joining it medially at lower level. ***6,*** Normal ductal system with anomalous right hepatic artery reaching the gallbladder wall, where it gives off cystic artery and then turns into liver. In this anomaly, which is not rare, the right hepatic artery is often ligated either with the cystic duct or as a separate structure erroneously identified as the cystic artery. ***7,*** Anomalous right hepatic artery in posterior position presenting the same dangers mentioned in **6**. ***8,*** Very dangerous anomaly of entire hepatic artery that follows cystic duct to gallbladder before turning into liver. Accidental ligation of entire hepatic artery was almost always fatal before the advent of antibiotics, and it is still hazardous. ***9,*** Anomalous bile duct entering gallbladder through its bed in liver. Cholecystectomy in such instances is usually followed by profuse drainage of bile and is likely to result in fatal peritonitis unless external drainage is afforded. ***10,*** Anomalous insertion of cystic duct into right hepatic duct. The section of right hepatic duct caudad to its junction with cystic duct can easily be mistaken for cystic duct and ligated, thus shutting off drainage of right lobe of liver into intestine. ***11,*** Anomalous arrangement of right hepatic duct in which it enters gallbladder so that all the bile from right lobe of liver must drain through cystic duct.

anomalous positions, and the presence of *heterotopic tissues*.[8–12] Both duplication (Fig. 21.7) and triplication of the gallbladder have been reported and are classified depending on the presence of a shared cystic duct, or a separate cystic duct for each gallbladder.[8] Agenesis of the gallbladder may be found incidentally during surgery or associated with biliary atresia (see later), duodenal atresia, and other congenital anomalies.[9–11] Septations of the gallbladder may be acquired (from chronic cholecystitis and cholelithiasis) or congenital. The septations may be single or multiple, and either longitudinal or transverse.[12] "Hourglass" or "dumbbell" gallbladder refers to a transverse septum that divides the gallbladder into two compartments, with central narrowing. The *phrygian cap* or "folded fundus" deformity represents an inversion of the fundus into the body of the organ, producing a prominent notch or angulation of the distal portion of the fundus that apparently resembles caps worn by the people of ancient Phrygia in Asia Minor.[12–14] There is no clinical significance, although this anomaly may cause confusion with a stone or tumor on radiographic examination. Malposition of the gallbladder is quite rare, and anomalous locations include the intrahepatic position, retroplaced gallbladder, suprahepatic gallbladder, and the so-called wandering or floating gallbladder, which has little or no connection to the liver and is at risk of torsion.[12] A variety of heterotopic tissues may be found in the gallbladder, most commonly gastric or pancreatic tissue (Fig. 21.8).[15–16] Congenital diverticula have been reported in 0.0008%–9% of gallbladders. They consist of single or multiple outpouchings of the wall that may occur anywhere in the organ. The presence of all of the layers of the gallbladder wall histologically distinguish them from Rokitansky–Aschoff sinuses. Rare instances

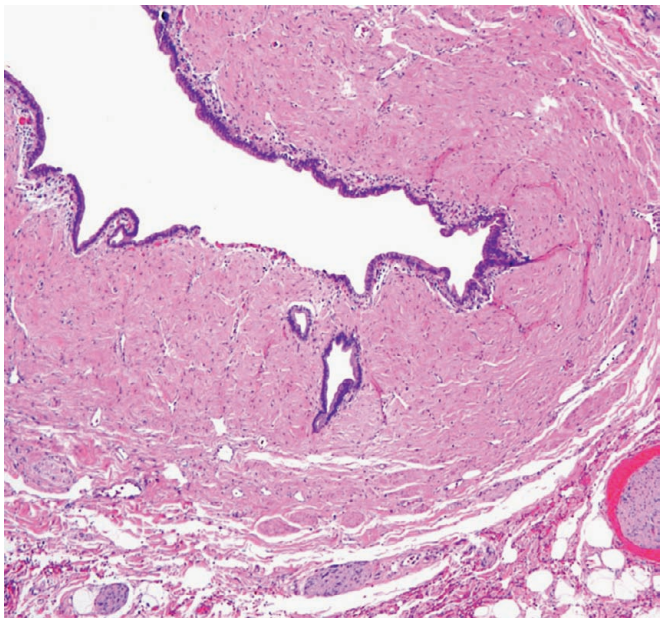

Figure 21.6 The epithelium within all the extrahepatic bile ducts is made up of a single layer of columnar cells resting on dense connective tissue.

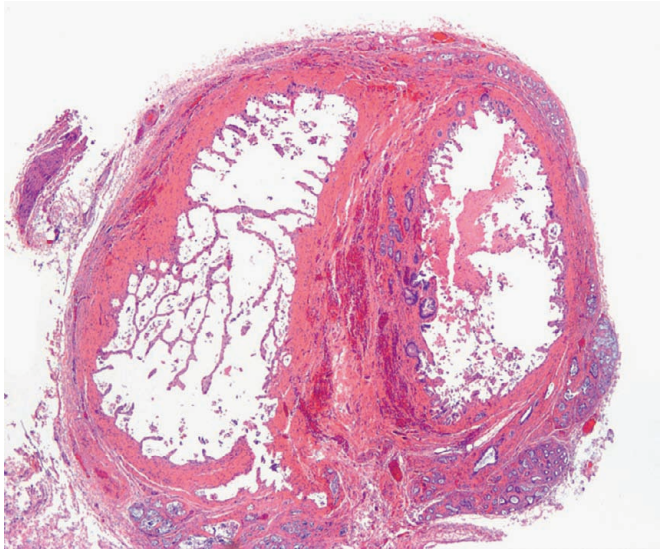

Figure 21.7 Cross section through a congenitally duplicated gallbladder showing duplication of all layers of the gallbladder wall.

of cholelithiasis, cholecystitis, and carcinoma occurring in congenital diverticula have been reported.[12,17]

Extrahepatic Biliary Tree

In **biliary atresia**, a progressive fibroinflammatory disease affecting both the extrahepatic and intrahepatic bile ducts, the gallbladder and extrahepatic ducts may be completely absent or may be represented by a fibrous cord without a lumen. This disease is the most common cause of pathologic jaundice in infants and the most common indication for liver transplantation in children. The etiology, which remains unknown, is likely multifactorial.[18,19] About 20% of patients have associated anomalies.[20] The histologic changes in the biliary tree are characterized by progressive inflammation and fibrosis (Fig. 21.9), with eventual obliteration of the lumen and intrahepatic

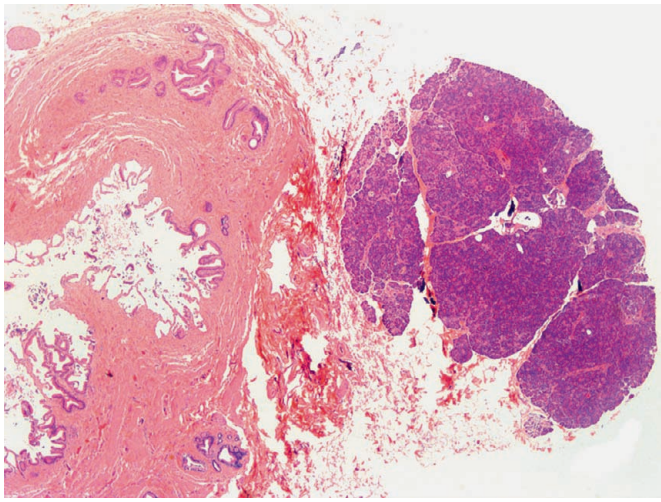

Figure 21.8 Island of heterotopic pancreas adjacent to gallbladder.

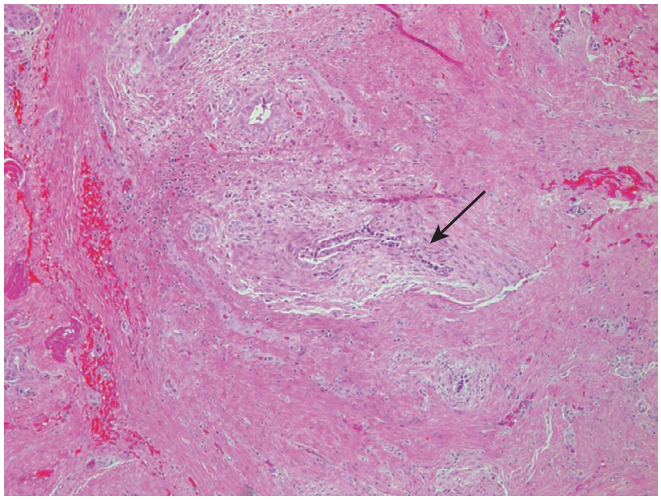

Figure 21.9 This section of the porta hepatis in an infant with biliary atresia shows extensive fibrosis and inflammation and severely damaged, atrophic biliary epithelium with a nearly obliterated lumen *(arrow)*.

bile duct injury and cholestasis (see Chapter 19).[20–23] Hypertrophic and hyperplastic changes of the hepatic artery and its branches are common.[22]

Biliary atresia has been divided into two types: (1) *fetal* (*congenital, syndromic or prenatal*; 10%–20% of cases), which is associated with other congenital anomalies, an earlier presentation, and abnormalities in Notch pathway signaling; and (2) *acquired* (*perinatal*; 80%–90% of cases), which is associated with a later presentation (1–2 weeks of age) and is not associated with extrahepatic congenital anomalies.[23] Biliary atresia is fatal within the first 2 years of life if untreated. Surgical interventions include portoenterostomy, that is, the Kasai operation, in which the fibrous tissue at the porta hepatis is transected and the open area anastomosed to a limb of jejunum (or to the gallbladder when present). This procedure is primarily palliative but may lead to 2 or more years before transplantation is necessary. Liver transplantation is essentially curative, and long-term survival post-transplant is excellent.[24]

Choledochal cysts are cystic dilatations of the biliary tree, typically extrahepatic, which may cause reflux of pancreatic secretions into the common bile duct. The majority develop in children under the age of 10, but they may also first present in adulthood.[25] It is more

Figure 21.10 Choledochal Cyst in a 5-Year-Old Female. The structure to the left is the attached gallbladder. (Courtesy of Dr. R.A. Cooke, Brisbane, Australia; from Cooke RA, Stewart B. *Colour Atlas of Anatomical Pathology*. Edinburgh: Churchill Livingstone; 2004.)

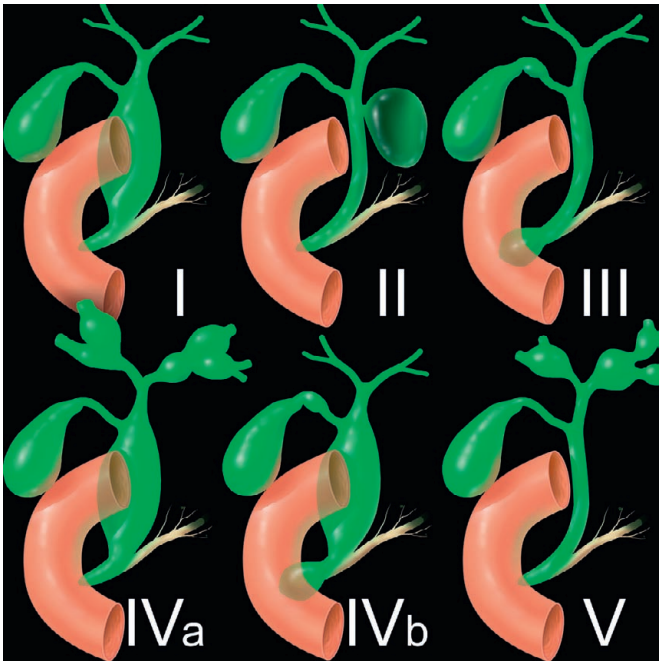

Figure 21.11 The Todani classification of choledochal cysts includes types I (segmental or diffuse dilatation of the common bile duct); II (isolated supraduodenal diverticulum); III (choledochocele, usually within duodenal wall); IVa (extrahepatic cysts and Caroli disease-like cystic dilatation of intrahepatic ducts); IVb (multiple extrahepatic cysts); and V (multiple intrahepatic cysts, equivalent to Caroli disease). Type I is the most common, accounting for 75%–90% of cases. (From Lamps LW, Kakar S. *Diagnostic Pathology: Hepatobiliary and Pancreas*. Salt Lake City: Amirsys; 2011.)

common in females and characteristically presents with pain, jaundice, and a mass.[25,26] Choledochal cysts are not true cysts, but rather a focal fusiform or spherical dilation of the common bile duct (Fig. 21.10), which may secondarily obstruct the other extrahepatic biliary ducts or even the duodenum. The pathogenesis is unknown.[26] Choledochal cysts may be associated with other congenital abnormalities of the biliary tract and other sites.[25]

Historically, choledochal cysts have been anatomically classified according to the Todani classification (Fig. 21.11).[27] Grossly, the cyst

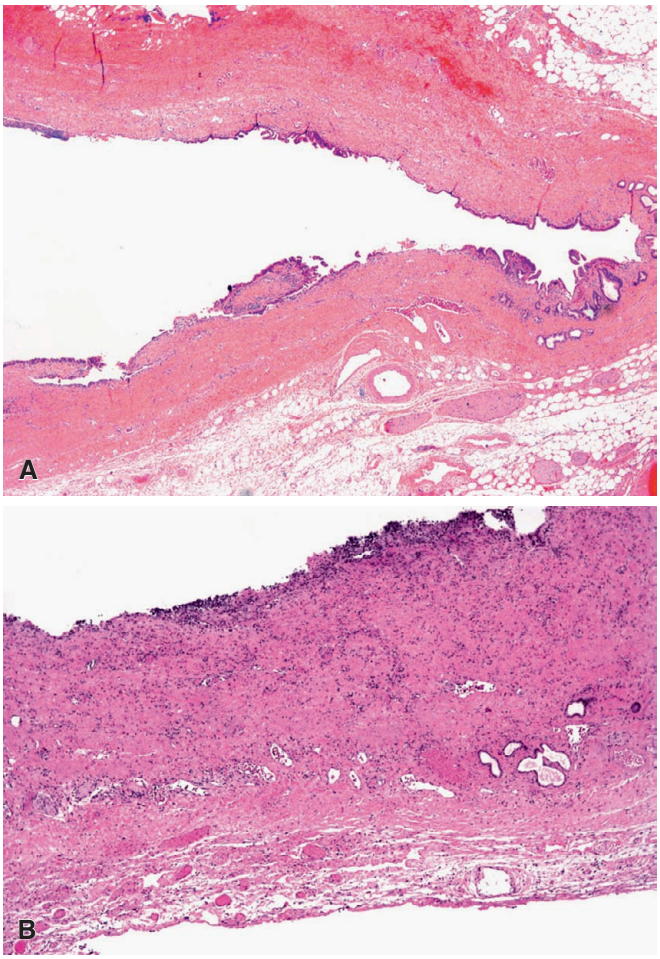

Figure 21.12 A, Choledochal cyst with an overall intact epithelial lining and minimal chronic inflammation. **B,** In contrast, this section from another case shows a completely denuded epithelial lining with underlying acute and chronic inflammation.

wall is fibrous and sometimes calcified, and the amount of bile in the cavity ranges from 30 to 5000 mL. Histologically, there is often chronic inflammation within the wall, and the epithelial lining may be intact, damaged/attenuated, or entirely absent (Fig. 21.12A). The microscopic appearance may also depend on the age of the patient at the time of excision[28]; infants are more likely to have intact columnar epithelium and scant inflammation, whereas older children typically have more pronounced inflammation and a discontinuous epithelial lining. In adults, there is often even greater inflammation as well as destruction of the epithelium (see Fig. 21.12B). Associated chronic cholecystitis is often present. There is a small but definite risk of cholangiocarcinoma associated with choledochal cyst, and thus complete resection is recommended to prevent the development of malignancy as well as pancreatitis and cholangitis.[25] Other tumor types have been reported within choledochal cysts as well, including well-differentiated neuroendocrine (carcinoid) tumor[29] and embryonal rhabdomyosarcoma.[30] The treatment of choice is excision with Roux-en-Y hepaticojejunostomy.[25]

Cholesterosis

Cholesterosis (or cholesterolosis) of the gallbladder is accumulation of lipid within macrophages in the lamina propria.[31] This lesion is fairly common, with surgical and autopsy series reporting a prevalence

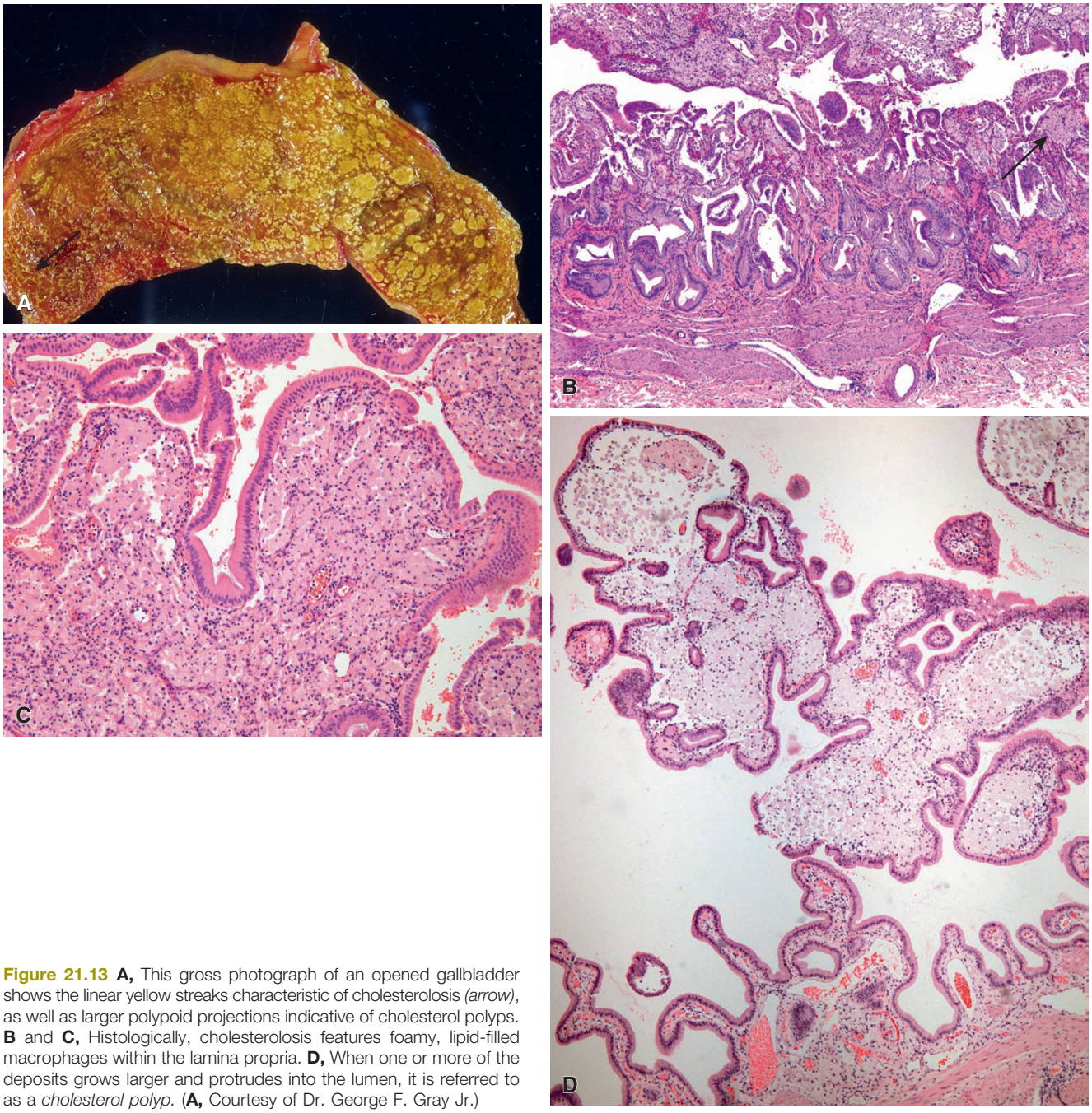

Figure 21.13 **A,** This gross photograph of an opened gallbladder shows the linear yellow streaks characteristic of cholesterolosis *(arrow)*, as well as larger polypoid projections indicative of cholesterol polyps. **B** and **C,** Histologically, cholesterolosis features foamy, lipid-filled macrophages within the lamina propria. **D,** When one or more of the deposits grows larger and protrudes into the lumen, it is referred to as a *cholesterol polyp.* (**A,** Courtesy of Dr. George F. Gray Jr.)

ranging between 9% and 26%.[32] The pathogenesis remains poorly understood, and the clinical significance also remains controversial. Cholesterolosis is often associated with cholesterol gallstones. The gross appearance is characteristic: linear yellow streaks are seen in the prominences of the mucosal ridges, surrounded by congested mucosa ("strawberry gallbladder"; Fig. 21.13A). Sometimes one or more of the deposits grow larger and protrude into the lumen, in which case they are referred to as *cholesterol polyps*. Microscopically, collections of lipid-filled foamy cells are present in the tips of the villi (see Fig. 21.13B–D). Inflammatory changes are usually insignificant, unless the cholesterosis is accompanied by stones in the cystic duct.

Cholelithiasis

Cholelithiasis is one of the most common gastrointestinal diseases worldwide, affecting 10%–20% of the population in Europe and the United States; the prevalence is particularly high in the Scandinavian countries, in Chile, and among Native Americans.[33,34] The incidence is 2–4 times higher in women than in men, and the risk of gallstones is associated with body weight, childbearing, and estrogens.[34] However, stones can occur in any age group, including infants and newborns, although cholelithiasis in this population is often associated with conditions such as hemolysis, Crohn disease, and congenital anomalies of the biliary tree.[35]

Gallstones are classified based on the amount of cholesterol in the stones, generally as cholesterol stones (>80% of stones in developed nations) and pigment stones, which are associated with a variety of medical conditions (see later). The proposed pathogenesis of cholesterol stones, based on human studies and experimental animal models, is bile supersaturation and destabilization, along with gallbladder hypomotility.[33,34] Before the appearance of stones, there is the formation of cholesterol crystals, which grow and aggregate with mucin proteins in bile to form stones.[34] Gallstones vary considerably in chemical composition and contain variable quantities of calcium bilirubinate, and calcium carbonate, either alone or in combination, in addition to cholesterol. The technique of ultrasonography has proven very successful in identifying gallbladder stones, and it has become the method of choice for their detection, as it detects cholelithiasis in approximately 98% of patients.[36]

Cholesterol gallstones, particularly *mixed* cholesterol stones, comprise the vast majority (80%) of stones in Western countries. They are composed of cholesterol, bile salts, and phospholipids. The prevalence of cholesterol gallstones increases with age, and risk factors also include female gender, pregnancy/multiparity, estrogen therapy, obesity, rapid weight loss, and many medications. Chronic cholecystitis is almost always present. *Mixed* cholesterol stones are typically multiple, round or faceted, and less than 2.0 cm in size (Fig. 21.14).[37] *Pure* cholesterol stones account for only 10% of gallstones. They are typically single, spheroidal, and coarsely nodular and may measure up to 4.0 cm in size. They have a translucent bluish white color, and on fracture, they show large, flat crystals. The gallbladder containing *pure* gallstones typically shows little or no inflammatory reaction if the cystic duct is not obstructed. Abnormal serum lipid profiles do not appear to correlate with the formation of cholesterol stones.[38] Sequential cholecystographic studies and carbon-14 dating suggest that gallbladder stones grow at a rate of approximately 1–2 mm/year and that they are usually present for 5–20 years before they are removed.[39]

Pigment stones account for approximately 10%–25% of gallstones in the United States but have a higher incidence in Africa and Asia. Black stones are composed of calcium bilirubinate, phosphate, and carbonate with very little cholesterol.[40,41] They are typically multiple, small, brown to jet black, and faceted; they measure 2–5 mm in diameter (Fig. 21.15). They are associated with hyperbilirubinemia and thus conditions such as cirrhosis and hemolytic disorders (sickle cell anemia, thalassemia, hereditary spherocytosis, and artificial cardiac valves); other associated conditions include malaria, total parenteral nutrition (TPN), and Crohn disease.[41,42] Brown stones contain calcium salts of bilirubin and palmitate, with a higher concentration of cholesterol than black stones. Calcium carbonate and phosphate are usually absent. Brown stones are soft, brown-green, and large. These are associated with infection, particularly *Escherichia coli* and biliary flukes.[40,41]

Other types of gallstones include calcium carbonate stones, phosphate stones, and various types of mixed stones. Some authors advocate more detailed classification of gallstones based on elemental composition analysis and microstructure.[43] *Barrel stones*, a type of combined stone, are usually two in number, large, and faceted on one surface, and the thick-walled gallbladder is closely wrapped around them. Combined stones are almost always accompanied by chronic inflammation of the gallbladder and occasionally by biliary fistulas.

Choledocholithiasis, with or without obstruction, is nearly always secondary to cholelithiasis, for in approximately 20% of cases of gallbladder stones there are synchronous common bile duct stones.[44] Gallstones are usually formed in the gallbladder, from which they may escape into the cystic and other extrahepatic ducts; therefore, the appearance of symptoms of choledocholithiasis sometime after cholecystectomy for stones is usually caused by stones that were overlooked at the time of surgery. The occasional finding of multiple small intrahepatic stones indicates that they can also form in the hepatic duct system outside the gallbladder; independent stone formation in the extrahepatic ducts is rare, however, and typically associated with brown gallstones and persistently dilated ducts or biliary diverticula.[45]

Impaction of a gallstone in the cystic duct may lead to hydrops[46,47] (an enlarged, distended gallbladder that is filled with clear, mucoid, or cloudy secretions; Fig. 21.16) or to acute cholecystitis. Impaction

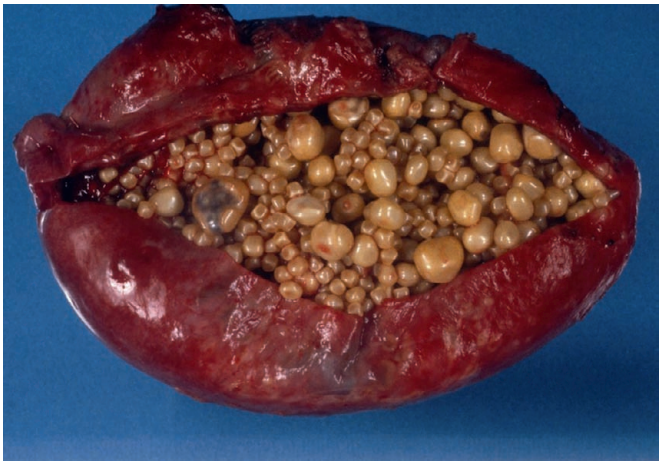

Figure 21.14 Numerous mixed cholesterol gallstones in a background of acute and chronic cholecystitis. (Courtesy of Dr. George F. Gray Jr.)

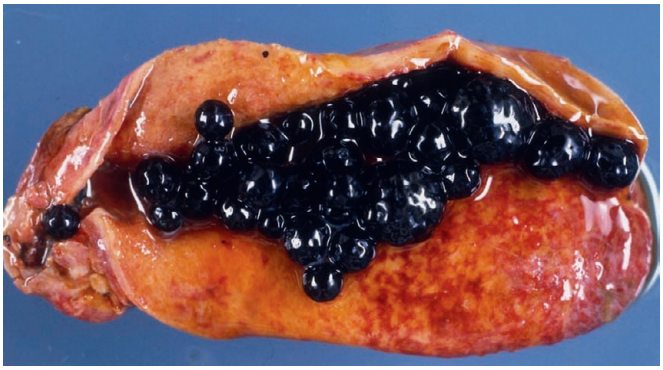

Figure 21.15 Dilated gallbladder containing multiple black (calcium bilirubinate) gallstones. (Courtesy of Dr. George F. Gray Jr.).

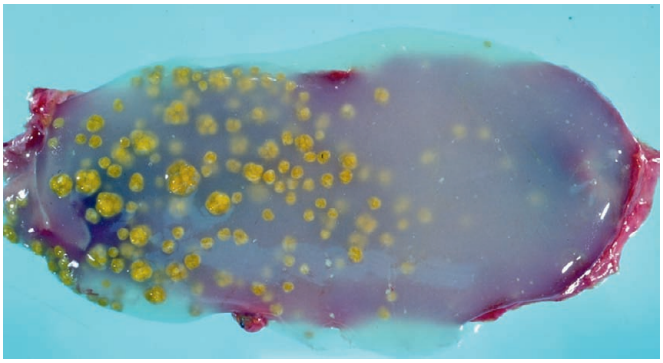

Figure 21.16 This opened gallbladder with hydrops features a very thin wall, abundant watery secretions, and numerous cholesterol stones within the lumen of the gallbladder. (Courtesy of Dr. George F. Gray Jr.)

of a stone in the terminal third of the common duct or ampulla of Vater will result in severe, colicky pain and obstructive jaundice. Sometimes an impacted cystic duct stone causes edema and compression/obstruction of the adjacent common hepatic duct, a condition known as *Mirizzi syndrome*.[48] Gallstones may also lead to *internal biliary fistulas*.[49] Over 90% of these fistulas are located between the gallbladder and the duodenum, the gallbladder and the colon, or the common bile duct and the duodenum. These fistulas are created by the formation of inflammatory adhesions between the biliary tree and adjacent organs and the subsequent erosion of a stone through the gallbladder or the common duct into the gastrointestinal tract. Continuing choledochal obstruction contributes to the persistence of the fistula. Biliary fistulas may become evident by the patient vomiting or passing per rectum a large gallstone, by detecting air in the biliary tree in a plain abdominal roentgenogram, or by seeing the outline of the biliary tree in an upper gastrointestinal series or a barium enema. With cholecystocolic fistulas, infection is often severe.

The standard treatment for symptomatic cholelithiasis is cholecystectomy, which is usually done laparoscopically.[50] Spillage of gallstones into the peritoneal cavity occurs not infrequently during this procedure and is generally of little consequence; however, sometimes it leads to peritonitis, intraperitoneal abscess, foreign body granuloma, and (exceptionally) implantation of the gallstones in the ovary.[51,52] The approach to individuals with asymptomatic gallstones remains controversial, but cholecystectomy for asymptomatic gallstones is not routinely recommended.[50] Although it has often been argued that all gallbladders containing stones should be removed surgically because of the risk of cancer, this argument lacks validity, since the incidence of carcinoma in gallbladders with lithiasis is less than 1%.[53]

Endoscopic sphincterotomy, sometimes combined with endoscopic papillary balloon dilatation, is being increasingly performed for the treatment of choledocholithiasis. Lithotripsy is also of interest in managing bile duct stones, but it requires special equipment and trained personnel and thus is not widely available. Lithotripsy is not recommended for treatment of stones within the gallbladder, due to the high recurrence rate and the chance of stone fragments migrating into the biliary tree.[44]

Acute Cholecystitis

The main clinical symptoms of acute cholecystitis are pain in the right upper quadrant, nausea and vomiting, and fever.[54] There are three types of acute cholecystitis: calculous, acalculous, and emphysematous.

Grossly, the gallbladder is enlarged and distended, with a hemorrhagic external surface (Fig. 21.17A).[47] There may be foci of gangrene or perforation as well. The wall is typically thickened and edematous, with variably present hemorrhage and pus. The luminal content often has a yellow, grumous appearance in acute calculous cholecystitis; this may appear grossly as empyema, but in reality the material is not pus but an emulsion of calcium carbonate and/or cholesterol. If the acute process is superimposed on chronic cholecystitis, which is often the case, fibrosis of the wall may be noted.

Histologically, acute cholecystitis features edema and fibrin within the gallbladder wall, often with mucosal ulceration and an overlying fibrinoinflammatory exudate (see Fig. 21.17B). Fresh thrombi are often found within small veins in the gallbladder wall as well. The presence of a significant neutrophilic infiltrate is very variable but, if present, is usually more prominent early in the course. In cases associated with common bile duct obstruction, intraepithelial aggregates of neutrophils in the mucosa have been reported and likened to the reaction seen in the wall of the common bile duct and liver as part of the process of ascending cholangitis.[55] A fibroblastic reaction occurs later in the course of disease (see Fig. 21.17C). Marked reactive changes can be present in the epithelium, which should not be confused with dysplasia or carcinoma in situ. Necrosis may be present, and if widespread, indicates gangrenous cholecystitis, a severe form of acute cholecystitis that is associated with diabetes, cardiovascular disease, and other comorbid conditions.[56]

Acute calculous cholecystitis accounts for more than 90% of cases.[57] The pathogenesis of most cases of acute calculous cholecystitis is probably chemical or ischemic rather than infectious. It is nearly always related to a stone impacted in the cystic duct,[57,58] which is thought to lead to changes in the concentration and composition of the bile as well as obstruction and congestion of the tortuous venous channels surrounding the cystic duct. Although primary bacterial infection is not thought to play a significant role in acute calculous cholecystitis, secondary infections (typically gram-negative enteric bacilli and anaerobes) complicates approximately 50% of cases.[58] Early (within 3 days) laparoscopic cholecystectomy is considered the therapy of choice for the majority of patients and is associated with shorter overall hospitalization.[57,59] Bile duct injury is the major complication of this procedure, but the incidence is quite low (<1%).[60]

Acute acalculous cholecystitis accounts for about 5%–10% of all cases of acute cholecystitis.[47] In adults, acute acalculous cholecystitis is often associated with serious medical and surgical illnesses such as major cardiac surgery, diabetes, end-stage renal disease, TPN, and sepsis, and the mortality rate is quite high (approaching 30%).[61,62] It accounts for more than 50% of acute cholecystitis cases in children, where it may also be seen in the context of critical illness. In otherwise healthy children, however, it is often associated with systemic infections such as hemolytic streptococcal septicemia, typhoid fever, or viral infection.[63] Acute acalculous cholecystitis has also been reported in HIV-infected patients secondary to cytomegalovirus (CMV) as well as a wide variety of other opportunistic infections.[64,65] Cases of chemical acalculous cholecystitis have been seen after the administration of hepatic arterial chemotherapy.[66]

Microscopically, in acute acalculous cholecystitis, there tends to be a greater degree of bile infiltration of the gallbladder wall and less mural necrosis than in the calculous counterpart, but there is a great deal of overlap.[47,67]

Bacterial invasion in acute calculous cholecystitis is usually a secondary event. If the organisms are of the gas-forming type, the condition known as *acute emphysematous* or *acute gaseous cholecystitis* may result[68]; this complication is particularly common in diabetics. Atherosclerosis of the cystic artery and its branches is thought to be a contributing factor. Many patients have positive blood cultures for clostridial organisms or gram-negative enteric bacilli, and the overall mortality rate approaches 15%. Histologically, the gallbladder shows acute inflammation with necrosis, and gas bubbles may be present within the wall of the gallbladder (see Fig. 21.17D).

Chronic Cholecystitis

Most cases of chronic cholecystitis are associated with cholelithiasis. However, the majority of people with gallstones have no history of pain. Those who are symptomatic typically experience upper abdominal or right upper quadrant pain, dyspepsia, belching, and bloating, but these symptoms are probably not related to the presence of gallstones, as they frequently persist after surgery.[69]

Grossly, the gallbladder may be enlarged, shrunken, or of normal size, and adhesions may be present. Stones are present in approximately 95% of cases. The wall is typically thickened, although this finding may not be impressive (Fig. 21.18A and B).[47] Microscopically,

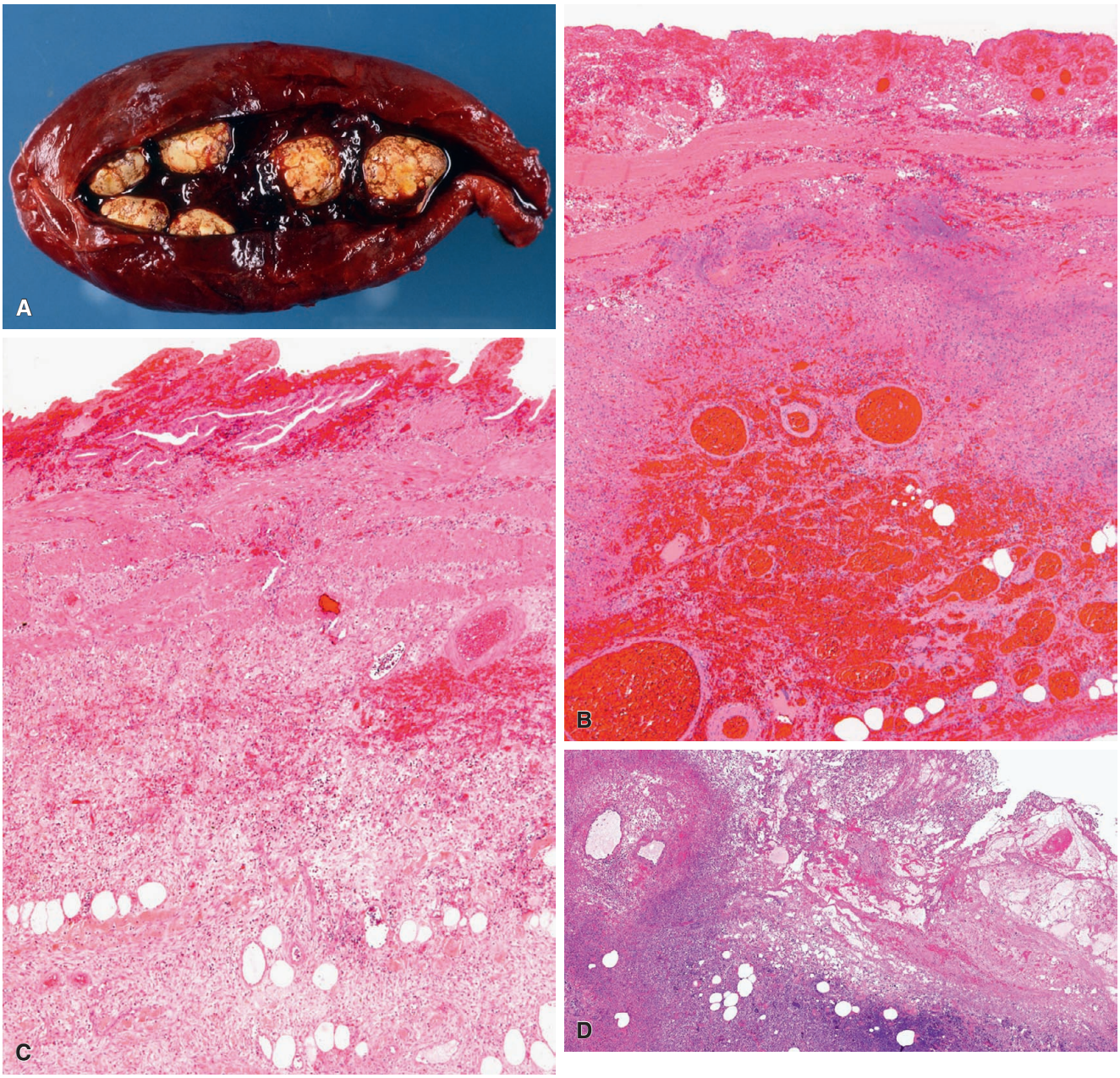

Figure 21.17 Acute Cholecystitis. A, Both the external surface and the mucosa have a characteristic "angry red" color; the mucosa also appears hemorrhagic. This example of acute calculous cholecystitis contains cholesterol stones. **B,** At low power, the mucosa has been replaced by a fibrinous exudate, and the wall contains extensive hemorrhage and necrosis. **C,** Another case of acute cholecystitis, later in the course of disease, shows mural edema, hemorrhage, and a fibroblastic response. Note that neutrophils are not prominent. **D,** This case of acute emphysematous cholecystitis shows both necrosis and gas bubbles in the wall of the gallbladder. (**A,** Courtesy of Dr. George F. Gray Jr. **D,** Courtesy of Dr. Jose Jessurun.)

the mucosa of a chronically inflamed gallbladder shows varying degrees of mononuclear infiltration and fibrosis (see Fig. 21.18C and D). Lymphocytes are usually the most prominent inflammatory cell, with admixed plasma cells and histiocytes; neutrophils and eosinophils may also be present. The inflammation may only involve the mucosa or may extend more deeply. It is important to note that, similar to the small bowel and colon, a complement of mononuclear cells is normally present within gallbladder mucosa, and this alone does not constitute a diagnosis of chronic cholecystitis. The gallbladder wall may show fibrosis, muscle hypertrophy, and/or encrusted stones. Irregularly shaped tubular structures, traditionally known as Rokitansky–Aschoff sinuses, are present within the wall in over half of cases. They are lined by columnar or cuboidal epithelium and may contain bile or stones.[47,70] These tubular structures are thought to represent herniations or diverticula resulting from increased intraluminal pressure.[71] The mucin present in Rokitansky–Aschoff sinuses can spill into the stroma and simulate mucinous adenocarcinoma.[72,73]

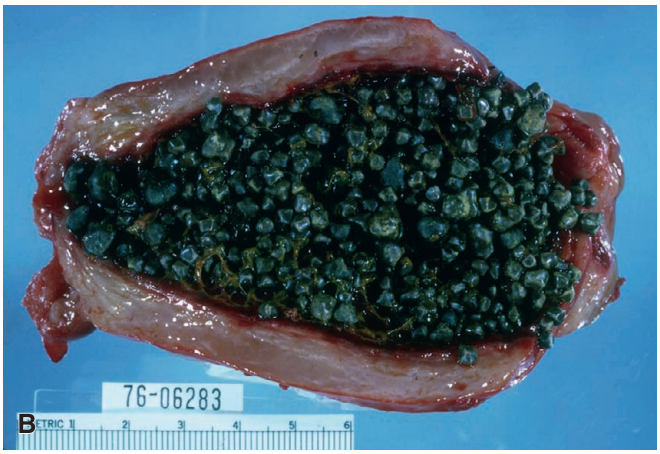

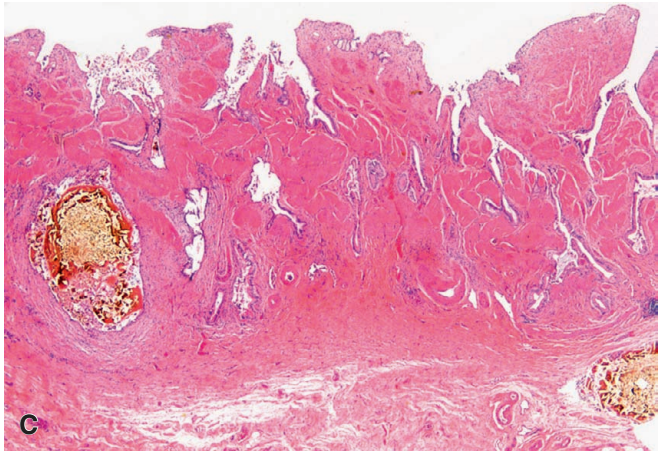

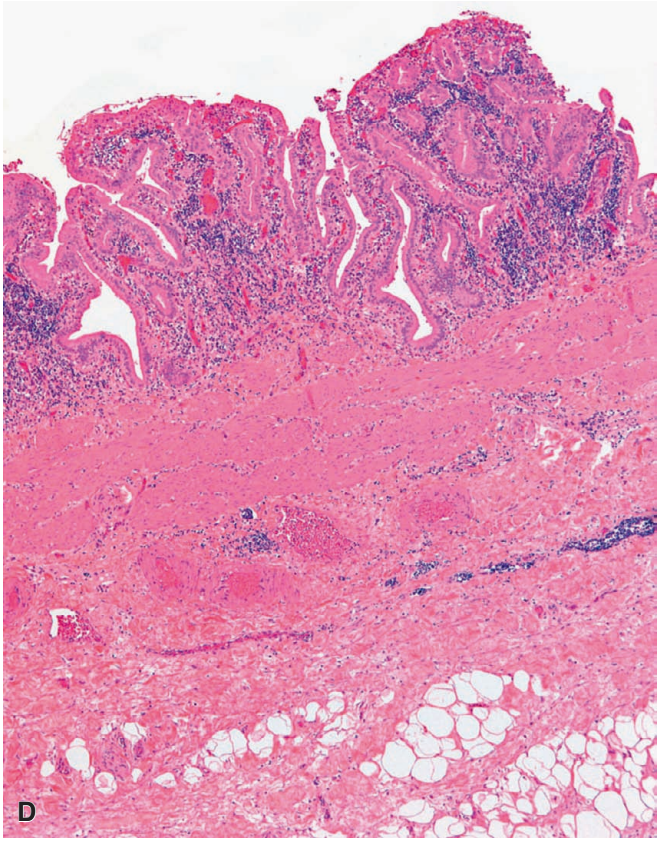

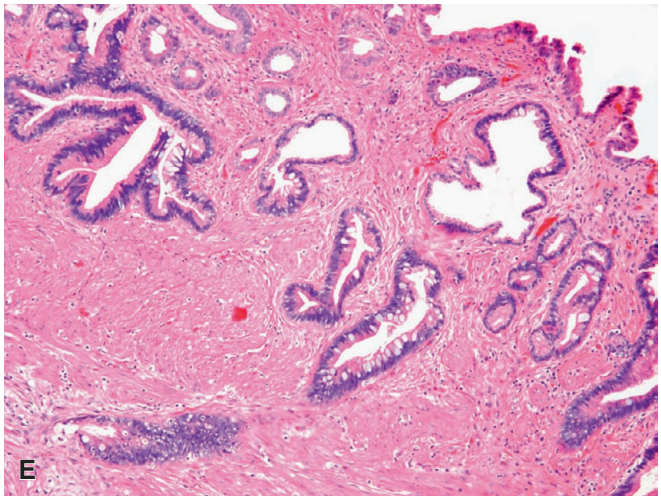

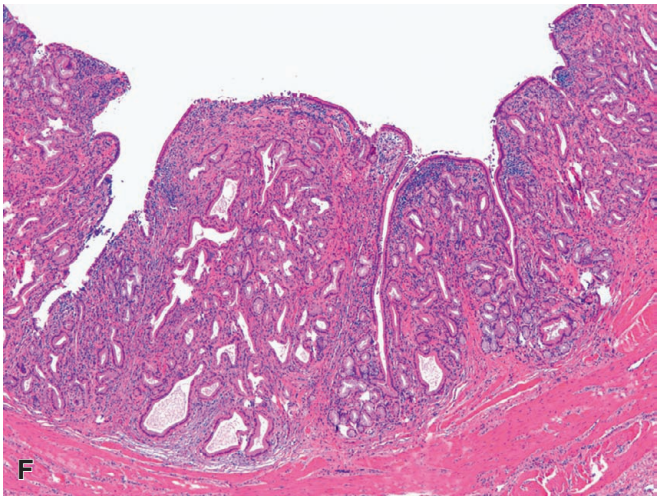

Figure 21.18 **A,** Gallbladder containing numerous mixed cholesterol stones. The wall is mildly thickened due to chronic cholecystitis. **B,** The wall of this gallbladder with chronic cholecystitis is markedly thickened, and it contains numerous bilirubin gallstones. **C,** This section of a case of chronic cholecystitis shows a markedly thickened wall with muscle hypertrophy and numerous Rokitansky–Aschoff sinuses, some of which contain inspissated thick bile. **D,** Chronic cholecystitis featuring a thickened fibrotic wall and mononuclear inflammation within the mucosa. **E,** Intestinal metaplasia is common in chronic cholecystitis; this case shows areas of intestinal metaplasia as well as epithelial dysplasia. **F,** Florid pyloric metaplasia in a case of chronic cholecystitis. (**B,** Courtesy of Dr. George F. Gray Jr.)

The epithelium in chronic cholecystitis may be relatively normal, atrophic, or show hyperplastic and metaplastic changes. The metaplasia can be of goblet cell (intestinal) or pyloric (antral) type, the former being accompanied by the appearance of Paneth cells and endocrine cells (see Fig. 21.18E and F).[47,74–76] Intestinal-type metaplasia is accompanied by CDX2 expression.[77] Pyloric metaplasia can be quite florid and may infiltrate smooth muscle fibers as well as surround nerves, mimicking perineural invasion.[78] The lobular arrangement of the metaplastic glands and the small, uniform nuclei help distinguish this change from adenocarcinoma. The incidence of these metaplastic changes increases steadily with age,[79] and these types of metaplasia can also be encountered in normal, uninflamed gallbladders. Osseous metaplasia has been rarely described as well.[80]

Several morphologic variants of chronic cholecystitis have been described. *Follicular cholecystitis* is characterized by widespread formation of lymphoid follicles in all layers of the gallbladder wall (Fig. 21.19).[47,81] Historically, this pattern has been associated with typhoid fever and other gram-negative enteric infections, as well as Crohn disease (see later).[47,81] *Xanthogranulomatous cholecystitis*,[82,83] also known as *cholecystic granuloma* or *ceroid granuloma*, is a reaction to bile that has penetrated into the wall of the gallbladder, often as a result of the rupture of Rokitansky–Aschoff sinuses (Fig. 21.20A). This form of cholecystitis features diffuse or nodular collections of macrophages containing neutral fat and granular brown lipofuscin (ceroid) pigment (see Fig. 21.20B). As these lesions age, they become densely fibrotic and may mimic cancer both radiographically and macroscopically.[83]

Gallbladders with marked diffuse calcification are known as *porcelain gallbladder* (Fig. 21.21). *Hyalinizing cholecystitis* is a recently proposed term for a type of chronic cholecystitis featuring replacement of the gallbladder wall by dense hyaline fibrosis, often with calcification and denuding of epithelium (Fig. 21.22). Inflammation is

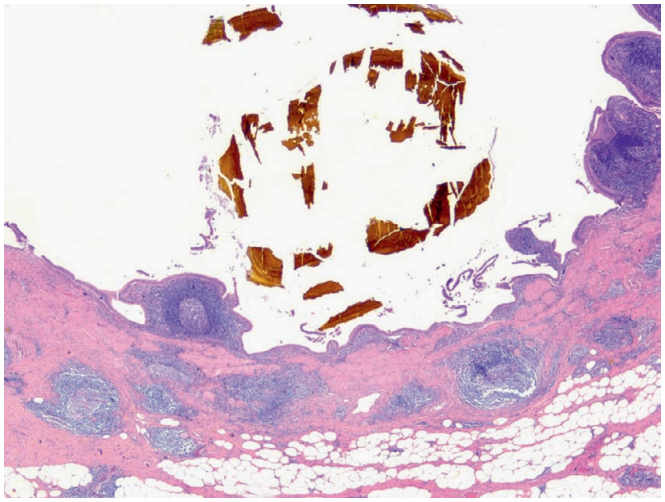

Figure 21.19 This case of follicular cholecystitis shows lymphoid follicles, many with germinal centers, throughout the wall of the gallbladder.

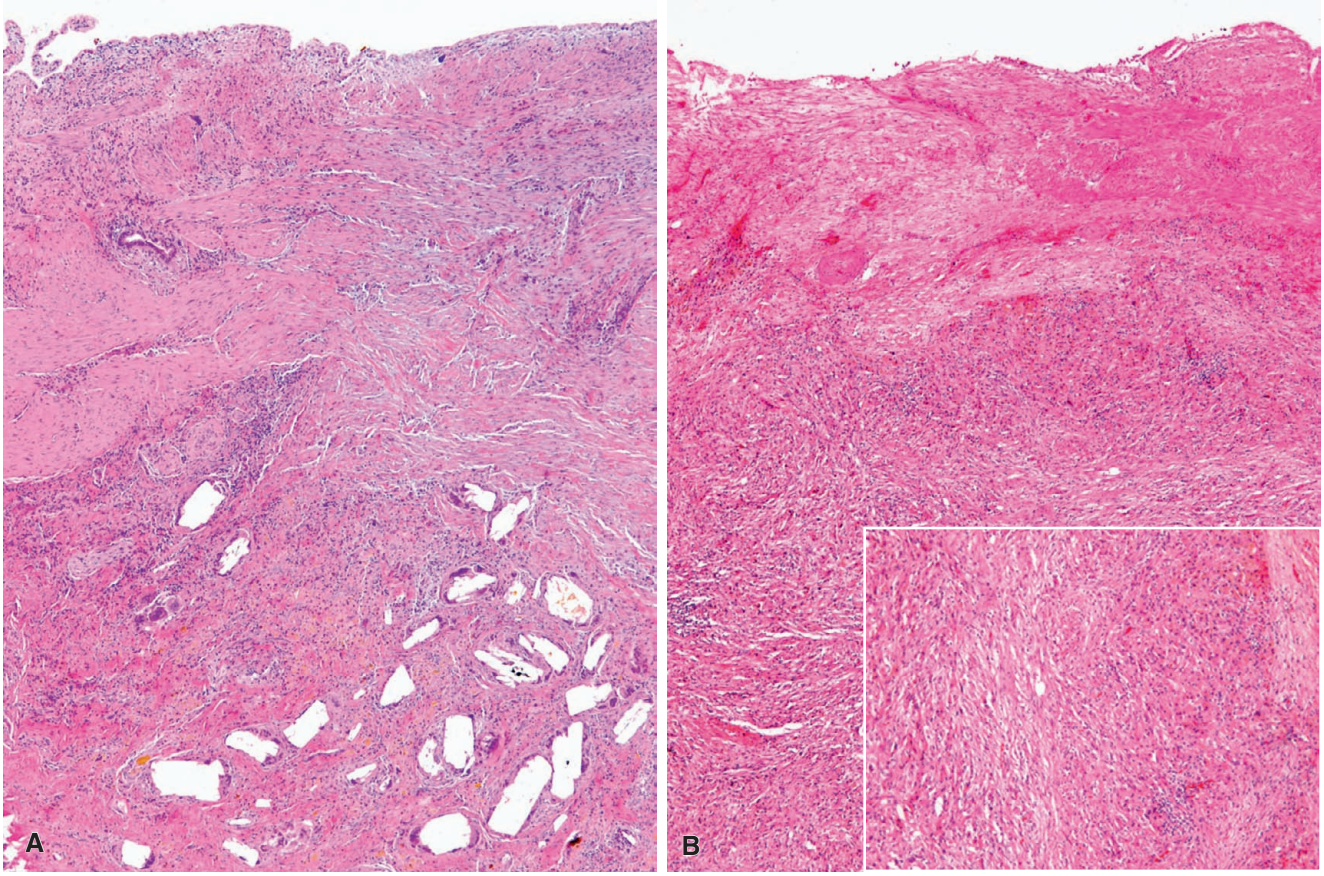

Figure 21.20 **A,** This case of xanthogranulomatous cholecystitis features a nodular collection of ceroid-laden histiocytes and cholesterol crystals with foreign body giant cell reaction in the wall of the gallbladder. **B,** Another case shows a more spindled nodule of histiocytes, with associated ceroid pigment and mural fibrosis (**B** inset).

Figure 21.21 This gallbladder wall is almost completely replaced by calcification, known as "porcelain" gallbladder.

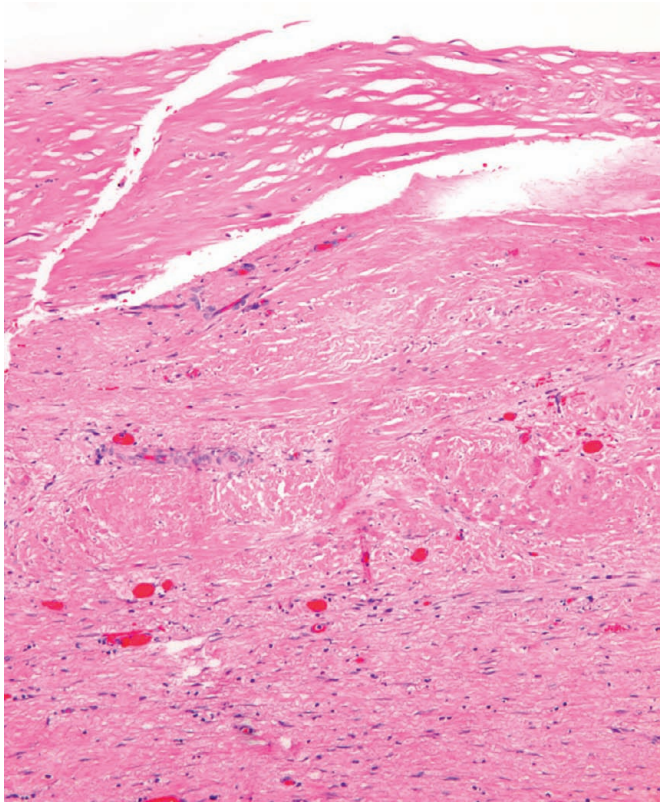

Figure 21.22 Hyalinizing cholecystitis features replacement of the gallbladder wall by dense hyaline fibrosis, with minimal inflammation and denuding of epithelium.

minimal, and the wall is typically attenuated. Cases with scant or no calcification, also known as "incomplete porcelain gallbladder," have been associated with a higher incidence of carcinoma.[84] In recent literature, diffusely calcified or "complete porcelain" gallbladders have not been associated with an increased risk of carcinoma.

Approximately 12%–13% of patients with chronic cholecystitis do not have stones,[58] and a variety of inflammatory conditions can be seen in this context. Three recently described inflammatory conditions within the spectrum of chronic acalculous cholecystitis are worthy of mention. *Eosinophilic cholecystitis* is usually acalculous and may be associated with hypersensitivity reactions or other eosinophilic diseases. "Pure" eosinophilic cholecystitis, as the name implies, features an infiltrate that is almost exclusively composed of eosinophils (Fig. 21.23), whereas "lymphoeosinophilic cholecystitis"

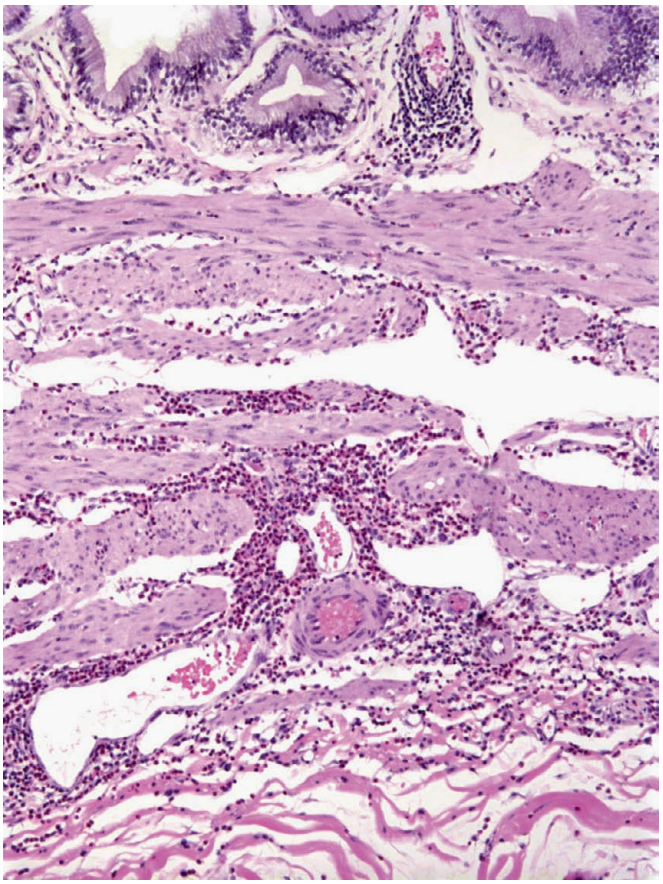

Figure 21.23 "Pure" eosinophilic cholecystitis contains an inflammatory infiltrate composed almost entirely of eosinophils.

contains a significant lymphocytic component, but at least 50% of the infiltrate must be composed of eosinophils.[85] *Diffuse lymphoplasmacytic cholecystitis* has been described in association with primary sclerosing cholangitis (PSC) and IgG4-related autoimmune pancreatitis (Fig. 21.24),[86,87] but it is not specific for either (see also later). Rare cases of acalculous cholecystitis featuring numerous intraepithelial lymphocytes have also been described, and this pattern has been termed *lymphocytic cholecystitis*; the pathogenesis is unknown.[88]

Other Inflammatory Processes Involving the Gallbladder

Ischemia of the gallbladder can result from atherosclerotic disease, compression of vessels by gallstones or tumor, or surgical misadventure.[89] Ischemia has also been described following transarterial chemoembolization for hepatocellular carcinoma using microspheres.[90] "Floating" gallbladders, or those that are surrounded by peritoneum and lack a firm attachment to the liver, are particularly susceptible to torsion and ischemia.[12] Similar to the bowel, ischemic gallbladders show thickened, edematous walls with hemorrhagic necrosis and sloughing of epithelium (Fig. 21.25).

A number of *vasculitides* affect the gallbladder, including (but not limited to) polyarteritis nodosa, Churg–Strauss syndrome, and vasculitis associated with rheumatoid arthritis.[91–94] Some patients with polyarteritis nodosa have isolated gallbladder involvement, although a subset of these may develop evidence of a multisystem disorder on follow-up. Other patients with polyarteritis nodosa involving the gallbladder have systemic autoimmune diseases such as lupus or scleroderma at the time of diagnosis, although finding

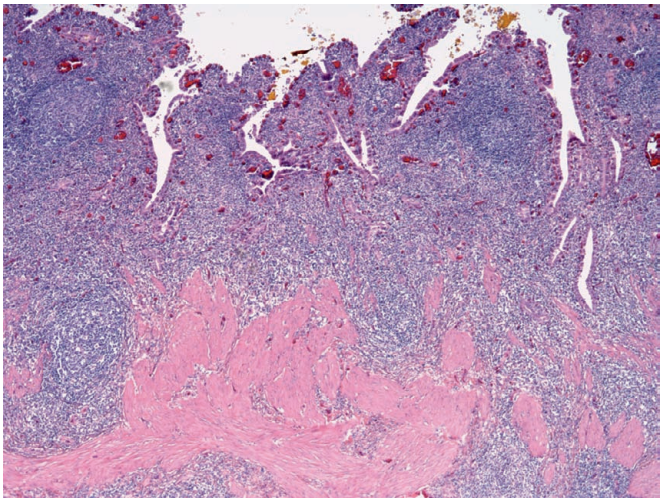

Figure 21.24 This case of diffuse lymphoplasmacytic cholecystitis contained numerous IgG4-positive plasma cells on immunostaining. (Courtesy of Dr. Rhonda K. Yantiss.)

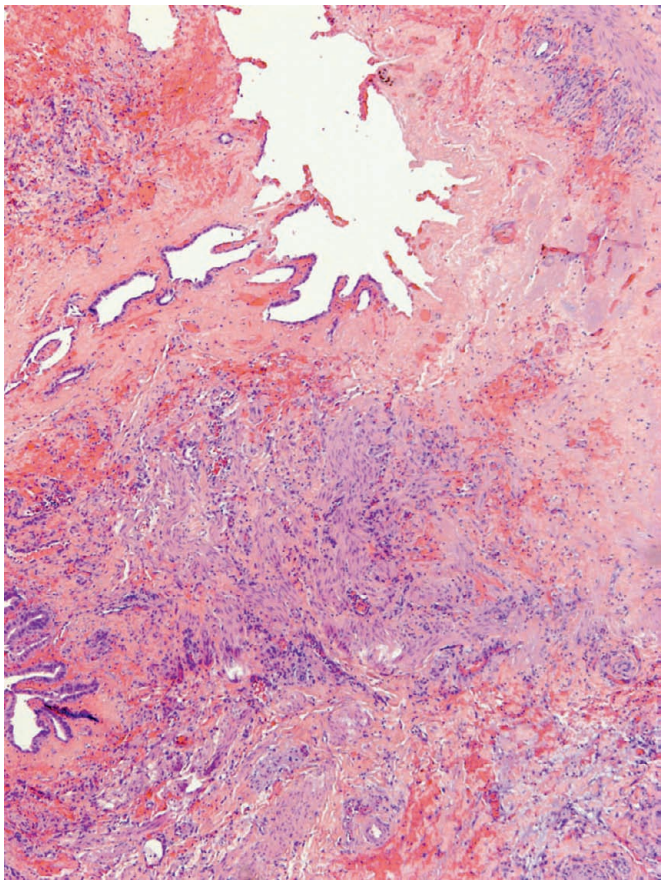

Figure 21.25 Hemorrhagic necrosis and mucosal ulceration in a case of gallbladder ischemia that occurred during liver transplant surgery.

vasculitis in a cholecystectomy specimen may precede the development of systemic disease (Fig. 21.26).

Infections of the gallbladder and extrahepatic bile ducts are discussed together later. Other inflammatory conditions that may rarely affect the gallbladder but are worthy of mention include *malakoplakia*, which is identified by a histiocytic infiltrate with

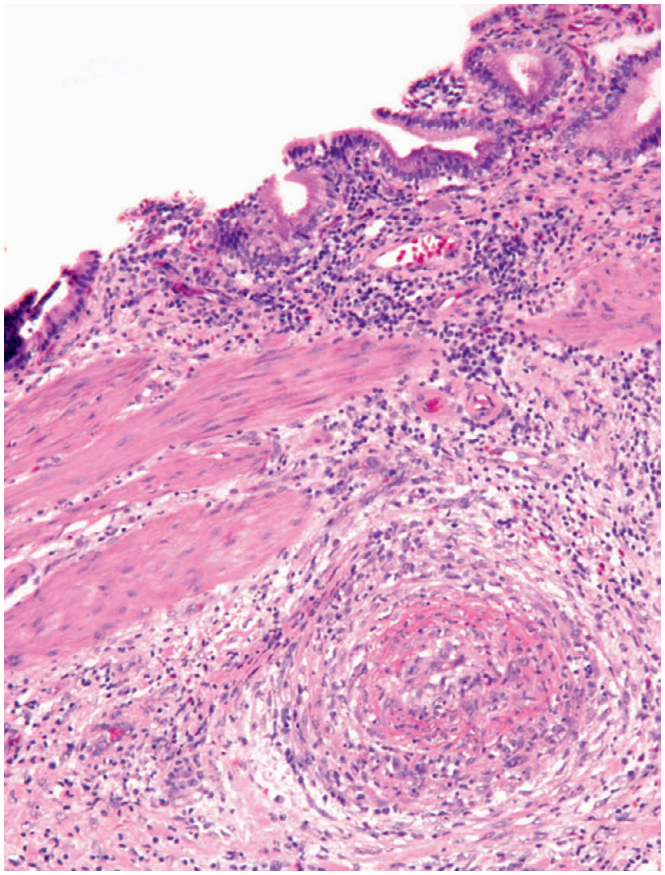

Figure 21.26 Fibrinoid necrosis in a medium-sized artery in a case of polyarteritis nodosa. At the time of cholecystectomy, the vasculitis was limited to the gallbladder.

calcium- and iron-positive Michaelis–Gutmann bodies in the cytoplasm.[95,96] Crohn disease of the gallbladder can feature a follicular cholecystitis pattern[97] or rarely granulomatous cholecystitis.[98,99] Although sarcoidosis frequently involves the liver, it has been only very rarely reported in the gallbladder.[100] So-called *pulse granulomas*, similar to those more commonly seen in the oral cavity and gastrointestinal tract, have also been described in the gallbladder in association with fistulae involving the gastrointestinal tract; they appear as hyaline rings that may be associated with inflammation, foreign body giant cells, calcifications or vegetable matter.[101]

Inflammatory Disorders of the Extrahepatic Bile Ducts

Strictures of the common duct are usually (~80% of the time) caused by surgical trauma in which the duct is inadvertently injured or ligated.[102,103] Anatomic variations of the ducts and blood vessels are often responsible for this complication, as well as obscuring fibrosis or inflammation.

Obstructive cholangitis may be seen in conjunction with calculous cholecystitis, secondary to stone impaction in the duct, or as a result of biliary cysts, fistulae, tumors, or iatrogenic obstruction. Histologic findings are nonspecific and include acute inflammation with reactive and regenerative epithelial changes. Chronically inflamed extrahepatic bile ducts may show metaplastic changes in the mucosa analogous to those more commonly seen in the gallbladder, that is, pyloric, intestinal, and squamous.[104]

PSC is a relatively rare disorder of unknown etiology characterized by fibrosis and inflammation of the intrahepatic and extrahepatic biliary tree,[105–107] ultimately leading to biliary strictures and cirrhosis (see also Chapter 19). This disease primarily affects men from 20 to 50 years of age, and it has been reported in association with retroperitoneal and mediastinal fibrosis, orbital pseudotumor, and chronic idiopathic inflammatory bowel disease (in particular, ulcerative colitis, which is present in ~70% of patients with PSC, but also Crohn disease).[108,109] A number of HLA susceptibility alleles have been identified, but none are specific for PSC, and the significance of the association has yet to be fully elucidated.[110] Many patients have antinuclear, perinuclear antineutrophilic cytoplasmic, and anti-smooth muscle antibodies as well, although these are also nonspecific.[111] The majority of cases involve both intrahepatic and extrahepatic bile ducts, which have alternating areas of short strictures with normal or dilated ducts, producing the characteristic beaded appearance on cholangiography.[111] The most typical microscopic changes seen in the early stages of the disease are not in the extrahepatic bile ducts but in the liver biopsy. Histologic findings within the bile ducts are nonspecific, featuring dense fibrosis, a lymphoplasmacytic infiltrate (sometimes containing eosinophils), and epithelium that may be intact or ulcerated (Fig. 21.27A).[111,112] Neural hyperplasia has also been described. Ultimately the fibrosis and inflammation lead to reduction or obliteration of the duct lumen (see Fig. 21.27B). Because the histologic changes are so nonspecific, cholangiography is considered the gold standard for diagnosis. Patients with PSC are at increased risk for cholangiocarcinoma in both the intrahepatic and extrahepatic ducts (see later), and it is very difficult to distinguish malignant from inflammatory strictures radiographically. No effective screening method has been established, but some patients with worrisome clinical or radiographic findings may benefit from ERCP with brush cytology or biopsy with fluorescence in situ hybridization (FISH) and measurement of serum CA 19-9.[113]

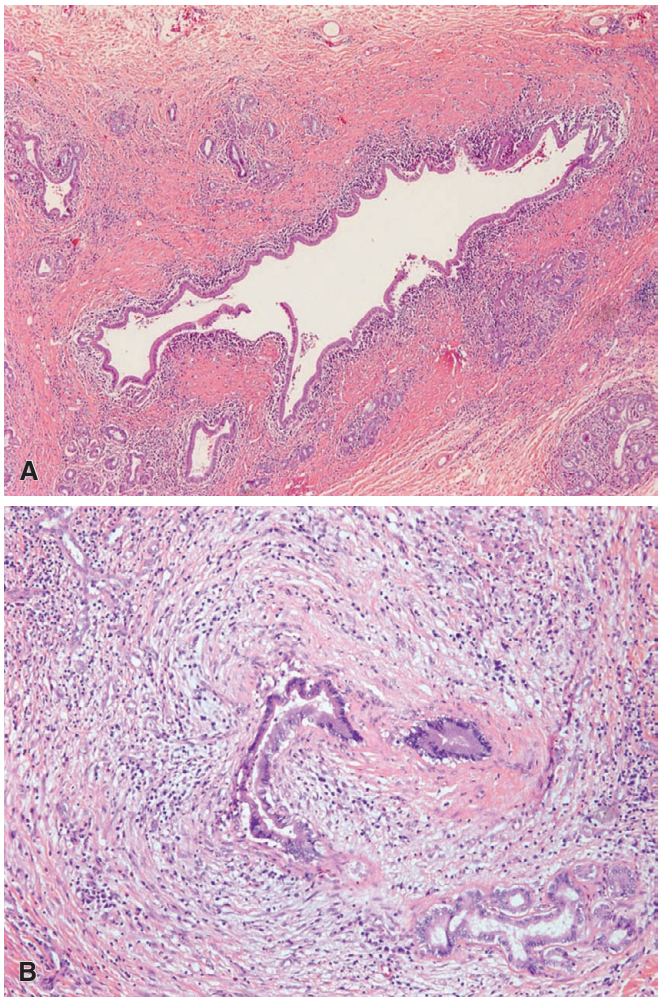

Figure 21.27 **A,** Common hepatic duct in primary sclerosing cholangitis shows a lymphoplasmacytic infiltrate underlying epithelium that is primarily intact. **B,** A more advanced case shows dense lymphoplasmacytic inflammation with fibrosis, epithelial disarray, and compromise of the duct lumen.

A recently described entity that may closely mimic PSC both clinically and radiographically is *IgG4-related sclerosing cholangitis*, which is part of the spectrum of IgG4-related diseases that includes sclerosing pancreatitis and a subtype of inflammatory pseudotumor (see also Chapters 19 and 22).[114–116] The majority of these patients (~90%) also have pancreatic involvement, which argues in favor of IgG4-related disease rather than PSC. Serum IgG4 is typically, but not always, elevated. Histologic findings include a dense lymphoplasmacytic infiltrate with associated fibrosis, obliterative phlebitis, and increased numbers of IgG4+ plasma cells (Fig. 21.28A–C); unfortunately, these findings are often not apparent on small mucosal bile duct biopsies. It should also be noted that bile duct carcinomas may be accompanied by increased numbers of IgG4+ plasma cells.[114] This disease responds extremely well to steroid therapy, and thus accurate diagnosis and distinction from PSC is important.

Other noninfectious inflammatory disorders of the extrahepatic bile ducts include *primary hepatolithiasis* (also known as recurrent pyogenic cholangitis or Oriental cholangiohepatitis), an idiopathic condition that occurs most commonly in Asians and infers an increased risk of cholangiocarcinoma;[117,118] and *eosinophilic cholangitis*, which may be associated with idiopathic eosinophilic gastroenteritis and can mimic carcinoma due to thickening of the duct wall.[119,120]

Infections of the Gallbladder and Extrahepatic Bile Ducts

A number of infections occur in the gallbladder and extrahepatic bile ducts, albeit rarely, and the majority are seen in the context of sclerosing cholangitis in immunocompromised patients. *Cryptosporidium*, an intracellular parasite, is the most commonly found biliary tract pathogen in patients with AIDS-associated cholangiopathy (Fig. 21.29A).[121–123] Other infections associated with AIDS-associated cholangiopathy, and cholecystitis, include *Microsporidia* (see Fig. 21.29B and C),[124] *Cystoisospora* (see Fig. 21.29D and E),[125] tuberculosis, *Mycobacterium avium-intracellulare*, and CMV, which is the second most common pathogen in AIDS-related biliary infections.[122,123,65] *Cystoisospora* has also been reported in the gallbladders of immunocompetent patients and appears to have little clinical significance in this context.[126]

Flukes, or trematodes, can infect the bile ducts, such as the liver flukes *Clonorchis sinensis*, *Opisthorchis* species, and *Fasciola* species (Fig. 21.30). Liver flukes are endemic in many parts of Asia, as well as Russia, Eastern Europe, and South America, and are acquired from eating contaminated fish, crawfish, or (in the case of *Fasciola*) watercress. Flukes can cause obstruction and/or biliary tract infections, and *Clonorchis* and *Opisthorchis* infection are risk factors for cholangiocarcinoma.[127,128] *Schistosoma* species (or blood flukes) rarely infect the extrahepatic bile ducts, causing fibrosis (see also Chapter 19).[129] The nematode *Ascaris lumbricoides* may occasionally migrate from the bowel into the bile ducts,[127] and amebiasis has been very rarely reported in the gallbladder.[130]

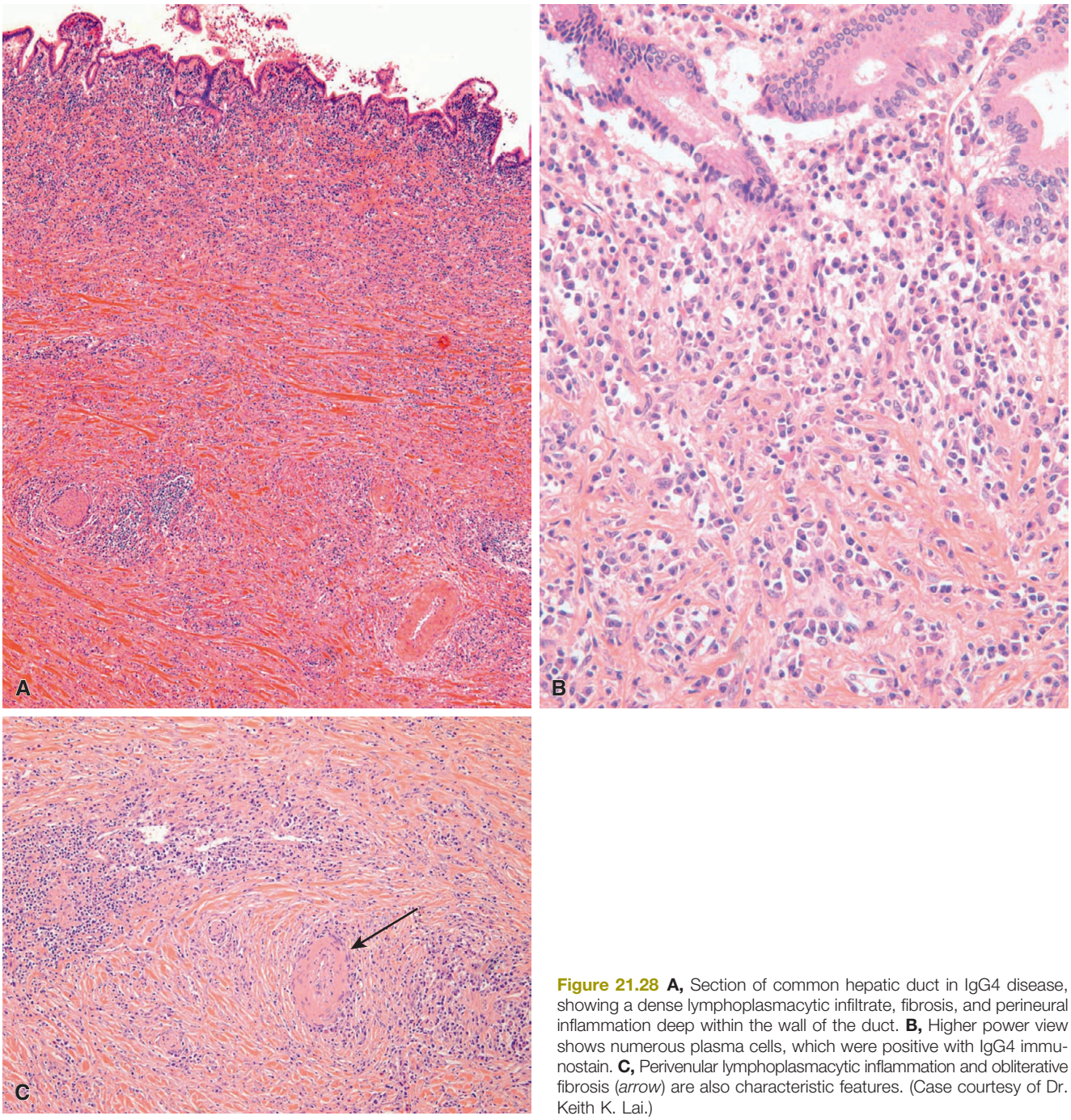

Figure 21.28 **A,** Section of common hepatic duct in IgG4 disease, showing a dense lymphoplasmacytic infiltrate, fibrosis, and perineural inflammation deep within the wall of the duct. **B,** Higher power view shows numerous plasma cells, which were positive with IgG4 immunostain. **C,** Perivenular lymphoplasmacytic inflammation and obliterative fibrosis (*arrow*) are also characteristic features. (Case courtesy of Dr. Keith K. Lai.)

Tumors and Tumorlike Conditions of the Gallbladder

Benign Tumors and Tumorlike Conditions

A variety of terms describing mucosal polyps of the gallbladder exist in the literature; these have poorly defined criteria, are often used interchangeably, and include *mucosal hyperplasia, hyperplastic polyp, villous hyperplasia*, and *inflammatory polyp*. Mucosal hyperplasia/hyperplastic polyps and inflammatory polyps are almost always seen in the context of chronic cholecystitis or some other inflammatory insult. These lesions are benign and typically clinically silent, and discovered incidentally at cholecystectomy. So-called *primary papillary hyperplasia* is a rare entity consisting of closely spaced villous folds that are taller than normal, but without a background of inflammation or metaplastic changes (hence the name primary hyperplasia).[131] Its significance is that it can mimic carcinoma radiographically. Both papillary mucosal hyperplasia and discrete polyps have been described in the gallbladders of both infants and adults with metachromatic leukodystrophy, which may result in massive hemobilia.[132,133] Cholesterol polyps are discussed previously.

Exaggerated examples of gallbladder ***diverticulosis*** associated with muscular hypertrophy have been dignified with the impressive but somewhat inaccurate names of ***adenomyomatous hyperplasia,***

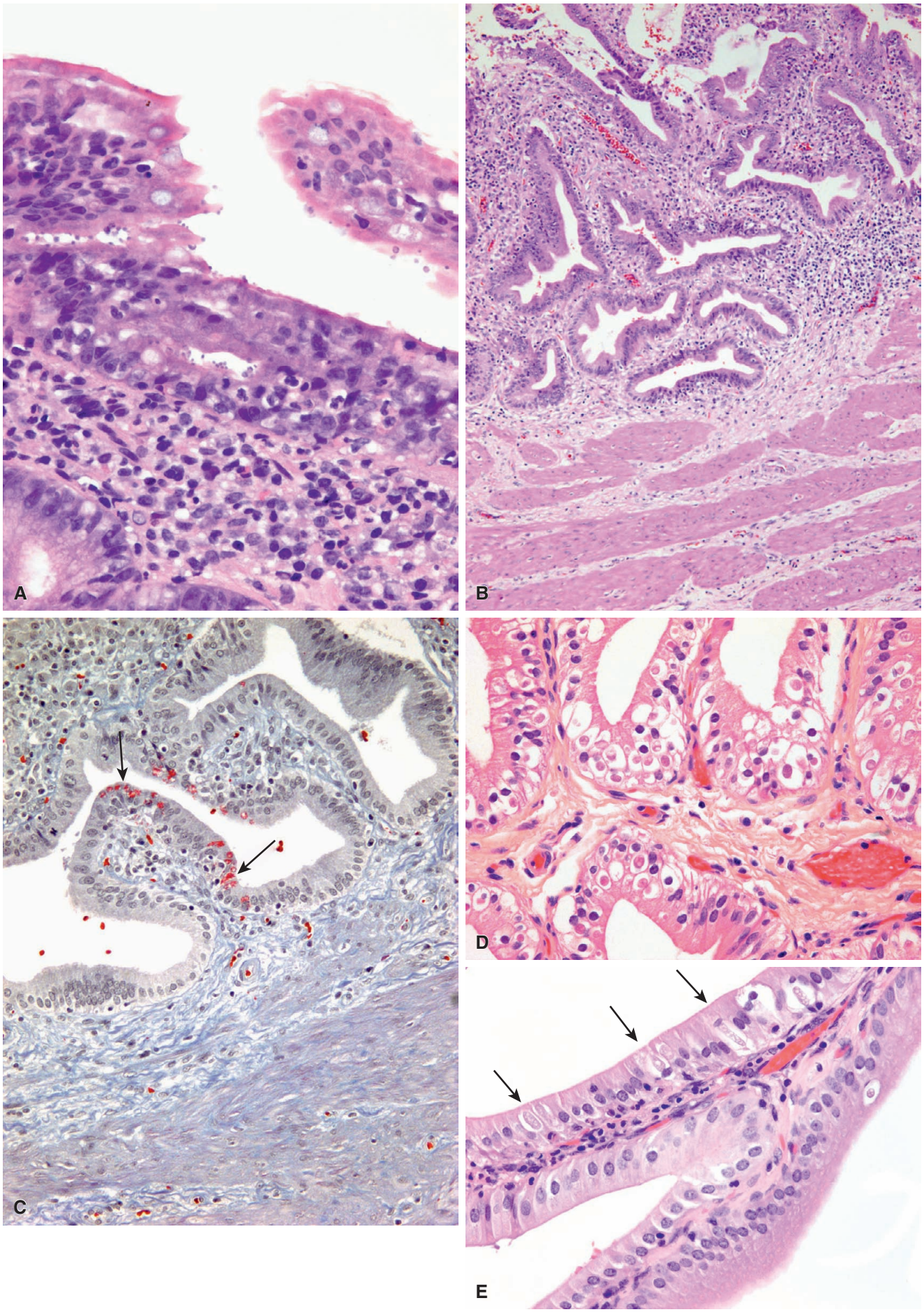

Figure 21.29 **A,** This ampullary biopsy shows round, basophilic organisms typical of *Cryptosporidia* within the apical cytoplasm of the epithelial cells. **B,** A gallbladder biopsy from a patient with microsporidiosis shows an increased mononuclear cell infiltrate in the lamina propria and increased intraepithelial lymphocytes. **C,** Modified trichrome stain highlights red-staining *Microsporidia* within the epithelium *(arrows)*. **D** and **E,** This gallbladder contains numerous *Cystoisospora* within parasitophorous vacuoles, with minimal inflammatory reaction (*arrows*; Case courtesy of Dr. Keith K. Lai).

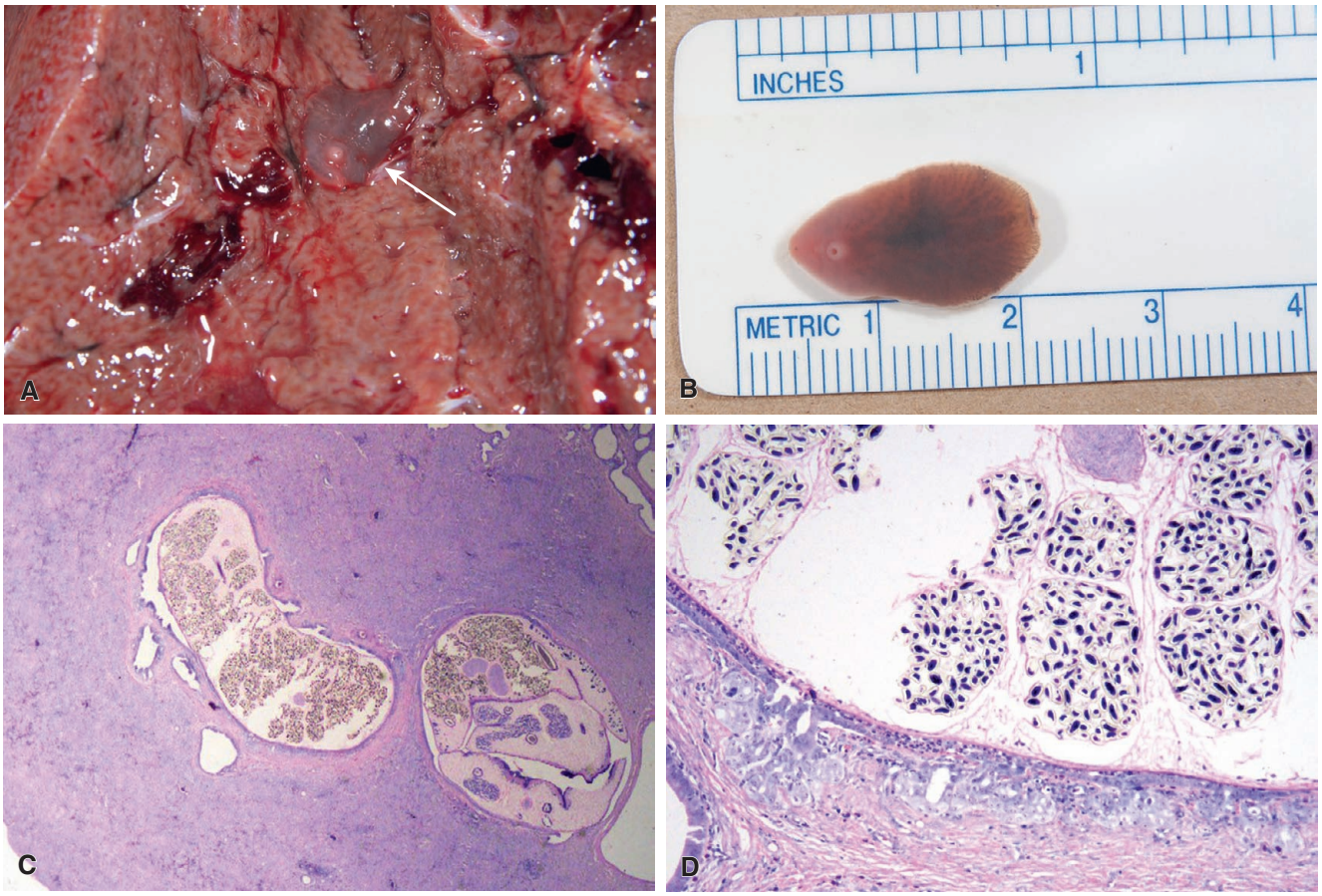

Figure 21.30 **A,** An autopsy specimen shows a fluke within a large intrahepatic bile duct *(arrow)*. **B,** Liver flukes are flat, slightly transparent, and tapered anteriorly with prominent oral and ventral suckers. **C,** *Clonorchis* within a large intrahepatic bile duct with associated cholangiocarcinoma **(D)**. (**A** and **B,** Courtesy of Dr. Jason Doss. **C** and **D,** Courtesy of Dr. Dan Milner.)

adenomyoma (when focal or **segmental**), and ***adenomyomatosis*** (when diffuse) (Fig. 21.31A).[134,135] This is a common condition, occurring in approximately 5% of cholecystectomy specimens. The localized form may involve any segment of the organ but in most cases is located in the fundus, where it results in a sharply circumscribed lesion that can mimic adenocarcinoma both grossly and radiographically. The lesion consists of cystically dilated glands, representing extension of Rokitansky–Aschoff sinuses, within hypertrophic smooth muscle (see Fig. 21.31B and C); the epithelium may show metaplastic or reactive changes. The dilated glands may be seen in close approximation to nerves, simulating intraneural and perineural invasion, thus adding the gallbladder to the increasing list of organs in which this phenomenon can occur in the absence of true malignant disease.[136]

Tumoral Intraepithelial Neoplasia

Historically, the clinical, pathologic, and prognostic features of pre-neoplastic and neoplastic gallbladder polyps have been poorly characterized, in large measure due to differences in terminology and classification. Recently, the terminology of noninvasive neoplastic lesions that form masses in the gallbladder has been revised significantly in order to clarify nomenclature as well as clinical significance.[137] Polypoid or papillary tumors, including lesions previously termed adenomas, noninvasive papillary neoplasms (including noninvasive carcinoma), and papillomatosis, are now grouped together as intracholecystic papillary-tubular neoplasms (ICPNs) (Fig. 21.32A–F). Dysplasia in these lesions is graded as low-grade or high-grade carcinoma in situ. Although the majority of invasive gallbladder cancers arise from flat dysplasia, approximately 5% arise from tumoral intraepithelial neoplasms,[137] and thus extensive sampling is required to exclude invasion. Grossly, ICPNs are typically villous and/or papillary and may grow to over 5 cm. They are typically very friable, and smaller ones may detach and be mistaken for necrotic tissue. Microscopically they are papillary, tubular, or tubulopapillary, and high-grade dysplasia and invasive carcinoma are more common in papillary and tubulopapillary lesions.[137]

ICPNs are frequently of mixed type, but the predominant cell type seen across the spectrum of ICPNs is biliary. ICPNs with a predominantly biliary cell type are most often papillary, and the most likely to be associated with invasive carcinoma. They express CK7 and MUC1, as well as other lineage markers in a minority. Other cell types include gastric, foveolar, oncocytic, pyloric, and intestinal. Most previous literature on "gallbladder adenomas" is based on pyloric-type lesions that may actually represent nodular metaplasia rather than a pre-neoplastic lesion. Some authors reserve

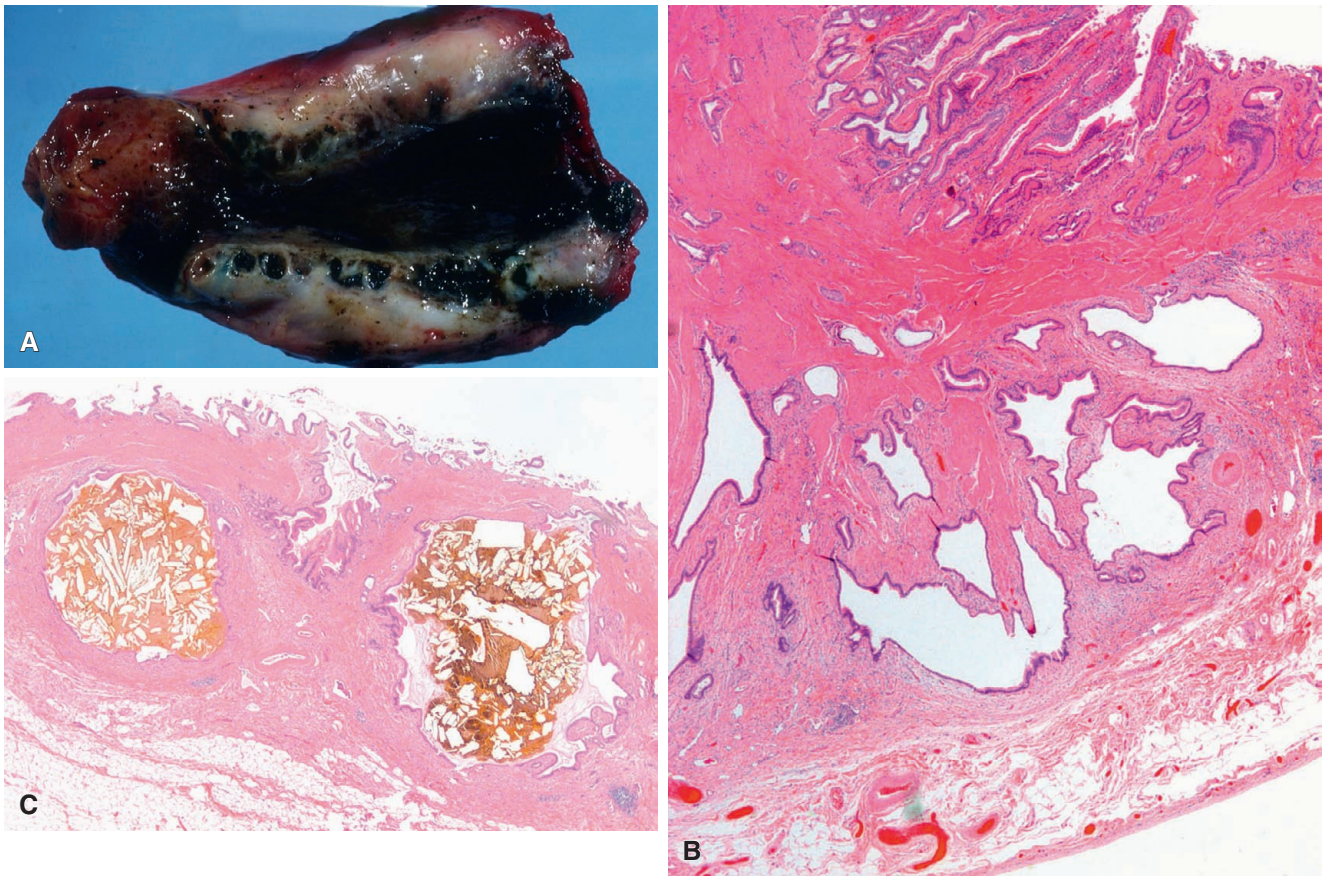

Figure 21.31 **A,** This gross specimen shows diffuse adenomyomatosis, characterized by a markedly thickened wall and grossly visible dilated glands filled with inspissated bile. **B,** This fundic adenomyoma shows hypertrophic, branching glands with prominent smooth muscle extending deeply into the wall of the gallbladder. **C,** Inspissated bile is a common finding. (**A,** Courtesy of Dr. George F. Gray Jr.)

the designation of neoplasm for discrete pyloric-type ICPNs that measure more than 1.0 cm and/or show obvious cytologic dysplasia.[137,138] These lesions are composed of tightly packed, small, pyloric-type glands with minimal stroma and no intracytoplasmic mucin. Squamous morules may be present,[138] and these lesions are characteristically MUC6 positive.[137] These lesions are infrequently associated with high-grade cytologic dysplasia or invasive adenocarcinoma, particularly if less than 1.0 cm.

A small minority of ICPNs resemble intestinal-type adenomas and have a similar CDX2+/CK20+ immunophenotype. As in the colorectum, the larger the lesion, the more likely that an area of dysplasia or carcinoma will be found. However, on the whole, they do not seem to represent an important precursor of gallbladder carcinoma (see next section). The frequent presence of *β-catenin* gene mutation in these lesions, but the rarity of this genetic change in gallbladder carcinoma provides, further evidence to support this observation.[139] Furthermore, *TP53*, *KRAS*, and *P16* mutations as found in gallbladder carcinomas are lacking in ICPNs.[140]

Flat/Nontumoral Preinvasive Lesions (Dysplasia/Carcinoma In Situ)

Unlike the mass-forming noninvasive neoplasms discussed above, flat (nontumoral) dysplasia is difficult to see grossly and often an incidental finding in cholecystectomy specimens. As in the stomach, it is believed that most cases of gallbladder adenocarcinoma are preceded by a sequence of intestinal metaplasia, dysplasia, and carcinoma in situ,[141–143] for which the term *biliary intraepithelial neoplasia* has also been suggested (Fig. 21.33A–C).[144] Flat dysplasia, like ICPNs, is also graded as low- or high-grade/carcinoma in situ. Because of the association between flat dysplasia and invasive carcinoma, extensive sampling of the gallbladder is required when dysplasia is found on initial sections. Intestinal metaplasia is also a very common finding in the gallbladder mucosa adjacent to both flat dysplasia and invasive adenocarcinoma (see Fig. 21.33D).[141,142] Flat dysplasia can have a totally flat or a papillary growth pattern and can consist of biliary, intestinal, or foveolar cell types; more than one cell type can be seen in a lesion. Interestingly, extension of dysplasia into Rokitansky–Aschoff sinuses is an adverse prognostic factor and predictor of recurrence (see Fig. 21.33E).[145] If flat dysplasia is detected in initial sections of a gallbladder, the remainder should be extensively sampled to exclude an adjacent adenocarcinoma (see Fig. 21.33E).

Overexpression of p53 and loss of heterozygosity in chromosome 5q have been found in gallbladder dysplasia, suggesting that they represent early events in the evolution of gallbladder carcinoma.[146,147] *KRAS* mutations and MSI have not been shown to play important roles in gallbladder dysplasia and carcinogenesis.[148]

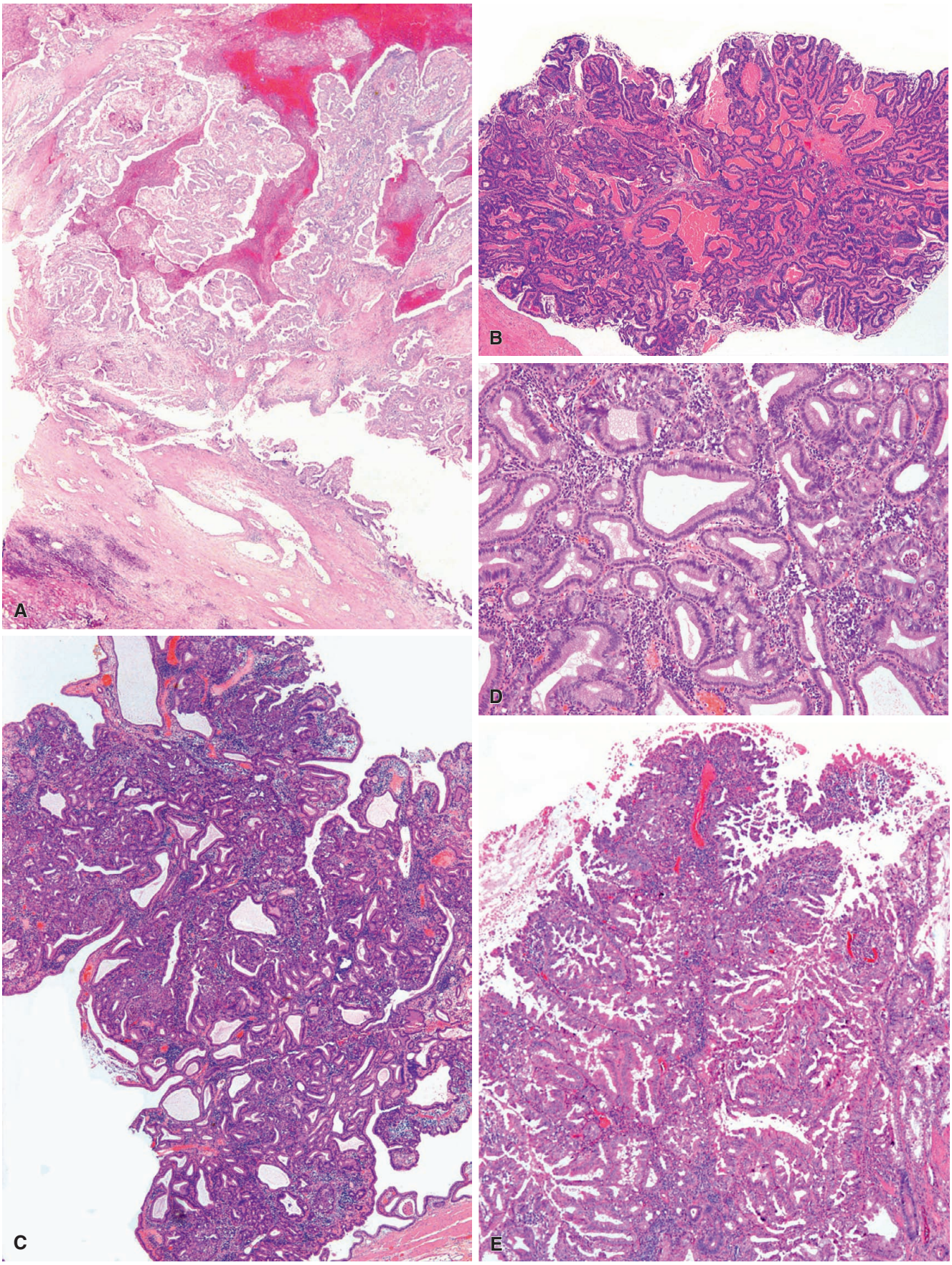

Figure 21.32 **A** and **B,** Intracholecystic papillary-tubular neoplasms (ICPNs) show a wide spectrum of papillary and tubular patterns and are often detached from the underlying gallbladder mucosa when the specimen is opened. The case illustrated in **B** would likely have been called an adenoma using previous terminology. **C** and **D,** This large ICPN has a gastric or pyloric cell type. **E,** This papillary lesion contained extensive high-grade dysplasia/carcinoma in situ and consisted of a mixture of cell types.

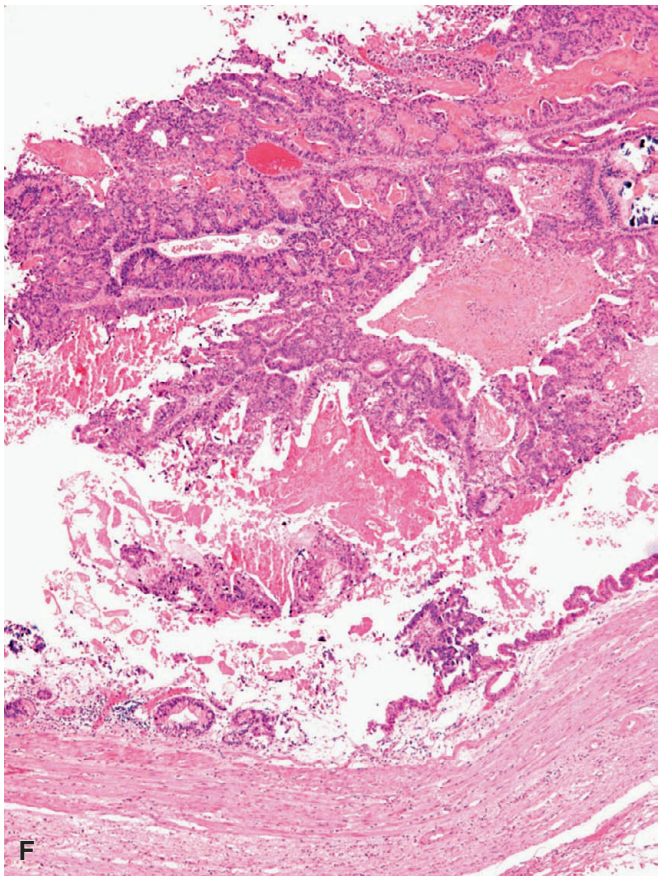

Figure 21.32, cont'd **F,** This ICPN also contains extensive high-grade dysplasia/carcinoma in situ; the original cell type is difficult to discern given the extensive dysplasia.

Carcinoma of the Gallbladder

General and Clinical Features

Adenocarcinoma of the gallbladder represents 80%–95% of biliary tract cancers.[148,149] Carcinoma of the gallbladder is more frequent in females than males (3–4 : 1 ratio), and over 90% of the patients are 50 years of age or older at the time of diagnosis.[148,149] It is much more common in some Latin American countries and parts of Asia than in the United States. In the United States, there is a concentration of cases in the southwest, north central, and Appalachian regions, and the incidence is high in Native Americans, relatively low in whites of European extraction, and very rare in blacks.[149,150] In Europe, the rate is very high in Germany and surrounding central countries, low in Mediterranean countries, and low and declining in Britain and Ireland.[149,151]

A definite epidemiologic parallel exists between gallbladder carcinoma and cholelithiasis, but the pathogenetic relationship between them remains controversial.[149] In the non-Native American, non-Hispanic population of the United States, the incidence of carcinoma in gallbladders with lithiasis is less than 1%.[149,152]

Other conditions said to be associated with an increased risk of gallbladder carcinoma are cholecystoenteric fistula, porcelain gallbladder, PSC, obesity, segmental adenomyomatosis,[153] familial adenomatous polyposis/Gardner syndrome,[154] and anomalous connection between the common bile duct and the pancreatic duct.[155] Many of the latter cases present at an advanced stage. Although almost half of gallbladder carcinomas are found incidentally at cholecystectomy, the most common clinical manifestations of gallbladder carcinoma are right upper quadrant abdominal pain and anorexia, and the most common abnormal laboratory finding is elevated alkaline phosphatase level.[156,157]

Gross Features

Grossly, gallbladder carcinoma may present as a diffusely growing (70%) or nodular, polypoid, or papillary mass (30%) mass (Fig. 21.34A–D).[158,159] When diffuse, the gross distinction from chronic cholecystitis may be difficult (see Fig. 21.34E and F); it is also important to note that a significant minority of gallbladder cancers (up to 30%) are not apparent grossly,[159] indicating the need for microscopic examination of every excised gallbladder. The vast majority arise in the fundus (70%–80%), with approximately one-third arising in the body and the remaining 10% in the neck.[159] Gallbladders with carcinomas usually also contain calculi (80%–90% of the cases) and exhibit marked fibrosis of the wall. The latter may represent a reaction to the tumor or the expression of a preexisting chronic cholecystitis. We (Dr. Juan Rosai) have seen several patients in whom an unexpected metastatic tumor was found in the liver sometime after the removal of a gallbladder thought to have only lithiasis and inflammation on gross examination by the surgeon and therefore discarded.

Microscopic Features

Microscopically, more than 90% of gallbladder cancers are adenocarcinomas, showing varying degrees of differentiation. Most tumors

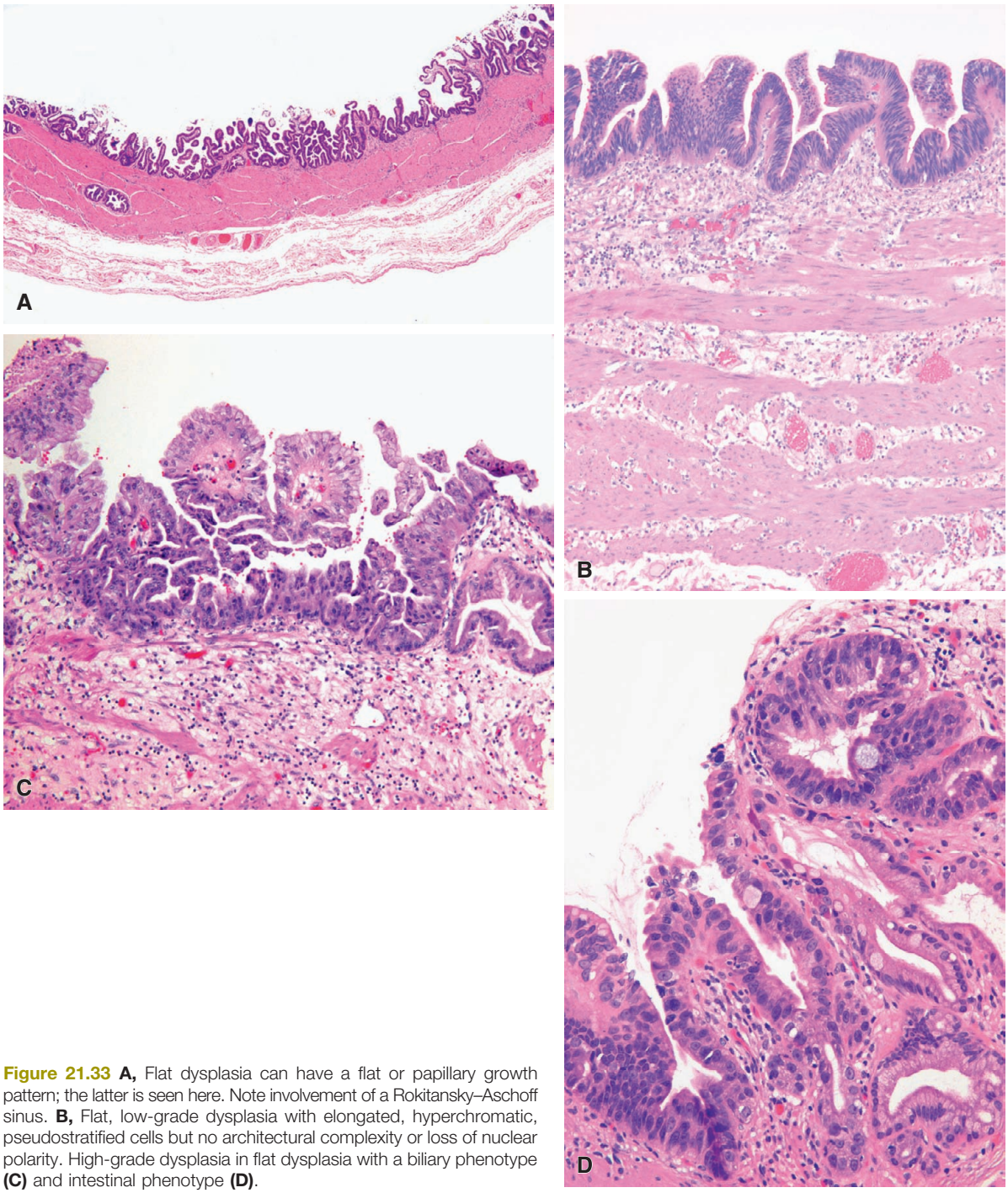

Figure 21.33 **A,** Flat dysplasia can have a flat or papillary growth pattern; the latter is seen here. Note involvement of a Rokitansky–Aschoff sinus. **B,** Flat, low-grade dysplasia with elongated, hyperchromatic, pseudostratified cells but no architectural complexity or loss of nuclear polarity. High-grade dysplasia in flat dysplasia with a biliary phenotype **(C)** and intestinal phenotype **(D)**.

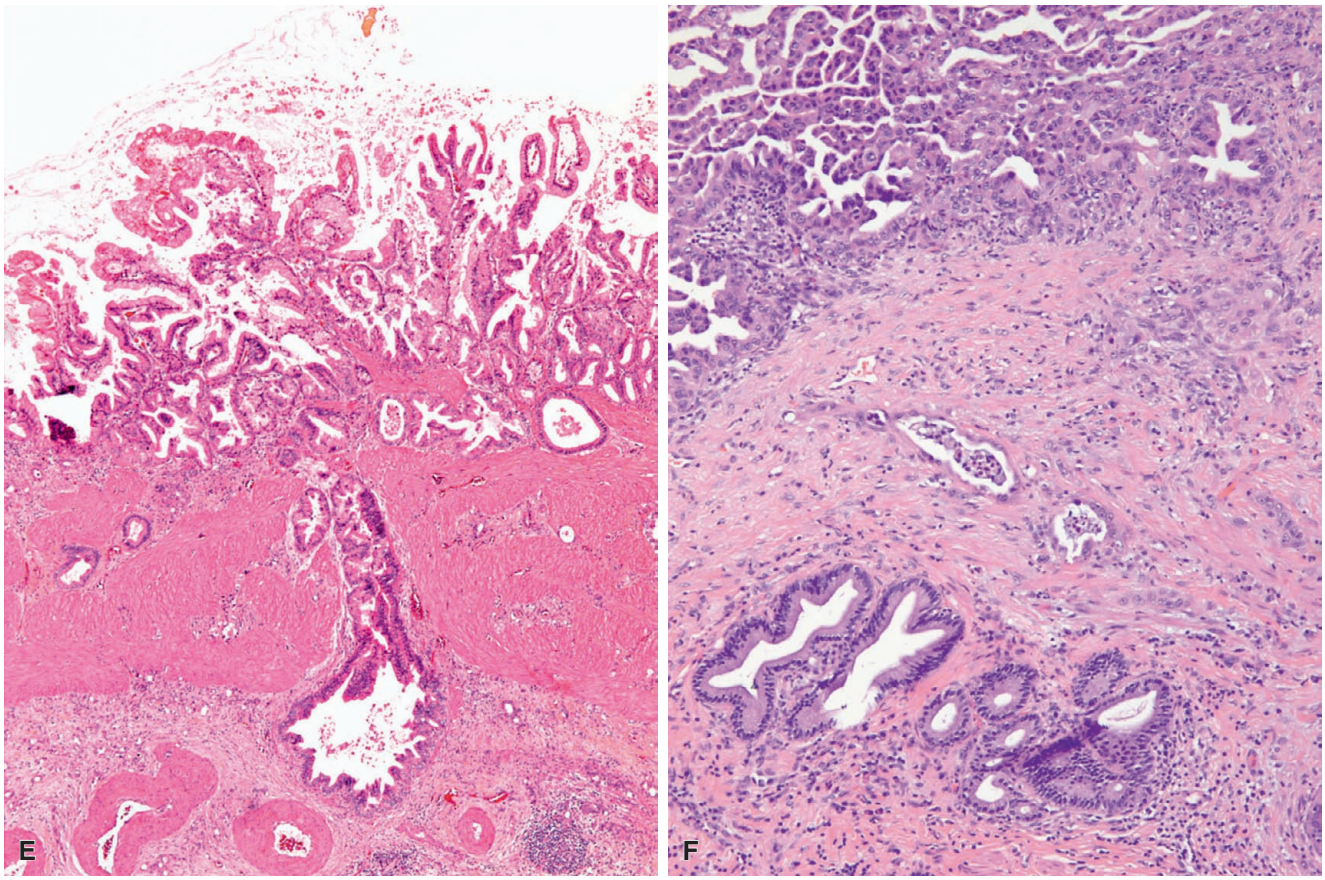

Figure 21.33, cont'd **E,** Extension of dysplasia into a Rokitansky–Aschoff sinus. **F,** Small focus of invasive adenocarcinoma arising beneath an area of flat dysplasia.

are of the pancreatobiliary type (Fig. 21.35A–E), having a morphologic appearance that is common to adenocarcinomas of the pancreatobiliary region—well-formed glands with wide lumina lined by one or a few rows of highly atypical cuboidal cells, surrounded by a dense cellular stroma often arranged concentrically.[158–160] It is characteristic for these glands to be well differentiated, or even atrophic-appearing, at an architectural level, but poorly differentiated at a cytologic level. The cytoplasm may be eosinophilic, or pale and almost clear or foamy. Sometimes the adenocarcinoma extends into Rokitansky–Aschoff sinuses in a manner analogous to endometrial adenocarcinoma extending into foci of adenomyosis; it is important not to misinterpret this finding as a sign of deep infiltration by the tumor.[161] Foci of perineurial invasion are common; however, as mentioned previously, the dilated glands of Rokitansky–Aschoff sinuses and adenomyomatosis may be seen in close approximation to nerves, simulating perineural invasion.[136]

As noted previously, *hyalinizing cholecystitis* is a recently proposed term for chronic cholecystitis featuring replacement of the gallbladder wall by dense hyaline fibrosis, typically with denuded epithelium.[84] Carcinomas are easily missed in these cases because of the thin, fibrous wall that lacks a discernible mass lesion. The malignant glands are typically widely spaced, well differentiated, and oriented parallel to the muscularis propria (Fig. 21.36A and B). The neoplastic epithelium may become markedly attenuated, leaving behind necrotic debris.

Other Microscopic Types

Tumors previous classified as noninvasive *papillary carcinomas* are now classified as ICPNs (see earlier). When there is an invasive component, it is typically pancreatobiliary and associated with a poor prognosis.[159,162] A micropapillary variant of gallbladder adenocarcinoma has also been recently described and, like those in other organ systems, is associated with aggressive behavior (Fig. 21.37).[163] *Adenosquamous carcinomas* of the gallbladder (Fig. 21.38) consist of both malignant glandular and squamous components (by definition, the squamous component must comprise 25%–99% of the tumor).[164] Pure *squamous cell carcinomas* are exceptional.

Mucinous adenocarcinomas are made up of more than 50% extracellular mucin (Fig. 21.39A),[159,165] and signet ring cells as well as clusters of neoplastic cells, including signet ring cells, can be seen floating in the mucin. These tumors are typically advanced at presentation and have a poor prognosis. *Clear cell* variants of adenocarcinoma have also been described,[159,166] which can mimic metastases from other clear cell neoplasms. *Signet ring cell* adenocarcinoma (see Fig. 21.39B) of the gallbladder[159,167] can mimic metastases from the breast and stomach and in turn can be mimicked by degenerative changes in mucosal goblet cells in cases of ulcerative cholecystitis.[168]

Occasionally, gallbladder adenocarcinomas are of *intestinal type* on morphologic, histochemical, and immunohistochemical grounds (Fig. 21.40A).[159,169] Patches of intestinal differentiation are frequent in pancreatobiliary gallbladder carcinomas as well (Fig. 21.40B), with the appearance of goblet cells, endocrine cells, and even Paneth cells[170]; in addition, differentiation may proceed along gastric foveolar lines. Sometimes the pattern of growth of the tumor is predominantly *cribriform*, closely resembling the appearance of the cribriform type of ductal carcinoma of the breast.[171]

Lymphoepithelioma-like carcinoma can be seen in the gallbladder or extrahepatic bile ducts; some of the cases were associated with

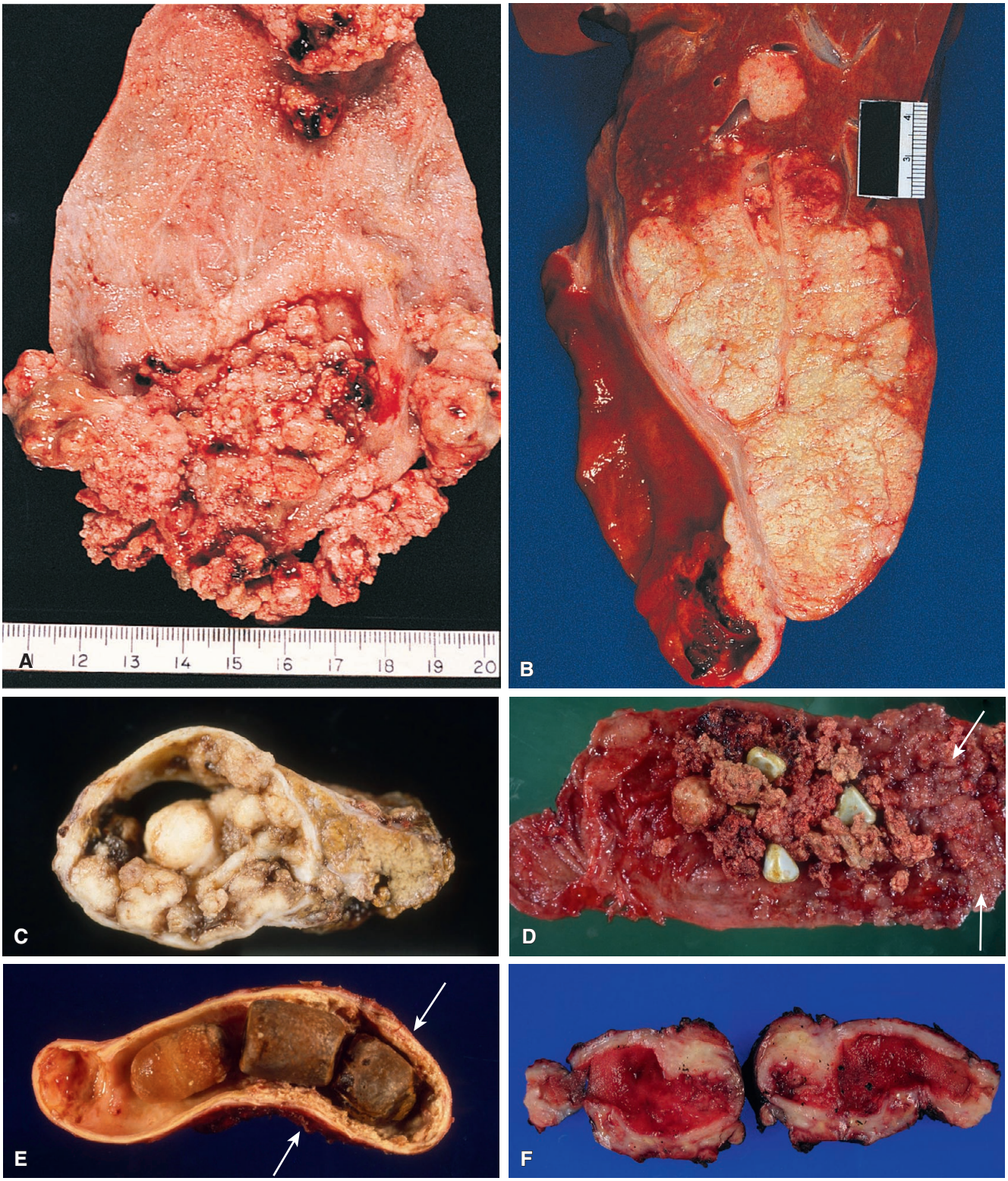

Figure 21.34 **A,** Grossly, gallbladder adenocarcinomas may have a polypoid, papillary, or diffuse configuration. This adenocarcinoma of the gallbladder has a predominantly papillary appearance. **B,** This tumor is growing in diffuse fashion in the distal wall of the gallbladder, associated with extensive involvement of the liver. **C,** This tumor has both polypoid and diffuse growth patterns; note the large polypoid tumor in the center, but the near-circumferential tumor visible around it. **D,** This tumor has a papillary component with admixed stones but a diffuse component indicated by the friable, thickened folds on the right *(arrow)*. It may be difficult to distinguish a diffuse pattern tumor from chronic cholecystitis. **E,** In this case, the adenocarcinoma appears as rough, thickened mucosa beneath three large stones *(arrow)*. **F,** The markedly thickened wall represents diffuse adenocarcinoma rather than chronic cholecystitis, and no distinct mass is easily identified. (**C–E,** Courtesy of Dr. George F. Gray Jr.)

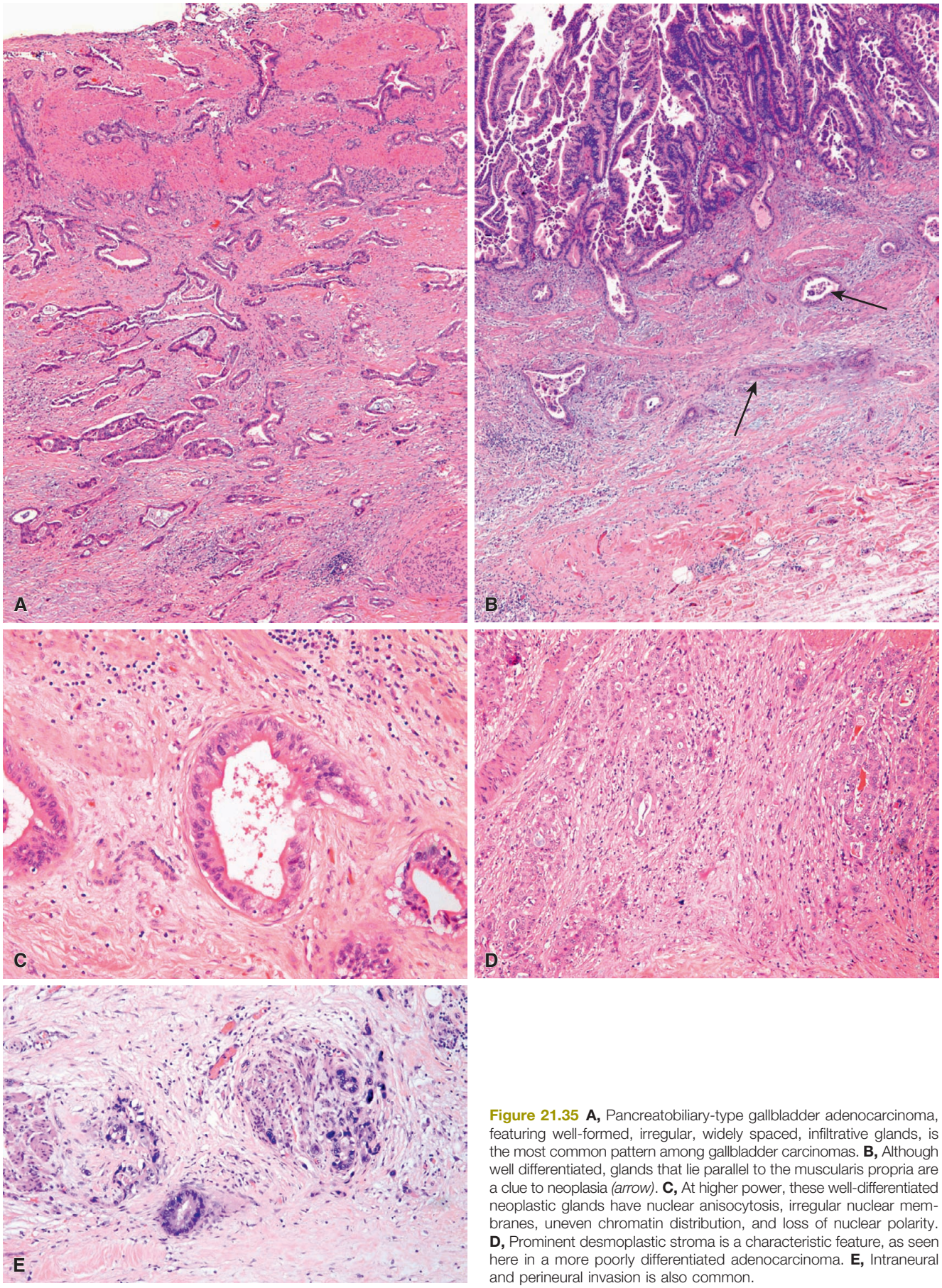

Figure 21.35 **A,** Pancreatobiliary-type gallbladder adenocarcinoma, featuring well-formed, irregular, widely spaced, infiltrative glands, is the most common pattern among gallbladder carcinomas. **B,** Although well differentiated, glands that lie parallel to the muscularis propria are a clue to neoplasia *(arrow)*. **C,** At higher power, these well-differentiated neoplastic glands have nuclear anisocytosis, irregular nuclear membranes, uneven chromatin distribution, and loss of nuclear polarity. **D,** Prominent desmoplastic stroma is a characteristic feature, as seen here in a more poorly differentiated adenocarcinoma. **E,** Intraneural and perineural invasion is also common.

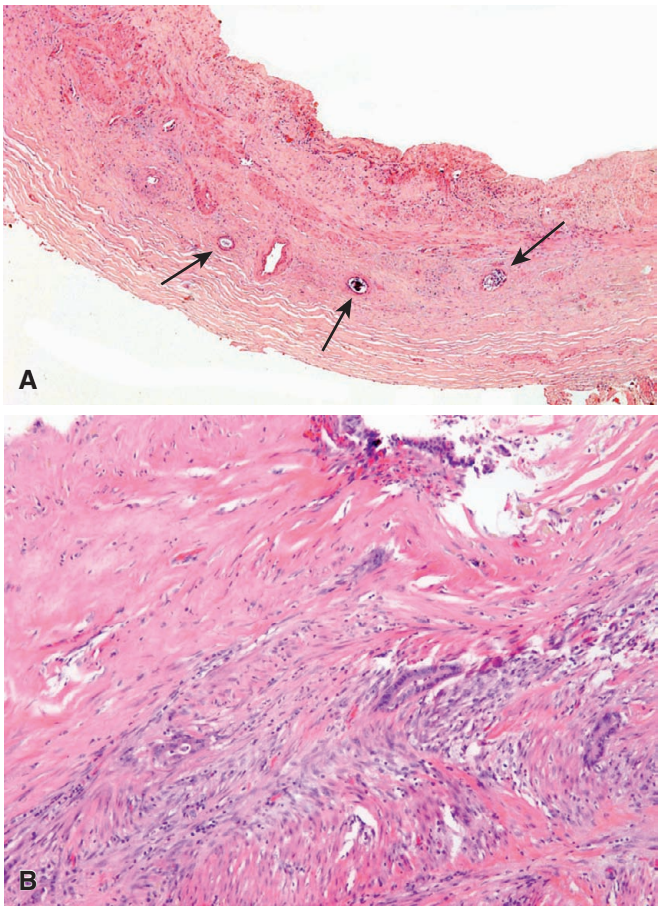

Figure 21.36 **A,** A low-power section from a case of hyalinizing cholecystitis with widely spaced, well-differentiated malignant glands with attenuated epithelium and prominent luminal debris *(arrows)*. Note that the overlying gallbladder epithelium is denuded. **B,** A higher-power view shows malignant glands lying parallel to the muscularis propria within densely hyalinized gallbladder wall.

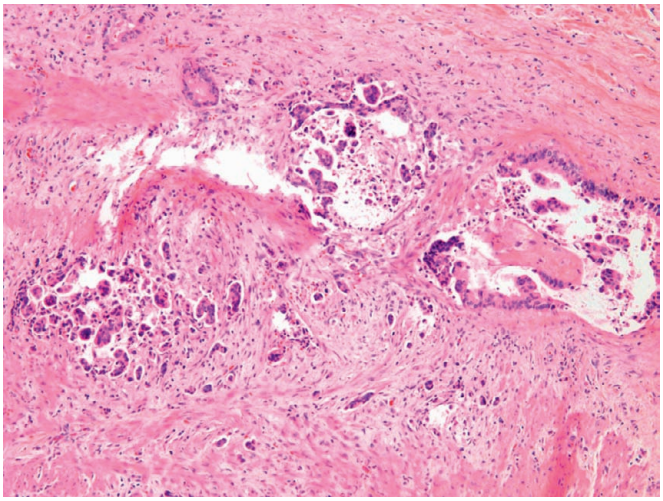

Figure 21.37 Micropapillary variant with clusters of cells in a papillary configuration within artifactual clefts.

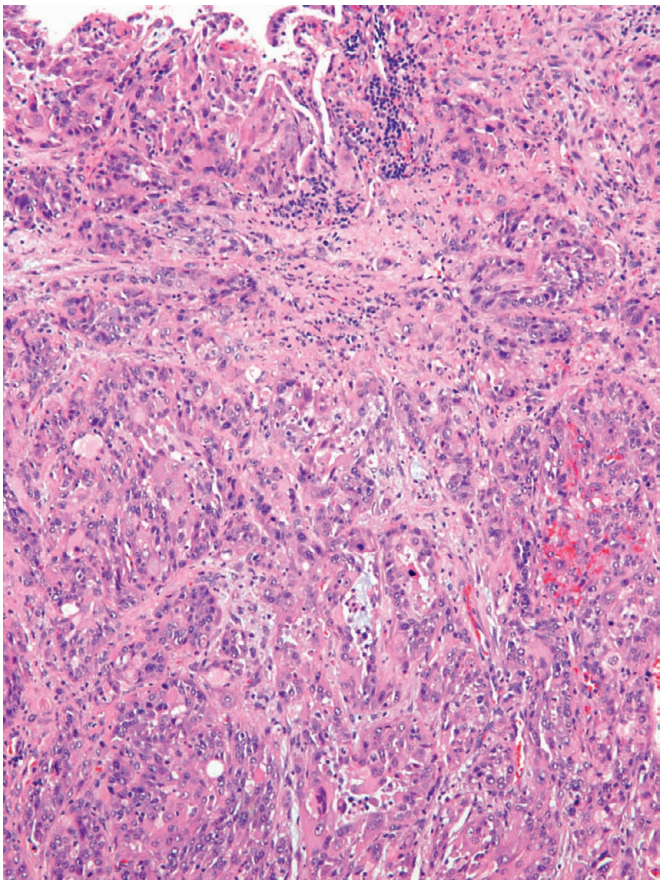

Figure 21.38 Adenosquamous carcinoma with overlying surface ulceration.

Epstein–Barr virus, but others were not.[172,173] *Undifferentiated (anaplastic, pleomorphic, spindle, sarcomatoid) carcinomas* (Fig. 21.41) are aggressive tumors that occur in various morphologic presentations (giant cell, spindle cell, pseudoangiosarcomatous), many of them closely simulating sarcomas (hence their alternative designation, carcinosarcoma, although most evidence suggests that the sarcoma-like component is also of epithelial derivation).[159,174–176] In exceptional cases, undifferentiated gallbladder adenocarcinomas or adenosquamous carcinomas have a component of osteoclast-like giant cells, similar to those seen more often in pancreatic adenocarcinoma.[159,177,178] Analogous to pancreatic tumors, the giant cells mark as histiocytes, whereas the undifferentiated tumors cells are epithelial. Other unusual types of gallbladder carcinoma include hepatoid adenocarcinoma, a rare variant that may closely resemble hepatocellular carcinoma morphologically and can express both alpha-fetoprotein (AFP) and hepatocyte antigen immunohistochemically; patients may also have an elevated serum AFP.[179,180] Adenocarcinoma with choriocarcinoma-like features has also been rarely reported; these tumors may be associated with β-hCG in the blood and urine.[181]

Neuroendocrine carcinomas (NECs) can manifest in the gallbladder with either a small or large cell phenotype; the former are morphologically analogous to the homonymous tumor in the lung and other sites (Fig. 21.42A and B).[182–186] These are highly aggressive neoplasms that metastasize early and cause death shortly after diagnosis. Mixed adenocarcinoma/NECs have also been described. As with adenocarcinomas in many other sites in the body, scattered neuroendocrine cells can be seen in conventional pancreatobiliary adenocarcinomas as well, but this has no clinical significance. Well-differentiated

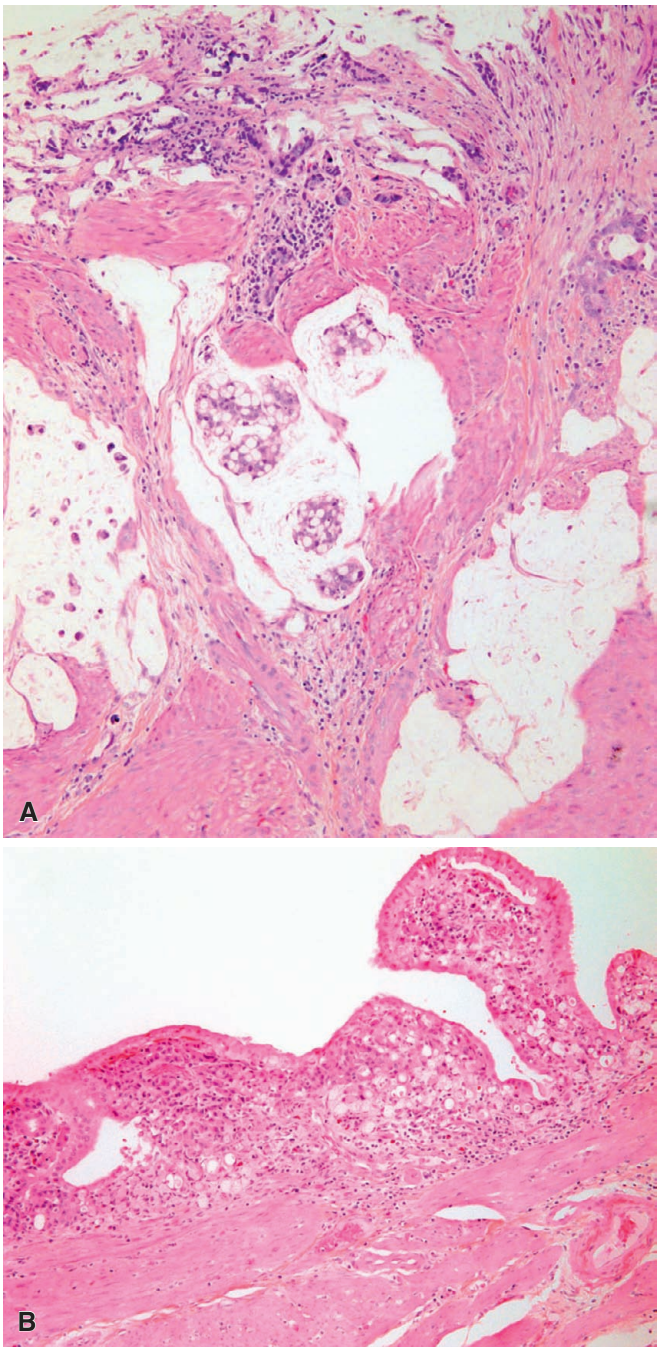

Figure 21.39 **A,** Mucinous adenocarcinoma of the gallbladder features abundant extracellular mucin. Clusters of malignant cells and individual signet ring cells float in the mucin. **B,** Primary signet ring cell carcinoma of the gallbladder. The majority of the malignant cells are in the lamina propria.

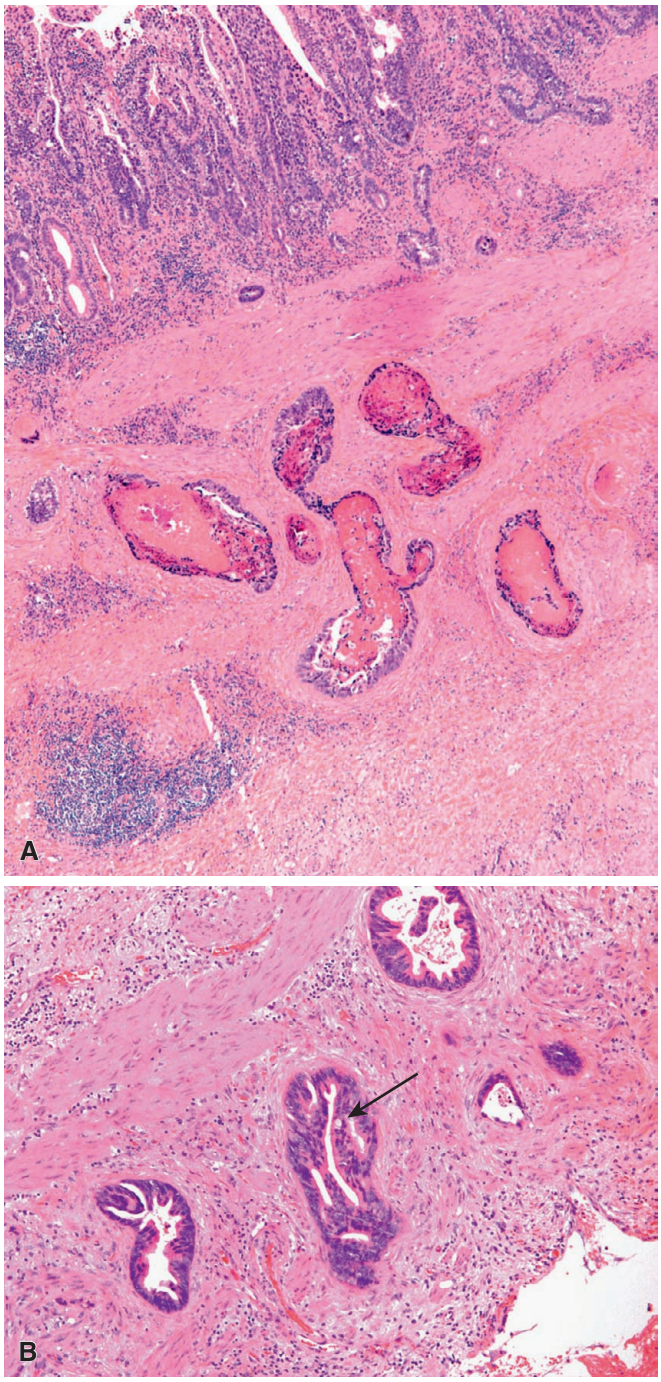

Figure 21.40 **A,** Adenocarcinoma of the gallbladder with intestinal features, including "dirty" luminal necrosis. Note the overlying dysplasia. **B,** This pancreatobiliary gallbladder carcinoma has both goblet cells *(arrow)* and a cribriform growth pattern in numerous foci.

neuroendocrine tumors (NETs) of the gallbladder *(carcinoid tumors)* also occur (Fig. 21.43A–C).[182,187] Clear cell NETs may be associated with von Hippel–Lindau disease but have also been described in patients who do not have it.[159,188]

Immunohistochemical Features

The usual keratin profile for carcinoma of the gallbladder and extrahepatic bile ducts is CK7+/CK20+, although the CK20 staining is often focal. In contrast, peripheral (intrahepatic) cholangiocarcinoma is usually CK7+/CK20–.[189,190] Other markers found in gallbladder adenocarcinoma include CK19, claudin-4, MUC1, CA19-9, and carcinoembryonic antigen (CEA).[159,191,192] A proportion of cases show CDX2 expression[193,194] but usually not as extensively and intensely as in colorectal carcinoma, and gallbladder adenocarcinomas may also express hepatocyte antigen.[193] Of note, the mucinous variant of gallbladder carcinoma is more likely to express CK7–, MUC5AC+, and MUC1–.[159]

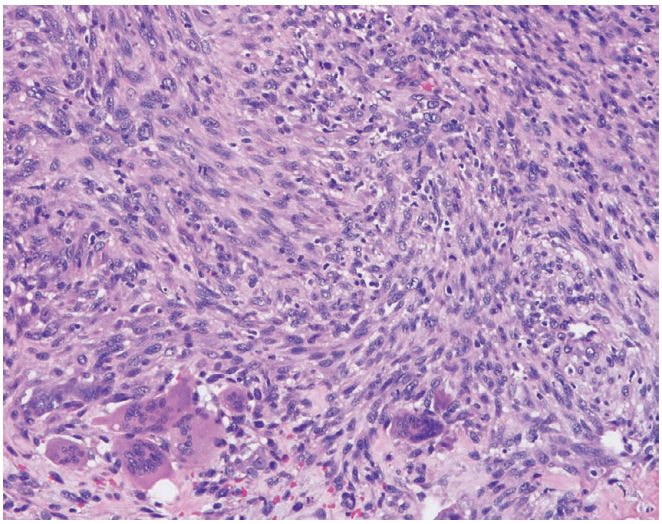

Figure 21.41 This undifferentiated adenocarcinoma shows a sarcomatoid epithelial component, along with scattered multinucleate giant cells. (Courtesy of Dr. Volkan Adsay.)

Molecular Genetic Features

Gallbladder carcinoma develops through accumulation of multiple genetic alterations, involving oncogenes, tumor suppressor genes, and DNA repair genes.[149,158,159] *KRAS* mutations have been reported with highly variable frequencies, ranging from less than 10% to over 60%,[158,159] and this phenomenon appears to be particularly prevalent in gallbladder carcinomas associated with anomalous arrangement of the pancreaticobiliary duct.[149,195] The demonstration of *KRAS* mutations does not appear to have prognostic significance, however.[196] HER-2/neu overexpression or gene amplification is seen in 10%–70% of gallbladder cancers, but this does not appear to correlate with prognosis.[158,159,197]

Among tumor suppressor genes, inactivation of *TP53* with associated accumulation of p53 appears in over 50% of cases.[158,159,198,199] This is more common in high-grade tumors.[200] Loss of fragile histidine triad expression is also common (75%) and may be an early event in gallbladder neoplasia.[159,201]

Other common molecular alterations include *p16* inactivation, telomerase activation, and mutations in cyclin D1, as well as a wide variety of other genes.[158,159,202] Microsatellite instability is present in approximately 10% of cases.[158,159] Despite this large number of identified molecular abnormalities, no clear model of carcinogenesis has been elucidated, and no promising molecular therapeutic targets exist as of yet.

Spread and Metastases

Gallbladder carcinoma has a great propensity to invade the liver directly,[203] and to less extent the stomach and duodenum; it also metastasizes frequently to liver (often through the portal tracts), cystic and pericholedochal lymph nodes in the lesser omentum, and lymph nodes behind the first portion of the duodenum.[204–206] The frequency of lymph node involvement is highly dependent on the depth of invasion of the primary tumor.[207] Almost half of the patients already have metastatic disease at the time of surgery.[208] Ovarian metastases from carcinoma of the gallbladder may simulate primary tumors of the ovary.[209]

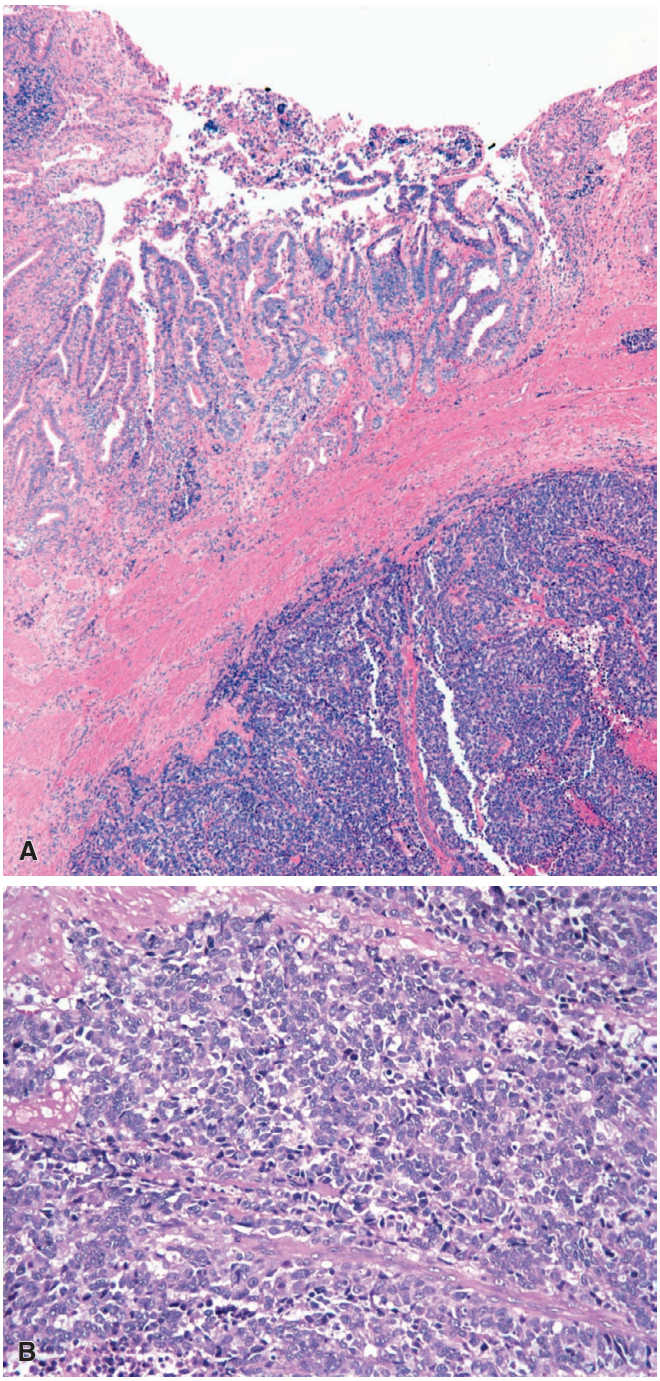

Figure 21.42 **A,** Neuroendocrine carcinoma of the gallbladder with overlying flat dysplasia. **B,** Higher-power view shows speckled chromatin, scant cytoplasm, and numerous mitoses. Synaptophysin and chromogranin were strongly positive.

Treatment and Prognosis

The treatment of gallbladder carcinoma is primarily surgical,[149,210–212] its extent depending on the stage of the disease. Current recommendations are simple cholecystectomy with negative margin for T1a disease (tumor limited to lamina propria). Some authors have advocated for more radical surgery for tumors in which the carcinoma involves Rokitansky–Aschoff sinuses, as this may portend a

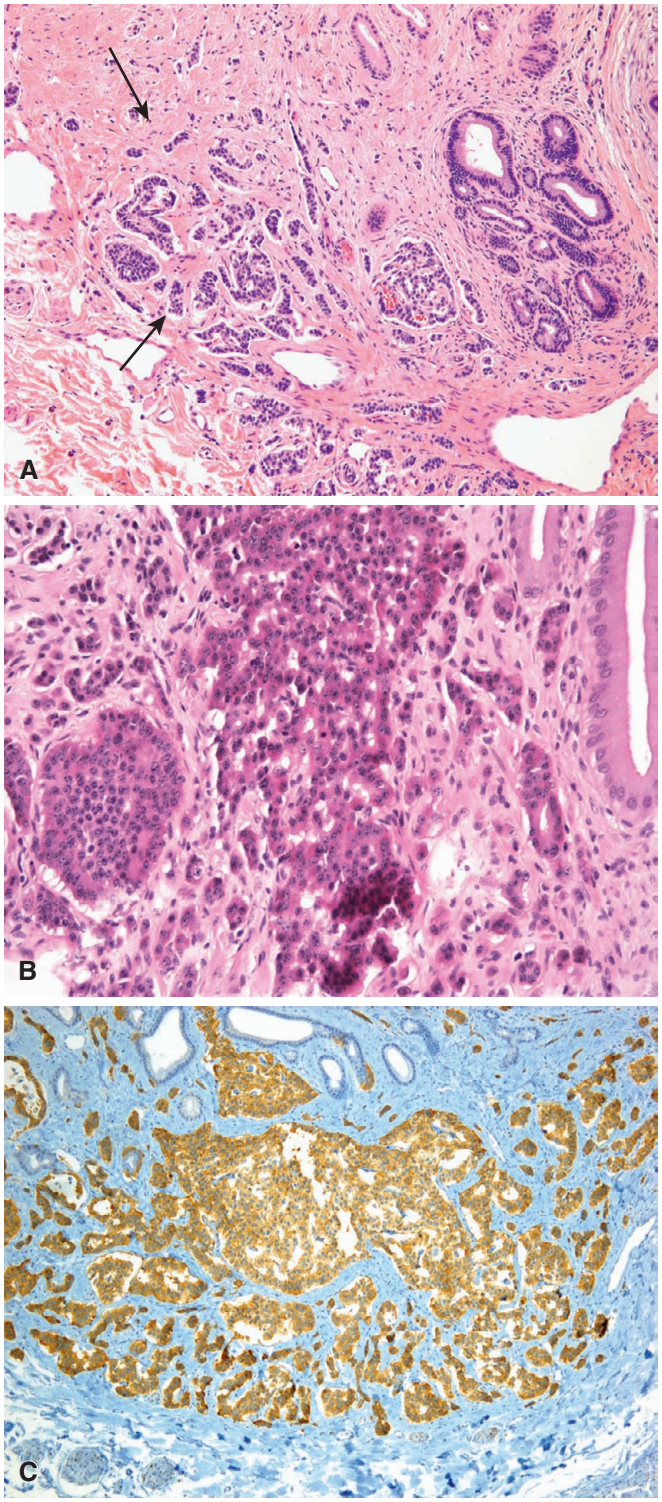

Figure 21.43 **A,** Incidental well-differentiated neuroendocrine tumor (carcinoid, *arrows*) within gallbladder wall. **B,** Another case, at higher power, shows uniform cells with a "salt and pepper" chromatin pattern. **C,** Synaptophysin highlights the tumor cells within the wall of the gallbladder.

worse prognosis.[145] Given the higher rate of lymph node metastases and tumor recurrence in T1b tumors (invasion of muscular wall), the treatment is more controversial, and some recommend more radical resection with lymph node dissection. T2 tumors (involving perimuscular connective tissue) are typically treated with radical cholecystectomy and lymphadenectomy. T3 (tumor penetrates visceral peritoneum or invades an adjacent structure) may be treated with radical surgery on a case-by-case basis, depending on resectability and the patient's fitness for surgery. T4 disease is treated palliatively. The importance of a systematic dissection of the various lymph node groups has been emphasized.[212] Historically, chemotherapy has been of limited benefit, although there is a growing opinion in favor of adjuvant chemotherapy in biliary tract carcinomas. Regardless, progression-free survival is typically measured in months,[213] and radiotherapy has shown survival benefit at the 1-year but not the 5-year mark in some studies.[149] Port site recurrences following laparoscopic cholecystectomy are a major concern and are reported in 14%–29% of patients within 6–10 months. These patients have a very poor prognosis (1-year survival of <30%); however, port site excision does not appear to improve survival.[214]

A number of factors have been evaluated as possible predictors of prognosis in gallbladder carcinoma. As in most other organs, the stage of the tumor is the most important prognostic determinant. The 5-year survival rate approaches 100% for T1a disease; however, very few cases are diagnosed at that early stage. Five-year survival in T1b disease is more variable, depending on the aggressiveness of the surgical procedure (see earlier) and ranges from 37.5% to 100%. The 5-year survival drops to 58%–70% for T2 disease and is 23% and 0%–12% for T3 and T4 disease, respectively.[214–216] By the time the diagnosis of carcinoma of the gallbladder can be made clinically, the tumor is advanced and usually inoperable (stage V).[216] Under such circumstances, the chances of cure—even after heroic surgical measures—are minimal, although some recent studies advocate for more radical surgical procedures in patients with advanced stages of gallbladder cancer.[215] The best possibility of cure is when the cancer is found incidentally by the pathologist on gross or microscopic examination.[217,218] Most such cases are stage I or II disease. Positive margin status, lymph node metastases, and moderate to poor tumor grade have unsurprisingly also been associated with a poorer prognosis.[219] A number of molecular targets have been evaluated as potential prognostic and therapeutic markers in gallbladder adenocarcinoma, but none are currently widely accepted for clinical use.[220]

Tumors of the Extrahepatic Bile Ducts

Benign Tumors of the Extrahepatic Bile Ducts

Benign tumors of the extrahepatic bile ducts are exceptional. *Granular cell tumors* may occur anywhere along the intrahepatic and extrahepatic biliary system (Fig. 21.44).[221,222] As in other sites, they may be associated with pseudoepitheliomatous changes of the overlying epithelium. *Traumatic neuromas* occur most often after operations in the area[223]; their most common site is the stump of the cystic duct following a cholecystectomy. They may cause post-cholecystectomy pain or obstructive jaundice. There are also isolated reported cases of *neurofibroma* and *PEComa* involving the common bile duct.[224,225]

Tumoral Intraepithelial Neoplasms

Preinvasive mass-forming neoplasms of the biliary tract are referred to as tumoral intraepithelial neoplasms and include intraductal

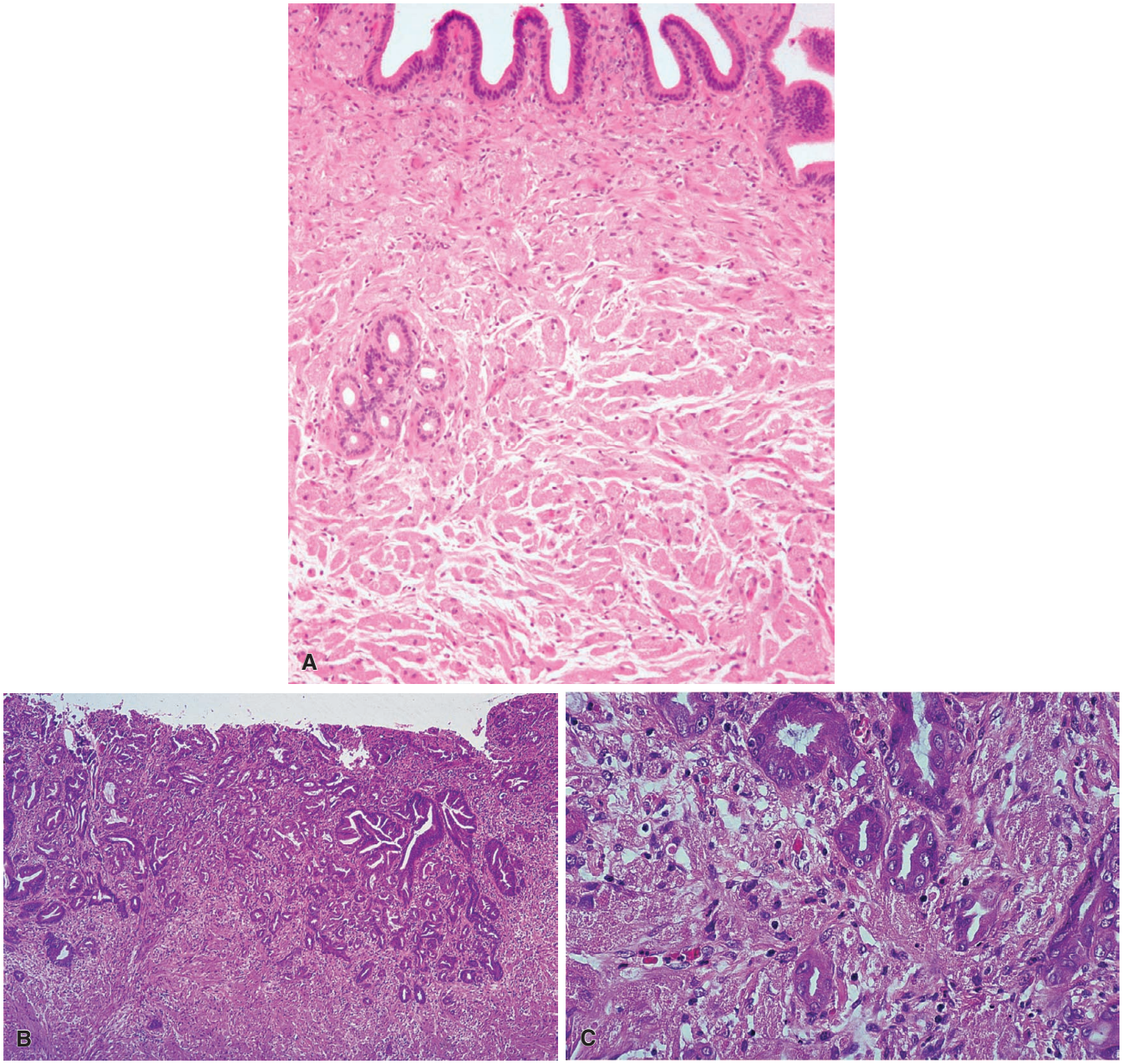

Figure 21.44 **A,** Granular cell tumor of the common bile duct from a young African-American woman. **B** and **C,** Some cases of granular cell tumor in the biliary tree are associated with hyperplasia of the overlying epithelium, similar to other organs. (**B** and **C,** Courtesy of Dr. Richard Eisen.)

papillary, tubular, and tubulopapillary neoplasms of the bile ducts as well as mucinous cystic neoplasms with ovarian-type stroma.[226–229] All of these neoplasms may show a spectrum of dysplasia ranging from low-grade to high-grade dysplasia/carcinoma in situ. The term intraductal papillary neoplasm of the bile duct (IPNB) encompasses those tumors previously designated papillary adenoma, papilloma, noninvasive papillary adenocarcinoma, and papillomatosis. The cell types are similar to homonymous lesions in the gallbladder (see earlier). High-grade dysplasia is common, and invasive components are often seen associated with these neoplasms (Fig. 21.45A–D). Tubular or tubulopapillary intraductal lesions are more commonly intrahepatic. The cystadenomas of the extrahepatic bile ducts resemble their more common hepatic, and pancreatic, counterparts.

Nontumoral (Flat) Dysplasia

These lesions are pre-invasive but also microscopic and flat, which distinguishes them from tumoral intraepithelial neoplasia. This spectrum of lesions is also known as biliary intraepithelial neoplasia, which is classified according to a three-tiered grading system.[144] Many pathologists continue to use a two-tiered grading system (low grade vs. high grade/carcinoma in situ), however. These lesions are typically incidental findings that are hard to detect grossly. As with their

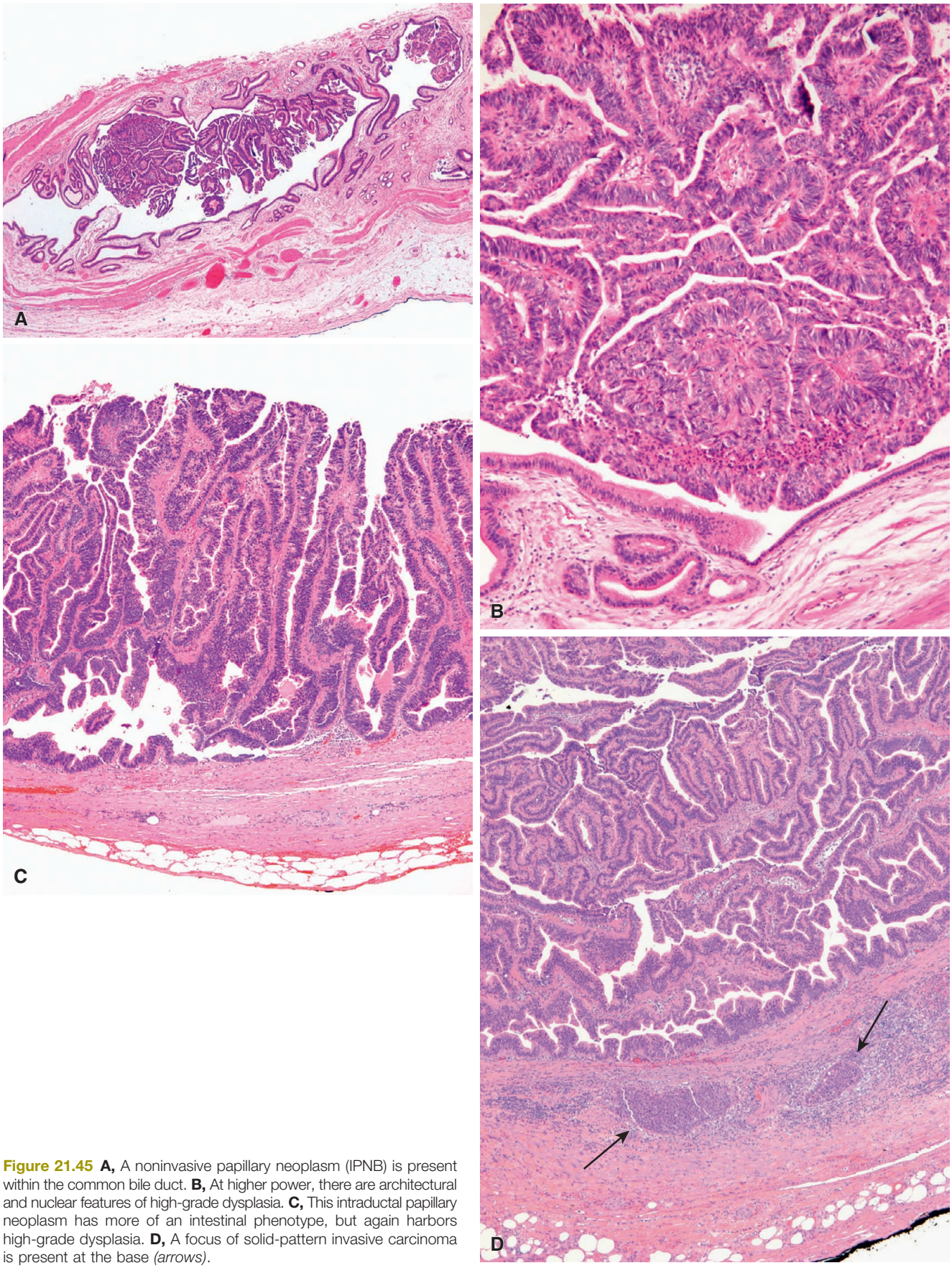

Figure 21.45 **A,** A noninvasive papillary neoplasm (IPNB) is present within the common bile duct. **B,** At higher power, there are architectural and nuclear features of high-grade dysplasia. **C,** This intraductal papillary neoplasm has more of an intestinal phenotype, but again harbors high-grade dysplasia. **D,** A focus of solid-pattern invasive carcinoma is present at the base *(arrows)*.

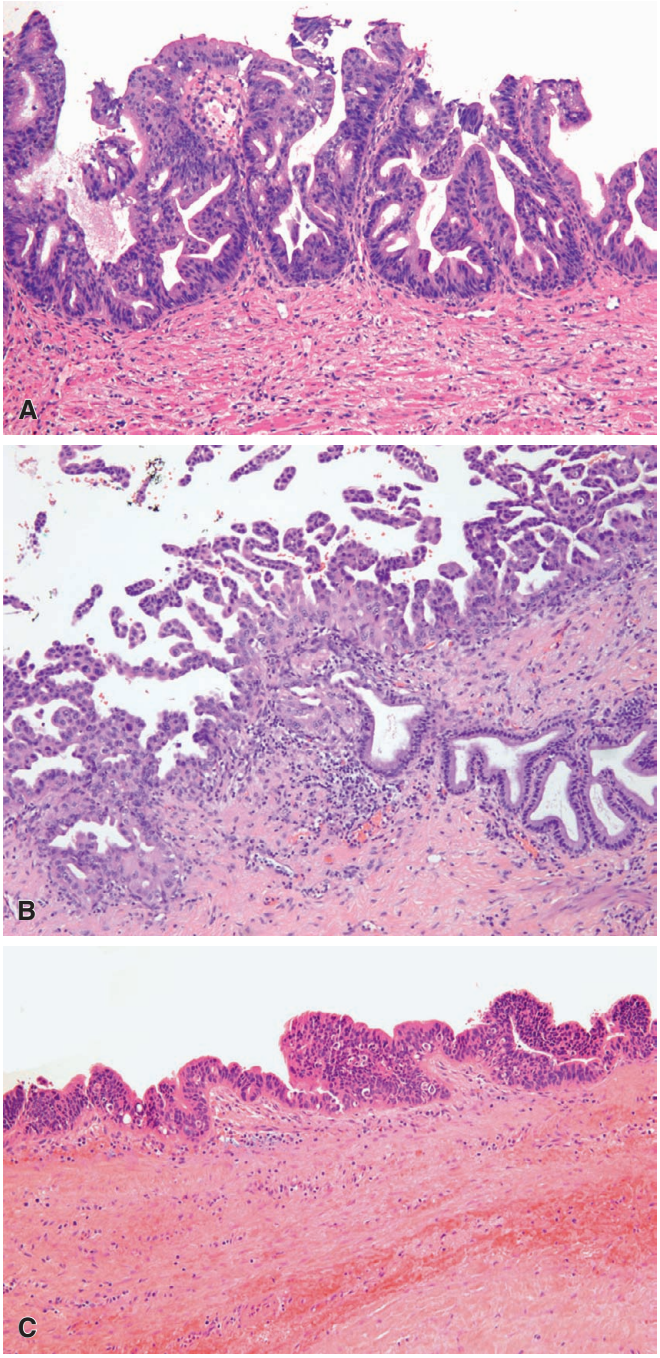

Figure 21.46 High-Grade Nontumoral Dysplasia. A, Although there are some small papillae, this lesion was found incidentally and did not form a mass. **B,** Another example shows fusion of the delicate epithelial projections, as well as oncocytic features. **C,** This example is virtually flat but shows enlarged, hyperchromatic nuclei with pseudostratification.

counterparts in the gallbladder, a number of cell types may be present (Fig. 21.46A–C). As these lesions are often found associated with invasive adenocarcinoma following resection, the natural history and risk implications are difficult to study. In many centers, high-grade dysplasia at a resection margin is cause for more extensive resection (if possible), whereas low-grade dysplasia at a margin is not. However, management of dysplasia at resection margins remains controversial.[230,231]

Adenocarcinoma of the Extrahepatic Bile Ducts

Bile duct carcinoma (cholangiocarcinoma) occurs with equal frequency in males and females[232] (in contrast with the female predominance for gallbladder carcinoma); the average age of presentation is 60 years. About 90% of patients present with jaundice. An increased incidence of this disease has been reported in patients with PSC,[233] *C. sinensis* infestation (see also earlier),[127,128] and in a variety of congenital abnormalities of the intrahepatic and extrahepatic bile ducts, such as congenital dilation of the bile duct (including choledochal cyst), Caroli disease, congenital hepatic fibrosis, and abnormal pancreaticocholedochal junction.[234–236]

These tumors can develop at any level of the biliary tree. They have been divided anatomically into those of the upper third, including the hilum (50%–75%); those of the middle third (upper half of the common bile duct, 10%–25%); and those of the lower third (distal half of the common bile duct, 10%–20%).[237,238] Brush cytology has a sensitivity of 45% and a specificity of 99% in the diagnosis of cholangiocarcinoma; intraductal biopsy has a similar sensitivity and specificity.[239] The use of fluorescence in situ hybridization may improve the sensitivity significantly.[240] Tumors arising from the intrahepatic bile ducts are discussed in this chapter and those located in the ampulla of Vater in Chapter 22.

Grossly, bile duct carcinomas can be polypoid and superficial, but most are nodular or sclerosing, with deep penetration into the wall (Fig. 21.47A).[241,242] Tumors previously classified as "papillary" carcinomas of the extrahepatic bile ducts predominantly represent intraductal tubular or papillary neoplasms (see earlier), or invasive adenocarcinomas associated with a prominent intraepithelial component. Occasionally, bile duct carcinomas are multicentric, accompanied by an extensive intraepithelial component,[243] or associated with carcinoma of the gallbladder.[242] Direct extension to the liver is common in upper third lesions (see Fig. 21.47B),[241,244] and distal lesions may involve the pancreas. Metastases to regional and peripancreatic nodes are also frequent; the lymph node groups most commonly affected are those around the lower portion of the hepatoduodenal ligament, the superoposterior pancreaticoduodenal group, and the superior mesenteric artery group.[245] Distant metastases to the ovary may develop and simulate primary tumors of this organ.[246]

Microscopically, the large majority of bile duct malignancies are well-differentiated pancreatobiliary-type adenocarcinomas similar to their counterparts in the gallbladder and pancreas (Fig. 21.48A). Bile duct carcinomas can be so well differentiated—even in metastatic sites—as to make their identification as malignant very difficult. Heterogeneity of cells within the same gland, increased nucleocytoplasmic ratio, nucleolar prominence, stromal and perineural invasion, and concentric layering of cellular stroma around the neoplastic glands are the most important identifying features (see Fig. 21.48B–E). As Weinbren and Mutum have emphasized,[247] the juxtaposition of normal-appearing cells and cells having large nuclei with prominent nucleoli is a particularly important diagnostic clue. Clusters of small acini, normally present in the wall of the bile duct and known as *periluminal sacculi of Beale*, should not be misinterpreted as invasive carcinoma.

In addition to these morphologic features, bile duct carcinoma resembles gallbladder carcinoma in its expression of mucosubstances and CEA,[248] frequent evidence of intestinal differentiation (as evidenced by the expression of CDX2 and MUC2),[249] common detection of metaplastic and dysplastic changes in the adjacent epithelium (biliary intraepithelial neoplasia),[144,250,251] and the occasional occurrence of variants with squamous metaplasia,[252] clear cell changes,[166] or signet ring cell features.[253] A type of extremely well differentiated adenocarcinoma featuring gastric foveolar-type epithelium and

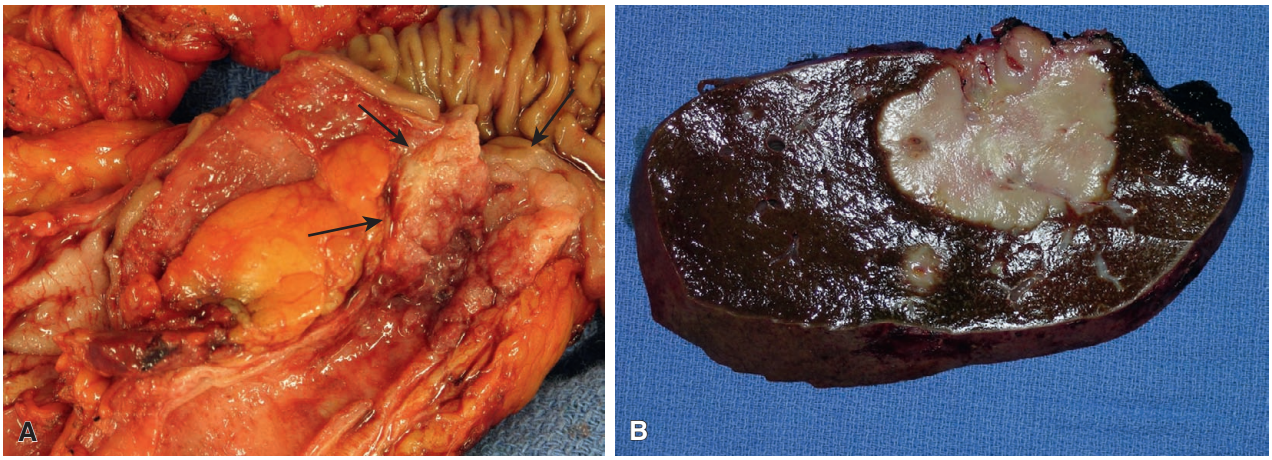

Figure 21.47 **A,** This Whipple resection shows a longitudinally opened common bile duct that contains a nodular tumor extending deeply into the wall *(arrows)*. **B,** Hilar cholangiocarcinoma with intraductal spread.

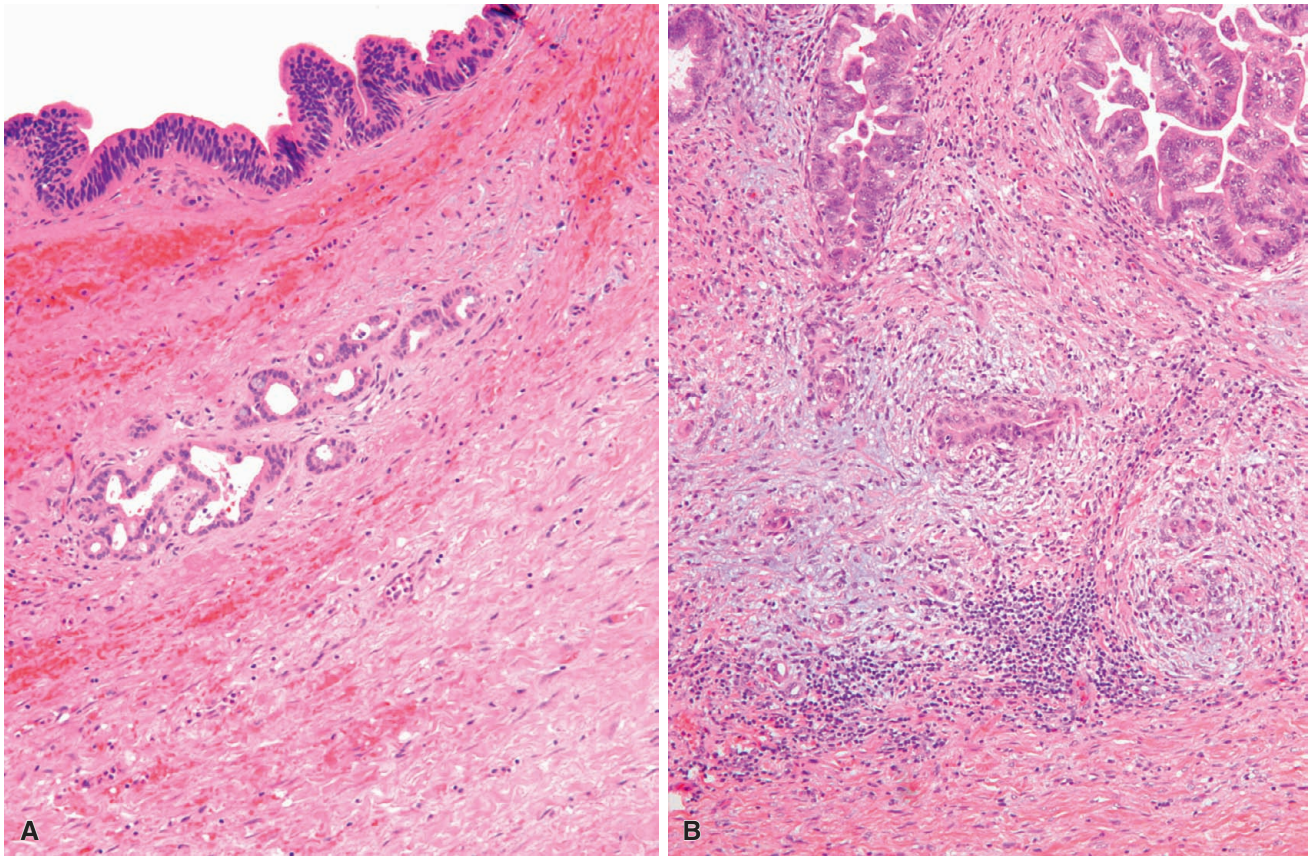

Figure 21.48 **A,** A focus of well-differentiated adenocarcinoma beneath flat dysplasia in the common bile duct. **B,** In this case, the infiltrative neoplastic glands are well differentiated, but the concentric layering of desmoplastic stroma around them is a clue to the diagnosis.

Continued

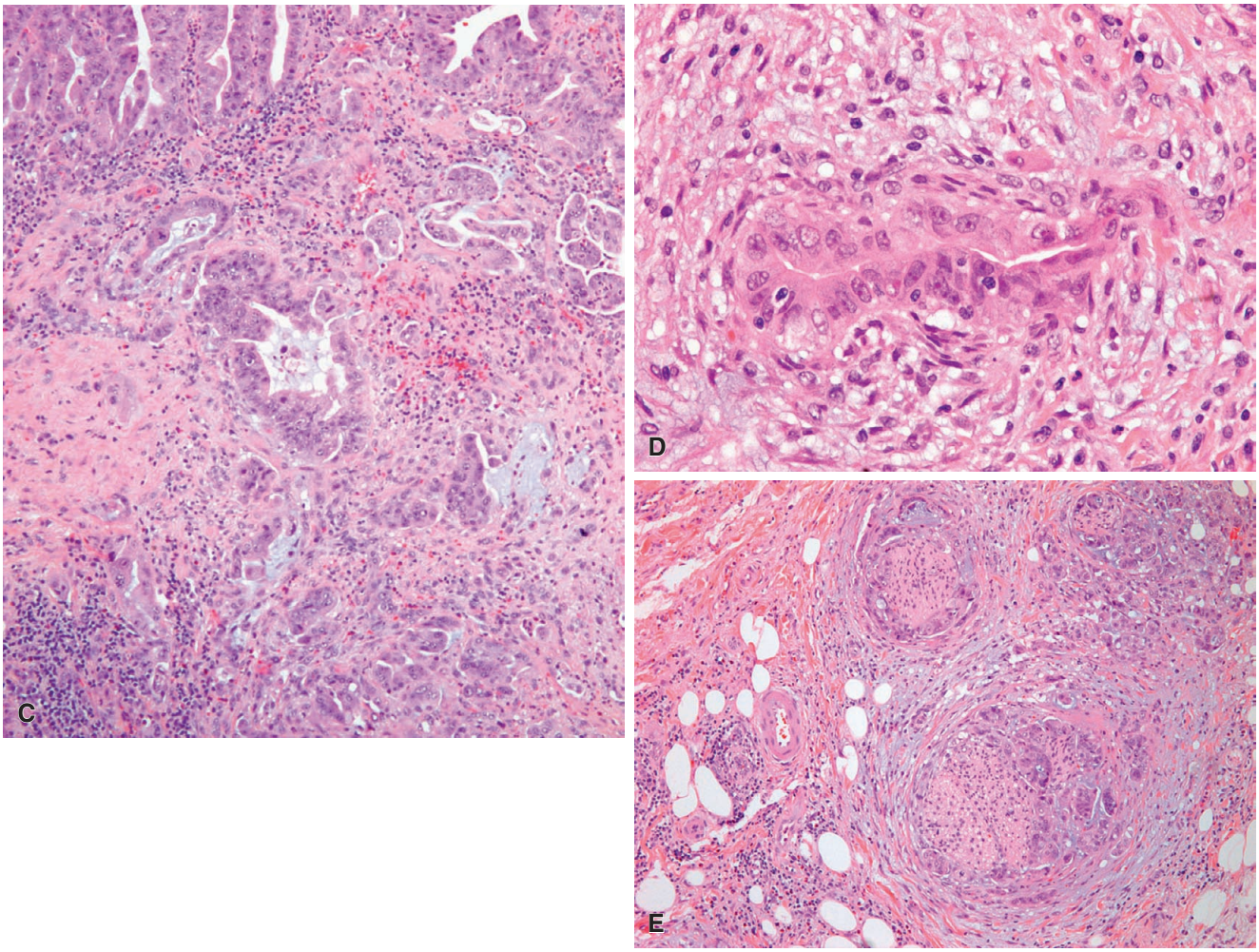

Figure 21.48, cont'd **C,** This more poorly differentiated example of adenocarcinoma of the extrahepatic bile duct has overlying dysplasia and associated lymphovascular invasion. **D,** Heterogeneity of cells within the same gland, increased nucleocytoplasmic ratio, nucleolar prominence, and loss of nuclear polarity are cytologic clues to the diagnosis of malignancy within this relatively well-formed gland. **E,** Perineural and intraneural invasion are frequent findings in adenocarcinomas of the bile ducts.

simulating adenoma has also been described.[254] NEC rarely occur in the extrahepatic biliary tract, as they do in the gallbladder.[255,256]

Tumors occurring at the hepatic duct junction have historically been termed *sclerosing carcinoma*, *Altemeier–Klatskin tumor*, or *Klatskin tumor*.[257,258] These lesions may spread to long segments of the biliary tree, and typically have a well-differentiated microscopic appearance associated with extensive fibrosis. The main differential diagnosis, both radiographically and pathologically, is with PSC.[259]

Molecular Features

Immunohistochemical features of extrahepatic bile duct carcinomas are similar to their gallbladder counterparts. p53 overexpression has been associated with adverse clinical features and poor prognosis, although studies have been conflicting.[260] Other studies have also found an interesting difference in the immunohistochemical overexpression of p53 in bile duct carcinomas but not in PSC.[261] Expression of p53, loss of expression of *DPC4* (a tumor-suppressor gene implicated in the genesis of pancreatic carcinoma), and *KRAS* mutations are significantly higher in distal than in proximal bile duct carcinoma.[262,263]

Treatment and Prognosis

Surgical resection offers the only possibility of cure for bile duct carcinoma; liver transplant may be considered in selected patients.[264] Proximal lesions are treated with resection (which may include hepatic lobectomy) and Roux-en-Y hepaticojejunostomy; distal lesions are treated by the Whipple procedure.[265] In advanced cases, often only palliative treatment is warranted in the form of biliary drainage, chemotherapy, and/or radiation therapy.[264] Although studies have shown conflicting data, some recent studies show a modest improvement in survival with a combined modality approach consisting of surgery, radiation therapy, and chemotherapy.[264,266]

For staging purposes, tumors of the bile ducts are divided into five groups: intrahepatic, perihilar, cystic duct, distal, and intraampullary common bile duct. Several authors have proposed modifications to the current AJCC/UICC TNM staging protocols to make them more reproducible and clinically relevant.[267,268] The overall 5-year survival rate is 11%,[267] although patients with completely resectable disease may have a better prognosis. Proximal carcinomas have a worse prognosis than distal ones, presumably due to the

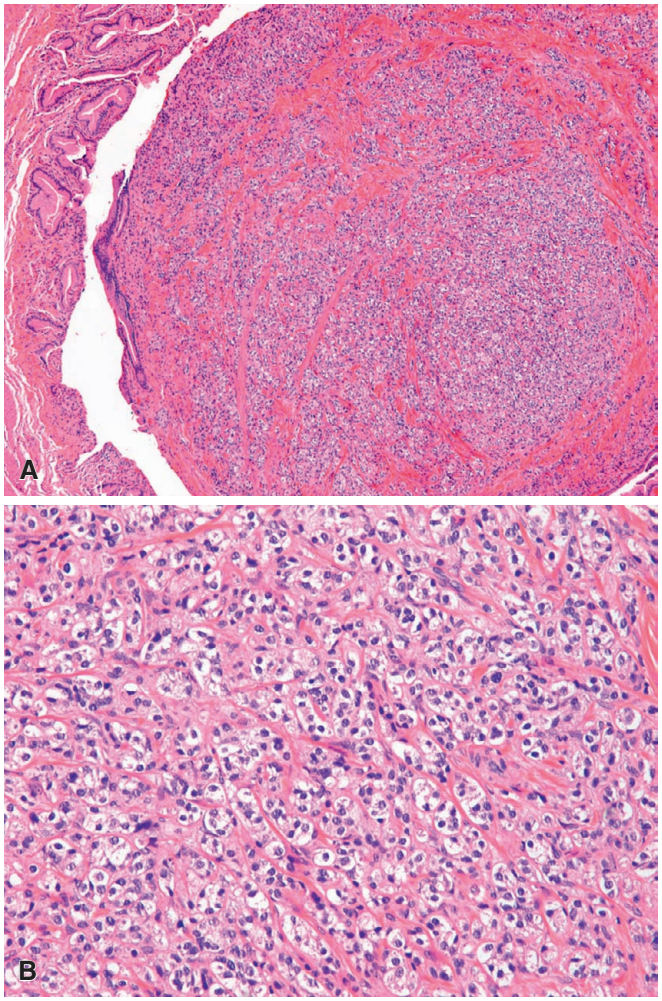

Figure 21.49 **A** and **B,** Clear cell well-differentiated neuroendocrine tumor (carcinoid) of the cystic duct.

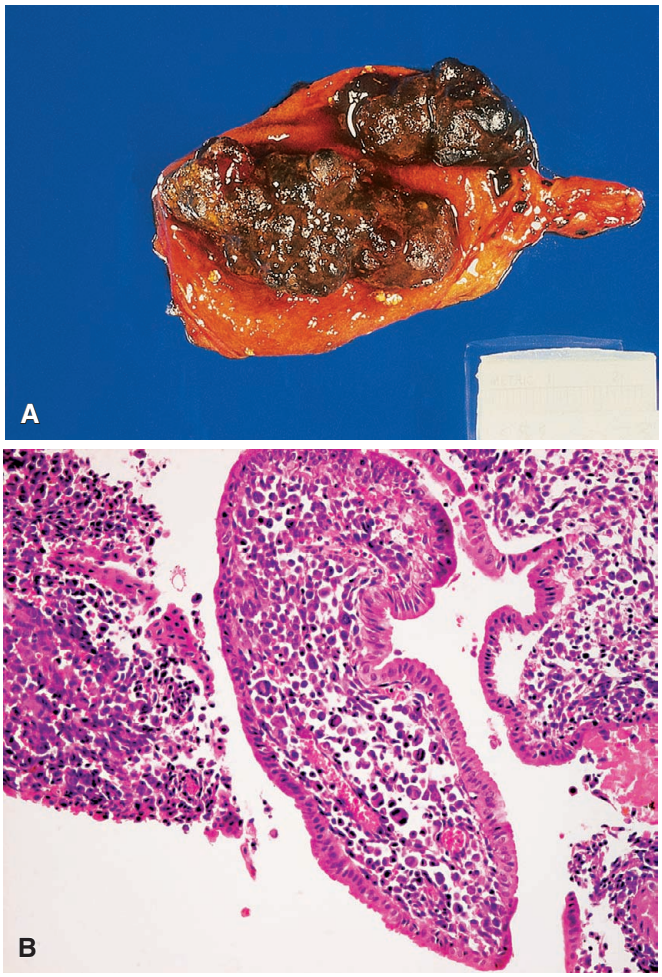

Figure 21.50 **Malignant Melanoma Metastatic to the Gallbladder.** **A,** The tumor nodules are heavily pigmented. **B,** Microscopic appearance of malignant melanoma metastatic to gallbladder mucosa.

feasibility of resection of distal tumors via Whipple.[265] In addition to location, stage of disease (particularly the presence and number of lymph node metastases), depth of invasion, and histologic grade are important prognostic indicators.[268–272]

Well-differentiated neuroendocrine tumors (carcinoid tumors) can occur in the extrahepatic bile ducts as well as the gallbladder (see earlier)[273–276] and can present with biliary obstruction. A *signet ring cell* variety has also been seen,[277] as well as a *clear cell variant* (Fig. 21.49A and B), sometimes in the setting of von Hippel–Lindau disease.[278,188]

Miscellaneous Tumors of the Gallbladder and Extrahepatic Bile Ducts

Primary malignant melanoma may present as a mass inside the gallbladder[279,280] or the extrahepatic bile ducts.[281–283] Some cases have occurred in the setting of the dysplastic nevus syndrome.[284] Most tumors have already metastasized by the time of diagnosis. Before making the diagnosis of primary melanoma of the gallbladder or biliary tree, the more likely possibility of a metastasis from a cutaneous or ocular source must be ruled out (Fig. 21.50A and B).

Malignant lymphoma and **leukemia** can involve the gallbladder or extrahepatic bile ducts as part of a systemic disease; their initial presentation in these sites is exceptional but has been recorded (Fig. 21.51).[285–287] As in other mucosa-lined organs, it has been postulated that some gallbladder lymphomas are of mucosa-associated lymphoid tissue (MALT) types, and cases have been reported to show the *API2–MALT1* gene fusion characteristic of this lymphoma type.[288–290]

The **botryoid variant of embryonal rhabdomyosarcoma** is the most common malignant tumor of extrahepatic bile ducts in children and is rarely described in adults.[291–294] It can also involve the gallbladder, and a few cases have been described in adults. Obstructive jaundice is the usual presenting sign. Grossly, it has a deceptively soft polypoid appearance. Microscopically, small, undifferentiated spindle cells concentrate beneath an intact epithelium ("cambium layer"). Cross striations may or may not be present (Fig. 21.52A and B). The combination of surgery, radiation therapy, and chemotherapy has resulted in many long-term survivals.

Other mesenchymal neoplasms of the gallbladder typically occur in adults and are usually malignant, such as *myxofibrosarcoma*,[295] *leiomyosarcoma*,[295] *angiosarcoma*[295,296] (including the epithelioid variety), and *gastrointestinal stromal tumor*.[295,297,298] Before a diagnosis of sarcoma is made in a spindle-cell lesion, however, the alternative possibility of sarcomatoid carcinoma should always be considered. *Kaposi sarcoma* of gallbladder has been seen in the setting of HIV infection.[299] Benign, mesenchymal tumors (other than granular cell tumors) rarely occur

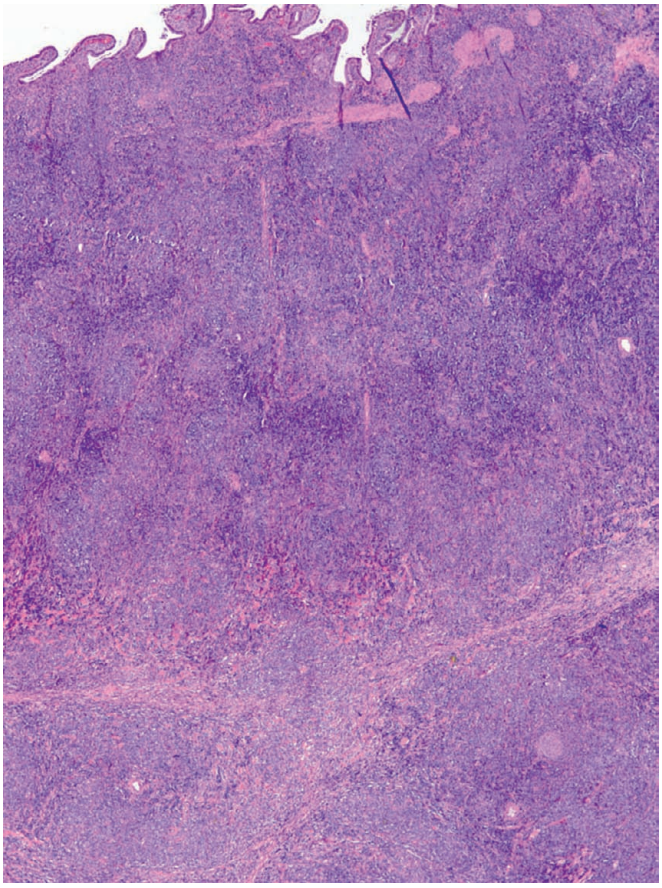

Figure 21.51 Diffuse large B cell lymphoma of the gallbladder, involving the entire thickness of the wall.

in the gallbladder and biliary tree. *Paragangliomas* arising from small paraganglia are known to occur in the gallbladder serosa and rarely in the extrahepatic bile ducts.[300–302] *Solitary fibrous tumors* have been rarely reported (Fig. 21.53A and B).[303]

Metastatic tumors to the gallbladder (Fig. 21.54) are exceptionally rare; most of the reported cases are malignant melanomas (see earlier). Metastases from renal cell carcinoma,[304,305] breast carcinoma,[306] and gastric carcinoma[307] have been reported. We have seen a single case of endometrial adenocarcinoma metastatic to gallbladder as well. Intrabiliary growth of colonic adenocarcinoma mimicking primary neoplasia at this site has also been observed.[308]

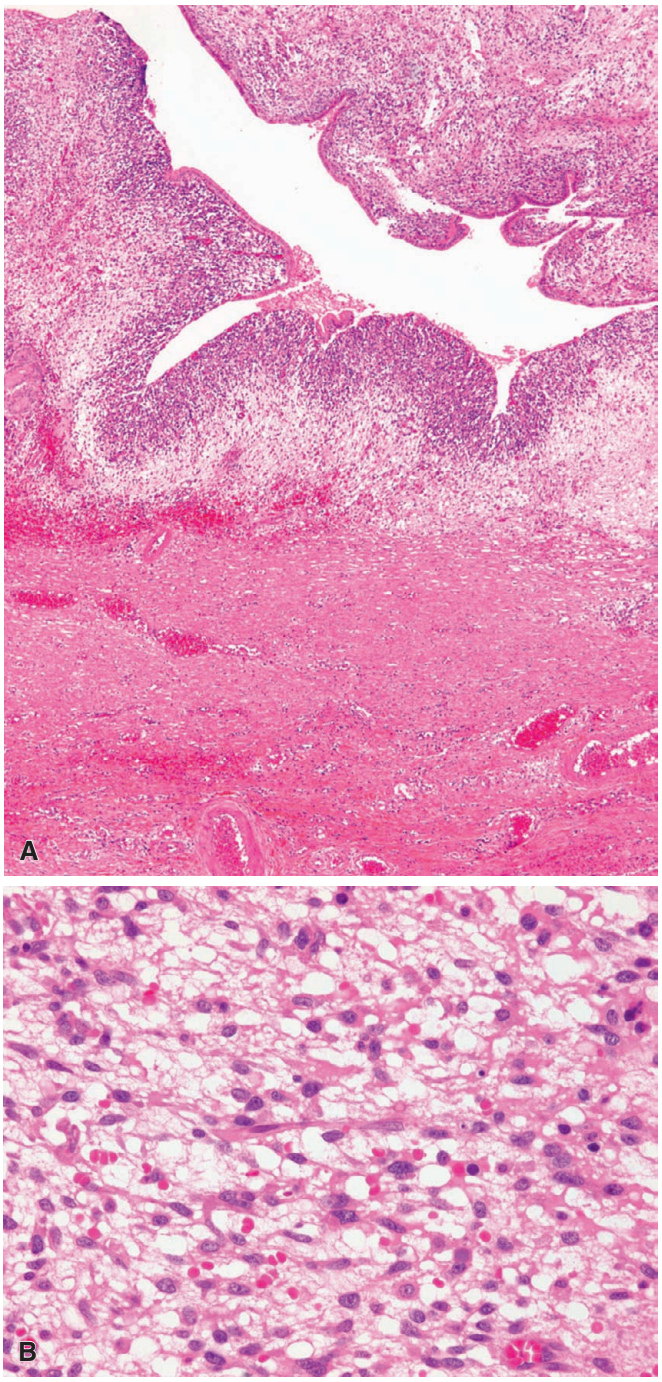

Figure 21.52 Embryonal Rhabdomyosarcoma of Botryoid Subtype. **A,** There is a prominent cambium layer beneath the biliary epithelium. **B,** High-power view of undifferentiated spindle cells.

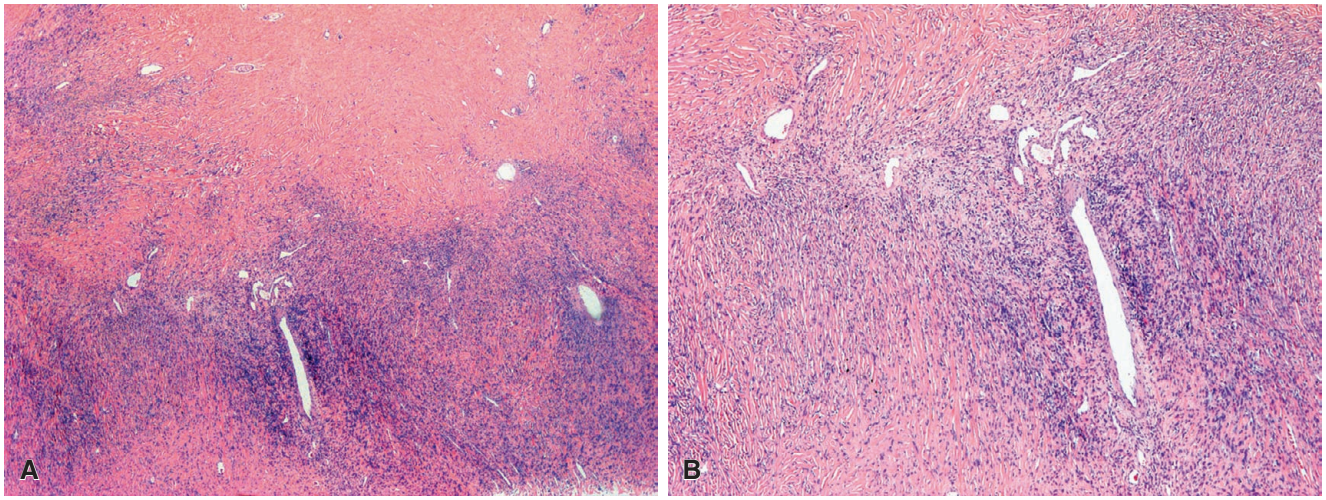

Figure 21.53 **A** and **B,** Solitary fibrous tumor of the gallbladder.

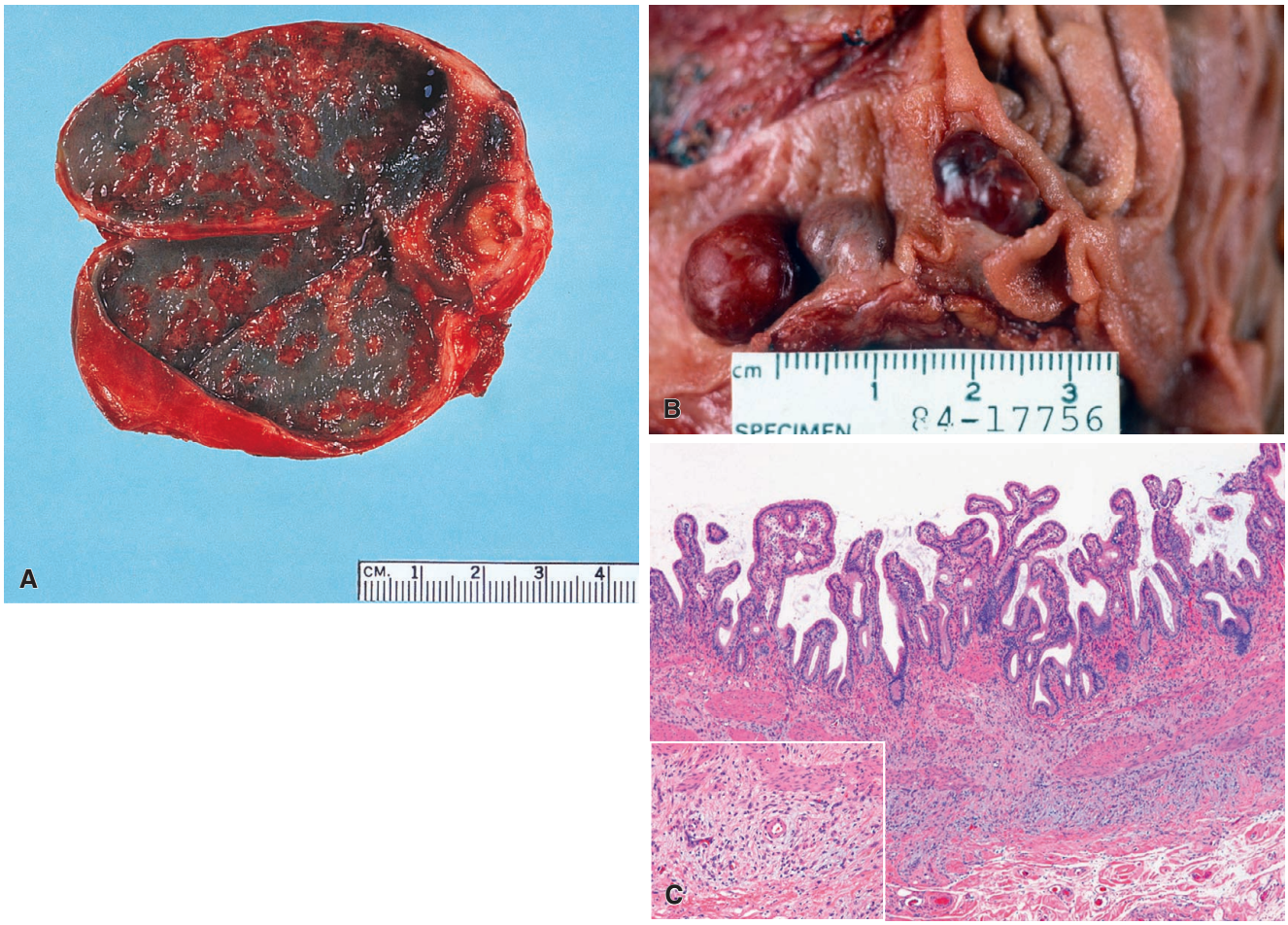

Figure 21.54 **A,** Gallbladder with metastatic breast carcinoma presenting in the form of multiple nodules protruding through the mucosa and associated with inflammatory changes. **B,** Metastatic renal cell carcinoma appears as multiple polypoid red nodules in the common bile duct. **C,** Metastatic lobular breast carcinoma is difficult to appreciate except for the prominent surrounding reactive stroma (low power; inset, high power).

Continued

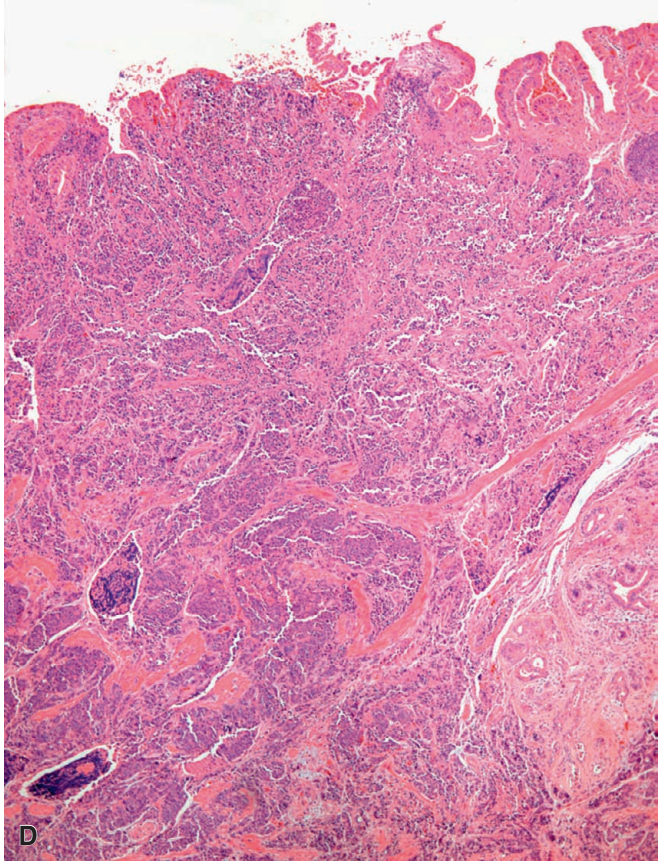

Figure 21.54, cont'd **D,** Metastatic endometrial cancer mimics a high-grade carcinoma of the gallbladder. (**B,** Courtesy of Dr. George F. Gray Jr.)

References

1. Lamps LW. Gallbladder. In: Lamps LW, ed. *Diagnostic Pathology—Normal Histology*. Park City, Utah: Amirsys; 2013:10-13.
2. Stelow EB, Hong SM, Frierson HF. Gallbladder and extrahepatic biliary system. In: Mills SE, ed. *Histology for Pathologists*. 3rd ed. Philadelphia, PA: Lippincott Williams & Wilkins; 2007:705-722.
3. Fine G, Raju UB. Paraganglia in the human gallbladder. *Arch Pathol Lab Med*. 1980;104(5):265-268.
4. Singhi AD, Adsay NV, Swierczynski SL, et al. Hyperplastic Luschka ducts: a mimic of adenocarcinoma in the gallbladder fossa. *Am J Surg Pathol*. 2011;35:883-890.
5. Schnelldorfer T, Sarr MG, Adams DB. What is the duct of Luschka? A systematic review. *J Gastrointest Surg*. 2012;16(3):656-662.
6. Lamah M, Karanjia ND, Dickson GH. Anatomical variations of the extrahepatic biliary tree: review of the world literature. *Clin Anat*. 2001;14(3):167-172.
7. Hong SM, Kang GH, Lee HY, Ro JY. Smooth muscle distribution in the extrahepatic bile duct: histologic and immunohistochemical studies of 122 cases. *Am J Surg Pathol*. 2000;24(5):660-667.
8. Causey MW, Miller S, Fernelius CA, et al. Gallbladder duplication: evaluation, treatment, and classification. *J Pediatr Surg*. 2010;45:443-446.
9. Chowbey PK, Dey A, Khullar R, et al. Agenesis of gallbladder—our experience and a review of the literature. *Indian J Surg*. 2009;71:188-192.
10. Bennion RS, Thompson JE, Tompkins RK. Agenesis of the gallbladder without extrahepatic biliary atresia. *Arch Surg*. 1988;123:1257-1260.
11. Coughlin JP, Rector FE, Klein MD. Agenesis of the gallbladder in duodenal atresia: two case reports. *J Pediatr Surg*. 1992;27(10):1304.
12. Weedon D. Congenital anomalies. In: Weedon D, ed. *Pathology of the Gallbladder*. New York, NY: Masson Publishing; 1984:6-22.
13. Ober WB, Wharton RN. On the Phrygian cap. *N Engl J Med*. 1956;255(12):571-572.
14. Van Kamp MJ, Bouman DE, Steenvoorde P, Klasse JM. A phrygian cap. *Case Rep Gastroenterol*. 2013;17:347-351.
15. Madrid C, Berrocal T, Gorospe L, et al. Heterotopic gastric mucosa involving the gallbladder and biliary tree. *Pediatr Radiol*. 2003;33:129-132.
16. Beltran MA, Barria C. Heterotopic pancreas in the gallbladder: the importance of an uncommon condition. *Pancreas*. 2007;34:488-491.
17. Rajguru J, Jain S, Khare S, et al. Embryological basis and clinical correlation of the rare congenital anomaly of the human gallbladder: "the diverticulum"-a morphologic study. *J Clin Diagn Res*. 2013;7:2107-2110.
18. Narkewicz MR. Biliary atresia: an update on our understanding of the disorder. *Curr Opin Pediatr*. 2001;13(5):435-440.
19. Goldman M, Pranikoff T. Biliary diseases in children. *Curr Gastroenterol Rep*. 2011;13:193-201.
20. Schwarz KB, Haber BH, Rosenthal P, et al. Extrahepatic anomalies in infants with biliary atresia: results of a large prospective North American multicenter study. *Hepatology*. 2013;58:1724-1731.
21. Roy P, Chatterjee U, Ganguli M, et al. A histopathological study of liver and biliary remnants with clinical outcome in cases of extrahepatic biliary atresia. *Indian J Pathol Microbiol*. 2010;53:101-105.
22. Ho CW, Shioda K, Shirasaki K, et al. The pathogenesis of biliary atresia: a morphological study of the hepatobiliary system and the hepatic artery. *J Pediatr Gastroenterol Nutr*. 1993;16(1):53-60.
23. Moreira RK, Cabral R, Cowles RA, Lobritto SJ. Biliary atresia: a multidisciplinary approach to diagnosis and management. *Arch Pathol Lab Med*. 2012;136:746-760.
24. Gallo A, Esquivel CO. Current options for management of biliary atresia. *Pediatr Transplant*. 2013;17:95-98.
25. Soares KC, Kim Y, Spolverato G, et al. Presentation and clinical outcomes of choledochal cysts in children and adults: a multi-institutional analysis. *JAMA Surg*. 2015;150:577-584.
26. Olbourne NA. Choledochal cysts. A review of the cystic anomalies of the biliary tree. *Ann R Coll Surg Engl*. 1975;56(1):26-32.
27. Todani T, Watanabe Y, Toki A, Morotomi Y. Classification of congenital biliary cystic disease: special reference to type Ic and IVA

cysts with primary ductal stricture. *J Hepatobiliary Pancreat Surg*. 2003;10(5):340-344.
28. Komi N, Tamura T, Tsuge S, et al. Relation of patient age to premalignant alterations in choledochal cyst epithelium: histochemical and immunohistochemical studies. *J Pediatr Surg*. 1986;21(5):430-433.
29. Ueyama T, Ding J, Hashimoto H, et al. Carcinoid tumor arising in the wall of a congenital bile duct cyst. *Arch Pathol Lab Med*. 1992;116(3):291-293.
30. Patil KK, Omojola MF, Khurana P, Iyengar JK. Embryonal rhabdomyosarcoma within a choledochal cyst. *Can Assoc Radiol J*. 1992;43(2):145-148.
31. Sandri L, Colecchia A, Larocca A, et al. Gallbladder cholesterol polyps and cholesterolosis. *Minerva Gastroenterol Dietol*. 2003;49:217-224.
32. Jacyna MR, Rouchier IA. Cholesterolosis: a physical cause of "functional" disorder. *Br Med J (Clin Res Ed)*. 1987;295(6599):619-620.
33. Grunhage F, Lammert F. Gallstone disease. Pathogenesis of gallstones: a genetic perspective. *Best Pract Res Clin Gastroenterol*. 2006;20:997-1015.
34. Johnston DE, Kaplan MM. Pathogenesis and treatment of gallstones. *N Engl J Med*. 1993;328(6):412-421.
35. St-Vil D, Yazbeck S, Luks FI, et al. Cholelithiasis in newborns and infants. *J Pediatr Surg*. 1992;27(10):1305-1307.
36. Strasberg SM. Acute calculous cholecystitis. *N Engl J Med*. 2008;358:2804-2811.
37. Weedon D. Cholelithiasis. In: Weedon D, ed. *Pathology of the Gallbladder*. New York, NY: Masson Publishing; 1984:147-160.
38. Weerakoon HT, Ranasinghe S, Navaratne A, et al. Serum lipid concentrations in patients with cholesterol and pigment gallstones. *BMC Res Notes*. 2014;7:548.
39. Mok HY, Druffel ER, Rampone WM. Chronology of cholelithiasis. Dating gallstones from atmospheric radiocarbon produced by nuclear bomb explosions. *N Engl J Med*. 1986;314(17):1075-1077.
40. Vitek L, Carey MC. New pathophysiological concepts underling pathogenesis of pigment gallstones. *Clin Res Hepatol Gastroenterol*. 2012;36:122-129.
41. Trotman BW. Pigment gallstone disease. *Gastroenterol Clin North Am*. 1991;20:111-126.
42. Vitek L, Carey MC. Enterohepatic cycling of bilirubin as a cause of "black" pigment gallstones in adult life. *Eur J Clin Invest*. 2003;33:799-810.
43. Qiao T, Ma RH, Luo XB, et al. The systematic classification of gallbladder stones. *PLoS ONE*. 2013;8:e74887.
44. Costi R, Gnocci A, Di Mario F, Sarli L. Diagnosis and management of choledocholithiasis in the golden age of imaging, endoscopy, and laparoscopy. *World J Gastroenterol*. 2014;20:13382-13401.
45. Kim DI, Kim MH, Lee SK, et al. Risk factors for recurrence of primary bile duct stones after endoscopic biliary sphincterotomy. *Gastrointest Endosc*. 2001;54:42-48.
46. Gambill EE, Hodgson JR, Priestley JT. Painless obstructive cholecystopathy. Hydrops or empyema of the gallbladder: clinical, roentgenologic, and surgical. Review of 10 cases. *Arch Intern Med*. 1962;110:442-448.
47. Weedon D. Cholecystitis and empyema. In: Weedon D, ed. *Pathology of the Gallbladder*. New York, NY: Masson Publishing; 1984:90-115.
48. Erben Y, Benavente-Chenhalls LA, Donohue JM, et al. Diagnosis and treatment of Mirizzi syndrome: 23 year Mayo Clinic experience. *J Am Coll Surg*. 2011;213:114-119.
49. Abou-Saif A, Al-Kawas FH. Complications of gallstone disease: Mirizzi syndrome, cholecystocholedochal fistula, and gallstone ileus. *Am J Gastroenterol*. 2002;97(2):249-254.
50. Gurusamy KS, Davidson BR. Surgical treatmenat of gallstones. *Gastroenterol Clin North Am*. 2010;39:229-244.
51. Lee W, Kwon J. Fate of lost gallstones during laparoscopic cholecystectomy. *Korean J Hepatobiliary Pancreat Surg*. 2013;17:66-69.
52. Vadlamudi G, Graebe R, Khoo M, Schinella R. Gallstones implanting in the ovary. A complication of laparoscopic cholecystectomy. *Arch Pathol Lab Med*. 1997;121(2):155-158.
53. de Groen PC, Gores GJ, LaRusso NF, et al. Biliary tract cancers. *N Engl J Med*. 1999;341(18):1368-1378.
54. Katabathina VS, Zafar AM, Suri R. Clinical presentation, imaging, and management of acute cholecystitis. *Tech Vasc Interv Radiol*. 2015;18:256-265.
55. Chitkara YK. Pathology of the gallbladder in common bile duct obstruction: the concept of ascending cholecystitis. *Hum Pathol*. 1993;24(3):279-283.
56. Bourikian S, Anand RJ, Aboutanos M, et al. Risk factors for acute gangrenous cholecystitis in emergency general surgery patients. *Am J Surg*. 2015;210:730-733.
57. Strasberg SM. Acute calculous cholecystitis. *N Engl J Med*. 2008;358:2804-2811.
58. Elwood DR. Cholecystitis. *Surg Clin N Am*. 2008;88(6):1241-1252, viii.
59. Polo M, Duclos A, Polazzi S, et al. Acute cholecystitis-optimal timing for early cholecystectomy: a French Nationwide Study. *J Gastrointest Surg*. 2015;19:2003-2010.
60. Halbert C, Pagkratis S, Yang J, et al. Beyond the learning curve: incidence of bile duct injuries following laparoscopic cholecystectomy normalize to open in the modern era. *Surg Endosc*. 2016;30:2239-2243.
61. Glenn F, Becker CG. Acute acalculous cholecystitis. An increasing entity. *Ann Surg*. 1982;195(2):131-136.
62. Barie PS, Eachempati SR. Acute acalculous cholecystitis. *Gastroenterol Clin North Am*. 2010;39:343-357.
63. Poddighe D, Tresoldi M, Licari A, Marseglia GL. Acalculous acute cholecystitis in previously healthy children: general overview and analysis of pediatric infectious causes. *Int J Hepatol*. 2015;2015:459608.
64. Adolph MD, Bass SN, Lee SK, et al. Cytomegaloviral acalculous cholecystitis in acquired immunodeficiency syndrome patients. *Am Surg*. 1993;59(10):679-684.
65. French AL, Beaudet LM, Benator DA, et al. Cholecystectomy in patients with AIDS: clinicopathologic correlations in 107 cases. *Clin Infect Dis*. 1995;21:852-858.
66. Marymont JV, Dakhil SR, Travers H, Housholder DF. Chemical cholecystitis associated with hepatic arterial chemotherapy delivered by a permanently implanted pump. *Hum Pathol*. 1985;16(10):986-990.
67. Laurila JJ, Ala-Kokko TI, Laurila PA, et al. Histopathology of acute acalculous cholecystitis in critically ill patients. *Histopathology*. 2005;47(5):485-492.
68. Abengowe CU, McManamon PJ. Acute emphysematous cholecystitis. *Can Med Assoc J*. 1974;111:1112-1114.
69. Diehl AK. Symptoms of gallstone disease. *Baillieres Clin Gastroenterol*. 1992;6:635-657.
70. Terada T. Histopathologic features and frequency of gallbladder lesions in consecutive 540 cholecystectomies. *Int J Clin Exp Pathol*. 2013;6:91-96.
71. Elfving G. Crypts and ducts in the gallbladder wall. *Acta Pathol Microbiol Scand Suppl*. 1960;49(suppl 135):1-45.
72. Dorantes-Heredia R, Chable-Montero F, Henson DE, Albores-Saavedra J. Rokitansky-Aschoff sinuses mimicking adenocarcinoma of the gallbladder: a study of 8 cases. *Am J Surg Pathol*. 2013;37:1269-1274.
73. Albores-Saavedra J, Galliani C, Chable-Montero F, et al. Mucin-containing Rokitansky-Aschoff sinuses with extracellular mucin deposits simulating mucinous carcinoma of the gallbladder. *Am J Surg Pathol*. 2009;33(11):1633-1638.
74. Albores-Saavedra J, Nadji M, Henson DE, et al. Intestinal metaplasia of the gallbladder: a morphologic and immunocytochemical study. *Hum Pathol*. 1986;17:614-620.
75. Fernandes JE, Franco MI, Suzuki RK, et al. Intestinal metaplasia in gallbladders: prevalence study. *Sao Paulo Med J*. 2008;126:220-222.
76. Tsutsumi Y, Nagura H, Osamura Y, et al. Histochemical studies of metaplastic lesions in the human gallbladder. *Arch Pathol Lab Med*. 1984;108(11):917-921.
77. Sakamoto H, Mutoh H, Ido K, et al. A close relationship between intestinal metaplasia and CDX2 expression in human gallbladders with cholelithiasis. *Hum Pathol*. 2007;38(1):66-71.
78. Albores-Saavedra J, Henson DE. Pyloric gland metaplasia with perineural invasion of the gallbladder: a lesion that can be confused with adenocarcinoma. *Cancer*. 1999;86(12):2625-2631.
79. Kozuka S, Hachisuka K. Incidence by age and sex of intestinal metaplasia in the gallbladder. *Hum Pathol*. 1984;15(8):779-784.
80. Nelson JJ, Kahn AG. A case of bone metaplasia of the gallbladder epithelium. *South Med J*. 2009;102:322-324.
81. Estrada RL, Brown NM, James CE. Chronic follicular cholecystitis. Radiological, pathological, and surgical aspects. *Br J Surg*. 1960;48:205-209.
82. Goodman ZD, Ishak KG. Xanthogranulomatous cholecystitis. *Am J Surg Pathol*. 1981;5(7):653-659.
83. Deng YL, Cheng NS, Zhang SJ, et al. Xanthogranulomatous cholecystitis mimicking gallbladder carcinoma: an analysis of 42 cases. *World J Gastroenterol*. 2015;21:12653-12659.
84. Patel S, Roa JC, Tapia O, et al. Hyalinizing cholecystitis and associated carcinomas: clinicopatholgoic analysis of a distinctive variant of cholecystitis with porcelain-like features and accompanying diagnostically challenging carcinomas. *Am J Surg Pathol*. 2011;35:1104-1113.
85. Dabbs DJ. Eosinophilic and lymphoeosinophilic cholecystitis. *Am J Surg Pathol*. 1993;17(5):497-501.
86. Abraham SC, Cruz-Correa M, Argani P, et al. Diffuse lymphoplasmacytic chronic cholecystitis is highly specific for extrahepatic biliary tract disease but does not distinguish between primary and secondary sclerosing cholangiopathy. *Am J Surg Pathol*. 2003;27(10):1313-1320.
87. Wang WL, Farris AB, Lauwers GY, Deshpande V. Autoimmune pancreatitis-related cholecystitis: a morphologically and immunologically distinctive form of lymphoplasmacytic sclerosing cholecystitis. *Histopathology*. 2009;54(7):829-836.
88. Jessurun J. Lymphocytic cholecystitis/cholangitis. *Am J Clin Pathol*. 2015;143:36-41.
89. Matz LR, Lawrence-Brown MM. Ischaemic cholecystitis and infarction of the gallbladder. *Aust N Z J Surg*. 1982;52:466-471.
90. Karaman B, Battal B, Oren NC, et al. Acute ischemic cholecystitis after transarterial chemoembolization with drug-eluting beads. *Clin Imaging*. 2012;36:861-864.
91. Hernandez-Rodriguez J, Tan CD, Rodriguez ER, Hoffman GS. Single organ gallbladder vasculitis: characterization and distinction from systemic vasculitis involving the gallbladder. An analysis of 61 patients. *Medicine (Baltimore)*. 2014;93:405-413.

92. Juliano J, Wilson KD, Gertner E. Vasculitis of the gallbladder: case report and spectrum of disease. *J Clin Rheumatol*. 2009;15:75-77.
93. De-Leon-Bojorge B, Zaltzman-Girsevich S, Ortega-Salgado A, et al. Thrombotic microangiopathy involving the gallbladder as an unusual manifestation of systemic lupus erythematosus and antiphospholipid syndrome: case report and review of the literature. *World J Gastroenterol*. 2006;12:7206-7209.
94. Burke AP, Sobin LH, Virmani R. Localized vasculitis of the gastrointestinal tract. *Am J Surg Pathol*. 1995;19:338-349.
95. Charpentier P, Prade M, Bognel C, et al. Malacoplakia of the gallbladder. *Hum Pathol*. 1983;14(9):827-828.
96. Di Tommaso L, Arizzi C, Roncalli M. Malacoplakia of the gallbladder. *Histopathology*. 2005;46(4):474-475.
97. Lin J, Shen B, Lee HJ, Goldblum JR. Histopathological characterization of cholecystectomy specimens in patients with inflammatory bowel disease. *J Crohns Colitis*. 2012;6:895-899.
98. Andoh A, Endo Y, Kushima R, et al. A case of Crohn's disease involving the gallbladder. *World J Gastroenterol*. 2006;12:977-978.
99. McClure J, Banerjee SS, Schofield PS. Crohn's disease of the gallbladder. *J Clin Pathol*. 1984;37(5):516-518.
100. Mert A, Avsar S, Ozaras R, et al. Gallbladder involvement in sarcoidosis. *J Clin Gastroenterol*. 2004;38:612-613.
101. Rhee DD, Wu ML. Pulse granulomas detected in gallbladder, fallopian tube, and skin. *Arch Pathol Lab Med*. 2006;130(12):1839-1842.
102. Maingot R. Post-operative strictures of the bile ducts. *Ann R Coll Surg Engl*. 1959;24:186-203.
103. Viste A, Horn A, Ovrebo K, et al. Bile duct injuries following laparoscopic cholecystectomy. *Scand J Surg*. 2015;104:233-237.
104. Hoang MP, Murakata LA, Padilla-Rodriguez AL, Albores-Saavedra J. Metaplastic lesions of the extrahepatic bile ducts: a morphologic and immunohistochemical study. *Mod Pathol*. 2001;14:1119-1125.
105. Cameron JL, Gayler BW, Sanfey H, et al. Sclerosing cholangitis. Anatomical distribution of obstructive lesions. *Ann Surg*. 1984;200(1):54-60.
106. Karlsen TH, Boberg KM. Update on primary sclerosing cholangitis. *J Hepatol*. 2013;59:571-582.
107. Wiesner RH, Ludwig J, LaRusso NF, MacCarty RL. Diagnosis and treatment of primary sclerosing cholangitis. *Semin Liver Dis*. 1985;5:241-253.
108. Lindor KD, Kowdley KV, Harrison ME, American College of Gastroenterology. ACG clinical guideline: primary sclerosing cholangitis. *Am J Gastroenterol*. 2015;110:646-659.
109. Lee YM, Kaplan MM. Primary sclerosing cholangitis. *N Engl J Med*. 1995;332(14):924-933.
110. Liaskou E, Hirschfield GM. Genetic distinctions in patients with primary sclerosing cholangitis: immunoglobulin G4 elevations and HLA risk. *Gastroenterology*. 2015;148:886-889.
111. Silveira MG, Lindor KD. Primary sclerosing cholangitis. *Can J Gastroenterol*. 2008;22:689-698.
112. Katabi N, Albores-Saavedra J. The extrahepatic bile duct lesions in end-stage primary sclerosing cholangitis. *Am J Surg Pathol*. 2003;27:349-355.
113. Fritcher EGB, Kipp BR, Halling KC, Clayton AC. Fishing for pancreatobiliary tract malignancy in endoscopic brushings enhances the sensitivity of routine cytology. *Cytopathology*. 2014;25:288-301.
114. Deshpande V. IgG4-related disease of the gastrointestinal tract: a 21st century chamelion. *Arch Pathol Lab Med*. 2015;139:742-749.
115. Zen Y, Harada K, Sasaki M, et al. IgG4-related sclerosing cholangitis with and without hepatic inflammatory pseudotumor, and sclerosing pancreatitis-associated sclerosing cholangitis: do they belong to a spectrum of sclerosing pancreatitis? *Am J Surg Pathol*. 2004;28(9):1193-1203.
116. Okazaki K, Uchida K, Koyabu M, et al. IgG4 cholangiopathy: current concept, diagnosis, and pathogenesis. *J Hepatol*. 2014;61:690-695.
117. Tsui WM, Lam PW, Lee WK, Chan YK. Primary hepatolithiasis, recurrent pyogenic cholangitis, and oriental cholangiohepatitis: a tale of 3 countries. *Adv Anat Pathol*. 2011;18:318-328.
118. Suzuki Y, Mori T, Yokoyama M, et al. Hepatolithiasis: analysis of Japanese nationwide surveys over a period of 40 years. *J Hepatobiliary Pancreat Sci*. 2014;21:617-622.
119. Jimenez-Saenz M, Villar-Rodriguez JL, Torres Y, et al. Biliary tract disease: a rare manifestation of eosinophilic gastroenteritis. *Dig Dis Sci*. 2003;48:624-627.
120. Chen WH, Yu CC, Wu CC, Jan YJ. Eosinophilic cholangitis with obstructive jaundice mimicking bile duct carcinoma. *J Hepatobiliary Pancreat Surg*. 2009;16:242-245.
121. Chen XM, LaRusso NF. Cryptosporidiosis and the pathogensis of AIDS-cholangiopathy. *Semin Liver Dis*. 2002;22:277-289.
122. Forbes A, Blanshard C, Gazzard B. Natural history of AIDS related sclerosing cholangitis: a study of 20 cases. *Gut*. 1993;34(1):116-121.
123. Cacciarelli AG, Naddaf SY, el Zeftawy HA, et al. Acute cholecystitis in AIDS patients: correlation of Tc-99m hepatobiliary scintigraphy with histopathologic laboratory findings and CD4 counts. *Clin Nucl Med*. 1998;23:226-228.
124. Bouche H, Housset C, Dumont JL, et al. AIDS-related cholangitis: diagnostic features and course in 15 patients. *J Hepatol*. 1993;17:34-39.
125. Walther Z, Topazian MD. Isospora cholangiopathy: case study with histologic characterization and molecular confirmation. *Hum Pathol*. 2009;40:1342-1346.
126. Lai KK, Miller KA, Procop GW, et al. Cystoisospora cholangiopathy in immunocompetent patients: a clinicopathologic review of 10 cases. *Mod Pathol*. 2014;27(suppl 2):391A.
127. Carpenter HA. Bacterial and parasitic cholangitis. *Mayo Clin Proc*. 1998;73: 473-478.
128. Sithithaworn P, Yongvanit P, Duenngai K, et al. Roles of liver fluke infection as risk factor for cholangiocarcinoma. *J Hepatobiliary Pancreat Sci*. 2014;21:301-308.
129. Brant PE, Kopke-Agular L, Shigueoka DC, et al. Anicteric cholangioipathy in schistosomiasis patients. *Acta Trop*. 2008;108:218-221.
130. Herrera Fernandez FA, Sarmiento Robles C, Blasco Carratala F, et al. Acute, non-lithiasic, amebic cholecystitis. *Rev Esp Enferm Dig*. 1990;78:41-42.
131. Baba H, Wakabayashi M, Oba A, et al. Primary papillary hyperplasia of the gallbladder mimicking gallbladder cancer. *Int Surg*. 2014;99:247-251.
132. Agarwal A, Shipman PJ. Gallbladder polyposis in metachromatic leukodystrophy. *Pediatr Radiol*. 2013;43:631-633.
133. Cappell MS, Marks M, Kirschenbaum H. Massive hemobilia and acalculous cholecystitis due to benign gallbladder polyp. *Dig Dis Sci*. 1993;38(6):1156-1161.
134. Revzin MV, Scoutt L, Smitaman E, Israel GM. The gallbladder: uncommon gallbladder conditions and unusual presentations of the common gallbladder pathological processes. *Abdom Imaging*. 2015;40:385-399.
135. Beilby JO. Diverticulosis of the gallbladder. The fundal adenoma. *Br J Exp Pathol*. 1967;48(4):455-461.
136. Albores-Saavedra J, Keenportz B, Bejarano PA, et al. Adenomyomatous hyperplasia of the gallbladder with perineural invasion: revisited. *Am J Surg Pathol*. 2007;31(10):1598-1604.
137. Adsay V, Jang KT, Roa JC, et al. Intracholecystic papillary-tubular neoplasms (ICPN) of the gallbladder (neoplastic polyps, adenomas, and papillary neoplasms that are >1.0 cm). *Am J Surg Pathol*. 2012;36:1279-1301.
138. Albores-Saavedra J, Chable-Montero F, Gonzalez-Romo MA, et al. Adenomas of the gallbladder. Morphologic features, expression of gastric and intestinal mucins, and incidence of high-grade dysplasia/carcinoma in situ and invasive carcinoma. *Hum Pathol*. 2012;43:1506-1513.
139. Chang HJ, Jee CD, Kim WH. Mutation and altered expression of beta-catenin during gallbladder carcinogenesis. *Am J Surg Pathol*. 2002;26(6):758-766.
140. Kim YT, Kim J, Jang YH, et al. Genetic alterations in gallbladder adenoma, dysplasia and carcinoma. *Cancer Lett*. 2001;169(1):59-68.
141. Albores-Saavedra J, Alcantra-Vazquez A, Cruz-Ortiz H, Herrera-Goepfert R. The precursor lesions of invasive gallbladder carcinoma. Hyperplasia, atypical hyperplasia and carcinoma in situ. *Cancer*. 1980;45(5):919-927.
142. Mukhopadhyay S, Landas SK. Putative precursors of gallbladder dysplasia: a review of 400 routinely resected specimens. *Arch Pathol Lab Med*. 2005;129(3):386-390.
143. Roa I, de Aretxabala X, Araya JC, Roa J. Preneoplastic lesions in gallbladder cancer. *J Surg Oncol*. 2006;93:615-623.
144. Zen Y, Adsay NV, Bardadin K, et al. Biliary intraepithelial neoplasia: an international interobserver agreement study and proposal for diagnostic criteria. *Mod Pathol*. 2007;20:701-709.
145. Roa JC, Tapia O, Manterola C, et al. Early gallbladder carcinoma has a favorable outcome but Rokitansky-Ashoff sinus involvement is an adverse prognostic factor. *Virchows Arch*. 2013;463:651-661.
146. Chang HJ, Kim SW, Kim YT, Kim WH. Loss of heterozygosity in dysplasia and carcinoma of the gallbladder. *Mod Pathol*. 1999;12(8):763-769.
147. Barreto SG, Dutt A, Chaudhary A. A genetic model for gallbladder carcinogenesis and its dissemination. *Ann Oncol*. 2014;25:1086-1097.
148. Donohue JH, Stewart AK, Menck HR. The National Cancer Data Base report on carcinoma of the gallbladder, 1989–1995. *Cancer*. 1998;83(12):2618-2628.
149. Hundal R, Shaffer EA. Gallbladder cancer: epidemiology and outcome. *Clin Epidemiol*. 2014;6:99-109.
150. Fraumeni JF Jr. Cancers of the pancreas and biliary tract: epidemiological considerations. *Cancer Res*. 1975;35(11 Pt 2):3437-3446.
151. Zatonski W, La Vecchia C, Levi F, et al. Descriptive epidemiology of gall-bladder cancer in Europe. *J Cancer Res Clin Oncol*. 1993;119(3):165-171.
152. Lazcano-Ponce EC, Miquel JF, Munoz N, et al. Epidemiology and molecular pathology of gallbladder cancer. *CA Cancer J Clin*. 2001;51(6):349-364.
153. Ootani T, Shirai Y, Tsukada K, Muto T. Relationship between gallbladder carcinoma and the segmental type of adenomyomatosis of the gallbladder. *Cancer*. 1992;69:2647-2652.
154. Komorowski RA, Tresp MG, Wilson SD. Pancreaticobiliary involvement in familial

polyposis coli/Gardner's syndrome. *Dis Colon Rectum*. 1886;29:55-58.
155. Tanaka K, Nishimura A, Yamada K, et al. Cancer of the gallbladder associated with anomalous junction of the pancreatobiliary duct system without bile duct dilatation. *Br J Surg*. 1993;80(5):622-624.
156. Duffy A, Capanu M, Abou-Alfa GK, et al. Gallbladder cancer (GBC): 10-year experience at Memorial Sloan-Kettering Cancer Centre (MSKCC). *J Surg Oncol*. 2008;98:485-489.
157. Lilic N, Addison B, Hammodat H. Gallbladder carcinoma: a New Zealand centre's 10-year experience with presentation, ethnic diversity, and survival rate. *ANZ J Surg*. 2015;85:260-263.
158. Goldin RD, Roa JC. Gallbladder cancer: a morphological and molecular update. *Histopathology*. 2009;55(2):218-229.
159. Bal MM, Ramadwar M, Deodhar K, Shrikhande S. Pathology of gallbladder carcinoma: current understanding and new perspectives. *Pathol Oncol Res*. 2015;21:509-525.
160. Katabi N. Neoplasia of gallbladder and biliary epithelium. *Arch Pathol Lab Med*. 2010;134:1621-1627.
161. Albores-Saavedra J, Shukla D, Carrick K, Henson DE. In situ and invasive adenocarcinomas of the gallbladder extending into or arising from Rokitansky-Aschoff sinuses: a clinicopathologic study of 49 cases. *Am J Surg Pathol*. 2004;28(5):621-628.
162. Albores-Saavedra J, Tuck M, McLaren BK, et al. Papillary carcinomas of the gallbladder: analysis of noninvasive and invasive types. *Arch Pathol Lab Med*. 2005;129(7):905-909.
163. Hara S, Kijima H, Okada K, Igarashi Y. Invasive micropapillary variant of the gallbladder adenocarcinoma and its aggressive potential for lymph node metastasis. *Biomed Res*. 2010;31:89-95.
164. Roa JC, Tapia O, Cakir A, et al. Squamous cell and adenosquamous carcinomas of the gallbladder: clinicopathological analysis of 34 cases. *Mod Pathol*. 2011;24:1069-1078.
165. Dursun N, Escalona OT, Roa JC, et al. Mucinous carcinomas of the gallbladder: clinicopathologic analysis of 15 cases. *Mod Pathol*. 2012;136:1347-1358.
166. Vardaman C, Albores-Saavedra J. Clear cell carcinomas of the gallbladder and extrahepatic bile ducts. *Am J Surg Pathol*. 1995;19(1):91-99.
167. Pavic I, Marusic Z, Mijic A, et al. A case of signet ring cell carcinoma of the gallbladder: immunohistochemistry and differential diagnosis. *Acta Clin Croat*. 2010;49:159-162.
168. Ragazzi M, Carbonara C, Rosai J. Nonneoplastic signet-ring cells in the gallbladder and uterine cervix. A potential source of overdiagnosis. *Hum Pathol*. 2009;40(3):326-331.
169. Albores-Saavedra J, Nadji M, Henson DE. Intestinal-type adenocarcinoma of the gallbladder. A clinicopathologic study of seven cases. *Am J Surg Pathol*. 1986;10(1):19-25.
170. Kushima R, Lohe B, Borchard F. Differentiation towards gastric foveolar, mucopeptic and intestinal goblet cells in gallbladder adenocarcinomas. *Histopathology*. 1996;29(5):443-448.
171. Albores-Saavedra J, Henson DE, Moran-Portela D, Lino-Silva S. Cribriform carcinoma of the gallbladder: a clinicopathologic study of 7 cases. *Am J Surg Pathol*. 2008;32(11):1694-1698.
172. Jeng YM, Chen CL, Hsu HC. Lymphoepithelioma-like cholangiocarcinoma: an Epstein-Barr virus-associated tumor. *Am J Surg Pathol*. 2001;25(4):516-520.
173. Kim YB, Park YN, Han JY, et al. Biliary lymphoepithelioma-like carcinoma not associated with Epstein-Barr virus. *Arch Pathol Lab Med*. 1999;123(5):441-443.
174. Appelman HD, Coopersmith N. Pleomorphic spindle-cell carcinoma of the gallbladder. Relation to sarcoma of the gallbladder. *Cancer*. 1970;25(3):535-541.
175. Guo KJ, Yamaguchi K, Enjoji M. Undifferentiated carcinoma of the gallbladder. A clinicopathologic, histochemical, and immunohistochemical study of 21 patients with a poor prognosis. *Cancer*. 1988;61(9):1872-1879.
176. Nishihara K, Tsuneyoshi M. Undifferentiated spindle cell carcinoma of the gallbladder: a clinicopathologic, immunohistochemical, and flow cytometric study of 11 cases. *Hum Pathol*. 1993;24(12):1298-1305.
177. Grosso LE, Gonzalez JG. Stromal osteoclast-like giant cells in an adenosquamous carcinoma of the gallbladder. *Hum Pathol*. 1992;23(6):703-706.
178. Albores-Saavedra J, Grider DJ, Wu J, et al. Giant cell tumor of the extrahepatic biliary tree: a clinicopathologic study of 4 cases and comparison with anaplastic spindle and giant cell carcinoma with osteoclast-like giant cells. *Am J Surg Pathol*. 2006;30(4):495-500.
179. Sakamoto K, Kimura N, Tokumura H, et al. Hepatoid adenocarcinoma of the gallbladder. *Histopathology*. 2005;47(6):649-651.
180. Gakiopoulou H, Givalos N, Liapis G, et al. Hepatoid adenocarcinoma of the gallbladder. *Dig Dis Sci*. 2007;52:3358-3362.
181. Abu-Farsakh H, Fraire AE. Adenocarcinoma and (extragonadal) choriocarcinoma of the gallbladder in a young woman. *Hum Pathol*. 1991;22:614-615.
182. Albores-Saavedra J, Batich K, Hossain S, et al. Carcinoid tumors and small-cell carcinomas of the gallbladder and extrahepatic bile ducts: a comparative study based on 221 cases from the surveillance, epidemiology, and end results program. *Ann Diagn Pathol*. 2009;13(6):378-383.
183. Lee JM, Hwang S, Lee SG, et al. Neuroendocrine tumors of the gallbladder: twelve cases in a single institution. *Hepatogastroenterology*. 2010;57:1064-1068.
184. Chen C, Wang L, Liu X, et al. Gallbladder neuroendocrine carcinoma: report of 10 cases and comparison of clinicopathologic features with gallbladder adenocarcinoma. *Int J Clin Exp Pathol*. 2015;8:8218-8226.
185. Maitra A, Tascilar M, Hruban RH, et al. Small cell carcinoma of the gallbladder: a clinicopathologic, immunohistochemical, and molecular pathology study of 12 cases. *Am J Surg Pathol*. 2001;25(5):595-601.
186. Papotti M, Cassoni P, Sapino A, et al. Large cell neuroendocrine carcinoma of the gallbladder: report of two cases. *Am J Surg Pathol*. 2000;24(10):1424-1428.
187. Koizumi M, Sata N, Kasahara N, et al. Carcinoid tumor of the gallbladder: report of two cases. *Clin J Gastroenterol*. 2011;4:323-330.
188. Sinkre PA, Murakata L, Rabin L, et al. Clear cell carcinoid tumor of the gallbladder: another distinctive manifestation of von Hippel-Lindau disease. *Am J Surg Pathol*. 2001;25:1334-1339.
189. Duval JV, Savas L, Banner BF. Expression of cytokeratins 7 and 20 in carcinomas of the extrahepatic biliary tract, pancreas, and gallbladder. *Arch Pathol Lab Med*. 2000;124:1196-2000.
190. Rullier A, Le Bail B, Fawaz R, et al. Cytokeratin 7 and 20 expression in cholangiocarcinomas varies along the biliary tract but still differs from that in colorectal carcinoma metastasis. *Am J Surg Pathol*. 2000;24(6):870-876.
191. Lodi C, Szabo E, Holczbauer A, et al. Claudin-4 differentiates biliary tract cancers from hepatocellular carcinomas. *Mod Pathol*. 2006;19:460-469.
192. Dowaki S, Kijima H, Kashiwagi H, et al. CEA immunohistochemical localization is correlated with growth and metastasis of human gallbladder carcinoma. *Int J Oncol*. 2000;16:49-52.
193. Li QL, Yang ZL, Liu JQ, Miao XY. Expression of CDX2 and hepatocyte antigen in benign and malignant lesions of gallbladder and its correlation with histopathologic type and clinical outcome. *Pathol Oncol Res*. 2011;17:561-568.
194. Chang YT, Hsu C, Jeng YM, et al. Expression of the caudal-type homeodomain transcription factor CDX2 is related to clinical outcome in biliary tract carcinoma. *J Gastroenterol Hepatol*. 2007;22(3):389-394.
195. Hanada K, Tsuchida A, Iwao T, et al. Gene mutations of K-ras in gallbladder mucosae and gallbladder carcinoma with an anomalous junction of the pancreaticobiliary duct. *Am J Gastroenterol*. 1999;94(6):1638-1642.
196. Chang YT, Chang MC, Huang KW, et al. Clinicopathological and prognostic significances of EGFR, KRAS, and BRAF mutations in biliary tract carcinomas. *J Gastroenterol Hepatol*. 2014;29:1119-1125.
197. Yoshida H, Shimada K, Kosuge T, Hiraoka N. A significant subgroup of resectable gallbladder cancer patients has an HER2 positive status. *Virchows Arch*. 2016;468:431-439.
198. Moreno M, Pimentel F, Gazdar AF, et al. TP53 abnormalities are frequent and early events in the sequential pathogenesis of gallbladder carcinoma. *Ann Hepatol*. 2005;4(3):192-199.
199. Wistuba II, Gazdar AF, Roa I, Albores-Saavedra J. p53 protein overexpression in gallbladder carcinoma and its precursor lesions: an immunohistochemical study. *Hum Pathol*. 1996;27(4):360-365.
200. Diamantis I, Karamitopoulou E, Perentes E, Zimmerman A. p53 protein immunoreactivity in extrahepatic bile duct and gallbladder cancer: correlation with tumor grade and survival. *Hepatology*. 1995;22:774-779.
201. Wistuba II, Ashfaq R, Maitra A, et al. Fragile histidine triad gene abnormalities in the pathogenesis of gallbladder carcinoma. *Am J Pathol*. 2002;160(6):2073-2079.
202. Maemura K, Natsugoe S, Takao S. Molecular mechanism of cholangiocarcinoma carcinogenesis. *J Hepatobiliary Pancreat Sci*. 2014;21:754-760.
203. Wakai T, Shirai Y, Sakata J, et al. Mode of hepatic spread from gallbladder carcinoma: an immunohistochemical analysis of 42 hepatectomized specimens. *Am J Surg Pathol*. 2010;34(1):65-74.
204. Fahim RB, McDonald JR, Richards JC, Ferris DO. Carcinoma of the gallbladder: a study of its modes of spread. *Ann Surg*. 1962;156:114-124.
205. Ohtsuka M, Miyazaki M, Itoh H, et al. Routes of hepatic metastasis of gallbladder carcinoma. *Am J Clin Pathol*. 1998;109(1):62-68.
206. Shirai Y, Tsukada K, Ohtani T, et al. Hepatic metastases from carcinoma of the gallbladder. *Cancer*. 1995;75(8):2063-2068.
207. Tsukada K, Kurosaki I, Uchida K, et al. Lymph node spread from carcinoma of the gallbladder. *Cancer*. 1997;80(4):661-667.
208. Hamrick RE Jr, Liner FJ, Hastings PR, Cohn I Jr. Primary carcinoma of the gallbladder. *Ann Surg*. 1982;195(3):270-273.
209. Young RH, Scully RE. Ovarian metastases from carcinoma of the gallbladder and extrahepatic bile ducts simulating primary tumors of the ovary. A report of six cases. *Int J Gynecol Pathol*. 1990;9(1):60-72.
210. Pilgrim C, Usatoff V, Evans PM. A review of the surgical strategies for the management of gallbladder carcinoma based on T stage and growth type of the tumor. *Eur J Surg Oncol*. 2009;35:903-907.

211. Shirai Y, Yoshida K, Tsukada K, Muto T. Inapparent carcinoma of the gallbladder. An appraisal of a radical second operation after simple cholecystectomy. *Ann Surg*. 1992;215(4):326-331.
212. Shimada H, Endo I, Togo S, et al. The role of lymph node dissection in the treatment of gallbladder carcinoma. *Cancer*. 1997;79(5):892-899.
213. Aloia TA, Jarufe N, Javie M, et al. Gallbladder cancer: expert consensus statement. *HPB (Oxford)*. 2015;17:681-690.
214. Kanthan R, Senger JL, Ahmed S, Kanthan SC. Gallbladder cancer in the 21st century. *J Oncol*. 2015;2015:967472. doi:10.1155/2015/967472.
215. Kai M, Chijiiwa K, Ohuchida J, et al. A curative resection improves the postoperative survival rate even in patients with advanced gallbladder carcinoma. *J Gastrointest Surg*. 2007;11:1025-1032.
216. Ouchi K, Mikuni J, Kakugawa Y, et al. Laparoscopic cholecystectomy for gallbladder carcinoma: results of a Japanese survey of 498 patients. *J Hepatobiliary Pancreat Surg*. 2002;9:256-260.
217. Kimura W, Nagai H, Kuroda A, Morioka Y. Clinicopathologic study of asymptomatic gallbladder carcinoma found at autopsy. *Cancer*. 1989;64(1):98-103.
218. Cavallaro A, Piccolo G, Panebianco V, et al. Incidental gallbladder cancer during laparoscopic cholecystectomy: managing an unexpected finding. *World J Gastroenterol*. 2012;18:4019-4027.
219. Groot Koerkamp B, Fong Y. Outcomes in biliary malignancy. *J Surg Oncol*. 2014;110:585-591.
220. Simbolo M, Fassan M, Ruzzenente A, et al. Multigene mutational profiling of cholangiocarcinomas identifies actionable molecular subgroups. *Oncotarget*. 2014;5:2839-2852.
221. Chandrasoma P, Fitzgibbons P. Granular cell tumor of the intrapancreatic common bile duct. *Cancer*. 1984;53(10):2178-2182.
222. Saito J, Kitagawa M, Kusanagi H, et al. Granular cell tumor of the common bile duct: a Japanese case. *World J Gastroenterol*. 2012;18:6324-6327.
223. Larson DM, Storsteen KA. Traumatic neuroma of the bile ducts with intrahepatic extension causing obstructive jaundice. *Hum Pathol*. 1984;15(3):287-289.
224. De Rosa A, Gomez D, Zaitoun AM, Cameron IC. Neurofibroma of the bile duct: a rare cause of obstructive jaundice. *Ann R Coll Surg Engl*. 2013;95:e38-e40.
225. Sadeghi S, Krigman H, Maluf H. Perivascular epithelioid clear cell tumor of the common bile duct. *Am J Surg Pathol*. 2004;28(8):1107-1110.
226. Rocha FG, Lee H, Katabi N, et al. Intraductal papillary neoplasm of the bile ducts: a biliary equivalent to intraductal papillary mucinous neoplasm of the pancreas? *Hepatology*. 2012;56:1352-1360.
227. Katabi N, Torres J, Klimstra DS. Intraductal tubular neoplasms of the bile ducts. *Am J Surg Pathol*. 2012;36:1647-1655.
228. Schlitter AM, Jang KT, Kloppel G, et al. Intraductal tubulopapillary neoplasms of the bile ducts: clinicopathologic, immunohistochemical, and molecular analysis of 20 cases. *Mod Pathol*. 2015;28:1249-1264.
229. Albores-Saavedra J, Cordova-Ramon JC, Chable-Montero F, et al. Cystadenomas of the liver and extrahepatic bile ducts: morphologic and immunohistochemical characterization of the biliary and intestinal variants. *Ann Diagn Pathol*. 2015;19:124-129.
230. Han IW, Jang JY, Lee KB, et al. Clinicopathological analysis and prognosis of extrahepatic bile duct cancer with a microscopic positive ductal margin. *HPB (Oxford)*. 2014;16:575-581.
231. Matthaei H, Lingohr P, Strasser A, et al. Biliary intraepithelial neoplasia (BilIN) is frequently found in surgical margins of biliary tract cancer resection specimens but has no clinical significance. *Virchows Arch*. 2015;466:133-141.
232. Strom BL, Hibberd PL, Soper KA. International variations in epidemiology of cancers of the extrahepatic biliary tract. *Cancer Res*. 1985;45(10):5165-5168.
233. Bonato G, Cristoferi L, Strazzabosco M, Fabris L. Malignancies in primary sclerosing cholangitis-a continuing threat. *Dig Dis*. 2015;33(suppl 2):140-148.
234. Gallagher PJ, Millis RR, Mitchinson MJ. Congenital dilatation of the intrahepatic bile ducts with cholangiocarcinoma. *J Clin Pathol*. 1972;25(9):804-808.
235. Sameshima Y, Uchimura M, Muto Y, et al. Coexistent carcinoma in congenital dilatation of the bile duct and anomalous arrangement of the pancreatico-bile duct. Carcinogenesis of coexistent gall bladder carcinoma. *Cancer*. 1987;60(8):1883-1890.
236. Plentz RR, Malek NP. Clinical presentation, risk factors and staging systems of cholangiocarcinoma. *Best Pract Res Clin Gastroenterol*. 2015;29:245-252.
237. Alexander F, Rossi RL, O'Bryan M, et al. Biliary carcinoma. A review of 109 cases. *Am J Surg*. 1984;147(4):503-509.
238. Okuda K, Kubo Y, Okazaki N, et al. Clinical aspects of intrahepatic bile duct carcinoma including hilar carcinoma: a study of 57 autopsy-proven cases. *Cancer*. 1977;39(1):232-246.
239. Navaneethan U, Njei B, Lourdusamy V, et al. Comparative effectiveness of biliary brush cytology and intraductal biopsy for detection of malignant biliary strictures: a systematic review and meta-analysis. *Gastrointest Endosc*. 2015;81:168-176.
240. Barr Fritcher EG, Voss JS, Brankley SM, et al. An optimized set of fluorescence in situ hybridization probes for detection of pancreaticobiliary tract cancer in cytology brush samples. *Gastroenterology*. 2015;149:1813-1824.
241. Beazley RM, Hadjis N, Benjamin IS, Blumgart LH. Clinicopathologic aspects of high bile duct cancer. Experience with resection and bypass surgical treatments. *Ann Surg*. 1984;199:623-636.
242. Kozuka S, Tsubone M, Hachisuka K. Evolution of carcinoma in the extrahepatic bile ducts. *Cancer*. 1984;54(1):65-72.
243. Nakanishi Y, Zen Y, Kawakami H, et al. Extrahepatic bile duct carcinoma with extensive intraepithelial spread: a clinicopathological study of 21 cases. *Mod Pathol*. 2008;21(7):807-816.
244. Hayashi S, Miyazaki M, Kondo Y, Nakajima N. Invasive growth patterns of hepatic hilar ductal carcinoma. A histologic analysis of 18 surgical cases. *Cancer*. 1994;73(12):2922-2929.
245. Kayahara M, Nagakawa T, Ueno K, et al. Lymphatic flow in carcinoma of the distal bile duct based on a clinicopathologic study. *Cancer*. 1993;72(7):2112-2117.
246. Khunamornpong S, Lerwill MF, Siriaunkgul S, et al. Carcinoma of extrahepatic bile ducts and gallbladder metastatic to the ovary: a report of 16 cases. *Int J Gynecol Pathol*. 2008;27(3):366-379.
247. Weinbren K, Mutum SS. Pathological aspects of cholangiocarcinoma. *J Pathol*. 1983;139:217-238.
248. Nagura H, Tsutsumi Y, Watanabe K, et al. Immunohistochemistry of carcinoembryonic antigen, secretory component and lysozyme in benign and malignant common bile duct tissues. *Virchows Arch A Pathol Anat Histopathol*. 1984;403(3):271-280.
249. Hong SM, Cho H, Moskaluk CA, et al. CDX2 and MUC2 protein expression in extrahepatic bile duct carcinoma. *Am J Clin Pathol*. 2005;124(3):361-370.
250. Laitio M. Carcinoma of extrahepatic bile ducts. A histopathologic study. *Pathol Res Pract*. 1983;178(1):67-72.
251. Kozuka S, Kurashina M, Tsubone M, et al. Significance of intestinal metaplasia for the evolution of cancer in the biliary tract. *Cancer*. 1984;54:2277-2285.
252. Hong SM, Kim MJ, Jang KT, et al. Adenosquamous carcinoma of extrahepatic bile duct: clinicopathologic study of 12 cases. *Int J Clin Exp Pathol*. 2008;1:147-156.
253. Kita E, Tsujimoto A, Nakamura K, et al. Signet ring cell carcinoma of the extrahepatic bile duct diagnosed by preoperative biopsy: a case report. *Case Rep Gastroenterol*. 2014;8:353-357.
254. Albores-Saavedra J, Delgado R, Henson DE. Well-differentiated adenocarcinoma, gastric foveolar type, of the extrahepatic bile ducts: a previously unrecognized and distinctive morphologic variant of bile duct carcinoma. *Ann Diagn Pathol*. 1999;3(2):75-80.
255. Sasatomi E, Nalesnik MA, Marsh JW. Neuroendocrine carcinoma of the extrahepatic bile duct: a case report and review of the literature. *World J Gastroenterol*. 2013;19:4616-4623.
256. van der Wal AC, Van Leeuwen DJ, Walford N. Small cell neuroendocrine (oat cell) tumour of the common bile duct. *Histopathology*. 1990;16(4):398-400.
257. Altemeier WA, Gall EA, Zinninger MM, Hoxworth PI. Sclerosing carcinoma of the major intrahepatic bile ducts. *AMA Arch Surg*. 1957;75(3):450-460, discussion 60-61.
258. Klatskin G. Adenocarcinoma of the hepatic duct at its bifurcation within the porta hepatis. An unusual tumor with distinctive clinical and pathological features. *Am J Med*. 1965;38:241-256.
259. Qualman SJ, Haupt HM, Bauer TW, Taxy JB. Adenocarcinoma of the hepatic duct junction. A reappraisal of the histologic criteria of malignancy. *Cancer*. 1984;53(7):1545-1551.
260. Wang J, Wang X, Xie S, et al. p53 status and its prognostic role in extrahepatic bile duct cancer: a meta-analysis of published studies. *Dig Dis Sci*. 2011;56:655-662.
261. Batheja N, Suriawinata A, Saxena R, et al. Expression of p53 and PCNA in cholangiocarcinoma and primary sclerosing cholangitis. *Mod Pathol*. 2000;13(12):1265-1268.
262. Argani P, Shaukat A, Kaushal M, et al. Differing rates of loss of DPC4 expression and of p53 overexpression among carcinomas of the proximal and distal bile ducts. *Cancer*. 2001;91:1332-1341.
263. Churi CR, Shroff R, Wang Y, et al. Mutation profiling in cholangiocarcinoma: prognostic and therapeutic implications. *PLoS ONE*. 2014;9(12):e115383.
264. Marsh Rde W, Alonzo M, Bajaj S, et al. Comprehensive review of the diagnosis and treatment of biliary tract cancer 2012. Part II: multidisciplinary management. *J Surg Oncol*. 2012;106:339-345.
265. Ishihara S, Miyakawa S, Takada T, et al. Status of surgical treatment of biliary tract cancer. *Dig Surg*. 2007;24:131-136.
266. McNamara MG, Walter T, Horgan AM, et al. Outcome of adjuvant therapy in biliary tract cancers. *Am J Clin Oncol*. 2015;38:382-387.
267. Adsay NV, Bagci P, Tajiri T, et al. Pathologic staging of pancreatic, ampullary, biliary, and gallbladder cancers: pitfalls and practical limitations of the current AJCC/UICC TNM staging system and opportunities for improvement. *Semin Diagn Pathol*. 2012;29:127-141.

268. Hong SM, Cho H, Moskaluk CA, Yu E. Measurement of the invasion depth of extrahepatic bile duct carcinoma: An alternative method overcoming the current T classification problems of the AJCC staging system. *Am J Surg Pathol*. 2007;31(2):199-206.
269. Henson DE, Albores-Saavedra J, Corle D. Carcinoma of the extrahepatic bile ducts. Histologic types, stage of disease, grade, and survival rates. *Cancer*. 1992;70(6):1498-1501.
270. Tompkins RK, Thomas D, Wile A, Longmire WP Jr. Prognostic factors in bile duct carcinoma: analysis of 96 cases. *Ann Surg*. 1981;194(4):447-457.
271. Hong SM, Cho H, Lee OJ, Ro JY. The number of metastatic lymph nodes in extrahepatic bile duct carcinoma as a prognostic factor. *Am J Surg Pathol*. 2005;29(9):1177-1183.
272. Klempnauer J, Ridder GJ, von Wasielewski R, et al. Resectional surgery of hilar cholangiocarcinoma: a multivariate analysis of prognostic factors. *J Clin Oncol*. 1997;15(3):947-954.
273. Yasuda T, Imai G, Takemoto M, et al. Carcinoid tumor of the extrahepatic bile duct: report of a case. *Clin J Gastroenterol*. 2013;6:177-187.
274. Rugge M, Sonego F, Militello C, et al. Primary carcinoid tumor of the cystic and common bile ducts. *Am J Surg Pathol*. 1992;16(8):802-807.
275. Chittal SM, Ra PM. Carcinoid of the cystic duct. *Histopathology*. 1989;15(6):643-646.
276. Maitra A, Krueger JE, Tascilar M, et al. Carcinoid tumors of the extrahepatic bile ducts: a study of seven cases. *Am J Surg Pathol*. 2000;24(11):1501-1510.
277. Papotti M, Galliano D, Monga G. Signet-ring cell carcinoid of the gallbladder. *Histopathology*. 1990;17(3):255-259.
278. Konishi E, Nakashima Y, Smyrk TC, Masuda S. Clear cell carcinoid tumor of the gallbladder. A case without von Hippel-Lindau disease. *Arch Pathol Lab Med*. 2003;127(6):745-747.
279. Virgilio E, Scorsi A, Amodio PM, et al. Primary malignant melanoma of the gallbladder: an outstandingly rare tumor. *Clin Exp Med*. 2016;16:479-480.
280. Peison B, Rabin L. Malignant melanoma of the gallbladder: report of three cases and review of the literature. *Cancer*. 1976;37(5):2448-2454.
281. Carstens HB, Ghazi C, Carnighan RH, Brewer MS. Primary malignant melanoma of the common bile duct. *Hum Pathol*. 1986;17(12):1282-1285.
282. Smith NE, Taube JM, Warczynski TM, et al. Primary biliary tract melanoma: report of a case and review of the literature. *Int J Surg Case Rep*. 2012;3:441-444.
283. Wagner MS, Shoup M, Pickleman J, Yong S. Primary malignant melanoma of the common bile duct: a case report and review of the literature. *Arch Pathol Lab Med*. 2000;124(3):419-422.
284. Ricci R, Maggiano N, Martini M, et al. Primary malignant melanoma of the gallbladder in dysplastic naevus syndrome. *Virchows Arch*. 2001;438(2):159-165.
285. Fidias P, Carey RW, Grossbard ML. Non-Hodgkin's lymphoma presenting with biliary tract obstruction. A discussion of seven patients and a review of the literature. *Cancer*. 1995;75(7):1669-1677.
286. Hwang DW, Lim CS, Jang JY, et al. Primary hematolymphoid malignancies involving the extrahepatic bile duct or gallbladder. *Leuk Lymphoma*. 2010;51:1278-1287.
287. Mani H, Climent F, Colomo L, et al. Gall bladder and extrahepatic bile duct lymphomas: clinicopathological observations and biological implications. *Am J Surg Pathol*. 2010;34(9):1277-1286.
288. Bisig B, Copie-Bergman C, Baia M, et al. Primary mucosa-associated lymphoid tissue lymphoma of the gallbladder: report of a case harboring API2/MALT1 gene fusion. *Hum Pathol*. 2009;40(10):1504-1509.
289. McCluggage WG, Mackel E, McCusker G. Primary low grade malignant lymphoma of mucosa-associated lymphoid tissue of gallbladder. *Histopathology*. 1996;29(3):285-287.
290. Mosnier JF, Brousse N, Sevestre C, et al. Primary low-grade B-cell lymphoma of the mucosa-associated lymphoid tissue arising in the gallbladder. *Histopathology*. 1992;20(3):273-275.
291. Davis GL, Kissane JM, Ishak KG. Embryonal rhabdomyosarcoma (sarcoma botryoides) of the biliary tree. Report of five cases and a review of the literature. *Cancer*. 1969;24(2):333-342.
292. Mihara S, Matsumoto H, Tokunaga F, et al. Botryoid rhabdomyosarcoma of the gallbladder in a child. *Cancer*. 1982;49(4):812-818.
293. Aldabagh SM, Shibata CS, Taxy JB. Rhabdomyosarcoma of the common bile duct in an adult. *Arch Pathol Lab Med*. 1986;110(6):547-550.
294. Ruymann FB, Raney RB Jr, Crist WM, et al. Rhabdomyosarcoma of the biliary tree in childhood. A report from the Intergroup Rhabdomyosarcoma Study. *Cancer*. 1985;56(3):575-581.
295. Al-Daraji WI, Makhlouf HR, Miettinen M, et al. Primary gallbladder sarcoma: a clinicopathologic study of 15 cases, heterogeneous sarcomas with poor outcome, except pediatric botryoid rhabdomyosarcoma. *Am J Surg Pathol*. 2009;33:826-834.
296. White J, Chan YF. Epithelioid angiosarcoma of the gallbladder. *Histopathology*. 1994;24(3):269-271.
297. Park JK, Choi SH, Lee S, et al. Malignant gastrointestinal stromal tumor of the gallbladder. *J Korean Med Sci*. 2004;19:763-767.
298. Mendoza-Marin M, Hoang MP, Albores-Saavedra J. Malignant stromal tumor of the gallbladder with interstitial cells of Cajal phenotype. *Arch Pathol Lab Med*. 2002;126(4):481-483.
299. Enad JG, Lapa JC, Jaklic B, et al. Kaposi's sarcoma of the gallbladder. *Mil Med*. 1992;157(10):559-561.
300. Miller TA, Weber TR, Appelman HD. Paraganglioma of the gallbladder. *Arch Surg*. 1972;105(4):637-639.
301. Mehra S, Chung-Park M. Gallbladder paraganglioma: a case report with review of the literature. *Arch Pathol Lab Med*. 2005;129:523-526.
302. Caceres M, Mosquera LF, Shih JA, O'Leary JP. Paraganglioma of the bile duct. *South Med J*. 2001;94:515-518.
303. Lazure T, Dimet S, Ndiaye N, et al. Giant cell-rich solitary fibrous tumor of the gallbladder. First case report. *Histopathology*. 2007;50:805-807.
304. Fullarton GM, Burgoyne M. Gallbladder and pancreatic metastases from bilateral renal carcinoma presenting with hematobilia and anemia. *Urology*. 1991;38(2):184-186.
305. Ueda I, Aoki T, Oki H, et al. Gallbladder metastases from renal cell carcinoma: a case report with review of the literature. *Magn Reson Med Sci*. 2015;14:133-138.
306. Fleres F, Rossitto M, Foti A, et al. Metastasis of the gallbladder from the breast cancer. *Ann Ital Chir*. 2014;85(ePub).
307. Bilici A, Seker M, Oven Ustaalioglu BB, et al. Gallbladder metastasis secondary to gastric cancer as a first site of recurrence presented with acute cholecystitis: case report and literature review. *Turk J Gastroenterol*. 2012;23:764-768.
308. Riopel MA, Klimstra DS, Godellas CV, et al. Intrabiliary growth of metastatic colonic adenocarcinoma: a pattern of intrahepatic spread easily confused with primary neoplasia of the biliary tract. *Am J Surg Pathol*. 1997;21(9):1030-1036.

22 Pancreas and Ampullary Region

Laura W. Lamps

CHAPTER CONTENTS

Pancreas, *886*
Normal anatomy, *886*
Congenital and developmental abnormalities, *887*
Pancreatitis, *888*
Miscellaneous inflammatory and infectious lesions, *895*
Pancreatic transplantation, *895*
Non-neoplastic cystic lesions, *896*
Tumors, *897*

Ampullary region, *921*
Adenomas and flat dysplasia, *921*
Intra-ampullary papillary-tubular neoplasm, *921*
Ampullary carcinoma, *921*
Neuroendocrine neoplasms, *922*
Miscellaneous tumors and tumorlike conditions, *922*

Pancreas

Normal Anatomy

The pancreas forms from two separate buds or *anlagen*, which later rotate and fuse. The ventral bud, which appears as a part of the developing hepatic duct, forms the posterior and inferior parts of the head and the uncinate process; the larger dorsal bud, which develops from the other side of the foregut and extends into the dorsal mesentery, forms the body, tail, and anterior part of the head. Abnormalities in this process result in *annular pancreas* and most types of *heterotopic pancreas* (see later). The pancreas is located in the retroperitoneum behind the stomach and transverse colon, and in front of the aorta and vena cava. It weighs on average between 40 and 180 g and measures 15–20 cm in length. It has no distinct capsule.[1,2]

The normal adult pancreas has a dual composition. The exocrine component is made of lobular units of acini, which comprise 80% or more of the gland (Fig. 22.1).[1] They empty into ducts of increasingly larger size that finally merge into the *main pancreatic duct (of Wirsung)* and the *accessory pancreatic duct (of Santorini)*. The duct of Wirsung ends in the *papilla of Vater*, usually in conjunction with the common bile duct (see also Chapter 21). The duct of Santorini ends separately in a minor duodenal papilla. Normally, the Wirsung and Santorini ducts are joined by numerous anastomotic connections; when this is not the case, and the duct of Santorini constitutes the principal drainage for the organ, the condition known as *pancreas divisum* results (see later).

Acinar cells are large, pyramidally shaped, and highly polarized. The luminal border has prominent microvilli, the apical cytoplasm is filled with markedly eosinophilic periodic acid–Schiff (PAS)-positive zymogen granules, and the basilar cytoplasm is intensely basophilic because of the abundance of granular endoplasmic reticulum. Centroacinar cells have paler cytoplasm and oval nuclei; as their name indicates, they are located in the central portion of the acinus. They blend with the cells of the intercalated duct, which drains the acinus. Focal collections of centroacinar cells sometimes occur and should not be confused with Langerhans islets.[3] The merging of intercalated ducts forms the intralobular ducts, which are lined by small cuboidal cells with pale cytoplasm.[1,4] These are continued by the much larger interlobular ducts, which are lined by mucin-producing columnar cells. The microscopic composition of Wirsung and Santorini ducts is similar to that of the interlobular ducts, except for a greater representation of goblet cells.

The endocrine component of the pancreas is mainly represented by the Langerhans islets (Fig. 22.2A and B).[1,4,5] These constitute 1%–2% of the adult pancreas but a much larger proportion (~20%) of the organ at the time of birth. Islets may be compact (90%) or diffuse; the latter are located in the portion of the pancreatic head derived from the ventral bud. Islets are not encapsulated and contain a rich capillary network. Their average diameter is 225 µm; individual variations in size exist, but any islet measuring over 400 µm should be regarded as abnormal. In adult humans, islets are composed of the following main cell types:

1. *B cells*. The insulin-secreting cells constitute two-thirds to three-fourths of the islet cell population and tend to group in center of the islet. B cells also secrete islet amyloid polypeptide (IAPP), a putative hormone that is thought to be co-released with insulin.[6]
2. *A cells*. The glucagon-secreting cells make up one-fifth to one-fourth of the total islet cell population and are mainly located at their periphery.
3. *D cells*. The somatostatin-secreting cells are scattered throughout the islets and represent less than 10% of islet cells.

Abstract

This chapter covers both the non-neoplastic and neoplastic pathology of the pancreas and ampullary region, including congenital anomalies, pancreatitis, cystic lesions, and exocrine and endocrine tumors.

Keywords

islet of Langerhans,
annular pancreas,
heterotopic pancreas,
congenital anomalies,
pancreatitis,
pseudocyst,
congenital cyst,
lymphoepithelial cyst,
ductal adenocarcinoma,
foamy gland,
medullary,
adenosquamous,
undifferentiated,
mucinous cystic neoplasm,
intraductal papillary mucinous neoplasm,
PanIN,
acinar cell tumor,
pancreatoblastoma,
nesidioblastosis,
cystic fibrosis,
diabetes,
solid-pseudopapillary tumor,
serous cystadenoma,
well-differentiated neuroendocrine tumor,
poorly differentiated neuroendocrine carcinoma,
ampullary carcinoma,
intra-ampullary tubulopapillary neoplasm

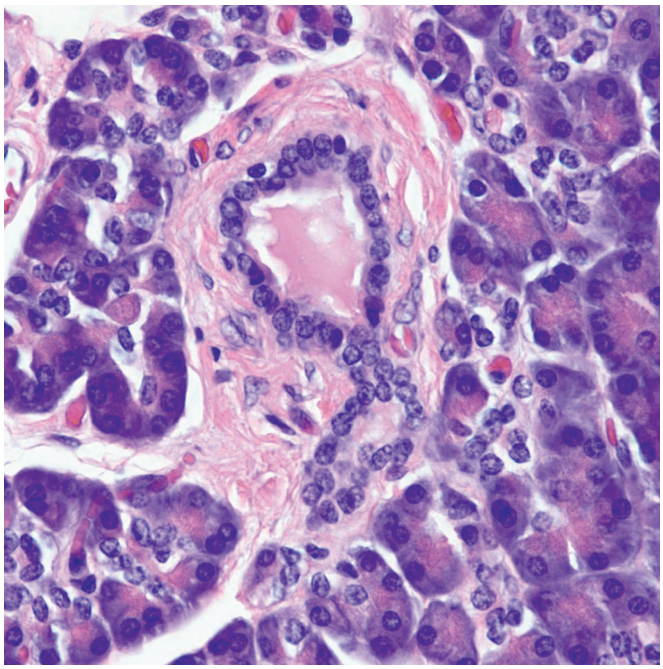

Figure 22.1 Normal pancreatic acini consist of tubular glands with round, basally located nuclei and prominent granules. A small duct is in the center of the photograph.

4. *PP cells*. The pancreatic polypeptide-secreting cells are scarce and usually present within diffuse islets.[7]

It should be pointed out that all of the endocrine cells present in the pancreas are of endodermal rather than neural crest derivation, as formerly believed.[8,9] Islet cells mark with synaptophysin, chromogranin, and CD56 and are typically pancytokeratin negative.

In addition to the Langerhans islets, endocrine cells can be found in connection with ducts and acini.[10] Most of these cells are of Kulchitsky (serotonin-producing) and PP type. It should be noted that G (gastrin-producing) cells are not normally present in the adult pancreas, a remarkable fact considering that this organ is the most common site for the occurrence of G cell tumors/gastrinomas.

Nesidioblastosis is a clinically heterogeneous term that refers to pancreatic islet hypertrophy in the context of hyperinsulinemic hypoglycemia.[11,12] It has been observed in infants with persistent neonatal hyperinsulinemic hypoglycemia, as well as infants of diabetic mothers, and has been associated with numerous conditions including Beckwith–Wiedemann syndrome and Zellweger syndrome.[11] Morphologically, islets are in intimate association with ducts, with formation of so-called *ductuloinsular complexes* (Fig. 22.3); islet cell hypertrophy and beta cells with pleomorphic nuclei may also be seen.[12,13] Focal and diffuse forms of this condition have been described.[12] The morphologic changes of nesidioblastosis can be seen in normal infants, as the endocrine component in neonates is more prominent than later in life.[11,14] The morphologic changes have been occasionally reported in adult patients with persistent hyperinsulinemic hypoglycemia and have also been encountered in adults who have had bariatric surgery.[15]

Congenital and Developmental Abnormalities

Complete pancreatic agenesis is an exceedingly rare lethal anomaly[16]; partial agenesis is also rare, and patients often present with diabetes.[17]

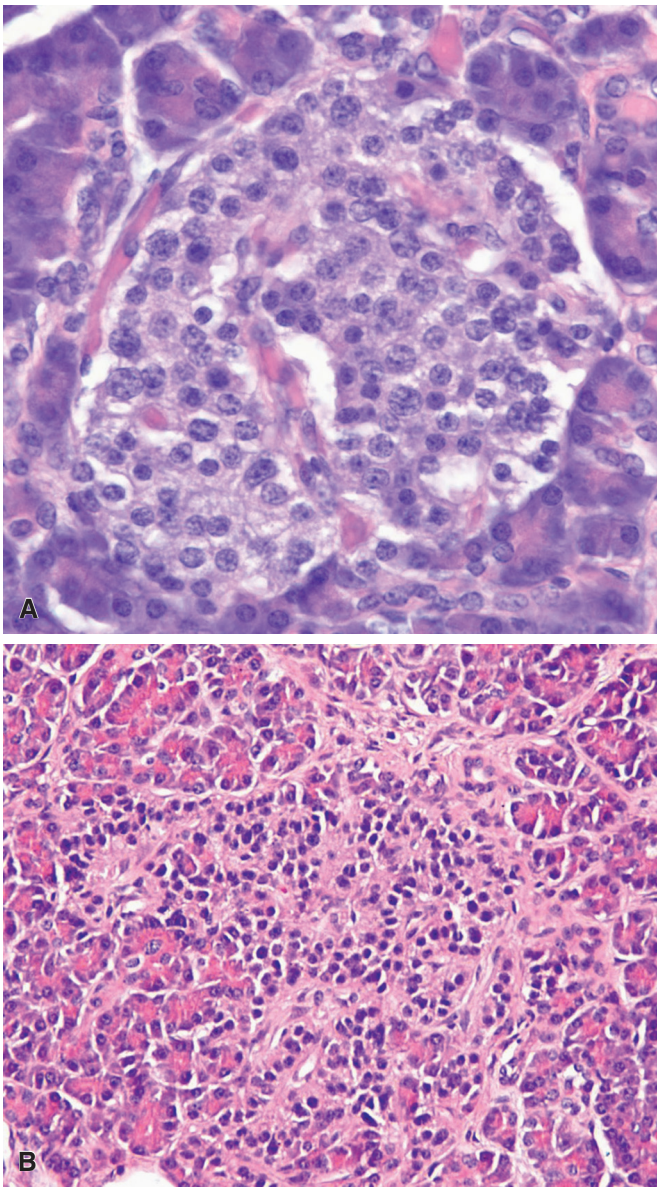

Figure 22.2 **A,** Compact islet with well-defined borders; note the small capillaries within the islet. Nuclei have speckled or "salt and pepper" chromatin typical of neuroendocrine cells. **B,** Diffuse islets have poorly defined borders and are often larger than compact islets; nuclei are typically more hyperchromatic.

Annular pancreas is a rare embryologic abnormality in which the ventral primordium of the pancreas fails to rotate properly.[18,19] It can be seen by itself or in combination with other congenital abnormalities of the gastrointestinal tract.[20] It is more common in females and is associated with Down syndrome.[21] Grossly, there is encirclement of the duodenum by pancreatic parenchyma, which may lead to constriction of the duodenal lumen.[22] The duct in the annular pancreas originates anteriorly and courses to the right over the duodenum and then posteriorly and to the left behind the duodenum, passing near the common duct and finally joining the main pancreatic duct.[23] These anatomic variations have to be kept in mind when surgery is contemplated. Microscopically, the annular pancreas contains a large number of PP cells in its many irregularly shaped islets, in keeping with its origin from the ventral bud (see

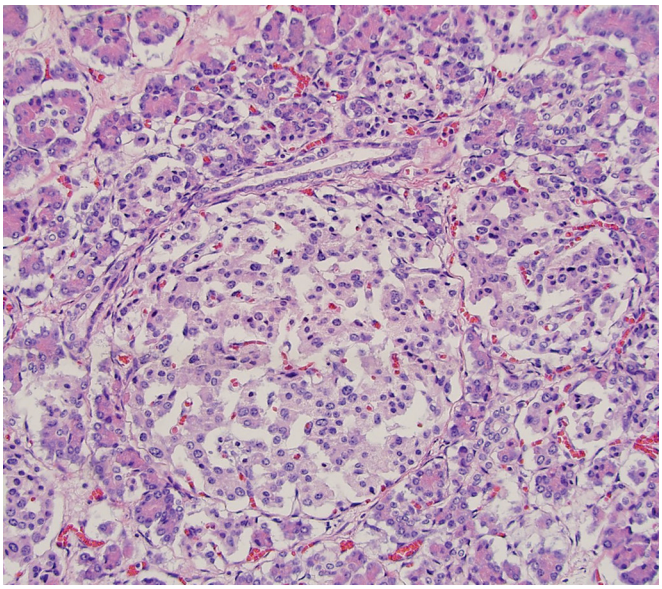

Figure 22.3 Hypertrophic, irregular islet with closely approximated duct (ductuloinsular complex) in a case of hyperinsulinemic hypoglycemia. (Courtesy of Dr. Jessica Comstock.)

previous section).[23] Pancreatitis may develop in association with this anomaly. *Pancreas divisum*, or a congenitally separate pancreatic ductal system, occurs in approximately 10% of individuals. It has been claimed to predispose to the development of pancreatitis, but the evidence for this is less than conclusive.[24,25]

Heterotopic Pancreas

Heterotopia of pancreatic tissue is a relatively frequent congenital anomaly.[26] It is most common in the duodenum (particularly the second portion), stomach, and jejunum but also occurs in the ileum, Meckel diverticulum, gastric and intestinal diverticula, gallbladder and bile ducts, large bowel, spleen (usually within or immediately beneath the capsule), omentum, abdominal wall, and several other locations.[26–29]

Grossly, the heterotopic tissue resembles normal pancreas. Firm, yellow, lobulated nodules measuring up to 4 cm are seen sharply circumscribed from the surrounding tissues (Fig. 22.4A). Central umbilication is often present in the cases located beneath mucosa, corresponding to a central duct that opens into the lumen (Fig. 22.4B); both the umbilication and the duct can be demonstrated radiographically and constitute an important diagnostic sign.[29] Microscopically, acinar and ductal tissues are always present, whereas islet tissue is found in only one-third of the cases (Fig. 22.4C and D). In some cases, there is also a component of pyloric-type mucous glands. The islet cell component contains all the major types of endocrine cells, but their relative number varies a great deal from case to case. In most instances, the islets are rich in A cells and poor in PP cells (dorsal type), but in others the reverse is true (ventral type).[30] True gastric heterotopic pancreas should be distinguished from pancreatic acinar metaplasia of the gastric or gastroesophageal junction mucosa.

Practically every pathologic change that occurs in the pancreas itself can occur in its heterotopic counterpart, including acute pancreatitis and neoplasms of either exocrine or endocrine type.[31–34] Heterotopic pancreas is often asymptomatic, but in the stomach may cause hemorrhage, ulceration, or pyloric obstruction.[35] When located in the area of the ampulla of Vater, it may result in obstructive jaundice. It has been postulated that some of the reported cases of intrasplenic mucinous cystadenomas and cystadenocarcinomas have arisen in heterotopic pancreatic tissue.[36]

Cystic Fibrosis

Cystic fibrosis is the most common inherited disorder among Caucasians and is due to genetic alterations in the cystic fibrosis transmembrane conductance regulator (CFTR) protein. The pancreas is the second most frequently affected organ after the lung; in fact, the disease was named for the cysts and fibrosis found in the pancreas in patients with this disease. The precipitation of secretions in the pancreatic ducts leads to obstruction and pancreatitis.[37] Pancreata often show fatty replacement, as well as cyst formation, and the accumulation of inspissated eosinophilic secretions in dilated pancreatic ducts (Fig. 22.5).[38]

Diabetes Mellitus

Both type 1 and type 2 diabetes may cause histologic changes in the pancreas. The pancreas decreases in size and weight as type 1 diabetes progresses, and islets show variability in size and shape, irregular shapes, reduced B cells, and patchy lymphocytic inflammation. Patients with type 2 diabetes also show reduction in number and density of islets, with reduction in A and B cells as well as islet amyloidosis (Fig. 22.6).[39,40]

Pancreatitis

Acute Pancreatitis

The main risk factors for acute pancreatitis are gallstones and alcohol abuse. Other factors include smoking (particularly when combined with alcohol use), type 2 diabetes, invasive pancreatobiliary procedures, and many drugs.[41] Experimental work has been hampered by the fact that most laboratory animals do not suffer naturally from this illness.

Duct obstruction from any cause results in upstream blockage of pancreatic secretions, with resulting autodigestive injury and inflammation.[41] Opie[42] postulated an obstructive mechanism in a classic work published in 1901, after demonstrating in his famous case of pancreatitis the presence of a small stone lodged in the ampulla, which had converted the common bile duct and the main pancreatic duct (duct of Wirsung) into a "common channel." The assumption was that the bile had passed from the common bile duct into the pancreatic duct and activated trypsinogen, thus beginning a series of events that included the digestion of the duct wall, adjacent parenchyma, and vessel walls by trypsin, as well as the splitting of fat and formation of calcium soaps by lipase. Fibrosis of the sphincter of Oddi or neoplasms in this region can induce a similar process, and cases of acute pancreatitis secondary to tumors of the ampullary area have been recorded.[43] The difficulty with this theory is that the formation of a common channel with a stone impacted in the ampulla, or another clearly identifiable anatomic cause of obstruction, occurs in less than 5% of patients with acute pancreatitis. This discrepancy could be explained by postulating a transient blockage of the ampulla of Vater by a migrating gallstone, by biliary sludge, or by a spasm of the sphincter of Oddi, all of which could produce a common channel in the absence of an identifiable impacted stone. Acosta and Ledesma[44] recovered gallstones in the feces of 34 of 36 patients with pancreatitis but in only 3 of 36 control subjects (patients with gallstones but no pancreatitis). Biliary sludge was found by Lee et al.[45] in 23 of 31 patients with "id iopathic" acute pancreatitis,

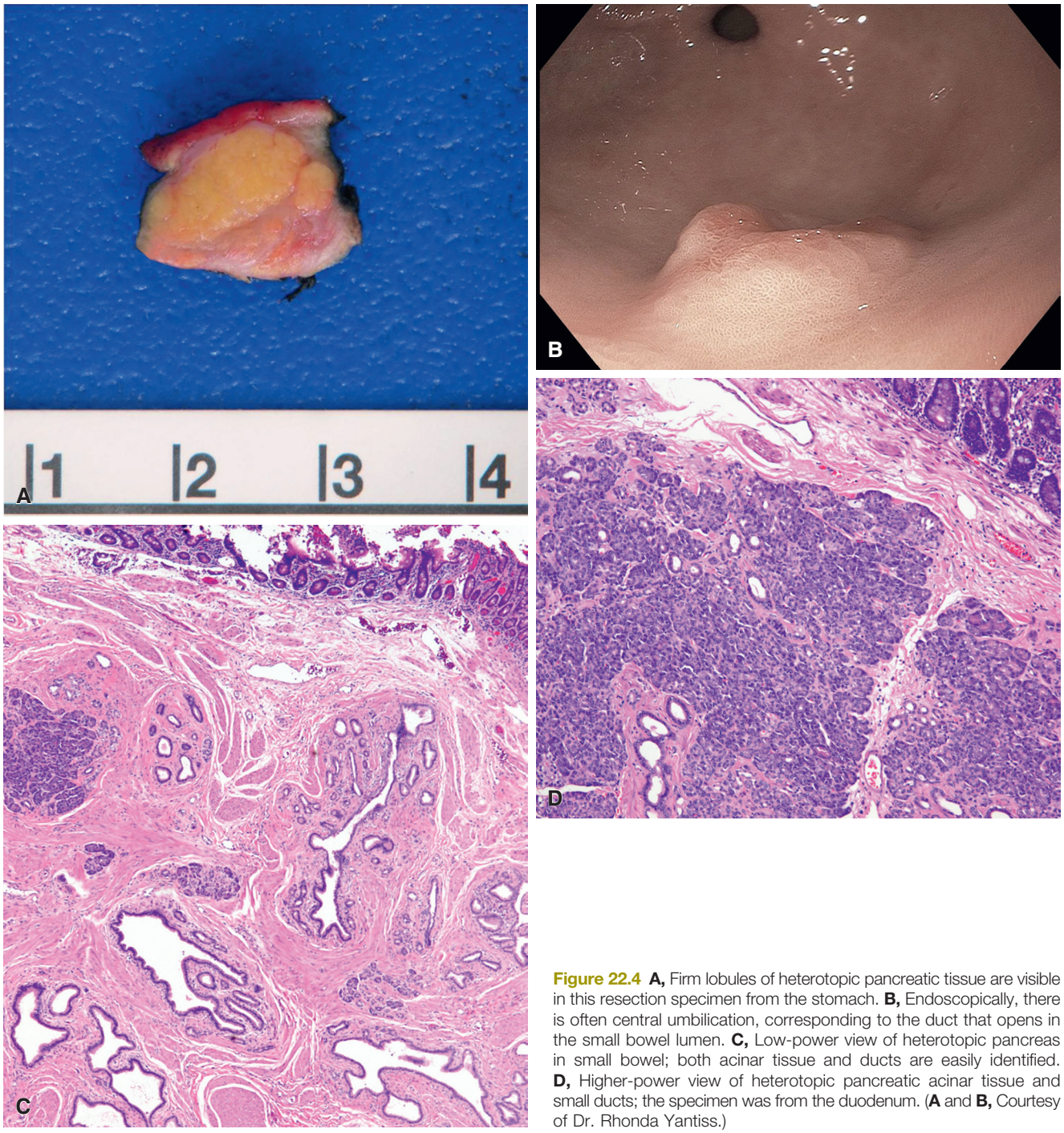

Figure 22.4 **A,** Firm lobules of heterotopic pancreatic tissue are visible in this resection specimen from the stomach. **B,** Endoscopically, there is often central umbilication, corresponding to the duct that opens in the small bowel lumen. **C,** Low-power view of heterotopic pancreas in small bowel; both acinar tissue and ducts are easily identified. **D,** Higher-power view of heterotopic pancreatic acinar tissue and small ducts; the specimen was from the duodenum. (**A** and **B,** Courtesy of Dr. Rhonda Yantiss.)

and sphincter spasm can be demonstrated in experimental animals and in humans under a variety of conditions. All these experiments demonstrate that a "common channel" may indeed occur under physiologic circumstances, and anomalous or variant pancreaticobiliary ductal anatomy may also contribute.[46]

The relationship between alcohol and acute pancreatitis remains poorly understood,[41,47] particularly as only a small percentage of alcohol users develop pancreatitis. Alcohol and its metabolites produce changes in acinar cells, which may promote activation of digestive enzymes and subsequent injury, but no specific predisposing or triggering factors have been identified. Regardless of the precise pathogenetic mechanism, it is a fact that the large majority of cases of acute pancreatitis are associated with biliary tract disease, alcohol use, and trauma.

The gross changes in acute pancreatitis vary from a swollen and edematous but otherwise well-preserved organ to a barely recognizable hemorrhagic and necrotic mass of tissue (Fig. 22.7A).[48] Yellow plaques and nodules representing fat necrosis are seen within the pancreas as well as throughout the mesenteric and peritoneal fat (Fig. 22.7B and C). The process sometimes spreads to the neighboring colon,

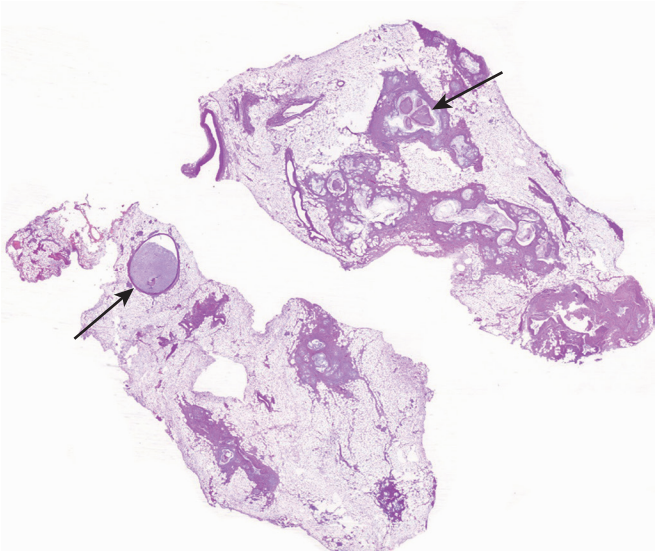

Figure 22.5 This case of cystic fibrosis shows fatty replacement of pancreatic parenchyma, cyst formation, and dilated ducts containing inspissated eosinophilic secretions (*arrows*). (Courtesy of Dr. Mari Mino-Kenudson.)

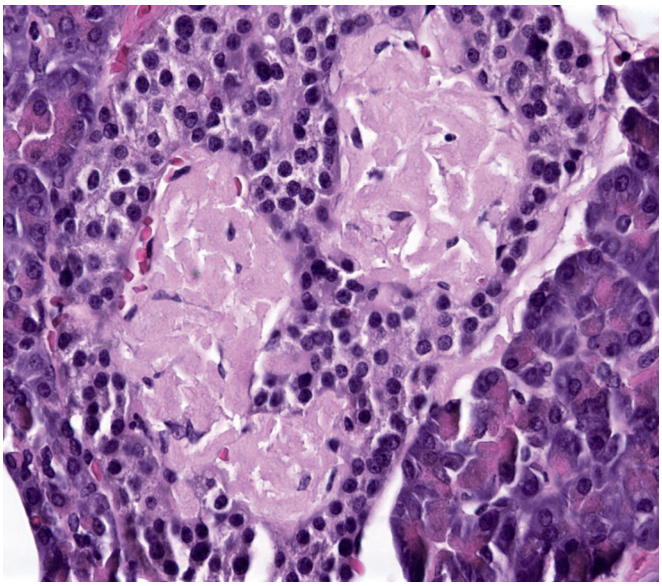

Figure 22.6 Islet cell amyloidosis in a patient with type 2 diabetes.

and it may result in localized ileus, stenosis, perforation, fistulous formations, or ischemic necrosis.[49]

Microscopically, early changes in the pancreas include acinar cell homogenization, ductal dilation with epithelial degeneration, diffuse interstitial edema, leukocytic infiltration, and fibroblastic reaction.[50] If the disease progresses, extensive necrosis and hemorrhage of pancreatic and peripancreatic tissue supervene (Fig. 22.7D). The foci of peritoneal fat necrosis become almost immediately surrounded and infiltrated by neutrophils; this population later changes to foamy histiocytes and lymphocytes. Calcification occurs early and extensively in these areas. The pancreatic necrotic foci can undergo secondary infection; this condition, termed *infected pancreatic necrosis*, is currently regarded as the most common, most severe, and most lethal of the infectious complications of acute pancreatitis.[51,52] Acute pancreatitis may evolve into a chronic form,[53] and in some clinical circumstances (such as alcoholic pancreatitis) the acute and chronic phases probably represent a continuum.[54]

Patients typically present with abdominal pain and serum amylase and/or lipase levels elevated above three times normal. Of note, however, patients with severe pancreatitis may have only mild enzyme elevations,[41] and elevated serum amylase can also be found with duodenal ulcer, volvulus, gangrenous cholecystitis, ruptured aortic aneurysm, and mesenteric thrombosis.[55] Serum C-reactive protein is a reliable marker for the presence of pancreatic necrosis and may correlate with disease severity.[56]

The overall mortality rate for acute pancreatitis is believed to be approximately 10%–20%, although both higher and lower mortality rates have been reported.[57,58] Prognosis worsens with increased pancreatic necrosis.[58] A number of classification schemes exist for stratifying severity of disease and prognosis.[41,58] Early treatment consists of supportive care (particularly fluid resuscitation), pain management, and nutritional support.[41] Endoscopic or surgical intervention may be necessary in patients with acute pancreatitis due to gallstones, and surgical necrosectomy may be required in patients with extensive pancreatic necrosis, particularly those who develop infected pancreatic necrosis, although many patients respond to antibiotics alone.[41,59]

Chronic Pancreatitis

The term "chronic pancreatitis" implies a chronic fibroinflammatory state that ultimately leads to pancreatic insufficiency. In addition to alcohol, there are a wide variety of causes, including autoimmune, metabolic, hereditary, and anatomic etiologies. Similar to acute pancreatitis, the pathogenesis of chronic pancreatitis is not well understood, although there are a number of proposed theories.[60] Some have proposed that alcohol predisposes patients to the formation of proteinaceous plugs and stones within the pancreatic ducts, leading to epithelial ulceration, scarring, and stricture formation. This theory has been questioned in the past, as only a minority of chronic pancreatitis patients have demonstrable stones or protein plugs within ducts, but has received renewed attention with the discovery of the link between chronic pancreatitis and the *CFTR* gene (see later).[61–63] Others have proposed oxidative stress, direct toxic effects of alcohol, and the consequence of repeated bouts of acute pancreatitis as explanations for chronic pancreatitis. It is likely that diverse causes lead to the fibroinflammatory condition known as "chronic pancreatitis" through different pathways. Alcohol continues to be the most important risk factor,[64–66] and smoking is also an important risk factor. Another contributing factor is prolonged ductal obstruction by tumor or stone (also known as chronic obstructive pancreatitis).

There is increasing evidence suggesting that a significant number of patients with idiopathic acute and chronic pancreatitis have underlying genetic alterations. Several of the identified mutations play a role in trypsinogen activation, pancreatic secretory function, or response to inflammation during pancreatic injury; affected genes include *PRSS1*, *SPINK1*, *CTRC*, and *CFTR*, as well as several others.[63] However, although these genes have been linked to pancreatitis, penetrance is incomplete and the presence of mutation does not necessarily confer disease.

Clinically, chronic pancreatitis characteristically presents with abdominal pain, which can be very severe and often radiates to the mid-back or scapula. Later in the course of disease, patients may present with diabetes or malabsorption due to deficiency of both exocrine and endocrine function.[67]

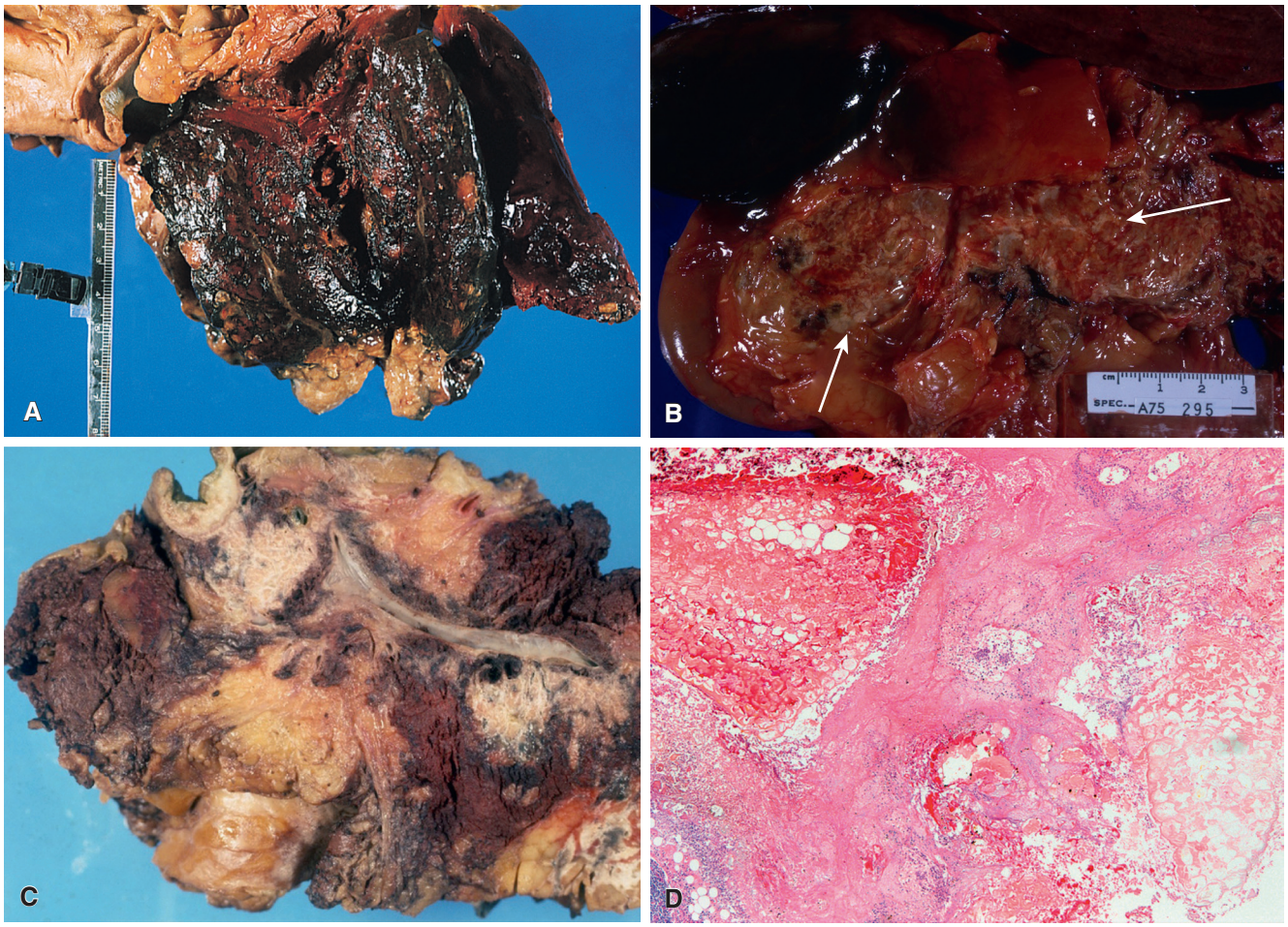

Figure 22.7 **A,** Extensive hemorrhagic necrosis of the pancreas spreads into the surrounding mesentery. **B,** A higher-power photograph from another case shows hemorrhagic acute pancreatitis with numerous foci of fat necrosis *(arrows)*. **C,** Hemorrhagic pancreatitis with large foci of fat necrosis extending into the mesenteric fat. **D,** Acute necrotizing pancreatitis with extensive hemorrhage and fat necrosis. There is no longer any recognizable pancreatic parenchyma. (**B** and **C,** Courtesy of Dr. George F. Gray Jr.)

Alcoholic Pancreatitis

Approximately 80% of chronic pancreatitis cases are due to alcohol.[68] The disease is characterized grossly by a nodular, firm, fibrotic, and misshapen pancreas that may be either enlarged or atrophic. The fibrosis typically affects the gland unevenly, leaving preserved architecture in some areas (Fig. 22.8A–C). Ducts embedded within the fibrosis may be irregular, stenotic, and/or dilated, and may contain calculi. Microscopically, the main features are fibrosis, initially interlobular, with chronic inflammation (Fig. 22.9A and B). As disease progresses, fibrosis increases, with loss of parenchyma, dilatation and distortion of ducts, and intraluminal eosinophilic mucoprotein plugs (which often calcify). When the calcification is very extensive, the term *chronic calcifying pancreatitis* has been used.[69] The ductal epithelium may be hyperplastic or contain squamous metaplasia, and eventually the epithelium may be atrophic or completely denuded.[68] Residual nerves and vessels may be prominent. The appearance of Langerhans islets in chronic pancreatitis varies considerably from case to case. Often, there is atrophy and distortion by the surrounding fibrotic tissue, with a relative decrease in the number of B cells.[70] Conversely, other cases show a marked proliferation of islet cells, which may grow in cords and small clusters (Fig. 22.9C).[68,71] Sometimes they may even simulate a malignant neoplasm (Fig. 22.9D).[71] Concomitant hyperplasia of Brunner glands in the duodenum is a common finding in chronic pancreatitis.[72]

A good correlation exists between the severity of the histologic alterations and pancreatic exocrine function tests.[73] Acinar necrosis and acute inflammation are seen more often in patients with persistent pain than in those who are free of pain.[74] However, cases exist in which severe abdominal pain of pancreatic origin is accompanied by minimal morphologic changes.[75]

Complications of chronic pancreatitis include both exocrine and endocrine insufficiency, stenosis of the common bile duct, pseudocysts, and pseudoaneurysm formation, which can lead to exsanguinating acute hemorrhage.[68,76,77] A rare complication of both acute and chronic pancreatitis is the occurrence of widespread metastatic fat necrosis, presumably as a consequence of the liberation of lipase by the damaged organ. Subcutaneous tissue (particularly in the legs), mediastinum, pleura, pericardium, bone marrow, periarticular fat, and liver can be involved.[78,79] Erythema nodosum–like lesions of the skin, polyarthropathy, and avascular bone necrosis are some of the alterations that may develop as a result.[78]

Endoscopy is playing a larger role in the treatment of chronic pancreatitis, including ERCP for treatment of strictures and stone removal, and endoscopic ultrasound for the treatment of pancreatic

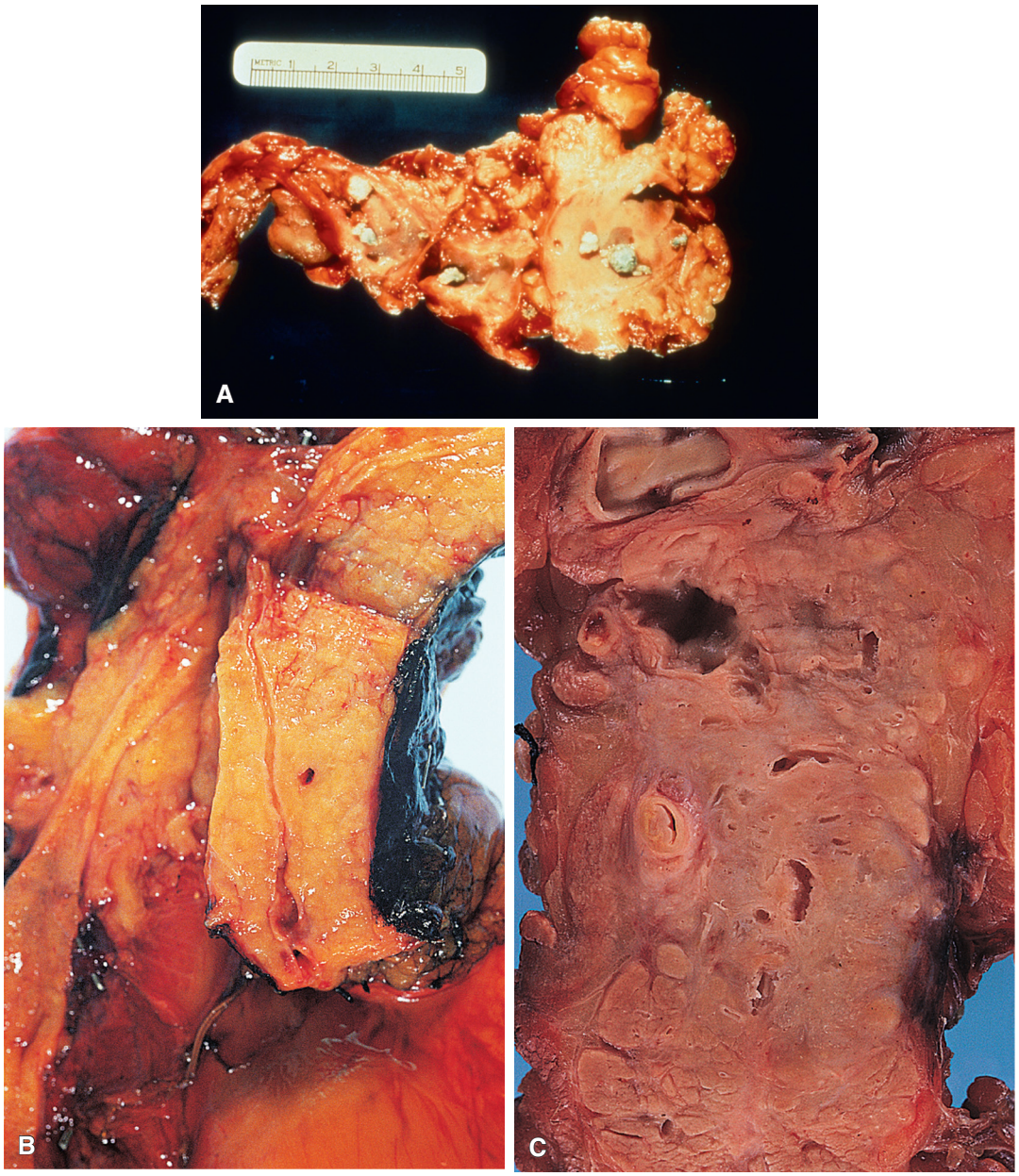

Figure 22.8 **A,** Alcoholic pancreatitis featuring large, irregular areas of fibrosis and calculi within dilated ducts. **B,** Another case shows diffuse fibrosis of the pancreas associated with stenosis and increased tortuosity of the main pancreatic duct. **C,** Close-up of another case of chronic pancreatitis, showing fibrosis and cystic dilation of ducts, some of which are occupied by a grumous secretory material. (**A,** Courtesy of Dr. George F. Gray Jr.)

fluid collections.[80,81] Surgical therapy may involve pancreatic duct drainage, partial pancreatic resection, and near-total pancreatectomy with or without islet autotransplantation.[81]

Autoimmune Pancreatitis

A great deal has been written recently on this disease, which is thought to have an autoimmune or hypersensitivity etiopathogenesis and shows good response to steroid therapy.[69,82–84] It is subclassified into two types, which appear to be two distinctly different diseases.[69] Occasional cases do not fit neatly into either of these two types but show intermediate histologic features.

Type 1 autoimmune pancreatitis is thought to be the pancreatic manifestation of a systemic fibroinflammatory disease that may involve a multitude of organs including the liver, gallbladder, biliary tree, lung, salivary gland, lacrimal duct, lymph node, kidney, and prostate.[82,83,85,86] A unifying theme is increased IgG4+ plasma cells, typically more than 20/HPF, although this is not an entirely sensitive or specific finding in either tissue samples or serum measurement of IgG4.[87,88] It occurs predominantly in middle-aged to elderly patients, with male predominance. Grossly, the pancreas is extremely firm, and the inflammatory process may form a mass lesion (most often in the pancreatic head) simulating pancreatic cancer clinically and intraoperatively (Fig. 22.10A).[82,89,90] Microscopically, it is characterized

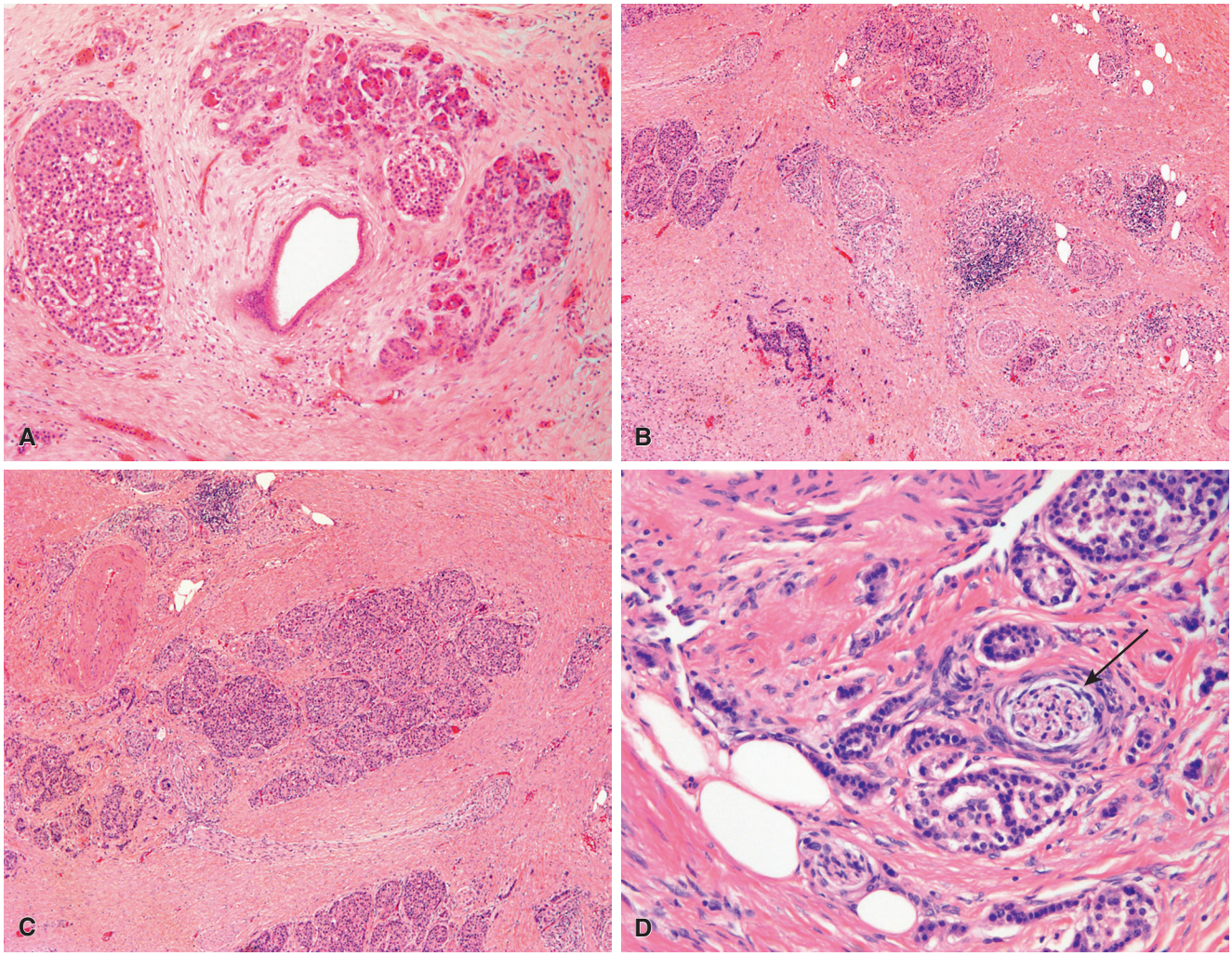

Figure 22.9 **A,** Chronic pancreatitis with fibrosis, mild chronic inflammation, and loss of acinar parenchyma. **B,** More extensive disease shows diffuse fibrosis, with prominent nerves, thick-walled vessels, and aggregates of islet cells. **C,** Residual islets may form aggregates (pseudohyperplasia) that can mimic a neuroendocrine neoplasm. **D,** Perineural extension of pancreatic endocrine cells *(arrow)* in chronic pancreatitis can mimic perineural invasion by a neoplasm.

by a dense lymphoplasmacytic infiltrate and fibrosis, hence the alternative term *lymphoplasmacytic sclerosing pancreatitis* (Fig. 22.10B–D). The fibrosis may be storiform, with plasma cells infiltrating between the stromal fibers. The fibroinflammatory process may center around the ducts, the lobules, or both, leading some workers to subdivide the disease into ductocentric, lobulocentric, and mixed subypes.[82,91] Non-necrotizing inflammation of veins and their surroundings ("venulitis" and "perivenulitis") are often present.[82,84,89,90] The inflammatory infiltrate can be patchy, rendering a biopsy diagnosis very difficult.[91] When the fibroblastic component is very prominent, the condition can be confused with inflammatory myofibroblastic tumor.[89] Increased numbers of IgG4-producing plasma cells may be found in ampullary/periampullary biopsies, as well as in pancreatic specimens,[88] and may be of some diagnostic assistance.[92]

Type 2 disease is also known as *idiopathic duct-centric chronic pancreatitis* or *autoimmune pancreatitis with granulocytic epithelial lesions*, and it is not associated with either elevated serum IgG4 or increased IgG4+ plasma cells, and thus some argue that it should not be called "autoimmune pancreatitis" at all.[93–95] Approximately one-third of cases are associated with chronic idiopathic inflammatory bowel disease, but patients do not manifest a multiorgan fibroinflammatory process like that seen in type 1 disease. Patients are typically younger than in type 1 disease, and there is no male predominance. A lymphoplasmacytic infiltrate is common, but diffuse inflammation, obliterative phlebitis, and storiform fibrosis are less common than in type 1 disease.[94] The most prominent feature is neutrophilic infiltration of the ductal epithelium ("granulocytic epithelial lesions") (Fig. 22.10E), which may lead to duct destruction. As mentioned previously, there are only rare or absent IgG4-positive plasma cells.

Paraduodenal Pancreatitis

This condition has also been described under a variety of names, including *cystic dystrophy of heterotopic pancreas, pancreatic hamartoma of duodenum, paraduodenal wall cyst,* or *groove pancreatitis,* the latter because it may involve the groove between the common bile duct, pancreas, and duodenum. The heterogeneity of names reflects various aspects of this disease.[96–98] This form of chronic pancreatitis typically occurs in male alcoholics, and it is clinically

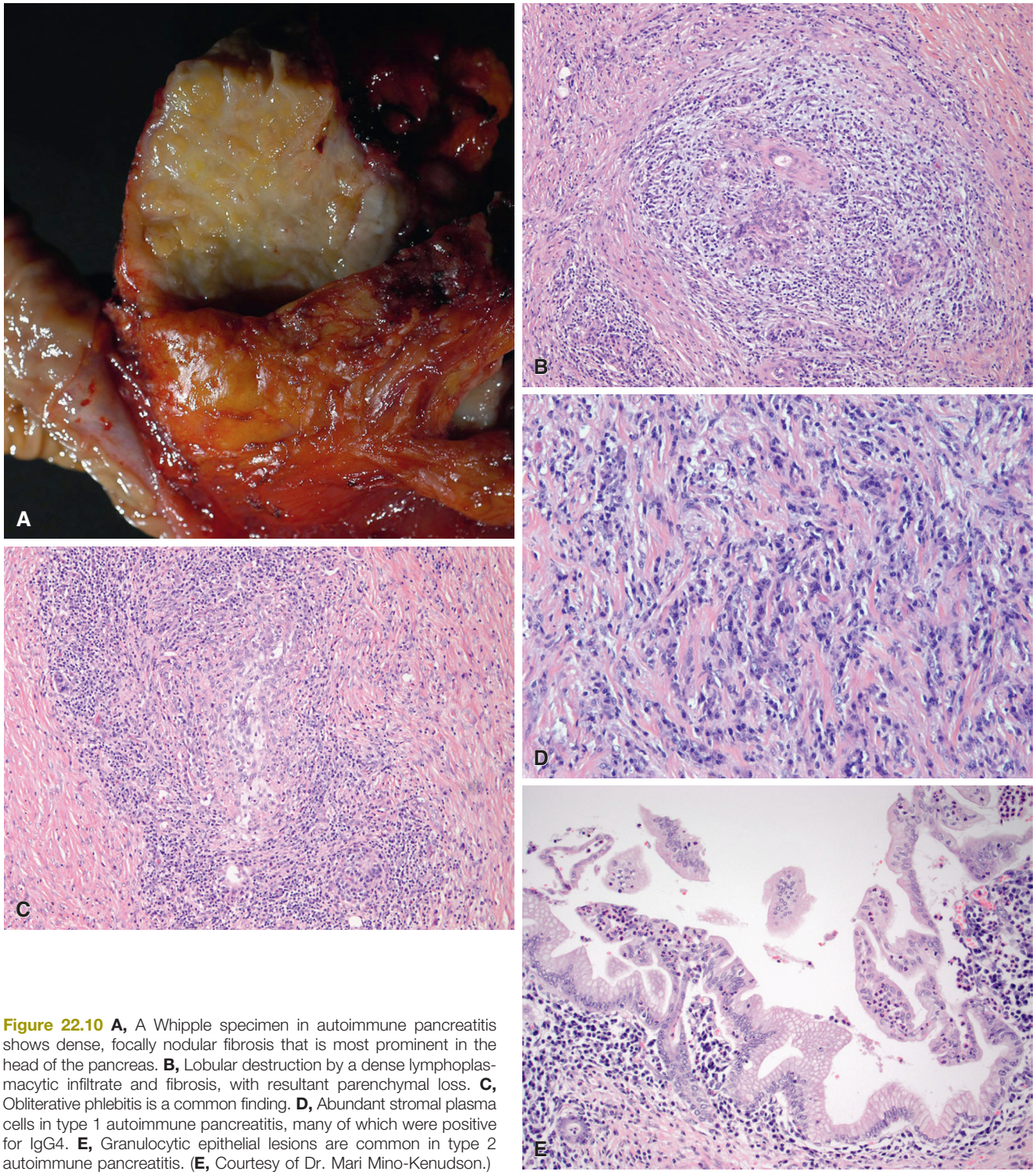

Figure 22.10 **A,** A Whipple specimen in autoimmune pancreatitis shows dense, focally nodular fibrosis that is most prominent in the head of the pancreas. **B,** Lobular destruction by a dense lymphoplasmacytic infiltrate and fibrosis, with resultant parenchymal loss. **C,** Obliterative phlebitis is a common finding. **D,** Abundant stromal plasma cells in type 1 autoimmune pancreatitis, many of which were positive for IgG4. **E,** Granulocytic epithelial lesions are common in type 2 autoimmune pancreatitis. (**E,** Courtesy of Dr. Mari Mino-Kenudson.)

significant because the dense fibrosis and irregular borders mimic neoplasia. Patients may present with signs and symptoms of duodenal obstruction.[97]

The fibroinflammatory process is typically centered on the duodenal wall, which is thickened, fibrotic, and trabecular, in the region of the minor papilla (Fig. 22.11).[96,97] Sometimes a scar plate develops between the head of the pancreas and the duodenum.[98] There are often numerous cysts, which may contain stones, fluid, or a grumous material, and which may be large enough to mimic intestinal duplication and/or compress the common bile duct.[96] Microscopically, there is myoid proliferation of the duodenal wall in the area of the minor ampulla, with associated cystically dilated ducts and sometimes acinar tissue and islets (although pancreatic elements may be difficult to locate).[96,97] The ducts contain inspissated secretions, which may rupture and induce a foreign body giant cell reaction. Neural hyperplasia and chronic inflammation may also

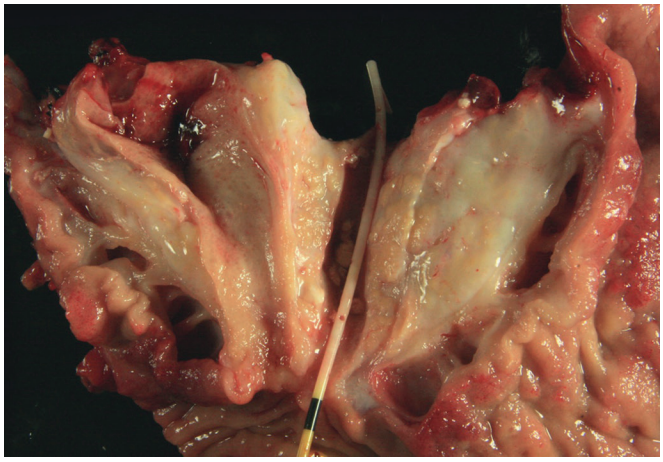

Figure 22.11 Both the pancreatic duct (stented) and the common bile duct are dilated, and there is extensive scarring of the paraduodenal pancreas in this case of paraduodenal pancreatitis. (Courtesy of Dr. Mari Mino-Kenudson.)

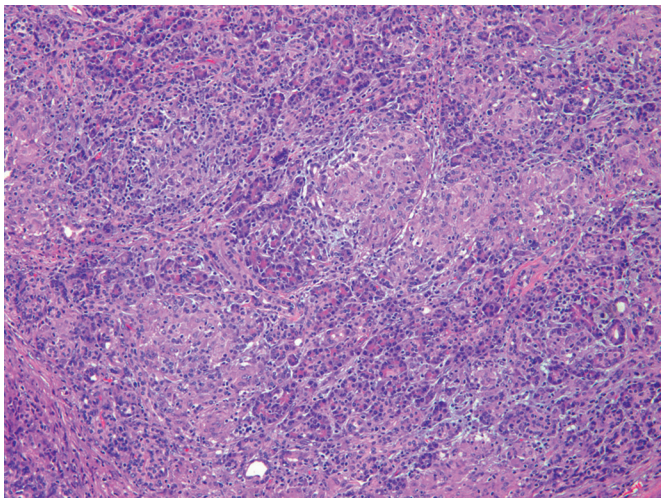

Figure 22.12 Numerous epithelioid, noncaseating granulomas in a case of pancreatic involvement by sarcoidosis.

be prominent. Although alcohol is clearly a risk factor, it is hypothesized that some anatomic variation in ductal anatomy, such as obstruction of an accessory pancreatic duct, makes this region susceptible to injury.[96–98]

Other Forms of Chronic Pancreatitis

True idiopathic *eosinophilic pancreatitis* is extremely rare; numerous eosinophils in the pancreas are more likely to be secondary to autoimmune pancreatitis, allograft rejection, or histiocytosis X.[99] *Tropical pancreatitis*, also known as *tropical calculous pancreatitis* or *fibrocalculous pancreatic diabetes* if patients are diabetic, is limited to Brazil and other countries close to the equator in central Africa and southern Asia.[68] Although originally described in adolescents who were malnourished in childhood, more recent studies have emphasized that this disease can also occur in older patients, and a number of genetic abnormalities have also been described.[100] Morphologic features are similar to alcoholic chronic pancreatitis. *Obstructive chronic pancreatitis* is the result of narrowing or occlusion of the pancreatic ducts, the most common causes being carcinoma and stones. Most of the stones are found in the duct of Wirsung within 2–4 cm of the ampulla of Vater and often restricted to a small portion of the gland.[101] *Hereditary pancreatitis* is a rare autosomal dominant hereditary fibroinflammatory and necrotizing disease that begins in childhood or adolescence.[68,97] It is the cause of only 1%–2% of patients with chronic pancreatitis. Clinically and pathologically it simulates chronic alcoholic pancreatitis, although some patients (particularly adults) show marked fatty replacement of the pancreas. The genetic alterations involve mutations in the *PRSS1* (most common), *SPINK1*, or *CFTR* genes.[68,97,102]

Miscellaneous Inflammatory and Infectious Lesions

Pancreatic abscesses are most often seen as complications of acute pancreatitis. They are bona fide infections, characterized by the presence of pus and the microbiologic identification of bacteria in over 90% of the cases.[103] They have different presentation, clinical course, and outcome than infected pseudocysts and necrosis, from which they should be distinguished.[104]

Although relatively rare, a number of viruses, bacteria, fungi, and parasites can cause pancreatitis, including mumps,[105] adenovirus,[106] CMV,[107] *Candida* species,[108] tuberculosis (which may mimic pancreatic adenocarcinoma radiographically),[109] *Clonorchis*,[110] *Ascaris*,[111] and toxoplasmosis.[112] Many of these cases, particularly adenovirus, CMV, and toxoplasmosis cases, are associated with immunocompromise.

Other inflammatory conditions include *sarcoidosis*, an exceptionally rare condition that is a manifestation of systemic disease (Fig. 22.12)[113,114]; *malakoplakia*[115]; vasculitides, including *Henoch–Schönlein purpura* and *polyarteritis nodosa*[116,117]; and *rheumatoid nodules*, which have been described in the pancreas in an adult patient with long-standing rheumatoid arthritis.[118]

Pancreatic Transplantation

In the past decade pancreatic transplants in the United States have declined by approximately 20%–30%, although the numbers continue to increase in other countries.[119] The two main indications for pancreatic transplantation are chronic pancreatitis and insulin-resistant diabetes mellitus.[120–122] At present, pancreatic graft survival rates are between 78% and 86%, depending on the type of transplant.[121,122] The most common complication of pancreatic transplantation is graft thrombosis, which is believed to be related to multiple factors including vascular injury during procurement, preservation/perfusion variables, hypercoagulability, and decreased fibrinolysis found in diabetic recipients.[123] The second most common complication is "graft pancreatitis," which often occurs early in the post-transplant period and is also associated with reperfusion injury, donor factors, and cold ischemia time; early graft pancreatitis is associated with a high rate of graft loss.[124,125] The two other important complications, which tend to occur at a later stage, are recurrence of the original disease and rejection. Biopsy evaluation of the pancreas allograft is crucial in establishing the cause of allograft dysfunction.[126] Microscopic changes specific for rejection are vascular alterations such as "endothelialitis," vasculitis, and obliterative endarteritis.[127,128] Another common abnormality is a periductal lymphocytic or mixed infiltrate. Morphologic features found to correlate strongly with a negative outcome include moderate to severe inflammation of acinar tissue, acinar tissue loss and fibrosis, and vascular luminal narrowing.[129] Vasculitis is a more aggressive and clinically more significant lesion than endothelialitis and defines the existence of severe rejection.[129]

Transplanted pancreata show a significant increase in glucagon-producing islet cells and a corresponding decrease in insulin-producing cells, particularly in those that have rejection.[130]

Recurrent diabetes in the graft occurs in approximately 6%–8% of patients and is characterized by selective loss of insulin-secreting cells and the presence of "isleitis"; the presence of circulating autoantibodies; and the presence of autoreactive T cells in the blood, graft, or peripancreatic lymph nodes.[131]

Non-Neoplastic Cystic Lesions

Pseudocysts

Pseudocysts are the most common type of pancreatic cyst, comprising approximately 75% of pancreatic cystic lesions, and are related to acute or chronic pancreatitis, trauma, and, rarely, to neoplastic obstruction of large ducts.[132,133] They can become very large and spread beyond the substance of the pancreas into the lesser peritoneal cavity, retroperitoneum, perirenal space, or subdiaphragmatic space.[133] They range from 3 to 20 cm in size and are multiple in 10%–20% cases.[133] Grossly, the wall is thick and irregular (Fig. 22.13). The inner surface is ragged, and the intraluminal content is cloudy or bloody. Microscopically, the lack of epithelial lining is the main distinguishing feature between true cysts and cystic neoplasms, and any evidence of epithelium should prompt additional sections as cystic neoplasms with sloughed epithelial linings may mimic pseudocysts.[132] Fibrin, inflammation, hemorrhage, and fibrosis are often prominent. The intraluminal fluid has a high amylase content.[132,133] Communication with the ductal system may or may not be present.[134]

Complications of pancreatic pseudocyst include perforation, infection, and hemorrhage. The splenic artery is the most common source of the latter, which can be massive and result in sudden death.[133,135]

Traditionally, internal drainage has been done by open or laparoscopic surgery in the form of transgastric cystogastrostomy or cystojejunostomy to a Roux-en-Y loop of jejunum,[136] but endoscopic (transpapillary or transmural) drainage is becoming the preferred approach as the rate of pseudocyst resolution is comparable. External drainage is preferred for infected or ruptured pseudocysts. Pseudocysts in the tail of the pancreas (particularly if there is splenic vein involvement) and lesions that are anatomically not amenable to drainage should be surgically resected.

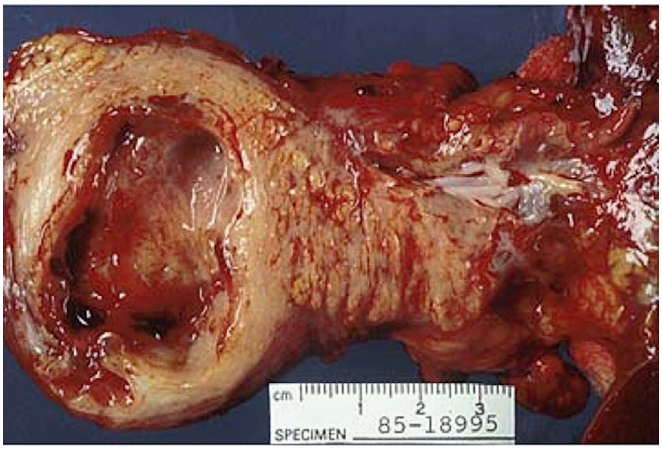

Figure 22.13 Pseudocyst with thick, irregular, fibrotic wall and hemorrhagic contents. (Courtesy of Dr. George F. Gray Jr.)

Congenital Cysts

These intrapancreatic cystic lesions do not communicate with the ductal system and are lined by a single layer of flat nonmucinous epithelium (Fig. 22.14).[133] They may be associated with von Hippel–Lindau (VHL) disease, fibropolycystic liver/kidney disease, or oral–facial–digital syndrome type I, particularly when multiple, and similar cysts of other viscera such as liver or kidney may be present.[133,137] This condition is also referred to as *pancreatic cystic dysplasia/dysgenesis* when associated with a malformation syndrome.[133,138]

Lymphoepithelial cysts are a distinctive variant of pancreatic cyst that are morphologically similar to the homonymous cysts of branchial pouch–derived structures. They are often multilocular and lined by squamous epithelium and feature abundant

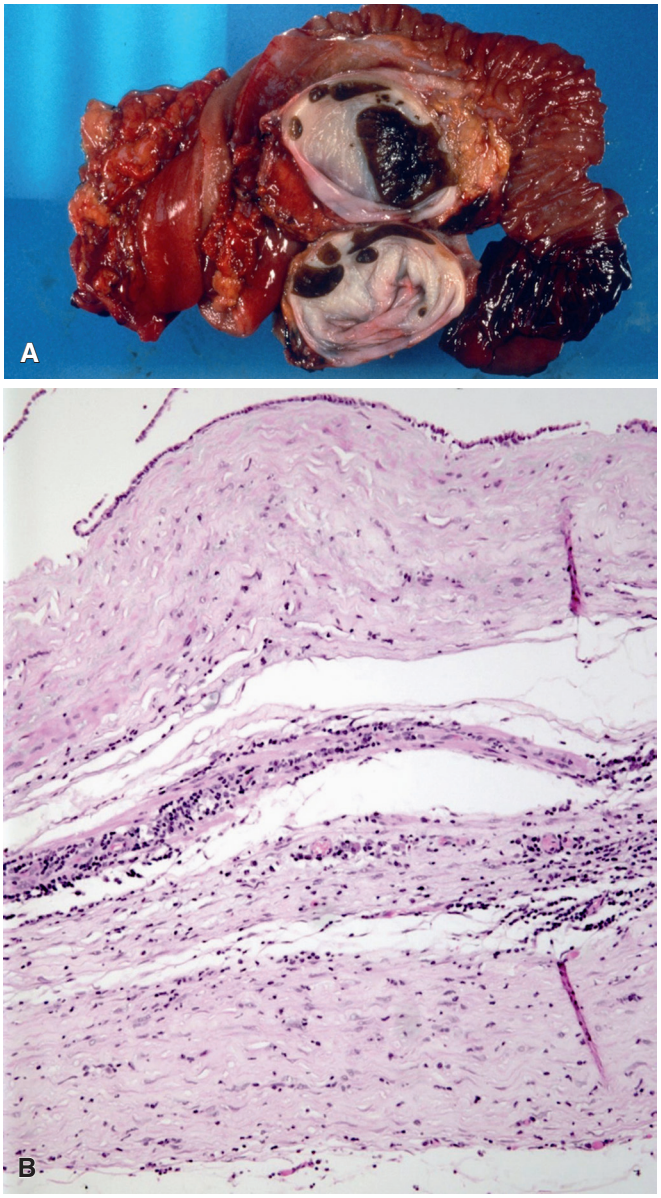

Figure 22.14 **A,** This large congenital cyst has a true epithelial lining and does not communicate with the pancreatic ductal system. **B,** Congenital cysts are lined by a single layer of flat nonmucinous epithelium.

lymphocytes in the wall, usually accompanied by germinal center formation (Fig. 22.15).[139–141] It has been suggested that these pancreatic lymphoepithelial cysts develop from pancreatic ducts protruding into a lymph node or an intrapancreatic accessory spleen.[139,142] Similar lesions include epidermoid cysts within intrapancreatic accessory spleens, and dermoid cysts (monodermal teratomas), which may contain sebaceous appendages, hair, and columnar or respiratory epithelium as well as squamous epithelium.[139]

Other non-neoplastic cysts of the pancreas include *retention cysts,* which are cystically dilated segments of pancreatic ducts that result from obstruction[133] (including *squamoid cysts*, lined by squamous epithelium but lacking lymphocytes in their wall)[143]; *para-ampullary duodenal wall cysts* (which may be derived from the ductal component of ectopic pancreatic tissue or be related to paraduodenal pancreatitis; see earlier)[133,144]; *enterogenous (enteric duplication) cysts*[133,145]; *mucinous non-neoplastic cysts*[146,147]; and *parasitic cysts* due to hydatid disease.[148] Mucinous non-neoplastic cysts can be unilocular or multilocular, and lack communication with the pancreatic ducts.[146,147] They have an apomucin phenotype different from that of intraductal papillary mucinous neoplasms (IPMNs), with which they can be confused.[147]

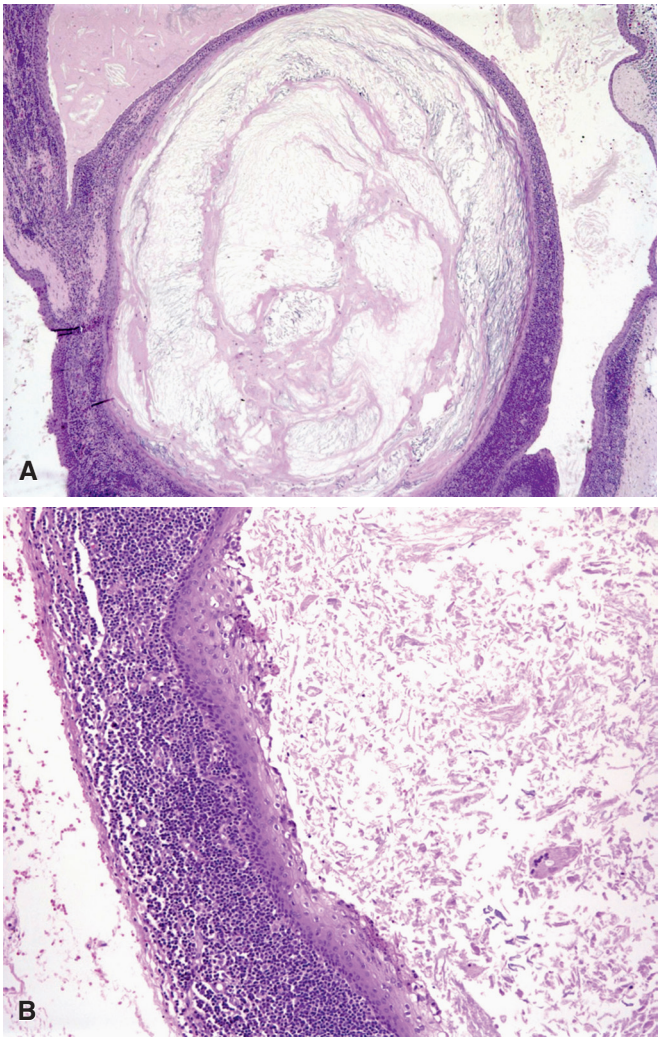

Figure 22.15 **A,** Lymphoepithelial cysts are often multilocular and contain abundant squamous debris. **B,** The cyst walls contain lymphoid tissue and are lined by squamous epithelium.

Cystic acinar transformation will be discussed later with acinar neoplasms.

Tumors

Ductal Adenocarcinoma

General and Clinical Features

Ductal adenocarcinoma of the exocrine pancreas comprises about 90% of all cases of pancreatic malignancy,[149] and it constitutes the fourth most common cause of death from cancer in the United States. Carcinomas of the pancreas share embryologic origin, differentiation pathways, population-related development, and microscopic features with tumors of the gallbladder, extrahepatic bile ducts, and ampulla of Vater, suggesting a field effect in carcinogenesis.[150]

Most patients with pancreatic carcinoma are elderly, and there is a slight male preponderance (1.6 : 1 ratio).[151,152] However, it can also occur in patients younger than 40 years.[153] With the exception of smoking, risk factors remain poorly elucidated.[149,151,152] It has been claimed that chronic pancreatitis is positively associated with an increased risk for pancreatic cancer, but the cause–effect relationship between the two diseases is often difficult to ascertain.[154–156] It has also been suggested that variations in pancreaticobiliary ductal anatomy may be related to the incidence of carcinoma, in view of the fact that lack of a common channel has been found at autopsy to be associated with microscopic abnormalities of the ductal epithelium.[157] There is an increase in the incidence of diabetes in patients with pancreatic carcinoma, but this usually develops within a short time after the diagnosis of cancer, suggesting that in most instances it represents a secondary event.[158] Overproduction of IAPP by beta cells may contribute to this complication.[159]

Presenting signs and symptoms depend on the location of the cancer within the pancreas, as well as the extent of disease at the time of diagnosis.[152] Vague abdominal pain is common, often in the upper abdomen and radiating to the back, which may be accompanied by nausea and weight loss.[152] Because of its strategic location in relation to the extrahepatic bile ducts, carcinoma of the head of the pancreas usually causes progressive jaundice that is associated with pain in at least half of the patients; however, the diagnosis in most cases is made when the tumor is relatively large (about 5 cm) and has extended beyond the pancreas (85% of the cases).[160] The rare small or microscopic pancreatic carcinomas that are found incidentally at autopsy also tend to be invasive and to be accompanied by perineural spread, regardless of small size.[161] Carcinomas of the body and tail of the pancreas grow insidiously and often have already metastasized at the time of diagnosis. Pancreatic adenocarcinoma is associated with deep venous thrombi in about 20% of patients, and the risk increases with initiation of chemotherapy[162,163]; these may be a late development in patients with overt carcinoma or may be present in patients with clinically silent tumor.[164,165] The syndrome is thought to be due to the release of tumor necrosis factor, interleukin-1, and interleukin-6 by macrophages present in tumor stroma. Another mechanism may be production of substances with procoagulant activity by the tumor cells themselves.[166]

It is estimated that about 10% of pancreatic cancers have an inherited component.[167,168] At least five such syndromes have been identified, including (1) hereditary breast and ovarian cancer syndrome associated with germline mutation of *BRCA2*; (2) familial atypical multiple mole melanoma syndrome with germline mutation in the *p16* gene; (3) Peutz–Jeghers syndrome with germline mutations in the *STK11/LKB1* gene; (4) hereditary nonpolyposis colorectal cancer with germline mutations in one of

the DNA mismatch repair genes; and (5) hereditary pancreatitis with germline mutations in the *PRSS1* gene that encodes cationic trypsinogen.[167–169]

Location and Gross Features

Pancreatic ductal carcinoma is located in the head of the pancreas in two-thirds of the patients and in the body or tail in the other third.[151] Multiple tumors are found in a minority of the cases. Most pancreatic ductal adenocarcinomas are poorly delineated, fibrotic, and firm, with a yellow-gray cut surface (Fig. 22.16).[170] It is frequently difficult to distinguish tumor from adjacent chronic pancreatitis grossly. Rarely, the tumor undergoes massive cystic degeneration and thus may mimic other cystic pancreatic tumors.[171] The duodenal wall is invaded by direct extension in one-fourth of the tumors arising from the pancreatic head. The involved pancreatic ducts may become greatly dilated and plugged with necrotic tumor, or compressed and even destroyed by tumor growth. Extrapancreatic extension is common; when extensive, it may be very difficult to determine whether or not a given tumor is of pancreatic origin versus ampulla, common bile duct, or duodenum.[172]

The non-neoplastic pancreas adjacent to the tumor may show extensive atrophy, chronic inflammation, and fibrosis, plus the ductal dilation previously mentioned. Precursor lesions, or pancreatic intraepithelial neoplasia (PanIN, see below) may also be present, especially in familial cases.[173,174]

Microscopic Features

Microscopically, typical pancreatic ductal adenocarcinomas consist of infiltrating, haphazard glands and ducts with surrounding desmoplastic stroma (Fig. 22.17A) and may be stratified as well, moderately, or poorly differentiated, although this has limited prognostic significance.[168,170] Poorly differentiated carcinomas often have more significant nuclear pleomorphism and less well developed glandular differentiation, along with areas of solid growth and easily identified mitoses. In well-differentiated tumors, the microscopic diagnosis in a biopsy specimen can be extremely difficult, and close attention must be given to cytologic details. At low-power examination, the glands are often well formed, have a large lumen, and are lined by one or a few layers of cylindrical or cuboidal epithelium. Their overall low-power appearance may not be particularly suggestive of carcinoma, except for the irregularities in the shape and distribution of the glands and the prominent concentric desmoplastic stroma that surrounds them; however, high-power examination of the lining epithelium will show one or more features that, in this location, are indicative of malignancy: marked nuclear pleomorphism, variation in nuclear size, loss of polarity, prominent nucleoli, and mitotic activity. This disparity between the high degree of cytologic atypia and the low level of architectural atypia is typical of tumors of the pancreaticobiliary region (Fig. 22.17B and C). Features useful in diagnosing carcinoma within small biopsy specimens include glands present outside the normal lobular architecture; the presence of glands immediately adjacent to muscular arteries (Fig. 22.17D); and necrotic debris within gland lumens.[170,175] Perineurial invasion (Fig. 22.17E), which is present in 90% of the cases, constitutes an additional important diagnostic sign. However, there are two caveats: benign epithelial inclusions have been observed in pancreatic nerves,[176] and perineurial extension of islet cells can occur in chronic pancreatitis (see earlier and Fig. 22.9D).[71] The perineurial invasion by carcinoma can extend from the intrapancreatic nerves into the extrapancreatic neural plexus, a fact that might have some bearing on the surgical procedure.[177] Invasion of blood vessels (Fig. 22.17F), particularly veins, is seen with half of the tumors. The presence of ducts surrounded by adipose tissue without intervening acini ("naked ducts") are also highly indicative of malignancy,[178,179] but this finding is rarely present in biopsy specimens.

The non-neoplastic lobular tissue surrounding ductal adenocarcinoma may show significant alterations as well. The islet tissue is usually well preserved; however, both atrophic and hypertrophic changes can occur in the islets, and rarely hypertrophy of the islets produces hypoglycemia. Most commonly, destruction of a variable amount of islet tissue mass results in a subclinical or overt diabetic picture. The surrounding parenchyma may be completely destroyed because of ductal occlusion by the invasive carcinoma and subsequent pancreatitis.

Microscopic precursor lesions, previously known as atypical hyperplasia, papillary hyperplasia, dysplasia, or carcinoma in situ, are currently classified as PanIN (Fig. 22.18).[170] This concept is supported by the realization that these lesions are often adjacent to invasive ductal adenocarcinomas and have been identified in pancreata years before the development of invasive carcinoma; and that the majority of the molecular alterations present in invasive ductal adenocarcinoma are present in PanIN, and the prevalence of genetic alterations increases with the degree of morphologic atypia.[180] Recently, the previous three-tiered system for classifying PanIN was combined into a two-tiered system, so that lesions formerly classified as PanIN-1 and PanIN-2 are now grouped as low-grade lesions (and are generally regarded as clinically inconsequential) and PanIN-3 is classified as a high-grade lesion.[181] Both low-grade and high-grade PanIN can be found in the duct epithelium adjacent to carcinoma in about 40% of cases, sometimes at a distance from the main tumor mass and even at the point of surgical transection.[182] Conversely, the incidence of these lesions, particularly high-grade PanIN, in the pancreata of control subjects is very low.[182] The

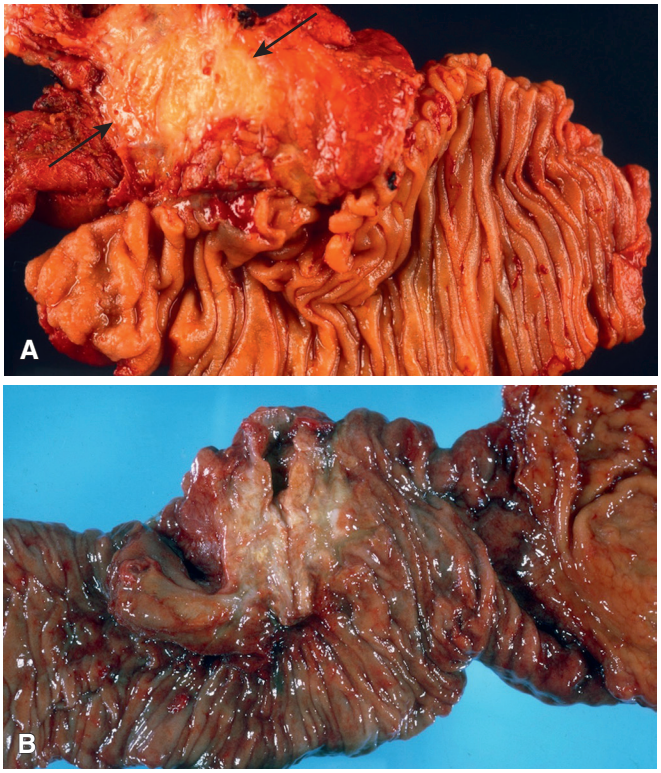

Figure 22.16 Gross Appearance of Invasive Pancreatic Ductal Adenocarcinoma. A, A poorly defined mass obliterates the normal pancreatic architecture *(arrows)*. **B,** A gritty, gelatinous poorly defined tumor surrounds common bile duct, which is markedly dilated. (**A,** Courtesy of Dr. George F. Gray Jr.)

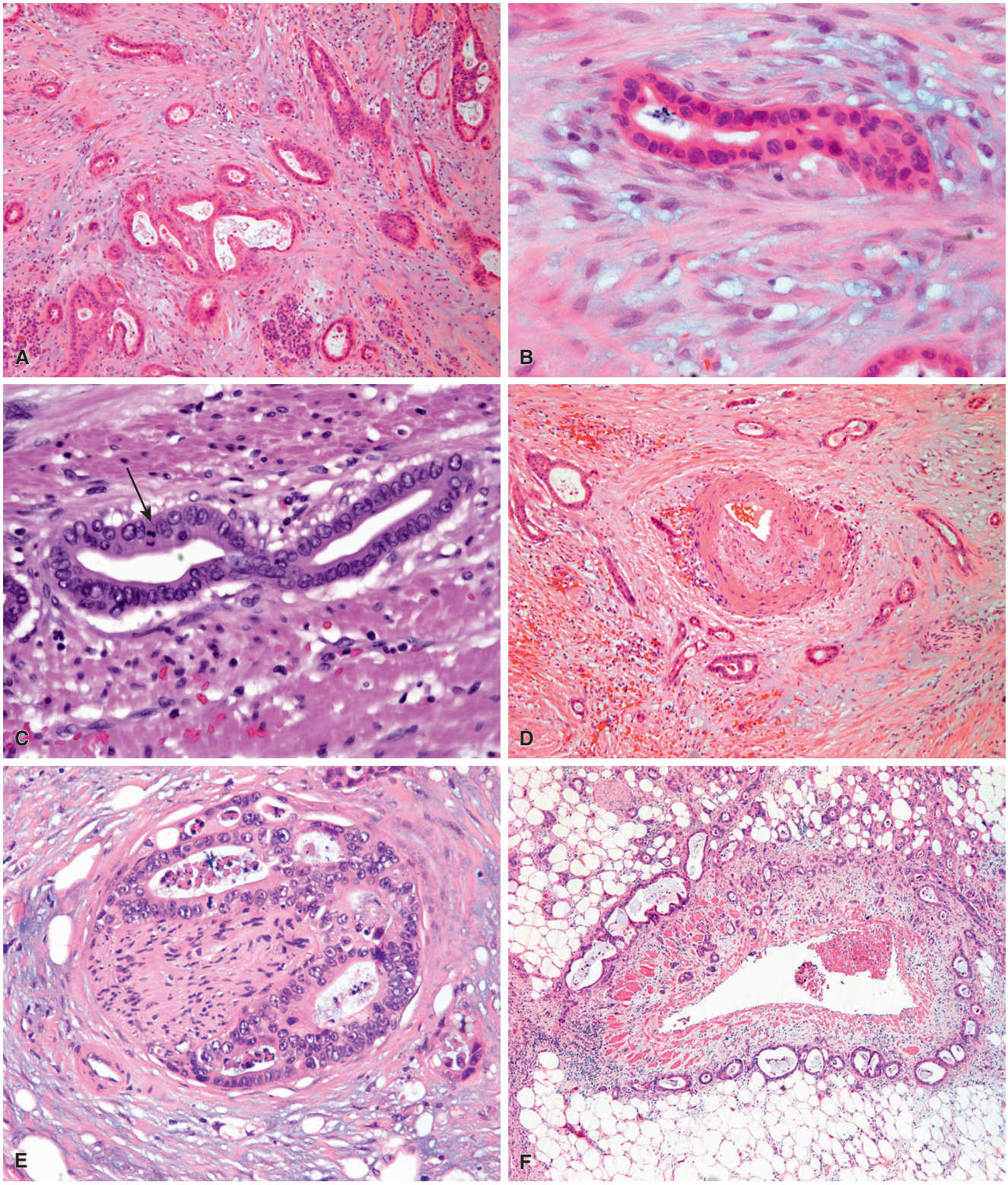

Figure 22.17 **A,** Well-differentiated ductal adenocarcinomas with infiltrating, haphazard glands and surrounding desmoplastic stroma. Well-differentiated neoplastic glands may be extremely bland at low power, and attention must be given to cytologic features such as marked nuclear pleomorphism, variation in nuclear size **(B)**, loss of polarity, prominent nucleoli, and mitotic activity (**C,** *arrow*). **D,** Neoplastic glands immediately adjacent to muscular arteries are a useful diagnostic feature of malignancy. Perineural invasion **(E)** and vascular invasion **(F)** are frequent findings in ductal adenocarcinoma.

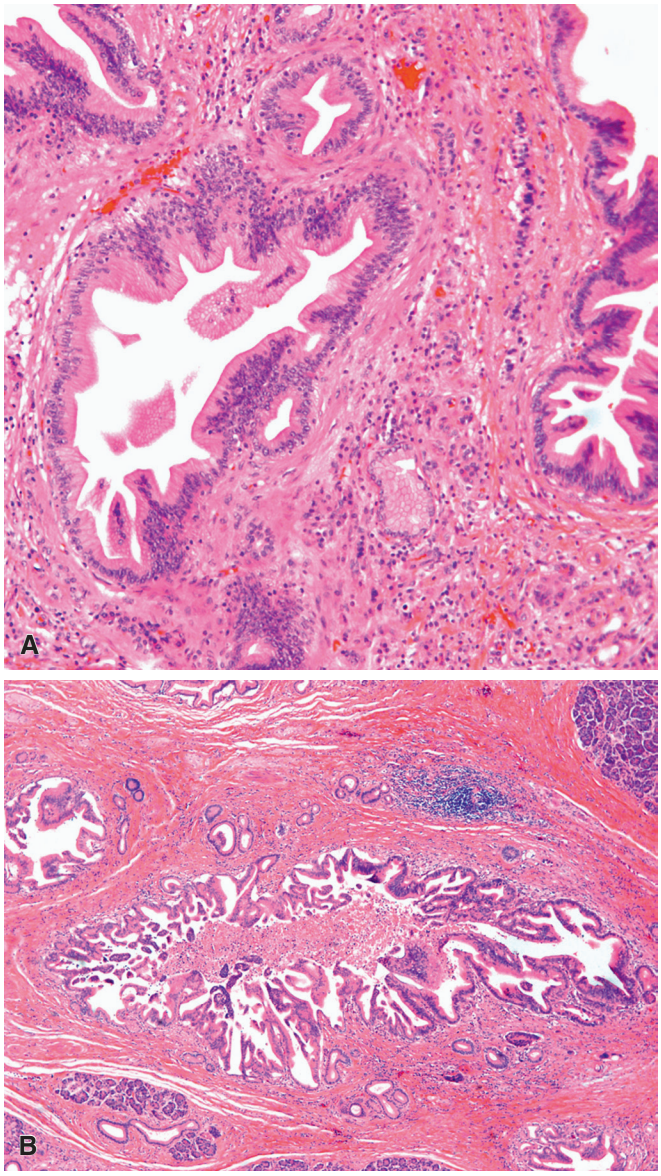

Figure 22.18 **A,** Low-grade PanIN characterized by tall columnar mucinous epithelium without nuclear atypia. **B,** High-grade PanIN features architectural complexity, unsupported tufts of epithelium in the lumen of the duct, and marked nuclear atypia.

presence of PanIN of any grade at a margin of resection for invasive ductal adenocarcinoma does not appear to affect patient survival, however.[181]

Other Microscopic Types

There are several patterns of ductal adenocarcinoma that do not differ significantly from the conventional type clinically or prognostically but do have distinctive morphologic features. The *foamy gland pattern* (Fig. 22.19A) has a deceptively benign appearance and may be confused with non-neoplastic mucinous ducts.[183] The *large duct pattern* has large, ectatic or microcystic malignant glands, which may be mistaken for benign dilated glands or a lower-grade noninvasive cystic neoplasm, particularly if the cytologic features are bland (Fig. 22.19B).[184] The *vacuolated pattern* consists of irregular or cribriforming nests of cells with prominent large, empty vacuoles, which may contain debris or mucin (Fig. 22.19C).[185] The *micropapillary pattern* resembles that in other anatomic sites. Some tumors may have a signet ring cell component or features that resemble colorectal adenocarcinoma.[186]

Other uncommon but reasonably distinctive variants of pancreatic adenocarcinoma include *adenosquamous* and *squamous carcinoma* (a term more accurate than mucoepidermoid carcinoma or adenoacanthoma) (Fig. 22.19D).[187,188] The squamous elements may range from benign-appearing to poorly differentiated or may show basaloid features (Fig. 22.19E).[189] Tumors should be at least 30% squamous to warrant the designation of adenosquamous per the WHO 2010 classification; pure squamous cell carcinomas of the pancreas are exceedingly rare, and some reported cases may represent adenosquamous carcinomas in which the squamous component has overrun the glandular elements, or the glandular elements were not sampled. *Medullary carcinoma* is similar to those found in the breast and GI tract (Fig. 22.19F), are sometimes multicentric, and are associated with wild-type (nonmutated) *KRAS*. Some have microsatellite instability as well, similar to their colonic counterparts, and regardless of MSI status they have been strongly associated with a family history of colon cancer.[190] Colloid carcinomas (Fig. 22.19G) are often associated with IPMNs or mucinous cystic neoplasms (MCNs) (see later) and have a more protracted clinical course than conventional ductal adenocarcinoma.[191,192] They express markers characteristic of intestinal differentiation (CDX2, CK20, and MUC2).[191] They are rarely associated with pseudomyxoma peritonei.[193] It has been postulated that the mucin in these tumors acts as a containment barrier, thus limiting the spread of the neoplastic cells.[191,192]

Poorly differentiated ductal adenocarcinomas may also have a *clear cell* phenotype (which is immunoreactive for hepatocyte nuclear factor-1 beta) or may have oncocytic features. These patterns can mimic both renal cell carcinoma and other oncocytic neoplasms.[194,195] *Hepatoid carcinomas* of the pancreas are a rare and heterogeneous group of tumors that may have pure hepatoid differentiation or exist in association with other histologic types, both ductal and neuroendocrine. These tumors are immunoreactive with Hep Par1, CD10, AFP, and polyclonal CEA, and must be distinguished from true hepatocellular carcinoma involving the pancreas.[196,197]

Microadenocarcinoma had originally been described as an allegedly distinct type of pancreatic ductal adenocarcinoma characterized by a microglandular appearance, but re-evaluation of the originally reported cases and study of new ones has led to the conclusion that it represents instead a pattern of growth associated with an aggressive clinical course rather than a distinctive morphologic entity.[198]

Tumors termed *undifferentiated carcinomas* of the pancreas include tumors previously classified as anaplastic carcinoma, sarcomatoid carcinoma, spindle cell carcinoma, pleomorphic carcinoma, carcinosarcoma, and undifferentiated carcinoma with osteoclast-like giant cells; the latter term also encompasses tumors previously known as giant cell tumors of the pancreas. In most cases these are variants of ductal adenocarcinomas; however, their appearance is so distinctive and their behavior so aggressive that a distinction from the ordinary ductal adenocarcinoma is warranted.[199,200] The majority of the patients are above the age of 50 at the time of diagnosis, and there is a male predilection. The prognosis is extremely poor overall.

Undifferentiated tumors with primarily anaplastic, spindled, or sarcomatoid morphology (Fig. 22.20A and B) often contain heterologous elements. Immunohistochemically, stains for keratin, EMA, and CEA are typically positive in the obvious epithelial component and sometimes, but certainly not always, in the sarcoma-like areas (Fig. 22.20C). Undifferentiated carcinomas can be accompanied by areas of conventional ductal adenocarcinoma, or a pre-invasive neoplasm such as a mucinous cystic tumor or intraductal papillary

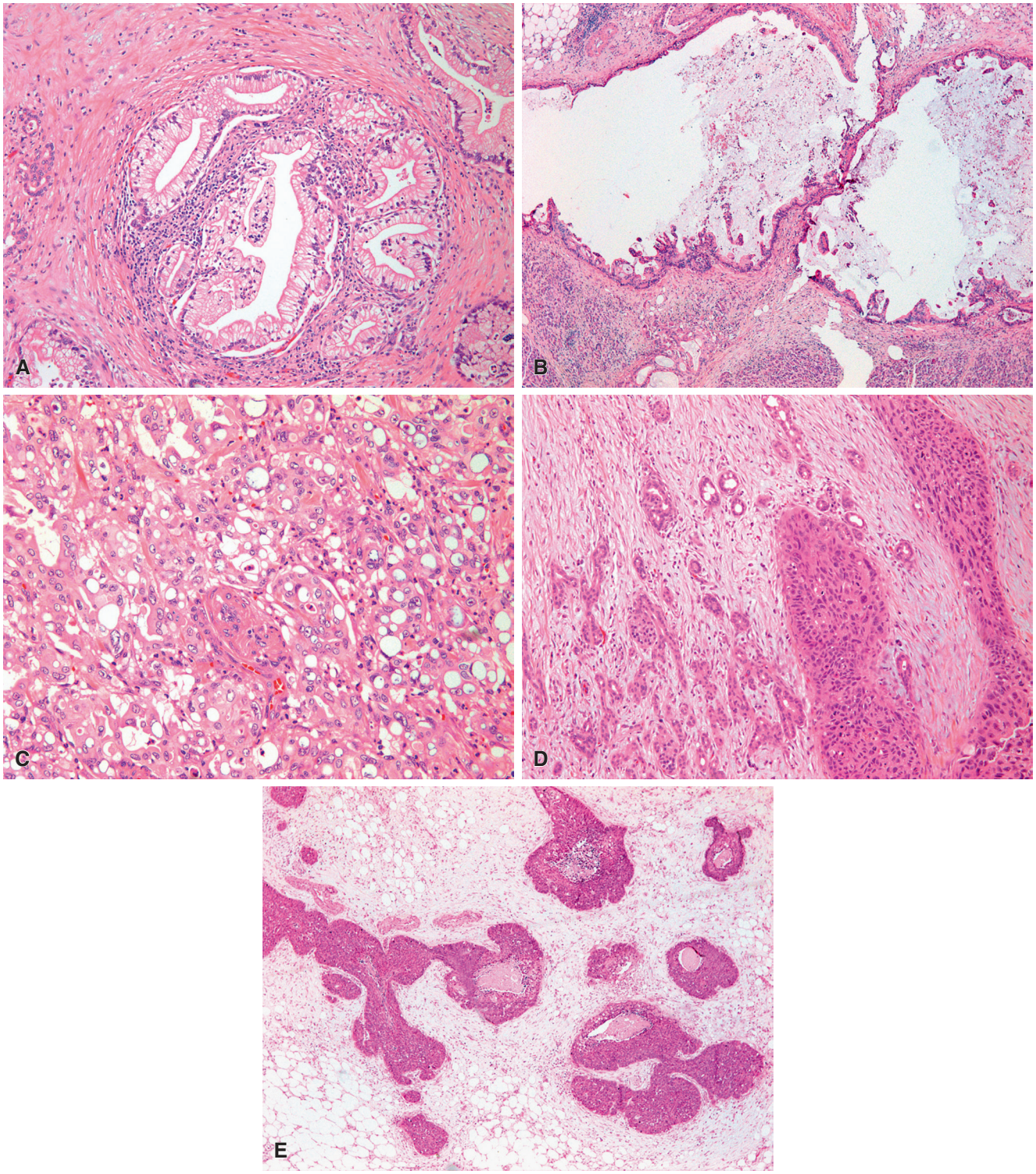

Figure 22.19 **A,** Foamy gland pattern of ductal adenocarcinoma features foamy, microvesicular cytoplasm; small, often basally located nuclei; and condensation of the cytoplasm at the luminal aspect of cell resembling a brush border. **B,** The neoplastic glands in the large duct pattern are large and microcystic, and may be mistaken for benign dilated glands or a lower-grade noninvasive cystic neoplasm. **C**, Vacuolated pattern with cribriformed nests of cells with prominent large, empty vacuoles. **D,** Adenosquamous carcinoma consists of both glandular and squamous components. **E,** Some adenosquamous variants may have prominent basaloid features.

Continued

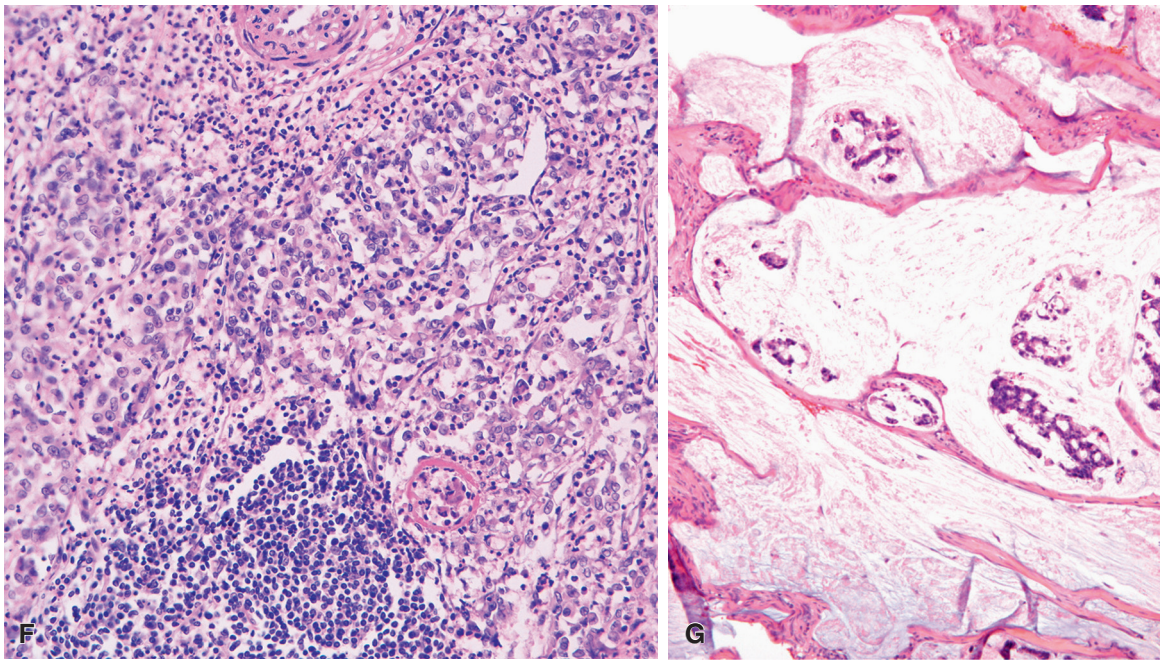

Figure 22.19 cont'd **F,** Medullary carcinoma is similar to that seen in other organs, with a solid growth pattern and numerous tumor-infiltrating lymphocytes. **G,** Colloid carcinoma features large pools of mucin-containing clusters of tumor cells, some of which have signet ring cell features. (**F,** Courtesy of Dr. Volkan Adsay.)

mucinous tumor[201–202]; biphasic tumors with a sarcomatoid component and a separate glandular component may be termed carcinosarcomas. The presence in both components of the same *KRAS* mutations suggests a common origin.[203–205]

Undifferentiated carcinomas with osteoclast-like giant cells are usually large and hemorrhagic, and occasionally they grow in a fashion simulating a pseudocyst.[206] Microscopically, the tumor has a dual population: relatively uniform spindle cells of mesenchymal appearance and atypical cytologic features (such as nuclear hyperchromasia and high mitotic activity) alternate with multinucleated giant cells having an appearance and a histochemical profile indistinguishable from that of normal osteoclasts.[200,207] The nuclei of these osteoclast-like cells are uniformly small, and mitoses are absent. Bizarre giant cells with atypical nuclei may also be found, however (Fig. 22.20D).

Histochemical and Immunohistochemical Features of Pancreatic Ductal Adenocarcinoma

Most pancreatic ductal adenocarcinomas express cell surface–associated mucins, including MUC1, MUC3, MUC4, and MUC5AC.[208–210] Immunohistochemically, glycoprotein MUC1 is expressed in over 80% of conventional invasive ductal carcinomas and in a similar percentage of high-grade PanIN, supporting a pathogenetic relationship between the two; this is in contrast to the intraductal papillary carcinomas discussed later, mucinous (colloid) carcinomas, ampullary carcinomas, and colorectal carcinomas, which are more often positive for MUC2.[211] MUC6 is expressed in approximately one-third of ductal adenocarcinomas.[212]

The keratins expressed are those of simple epithelia such as 7, 8, 18, and 19 (as normal ductal cells),[208] but also 20, 17, and occasionally cytokeratin 5/6.[213,214] Cytokeratin 20 is expressed less frequently in pancreatic ductal than in ampullary adenocarcinomas,[213] but the difference is not such as to be of diagnostic assistance. CK20 expression may be strong and diffuse in pancreatic colloid carcinomas, as they express markers of intestinal differentiation.[215] Ductal adenocarcinomas also frequently express EMA, CEA, CA125, mesothelin, TAG72, DUPAN2, and CA 19-9.[170,216–218] Unfortunately, ducts in cases of chronic pancreatitis also exhibit immunoreactivity for many of these markers, thus greatly diminishing their differential diagnostic utility. However, CEA, TAG72, and CA125 are not typically expressed in non-neoplastic ducts.[219–221] A high proportion of ductal adenocarcinomas also contain a minor population of neoplastic cells that are immunoreactive with neuroendocrine markers, such as synaptophysin or chromogranin.[222–223] There is also frequent expression of the neural cell adhesion molecule N-CAM.[224]

Molecular Genetic Features

A large number of molecular alterations have been described in pancreatic ductal adenocarcinoma.[170,225,226] The most commonly mutated genes include *KRAS*, *CDKN2A* (*p16*), *TP53*, *SMAD4*/*DPC4*, and *MKK4*. Mutations of the *KRAS* oncogene are found in over 90% of the cases and represent an early genetic alteration.[225] Mutations of *p16*/*CDKN2A*, *TP53*, and *SMAD4* occur in more than half of cases as well.[227,228] These molecular alterations are typical of pancreatic ductal adenocarcinoma and distinguish them at a molecular level from other pancreatic neoplasms.[229] It is worth mentioning that the search for genetic molecular alterations in the invasive component of pancreatic ductal adenocarcinoma and in precursor intraepithelial lesions of the same specimen have provided key information on the genetic progression of pancreatic carcinoma (Fig. 22.21).[230,231] It is important to point out that patients with chronic pancreatitis, but lacking microscopic features of invasive or in situ adenocarcinoma or ductal atypia, often have *KRAS* mutations in the non-neoplastic epithelium, indicating that this genetic alteration is not specific for malignancy or even premalignant conditions.[232] Obviously, this limits greatly the diagnostic utility of this marker in histologic or cytologic material. Since *DPC4* is inactivated in approximately half of

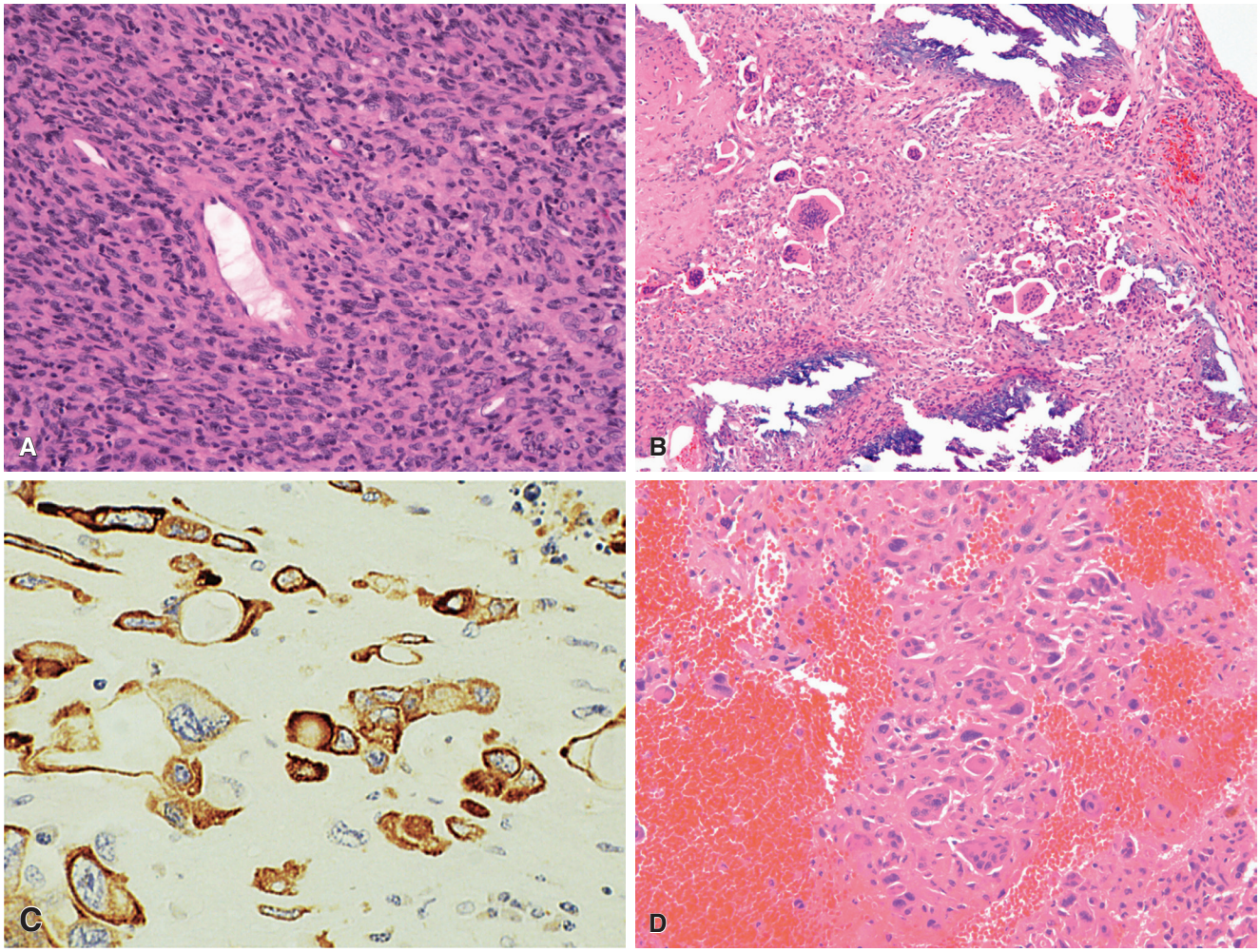

Figure 22.20 **A,** This undifferentiated carcinoma is composed entirely of spindle cells and should not be misinterpreted as a sarcoma. **B,** This example of undifferentiated carcinoma with osteoclast-like giant cells contains areas of cartilage with ossification. **C,** Anaplastic carcinoma of pancreas showing immunoreactivity for keratin. **D,** Some cases contain large anaplastic tumor cells as well as osteoclast-like giant cells (**A,** Courtesy of Dr. Volkan Adsay. **D,** Courtesy of Dr. Becky Wheeler.)

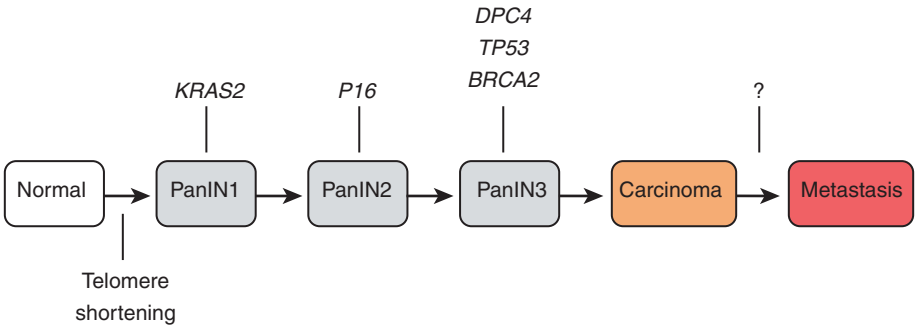

Figure 22.21 **Genetic Progression Model of Pancreatic Carcinogenesis.** The progression from histologically normal epithelium to low-grade pancreatic intraepithelial neoplasia (PanIN1 and PanIN2), to high-grade PanIN3, to invasive carcinoma *(left to right)* is associated with the accumulation of specific genetic alterations. On the basis of their temporal appearance in this progression model, the molecular abnormalities can be classified as early (*KRAS2* mutation, telomere shortening), intermediate (*P16/CDKN2A* loss), or late (mutations of *DPC4/SMAD4, TP53, BRCA2*). However, those changes that specifically promote progression to metastatic disease remain unknown. (From Yachida S, Iacobuzio-Donahue CA. The pathology and genetics of metastatic pancreatic cancer. *Arch Pathol Lab Med*. 2009;133:413–422.)

pancreatic ductal carcinomas but practically never in benign conditions, the immunohistochemical *absence* of the protein product in the ductal epithelium of a pancreatic biopsy specimen is strongly suggestive of carcinoma, while positive staining does not rule out this possibility.[170] Although Lynch syndrome patients have a seven- to eightfold increase in pancreatic ductal adenocarcinoma, MSI does not appear to play a significant role in sporadic ductal adenocarcinomas; the rare cases of pancreatic carcinoma that are MSI-high tend to have the medullary phenotype. These tumors typically do not have *KRAS* mutations but commonly exhibit mutations in the *BRAF* gene, a downstream component of the *KRAS* pathway.[226,233]

Spread and Metastases

Pancreatic ductal adenocarcinoma often spreads widely into the peripancreatic soft tissues.[234] Those located in the head may invade the duodenum (including the ampulla) and the common bile duct. They also tend to surround the mesenteric vessels and the nerve plexus, rendering a complete excision very difficult and often resulting in positive gross or microscopic margins.[235,236] Interestingly, nerve invasion has been correlated with expression of nestin (an intermediate filament found in neuroepithelial stem cells) in the tumor cells.[237]

Ductal adenocarcinomas also metastasize to multiple lymph nodes located around the organ. The lymph node groups most often involved in carcinoma of the head of the pancreas are those around the common hepatic artery, hepatoduodenal ligament, posterior pancreaticoduodenal, around the superior mesenteric artery, paraaortic, and anterior pancreaticoduodenal.[238–240] Of note, Cubilla et al.[241] found that in 33% of patients with pancreatic ductal carcinoma, nodal metastases were present in groups of nodes not usually removed with the standard Whipple procedure. Lymph node metastases may occur very early in the course of the disease, even in T1 and T2 tumors.[242,243] The most common sites of distant metastases are liver, peritoneum, lung, adrenal, bone, distant lymph node groups, skin, and central nervous system.[244] Sometimes, a distant nodal metastasis (particularly in the supraclavicular region) is the first manifestation of pancreatic carcinoma.[245]

Cytology

Endoscopic ultrasound-guided fine-needle aspiration (EUS-FNA) has become the method of choice for the diagnosis of both solid and cystic pancreatic tumors, with a sensitivity of approximately 85% and a specificity of approximately 98%, exceeding that of brush cytology.[246] The location of the lesion, size, consistency, and vascularity may all affect the ability to obtain a diagnostic specimen, however. Cytologic specimens may also be used for a variety of ancillary studies useful to the diagnosis of pancreatic ductal adenocarcinoma, including immunohistochemistry for *SMAD4* loss, mutational analysis for *KRAS* and *p16*, FISH (for a number of molecular abnormalities), and microRNA analysis.[247] It should be pointed out that EUS-FNA can also successfully identify cystic lesions such as IPMNs and mucinous cystic tumors,[248] and that in addition to the ancillary studies listed previously, cyst fluid can be analyzed for CEA and CA 19-9.

Surgical Exploration and Frozen Section

At the time of exploration for a presumptive or confirmed diagnosis of carcinoma of the pancreas or ampullary region, the surgeon will search for evidence of metastatic disease in the peripancreatic nodes, liver, and peritoneum, and typically a frozen section will be requested if a lesion at any of these sites is encountered. In the absence of detectable metastases, the surgery will proceed. If the diagnosis has not been confirmed preoperatively, and a mass is palpated in the pancreas, a frozen section on a core needle biopsy or an intraoperative fine-needle aspiration will often be requested. The last technique has become popular because it minimizes the possibilities of hemorrhage, pancreatitis, and tumor seeding that exist with the biopsy procedures.[249] When the pancreatic head is biopsied, experience is required to avoid the common bile duct, the gastroduodenal artery, and the portal vein.

Although current literature indicates that reexcision to try and achieve negative margin status is not associated with improved patient survival,[250,251] the performance of intraoperative frozen sections on margins during the resection of pancreatic adenocarcinomas is still routine practice in many institutions. Frozen section interpretation of pancreatic lesions can be very difficult because of the well-differentiated nature of many carcinomas on one hand, and the architectural distortion resulting from chronic pancreatitis on the other (see earlier).[252,253] One should search for perineurial invasion and also evaluate carefully the cytologic features of the glandular formations.[253] When examining sections from the terminal portion of the common bile duct or the ampullary region, one should be careful not to misinterpret accessory pancreatic ducts or periluminal sacculi of Beale as malignant.[254] If all of these precautions are heeded, the accuracy of the intraoperative frozen section diagnosis is very high, and the percentage of cases in which the diagnosis needs to be deferred is low.[255]

Treatment

Treatment of pancreatic adenocarcinoma may include surgery, chemotherapy, and radiation, depending on the stage of the tumor.[152,256] Surgery is considered to be the only curative treatment. Adenocarcinomas without distant metastases are categorized as resectable, borderline resectable, or locally advanced, although definitions of these terms are not standardized and depend on surgical techniques and the ability of a given center to perform en bloc resection of the portal vein, superior mesenteric vein, or both.[149,256] Surgical approaches include the Whipple operation (pancreaticoduodenectomy), total pancreatectomy, and distal pancreatectomy for neoplasms of the distal body/tail, and it is recommended that 12–15 lymph nodes be resected for optimal pathologic staging.[152] These operations have traditionally carried a 10%–20% mortality rate,[257,258] but this has decreased to less than 2% in recent times in specialized centers.[149] Surgical outcomes tend to correlate strongly with the volume of cases encountered by both the surgeon and the institution.[149,256] A plea has been made to include a retroperitoneal resection (with removal of nerve plexuses and lymph nodes) in curative resections for patients with stage I or II pancreatic carcinoma to diminish the frequency of retroperitoneal recurrence, but many authorities advise against this due to lack of evidence for survival advantage and compromised quality of life due to intractable diarrhea.[256]

Adjuvant chemotherapy may be given after surgery for resectable pancreatic cancer and may result in improved disease-free and overall survival; studies are ongoing regarding the optimal drug regimen.[152,256] The median overall survival remains at only 20–22 months, however.[152] The role of neoadjuvant chemotherapy in borderline resectable or locally advanced adenocarcinomas remains controversial.[149,256] Unfortunately the majority of patients present with metastatic disease, and chemotherapy is the mainstay of therapy for this group, typically with a gemcitabine-based regimen.[152] The advantages of adding radiation to a chemotherapy regimen remain controversial.[149,152,256] Patients requiring palliative care may benefit from surgical, radiologic, or endoscopic interventions for gastric, small bowel, or biliary obstruction.[256] Tumors treated with modern preoperative neoadjuvant chemoradiation regimes often show fibrosis and extensive necrosis.[259]

A certain number of Whipple operations (almost 10% in some large centers) performed for the clinical impression of pancreatic carcinoma will reveal only non-neoplastic disease upon microscopic examination of the resected specimen; a significant number of these cases are ultimately diagnosed as autoimmune pancreatitis (see earlier).[260] This occurrence should be reduced to a minimum, but at the current stage of knowledge it must be accepted as one of the inevitable occasional outcomes of the procedure.

Prognosis

As in most other organs, stage is the most important prognostic determinator. Pancreatic adenocarcinoma is staged using the tumor–node–metastasis classification (AJCC classification scheme in North America). Tumors are often clinically staged using contrast-enhanced CT scan, which is about 80% accurate.[149] Median overall survival is approximately 4 months. When segregated by stage, overall survival ranges from approximately 40% (stage I) to 8% (stage IV) at 1 year, to 12% (stage 1) and 0.7% (stage IV) at 5 years.[261] Tumor size, node status, and distant metastases are independent predictors of survival.[261] Other adverse prognostic factors include high tumor grade, markedly elevated serum CA 19-9, persistently elevated CA 19-9 postoperatively, and positive resection margins.[152] It has been claimed that cytokeratin 20 and maspin expression are associated with decreased overall survival,[262,263] and *SMAD4* gene inactivation is associated with a worse prognosis as well.[264]

Cystic Neoplasms

Secondary cystic changes can be seen in most types of pancreatic neoplasms, whether of exocrine or endocrine nature.[265] These are to be distinguished from tumors in which a cystic configuration is universally present and part of their definition (i.e., cystadenomas and cystadenocarcinomas). It is just as important for these to be clearly separated from the non-neoplastic cysts previously described, and it is recommended that confusing terms such as proliferative pancreatic cysts be avoided.[266] The large majority of cystic pancreatic neoplasms fall into two distinct categories—serous and mucinous—while acknowledging the fact that occasional examples are difficult to classify.[267]

Serous Cystic Neoplasms

Serous cystadenoma, also known as microcystic adenoma or glycogen-rich cystadenoma, usually presents grossly as a large multiloculated mass, the individual cystic cavities being small and filled with a clear ("serous") fluid (Fig. 22.22A and B).[268,269] The spongy appearance of the cut surface is reminiscent of that of infantile polycystic kidney. Occasionally, the gross appearance is macrocystic (either multilocular or unilocular) (Fig. 22.22C) or, rarely, solid.[268,269] Most cases are solitary, but a few multicentric examples are on record.[269] A central scar is present in nearly half of the cases.[269]

Microscopically, they are composed of multiple small cysts with varying amounts of fibrous stroma. The cysts are lined by small, flat, or cuboidal cells containing abundant glycogen but only an insignificant amount of mucin (Fig. 22.22D and E).[268–270] The nuclei are small and round, and the cytoplasm is clear. Small papillae that project into the cyst lumens may also be seen. The amount of stroma is very variable, ranging from delicate and highly vascular to dense and hyalinized[268]; exceptionally, the stroma of the tumor is found to contain amyloid deposits.[271] The stroma may feature calcifications, hemosiderin, or cholesterol clefts, and occasionally islets of Langerhans or acinar tissue can be present in the trabeculae.[268] Immunohistochemically, there is reactivity for EMA, low-molecular-weight and broad-spectrum keratins, alpha-inhibin, MUC6, and calponin.[272,273] The fluid contained in the cyst lumens has a low CEA level, in contrast to that of mucinous neoplasms.[274]

The patients are usually elderly, and these tumors occur more commonly in women.[269] The disease either is discovered incidentally or manifests as an abdominal mass with local discomfort or pain. Some of the cases occur in the context of VHL disease[275] and may harbor allelic deletions and mutations of the VHL tumor suppressor gene. Serous cystic tumors have been seen in pancreata harboring ductal adenocarcinoma, neuroendocrine tumors (NETs), or IPMN elsewhere.[269] Diabetes may be associated with these lesions if sufficient islet cell tissue is destroyed by the tumor. When located in the head of the pancreas, which is often the case, these tumors may result in gastrointestinal or biliary obstruction.[276] Excision is curative, although recent studies advocate for conservative management in the majority of these lesions.[276]

A malignant counterpart of this tumor has been described as *serous cystadenocarcinoma* or *microcystic adenocarcinoma*,[277,278] but the existence of a true malignant counterpart to serous cystadenomas remains controversial. Recent reappraisals have shown that most cases previously designated as "malignant" or "invasive" serous neoplasms were either adherent to or invading local structures, sometimes associated with inflammation and hemorrhage, but were neither cytologically malignant or truly metastatic.[269] Some cases have reportedly exhibited nuclear atypia, perineurial invasion, and an aneuploid DNA pattern,[279] but interestingly, aneuploidy has also been found in several morphologically unremarkable serous cystadenomas.[280] Exceptionally, true adenocarcinomas may arise from serous cystic neoplasms ("carcinoma ex microcystic adenoma").[281]

Mucinous Cystic Neoplasms

MCN of the pancreas are seen in a younger age group (mean age at diagnosis is late 40s) than the preceding type, and predominate in women. Most are found in the body and tail rather than in the head. The clinical presentation is similar to that of the microcystic adenomas and pancreatic pseudocysts.

MCN are typically large (over 10 cm) multilocular or, in rare cases, unilocular cystic neoplasms with smooth internal surfaces that may contain papillary projections or mural nodules (Fig. 22.23A).[282,283] The cysts are lined by tall, mucin-producing columnar cells (Fig. 22.23B), and the underlying stroma is often very cellular, its appearance closely resembling that of ovarian stroma; the presence of the ovarian-type stroma is a diagnostic criterion for this type of tumor. This similarity persists at the phenotypic level, in the sense that this stroma is reactive for estrogen and progesterone receptors and for inhibin (Figs. 22.23C and D).[284,285] Interestingly, stroma with these qualities is also present in neoplasms developing in male patients.[286] Degenerative changes such as hemorrhage, hemosiderin, cholesterol clefts, and calcification are common, as is sloughing of the epithelial lining; these features may lead to confusion with pseudocysts. Aspiration of the cyst fluid can be useful in the differential diagnosis, as the fluid contains higher levels of CEA than nonmucinous cysts.[287] MCN must be distinguished from intraductal papillary mucinous tumors (see later), some of which may exhibit a cyst-like fusiform dilation of the involved ducts; of note, MCN do not communicate with the pancreatic ducts.[288]

There is a range of epithelial atypia in MCN, ranging from bland, tall columnar mucinous epithelium with small, basally located nuclei to complex architecture with cribriforming, papillary formation, increased mitoses, and marked nuclear atypia. It is common to see a wide range of architectural and cytologic atypia within a single neoplasm (Fig. 22.23E and F). Previous classification schemes have divided MCN into mucinous cystadenomas,

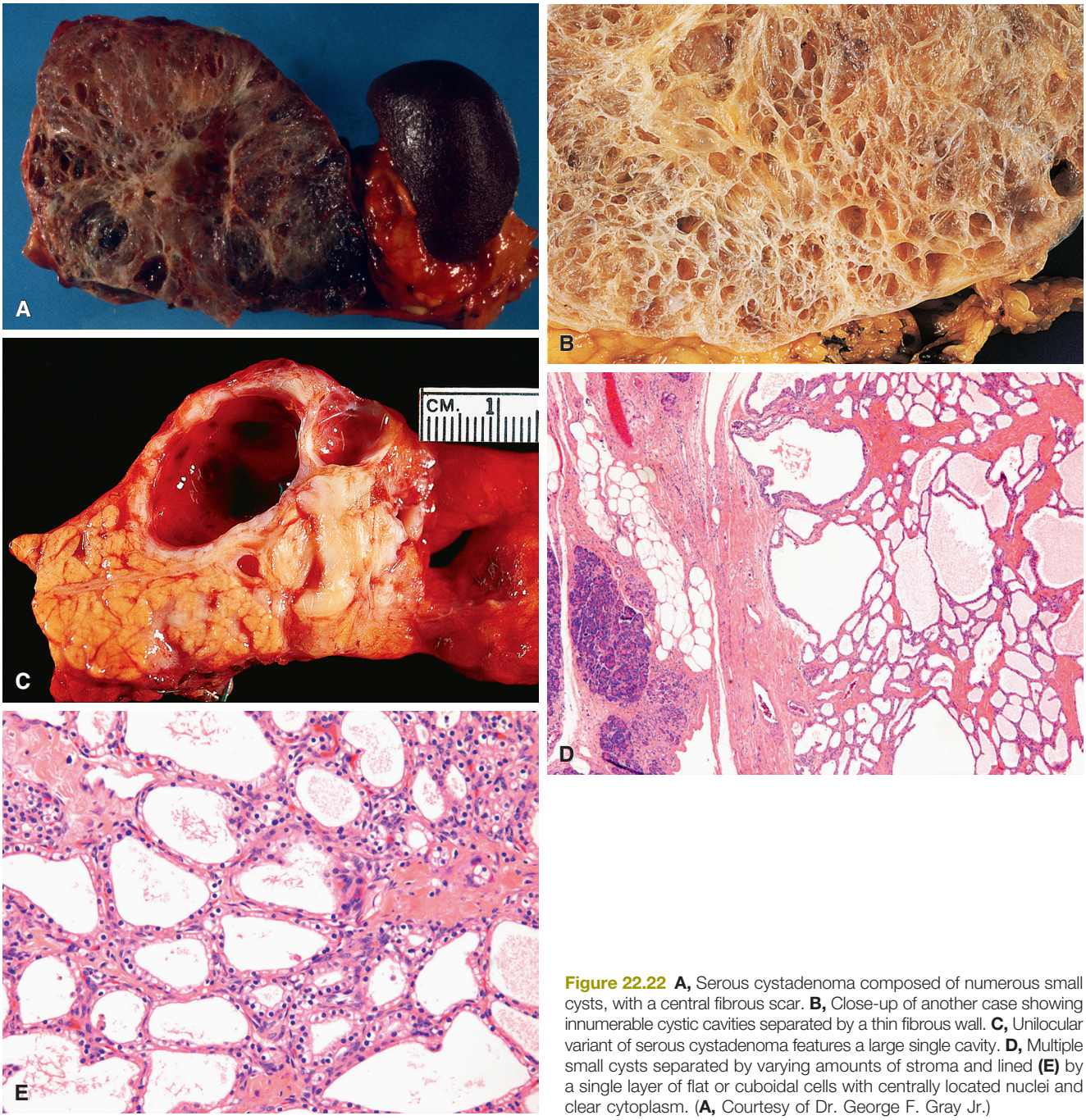

Figure 22.22 **A,** Serous cystadenoma composed of numerous small cysts, with a central fibrous scar. **B,** Close-up of another case showing innumerable cystic cavities separated by a thin fibrous wall. **C,** Unilocular variant of serous cystadenoma features a large single cavity. **D,** Multiple small cysts separated by varying amounts of stroma and lined **(E)** by a single layer of flat or cuboidal cells with centrally located nuclei and clear cytoplasm. (**A,** Courtesy of Dr. George F. Gray Jr.)

borderline MCN, and mucinous cystadenocarcinomas[282,283]; more recent authors have advocated for a two-tiered scheme (low grade/borderline vs. high grade/carcinoma in situ) so that greater uniformity of diagnosis and alignment with management considerations may be achieved.[181]

When invasive adenocarcinoma is present, a variety of patterns may be seen, including ductal adenocarcinoma, adenosquamous carcinoma, mucinous adenocarcinoma, and undifferentiated carcinoma (Fig. 22.24).[283] Invasive foci may be very small, and thus many authorities recommend entirely submitting these neoplasms following complete resection.[282,289] A morphologic variation on the theme of pancreatic MCN (which is again analogous to that having been reported more frequently in mucinous ovarian neoplasms) is represented by the occasional finding of a mural nodule with the features of a giant cell tumor, a pleomorphic sarcoma, or an anaplastic carcinoma.[290,291] As in the ovary, the nature of these various types of proliferation is debatable, but we regard all of them as neoplastic and of epithelial nature, as supported by the molecular evidence of a monoclonal origin.[292]

MCN without associated invasive adenocarcinoma tend to follow a benign course[289]; therefore, we do not subscribe to the extreme view that all MCN should be regarded as mucinous cystadenocarcinomas of low-grade malignant potential.[293] Noninvasive MCN have an excellent prognosis, but tumors with invasive components may

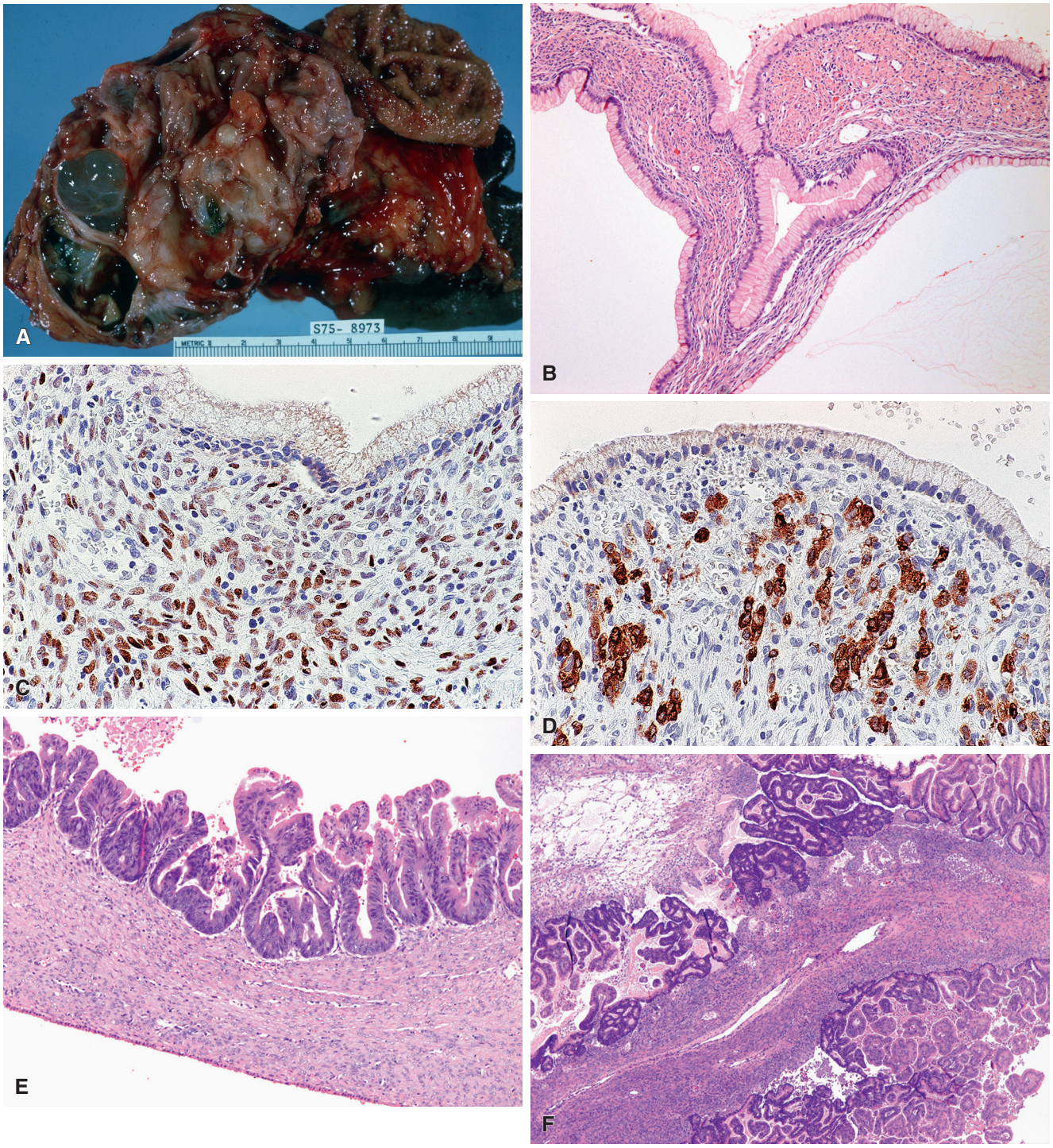

Figure 22.23 Mucinous Cystadenoma of Pancreas. A, This lesion is multilocular and contains abundant mucin; some of the cysts contain mural nodules. **B,** The lining consists of a single layer of tall columnar mucinous epithelium with small, basally located nuclei; note the underlying cellular ovarian-type stroma **(B)**. The ovarian-type stroma is positive for progesterone receptor **(C)** and inhibin **(D)**. **E,** High-grade dysplasia on one side of the cyst *(top)* and attenuated low-grade epithelium on the bottom side of the cyst. **F,** Carcinoma in situ featuring complex cribriforming architecture and high-grade nuclear atypia. Note the underlying ovarian-type stroma. (**A,** Courtesy of Dr. George F. Gray Jr.)

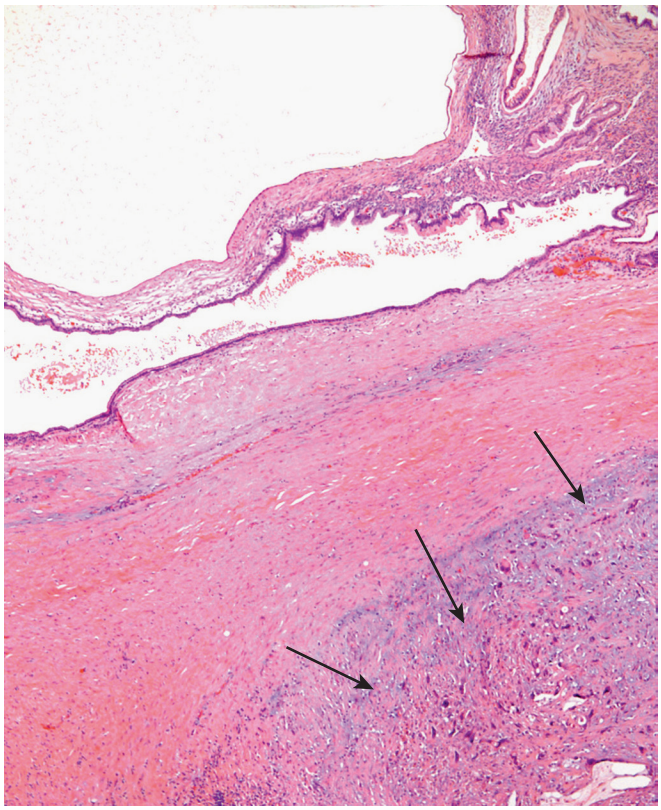

Figure 22.24 A focus of poorly differentiated adenocarcinoma is seen within the wall of a mucinous cystic neoplasm *(arrows)*. Note the overlying low-grade mucinous epithelium and ovarian-type stroma.

have an aggressive clinical course with a 5-year survival rate of approximately 26%.[294] Metastases of this tumor to the ovary may simulate a primary mucinous tumor of this organ.[295]

The cells of MCN express EMA, SOX9, and cytokeratins 7, 8, 18, and 19, as well as CK10 and CK20 in many cases.[296,297] MUC5AC and MUC6 expression is common but not absolute; MUC1 and MUC2 expression is often restricted to goblet cells, and MUC1 may also be limited to invasive components within MCN.[296,297] Reports of abnormal p53 expression in MCN have been inconsistent in the literature, but expression appears to increase with grade of dysplasia.[296] The majority of MCN with a component of invasive adenocarcinoma express EGFR and Her2/neu[296,298]; furthermore, the invasive component loses expression of the DPC4 protein, suggesting that loss of *DPC4* occurs late in neoplastic progression.[299]

Intraductal Neoplasms

Intraductal papillary mucinous neoplasm (IPMN) is a distinct type of intraductal pancreatic tumor that has been defined and segregated from other neoplasms of this organ (particularly MCN) only recently, and subsequently increasingly recognized in Europe and the United States as well as Japan.[132,300–302] As the name suggests, these tumors are defined grossly by their intraductal location and microscopically by the formation of papillary epithelial projections and the production of abundant intraluminal mucin that ultimately leads to dilatation of the ducts.[303] When fully developed, IPMN may feature cystic formations somewhat reminiscent of bronchiectasis in the lung, leading to the previous designations of mucus-hypersecreting, mucin-producing, or duct ectatic tumor.[304–308]

IPMN is most frequently found in the head of the pancreas, although it may involve any part of the ductal system. The tumor may involve the main pancreatic duct, branch ducts, or both (Fig. 22.25A).[303] It is imperative that documentation of the relationship between the tumor and the ducts occurs at gross evaluation. Some cases are multicentric, and multiple microscopic foci of IPMN have been described in atrophic pancreata from patients with a strong family history of pancreatic cancer.[174]

Microscopically, findings range from flat or papillary tall columnar mucinous epithelium with small, basally located nuclei (Fig. 22.25B and C) to complex architecture with high-grade nuclear features (Fig. 22.25D).[303,309] The epithelium is sometimes accompanied by a minor component of endocrine cells.[310] The supporting stroma is dense and fibrotic, but lacks the cellular "ovarian-type" appearance seen in MCN. Similar to MCN, previous classification schemes subclassified IPMN as to the degree of dysplasia (low, intermediate, or high grade),[309] but recent authors have advocated for a two-tiered scheme (low grade/borderline vs. high grade/carcinoma in situ).[181] IPMNs may consist of any one of several cell types, including intestinal (Fig. 22.25E), pancreatobiliary, gastric (null), and oncocytic (Fig. 22.25F), as identified by their respective immunohistochemical profiles; a mixture of cell types has also been described.[132,309,311–313] Although some have debated whether or not the oncocytic subtype is truly an IPMN, the principles discussed here apply regardless.[132] Intestinal type IPMNs are often large, located in the main pancreatic ducts, and frequently contain foci of high-grade dysplasia. Pancreatobiliary type IPMNs are frequently associated with high-grade dysplasia as well. Gastric-type tumors are often located in the branch ducts and may be easily confused with PanIN.[132,312]

The overall incidence of invasion in IPMN is approximately 15% for branch duct type lesions, and 30%–35% for main duct tumors.[309,314] The invasive component may be quite small, and thus submission of the entire IPMN is recommended so that invasive foci are not missed. Invasive adenocarcinomas associated with intestinal type IPMN are typically colloid type, whereas those associated with pancreatobiliary-type IPMN are typically tubular (Fig. 22.25G).[132,309,315] As discussed previously, cyst fluid analysis (particularly for CEA) may help to distinguish cystic mucinous lesions from cystic nonmucinous lesions, but it is not useful in distinguishing noninvasive from invasive IPMN. The prognosis of these tumors is largely dependent upon the presence and extent of the invasive component. Noninvasive IPMN have an excellent prognosis when completely resected with negative margins. IPMN with colloid carcinoma has a better prognosis than those with associated tubular carcinoma and much better than ductal adenocarcinoma without associated IPMN.[309,316] However, tubular carcinomas arising out of IPMN still have a better survival than those with ordinary ductal adenocarcinoma without associated IPMN.

At the molecular level, mutations of the *KRAS* gene are common (with the exception of the oncocytic type); they are found in IMPN with low-grade dysplasia and frequency appears to increase with grade of dysplasia, suggesting that this is an early event important to the neoplastic process.[132,309] Mutations in *GNAS* and *RNF43* are also common (again, with the exception of the oncocytic phenotype), whereas mutations in *TP53*, *STK11*, and *P16/CDKN2A* are much less frequent.[309] The protein product of the *DPC4* gene is present in virtually all cases, in contrast to its frequent absence in ordinary ductal carcinoma, suggesting a substantial difference in the pathogenesis of these two neoplasms.[317]

IPMNs are distinguished from MCN in that the latter do not communicate with the ductal system and usually have ovarian-type stroma beneath the epithelium.[309,318]

IPMNs (particularly gastric type) also have overlapping features with PanIN (see earlier). Strenuous attempts have been made to categorize the two processes and to separate them on the basis of

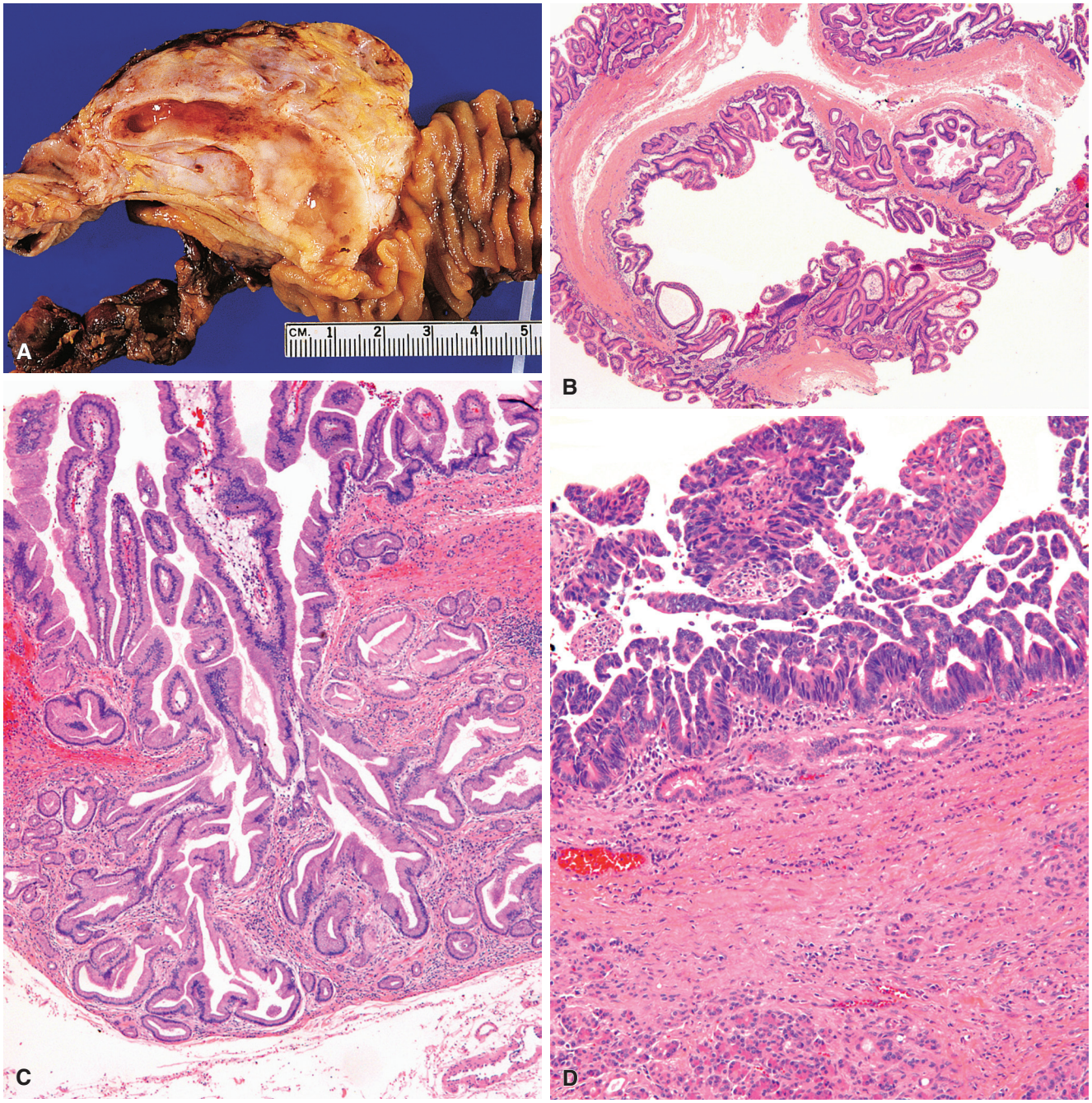

Figure 22.25 **A,** Intraductal papillary mucinous tumor showing marked dilation of the major pancreatic duct with grossly visible papillary excrescences. The duct contained a large amount of mucin in its lumen. The surrounding pancreas shows fibrosis and atrophy. **B,** Low-grade gastric-type IPMN with flat to papillary mucinous epithelium; note the relatively paucicellular dense fibrous stroma. **C,** In this low-grade IPMN, the epithelium is tall columnar with small, basally located nuclei. **D,** Pancreatobiliary type IPMN with high-grade dysplasia.

Continued

topographic, cytoarchitectural, immunohistochemical, and molecular genetic features. For practical purposes, IPMN is defined as a clinically detectable, grossly visible, mucin-producing, typically papillary lesion that produces a lesion of 1.0 cm or more. Conversely, PanINs are microscopic lesions typically involving ducts of less than 0.5 cm in diameter[319]; however, the overlap between the two lesions can produce a considerable amount of frustration. Fortunately, when this problem is encountered at a surgical margin, the important issue is to determine if there is high-grade dysplasia or carcinoma, because low-grade lesions are not clinically actionable.[309] It is obvious that a lot of additional work is needed in order to sort out this confusing state of affairs, which makes painfully clear—perhaps even more so than in other sites—how far we still are in reaching a full understanding of the elusive "precancerous conditions" in the pancreas.

Intraductal tubulopapillary neoplasms (ITPNs) are recently described, extremely rare neoplasms that can involve the head of the pancreas or the entire gland; they are similar to their counterparts in the bile

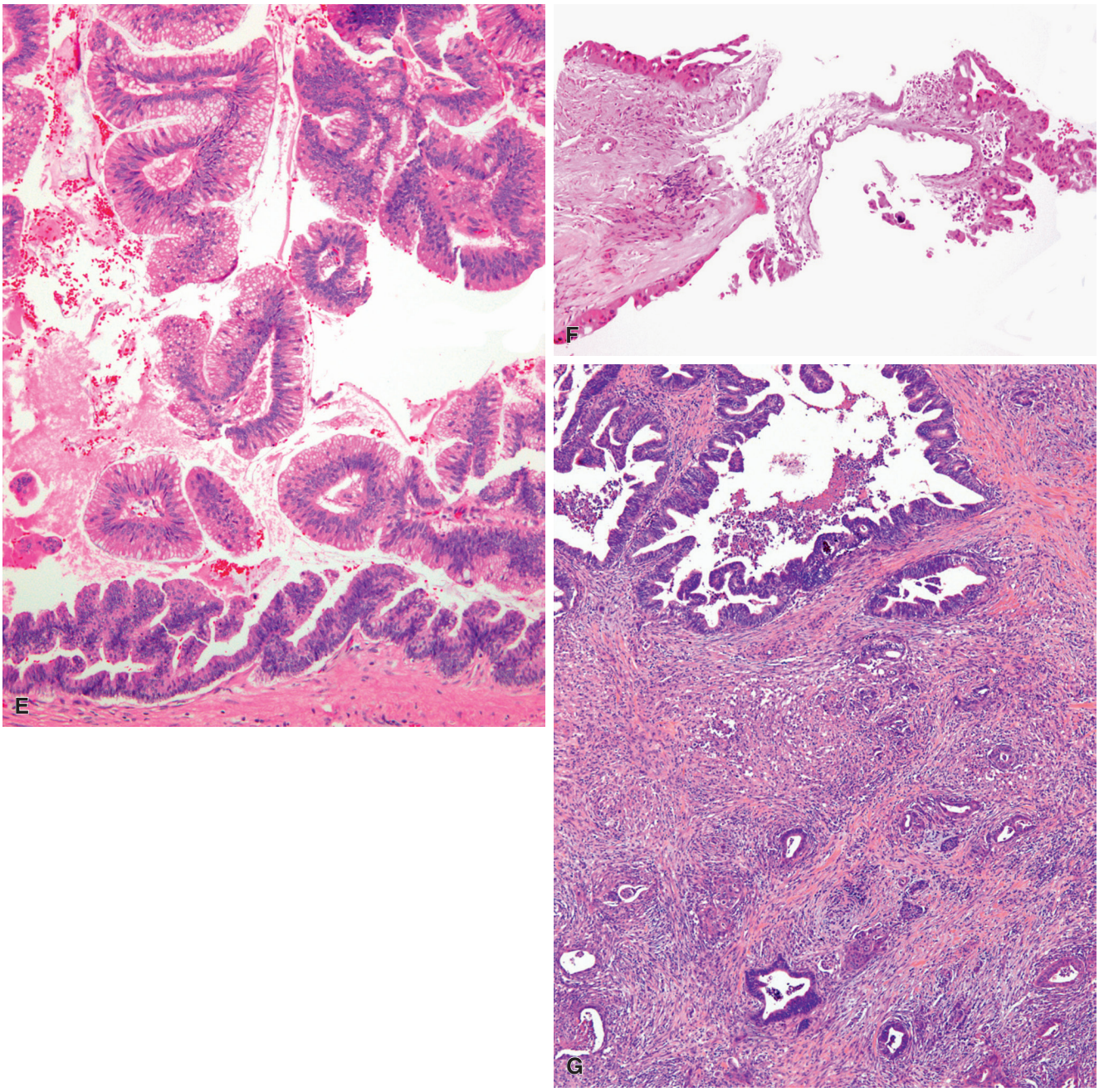

Figure 22.25 cont'd **E,** Intestinal-type IPMN with numerous goblet cells. **F,** Core needle biopsy of oncocytic type IPMN showing striking oncocytic epithelium with punched out spaces and scattered goblet cells. **G,** Adenocarcinoma with a tubular pattern arising from an IPMN with high-grade dysplasia. (**A,** Courtesy of Dr. David S. Klimstra.)

ducts.[320] These are solid, fleshy intraductal masses in which cyst formation is rare. The tumors consist of densely packed tubular glands with some degree of nuclear atypia (Fig. 22.26).[309,321] Occasionally there is formation of papillary structures, and some cases have comedo-type necrosis. Obvious mucin production is rare. In the majority of cases, tumor cells are positive for MUC1 and MUC6 but negative for MUC5AC and MUC2. An invasive component is present in about 40% of cases, but prognosis is better than in ductal adenocarcinoma.[309,322]

Intraductal tubular pyloric gland–type adenoma is a rare polypoid lesion that occurs in the main pancreatic duct of elderly individuals.[323–325] It can be sessile or pedunculated. Microscopically, it is composed of lobules of closely packed tubular glands resembling pyloric glands. Immunohistochemically, these tumors are CK7+/CK20– and express MUC5AC.[309,323] Local excision has been uniformly curative.

Acinar Cell Tumors and Related Neoplasms

Acinar cell carcinoma usually occurs in adults but may also develop in children.[326,327] In most cases, presenting signs are nonspecific, such as nausea, vomiting, and abdominal pain, and jaundice is rare.[327] Approximately 15% of patients present with widespread

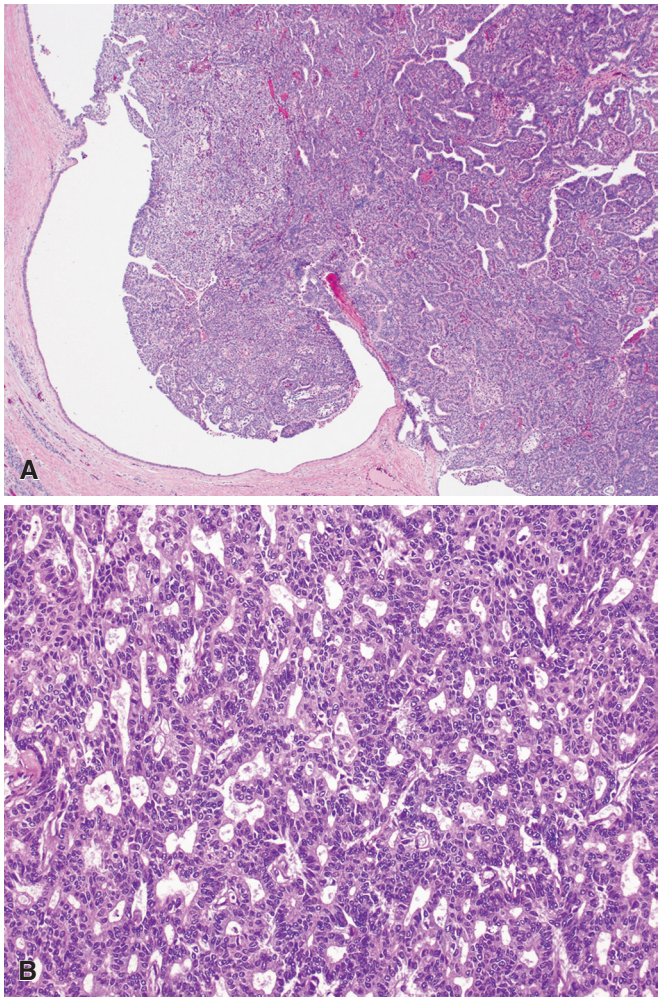

Figure 22.26 **A** and **B,** Intraductal tubulopapillary neoplasm showing intraductal growth of densely packed tubular glands and papillae with mild nuclear atypia. There is no mucin production. (**A** and **B,** Courtesy of Dr. Olca Basturk.)

subcutaneous fat necrosis, eosinophilia, and arthralgia, as a result of the secretion of lipase by the tumor.[327,328] This peculiar clinical syndrome is more common in patients with metastatic disease.

Acinar cell carcinoma presents grossly as a relatively well-circumscribed fleshy mass, averaging 11 cm in greatest diameter, with variably present hemorrhage, cystic degeneration, and necrosis (Fig. 22.27A). Occasionally the pattern of growth is primarily intraductal, a feature possibly associated with a less aggressive course.[329–331] Microscopically, the pattern of growth may be solid, trabecular, glandular, or papillary (Fig. 22.27B), or it may reproduce the normal acinar structure, sometimes to the point of simulating normal pancreas.[326,327] Stroma is typically not prominent. The nuclei are round to oval, with only mild pleomorphism, single prominent nucleoli, and variable mitotic activity (Fig. 22.27C). The cytoplasm tends to be abundant, eosinophilic, and granular. PAS-positive, diastase-resistant cytoplasmic zymogen granules may be present, but may be scant in some cases (Fig. 22.27D). There is typically immunoreactivity for trypsin, chymotrypsin, lipase, and amylase, as well as BCL10[326,327]; the latter shows homology with carboxyl ester hydrolase, an enzyme produced by pancreatic acinar cells.[332] Occasional examples of acinar cell carcinoma (and of pancreatoblastoma, which can be considered its infantile counterpart) can be accompanied by production of alpha-fetoprotein and elevated serum levels of this marker.[333] At the molecular genetic level, acinar cell carcinomas show mutations in the *APC*/β-catenin pathway in about 20% of tumors. Mutations in *KRAS*, *SMAD4*, and *TP53* are rare, a pattern distinct from pancreatic ductal adenocarcinoma[327,334] The prognosis is poor overall, with a 5-year survival of approximately 25%.[327] Metastases are already present at the time of diagnosis in approximately one-half of cases[326]; regional lymph nodes and liver are the most common metastatic sites, but metastases to other sites, such as the ovary, have been reported.[335]

Acinar cell cystadenoma is a rare entity consisting of a unicystic or multicystic lesion lined by well-differentiated acinar cells, usually not connected with the pancreatic ductal system.[336,337] It is regarded as the benign counterpart of acinar cell cystadenocarcinoma, which are large multilocular cystic tumors that may mimic serous cystadenoma grossly. They show a greater degree of cytologic atypia than acinar cell cystadenoma and manifest malignant behavior such as invasion of locoregional structures and metastases.[338,339]

Mixed Acinar Neoplasms

A minor endocrine component (identifiable with chromogranin and/or islet cell hormones) is present in one-third to one-half of the cases of acinar cell carcinomas, but if more than 25% of cells have neuroendocrine differentiation by morphology and/or immunohistochemistry, then the designation of *mixed acinar–neuroendocrine carcinoma (NEC)* should be used.[327,340,341] *Mixed acinar–ductal carcinomas* also occur, a surprising finding in view of the early embryologic divergence of the acinar and ductal cell lineages; the ductal component should comprise at least 25% of the tumor.[327,342] Rarely, cases of mixed acinar–neuroendocrine–ductal carcinoma have been reported.[327,342] It ought to be pointed out that one or more markers of acinar differentiation (such as lipase, chymotrypsin, or trypsin) are present in about two-thirds of pancreatic tumors having the otherwise typical features of pancreatic endocrine neoplasms; this feature is of no prognostic significance and should not alter the tumor designation.[343]

There are variations in acinar architecture that may mimic a neoplasm and have been termed *acinar cell nodule* (which may also mimic islets of Langerhans, Fig. 22.28), *focal acinar transformation*, *acinar cell hyperplasia*, or *eosinophilic degeneration*. These lesions have no known preneoplastic potential in humans.[344–347]

Pancreatoblastoma

Pancreatoblastoma is the most common form of pancreatic neoplasia in childhood, accounting for 25% of pancreatic tumors in the first 10 years of life,[327] but it can also occur in adults; there is a slight male predominance.[348] Isolated cases have been reported in patients with the Beckwith–Wiedemann syndrome and with familial adenomatous polyposis of the colon.[349] Overall survival is approximately 50%.[327]

The mean tumor size is 10 cm, and partial encapsulation is the rule. Microscopically, these are very cellular tumors, often lobular at low power, and made up of solid sheets and acini of uniform cells (Fig. 22.29). Squamoid nests or corpuscles are a constant and characteristic finding. The tumor cells present within these corpuscles often have optically clear nuclei, apparently due to the accumulation of biotin.[350] The stroma may be abundant and occasionally hypercellular, and there may be heterologous cartilage or bone. Neuroendocrine components, ductal components, and/or a primitive small round blue cell component may be present.[327] Immunohistochemically, these tumors show evidence of acinar (pancreatic enzymes), endocrine (synaptophysin and chromogranin), and ductal (CK7 and CK19) differentiation.[327,351] AFP may be produced by the tumor, in keeping with

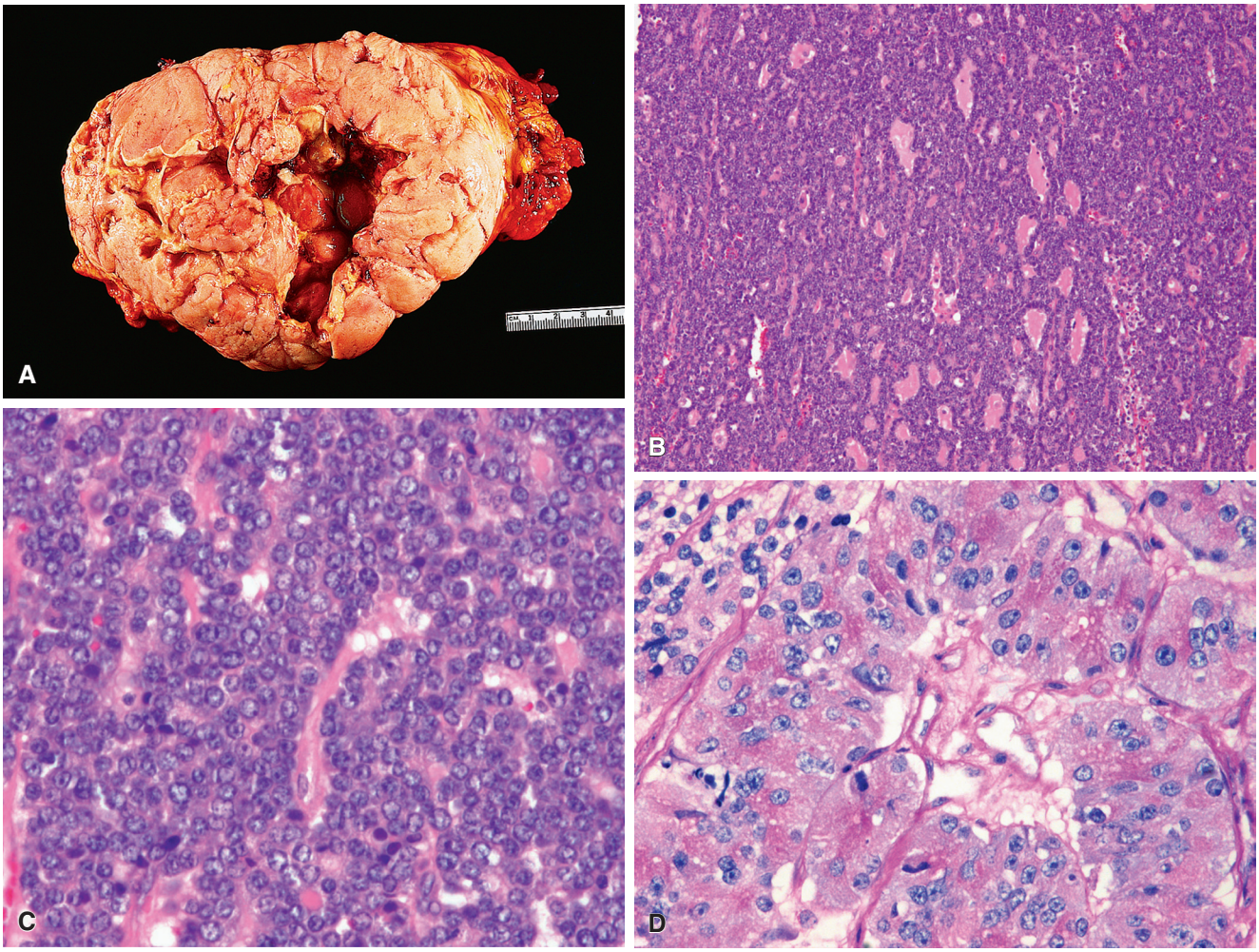

Figure 22.27 **A,** The cut surface of this acinar cell carcinoma is solid and has a necrotic center. It lacks the fibrous component usually seen in ductal adenocarcinoma. **B,** Prominent acinar architecture with minimal stroma is characteristic. **C,** The nuclei are round with mild pleomorphism and a single prominent nucleolus. **D,** PAS-positive, diastase-resistant cytoplasmic granules are seen in some cases (PAS stain).

its primitive nature.[333] The squamoid corpuscles have a characteristic phenotype: they are CK8/CK18/CK19/EMA positive and CK7 negative. There is characteristic nuclear translocation of β-catenin as a result of mutations in the β-catenin *(CTNNB1)* or *APC* gene, and the majority of cases show loss of heterozygosity of the highly imprinted region of chromosome 11p, similar to Wilms tumor and hepatoblastoma (both of which can occur as a component of Beckwith–Wiedemann syndrome).[226,327] Indeed, pancreatoblastoma could be regarded as the infantile counterpart of acinar cell carcinoma, just as hepatoblastoma is the infantile counterpart of hepatocellular carcinoma.[352] It should be kept in mind that not all pancreatic tumors in childhood are pancreatoblastoma; solid pseudopapillary tumors, endocrine tumors, lymphoma, and metastatic tumors also occur.[353,354]

Solid–Pseudopapillary Tumor

Solid–pseudopapillary tumor (SPPT) is the preferred term for a distinctive type of pancreatic tumor previously known as papillary and solid epithelial neoplasm, papillary–cystic neoplasm, or cystic–solid papillary carcinoma. Most (>90%) cases are found in young women, who typically present with abdominal pain. A significant minority of cases are found incidentally on imaging for another reason.[355] Grossly, tumors are usually large and solitary; multicentricity is exceptionally rare.[356] The appearance on cross section range from solid to almost entirely cystic, and often there are areas of hemorrhage and necrosis (Fig. 22.30A). Most cases are surrounded by a well-developed capsule, but in some instances the edges are infiltrative into the adjacent pancreas; invasion of adjacent organs is very rare.[355,357] A few cases have been found anatomically separate from the pancreas, arising from the ovary, retroperitoneum, or GI tract; some of these have occurred in the context of ectopic pancreas.[358]

Microscopically, SPPT is very cellular and simulates somewhat the appearance of a pancreatic endocrine neoplasm. They may have solid and cystic components, in addition to the most distinctive feature, which is the presence of pseudopapillae covered by several layers of epithelial cells (Fig. 22.30B).[355,359] The cells around the pseudopapillae are discohesive, and the fibrovascular cores are often hyalinized; there is also typically cystic degeneration, cholesterol crystals, and foamy histiocytes. Small vessels may be surrounded by a mucoid or myxoid material. The nuclei are ovoid and folded, with indistinct nucleoli and longitudinal grooves; mitoses are few (Fig. 22.30C). Hyaline globules may be present within the cytoplasm of

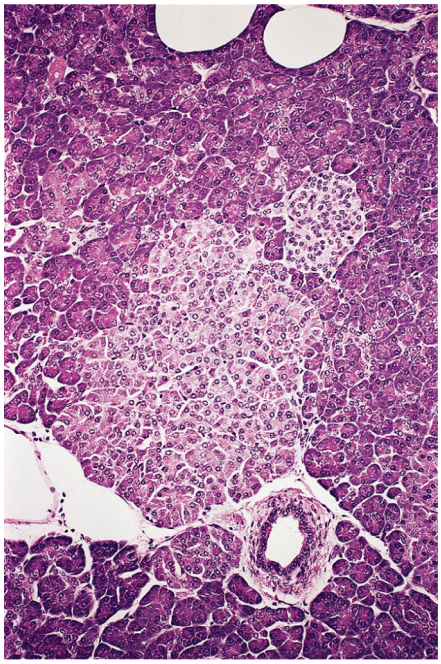

Figure 22.28 Incidental acinar cell hyperplasia, which may be confused with hyperplastic islets of Langerhans.

the tumor cells (Fig. 22.30D). Clear cells can be prominent, and pleomorphic and oncocytic variants have also been reported.[355,360]

Immunohistochemically, there is usually only focal, faint reactivity for keratin. Synaptophysin and CD56 can be focally or diffusely positive, but chromogranin is characteristically negative.[355,361] Tumor cells may also stain with claudin 5 (membranous), claudin 2 (cytoplasmic), galectin 3, progesterone receptor, estrogen receptor beta, CD10, CD99 (dot-like), and α-antitrypsin.[355,361–366] Immunoreactivity for pancreatic enzymes is typically absent.[355] There is membrane loss and aberrant nuclear localization of E-cadherin and β-catenin, with the latter being the most helpful diagnostic immunohistochemical marker (Fig. 22.30E).[366,367] CD117 expression is found immunohistochemically in about half of the cases,[368] but it is not associated with mutations of *KIT* and therefore does not represent an indication for Gleevec therapy. DOG1 reactivity has also been reported.[369] FLI-1 expression has been described as well, but SPPT do not contain the *EWS/FLI-1* translocation.[370]

Despite extensive investigation, the histogenesis of SPPT remains elusive. Progesterone receptors have been detected both immunohistochemically and by the conventional biochemical method.[371,372] These results, in addition to the predilection of SPPT for females and the proximity of the pancreas to the genital ridges during embryogenesis, have led to the hypothesis that SPPT could be derived from genital ridge/ovarian anlage-related stem cells that were attached to the pancreatic tissue during early embryogenesis.[355,373] This theory may gain some support from the recent description of three cases of this tumor type primitive in the ovary.[374] Genetically, SPPTs of the pancreas are different from ordinary ductal adenocarcinomas and almost always exhibit β-catenin *(CTNNB1)* gene mutations.[375] The translocation der(17)t(13;17)(q14;p11) has been detected in a case,[376] and abnormalities have also been reported within chromosomes 11q, 13q, 17q, 1q, and 8q.[377]

The treatment is surgical, and the overall prognosis is excellent.[378,379] However, approximately 10%–15% of the reported cases have resulted in local recurrence and/or metastases, usually in the liver or peritoneum; however, even these patients may have significant long-term survival.[380,381] Therefore, SPPT should be regarded as a neoplasm of low malignant potential.[355] Larger tumor size, invasion into muscular vessels and/or adjacent structures, and histologic features such as diffuse growth pattern, extensive necrosis, and high mitotic rate have been correlated with aggressive behavior.[380,382] Cases having an undifferentiated component and a very aggressive clinical course have been seen rarely.[380]

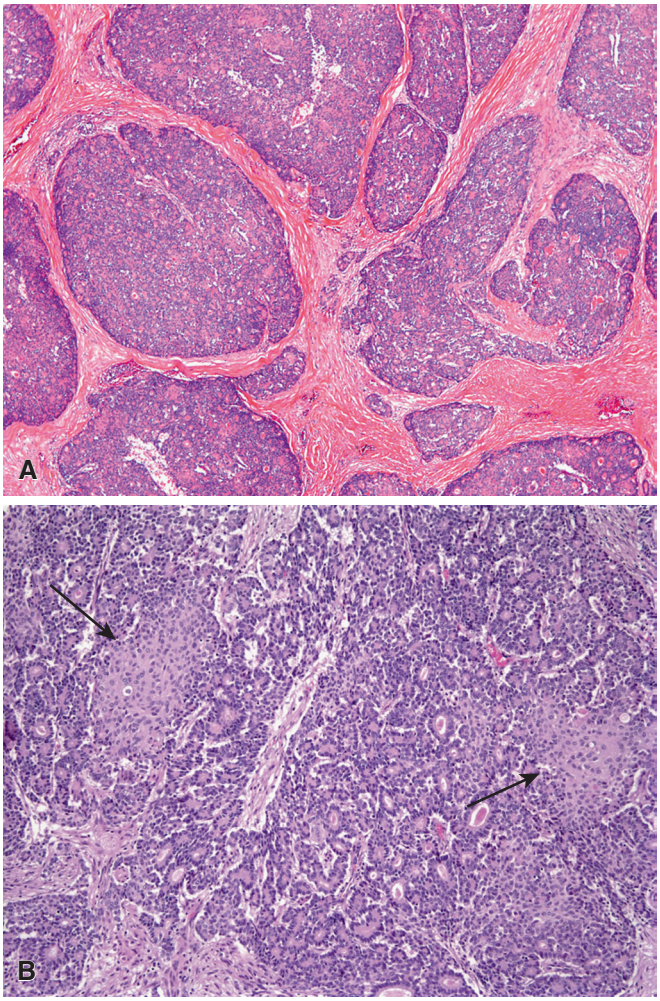

Figure 22.29 **A,** Pancreatoblastomas are often lobular at low power, with prominent stroma. **B,** The cells are arranged in a prominent acinar pattern, and squamoid corpuscles *(arrows)* are prominent.

Pancreatic Neuroendocrine Neoplasms

Endocrine tumors of the pancreas (PanNET) have historically been designated *islet cell tumors* but are now classified as *well-differentiated NET* or *poorly differentiated NEC*.[383] Endocrine tumors account for 5% all pancreatic malignancies.[383] Most occur in adults, although a few have been described in children and even in newborns and infants, typically in the context of a syndrome.[354,384] Several syndromes are associated with PanNET, including the multiple endocrine neoplasia (MEN) syndromes, VHL disease, neurofibromatosis type 1, and tuberous sclerosis (see later).[383] A few cases have been reported in association with chronic pancreatitis, although the relationship between the two is debatable[385]; caution should be exercised, however, not to overdiagnose as neoplastic the proliferating islet cells often seen in that condition (see above and see Fig. 22.9C).

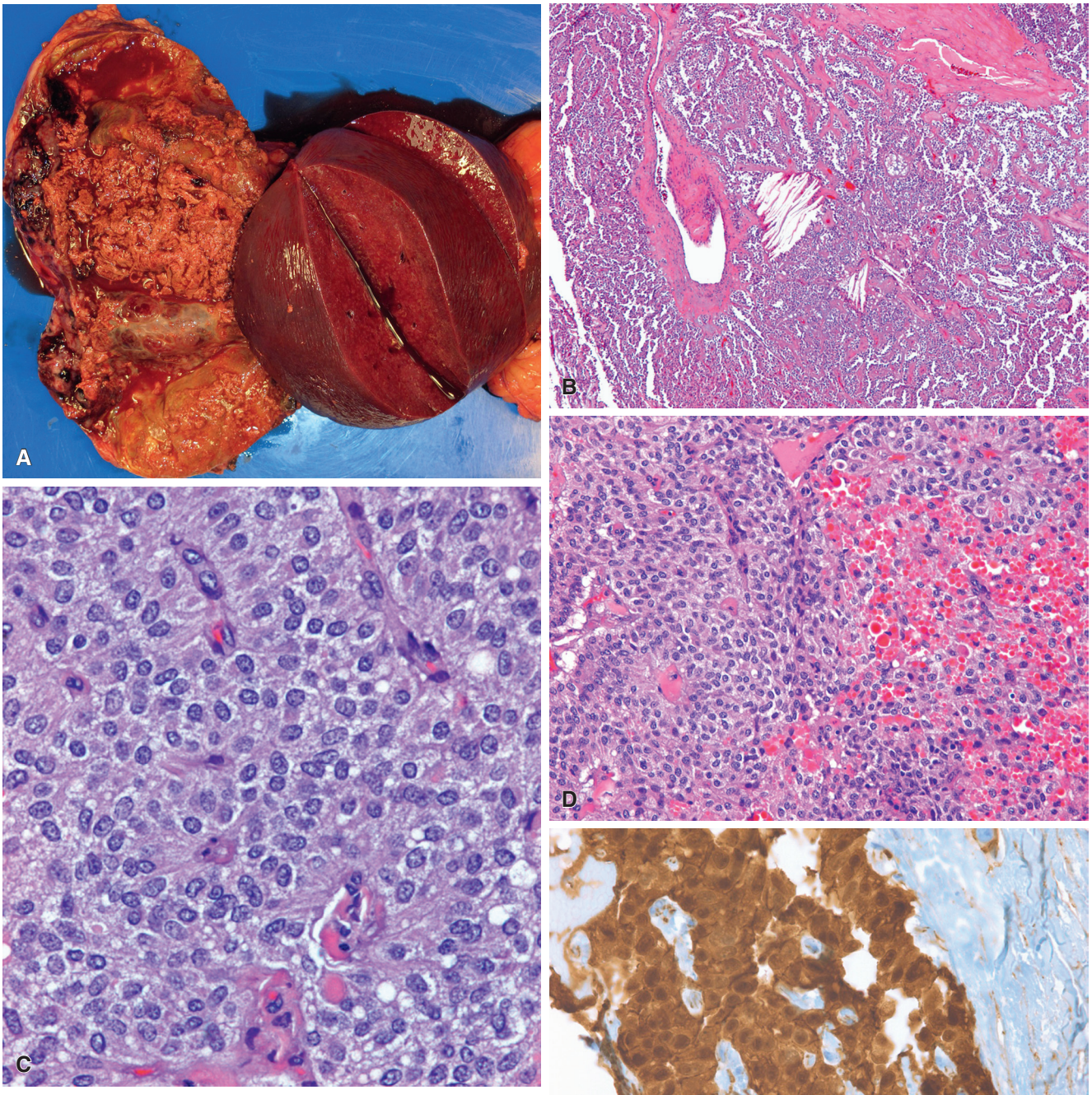

Figure 22.30 **A,** Large solid pseudopapillary tumor with hemorrhage, necrosis, and cystic degeneration. **B,** Pseudopapillae covered by several layers of discohesive cells, with fibrovascular cores. Cholesterol clefts are also present. **C,** Nuclei are ovoid, with indistinct nucleoli and occasional longitudinal grooves. **D,** Cytoplasmic hyaline globules may be very prominent . **E,** Nuclear reactivity with β-catenin is a helpful diagnostic finding.

PanNETs can be located anywhere in the pancreas. Grossly, they are usually solitary, homogeneous masses that lack a well-defined capsule (Fig. 22.31A–D).[386] The appearance of the cut surface depends on the amount of fibrous tissue and vascularity, ranging from tan-yellow to red, resembling spleen or a congested lymph node. Some tumors contain hemorrhage or necrotic foci (Fig. 22.31E), and some may even contain calcium and bone. A few have a predominantly cystic appearance, often in patients with MEN syndrome.[386,387] This secondary, probably degenerative change is to be distinguished from the exceptional PanNET arising within another type of pancreatic cystic neoplasm.[388] On occasion they may have a primarily intraductal pattern of growth.[389]

Microscopically, these tumors are usually composed of small, relatively uniform cuboidal cells with centrally located nuclei and acidophilic or amphophilic, finely granular cytoplasm (Fig. 22.32A). Marked nuclear enlargement and pleomorphism may be present

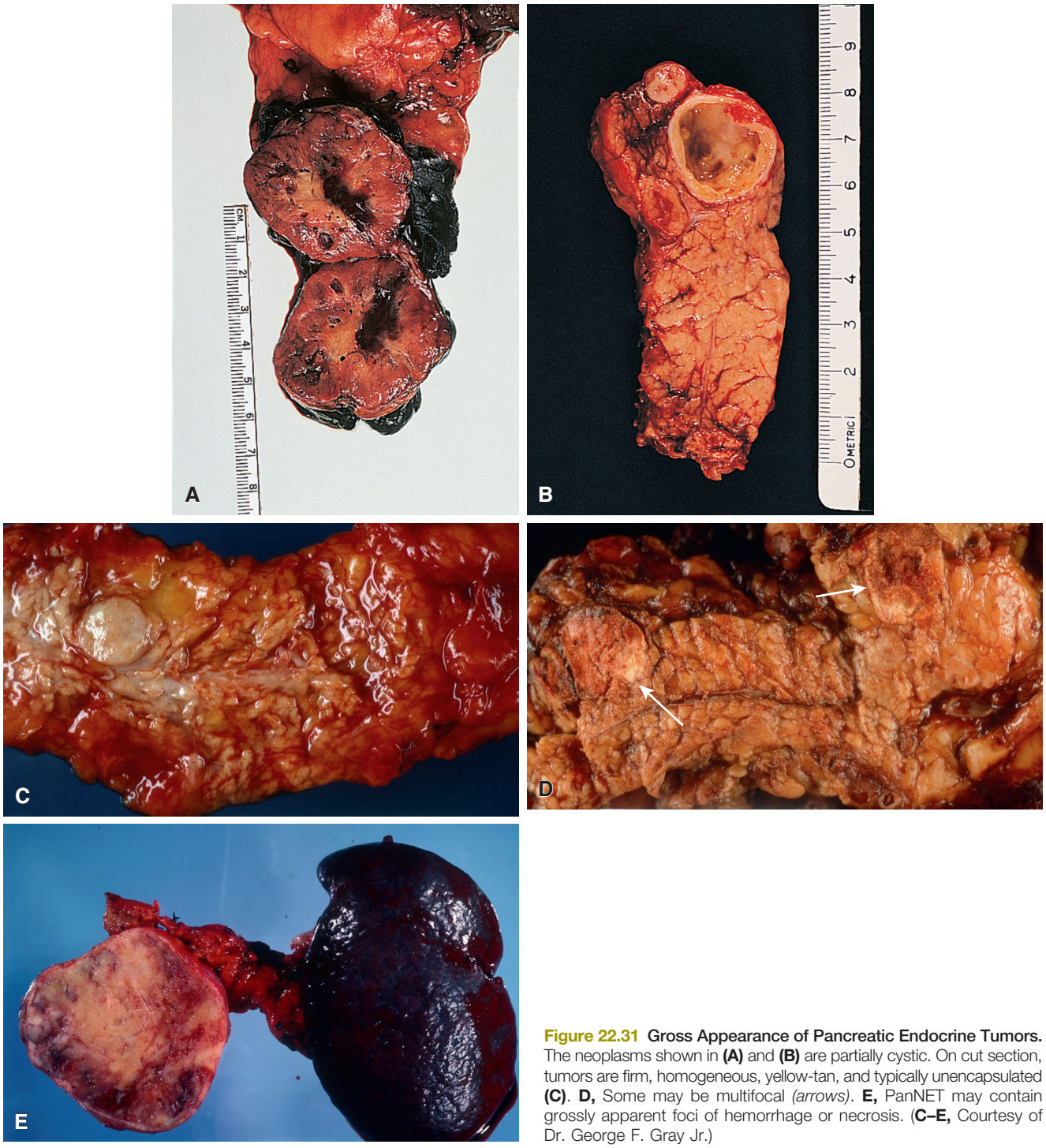

Figure 22.31 Gross Appearance of Pancreatic Endocrine Tumors. The neoplasms shown in **(A)** and **(B)** are partially cystic. On cut section, tumors are firm, homogeneous, yellow-tan, and typically unencapsulated **(C)**. **D,** Some may be multifocal *(arrows)*. **E,** PanNET may contain grossly apparent foci of hemorrhage or necrosis. (**C–E,** Courtesy of Dr. George F. Gray Jr.)

and on occasion can be extreme, but this has no clinical significance (Fig. 22.32B).[386,390] Architectural growth patterns include solid nests, trabecular patterns, and rosettes, and multiple patterns may be present within a single tumor (Fig. 22.32C–E).[383,386] There are a number of unusual morphologic variants. Clear cell PanNETs (Fig. 22.33A), which are associated with VHL syndrome but can also be seen in sporadic tumors, may mimic renal cell carcinoma histologically.[386,391,392] The cytoplasmic vacuolization is due to the accumulation of cytoplasmic lipid.[393,394] Oncocytic PanNETs are very rare but can mimic hepatocellular carcinoma morphologically (Fig. 22.33B).[386,395] Other unusual morphologic findings include mucin production,[396] black pigmentation (due to the presence of lipofuscin-type granules),[397] spindling of tumor cells (Fig. 22.33C),[398] psammoma bodies (often associated with somatostatinomas) (Fig. 22.33D), and rhabdoid features.[399,400] Rare cases of otherwise typical PanNET with foci of sarcomatoid transformation have also been reported.[401,402]

PanNETs are highly vascular, with small vessels surrounding nests of neoplastic cells. Stroma is typically not prominent (Fig. 22.34A), but in some cases, abundant hyaline stroma is present that may contain calcifications. Some tumors with dense stromal

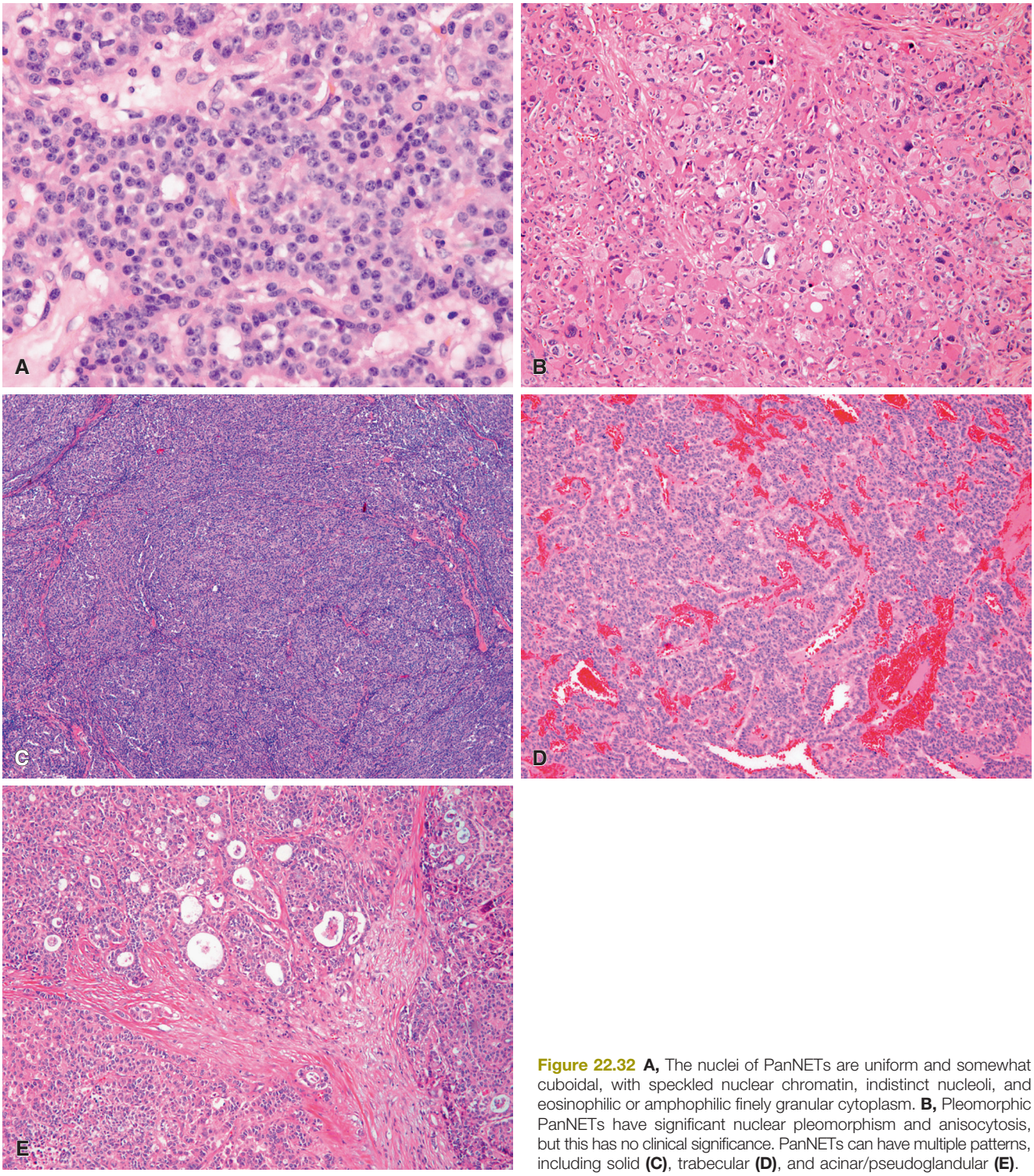

Figure 22.32 **A,** The nuclei of PanNETs are uniform and somewhat cuboidal, with speckled nuclear chromatin, indistinct nucleoli, and eosinophilic or amphophilic finely granular cytoplasm. **B,** Pleomorphic PanNETs have significant nuclear pleomorphism and anisocytosis, but this has no clinical significance. PanNETs can have multiple patterns, including solid **(C)**, trabecular **(D)**, and acinar/pseudoglandular **(E)**.

fibrosis contain neoplastic cells arranged in small nests or tubules and have an infiltrative growth pattern (Fig. 22.34B).[383] Amyloid (Fig. 22.34C) may be encountered in PanNETs, particularly in insulin-secreting neoplasms,[403] but also in other tumor types.[404] The amyloid in these cases, which may have a crystalline configuration, has been designated IAPP and can be detected immunohistochemically.[405,406]

The majority of PanNETs are nonfunctioning, although they may secrete a number of substances at a subclinical level.[407] In other instances PanNETs present with an endocrine abnormality resulting from the secretion of one or more hormones. *Insulinoma* is the most common of these, followed by gastrinoma, VIPoma, and glucagonoma.[383,407] Insulinomas (formerly known as beta cell tumors) typically occur in adults, with a slight female predominance.[407] Only a minority of patients (<10%) are affected by MEN 1. The classic syndrome, known as the Whipple triad, consists of: (1) mental confusion, weakness, fatigue, and convulsions; (2) fasting blood

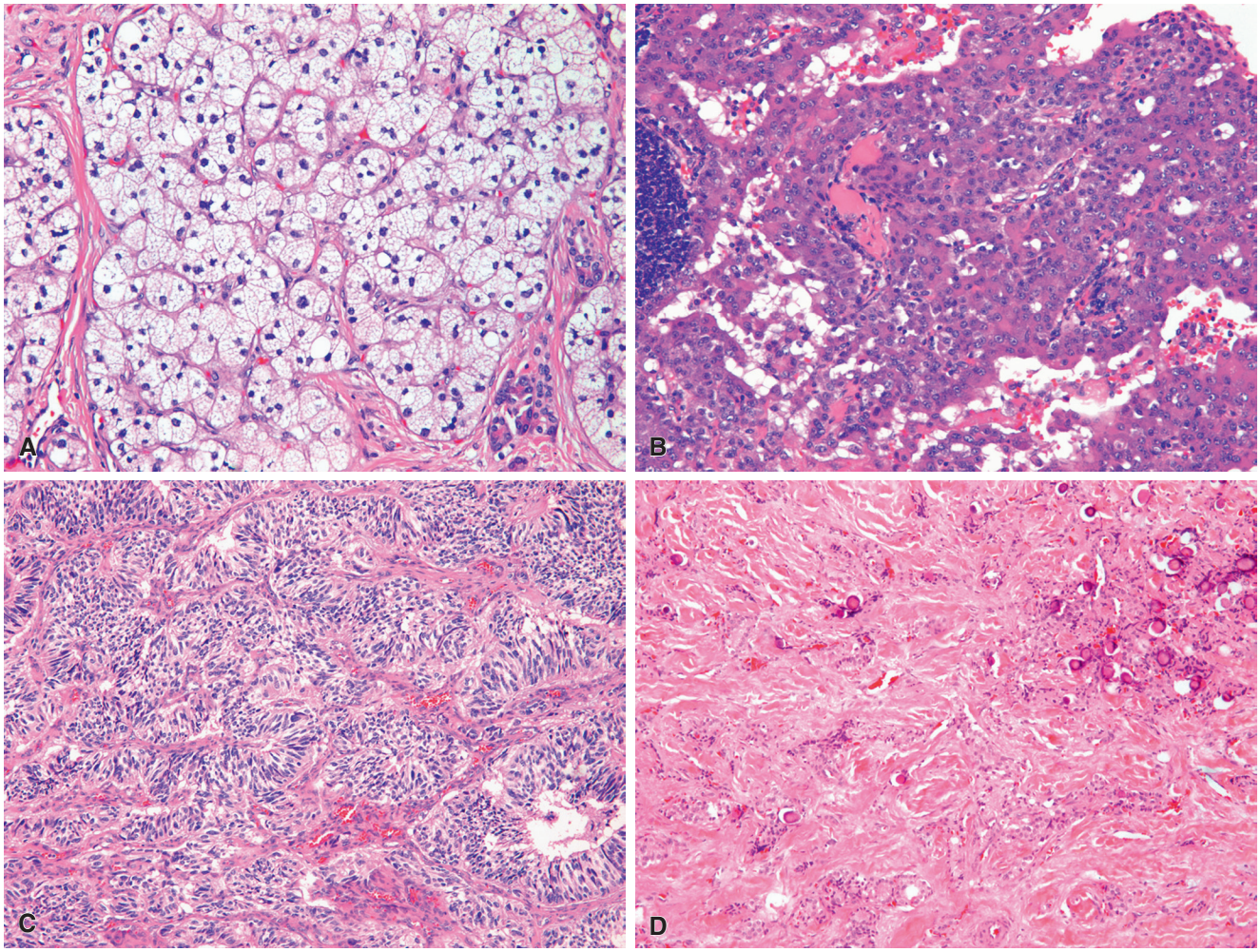

Figure 22.33 Morphologic variants of PanNET include clear cell **(A)** and oncocytic **(B)** tumors, as well as spindled variants **(C)**. Psammoma bodies are associated with somatostatinomas **(D)**.

glucose levels below 50 mg; and (3) relief of symptoms by the administration of glucose. Practically all insulinomas are located within the substance of the pancreas; only 2% of the cases are seen in adjacent areas, such as the duodenal wall. About 70% of them measure 1.5 cm or less, sometimes as little as 3 or 4 mm.[383,407] Presurgical localization of insulinomas is recommended so that the optimal procedure and extent of surgery can be planned. CT and MRI scans are commonly used noninvasive imaging modalities. Endoscopic ultrasound has become the test of choice in many centers, although this technique is most sensitive for tumors in the head of the pancreas. Angiography combined with arterial stimulation venous sampling is another highly sensitive technique for precise localization, with reported 94%–100% accuracy.[408] Over 90% of insulinomas are solitary, but a rare multicentric form also exists ("insulinomatosis").[409] Insulinomas typically pursue an indolent course, with only 7%–10% behaving in an aggressive manner.[383,407,410] Neither conventional morphology nor DNA ploidy patterns are good predictors of behavior.[411] The treatment of insulinomas is surgical, ranging from enucleation to subtotal pancreatic resection depending on the size and location of the tumor.[408]

It is important to recognize that extrapancreatic neoplasms may also be a source of hypoglycemia, which typically disappears upon removal of the tumor.[412] Most reported cases have been due to hepatocellular carcinomas or mesenchymal neoplasms, particularly solitary fibrous tumor[413]; the latter are typically found in the pleura or retroperitoneum, and they tend to attain a very large size. The hypoglycemia is caused by the secretion of insulin-like growth factor II by the tumor cells.[414]

Glucagonomas (formerly alpha cell tumors) can be divided into two distinct types. Those associated with the glucagonoma syndrome are usually solitary and large and have a high incidence of malignancy.[383,415] The glucagonoma syndrome features an abnormal glucose tolerance test, normocytic normochromic anemia, a skin rash known as necrolytic migratory erythema, sore red tongue, angular stomatitis, severe weight loss, depression, and deep vein thrombosis.[407] There are rare reports of glucagonomas that are not associated with the glucagonoma syndrome; they have been reported as multiple and small, and unlike their syndromic counterparts, are nearly always benign.[416] Approximately 20% of tumors are associated with MEN 1.[383]

Gastrinomas (formerly G-cell tumors) can produce the Zollinger–Ellison syndrome as a result of excessive production of gastrin.[417,420] Over half are found in the duodenum, and most of the remainder are located in the pancreas; in a minority of cases, gastrinomas are found in the gastric antrum or in lymph nodes adjacent to the pancreas.[407,417] In the latter, it is not clear whether the tumors arise in ectopic endocrine cells in the lymph nodes or whether they represent metastases from undetected small primary neoplasms.[418,419]

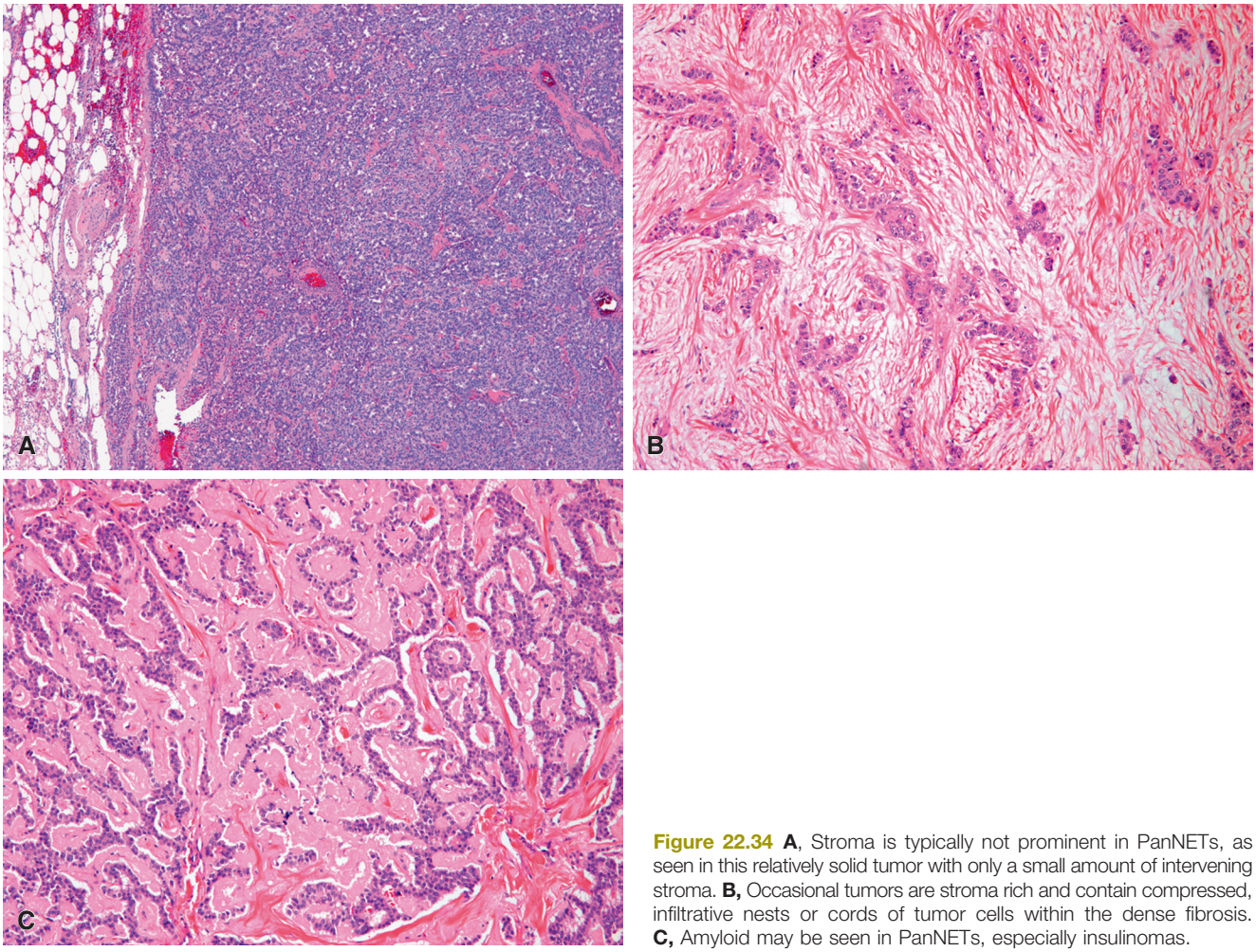

Figure 22.34 **A**, Stroma is typically not prominent in PanNETs, as seen in this relatively solid tumor with only a small amount of intervening stroma. **B,** Occasional tumors are stroma rich and contain compressed, infiltrative nests or cords of tumor cells within the dense fibrosis. **C,** Amyloid may be seen in PanNETs, especially insulinomas.

Rare cases of Zollinger–Ellison syndrome have also been reported in association with tumors of the ovary, mesentery, liver, and intra-abdominal (usually peripancreatic) lymph nodes.[420–423] The Zollinger–Ellison syndrome is characterized by gastric hyperacidity and the formation of gastric, duodenal, or jejunal ulcers. Diarrhea is seen in one-third of the patients as a result of the excessive gastric secretion. Although the original reports emphasized the atypical location of the ulcers, this has not been substantiated in subsequent series. Fasting gastrin levels and the secretin stimulation test are useful diagnostic assays.[417]

Sporadic gastrinomas associated with the Zollinger–Ellison syndrome are nearly always solitary, located in either the pancreas (slightly more often) or the duodenal wall, and often clinically malignant; cases presenting as a component of MEN 1 (~20%) tend to be multicentric, are usually located in the duodenal wall (and very rarely in the pancreas), and are less likely to be clinically malignant.[424,425] The non-neoplastic pancreas in patients with gastrinomas may show islet cell hyperplasia.[426]

Proton pump inhibitors have become the mainstay of medical therapy for patients with hypergastrinemia, and thus gastrectomy is no longer recommended.[417] Surgical approaches to gastrinomas differ between sporadic tumors and those associated with MEN 1. Surgery plays an important role in the management of sporadic gastrinomas, even those presenting with metastases, as resection is believed to decrease the prevalence of metastases and decrease the need for ongoing medical therapy. Resection of hepatic metastases may also be considered in selected patients.[427] Surgical therapy in patients with MEN 1 is more controversial, given that tumors are often small and multiple and that approximately 50% of patients with gastrinomas and MEN 1 present with nodal, hepatic, or distant metastases.[428] Regardless, most follow a protracted course with excellent 10-year survival rates.[427]

Other functional PanNETs include *VIPomas, somatostatinomas* (formerly known as delta cell tumors), and *PP cell tumors*. VIPomas are associated with a severe diarrheal illness (so-called pancreatic cholera) caused by the secretion of vasoactive intestinal peptide (VIP). Only a small percentage of tumors are associated with MEN 1, and an aggressive clinical course is seen in approximately half of cases.[383,407] The majority of somatostatinomas do not produce a clinical syndrome and are discovered incidentally or after evaluation for nonspecific symptoms.[429] The syndrome, seen only in a minority of patients, features diabetes, cholecystolithiasis, steatorrhea, indigestion, hypochlorhydria, and occasionally anemia. Some somatostatinomas are located in the duodenal wall instead of in the pancreas.[430] Psammoma bodies are commonly found among the tumor cells. PP cell tumors are rare if one restricts the definition of the term to neoplasms composed exclusively or predominantly of this cell type.[431] However, a secondary and minor component of PP cells is found in a high proportion of pancreatic endocrine neoplasms of other cell types, including their metastases.[432] Some authors have historically referred to PanNETs that secrete serotonin as "pancreatic carcinoid tumors,"[433] but most currently do not use this term and include

these lesions in the category of well differentiated pancreatic NET. PanNETs (as well as other neuroendocrine neoplasms) can also secrete the alpha and/or beta subunits of hCG. This phenomenon, which can be detected by serum assays or immunohistochemical staining of the tumor, is more commonly seen with malignant neoplasms.[434,435]

As discussed previously, surgery is the mainstay of therapy for the majority of PanNETs. Chemotherapy (particularly streptozotocin), molecular-targeted therapies, and radionuclide therapy may be offered to patients with symptoms and/or progressive disease.[383]

Historically, there has been a great deal of interest in the immunohistochemical staining of PanNETs for peptide hormones. Although it may be possible to document the production of a specific hormone in a given tumor, functional tumors are defined clinically, not by immunohistochemistry, and the hormone staining profile does not have clinical or prognostic significance.[436] For these reasons, staining for peptide hormones is now largely a matter of academic interest.

Examination of routine hematoxylin and eosin sections is often all that is needed to diagnose a PanNET. Immunohistochemically, synaptophysin and chromogranin A may be useful in confirming the diagnosis[383]; CD56 and NSE may also be expressed but are less specific. PanNETs may also express PDX-1, PAX8, Isl1, and GNAS (NESP-55), and CK7, TTF-1, CK20, and CDX2 may be useful in distinguishing NETs of pancreatic origin from those of pulmonary (CK7 and TTF-1 positive) and GI (CDX2 and CK20 positive) origin.[437–440]

The molecular genetics of PanNETs differ significantly from those of pancreatic ductal adenocarcinoma. PanNETs do not typically have mutations in *KRAS*, *CDKN2A*, or *SMAD4*, and only a small minority harbor *TP53* mutations. A total of 45% of sporadic PanNETs have mutually exclusive mutations in *DAXX* or *ATRX*, and *MEN1* mutations are seen in both patients with the syndrome and about half of patients with sporadic PanNETs. Mutations have also been found in elements of the *MTOR* pathway.[383,441,442]

Grading and Prognosis

The 2010 WHO classification of gastrointestinal NET classifies pancreatic NET into three grades, based on mitotic count and Ki-67 proliferation index. G1 (mitoses <2/10HPF and Ki67 index <3%) and G2 (mitoses 2–20/10/HPF or Ki67 index 3%–20%) tumors are considered well differentiated. G3 tumors (mitoses >20/10HPF or Ki67 index >20%) are considered poorly differentiated. Controversy remains over the classification of tumors with morphologic features of well-differentiated PanNETs, but proliferation indices that correlate with a G3 tumor.[383,443,444] In terms of other predictors of clinical malignancy, nuclear pleomorphism is a particularly unreliable criterion (see earlier). The clinical factors that correlate with prognosis in PanNET are age of the patient and extent of the disease at presentation.[445] A number of immunohistochemical markers are reported to be associated with aggressive behavior, including but not limited to CD117, CD10, CK19, PAX8, CD99 (loss), PTEN (loss), fibroblast growth factor receptor, palladin, and p21. However, these have not been tested in large studies and are generally not used for clinical purposes.[383,445–451]

Poorly differentiated neuroendocrine carcinoma (also known as small cell carcinoma of the pancreas) is morphologically similar to its more common pulmonary counterpart, although pancreas NEC often has a large cell phenotype (Fig. 22.35). Expression of at least one neuroendocrine marker is required for the diagnosis of large cell NEC but not for small cell NEC. Metastases to the pancreas from a lung primary must always be considered with the latter type of tumor.[383] It is sometimes associated with ectopic ACTH secretion[452] or hypercalcemia.[453] NECs should be distinguished from Ewing sarcoma/primitive neuroectodermal tumor (PNET), which has also been described in an intrapancreatic location.[454]

Mixed NEC are composed of neuroendocrine elements as well as exocrine elements, including acinar, ductal, or both components.[340,341,455–458] By definition, these tumors must contain morphologically and immunohistochemically separate components of neuroendocrine and ductal or acinar differentiation[443]; focal glandular differentiation or mucin positivity in a PanNET does not meet these criteria. The distinction is important as the ductal adenocarcinoma component implies more aggressive behavior, particularly if the neuroendocrine component is a poorly differentiated NEC. It is also important to be aware that non-neoplastic ducts may be entrapped by PanNETs, and this should not lead to a mistaken diagnosis of mixed endocrine–ductal carcinoma.[459]

Multiple Endocrine Neoplasia

MEN syndromes are inherited in an autosomal dominant fashion and are characterized by hyperplastic or neoplastic proliferation of more than one endocrine gland.[460,461] They are discussed here because some forms of MEN frequently have a clinically important pancreatic endocrine component. The classic forms of MEN include MEN 1 and MEN 2, but VHL, Cowden syndrome, Carney complex, and several other familial endocrine neoplasia syndromes (with both known and unknown genetic basis) also fall into this category.[462,463]

MEN type 1 (Werner syndrome) is characterized by involvement of the anterior pituitary gland (adenomas), pancreas (PanNETs), and parathyroid glands (chief cell hyperplasia).[462,464,465] The disease is due to a variety of inactivating mutations of the *MEN1* gene, located on chromosome 11q13.[462]

Gastrinomas occur in approximately 40% of patients with MEN 1, insulinomas in 10%, and the other functional PanNETs in less than 5% of patients.[462] Thus the main clinical manifestations are primary hyperparathyroidism, the Zollinger–Ellison syndrome, and acromegaly or hypopituitarism. Nonfunctional PanNETs are also very common in this syndrome. Other abnormalities, although less common, involve the adrenal cortex and thyroid gland (in the form of nodular hyperplasia or adenomas), carcinoid tumors of various locations but mainly of foregut derivatives (lung, thymus, and gastrointestinal tract), multiple soft tissue lipomas, multiple leiomyomas at various sites, and Ménétrier disease of the stomach.[462,466] We have seen patients with MEN 1 with thymic carcinoid tumors[467] and with multiple carcinoid tumors of the gastric fundus.[468]

MEN type 2 comprises three variants (MEN 2a, MEN 2b, and familial medullary thyroid carcinoma [FMTC]), all of them caused by germline mutations in the *RET* proto-oncogene, located on chromosome 10q11.2[462,469] and all sharing medullary thyroid carcinoma as part of the disease. Parenthetically, the *RET* oncogene is also commonly mutated in Hirschsprung disease[470,471] and frequently rearranged in papillary thyroid carcinoma (see Chapter 8).

MEN 2a (Sipple syndrome) is characterized by C-cell hyperplasia and medullary carcinoma of the thyroid gland (often multiple and/or bilateral), pheochromocytoma of the adrenal glands (often bilateral and accompanied by adrenal medullary hyperplasia), and primary hyperparathyroidism.[462,472] Thus the overlap between MEN types 1 and 2a is represented by the parathyroid involvement, which is morphologically and functionally similar in these two disorders. *MEN 2b (Gorlin syndrome)* is characterized by medullary carcinoma of the thyroid, adrenal pheochromocytoma (with features similar to those seen in MEN 2a), so-called mucosal neuromas (resulting in hypertrophied corneal nerves, bumpy lips, and enlarged nodular tongue), skeletal abnormalities, and a marfanoid habitus.[462,473,474] Mucosal neuromas (which Carney et al.[475] prefer to designate

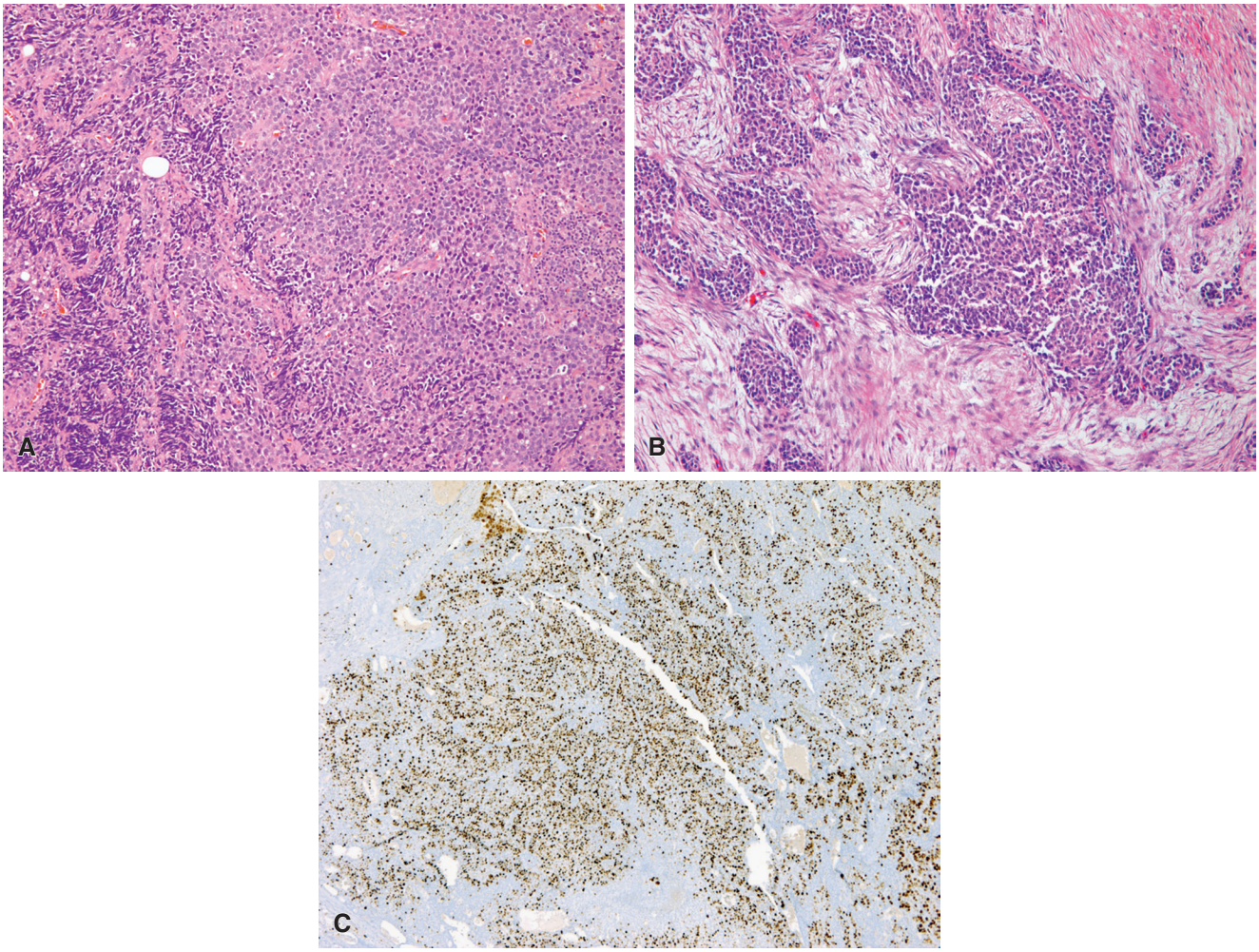

Figure 22.35 Poorly differentiated neuroendocrine carcinomas may have a large cell **(A)** or a small cell **(B)** phenotype. Necrosis and nuclear crush artifact are common, as in the lung. By definition these tumors are G3 **(C)**, with a Ki-67 proliferation index of greater than 20%.

mucosal ganglioneuromas or ganglioneuromatosis) represent the most constant feature of this syndrome. In many cases, there is extensive ganglioneuromatosis of the digestive tract, which may result in constipation, diarrhea, and even the production of megacolon.[476] Sometimes the gastrointestinal manifestations represent the initial manifestation of the disease, and patients with MEN 2b with adenomatous polyposis coli have been rarely reported.[477] Parathyroid disease is distinctly unusual in MEN 2b. It should be noted that in older reports MEN 2b (IIB) was referred to as MEN III.[478] *FMTC* is characterized by the development of medullary thyroid carcinoma in at least four family members, but patients do not have other endocrinopathies.[462] Other combinations of endocrinopathy have also been described, suggesting the existence of additional types or varieties of MEN.[479,480]

Lymphoid Tumors and Tumorlike Conditions

Most malignant lymphomas involving the pancreas originate in peripancreatic or retroperitoneal lymph nodes,[481,482] although rare cases of primary pancreatic lymphoma have been reported (Fig. 22.36), including *diffuse large B-cell lymphoma*, *lymphoblastic lymphoma*, and *anaplastic large cell lymphoma*.[483–485] *Post-transplant lymphoproliferative disorder* rarely involves the pancreas and may mimic pancreatitis or

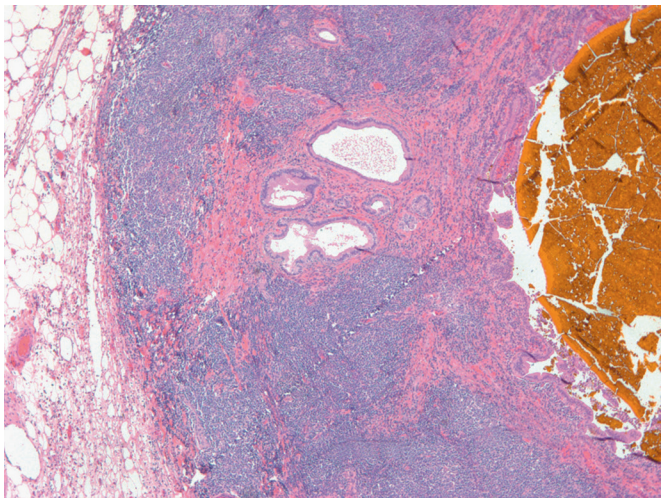

Figure 22.36 Primary diffuse large B-cell lymphoma extending to involve the common bile duct. The patient presented with jaundice and radiographically was thought to have pancreatic ductal adenocarcinoma.

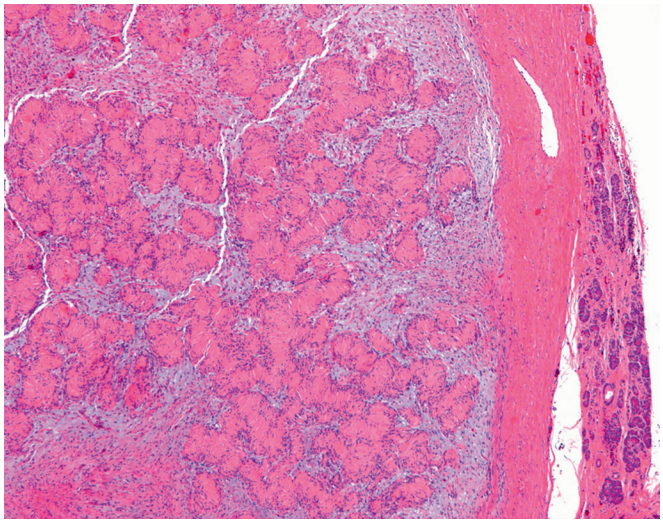

Figure 22.37 Intrapancreatic schwannoma with numerous Verocay bodies.

rejection of the pancreatic allograft.[486] *Multiple myeloma* and both B- and T-cell leukemias rarely involve the pancreas as well and may also mimic pancreatitis or other neoplasms.[487–489] Pancreatic *Castleman's disease* and *Rosai–Dorfman disease* have also been rarely reported.[490,491]

Mesenchymal and Other Primary Tumors

Benign mesenchymal tumors of the pancreas, all extremely rare, include *lymphangioma* (not to be confused with the more common microcystic cystadenoma),[492,493] *adenomatoid tumor*,[494] *schwannoma* (Fig. 22.37),[495,496] *solitary fibrous tumor* (which can behave in a malignant fashion),[497,498] and PEComas.[499–501]

Primary sarcomas of the pancreas are also rare, and most malignant tumors of sarcomatous appearance involving the pancreas are either anaplastic carcinomas or pancreatic involvement by retroperitoneal sarcomas. Primary *liposarcomas*,[502] *leiomyosarcomas*,[503] *clear cell sarcoma*,[504] *angiosarcoma*,[505] *malignant peripheral nerve sheath tumor*,[506] *follicular dendritic cell sarcomas*,[507] and *phyllodes tumor*[508] have been rarely described. There have also been descriptions of pancreatic *gastrointestinal stromal tumor* (*GIST*)[509] and *inflammatory myofibroblastic tumor*[510,511] of the pancreas.

Miscellaneous Tumors and Tumorlike Lesions

Other rare tumors and tumorlike lesions include *intrapancreatic malignant mesothelioma*[512]; *intrapancreatic accessory spleen*[513]; *lipomatous pseudohypertrophy*, which may mimic adenocarcinoma radiographically[514]; and "*solid*" or "*cellular*" *hamartoma*, an exceedingly rare tumor which is CD117 positive and may mimic a GIST.[515]

Metastatic Tumors

Most tumors metastatic to the pancreas involve the organ by direct extension, either from an adjacent viscus or peripancreatic lymph nodes. The lung, large bowel, kidney, and breast are the most common sites for the primary tumor.[516,517] Melanomas, sarcomas, and mesotheliomas can also involve the pancreas secondarily.[518] In some cases, the metastatic tumor has been seen to involve the epithelium of the pancreatic ducts and even to exhibit pagetoid features.[519]

Figure 22.38 This intra-ampullary papillary tubular neoplasm is located entirely within the ampullary channel. (Courtesy of Dr. George F. Gray Jr.)

Ampullary Region

Adenomas and Flat Dysplasia

Ampullary adenomas (adenomas of the duodenal surface of the ampulla) may occur sporadically or in the context of familial adenomatous polyposis.[520] In the past, by the time exploration was carried out, an invasive carcinoma was almost invariably present at the base. As a result, the whole lesion was regarded as malignant. With the increased use of endoscopic procedures for the early detection of these lesions, the clinicopathologic features of these lesions have become better characterized. Ampullary adenomas may be tubular or villous, and the morphologic characteristics are akin to those of colorectal adenomas.[521] Paneth cells and neuroendocrine cells are particularly common in this location.[522] The presence of invasive adenocarcinoma increases with increasing size of the adenoma.[523] Endoscopic resection has essentially replaced pancreaticoduodenectomy in the management of these lesions, and the prognosis is excellent with complete excision.[524] Flat dysplasia in this area has not been well characterized, presumably because these lesions do not cause symptoms or are overrun by associated adenocarcinoma prior to resection.[525]

Intra-ampullary Papillary–Tubular Neoplasm

Intra-ampullary papillary–tubular neoplasms (IAPNs) are, by definition, preinvasive, mass-forming neoplasms that are located almost exclusively within the ampulla; that is, more than 75% of the lesion must be within the ampullary channel (Fig. 22.38) and/or the distalmost segments of the pancreatic or common bile duct, with only minimal involvement of the duodenal mucosa or proximal pancreatic or common bile ducts.[526] Similar to IPMN and counterparts in the gallbladder, the epithelium may be of intestinal or gastric/pancreatobiliary type, and shows various degrees of papillary or tubular growth patterns. Approximately 75% are associated with an invasive component.

Ampullary Carcinoma

Ampullary carcinoma has historically been the term employed for any malignant epithelial tumor centered in the ampulla of Vater, but because of the anatomic complexity inherent in this area, it can be challenging to distinguish between adenocarcinomas of the distal common bile duct, periampullary duodenum, pancreatic head, and true ampulla. Controversy regarding terminology remains, but current

literature classifies ampullary carcinomas into four distinct groups based on anatomic location[527,528]: (1) intra-ampullary carcinomas associated with IAPNs; (2) ductal ampullary carcinomas; (3) periampullary/duodenal carcinomas; and (4) ampullary carcinoma not otherwise specified (N.O.S.). Adenocarcinomas associated with IAPN have the best prognosis. The ductal type is characterized by a constrictive, stenotic growth in the distalmost common bile duct or pancreatic duct at the ampulla, without a significant noninvasive component. These have the worst prognosis but are still less aggressive than pancreatic ductal adenocarcinomas. Periampullary/duodenal carcinomas bulge into the duodenal lumen and have only minimal intra-ampullary extent, although they typically eccentrically involve the ampullary orifice. Ampullary carcinomas N.O.S. are located at the papilla of Vater but do not have the distinguishing characteristics of the other three types. Ampullary carcinomas should be distinguished from carcinomas of pancreas, common bile duct, and duodenum with secondary involvement of the ampulla, because true ampullary carcinomas tend to have a better prognosis.[529,530] Such a distinction, however, may not be possible in advanced cases. Furthermore, underlying pancreatic head adenocarcinomas and other non-ampullary primary tumors may colonize the ampullary mucosa, leading to diagnostic confusion.

Clinically, most individuals are over the age of 60, and there is a slight male predominance.[528] Several cases have been described in patients with familial adenomatous polyposis and with neurofibromatosis type 1.[531,532]

As discussed previously, the gross appearance depends upon the subtype of ampullary carcinoma.[528] Periampullary/duodenal tumors usually bulge into the duodenal lumen, whereas those associated with IAPNs tend to fill the ampullary channel. The ductal type tumors typically have only a small lesion at the ampulla but cause a plaque-like or stenotic growth in the distal ducts. Microscopically, nearly all ampullary malignant tumors are adenocarcinomas (Fig. 22.39), often poorly differentiated, with intestinal, pancreatobiliary, or a mixed phenotype. Morphologic variations on the theme of ampullary carcinoma include examples with a prominent Paneth cell component,[522] adenosquamous carcinoma,[533] micropapillary carcinoma,[534] and cases exhibiting hepatoid differentiation.[535]

Immunohistochemically, the keratin profile tends to match the morphology, in the sense that the tumors with pancreatobiliary appearance are CK7+/CK20–, whereas those with an intestinal morphology are usually CK7–/CK20+.[536] Furthermore, the combination of MUC2 and CDX2 positivity is typical of the intestinal type tumors but not pancreatobiliary type.[537] Mutations of *TP53* have been detected in the majority of ampullary carcinomas, with a corresponding accumulation of the abnormal product as detected immunohistochemically.[538,539] *DPC4* mutations are rare in ampullary adenocarcinoma, and only a minority (30%–40%) harbor *KRAS* gene mutations.[540,541]

Ampullary carcinoma may invade the adjacent duodenal mucosa, duodenal wall, pancreas, and common bile duct by direct extension. Perineural invasion may also be present. Regional lymph node metastases are found in 35%–50% of the cases.[542,543] As noted previously, the prognosis of ampullary carcinoma is significantly better than that of pancreatic carcinoma and bile duct carcinoma, hence the importance of the distinction. The overall 5-year survival rate, which was around 25% in former series, has risen to 40%–50% or above in more recent studies.[528,529,544] As expected, this figure is even higher in the absence of lymph node metastases.[528] As in most other sites, the stage of disease is the most important prognostic indicator.[545,546] Other adverse prognostic factors include pancreatobiliary histologic subtype and tumor budding is said to be a strong negative prognostic indicator.[545,547] The treatment of choice of ampullary carcinoma remains the Whipple procedure; however, ampullectomy may be considered in patients with small, superficial carcinomas or who are poor operative risks.[548]

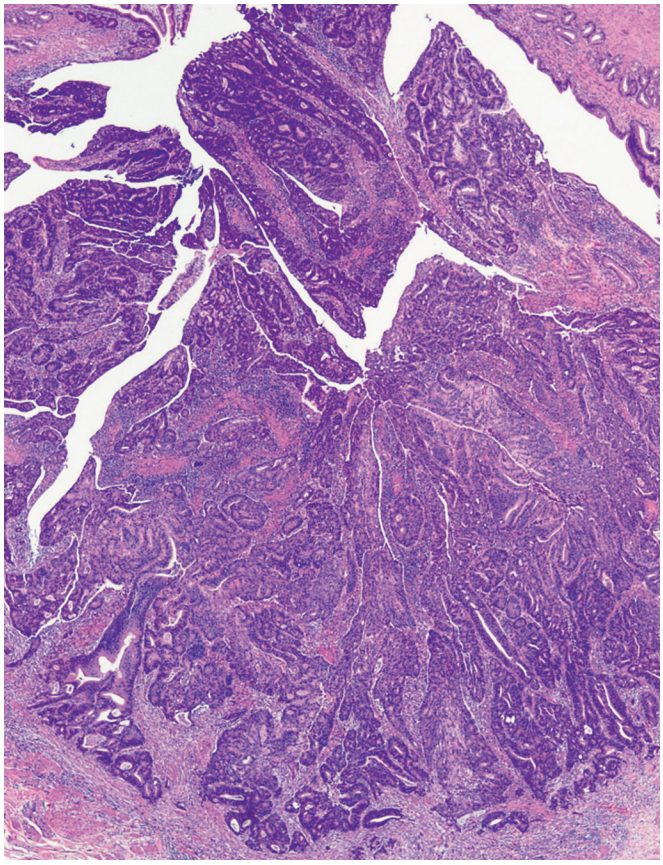

Figure 22.39 Invasive ampullary adenocarcinoma arising from an intra-ampullary papillary–tubular neoplasm of intestinal type.

Neuroendocrine Neoplasms

Well-differentiated neuroendocrine neoplasms can also occur in this location, as well as *poorly differentiated NEC*.[549–552] In contrast to their counterparts in the rest of the duodenum, ampullary carcinoid tumors are more likely to be associated with neurofibromatosis type 1.[553] Mixed adenocarcinoma/NET and mixed acinar/NECs have been rarely reported.[554–556]

Miscellaneous Tumors and Tumorlike Lesions

Other tumors and tumorlike conditions at this site include *adenomyoma*[557,558] and *adenomyomatous hyperplasia*,[559,560] the latter thought to be a sequela of chronic papillitis, and GISTs.[561] *Gangliocytic paraganglioma* is almost exclusively found in this location but will be discussed in detail in Chapter 15.[562] Primary *malignant lymphomas* have also been rarely described in this location.[563–564]

The diagnosis of *fibrosis of the papilla of Vater* is sometimes made in patients with right upper abdominal pain in whom a "pinpoint ampullary opening" is found at surgery.[557] More often than not, the microscopic sections show no significant abnormalities. In our experience, clear-cut inflammatory or fibrotic changes in the papilla of Vater have always been associated with chronic gallbladder or pancreatic disease, or previous surgical/endoscopic manipulation.[565] Of note, patients with sclerosing IgG4 disease may have involvement of the ampulla.[566]

References

1. Lamps LW. Pancreas. In: Lamps LW, ed. *Diagnostic Pathology—Normal Histology*. Park City, Utah: Amirsys; 2013 11:18-23.
2. Innes JT, Carey LC. Normal pancreatic dimensions in the adult human. *Am J Surg*. 1994;167:261-263.
3. Oertel JE. The pancreas. Nonneoplastic alterations. *Am J Surg Pathol*. 1989;13(suppl 1):50-65.
4. Klimstra DS, Hruban RH, Pitman MB. Pancreas. In: Mills SE, ed. *Histology for Pathologists*. 3rd ed. Philadelphia: Lippincott Williams and Wilkins; 2007:723-760.
5. Pelletier G. Identification of four cell types in the human endocrine pancreas by immunoelectron microscopy. *Diabetes*. 1977;26:749-756.
6. Westermark P, Andersson A, Westermark GT. Islet amyloid polypeptide, islet amyloid, and diabetes mellitus. *Physiol Rev*. 2011;91:795-826.
7. Stefan Y, Grasso S, Perrelet A, Orci L. The pancreatic polypeptide-rich lobe of the human pancreas: definitive identification of its derivation from the ventral pancreatic primordium. *Diabetologia*. 1982;23(2):141-142.
8. Peters J, Jurgensen A, Kloppel G. Ontogeny, differentiation and growth of the endocrine pancreas. *Virchows Arch*. 2000;436(6):527-538.
9. Mastracci TL, Sussel L. The endocrine pancreas: insights into development, differentiation, and diabetes. *Wiley Interdiscip Rev Membr Transp Signal*. 2012;5:609-628.
10. Bendayan M. Presence of endocrine cells in pancreatic ducts. *Pancreas*. 1987;2(4):393-397.
11. Comstock JM. Hypertrophy of pancreatic islets. In: Putnam AR, ed. *Diagnostic Pathology—Nonneoplastic Pediatrics*. Park City, Utah: Amirsys; 2014 5:38-39.
12. Kaczirek K, Niederle B. Nesidioblastosis: an old term and a new understanding. *World J Surg*. 2004;28:1227-1230.
13. Goossens A, Gepts W, Saudubray JM, et al. Diffuse and focal nesidioblastosis: a clinicopathological study of 24 patients with persistent neonatal hyperinsulinemic hypoglycemia. *Am J Surg Pathol*. 1989;13(9):766-775.
14. Gould VE, Memoli VA, Dardi LE, Gould NS. Nesidiodysplasia and nesidioblastosis of infancy: structural and functional correlations with the syndrome of hyperinsulinemic hypoglycaemia. *Pediatr Pathol*. 1983;1:7-31.
15. Kloppel G, Anlauf M, Raffel A, et al. Adult diffuse nesidioblastosis: genetically or environmentally induced? *Hum Pathol*. 2008;39:3-8.
16. Voldsgaard P, Kryger-Baggesen N, Lisse I. Agenesis of the pancreas. *Acta Paediatr*. 1994;83:791-793.
17. Joo YE, Kang HC, Kim HS, et al. Agenesis of the dorsal pancreas: a case report and review of the literature. *Korean J Intern Med*. 2006;21:236-239.
18. Kiernan PD, ReMine SG, Kiernan PC, ReMine WH. Annular pancreas: Mayo Clinic experience from 1957 to 1976 with review of the literature. *Arch Surg*. 1980;115(1):46-50.
19. Etienne D, John A, Menias CO, et al. Annular pancreas: a review of its molecular embryology, genetic basis and clinical considerations. *Ann Anat*. 2012;194:422-428.
20. Grosfeld JL, Rescorla FJ. Duodenal atresia and stenosis: reassessment of treatment and outcome based on antenatal diagnosis, pathologic variance, and long-term follow-up. *World J Surg*. 1993;17(3):301-309.
21. Zyromski NJ, Sandoval JA, Pitt HA, et al. Annular pancreas: dramatic differences between children and adults. *J Am Coll Surg*. 2008;206:1019-1025.
22. Bailey PV, Tracy TF Jr, Connors RH, et al. Congenital duodenal obstruction: a 32-year review. *J Pediatr Surg*. 1993;28(1):92-95.
23. Suda K. Immunohistochemical and gross dissection studies of annular pancreas. *Acta Pathol Jpn*. 1990;40(7):505-508.
24. Delhaye M, Cremer M. Clinical significance of pancreas divisum. *Acta Gastroenterol Belg*. 1992;55(3):306-313.
25. DiMagno MJ, Wamsteker EJ. Pancreas divisum. *Curr Gastroenterol Rep*. 2011;13:150-156.
26. Eisenberger CF, Gocht A, Knoefel WT, et al. Heterotopic pancreas: clinical presentation and pathology with review of the literature. *Hepatogastroenterology*. 2004;51(57):854-858.
27. Trifan A, Tarcoveanu E, Danciu M, et al. Gastric heterotopic pancreas: an unusual case and a review of the literature. *J Gastrointest Liver Dis*. 2012;21:209-212.
28. Limaiem F, Haddad I, Marsaoui L, et al. Mzabi S. Pancreatic heterotopia of the small intestine: two case reports. *Pathologica*. 2013;105:18-20.
29. Dolan RV, ReMine WH, Dockerty MB. The fate of heterotopic pancreatic tissue. A study of 212 cases. *Arch Surg*. 1974;109(6):762-765.
30. Hara M, Tsutsumi Y. Immunohistochemical studies of endocrine cells in heterotopic pancreas. *Virchows Arch A Pathol Anat Histopathol*. 1986;408(4):385-394.
31. Fukino N, Oida T, Mimatsu K, et al. Adenocarcinoma arising from heterotopic pancreas at the third portion of the duodenum. *World J Gastroenterol*. 2015;21:4082-4088.
32. Okamoto H, Fujishima F, Ishida K, et al. Intraductal papillary mucinous neoplasm originating from a jejunal heterotopic pancreas: report of a case. *Surg Today*. 2014;44:349-353.
33. Sapino A, Pietribiasi F, Papotti M, Bussolati G. Ectopic endocrine pancreatic tumour simulating splenic angiosarcoma. *Path Res Pract*. 1989;184(3):292-296.
34. Ginsburg M, Ahmed O, Rana KA, et al. Ectopic pancreas presenting with pancreatitis and a mesenteric mass. *J Pediatr Surg*. 2013;48:e29-e32. doi:10.1016/j.pedsurg.2012.10.062.
35. Rimal D, Thapa SR, Munasinghe N, Chitre VV. Symptomatic gastric heterotopic pancreas: clinical presentation and review of the literature. *Int J Surg*. 2008;6:E52-E54. [Epub Feb 12, 2007].
36. Nisar PJ, Zaitoun AM, Lobo DN, Rowlands BJ. Heterotopic pancreas in the spleen: malignant degeneration to mucinous cystadenocarcinoma. *Eur J Gastroenterol Hepatol*. 2002;14(7):793-796.
37. Kelly T, Buxbaum J. Gastrointestinal manifestations of cystic fibrosis. *Dig Dis Sci*. 2015;60:1903-1913.
38. Mino-Kenudson M. Cystic fibrosis, pancreas. In: Lamps LW, ed. *Diagnostic Pathology—Hepatobiliary and Pancreatic*. Park City, Utah: Amirsys; 2011 II(1):4-5.
39. Waguri M, Hanafusa T, Itoh N, et al. Histopathologic study of the pancreas shows a characteristic lymphocytic infiltration in Japanese patients with IDDM. *Endocr J*. 1997;44:23-33.
40. Maloy AL, Longnecker DS, Greenberg ER. The relation of islet amyloid to the clinical type of diabetes. *Hum Pathol*. 1981;12: 917-922.
41. Lankisch PG, Apte M, Banks PA. Acute pancreatitis. *Lancet*. 2015;386:85-96.
42. Opie EL. The etiology of acute hemorrhagic pancreatitis. *Bull Hopkins Hosp*. 1901;12:182-188.
43. Petrou A, Bramis K, Williams T, et al. Acute recurrent pancreatitis: a possible clinical manifestation of ampullary cancer. *JOP*. 2011;12:593-597.
44. Acosta JM, Ledesma CL. Gallstone migration as a cause of acute pancreatitis. *N Engl J Med*. 1974;290(9):484-487.
45. Lee SP, Nicholls JF, Park HZ. Biliary sludge as a cause of acute pancreatitis. *N Engl J Med*. 1992;326(9):589-593.
46. Ishii H, Arai K, Fukushima M, et al. Fusion variations of pancreatic ducts in patients with anomalous arrangement of pancreaticobiliary ductal system. *J Hepatobiliary Pancreat Surg*. 1998;5:327-332.
47. Apte MV, Pirola RC, Wilson JS. Mechanisms of alcoholic pancreatitis. *J Gastroenterol Hepatol*. 2010;25:1816-1826.
48. Kloppel G. Acute pancreatitis. *Sem Diag Pathol*. 2004;21(4):221-226.
49. Kukora JS. Extensive colonic necrosis complicating acute pancreatitis. *Surgery*. 1985;97(3):290-293.
50. Phat VN, Guerrieri MT, Alexandre JH, Camilleri JP. Early histological changes in acute necrotizing hemorrhagic pancreatitis. A retrospective pathological study of 20 total pancreatectomy specimens. *Path Res Pract*. 1984;178(3):273-279.
51. Bradley EL 3rd. A fifteen year experience with open drainage for infected pancreatic necrosis. *Surg Gynecol Obstet*. 1993;177(3):215-222.
52. Wronski M, Cebulski W, Slodkowski M, Krasnodebski IW. Minimally invasive treatment of infected pancreatic necrosis. *Prz Gastroenterol*. 2014;9:317-324.
53. Kloppel G, Maillet B. Chronic pancreatitis: evolution of the disease. *Hepatogastroenterology*. 1991;38(5):408-412.
54. Standop J, Standop S, Itami A, et al. ErbB2 oncogene expression supports the acute pancreatitis-chronic pancreatitis sequence. *Virchows Arch*. 2002;441(4):385-391.
55. Yadav D, Agarwal N, Pitchumoni CS. A critical evaluation of laboratory tests in acute pancreatitis. *Am J Gastroenterol*. 2002;97(6):1309-1318.
56. Jia R, Tang M, Qiu L, et al. Increased interleukin-23/17 axis and C-reactive protein are associated with severity of acute pancreatitis in patients. *Pancreas*. 2015;44:321-325.
57. Maheshwari R, Subramanian RM. Severe acute pancreatitis and necrotizing pancreatitis. *Crit Care Clin*. 2016;32:279-290.
58. Al Mofleh IA. Severe acute pancreatitis: pathogenetic aspects and prognostic factors. *World J Gastroenterol*. 2008;14:675-684.
59. Tonsi AF, Bacchion M, Crippa S, et al. Acute pancreatitis at the beginning of the 21st century: the state of the art. *World J Gastroenterol*. 2009;15:2945-2959.
60. Stevens T, Conwell DL, Zuccaro G. Pathogenesis of chronic pancreatitis: an evidence-based review of past theories and recent developments. *Am J Gastroenterol*. 2004;99:2256-2270.
61. Cohn JA, Friedman KJ, Noone PG, et al. Relation between mutations of the cystic fibrosis gene and idiopathic pancreatitis. *N Engl J Med*. 1998;339(10):653-658.
62. Sharer N, Schwarz M, Malone G, et al. Mutations of the cystic fibrosis gene in patients with chronic pancreatitis. *N Engl J Med*. 1998;339(10):645-652.
63. Kanth VVR, Reddy DN. Genetics of acute and chronic pancreatitis. *World J Gastrointest Pathophysiol*. 2014;5:427-437.
64. Yadav D, Lowenfels AB. The epidemiology of pancreatitis and pancreatic cancer. *Gastroenterology*. 2013;144:1252-1261.

65. Strum WB, Spiro HM. Chronic pancreatitis. *Ann Int Med*. 1971;74(2):264-277.
66. Strate T, Yekebas E, Knoefel WT, et al. Pathogenesis and the natural course of chronic pancreatitis. *Eur J Gastroenterol Hepatol*. 2002;14(9):929-934.
67. Steer ML, Waxman I, Freedman S. Chronic pancreatitis. *N Engl J Med*. 1995;332(22):1482-1490.
68. Kloppel G. Chronic pancreatitis of alcoholic and nonalcoholic origin. *Semin Diagn Pathol*. 2004;21(4):227-236.
69. Majumder S, Chari ST. Chronic pancreatitis. *Lancet*. 2016;387(10031):1957-1966.
70. Kloppel G, Bommer G, Commandeur G, Heitz P. The endocrine pancreas in chronic pancreatitis. Immunocytochemical and ultrastructural studies. *Virchows Arch A Path Anat Histol*. 1978;377(2):157-174.
71. Bartow SA, Mukai K, Rosai J. Pseudoneoplastic proliferation of endocrine cells in pancreatic fibrosis. *Cancer*. 1981;47(11):2627-2633.
72. Stolte M, Schwabe H, Prestele H. Relationship between diseases of the pancreas and hyperplasia of Brunner's glands. *Virchows Arch A Path Anat Histol*. 1981;394(1-2):75-87.
73. Hayakawa T, Kondo T, Shibata T, et al. Relationship between pancreatic exocrine function and histological changes in chronic pancreatitis. *Am J Gastroenterol*. 1992;87(9):1170-1174.
74. Proca DM, Ellison EC, Hibbert D, Frankel WL. Major pancreatic resections for chronic pancreatitis. *Arch Pathol Lab Med*. 2001;125(8):1051-1054.
75. Walsh TN, Rode J, Theis BA, Russell RC. Minimal change chronic pancreatitis. *Gut*. 1992;33(11):1566-1571.
76. Verde F, Fishman EK, Johnson PT. Arterial pseudoaneurysms complicating pancreatitis: literature review. *J Comput Assist Tomogr*. 2015;39:7-12.
77. El Hamel A, Parc R, Adda G, et al. Bleeding pseudocysts and pseudoaneurysms in chronic pancreatitis. *Br J Surg*. 1991;78(9):1059-1063.
78. Mullin GT, Caperton EM Jr, Crespin SR, Williams RC Jr. Arthritis and skin lesions resembling erythema nodosum in pancreatic disease. *Ann Int Med*. 1968;68(1):75-87.
79. Kusum D, Semlani S, Deshpande JR. Migration of steatonecrosis in pancreatitis. *Indian J Pathol Microbiol*. 2006;49:546-547.
80. Wamsteker EJ. Endoscopic approach to the diagnosis and treatment of chronic pancreatitis. *Curr Opin Gastroenterol*. 2014;30:524-530.
81. Issa Y, van Santvoort HC, van Goor H, et al. Surgical and endoscopic treatment of pain in chronic pancreatitis: a multidisciplinary update. *Dig Surg*. 2013;30:35-50.
82. Deshpande V, Chicano S, Finkelberg D, et al. Autoimmune pancreatitis: a systemic immune complex mediated disease. *Am J Surg Pathol*. 2006;30(12):1537-1545.
83. Cheuk W, Chan JK. IgG4-related sclerosing disease: a critical appraisal of an evolving clinicopathologic entity. *Adv Anat Pathol*. 2010;17(5):303-332.
84. Klimstra DS, Adsay NV. Lymphoplasmacytic sclerosing (autoimmune) pancreatitis. *Semin Diagn Pathol*. 2004;21(4):237-246.
85. Cornell LD, Chicano SL, Deshpande V, et al. Pseudotumors due to IgG4 immune-complex tubulointerstitial nephritis associated with autoimmune pancreatocentric disease. *Am J Surg Pathol*. 2007;31(10):1586-1597.
86. Uehara T, Hamano H, Kawakami M, et al. Autoimmune pancreatitis-associated prostatitis: distinct clinicopathological entity. *Pathol Int*. 2008;58(2):118-125.
87. Kojima M, Sipos B, Klapper W, et al. Autoimmune pancreatitis: frequency, IgG4 expression, and clonality of T and B cells. *Am J Surg Pathol*. 2007;31(4):521-528.
88. Dhall D, Suriawinata AA, Tang LH, et al. Use of immunohistochemistry for IgG4 in the distinction of autoimmune pancreatitis from peritumoral pancreatitis. *Hum Pathol*. 2010;41(5):643-652.
89. Adsay NV, Basturk O, Thirabanjasak D. Diagnostic features and differential diagnosis of autoimmune pancreatitis. *Semin Diagn Pathol*. 2005;22(4):309-317.
90. Notohara K, Burgart LJ, Yadav D, et al. Idiopathic chronic pancreatitis with periductal lymphoplasmacytic infiltration: clinicopathologic features of 35 cases. *Am J Surg Pathol*. 2003;27:1119-1127.
91. Chandan VS, Iacobuzio-Donahue C, Abraham SC. Patchy distribution of pathologic abnormalities in autoimmune pancreatitis: implications for preoperative diagnosis. *Am J Surg Pathol*. 2008;32(12):1762-1769.
92. Sepehr A, Mino-Kenudson M, Ogawa F, et al. IgG4+ to IgG+ plasma cells ratio of ampulla can help differentiate autoimmune pancreatitis from other "mass forming" pancreatic lesions. *Am J Surg Pathol*. 2008;32(12):1770-1779.
93. Okazaki K, Uchida K. Autoimmune pancreatitis: the past, present, and future. *Pancreas*. 2015;44:1006-1016.
94. Chari ST, Kloeppel G, Zhang L, et al. Histopathologic and clinical subtypes of autoimmune pancreatitis: the Honolulu consensus document. *Pancreas*. 2010;39:549-554.
95. Kloppel G, Detlefsen S, Chari ST, et al. Autoimmune pancreatitis: the clinicopathological characteristics of the subtype with granulocytic epithelial lesions. *J Gastroenterol*. 2010;45(8):787-793.
96. Adsay NV, Zamboni G. Paraduodenal pancreatitis: a clinico-pathologically distinct entity unifying "cystic dystrophy of heterotopic pancreas," "para-duodenal wall cyst," and "groove pancreatitis.". *Semin Diagn Pathol*. 2004;21:247-254.
97. Kloppel G. Chronic pancreatitis, pseudotumors and other tumor-like lesions. *Mod Pathol*. 2007;20(suppl 1):S113-S131.
98. Becker V, Mischke U. Groove pancreatitis. *Int J Pancreatol*. 1991;10(3-4):173-182.
99. Abraham SC, Leach S, Yeo CJ, et al. Eosinophilic pancreatitis and increased eosinophils in the pancreas. *Am J Surg Pathol*. 2003;27(3):334-342.
100. Paliwal S, Bhaskar S, Chandak GR. Genetic and phenotypic heterogeneity in tropical calcific pancreatitis. *World J Gastroenterol*. 2014;20:17314-17323.
101. Edmondson HA, Bullock WK, Mehl JW. Chronic pancreatitis and lithiasis: pathology and pathogenesis of pancreatic lithiasis. *Am J Pathol*. 1950;26(1):37-55.
102. Singhi AD, Pai RK, Kant JA, et al. The histopathology of PRSS1 hereditary pancreatitis. *Am J Surg Pathol*. 2014;38:346-353.
103. Warshaw AL, Jin GL. Improved survival in 45 patients with pancreatic abscess. *Ann Surg*. 1985;202:408-417.
104. Fedorak IJ, Ko TC, Djuricin G, et al. Secondary pancreatic infections: are they distinct clinical entities? *Surgery*. 1992;112(4):824-830, discussion 830-831.
105. Hviid A, Rubin S, Muhlemann K. Mumps. *Lancet*. 2008;371(9616):932-944.
106. Niemann TH, Trigg ME, Winick N, Penick GD. Disseminated adenoviral infection presenting as acute pancreatitis. *Hum Pathol*. 1993;24(10):1145-1148.
107. Osiro S, Muhammad R, Ruiz J, et al. Acute necrotizing pancreatitis in the setting of CMV viremia and AIDS: a case report and review of literature from 1980 to 2012. *JOP*. 2012;13:705-711.
108. Kochhar R, Noor MT, Wig J. Fungal infections in severe acute pancreatitis. *J Gastroenterol Hepatol*. 2011;26:952-959.
109. Chaudhary P, Bhadana U, Arora MP. Pancreatic tuberculosis. *Indian J Surg*. 2015;77:517-524.
110. Sun T. Clonorchiasis: a report of four cases and discussion of unusual manifestations. *Am J Trop Med Hyg*. 1980;29:1223-1227.
111. Parenti DM, Steinberg W, Kang P. Infectious causes of acute pancreatitis. *Pancreas*. 1996;13:356-371.
112. Ahuja SK, Ahuja SS, Thelmo W, et al. Necrotizing pancreatitis and multisystem organ failure associated with toxoplasmosis in a patient with AIDS. *Clin Infect Dis*. 1993;16(3):432-434.
113. Harder H, Buchler MW, Frohlich B, et al. Extrapulmonary sarcoidosis of liver and pancreas: a case report and review of literature. *World J Gastroenterol*. 2007;13(17):2504-2509.
114. Brady MS, Garfein CF, Klimstra D, Brenann MF. Sarcoidosis of the pancreas. *J Surg Oncol*. 1993;54(2):132-137.
115. Guha S, Liu H. Malakoplakia of the pancreas with simultaneous colon involvement: case report and review of the literature. *Case Rep Pathol*. 2015;2015:649136. doi:10.1155/2015/649136. [Epub May 21, 2015].
116. Helbling R, Lava SA, Simonetti GD, et al. Gallbladder and panreas in Henoch-Schonlein purpura: review of the literature. *J Pediatr Gastroenterol Nutr*. 2016;62:457-461.
117. Yokoi Y, Nakamura I, Kaneko T, et al. Pancreatic mass as an initial manifestation of polyarteritis nodosa: a case report and review of the literature. *World J Gastroenterol*. 2015;21:1014-1019.
118. Riedlinger WF, Lairmore TC, Balfe DM, Dehner LP. Tumefactive necrobiotic granulomas (nodulosis) of the pancreas in an adult with long-standing rheumatoid arthritis. *Int J Surg Pathol*. 2005;13(2):207-210.
119. Stratta RJ, Fridell JA, Gruessner AC, et al. Pancreas transplantation: a decade of decline. *Curr Opin Organ Transplant*. 2016;21(4):386-392. [Epub ahead of print].
120. Barker CF, Naji A. Perspectives in pancreatic and islet transplantation. *N Engl J Med*. 1992;327(4):271-273.
121. Dholakia S, Mittal S, Quiroga I, et al. Pancreas transplantation: past, present, future. *Am J Med*. 2016;129(7):667-673. doi:10.1016/j.amjmed.2016.02.011.
122. White SA, Shaw JA, Sutherland DE. Pancreas transplantation. *Lancet*. 2009;373(9677):1808-1817.
123. Aboalsamh G, Anderson P, Al-Abbassi A, et al. Heparin infusion in simultaneous pancreas and kidney transplants reduces graft thrombosis and improves graft survival. *Clin Transplant*. 2016;30(9):1002-1009. doi:10.1111/ctr.12780.
124. van Dellen D, Summers A, Trvelyan S, et al. Incidence and histologic features of transplant graft pancreatitis: a single center experience. *Exp Clin Transplant*. 2015;13:449-452.
125. Nadalin S, Girotti P, Konigsrainer A. Risk factors for and management of graft pancreatitis. *Curr Opin Organ Transplant*. 2013;18:89-96.
126. Gaber LW. Pancreas allograft biopsies in the management of pancreas transplant recipients: histopathologic review and clinical correlations. *Arch Pathol Lab Med*. 2007;131(8):1192-1199.
127. Drachenberg CB, Papadimitriou JC. The inflamed pancreas transplant: histological differential diagnosis. *Semin Diagn Pathol*. 2004;21(4):255-259.

128. Nakhleh RE, Gruessner RW, Swanson PE, et al. Pancreas transplant pathology. A morphologic, immunohistochemical, and electron microscopic comparison of allogeneic grafts with rejection, syngeneic grafts, and chronic pancreatitis. *Am J Surg Pathol*. 1991;15(3):246-256.
129. Nakhleh RE, Sutherland DE. Pancreas rejection. Significance of histopathologic findings with implications for classification of rejection. *Am J Surg Pathol*. 1992;16(11):1098-1107.
130. Lloyd RV, Dafoe DC, Campbell DA Jr, et al. Pancreas transplantation: an immunohistochemical analysis of pancreatic hormones and HLA-DR expression. *Mod Pathol*. 1989;2(4):323-330.
131. Burke GW 3rd, Vendrame F, Virdi SK, et al. Lesson from pancreas transplantation in type 1 diabetes: recurrence of islet autoimmunity. *Curr Diab Rep*. 2015;15(12):121.
132. Basturk O, Coban I, Adsay NV. Pancreatic cysts: pathologic classification, differential diagnosis, and clinical implications. *Arch Pathol Lab Med*. 2009;133(3):423-438.
133. Kloppel G. Pseudocysts and other non-neoplastic cysts of the pancreas. *Semin Diagn Pathol*. 2000;17(1):7-15.
134. D'Egidio A, Schein M. Pancreatic pseudocysts: a proposed classification and its management implications. *Br J Surg*. 1991;78(8):981-984.
135. Stanley JC, Frey CF, Miller TA, et al. Major arterial hemorrhage: a complication of pancreatic pseudocysts and chronic pancreatitis. *Arch Surg*. 1976;111:435-440.
136. Karoumpalis I, Christodoulou DK. Cystic lesions of the pancreas. *Ann Gastroenterol*. 2016;29:155-161.
137. Kennedy SM, Hashida Y, Malatack JJ. Polycystic kidneys, pancreatic cysts, and cystadenomatous bile ducts in the oral-facial-digital syndrome type I. *Arch Pathol Lab Med*. 1991;115(5):519-523.
138. Drut R, Drut M. Pancreatic cystic dysplasia (dysgenesis) presenting as a surgical pathology specimen in a patient with multiple malformations and familial ear pits. *Int J Surg Pathol*. 2002;10(4):303-308.
139. Adsay NV, Hasteh F, Cheng JD, Klimstra DS. Squamous-lined cysts of the pancreas: lymphoepithelial cysts, dermoid cysts (teratomas), and accessory-splenic epidermoid cysts. *Semin Diagn Pathol*. 2000;17(1):56-65.
140. Ramsden KL, Newman J. Lymphoepithelial cyst of the pancreas. *Histopathology*. 1991;18(3):267-268.
141. Truong LD, Stewart MG, Hao H, et al. A comprehensive characterization of lymphoepithelial cyst associated with the pancreas. *Am J Surg*. 1995;170:27-32.
142. Tateyama H, Tada T, Murase T, et al. Lymphoepithelial cyst and epidermoid cyst of the accessory spleen in the pancreas. *Mod Pathol*. 1998;11(12):1171-1177.
143. Othman M, Basturk O, Groisman G, et al. Squamoid cyst of pancreatic ducts: a distinct type of cystic lesion in the pancreas. *Am J Surg Pathol*. 2007;31(2):291-297.
144. Suda K, Takase M, Shiono S, et al. Duodenal wall cysts may be derived from a ductal component of ectopic pancreatic tissue. *Histopathology*. 2002;41(4):351-356.
145. Hunter CJ, Connelly ME, Ghaffari N, et al. Enteric duplication cysts of the pancreas: a report of two cases and review of the literature. *Pediatr Surg Int*. 2008;24:227-233.
146. Kosmahl M, Egawa N, Schroder S, et al. Mucinous nonneoplastic cyst of the pancreas: a novel nonneoplastic cystic change? *Mod Pathol*. 2002;15(2):154-158.
147. Cao W, Adley BP, Liao J, et al. Mucinous nonneoplastic cyst of the pancreas: apomucin phenotype distinguishes this entity from intraductal papillary mucinous neoplasm. *Hum Pathol*. 2010;41(4):513-521.
148. Akbulut S, Yavuz R, Sogutcu N, et al. Hydatid cyst of the pancreas: report of an undiagnosed case of pancreatic hydatid cyst and brief literature review. *World J Gastrointest Surg*. 2014;6:190-200.
149. Ansari D, Gustafson A, Anderson R. Update on the management of pancreatic cancer: surgery is not enough. *World J Gastroenterol*. 2015;21:3157-3165.
150. Henson DE, Schwartz AM, Nosily H, Albores-Saavedra J. Carcinomas of the pancreas, gallbladder, extrahepatic bile ducts, and ampulla of vater share a field for carcinogenesis: a population-based study. *Arch Pathol Lab Med*. 2009;133(1):67-71.
151. Warshaw AL, Fernandez-del Castillo C. Pancreatic carcinoma. *N Engl J Med*. 1992;326(7):455-465.
152. Hidalgo M. Pancreatic cancer. *N Engl J Med*. 2010;362:1605-1607.
153. Luttges J, Stigge C, Pacena M, Kloppel G. Rare ductal adenocarcinoma of the pancreas in patients younger than age 40 years. *Cancer*. 2004;100(1):173-182.
154. Lowenfels AB, Maisonneuve P, Cavallini G, et al. Pancreatitis and the risk of pancreatic cancer. International Pancreatitis Study Group. *N Engl J Med*. 1993;328(20):1433-1437.
155. Raimondi S, Maisonneuve P, Lowenfels AB. Epidemiology of pancreatic cancer: an overview. *Nat Rev Gastroenterol Hepatol*. 2009;6:699-708.
156. Yamaguchi K. Pancreatic carcinoma associated with chronic calcifying pancreatitis. *Int J Pancreatol*. 1992;12(3):297-303.
157. DiMagno EP, Shorter RG, Taylor WF, Go VL. Relationships between pancreaticobiliary ductal anatomy and pancreatic ductal and parenchymal histology. *Cancer*. 1982;49(2):361-368.
158. Gullo L, Pezzilli R, Morselli-Labate AM. Diabetes and the risk of pancreatic cancer. *N Engl J Med*. 1994;331(2):81-84.
159. Permert J, Larsson J, Westermark GT, et al. Islet amyloid polypeptide in patients with pancreatic cancer and diabetes. *N Engl J Med*. 1994;330(5):313-318.
160. Wanebo HJ, Vezeridis MP. Pancreatic carcinoma in perspective. A continuing challenge. *Cancer*. 1996;78(3 suppl):580-591.
161. Furukawa H, Okada S, Saisho H, et al. Clinicopathologic features of small pancreatic adenocarcinoma. A collective study. *Cancer*. 1996;78(5):986-990.
162. Habib M, Saif MW. Thromboembolism and anticoagulation in pancreatic cancer. *JOP*. 2013;14:135-137.
163. Lafler CJ, Hinerman DL. A morphologic study of pancreatic carcinoma with reference to multiple thrombi. *Cancer*. 1961;14:944-952.
164. Naschitz JE, Yeshurun D, Eldar S, Lev LM. Diagnosis of cancer-associated vascular disorders. *Cancer*. 1996;77(9):1759-1767.
165. Prandoni P, Lensing AW, Buller HR, et al. Deep-vein thrombosis and the incidence of subsequent symptomatic cancer. *N Engl J Med*. 1992;327(16):1128-1133.
166. Bick RL. Cancer-associated thrombosis. *N Engl J Med*. 2003;349(2):109-111.
167. Shi C, Hruban RH, Klein AP. Familial pancreatic cancer. *Arch Pathol Lab Med*. 2009;133(3):365-374.
168. Hacking WM, Hruban RH, Offerhaus JA, Brosens LAA. Surgical and molecular pathology of pancreatic neoplasms. *Diagn Pathol*. 2016;11:47. doi:10.1186/s13000-016-0497-z.
169. Rebours V, Levy P, Ruszniewski P. An overview of hereditary pancreatitis. *Dig Liver Dis*. 2012;44:8-15.
170. Hruban RH, Fukushima N. Pancreatic adenocarcinoma: update on the surgical pathology of carcinomas of ductal origin and PanINs. *Mod Pathol*. 2007;20(suppl 1):S61-S70.
171. Kosmahl M, Pauser U, Anlauf M, Kloppel G. Pancreatic ductal adenocarcinomas with cystic features: neither rare nor uniform. *Mod Pathol*. 2005;18(9):1157-1164.
172. Deshpande V, Konstantinidis IT, Castillo CF, et al. Intra-pancreatic distal bile duct carcinoma is morphologically, genetically, and clinically distinct from pancreatic ductal adenocarcinoma. *J Gastrointest Surg*. 2016;20:953-959.
173. Shi C, Klein AP, Goggins M, et al. Increased prevalence of precursor lesions in familial pancreatic cancer patients. *Clin Can Res*. 2009;15(24):7737-7743.
174. Brune K, Abe T, Canto M, et al. Multifocal neoplastic precursor lesions associated with lobular atrophy of the pancreas in patients having a strong family history of pancreatic cancer. *Am J Surg Pathol*. 2006;30:1067-1076.
175. Sharma S, Green KB. The pancreatic duct and its arteriovenous relationship: an underutilized aid in the diagnosis and distinction of pancreatic adenocarcinoma from pancreatic intraepithelial neoplasia. A study of 126 pancreatectomy specimens. *Am J Surg Pathol*. 2004;28(5):613-620.
176. Costa J. Benign epithelial inclusions in pancreatic nerves. *Am J Clin Pathol*. 1977;67(3):306-307.
177. Nagakawa T, Kayahara M, Ueno K, et al. A clinicopathologic study on neural invasion in cancer of the pancreatic head. *Cancer*. 1992;69(4):930-935.
178. Bandyopadhyay S, Basturk O, Coban I, et al. Isolated solitary ducts (naked ducts) in adipose tissue: a specific but underappreciated finding of pancreatic adenocarcinoma and one of the potential reasons of understaging and high recurrence rate. *Am J Surg Pathol*. 2009;33(3):425-429.
179. Kloppel G, Adsay NV. Chronic pancreatitis and the differential diagnosis versus pancreatic cancer. *Arch Pathol Lab Med*. 2009;133(3):382-387.
180. Hruban RH, Goggins M, Parsons J, Kern SE. Progression model for pancreatic cancer. *Clin Cancer Res*. 2000;6:2969-2972.
181. Basturk O, Hong SM, Wood LD, et al. A revised classification system and recommendations from the Baltimore consensus meeting for neoplastic precursor lesions of the pancreas. *Am J Surg Pathol*. 2015;39:1730-1741.
182. Andea A, Sarkar F, Adsay VN. Clinicopathological correlates of pancreatic intraepithelial neoplasia: a comparative analysis of 82 cases with and 152 cases without pancreatic ductal adenocarcinoma. *Mod Pathol*. 2003;16(10):996-1006.
183. Adsay V, Logani S, Sarkar F, et al. Foamy gland pattern of pancreatic ductal adenocarcinoma: a deceptively benign-appearing variant. *Am J Surg Pathol*. 2000;24(4):493-504.
184. Pagci P, Andea AA, Basturk O, et al. Large duct type invasive adenocarcinoma of the pancreas with microcystic and papillary patterns: a potential mimic of non-invasive ductal neoplasia. *Mod Pathol*. 2012;25:439-448.
185. Dursun N, Feng J, Basturk O, et al. Vacuolated cell pattern of pancreatobiliary adenocarcinoma: a clinicopathologic analysis of 24 cases of a poorly recognized distinctive morphologic variant important in the differential diagnosis. *Virchows Arch*. 2010;457:643-649.
186. Albores-Saavedra J, Simpson K, Dancer YJ, Hruban R. Intestinal type adenocarcinoma: a previously unrecognized histologic variant of ductal carcinoma of the pancreas. *Ann Diagn Pathol*. 2007;11(1):3-9.
187. Kardon DE, Thompson LD, Przygodzki RM, Heffess CS. Adenosquamous carcinoma of the

pancreas: a clinicopathologic series of 25 cases. *Mod Pathol*. 2001;14(5):443-451.
188. Voong KR, Davison J, Pawlik TM, et al. Resected pancreatic adenosquamous carcinoma: clinicopathologic review and evaluation of adjuvant chemotherapy and radiation in 38 patients. *Hum Pathol*. 2010;41(1):113-122.
189. Marucci G, Betts CM, Liguori L, Eusebi V. Basaloid carcinoma of the pancreas. *Virchows Arch*. 2005;446(3):322-324.
190. Wilentz RE, Goggins M, Redston M, et al. Genetic, immunohistochemical, and clinical features of medullary carcinoma of the pancreas: a newly described and characterized entity. *Am J Surg Pathol*. 2000;156(5):1641-1651.
191. Adsay NV, Merati K, Nassar H, et al. Pathogenesis of colloid (pure mucinous) carcinoma of exocrine organs: coupling of gel-forming mucin (MUC2) production with altered cell polarity and abnormal cell-stroma interaction may be the key factor in the morphogenesis and indolent behavior of colloid carcinoma in the breast and pancreas. *Am J Surg Pathol*. 2003;27(5):571-578.
192. Adsay NV, Pierson C, Sarkar F, et al. Colloid (mucinous noncystic) carcinoma of the pancreas. *Am J Surg Pathol*. 2001;25(1):26-42.
193. Chejfec G, Rieker WJ, Jablokow VR, Gould VE. Pseudomyxoma peritonei associated with colloid carcinoma of the pancreas. *Gastroenterology*. 1986;90(1):202-205.
194. Kim L, Liao J, Zhang M, et al. Clear cell carcinoma of the pancreas: histopathologic features and a unique biomarker: hepatocyte nuclear factor-1beta. *Mod Pathol*. 2008;21(9):1075-1083.
195. Luttges J, Vogel I, Menke M, et al. Clear cell carcinoma of the pancreas: an adenocarcinoma with ductal phenotype. *Histopathology*. 1998;32(5):444-448.
196. Kelly PJ, Spence R, Dasari BV, et al. Primary hepatocellular carcinoma of the pancreas: a case report and review of the heterogeneous group of pancreatic hepatoid carcinomas. *Histopathology*. 2012;60:1012-1015.
197. Hameed O, Xu H, Saddeghi S, Maluf H. Hepatoid carcinoma of the pancreas: a case report and literature review of a heterogeneous group of tumors. *Am J Surg Pathol*. 2007;31(1):146-152.
198. Lonardo F, Cubilla AL, Klimstra DS. Microadenocarcinoma of the pancreas—morphologic pattern or pathologic entity? A reevaluation of the original series. *Am J Surg Pathol*. 1996;20(11):1385-1393.
199. Paal E, Thompson LD, Frommelt RA, et al. A clinicopathologic and immunohistochemical study of 35 anaplastic carcinomas of the pancreas with a review of the literature. *Ann Diagn Pathol*. 2001;5(3):129-140.
200. Molberg KH, Heffess C, Delgado R, Albores-Saavedra J. Undifferentiated carcinoma with osteoclast-like giant cells of the pancreas and periampullary region. *Cancer*. 1998;82(7):1279-1287.
201. Fujii K, Nitta T, Kawasaki H, et al. Anaplastic carcinoma of the pancreas arising in an intraductal papillary mucinous neoplasm: a case report. *Mol Clin Oncol*. 2016;4:39-42.
202. Hirano H, Morita K, Tachibana S, et al. Undifferentiated carcinoma with osteoclast-like giant cells arising in a mucinous cystic neoplasm of the pancreas. *Pathol Int*. 2008;58:383-389.
203. Hoorens A, Prenzel K, Lemoine NR, Kloppel G. Undifferentiated carcinoma of the pancreas: analysis of intermediate filament profile and Ki-ras mutations provides evidence of a ductal origin. *J Pathol*. 1998;185:53-60.
204. Westra WH, Sturm P, Drillenburg P, et al. K-ras oncogene mutations in osteoclast-like giant cell tumors of the pancreas and liver: genetic evidence to support origin from the ductal epithelium. *Am J Surg Pathol*. 1998;22:1247-1254.
205. Gocke CD, Dabbs DJ, Benko FA, Silverman JF. KRAS oncogene mutations suggest a common histogenetic origin for pleomorphic giant cell tumor of the pancreas, osteoclastoma of the pancreas, and pancreatic duct adenocarcinoma. *Hum Pathol*. 1997;28(1):80-83.
206. Oehler U, Jurs M, Kloppel G, Helpap B. Osteoclast-like giant cell tumour of the pancreas presenting as a pseudocyst-like lesion. *Virchows Arch*. 1997;431(3):215-218.
207. Sakai Y, Kupelioglu AA, Yanagisawa A, et al. Origin of giant cells in osteoclast-like giant cell tumors of the pancreas. *Hum Pathol*. 2000;31(10):1223-1229.
208. Lee MJ, Lee HS, Kim WH, et al. Expression of mucins and cytokeratins in primary carcinomas of the digestive system. *Mod Pathol*. 2003;16:403-410.
209. Andrianifahanana M, Moniaux N, Schmied BM, et al. Mucin (MUC) gene expression in human pancreatic adenocarcinoma and chronic pancreatitis: a potential role of MUC4 as a tumor marker of diagnostic significance. *Clin Cancer Res*. 2001;7:4033-4040.
210. Luttges J, Zamboni G, Longnecker D, Kloppel G. The immunohistochemical mucin expression pattern distinguishes different types of intraductal papillary mucinous neoplasms of the pancreas and determines their relationship to mucinous noncystic carcinoma and ductal adenocarcinoma. *Am J Surg Pathol*. 2001;25:942-948.
211. Adsay NV, Merati K, Andea A, et al. The dichotomy in the preinvasive neoplasia to invasive carcinoma sequence in the pancreas: differential expression of MUC1 and MUC2 supports the existence of two separate pathways of carcinogenesis. *Mod Pathol*. 2002;15(10):1087-1095.
212. Basturk O, Khayyata S, Klimstra DS, et al. Preferential expression of MUC6 in oncocytic and pancreaticobiliary types of intraductal papillary neoplasms highlights a pyloropancreatic pathway, distinct from the intestinal pathway, in pancreatic carcinogenesis. *Am J Surg Pathol*. 2010;34:364-370.
213. Goldstein NS, Bassi D. Cytokeratins 7, 17, and 20 reactivity in pancreatic and ampulla of vater adenocarcinomas. Percentage of positivity and distribution is affected by the cut-point threshold. *Am J Clin Pathol*. 2001;115(5):695-702.
214. Vlasoff DM, Baschinsky DY, Frankel WL. Cytokeratin 5/6 immunostaining in hepatobiliary and pancreatic neoplasms. *Appl Immunohistochem Mol Morphol*. 2002;10(2):147-151.
215. Reid MD, Bagci P, Adsay NV. Histopathologic assessment of pancreatic cancer: does one size fit all? *J Surg Oncol*. 2013;107:67-77.
216. Geller SA, Dhall D, Alsabeh R. Application of immunohistochemistry to liver and gastrointestinal neoplasms: liver, stomach, colon, and pancreas. *Arch Pathol Lab Med*. 2008;132(3):490-499.
217. Hruban RH, Klimstra DS. Adenocarcinoma of the pancreas. *Semin Diagn Pathol*. 2014;31:443-451.
218. Toshkov I, Mogaki M, Kazakoff K, Pour PM. The patterns of co-expression of tumor-associated antigens CA19-9, Tag-72, and DU-PAN-2 in human pancreatic cancer. *Int J Pancreatol*. 1994;15:97-103.
219. Takasaki H, Tempero MA, Uchida E, et al. Comparative studies on the expression of tumor-associated glycoprotein (TAG-72, CA 19-9, and DU-PAN-2 in normal, benign, and malignant pancreatic tissues. *Int J Cancer*. 1988;42:681-686.
220. Batge B, Bosslet K, Sedlacek HH, et al. Monoclonal antibodies against CEA-related components discriminate between pancreatic duct type carcinomas and nonneoplastic duct lesions as well as nonduct type neoplasias. *Virchows Arch A Pathol Anat Histopathol*. 1986;408(4):361-374.
221. Loy TS, Springer D, Chapman RK, et al. Lack of specificity of monoclonal antibody B72.3 in distinguishing chronic pancreatitis from pancreatic adenocarcinoma. *Am J Clin Pathol*. 1991;96(6):684-688.
222. Kamisawa T, Fukayama M, Tabata I, et al. Neuroendocrine differentiation in pancreatic duct carcinoma special emphasis on duct-endocrine cell carcinoma of the pancreas. *Pathol Res Pract*. 1996;192(9):901-908.
223. Sakaki M, Sano T, Hirokawa M, et al. Immunohistochemical study of endocrine cells in ductal adenocarcinoma of the pancreas. *Virchows Arch*. 2002;441(3):249-255.
224. Dhodapkar KM, Friedlander D, Scholes J, Grumet M. Differential expression of the cell-adhesion molecule Nr-CAM in hyperplastic and neoplastic human pancreatic tissue. *Hum Pathol*. 2001;32(4):396-400.
225. Hruban RH, van Mansfeld AD, Offerhaus GJ, et al. K-ras oncogene activation in adenocarcinoma of the human pancreas. A study of 82 carcinomas using a combination of mutant-enriched polymerase chain reaction analysis and allele-specific oligonucleotide hybridization. *Am J Pathol*. 1993;143(2):545-554.
226. Shi C, Daniels JA, Hruban RH. Molecular characterization of pancreatic neoplasms. *Adv Anat Pathol*. 2008;15(4):185-195.
227. Caldas C, Hahn SA, da Costa LT, et al. Frequent somatic mutations and homozygous deletions of the p16 (MTS1) gene in pancreatic adenocarcinoma. *Nat Genet*. 1994;8(1):27-32.
228. Waddell N, Pajic M, Patch AM, et al. Whole genomes redefine the mutational landscape of pancreatic cancer. *Nature*. 2015;518(7540):495-501.
229. Hruban RH, Wilentz RE, Kern SE. Genetic progression in the pancreatic ducts. *Am J Surg Pathol*. 2000;156(6):1821-1825.
230. Luttges J, Feyerabend B, Buchelt T, et al. The mucin profile of noninvasive and invasive mucinous cystic neoplasms of the pancreas. *Am J Surg Pathol*. 2002;26(4):466-471.
231. Heinmoller E, Dietmaier W, Zirngibl H, et al. Molecular analysis of microdissected tumors and preneoplastic intraductal lesions in pancreatic carcinoma. *Am J Pathol*. 2000;157(1):83-92.
232. Luttges J, Diederichs A, Menke MA, et al. Ductal lesions in patients with chronic pancreatitis show K-ras mutations in a frequency similar to that in the normal pancreas and lack nuclear immunoreactivity for p53. *Cancer*. 2000;88(11):2495-2504.
233. Laghi L, Beghelli S, Spinelli A, et al. Irrelevance of microsatellite instability in the epidemiology of sporadic pancreatic ductal adenocarcinoma. *PLoS ONE*. 2012;7(9):e46002. doi:10.1371/journal.pone.0046002.
234. Saka B, Balci S, Basturk O, et al. Pancreatic ductal adenocarcinoma is spread to the peripancreatic soft tissue in the majority of resected cases, rendering the AJCC T-stage protocol (7th edition) inapplicable and insignificant: a size-based staging system (pT1: ≤ 2, pT2: >2–≤4, pT3: >4 cm) is more valid and clinically relevant. *Ann Surg Oncol*. 2016;23:2010-2018.
235. Mitsunaga S, Hasebe T, Kinoshita T, et al. Detail histologic analysis of nerve plexus invasion in invasive ductal carcinoma of the pancreas and its prognostic impact. *Am J Surg Pathol*. 2007;31(11):1636-1644.

236. Noto M, Miwa K, Kitagawa H, et al. Pancreas head carcinoma: frequency of invasion to soft tissue adherent to the superior mesenteric artery. *Am J Surg Pathol*. 2005;29(8):1056-1061.
237. Kawamoto M, Ishiwata T, Cho K, et al. Nestin expression correlates with nerve and retroperitoneal tissue invasion in pancreatic cancer. *Hum Pathol*. 2009;40(2):189-198.
238. Kayahara M, Nagakawa T, Kobayashi H, et al. Lymphatic flow in carcinoma of the head of the pancreas. *Cancer*. 1992;70(8):2061-2066.
239. Kayahara M, Nagakawa T, Ohta T, et al. Analysis of paraaortic lymph node involvement in pancreatic carcinoma: a significant indication for surgery? *Cancer*. 1999;85(3):583-590.
240. Nagakawa T, Kobayashi H, Ueno K, et al. Clinical study of lymphatic flow to the paraaortic lymph nodes in carcinoma of the head of the pancreas. *Cancer*. 1994;73(4):1155-1162.
241. Cubilla AL, Fortner J, Fitzgerald PJ. Lymph node involvement in carcinoma of the head of the pancreas area. *Cancer*. 1978;41(3):880-887.
242. Nagai H, Kuroda A, Morioka Y. Lymphatic and local spread of T1 and T2 pancreatic cancer. A study of autopsy material. *Ann Surg*. 1986;204(1):65-71.
243. Tsuchiya R, Oribe T, Noda T. Size of the tumor and other factors influencing prognosis of carcinoma of the head of the pancreas. *Am J Gastroenterol*. 1985;80(6):459-462.
244. Peixoto RD, Speers C, McGahan CE, et al. Prognostic factors and sites of metastasis in unresectable locally advanced pancreatic cancer. *Cancer Med*. 2015;4:1171-1177.
245. Soman AD, Collins JM, DePetris G, et al. Isolated supraclavicular lymph node metastasis in pancreatic adenocarcinoma: a report of three cases and review of the literature. *JOP*. 2010;11:604-609.
246. Matsubayashi H, Matsui T, Yabuuchi Y, et al. Endoscopic ultrasonography guided-fine needle aspiration for the diagnosis of solid pancreaticobiliary lesions: clinical aspects to improve the diagnosis. *World J Gastroenterol*. 2016;22:628-640.
247. Layfield LJ, Ehya H, Filie AC, et al. Utilization of ancillary studies in the cytologic diagnosis of biliary and pancreatic lesions. *Diagn Cytopathol*. 2014;42:351-362.
248. Nelsen EM, Buehler D, Soni AV, Gopal DV. Endoscopic ultrasound in the evaluation of pancreatic neoplasms-solid and cystic: a review. *World J Gastrointest Endosc*. 2015;7:318-327.
249. Saez A, Catala I, Brossa R, et al. Intraoperative fine needle aspiration cytology of pancreatic lesions. A study of 90 cases. *Acta Cytol*. 1995;39:485-488.
250. Liu YJ, Smith-Chakmakova F, Rassaei N, et al. Frozen section interpretation of pancreatic margins: subspecialized gastrointestinal pathologists versus general pathologists. *Int J Surg Pathol*. 2016;24:108-115.
251. Kooby DA, Lad NL, Squires MH 3rd, et al. Value of intraoperative neck margin analysis during Whipple for pancreatic adenocarcinoma: a multicenter analysis of 1399 patients. *Ann Surg*. 2014;260:494-501.
252. Spjut HJ, Ramos AJ. An evaluation of biopsy-frozen section of the ampullary region and pancreas: a report of 68 consecutive patients. *Ann Surg*. 1957;146(6):923-930.
253. Hyland C, Kheir SM, Kashlan MB. Frozen section diagnosis of pancreatic carcinoma: a prospective study of 64 biopsies. *Am J Surg Pathol*. 1981;5(2):179-191.
254. Furukawa T, Higuchi R, Yamamoto M. Clinical relevance of frozen diagnosis of ductal margins in surgery of bile duct cancer. *J Hepatobiliary Pancreat Sci*. 2014;21:459-462.
255. Cioc AM, Ellison EC, Proca DM, et al. Frozen section diagnosis of pancreatic lesions. *Arch Pathol Lab Med*. 2002;126(10):1169-1173.
256. Kamisawa T, Wood LD, Takaori K. Pancreatic cancer. *Lancet*. 2016;388:73-85.
257. Newton WT. Mortality and morbidity associated with resection of pancreaticoduodenal cancers. *Am Surg*. 1961;27:74-79.
258. Tepper J, Nardi G, Sutt H. Carcinoma of the pancreas: review of MGH experience from 1963 to 1973. Analysis of surgical failure and implications for radiation therapy. *Cancer*. 1976;37(3):1519-1524.
259. Nolan NJ, Stokes JB, Bauer TW, et al. Histologic description of pancreatectomy specimens after current neoadjuvant therapies. *Lab Invest*. 2009;89(suppl 1).
260. Abraham SC, Wilentz RE, Yeo CJ, et al. Pancreaticoduodenectomy (Whipple resections) in patients without malignancy: are they all 'chronic pancreatitis'? *Am J Surg Pathol*. 2003;27(1):110-120.
261. Bilimoria KY, Bentrem DJ, Ko CY, et al. Validation of the 6th edition AJCC pancreatic cancer staging system: report from the National Cancer Database. *Cancer*. 2007;110:738-744.
262. Matros E, Bailey G, Clancy T, et al. Cytokeratin 20 expression identifies a subtype of pancreatic adenocarcinoma with decreased overall survival. *Cancer*. 2006;106(3):693-702.
263. Cao D, Zhang Q, Wu LS, et al. Prognostic significance of maspin in pancreatic ductal adenocarcinoma: tissue microarray analysis of 223 surgically resected cases. *Mod Pathol*. 2007;20(5):570-578.
264. Blackford A, Serrano OK, Wolfgang CL, et al. SMAD4 gene mutations are associated with poor prognosis in pancreatic cancer. *Clin Can Res*. 2009;15(14):4674-4679.
265. Adsay NV, Klimstra DS. Cystic forms of typically solid pancreatic tumors. *Semin Diag Pathol*. 2000;17:81-88.
266. Hoover E, Natesha R, Dao A, et al. Proliferative pancreatic cysts: pathogenesis and treatment options. *Am J Surg*. 1991;162(3):274-277.
267. Campbell F, Azadeh B. Cystic neoplasms of the exocrine pancreas. *Histopathology*. 2008;52(5):539-551.
268. Compton CC. Serous cystic tumors of the pancreas. *Semin Diagn Pathol*. 2000;17(1):43-55.
269. Reid MD, Choi HJ, Memis B, et al. Serous neoplasms of the pancreas: a clinicopathologic analysis of 193 cases and literature review with new insights on macrocystic and solid variants and critical reappraisal of so-called "serous cystadenocarcinoma. *Am J Surg Pathol*. 2015;39:1597-1610.
270. Compagno J, Oertel JE. Microcystic adenomas of the pancreas (glycogen-rich cystadenomas): a clinicopathologic study of 34 cases. *Am J Clin Pathol*. 1978;69(3):289-298.
271. Tripodi SA, Civitelli S, Schurfeld K, Cintorino M. Microcystic adenoma of the pancreas (glycogen-rich cystadenoma) with stromal amyloid deposits. *Histopathology*. 2000;37(2):147-149.
272. Marsh WL, Colonna J, Yearsley M, et al. Calponin is expressed in serous cystadenomas of the pancreas but not in adenocarcinomas or endocrine tumors. *Appl Immunohistochem Mol Morphol*. 2009;17(3):216-219.
273. Kosmahl M, Wagner J, Peters K, et al. Serous cystic neoplasms of the pancreas: an immunohistochemical analysis revealing alpha-inhibin, neuron-specific enolase, and MUC6 as new markers. *Am J Surg Pathol*. 2004;28(3):339-346.
274. Lewandrowski KB, Southern JF, Pins MR, et al. Cyst fluid analysis in the differential diagnosis of pancreatic cysts. A comparison of pseudocysts, serous cystadenomas, mucinous cystic neoplasms, and mucinous cystadenocarcinoma. *Ann Surg*. 1993;217(1):41-47.
275. Mohr VH, Vortmeyer AO, Zhuang Z, et al. Histopathology and molecular genetics of multiple cysts and microcystic (serous) adenomas of the pancreas in von Hippel-Lindau patients. *Am J Pathol*. 2000;157:1615-1621.
276. Jais B, Rebours V, Malleo G, et al. Serous cystic neoplasm of the pancreas: a multinational study of 2622 patients under the auspices of the International Association of Pancreatology and European Pancreatic Club (European Study Group on Cystic Tumors of the Pancreas). *Gut*. 2016;65:305-312.
277. Shintaku M, Arimoto A, Sakita N. Serous cystadenocarcinoma of the pancreas. *Pathol Int*. 2005;55(7):436-439.
278. Yoshimi N, Sugie S, Tanaka T, et al. A rare case of serous cystadenocarcinoma of the pancreas. *Cancer*. 1992;69(10):2449-2453.
279. Kamei K, Funabiki T, Ochiai M, et al. Some considerations on the biology of pancreatic serous cystadenoma. *Int J Pancreatol*. 1992;11(2):97-104.
280. Unger PD, Danque PO, Fuchs A, Kaneko M. DNA flow cytometric evaluation of serous and mucinous cystic neoplasms of the pancreas. *Arch Pathol Lab Med*. 1991;115(6):563-565.
281. Zhu H, Qin L, Zhong M, et al. Carcinoma ex microcystic adenoma of the pancreas: a report of a novel form of malignancy in serous neoplasms. *Am J Surg Pathol*. 2012; 36:305-310.
282. Wilentz RE, Albores-Saavedra J, Hruban RH. Mucinous cystic neoplasms of the pancreas. *Semin Diagn Pathol*. 2000;17(1):31-42.
283. Zamboni G, Scarpa A, Bogina G, et al. Mucinous cystic tumors of the pancreas: clinicopathological features, prognosis, and relationship to other mucinous cystic tumors. *Am J Surg Pathol*. 1999;23(4):410-422.
284. Lam MM, Swanson PE, Upton MP, Yeh MM. Ovarian-type stroma in hepatobiliary cystadenomas and pancreatic mucinous cystic neoplasms: an immunohistochemical study. *Am J Clin Pathol*. 2008;129(2):211-218.
285. Yeh MM, Tang LH, Wang S, et al. Inhibin expression in ovarian-type stroma in mucinous cystic neoplasms of the pancreas. *Appl Immunohistochem Mol Morphol*. 2004;12(2):148-152.
286. Wouters K, Ectors N, Van Steenbergen W, et al. A pancreatic mucinous cystadenoma in a man with mesenchymal stroma, expressing oestrogen and progesterone receptors. *Virchows Arch*. 1998;432(2):187-189.
287. Cizginer S, Turner BG, Bilge AR, et al. Cyst fluid carcinoembryonic antigen is an accurate diagnostic marker of pancreatic mucinous cysts. *Pancreas*. 2011;40:1024-1028.
288. Klimstra DS. Cystic, mucin-producing neoplasms of the pancreas: the distinguishing features of mucinous cystic neoplasms and intraductal papillary mucinous neoplasms. *Semin Diagn Pathol*. 2005;22(4):318-329.
289. Wilentz RE, Albores-Saavedra J, Zahurak M, et al. Pathologic examination accurately predicts prognosis in mucinous cystic neoplasms of the pancreas. *Am J Surg Pathol*. 1999;23(11):1320-1327.
290. Garcia Rego JA, Valbuena Ruvira L, Alvarez Garcia A, et al. Pancreatic mucinous cystadenocarcinoma with pseudosarcomatous mural nodules. A report of a case with immunohistochemical study. *Cancer*. 1991;67(2):494-498.
291. Wenig BM, Albores-Saavedra J, Buetow PC, Heffess CS. Pancreatic mucinous cystic neoplasm with sarcomatous stroma: a report

of three cases. *Am J Surg Pathol*. 1997;21(1):70-80.
292. van den Berg W, Tascilar M, Offerhaus GJ, et al. Pancreatic mucinous cystic neoplasms with sarcomatous stroma: molecular evidence for monoclonal origin with subsequent divergence of the epithelial and sarcomatous components. *Mod Pathol*. 2000;13(1):86-91.
293. Thompson LD, Becker RC, Przygodzki RM, et al. Mucinous cystic neoplasm (mucinous cystadenocarcinoma of low-grade malignant potential) of the pancreas: a clinicopathologic study of 130 cases. *Am J Surg Pathol*. 1999;23(1):1-16.
294. Jang KT, Park SM, Basturk O, et al. Clinicopathologic characterisitcs of 29 invasive carcinomas arising in 178 pancreatic mucinous cystic neoplasms with ovarian-type stroma: implications for management and prognosis. *Am J Surg Pathol*. 2015;39:179-187.
295. Young RH, Hart WR. Metastases from carcinomas of the pancreas simulating primary mucinous tumors of the ovary. A report of seven cases. *Am J Surg Pathol*. 1989;13(9):748-756.
296. Fukushima N, Zamboni G. Mucinous cystic neoplasms of the pancreas: update on the surgical pathology and molecular genetics. *Semin Diag Pathol*. 2014;31:467-474.
297. Handra-Luca A, Flejou JF, Rufat P, et al. Human pancreatic mucinous cystadenoma is characterized by distinct mucin, cytokeratin and CD10 expression compared with intraductal papillary-mucinous adenoma. *Histopathology*. 2006;48(7):813-821.
298. Zhao J, Liang SX, Savas L, Banner BF. An immunostaining panel for diagnosis of malignancy in mucinous tumors of the pancreas. *Arch Pathol Lab Med*. 2001;125(6):765-769.
299. Iacobuzio-Donahue CA, Wilentz RE, Argani P, et al. Dpc4 protein in mucinous cystic neoplasms of the pancreas: frequent loss of expression in invasive carcinomas suggests a role in genetic progression. *Am J Surg Pathol*. 2000;24(11):1544-1548.
300. Sessa F, Solcia E, Capella C, et al. Intraductal papillary-mucinous tumours represent a distinct group of pancreatic neoplasms: an investigation of tumour cell differentiation and K-ras, p53 and c-erbB-2 abnormalities in 26 patients. *Virchows Arch*. 1994;425(4):357-367.
301. Santini D, Campione O, Salerno A, et al. Intraductal papillary-mucinous neoplasm of the pancreas. A clinicopathologic entity. *Arch Pathol Lab Med*. 1995;119(3):209-213.
302. Paal E, Thompson LD, Przygodzki RM, et al. A clinicopathologic and immunohistochemical study of 22 intraductal papillary mucinous neoplasms of the pancreas, with a review of the literature. *Mod Pathol*. 1999;12(5):518-528.
303. Adsay NV, Longnecker DS, Klimstra DS. Pancreatic tumors with cystic dilatation of the ducts: intraductal papillary mucinous neoplasms and intraductal oncocytic papillary neoplasms. *Semin Diagn Pathol*. 2000;17(1):16-30.
304. Obara T, Maguchi H, Saitoh Y, et al. Mucin-producing tumor of the pancreas: natural history and serial pancreatogram changes. *Am J Gastroenterol*. 1993;88(4):564-569.
305. Ohta T, Nagakawa T, Akiyama T, et al. The "duct-ectatic" variant of mucinous cystic neoplasm of the pancreas: clinical and radiologic studies of seven cases. *Am J Gastroenterol*. 1992;87(3):300-304.
306. Rickaert F, Cremer M, Deviere J, et al. Intraductal mucin-hypersecreting neoplasms of the pancreas. A clinicopathologic study of eight patients. *Gastroenterology*. 1991;101(2):512-519.
307. Yamada M, Kozuka S, Yamao K, et al. Mucin-producing tumor of the pancreas. *Cancer*. 1991;68(1):159-168.
308. Furukawa T, Takahashi T, Kobari M, Matsuno S. The mucus-hypersecreting tumor of the pancreas. Development and extension visualized by three-dimensional computerized mapping. *Cancer*. 1992;70(6):1505-1513.
309. Kloppel G, Basturk O, Schlitter AM, et al. Intraductal neoplasms of the pancreas. *Semin Diagn Pathol*. 2014;31:452-466.
310. Terada T, Ohta T, Kitamura Y, et al. Endocrine cells in intraductal papillary-mucinous neoplasms of the pancreas: a histochemical and immunohistochemical study. *Virchows Arch*. 1997;431(1):31-36.
311. Adsay NV, Merati K, Basturk O, et al. Pathologically and biologically distinct types of epithelium in intraductal papillary mucinous neoplasms: delineation of an "intestinal" pathway of carcinogenesis in the pancreas. *Am J Surg Pathol*. 2004;28(7):839-848.
312. Ban S, Naitoh Y, Mino-Kenudson M, et al. Intraductal papillary mucinous neoplasm (IPMN) of the pancreas: its histopathologic difference between 2 major types. *Am J Surg Pathol*. 2006;30(12):1561-1569.
313. Adsay NV, Adair CF, Heffess CS, Klimstra DS. Intraductal oncocytic papillary neoplasms of the pancreas. *Am J Surg Pathol*. 1996;20(8):980-994.
314. Terris B, Ponsot P, Paye F, et al. Intraductal papillary mucinous tumors of the pancreas confined to secondary ducts show less aggressive pathologic features as compared with those involving the main pancreatic duct. *Am J Surg Pathol*. 2000;24(10):1372-1377.
315. Adsay NV, Conlon KC, Zee SY, et al. Intraductal papillary-mucinous neoplasms of the pancreas: an analysis of in situ and invasive carcinomas in 28 patients. *Cancer*. 2002;94(1):62-77.
316. Fukushima N, Sakamoto M, Mukai K, et al. Intraductal papillary components in invasive ductal carcinoma of the pancreas are associated with long-term survival of patients. *Hum Pathol*. 2001;32(8):834-841.
317. Iacobuzio-Donahue CA, Klimstra DS, Adsay NV, et al. Dpc-4 protein is expressed in virtually all human intraductal papillary mucinous neoplasms of the pancreas: comparison with conventional ductal adenocarcinomas. *Am J Pathol*. 2000;157(3):755-761.
318. Fukushima N, Mukai K. Differential diagnosis between intraductal papillary-mucinous tumors and mucinous cystic tumors of the pancreas. *Int J Surg Pathol*. 2000;8(4):271-278.
319. Hruban RH, Takaori K, Klimstra DS, et al. An illustrated consensus on the classification of pancreatic intraepithelial neoplasia and intraductal papillary mucinous neoplasms. *Am J Surg Pathol*. 2004;28(8):977-987.
320. Schlitter AM, Jang KT, Kloppel G, et al. Intraductal tubulopapillary neoplasms of the bile ducts: clinicopathologic, immunohistochemical, and molecular analysis of 20 cases. *Mod Pathol*. 2015;28:1249-1264.
321. Konigsrainer I, Glatzle J, Kloppel G, et al. Intraductal and cystic tubulopapillary adenocarcinoma of the pancreas—a possible variant of intraductal tubular carcinoma. *Pancreas*. 2008;36:92-95.
322. Yamaguchi H, Shimizu M, Ban S, et al. Intraductal tubulopapillary neoplasms of the pancreas distinct from pancreatic intraepithelial neoplasia and intraductal papillary mucinous neoplasms. *Am J Surg Pathol*. 2009;33(8):1164-1172.
323. Albores-Saavedra J, Sheahan K, O'Riain C, Shukla D. Intraductal tubular adenoma, pyloric type, of the pancreas: additional observations on a new type of pancreatic neoplasm. *Am J Surg Pathol*. 2004;28(2):233-238.
324. Chetty R, Serra S. Intraductal tubular adenoma (pyloric gland-type) of the pancreas: a reappraisal and possible relationship with gastric-type intraductal papillary mucinous neoplasm. *Histopathology*. 2009;55(3):270-276.
325. Nakayama Y, Inoue H, Hamada Y, et al. Intraductal tubular adenoma of the pancreas, pyloric gland type: a clinicopathologic and immunohistochemical study of 6 cases. *Am J Surg Pathol*. 2005;29(5):607-616.
326. Klimstra DS, Heffess CS, Oertel JE, Rosai J. Acinar cell carcinoma of the pancreas. A clinicopathologic study of 28 cases. *Am J Surg Pathol*. 1992;16(9):815-837.
327. Wood LD, Klimstra DS. Pathology and genetics of pancreatic neoplasms with acinar differentiation. *Semin Diagn Pathol*. 2014;31:491-497.
328. Burns WA, Matthews MJ, Hamosh M, et al. Lipase-secreting acinar cell carcinoma of the pancreas with polyarthropathy. A light and electron microscopic, histochemical, and biochemical study. *Cancer*. 1974;33(4):1002-1009.
329. Ban D, Shimada K, Sekine S, et al. Pancreatic ducts as an important route of tumor extension for acinar cell carcinoma of the pancreas. *Am J Surg Pathol*. 2010;34(7):1025-1036.
330. Basturk O, Zamboni G, Klimstra DS, et al. Intraductal and papillary variants of acinar cell carcinomas: a new addition to the challenging differential diagnosis of intraductal neoplasms. *Am J Surg Pathol*. 2007;31(3):363-370.
331. Fabre A, Sauvanet A, Flejou JF, et al. Intraductal acinar cell carcinoma of the pancreas. *Virchows Arch*. 2001;438(3):312-315.
332. La Rosa S, Franzi F, Marchet S, et al. The monoclonal anti-BCL10 antibody (clone 331.1) is a sensitive and specific marker of pancreatic acinar cell carcinoma and pancreatic metaplasia. *Virchows Arch*. 2009;454(2):133-142.
333. Cingolani N, Shaco-Levy R, Farruggio A, et al. Alpha-fetoprotein production by pancreatic tumors exhibiting acinar cell differentiation: study of five cases, one arising in a mediastinal teratoma. *Hum Pathol*. 2000;31(8):938-944.
334. Abraham SC, Wu TT, Hruban RH, et al. Genetic and immunohistochemical analysis of pancreatic acinar cell carcinoma: frequent allelic loss on chromosome 11p and alterations in the APC/beta-catenin pathway. *Am J Pathol*. 2002;160(3):953-962.
335. Vakiani E, Young RH, Carcangiu ML, Klimstra DS. Acinar cell carcinoma of the pancreas metastatic to the ovary: a report of 4 cases. *Am J Surg Pathol*. 2008;32(10):1540-1545.
336. Chatelain D, Paye F, Mourra N, et al. Unilocular acinar cell cystadenoma of the pancreas: an unusual acinar cell tumor. *Am J Clin Pathol*. 2002;118(2):211-214.
337. Zamboni G, Terris B, Scarpa A, et al. Acinar cell cystadenoma of the pancreas: a new entity? *Am J Surg Pathol*. 2002;26(6):698-704.
338. Cantrell BB, Cubilla AL, Erlandson RA, et al. Acinar cell cystadenocarcinoma of human pancreas. *Cancer*. 1981;47(2):410-416.
339. Stamm B, Burger H, Hollinger A. Acinar cell cystadenocarcinoma of the pancreas. *Cancer*. 1987;60(10):2542-2547.
340. Klimstra DS, Rosai J, Heffess CS. Mixed acinar-endocrine carcinomas of the pancreas. *Am J Surg Pathol*. 1994;18(8):765-778.
341. Ohike N, Kosmahl M, Kloppel G. Mixed acinar-endocrine carcinoma of the pancreas. A clinicopathological study and comparison

with acinar-cell carcinoma. *Virchows Arch*. 2004;445(3):231-235.
342. Stelow EB, Shaco-Levy R, Bao F, et al. Pancreatic acinar cell carcinomas with prominent ductal differentiation: mixed acinar ductal carcinoma and mixed acinar endocrine ductal carcinoma. *Am J Surg Pathol*. 2010;34(4):510-518.
343. Yantiss RK, Chang HK, Farraye FA, et al. Prevalence and prognostic significance of acinar cell differentiation in pancreatic endocrine tumors. *Am J Surg Pathol*. 2002;26(7):893-901.
344. Stamm BH. Incidence and diagnostic significance of minor pathologic changes in the pancreas at autopsy: a systematic study of 112 autopsies in patients without known pancreatic disease. *Hum Pathol*. 1984;15:677-683.
345. Tanaka T, Mori H, Williams GM. Atypical and neoplastic acinar cell lesions of the pancreas in an autopsy study of Japanese patients. *Cancer*. 1988;61:2278-2285.
346. Kodama T, Mori W. Atypical acinar cell nodules of the human pancreas. *Acta Pathol Jn*. 1983;33:701-714.
347. Shinozuka H, Lee RE, Dunn JL, Longnecker DS. Multiple atypical acinar nodules of the pancreas. *Hum Pathol*. 1980;11:389-391.
348. Dunn JL, Longnecker DS. Pancreatoblastoma in an older adult. *Arch Pathol Lab Med*. 1995;119(6):547-551.
349. Abraham SC, Wu TT, Klimstra DS, et al. Distinctive molecular genetic alterations in sporadic and familial adenomatous polyposis-associated pancreatoblastomas: frequent alterations in the APC/beta-catenin pathway and chromosome 11p. *Am J Pathol*. 2001;159(5):1619-1627.
350. Tanaka Y, Ijiri R, Yamanaka S, et al. Pancreatoblastoma: optically clear nuclei in squamoid corpuscles are rich in biotin. *Mod Pathol*. 1998;11(10):945-949.
351. Klimstra DS, Wenig BM, Adair CF, Heffess CS. Pancreatoblastoma. A clinicopathologic study and review of the literature. *Am J Surg Pathol*. 1995;19(12):1371-1389.
352. Nishimata S, Kato K, Tanaka M, et al. Expression pattern of keratin subclasses in pancreatoblastoma with special emphasis on squamoid corpuscles. *Pathol Int*. 2005;55(6):297-302.
353. Nasher O, Hall NJ, Sebire NJ, et al. Pancreatic tumours in children: diagnosis, treatment, and outcome. *Pediatr Surg Intl*. 2015;31:831-835.
354. Rojas Y, Warneke CL, Dhamne CA, et al. Primary malignant pancreatic neoplasms in children and adolescents: a 20 year experience. *J Pediatr Surg*. 2012;47:2199-2204.
355. Terris B, Cavard C. Diagnosis and molecular aspects of solid-pseudopapillary neoplasms of the pancreas. *Semin Diagn Pathol*. 2014;31:484-490.
356. Hu S, Lin X, Song Q, Chen K. Multidetector CT of multicentric solid pseudopapillary tumor of the pancreas: a case report and review of the literature. *Cancer Imaging*. 2011;11:175-178.
357. Matsunou H, Konishi F, Yamamichi N, et al. Solid, infiltrating variety of papillary cystic neoplasm of the pancreas. *Cancer*. 1990;65(12):2747-2757.
358. Zhu H, Xia D, Wang B, Meng H. Extrapancreatic solid pseudopapillary neoplasm: report of a case of primary retroperitoneal origin and review of the literature. *Oncol Lett*. 2013;5:1501-1504.
359. Lieber MR, Lack EE, Roberts JR Jr, et al. Solid and papillary epithelial neoplasm of the pancreas. An ultrastructural and immunocytochemical study of six cases. *Am J Surg Pathol*. 1987;11(2):85-93.
360. Albores-Saavedra J, Simpson KW, Bilello SJ. The clear cell variant of solid pseudopapillary tumor of the pancreas: a previously unrecognized pancreatic neoplasm. *Am J Surg Pathol*. 2006;30(10):1237-1242.
361. Notohara K, Hamazaki S, Tsukayama C, et al. Solid-pseudopapillary tumor of the pancreas: immunohistochemical localization of neuroendocrine markers and CD10. *Am J Surg Pathol*. 2000;24(10):1361-1371.
362. Comper F, Antonello D, Beghelli S, et al. Expression pattern of claudins 5 and 7 distinguishes solid-pseudopapillary from pancreatoblastoma, acinar cell and endocrine tumors of the pancreas. *Am J Surg Pathol*. 2009;33(5):768-774.
363. Geers C, Moulin P, Gigot JF, et al. Solid and pseudopapillary tumor of the pancreas—review and new insights into pathogenesis. *Am J Surg Pathol*. 2006;30(10):1243-1249.
364. Pettinato G, Manivel JC, Ravetto C, et al. Papillary cystic tumor of the pancreas. A clinicopathologic study of 20 cases with cytologic, immunohistochemical, ultrastructural, and flow cytometric observations, and a review of the literature. *Am J Clin Pathol*. 1992;98(5):478-488.
365. Bhatnagar R, Olson MT, Fishman EK, et al. Solid-pseudopapillary neoplasm of the pancreas: cytomorphologic findings and literature review. *Acta Cytol*. 2014;58:347-355.
366. Chetty R, Serra S. Membrane loss and aberrant nuclear localization of E-cadherin are consistent features of solid pseudopapillary tumour of the pancreas. An immunohistochemical study using two antibodies recognizing different domains of the E-cadherin molecule. *Histopathology*. 2008;52(3):325-330.
367. El-Bahrawy MA, Rowan A, Horncastle D, et al. E-cadherin/catenin complex status in solid pseudopapillary tumor of the pancreas. *Am J Surg Pathol*. 2008;32(1):1-7.
368. Cao D, Antonescu C, Wong G, et al. Positive immunohistochemical staining of KIT in solid-pseudopapillary neoplasms of the pancreas is not associated with KIT/PDGFRA mutations. *Mod Pathol*. 2006;19(9):1157-1163.
369. Bergmann F, Andrulis M, Hartwig W, et al. Discovered on gastrointestinal stromal tumor 1 (DOG1) is expressed in pancreatic centroacinar cells and in solid-pseudopapillary neoplasms-novel evidence for a histogenetic relationship. *Hum Pathol*. 2011;42:817-823.
370. Tiemann K, Kosmahl M, Ohlendorf J, et al. Solid pseudopapillary neoplasms of the pancreas are associated with FLI-1 expression, but not with EWS/FLI-1 translocation. *Mod Pathol*. 2006;19(11):1409-1413.
371. Nishihara K, Tsuneyoshi M, Ohshima A, Yamaguchi K. Papillary cystic tumor of the pancreas. Is it a hormone-dependent neoplasm? *Pathol Res Pract*. 1993;189(5):521-526.
372. Zamboni G, Bonetti F, Scarpa A, et al. Expression of progesterone receptors in solid-cystic tumour of the pancreas: a clinicopathological and immunohistochemical study of ten cases. *Virchows Arch A Pathol Anat Histopathol*. 1993;423(6):425-431.
373. Kosmahl M, Seada LS, Janig U, et al. Solid-pseudopapillary tumor of the pancreas: its origin revisited. *Virchows Arch*. 2000;436(5):473-480.
374. Deshpande V, Oliva E, Young RH. Solid pseudopapillary neoplasm of the ovary: a report of 3 primary ovarian tumors resembling those of the pancreas. *Am J Surg Pathol*. 2010;34(10):1514-1520.
375. Abraham SC, Klimstra DS, Wilentz RE. Solid-pseudopapillary tumors of the pancreas are genetically distinct from pancreatic ductal adenocarcinomas and almost always harbor beta-catenin mutations. *Am J Pathol*. 2002;160(4):1361-1369.
376. Grant LD, Lauwers GY, Meloni AM, et al. Unbalanced chromosomal translocation, der(17)t(13;17)(q14;p11) in a solid and cystic papillary epithelial neoplasm of the pancreas. *Am J Surg Pathol*. 1996;20(3):339-345.
377. Rund CR, Moser AJ, Lee KK, et al. Array comparative genomic hybridization analysis of solid pseudopapillary neoplasms of the pancreas. *Mod Pathol*. 2008;21:559-564.
378. Irtan S, Galmiche-Rolland L, Elie C, et al. Recurrence of solid pseudopapillary neoplasms of the pancreas: results of a nationwide study of risk factors and treatment modalities. *Pediatr Blood Cancer*. 2016;63:1515-1521.
379. Li G, Baek NH, Yoo K, et al. Surgical outcomes for solid pseudopapillary neoplasm of the pancreas. *Hepatogastroenterology*. 2014;61:1780-1784.
380. Tang LH, Aydin H, Brennan MF, Klimstra DS. Clinically aggressive solid pseudopapillary tumors of the pancreas: a report of two cases with components of undifferentiated carcinoma and a comparative clinicopathologic analysis of 34 conventional cases. *Am J Surg Pathol*. 2005;29(4):512-519.
381. Klimstra DS, Wenig BM, Heffess CS. Solid-pseudopapillary tumor of the pancreas: a typically cystic carcinoma of low malignant potential. *Semin Diagn Pathol*. 2000;17(1):66-80.
382. Estrella JS, Li L, Rashid A, et al. Solid pseudopapillary neoplasm of the pancreas: clinicopathologic and survival analysis of 64 cases from a single institution. *Am J Surg Pathol*. 2014;38:147-157.
383. Shi C, Klimstra DS. Pancreatic neuroendocrine tumors: pathologic and molecular characteristics. *Semin Diagn Pathol*. 2014;31:498-511.
384. Goudet P, Dalac A, Le Bras M, et al. MEN1 disease occurring before 21 years old: a 160-patient cohort study from the Groupe d'etude des Tumeurs Endocrines. *J Clin Endocrinol Metab*. 2015;100:1568-1577.
385. Shrikhande S, Kleeff J, Zimmermann A, Friess H. Büchler MW. Co-existent chronic pancreatitis and pancreatic neuroendocrine tumor. Case report and review of the literature. *Pancreatology*. 2001;1:117-122.
386. Capelli P, Martignoni G, Pedica F, et al. Endocrine neoplasms of the pancreas: pathologic and genetic features. *Arch Pathol Lab Med*. 2009;133(3):350-364.
387. Ligneau B, Lombard-Bohas C, Partensky C, et al. Cystic endocrine tumors of the pancreas: clinical, radiologic, and histopathologic features in 13 cases. *Am J Surg Pathol*. 2001;25(6):752-760.
388. Keel SB, Zukerberg L, Graeme-Cook F, Compton CC. A pancreatic endocrine tumor arising within a serous cystadenoma of the pancreas. *Am J Surg Pathol*. 1996;20(4):471-475.
389. Chetty R, El-Shinnawy I. Intraductal pancreatic neuroendocrine tumor. *Endocr Pathol*. 2009;20(4):262-266.
390. Zee SY, Hochwald SN, Conlon KC, et al. Pleomorphic pancreatic endocrine neoplasms: a variant commonly confused with adenocarcinoma. *Am J Surg Pathol*. 2005;29(9):1194-1200.
391. Guarda LA, Silva EG, Ordonez NG, et al. Clear cell islet cell tumor. *Am J Clin Pathol*. 1983;79(4):512-517.
392. Hoang MP, Hruban RH, Albores-Saavedra J. Clear cell endocrine pancreatic tumor mimicking renal cell carcinoma: a distinctive neoplasm of von Hippel-Lindau disease. *Am J Surg Pathol*. 2001;25(5):602-609.
393. Ordonez NG, Silva EG. Islet cell tumour with vacuolated lipid-rich cytoplasm: a new histological variant of islet cell tumour. *Histopathology*. 1997;31(2):157-160.

394. Singh R, Basturk O, Klimstra DS, et al. Lipid-rich variant of pancreatic endocrine neoplasms. *Am J Surg Pathol*. 2006;30(2):194-200.
395. Volante M, La Rosa S, Castellano I, et al. Clinico-pathological features of a series of 11 oncocytic endocrine tumours of the pancreas. *Virchows Arch*. 2006;448(5):545-551.
396. Tomita T, Bhatia P, Gourley W. Mucin producing islet cell adenoma. *Hum Pathol*. 1981;12(9):850-853.
397. Smith AE, Levi AW, Nadasdy T, et al. The pigmented "black" neuroendocrine tumor of the pancreas: a question of origin. *Cancer*. 2001;92(7):1984-1991.
398. Chetty R, Serra S. Spindle cell pancreatic endocrine tumor associated with Cushing's syndrome. *Endocr Pathol*. 2005;16(2):145-151.
399. Perez-Montiel MD, Frankel WL, Suster S. Neuroendocrine carcinomas of the pancreas with 'Rhabdoid' features. *Am J Surg Pathol*. 2003;27(5):642-649.
400. Serra S, Asa SL, Chetty R. Intracytoplasmic inclusions (including the so-called "rhabdoid" phenotype) in pancreatic endocrine tumors. *Endocr Pathol*. 2006;17(1):75-81.
401. Emerson L, Layfield LJ, Reiss R, et al. Malignant islet cell tumor with sarcomatous differentiation. *Mod Pathol*. 2001;14(11):1187-1191.
402. Ferreiro J, Lewin K, Herron RM, Bhuta S. Malignant islet cell tumor with rhabdomyosarcomatous differentiation. *Am J Surg Pathol*. 1989;13(5):422-427.
403. Westermark P, Grimelius L, Polak JM, et al. Amyloid in polypeptide hormone-producing tumors. *Lab Invest*. 1977;37(2):212-215.
404. Takahashi M, Hoshii Y, Kawano H, et al. Multihormone-producing islet cell tumor of the pancreas associated with somatostatin-immunoreactive amyloid: immunohistochemical and immunoelectron microscopic studies. *Am J Surg Pathol*. 1998;22(3):360-367.
405. Tischler AS, Compagno J. Crystal-like deposits of amyloid in pancreatic islet cell tumors. *Arch Pathol Lab Med*. 1979;103(5):247-251.
406. Williams AJ, Coates PJ, Lowe DG, et al. Immunochemical investigation of insulinomas for islet amyloid polypeptide and insulin: evidence for differential synthesis and storage. *Histopathology*. 1992;21(3):215-223.
407. Grozinsky-Glasberg S, Mazeh H, Gross DJ. Clinical features of pancreatic neuroendocrine tumors. *J Hepatobiliary Pancreat Sci*. 2015;22:578-585.
408. Okabayashi T, Shima Y, Sumiyoshi T, et al. Diagnosis and management of insulinoma. *World J Gastroenterol*. 2013;19:829-837.
409. Anlauf M, Bauersfeld J, Raffel A, et al. Insulinomatosis: a multicentric insulinoma disease that frequently causes early recurrent hyperinsulinemic hypoglycemia. *Am J Surg Pathol*. 2009;33(3):339-346.
410. Baudin E, Caron P, Lombard-Bohas C, et al. Malignant insulinoma: recommendations for characterisation and treatment. *Ann Endocrinol (Paris)*. 2013;74:523-533.
411. Graeme-Cook F, Bell DA, Flotte TJ, et al. Aneuploidy in pancreatic insulinomas does not predict malignancy. *Cancer*. 1990;66(11):2365-2368.
412. Lloyd RV, Erickson LA, Nascimento AG, Kloppel G. Neoplasms causing nonhyperinsulinemic hypoglycemia. *Endocr Pathol*. 1999;10(4):291-297.
413. Ahluwalia N, Attia R, Green A, et al. Doege-Potter syndrome. *Ann R Coll Surg Engl*. 2015;97(7):e105-e107.
414. Daughaday WH, Emanuele MA, Brooks MH, et al. Synthesis and secretion of insulin-like growth factor II by a leiomyosarcoma with associated hypoglycemia. *N Engl J Med*. 1988;319(22):1434-1440.
415. Hamid QA, Bishop AE, Sikri KL, et al. Immunocytochemical characterization of 10 pancreatic tumours, associated with the glucagonoma syndrome, using antibodies to separate regions of the pro-glucagon molecule and other neuroendocrine markers. *Histopathology*. 1986;10(2):119-133.
416. Bordi C, Ravazzola M, Baetens D, et al. A study of glucagonomas by light and electron microscopy and immunofluorescence. *Diabetes*. 1979;28:925-936.
417. Epelboym I, Mazeh H. Zollinger-Ellison syndrome: classical considerations and current controversies. *Oncologist*. 2014;19:44-50.
418. Anlauf M, Enosawa T, Henopp T, et al. Primary lymph node gastrinoma or occult duodenal microgastrinoma with lymph node metastases in a MEN1 patient: the need for a systematic search for the primary tumor. *Am J Surg Pathol*. 2008;32(7):1101-1105.
419. Herrmann ME, Ciesla MC, Chejfec G, et al. Primary nodal gastrinomas. *Arch Pathol Lab Med*. 2000;124(6):832-835.
420. Bhagavan BS, Slavin RE, Goldberg J, Rao RN. Ectopic gastrinoma and Zollinger-Ellison syndrome. *Hum Pathol*. 1986;17(6):584-592.
421. Moriura S, Ikeda S, Hirai M, et al. Hepatic gastrinoma. *Cancer*. 1993;72(5):1547-1550.
422. Thompson NW, Vinik AI, Eckhauser FE, Strodel WE. Extrapancreatic gastrinomas. *Surgery*. 1985;98(6):1113-1120.
423. Wolfe MM, Alexander RW, McGuigan JE. Extrapancreatic, extraintestinal gastrinoma: effective treatment by surgery. *N Engl J Med*. 1982;306(25):1533-1536.
424. Donow C, Pipeleers-Marichal M, Schroder S, et al. Surgical pathology of gastrinoma. Site, size, multicentricity, association with multiple endocrine neoplasia type 1, and malignancy. *Cancer*. 1991;68(6):1329-1334.
425. Anlauf M, Garbrecht N, Henopp T, et al. Sporadic versus hereditary gastrinomas of the duodenum and pancreas: distinct clinico-pathological and epidemiological features. *World J Gastroenterol*. 2006;12:5440-5446.
426. Sawady J, Mendelsohn G. Extrapancreatic gastrinoma with pancreatic islet cell hyperplasia. *Arch Pathol Lab Med*. 1989;113:536-538.
427. Abood GJ, Go A, Malhotra D, Shoup M. The surgical and systemic management of neuroendocrine tumors of the pancreas. *Surg Clin North Am*. 2009;89:249-266.
428. Doi R. Determinants of surgical resection for pancreatic neuroendocrine tumors. *J Hepatobiliary Pancreat Sci*. 2015;22:610-617.
429. Ito T, Igarashi H, Jensen RT. Pancreatic neuroendocrine tumors: clinical features, diagnosis, and medical treatment: advances. *Best Pract Res Clin Gastroenterol*. 2012;26:737-753.
430. Tanaka S, Yamasaki S, Matsushita H, et al. Duodenal somatostatinoma: a case report and review of 31 cases with special reference to the relationship between tumor size and metastasis. *Pathol Int*. 2000;50(2):146-152.
431. Tomita T, Friesen SR, Kimmel JR, et al. Pancreatic polypeptide-secreting islet-cell tumors. A study of three cases. *Am J Pathol*. 1983;113(2):134-142.
432. Tomita T, Kimmel JR, Friesen SR, et al. Pancreatic polypeptide in islet cell tumors. Morphologic and functional correlations. *Cancer*. 1985;56(7):1649-1657.
433. Soga J. Carcinoids of the pancreas: an analysis of 156 cases. *Cancer*. 2005;104:1180-1187.
434. Graeme-Cook F, Nardi G, Compton CC. Immunocytochemical staining for human chorionic gonadotropin subunits does not predict malignancy in insulinomas. *Am J Clin Pathol*. 1990;93(2):273-276.
435. Kahn CR, Rosen SW, Weintraub BD, et al. Ectopic production of chorionic gonadotropin and its subunits by islet-cell tumors. A specific marker for malignancy. *N Engl J Med*. 1977;297(11):565-569.
436. Liu TH, Zhu Y, Cui QC, et al. Nonfunctioning pancreatic endocrine tumors. An immunohistochemical and electron microscopic analysis of 26 cases. *Pathol Res Pract*. 1992;188:191-198.
437. Chan ES, Alexander J, Swanson PE, et al. PDX-1, CDX-2, TTF-1, and CK7: a reliable immunohistochemical panel for pancreatic neuroendocrine neoplasms. *Am J Surg Pathol*. 2012;36:737-743.
438. Sangoi AR, Ohgami RS, Pai RK, et al. PAX8 expression reliably distinguishes pancreatic well-differentiated neuroendocrine tumors from ileal and pulmonary well-differentiated neuroendocrine tumors and pancreatic acinar cell carcinomas. *Mod Pathol*. 2011;24:412-424.
439. Srivastava A, Hornick JL. Immunohistochemical staining for CDX-2, NESp-55, and TTF-1 can help distinguish gastrointestinal carcinoid tumors from pancreatic endocrine and pulmonary carcinoid tumors. *Am J Surg Pathol*. 2009;33:626-632.
440. Schmitt AM, Riniker F, Anlauf M, et al. Islet 1 (Isl1) expression is a reliable marker for pancreatic endocrine tumors and their metastases. *Am J Surg Pathol*. 2008;32(3):420-425.
441. Jiao Y, Shi C, Edil BH, et al. DAXX/ATRX, MEN1, and MTOR pathway genes are frequently altered in pancreatic neuroendocrine tumors. *Science*. 2011;331:1199-1203.
442. D'Adda T, Pizzi S, Azzoni C, et al. Different patterns of 11q allelic losses in digestive endocrine tumors. *Hum Pathol*. 2002;33(3):322-329.
443. Rindi G, Arnoid R, Bosman FT, et al. Nomenclature and classification of neuroendocrine neoplasms of the digestive system. In: Bosman FT, Carneiro F, Hruban RH, Theise ND, eds. *WHO Classification of Tumors of the Digestive System*. 4th ed. Lyon: International Agency for Research on Cancer; 2010.
444. Tang LH, Basturk O, Sue JJ, Klimstra DS. A practical approach to the classification of WHO grade 3 (G3) well-differentiated neuroendocrine tumor (WD-NET) and poorly differentiated neuroendocrine carcinoma (PD-NEC) of the pancreas. *Am J Surg Pathol*. 2016;40:1192-1202.
445. Deschamps L, Handra-Luca A, O'Toole D, et al. CD10 expression in pancreatic endocrine tumors: correlation with prognostic factors and survival. *Hum Pathol*. 2006;37(7):802-808.
446. Goto A, Niki T, Terado Y, et al. Prevalence of CD99 protein expression in pancreatic endocrine tumours (PETs). *Histopathology*. 2004;45(4):384-392.
447. Hafez NA, Turner L, Henderson-Jackson EB, et al. Overexpression of p21 is a marker of tumor metastasis in primary pancreatic neuroendocrine neoplasms. *Lab Invest*. 2009;89(suppl 1):116-117A.
448. Henderson-Jackson EB, Turner L, Hafez N, et al. Palladin is a novel marker of metastasis in primary pancreatic endocrine neoplasms. *Lab Invest*. 2009;89(suppl 1).
449. Long KB, Srivastava A, Hirsch MS, Hornick JL. PAX8 Expression in well-differentiated pancreatic endocrine tumors: correlation with clinicopathologic features and comparison with gastrointestinal and pulmonary carcinoid tumors. *Am J Surg Pathol*. 2010;34(5):723-729.
450. Serra S, Ezzat S, Chetty R, Asa SL. The role FGFR4 in pancreatic endocrine tumors. *Lab Invest*. 2009;89(suppl 1).
451. Zhang L, Smyrk TC, Oliveira AM, et al. KIT is an independent prognostic marker for pancreatic endocrine tumors: a finding derived from analysis of islet cell differentiation

markers. *Am J Surg Pathol*. 2009;33(10):1562-1569.
452. Corrin B, Gilby ED, Jones NF, Patrick J. Oat cell carcinoma of the pancreas with ectopic ACTH secretion. *Cancer*. 1973;31(6):1523-1527.
453. Hobbs RD, Stewart AF, Ravin ND, Carter D. Hypercalcemia in small cell carcinoma of the pancreas. *Cancer*. 1984;53(7):1552-1554.
454. Nishizawa N, Kumamoto Y, Igarashi K, et al. A peripheral primitive neuroectodermal tumor originating from the pancreas: a case report and review of the literature. *Surg Case Rep*. 2015;1:80. doi:10.1186/s40792-015-0084-7.
455. Kloppel G. Mixed exocrine-endocrine tumors of the pancreas. *Semin Diagn Pathol*. 2000;17:104-108.
456. Terada T, Kawaguchi M, Furukawa K, et al. Minute mixed ductal-endocrine carcinoma of the pancreas with predominant intraductal growth. *Pathol Int*. 2002;52:740-746.
457. Regitnig P, Spuller E, Denk H. Insulinoma of the pancreas with insular-ductular differentiation in its liver metastasis—indication of a common stem-cell origin of the exocrine and endocrine components. *Virchows Arch*. 2001;438(6):624-628.
458. Chatelain D, Parc Y, Christin-Maitre S, et al. Mixed ductal-pancreatic polypeptide-cell carcinoma of the pancreas. *Histopathology*. 2002;41(2):122-126.
459. van Eeden S, de Leng WW, Offerhaus GJ, et al. Ductuloinsular tumors of the pancreas: endocrine tumors with entrapped nonneoplastic ductules. *Am J Surg Pathol*. 2004;28(6):813-820.
460. Thakker RV, Newey PJ, Walls GV, et al. Clinical practice guidelines for multiple endocrine neoplasia type 1 (MEN1). *J Clin Endocrinol Metab*. 2012;97:2990-3011.
461. Marini F, Falchetti A, Del Monte F, et al. Multiple endocrine neoplasia type 1. *Orphanet J Rare Dis*. 2006;1:38.
462. Callender GG, Rich TA, Perrier ND. Multiple endocrine neoplasia syndromes. *Surg Clin North Am*. 2008;88(4):863-895.
463. White ML, Doherty GM. Multiple endocrine neoplasia. *Surg Oncol Clin North Am*. 2008;17(2):439-459.
464. Brandi ML, Gagel RF, Angeli A, et al. Guidelines for diagnosis and therapy of MEN type 1 and type 2. *J Clin Endocrinol Metab*. 2001;86(12):5658-5671.
465. Tsukada T, Yamaguchi K, Kameya T. The MEN1 gene and associated diseases: an update. *Endocr Pathol*. 2001;12(3):259-273.
466. McKeeby JL, Li X, Zhuang Z, et al. Multiple leiomyomas of the esophagus, lung, and uterus in multiple endocrine neoplasia type 1. *Am J Pathol*. 2001;159(3):1121-1127.
467. Rosai J, Higa E, Davie J. Mediastinal endocrine neoplasm in patients with multiple endocrine adenomatosis. A previously unrecognized association. *Cancer*. 1972;29(4):1075-1083.
468. Solcia E, Capella C, Fiocca R, et al. Gastric argyrophil carcinoidosis in patients with Zollinger-Ellison syndrome due to type 1 multiple endocrine neoplasia. A newly recognized association. *Am J Surg Pathol*. 1990;14(6):503-513.
469. Pasini B, Ceccherini I, Romeo G. RET mutations in human disease. *Trends Genet*. 1996;12(4):138-144.
470. Pasini B, Rossi R, Ambrosio MR, et al. RET mutation profile and variable clinical manifestations in a family with multiple endocrine neoplasia type 2A and Hirschsprung's disease. *Surgery*. 2002;131(4):373-381.
471. van Heyningen V. Genetics. One gene—four syndromes. *Nature*. 1994;367(6461):319-320.
472. Rubinstein WS. Endocrine cancer predisposition syndromes: hereditary panraganglioma, multiple endocrine neoplasia type 1, multiple endocrine neoplasia type 2, and hereditary thyroid cancer. *Hematol Oncol Clin North Am*. 2010;24:907-937.
473. Gorlin RJ, Sedano HO, Vickers RA, Cervenka J. Multiple mucosal neuromas, pheochromocytoma and medullary carcinoma of the thyroid—a syndrome. *Cancer*. 1968;22(2):293-299 passim.
474. Lee NC, Norton JA. Multiple endocrine neoplasia type 2B—genetic basis and clinical expression. *Surg Oncol*. 2000;9(3):111-118.
475. Carney JA, Sizemore GW, Lovestedt SA. Mucosal ganglioneuromatosis, medullary thyroid carcinoma, and pheochromocytoma: multiple endocrine neoplasia, type 2b. *Oral Surg Oral Med Oral Pathol*. 1976;41(6):739-752.
476. Carney JA, Go VL, Sizemore GW, Hayles AB. Alimentary-tract ganglioneuromatosis. A major component of the syndrome of multiple endocrine neoplasia, type 2b. *N Engl J Med*. 1976;295(23):1287-1291.
477. Perkins JT, Blackstone MO, Riddell RH. Adenomatous polyposis coli and multiple endocrine neoplasia type 2b. A pathogenetic relationship. *Cancer*. 1985;55(2):375-381.
478. Khairi MR, Dexter RN, Burzynski NJ, Johnston CC Jr. Mucosal neuroma, pheochromocytoma and medullary thyroid carcinoma: multiple endocrine neoplasia type 3. *Medicine (Baltimore)*. 1975;54(2):89-112.
479. Gould E, Albores-Saavedra J, Shuman J. Pituitary prolactinoma, pancreatic glucagonomas, and aldosterone-producing adrenal cortical adenoma: a suggested variant of multiple endocrine neoplasia type I. *Hum Pathol*. 1987;18(12):1290-1293.
480. Tateishi R, Wada A, Ishiguro S, et al. Coexistence of bilateral pheochromocytoma and pancreatic islet cell tumor: report of a case and review of the literature. *Cancer*. 1978;42(6):2928-2934.
481. Bernardeau M, Auroux J, Cavicchi M, et al. Delchier JC. Secondary pancreatic involvement by diffuse large B-cell lymphoma presenting as acute pancreatitis: treatment and outcome. *Pancreatology*. 2002;2(4):427-430.
482. Hirata S, Yamaguchi K, Bandai S, et al. Secondary extramedullary plasmacytoma involving the pancreas. *J Hepatobiliary Pancreat Surg*. 2002;9(1):111-115.
483. Fukuba N, Moriyama I, Ishihara S, et al. Primary pancreatic malignant lymphoma diagnosed from endoscopic ultrasound-guided fine-needle aspiration findings. *Intern Med*. 2016;55:31-35.
484. Nakaji S, Hirata N, Shiratori T, et al. A case of primary pancreatic lymphoblastic lymphoma diagnosed by endoscopic ultrasound-guided fine-needle aspiration. *Clin J Gastroenterol*. 2014;7:180-184.
485. Chim CS, Ho J, Ooi GC, et al. Primary anaplastic large cell lymphoma of the pancreas. *Leuk Lymphoma*. 2005;46(3):457-459.
486. Dyckmans K, Lerut E, Gillard P, et al. Post-transplant lymphoma of the pancreatic allograft in a kidney-pancreas transplant recipient: a misleading presentation. *Nephrol Dial Transplant*. 2006;21:3306-3310.
487. Akyuz F, Sahin D, Akyuz U, Vatansever S. Rare pancreas tumor mimicking adenocarcinoma: extramedullary plasmacytoma. *World J Gastrointest Endosc*. 2014;6:99-100.
488. Yadav YK, Mallya V, Ahluwalia C, Gupta O. Secondary pancreatic involvement by precursor T-cell acute lymphoblastic leukemia presenting as acute pancreatitis. *Indian J Cancer*. 2015;52:465-467.
489. Malbora B, Avci Z, Alioglu B, et al. A case with mature B-cell acute lymphoblastic leukemia and pancreatic involvement at the time of diagnosis. *J Pediatr Hematol Oncol*. 2008;30:87-89.
490. Wang H, Wieczorek RL, Zenilman ME, et al. Castleman's disease in the head of the pancreas: report of a rare clinical entity and current perspective on diagnosis, treatment, and outcome. *World J Surg Oncol*. 2007;5:133.
491. Podberezin M, Angeles R, Guzman G, et al. Primary pancreatic sinus histiocytosis with massive lymphadenopathy (Rosai-Dorfman disease): an unusual extranodal manifestation clinically simulating malignancy. *Arch Pathol Lab Med*. 2010;134(2):276-278.
492. Paal E, Thompson LD, Heffess CS. A clinicopathologic and immunohistochemical study of ten pancreatic lymphangiomas and a review of the literature. *Cancer*. 1998;82(11):2150-2158.
493. Coe AW, Evans J, Conway J. Pancreas cystic lymphangioma diagnosed with EUS-FNA. *JOP*. 2012;13:282-284.
494. Overstreet K, Wixom C, Shabaik A, et al. Adenomatoid tumor of the pancreas: a case report with comparison of histology and aspiration cytology. *Mod Pathol*. 2003;16(6):613-617.
495. Brown SZ, Owen DA, O'Connell JX, Scudamore CH. Schwannoma of the pancreas: a report of two cases and a review of the literature. *Mod Pathol*. 1998;11(12):1178-1182.
496. Tafe LJ, Suriawinata AA. Cystic pancreatic schwannoma in a 46-year-old man. *Ann Diagn Pathol*. 2008;12(4):296-300.
497. Luttges J, Mentzel T, Hubner G, Kloppel G. Solitary fibrous tumour of the pancreas: a new member of the small group of mesenchymal pancreatic tumours. *Virchows Arch*. 1999;435(1):37-42.
498. Paramythiotis D, Kofina K, Bangeas P, et al. Solitary fibrous tumor of the pancreas: case report and review of the literature. *World J Gastrointest Surg*. 2016;8:461-466.
499. Jiang H, Ta N, Huang XY, et al. Pancreatic perivascular epithelioid tumor: a case report with clinicopathologic features and a literature review. *World J Gastroenterol*. 2016;22:3693-3700.
500. Hirabayashi K, Nakamura N, Kajiwara H, et al. Perivascular epithelioid cell tumor (PEComa) of the pancreas: immunoelectron microscopy and review of the literature. *Pathol Int*. 2009;59(9):650-655.
501. Zamboni G, Pea M, Martignoni G, et al. Clear cell "sugar" tumor of the pancreas. A novel member of the family of lesions characterized by the presence of perivascular epithelioid cells. *Am J Surg Pathol*. 1996;20(6):722-730.
502. Machado MC, Fonseca GM, de Meierelles LR, et al. Primary liposarcoma of the pancreas: a review illustrated by findings from a recent case. *Pancreatology*. 2016;16(5):715-718. doi:10.1016/j.pan.2016.07.003.
503. Zhang H, Hensen MH, Farnell MB, et al. Primary leiomyosarcoma of the pancreas: study of 9 cases and review of the literature. *Am J Surg Pathol*. 2010;34:1849-1856.
504. Huang J, Luo RK, Du M, et al. Clear cell sarcoma of the pancreas: a case report and review of literature. *Int J Clin Exp Pathol*. 2015;8:2171-2175.
505. Csiszko A, Laszlo I, Palatka K, et al. Primary angiosarcoma of the pancreas mimicking severe acute pancreatitis—case report. *Pancreatology*. 2015;15:84-87.
506. Titus AS, Pinckard NB, Cook WJ, Vickers SM. Solitary malignant peripheral nerve sheath tumor of the pancreas. *Hepatgastroenterology*. 1999;46:514-517.
507. Liang W, He W, Li Z. Extranodal follicular dendritic cell sarcoma originating in the pancreas: a case report. *Medicine (Baltimore)*. 2016;95(15):e3377. doi:10.1097/MD.0000000000003377.
508. Hirabayashi K, Fujihira T, Oyamada H, et al. First case of primary phyllodes tumor of the pancreas: case report and findings of

immunohistochemical and ultrastructural studies. *Virchows Arch*. 2010;456(5):587-593.
509. Phan M, Jones S, Jenkins J, et al. Pancreatic GIST in a patient with limited stage small cell lung cancer: a case report and review of published cases. *Case Rep Oncol Med*. 2016;2016:9604982. doi:10.1155/2016/9604982. [Epub Aug 8, 2016].
510. Walsh SV, Evangelista F, Khettry U. Inflammatory myofibroblastic tumor of the pancreaticobiliary region: morphologic and immunocytochemical study of three cases. *Am J Surg Pathol*. 1998;22(4):412-418.
511. Wreesmann V, van Eijck CH, Naus DC, et al. Inflammatory pseudotumour (inflammatory myofibroblastic tumour) of the pancreas: a report of six cases associated with obliterative phlebitis. *Histopathology*. 2001;38(2):105-110.
512. Espinal-Witter R, Servais EL, Klimstra DS, et al. Localized intrapancreatic malignant mesothelioma: a rare entity that may be confused with other pancreatic neoplasms. *Virchows Arch*. 2010;456(4):455-461.
513. Saunders TA, Miller TR, Khanafshar E. Intrapancreatic accessory spleen: utilization of fine needle aspiration for diagnosis of a potential mimic of a pancreatic neoplasm. *J Gastrointest Oncol*. 2016;7(suppl 1):S62-S65.
514. Altinel D, Basturk O, Sarmiento JM, et al. Lipomatous pseudohypertrophy of the pancreas: a clinicopathologically distinct entity. *Pancreas*. 2010;39:392-397.
515. Pauser U, da Silva MT, Placke J, et al. Cellular hamartoma resembling gastrointestinal stromal tumor: a solid tumor of the pancreas expressing c-kit (CD117). *Mod Pathol*. 2005;18(9):1211-1216.
516. Charnsangavej C, Whitley NO. Metastases to the pancreas and peripancreatic lymph nodes from carcinoma of the right side of the colon: CT findings in 12 patients. *AJR Am J Roentgenol*. 1993;160(1):49-52.
517. Thompson LD, Heffess CS. Renal cell carcinoma to the pancreas in surgical pathology material. *Cancer*. 2000;89(5):1076-1088.
518. Adsay NV, Andea A, Basturk O, et al. Secondary tumors of the pancreas: an analysis of a surgical and autopsy database and review of the literature. *Virchows Arch*. 2004;444(6):527-535.
519. Matsukuma S, Suda K, Abe H, et al. Metastatic cancer involving pancreatic duct epithelium and its mimicry of primary pancreatic cancer. *Histopathology*. 1997;30(3):208-213.
520. Bjork J, Akerbrant H, Iselius L, et al. Periampullary adenomas and adenocarcinomas in familial adenomatous polyposis: cumulative risks and AOC gene mutations. *Gastroenterology*. 2001;121:1127-1135.
521. Baczako K, Buchler M, Beger HG, et al. Morphogenesis and possible precursor lesions of invasive carcinoma of the papilla of Vater: epithelial dysplasia and adenoma. *Hum Pathol*. 1985;16(3):305-310.
522. Ferrell LD, Beckstead JH. Paneth-like cells in an adenoma and adenocarcinoma in the ampulla of Vater. *Arch Pathol Lab Med*. 1991;115(9):956-958.
523. Genta RM, Feagins LA. Advanced precancerous lesions in the small bowel mucosa. *Best Pract Res Clin Gastroenterol*. 2013;27:225-233.
524. Patel R, Varadarajulu S, Wilcox CM. Endoscopic ampullectomy: techniques and outcomes. *J Clin Gastroenterol*. 2012;46:8-15.
525. Jang KT, Ahn S. Tumoral versus flat intraepithelial neoplasia of the pancreatobiliary tract, gallbladder, and ampulla of Vater. *Arch Pathol Lab Med*. 2016;140:429-436.
526. Ohike N, Kim GE, Tajiri T, et al. Intra-ampullary papillary tubular neoplasm (IAPN): characterization of tumoral intraepithelial neoplasia occurring within the ampulla. *Am J Surg Pathol*. 2010;34: 1731-1748.
527. Edge SE, Byrd DR, Compton CC, et al. Ampulla of Vater. In: Compton CC, Byrd DR, Garcia-Aguilar J, et al, eds. *AJCC Cancer Staging Manual and Handbook*. 7th ed. New York: Springer; 2010:235-240.
528. Adsay V, Ohike N, Tajiri T, et al. Ampullary region carcinomas: definition and site specific classification with delineation of four clinicopathologically and prognostically distinct subsets in an analysis of 249 cases. *Am J Surg Pathol*. 2012;36:1592-1608.
529. Gonzalez RS, Bagci P, Basturk O, et al. Intrapancreatic distal common bile duct adenocarcinoma: analysis, staging considerations, and comparison with pancreatic ductal and ampullary adenocarcinomas. *Mod Pathol*. 2016;29(11):1358-1369. doi:10.1038/modpathol.2016.125.
530. Chandrasegaram MD, Chiam SC, Chen JW, et al. Distribution and pathological features of pancreatic, ampullary, biliary and duodenal cancers resected with pancreaticoduodenecenectomy. *World J Surg Oncol*. 2015;13:85.
531. Costi R, Caruana P, Sarli L, et al. Ampullary adenocarcinoma in neurofibromatosis type 1. Case report and literature review. *Mod Pathol*. 2001;14(11):1169-1174.
532. Wagner PL, Chen YT, Yantiss RK. Immunohistochemical and molecular features of sporadic and FAP-associated duodenal adenomas of the ampullary and nonampullary mucosa. *Am J Surg Pathol*. 2008;32(9):1388-1395.
533. Hoshimoto S, Aiura K, Shito M, et al. Adenosquamous carcinoma of the ampulla of Vater: a case report and literature review. *World J Surg Oncol*. 2015;13:287.
534. Khayyata S, Basturk O, Adsay NV. Invasive micropapillary carcinomas of the ampullo-pancreatobiliary region and their association with tumor-infiltrating neutrophils. *Mod Pathol*. 2005;18(11):1504-1511.
535. Gardiner GW, Lajoie G, Keith R. Hepatoid adenocarcinoma of the papilla of Vater. *Histopathology*. 1992;20(6):541-544.
536. Zhou H, Schaefer N, Wolff M, Fischer HP. Carcinoma of the ampulla of Vater: comparative histologic/immunohistochemical classification and follow-up. *Am J Surg Pathol*. 2004;28(7):875-882.
537. Chu PG, Schwarz RE, Lau SK, et al. Immunohistochemical staining in the diagnosis of pancreatobiliary and ampulla of Vater adenocarcinoma: application of CDX2, CK17, MUC1, and MUC2. *Am J Surg Pathol*. 2005;29(3):359-367.
538. Takashima M, Ueki T, Nagai E, et al. Carcinoma of the ampulla of Vater associated with or without adenoma: a clinicopathologic analysis of 198 cases with reference to p53 and Ki-67 immunohistochemical expressions. *Mod Pathol*. 2000;13(12):1300-1307.
539. Guo R, Overman M, Chatterjee D, et al. Aberrant expression of p53, p21, cyclin D1, and Bcl2 and their clinicopathologic correlation in ampullary adenocarcinoma. *Hum Pathol*. 2014;45:1015-1023.
540. McCarthy DM, Hruban RH, Argani P, et al. Role of the DPC4 tumor suppressor gene in adenocarcinoma of the ampulla of Vater: analysis of 140 cases. *Mod Pathol*. 2003;16(3):272-278.
541. Kwon MJ, Kim JW, Jung JP, et al. Low incidence of KRAS, BRAF, and PIK3CA mutations in adenocarcinomas of the ampulla of Vater and their prognostic value. *Hum Pathol*. 2016;50:90-100.
542. Balci S, Basturk O, Saka B, et al. Substaging nodal status in ampullary carcinomas has significant prognostic value: proposed revised staging based on an analysis of 313 well-characterized cases. *Ann Surg Oncol*. 2015;22:4392-4401.
543. Okano K, Asano E, Kushida Y, et al. Factors influencing lymph node metastasis in patients with ampullary adenocarcinoma. *Dig Surg*. 2014;31:459-467.
544. Beger HG, Treitschke F, Gansauge F, et al. Tumor of the ampullar of Vater: experience with local or radical resection in 171 consecutively treated patients. *Arch Surg*. 1999;134:526-532.
545. Carter JT, Grenert JP, Rubenstein L, et al. Tumors of the ampulla of Vater: histopathologic classification and predictors of survival. *J Am Coll Surg*. 2008;207:210-218.
546. Sessa F, Furlan D, Zampatti C, et al. Prognostic factors for ampullary adenocarcinomas: tumor stage, tumor histology, tumor location, immunohistochemistry and microsatellite instability. *Virchows Arch*. 2007;451(3):649-657.
547. Ohike N, Coban I, Kim GE, et al. Tumor budding as a strong prognostic indicator in invasive ampullary adenocarcinomas. *Am J Surg Pathol*. 2010;34(10):1417-1424.
548. Song J, Liu H, Li Z, et al. Long-term prognosis of surgical treatment for early ampullary cancers and implications for local ampullectomy. *BMC Surg*. 2015;15:32. doi:10.1186/s12893-015-0019-z.
549. Bornstein-Quevedo L, Gamboa-Dominguez A. Carcinoid tumors of the duodenum and ampulla of vater: a clinicomorphologic, immunohistochemical, and cell kinetic comparison. *Hum Pathol*. 2001;32(11):1252-1256.
550. Hatzitheoklitos E, Buchler MW, Friess H, et al. Carcinoid of the ampulla of Vater. Clinical characteristics and morphologic features. *Cancer*. 1994;73(6):1580-1588.
551. Lee CS, Machet D, Rode J. Small cell carcinoma of the ampulla of vater. *Cancer*. 1992;70(6):1502-1504.
552. Zamboni G, Franzin G, Bonetti F, et al. Small-cell neuroendocrine carcinoma of the ampullary region. A clinicopathologic, immunohistochemical, and ultrastructural study of three cases. *Am J Surg Pathol*. 1990;14(8):703-713.
553. Makhlouf HR, Burke AP, Sobin LH. Carcinoid tumors of the ampulla of Vater: a comparison with duodenal carcinoid tumors. *Cancer*. 1999;85(6):1241-1249.
554. Max N, Rothe A, Langner C. Mixed adenoneuroendocrine carcinoma of the ampulla of Vater: a case report. *Mol Clin Oncol*. 2016;5:95-98.
555. Zhang L, DeMay RM. Cytological features of mixed adenoneuroendocrine carcinoma of the ampulla: two case reports with review of literature. *Diagn Cytopathol*. 2014;42:1075-1084.
556. Moncur JT, Lacy BE, Longnecker DS. Mixed acinar-endocrine carcinoma arising in the ampulla of Vater. *Hum Pathol*. 2002;33(4):449-451.
557. Handra-Luca A, Terris B, Couvelard A, et al. Adenomyoma and adenomyomatous hyperplasia of the Vaterian system: clinical, pathological, and new immunohistochemical features of 13 cases. *Mod Pathol*. 2003;16(6):530-536.
558. Ulich TR, Kollin M, Simmons GE, et al. Adenomyoma of the papilla of Vater. *Arch Pathol Lab Med*. 1987;111(4):388-390.
559. Narita T, Yokoyama M. Adenomyomatous hyperplasia of the papilla of Vater: a sequela of chronic papillitis? *Ann Diagn Pathol*. 1999;3(3):174-177.

560. Adsay NV, Basturk O, Klimstra DS, Kloppel G. Pancreatic pseudotumors: non-neoplastic solid lesions of the pancreas that clinically mimic pancreas cancer. *Semin Diagn Pathol*. 2004;21(4):260-267.
561. Kobayashi M, Hirata N, Nakaji S, et al. Gastrointestinal stromal tumor of the ampulla of Vater: a case report. *World J Gastroenterol*. 2014;20:4817-4821.
562. Lei L, Cobb C, Perez MN. Functioning gangliocytic paraganglioma of the ampulla: clinicopathologic correlations and cytologic features. *J Gastrointest Oncol*. 2016;7(suppl 1):S107-S113.
563. Misdraji J, Fernandez del Castillo C, Ferry JA. Follicle center lymphoma of the ampulla of Vater presenting with jaundice: report of a case. *Am J Surg Pathol*. 1997;21(4):484-488.
564. Pawade J, Lee CS, Ellis DW, et al. Primary lymphoma of the ampulla of Vater. *Cancer*. 1994;73(8):2083-2086.
565. Shingleton WW, Gamburg D. Stenosis of the sphincter of Oddi. *Am J Surg*. 1970;119(1):35-37.
566. Kawakami H, Zen Y, Kuwatani M, et al. IgG4-related sclerosing cholangitis and autoimmune pancreatitis: histological assessment of biopsies from Vater's ampulla and the bile duct. *J Gastroenterol Hepatol*. 2010;25:1648-1655.

23 Kidney: Non-Neoplastic Diseases

Neeraja Kambham

CHAPTER CONTENTS

Renal biopsy, *937*
Handling of the biopsy, *937*
Biopsy interpretation, *938*
Normal structure of the glomerulus, *938*
Classification of glomerular disease, *940*
Glomerular lesions associated with the nephrotic syndrome, *940*
Minimal change disease, *940*
Focal segmental glomerulosclerosis, *942*
C1q nephropathy, *945*
Membranous glomerulonephritis, *945*
Diabetic nephropathy, *948*
Amyloidosis, *950*
Fibrillary glomerulonephritis, *954*
Immunotactoid glomerulopathy, *954*
Light chain deposition disease, *954*
Heavy chain deposition disease, *956*
Proliferative glomerulonephritis with monoclonal immunoglobulin G deposits, *956*
Congenital nephrotic syndrome, *957*
Glomerular lesions associated with the syndrome of acute nephritis, *958*
Diffuse endocapillary proliferative glomerulonephritis, *958*
C3-related glomerular diseases and membranoproliferative glomerulonephritis, *960*
Diffuse mesangioproliferative glomerulonephritis, *964*
Crescentic glomerulonephritis, *966*
Lupus nephritis, *969*
Glomerular lesions associated with vascular diseases, *973*
Systemic vasculitis, *973*
Hemolytic uremic syndrome and thrombotic thrombocytopenic purpura, *976*
Systemic sclerosis, *978*
Renal diseases of pregnancy, *979*
Preeclampsia, *979*
Hereditary glomerular diseases, *980*
Alport syndrome, *980*
Thin basement membrane nephropathy, *981*
Fabry disease, *982*
Nail–patella syndrome, *983*
Collagen type III glomerulopathy, *983*
Fibronectin glomerulopathy, *983*
Renal transplant pathology, *984*
Allograft rejection, *984*
The Banff classification, *986*
Cyclosporine A (cyclosporin) toxicity, *987*
Tacrolimus (FK506) toxicity, *988*
Polyomavirus nephropathy, *988*
Tubulointerstitial diseases, *989*
Acute tubular necrosis, *989*
Acute and chronic pyelonephritis, *990*
Acute allergic tubulointerstitial nephritis, *992*
Immunoglobulin G4–related tubulointerstitial nephritis, *992*
Analgesic abuse nephropathy, *992*
Heavy metals nephrotoxicity, *993*
Nephrolithiasis and nephrocalcinosis, *993*
Light chain cast nephropathy, *994*
Renal vascular disease, *995*
Renal arteriolar disease, *995*
Renal arterial disease, *996*
Radiation nephropathy, *998*
Hematopoietic stem cell transplantation–associated thrombotic microangiopathy, *998*
Cystic diseases of the kidney, *998*
Multicystic renal dysplasia, *998*
Autosomal dominant polycystic kidney disease, *999*
Autosomal recessive polycystic kidney disease, *1000*
Nephronophthisis, *1000*
Autosomal dominant tubulointerstitial kidney disease, *1001*
Medullary sponge kidney, *1001*
Acquired renal cystic disease, *1001*
Simple cysts, *1002*

Abstract

A renal biopsy is an important tool in the evaluation of a patient with medical kidney disease. There is extensive overlap of clinical manifestations of a variety of kidney diseases, and the pathologic examination of tissues using light microscopy, immunofluorescence microscopy, and electron microscopy enables a renal pathologist to render an accurate diagnosis. Unfortunately, the host response to a variety of injurious agents also shows significant morphologic overlap. Hence, the renal biopsy interpretation should not be performed in a clinical vacuum and the value of timely communication with the nephrologist can never be underestimated. A thorough and systematic evaluation of various compartments, that is, glomeruli, tubules, interstitium, and blood vessels, points to the primary site of injury. The glomerular diseases are traditionally classified based on the presenting clinical syndrome, laboratory investigations, and morphologic pattern. Over the last two decades, many scientific advances have helped us gain insights into the relevant pathophysiological mechanisms, and these etiologic factors are being increasingly utilized in the classification of diseases. Better understanding of specific diseases such as focal segmental glomerulosclerosis, membranous glomerulonephritis, membranoproliferative glomerulonephritis, atypical hemolytic uremic syndrome, immunoglobulin (Ig)G4-related tubulointerstitial nephritis, and autosomal dominant tubulointerstitial kidney disease can aid in identifying more specific therapeutic targets. An allograft biopsy is the gold standard for assessment of graft dysfunction and institution of appropriate therapy. In addition to rejection, infections and drug toxicities can be diagnosed on biopsy and the extent of irreversible chronic changes can be estimated. Better laboratory tools and morphologic assessment methods have helped characterize the diagnostic and prognostic features of antibody-mediated rejection.

Keywords

Glomerulonephritis,
Vasculitis,
Thrombotic microangiopathy,
Renal transplant pathology,
Kidney rejection,
Polyomavirus nephropathy,
Tubulointerstitial nephritis,
Renal cystic diseases,
Medical kidney disease,
Renal biopsy

Renal Biopsy

Renal biopsy is an important tool used in the evaluation of patients with renal disease.[1–3] Utilizing this procedure, it is possible to establish an accurate diagnosis, obtain critical information on the evolution and prognosis of the disease process, and develop a rational approach to the treatment of a renal disorder.[4–6] Even in advanced stages of kidney damage, a biopsy can provide clues regarding the possibility of recurrence of the disease following transplantation. The renal biopsy is also important in the management of the transplant recipient, representing the most accurate method for determining the presence of antibody- or T cell–mediated rejection, acute tubular injury, calcineurin inhibitor nephrotoxicity, or the development of de novo or recurrent glomerulonephritis in the allograft.

Renal disease is usually manifested by a limited number of symptoms that are commonly grouped in clinical syndromes, that is, nephrotic syndrome, persistent proteinuria, acute nephritic syndrome, persistent or recurrent hematuria, asymptomatic renal insufficiency, hypertension, rapidly progressive renal failure, acute renal failure, and chronic renal failure. Given the fact that the kidney reacts to a variety of injurious agents with a limited number of histopathologic patterns of injury, a given clinical syndrome can be associated with several histopathologic patterns, while a single histopathologic pattern may be linked to more than one syndrome. The accurate interpretation of a renal biopsy requires detailed knowledge of the structure and function of the normal kidney, as well as an understanding of the clinical, morphologic, and histopathogenic aspects of renal disease. To evaluate a kidney biopsy, the pathologist should correlate the clinical and laboratory information with light microscopic, immunofluorescence, and ultrastructural findings.

Handling of the Biopsy

Most renal biopsies are done by either the percutaneous route using a cutting needle or by direct exposure of the kidney (open biopsy, often a wedge sampling of outer cortex). Most centers use 16–18-gauge needles for adults and 18-gauge needles for children less than 8 years of age. The specimen should be divided for light microscopy, immunofluorescence, and electron microscopy. Ideally, two biopsy cores should be obtained when a needle biopsy is performed. From the first core, two or more samples measuring 0.5–1 mm in thickness are taken from each end with a fresh razor or scalpel blade and placed in a cold solution of 2% glutaraldehyde in phosphate or cacodylate buffer for electron microscopy studies while the remaining tissue is placed in saline. If the second core is adequate, samples should also be taken from each end for electron microscopy, while the remainder is snap frozen in liquid nitrogen or in isopentane cooled on dry ice for immunofluorescence. For light microscopy, the tissue that was placed in saline should be transferred to a fixative, most common being 10% buffered formalin. If only one core is obtained, material should be taken from each end for electron microscopy and the remainder divided for light microscopy and immunofluorescence. If the core is too small, the specimen should be divided for electron microscopy and immunofluorescence studies since most of the light microscopic information can be obtained from the study of semi-thin sections of the plastic-embedded tissue processed for electron microscopy. Longitudinal division of the cores should be avoided. The triaging of the biopsy sample should ideally ensure that all three portions include cortex. On gross examination of the cores under dissecting microscope or loupe (magnifying device), glomeruli in well-preserved cortex appear as pale or congested bulges; however, this may not be evident when cores with sclerotic glomeruli or fibrotic interstium are examined.

Light Microscopy

A variety of fixatives have been recommended for the light microscopic study of renal biopsies. Zenker, Helly, Bouin, and Van der Griff fixatives are sometimes used and many pathologists feel that mercuric solutions provide the best architectural and cytologic detail. However, 10% neutral formalin can also provide good morphologic detail while also preserving the sample for future immunohistochemical studies or immunofluorescence microscopy on paraffin-embedded tissues, if needed.[7,8] To evaluate for glycogen or crystals of urate, uric acid, and other water-soluble substances, tissue should be fixed in ethanol. A panel of hematoxylin and eosin (H&E), periodic acid–Schiff (PAS), methenamine silver, and trichrome stains are recommended for the routine evaluation of renal biopsies, but from the practical point of view, PAS is the most useful, is easiest to perform, and can also provide most of the information obtained from other stains. It is recommended that the biopsy core be serially sectioned (2–3 μm thick) and that three to four tissue sections be placed on each slide. At regular intervals, one slide is stained with H&E, one with PAS, one with trichrome, and another with silver stain. By following this procedure, the maximum number of glomeruli can be examined. The remaining unstained slides are saved in case special stains or immunohistochemical stains are needed.

Electron Microscopy

There is a general misconception that electron microscopy is a complex and time-consuming procedure. In fact, satisfactory processing methods have been developed that require less than 5 hours.[9] Many fixatives have been developed for this procedure, each of which has specific advantages. Some pathologists prefer a primary fixation in osmium tetroxide for the optimal demonstration of deposits and basement membrane structure, but glutaraldehyde fixation with post-osmification is more convenient and is suitable as a routine procedure. For tissue embedding, various epoxy resins with comparable characteristics are available and their selection is a matter of personal preference. Semi-thin (1 μm thick) sections obtained from the plastic-embedded tissue blocks are stained with toluidine blue or methylene blue and carefully studied as they can yield a great deal of information, especially when examined at high magnification (Fig. 23.1).[10] Thin sections from the blocks selected for ultrastructural study are double-stained with uranyl acetate and lead citrate for electron microscopic examination.

Immunofluorescence Microscopy

Direct immunofluorescence performed on frozen sections is the simpler, faster, and most satisfactory method for the routine evaluation of a renal biopsy, but indirect methods may be used for extra sensitivity or for a specific antibody. The portion of the biopsy specimen selected for immunofluorescence is oriented in standard frozen section embedding compound on a piece of cork and is snap frozen by immersion in a beaker containing either isopentane or methylbutane surrounded by liquid nitrogen or dry ice. Frozen sections of 2–4 μm thick are cut and stained with specific antibodies and examined under ultraviolet light using either transmitted or incident illumination, and the reactions are graded subjectively using a scale of 0 to 3+ (or 4+, depending on individual labs) and recorded by photography. The antibodies that are most commonly used are those against immunoglobulin (Ig)G, IgA, IgM, kappa and lambda light chains, C1q, C3, C4, and fibrinogen or fibrin. Immunostaining for a variety of other antigens can also be performed for selective diagnostic purposes. For example, C4d is very useful for the diagnosis of antibody-mediated acute allograft rejection.[11,12] IgG subclass

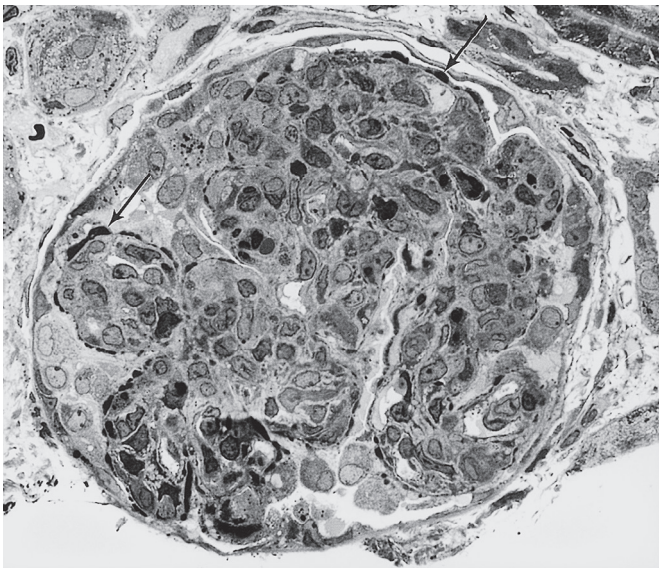

Figure 23.1 Plastic-embedded semi-thin section stained with toluidine blue showing numerous humps along the capillary walls *(arrows)* and obliteration of the glomerular capillary loops by endocapillary cell proliferation in a case of poststreptococcal glomerulonephritis.

identification (IgG1, IgG2, IgG3, IgG4) and phospholipase A2 receptor 1 (PLA_2R) staining is helpful in the diagnosis of primary membranous nephropathy.

In those cases in which glomeruli are not present in the portion of the submitted biopsy specimen, immunofluorescence studies can be successfully performed on pronase predigested tissue sections prepared from the portion of the biopsy allocated for light microscopy.[8] It should be mentioned, however, that immunofluorescence for detecting C3 on these specimens is less sensitive when compared with that performed on frozen tissue sections. In addition, anti-glomerular basement membrane (GBM) disease cannot be diagnosed by this pronase method due to high background staining.

Immunohistochemical studies can also be performed on formalin-fixed, paraffin-embedded biopsy specimens. In addition to extensive panel needed in the evaluation of incidental solid tumors or hematolymphoid neoplasms, the commonly used immunohistochemical stains in the context of medical renal biopsies include BK (or SV40) stain in the diagnosis of BK polyomavirus nephropathy,[13,14] adenovirus stain, cytomegalovirus stain, and C4d and amyloid A stain. Epstein–Barr virus (EBV) in situ hybridization is helpful in suspected cases of post-transplant lymphoproliferative disorders.

Biopsy Interpretation

Although potentially challenging, the diagnosis of renal biopsy specimens is based on the same foundation of careful observation and clinicopathologic correlation that is used in other areas of pathology. A knowledge of normal morphology is essential for the recognition of any alteration that may occur in the various components of the kidney. Obtaining adequate clinical history is crucial to any renal biopsy interpretation. A checklist that can be used during the biopsy evaluation is provided in Table 23.1.

A renal biopsy must contain glomeruli to be considered adequate, but there is disagreement over the number of glomeruli required to make a diagnosis. The definition of adequacy largely depends on the disease under consideration. In disorders characterized by irregular or crescentic proliferation, the assessment should be based on a minimum of 10 glomeruli, whereas, in diffuse lesions (such as membranous glomerulonephritis [MGN]), the identification of specific features in a single glomerulus may be sufficient, especially if ultrastructural studies are also performed. While there is often a variation in the severity of a specific lesion among different glomeruli, even in diffuse processes, a good guideline to follow is that at least 5–10 glomeruli should be examined to properly assess the extent of the disease.

Normal Structure of the Glomerulus

Since most of the changes seen in renal biopsies occur in the glomerulus, we will briefly review the morphology of this structure. The glomerulus is a vascular structure composed of a tuft of specialized capillaries that arise from the afferent arteriole to form lobules, then rejoin the vascular pole to drain into the efferent arteriole. Normally, the lobules are poorly defined, but they are highlighted in some disease processes. Each lobule consists of a cluster of capillaries supported by the mesangium, which forms the centrolobular or axial framework of the glomerular tuft. The tuft of capillaries lies within the lumen of the expanded proximal end of the nephron, or Bowman space, which is lined on its parietal aspect by a layer of attenuated epithelial cells overlying a thick basement membrane. Together, the latter two structures make up the **Bowman capsule**, which is continuous at the vascular pole of the glomerulus with the adventitia of the afferent and efferent arterioles. At the urinary pole, the basement membrane of the Bowman capsule merges with that of the proximal tubule. Each glomerulus measures approximately 200 μm in diameter, but they are all not of the same size. Those located in the juxtamedullary area are about 20% larger than those elsewhere in the cortex. The cellularity of the glomerulus varies in different diseases, and an accurate assessment requires histologic preparations of 2–4 μm thickness. The presence of more than three cells in an individual glomerular mesangial region away from the vascular pole is considered hypercellularity.

The walls of the glomerular capillaries are clothed by a reflected layer of cells of the Bowman capsule. These highly specialized epithelial cells are known as podocytes (visceral epithelial cells) because they have numerous tiny foot processes that rest on the basement membrane that separates them from the attenuated, fenestrated endothelium of the capillaries. The **GBM** is a trilaminar structure composed of a central electron-dense zone, or lamina densa, bordered by two narrow electron-lucent layers: the lamina rara interna and the lamina rara externa. The major components of the GBM are type IV collagen, laminin, heparan sulfate proteoglycans, and entactin, but minor amounts of other proteins have also been found.[15]

The principal function of the glomerulus is filtration, and the GBM is the main component of the filtration barrier. In normal adults, the GBM measures 310–380 nm in thickness; it is somewhat thinner in children (and achieving adult thickness by 10–12 years age), and slightly thicker in males than in females.[16] The GBM does not completely surround the capillary lumen since the vessel is attached to the mesangium, which consists of mesangial cells embedded in a basement membrane–like material, the mesangial matrix (Fig. 23.2). By electron microscopy, the mesangial matrix appears more fibrillar than the GBM. It is composed of collagen types IV, V, and VI, fibronectin, laminin, entactin, and sulfated glycosaminoglycans, including heparan sulfate and chondroitin sulfate.[17] The mesangial cells have cytoplasmic processes that contain α-smooth muscle actin, α-actinin, and myosin filaments, characteristics shared by smooth muscle cells, pericytes, and myofibroblasts.[16,18,19] Mesangial cells thus possess contractile properties and are probably involved in the regulation of blood flow through the glomeruli and modulation of the filtration process.[20] They produce growth factors that allow normal cell turnover.[19] Mesangial cells may also have some phagocytic

Table 23.1 Biopsy evaluation checklist

	LIGHT MICROSCOPY	IMMUNOFLUORESCENCE	ELECTRON MICROSCOPY
Glomeruli	Size and cellularity Segmental or global changes Mesangium Leukocytes Capillary walls/lumens Necrosis Thrombi (type) Adhesions to Bowman capsule Deposits (type and location) Crescents (type and %) Sclerosis (distribution and %)	Positive/negative reaction Reagent Igs, complement, fibrin, etc. Distribution (mesangium, capillary wall, intracapillary globules) Pattern (linear or granular or smudgy) Intensity Necrosis, cellular crescents or intracapillary thrombi on fibrin stain	Basement membrane (thickness, density, contours, disruptions) Cellular changes Mesangium Deposits (type, location, and substructure) Inclusions in endothelial cells
Tubules	Necrosis Reparative changes Dilation Casts (type) Crystals Cellular inclusions Vacuolization Basement membrane	Reactions and pattern Intensity	Cellular changes Inclusions Basement membrane Deposits (type and location)
Blood vessels	Intimal thickening (type) Elastica changes Media hypertrophy Hyalinosis Thrombi Necrosis Inflammation Juxtaglomerular apparatus	Reactions and distribution Thrombi or vasculitis on fibrin stain	Intimal and medial changes Deposits
Interstitium	Edema Inflammation and fibrosis (cell type and %)	Reactions and distribution	Cellular infiltrates Deposits

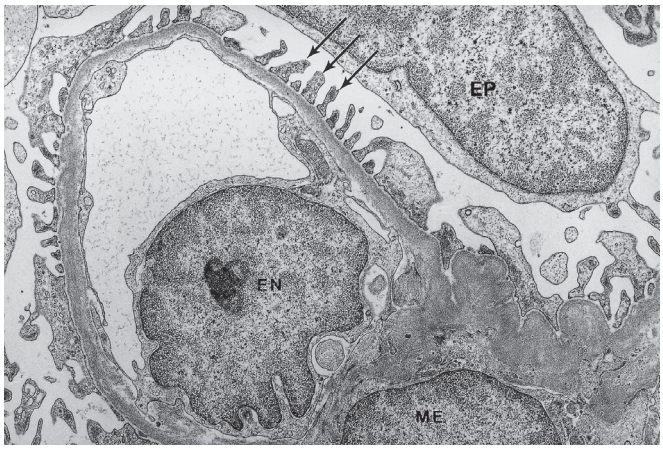

Figure 23.2 Electron Micrograph of Normal Glomerulus Showing the Relationship of Different Cell Types. The epithelial aspect of the basement membrane is covered by foot processes *(arrows)* and the capillary lumen lined by attenuated endothelium. *EN*, Endothelial cell; *EP*, epithelial cell; *ME*, mesangium (×13,000).

activity and play a role in the clearance of debris, including immune deposits from the mesangium.[21] Although obvious ultrastructural differences exist between the endothelial and mesangial cells, these differences are not always evident in glomerular diseases, and the distinction between the endothelium and the mesangium is usually based on the location of these structures in the glomerulus.

The visceral epithelial cells/podocytes are involved in basement membrane synthesis and, by their unique structure, play an important role in glomerular permeability. These cells cover the GBM on its urinary side and are attached to it by cytoplasmic extensions or foot processes that, under the scanning electron microscope, appear as a complex of interdigitating structures originating from different epithelial cells (Fig. 23.3). The foot processes are approximately 25–60 nm apart, with a connecting slit-pore diaphragm 4–7 nm thick that shows similarities with tight and adherens junctions. Several molecules identified in podocyte foot processes and slit diaphragms over the last two decades contribute to the structural integrity and permselectivity of the filtration barrier.[22] Bowman capsule limits the urinary space and is lined by a layer of flattened parietal epithelial cells that express cytokeratin proteins. In contrast, the visceral epithelial cells do not immunoreact for cytokeratin but do for vimentin and desmin.[23] Recent evidence suggests that parietal epithelial stem

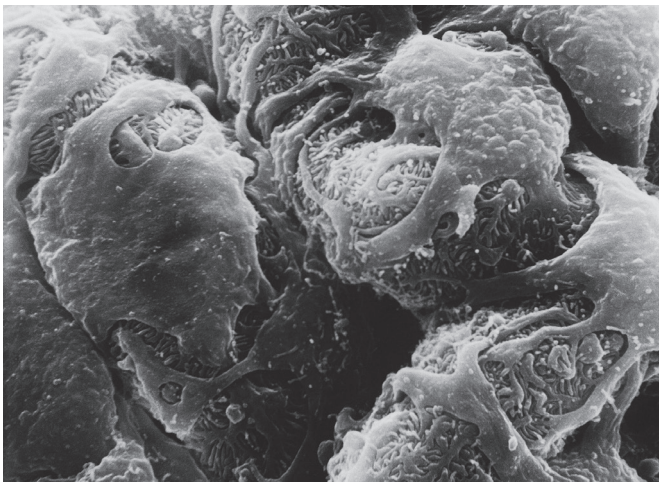

Figure 23.3 Scanning electron micrograph showing the capillary loops covered by visceral epithelial cells and interdigitating foot processes (×8000).

Box 23.1 Classification of glomerular disease by distribution

Classification of disease distribution when many glomeruli are considered
- Focal: disease affecting only some of the glomeruli
- Diffuse: disease affecting most or all glomeruli

Classification of disease distribution when single glomeruli are considered
- Segmental: a lesion involving only a part of the glomerulus
- Global: a lesion involving the entire glomerulus

cells are critical in glomerular repair and maybe involved in the regeneration of podocytes and tubular epithelial cells.[24,25]

Classification of Glomerular Disease

Glomerulonephritis is a term denoting an inflammation of the glomerulus, while **glomerulopathy** is an all-embracing term for disorders affecting this structure. In glomerular diseases, other parts of the nephron may also be involved, but the diagnosis hinges on the identification of a derangement of the normal glomerular configuration. While the changes may be recognizable by routine light microscopy, the findings from immunofluorescence are often significant. Electron microscopy is always informative and is sometimes the only means whereby the structural changes can be detected and defined. The damage to the glomeruli may take the form of definable morphologic patterns, and subdivisions in the character or distribution of the glomerular lesions are used to classify glomerulonephritis. Although there is general agreement on the definitions applied to the distribution of glomerular lesions (Box 23.1), more specific categorizations are sometimes controversial.

In this chapter, glomerular lesions are subdivided into those associated with the nephrotic syndrome or persistent proteinuria, those seen in acute nephritis or hematuria, and lesions associated with vascular diseases, such as systemic vasculitis, hemolytic uremic syndrome (HUS), and systemic sclerosis. Separate sections, including those describing tubulointerstitial lesions, renal vascular disorders, cystic diseases, and the interpretation of biopsies of transplanted kidneys, will be presented.

Glomerular Lesions Associated With the Nephrotic Syndrome

The nephrotic syndrome is clinically characterized by the occurrence of massive proteinuria, hypoproteinemia, edema, and hyperlipidemia. Damage to the filtration barrier of the glomerulus allows proteins, particularly albumin, to be filtered into the urine. The criterion for the syndrome is the excretion of more than 3.5 g of protein in a 24-hour period. A spectrum of morphology has been correlated with the syndrome, but some glomerular lesions are not accompanied by significant inflammatory or proliferative response within the glomerulus, including primary nephrotic syndrome with minimal change disease (MCD), MGN, diabetes mellitus, amyloidosis, and various forms of congenital nephrotic syndrome. The major histologic, electron microscopic, and immunofluorescence findings in each of these conditions are summarized in Table 23.2.

Minimal Change Disease

MCD (also known as nil lesion, and minimal change nephrotic syndrome) is the most common cause of idiopathic nephrotic syndrome in children, accounting for 80%–90% of all cases of idiopathic nephrotic syndrome in childhood,[26,27] and 10%–15% of adult cases.[28,29] Most of the affected children are under the age of 6 years at initial diagnosis, the majority being 3 or 4 years old.[26,27] There appears to be a male predominance, especially in children, where the male to female ratio is 2 to 3 : 1.[30] MCD is more common among whites, Asians, and Hispanics than blacks.[31] While MCD is idiopathic in 80%–90% of children, in a minority of cases it has been associated with viral infections, recent immunizations, ingestion of heavy metals (e.g., mercury or lead), allergies to some foods, dust, bee stings, and poison ivy, and drug reactions to a variety of agents, including lithium, interferon, and pamidronate. While the exact mechanism of MCD development is unclear, the final common event likely involves podocyte injury. In adult patients, especially the elderly, MCD can manifest as a hypersensitivity reaction to the use of nonsteroidal anti-inflammatory drugs.[32] In these cases, the disease is often accompanied by renal insufficiency and the development of acute interstitial nephritis.[33] In most of these patients, cessation of the offensive medication results in resolution of the proteinuria. MCD has also been reported in association with lymphoid malignancies, usually Hodgkin lymphoma.[34] Remission of the nephrotic syndrome has been obtained in these cases with the cure of the lymphoma. Other neoplastic diseases that might cause MCD include leukemias, carcinomas, and thymomas, among others. MCD is a now well-defined renal manifestation of lupus nephritis or may be seen in recipients of hematopoietic stem cell transplantation.[35,36] De novo MCD has been reported in patients with post-transplant nephrotic syndrome.[37] None of the recipients had focal segmental glomerulosclerosis (FSGS) as a primary disease. The pathogenesis of idiopathic MCD remains unknown, but it has been suggested that a circulating factor/s produced by T lymphocytes that damage one or more elements of the glomerular permeability barrier is responsible for the proteinuria seen in this condition.[38,39] Patients with MCD do show T-cell subset abnormalities, and elevated levels of interleukin-13 (IL-13) were demonstrated during relapses.[40] IL-13 has been shown to increase the expression of CD80 in podocytes. CD80, in turn, has been identified in the urine of patients of MCD and appears to be a potential diagnostic biomarker.[41] Various injurious stimuli appear to activate the podocyte enzymatic pathways, resulting in disruption of actin cytoskeleton and slit diaphragm. In addition to structural disruption of the permeability barrier, the loss of podocyte negatively charged glycocalyx may contribute to the selective leakage of anionic plasma proteins such as albumin.

Table 23.2 Glomerular lesions associated with the nephrotic syndrome

DISEASE	LIGHT MICROSCOPY	IMMUNOFLUORESCENCE	ELECTRON MICROSCOPY
Minimal change disease	Normal; minimal or no mesangial prominence	Usually negative for Ig and C3	Extensive foot process effacement
Focal and segmental glomerulosclerosis	Focal and segmental glomerulosclerosis	Nonspecific trapping of IgM and C3 in sclerosed segments	Extensive foot process effacement
C1q nephropathy	Mesangial hypercellularity common, ± focal segmental glomerulosclerosis	C1q mesangial granular deposits	Mesangial deposits
Membranous glomerulopathy	Uniform capillary wall thickening, sometimes with spike and dome pattern	IgG and C3 granular deposits along capillary wall (IgM, IgA, C1q in membranous lupus nephritis)	Four stages of subepithelial and intramembranous deposits
Diabetic nephropathy	Nodular and diffuse mesangial sclerosis; insudative lesions	IgG linear staining along capillary walls and tubular basement membranes	Diffuse thickening of basement membranes; increased mesangial matrix
Amyloidosis	Mesangial, capillary wall, and vascular amorphous deposits; weak PAS; methenamine silver negative; Congo red positive with apple-green birefringence	Based on subtype, smudgy staining for Ig light or heavy chains, amyloid AA, or other	Fibrils 8–10 nm in diameter
Light chain deposition disease	Mesangial widening and deposition of PAS-positive material	Kappa or lambda light chain restricted; granular mesangial and linear basement membranes	Finely granular material along the basement membranes, mesangium
Heavy chain deposition disease	Mesangial widening and deposition of PAS-positive material	Isolated heavy chain–restricted (frequently γ); granular mesangial and linear basement membranes	Finely granular material along the basement membranes, mesangium
Fibrillary glomerulonephritis	Mesangial widening and occasional hypercellularity, capillary wall thickening	Variable IgG, C3, occasional IgM, IgA; frequently polytypic	Fibrils 16–20 nm in diameter
Immunotactoid glomerulopathy	Mesangial widening and occasional hypercellularity, capillary wall thickening	Variable IgG, C3, occasional IgM; frequently monotypic with light chain restriction	Fibrils 30–50 nm in diameter, often in parallel bundles
Congenital Nephrotic Syndrome			
Finnish type	Tubular ectasia, microcysts, glomerular sclerosis	Nonspecific trapping of IgM and C3	Diffuse foot process effacement
Diffuse mesangial sclerosis	Mesangial consolidation, pseudocrescents, fetal glomeruli	Negative or nonspecific trapping of IgM and C3	Diffuse foot process effacement

MCD typically presents with heavy proteinuria, often of selective type, leading to the nephrotic syndrome. Microscopic hematuria is seen in less than 15% of patients,[42] but macroscopic hematuria is rare. Blood pressure is usually normal at onset, and less than 20% of patients have hypertension.[43] Given the high probability that nephrotic syndrome in a child is due to MCD, pediatric patients are treated empirically with steroids and do not undergo a renal biopsy unless the nephrotic syndrome is steroid resistant. Complete remission is common within 8 weeks of starting corticosteroid therapy.[26,27] After withdrawal of the steroids, however, about half of the patients have intermittent relapses, a phase which may last for up to 10 years. The relapses are usually steroid responsive and the disease does not progress to chronic renal failure. Patients who achieve only partial remission with corticosteroid therapy may benefit from immunosuppressive drugs such as cyclophosphamide or cyclosporine.[29] Newer agents such as anti-CD20 and anti-CTLA-4 (cytotoxic T-lymphocyte-associated protein 4) antibodies are being tested in such patients.[44,45] The development of azotemia should suggest an incorrect diagnosis and should raise the possibility of missed FSGS. Relapse is uncommon after a disease-free interval of 2 years.

The glomeruli in MCD appear normal or show minimal abnormality by light microscopy (Fig. 23.4). The glomerular capillaries are patent, and there is no increase in the thickness of the capillary walls, but podocyte hypertrophy may be appreciated. Some cases may show minor degrees of mesangial enlargement with a minimal increase in mesangial matrix and cellularity. The convoluted tubules may present focal vacuolization due to the accumulation of large amounts of lipid and protein transport droplets. Because of these light microscopic features and the finding of lipoid particles (oval fat bodies) in the urine of these patients, Munk in 1913 proposed the term lipoid nephrosis for this condition.[46] Only after ultrastructural studies were done in such cases was it established that the glomeruli, rather than the tubules, were the primary site of pathology. It should be borne in mind that biopsies from adult or elderly patients may

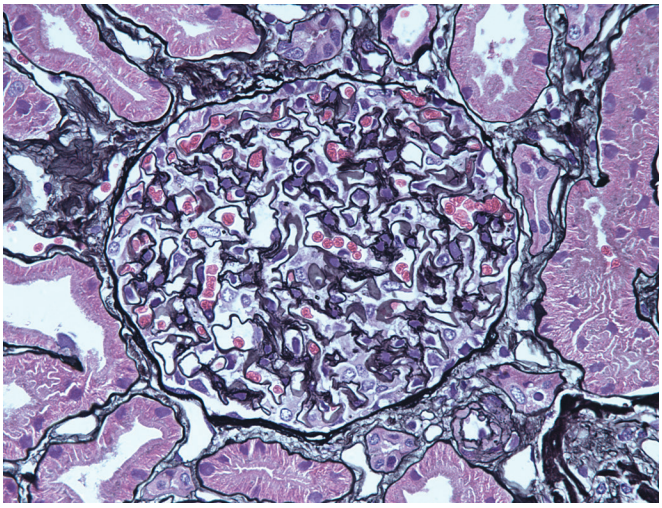

Figure 23.4 Glomerulus From a Patient With Minimal Change Disease. The glomerulus is normocellular, the capillary loops are patent, and the basement membrane is normal in thickness.

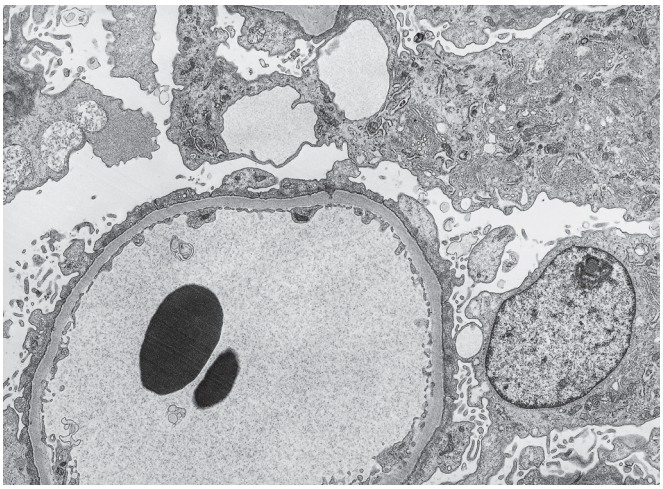

Figure 23.5 Portion of a glomerulus from a patient with minimal change disease showing obliteration of foot processes. The visceral epithelial cell cytoplasm shows microvillus and cyst formation (×8400).

not be entirely normal on light microscopy and can show a variety of preexisting pathologies such as age-related glomerulosclerosis, hypertensive arteriosclerosis, chronic tubulointerstitial damage, or mild diabetic nephropathy.

The characteristic ultrastructural appearance of the glomeruli is of total foot process effacement with the basement membrane being covered by sheets of cytoplasm. Loss of the visceral epithelial processes is accompanied by distortion of the filtration slits, with a decrease in the number of slit diaphragms.[47] Visceral epithelial cells/podocytes show prominent intracytoplasmic organelles, suggesting increased cytoplasmic activity, and frequently contain cystoplasmic cysts/vacuoles. Numerous microvilli (i.e., villous projections of podocyte cytoplasm into urinary space) are often seen in MCD (Fig. 23.5). There is a frequent increase in the density of the cytoskeleton, especially actin filaments, in the cytoplasm adjacent to the basement membrane, but no electron-dense deposits are present. Lower degrees of podocyte foot process effacement maybe observed in MCD patients with partial response to therapy.

Immunofluorescence studies are almost invariably negative for immunoglobulin and complement, but small amounts of IgM and C3 can occasionally be seen in cases with mesangial prominence. Albumin can be demonstrated as fine droplets in the cytoplasm of the proximal tubule cells when the tissue is stained for this protein (Fig. 23.6).

Because a biopsy is susceptible to sampling error, it should be kept in mind that lesions that affect only some glomeruli, such as FSGS, can lead to a misdiagnosis of MCD. Conversely, since tubular atrophy (TA) and interstitial scarring are not features of MCD, a diagnosis of FSGS should be considered if these findings are seen on a biopsy, especially in a child. It has been recently proposed that reduced expression of dystroglycan and CD44 observed in MCD can help differentiate it from FSGS, but further confirmation is needed.[48,49]

Focal Segmental Glomerulosclerosis

FSGS, as a disease entity, is a clinicopathologic syndrome characterized by proteinuria, commonly in the nephrotic range, a high incidence of progressive renal failure, and focal and segmental sclerotic glomerular lesions. The segmental sclerosis results from an increase in mesangial matrix, causing obliteration of the glomerular capillaries.

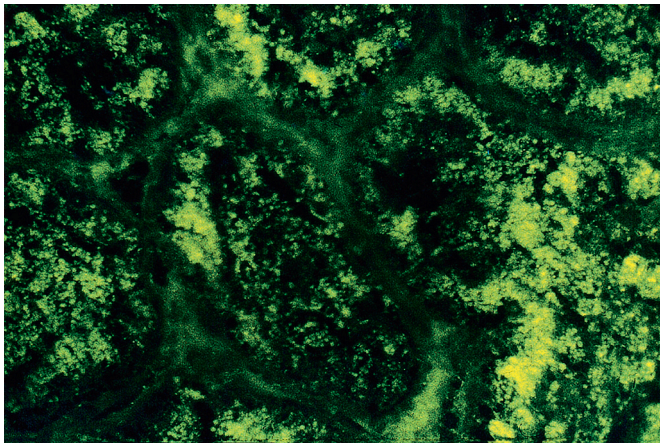

Figure 23.6 Immunofluorescence preparation demonstrating numerous albumin-positive resorption droplets in the proximal tubular epithelial cells.

Five histologic subtypes have been described, including collapsing variant, "tip" lesion, cellular variant, perihilar lesion, and FSGS-NOS (not otherwise specified) variant.[50,51] This histologic classification is hierarchical and is referred to as "Columbia classification of FSGS." The presence of even a single collapsing lesion qualifies for a diagnosis of collapsing variant of FSGS. In the absence of a collapsing FSGS lesion, a "tip lesion," if present, trumps other variants. The next lesion in the hierarchy is cellular FSGS, followed by perihilar and NOS variants. Although the FSGS lesion identified in the biopsy may change over time in an individual patient, these morphologic variants do have clinical relevance.[52–54] The patients with collapsing FSGS have poor outcomes while patients with a "tip" variant respond well to immunosuppressive therapy, akin to MCD. Perihilar variants often point to a structural adaptive response to renal parenchymal loss or glomerular hyperfiltration due to a variety of other etiologies; the renal presentation is usually subnephrotic proteinuria rather than a full nephrotic syndrome as would be more common with collapsing and tip variants.

From an etiologic standpoint, FSGS may be primary or secondary to various forms of injuries or pathogenic mechanisms. The morphologic variants of FSGS are not helpful in distinguishing primary

from secondary FSGS and a biopsy diagnosis of FSGS should prompt an evaluation of etiology. The pathogenesis of primary FSGS is unknown, but it appears to be the result of circulating "permeability" factor(s), possibly a lymphokine or a cytokine, which leads to epithelial cell injury resulting in segmental scar and ultimately glomerular obsolescence.[55] The potential circulating permeability factors include cardiotrophin-like cytokine 1 and urokinase plasminogen activator receptor, but they have not been shown to be entirely sensitive or specific.[52,56]

FSGS can be secondary to a variety of conditions including drugs, viral infections, healed glomerulonephritis, and structural adaptive responses. In addition, genetic associations with either autosomal dominant or recessive mode of inheritances are being increasingly recognized as a cause of FSGS.[52,57,58] Mutations have been detected in several podocyte genes encoding proteins in the slit diaphragm, cytoskeleton, mitochondria, transcription, and DNA repair. Several patients with FSGS who would have been previously categorized as a "idiopathic" FSGS might in fact have a genetic form of FSGS.[52,59] Even in cases without a single gene mutation, there appears to be a familial susceptibility to developing FSGS. Recent studies have established a strong association between apolipoprotein L1 *(APOL1)* gene and FSGS in blacks.[60,61] The risk alleles G1 and G2 are more commonly seen in blacks and are also linked to higher rates of progressive kidney disease. The *APOL1* gene product is expressed in podocytes and platelets and although the exact mechanism of kidney disease causation is unknown, the risk alleles appear to confer an evolutionary protection against *Trypanosoma brucei* infections.[60]

The glomerular lesion of secondary FSGS can be histologically identical to that seen in primary FSGS and can occur in a variety of clinical settings with a clinical presentation indistinguishable from that of primary FSGS. Since the pathogenetic mechanisms involved in these disorders and their treatment differs significantly from that of primary FSGS, it is of paramount importance that they be excluded before a diagnosis of primary FSGS is made.[62–64] In Box 23.2 are listed the conditions most commonly associated with FSGS which should be excluded before making the diagnosis of primary FSGS.

Primary FSGS is responsible for approximately 10%–15% of the cases of nephrotic syndrome in children and 20%–30% in adults. It constitutes the predominant cause of idiopathic nephrotic syndrome in adult patients, especially in blacks.[65] Nephrotic range proteinuria is common and the clinical manifestation can be an abrupt onset of nephrotic syndrome or insidious onset of subnephrotic proteinuria. Examination of the urinary sediment will often lead to the detection of microscopic hematuria. Forty to 60% of patients have been shown to develop end-stage renal disease (ESRD) within 10–20 years,[66,67] and recurrence following transplantation has been reported in 30%–40% of patients, often within weeks, leading to graft loss.[68–72] The response to steroid therapy is limited, often prompting a second line of aggressive immunosuppressive therapy and plasmapheresis that aids the removal of the circulating permeability factor.

Pathologically, in primary or secondary FSGS, the segmental sclerosis, collapse, or obliteration of capillary lumen (i.e., depending on the morphologic variants) usually affects one or more lobules of the glomerular tuft. Early lesions may show an increased mesangial matrix and mild mesangial hypercellularity; only when the sclerosis is advanced do these areas become hypocellular, often with adhesions to the Bowman capsule (Fig. 23.7). The visceral epithelial cells can line the sclerotic segments and these adhesions, and hence the term "podocyte capping." The loops in the sclerosed areas are distorted, and they may contain hyaline material (hyalinosis), which is thought to represent plasmatic insudation, and lipid-laden "foam" cells.[73] These findings in the absence of collapsing, cellular and tip variant features (described later) and present in a nonperihilar distribution define a FSGS-NOS subtype.[50,58]

Box 23.2 Focal segmental glomerulosclerosis: etiologic classification

- Primary (idiopathic) FSGS
- Secondary FSGS
- Genetic
- Mutations in podocyte genes *NPHS1* (nephrin), *NPHS2* (podocin), *PLCE1* (phospholipase C ε1), *ACTN4* (α-actinin 4), *CD2AP* (CD2-associated protein), *WT1* (Denys–Drash syndrome),
- Mutations in basement membrane genes *COLA3, COLA4* (Alport syndrome), genes encoding β_4 integrin and laminin β_2
- Mitochondrial cytopathies
- Others
  - Viral infections
    - HIV-1, parvovirus B19, cytomegalovirus, simian virus 40, Epstein–Barr virus
  - Drugs
    - Heroin, interferon α and β, lithium, bisphosphonates, sirolimus, calcineurin inhibitors, anabolic steroids
  - Glomerulonephritis
    - Healed focal segmental glomerular lesions
  - Mediated by adaptive-functional responses
    - *Reduced renal mass and/or nephrons*: unilateral renal agenesis, dysplasia/hypoplasia, oligomeganephropenia, prematurity/low birth weight, partial cortical necrosis, surgical renal ablation, reflux nephropathy, any advanced renal disease with reduction in functional nephrons
    - *Initially normal renal mass*: hypertension, morbid obesity, cyanotic congenital heart disease, glycogen storage diseases, sickle cell anemia

Modified from D'Agati VD, Kaskel FJ, Falk RJ. Focal segmental glomerulosclerosis. *N Engl J Med*. 2011;365(25):2398–2411.

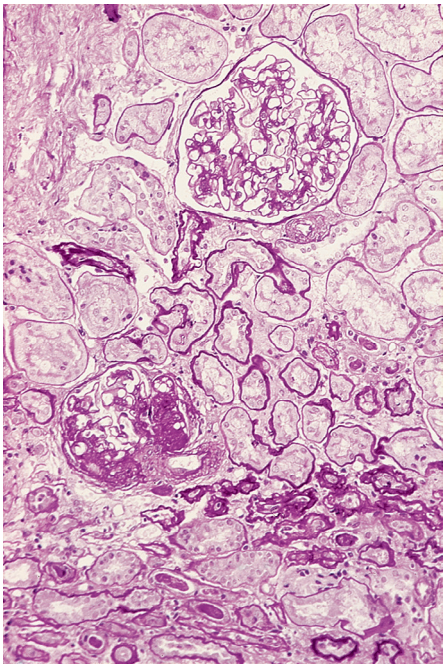

Figure 23.7 Biopsy From a Patient With Focal and Segmental Glomerulosclerosis. One of the glomeruli shows segmental sclerosis, while the other appears unremarkable. Tubular atrophy is also seen (periodic acid–Schiff stain; PAS).

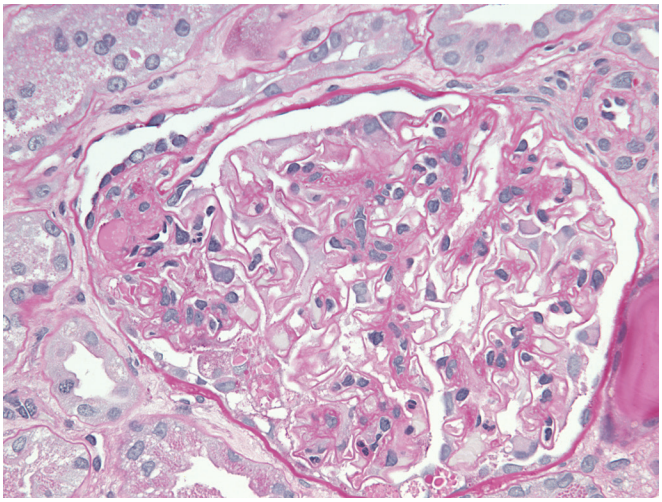

Figure 23.8 Tip variant of focal segmental glomerulosclerosis shows Bowman capsular adhesion and hyaline insudation at the tubular pole. The adjacent podocytes also show hypertrophy with cytoplasmic protein droplets (PAS).

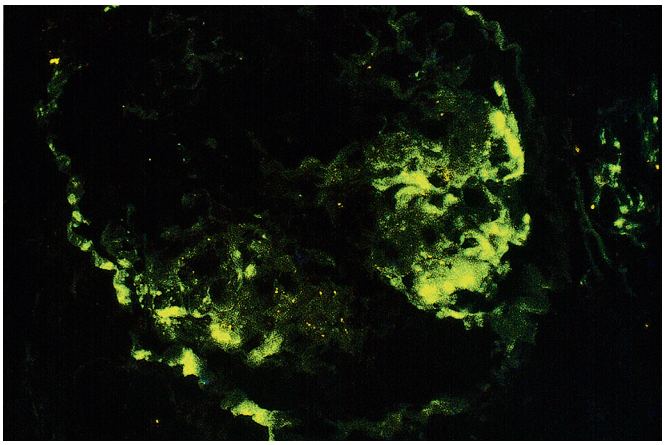

Figure 23.9 Immunofluorescence microscopy demonstrating segmental deposition of IgM in a biopsy from a patient with focal and segmental glomerulosclerosis (anti-IgM).

On occasion, sclerosis or consolidation is seen in the portion of the glomerulus opposite the hilus forming an adhesion in the vicinity of the opening of the Bowman space into the proximal tubule (glomerular tip lesion).[74] The consolidated portion of the capillary tuft in "tip" lesion may display endothelial swelling and entrapped foam cells (Fig. 23.8). The visceral epithelial cells overlying the involved segment are enlarged and vacuolated and often contain intracytoplasmic hyaline droplets. Some lesions are less cellular with an increase in mesangial matrix. The sclerotic segments in "perihilar" variant are localized next to the vascular pole, and it is a typical finding in secondary forms of FSGS attributable to adaptive functional response. The most controversial and least common subtype is the "cellular" variant in which the segmental lesion demonstrates intracapillary hypercellularity, and sometimes foam cells and karyorrhexis; hyperplasia of overlying podocytes is quite common. The collapsing FSGS lesion is described in detail in the subsequent section.

The extent of capillary tuft affected by sclerosis increases with eventual global sclerosis as the disease progresses. Areas of TA are common, and while this finding is not by itself diagnostic of FSGS, it should raise the possibility in biopsies which otherwise show MCD.[75] Interstitial fibrosis (IF) accompanies tubular loss and atrophy, and the extent of the tubulointerstitial damage is a prognostic indicator of the disease.[64,76,77] Since the glomerular injury in FSGS typically begins in the corticomedullary region, the lesion can be missed if this population of glomeruli is not included in the biopsy.

As FSGS represents podocyte injury, the most significant ultrastructural feature to be evaluated is podocyte foot process effacement, especially in capillary loops (and glomeruli) unaffected by sclerosis. Extensive podocyte foot process effacement is a feature of primary FSGS and is often seen in collapsing, tip, and cellular FSGS subtypes. Some secondary forms of FSGS and perihilar morphologic variants typically have less degree of foot process effacement.[53,78,79] A variable increase in mesangial matrix is customary in all glomeruli, and some degree of mesangial hypercellularity is not uncommon. In sclerosed segments, the GBMs are often folded and focally thickened; on occasion, foci of podocyte cell membrane detachment from GBM are seen and intervening space can accumulate multilayered basement membrane–like material and cellular debris. The hyaline deposits are composed of finely granular material that has a similar appearance and electron density to that of the insudative material seen in diabetic nephropathy. These insudations are predominantly subendothelial and located in the areas of segmental sclerosis; immunofluorescence studies show that they contain IgM and C3 (Fig. 23.9), but no immunoglobulin or complement deposition is seen in unaffected glomeruli.

Collapsing Glomerulopathy

Collapsing glomerulopathy is a clinically and pathologically distinct variant of FSGS that is characterized by the widespread collapse of glomerular capillary loops, and predominance in blacks attributable to the *APOL1* risk alleles.[50,60,80] Patients usually present with abrupt onset of nephrotic syndrome or nephrotic range proteinuria and renal impairment. An idiopathic form of collapsing FSGS[81,82] has poor prognosis with rapid loss of renal function and virtually no response to immunosuppressive therapy.[83] A circulating permeability factor might be responsible as evidenced by a rapid recurrence in an allograft.[84] Collapsing FSGS can be a secondary process associated with intravenous (IV) drug abuse and/or human immunodeficiency virus (HIV) infection.[85–87] This variant of FSGS constitutes about 80%–85% of the glomerular changes reported in HIV-infected patients.[88] Collapsing glomerulopathy has also been reported in association with some autoimmune diseases, lymphoproliferative disorders, drugs such as bisphosphonates and interferons, severe allograft ischemia, and non-HIV viral infections, such as hepatitis C, cytomegalovirus, and parvovirus B19.[52,85,89,90] Treatment of the underlying cause is helpful in inducing remission in these secondary forms.

The characteristic histologic feature is a predominantly collapsing type of focal glomerulosclerosis that is segmental and often global. The segmental sclerosis is characterized by localized hypertrophy and hyperplasia of the epithelial cells overlying the collapsed segment (Fig. 23.10).[91] These cells are often swollen and vacuolated and may contain abundant resorption droplets. The presence of even a single glomerulus with collapsing FSGS lesion is adequate for this diagnosis. The hyperplastic epithelial cells in this lesion represent either a proliferation of dysregulated podocytes or migrated parietal epithelial cell in response to injury.[92–94] Relative to the extent of glomerular sclerosis, tubulointerstitial injury is more severe in collapsing glomerulopathy than in typical FSGS. The tubular epithelial cells may present degenerative changes and the tubular lumens are often markedly dilated and show extensive proteinaceous cast formation.

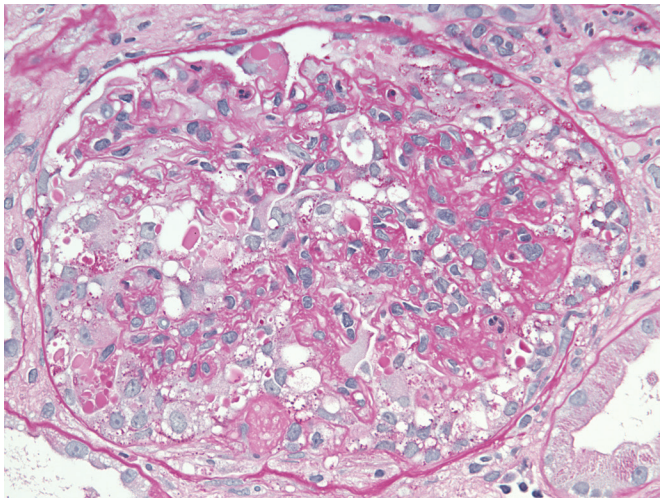

Figure 23.10 Collapsing variant of focal segmental glomerulosclerosis lesion is characterized by the retracted glomerular basement membrane and hyperplastic overlying podocytes obliterating the Bowman space. The podocytes have prominent cytoplasm protein droplets (PAS).

The interstitium often exhibits a prominent inflammatory infiltrate mainly composed of lymphocytes.

The most common immunofluorescence finding in the glomeruli in patients with collapsing glomerulopathy is IgM and C3 in a segmental distribution in the lesional glomerulus. Less commonly, C1q may also be localized. The podocyte protein resorption droplets are highlighted by IgG, IgA, and albumin. The changes seen by electron microscopy are generally those of typical FSGS, and the podocyte foot processes are extensively effaced. The GBM is diffusely wrinkled in areas of collapse. A distinctive but nonspecific feature is the finding of endothelial tubuloreticular inclusions in over 90% of patients with HIV-associated collapsing glomerulopathy.[95,96] These structures are rarely seen in idiopathic collapsing glomerulopathy or in collapsing glomerulopathy associated with other causes. Numerous endothelial tubuloreticular inclusions are also seen in patients with systemic lupus erythematosus (SLE) or in patients treated with interferon alpha.

C1q Nephropathy

C1q nephropathy is a relatively uncommon and controversial immune complex–mediated glomerulopathy that is characterized by the presence of dominant or codominant C1q deposition in the mesangium. Patients may present with nephrotic syndrome or mild proteinuria with or without hematuria.[97–100] The condition typically affects adolescents and young adults and appears to be more common in blacks than in whites.[99,101,102] C1q nephropathy with normal histology or mesangial proliferation responds to corticosteroids, but FSGS histology is associated with poorer outcome.[103] Progression to renal failure is slow, and it has been estimated that the 5-year renal survival rate is about 78%.[101] It is not entirely clear as to whether C1q nephropathy is a specific clinical entity or is part of the clinicopathologic spectrum of MCD and FSGS.[102,104]

Light microscopic findings vary from slight to marked mesangial hypercellularity with an increase in mesangial matrix, with or without segmental glomerulosclerosis. Electron microscopy studies invariably demonstrate mesangial immune complex deposits. Subendothelial or subepithelial deposits are uncommon. On immunofluorescence, C1q is often accompanied by IgG, IgM, and C3; IgA has been reported in about 60% of the cases.[100] The main differential diagnosis of C1q nephropathy is lupus nephritis which can also have prominent C1q deposition in the mesangium together with immunoglobulins and C3. Clinical presentation, serologic evidence, extraglomerular deposits, and presence of tubuloreticular inclusions help differentiate between class II lupus nephritis and C1q nephropathy.

Box 23.3 Entities associated with membranous glomerulopathy

Autoimmune disease

Autoantibodies to phospholipase A2 receptor (~80% of "primary" MGN)

Autoantibodies to THSD7A (~10% of "primary" MGN)

Systemic lupus erythematosus, mixed connective tissue diseases, Sjögren syndrome, rheumatoid arthritis, IgG4-related systemic disease, sarcoidosis, Hashimoto thyroiditis, Graves disease, Weber–Christian panniculitis, myasthenia gravis, bullous pemphigoid, autoimmune enteropathy, primary biliary cholangitis

Infections

Hepatitis B, hepatitis C, syphilis, Epstein–Barr virus, malaria, leprosy, tuberculosis, schistosomiasis, filariasis, hydatid disease, enterococcal endocarditis, brucellosis, staphylococcal infection

Neoplastic diseases

Carcinoma (lung, gastrointestinal tract, breast, prostate, kidney), seminoma, lymphoma (especially non-Hodgkin), leukemia, melanoma

Drugs and toxic agents

Nonsteroidal anti-inflammatory drugs, D-penicillamine, bucillamine, anti-tumor necrosis factor agents, organic gold, probenecid, captopril, trimethadione, lithium, clomethiazole, diclofenac, hydrocarbons, formaldehyde, solvents, mercury

Alloimmune etiology

De novo MGN due to chronic antibody-mediated rejection, graft versus host disease in hematopoietic stem cell transplantation, neutral endopeptidase directed response in neonatal MGN, replacement therapy with recombinant aryl sulfatase and α-glucosidase

Miscellaneous associations

Sickle cell disease, diabetes mellitus, Kimura disease, sclerosing cholangitis, antiglomerular basement membrane disease, cryoglobulinemia, Guillain–Barré syndrome

MGN, Membranous glomerulonephritis; *THSD7A*, thrombospondin type-1 domain–containing 7A.

Membranous Glomerulonephritis

MGN (a.k.a. membranous nephropathy) is a glomerular disease of diverse etiology characterized by subepithelial immune complex deposits and variable basement membrane thickening, without infiltration by inflammatory cells. MGN accounts for 20%–30% of all cases of idiopathic nephrotic syndrome in adults[105] and 1%–9% in children.[106] In large majority of cases, this condition occurs in a primary ("idiopathic") form, but the disease has been related to a wide variety of conditions (secondary) in approximately 20%–25% of adults and 80% of children with MGN (Box 23.3).[107] Over 85% of cases of secondary MGN are caused by infection, neoplasia, or SLE. The most common causes worldwide are malaria and schistosomiasis, while SLE, neoplasia, hepatitis B infection, and drugs are the most frequent in the United States.[107] Rare familial cases of MGN, probably related to a genetically transmitted mechanism, have been reported.[108]

The pathogenetic mechanism that leads to the immune complex localization in the subepithelial aspect of the GBM, especially in primary forms, is being increasingly understood. Two mechanisms presumed responsible for the development and localization of the deposits along the GBM are that of *in situ* immune complex formation in the subepithelial capillary wall or that of circulating immune complexes being deposited in that location. Experimental studies suggest that in most cases, the immune complexes are formed *in situ* by the binding of circulating antibodies with antigens that are normally present in the glomerulus or with extrinsic antigens that have previously been planted as free antigens in the subepithelial area.[109]

Primary human MGN appears to be largely an autoimmune disease with *in situ* glomerular immune complex formation. Over 70%–80% of primary MGN patients have autoantibodies directed against PLA_2R expressed in podocytes and proximal tubules.[110,111] These circulating PLA2R autoantibodies are IgG4 subtype and the plasma levels correlate with disease activity and therapeutic response,[112] and may predict the risk of post-transplantation recurrence.[113] Genome-wide association studies have strongly linked the disease to specific HLA-DQA1 and PLA2R alleles. Individuals with at risk polymorphisms may have increased propensity to present the autoantigen, precipitating MGN.[114] Approximately 5%–10% of patients with primary MGN have autoantibodies (IgG4 subtype) to a recently described second podocyte antigen, thrombospondin type-1 domain–containing 7A (THSD7A), further expanding the role of autoimmunity in these patients.[115,116]

In a subset of patients with MGN, alloimmune response appears to play a role in developing MGN. Neutral endopeptidase (NEP), expressed in podocytes and proximal tubular brush border, has been identified as the target antigen of antibodies deposited in the subepithelial space in patients with antenatal MGN.[117] In these cases, it is likely that the anti-NEP antibodies produced by the mother are transplacentally transferred to her child with genetic deficiency of NEP.[118] Some patients with Pompe disease and mucopolysaccharidosis IV receiving recombinant α glucosidase and aryl sulfatase B, respectively, also develop alloimmune responses resulting in MGN.[114] Lastly, *de novo* MGN in allografts also appears to be an alloimmune response.

Conditions associated with secondary MGN include chronic infections, neoplasms, autoimmune diseases (SLE, rheumatoid arthritis, IgG4-related systemic disease), drugs, and sarcoidosis. Drugs commonly associated with MGN include nonsteroidal anti-inflammatory drugs, penicillamine, gold, lithium, mercury, captopril, and anti-tumor necrosis factor agents. In some instances of secondary MGN, hepatitis B antigens (HBsAg, HBcAg, and HBeAg), virus-like particles (hepatitis C), tumor antigens, thyroglobulin, and DNA-containing material have been identified in the immune complexes, but it is unclear if these antigens are indeed pathogenic.[119] Exogenous antigen such as cationic bovine serum albumin (BSA) derived from milk has been identified within subepithelial deposits in young children with MGN.[120] These children have no other evidence of milk allergy but have anti-BSA antibodies in circulation. Secondary forms of MGN typically lack circulating PLA2R, but a small subset of patients with hepatitis B, hepatitis C, malignant neoplasm, and sarcoidosis have circulating serum PLA2R. While this may be coincidental, it also raises the possibility that "primary" MGN is triggered by an underlying disease. In both primary and secondary forms, complement is activated at the capillary wall site and appears to have a role in the development of the proteinuria.

The incidence of MGN in different populations varies; there is a particularly high frequency in Japanese children[121] and in certain African populations,[122,123] probably related to a high incidence of hepatitis B infection and parasitic infestations. Although MGN may occur at any age, it is rare in children and adolescents. Eighty to 90% of the patients are over the age of 30 at the time of diagnosis, with a peak incidence in the fourth and fifth decades.[124] The disease is twice as common in males. Sixty to 80% of patients have the nephrotic syndrome at onset, and others are usually referred for investigation of asymptomatic proteinuria or an abnormal urinalysis.[125] The proteinuria is usually nonselective, but a highly selective proteinuria is seen in about 20% of cases.[124] Macroscopic hematuria is rare, but as many as 90% of patients have microscopic hematuria at some time during the course of the disease.[124,126] Hypertension is usually found after renal insufficiency has developed, but it can be seen in 30% of the patients at presentation.[107] Rare cases with circulating anti-GBM antibody and/or antineutrophil cytoplasmic antibody (ANCA) have also been reported.[125] Serum levels of C3, as well as other components of complement, are normal; however, if reduced, this suggests a secondary form of the disease.

The natural history and overall prognosis of MGN can be significantly affected by the underlying disease and the way it is treated. When MGN is secondary to drugs, toxic substances, or infections, removal of the etiologic agent will often result in the disappearance of the clinical symptoms and resolution of the renal lesion. The nephrotic syndrome may abate and the glomerular changes regress after resection and treatment of a malignant tumor. In patients with membranous lupus nephritis, the course is indolent, whereas those who develop a superimposed anti-GBM antibody disease undergo a rapid progression to renal failure. Most patients with primary MGN present with chronic proteinuria and have recurrent episodes of nephrotic syndrome persisting over many years. Only 20%–25% of these patients progress to renal failure terminating in ESRD.[127] Partial or complete spontaneous remission has been reported in 20%–65% of cases.[127,128] The likelihood of spontaneous remission is greatly increased in children[106] and in patients who presented with proteinuria without the nephrotic syndrome and in whom the biopsy demonstrated a stage I glomerular lesion.[129] Recurrence or *de novo* development of MGN after renal transplantation can occur. The recurrence rates have ranged from 10% to 30% in different series, while the *de novo* rate is more common, accounting for about twice as many cases of MGN in transplant recipients.[130]

The structural features of the glomerular capillary wall have been used to define four histopathologic stages of the disease.[131] In **stage I**, the glomeruli appear normal by light microscopy, and there are no significant changes in the thickness of the basement membrane. At this early stage, an incorrect diagnosis of MCD is possible if the biopsy is only studied by light microscopy. With the electron microscope, these cases show sparse immune complex deposits between the epithelial cell cytoplasm and the lamina densa of the basement membrane, but the latter appears homogeneous and uniform in thickness. The deposits can be irregular, dome shaped, or appear as small humps with a well-defined line between the lamina densa and the epithelial cell. Foot processes over the deposits are obliterated, but they often appear normal elsewhere (Fig. 23.11).

In **stage II**, the capillary walls are thickened and many subepithelial deposits are present, separated by extensions of basement membrane (Fig. 23.12A). The deposits do not stain with silver impregnation techniques, but the extensions of basement membrane do, thus creating the impression that the capillary loop is covered by spikes (see Fig. 23.12B). These spikes have been shown to be composed of type IV collagen and noncollagenous extracellular matrix components, including laminin, heparan sulfate, proteoglycans, and vitronectin. The epithelial foot process effacement is extensive throughout the loops.

When the disease is more advanced (**stage III**), the deposits are encircled by a newly formed basement membrane (Fig. 23.13). The capillary walls are markedly thickened and the capillary lumina

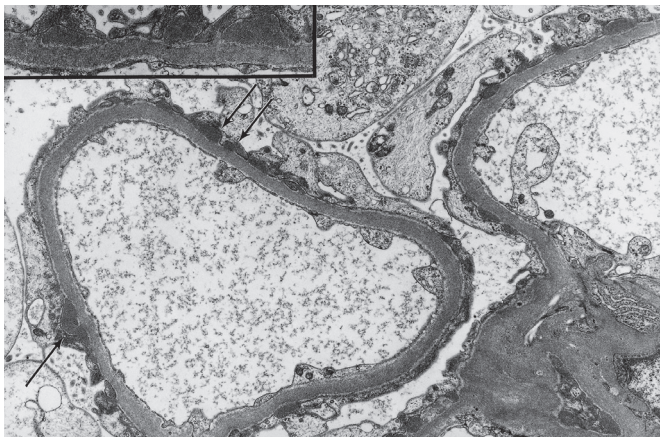

Figure 23.11 Membranous Glomerulonephritis, Stage I. Basement membrane is normal thickness. Small subepithelial deposits *(arrows)* are separated from the basement membrane by a thin clear zone *(inset)*. The epithelial foot processes are obliterated (×6000; inset ×9100).

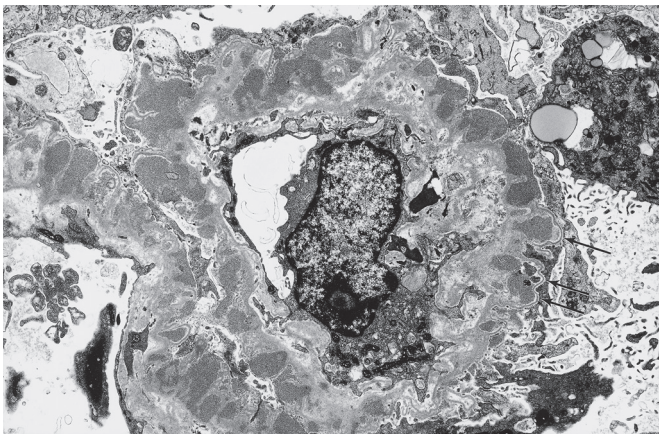

Figure 23.13 Membranous Glomerulonephritis, Stage III. The basement membrane is markedly thickened and the deposits appear surrounded by a newly formed basement membrane *(arrows)* (×6900).

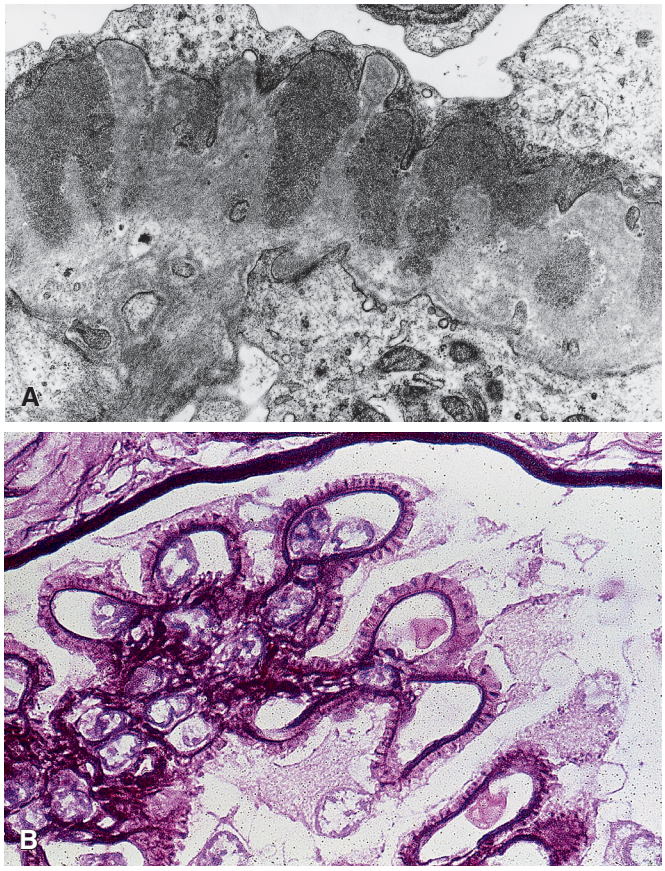

Figure 23.12 A, Membranous glomerulonephritis, stage II. Subepithelial deposits are separated by projections of the basement membrane (×18,000). **B,** Silver preparation showing spike formation along the thickened basement membrane (methenamine silver).

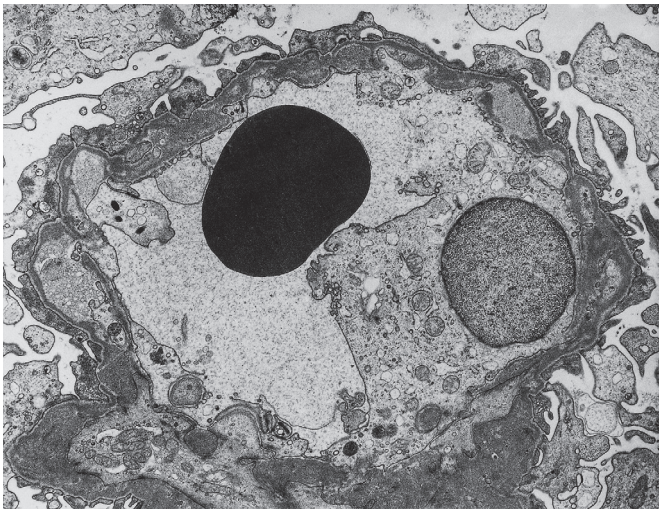

Figure 23.14 Membranous Glomerulonephritis, Stage IV. The basement membrane is markedly irregular and most of the deposits have been reabsorbed, leaving large electron-lucent areas (×9360).

narrowed. The basement membrane shows a reduplicated or moth-eaten appearance with PAS and silver stains. By electron microscopy, many of the deposits in stage III disease have a rarefied appearance that indicates resolution, and small spherical structures, which have been confused with virus particles, may be present during dissolution of the deposits. Individual deposits may also contain striated membranous bodies that are probably formed by degeneration of entrapped cellular components.

During the late stage of the disease (**stage IV**), deposits gradually lose their electron density and the basement membrane becomes vacuolated, folded, and thickened. Deposits may no longer be evident (Fig. 23.14). Capillary lumina become obliterated, and the glomerular tufts show segmental or global sclerosis. TA and vascular sclerosis can be prominent, making the diagnosis difficult. In the end-stage of the disease, the differential diagnosis includes various types of chronic glomerulonephritis. Although the degree of proteinuria does not parallel the stages of the renal lesion, stage I carries a better prognosis than more advanced disease and spontaneous remission is more likely. However, there seems to be no difference in prognosis between stages II, III, and IV. Histologic progression can occur without clinical progression, and clinical remission can occur in the absence of histologic regression.[107]

Immunofluorescence microscopy in all stages of MGN reveals a generalized, peripheral granular pattern of IgG, C3, kappa and lambda, sometimes with IgM (Fig. 23.15). The reaction for IgA is usually absent, and if it is strong and associated with the early components

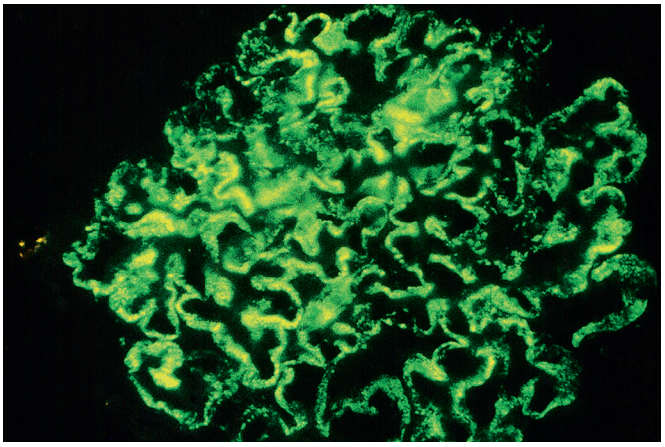

Figure 23.15 Immunofluorescence preparation of membranous glomerulonephritis showing peripheral granular deposits of IgG (anti-IgG).

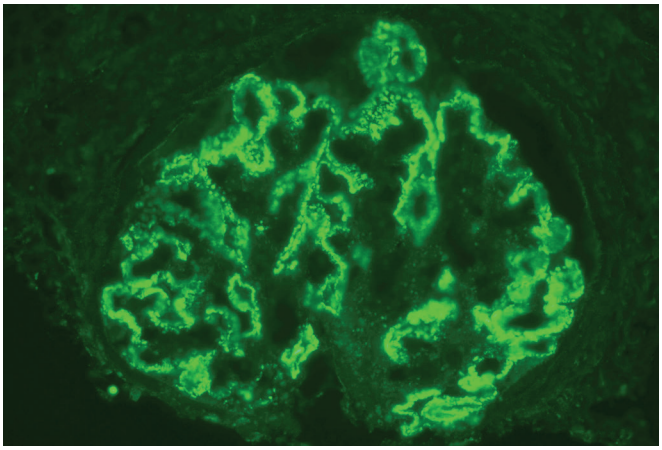

Figure 23.16 Diffuse granular capillary wall staining with antibody to PLA2R supports a diagnosis of primary membranous nephropathy (anti-PLA2R).

of complement (C1q and C4), the possibility of lupus MGN must be considered. Although not evaluated on routine diagnostic studies, there is strong reactivity for terminal complement components (i.e., C5b–C9 membrane attack complex). Extraglomerular deposits have only rarely been reported in primary MGN.[126] The finding of granular deposits along the tubular basement membrane (TBM) should always raise the possibility of membranous lupus nephritis.[132] MGN with anti-TBM antibodies typically have linear TBM staining for IgG and sometimes with C3. Although not entirely sensitive or specific, with regards to IgG subclass staining, primary MGN deposits are mainly IgG4+, while membranous lupus nephritis deposits are positive for IgG1–IgG4 with IgG3 dominance. Primary MGN deposits stain for PLA2R by immunofluorescence microscopy and can be positive despite the lack of circulating antibodies as in early remission stage (Fig. 23.16).[133,134] Hence, renal biopsy is considered a sensitive tool for diagnosing primary MGN. Recurrent MGN in post-transplantation biopsies is also characterized by deposits that are IgG4 dominant and PLA2R positive. In contrast, *de novo* MGN deposits are IgG1 dominant and PLA2R negative.[135,136] *De novo* MGN is often associated with chronic antibody-mediated rejection (AMR) and hence is considered an alloimmune phenomenon.

Notable morphologic characteristics of MGN throughout its evolution are the absence of mesangial hypercellularity and a lack of inflammatory cells within the glomeruli. On occasion, however, mesangial hypercellularity can occur, especially in patients with secondary forms of MGN, such as SLE, hepatitis B, or gold- or penicillamine-associated disease. In addition to epimembranous and intramembranous deposits, small amounts of immune complex deposition may be seen in the mesangial and/or subendothelial areas.[137] Margination of leukocytes in the glomerular capillaries may be an indication of renal vein thrombosis.[138] Crescent formation is uncommon and if focal, should suggest secondary MGN (e.g., due to SLE) or a superimposed disease. Diffuse fulminant crescentic disease is a rare and late consequence of the superimposition of anti-GBM or ANCA disease.[125] Rarely, patients with MGN have tubulointerstitial nephritis (TIN) because of antitubular basement membrane antibodies. These patients are almost invariably children, present with nephrotic syndrome and Fanconi syndrome and progress to ESRD.[139]

Diabetic Nephropathy

Diabetic nephropathy is a clinical syndrome characterized by persistent proteinuria, hypertension, and progressive decline in renal function. It is considered to be the leading cause of ESRD, accounting for approximately 40% of the new cases in the United States undergoing long-term dialysis.[140] It is estimated that 20%–40% of all diabetic patients will develop diabetic nephropathy.[141] In type 1 diabetes, the cumulative incidence of diabetic nephropathy is about 25% after 25–40 years of disease.[142] Evidence suggests that the risk of overt nephropathy and progression to ESRD is similar in type 2 diabetes.[143] Microalbuminuria is the earliest manifestation of diabetic nephropathy but cannot be detected by standard urine dipstick method. Proteinuria, usually of nonselective type, is the most consistent overt manifestation of diabetic nephropathy. The nephrotic syndrome has been reported in 6%–40% of the cases and constitutes a sign of poor prognosis. About 28%–48% of patients may present with moderate microscopic hematuria. Hypertension is a late complication seen with advanced renal failure. The rate of progression to end-stage kidney disease is dependent on a variety of factors including genetics, environmental factors, therapeutic interventions, and comorbidities. Blacks and Native Americans with type II diabetes mellitus are at greater risk of developing diabetic nephropathy.

The development of diabetic nephropathy is related to multiple factors, and inadequate glycemic control is one of the most important. Persistent hyperglycemia causes accumulation of advanced glycosylated end products in various organs including kidney with resultant injury, tissue remodeling, and extracellular matrix deposition. It also causes defects in mitochondrial electron transport, increased production of reactive oxygen species, and increased oxidative stress. Many cellular proteins, including GBM collagen and matrix proteins, are affected. Inherited risk factors such as certain polymorphisms in genes involved in the renin angiotensin system and insulin resistance appear to play a role.[144]

Diabetic microangiopathy occurring throughout the body is the most characteristic morphologic change in the diabetic, and its hallmark is an increase in the amount of vascular basement membrane material. There are no significant morphologic differences in the renal lesions caused by type 1 and type 2 diabetes.[145] All areas of the kidney may be affected by diabetes, but the most striking lesions are found in the glomeruli and blood vessels, including diffuse glomerulosclerosis, nodular glomerulosclerosis, and the so-called insudative lesions (fibrin caps, capsular drops, and arteriolar hyalinosis).[146] Diabetic glomerulosclerosis is the general term for all of these lesions, and they are considered to be an expression of the microangiopathy.

Diffuse glomerulosclerosis, the most common lesion in diabetic nephropathy, is characterized by a diffuse increase in the mesangial

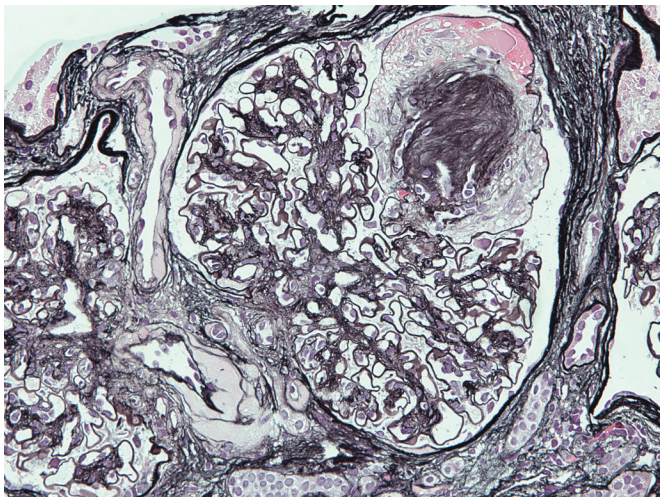

Figure 23.17 Diabetic glomerulosclerosis with segmental mesangial Kimmelstiel–Wilson nodule and adjacent microaneurysm. Other mesangial areas have mild diffuse mesangial sclerosis. Arteriolar hyaline insudation is seen near the vascular pole (methenamine silver stain).

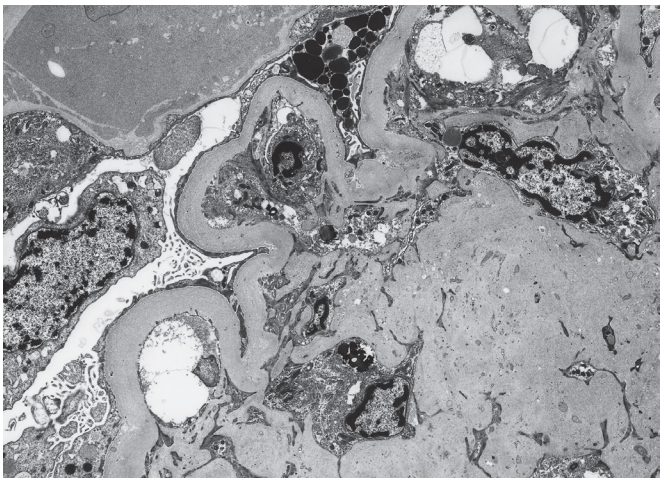

Figure 23.18 Nodular Diabetic Glomerulosclerosis. The massive enlargement of the mesangium is due to an increase in mesangial matrix. The basement membrane is markedly thickened and a capsular drop is present at the left upper corner of the figure (×4400).

matrix and thickening of the capillary walls (Fig. 23.17). Thickening of the GBM is the most consistent finding in diabetic nephropathy and is often seen in both diffuse and nodular glomerulosclerosis. Although minor degrees of basement membrane thickening are not specific for diabetes, measurement of the basement membrane width is the most effective way to quantitate early diabetic glomerular lesions. In advanced stages, the GBM may be many times its normal thickness, often with accentuation of the normal fibrillar structure. The GBM thickening and mesangial changes can be seen by electron microscopy before the damage is visible by light microscopy. The earliest structural alteration in diabetic glomerulopathy that can be quantified is increased thickness of the GBM, which can be documented as early as 1.5–2.5 years after the onset of type I diabetes mellitus. A clear increase in the mesangial matrix and cellularity can be detected on light microscopy as early as 5–7 years after the onset of diabetes mellitus[147] or within 2–5 years following renal transplantation.[148] Recently, a histologic classification of diabetic nephropathy has been proposed, but its clinical utility has not yet been validated.[149]

Nodular glomerulosclerosis (Kimmelstiel–Wilson lesion) is the characteristic histopathologic lesion in diabetic glomerulosclerosis. It consists of large acellular nodules located in the intercapillary regions (see Fig. 23.17). These nodules vary in size and often have a laminated appearance. They are eosinophilic, argyrophilic, and PAS positive and blue with trichrome stain. Ultrastructurally, the nodules are composed of masses of extracellular mesangial matrix (Fig. 23.18). Both the mesangial widening and the nodules are the result of an increase in the synthesis and/or decrease in the degradation of the mesangial matrix.[146] The capillary loops that surround the nodules may have narrow lumens because of the expansion of the mesangium, but they can also be aneurysmally dilated and some have peripheral mesangial extensions. Focal areas of mesangiolysis may also be present. Diffuse and nodular diabetic glomerulosclerosis can be found together, not only in the same patient, but also in the same glomerulus. Although nodular glomerulosclerosis is virtually pathognomonic of diabetic nephropathy, identical light microscopic lesions can be found in cases of light chain deposition disease (LCDD). In the latter condition, however, the nodules are composed of granular electron-dense material that shows light chain restriction with antibodies to kappa and lambda light chains. Nodular glomerulosclerosis mimicking diabetic nephropathy has rarely been reported in patients without manifested diabetes, but with longstanding hypertension and/or smoking history, and is referred to as "idiopathic" nodular glomerulosclerosis.[150] Diffuse nodular deposits of amyloid can sometimes be confused with diabetic glomerulosclerosis by light microscopy, but the ultrastructural identification of amyloid fibrils will establish the diagnosis.

Insudative lesions are the least specific of the glomerular changes in diabetes. Ultrastructurally, they are seen to be masses of electron-dense material, often containing lipid droplets. Common locations of these lesions are the periphery of the loop in a subendothelial location (fibrin caps), within the basement membrane of the Bowman capsule (capsular drops), or in the mesangium or GBM. In blood vessels, they are more extensive in the subintima and media but can also involve the adventitia. This insudative lesion, known as hyalinosis, can affect the afferent and efferent arterioles and may ultimately replace the smooth muscle cells. The severity of the arteriolar hyalinosis correlates significantly with the percentage of sclerosed glomeruli, suggesting that the vascular lesion contributes to the ischemic global glomerulosclerosis. Histochemical and immunofluorescence studies indicate that the insudative material represents infiltration by constituents of the plasma, including proteins, lipids, and mucopolysaccharides.

Atubular glomeruli can also be found in diabetic glomerulosclerosis as a late manifestation of the disease, predominantly in patients with proteinuria.[151] Atubular glomeruli are defined as those glomeruli that have open glomerular capillaries but have lost their connection with the proximal tubule and are presumably nonfunctioning. Although accurate identification of these glomeruli requires serial sections, small glomeruli surrounded by tissue with marked tubular loss are most probably atubular.

The most characteristic tubular change is diffuse thickening of the tubular basement membrane. When the disease is advanced, there is also TA and interstitial scarring that may be accompanied by chronic inflammatory infiltrate. The presence of interstitial neutrophils or tubular neutrophil casts should raise concern for superimposed acute pyelonephritis. Glycogen vacuolization of the renal proximal tubular epithelial cells (Armanni–Ebstein lesion), associated with uncontrolled hyperglycemia, was common in the past, but is rarely seen today. Approximately a third of renal biopsies

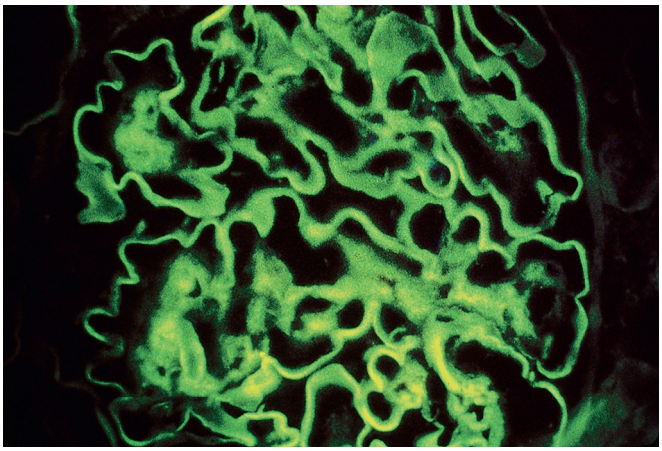

Figure 23.19 Diabetic glomerulosclerosis with linear staining for IgG along the glomerular basement membrane (anti-IgG).

with diabetic nephropathy have superimposed glomerular disease,[152] and this list includes membranous nephropathy, IgA nephropathy (IgAN), postinfectious glomerulonephritis (especially IgA-dominant variant described later), and others. Cellular crescents are rare in diabetic glomerulosclerosis, but foci of organizing fibroepithelial crescents occur with superimposed ANCA-mediated glomerulonephritis,[153] and their presence is associated with aggressive clinical course.[154]

Diffuse linear reaction for IgG along the glomerular capillary, tubular, and Bowman capsular basement membranes is the most characteristic immunofluorescence finding in diabetic nephropathy (Fig. 23.19). Less intense reaction in a similar distribution may also be seen for IgM, fibrin, and albumin, but staining for C3, if present, is often granular. These linear reactions are unrelated to either the duration or the severity of the glomerular lesions and evaluation studies do not show specific antibody activity to basement membrane antigens. Insudative lesions may react with a variety of reagents but most frequently contain IgM and C3.

Amyloidosis

The term amyloidosis designates a heterogeneous group of disorders characterized by the extracellular deposition of nonbranching linear fibrils with a mean diameter of 10 nm and a β-pleated sheet configuration on x-ray diffraction analysis. It is this configuration that is responsible for the tinctorial and optical characteristics seen on Congo red staining, which produces the typical apple-green birefringence seen on tissue sections when they are examined under polarized light. Amyloid itself does not have a consistent chemical composition but is instead a group of proteins that share common physical characteristics. At present, more than 30 structurally unrelated proteins have been identified as amyloid precursors associated with human disease, but most forms are localized with rare or no involvement of kidney (Table 23.3).[155–157] In addition to the fibrillary protein, amyloid deposits contain nonfibrillary proteins, including glycosaminoglycans, apolipoprotein E (Apo E), and amyloid P component. The amyloid P component (also known as serum amyloid P or SAP) is a 25-kDa glycoprotein member of the pentraxin family that includes C-reactive protein. Amyloid P component is present in all types of amyloid, accounting for about 15% of their mass. It is believed that amyloid P component may prevent degradation of the amyloid fibrils once they are formed.[158] Better understanding of the amyloid fibril composition, formation, and stabilization has helped the emerging field of targeted therapies in amyloidosis.[159]

The classification of amyloidosis is based on the type of precursor protein that forms the amyloid fibrils and the distribution of the amyloid deposits as to whether it is systemic or localized (see Table 23.3). By convention, the amyloid fibril type is designated A for amyloid, followed by an abbreviated form of the name of the fibril protein. **Amyloid light-chain (AL) amyloidosis** (formerly known as "primary" or "associated with multiple myeloma") is the most common form of systemic amyloidosis in the Western world.[157] In this type of amyloidosis, the amyloid fibrils are composed of the N-terminal residues of the variable region of an immunoglobulin light chain. The specific amino acid sequences and post-translational modifications of light chains confer the amyloidogenicity. A minority have overt multiple myeloma, while others have monoclonal spike in the serum and/or urine. The amyloidogenic light chains are more frequently lambda than kappa type, in contrast to normal or cast nephropathy light chains.[160] Rarely, the amyloid deposits are derived from monoclonal immunoglobulin light and heavy chains or just heavy chains, and the disease is referred to as AHL amyloidosis or AH amyloidosis, respectively.

Amyoid A (AA) amyloidosis (formerly known as secondary amyloidosis) is a rare complication of persistent inflammation that may develop in patients affected by chronic rheumatic diseases, long-lasting infections, inflammatory bowel disease, periodic fever syndromes, familial Mediterranean fever, and malignancies.[161–163] It is the most common type of amyloidosis in the parts of developing world with endemic tuberculosis and leprosy. In this type of amyloidosis, the AA amyloid deposits are formed by the N-terminal proteolytic fragments of the acute-phase reactant serum amyloid A (SAA), a polymorphic apolipoprotein of high density that, upon chronic inflammatory stimuli, may reach persistently high plasma concentrations.[164,165] Certain polymorphisms in *SAA* gene appear to confer increased risk of developing AA amyloidosis in patients.[163]

Hereditary systemic amyloidosis is a diverse group of autosomal dominant, late-onset (sometimes sixth or seventh decade of life) disorders that occurs much less frequently than AL or AA amyloidosis. These amyloidoses are caused by mutations in the genes coding for some plasma proteins, including transthyretin, apolipoprotein A-I, apolipoprotein A-II, apolipoprotein A-IV, fibrinogen A α-chain, gelsolin, cystatin C, and lysozyme.[166] Specific amino acid substitutions allow each of these soluble circulating proteins to be prone to aggregate and form amyloid fibrils in organs and tissues. The natural history of these conditions varies by the protein, as well as the tissue distribution. For example, transthyretin amyloidosis, which is the most common form of hereditary systemic amyloidosis, typically affects the peripheral and autonomic nervous systems, manifesting as progressive sensory–motor neuropathy, gastrointestinal and bladder dysfunction, impotence, and orthostatic hypotension, whereas apolipoprotein A-I, apolipoprotein A-II, apolipoprotein A-IV, fibrinogen α-chain, and lysozyme amyloidosis are more often associated with a marked visceral burden of amyloid that clinically results in progressive kidney and liver disease.[162]

Familial Mediterranean fever is a common form of the nephropathic familial amyloidoses. The deposits of amyloid in this condition consist of amyloid AA, and, in contrast to other forms of familial amyloidosis which are autosomal dominant, familial Mediterranean fever is associated with autosomal recessive inheritance.[167] Mutations in *MEFV* gene encoding pyrin/marenostrin result in activation of IL-1β pathway with subsequent elevations of SAA levels, especially during febrile episodes. Other related periodic fever syndromes due to mutations in genes encoding cryopyrin, and tumor necrosis factor also cause autoinflammation with eventual precipitation of AA amyloid.[163]

A subtype of amyloidosis of ill-defined etiology is ALECT2, characterized by accumulation of leukocyte chemotactic factor 2.[168,169] No mutation in *LECT2* gene has been identified, but all sequenced

Table 23.3 Amyloid fibril proteins and their precursors in humans

AMYLOID PROTEIN	PRECURSOR PROTEIN	DISTRIBUTION	RENAL BIOPSY FEATURES OR ASSOCIATED CONDITION
Neoplasm-Associated (AL) Amyloidosis			
AL	Immunoglobulin light chain	Systemic or localized	Glomerular, interstitial, and vascular deposits; multiple myeloma, B-cell lymphoma
AH	Immunoglobulin heavy chain	Systemic or localized	Glomerular, interstitial, and vascular deposits; multiple myeloma, B-cell lymphoma
Chronic Inflammation-Associated Amyloidosis			
AA	(Apo) serum AA	Systemic	Chronic infections or inflammation. Seen in hereditary inflammatory syndromes (Familial Mediterranean fever, hyper-IgD syndrome, familial cold urticarial, Muckle-Wells syndrome)
Hereditary (or Mutation Associated) Amyloidosis			
ATTR	Transthyretin	Systemic	Predominantly glomerular deposits or limited to medullary interstitium
AApoAI	Apolipoprotein AI	Systemic	Arterial and medullary interstitial deposits in kidney; localized deposits in aorta, meniscus
AApoAII	Apolipoprotein AII	Systemic	Medullary interstitial and vascular deposits
AGel	Gelsolin	Systemic	Glomerular deposits
ALys	Lysozyme	Systemic	Glomerular and vascular deposits
AFib	Fibrinogen alpha-chain	Systemic	Only glomerular deposits that stain for fibrinogen
ACys	Cystatin C	Systemic	Cerebral vessels (no renal involvement)
ALECT2	Leukocyte chemotactic factor 2	Localized	Glomerular, cortical interstitial and vascular deposits. No mutation, only a common polymorphism in *LECT2* gene identified
ABri	ABriPP	Systemic	Familial dementia
Other Types of Amyloid Deposition			
AApoAIV	Apolipoprotein AIV	Systemic	Sporadic, associated with aging
ATTR	Transthyretin	Systemic	Nonfamilial senile form
Aβ_2M	β_2-Microglobulin	Systemic or localized	Hemodialysis associated; localized form in joints
ADan	ADanPP	Localized	Familial dementia (Danish type)
Aβ	Aβ protein precursor (AβPP)	Localized	Alzheimer disease, associated with aging

Continued

Table 23.3 Amyloid fibril proteins and their precursors in humans—cont'd

AMYLOID PROTEIN	PRECURSOR PROTEIN	DISTRIBUTION	RENAL BIOPSY FEATURES OR ASSOCIATED CONDITION
APrP	Prion protein	Localized	Spongiform encephalopathies
ACal	(Pro) calcitonin	Localized	Medullary thyroid carcinoma
AIAPP	Islet amyloid polypeptide	Localized	Islet of Langerhans; Insulinomas
AANF	Atrial natriuretic factor	Localized	Cardiac atria
APro	Prolactin	Localized	Aging pituitary, Prolactinomas
AIns	Insulin	Localized	Iatrogenic
AMed	Lactadherin	Localized	Senile aortic, arterial media
AKer	Kerato-epithelin	Localized	Cornea, familial
ALac	Lactoferrin	Localized	Cornea (trichiasis)
AOaap	Odontogenic ameloblast-associated protein	Localized	Odontogenic tumors
ASemi	Semenogelin I	Localized	Seminal vesicle
ATau	Tau	Localized	Alzheimer disease, frontotemporal dementia, aging, other cerebral conditions

Modified from Westermark P, Benson MD, Buxbaum JN, et al. A primer of amyloid nomenclature. *Amyloid*. 2007;14:179–183.

cases show a specific polymorphism. Produced in the liver, LECT2 is a plasma cytokine that increases the phagocytic and bacteriocidal activity of macrophages. ALECT2 is typically seen in elderly individuals of Mexican ancestry, although other ethnic populations can be affected. These patients often have comorbidities such as diabetes mellitus and hypertension.

Another form of amyloidosis is **dialysis-related amyloidosis**, a serious complication in patients undergoing long-term dialysis that is caused by the deposition of fibrillar β_2-microglobulin (amyloid β_2M).[170] This type of amyloid has a predilection for musculoskeletal deposition. β_2-Amyloid can cause carpal tunnel syndrome and a destructive arthropathy of medium-sized and large joints, especially of the shoulders and knees. Visceral amyloid deposition occurs late, usually after 15 years of hemodialysis, and may involve the heart, liver, lungs, and gastrointestinal system.[162] End-stage kidneys may also be involved by β_2-microglobulin amyloidosis, but this has no clinical significance.

Nonselective proteinuria, with or without the nephrotic syndrome, is the most common manifestation of renal involvement by amyloidosis. Approximately 25% of the patients with AL amyloidosis have the nephrotic syndrome at diagnosis, and a total of about 40% will develop the syndrome during the course of the disease.[171] Over 90% of patients with AA amyloidosis have renal insufficiency or nephrotic syndrome at diagnosis; however, the degree of proteinuria does not correlate with the extent of the amyloid deposition in the kidney. The prognosis for a patient with renal amyloidosis is poor, especially in those with AL amyloidosis.[171,172]

Because the kidney is frequently affected in AL, AA, and several familial amyloidoses, a kidney biopsy is often a method by which the disease is identified.[173,174] Amyloid can be found anywhere in the kidney but especially accumulates in glomeruli. Deposition is initially mesangial, producing diffuse widening of axial areas but progressively involves the capillary walls (Fig. 23.20A and B). Substantial mesangial deposition can produce nodules that may resemble those of diabetic glomerulosclerosis or LCDD. However, in amyloidosis, because the nodules are composed of amyloid protein rather than mesangial matrix, PAS staining is weak and trichrome stain is grayish blue in mesangium. Diffuse spread throughout the glomerulus can produce a picture reminiscent of membranous nephropathy, especially with the formation of basement membrane spicules. Amyloid deposition in the tubulointerstitium produces TA and IF, and in a small percentage of patients (~10%), the glomerular deposits are absent and amyloid is restricted to the tubulointerstitium or blood vessels. Several differences have been described in the distribution of amyloid deposits in various subtypes. For example, ALECT2 primarily affects cortical interstitium along with glomeruli and blood vessels, but the medulla is spared; AFib-α exclusively involves glomeruli and AApoAI/AII/AIV affects medullary interstitium with relative glomerular sparing.[157] Histochemical techniques used for the diagnosis of amyloid include Congo red and thioflavin T stains (Fig. 23.21A and B). Thioflavin T is extremely sensitive but not entirely specific, whereas the production of an apple-green color by polarized light in Congo red–stained sections is accepted as the most reliable light microscopic method for diagnosis. Each technique requires a critical amount of amyloid before a positive reaction can be elicited. Because of this, small amounts of amyloid may be missed and, even more important, neither technique is effective with very thin sections. The staining should be performed on sections cut at least 8 µm thick and always with appropriate controls. The fibrils of AL and AA amyloidosis can be distinguished by pretreating tissue sections with potassium permanganate before the Congo red staining. Under these conditions, AA amyloid fibrils lose their affinity for the Congo red stain, and the birefringence is lost, whereas AL amyloid is not affected. This technique, however, is not as reliable as immunostaining with currently available AA antibodies.

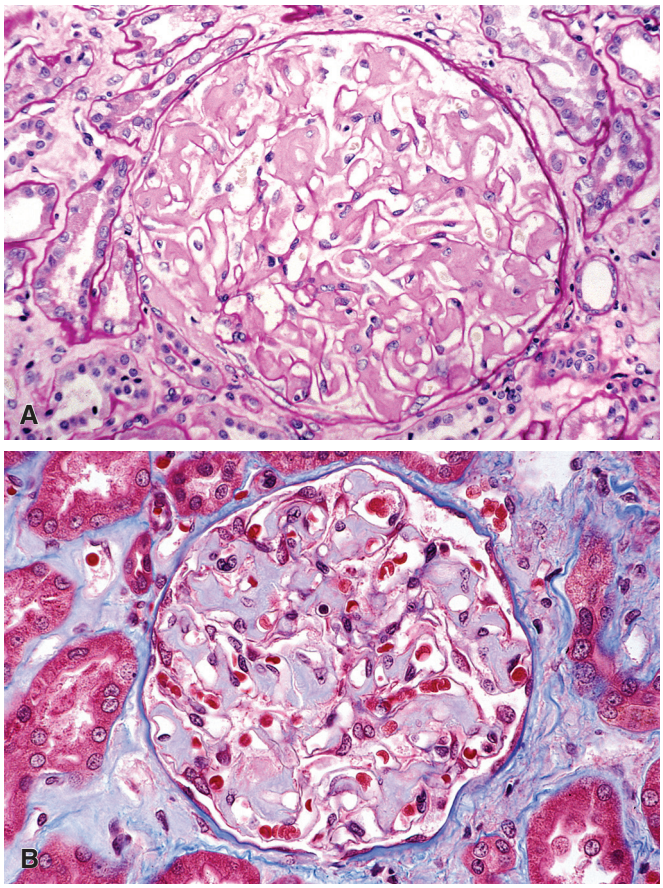

Figure 23.20 Acellular Amorphous Deposits of Amyloid in the Mesangium With Patchy Glomerular Capillary Wall Extension. A, These deposits are weakly PAS positive in comparison to the Bowman capsule. **B,** Amyloid deposits have a grayish blue appearance on trichrome stain.

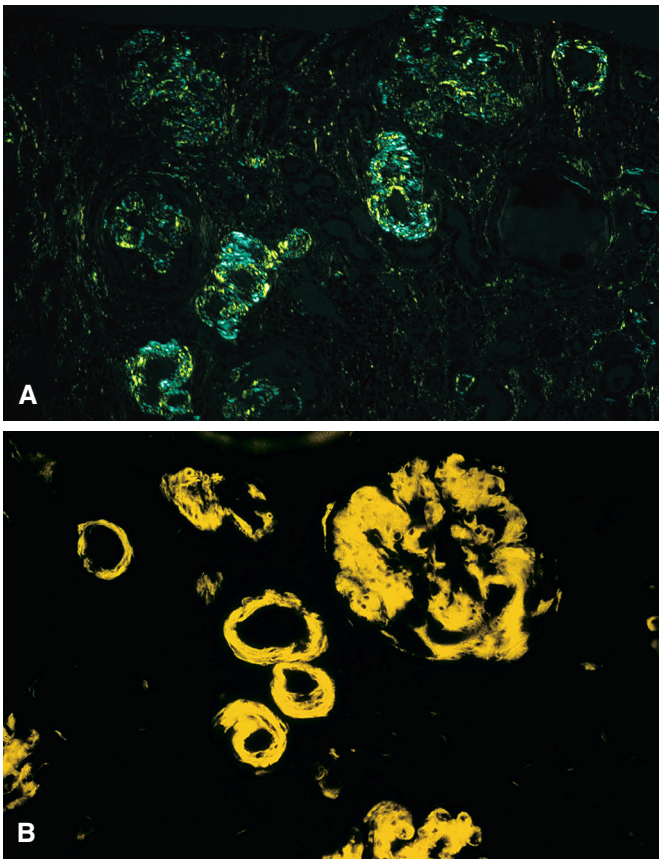

Figure 23.21 A, Deposits of amyloid exhibiting birefringence under polarized light (Congo red stain). **B,** Fluorescence of amyloid under ultraviolet light (thioflavin T stain).

In the early stages of renal involvement when histochemical preparations fail to detect the deposits of amyloid, electron microscopy is the only method available to establish the diagnosis. Ultrastructurally, the amyloid fibrils in tissue sections form random aggregates of rigid, nonbranching fibrils measuring 8–10 nm in diameter (Fig. 23.22). Initially, the amyloid is seen in mesangium and the deposition subsequently extends into the subendothelial zone and through the basement membrane. When amyloid penetrates the basement membrane, epithelial foot processes are effaced and are often separated from the membrane.

Because the amyloidogenic light chain in AL amyloidosis is produced by clonal plasma cells, immunofluorescence or immunoperoxidase studies will show restrictive immunoreactivity for either kappa or, more frequently, lambda light chain. It should be emphasized, however, that a negative reaction for both light chains does not exclude the diagnosis of AL amyloidosis. This is because the main constituent of amyloid deposits in some cases of AL amyloidosis is the light chain variable region alone and the commercially available antibodies are typically raised against the light chain constant region.[175] Monoclonal heavy chain staining (IgG, IgA, or IgM) may instead be seen in AH amyloidosis or may be present in addition to light chain restriction, as in AHL amyloidosis. Sometimes the "stickiness" of amyloid causes nonspecific immunoglobulin staining and an erroneous subtyping of amyloid deposits.[175] Amyloid A usually can be demonstrated by the currently available anti-AA protein

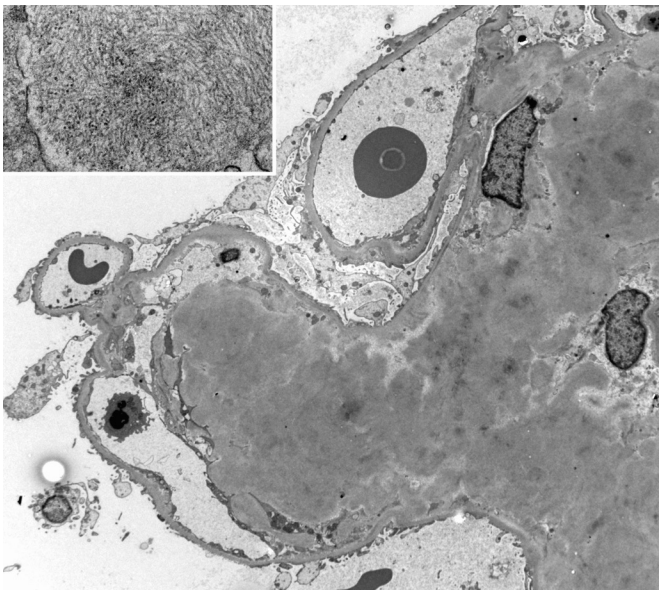

Figure 23.22 Portion of a glomerulus with large amounts of mesangial deposits of amyloid. The typical fibrillary ultrastructural appearance of the amyloid fibrils is shown at high magnification (×5000; inset ×54,000).

antibodies. Since amyloid P component is present in all types of amyloid, it can be used as a pan-amyloid marker to highlight the extent of amyloid deposition. It is important to keep in mind, however, that amyloid P component is not specific for amyloid and is present in the organized deposits of immunotactoid glomerulopathy[176] and in normal GBM and blood vessels[177]; therefore, a positive stain does not denote the presence of true amyloid deposition, and it is necessary to establish the presence of amyloid by a positive Congo red stain.

Other less common amyloid subtypes such as LECT2, ApoAI, ApoAII, and transthyretin can be characterized by performing immunohistochemical stains. However, the list of amyloid subtypes is quite extensive, and given the limited renal biopsy material, it is now standard of care to perform mass spectrometry on laser microdissected amyloid deposits on paraffin sections. Approximately 90% of renal amyloidosis cases belong to either AL or AA type. An initial panel of immunofluorescence and/or immunohistochemistry can be performed to evaluate for AL and AA amyloidosis and failure to subtype the amyloid with this initial testing should prompt mass spectrometry analysis.[175]

Fibrillary Glomerulonephritis

Fibrillary glomerulonephritis is characterized by extracellular deposition of nonbranching, randomly arrayed fibrils approximately 10–30 nm in diameter.[178–180] Reported in just 0.5%–1.0% of the cases in three large series of native kidney biopsies,[180–182] it most commonly affects middle-aged adults but can also occur in older individuals and children as young as 10 years of age.[181,183] It is more common in whites than in blacks (ratio 8.3 : 1) and affects females more often than males (1.8 : 1).[181,184] Patients typically present with heavy proteinuria, often in the nephrotic range.[181] Microscopic hematuria is common, but on occasion gross hematuria may occur. About 75% of patients develop hypertension, sometimes severe.[182,184] Low serum complements are only rarely encountered in fibrillary glomerulonephritis. No specific serum or urine protein abnormalities have been recorded, and the patients have a low incidence of associated lymphoproliferative malignancy. The prognosis for patients with fibrillary glomerulonephritis is poor. Roughly half of these patients progress to ESRD within 2 years of the initial diagnosis.[181,182] Fibrillary glomerulonephritis has been reported to recur in almost a third of the patients who undergo renal transplantation.[184–186]

The light microscopic findings of fibrillary glomerulonephritis can be variable. Common features include mesangial hypercellularity, mesangial expansion with amorphous PAS-positive material, and thickening of the glomerular capillary walls (Fig. 23.23A). The overall appearance of the lesions can resemble mesangial proliferative, membranoproliferative, focal and diffuse proliferative, and MGN. Crescents are not uncommon and can occur in about one-fourth to one-third of cases. An important characteristic of these amorphous deposits is that they do not stain with Congo red or thioflavin T stains (thus differentiating them from amyloid fibrils) and they are observed in the absence of circulating cryoglobulins.

Ultrastructurally, the deposits can be found in all glomerular compartments, including the mesangium, GBM, and subendothelial and subepithelial areas. The fibrillary deposits in fibrillary glomerulonephritis are randomly oriented and measure 10–30 nm in diameter (see Fig. 23.23B). In rare cases of fibrillary glomerulonephritis, fibrils have been reported in the peritubular capillary walls and in the tubular basement membrane.[187,188] Patients usually exhibit extensive effacement of the podocyte foot processes, a finding that correlates with severe proteinuria observed in these patients. Immunofluorescence microscopy most often reveals IgG and C3 in a distribution that corresponds to the fibrillary deposits (see Fig. 23.23C). On occasion, small amounts of IgM and IgA can also be seen.[181] With regards to IgG subclasses deposited, IgG4 is the dominant one, often in combination with IgG1.[181] Both kappa and lambda light chains are detected in most cases of fibrillary glomerulonephritis. Light chain restriction is seen in approximately 15% of patients with fibrillary glomerulonephritis.

Immunotactoid Glomerulopathy

Although initially described together with fibrillary glomerulonephritis, immunotactoid glomerulopathy is recognized as a distinct entity. When strict diagnostic criteria are used, immunotactoid glomerulopathy is exceedingly rare, occurring with only one-tenth the frequency of fibrillary glomerulonephritis.[181] Although the clinical presentation of immunotactoid glomerulopathy is quite similar to that of fibrillary glomerulonephritis, these conditions differ in that immunotactoid glomerulopathy tends to occur in older individuals and is more likely to have an associated monoclonal gammopathy or lymphoproliferative malignancy, serum M-spike, and a worse long-term survival.[180]Approximately 40% of immunotactoid glomerulopathy patients have associated hypocomplementemia suggestive of complement activation by pathogenic immunoglobulins. The light microscopy findings are variable and amorphous Congo red negative deposits are often seen in the mesangium and capillary walls. The immunotactoid deposits consist of microtubular structures with a hollow core ranging from 30 to 50 nm in width and arranged in parallel or stacked arrays.[178–180] Vast majority of immunotactoid deposits (in 70%–90% of patients) are composed of monoclonal light chains, most often kappa type. When such monotypic deposits are seen in immunotactoid glomerulopathy, the IgG deposits often belong to IgG1 subclass.

Light Chain Deposition Disease

LCDD is a rare systemic disorder caused by the overproduction and extracellular deposition of monoclonal immunoglobulin light chain.[189,190] A minority of cases may also have heavy chain determinants, and these cases are regarded as having light and heavy chain deposition disease (LHCDD).[189] On rare occasion, isolated heavy chain is deposited (HCDD, discussed later), and all these disorders with similar pathology constitute monoclonal immunoglobulin deposition disease (MIDD).[191] Although the principal clinical manifestations are dominated by renal disease, patients may present secondary symptoms produced by cardiac, hepatic, or neural damage.[192] In addition, abnormal light chains can be deposited in many other organs, including the skin, spleen, thyroid gland, adrenal glands, gastrointestinal tract, and lungs.[192]

LCDD has many histologic features in common with AL amyloidosis; however, in contrast to amyloidosis where the deposits are fibrillar, LCDD deposits are granular, do not stain with Congo red or thioflavin T, and do not contain amyloid P protein.[193,194] Also, while the deposits in amyloidosis consist mainly of lambda light chains, 80% of LCDD cases are composed of kappa light chains. The pathogenic light chains in LCDD have unique alterations in the complementarity-determining and framework portions of the variable region.[189,195] Males are more frequently affected, with a ratio of approximately 2 : 1.[191] About 60%–70% of the reported patients with LCDD have had well-documented multiple myeloma or another lymphoplasmacytic disorder at the time of, or subsequent to, the diagnosis of the nephropathy.[191,196] Although 15%–20% of patients lack monoclonal light chains in serum or urine by immunofixation method, abnormal serum free light chain ratio is detectable in all patients with LCDD and LHCDD.[191] Serum complement levels are typically normal unless associated with monoclonal heavy chains (as in LHCDD). LCDD occurs more frequently in middle aged to

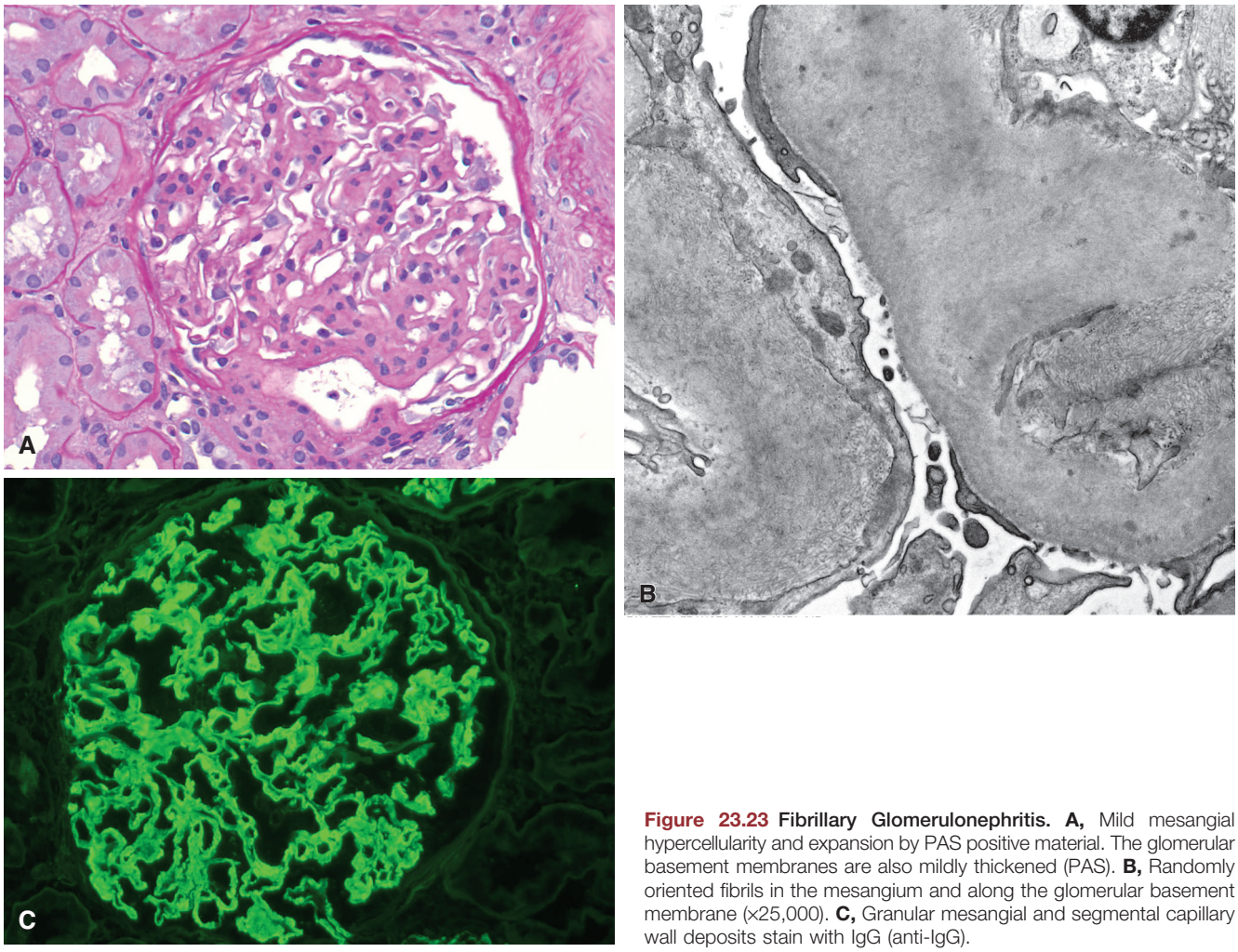

Figure 23.23 Fibrillary Glomerulonephritis. A, Mild mesangial hypercellularity and expansion by PAS positive material. The glomerular basement membranes are also mildly thickened (PAS). **B,** Randomly oriented fibrils in the mesangium and along the glomerular basement membrane (×25,000). **C,** Granular mesangial and segmental capillary wall deposits stain with IgG (anti-IgG).

older individuals, but it has been reported in older children.[197] Most patients present with renal failure associated with heavy and nonselective proteinuria, reaching nephrotic range in over a third.[191] Concurrent cast nephropathy has been diagnosed in a third of patients with LCDD and the presenting feature is typically acute renal failure.[189] Microscopic hematuria is common. Renal insufficiency can progress to an end-stage kidney disease, at which time the patient will require dialysis or renal transplant. Without effective treatment to reduce light chain production, LCDD almost invariably recurs after renal transplantation, and the recurrence may occur within weeks to years after transplantation.[198] The prognosis for patients with LCDD is generally poor, and death is often attributed to cardiac disease or complications of infection.[199] The 5-year survival is approximately 70% but is less if there is coexisting multiple myeloma or light chain cast nephropathy.

Affected glomeruli are enlarged, and the deposition of the markedly PAS-positive material produces capillary wall thickening and nodular expansion of the mesangium. The extent of glomerular involvement can vary in a biopsy from minimal mesangial expansion to a fully developed nodular glomerulosclerosis that resembles diabetic glomerulosclerosis,[193] but other morphologic features characteristic of diabetes, such as severe arteriolar hyalinosis, fibrin caps, and capsular drops are absent (Fig. 23.24). Although the pathogenesis of the glomerulosclerosis in LCDD is not entirely clear, experimental studies have shown that mesangial cells exposed to light chains obtained from a patient with LCDD produce transforming growth factor β (TGF-β), which triggers the production of matrix proteins, such as type IV collagen, laminin, and fibronectin.[174,200,201] The tubular basement membranes are thickened and present a homogeneous glassy appearance. Light chain–restricted casts are found in rare cases with concurrent cast nephropathy, and a minority of patients have concurrent AL amyloidosis.[189]

Immunofluorescence microscopy demonstrates linear staining of the monoclonal light chain along the glomerular and tubular basement membranes, as well as the vessel wall; mesangial deposits are also highlighted by the monoclonal light chain (Fig. 23.25). Electron microscopy studies reveal a continuous deposition of a powdery electron-dense material in the GBM, the mesangium, and along the tubular and vascular basement membranes (Fig. 23.26A).[190] Ultrastructurally, the material differs from dense deposit disease (DDD) in that it is finely granular, relatively homogeneous in thickness, and distributed along the inner aspect of the GBM and in the outer aspect of the tubular basement membrane (see Fig. 23.26B).

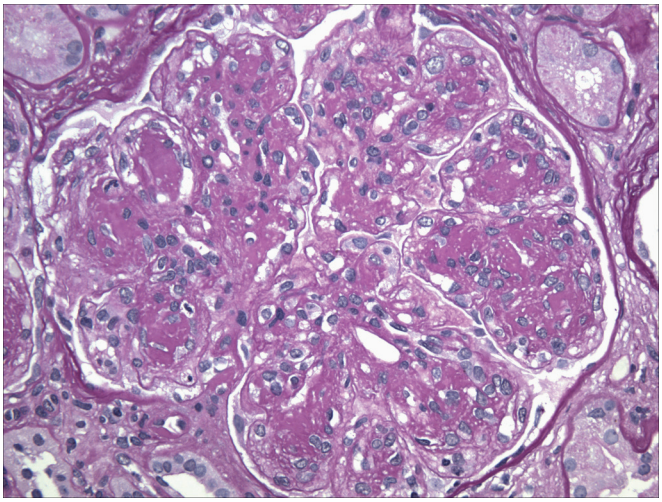

Figure 23.24 Biopsy from a patient with light chain deposition disease showing nodular mesangial lesions resembling those of diabetes mellitus.

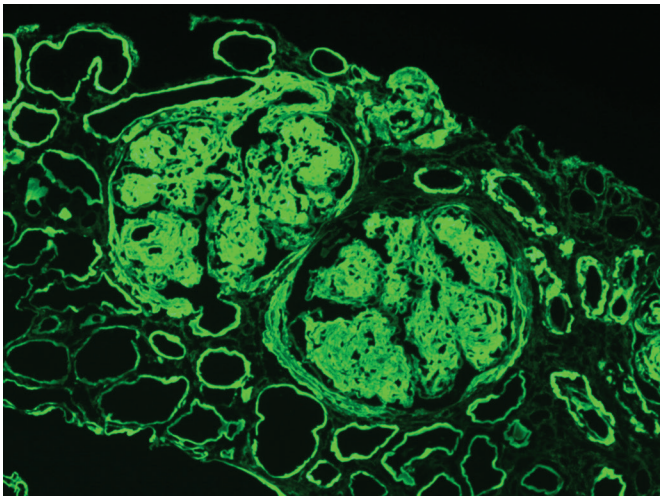

Figure 23.25 Light Chain Deposition Disease. Immunofluorescence preparation demonstrating reactivity for kappa light chain along the glomerular basement membrane, mesangium, Bowman capsule, tubular basement membrane and vessel walls (anti-kappa).

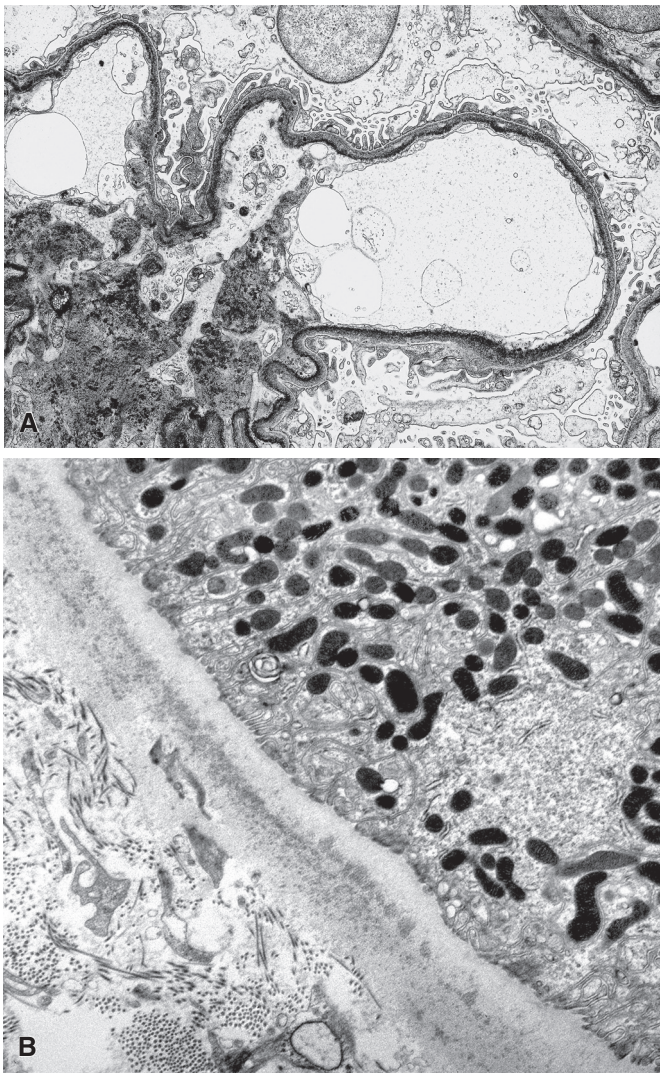

Figure 23.26 Light Chain Deposition Disease. A, Subendothelial and mesangial deposition of granular electron dense material (×7000). **B,** Similar granular electron-dense deposits are seen along the outer aspect of tubular basement membrane (×8000).

Heavy Chain Deposition Disease

Heavy chain deposition disease (HCDD) is much less common than LCDD.[191,195] It is characterized by systemic deposition of a monoclonal immunoglobulin heavy chain. The deposited heavy chain is gamma in most cases, and all subclasses of gamma heavy chain have been reported to participate in the disease. A deletion of the first constant domain (CH1) of the heavy chain has been reported in all documented cases and is likely necessary for the secretion of a free heavy chain by a plasma cell clone of HCDD.[189] The clinical manifestations and histologic features of HCDD are quite similar to those of LCDD.[189,191,202] In contrast to amyloidosis and LCDD, patients with HCDD often manifest hypocomplementemia, possibly due to the complement-fixing properties of IgG subclass deposited.[203] The diagnosis of HCDD can be done by the immunofluorescent demonstration of positivity for heavy chains (usually gamma, IgG) and negativity for both kappa and lambda light chains. The reactivity for the heavy chain occurs along the glomerular, tubular, and vascular basement membranes and in the mesangium.[202]

Proliferative Glomerulonephritis With Monoclonal Immunoglobulin G Deposits

Proliferative glomerulonephritis with monoclonal immunoglobulin G deposits (PGNMIGD) is a recently described, rare proliferative glomerular disease with monoclonal immunoglobulin G deposits.[204] It is often seen in middle aged or older individuals, with a female predominance. Over two-thirds of these patients present with nephrotic syndrome and renal impairment, while others have less degrees of proteinuria and hematuria. Despite having monoclonal IgG deposits on kidney biopsy, monoclonal gammopathy is seen in less than 30% of patients and underlying multiple myeloma is rare. A minority of patients (~25%) have reduced serum complement levels, but there is no clinical or serologic evidence of connective tissue disorder or cryoglobulinemia. While some patients may respond to steroids or other immunosuppressive therapy such as rituximab,

PGNMIGN is typically a slowly progressive kidney disease that recurs in allografts.[205] The light microscopic findings are quite variable with membranoproliferative pattern being the most common; endocapillary proliferation, crescents, membranous, mesangioproliferative, and segmental sclerosis patterns have also been described.[204,206] Immunofluorescence microscopy reveals granular mesangial and capillary wall deposits composed of IgG and C3 with associated light chain restriction (IgG3κ most common); IgM and C1q may sometimes be seen. PGNMIGD is defined by IgG subclass restriction and cannot be rendered without immunofluorescence microscopy analysis of IgG subclasses (IgG1–4). IgG3 deposition is most common (followed by IgG1) in PGNMIGD, and its frequent association with hypocomplementemia is possibly related to its complement-fixing abilities and nephritogenicity. Ultrastructural examination localizes the deposits to mesangium and subendothelium with occasional subepithelial deposits identified. Extraglomerular deposits and organized substructure are not typical features of this entity.

Congenital Nephrotic Syndrome

The nephrotic syndrome is uncommon in the first year of life[207] but is being increasingly recognized that in majority of cases, it is caused by mutations in just one of four genes.[208] The term congenital nephrotic syndrome encompasses a heterogeneous group of conditions but is reserved for patients who present clinical symptoms of nephrotic syndrome at birth or within the first 3 months of life. Two distinct inherited types have been recognized: congenital nephrotic syndrome of the Finnish type and diffuse mesangial sclerosis (DMS). Neither form responds to steroids or immunosuppressive therapy, and renal transplantation is the only way to prolong and improve the quality of life. A renal biopsy is essential to differentiate these two types of congenital nephrotic syndrome from other renal disorders of the neonatal period, including MGN (associated with congenital syphilis or mercury intoxication), congenital toxoplasmosis, HIV (especially in the offspring of narcotic addicts), malaria, cytomegalovirus infection, and MCD.[209–211] In the absence of infections, routine molecular testing of steroid-resistant congenital and infantile nephrotic syndrome is now standard clinical practice.[212]

Congenital Nephrotic Syndrome of the Finnish Type

Congenital nephrotic syndrome of the Finnish type is a rare autosomal recessive disease caused by mutations of the *NPHS1* gene located on chromosome 19q13.1.[213,214] This gene encodes nephrin protein that is an integral component of the podocyte slit membrane and plays a crucial role in normal glomerular filtration.[215,216] The estimated incidence of the disease in the genetically isolated population of Finland is approximately 1 : 10,000 newborns,[217] but it has been reported, though with much less frequency, throughout the world in families with no known Finnish ancestry.[43] More than 70 mutations in *NPHS1* gene have been identified worldwide, and majority are frameshift mutations (Fin-major) leading to complete absence of nephrin expression and an early onset severe nephrotic syndrome with rapid progression to end-stage kidney disease. The Fin-minor nonsense mutations result in truncated or nonfunctioning nephrin protein with less severe disease.

The diagnosis may be suspected in utero from the characteristic family history and the finding of elevated alpha-fetoprotein levels in the amniotic fluid and maternal serum, but this is neither highly specific nor sensitive. More recently, *NPHS1* gene sequencing for known and novel mutations is being performed for the prenatal diagnosis of the disease. The disease manifests in the fetal stage with heavy proteinuria in utero. At birth, the patients have large placentas, proteinuria, edema, and a high susceptibility to infections.[43]

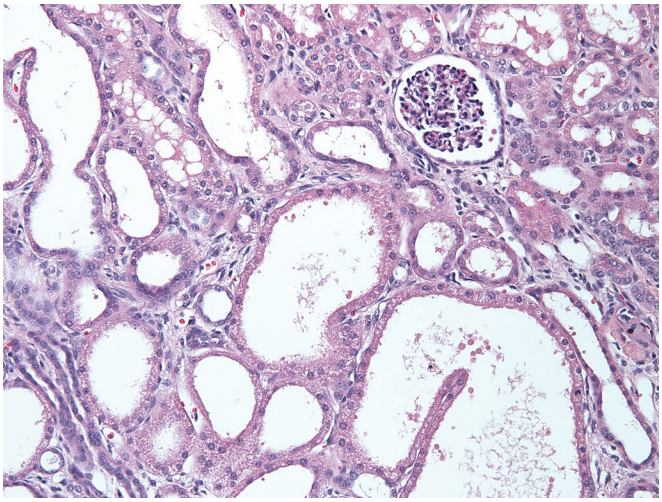

Figure 23.27 Microcystic dilation of proximal tubules and interstitial scarring in a 1-year-old child with congenital nephrotic syndrome, Finnish type.

Premature birth, mild abnormalities in face and limbs, and poor somatic development are common findings. The nephrotic syndrome often makes its appearance during the first days of life and does not respond to steroid therapy. The disease is progressive during the first 2 years of life, and kidney transplantation is the only successful life-saving treatment. The nephrotic syndrome recurs post transplantation in 20%–30% of cases and is attributed to circulating antinephrin antibodies, detected especially in patients with Fin-major mutations.[218,219]

The most striking histologic feature is ectasia of the proximal and distal tubules with flattening of the tubular epithelium (Fig. 23.27). The glomeruli show minimal changes early on but subsequently develop varying degrees of mesangial proliferation, sclerosis, and dilation of the Bowman space. There may also be an increased number of immature glomeruli. Progressive renal disease is associated with increased TA and IF. Obliteration of epithelial foot processes and other podocyte changes seen in MCD are observed by electron microscopy. Immunofluorescence is usually negative for immunoglobulins and complement components, but mesangial and capillary staining for IgM and C3 have been reported in partially sclerosed glomeruli.

Diffuse Mesangial Sclerosis

DMS is a rare condition characterized by the early onset of severe proteinuria, characteristic glomerular morphology, and rapid progression to end-stage renal failure before the age of 3 years.[220] DMS can occur in an isolated form or associated with some well-characterized syndromes. Denys–Drash syndrome (DDS), a rare autosomal dominant disorder, is characterized by early onset nephrotic syndrome, male pseudohermaphroditism, and Wilms tumor. Incomplete forms of the syndrome, consisting of glomerulopathy associated with either genital abnormality or Wilms tumor, have also been described. Mutations of the *WT1* suppressor gene located on chromosome 11p13 have been demonstrated in nearly all patients with the complete or incomplete forms of the syndrome.[221,222] Other syndromes described with glomerular pathology of DMS include Galloway–Mowat syndrome (*WDR73* gene mutation), Pierson syndrome (*LAMB2* gene mutation), and a familial steroid resistant nephrotic syndrome (with mutations in *PLCE1* gene), all with autosomal recessive modes of inheritance.[208,223] Young children with Galloway–Mowat syndrome

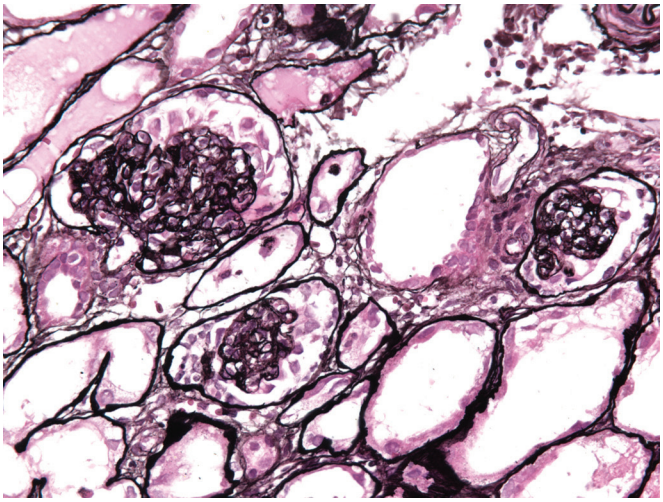

Figure 23.28 Mesangial sclerosis and consolidation with prominent overlying podocytes are typical for diffuse mesangial sclerosis (methenamine silver).

have microcephaly and seizures in addition to steroid-resistant nephrotic syndrome. Ocular abnormalities such as microcoria, neurologic deficits, and congenital nephrotic syndrome characterize Pierson syndrome. The proteins encoded by all these candidate genes have a role in either podocyte differentiation or function of glomerular filtration barrier. A genetic basis for the sporadic cases of DMS is very much plausible but is unclear in most instances. On rare occasions, cytomegalovirus inclusions were identified in newborns with congenital nephrotic syndrome and glomerular changes of DMS.[209]

In patients with DMS, the nephrotic syndrome can develop as early as first week of life, but it is more likely to appear after the third month. In contrast to the Finnish type, the nephrotic syndrome in DMS is not associated with a large placenta, premature birth, or low birth weight. DMS does not recur after transplantation.[220]

By light microscopy, the glomeruli in early DMS show prominent crowded podocytes reminiscent of fetal appearance. Pseudocrescents with proliferating visceral and parietal epithelial cells have been observed.[43] Subsequently, the glomeruli display increased mesangial sclerosis and consolidation (Fig. 23.28). In advanced stages, there is marked TA with IF. The findings by electron microscopy are extensive obliteration of the epithelial foot processes, basement membrane thickening and lamellation, and an increase in the mesangial matrix. By immunofluorescence, deposition of IgM, C3, and C1q is demonstrable in the sclerotic mesangial areas.

Glomerular Lesions Associated With the Syndrome of Acute Nephritis

Another major clinical presentation of patients with glomerular lesions is the acute nephritis syndrome. Patients with this syndrome present with hematuria, azotemia, oliguria, and mild to moderate hypertension. Urinalysis reveals an "active" sediment, which consists of the presence of red blood cells, leukocytes, and red blood cell casts. Proteinuria is common but is rarely in the nephrotic range. Edema, when present, is usually mild and is frequently manifested by facial puffiness. Variants of the clinical syndrome include milder forms with microscopic hematuria and non-nephrotic proteinuria, on occasion associated with mild hypertension, and a fulminant form known as rapidly progressive glomerulonephritis. As with the nephrotic syndrome, the histopathologic lesions that can give rise to this clinical presentation are varied.

Diffuse Endocapillary Proliferative Glomerulonephritis

Diffuse endocapillary (or intracapillary) proliferative glomerulonephritis is a term used to describe lesions characterized by both mesangial and endothelial proliferation. Although this category has become virtually synonymous with acute poststreptococcal glomerulonephritis, it may occur after infections caused by other bacteria including staphylococci, meningococci, pneumococci, *Klebsiella*, *Salmonella*, enterococci, *Brucella*, *Leptospira*, and mycobacteria.[224,225] It can also arise as a complication of rickettsial infections; viral diseases including hepatitis B, varicella, mumps, measles, cytomegalic virus, and infectious mononucleosis; and parasitic conditions such as malaria, trichinosis, and toxoplasmosis.[226]

Acute Poststreptococcal Glomerulonephritis

Poststreptococcal glomerulonephritis is primarily a disease of childhood, usually occurring between the ages of 5 and 15 years, but it can affect individuals of any age.[227] Approximately 5% of the patients are younger than 2 years of age.[225] Males are affected more commonly than females, with a ratio of 2 : 1.[226,227] Significantly higher incidence of poststreptococcal glomerulonephritis is seen in less developed countries when compared to the Western world and may even be underestimated due to subclinical cases.[228] The disease profile in developed countries is often different, more frequently affecting elderly individuals with comorbidities.[227]

In the classic form, the disease occurs within 1–4 weeks after infection with a nephritogenic strain of group A β-hemolytic streptococci. The rheumatogenic strains of group A β-hemolytic streptococci (causing rheumatic fever) differ from the nephrotogenic strains by the surface M proteins. Primary infections may be either pharyngeal or, less commonly, cutaneous. The principal serotypes implicated in glomerulonephritis are streptococci of group M types 12, 4, 1, and 49.[226] The risk for developing glomerulonephritis after infection with a nephritogenic streptococcus is variable, depending on a variety of host and virulence factors, but the overall risk is estimated to be about 15%.[229] The clinical, morphologic, and serologic findings indicate that poststreptococcal glomerulonephritis is an immune complex disease, and the main target antigens implicated thus far include "streptococcal pyrogenic exotoxin B" (SPEB) and "nephritis-associated plasmin receptor."[230] SPEB is a cationic protein that colocalizes in the subepithelial deposits and both antigens promote plasmin activity, contributing to glomerular tissue injury. In addition, the circulating antigen-antibody complexes deposit in subendothelium, activate the alternative and possibly lectin complement pathway, and trigger an inflammatory response.[228]

Clinically, this disease is manifested by a rather abrupt onset of gross hematuria, edema, proteinuria, hypertension, and impaired renal function.[228,231] Antibodies to certain streptococcal antigens, such as antistreptolysin O (ASO), are elevated, but this finding may not be helpful in diagnosis due to the ubiquitous nature of streptococcal infections. The serum levels of hemolytic complement activity and C3 protein are abnormally reduced early in course of the disease, but the values return to normal in less than 8 weeks. During the acute episode of poststreptococcal glomerulonephritis, 2%–5% of the patients die as a result of complications such as pulmonary edema, hypertensive encephalopathy, or rapidly progressive renal failure due to crescentic glomerulonephritis; and these figures are much higher in elderly patients.[228,232] The long-term prognosis of patients with acute poststreptococcal glomerulonephritis is good, especially in children, with only a small number of patients progressing to chronic renal failure many years after the acute episode.[225,233] Recovery in adults is less predictable than in children, especially

with persistent proteinuria or when the initial episode is associated with severe renal impairment and nephrotic syndrome.[226,227,230] Progression of renal disease is more common in patients who develop crescentic glomerulonephritis. Since the clinical syndrome of acute poststreptococcal glomerulonephritis may be quite distinctive and the overall prognosis is excellent, biopsies are not commonly performed unless atypical features complicate the presentation, such as nephrotic syndrome, anuria, acute renal failure, persistent or severe hypertension, or lack of recovery after 6 weeks. On long-term follow-up, approximately 17% of the patients have persistent mild proteinuria, microhematuria, or hypertension.[230] Recent studies have indicated an overlap between atypical postinfectious glomerulonephritis and C3 glomerulonephritis (C3GN), as several of these patients with persistent late symptoms have alternative complement pathway abnormalities.[234] In addition, it appears that streptococcal infections may act as a trigger for precipitating C3 glomerulopathy in a genetically predisposed individual.[235,236]

Light microscopic examination of biopsies taken within a few weeks of onset of disease shows diffuse enlargement of the glomerular tufts that tend to narrow the Bowman space. Glomerular intracapillary cellularity is increased due to mesangial proliferation and, to a lesser extent, proliferating and swollen endothelial cells. This results in narrowing of the capillary lumina and accentuation of the lobular glomerular pattern. Infiltration by leukocytes can contribute to the capillary obstruction as well, and, when prominent, the term *exudative* glomerulonephritis has been used (Fig. 23.29). Accompanying the polymorphonuclear leukocytes are mononuclear cells and, on occasion, eosinophils. Segmental necrosis and thrombosis with crescent formation are uncommon findings but indicate poor prognosis.

The most characteristic ultrastructural feature in the early stages of the disease is the presence of subepithelial, dome-shaped, electron-dense deposits called humps (Fig. 23.30). The deposits are separated from the lamina densa by a recognizable lamina rara externa, and the foot processes of the podocytes overlying the humps are usually obliterated. In general, there is a correlation between the number of humps and the degree of polymorphonuclear cell infiltration, but the humps may occur in loops devoid of leukocytes. Intramembranous deposits, some of them in continuity with the humps, and small subendothelial and mesangial deposits are not uncommon.

Immunofluorescence studies during the acute phase of the disease typically reveal granular staining for IgG and C3 along the capillary loops where the humps are located (Fig. 23.31). Small amounts of IgM and IgA may be found. Properdin is frequently present and this, coupled with the strong reactivity for C3 and the absence of C1q and C4 in the deposits, suggests involvement of the alternative complement pathway.

Serial biopsies show a gradual resolution of the glomerular changes. Cellularity decreases and the humps generally disappear in 6–8 weeks, though they can be identified up to 6 months after the onset of the disease. During the resolving phase, the basement membrane may show focal irregularities with decreased electron density, the capillary lumina become patent, and the endothelial swelling and polymorphonuclear leukocytic infiltration disappear. Electron-dense deposits either are no longer visible or are confined to the mesangium.[228] IgG may not be demonstrable, and C3 staining gradually disappears from the periphery and becomes restricted to the mesangial areas. Complete restoration to normal histology occurs as early as 6 months and certainly within 2–3 years. In a small

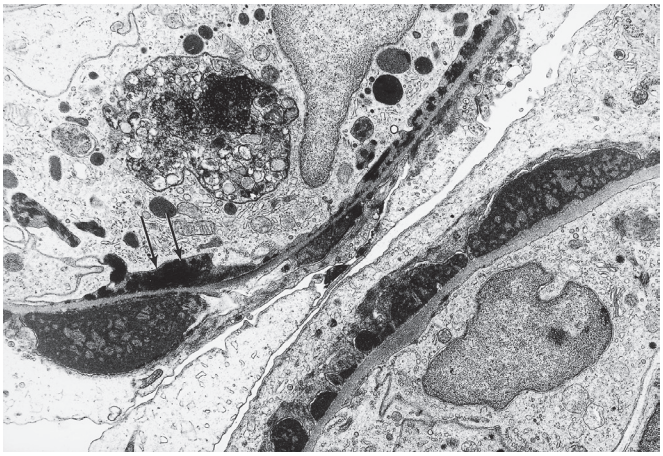

Figure 23.30 Biopsy From a Patient With Acute Poststreptococcal Glomerulonephritis. There are numerous humps along the basement membrane. The capillary loops are obliterated by cell proliferation and inflammatory cells. Small amounts of fibrin are present in the subendothelial areas *(arrows)* (×9800).

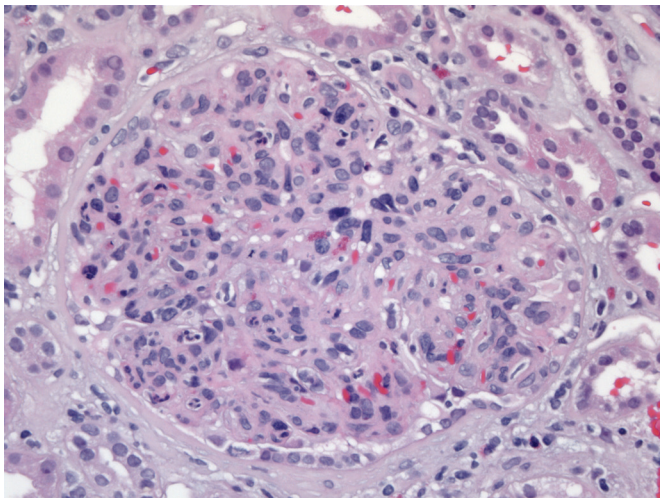

Figure 23.29 Diffuse Proliferative Glomerulonephritis. There is marked hypercellularity due to an increase in mesangial and endothelial cells and infiltration by inflammatory cells.

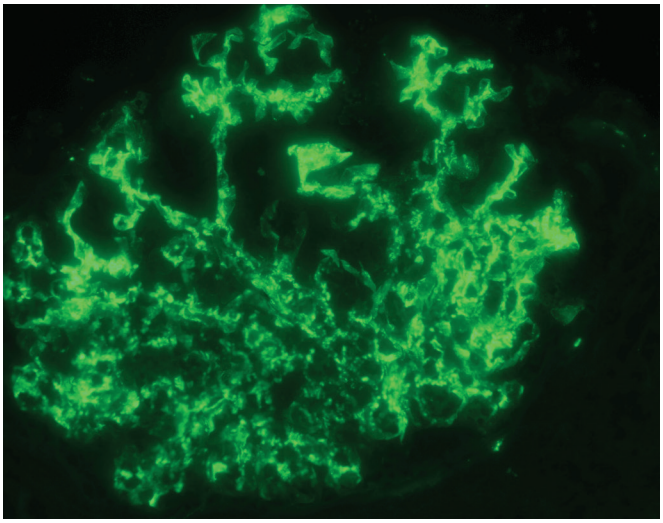

Figure 23.31 Poststreptococcal Glomerulonephritis. The coarse granular immunostaining for C3 along the capillary loops corresponds to the humps seen by electron microscopy (anti-C3).

percentage of cases, mesangial hypercellularity, mesangial deposits, and increased mesangial matrix may persist for years after the acute episode, and the mesangial prominence tends to be focal and segmental.

IgA-Dominant Staphylococcal Infection-Associated Glomerulonephritis

Infection-associated glomerulonephritis in the developed countries is being increasingly caused by *Staphylococcus aureus*, especially the drug-resistant strains.[237,238] Unlike poststreptococcal glomerulonephritis, staphylococcal infection-associated glomerulonephritides are more common in the elderly population (over 60 years of age) with comorbidities such as diabetes mellitus, drug abuse, alcoholism, and malignancy.[228,238] The underlying infection is typically ongoing (rather than "post-infection") and is often brought to attention by the kidney disease. The characteristic feature of this entity is IgA-dominant or co-dominant immune deposits that are seen in addition to C3.[227,239,240] The IgA-dominant host immune responses appear to play a role in this morphologic variant of infection-associated glomerulonephritis. It has been postulated that the *S. aureus* enterotoxins and possibly other antigens function as "superantigens," capable of binding directly to the major histocompatibility complex (MHC) class II molecules on antigen presenting cells without the required intracellular antigen processing to form receptor-fitting peptides.[241,242] In addition, these superantigens bind to T-cell receptors, causing massive T-cell activation, proliferation, and cytokine release. These events in turn trigger polyclonal B-cell activation, and patients with *S. aureus* infections were shown to have polyclonal elevation of serum IgA and IgG. The most common presentation is acute renal injury, proteinuria often in the nephrotic range, and hematuria.[239,243] There appears to be a male predominance, and two-thirds of the patients have mild hypocomplementemia. A small percentage of patients may present with lower extremity rash, reminiscent of Henoch–Schönlein purpura (HSP).[226,244] Reported underlying infections have included osteomyelitis, pneumonia, septic arthritis, empyema, sinusitis, and endocarditis, among others. The latent period between the onset of infection and renal manifestations appears to be 4–5 weeks, but in most cases the infection is not recognized until the time of the kidney biopsy. Treatment of underling infection is the main form of therapy and overall, the prognosis is inferior to poststreptococcal glomerulonephritis, possibly related to the patient's age and associated comorbidities.

The glomerular changes on biopsy can be variable,[226] ranging from mild mesangial hypercellularity to diffuse endocapillary proliferation and on occasion, crescents; exudative features are not uncommon, although seen less frequently than in poststreptococcal glomerulonephritis. There is usually accompanying acute tubular injury and interstitial inflammation, but vasculitis is not a feature observed on kidney biopsy. In patients with diabetes mellitus, subtle changes of glomerular endocapillary proliferation may be masked by prominent Kimmelstiel–Wilson nodules.[245] The electron-dense deposits are primarily in the mesangium and paramesangium, but occasional subendothelial deposits are not uncommon. The subepithelial "humps," the hallmark of infection-related glomerulonephritis, are seen in less than 50% of patients. When present, these subepithelial deposits are often smaller and less "hump"-like. The glomerular immune deposits are composed predominantly of IgA and C3 with less intense or absent IgG. Light chain κ and λ staining is usually seen, and λ can be more intense than κ. These immunofluorescence findings can lead to a misdiagnosis of IgAN, especially in the absence of obvious infection or if the skin rash is reminiscent of HSP. Distinguishing between these two entities is extremely important as immunosuppression for a presumed IgAN will exacerbate an unrecognized infection. Low serum complement levels and subepithelial humps, if present, indicate infection-associated glomerulonephritis rather than IgAN.[226,246]

C3-Related Glomerular Diseases and Membranoproliferative Glomerulonephritis

Membranoproliferative glomerulonephritis (MPGN; also known as *mesangiocapillary glomerulonephritis*) is a term used to designate a distinctive histopathologic pattern of glomerular injury characterized by a combination of mesangial cell proliferation with lobular accentuation (Fig. 23.32) and capillary wall thickening with double contours and extension of the mesangial cell cytoplasm into the periphery of the loop (Fig. 23.33). Based on the ultrastructural morphology and distribution of the deposits, MPGN was traditionally subdivided into two major types: in the first (type I), the deposits are primarily subendothelial (Fig. 23.34); in the second (type II), the deposits are extremely dense and lie within the basement membrane. However, only a minority of later group (about 25%) exhibit the membranoproliferative pattern, and hence the preferred

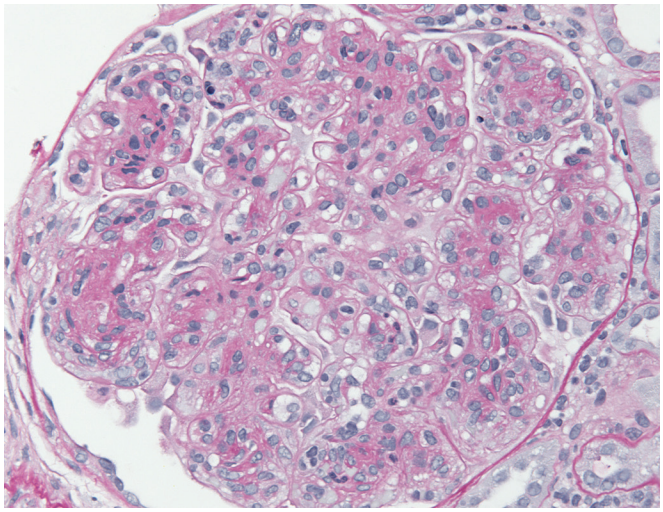

Figure 23.32 Membranoproliferative Pattern Glomerulonephritis. There is an increase in lobulation, diffuse mesangial hypercellularity, and thickening of the capillary walls.

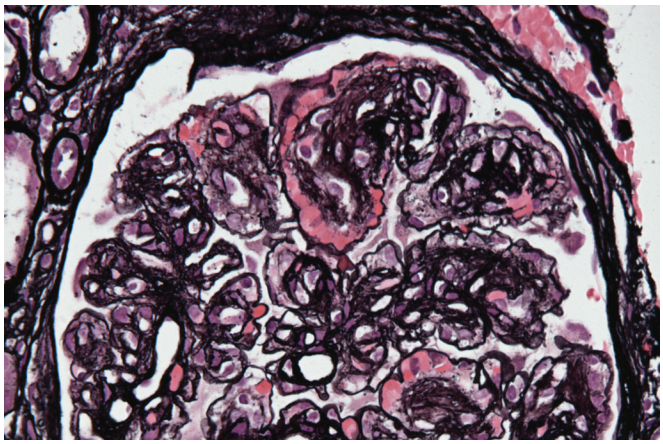

Figure 23.33 Silver preparation showing marked increase in mesangial matrix in the centrolobular areas with peripheral extension of the mesangium producing a double contour (membranoproliferative) pattern in the loops (methenamine silver).

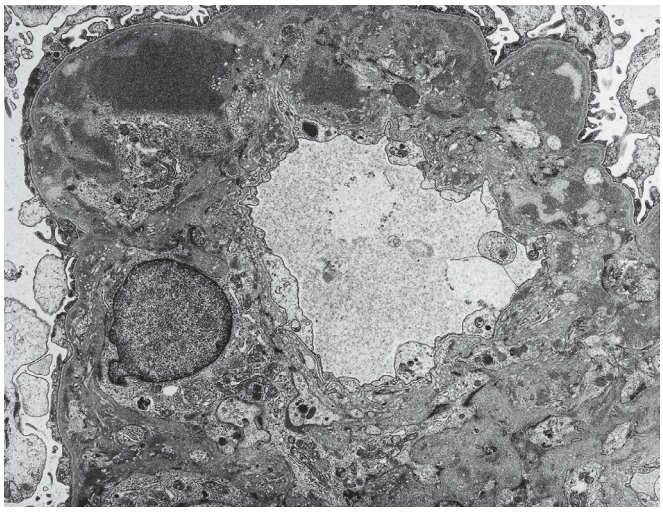

Figure 23.34 Glomerular capillary loop from a patient with membranoproliferative pattern glomerulonephritis showing peripheral extension of the mesangium into capillary loop, basement membrane duplication, and subendothelial deposits (×5400).

and currently used term DDD instead of MPGN type II.[247] In addition, other variants referred to as type III, which show either extensive disruptions of the lamina densa or frequent subepithelial deposits, have been described.[248–250]

Although the traditional subdivision of MPGN implied various morphologic patterns of a single clinicopathologic entity, the conditions do not share a common pathogenesis and they are linked only by the morphologic similarities on routine light microscopy. Recent studies have helped gain insight into the pathophysiological mechanisms of "MPGN" and related entity of C3GN.[251–253] Although the classification scheme is evolving, these disorders fall broadly into two categories (Box 23.4).[254,255] The first, *C3 glomerulopathy*, consists of glomerular diseases with prominent C3 deposition with little or no immunoglobulin deposition. It encompasses DDD, C3GN, and familial forms of MPGN and is associated with dysregulation of alternative complement pathway. A subset of previously designated MPGN type I and type III belongs to C3 glomerulopathy category under this new classification. The second group, *idiopathic MPGN with prominent immune complex deposition* (in addition to C3), includes approximately 70% of type I and 60% type III MPGN, as defined by the traditional classification.[256] Several patients in the second group also appear to have alternative complement pathway abnormalities, posing a challenge for an immunofluorescence-based classification system.[254]

Box 23.4 C3-related glomerular diseases and membranoproliferative glomerulonephritis (MPGN)

C3 glomerulopathy (isolated/predominant C3 deposits)
- Dense deposit disease (previous term type II MPGN)
- C3 glomerulonephritis
- Familial C3 glomerulopathy (abnormal CFHR3-1 protein, type III MPGN features)
- CFHR5 nephropathy (mutations in *CFHR5* gene)

Idiopathic MPGN (immune complex deposition; C3 and immunoglobulin deposition)
- MPGN type I morphology
- MPGN type III morphology

Secondary causes of MPGN morphology

Infections
Hepatitis B and C, endocarditis, visceral abscesses, shunt nephritis, malaria, schistosomiasis, mycoplasma, HIV, and Epstein–Barr virus infections

Immunologic and systemic disorders
Systemic lupus erythematosus, scleroderma, Sjögren syndrome, rheumatoid arthritis, sarcoidosis, mixed essential cryoglobulinemia with or without hepatitis C infection, ulcerative colitis, sickle cell disease

Dysproteinemia
MGUS, type I cryoglobulinemia, Waldenström macroglobulinemia, fibrillary glomerulonephritis, immunotactoid glomerulopathy

Neoplastic diseases
Carcinoma, chronic lymphocytic leukemia, non-Hodgkin lymphoma, melanoma

Hereditary diseases
α1-Antitrypsin deficiency, complement deficiency, hereditary angioedema, Wiskott–Aldrich syndrome, Sherwood–Proesmans syndrome, autosomal recessive MPGN type I

Miscellaneous
Drug abuse (heroin, pentazocine), Kartagener syndrome, Turner syndrome, Down syndrome, transplant glomerulopathy, chronic thrombotic microangiopathy

CFHR, Complement factor H-related protein or gene; *MGUS*, monoclonal gammopathy of undetermined significance; *MPGN*, membranoproliferative glomerulonephritis.

C3 Glomerulopathy

C3 glomerulopathy is characterized by abnormal persistent activation of alternative complement pathway and predominant glomerular deposition of C3, with a proposed definition of C3 immunofluorescence intensity ≥2 levels (scale 0–3+) above immunoglobulins or C1q.[254] These patients often have genetic abnormalities of, or circulating autoantibodies directed against, complement components.[251,257,258] Serum C3 levels are often reduced, and histology is variable, including some with membranoproliferative features. The main entities in this category are DDD and C3GN. Others include familial forms with type III MPGN features caused by an abnormal complement factor H-related protein (CFHR3-1), and an autosomal dominant form with mutations in *CFHR5* (see Box 23.4).[253,259] It is interesting that some patients with "atypical" postinfectious glomerulonephritis (with or without documented infection) also have mutations in complement genes or have related autoantibodies.[234] It has been suggested that an infection or other triggers unmask a C3GN in a predisposed individual.[235,236] Novel treatment approaches are being developed to treat C3 glomerulopathy, hence the importance of accurate diagnosis.[260,261] Plasma infusions and plasmapheresis aim to correct complement deficiencies or remove circulating autoantibodies. Inhibition of alternative complement pathway (C5 inhibition) and restoration of normal functional state may also be effective in these patients.

Dense Deposit Disease

DDD, previously termed as type II MPGN, is a C3 glomerulopathy characterized by a unique broad, linear intramembranous electron-dense deposits. DDD is rare and has been estimated to affect two to three people per one million population.[261,262] Both sexes are equally affected, with the diagnosis usually made in children between the ages of 5 and 15 years.[263] Affected patients typically present with nephrotic proteinuria, hematuria, and renal insufficiency. Most patients with DDD have hypocomplementemia and continue to have low levels of complement throughout the course of the disease. C4 levels are usually normal.[264] Over 80% of patients with DDD

are positive for serum C3 nephritic factor (C3NeF), an autoantibody directed against C3bBb, a convertase of the alternative pathway of complement cascade. Because C3NeF can be found in idiopathic MPGN and C3GN (previously type I and III MPGN), a definitive diagnosis of DDD depends on the ultrastructural demonstration of dense deposits within the GBM. Other unusual aspect of DDD is its association with macular degeneration and acquired partial lipodystrophy (loss of subcutaneous fat in upper half of the body) in approximately 3%–5% of cases. Patients with these conditions were found to have hypocomplementemia and C3NeF regardless of whether or not they develop DDD.[265–269]

DDD has a poor prognosis and in about 50% of the cases, the lesion slowly progresses to an end-stage kidney within 10–15 years of diagnosis. Abrupt decline in renal function can be seen with crescentic disease. On rare occasions, there have been reports of morphologic regression.[270–272] Recurrence after renal transplantation occurs in virtually all renal allografts.[273] Chronic activation of alternative complement pathway is the culprit and is mediated in most instances by C3NeF that inhibits the activation blocker, C3 convertase. Other less common autoantibodies documented in DDD are against factor H, factor B, and C3. Genetic predisposition plays a role and mutations in *CFH* gene have been detected in 17% of patients. Certain allelic variants of *CFH*, *CFI*, *C3*, and *CFHR5* and *C3* mutations have been associated with DDD.[257,258,262] It appears that infections, chemotherapy, and other unknown factors may precipitate DDD in these predisposed patients. Interestingly, adults with DDD may have coexistent monoclonal gammopathy, and the pathogenic light (or heavy) chains interfere with the control of the alternative complement pathway.[274]

On light microscopy, the general morphologic features can be quite variable. In a study of a large series of renal biopsies, nearly half showed mild, mesangial hypercellularity, whereas only about 25% had the typical membranoproliferative pattern (see Figs. 23.32 and 23.33). Approximately 17% had a crescentic glomerulonephritis pattern (Fig. 23.35), and 12% had an acute proliferative and exudative pattern that could be easily confused with postinfectious glomerulonephritis.[247] A feature that establishes the diagnosis is an eosinophilic, refractile, and ribbon-like thickening of the basement membrane, which is most pronounced along the GBM, although it can be seen in the Bowman capsule and in the tubular basement membrane. The deposited material is strongly PAS positive, stains blue with Masson trichrome, is pale on Jones stain, and can easily be recognized by its dark color on toluidine blue–stained plastic-embedded tissue sections. Ultrastructurally, the material is extremely electron dense and lacks the prominent granularity of immune complex deposits. It is centrally positioned within the lamina densa of basement membrane but may vary in thickness or be focally discontinuous (Fig. 23.36A). Similar deposits can be found in the mesangium as homogeneous nodules or, less frequently, subepithelial humps.[275] These deposits can be seen in choroidal blood vessels and ocular Bruch membrane. The immunofluorescence pattern is typical and diagnostic. A linear or double-contoured staining for C3 along the glomerular capillary walls is associated with a bright nodular or ring-like reaction in the mesangium (see Fig. 23.36B). A focal and often discontinuous linear C3 reaction can be seen in the Bowman capsule and in some tubular basement membranes. Immunoglobulin and early components of complement are usually absent and if present, significantly less intense than C3. Using laser-capture mass spectrometry, it has been found that these deposits are composed of C3 and other late complement components, CFHP1, clusterin, vitronectin, and unsaturated lipids associated with ApoE among others.[276]

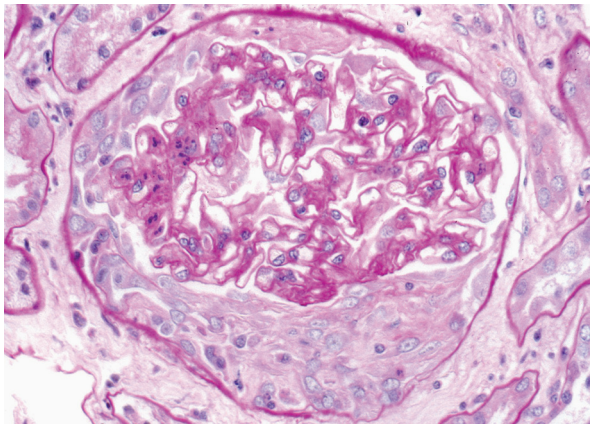

Figure 23.35 Dense deposit disease has variable histologic manifestations. Crescent formation with mild segmental mesangial expansion by inflammatory cells in a young patient (PAS).

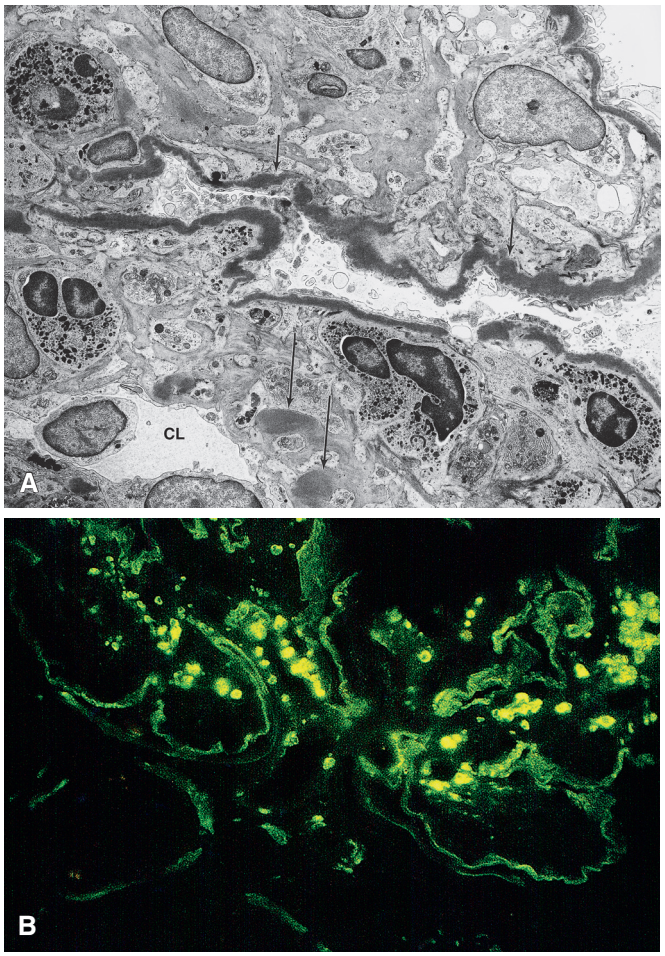

Figure 23.36 **A,** There is homogeneous, highly dense material within the lamina densa *(short arrows)* and nodular deposits *(long arrows)* of the same electron density in the mesangium. The capillary lumen (CL) in the left lower portion of the figure is narrowed due to peripheral extension of the mesangium. Numerous neutrophils are also present (×4000). **B,** Immunofluorescent staining for C3 showing weak linear staining along glomerular capillary and tubular basement membranes *(right lower corner)* and bright granular deposits in the mesangium, some of which have a ring-like pattern.

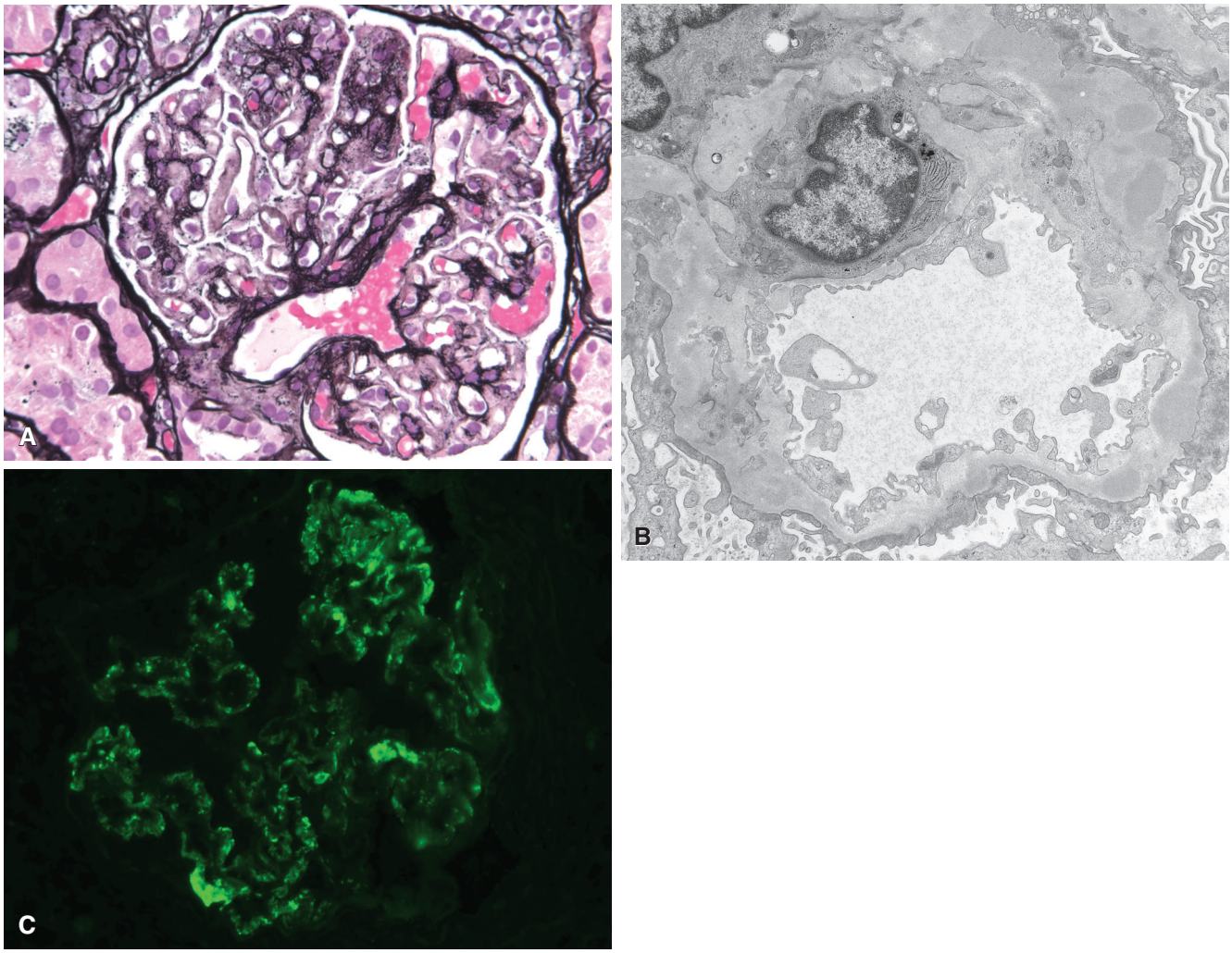

Figure 23.37 C3 Glomerulonephritis. A, Segmental mesangial proliferation and glomerular basement membrane thickening (methenamine silver). **B,** Intramembranous and subepithelial electron-dense deposits with focal glomerular basement membrane duplication (×7000). **C,** Granular segmental mesangial and capillary wall deposits with C3. No immunoglobulin staining was observed by immunofluorescence (anti-C3).

C3 Glomerulonephritis

C3GN is a type of C3 glomerulopathy characterized by isolated C3 deposits, minimal or no immunoglobulin deposition, and dysregulated alternative complement pathway. However, unlike DDD, the electron-dense deposits are amorphous and not as electron dense, broad, or linear. It includes majority of cases previously designated as type I and III MPGN and other glomerulonephritides without membranoproliferative morphology.[254,256,277] Patients with C3GN are often adults, with a mean age of 30 years at presentation, but it has been reported in children as young as 7 years and elderly individuals older than 70 years. The renal manifestations are variable, ranging from mild proteinuria to nephrotic syndrome. Microscopic hematuria, hypertension, and renal insufficiency are frequently present. Serum complement C3 levels are low in approximately 40% of patients, but C4 is typically normal.[278] C3NeF is detectable in approximately 45% of patients. Older individuals with C3GN can also have circulating monoclonal immunoglobulins, although a direct pathogenic link to C3GN has not been established. The light microscopic findings of C3GN are variable, ranging from minimal changes to diffuse proliferative to membranoproliferative patterns (Fig. 23.37A).[256] Crescents are occasionally present and proliferative glomerulonephritis can also show exudative features, reminiscent of postinfectious glomerulonephritis.[234] The chronic tubulointerstitial damage typically ranges from mild to moderate depending on the chronicity of the disease. Ultrastructurally, amorphous deposits are predominantly in the mesangium and the capillary wall deposits can be in subendothelial, and/or subepithelial and intramembranous (type I or III MPGN pattern described in the next section) (see Fig. 23.37B). By mass spectrometry, these deposits are composed of alternative and terminal complement pathway components, identical to DDD.[277] As mentioned earlier, the glomerular deposits stain strongly for C3 with little or no immunoglobulin (see Fig. 23.37C).[254]

A diagnosis of C3GN (and DDD) should prompt thorough investigation for complement factor levels (factor H, factor I, factor B, membrane attack complex), anti-factor H autoantibodies and alternative complement pathway functional and hemolytic assays.[254] Mutations in genes encoding complement regulatory factors (factor H, factor I, CD46, CFHR5) and certain complement factor alleles that confer higher risk of developing disease have also been

documented in C3GN. Patients can have more than one acquired or inherited abnormality related to C3GN.[277]

Membranoproliferative Glomerulonephritis With Immune Complexes

This group of diseases is characterized by mesangial hypercellularity and GBM duplication, with prominent C3 and immunoglobulin (and/or C1q) deposition, indicative of both classical and alternative complement pathway activation.[254,279] Extrapolating the historical data of type I MPGN, it likely accounts for approximately 5% of ESRD cases secondary to glomerulonephritis. Membranoproliferative pattern with immune complexes can be primary/idiopathic or more commonly, secondary to chronic infections, monoclonal gammopathy, systemic autoimmunity, and hereditary diseases (see Box 23.4). It is also believed that the majority of cases once thought to be "idiopathic" are associated with hepatitis C infection.[280] Further, recent advances in elucidating the pathogenetic mechanisms of MPGN, especially C3 glomerulopathy, has altered the prevalence of "idiopathic" MPGN. It is now a *diagnosis of exclusion*, especially in adults, and perhaps will become an increasingly uncommon diagnosis in the future.[279,281] Based on the historical data, primary/idiopathic form of the disease, affects primarily children and young adults, with 90% of patients being between 8 and 16 years of age at the time of diagnosis.[275,282] Onset before the age of 4 years is rare. Clinical presentation varies, and there does not appear to be a gender predominance. At least 50% of the patients present with nephrotic syndrome, and 25% may present with a combination of asymptomatic hematuria and asymptomatic proteinuria. Finally, up to one-third of patients may present with acute nephritic syndrome associated with abnormal urinary sediment, hypertension, and renal insufficiency.[275,282,283]

About two-thirds of the patients have hypocomplementemia with marked variation of its level over the course of the disease. The predominant complement depletion is C3, but early (i.e., C1q, C4, and C2) and terminal (C5, C6, C7, and C9) components of the classic pathway of complement activation maybe reduced as well. Components of the alternative pathway (i.e., factor B), are also frequently low,[284] and C3NeF is detected in more than half of patients with type I MPGN. Mutations in alternative complement pathway genes (*CFH* and *CFI*) have been detected in a minority of these patients (with type I pattern), blurring the line between the categories of C3 glomerulopathy and MPGN with immune complexes.[257] It has been speculated that in these cases, the underlying genetic or acquired complement dysregulation is triggered or exacerbated by the immune complex deposition[251] Historically, the clinical course of "primary/idiopathic" MPGN is usually indolent but relentless, progressing to renal failure over a period of 10 or more years.[285] The disease has been reported to recur in 30%–50% of the patients who undergo renal transplantation[273,286] and the risk of recurrence appears to be higher in patients with low serum complement levels.[287]

On light microscopy, the glomeruli appear diffusely enlarged, with thickening of the capillary walls and prominent mesangial proliferation that produces lobulation of the tuft (see Fig. 23.32). Mesangial matrix accumulates in the center of the lobules, forming nodules resembling diabetic glomerulosclerosis. In addition to the lobular pattern, exudative, crescentic, and focal segmental histologic variants have been described.[283] In sections stained with PAS or Jones methenamine silver stain, continuation of the mesangial matrix can be seen to surround capillary loops, producing a double contour or "tram-track" pattern (see Fig. 23.33). Within the double contours, hyaline material corresponding to subendothelial deposits are often prominent. The presence of hyaline thrombi within the capillary lumens should raise the possibility of cryoglobulinemia or lupus nephritis.

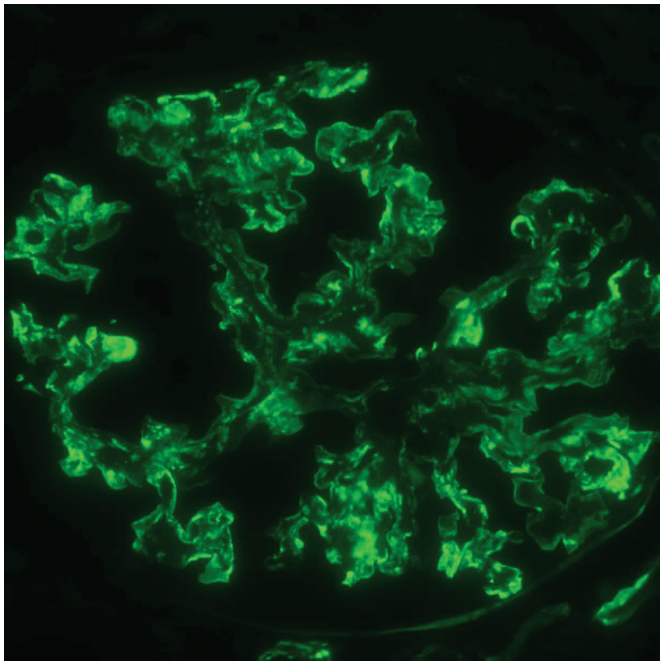

Figure 23.38 Membranoproliferative Glomerulonephritis With Immune Complexes. Immunofluorescence preparation demonstrating immunoreactivity for IgG (and C3) in the mesangium and along patchy capillary loops (anti-IgG).

Immunofluorescence usually demonstrates a granular reaction for IgG and C3 along the capillary walls and mesangium (Fig. 23.38). In addition, IgM, C1q, and C4 can be present. Electron microscopy demonstrates that the mesangial areas are enlarged by cellular proliferation and accumulated matrix, and that the capillary lumina are reduced by a combination of peripheral mesangial expansion and interposition of cells and matrix beneath the endothelium. Typically, there is a continuous layer of mesangial cytoplasm around the entire capillary with an irregular layer of new matrix underlying the intact basement membrane. Electron-dense deposits in type I MPGN pattern are typically seen in the mesangial and subendothelial regions (see Fig. 23.34). Type III pattern MPGN is a very uncommon and controversial variant of MPGN, of which two morphologic subtypes have been defined. In the first subtype, referred to as the Burkholder variant, the glomerular lesion presents combined features of MPGN type I and MGN.[249] Ultrastructural examination of the capillary walls demonstrates mesangial interposition, subendothelial deposits, and numerous subepithelial deposits associated with basement membrane spikes. In the second subtype described by Anders and associates in 1977, the glomerular lesion resembles a hybrid between type I and type II MPGN.[248,250,288] Despite the pathologic differences, both variants of type III MPGN are clinically similar and do not differ significantly from MPGN type I.

Diffuse Mesangioproliferative Glomerulonephritis

Diffuse proliferation of the mesangial cells and matrix without significant involvement of capillary walls or lumina occurs in a variety of renal diseases, including IgAN, HSP, SLE, and the resolving stage of postinfectious glomerulonephritis. The differential diagnosis of these conditions requires correlation of the light, electron, and immunofluorescent microscopic findings with the patient's clinical data. Only IgAN is discussed in this section.

IgA Nephropathy

IgAN (previously called Berger disease) is defined by the predominant deposition of IgA in the glomerular mesangium. The distribution of IgAN varies greatly among different geographic regions of the world. It is the most common primary glomerular disease diagnosed in some Asian countries, including Japan, mainland China, and Singapore, accounting for about one-third of all renal biopsy diagnoses in these regions, 20% in Europe, and 10% in the United States.[289,290] The cause of these wide differences in incidence has partially been attributed to differences in the indication for renal biopsy in Asia when compared to the United States. Familial clustering has been reported in approximately 10% of the patients.[291–293] The familial forms of IgAN follow autosomal dominant transmission with incomplete penetrance. The first-degree relatives without clinical evidence of IgAN have high levels of galactose-deficient IgA (GD-IgA). Genome-wide associated studies using single nucleotide polymorphisms have revealed several susceptibility loci, the most common being MHC locus on 6p21.[294] These studies have also highlighted the role of mucosal defense systems and alternative complement pathway in the pathogenesis of IgAN.[295]

The diagnosis of IgAN is primarily based on the demonstration of IgA deposits in the mesangium, a feature seen in association with several conditions. HSP nephritis and IgAN are two closely related conditions that form part of the syndrome.[296] Mesangial IgA deposition has also been described in association with a variety of diseases, including chronic liver disease, inflammatory bowel disease, connective tissue disorders, neoplastic diseases, and viral and bacterial infections (Box 23.5).[297] IgAN results from the deposition of circulating immune complexes in the glomerular mesangium, leading to the activation of the complement cascade via the alternative pathway. The deposited IgA in idiopathic form is predominantly aberrantly glycosylated polymeric IgA1.[298,299] The serum levels of this GD-IgA are elevated in IgAN patients and this is reportedly an independent risk factor for progression of renal disease.[300] It appears that GD-IgA serves as an autoantigen and the subsequent immune complex deposition stimulates mesangial cell proliferation.

IgAN can occur at any age, but it is more common in the second and third decades.[301] It is uncommon in children under the age of 10.[297] Males are affected two to six times more often than females. Most patients are diagnosed upon detection of microscopic hematuria during routine physical examination. About less than half the patients have a history of recurrent episodes of macroscopic hematuria, one-third of which occurred synchronously or within a few days after a respiratory or, less commonly, a gastrointestinal or urinary tract infection.[297,302] This may be related to increased host IgA response to mucosal antigens. Patients often have proteinuria, which is usually mild though it can on occasion be severe. Roughly 5%–10% develop the nephrotic syndrome. It is currently estimated that 25%–40% of the cases slowly progress to chronic renal failure over a period of 20 years.[303] About 60% of the patients who received transplants experienced recurrence of the disease in the donor kidney and a small percentage of them lose their graft to recurrent disease.[304]

It is now recognized that IgAN may display a wide variety of histologic patterns, ranging from normal or nearly normal to a diffuse crescentic glomerulonephritis.[289,290] Widening of the mesangium by increased matrix and hypercellularity is the most common microscopic finding (Fig. 23.39). The mesangial involvement is often uneven and varies among the glomeruli and glomerular lobules. Healing of the focal proliferative lesion may lead to FSGS. Glomerular scarring is associated with TA and IF. Various classification systems, such as Haas and more recently Oxford, are used to score and characterize the histologic features, and several studies have validated these systems in predicting the renal outcomes.[305–308] By electron microscopy, it is possible to demonstrate mesangial deposits in all glomeruli, indicating that the lesion is diffuse, not focal (Fig. 23.40). On occasion, small subendothelial or subepithelial deposits may also be found, especially in patients with more severe disease.

The immunofluorescence pattern parallels the distribution of the deposits seen by electron microscopy. There is strong diffuse mesangial reactivity for IgA, and it can extend into the capillary loops (Fig. 23.41). IgG is also common and may rival IgA in intensity. About one-third of the cases show weak reactivity for IgM and fibrinogen. C3 reactivity is strong, with a pattern identical to immunoglobulins, but no reactivity for either C1q or C4 is seen, indicating that the complement is activated via the alternative pathway. Deposits of IgA are not limited to the glomeruli in IgAN. They can also be demonstrated in the blood vessels of the superficial dermis of normal-appearing skin in patients with IgAN without systemic manifestations of HSP.[309,310] These findings, together with the

Box 23.5 Entities associated with secondary IgA nephropathy

Liver diseases

Alcoholic cirrhosis, viral hepatitis, toxic liver disease, cystic fibrosis

Gastrointestinal diseases

Crohn disease, ulcerative colitis, celiac disease

Infectious diseases

HIV infection, tuberculosis, brucellosis, leprosy, *Staphylococcus aureus*, *Mycoplasma pneumoniae*, *Clostridium difficile*, *Yersinia enterocolitica*

Rheumatologic diseases

Rheumatoid arthritis, ankylosing spondylitis, psoriatic arthritis, Behçet disease, Reiter syndrome

Neoplastic diseases

Various carcinomas, including squamous cell carcinomas, small cell lung carcinoma, renal cell carcinoma, and a variety of adenocarcinomas, non-Hodgkin lymphoma, polycythemia vera, mycosis fungoides/Sézary syndrome

Skin diseases

Dermatitis herpetiformis, psoriasis

Miscellaneous diseases

Sarcoidosis, silicosis, bronchiolitis obliterans, uveitis with retinal vasculitis

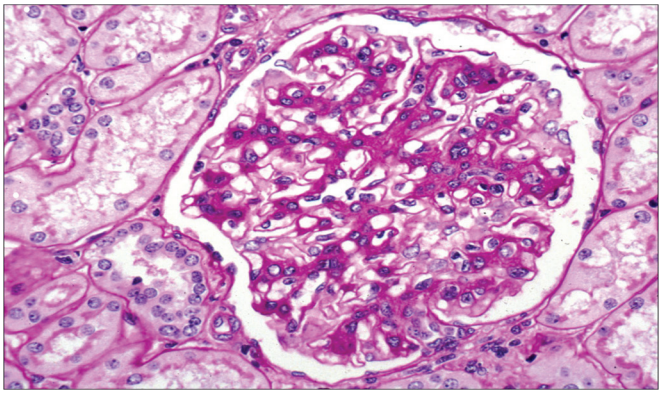

Figure 23.39 Mesangial enlargement with increase in mesangial matrix and cellularity in IgA nephropathy (PAS).

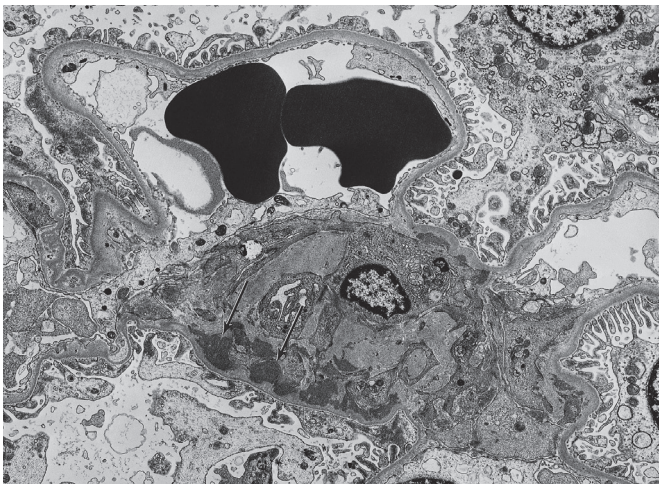

Figure 23.40 Portion of a glomerulus from a patient with IgA nephropathy showing paramesangial electron-dense mesangial deposits *(arrows)* (×6000).

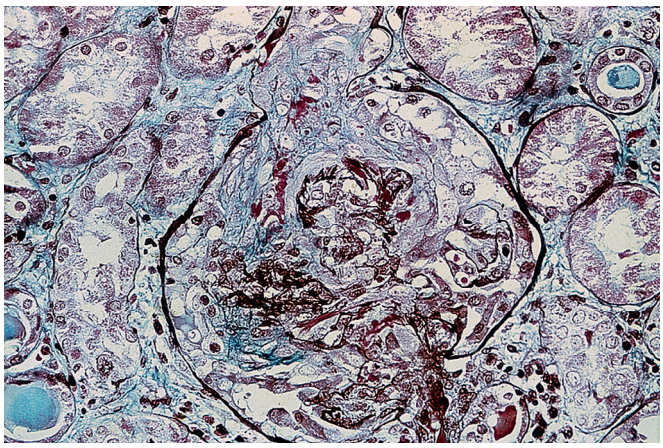

Figure 23.42 Silver-stained histologic preparation of a glomerulus with epithelial crescent obliterating the Bowman space and extending into the proximal tubule. The glomerular tuft is entrapped in the crescent.

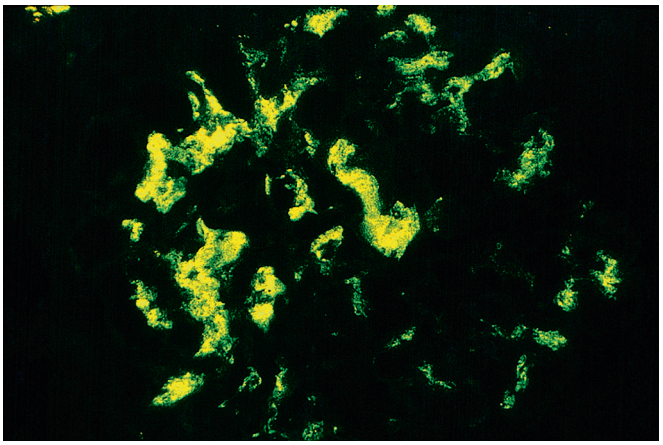

Figure 23.41 Immunofluorescence preparation of a glomerulus demonstrating mesangial deposits of IgA (anti-IgA).

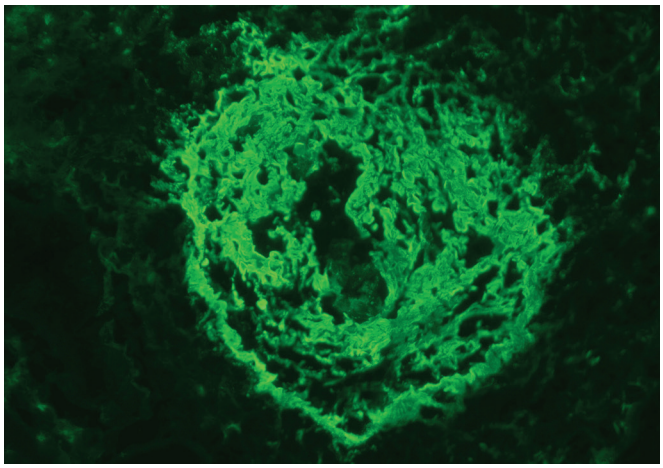

Figure 23.43 Immunofluorescent preparation showing massive fibrin deposition within the crescent and glomerular capillary tuft (anti-fibrinogen).

phenotypic and pathogenetic similarities shared by these conditions, suggest that HSP may be a systemic form of primary IgAN or, conversely, that IgAN is a renal-limited form of HSP.[311,312]

Crescentic Glomerulonephritis

Crescentic glomerulonephritis is a histopathologic term used to designate a severe form of glomerulonephritis in which 50% or more of the glomeruli are involved by epithelial crescents. This type of glomerular injury is associated with a clinical syndrome known as rapidly progressive glomerulonephritis that is characterized by the rapid and progressive loss of renal function accompanied by hematuria, red cell casts in urine, variable degrees of proteinuria, and severe oliguria. Untreated, this disease can result in death within weeks. The terms crescentic glomerulonephritis and *rapidly progressive glomerulonephritis* are often used interchangeably. Like crescentic glomerulonephritis, *extracapillary proliferative glomerulonephritis* is a pathologic term for this lesion which indicates that the cell proliferation is primarily in the Bowman space. All three of the previous terms are considered proper designations for this form of glomerular injury.

Studies using cell markers showed that the crescents are composed of a mixed population of cells primarily consisting of glomerular epithelial cells and macrophages. It has been postulated that crescent formation results from disruption of the glomerular capillaries that allows leukocytes, fibrin, and other plasma proteins to escape into the Bowman space, where they induce epithelial cell proliferation and macrophage maturation that together produce cellular crescents (Fig. 23.42). This is supported by the invariable immunofluorescent finding of fibrin in active crescentic glomerulonephritis (Fig. 23.43) and the demonstration of GBM ruptures that are better visualized on silver-stained histologic preparations or by electron microscopy (Fig. 23.44). As the disease progresses, the extracapillary proliferating cells are transformed into fibroepithelial crescents which incorporate fibroblasts and collagen. Over time, the sclerosis progresses and the glomeruli become completely scarred.

Crescentic glomerulonephritis can be caused by a wide variety of diseases either restricted to the kidney or systemic. Using immunofluorescence and electron microscopy techniques, three main categories that reflect different pathogenic mechanisms have been identified: (1) anti-GBM glomerulonephritis; (2) immune complex crescentic glomerulonephritis; and (3) pauci-immune crescentic glomerulonephritis, usually associated with ANCA (Table 23.4). In each group, the disease may be associated with a known disorder or may be idiopathic.

Antiglomerular Basement Membrane Disease

This form of glomerulonephritis is characterized by the immunofluorescent demonstration of linear deposits of IgG and, in many instances, C3 along the GBM. Anti-GBM disease is a rare autoimmune disease and accounts for 15% of the cases of crescentic glomerulonephritis.[313] It can occur as a renal-limited disease or as a pulmonary renal syndrome induced by a cross reaction of the anti-GBM antibodies with pulmonary basement membranes (Goodpasture syndrome). The incidence of anti-GBM disease has two peaks with respect to patient age.[314,315] The first is in the second and third decades of life, has a male predominance, and a higher frequency of pulmonary involvement (Goodpasture syndrome). The second occurs in the sixth and seventh decades, has a female predominance, and is more often a renal-limited disease.

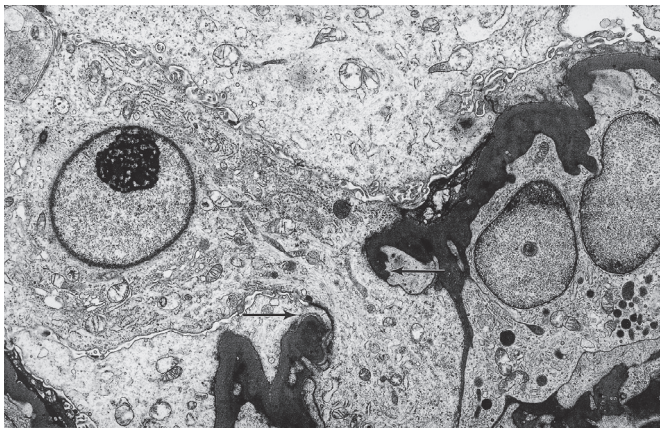

Figure 23.44 Disruption of the glomerular basement membrane *(arrows)* in a case of crescentic glomerulonephritis (×9000).

Renal anti-GBM disease is typically characterized by an abrupt onset of acute glomerulonephritis with severe oliguria or anuria.[315] On rare occasions, however, the onset is more insidious and the patient may remain essentially asymptomatic until the development of uremic symptoms. Patients with Goodpasture syndrome present with glomerulonephritis and pulmonary involvement, which is more often in the form of severe pulmonary hemorrhage. A preceding upper respiratory infection has been documented in about one-fourth of these patients. Pulmonary hemorrhage has also been observed after exposure to various inhalants, particularly hydrocarbons and there is an association with cigarette smoking. The circulating anti-GBM antibodies can be detected by enzyme immunoassay, but the titers do not correlate with disease severity. Treatment includes cytotoxic agents and plasmapheresis, but serum creatinine at presentation greater than 5 mg/dL is associated with poor prognosis.

The principal antigen to which anti-GBM antibodies react is localized to the carboxyl terminus of the NC1 domain of the α3 chain of type IV collagen (Goodpasture epitope).[316,317] It has been suggested that hydrocarbons inhibit the enzyme that catalyzes the formation of sulfilimine bonds between collagen hexamers, thus causing conformational change, neo-epitope exposure, and subsequent autoantibody formation against the Goodpasture antigen.[318,319] Genetic predisposition may play a role, and there is a strong association between certain HLA class II antigens and risk of developing anti-GBM nephritis.

Anti-GBM disease can complicate other diseases. It can arise de novo following renal transplantation in patients with Alport syndrome (AS)[320,321] and has been reported in association with membranous nephropathy preceding, concurrent with, or following this disease.[322,323] Up to one-third of the patients with anti-GBM disease have circulating ANCA, especially with specificity for myeloperoxidase (MPO).[324–326]

Table 23.4 Differential diagnosis of crescentic glomerulonephritis

CATEGORY	ANTI-GLOMERULAR BASEMENT MEMBRANE NEPHRITIS	PAUCI-IMMUNE GLOMERULONEPHRITIS	IMMUNE COMPLEX–MEDIATED GLOMERULONEPHRITIS
Light microscopy	No mesangial or endocapillary proliferation in unaffected glomeruli or tufts	No mesangial or endocapillary proliferation in unaffected glomeruli or tufts	Variable mesangial or endocapillary proliferation typically present
IF (other than fibrinogen in glomerular necrosis)	Linear lace-like staining in GBM (±TBM)	Absent (± nonspecific C3 in glomerular tuft)	Present (varies based on the disease entity)
Electron-dense deposits (on EM)	Absent	Absent	Present
Serology	Anti-GBM antibodies +	ANCA + (in 85% of patients)	ANA, ds-DNA, ASO, cryoglobulins, etc. (based on entity)
Comments	No small vessel vasculitis unless associated with ANCA	Vasculitis may be present	Vasculitis present, but less common than in pauci-immune GN
Other associations and examples	Goodpasture syndrome with pulmonary involvement	Microscopic polyangiitis, granulomatosis with polyangiitis, eosinophilic granulomatosis with polyangiitis	Examples include lupus nephritis, IgA nephropathy, infection-associated GN, cryoglobulinemic GN, membranoproliferative GN

ANA, Antinuclear antibodies; *ANCA*, antineutrophil cytoplasmic antibodies; ASO, antistreptolysin O; *EM*, electron microscopy; *GBM*, glomerular basement membrane; *GN*, glomerulonephritis; *IF*, immunofluorescence microscopy; *TBM*, tubular basement membrane.

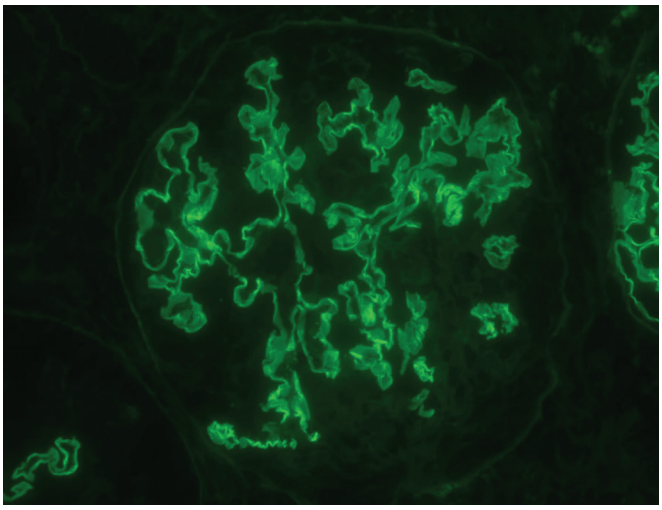

Figure 23.45 Continuous linear IgG reactivity along the capillary walls in a case of anti-GBM glomerulonephritis (anti-IgG).

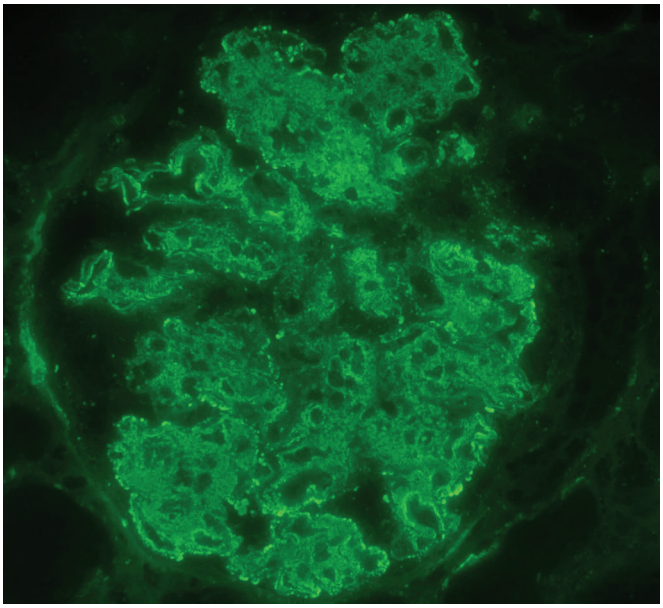

Figure 23.46 Coarse granular deposits of IgG are prominent in the mesangium and along the capillary walls in a patient with crescentic lupus nephritis (anti-IgG).

The presence of ANCA in patients with anti-GBM disease is associated with small vessel vasculitis in various organs in addition to lung and kidney.

The typical light microscopic lesion in renal anti-GBM disease is that of a necrotizing glomerulonephritis with crescent formation either in a focal or diffuse pattern. In the involved areas, the glomerular capillaries are disrupted and clusters of granulocytes are often present, but there is minimal intracapillary cell proliferation. The uninvolved segments may appear normal or slightly infiltrated by leukocytes or mononuclear inflammatory cells. The most severely involved glomeruli may exhibit extensive necrosis, disruption of the Bowman capsule, and intense periglomerular inflammation with multinucleated giant cells. Electron microscopy may demonstrate the presence of a subendothelial lucent zone near foci of necrosis, but this is not a constant or specific feature. Disruptions of the GBM and fibrin deposition can also be seen. An important negative ultrastructural finding in anti-GBM disease is the absence of electron-dense deposits.

Immunofluorescence studies demonstrate a continuous linear immunostaining of the glomerular capillaries for IgG, often accompanied by a focal linear staining for C3 and in several instances both κ and λ (Fig. 23.45). Distal tubules also express α3 chain, and hence, linear tubular basement membrane staining with IgG is not uncommon. It must be kept in mind that a similar IgG immunofluorescence pattern of GBM can be seen in other glomerular lesions, including diabetic nephropathy and HCDD, so it is necessary to confirm the diagnostic impression with the demonstration of circulating anti-GBM antibodies. It is helpful to note that diabetic nephropathy is usually associated with strong linear staining of all basement membranes with albumin in addition to IgG; HCDD has diffuse linear staining of vascular and tubular basement membranes, in addition to GBM, with IgG.

Immune Complex Crescentic Glomerulonephritis

Immune complex crescentic glomerulonephritis represents about 25% of all cases of crescentic glomerulonephritis.[313] It occurs most frequently as a complication of any of the immune complex glomerulonephritides, including postinfectious glomerulonephritis, MPGN, cryoglobulinemic glomerulonephritis, SLE, IgAN, and HSP (Fig. 23.46). In a minority of the cases of immune complex crescentic glomerulonephritis, the underlying cause cannot be determined. These patients are diagnosed as having idiopathic immune complex glomerulonephritis, and underlying infection should always be excluded in these cases. The prognosis of idiopathic immune complex crescentic glomerulonephritis, although poor, is better than that of anti-GBM disease.[313]

The light microscopic features of immune complex crescentic glomerulonephritis depend upon the underlying glomerular disease. The glomerular segments adjacent to the crescents usually present some degree of necrosis, but this is not as extensive as that seen in anti-GBM or pauci-immune glomerulonephritis. An important finding that can help distinguish immune complex crescentic glomerulonephritis from both anti-GBM and pauci-immune crescentic glomerulonephritis is the presence of various combinations of capillary wall thickening and mesangial/endocapillary cell proliferation, features that are typically absent in the latter two types of crescentic glomerulonephritis (Fig. 23.47).[313] Electron microscopy and immunofluorescence allow the confirmation of immune complex deposits, thus establishing the diagnosis of immune complex crescentic glomerulonephritis. The diagnosis of a specific category of immune complex crescentic glomerulonephritis can usually be achieved by the careful correlation of the patient's clinical and laboratory data with light, immunofluorescence, and electron microscopic findings.

Pauci-Immune Crescentic Glomerulonephritis

Pauci-immune crescentic glomerulonephritis is characterized by the absence or minimal staining for immunoglobulin by immunofluorescence. It is the most common form of crescentic glomerulonephritis diagnosed by renal biopsy (about 60% of the cases), more frequently affects elderly individuals, and is equally distributed between the genders.[313,327]

Pauci-immune crescentic glomerulonephritis can occur as a renal-limited disease or as a component of systemic necrotizing small vessel vasculitis. Constitutional symptoms include fever, arthralgias, and myalgias, and the extrarenal manifestations in systemic disease vary by the organ/s affected. Patients with pauci-immune

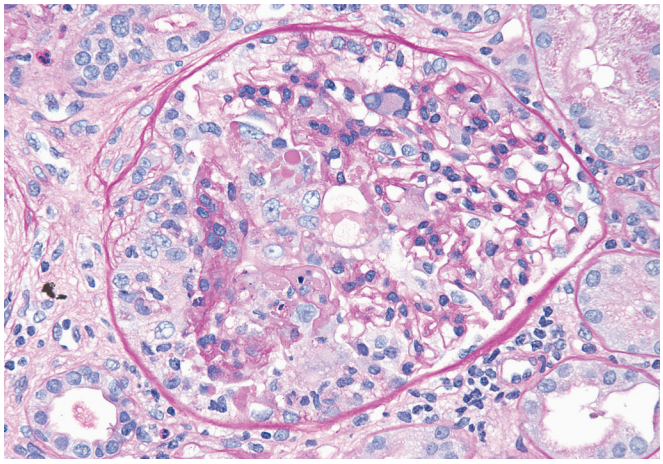

Figure 23.47 Destruction of the capillary tuft by a cellular crescent in a patient with pauci-immune glomerulonephritis. It is characterized by the absence of deposits on immunofluorescence, and note the lack of mesangial or endocapillary proliferation in preserved portions of the capillary tuft.

crescentic glomerulonephritis tend to respond better to treatment than those with anti-GBM glomerulonephritis and, therefore, have a better prognosis. Treatment options for remission induction include steroids, cyclophosphamide, and rituximab, and disease relapses are not uncommon.[328–330]

Approximately 80%–90% of pauci-immune crescentic glomerulonephritis cases occur in ANCA-positive patients.[328] ANCAs have been recognized as serologic markers for pauci-immune glomerulonephritis with or without evidence of extrarenal disease.[331,332] By indirect immunofluorescence with ethanol-fixed neutrophils as substrate, two distinct immunostaining patterns have been recognized: cytoplasmic (C-ANCA) and perinuclear (P-ANCA). Enzyme-linked immunosorbent assay (ELISA) has shown that most C-ANCA– and P-ANCA–positive sera recognize proteinase 3 (PR3), which is a serine protease of 29 kDa, and MPO, respectively. Both are localized to the azurophilic granules of the neutrophils and monocytes, are translocated to the cell surface during cell activation, and are thus able to interact directly with circulating ANCA. Subsequent activation of cell signal transduction pathways and alternative complement pathway facilitate leukocyte adhesion to endothelial cells and vessel damage. Patients with pauci-immune crescentic glomerulonephritis without evidence of extrarenal vasculitis most often have P-ANCA/MPO-ANCA, those with granulomatosis with polyangiitis (GPA) most often have C-ANCA/PR3-ANCA, while those with microscopic polyangiitis have approximately an equal incidence of P-ANCA and C-ANCA.[328] The potential triggers for ANCA production include immune dysregulation, molecular mimicry of microbial factors, and drugs such as propothiouracil, hydralazine, penicillamine, minocycline, and others. Genetic predisposition may play a role as evidenced by HLA class II associations, frequency of certain gene polymorphisms and presence of epigenetic alteration of MPO and PR3 surface expression.[333] Approximately 10%–20% of pauci-immune glomerulonephritis patients lack ANCA, and other less frequent autoantibodies may have potential pathogenic role.[334,335] These include anti-LAMP2 (lysosomal-associated membrane protein-2), anti-moesin, and anti-plasminogen antibodies. Serum complement levels are typically normal in pauci-immune glomerulonephritis, but recent studies have highlighted the role of alternative complement pathway in the pathogenesis of this disease.[336] Cell mediated immune mechanisms also seem to play a role in the development of crescentic lesions.[328]

The light microscopic appearance of pauci-immune crescentic glomerulonephritis is indistinguishable from that of anti-GBM disease (see Fig. 23.47). Immunofluorescence studies may reveal small irregular focal staining for C3. Fibrinogen is frequently found in the crescents or in the necrotic areas of the glomerular tuft. Electron microscopy often demonstrates ruptures of the GBM as well as fibrin deposition. The absence of immune complex deposits differentiates pauci-immune crescentic glomerulonephritis from immune complex crescentic glomerulonephritis.

Lupus Nephritis

SLE is a multisystem, autoimmune disease with a broad range of clinical presentation that has a high morbidity and mortality. The American Rheumatism Association has established diagnostic criteria for this condition based on clinical and serologic manifestations.[337] SLE can affect adults as well as children; two-thirds of patients present symptoms between 16 and 30 years of age. In children, SLE usually occurs in adolescence; it is uncommon before the age of 10 and very rare before the age of 5.[338,339] It is 10 times more common in females than males, with black females being affected more frequently than white. A drug-induced lupus-like disease, most commonly linked with hydralazine, procainamide, isoniazid, methyldopa, chlorpromazine, and quinidine, has also been recognized.[340,341] The renal lesions in these cases are similar to those seen in spontaneous SLE.

Serum antinuclear antibodies (ANAs) are detected in over 95% of patients and their presence is a sensitive marker of SLE, while anti-double-stranded DNA and anti-Sm antibodies are more specific markers. Other notable antibodies detected in SLE patients include antiphospholipid antibodies, ADAMTS13, and lupus anticoagulant.[342] There is a genetic predisposition for developing SLE, and recent genome-wide association studies have identified polymorphisms in several immunity-related genes that confer an increased risk.[343,344] This extensive loss of self-tolerance to a variety of intrinsic antigens in genetically susceptible individuals can be triggered by environmental factors such as ultraviolet light, estrogens, and drugs.

Immune-mediated nephritis is a common complication of SLE. The immune deposits in the kidney (and elsewhere) are derived from either circulating complexes or from an *in situ* combination of antigen and antibody.[342] Complement activation follows along with inflammatory response and organ damage. Immune-complex deposition is the most common form of glomerular injury, but immune deposits are absent in lupus-associated thrombotic microangiopathy (TMA) and podocytopathies (such as MCD) and the injury in these settings is antibody mediated. It appears that the tubulointerstitial inflammation in SLE is more T-cell mediated.

Clinical evidence of renal involvement, as determined by urinalysis, or impaired renal function is seen in approximately 40%–80% of unselected patients with SLE. It is likely, however, that clinical assessment underestimates the actual frequency since histologic evidence of renal disease may be present even when the urinalysis is essentially normal. The clinical spectrum of lupus nephritis is wide, encompassing the acute nephritic syndrome, the nephrotic syndrome, acute and chronic renal failure, and isolated abnormalities in the urinary sediment. The most constant feature found in nearly all patients with clinical lupus nephritis is proteinuria. Microscopic hematuria is almost always present, but rarely does it develop in isolation; macroscopic hematuria is rare.

A kidney biopsy is essential in the renal assessment of patients with SLE and is indicated in all patients with abnormalities of urine sediment or renal function. In patients with these abnormalities, the clinical presentation does not accurately predict the disease

Table 23.5 International Society of Nephrology/Renal Pathology Society classification of lupus nephritis

CLASS	PATHOLOGY DIAGNOSIS	DESCRIPTION
I	Minimal mesangial LN	Normal by LM, mesangial deposits by IF and EM
II	Mesangial proliferative LN	Mesangial proliferation on LM, mesangial deposits by IF and EM
III	Focal LN (<50% of glomeruli)	Active or chronic lesions by LM in <50% glomeruli, usually subendothelial (in addition to mesangial) deposits by IF and EM
III (A)	Active lesions	Active lesions include endocapillary proliferation, cellular crescents, karyorrhexis/necrosis, neutrophils, and wire loops
III (A/C)	Active and chronic lesions	
III (C)	Chronic lesions	Chronic lesions include segmental or global glomerulosclerosis attributable to LN, and fibrous crescents
IV	Diffuse LN (≥50% of glomeruli)	Active or chronic lesions by LM in >50% glomeruli, usually subendothelial (in addition to mesangial) deposits by IF and EM
IV (A)	Active lesions	Subclassification of active lesions as S (segmental) or G (global) based on extent of glomerular tuft affected
IV (A/C)	Active and chronic lesions	
IV (C)	Chronic lesions	Subclassification of chronic lesions as S (segmental) or G (global) based on extent of glomerular tuft affected
V	Membranous LN	Subepithelial deposits present by LM, IF, and EM; can co-exist with class III or IV
VI	Advanced sclerosing LN (≥90% globally sclerosed glomeruli without residual activity)	Global glomerulosclerosis attributable to LN

EM, Electron microscopy; *IF*, immunofluorescence microscopy; *LN*, lupus nephritis.

severity and the renal biopsy findings provide prognostic information and aid in the formulation of the treatment plan.

The pathologic findings of lupus nephritis are extremely diverse and may occur in all four renal compartments: glomeruli, tubules, interstitium, and blood vessels. This diversity may be the result of differences in the immune response in different patients or in the same individual over time. Standardized histologic classification of lupus nephritis developed by the International Society of Nephrology (ISN)/Renal Pathology Society (RPS)[345] provides clear definitions for diagnostic categories based on quantitative assessment of individual histologic lesions. This classification has preserved some of the basic structure of earlier WHO classifications[346–348] but has successfully eliminated some of the ambiguities that existed in the WHO classifications. The ISN/RPS classification defines six major classes (Table 23.5) and several published studies have shown a significant improvement in interobserver reproducibility and in predicting renal outcome when this classification is used.[349–352]

As per the ISN/RPS classification, class I (minimal mesangial lupus nephritis) comprises those cases in which the glomeruli appear normal by light microscopy but show immune complex deposits by immunofluorescence and/or electron microscopy. Patients with class I nephritis usually manifest mild microscopic hematuria and/or mild proteinuria, and renal function is typically normal.

Class II (mesangial proliferative lupus nephritis) is defined by any degree of mesangial hypercellularity and/or mesangial matrix expansion as seen by light microscopy, accompanied by the demonstration of mesangial immune complex deposits by immunofluorescence and electron microscopy (Fig. 23.48). The classification allows for the presence of rare minute subepithelial or subendothelial deposits identifiable only by electron microscopy or immunofluorescence, but not by light microscopy. Clinically, majority of patients have mild renal involvement as demonstrated by an inactive urine sediment. Less than 50% of the patients have mild hematuria and/or proteinuria, which usually does not exceed 1 g per 24 hours. The nephrotic syndrome is exceedingly rare, and, when present, it may be a manifestation of concomitant MCD.[353,354]

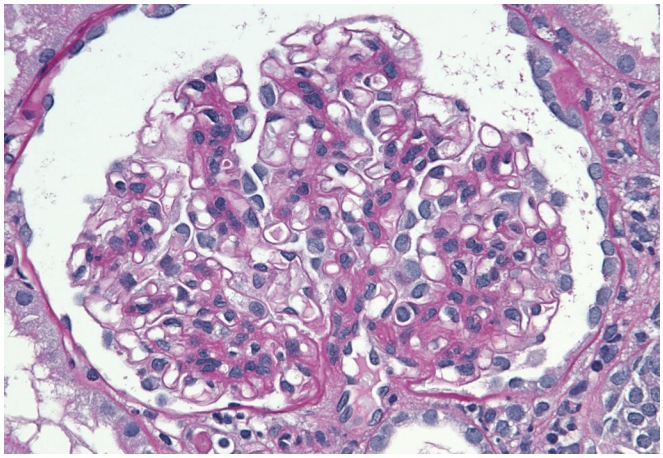

Figure 23.48 Lupus Nephritis, ISN/RPS Class II. There is mild diffuse mesangial hypercellularity and an increase in matrix. Mesangial deposits can be identified by immunofluorescence and electron microscopy.

Class III (focal lupus nephritis) is defined as focal segmental and/or global endocapillary, and/or extracapillary glomerulonephritis affecting less than 50% of the glomeruli. The biopsy may reveal a variable admixture of proliferative, necrotizing, and sclerosing lesions. The less affected glomeruli usually exhibit a diffuse mesangial prominence as seen in class II. The segmental proliferative lesions may be associated with leukocyte infiltration, fibrinoid material, and necrotic debris (Fig. 23.49A). Focal areas of necrosis containing fragmented nuclei known as hematoxylin bodies may be present (see Fig. 23.49B). These structures are considered pathognomonic

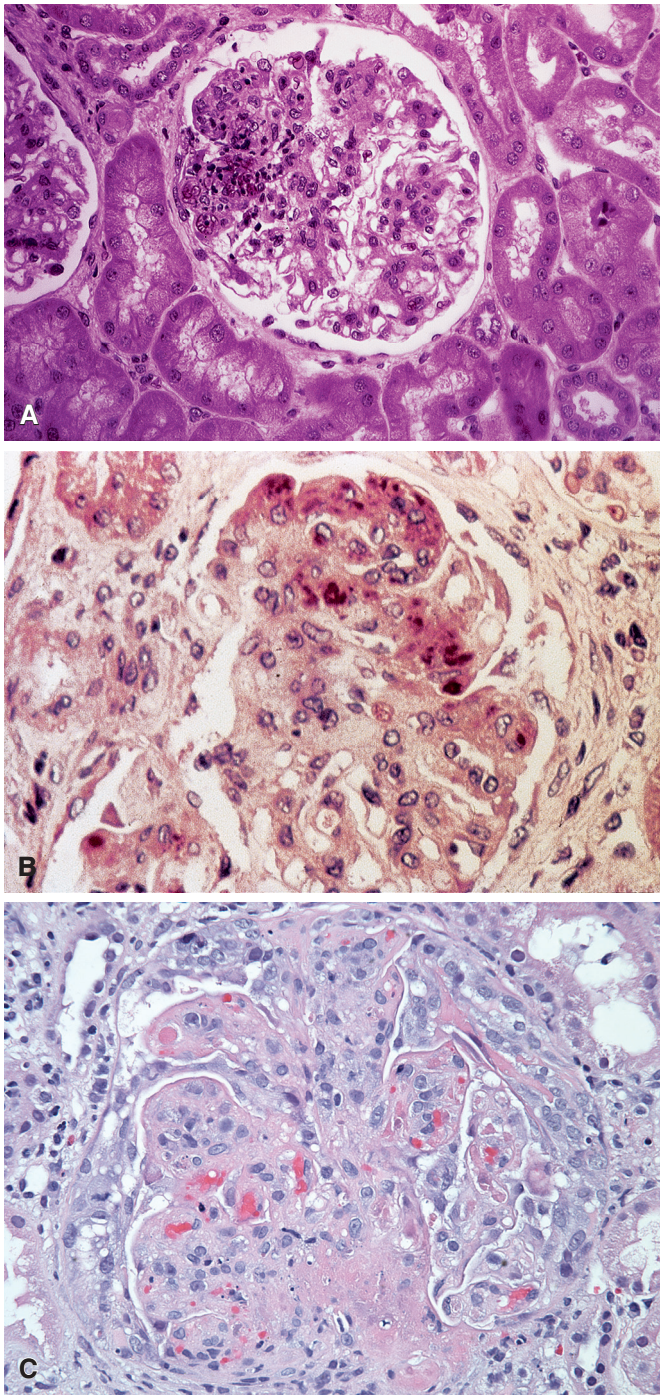

Figure 23.49 Lupus Nephritis, International Society of Nephrology/Renal Pathology Society Class III. A, There is focal and segmental glomerulonephritis characterized by segmental necrosis, adhesions to the Bowman capsule, and leukocytic infiltration. **B,** A glomerulus with a well-circumscribed area of necrosis containing numerous small hematoxylin bodies. **C,** Glomerulus with necrosis, fibrin extravasation, and a cellular crescent.

of lupus nephritis but are found in only 1%–2% of renal biopsies from these patients.[342] They range considerably in size from minute fragments to round masses approximately the size of the nucleus and have a characteristic lilac tinge on H&E-stained sections.[342,355] The segmental necrotic lesions may be associated with cellular crescent formation (see Fig. 23.49C) and tend to resolve by segmental sclerosis

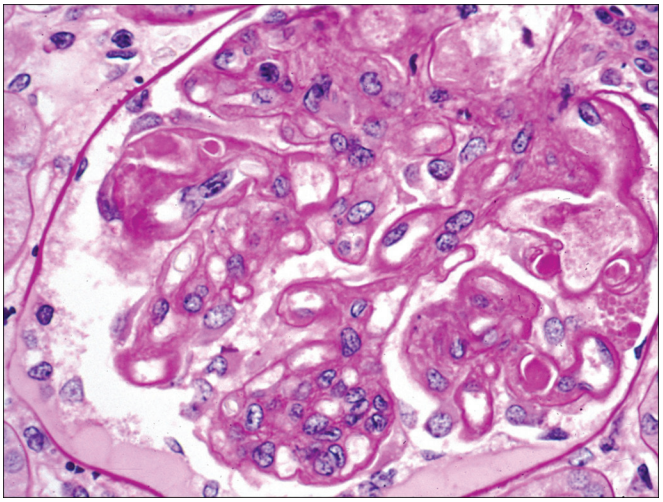

Figure 23.50 Lupus Nephritis, ISN/RPS Class IV. Glomerulus from a patient showing several wire loops (subendothelial deposits) and intraluminal hyaline thrombi (deposits) (PAS).

with focal capsular adhesions or the development of fibrous crescents. Despite the focal nature of the lesion by light microscopy, immunofluorescence generally reveals a more diffuse deposition of immunoglobulins and complement. Electron microscopy often demonstrates deposits in the mesangial and subendothelial regions, and, less frequently, in the subepithelial areas. In the ISN/RPS classification, III (A) refers to active lesions, III (C) refers to healed, chronic, inactive lesions, and III (A/C) indicates a combination of active and chronic lesions. The proportion of glomeruli affected by active or healed lesions should be included in the diagnostic report. The clinical picture of patients with class III lupus nephritis is quite variable. Approximately half of the patients have active urinary sediment, and about 50% have proteinuria, which may be in the nephrotic range in up to one-third of the cases. Renal insufficiency is rather uncommon and occurs in 10%–25% of the patients.

Class IV (diffuse lupus nephritis) is defined as diffuse segmental and/or global endocapillary and/or extracapillary glomerulonephritis affecting 50% or more of the glomeruli included in the biopsy. The lesions in this class are identical to class III but tend to be diffuse and more global, and the immune complexes are more abundant. It has been suggested that classes III and IV lupus nephritis are ends of a pathologic continuum since the differences between these classes are quantitative rather than qualitative. The immune deposits in the subendothelial areas may produce marked thickening of the capillary walls to form the characteristic "wire loop" lesions (Fig. 23.50). On occasion, the capillary lumina can be occluded by massive deposition of immune complexes ("hyaline thrombi"). Immunofluorescence studies often reveal more than one class of immunoglobulin in a coarse granular pattern in the mesangium and peripheral capillary walls in all glomeruli. IgG is almost invariably present, but IgM and IgA are also frequently found. Both C3 and C1q are frequently found and the staining for C1q is particularly strong. When all immunoglobulins and complement components are present, the pattern is often referred to as "full house," an immunofluorescent profile seen in all lupus classes and is considered characteristic of lupus nephritis (Fig. 23.51). Reactivity for fibrin and fibrinogen are commonly seen in crescentic and necrotizing lesions. Electron microscopy demonstrates large subendothelial electron-dense deposits usually accompanied by mesangial and sometimes subepithelial and/or intramembranous deposits (Fig. 23.52A). Subendothelial deposits are primarily found in proliferative lupus nephritis (classes III and

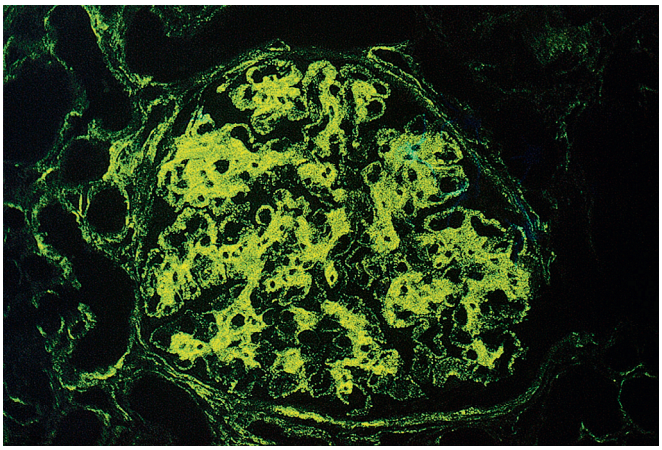

Figure 23.51 Immunofluorescence showing large amounts of granular immune complex deposits not only in the mesangium and glomerular capillary loops, but also along tubular basement membranes, interstitium, blood vessels, and Bowman capsule (anti-IgG).

IV) and are considered to be a marker of activity.[356] On occasion, electron-dense deposits may show a distinctive fingerprint-like crystalline pattern, possibly representing cryoglobulins (see Fig. 23.52B).[357] This substructure, although nonspecific for lupus nephritis, are usually associated with class IV lesion. The endothelial cells may be swollen and contain tubuloreticular inclusions (see Fig. 23.52C). Studies have demonstrated that these *myxovirus-like* structures are inducible *in vitro* in normal lymphocytes on exposure to interferon alpha, earning them the descriptive term "interferon footprints."[358] The ISN/RPS classification subdivides class IV lupus nephritis into those cases with diffuse segmental versus diffuse global proliferations. The designation IV-S is used if over 50% of the involved glomeruli exhibit segmental lesions; the designation of IV-G is used if over 50% of affected glomeruli show global lesions. This subdivision is rather arbitrary and of unclear significance but was included to further investigate possible differences in outcome and pathogenesis between these subgroups.[359] The clinical symptoms in patients with class IV lesions are quite severe and may include nephrotic range proteinuria and active urine sediment. Without therapy, these patients are considered to have the worst prognosis since a high percentage progress rapidly to renal failure.

Class V (membranous lupus nephritis) is defined by the presence of global or segmental continuous subepithelial immune complex deposits or their morphologic sequelae by light microscopy. The membranous changes may occur alone or with a background of mesangial hypercellularity and mesangial immune complex deposits. Small subendothelial deposits can be identified by immunofluorescence or electron microscopy but not by light microscopy. The peripheral glomerular capillary walls often appear diffusely thickened (Fig. 23.53) and the so-called spike and dome pattern may be demonstrated on silver methenamine stain. By electron microscopy, the GBM shows the same ultrastructural stages seen in idiopathic MGN. However, in contrast to this condition, mesangial deposits are commonly found in membranous lupus nephritis patients. Virtually all patients have proteinuria at presentation, and 60%–70% have the nephrotic syndrome. About 50% of the patients have hematuria.

Class VI (advanced sclerosing lupus nephritis) is defined by global glomerulosclerosis affecting over 90% of the glomeruli without residual activity. In less advanced lesions, mesangial and endocapillary hypercellularity may be seen and small amounts of immune complex deposits can be detected by immunofluorescence or electron

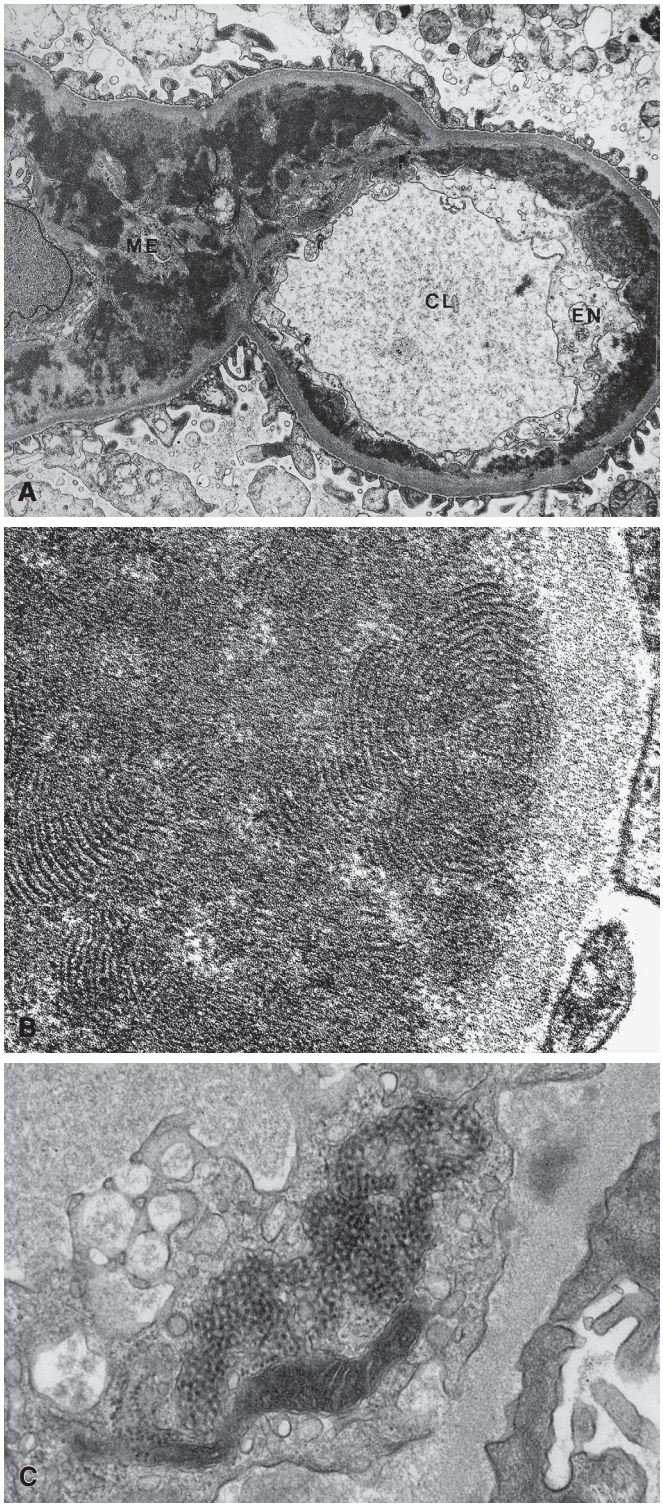

Figure 23.52 **A,** Capillary loop showing marked accumulation of deposits in the mesangium and subendothelial regions. The deposits in the latter location represent the wire loop seen by light microscopy. *CL*, Capillary lumen; *EN*, endothelial cell; *ME*, mesangium (×7000). **B,** Subendothelial deposits displaying a fingerprint-like pattern (×77,000). **C,** Tubuloreticular inclusions in an endothelial cell (×30,000).

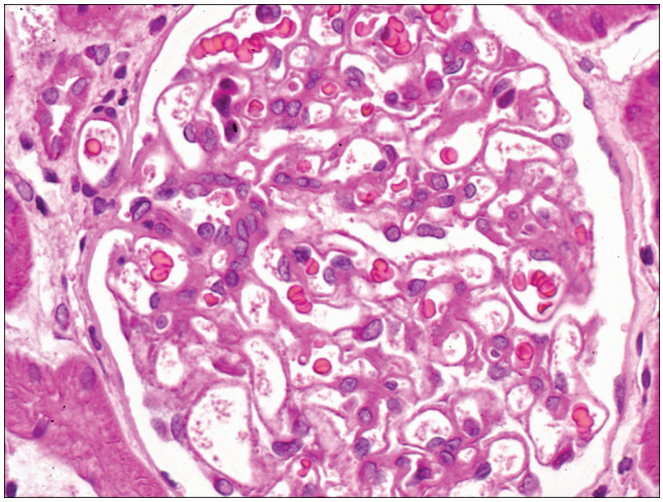

Figure 23.53 Lupus Nephritis, ISN/RPS Class V. The capillary walls are thickened and the mesangial matrix is segmentally increased.

microscopy in the mesangium and thickened capillary walls. Severe TA, IF, inflammation, and arteriosclerosis are usually present. Patients with class VI lesions often have significant proteinuria and severe renal insufficiency and are unlikely to respond to immunosuppressive therapy.

While most cases of lupus nephritis fall into the above categories, some overlap between classes exists. The most common involves classes III and V, and IV and V, and have been designated as combined classes III + V, and IV + V. The transformation of lupus nephritis lesions from one class to another is not uncommon over the course of the disease. It has been reported in 10%–50% of patients who undergo successive renal biopsies,[360,361] and it has occurred between all morphologic types: focal to diffuse,[362] focal to membranous, diffuse to membranous,[363] membranous to diffuse proliferative, and membranous to membranous with focal proliferative lesions.[361,364,365]

Tubulointerstitial inflammation can be found in all classes of lupus nephritis, even in those with minimal glomerular lesions.[360] Severe active TIN is most frequently seen in patients with classes III and IV lupus nephritis, is important in disease progression, and should be adequately assessed.[366,367] In most instances, the interstitial inflammatory infiltrate is composed of mononuclear leukocytes, including lymphocytes, monocytes, and plasma cells, although neutrophils and eosinophils can sometimes be seen. In severe cases, there is inflammatory infiltration of the tubules and the tubular epithelial cells present degenerative and regenerative changes. Tubular casts made of neutrophils, erythrocytes, and shed tubular epithelial cells may be seen in the most severe cases. In about 50% of the patients, immunofluorescence and electron microscopy can demonstrate granular immune deposits along the peritubular capillaries, basement membranes of the proximal convoluted tubules, and interstitium (see Fig. 23.51). These deposits occur more frequently in diffuse lupus nephritis than in the focal variant but may also be found in patients with membranous and mesangial proliferative forms. Lupus nephritis is one of the few renal diseases in which immune deposits can be found not only in the glomeruli but also in the extraglomerular sites. The severity of the tubulointerstitial inflammation roughly correlates with the glomerular proliferative lesions; however, a few cases of severe tubulointerstitial damage without the significant glomerular disease leading to acute renal failure have been reported.[368,369]

Renal vascular lesions are relatively common in SLE and can assume a variety of morphologic forms, including uncomplicated vascular immune deposits, noninflammatory necrotizing vasculopathy, true vasculitis with leukocyte infiltration and necrosis of the vessels walls, and TMA. All these vascular changes are signs of poor prognosis and, thus, should be recognized but are not currently included in histologic classification or activity and chronicity indices.[370]

Some authors have proposed that histologic indices derived from the semiquantitative analysis of activity and chronicity in renal biopsies of patients with SLE have a prognostic value and can serve as a therapy guide.[371] The activity index is calculated by the assessment of the following six histologic parameters: glomerular endocapillary proliferation, glomerular leukocyte infiltration, wire loop deposits and hyaline thrombi, glomerular fibrinoid necrosis and karyorrhexis, cellular crescents, and interstitial inflammation. The severity of each of these features is scored on a scale of 0 to 3+, and the fibrinoid necrosis/karyorrhexis and cellular crescents scores are doubled. Thus, the maximum activity score is 24. The chronicity index is computed by the sum of individual scores (0–3+) of the following four parameters: global glomerulosclerosis, fibrous crescents, TA, and IF. Thus, the maximum chronicity score is 12. Although the validity and the reproducibility of activity and chronicity indices have been questioned,[372] these indices help guide the management of individual cases as they provide useful information about the efficacy of therapy and the potential reversibility of the renal lesions.

Although in the past the recurrence of lupus nephritis after renal transplantation was reported to be rare, affecting only 1%–4% of the allografts, more recent studies indicate that the recurrence rate is higher (ranging from 8% to 30%) than was previously believed.[373–375]

Glomerular Lesions Associated With Vascular Diseases

Systemic Vasculitis

Vasculitis may occur in a variety of conditions, particularly in connective tissue diseases such as SLE and rheumatoid arthritis, and in hypersensitivity reactions caused by infections and drug reactions. Vasculitis may also occur as the primary manifestation of a variety of clinical conditions known as idiopathic systemic vasculitides. Clinical symptoms depend on the organ distribution, the size of the affected vessels, and the severity of the inflammation. The kidneys can be affected in different ways in systemic vasculitis. Large vessel vasculitides, such as giant cell (temporal) arteritis and Takayasu disease, can produce narrowing of the renal arteries, resulting in renal ischemia and hypertension. Medium-sized vessel vasculitides, such as polyarteritis nodosa (PAN) and Kawasaki disease, can affect intrarenal arteries and cause infarction and hemorrhage, whereas in small vessel vasculitides, such as microscopic polyangiitis (previously microscopic polyarteritis), GPA (previously Wegener granulomatosis), eosinophilic GPA (previously Churg–Strauss syndrome), HSP, and cryoglobulinemic vasculitis, the renal involvement is often manifested by glomerulonephritis.[376]

The vasculitides differ not only in their clinical and pathologic characteristics but also in their presumed pathogenesis. The large vessel vasculitides are supposedly caused by cell-mediated immune reactions to poorly defined (auto) antigens.[377] Immune complexes are involved in the pathogenesis of some small vessel vasculitides, such as HSP and cryoglobulinemia, whereas vasculitic lesions associated with microscopic polyangiitis, GPA, and eosinophilic GPA lack immune complexes and because of this, are collectively designated pauci-immune necrotizing vasculitides. Pauci-immune vasculitides are characterized by the presence of ANCA, which are valuable serologic markers for the diagnosis and monitoring of this group of vasculitides.[378,379] There is also evidence that ANCA are directly involved in the pathogenesis of these conditions.[380,381] Some of the

diseases in which vasculitis appears to be the primary histopathologic lesion will be discussed in this section.

Polyarteritis Nodosa

PAN is a primary vasculitis of largely unknown etiology that affects muscular medium-sized arteries and produces lesions of varying stages (acute and healed) with aneurysm formation. The kidneys and gastrointestinal tract are among the organs most commonly affected, while the lungs are usually spared. The clinical manifestations are related to ischemia and disease severity of the involved organ.[382] Peripheral neuropathy has been reported in approximately 75% of the cases.[383] The estimated incidence is two to three cases per million.[384] Males are affected twice as often as females, and the peak incidence is in the sixth decade of life. There is no serum marker for PAN and, by disease definition, there should be no glomerular or other capillary involvement in classic PAN.[376] ANCA serology is typically negative unless there is a rare clinical overlap with microscopic polyangiitis.[385] About one-third of the patients may be carriers of the hepatitis B virus.[386,387] It has also been reported in hepatitis C and HIV-infected patients.[388] Recently mutations in *CECR1*, a gene encoding adenosine deaminase 2, an adenosine inactivating extracellular enzyme, have been detected in familial form of PAN with autosomal recessive inheritance.[389]

The kidneys are involved in 80%–90% of the cases.[382] Renal infarctions occur frequently and may be manifested by loin pain and hematuria. Hypertension is common and may be severe or malignant.[390] The renal lesion in PAN is a necrotizing vasculitis that involves medium-sized muscular arteries, such as the renal, interlobar, and arcuate arteries (Fig. 23.54). The lesions are quite focal and tend to localize to the bifurcations, and weakening of the vessel wall leads to the formation of aneurysmal dilations, detectable on Doppler ultrasonography or CT angiography. The inflammatory process may involve part of or the entire vessel wall and is characterized by fibrinoid necrosis and leukocytic infiltration, sometimes associated with intraluminal thrombosis. The acute phase evolves into a healing phase in which the necrosis subsides and the leukocytic inflammation is replaced by mononuclear infiltrate. In the healed stage, there is fibrosis of the media and perivascular tissue, disruption of elastic lamina, and recanalization of the thrombosed vessels.[391,392]

Because of the focal nature of the vessel lesion and involvement of medium-sized vessels, evidence of vasculitis may not be seen on a needle biopsy. The glomeruli show changes associated with ischemia consisting of variable degrees of collapse and sclerosis of the tufts; glomerular necrosis or crescents are not a feature of typical PAN. Immunofluorescence and electron microscopy typically do not reveal evidence of immune complex deposits.[391]

Microscopic Polyangiitis

Microscopic polyangiitis, formerly known as microscopic polyarteritis, is a necrotizing systemic vasculitis with few or no immune complexes (pauci-immune) that affects small vessels (capillaries, venules, and arterioles) (Fig. 23.55). Involvement of small and rarely medium-sized arteries can also occur, but this is not a constant feature.[393] Because of the absence of arterial involvement in many cases, and the frequent involvement of venules, arterioles, and capillaries (including glomeruli), the term microscopic polyangiitis is now considered more appropriate for this form of vasculitis than the designation of microscopic polyarteritis.[394] Microscopic polyangiitis is distinct from PAN, is mediated by ANCA, and falls under the category of pauci-immune glomerulonephritis/vasculitis.[376] The incidence of microscopic polyangiitis is approximately 1 per 100,000.[395] Males are affected slightly more than females, and although it can occur at any age, it is more frequent during the sixth decade of life. Clinical manifestations are quite varied and nonspecific. Depending upon the organ(s) affected, the most common clinical features are hematuria and proteinuria, hemoptysis, palpable purpura, abdominal pain, myalgias, and arthralgias. Hypertension may occur, but it is usually mild. About 80%–90% of the patients have renal involvement.[396] In contrast to PAN, however, the lungs are commonly affected in microscopic polyangiitis.[397] A frequent clinical presentation of microscopic polyangiitis is as pulmonary–renal syndrome. This syndrome raises the possibility of anti-GBM disease (Goodpasture syndrome); however, the demonstration of ANCA in microscopic polyangiitis or anti-GBM antibodies in anti-GBM disease will establish the correct diagnosis. Over 80% of patients have detectable ANCA, most often P-ANCA (and anti-MPO). In addition to ANCAs, a recent study suggested a pathogenic role for anti-moesin antibodies in MPO-ANCA-associated vasculitis.[335] In the kidney, the most frequent lesion is glomerulonephritis, and the glomerular involvement ranges from a focal and

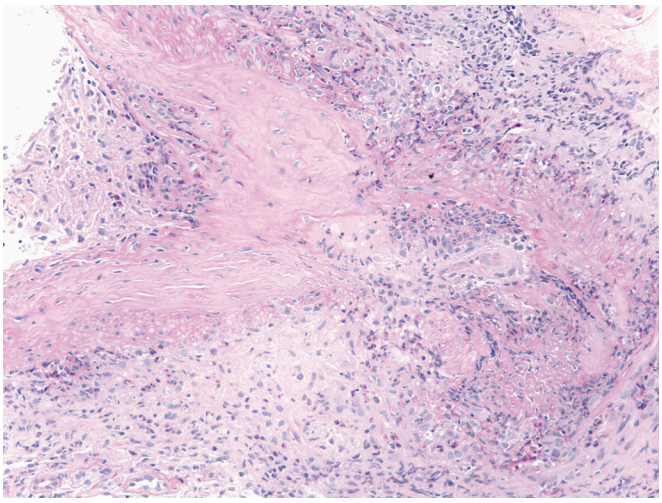

Figure 23.54 Transmural vasculitis and fibrinoid necrosis involving a medium-sized artery, likely an interlobar artery, in polyarteritis nodosa. The glomeruli sampled in the kidney biopsy lacked crescents.

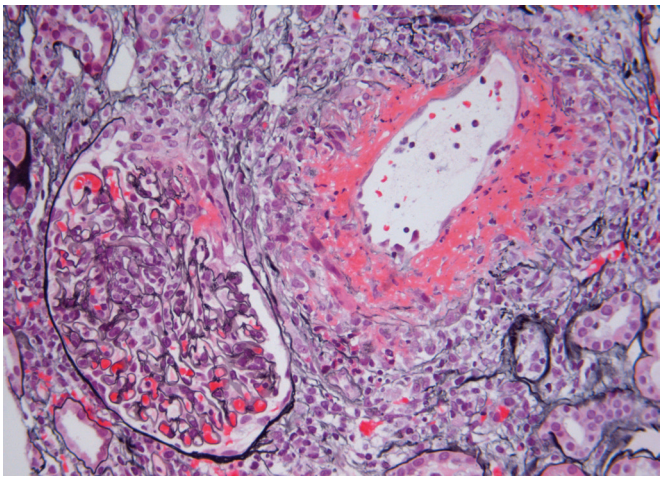

Figure 23.55 Renal biopsy from a patient with microscopic polyangiitis showing a small vessel with necrosis and inflammatory infiltrate. The glomerulus has a segmental area of necrosis, and an early crescent (methenamine silver). (Image courtesy Megan Troxell, MD, PhD.)

segmental necrosis to a severe diffuse crescentic glomerulonephritis (see Fig. 23.55).[395,396] When present, necrotizing arteritis most often affects the interlobular arteries and rarely arcuate arteries.[397] Histologically, vasculitis in microscopic polyangiitis may be indistinguishable from that seen in PAN. However, in contrast to the lesions seen in PAN, which are usually in varying stages of evolution, those in microscopic polyangiitis almost invariably appear to be temporally uniform; glomerular involvement indicates a diagnosis of microscopic polyangiitis.[398] A tubulointerstitial infiltrate including eosinophils is frequently present. Immune complex deposits are not usually seen in the glomeruli, though there have been reports of sparse deposits containing IgG or IgM with C3 in various intraglomerular locations.[398]

Granulomatosis With Polyangiitis

GPA (previously known as Wegener granulomatosis) is a multisystem disease of unknown etiology characterized by the triad of: (1) necrotizing granulomatous inflammation involving the upper respiratory tract (ear, nose, throat, and sinuses) and/or lungs; (2) necrotizing vasculitis affecting small- to medium-sized vessels (capillaries, venules, arterioles, and arteries) most prominently in the lungs and upper airways but also involving other sites as well; and (3) renal disease, most often manifested in the form of focal necrotizing glomerulonephritis.[399] Those patients who do not manifest the full triad are considered to have limited GPA. In these cases, involvement is limited to the respiratory tract and the kidneys are unaffected. The prevalence of GPA in the United States has been estimated to be 3 per 100,000,[400] with slight male predominance. It may occur at any age, but it is more common in the fourth and fifth decades.[401] The first clinical indication is usually upper respiratory symptoms which are followed by systemic phenomena related to the vasculitis.[402] About 80%–85% of patients present some signs of renal involvement, usually simultaneously with other clinical features,[403] but fewer than 20% actually present with renal functional impairment. Patients with renal involvement, if untreated, usually have a rapidly progressive and fatal disease. Therapy with cyclophosphamide, rituximab, and corticosteroids produces remission in most patients, but up to 50% of the patients may relapse.[329,403]

The differentiation of GPA from other types of vasculitis can be difficult clinically and morphologically. A positive ANCA test, especially C-ANCA (and/or PR3), can be extremely helpful in establishing or supporting the diagnosis of GPA. The specificity of C-ANCA in biopsy-proven GPA has been shown to be about 90%. The sensitivity depends upon the extent and activity of the disease. Although it has been shown that serum levels parallel the clinical activity of the disease[404] and that rising levels may be used as a predictor of relapse, there are some patients in whom C-ANCA titers do not follow disease activity.[401,403] The pathogenic role of ANCA with specificity to PR3 has been previously well established,[399] but recent studies have pointed to several pathways involving cell-mediated processes, neutrophil traps, and inflammatory mediators mediating tissue injury in GPA.[405]

The most common renal lesion is focal necrotizing glomerulonephritis, often with crescents.[406] Granulomatous glomerulonephritis occurs but it is uncommon, even in autopsy series, and is usually accompanied by necrosis of the hilar arterioles.[407] Necrotizing vasculitis involving the arterioles and small arteries occurs, but it is not a common finding in kidney biopsies. Interstitial inflammatory infiltrates are common, but necrotizing granulomata are rarely seen in renal biopsy specimens.[403]

As a rule, immune complex deposits are absent in GPA by electron microscopy, though there have been reports of the occurrence of sparse electron-dense deposits at different sites in the glomerulus.[406,408] Immunofluorescence shows fibrinogen in glomeruli and the walls of involved vessels, and small amounts of IgM and/or IgG and C3 have been reported in glomeruli and vessels.

Eosinophilic Granulomatosis With Polyangiitis

Eosinophilic granulomatosis with polyangiitis (EGPA), also known as Churg–Strauss syndrome or allergic granulomatosis, is a rare disorder characterized by asthma, eosinophilia, and systemic vasculitis affecting small- to medium-sized vessels.[409,410] The syndrome has no gender predilection, and while it has been reported in all ages, the mean age at diagnosis is approximately 50 years.[411–414] Renal involvement can be seen in 50% or more of these patients.[411–413] Patients with EGPA often have elevated IgE levels in their serum, and ANCA positivity (P-ANCA and anti-MPO) has been reported in 40%–80% of the cases.[414–416] In contrast to other vasculitides, renal involvement in EGPA rarely predominates. It is manifested by microscopic hematuria and mild proteinuria and, less frequently, by the nephrotic syndrome or rapidly progressive renal failure.[411–414,417] The renal prognosis in EGPA is generally better than that of other pauci-immune vasculitides, such as GPA or microscopic polyangiitis.[417] Patients usually respond to high dose steroids, but cyclophosphamide and rituximab are effective in refractory cases.[418]

The most common light microscopic abnormality on renal biopsy is that of a focal and segmental necrotizing glomerulonephritis with crescent formation similar to that found in other ANCA-associated vasculitides, with eosinophil-rich arteritis (a distinctive feature) in a minority of cases.[419,420] The interstitium may be affected by inflammatory cells, including eosinophils, lymphocytes, and plasma cells. Interstitial granulomas can also occur but are uncommon. Immunofluorescence studies may show positivity for IgM, C3, and fibrinogen in glomeruli in the segmental areas of necrosis. No immune complex deposits are found by electron microscopy.

Henoch–Schönlein Purpura

HSP is a distinct systemic vasculitic syndrome that is characterized by palpable purpura (most often symmetrically distributed over the extensor-dependent surfaces of the lower extremities and buttocks), migratory arthralgias, abdominal manifestations (including pain, vomiting, and intestinal bleeding), and renal disease.[421,422] The clinical manifestations of the syndrome are caused by a systemic small vessel vasculitis of the leukocytoclastic type. The inflammatory reaction seen in the skin, kidney, and other organs is caused by deposition of IgA-containing immune complexes. HSP can occur at any age but is more common in young children, with over 50% of the cases under 5 years and over 75% under 10 years.[423,424] A male predominance has been reported in both children and adults, with a ratio of up to 2 : 1.[422,423] HSP is uncommon in blacks, and familial cases have rarely been reported.[425] About one-fourth of the patients have a history of allergies. Renal involvement has been reported to occur in approximately 20%–55% of children[426,427] and 50%–85% of adults[423,428] and ranges from mild hematuria and proteinuria with no reduction in renal function to the nephrotic syndrome and severe renal insufficiency. Upper respiratory tract infections often precede the onset of HSP. The disease undergoes complete, spontaneous remission in half of the patients, usually within a year of onset, but in many others, it progresses to ESRD over a period of 5–10 years. The prognosis in children is excellent with ESRD reportedly occurring in only 2% of patients. In general, there is good correlation between the severity of the lesion and the clinical manifestations, and patients with the nephrotic syndrome usually progress to renal failure.[428] Recurrence can occur in allografts, but it is rarely responsible for graft failure.

By light microscopy, the most characteristic feature is a mesangial proliferative glomerulonephritis with a variable degree of crescent formation. The mesangial changes, which may be focal or diffuse, include both mesangial hypercellularity and an increase in mesangial matrix. Occasional cases may show a membranoproliferative pattern. In the most severe cases, the glomerular tufts may be infiltrated by polymorphonuclear leukocytes and mononuclear cells and may exhibit areas of necrosis. Vasculitis involving glomerular arterioles and interlobular arteries can also occur, but this is rare finding on renal biopsies. Tubulointerstitial changes of atrophy and IF correlate with the degree of glomerular damage. Electron microscopy shows mesangial deposits that may extend into the subendothelial areas. Subepithelial deposits similar to those in membranous nephropathy or resembling the humps of postinfectious glomerulonephritis have been reported.[429] But in such instances, a recently characterized entity, IgA-dominant postinfectious glomerulonephritis, associated with co-dominant C3 staining and frequent hypocomplementemia, should be considered.[239] The most distinctive feature of HSP is the demonstration of dominant or co-dominant IgA by immunofluorescence. As in IgAN, the deposits may also contain IgG, IgM, C3, and properdin but not C1q or C4. The fact that the deposits consist mainly of aberrantly glycosylated polymeric IgA1 supports the notion that IgAN and HSP are spectra of the same disease.[311,430]

Cryoglobulinemic Vasculitis

Cryoglobulins are immunoglobulins or complexes of immunoglobulins that precipitate at low temperatures (4°C) and redissolve when the serum is heated to 37°C. Three types of cryoglobulinemia are recognized: type I, in which the cryoglobulins are composed exclusively of a single monoclonal immunoglobulin of either IgG or IgM class, usually generated by a lymphoplasmacytic disorder, and types II and III, which are composed of "mixed" cryoglobulins, a designation based on their composition as complexes of immunoglobulins. Type II cryoglobulins consist of a complex of monoclonal immunoglobulins (typically IgM) with rheumatoid factor activity, causing it to bind to polyclonal IgG, whereas type III cryoglobulins are a mixture of polyclonal IgM and IgG. Mixed cryoglobulins (types II and III) can be found in the serum of patients with a variety of clinical conditions, including lymphoproliferative disorders, chronic infections, chronic liver disease, and autoimmune diseases, particularly SLE.[431] In the past, no clear cause could be found in about 30% of all mixed cryoglobulinemias (and so referred to as "essential" cryoglobulinemia), but it now clear that majority are associated with hepatitis C virus infection.[432] Approximately 10%–15% of all cases of cryoglobulinemia involve type I cryoglobulins, 50%–60% type II, and 25%–40% type III.[178,432] Any of the three types of cryoglobulin can precipitate in the vasculature, forming thrombi in virtually any organ of the body, and may elicit an inflammatory reaction (vasculitis) in the vessel wall.[433,434]

A distinctive clinical syndrome characterized by a variable combination of fatigue, purpura, arthralgias, hepatosplenomegaly, lymphadenopathy, Raynaud phenomenon, and glomerulonephritis has been observed in patients with mixed cryoglobulinemia. Both sexes are affected, though it is most common in women in the fourth and fifth decades.[435] Purpura is almost always present and is usually distributed over the lower extremities. Renal disease occurs in about 50% of the patients and becomes apparent 1–3 years after the purpura, but it can be a presenting symptom.[436] Typical clinical manifestations are nephrotic-range proteinuria, microscopic hematuria, and hypertension. Acute nephritic syndrome occurs in 20%–30% of the cases, and oliguric acute renal failure in about 5% of patients with renal disease. Although rare, renal involvement can occur in type I cryoglobulinemia. In the few reported cases, the clinical manifestations and pathologic features of type I cryoglobulinemia are identical to those of mixed cryoglobulinemia.[433] Hypocomplementemia is common, especially low C4, but several cases have reduced levels of C3 as well. False negative result for serum cryoglobulins is real concern, and appropriate sample collection and transportation to maintain the serum temperature at 37°C is extremely important. Some cryoglobulins, especially type III, can take up to 7 days or more to precipitate.[437]

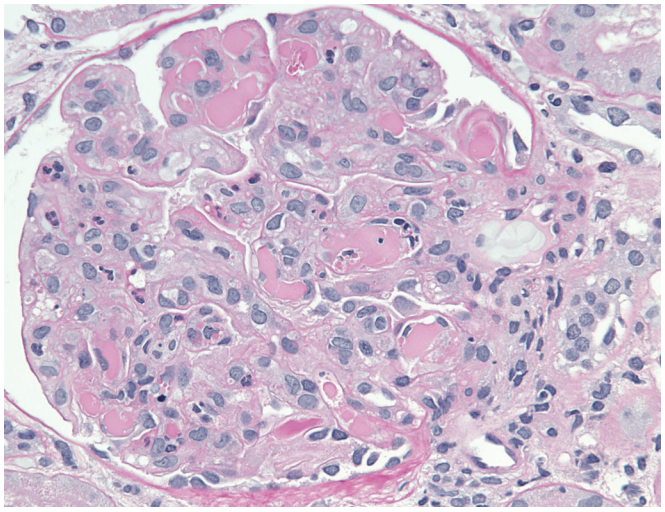

Figure 23.56 Cryoglobulinemic glomerulonephritis with diffuse proliferation, lobular accentuation and intraluminal hyaline thrombi (deposits) (PAS).

The most common renal biopsy finding in patients with all types of cryoglobulinemia is a diffuse proliferative glomerulonephritis (often with a membranoproliferative pattern). Focal and segmental glomerulonephritis and, less frequently, membranous or crescentic glomerulonephritis can also occur. Abundant glomerular intracapillary macrophages are a frequent feature. In more acute cases, the bulky deposits produce the appearance of thrombi or wire loops as can be seen in lupus nephritis (Fig. 23.56). Vasculitis is the basic pathologic lesion in every affected tissue including the kidney, where it tends to involve the interlobular arteries and afferent arterioles. Electron microscopy often demonstrates abundant subendothelial deposits and, less frequently, mesangial, intramembranous, or subepithelial deposits. In approximately half of the cases, the glomerular deposits appear as fibrillar, tubular, or annular structures or may exhibit a fingerprint-like pattern (Fig. 23.57).[438] In some cases, especially those associated with plasma cell dyscrasias, it is possible to find rhomboid- or needle-shaped crystals in the cytoplasm of glomerular epithelial and mesangial cells.[439] Immunofluorescence usually demonstrates positivity for the immunoglobulins present in the cryoglobulins in the glomeruli and vessels. C3 deposition is often found in these locations, whereas C1q and C4 occur in only about one-third of the cases. Heavy and/or light chain restriction can be observed in type I cryoglobulinemia.

Hemolytic Uremic Syndrome and Thrombotic Thrombocytopenic Purpura

TMAs constitute a group of microvascular occlusive disorders characterized by hemolytic anemia that is caused by fragmentation of erythrocytes, thrombocytopenia due to increased platelet aggregation, and thrombus formation that produces variable signs and symptoms of organ ischemia.[440] In addition to schistocytes on peripheral smear, patients with TMA have elevated serum lactate dehydrogenase, low

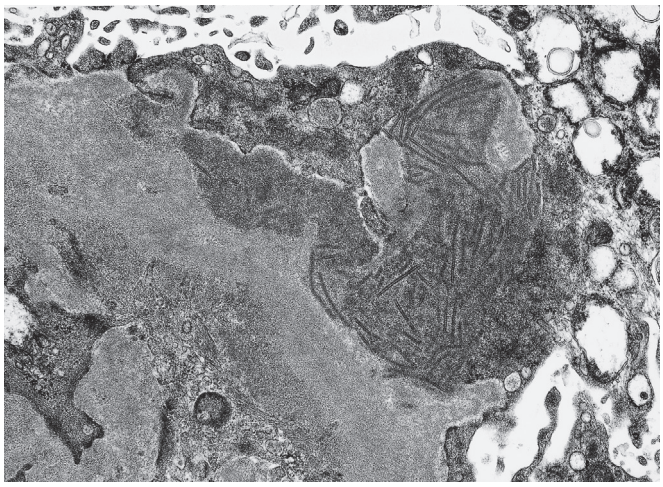

Figure 23.57 Subepithelial deposits demonstrating fibrillary configuration in a case of cryoglobulinemic glomerulonephritis (×21,500).

haptoglobin levels, and negative Coombs test. Although TMA may be a manifestation of various disease states,[441] the two most prominent conditions are thrombotic thrombocytopenic purpura (TTP) and HUS. Traditionally, the diagnosis of HUS was made when renal failure was the predominant feature and children were the ones primarily affected, whereas the term TTP was used for adult patients having predominantly central nervous system impairment. Because of the overlap of clinical manifestations, these two syndromes were previously considered to be a continuum of a single disease entity. However, newly identified pathophysiologic mechanisms have allowed these syndromes to be distinguished from each other on a molecular basis.[442] Studies have shown that patients with TTP are severely deficient in a plasma protein ADAMS13, while those with HUS have either normal or only moderately reduced levels.[443,444] ADAMS13 is a metalloprotease that cleaves the large von Willebrand factor (vWF) multimers produced by the endothelial cells. When ADAMS13 activity is deficient, the resulting abnormally large vWF multimers in the plasma have a greater ability to react with platelets and cause the disseminated platelet microthrombi characteristic of TTP. These microthrombi can be found in arterioles and capillaries in a variety of organs, including the brain, gastrointestinal tract, pancreas, skin, heart, adrenal glands, and kidneys.[445,446] The deficiency of ADAMS13 activity can be inherited, but it is more commonly caused by an acquired autoantibody (as triggered by drugs such as ticlopidine and clopidogrel) that binds and inhibits the metalloprotease.[447]

HUS is defined by the triad of thrombocytopenia, microangiopathic hemolysis, and acute renal failure. The underlying causes of HUS have been broadly divided into diarrhea-associated (D+ HUS), also known as classic HUS, and nondiarrheal forms (D− HUS), also known as atypical HUS.[448,449] The classic form occurs primarily in infants and young children, but it may appear at any age, and both sexes are equally affected. It accounts for most of the cases of HUS in North America and is characterized by sometimes occurring in small epidemics after exposure to contaminated foods, such as undercooked ground beef, unpasteurized apple juice, and dairy products, with verotoxin-producing *Escherichia coli* O157:H7 and, less commonly, with *Shigella dysenteriae* type I.[450,451] The verotoxin/Shiga-like toxin binds to globotriaosylceramide (Gb3) receptors that are expressed in highest concentration in microvascular endothelial cells in kidney, gut, pancreas, and brain and mediate endothelial damage. Patients usually present with prodromal diarrhea (often bloody) followed by acute renal failure. About one-third of the patients may present symptoms of neurologic involvement, commonly manifested by seizures, altered consciousness, and focal neurologic signs. Because thrombotic changes are most often confined to the glomeruli, patients with classic HUS usually have a good prognosis and recovery occurs in about 80%–90% of the cases. About 5% of the patients, however, die of disease, usually of cerebral causes.

D− HUS is much less common than the classic type and accounts for only 5%–10% of all cases of the disease.[449] It may occur at any age but is more frequent in adults. The etiology of D− HUS is heterogeneous.[452,453] It can be associated with nonenteric infections caused by bacteria, such as *Streptococcus pneumoniae*, *Mycoplasma pneumonia*, *and Legionella* or viruses, such as influenza A virus and HIV. Infection caused by *Streptococcus pneumoniae* accounts for 40% of D− HUS and 4.7% of all cases of HUS in children in the United States.[454] D− HUS can also occur in association with disorders such as SLE, systemic sclerosis, antiphospholipid antibody syndrome, malignant hypertension, or various forms of cancer, especially prostatic, gastric, breast, and pancreatic carcinomas.[440,452,453] This form of HUS can be induced by total body irradiation, antineoplastic agents (mitomycin, cisplatin, bleomycin, and gemcitabine, anti-vascular endothelial growth factor [VEGF]) or immunosuppressive drugs (cyclosporine, tacrolimus, OKT3, sirolimus, and interferon), quinine, and oral contraceptives. A severe form occurs in association with pregnancy, especially in the postpartum period.[455] The overall prognosis of these patients is poor, with a high mortality rate from central nervous system disease or uncontrollable bleeding, and, if they survive, usually develop chronic renal failure.

Several forms of D− HUS are hereditary, involving complement regulatory proteins, factor H, factor B, C3, membrane cofactor protein (MCP or CD46), or factor I.[453,456] Defects in these proteins as a result of mutations of the corresponding genes cause excessive alternative complement pathway activation that damages endothelial cells, leading to a prothrombotic stage and local accumulation of platelet–fibrin thrombi. Certain high-risk haplotypes have also been identified and might account for variability in penetrance among family members. It has also been proposed that environmental triggers such as infection, pregnancy, transplantation, oral contraceptive pills, and drugs act as a second hit, overwhelm the delicate complement "balance" in these patients, and precipitate atypical HUS in adult life. Low serum C3 levels in HUS may indicate a genetic component.[457] Other genetic disorders affecting cobalamin metabolism and coagulation pathway also cause clinical features and histologic changes of TMA.[441]

A biopsy taken early in the disease course shows fibrinoid necrosis, intimal and subintimal fibrin deposits with entrapped fragmented red cells, thrombosis, and endothelial cell proliferation in small arteries and arterioles. The glomeruli may be affected similarly (Fig. 23.58), exhibit acute ischemic changes, or be infarcted. There is endothelial swelling with narrowing of the capillary lumina. The mesangium is expanded, and, in severe cases, mesangiolysis may occur. As the lesion progresses, there is an intense basophilic intimal thickening in the small arteries and arterioles which greatly restricts the vascular lumina. These mucoid intimal changes usually develop over several weeks, although they may be seen in very early phase of the disease. Aneurysmal dilation, accompanied by proliferation of some arterioles, particularly at the hilus of the glomerulus is a typical finding. Insidious presentation and chronic glomerular TMA lesions are characterized mainly by mesangiolysis and basement membrane irregularities and double contours (Fig. 23.59).

Electron microscopy reveals the most characteristic feature of HUS: narrowing of the capillary lumen due to marked widening of the subendothelial space that is filled with a pale, finely particulated

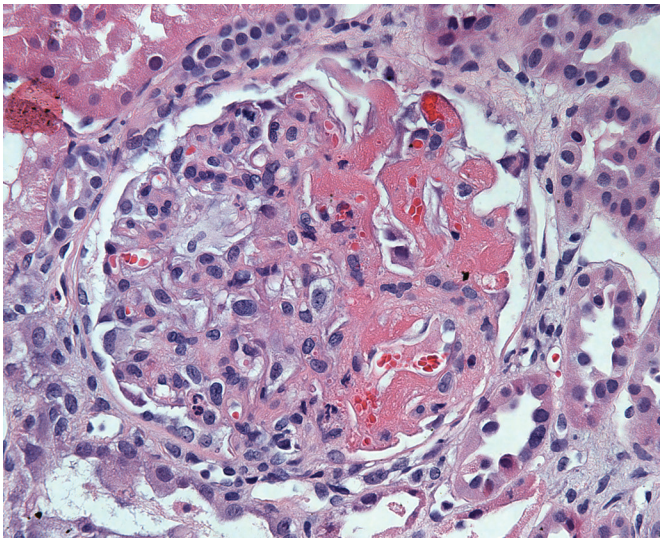

Figure 23.58 Glomerulus with capillary fibrin thrombi, karyorrhexis and entrapped fragmented red blood cells in acute thrombotic microangiopathy.

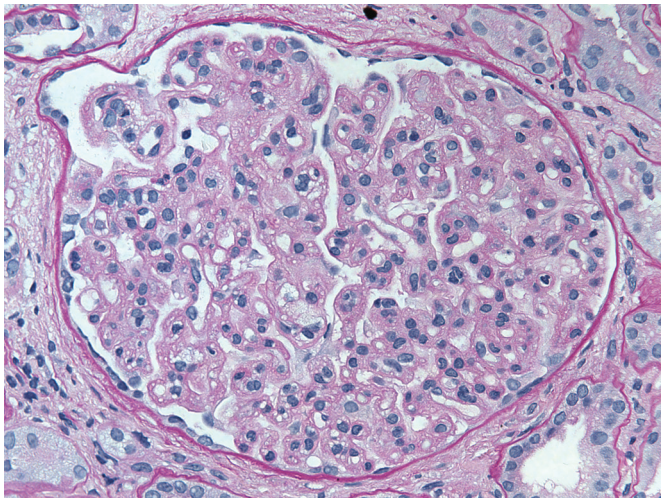

Figure 23.59 Glomerulus From a Patient With Antiphospholipid Antibody Syndrome. Diffuse glomerular basement membrane multilayering is seen along with mesangiolysis and endothelial swelling (PAS).

or fibrillar material that stains positively for fibrinogen by immunohistochemical methods (Fig. 23.60). In the chronic phase, an irregular, thin layer of basement membrane–like substance is present between the endothelial cell cytoplasm and the electron-lucent area. Because of its argyrophilic characteristics, this material can produce a double contour on light microscopy, thus simulating a membranoproliferative pattern (see Fig. 23.59). Fibrin and platelet aggregates may occlude the capillary lumina, and the endothelium is often disrupted in these thrombosed areas. The mesangial cells are swollen and hypertrophic and contain many phagolysosomes. Extensive foot process effacement is seen in the areas of capillary wall collapse. In the later stages, interlobular arteries and arterioles are affected by a mucinous, onion-skin–like obliterating vasculopathy devoid of inflammation. The vascular lesions are identical to those seen in systemic sclerosis and malignant hypertension, so careful analysis of the clinical data is required for accurate diagnosis.

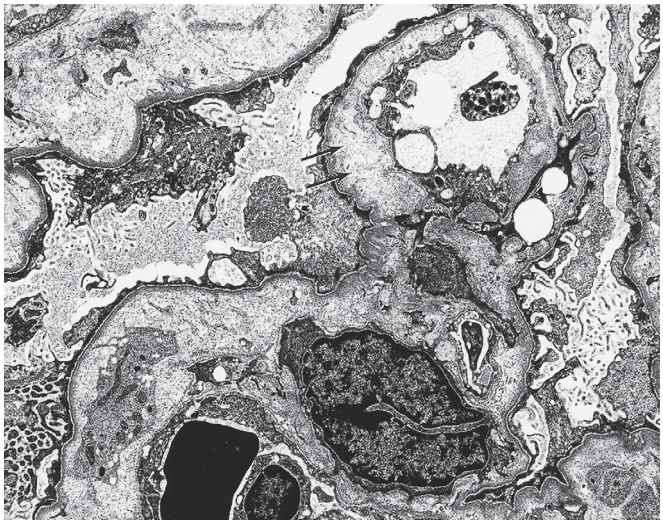

Figure 23.60 Portion of a glomerulus showing a prominent subendothelial electron-lucent zone *(arrows)* and mesangiolysis in a case of acute thrombotic microangiopathy (×9000).

Systemic Sclerosis

Systemic sclerosis, progressive systemic sclerosis, or systemic scleroderma are terms used to designate a connective tissue disorder of unknown etiology characterized by multiple organ system involvement. Although a rare disease, with a reported prevalence ranging from 3.1 to 20.8 per 100,000,[458] systemic sclerosis is associated with significant morbidity and mortality. Women are more commonly affected than men, with a ratio of approximately 3 : 1.[459] It may occur at any age but is more common between the fourth and sixth decades of life. The pathogenesis of systemic sclerosis is not fully understood but most likely involves a complex interplay of excessive fibrosis, vascular abnormalities, and abnormalities in the immune system.[460,461] Most patients are ANA positive, which is a rather nonspecific feature. Several other autoantibodies such as RNA polymerase III, antitopoisomerase-1, and anticentromere antibodies are specific markers of systemic sclerosis but are not clearly linked to the pathogenesis of systemic sclerosis.[462] The autoimmune mechanisms in these patients potentially target endothelial cells and fibroblasts. The downstream effects of this targeted injury include increased vascular permeability, endothelial apoptosis, and platelet aggregation, and increased matrix production mediated by fibroblast-derived TGF-β and reduced matrix degradation.

The clinical features of the disease are produced by differing combinations of excessive collagen deposition and vascular disease, the former causing deformation and morbidity, and the latter being the mechanism of most systemic complications. Diffuse form of the disease with widespread cutaneous fibrosis is frequently associated with severe organ involvement while a disease limited to the distal extremities has milder organ involvement. Raynaud syndrome, skin thickening, digital pulp atrophy (sclerodactyly), and telangiectasia are the primary clinical manifestations of systemic sclerosis. Musculoskeletal involvement includes periarticular, tendon, and nerve entrapment, flexion contractures, acral osteolysis, and myopathy. In the gastrointestinal tract, the disease can cause esophageal dysmotility and malabsorption. Pulmonary hypertension and IF, cardiomyopathy, and scleroderma renal crisis are the major causes of mortality. Renal involvement occurs in 60%–70% of the patients.[463,464] Two clinical forms of renal involvement have been recognized: an acute and rapidly progressive form of renal failure often associated with malignant hypertension, systemic vasoconstriction,

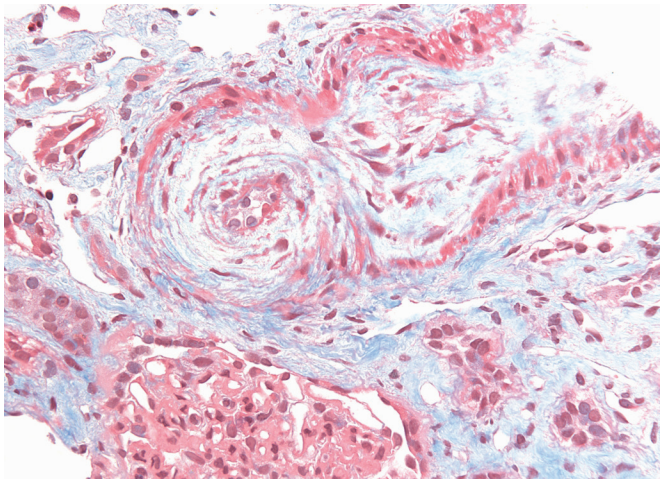

Figure 23.61 Interlobular artery showing stenosing intimal mucoid edema in a patient with systemic sclerosis and acute renal failure (trichrome).

and microangiopathic hemolytic anemia (referred to as scleroderma renal crisis); and a more common, slowly progressive chronic form that is manifested by varying combinations of proteinuria, hypertension, and azotemia.[464–466] Scleroderma renal crisis in most cases can be successfully treated with angiotensin-converting enzyme (ACE) inhibitors and effective blood pressure control, but some patients do progress to end-stage kidney.[465]

The main morphologic changes in scleroderma renal crisis are in the interlobular arteries that show intimal thickening by loose, myxoid fibrous tissue (Fig. 23.61).[440] Subendothelial fibrin deposition and intimal hemorrhage may also be seen. The muscular wall of the artery is usually attenuated and stretched around the excessive intima, and periarterial fibrosis may be prominent. Arterioles frequently exhibit fibrinoid necrosis and thrombosis, which may continue uninterrupted into the glomeruli. The arcuate and interlobar arteries are minimally involved in acute systemic sclerosis renal damage, but in chronic disease, they may show nonspecific, sclerotic intimal thickening that can be difficult to distinguish from normal age-related changes. The glomeruli are typically small and show varying degrees of acute ischemic changes and, on occasion, intracapillary fibrin thrombi. Juxtaglomerular hyperplasia may be prominent, especially in patients with malignant hypertension and hyperreninemia. In the chronic form, varying degrees of glomerulosclerosis, TA, and interstitial scarring are observed.[467]

By electron microscopy, affected blood vessels show intimal widening by amorphous electron-lucent material corresponding to the myxoid ground substance seen by light microscopy. The glomeruli present basement membrane wrinkling with focal widening of the subendothelial area, which may contain fibrin strands. In the chronic form, the vascular lumina of the arteries are narrowed by dense concentric intimal fibroelastosis. Immunofluorescence studies often demonstrate reactivity for fibrinogen, with or without IgM and C3, in the intima of blood vessels and along the glomerular capillaries. Since the renal lesions in systemic sclerosis, HUS, and malignant hypertension can be identical, careful evaluation of the patient's clinical history and laboratory data is essential in establishing the diagnosis.

Renal Diseases of Pregnancy

Renal disease may be initiated or exacerbated during pregnancy. Because of the extent and complexity of the topic and space limitations, only preeclampsia will be discussed here.

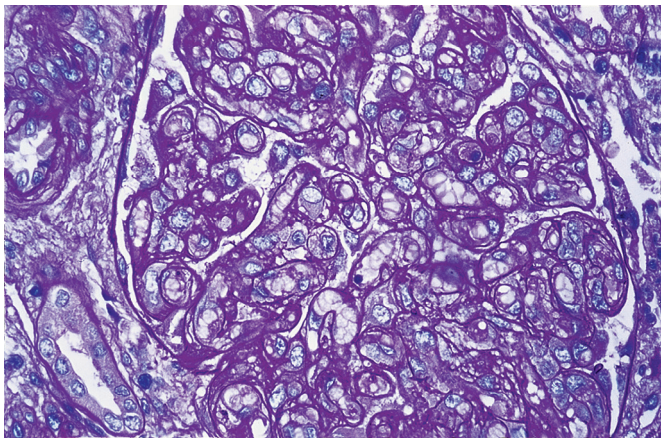

Figure 23.62 Preeclamptic Renal Disease. The glomerular capillary lumina are obliterated by swollen endothelial cells.

Preeclampsia

Preeclampsia is a pregnancy-induced systemic syndrome characterized by new-onset hypertension, proteinuria, and edema that usually occurs after the 20th week of gestation. When the syndrome progresses to a convulsive stage, it is termed eclampsia, and HELLP syndrome refers to a subset of preeclampsia patients with hemolysis, elevated liver enzymes, and low platelets. Preeclampsia affects approximately 3%–5% of pregnancies worldwide. Most cases occur in primigravidas, with an incidence as high as 7.5%.[468,469] Although the etiology of the syndrome remains unknown, recent studies have shown that a reduction of VEGF—caused by an excess circulating antiangiogenic factors, most notably soluble FMS-like tyrosinase kinase (sFlt1) and soluble endoglin, which are highly elevated during preeclampsia—plays an important role in the pathogenesis of the syndrome.[468–470] Derived from placenta, sFlt1 serves as a receptor for VEGF. VEGF is important not only in angiogenesis but is also a critical factor for the maintenance and health of the fenestrated and sinusoidal endothelium found in the renal glomerulus, brain, and liver.[471]

The changes in preeclampsia occur primarily in the glomeruli, which appear characteristically enlarged, swollen, and bloodless, with thickened capillary walls (Fig. 23.62). The bloodless pattern is produced by an intense swelling and hypertrophy of the endothelial and, to a lesser extent, the mesangial cells (endotheliosis).[470] Glomerular cellularity is usually normal or mildly increased. By electron microscopy, the capillary lumens appear narrow or obliterated by swollen endothelium, which often exhibits a loss of its normal fenestration. When mesangial cell hypertrophy is severe, the mesangium may become interposed between the endothelium and the basement membrane. Distinct strands of fibrin are present in translucent subendothelial zones containing loose fibrillar material.[472] Immunofluorescence studies have shown that the deposits in the glomeruli consist mainly of fibrinogen. Immunoglobulins, especially IgM, may on occasion be present due to nonspecific trapping in injured glomeruli. The afferent arterioles and their endothelial cells retain a normal appearance, which is striking in contrast to the swollen, vacuolated glomerular endothelial cells. Patients in whom preeclampsia nephropathy is superimposed on essential hypertension have hypertensive arterial and arteriolar changes in addition to the glomerular lesion.

Preeclampsia usually carries a good prognosis, and the changes in the glomerular capillaries disappear in a few weeks following delivery. Blood pressure falls to normal levels within a month. However, preeclampsia recurs in approximately 20% of subsequent pregnancies.

The clinical presentation of HELLP syndrome in a pregnant woman might indicate an underlying atypical HUS due to mutations in genes encoding alternative complement pathway components or circulating autoantibodies to complement factors.[473] It is being recognized that pregnancy-related stress may serve as a trigger for precipitating atypical HUS in a genetically predisposed individual.

Hereditary Glomerular Diseases

Alport Syndrome

AS (also known as hereditary nephritis) is an inherited type IV collagen disorder of the basement membranes manifested by progressive nephritis associated with deafness and ocular abnormalities.[474–476] In the United States, it accounts for 2.5% of children and 0.3% of adults with ESRD.[140] Males are more commonly affected than females. AS is a genetically heterogeneous disorder. Approximately 85% of the patients have the X-linked dominant form of the syndrome resulting from mutations in the *COL4A5* gene located at Xq22, which encodes the α5 chain of type IV collagen. Most of the remaining patients have autosomal recessive AS due to mutations in either the *COL4A3* or *COL4A4* genes, while only a minority of families exhibit the autosomal dominant disease that also arises from mutations in these genes.[477–481] To date, over 800 different mutations have been identified in X-linked dominant AS by different groups of investigators in various parts of the world.[475,480]

The disorder is usually manifested in children and young adults by recurrent microscopic or gross hematuria. Although proteinuria is usually mild, in advanced stages of the disease it can be in the nephrotic range. In males, the disease is usually progressive. In X-linked disease, the risk for males progressing to ESRD before the age of 40 is 90% compared with only 12% in females,[475,482] and the location of the mutation appears to determine the age of onset of ESRD.[483] In autosomal recessive AS, females are affected as severely and as early as males with X-linked disease. While patients with autosomal dominant disease show a great variability in their clinical course, this is generally milder than in males with X-linked AS. Bilateral high-frequency sensorineural hearing loss is the most common extrarenal manifestation of AS, often occurring in childhood in males, with females being affected later in life. Hearing impairment is always accompanied by renal involvement, but there is no relationship between the severity of the hearing loss and renal disease. Ocular abnormalities occur in 15%–30% of patients and appear to be confined to juvenile kindreds.[483,484]

Other uncommon variant of AS includes its association with diffuse leiomyomatosis (esophagus, tracheobronchial tree, and urogenital tract), which has been reported in 2%–3% of families with the juvenile form of the disease.[474,485] After transplantation, 3%–5% of males with AS develop anti-GBM nephritis, presumably because tolerance for the normal GBM antigen has not been acquired at birth.[475,486] Most patients with X-linked AS and anti-GBM nephritis in the allograft have antibodies to the NC1 domain of the α5 chain of collagen IV, but antibodies against the NC1 domain of the α3 chain have also been reported.[487]

The light microscopic features in the kidney are nonspecific, and the diagnosis depends on the electron microscopic and immunofluorescence findings. In biopsies taken in the early stage of the disease, the glomeruli appear normal or may show mild mesangial hypercellularity with minor thickening of the capillary walls. As the disease progresses, however, the glomeruli undergo segmental and global sclerosis. Tubulointerstitial changes appear relatively early, and consist of irregular areas of nonspecific sclerosis. The presence of interstitial foam cells in the absence of nephrotic-range proteinuria is a characteristic but nonspecific feature of AS (Fig. 23.63).

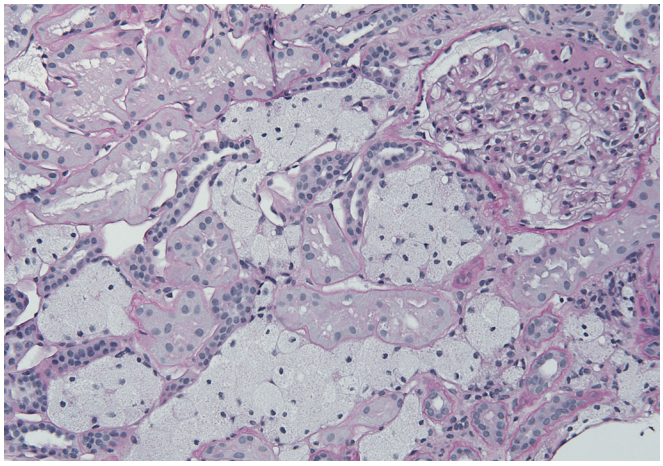

Figure 23.63 Interstitial foam cells and focal segmental glomerulosclerosis in a patient with microscopic hematuria and ultrastructural features of Alport syndrome (PAS).

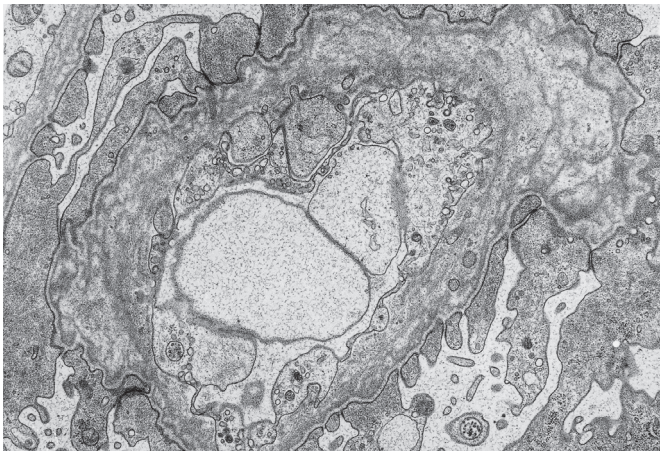

Figure 23.64 Glomerular capillary loop showing diffuse, irregular, thickening of the glomerular basement membrane. The lamina densa is split into multiple interwoven lamellae (×11,400).

The most specific finding of AS can only be seen by electron microscopic examination of the glomeruli. The typical lesion is thickening of the GBM with transformation of the lamina densa into multiple interwoven lamellae (Fig. 23.64). The epithelial aspect of the basement membrane often has a scalloped appearance, whereas the endothelial surface is usually smooth. The typical lesion of the GBM occurs in most but not all patients with AS. Affected young males and heterozygous females of any age may only have attenuated GBM measuring as little as 100 nm or even less,[488] representing the earliest manifestation of disease; the extent and severity of the multilamellation increases with age. Some authors have found a correlation between the percentage of the GBM having a splitting of the lamina densa and the degree of proteinuria in patients with AS, which suggests that the increased permeability of the GBM to protein is the functional consequence of the GBM alteration.[489] Although multilamellation of the GBM suggests hereditary nephritis, it can also be seen in other conditions, such as in the resolving stages of MGN and in IgAN-associated GBM repair.[490]

The panel of antibodies used in routine immunofluorescence studies usually fails to show any reactivity, although small and

Table 23.6 Immunohistochemical findings in the basement membranes of patients with Alport syndrome using antibodies to α3, α4, and α5 chains of type IV collagen

	GLOMERULAR BASEMENT MEMBRANE	BOWMAN'S CAPSULE	DISTAL TUBULAR BASEMENT MEMBRANE	EPIDERMAL BASEMENT MEMBRANE
Normal (Both Sexes)				
α3 (or α4)	Present	Present	Present	Absent
α5	Present	Present	Present	Present
X-Linked (Males)[a]				
α3 (or α4)	Absent	Absent	Absent	Absent
α5	Absent	Absent	Absent	Absent
X-Linked (Females)[b]				
α3 (or α4)	Mosaic	Mosaic	Mosaic	Absent
α5	Mosaic	Mosaic	Mosaic	Mosaic
Autosomal Recessive (Both Sexes)[c]				
α3 (or α4)	Absent	Absent	Absent	Absent
α5	Absent	Present	Present	Present
Autosomal Dominant (Both Sexes)				
α3 (or α4)	Present	Present	Present	Absent
α5	Present	Present	Present	Present
Thin Basement Membrane Nephropathy (Both Sexes)				
α3 (or α4)	Present[d]	Present	Present	Absent
α5	Present[d]	Present	Present	Present

[a]Approximately 10% of males with X-linked AS (attributable to missense and intron mutations) exhibit positive immunostaining of the renal basement membranes for the α3, α4, and α5 chains, and the epidermal basement membranes for the α5 chain.
[b]Approximately 30% of females with X-linked AS exhibit positive uninterrupted immunostaining (with reduced intensity in some) of the renal basement membranes for the α3, α4, and α5 chains, and the epidermal basement membranes for the α5 chain.
[c]Some patients with autosomal recessive AS exhibit positive immunostaining (but reduced intensity) of the renal basement membranes for the α3, α4, and α5 chains.
[d]Some patients with thin basement membrane disease exhibit reduced intensity staining of the glomerular basement membranes for the α3, α4, and α5 chains.
Modified from Kashtan CE. The nongenetic diagnosis of thin basement membrane nephropathy. *Semin Nephrol*. 2005;25:159–162.

scattered deposits of IgM and C3 can sometimes be seen in partially sclerosed glomeruli. Staining for specific monoclonal antibodies directed against different subunits of type IV collagen has greatly facilitated the diagnosis of AS.[491,492] Kidneys from individuals who are not affected by AS show strong continuous immunostaining with antibodies to the α3, α4, and α5 chains along the GBM, and the basement membrane of the Bowman capsule and the distal convoluted tubules. This reactivity is absent in male patients with X-linked AS. Skin biopsies examined by immunofluorescence can also be an important diagnostic tool since the α5 chain is expressed in the normal epidermal basement membrane but not in X-linked AS patients. Therefore, in male patients with a clinical and familial history suggestive of X-linked AS, skin examination for the α5 chain may obviate the necessity for a kidney biopsy. It should be borne in mind, however, that some affected males do retain the expression of the α5 chain in their basement membranes.[493] A mosaic staining pattern (interrupted or segmentally weaker staining) for the α5 chain is frequently seen in the epidermal and renal basement membranes of heterozygous females with X-linked AS, reflective of random inactivation of X chromosome in females. While this finding is diagnostic of the carrier state, a normal result does not exclude heterozygosity. The immunofluorescence/immunohistology findings in the basement membranes of patients with AS are summarized in Table 23.6.

When the diagnosis of AS cannot be unequivocally excluded on a kidney biopsy or if a female relative of a patient with X-linked AS is suspected to be the carrier of the disease, genetic testing should be performed. The sensitivity of the linkage analysis is only 60%, but the next-generation sequencing has proven to be vastly more sensitive (90%) in detecting the mutations in AS, especially in patients with autosomal dominant AS.[480] Genetic testing is increasingly considered standard of care in all patients suspected of AS and thin basement membrane nephropathy (TBMN).[494]

Thin Basement Membrane Nephropathy

The descriptive term TBMN is used to designate a hereditary renal disease that is characterized by the uniform thinning of the GBM and normal patient survival without deterioration of renal function. Benign familial hematuria is another designation that has also been

used for this condition; however, it is now considered inappropriate since it could embrace other pathologic entities, such as familial cases of IgAN, in which the prognosis is not always benign. Although TBMN has generally been considered an autosomal dominant hereditary condition, recent genetic studies indicate that it is a heterogeneous disease with some being related to mutations in the *COL4A3* and *COL4A4* genes with autosomal recessive inheritance.[495,496] It has been shown that patients with TBMN exhibiting these *COL4A3 and COL4A4* mutations are in fact carriers of autosomal recessive AS, and thus TBMN falls within the spectrum of type IV collagen diseases.[497,498] These findings further emphasize the importance of genetic testing in TBMN.[494]

TBMN is the most common cause of persistent hematuria in children and adults, and although its true incidence is unknown, it has been estimated that it affects at least 1% of the population.[499,500] Both sexes are equally affected, and even though it can manifest at any age, it is seldom reported after the age of 50 years. The onset of the hematuria is usually in childhood, and it is typically microscopic and persistent; however, on occasion, it may be macroscopic and recurrent.[499] Mild proteinuria is not uncommon, but heavy proteinuria in the nephrotic range is rare. Severe proteinuria likely represents a manifestation of a coexistent glomerular lesion, such as MCD, IgAN, focal glomerulosclerosis, or MGN.[501] In contrast to patients with AS, those with TBMN have only rarely been reported to exhibit extrarenal manifestations of AS.[499]

Aside from finding erythrocytes in the Bowman space and renal tubules, renal biopsies appear normal by light microscopy.[492,502] The diagnosis is made by the ultrastructural demonstration of a uniform thinning of the lamina densa of the GBM (Fig. 23.65). The overall width of the GBM is reduced to one-third or is ≤200 nm.[492,498,502] Immunofluorescence studies are usually negative for immunoglobulins and complement components, but deposits of IgM and IgG, with and without C3, have occasionally been reported.[502] Immunohistochemical evaluation for type IV collagen may assist in distinguishing TBMN from AS. A normal distribution of type IV collagen α chains is supportive of the diagnosis of TBMN.[492]

Fabry Disease

Fabry disease, also known as Anderson–Fabry disease and angiokeratoma corporis diffusum universalis, is an uncommon inherited X-linked disorder caused by a deficiency of the enzyme α-galactosidase A found in lysosomes. This results in the accumulation of the neutral glycosphingolipid Gb3 in the lysosomes of many tissues, including the kidneys, heart, neurons of the dorsal root of ganglia, and blood vessels in affected males and, to less extent, in female carriers. The incidence of the disease has been estimated to range from 1 in 40,000 to 1 in 117,000 live male births. About 5% of the cases are sporadic. More than 500 mutations of the α-galactosidase gene located on chromosome Xq22.1 have been described and most are family specific.[503] The most common presenting symptoms of the disease in children or adolescents are painful paresthesias in the lower extremities, hypohidrosis or anhidrosis, corneal opacities, and skin lesions that consist of small angiokeratomas scattered throughout the body, especially the abdomen, buttocks, lips, genitalia, and upper thighs. These patients have little or no α-galactosidase A enzyme activity. In contrast, males with residual α-galactosidase A enzyme present with renal failure and cardiac disease in the fourth decade of life. Female carriers, being heterozygous for the genetic abnormality, are usually only mildly affected, with rare occurrence of end-stage kidney disease.

Renal involvement is often manifested by hematuria and proteinuria in the second decade of life, followed by gradual deterioration of renal function in the third and fourth decades. Death occurs around the fifth decade from renal, cardiac, or cerebrovascular involvement. Recurrence in the transplanted kidney has been reported, but there is no indication that this event has a significant impact on long-term allograft survival in most patients.[504] Treatment of extrarenal disease includes enzyme replacement therapy with recombinant α-galactosidase.[505,506]

On light microscopy, the visceral epithelial cells are enlarged and vacuolated, giving a honeycomb appearance to the glomeruli. Similar changes are seen in the parietal epithelium, and in endothelial and mesangial cells (Fig. 23.66). There is also prominent vacuolization in the distal convoluted tubules and loops of Henle, as well as in the arteries. The vacuoles in each of these locations are PAS negative. With increasing age, there is segmental and global glomerulosclerosis with interstitial scarring and nodular arteriolar hyalinosis. Electron microscopy demonstrates a massive accumulation of laminated

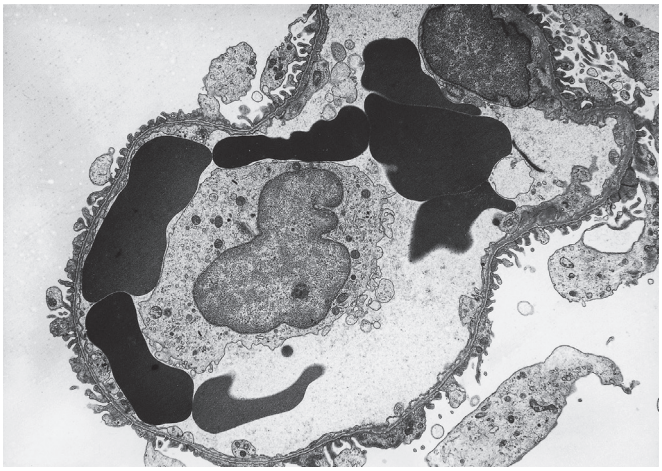

Figure 23.65 Capillary loop showing marked uniform thinning of the glomerular basement membrane (×4200). (Reproduced from Spargo BH, Seymour AE, Ordóñez NG. *Renal Biopsy Pathology with Diagnostic and Therapeutic Implications*. New York, NY: John Wiley and Sons; 1980:398. By permission of John Wiley and Sons, Inc.)

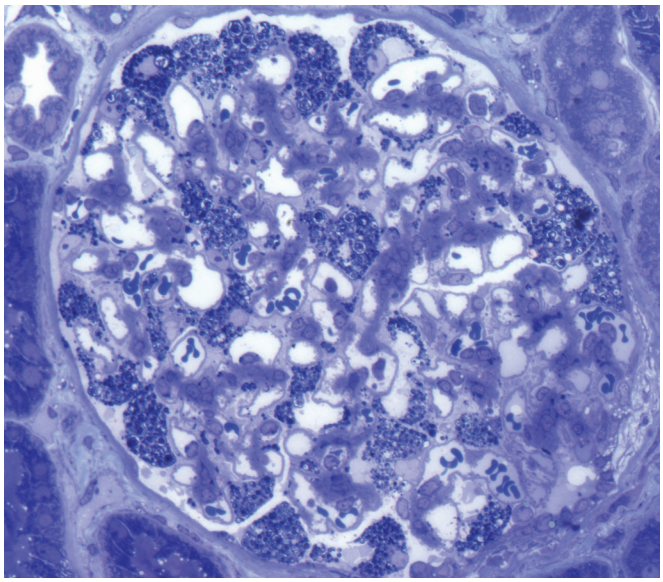

Figure 23.66 Plastic-embedded semi-thin section of a portion of a glomerulus stained with toluidine blue showing numerous deeply stained visceral epithelial cell inclusions in a case of Fabry disease.

Figure 23.67 Portion of a glomerulus from a patient with Fabry disease demonstrating numerous laminated inclusions in the epithelial cell cytoplasm (×7750).

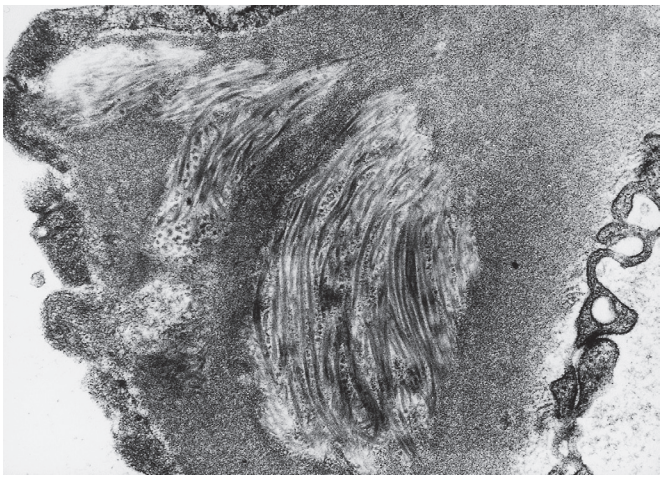

Figure 23.68 Collagen-like fibers in the glomerular basement membrane in nail–patella syndrome (×35,000). (Reproduced from Spargo BH, Seymour AE, Ordóñez NG. *Renal Biopsy Pathology with Diagnostic and Therapeutic Implications*. New York, NY: John Wiley and Sons; 1980:400. By permission of John Wiley and Sons, Inc.)

inclusion bodies in the cytoplasm of the affected cells. Each is surrounded by a single unit membrane and measures up to 5 μm in diameter. They are either round with a concentric myelin-like structure, or ovoid with parallel layers ("zebra" bodies) (Fig. 23.67). Similar inclusions are present outside of the glomeruli in the endothelial and smooth muscle cells of blood vessels, and in the tubular epithelium, especially those of the convoluted tubule and the loops of Henle. Although the ultrastructural pattern is almost diagnostic of the disease, similar inclusions are seen in other conditions such as chloroquine toxicity and I-cell disease[507,508] and, hence the importance of clinical and biochemical correlation.

Nail–Patella Syndrome

Nail–patella syndrome (NPS; also known as hereditary onychoosteodysplasia) is an uncommon autosomal dominant disorder defined by the association of nail dysplasia, absent or hypoplastic patella, elbow dysplasia, iliac horns, open angle glaucoma, and nephropathy.[509] It is caused by mutations of the *LMX1B* gene located on chromosome 9q34.1. T[510] The *LMX1B* gene encodes LIM homeodomain transcription factor expressed in podocytes and is crucial in limb development. The incidence of the syndrome has been estimated to be 1 per 50,000 live births. Nail dysplasia is the most constant feature of the syndrome and can be observed at birth, but nephropathy and glaucoma are the most relevant clinical manifestations. Renal involvement occurs in about 30%–50% of patients.[511,512] Asymptomatic proteinuria is the most common event, but the nephrotic syndrome can occur and some patients progress to renal failure.[512]

Light microscopy of the kidney shows nonspecific changes such as focal thickening of the glomerular capillary walls and FSGS. By electron microscopy, the GBM appears irregularly thickened and often exhibits electron-lucent areas, giving it the so-called moth-eaten appearance. Collagen-like fibers are seen in the electron-lucent areas and in the mesangium, further enhanced by phosphotungstic acid stain (Fig. 23.68). The LIM homeodomain transcription factor regulates the transcription of type IV collagen and podocyte proteins, thus contributing to these ultrastructural changes. No recurrences of the renal changes have been reported after transplantation.[513]

Collagen Type III Glomerulopathy

Collagen type III glomerulopathy (also known as collagenofibrotic glomerulopathy)[514] is an idiopathic glomerular disease that is characterized by the massive accumulation of atypical type III collagen fibrils within the mesangial matrix and subendothelial space and an increase in serum type III procollagen peptide levels. This type of collagen is absent in normal human kidneys. Although initially thought to be a clinical variant of NPS, it is now considered to be a separate clinicopathologic entity.[515] Collagen type III glomerulopathy occurs in both familial and sporadic forms, and the familial cases show an autosomal recessive pattern of inheritance.[516–518] The disease affects both sexes equally and manifests during childhood. Children often present with increasing proteinuria leading to the nephrotic syndrome, hypertension, and progressive renal failure.[514,517] An important feature in these patients is that they may develop HUS,[517] and associated inherited factor H deficiency has been documented in the literature.[519] In adults, the disease is often sporadic and has a more indolent course.

Light microscopy shows a diffuse increase in the mesangial matrix and generalized widening of the glomerular capillary walls, sometimes associated with mesangial cell interposition. By electron microscopy, there is a large accumulation of fibrils in the subendothelial aspect of the GBM and in the mesangial matrix. These curvilinear fibrils have a distinctive transverse band periodicity of approximately 60 nm, characteristic of type III collagen. Conventional immunofluorescence studies are either negative or show nonspecific deposits of immunoglobulins, especially IgM and complement components. The most important diagnostic feature is the presence of strong mesangial and capillary loop reactivity with anticollagen type III antibodies. Type III collagen deposition can also be seen in other organs, including the liver, spleen, myocardium, and thyroid gland.[520,521]

Fibronectin Glomerulopathy

Fibronectin glomerulopathy is an autosomal dominant disease with age-related penetrance, characterized by massive fibronectin deposition in the glomeruli.[522–524] Both sexes are equally affected, and in approximately 40% of the patients, it is caused by mutations of the *FN1* gene located on chromosome 2q34.[525] Clinically, the disease

usually manifests as proteinuria (often within the nephrotic range), microscopic hematuria, and the slow deterioration of renal function that occurs over a period of several years.

By light microscopy, the glomeruli appear enlarged and lobulated, with a minimal degree of hypercellularity. The most characteristic feature is a marked enlargement of the mesangium and subendothelial space, resulting from the deposition of a homogeneous PAS-positive, Congo red–negative material that, by electron microscopy, has a dense granular appearance. Intermixed within the deposits are focal filamentous structures measuring 12–16 nm in diameter. Immunohistochemical or immunofluorescence studies demonstrate strong positivity for fibronectin in the areas corresponding to the deposits, but immunoglobulins and complement deposition are absent or scant at best. The disease has been reported to recur after renal transplantation, and an underlying abnormality in the metabolism of circulating fibronectin is involved in the pathogenesis of this condition.[526] The *FN1* mutations detected thus far affect the heparin-binding domains of the fibronectin, causing conformational changes to the protein. It has been suggested that the mutant fibronectin deposited in the glomerulus results in defective endothelial spreading and podocyte cytoskeletal organization, contributing to the proteinuria.[525,527]

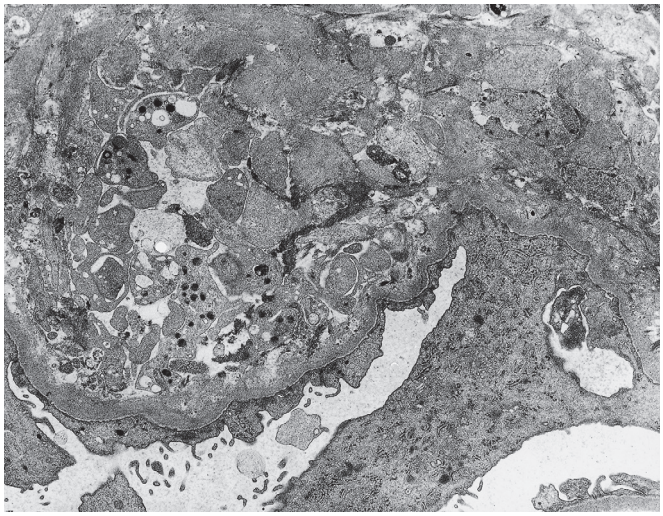

Figure 23.69 Hyperacute Rejection. There is endothelial denudation of the glomerular basement membrane and capillary occlusion by degranulated platelets (×7980).

Renal Transplant Pathology

Renal biopsies on transplanted kidneys are performed to determine: (1) whether the failure of the graft is due to rejection, nephrotoxicity caused by immunosuppressive drugs (i.e., cyclosporine A [CsA], tacrolimus), or other causes, such as acute tubular necrosis (ATN), acute infectious pyelonephritis, obstruction of the vasculature or urinary outflow tract, or recurrent or de novo glomerular disease; or (2) if rejection is present, to evaluate the intensity and nature of the rejection and to predict the potential reversibility of the lesions with therapy.

Allograft Rejection

Traditionally, rejection has been classified as hyperacute, acute, and chronic. Hyperacute rejection is antibody-mediated, while acute and chronic rejections can be either T-cell mediated (cellular rejection) or antibody mediated (humoral).

Hyperacute Rejection

Hyperacute rejection may occur within minutes or hours after revascularization, the immediate result being the abrupt cessation of urine flow. The diagnosis may be obvious to the surgeon with mottling cyanosis and diminished turgor in the graft. The reaction is produced by the interaction of preformed circulating antibodies in the recipient with antigens on donor endothelial cells such as HLA, ABO, and other less characterized endothelial antigens.[528,529] These preformed antibodies are often related to previous pregnancies, blood transfusions, or previous kidney transplant.[530] The introduction of routine transplant screening and cross-matching techniques has made this a rare complication, with an estimated incidence of less than 0.5% of transplants.[530,531]

In hyperacute rejection, fibrin thrombi are present in all the renal vessels, including the glomerular and peritubular capillaries. Early features (1–12 hours after implantation) may be limited to platelet and neutrophil margination in these vascular spaces. The thrombosis is associated with infarction and cortical and medullary tubular necrosis. These histologic features resemble those of severe acute AMR. Immunofluorescence may show linear staining for IgM or IgG and C3 along the glomerular and peritubular capillaries. Positive staining for C4d in peritubular capillaries supports the diagnosis, but poor perfusion and tissue necrosis often precludes demonstration of C4d deposition. Electron microscopy shows platelets, fibrin, sludged red blood cells, and evidence of necrosis of the endothelial cells of glomerular capillaries and other vessels (Fig. 23.69).[530]

Acute Rejection

Acute rejection, despite its name, can occur at any time during the post-transplantation period. It is most often seen in the months following implantation and becomes less common after the first year. Two types of acute allograft rejection are recognized: antibody mediated and T-cell mediated.

AMR is caused by anti-donor-specific antibodies (DSAs) directed against graft endothelium in glomeruli and peritubular capillaries. The target antigens are HLA class I and II molecules and in ABO-incompatible grafts, ABO antigens.[530] Less common endothelial cell–specific antigens, angiotensin II type I receptor, and other non-MHC antigens have also been implicated. Early on, these pathogenic DSAs are preformed in recipient circulation (resulting in positive cross match) but late post-transplant acute AMR is caused by *de novo* DSA.[532] The histologic features of acute AMR are mainly in glomeruli, peritubular capillaries, and arteries. The glomeruli show endothelial cell swelling, an increase in cellularity, and occasional fibrin thrombi.[533] The peritubular capillaries are dilated with intraluminal cells, referred to as "peritubular capillaritis" (Fig. 23.70). Neutrophils and monocytes predominate the glomerular and peritubular capillary infiltrate.[534] The arteries (and arterioles) may show endothelialitis or fibrinoid necrosis.[530] Interstitial hemorrhage, tubular necrosis, and infarction are also seen, but interstitial inflammation and tubulitis are not predominant features unless combined with T cell–mediated rejection. On occasion, the histology of acute AMR is limited to acute tubular injury alone. Electron microscopy demonstrates endothelial cell swelling associated with separation of the endothelium from the basement membrane by fluffy fibrillar material, which occasionally contains fibrin strands and platelet fragments (Fig. 23.71). The immunofluorescence or immunohistochemical demonstration of C4d deposition in graft peritubular capillaries is a durable and reliable marker of AMR, circulating anti-donor antibodies, and poor graft survival (Fig. 23.72).[11,534,535] C4d is a 44.5-kDa

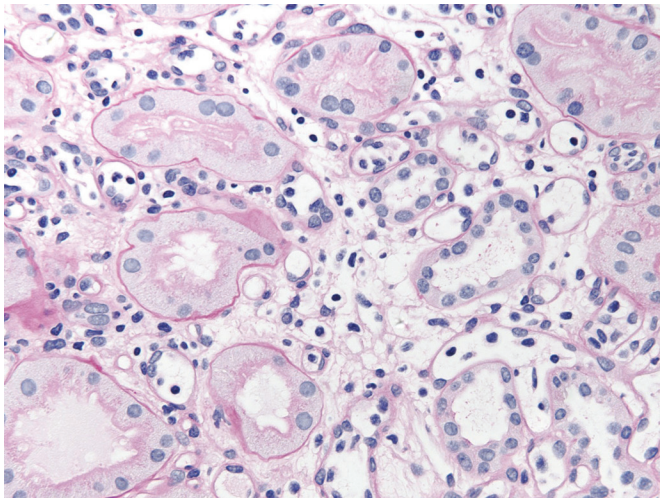

Figure 23.70 Peritubular Capillaritis With Dilated Capillaries and Intraluminal Mononuclear Cells. Prominent interstitial edema is also seen (PAS).

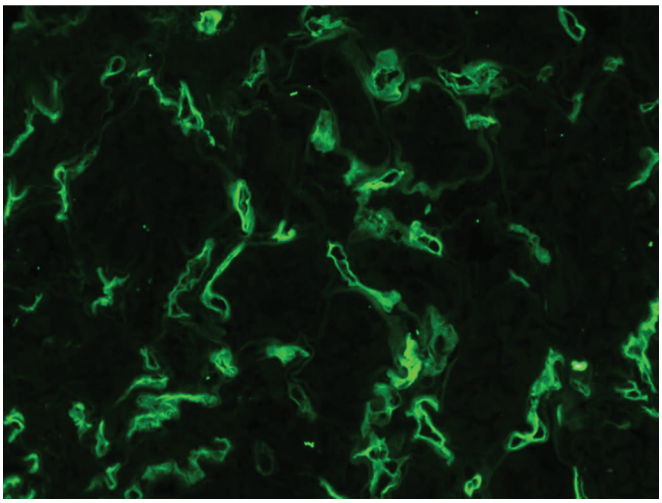

Figure 23.72 Immunofluorescence microscopy testing with antibody to C4d shows diffuse peritubular capillary wall staining (anti-C4d).

Figure 23.71 Endothelial Injury in Antibody-Mediated Rejection. Portion of a glomerulus showing prominent widening of the subendothelial region by electron lucent material *(arrows)* (×3500).

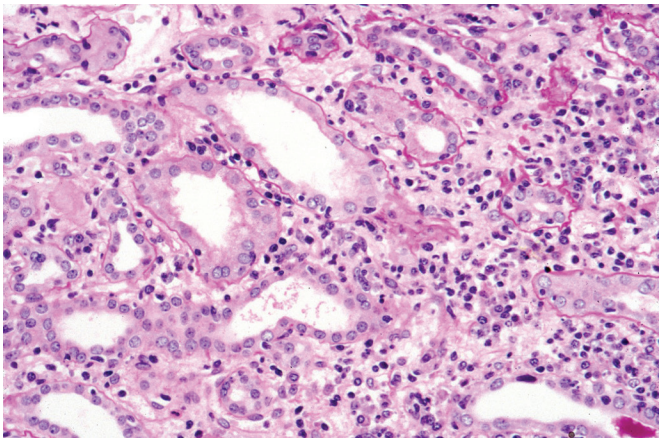

Figure 23.73 Tubulointerstitial T cell–mediated acute rejection with interstitial edema and inflammation. Intraepithelial lymphocytes are seen in the tubules and many demonstrate acute injury with dilated lumens and brush border loss (PAS).

stable inactive degradation product of the complement factor C4 that is formed when the classic complement cascade is activated by binding of DSA to the endothelium of the graft.[536] Overall, immunofluorescence method is more sensitive than the immunohistochemical method, and it is taken into account in the scoring of positive C4d staining in peritubular capillaries.[537] Interestingly, diffuse peritubular capillary C4d is a constant feature in ABO-incompatible grafts, even in the absence of other histologic features of AMR, likely representing an accommodation reaction.[538] It is increasingly being recognized that AMR can occur in the absence of C4d deposition, prompting further study of C4d-negative AMR.[539,540] AMR is not steroid responsive, and treatment modalities have included plasmapheresis, IV immunoglobulin, rituximab, and more recently, complement inhibition.

In the early stages of **acute T cell–mediated rejection**, light microscopy reveals edema and focal infiltration of the interstitium by lymphocytes (Fig. 23.73). As the rejection progresses, the inflammatory infiltrate becomes more diffuse and the lymphocytes, many of them immunoblasts, are accompanied by plasma cells, monocytes, and macrophages. Granulocytes may be present, but they are not numerous. When they are abundant, the possibility of AMR or pyelonephritis should be considered.[541] Eosinophils can also be present but rarely in large numbers. A characteristic finding in acute T cell–mediated rejection is invasion of the tubular epithelial cells by lymphocytes, a feature referred to as tubulitis. Tubulitis has been regarded as a reliable marker for acute rejection even though it can be seen in other forms of interstitial nephritis.[541,542] The intensity of the infiltrate and tubular injury are features often used to grade the rejection. The infiltrate is more concentrated in the cortex than in the renal medulla. Immunophenotyping shows that most of the

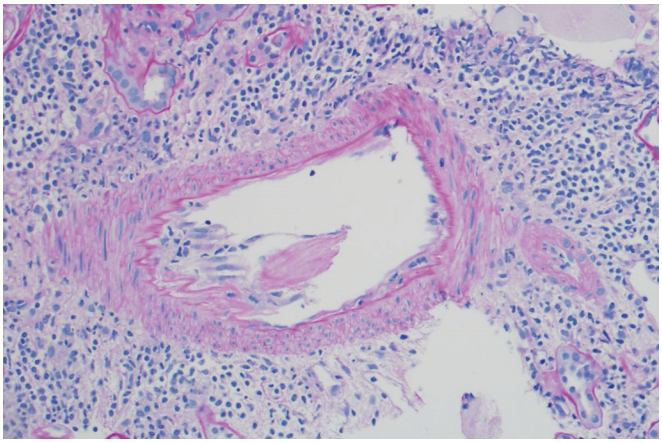

Figure 23.74 Acute Vascular Rejection (Banff IIA). An interlobular artery with intimal arteritis (PAS).

lymphoid cells are T lymphocytes, and as many as 60%–80% are CD8-positive cells, the remainder being CD4-positive T lymphocytes, plasma cells, and monocytes/macrophages. This immunologic tissue injury mediated by T cells is directed against MHC and non-MHC donor antigens. Immunofluorescence is generally negative, except for focal fibrin in affected vessels in a few cases and immunoglobulins in inflammatory cells. C4d stain is negative in a pure T cell–mediated rejection. Electron microscopy shows tubular damage and regeneration, and many inflammatory cells in the interstitium. Glomeruli are usually spared, but mononuclear cells in glomeruli (i.e., glomerulitis) can on occasion be a feature of T cell–mediated rejection and is unclear if it represents a component of AMR. Tubulointerstitial rejection that is predominantly T-cell mediated is considered readily reversible with pulse steroid therapy.

Mononuclear cells may infiltrate beneath the endothelium of arteries or arterioles, and it signifies early vascular rejection (Fig. 23.74). The cells are typically CD3+ T cells or CD68+ monocytes/macrophages. Associated swelling and vacuolization of vascular endothelial cells are often present, and the adjacent smooth muscle cells may show vacuolization caused by dilation of the endoplasmic reticulum. The intimal changes can be accompanied by either thrombosis or intimal proliferation. Thromboses are often small and nonocclusive, but in those cases progressing to irreversible rejection, they become obliterative and widespread with transmural necrosis of the vessel walls. Milder forms of intimal arteritis are often considered T-cell mediated, while AMR likely mediates most cases of transmural arteritis. Endarteritis is usually present in the background of severe tubulointerstitial inflammation. On occasion, it is observed with little or no interstitial inflammation (isolated endarteritis), and recent data suggest these cases mimic the behavior and survival of T cell–mediated tubulointerstitial and vascular rejection.[543] The diagnostic criteria and scoring of cellular rejection and AMR are delineated in Box 23.6.

Although it is convenient for descriptive purposes to consider the two types of allograft rejection reactions separately, many cases are a combination of antibody- and T cell–mediated changes. Since the T cell–mediated component of allograft rejection is more responsive to some forms of therapy than the antibody-mediated form, it is important to identify and, as far as possible, quantitate the relative contribution of the two components. This is essential in assisting the clinician in determining the appropriate form of treatment. It is also of importance in studying follow-up biopsies after therapy, particularly when the therapeutic response has not been favorable.

Chronic Rejection

Chronic rejection occurs anywhere from several months to several years after transplantation and, once initiated, can be progressive and irreversible. It constitutes the most common cause of graft failure after the initial 6–12 months post transplantation. Chronic rejection is not a distinct entity but rather the end stage of repeated episodes of acute antibody- and/or T cell–mediated rejection.[544] In addition, long-term administration of CsA or tacrolimus probably contributes to the development of some of the changes seen in chronic rejection.

Clinically, there is a gradual decrease in renal function. The deterioration may be preceded by proteinuria, sometimes nephrotic range,[545] and is commonly associated with hypertension. Microscopically, the changes can be seen in glomeruli, arteries, and tubulointerstitium. Nonspecific features of TA and IF may be accompanied by features of underlying T cell–mediated rejection such as interstitial inflammation and tubulitis in nonatrophic cortex. The blood vessels, especially the interlobular and arcuate arteries, show severe obliterative fibrointimal proliferation or mucoid widening of the intima, referred to as chronic transplant arteriopathy.[541] Fibrosis of the media and intimal foam cells may be seen, but reduplication of the elastic lamina is typically a feature of hypertensive arteriosclerosis. The distribution of the vascular lesions is irregular and some blood vessels appear normal while others present lesions of variable degrees of severity. The glomerular lesions consist of ischemic glomerular capillary collapse, and segmental and global sclerosis.[546] While these changes described may be present in T cell– or antibody-mediated alloimmune injury, the hallmarks of chronic AMR are transplant glomerulopathy and peritubular capillaropathy.[541] Reflective of repeated insults to the glomerular and peritubular capillary endothelium, this histologic evidence of chronic AMR is often accompanied by positive C4d stain in peritubular capillaries and circulating DSA.[539] Transplant glomerulopathy is characterized by duplication of GBMs, often accompanied by mononuclear glomerulitis and peritubular capillaritis (Fig. 23.75). The capillary walls are thickened due to marked widening of the subendothelial space or mesangial interposition, better demonstrated by silver staining or electron microscopy. Similar multilamination of peritubular capillary basement membranes is evident on electron microscopy.[547] No immune complexes are seen, although immunofluorescent studies occasionally show linear or granular deposition of IgM, IgG, and complement components. Peritubular capillary C4d deposition in chronic AMR may be patchy and focal, perhaps in part due to loss of peritubular capillaries with repeated endothelial insults. Of note, immunohistochemical staining of glomerular endothelium with C4d suggests chronic AMR, especially if immune complex glomerulonephritis is excluded.

The Banff Classification

To help establish uniform therapeutic guidelines for clinical management and to provide an objective evaluation of clinical trials of new antirejection agents, several classification systems for the evaluation of the histologic appearance of renal allograft biopsies have been developed over the past several decades. The best known of these is the Banff Working Classification of Renal Allograft Pathology, which was formulated by an international group of renal pathologists, nephrologists, and transplant surgeons who met in Banff, Canada, in August, 1991, and which was first published in 1993.[548] Since its introduction, this classification has undergone several revisions, the latest of which was published in 2014.[540]

Per Banff classification, there are six diagnostic categories: normal, AMR, borderline changes, T cell–mediated rejection, IF and TA without evidence of any specific etiology, and other changes not considered

Box 23.6 Banff diagnostic categories for renal allograft biopsies

1. Normal
2. ABMR
   Hyperacute rejection
   Acute/active ABMR; all three features must be present for diagnosis
   a. Histologic evidence of acute tissue injury, including one or more of the following:
      Microvascular inflammation (*g* > 0 and/or ptc > 0), intimal or transmural arteritis (*v* > 0), acute thrombotic microangiopathy, in the absence of any other cause, acute tubular injury, in the absence of any other apparent cause
   b. Evidence of current/recent antibody interaction with vascular endothelium, including at least one of the following:
      Linear C4d staining in peritubular capillaries (C4d2 or C4d3 by IF on frozen sections, or C4d > 0 by IHC on paraffin sections[a]), at least moderate microvascular inflammation ([*g* + ptc] ≥ 2), increased expression of gene transcripts in the biopsy tissue indicative of endothelial injury, if thoroughly validated
   c. Serologic evidence of DSAs (HLA or other antigens)
   Chronic, active ABMR; all three features must be present for diagnosis
   a. Morphologic evidence of chronic tissue injury, including one or more of the following:
      TG (cg > 0), if no evidence of chronic thrombotic microangiopathy due to other causes, severe peritubular capillary basement membrane multilayering (requires EM), arterial intimal fibrosis of new onset, excluding other causes
   b. Evidence of current/recent antibody interaction with vascular endothelium, including at least one of the following:
      Linear C4d staining in peritubular capillaries (C4d2 or C4d3 by IF on frozen sections, or C4d > 0 by IHC on paraffin sections), at least moderate microvascular inflammation ([g + ptc] ≥ 2), increased expression of gene transcripts in the biopsy tissue indicative of endothelial injury, if thoroughly validated
   c. Serologic evidence of DSAs (HLA or other antigens)
   C4d staining without evidence of rejection; all three features must be present for diagnosis
      Linear C4d staining in peritubular capillaries (C4d2 or C4d3 by IF on frozen sections, or C4d > 0 by IHC on paraffin sections[a]), g = 0, ptc = 0, cg = 0 (by light microscopy and by EM if available), v = 0; no thrombotic microangiopathy, no peritubular capillary basement membrane multilayering, no acute tubular injury (in the absence of another apparent cause for this), no acute T cell–mediated rejection (Banff 97 type 1A or greater) or borderline changes
3. Borderline changes: "Suspicious" for acute T cell–mediated rejection
   Focal moderate tubulitis with mild interstitial inflammation or interstitial inflammation with focal mild tubulitis (not meeting criteria for type IA); no intimal arteritis
4. T cell–mediated rejection
   Acute T cell–mediated rejection
      Type IA: Significant interstitial infiltration (>25% of parenchyma affected) and foci of moderate tubulitis (5–10 mononuclear cells/tubular cross section)
      Type IB: Significant interstitial infiltration (>25% of parenchyma affected) and foci of severe tubulitis (>10 mononuclear cells/tubular cross section)
      Type IIA: Mild to moderate intimal arteritis comprising <25% of the luminal area (v1)
      Type IIB: Severe intimal arteritis comprising >25% of the luminal area (v2)
      Type III: "Transmural" arteritis and/or arterial fibrinoid change and necrosis of medial smooth muscle cells with accompanying lymphocytic inflammation (v3)
   Chronic active T cell–mediated rejection
      "Chronic allograft arteriopathy" (arterial intimal fibrosis with mononuclear cell infiltration in fibrosis, formation of neo-intima)
5. Interstitial fibrosis and tubular atrophy, no evidence of any specific etiology
   I. Mild interstitial fibrosis and tubular atrophy (<25% of cortical area)
   II. Moderate interstitial fibrosis and tubular atrophy (26%–50% of cortical area)
   III. Severe interstitial fibrosis and tubular atrophy/loss (>50% of cortical area)
6. Other
   Changes not considered to be due to rejection—acute and/or chronic
   Calcineurin inhibitor toxicity, polyomavirus infection and others

[a]C4d scoring in peritubular capillaries: C4d0: 0%; C4d1: 1%–9%; C4d2: 10%–50%; C4d3: >50%.
ABMR, Antibody-mediated rejection; *DSAs*, donor-specific antibodies; *EM*, electron microscopy; *IF*, immunofluorescence; *IHC*, immunohistochemistry; *TG*, transplant glomerulopathy.
Adapted from Haas M, Sis B, Racusen LC, et al. Banff 2013 meeting report: inclusion of C4d negative antibody-mediated rejection and antibody-associated arterial lesions. *Am J Transplant*. 2014;14(2):272–283.

to be due to rejection. The details of the current Banff classification are shown in Box 23.6. In this classification, an adequate core biopsy must contain a minimum of 10 glomeruli and at least two arteries; a marginal sample is that with 7–10 glomeruli and one artery; and an unsatisfactory biopsy is a core with fewer than 7 glomeruli or no arteries.

Cyclosporine A (Cyclosporin) Toxicity

CsA is an immunosuppressant drug that belongs to the calcineurin inhibitors group which selectively targets IL-2–dependent T-cell proliferation.[549] It is extremely effective in controlling transplant rejection; unfortunately, however, it is nephrotoxic. Other CsA-related toxicities include hepatotoxicity, neurotoxicity, gingival hyperplasia, hypertrichosis, and malignancies, particularly lymphomas.[550,551] Nephrotoxicity can occur not only in patients receiving renal transplants but also in those receiving the drug for any other reason. CsA nephrotoxicity is dose related and has been classified into functional toxicity in which there are no structural changes and morphologic forms in which the toxicity is manifested by a variety of lesions affecting tubules, vessels, and renal interstitium. Three major morphologic forms are recognized: acute nephrotoxicity, chronic nephrotoxicity, and TMA.[541]

Functional Toxicity

Functional CsA toxicity probably affects every patient who receives this medication. A mild decrease in renal function and a mild elevation of serum creatinine levels are seen soon after therapy starts, but both are reversible if the dosage is reduced. Hypertension is seen in up to 50% of the patients.[552] Renal biopsies in these patients appear normal or at most show some dilation and congestion of

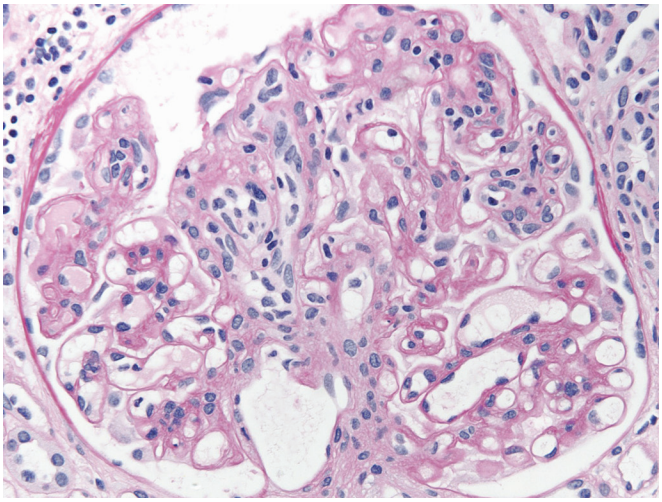

Figure 23.75 Transplant Glomerulitis and Glomerulopathy. The glomerulus shows increased intraluminal mononuclear inflammatory cells, consistent with transplant glomerulitis. The glomerular basement membrane double contours are a feature of chronic rejection (PAS).

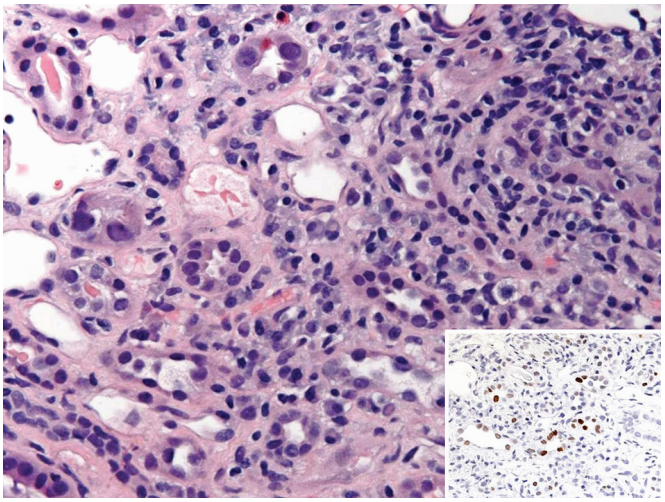

Figure 23.76 Prominent Interstitial Lymphoplasmacytic Inflammation in Polyomavirus Nephropathy. A few tubular nuclei are enlarged with fine chromatin. The presence of viral inclusions is confirmed on immunohistochemical stain (anti-SV40) as seen in the inset.

peritubular capillaries. The pathogenesis is an alteration of intrarenal hemodynamics that results from the ability of CsA to induce intense renal vasoconstriction.

Acute Toxicity

The clinical manifestations of acute CsA toxicity are similar to that seen in functional toxicity, but tend to be more severe. Genetic factors seem to account for dose-independent susceptibility to acute toxicity in an individual.[553] Histologically, the lesion is characterized by vacuolization of the proximal tubules, often in an isometric pattern, with giant mitochondria, large lysosomes, and microcalcifications.[552] Electron microscopic studies have demonstrated that the vacuolization is the result of dilation of the endoplasmic reticulum. In addition, the arterioles may show individual medial smooth-muscle cell degeneration, necrosis/apoptosis and myocyte drop-out, endothelial cell swelling, intimal thickening, and mucoid medial edema, which together may result in significant narrowing of the vascular lumina. Acute nephrotoxicity is usually dose dependent and reversible.

Thrombotic Microangiopathy

Patients with CsA toxicity can develop symptoms of HUS a few days or weeks after transplantation. The histologic findings are those of TMA with platelet and fibrin thrombi in the glomeruli and vessels, and minimal inflammatory infiltrate.[541] The prognosis of these patients is generally poor, but in some instances the lesions have resolved after the drug has been withdrawn.

Chronic Toxicity

Chronic CsA toxicity is clinically manifested by slow progression into renal failure and hypertension. Biopsies show arteriolopathy and IF with TA, features that are not entirely specific.[554,555] The arteriolopathy consists of nodular or diffuse hyalinosis of the vessel walls, or mucoid thickening of the intima, resulting in the narrowing or complete occlusion of the vascular lumina.[541] The nodular hyalinosis replaces the necrotic myocytes and typically affects the outer media with eventual circumferential involvement. The changes are usually accompanied by patchy IF and TA (striped fibrosis), best seen in the cortex. The glomeruli are usually spared in the early stages, but subsequent segmental and global glomerulosclerosis ensues.[554] In contrast to acute nephrotoxicity, the changes in chronic nephrotoxicity are irreversible.

Tacrolimus (FK506) Toxicity

Tacrolimus is an immunosuppressant drug that is also used in the control of transplant rejection. The morphologic changes associated with tacrolimus toxicity are identical to those of CsA toxicity.[556] These changes include vacuolization of the straight and convoluted portion of the proximal tubules, myocyte vacuolization, peritubular calcifications, TMA, arteriolar hyalinosis, and IF.

Polyomavirus Nephropathy

The human polyoma virus type I has surfaced as a significant pathogen in kidney transplant recipients, causing polyomavirus nephropathy. Approximately 85% of polyomavirus nephropathy is attributed to BK virus, with the remainder caused by JC virus.[557] BK virus reactivation occurs in 10%–60% of renal transplants and 1%–5% of renal allografts develop BK nephropathy.[558] High-risk patients are monitored by serial measurements of urine and plasma polyoma viral loads. A plasma level of 10^4 virions/mL is considered highly specific (but significantly less sensitive) for polyomavirus nephropathy. The typical presentation is impaired renal function that is resistant to immunosuppressive therapy. The definite diagnosis of polyomavirus nephropathy requires the histologic demonstration of polyomavirus. The interstitium usually is infiltrated by mononuclear inflammatory cells, mimicking the changes seen in acute rejection.[559] Renal tubular epithelial cells typically show enlarged nuclei with amorphous basophilic viral inclusions.[560] Immunohistochemical stains can be helpful in assisting in the demonstration of the infected cells (Fig. 23.76). The immunostains can either be directed specifically to BK and JC virus or can be for SV40, another polyomavirus that has a shared large T antigen. Treatment of polyomavirus nephropathy primarily includes reduced immunosuppression. A coexistent acute rejection poses a diagnostic challenge, and the presence of endarteritis confirms the presence of acute rejection.

Tubulointerstitial Diseases

Tubulointerstitial disease is a generic term used to designate a heterogeneous group of disorders that primarily affect the renal interstitium and tubules and only secondarily involves the other structures of the kidney. The frequency with which tubulointerstitial diseases affect the kidney is difficult to determine; however, it is believed that primary tubulointerstitial disease is the cause of renal failure in an estimated 20%–40% of all patients undergoing treatment for ESRD. The clinical presentations are usually very similar, but the etiologies are quite different and include infection, obstruction, and immune-mediated and toxic-tubulointerstitial diseases (Box 23.7). The functional manifestations include impaired concentrating ability, impaired ability to secrete acid, diminished reabsorption of sodium, hyperkalemia, and azotemia. Symptoms may be acute or chronic with corresponding morphologic changes.

Box 23.7 Classification of tubulointerstitial diseases

Genetic
- Ciliopathies
- Nephronophthisis
- ADTKD
  - Mutations in UMOD, MUC1, HNF1β
- Mitochondrionopathies
- Crystal deposition and transport diseases

Infections
- Acute pyelonephritis
- Ascending infection
- Hematogenous spread
- Bacterial, fungal, viral, other
- Chronic pyelonephritis
- Nonobstructive (reflux associated)
- Obstructive
- Xanthogranulomatous
- Malakoplakia

Obstructive uropathy
- Hydronephrosis without infection
- Reflux-associated nephropathy

Metabolic
- Nephrocalcinosis
- Acute phosphate nephropathy
- Urate nephropathy
- Secondary oxalosis

Immunologic tubulointerstitial nephritis
- Drug induced (antibiotics, diuretics, nonsteroidals)
- Associated with systemic vasculitis
- Lupus associated, Sjögren syndrome-associated
- Antitubular basement membrane disease
- IgG4-related tubulointerstitial nephritis
- Tubulointerstitial nephritis with uveitis

Toxic tubulointerstitial nephritis
- Drug induced
- Aminoglycosides
- Cyclosporine
- Lithium
- Analgesics
- Cisplatin
- Heavy metals toxicity
- Lead, mercury, and others
- Other
- Radiation
- Sarcoid
- Idiopathic

ADTKD, Autosomal dominant tubulointerstitial kidney disease; *HNF1β*, HNF1β mutation; *MUC-1*, mucin-1 related kidney disease; *UMOD*, uromodulin-related kidney disease.

Acute Tubular Necrosis

ATN is a clinicopathologic syndrome that is characterized by the acute suppression of renal function accompanied by morphologic evidence of tubular epithelial cell injury. Two subtypes of ATN have been recognized: ischemic and toxic.

The ischemic form of ATN is the most common and results from hypoperfusion of the kidney. It is usually associated with hypotension that occurs in a wide variety of conditions such as severe traumatic lesions and burns, shock after a surgical operation, septic shock, pancreatitis, and dehydration after diarrhea, vomiting, or extensive sweating.

The less common nephrotoxic form is a chemically induced injury of the tubular epithelial cells that can be caused by a wide variety of substances, including organic solvents (e.g., carbon tetrachloride, ethylene glycol), heavy metals (e.g., mercury, lead), drugs such as antibiotics (e.g., amphotericin B, gentamicin), antivirals (tenofovir, acyclovir, indinavir), chemotherapeutic agents (e.g., methotrexate, cisplatin), nonsteroidal anti-inflammatory agents, calcineurin inhibitors, and radiographic contrast agents. Hemoglobin and myoglobin are considered endogenous toxins capable of causing ATN when present in urine in high concentrations. Hemoglobinuria can be due to incompatible blood transfusion, malaria, and paroxysmal hemoglobinuria. Myoglobinuric acute renal failure can be caused by the liberation of myoglobin from muscles caused by trauma (crush injury), myositis, ischemia, excessive exertion, or exposure to toxins (snake venom, alcohol, cocaine). It is believed that, while the toxicity of the hemoglobin and myoglobin may contribute to the pathogenesis of ATN, ischemia and microcirculatory disturbances probably play a greater role in its development.[561]

Clinically, ATN is manifested by rapidly increasing serum creatinine levels associated with oliguria or anuria. Less frequently, ATN induces nonoliguric renal failure. Urinalysis typically demonstrates sloughed degenerated epithelial cells and granular casts. The clinical course of ATN is highly variable, and the prognosis largely depends on the clinical setting in which it occurs.

The morphologic changes in ischemic ATN depend on the severity of the renal failure and the evolution of the lesion.[561,562] In early stages, the cellular changes can range from minimal cell swelling to individual cell necrosis accompanied by focal denudation of the basement membrane and desquamation of the necrotic cells into the tubular lumen (Fig. 23.77A). The proximal tubules may appear dilated and their PAS-positive brush border thinned or absent. Hyaline, granular, and pigmented casts are common, especially in the distal and collecting ducts. These casts consist mainly of Tamm–Horsfall protein mixed with cellular necrotic debris. Other findings in ischemic ATN are interstitial edema and the accumulation of mononuclear leukocytes within the vasa recta of the outer medulla. As the disease progresses after the initial injury, evidence of tubular regeneration can be seen. Changes that are believed to represent regeneration include flattened epithelium with dilation of the tubular lumen, the presence of large nuclei with prominent nucleoli, and mitotic activity (see Fig. 23.77B).

Toxic ATN is characterized by extensive necrosis of the tubular cells along segments of the proximal tubule. Depending on the type of poisoning, several patterns of injury have been recognized.[561,563] For example, ethylene glycol produces marked ballooning and

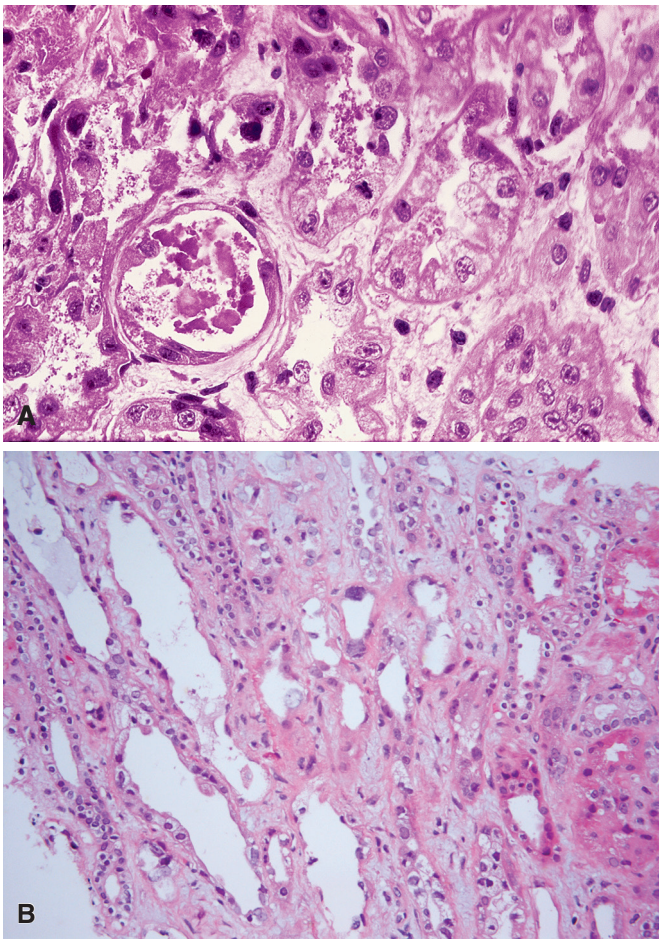

Figure 23.77 Acute Tubular Necrosis. A, There is focal necrosis and desquamation of the cells into the tubular lumen. **B,** The tubules are dilated and lined by flattened epithelium.

hydropic or vacuolar degeneration of the proximal convoluted tubules, and extensive deposition of oxalate crystals in the tubular lumina, whereas carbon tetrachloride poisoning is characterized by the accumulation of neutral lipids in the injured cells followed by necrosis.[563] In acute lead nephropathy, dark intranuclear eosinophilic inclusions are seen in addition to the cellular necrosis. Hemoglobinuric and myoglobinuric ATN following hemolysis or severe muscle damage shows histologic features of ischemic ATN, with numerous deeply pigmented, red–brown casts in the distal and collecting ducts. These casts stain positively with hemoglobin A and myoglobin immunohistochemical stains, respectively. Tenofovir and related antiviral drugs cause tubular nucleomegaly and pleomorphism, and sometimes megamitochondria can be visualized.

Recent studies have suggested that kidney injury molecule-1 (KIM-1) can be a useful immunohistochemical marker that can assist in the histopathologic diagnosis of tubular injury. KIM-1 is an immunoglobulin superfamily cell-surface protein that is undetectable in normal kidney but is highly overexpressed in proximal tubule cells after ischemic or nephrotoxic acute renal injury.[564,565] KIM-1 is a sensitive and specific early indicator of proximal tubular injury and can be detected in the urine and blood of individuals with acute renal injury.[566–568] Acute kidney injury can lead to chronic kidney disease and a progression to end-stage kidney disease especially in the presence of other predisposing factors or preexisting chronic kidney disease.[569]

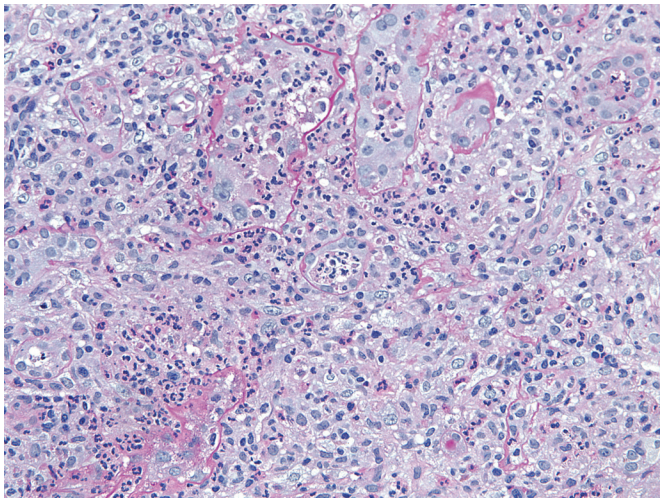

Figure 23.78 Acute Pyelonephritis in a Patient Presenting With Fever and Elevated Serum Creatinine. There is acute inflammatory infiltrate in the interstitium and tubular lumina.

Acute and Chronic Pyelonephritis

Infectious TIN is generally designated as pyelonephritis, implying that the inflammatory process involves the collecting system, as well as the renal parenchyma.[570] There are three peaks of incidence: infancy and early childhood, women of childbearing age, and both men and women older than 60 years of age. Both acute and chronic pyelonephritis are frequently associated with congenital or acquired obstructive lesions of the lower urinary tract or are associated with conditions resulting in residual retention of urine in the bladder. Congenital lesions are often the cause of pyelonephritis in infancy and early childhood. In older adults, obstruction by nodular hyperplasia of the prostate gland in men and the development of cystoceles in women are important etiologic factors. In addition, conditions such as cancer of the cervix and nephrolithiasis are also commonly associated with renal infection.

Acute pyelonephritis is most often associated with an ascending infection and the acute inflammatory infiltrate involves the renal medulla and cortex (Fig. 23.78). The inflammatory cells are mostly polymorphonuclear leukocytes, and they are present in the interstitium and within the tubular lumina. Foci of necrosis and abscess formation can also be present in the cortex. The kidney can occasionally be infected by organisms arriving via the hematogenous route, resulting in the formation of many small cortical abscesses with little involvement of the medulla. Special stains may reveal the responsible pathogens. The ascending infections are caused by the normal gram-negative flora of the intestinal tract. By far the most common is *Escherichia coli*, followed by *Klebsiella* and *Enterobacter*. *S. aureus* or fungal organisms, including *Candida* and *Aspergillus*, may be the cause of hematogenous infections, and they are seen more often in immunosuppressed individuals.

Chronic pyelonephritis produces a coarse fibrosis of the kidney parenchyma that is distinctly focal in its distribution. Cortical and papillary scars overlie dilated, blunted, deformed calyces. The architecture of the medulla is distorted, and papillae may be flattened. Light microscopy shows tubular damage, interstitial inflammation, and fibrosis (Fig. 23.79). The tubules are atrophic or dilated and are lined by flattened epithelium and filled with hyaline casts, a pattern that has been called thyroidization. Lymphocytes, histiocytes, and plasma cells form the bulk of the inflammatory infiltrate. In chronic pyelonephritis associated with reflux or obstruction,

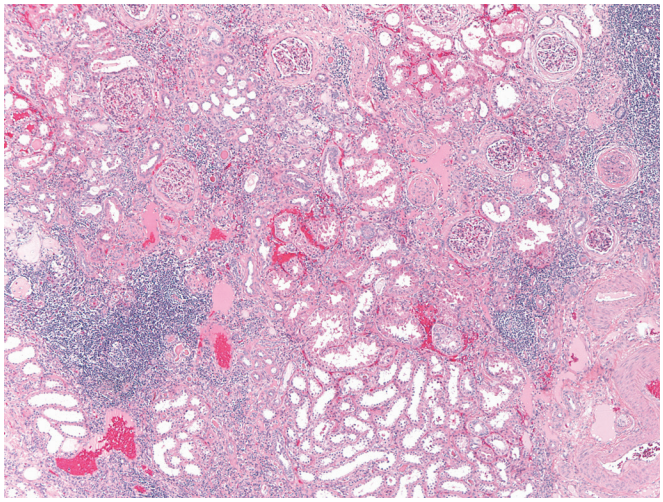

Figure 23.79 Nephrectomy Specimen From a Patient With Obstructive Hydronephrosis. There is interstitial scarring with intense mononuclear inflammatory cell infiltration. The tubules are atrophic, and the glomeruli are relatively spared with periglomerular fibrosis.

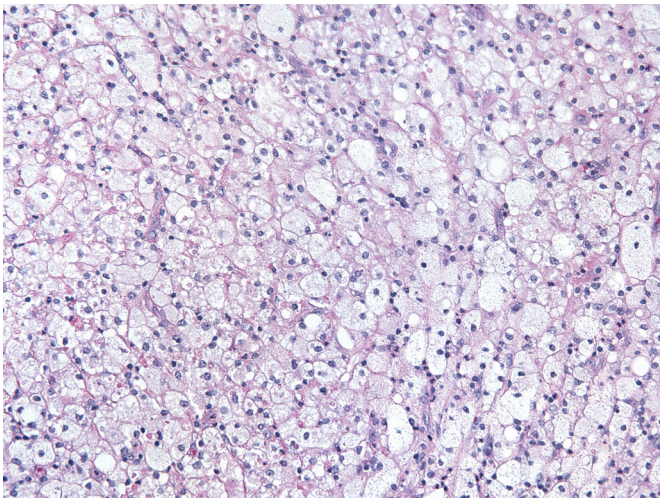

Figure 23.80 Foamy Histiocytes in Xanthogranulomatous Pyelonephritis. Lymphocytes and plasma cells were also present at the edges of this mass-like lesion.

Tamm–Horsfall protein can be identified in the interstitium as small bodies of amorphous fibrillary material that are strongly PAS positive and surrounded by inflammatory cells. The glomeruli are not primarily involved, but they can be initially affected by periglomerular fibrosis (see Fig. 23.79). Ischemic changes consisting of focal and segmental sclerosis and hyalinosis may also occur.

The histopathologic changes associated with chronic pyelonephritis have also been described in vesicoureteral reflux and chronic urinary obstruction.[571] An extreme form of localized scarring is seen in the so-called Ask–Upmark kidney, where total fibrosis of a lobule produces an appearance of segmental hypoplasia.

Xanthogranulomatous pyelonephritis is an uncommon and distinct type of chronic infectious pyelonephritis in which yellow, lobulated masses diffusely replace the renal architecture.[572] There are cases in which only a portion of the kidney, such as one pole, is involved. The condition is usually unilateral, although rare bilateral cases have been reported. This disease can occur at any age: it has been reported in patients as young as 11 months to as old as 89 years but is more common in adults in the fifth through the seventh decades.[570,573] It is twice as common in women as in men.[570,574] Urinary obstruction is almost invariably present and is most often caused by stones. Other causes of obstruction include postradiation strictures, congenital pelviureteric stenosis, and tumors.[575] The mass-occupying nature of this lesion frequently mimics that of a renal cell carcinoma and can result in unnecessary nephrectomies. A correct preoperative diagnosis is rarely made. Microscopically, there is a diffuse granulomatous inflammatory infiltrate that includes large numbers of foamy histiocytes and some multinucleated giant cells, as well as lymphocytes, plasma cells, and neutrophils (Fig. 23.80).[576] If renal cell carcinoma is suspected, the presence of histiocytes in xanthogranulomatous pyelonephritis can be confirmed on CD163 immunostain and the lack of infiltrating carcinoma can be demonstrated by the absence of cytokeratin expression. Electron microscopy shows that the foamy macrophages initially contain bacteria and subsequently contain numerous phagolysosomes with a myeloid configuration and amorphous material.[577] The lesion is destructive, tending to obliterate renal parenchyma within the affected areas. *E. coli* is the usual etiologic agent, but *Proteus mirabilis* and *S. aureus* have also been found to be responsible.[570]

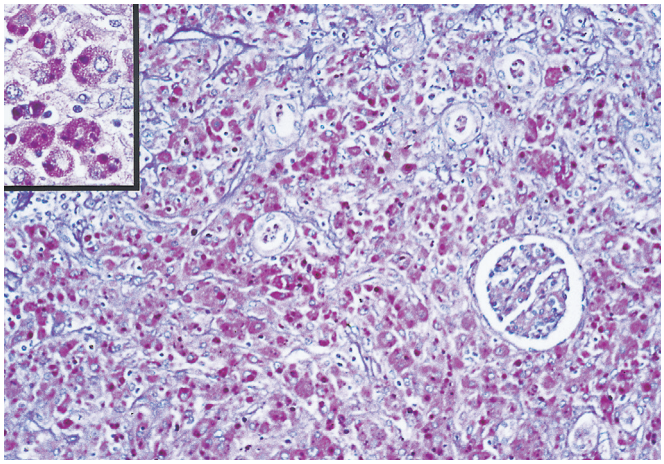

Figure 23.81 Nephrectomy Specimen From a Patient With Malakoplakia. The interstitium is infiltrated by numerous macrophages with granular cytoplasm. *Inset:* Several Michaelis–Gutmann bodies are seen in the cytoplasm.

Malakoplakia is a rare, histologically distinct, inflammatory reaction usually caused by enteric bacteria that can involve many organs but most frequently affects the urinary system.[578] In the kidney, the gross and microscopic appearances of this condition resemble those of xanthogranulomatous pyelonephritis. Confluent nodules of homogeneous yellow–tan tissue replace large areas of renal parenchyma. Fibrosis is also prominent. The inflammatory infiltrate consists largely of histiocytes with relatively few lymphocytes and plasma cells. The distinctive Michaelis–Gutmann bodies, composed of iron and calcium, are found both within the histiocytes and extracellularly in the stroma (Fig. 23.81). Ultrastructurally, these bodies are round with a core of concentric membranes, amorphous material or foci of calcification, and are highlighted on PAS stain (see Figs. 23.81 inset, and 23.82).[579] The pathogenesis of this cellular accumulation is unknown, but there is evidence that the lesions result from a defective macrophage function that compromises the lysosomal degradation of engulfed bacteria and overloads the cytoplasm with undigested cellular debris.[580]

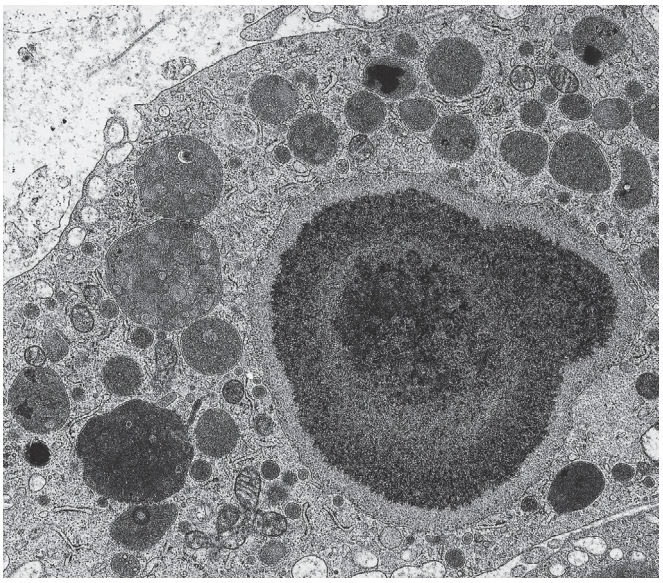

Figure 23.82 Electron micrograph of a histiocyte showing numerous phagolysosomes and a Michaelis–Gutmann body with calcified central core (×11,400).

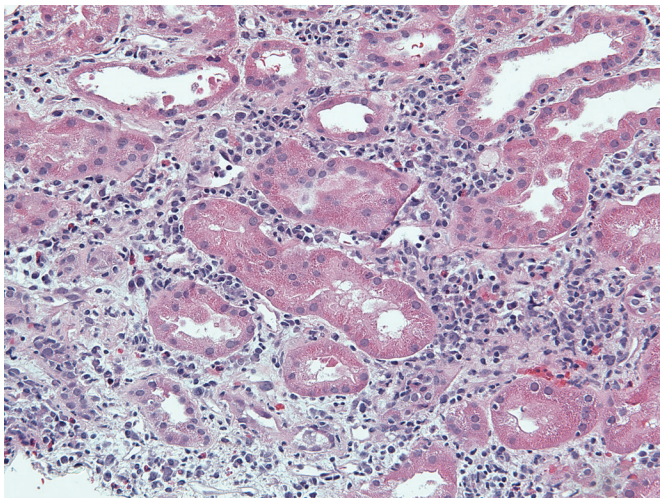

Figure 23.83 Antibiotic therapy–related acute allergic tubulointerstitial nephritis with interstitial edema and inflammation composed of lymphocytes, monocytes, plasma cells, and eosinophils.

Acute Allergic Tubulointerstitial Nephritis

Many drugs, including β-lactam antibiotics, proton pump inhibitors, nonsteroidal anti-inflammatory drugs, diuretics, and diverse other substances, can be responsible for acute TIN.[581–583] According to a series, omeprazole, amoxicillin, and ciprofloxacin are the most common offenders.[584] The clinical presentation is quite variable, but fevers and azotemia are common, and eosinophilia occurs in a majority of cases. Microscopic hematuria is not uncommon. A skin rash, usually described as maculopapular, is sometimes seen. Urinalysis reveals hematuria, sterile pyuria, and moderate proteinuria, and eosinophils may be detected in the sediment.[585] Acute interstitial nephritis combined with MCD producing nephrotic-range proteinuria has been described with nonsteroidal anti-inflammatory drugs.[586]

Light microscopy reveals generalized interstitial edema and infiltration of the interstitium by lymphocytes, macrophages, plasma cells, and eosinophils (Fig. 23.83).[587] Damage to tubular epithelial cells with evidence of regeneration is always found, and lymphocytes maybe seen infiltrating the epithelium. The glomeruli and vessels are not usually involved. Occasionally, ill-formed granulomas with giant cells can be seen with some drugs and in that setting, the differential diagnosis includes sarcoidosis, infections, and GPA.[588]

Although bacterial infection and drugs are the most common causes of acute interstitial nephritis, a similar picture can be found in patients with autoimmune or immunologic disease such as SLE, Sjögren syndrome, IgG4-related TIN, TIN with uveitis, or, rarely, in association with antitubular basement membrane antibodies.[589] The clinical and pathologic findings are parallel to those seen in allergic TIN. Although the renal disease in SLE predominantly affects glomeruli, coexistent interstitial inflammation is common and, on rare occasion, TIN exists in isolation. Sjögren's syndrome-related TIN is characterized by lymphoplasmacytic infiltrate and associated glomerular disease is uncommon. The clinical presentation, extrarenal manifestations, and serologic studies are helpful in the diagnosis of SLE and Sjögren's syndrome. In both diseases, the tubular basement membrane and interstitial deposits, when present, stain for IgG and C3 and, in the case of SLE, can show a full-house pattern. A syndrome of acute TIN with anterior uveitis and constitutional symptoms such as fever, weight loss, and anorexia can occur, usually in adolescent and young adult women.[590] Renal presentation of mild proteinuria and Fanconi syndrome is typical and the etiology is unclear. Interstitial granulomas can be present in a minority of these cases and potential etiologic factors include autoimmune, genetic, and infections such as *Mycoplasma*, *Klebsiella*, *Toxoplasma*, EBV, and herpes zoster.

Immunoglobulin G4–Related Tubulointerstitial Nephritis

IgG4-related related disease is a systemic fibroinflammatory disease, and the kidney involvement is characterized by polyclonal plasma cell–rich interstitial inflammation.[591] The frequent clinical presentation of IgG4-related TIN is chronic renal insufficiency and proteinuria that is typically mild unless the patient has glomerular involvement resulting in nephrotic syndrome. The presence of hypergammaglobulinemia and elevated serum IgG and IgG4 levels supports the diagnosis and approximately 50% of the patients have hypocomplementemia. Serum ANA is occasionally positive, and peripheral eosinophilia may be present. Imaging studies can reveal low attenuation cortical mass–like lesions, corresponding to patchy fibroinflammatory process. The plasma cell–rich interstitial infiltrate frequently alternates with paucicellular fibrotic areas, especially with increasing chronicity. The dense IF has a characteristic storiform pattern. The presence of greater than 10 IgG4+ cells/40× field, although not entirely specific, meets the criteria for renal IgG4-related TIN (Fig. 23.84).[592] Immunofluorescence and electron microscopy reveal tubular basement membrane deposits in greater than 80% of cases and these are IgG, C3, κ and λ positive. It should be noted that plasma cell–rich and IgG4 cell–rich infiltrate can be observed in a variety of lesions such as chronic pyelonephritis and vasculitis-associated tubulointerstitial inflammation. The accurate diagnosis of IgG4-related TIN rests on evidence of systemic disease either in the form of elevated IgG4 levels or extrarenal disease.[592] Glomerular involvement is seen in less than 10% of IgG4-related TIN, often represented by a secondary membranous nephropathy with the deposits being PLA2R negative.[593]

Analgesic Abuse Nephropathy

Analgesic abuse nephropathy is a bilateral renal disease characterized by papillary necrosis and chronic TIN that results from the

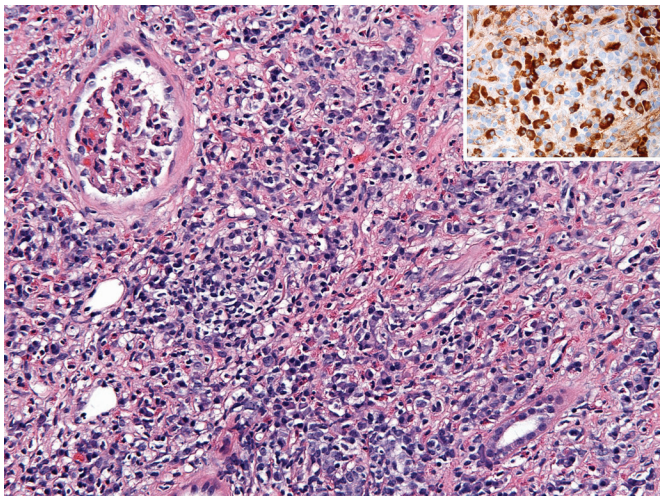

Figure 23.84 IgG4-related tubulointerstitial nephritis with dense storiform fibrosis, tubular destruction, and intense lymphoplasmacytic infiltrate. In the appropriate clinical setting, the presence of greater than 10 IgG4+ cells/HPF supports the diagnosis.

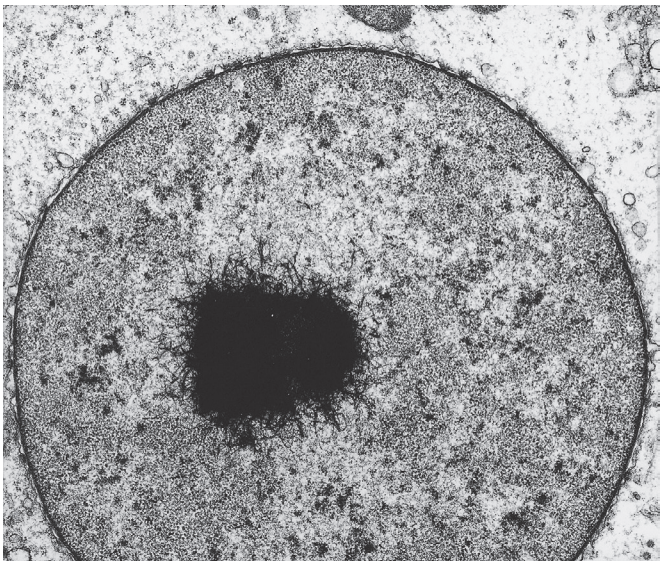

Figure 23.85 Intranuclear lead inclusions showing dense central cores surrounded by fibrillar material (×15,600).

excessive intake of analgesic mixtures containing aspirin or antipyrine, combined with phenacetin, acetaminophen (paracetamol), or salicylamide, and caffeine or codeine.[594] The incidence of analgesic nephropathy varies in different countries. In the early 1990s, the reported incidence of analgesic nephropathy among patients receiving dialysis was estimated to be 0.8% in the United States, 3% in Europe, and 9% in Australia.[595,596] The condition is more common in women than in men. Phenacetin has been removed from the United States market more than 20 years ago and since then, the incidence of analgesic nephropathy, although not eliminated, has reduced dramatically.[597,598]

The most important diagnostic feature is a history of chronic pain syndromes and analgesic abuse over several years or decades. Renal function abnormalities include impaired urine concentration defects and impaired sodium conservation. Urinary infection is a complication in about 50% of the cases. On occasion, fragments of necrotic papillae are excreted. This may cause gross hematuria or renal colic due to obstruction of the ureter by the necrotic tissue. Renal imaging studies are helpful in detecting papillary necrosis and calcification. Progressive impairment of renal function may lead to chronic renal failure. An important association in analgesic nephropathy is the increased risk for developing transitional cell carcinoma.[599]

In the early stages of analgesic nephropathy, the cortex is normal, but the papillae are firmer and show gray streaks. Microscopically, there is interstitial homogenization, and thickening of the basement membranes of the loops of Henle and peritubular capillaries. Foci of necrotic epithelial, endothelial, and interstitial cells are associated with fine calcification. As the disease progresses, the papillae are shrunken and they have a brown coloration. Microscopically, confluent zones of necrosis within the inner medulla involve the loops of Henle, peritubular capillaries, and vasa recta, and the cortex may contain foci of TA, IF, and patches of chronic inflammation. In advanced disease, the kidneys are shrunken and the gross and microscopic changes mimic chronic pyelonephritis. Total papillary necrosis occurs and extensive calcification is usually present. Papillary necrosis is not specific for analgesic nephropathy. It can also occur in a variety of other conditions including diabetes mellitus, urinary tract obstruction, and sickle cell disease.[600]

Heavy Metals Nephrotoxicity

Renal damage can result from environmental or occupational exposure to heavy metals, such as lead, cadmium, mercury, uranium, chromium, copper, and arsenic,[601–604] or the administration of therapeutic forms of platinum,[605] gold,[606] and bismuth.[607,608] Due to its rather characteristic morphologic features and clinical importance, only the changes in the kidney produced by lead exposure will be discussed.

Lead Nephropathy

Lead poisoning may be the result of occupational or environmental exposure.[609,610] Workers at risk include electric storage battery makers, painters, welders, foundrymen, and jewelers. Children may be exposed by eating flaking lead paint. Inadvertent ingestion of lead can occur from drinking water contaminated by lead pipes, earthenware, or from adulterated wine or moonshine liquor. Lead is also present as an atmospheric contaminant resulting from the use of lead-containing gasoline and various industrial processes. Associated with chronic kidney disease, it can often go unrecognized in the modern era.[611]

The organs most commonly affected by lead exposure are the central and peripheral nervous systems, gastrointestinal tract, and kidney. The most striking morphologic changes in lead exposure occur in the tubules and consist of eosinophilic intranuclear or cytoplasmic acid-fast inclusions that stain red with Giemsa stain. These inclusions consist of a lead–protein complex that by electron microscopy appear as compact cores surrounded by a loose meshwork of fibrils (Fig. 23.85). They may be seen in tubular epithelial cells in urinary sediment during acute poisoning.[612] Lead-containing inclusions have also been found in the liver and neural tissue.

Renal biopsies in chronic lead nephropathy often show TA and IF with minimal inflammatory reaction. Arteriolar changes reminiscent of hypertensive nephrosclerosis may be present even in the absence of hypertension. The inclusions are often absent when the disease is longstanding or after the administration of chelating agents.

Nephrolithiasis and Nephrocalcinosis

Nephrolithiasis is a common disorder defined as the development and accumulation of stones within the collecting system of the kidney.

The estimated incidence in the United States ranges from 7 to 21 cases per 10,000 population.[613] Men are affected approximately four times more frequently than women, and the predominant age at onset is in the third to fifth decades. The most characteristic symptoms of nephrolithiasis are pain and hematuria. The classic pain is that of severe, abrupt, flank pain (renal colic) that only resolves after the passage or removal of the stone. The hematuria can be gross or microscopic and most commonly occurs with large calculi during infection or colic. About 75% of the stones are composed of a combination of calcium oxalate or calcium oxalate mixed with calcium phosphate; 15% are the so-called struvite stones that are composed of magnesium ammonium phosphate and are often associated with urea-splitting bacterial infections; 6%–10% consist of uric acid; and 1%–2% of cystine. Renal stones within the pelvic calyceal system can cause gross and microscopic changes in the renal parenchyma that are identical to those seen in pyelonephritis and hydronephrosis.

The presence of calcium within the renal parenchyma is known as nephrocalcinosis.[614] Calcium deposition occurs on tubular basement membranes and in the interstitium. TA, IF, and periglomerular fibrosis are also present. Some of the glomeruli may be sclerosed. Several systemic disorders are associated with nephrocalcinosis and the formation of stones. Calcium phosphate and oxalate stones occur in hyperparathyroidism, sarcoidosis, milk–alkali syndrome, excessive dietary intake of vitamin D, multiple myeloma, and renal tubular acidosis. Abundant intratubular calcium phosphate deposition can occur in patients who receive oral sodium phosphate bowel purgative prior to colonoscopy. Referred to as acute phosphate nephropathy, it is often associated with inadequate hydration and concomitant use of diuretics, ACE inhibitors, or angiotensin receptor blockers. Renal insufficiency occurs weeks or months after the colonoscopy was performed.[615]

Uric acid stone formation takes place in an acid urine in the presence of hyperuricosuria, which may result from an inborn error of metabolism such as gout or the Lesch–Nyhan syndrome, glycogen storage disease following treatment of hematopoietic malignancies, overindulgence in dietary proteins, or the use of uricosuric drugs.[616] Uric acid stones are usually radiolucent, and because they are often small they may be passed, but larger ones in the renal pelvis can grow and become staghorn calculi. Uric acid crystals are also deposited within the renal parenchyma, and they can be seen within the collecting tubules as elongated or rectangular crystals or as doubly refractile crystals in the interstitium surrounded by a giant cell reaction.[617,618]

A clinical sign of cystinuria is calculi in the urinary tract. The stones are formed in acid urine. They are typically yellow–brown and radiopaque. Cystine crystals appear as microscopic, flat hexagons in the urine, and this feature constitutes the clue for the diagnosis. The disorder is characterized by the defective transport of cystine, lysine, arginine, and ornithine by epithelial cells of the renal tubules and the gastrointestinal tract; it is transmitted as an autosomal recessive trait with an incidence of 1 in 20,000.[619,620] Complications of calculi formation include urinary tract obstruction and infection, which may result in renal failure. This entity is distinct from cystinosis, a lysosomal storage disorder that presents as a severe nephropathic form in infants.[621]

Hyperoxaluria is characterized by recurring calcium oxalate nephrolithiasis and/or nephrocalcinosis, often terminating in chronic renal failure (Fig. 23.86). Primary hyperoxaluria is a rare autosomal recessive disorder of glyoxylate metabolism resulting in hyperoxaluria in children.[622] Approximately 80% of mutations detected in these patients affect gene encoding alanine glyoxylate aminotransferase.[623] Ethylene glycol poisoning, methoxyflurane anesthesia, pyridoxine deficiency, excess ascorbic acid ingestion, pyridoxine (vitamin B6) deficiency, and various chronic gastrointestinal disorders (including Crohn disease, chronic pancreatitis, celiac sprue, and status post-jejunoileal bypass procedure) have been associated with oxalosis.[624,625] In the kidney, oxalate crystals are deposited in the interstitium, tubules, and, rarely, the glomeruli. They have radial striations that show up particularly well with polarized light (Fig. 23.87). TA, IF and inflammation, and glomerulosclerosis are the end results.

Figure 23.86 Severely distorted kidney with dilated pelvicalyceal system containing numerous stones in a case of primary oxalosis.

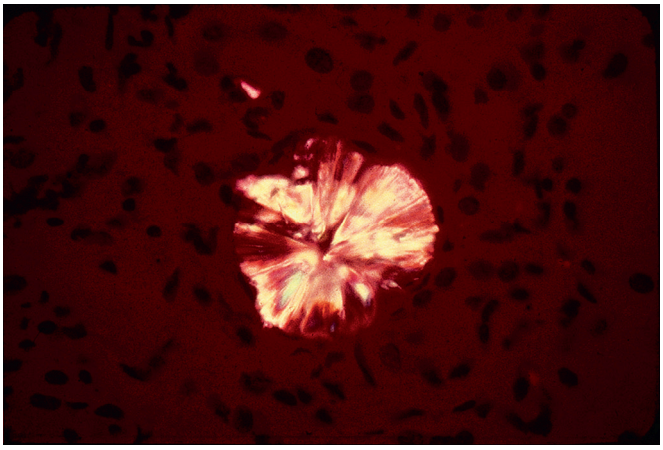

Figure 23.87 Oxalate Crystal Under Polarized Light.

Xanthinuria is a rare hereditary condition transmitted as an autosomal recessive trait. The enzyme xanthine oxidase, which is responsible for the conversion of xanthine and hypoxanthine to uric acid, is deficient. Xanthine stone formation occurs in one-third of patients with this disorder. Similar stones are seen as a complication of allopurinol therapy since this drug blocks xanthine oxidase activity.[626]

Light Chain Cast Nephropathy

Light chain cast nephropathy, also known as Bence Jones cast nephropathy, myeloma cast nephropathy, or myeloma kidney, is the most common form of renal disease associated with multiple myeloma.[627] Clinically, it may present as progressive renal insufficiency or acute renal failure, often precipitated by dehydration, hypercalcemia, IV infusion of contrast media, nonsteroidal anti-inflammatory drugs, hyperuricemia, nephrotoxic infections, or loop diuretics, such

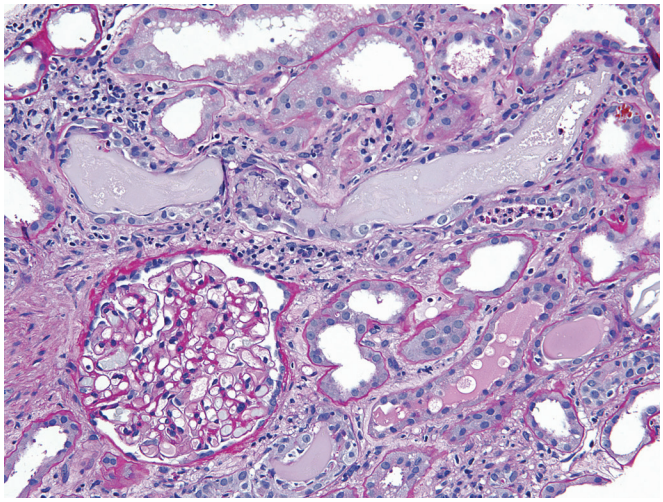

Figure 23.88 Light Chain Cast Nephropathy. Large, dense PAS-negative tubular casts associated with tubular injury and intratubular neutrophils (PAS).

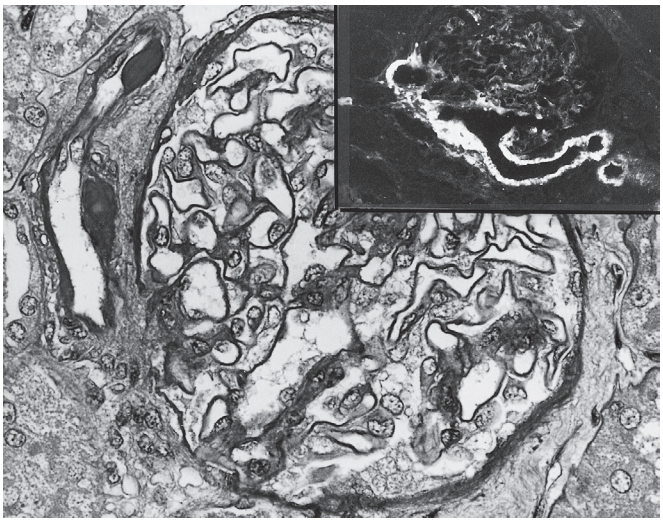

Figure 23.89 Afferent Arteriole With Subintimal Homogeneous Hyaline Material. *Inset:* Immunofluorescence preparation showing reaction for C3. (Reproduced from Spargo BH, Seymour AE, Ordóñez NG. *Renal Biopsy Pathology with Diagnostic and Therapeutic Implications*. New York, NY: John Wiley and Sons; 1980:297. By permission of John Wiley and Sons, Inc.)

as furosemide. Proteinuria is found, although not usually in the nephrotic range, and it most often consists predominantly of immunoglobulin light chains (Bence Jones protein). Circulating monoclonal light chains can be confirmed by serum protein electrophoresis or free light chain assay. The light chains are normally filtered by the glomeruli and reabsorbed and metabolized by proximal tubular cells. In patients with multiple myeloma, the excess monoclonal light chains overwhelm the catabolic capacity of the proximal tubules, thus allowing them to reach the distal nephron where the presence of Tamm–Horsfall protein may facilitate their precipitation in the form of voluminous casts. These monoclonal free light chains can also cause proximal tubular cell cytotoxicity, TIN, and ultimately damage the entire nephron, resulting in renal failure.[628]

By light microscopy, the distal and collecting tubules appear occluded by numerous dense, markedly eosinophilic, lamellated and fractured casts, sometimes surrounded by multinucleated giant cells derived from interstitial macrophages that invade the tubules through breaks in the basement membrane (Fig. 23.88).[629,630] Some casts may exhibit Congo red and thioflavin T positivity, but this alone is not indicative of amyloidosis. The tubular cells may appear flattened or can show varying degrees of degeneration with necrosis and denudation of the tubular basement membranes. Depending on the stage of the disease, there is a variable degree of IF usually associated with acute and/or chronic inflammatory cell infiltrates. Prominent intratubular collections of neutrophils may be seen, mimicking acute pyelonephritis. Sometimes the casts may contain rhomboid or needle-shaped crystalline structures that may also be found in the tubular epithelium and, on rare occasions, in the glomeruli.[631] Immunofluorescence studies demonstrate that the casts are largely made of the pathogenic light chain, either kappa or lambda (although kappa tends to be more frequent).

Renal Vascular Disease

Renal Arteriolar Disease

The kidney plays an essential role in hypertension, and the vessels of the kidney are susceptible to a variety of pathologic changes directly related to increased pressure.[632] The vessels most susceptible are small arteries and arterioles, with preglomerular vessels being more prominently affected. Vascular narrowing of these intrarenal vessels eventually leads to glomerular sclerosis, TA, and IF (nephrosclerosis). The hypertensive vascular changes of the small vessels of the kidney fall into three general categories: hyaline arteriolosclerosis, myointimal hypertrophy and hyperplasia, and fibrinoid necrosis.[633]

In **hyaline arteriolosclerosis**, the outer part of the wall of affected vessels is thickened by deposition of a homogeneous, eosinophilic, PAS-positive material (Fig. 23.89). Associated changes are atrophy of the smooth muscle cells in the vessel walls and a uniform thickening of the basement membrane. Hyaline arteriolosclerosis is most marked in the afferent arteriole and in smaller vessels lacking an internal elastic lamina. Mild hyaline arteriolosclerosis is often seen with increasing age, but it is more prominent in patients with hypertension or diabetes. The effects are more marked in hypertension where the arteriolar lumens become severely narrowed, causing diffuse renal ischemia and symmetric shrinking of the kidneys. It is believed that the hyaline deposition results from leakage of plasma components across the vascular endothelium, triggering extracellular matrix production by smooth muscle cells. The hyalinized arterioles usually immunoreact for IgM and complement components, especially C3 (see Fig. 23.89 inset). Hyaline arteriolosclerosis is a major morphologic feature in benign nephrosclerosis, in which the interlobular and arcuate arteries may also exhibit medial hypertrophy and reduplication of the elastic lamina.

The second type of vascular abnormality seen in hypertension is that hyperplasia involving the smooth muscle and intima of small arteries and arterioles **(myointimal hypertrophy and hyperplasia)**. Hyperplastic arteriolosclerosis is generally associated with acute or persistent severe high blood pressure and, therefore, is seen more often in accelerated/malignant than benign hypertension. In the early stages, the lesions are characterized by profuse intimal thickening by myxoid and sparse cellular connective tissue that drastically reduces the vascular lumen. Over time, this acute change shows progressive intimal scarring and uniform concentric thickening of the vessel wall by a proliferation of myointimal cells, and deposition of basement membrane–like material. The microscopic appearance of this lesion has led to the descriptive term of "onion skinning" (Fig. 23.90). These changes are more pronounced in arcuate and

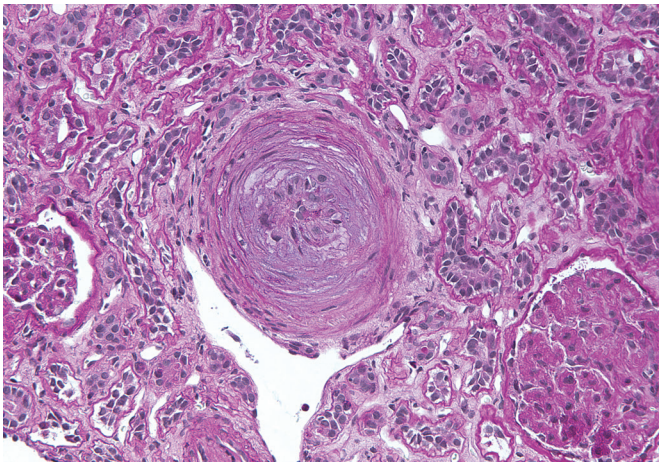

Figure 23.90 Malignant Hypertension. Interlobular artery with thinning of the media and marked intimal edema and early fibrosis. The cortex shows glomerular ischemic changes and extensive tubular atrophy (PAS).

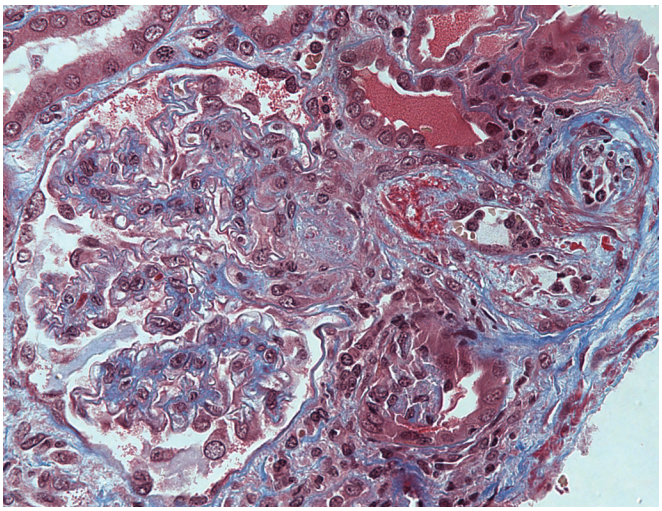

Figure 23.91 Malignant Hypertension. Fibrinoid necrosis and intimal edema of the afferent arteriole with ischemic shrinkage of the glomerular capillary tuft (trichrome).

interlobular arteries but extend into the arterioles where they may coexist with hyalinosis from longstanding hypertension.

Fibrinoid necrosis of the afferent arteriole has been regarded as the hallmark of accelerated (malignant) hypertension. The necrosis is usually superimposed on a preexisting hyperplastic or hyaline lesion, but it can be the initial event in young patients with severe acute malignant hypertension. The architecture of the media of affected vessels is obliterated by the necrotizing process and further obscured by deposition of deeply eosinophilic, fibrillar material which, by histochemical and immunofluorescent techniques, has been demonstrated to be fibrin and fibrinogen.[634] The arteriolar lumen may be reduced in size as a result of wall thickening, extravasation of red blood cells, and intraluminal thrombosis.

In malignant hypertension, the glomeruli often show variable degrees of ischemic change, characterized by wrinkling and collapse of the capillary walls (Fig. 23.91). In addition to this diffuse pattern of ischemic damage, segmental lesions such as apparent necrosis in direct continuity with arteriolar lesions may be seen. By electron microscopy, the endothelium often appears swollen and sometimes

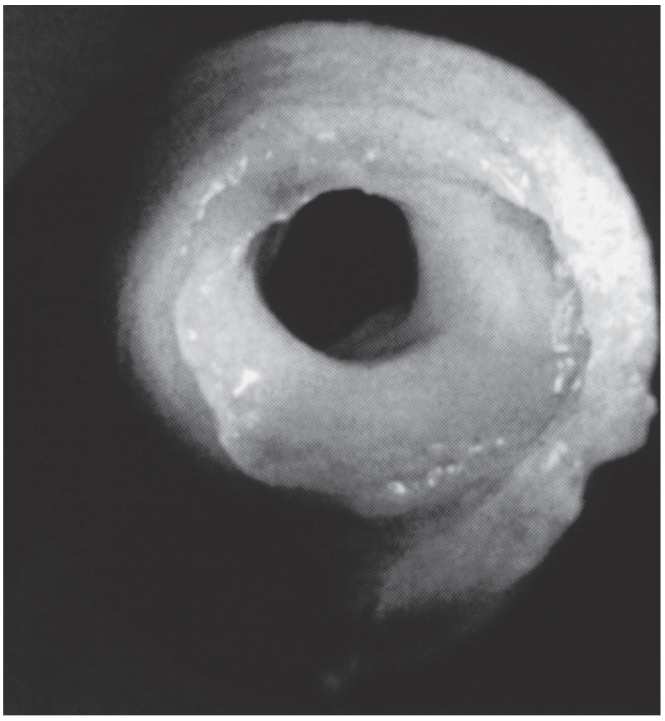

Figure 23.92 Eccentric arteriosclerotic plaque in renal artery causing almost complete obstruction and hypertension. This was resected and arterial continuity reestablished.

focally disrupted or separated from the GBM by the accumulation of electron-lucent material. On occasion, subendothelial or intracapillary strands of fibrin may be seen. Immunofluorescence microscopy may reveal fibrin, fibrinogen, IgM, and complement components in a segmental distribution.

Renal Arterial Disease

The larger arteries in the kidney can also be the site of renal vascular disease. Atheromatous involvement is accelerated in patients with hypertension and may be a source of atheromatous emboli and give rise to renal parenchymal infarcts. Arteries down to the arcuate size can show arteriosclerotic changes, but smaller vessels are more commonly involved by intimal thickening of the hyperplastic type, similar to that seen in the small arteries. Disease of the major arteries becomes particularly important when it involves a main renal artery and causes significant stenosis, resulting in secondary hypertension (Fig. 23.92).[635] The lesions involving the main renal artery can be broken down into three categories: atherosclerosis, dysplastic diseases of the fibromuscular vessels, and a miscellaneous group that includes congenital anomalies, Takayasu aortitis, and radiation injury.

The most common cause of renal artery stenosis is obstruction of the lumen by an **atheromatous plaque** at the orifice of the main renal artery.[635] It is usually associated with severe atheromatous disease of the aorta and is seen more often in males and in patients with diabetes mellitus. Major complications of the lesions include saccular or dissecting aneurysm formation and the occurrence of cholesterol emboli. Microscopically, these emboli appear as needle-like spaces representing cholesterol crystals embedded in amorphous debris frequently surrounded by multinucleated giant cells. Although symptomatic presentation is rare, cholesterol emboli occur immediately after or with a few months of angiographic or surgical procedures involving vessels.

Table 23.7 Dysplastic lesions of the renal artery

DIAGNOSIS	AGE INCIDENCE	SEX INCIDENCE	RELATIVE FREQUENCY (%)	LESION
Intimal fibroplasia	1–50	M = F	1–2	Narrowing by intimal proliferation without lipid
Medial fibroplasia with aneurysms	30–60	F > M	60–70	"String of beads," alternating stenosis and mural thinning
Medial hyperplasia	30–60	F > M	5–15	Smooth muscle hyperplasia and thickening
Perimedial fibroplasia	30–60	F > M	15–24	Fibrosis of outer media, occasionally aneurysms
Medial dissection	30–60	F > M	5–15	Fibrosis of media with dissecting aneurysms
Periarterial fibroplasia	15–50	F > M	1	Perivascular fibrosis and inflammation

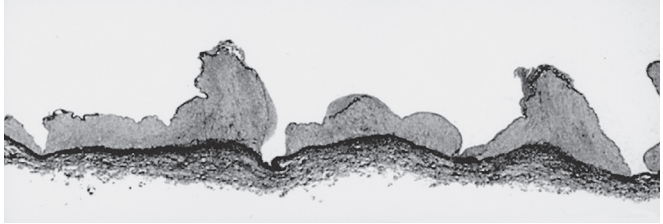

Figure 23.93 Fibromuscular Dysplasia in a Young Woman With Hypertension. Note aneurysmal formations in this longitudinally sectioned artery demonstrating medial fibrodysplasia with mural aneurysms.

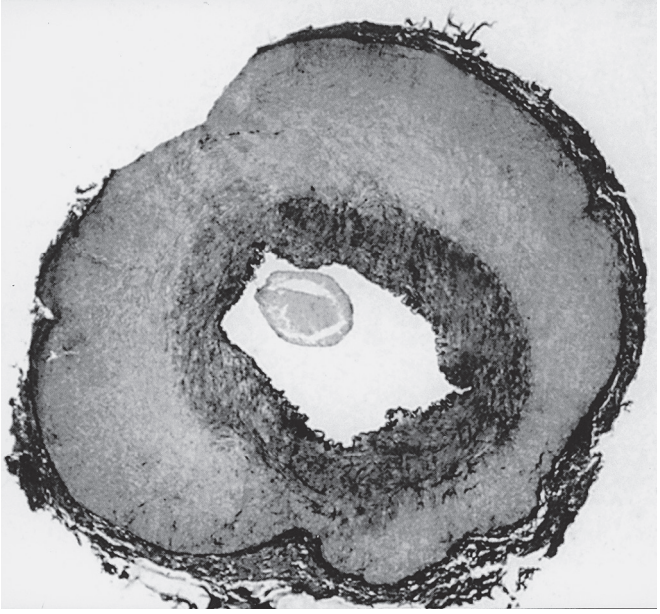

Figure 23.94 Fibromuscular Dysplasia in a 23-Year-Old Woman With Hypertension. Segmental resection revealed an artery with the perimedial variety of fibrodysplasia.

The second group of conditions that leads to stenosis are **dysplastic lesions of the renal artery,** currently termed **fibromuscular dysplasia**, which account for less than 10% of the cases of renal artery stenosis.[636–638] These lesions can involve other systemic vessels, suggesting that there may be an underlying defect in vessel structure, and can become clinically important when they cause obstruction of a major renal artery, thereby leading to severe hypertension unresponsive to antihypertensive drugs. Typically, these lesions occur in the distal two-thirds of the artery and are bilateral in 50% of the cases. Fibromuscular dysplasia can be divided into three types: intimal, medial, and periarterial/adventitial. The medial category in turn consists of three subtypes: medial fibroplasia, medial hyperplasia, and perimedial fibroplasia. As the terms indicate, differences are somewhat subtle, but given that different patient populations may be affected in each subgroup, this categorization is clinically useful (Table 23.7).

The lesion in *intimal fibromuscular dysplasia* is hyperplasia of the intima, and microscopically it is virtually indistinguishable from the proliferative stage of atherosclerosis, although it is not associated with an increased deposition of lipids. The architecture of the elastica and media are preserved so the only abnormality in the vessel wall is the intimal hyperplasia. Individuals as young as 1 year of age have been affected, but it is seen more often in the third and fourth decades. The most common of the dysplastic lesions is *medial fibroplasia*. In this condition, multiple foci of stenosis alternating with microaneurysms produce a "string of beads" appearance (Fig. 23.93).[637] Microscopically, atrophy of the muscle coat and fibrosis of the media near small aneurysms alternate with foci of muscular hypertrophy and fibrosis in the stenotic areas. Second in frequency is *perimedial fibroplasia* (Fig. 23.94). In this variant, segmental aneurysmal dilation does not occur, and the outer half of the media, elastica, and intima maintain their normal architecture. *Medial hyperplasia* is seen less frequently. Hyperplasia of the muscle produces a uniform circumferential thickening of the vessel wall with narrowing of the lumen. *Periarterial fibromuscular dysplasia* is a rare lesion in which fibrosis of the adventitia extends into the surrounding adipose and connective tissue, causing extrinsic constriction of the vessel (rather than thickening from within the wall).

Among the **miscellaneous causes** of renal artery stenosis, *radiation injury* is of particular interest.[639] The lesion is characterized by a loss of muscle and an intense fibrosis in all layers of the vessel wall. It is usually a distant event that follows radiation therapy for a malignant tumor where the renal artery was included in the irradiated area. *Takayasu aortitis* or pulseless disease is a chronic sclerosing aortitis of unknown etiology that can cause renal artery stenosis from narrowing of the ostium.[640] An inflammatory infiltrate with giant cells is frequently present, suggesting an immunologic mechanism.

An ischemic kidney is smaller than the contralateral kidney, irrespective of the etiology. Glomeruli are small with ischemic wrinkling of the basement membranes, and the tubules are atrophic. The atrophic tubules have simplified epithelium with inconspicuous lumina mimicking parathyroid, often referred to as "endocrine

change." IF is present, and the hyperplastic juxtaglomerular apparatus shows increased granularity with special stains. The small vessels are protected from the hypertension, in contrast to the contralateral kidney, where biopsy may show hypertensive microvascular disease.

Radiation Nephropathy

Radiation nephropathy is the term used to designate the renal disease that occurs with irradiation of the abdomen (or total body) during the treatment of malignant tumors. More recently, this has also been noted in association with use of radiolabeled substances such as monoclonal antibodies, antibody fragments, and low-molecular-weight oncophilic peptides.[440] Although the term acute radiation nephritis has also been used for this disease, since no inflammation occurs immediately after kidney irradiation and histologic examination of the radiation-damaged kidneys usually reveals only minimal proliferation and inflammatory changes, the terms acute and chronic radiation nephropathy, rather than nephritis, are preferred.[440,641] The severity of the pathologic changes in the damaged kidney depends upon multiple factors, including radiation dosage, method of irradiation, age of the patient, amount of perirenal fat, preexistence of renal disease, and the concomitant use of chemotherapeutic agents, as well as individual susceptibility. In general, a radiation dose of 9.8 Gy in the absence of exposure to nephrotoxic drugs and other predisposing factors is associated with 5% incidence of kidney toxicity.[642]

Acute radiation nephropathy usually occurs 6–12 months after radiation exposure.[440] However, the period of latency can be shorter, especially in children. Clinically, the disease is manifested by the gradual onset of edema, hypertension, dyspnea on exercise, pleural and peritoneal serous effusions, anemia, headaches, and urinary changes, which include proteinuria and the presence of casts. Rare cases of radiation nephropathy causing nephrotic syndrome have been reported.[643] The glomerular filtration rate decreases and over half of the patients progress to renal failure. Those who recover from the acute episode usually have persistent proteinuria and renal impairment. On occasion, malignant hypertension may develop during the acute radiation syndrome. The mortality of patients with this complication is high.

Chronic radiation nephropathy either follows the acute phase or develops insidiously over a period of years. Although no specific threshold has been established for total cumulative radiation exposure that leads to this form of injury, it appears that relatively small doses of radiation (500–1000 rad) may, in susceptible individuals, cause renal damage. In most patients, the findings of mild proteinuria and moderate hypertension are not detected until many years after radiation exposure.

Depending on the severity and the stage of the disease, kidney biopsies from patients with radiation nephropathy will show a wide range of glomerular changes.[440] Some glomeruli may appear segmentally or completely scarred, while others may show no significant changes. Segmental areas of fibrinoid necrosis of the tuft in continuity with similar changes in the arterioles may be seen. The glomerular capillary walls may be thickened, and a double contour may be demonstrated by silver impregnation techniques.[644] The mesangium may be prominent as a result of an increase in mesangial matrix. Mesangiolysis and adhesions to the Bowman capsule may be seen. Vascular injury is manifested by fibrinoid necrosis of the arterioles and small arteries, sometimes accompanied by thrombosis. A loose myxoid intimal thickening involving arterioles and interlobular arteries is a frequent feature. The glomerular and vascular changes are within the spectrum of pathology seen in TMA. Swelling of the tubular epithelium with desquamation of the cells, and basement membrane thickening and splitting followed by tubular loss and atrophy are common findings and may be severe. Regeneration is often abnormal so that the cells may have poorly formed cytoplasm and abnormal nuclei. The interstitium is focally scarred and has no significant inflammation.

Electron microscopic examination of the glomeruli shows a widening of the subendothelial zone that may contain flocculent material or strands of fibrin. Focal extension of the mesangium into the subendothelial space may also be seen, sometimes associated with GBM duplication. The endothelial cells may appear swollen or focally detached from the endothelial aspect of the GBM. Immunofluorescence may show focal deposition of IgM and fibrinogen in glomeruli and blood vessels.

Hematopoietic Stem Cell Transplantation–Associated Thrombotic Microangiopathy

Hematopoietic stem cell transplantation (HSCT)-associated TMA is the term used to designate a syndrome of late-onset renal insufficiency that has been reported to occur in up to 20% of patients who have received a bone marrow transplant and was previously referred to as bone marrow transplant nephropathy.[440,645] Although hematopoietic stem cells can be derived from bone marrow, peripheral blood is the most common source now.[36] Total body irradiation is an important component of the treatment in these patients and appears to be the main factor in the development of HSCT-associated TMA. However, other factors, such as drug therapy and infections also contribute to this syndrome.[440,645] It is also known that HSCT-associated TMA can occur in autologous or allogeneic HSCT, in the absence of graft versus host disease, total body irradiation, cyclosporine use, or infections. Individual susceptibility may also be an important factor, as a few pediatric patients with HSCT-associated TMA were found to have mutations in complement genes or develop autoantibodies against complement factors posttransplantation.[646]

The renal insufficiency usually manifests 9–12 months after the transplant but can be variable given the wide variety of treatment protocols and associated comorbidities.[36] In some patients, the clinical picture can be similar to that of HUS with a rapid decline of renal function, while in others there may be a slow decline in renal function without apparent ongoing hemolysis.[647–649] The renal lesions, regardless of whether or not the patient has clinical evidence of systemic HUS, typically affect the glomeruli, small arteries, and arterioles and are histologically similar to those reported in radiation nephropathy and HUS.[440]

Cystic Diseases of the Kidney

Renal cystic diseases are a large family of hereditary, sporadic, developmental, and acquired disorders characterized by the presence of cysts in one or both kidneys.[650–653] Only the most common cystic renal diseases will be discussed in this section. A subset of hereditary cystic diseases with gene mutations involving primary (nonmotile) cilia is now being reclassified as "ciliopathies." This category of disease includes autosomal dominant polycystic kidney disease (ADPKD), autosomal recessive polycystic kidney disease (ARPKD), and nephronophthisis (NPHP), and other related ciliopathies. Primary cilia are antenna-like projections on the apical surfaces of almost all cells and consist of a basal body and an axoneme with nine peripheral doublets. Primary cilia detect flow as well as a variety of stimuli and participate in transmembrane transport of proteins.

Multicystic Renal Dysplasia

In this disorder, the development of the kidney is disorganized because of anomalous differentiation of the metanephros (Fig. 23.95).

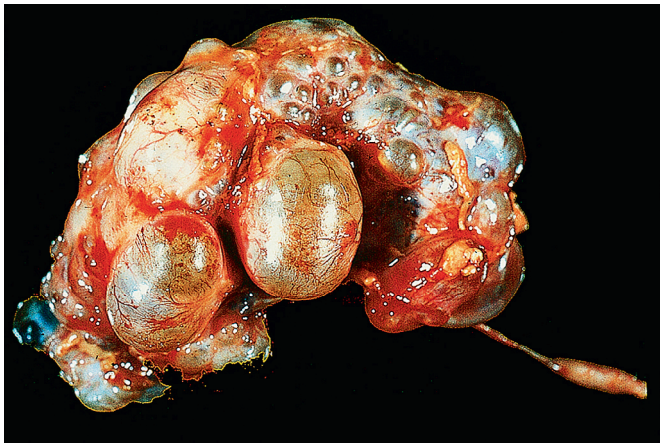

Figure 23.95 Dysplastic Kidney of an Infant. Opposite kidney appeared normal by pyelogram.

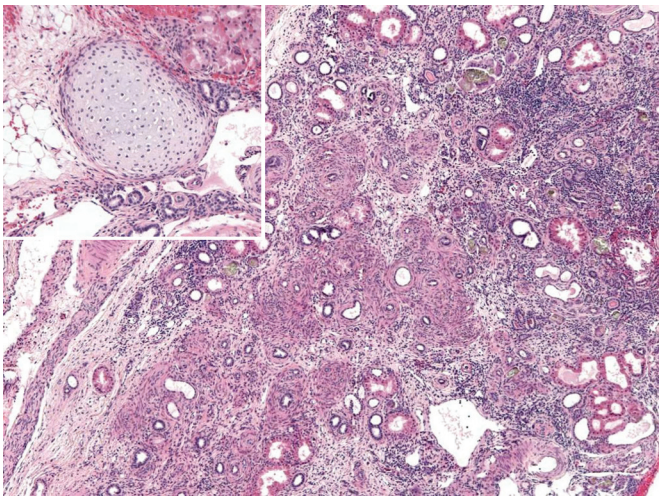

Figure 23.96 Dysplastic kidney showing embryonic-like connective tissue and primitive tubules. Immature cartilage is also seen focally *(inset)*.

Multicystic renal dysplasia is the most common form of cystic renal disease in children and the most common cause of abdominal masses in newborns. The dysplasia is usually unilateral but can be bilateral, segmental, or focal. Abnormalities of the collecting system are common and include obstruction of the uretero-pelvic junction, ureteral atresia, and urethral obstruction. Malformations of other organs, especially of the heart, can occur in conjunction with renal dysplasia. The clinical presentation largely depends on the extent of the dysplastic involvement and the degree of associated urinary obstruction. Most dysplastic kidneys arise sporadically but a few are familial or occur in syndromes of multiple malformations.[654,655] A large reniform mass of cysts of various sizes obscures any renal parenchyma that may be present. In focal and segmental dysplasia, only part of the kidney is involved by the dysplasia and cyst formation. Microscopically, the findings are quite characteristic.[656,657] The cysts are lined by cuboidal epithelial cells and surrounded by immature stromal elements. Primitive tubules and glomerular structures may be present, as may islands of dysplastic mesenchyme including cartilage and fibromuscular tissue (Fig. 23.96).

Autosomal Dominant Polycystic Kidney Disease

ADPKD is a hereditary condition characterized by expanding cysts that progressively destroy the renal parenchyma of both kidneys, ultimately causing renal failure. It is one of the most common hereditary human disorders, occurring in about 1 or 2 per 1000 live births and accounting for approximately 10% of cases requiring dialysis or renal transplantation.[658] The pattern of inheritance is autosomal dominant with complete penetrance, and each offspring of an affected individual has a 50% chance of inheriting the disease. The disease is genetically heterogeneous and is caused by a mutation in two genes, *PKD1* and *PKD2*, that are located on chromosomes 16p13.3 and 4q13–23, respectively.[659,660] The protein products of the PKD genes, polycystin-1 and polycystin-2, have similar cellular distribution resulting in phenotypic similarities between *PKD1*- and *PKD2*-mutated ADPKD.[661,662] Polycystin-1 is an epithelial cell membrane receptor involved in signaling of renal tubular epithelial cell proliferation and differentiation. Polycystin-2 has similarities to a sodium/calcium channel and likely modulates intracellular calcium levels; this ion channel function is enabled by heterodimerization of polycystin 1 and 2. The polycystin complex is implicated in the regulation of the cell cycle via multiple transduction pathways, as well as in the mechanosensory function of the renal primary cilium.[663] Abnormalities in tubular cell proliferation, apoptosis, cell polarity, and secretions have been detected within the cysts. Mutations in the *PKD1* gene are responsible for about 85%–90% of all cases of ADPKD, while mutations in *PKD2* cause the disease in majority of the remaining patients. A small number of families with ADPKD do not demonstrate linkage to either *PKD1* or *PKD2*, which suggests the potential presence of an as yet unidentified *PKD3* gene.[664] Males and females are affected equally, and there is no racial predilection. Although it can present at any time during life, it most frequently becomes symptomatic during the fourth and fifth decades with a gradual onset of renal failure. Early-onset ADPKD can occur rarely in children, causing a diagnostic challenge, and the presence of glomerular cysts should favor ADPKD.[665]

Clinical manifestations of ADPKD include flank pain, flank masses, hematuria, hypertension, and renal failure. Approximately 20% of patients with ADPKD develop nephrolithiasis, and uric acid stones are more common than calcium oxalate stones.[666] Although individuals with *PKD1* are clinically indistinguishable from those with *PKD2*, the latter patients have a less severe disease course with a later mean age at diagnosis, onset of hypertension, and ESRD.[667] Radiographic findings are usually diagnostic, and sonography and computed tomography are reliable procedures for the demonstration of early involvement. Gene linkage analysis allows prenatal diagnosis but requires at least four affected family members.[658] Although direct sequencing is more sensitive, even by this method, only 70% of ADPKD mutations are detected.

ADPKD is bilateral, but significant asynchrony of involvement of the kidneys may be noted on occasion. The kidneys are markedly enlarged and have a bosselated outer cortical surface produced by multiple cysts of varying sizes (Fig. 23.97). When the disease is severe, normal renal parenchyma is apparent only microscopically. The cysts develop in all segments of the renal tubule and glomerular capsule as saccular expansions or diverticula. In the early stages, the fluid of the cysts is derived from glomerular filtrate. As the cysts enlarge, however, they commonly become disconnected from the tubule of origin, thereafter filling with fluid exclusively by transepithelial secretion.[668] On light microscopy, the cysts are lined by cuboidal, flattened epithelium, and hyperplastic polypoid foci are often found. Intervening renal parenchyma appears relatively normal, although foci of interstitial scarring, TA, and IF are common. The development of renal adenomas has been reported to occur in about 20% of patients with ADPKD.[669] ADPKD is considered

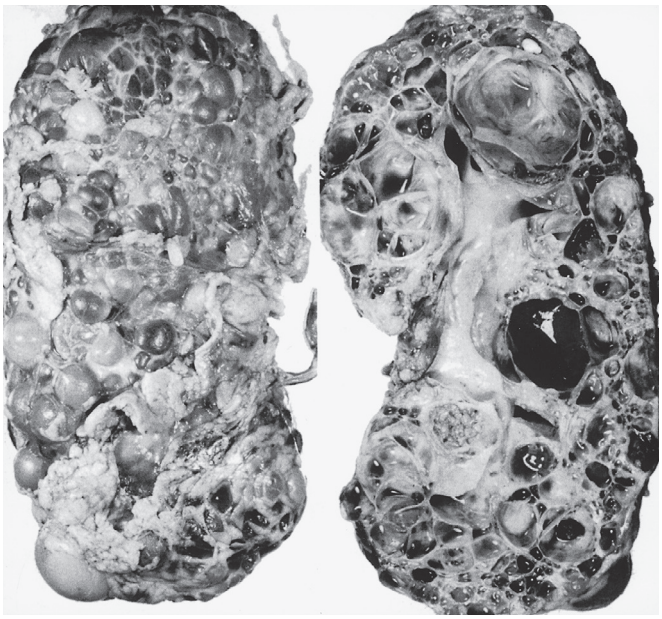

Figure 23.97 External and cut surface of a nephrectomy specimen from a patient with autosomal dominant polycystic kidney disease.

a systemic condition since over half of the patients develop cysts in other organs including the liver, pancreas, spleen, pineal gland, seminal vesicles, and lungs.[670] Other abnormalities include the presence of cerebral and coronary artery aneurysms, mitral valve prolapse, abnormal aortic valves, colonic diverticula, and skeletal malformations,[658,671,672]

Autosomal Recessive Polycystic Kidney Disease

ARPKD is a rare hereditary disorder with an estimated incidence of 1 per 20,000 live births.[673] ARPKD is caused by mutations of a gene located on chromosome 6p21.1–p12 named polycystic kidney hepatic disease gene *(PKHD1)*[674,675] whose related protein polyductin,[676] also known as fibrocystin,[677] is highly expressed in the epithelial cells of the collecting ducts and thick ascending loops of Henle and, to a lesser extent, in the biliary and pancreatic duct epithelia.[678] Of date, more than 300 *PKHD1* mutations have been identified and the majority of patients are compound heterozygotes.[679] As in other polycystic kidney diseases, polyductin localizes to the primary cilia of the renal epithelial cells.[678] Although the liver and both kidneys are invariably affected, the severity of involvement varies, thus creating a spectrum of clinical presentation.[680] In the neonatal period, the renal symptoms usually predominate.[681] Truncating *PKHD1* mutations are associated with severe neonatal disease.[682] Later in life, patients seek medical attention because of hepatic disease, which consists of congenital hepatic fibrosis with a variable degree of biliary dysgenesis and bile duct ectasia. These patients may also develop portal hypertension with hepatosplenomegaly and esophageal varices. Occasional patients may present with liver cysts, but cysts in other viscera aside from the kidneys and liver are rare and their presence should suggest an alternate diagnosis.

Majority of patients with ARPKD present with large abdominal masses at birth. They may also have the "Potter" phenotype with its characteristic facies secondary to oligohydramnios, joint deformities, and pulmonary hypoplasia. Newborns that have the severe form of the disease die shortly after birth, usually due to respiratory failure. Patients who survive the perinatal period develop renal failure, hypertension, and portal hypertension. The estimated perinatal mortality is 30%–50%; for those who survive the first month of life, the reported mean 5-year survival rate is 80%–95%.[676,683]

The kidneys are markedly enlarged bilaterally but retain their reniform configuration. The cysts tend to be linear and radiate from the medulla to the outer cortex. They develop in the collecting ducts, which expand to a large size due to fluid accumulation within the cyst cavity. Microscopically, the cysts appear as dilated tubular structures lined by cuboidal or flattened epithelium. The intervening tissue may contain uninvolved nephrons, but this depends on the severity of the disorder.

Nephronophthisis

Although NPHP has traditionally been grouped with medullary cystic kidney disease based on similarities in their clinical and pathologic features, these conditions are now regarded as two distinct entities.[684] NPHP is an autosomal *recessive* cystic disease characterized by tubular basement membrane disruption, IF, and cyst formation. It is the most frequent genetic cause of ESRD in children and adolescents, accounting for 10%–20% of cases of renal failure in this age group.[685] Three clinical forms, referred to as juvenile,[686] infantile,[687] and adolescent,[688] with a median age at onset of ESRD of 13 years, 1–3 years, and 19 years, respectively, have been recognized. NPHP is genetically heterogeneous, and mutations have been detected in increasing number of genes.[689] The mutations are in genes encoding primary cilia proteins *(NPHP1-NPHP18, NPHPL1, NPHP2L, AHI1, CC2D2A, MSK1, ATXN10, B9D2)*, and patients often have associated renal disease of NPHP, which is now considered a form of "ciliopathy."[690,691] Majority of proteins encoded by the NPHP genes are known as nephrocystins, and it has been proposed that mutated proteins alter the function of primary cilia, causing renal cystic disease and, in some, extrarenal manifestations.[684,691]

Typical signs and symptoms of NPHP include the inability to concentrate urine, polydipsia, anuresis, severe anemia, and growth retardation. The disease occurs in a pure renal from in approximately 85% of the patients. About 12% of the cases are associated with retinitis pigmentosa (Senior–Løken syndrome).[692–694] Other less common associations that have been described include hepatic fibrosis, skeletal malformations, and various defects in the central nervous system. Clinical syndromes described with NPHP and extrarenal manifestations include Bardet–Biedl syndrome, Joubert syndrome, and Meckel–Gruber syndrome.[690,691]

All types of NPHP have similar macroscopic and histopathologic features. Renal involvement is always bilateral. Both kidneys are moderately reduced in size and exhibit a granular surface. On cut sections, the cortex and medulla are both thinned. The corticomedullary junction is indistinct and typically the site of a variable number of thin-walled, fluid-filled cysts, ranging in size from barely visible up to 2.0 cm in diameter. The cysts may also occur deeper in the renal medulla and occasionally in the papillae. Microdissection studies have shown that the cysts arise from the loop of Henle, distal convoluted tubules, and collecting ducts. Histologic findings are nonspecific and depend on the severity of the disease. Tubulointerstitial fibrosis with lymphocytic inflammatory infiltrate, TA, and cyst formation is seen. The TA is often accompanied by a marked thickening of the tubular basement membrane and is better seen in PAS-stained sections. Pools of Tamm–Horsfall protein without clinical evidence of obstructive or reflux nephropathy in a young patient should prompt genetic evaluation for NPHP. By electron microscopy, these basement membranes can appear homogeneously thickened, split into thin lamellae, reticulated, or completely disintegrated.[695]

Autosomal Dominant Tubulointerstitial Kidney Disease

Autosomal *dominant* tubulointerstitial kidney disease (ADTKD) represents a new terminology for a group of disorders that are characterized by TA, IF, thickening and lamellation of tubular basement membranes, and in some cases, tubular microcysts. This entity encompasses mucin-1–related kidney disease (MUC-1), uromodulin-related kidney disease (UMOD), renin mutation with tubulointerstitial nephritis *(REN)*, and kidney disease due to *HNF1β* mutation (HNF1B), with two former diseases being most frequently encountered.[696,697] ADTKD-MUC1 was previously referred to as medullary cystic kidney disease type I (MCKD1), and the previous terminology for ADTKD-UMOD was medullary cystic kidney disease type 2 (MCKD2). These disorders share clinical and morphologic similarities with NPHP, but cysts are not uniformly observed.[650,696]

Patients with ADTKD-MUC1 develop progressive renal failure in adulthood. The median age at end-stage kidney disease is 62 years, although it varies within families.[698] The disease is caused by mutations in *MUC1* gene that maps to chromosome 1q21.[696,699] The protein, mucin-1, is expressed in distal tubules and collecting ducts and presumably protects the epithelial surfaces from bacteria. ADTKD-UMOD is caused by mutations in *UMOD* gene located on chromosome 16p12.[700,701] The mutant uromodulin (Tamm–Horsfall protein) is misfolded, leading to accumulation within the endoplasmic reticulum of the thick ascending loop of Henle and distal tubules. The end-stage renal failure occurs from 20–70 years, with a median age being 54 years.[700,701]

Both MUC-1 and UMOD-associated ADTKD patients have minimal proteinuria accompanying chronic renal failure and usually lack extrarenal disease.[696,697] There is an association with hyperuricemia and gout, especially in ADTKD-UMOD patients.[700,701] The kidneys are normal or moderately reduced in size. Small corticomedullary cysts maybe seen in both diseases and in ADTKD-UMOD, cysts can also be detected in cortex and medulla. Microscopically, there is diffuse interstitial inflammation with fibrosis and TA interspersed with hypertrophied and dilated tubules. Ultrastructural similarities with NPHP include tubular basement membrane lamellation. Patients with UMOD mutations have characteristic intracytoplasmic fibrillar inclusions composed of uromodulin in the thick ascending loops of Henle and on rare occasion, glomerular cysts.[702]

Interstitial nephritis attributable to mutated *REN*, a gene encoding renin, is rare, and renal cysts are not a typical feature in these patients. Anemia and hyperuricemia are common presenting features along with chronic renal failure.[696] Heterozygous mutations in *REN* result in reduced production of renin in juxtaglomerular cells and intracellular accumulation of unfolded precursor protein causes accelerated apoptosis and nephron loss.[703,704] Up to a third of patients with *HNF1β* mutations have congenital abnormalities of the kidney and urinary tract, and the age at presentation in such instances is typically in utero and in young children.[705] The renal cysts can be either widespread or limited to glomeruli and adjacent parenchyma often shows features of dysplasia. Adults with these mutations come to attention due to unexplained chronic renal failure, minimal proteinuria, and tubulointerstitial disease.[706] The transcription factor HNF1β is also expressed in pancreas and hence the association with maturity onset diabetes mellitus.

Medullary Sponge Kidney

Medullary sponge kidney (MSK) is a renal cystic disorder characterized by tubular ectasia of the collecting ducts and cyst formation confined to the medullary pyramids.[707] It typically affects both kidneys and represents developmental malformation of the collecting system. The true incidence of MSK is unknown, although it has been estimated at 1 per 5000 population.[708] The disease is asymptomatic unless complicated by nephrolithiasis, hematuria, or infections. In these instances, the diagnosis is established when the patient undergoes radiographic examination.[709] Typically, symptoms start in adulthood, but presentation in adolescence and childhood has been reported.[710] In patients with recurrent nephrolithiasis, the stones are composed of calcium oxalate and/or calcium phosphate and a third of the patients have distal renal tubular acidosis. Both sexes are equally affected. Most cases appear sporadically, but a few familial clusters have been documented.[710] MSK has been reported in association with various conditions such as hemihypertrophy, Wilms tumor, congenital hepatic fibrosis, multiple endocrine neoplasia type 2 (MEN2), Marfan syndrome, and Ehlers–Danlos syndrome. Mutations or polymorphisms of glial cell line–derived neurotrophic factor (GDNF) and receptor tyrosine kinase (RET) genes (previously known to be involved in genitourinary development) have been recently reported in MSK, confirming a genetic component in a minority of patients.[711]

The involved kidneys are usually normal in size, but they can be slightly enlarged in those cases with pronounced sponge-like changes. The cysts are multiple, small, and limited to the medullary pyramids and papillae. They usually affect all pyramids in both kidneys; however, on occasion, only one or two pyramids or only one kidney may be affected. The cysts are lined by collecting duct epithelium and usually communicate with collecting tubules. Concretions adherent to the walls of the cysts and the dilated collecting ducts may be seen. The interstitium often shows severe inflammation and scaring, frequently accompanied by TA, especially near the papillary tips. In instances where there is nephrolithiasis and pyelonephritis, the cortex may show significant cortical scarring.

Acquired Renal Cystic Disease

Although acquired renal cystic disease (ARCD) was initially reported in patients undergoing long-term dialysis, similar changes can also occur in uremic nondialyzed patients.[712] ARCD has been reported to occur in 7%–22% of patients with renal failure who are not on dialysis, 40% of patients who have been on dialysis for 3 years, and 80%–90% of patients who have been on dialysis for 10 years or more.[713] The etiology of ARCD has not yet been well established, and it has been suggested that the cysts found in this condition result from obstruction of the renal tubules by local fibrosis, oxalate deposition, or epithelial hyperplasia. The cysts often regress after transplantation. Men are more affected than women. In most cases, the disease is asymptomatic, but sometimes the cysts bleed, rupture, or become infected, causing fever, hematuria, and flank pain. The most serious complication, however, is the development of renal carcinomas in the walls of the cysts. It has been estimated that renal cell carcinoma is found 50 times more frequently in dialysis patients with ARCD than in the general population.

The cysts in ARCD are usually bilateral and occur in both the renal cortex and medulla.[714] Their number can vary from a few subcapsular cysts to diffuse involvement of almost the entire renal parenchyma. A diagnosis of ARCD requires five or more cysts are found on imaging studies and absence of known cystic renal disease as the cause of renal failure. The cysts are filled with straw-colored or hemorrhagic fluid and often contain calcium oxalate crystals. Most cysts are less than 0.5 cm, but they can measure up to 2–3 cm in diameter. Microscopically, cysts are lined by flattened epithelium or by hyperplastic cuboidal or columnar cells with prominent eosinophilic cytoplasm, sometimes forming papillary projections. Renal neoplasms arising in this setting are fully discussed in Chapter 24.[715]

Simple Cysts

Simple cysts are the most common cystic abnormality encountered in the kidneys.[716] They are found in about 5%–12% of the general population undergoing abdominal ultrasound examination for various reasons.[717,718] Their occurrence increases with age, with an incidence of less than 0.1% in children and up to 20% in individuals over 50 years of age.[713] They are usually asymptomatic and are often detected at autopsy or as an incidental finding in the radiologic evaluation for other diseases. On occasion, however, when complicated by hemorrhage or infection, they can cause pain. Simple cysts can be solitary or multiple and bilateral. They occur more commonly in the renal cortex, and although their etiology has not been well established, it is believed that they originate from diverticula of cortical tubules.[719] Most are under 5 cm in diameter, but larger cysts have been documented.[718] Usually unilocular, on occasion they can be bilocular or multilocular. The cysts are normally translucent, filled with clear serous fluid, and lined by a single layer of cuboidal or flattened epithelium. Cases complicated by hemorrhage or infection can have thick capsular walls with hemosiderin-laden macrophages and atrophic lining epithelium.

References

1. Israni A, Kasiske BL. Laboratory assessment of kidney disease: clearance, urinalysis, and kidney biopsy. In: Brenner BM, ed. *Brenner and Rector's the Kidney*. 8th ed. Philadelphia, PA: WB Saunders; 2008:724-756.
2. Piotto GH, Moraes MC, Malheiros DM, et al. Percutaneous ultrasound-guided renal biopsy in children—safety, efficacy, indications and renal pathology findings: 14-year Brazilian university hospital experience. *Clin Nephrol*. 2008;69:417-424.
3. Rivera F, Lopez-Gomez JM, Perez-Garcia R. Clinicopathologic correlations of renal pathology in Spain. *Kidney Int*. 2004;66:898-904.
4. Richards NT, Darby S, Howie AJ, et al. Knowledge of renal histology alters patient management in over 40% of cases. *Nephrol Dial Transplant*. 1994;9:1255-1259.
5. Shah RP, Vathsala A, Chiang GS, et al. The impact of percutaneous renal biopsies on clinical management. *Ann Acad Med Singapore*. 1993;22:908-911.
6. Turner MW, Hutchinson TA, Barre PE, et al. A prospective study on the impact of the renal biopsy in clinical management. *Clin Nephrol*. 1986;26:217-221.
7. Messias NC, Walker PD, Larsen CP. Paraffin immunofluorescence in the renal pathology laboratory: more than a salvage technique. *Mod Pathol*. 2015;28:854-860.
8. Nasr SH, Galgano SJ, Markowitz GS, et al. Immunofluorescence on pronase-digested paraffin sections: a valuable salvage technique for renal biopsies. *Kidney Int*. 2006;70:2148-2151.
9. Johannessen JV. Rapid processing of kidney biopsies for electron microscopy. *Kidney Int*. 1973;3:46-50.
10. Hoffmann EO, Flores TR. High resolution light microscopy in renal pathology. *Am J Clin Pathol*. 1981;76:636-643.
11. Colvin RB. Antibody-mediated renal allograft rejection: diagnosis and pathogenesis. *J Am Soc Nephrol*. 2007;18:1046-1056.
12. Truong LD, Barrios R, Adrogue HE, Gaber LW. Acute antibody-mediated rejection of renal transplant: pathogenetic and diagnostic considerations. *Arch Pathol Lab Med*. 2007;131:1200-1208.
13. Boldorini R, Veggiani C, Barco D, Monga G. Kidney and urinary tract polyomavirus infection and distribution: molecular biology investigation of 10 consecutive autopsies. *Arch Pathol Lab Med*. 2005;129:69-73.
14. Eyzaguirre E, Haque AK. Application of immunohistochemistry to infections. *Arch Pathol Lab Med*. 2008;132:424-431.
15. Weber M. Basement membrane proteins. *Kidney Int*. 1992;41:620-628.
16. Clapp WL, Croker BP. Adult kidney. In: Mills SE, ed. *Histology for Pathologists*. 3rd ed. Philadelphia, PA: Lippincott Williams & Wilkins; 2007:839-907.
17. Sraer JD, Adida C, Peraldi MN, et al. Species-specific properties of the glomerular mesangium. *J Am Soc Nephrol*. 1993;3:1342-1350.
18. Drenckhahn D, Schnittler H, Nobiling R, Kriz W. Ultrastructural organization of contractile proteins in rat glomerular mesangial cells. *Am J Pathol*. 1990;137:1343-1351.
19. Johnson RJ, Floege J, Yoshimura A, et al. The activated mesangial cell: a glomerular "myofibroblast"? *J Am Soc Nephrol*. 1992;2:S190-S197.
20. Mene P, Simonson MS, Dunn MJ. Physiology of the mesangial cell. *Physiol Rev*. 1989;69:1347-1424.
21. Michael AF, Keane WF, Raij L, et al. The glomerular mesangium. *Kidney Int*. 1980;17:141-154.
22. Mathieson PW. Update on the podocyte. *Curr Opin Nephrol Hypertens*. 2009;18:206-211.
23. Stamenkovic I, Skalli O, Gabbiani G. Distribution of intermediate filament proteins in normal and diseased human glomeruli. *Am J Pathol*. 1986;125:465-475.
24. Shankland SJ, Smeets B, Pippin JW, Moeller MJ. The emergence of the glomerular parietal epithelial cell. *Nat Rev Nephrol*. 2014;10:158-173.
25. Winyard PJ, Price KL. Experimental renal progenitor cells: repairing and recreating kidneys? *Pediatr Nephrol*. 2014;29: 665-672.
26. Habib R, Kleinknecht C. The primary nephrotic syndrome in children. Classification and clinicopathologic study of 406 cases. In: Sommers SC, ed. *Kidney Pathology Decennial, 1966–1975*. New York, NY: Appleton-Century-Crofts; 1975:165-224.
27. Primary nephrotic syndrome in children: clinical significance of histopathologic variants of minimal change and of diffuse mesangial hypercellularity. A Report of the International Study of Kidney Disease in Children. *Kidney Int*. 1981;20:765-771.
28. Cameron JS. Nephrotic syndrome in the elderly. *Semin Nephrol*. 1996;16:319-329.
29. Waldman M, Crew RJ, Valeri A, et al. Adult minimal-change disease: clinical characteristics, treatment, and outcomes. *Clin J Am Soc Nephrol*. 2007;2:445-453.
30. Wyatt RJ, Marx MB, Kazee M, Holland NH. Current estimates of the incidence of steroid responsive idiopathic nephrosis in Kentucky children 1–9 years of age. *Int J Pediatr Nephrol*. 1982;3:63-65.
31. van den Berg JG, Weening JJ. Role of the immune system in the pathogenesis of idiopathic nephrotic syndrome. *Clin Sci*. 2004;107:125-136.
32. Artinano M, Etheridge WB, Stroehlein KB, Barcenas CG. Progression of minimal-change glomerulopathy to focal glomerulosclerosis in a patient with fenoprofen nephropathy. *Am J Nephrol*. 1986;6:353-357.
33. Warren GV, Korbet SM, Schwartz MM, Lewis EJ. Minimal change glomerulopathy associated with nonsteroidal antiinflammatory drugs. *Am J Kidney Dis*. 1989;13:127-130.
34. Audard V, Larousserie F, Grimbert P, et al. Minimal change nephrotic syndrome and classical Hodgkin's lymphoma: report of 21 cases and review of the literature. *Kidney Int*. 2006;69:2251-2260.
35. Kraft SW, Schwartz MM, Korbet SM, Lewis EJ. Glomerular podocytopathy in patients with systemic lupus erythematosus. *J Am Soc Nephrol*. 2005;16:175-179.
36. Troxell ML, Higgins JP, Kambham N. Renal pathology associated with hematopoietic stem cell transplantation. *Adv Anat Pathol*. 2014;21:330-340.
37. Zafarmand AA, Baranowska-Daca E, Ly PD, et al. De novo minimal change disease associated with reversible post-transplant nephrotic syndrome. A report of five cases and review of literature. *Clin Transplant*. 2002;16:350-361.
38. Grimbert P, Audard V, Remy P, et al. Recent approaches to the pathogenesis of minimal-change nephrotic syndrome. *Nephrol Dial Transplant*. 2003;18:245-248.
39. Tesar V, Zima T. Recent progress in the pathogenesis of nephrotic proteinuria. *Crit Rev Clin Lab Sci*. 2008;45:139-220.
40. Ishimoto T, Shimada M, Araya CE, et al. Minimal change disease: a CD80 podocytopathy? *Semin Nephrol*. 2011;31:320-325.
41. Ling C, Liu X, Shen Y, et al. Urinary CD80 levels as a diagnostic biomarker of minimal change disease. *Pediatr Nephrol*. 2015;30:309-316.
42. White RH, Glasgow EF, Mills RJ. Clinicopathological study of nephrotic syndrome in childhood. *Lancet*. 1970;1:1353-1359.
43. Olson JL. The nephrotic syndrome and minimal change disease. In: Jennette JC, Olson JL, Silva FG, A'gati VD, eds. *Heptinstall's Pathology of the Kidney*. 7th ed. Philadelphia, PA: Wolters Kluwer; 2015:173-206.
44. Munyentwali H, Bouachi K, Audard V, et al. Rituximab is an efficient and safe treatment in adults with steroid-dependent minimal change disease. *Kidney Int*. 2013;83: 511-516.
45. Garin EH, Reiser J, Cara-Fuentes G, et al. Case series: CTLA4-IgG1 therapy in minimal change disease and focal segmental glomerulosclerosis. *Pediatr Nephrol*. 2015;30:469-477.
46. Munk F. Klinische Diagnostik der degenerativen Nierenerkrankungen. *Z Klin Med*. 1913;78:1-52.
47. Patrakka J, Lahdenkari AT, Koskimies O, et al. The number of podocyte slit diaphragms is decreased in minimal change nephrotic syndrome. *Pediatr Res*. 2002;52:349-355.

48. Fatima H, Moeller MJ, Smeets B, et al. Parietal epithelial cell activation marker in early recurrence of FSGS in the transplant. *Clin J Am Soc Nephrol*. 2012;7:1852-1858.
49. Giannico G, Yang H, Neilson EG, Fogo AB. Dystroglycan in the diagnosis of FSGS. *Clin J Am Soc Nephrol*. 2009;4:1747-1753.
50. D'Agati VD, Fogo AB, Bruijn JA, Jennette JC. Pathologic classification of focal segmental glomerulosclerosis: a working proposal. *Am J Kidney Dis*. 2004;43:368-382.
51. D'Agati VD. The spectrum of focal segmental glomerulosclerosis: new insights. *Curr Opin Nephrol Hypertens*. 2008;17:271-281.
52. Fogo AB. Causes and pathogenesis of focal segmental glomerulosclerosis. *Nat Rev Nephrol*. 2015;11:76-87.
53. Stokes MB, D'Agati VD. Morphologic variants of focal segmental glomerulosclerosis and their significance. *Adv Chronic Kidney Dis*. 2014;21:400-407.
54. D'Agati VD, Alster JM, Jennette JC, et al. Association of histologic variants in FSGS clinical trial with presenting features and outcomes. *Clin J Am Soc Nephrol*. 2013;8:399-406.
55. Savin VJ, Sharma R, Sharma M, et al. Circulating factor associated with increased glomerular permeability to albumin in recurrent focal segmental glomerulosclerosis. *N Engl J Med*. 1996;334:878-883.
56. Wei C, El Hindi S, Li J, et al. Circulating urokinase receptor as a cause of focal segmental glomerulosclerosis. *Nat Med*. 2011;17:952-960.
57. Barisoni L, Schnaper HW, Kopp JB. Advances in the biology and genetics of the podocytopathies: implications for diagnosis and therapy. *Arch Pathol Lab Med*. 2009;133:201-216.
58. D'Agati VD, Kaskel FJ, Falk RJ. Focal segmental glomerulosclerosis. *N Engl J Med*. 2011;365:2398-2411.
59. Sadowski CE, Lovric S, Ashraf S, et al. A single-gene cause in 29.5% of cases of steroid-resistant nephrotic syndrome. *J Am Soc Nephrol*. 2015;26:1279-1289.
60. Genovese G, Friedman DJ, Ross MD, et al. Association of trypanolytic ApoL1 variants with kidney disease in African Americans. *Science*. 2010;329:841-845.
61. Parsa A, Kao WH, Xie D, et al. APOL1 risk variants, race, and progression of chronic kidney disease. *N Engl J Med*. 2013;369:2183-2196.
62. Deegens JK, Steenbergen EJ, Wetzels JF. Review on diagnosis and treatment of focal segmental glomerulosclerosis. *Neth J Med*. 2008;66:3-12.
63. Del Rio M, Kaskel F. Evaluation and management of steroid-unresponsive nephrotic syndrome. *Curr Opin Pediatr*. 2008;20:151-156.
64. Korbet SM. Clinical picture and outcome of primary focal segmental glomerulosclerosis. *Nephrol Dial Transplant*. 1999;14(suppl 3):68-73.
65. Braden GL, Mulhern JG, O'Shea MH, et al. Changing incidence of glomerular diseases in adults. *Am J Kidney Dis*. 2000;35:878-883.
66. Beaufils H, Alphonse JC, Guedon J, Legrain M. Focal glomerulosclerosis: natural history and treatment. A report of 70 cases. *Nephron*. 1978;21:75-85.
67. Mongeau JG, Robitaille PO, Clermont MJ, et al. Focal segmental glomerulosclerosis (FSG) 20 years later. From toddler to grown up. *Clin Nephrol*. 1993;40:1-6.
68. Artero M, Biava C, Amend W, et al. Recurrent focal glomerulosclerosis: natural history and response to therapy. *Am J Med*. 1992;92:375-383.
69. Crosson JT. Focal segmental glomerulosclerosis and renal transplantation. *Transplant Proc*. 2007;39:737-743.
70. Fine RN. Recurrence of nephrotic syndrome/focal segmental glomerulosclerosis following renal transplantation in children. *Pediatr Nephrol*. 2007;22:496-502.
71. Stephanian E, Matas AJ, Mauer SM, et al. Recurrence of disease in patients retransplanted for focal segmental glomerulosclerosis. *Transplantation*. 1992;53:755-757.
72. Cameron JS, Senguttuvan P, Hartley B, et al. Focal segmental glomerulosclerosis in fifty-nine renal allografts from a single centre; analysis of risk factors for recurrence. *Transplant Proc*. 1989;21:2117-2118.
73. Schonholzer KW, Waldron M, Magil AB. Intraglomerular foam cells and human focal glomerulosclerosis. *Nephron*. 1992;62:130-136.
74. Howie AJ, Brewer DB. Further studies on the glomerular tip lesion: early and late stages and life table analysis. *J Pathol*. 1985;147:245-255.
75. Magil AB. Focal and segmental glomerulosclerosis. *Mod Pathol*. 1991;4:383-391.
76. Schwartz MM, Korbet SM, Rydell J, et al. Primary focal segmental glomerular sclerosis in adults: prognostic value of histologic variants. *Am J Kidney Dis*. 1995;25:845-852.
77. Wehrmann M, Bohle A, Held H, et al. Long-term prognosis of focal sclerosing glomerulonephritis. An analysis of 250 cases with particular regard to tubulointerstitial changes. *Clin Nephrol*. 1990;33:115-122.
78. Deegens JK, Dijkman HB, Borm GF, et al. Podocyte foot process effacement as a diagnostic tool in focal segmental glomerulosclerosis. *Kidney Int*. 2008;74:1568-1576.
79. Stokes MB, Valeri AM, Markowitz GS, D'Agati VD. Cellular focal segmental glomerulosclerosis: clinical and pathologic features. *Kidney Int*. 2006;70:1783-1792.
80. Kopp JB, Nelson GW, Sampath K, et al. APOL1 genetic variants in focal segmental glomerulosclerosis and HIV-associated nephropathy. *J Am Soc Nephrol*. 2011;22:2129-2137.
81. Detwiler RK, Falk RJ, Hogan SL, Jennette JC. Collapsing glomerulopathy: a clinically and pathologically distinct variant of focal segmental glomerulosclerosis. *Kidney Int*. 1994;45:1416-1424.
82. Singh HK, Baldree LA, McKenney DW, et al. Idiopathic collapsing glomerulopathy in children. *Pediatr Nephrol*. 2000;14:132-137.
83. El-Refaey AM, Kapur G, Jain A, et al. Idiopathic collapsing focal segmental glomerulosclerosis in pediatric patients. *Pediatr Nephrol*. 2007;22:396-402.
84. Clarkson MR, O'Meara YM, Murphy B, et al. Collapsing glomerulopathy—recurrence in a renal allograft. *Nephrol Dial Transplant*. 1998;13:503-506.
85. Albaqumi M, Barisoni L. Current views on collapsing glomerulopathy. *J Am Soc Nephrol*. 2008;19:1276-1281.
86. D'Agati V, Appel GB. Renal pathology of human immunodeficiency virus infection. *Semin Nephrol*. 1998;18:378-395.
87. Ross MJ, Klotman PE. HIV-associated nephropathy. *AIDS*. 2004;18:1089-1099.
88. Nochy D, Glotz D, Dosquet P, et al. Renal lesions associated with human immunodeficiency virus infection: North American vs. European experience. *Adv Nephrol Necker Hosp*. 1993;22:269-286.
89. Markowitz GS, Appel GB, Fine PL, et al. Collapsing focal segmental glomerulosclerosis following treatment with high-dose pamidronate. *J Am Soc Nephrol*. 2001;12:1164-1172.
90. Moudgil A, Nast CC, Bagga A, et al. Association of parvovirus B19 infection with idiopathic collapsing glomerulopathy. *Kidney Int*. 2001;59:2126-2133.
91. Kriz W, Lemley KV. The role of the podocyte in glomerulosclerosis. *Curr Opin Nephrol Hypertens*. 1999;8:489-497.
92. Sakamoto K, Ueno T, Kobayashi N, et al. The direction and role of phenotypic transition between podocytes and parietal epithelial cells in focal segmental glomerulosclerosis. *Am J Physiol Renal Physiol*. 2014;306:F98-F104.
93. Hakroush S, Cebulla A, Schaldecker T, et al. Extensive podocyte loss triggers a rapid parietal epithelial cell response. *J Am Soc Nephrol*. 2014;25:927-938.
94. Barisoni L, Kriz W, Mundel P, D'Agati V. The dysregulated podocyte phenotype: a novel concept in the pathogenesis of collapsing idiopathic focal segmental glomerulosclerosis and HIV-associated nephropathy. *J Am Soc Nephrol*. 1999;10:51-61.
95. Chander P, Soni A, Suri A, et al. Renal ultrastructural markers in AIDS-associated nephropathy. *Am J Pathol*. 1987;126:513-526.
96. Laurinavicius A, Hurwitz S, Rennke HG. Collapsing glomerulopathy in HIV and non-HIV patients: a clinicopathological and follow-up study. *Kidney Int*. 1999;56:2203-2213.
97. Fukuma Y, Hisano S, Segawa Y, et al. Clinicopathologic correlation of C1q nephropathy in children. *Am J Kidney Dis*. 2006;47:412-418.
98. Iskandar SS, Browning MC, Lorentz WB. C1q nephropathy: a pediatric clinicopathological study. *Am J Kidney Dis*. 1991;18:459-465.
99. Jennette JC, Hipp CG. C1q nephropathy: a distinct pathologic entity usually causing nephrotic syndrome. *Am J Kidney Dis*. 1985;6:103-110.
100. Kersnik Levart T, Kenda RB, Avgustin Cavic M, et al. C1Q nephropathy in children. *Pediatr Nephrol*. 2005;20:1756-1761.
101. Lau KK, Gaber LW, Delos Santos NM, Wyatt RJ. C1q nephropathy: features at presentation and outcome. *Pediatr Nephrol*. 2005;20:744-749.
102. Markowitz GS, Schwimmer JA, Stokes MB, et al. C1q nephropathy: a variant of focal segmental glomerulosclerosis. *Kidney Int*. 2003;64:1232-1240.
103. Wenderfer SE, Swinford RD, Braun MC. C1q nephropathy in the pediatric population: pathology and pathogenesis. *Pediatr Nephrol*. 2010;25:1385-1396.
104. Gunasekara VN, Sebire NJ, Tullus K. C1q nephropathy in children: clinical characteristics and outcome. *Pediatr Nephrol*. 2014;29:407-413.
105. Hayslett JP, Kashgarian M, Bensch KG, et al. Clinicopathological correlations in the nephrotic syndrome due to primary renal disease. *Medicine (Baltimore)*. 1973;52:93-120.
106. Ramirez F, Brouhard BH, Travis LB, Ellis EN. Idiopathic membranous nephropathy in children. *J Pediatr*. 1982;101:677-681.
107. Wasserstein AG. Membranous glomerulonephritis. *J Am Soc Nephrol*. 1997;8:664-674.
108. Scolari F, Amoroso A, Savoldi S, et al. Familial membranous nephropathy. *J Nephrol*. 1998;11:35-39.
109. Couser WG, Nangaku M. Cellular and molecular biology of membranous nephropathy. *J Nephrol*. 2006;19:699-705.
110. Beck LH Jr, Bonegio RG, Lambeau G, et al. M-type phospholipase A2 receptor as target antigen in idiopathic membranous nephropathy. *N Engl J Med*. 2009;361:11-21.
111. Ronco P, Debiec H, Imai H. Circulating antipodocyte antibodies in membranous nephropathy: pathophysiologic and clinical relevance. *Am J Kidney Dis*. 2013;62:16-19.
112. Hofstra JM, Beck LH Jr, Beck DM, et al. Anti-phospholipase A(2) receptor antibodies correlate with clinical status in idiopathic

membranous nephropathy. *Clin J Am Soc Nephrol*. 2011;6:1286-1291.
113. Kattah A, Ayalon R, Beck LH Jr, et al. Anti-phospholipase A(2) receptor antibodies in recurrent membranous nephropathy. *Am J Transplant*. 2015;15:1349-1359.
114. Debiec H, Ronco P. Immunopathogenesis of membranous nephropathy: an update. *Semin Immunopathol*. 2014;36:381-397.
115. Tomas NM, Hoxha E, Reinicke AT, et al. Autoantibodies against thrombospondin type 1 domain-containing 7A induce membranous nephropathy. *J Clin Invest*. 2016;126:2519-2532.
116. Tomas NM, Beck LH Jr, Meyer-Schwesinger C, et al. Thrombospondin type-1 domain-containing 7A in idiopathic membranous nephropathy. *N Engl J Med*. 2014;371:2277-2287.
117. Debiec H, Guigonis V, Mougenot B, et al. Antenatal membranous glomerulonephritis due to anti-neutral endopeptidase antibodies. *N Engl J Med*. 2002;346:2053-2060.
118. Ronco P, Debiec H. New insights into the pathogenesis of membranous glomerulonephritis. *Curr Opin Nephrol Hypertens*. 2006;15:258-263.
119. Horl WH, Kerjaschki D. Membranous glomerulonephritis (MGN). *J Nephrol*. 2000;13:291-316.
120. Debiec H, Lefeu F, Kemper MJ, et al. Early-childhood membranous nephropathy due to cationic bovine serum albumin. *N Engl J Med*. 2011;364:2101-2110.
121. Takekoshi Y, Tanaka M, Shida N, et al. Strong association between membranous nephropathy and hepatitis-B surface antigenaemia in Japanese children. *Lancet*. 1978;2:1065-1068.
122. Seggie J, Nathoo K, Davies PG. Association of hepatitis B (HBs) antigenaemia and membranous glomerulonephritis in Zimbabwean children. *Nephron*. 1984;38:115-119.
123. Wing AJ, Hutt MS, Kibukamusoke JW. Progression and remission in the nehprotic syndrome associated with quartan malaria in Uganda. *Q J Med*. 1972;41:273-289.
124. Coggins CH, Frommer JP, Glassock RJ. Membranous nephropathy. *Sem Nephrol*. 1982;2:264-273.
125. Markowitz GS, D'Agati VD. Membranous glomerulonephritis. In: Jennette JC, Olson JL, Silva FG, A'gati VD, eds. *Heptinstall's Pathology of the Kidney*. 7th ed. Philadelphia, PA: Wolters Kluwer; 2015:255-300.
126. Schwartz MM. Membranous glomerulonephritis. In: Jennette JC, Olson JL, Schwartz MM, Silva FG, eds. *Heptinstall's Pathology of the Kidney*. 6th ed. Philadelphia, PA: Lippincott Williams & Wilkins; 2007:205-251.
127. Schieppati A, Mosconi L, Perna A, et al. Prognosis of untreated patients with idiopathic membranous nephropathy. *N Engl J Med*. 1993;329:85-89.
128. Donadio JV Jr, Torres VE, Velosa JA, et al. Idiopathic membranous nephropathy: the natural history of untreated patients. *Kidney Int*. 1988;33:708-715.
129. Noel LH, Zanetti M, Droz D, Barbanel C. Long-term prognosis of idiopathic membranous glomerulonephritis. Study of 116 untreated patients. *Am J Med*. 1979;66:82-90.
130. Poduval RD, Josephson MA, Javaid B. Treatment of de novo and recurrent membranous nephropathy in renal transplant patients. *Semin Nephrol*. 2003;23:392-399.
131. Ehrenreich T, Churg J. Pathology of membranous nephropathy. *Pathol Annu*. 1968;3:145-186.
132. Jennette JC, Iskandar SS, Dalldorf FG. Pathologic differentiation between lupus and nonlupus membranous glomerulopathy. *Kidney Int*. 1983;24:377-385.
133. Svobodova B, Honsova E, Ronco P, et al. Kidney biopsy is a sensitive tool for retrospective diagnosis of PLA2R-related membranous nephropathy. *Nephrol Dial Transplant*. 2013;28:1839-1844.
134. Larsen CP, Messias NC, Silva FG, et al. Determination of primary versus secondary membranous glomerulopathy utilizing phospholipase A2 receptor staining in renal biopsies. *Mod Pathol*. 2013;26:709-715.
135. Larsen CP, Walker PD. Phospholipase A2 receptor (PLA2R) staining is useful in the determination of de novo versus recurrent membranous glomerulopathy. *Transplantation*. 2013;95:1259-1262.
136. Kearney N, Podolak J, Matsumura L, et al. Patterns of IgG subclass deposits in membranous glomerulonephritis in renal allografts. *Transplant Proc*. 2011;43:3743-3746.
137. Comparison of idiopathic and systemic lupus erythematosus-associated membranous glomerulonephropathy in children. The Southwest Pediatric Nephrology Study Group. *Am J Kidney Dis*. 1986;7:115-124.
138. Llach F, Arieff AI, Massry SG. Renal vein thrombosis and nephrotic syndrome. A prospective study of 36 adult patients. *Ann Intern Med*. 1975;83:8-14.
139. Katz A, Fish AJ, Santamaria P, et al. Role of antibodies to tubulointerstitial nephritis antigen in human anti-tubular basement membrane nephritis associated with membranous nephropathy. *Am J Med*. 1992;93:691-698.
140. Incidence of reported ESRD by primary diagnosis. USRDS. United States Renal Data System annual data report. 2015 https://www.usrds.org/2015/download/vol2_USRDS_ESRD_15.pdf.
141. Dronavalli S, Duka I, Bakris GL. The pathogenesis of diabetic nephropathy. *Nat Clin Pract Endocrinol Metab*. 2008;4:444-452.
142. Vora JP, Ibrahim H. Clinical manifestations and natural history of diabetic nephropathy. In: Johnson RJ, Feehally J, eds. *Comprehensive Clinical Nephrology*. 2nd ed. Edinberg, NY: Mosby; 2003:425.
143. Rajashekar A, Perazella MA, Crowley S. Systemic diseases with renal manifestations. *Prim Care*. 2008;35:297-328, vi-vii.
144. D'Agati V, Schmidt AM. RAGE and the pathogenesis of chronic kidney disease. *Nat Rev Nephrol*. 2010;6:352-360.
145. Ritz E, Stefanski A. Diabetic nephropathy in type II diabetes. *Am J Kidney Dis*. 1996;27:167-194.
146. Fioretto P, Mauer M. Histopathology of diabetic nephropathy. *Semin Nephrol*. 2007;27:195-207.
147. Mauer SM, Steffes MW, Ellis EN, et al. Structural-functional relationships in diabetic nephropathy. *J Clin Invest*. 1984;74:1143-1155.
148. Mauer SM, Steffes MW, Connett J, et al. The development of lesions in the glomerular basement membrane and mesangium after transplantation of normal kidneys to diabetic patients. *Diabetes*. 1983;32:948-952.
149. Tervaert TW, Mooyaart AL, Amann K, et al. Pathologic classification of diabetic nephropathy. *J Am Soc Nephrol*. 2010;21:556-563.
150. Markowitz GS, Lin J, Valeri AM, et al. Idiopathic nodular glomerulosclerosis is a distinct clinicopathologic entity linked to hypertension and smoking. *Hum Pathol*. 2002;33:826-835.
151. Najafian B, Alpers CE, Fogo AB. Pathology of human diabetic nephropathy. *Contrib Nephrol*. 2011;170:36-47.
152. Sharma SG, Bomback AS, Radhakrishnan J, et al. The modern spectrum of renal biopsy findings in patients with diabetes. *Clin J Am Soc Nephrol*. 2013;8:1718-1724.
153. Nasr SH, D'Agati VD, Said SM, et al. Pauci-immune crescentic glomerulonephritis superimposed on diabetic glomerulosclerosis. *Clin J Am Soc Nephrol*. 2008;3:1282-1288.
154. Elfenbein IB, Reyes JW. Crescents in diabetic glomerulopathy. Incidence and clinical significance. *Lab Invest*. 1975;33:687-695.
155. Westermark P, Benson MD, Buxbaum JN, et al. A primer of amyloid nomenclature. *Amyloid*. 2007;14:179-183.
156. Sethi S, Vrana JA, Theis JD, et al. Laser microdissection and mass spectrometry-based proteomics aids the diagnosis and typing of renal amyloidosis. *Kidney Int*. 2012;82:226-234.
157. Said SM, Sethi S, Valeri AM, et al. Renal amyloidosis: origin and clinicopathologic correlations of 474 recent cases. *Clin J Am Soc Nephrol*. 2013;8:1515-1523.
158. Pepys MB. Amyloidosis. *Annu Rev Med*. 2006;57:223-241.
159. Sayed RH, Hawkins PN, Lachmann HJ. Emerging treatments for amyloidosis. *Kidney Int*. 2015;87:516-526.
160. Falk RH, Comenzo RL, Skinner M. The systemic amyloidoses. *N Engl J Med*. 1997;337:898-909.
161. Buxbaum JN. The systemic amyloidoses. *Curr Opin Rheumatol*. 2004;16:67-75.
162. Obici L, Perfetti V, Palladini G, et al. Clinical aspects of systemic amyloid diseases. *Biochim Biophys Acta*. 2005;1753:11-22.
163. Westermark GT, Fandrich M, Westermark P. AA amyloidosis: pathogenesis and targeted therapy. *Annu Rev Pathol*. 2015;10:321-344.
164. Husby G, Marhaug G, Dowton B, et al. Serum amyloid A (SAA): biochemistry, genetics and the pathogenesis of AA amyloidosis. *Amyloid*. 1994;1:119-137.
165. Uhlar CM, Whitehead AS. Serum amyloid A, the major vertebrate acute-phase reactant. *Eur J Biochem*. 1999;265:501-523.
166. Benson MD. The hereditary amyloidoses. *Best Pract Res Clin Rheumatol*. 2003;17:909-927.
167. Padeh S. Periodic fever syndromes. *Pediatr Clin North Am*. 2005;52:577-609, vii.
168. Said SM, Sethi S, Valeri AM, et al. Characterization and outcomes of renal leukocyte chemotactic factor 2-associated amyloidosis. *Kidney Int*. 2014;86:370-377.
169. Larsen CP, Kossmann RJ, Beggs ML, et al. Clinical, morphologic, and genetic features of renal leukocyte chemotactic factor 2 amyloidosis. *Kidney Int*. 2014;86:378-382.
170. Gejyo F, Narita I. Current clinical and pathogenetic understanding of beta2-m amyloidosis in long-term haemodialysis patients. *Nephrology (Carlton)*. 2003;8(suppl):S 45-S49.
171. Kyle RA, Gertz MA. Primary systemic amyloidosis: clinical and laboratory features in 474 cases. *Semin Hematol*. 1995;32:45-59.
172. Bohle A, Wehrmann M, Eissele R, et al. The long-term prognosis of AA and AL renal amyloidosis and the pathogenesis of chronic renal failure in renal amyloidosis. *Pathol Res Pract*. 1993;189:316-331.
173. Dember LM. Amyloidosis-associated kidney disease. *J Am Soc Nephrol*. 2006;17:3458-3471.
174. Herrera GA, Picken MM. Renal diseases associated with plasma cell dyscrasias, amyloidoses, and Waldenström macroglobulinemia. In: Jennette JC, Olson JL, Silva FG, A'gati VD, eds. *Heptinstall's Pathology of the Kidney*. 7th ed. Philadelphia, PA: Wolters Kluwer; 2015:951-1014.
175. Satoskar AA, Burdge K, Cowden DJ, et al. Typing of amyloidosis in renal biopsies: diagnostic pitfalls. *Arch Pathol Lab Med*. 2007;131:917-922.
176. Yang GC, Nieto R, Stachura I, Gallo GR. Ultrastructural immunohistochemical localization of polyclonal IgG, C3, and amyloid P component on the congo

red-negative amyloid-like fibrils of fibrillary glomerulopathy. *Am J Pathol*. 1992;141:409-419.
177. Dyck RF, Lockwood CM, Kershaw M, et al. Amyloid P-component is a constituent of normal human glomerular basement membrane. *J Exp Med*. 1980;152:1162-1174.
178. Alpers CE, Kowalewska J. Fibrillary glomerulonephritis and immunotactoid glomerulopathy. *J Am Soc Nephrol*. 2008;19:34-37.
179. Brady HR. Fibrillary glomerulopathy. *Kidney Int*. 1998;53:1421-1429.
180. Fogo A, Qureshi N, Horn RG. Morphologic and clinical features of fibrillary glomerulonephritis versus immunotactoid glomerulopathy. *Am J Kidney Dis*. 1993;22:367-377.
181. Iskandar SS, Falk RJ, Jennette JC. Clinical and pathologic features of fibrillary glomerulonephritis. *Kidney Int*. 1992;42:1401-1407.
182. Rosenstock JL, Markowitz GS, Valeri AM, et al. Fibrillary and immunotactoid glomerulonephritis: distinct entities with different clinical and pathologic features. *Kidney Int*. 2003;63:1450-1461.
183. Devaney K, Sabnis SG, Antonovych TT. Nonamyloidotic fibrillary glomerulopathy, immunotactoid glomerulopathy, and the differential diagnosis of filamentous glomerulopathies. *Mod Pathol*. 1991;4:36-45.
184. Nasr SH, Valeri AM, Cornell LD, et al. Fibrillary glomerulonephritis: a report of 66 cases from a single institution. *Clin J Am Soc Nephrol*. 2011;6:775-784.
185. Pronovost PH, Brady HR, Gunning ME, et al. Clinical features, predictors of disease progression and results of renal transplantation in fibrillary/immunotactoid glomerulopathy. *Nephrol Dial Transplant*. 1996;11:837-842.
186. Samaniego M, Nadasdy GM, Laszik Z, Nadasdy T. Outcome of renal transplantation in fibrillary glomerulonephritis. *Clin Nephrol*. 2001;55:159-166.
187. Churg J, Venkataseshan VS. Fibrillary glomerulonephritis without immunoglobulin deposits in the kidney. *Kidney Int*. 1993;44:837-842.
188. Duffy JL, Khurana E, Susin M, et al. Fibrillary renal deposits and nephritis. *Am J Pathol*. 1983;113:279-290.
189. Lin J, Markowitz GS, Valeri AM, et al. Renal monoclonal immunoglobulin deposition disease: the disease spectrum. *J Am Soc Nephrol*. 2001;12:1482-1492.
190. Herrera GA, Turbat-Herrera EA. Renal diseases with organized deposits: an algorithmic approach to classification and clinicopathologic diagnosis. *Arch Pathol Lab Med*. 2010;134:512-531.
191. Nasr SH, Valeri AM, Cornell LD, et al. Renal monoclonal immunoglobulin deposition disease: a report of 64 patients from a single institution. *Clin J Am Soc Nephrol*. 2012;7:231-239.
192. Buxbaum J, Gallo G. Nonamyloidotic monoclonal immunoglobulin deposition disease. Light-chain, heavy-chain, and light- and heavy-chain deposition diseases. *Hematol Oncol Clin North Am*. 1999;13:1235-1248.
193. Preud'homme JL, Aucouturier P, Touchard G, et al. Monoclonal immunoglobulin deposition disease (Randall type). Relationship with structural abnormalities of immunoglobulin chains. *Kidney Int*. 1994;46:965-972.
194. Sanders PW, Herrera GA. Monoclonal immunoglobulin light chain-related renal diseases. *Semin Nephrol*. 1993;13:324-341.
195. Ronco P, Plaisier E, Mougenot B, Aucouturier P. Immunoglobulin light (heavy)-chain deposition disease: from molecular medicine to pathophysiology-driven therapy. *Clin J Am Soc Nephrol*. 2006;1:1342-1350.
196. Pozzi C, D'Amico M, Fogazzi GB, et al. Light chain deposition disease with renal involvement: clinical characteristics and prognostic factors. *Am J Kidney Dis*. 2003;42:1154-1163.
197. Shimamura T, Weiss LS, Walker JA, et al. Light chain nephropathy in a 19-month-old boy with AIDS. *Acta Pathol Jpn*. 1992;42:500-503.
198. Leung N, Lager DJ, Gertz MA, et al. Long-term outcome of renal transplantation in light-chain deposition disease. *Am J Kidney Dis*. 2004;43:147-153.
199. Pozzi C, Fogazzi GB, Banfi G, et al. Renal disease and patient survival in light chain deposition disease. *Clin Nephrol*. 1995;43:281-287.
200. Herrera GA, Russell WJ, Isaac J, et al. Glomerulopathic light chain-mesangial cell interactions modulate in vitro extracellular matrix remodeling and reproduce mesangiopathic findings documented in vivo. *Ultrastruct Pathol*. 1999;23:107-126.
201. Zhu L, Herrera GA, Murphy-Ullrich JE, et al. Pathogenesis of glomerulosclerosis in light chain deposition disease. Role for transforming growth factor-beta. *Am J Pathol*. 1995;147:375-385.
202. Aucouturier P, Khamlichi AA, Touchard G, et al. Brief report: heavy-chain deposition disease. *N Engl J Med*. 1993;329:1389-1393.
203. Kambham N, Markowitz GS, Appel GB, et al. Heavy chain deposition disease: the disease spectrum. *Am J Kidney Dis*. 1999;33:954-962.
204. Nasr SH, Satoskar A, Markowitz GS, et al. Proliferative glomerulonephritis with monoclonal IgG deposits. *J Am Soc Nephrol*. 2009;20:2055-2064.
205. Nasr SH, Sethi S, Cornell LD, et al. Proliferative glomerulonephritis with monoclonal IgG deposits recurs in the allograft. *Clin J Am Soc Nephrol*. 2011;6:122-132.
206. Larsen CP, Ambuzs JM, Bonsib SM, et al. Membranous-like glomerulopathy with masked IgG kappa deposits. *Kidney Int*. 2014;86:154-161.
207. Habib R. Nephrotic syndrome in the 1st year of life. *Pediatr Nephrol*. 1993;7:347-353.
208. Hinkes BG, Mucha B, Vlangos CN, et al. Nephrotic syndrome in the first year of life: two thirds of cases are caused by mutations in 4 genes (NPHS1, NPHS2, WT1, and LAMB2). *Pediatrics*. 2007;119:e907-e919.
209. Besbas N, Bayrakci US, Kale G, et al. Cytomegalovirus-related congenital nephrotic syndrome with diffuse mesangial sclerosis. *Pediatr Nephrol*. 2006;21:740-742.
210. Ramirez-Seijas F, Granado-Villar D, Cepero-Akselrad A, et al. Congenital nephrotic syndrome. *Int Pediatr*. 2000;15:121-122.
211. Kari JA, Montini G, Bockenhauer D, et al. Clinico-pathological correlations of congenital and infantile nephrotic syndrome over twenty years. *Pediatr Nephrol*. 2014;29:2173-2180.
212. Liapis H. Molecular pathology of nephrotic syndrome in childhood: a contemporary approach to diagnosis. *Pediatr Dev Pathol*. 2008;11:154-163.
213. Frishberg Y, Ben-Neriah Z, Suvanto M, et al. Misleading findings of homozygosity mapping resulting from three novel mutations in NPHS1 encoding nephrin in a highly inbred community. *Genet Med*. 2007;9:180-184.
214. Kestila M, Lenkkeri U, Mannikko M, et al. Positionally cloned gene for a novel glomerular protein—nephrin—is mutated in congenital nephrotic syndrome. *Mol Cell*. 1998;1:575-582.
215. Kestila M, Mannikko M, Holmberg C, et al. Congenital nephrotic syndrome of the Finnish type maps to the long arm of chromosome 19. *Am J Hum Genet*. 1994;54:757-764.
216. Ruotsalainen V, Ljungberg P, Wartiovaara J, et al. Nephrin is specifically located at the slit diaphragm of glomerular podocytes. *Proc Natl Acad Sci USA*. 1999;96:7962-7967.
217. Jackson LW. Congenital nephrotic syndrome. *Neonatal Netw*. 2007;26:47-55.
218. Patrakka J, Ruotsalainen V, Reponen P, et al. Recurrence of nephrotic syndrome in kidney grafts of patients with congenital nephrotic syndrome of the Finnish type: role of nephrin. *Transplantation*. 2002;73:394-403.
219. Holmberg C, Jalanko H. Congenital nephrotic syndrome and recurrence of proteinuria after renal transplantation. *Pediatr Nephrol*. 2014;29:2309-2317.
220. Habib R, Gubler MC, Antignac C, Gagnadoux MF. Diffuse mesangial sclerosis: a congenital glomerulopathy with nephrotic syndrome. *Adv Nephrol Necker Hosp*. 1993;22:43-57.
221. Yang Y, Jeanpierre C, Dressler GR, et al. WT1 and PAX-2 podocyte expression in Denys-Drash syndrome and isolated diffuse mesangial sclerosis. *Am J Pathol*. 1999;154:181-192.
222. Lipska BS, Ranchin B, Iatropoulos P, et al. Genotype-phenotype associations in WT1 glomerulopathy. *Kidney Int*. 2014;85:1169-1178.
223. Gbadegesin R, Hinkes BG, Hoskins BE, et al. Mutations in PLCE1 are a major cause of isolated diffuse mesangial sclerosis (IDMS). *Nephrol Dial Transplant*. 2008;23:1291-1297.
224. Montseny JJ, Meyrier A, Kleinknecht D, Callard P. The current spectrum of infectious glomerulonephritis. Experience with 76 patients and review of the literature. *Medicine (Baltimore)*. 1995;74:63-73.
225. Rodríguez-Iturbe B. Acute poststreptococcal glomerulonephritis. In: Schrier RW, Gottschalk CW, eds. *Diseases of the Kidney*. 5th ed. Boston, MA: Little, Brown & Co; 1993:1715-1730.
226. Satoskar AA, Nadasdy T, Silva FG. Acute postinfectious glomerulonephritis and glomerulonephritis caused by persistent bacterial infection. In: Jennette JC, Olson JL, Silva FG, A'gati VD, eds. *Heptinstall's Pathology of the Kidney*. 7th ed. Philadelphia, PA: Lippincott Williams & Wilkins; 2015:367-436.
227. Nasr SH, Fidler ME, Valeri AM, et al. Postinfectious glomerulonephritis in the elderly. *J Am Soc Nephrol*. 2011;22:187-195.
228. Kambham N. Postinfectious glomerulonephritis. *Adv Anat Pathol*. 2012;19:338-347.
229. Yoshizawa N. Acute glomerulonephritis. *Intern Med*. 2000;39:687-694.
230. Rodriguez-Iturbe B, Musser JM. The current state of poststreptococcal glomerulonephritis. *J Am Soc Nephrol*. 2008;19:1855-1864.
231. Ferrario F, Kourilsky O, Morel-Maroger L. Acute endocapillary glomerulonephritis in adults: a histologic and clinical comparison between patients with and without initial acute renal failure. *Clin Nephrol*. 1983;19:17-23.
232. Melby PC, Musick WD, Luger AM, Khanna R. Poststreptococcal glomerulonephritis in the elderly. Report of a case and review of the literature. *Am J Nephrol*. 1987;7:235-240.
233. Dodge WF, Spargo BH, Bass JA, Travis LB. The relationship between the clinical and pathologic features of poststreptococcal glomerulonephritis. A study of the early natural history. *Medicine (Baltimore)*. 1986;47:227-267.
234. Sethi S, Fervenza FC, Zhang Y, et al. Atypical postinfectious glomerulonephritis is associated with abnormalities in the alternative pathway of complement. *Kidney Int*. 2013;83:293-299.
235. Prasto J, Kaplan BS, Russo P, et al. Streptococcal infection as possible trigger for

dense deposit disease (C3 glomerulopathy). *Eur J Pediatr*. 2014;173:767-772.
236. Vernon KA, Goicoechea de Jorge E, Hall AE, et al. Acute presentation and persistent glomerulonephritis following streptococcal infection in a patient with heterozygous complement factor H-related protein 5 deficiency. *Am J Kidney Dis*. 2012;60:121-125.
237. Stratta P, Musetti C, Barreca A, Mazzucco G. New trends of an old disease: the acute post infectious glomerulonephritis at the beginning of the new millenium. *J Nephrol*. 2014;27:229-239.
238. Nast CC. Infection-related glomerulonephritis: changing demographics and outcomes. *Adv Chronic Kidney Dis*. 2012;19:68-75.
239. Nasr SH, D'Agati VD. IgA-dominant postinfectious glomerulonephritis: a new twist on an old disease. *Nephron Clin Pract*. 2011;119:c18-c25, discussion c26.
240. Haas M, Racusen LC, Bagnasco SM. IgA-dominant postinfectious glomerulonephritis: a report of 13 cases with common ultrastructural features. *Hum Pathol*. 2008;39:1309-1316.
241. Koyama A, Kobayashi M, Yamaguchi N, et al. Glomerulonephritis associated with MRSA infection: a possible role of bacterial superantigen. *Kidney Int*. 1995;47:207-216.
242. Koyama A, Sharmin S, Sakurai H, et al. *Staphylococcus aureus* cell envelope antigen is a new candidate for the induction of IgA nephropathy. *Kidney Int*. 2004;66:121-132.
243. Nasr SH, Markowitz GS, Stokes MB, et al. Acute postinfectious glomerulonephritis in the modern era: experience with 86 adults and review of the literature. *Medicine (Baltimore)*. 2008;87:21-32.
244. Satoskar AA, Molenda M, Scipio P, et al. Henoch-Schonlein purpura-like presentation in IgA-dominant Staphylococcus infection—associated glomerulonephritis—a diagnostic pitfall. *Clin Nephrol*. 2013;79:302-312.
245. Haas M. Postinfectious glomerulonephritis complicating diabetic nephropathy: a frequent association, but how clinically important? *Hum Pathol*. 2003;34:1225-1227.
246. Wen YK, Chen ML. Discrimination between postinfectious IgA-dominant glomerulonephritis and idiopathic IgA nephropathy. *Ren Fail*. 2010;32:572-577.
247. Walker PD, Ferrario F, Joh K, Bonsib SM. Dense deposit disease is not a membranoproliferative glomerulonephritis. *Mod Pathol*. 2007;2007:605-616.
248. Anders D, Agricola B, Sippel M, Thoenes W. Basement membrane changes in membranoproliferative glomerulonephritis. II. Characterization of a third type by silver impregnation of ultra thin sections. *Virchows Arch A Pathol Anat Histol*. 1977;376:1-19.
249. Burkholder PM, Marchand A, Krueger RP. Mixed membranous and proliferative glomerulonephritis. A correlative light, immunofluorescence, and electron microscopic study. *Lab Invest*. 1970;23:459-479.
250. Strife CF, Jackson EC, McAdams AJ. Type III membranoproliferative glomerulonephritis: long-term clinical and morphologic evaluation. *Clin Nephrol*. 1984;21:323-334.
251. Fakhouri F, Fremeaux-Bacchi V, Noel LH, et al. C3 glomerulopathy: a new classification. *Nat Rev Nephrol*. 2010;6:494-499.
252. Servais A, Fremeaux-Bacchi V, Lequintrec M, et al. Primary glomerulonephritis with isolated C3 deposits: a new entity which shares common genetic risk factors with haemolytic uraemic syndrome. *J Med Genet*. 2007;44:193-199.
253. Bomback AS, Appel GB. Pathogenesis of the C3 glomerulopathies and reclassification of MPGN. *Nat Rev Nephrol*. 2012;8:634-642.
254. Pickering MC, D'Agati VD, Nester CM, et al. C3 glomerulopathy: consensus report. *Kidney Int*. 2013;84:1079-1089.
255. Hou J, Markowitz GS, Bomback AS, et al. Toward a working definition of C3 glomerulopathy by immunofluorescence. *Kidney Int*. 2014;85:450-456.
256. Cook HT, Pickering MC. Histopathology of MPGN and C3 glomerulopathies. *Nat Rev Nephrol*. 2015;11:14-22.
257. Servais A, Noel LH, Roumenina LT, et al. Acquired and genetic complement abnormalities play a critical role in dense deposit disease and other C3 glomerulopathies. *Kidney Int*. 2012;82:454-464.
258. Barbour TD, Pickering MC, Terence Cook H. Dense deposit disease and C3 glomerulopathy. *Semin Nephrol*. 2013;33:493-507.
259. Gale DP, de Jorge EG, Cook HT, et al. Identification of a mutation in complement factor H-related protein 5 in patients of Cypriot origin with glomerulonephritis. *Lancet*. 2010;376:794-801.
260. Bomback AS, Smith RJ, Barile GR, et al. Eculizumab for dense deposit disease and C3 glomerulonephritis. *Clin J Am Soc Nephrol*. 2012;7:748-756.
261. Smith RJ, Alexander J, Barlow PN, et al. New approaches to the treatment of dense deposit disease. *J Am Soc Nephrol*. 2007;18:2447-2456.
262. Xiao X, Pickering MC, Smith RJ. C3 glomerulopathy: the genetic and clinical findings in dense deposit disease and C3 glomerulonephritis. *Semin Thromb Hemost*. 2014;40:465-471.
263. Appel GB, Cook HT, Hageman G, et al. Membranoproliferative glomerulonephritis type II (dense deposit disease): an update. *J Am Soc Nephrol*. 2005;16:1392-1403.
264. Walker PD. Dense deposit disease: new insights. *Curr Opin Nephrol Hypertens*. 2007;16:204-212.
265. Abrera-Abeleda MA, Nishimura C, Smith JL, et al. Variations in the complement regulatory genes factor H (CFH) and factor H related 5 (CFHR5) are associated with membranoproliferative glomerulonephritis type II (dense deposit disease). *J Med Genet*. 2006;43:582-589.
266. Gold B, Merriam JE, Zernant J, et al. Variation in factor B (BF) and complement component 2 (C2) genes is associated with age-related macular degeneration. *Nat Genet*. 2006;38:458-462.
267. Mathieson PW, Peters DK. Lipodystrophy in MCGN type II: the clue to links between the adipocyte and the complement system. *Nephrol Dial Transplant*. 1997;12: 1804-1806.
268. Misra A, Peethambaram A, Garg A. Clinical features and metabolic and autoimmune derangements in acquired partial lipodystrophy: report of 35 cases and review of the literature. *Medicine (Baltimore)*. 2004;83:18-34.
269. Zipfel PF, Heinen S, Jozsi M, Skerka C. Complement and diseases: defective alternative pathway control results in kidney and eye diseases. *Mol Immunol*. 2006;43:97-106.
270. Kher KK, Makker SP, Aikawa M, Kirson IJ. Regression of dense deposits in type II membranoproliferative glomerulonephritis: case report of clinical course in a child. *Clin Nephrol*. 1982;17:100-103.
271. McEnery PT, McAdams AJ. Regression of membranoproliferative glomerulonephritis type II (dense deposit disease): observations in six children. *Am J Kidney Dis*. 1988;12:138-146.
272. Figueres ML, Fremeaux-Bacchi V, Rabant M, et al. Heterogeneous histologic and clinical evolution in 3 cases of dense deposit disease with long-term follow-up. *Hum Pathol*. 2014;45:2326-2333.
273. Hariharan S. Recurrent and de novo diseases after renal transplantation. *Semin Dial*. 2000;13:195-199.
274. Sethi S, Sukov WR, Zhang Y, et al. Dense deposit disease associated with monoclonal gammopathy of undetermined significance. *Am J Kidney Dis*. 2010;56:977-982.
275. Habib R, Kleinknecht C, Gubler MC, Levy M. Idiopathic membranoproliferative glomerulonephritis in children. Report of 105 cases. *Clin Nephrol*. 1973;1:194-214.
276. Sethi S, Gamez JD, Vrana JA, et al. Glomeruli of Dense Deposit Disease contain components of the alternative and terminal complement pathway. *Kidney Int*. 2009;75:952-960.
277. Sethi S, Fervenza FC, Zhang Y, et al. C3 glomerulonephritis: clinicopathological findings, complement abnormalities, glomerular proteomic profile, treatment, and follow-up. *Kidney Int*. 2012;82:465-473.
278. Zhang Y, Nester CM, Martin B, et al. Defining the complement biomarker profile of C3 glomerulopathy. *Clin J Am Soc Nephrol*. 2014;9:1876-1882.
279. Sethi S, Fervenza FC. Membranoproliferative glomerulonephritis—a new look at an old entity. *N Engl J Med*. 2012;366:1119-1131.
280. Smith KD, Alpers CE. Pathogenic mechanisms in membranoproliferative glomerulonephritis. *Curr Opin Nephrol Hypertens*. 2005;14:396-403.
281. Fervenza FC, Sethi S, Glassock RJ. Idiopathic membranoproliferative glomerulonephritis: does it exist? *Nephrol Dial Transplant*. 2012;27:4288-4294.
282. West CD. Idiopathic membranoproliferative glomerulonephritis in childhood. *Pediatr Nephrol*. 1992;6:96-103.
283. D'Amico G, Ferrario F. Mesangiocapillary glomerulonephritis. *J Am Soc Nephrol*. 1992;2:S159-S166.
284. Zhou XJ, Silva FG. Membranoproliferative glomerulonephritis. In: Jennette JC, Olson JL, Silva FG, A'gati VD, eds. *Heptinstall's Pathology of the Kidney*. 7th ed. Philadelphia, PA: Wolters Kluwer; 2015:301-340.
285. Schmitt H, Bohle A, Reineke T, et al. Long-term prognosis of membranoproliferative glomerulonephritis type I. Significance of clinical and morphological parameters: an investigation of 220 cases. *Nephron*. 1990;55:242-250.
286. Lien YH, Scott K. Long-term cyclophosphamide treatment for recurrent type I membranoproliferative glomerulonephritis after transplantation. *Am J Kidney Dis*. 2000;35:539-543.
287. Lorenz EC, Sethi S, Leung N, et al. Recurrent membranoproliferative glomerulonephritis after kidney transplantation. *Kidney Int*. 2010;77:721-728.
288. Strife CF, McEnery PT, McAdams AJ, West CD. Membranoproliferative glomerulonephritis with disruption of the glomerular basement membrane. *Clin Nephrol*. 1977;7:65-72.
289. Haas M. Histology and immunohistology of IgA nephropathy. *J Nephrol*. 2005;18: 676-680.
290. Tumlin JA, Madaio MP, Hennigar R. Idiopathic IgA nephropathy: pathogenesis, histopathology, and therapeutic options. *Clin J Am Soc Nephrol*. 2007;2:1054-1061.
291. Beerman I, Novak J, Wyatt RJ, et al. The genetics of IgA nephropathy. *Nat Clin Pract Nephrol*. 2007;3:325-338.
292. Hsu SI, Ramirez SB, Winn MP, et al. Evidence for genetic factors in the development and progression of IgA nephropathy. *Kidney Int*. 2000;57:1818-1835.
293. Scolari F. Familial IgA nephropathy. *J Nephrol*. 1999;12:213-219.
294. Gharavi AG, Kiryluk K, Choi M, et al. Genome-wide association study identifies

susceptibility loci for IgA nephropathy. *Nat Genet*. 2011;43:321-327.
295. Kiryluk K, Novak J. The genetics and immunobiology of IgA nephropathy. *J Clin Invest*. 2014;124:2325-2332.
296. Davin JC, Ten Berge IJ, Weening JJ. What is the difference between IgA nephropathy and Henoch-Schonlein purpura nephritis? *Kidney Int*. 2001;59:823-834.
297. Haas M. IgA nephropathy and IgA vasculitis (Henoch-Schönlein purpura nephritis). In: Jennette JC, Olson JL, Silva FG, A'gati VD, eds. *Heptinstall's Pathology of the Kidney*. 7th ed. Philadelphia, PA: Wolters Kluwer; 2015:463-524.
298. Barratt J, Smith AC, Molyneux K, Feehally J. Immunopathogenesis of IgAN. *Semin Immunopathol*. 2007;29:427-443.
299. Novak J, Julian BA, Tomana M, Mestecky J. IgA glycosylation and IgA immune complexes in the pathogenesis of IgA nephropathy. *Semin Nephrol*. 2008;28:78-87.
300. Zhao N, Hou P, Lv J, et al. The level of galactose-deficient IgA1 in the sera of patients with IgA nephropathy is associated with disease progression. *Kidney Int*. 2012;82:790-796.
301. D'Amico G. Natural history of idiopathic IgA nephropathy: role of clinical and histological prognostic factors. *Am J Kidney Dis*. 2000;36:227-237.
302. Niaudet P, Murcia I, Beaufils H, et al. Primary IgA nephropathies in children: prognosis and treatment. *Adv Nephrol Necker Hosp*. 1993;22:121-140.
303. Donadio JV Jr, Grande JP. Immunoglobulin A nephropathy: a clinical perspective. *J Am Soc Nephrol*. 1997;8:1324-1332.
304. Floege J. Recurrent IgA nephropathy after renal transplantation. *Semin Nephrol*. 2004;24:287-291.
305. Roberts IS. Pathology of IgA nephropathy. *Nat Rev Nephrol*. 2014;10:445-454.
306. Haas M. Histologic subclassification of IgA nephropathy: a clinicopathologic study of 244 cases. *Am J Kidney Dis*. 1997;29:829-842.
307. Working Group of the International Ig ANN, the Renal Pathology Society, Cattran DC, Coppo R, et al. The Oxford classification of IgA nephropathy: rationale, clinicopathological correlations, and classification. *Kidney Int*. 2009;76:534-545.
308. Haas M, Rastaldi MP, Fervenza FC. Histologic classification of glomerular diseases: clinicopathologic correlations, limitations exposed by validation studies, and suggestions for modification. *Kidney Int*. 2014;85:779-793.
309. Faille-Kuyper EH, Kater L, Kuijten RH, et al. Occurrence of vascular IgA deposits in clinically normal skin of patients with renal disease. *Kidney Int*. 1976;9:424-429.
310. Thompson AJ, Chan YL, Woodroffe AJ, et al. Vascular IgA deposits in clinically normal skin of patients with renal disease. *Pathology*. 1980;12:407-413.
311. Sanders JT, Wyatt RJ. IgA nephropathy and Henoch-Schonlein purpura nephritis. *Curr Opin Pediatr*. 2008;20:163-170.
312. Waldo FB. Is Henoch-Schonlein purpura the systemic form of IgA nephropathy? *Am J Kidney Dis*. 1988;12:373-377.
313. Jennette JC, Nickeleit V. Anti-glomerular basement membrane glomerulonephritis and Goodpasture's syndrome. In: Jennette JC, Olson JL, Silva FG, A'gati VD, eds. *Heptinstall's Pathology of the Kidney*. 7th ed. Philadelphia, PA: Wolters Kluwer; 2015:657-684.
314. Nachman PH, Jennette JC, Falk RJ. Rapidly progressive glomerulonephritis and crescentic glomerulonephritis. In: Brenner M, ed. *Brenner and Rector's the Kidney*. 8th ed. Philadelphia, PA: WB Saunders; 2006:1034-1046.
315. Fischer EG, Lager DJ. Anti-glomerular basement membrane glomerulonephritis: a morphologic study of 80 cases. *Am J Clin Pathol*. 2006;125:445-450.
316. Hudson BG, Kalluri R, Gunwar S, et al. Molecular characteristics of the Goodpasture autoantigen. *Kidney Int*. 1993;43:135-139.
317. Kalluri R, Wilson CB, Weber M, et al. Identification of the alpha 3 chain of type IV collagen as the common autoantigen in antibasement membrane disease and Goodpasture syndrome. *J Am Soc Nephrol*. 1995;6:1178-1185.
318. Pedchenko V, Bondar O, Fogo AB, et al. Molecular architecture of the Goodpasture autoantigen in anti-GBM nephritis. *N Engl J Med*. 2010;363:343-354.
319. Cui Z, Zhao MH. Advances in human antiglomerular basement membrane disease. *Nat Rev Nephrol*. 2011;7:697-705.
320. Goldman M, Depierreux M, De Pauw L, et al. Failure of two subsequent renal grafts by anti-GBM glomerulonephritis in Alport's syndrome: case report and review of the literature. *Transpl Int*. 1990;3:82-85.
321. Oliver TB, Gouldesbrough DR, Swainson CP. Acute crescentic glomerulonephritis associated with antiglomerular basement membrane antibody in Alport's syndrome after second transplantation. *Nephrol Dial Transplant*. 1991;6:893-895.
322. Hecht N, Omoloja A, Witte D, Canessa L. Evolution of antiglomerular basement membrane glomerulonephritis into membranous glomerulonephritis. *Pediatr Nephrol*. 2008;23:477-480.
323. Troxell ML, Saxena AB, Kambham N. Concurrent anti-glomerular basement membrane disease and membranous glomerulonephritis: a case report and literature review. *Clin Nephrol*. 2006;66:120-127.
324. Bonsib SM, Goeken JA, Kemp JD, et al. Coexistent anti-neutrophil cytoplasmic antibody and antiglomerular basement membrane antibody associated disease = report of six cases. *Mod Pathol*. 1993;6:526-530.
325. Levy JB, Hammad T, Coulthart A, et al. Clinical features and outcome of patients with both ANCA and anti-GBM antibodies. *Kidney Int*. 2004;66:1535-1540.
326. Rutgers A, Slot M, van Paassen P, et al. Coexistence of anti-glomerular basement membrane antibodies and myeloperoxidase-ANCAs in crescentic glomerulonephritis. *Am J Kidney Dis*. 2005;46:253-262.
327. Lionaki S, Jennette JC, Falk RJ. Anti-neutrophil cytoplasmic (ANCA) and anti-glomerular basement membrane (GBM) autoantibodies in necrotizing and crescentic glomerulonephritis. *Semin Immunopathol*. 2007;29:459-474.
328. Jennette JC, Thomas DB. Pauci-immune and anti-neutrophil cytoplasmic autoantibody-mediated crescentic glomerulonephritis and vasculitis. In: Jennette JC, Olson JL, Silva FG, A'gati VD, eds. *Heptinstall's Pathology of the Kidney*. 7th ed. Philadelphia, PA: Wolters Kluwer; 2015:685-714.
329. Stone JH, Merkel PA, Spiera R, et al. Rituximab versus cyclophosphamide for ANCA-associated vasculitis. *N Engl J Med*. 2010;363:221-232.
330. Jones RB, Tervaert JW, Hauser T, et al. Rituximab versus cyclophosphamide in ANCA-associated renal vasculitis. *N Engl J Med*. 2010;363:211-220.
331. Falk RJ, Hogan S, Carey TS, Jennette JC. Clinical course of anti-neutrophil cytoplasmic autoantibody-associated glomerulonephritis and systemic vasculitis. The Glomerular Disease Collaborative Network. *Ann Intern Med*. 1990;113:656-663.
332. Falk RJ, Jennette JC. Proceedings of the Third International Workshop on ANCA. *Am J Kidney Dis*. 1991;18:145-193.
333. Jennette JC, Falk RJ. Pathogenesis of antineutrophil cytoplasmic autoantibody-mediated disease. *Nat Rev Rheumatol*. 2014;10:463-473.
334. Furuta S, Jayne DR. Antineutrophil cytoplasm antibody-associated vasculitis: recent developments. *Kidney Int*. 2013;84:244-249.
335. Suzuki K, Nagao T, Itabashi M, et al. A novel autoantibody against moesin in the serum of patients with MPO-ANCA-associated vasculitis. *Nephrol Dial Transplant*. 2014;29:1168-1177.
336. Charles Jennette J, Xiao H, Hu P. Complement in ANCA-associated vasculitis. *Semin Nephrol*. 2013;33:557-564.
337. Hochberg MC. Updating the American College of Rheumatology revised criteria for the classification of systemic lupus erythematosus. *Arthritis Rheum*. 1997; 40:1725.
338. Gloor JM. Lupus nephritis in children. *Lupus*. 1998;7:639-643.
339. Perfumo F, Martini A. Lupus nephritis in children. *Lupus*. 2005;14:83-88.
340. Hess E. Drug-related lupus. *N Engl J Med*. 1988;318:1460-1462.
341. Yung RL, Richardson BC. Drug-induced lupus. *Rheum Dis Clin North Am*. 1994;20:61-86.
342. D'Agati VD, Stokes MB. Renal disease in systemic lupus erythematosus, mixed connective tissue disease, Sjögren's syndrome, and rheumatoid arthritis. In: Jennette JC, Olson JL, Silva FG, A'gati VD, eds. *Heptinstall's Pathology of the Kidney*. Philadelphia, PA: Wolters Kluwer; 2015:559-656.
343. Armstrong DL, Zidovetzki R, Alarcon-Riquelme ME, et al. GWAS identifies novel SLE susceptibility genes and explains the association of the HLA region. *Genes Immun*. 2014;15:347-354.
344. Harley IT, Kaufman KM, Langefeld CD, et al. Genetic susceptibility to SLE: new insights from fine mapping and genome-wide association studies. *Nat Rev Genet*. 2009;10:285-290.
345. Weening JJ, D'Agati VD, Schwartz MM, et al. The classification of glomerulonephritis in systemic lupus erythematosus revisited. *J Am Soc Nephrol*. 2004;15:241-250.
346. McCluskey RT. Lupus nephritis. In: Sommers SC, ed. *Kidney Pathology Decennial*. East Norwalk, CT: Appleton-Century-Crofts; 1975:435-450.
347. Churg J, Sobin LH. *Lupus Nephritis*. 2nd ed. New York, NY: Igaku-Shoin; 1982.
348. Churg J, Bernstein J, Glassock RJ. *Renal Disease: Classification and Atlas of Glomerular Diseases*. 2nd ed. New York, NY: Igaku-Shoin; 1995.
349. Furness PN, Taub N. Interobserver reproducibility and application of the ISN/RPS classification of lupus nephritis—a UK-wide study. *Am J Surg Pathol*. 2006;30:1030-1035.
350. Hiramatsu N, Kuroiwa T, Ikeuchi H, et al. Revised classification of lupus nephritis is valuable in predicting renal outcome with an indication of the proportion of glomeruli affected by chronic lesions. *Rheumatology (Oxford)*. 2008;47:702-707.
351. Markowitz GS, D'Agati VD. The ISN/RPS 2003 classification of lupus nephritis: an assessment at 3 years. *Kidney Int*. 2007;71:491-495.
352. Yokoyama H, Wada T, Hara A, et al. The outcome and a new ISN/RPS 2003 classification of lupus nephritis in Japanese. *Kidney Int*. 2004;66:2382-2388.
353. Dube GK, Markowitz GS, Radhakrishnan J, et al. Minimal change disease in systemic lupus erythematosus. *Clin Nephrol*. 2002;57:120-126.

354. Watanabe T. Nephrotic syndrome in mesangial proliferative lupus nephritis. *Pediatr Int*. 2007;49:1009-1011.
355. Ordonez NG, Gomez LG. The ultrastructure of glomerular haematoxylin bodies. *J Pathol*. 1981;135:259-265.
356. Herrera GA. The value of electron microscopy in the diagnosis and clinical management of lupus nephritis. *Ultrastruct Pathol*. 1999;23:63-77.
357. Su CF, Chen HH, Yeh JC, et al. Ultrastructural 'fingerprint' in cryoprecipitates and glomerular deposits: a clinicopathologic analysis of fingerprint deposits. *Nephron*. 2002;90:37-42.
358. Rich SA. Human lupus inclusions and interferon. *Science*. 1981;213:772-775.
359. Haring CM, Rietveld A, van den Brand JA, Berden JH. Segmental and global subclasses of class IV lupus nephritis have similar renal outcomes. *J Am Soc Nephrol*. 2012;23:149-154.
360. Le Thi Huong D, Papo T, Beaufils H, et al. Renal involvement in systemic lupus erythematosus: a study of 180 patients from a single center. *Medicine (Baltimore)*. 1999;78:148-166.
361. Mahajan SK, Ordonez NG, Spargo BH, Katz AI. Changing histopathology patterns in lupus nephropathy. *Clin Nephrol*. 1978;10:1-8.
362. Zimmerman SW, Jenkins PG, Shelf WD, et al. Progression from minimal or focal to diffuse proliferative lupus nephritis. *Lab Invest*. 1975;32:665-672.
363. Hecht B, Siegel N, Adler M, et al. Prognostic indices in lupus nephritis. *Medicine (Baltimore)*. 1976;55:163-181.
364. Appel GB, Silva FG, Pirani CL, et al. Renal involvement in systemic lupud erythematosus (SLE): a study of 56 patients emphasizing histologic classification. *Medicine (Baltimore)*. 1978;57:371-410.
365. Schwartz MM, Kawala K, Roberts JL, et al. Clinical and pathological features of membranous glomerulonephritis of systemic lupus erythematosus. *Am J Nephrol*. 1984;4:301-311.
366. Chang A, Henderson SG, Brandt D, et al. In situ B cell-mediated immune responses and tubulointerstitial inflammation in human lupus nephritis. *J Immunol*. 2011;186:1849-1860.
367. Alsuwaida AO. Interstitial inflammation and long-term renal outcomes in lupus nephritis. *Lupus*. 2013;22:1446-1454.
368. Michail S, Stathakis C, Marinaki S, et al. Relapse of predominant tubulointerstitial lupus nephritis. *Lupus*. 2003;12:728-729.
369. Mori Y, Kishimoto N, Yamahara H, et al. Predominant tubulointerstitial nephritis in a patient with systemic lupus nephritis. *Clin Exp Nephrol*. 2005;9:79-84.
370. Wu LH, Yu F, Tan Y, et al. Inclusion of renal vascular lesions in the 2003 ISN/RPS system for classifying lupus nephritis improves renal outcome predictions. *Kidney Int*. 2013;83:715-723.
371. Austin HA 3rd, Muenz LR, Joyce KM, et al. Prognostic factors in lupus nephritis. Contribution of renal histologic data. *Am J Med*. 1983;75:382-391.
372. Schwartz MM, Lan SP, Bernstein J, et al. Irreproducibility of the activity and chronicity indices limits their utility in the management of lupus nephritis. Lupus Nephritis Collaborative Study Group. *Am J Kidney Dis*. 1993;21:374-377.
373. Azevedo LS, Romao JE Jr, Malheiros D, et al. Renal transplantation in systemic lupus erythematosus. A case control study of 45 patients. *Nephrol Dial Transplant*. 1998;13:2894-2898.
374. Ponticelli C, Moroni G. Renal transplantation in lupus nephritis. *Lupus*. 2005;14:95-98.
375. Stone JH, Millward CL, Olson JL, et al. Frequency of recurrent lupus nephritis among ninety-seven renal transplant patients during the cyclosporine era. *Arthritis Rheum*. 1998;41:678-686.
376. Jennette JC, Falk RJ, Bacon PA, et al. 2012 revised International Chapel Hill Consensus Conference Nomenclature of Vasculitides. *Arthritis Rheum*. 2013;65:1-11.
377. Weyand CM, Goronzy JJ. Medium- and large-vessel vasculitis. *N Engl J Med*. 2003;349:160-169.
378. Puechal X. Antineutrophil cytoplasmic antibody-associated vasculitides. *Joint Bone Spine*. 2007;74:427-435.
379. Radice A, Sinico RA. Antineutrophil cytoplasmic antibodies (ANCA). *Autoimmunity*. 2005;38:93-103.
380. Kallenberg CG. Antineutrophil cytoplasmic autoantibody-associated small-vessel vasculitis. *Curr Opin Rheumatol*. 2007;19:17-24.
381. Kallenberg CG. Pathogenesis of PR3-ANCA associated vasculitis. *J Autoimmun*. 2008;30:29-36.
382. Pagnoux C, Seror R, Henegar C, et al. Clinical features and outcomes in 348 patients with polyarteritis nodosa: a systematic retrospective study of patients diagnosed between 1963 and 2005 and entered into the French Vasculitis Study Group Database. *Arthritis Rheum*. 2010;62:616-626.
383. Agard C, Mouthon L, Mahr A, Guillevin L. Microscopic polyangiitis and polyarteritis nodosa: how and when do they start? *Arthritis Rheum*. 2003;49:709-715.
384. Bonsib SM. Polyarteritis nodosa. *Semin Diagn Pathol*. 2001;18:14-23.
385. Hernandez-Rodriguez J, Alba MA, Prieto-Gonzalez S, Cid MC. Diagnosis and classification of polyarteritis nodosa. *J Autoimmun*. 2014;48-49:84-89.
386. Drueke T, Barbanel C, Jungers P, et al. Hepatitis B antigen-associated periarteritis nodosa in patients undergoing long-term hemodialysis. *Am J Med*. 1980;68:86-90.
387. Guillevin L, Lhote F, Cohen P, et al. Polyarteritis nodosa related to hepatitis B virus. A prospective study with long-term observation of 41 patients. *Medicine (Baltimore)*. 1995;74:238-253.
388. Saadoun D, Terrier B, Semoun O, et al. Hepatitis C virus-associated polyarteritis nodosa. *Arthritis Care Res (Hoboken)*. 2011;63:427-435.
389. Navon Elkan P, Pierce SB, Segel R, et al. Mutant adenosine deaminase 2 in a polyarteritis nodosa vasculopathy. *N Engl J Med*. 2014;370:921-931.
390. Minardi D, Dessi-Fulgheri P, Sarzani R, et al. Massive spontaneous perirenal hematoma and accelerated hypertension in a patient with polyarteritis nodosa. *Urol Int*. 2003;70:227-231.
391. Jennette JC, Singh HK. Renal involvement in polyarteritis nodosa, Kawasaki disease, Takayasu arteritis, and giant cell arteritis. In: Jennette JC, Olson JL, Silva FG, A'gati VD, eds. *Heptinstall's Pathology of the Kidney*. 7th ed. Philadelphia, PA: Wolters Kluwer; 2015:715-738.
392. Masuda M, Kai K, Takase Y, Tokunaga O. Pathological features of classical polyarteritis nodosa: analysis of 19 autopsy cases. *Pathol Res Pract*. 2013;209:161-166.
393. Kallenberg CG. The diagnosis and classification of microscopic polyangiitis. *J Autoimmun*. 2014;48-49:90-93.
394. Jennette JC, Falk RJ. Small-vessel vasculitis. *N Engl J Med*. 1997;337:1512-1522.
395. Jennette JC, Thomas DB, Falk RJ. Microscopic polyangiitis (microscopic polyarteritis). *Semin Diagn Pathol*. 2001;18:3-13.
396. Guillevin L, Durand-Gasselin B, Cevallos R, et al. Microscopic polyangiitis: clinical and laboratory findings in eighty-five patients. *Arthritis Rheum*. 1999;42:421-430.
397. Lhote F, Cohen P, Guillevin L. Polyarteritis nodosa, microscopic polyangiitis and Churg-Strauss syndrome. *Lupus*. 1998;7:238-258.
398. D'Agati V, Chander P, Nash M, Mancilla-Jimenez R. Idiopathic microscopic polyarteritis nodosa: ultrastructural observations on the renal vascular and glomerular lesions. *Am J Kidney Dis*. 1986;7:95-110.
399. Lutalo PM, D'Cruz DP. Diagnosis and classification of granulomatosis with polyangiitis (aka Wegener's granulomatosis). *J Autoimmun*. 2014;48-49:94-98.
400. Cotch MF, Hoffman GS, Yerg DE, et al. The epidemiology of Wegener's granulomatosis. Estimates of the five-year period prevalence, annual mortality, and geographic disease distribution from population-based data sources. *Arthritis Rheum*. 1996;39:87-92.
401. Hoffman GS. Wegener's granulomatosis. *Curr Opinion Rheumatol*. 1993;5:11-17.
402. Yi ES, Colby TV. Wegener's granulomatosis. *Semin Diagn Pathol*. 2001;18:34-46.
403. Hoffman GS, Kerr GS, Leavitt RY, et al. Wegener granulomatosis: an analysis of 158 patients. *Ann Intern Med*. 1992;116:488-498.
404. Cohen Tervaert JW, Huitem MG, Hene RJ, Sluiter WJ. Prevention of relapses in Wegener's granulomatosis by treatment based on anti-neutrophil cytoplasmic antibody titer. *Lancet*. 1990;336:709-711.
405. Csernok E, Gross WL. Current understanding of the pathogenesis of granulomatosis with polyangiitis (Wegener's). *Expert Rev Clin Immunol*. 2013;9:641-648.
406. Weiss MA, Crissman JD. Renal biopsy findings in Wegener's granulomatosis: segmental necrotizing glomerulonephritis with glomerular thrombosis. *Hum Pathol*. 1984;15:943-956.
407. Yoshikawa Y, Watanabe T. Granulomatous glomerulonephritis in Wegener's granulomatosis. *Virchows Arch A Pathol Anat Histopathol*. 1984;402:361-372.
408. Gaber LW, Wall BM, Cooke CR. Coexistence of anti-neutrophil cytoplasmic antibody-associated glomerulonephritis and membranous glomerulopathy. *Am J Clin Pathol*. 1993;99:211-215.
409. Greco A, Rizzo MI, De Virgilio A, et al. Churg-Strauss syndrome. *Autoimmun Rev*. 2015;14:341-348.
410. Comarmond C, Pagnoux C, Khellaf M, et al. Eosinophilic granulomatosis with polyangiitis (Churg-Strauss): clinical characteristics and long-term followup of the 383 patients enrolled in the French Vasculitis Study Group cohort. *Arthritis Rheum*. 2013;65:270-281.
411. Abril A, Calamia KT, Cohen MD. The Churg Strauss syndrome (allergic granulomatous angiitis): review and update. *Semin Arthritis Rheum*. 2003;33:106-114.
412. Guillevin L, Cohen P, Gayraud M, et al. Churg-Strauss syndrome. Clinical study and long-term follow-up of 96 patients. *Medicine (Baltimore)*. 1999;78:26-37.
413. Hellmich B, Ehlers S, Csernok E, Gross WL. Update on the pathogenesis of Churg-Strauss syndrome. *Clin Exp Rheumatol*. 2003;21:S69-S77.
414. Sinico RA, Di Toma L, Maggiore U, et al. Renal involvement in Churg-Strauss syndrome. *Am J Kidney Dis*. 2006;47:770-779.
415. Hellmich B, Gross WL. Recent progress in the pharmacotherapy of Churg-Strauss syndrome. *Expert Opin Pharmacother*. 2004;5:25-35.
416. Mouthon L, Dunogue B, Guillevin L. Diagnosis and classification of eosinophilic granulomatosis with polyangiitis (formerly named Churg-Strauss syndrome). *J Autoimmun*. 2014;48-49:99-103.
417. Samarkos M, Loizou S, Vaiopoulos G, Davies KA. The clinical spectrum of primary renal

vasculitis. *Semin Arthritis Rheum*. 2005;35:95-111.
418. Thiel J, Hassler F, Salzer U, et al. Rituximab in the treatment of refractory or relapsing eosinophilic granulomatosis with polyangiitis (Churg-Strauss syndrome). *Arthritis Res Ther*. 2013;15:R133.
419. Kikuchi Y, Ikehata N, Tajima O, et al. Glomerular lesions in patients with Churg-Strauss syndrome and the anti-myeloperoxidase antibody. *Clin Nephrol*. 2001;55:429-435.
420. Sinico RA, Di Toma L, Maggiore U, et al. Prevalence and clinical significance of antineutrophil cytoplasmic antibodies in Churg-Strauss syndrome. *Arthritis Rheum*. 2005;52:2926-2935.
421. Roberts PF, Waller TA, Brinker TM, et al. Henoch-Schonlein purpura: a review article. *South Med J*. 2007;100:821-824.
422. Davin JC, Coppo R. Henoch-Schonlein purpura nephritis in children. *Nat Rev Nephrol*. 2014;10:563-573.
423. Blanco R, Martinez-Taboada VM, Rodriguez-Valverde V, et al. Henoch-Schonlein purpura in adulthood and childhood: two different expressions of the same syndrome. *Arthritis Rheum*. 1997;40:859-864.
424. Gedalia A. Henoch-Schonlein purpura. *Curr Rheumatol Rep*. 2004;6:195-202.
425. Cakir N, Pamuk ON, Donmez S. Henoch-Schonlein purpura in two brothers imprisoned in the same jail: presentation two months apart. *Clin Exp Rheumatol*. 2004;22:235-237.
426. Chang WL, Yang YH, Wang LC, et al. Renal manifestations in Henoch-Schonlein purpura: a 10-year clinical study. *Pediatr Nephrol*. 2005;20:1269-1272.
427. Garcia-Porrua C, Calvino MC, Llorca J, et al. Henoch-Schonlein purpura in children and adults: clinical differences in a defined population. *Semin Arthritis Rheum*. 2002;32:149-156.
428. Saulsbury FT. Henoch-Schonlein purpura. *Curr Opin Rheumatol*. 2001;13:35-40.
429. Urizar RE, Singh JK, Muhammad T, Hines O. Henoch-Schonlein anaphylactoid purpura nephropathy: electron microscopic lesions mimicking acute poststreptococcal nephritis. *Hum Pathol*. 1978;9:223-229.
430. Lau KK, Suzuki H, Novak J, Wyatt RJ. Pathogenesis of Henoch-Schonlein purpura nephritis. *Pediatr Nephrol*. 2010;25:19-26.
431. Dispenzieri A, Gorevic PD. Cryoglobulinemia. *Hematol Oncol Clin North Am*. 1999;13:1315-1349.
432. Alpers CE, Smith KD. Cryoglobulinemia and renal disease. *Curr Opin Nephrol Hypertens*. 2008;17:243-249.
433. Karras A, Noel LH, Droz D, et al. Renal involvement in monoclonal (type I) cryoglobulinemia: two cases associated with IgG3 kappa cryoglobulin. *Am J Kidney Dis*. 2002;40:1091-1096.
434. Cacoub P, Comarmond C, Domont F, et al. Cryoglobulinemia vasculitis. *Am J Med*. 2015;128:950-955.
435. D'Amico G, Colasanti G, Ferrario F, Sinico RA. Renal involvement in essential mixed cryoglobulinemia. *Kidney Int*. 1989;35:1004-1014.
436. Gorevic PD, Kassab HJ, Levo Y, et al. Mixed cryoglobulinemia: clinical aspects and long-term follow-up of 40 patients. *Am J Med*. 1980;69:287-308.
437. Ramos-Casals M, Stone JH, Cid MC, Bosch X. The cryoglobulinaemias. *Lancet*. 2012;379:348-360.
438. Iskandar SS, Herrera GA. Glomerulopathies with organized deposits. *Semin Diagn Pathol*. 2002;19:116-132.
439. Rossmann P, Hornych A, Englis M. Histology and ultrastructure of crystalloid inclusions in the podocytes in a case of paraproteinemia. *Virchows Arch Pathol Anat Physiol Klin Med*. 1968;344:151-158.
440. Laszik Z, Kambham N, Silva FG. Thrombotic Microangiopathies. In: Jennette JC, Olson JL, Silva FG, A'gati VD, eds. *Heptinstall's Pathology of the Kidney*. 7th ed. Philadelphia, PA: Wolters Kluwer; 2015:739-814.
441. George JN, Nester CM. Syndromes of thrombotic microangiopathy. *N Engl J Med*. 2014;371:654-666.
442. Tsai HM. The molecular biology of thrombotic microangiopathy. *Kidney Int*. 2006;70:16-23.
443. Furlan M, Robles R, Galbusera M, et al. von Willebrand factor-cleaving protease in thrombotic thrombocytopenic purpura and the hemolytic-uremic syndrome. *N Engl J Med*. 1998;339:1578-1584.
444. Tsai HM, Lian EC. Antibodies to von Willebrand factor-cleaving protease in acute thrombotic thrombocytopenic purpura. *N Engl J Med*. 1998;339:1585-1594.
445. Moake JL. Thrombotic microangiopathies. *N Engl J Med*. 2002;347:589-600.
446. Zheng XL, Sadler JE. Pathogenesis of thrombotic microangiopathies. *Annu Rev Pathol*. 2008;3:249-277.
447. Zakarija A, Bennett C. Drug-induced thrombotic microangiopathy. *Semin Thromb Hemost*. 2005;31:681-690.
448. Kavanagh D, Goodship TH, Richards A. Atypical haemolytic uraemic syndrome. *Br Med Bull*. 2006;77-78:5-22.
449. Noris M, Remuzzi G. Hemolytic uremic syndrome. *J Am Soc Nephrol*. 2005;16:1035-1050.
450. Gordjani N, Sutor AH, Zimmerhackl LB, Brandis M. Hemolytic uremic syndromes in childhood. *Semin Thromb Hemost*. 1997;23:281-293.
451. Keusch GT, Acheson DW. Thrombotic thrombocytopenic purpura associated with Shiga toxins. *Semin Hematol*. 1997;34:106-116.
452. Noris M, Remuzzi G. Atypical hemolytic-uremic syndrome. *N Engl J Med*. 2009;361:1676-1687.
453. Kavanagh D, Goodship TH, Richards A. Atypical hemolytic uremic syndrome. *Semin Nephrol*. 2013;33:508-530.
454. Constantinescu AR, Bitzan M, Weiss LS, et al. Non-enteropathic hemolytic uremic syndrome: causes and short-term course. *Am J Kidney Dis*. 2004;43:976-982.
455. George JN. The association of pregnancy with thrombotic thrombocytopenic purpura-hemolytic uremic syndrome. *Curr Opin Hematol*. 2003;10:339-344.
456. Niaudet P, Gagnadoux MF, Broyer M, Salomon R. Hemolytic-uremic syndrome: hereditary forms and forms associated with hereditary diseases. *Adv Nephrol Necker Hosp*. 2000;30:261-280.
457. Rodriguez de Cordoba S, Hidalgo MS, Pinto S, Tortajada A. Genetics of atypical hemolytic uremic syndrome (aHUS). *Semin Thromb Hemost*. 2014;40:422-430.
458. Agarwal SK, Tan FK, Arnett FC. Genetics and genomic studies in scleroderma (systemic sclerosis). *Rheum Dis Clin North Am*. 2008;34:17-40, v.
459. Rocco VK, Hurd ER. Scleroderma and scleroderma-like disorders. *Semin Arthritis Rheum*. 1986;16:22-69.
460. Kahaleh B. Vascular disease in scleroderma: mechanisms of vascular injury. *Rheum Dis Clin North Am*. 2008;34:57-71, vi.
461. Yazawa N, Fujimoto M, Tamaki K. Recent advances on pathogenesis and therapies in systemic sclerosis. *Clin Rev Allergy Immunol*. 2007;33:107-112.
462. Kayser C, Fritzler MJ. Autoantibodies in systemic sclerosis: unanswered questions. *Front Immunol*. 2015;6:167.
463. Eknoyan G, Suki WN. Renal vascular phenomena in systemic sclerosis (scleroderma). *Semin Nephrol*. 1985;5:34-45.
464. Woodworth TG, Suliman YA, Furst DE, Clements P. Scleroderma renal crisis and renal involvement in systemic sclerosis. *Nat Rev Nephrol*. 2016;12:678-691.
465. Bose N, Chiesa-Vottero A, Chatterjee S. Scleroderma renal crisis. *Semin Arthritis Rheum*. 2015;44:687-694.
466. Steen VD. Kidney involvement in systemic sclerosis. *Presse Med*. 2014;43:e305-e314.
467. Stone RA, Tisher CC, Hawkins HK, Robinson RR. Juxtaglomerular hyperplasia and hyperreninemia in progressive systemic sclerosis complicated acute renal failure. *Am J Med*. 1974;56:119-123.
468. Baumwell S, Karumanchi SA. Pre-eclampsia: clinical manifestations and molecular mechanisms. *Nephron Clin Pract*. 2007;106:c72-c81.
469. Maynard S, Epstein FH, Karumanchi SA. Preeclampsia and angiogenic imbalance. *Annu Rev Med*. 2008;59:61-78.
470. Stillman IE, Karumanchi SA. The glomerular injury of preeclampsia. *J Am Soc Nephrol*. 2007;18:2281-2284.
471. Esser S, Wolburg K, Wolburg H, et al. Vascular endothelial growth factor induces endothelial fenestrations in vitro. *J Cell Biol*. 1998;140:947-959.
472. Sheehan HL. Renal morphology in preeclampsia. *Kidney Int*. 1980;18:241-252.
473. Fakhouri F, Jablonski M, Lepercq J, et al. Factor H, membrane cofactor protein, and factor I mutations in patients with hemolysis, elevated liver enzymes, and low platelet count syndrome. *Blood*. 2008;112:4542-4545.
474. Gubler MC. Inherited diseases of the glomerular basement membrane. *Nat Clin Pract Nephrol*. 2008;4:24-37.
475. Jais JP, Knebelmann B, Giatras I, et al. X-linked Alport syndrome: natural history in 195 families and genotype-phenotype correlations in males. *J Am Soc Nephrol*. 2000;11:649-657.
476. Kashtan CE. Alport syndromes: phenotypic heterogeneity of progressive hereditary nephritis. *Pediatr Nephrol*. 2000;14:502-512.
477. Jefferson JA, Lemmink HH, Hughes AE, et al. Autosomal dominant Alport syndrome linked to the type IV collage alpha 3 and alpha 4 genes (COL4A3 and COL4A4). *Nephrol Dial Transplant*. 1997;12:1595-1599.
478. Longo I, Porcedda P, Mari F, et al. COL4A3/COL4A4 mutations: from familial hematuria to autosomal-dominant or recessive Alport syndrome. *Kidney Int*. 2002;61:1947-1956.
479. Pescucci C, Mari F, Longo I, et al. Autosomal-dominant Alport syndrome: natural history of a disease due to COL4A3 or COL4A4 gene. *Kidney Int*. 2004;65:1598-1603.
480. Moriniere V, Dahan K, Hilbert P, et al. Improving mutation screening in familial hematuric nephropathies through next generation sequencing. *J Am Soc Nephrol*. 2014;25:2740-2751.
481. Storey H, Savige J, Sivakumar V, et al. COL4A3/COL4A4 mutations and features in individuals with autosomal recessive Alport syndrome. *J Am Soc Nephrol*. 2013;24:1945-1954.
482. Jais JP, Knebelmann B, Giatras I, et al. X-linked Alport syndrome: natural history and genotype-phenotype correlations in girls and women belonging to 195 families: a "European Community Alport Syndrome Concerted Action" study. *J Am Soc Nephrol*. 2003;14:2603-2610.
483. Bekheirnia MR, Reed B, Gregory MC, et al. Genotype-phenotype correlation in X-linked Alport syndrome. *J Am Soc Nephrol*. 2010;21:876-883.

484. Colville DJ, Savige J. Alport syndrome. A review of the ocular manifestations. *Ophthalmic Genet*. 1997;18:161-173.
485. Antignac C, Heidet L. Mutations in Alport syndrome associated with diffuse esophageal leiomyomatosis. *Contrib Nephrol*. 1996;117:172-182.
486. Kashtan CE. Renal transplantation in patients with Alport syndrome. *Pediatr Transplant*. 2006;10:651-657.
487. Brainwood D, Kashtan C, Gubler MC, Turner AN. Targets of alloantibodies in Alport anti-glomerular basement membrane disease after renal transplantation. *Kidney Int*. 1998;53:762-766.
488. Kashtan CE. Alport syndrome. An inherited disorder of renal, ocular, and cochlear basement membranes. *Medicine (Baltimore)*. 1999;78:338-360.
489. Rumpelt HJ. Alport's syndrome: specificity and pathogenesis of glomerular basement membrane alterations. *Pediatr Nephrol*. 1987;1:422-427.
490. Hill GS, Jenis EH, Goodloe S Jr. The nonspecificity of the ultrastructural alterations in hereditary nephritis with additional observations on benign familial hematuria. *Lab Invest*. 1974;31:516-532.
491. Kashtan CE. The nongenetic diagnosis of thin basement membrane nephropathy. *Semin Nephrol*. 2005;25:159-162.
492. Haas M. Alport syndrome and thin glomerular basement membrane nephropathy: a practical approach to diagnosis. *Arch Pathol Lab Med*. 2009;133:224-232.
493. Kashtan CE, Michael AF. Alport syndrome. *Kidney Int*. 1996;50:1445-1463.
494. Savige J, Gregory M, Gross O, et al. Expert guidelines for the management of Alport syndrome and thin basement membrane nephropathy. *J Am Soc Nephrol*. 2013;24:364-375.
495. Rana K, Wang YY, Buzza M, et al. The genetics of thin basement membrane nephropathy. *Semin Nephrol*. 2005;25:163-170.
496. Kashtan CE, Segal Y. Genetic disorders of glomerular basement membranes. *Nephron Clin Pract*. 2011;118:c9-c18.
497. Frasca GM, Onetti-Muda A, Renieri A. Thin glomerular basement membrane disease. *J Nephrol*. 2000;13:15-19.
498. Tryggvason K, Patrakka J. Thin basement membrane nephropathy. *J Am Soc Nephrol*. 2006;17:813-822.
499. Gregory MC. The clinical features of thin basement membrane nephropathy. *Semin Nephrol*. 2005;25:140-145.
500. Wang YY, Savige J. The epidemiology of thin basement membrane nephropathy. *Semin Nephrol*. 2005;25:136-139.
501. Norby SM, Cosio FG. Thin basement membrane nephropathy associated with other glomerular diseases. *Semin Nephrol*. 2005;25:176-179.
502. Foster K, Markowitz GS, D'Agati VD. Pathology of thin basement membrane nephropathy. *Semin Nephrol*. 2005;25: 149-158.
503. Stenson PD, Ball EV, Mort M, et al. Human Gene Mutation Database (HGMD): 2003 update. *Hum Mutat*. 2003;21:577-581.
504. Ojo A, Meier-Kriesche HU, Friedman G, et al. Excellent outcome of renal transplantation in patients with Fabry's disease. *Transplantation*. 2000;69:2337-2339.
505. Rohrbach M, Clarke JT. Treatment of lysosomal storage disorders: progress with enzyme replacement therapy. *Drugs*. 2007;67:2697-2716.
506. Rombach SM, Smid BE, Bouwman MG, et al. Long term enzyme replacement therapy for Fabry disease: effectiveness on kidney, heart and brain. *Orphanet J Rare Dis*. 2013;8:47.
507. Bracamonte ER, Kowalewska J, Starr J, et al. Iatrogenic phospholipidosis mimicking Fabry disease. *Am J Kidney Dis*. 2006;48:844-850.
508. van der Tol L, Svarstad E, Ortiz A, et al. Chronic kidney disease and an uncertain diagnosis of Fabry disease: approach to a correct diagnosis. *Mol Genet Metab*. 2015;114:242-247.
509. McIntosh I, Dunston JA, Liu L, et al. Nail patella syndrome revisited: 50 years after linkage. *Ann Hum Genet*. 2005;69:349-363.
510. Bongers EM, Huysmans FT, Levtchenko E, et al. Genotype-phenotype studies in nail-patella syndrome show that LMX1B mutation location is involved in the risk of developing nephropathy. *Eur J Hum Genet*. 2005;13:935-946.
511. Bongers EM, Gubler MC, Knoers NV. Nail-patella syndrome. Overview on clinical and molecular findings. *Pediatr Nephrol*. 2002;17:703-712.
512. Meyrier A, Rizzo R, Gubler MC. The nail-patella syndrome. A review. *J Nephrol*. 1990;2:133-140.
513. Chan PC, Chan KW, Cheng IK, Chan MK. Living-related renal transplantation in a patient with nail-patella syndrome. *Nephron*. 1988;50:164-166.
514. Alchi B, Nishi S, Narita I, Gejyo F. Collagenofibrotic glomerulopathy: clinicopathologic overview of a rare glomerular disease. *Am J Kidney Dis*. 2007;49:499-506.
515. Cohen AH. Collagen type III glomerulopathies. *Adv Chronic Kidney Dis*. 2012;19:101-106.
516. Chen N, Pan X, Xu Y, et al. Two brothers in one Chinese family with collagen type III glomerulopathy. *Am J Kidney Dis*. 2007;50:1037-1042.
517. Gubler MC, Dommergues JP, Foulard M, et al. Collagen type III glomerulopathy: a new type of hereditary nephropathy. *Pediatr Nephrol*. 1993;7:354-360.
518. Tamura H, Matsuda A, Kidoguchi N, et al. A family with two sisters with collagenofibrotic glomerulonephropathy. *Am J Kidney Dis*. 1996;27:588-595.
519. Vogt BA, Wyatt RJ, Burke BA, et al. Inherited factor H deficiency and collagen type III glomerulopathy. *Pediatr Nephrol*. 1995;9:11-15.
520. Mizuiri S, Hasegawa A, Kikuchi A, et al. A case of collagenofibrotic glomerulopathy associated with hepatic perisinusoidal fibrosis. *Nephron*. 1993;63:183-187.
521. Yasuda T, Imai H, Nakamoto Y, et al. Collagenofibrotic glomerulopathy: a systemic disease. *Am J Kidney Dis*. 1999;33:123-127.
522. Assmann KJ, Koene RA, Wetzels JF. Familial glomerulonephritis characterized by massive deposits of fibronectin. *Am J Kidney Dis*. 1995;25:781-791.
523. Mazzucco G, Maran E, Rollino C, Monga G. Glomerulonephritis with organized deposits: a mesangiopathic, not immune complex-mediated disease? A pathologic study of two cases in the same family. *Hum Pathol*. 1992;23:63-68.
524. Strom EH, Hurwitz N, Mayr AC, et al. Immunotactoid-like glomerulopathy with massive fibrillary deposits in liver and bone marrow in monoclonal gammopathy. *Am J Nephrol*. 1996;16:523-528.
525. Castelletti F, Donadelli R, Banterla F, et al. Mutations in FN1 cause glomerulopathy with fibronectin deposits. *Proc Natl Acad Sci USA*. 2008;105:2538-2543.
526. Strom EH, Banfi G, Krapf R, et al. Glomerulopathy associated with predominant fibronectin deposits: a newly recognized hereditary disease. *Kidney Int*. 1995;48:163-170.
527. Nadamuni M, Piras R, Mazbar S, et al. Fibronectin glomerulopathy: an unusual cause of adult-onset nephrotic syndrome. *Am J Kidney Dis*. 2012;60:839-842.
528. Jackson AM, Kuperman MB, Montgomery RA. Multiple hyperacute rejections in the absence of detectable complement activation in a patient with endothelial cell reactive antibody. *Am J Transplant*. 2012;12:1643-1649.
529. Jackson AM, Sigdel TK, Delville M, et al. Endothelial cell antibodies associated with novel targets and increased rejection. *J Am Soc Nephrol*. 2015;26:1161-1171.
530. Racusen LC, Haas M. Antibody-mediated rejection in renal allografts: lessons from pathology. *Clin J Am Soc Nephrol*. 2006;1:415-420.
531. Iwaki Y, Terasaki PI. Primary nonfunction in human cadaver kidney transplantation: evidence for hidden hyperacute rejection. *Clin Transplant*. 1987;1:125-131.
532. Burns JM, Cornell LD, Perry DK, et al. Alloantibody levels and acute humoral rejection early after positive crossmatch kidney transplantation. *Am J Transplant*. 2008;8:2684-2694.
533. Verani RR, Bergman D, Kerman RH. Glomerulopathy in acute and chronic rejection: relationship of ultrastructure to graft survival. *Am J Nephrol*. 1983;3:253-263.
534. Mauiyyedi S, Crespo M, Collins AB, et al. Acute humoral rejection in kidney transplantation: II. Morphology, immunopathology, and pathologic classification. *J Am Soc Nephrol*. 2002;13:779-787.
535. Collins AB, Schneeberger EE, Pascual MA, et al. Complement activation in acute humoral renal allograft rejection: diagnostic significance of C4d deposits in peritubular capillaries. *J Am Soc Nephrol*. 1999;10:2208-2214.
536. Nickeleit V, Zeiler M, Gudat F, et al. Detection of the complement degradation product C4d in renal allografts: diagnostic and therapeutic implications. *J Am Soc Nephrol*. 2002;13:242-251.
537. Solez K, Colvin RB, Racusen LC, et al. Banff 07 classification of renal allograft pathology: updates and future directions. *Am J Transplant*. 2008;8:753-760.
538. Haas M, Segev DL, Racusen LC, et al. C4d deposition without rejection correlates with reduced early scarring in ABO-incompatible renal allografts. *J Am Soc Nephrol*. 2009;20:197-204.
539. Mengel M, Sis B, Haas M, et al. Banff 2011 Meeting report: new concepts in antibody-mediated rejection. *Am J Transplant*. 2012;12:563-570.
540. Haas M, Sis B, Racusen LC, et al. Banff 2013 meeting report: inclusion of C4d-negative antibody-mediated rejection and antibody-associated arterial lesions. *Am J Transplant*. 2014;14:272-283.
541. Nickeleit V, Mengel M, Colvin RB. Renal transplant pathology. In: Jennette JC, Olson JL, Silva FG, A'gati VD, eds. *Heptinstall's Pathology of the Kidney*. 6th ed. Philadelphia, PA: Wolters Kluwer; 2015:1321-1459.
542. Colvin RB. The renal allograft biopsy. *Kidney Int*. 1996;50:1069-1082.
543. Sis B, Bagnasco SM, Cornell LD, et al. Isolated endarteritis and kidney transplant survival: a multicenter collaborative study. *J Am Soc Nephrol*. 2015;26:1216-1227.
544. Gago M, Cornell LD, Kremers WK, et al. Kidney allograft inflammation and fibrosis, causes and consequences. *Am J Transplant*. 2012;12:1199-1207.
545. Petersen VP, Olsen TS, Kissmeyer-Nielsen F, et al. Late failure or human renal transplants. An analysis of transplant disease and graft failure among 125 recipients surviving for one to eight years. *Medicine (Baltimore)*. 1975;54:45-71.

546. Maryniak RK, First MR, Weiss MA. Transplant glomerulopathy: evolution of morphologically distinct changes. *Kidney Int*. 1985;27:799-806.
547. Regele H, Bohmig GA, Habicht A, et al. Capillary deposition of complement split product C4d in renal allografts is associated with basement membrane injury in peritubular and glomerular capillaries: a contribution of humoral immunity to chronic allograft rejection. *J Am Soc Nephrol*. 2002;13:2371-2380.
548. Solez K, Axelsen RA, Benediktsson H, et al. International standardization of criteria for the histologic diagnosis of renal allograft rejection: the Banff working classification of kidney transplant pathology. *Kidney Int*. 1993;44:411-422.
549. Kahan BD. Cyclosporine. *N Engl J Med*. 1989;321:1725-1738.
550. Atkinson A, Biggs J, Dodds A, Concannon A. Cyclosporine-associated hepatotoxicity after allogeneic marrow transplantation in man: differentiation from other causes of posttransplant liver disease. *Transplant Proc*. 1983;15:2761-2767.
551. Graham RM. Cyclosporine: mechanisms of action and toxicity. *Cleve Clin J Med*. 1994;61:308-313.
552. Mihatsch MJ, Thiel G, Ryffel B. Morphologic diagnosis of cyclosporine nephrotoxicity. *Semin Diagn Pathol*. 1988;5:104-121.
553. Jacobson PA, Schladt D, Israni A, et al. Genetic and clinical determinants of early, acute calcineurin inhibitor-related nephrotoxicity: results from a kidney transplant consortium. *Transplantation*. 2012;93:624-631.
554. Morozumi K, Takeda A, Uchida K, Mihatsch MJ. Cyclosporine nephrotoxicity: how does it affect renal allograft function and transplant morphology? *Transplant Proc*. 2004;36:251s-256s.
555. Snanoudj R, Royal V, Elie C, et al. Specificity of histological markers of long-term CNI nephrotoxicity in kidney-transplant recipients under low-dose cyclosporine therapy. *Am J Transplant*. 2011;11:2635-2646.
556. Morozumi K, Sugito K, Oda A, et al. A comparative study of morphological characteristics of renal injuries of tacrolimus (FK506) and cyclosporin (CyA) in renal allografts: are the morphologic characteristics of FK506 and CyA nephrotoxicity similar? *Transplant Proc*. 1996;28:1076-1078.
557. Hirsch HH. BK virus: opportunity makes a pathogen. *Clin Infect Dis*. 2005;41:354-360.
558. Hirsch HH, Knowles W, Dickenmann M, et al. Prospective study of polyomavirus type BK replication and nephropathy in renal-transplant recipients. *N Engl J Med*. 2002;347:488-496.
559. Nickeleit V, Singh HK, Mihatsch MJ. Polyomavirus nephropathy: morphology, pathophysiology, and clinical management. *Curr Opin Nephrol Hypertens*. 2003;12:599-605.
560. Randhawa PS, Finkelstein S, Scantlebury V, et al. Human polyoma virus-associated interstitial nephritis in the allograft kidney. *Transplantation*. 1999;67:103-109.
561. Moeckel GW, Kashgarian M, Racusen LC. Ischemic and toxic acute tubular injury and other ischemic renal injury. In: Jennette JC, Olson JL, Silva FG, A'gati VD, eds. *Heptinstall's Pathology of the Kidney*. 7th ed. Philadelphia, PA: Wolters Kluwer; 2015:1167-1222.
562. Rosen S, Stillman IE. Acute tubular necrosis is a syndrome of physiologic and pathologic dissociation. *J Am Soc Nephrol*. 2008;19:871-875.
563. Seshan SV, D'Agati VD, Appel GA, Churg J. *Acute Vasomotor Injury/Toxic Tubular Necrosis*. Baltimore, MD: Williams & Wilkins; 1999.
564. Han WK, Bailly V, Abichandani R, et al. Kidney Injury Molecule-1 (KIM-1): a novel biomarker for human renal proximal tubule injury. *Kidney Int*. 2002;62:237-244.
565. Ichimura T, Hung CC, Yang SA, et al. Kidney injury molecule-1: a tissue and urinary biomarker for nephrotoxicant-induced renal injury. *Am J Physiol Renal Physiol*. 2004;286:F552-F563.
566. Han WK, Alinani A, Wu CL, et al. Human kidney injury molecule-1 is a tissue and urinary tumor marker of renal cell carcinoma. *J Am Soc Nephrol*. 2005;16:1126-1134.
567. Vaidya VS, Ramirez V, Ichimura T, et al. Urinary kidney injury molecule-1: a sensitive quantitative biomarker for early detection of kidney tubular injury. *Am J Physiol Renal Physiol*. 2006;290:F517-F529.
568. Sabbisetti VS, Waikar SS, Antoine DJ, et al. Blood kidney injury molecule-1 is a biomarker of acute and chronic kidney injury and predicts progression to ESRD in type I diabetes. *J Am Soc Nephrol*. 2014;25: 2177-2186.
569. Sharfuddin AA, Molitoris BA. Pathophysiology of ischemic acute kidney injury. *Nat Rev Nephrol*. 2011;7:189-200.
570. Tolkoff-Rubin NE, Cotran RS, Rubin RH. Urinary tract infection, pyelonephritis and reflux nephropathy. In: Brenner BM, ed. *Brenner's and Rector's the Kidney*. 8th ed. Philadelphia, PA: WB Saunders; 2008:1239-1264.
571. Becker GJ, Kincaid-Smith P. Reflux nephropathy: the glomerular lesion and progression of renal failure. *Pediatr Nephrol*. 1993;7:365-369.
572. Goodman M, Curry T, Russell T. Xanthogranulomatous pyelonephritis (XGP): a local disease with systemic manifestations. Report of 23 patients and review of the literature. *Medicine (Baltimore)*. 1979;58:171-181.
573. Hammadah MY, Nicholls CJ, Calder JC, et al. Xanthomatous pyelonephritis in childhood: pre-operatory diagnosis is possible. *Br J Urol*. 1994;73:83-86.
574. Kim SW, Yoon BI, Ha US, et al. Xanthogranulomatous pyelonephritis: clinical experience with 21 cases. *J Infect Chemother*. 2013;19:1221-1224.
575. Huisman TK, Sands JP. Focal xanthogranulomatous pyelonephritis associated with renal cell carcinoma. *Urology*. 1992;39:281-284.
576. Li L, Parwani AV. Xanthogranulomatous pyelonephritis. *Arch Pathol Lab Med*. 2011;135:671-674.
577. Khalyl-Mawad J, Greco MA, Schinella RA. Ultrastructural demonstration of intracellular bacteria in xanthogranulomatous pyelonephritis. *Hum Pathol*. 1982;13:41-47.
578. Kobayashi A, Utsunomiya Y, Kono M, et al. Malakoplakia of the kidney. *Am J Kidney Dis*. 2008;51:326-330.
579. Esparza AR, McKay DB, Cronan JJ, Chazan JA. Renal parenchymal malakoplakia. Histologic spectrum and its relationship to megalocytic interstitial nephritis and xanthogranulomatous pyelonephritis. *Am J Surg Pathol*. 1989;13:225-236.
580. Abdou NI, NaPombejara C, Sagawa A, et al. Malakoplakia: evidence for monocyte lysosomal abnormality correctable by cholinergic agonist in vitro and in vivo. *N Engl J Med*. 1977;297:1413-1419.
581. Murray KM, Keane WR. Review of drug-induced acute interstitial nephritis. *Pharmacotherapy*. 1992;12:462-467.
582. Remuzzi G, Ruggenenti P. The hemolytic uremic syndrome. *Kidney Int Suppl*. 1998;66:S54-S57.
583. Rossert J. Drug-induced acute interstitial nephritis. *Kidney Int*. 2001;60:804-817.
584. Muriithi AK, Leung N, Valeri AM, et al. Biopsy-proven acute interstitial nephritis, 1993-2011: a case series. *Am J Kidney Dis*. 2014;64:558-566.
585. Corwin HL, Korbet SM, Schwartz MM. Clinical correlates of eosinophiluria. *Arch Intern Med*. 1985;145:1097-1099.
586. Kleinknecht D. Interstitial nephritis, the nephrotic syndrome, and chronic renal failure secondary to nonsteroidal anti-inflammatory drugs. *Semin Nephrol*. 1995;15:228-235.
587. Brodsky SV, Nadasdy T. Acute and chronic tubulointerstitial nephritis. In: Jennette JC, Olson JL, Silva FG, A'gati VD, eds. *Heptinstall's Pathology of the Kidney*. 7th ed. Philadelphia, PA: Wolters Kluwer; 2015:1111-1166.
588. Magil AB. Drug-induced acute interstitial nephritis with granulomas. *Hum Pathol*. 1983;14:36-41.
589. Praga M, Sevillano A, Aunon P, Gonzalez E. Changes in the aetiology, clinical presentation and management of acute interstitial nephritis, an increasingly common cause of acute kidney injury. *Nephrol Dial Transplant*. 2015;30:1472-1479.
590. Okada K, Okamoto Y, Kagami S, et al. Acute interstitial nephritis and uveitis with bone marrow granulomas and anti-neutrophil cytoplasmic antibodies. *Am J Nephrol*. 1995;15:337-342.
591. Saeki T, Nishi S, Imai N, et al. Clinicopathological characteristics of patients with IgG4-related tubulointerstitial nephritis. *Kidney Int*. 2010;78:1016-1023.
592. Cornell LD. IgG4-related kidney disease. *Curr Opin Nephrol Hypertens*. 2012;21:279-288.
593. Alexander MP, Larsen CP, Gibson IW, et al. Membranous glomerulonephritis is a manifestation of IgG4-related disease. *Kidney Int*. 2013;83:455-462.
594. Gault MH, Barrett BJ. Analgesic nephropathy. *Am J Kidney Dis*. 1998;32:351-360.
595. De Broe ME, Elseviers MM. Analgesic nephropathy. *N Engl J Med*. 1998;338:446-452.
596. United States Renal Data System. 1996 Annual Data Report. Bethesda, MD, 1996.
597. Mihatsch MJ, Khanlari B, Brunner FP. Obituary to analgesic nephropathy—an autopsy study. *Nephrol Dial Transplant*. 2006;21:3139-3145.
598. De Broe ME, Elseviers MM. Over-the-counter analgesic use. *J Am Soc Nephrol*. 2009;20:2098-2103.
599. Bokemeyer C, Thon WF, Brunkhorst T, et al. High frequency of urothelial cancers in patients with kidney transplantations for end-stage analgesic nephropathy. *Eur J Cancer*. 1996;32a:175-176.
600. Griffin MD, Bergstralh EJ, Larson TS. Renal papillary necrosis: a 16-year clinical experience. *J Am Soc Nephrol*. 1995;6:248-256.
601. Fowler BA. Mechanisms of kidney cell injury from metals. *Environ Health Perspect*. 1993;100:57-63.
602. Prasad GV, Rossi NF. Arsenic intoxication associated with tubulointerstitial nephritis. *Am J Kidney Dis*. 1995;26:373-376.
603. Yasuda M, Miwa A, Kitagawa M. Morphometric studies of renal lesions in Itai-itai disease: chronic cadmium nephropathy. *Nephron*. 1995;69:14-19.
604. Li SJ, Zhang SH, Chen HP, et al. Mercury-induced membranous nephropathy: clinical and pathological features. *Clin J Am Soc Nephrol*. 2010;5:439-444.
605. Friedman AC, Lautin EM. Cis-platinum (II) diaminedichloride: another cause of bilateral small kidneys. *Urology*. 1980;16:584-586.
606. Hall CL, Fothergill NJ, Blackwell MM, et al. The natural course of gold nephropathy: long term study of 21 patients. *Br Med J (Clin Res Ed)*. 1987;295:745-748.
607. Randall RE Jr, Osheroff RJ, Bakerman S, Setter JG. Bismuth nephrotoxicity. *Ann Intern Med*. 1972;77:481-482.

608. Sabath E, Robles-Osorio ML. Renal health and the environment: heavy metal nephrotoxicity. *Nefrologia*. 2012;32:279-286.
609. Lockitch G. Perspectives on lead toxicity. *Clin Biochem*. 1993;26:371-381.
610. Newman LS. Occupational illness. *N Engl J Med*. 1995;333:1128-1134.
611. Brewster UC, Perazella MA. A review of chronic lead intoxication: an unrecognized cause of chronic kidney disease. *Am J Med Sci*. 2004;327:341-347.
612. Schumann GB, Lerner SI, Weiss MA, et al. Inclusion-bearing cells in industrial workers exposed to lead. *Am J Clin Pathol*. 1980;74:192-196.
613. Bushinsky DA. Nephrolithiasis. *J Am Soc Nephrol*. 1998;9:917-924.
614. Vervaet BA, Verhulst A, D'Haese PC, De Broe ME. Nephrocalcinosis: new insights into mechanisms and consequences. *Nephrol Dial Transplant*. 2009;24:2030-2035.
615. Markowitz GS, Perazella MA. Acute phosphate nephropathy. *Kidney Int*. 2009;76:1027-1034.
616. Gutman AB, Yu TF. Uric acid nephrolithiasis. *Am J Med*. 1968;45:756-779.
617. Johnson RJ, Kivlighn SD, Kim YG, et al. Reappraisal of the pathogenesis and consequences of hyperuricemia in hypertension, cardiovascular disease, and renal disease. *Am J Kidney Dis*. 1999;33:225-234.
618. Nickeleit V, Mihatsch MJ. Uric acid nephropathy and end-stage renal disease—review of a non-disease. *Nephrol Dial Transplant*. 1997;12:1832-1838.
619. Crawhall JC, Purkiss P, Watts RW, Young EP. The excretion of amino acids by cystinuric patients and their relatives. *Ann Hum Genet*. 1969;33:149-169.
620. Sakhaee K. Pathogenesis and medical management of cystinuria. *Semin Nephrol*. 1996;16:435-447.
621. Emma F, Nesterova G, Langman C, et al. Nephropathic cystinosis: an international consensus document. *Nephrol Dial Transplant*. 2014;29(suppl 4):iv87-iv94.
622. Lieske JC, Toback FG. Renal cell-urinary crystal interactions. *Curr Opin Nephrol Hypertens*. 2000;9:349-355.
623. Rumsby G, Cochat P. Primary hyperoxaluria. *N Engl J Med*. 2013;369:2163.
624. Asplin JR. Hyperoxaluric calcium nephrolithiasis. *Endocrinol Metab Clin North Am*. 2002;31:927-949.
625. Nasr SH, D'Agati VD, Said SM, et al. Oxalate nephropathy complicating Roux-en-Y Gastric Bypass: an underrecognized cause of irreversible renal failure. *Clin J Am Soc Nephrol*. 2008;3:1676-1683.
626. Smith LH. The pathophysiology and medical treatment of urolithiasis. *Semin Nephrol*. 1990;10:31-52.
627. Leung N, Nasr SH. Myeloma-related kidney disease. *Adv Chronic Kidney Dis*. 2014;21:36-47.
628. Hutchison CA, Batuman V, Behrens J, et al. The pathogenesis and diagnosis of acute kidney injury in multiple myeloma. *Nat Rev Nephrol*. 2011;8:43-51.
629. Sedmak DD, Tubbs RR. The macrophagic origin of multinucleated giant cells in myeloma kidney: an immunohistologic study. *Hum Pathol*. 1987;18:304-306.
630. Start DA, Silva FG, Davis LD, et al. Myeloma cast nephropathy: immunohistochemical and lectin studies. *Mod Pathol*. 1988;1:336-347.
631. Carstens PH, Woo D. Crystalline glomerular inclusions in multiple myeloma. *Am J Kidney Dis*. 1989;14:56-60.
632. Bohle A, Ratschek M. The compensated and the decompensated form of benign nephrosclerosis. *Pathol Res Pract*. 1982;174:357-367.
633. Kashgarian M. Pathology of the kidney in hypertension. In: Kaplan NM, Brenner BM, Laragh JH, eds. *The Kidney in Hypertension*. New York, NY: Raven Press; 1987:77-89.
634. Valenzuela R, Gogate PA, Deodar SD, Gifford RW. Hyaline arteriolonephrosclerosis. Immunofluorescent findings in vascular lesions. *Lab Invest*. 1980;43:530-534.
635. Ram CV. Current concepts in renovascular hypertension. *Am J Med Sci*. 1992;304:53-71.
636. Harrison EG Jr, McCormack LJ. Pathologic classification of renal arterial disease in renovascular hypertension. *Mayo Clin Proc*. 1971;46:161-167.
637. Plouin PF, Perdu J, La Batide-Alanore A, et al. Fibromuscular dysplasia. *Orphanet J Rare Dis*. 2007;2:28.
638. Slovut DP, Olin JW. Fibromuscular dysplasia. *N Engl J Med*. 2004;350:1862-1871.
639. Gerlock AJ Jr, Goncharenko VA, Ekelund L. Radiation-induced stenosis of the renal artery causing hypertension: case report. *J Urol*. 1977;118:1064-1065.
640. Chugh KS, Jain S, Sakhuja V, et al. Renovascular hypertension due to Takayasu's arteritis among Indian patients. *Q J Med*. 1992;85:833-843.
641. Crosson JT, Keane WF, Anderson WR. Radiation nephropathy. In: Tisher CC, Brenner BM, eds. *Renal Pathology: with Clinical and Functional Correlations*. 2nd ed. Philadelphia, PA: JB Lippincott Co; 1994:937-947.
642. Cheng JC, Schultheiss TE, Wong JY. Impact of drug therapy, radiation dose, and dose rate on renal toxicity following bone marrow transplantation. *Int J Radiat Oncol Biol Phys*. 2008;71:1436-1443.
643. Jennette JC, Ordonez NG. Radiation nephritis causing nephrotic syndrome. *Urology*. 1983;22:631-634.
644. Keane WF, Crosson JT, Staley NA, et al. Radiation-induced renal disease. A clinicopathologic study. *Am J Med*. 1976;60:127-137.
645. Cohen EP, Lawton CA, Moulder JE. Bone marrow transplant nephropathy: radiation nephritis revisited. *Nephron*. 1995;70:217-222.
646. Jodele S, Licht C, Goebel J, et al. Abnormalities in the alternative pathway of complement in children with hematopoietic stem cell transplant-associated thrombotic microangiopathy. *Blood*. 2013;122:2003-2007.
647. Cohen EP, Lawton CA, Moulder JE, et al. Clinical course of late-onset bone marrow transplant nephropathy. *Nephron*. 1993;64:626-635.
648. George JN, Li X, McMinn JR, et al. Thrombotic thrombocytopenic purpura-hemolytic uremic syndrome following allogeneic HPC transplantation: a diagnostic dilemma. *Transfusion*. 2004;44:294-304.
649. Ho VT, Cutler C, Carter S, et al. Blood and marrow transplant clinical trials network toxicity committee consensus summary: thrombotic microangiopathy after hematopoietic stem cell transplantation. *Biol Blood Marrow Transplant*. 2005;11:571-575.
650. Bisceglia M, Galliani CA, Senger C, et al. Renal cystic diseases: a review. *Adv Anat Pathol*. 2006;13:26-56.
651. Rohatgi R. Clinical manifestations of hereditary cystic kidney disease. *Front Biosci*. 2008;13:4175-4197.
652. Torres VE, Grantham JJ. Cystic diseases of the kidney. In: Brenner BM, ed. *Brenner's and Rector's the Kidney*. 8th ed. Philadelphia, PA: WB Saunders; 2008:1428-1462.
653. Liapis H, Winyard PJD. Cystic diseases and developmental kidney defects. In: Jennette JC, Olson JL, Silva FG, A'gati VD, eds. *Heptinstall's Pathology of the Kidney*. 7th ed. Philadelphia, PA: Wolters Kluwer; 2015:119-172.
654. Deeb A, Robertson A, MacColl G, et al. Multicystic dysplastic kidney and Kallmann's syndrome: a new association? *Nephrol Dial Transplant*. 2001;16:1170-1175.
655. Weber S, Moriniere V, Knuppel T, et al. Prevalence of mutations in renal developmental genes in children with renal hypodysplasia: results of the ESCAPE study. *J Am Soc Nephrol*. 2006;17:2864-2870.
656. Okayasu I, Kajita A. Histopathological study of congenital cystic kidneys with special reference to the multicystic, dysplastic type. *Acta Pathol Jpn*. 1978;28:427-434.
657. Risdon RA. Renal dysplasia. Part I. A clinical pathologic study of 76 cases. Part II. A necroscopy study of 41 cases. *J Clin Pathol*. 1971;24:57-71.
658. Turco AE, Padovani EM, Chiaffoni GP, et al. Molecular genetic diagnosis of autosomal dominant polycystic kidney disease in a newborn with bilateral cystic kidneys detected prenatally and multiple skeletal malformations. *J Med Genet*. 1993;30:419-422.
659. Kimberling WJ, Kumar S, Gabow PA, et al. Autosomal dominant polycystic kidney disease: localization of the second gene to chromosome 4q13–q23. *Genomics*. 1993;18:467-472.
660. Reeders ST, Breuning MH, Davies KE, et al. A highly polymorphic DNA marker linked to adult polycystic kidney disease on chromosome 16. *Nature*. 1985;317:542-544.
661. Rossetti S, Harris PC. Genotype-phenotype correlations in autosomal dominant and autosomal recessive polycystic kidney disease. *J Am Soc Nephrol*. 2007;18:1374-1380.
662. Yoder BK, Mulroy S, Eustace H, et al. Molecular pathogenesis of autosomal dominant polycystic kidney disease. *Expert Rev Mol Med*. 2006;8:1-22.
663. Yoder BK, Hou X, Guay-Woodford LM. The polycystic kidney disease proteins, polycystin-1, polycystin-2, polaris, and cystin, are co-localized in renal cilia. *J Am Soc Nephrol*. 2002;13:2508-2516.
664. Rizk D, Chapman A. Treatment of autosomal dominant polycystic kidney disease (ADPKD): the new horizon for children with ADPKD. *Pediatr Nephrol*. 2008;23:1029-1036.
665. Rapola J, Kaariainen H. Polycystic kidney disease. Morphological diagnosis of recessive and dominant polycystic kidney disease in infancy and childhood. *APMIS*. 1988;96:68-76.
666. Grantham JJ. Clinical practice. Autosomal dominant polycystic kidney disease. *N Engl J Med*. 2008;359:1477-1485.
667. Chapman AB. Autosomal dominant polycystic kidney disease: time for a change? *J Am Soc Nephrol*. 2007;18:1399-1407.
668. Grantham JJ. Polycystic kidney disease: hereditary and acquired. *Adv Intern Med*. 1993;38:409-420.
669. Gregoire JR, Torres VE, Holley KE, Farrow GM. Renal epithelial hyperplastic and neoplastic proliferation in autosomal dominant polycystic kidney disease. *Am J Kidney Dis*. 1987;9:27-38.
670. Gabow PA, Johnson AM, Kaehny WD, et al. Risk factors for the development of hepatic cysts in autosomal dominant polycystic kidney disease. *Hepatology*. 1990;11:1033-1037.
671. Gabow PA. Autosomal dominant polycystic kidney disease—more than a renal disease. *Am J Kidney Dis*. 1990;16:403-413.
672. Hossack KF, Leddy CL, Johnson AM, et al. Echocardiographic findings in autosomal dominant polycystic kidney disease. *N Engl J Med*. 1988;319:907-912.
673. Guay-Woodford LM, Desmond RA. Autosomal recessive polycystic kidney disease: the clinical experience in North America. *Pediatrics*. 2003;111:1072-1080.
674. Guay-Woodford LM, Muecher G, Hopkins SD, et al. The severe perinatal form of autosomal recessive polycystic kidney disease maps to chromosome 6p21.1-p12: implications for

genetic counseling. *Am J Hum Genet*. 1995;56:1101-1107.
675. Zerres K, Mucher G, Bachner L, et al. Mapping of the gene for autosomal recessive polycystic kidney disease (ARPKD) to chromosome 6p21-cen. *Nat Genet*. 1994;7:429-432.
676. Onuchic LF, Furu L, Nagasawa Y, et al. PKHD1, the polycystic kidney and hepatic disease 1 gene, encodes a novel large protein containing multiple immunoglobulin-like plexin-transcription-factor domains and parallel beta-helix 1 repeats. *Am J Hum Genet*. 2002;70:1305-1317.
677. Ward CJ, Hogan MC, Rossetti S, et al. The gene mutated in autosomal recessive polycystic kidney disease encodes a large, receptor-like protein. *Nat Genet*. 2002;30:259-269.
678. Menezes LF, Cai Y, Nagasawa Y, et al. Polyductin, the PKHD1 gene product, comprises isoforms expressed in plasma membrane, primary cilium, and cytoplasm. *Kidney Int*. 2004;66:1345-1355.
679. Gunay-Aygun M, Tuchman M, Font-Montgomery E, et al. PKHD1 sequence variations in 78 children and adults with autosomal recessive polycystic kidney disease and congenital hepatic fibrosis. *Mol Genet Metab*. 2010;99:160-173.
680. Buscher R, Buscher AK, Weber S, et al. Clinical manifestations of autosomal recessive polycystic kidney disease (ARPKD): kidney-related and non-kidney-related phenotypes. *Pediatr Nephrol*. 2014;29:1915-1925.
681. Gunay-Aygun M, Font-Montgomery E, Lukose L, et al. Correlation of kidney function, volume and imaging findings, and PKHD1 mutations in 73 patients with autosomal recessive polycystic kidney disease. *Clin J Am Soc Nephrol*. 2010;5:972-984.
682. Denamur E, Delezoide AL, Alberti C, et al. Genotype-phenotype correlations in fetuses and neonates with autosomal recessive polycystic kidney disease. *Kidney Int*. 2010;77:350-358.
683. Zerres K, Rudnik-Schoneborn S, Deget F, et al. Autosomal recessive polycystic kidney disease in 115 children: clinical presentation, course and influence of gender. Arbeitsgemeinschaft fur Padiatrische, Nephrologie. *Acta Paediatr*. 1996;85:437-445.
684. Hildebrandt F, Zhou W. Nephronophthisis-ass ociated ciliopathies. *J Am Soc Nephrol*. 2007;18:1855-1871.
685. Liapis H, Gaut JP, Tomaszewski JE, Arend LJ. Pyelonephritis and other direct renal infections, reflux nephropathy, hydronephrosis, hypercalcemia and nephrolithiasis. In: Jennette JC, Olson JL, Silva FG, A'gati VD, eds. *Heptinstall's Pathology of the Kidney*. 7th ed. Philadelphia, PA: Wolters Kluwer; 2015:1039-1110.
686. Fanconi G, Hanhart E, Albertini A. Die familiare juvenile Nephronophthise. *Hel Pediatr Acta*. 1951;6:1-49.
687. Gagnadoux MF, Bacri JL, Broyer M, Habib R. Infantile chronic tubulo-interstitial nephritis with cortical microcysts: variant of nephronophthisis or new disease entity? *Pediatr Nephrol*. 1989;3:50-55.
688. Omran H, Fernandez C, Jung M, et al. Identification of a new gene locus for adolescent nephronophthisis, on chromosome 3q22 in a large Venezuelan pedigree. *Am J Hum Genet*. 2000;66:118-127.
689. Halbritter J, Porath JD, Diaz KA, et al. Identification of 99 novel mutations in a worldwide cohort of 1,056 patients with a nephronophthisis-related ciliopathy. *Hum Genet*. 2013;132:865-884.
690. Chaki M, Hoefele J, Allen SJ, et al. Genotype-phenotype correlation in 440 patients with NPHP-related ciliopathies. *Kidney Int*. 2011;80:1239-1245.
691. Wolf MT. Nephronophthisis and related syndromes. *Curr Opin Pediatr*. 2015;27:201-211.
692. Loken AC, Hanssen O, Halvorsen S, Jolster NJ. Hereditary renal dysplasia and blindness. *Acta Paediatr*. 1961;50:177-184.
693. Senior B, Friedmann AI, Braudo JL. Juvenile familial nephropathy with tapetoretinal degeneration. A new oculorenal dystrophy. *Am J Ophthalmol*. 1961;52:625-633.
694. Ronquillo CC, Bernstein PS, Baehr W. Senior-Loken syndrome: a syndromic form of retinal dystrophy associated with nephronophthisis. *Vision Res*. 2012;75:88-97.
695. Cohen AH, Hoyer JR. Nephronophthisis. A primary tubular basement membrane defect. *Lab Invest*. 1986;55:564-572.
696. Eckardt KU, Alper SL, Antignac C, et al. Autosomal dominant tubulointerstitial kidney disease: diagnosis, classification, and management—a KDIGO consensus report. *Kidney Int*. 2015;88:676-683.
697. Ekici AB, Hackenbeck T, Moriniere V, et al. Renal fibrosis is the common feature of autosomal dominant tubulointerstitial kidney diseases caused by mutations in mucin 1 or uromodulin. *Kidney Int*. 2014;86:589-599.
698. Bleyer AJ, Kmoch S, Antignac C, et al. Variable clinical presentation of an MUC1 mutation causing medullary cystic kidney disease type 1. *Clin J Am Soc Nephrol*. 2014;9:527-535.
699. Kirby A, Gnirke A, Jaffe DB, et al. Mutations causing medullary cystic kidney disease type 1 lie in a large VNTR in MUC1 missed by massively parallel sequencing. *Nat Genet*. 2013;45:299-303.
700. Bollee G, Dahan K, Flamant M, et al. Phenotype and outcome in hereditary tubulointerstitial nephritis secondary to UMOD mutations. *Clin J Am Soc Nephrol*. 2011;6:2429-2438.
701. Dahan K, Devuyst O, Smaers M, et al. A cluster of mutations in the UMOD gene causes familial juvenile hyperuricemic nephropathy with abnormal expression of uromodulin. *J Am Soc Nephrol*. 2003;14:2883-2893.
702. Nasr SH, Lucia JP, Galgano SJ, et al. Uromodulin storage disease. *Kidney Int*. 2008;73:971-976.
703. Bleyer AJ, Zivna M, Hulkova H, et al. Clinical and molecular characterization of a family with a dominant renin gene mutation and response to treatment with fludrocortisone. *Clin Nephrol*. 2010;74:411-422.
704. Zivna M, Hulkova H, Matignon M, et al. Dominant renin gene mutations associated with early-onset hyperuricemia, anemia, and chronic kidney failure. *Am J Hum Genet*. 2009;85:204-213.
705. Clissold RL, Hamilton AJ, Hattersley AT, et al. HNF1B-associated renal and extra-renal disease-an expanding clinical spectrum. *Nat Rev Nephrol*. 2015;11:102-112.
706. Musetti C, Quaglia M, Mellone S, et al. Chronic renal failure of unknown origin is caused by HNF1B mutations in 9% of adult patients: a single centre cohort analysis. *Nephrology (Carlton)*. 2014;19:202-209.
707. Gambaro G, Feltrin GP, Lupo A, et al. Medullary sponge kidney (Lenarduzzi-Cacchi-Ricci disease): a Padua Medical School discovery in the 1930s. *Kidney Int*. 2006;69:663-670.
708. Kuiper JJ. Medullary sponge kidney. In: Gardner KDJ, ed. *Cystic Disease of the Kidney*. New York, NY: John Wiley and Sons, Inc; 1976:151-172.
709. Yendt ER. Medullary sponge kidney and nephrolithiasis. *N Engl J Med*. 1982;306:1106-1107.
710. Fabris A, Anglani F, Lupo A, Gambaro G. Medullary sponge kidney: state of the art. *Nephrol Dial Transplant*. 2013;28:1111-1119.
711. Fabris A, Lupo A, Ferraro PM, et al. Familial clustering of medullary sponge kidney is autosomal dominant with reduced penetrance and variable expressivity. *Kidney Int*. 2013;83:272-277.
712. Levine E. Acquired cystic kidney disease. *Radiol Clin North Am*. 1996;34:947-964.
713. Gabow PA. Polycystic and acquired cystic diseases. In: Greenberg A, ed. *Primer on Kidney Diseases*. 2nd ed. San Diego, CA: Academic Press; 1998:313-318.
714. Kuroda N, Ohe C, Mikami S, et al. Review of acquired cystic disease-associated renal cell carcinoma with focus on pathobiological aspects. *Histol Histopathol*. 2011;26: 1215-1218.
715. Zhou XJ, Fenves AZ, Vaziri ND, Saxena R. Renal changes with aging and end-stage renal disease. In: Jennette JC, Olson JL, Silva FG, A'gati VD, eds. *Heptinstall's Pathology of the Kidney*. 7th ed. Philadelphia, PA: Wolters Kluwer; 2015:1281-1320.
716. Nahm AM, Ritz E. The simple renal cyst. *Nephrol Dial Transplant*. 2000;15: 1702-1704.
717. Murshidi MM, Suwan ZA. Simple renal cysts. *Arch Esp Urol*. 1997;50:928-931.
718. Terada N, Ichioka K, Matsuta Y, et al. The natural history of simple renal cysts. *J Urol*. 2002;167:21-23.
719. Baert L, Steg A. Is the diverticulum of the distal and collecting tubules a preliminary stage of the simple cyst in the adult? *J Urol*. 1977;118:707-710.

24 Kidney: Tumors and Tumorlike Conditions

Jesse K. McKenney

CHAPTER CONTENTS

Pediatric tumors and tumorlike conditions, *1014*
Nephroblastic tumors, *1014*
Congenital mesoblastic nephroma, *1019*
Clear cell sarcoma, *1020*
Rhabdoid tumor, *1022*
Pediatric-type cystic nephroma and DICER1 renal sarcoma, *1023*
Intrarenal neuroblastoma, *1023*
Intrarenal Ewing sarcoma, *1024*
Intrarenal synovial sarcoma, *1024*
Metanephric tumors, *1024*
Renal cell carcinoma, *1025*
Other pediatric tumor types, *1025*
Adult tumors and tumorlike conditions, *1025*
Renal cell carcinoma, *1025*
Adenomas, *1040*
Oncocytoma, "difficult to classify" oncocytic tumors, and oncocytosis, *1040*
Neuroendocrine tumors, *1042*
Other epithelial tumors, *1042*
Angiomyolipoma, *1043*
Juxtaglomerular cell tumor, *1044*
Other benign tumors and tumorlike conditions, *1045*
Sarcomas, *1047*
Malignant lymphoma and related lymphoid lesions, *1047*
Metastatic tumors, *1047*
Tumors of renal pelvis and ureter, *1047*

Pediatric Tumors and Tumorlike Conditions

Nephroblastic Tumors

Wilms Tumor (Nephroblastoma)

General Features

Wilms tumor is also known as nephroblastoma (currently the preferred term).[1,2] It constitutes the prototypical example of a neoplastic process that faithfully recapitulates embryogenesis at the morphologic and molecular levels.[3-5] It is seen primarily in infants, 50% of the cases occurring before the age of 3 years and 90% before the age of 6 years.[6-8] However, Wilms tumor is only exceptionally seen as a congenital neoplasm, a point of great importance in the differential diagnosis with mesoblastic nephroma.[9] There are also well-documented cases of Wilms tumors in adolescents[10] and adults, but this may represent a somewhat different disease with distinct genetic features and significantly worse clinical outcomes.[11-15] There is no appreciable sex predilection. The risk in Caucasians is lower than in Asians, but higher than in patients of African descent.

The classic location for Wilms tumor is the kidney. Both kidneys are equally affected, the incidence of synchronous or metachronous bilateral involvement being 5%–10%.[16,17] Cases with the typical morphologic features of Wilms tumor have rarely been recorded in extrarenal sites, including retroperitoneum, sacrococcygeal region, testis, uterus (sometimes presenting as a cervical polyp), inguinal canal, and mediastinum.[18-24] Some of them have arisen within a teratoma, and even those in which this feature was not evident have been viewed by some authors as teratomas with a predominant or exclusive nephroblastic component.

Wilms tumor has been reported in monozygous twins and other familial settings.[7] Conditions associated with the highest risk of Wilms tumor are Wilms–aniridia genital anomaly–retardation (WAGR) syndrome, omphalocele–macroglossia (Beckwith–Wiedemann syndrome), hemihypertrophy, Denys–Drash syndrome, and familial nephroblastoma.[25-28] Other conditions associated with Wilms tumor are renal and genital malformations, cutaneous nevi and angiomas, trisomy 18, Klippel–Trénaunay syndrome, neurofibromatosis, Bloom syndrome, Frasier syndrome, Simpson-Golabi-Behmel syndrome, Perlman syndrome, and cerebral gigantism (Sotos syndrome).[28-32] The incidence of congenital abnormalities of the urogenital tract is particularly high for Wilms tumors occurring during the first

Abstract

This chapter covers the entire spectrum of neoplasms and non-neoplastic tumoral lesions that may involve the kidney. Pediatric tumors are detailed and include Wilms tumor (nephroblastoma), clear cell sarcoma of kidney, congenital mesoblastic nephroma, rhabdoid tumor, and cystic nephroma. The metanephric family of tumors is also addressed. An update on specific subtypes of renal cell carcinoma is provided, based on the 2016 WHO classification, and newer emerging entities are also covered. Other less common intrarenal neoplasms are also highlighted. Finally, lesions of the upper urinary tract (i.e. renal pelvis and ureter) are discussed.

Keywords

Wilms tumor
clear cell sarcoma of kidney
renal rhabdoid tumor
congenital mesoblastic nephroma
metanephric adenoma
renal cell carcinoma
oncocytoma
papillary adenoma
angiomyolipoma
urothelial carcinoma
ureter
renal pelvis

year of life and/or involving both kidneys. Wilms tumor has also been encountered in association with other malignancies, such as osteosarcoma, botryoid variant of embryonal rhabdomyosarcoma, retinoblastoma, hepatocellular carcinoma, and neuroblastoma.[33-36]

Clinical Features

The classic clinical presentation of Wilms tumor is in the form of an abdominal mass felt by the mother when handling the child. Hematuria and pain are rare. Hypertension, present in a minority of the cases, has been shown to be caused by renin secretion by the tumor.[37] Proteinuria may be the result of tumor-associated glomerular disease in the non-neoplastic kidney.[38] Sometimes the first symptoms are related to traumatic rupture. Cases have been reported presenting as sudden death resulting from tumor embolism.[39]

Imaging studies show a solid intrarenal mass that often displaces and distorts the collecting system. Foci of calcification may be identified.[40]

Morphologic Features

Grossly, most Wilms tumors are solitary, well circumscribed, rounded, and of soft consistency. Their size is extremely variable, and their median weight is 550 g. The cut section is predominantly solid and pale gray or tan and often exhibits areas of cystic change, necrosis, and hemorrhage (Fig. 24.1). A lobular pattern resulting from fibrous septation is common. Multicentric tumor foci are found in 7% of the cases.

Microscopically, three major components are identified: undifferentiated blastema, mesenchymal (stromal) tissue, and epithelial tissue.[41-43] Most Wilms tumors show a representation of all three components, but the proportions vary widely from case to case and sometimes from region to region in the same tumor. Some tumors are biphasic, and still others are monophasic (monomorphous). The *blastomatous* areas are extremely cellular and composed of small round-to-oval primitive cells; the cytoplasm is usually very scant, but sometimes is more abundant and exhibits an oncocytoid appearance. Adjacent nuclei commonly appear to overlap. The pattern of growth may be diffuse, nodular, cordlike (serpentine), or basaloid (with peripheral palisading). Particularly on biopsy, Wilms tumors in which the blastomatous component predominates can be confused with any of the small round cell tumors (including neuroblastoma), rhabdoid tumor, or clear cell sarcoma of kidney. The *mesenchymal* elements usually have spindle cells with fibroblastic or smooth muscle features, but may also exhibit differentiation toward various heterologous cell types, particularly skeletal muscle.[44]

The *epithelial* component is characterized by the formation of embryonic tubular (and sometimes glomerular) structures that closely recapitulate the appearance of normal developing metanephric tubules (and glomeruli) at the light microscopic, ultrastructural, and lectin histochemistry levels (Fig. 24.2).[45-48] The differentiation can be so pronounced that tumor analogues of nearly all segments of the normal nephron can be formed.[49] These tubular structures can be small and round, thus simulating the rosettes of neuroblastoma. Features favoring tubules over rosettes are presence of a lumen, single cell layer, distinct basal lamina, and surrounding fibromyxoid stroma.[41] The differential diagnosis of predominantly epithelial Wilms tumors also includes cystic nephroma, renal cell carcinoma (RCC), and metanephric adenoma.[41,50] Exceptionally, marked hydropic changes are seen in the tubular epithelial component.[51] Heterologous epithelium may include ciliated, mucinous, squamous, or transitional epithelium (Fig. 24.3).[41,52]

In the type known as *papillonodular*, grossly evident projections are seen extending from the septa into the cyst lumina, resulting in a fibroadenoma-like appearance on low-power microscopic examination.[53,54]

Other heterologous tissues described in Wilms tumor are endocrine cells of various types[52]; renin-producing cells[55]; neuroepithelium, neuroblasts, and mature ganglion cells[56,57]; neuroglia[58]; adipose tissue; and cartilage, bone, and hematopoietic cells.[41] Sometimes the variety of tissues present is such that the distinction between Wilms tumor and teratoma becomes blurred[41]; the term *teratoid Wilms tumor* has been used to describe these cases.[59,60]

The distinct cystic partially differentiated Wilms tumor is discussed separately later.

Anaplastic features may be present focally or extensively in Wilms tumors (approximately 5%–8% of cases); they are discussed fully in the section on prognosis.

Immunohistochemical Features

The immunohistochemical profile of the various components of Wilms tumor mirrors that of their counterparts in the developing kidney.[61-63]

The epithelial elements react for keratin and epithelial membrane antigen (EMA)[61,64]; the mesenchymal elements show a reactivity pattern consonant with their morphologic appearance (such as

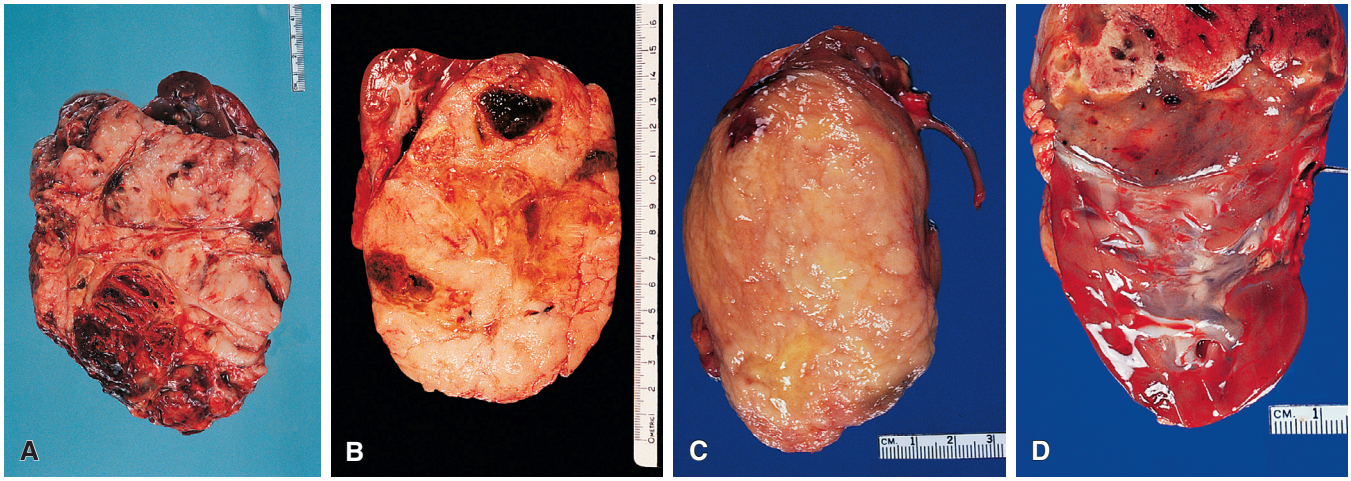

Figure 24.1 Various Gross Appearances of Wilms Tumor. A and **B,** Variegated appearance. **C,** More homogeneous and nodular. **D,** Extensive areas of infarct-like necrosis.

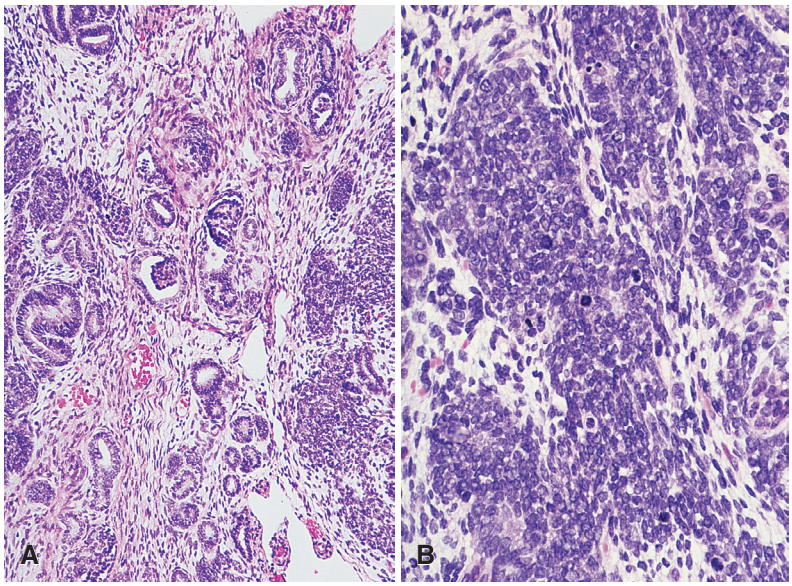

Figure 24.2 Microscopic Appearance of Wilms Tumor. A, Low-power microscopic view showing a combination of blastema, stroma, epithelial tubular formations, and immature glomeruli. **B,** High-power view showing blastema, stroma, and immature tubular formations.

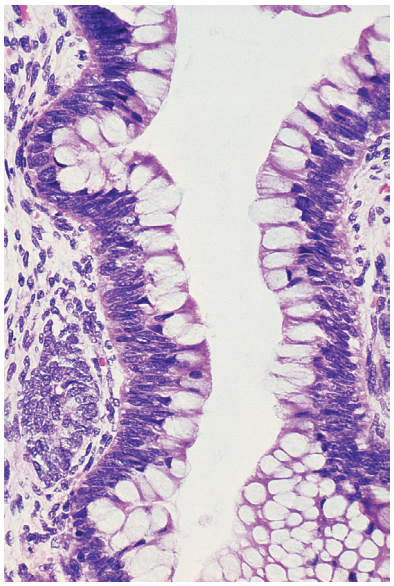

Figure 24.3 Mucinous epithelium in Wilms tumor.

positivity for myogenin and desmin in the rhabdomyomatous foci)[65]; and the neural elements—when present—exhibit reactivity for neuron-specific enolase, glial fibrillary acidic protein, and S-100 protein.[64] Additional immunoreactivities of Wilms tumor include nuclear WT1 (80%, typically in epithelial and blastemal components), nuclear PAX8, CD56 (96%), and (unexpectedly) TTF-1; the latter, which is found in 17% of cases, represents a potential source of misdiagnosis.[66,67]

Molecular Genetic Features

The genetic loci predisposing to Wilms tumor are *WT1* and *WT2*. The former is located in 11p13 and encodes a zinc finger transcription factor that is expressed in the early development of the urogenital system, with its germline point mutation and deletion being the underlying genetic alteration in Denys–Drash syndrome and WAGR syndrome, respectively.[68-70] *WT2* is located in 11p15.5, which contains the gene for insulin growth factor II, and is implicated in tumors associated with Beckwith–Wiedemann syndrome.[71-74] Alterations of these genes may also be identified in sporadic tumors. A relationship has been shown between the level of expression of these genes and the microscopic features of the tumor.[68,75-79]

Inactivation of the *WTX* gene located on the X chromosome is found in 6%–30% of cases of sporadic Wilms tumor.[79,80] This results from somatic deletion or, less commonly, inactivating mutation of the gene on the single X chromosome in tumors of males or the active X chromosome in tumors of females.[81-83] The pathogenetic role of *WTX* alteration in Wilms tumor is not fully elucidated, but downregulation of WTX leads to increased signaling in the Wnt pathway.[83]

Activating mutation of the β-catenin gene *CTNNB1* is found in 14%–20% of Wilms tumors, resulting in disturbance of the Wnt signaling pathway. It may be found in tumors with *WT1* mutation, but not with *WT1* wild-type.[84-86]

Abnormalities in other chromosomes—1, 7q, 8, 12, and 16—have also been encountered.[14,87,88] These genetic changes are identical in the various histologic components of the tumor, and 1p and 16q loss of heterozygosity (LOH) are discussed further under prognosis.[89] Mutations of *TP53* and/or overexpression of the protein are found in only 5% of the cases of Wilms tumor. They are largely restricted to the anaplastic foci and carry an unfavorable prognostic connotation.[90,91] Similarly, MYCN amplification is seen in rare cases with aggressive behavior, most commonly with diffuse anaplasia. More recently, mutations in the SIX/2 pathway and the DROSHA/DGCR8 miRNA microprocessor complex have been described in high-risk blastemal Wilms tumors.[92]

Spread and Metastases

In advanced cases, local spread occurs in the perirenal soft tissues. From here, the tumor may directly involve the adrenal glands, bowel, liver, vertebrae, and paraspinal region; the latter may result in spinal cord compression.[93] Invasion of the renal vein is common, but extension into the renal pelvis or ureter is a rare and late event.

Table 24.1 Staging of nephroblastoma, rhabdoid tumor of the kidney, clear cell sarcoma of the kidney (Children's Oncology Group)

STAGE	DESCRIPTION
Stage I	Completely resected tumor limited to the kidney. No intraoperative rupture or biopsy of the tumor prior to removal. No involvement of the vessels of the renal sinus. No evidence of tumor beyond the margins of resection. Regional lymph nodes confirmed negative microscopically.
Stage II	Completely resected tumor with no evidence of tumor at or beyond margins of resection. Tumor extends beyond the kidney as evidenced by regional extension of the tumor (through renal capsule, extensive invasion of the soft tissue of the renal sinus) or tumor in blood vessels within the nephrectomy specimen, but outside renal parenchyma. This includes blood vessels of the renal sinus.
Stage III	Residual tumor present after surgery, confined to abdomen. This includes the following: • Lymph nodes within the abdomen/pelvis are involved by tumor. • Tumor has penetrated through the peritoneal surface. • Tumor implants are on the peritoneal surface. • Gross or microscopic tumor remains postoperatively (positive surgical margins on microscopic exam). • Involvement of vital structures precludes complete resection. • Tumor spillage before or during surgery. • Tumor is treated with preoperative chemotherapy (with or without any prior biopsy, including fine-needle aspiration). • Tumor is removed in more than one piece (e.g. tumor is found in tissues separate from nephrectomy specimen, such as separately excised adrenal, or separately removed thrombus from renal vein). • Extension of primary tumor into thoracic vena cava and/or heart.
Stage IV	Hematogenous metastases or lymph node metastases outside the abdominopelvic region
Stage V	Bilateral renal involvement present at diagnosis. Each kidney should be substaged separately by above criteria.

Metastases in regional lymph nodes are found in 15% of the cases. The most common sites of distant metastases are lungs, liver, and peritoneum.[94] The presence of lung metastases in a child with a retroperitoneal neoplasm strongly favors a diagnosis of Wilms tumor over that of neuroblastoma. Conversely, the presence of bone metastases suggests a diagnosis other than Wilms tumor, since they occur in only 1% of the cases.

Therapy

The therapy for Wilms tumor has been relatively standardized and is based largely on protocols from either the International Society of Paediatric Oncology (SIOP) or the Children's Oncology Group (COG).[2,95-98] The specifics of these protocols are being continuously updated.[99] The main differences between the two approaches are based on the use of presurgical therapy. The SIOP typically espouses preoperative chemotherapy followed by surgical resection. In this model, some regions require biopsies to confirm diagnosis prior to chemotherapy, while others do not. Further therapy is based on the initial response as measured by a post-therapy classification.[100] Advocates of the SIOP approach cite fewer intraoperative tumor ruptures (due to therapy-related tumor shrinkage) and less upstaging. The COG typically advocates for initial surgical resection with subsequent therapy determined by tumor histology and stage. Its advocates cite prognostic stratification that allows for more tailored therapy. Despite these differences, the clinical outcomes for both the SIOP and COG approaches are very similar.[99,101]

Prognosis

The overall cure rate for unilateral Wilms tumor is 80%–90%.[102] A small percentage of long-term survivors of Wilms tumor develop a second malignant neoplasm, either because of a genetic predisposition to neoplasia or secondary to therapy.[103]

The prognostic connotations of various clinical and morphologic parameters are as follows:

1. *Age*. Patients under 2 years of age have significantly fewer metastases and a better 5-year survival rate than those over 2 years.[104,105]
2. *Stage*. Clinicopathologic staging of Wilms tumor is the most important prognostic determinant, based on either the SIOP or the COG systems (Table 24.1). Capsular invasion, rupture at surgery, extrarenal vein invasion, tumor implants, lymph node metastases, distant metastases, and bilaterality are the main criteria used.[106] Unfortunately, staging of Wilms tumor by the pathologist is fraught with pitfalls. The tumor "capsule" (or pseudocapsule) can be confused with the renal capsule; the renal sinus and surgical margins may be difficult to evaluate; and the renal vein may retract considerably, giving a false impression—when invaded—that tumor is present at the margin. It is important for sections to be taken from the renal sinus, the junction between tumor and normal kidney, the tumor capsule, and the uninvolved renal parenchyma. In a study of stage I cases, the following four features were found to be associated with increased rate of relapse: presence of an inflammatory pseudocapsule, invasion of the renal sinus, extensive infiltration of the renal capsule, and tumor infiltration of intrarenal vessels.[107]
3. *Size*. Tumor mass, as measured by the weight of the excised specimen, is an important determinant of outcome, especially in stage I tumors.[108]
4. *Anaplasia*. For a case of Wilms tumor to be placed into the anaplastic category, it should meet the following three criteria: (1) marked enlargement of nuclei within the blastemal, epithelial, or stromal cell lines (excepting skeletal muscle cells) to at least three times the diameter of adjacent nuclei of the same cell type; (2) obvious hyperchromasia of the enlarged nuclei; and (3) multipolar mitotic figures (Fig. 24.4).[109]

   Anaplasia thus defined is present in about 4% of the cases, the incidence being higher in patients of African descent and in older patients.[110] It is very uncommon in tumors from patients under 2 years of age; this is probably the reason for the better prognosis exhibited by this age group. Sometimes it is found in the metastases and not in the primary tumor.

   Currently, *focal* anaplasia applies only to cases in which the previously defined changes are restricted *to one or a few discrete*

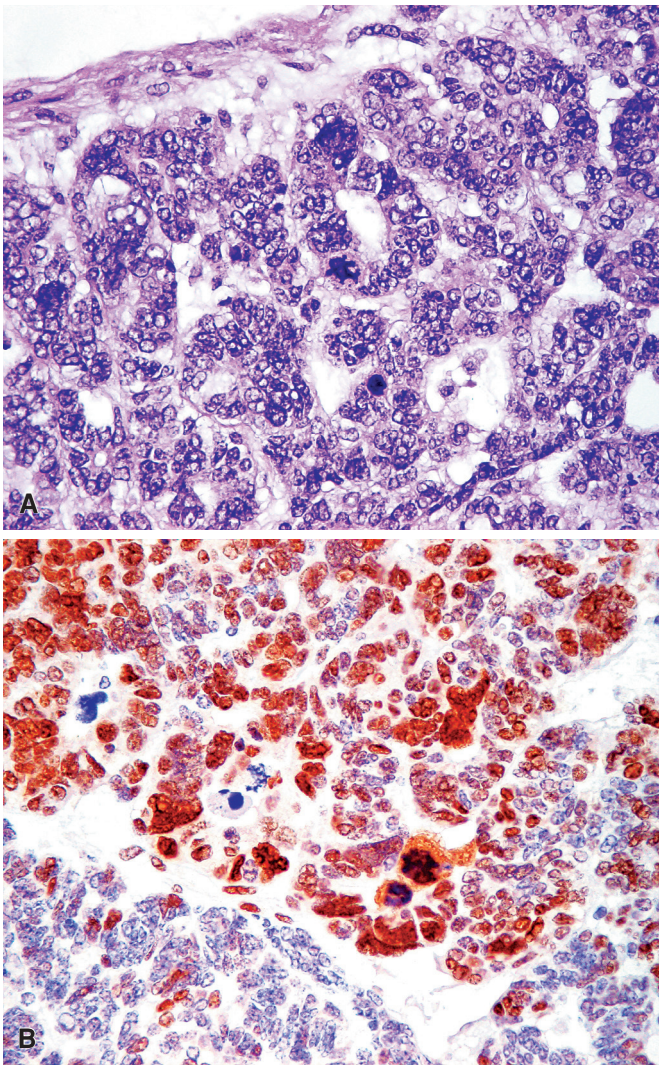

Figure 24.4 Anaplastic ("Unfavorable Histology") Wilms Tumor. A, Marked pleomorphism with giant hyperchromatic nuclei and atypical mitoses. **B,** Strong nuclear immunoreactivity for p53.

loci within the primary tumor, with no anaplasia or marked nuclear atypia elsewhere.[111] Specifically, focal anaplasia cannot be present in tumor infiltrating outside the kidney (e.g. renal sinus) or in intravascular tumor. Thorough tumor sampling (one section for each centimeter of tumor diameter) and careful mapping of where sections were taken is obviously needed to evaluate this feature properly.[112] Cases with localized anaplasia in which the background tumor shows a degree of "marked" atypia (i.e. bordering on anaplasia, but falling short of the minimal threshold, typically due to nuclear pleomorphism without other features) have been referred to as showing "nuclear unrest" and are classified as diffuse anaplasia. Wilms tumors with anaplasia are referred to as having "unfavorable histology" in the sense of exhibiting a lesser response to chemotherapy. This predictive connotation is greater when the anaplasia is diffuse rather than focal, and since anaplasia predicts response to therapy, its significance in stage I tumors is debated.[113]

5. *Extensive tubular differentiation*. This is said to be a good prognostic sign. According to some authors, this is also true for cases with extensive glomerular differentiation.[114-116] This finding does not currently direct initial therapy.
6. *Skeletal muscle differentiation*. This feature does not seem to have a significant effect on prognosis, except when present in massive amounts. In the latter instance it is said to be associated with a better prognosis.[116-118] This finding does not currently direct initial therapy.
7. *Post-chemotherapy morphology*. The SIOP classification is based largely on response to chemotherapy with three simple categories: completely necrotic (low risk), blastemal predominant (high risk), and "others" (intermediate risk).[100] The incidence of anaplasia does not seem to be affected by this treatment modality (i.e. there is no evidence that therapy induces cytologic changes mimicking anaplasia).[119]
8. *TP53 mutation*. Mutations of the *TP53* gene, evaluated indirectly through the immunohistochemical detection of P53 protein overexpression, correlate with the presence of anaplasia at the histologic level and therefore with an unfavorable outcome.[120,121]
9. LOH at 1p and 16q. Some studies have suggested that LOH at 1p and 16 q is an adverse prognostic factor in favorable histology Wilms tumors.[122-125] Future COG and/or SIOP trials will likely attempt to further validate this finding.

Many of these prognostic parameters are used in the revised SIOP working classification for nephroblastoma (Table 24.2).

Cystic Partially Differentiated Wilms Tumor (Nephroblastoma)

Cystic partially differentiated Wilms tumor typically occurs in very young children, most less than 24 months old.[126] By definition, this tumor should have an exclusively cystic gross appearance with thin septa and no solid nodules. It is typically large (mean of 10 cm), but well circumscribed. Histologically, the thin septa contain an admixture of different tissues, including fibrous tissue, skeletal muscle, fat, cartilage, blastema, and nephroblastomatous epithelium. Cysts may show papillary infolding, but no microscopic nodular masses should protrude from the cyst wall, as their presence suggests a cystic Wilms tumor. Hemorrhage, necrosis, and calcification are not features of cystic partially differentiated Wilms tumor. Surgical resection is typically curative and adjuvant therapy is not recommended for this clinically benign neoplasm. The main differential diagnosis is pediatric cystic nephroma, which (by definition) does not contain nephroblastomatous elements.

Nephroblastomatosis and Nephrogenic Rests

Nephroblastomatosis and *nephrogenic rests* are defined as persistent foci of embryonal cells (after 36 weeks gestation), but they are discussed here because of their frequent confusion and histogenetic relationship with Wilms tumor.[2,127-129] Nephrogenic rests are seen in up to 40% of patients with Wilms tumor and approximately 1% of neonates.[127] The term nephroblastomatosis refers to diffuse or multifocal nephrogenic rests. In its most florid form, the process is often associated with a variety of congenital anomalies and with hypertension.[130]

Nephrogenic rests have been divided into *perilobar* and *intralobar* forms (Fig. 24.5). The former, which is more common, is located peripherally, has sharply demarcated margins, is composed predominantly of blastema and tubules with scanty (or sclerotic) stroma, and is often multifocal. The intralobar form is randomly distributed in the cortex and medulla and has irregular margins. It shows a predominance of stroma over blastema and tubules and is usually solitary.[131-133] Further methods of nephrogenic rest subclassification have also been proposed.[132]

Nephroblastomatosis can be diagnosed by computed tomography (CT) scan, magnetic resonance imaging (MRI), or ultrasound.[134] Grossly, the most exuberant examples of this disease can be

Table 24.2 Staging of pediatric renal tumors (International Society of Paediatric Oncology) (post-chemotherapy)

Stage I	Viable tumor limited to the kidney, or surrounded by an intact fibrous pseudocapsule and completely resected. No renal sinus invasion of soft tissue or vessels. Necrotic tumor or chemotherapy induced changes may be present in renal sinus or soft tissue outside of kidney without upstaging, as long as these changes do not extend to resection margins. Prior percutaneous core needle (Tru-cut) biopsy or fine-needle aspiration does not upstage the tumor. Tumor may infiltrate adrenal gland if adrenal capsule is intact. Tumor may be adherent to liver capsule but may not infiltrate liver parenchyma.
Stage II	Completely resected viable tumor extends beyond kidney or penetrates through the renal capsule or fibrous tumor pseudocapsule into perirenal fat. Tumor may infiltrate the renal sinus and/or invade blood vessels, but resection margins are clear. Tumor may infiltrate adjacent organs or vena cava, if completely resected with clear margins.
Stage III	Incomplete excision. Gross residual tumor remains in the patient, or tumor extends to resection margins on microscopic exam, including necrotic tumor or chemotherapy induced changes at resection margin. • Tumor in any abdominal lymph node, including necrotic tumor or tumor with chemotherapy effect. • Tumor rupture before or during resection surgery • Tumor penetrates peritoneal surface. • Tumor thrombi present at resection margins of vessels or ureter, transected or removed piecemeal. • Wedge biopsy of the tumor prior to preoperative chemotherapy or surgery.
Stage IV	Hematogenous metastases or spread of tumor beyond the abdomen and pelvis.
Stage V	Bilateral renal tumors. Each side should be substaged by above criteria.

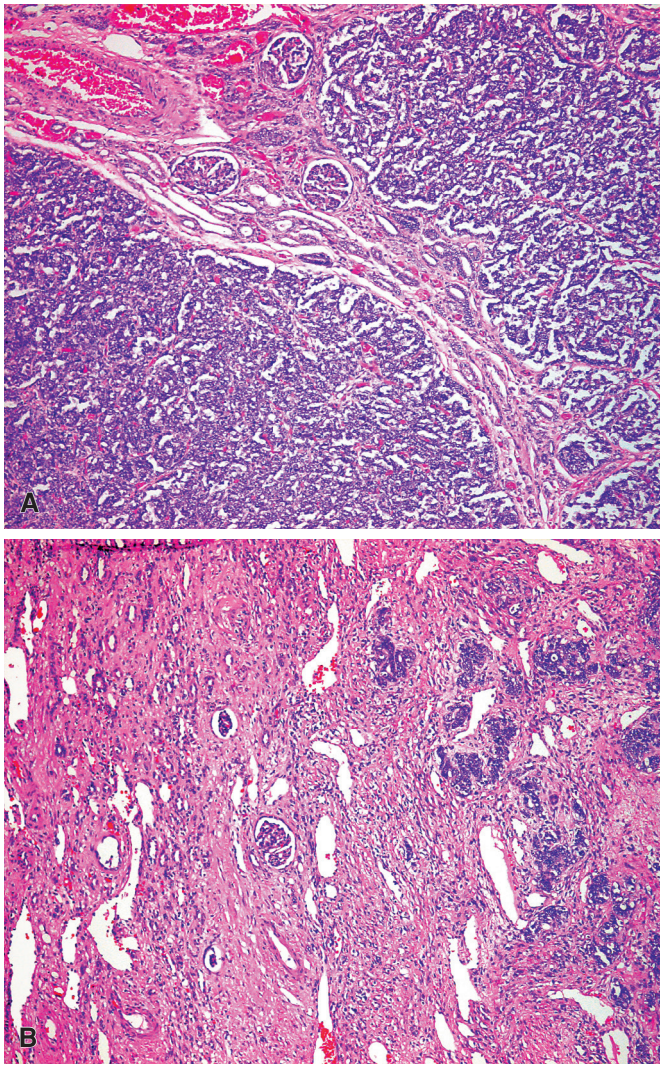

Figure 24.5 Nephrogenic rests. Perilobar **(A)** and intralobar **(B)** types.

distinguished from Wilms tumor because of the diffuse or multifocal nature of the process and the involvement of the entire subcapsular region. Microscopically, the mass is typically unencapsulated and composed of tightly packed nephrogenic epithelial cells that have a primitive but not anaplastic appearance. Stromal tissue is scanty; cartilage, striated cells, and primitive mesenchyme are absent. However, hyperplastic rests may have some foci that are cytologically indistinguishable from Wilms tumor, but have the distribution of a rest and no capsule. Other histologic mimics of nephrogenic rests include dysplastic medullary ray nodules (most commonly in Beckwith–Wiedemann syndrome) and embryonal hyperplasia (often in multicystic dysplasia and end-stage kidneys).[135,136]

In cases associated with Wilms tumor, they have been found to share similar mutations.[137] Perilobar rests often have 11p15 alterations and are commonly associated with hemihypertrophy and/or Beckwith–Wiedemann syndrome, while intralobar rests commonly have *WT1* mutations and may be associated with Denys–Drash syndrome.[138] CTNNB1 mutations are seen in intralobar rests, even in the absence of *WT1* mutation.[139]

A conservative therapeutic approach is indicated in cases of nephrogenic rests and nephroblastomatosis[140]; however, nephrogenic rests in patients less than 1 year of age (particularly if perilobar) and especially diffuse hyperplastic nephroblastomatosis are associated with the highest risk of contralateral Wilms tumor.[141]

Congenital Mesoblastic Nephroma

Congenital mesoblastic nephroma represents the most common renal tumor of newborns and is usually discovered before 6 months of age.[142] Extraordinary examples in adults have been reported, but the diagnosis is rare after 2 years of age and should be carefully scrutinized outside that setting.[143,144] Grossly, the tumor is solid, yellow-gray to tan, with a whorled configuration reminiscent of uterine leiomyoma (Fig. 24.6). Most are centered near the hilus of the kidney. The tumor often appears well circumscribed, but it may infiltrate the renal parenchyma and even the perirenal fat microscopically. Areas of hemorrhage and necrosis are usually absent. A cystic variant of this tumor has been described.[145,146]

Microscopically, two distinct patterns are seen. "Classic" congenital mesoblastic nephroma resembles "infantile fibromatosis" of the renal sinus with long sweeping and intersecting fascicles composed

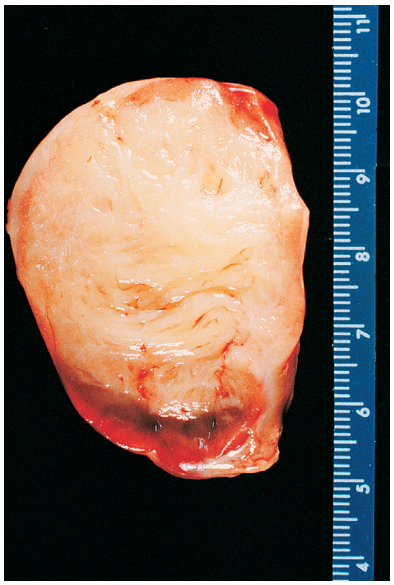

Figure 24.6 Congenital Mesoblastic Nephroma. Gross appearance of the well-circumscribed character of this tumor and its white fibrous cut surface are well illustrated.

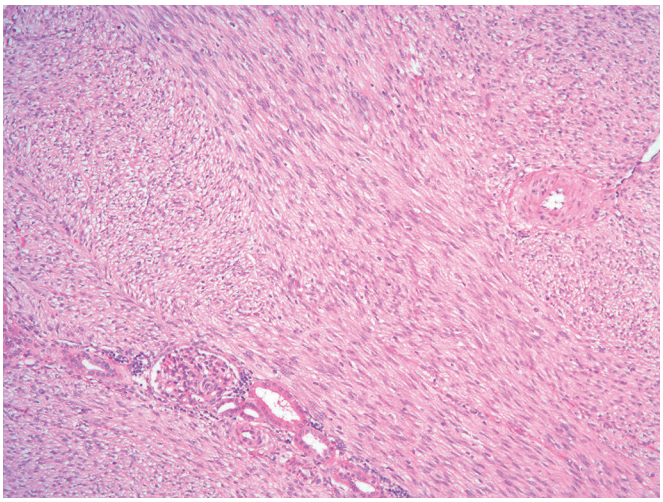

Figure 24.7 Congenital Mesoblastic Nephroma, Classic Type. Microscopic appearance showing a monotonous proliferation of spindle cells with bland nuclei, resembling fibromatosis.

of cytologically bland, elongated spindle cells (Fig. 24.7).[147] There is typically fine intracellular collagen imparting a light eosinophilic appearance. Tubules and glomeruli (sometimes exhibiting hyperplastic or metaplastic changes) may be entrapped by the spindle tumor cells. Small islands of hyaline cartilage and foci of extramedullary hematopoiesis may be present. There is no capsule separating the tumor from the uninvolved renal parenchyma.

Cellular congenital mesoblastic nephroma is comprised of more densely cellular plump spindle cells with larger nuclei, resembling infantile fibrosarcoma (Fig. 24.8).[148,149] They are mitotically active, have a tendency to infiltrate the renal pelvis or perirenal tissue, and may contain areas of hemorrhage and necrosis.[150] When classic and cellular patterns coexist, the tumors are designated as mixed.

Immunohistochemically, the neoplastic cells often show expression of smooth muscle actin, while desmin staining is rare. CD34 is typically negative.

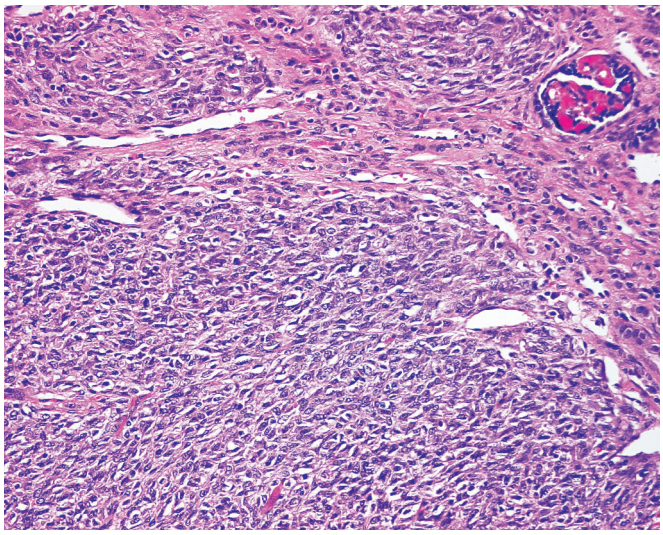

Figure 24.8 Congenital Mesoblastic Nephroma, Cellular Type, Accompanied by Mitotic Activity. An entrapped glomerulus is present in a corner. Some of these tumors behave in an aggressive fashion.

Congenital mesoblastic nephromas lack the abnormalities in chromosome 11 that characterize Wilms tumor and are associated instead with polysomies for chromosomes 8, 11, 17, and 20.[151-153] Cellular congenital mesoblastic nephroma contains the t(12;15)(p13;q25) translocation, which results in the *ETV6–NTRK3* gene fusion, the latter being detectable in paraffin-embedded material.[154] This gene fusion is not found in classic mesoblastic nephroma.[154,155] It appears that the occurrence of gene fusion antedates acquisition of chromosomal polysomies.[152] The sharing of the same genetic abnormality between cellular congenital mesoblastic nephroma and infantile fibrosarcoma supports the notion that these two tumors represent a single neoplastic entity.[152] Most mixed congenital mesoblastic nephromas lack the ETV6 fusion.[156]

The large majority of congenital mesoblastic nephromas are cured following nephrectomy.[157] Therefore, radiation therapy or chemotherapy is not indicated. In up to 7% of the cases, recurrence with local invasion of retroperitoneum will occur and may prove fatal.[148,158] Cases associated with distant metastases to lung and brain have rarely been reported[159,160]; most of these aggressive tumors have had atypical morphologic features.[148,161] Beckwith and Weeks[162] have pointed out that in all but one of the recurrent congenital mesoblastic nephromas the patients were over 3 months of age at the time of the original nephrectomy; they believe that age at diagnosis and adequacy of excision may be more important prognostic factors than the morphologic features of the tumor. In a recent series, stage III cellular congenital mesoblastic nephromas in patients aged 3 months or older were particularly prone to develop local recurrences.[163]

Clear Cell Sarcoma

Clear cell sarcoma, formerly known as bone-metastasizing renal tumor and not to be confused with clear cell sarcoma of soft tissue, is a distinctive renal malignancy.[142,164-166] It comprises approximately 4% of childhood renal tumors; its incidence peaks during the second year of life. Isolated cases have been described in adults[167,168] and in association with familial colonic polyposis.[169] Grossly, the tumor tends to be large, sharply outlined, and centered in the medullary or mid region of the kidney. They have a homogeneous cut surface of light brown-to-gray color and myxoid appearance

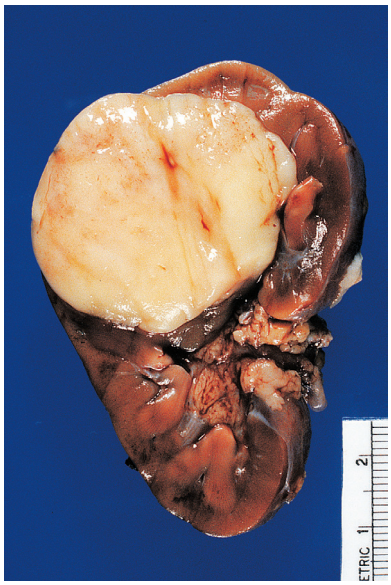

Figure 24.9 Gross Appearance of Clear Cell Sarcoma of Kidney. The tumor is well circumscribed and whitish, and it bulges on the cut surface.

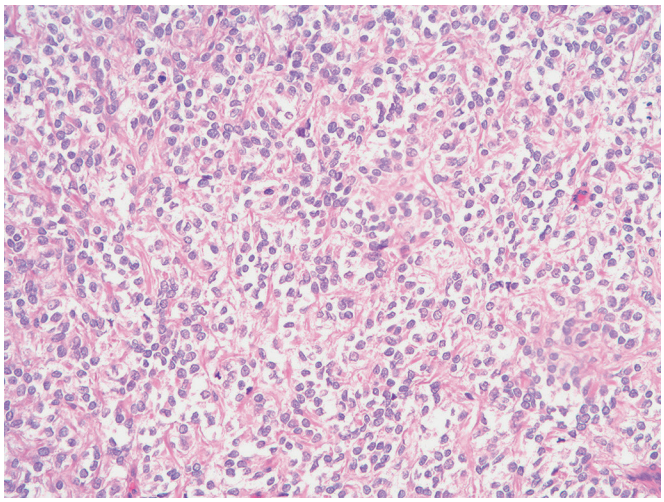

Figure 24.10 Clear cell sarcoma of kidney, prototypical appearance.

(Fig. 24.9). The consistency is usually hard, and cystic formations are common.

Microscopically, the most common pattern is that of a diffuse growth of relatively small cells with round normochromatic nuclei, inconspicuous nucleoli, light-staining (sometimes vacuolated) cytoplasm, and indistinct cell margins (Fig. 24.10); however, the morphology is very heterogeneous. Despite the tumor name, clear cytoplasm is a prominent feature in only 20% of the cases. Nuclear grooves are common, and mitoses are infrequent. The fibrovascular stroma may result in arrangements of the tumor cells in nests, palisades, cords, or trabeculae (Fig. 24.11). The latter should not be confused with the tubules or the serpentine arrangement of Wilms tumor. Myxoid changes, fibrosis, and hyalinization may be present, the appearance of the hyalinized tissue sometimes simulating osteoid (Fig. 24.12). Cysts may result from dilation of entrapped tubules or from stromal degeneration. It has been remarked that the distinctive alveolar and arborizing vascular stroma is a more reliable diagnostic

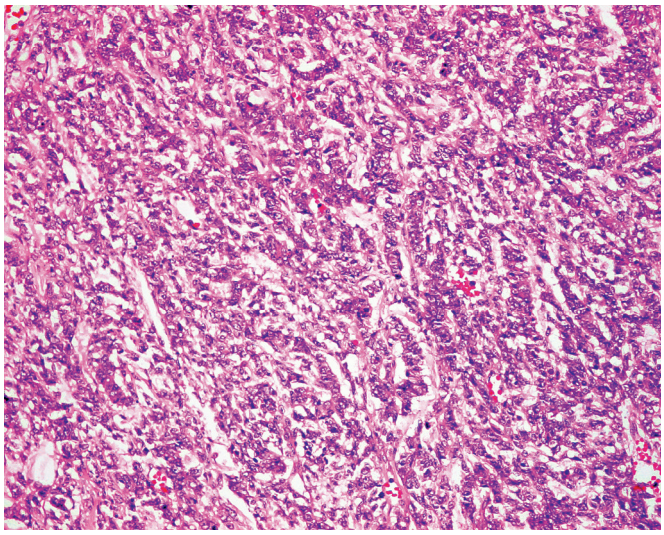

Figure 24.11 Clear cell sarcoma of kidney, trabecular pattern of growth.

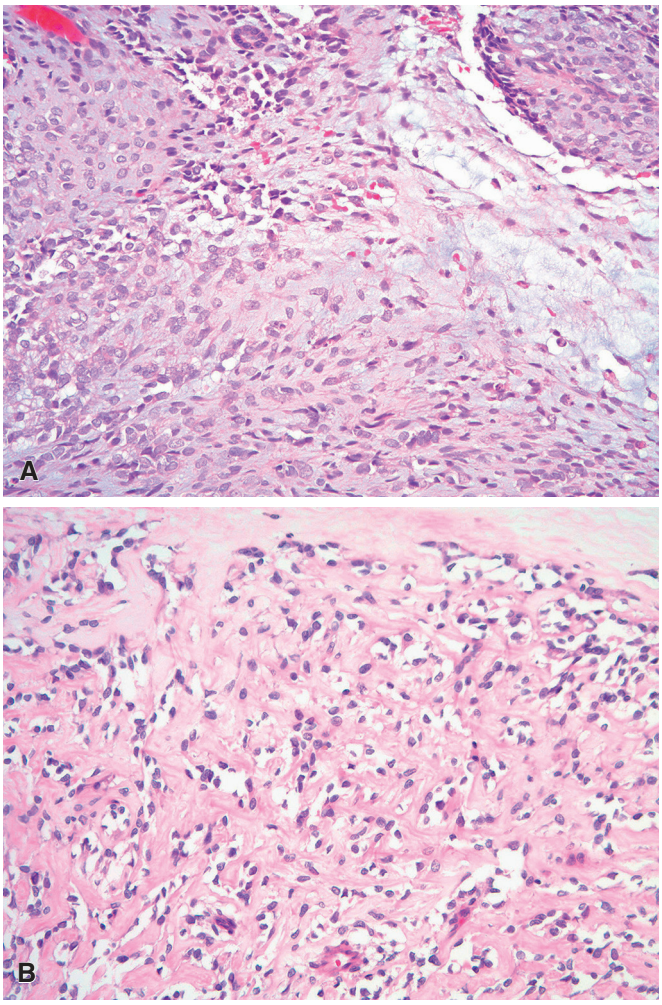

Figure 24.12 Clear Cell Sarcoma of Kidney. A, Myxoid pattern. **B,** Sclerotic pattern.

feature than the clear cells or the sclerosis.[170] As many as nine histologic patterns of this tumor have been described, that is, classic, myxoid, sclerosing, cellular, epithelioid, palisading, spindle, storiform, and anaplastic.[171]

Clear cell sarcoma of kidney has recently been shown to harbor two main, and mutually exclusive, genetic events: somatic internal tandem duplication within the *BCOR* gene sequence (approximately 85%) and YWHAE-NUTM2 fusion (approximately 10%).[172-175] A small subset of cases harbor neither event.[172] These genetic features, as well as typical patient age and histology, are shared by a subset of extrarenal undifferentiated round cell sarcomas of infancy,[176] suggesting a close relationship that was first noted histologically and ultrastructurally in 1991.[177] Immunohistochemistry has historically not been helpful in confirming the diagnosis of clear cell sarcoma of kidney, but they are usually PAX8 negative.[67] A new commercially available BCOR antibody has high sensitivity and specificity for clear cell sarcoma of kidney (and the other tumors harboring these same genetic events).[178] One caveat is that a rare subset of synovial sarcomas may show BCOR overexpression.[179]

Untreated clear cell sarcoma is a very malignant tumor, with a high tendency for relapse and a propensity for skeletal metastases, particularly skull.[166] In this regard, it should be noted that skeletal metastases are extraordinarily rare in conventional Wilms tumors. Metastases of clear cell sarcoma also occur to regional lymph nodes, brain, lung, and liver. In contrast to Wilms tumor, these metastases tend to develop after long intervals following the removal of the primary tumor (5 years or more).

The overall survival rate in a series of 351 cases entered in a National Wilms Tumor Study (NWTS) trial was 69%. Multivariate analysis showed that treatment with doxorubicin, stage, age at diagnosis, and tumor necrosis were independent prognostic factors. Of note, stage I patients had a 98% survival rate.[171]

Rhabdoid Tumor

Rhabdoid tumor of kidney is a distinct aggressive malignancy that is part of a larger family of SMACRB1-associated neoplasms.[142,180] Most cases occur in young infants, the median age at diagnosis being 18 months; 80% occur before 2 years of age.[181] Some of the cases have resulted in hypercalcemia.[182,183]

Grossly, rhabdoid tumor is solid, soft, and relatively well circumscribed. Microscopically, it is a monomorphic neoplasm that always involves the medullary region and has a generally diffuse but sometimes alveolar or trabecular pattern of growth. The tumor cells are medium sized and generally round or oval with vesicular nuclei and prominent nucleoli and indistinct cell borders (Fig. 24.13). However, they can also be spindled, prompting the possibility of confusion with mesoblastic nephroma or clear cell sarcoma. The most characteristic feature is the presence of a large cytoplasmic eosinophilic hyaline globule that displaces the nucleus laterally to result in a plasmacytoid or rhabdomyosarcomatous appearance (Fig. 24.14). Ultrastructurally, this globule is made up of a tangle of intermediate filaments.[184] Immunohistochemically, there is strong reactivity for vimentin and usually also for keratin, but generally not muscle (i.e. myogenin) or neural markers. It should be remarked that focal rhabdoid features resulting from accumulation of cytoplasmic filaments can be seen in many other renal tumors, including Wilms tumor, mesoblastic nephroma, and RCC.[185] Loss of immunohistochemical expression of SMARCB1 (INI1/hSNF5/BAF47) is a feature of great help in the differential diagnosis with other pediatric small cell tumors.[186,187] This results from biallelic alteration (deletion or mutation) of the *hSNF5/INI1* locus at chromosome 22q11.2.[188] Rare tumors retain SMARCB1 expression due to an alternative mutation in SMARCA4/BRG1. In about 15% of the cases, renal rhabdoid tumor is associated with primary atypical teratoid/rhabdoid tumors in the posterior fossa, and those patients typically harbor germline mutations in SMARCB1.

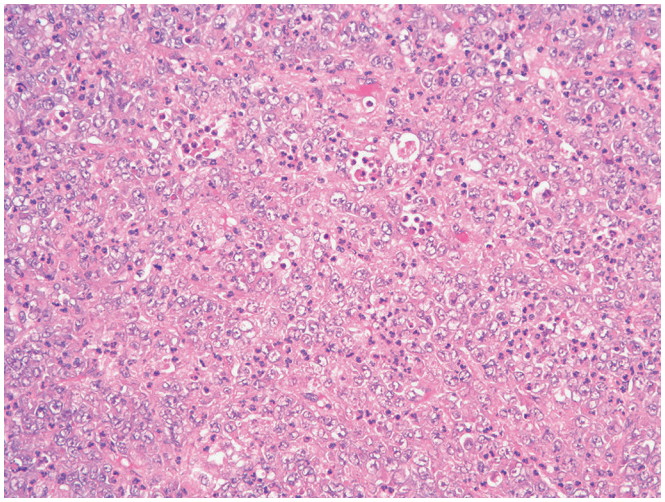

Figure 24.13 Rhabdoid Tumor of Kidney. Syncytial sheets of highly atypical cells, often with admixed inflammation.

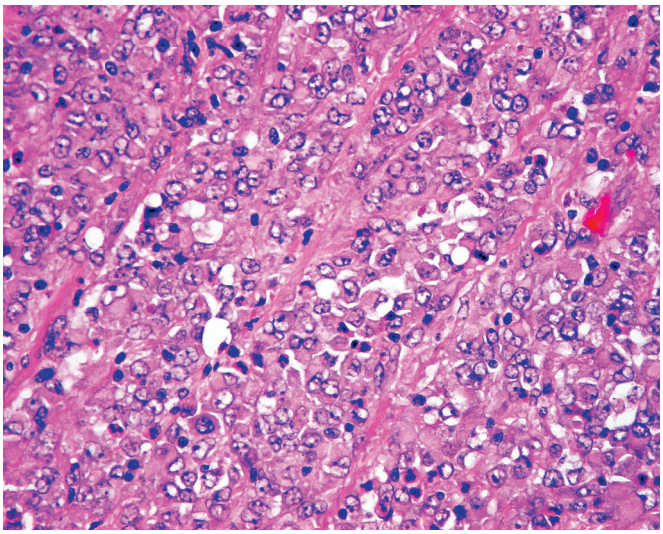

Figure 24.14 Rhabdoid Tumor of Kidney. The nuclear grade is high. An eosinophilic amorphous ("hyaline") material fills the scanty cytoplasm and pushes the nucleus aside.

The behavior is extremely aggressive, even when occurring in young infants. The death rate is over 75%. High tumor stage and male sex are unfavorable prognostic signs.[185]

Tumors morphologically, immunophenotypically, and genetically indistinguishable from rhabdoid tumor of kidney have been reported in many other anatomic sites.[189-191]

Rhabdoid tumor of infantile kidney should not be equated to RCC with rhabdoid features (see later). Medullary carcinoma of the kidney may have significant histologic overlap with rhabdoid tumor, including loss of SMARCB1/INI-1 nuclear expression; however, patients with medullary carcinoma present at an older age and often have sickle cell trait. Many reported examples of rhabdoid tumor in patients over 5 years of age likely represent renal medullary carcinoma.[181]

Figure 24.15 Gross appearance of pediatric cystic nephroma involving most of the kidney.

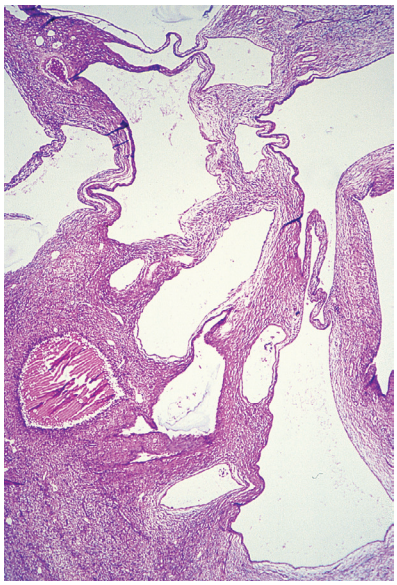

Figure 24.16 Low-power microscopic appearance of pediatric cystic nephroma showing multiple cysts lined by flattened epithelium and separated by a cellular spindle cell stroma.

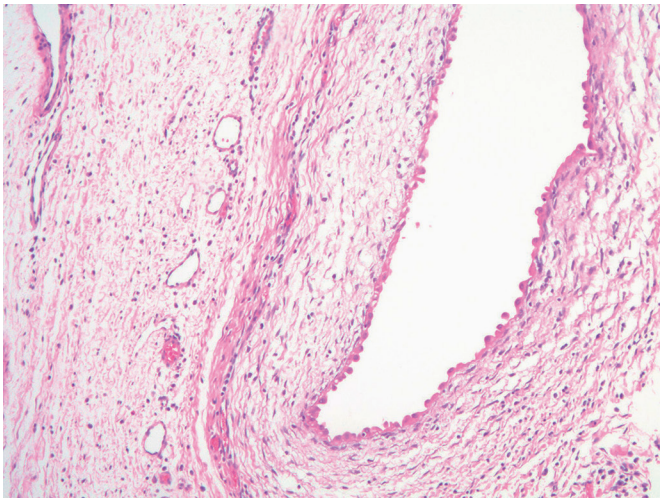

Figure 24.17 **Pediatric Cystic Nephroma.** The epithelial lining of the cyst has a hobnail quality and the stroma is loose and hypocellular.

Pediatric-Type Cystic Nephroma and DICER1 Renal Sarcoma

Pediatric cystic nephroma (multilocular cystic nephroma, multilocular cyst) is an uncommon but distinctive lesion that arises in early infancy.[192] While this diagnostic term has previously been applied to tumors in all age groups, the World Health Organization (WHO) recommends that the term be restricted to infants, given that those tumors are genetically distinct and may be associated with a tumor predisposition syndrome (i.e. germline mutation in DICER1).[193-195] Clinical manifestations result from the presence of a mass or, not uncommonly, from ureteral obstruction by one of the daughter locules.

Grossly, the lesion is usually solitary, unilateral, and sharply delineated from the uninvolved renal parenchyma.[196] The usual size range is between 5 and 15 cm, and the outer surface is coarsely nodular. The cut surface shows a multilocular appearance, the individual cysts measuring from 1 mm to 3 cm or more (Fig. 24.15). The wall of these cysts is thin and sometimes translucent and lacks papillary projections. The fluid within the cavity is usually serous. The cysts do not communicate with each other or with the pelvis. The remaining renal parenchyma is normal. Extension of the lesion beyond the renal capsule may occur.

Microscopically, there are cysts of varying caliber separated by a spindled stroma (Fig. 24.16). The cysts are lined by epithelium that ranges in height from columnar to extremely flat, resembling endothelium and simulating the appearance of lymphangioma. A "hobnail" pattern is common (Fig. 24.17). The stroma between the cysts usually has a fibroblastic, nondescript nature (sometimes immunoreactive for hormone receptors), with variable stromal condensation adjacent to the cyst lining (Fig. 24.18).[197] Small well-differentiated tubules may be seen, but the presence of nephroblastomatous elements would preclude the diagnosis of cystic nephroma. As noted, many pediatric cystic nephromas have underlying *DICER1* mutations,[192] explaining their reported association with pleuropulmonary blastoma.

Rarely, intrarenal spindle cell sarcomas are identified in pediatric patients and have been described under various names, including embryonal sarcoma and anaplastic sarcoma.[198-200] The location may be parenchymal or pelvicalyceal. Microscopically, the common denominator is a spindle cell component containing (either in a diffuse fashion or as multiple foci) varying levels of pleomorphism with some examples showing bizarre pleomorphic cells and atypical mitotic figures. Chondromatous and osteoid foci are sometimes present. Immunohistochemically, a haphazard pattern of reactivity is recorded; however, keratin stains are negative. An associated cystic component, sometimes with features of cystic nephroma, has been described.[201] The behavior has been very aggressive.[198] The overall appearance of this tumor resembles pleuropulmonary blastoma of childhood, of which it may represent the renal counterpart. Recent studies have supported this histologic impression, showing frequent *DICER1* mutations and proposing a genetic pathogenesis of cystic nephroma and *DICER1*-renal sarcoma that parallels type 1 to type II/III malignant progression in pleuropulmonary blastoma.[202]

Intrarenal Neuroblastoma

Neuroblastoma can invade the kidney secondarily from the adrenal or other retroperitoneal site, or it may initially present as a primary intrarenal tumor, and should be classified as outlined in the chapter

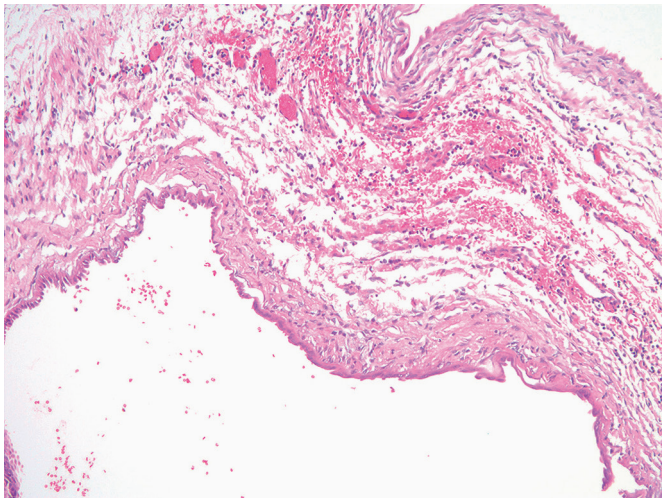

Figure 24.18 Pediatric Cystic Nephroma. The stroma shows subtle cellularity adjacent to the epithelium, which is more atrophic.

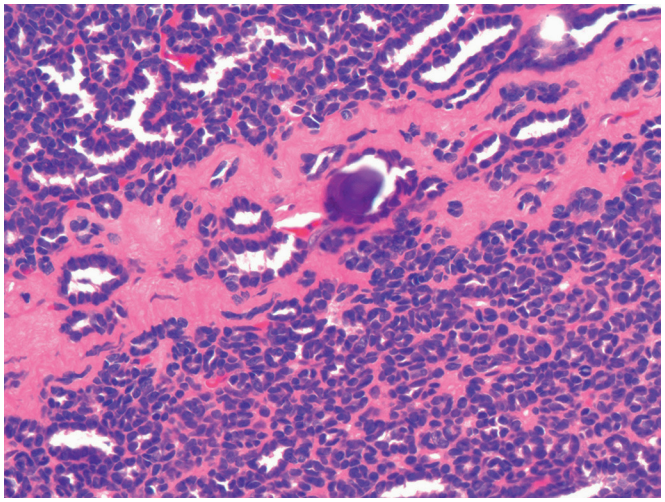

Figure 24.20 Metanephric Adenoma. The lesion is extremely cellular with a small tubular pattern.

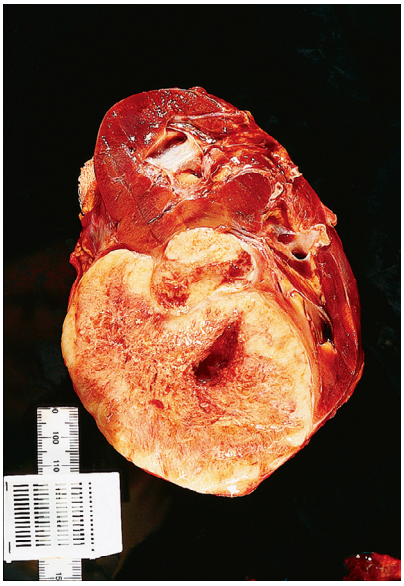

Figure 24.19 Gross appearance of Ewing sarcoma, primary in the kidney.

on adrenal pathology.[203] When intrarenal, a misdiagnosis of Wilms tumor is likely. This issue is further complicated by the fact that the embryonal tubules of Wilms tumor can simulate rosettes and that true neuroblastic elements can occur in Wilms tumor. Immunohistochemical and molecular genetic evaluation are of help in this differential diagnosis.[41,204]

Intrarenal Ewing Sarcoma

Ewing sarcoma can also occur as a primary renal mass.[205,206] Its morphologic, immunohistochemical, and molecular genetic features are analogous to those at other sites. Most patients are young adults, and the clinical course is very aggressive.[207] Many of the cases are centered in the medullary/pelvic region (Fig. 24.19). The main differential diagnosis is with blastema-predominant Wilms tumor, from which it is distinguished by its positivity for CD99 and its (usual) negativity for WT1.[205] Ideally, the diagnosis should be confirmed by the demonstration by cytogenetics, fluorescence in situ hybridization (FISH), or reverse transcriptase-polymerase chain reaction (RT-PCR) of the t(11;22) translocation involving *EWSR1*.[208,209]

The initial analysis of 146 cases of primary malignant "neuroepithelial" tumors of the kidney from the NWTS Pathology Center files[210] and a subsequent review of additional cases[205] led the authors to the frustrating conclusion that these represent a diverse group of high-grade tumors which are not always easy to place in a specific category, even after their evaluation with immunohistochemical and molecular genetic tools. We would recommend keeping the diagnosis of Ewing sarcoma pure by requiring molecular confirmation. In our opinion, unusual tumors that do not fit into the Ewing sarcoma family, and for which other specific diagnostic categories are excluded (e.g. Wilms tumor), are best reported descriptively under terms such as "malignant neoplasm with neuroectodermal (or neuroepithelial) differentiation."

Rarely, other undifferentiated round cell sarcomas have been reported in the kidney, such as those associated with CIC-DUX4 fusion.[211,212]

Intrarenal Synovial Sarcoma

Synovial sarcoma, which is histologically and genetically identical to its soft tissue counterpart, may rarely occur in the kidney.[213,214] It is important to note that there are variable reports of PAX-8 expression in synovial sarcoma, some reporting reactivity in the spindle cells and some in glands (which may simply represent entrapped renal tubules).[67,215,216]

Metanephric Tumors

Metanephric adenoma tends to occur in young or middle-aged female patients. While more common in adults, metanephric adenoma is described here to include the related forms with a stromal component, which are more common in children. Grossly, they are solid and tan to gray in color. Microscopically, they are mostly composed of tightly packed small back-to-back tubules with minute lumina accompanied by very scanty stroma (Figs. 24.20 and 24.21).[217-219] More elongated branching tubules and areas with papillary architecture are not uncommon. The neoplastic cells are small and basophilic with almost no cytoplasm; nuclear features are bland. The overall appearance is very reminiscent of developing metanephric tubular epithelium.[220] Psammoma bodies are very common and

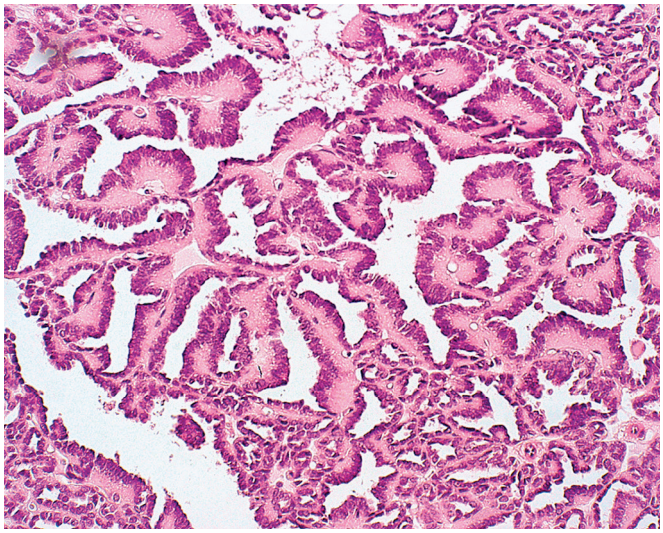

Figure 24.21 Papillary pattern of growth of metanephric adenoma.

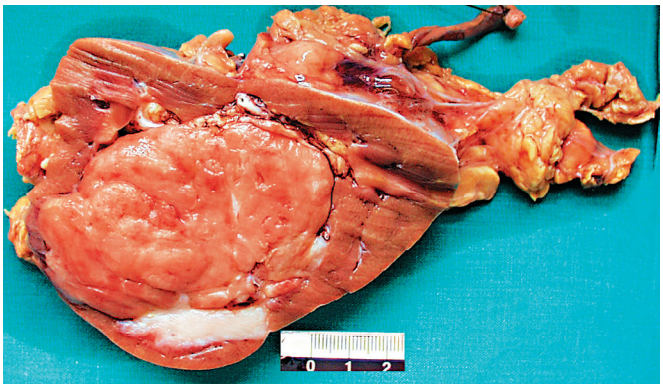

Figure 24.22 **Gross Appearance of Metanephric Adenofibroma.** The tumor is solid and vaguely nodular.

may be numerous. Secondary changes such as hemorrhage or cyst formation are common. Some of these features are also apparent on cytologic examination.[221]

Immunophenotypically, metanephric adenomas express both nuclear PAX8 and WT1, and cytoplasmic CD57 staining is common.[222] CK7 is negative or only focally positive. Genetically, approximately 90% have BRAF V600E mutations,[223] and BRAF immunohistochemistry (diffuse cytoplasmic staining) may serve as a surrogate marker.[224,225] The genetic features indicative of Wilms tumor and papillary RCC are absent.

The behavior of metanephric adenoma is benign.

Metanephric stromal tumor is a recently described pediatric renal neoplasm, occurring primarily in early childhood. It typically presents grossly as a fibrous lesion centered in the renal medulla that contains smooth-walled cysts. Microscopically, the neoplastic cells are spindle shaped, but admixed epithelioid features occur. The tumor entraps native renal tubules and blood vessels with onion-skin cuffing and myxoid change around each of the structures. Juxtaglomerular cell hyperplasia may also be seen within entrapped glomeruli (which may be associated with hypertension). There may be heterologous differentiation in the form of glia or cartilage and various types of associated vascular alterations (i.e. angiodysplasia). Immunohistochemically, most cases are reactive for CD34. Surgical excision is curative.[226]

Metanephric adenofibroma is a biphasic tumor in which an epithelial component similar to that of metanephric adenoma is intimately admixed with a bland spindle cell stroma similar to that of metanephric stromal tumor (Fig. 24.22).[227,228] Ages range from 1 to 36 years, but the mean is 7 years. The spindle cell component commonly expresses CD34 and entraps normal renal structures. The epithelial component has similar morphology and immunophenotype to metanephric adenoma. In some reported cases, part of the epithelial component was indistinguishable from that of Wilms tumor and in others it closely resembled papillary RCC.[227] The behavior of typical metanephric adenofibroma is benign.

Renal Cell Carcinoma

While **MiT family translocation RCCs** represent the most common RCC subtype in children, they are fully described in the adult renal neoplasia section since they are more commonly seen in that setting (due to much higher incidence of RCC in adults). Most other subtypes of renal cell carcinoma have also been reported in children and young adults.

Other Pediatric Tumor Types

Isolated examples of pediatric neoplasms not clearly belonging to any of the previous categories have been described. They include *ossifying renal tumor of infancy* (presenting as a calcified mass in the renal pelvis and composed of spindle cells in a partially calcified osteoid matrix),[229] *intrarenal teratoma* (to be distinguished from teratoid Wilms tumor),[230] intrarenal pure *yolk sac tumor*,[231] and desmoplastic small round cell tumor.[232-234]

Adult Tumors and Tumorlike Conditions

Renal Cell Carcinoma

General Features

RCC is generally a tumor of adults (average age at diagnosis: 55–60 years).[235] Many of the RCCs occurring in children have an appearance and behavior equivalent to those developing in adults,[236-239] but a high percentage belong to the MiT family translocation types.[240,241] The male to female ratio of adult RCC is about 2:1, and the incidence of bilaterality is 1%. Cigarette smoking and high blood pressure are said to increase the risk for development of the disease.[242] The list of diseases, hereditary and non-hereditary, that are associated with increased risk of RCC (including disease specific subtypes) continues to expand.[243]

Conditions that may be complicated by RCC are the following:

1. *von Hippel–Lindau (VHL) disease*. RCC occurs in 50% or more of individuals with this autosomal dominant syndrome, which is also characterized by the presence of CNS (usually cerebellar) and retinal hemangioblastomas; cysts of kidney, liver, and pancreas; clear cell tumors in a variety of sites (including inner ear and paratestis); and pheochromocytomas.[244,245] RCCs (of the clear cell subtype) in these patients tend to be multiple and associated with cysts, some of which show atypical changes in the lining epithelium.[246-248] The cysts, atypical cysts, and renal tumors of these patients have a similar immunohistochemical profile.[249] The VHL disease gene, called *VHL*, has been identified at chromosome 3p25.5. This tumor-suppressor gene is mutated in the germline of affected individuals, and in VHL-associated RCCs it is associated with a subsequent deletion of *VHL* in the wild-type allele. The marked degree of vascularization that often accompanies RCC (and other VHL-defective tumors, such as

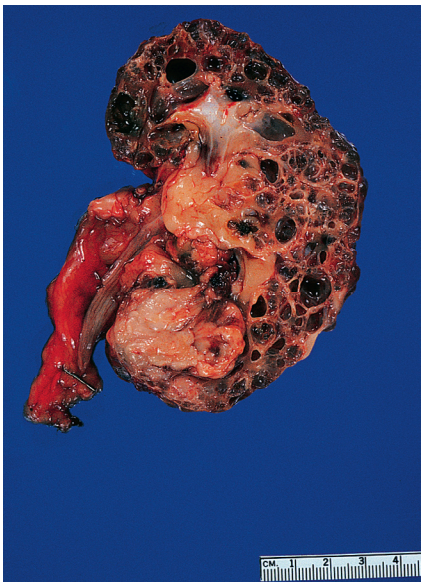

Figure 24.23 Renal Cell Carcinoma Developing in the Adult Form of Polycystic Kidney Disease. The tumor was multicentric.

cerebellar hemangioblastoma) is probably explained by the tumor's overproduction of hypoxia-inducible factor and its targets, such as vascular endothelial growth factor (VEGF), platelet-derived growth factor (PDGF), transforming growth factor alpha (TGF-α), and erythropoietin.[250] Microscopically, a small subset of clear cell RCCs associated with VHL disease have some features reminiscent of clear cell–papillary RCC.[251] Additionally, the background kidney parenchyma may contain multiple microscopic clear cell "tumorlets."

2. *Acquired cystic disease of the kidney*. Approximately 30%–40% of patients on long-term dialysis develop an acquired form of polycystic renal disease,[252] and 3%–7% of these are complicated by the appearance of RCC.[253] Atypical cysts with papillary hyperplasia of the lining epithelium is a consistent feature in these cases and the likely pathogenetic basis for tumor development.[253] While any subtype may be seen in this setting, a subset has unique morphologic, immunohistochemical, and molecular genetic features described later (see section "Acquired Cystic Kidney Disease Associated Renal Cell Carcinoma").[254]
3. *Adult form of polycystic kidney disease* (Fig. 24.23). As with the preceding entity, the carcinoma in these cases is accompanied and probably preceded by atypical cysts that begin as foci of papillary epithelial hyperplasia.[255] The tumors are frequently multifocal/bilateral and often have papillary or clear cell morphology.[256]
4. *Birt-Hogg-Dubé syndrome (germline folliculin mutation)* is characterized by a constellation of findings that include skin adnexal tumors (fibrofolliculoma), basilar pulmonary cysts with frequent spontaneous pneumothorax, and renal neoplasia.[257] The renal tumors are often oncocytic and include oncocytoma, chromophobe RCC, and hybrid oncocytic tumors.[258] The hybrid tumors may have a unique appearance with a so-called checkerboard pattern characterized by alternating eosinophilic and clear cells; however, unlike chromophobe RCC, the nuclei are small and almost pyknotic while the cytoplasm is somewhat vacuolated. The background kidney parenchyma may also show renal oncocytosis.[259]
5. *Hereditary leiomyomatosis and RCC syndrome (germline fumarate hydratase mutation)* is autosomal dominant and characterized by the presence of cutaneous and uterine leiomyomas and RCCs. These renal tumors are now regarded as a specific subtype of RCC (i.e. HLRCC associated [or fumarate hydratase deficient] RCC).[260,261]
6. *Hereditary paraganglioma syndrome (germline succinate dehydrogenase mutation)*. Patients are predisposed to paragangliomas, renal neoplasms, pituitary adenomas, and a unique type of gastrointestinal stromal tumor (GIST). Recent studies have shown that the renal tumors represent a distinct subtype, described later as "SDH-deficient RCC."[262-264]
7. *Tuberous sclerosis*. Although the classic renal tumor associated with this neurocutaneous syndrome is angiomyolipoma (AML), RCCs may be encountered, sometimes seen in intimate connection with the former.[265,266] While cases of oncocytoma have been described in this setting, the main RCC subtypes seem identical to sporadic tumors classified as "eosinophilic solid and cystic (ESC)," "RCC with angioleiomyomatous stroma," and a heterogeneous spectrum of oncocytic tumors resembling either chromophobe RCC or hybrid oncocytic tumors (further described under individual RCC subtypes later).[265-267]
8. *Neuroblastoma*. Several cases of RCC developing in children previously treated for neuroblastoma have been reported; however, this seems to be a heterogeneous group of tumors that include post-therapy–related MiT family translocation carcinomas, sporadic type RCCs, and a unique renal neoplasm with "oncocytoid" features that, in our opinion, shares some features with the recently described "ESC" RCC.[268,269]
9. *PTEN Hamartoma Tumor Syndrome (germline PTEN mutation)* is the molecular diagnostic term used for the disorders that include Cowden syndrome, Bannayan-Riley-Ruvalcaba syndrome, and a spectrum of other clinical presentations. This syndrome is rarely associated with RCCs with a papillary, clear cell, or chromophobe morphology.[270,271]
10. *Hereditary papillary RCC syndrome* is associated with a germline mutation in the *MET* gene. It predisposes to type 1 papillary RCCs, which may number in the hundreds.
11. *Hemoglobinopathy* (most commonly sickle cell trait) is associated with two types of RCC that occur a young age, renal medullary carcinoma and the extremely rare *VCL-ALK* fusion associated renal neoplasm.
12. Other rare syndromes with an increased risk of renal neoplasia are described, such as BAP1 tumor predisposition syndrome and MiTF-associated cancer syndrome.

Clinical Features

RCC usually presents with hematuria (59%), flank pain (41%), or as an abdominal mass (45%). However, the combination of these three features, classically regarded as the diagnostic triad of RCC, occurs in only 9% of the patients.[272] Other manifestations are weight loss (28%), anemia (21%), fever (7%), and symptoms caused by a metastatic deposit (10%). Rare systemic/paraneoplastic manifestations include leukemoid reaction, systemic amyloidosis, polyneuromyopathy, gastrointestinal disturbances, hepatosplenomegaly, hypercalcemia, polycythemia, and hepatic dysfunction.[273-282]

In general, the investigation of a suspected renal mass begins with CT scan or MRI.[283] With the increasing use of these modalities, the number of incidentally detected RCCs has increased substantially.[284,285] In expert hands, core needle biopsy has been shown to provide adequate diagnostic material in about 80% of the cases.[286] Many centers proceed directly to partial nephrectomy without biopsy in surgical candidates; however, as active surveillance of renal mass lesions and local ablation techniques gain acceptance, biopsy rates will likely increase.[287]

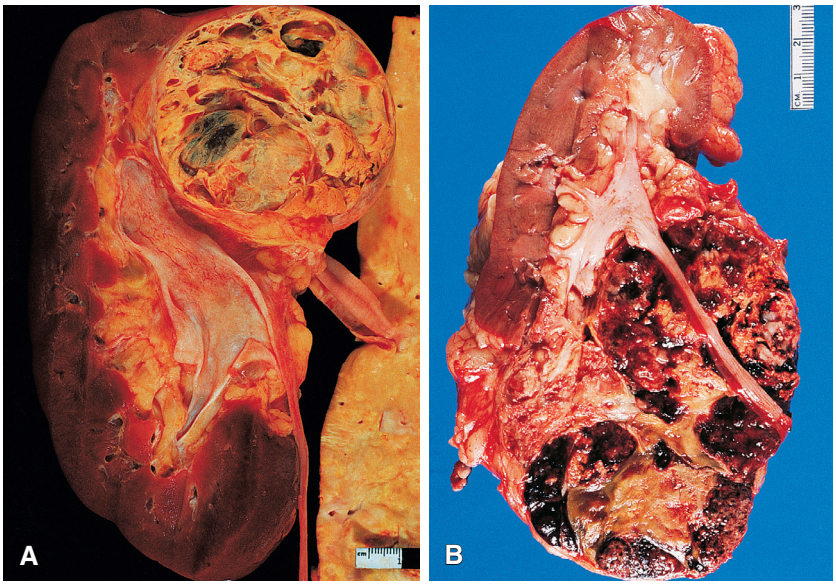

Figure 24.24 Gross Appearances of Renal Cell Carcinoma. Both tumors are relatively well circumscribed and variegated, with a combination of cystic, solid, and hemorrhagic areas. The tumor shown in **A** has a bright yellow color, whereas that portrayed in **B** has extensive areas of hemorrhage.

Subtypes of Renal Cell Carcinoma

Subtyping of RCC has become increasingly complicated since the modern classification was proposed in 1997.[288,289] Diagnosing specific subtypes is important because each has distinct underlying molecular correlates, unique immunophenotypes, varying biologic potential for aggressive behavior, emerging therapeutic implications, and in some cases important predisposition information for family members.[290,291] Therefore, each of the specific RCC subtypes is discussed separately to include histology, immunohistochemistry, and any known genetic features.

Clear Cell Renal Cell Carcinoma

Clear cell RCC is the most common type of RCC, accounting for 65%–70% of all renal cancers. Grossly, most clear cell RCCs are well delineated and centered on the cortex (Fig. 24.24). On occasion, only a small portion is connected with the cortex, the bulk of the tumor appearing as an extrarenal mass. Extension to the renal pelvis occurs only late in the course of the disease. In approximately 5% of the cases, multiple tumor nodules are seen scattered throughout the organ, but in some cases this may represent retrograde venous extension from the dominant tumor.[292,293]

In a typical case of clear cell RCC, the cut surface shows a solid, golden-yellow tumor, sharply separated from the surrounding tissues by a fibrous pseudocapsule. The common occurrences of hemorrhage, necrosis, calcification, and cystic change result in the variegated appearance that is so characteristic of this neoplasm (Fig. 24.25). On occasion, the cystic degeneration is so advanced that a mural nodule remains as the only evidence of the real nature of the lesion. Sometimes even this disappears, and the diagnosis is made only on microscopic examination.[294]

Microscopically, the tumor cells of clear cell RCC are relatively large, the appearance of the cytoplasm ranging from optically clear to deeply granular, with many transitional forms (Fig. 24.26).[295-298] The clear cell appearance of the tumor cells results from the accumulation of glycogen (because of abnormalities of carbohydrate metabolism)[299] and lipids. The nuclei are generally centrally located; their size, chromatin pattern, and nucleolar appearance vary notably from case to case, this constituting the main basis for microscopic grading (Table 24.3). In the usual case, the pattern of growth is predominantly solid, with formation of alveolar and acinar patterns of tumor cells separated by a stroma that is characteristically endowed with a prominent network of small, thin-walled blood vessels. This vascular pattern is an important diagnostic criterion, especially for cases with granular eosinophilic cytoplasm. Other patterns include tubular formation, microscopic and/or macroscopic cysts, associated intraluminal erythrocytes, and regression. Rarely, pseudopapillary architecture may be present. Tumors with extensive regression show large areas of edematous or collagenized stroma that contain a well-formed arborizing vasculature; in difficult cases, low-molecular-weight cytokeratin or EMA immunostains can highlight the subtle population of residual neoplastic cells that mimic histiocytes. Multiple sections usually show diverse patterns within

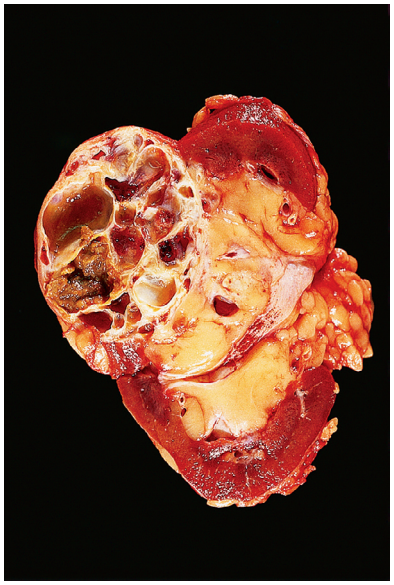

Figure 24.25 Renal cell carcinoma with multilocular gross appearance.

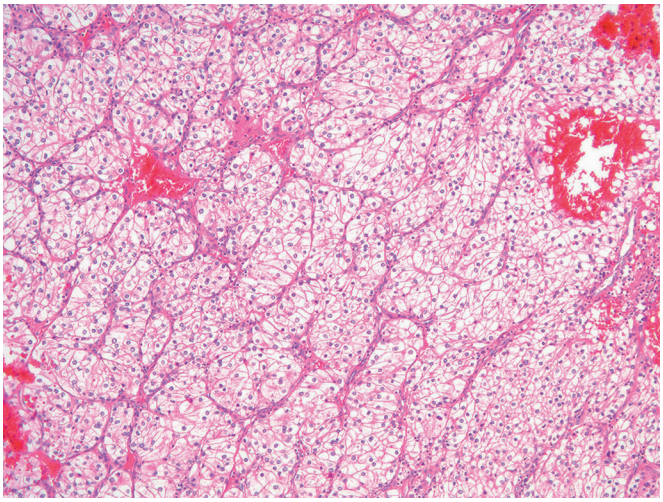

Figure 24.26 Renal cell carcinoma, clear cell type.

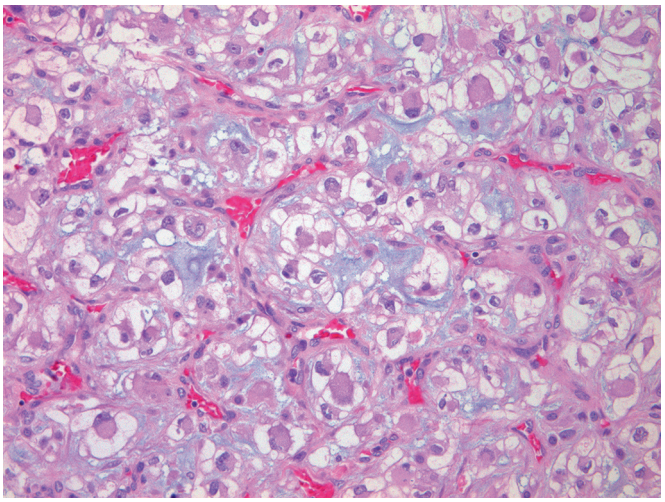

Figure 24.27 Renal cell carcinoma, clear cell type, with rhabdoid differentiation.

Table 24.3 World Health Organization/International Society of Urological Pathology Grading System for clear cell renal cell carcinoma and papillary renal cell carcinoma

GRADE	CRITERIA
1	Nucleoli are absent or inconspicuous and basophilic at ×400 magnification
2	Nucleoli are conspicuous and eosinophilic at ×400 magnification and visible but not prominent at ×100 magnification
3	Nucleoli are conspicuous and eosinophilic at ×100 magnification
4	Extreme nuclear pleomorphism and/or rhabdoid differentiation and or sarcomatoid differentiation

the same tumor. High-grade progression may lead to sarcomatoid and/or rhabdoid histologic patterns. Rhabdoid differentiation is characterized by abundant homogeneous eosinophilic cytoplasm and an eccentric nucleus; the background architecture may retain a nested pattern with associated blood vessels (Fig. 24.27) or undifferentiated sheet-like growth. The stroma of RCC is nondescript and, in general, not desmoplastic as typical of collecting duct carcinoma or urothelial carcinoma. A lymphocytic infiltrate of variable degree is often present.

Immunohistochemically, clear cell RCC shows reactivity for epithelial markers such as keratin and EMA. Coexpression of keratins and vimentin is the rule, a feature not present in normal tubular cells.[300,301] Other antigens detected in the cells of clear cell RCC are CD10,[302] carbonic anhydrase IX,[303,304] RCC marker, PAX-2[305] and PAX-8. With current antibodies, PAX-8 has higher sensitivity. Cytokeratin 7 expression, which may be used in the differential diagnosis of other renal neoplasms with clear cytoplasm, is typically rare in clear cell RCC and limited to a focal or patchy pattern of reactivity. It should be recognized that any epithelial cyst lining in the kidney may stain strongly for cytokeratin 7.

From the standpoint of differential diagnosis, the choice of the markers to use depends on the specific situation at hand (i.e. whether one is trying to decide to which subtype a given RCC belongs [to be discussed later] or whether a given clear cell carcinoma in an extrarenal site represents a metastasis of a RCC or not).[306] In regard to the latter, the most useful *positive* markers are the coexpression of keratin and PAX-8. It is, however, the *negative* markers that are of greatest use depending on the circumstance, to wit: (1) in the differential diagnosis with adrenal cortical carcinoma, the fact that clear cell RCC is negative for inhibin, MelanA, and SF-1[307,308]; (2) in the differential diagnosis with clear cell carcinoma of the ovary, the fact that clear cell RCC is usually negative for keratin 34βE12 and CK7[309-311]; (3) in the differential diagnosis with clear cell carcinoma of the thyroid, the fact that RCC is negative for thyroglobulin and TTF-1; (4) in the differential diagnosis with mesothelioma the fact that RCC is negative for calretinin, mesothelin, and CK 5/6,[312] and so forth.[313-317] While we generally find PAX-8 to be the most useful renal epithelial marker based on sensitivity and specificity, the number of tumors that may express PAX-8 must be carefully considered.[318] In addition, one must be aware of the possibility of cross-reactivity with other PAX epitopes when using a polyclonal antibody (e.g. cross-reactivity with PAX5 in B-cell lymphoma).

The notable feature of the genetic aspects of RCC is that there is a very close relationship with the various morphologic subtypes,[319,320] which can be investigated by conventional cytogenetics, PCR, FISH, microsatellite analysis, single nucleotide polymorphism (SNP) microarray, or sequencing techniques.[321-324] A distinctive abnormality found in most cases of clear cell RCC is alteration of the *VHL* tumor suppressor, either by a terminal deletion of the short arm of chromosome 3, beginning at 3p13,[325-334] silencing through promoter methylation, and somatic mutation. Since this abnormality does not characterize other types of RCC, its detection could be utilized to aid in differential diagnosis; however, this is rarely done in routine practice due to the different possible modes of *VHL* alteration. While the *VHL* gene on 3p25–26 is typically implicated (with inactivation of both copies), other tumor suppressor genes on 3p may also play a role, such as *KD-M6A*, *KMM5C*, *SETD2*, and *PBRM1*.[325,328,330,332,333,335-338] Mutations in *BAP1* have been associated with high-grade tumors and poor outcome. The molecular changes have shed light on the pathogenesis of some clinical and morphologic features of clear cell RCC, as well as provided the basis for the design of various targeted therapies. The VHL gene product is required for degradation of HIF-1α (hypoxia inducible factor α). With loss of VHL protein in clear cell RCC, HIF-1α accumulates, resulting in activation of a variety of

hypoxia-inducible genes and hence increased production of their products. These include VEGF, platelet-derived growth factor-B (PDGF-B), TGF-α, GLUT-1, metalloproteinases, and erythropoietin.[322,339,340] Furthermore, the AKT-mTOR pathway can also affect HIF-1α, since mTOR normally promotes translation of HIF-1α.[339] Targeted therapy may therefore utilize tyrosine kinase inhibitors for VEGF receptor and PDGF receptor (such as sunitinib and sorafenib), inhibitors for mTOR (such as temsirolimus), and/or antibodies targeting VEGF (bevacizumab).[322,339]

Clear cell RCC has a high rate of metastatic disease, sometimes years after initial diagnosis. Prognostic factors are discussed later in a separate section.

Papillary Renal Cell Carcinoma

Papillary RCC is the second most common subtype with series typically reporting that it accounts for 15% to 18% of all RCCs. Classification within this category continues to rapidly evolve. It has been proposed that papillary RCC can be further subdivided into two types: *type 1*, in which the papillae are lined by a single layer of cells with scanty pale cytoplasm; and *type 2*, in which the papillae are lined by a pseudostratified epithelium composed of cells with abundant eosinophilic cytoplasm, typically of higher nuclear grade.[341,342] Molecular studies have confirmed the type II category to be a very heterogeneous group of tumors, and one could argue that these should not be combined with type 1 in the classification scheme.[343]

Type 1 papillary RCC represents the prototypical papillary RCC. They are more likely than clear cell RCC to be localized to the kidney, but also more likely to be multicentric or bilateral.[344-346] Grossly, the tumors are often encapsulated and the cut surface has a tan-brown appearance; the intracystic papillary growth may mimic extensive necrosis. Microscopically, a thick fibrous capsule is typical, and the individual neoplastic cells line the inner layer of the capsule. Complex papillary formations fill the intracystic space (Fig. 24.28A), often accompanied by prominent stromal infiltration by neutrophils or foamy macrophages.[347,348] The neoplastic cells lining the papillae consist of a single layer of low cuboidal epithelium, often with little cytoplasm (see Fig. 24.28B). Psammoma bodies may be numerous and the nuclear grade is variable.[349,350] Other, histologic patterns of type 1 papillary RCC include solid growth, in which papillae are collapsed together (Fig. 24.29), and the "biphasic squamoid alveolar" pattern (Fig. 24.30). Papillary RCCs may undergo intratumoral hemorrhage and necrosis; intracytoplasmic hemosiderin deposition and cytoplasmic clearing are not uncommon in such foci. In fact, type 1 papillary RCC may undergo near complete infarction leaving only a thick fibrous capsule filled with necrosis and cholesterol granulomas. Numerous sections of the capsule will often reveal foci of residual viable tumor.

Immunohistochemically (and in contrast with clear cell RCC) there is strong expression of keratin 7 and AMACR in type 1 tumors.[351] According to this classification scheme, it is the type 1 tumors that have the underlying chromosome 7, 17, and Y abnormalities.[352-354] In contrast to clear cell RCC, there is no loss of 3p. Type 1 papillary RCC has a better prognosis than clear cell RCC.[344,355] In rare instances, type I papillary RCC is hereditary, associated with germline mutations of the *c-MET* oncogene, often presenting with hundreds of small tumors.[356]

Type 2 papillary RCC represents a heterogeneous collection of high-grade RCCs with papillary architecture (Fig. 24.31). Recent molecular studies have shown that MiT family translocation RCCs and RCCs associated with hereditary leiomyomatosis are frequently misclassified as "type 2" papillary RCC. Of the remaining type 2 tumors, different genetic subgroups include sporadic fumarate

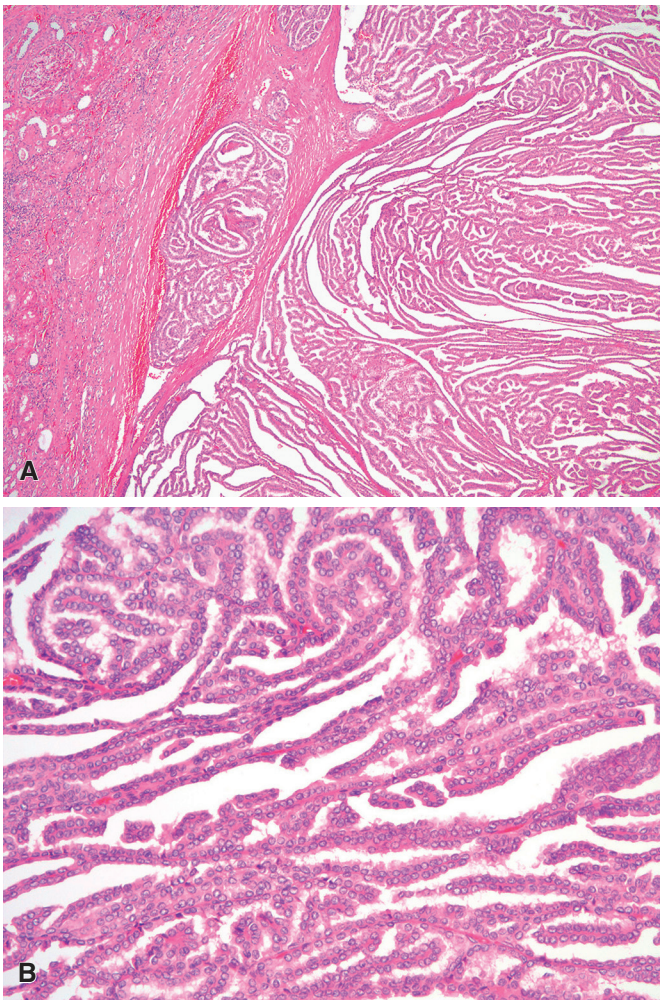

Figure 24.28 Renal Cell Carcinoma, Papillary Type 1. A, Typical thick fibrous capsule with papillary tumor filling a cystic space. **B,** Single cuboidal layer of cytologically bland cells.

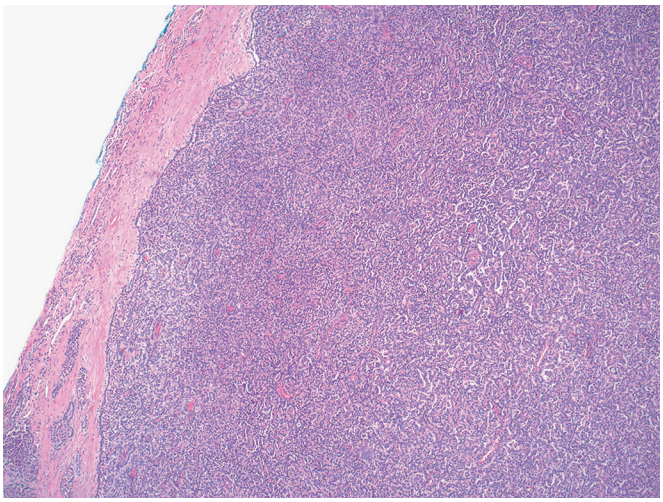

Figure 24.29 Renal cell carcinoma, papillary type 1, with solid growth.

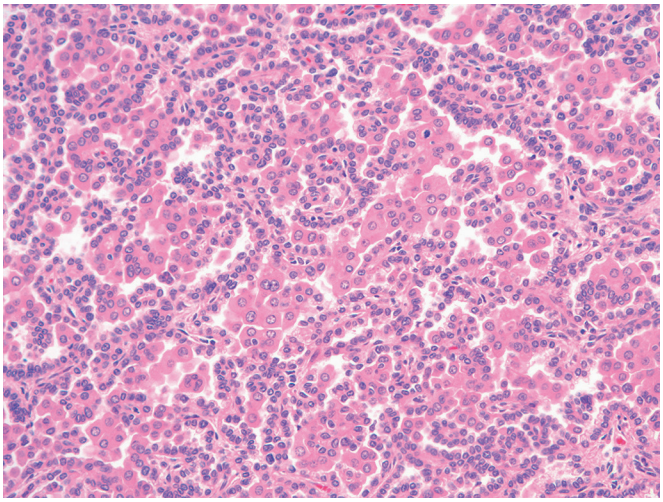

Figure 24.30 Renal cell carcinoma, papillary type 1, with so-called squamo-alveolar pattern.

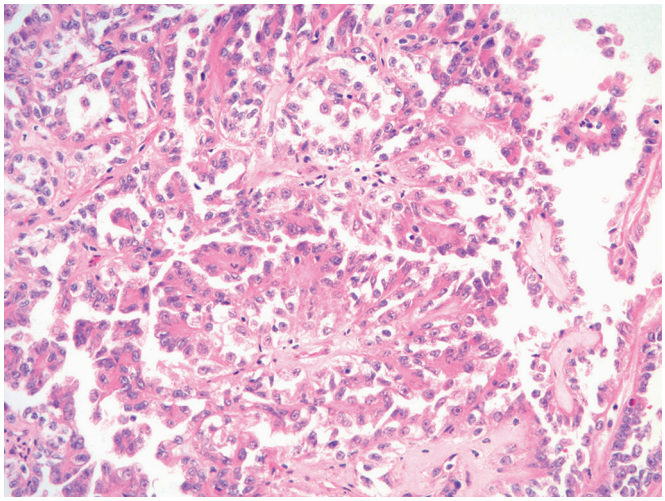

Figure 24.31 Renal cell carcinoma, papillary type 2.

hydratase mutation (i.e. not associated with hereditary leiomyomatosis), *CDKN2A* silencing mutation, *SETD2* mutation, *NF2* mutation (Hippo pathway tumor suppresser), and *NRF2-ARE*.[343] It is provocative that a subset of the studied carcinomas share alterations in the Hippo pathway with the "mucinous, tubular, and spindle cell carcinoma" of the kidney (which has known histologic and immunophenotypic overlap with papillary RCC), suggesting a close relationship in that subgroup. It is likely that the type 2 category will undergo changes as distinct molecular, and possibly morphologic, subtypes emerge.

Some papillary RCCs have mixed histologic features that are difficult to classify as either type 1 or type 2, but genetic and clinical outcome studies suggest a closer relationship to type 1 papillary RCC in many of these tumors[357,358]; grading and staging should be emphasized in such cases.

Another morphologic subset of cases is "oncocytic papillary carcinoma." These are not fully characterized, but often have a single layer of lower-grade round nuclei, and some show elevation of the nuclei off the basement membrane (i.e. reverse polarity).[359-361]

It should also be realized that papillary RCC (like all other types) can undergo anaplastic or sarcomatoid changes, but rhabdoid differentiation is uncommon.[362-364]

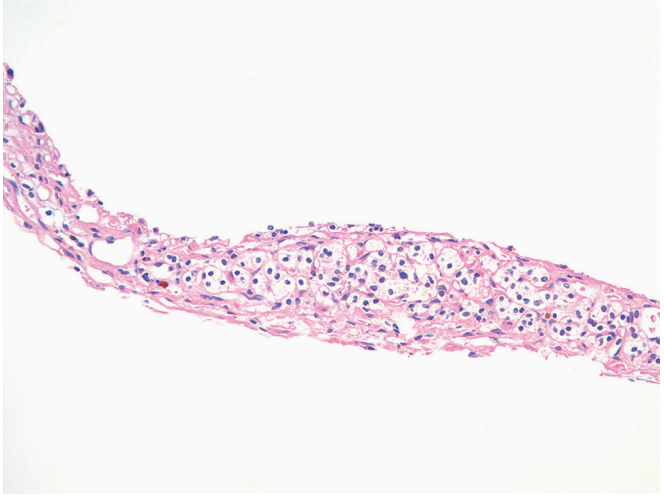

Figure 24.32 Multilocular cystic renal neoplasm of low malignant potential.

Multilocular Cystic Renal Neoplasm of Low Malignant Potential

These are rare macrocystic renal tumors, representing less than 1% of renal neoplasms, that are composed of thin septa without any macroscopic tumor nodules or expansile growth. Microscopically, the cysts are lined by a layer of clear epithelial cells, but the key diagnostic feature is the presence of small clusters of clear neoplastic cells in the thin walls of the septa (Fig. 24.32).[365] The presence of any solid nodules of tumor cells would warrant a diagnosis of clear cell RCC. Genetically, these tumors have 3p alterations similar to clear cell RCC, so they may simply represent an early phase of clear cell. When solid foci of tumor regression are present, the tumors are probably best diagnosed as clear cell RCC.[366] If diagnosed using strict histologic criteria with very close gross correlation, multilocular cystic renal neoplasm of low malignant potential follows a benign clinical course.[365] It is likely that staging has little prognostic value in these tumors.[367] The main differential diagnostic considerations are clear cell RCC, clear cell–papillary RCC, benign renal cortical cysts, and cystic nephroma (mixed epithelial and stromal tumor [MEST]).

Chromophobe Renal Cell Carcinoma

Chromophobe RCC comprises about 5% of all cases of RCC. It is grossly well circumscribed, solitary, with a homogeneous gray to brown cut surface, typically devoid of hemorrhage or necrosis (Fig. 24.33).[368] Microscopically, there is a characteristic broad "alveolar" arrangement of the tumor at low power, but some cases have smaller nests. There are two main histologies: classic (or "plant-cell") type and eosinophilic variant. In the classic type, the neoplastic cells have sharply defined borders and abundant cytoplasm with very prominent cell membranes (Fig. 24.34).[369] The cytoplasm has a pale, acidophilic quality, and there is often a vague clear perinuclear region.[370] The eosinophilic variant has more pronounced perinuclear clearing, but less prominent cell membranes (Fig. 24.35). Some cases have mixed features. Calcification is present in nearly half of the cases. The nuclear features, which are critical to diagnosis, are characterized by irregular nuclear membranes, hyperchromasia, and frequent binucleation. In our opinion, these specific nuclear features are both necessary and sufficient for classification as chromophobe RCC. Rare cases are associated with multicystic, microcystic, and adenomatous patterns of growth or neuroendocrine-like features (Fig. 24.36).[371-373] The characteristic cytoplasmic and nuclear features of

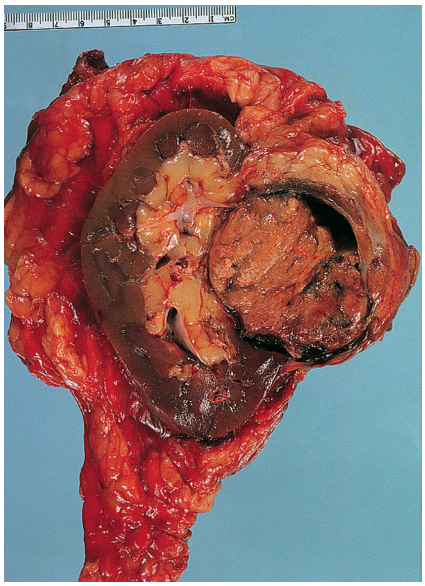

Figure 24.33 Gross Appearance of Renal Chromophobe Cell Carcinoma. The tumor is well circumscribed and has a light brown color.

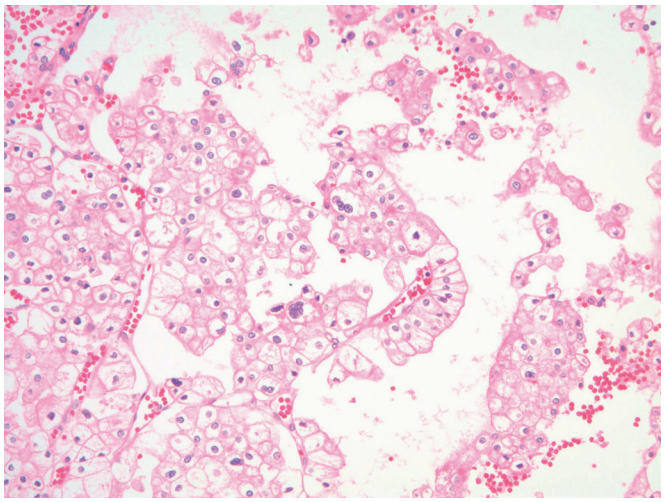

Figure 24.34 Chromophobe renal cell carcinoma, classic type, with thick cell membranes.

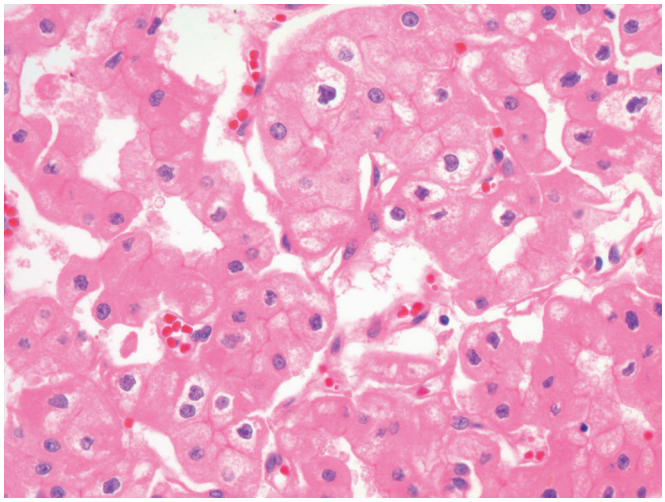

Figure 24.35 Chromophobe renal cell carcinoma, eosinophilic type, with prominent perinuclear halos.

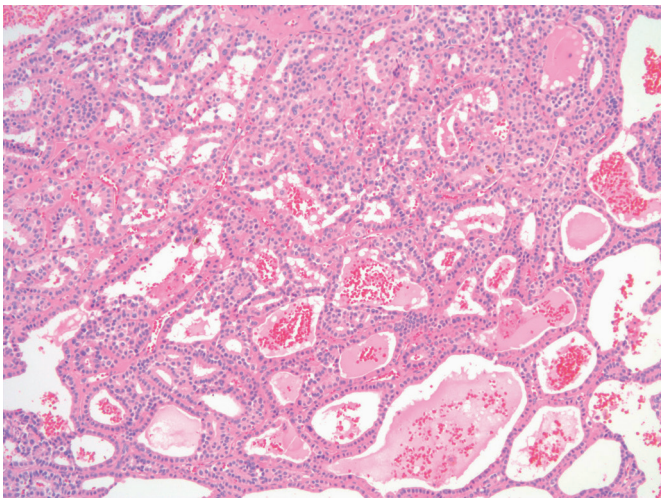

Figure 24.36 Chromophobe renal cell carcinoma, microcystic pattern.

the tumor can be recognized in fine-needle aspiration specimens and biopsies.[374,375]

This cytoplasmic appearance is due to the presence of numerous cytoplasmic microvesicles that are well appreciated by electron microscopy, but this is no longer employed for routine diagnosis.[376] These microvesicles stain for Hale colloidal iron; however, the stain is technically difficult to perform and we do not require its use.[368,377-379] The number of publications promoting the use of adjunctive immunohistochemistry in the distinction between chromophobe RCC and oncocytoma is overwhelming, to say the least. In our experience, the immunophenotype of cases with prototypical histologic features of chromophobe RCC can be much more heterogenous than would be suggested by the literature. Therefore, we rely almost exclusively on H&E morphology for this distinction (see section on renal oncocytoma for full discussion on the handling of "difficult to classify" cases). Based on a recent publication, even expert pathologists' use of immunohistochemistry and special stains in this setting varies quite dramatically.[380] With that caveat, chromophobe RCC is reported to commonly express EMA, CD117, keratin 7, CD9, CD82,[381] paxillin, parvalbumin,[382] claudin-7 and -8,[383,384] Ep-Cam (an epithelial adhesion molecule),[385] and E-cadherin, but not N-cadherin or vimentin.[386-389] A high percentage of chromophobe RCCs have been found to be immunoreactive for CD10 at least focally.[390] It should also be highlighted that, in contrast to most RCC subtypes, at least 20% of chromophobe RCCs are negative for PAX-8.[391,392]

Frequent loss of chromosomes 1, 2, 6, 10, 13, 17, and 21 has been found by comparative genomic hybridization[393] and microsatellite markers.[394,395] Other reported losses include chromosomes 3, 5, 8, 9, 11, 18, and Y. While the important work reported by The Cancer Genome Atlas (TCGA) revealed fascinating insights into the biology of chromophobe RCC, the molecular events were very heterogeneous, and a practical diagnostic marker was not identified.[396]

Chromophobe RCC can undergo sarcomatoid transformation; as a matter of fact, it may have a greater tendency to this event than many other types.[395,397] As a whole, the prognosis of chromophobe RCC is much more favorable than that of clear cell RCC, but distant metastases can develop (particularly liver), especially when the tumors are high stage at presentation.[398,399] The current consensus is that grade does not provide additional prognostic information for

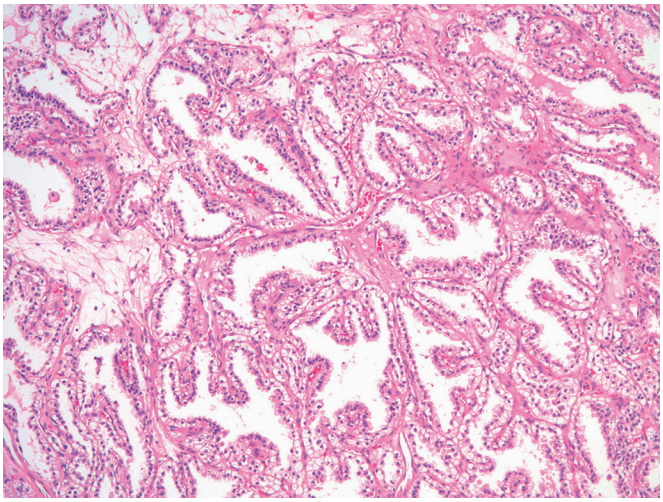

Figure 24.37 Clear cell–papillary renal cell carcinoma with predominant papillary architecture. The linear nuclear alignment and sub-nuclear cytoplasm are also evident.

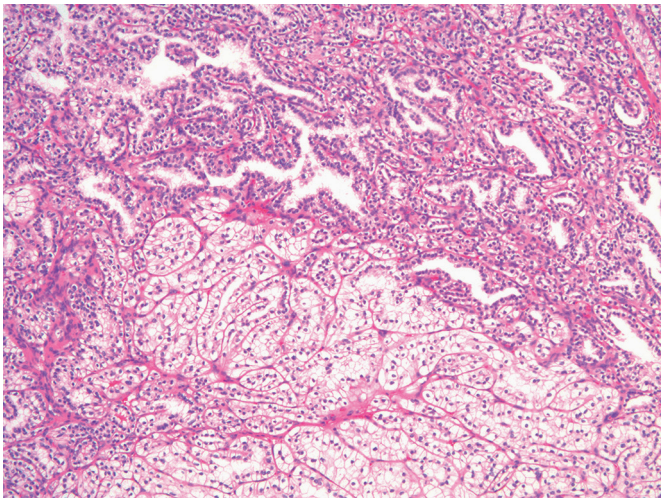

Figure 24.38 Clear cell–papillary renal cell carcinoma with mixed branching tubules and more solid clear cell pattern.

chromophobe RCC[400]; however, if sarcomatoid transformation has developed, the prognosis becomes very poor.

Clear Cell–Papillary Renal Cell Carcinoma

Clear cell–papillary RCC was first described by Tickoo et al. within a series of RCCs arising in end-stage kidney disease, but it is now recognized as more common in a sporadic setting.[401-403] In fact, two large studies have similarly shown that it represents the fourth most common RCC after clear cell, papillary, and chromophobe.[404,405] Grossly, clear cell–papillary RCC is circumscribed and often encapsulated. It may be solid, but is often cystic. Microscopically, cystic areas are lined by a single low cuboidal layer of clear cells with areas of papillary tufts lined by similar cells. More solid areas have an admixture of architectural patterns, including tubular, acinar, and nested. The clear cells are cytologically low grade (International Society of Urological Pathology [ISUP] nuclear grade 1–2), and there is frequently reverse polarity with subnuclear clearing and a linear arrangement of the nuclei (Fig. 24.37). The tubular pattern almost always shows branching. Solid and nested areas may have significant overlap with clear cell carcinoma, but the absence of the dense fibrovascular septa, the linear nuclear arrangement, and the presence of other architectural patterns aid in diagnosis as clear cell–papillary RCC (Fig. 24.38). Tumor cell necrosis and invasion of renal sinus vessels should be absent.

The capsule of the tumor may show smooth muscle metaplasia, but this should not change the classification as clear cell–papillary RCC if other features are typical. Such tumors were originally described as part of the spectrum of "renal angiomyoadenomatous tumor,"[402,406] but clear cell–papillary RCC is now considered distinct from "RCC with (angio)leiomyomatous stroma."

Immunophenotypically, these tumors show strong and diffuse immunoreactivity for cytokeratin 7. CD10 and racemase are typically negative, while CA-IX ("cup-like" pattern), PAX-8, and high-molecular-weight keratin are often positive. Nuclear GATA-3 expression has been recently reported.[407,408] When immunohistochemistry is needed, cytokeratin 7 often provides sufficient support to exclude clear cell subtype (which is negative or shows only focal staining); in fact, the absence of cytokeratin 7 staining should prompt careful reconsideration of a clear cell–papillary diagnosis. Cytokeratin 7 stains should be evaluated in solid foci because cyst-lining epithelial cells of many tumor types show strong immunoreactivity. Genetically, there is no specific finding in clear cell–papillary RCC, but they do not have the changes characteristic of either clear cell RCC or papillary RCC.[409-411]

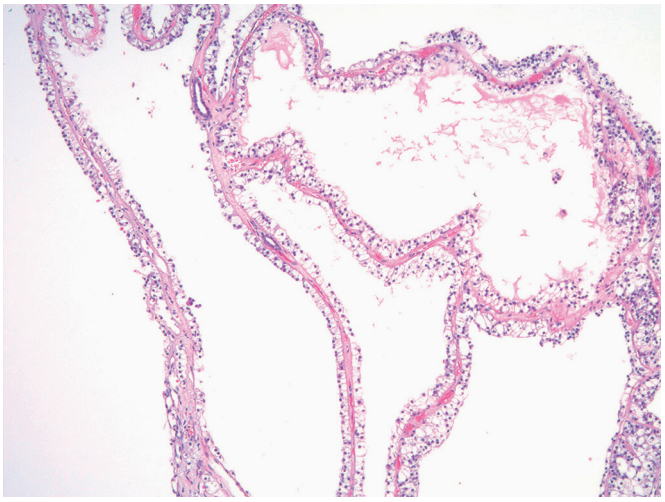

Figure 24.39 MiT Family Translocation Renal Cell Carcinoma. Rare cases may mimic clear cell–papillary or multilocular cystic renal neoplasm.

When diagnosed by strict criteria, no recurrence or metastasis has been reported in clear cell–papillary RCC[402,412,413]; therefore, the differential diagnostic distinction from clear cell RCC and a subset of MiT family translocation RCC is critical. Other less critical distinctions, such as multilocular cystic renal neoplasm of low malignant potential and atypical renal cysts, may be difficult and somewhat subjective.[414,415] In our experience, papillary RCC rarely enters into consideration. It is important to note that some low-grade clear cell RCCs have foci reminiscent of clear-cell papillary RCC, often due to linear alignment of nuclei. Studies have shown that tumors with such mixed features have genetic features and a clinical outcome supporting clear cell subtype.[416,417] Rare subsets of MiT family translocation carcinomas (specifically fusion types SFPQ-TFE3 and NONO-TFE3) may also mimic clear cell–papillary RCC (or possibly multilocular cystic renal neoplasm) based on suprabasal nuclear palisading and subnuclear vacuoles (Fig. 24.39).[418,419] In our practice, we would generally regard the presence of intracystic

papillary excrescences as favoring clear cell–papillary RCC over multilocular cystic renal neoplasm of low malignant potential. The distinction of an atypical renal cyst (with focal papillary excrescences lined by clear cells) from a macrocystic clear cell–papillary may be very subjective.[414] In the presence of papillary tufts within multiple cystic locules of the same lesion, we would favor clear cell–papillary RCC.

Finally, some patients with VHL disease have tumors with morphologic features similar to clear cell–papillary RCC; these are controversial, but in our opinion they are best interpreted as clear cell RCC, given their association with 3p abnormality.[251]

MiT Family Translocation Renal Cell Carcinomas

An exciting new chapter of renal tumor pathology opened with the discovery that some tumors are associated with nonrandom chromosomal alterations involving members of the microphthalmia transcription factor subfamily.[420-422] The better studied of these are those involving region Xp11.2, resulting in fusion of the *TFE3* gene.[423] Most of the initial cases were reported in young people; while they represent approximately 40% of pediatric RCCs, they can also develop in adults.[424,425] Microscopically, the overall features are typically those of an RCC but are very heterogeneous. Papillary structures may be prominent, and the tumor cells can be either clear or have a markedly granular eosinophilic cytoplasm; however, some cases are more solid and clear cell predominant, closely mimicking clear cell RCC (Fig. 24.40). Admixed psammoma bodies may be abundant. There are numerous fusion partners reported, some correlations having been found between the type of gene fusion and the tumor morphology.[419] Aberrant increased nuclear immunoreactivity for *TFE3* is consistently detected in these cases, but many labs find the antibody technically challenging to use and prefer FISH testing (as do we).[426] These tumors usually express PAX2 and PAX8, but do not usually express MiTF.[427] One specific fusion (RBM10-TFE3) may be difficult to detect by FISH due to cryptic inversion.[428,429]

Another, even less common translocation-associated RCC involves t(6;11), the resulting fusion affecting the *TFEB* gene at 6p21.[430] Microscopically, these tumors show nested and acinar-like areas of cells with clear or granular acidophilic cytoplasm with round nuclei. Some cases show a biphasic pattern with a population of smaller cells surrounding eosinophilic basement membrane–like material (Fig. 24.41). They may be difficult to morphologically distinguish from Xp11.2-related tumors, and they may express HMB45 or Melan-A. It is clear that the subject is rapidly evolving and that additional variations, both at the morphologic and the molecular genetic level, are being described.[431] Case in point, aggressive RCCs with TFEB amplification are recently described.[432-434]

Rare hybrid melanotic tumors showing mixed features of MiT family translocation carcinoma and AML are also described. [435]

Collecting Duct Carcinoma

Collecting duct carcinoma constitutes less than 1% of all RCCs under current criteria. These tumors are centered in the medulla, have destructive infiltrative growth often with surrounding desmoplastic reaction, and are almost always high stage at diagnosis.[436-438] Common histologic patterns include tubulopapillary, solid sheets, nests, cords, cribriform, and infiltrating glands or elongated tubules (Fig. 24.42).[438] Sarcomatoid differentiation may also be present. Atypical changes in the adjacent ducts (i.e. dysplasia) may be seen, but distinction from reactive tubular changes is often subjective.

Genetic profile information is limited for collecting duct carcinoma because of its rarity and the evolving diagnostic criteria that now further restricts its diagnosis.[439,440] Likewise, immunophenotypic data

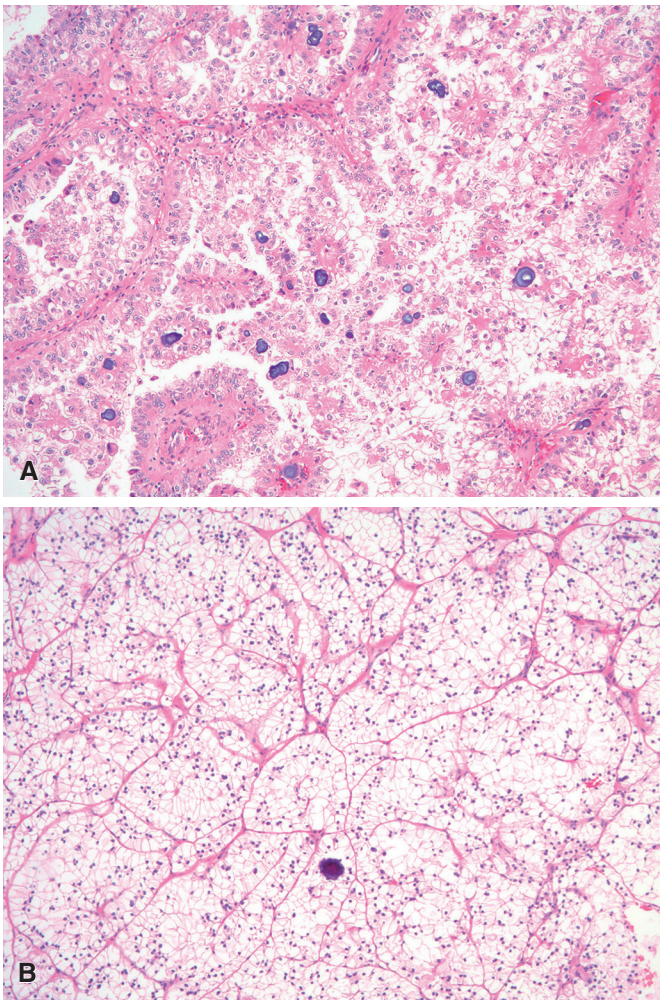

Figure 24.40 MiT Family Translocation Renal Cell Carcinoma, TFE3 Type, With Psammoma Bodies. A, Papillary pattern. **B,** Nested pattern mimicking clear cell RCC.

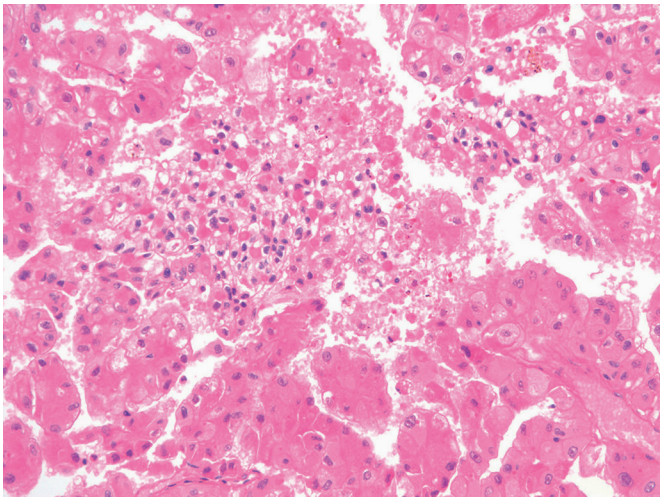

Figure 24.41 MiT family translocation renal cell carcinoma, TFEB type, with classic biphasic pattern.

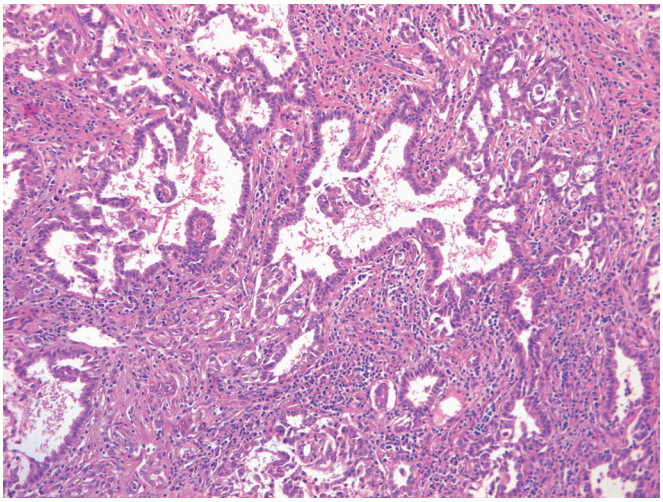

Figure 24.42 Collecting duct carcinoma.

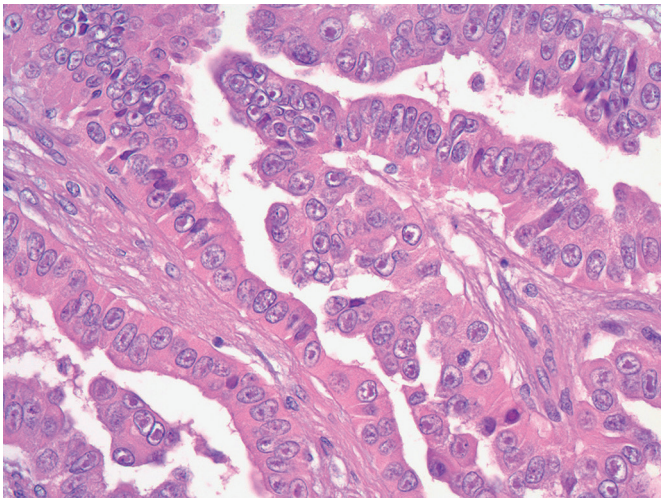

Figure 24.43 Fumarate hydratase–deficient renal cell carcinoma with prototypical peri-nucleolar halos.

have historically varied, likely due to inclusion of a broad spectrum of tumors in the past.

The behavior of collecting duct carcinoma is generally very aggressive, many of the patients having distant metastases at the time of presentation.[441,442] Most importantly, collecting duct carcinoma should be a diagnosis of exclusion. Urothelial carcinoma (with or without glandular differentiation), metastatic carcinoma from a distant site, renal medullary carcinoma, and RCC with fumarate hydratase mutation should be carefully considered because each is more common. Additional sections from the collecting system may be most helpful in distinction from urothelial carcinoma, but immunohistochemistry may be needed if no definitive urothelial precursor lesion is identified. We would generally require at least a PAX8-positive/p63-negative phenotype for this diagnosis. Unfortunately, at least 25% of upper tract urothelial carcinoma express PAX8, so even immunohistochemical distinction may be difficult in some cases. Nuclear SMARCB1 should be retained, which is a distinguishing feature from medullary carcinoma.[443-445] Fumarate hydratase (FH) loss by immunohistochemistry and/or genetic counseling/testing may be needed to exclude fumarate hydratase–deficient RCC (hereditary leiomyomatosis and RCC syndrome).[446]

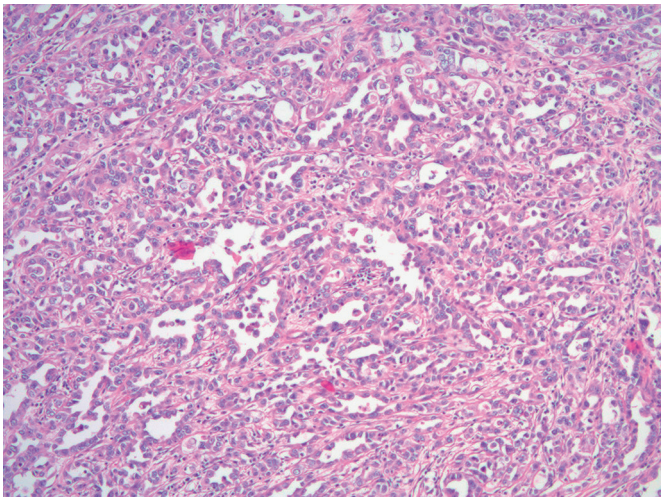

Figure 24.44 Fumarate hydratase–deficient renal cell carcinoma with infiltrating glandular pattern.

Fumarate Hydratase–Deficient Renal Cell Carcinoma (Hereditary Leiomyomatosis and Renal Cell Carcinoma–Associated Renal Cell Carcinoma)

These aggressive RCCs are associated with mutations in *FH* (the gene encoding fumarate hydratase), most of which are germline and associated with hereditary leiomyomatosis and RCC syndrome.[261,446,447] Many of these patients have cutaneous leiomyomas, and women may have a personal or family history of early hysterectomy for uterine leiomyomas. The renal tumors have significant morphologic overlap with collecting duct carcinoma and type II papillary RCC; however, it is no longer appropriate to diagnose or refer to these tumors as the latter. Unlike other hereditary renal neoplasia syndromes, patients may present with only a single unilateral mass due to low penetrance. Macroscopically, tumors are very heterogeneous with variable cystic and solid appearance; in some cases background renal cortical cysts can be seen. Microscopically, the classic pattern is papillary with abundant eosinophilic cytoplasm and large nucleoli with surrounding peri-nucleolar halos (Fig. 24.43).[261] Other patterns include tubular, tubulocytsic, solid, and cribriform, with admixtures being common (Fig. 24.44).[261,446,448] The characteristic peri-nucleolar clearing may be present only focally. Many tumors previously regarded as "de-differentiated tubulocystic carcinoma" represent FH-deficient RCC (Fig. 24.45).[449] Finally, rare cases, especially in younger patients, may not have fully developed features and can overlap with lower-grade oncocytic tumors (Fig. 24.46).[450] Immunohistochemistry can play an important role in this diagnosis, as tumors typically lose cytoplasmic expression for FH (but not in all cases). Overexpression of modified cysteine (S-(2-succino)cysteine) may also be helpful, but the antibody is not currently available from a commercial source.[446] A recent study from the TCGA reported that a subset of tumors with papillary morphology have somatic mutations in FH, suggesting a sporadic counterpart.[451] FH-deficient RCC often presents at high stage with distant metastases, and aggressive behavior may be seen even with small tumors.

Renal Medullary Carcinoma

Medullary carcinoma is a rare malignant renal neoplasm occurring most commonly in young patients of African descent (typically 20–30 years of age) with sickle cell trait, but it is rarely seen with other hemoglobinopathies.[452,453] It is centered in the medulla, and is microscopically heterogeneous with mixed morphologic patterns

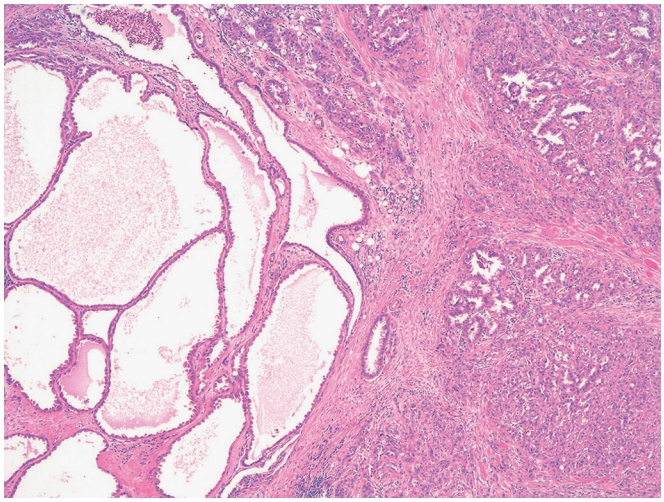

Figure 24.45 Fumarate hydratase–deficient renal cell carcinoma with mixed tubulocystic and solid pattern.

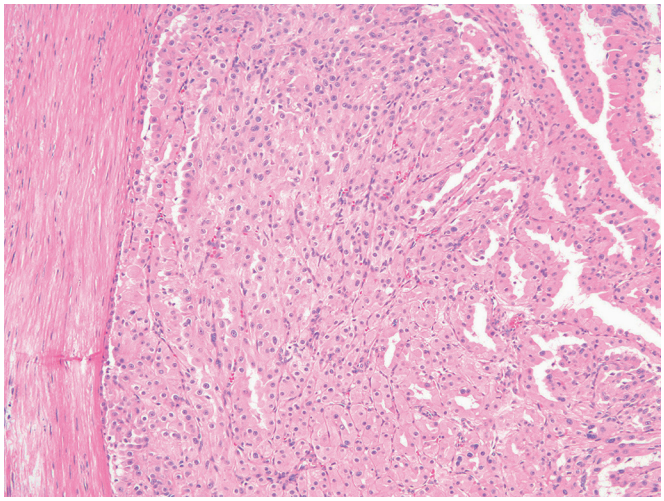

Figure 24.46 Fumarate hydratase–deficient renal cell carcinoma with deceptive "low-grade" appearance.

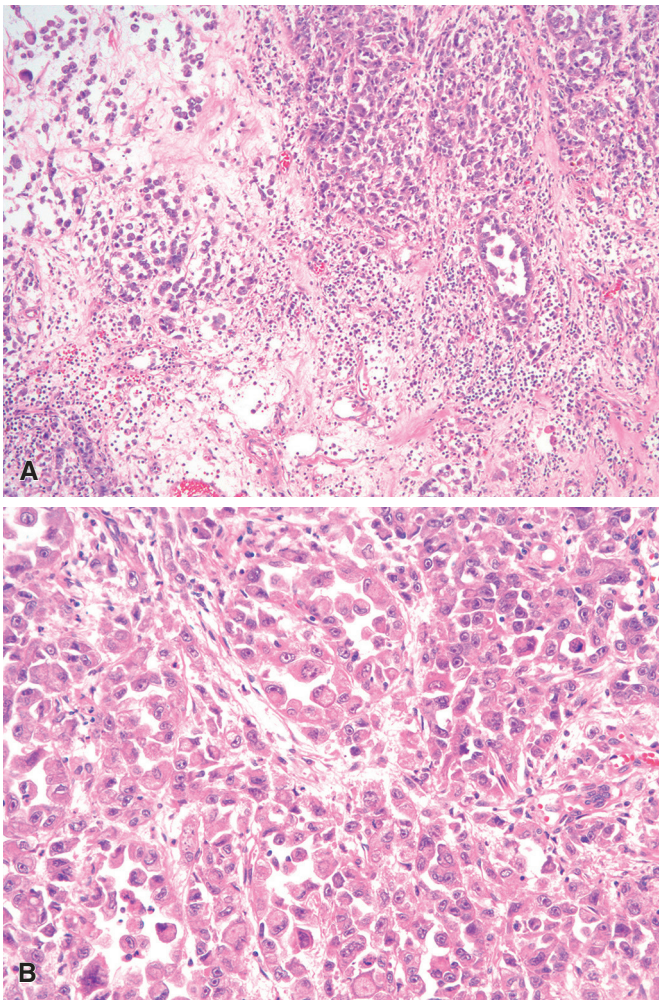

Figure 24.47 Renal Medullary Carcinoma. A, Admixture of glands, single cells, and cords. **B,** Rhabdoid features.

that include reticular (reminiscent of yolk sac tumor), rhabdoid, cribriform, tubulopapillary, and poorly differentiated solid areas, often in a background of desmoplastic stroma admixed with neutrophils and usually marginated by lymphocytes (Fig. 24.47).[454,455] Associated myxoid stroma is also common. Immunohistochemically, demonstration of nuclear SMARCB1 (INI-1) loss has become required for diagnosis.[456] Patchy nuclear expression of OCT3/4 is also characteristic. Metastases are usually present at the time of the diagnosis, and a rapidly fatal course is typical.[457,458]

A separate but seemingly very rare renal neoplasm with a *VCL-ALK* fusion has recently been described in children with sickle cell trait. This *VCL-ALK* fusion–associated RCC is distinct from renal medullary carcinoma with a unique spindled to polygonal eosinophilic cell population containing conspicuous intracytoplasmic vacuoles. Unlike renal medullary carcinoma, these have followed an indolent clinical course.[459-461]

Tubulocystic Carcinoma

Tubulocystic carcinoma is a rare subtype of RCC with unique pathologic features that constitutes less than 1% of renal neoplasms. Grossly, its appearance has been described as spongy and "bubble wrap."[462] Microscopically, there are variably sized cystically dilated tubules lined by a single layer of eosinophilic epithelium with a cuboidal, flat, or hobnail appearance (Fig. 24.48).[462,463] The nuclei are often enlarged with prominent nucleoli. The individual cysts are separated by a scant fibrous stroma. The prognosis tends to be favorable.[462] While a subset of cases with high-grade areas showing solid or destructive growth are described under the term "dedifferentiated tubulocystic carcinoma," many of these represent fumarate hydratase–deficient RCC.[449,464,465] While there has been suggestion of a genetic relationship to papillary RCC, this remains controversial and no distinct genetic signature has been reported for tubulocystic carcinoma.[466,467]

Mucinous Tubular and Spindle Cell Carcinoma

Mucinous tubular and spindle cell carcinoma (MTSCC) is a unique type of low-grade RCC. Microscopically, the tumor is composed of an admixture of spindle cells and elongated tubules lined by bland cuboidal cells with variable amounts of myxoid/mucinous stroma (Fig. 24.49).[468-470] Cases containing scanty mucin ("mucin-poor") can be easily misdiagnosed, the presence of a spindle cell component being an important clue for their correct identification.[471] Focal neuroendocrine features have been occasionally found.[472] The immunohistochemical profile of MTSCC is similar to that of papillary

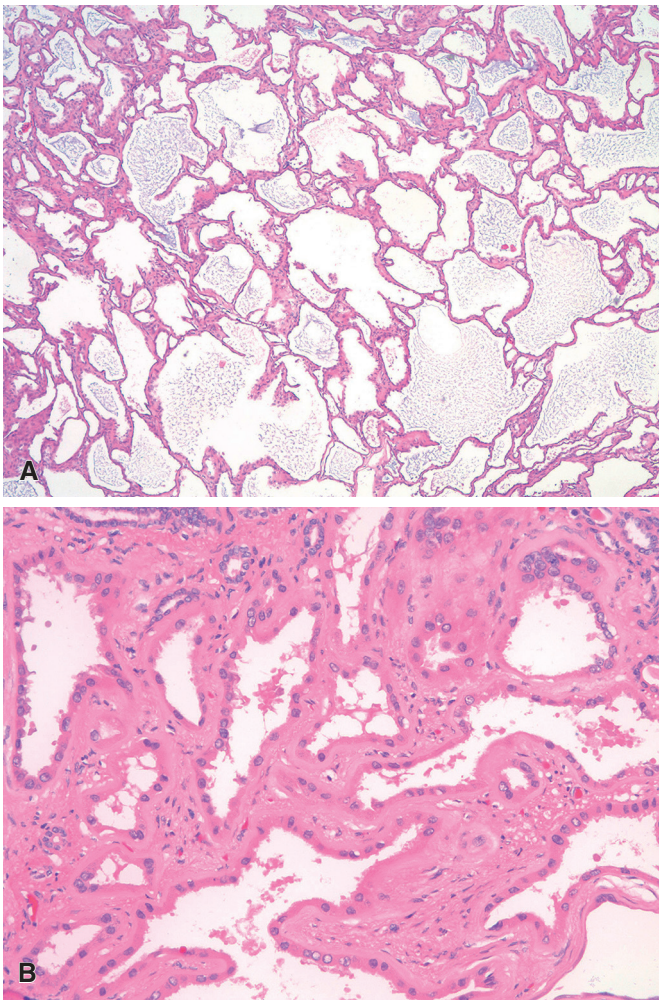

Figure 24.48 Tubulocystic Carcinoma. A, Prototypical low-power architecture. **B,** Lining cells are eosinophilic and atypical.

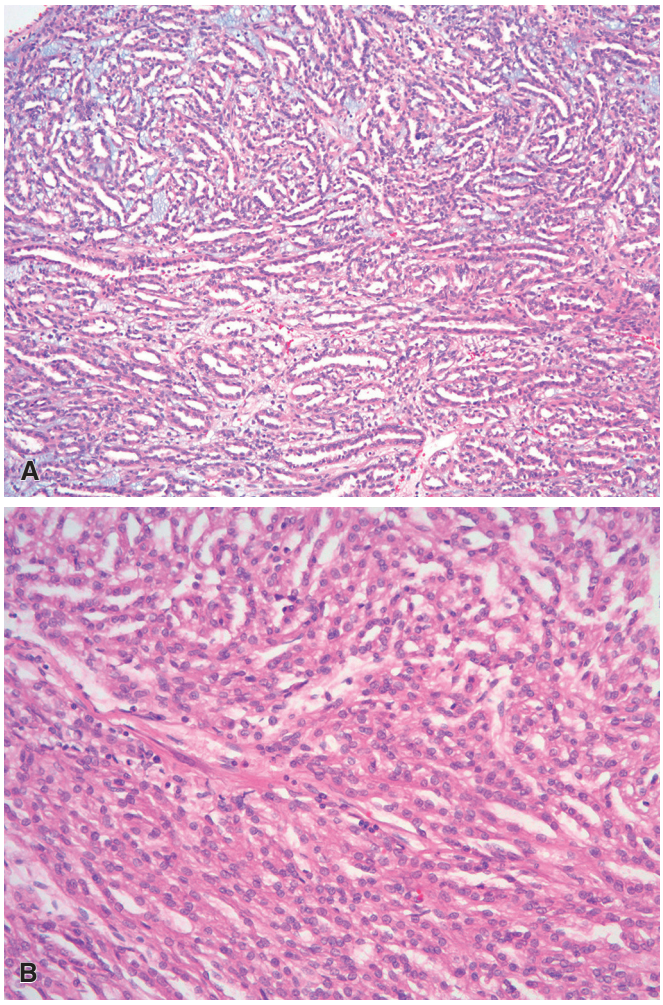

Figure 24.49 Mucinous, Tubular, and Spindle Cell Carcinoma. A, Classic tubular architecture with interspersed mucin. **B,** Spindled morphology with bland cytologic features.

RCC,[473] but their cytogenetic profile is different.[474] Whether MTSCC is a variant of papillary RCC or a distinct tumor subtype has been debated; however, the recent finding of recurring alterations in the Hippo pathway in MTSCC provides strong evidence for the latter.[475-477] The prognosis is generally favorable, unless the tumor is accompanied by a high grade sarcomatoid component, an exceedingly rare event.[478]

Acquired Cystic Kidney Disease–Associated Renal Cell Carcinoma

This neoplasm is seen only in patients with acquired cystic kidney disease related to dialysis. Patients with acquired cystic kidney disease are at a high risk for developing RCC of any subtype.[253,401,479] The diagnosis of "acquired cystic kidney disease–associated RCC" should be reserved for cases with unique and specific histologic features.[401,480,481] The tumors often have macrocystic growth, but solid and papillary architecture is also frequent. The cytoplasm of the neoplastic cells is typically eosinophilic, and prominent nucleoli are common. Two characteristic features include intratumoral oxalate crystals and a unique sieve-like architecture characterized by inter- and intracellular "lumina" separated by very thin strands of cytoplasm (Fig. 24.50). The background kidney, in addition to acquired cystic disease, may contain cysts with atypical papillary proliferations. Immunophenotypically, these RCCs are often negative (or only focally positive) for cytokeratin 7, but they often express AMACR. While

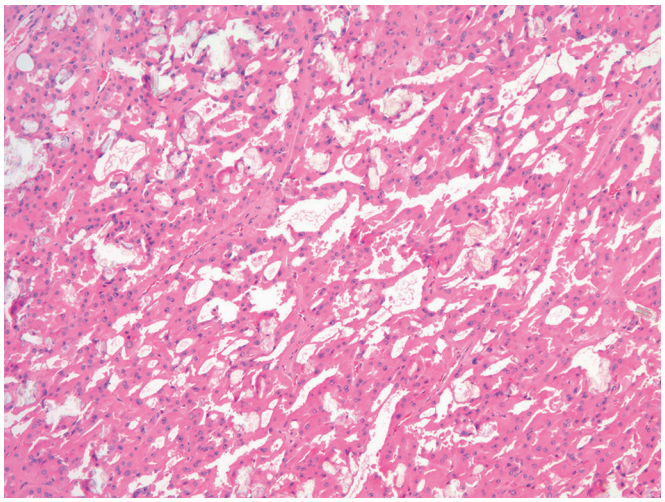

Figure 24.50 Acquired cystic kidney disease–associated renal cell carcinoma.

studies have shown no 3p loss and no chromosome 7 or 17 trisomies, a specific genetic signature has not been identified. Acquired cystic kidney disease–associated RCC generally presents at low stage (possibly due to radiographic surveillance for known cystic disease) and follows an indolent clinical course. However, rare cases may have sarcomatoid or rhabdoid differentiation and are associated with an aggressive behavior.[482]

Succinate Dehydrogenase–Deficient Renal Cell Carcinoma

This recently described subtype of RCC has distinct morphologic features, but is defined by loss of cytoplasmic SDHB expression by immunohistochemistry.[262-264] It is almost always associated with germline mutations in an *SDH* gene (most commonly *SDHB*) and occurs in a younger age range (mean, 38 years). Because of the syndromic association, patients may have a history of paraganglioma, SDH-deficient GIST, or pituitary adenoma. Grossly, the tumors are well circumscribed with tan-brown or red color; cystic areas may be seen. Morphologically, the neoplastic cells of SDH-deficient RCC have eosinophilic cytoplasm and are arranged in solid, nested, or tubular architecture, and cystic areas are common. The individual cells are monomorphic with round, cytologically bland nuclei. The most helpful diagnostic feature is the presence of an intracytoplasmic vacuole or inclusion that contains eosinophilic material, the consistency of which varies from pale and wispy to densely eosinophilic (Fig. 24.51). The tumor has a rounded, well-delineated border but commonly entraps normal renal tubules. While these typical morphologic patterns are most common, rare tumors show high-grade transformation in which the inclusions are focal and more difficult to appreciate. These cases show more cytologic atypia, denser cytoplasm, and increased mitotic activity and may invade the renal sinus (Fig. 24.52). Frank sarcomatoid change is also reported. Immunophenotypically, reactivity for CD117 and cytokeratin 7 is very rare, but PAX8 and kidney-specific cadherin are consistently positive. By definition, SDHB immunostains show loss of cytoplasmic reactivity in the neoplastic cells, while internal intratumoral blood vessels or entrapped renal tubules are positive (Fig. 24.53). SDH-deficient RCCs with typical morphologic features most commonly follow an indolent course, but metastases may occur many years after initial diagnosis (~11% of patients). Cases with high-grade transformation have an aggressive clinical course.

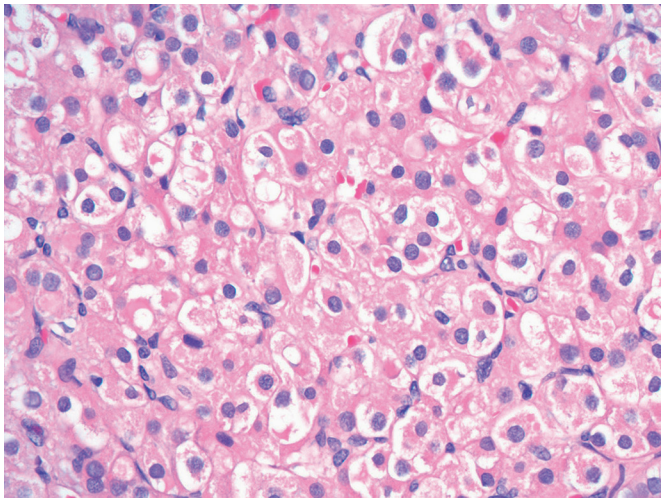

Figure 24.51 SDH-deficient renal cell carcinoma.

Eosinophilic Solid and Cystic Renal Cell Carcinoma

ESC RCC is an emerging subtype of renal neoplasia that was formally described in a series of tuberous sclerosis–associated RCCs[265]; however, it is now recognized to occur more frequently in a sporadic setting.[483,484] The sporadic tumors appear to occur exclusively in women with a wide age range. Grossly, these tumors are often tan with mixed solid and macrocytic appearance (Fig. 24.54). Histologically, the neoplastic cells are characterized by abundant eosinophilic cytoplasm, prominent granular cytoplasmic stippling (said to resemble leishmaniasis), and large round to oval nuclei with prominent nucleoli (Fig. 24.55). In cystic areas, thin septa are lined by these large eosinophilic cells, often with a hobnail arrangement. Immunohistochemically, the cells most commonly have an unusual CK20-positive/CK7-negative phenotype. Common molecular karyotype alterations, distinct from other subtypes of RCC, are described.[483,484]

While these tumors seem to have a more indolent behavior than their nuclear grade would predict, we have seen one metastasis to a regional lymph node and are aware of one liver metastasis (personal communication, Dr. Peter Argani, Johns Hopkins University). As

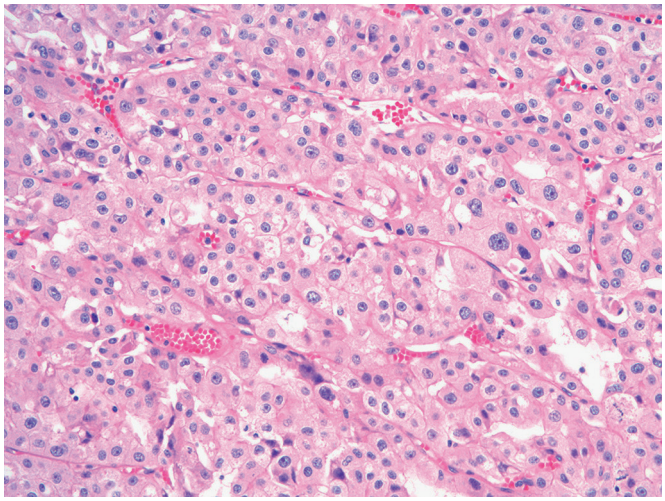

Figure 24.52 SDH-deficient renal cell carcinoma with nuclear pleomorphism and mitotic activity, clinically malignant.

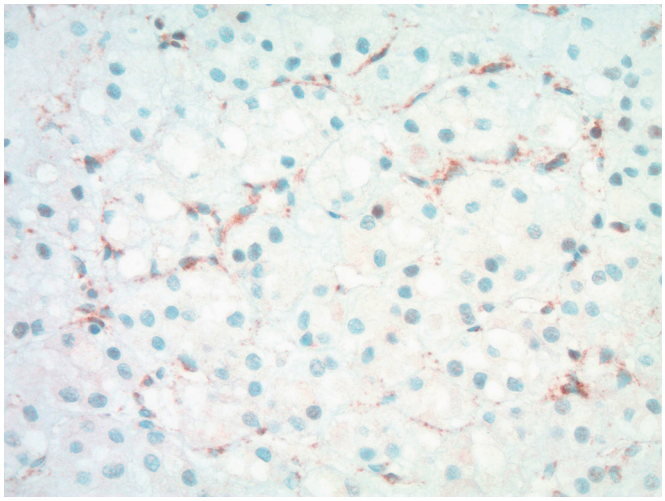

Figure 24.53 SDH-Deficient Renal Cell Carcinoma (SDHB Immunostain). Cytoplasmic loss in neoplastic cells, but retained in endothelial cells.

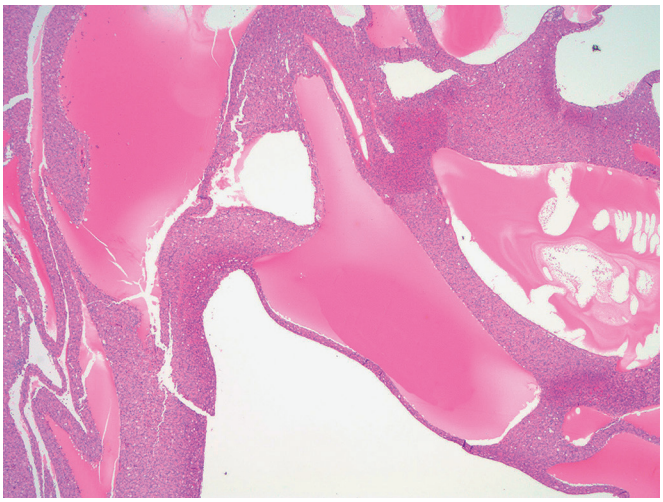

Figure 24.54 Eosinophilic, solid, and cystic (ESC) renal cell carcinoma, low-power magnification.

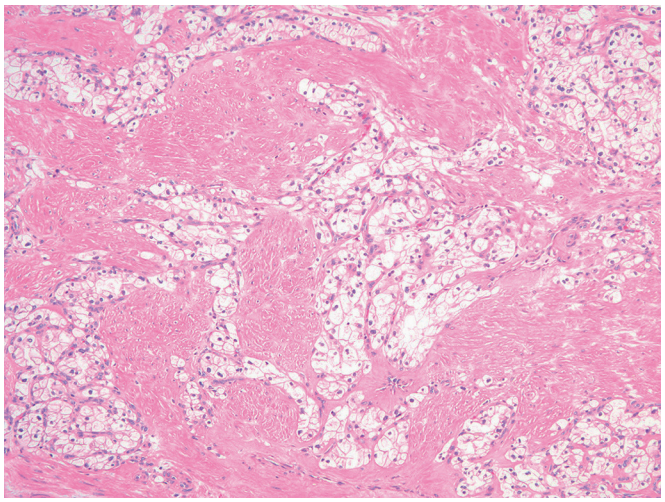

Figure 24.56 Renal cell carcinoma with (angio)leiomyomatous stroma.

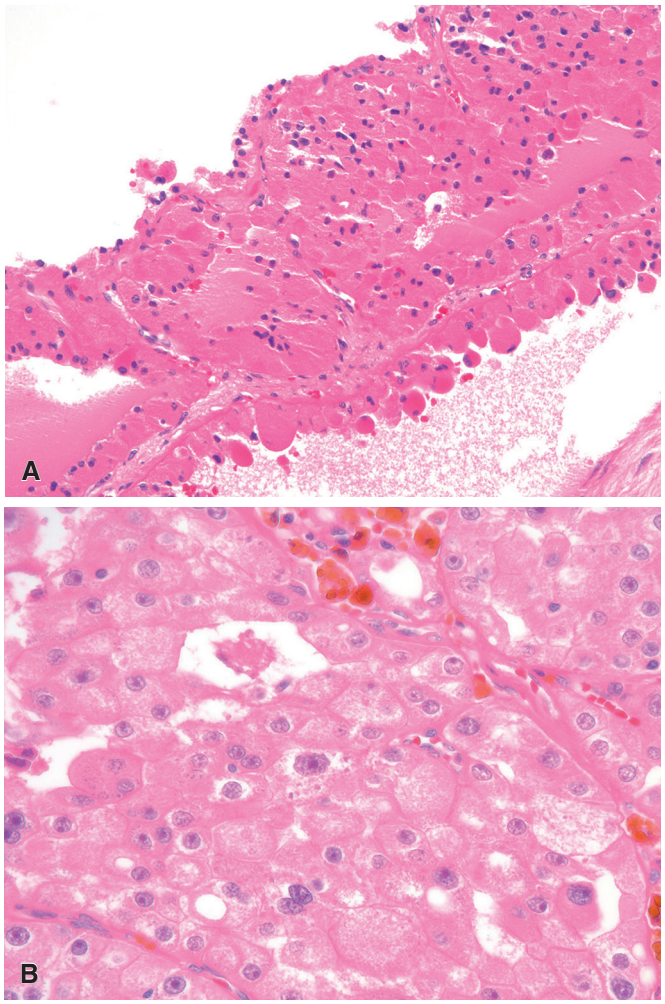

Figure 24.55 Eosinophilic, Solid, and Cystic (ESC) Renal Cell Carcinoma. A, Eosinophilic cells lining septa have a hobnail appearance. **B,** Nuclei are large with variable nucleoli and coarse cytoplasmic stippling.

discussed previously, it is our observation that "oncocytoid RCC following neuroblastoma" (when MiT family translocation carcinomas are excluded) seems to have many similarities with ESC RCC.[268,269]

Renal Cell Carcinoma, Unclassified

Some RCCs do not precisely fit one of the well-described subtypes and are designated "RCC, unclassified type."[485] Most of these tumors are large, high grade, and high stage; however, a rare subset of low grade RCCs do not fit a distinct subtype and might be considered "unclassified." In such cases, it is important to comment on the low grade nature of the tumor, since most urologists equate "unclassified RCC" with very high risk disease. Immunohistochemistry with PAX8 may be useful to confirm renal epithelial origin, but urothelial markers (p63 and high-molecular-weight keratin) are also helpful since up to 25% of upper tract urothelial carcinoma express PAX8, sometimes diffusely. Recent studies suggest distinct molecular subtypes can be identified.[486]

Other Types

Rare low-grade RCCs made up of well-differentiated, branching tubular glands lined by clear cells with abundant cytoplasm and surrounded and closely intermingled with abundant smooth muscle bundles have been described under various names (Fig. 24.56).[487-493] When clear cell–papillary RCCs are carefully separated from this group, it is thought that this represents a distinct set of clear cell–like renal neoplasms with a more indolent clinical course, currently listed as a WHO provisional entity under the name "RCC with (angio) leiomyomatous stroma." Unlike clear cell RCC, these tumors have strong and diffuse reactivity for CK7. Recent sequencing studies identified a subset with mutation in the *TCEB1* gene, but not all cases have this alteration.[492] Importantly, they do not show 3p abnormalities.[337] Interestingly, a subset of RCCs in patients with tuberous sclerosis have an identical morphology; therefore, we recommend a careful evaluation of the background kidney for AML tumorlets.[496] Based on the limited data available, these tumors seem to have an indolent clinical course (with no reported metastases) when carefully separated from clear cell RCC.

Other peculiar forms of RCC have been recently described, including a type closely simulating the appearance of a thyroid follicular carcinoma.[494-496] Additionally, renal neoplasms with ALK translocations are reported (separate from the *VCL-ALK* fusion tumors), but classification of these tumors is still evolving.

Spread and Metastases

Because of the importance of subtype, most general RCC data are heavily driven by the most common subtype, clear cell RCC. Approximately one-third of RCCs are found to invade perinephric fat and/or regional lymph nodes at the time of operation.[272] Invasion of the main renal vein used to be a common finding, but now it is seen less frequently, likely due to earlier imaging detection. From the renal vein, the tumor may extend into the inferior vena cava and occasionally even into the right atrium. RCC, like Wilms tumor, can invade the *renal sinus* (the adipose tissue compartment located within the confines of the kidney and containing numerous veins and lymphatics), a fact which is likely to increase the risk for metastatic spread.[497] As a matter of fact, it has been claimed that the renal sinus is the *principal* pathway of invasion of RCC and the explanation for the rare cases of tumor-related death in patients with small tumors.[498,499] Therefore, very careful gross examination and sampling of the renal sinus are critical.

Satellite tumors, which may represent intrarenal tumor spread or independent primaries (see earlier), are seen in approximately 6% of the cases.[292]

Approximately one-third of patients with RCC already have distant metastases at the time they seek medical attention.[500] The most common sites of distant metastases are the lung and skeleton. The bones most often involved are the pelvis and femur, but there is also a predilection for the sternum, scapula, and small bones of the hands and feet.[501,502] Metastases can also develop in the adrenal gland, liver, skin, soft tissue, central nervous system, ovary, and almost any other site.[503] RCC is actually notorious (together with malignant melanoma and choriocarcinoma) for metastasizing to the most unusual places, such as the nasal cavity, oral cavity, larynx, parotid, thyroid, heart, bladder, testis, prostate, and pituitary gland.[504-511] These metastases are often solitary, at least at the clinical level.[512] Even at autopsy, 8% of the patients have metastatic involvement of only one or two organs.[513] Because of this and the fact that the primary tumor is often clinically silent, these metastases tend to be confused with primary tumors of the organs in which they lodge. That can be the case when RCC metastasizes to the ovary,[514] and even more so when it metastasizes to the *contralateral* adrenal gland.[515,516] In these instances, detection of EMA, keratin, and PAX-8 positivity favors a diagnosis of RCC.[517] An additional source of misinterpretation stems from the fact that sometimes these metastases develop years or decades after the removal of the primary tumor.[518,519] Several cases have been documented in which these metastases have undergone spontaneous regression.[520,521]

Metastases are extremely rare in tumors that measure 3 cm or less, but they can certainly occur, indicating that the once-popular practice of separating RCC from adenoma on the basis of size alone is unreliable.[522]

Therapy

The primary treatment of RCC is surgical excision. While transabdominal or thoracoabdominal radical nephrectomy with removal of the entire kidney, surrounding fat, Gerota fascia, and adrenal gland has historically been preferred, a laparoscopic approach with only a segmental resection of the kidney is now more common and yields long-term results comparable to those of open surgery.[523-527] No consistent benefits have yet been demonstrated for administration of adjunctive radiation therapy or chemotherapy; neoadjuvant therapy is sometimes utilized in select cases in an attempt to reduce tumor size prior to surgery.[528]

RCCs that are bilateral, that develop in the setting of VHL disease, or that occur in a solitary kidney are treated with partial nephrectomy, if technically feasible.[529-533] Some authors have proposed this approach for small RCCs in general.[287,534,535]

Various immune-based therapeutic approaches (such as interleukin-2 and α-interferon) are currently being tried in metastatic RCC; these have met with erratic if occasionally impressive results.[536-538] In recent years, targeted therapy using various agents such as sunitinib (multitargeted receptor tyrosine kinase inhibitor), bevacizumab (antibody-blocking VEGF A), temsirolimus (mTOR inhibitor), and everolimus (mTOR inhibitor) has yielded promising responses for metastatic RCC.[539] Targeted therapies that might selectively treat specific subtypes of RCC are the source of many ongoing studies.

Prognosis

The overall 5-year survival rate for RCC is approximately 70%. The prognosis is related to several clinicopathologic parameters.

1. *RCC subtype*. The prognostic significance associated with the various microscopic variants of RCC is discussed in connection with those variants.[540]
2. *Staging*. In patients who do not have distant metastases at diagnosis, stage on the basis of surgical findings is one of the strongest prognostic factors. The AJCC 8th edition bases staging on tumor size and spread beyond the kidney.[541] Based on numerous studies by Bonsib, it is clear that the main route of RCC extension outside of the kidney parenchyma involves the blood vessels of the renal sinus.[498,542,543] While renal vein involvement is typically easy to recognize grossly, very careful gross inspection of the tumor/stromal interface where tumor abuts fat is critical (Fig. 24.57).[544] Any separate tumor nodule present in the sinus fat is almost certainly pT3 disease based on involvement of renal sinus blood vessels. A bulging interface at the renal sinus should be carefully sampled to determine if the tumor is microscopically entering a blood vessel. Destructive invasion of adipocytes is actually rare and likely represents late invasion through the wall of a blood vessel. Direct contiguous invasion of the adrenal gland (pT4) should be distinguished from a separate adrenal nodule (pM1). The prognosis seems to be particularly poor in cases with invasion of the adrenal gland.[545]
3. *Distant metastases*. The presence of distant metastasis at the time of operation is, not surprisingly, the single most important unfavorable prognostic parameter.[546]
4. *Tumor size*. Size of the primary tumor relates to prognosis for the very small (<4 cm) and the very large (>10 cm) tumors but not for those between these extremes, which represent the large majority.[547-549] For such tumors (4–10 cm), size seems to be a

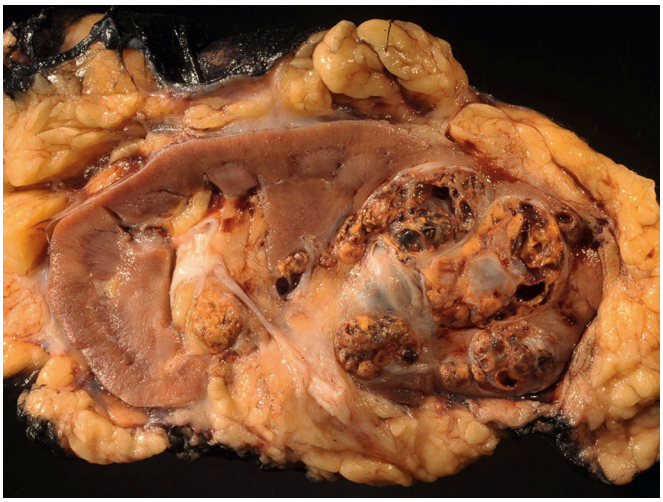

Figure 24.57 Clear cell renal cell carcinoma with definitive macroscopic invasion of renal sinus (pT3).

continuous and therefore relative variable.[550] Out of necessity, an arbitrary size cutoff is needed, and this cutoff has been established to be 7 cm between T1 and T2 tumors in the 2016 TNM staging system; however, it has been suggested that different size cutoffs might be more predictive of the survival of stage I patients after radical nephrectomy.[551,552] As Bonsib has emphasized, increasing tumor size correlates very highly with invasion of the renal sinus, such that it is difficult to identify a pT2 clear cell RCC after very careful gross evaluation.[543]

5. *Renal vein invasion*. Gross invasion of the renal vein has been regarded as a poor prognostic sign and therefore constitutes a criterion for surgical staging.[541,549] Microscopic lymphovascular invasion has also been found to be an important predictor of relapse, but this has been variably defined.[553-555]
6. *Microscopic grade*. Nuclear grade of the tumor as determined in microscopic sections is an important predictor of survival in clear cell carcinoma (but not in chromophobe cell carcinoma, and possibly some rare variants as noted earlier).[400,556-559] It is strongly correlated with surgical staging, but it also maintains statistical validity independently from it.[547,560] Grading is performed using the WHO/ISUP grading system, which has proven utility in clear cell and papillary RCC (see Table 24.3).[559,561,562] Rhabdoid and sarcomatoid differentiation have now been incorporated into the grading system and are regarded as grade 4. Some have advocated for the use of nuclear morphometry to further refine the criteria for nuclear grading, but this is not standard practice.[563-565]
7. *Necrosis*. Coagulative tumor necrosis has been shown to be a strong predictor of outcome, and there has been a proposal to integrate necrosis into the grading system.[566-568]

Adenomas

Renal papillary adenomas, defined as minute cortical foci of tubular or (more commonly) papillary epithelium, are present in approximately 20% or more of adult kidneys; most of them measure 1–3 mm in diameter and by the latest WHO definition are less than 1.5 cm, lack a tumor capsule, and are no more than nucleolar grade 2.[569-572] The cytoplasm of the proliferating cells is typically acidophilic rather than clear and not particularly abundant.[573] Psammoma bodies may be present. Papillary adenomas are particularly common and numerous in end-stage kidneys in patients on long-term dialysis *(renal adenomatosis)*.[574,575] Since these adenomas share the same cytogenetic findings as type 1 papillary RCC, they likely represent early forms of the disease without metastatic potential. In contrast, other subtypes of renal neoplasia are no longer divided into adenomas and carcinomas based on size, such that small clear cell RCCs are still diagnosed as carcinoma.

Oncocytoma, "Difficult to Classify" Oncocytic Tumors, and Oncocytosis

The diagnosis of renal oncocytoma represents one of the more problematic and controversial topics in renal neoplasia classification today.[380] Renal oncocytomas reportedly make up 5%–9% of all primary nonurothelial epithelial renal neoplasms; however, this number depends largely on the diagnostic criteria employed.[576] Our diagnostic approach is to identify three histologic groups of low-risk oncocytic tumors: classic prototypical oncocytoma, classic prototypical chromophobe RCC, and oncocytic tumors that are "difficult to classify." This section describes classic oncocytoma, followed by comments on handling problematic cases. Grossly, renal oncocytoma is typically solid and mahogany brown, often has a central stellate scar, and can reach large sizes (Fig. 24.58).[577] They can be multicentric and bilateral.[578] Invasion of the perirenal tissues or renal vein may be encountered.[576,579-582] Some of these gross features (particularly the central scar) have been used to distinguish oncocytomas from RCC on CT scan, but the level of accuracy is poor.[583] Microscopically, oncocytomas are composed entirely of cells with abundant acidophilic granular cytoplasm, growing in a nesting ("alveolar") or tubular fashion (Fig. 24.59). In some foci, nests and tubules often "float" in an edematous stroma. The nuclei of oncocytoma cells are usually small, round, and regular (Fig. 24.60).[584] Pockets of "degenerative type" nuclear atypia can occur, and some scattered binucleate cells may be present..[585,586] Psammoma bodies can be present, most of them in an intraluminal location. A variant of oncocytoma has been described composed of small cells (i.e. "oncoblasts"), which can easily be misinterpreted.[587,588] Renal tumors with oncocytic cytoplasm and a predominant papillary pattern should probably be placed with the papillary RCCs.[589] Immunohistochemically, the tumor cells express pancytokeratin, low-molecular-weight keratins, CD117, S-100A1 protein,[590] and E-cadherin, but show only focal or no

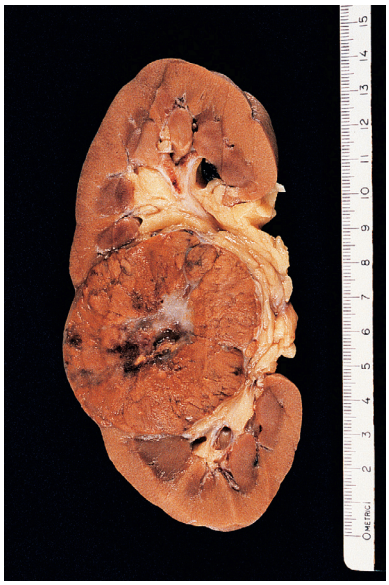

Figure 24.58 Gross Appearance of Oncocytoma of Kidney. The tumor is characteristically well circumscribed, mahogany brown, and has a central fibrous scar.

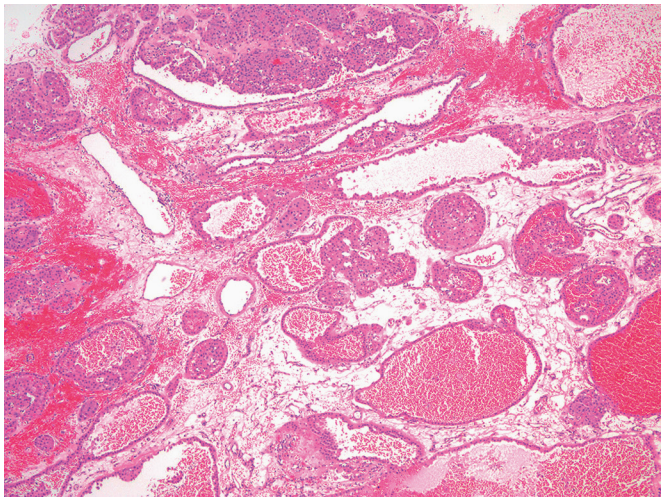

Figure 24.59 Typical nesting and cystic pattern of renal oncocytoma.

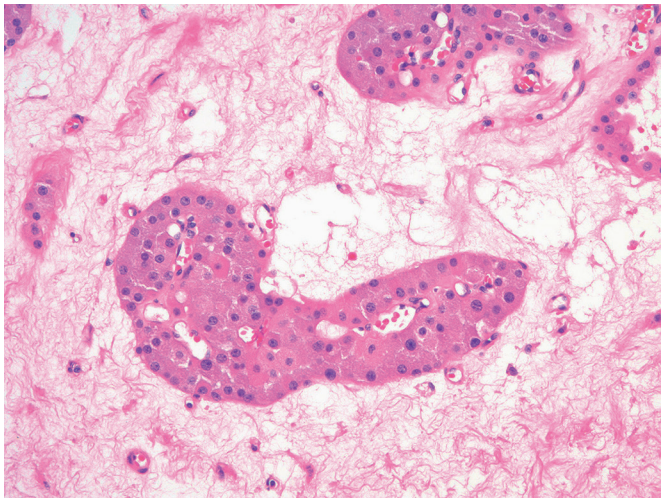

Figure 24.60 Renal Oncocytoma. Nuclei are round and monomorphic.

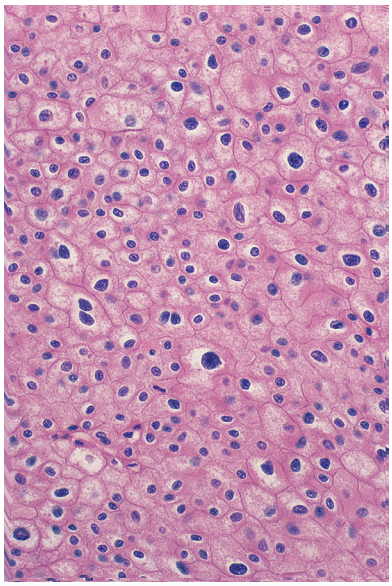

Figure 24.61 Perinuclear halos, binucleation, and "koilocytotic atypia" are features of a prototypical chromophobe renal cell carcinoma.

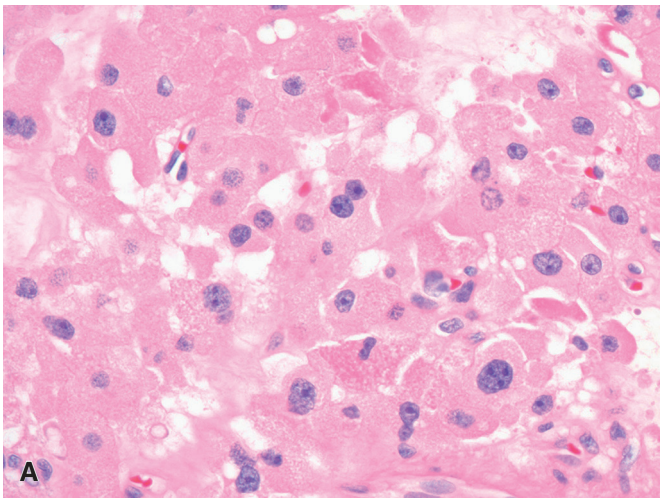

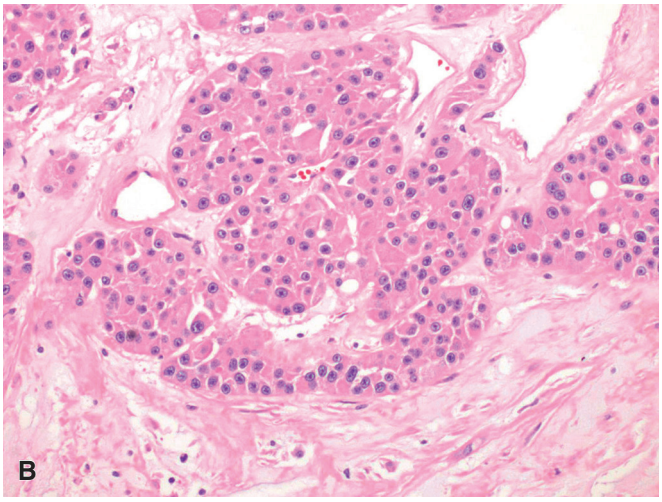

Figure 24.62 Oncocytic Renal Neoplasms With Features Not Prototypical for Either Oncocytoma or Chromophobe. A, This tumor has more variability in nuclear size with multiple nucleoli, but nuclei remain relatively round with no perinuclear clearing. **B,** This case has very prominent and consistent macronucleoli. Other foci showed solid growth. Such tumors have significant variability in diagnosis, even among experts.

reactivity for vimentin.[591-593] Cytokeratin 7 is usually negative or only positive in scattered cells; however, entrapped tumor nests within the central scar (often associated with cytoplasmic clearing) have stronger expression of cytokeratin 7.[594] Hale colloidal iron is typically negative.[379] Ultrastructurally, packing of the cytoplasm by mitochondria is the most striking feature.[595-598] Cytogenetically, oncocytomas lack the 3p abnormalities of clear cell RCC and display different chromosomal alterations, particularly loss of chromosome 1, rearrangements of 11q13, and deletion of chromosome 14.[599,600]

If strict morphologic criteria are employed, the overwhelming majority of oncocytomas will be cured by excision regardless of size[582,584,601-605] and/or the presence of atypical microscopic features such as vascular invasion or perirenal fat infiltration.[606,607] Only exceptional cases of well-documented renal oncocytomas have been reported to metastasize.[576,608]

The main differential diagnosis of renal oncocytoma is with the eosinophilic variant of chromophobe RCC, succinate dehydrogenase–deficient RCC, and less commonly epithelioid AML. The cells of chromophobe RCC have wrinkled, raisin-like hyperchromatic nuclei, whereas those of oncocytoma tend to be perfectly round. As stated before, the presence of well-developed perinuclear halos and/or irregular nuclear membranes with frequent binucleation are sufficient for classification as chromophobe RCC (Fig. 24.61).[427]

Some cases are more difficult to classify, and expert consultants often differ in their methods and terminology used to diagnose such cases. There are several approaches: (1) divide all cases into either chromophobe or oncocytoma by morphology, (2) classify difficult cases as chromophobe or oncocytoma using adjunctive immunostains/special stains, or (3) keep strict diagnostic criteria for the diagnosis of chromophobe RCC and oncocytoma by using a separate diagnostic term for "gray zone" cases. Until this diagnostic problem is better addressed by studies, we prefer the latter and have adopted what we find to be a practical diagnostic approach. Most of these "gray zone" cases maintain round nuclear contours without perinuclear clearing (i.e. not classic chromophobe) but have greater variability in nuclear size, greater degree of irregular nuclear chromatin, and variable macronucleoli (Fig. 24.62). To our knowledge, no adjunctive test (whether immunostain, histochemical stain, or cytogenetic test)

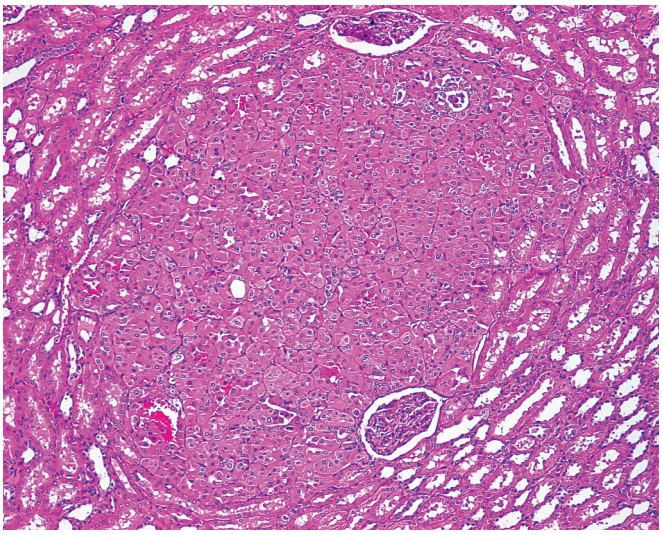

Figure 24.63 So-called renal oncocytosis. Many similar nodules were scattered throughout the kidney.

has been shown to predict behavior in such tumors. This approach avoids arbitrarily dividing some cases into either a benign or malignant category. Therefore, we prefer to simply utilize the diagnostic term "oncocytic renal neoplasm of low malignant potential," but other similar terms have been applied. While we have seen extremely rare liver metastases in such cases (far less than 1% based on several hundred cases), it is our anecdotal experience that the vast majority behave in a benign fashion.

As alluded to in the section on unclassified RCC, rare low grade RCCs may have significant overlap with this oncocytic spectrum of neoplasia. We generally reserve the rare diagnosis of "RCC, low-grade oncocytic type" for cases with sheet-like growth and obvious mitotic activity, but without nuclear features of chromophobe RCC.

Oncocytosis is the term proposed for a condition characterized by the presence of innumerable oncocytic nodules in one or both kidneys, usually associated with the presence of a dominant nodule (Fig. 24.63). The disease can affect adults and children, and many cases are likely related to Birt-Hogg-Dubé syndrome.[609] Microscopically, the oncocytic tubules intermingle with the normal parenchyma and may be associated with diffuse oncocytic change in the renal tubules and oncocytic cortical cysts.[259] The larger oncocytic nodules/tumors show morphologic features reminiscent of both oncocytoma and chromophobe RCC, but often show immunohistochemical and cytogenetic profiles distinct from them.[610]

Neuroendocrine Tumors

Small cell neuroendocrine carcinomas of the kidney (or other high-grade neuroendocrine carcinomas) with features similar to those of the lung have been described.[611-613] They show evidence of neuroendocrine differentiation ultrastructurally and immunohistochemically.[611,614,615] These should be distinguished from urothelial carcinoma of the renal pelvis with neuroendocrine differentiation.[616-618] The behavior of the few reported cases has been very aggressive.

Carcinoid tumor (well-differentiated neuroendocrine neoplasm), which should be sharply segregated from small cell carcinoma, has been reported in a pure form[619-621] and as a component of cystic teratoma.[622-624] Microscopically, the tumor cells are well differentiated at the morphologic, immunohistochemical, and ultrastructural levels.[625-627] The pattern of growth is often trabecular (and therefore similar to that seen in rectal carcinoid and in the carcinoid component of strumal carcinoid of the ovary), but a wide range of appearances has been documented, including nesting (insular) and glandular.[625,628] The cytoplasm of the tumor cells may have an oncocytic quality.[629] Stage at presentation is the most important factor in determining outcome.[627,630] It is important for a metastasis from another anatomic site (e.g. gastrointestinal tract) to be excluded clinically.

Paraganglioma may also rarely involve the kidney.[631]

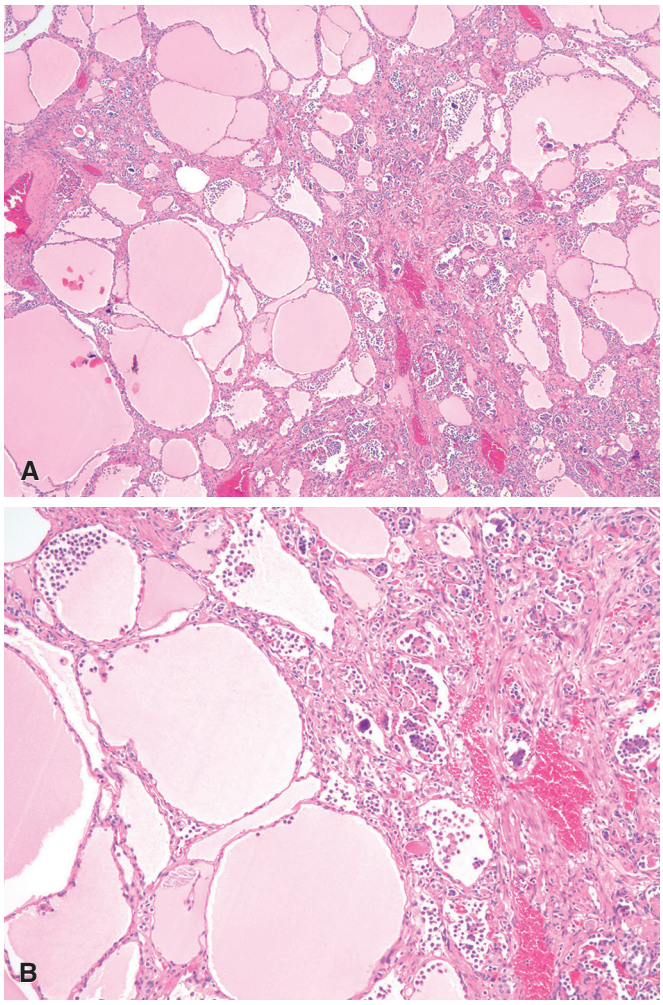

Figure 24.64 "Atrophic Kidney-Like Tumor." A, Cystically dilated follicles of various sizes are typical, with admixed smaller tubules. **B,** Follicles are lined by a flattened epithelium, and psammoma bodies and amorphous calcifications are present.

Other Epithelial Tumors

We have seen several examples of "atrophic kidney-like tumor," which was described by Hes et al. in 2014 as a "distinctive renal neoplasm simulating atrophic kidneys with 2 types of microcalcifications."[632] These are characterized by a circumscribed and encapsulated collection of cystically dilated "follicles" filled with eosinophilic secretions and admixed with smaller renal tubular-like structures (Fig. 24.64). The follicles are lined by an atrophic lining epithelium, and the lumina may contain "sloughed" cells. Variable loose to collagenized stroma is present, and psammoma bodies or more amorphous calcifications are numerous. Some similar tumoral masses have been reported as "thyroid-like follicular RCC," which we believe is a different lesion. These "atrophic kidney-like tumors" have all

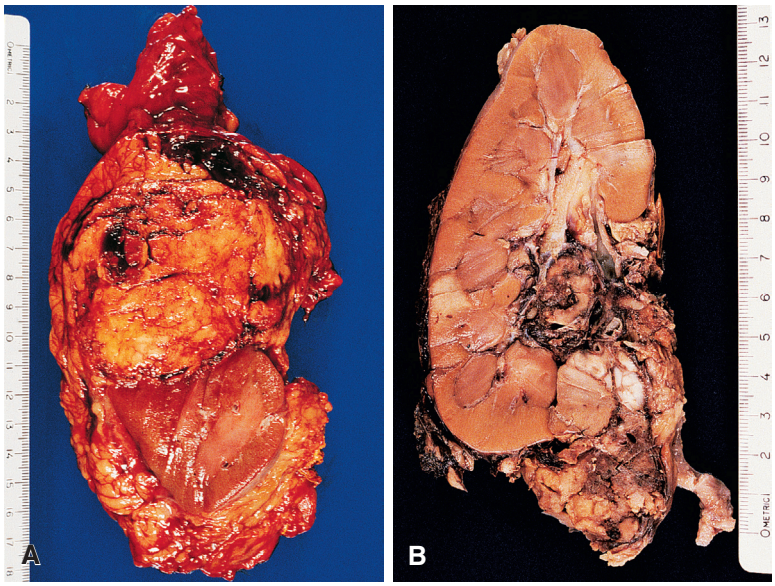

Figure 24.65 **A** and **B,** Gross appearances of angiomyolipoma of kidney. Both tumors are variegated, with a predominance of yellow areas, admixed with hemorrhagic foci.

occurred in young patients (typically 20–40 years of age but also in young children) and have followed a benign clinical course. Their exact nature is still debated.

Very unusual and as yet not fully characterized morphologic types of renal epithelial neoplasms include *myoepithelioma and myoepithelial carcinoma*[633,634]; *spiradenocylindroma* (a sweat gland tumorlike renal neoplasm developing in the wall of a renal cyst and having a somatic mutation in the *CYLD1* gene)[635]; and *papillary tumor of the renal medulla* (a type of carcinoma that is different morphologically and cytogenetically from the usual papillary RCC and from collecting duct carcinoma).[636]

Angiomyolipoma

AML has undergone a remarkable transformation, from a rare and rather pedestrian tumor type restricted to the kidney to a biologically fascinating and morphologically heterogeneous entity that can occur in a wide variety of extrarenal sites, including liver, pelvic region, retroperitoneum (unconnected to the kidney), uterus, somatic soft tissues, large bowel, nasal cavity, and bone.[637-641] This family of phenotypically similar tumors is now collectively known as PEComa, which include lymphangiomyoma(tosis) of lung and lymph nodes and so-called clear cell tumor ("sugar tumor") of lung.[642-647] This section will focus specifically on primary renal AML.

Most patients are adults. The tumor may be found incidentally or result in retroperitoneal hemorrhage, which can be massive and even fatal.[648] Approximately one-third of the patients with renal AML suffer from tuberous sclerosis, the incidence being higher if the tumors are multiple or bilateral. It has been estimated that approximately 80% of the patients with the complete or severe form of tuberous sclerosis have renal AMLs,[649] and it has been shown that patients with the closely related genetic disease known as *TSC2/PKD1 contiguous gene syndrome* also have an increased incidence of renal AML.[650]

In some cases, the appearance of AML on ultrasonography and CT scan is highly characteristic,[651] and the diagnosis can be confirmed by fine-needle aspiration or needle biopsy, supplemented by immunocytochemistry as needed.[652,653]

The gross appearance of the tumor depends on the relative amounts of the various components and may closely simulate RCC because of the admixture of yellow areas (lipid rich) and hemorrhagic areas (vessels) (Fig. 24.65). Capsular invasion is present in one-fourth of the cases, and there can be extension into the perirenal soft tissues. In its conventional form, AML is composed of an intimate admixture of blood vessels and tumor cells; the neoplastic cells are heterogenous, having either an eosinophilic spindle cell appearance imparting "myoid" features or intracytoplasmic lipid closely mimicking adipocytes (Fig. 24.66).[654,655] Less commonly, epithelioid cells are the predominant cell type. The associated tortuous thick-walled blood vessels lacking elastic tissue lamina often have bundles of tumor cells that seem to emanate from the vessel walls, a very helpful diagnostic feature (Fig. 24.67). Some epithelioid AMLs may have marked cytologic atypia that closely mimics a poorly differentiated RCC (Fig. 24.68). Multicentric microscopic foci are common and suggest tuberous sclerosis; exceptionally, they may be seen involving the glomeruli.[656] In some cases, the AML proliferation is accompanied by cysts lined by cuboidal to hobnail cells resting on a cellular spindle cell stroma with a cambium layer-like appearance. This

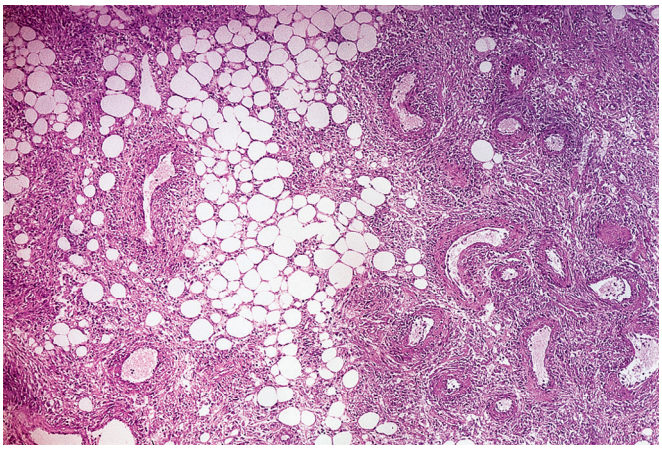

Figure 24.66 **Typical Renal Angiomyolipoma.** The tumor is composed of lipid-rich and myoid-like cells with admixed blood vessels.

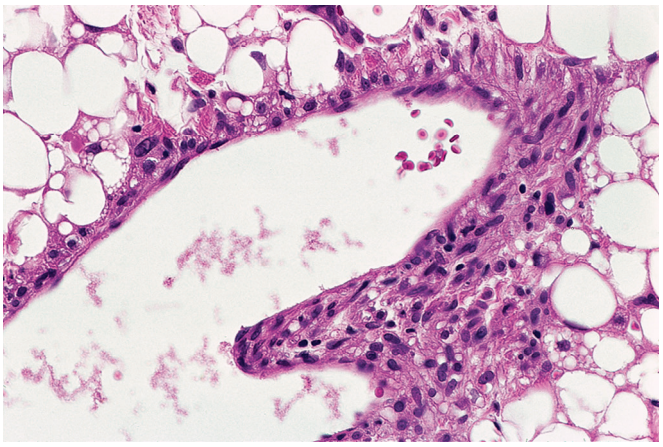

Figure 24.67 Intimate relationship of the eosinophilic neoplastic cells of angiomyolipoma with a large vessel. This is an important diagnostic clue.

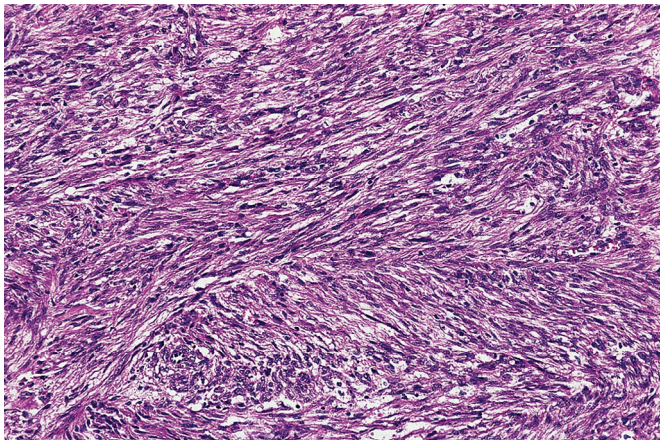

Figure 24.69 Renal angiomyolipoma showing a predominant myoid appearance.

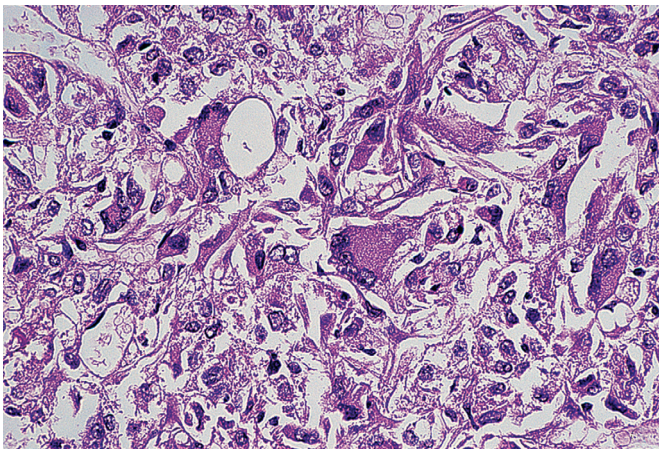

Figure 24.68 Epithelioid angiomyolipoma of the kidney showing marked pleomorphism of the tumor cells. This tumor recurred locally and later metastasized to lung.

peculiar cystic variant of AML (AMLEC) is also characterized by the frequent expression of hormone receptors.[657,658]

Immunohistochemically, AMLs (and all PEComas) are notable because, in addition to the expected smooth muscle markers (such as actin), they regularly express melanocytic markers such as HMB-45, Mart-1/Melan-A, microphthalmia transcription factor, and tyrosinase; however, expression of melanocytic markers may be quite focal.[659-666] Cathepsin-K is strongly and diffusely expressed in AML, and (in the kidney) we find it more useful than other melanocytic markers; however, it is also commonly expressed in MiT family translocation RCC.[667-669] To our knowledge, nuclear PAX8 expression has not been reported in AML; therefore, it has utility in the distinction from RCC. At the ultrastructural level, this immunohistochemical profile is associated with the presence of unique cytoplasmic crystalloids[642] and of organelles consistent with premelanosomes.[670-672] Unfortunately, the renal AMLs of tuberous sclerosis patients with mutation of the *TSC1* and *TSC2* genes have been found to show inconsistent hamartin and tuberin expression.[673-675]

Recently, our concepts on the nature of PEComas have become ever murkier by the demonstration that a subset of these tumors harbors *TFE3* gene fusions and exhibits aberrant immunoreactivity for TFE3 protein (like translocation-associated RCCs and alveolar soft part sarcoma).[676] Apparently, these tumors differ in several respects from the "conventional" PEComas lacking these molecular features.[677]

AMLs in which spindle cells with a smooth muscle appearance predominate may mimic leiomyomas, leiomyosarcomas, or GISTs (Fig. 24.69).[666,678] Lipid-rich AMLs, in which the adipose tissue is predominant, can be easily confused with an atypical lipomatous tumor (well-differentiated liposarcoma). It should be highlighted that AMLs may express MDM-2 by immunohistochemistry (an adjunctive test for atypical lipomatous tumor/well-differentiated liposarcoma); therefore, FISH evaluation for MDM-2 amplification is more useful in this specific context[679] Highly pleomorphic AMLs rich in epithelioid cells closely resemble RCC.[680-682] AMLs composed of monomorphic epithelioid cells with homogeneous acidophilic cytoplasm may be mistaken for oncocytomas.[683-685]

The treatment of renal AML is surgical, and excision is usually curative.[686] However, cases resulting in death from massive local recurrence are on record.[687] It is also now abundantly clear that AML is capable of distant metastases; however, the regional lymph node involvement that sometimes accompanies renal AML is an expression of multicentricity rather than true embolic metastases.[688-690] Cases with indisputable metastatic spread in the form of huge retroperitoneal deposits or nodules in the lung and other organs have been documented.[691-694] Practically all of these biologically malignant cases had highly atypical epithelioid features morphologically, which leads to the question as to whether it is possible to make a diagnosis of malignant AML on morphologic grounds.[695,696] It is obvious that a potential for malignant behavior cannot be excluded for AMLs with "aggressive" morphologic features.[682,697] According to a recent study, presence of three or more of the following features is predictive of malignant behavior: (1) ≥70% atypical epithelioid cells (polygonal cells with prominent nucleoli and nuclear size exceeding twice the size of adjacent nuclei); (2) ≥2 mitotic figures per 10 high-power fields; (3) atypical mitotic figures; and (4) necrosis.[696]

Juxtaglomerular Cell Tumor

Patients with juxtaglomerular cell tumor usually present clinically with hypertension because of excessive renin production,[698] but some cases are nonfunctioning.[699] Most patients are adult, but cases have also been reported in children.[700] Grossly, all reported cases have been unilateral and solitary. Most have been less than 3 cm in diameter and located in the cortex, but occasional examples have reached 8 cm.[701] They are solid and well circumscribed, with a gray-white to light yellow cut surface.

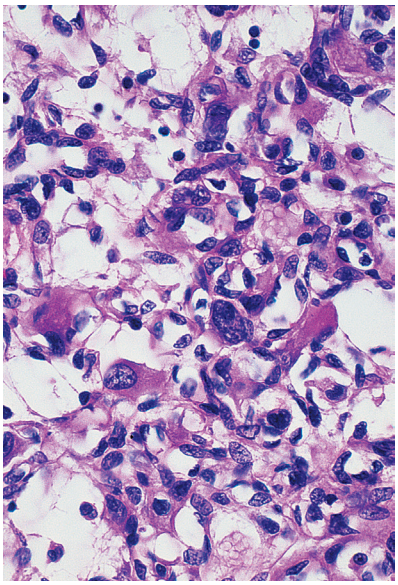

Figure 24.70 Microscopic Appearance of Juxtaglomerular Cell Tumor. The lesion has a distinct vascular background.

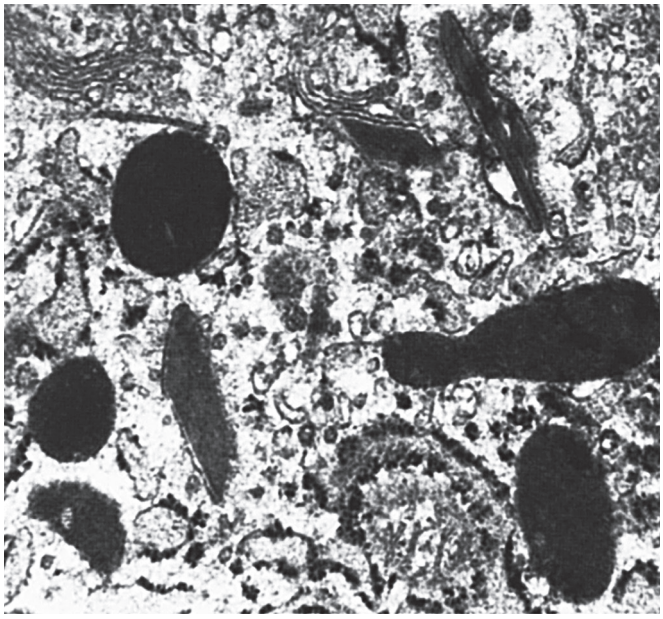

Figure 24.71 Secretory Granules of Juxtaglomerular Cell Tumor as Seen Ultrastructurally. Some of them are diamond shaped, identical to those seen in normal juxtaglomerular cells. This case has been reported by Conn et al.[848] (Courtesy of Dr. M.R. Abell, Ann Arbor, MI.)

The light microscopic appearance is reminiscent of hemangiopericytoma and glomus tumor, not surprisingly considering the fact that juxtaglomerular cells are specialized vessel-related epithelioid smooth muscle cells.[701,702] The tumor cells are uniform and round to polyhedral and have a granular acidophilic cytoplasm (Fig. 24.70). Mast cells are numerous. In some cases the tumor cells are spindled, and the pattern of growth may be papillary.[703] The intracytoplasmic renin granules may be demonstrated with PAS and Bowie stains, and their nature may be confirmed with immunohistochemical techniques.[698,702,704] In contrast to conventional or epithelioid AML, juxtaglomerular cell tumor is negative for HMB-45.[705] They are consistently positive for CD34 and CD117 and show focal staining for smooth muscle actin.[706] Ultrastructurally, adrenergic nerve terminals are seen in contact with the tumor cells, which have various types of secretory granules, some of them containing a typical rhomboid crystalline material thought to be renin protogranules (Fig. 24.71).[704,707-709] Cytogenetically, some recurrent chromosome imbalances have been reported.[710,711] All but one of the reported cases have behaved in a benign fashion,[699] but some patients have remained hypertensive following nephrectomy.[701,712]

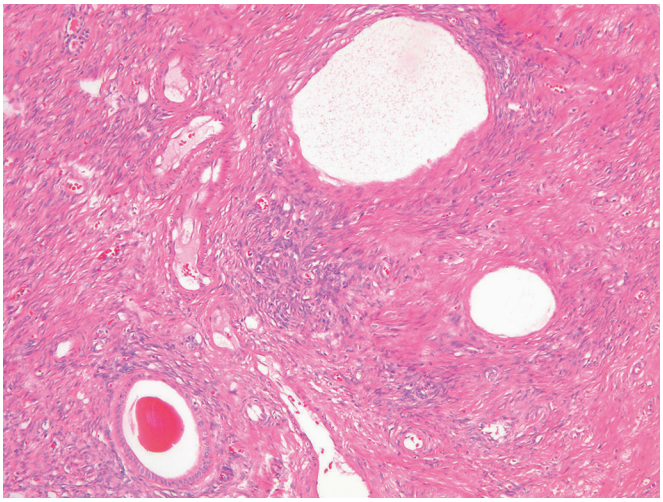

Figure 24.72 Mixed epithelial and stromal tumor with classic ovarian-like stroma.

It should be noted that renin secretion can be associated with other renal and extrarenal neoplasms, such as RCC, Wilms tumor, and pancreatic adenocarcinoma.[713-715]

MEST is the preferred diagnostic term applied to biphasic tumors, generally occurring in middle-aged and older women, that have been called cystic nephroma, MEST, or REST in adults.[716,717] Several recent studies have shown that the similarities, overlaps, and hybrid forms at the clinical, morphologic, phenotypic, and molecular levels are such as to suggest that cystic nephroma and MEST are two different manifestations of the same basic process.[717-720] As discussed in the section on pediatric renal neoplasia, the name cystic nephroma is now preferred for the pediatric cases that often have *DICER1* mutations and frequent syndromic association. MEST may be solid and cystic and may bulge into the renal pelvis. Microscopically, the spindle cell proliferation in between the individual cysts resembles ovarian stroma (Fig. 24.72), including the expression of hormone receptors. The epithelial component is, for the most part, is similar to cystic nephroma (and therefore consistent with renal ductal epithelium, also at the immunohistochemical and ultrastructural level[721]), but is more heterogeneous and may exhibit features suggestive of müllerian-type differentiation, including epithelium of endometrioid, tubal, clear cell, and squamous cell type. In addition, the epithelial component may be more predominant than typically seen in pediatric cases (Fig. 24.73). Cases with great predominance of the stromal or adipose component can be confused with leiomyomas or AMLs.[722] The behavior is generally benign, although a few histologically malignant examples have been reported.[723,724]

Other Benign Tumors and Tumorlike Conditions

Medullary fibroma is also referred to as *renomedullary interstitial cell tumor*, under the assumption that it arises from the medullary interstitial cell.[725] The latter is a specialized stromal element that

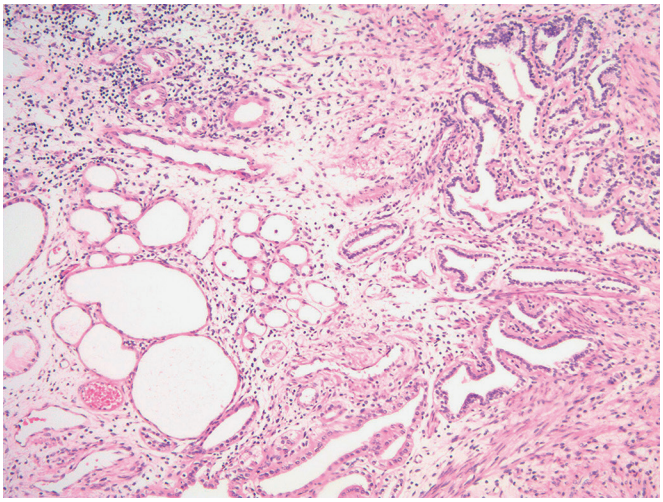

Figure 24.73 Mixed epithelial and stromal tumor with crowded and various shaped glands.

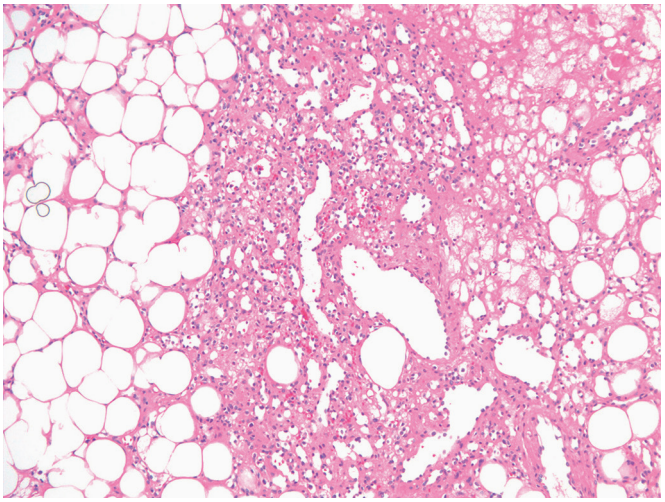

Figure 24.74 Anastomosing hemangioma in the renal hilum.

produces prostaglandins and is believed to be involved in the regulation of intrarenal blood pressure.[726] The tumors are asymptomatic and invariably found incidentally as minute (usually 3 mm or less) white nodules in the midportion of the medullary pyramids.[727] Microscopically, they are composed of small, stellate, or polygonal cells in a loose stromal background, with entrapped tubules at the periphery.

The rare renal **leiomyoma** is usually located in the cortex or capsule but may also arise in association with hilar blood vessels.[668,728] True leiomyomas occur almost exclusively in women. They may represent an incidental histologic finding at surgery or, as with many tumors, an incidental radiographic finding.[729] In our opinion, many "leiomyomas" reported in the literature represent "lipid-poor" AMLs that closely resemble smooth muscle.[668,730] Immunophenotypically, strong and diffuse desmin expression and absence of cathepsin-K is most helpful since most AMLs show the opposite pattern.[668]

Although reported in the literature, the diagnosis of a renal **lipoma** should be met with great suspicion.[731,732] Before the diagnosis is made, alternative (and more likely) possibilities should be considered: lipid-rich AML or atypical lipomatous tumor of the retroperitoneum (some of which are centered in the perirenal region and which can look very "lipoma-like"). Pelvic/parapelvic lipomatosis could also be considered.

Primary **hemangioblastomas** have been reported in the kidney. These may be difficult to distinguish from clear cell RCC, given the significant overlap in immunophenotype.[733,734]

Myxoma presents as a gelatinous intraparenchymal tumor; its appearance is identical to that of myxoma of soft tissue.[735]

Benign peripheral nerve tumors of both *schwannoma*[736-738] and *perineurioma* type[739] have been described.

Vascular tumors and tumorlike conditions of various types rarely arise in the kidney.[740] *Arteriovenous malformations* are identical to their soft tissue counterparts.[740] *Hemangioma* is frequently located in the medullary portion, where it can give rise to copious hematuria.[727] Microscopically, most are of the capillary type, with a sieve-like pattern reminiscent of splenic pulp.[740] Many exhibit an anastomosing pattern mimicking angiosarcoma (Fig. 24.74).[741] They should be distinguished from RCCs with a prominent angiomatoid component. *Lymphangioma* can also involve the kidney,[742,743] but before this diagnosis is made, the more likely possibility of cystic nephroma/MEST should be considered and ruled out. The myopericytoma family of tumors, predominantly *glomus tumor* (some of them with atypical features)[744] and the closely related *glomangiomyoma*, can present as intrarenal masses, raising the differential diagnosis with juxtaglomerular cell tumor.[745-747]

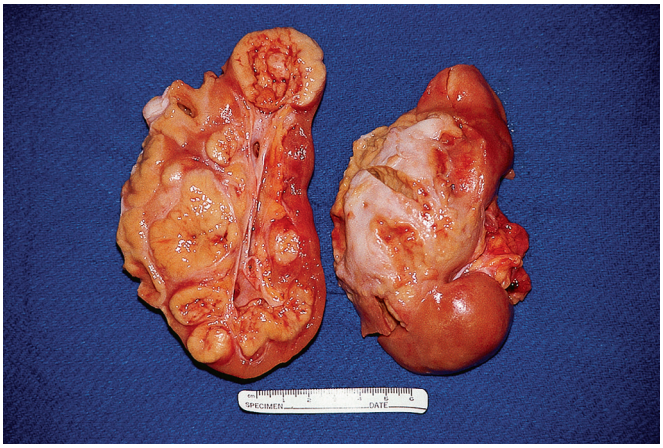

Figure 24.75 Massive renal involvement by malakoplakia.

Solitary fibrous tumor (SFT) has been seen involving the renal parenchyma or the renal capsule, sometimes in association with hypoglycemia.[748-750] Many of the cases historically reported as renal hemangiopericytoma are now considered SFT.[751] As in other sites, most SFTs are benign, with occasional examples behaving aggressively.[752]

Inflammatory myofibroblastic tumor may affect primarily the kidney; the behavior is generally indolent.[753]

Hydatid cyst can present as an intrarenal mass in countries where this parasitosis is endemic.

Hematomas can develop in the kidney or perirenal tissues as a result of trauma, from rupture of hemangiomas, and sometimes for no apparent cause. Some perirenal hematomas may contain peculiar periodic formations ("Liesegang structures") with radial striations that can simulate the appearance of parasites and that have been confused with such.[754]

Rosai–Dorfman disease (sinus histiocytosis with massive lymphadenopathy) and **malakoplakia** can result in renal masses (Fig. 24.75).[755-759]

Sarcomas

Sarcomas of various types can arise in the adult kidney, including the renal capsule.[760-762] These include *leiomyosarcoma* (classic or myxoid),[763-765] *synovial sarcoma* (increasingly recognized at this site),[766-769] *fibrosarcoma* (exceptional), *pleomorphic rhabdomyosarcoma* (just as rare),[770] so-called *malignant fibrous histiocytoma (pleomorphic undifferentiated sarcoma, NOS)*,[771] *liposarcoma* (but need to rule out renal extension of a retroperitoneal tumor),[772] *angiosarcoma*,[740,773,774] *osteosarcoma*,[775-777] *chondrosarcoma*,[778] *malignant mesenchymoma*,[779,780] and *clear cell sarcoma* (malignant melanoma of soft parts, not to be confused with the pediatric-type renal clear cell sarcoma).[781] Some of the chondrosarcomas have been of the mesenchymal variety.[782] Some of the smooth muscle tumors have occurred in immunosuppressed patients in association with Epstein–Barr virus infection.[783] The synovial sarcomas, before the possibility of their intrarenal occurrence was realized and documented by molecular studies, were probably included in the heterogeneous group of embryonal sarcomas of the kidney.[766] The reported cases have been of the monophasic type and some had rhabdoid features.[784] It is well to remember that the entrapment of cystically dilated tubules lined by hobnail epithelium can simulate a biphasic appearance (just as the entrapment of bronchoalveolar epithelium can result in a similar appearance in primary or metastatic monophasic synovial sarcoma in the lung).

An important warning is appropriate at this point: Before a diagnosis of primary sarcoma of the kidney of any type is made, the more common possibilities of sarcomatoid RCC (or urothelial carcinoma) and primary retroperitoneal soft tissue sarcoma (particularly de-differentiated liposarcoma) with secondary renal invasion should be considered.

Malignant Lymphoma and Related Lymphoid Lesions

Malignant lymphoma of the kidney is usually the expression of generalized disease,[785] but sometimes the kidney is the only site of tumor.[786-788] Bilaterality is common in either situation. Renal failure may result from diffuse involvement of the organ.[789,790] The majority of the cases are of large B-cell type.[791] Other types have been described, including low-grade B-cell lymphoma of so-called MALT type (containing lymphoepithelial lesions within renal tubules).[792,793] Some such cases have been reported in the setting of AIDS[794] and others in organ transplant recipients,[795] sometimes with involvement of the renal allograft.[796]

Two varieties of lymphoma with a predilection for secondary renal involvement are thymic large B-cell lymphoma with sclerosis and lymphomatoid granulomatosis/angiotrophic large cell lymphoma.[797]

Plasmacytomas may be found within the kidney, usually as a result of dissemination in multiple myeloma but sometimes as an expression of extramedullary tumor.[798]

Metastatic Tumors

Metastatic carcinoma can affect the kidney as a part of a disseminated process, but the renal involvement is only rarely of clinical significance.[799,800] The metastasis may appear years or decades after the removal of the primary tumor.[801] On CT scan, renal metastases tend to be small, multiple, bilateral, wedge shaped, intracortical, and less exophytic than primary RCC.[802] In contrast to the latter, metastatic tumors are bilateral in a high proportion (over 50%) of cases.[803] About one-third of the patients have microscopic hematuria.[803] Sometimes the metastases are exclusively limited to the renal glomeruli, in an intracapillary or extracapillary fashion, and may be diagnosed by needle biopsy.[804,805] The most common primary sites are the lung, skin (malignant melanoma), breast, gastrointestinal tract, pancreas, ovary, and testis (nonseminomatous germ cell tumors, particularly choriocarcinoma).[806] Examples of odd types of metastatic tumors to the kidney simulating primary renal tumors include SETTLE, adenoid cystic carcinoma of breast,[807] and the follicular variant of papillary thyroid carcinoma.[808]

Tumors of Renal Pelvis and Ureter

Urothelial Carcinoma

Most urothelial carcinomas of the renal pelvis occur in adults (in whom they constitute about 7% of all primary renal carcinomas).[809,810] While a history of analgesic abuse and/or coexistence of renal papillary necrosis,[811,812] Thorotrast exposure for radiographic purposes,[813] or cyclophosphamide therapy[814] may be predisposing factors in a small subset of cases, smoking is likely the greatest risk factor. These tumors have also been reported in horseshoe kidneys; their incidence may actually be increased in this congenital abnormality.[815] Some cases have developed as a manifestation of the hereditary nonpolyposis colorectal cancer syndrome, and these rare cases may show abnormal expression of mismatch repair proteins by immunohistochemistry.[816,817] Hematuria is the most common clinical presentation.[818,819] Synchronous or metachronous tumors elsewhere in the urinary tract (most of them in the bladder) are found in over half of the patients[811,820]; exceptionally, an independent RCC may be found in the same kidney.[821-823] Intravenous and retrograde pyelography provides the most accurate means of diagnosis.[818] The sensitivity and accuracy of cytologic examination are higher than for RCC, particularly for the high-grade tumors.[824]

Grossly, these tumors form soft, gray-to-red masses with smooth, glistening surfaces that resemble the urothelial tumors of the bladder (Fig. 24.76).[812] They often diffusely involve the entire renal pelvis and form arborescent masses that may extend down the ureter. Occasionally, they are circumscribed to a calyx or even to the inside of a calyceal cyst.[825] High-grade lesions can spread massively into the renal parenchyma and even reach the renal capsule. They can be distinguished grossly from RCC because of their granular appearance and extensive pelvic involvement.

Urothelial carcinomas of the ureter may be located anywhere along the length of the organ and usually result in dilation of the proximal portion due to lumen obstruction by the tumor.[826,827]

The microscopic appearance of these urothelial carcinomas, whether located in the renal pelvis or ureter, is identical to that of their more common homologues in the bladder. The majority are high-grade neoplasms, the percentage (about 70%) being much higher than for the same tumor type in the bladder.[828] The pelvic neoplasms sometimes extend proximally along the collecting tubules, a pattern that should not be confused with adenocarcinoma.[829] The adjacent urothelium may show urothelial carcinoma in situ.[830] It should be pointed out that upper tract biopsies are fraught with artifacts that can mimic urothelial neoplasia.[831,832] The similarities with urothelial carcinomas of the bladder also apply to the occurrence of variants such as the *micropapillary type*[833,834] and others,[835] as well as their immunohistochemical profile, including coexpression of keratins 7 and 20[836] and overexpression of p53 protein (particularly in the high-grade tumors).[837] In our experience, up to 25% of upper tract urothelial carcinomas may express nuclear PAX-8.[838,839]

The standard treatment of pyeloureteral urothelial carcinoma is nephroureterectomy. Segmental resection has sometimes been employed for midureteral lesions,[825] and endoscopic removal has been done for low-grade noninvasive lesions, but the high incidence of multicentricity and coexistent carcinoma in situ (particularly with

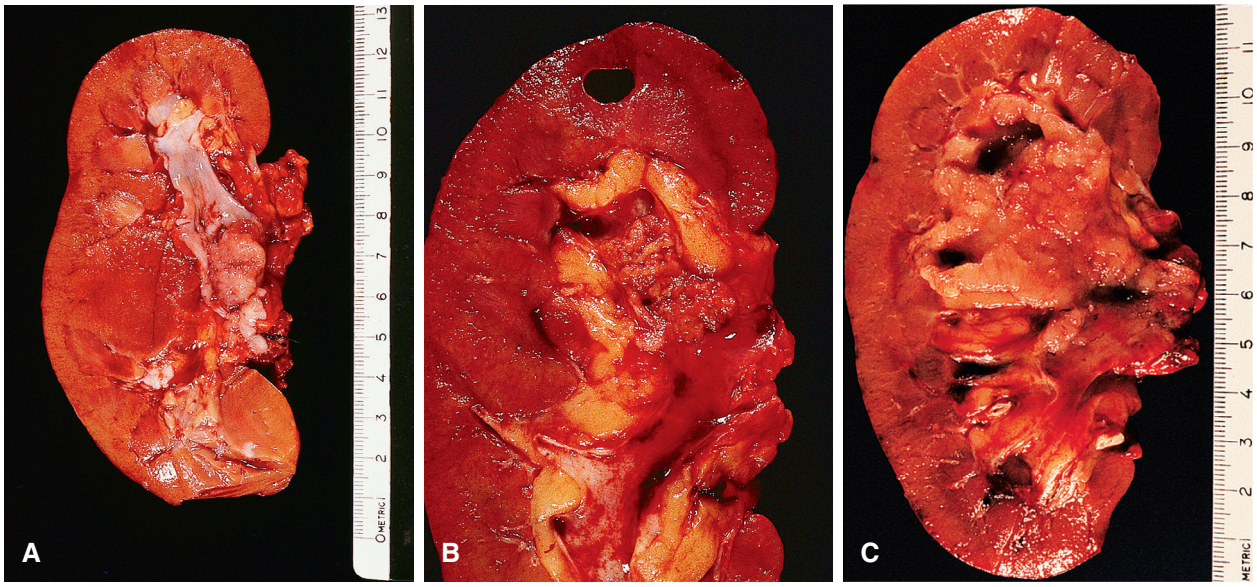

Figure 24.76 Gross Appearances of Urothelial Carcinoma of Renal Pelvis. A and **B,** The tumor protrudes into the pelvic cavity and has a granular surface. **C,** The tumor coats the pelvis and calyces.

the high-grade tumors) indicates that radical surgery is the treatment of choice for the large majority of cases.[840,841] Furthermore, these tumors have a tendency to implant along the ureter, especially in its terminal (intramural) portion. Therefore a resection of the bladder cuff may be performed to avoid tumor recurrence.[842,843] The overall 5-year survival rate in the surgically resected cases is about 50%.[809,811] The prognosis is largely determined by the stage of the lesion for both the pelvic and ureteral lesions.[844-848] Unfortunately, most of the patients present with locally advanced (pT2 or more) disease at the time of surgery.[828,835]

Other Carcinoma Types

Primary squamous cell carcinoma[813,819,849,850] and *primary adenocarcinoma*[851-854] rarely occur in the upper urinary tract. Essentially all rare subtypes and urothelial carcinoma variants described in the urinary bladder may also be identified in the pelvicalyceal and ureteral system, including hepatoid carcinoma,[855] *lymphoepithelioma-like carcinoma,*[856] sarcomatoid urothelial carcinoma,[835,857-859] giant cell carcinoma,[860-862] small cell neuroendocrine carcinoma,[618,863] carcinoma with trophoblastic features,[864-867] and carcinoma with rhabdoid features.[868] **Verrucous carcinoma** has been reported in the pelvis of a horseshoe kidney associated with staghorn calculi.[869] Clinicopathologic features are identical to those described in the urinary bladder.

Other Tumors and Tumorlike Conditions

Fibroepithelial polyp[870,871] (Fig. 24.77) and **hypertrophic infundibular stenosis of the calyces**[872] are two rare tumorlike masses of the pelvic region.

Pelvic lipomatosis and **fibrolipomatosis** result from excessive proliferation of peripelvic fat with or without accompanying fibrous tissue and may simulate a neoplasm radiographically.[873]

Amyloidosis can present as a localized nodule in the wall of one or both ureters (so-called amyloid tumor).[874]

Myelolipoma morphologically similar to its more common adrenal counterpart can present as a mass in the renal sinus.[875]

Malakoplakia of the pelvis or ureter may result in obstruction and hydronephrosis.[876,877]

Figure 24.77 Benign fibroepithelial polyp emerging from lower calyx of the left kidney in a 61-year-old woman. The tumor caused hematuria, and total nephrectomy was performed.

Stone granuloma is a complication of ureteroscopy and ureteral stone fragmentation; it is characterized by the presence of embedded particles of calcium oxalate associated with macrophages and foreign body giant cells, with surrounding fibrosis and dilation of the proximal ureter.[878]

Endometriosis of the ureter presents with hydroureter, often accompanied by hydronephrosis. The disease may be extrinsic to the ureter or present within its wall. As in other sites, endometriosis may rarely be associated with secondary Müllerian neoplasms.

Most patients have a past history of hysterectomy with salpingo-oophorectomy.[879]

Subepithelial hematoma of the renal pelvis (Antopol–Goldman lesion) can present with gross hematuria and radiographically simulate a malignant tumor. The etiology is unknown.[880,881]

"**Urinoma**" results from the extravasation of urine into the renal perihilar and peripelvic fat; in the early stages there is lipolysis with foamy macrophages and multinucleated giant cells, followed by fibrosis and deposition of "urinary precipitates." Demonstration of Tamm–Horsfall protein by immunostaining confirms the fact that the amorphous extracellular precipitates are derived from uroprotein.[882]

Benign pyeloureteral tumors include *inverted papilloma* (sometimes multiple),[883,884] *nephrogenic adenoma*,[885-888] *villous adenoma*,[889] *hemangioma*,[890] *leiomyoma*,[891] *SFT*,[892] *neurofibroma*, *granular cell tumor*,[893] and *glomus tumor*.[894] The hemangiomas are often located at the tips of the papillae, are multiple in about 10% of the cases, and may result in recurrent episodes of hemorrhage.[895,896] Owing to their small size, extensive sectioning may be needed to find the lesion. The nephrogenic adenoma may show gastric metaplasia.[897]

Malignant tumors of nonepithelial type are exceptional. A few cases of *leiomyosarcoma* have been reported.[898] Non-Hodgkin *malignant lymphoma* of the retroperitoneum can involve the ureter secondarily.[899] A case of primary malignant lymphoma has been reported in the pelvis of a transplanted kidney.[900] A few cases of benign and malignant tumors have been reported in ureteroileal conduits.[901,902]

Metastatic carcinomas to the retroperitoneum can invade the ureteral wall and result in obstruction; the breast and lung are the most common sites for the primary tumors.[903,904]

References

1. Sebire NJ, Vujanic GM. Paediatric renal tumours: recent developments, new entities and pathological features. *Histopathology*. 2009;54(5):516-528.
2. Argani P, Bruder E, Dehner L, Vujanic GM. Nephroblastic and cystic tumours occurring mainly in children. In: Moch H, Humphrey PA, Ulbright TM, Reuter VE, eds. *WHO Classification of Tumours of the Urinary System and Male Genital Organs*. Lyon: IARC Press; 2016.
3. Chevalier G, Yeger H, Martinerie C, et al. novH: differential expression in developing kidney and Wilm's tumors. *Am J Pathol*. 1998;152(6):1563-1575.
4. Li CM, Guo M, Borczuk A, et al. Gene expression in Wilms' tumor mimics the earliest committed stage in the metanephric mesenchymal-epithelial transition. *Am J Pathol*. 2002;160(6):2181-2190.
5. Yashima K, Maitra A, Timmons CF, et al. Expression of the RNA component of telomerase in Wilms tumor and nephrogenic rest recapitulates renal embryogenesis. *Hum Pathol*. 1998;29(5):536-542.
6. Crist WM, Kun LE. Common solid tumors of childhood. *N Engl J Med*. 1991;324(7):461-471.
7. Juberg RC, St Martin EC, Hundley JR. Familial occurrence of Wilms' tumor: nephroblastoma in one of monozygous twins and in another sibling. *Am J Hum Genet*. 1975;27(2):155-164.
8. Webber BL, Parham DM, Drake LG, Wilimas JA. Renal tumors in childhood. *Pathol Ann*. 1992;27(Pt 1):191-232.
9. Hrabovsky EE, Othersen HB Jr, deLorimier A, et al. Wilms' tumor in the neonate: a report from the National Wilms' Tumor Study. *J Pediatr Surg*. 1986;21(5):385-387.
10. Merten DF, Yang SS, Bernstein J. Wilms' tumor in adolescence. *Cancer*. 1976;37(3):1532-1538.
11. Huser J, Grignon DJ, Ro JY, et al. Adult Wilms' tumor: a clinicopathologic study of 11 cases. *Mod Pathol*. 1990;3(3):321-326.
12. Terenziani M, Spreafico F, Collini P, et al. Adult Wilms' tumor: a monoinstitutional experience and a review of the literature. *Cancer*. 2004;101(2):289-293.
13. Williams G, Colbeck RA, Gowing NF. Adult Wilms' tumour: review of 14 patients. *Br J Urol*. 1992;70(3):230-235.
14. Rubin BP, Pins MR, Nielsen GP, et al. Isochromosome 7q in adult Wilms' tumors: diagnostic and pathogenetic implications. *Am J Surg Pathol*. 2000;24(12):1663-1669.
15. Chen I, Pasalic D, Fischer-Valuck B, et al. Disparity in outcomes for adolescent and young adult patients diagnosed with pediatric solid tumors across 4 decades. *Am J Clin Oncol*. 2016.
16. Paulino AC, Thakkar B, Henderson WG. Metachronous bilateral Wilms' tumor: the importance of time interval to the development of a second tumor. *Cancer*. 1998;82(2):415-420.
17. Shearer P, Parham DM, Fontanesi J, et al. Bilateral Wilms tumor. Review of outcome, associated abnormalities, and late effects in 36 pediatric patients treated at a single institution. *Cancer*. 1993;72(4):1422-1426.
18. Benatar B, Wright C, Freinkel AL, Cooper K. Primary extrarenal Wilms' tumor of the uterus presenting as a cervical polyp. *Int J Gynecol Pathol*. 1998;17(3):277-280.
19. Ho J, Ma L, Wong KC. An extrarenal Wilms' tumour arising from an undescended testis. *Pathology*. 1981;13(3):619-624.
20. Luchtrath H, de Leon F, Giesen H, Gok Y. Inguinal nephroblastoma. *Virchows Arch A Pathol Anat Histopathol*. 1984;405(1):113-118.
21. Mount SL, Dickerman JD, Taatjes DJ. Extrarenal Wilms' tumor: an ultrastructural and immunoelectron microscopic case report. *Ultrastruct Pathol*. 1996;20(2):155-165.
22. Roberts DJ, Haber D, Sklar J, Crum CP. Extrarenal Wilms' tumors. A study of their relationship with classical renal Wilms' tumor using expression of WT1 as a molecular marker. *Lab Invest*. 1993;68(5):528-536.
23. Wakely PE Jr, Sprague RI, Kornstein MJ. Extrarenal Wilms' tumor: an analysis of four cases. *Hum Pathol*. 1989;20(7):691-695.
24. Ward SP, Dehner LP. Sacrococcygeal teratoma with nephroblastoma (Wilm's tumor): a variant of extragonadal teratoma in childhood. A histologic and ultrastructural study. *Cancer*. 1974;33(5):1355-1363.
25. Clericuzio CL. Clinical phenotypes and Wilms tumor. *Med Pediatr Oncol*. 1993;21(3):182-187.
26. Manivel JC, Sibley RK, Dehner LP. Complete and incomplete Drash syndrome: a clinicopathologic study of five cases of a dysontogenetic-neoplastic complex. *Hum Pathol*. 1987;18(1):80-89.
27. Miller RW, Fraumeni JF Jr, Manning MD. Association of Wilms's tumor with aniridia, hemihypertrophy and other congenital malformations. *N Engl J Med*. 1964;270:922-927.
28. Sotelo-Avila C, Gooch WM 3rd. Neoplasms associated with the Beckwith-Wiedemann syndrome. *Perspect Pediatr Pathol*. 1976;3:255-272.
29. Auber F, Jeanpierre C, Denamur E, et al. Management of Wilms tumors in Drash and Frasier syndromes. *Pediatr Blood Cancer*. 2009;52:55-59.
30. Bolande RP. Neoplasia of early life and its relationships to teratogenesis. *Perspect Pediatr Pathol*. 1976;3:145-183.
31. Olshan AF, Breslow NE, Falletta JM, et al. Risk factors for Wilms tumor. Report from the National Wilms Tumor Study. *Cancer*. 1993;72(3):938-944.
32. Rajfer J. Association between Wilms tumor and gonadal dysgenesis. *J Urol*. 1981;125(3):388-390.
33. Bissig H, Staehelin F, Tolnay M, et al. Co-occurrence of neuroblastoma and nephroblastoma in an infant with Fanconi's anemia. *Hum Pathol*. 2002;33(10):1047-1051.
34. Breslow NE, Takashima JR, Whitton JA, et al. Second malignant neoplasms following treatment for Wilm's tumor: a report from the National Wilms' Tumor Study Group. *J Clin Oncol*. 1995;13(8):1851-1859.
35. Kovalic JJ, Thomas PR, Beckwith JB, et al. Hepatocellular carcinoma as second malignant neoplasms in successfully treated Wilms' tumor patients. A National Wilms' Tumor Study report. *Cancer*. 1991;67(2):342-344.
36. Nakamura Y, Nakashima T, Nakashima H, Hashimoto T. Bilateral cystic nephroblastomas and botryoid sarcoma involving vagina and urinary bladder in a child with microcephaly, arhinencephaly, and bilateral cataracts. *Cancer*. 1981;48(4):1012-1015.
37. Stern M, Longaker MT, Adzick NS, et al. Hyaluronidase levels in urine from Wilms' tumor patients. *J Natl Cancer Inst*. 1991;83(21):1569-1574.
38. Thorner P, McGraw M, Weitzman S, et al. Wilms' tumor and glomerular disease. Occurrence with features of membranoproliferative glomerulonephritis and secondary focal, segmental glomerulosclerosis. *Arch Pathol Lab Med*. 1984;108(2):141-146.
39. Zakowski MF, Edwards RH, McDonough ET. Wilms' tumor presenting as sudden death due to tumor embolism. *Arch Pathol Lab Med*. 1990;114(6):605-608.
40. Lowe LH, Isuani BH, Heller RM, et al. Pediatric renal masses: Wilms tumor and beyond. *Radiographics*. 2000;20:1585-1603.
41. Beckwith JB. Wilms' tumor and other renal tumors of childhood: a selective review from the National Wilms' Tumor Study Pathology Center. *Hum Pathol*. 1983;14(6):481-492.
42. Charles AK, Vujanic GM, Berry PJ. Renal tumours of childhood. *Histopathology*. 1998;32(4):293-309.

43. Marsden HB. The pathology and natural history of childhood tumours. *Recent Results Cancer Res*. 1983;88:11-25.
44. Garvin AJ, Surrette F, Hintz DS, et al. The in vitro growth and characterization of the skeletal muscle component of Wilms' tumor. *Am J Pathol*. 1985;121(2):298-310.
45. Balsaver AM, Gibley CW Jr, Tessmer CF. Ultrastructural studies in Wilms's tumor. *Cancer*. 1968;22(2):417-427.
46. Chatten J. Epithelial differentiation in Wilms' tumor: a clinicopathologic appraisal. *Perspect Pediatr Pathol*. 1976;3:225-254.
47. Mierau GW, Beckwith JB, Weeks DA. Ultrastructure and histogenesis of the renal tumors of childhood: an overview. *Ultrastruct Pathol*. 1987;11(2-3):313-333.
48. Yeger H, Baumal R, Harason P, Phillips MJ. Lectin histochemistry of Wilms' tumor. Comparison with normal adult and fetal kidney. *Am J Clin Pathol*. 1987;88(3): 278-285.
49. Hennigar RA, Spicer SA, Sens DA, et al. Histochemical evidence for tubule segmentation in a case of Wilms' tumor. *Am J Clin Pathol*. 1986;85(6):724-731.
50. Kodet R, Marsden HB. Papillary Wilms' tumour with carcinoma-like foci and renal cell carcinoma in childhood. *Histopathology*. 1985;9(10):1091-1102.
51. Edwards O, Chatten J. Hydropic cell variant (clear cell variant) of Wilms' tumor. *Arch Pathol Lab Med*. 1985;109(10):956-958.
52. Hou LT, Azzopardi JG. Muco-epidermoid metaplasia and argentaffin cells in nephroblastoma. *J Pathol Bacteriol*. 1967;93(2):477-481.
53. Delemarre JF, Sandstedt B, Tournade MF. Nephroblastoma with fibroadenomatous-like structures. *Histopathology*. 1984;8(1):55-62.
54. Joshi VV, Beckwith JB. Pathologic delineation of the papillonodular type of cystic partially differentiated nephroblastoma. A review of 11 cases. *Cancer*. 1990;66(7):1568-1577.
55. Lindop GB, Fleming S, Gibson AA. Immunocytochemical localisation of renin in nephroblastoma. *J Clin Pathol*. 1984;37(7):738-742.
56. Grimes MM, Wolff M, Wolff JA, et al. Ganglion cells in metastatic Wilms' tumor. Review of a histogenetic controversy. *Am J Surg Pathol*. 1982;6(6):565-571.
57. Masson P. The role of the neural crest in the embryonal adenosarcomas of the kidney. *Am J Cancer*. 1938;33:1-32.
58. Jenkins MC, Allibone EB, Berry PJ. Neuroglial tissue in partially cystic Wilms' tumour. *Histopathology*. 1991;18(4):309-313.
59. Magee JF, Ansari S, McFadden DE, Dimmick J. Teratoid Wilms' tumour: a report of two cases. *Histopathology*. 1992;20(5):427-431.
60. Variend S, Spicer RD, Mackinnon AE. Teratoid Wilms' tumor. *Cancer*. 1984;53(9):1936-1942.
61. Droz D, Rousseau-Merck MF, Jaubert F, et al. Cell differentiation in Wilms' tumor (nephroblastoma): an immunohistochemical study. *Hum Pathol*. 1990;21(5):536-544.
62. Hennigar RA, Garvin AJ, Hazen-Martin DJ, Schulte BA. Immunohistochemical localization of transport mediators in Wilms' tumor: comparison with fetal and mature human kidney. *Lab Invest*. 1989;61(2):192-201.
63. Vasei M, Moch H, Mousavi A, et al. Immunohistochemical profiling of Wilms tumor: a tissue microarray study. *Appl Immunohistochem Mol Morphol*. 2008;16(2):128-134.
64. Magee F, Mah RG, Taylor GP, Dimmick JE. Neural differentiation in Wilms' tumor. *Hum Pathol*. 1987;18(1):33-37.
65. Folpe AL, Patterson K, Gown AM. Antibodies to desmin identify the blastemal component of nephroblastoma. *Mod Pathol*. 1997;10(9):895-900.
66. Bisceglia M, Ragazzi M, Galliani CA, et al. TTF-1 expression in nephroblastoma. *Am J Surg Pathol*. 2009;33(3):454-461.
67. Arva NC, Bonadio J, Perlman EJ, Cajaiba MM. Diagnostic utility of Pax8, Pax2, and NGFR immunohistochemical expression in pediatric renal tumors. *Appl Immunohistochem Mol Morphol*. 2017.
68. Coppes MJ, Haber DA, Grundy PE. Genetic events in the development of Wilms' tumor. *N Engl J Med*. 1994;331(9):586-590.
69. Telerman A, Dodemont H, Degraef C, et al. Identification of the cellular protein encoded by the human Wilms' tumor (WT1) gene. *Oncogene*. 1992;7(12):2545-2548.
70. van Heyningen V, Bickmore WA, Seawright A, et al. Role for the Wilms tumor gene in genital development? *Proc Natl Acad Sci USA*. 1990;87(14):5383-5386.
71. Dowdy SF, Fasching CL, Araujo D, et al. Suppression of tumorigenicity in Wilms tumor by the p15.5–p14 region of chromosome 11. *Science*. 1991;254(5029):293-295.
72. Malik K, Yan P, Huang TH, Brown KW. Wilms' tumor: a paradigm for the new genetics. *Oncol Res*. 2001;12(11-12):441-449.
73. Slater RM, de Kraker J. Chromosome number 11 and Wilms' tumor. *Cancer Genet Cytogenet*. 1982;5(3):237-245.
74. Slater RM, Mannens MM. Cytogenetics and molecular genetics of Wilms' tumor of childhood. *Cancer Genet Cytogenet*. 1992;61(2):111-121.
75. Gerald WL, Gramling TS, Sens DA, Garvin AJ. Expression of the 11p13 Wilms' tumor gene, WT1, correlates with histologic category of Wilms' tumor. *Am J Pathol*. 1992;140(5):1031-1037.
76. Kikuchi H, Akasaka Y, Nagai T, et al. Genomic changes in the WT-gene (WT1) in Wilms' tumors and their correlation with histology. *Am J Pathol*. 1992;140(4):781-786.
77. Re GG, Hazen-Martin DJ, Sens DA, Garvin AJ. Nephroblastoma (Wilms' tumor): a model system of aberrant renal development. *Semin Diagn Pathol*. 1994;11(2):126-135.
78. Yeger H, Cullinane C, Flenniken A, et al. Coordinate expression of Wilms' tumor genes correlates with Wilms' tumor phenotypes. *Cell Growth Differ*. 1992;3(12):855-864.
79. Fukuzawa R, Holman SK, Chow CW, et al. WTX mutations can occur both early and late in the pathogenesis of Wilms tumour. *J Med Genet*. 2010;47:791-794.
80. Perotti D, Gamba B, Sardella M, et al. Functional inactivation of the WTX gene is not a frequent event in Wilms' tumors. *Oncogene*. 2008;27:4625-4632.
81. Rivera MN, Kim WJ, Wells J, et al. An X chromosome gene, WTX, is commonly inactivated in Wilms tumor. *Science*. 2007;315(5812):642-645.
82. Ruteshouser EC, Robinson SM, Huff V. Wilms tumor genetics: mutations in WT1, WTX, and CTNNB1 account for only about one-third of tumors. *Genes Chromosomes Cancer*. 2008;47(6):461-470.
83. Wegert J, Wittmann S, Leuschner I, et al. WTX inactivation is a frequent, but late event in Wilms tumors without apparent clinical impact. *Genes Chromosomes Cancer*. 2009;48(12):1102-1111.
84. Kusafuka T, Miao J, Kuroda S, et al. Codon 45 of the beta-catenin gene, a specific mutational target site of Wilms' tumor. *Int J Mol Med*. 2002;10(4):395-399.
85. Maiti S, Alam R, Amos CI, Huff V. Frequent association of beta-catenin and WT1 mutations in Wilms tumors. *Cancer Res*. 2000;60(22):6288-6292.
86. Royer-Pokora B, Weirich A, Schumacher V, et al. Clinical relevance of mutations in the Wilms tumor suppressor 1 gene WT1 and the cadherin-associated protein beta1 gene CTNNB1 for patients with Wilms tumors: results of long-term surveillance of 71 patients from International Society of Pediatric Oncology Study 9/Society for Pediatric Oncology. *Cancer*. 2008;113(5):1080-1089.
87. Govender D. The genetics of Wilms tumor. *Adv Anat Pathol*. 1997;4:202-206.
88. Sheng WW, Soukup S, Bove K, et al. Chromosome analysis of 31 Wilms' tumors. *Cancer Res*. 1990;50(9):2786-2793.
89. Zhuang Z, Merino MJ, Vortmeyer AO, et al. Identical genetic changes in different histologic components of Wilms' tumors. *J Natl Cancer Inst*. 1997;89(15):1148-1152.
90. el Bahtimi R, Hazen-Martin DJ, Re GG, et al. Immunophenotype, mRNA expression, and gene structure of p53 in Wilms' tumors. *Mod Pathol*. 1996;9(3):238-244.
91. Takeuchi S, Bartram CR, Ludwig R, et al. Mutations of p53 in Wilms' tumors. *Mod Pathol*. 1995;8(5):483-487.
92. Wegert J, Ishaque N, Vardapour R, et al. Mutations in the SIX1/2 pathway and the DROSHA/DGCR8 miRNA microprocessor complex underlie high-risk blastemal type Wilms tumors. *Cancer Cell*. 2015;9:298-311.
93. Ebb DH, Kerasidis H, Vezina G, et al. Spinal cord compression in widely metastatic Wilms' tumor. Paraplegia in two children with anaplastic Wilms' tumor. *Cancer*. 1992;69(11):2726-2730.
94. Lowis SP, Foot A, Gerrard MP, et al. Central nervous system metastasis in Wilms' tumor: a review of three consecutive United Kingdom trials. *Cancer*. 1998;83(9):2023-2029.
95. D'Angio GJ, Breslow N, Beckwith JB, et al. Treatment of Wilms' tumor. Results of the Third National Wilms' Tumor Study. *Cancer*. 1989;64(2):349-360.
96. D'Angio GJ, Evans A, Breslow N, et al. The treatment of Wilms' tumor: results of the Second National Wilms' Tumor Study. *Cancer*. 1981;47(9):2302-2311.
97. Green DM, Beckwith JB, Breslow NE, et al. Treatment of children with stages II to IV anaplastic Wilms' tumor: a report from the National Wilms' Tumor Study Group. *J Clin Oncol*. 1994;12(10):2126-2131.
98. Tournade MF, Com-Nougue C, Voute PA, et al. Results of the Sixth International Society of Pediatric Oncology Wilms' Tumor Trial and Study: a risk-adapted therapeutic approach in Wilms' tumor. *J Clin Oncol*. 1993;11(6): 1014-1023.
99. Perlman EJ. Pediatric renal tumors: practical updates for the pathologist. *Pediatr Dev Pathol*. 2005;8(3):320-338.
100. Vujanic GM, Sandstedt B, Harms D, et al. Revised International Society of Paediatric Oncology (SIOP) working classification of renal tumors of childhood. *Med Pediatr Oncol*. 2002;38:79-82.
101. Vujanic GM, Sandstedt B. The pathology of Wilms' tumour (nephroblastoma): the International Society of Paediatric Oncology approach. *J Clin Pathol*. 2010;63:102-109.
102. D'Angio GJ. Oncology seen through the prism of Wilms tumor. *Med Pediatr Oncol*. 1985;13(2):53-58.
103. Antman KH, Ruxer RL Jr, Aisner J, Vawter G. Mesothelioma following Wilms' tumor in childhood. *Cancer*. 1984;54(2):367-369.
104. Arrigo S, Beckwith JB, Sharples K, et al. Better survival after combined modality care for adults with Wilms' tumor. A report from the National Wilms' Tumor Study. *Cancer*. 1990;66(5):827-830.
105. Breslow NE, Palmer NF, Hill LR, et al. Wilms' tumor: prognostic factors for patients without metastases at diagnosis: results of the National Wilms' Tumor Study. *Cancer*. 1978;41(4):1577-1589.

106. Jereb B, Tournade MF, Lemerle J, et al. Lymph node invasion and prognosis in nephroblastoma. *Cancer*. 1980;45(7):1632-1636.
107. Weeks DA, Beckwith JB, Luckey DW. Relapse-associated variables in stage I favorable histology Wilms' tumor. A report of the National Wilms' Tumor Study. *Cancer*. 1987;60(6):1204-1212.
108. Breslow N, Sharples K, Beckwith JB, et al. Prognostic factors in nonmetastatic, favorable histology Wilms' tumor. Results of the Third National Wilms' Tumor Study. *Cancer*. 1991;68(11):2345-2353.
109. Buchino JJ. Wilms' tumor—the continuing search for the true meaning of anaplasia. *Adv Anat Pathol*. 1997;4:239-243.
110. Bonadio JF, Storer B, Norkool P, et al. Anaplastic Wilms' tumor: clinical and pathologic studies. *J Clin Oncol*. 1985;3(4):513-520.
111. Faria P, Beckwith JB, Mishra K, et al. Focal versus diffuse anaplasia in Wilms tumor—new definitions with prognostic significance: a report from the National Wilms Tumor Study Group. *Am J Surg Pathol*. 1996;20(8):909-920.
112. Zuppan CW. Handling and evaluation of pediatric renal tumors. *Am J Clin Pathol*. 1998;109(4 suppl 1):S31-S37.
113. Zuppan CW, Beckwith JB, Luckey DW. Anaplasia in unilateral Wilms' tumor: a report from the National Wilms' Tumor Study Pathology Center. *Hum Pathol*. 1988;19(10):1199-1209.
114. Kheir S, Pritchett PS, Moreno H, Robinson CA. Histologic grading of Wilms' tumor as potential prognostic factor: results of a retrospective study of 26 patients. *Cancer*. 1978;41(3):1199-1207.
115. Lawler W, Marsden HB, Palmer MK. Wilms' tumor—histologic variation and prognosis. *Cancer*. 1975;36(3):1122-1126.
116. Verschuur AC, Vujanic GM, Van Tinteren H, et al. Stromal and epithelial predominant Wilms tumours have an excellent outcome: the SIOP 93 01 experience. *Pediatr Blood Cancer*. 2010;55:233-238.
117. Gonzalez-Crussi F, Hsueh W, Ugarte N. Rhabdomyogenesis in renal neoplasia of childhood. *Am J Surg Pathol*. 1981;5(6):525-532.
118. Wigger HJ. Fetal rhabdomyomatous nephroblastoma—a variant of Wilms' tumor. *Hum Pathol*. 1976;7(6):613-623.
119. Zuppan CW, Beckwith JB, Weeks DA, et al. The effect of preoperative therapy on the histologic features of Wilms' tumor. An analysis of cases from the Third National Wilms' Tumor Study. *Cancer*. 1991;68(2):385-394.
120. Cheah PL, Looi LM, Chan LL. Immunohistochemical expression of p53 proteins in Wilms' tumour: a possible association with the histological prognostic parameter of anaplasia. *Histopathology*. 1996;28(1):49-54.
121. Lahoti C, Thorner P, Malkin D, Yeger H. Immunohistochemical detection of p53 in Wilms' tumors correlates with unfavorable outcome. *Am J Pathol*. 1996;148(5):1577-1589.
122. Grundy PE, Breslow NE, Li S, et al. Loss of heterozygosity for chromosomes 1p and 16q is an adverse prognostic factor in favorable-histology Wilms tumor: a report from the National Wilms Tumor Study Group. *J Clin Oncol*. 2005;23(29):7312-7321.
123. Grundy PE, Telzerow PE, Breslow N, et al. Loss of heterozygosity for chromosomes 16q and 1p in Wilms' tumors predicts an adverse outcome. *Cancer Res*. 1994;54(9): 2331-2333.
124. Messahel B, Williams R, Ridolfi A, et al. Allele loss at 16q defines poorer prognosis Wilms tumour irrespective of treatment approach in the UKW1-3 clinical trials: a Children's Cancer and Leukaemia Group (CCLG) Study. *Eur J Cancer*. 2009;45(5):819-826.
125. Chagtai T, Zill C, Dainese L, et al. Gain of 1q As a prognostic biomarker in wilms tumors (WTs) treated with preoperative chemotherapy in the International Society of Paediatric Oncology (SIOP) WT 2001 trial: a SIOP renal tumours biology consortium study. *J Clin Oncol*. 2016;10:3195-3203.
126. Joshi VV, Beckwith JB. Multilocular cyst of the kidney (cystic nephroma) and cystic, partially differentiated nephroblastoma. Terminology and criteria for diagnosis. *Cancer*. 1989;64:466-479.
127. Bove KE, McAdams AJ. The nephroblastomatosis complex and its relationship to Wilms' tumor: a clinicopathologic treatise. *Perspect Pediatr Pathol*. 1976;3:185-223.
128. Heideman RL, Haase GM, Foley CL, et al. Nephroblastomatosis and Wilms' tumor. Clinical experience and management of seven patients. *Cancer*. 1985;55(7):1446-1451.
129. Stambolis C. Benign epithelial nephroblastoma. A contribution to its histogenesis. *Virchows Arch A Pathol Anat Histopathol*. 1977;376(3):267-272.
130. Perlman M, Levin M, Wittels B. Syndrome of fetal gigantism, renal hamartomas, and nephroblastomatosis with Wilms' tumor. *Cancer*. 1975;35(4):1212-1217.
131. Beckwith JB. Precursor lesions of Wilms tumor: clinical and biological implications. *Med Pediatr Oncol*. 1993;21(3):158-168.
132. Beckwith JB, Kiviat NB, Bonadio JF. Nephrogenic rests, nephroblastomatosis, and the pathogenesis of Wilms' tumor. *Pediatr Pathol*. 1990;10(1-2):1-36.
133. Machin GA, McCaughey WT. A new precursor lesion of Wilms' tumour (nephroblastoma): intralobar multifocal nephroblastomatosis. *Histopathology*. 1984;8(1):35-53.
134. White KS, Kirks DR, Bove KE. Imaging of nephroblastomatosis: an overview. *Radiology*. 1992;182(1):1-5.
135. Benjamin DR, Beckwith JB. Medullary ray nodules in infancy and childhood. *Arch Pathol*. 1973;96:33-35.
136. Hughson MD, McManus JF, Hennigar GR. Studies on "end-stage" kidneys. II. Embryonal hyperplasia of Bowman's capsular epithelium. *Am J Pathol*. 1978;91:71-84.
137. Park S, Bernard A, Bove KE, et al. Inactivation of WT1 in nephrogenic rests, genetic precursors to Wilms' tumour. *Nat Genet*. 1993;5(4):363-367.
138. Vuononvirta R, Sebire NJ, Dallosso AR, et al. Perilobar nephrogenic rests are nonobligate molecular genetic precursor lesions of insulin-like growth factor-II-associated Wilms tumors. *Clin Cancer Res*. 2008;14:7635-7644.
139. Fukuzawa R, Anaka MR, Heathcott RW, et al. Wilms tumour histology is determined by distinct types of precursor lesions and not epigenetic changes. *J Pathol*. 2008;215:377-387.
140. de Chadarevian JP, Fletcher BD, Chatten J, Rabinovitch HH. Massive infantile nephroblastomatosis: a clinical, radiological, and pathological analysis of four cases. *Cancer*. 1977;39(5):2294-2305.
141. Coppes MJ, Arnold M, Beckwith JB, et al. Factors affecting the risk of contralateral Wilms tumor development: a report from the National Wilms Tumor Study Group. *Cancer*. 1999;85:1616-1625.
142. Argani P, Dehner L, Leuschner I. Mesenchymal tumours occurring mainly in children. In: Moch H, Humphrey PA, Ulbright TM, Reuter VE, eds. *WHO Classification of Tumours of the Urinary System and Male Genital Organs*. Lyon: IARC Press; 2016.
143. Truong LD, Williams R, Ngo T, et al. Adult mesoblastic nephroma: expansion of the morphologic spectrum and review of literature. *Am J Surg Pathol*. 1998;22(7):827-839.
144. Tulbah A, Kardar AH, Akhtar M. Mesoblastic nephroma in an adult. *J Urol Pathol*. 1997;6:67-74.
145. Drut R. Multicystic congenital mesoblastic nephroma. *Int J Surg Pathol*. 2002;10(1): 59-63.
146. Ganick DJ, Gilbert EF, Beckwith JB, Kiviat N. Congenital cystic mesoblastic nephroma. *Hum Pathol*. 1981;12(11):1039-1043.
147. Shen SC, Yunis EJ. A study of the cellularity and ultrastructure of congenital mesoblastic nephroma. *Cancer*. 1980;45(2):306-314.
148. Joshi VV, Kasznica J, Walters TR. Atypical mesoblastic nephroma. Pathologic characterization of a potentially aggressive variant of conventional congenital mesoblastic nephroma. *Arch Pathol Lab Med*. 1986;110(2):100-106.
149. Pettinato G, Manivel JC, Wick MR, Dehner LP. Classical and cellular (atypical) congenital mesoblastic nephroma: a clinicopathologic, ultrastructural, immunohistochemical, and flow cytometric study. *Hum Pathol*. 1989;20(7):682-690.
150. Sandstedt B, Delemarre JF, Krul EJ, Tournade MF. Mesoblastic nephromas: a study of 29 tumours from the SIOP nephroblastoma file. *Histopathology*. 1985;9(7):741-750.
151. Carpenter PM, Mascarello JT, Krous HF, Kaplan GW. Congenital mesoblastic nephroma: cytogenetic comparison to leiomyoma. *Pediatr Pathol*. 1993;13(4):435-441.
152. Rubin BP, Chen CJ, Morgan TW, et al. Congenital mesoblastic nephroma t(12;15) is associated with ETV6-NTRK3 gene fusion: cytogenetic and molecular relationship to congenital (infantile) fibrosarcoma. *Am J Pathol*. 1998;153(5):1451-1458.
153. Schofield DE, Yunis EJ, Fletcher JA. Chromosome aberrations in mesoblastic nephroma. *Am J Pathol*. 1993;143(3):714-724.
154. Argani P, Fritsch M, Kadkol SS, et al. Detection of the ETV6-NTRK3 chimeric RNA of infantile fibrosarcoma/cellular congenital mesoblastic nephroma in paraffin-embedded tissue: application to challenging pediatric renal stromal tumors. *Mod Pathol*. 2000;13(1):29-36.
155. Knezevich SR, Garnett MJ, Pysher TJ, et al. ETV6-NTRK3 gene fusions and trisomy 11 establish a histogenetic link between mesoblastic nephroma and congenital fibrosarcoma. *Cancer Res*. 1998;58(22):5046-5048.
156. Anderson J, Gibson S, Sebire NJ. Expression of ETV6-NTRK in classical, cellular and mixed subtypes of congenital mesoblastic nephroma. *Histopathology*. 2006;48:748-753.
157. Howell CG, Othersen HB, Kiviat NE, et al. Therapy and outcome in 51 children with mesoblastic nephroma: a report of the National Wilms' Tumor Study. *J Pediatr Surg*. 1982;17(6):826-831.
158. Gonzalez-Crussi F, Sotelo-Avila C, Kidd JM. Mesenchymal renal tumors in infancy: a reappraisal. *Hum Pathol*. 1981;12(1): 78-85.
159. Heidelberger KP, Ritchey ML, Dauser RC, et al. Congenital mesoblastic nephroma metastatic to the brain. *Cancer*. 1993;72(8):2499-2502.
160. Vujanic GM, Delemarre JF, Moeslichan S, et al. Mesoblastic nephroma metastatic to the lungs and heart—another face of this peculiar lesion: case report and review of the literature. *Pediatr Pathol*. 1993;13(2):143-153.
161. Gonzalez-Crussi F, Sotelo-Avila C, Kidd JM. Malignant mesenchymal nephroma of infancy:

report of a case with pulmonary metastases. *Am J Surg Pathol*. 1980;4(2):185-190.
162. Beckwith JB, Weeks DA. Congenital mesoblastic nephroma. When should we worry? *Arch Pathol Lab Med*. 1986;110(2):98-99.
163. Furtwaengler R, Reinhard H, Leuschner I, et al. Mesoblastic nephroma—a report from the Gesellschaft fur Padiatrische Onkologie und Hamatologie (GPOH). *Cancer*. 2006;106(10):2275-2283.
164. Marsden HB, Lawler W, Kumar PM. Bone metastasizing renal tumor of childhood: morphological and clinical features, and differences from Wilms' tumor. *Cancer*. 1978;42(4):1922-1928.
165. Morgan E, Kidd JM. Undifferentiated sarcoma of the kidney: a tumor of childhood with histopathologic and clinical characteristics distinct from Wilms' tumor. *Cancer*. 1978;42(4):1916-1921.
166. Sotelo-Avila C, Gonzalez-Crussi F, Sadowinski S, et al. Clear cell sarcoma of the kidney: a clinicopathologic study of 21 patients with long-term follow-up evaluation. *Hum Pathol*. 1985;16(12):1219-1230.
167. Oda H, Shiga J, Machinami R. Clear cell sarcoma of kidney. Two cases in adults. *Cancer*. 1993;71(7):2286-2291.
168. Amin MB, de Peralta-Venturina MN, Ro JY. Clear cell sarcoma of kidney in an adolescent and in young adults: a report of four cases with ultrastructural, immunohistochemical, and DNA flow cytometric analysis. *Am J Surg Pathol*. 1999;23:1455-1463.
169. Uzoaru I, Podbielski FJ, Chou P, et al. Familial adenomatous polyposis coli and clear cell sarcoma of the kidney. *Pediatr Pathol*. 1993;13(2):133-141.
170. Sandstedt BE, Delemarre JF, Harms D, Tournade MF. Sarcomatous Wilms' tumour with clear cells and hyalinization. A study of 38 tumours in children from the SIOP nephroblastoma file. *Histopathology*. 1987;11(3):273-285.
171. Argani P, Perlman EJ, Breslow NE, et al. Clear cell sarcoma of the kidney: a review of 351 cases from the National Wilms Tumor Study Group Pathology Center. *Am J Surg Pathol*. 2000;24(1):4-18.
172. Kenny C, Bausenwein S, Lazaro A, et al. Mutually exclusive BCOR internal tandem duplications and YWHAE-NUTM2 fusions in clear cell sarcoma of kidney: not the full story. *J Pathol*. 2016;238:617-620.
173. Roy A, Kumar V, Zorman B, et al. Recurrent internal tandem duplications of BCOR in clear cell sarcoma of the kidney. *Nat Commun*. 2015;6:8891.
174. Karlsson J, Valind A, Gisselsson D. BCOR internal tandem duplication and YWHAE-NUTM2B/E fusion are mutually exclusive events in clear cell sarcoma of the kidney. *Genes Chromosomes Cancer*. 2016;55:120-123.
175. Ueno-Yokohata H, Okita H1, Nakasato K, et al. Consistent in-frame internal tandem duplications of BCOR characterize clear cell sarcoma of the kidney. *Nat Genet*. 2015;47:861-863.
176. Kao YC, Sung YS, Zhang L, et al. Recurrent BCOR internal tandem duplication and YWHAE-NUTM2B fusions in soft tissue undifferentiated round cell sarcoma of infancy: overlapping genetic features with clear cell sarcoma of kidney. *Am J Surg Pathol*. 2016;40:1009-1020.
177. Weeks DA, Malott RL, Zuppan C, et al. Primitive pelvic sarcoma resembling clear cell sarcoma of kidney. *Ultrastruct Pathol*. 1991;15(4-5):403-408.
178. Kao YC, Sung YS, Zhang L, et al. BCOR overexpression is a highly sensitive marker in round cell sarcomas with BCOR genetic abnormalities. *Am J Surg Pathol*. 2016;40:1670-1678.
179. Kao YC, Sung YS, Zhang L, et al. BCOR upregulation in a poorly differentiated synovial sarcoma with SS18L1-SSX1 fusion-A pathologic and molecular pitfall. *Genes Chromosomes Cancer*. 2017;56:296-302.
180. Berry PJ, Vujanic GM. Malignant rhabdoid tumour. *Histopathology*. 1992;20(2):189-193.
181. Weeks DA, Beckwith JB, Mierau GW, Luckey DW. Rhabdoid tumor of kidney. A report of 111 cases from the National Wilms' Tumor Study Pathology Center. *Am J Surg Pathol*. 1989;13(6):439-458.
182. Mayes LC, Kasselberg AG, Roloff JS, Lukens JN. Hypercalcemia associated with immunoreactive parathyroid hormone in a malignant rhabdoid tumor of the kidney (rhabdoid Wilms' tumor). *Cancer*. 1984;54(5):882-884.
183. Vujanic GM, Sandstedt B, Harms D, et al. Rhabdoid tumour of the kidney: a clinicopathological study of 22 patients from the International Society of Paediatric Oncology (SIOP) nephroblastoma file. *Histopathology*. 1996;28(4):333-340.
184. Haas JE, Palmer NF, Weinberg AG, Beckwith JB. Ultrastructure of malignant rhabdoid tumor of the kidney. A distinctive renal tumor of children. *Hum Pathol*. 1981;12(7):646-657.
185. Weeks DA, Beckwith JB, Mierau GW, Zuppan CW. Renal neoplasms mimicking rhabdoid tumor of kidney. A report from the National Wilms' Tumor Study Pathology Center. *Am J Surg Pathol*. 1991;15(11):1042-1054.
186. Bishu S, Bolton BD, Rajaram B, Chou PM. Malignant rhabdoid tumors: a twelve year experience. *Lab Invest*. 2009;89(suppl 1):345A.
187. Hoot AC, Russo P, Judkins AR, et al. Immunohistochemical analysis of hSNF5/INI1 distinguishes renal and extra-renal malignant rhabdoid tumors from other pediatric soft tissue tumors. *Am J Surg Pathol*. 2004;28(11):1485-1491.
188. Biegel JA, Tan L, Zhang F, et al. Alterations of the hSNF5/INI1 gene in central nervous system atypical teratoid/rhabdoid tumors and renal and extrarenal rhabdoid tumors. *Clin Cancer Res*. 2002;8(11):3461-3467.
189. Sotelo-Avila C, Gonzalez-Crussi F, deMello D, et al. Renal and extrarenal rhabdoid tumors in children: a clinicopathologic study of 14 patients. *Semin Diagn Pathol*. 1986;3(2):151-163.
190. Tsokos M, Kouraklis G, Chandra RS, et al. Malignant rhabdoid tumor of the kidney and soft tissues. Evidence for a diverse morphological and immunocytochemical phenotype. *Arch Pathol Lab Med*. 1989;113(2):115-120.
191. Tsuneyoshi M, Daimaru Y, Hashimoto H, Enjoji M. Malignant soft tissue neoplasms with the histologic features of renal rhabdoid tumors: an ultrastructural and immunohistochemical study. *Hum Pathol*. 1985;16(12):1235-1242.
192. Li Y, Pawel BR, Hill DA, et al. Pediatric cystic nephroma is morphologically, immunohistochemically, and genetically distinct from adult cystic nephroma. *Am J Surg Pathol*. 2017;41:472-481.
193. Bisceglia M, Creti G. AMR series unilateral (localized) renal cystic disease. *Adv Anat Pathol*. 2005;12(4):227-232.
194. Kajani N, Rosenberg BF, Bernstein J. Multilocular cystic nephroma. *J Urol Pathol*. 1993;1:33-42.
195. Nagao T, Sugano I, Ishida Y, et al. Cystic partially differentiated nephroblastoma in an adult: an immunohistochemical, lectin histochemical and ultrastructural study. *Histopathology*. 1999;35(1):65-73.
196. Baldauf MC, Schulz DM. Multilocular cyst of the kidney. Report of three cases with review of the literature. *Am J Clin Pathol*. 1976;65(1):93-102.
197. Gallo GE, Penchansky L. Cystic nephroma. *Cancer*. 1977;39(3):1322-1327.
198. Vujanic GM, Kelsey A, Perlman EJ, et al. Anaplastic sarcoma of the kidney: a clinicopathologic study of 20 cases of a new entity with polyphenotypic features. *Am J Surg Pathol*. 2007;31(10):1459-1468.
199. Delahunt B, Beckwith JB, Eble JN, et al. *Cancer*. 1998;82:2427-2433.
200. Raney B, Anderson J, Arndt C, et al. Primary renal sarcomas in the Intergroup Rhabdomyosarcoma Study Group (IRSG) experience, 1972–2005: a report from the Children's Oncology Group. *Pediatr Blood Cancer*. 2008;51:339-343.
201. Wu MK, Cotter MB, Pears J, et al. Tumor progression in DICER1-mutated cystic nephroma-witnessing the genesis of anaplastic sarcoma of the kidney. *Hum Pathol*. 2016;53:114-120.
202. Doros LA, Rossi CT, Yang J, et al. DICER1 mutations in childhood cystic nephroma and its relationship to DICER1-renal sarcoma. *Mod Pathol*. 2014;27:1267-1280.
203. Panuel M, Bourliere-Najean B, Gentet JC, et al. Aggressive neuroblastoma with initial pulmonary metastases and kidney involvement simulating Wilms' tumor. *Eur J Radiol*. 1992;14(3):201-203.
204. Nisen PD, Rich MA, Gloster E, et al. N-myc oncogene expression in histopathologically unrelated bilateral pediatric renal tumors. *Cancer*. 1988;61(9):1821-1826.
205. Ellison DA, Parham DM, Bridge J, Beckwith JB. Immunohistochemistry of primary malignant neuroepithelial tumors of the kidney: a potential source of confusion? A study of 30 cases from the National Wilms Tumor Study Pathology Center. *Hum Pathol*. 2007;38(2):205-211.
206. Marley EF, Liapis H, Humphrey PA, et al. Primitive neuroectodermal tumor of the kidney—another enigma: a pathologic, immunohistochemical, and molecular diagnostic study. *Am J Surg Pathol*. 1997;21(3):354-359.
207. Jimenez RE, Folpe AL, Lapham RL, et al. Primary Ewing's sarcoma/primitive neuroectodermal tumor of the kidney: a clinicopathologic and immunohistochemical analysis of 11 cases. *Am J Surg Pathol*. 2002;26(3):320-327.
208. Quezado M, Benjamin DR, Tsokos M. EWS/FLI-1 fusion transcripts in three peripheral primitive neuroectodermal tumors of the kidney. *Hum Pathol*. 1997;28(7):767-771.
209. Sheaff M, McManus A, Scheimberg I, et al. Primitive neuroectodermal tumor of the kidney confirmed by fluorescence in situ hybridization. *Am J Surg Pathol*. 1997;21(4):461-468.
210. Parham DM, Roloson GJ, Feely M, et al. Primary malignant neuroepithelial tumors of the kidney: a clinicopathologic analysis of 146 adult and pediatric cases from the National Wilms' Tumor Study Group Pathology Center. *Am J Surg Pathol*. 2001;25(2):133-146.
211. Mangray S, Somers GR, He J, et al. Primary Undifferentiated Sarcoma of the Kidney Harboring a Novel Variant of CIC-DUX4 Gene Fusion. *Am J Surg Pathol*. 2016;40:1298-1301.
212. Bergerat S, Barthelemy P, Mouracade P, et al. Primary CIC-DUX4 round cell sarcoma of the kidney: a treatment-refractory tumor with poor outcome. *Pathol Res Pract*. 2017;213:154-160.
213. Argani P, Faria PA, Epstein JI, et al. Primary renal synovial sarcoma: molecular and morphologic delineation of an entity previously included among embryonal sarcomas of the kidney. *Am J Surg Pathol*. 2000;24:1087-1096.

214. Kim DH, Sohn JH, Lee MC, et al. Primary synovial sarcoma of the kidney. *Am J Surg Pathol*. 2000;24:1097-1104.
215. Lordello L, Bur ME, Oliva E, Lennerz JK. PAX8-positive biphasic synovial sarcoma expressing hormonal receptors. *Appl Immunohistochem Mol Morphol*. 2017.
216. Karafin M, Parwani AV, Netto GJ, et al. Diffuse expression of PAX2 and PAX8 in the cystic epithelium of mixed epithelial stromal tumor, angiomyolipoma with epithelial cysts, and primary renal synovial sarcoma: evidence supporting renal tubular differentiation. *Am J Surg Pathol*. 2011;35:1264-1273.
217. Davis CJ Jr, Barton JH, Sesterhenn IA, Mostofi FK. Metanephric adenoma. Clinicopathological study of fifty patients. *Am J Surg Pathol*. 1995;19(10):1101-1114.
218. Jones EC, Pins M, Dickersin GR, Young RH. Metanephric adenoma of the kidney. A clinicopathological, immunohistochemical, flow cytometric, cytogenetic, and electron microscopic study of seven cases. *Am J Surg Pathol*. 1995;19:615-626.
219. Strong JW, Ro JY. Metanephric adenoma of the kidney: a newly characterized entity. *Adv Anat Pathol*. 1996;3:172-178.
220. Gatalica Z, Grujic S, Kovatich A, Petersen RO. Metanephric adenoma: histology, immunophenotype, cytogenetics, ultrastructure. *Mod Pathol*. 1996;9(3):329-333.
221. Granter SR, Fletcher JA, Renshaw AA. Cytologic and cytogenetic analysis of metanephric adenoma of the kidney: a report of two cases. *Am J Clin Pathol*. 1997;108(5):544-549.
222. Muir TE, Cheville JC, Lager DJ. Metanephric adenoma, nephrogenic rests, and Wilms' tumor: a histologic and immunophenotypic comparison. *Am J Surg Pathol*. 2001;25:1290-1296.
223. Choueiri TK, Cheville J, Palescandolo E, et al. BRAF mutations in metanephric adenoma of the kidney. *Eur Urol*. 2012;62:917-922.
224. Pinto A, Signoretti S, Hirsch MS, Barletta JA. Immunohistochemical staining for BRAF V600E supports the diagnosis of metanephric adenoma. *Histopathology*. 2015;66:901-904.
225. Udager AM, Pan J, Magers MJ, et al. Molecular and immunohistochemical characterization reveals novel BRAF mutations in metanephric adenoma. *Am J Surg Pathol*. 2015;39:549-557.
226. Argani P, Beckwith JB. Metanephric stromal tumor: report of 31 cases of a distinctive pediatric renal neoplasm. *Am J Surg Pathol*. 2000;24(7):917-926.
227. Arroyo MR, Green DM, Perlman EJ, et al. The spectrum of metanephric adenofibroma and related lesions: clinicopathologic study of 25 cases from the National Wilms Tumor Study Group Pathology Center. *Am J Surg Pathol*. 2001;25(4):433-444.
228. Hennigar RA, Beckwith JB. Nephrogenic adenofibroma. A novel kidney tumor of young people. *Am J Surg Pathol*. 1992;16:325-334.
229. Chatten J, Cromie WJ, Duckett JW. Ossifying tumor of infantile kidney: report of two cases. *Cancer*. 1980;45(3):609-612.
230. Dehner LP. Intrarenal teratoma occurring in infancy: report of a case with discussion of extragonodal germ cell tumors in infancy. *J Pediatr Surg*. 1973;8(3):369-378.
231. Kumar Y, Bhatia A, Kumar V, Vaiphei K. Intrarenal pure yolk sac tumor: an extremely rare entity. *Int J Surg Pathol*. 2007;15(2):204-206.
232. Collardeau-Frachon S, Ranchere-Vince D, Delattre O, et al. Primary desmoplastic small round cell tumor of the kidney: a case report in a 14-year-old girl with molecular confirmation. *Pediatr Dev Pathol*. 2007;10(4):320-324.
233. Su MC, Jeng YM, Chu YC. Desmoplastic small round cell tumor of the kidney. *Am J Surg Pathol*. 2004;28(10):1379-1383.
234. Wang LL, Perlman EJ, Vujanic GM, et al. Desmoplastic small round cell tumor of the kidney in childhood. *Am J Surg Pathol*. 2007;31(4):576-584.
235. Cohen HT, McGovern FJ. Renal-cell carcinoma. *N Engl J Med*. 2005;353(23):2477-2490.
236. Dehner LP, Leestma JE, Price EB Jr. Renal cell carcinoma in children: a clinicopathologic study of 15 cases and review of the literature. *J Pediatr*. 1970;76(3):358-368.
237. Hartman DS, Davis CJ Jr, Madewell JE, Friedman AC. Primary malignant renal tumors in the second decade of life: Wilms tumor versus renal cell carcinoma. *J Urol*. 1982;127(5):888-891.
238. Lack EE, Cassady JR, Sallan SE. Renal cell carcinoma in childhood and adolescence: a clinical and pathological study of 17 cases. *J Urol*. 1985;133(5):822-828.
239. Renshaw AA, Granter SR, Fletcher JA, et al. Renal cell carcinomas in children and young adults: increased incidence of papillary architecture and unique subtypes. *Am J Surg Pathol*. 1999;23(7):795-802.
240. Bruder E, Passera O, Harms D, et al. Morphologic and molecular characterization of renal cell carcinoma in children and young adults. *Am J Surg Pathol*. 2004;28(9):1117-1132.
241. Ramphal R, Pappo A, Zielenska M, et al. Pediatric renal cell carcinoma: clinical, pathologic, and molecular abnormalities associated with the members of the mit transcription factor family. *Am J Clin Pathol*. 2006;126(3):349-364.
242. Coughlin SS, Neaton JD, Randall B, Sengupta A. Predictors of mortality from kidney cancer in 332,547 men screened for the Multiple Risk Factor Intervention Trial. *Cancer*. 1997;79(11):2171-2177.
243. Berg S, Jacobs SC, Cohen AJ, et al. The surgical management of hereditary multifocal renal carcinoma. *J Urol*. 1981;126(3):313-315.
244. Friedrich CA. Von Hippel-Lindau syndrome. A pleomorphic condition. *Cancer*. 1999;86(11 suppl):2478-2482.
245. Shen T, Zhuang Z, Gersell DJ, Tavassoli FA. Allelic deletion of VHL gene detected in papillary tumors of the broad ligament, epididymis, and retroperitoneum in von Hippel-Lindau disease patients. *Int J Surg Pathol*. 2000;8(3):207-212.
246. Kragel PJ, Walther MM, Pestaner JP, Filling-Katz MR. Simple renal cysts, atypical renal cysts, and renal cell carcinoma in von Hippel-Lindau disease: a lectin and immunohistochemical study in six patients. *Mod Pathol*. 1991;4(2):210-214.
247. Malek RS, Omess PJ, Benson RCJ, Zincke H. Renal cell carcinoma in von Hippel-Lindau syndrome. *Am J Med Genet A*. 1987;82:236-238.
248. Stornes I, Jorgensen TM. Renal malignancy in von Hippel-Lindau's disease. Case reports. *Scand J Urol Nephrol*. 1993;27(1):139-142.
249. Paraf F, Chauveau D, Chretien Y, et al. Renal lesions in von Hippel-Lindau disease: immunohistochemical expression of nephron differentiation molecules, adhesion molecules and apoptosis proteins. *Histopathology*. 2000;36(5):457-465.
250. George DJ, Kaelin WG Jr. The von Hippel-Lindau protein, vascular endothelial growth factor, and kidney cancer. *N Engl J Med*. 2003;349(5):419-421.
251. Williamson SR, Zhang S, Eble JN, et al. Clear cell papillary renal cell carcinoma-like tumors in patients with von Hippel-Lindau disease are unrelated to sporadic clear cell papillary renal cell carcinoma. *Am J Surg Pathol*. 2013;37(8):1131-1139.
252. Dunnill MS, Millard PR, Oliver D. Acquired cystic disease of the kidneys: a hazard of long-term intermittent maintenance haemodialysis. *J Clin Pathol*. 1977;30:868-977.
253. Hughson MD, Buchwald D, Fox M. Renal neoplasia and acquired cystic kidney disease in patients receiving long-term dialysis. *Arch Pathol Lab Med*. 1986;110(7):592-601.
254. Pan CC, Chen YJ, Chang LC, et al. Immunohistochemical and molecular genetic profiling of acquired cystic disease-associated renal cell carcinoma. *Histopathology*. 2009;55(2):145-153.
255. Bernstein J, Evan AP, Gardner KD Jr. Epithelial hyperplasia in human polycystic kidney diseases. Its role in pathogenesis and risk of neoplasia. *Am J Pathol*. 1987;129(1):92-101.
256. Bai SHO. Renal carcinomas arising in patients with autosomal dominant polycystic kidney disease (ADPKD): a clinicopathological review. *Lab Invest*. 2009;89(suppl 1):158A.
257. Toro JR, Wei MH, Glenn GM, et al. BHD mutations, clinical and molecular genetic investigations of Birt-Hogg-Dubé syndrome: a new series of 50 families and a review of published reports. *Cancer Genet Cytogenet*. 2008;45(6):321-331.
258. Pavlovich CP, Walther MM, Eyler RA, et al. Renal tumors in the Birt-Hogg-Dubé syndrome. *Am J Surg Pathol*. 2002;26(12):1542-1552.
259. Tickoo SK, Reuter VE, Amin MB, et al. Renal oncocytosis: a morphologic study of fourteen cases. *Am J Surg Pathol*. 1999;23(9):1094-1101.
260. Kiuru M, Launonen V, Hietala M, et al. Familial cutaneous leiomyomatosis is a two-hit condition associated with renal cell cancer of characteristic histopathology. *Am J Pathol*. 2001;159(3):825-829.
261. Merino MJ, Torres-Cabala C, Pinto P, Linehan WM. The morphologic spectrum of kidney tumors in hereditary leiomyomatosis and renal cell carcinoma (HLRCC) syndrome. *Am J Surg Pathol*. 2007;31(10):1578-1585.
262. Gill AJ, Hes O, Papathomas T. Succinate dehydrogenase (SDH)-deficient renal carcinoma: a morphologically distinct entity: a clinicopathologic series of 36 tumors from 27 patients. *Am J Surg Pathol*. 2014;38(12):1588-1602.
263. Gill AJ, Pachter NS, Chou A, et al. *Am J Surg Pathol*. 2011;35(10):1578-1585.
264. Williamson SR, Eble JN, Amin MB, et al. Succinate dehydrogenase-deficient renal cell carcinoma: detailed characterization of 11 tumors defining a unique subtype of renal cell carcinoma. *Mod Pathol*. 2015;28(1):80-94.
265. Guo J, Tretiakova MS, Troxell ML, et al. Tuberous sclerosis-associated renal cell carcinoma: a clinicopathologic study of 57 separate carcinomas in 18 patients. *Am J Surg Pathol*. 2014;38(11):1457-1467.
266. Yang P, Cornejo KM, Sadow PM, et al. Renal cell carcinoma in tuberous sclerosis complex. *Am J Surg Pathol*. 2014;38(7):895-909.
267. Chowdhuri SR, Vicens J, Teller L, et al. Renal cancer in tuberous sclerosis: an underdiagnosed disease? Molecular, IHC and pathologic correlation. *Lab Invest*. 2009;89(suppl 1):191A.
268. Medeiros LJ, Palmedo G, Krigman HR, et al. Oncocytoid renal cell carcinoma after neuroblastoma: a report of four cases of a distinct clinicopathologic entity. *Am J Surg Pathol*. 1999;23(7):772-780.
269. Falzarano SM, McKenney JK, Montironi R, et al. Renal cell carcinoma occurring in patients with prior neuroblastoma: a heterogenous group of neoplasms. *Am J Surg Pathol*. 2016;40(7):989-997.
270. Mester JL, Zhou M, Prescott N, Eng C. Papillary renal cell carcinoma is associated

with PTEN hamartoma tumor syndrome. *Urology*. 2012;79(5):1187.e1-1187.e7.
271. Shuch B, Ricketts CJ, Vocke CD, et al. Germline PTEN mutation Cowden syndrome: an underappreciated form of hereditary kidney cancer. *J Urol*. 2013;190(6):1990-1998.
272. Skinner DG, Colvin RB, Vermillion CD, et al. Diagnosis and management of renal cell carcinoma. A clinical and pathologic study of 309 cases. *Cancer*. 1971;28(5):1165-1177.
273. Dalakas MC, Fujihara S, Askanas V, et al. Nature of amyloid deposits in hypernephroma. Immunocytochemical studies in 2 cases associated with amyloid polyneuropathy. *Am J Pathol*. 1984;116(3):447-454.
274. Fletcher MS, Packham DA, Pryor JP, Yates-Bell AJ. Hepatic dysfunction in renal carcinoma. *Br J Urol*. 1981;53(6):533-536.
275. Maesaka JK, Mittal SK, Fishbane S. Paraneoplastic syndromes of the kidney. *Semin Oncol*. 1997;24(3):373-381.
276. Ramos CV, Taylor HB. Hepatic dysfunction associated with renal carcinoma. *Cancer*. 1972;29(5):1287-1292.
277. Vanatta PR, Silva FG, Taylor WE, Costa JC. Renal cell carcinoma and systemic amyloidosis: demonstration of AA protein and review of the literature. *Hum Pathol*. 1983;14(3):195-201.
278. Aoyagi T, Mori I, Ueyama Y, Tamaoki N. Sinusoidal dilatation of the liver as a paraneoplastic manifestation of renal cell carcinoma. *Hum Pathol*. 1989;20(12):1193-1197.
279. Fan K, Smith DJ. Hypercalcemia associated with renal cell carcinoma: probable role of neoplastic stromal cells. *Hum Pathol*. 1983;14(2):168-171.
280. Goldberg MF, Tashjian AH Jr, Order SE, Dammin GJ. Renal adenocarcinoma containing a parathyroid hormone-like substance and associated with marked hypercalcemia. *Am J Med*. 1964;36:805-814.
281. Hollifield JW, Page DL, Smith C, et al. Renin-secreting clear cell carcinoma of the kidney. *Arch Int Med*. 1975;135(6):859-864.
282. Okabe T, Urabe A, Kato T, et al. Production of erythropoietin-like activity by human renal and hepatic carcinomas in cell culture. *Cancer*. 1985;55(9):1918-1923.
283. Frohmuller HG, Grups JW, Heller V. Comparative value of ultrasonography, computerized tomography, angiography and excretory urography in the staging of renal cell carcinoma. *J Urol*. 1987;138(3):482-484.
284. Aso Y, Homma Y. A survey on incidental renal cell carcinoma in Japan. *J Urol*. 1992;147(2):340-343.
285. Konnak JW, Grossman HB. Renal cell carcinoma as an incidental finding. *J Urol*. 1985;134(6):1094-1096.
286. Brunelli M, Gobbo S, Menestrina F, et al. Core biopsies of renal tumors: accuracy for histopatholigical evaluation. *Lab Invest*. 2009;89(suppl 1):161A.
287. Campbell S, Uzzo RG1, Allaf ME, et al. Renal mass and localized renal cancer: AUA guideline. *J Urol*. 2017;198(3):520-529.
288. Kovacs G, Akhtar M, Beckwith BJ, et al. The Heidelberg classification of renal cell tumours. *J Pathol*. 1997;183(2):131-133.
289. Storkel S, Eble JN, Adlakha K, et al. Classification of renal cell carcinoma: Workgroup No. 1. Union Internationale Contre le Cancer (UICC) and the American Joint Committee on Cancer (AJCC). *Cancer*. 1997;80(5):987-989.
290. Nguyen DP, Vertosick EA, Corradi RB, et al. Histological subtype of renal cell carcinoma significantly affects survival in the era of partial nephrectomy. *Urol Oncol*. 2016;34:259.e1-259.e8.
291. Moch H, Amin MB, Argani P, et al. Renal cell tumours. In: Moch H, Humphrey PA, Ulbright TM, Reuter VE, eds. *WHO Classification of Tumours of the Urinary System and Male Genital Organs*. Lyon: IARC Press; 2016.
292. Kinouchi T, Mano M, Saiki S, et al. Incidence rate of satellite tumors in renal cell carcinoma. *Cancer*. 1999;86(11):2331-2336.
293. Bonsib SM, Bhalodia A. Retrograde venous invasion in renal cell carcinoma: a complication of sinus vein and main renal vein invasion. *Mod Pathol*. 2011;24(12):1578-1585.
294. Brinker DA, Amin MB, de Peralta-Venturina M, et al. Extensively necrotic cystic renal cell carcinoma: a clinicopathologic study with comparison to other cystic and necrotic renal cancers. *Am J Surg Pathol*. 2000;24(7):988-995.
295. Fleming S, O'Donnell M. Surgical pathology of renal epithelial neoplasms: recent advances and current status. *Histopathology*. 2000;36(3):195-202.
296. Humphrey PA. Clear cell neoplasms of the urinary tract and male reproductive system. *Semin Diagn Pathol*. 1997;14(4):240-252.
297. Montironi R, Mikuz G, Algaba F, et al. Epithelial tumours of the adult kidney. *Virchows Arch*. 1999;434(4):281-290.
298. Thoenes W, Storkel S, Rumpelt HJ. Histopathology and classification of renal cell tumors (adenomas, oncocytomas and carcinomas). The basic cytological and histopathological elements and their use for diagnostics. *Pathol Res Pract*. 1986;181(2):125-143.
299. Steinberg P, Storkel S, Oesch F, Thoenes W. Carbohydrate metabolism in human renal clear cell carcinomas. *Lab Invest*. 1992;67:506-511.
300. Kim MK, Kim S. Immunohistochemical profile of common epithelial neoplasms arising in the kidney. *Appl Immunohistochem Mol Morphol*. 2002;10(4):332-338.
301. Waldherr R, Schwechheimer K. Co-expression of cytokeratin and vimentin intermediate-sized filaments in renal cell carcinomas. Comparative study of the intermediate-sized filament distribution in renal cell carcinomas and normal human kidney. *Virchows Arch A Pathol Anat Histopathol*. 1985;408(1):15-27.
302. Avery AK, Beckstead J, Renshaw AA, Corless CL. Use of antibodies to RCC and CD10 in the differential diagnosis of renal neoplasms. *Am J Surg Pathol*. 2000;24(2):203-210.
303. Al-Ahmadie HA, Alden D, Qin LX, et al. Carbonic anhydrase IX expression in clear cell renal cell carcinoma: an immunohistochemical study comparing 2 antibodies. *Am J Surg Pathol*. 2008;32(3):377-382.
304. Genega EM, Ghebremichael M, Najarian R, et al. Carbonic anhydrase IX expression in renal neoplasms: correlation with tumor type and grade. *Am J Clin Pathol*. 2010;134(6):873-879.
305. Mazal PR, Stichenwirth M, Koller A, et al. Expression of aquaporins and PAX-2 compared to CD10 and cytokeratin 7 in renal neoplasms: a tissue microarray study. *Mod Pathol*. 2005;18(4):535-540.
306. Skinnider BF, Folpe AL, Hennigar RA, et al. Distribution of cytokeratins and vimentin in adult renal neoplasms and normal renal tissue: potential utility of a cytokeratin antibody panel in the differential diagnosis of renal tumors. *Am J Surg Pathol*. 2005;29(6):747-754.
307. Fetsch PA, Powers CN, Zakowski MF, Abati A. Anti-alpha-inhibin: marker of choice for the consistent distinction between adrenocortical carcinoma and renal cell carcinoma in fine-needle aspiration. *Cancer*. 1999;87(3):168-172.
308. Renshaw AA, Granter SR. A comparison of A103 and inhibin reactivity in adrenal cortical tumors: distinction from hepatocellular carcinoma and renal tumors. *Mod Pathol*. 1998;11(12):1160-1164.
309. Nolan LP, Heatley MK. The value of immunocytochemistry in distinguishing between clear cell carcinoma of the kidney and ovary. *Int J Gynecol Pathol*. 2001;20(2):155-159.
310. Ohta Y, Suzuki T, Shiokawa A, et al. Expression of CD10 and cytokeratins in ovarian and renal clear cell carcinoma. *Int J Gynecol Pathol*. 2005;24(3):239-245.
311. Cameron RI, Ashe P, O'Rourke DM, et al. A panel of immunohistochemical stains assists in the distinction between ovarian and renal clear cell carcinoma. *Int J Gynecol Pathol*. 2003;22:272-276.
312. Ordonez NG. The diagnostic utility of immunohistochemistry in distinguishing between mesothelioma and renal cell carcinoma: a comparative study. *Hum Pathol*. 2004;35(6):697-710.
313. Ingold B, Wild PJ, Nocito A, et al. Renal cell carcinoma marker reliably discriminates central nervous system haemangioblastoma from brain metastases of renal cell carcinoma. *Histopathology*. 2008;52(6):674-681.
314. Jung SM, Kuo TT. Immunoreactivity of CD10 and inhibin alpha in differentiating hemangioblastoma of central nervous system from metastatic clear cell renal cell carcinoma. *Mod Pathol*. 2005;18(6):788-794.
315. MacLennan GT, Farrow GM, Gostwick DG. Immunohistochemistry in the evaluation of renal cell carcinoma: a critical appraisal. *J Urol Pathol*. 1997;6:195-204.
316. Nappi O, Mills SE, Swanson PE, Wick MR. Clear cell tumors of unknown nature and origin: a systematic approach to diagnosis. *Semin Diagn Pathol*. 1997;14(3):164-174.
317. Pan CC, Chen PC, Tsay SH, Ho DM. Differential immunoprofiles of hepatocellular carcinoma, renal cell carcinoma, and adrenocortical carcinoma: a systemic immunohistochemical survey using tissue array technique. *Appl Immunohistochem Mol Morphol*. 2005;13(4):347-352.
318. Sangoi AR, Karamchandani J, Kim J, et al. The use of immunohistochemistry in the diagnosis of metastatic clear cell renal cell carcinoma: a review of PAX-8, PAX-2, hKIM-1, RCCma, and CD10. *Adv Anat Pathol*. 2010;17:377-393.
319. Iqbal MA, Akhtar M, Ali MA. Cytogenetic findings in renal cell carcinoma. *Hum Pathol*. 1996;27(9):949-954.
320. Moch H, Mihatsch MJ. Genetic progression of renal cell carcinoma. *Virchows Arch*. 2002;441(4):320-327.
321. Amo-Takyi BK, Handt S, Gunawan B, et al. A cytogenetic approach to the differential diagnosis of metastatic clear cell renal carcinoma. *Histopathology*. 1998;32(5):436-443.
322. Kim WY, Kaelin WG Jr. Molecular pathways in renal cell carcinoma—rationale for targeted treatment. *Semin Oncol*. 2006;33(5):588-595.
323. Pei J, Feder MM, Al-Saleem T, et al. Combined classical cytogenetics and microarray-based genomic copy number analysis reveal frequent 3;5 rearrangements in clear cell renal cell carcinoma. *Genes Chromosomes Cancer*. 2010;49(7):610-619.
324. Hakimi AA, Reznik E, Lee CH, et al. An integrated metabolic atlas of clear cell renal cell carcinoma. *Cancer Cell*. 2016;29(1):104-116.
325. el-Naggar AK, Batsakis JG, Wang G, Lee MS. PCR-based RFLP screening of the commonly deleted 3p loci in renal cortical neoplasms. *Diagn Mol Pathol*. 1993;2(4):269-276.

326. Fleming S. The impact of genetics on the classification of renal carcinoma. *Histopathology*. 1993;22(1):89-92.
327. Hadaczek P, Podolski J, Toloczko A, et al. Losses at 3p common deletion sites in subtypes of kidney tumours: histopathological correlations. *Virchows Arch*. 1996;429(1):37-42.
328. Kovacs G. Molecular differential pathology of renal cell tumours. *Histopathology*. 1993;22(1):1-8.
329. McCue PA, Gorstein F. Genetic markers in renal cell carcinomas. *Hum Pathol*. 2001;32(10):1027-1028.
330. Presti JC Jr, Reuter VE, Cordon-Cardo C, et al. Allelic deletions in renal tumors: histopathological correlations. *Cancer Res*. 1993;53(23):5780-5783.
331. Teyssier JR, Henry I, Dozier C, et al. Recurrent deletion of the short arm of chromosome 3 in human renal cell carcinoma: shift of the c-raf 1 locus. *J Natl Cancer Inst*. 1986;77(6):1187-1195.
332. Toma MI, Grosser M, Herr A, et al. Loss of heterozygosity and copy number abnormality in clear cell renal cell carcinoma discovered by high-density affymetrix 10K single nucleotide polymorphism mapping array. *Neoplasia*. 2008;10(7):634-642.
333. van der Hout AH, van den Berg E, van der Vlies P, et al. Loss of heterozygosity at the short arm of chromosome 3 in renal-cell cancer correlates with the cytological tumour type. *Int J Cancer*. 1993;53(3):353-357.
334. Weiss LM, Gelb AB, Medeiros LJ. Adult renal epithelial neoplasms. *Am J Clin Pathol*. 1995;103(5):624-635.
335. Foster K, Crossey PA, Cairns P, et al. Molecular genetic investigation of sporadic renal cell carcinoma: analysis of allele loss on chromosomes 3p, 5q, 11p, 17 and 22. *Br J Cancer*. 1994;69(2):230-234.
336. Morita R, Ishikawa J, Tsutsumi M, et al. Allelotype of renal cell carcinoma. *Cancer Res*. 1991;51(3):820-823.
337. Cancer Genome Atlas research Network. Comprehensive molecular characterization of clear cell renal cell carcinoma. *Nature*. 2013;499:43-49.
338. Dalgliesh GL, Furge K, Greenman C, et al. Systematic sequencing of renal carcinoma reveals inactivation of histone modifying genes. *Nature*. 2010;463:360-363.
339. Sirintrapun SJ, Parwani AV. Molecular pathology of the genitourinary tract: molecular pathology of kidney and testis. *Surg Pathol Clin*. 2009;2:199-223.
340. Sudarshan S, Linehan WM. Genetic basis of cancer of the kidney. *Semin Oncol*. 2006;33(5):544-551.
341. Delahunt B, Eble JN. Papillary renal cell carcinoma: a clinicopathologic and immunohistochemical study of 105 tumors. *Mod Pathol*. 1997;10(6):537-544.
342. Delahunt B, Eble JN, McCredie MR, et al. Morphologic typing of papillary renal cell carcinoma: comparison of growth kinetics and patient survival in 66 cases. *Hum Pathol*. 2001;32(6):590-595.
343. The Cancer Genome Atlas Research Network, Linehan WM, Spellman PT, et al. Comprehensive molecular characterization of papillary renal-cell carcinoma. *N Engl J Med*. 2016;374:135-145.
344. Amin MB, Corless CL, Renshaw AA, et al. Papillary (chromophil) renal cell carcinoma: histomorphologic characteristics and evaluation of conventional pathologic prognostic parameters in 62 cases. *Am J Surg Pathol*. 1997;21(6):621-635.
345. Henn W, Zwergel T, Wullich B, et al. Bilateral multicentric papillary renal tumors with heteroclonal origin based on tissue-specific karyotype instability. *Cancer*. 1993;72(4):1315-1318.
346. Kovacs G, Kovacs A. Parenchymal abnormalities associated with papillary renal cell tumors. A morphological study. *J Urol Pathol*. 1993;1:301-312.
347. Mancilla-Jimenez R, Stanley RJ, Blath RA. Papillary renal cell carcinoma: a clinical, radiologic, and pathologic study of 34 cases. *Cancer*. 1976;38(6):2469-2480.
348. Renshaw AA, Corless CL. Papillary renal cell carcinoma. Histology and immunohistochemistry. *Am J Surg Pathol*. 1995;19(7):842-849.
349. Leroy X, Zini L, Leteurtre E, et al. Morphologic subtyping of papillary renal cell carcinoma: correlation with prognosis and differential expression of MUC1 between the two subtypes. *Mod Pathol*. 2002;15(11):1126-1130.
350. Park BH, Ro JY, Park WS, et al. Oncocytic papillary renal cell carcinoma with inverted nuclear pattern: distinct subtype with an indolent clinical course. *Pathol Int*. 2009;59(3):137-146.
351. Gatalica Z, Kovatich A, Miettinen M. Consistent expression of cytokeratin 7 in papillary renal-cell carcinoma. An immunohistochemical study in formalin-fixed, paraffin-embedded tissues. *J Urol Pathol*. 1995;3:205-211.
352. Corless CL, Aburatani H, Fletcher JA, et al. Papillary renal cell carcinoma: quantitation of chromosomes 7 and 17 by FISH, analysis of chromosome 3p for LOH, and DNA ploidy. *Diagn Mol Pathol*. 1996;5(1):53-64.
353. Jiang F, Richter J, Schraml P, et al. Chromosomal imbalances in papillary renal cell carcinoma: genetic differences between histological subtypes. *Am J Pathol*. 1998;153(5):1467-1473.
354. Kattar MM, Grignon DJ, Wallis T, et al. Clinicopathologic and interphase cytogenetic analysis of papillary (chromophilic) renal cell carcinoma. *Mod Pathol*. 1997;10(11):1143-1150.
355. Allory Y, Ouazana D, Boucher E, et al. Papillary renal cell carcinoma. Prognostic value of morphological subtypes in a clinicopathologic study of 43 cases. *Virchows Arch*. 2003;442(4):336-342.
356. Lubensky IA, Schmidt L, Zhuang Z, et al. Hereditary and sporadic papillary renal carcinomas with c-met mutations share a distinct morphological phenotype. *Am J Pathol*. 1999;155(2):517-526.
357. Chevarie-Davis M, Riazalhosseini Y, Arseneault M, et al. The morphologic and immunohistochemical spectrum of papillary renal cell carcinoma: study including 132 cases with pure type 1 and type 2 morphology as well as tumors with overlapping features. *Am J Surg Pathol*. 2014;38:887-894.
358. Warrick JI, Tsodikov A, Kunju LP, et al. Papillary renal cell carcinoma revisited: a comprehensive histomorphologic study with outcome correlations. *Hum Pathol*. 2014;45:1139-1146.
359. Hes O, Brunelli M, Michal M, et al. Oncocytic papillary renal cell carcinoma: a clinicopathologic, immunohistochemical, ultrastructural, and interphase cytogenetic study of 12 cases. *Ann Diagn Pathol*. 2006;10:133-139.
360. Xia QY, Rao Q, Shen Q, et al. Oncocytic papillary renal cell carcinoma: a clinicopathological study emphasizing distinct morphology, extended immunohistochemical profile and cytogenetic features. *Int J Clin Exp Pathol*. 2013;6:1392-1399.
361. Kunju LP, Wojno K, Wolf JS Jr, et al. Papillary renal cell carcinoma with oncocytic cells and nonoverlapping low grade nuclei: expanding the morphologic spectrum with emphasis on clinicopathologic, immunohistochemical and molecular features. *Hum Pathol*. 2008;39:96-101.
362. Baer SC, Ro JY, Ordonez NG, et al. Sarcomatoid collecting duct carcinoma: a clinicopathologic and immunohistochemical study of five cases. *Hum Pathol*. 1993;24(9):1017-1022.
363. Cohen RJ, McNeal JE, Susman M, et al. Sarcomatoid renal cell carcinoma of papillary origin. A case report and cytogenic evaluation. *Arch Pathol Lab Med*. 2000;124(12):1830-1832.
364. Renshaw AA, Morgan IW, Fletcher JA. A sarcomatoid renal cell carcinoma with a 'hobnail pattern' and immunohistochemical and cytogenetic features of papillary carcinoma. *J Urol Pathol*. 1998;9:93-102.
365. Suzigan S, López-Beltrán A, Montironi R, et al. Multilocular cystic renal cell carcinoma : a report of 45 cases of a kidney tumor of low malignant potential. *Am J Clin Pathol*. 2006;125:217-222.
366. Williamson SR, MacLennan GT, Lopez-Beltran A, et al. Cystic partially regressed clear cell renal cell carcinoma: a potential mimic of multilocular cystic renal cell carcinoma. *Histopathology*. 2013;63:767-779.
367. Bhatt JR, Jewett MA, Richard PO, et al. Multilocular cystic renal cell carcinoma: pathological T staging makes no difference to favorable outcomes and should be reclassified. *J Urol*. 2016;196:1350-1355.
368. Bonsib SM, Lager DJ. Chromophobe cell carcinoma. Analysis of 5 cases. *Am J Surg Pathol*. 1990;14:260-267.
369. Akhtar M, Kardar H, Linjawi T, et al. Chromophobe cell carcinoma of the kidney. A clinicopathologic study of 21 cases. *Am J Surg Pathol*. 1995;19(11):1245-1256.
370. Durham JR, Keohane M, Amin MB. Chromophobe renal cell carcinoma. *Adv Anat Pathol*. 1996;3:336-342.
371. Hes O, Vanecek T, Perez-Montiel DM, et al. Chromophobe renal cell carcinoma with microcystic and adenomatous arrangement and pigmentation—a diagnostic pitfall. Morphological, immunohistochemical, ultrastructural and molecular genetic report of 20 cases. *Virchows Arch*. 2005;446(4):383-393.
372. Foix MP, Dunatov A, Martinek P, et al. Morphological, immunohistochemical, and chromosomal analysis of multicystic chromophobe renal cell carcinoma, an architecturally unusual challenging variant. *Virchows Arch*. 2016;469:669-678.
373. Peckova K, Martinek P, Ohe C, et al. Chromophobe renal cell carcinoma with neuroendocrine and neuroendocrine-like features. Morphologic, immunohistochemical, ultrastructural, and array comparative genomic hybridization analysis of 18 cases and review of the literature. *Ann Diagn Pathol*. 2015;19:261-268.
374. Granter SR, Renshaw AA. Fine-needle aspiration of chromophobe renal cell carcinoma: analysis of six cases. *Cancer Cytopathol*. 1997;81:122-128.
375. Wiatrowska BA, Zakowski MF. Fine-needle aspiration biopsy of chromophobe renal cell carcinoma and oncocytoma: comparison of cytomorphologic features. *Cancer Cytopathol*. 1999;87:161-167.
376. Moreno SM, Benitez IA, Martinez Gonzalez MA. Ultrastructural studies in a series of 18 cases of chromophobe renal cell carcinoma. *Ultrastruct Pathol*. 2005;29(5):377-387.
377. Skinnider BF, Jones EC. Renal oncocytoma and chromophobe renal cell carcinoma. A comparison of colloidal iron staining and electron microscopy. *Am J Clin Pathol*. 1999;111(6):796-803.
378. Thoenes W, Storkel S, Rumpelt HJ. Human chromophobe cell renal carcinoma. *Virchows*

Arch B Cell Pathol Incl Mol Pathol. 1985;48(3):207-217.
379. Tickoo SK, Amin MB, Zarbo RJ. Colloidal iron staining in renal epithelial neoplasms, including chromophobe renal cell carcinoma: emphasis on technique and patterns of staining. *Am J Surg Pathol*. 1998;22(4):419-424.
380. Williamson SR, Gadde R, Trpkov K, et al. Diagnostic criteria for oncocytic renal neoplasms: a survey of urologic pathologists. *Hum Pathol*. 2017;63:149-156.
381. Yusenko MV, Kovacs G. Identifying CD82 (KAI1) as a marker for human chromophobe renal cell carcinoma. *Histopathology*. 2009;55(6):687-695.
382. Martignoni G, Pea M, Chilosi M, et al. Parvalbumin is constantly expressed in chromophobe renal carcinoma. *Mod Pathol*. 2001;14(8):760-767.
383. Hornsby CD, Cohen C, Amin MB, et al. Claudin-7 immunohistochemistry in renal tumors: a candidate marker for chromophobe renal cell carcinoma identified by gene expression profiling. *Arch Pathol Lab Med*. 2007;131(10):1541-1546.
384. Osunkoya AO, Cohen C, Lawson D, et al. Claudin-7 and claudin-8: immunohistochemical markers for the differential diagnosis of chromophobe renal cell carcinoma and renal oncocytoma. *Hum Pathol*. 2009;40(2):206-210.
385. Went P, Dirnhofer S, Salvisberg T, et al. Expression of epithelial cell adhesion molecule (EpCam) in renal epithelial tumors. *Am J Surg Pathol*. 2005;29(1):83-88.
386. DeLong WH, Sakr W, Grignon DJ. Chromophobe renal cell carcinoma: a comparative histochemical and immunohistochemical study. *J Urol Pathol*. 1996;4:1-8.
387. Khoury JD, Abrahams NA, Levin HS, MacLennan GT. The utility of epithelial membrane antigen and vimentin in the diagnosis of chromophobe renal cell carcinoma. *Ann Diagn Pathol*. 2002;6(3):154-158.
388. Kuroda N, Inoue K, Guo L, et al. Expression of CD9/motility-related protein 1 (MRP-1) in renal parenchymal neoplasms: consistent expression in papillary and chromophobe renal cell carcinomas. *Hum Pathol*. 2001;32(10):1071-1077.
389. Taki A, Nakatani Y, Misugi K, et al. Chromophobe renal cell carcinoma: an immunohistochemical study of 21 Japanese cases. *Mod Pathol*. 1999;12(3):310-317.
390. Martignoni G, Pea M, Brunelli M, et al. CD10 is expressed in a subset of chromophobe renal cell carcinomas. *Mod Pathol*. 2004;17(12):1455-1463.
391. Ozcan A, de la Roza G, Ro JY, et al. PAX2 and PAX8 expression in primary and metastatic renal tumors: a comprehensive comparison. *Arch Pathol Lab Med*. 2012;136:1541-1551.
392. Tacha D, Zhou D, Cheng L. Expression of PAX8 in normal and neoplastic tissues: a comprehensive immunohistochemical study. *Appl Immunohistochem Mol Morphol*. 2011;19:293-299.
393. Speicher MR, Schoell B, du Manoir S, et al. Specific loss of chromosomes 1, 2, 6, 10, 13, 17, and 21 in chromophobe renal cell carcinomas revealed by comparative genomic hybridization. *Am J Pathol*. 1994;145(2):356-364.
394. Bugert P, Gaul C, Weber K, et al. Specific genetic changes of diagnostic importance in chromophobe renal cell carcinomas. *Lab Invest*. 1997;76(2):203-208.
395. Akhtar M, Tulbah A, Kardar AH, Ali MA. Sarcomatoid renal cell carcinoma: the chromophobe connection. *Am J Surg Pathol*. 1997;21(10):1188-1195.
396. Davis CF, Ricketts CJ, Wang M, et al. The somatic genomic landscape of chromophobe renal cell carcinoma. *Cancer Cell*. 2014;26:319-330.
397. Wilson EJ, Resnick MI, Jacobs G. Sarcomatoid chromophobe renal cell carcinoma: report of an additional case with ultrastructural findings. *J Urol Pathol*. 1999;11:113-122.
398. Amin MB, Paner GP, Alvarado-Cabrero I, et al. Chromophobe renal cell carcinoma: histomorphologic characteristics and evaluation of conventional pathologic prognostic parameters in 145 cases. *Am J Surg Pathol*. 2008;32(12):1822-1834.
399. Renshaw AA, Henske EP, Loughlin KR, et al. Aggressive variants of chromophobe renal cell carcinoma. *Cancer*. 1996;78(8):1756-1761.
400. Delahunt B, Sika-Paotonu D, Bethwaite PB, et al. Fuhrman grading is not appropriate for chromophobe renal cell carcinoma. *Am J Surg Pathol*. 2007;31:957-960.
401. Tickoo SK, dePeralta-Venturina MN, Harik LR, et al. Spectrum of epithelial neoplasms in end-stage renal disease: an experience from 66 tumor-bearing kidneys with emphasis on histologic patterns distinct from those in sporadic adult renal neoplasia. *Am J Surg Pathol*. 2006;30:141-153.
402. Aron M, Chang E, Herrera L, et al. Clear cell-papillary renal cell carcinoma of the kidney not associated with end-stage renal disease: clinicopathologic correlation with expanded immunophenotypic and molecular characterization of a large cohort with emphasis on relationship with renal angiomyoadenomatous tumor. *Am J Surg Pathol*. 2015;39:873-888.
403. Aydin H, Chen L, Cheng L, et al. Clear cell tubulopapillary renal cell carcinoma: a study of 36 distinctive low-grade epithelial tumors of the kidney. *Am J Surg Pathol*. 2010;34:1608-1621.
404. Raspollini MR, Montagnani I, Montironi R, et al. A contemporary series of renal masses with emphasis on recently recognized entities and tumors of low malignant potential: a report based on 624 consecutive tumors from a single tertiary center. *Pathol Res Pract*. 2017;213:804-808.
405. Zhou H, Zheng S, Truong LD, et al. Clear cell papillary renal cell carcinoma is the fourth most common histologic type of renal cell carcinoma in 290 consecutive nephrectomies for renal cell carcinoma. *Hum Pathol*. 2014;45:59-64.
406. Hes O, Compérat EM, Rioux-Leclercq N. Clear cell papillary renal cell carcinoma, renal angiomyoadenomatous tumor, and renal cell carcinoma with leiomyomatous stroma relationship of 3 types of renal tumors: a review. *Ann Diagn Pathol*. 2016;21:59-64.
407. Mantilla JG, Antic T, Tretiakova M. GATA3 as a valuable marker to distinguish clear cell papillary renal cell carcinomas from morphologic mimics. *Hum Pathol*. 2017;66:152-158.
408. Brunelli M, Erdini F, Cima L, et al. Proximal CD13 versus distal GATA-3 expression in renal neoplasia according to WHO 2016 classification. *Appl Immunohisotchem Mol Morphol*. 2016.
409. Gobbo S, Eble JN, Grignon DJ, et al. Clear cell papillary renal cell carcinoma: a distinct histopathologic and molecular genetic entity. *Am J Surg Pathol*. 2008;32:1239-1245.
410. Rohan SM, Xiao Y, Liang Y, et al. Clear-cell papillary renal cell carcinoma: molecular and immunohistochemical analysis with emphasis on the von Hippel-Lindau gene and hypoxia-inducible factor pathway-related proteins. *Mod Pathol*. 2011;24:1207-1220.
411. Adam J, Couturier J, Molinié V, et al. Clear-cell papillary renal cell carcinoma: 24 cases of a distinct low-grade renal tumour and a comparative genomic hybridization array study of seven cases. *Histopathology*. 2011;58:1064-1071.
412. Diolombi ML, Cheng L, Argani P, Epstein JI. Do clear cell papillary renal cell carcinomas have malignant potential? *Am J Surg Pathol*. 2015;39:1621-1634.
413. Williamson SR. What is the malignant potential of clear cell papillary renal cell carcinoma? *Urol Oncol*. 2016;34:420-421.
414. Matoso A, Chen YB, Rao V, et al. Atypical renal cysts: a morphologic, immunohistochemical, and molecular study. *Am J Surg Pathol*. 2016;40:202-211.
415. Brimo F, Atallah C, Li G, Srigley JR. Cystic clear cell papillary renal cell carcinoma: is it related to multilocular clear cell cystic neoplasm of low malignant potential? *Histopathology*. 2016;68:666-672.
416. Williamson SR, Gupta NS, Eble JN, et al. Clear cell renal cell carcinoma with borderline features of clear cell papillary renal cell carcinoma: combined morphologic, immunohistochemical, and cytogenetic analysis. *Am J Surg Pathol*. 2015;39:1502-1510.
417. Dhakal HP, McKenney JK, Khor LY, et al. Renal neoplasms with overlapping features of clear cell renal cell carcinoma and clear cell papillary renal cell carcinoma: a clinicopathologic study of 37 cases from a single institution. *Am J Surg Pathol*. 2016;40:141-154.
418. Parihar A, Tickoo SK, Kumar S, Arora VK. Xp11 translocation renal cell carcinoma morphologically mimicking clear cell-papillary renal cell carcinoma in an adult patient: report of a case expanding the morphologic spectrum of Xp11 translocation renal cell carcinomas. *Int J Surg Pathol*. 2015;23:234-237.
419. Argani P, Zhong M, Reuter VE, et al. TFE3-fusion variant analysis defines specific clinicopathologic associations among Xp11 translocation cancers. *Am J Surg Pathol*. 2016;40:723-737.
420. Argani P, Antonescu CR, Couturier J, et al. PRCC-TFE3 renal carcinomas: morphologic, immunohistochemical, ultrastructural, and molecular analysis of an entity associated with the t(X;1)(p11.2;q21). *Am J Surg Pathol*. 2002;26(12):1553-1566.
421. Argani P, Ladanyi M. The evolving story of renal translocation carcinomas. *Am J Clin Pathol*. 2006;126(3):332-334.
422. Wu A, Kunju LP, Cheng L, Shah RB. Renal cell carcinoma in children and young adults: analysis of clinicopathological, immunohistochemical and molecular characteristics with an emphasis on the spectrum of Xp11.2 translocation-associated and unusual clear cell subtypes. *Histopathology*. 2008;53(5):533-544.
423. Argani P, Antonescu CR, Illei PB, et al. Primary renal neoplasms with the ASPL-TFE3 gene fusion of alveolar soft part sarcoma: a distinctive tumor entity previously included among renal cell carcinomas of children and adolescents. *Am J Pathol*. 2001;159(1):179-192.
424. Argani P, Olgac S, Tickoo SK, et al. Xp11 translocation renal cell carcinoma in adults: expanded clinical, pathologic, and genetic spectrum. *Am J Surg Pathol*. 2007;31(8):1149-1160.
425. Zhong M, Haberman J, Andraws N, et al. Xp11.2 translocation renal cell carcinoma (RCC) in adults—a TMA study of 120 RCC cases. *Lab Invest*. 2009;89(suppl 1):203A.
426. Argani P, Lal P, Hutchinson B, et al. Aberrant nuclear immunoreactivity for TFE3 in neoplasms with TFE3 gene fusions: a sensitive and specific immunohistochemical assay. *Am J Surg Pathol*. 2003;27(6):750-761.

427. Argani P, Hicks J, De Marzo AM, et al. Xp11 translocation renal cell carcinoma (RCC): extended immunohistochemical profile emphasizing novel RCC markers. *Am J Surg Pathol*. 2010;34(9):1295-1303.
428. Argani P, Zhang L, Reuter VE, et al. RBM10-TFE3 renal cell carcinoma: a potential diagnostic pitfall due to cryptic intrachromosomal Xp11.2 inversion resulting in false-negative TFE3 FISH. *Am J Surg Pathol*. 2017;41:655-662.
429. Xia QY, Wang XT, Zhan XM, et al. Xp11 translocation renal cell carcinomas (RCCs) With RBM10-TFE3 gene fusion demonstrating melanotic features and overlapping morphology with t(6;11) RCC: interest and diagnostic pitfall in detecting a paracentric inversion of TFE3. *Am J Surg Pathol*. 2017;41:663-676.
430. Argani P, Lae M, Hutchinson B, et al. Renal carcinomas with the t(6;11)(p21;q12): clinicopathologic features and demonstration of the specific alpha-TFEB gene fusion by immunohistochemistry, RT-PCR, and DNA PCR. *Am J Surg Pathol*. 2005;29(2):230-240.
431. Suzigan S, Drut R, Faria P, et al. Xp11 translocation carcinoma of the kidney presenting with multilocular cystic renal cell carcinoma-like features. *Int J Surg Pathol*. 2007;15(2):199-203.
432. Williamson SR, Grignon DJ, Cheng L, et al. Renal cell carcinoma with chromosome 6p amplification including the TFEB gene: a novel mechanism of tumor pathogenesis? *Am J Surg Pathol*. 2017;41:287-298.
433. Argani P, Reuter VE, Zhang L, et al. TFEB-amplified renal cell carcinomas: an aggressive molecular subset demonstrating variable melanocytic marker expression and morphologic heterogeneity. *Am J Surg Pathol*. 2016;40:1484-1495.
434. Peckova K, Vanecek T, Martinek P, et al. Aggressive and nonaggressive translocation t(6;11) renal cell carcinoma: comparative study of 6 cases and review of the literature. *Ann Diagn Pathol*. 2014;18:351-357.
435. Argani P, Aulmann S, Karanjawala Z, et al. Melanotic Xp11 translocation renal cancers: a distinctive neoplasm with overlapping features of PEComa, carcinoma, and melanoma. *Am J Surg Pathol*. 2009;33(4):609-619.
436. Fleming S, Lewi HJ. Collecting duct carcinoma of the kidney. *Histopathology*. 1986;10(11):1131-1141.
437. Morell-Quadreny L, Gregori-Romero A, Carda-Batalla C, Llombart-Bosch A. Collecting duct carcinoma of the kidney: a morphologic and DNA flow cytometric study of seven cases. *J Urol Pathol*. 1998;8:69-84.
438. Gupta R, Billis A, Shah RB, et al. Carcinoma of the collecting ducts of Bellini and renal medullary carcinoma: clinicopathologic analysis of 52 cases of rare aggressive subtypes of renal cell carcinoma with a focus on their interrelationship. *Am J Surg Pathol*. 2012;36:1265-1278.
439. Fuzesi L, Cober M, Mittermayer C. Collecting duct carcinoma: cytogenetic characterization. *Histopathology*. 1992;21(2):155-160.
440. Osunkoya AO, Young AN, Wang W, et al. Comparison of gene expression profiles in tubulocystic carcinoma and collecting duct carcinoma of the kidney. *Am J Surg Pathol*. 2009;33(7):1103-1106.
441. Amin MB, Gupta R, Osunkoya AO, et al. Carcinoma of collecting ducts of Bellini: analysis of 27 distinctive cases of renal cell carcinoma with aggressive clinical behaviour. *Lab Invest*. 2009;89(suppl 1):157A.
442. Srigley JR, Eble JN. Collecting duct carcinoma of kidney. *Semin Diagn Pathol*. 1998;15(1):54-67.
443. Sirohi D, Smith SC, Ohe C, et al. Renal cell carcinoma, unclassified with medullary phenotype: poorly-differentiated adenocarcinomas overlapping with renal medullary carcinoma. *Hum Pathol*. 2017;[epub ahead of print].
444. Colombo P, Smith SC, Massa S, et al. Unclassified renal cell carcinoma with medullary phenotype versus renal medullary carcinoma: lessons from diagnosis in an Italian man found to harbor sickle cell trait. *Urol Case Rep*. 2015;3:215-218.
445. Amin MB, Smith SC, Agaimy A, et al. Collecting duct carcinoma versus renal medullary carcinoma: an appeal for nosologic and biological clarity. *Am J Surg Pathol*. 2014;28:871-874.
446. Chen YB, Brannon AR, Toubaji A, et al. Hereditary leiomyomatosis and renal cell carcinoma syndrome-associated renal cancer: recognition of the syndrome by pathologic features and the utility of detecting aberrant succination by immunohistochemistry. *Am J Surg Pathol*. 2014;38:627-637.
447. Toro JR, Nickerson ML, Wei MH, et al. Mutations in the fumarate hydratase gene cause hereditary leiomyomatosis and renal cell cancer in families in North America. *Am J Hum Genet*. 2003;73:95-106.
448. Trpkov K, Hes O, Agaimy A, et al. Fumarate hydratase-deficient renal cell carcinoma is strongly correlated with fumarate hydratase mutation and hereditary leiomyomatosis and renal cell carcinoma syndrome. *Am J Surg Pathol*. 2016;40:865-875.
449. Smith SC, Trpkov K, Chen YB, et al. Tubulocystic carcinoma of the kidney with poorly differentiated foci: a frequent morphologic pattern of fumarate hydratase-deficient renal cell carcinoma. *Am J Surg Pathol*. 2016;40:1457-1472.
450. Smith SC, Sirohi D, Ohe C, et al. A distinctive, low-grade oncocytic fumarate hydratase-deficient renal cell carcinoma, morphologically reminiscent of succinate dehydrogenase-deficient renal cell carcinoma. *Histopathology*. 2017;71:42-52.
451. Linehan WM, Spellman PT, Ricketts CJ, et al. Comprehensive molecular characterization of papillary renal-cell carcinoma. *N Engl J Med*. 2015374(2):135-145.
452. Adsay NV, deRoux SJ, Sakr W, Grignon D. Cancer as a marker of genetic medical disease: an unusual case of medullary carcinoma of the kidney. *Am J Surg Pathol*. 1998;22(2):260-264.
453. Bruno D, Wigfall DR, Zimmerman SA, et al. Genitourinary complications of sickle cell disease. *J Urol*. 2001;166(3):803-811.
454. Eble JN. Renal medullary carcinoma: a distinct entity emerges from the confusion of 'collecting duct carcinoma'. *Adv Anat Pathol*. 1996;3:233-238.
455. Rodriguez-Jurado R, Gonzalez-Crussi F. Renal medullary carcinoma: immunohistochemical and ultrastructural observations. *J Urol Pathol*. 1996;4:191-203.
456. Liu Q, Wrathall L, Galli S, et al. Renal medullary carcinoma: molecular, IHC, and pathologic correlation. *Lab Invest*. 2009;89(suppl 1):179A.
457. Davis CJ Jr, Mostofi FK, Sesterhenn IA. Renal medullary carcinoma. The seventh sickle cell nephropathy. *Am J Surg Pathol*. 1995;19(1):1-11.
458. Cheng JX, Tretiakova M, Gong C, et al. Renal medullary carcinoma: rhabdoid features and the absence of INI1 expression as markers of aggressive behavior. *Mod Pathol*. 2008;21(6):647-652.
459. Debelenko LV, Raimondi SC, Daw N, et al. Renal cell carcinoma with novel VCL-ALK fusion: new representative of ALK-associated tumor spectrum. *Mod Pathol*. 2011;24:430-442.
460. Mariño-Enríquez A, Ou WB, Weldon CB, et al. ALK rearrangement in sickle cell trait-associated renal medullary carcinoma. *Genes Chromosomes Cancer*. 2011;50:146-153.
461. Smith NE, Deyrup AT, Mariño-Enriquez A, et al. VCL-ALK renal cell carcinoma in children with sickle-cell trait: the eighth sickle-cell nephropathy? *Am J Surg Pathol*. 2014;38:858-863.
462. Amin MB, MacLennan GT, Gupta R, et al. Tubulocystic carcinoma of the kidney: clinicopathologic analysis of 31 cases of a distinctive rare subtype of renal cell carcinoma. *Am J Surg Pathol*. 2009;33(3):384-392.
463. Yang XJ, Zhou M, Hes O, et al. Tubulocystic carcinoma of the kidney: clinicopathologic and molecular characterization. *Am J Surg Pathol*. 2008;32:177-187.
464. Al-Hussain TO, Cheng L, Zhang S, Epstein JI. Tubulocystic carcinoma of the kidney with poorly differentiated foci: a series of 3 cases with fluorescence in situ hybridization analysis. *Hum Pathol*. 2013;44:1406-1411.
465. Ulamec M1, Skenderi F, Zhou M, et al. Molecular genetic alterations in renal cell carcinomas with tubulocystic pattern: tubulocystic renal cell carcinoma, tubulocystic renal cell carcinoma with heterogenous component and familial leiomyomatosis-associated renal cell carcinoma. Clinicopathologic and molecular genetic analysis of 15 cases. *Appl Immunohistochemistry Mol Morphol*. 2016;24:521-530.
466. Chen N, Nie L, Gong J, et al. Gains of chromosomes 7 and 17 in tubulocystic carcinoma of kidney: two cases with fluorescence in situ hybridisation analysis. *J Clin Pathol*. 2014;67:1006-1009.
467. Zhou M, Yang XJ, Lopez JI, et al. Renal tubulocystic carcinoma is closely related to papillary renal cell carcinoma: implications for pathologic classification. *Am J Surg Pathol*. 2009;33:1840-1849.
468. Aubert S, Duchene F, Augusto D, et al. Low-grade tubular myxoid renal tumors: a clinicopathological study of 3 cases. *Int J Surg Pathol*. 2004;12(2):179-183.
469. Ferlicot S, Allory Y, Comperat E, et al. Mucinous tubular and spindle cell carcinoma: a report of 15 cases and a review of the literature. *Virchows Arch*. 2005;447(6): 978-983.
470. Parwani AV, Husain AN, Epstein JI, et al. Low-grade myxoid renal epithelial neoplasms with distal nephron differentiation. *Hum Pathol*. 2001;32(5):506-512.
471. Fine SW, Argani P, DeMarzo AM, et al. Expanding the histologic spectrum of mucinous tubular and spindle cell carcinoma of the kidney. *Am J Surg Pathol*. 2006;30(12):1554-1560.
472. Jung SJ, Yoon HK, Chung JI, et al. Mucinous tubular and spindle cell carcinoma of the kidney with neuroendocrine differentiation: report of two cases. *Am J Clin Pathol*. 2006;125(1):99-104.
473. Paner GP, Srigley JR, Radhakrishnan A, et al. Immunohistochemical analysis of mucinous tubular and spindle cell carcinoma and papillary renal cell carcinoma of the kidney: significant immunophenotypic overlap warrants diagnostic caution. *Am J Surg Pathol*. 2006;30(1):13-19.
474. Cossu-Rocca P, Eble JN, Delahunt B, et al. Renal mucinous tubular and spindle carcinoma lacks the gains of chromosomes 7 and 17 and losses of chromosome Y that are prevalent in papillary renal cell carcinoma. *Mod Pathol*. 2006;19(4):488-493.
475. Argani P, Netto GJ, Parwani AV. Papillary renal cell carcinoma with low-grade spindle cell foci: a mimic of mucinous tubular and

spindle cell carcinoma. *Am J Surg Pathol*. 2008;32(9):1353-1359.
476. Shen SS, Ro JY, Tamboli P, et al. Mucinous tubular and spindle cell carcinoma of kidney is probably a variant of papillary renal cell carcinoma with spindle cell features. *Ann Diagn Pathol*. 2007;11(1):13-21.
477. Mehra R, Vats P, Cieslik M, et al. Biallelic alteration and dysregulation of the hippo pathway in mucinous tubular and spindle cell carcinoma of the kidney. *Cancer Discov*. 2016;6:1258-1266.
478. Dhillon J, Amin MB, Selbs E, et al. Mucinous tubular and spindle cell carcinoma of the kidney with sarcomatoid change. *Am J Surg Pathol*. 2009;33(1):44-49.
479. Gehrig JJ Jr, Gottheiner TI, Swenson RS. Acquired cystic disease of the end-stage kidney. *Am J Med*. 1985;79:609-620.
480. Rioux-Leclercq NC, Epstein JI. Renal cell carcinoma with intratumoral calcium oxalate crystal deposition in patients with acquired cystic disease of the kidney. *Arch Pathol Lab Med*. 2003;127:E89-E92.
481. Sule N, Yakupoglu U, Shen SS, et al. Calcium oxalate deposition in renal cell carcinoma associated with acquired cystic kidney disease: a comprehensive study. *Am J Surg Pathol*. 2005;29:443-451.
482. Kuroda N, Tamura M, Hamaguchi N, et al. Acquired cystic disease-associated renal cell carcinoma with sarcomatoid change and rhabdoid features. *Ann Diagn Pathol*. 2011;15:462-466.
483. Trpkov K, Hes O, Bonert M, et al. Eosinophilic, solid, and cystic renal cell carcinoma: clinicopathologic study of 16 unique, sporadic neoplasms occurring in women. *Am J Surg Pathol*. 2016;40:60-71.
484. Trpkov K, Abou-Ouf H, Hes O, et al. Eosinophilic solid and cystic renal cell carcinoma (ESC RCC): further morphologic and molecular characterization of ESC RCC as a distinct entity. *Am J Surg Pathol*. 2017;41(10):1299-1308.
485. Cheng L, Amin MB, Lopez-Beltran A, Montironi R. Unclassified renal cell carcinoma. In: Moch H, Humphrey PA, Ulbright TM, Reuter VE, eds. *WHO Classification of Tumours of the Urinary System and Male Genital Organs*. Lyon: IARC Press; 2016.
486. Chen YB, Xu J, Skanderup AJ, et al. Molecular analysis of aggressive renal cell carcinoma with unclassified histology reveals distinct subsets. *Nat Commun*. 2016;7:13131.
487. Kuhn E, De Anda J, Manoni S, et al. Renal cell carcinoma associated with prominent angioleiomyoma-like proliferation: report of 5 cases and review of the literature. *Am J Surg Pathol*. 2006;30(11):1372-1381.
488. Brunelli M, Menestrina F, Segala D, et al. Renal cell carcinoma associated with prominent leiomyomatous proliferation appears not to be a variant of clear cell renal cell carcinoma. *Lab Invest*. 2009;89(suppl 1):160A.
489. Michal M, Hes O, Nemcova J, et al. Renal angiomyoadenomatous tumor: morphologic, immunohistochemical, and molecular genetic study of a distinct entity. *Virchows Arch*. 2009;454(1):89-99.
490. Shannon BA, Cohen RJ, Segal A, et al. Clear cell renal cell carcinoma with smooth muscle stroma. *Hum Pathol*. 2009;40(3):425-429.
491. Lan TT, Keller-Ramey J, Fitzpatrick C, et al. Unclassified renal cell carcinoma with tubulopapillary architecture, clear cell phenotype, and chromosome 8 monosomy: a new kid on the block. *Virchows Arch*. 2016;469:81-91.
492. Hakimi AA, Tickoo SK, Jacobsen A, et al. TCEB1-mutated renal cell carcinoma: a distinct genomic and morphological subtype. *Mod Pathol*. 2015;28:845-853.
493. Williamson SR, Cheng L, Eble JN, et al. Renal cell carcinoma with angioleiomyoma-like stroma: clinicopathological, immunohistochemical, and molecular features supporting classification as a distinct entity. *Mod Pathol*. 2015;28:279-294.
494. Amin MB, Gupta R, Ondrej H, et al. Primary thyroid-like follicular carcinoma of the kidney: report of 6 cases of a histologically distinctive adult renal epithelial neoplasm. *Am J Surg Pathol*. 2009;33(3):393-400.
495. Jung SJ, Chung JI, Park SH, et al. Thyroid follicular carcinoma-like tumor of kidney: a case report with morphologic, immunohistochemical, and genetic analysis. *Am J Surg Pathol*. 2006;30(3):411-415.
496. Sterlacci W, Verdorfer I, Gabriel M, Mikuz G. Thyroid follicular carcinoma-like renal tumor: a case report with morphologic, immunophenotypic, cytogenetic, and scintigraphic studies. *Virchows Arch*. 2008;452(1):91-95.
497. Bonsib SM, Gibson D, Mhoon M, Greene GF. Renal sinus involvement in renal cell carcinomas. *Am J Surg Pathol*. 2000;24(3):451-458.
498. Bonsib SM. The renal sinus is the principal invasive pathway: a prospective study of 100 renal cell carcinomas. *Am J Surg Pathol*. 2004;28(12):1594-1600.
499. Thompson RH, Blute ML, Krambeck AE, et al. Patients with pT1 renal cell carcinoma who die from disease after nephrectomy may have unrecognized renal sinus fat invasion. *Am J Surg Pathol*. 2007;31(7):1089-1093.
500. Holland JM. Proceedings: cancer of the kidney—natural history and staging. *Cancer*. 1973;32(5):1030-1042.
501. Gurney H, Larcos G, McKay M, et al. Bone metastases in hypernephroma. Frequency of scapular involvement. *Cancer*. 1989;64(7):1429-1431.
502. Troncoso A, Ro JY, Grignon DJ, et al. Renal cell carcinoma with acrometastasis: report of two cases and review of the literature. *Mod Pathol*. 1991;4(1):66-69.
503. Insabato L, De Rosa G, Franco R, et al. Ovarian metastasis from renal cell carcinoma: a report of three cases. *Int J Surg Pathol*. 2003;11(4):309-312.
504. Datta MW, Ulbright TM, Young RH. Renal cell carcinoma metastatic to the testis and its adnexa: a report of five cases including three that accounted for the initial clinical presentation. *Int J Surg Pathol*. 2001;9(1):49-56.
505. Leung CS, Srigley JR, Robertson AR. Metastatic renal cell carcinoma presenting as solitary bleeding prostatic metastasis. *J Urol Pathol*. 1997;7:127-132.
506. Marlowe SD, Swartz JD, Koenigsberg R, et al. Metastatic hypernephroma to the larynx: an unusual presentation. *Neuroradiology*. 1993;35(3):242-243.
507. Matias-Guiu X, Garcia A, Curell R, Prat J. Renal cell carcinoma metastatic to the thyroid gland: a comparative molecular study between the primary and the metastatic tumor. *Endocr Pathol*. 1998;9(3):255-260.
508. Melnick SJ, Amazon K, Dembrow V. Metastatic renal cell carcinoma presenting as a parotid tumor: a case report with immunohistochemical findings and a review of the literature. *Hum Pathol*. 1989;20(2):195-197.
509. Nishio S, Tsukamoto H, Fukui M, Matsubara T. Hypophyseal metastatic hypernephroma mimicking a pituitary adenoma. Case report. *Neurosurg Rev*. 1992;15(4):319-322.
510. Okabe Y, Ohoka H, Miwa T, et al. View from beneath: pathology in focus. Renal cell carcinoma metastasis to the tongue. *J Laryngol Otol*. 1992;106(3):282-284.
511. Sim SJ, Ro JY, Ordonez NG, et al. Metastatic renal cell carcinoma to the bladder: a clinicopathologic and immunohistochemical study. *Mod Pathol*. 1999;12(4):351-355.
512. Radley MG, McDonald JV, Pilcher WH, Wilbur DC. Late solitary cerebral metastases from renal cell carcinoma: report of two cases. *Surg Neurol*. 1993;39(3):230-234.
513. Saitoh H, Hida M, Nakamura K, et al. Metastatic processes and a potential indication of treatment for metastatic lesions of renal adenocarcinoma. *J Urol*. 1982;128(5):916-918.
514. Young RH, Hart WR. Renal cell carcinoma metastatic to the ovary: a report of three cases emphasizing possible confusion with ovarian clear cell adenocarcinoma. *Int J Gynecol Pathol*. 1992;11(2):96-104.
515. Foucar E, Dehner LP. Renal cell carcinoma occurring with contralateral adrenal metastasis: a clinical and pathological trap. *Arch Surg*. 1979;114(8):959-963.
516. Previte SR, Willscher MK, Burke CR. Renal cell carcinoma with solitary contralateral adrenal metastasis: experience with 2 cases. *J Urol*. 1982;128(1):132-134.
517. Wick MR, Cherwitz DL, McGlennen RC, Dehner LP. Adrenocortical carcinoma. An immunohistochemical comparison with renal cell carcinoma. *Am J Pathol*. 1986;122(2):343-352.
518. McNichols DW, Segura JW, DeWeerd JH. Renal cell carcinoma: long-term survival and late recurrence. *J Urol*. 1981;126(1):17-23.
519. Shah IA, Haddad FS, Wheeler L, Chinichian A. Metastatic renal cell carcinoma: late recurrence and prolonged survival. *J Urol Pathol*. 1996;4:289-298.
520. Fairlamb DJ. Spontaneous regression of metastases of renal cancer: a report of two cases including the first recorded regression following irradiation of a dominant metastasis and review of the world literature. *Cancer*. 1981;47(8):2102-2106.
521. Garfield DH, Kennedy BJ. Regression of metastatic renal cell carcinoma following nephrectomy. *Cancer*. 1972;30(1):190-196.
522. Aizawa S, Suzuki M, Kikuchi Y, et al. Clinicopathological study on small renal cell carcinomas with metastases. *Acta Pathol Jpn*. 1987;37(6):947-954.
523. Berger A, Brandina R, Atalla MA, et al. Laparoscopic radical nephrectomy for renal cell carcinoma: oncological outcomes at 10 years or more. *J Urol*. 2009;182(5):2172-2176.
524. Bissada NK. Renal cell adenocarcinoma. *Surg Gynecol Obstetr*. 1977;145(1):97-104.
525. deKernion JB, Berry D. The diagnosis and treatment of renal cell carcinoma. *Cancer*. 1980;45(7 suppl):1947-1956.
526. Robson CJ, Churchill BM, Anderson W. The results of radical nephrectomy for renal cell carcinoma. *Trans Am Assoc Genitourin Surg*. 1968;60:122-129.
527. Waters WB, Richie JP. Aggressive surgical approach to renal cell carcinoma: review of 130 cases. *J Urol*. 1979;122(3):306-309.
528. Rini BI, Garcia J, Elson P, et al. The effect of sunitinib on primary renal cell carcinoma and facilitation of subsequent surgery. *J Urol*. 2012;187:1548-1554.
529. Frydenberg M, Malek RS, Zincke H. Conservative renal surgery for renal cell carcinoma in von Hippel-Lindau's disease. *J Urol*. 1993;149(3):461-464.
530. Lund GO, Fallon B, Curtis MA, Williams RD. Conservative surgical therapy of localized renal cell carcinoma in von Hippel-Lindau disease. *Cancer*. 1994;74(9):2541-2545.
531. Marshall FF, Walsh PC. In situ management of renal tumors: renal cell carcinoma and transitional cell carcinoma. *J Urol*. 1984;131(6):1045-1049.

532. Novick AC. Partial nephrectomy for renal cell carcinoma. *Urol Clin North Am*. 1987;14(2):419-433.
533. Topley M, Novick AC, Montie JE. Long-term results following partial nephrectomy for localized renal adenocarcinoma. *J Urol*. 1984;131(6):1050-1052.
534. Steinbach F, Stockle M, Muller SC, et al. Conservative surgery of renal cell tumors in 140 patients: 21 years of experience. *J Urol*. 1992;148(1):24-29, discussion 29-30.
535. Stephens R, Graham SD Jr. Enucleation of tumor versus partial nephrectomy as conservative treatment of renal cell carcinoma. *Cancer*. 1990;65(12):2663-2667.
536. Atkins MB, Dutcher J, Weiss G, et al. Kidney cancer: the Cytokine Working Group experience (1986–2001): part I. IL-2-based clinical trials. *Med Oncol*. 2001;18(3): 197-207.
537. Nathan PD, Eisen TG. The biological treatment of renal-cell carcinoma and melanoma. *Lancet Oncol*. 2002;3(2):89-96.
538. Pantuck AJ, Zisman A, Belldegrun A. Gene and immune therapy for renal cell carcinoma. *Int J Urol*. 2001;8(7):S1-S4.
539. Herrmann E, Bierer S, Wulfing C. Update on systemic therapies of metastatic renal cell carcinoma. *World J Urol*. 2010;28(3): 303-309.
540. Cheville JC, Lohse CM, Zincke H, et al. Comparisons of outcome and prognostic features among histologic subtypes of renal cell carcinoma. *Am J Surg Pathol*. 2003;27(5):612-624.
541. Rini B, McKiernan JM, Chang SS, et al. Amin MB, ed. *AJCC Cancer Staging Manual*. 8th ed. New York: Springer; 2017.
542. Bonsib SM, Gibson D, Mhoon M, Greene GF. Renal sinus involvement in renal cell carcinomas. *Am J Surg Pathol*. 2000;24:451-458.
543. Bonsib SM. T2 clear cell renal cell carcinoma is a rare entity: a study of 120 clear cell renal cell carcinomas. *Am J Surg Pathol*. 2005;174:1199-1202.
544. Trpkov K, Grignon DJ, Bonsib SM, et al. Handling and staging of renal cell carcinoma: the International Society of Urological Pathology Consensus (ISUP) conference recommendations. *Am J Surg Pathol*. 2013;37:1505-1517.
545. Jung SJ, Ro JY, Truong LD, et al. Reappraisal of T3N0/NxM0 renal cell carcinoma: significance of extent of fat invasion, renal vein invasion, and adrenal invasion. *Hum Pathol*. 2008;39(11):1689-1694.
546. Selli C, Hinshaw WM, Woodard BH, Paulson DF. Stratification of risk factors in renal cell carcinoma. *Cancer*. 1984;52:270-275.
547. Fuhrman SA, Lasky LC, Limas C. Prognostic significance of morphologic parameters in renal cell carcinoma. *Am J Surg Pathol*. 1982;6(7):655-663.
548. Kay S. Renal carcinoma. A 10-year study. *Am J Clin Pathol*. 1968;50(4):428-432.
549. Medeiros LJ, Gelb AB, Weiss LM. Renal cell carcinoma. Prognostic significance of morphologic parameters in 21 cases. *Cancer*. 1988;61:1639-1651.
550. Delahunt B, Kittelson JM, McCredie MR, et al. Prognostic importance of tumor size for localized conventional (clear cell) renal cell carcinoma: assessment of TNM T1 and T2 tumor categories and comparison with other prognostic parameters. *Cancer*. 2002;94(3):658-664.
551. Elmore JM, Kadesky KT, Koeneman KS, Sagalowsky AI. Reassessment of the 1997 TNM classification system for renal cell carcinoma: a 5-cm T1/T2 cutoff is a better predictor of clinical outcome. *Cancer*. 2003;98:2329-2334.
552. Kinouchi T, Saiki S, Meguro N, et al. Impact of tumor size on the clinical outcomes of patients with Robson State I renal cell carcinoma. *Cancer*. 1999;85(3):689-695.
553. Herrera LP, Jorda M, Reis I, et al. The potential value of a simple two-level grading system for renal cell carcinomas. *Lab Invest*. 2009;89(suppl 1):172A.
554. Mrstik C, Salamon J, Weber R, Stogermayer F. Microscopic venous infiltration as predictor of relapse in renal cell carcinoma. *J Urol*. 1992;148(2 Pt 1):271-274.
555. Van Poppel H, Vandendriessche H, Boel K, et al. Microscopic vascular invasion is the most relevant prognosticator after radical nephrectomy for clinically nonmetastatic renal cell carcinoma. *J Urol*. 1997;158(1): 45-49.
556. Lanigan D, Conroy R, Barry-Walsh C, et al. A comparative analysis of grading systems in renal adenocarcinoma. *Histopathology*. 1994;24(5):473-476.
557. Medeiros LJ, Jones EC, Aizawa S, et al. Grading of renal cell carcinoma: Workgroup No. 2. Union Internationale Contre le Cancer and the American Joint Committee on Cancer (AJCC). *Cancer*. 1997;80(5):990-991.
558. Minervini A, Lilas L, Minervini R, Selli C. Prognostic value of nuclear grading in patients with intracapsular (pT1–pT2) renal cell carcinoma. Long-term analysis in 213 patients. *Cancer*. 2002;94(10):2590-2595.
559. Sika-Paotonu D, Bethwaite PB, McCredie MR, et al. Nucleolar grade but not Fuhrman grade is applicable to papillary renal cell carcinoma. *Am J Surg Pathol*. 2006;30:1091-1096.
560. Gelb AB, Shibuya RB, Weiss LM, Medeiros LJ. Stage I renal cell carcinoma. A clinicopathologic study of 82 cases. *Am J Surg Pathol*. 1993;17(3):275-286.
561. Delahunt B, Cheville JC, Martignoni G, et al. The International Society of Urological Pathology (ISUP) grading system for renal cell carcinoma and other prognostic parameters. *Am J Surg Pathol*. 2013;37:1490-1504.
562. Dagher J, Delahunt B, Rioux-Leclercq N, et al. Clear cell renal cell carcinoma: validation of WHO/ISUP grading. *Histopathol*. 2017.
563. Lohse CM, Blute ML, Zincke H, et al. Comparison of standardized and nonstandardized nuclear grade of renal cell carcinoma to predict outcome among 2,042 patients. *Am J Clin Pathol*. 2002;118(6):877-886.
564. Montironi R, Santinelli A, Pomante R, et al. Morphometric index of adult renal cell carcinoma. Comparison with the Fuhrman grading system. *Virchows Arch*. 2000;437(1):82-89.
565. Pound CR, Partin AW, Epstein JI, et al. Nuclear morphometry accurately predicts recurrence in clinically localized renal cell carcinoma. *Urology*. 1993;42(3):243-248.
566. Sengupta S, Lohse CM, Leibovich BC, et al. Histologic coagulative tumor necrosis as a prognostic indicator of renal cell carcinoma aggressiveness. *Cancer*. 2005;104(3):511-520.
567. Khor LY, Dhakal HP, Jia X, et al. Tumor necrosis adds prognostically significant information to grade in clear cell renal cell carcinoma: a study of 842 consecutive cases from a single institution. *Am J Surg Pathol*. 2016;40:1224-1231.
568. Delahunt B, McKenney JK, Lohse CM, et al. A novel grading system for clear cell renal cell carcinoma incorporating tumor necrosis. *Am J Surg Pathol*. 2013;37:311-322.
569. Delahunt B, Eble JN. Papillary adenoma of the kidney: an evolving concept. *J Urol Pathol*. 1997;7:99-112.
570. Grignon DJ, Eble JN. Papillary and metanephric adenomas of the kidney. *Semin Diagn Pathol*. 1998;15(1):41-53.
571. Ligato S, Ro JY, Tamboli P, et al. Benign tumors and tumor-like lesions of the adult kidney. Part I: benign renal epithelial neoplasms. *Adv Anat Pathol*. 1999;6(1):1-11.
572. Eble J, Moch H, Amin MB, et al. Papillary adenoma. In: Moch H, Humphrey PA, Ulbright TM, Reuter VE, eds. *WHO Classification of Tumours of the Urinary System and Male Genital Organs*. Lyon: IARC Press; 2016.
573. Suzuki M, Nikaido T, Ikegami M, et al. Renal adenoma. Clinicopathological and histochemical studies. *Acta Pathol Jpn*. 1989;39(11):731-736.
574. Hughson MD, Hennigar GR, McManus JF. Atypical cysts, acquired renal cystic disease, and renal cell tumors in end stage dialysis kidneys. *Lab Invest*. 1980;42(4):475-480.
575. Kobs DGI, Crotty K, Orihuela E, Cowan DF. Renal adenomatosis in acquired renal cystic disease without dialysis. *J Urol Pathol*. 1996;4:273-282.
576. Perez-Ordonez B, Hamed G, Campbell S, et al. Renal oncocytoma: a clinicopathologic study of 70 cases. *Am J Surg Pathol*. 1997;21(8):871-883.
577. Choi H, Almagro UA, McManus JT, et al. Renal oncocytoma. A clinicopathologic study. *Cancer*. 1983;51(10):1887-1896.
578. Kadesky KT, Fulgham PF. Bilateral multifocal renal oncocytoma: case report and review of the literature. *J Urol*. 1993;150(4):1227-1228.
579. Hes O, Michal M, Sima R, et al. Renal oncocytoma with and without intravascular extension into the branches of renal vein have the same morphological, immunohistochemical and genetic features. *Virchows Arch*. 2008;452(3):285-293.
580. Trpkov K, Yilmaz A, Uzer D, et al. Renal oncocytoma revisited: a clinicopathological study of 109 cases with emphasis on problematic diagnostic features. *Histopathol*. 2010;57:893-906.
581. Wobker SE, et al. Renal oncocytoma with vascular invasion: a series of 22 cases. *Hum Pathol*. 2016;58:1-6.
582. Amin MB, Crotty TB, Tickoo SK, Farrow GM. Renal oncocytoma: a reappraisal of morphologic features with clinicopathologic findings in 80 cases. *Am J Surg Pathol*. 1997;21:1-12.
583. Davidson AJ, Hayes WS, Hartman DS, et al. Renal oncocytoma and carcinoma: failure of differentiation with CT. *Radiology*. 1993;186(3):693-696.
584. Lieber MM, Tomera KM, Farrow GM. Renal oncocytoma. *J Urol*. 1981;125:481-485.
585. Barnes CA, Beckman EN. Renal oncocytoma and its congeners. *Am J Clin Pathol*. 1983;79(3):312-318.
586. Merino MJ, Livolsi VA. Oncocytomas of the kidney. *Cancer*. 1982;50(9):1852-1856.
587. Hes O, Michal M, Boudova L, et al. Small cell variant of renal oncocytoma—a rare and misleading type of benign renal tumor. *Int J Surg Pathol*. 2001;9(3):215-222.
588. Shimazaki H, Tanaka K, Aida S, et al. Renal oncocytoma with intracytoplasmic lumina: a case report with ultrastructural findings of "oncoblasts.". *Ultrastruct Pathol*. 2001;25(2):153-158.
589. Lefèvre M, Couturier J, Sibony M, et al. Adult papillary renal tumor with oncocytic cells: clinicopathologic, immunohistochemical, and cytogenetic features of ten cases. *Am J Surg Pathol*. 2005;29:1576-1581.
590. Li G, Barthelemy A, Feng G, et al. S100A1: a powerful marker to differentiate chromophobe renal cell carcinoma from renal oncocytoma. *Histopathology*. 2007;50(5):642-647.
591. Hes O, Michal M, Kuroda N, et al. Vimentin reactivity in renal oncocytoma: immunohistochemical study of 234 cases. *Arch Pathol Lab Med*. 2007;131(12):1782-1788.

592. Pitz S, Moll R, Storkel S, Thoenes W. Expression of intermediate filament proteins in subtypes of renal cell carcinomas and in renal oncocytomas. Distinction of two classes of renal cell tumors. *Lab Invest*. 1987;56(6):642-653.
593. Zhou M, Roma A, Magi-Galluzzi C. The usefulness of immunohistochemical markers in the differential diagnosis of renal neoplasms. *Clin Lab Med*. 2005;25:247-257.
594. Wu SL, Kothari P, Wheeler TM, et al. Cytokeratins 7 and 20 immunoreactivity in chromophobe renal cell carcinomas and renal oncocytomas. *Mod Pathol*. 2002;15(7):712-717.
595. Chang A, Harawi SJ. Oncocytes, oncocytosis, and oncocytic tumors. *Pathol Ann*. 1992;27(Pt 1):263-304.
596. Eble JN, Hull MT. Morphologic features of renal oncocytoma: a light and electron microscopic study. *Hum Pathol*. 1984;15(11):1054-1061.
597. Lloreta-Trull J, Serrano S. Biology and pathology of the mitochondrion. *Ultrastruct Pathol*. 1998;22(5):357-367.
598. Tallini G. Oncocytic tumours. *Virchows Arch*. 1998;433(1):5-12.
599. Paner GP, Lindgren V, Jacobson K, et al. High incidence of chromosome 1 abnormalities in a series of 27 renal oncocytomas: cytogenetic and fluorescence in situ hybridization studies. *Arch Pathol Lab Med*. 2007;131(1):81-85.
600. Brunelli M1, Delahunt B, Gobbo S, et al. Diagnostic usefulness of fluorescent cytogenetics in differentiating chromophobe renal cell carcinoma from renal oncocytoma: a validation study combining metaphase and interphase analyses. *Am J Clin Pathol*. 2010;133:116-126.
601. Alanen KA, Ekfors TO, Lipasti JA, Nurmi MJ. Renal oncocytoma: the incidence of 18 surgical and 12 autopsy cases. *Histopathology*. 1984;8(5):731-737.
602. Davis CJJ, Sesterhenn IA, Mostofi FK, Ho CK. Renal oncocytoma. Clinicopathological study of 166 patients. *J Urogen Pathol*. 1991;1:41-52.
603. Klein MJ, Valensi QJ. Proximal tubular adenomas of kidney with so-called oncocytic features. A clinicopathologic study of 13 cases of a rarely reported neoplasm. *Cancer*. 1976;38(2):906-914.
604. Lewi HJE, Alexander CA, Fleming S. Renal oncocytoma. *Br J Urol*. 1986;58:12-15.
605. Medeiros LJ, Gelb AB, Weiss LM. Low-grade renal cell carcinoma. A clinicopathologic study of 53 cases. *Am J Surg Pathol*. 1987;11(8):633-642.
606. Dishongh KM, Quick CM, Gokden N. Renal oncocytomas with atypical features: a clinicopathologic analysis of 34 cases. *Lab Invest*. 2009;89(suppl 1):166A.
607. Uzer D, Yilmaz A, Bismar T, Trpkov K. Worrisome and atypical features in renal oncocytoma: clinicopathological analysis of 76 cases. *Lab Invest*. 2009;89(suppl 1):199A.
608. Tickoo SK, Amin MB. Discriminant nuclear features of renal oncocytoma and chromophobe renal cell carcinoma. Analysis of their potential utility in the differential diagnosis. *Am J Clin Pathol*. 1998;110(6):782-787.
609. Chen TS, McNally M, Hulbert W, et al. Renal oncocytosis presenting in childhood: a case report. *Int J Surg Pathol*. 2003;11(4):325-329.
610. Gobbo S, Eble JN, Delahunt B, et al. Renal cell neoplasms of oncocytosis have distinct morphologic, immunohistochemical, and cytogenetic profiles. *Am J Surg Pathol*. 2010;34(5):620-626.
611. Capella C, Eusebi V, Rosai J. Primary oat cell carcinoma of the kidney. *Am J Surg Pathol*. 1984;8(11):855-861.
612. Gonzalez-Lois C, Madero S, Redondo P, et al. Small cell carcinoma of the kidney: a case report and review of the literature. *Arch Pathol Lab Med*. 2001;125(6):796-798.
613. Lane BR, Chery F, Jour G, et al. Renal neuroendocrine tumours: a clinicopathological study. *BJU Int*. 2007;100:1030-1035.
614. Morgan KG, Banerjee SS, Eyden BP, Barnard RJ. Primary small cell neuroendocrine carcinoma of the kidney. *Ultrastruct Pathol*. 1996;20(2):141-144.
615. Tetu B, Ro JY, Ayala AG, et al. Small cell carcinoma of the kidney. A clinicopathologic, immunohistochemical, and ultrastructural study. *Cancer*. 1987;60(8):1809-1814.
616. Essenfeld H, Manivel JC, Benedette P, Albores-Saavedra J. Small cell carcinoma of the renal pelvis. A clinicopathologic, morphologic and histochemical study of 2 cases. *J Urol*. 1991;144:344-347.
617. La Rosa S, Bernasconi B, Micello D, et al. Primary small cell neuroendocrine carcinoma of the kidney: morphological, immunohistochemical, ultrastructural, and cytogenetic study of a case and review of the literature. *Endocr Pathol*. 2009;20(1):24-34.
618. Mills SE, Weiss MA, Swanson PE, Wick MR. Small cell undifferentiated carcinoma of the renal pelvis. A light microscopic, immunocytochemical, and ultrastructural study. *Surg Pathol*. 1988;1:83-88.
619. Bégin LR, Jamison BM. Renal carcinoid—a tumor of probable hindgut neuroendocrine phenotype. Report of a case and literature review. *J Urol Pathol*. 1993;3:269-282.
620. Unger PD, Russell A, Thung SN, Gordon RE. Primary renal carcinoid. *Arch Pathol Lab Med*. 1990;114(1):68-71.
621. Zak FG, Jindrak K, Capozzi F. Carcinoidal tumor of the kidney. *Ultrastruct Pathol*. 1983;4(1):51-59.
622. Fetissof F, Benatre A, Dubois MP, et al. Carcinoid tumor occurring in a teratoid malformation of the kidney. An immunohistochemical study. *Cancer*. 1984;54(10):2305-2308.
623. Kojiro M, Ohishi H, Isobe H. Carcinoid tumor occurring in cystic teratoma of the kidney: a case report. *Cancer*. 1976;38(4):1636-1640.
624. Yoo J, Park S, Jung Lee H, et al. Primary carcinoid tumor arising in a mature teratoma of the kidney: a case report and review of the literature. *Arch Pathol Lab Med*. 2002;126(8):979-981.
625. Huettner PC, Bird DJ, Chang YC, Seiler MW. Carcinoid tumor of the kidney with morphologic and immunohistochemical profile of a hindgut endocrine tumor: report of a case. *Ultrastruct Pathol*. 1991;15(6):655-661.
626. Murali R, Kneale K, Lalak N, Delprado W. Carcinoid tumors of the urinary tract and prostate. *Arch Pathol Lab Med*. 2006;130(11):1693-1706.
627. Raslan WF, Ro JY, Ordonez NG, et al. Primary carcinoid of the kidney. Immunohistochemical and ultrastructural studies of five patients. *Cancer*. 1993;72(9):2660-2666.
628. Takeshima Y, Inai K, Yoneda K. Primary carcinoid tumor of the kidney with special reference to its histogenesis. *Pathol Int*. 1996;46(11):894-900.
629. Hannah J, Lippe B, Lai-Goldman M, Bhuta S. Oncocytic carcinoid of the kidney associated with periodic Cushing's syndrome. *Cancer*. 1988;61(10):2136-2140.
630. Hansel DE, Epstein JI, Berbescu E, et al. Renal carcinoid tumor: a clinicopathologic study of 21 cases. *Am J Surg Pathol*. 2007;31(10):1539-1544.
631. Pagni F, Galbiati E, Bono F, Di Bella C. Renal hilus paraganglioma: a case report and brief review. *Pathologica*. 2009;101:89-92.
632. Hes O, de Souza TG, Pivovarcikova K, et al. Distinctive renal cell tumor simulating atrophic kidney with 2 types of microcalcifications. Report of 3 cases. *Ann Diagn Pathol*. 2014;18:82-88.
633. Pacchioni D, Volante M, Casetta G, et al. Myxoid renal tumor with myoepithelial differentiation mimicking a salivary gland pleomorphic adenoma: description of a case. *Am J Surg Pathol*. 2007;31(4):632-636.
634. Cajaiba MM, Jennings LJ, Rohan SM, et al. Expanding the spectrum of renal tumors in children: primary renal myoepithelial carcinomas with a novel EWSR1-KLF15 fusion. *Am J Surg Pathol*. 2016;40:386-394.
635. Strobel P, Zettl A, Ren Z, et al. Spiradenocylindroma of the kidney: clinical and genetic findings suggesting a role of somatic mutation of the CYLD1 gene in the oncogenesis of an unusual renal neoplasm. *Am J Surg Pathol*. 2002;26(1):119-124.
636. Renshaw AA, Shapiro C, Fletcher JA, Pins MR. An unusual papillary tumor of the renal medulla. Distinction from usual papillary renal cell carcinoma and collecting duct carcinoma. *J Urol Pathol*. 1998;8:121-133.
637. Ditonno P, Smith RB, Koyle MA, et al. Extrarenal angiomyolipomas of the perinephric space. *J Urol*. 1992;147(2):447-450.
638. Hruban RH, Bhagavan BS, Epstein JI. Massive retroperitoneal angiomyolipoma. A lesion that may be confused with well-differentiated liposarcoma. *Am J Clin Pathol*. 1989;92(6):805-808.
639. Righi A, Dimosthenous K, Rosai J. PEComa: another member of the MiT tumor family? *Int J Surg Pathol*. 2008;16(1):16-20.
640. Hornick JL, Fletcher CD. PEComa: what do we know so far? *Histopathology*. 2006;48(1):75-82.
641. Martignoni G, Pea M, Reghellin D, et al. PEComas: the past, the present and the future. *Virchows Arch*. 2008;452(2):119-132.
642. Mukai M, Torikata C, Iri H, et al. Crystalloids in angiomyolipoma. 1. A previously unnoticed phenomenon of renal angiomyolipoma occurring at a high frequency. *Am J Surg Pathol*. 1992;16(1):1-10.
643. Monga G, Ramponi A, Falzoni PU, Boldorini R. Renal and hepatic angiomyolipomas in a child without evidence of tuberous sclerosis. *Pathol Res Pract*. 1994;190(12):1208-1211, discussion 1212-1213.
644. Chan JK, Tsang WY, Pau MY, et al. Lymphangiomyomatosis and angiomyolipoma: closely related entities characterized by hamartomatous proliferation of HMB-45-positive smooth muscle. *Histopathology*. 1993;22(5):445-455.
645. Monteforte WJ Jr, Kohnen PW. Angiomyolipomas in a case of lymphangiomyomatosis syndrome: relationships to tuberous sclerosis. *Cancer*. 1974;34(2):317-321.
646. Fetsch PA, Fetsch JF, Marincola FM, et al. Comparison of melanoma antigen recognized by T cells (MART-1) to HMB-45: additional evidence to support a common lineage for angiomyolipoma, lymphangiomyomatosis, and clear cell sugar tumor. *Mod Pathol*. 1998;11(8):699-703.
647. Yavuz E, Cakr C, Tuzlal S, et al. Uterine perivascular epithelioid cell tumor coexisting with pulmonary lymphangioleiomyomatosis and renal angiomyolipoma: a case report. *Appl Immunohistochem Mol Morphol*. 2008;16(4):405-409.
648. Steiner MS, Goldman SM, Fishman EK, Marshall FF. The natural history of renal angiomyolipoma. *J Urol*. 1993;150(6):1782-1786.
649. Bernstein J, Robbins TO, Kissane JM. The renal lesions of tuberous sclerosis. *Semin Diagn Pathol*. 1986;3(2):97-105.

650. Martignoni G, Bonetti F, Pea M, et al. Renal disease in adults with TSC2/PKD1 contiguous gene syndrome. *Am J Surg Pathol*. 2002;26(2):198-205.
651. Daughtry JD, Rodan BA. Renal angiomyolipoma: definitive diagnosis by ultrasonography and computerized tomography. *South Med J*. 1985;78(2):195-197.
652. Bonzanini M, Pea M, Martignoni G, et al. Preoperative diagnosis of renal angiomyolipoma: fine needle aspiration cytology and immunocytochemical characterization. *Pathology*. 1994;26(2):170-175.
653. Granter SR, Renshaw AA. Cytologic analysis of renal angiomyolipoma: a comparison of radiologically classic and challenging cases. *Cancer*. 1999;87(3):135-140.
654. Eble JN. Angiomyolipoma of kidney. *Semin Diagn Pathol*. 1998;15(1):21-40.
655. Hayashi T, Tsuda N, Chowdhury PR, et al. Renal angiomyolipoma: clinicopathologic features and differential diagnosis. *J Urol Pathol*. 1999;10:121-140.
656. Kilicaslan I, Gulluoglu MG, Dogan O, Uysal V. Intraglomerular microlesions in renal angiomyolipoma. *Hum Pathol*. 2000;31(10):1325-1328.
657. Davis CJ, Barton JH, Sesterhenn IA. Cystic angiomyolipoma of the kidney: a clinicopathologic description of 11 cases. *Mod Pathol*. 2006;19(5):669-674.
658. Fine SW, Reuter VE, Epstein JI, Argani P. Angiomyolipoma with epithelial cysts (AMLEC): a distinct cystic variant of angiomyolipoma. *Am J Surg Pathol*. 2006;30(5):593-599.
659. Hoon V, Thung SN, Kaneko M, Unger PD. HMB-45 reactivity in renal angiomyolipoma and lymphangioleiomyomatosis. *Arch Pathol Lab Med*. 1994;118(7):732-734.
660. Jungbluth AA, Iversen K, Coplan K, et al. Expression of melanocyte-associated markers gp-100 and Melan-A/MART-1 in angiomyolipomas. An immunohistochemical and rt-PCR analysis. *Virchows Arch*. 1999;434(5):429-435.
661. Makhlouf HR, Ishak KG, Shekar R, et al. Melanoma markers in angiomyolipoma of the liver and kidney: a comparative study. *Arch Pathol Lab Med*. 2002;126(1):49-55.
662. Pea M, Bonetti F, Zamboni G, et al. Melanocyte-marker-HMB-45 is regularly expressed in angiomyolipoma of the kidney. *Pathology*. 1991;23(3):185-188.
663. Roma AA, Magi-Galluzzi C, Zhou M. Differential expression of melanocytic markers in myoid, lipomatous, and vascular components of renal angiomyolipomas. *Arch Pathol Lab Med*. 2007;131(1):122-125.
664. Stone CH, Lee MW, Amin MB, et al. Renal angiomyolipoma: further immunophenotypic characterization of an expanding morphologic spectrum. *Arch Pathol Lab Med*. 2001;125(6):751-758.
665. Weeks DA, Chase DR, Malott RL, et al. HMB-45 staining in angiomyolipoma,cardiac rhabdomyoma, other mesenchymal processes, and tuberous sclerosis-associated brain lesions. *Int J Surg Pathol*. 1994;1:191-198.
666. Zamecnik M, Majercik M, Gomolcak P. Renal angiomyolipoma resembling gastrointestinal stromal tumor with skenoid fibers. *Ann Diagn Pathol*. 1999;3(2):88-91.
667. Martignoni G, Pea M, Gobbo S, et al. Cathepsin-K immunoreactivity distinguishes MiTF/TFE family renal translocation carcinomas from other renal carcinomas. *Mod Pathol*. 2009;22:1016-1022.
668. Patil PA, McKenney JK, Trpkov K, et al. Renal leiomyoma: a contemporary multi-institution study of an infrequent and frequently misclassified neoplasm. *Am J Surg Pathol*. 2015;39:349-356.
669. Martignoni G, Bonetti F, Chilosi M, et al. Cathepsin K expression in the spectrum of perivascular epithelioid cell (PEC) lesions of the kidney. *Mod Pathol*. 2012;25:100-111.
670. Barnard M, Lajoie G. Angiomyolipoma: immunohistochemical and ultrastructural study of 14 cases. *Ultrastruct Pathol*. 2001;25(1):21-29.
671. Kaiserling E, Krober S, Xiao JC, Schaumburg-Lever G. Angiomyolipoma of the kidney. Immunoreactivity with HMB-45. Light- and electron-microscopic findings. *Histopathology*. 1994;25(1):41-48.
672. Liwnicz BH, Weeks DA, Zuppan CW. Extrarenal angiomyolipoma with melanocytic and hibernoma-like features. *Ultrastruct Pathol*. 1994;18(4):443-448.
673. Plank TL, Logginidou H, Klein-Szanto A, Henske EP. The expression of hamartin, the product of the TSC1 gene, in normal human tissues and in TSC1- and TSC2-linked angiomyolipomas. *Mod Pathol*. 1999;12(5):539-545.
674. Johnson SR, Clelland CA, Ronan J, et al. The TSC-2 product tuberin is expressed in lymphangioleiomyomatosis and angiomyolipoma. *Histopathology*. 2002;40(5):458-463.
675. Bonsib SM, Boils C, Gokden N, et al. Tuberous sclerosis complex: hamartin and tuberin expression in renal cysts and its discordant expression in renal neoplasms. *Pathol Res Pract*. 2016;212:972-979.
676. Argani P, Aulmann S, Illei PB, et al. A distinctive subset of PEComas harbors TFE3 gene fusions. *Am J Surg Pathol*. 2010;34(10):1395-1406.
677. Malinowska I, Kwiatkowski DJ, Weiss S, et al. Perivascular epithelioid cell tumors (PEComas) harboring TFE3 gene rearrangements lack the TSC2 alterations characteristic of conventional PEComas: further evidence for a biological distinction. *Am J Surg Pathol*. 2012;36:783-784.
678. Eble JN, Amin MB, Young RH. Epithelioid angiomyolipoma of the kidney: a report of five cases with a prominent and diagnostically confusing epithelioid smooth muscle component. *Am J Surg Pathol*. 1997;21(10):1123-1130.
679. Asch-Kendrick RJ, Shetty S, Goldblum JR, et al. A subset of fat-predominant angiomyolipomas label for MDM2: a potential diagnostic pitfall. *Hum Pathol*. 2016;57:7-12.
680. Delgado R, de Leon Bojorge B, Albores-Saavedra J. Atypical angiomyolipoma of the kidney: a distinct morphologic variant that is easily confused with a variety of malignant neoplasms. *Cancer*. 1998;83(8):1581-1592.
681. Mai KT, Perkins DG, Collins JP. Epithelioid cell variant of renal angiomyolipoma. *Histopathology*. 1996;28(3):277-280.
682. Nese N, Martignoni G, Fletcher CD, et al. Renal perivascular epithelioid cell tumors [(PEComa), so called epithelioid angiomyolipoma (EAML)]: analysis of 61 cases including 44 with pure/predominant epithelioid (P-PEComa) morphology and parameters associated with malignant outcome. *Lab Invest*. 2009;89(suppl 1):186A.
683. Hes O, Michal M. Renal oncocytic angiomyolipoma. *Int J Surg Pathol*. 2004;12(4):421, author reply 422.
684. Martignoni G, Pea M, Bonetti F, et al. Oncocytoma-like angiomyolipoma. A clinicopathologic and immunohistochemical study of 2 cases. *Arch Pathol Lab Med*. 2002;126(5):610-612.
685. Sironi M, Spinelli M. Oncocytic angiomyolipoma of the kidney: a case report. *Int J Surg Pathol*. 2003;11(3):229-234.
686. Oesterling JE, Fishman EK, Goldman SM, Marshall FF. The management of renal angiomyolipoma. *J Urol*. 1986;135(6):1121-1124.
687. Kragel PJ, Toker C. Infiltrating recurrent renal angiomyolipoma with fatal outcome. *J Urol*. 1985;133(1):90-91.
688. Ansari SJ, Stephenson RA, Mackay B. Angiomyolipoma of the kidney with lymph node involvement. *Ultrastruct Pathol*. 1991;15(4-5):531-538.
689. Brecher ME, Gill WB, Straus FH 2nd. Angiomyolipoma with regional lymph node involvement and long-term follow-up study. *Hum Pathol*. 1986;17(9):962-963.
690. Ro JY, Ayala AG, el-Naggar A, et al. Angiomyolipoma of kidney with lymph node involvement. DNA flow cytometric analysis. *Arch Pathol Lab Med*. 1990;114(1):65-67.
691. Cibas ES, Goss GA, Kulke MH, et al. Malignant epithelioid angiomyolipoma ('sarcoma ex angiomyolipoma') of the kidney: a case report and review of the literature. *Am J Surg Pathol*. 2001;25(1):121-126.
692. Ferry JA, Malt RA, Young RH. Renal angiomyolipoma with sarcomatous transformation and pulmonary metastases. *Am J Surg Pathol*. 1991;15(11):1083-1088.
693. Kawaguchi K, Oda Y, Nakanishi K, et al. Malignant transformation of renal angiomyolipoma: a case report. *Am J Surg Pathol*. 2002;26(4):523-529.
694. Martignoni G, Pea M, Rigaud G, et al. Renal angiomyolipoma with epithelioid sarcomatous transformation and metastases: demonstration of the same genetic defects in the primary and metastatic lesions. *Am J Surg Pathol*. 2000;24(6):889-894.
695. He W, Cheville JC, Sadow PM, et al. Epithelioid angiomyolipoma of the kidney: pathological features and clinical outcome in a series of consecutively resected tumors. *Mod Pathol*. 2013;26:1355-1364.
696. Brimo F, Robinson B, Guo C, et al. Renal epithelioid angiomyolipoma with atypia: a series of 40 cases with emphasis on clinicopathologic prognostic indicators of malignancy. *Am J Surg Pathol*. 2010;34(5):715-722.
697. Aydin H, Magi-Galluzzi C, Lane BR, et al. Renal angiomyolipoma: clinicopathologic study of 194 cases with emphasis on the epithelioid histology and tuberous sclerosis association. *Am J Surg Pathol*. 2009;33(2):289-297.
698. Conn JW, Cohen EL, Lucas CP, et al. Primary reninism. Hypertension, hyperreninemia, and secondary aldosteronism due to renin-producing juxtaglomerular cell tumors. *Arch Int Med*. 1972;130(5):682-696.
699. Duan X, Bruneval P, Hammadeh R, et al. Metastatic juxtaglomerular cell tumor in a 52-year-old man. *Am J Surg Pathol*. 2004;28(8):1098-1102.
700. Kodet R, Taylor M, Vachalova H, Pycha K. Juxtaglomerular cell tumor. An immunohistochemical, electron-microscopic, and in situ hybridization study. *Am J Surg Pathol*. 1994;18(8):837-842.
701. Martin SA, Mynderse LA, Lager DJ, Cheville JC. Juxtaglomerular cell tumor: a clinicopathologic study of four cases and review of the literature. *Am J Clin Pathol*. 2001;116(6):854-863.
702. Gherardi GJ, Arya S, Hickler RB. Juxtaglomerular body tumor: a rare occult but curable cause of lethal hypertension. *Hum Pathol*. 1974;5(2):236-240.
703. Tetu B, Vaillancourt L, Camilleri JP, et al. Juxtaglomerular cell tumor of the kidney:

report of two cases with a papillary pattern. *Hum Pathol*. 1993;24(11):1168-1174.
704. Camilleri JP, Hinglais N, Bruneval P, et al. Renin storage and cell differentiation in juxtaglomerular cell tumors: an immunohistochemical and ultrastructural study of three cases. *Hum Pathol*. 1984;15(11):1069-1079.
705. Bonsib SM, Hansen KK. Juxtaglomerular cell tumors: a report of two cases with HMB-45 immunostaining. *J Urol Pathol*. 1998;9:61-72.
706. Kim HJ, Kim CH, Choi YJ, et al. Juxtaglomerular cell tumor of kidney with CD34 and CD117 immunoreactivity: report of 5 cases. *Arch Pathol Lab Med*. 2006;130(5):707-711.
707. Hasegawa A. Juxtaglomerular cells tumor of the kidney: a case report with electron microscopic and flow cytometric investigation. *Ultrastruct Pathol*. 1997;21(2):201-208.
708. Kim CH, Park YW, Ordonez NG, et al. Juxtaglomerular cell tumor of the kidney: case report with immunohistochemical and electron microscopic investigations and review of the literature. *Int J Surg Pathol*. 1999;7:115-123.
709. Lindop GB, Stewart JA, Downie TT. The immunocytochemical demonstration of renin in a juxtaglomerular cell tumour by light and electron microscopy. *Histopathology*. 1983;7(3):421-431.
710. Brandal P, Busund LT, Heim S. Chromosome abnormalities in juxtaglomerular cell tumors. *Cancer*. 2005;104(3):504-510.
711. Capovilla M, Couturier J, Molinie V, et al. Loss of chromosomes 9 and 11 may be recurrent chromosome imbalances in juxtaglomerular cell tumors. *Hum Pathol*. 2008;39(3):459-462.
712. Squires JP, Ulbright TM, DeSchryver-Kecskemeti K, Engleman W. Juxtaglomerular cell tumor of the kidney. *Cancer*. 1984;53(3):516-523.
713. Lindop GB, Leckie B, Winearls CG. Malignant hypertension due to a renin-secreting renal cell carcinoma—an ultrastructural and immunocytochemical study. *Histopathology*. 1986;10(10):1077-1088.
714. Ruddy MC, Atlas SA, Salerno FG. Hypertension associated with a renin-secreting adenocarcinoma of the pancreas. *N Engl J Med*. 1982;307(16):993-997.
715. Tomita T, Poisner A, Inagami T. Immunohistochemical localization of renin in renal tumors. *Am J Pathol*. 1987;126(1):73-80.
716. Michal M, Hes O, Bisceglia M, et al. Mixed epithelial and stromal tumors of the kidney. A report of 22 cases. *Virchows Arch*. 2004;445(4):359-367.
717. Turbiner J, Amin MB, Humphrey PA, et al. Cystic nephroma and mixed epithelial and stromal tumor of kidney: a detailed clinicopathologic analysis of 34 cases and proposal for renal epithelial and stromal tumor (REST) as a unifying term. *Am J Surg Pathol*. 2007;31(4):489-500.
718. Antic T, Perry KT, Harrison K, et al. Mixed epithelial and stromal tumor of the kidney and cystic nephroma share overlapping features: reappraisal of 15 lesions. *Arch Pathol Lab Med*. 2006;130(1):80-85.
719. Eble JN, Bonsib SM. Extensively cystic renal neoplasms: cystic nephroma, cystic partially differentiated nephroblastoma, multilocular cystic renal cell carcinoma, and cystic hamartoma of renal pelvis. *Semin Diagn Pathol*. 1998;15(1):2-20.
720. Zhou M, Kort E, Hoekstra P, et al. Adult cystic nephroma and mixed epithelial and stromal tumor of the kidney are the same disease entity: molecular and histologic evidence. *Am J Surg Pathol*. 2009;33(1):72-80.
721. Picken MM, Fresco R. Mixed epithelial and stromal tumor of the kidney: preliminary immunohistochemical and electron microscopic studies of the epithelial component. *Ultrastruct Pathol*. 2005;29(3-4):283-286.
722. Parikh P, Chan TY, Epstein JI, Argani P. Incidental stromal-predominant mixed epithelial-stromal tumors of the kidney: a mimic of intraparenchymal renal leiomyoma. *Arch Pathol Lab Med*. 2005;129(7):910-914.
723. Jung SJ, Shen SS, Tran T, et al. Mixed epithelial and stromal tumor of kidney with malignant transformation: report of two cases and review of literature. *Hum Pathol*. 2008;39(3):463-468.
724. Nakagawa T, Kanai Y, Fujimoto H, et al. Malignant mixed epithelial and stromal tumours of the kidney: a report of the first two cases with a fatal clinical outcome. *Histopathology*. 2004;44(3):302-304.
725. Glover SD, Buck AC. Renal medullary fibroma: a case report. *J Urol*. 1982;127(4):758-760.
726. Lerman RJ, Pitcock JA, Stephenson P, Muirhead EE. Renomedullary interstitial cell tumor (formerly fibroma of renal medulla). *Hum Pathol*. 1972;3(4):559-568.
727. Tamboli P, Ro JY, Amin MB, et al. Benign tumors and tumor-like lesions of the adult kidney. Part II: benign mesenchymal and mixed neoplasms, and tumor-like lesions. *Adv Anat Pathol*. 2000;7(1):47-66.
728. Gupta S, et al. *Am J Surg Pathol*. 2016;40:1557-1563.
729. Bossart MI, Spjut HJ, Wright JE, Pranke DW. Multilocular cystic leiomyoma of the kidney. *Ultrastruct Pathol*. 1982;3(4):367-374.
730. Calio A, Warfel KA, Eble JN. Pathological features and clinical associations of 58 small incidental angiomyolipomas of the kidney. *Hum Pathol*. 2016;58:41-46.
731. Dineen MK, Venable DD, Misra RP. Pure intrarenal lipoma—report of a case and review of the literature. *J Urol*. 1984;132(1):104-107.
732. Stone NN, Cherry J. Renal capsular lipoma. *J Urol*. 1985;134(1):118-119.
733. Ip YT, Yuan JQ, Cheung H, Chan JK. Sporadic hemangioblastoma of the kidney: an underrecognized pseudomalignant tumor? *Am J Surg Pathol*. 2010;34:1695-1700.
734. Zhou M, Williamson SR, Yu J, et al. PAX8 expression in sporadic hemangioblastoma of the kidney supports a primary renal cell lineage: implications for differential diagnosis. *Hum Pathol*. 2013;44:2247-2255.
735. Melamed J, Reuter VE, Erlandson RA, Rosai J. Renal myxoma. A report of two cases and review of the literature. *Am J Surg Pathol*. 1994;18(2):187-194.
736. Alvarado-Cabrero I, Folpe AL, Srigley JR, et al. Intrarenal schwannoma: a report of four cases including three cellular variants. *Mod Pathol*. 2000;13(8):851-856.
737. Gobbo S, Eble JN, Huang J, et al. Schwannoma of the kidney. *Mod Pathol*. 2008;21(6):779-783.
738. Ma KF, Tse CH, Tsui MS. Neurilemmoma of kidney—a rare occurrence. *Histopathology*. 1990;17(4):378-380.
739. Kahn DG, Duckett T, Bhuta SM. Perineurioma of the kidney. Report of a case with histologic, immunohistochemical, and ultrastructural studies. *Arch Pathol Lab Med*. 1993;117(6):654-657.
740. Brown JG, Folpe AL, Rao P, et al. Primary vascular tumors and tumor-like lesions of the kidney: a clinicopathologic analysis of 25 cases. *Am J Surg Pathol*. 2010;34(7): 942-949.
741. Montgomery E, Epstein JI. Anastomosing hemangioma of the genitourinary tract: a lesion mimicking angiosarcoma. *Am J Surg Pathol*. 2009;33(9):1364-1369.
742. Anderson C, Knibbs DR, Ludwig ME, Ely MG 3rd. Lymphangioma of the kidney: a pathologic entity distinct from solitary multilocular cyst. *Hum Pathol*. 1992;23(4):465-468.
743. Levine E. Lymphangioma presenting as a small renal mass during childhood. *Urol Radiol*. 1992;14(3):155-158.
744. Gill J, Van Vliet C. Infiltrating glomus tumor of uncertain malignant potential arising in the kidney. *Hum Pathol*. 2010;41(1):145-149.
745. Al-Ahmadie HA, Yilmaz A, Olgac S, Reuter VE. Glomus tumor of the kidney: a report of 3 cases involving renal parenchyma and review of the literature. *Am J Surg Pathol*. 2007;31(4):585-591.
746. Siddiqui NH, Rogalska A, Basil IS. Glomangiomyoma (glomus tumor) of the kidney. *Arch Pathol Lab Med*. 2005;129(9):1172-1174.
747. Sirohi D, Smith SC, Epstein JI, et al. Pericytic tumors of the kidney—a clinicopathologic analysis of 17 cases. *Hum Pathol*. 2017;64:106-117.
748. Fain JS, Eble J, Nascimento AG, et al. Solitary fibrous tumor of the kidney: report of three cases. *J Urol Pathol*. 1996;4:227-238.
749. Gelb AB, Simmons ML, Weidner N. Solitary fibrous tumor involving the renal capsule. *Am J Surg Pathol*. 1996;20(10):1288-1295.
750. Wang J, Arber DA, Frankel K, Weiss LM. Large solitary fibrous tumor of the kidney: report of two cases and review of the literature. *Am J Surg Pathol*. 2001;25(9):1194-1199.
751. Richard GK, Freeborn WA, Zaatari GS. Hemangiopericytoma of the renal capsule. *J Urol Pathol*. 1996;4:85-98.
752. Fine SW, McCarthy DM, Chan TY, et al. Malignant solitary fibrous tumor of the kidney: report of a case and comprehensive review of the literature. *Arch Pathol Lab Med*. 2006;130(6):857-861.
753. Kapusta LR, Weiss MA, Ramsay J, et al. Inflammatory myofibroblastic tumors of the kidney: a clinicopathologic and immunohistochemical study of 12 cases. *Am J Surg Pathol*. 2003;27(5):658-666.
754. Sneige N, Dekmezian RH, Silva EG, et al. Pseudoparasitic Liesegang structures in perirenal hemorrhagic cysts. *Am J Clin Pathol*. 1988;89(2):148-153.
755. Afzal M, Baez-Giangreco A, al Jaser AN, Onuora VC. Unusual bilateral renal histiocytosis. Extranodal variant of Rosai-Dorfman disease. *Arch Pathol Lab Med*. 1992;116(12):1366-1367.
756. August C, Holzhausen HJ, Schroder S. Renal parenchymal malakoplakia: ultrastructural findings in different stages of morphogenesis. *Ultrastruct Pathol*. 1994;18(5):483-491.
757. Esparza AR, McKay DB, Cronan JJ, Chazan JA. Renal parenchymal malakoplakia. Histologic spectrum and its relationship to megalocytic interstitial nephritis and xanthogranulomatous pyelonephritis. *Am J Surg Pathol*. 1989;13(3):225-236.
758. Harik L, Nassar A. Extranodal Rosai-Dorfman disease of the kidney and coexistent poorly differentiated prostatic adenocarcinoma. *Arch Pathol Lab Med*. 2006;130(8):1223-1226.
759. Lloreta J, Canas MA, Munne A, et al. Renal malakoplakia: report of a case with multifocal involvement. *Ultrastruct Pathol*. 1997;21(6):575-585.
760. Farrow GM, Harrison EG Jr, Utz DC. Sarcomas and sarcomatoid and mixed malignant tumors of the kidney in adults. 3. *Cancer*. 1968;22(3):556-563.
761. Grignon DJ, Ayala AG, Ro JY, et al. Primary sarcomas of the kidney. A clinicopathologic and DNA flow cytometric study of 17 cases. *Cancer*. 1990;65(7):1611-1618.
762. Vogelzang NJ, Fremgen AM, Guinan PD, et al. Primary renal sarcoma in adults. A natural history and management study by the

American Cancer Society, Illinois Division. *Cancer*. 1993;71(3):804-810.
763. Deyrup AT, Montgomery E, Fisher C. Leiomyosarcoma of the kidney: a clinicopathologic study. *Am J Surg Pathol*. 2004;28(2):178-182.
764. Miller JS, Zhou M, Brimo F, et al. Primary leiomyosarcoma of the kidney: a clinicopathologic study of 27 cases. *Am J Surg Pathol*. 2010;34(2):238-242.
765. Yokose T, Fukuda H, Ogiwara A, et al. Myxoid leiomyosarcoma of the kidney accompanying ipsilateral ureteral transitional cell carcinoma. A case report with cytological, immunohistochemical and ultrastructural study. *Acta Pathol Jpn*. 1991;41(9):694-700.
766. Argani P, Faria PA, Epstein JI, et al. Primary renal synovial sarcoma: molecular and morphologic delineation of an entity previously included among embryonal sarcomas of the kidney. *Am J Surg Pathol*. 2000;24(8):1087-1096.
767. Chen S, Bhuiya T, Liatsikos EN, et al. Primary synovial sarcoma of the kidney: a case report with literature review. *Int J Surg Pathol*. 2001;9(4):335-339.
768. Divetia M, Karpate A, Basak R, Desai SB. Synovial sarcoma of the kidney. *Ann Diagn Pathol*. 2008;12(5):333-339.
769. Kim DH, Sohn JH, Lee MC, et al. Primary synovial sarcoma of the kidney. *Am J Surg Pathol*. 2000;24(8):1097-1104.
770. Dalfior D, Eccher A, Gobbo S, et al. Primary pleomorphic rhabdomyosarcoma of the kidney in an adult. *Ann Diagn Pathol*. 2008;12(4):301-303.
771. Scriven RR, Thrasher TV, Smith DC, Stewart SC. Primary renal malignant fibrous histiocytoma: a case report and literature review. *J Urol*. 1984;131(5):948-949.
772. Mayes DC, Fechner RE, Gillenwater JY. Renal liposarcoma. *Am J Surg Pathol*. 1990;14(3):268-273.
773. Cerilli LA, Huffman HT, Anand A. Primary renal angiosarcoma: a case report with immunohistochemical, ultrastructural, and cytogenetic features and review of the literature. *Arch Pathol Lab Med*. 1998;122(10):929-935.
774. Tsuda N, Chowdhury PR, Hayashi T, et al. Primary renal angiosarcoma: a case report and review of the literature. *Pathol Int*. 1997;47(11):778-783.
775. Eble JN, Young RHJ, Störkel CS, Thoenes W. Primary osteosarcoma of the kidney. A report of three cases. *J Urogen Pathol*. 1991;1:83-88.
776. Micolonghi TS, Liang D, Schwartz S. Primary osteogenic sarcoma of the kidney. *J Urol*. 1984;131(6):1164-1166.
777. O'Malley FP, Grignon DJ, Shepherd RR, Harker LA. Primary osteosarcoma of the kidney. Report of a case studied by immunohistochemistry, electron microscopy, and DNA flow cytometry. *Arch Pathol Lab Med*. 1991;115(12):1262-1265.
778. Nativ O, Horowitz A, Lindner A, Many M. Primary chondrosarcoma of the kidney. *J Urol*. 1985;134(1):120-121.
779. Mead JH, Herrera GA, Kaufman MF, Herz JH. Case report of a primary cystic sarcoma of the kidney, demonstrating fibrohistiocytic, osteoid, and cartilaginous components (malignant mesenchymoma). *Cancer*. 1982;50(10):2211-2214.
780. Quinn CM, Day DW, Waxman J, Krausz T. Malignant mesenchymoma of the kidney. *Histopathology*. 1993;23(1):86-88.
781. Rubin BP, Fletcher JA, Renshaw AA. Clear cell sarcoma of soft parts: report of a case primary in the kidney with cytogenetic confirmation. *Am J Surg Pathol*. 1999;23(5):589-594.
782. Malhotra CM, Doolittle CH, Rodil JV, Vezeridis MP. Mesenchymal chondrosarcoma of the kidney. *Cancer*. 1984;54(11):2495-2499.
783. Creager AJ, Maia DM, Funkhouser WK. Epstein-Barr virus-associated renal smooth muscle neoplasm: report of a case with review of the literature. *Arch Pathol Lab Med*. 1998;122(3):277-281.
784. Jun SY, Choi J, Kang GH, et al. Synovial sarcoma of the kidney with rhabdoid features: report of three cases. *Am J Surg Pathol*. 2004;28(5):634-637.
785. Richmond J, Sherman RS, Diamond HD, Craver LF. Renal lesions associated with malignant lymphomas. *Am J Med*. 1962;32:184-207.
786. Ferry JA, Harris NL, Papanicolaou N, Young RH. Lymphoma of the kidney. A report of 11 cases. *Am J Surg Pathol*. 1995;19(2):134-144.
787. Okuno SH, Hoyer JD, Ristow K, Witzig TE. Primary renal non-Hodgkin's lymphoma. An unusual extranodal site. *Cancer*. 1995;75(9):2258-2261.
788. Osborne BM, Brenner M, Weitzner S, Butler JJ. Malignant lymphoma presenting as a renal mass: four cases. *Am J Surg Pathol*. 1987;11(5):375-382.
789. Ellman L, Davis J, Lichtenstein NS. Uremia due to occult lymphomatous infiltration of the kidneys. *Cancer*. 1974;33(1):203-205.
790. Randolph VL, Hall W, Bramson W. Renal failure due to lymphomatous infiltration of the kidneys. *Cancer*. 1983;52(6):1120-1121.
791. Schniederjan SD, Osunkoya AO. Lymphoid neoplasms of the urinary tract and male genital organs: a clinicopathological study of 40 cases. *Mod Pathol*. 2009;22(8):1057-1065.
792. Parveen T, Navarro-Roman L, Medeiros LJ, et al. Low-grade B-cell lymphoma of mucosa-associated lymphoid tissue arising in the kidney. *Arch Pathol Lab Med*. 1993;117(8):780-783.
793. Qiu L, Unger PD, Dillon RW, Strauchen JA. Low-grade mucosa-associated lymphoid tissue lymphoma involving the kidney: report of 3 cases and review of the literature. *Arch Pathol Lab Med*. 2006;130(1):86-89.
794. Tsang K, Kneafsey P, Gill MJ. Primary lymphoma of the kidney in the acquired immunodeficiency syndrome. *Arch Pathol Lab Med*. 1993;117(5):541-543.
795. Weissmann DJ, Ferry JA, Harris NL, et al. Posttransplantation lymphoproliferative disorders in solid organ recipients are predominantly aggressive tumors of host origin. *Am J Clin Pathol*. 1995;103(6):748-755.
796. Randhawa PS, Magnone M, Jordan M, et al. Renal allograft involvement by Epstein-Barr virus associated post-transplant lymphoproliferative disease. *Am J Surg Pathol*. 1996;20(5):563-571.
797. D'Agati V, Sablay LB, Knowles DM, Walter L. Angiotropic large cell lymphoma (intravascular malignant lymphomatosis) of the kidney: presentation as minimal change disease. *Hum Pathol*. 1989;20(3):263-268.
798. Kandel LB, Harrison LH, Woodruff RD, et al. Renal plasmacytoma: a case report and summary of reported cases. *J Urol*. 1984;132(6):1167-1169.
799. Davis RI, Corson JM. Renal metastases from well differentiated follicular thyroid carcinoma: a case report with light and electron microscopic findings. *Cancer*. 1979;43(1):265-268.
800. Herzberg AJ, Bossen EH, Walther PJ. Adenoid cystic carcinoma of the breast metastatic to the kidney. A clinically symptomatic lesion requiring surgical management. *Cancer*. 1991;68(5):1015-1020.
801. Johnson MW, Morettin LB, Sarles HE, Zaharopoulos P. Follicular carcinoma of the thyroid metastatic to the kidney 37 years after resection of the primary tumor. *J Urol*. 1982;127(1):114-116.
802. Honda H, Coffman CE, Berbaum KS, et al. CT analysis of metastatic neoplasms of the kidney. Comparison with primary renal cell carcinoma. *Acta Radiol*. 1992;33(1):39-44.
803. Wagle DG, Moore RH, Murphy GP. Secondary carcinomas of the kidney. *J Urol*. 1975;114(1):30-32.
804. Belghiti D, Hirbec G, Bernaudin JF, et al. Intraglomerular metastases. Report of two cases. *Cancer*. 1984;54(10):2309-2312.
805. Toth T. Extracapillary tumourous metastatic crescents in glomeruli of the kidney. *Pathol Res Pract*. 1987;182(2):240-243.
806. Bates AW, Baithun SI. The significance of secondary neoplasms of the urinary and male genital tract. *Virchows Arch*. 2002;440(6):640-647.
807. Colome MI, Ro JY, Ayala AG, et al. Adenoid cystic carcinoma of the breast metastatic to the kidney: an unusual site of initial distant metastasis, mimicking a primary renal tumor. *J Urol Pathol*. 1996;4:69-78.
808. Gamboa-Dominguez A, Tenorio-Villalvazo A. Metastatic follicular variant of papillary thyroid carcinoma manifested as a primary renal neoplasm. *Endocr Pathol*. 1999;10(3):256-268.
809. Guinan P, Vogelzang NJ, Randazzo R, et al. Renal pelvic cancer: a review of 611 patients treated in Illinois 1975–1985. Cancer Incidence and End Results Committee. *Urology*. 1992;40(5):393-399.
810. Koyanagi T, Sasaki K, Arikado K, et al. Transitional cell carcinoma of renal pelvis in an infant. *J Urol*. 1975;113(1):114-117.
811. Johansson S, Angervall L, Bengtsson U, Wahlqvist L. Uroepithelial tumors of the renal pelvis associated with abuse of phenacetin-containing analgesics. *Cancer*. 1974;33(3):743-753.
812. Johansson S, Angervall L, Bengtsson U, Wahlqvist L. A clinicopathologic and prognostic study of epithelial tumors of the renal pelvis. *Cancer*. 1976;37(3):1376-1383.
813. Verhaak RL, Harmsen AE, van Unnik AJ. On the frequency of tumor induction in a thorotrast kidney. *Cancer*. 1974;34(6):2061-2068.
814. McDougal WS, Cramer SF, Miller R. Invasive carcinoma of the renal pelvis following cyclophosphamide therapy for nonmalignant disease. *Cancer*. 1981;48(3):691-695.
815. Murphy DM, Zincke H. Transitional cell carcinoma in the horseshoe kidney: report of 3 cases and review of the literature. *Br J Urol*. 1982;54(5):484-485.
816. Blaszyk H, Wang L, Dietmaier W, et al. Upper tract urothelial carcinoma: a clinicopathologic study including microsatellite instability analysis. *Mod Pathol*. 2002;15(8):790-797.
817. Harper HL, McKenney JK, Heald B, et al. Upper tract urothelial carcinomas: frequency of association with mismatch repair protein loss and lynch syndrome. *Mod Pathol*. 2017;30:146-156.
818. Raabe NK, Fossa SD, Bjerkehagen B. Carcinoma of the renal pelvis. Experience of 80 cases. *Scand J Urol Nephrol*. 1992;26(4):357-361.
819. Strobel SL, Jasper WS, Gogate SA, Sharma HM. Primary carcinoma of the renal pelvis and ureter. Evaluation of clinical and pathologic features. *Arch Pathol Lab Med*. 1984;108(9):697-700.
820. Holmang S, Johansson SL. Synchronous bilateral ureteral and renal pelvic carcinomas: incidence, etiology, treatment and outcome. *Cancer*. 2004;101(4):741-747.
821. Hart AP, Brown R, Lechago J, Truong LD. Collision of transitional cell carcinoma and renal cell carcinoma. An immunohistochemical study and review of the literature. *Cancer*. 1994;73(1):154-159.

822. Wegner HE, Bornhoft G, Dieckmann KP. Renal cell cancer and concomitant transitional cell cancer of the renal pelvis and ureter in the same kidney—report of 4 cases and review of the literature. *Urol Int*. 1993;51(3):158-163.
823. Yokoyama I, Berman E, Rickert RR, Bastidas J. Simultaneous occurrence of renal cell adenocarcinoma and urothelial carcinoma of the renal pelvis in the same kidney diagnosed by preoperative angiography. *Cancer*. 1981;48(12):2762-2766.
824. Potts SA, Thomas PA, Cohen MB, Raab SS. Diagnostic accuracy and key cytologic features of high-grade transitional cell carcinoma in the upper urinary tract. *Mod Pathol*. 1997;10(7):657-662.
825. Mai KT, Gerridzen RG, Millward SF. Papillary transitional cell carcinoma arising in a calyceal cyst and masquerading as a renal cyst. *Arch Pathol Lab Med*. 1996;120(9):879-882.
826. Bloom NA, Vidone RA, Lytton B. Primary carcinoma of the ureter: a report of 102 new cases. *J Urol*. 1970;103(5):590-598.
827. McIntyre D, Pyrah LN, Raper FP. Primary ureteric neoplasms. Report of 40 cases. *Br J Urol*. 1965;37:160-191.
828. Olgac S, Mazumdar M, Dalbagni G, Reuter VE. Urothelial carcinoma of the renal pelvis: a clinicopathologic study of 130 cases. *Am J Surg Pathol*. 2004;28(12):1545-1552.
829. Balslev E, Fischer S. Transitional cell carcinoma of the renal collecting tubules ("renal urothelioma"). *Acta Pathol Microbiol Immunol Scand [A]*. 1983;91(6):419-424.
830. Mahadevia PS, Karwa GL, Koss LG. Mapping of urothelium in carcinomas of the renal pelvis and ureter. A report of nine cases. *Cancer*. 1983;51(5):890-897.
831. Wobker SE, Aron M, Epstein JI. Mechanical implantation of urothelium into periureteral soft tissue: a series of 4 cases mimicking high-stage urothelial carcinoma. *Am J Surg Pathol*. 2016;40:1564-1570.
832. Tavora F, Fajardo DA, Lee TK, et al. Small endoscopic biopsies of the ureter and renal pelvis: pathologic pitfalls. *Am J Surg Pathol*. 2009;33:1540-1546.
833. Guo CC, Tamboli P, Czerniak B. Micropapillary variant of urothelial carcinoma in the upper urinary tract: a clinicopathologic study of 11 cases. *Arch Pathol Lab Med*. 2009;133(1):62-66.
834. Perez-Montiel D, Hes O, Michal M, Suster S. Micropapillary urothelial carcinoma of the upper urinary tract: clinicopathologic study of five cases. *Am J Clin Pathol*. 2006;126(1):86-92.
835. Perez-Montiel D, Wakely PE, Hes O, et al. High-grade urothelial carcinoma of the renal pelvis: clinicopathologic study of 108 cases with emphasis on unusual morphologic variants. *Mod Pathol*. 2006;19(4):494-503.
836. Han AC, Duszak R Jr. Coexpression of cytokeratins 7 and 20 confirms urothelial carcinoma presenting as an intrarenal tumor. *Cancer*. 1999;86(11):2327-2330.
837. Rey A, Lara PC, Redondo E, et al. Overexpression of p53 in transitional cell carcinoma of the renal pelvis and ureter. Relation to tumor proliferation and survival. *Cancer*. 1997;79(11):2178-2185.
838. Young A, Kunju LP. High-grade carcinomas involving the renal sinus: report of a case and review of the differential diagnosis and immunohistochemical expression. *Arch Pathol Lab Med*. 2012;136:907-910.
839. Albadine R, Schultz L, Illei P, et al. PAX8 (+)/p63 (-) immunostaining pattern in renal collecting duct carcinoma (CDC): a useful immunoprofile in the differential diagnosis of CDC versus urothelial carcinoma of upper urinary tract. *Am J Surg Pathol*. 2010;34:965-969.
840. Auld CD, Grigor KM, Fowler JW. Histopathological review of transitional cell carcinoma of the upper urinary tract. *Br J Urol*. 1984;56(5):485-489.
841. McCarron JP Jr, Chasko SB, Gray GF Jr. Systematic mapping of nephroureterectomy specimens removed for urothelial cancer: pathological findings and clinical correlations. *J Urol*. 1982;128(2):243-246.
842. Strong DW, Pearse HD. Recurrent urothelial tumors following surgery for transitional cell carcinoma of the upper urinary tract. *Cancer*. 1976;38(5):2173-2183.
843. Wagle DG, Moore RH, Murphy GP. Primary carcinoma of the renal pelvis. *Cancer*. 1974;33(6):1642-1648.
844. Akaza H, Koiso K, Niijima T. Clinical evaluation of urothelial tumors of the renal pelvis and ureter based on a new classification system. *Cancer*. 1987;59(7):1369-1375.
845. Batata MA, Whitmore WF, Hilaris BS, et al. Primary carcinoma of the ureter: a prognostic study. *Cancer*. 1975;35(6):1626-1632.
846. Melamed MR, Reuter VE. Pathology and staging of urothelial tumors of the kidney and ureter. *Urol Clin North Am*. 1993;20(2):333-347.
847. Mills C, Vaughan ED Jr. Carcinoma of the ureter: natural history, management and 5-year survival. *J Urol*. 1983;129(2):275-277.
848. Werth DD, Weigel JW, Mebust WK. Primary neoplasms of the ureter. *J Urol*. 1981;125(5):628-631.
849. Hertle L, Androulakakis P. Keratinizing desquamative squamous metaplasia of the upper urinary tract: leukoplakia—cholesteatoma. *J Urol*. 1982;127(4):631-635.
850. Nativ O, Reiman HM, Lieber MM, Zincke H. Treatment of primary squamous cell carcinoma of the upper urinary tract. *Cancer*. 1991;68(12):2575-2578.
851. Kobayashi S, Ohmori M, Akaeda T, et al. Primary adenocarcinoma of the renal pelvis. Report of two cases and brief review of literature. *Acta Pathol Jpn*. 1983;33(3):589-597.
852. Aufderheide AC, Streitz JM. Mucinous adenocarcinoma of the renal pelvis. Report of two cases. *Cancer*. 1974;33(1):167-173.
853. Shibahara N, Okada S, Onishi S, et al. Primary mucinous carcinoma of the renal pelvis. *Pathol Res Pract*. 1993;189(8):946-949, discussion 950.
854. Spires SE, Banks ER, Cibull ML, et al. Adenocarcinoma of renal pelvis. *Arch Pathol Lab Med*. 1993;117(11):1156-1160.
855. Ishikura H, Ishiguro T, Enatsu C, et al. Hepatoid adenocarcinoma of the renal pelvis producing alpha-fetoprotein of hepatic type and bile pigment. *Cancer*. 1991;67(12):3051-3056.
856. Fukunaga M, Ushigome S. Lymphoepithelioma-like carcinoma of the renal pelvis: a case report with immunohistochemical analysis and in situ hybridization for the Epstein-Barr viral genome. *Mod Pathol*. 1998;11(12):1252-1256.
857. Genega E, Ittmann M, Wieczorek R, Sidhu G. Carcinosarcoma of the renal pelvis with immunohistochemistry and review of the literature. *J Urol Pathol*. 1997;6:205-212.
858. Suster S, Robinson MJ. Spindle cell carcinoma of the renal pelvis. Immunohistochemical and ultrastructural study of a case demonstrating coexpression of keratin and vimentin intermediate filaments. *Arch Pathol Lab Med*. 1989;113(4):404-408.
859. Wick MR, Perrone TL, Burke BA. Sarcomatoid transitional cell carcinomas of the renal pelvis. An ultrastructural and immunohistochemical study. *Arch Pathol Lab Med*. 1985;109(1):55-58.
860. Akhtar M, Aslam M, Lindstedt E, et al. Osteoclast-like giant cell tumor of renal pelvis. *J Urol Pathol*. 1999;11:181-194.
861. Molinie V, Pouchot J, Vinceneux P, Barge J. Osteoclastoma-like giant cell tumor of the renal pelvis associated with papillary transitional cell carcinoma. *Arch Pathol Lab Med*. 1997;121(2):162-166.
862. Zanella M, Falconieri G. Sarcomatoid urothelial carcinoma of the renal pelvis: report of two cases with extensive osteoclast-like giant cell component. *J Urol Pathol*. 2000;12:13-28.
863. Guillou L, Duvoisin B, Chobaz C, et al. Combined small-cell and transitional cell carcinoma of the renal pelvis. A light microscopic, immunohistochemical, and ultrastructural study of a case with literature review. *Arch Pathol Lab Med*. 1993;117(3):239-243.
864. Deodhare S, Leung CS, Bullock M. Choriocarcinoma associated with transitional cell carcinoma in-situ of the ureter. *Histopathology*. 1996;28(4):363-365.
865. Grammatico D, Grignon DJ, Eberwein P, et al. Transitional cell carcinoma of the renal pelvis with choriocarcinomatous differentiation. Immunohistochemical and immunoelectron microscopic assessment of human chorionic gonadotropin production by transitional cell carcinoma of the urinary bladder. *Cancer*. 1993;71(5):1835-1841.
866. Vahlensieck W Jr, Riede U, Wimmer B, Ihling C. Beta-human chorionic gonadotropin-positive extragonadal germ cell neoplasia of the renal pelvis. *Cancer*. 1991;67(12):3146-3149.
867. Zettl A, Konrad MA, Polzin S, et al. Urothelial carcinoma of the renal pelvis with choriocarcinomatous features: genetic evidence of clonal evolution. *Hum Pathol*. 2002;33(12):1234-1237.
868. Kumar S, Kumar D, Cowan DF. Transitional cell carcinoma with rhabdoid features. *Am J Surg Pathol*. 1992;16(5):515-521.
869. Sheaff M, Fociani P, Badenoch D, Baithun S. Verrucous carcinoma of the renal pelvis: case presentation and review of the literature. *Virchows Arch*. 1996;428(6):375-379.
870. Macksood MJ, Roth DR, Chang CH, Perlmutter AD. Benign fibroepithelial polyps as a cause of intermittent ureteropelvic junction obstruction in a child: a case report and review of the literature. *J Urol*. 1985;134(5):951-952.
871. Nowak MA, Marzich CS, Scheetz KL, McElroy JB. Benign fibroepithelial polyps of the renal pelvis. *Arch Pathol Lab Med*. 1999;123(9):850-852.
872. MacMahon HE. Hypertrophic infundibular stenosis of the calyces of the kidney. *Hum Pathol*. 1974;5(3):363-364.
873. Hurwitz RS, Benjamin JA, Cooper JF. Excessive proliferation of peripelvic fat of the kidney. *Urology*. 1978;11(5):448-456.
874. Farrands PA, Tribe CR, Slade N. Localized amyloid of the ureter—case report and review of the literature. *Histopathology*. 1983;7(4):613-622.
875. Amin MB, Tickoo SK, Schultz D. Myelolipoma of the renal sinus. An unusual site for a rare extra- adrenal lesion. *Arch Pathol Lab Med*. 1999;123(7):631-634.
876. Matthews PN, Greenwood RN, Hendry WF, Cattell WR. Extensive pelvic malacoplakia: observations on management. *J Urol*. 1986;135(1):132-134.
877. Rudd EG, Matthews MD. Malacoplakia: an unusual etiology of ureteral obstruction. *Obstet Gynecol*. 1982;60(1):134-136.
878. Dretler SP, Young RH. Stone granuloma: a cause of ureteral stricture. *J Urol*. 1993;150(6):1800-1802.

879. Al-Khawaja M, Tan PH, MacLennan GT, et al. Ureteral endometriosis: clinicopathological and immunohistochemical study of 7 cases. *Hum Pathol*. 2008;39(6):954-959.
880. Demirkan NC, Tuncay L, Duzcan E, et al. Subepithelial haematoma of the renal pelvis (Antopol-Goldman lesion). *Histopathology*. 1999;35(3):282-283.
881. Kim SJ, Ahn HS, Chung DY, et al. Subepithelial hematoma of the renal pelvis simulating neoplasm (Antopol-Goldman lesion). *Urol Int*. 1997;59(4):260-262.
882. Carr RA, Newman J, Antonakopulos GN, Parkinson MC. Lesions produced by the extravasation of urine from the upper urinary tract. *Histopathology*. 1997;30(4):335-340.
883. Fromowitz FB, Steinbook ML, Lautin EM, et al. Inverted papilloma of the ureter. *J Urol*. 1981;126(1):113-116.
884. Kyriakos M, Royce RK. Multiple simultaneous inverted papillomas of the upper urinary tract. A case report with a review of ureteral and renal pelvic inverted papillomas. *Cancer*. 1989;63(2):368-380.
885. Fernandez PL, Nogales FF, Zuluaga A. Nephrogenic adenoma of the ureter. *Br J Urol*. 1991;68(1):104-105.
886. Gokaslan ST, Krueger JE, Albores-Saavedra J. Symptomatic nephrogenic metaplasia of ureter: a morphologic and immunohistochemical study of four cases. *Mod Pathol*. 2002;15(7):765-770.
887. Kunze E, Fischer G, Dembowski J. Tubulo-papillary adenoma (so-called nephrogenic adenoma) arising in the renal pelvis. Report of a case with a critical consideration of histogenesis and terminology. *Pathol Res Pract*. 1993;189(2):217-225, discussion 225-227.
888. Martinez-Pineiro L, Hidalgo L, Picazo ML, et al. Nephrogenic adenoma of the renal pelvis. *Br J Urol*. 1991;67(1):101.
889. Seibel JL, Prasad S, Weiss RE, et al. Villous adenoma of the urinary tract: a lesion frequently associated with malignancy. *Hum Pathol*. 2002;33(2):236-241.
890. Cubillo E, Hesker AE, Stanley RJ. Cavernous hemangioma of the kidney: an angiographic-pathologic correlation. *J Can Assoc Radiol*. 1973;24(3):254-256.
891. Uchida M, Watanabe H, Mishina T, Shimada N. Leiomyoma of the renal pelvis. *J Urol*. 1981;125(4):572-574.
892. Fukunaga M, Nikaido T. Solitary fibrous tumour of the renal peripelvis. *Histopathology*. 1997;30(5):451-456.
893. Madi R, Gokden N, Greene G. Granular cell tumour of the ureter: first case reported. *Can Urol Assoc J*. 2009;3:156-158.
894. Herawi M, Parwani AV, Edlow D, et al. Glomus tumor of renal pelvis: a case report and review of the literature. *Hum Pathol*. 2005;36(3):299-302.
895. Chabrel CM, Hickey BB, Parkinson C. Pericaliceal haemangioma-a cause of papillary necrosis? Case report and review of 7 similar vascular lesions. *Br J Urol*. 1982;54(4):334-340.
896. Edward HG, Deweerd JH, Woolner LB. Renal hemangiomas. *Proc Staff Meetings Mayo Clin*. 1962;37:545-551.
897. Nasu M, Hamasaki K, Kishi H, Matsubara O. Nephrogenic adenoma of the ureter with gastric metaplasia. *J Urol Pathol*. 1997;7:63-69.
898. Werner JR, Klingensmith W, Denko JV. Leiomyosarcoma of the ureter: case report and review of literature. *J Urol*. 1959;82(1):68-71.
899. Scharifker D, Chalasani A. Ureteral involvement by malignant lymphoma. Ten years' experience. *Arch Pathol Lab Med*. 1978;102(10):541-542.
900. Maeda K, Hawkins ET, Oh HK, et al. Malignant lymphoma in transplanted renal pelvis. *Arch Pathol Lab Med*. 1986;110(7):626-629.
901. Kochevar J. Adenocarcinoid tumor, goblet cell type, arising in a ureteroileal conduit: a case report. *J Urol*. 1984;131(5):957-959.
902. Peterson NE. Adenoma of ileal urinary conduit. *J Urol*. 1984;131(6):1171-1172.
903. Geller SA, Lin C. Ureteral obstruction from metastatic breast carcinoma. *Arch Pathol*. 1975;99(9):476-478.
904. Recloux P, Weiser M, Piccart M, Sculier JP. Ureteral obstruction in patients with breast cancer. *Cancer*. 1988;61(9):1904-1907.

25 Bladder

Jesse K. McKenney

CHAPTER CONTENTS

Normal anatomy, *1066*
Congenital abnormalities, *1067*
Urachal lesions, *1067*
Exstrophy, *1067*
Diverticulosis, *1068*
Lithiasis, *1068*
Endometriosis and related müllerian-type changes, *1068*
Amyloidosis, *1068*
Cystitis, *1068*
Interstitial cystitis (painful bladder syndrome), *1068*
Eosinophilic cystitis, *1069*
Emphysematous cystitis, *1069*
Tuberculosis and BCG-induced granulomas, *1069*
Malakoplakia and related conditions, *1069*
Other forms of cystitis, *1070*
Metaplastic and tumorlike conditions, *1070*
Urothelial carcinoma, *1072*
General and clinical features, *1072*
Immunohistochemical features, *1079*
Molecular genetic features, *1079*
Treatment, *1079*
Other primary carcinomas, *1080*
Primary glandular lesions of the bladder (adenocarcinoma and related tumors), *1080*
Neuroendocrine neoplasms, *1081*
Squamous cell carcinoma and related tumors, *1082*
Myofibroblastic proliferations of the urinary bladder, *1083*
Other tumors, *1086*

Normal Anatomy

The bladder is a hollow viscus with the shape of a four-sided inverted pyramid when empty and of a rounded structure when distended. It is divided into the following portions: *superior surface* (also known as *dome*, and covered by the pelvic parietal peritoneum), *posterior surface* (also known as *base*), and the two *inferolateral surfaces*.[1] The *trigone* is located at the base of the bladder and is continuous with the *bladder neck*, in which the posterior and inferolateral walls converge to open into the urethra. The lymphatic drainage of the bladder is primarily through the external and internal iliac nodes; portions of the bladder neck region may drain to the sacral or common iliac nodes.

The layers of the bladder are the mucosa, muscularis propria (MP), and adventitia. The latter is covered by serosa at the dome. The mucosa is formed by the epithelium and lamina propria, which often contains (rarely) a continuous or discontinuous muscularis mucosae (MM). The epithelium of the bladder has been traditionally referred to as *transitional*, but the preferred term *urothelium* is more informative and accurate. It is generally six to seven cells thick in the contracted bladder, but only two or three cells thick in the distended bladder. It has three layers: superficial, intermediate, and basal. The superficial layer is made up of a single row of large cells having abundant eosinophilic cytoplasm and referred to as umbrella cells. The umbrella cells may also have large multilobated nuclei and prominent cytoplasmic vacuolization. The intermediate cells have a cuboidal to low columnar shape, oval nuclei with fine chromatin and frequent nuclear grooves, moderately abundant cytoplasm, and well-defined margins. The basal layer is made up of a row of cuboidal cells that lie on a thin continuous basal lamina.

The lamina propria is composed of loose connective tissue containing a rich vascular network, lymph vessels, and a few elastic fibers. A rather prominent collection of arteries and veins is present in the midportion of the lamina propria and divides this layer into an inner and an outer zone. Smooth muscle cells are also present in the lamina propria, usually as isolated bundles, sometimes as a discontinuous thin layer, and rarely as a continuous layer.[2] This layer of smooth muscle is designated as MM. These can be confused with the muscle bundles of the MP when evaluating the depth of invasion of a bladder neoplasm (particularly in a biopsy specimen), a serious problem since tumor staging and treatment are largely based on the presence or absence of MP invasion. Isolated bundles of muscle immediately adjacent to urothelium, with loose haphazard fiber orientation and irregular outlines, favor MM. Topographic and morphologic variations exist that complicate this evaluation: (1) the more superficial location of the MP and the inconspicuousness of the MM in the trigone; (2) the occurrence of *hyperplastic MM*,

Abstract

This chapter reviews the spectrum of diseases that occur in the urinary bladder, ranging from congenital malformations to inflammatory conditions to neoplasms. Congenital lesions include exstrophy and urachal remnants. The spectrum of cystitis includes infectious (e.g. emphysematous and granulomatous), malakoplakia, eosinophilic, and interstitial cystitis. Urothelial carcinoma is covered in detail to include variant forms, grading, and staging. Finally, rare mesenchymal lesions (e.g. myofibroblastic proliferations, sarcomas, and various benign lesions) are discussed.

Keywords

bladder
exstrophy
cystitis
urothelial carcinoma
variants
squamous cell carcinoma
adenocarcinoma
myofibroblastic
sarcoma

defined as MM composed of more than three layers of muscle fibers appearing as fascicles parallel to the surface epithelium or as rounded bundles, this being particularly prominent in the dome[2,3]; (3) the presence of superficially located MM at the insertion of the ureter into the bladder; and (4) an indistinct border between the MP and the lamina propria.[3,4] In general, if individual muscle bundles, either as individual small fascicles or separate distinct rounded bundles, are separated by intervening stroma, then MM should be carefully considered. Immunostaining for smoothelin (a novel smooth muscle-specific marker expressed only in fully differentiated smooth muscle cells) has been touted as having utility in this distinction, in the sense that a strong and diffuse reaction is characteristic of MP, in contrast with MM, in which the staining is absent or weak and focal.[5–8] Not surprisingly, some degree of overlap exists in the degree of reactivity for smoothelin (not to mention significant variability between titers), which calls for extreme caution in its interpretation.[9] Because of these issues, we do not use smoothelin for staging.

The MP is vaguely divided into inner, central circular, and outer longitudinal layers; these are best individualized in the bladder neck region.

Islands of mature adipose tissue are commonly present throughout the wall of the urinary bladder, particularly in the deep portion of the lamina propria; therefore, the presence of carcinoma in adipose tissue is not sufficient for designation as extravesical invasion.[10]

Small paraganglia may be found in the adjacent connective tissue, usually in association with neural structures.[11]

Congenital Abnormalities

Urachal Lesions

The urachus is a 5–6-cm vestigial structure located between the dome of the bladder and the umbilicus that results from the involution of the allantoic duct and the cloaca.[12] During development, it connects the bladder with the allantois. At birth the urachus retracts from the bladder, and when regressed into a fibrous cord, it is called the median umbilical ligament. Its lumen may persist within the bladder wall and be continuous with the bladder cavity. The lining may be of transitional or columnar type. Schubert et al.[13] found tubular urachal remnants in 32% of 122 bladders studied at autopsy.

Anomalies related to urachal remnants most often occur in children, but they can also first present in adults.[14] They include the following: *patent urachus* through which urine may pass, *blind sinuses* in the anterior abdominal wall, *abscesses*, *granulomatous omphalitis*, and intravesical polypoid multicystic masses (*"hamartomas"*).[15–19]

Tumors may also develop from this structure, of which *adenocarcinoma* is the most common; the majority of these cases are well-differentiated, mucin-producing tumors, but enteric type and signet ring carcinomas also occur (Fig. 25.1).[20–23] Other tumor types include *villous adenoma*, *transitional cell (urothelial) carcinoma*, *small cell carcinoma*, and *squamous cell carcinoma*.[21,24–26] Most of these tumors arise from the intramural portion of the urachus and grow into the wall of the bladder, sometimes in the absence of mucosal involvement. Others occur beneath the peritoneum of the anterior abdominal wall between the umbilicus and the bladder dome. The overall prognosis is poor, the main reason being that the location of the tumor does not result in early symptoms and precludes a timely diagnosis. Depending on the extent of the disease, the treatment can be either umbilectomy with partial cystectomy or en bloc radical cystoprostatectomy/umbilectomy.[27,28] Because of the unique anatomic considerations, a specific urachal staging system is often utilized.[29]

Figure 25.1 Gross Appearance of Adenocarcinoma Arising From Urachal Remnants. A, The tumor protrudes as a polypoid ulcerated mass from the dome of the bladder. **B**, The cut surface shows a large intramural mass of mucinous appearance.

Exstrophy

Bladder (cloacal) exstrophy is a congenital abnormality characterized by absence of the anterior vesicle and lower abdominal wall, with eversion of the posterior bladder wall.[30] These changes may be partial or complete and are often associated with other anomalies of the urogenital tract. Malignant change was found in 3 (7.5%) of 42 patients with exstrophic bladder reported by Engel and Wilkinson.[31] It has been calculated that the risk of neoplasia in adults born with exstrophy is 17.5% and that the highest risk (38%) is for those patients who have been exposed to mixing of urine and feces in a colorectal reservoir.[32] The tumor type in most series has usually been adenocarcinoma, occasionally admixed with squamous elements.[31,33] In addition, the occurrence of a unique benign "bladder exstrophy polyp" has been proposed.[34]

The treatment of bladder exstrophy depends on the specific features of the malformation and may consist of reapproximating or closing

the defect, in addition to repairing the other abnormalities that often accompany this condition.[35,36]

Diverticulosis

Most diverticula of the bladder are acquired and develop because of partial urinary obstruction in the urethra or bladder neck, usually as a result of prostatic nodular hyperplasia.[37,38] The longstanding increased muscular contractions required to empty the bladder cause thickening of the wall and mucosal herniation in areas of weakness. Other diverticula are thought to be congenital.[39]

Bladder diverticula are most commonly located in the posterior wall above the trigone, in the region of the ureteral orifices, or in the dome at the site of an obliterated urachus. The communication into the bladder is usually large but may be pinpoint in size. The wall of the diverticulum usually consists of fibrous tissue with little or no muscle. Squamous metaplasia of the lining epithelium often occurs if there is associated inflammation, and associated nephrogenic adenomas are not uncommon.

Complications of bladder diverticula include lithiasis, free perforation into the peritoneal cavity, and tumor development.[40] The tumors are usually urothelial carcinomas,[41,42] but there seems to be a higher incidence of other tumor types.[43–45] They may grow to a large size before detection because of their hidden location. The development of neoplasia may be related to the obstruction, chronic inflammation, epithelial hyperplasia, and squamous metaplasia to which these diverticula are prone. Staging is difficult with invasive carcinomas in diverticula because of the absence of MP, but most large tumors are regarded as pT3.

Lithiasis

Bladder calculi occur much more often in male than in female individuals. Most of the patients are elderly, but children are at high risk in endemic areas, such as Turkey and the Far East.[46] They represent a frequent complication in paraplegics and quadriplegics. The majority of these stones are solitary and composed of phosphate salts; others are made up of urate and oxalate salts.[47] The most common associated abnormality is nodular hyperplasia of the prostate gland, likely secondary to urinary stasis.

Treatment modalities include removal by cystostomy, mechanical (endoscopic) cystolithotripsy, and extracorporeal shock wave therapy. The latter has been found to be a simple, effective, and safe modality for the treatment of most cases and is becoming the therapy of choice, particularly in adult patients.[48–50] Recurrence develops in about 10% of the patients.

Endometriosis and Related Müllerian-Type Changes

Endometriosis may involve the bladder as an isolated focus or in association with similar lesions in other sites (Fig. 25.2).[51] In most instances, there is a history of a previous operation in the area or of symptoms related to the female genital tract.[52] The disease is also rarely reported in men following estrogen therapy for prostatic carcinoma. In the most florid cases, a mass can be palpated at the base of the bladder. Serosal foci are the most common and are usually asymptomatic. Foci occurring in the bladder wall, beneath an intact mucosa, result in a bluish cast on cystoscopic examination and may be accompanied by marked hyperplasia of the vesical muscle in a fashion analogous to that seen in uterine adenomyosis[53]; these can present with persistent hematuria during menstruation. Radiographically, the lesion may be indistinguishable from an intravesical neoplasm.[54]

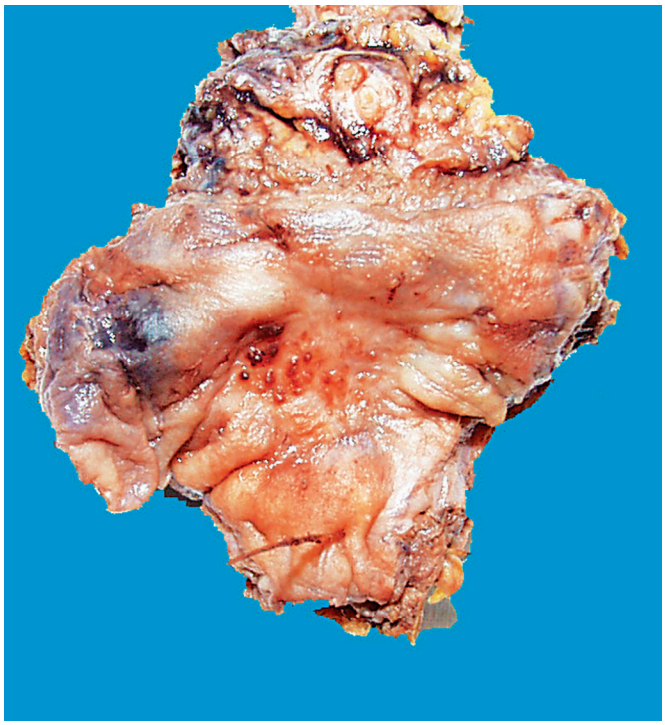

Figure 25.2 Gross Appearance of Endometriosis of Bladder. Multiple small red nodules protrude from the bladder surface.

In addition to classic endometriosis composed of endometrial glands and stroma, one can encounter tubal-type epithelium (including ciliated cells, peg cells, and intercalated cells) and endocervical-type epithelium (columnar mucinous cells). The former change is referred to as *endosalpingiosis* and the latter as *endocervicosis*. When they occur in combination, the picturesque term *müllerianosis* is sometimes used.[55,56] Florid cases of endocervicosis may simulate adenocarcinoma.[57–59] True malignant tumors can develop in this setting, including endometrioid adenocarcinoma,[60] clear cell carcinoma,[61] endometrioid adenosarcoma,[62] and endometrial stromal sarcoma.

The treatment of endometriosis of the bladder includes hormonal manipulation and resection; depending on the location, the latter may be carried out laparoscopically.[63–65]

Amyloidosis

Amyloidosis of the bladder may be the expression of a generalized process or (more commonly) present as a nodular localized mass ("amyloid tumor").[66] The latter are often misinterpreted as neoplasms, both clinically and cystoscopically.[67,68] The histologic appearance is diagnostic. The amyloid material is made up in most instances of AL protein (immunoglobulin [Ig] light chain), but some cases have been found to be transthyretin related.[69–71] Most reported patients with adequate follow-up have remained free of disease following local excision of the mass; therefore, the presence of an amyloid tumor should not be necessarily regarded as a manifestation of myeloma or plasmacytoma.[71–73]

Cystitis

Interstitial Cystitis (Painful Bladder Syndrome)

The classic clinical description of interstitial (Hunner) cystitis (or painful bladder syndrome) is that of an adult or elderly female with ulceration and marked submucosal edema of the bladder resulting in prominent

lower abdominal, suprapubic, or perineal pain and urinary frequency, unresponsive to medical therapy.[74] Because of the consistent presence of ulceration, the disease is also known as *Hunner ulcer*.

The lesion can be located anywhere in the bladder. Microscopically, there is mucosal ulceration covered by fibrin and necrotic material. The underlying lamina propria and muscularis show edema, hemorrhage, granulation tissue, and a mononuclear inflammatory infiltrate that sometimes exhibits a predominantly perineural location.[75,76] Mast cells are usually present and sometimes numerous; they are found beneath the ulcer, within the detrusor muscle bundles, and between the epithelial cells in the adjacent mucosa, but CD117 immunostains have not proven helpful in establishing a more definitive diagnosis.[77,78] None of these microscopic features is pathognomonic.[79] Cases lacking ulceration are considered by some authors to represent a different condition affecting a younger patient population.[80]

The etiology of this disorder remains obscure.[81] The search for infectious organisms has been unrewarding.[82] Hyperexpression of human leukocyte antigen (HLA) class I molecules,[83,84] strong urothelial staining for IgA,[85] and increased sympathetic outflow into the bladder[86,87] suggest the participation of autoimmune mechanisms, whereas the finding of a reduction in the expression of heat shock protein 60 suggests a defect in the proliferative response of the urothelium.[88] The treatment is usually medical, but surgical intervention (including supratrigonal or total cystectomy) may be necessary in severe cases.[89–92]

Eosinophilic Cystitis

Eosinophilic cystitis is a descriptive term that is used in distinct clinical settings. The first is seen in women and children and is often associated with allergic disorders and eosinophilia.[92,93] The second presents in older men and is usually an incidental finding associated with bladder injury related to other disorders of the bladder and prostate.[94,95] Exceptionally, the disease is due to parasitic infestation.[96]

Clinically, the allergic associated form of eosinophilic cystitis presents with dramatic and recurrent episodes of dysuria and hematuria.[97] Rarely, it may result in ureteral obstruction.[98] The cystoscopic appearance is that of a diffusely edematous and erythematous mucosa, with broad-based polypoid growths that may simulate a neoplastic process.[99] Microscopically, a dense inflammatory infiltrate rich in eosinophils, often accompanied by fibrosis and muscle necrosis and sometimes by giant cells, is present.[100,101] This condition is not related to Langerhans cell histiocytosis. The treatment of choice is transurethral resection (TUR) of the bladder lesions and a combination of steroids and antihistamines.[102,103]

Emphysematous Cystitis

Emphysematous cystitis (cystitis emphysematosa) is an inflammatory condition caused by gas-forming bacteria (such as *Clostridium perfringens*) and characterized by the presence of gas-filled vesicles in the bladder wall.[104] Patients with diabetes, neurogenic bladder, chronic urinary infection, and malignant hematologic conditions are predisposed to the disease.[105–108] In some series, as many as half of the patients with emphysematous cystitis suffered from diabetes. Microscopically, multinucleated giant cells are seen partially lining the cysts.[108] The treatment consists of antibiotic therapy and relief of bladder outlet obstruction.[106]

Tuberculosis and Bacillus Calmette–Guérin-Induced Granulomas

Tuberculosis remains the most frequent cause of granulomatous inflammation of the bladder in many parts of the world. It invariably

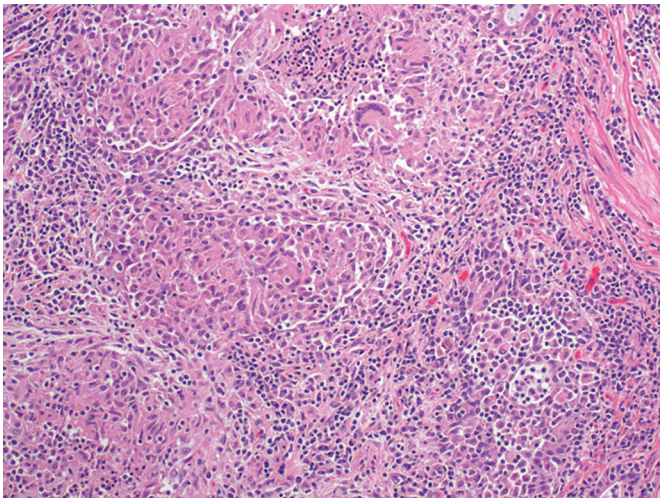

Figure 25.3 Granulomas induced by BCG therapy for urothelial carcinoma.

develops from secondary foci, most often located in the kidney, as demonstrated in the classic study by Auerbach in 1940.[109] About 10% of the patients have a history of pulmonary tuberculosis.[110] Most bladder lesions are found in the region of the trigone, especially around the ureteral orifices. Early lesions are superficial and small, with a floor of soft caseous material and a peripheral hyperemic zone. As the disease progresses, multiple ulcers coalesce to form larger ones that illicit fibrosis and involve the underlying musculature. In males, there may be secondary involvement of the prostate, whereas in females the disease may be complicated by vesico-vaginal fistula.[111]

Intravesical administration of bacillus Calmette–Guérin (BCG), as used for the treatment of superficial carcinoma of the bladder, can result in granulomatous inflammation of this organ, which may be detected microscopically or on cytologic examination of bladder wash specimens (Fig. 25.3).[112,113] The changes can extend to the prostate[114] and sometimes may even lead to systemic clinical disease, including lung involvement.[115,116]

Malakoplakia and Related Conditions

Malakoplakia of the bladder is characterized by the appearance of multiple nodular thickenings of the mucosa and underlying stroma, usually in the region of the trigone, which may be mistaken for carcinoma.[117,118] It has been associated with immune deficiency states and has been reported on several occasions in renal transplant recipients.[119,120]

Microscopically, collections of histiocytes with granular eosinophilic cytoplasm accumulate beneath the surface epithelium. In some of these cells, rounded, concentrically layered intracytoplasmic inclusions known as Michaelis–Gutmann bodies (or calcospherites) are seen (Fig. 25.4); these are basophilic and periodic acid–Schiff (PAS) positive and stain for iron and calcium. Ultrastructurally and immunohistochemically, intracellular bacteria can be identified.[121–123] The presence of transitional forms between these bacteria, lipid inclusions, and Michaelis–Gutmann bodies suggests that the latter represent the result of bacterial degradation.[124] Accordingly, malakoplakia is presently regarded as a defect in the host macrophage (phagolysosomal) response to a bacterial infection, usually from gram-negative coliform bacilli.[124–126] **Xanthogranulomatous cystitis** is morphologically and probably pathogenetically similar to malakoplakia, but it lacks Michaelis–Gutmann bodies.[127] Some of the reported cases have been associated with malignant tumors.[128]

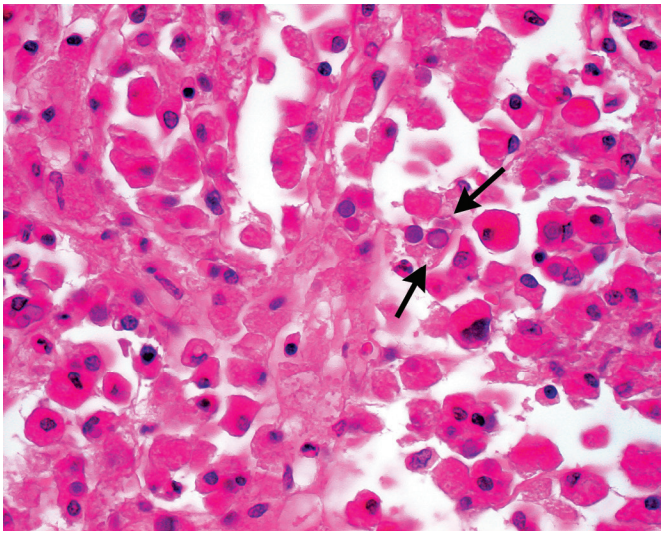

Figure 25.4 High-power view of malakoplakia of bladder, showing numerous histiocytes with Michaelis–Gutmann bodies *(arrows)*.

Malakoplakia may also involve the renal pelvis and parenchyma, ureter, prostate gland, testis, epididymis, broad ligament, endometrium, retroperitoneal structures, colon, stomach, appendix, lymph nodes, brain, lungs, bones, skin, and several other sites.[129–132]

It is important to keep in mind that, on rare occasion, malakoplakia of the bladder coexists with other lesions, such as tuberculosis and carcinoma.[133]

Other Forms of Cystitis

Other reasonably distinct types of cystitis that have been described are *hemorrhagic cystitis*, *giant cell cystitis*, *follicular cystitis*, *radiation cystitis*, *gangrenous cystitis*,[134] *myxoid cystitis* (which may contain lymphocytes with a chordoid appearance),[135] and *encrusted cystitis*.[136]

Hemorrhagic cystitis is a well-recognized complication of cyclophosphamide therapy for bone marrow transplantation and systemic vasculitis,[137–139] but it has also been seen in the absence of medication.[140] Some cases of hemorrhagic cystitis have been found to result from herpes simplex virus or cytomegalovirus.[141,142] Severe cases of hemorrhagic cystitis may necessitate the performance of a total cystectomy.[143]

HIV-infected and other immunosuppressed patients may develop cystitis of various types, including malakoplakia (see previous section) and *Toxoplasma* cystitis.[144]

Cystitis secondary to *ketamine administration* (an anesthetic agent also used in the management of pain) or ketamine abuse can be accompanied by prominent reactive urothelial changes that can mimic carcinoma.[145]

Metaplastic and Tumorlike Conditions

The bladder epithelium is prone to a remarkably wide range of metaplastic changes, most of them induced by chronic inflammation. Although clearly related to each other and often coexisting, they have traditionally been regarded as distinct entities of either inflammatory or neoplastic nature.

Intestinal metaplasia and **cystitis glandularis** result from chronic inflammation or other causes of mucosal irritation and are seen commonly with ureteral reimplantation, neurogenic bladder, or bladder exstrophy.[146,147] They may regress completely if the underlying pathogenetic factor is removed. Grossly, they usually present as irregular lesions that may be confused cystoscopically with carcinoma. The trigone is the area most commonly affected, but rare instances of involvement of the entire bladder mucosa have been reported.[148] Similar lesions may be present in the ureter and renal pelvis.

Microscopically, the initial change is focal proliferation of the basal layer of the urothelium, which produces buds that later become solid nodules (*von Brunn nests* or *islands*) located within the lamina propria. Some of these nodules develop a central cystic area. When the cells lining the cyst maintain an urothelial appearance, the condition is called *cystitis cystica*; when the luminal cells acquire luminal oriented cytoplasm imparting a glandular appearance, it is referred to as *cystitis glandularis* (Fig. 25.5). When morphologic features analogous to those of colonic epithelium are present, the process is designated as *intestinal (glandular, colonic) metaplasia* (see Fig. 25.5).[149–151] As would be expected, intestinal metaplasia is characterized by reactivity for CDX2 and CK20, whereas cystitis glandularis shows positivity for CK7.[152] We have anecdotally seen very rare examples with gastric type metaplasia. The common occurrence of transitional forms suggests that these represent various stages or manifestations of the same basic process.

When very florid, these metaplastic changes can mimic urothelial carcinoma, particularly the nested variant.[153] Rare cases may also be associated with extensive mucin extravasation, but reported follow-up data have confirmed a benign outcome (Fig. 25.6).[154]

Although intestinal metaplasia, especially when extensive, has been suggested as a risk factor for the development of adenocarcinoma,[153] most studies have not shown increased risk.[155] Certainly, the rare cases with associated glandular dysplasia may progress.[156]

Nephrogenic adenoma (nephrogenic metaplasia) has been regarded in the past as a benign neoplasm and designated as nephrogenic adenoma, but most authors currently favor the interpretation that it represents a localized or diffuse metaplastic change of the urothelium in response to chronic infection, calculi, or prolonged catheterization.[157] However, the startling claim has been made, backed by very convincing cytogenetic data, that at least some of these lesions—as seen in renal transplant recipients—represent implants into eroded bladder mucosa of tubular cells from the kidney.[158] Regardless of histogenesis, these are benign lesions.

Most cases are seen in adults, but children can also be affected.[159] Grossly, these lesions can be papillary, polypoid, or sessile; approximately 20% are multiple.[160] Their microscopic appearance is quite heterogeneous with numerous architectural patterns that are often admixed including small tubular, papillary, sheet-like with clear cytoplasm (diffuse), fibromyxoid, and flat (Fig. 25.7).[161–163] The lesional cells are low cuboidal and may have a hobnail arrangement in tubules or on papillae; thick basement membrane material often surrounds the tubules. Small tubules often have an intraluminal blue myxoid material that may simulate a signet ring cell. Immunohistochemically, they are positive for keratin 7 and PAX-8. Expression of racemase, GATA-3 (often patchy), and rarely focal high molecular weight cytokeratin or p63 may cause confusion with prostatic or urothelial carcinoma, but NKX3.1 is negative in nephrogenic adenoma.[164,165,165a,165b] Rare cases are associated with some degree of nuclear enlargement, hyperchromasia, and pleomorphism; there is no evidence that these cases, referred to as *atypical*, have a precancerous potential.[166] The main differential diagnosis is with clear adenocarcinoma and signet ring adenocarcinoma. In the rare cases in which the pattern of growth is papillary, the lesion may simulate a papilloma or papillary carcinoma of urothelial type, but the single cuboidal lining of nephrogenic adenoma is distinct.

Polypoid cystitis is a benign process of a reactive nature which may simulate a neoplasm grossly.[167] The typical site of involvement is the posterior wall above the trigone, but on occasion the entire

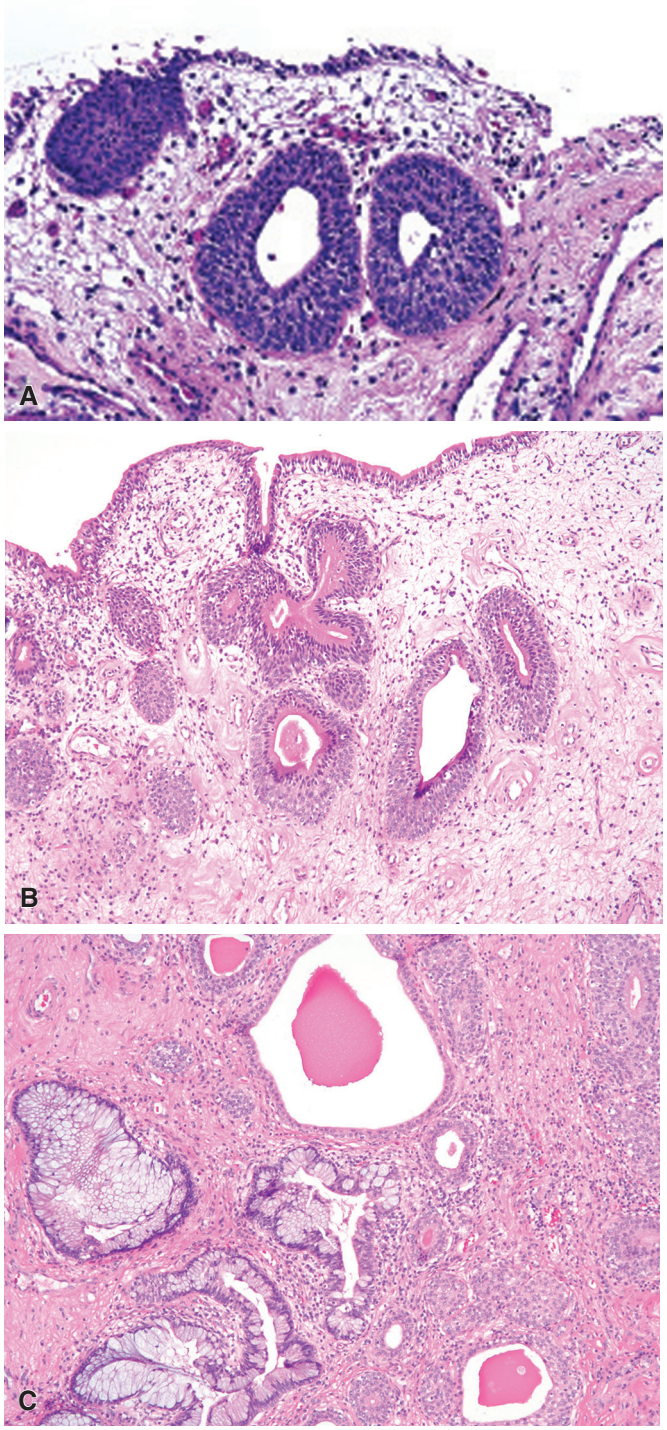

Figure 25.5 **A,** Cystitis cystica has invaginated urothelial nests with a central lumen lined by urothelial cells, while **(B)** cystitis glandularis is characterized by luminally oriented eosinophilic cytoplasm. **C,** Some cases of cystitis glandularis have intracytoplasmic mucin (intestinal metaplasia) that is often admixed with otherwise typical von Brunn nests and cystitis cystica.

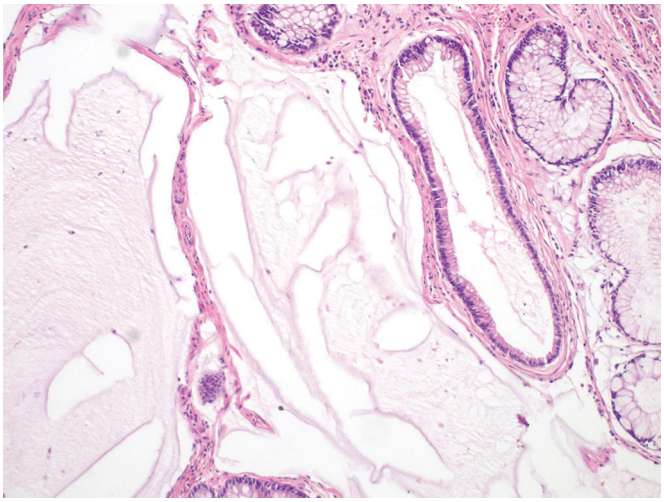

Figure 25.6 Rare cases of cystitis glandularis with intestinal metaplasia have abundant extravasated mucin that may cause a large mass lesion simulating malignancy.

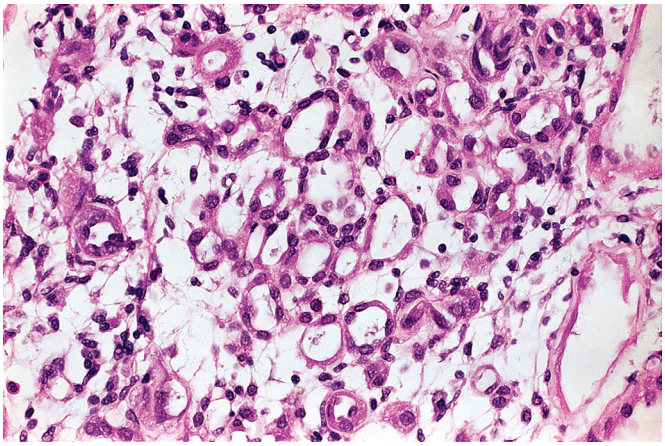

Figure 25.7 **Nephrogenic Adenoma.** A complex clustering of gland-like formations lined by cuboidal to flattened cells is seen surrounded by an edematous stroma.

bladder is affected. Gross variants of this condition include *bullous cystitis*, in which the elevations are broad and rounded, and *papillary cystitis*, in which they are thin and filiform.[167] The latter, which is thought to represent a late stage of the disease, is often overdiagnosed as a low-grade papillary urothelial neoplasm by the pathologist (but less so by the urologist). The diagnosis is best made at low power by virtue of the edematous or fibrous nature of the inflamed stroma, the broad-based, simple, nonbranching appearance of the fronds, and the normal or reactive appearance of their lining epithelium in terms of thickness and cytology (Fig. 25.8).[168] Inflammation is scanty, and significant epithelial atypia is absent; however, reactive urothelial atypia may be prominent.[169] Stellate mononuclear or multinucleated fibroblasts may be present; these are similar to those seen in analogous reactive conditions beneath other epithelium-covered surfaces, such as the nasal cavity, oral cavity, and vagina.

The better known cause of polypoid cystitis is catheterization of the bladder; the more frequent the procedure, the greater the frequency and severity of the condition, which reaches its peak at 3 months.[169] However, in only a minority of reported cases of polypoid cystitis is there a history of recent catheterization.[167] It has also been seen in association with radiation therapy and malignant tumors.

Postoperative granulomas can develop following catheterization and diathermy. The microscopic appearance may be that of a foreign-body granuloma or resemble a rheumatoid nodule by virtue of central necrosis surrounded by a palisading of histiocytes and scattered

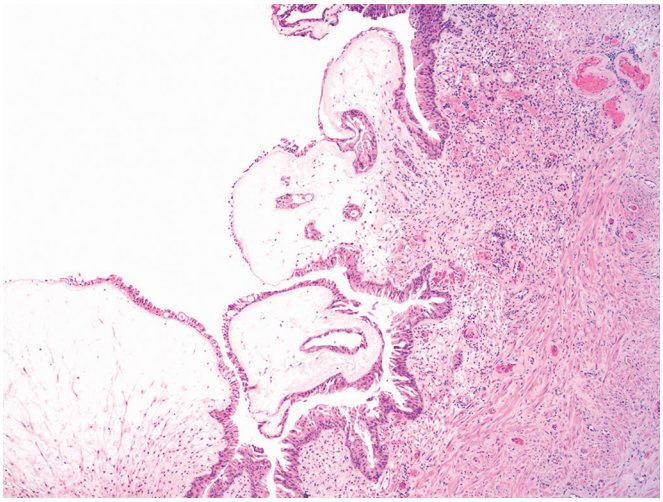

Figure 25.8 Papillary/polypoid cystitis is characterized by either broad bulbous projections or relatively broad-based simple excrescences, often with marked lamina propria edema.

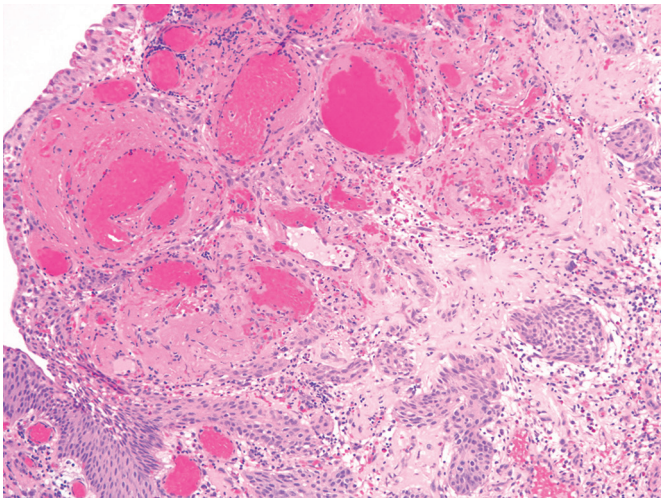

Figure 25.9 Postradiation architectural and cytologic atypia of bladder epithelium. These changes are sometimes overinterpreted as carcinoma, but the admixture of epithelium and fibrin, and the associated vascular ectasia and congestion are characteristic of this benign process.

giant cells.[170,171] There is often an associated granular eosinophilic material.[171a] These lesions heal by fibrous scarring.

Prostatic-type polyps similar to those more commonly occurring in the prostatic urethra have been seen in the bladder neck, around the ureteral orifices, and at the dome.[172]

Fibroepithelial polyps are most commonly seen in children. Most are located near the verumontanum or bladder neck. Microscopically, they are lined by normal-appearing urothelium. The stroma is fibrous, without the prominent edema and inflammation seen in polypoid cystitis.[173] The pattern of growth is polypoid, with or without papillary projections. The most important differential diagnosis is with the botryoid variant of embryonal rhabdomyosarcoma.[174]

Pseudocarcinomatous proliferation can occur as a result of radiation therapy, with or without associated ulceration.[175] Very rarely, morphologically similar changes have been reported unassociated with irradiation or chemotherapy in patients with systemic diseases of one type or another.[176] The atypical epithelium is urothelial, but a "squamoid" appearance is common, and it may extend to the subepithelial tissues (Fig. 25.9).[177] The presence of vascular ectasia and atypical fibroblasts in the stroma represent important diagnostic clues.[178,179] Another important key to the diagnosis is the presence of pseudoinvasive urothelial nests wrapping around blood vessels associated with fibrin deposition.[179]

"Collagen polyps" result from the injection of collagen into the bladder or urethral wall as treatment of urinary stress incontinence. Microscopically, the polyps show a submucosal accumulation of degraded collagen surrounded by a modest inflammatory reaction.[180]

Other reported types of tumorlike conditions of the bladder include **xanthoma**,[181] **extramedullary hematopoiesis**,[182] and **hamartoma** (occurring in association with the Beckwith–Wiedemann syndrome).[183]

Urothelial Carcinoma

General and Clinical Features

Urothelial carcinoma (historically known as transitional cell carcinoma or "TCC") comprises approximately 90% of all primary tumors of the bladder (Fig. 25.10). As with most other carcinomas, its development seems to depend on a combination of genetic and environmental factors.[184–186] Among the latter, chemical factors are thought to be of great importance.[186] Bladder tumors are more common in industrial areas (especially in those associated with petrochemicals), and their incidence is increased with exposure to cigarette smoke and arylamines.[187–190]

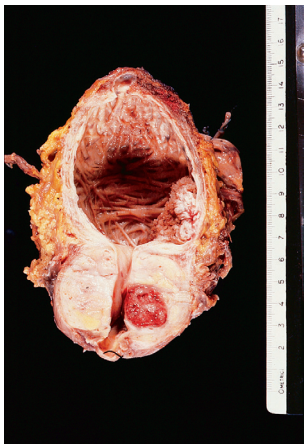

Figure 25.10 Exophytic and papillary pattern of growth of a urothelial carcinoma arising in a bladder with hypertrophy of the wall due to prostatic nodular hyperplasia. The tumor, which was located in the left lateral wall, was treated by total cystoprostatectomy. The prostate shows an incidental infarct.

Other environmental factors include aniline dyes (particularly benzidine and β-naphthylamine),[191,192] auramines, phenacetin, and cyclophosphamide.[193–195] *Schistosoma haematobium* is pathogenetically related to both urothelial and squamous cell carcinoma of the bladder.[196,197] The role of HPV has been controversial, but most of the available evidence suggests that it does not play a significant role in the genesis of this tumor.[197–199] It is believed that there is a slight increased risk for the development of bladder carcinomas in patients who had been treated with radiation therapy for prostatic carcinoma.[200]

Most cases of urothelial carcinoma of the bladder present in patients over the age of 50 years, but they can also rarely occur in

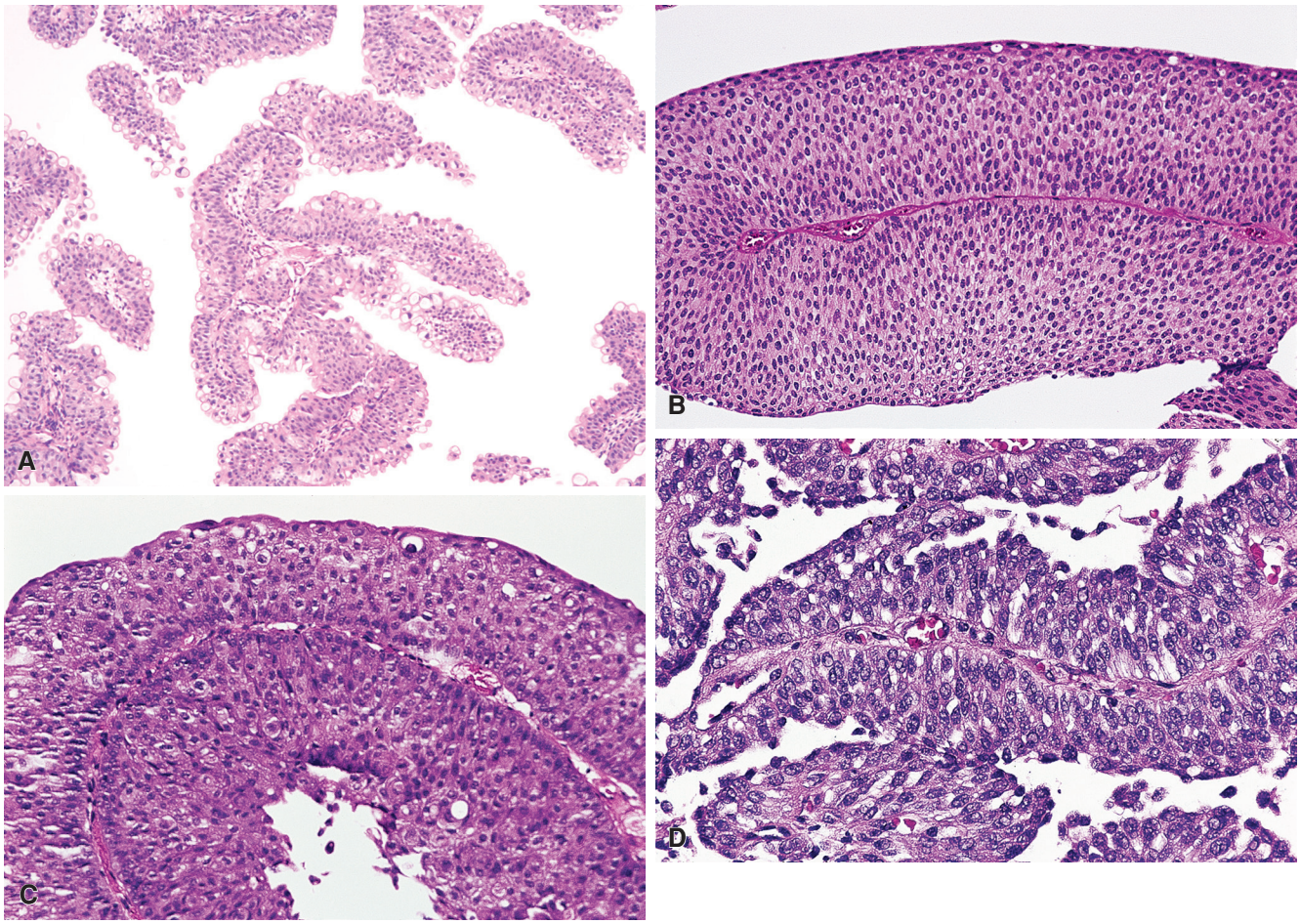

Figure 25.11 Various Types of Noninvasive Papillary Urothelial Neoplasms of the Bladder. A, Papilloma. **B,** Papillary urothelial neoplasm of low malignant potential (PUNLMP). **C,** Low-grade papillary urothelial carcinoma. **D,** High-grade papillary urothelial carcinoma.

younger adults and children.[201–204] The latter tend to be low-grade, indolent neoplasms, but occasional highly aggressive examples are reported in young adults.[205]

Men are affected more often than women, and white individuals more often than patients of African descent. Gross or microscopic hematuria is the most common form of presentation, followed by symptoms related to secondary urinary tract infection. Dysuria is more often seen with high-grade tumors, perhaps because of involvement of the bladder wall.

Urothelial tumors can arise anywhere in the bladder. In a series of approximately 1000 cases, the location was listed as follows: lateral walls, 37%; posterior wall, 18%; trigone, 12%; neck, 11%; ureteric orifices, 10%; dome, 8%; and anterior wall, 4%.[206] They have also been reported within bladder diverticula. When located around the ureteral orifices, they may produce partial or complete blockage of one or both ureters, with resulting hydronephrosis and pyelonephritis. Synchronous or metachronous multicentricity is common.

Noninvasive Papillary Urothelial Neoplasia

Several classification systems for urothelial carcinoma have been proposed over the years. These represent attempts at grading the increasing degrees of architectural disarray and particularly *cytologic* atypia of a single tumor type. The main such systems were those of Ash in 1940,[207] Mostofi in 1960,[208] Bergkvist et al. in 1965,[209] Malmstrom et al. in 1987, and World Health Organization (WHO) in 1973.[210] These have been superseded by the classification jointly proposed in 1998 by the WHO and the International Society of Urological Pathology (ISUP) and recommended by the current 2016 WHO classification.[211–216] Its main features are the division of the neoplastic lesions into flat and papillary, and the separate evaluation of the papillary neoplasms for grade (based on architecture and cytology) and invasiveness (divided into lamina propria and MP levels). The types of papillary neoplasms recognized in this classification are the following: *urothelial papilloma*; *papillary urothelial neoplasm of low malignant potential (PUNLMP)*; *low-grade papillary urothelial carcinoma*; and *high-grade papillary urothelial carcinoma* (Fig. 25.11). The criteria used to place the tumors into these categories are listed in Table 25.1. The major changes from the traditional 1973 WHO grading system were to label the lowest risk tumors as "papilloma" and "low malignant potential" (avoiding the term carcinoma for the latter group that was formerly called grade 1 carcinomas) and to lower the diagnostic threshold for a high-grade diagnosis, which was a consensus decision based on clinical follow-up data showing higher progression rates for the more atypical subset of WHO 1973 "grade 2" carcinomas.[210]

The grading of urothelial tumors of the bladder is of great prognostic significance. Thus, the tumors at the lower end of the spectrum (called papillomas in the WHO/ISUP scheme) have a low

Table 25.1 Histologic features used to classify urothelial papillary lesions according to the scheme proposed by the World Health Organization/International Society of Urological Pathology

	PAPILLOMA	PAPILLARY NEOPLASM OF LOW MALIGNANT POTENTIAL	LOW-GRADE PAPILLARY CARCINOMA	HIGH-GRADE PAPILLARY CARCINOMA
Architecture				
Papillae	Delicate	Delicate; occasionally fused	Fused, branching, and delicate	Fused, branching, and delicate
Organization of cells	Identical to normal	Polarity identical to normal; any thickness; cohesive	Predominantly ordered, yet minimal crowding and minimal loss of polarity; any thickness; cohesive	Predominantly disordered with frequent loss of polarity; any thickness; often discohesive
Cytology				
Nuclear size	Identical to normal	May be uniformly enlarged	Enlarged with variation in size	Enlarged with variation in size
Nuclear shape	Identical to normal	Elongated, round–oval, uniform	Round–oval; slight variation in shape and contour	Moderate–marked pleomorphism
Nuclear chromatin	Fine	Fine	Mild variation within and between cells	Moderate–marked variation both within and between cells with hyperchromasia
Nucleoli	Absent	Absent to inconspicuous	Usually inconspicuous[a]	Multiple prominent nucleoli may be present
Mitoses	Absent	Rare, basal	Occasional, at any level	Usually frequent, at any level
Umbrella cells	Uniformly present	Present	Usually present	May be absent

[a]If present, small and regular and not accompanied by other features of high-grade carcinoma.
From Epstein JI, Amin MB, Reuter VR, Mostofi FK; the Bladder Consensus Conference Committee. The World Health Organization/International Society of Urological Pathology consensus classification of urothelial (transitional cell) neoplasms of the urinary bladder. *Am J Surg Pathol*. 1998;22:1435–1448.

incidence of recurrence and a negligible incidence of concurrent in situ or invasive carcinoma, while higher grade tumors have more propensity for recurrence and progression.[217,218]

It should be kept in mind that the differentiation of these neoplasms may vary from area to area[219]; therefore, a biopsy or TUR may show a different grade from the one that will be found in the surgical specimen.[220–222] It is also good to remember that this grading system has been devised for its application to noninvasive urothelial neoplasms and that it does not have much discriminatory power when applied to the invasive component.[223]

Urothelial papilloma of exophytic type is characterized by a relatively simple branching papillary architecture, typically without epithelial confluence between papillary excrescences.[217,218,224,225] The lining urothelium appears histologically normal with orientation of the neoplastic cells streaming upward (perpendicular to the basement membrane), often with very prominent umbrella cells. Not uncommonly, the papillary cores contain dilated lymphatics or a distinct gland-in-gland pattern. *PUNLMP* is similar, but the lining appears thickened (hyperplastic) on low-power examination compared with normal urothelium.[212,226] In contrast, *noninvasive low-grade papillary urothelial carcinoma* has a more disorganized urothelium that loses polarity with mild cytologic atypia. The papillae may be more complex and confluent compared with papilloma and PUNLMP. *Noninvasive high-grade papillary urothelial carcinoma* are not all markedly pleomorphic, but at a minimum show cellular disorder with a combination of nucleomegaly, some variation in nuclear size and shape, and irregular nuclear chromatin (i.e., hyperchromasia). At the extreme end of the high-grade spectrum, there may be solid confluent epithelial growth between papillae and marked anaplasia.

While "papillary urothelial hyperplasia" with or without atypia was recently proposed as a urinary bladder lesion consisting of undulating folds of urothelium without the cytologic atypia and the well-developed branching fibrovascular cases of papillary neoplasms,[227–229] the WHO classification has recommended classifying true papillary lesions as neoplasms using the previously described categories. In cases with very early epithelial tufting in which the diagnosis as a papillary neoplasm is uncertain, the descriptive diagnostic term "urothelial proliferation of uncertain malignant potential" has been suggested.[216]

Endophytic/Inverted Urothelial Neoplasia

Inverted urothelial papilloma is thought to represent a benign epithelial tumor that may be distinct from exophytic urothelial papilloma. It is more commonly seen in adult and elderly males and is almost always located in the trigone, bladder neck, or prostatic urethra.[230,231] It is usually solitary and presents with hematuria and/or obstruction.

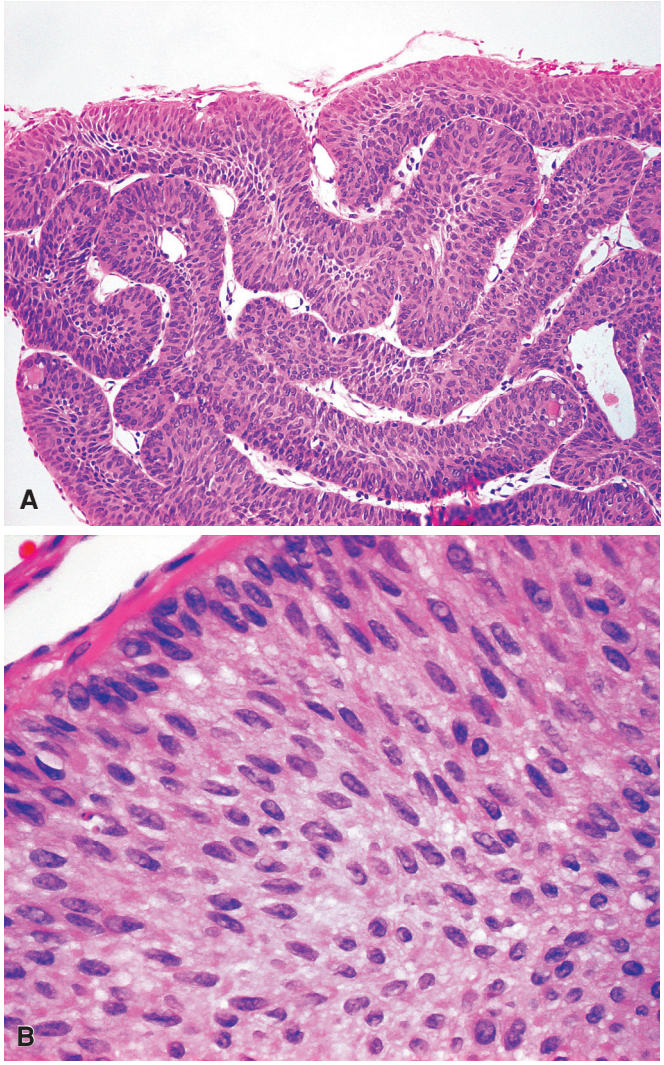

Figure 25.12 Inverted Papilloma of Bladder. A, The proliferation has a festoon-like quality and is located below a flat epithelium. **B,** High-power view showing the oval to spindle shape of the cells and their lack of atypia.

Cystoscopy reveals a polypoid and usually pedunculated lesion of smooth contours (Fig. 25.12). Microscopically, the most characteristic feature is the invagination of the epithelium, which usually shows no atypical features (see Fig. 25.12). Occasionally, this epithelium may show a foamy or vacuolated cytoplasm.[232] Papillae are absent or present only very focally, and connective tissue is very scanty.[233] In some lesions, there is a distinct trabecular arrangement, with peripheral palisading of the tumor cells and central cellular spindling; in others, there are islands of urothelial cells accompanied by gland-like and mucin-secreting structures.[234] The latter type may actually represent an unduly proliferative form of cystitis glandularis or cystica.[234,235] Exceptionally, a neuroendocrine component made up of granular eosinophilic cells is present.[236] There is no evidence that inverted papilloma (even if accompanied by some degree of supposedly "degenerative" type epithelial atypia)[237] predisposes to the development of carcinoma, but there is occasional coexistence of the two lesions.[238,239]

The entire spectrum of urothelial neoplasia seen in papillary lesions may have a similar noninvasive inverted growth with anastomosing cords and endophytic nests of urothelium.[240] *Inverted PUNLMP* has not been extensively studied, but rare urothelial neoplasms with an inverted pattern have some features of papilloma but have other areas with mild expansion of the nests or cords.[226] These areas maintain a relatively ordered arrangement of the bland urothelial cells. *Noninvasive low-grade papillary urothelial carcinoma, inverted type* has similarly expanded cords and nests but has a degree of architectural disorder and mild atypia similar to its exophytic counterpart. *Noninvasive high-grade papillary urothelial carcinoma, inverted type* has a similar low-power expanded cord-like architectural growth with rounded contours; however, the cytological features are sufficient for designation as high grade.

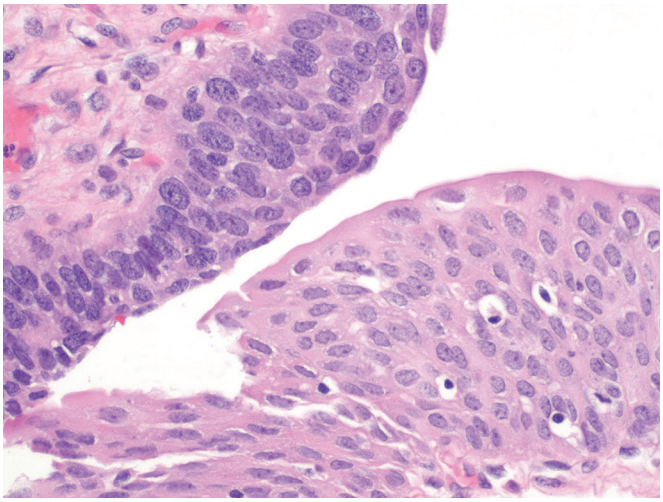

Figure 25.13 Urothelial Carcinoma in situ of Bladder. Note the nucleomegaly and irregular, clumpy chromatin *(upper left)* as compared to adjacent normal urothelium *(lower right)*.

Flat Urothelial Lesions With Atypia

Historically, flat urothelial lesions with atypia were classified at different centers using variable terminology, but the WHO/ISUP 2016 classification (based on modifications from WHO/ISUP 1998)[212] is now more uniformly utilized throughout the world. The diagnostic categories include **reactive urothelial atypia**, **urothelial atypia of unknown significance**, **urothelial dysplasia**, and **urothelial carcinoma in situ (CIS)**. The most important diagnostic thresholds are those for definitive reactive changes and definitive CIS.

Reactive urothelial atypia is frequently associated with acute and chronic inflammation from a variety of causes (e.g., infection, indwelling catheter, calculi).[241] The inflammatory cell infiltrate may involve the lamina propria, but intraurothelial inflammation is most common. Urothelium with reactive atypia often has a basophilic appearance; their nuclei are enlarged and may be somewhat rounded, but they are typically monomorphic without significant variation in size and shape. In general, the nuclei are no larger than the size of approximately three lymphocytes. Importantly, the nuclear chromatin remains fine, but prominent nucleoli (sometimes multiple) are not infrequent. Mitoses may be frequent and can involve the upper levels of the urothelium, especially in patients with recent indwelling catheters.

Urothelial CIS is histologically heterogeneous, but there are general over-reaching features (Fig. 25.13).[242] Compared with normal urothelium, nuclei are often more rounded and enlarged, often greater than 4–5 times the size of a lymphocyte.[243] The urothelial cells, in contrast to reactive atypia, become disorganized, losing their orientation perpendicular to the basement membrane. The

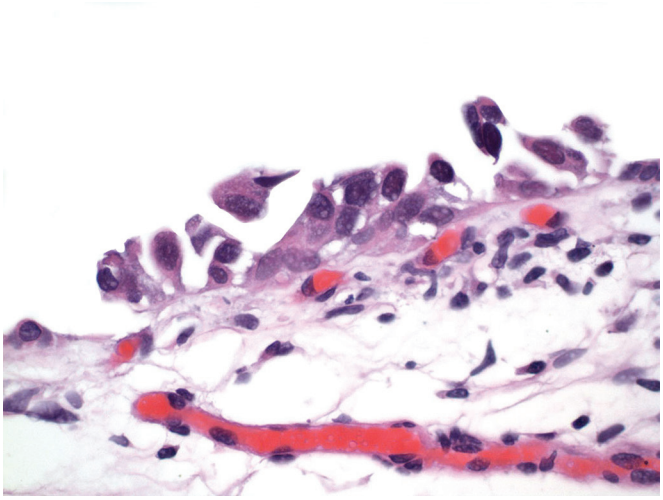

Figure 25.14 Urothelial Carcinoma in situ of Bladder. The tumor has detached from the underlying stroma, only a few residual malignant cells remaining, resulting in the picture known as clinging or denuding carcinoma in situ.

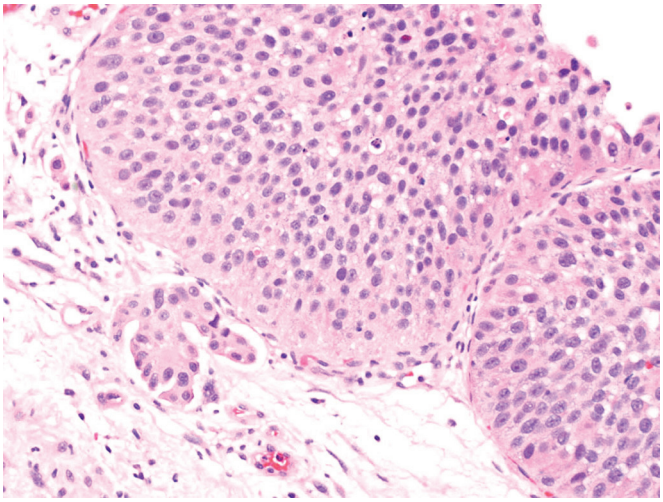

Figure 25.15 Focal superficial lamina propria invasion by urothelial carcinoma of bladder, which is characterized by detached clusters of urothelium with cytoplasmic eosinophilia, irregular contours, and surrounding stromal retraction.

nuclear chromatin becomes coarse, nuclear membranes are often irregular, and nucleoli may be present or absent. Mitotic figures are often easily seen and may be atypical. Unlike many other anatomic sites, the nuclear-to-cytoplasmic ratio of the neoplastic cells may not be increased as abundant cytoplasm is often preserved. Diverse patterns of CIS may be seen and include undermining growth, pagetoid spread, and denuding/clinging CIS (Fig. 25.14). Rare cases may show glandular differentiation.[244] It is important for the term CIS not to be equated with "*superficial carcinoma*"; the latter is used by urologists for tumors that have not invaded into the MP regardless of their type and grade, and therefore it does not represent a pathologic entity.[211] Similarly, one should realize that while papillary urothelial carcinomas that do not invade the stroma could be conceptually considered "carcinomas in situ" (pTa), they are not designated as such to avoid lumping together two conditions with markedly different morphologic features, natural history, and probably molecular pathways.[245,246]

Classification of flat urothelial atypias that fall short of the threshold for CIS, yet have cytologic features beyond definitive reactive atypia are more problematic. Urothelial dysplasia suffers from poor interobserver reproducibility, and large studies that link dysplasia (excluding cases that would be regarded as CIS by current definitions) to the risk of developing CIS are, in our opinion, lacking. Lesions classified as dysplasia typically have some degree of cellular disorganization but only mild nuclear enlargement and only mild atypia. Subtle cellular crowding or overlap may be seen in normal urothelium and should not be interpreted as "atypical." Because of these problems, some experts prefer to combine the categories of "atypia of unknown significance" and "urothelial dysplasia" into a single category for daily practice, such as "flat urothelial atypia, cannot exclude early flat neoplasia (dysplasia)." In general, both diagnostic categories would simply be followed clinically to exclude development of a more definitive, higher-grade lesion, so the distinction is not critical to clinical management. Adjunctive testing by immunohistochemistry (e.g., CK20, CD44, p53, Ki-67, CK5/6) has been evaluated in this setting,[247–249] but studies have not documented independent predictive value for disease progression in these borderline cases; therefore, it is our opinion that true clinical utility is questionable. The critical morphologic task is the distinction of atypia/dysplasia from CIS as the later diagnosis prompts therapy. The presence of marked nuclear enlargement (≥5–6 times the size of a lymphocyte), significant nuclear chromatin hyperchromasia, and brisk mitotic activity generally strongly suggest CIS.

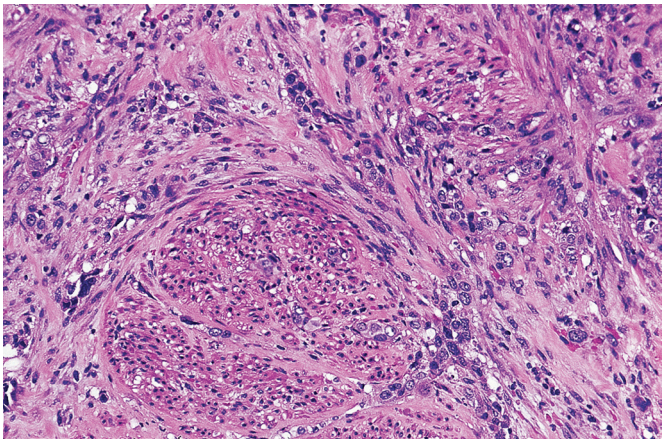

Figure 25.16 Muscularis propria invasion by urothelial carcinoma of bladder.

Invasive Urothelial Carcinoma

Invasive urothelial carcinoma has a heterogeneous morphology, including numerous described variant forms. Typical invasive urothelial carcinoma shows irregularly distributed nests of urothelial cells, either with rounded or jagged contours. Stromal response to invasive urothelial carcinoma varies widely but includes fibrosis, inflammatory reaction, desmoplasia, myxoid change, stromal retraction clefts, or no response. Early invasion into the lamina propria may consist of small solid nests and/or clusters of urothelial cells with cytoplasmic eosinophilia (so-called paradoxical maturation), often with surrounding retraction (Fig. 25.15).[250] Irregular infiltration to level of the MP is diagnostic of malignancy and represents a critical treatment threshold (Fig. 25.16).

Invasive urothelial carcinomas with divergent differentiation are not uncommon, and most are characterized by squamous or less commonly glandular differentiation (Fig. 25.17). The presence of

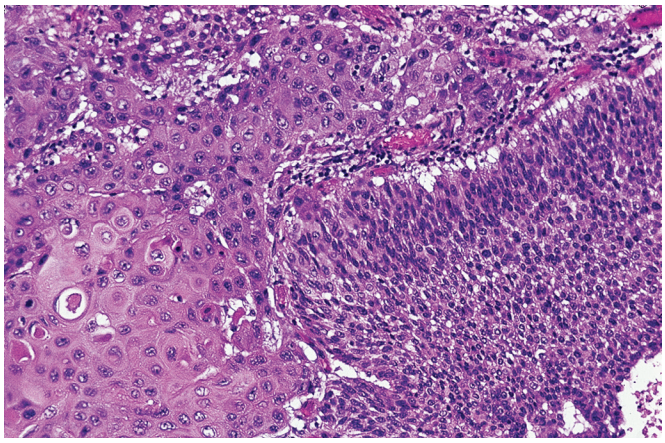

Figure 25.17 Urothelial carcinoma with squamous differentiation.

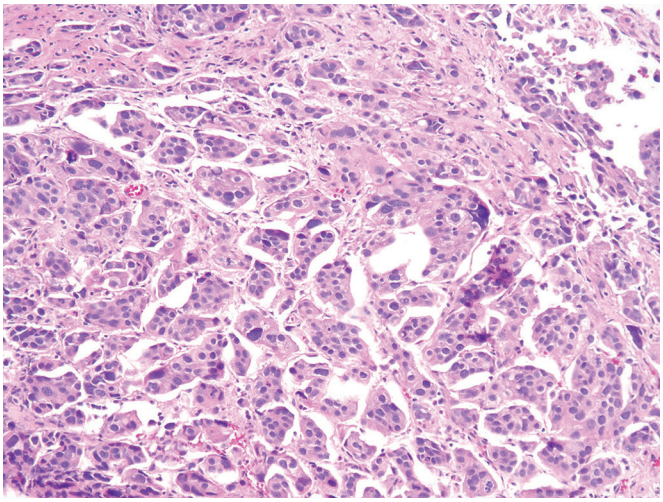

Figure 25.18 Invasive micropapillary carcinoma of the bladder.

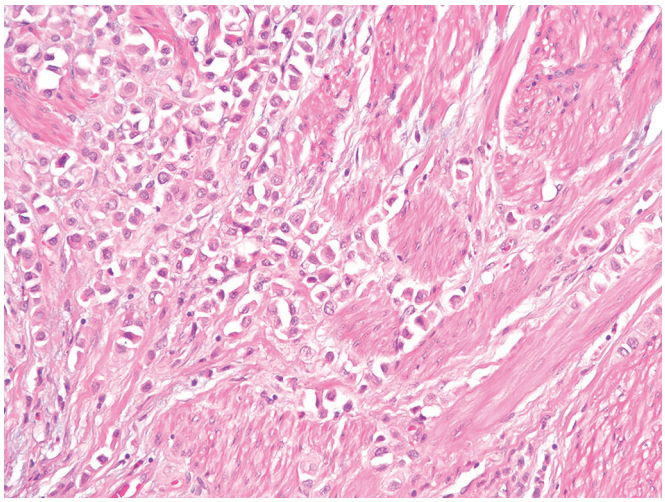

Figure 25.19 Plasmacytoid carcinoma of the bladder.

a typical urothelial carcinoma component (either invasive, papillary, or in situ) is usually sufficient for classification as urothelial, as opposed to primary squamous cell carcinoma or adenocarcinoma (discussed later). Urothelial carcinomas may have areas with morphologic and immunohistochemical features indicative of trophoblastic differentiation (often admixed syncytiotrophoblasts) and are sometimes accompanied by serum elevations of hCG.[251,252] Occasionally the entire lesion has the appearance of a *choriocarcinoma*, in which case it needs to be distinguished from a metastatic tumor.[253,254] Some urothelial carcinomas are associated with immunohistochemical reactivity for hCG and other placental glycoproteins, even if they lack identifiable foci of choriocarcinoma.[255] This feature is particularly common in the high-grade tumors but is not usually pursued diagnostically because of questionable independent clinical significance.[256]

Many variant forms of urothelial carcinoma are described, but not all have independent prognostic significance. A few variant forms may have important clinical significance, particularly micropapillary, plasmacytoid, and small cell carcinoma (the later discussed in the neuroendocrine section). In addition, some variants of urothelial carcinoma are histologically subtle, and awareness is important to avoid underdiagnosis. A discussion of some specific variant patterns follows:

Micropapillary carcinoma of the bladder was described in 1994 as a variant that histologically mimics ovarian serous carcinoma.[257] It is typically characterized by rather confluent "back-to-back" retraction spaces and multiple epithelial aggregates/nests in a single retraction space (Fig. 25.18).[258] Most are invasive into the MP at diagnosis, and lymph node metastases are common.[259–261] While controversial, some have advocated for immediate cystectomy for micropapillary carcinoma, regardless of stage; for that reason, it is important to not overdiagnosis micropapillary based on stromal retraction alone.[262] Also, noninvasive carcinomas with micropapillary excrescences should not be designated as "micropapillary" because they do not seem to have the same clinical implications as invasive disease.[263] Recent data suggest that prominent stromal retraction clefts may be an independent prognostic factor, independent of classic micropapillary morphology.[264]

Plasmacytoid carcinoma is morphologically similar to lobular breast cancer and diffuse-type gastric cancer.[265–268] The monomorphic round neoplastic cells are discohesive and grow singly or in clusters (Fig. 25.19). They often have homogeneous eosinophilic cytoplasm and an eccentrically placed nucleus, but intracytoplasmic vacuoles are also common in scattered cells. Because of this latter feature, distinction from signet ring cell type adenocarcinoma is based on the presence of associated extracellular mucin.[216] Immunophenotypically, plasmacytoid carcinoma typically expresses cytokeratins, CD138, CK20, and GATA3, but p63 is less sensitive in this variant.[269] ER expression is typically absent, a helpful feature in the distinction from metastatic lobular breast cancer (which also expresses GATA3). Intraoperative evaluation of the ureters at the time of cystectomy must carefully focus on the periureteral tissues, as plasmacytoid carcinoma not uncommonly extends along the adipose tissue.[270] Plasmacytoid carcinoma has a pattern of spread that is distinct from typical urothelial carcinoma, with involvement of serosal surfaces, parenchymal organs (e.g., ovary), and recurrence as malignant effusions.[271] A recent study has shown frequent somatic *CDH-1* loss-of-function mutations in plasmacytoid variant.[272]

Nested urothelial carcinoma (along with the similar carcinomas large nested, tubular, and microcystic) were originally described as "deceptively bland," an apt name.[273] Because nested carcinoma is characterized by rounded aggregates of cytologically bland urothelium, the irregular distribution of these aggregates in the suburothelial tissues is diagnostically important in the distinction from benign von Brunn nests (Fig. 25.20).[274–276] Some cases have central cystic change (i.e., microcystic variant) mimicking cystitis cystica or glandularis,

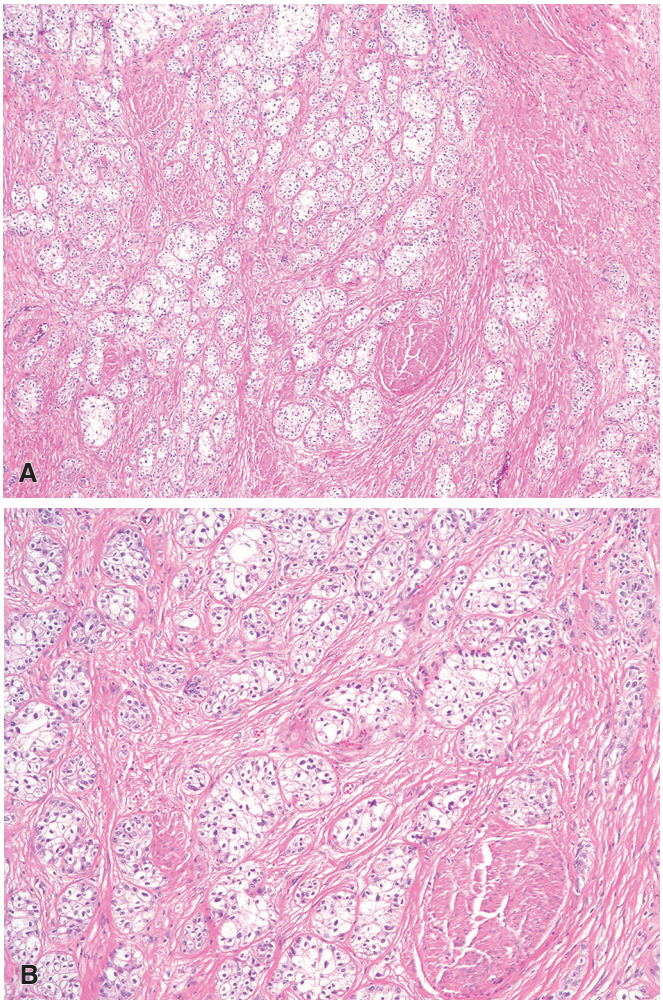

Figure 25.20 Nested Urothelial Carcinoma. A, Low-power magnification shows the irregular deep infiltration by the urothelial nests despite bland cytologic features **(B)**.

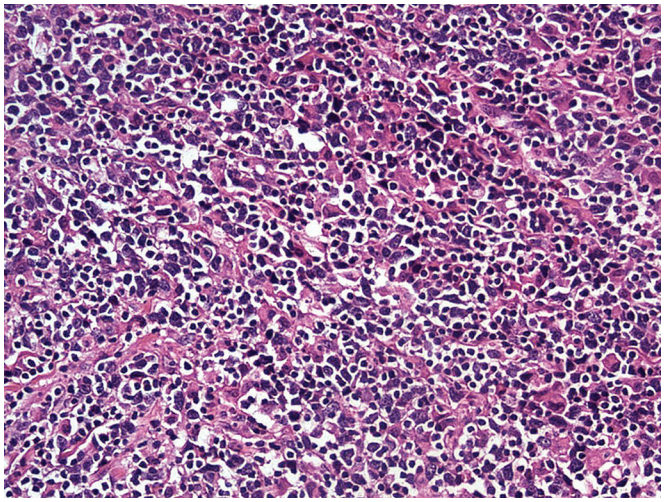

Figure 25.21 Lymphoepithelial-like carcinoma of the bladder.

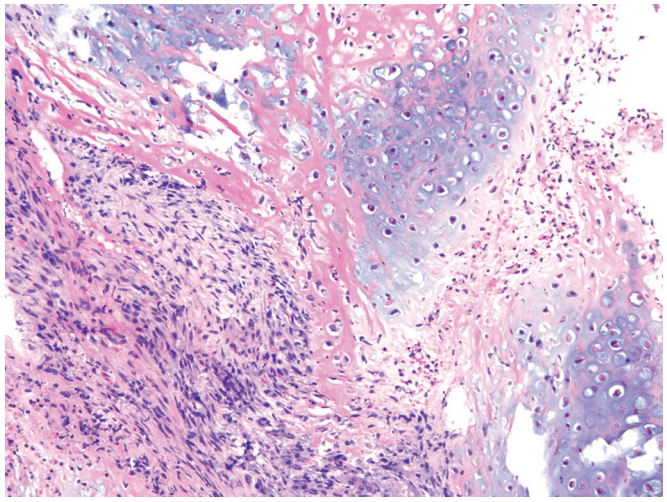

Figure 25.22 Sarcomatoid carcinoma of bladder with heterologous differentiation.

but they too have an irregular distribution that often extends deeply into the underlying tissues.[273] A recent study has suggested that *TERT* promoter mutation is common in nested urothelial carcinoma and may have diagnostic utility in difficult cases.[277]

Lymphoepithelioma-like carcinoma has only recently been described at this site; its appearance is that of a nonkeratinizing carcinoma associated with a heavy inflammatory infiltrate.[278–280] Some cases are pure, in which the carcinoma may be masked by the inflammatory cells (Fig. 25.21), but most represent a focal or extensive change in a tumor having otherwise the appearance of a urothelial carcinoma.[281–283] None of the cases so far studied has shown evidence of Epstein–Barr virus (EBV) infection by in situ hybridization.[283]

Sarcomatoid (spindle cell, metaplastic) carcinoma is a high-grade neoplasm of the bladder in which a malignant epithelial component, clearly identifiable as such (of urothelial, glandular, squamous, or undifferentiated type), coexists with areas having a spindled "sarcoma-like" appearance (Fig. 25.22).[284–289] The latter may have a nonspecific spindle cell or pleomorphic morphology (sometimes admixed with osteoclast-like giant cells),[290–296] or may exhibit specific features of mesenchymal differentiation, such as rhabdomyosarcoma, chondrosarcoma, osteosarcoma, liposarcoma, or pleomorphic undifferentiated sarcoma.[297,298] When such specific features are present, the tumor may be designated as *carcinosarcoma*,[294,299] but we view this as a variation of the same basic process. Whether areas of specific mesenchymal differentiation occur or not, transitions may be seen between the two major components, suggesting that the sarcoma-like areas are also of epithelial nature.[300] Further evidence of the epithelial nature of these proliferations is provided by the immunoreactivity for keratin often detected in the sarcoma-like component.[301–303] Exceptionally, the epithelial component is made up of small cells with neuroendocrine features.[304] On other occasions, the tumor has prominent myxoid or sclerosing features.[305]

Grossly, these tumors are often large and polypoid. They are equivalent in most respects to their more common counterparts located in the upper aerodigestive tract[300]; as in those, the obvious epithelial component is sometimes present only in the form of CIS on the surface and at the periphery of the invasive sarcoma-like tumor.[306] The differential diagnosis includes true sarcomas, inflammatory myofibroblastic tumor, and urothelial carcinomas with reactive stroma.[307]

Most patients with sarcomatoid carcinoma are elderly males, and the death rate is about 50%.[298] Sequential involvement of ureter and renal pelvis may occur.[308] Metastases develop in regional lymph nodes and distantly; they may consist of only the epithelial

or the sarcoma-like component.[309] The treatment of this tumor should be the same as for high-grade urothelial carcinoma of equivalent stage.[285]

Immunohistochemical Features

The immunophenotype of urothelial carcinoma is heterogeneous, particularly across variant forms. The neoplastic cells typically express CK7, CK20, p63, and high-molecular-weight cytokeratin.[310] GATA3 commonly shows nuclear staining in urothelial carcinoma, but the specificity is poor for a work-up of "carcinoma of unknown primary," and is less commonly expressed in variant types.[311,312] Different uroplakin antibodies have also been reported to show immunoreactivity in urothelial carcinoma, but there is less experience with their use and their sensitivity and specificity in invasive carcinomas has been questioned; however, uroplakin II may have more utility as collective experience increases.[313–316]

Molecular Genetic Features

The underlying genetic profile of urothelial carcinoma is complex and has not yet been incorporated into standard pathologic evaluation. There are two independent pathways of urothelial carcinoma development, although occasional overlaps between the two can occur.[317–321] One pathway is represented by low-grade papillary urothelial neoplasm (including PUNLMP and low-grade papillary urothelial carcinoma), which is characterized by frequent local recurrence but not metastasis, and which only uncommonly progresses to high-grade papillary urothelial carcinoma or muscle-invasive urothelial carcinoma. Low-grade papillary urothelial neoplasms show activation of the RAS-MAPK pathway, which results from activating mutation of the fibroblast growth factor receptor gene *FGFR3* (60%–80%) or *HRAS* gene (15%–30%). Interestingly, mutations of these two genes are mutually exclusive. Chromosome 9q deletion is common, with several candidate genes having been implicated, including *TSC1* (tuberous sclerosis complex 1), *PTCH* (patched homolog) and *DBC1* (deleted in bladder cancer 1). *PI3KCA* gene mutation is present in 10%–27% of cases.

The second pathway, which is less common, is represented by CIS and ≥pT2 urothelial carcinoma; there is a tendency for the former to progress into the latter (60%–80% in 5 years), which then acquires metastatic potential. Urothelial CIS commonly shows mutations or deletions in the tumor suppressor genes *TP53* (70%), *RB* (37%), and *PTEN* (35%), frequently accompanied by deletion of chromosome 9. Similar changes are seen in muscle-invasive urothelial carcinomas (pT2–pT4), but there are often additional genetic alterations, such as 3pDel, 5qDel, 6qDel, 10qDel, 11pDel, and 18qDel.

It is unclear whether there is a third molecular pathway, involving high-grade papillary urothelial carcinoma and pT1 carcinoma, which may evolve from flat dysplasia or high-grade transformation of low-grade papillary neoplasm. In such tumors, there is a high frequency of 9pDel, with homozygous deletion of the *CDKN2A (INK4A)* gene, which encodes P16. *FGFR3* and *TP53* mutations may also be present. Recent studies have suggested molecular subtypes that are similar to those described in breast adenocarcinoma (i.e., luminal, basal, etc.), but this has not been implemented into standard practice.[322] Other commonly reported genetic abnormalities involve *TERT* and *Notch*.[323,324]

Reporting in Transurethral Resection and Cystectomy Specimens

Bladder tumors should be sampled or removed with a "cold" biopsy instrument. Ideally, the biopsy should include a portion of the underlying muscle. The urologist should not fulgurate a papillary tumor without biopsy simply because it appears benign. It is recommended that, in addition to the main tumor, biopsies be taken from apparently normal adjacent mucosa and from three other sites (one lateral to each ureteral orifice and one from the upper posterior wall).[325] These biopsies should be submitted separately and sectioned at various levels. The pathology report of a bladder biopsy that contains a tumor should clearly include: invasive or noninvasive, grade (ISUP 1998/WHO 2016), depth of invasion, presence of muscle, lymphovascular invasion, and concomitant lesions (e.g., CIS). A synoptic checklist, such as provided by the College of American Pathologists, for examination and reporting of bladder specimens is commonly utilized.[326] Two important points: (1) the term "muscle invasion" is imprecise, and depending on the depth of invasion we recommend using the terms either invasive into "lamina propria" or "MP (detrusor muscle)," as appropriate; (2) retraction artifact is common and the diagnosis of definitive lymphovascular invasion should be rendered only when unequivocal blood vessel wall is seen. We do not generally use immunohistochemistry for endothelial markers in routine practice.

Detection of residual tumor cells in biopsy specimens from patients having had a prior biopsy or TUR can be very challenging. Immunostains for keratin should be used only with great care since reactive myofibroblasts are commonly positive as well.[327]

Treatment

The therapy of bladder carcinoma needs to be individualized, taking into account the age of the patient and the surgical risk; the extent, stage, and microscopic grade of the tumor; and the presence of CIS elsewhere in the bladder.[328–333]

The recommended treatment for extensive CIS is total cystectomy. For small and apparently localized lesions, intravesical chemotherapy may induce temporary and sometimes complete remission[334–336]; however, in 40%–70% of the cases, new tumors will develop, usually within a 6–12-month period.[337] An initially controversial but now widely accepted therapy for "superficial" bladder carcinomas (either pTa or pT1 papillary and/or CIS) is intravesical immunotherapy with the BCG, which in some series has shown remarkable reduction of the tumor recurrence rate[338–341]; microscopically, this therapy results in superficial mucosal erosion, submucosal granulomatous inflammation, and reactive epithelial atypia.[342]

Urothelial carcinomas without MP invasion are usually treated initially with TUR, and in high-grade or invasive pT1 tumors this is often supplemented with intravesical chemotherapy, especially in cases of multiple or recurrent tumors.[343–346] Carcinomas with MP invasion irrespective of grade, and tumors resistant to conservative therapy are generally best treated by radical cystectomy, with or without preoperative chemotherapy.[336,347–350] In some centers, they have also been treated by radiation alone.[351–353]

Radical cystectomy in the male includes the bladder, prostate, seminal vesicles, and adjacent perivesical tissues; in the female, it may include the bladder, uterus, tubes, ovaries, anterior vagina, and urethra. Argument persists as to whether a total urethrectomy should be part of the procedure in males.[354] In some centers, the radical cystectomy is combined with en bloc pelvic lymph node dissection.[355,356] At present, operative mortality for radical cystectomy is low, and pyelonephritis is no longer a frequent complication.

The addition of neoadjuvant chemotherapy to the cystectomy has improved the survival of patients with advanced bladder carcinoma,[357] and emerging immune-modulators show some initial promise (e.g., anti-PD-L1).[358] Segmental (partial) cystectomy has fallen into disfavor because of the high rate of recurrence in the residual bladder.

Other Primary Carcinomas

Primary Glandular Lesions of the Bladder (Adenocarcinoma and Related Tumors)

Villous adenoma is microscopically similar to its colorectal counterpart.[359] As in the latter location, it can be pure or associated with a tubular component (tubulovillous adenoma).[360] It is often associated with cystitis glandularis or cystica,[361] and it should be distinguished from bladder extension of well-differentiated colorectal carcinoma or appendiceal low-grade mucinous epithelial neoplasia (the latter pitfall having been learned the hard way).[362] As is also the case in other locations, villous adenoma of the bladder has a tendency to undergo malignant transformation in the form of invasive adenocarcinoma, so complete sampling of the lesion for histologic examination is important.[363,364]

In situ adenocarcinoma is an extremely rare form of intraepithelial bladder malignancy, which is associated with an elevated risk of development of high-grade urothelial carcinoma, including small cell carcinoma and micropapillary carcinoma.[365] This is particularly the case if the in situ adenocarcinoma is present in a pure form.[366]

Bladder adenocarcinomas constitute approximately 2% of the malignant tumors of this organ.[367] These likely develop from sequential changes in the surface urothelium initiated by chronic inflammation—from cystitis glandularis with intestinal metaplasia to dysplasia and finally to adenocarcinoma. It is important to reiterate that this is a rare event, and cystitis glandularis should not be regarded (or treated) as a precursor lesion in the absence of dysplasia.[368] The tumors arising on this basis are usually located in the trigone area.[369] Other adenocarcinomas arise in bladders with exstrophy,[31] in diverticula,[43] or at the dome of the bladder from urachal remnants (Fig. 25.23).[21,369,370]

Grossly, advanced cases appear as fungating masses that ulcerate the mucosa and invade the bladder wall. The surface of the mucin-producing tumors is covered with thick, slimy, gelatinous material.[371] Microscopically, there is a wide range of glandular differentiation, the better differentiated examples eliciting the differential diagnosis with intestinal metaplasia (Fig. 25.24).[372,373] Deep invasion of the muscle is the rule, but very superficial examples of this tumor have been observed.[366] The mucin histochemical profile is similar but not identical to that of colorectal adenocarcinoma.[374–378] Some tumors have been found to contain both Paneth cells and endocrine cells.[379,380]

Immunohistochemically, primary bladder adenocarcinoma differs from colorectal adenocarcinoma by the fact that the pattern of staining for β-catenin, if present, is primarily membranous (and to a lesser degree cytoplasmic) rather than nuclear.[381] It is also more commonly positive for keratin 7 (6.5% vs. 0%) and less commonly for keratin 20 (53% vs. 94%).[382,383] GATA3 nuclear reactivity is relatively rare in bladder adenocarcinomas.[384] Additionally, a recent study documented SATB2 nuclear expression in approximately 50% of primary bladder adenocarcinomas, precluding its use in the distinction from colorectal primary adenocarcinoma.[384a] Because of the degree of morphologic and immunophenotypic overlap, in our opinion the possibility of a colorectal adenocarcinoma should almost always be excluded by radiographic and optimally endoscopic evaluation.

The overall prognosis of primary adenocarcinoma is poor: in one series of 64 cases, the 5-year survival was only 18%.[372] As in the case of urothelial carcinoma, stage is the most important prognostic factor. The pattern and frequency of metastases are also similar to those of high-grade, conventional urothelial carcinoma.

A distinct variant of bladder adenocarcinoma is the **clear cell type**,[383,385] which is morphologically identical to its counterpart in the gynecologic tract, can also occur in the urethra (Fig. 25.25). It is usually papillary and is characterized microscopically by a mixture of tubular glands, papillae, cysts, and areas of solid growth. Two of its most distinctive features are the presence of hobnail cells and abundant cytoplasmic glycogen.[385,386] This lesion is distinguished

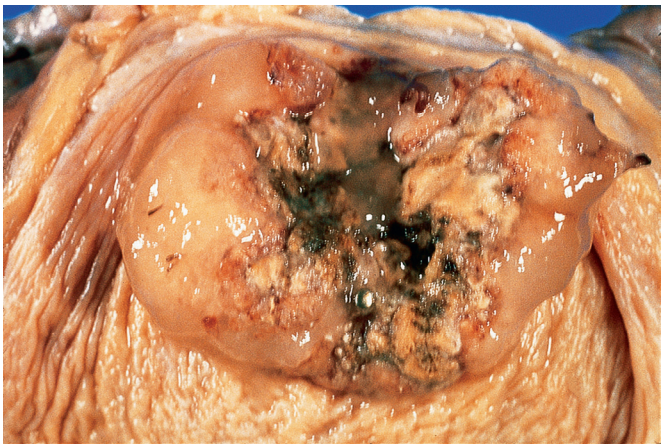

Figure 25.23 Mucinous adenocarcinoma located in the dome of the bladder, probably arising from urachal remnants.

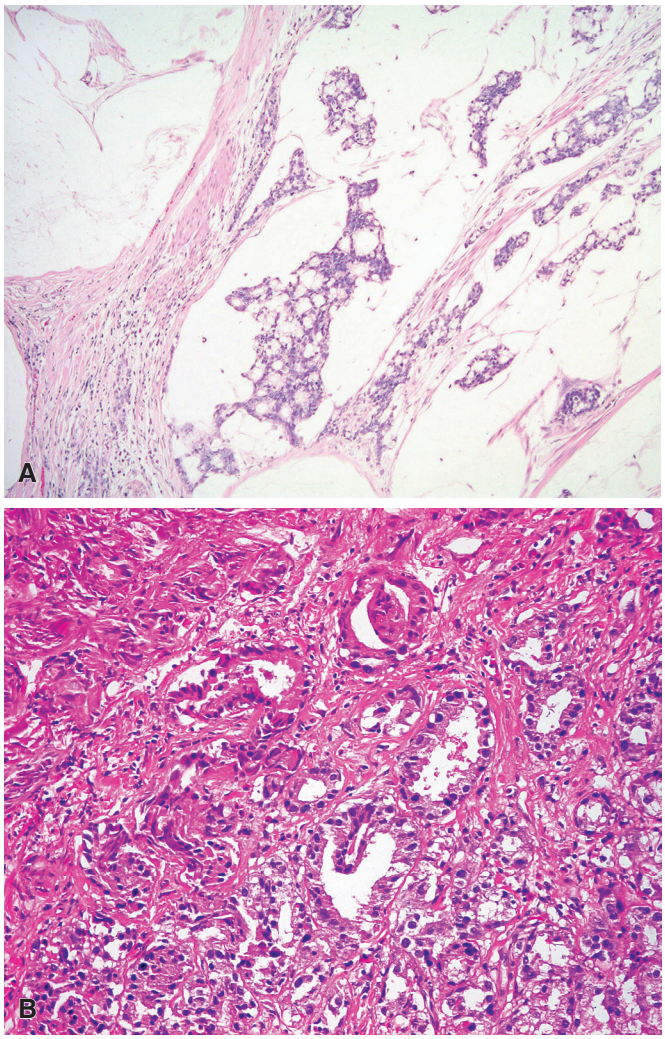

Figure 25.24 **A,** Primary mucinous adenocarcinoma of bladder may be histologically indistinguishable from secondary involvement by colorectal adenocarcinoma, but **(B)** some rare adenocarcinomas may not have a mucinous or enteric appearance.

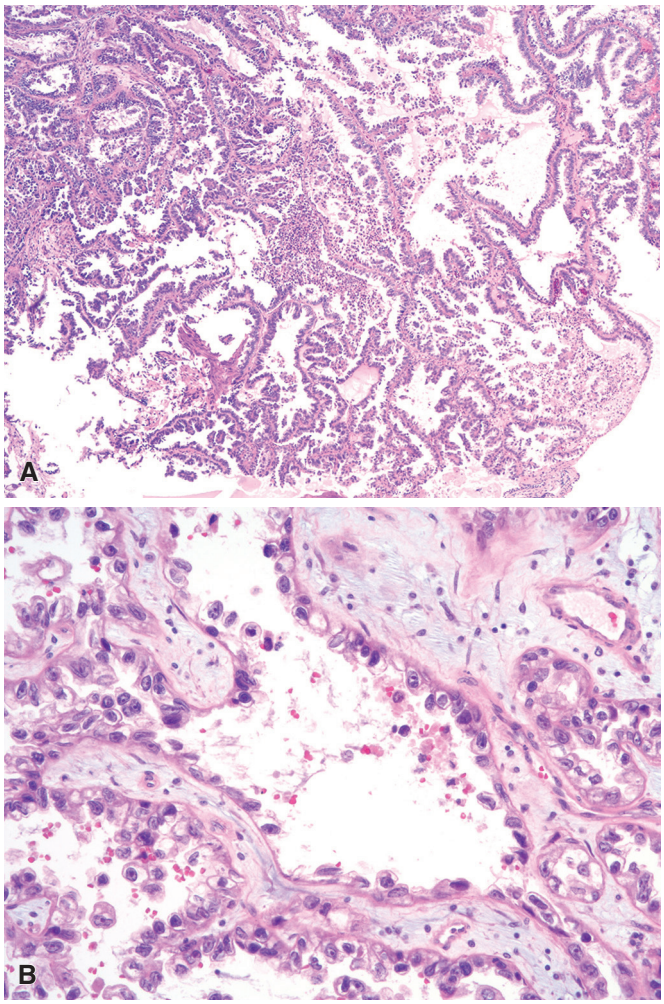

Figure 25.25 Low-power **(A)** and high-power **(B)** views of clear cell adenocarcinoma of bladder. This rare tumor should be distinguished from the much more common nephrogenic adenoma.

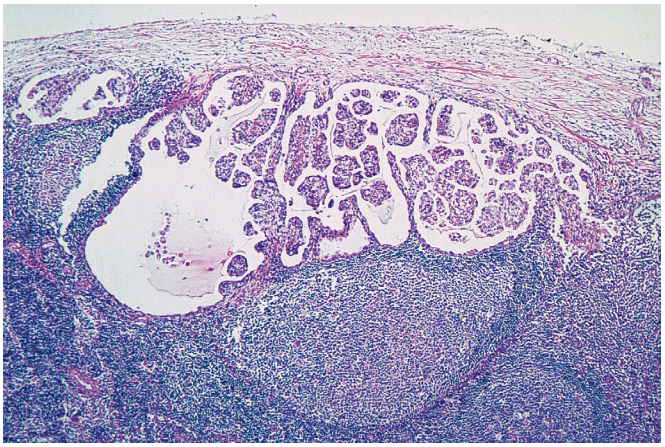

Figure 25.26 Clear cell adenocarcinoma of bladder metastatic to regional lymph node.

Figure 25.27 Gross appearance of paraganglioma of bladder. The tumor is well circumscribed and yellow.

from the more common nephrogenic adenoma on the basis of clinical, gross, and microscopic features; sheets of clear cells, marked pleomorphism, mitotic activity, and necrosis favor a diagnosis of malignancy.[160,385] Some cases are more monomorphic and more closely mimic nephrogenic adenoma; in such cases areas with more pronounced atypia or invasive patterns of growth are typically found.[387] On occasion, clear cell carcinoma is seen admixed with urothelial carcinoma.[388] Nearly all of these tumors are thought to arise from the urothelial epithelium of the bladder by a process of metaplasia, as also suggested by their similar immunohistochemical profile.[61,389] However, some are probably of müllerian origin and related to endometriosis/müllerianosis, as suggested by the great female preponderance and the presence in some of these tumors of benign müllerian components.[61,390] The immunoreactivity for PAX8 that they share with nephrogenic adenoma adds another layer of complexity to their histogenesis.[391] Metastases can develop in regional lymph nodes and distally (Fig. 25.26).

Another distinct type of adenocarcinoma is **signet ring carcinoma**. Microscopically, the tumor cells are usually small and uniform with an eccentric nucleus caused by an intracytoplasmic mucin vacuole. Because of significant overlap with plasmacytoid urothelial carcinoma, the 2016 WHO classification has defined signet ring cell adenocarcinoma as those cases in which the cells are associated with pools of extravasated mucin.[392] The clinical course of the disease has been rapidly progressive and fatal in nearly all the reported cases with follow-up information, but these previous reports likely include cases that would now be regarded as plasmacytoid.[393]

Yet another variant of bladder adenocarcinoma is **hepatoid adenocarcinoma**, thus adding the bladder to the increasingly long list of organs in which this tumor type—which mimics the morphologic and immunohistochemical features of hepatocellular carcinoma—can occur.[394–396]

Neuroendocrine Neoplasms

Paraganglioma (extra-adrenal pheochromocytoma) can present as a primary bladder neoplasm localized within the wall (Fig. 25.27).[397] Most patients are young adult women.[398] The histologic appearance and immunohistochemical profile are the same as for paragangliomas in other sites (Fig. 25.28).[399] The tumor can be misdiagnosed as urothelial carcinoma, especially in TUR specimens, and especially those tumors with sclerotic stroma.[400] The expression of GATA3 is typical in paraganglioma, another feature that may cause diagnostic confusion. Morphologic variants include *oncocytic paraganglioma*[401] and *composite paraganglioma–ganglioneuroma*.[402] Some patients have symptoms produced by the excessive secretion of catecholamines, sometimes associated with voiding.[403] Multicentricity is rare. Local recurrence and metastases may occur, an indication that these tumors

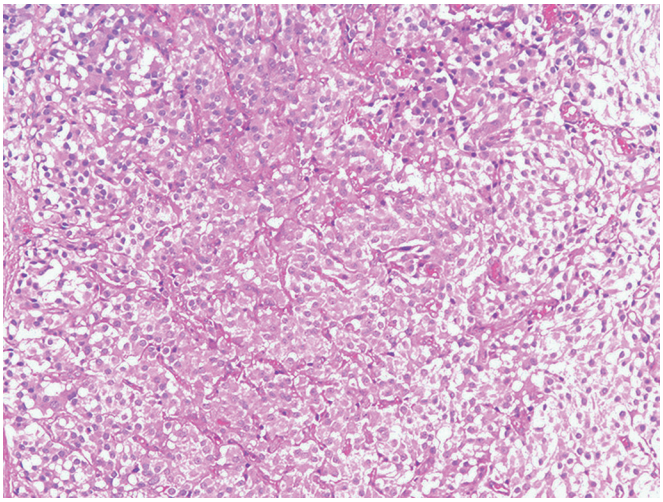

Figure 25.28 Microscopically, paragangliomas often show this subtle nested pattern, but sheet-like growth and stromal hyalinization may also occur.

should not be necessarily regarded as benign. As usual, clinical stage is the most useful prognostic indicator.[398] Recently, it has been noted that paraganglioma of the urinary bladder may be more frequently associated with a genetic predisposition syndrome (germline *SDH* mutation) and immunohistochemical screening with the SDHB antibody might be warranted.[404,405] Recent series reported that 27% and 17% of bladder paragangliomas had loss of SDHB and verified mutations; additionally, they were more commonly clinically malignant.[404,406] Finally, some cases may also be associated with von Hippel–Lindau disease.[407]

Like most other epithelium-lined organs, the urinary bladder can be the site of tumors exhibiting various degrees of endocrine differentiation. One manifestation of this phenomenon is the presence of scattered endocrine cells in otherwise typical adenocarcinomas; these tumors behave like adenocarcinomas lacking these elements and should be labeled as such. Another is the exceptionally rare **carcinoid tumor** of the bladder, which exhibits typical architectural features at the light microscopic level and numerous dense-core granules on ultrastructural examination.[408–410] More common is the highly malignant bladder tumor known as **small cell carcinoma**, which is morphologically similar to its homonyms in the lung and other organs (Fig. 25.29).[411–416] This may be seen in a pure form or combined with in situ or invasive urothelial carcinoma, adenocarcinoma, squamous cell carcinoma, or sarcomatoid carcinoma.[414,416,417] Age, sex, and symptoms at presentation are comparable to those of urothelial carcinoma.[418] Most cases are already advanced when first diagnosed.[419] Microscopically, small cells with very hyperchromatic nuclei and extremely scanty cytoplasm are seen growing in a predominantly solid fashion. Immunohistochemically, there is often reactivity for chromogranin and/or synaptophysin, but by WHO criteria the morphologic features are sufficient for diagnosis in classic cases. The staining pattern for low-molecular-weight keratin (CAM 5.2) has a dot-like perinuclear pattern, and CD44 v6 is usually absent (in contrast to urothelial carcinoma).[420] Close to half of the cases stain for TTF-1, sometimes leading to a mistaken diagnosis of metastatic pulmonary small cell carcinoma.[421] The typical profile of small cell carcinoma of the bladder (as opposed to high-grade urothelial carcinoma) is p16+, p63–, and CK20–.[422]

Some small cell carcinomas of the bladder have been associated with hypercalcemia[423] or ectopic ACTH production.[424] The diagnosis can be suspected on cytologic preparations,[425] and the behavior is

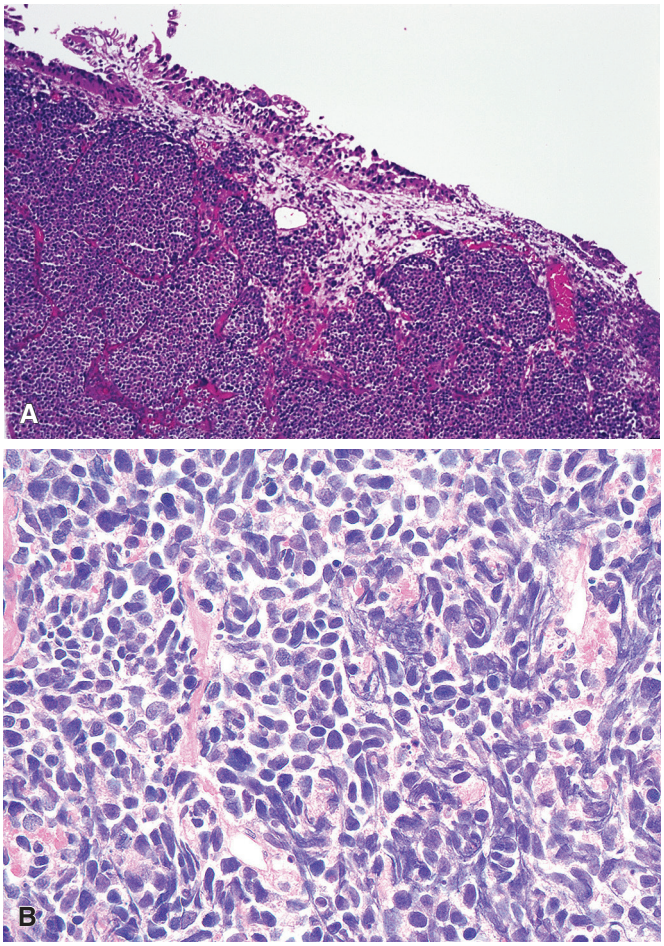

Figure 25.29 **Small Cell Neuroendocrine Carcinoma of Bladder.** **A,** Low-power view showing a solid mass of small cell carcinoma covered by mucosa with carcinoma in situ. **B,** High-power view of the invasive small cell component.

extremely aggressive.[417,418] Metastatic spread occurs quickly, the most frequent sites of involvement being regional lymph nodes, liver, bones, and peritoneal cavity.[418]

Large cell neuroendocrine carcinoma is defined in the bladder, as in other sites, as a high-grade neoplasm exhibiting neuroendocrine features at the H&E level, high mitotic activity, and evidence of neuroendocrine differentiation at the immunohistochemical level.[426–428]

Squamous Cell Carcinoma and Related Tumors

Condyloma acuminatum can involve the bladder, often in conjunction with similar lesions in the external genitalia and adjacent areas.[429] Koilocytosis may be seen microscopically, and HPV may be detected by surrogate techniques (e.g., CISH or PCR).

Squamous papilloma is architecturally similar to condyloma acuminatum, but it lacks cytopathic (HPV-type) epithelial changes and is negative for HPV DNA, suggesting a lack of relation among the two lesions. Most occur in elderly women and follow a benign clinical course, with occasional local recurrences.[430]

Squamous metaplasia refers to the replacement of urothelium by stratified squamous epithelium. This has been subdivided into

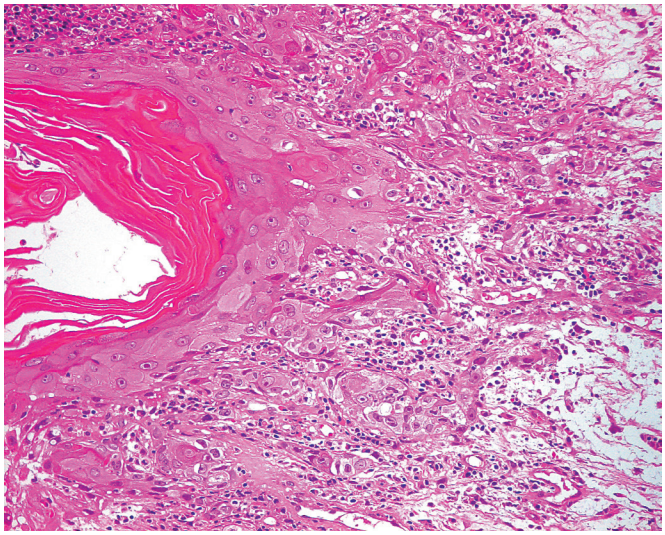

Figure 25.30 Pure Squamous Cell Carcinoma of Bladder. The tumor is heavily keratinized.

a *nonkeratinizing* and a *keratinizing* type.[151,431] The former, seen only in females, is so common in the trigone as to be regarded as normal. The keratinizing type is more common in males and is usually associated with chronic irritation.[432,433]

Squamous cell carcinoma comprises approximately 5% of all malignant bladder tumors.[434] Some of these neoplasms arise on a background of chronic cystitis with marked squamous metaplasia and/or dysplasia.[433,435,436] Cases have also been reported in association with exstrophy, defunctionalized bladder, chronic infection, lithiasis, chronic indwelling catheters, and prolonged medication with cyclophosphamide.[437] Another well-known association, reported from Egypt, Sudan, and other countries, is with schistosomiasis.[438–440] Some neoplasms classified as pure squamous cell carcinomas of the bladder probably represent metaplastic changes in tumors that were originally of urothelial type.[441]

Since focal squamous cell changes are common in high-grade urothelial tumors, the term *squamous cell carcinoma* should be reserved for those tumors that are purely squamous throughout, typically with associated background keratinizing squamous metaplasia (Fig. 25.30).

Grossly, these tumors are usually large, ulcerated, and necrotic. Microscopically, most are poorly differentiated and have nearly always invaded the muscularis mucosa at the time of diagnosis.[442] Immunohistochemically, they show reactivity for high-molecular-weight keratin and p63; therefore, these markers cannot be used in the differential diagnosis with squamous cell carcinoma of the uterine cervix.[443] The prognosis is very poor regardless of the degree of differentiation.[444] Death within the first year occurred in 59% of the patients reviewed by Newman et al.[445] In another series, the 5-year survival rate was 37% for patients with submucosal or muscular invasion and 13% for those with perivesical invasion.[446]

A high frequency of chromosome 9p allelic loss and *CDKN2* tumor-suppressor gene alterations have been found in squamous cell carcinoma of the bladder, in contrast with urothelial carcinomas.[447]

Basaloid squamous cell carcinoma morphologically similar to its counterpart in the upper aerodigestive tract occurs exceptionally in the bladder.[448]

Verrucous carcinoma of the bladder has also been described in the urinary bladder and is identical to that seen in the head and neck region.[449]

Warty carcinoma arising from condyloma, morphologically similar to the homonymous penile tumor, has been described in the bladder.[450]

Squamous cell CIS, without associated invasive carcinoma, is exceptionally rare in the bladder. It should be distinguished from keratinizing squamous metaplasia, verrucous squamous metaplasia, squamous papilloma, and condyloma acuminatum.[451]

Myofibroblastic Proliferations of the Urinary Bladder

All myofibroblastic proliferations of the urinary bladder have fairly similar morphology and immunophenotype, regardless of etiology. Many classification schemes, such as the WHO 2016, term most of these proliferations as "inflammatory myofibroblastic tumor"; however, numerous diagnostic terms have been use in the literature, creating significant confusion for urologists, oncologists, and pathologists alike. We discuss three separate scenarios, procedure related (postoperative spindle cell nodule), carcinoma related (pseudosarcomatous stromal proliferation adjacent to carcinoma), and those unrelated to a known local insult (inflammatory myofibroblastic tumor). Most importantly, these lesions should be distinguished from malignant spindle cell lesions based largely on recognition of the cytologic features of myofibroblasts.[452] Compared to myofibroblasts in other sites, bladder lesions more commonly show a strong and diffuse reactivity for low-molecular-weight keratin (Fig. 25.31A)[303]; they also stain for actin and variably desmin, but are negative for EMA and high-molecular-weight cytokeratin (see Fig. 25.31B).[303]

Postoperative spindle cell nodule is a lesion that may follow surgical interventions in the area, particularly TUR.[453,454] Microscopically, it may simulate the appearance of a sarcoma (particularly leiomyosarcoma) because of its marked cellularity and high mitotic activity (Fig. 25.32).[453,455] It appears a few weeks following a TUR procedure and is characteristically located in the operative area. Cystoscopically, it typically presents as a small sessile friable nodule that bleeds easily. The fascicular pattern of growth, ulcerated surface, red blood cell extravasation, and lack of significant nuclear hyperchromasia, together with the history of a recent surgical procedure, are distinctive.

Inflammatory myofibroblastic tumor is the term currently favored by the WHO for the entity originally described as *inflammatory pseudotumor.*[456] It is a polypoid bladder growth, characterized by the proliferation of generally spindle cells in a myxoid and inflammatory background (Fig. 25.33).[457,458] While it is often described as most commonly seen in children, we anecdotally see more cases in adults, possibly due to our specific consult bias. The main differences with postoperative spindle cell nodule (which we regard as a similar condition) are a tendency to reach a larger size, greater prominence of the myxoid stroma, lesser degree of cellularity, greater variability in nuclear size, and more prominent nucleoli.[457–459] Fibrosclerotic areas may be present.[416,460] The differential diagnosis includes embryonal/botryoid rhabdomyosarcoma in children and leiomyosarcoma and sarcomatoid carcinoma in adults. Close evaluation of cytologic features is usually sufficient for classification as myofibroblastic, particularly in adults, but immunohistochemical evaluation can be of help in selected cases. Since myogenin is expressed only by rhabdomyosarcoma, it is a very useful exclusionary test in children. High-molecular-weight cytokeratin and p63 are markers of sarcomatoid carcinoma, while h-caldesmon is more strongly and diffusely expressed by smooth muscle tumors.[461]

Inflammatory myofibroblastic tumor was previously regarded as a reactive condition, as implied by its original name.[454,462] Its distinction from ordinary sarcomas and carcinomas is certainly of importance because of its generally indolent nature.[463] However, several pieces

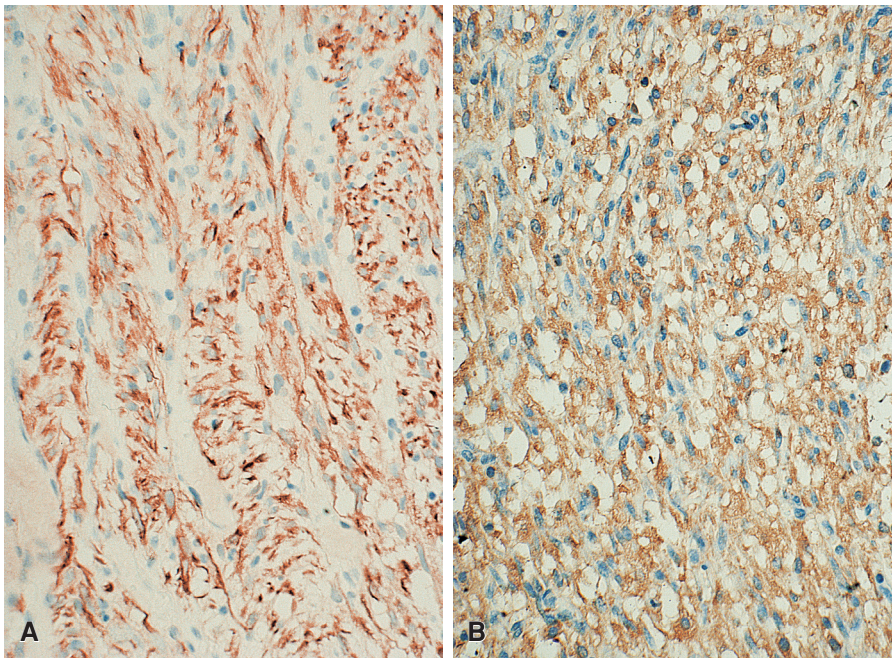

Figure 25.31 Immunophenotype of myofibroblastic proliferations of the urinary bladder. Strong immunoreactivity for keratin **(A)** and actin **(B)**.

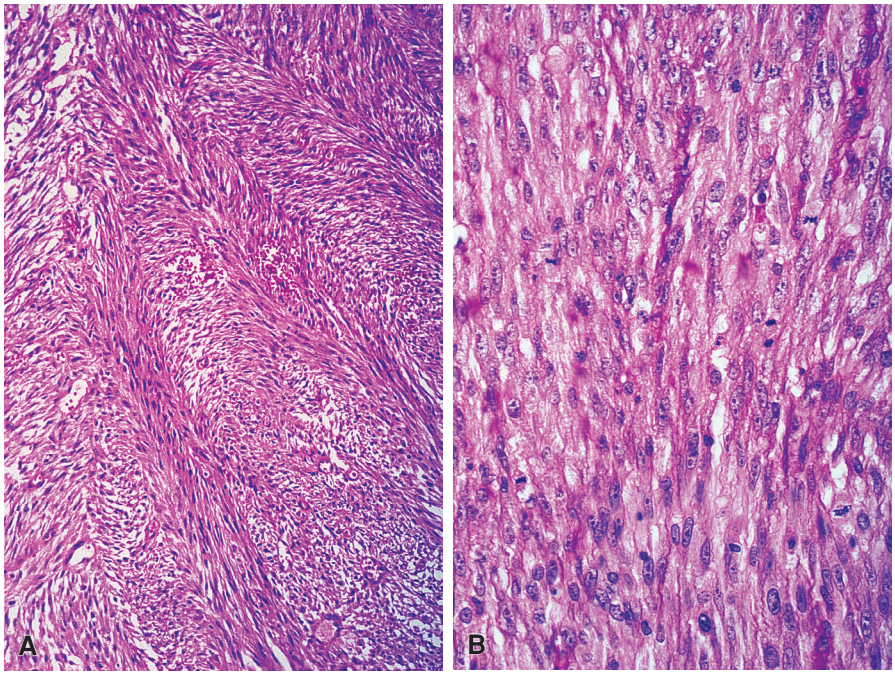

Figure 25.32 **Postoperative Spindle Cell Nodule. A,** Low-power microscopic view showing well-developed fascicular arrangement of the proliferating cells. **B,** High-power view showing extreme cellularity and numerous mitotic figures.

of evidence have accumulated in recent years which suggest that this entity is a neoplastic process, albeit of a low-grade nature. This includes the occurrence of cases with deep infiltration of the wall and extension into the perivesical soft tissue,[457] the occurrence of cases with focally obvious sarcomatous features,[464] and the demonstration of a nonrandom chromosomal translocation involving 2p23 that results in the expression of anaplastic lymphoma kinase (ALK).[465–467] Accordingly, this entity has been renamed *inflammatory myofibroblastic tumor.*[468] Of diagnostic importance is the fact that ALK immunoreactivity or rearrangement is not reported in conventional sarcomas or in sarcomatoid carcinomas of the bladder.[469]

Pseudosarcomatous stromal reactions have been described adjacent to urothelial carcinomas, the reactive tissue having a nodular fasciitis-like appearance.[470,471] The distinction from sarcomatoid (spindle) urothelial carcinoma may be difficult. Like inflammatory myofibroblastic tumor, these pseudosarcomatous lesions may show

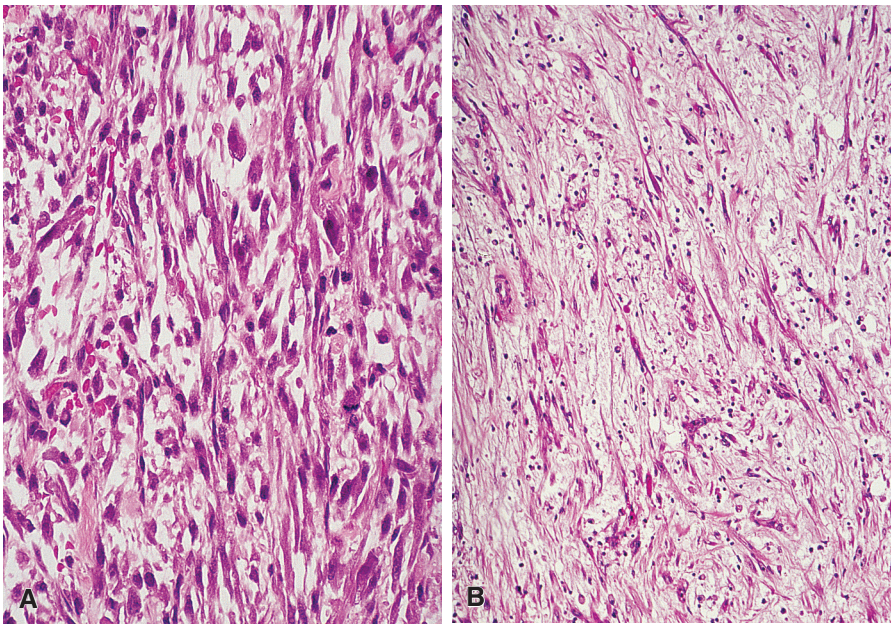

Figure 25.33 **A** and **B**, Inflammatory myofibroblastic tumor. Highly cellular spindle cell proliferation showing a moderate degree of atypia and somewhat edematous stroma. There is an associated inflammatory mononuclear component.

immunoreactivity for ALK, but differ from them in the sense of not showing consistent ALK rearrangement at the molecular genetic level.[466] These associated myofibroblastic proliferations are not infrequently misinterpreted as muscularis propria, which would impact staging.

Leiomyosarcoma is most commonly seen in adults. Approximately half of the cases are located in the bladder dome.[472,473] They infiltrate the bladder muscle, an important feature in the differential diagnosis with leiomyoma.[474] Microscopic grading of the tumor based on nuclear atypia, mitotic activity, and tumor necrosis correlates closely with outcome.[475] Some of these tumors are partially or extensively myxoid, resembling inflammatory myofibroblastic tumor (inflammatory pseudotumor) to such a degree that the distinction may become impossible.[472,476,477] Immunohistochemically, they are reactive for actin and typically desmin.[472]

Embryonal rhabdomyosarcoma (particularly the botryoid subtype) is the most common malignant tumor of the bladder in children. Sporadic cases have been seen in association with Wilms tumor; one such case was reported in a child with Dandy–Walker syndrome.[478] The trigone is the most common location. Grossly, the tumor has a myxoid appearance and polypoid shape (Fig. 25.34). It infiltrates surrounding tissues, but distant metastases are rare. Microscopically, it shows myxoid tissue in which small malignant cells are seen (Fig. 25.35A). These are characteristically grouped beneath the epithelium ("cambium layer") (see Fig. 25.35B). Cross striations may or may not be present. Desmin and (first and foremost) myogenin are the immunostains to be employed for confirmation of the diagnosis. In the past, the prognosis for this tumor was poor, with isolated cures being achieved with radical cystectomy or radiation therapy. The addition of multidrug chemotherapy to these modalities has notably increased the survival rates, even when the surgical resection was incomplete.[479] The prognosis is better for tumors exhibiting the classic polypoid pattern of growth than for those with diffuse intramural spread. Specimens from recurrences often show a marked maturation of the rhabdomyosarcomatous elements, presumably induced by chemotherapy.[480]

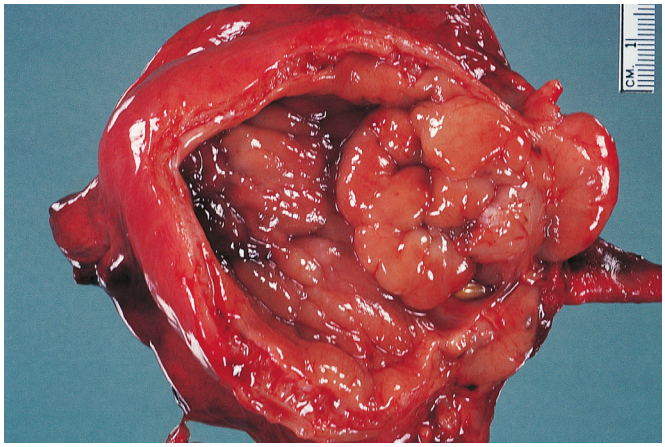

Figure 25.34 Gross appearance of botryoid rhabdomyosarcoma of bladder. A huge tumor mass is seen filling the bladder lumen.

Solitary fibrous tumor can present as a mass in the bladder wall with histologic features identical that seen in other sites. The availability of a dependable STAT6 antibody as a sensitive and specific surrogate for the *NAB2-STAT6* fusion makes diagnosis straightforward in most cases. Most reported cases have behaved in a benign fashion, but general prognostic rules may be applied regardless of anatomic site.[481,482]

Other rare **benign tumors** of the bladder include *mucin-secreting "cystadenoma" of possible müllerian origin*,[483,484] *leiomyoma*,[485] *hemangioma*,[486–488] *intravascular papillary endothelial hyperplasia* (Masson lesion),[489] *arteriovenous malformation*,[490] *lymphangioma*,[491] *chondroma*,[492] *granular cell tumor*,[493] *schwannoma*,[494,495] *neurofibroma(tosis)*,[496–499] *diffuse ganglioneuromatosis*,[498] and various morphologic types of *PEComa*[500] (*angiomyolipoma*[501] and *clear cell myomelanocytic tumor*[502]). The hemangiomas are usually seen in children; they are usually located in the lateral or posterior walls, are sessile, are sometimes associated

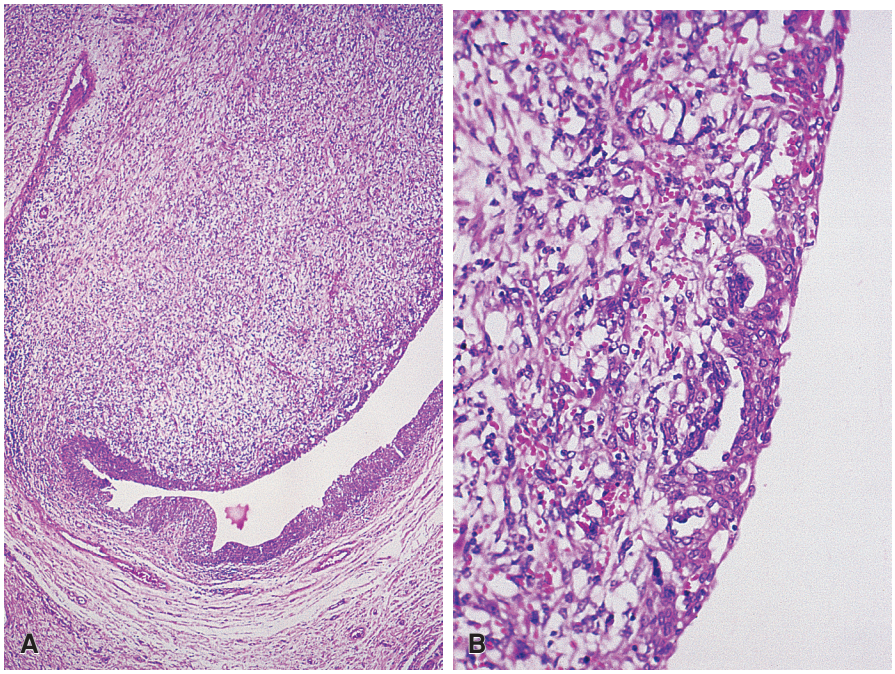

Figure 25.35 Microscopic Appearance of Botryoid Rhabdomyosarcoma. A, Low-power view showing polypoid mass protruding beneath a flattened epithelium. **B,** High-power view showing "cambium layer." Clusters of tumor cells present immediately beneath the epithelium result in a nevoid appearance.

with cutaneous hemangiomas, and may be the cause of gross painless hematuria.[488] The diagnosis of leiomyoma should be reserved for those smooth muscle tumors that are noninfiltrative and lack mitotic activity, cytologic atypia, and necrosis.[475]

Other sarcomas of the adult bladder include (nonbotryoid) *rhabdomyosarcoma*[503] (often with an alveolar morphology and morphologically similar to small cell carcinoma[504,505]), *rhabdoid tumor*,[506–508] *angiosarcoma* (including the epithelioid variety),[509,510] *alveolar soft part sarcoma*,[511] *malignant peripheral nerve sheath tumor*,[512] so-called *malignant fibrous histiocytoma*[513,514] (including its inflammatory[515] and myxoid[516] variants), *osteosarcoma*,[298,517] *soft tissue–type clear cell sarcoma*,[518] *malignant PEComa*,[519] *GIST-type tumor*,[520] and *malignant mesenchymoma*.[521] Care should be exercised to rule out by appropriate sampling and immunohistochemical testing the alternative possibility of a sarcomatoid carcinoma (carcinosarcoma)(see previous section).[522]

Ewing sarcoma has been described presenting as a bladder mass. It is immunoreactive for CD99, is associated with a fusion of *EWSR1* with one of several members of the ETS family of transcription factors, and should not be confused with small cell neuroendocrine carcinoma.[523,524]

Other Tumors

Primary **malignant melanoma** can occur in the bladder,[525–527] although not as commonly as in the urethra or as metastases in the bladder from a melanoma arisen elsewhere.[528] Variants have been described having clear cell features,[529] or associated with melanosis (i.e., pigmentation of the basal layer of the non-neoplastic transitional epithelium).[527]

Malignant lymphoma can involve the bladder as a primary site. Grossly, it may appear as a solitary mass, as multiple masses, or as a diffuse lesion with mass formation. Often the lesions are covered by normal mucosa. Microscopically, they are nearly always of non-Hodgkin type, and most are low-grade small cell lymphomas of the so-called *MALT type*.[530–532] Accordingly, they tend to remain localized for a long period of time. The bladder also can be involved by *leukemia*, *plasmacytoma*,[533,534] *multiple myeloma*,[535] *peripheral T-cell lymphoma*,[536] *Hodgkin lymphoma*,[537] and *anaplastic large cell lymphoma* (including its sarcomatoid variant).[538,539]

Most cases of **metastatic tumor** in the bladder are from breast carcinoma[540–542] and malignant melanoma,[528] but they have also been reported from several other sites, including lung, kidney, stomach, pancreas, and ovary.[543–545] The latter may closely mimic a primary bladder neoplasm.[546] The large majority of these metastatic deposits are solitary.[543] Direct extension into the bladder can occur with carcinomas of large bowel, prostate, and cervix.[543,547,548] In difficult cases, immunohistochemistry is very useful in the distinction of urothelial from poorly differentiated prostatic adenocarcinoma. Urothelial carcinomas generally express p63 and GATA3, while prostatic carcinomas express PSA and NKX3.1.[549,550]

References

1. Reuter VE. Urinary bladder, ureter, and renal pelvis. In: Mills SE, ed. *Histology for Pathologists*. 3rd ed. Philadelphia: Lippincott Williams & Wilkins; 2007:909-942.
2. Ro JY, Ayala AG, el-Naggar A. Muscularis mucosa of urinary bladder. Importance for staging and treatment. *Am J Surg Pathol*. 1987;11:668-673.
3. Vakar-Lopez F, Shen SS, Zhang S, et al. Muscularis mucosae of the urinary bladder revisited with emphasis on its hyperplastic patterns: a study of a large series of cystectomy specimens. *Ann Diagn Pathol*. 2007;11(6):395-401.
4. Paner GP, Ro JY, Wojcik EM, et al. Further characterization of the muscle layers and lamina propria of the urinary bladder by systematic histologic mapping: implications for pathologic staging of invasive urothelial carcinoma. *Am J Surg Pathol*. 2007;31(9):1420-1429.
5. Bovio IM, Al-Quran SZ, Rosser CJ, et al. Smoothelin immunohistochemistry is a useful adjunct for assessing muscularis propria

invasion in bladder carcinoma. *Histopathology*. 2010;56(7):951-956.
6. Council L, Hameed O. Differential expression of immunohistochemical markers in bladder smooth muscle and myofibroblasts, and the potential utility of desmin, smoothelin, and vimentin in staging of bladder carcinoma. *Mod Pathol*. 2009;22(5):639-650.
7. Khayyata S, Dudas M, Rohan SM, et al. Distribution of smoothelin expression in the musculature of the genitourinary tract. *Lab Invest*. 2009;89(suppl 1).
8. Paner GP, Shen SS, Lapetino S, et al. Diagnostic utility of antibody to smoothelin in the distinction of muscularis propria from muscularis mucosae of the urinary bladder: a potential ancillary tool in the pathologic staging of invasive urothelial carcinoma. *Am J Surg Pathol*. 2009;33(1):91-98.
9. Miyamoto H, Sharma RB, Illei PB, Epstein JI. Pitfalls in the use of smoothelin to identify muscularis propria invasion by urothelial carcinoma. *Am J Surg Pathol*. 2010;34(3):418-422.
10. Philip AT, Amin MB, Tamboli P, et al. Intravesical adipose tissue: a quantitative study of its presence and location with implications for therapy and prognosis. *Am J Surg Pathol*. 2000;24(9):1286-1290.
11. Hervonen A, Vaalasti A, Partanen M. Paraganglia of the bladder. *J Urol*. 1978;119:335-337.
12. Cappele O, Sibert L, Descargues J, et al. A study of the anatomic features of the duct of the urachus. *Surg Radiol Anat*. 2001;23(4):229-235.
13. Schubert GE, Pavkovic MB, Bethke-Bedurftig BA. Tubular urachal remnants in adult bladders. *J Urol*. 1982;127(1):40-42.
14. Risher WH, Sardi A, Bolton J. Urachal abnormalities in adults: the Ochsner experience. *South Med J*. 1990;83(9):1036-1039.
15. Chen WJ, Hsieh HH, Wan YL. Abscess of urachal remnant mimicking urinary bladder neoplasm. *Br J Urol*. 1992;69(5):510-512.
16. DiSantis DJ, Siegel MJ, Katz ME. Simplified approach to umbilical remnant abnormalities. *Radiographics*. 1991;11(1):59-66.
17. Iuchtman M, Rahav S, Zer M, et al. Management of urachal anomalies in children and adults. *Urology*. 1993;42(4):426-430.
18. Park C, Kim H, Lee YB, et al. Hamartoma of the urachal remnant. *Arch Pathol Lab Med*. 1989;113(12):1393-1395.
19. Steck WD, Helwig EB. Umbilical granulomas, pilonidal disease, and the urachus. *Surg Gynecol Obstet*. 1965;120:1043-1057.
20. Paner GP, McKenney JK, Yao JL, et al. Immunohistochemical analysis of urachal carcinoma (UC) with emphasis on its morphologic types and their differential diagnosis with metastatic colonic adenocarcinoma (CAC): diagnostic role of traditional and novel markers. *Lab Invest*. 2009;89(suppl 1).
21. Gopalan A, Sharp DS, Fine SW, et al. Urachal carcinoma: a clinicopathologic analysis of 24 cases with outcome correlation. *Am J Surg Pathol*. 2009;33:659-668.
22. Amin MB, Smith SC, Eble JN, et al. Glandular neoplasms of the urachus: a report of 55 cases emphasizing mucinous cystic tumors with proposed classification. *Am J Surg Pathol*. 2014;38:1033-1045.
23. Dhillon J, Liang Y, Kamat AM, et al. Urachal carcinoma: a pathologic and clinical study of 46 cases. *Hum Pathol*. 2015;46:1808-1814.
24. Chow YC, Lin WC, Tzen CY, et al. Squamous cell carcinoma of the urachus. *J Urol*. 2000;163(3):903-904.
25. Eble JN, Hull MT, Rowland RG, Hostetter M. Villous adenoma of the urachus with mucusuria: a light and electron microscopic study. *J Urol*. 1986;135(6):1240-1244.
26. Paner GP, Barkan GA, Mehta V, et al. Urachal carcinomas of the nonglandular type: salient features and considerations in pathologic diagnosis. *Am J Surg Pathol*. 2012;36:432-442.
27. Henly DR, Farrow GM, Zincke H. Urachal cancer: role of conservative surgery. *Urology*. 1993;42(6):635-639.
28. Herr HW. Urachal carcinoma: the case for extended partial cystectomy. *J Urol*. 1994;151(2):365-366.
29. Sheldon CA, Clayman RV, Gonzalez R, et al. Malignant urachal lesions. *J Urol*. 1984;131:1-8.
30. Yiee J, Wilcox D. Abnormalities of the fetal bladder. *Semin Fetal Neonatal Med*. 2008;13(3):164-170.
31. Engel RM, Wilkinson HA. Bladder exstrophy. *J Urol*. 1970;104(5):699-704.
32. Smeulders N, Woodhouse CR. Neoplasia in adult exstrophy patients. *BJU Int*. 2001;87(7):623-628.
33. Davillas N, Thanos A, Liakatas J, Davillas E. Bladder exstrophy complicated by adenocarcinoma. *Br J Urol*. 1991;68(1):107.
34. Fan R, Grignon DJ, Rhee A, et al. Exstrophy polyp is a unique pathology entity. *Pediatr Dev Pathol*. 2012;15:471-477.
35. Lund DP, Hendren WH. Cloacal exstrophy: a 25-year experience with 50 cases. *J Pediatr Surg*. 2001;36(1):68-75.
36. Ricketts RR, Woodard JR, Zwiren GT, et al. Modern treatment of cloacal exstrophy. *J Pediatr Surg*. 1991;26(4):444-448; discussion 8-50.
37. Fox M, Power RF, Bruce AW. Diverticulum of the bladder—presentation and evaluation of treatment of 115 cases. *Br J Urol*. 1962;34:286-298.
38. Kretschmer HL. Diverticula of the urinary bladder. A clinical study of 236 cases. *Surg Gynecol Obstet*. 1940;71:491-503.
39. Stage KH, Tank ES. Primary congenital bladder diverticula in boys. *Urology*. 1992;40(6):536-538.
40. Mitchell RJ, Hamilton SG. Spontaneous perforation of bladder diverticula. *Br J Surg*. 1971;58(9):712.
41. Faysal MH, Freiha FS. Primary neoplasm in vesical diverticula. A report of 12 cases. *Br J Urol*. 1981;53(2):141-143.
42. Shirai T, Arai M, Sakata T, et al. Primary carcinomas of urinary bladder diverticula. *Acta Pathol Jpn*. 1984;34(2):417-424.
43. Lam KY, Ma L, Nicholls J. Adenocarcinoma arising in a diverticulum of the urinary bladder. *Pathology*. 1992;24(1):40-42.
44. McCormick SR, Dodds PR, Kraus PA, Lowell DM. Nonepithelial neoplasms arising within vesical diverticula. *Urology*. 1985;25(4):405-408.
45. Tamas EF, Stephenson AJ, Campbell SC, et al. Histopathologic features and clinical outcomes in 71 cases of bladder diverticula. *Arch Pathol Lab Med*. 2009;133(5):791-796.
46. Bartosh SM. Medical management of pediatric stone disease. *Urol Clin North Am*. 2004;31(3):575-587, x-xi.
47. Wishard WN, Nourse MH. Vesical calculus with report of a gigantic stone in the female bladder. *J Urol*. 1950;63(5):794-801.
48. Bhatia V, Biyani CS. Vesical lithiasis: open surgery versus cystolithotripsy versus extracorporeal shock wave therapy. *J Urol*. 1994;151(3):660-662.
49. Kojima Y, Yoshimura M, Hayashi Y, et al. Extracorporeal shock wave lithotripsy for vesical lithiasis. *Urol Int*. 1998;61(1): 35-38.
50. Papatsoris AG, Varkarakis I, Dellis A, Deliveliotis C. Bladder lithiasis: from open surgery to lithotripsy. *Urol Res*. 2006;34(3):163-167.
51. Lichtenheld FR, McCauley RT, Staples PP. Endometriosis involving the urinary tract. A collective review. *Obstet Gynecol*. 1961;17:762-768.
52. Vermesh M, Zbella EA, Menchaca A, et al. Vesical endometriosis following bladder injury. *Am J Obstet Gynecol*. 1985;153(8):894-895.
53. Donnez J, Spada F, Squifflet J, Nisolle M. Bladder endometriosis must be considered as bladder adenomyosis. *Fertil Steril*. 2000;74(6):1175-1181.
54. Schwartzwald D, Mooppan UM, Ohm HK, Kim H. Endometriosis of bladder. *Urology*. 1992;39(3):219-222.
55. Donne C, Vidal M, Buttin X, et al. Mullerianosis of the urinary bladder: clinical and immunohistochemical findings. *Histopathology*. 1998;33(3):290-292.
56. Young RH, Clement PB. Mullerianosis of the urinary bladder. *Mod Pathol*. 1996;9(7):731-737.
57. Chitale SV, Whymark A, Wadood SU, et al. Tumor-like mullerianosis of the urinary bladder. *J Urol Pathol*. 1999;10:169-176.
58. Clement PB, Young RH. Endocervicosis of the urinary bladder. A report of six cases of a benign mullerian lesion that may mimic adenocarcinoma. *Am J Surg Pathol*. 1992;16(6):533-542.
59. New NE, Roberts PF. Mucinous metaplasia in endometriosis of the bladder. *Histopathology*. 1990;16(3):307-308.
60. al-Izzi MS, Horton LW, Kelleher J, Fawcett D. Malignant transformation in endometriosis of the urinary bladder. *Histopathology*. 1989;14(2):191-198.
61. Oliva E, Amin MB, Jimenez R, Young RH. Clear cell carcinoma of the urinary bladder: a report and comparison of four tumors of mullerian origin and nine of probable urothelial origin with discussion of histogenesis and diagnostic problems. *Am J Surg Pathol*. 2002;26(2):190-197.
62. Vara AR, Ruzics EP, Moussabeck O, Martin DC. Endometrioid adenosarcoma of the bladder arising from endometriosis. *J Urol*. 1990;143(4):813-815.
63. Chapron C, Dubuisson JB. Laparoscopic management of bladder endometriosis. *Acta Obstet Gynecol Scand*. 1999;78(10):887-890.
64. Seracchioli R, Mabrouk M, Montanari G, et al. Conservative laparoscopic management of urinary tract endometriosis (UTE): surgical outcome and long-term follow-up. *Fertil Steril*. 2010;94(3):856-861.
65. Westney OL, Amundsen CL, McGuire EJ. Bladder endometriosis: conservative management. *J Urol*. 2000;163(6):1814-1817.
66. Malek RS, Greene LF, Farrow GM. Amyloidosis of the urinary bladder. *Br J Urol*. 1971;43(2):189-200.
67. Khan SM, Birch PJ, Bass PS, et al. Localized amyloidosis of the lower genitourinary tract: a clinicopathological and immunohistochemical study of nine cases. *Histopathology*. 1992;21(2):143-147.
68. Merrimen JL, Alkhudair WK, Gupta R. Localized amyloidosis of the urinary tract: case series of nine patients. *Urology*. 2006;67(5):904-909.
69. Ehara H, Deguchi T, Yanagihara M, et al. Primary localized amyloidosis of the bladder: an immunohistochemical study of a case. *J Urol*. 1992;147(2):458-460.
70. Fujihara S, Glenner GG. Primary localized amyloidosis of the genitourinary tract: immunohistochemical study on eleven cases. *Lab Invest*. 1981;44(1):55-60.
71. Tirzaman O, Wahner-Roedler DL, Malek RS, et al. Primary localized amyloidosis of the urinary bladder: a case series of 31 patients. *Mayo Clin Proc*. 2000;75(12):1264-1268.

72. Biewend ML, Menke DM, Calamia KT. The spectrum of localized amyloidosis: a case series of 20 patients and review of the literature. *Amyloid*. 2006;13(3):135-142.
73. Lipper S, Kahn LB. Amyloid tumor. A clinicopathologic study of four cases. *Am J Surg Pathol*. 1978;2(2):141-145.
74. Koziol JA, Clark DC, Gittes RF, Tan EM. The natural history of interstitial cystitis: a survey of 374 patients. *J Urol*. 1993;149(3):465-469.
75. Smith BH, Dehner LP. Chronic ulcerating interstitial cystitis (Hunner's ulcer). A study of 28 cases. *Arch Pathol*. 1972;93(1):76-81.
76. Tomaszewski JE, Landis JR, Russack V, et al. Biopsy features are associated with primary symptoms in interstitial cystitis: results from the interstitial cystitis database study. *Urology*. 2001;57(6 suppl 1):67-81.
77. Larsen S, Thompson SA, Hald T, et al. Mast cells in interstitial cystitis. *Br J Urol*. 1982;54(3):283-286.
78. Sant GR, Theoharides TC. The role of the mast cell in interstitial cystitis. *Urol Clin North Am*. 1994;21(1):41-53.
79. Lynes WL, Flynn SD, Shortliffe LD, Stamey TA. The histology of interstitial cystitis. *Am J Surg Pathol*. 1990;14(10):969-976.
80. Peeker R, Fall M. Toward a precise definition of interstitial cystitis: further evidence of differences in classic and nonulcer disease. *J Urol*. 2002;167(6):2470-2472.
81. Ratliff TL, Klutke CG, McDougall EM. The etiology of interstitial cystitis. *Urol Clin North Am*. 1994;21(1):21-30.
82. Hampson SJ, Christmas TJ, Moss MT. Search for mycobacteria in interstitial cystitis using mycobacteria-specific DNA probes with signal amplification by polymerase chain reaction. *Br J Urol*. 1993;72(3):303-306.
83. Christmas TJ, Bottazzo GF. Abnormal urothelial HLA-DR expression in interstitial cystitis. *Clin Exp Immunol*. 1992;87(3):450-454.
84. Liebert M, Wedemeyer G, Stein JA, et al. Evidence for urothelial cell activation in interstitial cystitis. *J Urol*. 1993;149(3):470-475.
85. Said JW, Van de Velde R, Gillespie L. Immunopathology of interstitial cystitis. *Mod Pathol*. 1989;2(6):593-602.
86. Hohenfellner M, Nunes L, Schmidt RA, et al. Interstitial cystitis: increased sympathetic innervation and related neuropeptide synthesis. *J Urol*. 1992;147(3):587-591.
87. Lundeberg T, Liedberg H, Nordling L, et al. Interstitial cystitis: correlation with nerve fibres, mast cells and histamine. *Br J Urol*. 1993;71(4):427-429.
88. Somji S, Sens DA, Todd JH, et al. Expression of heat shock protein 60 is reduced in the bladder of patients with interstitial cystitis. *J Urol Pathol*. 1999;10:97-108.
89. Homma Y, Ueda T, Tomoe H, et al. Clinical guidelines for interstitial cystitis and hypersensitive bladder syndrome. *Int J Urol*. 2009;16(7):597-615.
90. Irwin PP, Galloway NT. Surgical management of interstitial cystitis. *Urol Clin North Am*. 1994;21(1):145-151.
91. Marinkovic SP, Moldwin R, Gillen LM, Stanton SL. The management of interstitial cystitis or painful bladder syndrome in women. *BMJ*. 2009;339:b2707.
92. Moldwin RM, Sant GR. Interstitial cystitis: a pathophysiology and treatment update. *Clin Obstet Gynecol*. 2002;45(1):259-272.
93. Verhagen PC, Nikkels PG, de Jong TP. Eosinophilic cystitis. *Arch Dis Child*. 2001;84(4):344-346.
94. Hellstrom HR, Davis BK, Shonnard JW. Eosinophilic cystitis. A study of 16 cases. *Am J Clin Pathol*. 1979;72(5):777-784.
95. Itano NM, Malek RS. Eosinophilic cystitis in adults. *J Urol*. 2001;165(3):805-807.
96. Oh SJ, Chi JG, Lee SE. Eosinophilic cystitis caused by vesical sparganosis: a case report. *J Urol*. 1993;149(3):581-583.
97. Marshall FF, Middleton AW Jr. Eosinophilic cystitis. *J Urol*. 1974;112(3):335-337.
98. Johansson SL, Smout MS, Taylor RJ. Eosinophilic cystitis associated with symptomatic ureteral involvement. A report of two cases. *J Urol Pathol*. 1993;1:69-77.
99. Hansen MV, Kristensen PB. Eosinophilic cystitis simulating invasive bladder carcinoma. *Scand J Urol Nephrol*. 1993;27(2):275-277.
100. Antonakopoulos GN, Newman J. Eosinophilic cystitis with giant cells. A light microscopic and ultrastructural study. *Arch Pathol Lab Med*. 1984;108(9):728-731.
101. Popescu OE, Landas SK, Haas GP. The spectrum of eosinophilic cystitis in males: case series and literature review. *Arch Pathol Lab Med*. 2009;133(2):289-294.
102. Teegavarapu PS, Sahai A, Chandra A, et al. Eosinophilic cystitis and its management. *Int J Clin Pract*. 2005;59(3):356-360.
103. van den Ouden D. Diagnosis and management of eosinophilic cystitis: a pooled analysis of 135 cases. *Eur Urol*. 2000;37(4):386-394.
104. Hung SF, Liu KL, Yu HJ, Huang KH. Medical imagery. Emphysematous cystitis. *Int J Infect Dis*. 2010;14(3):e269-e270.
105. Greene MH. Emphysematous cystitis due to *Clostridium perfringens* and *Candida albicans* in two patients with hematologic malignant conditions. *Cancer*. 1992;70(11):2658-2663.
106. Patel NP, Lavengood RW, Fernandes M, et al. Gas-forming infections in genitourinary tract. *Urology*. 1992;39(4):341-345.
107. Quint HJ, Drach GW, Rappaport WD, Hoffmann CJ. Emphysematous cystitis: a review of the spectrum of disease. *J Urol*. 1992;147(1):134-137.
108. Rocca JM, McClure J. Cystitis emphysematosa. *Br J Urol*. 1985;57(5):585.
109. Auerbach O. The pathology of urogenital tuberculosis. *New Int Clin*. 1940;3:21-61.
110. Wise GJ, Shteynshlyuger A. An update on lower urinary tract tuberculosis. *Curr Urol Rep*. 2008;9(4):305-313.
111. Ba-Thike K, Than A, Nan O. Tuberculous vesico-vaginal fistula. *Int J Gynaecol Obstet*. 1992;37(2):127-130.
112. Betz SA, See WA, Cohen MB. Granulomatous inflammation in bladder wash specimens after intravesical bacillus Calmette-Guerin therapy for transitional cell carcinoma of the bladder. *Am J Clin Pathol*. 1993;99(3):244-248.
113. Lamm DL. Complications of bacillus Calmette-Guerin immunotherapy. *Urol Clin North Am*. 1992;19(3):565-572.
114. Miyashita H, Troncoso P, Babaian RJ. BCG-induced granulomatous prostatitis: a comparative ultrasound and pathologic study. *Urology*. 1992;39(4):364-367.
115. Nadasy KA, Patel RS, Emmett M, et al. Four cases of disseminated Mycobacterium bovis infection following intravesical BCG instillation for treatment of bladder carcinoma. *South Med J*. 2008;101(1):91-95.
116. Smith RL, Alexander RF, Aranda CP. Pulmonary granulomata. A complication of intravesical administration of bacillus Calmette-Guerin for superficial bladder carcinoma. *Cancer*. 1993;71(5):1846-1847.
117. Long JP Jr, Althausen AF. Malacoplakia: a 25-year experience with a review of the literature. *J Urol*. 1989;141(6):1328-1331.
118. Stanton MJ, Maxted W. Malacoplakia: a study of the literature and current concepts of pathogenesis, diagnosis and treatment. *J Urol*. 1981;125(2):139-146.
119. Biggar WD, Crawford L, Cardella C, et al. Malakoplakia and immunosuppressive therapy. Reversal of clinical and leukocyte abnormalities after withdrawal of prednisone and azathioprine. *Am J Pathol*. 1985;119(1):5-11.
120. Streem SB. Genitourinary malacoplakia in renal transplant recipients: pathogenic, prognostic and therapeutic considerations. *J Urol*. 1984;132(1):10-12.
121. McClure J, Cameron CH, Garrett R. The ultrastructural features of malakoplakia. *J Pathol*. 1981;134(1):13-25.
122. McClurg FV, D'Agostino AN, Martin JH, Race GJ. Ultrastructural demonstration of intracellular bacteria in three cases of malakoplakia of the bladder. *Am J Clin Pathol*. 1973;60(6):780-788.
123. Qualman SJ, Gupta PK, Mendelsohn G. Intracellular Escherichia coli in urinary malakoplakia: a reservoir of infection and its therapeutic implications. *Am J Clin Pathol*. 1984;81(1):35-42.
124. Lou TY, Teplitz C. Malakoplakia: pathogenesis and ultrastructural morphogenesis. A problem of altered macrophage (phagolysosomal) response. *Hum Pathol*. 1974;5(2):191-207.
125. Lewin KJ, Fair WR, Steigbigel RT, et al. Clinical and laboratory studies into the pathogenesis of malacoplakia. *J Clin Pathol*. 1976;29(4):354-363.
126. Thorning D, Vracko R. Malakoplakia. Defect in digestion of phagocytized material due to impaired vacuolar acidification? *Arch Pathol*. 1975;99(9):456-460.
127. Walther M, Glenn JF, Vellios F. Xanthogranulomatous cystitis. *J Urol*. 1985;134(4):745-746.
128. Bates AW, Fegan AW, Baithun SI. Xanthogranulomatous cystitis associated with malignant neoplasms of the bladder. *Histopathology*. 1998;33(3):212-215.
129. Brown RC, Smith BH. Malacoplakia of the testis. *Am J Clin Pathol*. 1967;47(2):135-147.
130. Moore WM 3rd, Stokes TL, Cabanas VY. Malakoplakia of the skin: report of a case. *Am J Clin Pathol*. 1973;60(2):218-221.
131. Terner JY, Lattes R. Malakoplakia of colon and retroperitoneum. Report of a case with a histochemical study of the Michaelis-Gutman inclusion bodies. *Am J Clin Pathol*. 1965;44:20-31.
132. Yunis EJ, Estevez JM, Pinzon GJ, Moran TJ. Malacoplakia. Discussion of pathogenesis and report of three cases including one of fatal gastric and colonic involvement. *Arch Pathol*. 1967;83(2):180-187.
133. Yousef GM. Notice of retraction: omission of author in "Malakoplakia outside the urinary tract" (Arch Pathol Lab Med. 2007;131(2):297-300). *Arch Pathol Lab Med*. 2009;133(6):850.
134. Devitt AT, Sethia KK. Gangrenous cystitis: case report and review of the literature. *J Urol*. 1993;149(6):1544-1545.
135. Hameed O. Myxoid cystitis with "chordoid" lymphocytes: another mimic of invasive urothelial carcinoma. *Am J Surg Pathol*. 2010;34(7):1061-1065.
136. Young RH. Pseudoneoplastic lesions of the urinary bladder. *Pathol Annu*. 1988;23(Pt 1):67-104.
137. Letendre L, Hoagland HC, Gertz MA. Hemorrhagic cystitis complicating bone marrow transplantation. *Mayo Clin Proc*. 1992;67(2):128-130.
138. Sencer SF, Haake RJ, Weisdorf DJ. Hemorrhagic cystitis after bone marrow transplantation. Risk factors and complications. *Transplantation*. 1993;56(4):875-879.
139. Stillwell TJ, Benson RC Jr. Cyclophosphamide-induced hemorrhagic cystitis. A review of 100 patients. *Cancer*. 1988;61(3):451-457.
140. Block JA. Hemorrhagic cystitis complicating untreated necrotizing vasculitis. *Arthritis Rheum*. 1993;36(6):857-859.

141. McClanahan C, Grimes MM, Callaghan E, Stewart J. Hemorrhagic cystitis associated with herpes simplex virus. *J Urol*. 1994;151(1):152-153.
142. Spach DH, Bauwens JE, Myerson D, et al. Cytomegalovirus-induced hemorrhagic cystitis following bone marrow transplantation. *Clin Infect Dis*. 1993;16(1):142-144.
143. Okaneya T, Kontani K, Komiyama I, Takezaki T. Severe cyclophosphamide-induced hemorrhagic cystitis successfully treated by total cystectomy with ileal neobladder substitution: a case report. *J Urol*. 1993;150(6):1909-1910.
144. Hofman P, Quintens H, Michiels JF, et al. Toxoplasma cystitis associated with acquired immunodeficiency syndrome. *Urology*. 1993;42(5):589-592.
145. Oxley JD, Cottrell AM, Adams S, Gillatt D. Ketamine cystitis as a mimic of carcinoma in situ. *Histopathology*. 2009;55(6):705-708.
146. Kroovand RL, Chang CH, Broecker BH, et al. Epithelial lesions of bladder mucosa following ureteral reimplantation. *J Urol*. 1981;126(6):822-823.
147. Walther MM, Campbell WGJ, O'Brien DPI, et al. An electron and immunofluorescence microscopic study. *J Urol*. 1987;137:764-768.
148. Bell TE, Wendel RG. Cystitis glandularis: benign or malignant? *J Urol*. 1968;100(4):462-465.
149. Bullock PS, Thoni DE, Murphy WM. The significance of colonic mucosa (intestinal metaplasia) involving the urinary tract. *Cancer*. 1987;59(12):2086-2090.
150. Lapertosa G, Baracchini P, Fulcheri E, Tanzi R. O-acetylated sialic acid variants in intestinal glandular metaplasia of the urinary tract. *Histopathology*. 1986;10(7):707-712.
151. Wiener DP, Koss LG, Sablay B, Freed SZ. The prevalence and significance of Brunn's nests, cystitis cystica and squamous metaplasia in normal bladders. *J Urol*. 1979;122(3):317-321.
152. Sung MT, Lopez-Beltran A, Eble JN, et al. Divergent pathway of intestinal metaplasia and cystitis glandularis of the urinary bladder. *Mod Pathol*. 2006;19(11):1395-1401.
153. Volmar KE, Chan TY, De Marzo AM, Epstein JI. Florid von Brunn nests mimicking urothelial carcinoma: a morphologic and immunohistochemical comparison to the nested variant of urothelial carcinoma. *Am J Surg Pathol*. 2003;27(9):1243-1252.
154. Young RH, Bostwick DG. Florid cystitis glandularis of intestinal type with mucin extravasation: a mimic of adenocarcinoma. *Am J Surg Pathol*. 1996;20:1462-1468.
155. Smith AK, Hansel DE, Jones JS. Role of cystitis cystica et glandularis and intestinal metaplasia in development of bladder carcinoma. *Urology*. 2008;71:915-918.
156. Gordetsky J, Epstein JI. Intestinal metaplasia of the bladder with dysplasia: a risk factor for carcinoma? *Histopathology*. 2015;67:325-330.
157. Ford TF, Watson GM, Cameron KM. Adenomatous metaplasia (nephrogenic adenoma) of urothelium. An analysis of 70 cases. *Br J Urol*. 1985;57(4):427-433.
158. Mazal PR, Schaufler R, Altenhuber-Muller R, et al. Derivation of nephrogenic adenomas from renal tubular cells in kidney-transplant recipients. *N Engl J Med*. 2002;347(9):653-659.
159. Kay R, Lattanzi C. Nephrogenic adenoma in children. *J Urol*. 1985;133(1):99-101.
160. Young RH, Scully RE. Nephrogenic adenoma. A report of 15 cases, review of the literature, and comparison with clear cell adenocarcinoma of the urinary tract. *Am J Surg Pathol*. 1986;10(4):268-275.
161. Oliva E, Young RH. Nephrogenic adenoma of the urinary tract: a review of the microscopic appearance of 80 cases with emphasis on unusual features. *Mod Pathol*. 1995;8(7):722-730.
162. Hansel DE, Nadasdy T, Epstein JI. Fibromyxoid nephrogenic adenoma: a newly recognized variant mimicking mucinous adenocarcinoma. *Am J Surg Pathol*. 2007;31(8):1231-1237.
163. Piña-Oviedo S, Shen SS, Truong LD, et al. Flat pattern of nephrogenic adenoma: previously unrecognized pattern unveiled using PAX2 and PAX8 immunohistochemistry. *Mod Pathol*. 2013;26:792-798.
164. Oliva E, Moch H, Cabrera R, et al. Nephrogenic adenoma (NA): an immunohistochemical (ICH) study of 40 cases [abstract]. *Mod Pathol*. 2003;16.
165. Skinnider BF, Oliva E, Young RH, Amin MB. Expression of alpha-methylacyl-CoA racemase (P504S) in nephrogenic adenoma: a significant immunohistochemical pitfall compounding the differential diagnosis with prostatic adenocarcinoma. *Am J Surg Pathol*. 2004;28(6):701-705.
165a. McDaniel AS, Chinnaiyan AM, Siddiqui J, et al. Immunohistochemical staining characteristics of nephrogenic adenoma using the PIN-4 cocktail (p63, AMACR, and CK903) and GATA3. *Am J Surg Pathol*. 2014;38(12):1664-1671.
165b. Zhang G, McDaniel AS, Mehra R, et al. Nephrogenic adenoma does not express NKX3.1. *Histopathology*. 2017 [June 5, epub ahead of print].
166. Cheng L, Cheville JC, Sebo TJ, et al. Atypical nephrogenic metaplasia of the urinary tract: a precursor lesion? *Cancer*. 2000;88(4):853-861.
167. Young RH. Papillary and polypoid cystitis. A report of eight cases. *Am J Surg Pathol*. 1988;12(7):542-546.
168. Lane Z, Epstein JI. Polypoid/papillary cystitis: a series of 41 cases misdiagnosed as papillary urothelial neoplasia. *Am J Surg Pathol*. 2008;32(5):758-764.
169. Ekelund P, Johansson S. Polypoid cystitis: a catheter associated lesion of the human bladder. *Acta Pathol Microbiol Scand [A]*. 1979;87A(3):179-184.
170. Sorensen FB, Marcussen N. Iatrogenic granulomas of the prostate and the urinary bladder. *Pathol Res Pract*. 1987;182(6):822-830.
171. Spagnolo DV, Waring PM. Bladder granulomata after bladder surgery. *Am J Clin Pathol*. 1986;86(4):430-437.
171a. Eble JN, Banks ER. Post-surgical necrobiotic granulomas of urinary bladder. *Urology*. 1990;35(5):454-457.
172. Chan JK, Chow TC, Tsui MS. Prostatic-type polyps of the lower urinary tract: three histogenetic types? *Histopathology*. 1987;11(8):789-801.
173. Tsuzuki T, Epstein JI. Fibroepithelial polyp of the lower urinary tract in adults. *Am J Surg Pathol*. 2005;29(4):460-466.
174. Lum DJ, Upadhyay V, Smith A, McFarlane J. Botryoid fibroepithelial polyp of the urinary bladder. A clinicopathological case report including frozen section findings. *Histopathology*. 2007;51(5):704-707.
175. Young RH. Tumor-like lesions of the urinary bladder. *Mod Pathol*. 2009;22(suppl 2):S37-S52.
176. Lane Z, Epstein JI. Pseudocarcinomatous epithelial hyperplasia in the bladder unassociated with prior irradiation or chemotherapy. *Am J Surg Pathol*. 2008;32(1):92-97.
177. Dillon KM, O'Rourke DM, McCluggage WG. Radiation-induced atypical squamous metaplasia of the urinary bladder mucosa with involvement of subepithelial tissue mimicking metastatic cervical squamous carcinoma. *Histopathology*. 2005;46(1):105-106.
178. Baker PM, Young RH. Radiation-induced pseudocarcinomatous proliferations of the urinary bladder: a report of 4 cases. *Hum Pathol*. 2000;31(6):678-683.
179. Chan TY, Epstein JI. Radiation or chemotherapy cystitis with "pseudocarcinomatous" features. *Am J Surg Pathol*. 2004;28(7):909-913.
180. Smith VC, Boone TB, Truong LD. Collagen polyp of the urinary tract: a report of two cases. *Mod Pathol*. 1999;12(12):1090-1093.
181. Miliauskas JR. Bladder xanthoma. *Histopathology*. 1992;21(2):177-178.
182. Iyengar V, Smith DK, Jablonski DV, Gallivan MV. Extramedullary hematopoiesis in the urinary bladder in a case of agnogenic myeloid metaplasia. *J Urol Pathol*. 1993;1:419-423.
183. Williams MP, Ibrahim SK, Rickwood AM. Hamartoma of the urinary bladder in an infant with Beckwith-Wiedemann syndrome. *Br J Urol*. 1990;65(1):106-107.
184. Humphrey PA. Urinary bladder pathology 2004: an update. *Ann Diagn Pathol*. 2004;8(6):380-389.
185. Kroft SH, Oyasu R. Urinary bladder cancer: mechanisms of development and progression. *Lab Invest*. 1994;71(2):158-174.
186. Lower GM Jr. Concepts in causality: chemically induced human urinary bladder cancer. *Cancer*. 1982;49(5):1056-1066.
187. Anton-Culver H, Lee-Feldstein A, Taylor TH. Occupation and bladder cancer risk. *Am J Epidemiol*. 1992;136(1):89-94.
188. Chowaniec J, ed. *Aetiology: Epidemiological and Experimental Considerations*. Geneva: International Union against Cancer; 1981:118-138.
189. Friedell GH. National bladder cancer conference. *Cancer Res*. 1977;37:2737-2969.
190. Morrison AS, Buring JE, Verhoek WG, et al. An international study of smoking and bladder cancer. *J Urol*. 1984;131(4):650-654.
191. Schulte PA, Ringen K, Hemstreet GP, et al. Risk factors for bladder cancer in a cohort exposed to aromatic amines. *Cancer*. 1986;58(9):2156-2162.
192. Vineis P, Magnani C. Occupation and bladder cancer in males: a case-control study. *Int J Cancer*. 1985;35(5):599-606.
193. Fuchs EF, Kay R, Poole R, et al. Uroepithelial carcinoma in association with cyclophosphamide ingestion. *J Urol*. 1981;126(4):544-545.
194. Murphy WM, ed. *Diseases of the Urinary Bladder, Urethra, Ureters, and Renal Pelves*. Philadelphia, PA: W.B. Saunders; 1989.
195. Pedersen-Bjergaard J, Ersboll J, Hansen VL, et al. Carcinoma of the urinary bladder after treatment with cyclophosphamide for non-Hodgkin's lymphoma. *N Engl J Med*. 1988;318(16):1028-1032.
196. Fukushima S, Asamoto M, Imaida K, et al. Comparative study of urinary bladder carcinomas in Japanese and Egyptians. *Acta Pathol Jpn*. 1989;39(3):176-179.
197. Chetsanga C, Malmstrom PU, Gyllensten U, et al. Low incidence of human papillomavirus type 16 DNA in bladder tumor detected by the polymerase chain reaction. *Cancer*. 1992;69(5):1208-1211.
198. Knowles MA. Human papillomavirus sequences are not detectable by Southern blotting or general primer-mediated polymerase chain reaction in transitional cell tumors of the bladder. *Urol Res*. 1992;20:297-301.
199. Shibutani YF, Schoenberg MP, Carpiniello VL, Malloy TR. Human papillomavirus associated with bladder cancer. *Urology*. 1992;40(1):15-17.
200. Neugut AI, Ahsan H, Robinson E, Ennis RD. Bladder carcinoma and other second malignancies after radiotherapy for prostate carcinoma. *Cancer*. 1997;79(8):1600-1604.
201. Benson RC Jr, Tomera KM, Kelalis PP. Transitional cell carcinoma of the bladder in

children and adolescents. *J Urol*. 1983;130(1):54-55.
202. Kutarski PW, Padwell A. Transitional cell carcinoma of the bladder in young adults. *Br J Urol*. 1993;72(5 Pt 2):749-755.
203. Wan J, Grossman HB. Bladder carcinoma in patients age 40 years or younger. *Cancer*. 1989;64(1):178-181.
204. Fine SW, Humphrey PA, Dehner LP, et al. Urothelial neoplasms in patients 20 years or younger: a clinicopathological analysis using the world health organization 2004 bladder consensus classification. *J Urol*. 2005;174:1976-1980.
205. Scott AA, Stanley W, Worsham GF, et al. Aggressive bladder carcinoma in an adolescent. Report of a case with immunohistochemical, cytogenetic, and flow cytometric characterization. *Am J Surg Pathol*. 1989;13(12):1057-1063.
206. Stephenson WT, Holmes FF, Noble MJ, Gerald KB. Analysis of bladder carcinoma by subsite. Cystoscopic location may have prognostic value. *Cancer*. 1990;66(7):1630-1635.
207. Ash JE. Epithelial tumors of the bladder. *J Urol*. 1940;44:135-145.
208. Mostofi FK. Standardization of nomenclature and criteria for diagnosis of epithelial tumors of urinary bladder. *Acta Unio Int Contra Cancrum*. 1960;16:310-314.
209. Bergkvist A, Ljungqvist A, Moberger G. Classification of bladder tumours based on the cellular pattern. Preliminary report of a clinical-pathological study of 300 cases with a minimum follow-up of eight years. *Acta Chir Scand*. 1965;130(4):371-378.
210. Malmstrom PU, Busch C, Norlen BJ. Recurrence, progression and survival in bladder cancer. A retrospective analysis of 232 patients with greater than or equal to 5-year follow-up. *Scand J Urol Nephrol*. 1987;21(3):185-195.
211. Cheng L, Montironi R, Davidson DD, Lopez-Beltran A. Staging and reporting of urothelial carcinoma of the urinary bladder. *Mod Pathol*. 2009;22(suppl 2):S70-S95.
212. Epstein JI, Amin MB, Reuter VR, Mostofi FK. The World Health Organization/International Society of Urological Pathology consensus classification of urothelial (transitional cell) neoplasms of the urinary bladder. Bladder Consensus Conference Committee. *Am J Surg Pathol*. 1998;22(12):1435-1448.
213. Grignon DJ. The current classification of urothelial neoplasms. *Mod Pathol*. 2009;22(suppl 2):S60-S69.
214. Oyasu R. World Health Organization and International Society of Urological Pathology classification and two-number grading system of bladder tumors. *Cancer*. 2000;88(7):1509-1512.
215. Reuter VR, Epstein JI, Amin MA, et al. A newly illustrated synopsis of the World Health Organization/International Society of Urological Pathology (WHO/ISUP) consensus classification of urothelial (transitional cell) neoplasms of the urinary bladder. *J Urol Pathol*. 1999;11:1-28.
216. Moch H, Humphrey PA, Ulbright TM, Reuter VE, eds. *WHO Classification of Tumours of the Urinary System and Male Genital Organs*. 4th ed. Lyon: IARC press; 2016:11-76.
217. Cheng L, Darson M, Cheville JC, et al. Urothelial papilloma of the bladder. Clinical and biologic implications. *Cancer*. 1999;86(10):2098-2101.
218. McKenney JK, Amin MB, Young RH. Urothelial (transitional cell) papilloma of the urinary bladder: a clinicopathologic study of 26 cases. *Mod Pathol*. 2003;16(7):623-629.
219. Cheng L, Neumann RM, Nehra A, et al. Cancer heterogeneity and its biologic implications in the grading of urothelial carcinoma. *Cancer*. 2000;88(7):1663-1670.
220. Cheng L, Neumann RM, Weaver AL, et al. Grading and staging of bladder carcinoma in transurethral resection specimens. Correlation with 105 matched cystectomy specimens. *Am J Clin Pathol*. 2000;113(2):275-279.
221. Jewett HJ, Blackman SS. Infiltrating carcinoma of the bladder; histologic pattern and degree of cellular differentiation in 97 autopsy cases. *J Urol*. 1946;56(2):200-210.
222. Lee SR, Park BH, Cho YM, Ro JY. Clinicopathologic features of transurethral resection of bladder tumor (TURBT) for prediction of TNM Stage of urothelial carcinoma of urinary bladder. *Lab Invest*. 2009;89(suppl 1).
223. Jimenez RE, Gheiler E, Oskanian P, et al. Grading the invasive component of urothelial carcinoma of the bladder and its relationship with progression-free survival. *Am J Surg Pathol*. 2000;24(7):980-987.
224. Magi-Galluzzi C, Epstein JI. Urothelial papilloma of the bladder: a review of 34 de novo cases. *Am J Surg Pathol*. 2004;28:1615-1620.
225. Al Bashir S, Yilmaz A, Gotto G, Trpkov K. Long term outcome of primary urothelial papilloma: a single institution cohort. *Pathology*. 2014;46:37-40.
226. Maxwell JP, Wang C, Wiebe N, et al. Long-term outcome of primary Papillary Urothelial Neoplasm of Low Malignant Potential (PUNLMP) including PUNLMP with inverted growth. *Diagn Pathol*. 2015;10:3.
227. Swierczynski SL, Epstein JI. Prognostic significance of atypical papillary urothelial hyperplasia. *Hum Pathol*. 2002;33(5): 512-517.
228. Obermann EC, Junker K, Stoehr R, et al. Frequent genetic alterations in flat urothelial hyperplasias and concomitant papillary bladder cancer as detected by CGH, LOH, and FISH analyses. *J Pathol*. 2003;199:50-57.
229. Readal N, Epstaein JI. Papillary urothelial hyperplasia: relationship to urothelial neoplasms. *Pathology*. 2010;42:360-363.
230. Caro DJ, Tessler A. Inverted papilloma of the bladder: a distinct urological lesion. *Cancer*. 1978;42(2):708-713.
231. Kim YH, Reiner L. Brunnian adenoma (inverted papilloma) of the urinary bladder: report of a case. *Hum Pathol*. 1978;9(2):229-231.
232. Fine SW, Epstein JI. Inverted urothelial papillomas with foamy or vacuolated cytoplasm. *Hum Pathol*. 2006;37(12):1577-1582.
233. Albores-Saavedra J, Chable-Montero F, Hernandez-Rodriguez OX, et al. Inverted urothelial papilloma of the urinary bladder with focal papillary pattern: a previously undescribed feature. *Ann Diagn Pathol*. 2009;13(3):158-161.
234. Kunze E, Schauer A, Schmitt M. Histology and histogenesis of two different types of inverted urothelial papillomas. *Cancer*. 1983;51(2):348-358.
235. DeMeester LJ, Farrow GM, Utz DC. Inverted papillomas of the urinary bladder. *Cancer*. 1975;36(2):505-513.
236. Summers DE, Rushin JM, Frazier HA, Cotelingam JD. Inverted papilloma of the urinary bladder with granular eosinophilic cells. An unusual neuroendocrine variant. *Arch Pathol Lab Med*. 1991;115(8):802-806.
237. Broussard JN, Tan PH, Epstein JI. Atypia in inverted urothelial papillomas: pathology and prognostic significance. *Hum Pathol*. 2004;35(12):1499-1504.
238. Anderstrom C, Johansson S, Pettersson S. Inverted papilloma of the urinary tract. *J Urol*. 1982;127(6):1132-1134.
239. Lazarevic B, Garret R. Inverted papilloma and papillary transitional cell carcinoma of urinary bladder: report of four cases of inverted papilloma, one showing papillary malignant transformation and review of the literature. *Cancer*. 1978;42(4):1904-1911.
240. Amin MB, Gomez JA, Young RH. Urothelial transitional cell carcinoma with endophytic growth patterns: a discussion of patterns of invasion and problems associated with assessment of invasion in 18 cases. *Am J Surg Pathol*. 1997;21:1057-1068.
241. Amin MB, McKenney JK. An approach to the diagnosis of flat intraepithelial lesions of the urinary bladder using the World Health Organization/International Society of Urological Pathology consensus classification system. *Adv Anat Pathol*. 2002;9(4):222-232.
242. McKenney JK, Gomez JA, Desai S, et al. Morphologic expressions of urothelial carcinoma in situ: a detailed evaluation of its histologic patterns with emphasis on carcinoma in situ with microinvasion. *Am J Surg Pathol*. 2001;25(3):356-362.
243. Milord RA, Lecksell K, Epstein JI. An objective morphologic parameter to aid in the diagnosis of flat urothelial carcinoma in situ. *Hum Pathol*. 2001;32:997-1002.
244. Lopez-Beltran A, Jimenez RE, Montironi R, et al. Flat urothelial carcinoma in situ of the bladder with glandular differentiation. *Hum Pathol*. 2011;42:1653-1659.
245. Amin MB, Young RH. Intraepithelial lesions of the urinary bladder with a discussion of the histogenesis of urothelial neoplasia. *Semin Diagn Pathol*. 1997;14(2):84-97.
246. Spruck CH 3rd, Ohneseit PF, Gonzalez-Zulueta M, et al. Two molecular pathways to transitional cell carcinoma of the bladder. *Cancer Res*. 1994;54(3):784-788.
247. McKenney JK, Desai S, Cohen C, Amin MB. Discriminatory immunohistochemical staining of urothelial carcinoma in situ and non-neoplastic urothelium: an analysis of cytokeratin 20, p53, and CD44 antigens. *Am J Surg Pathol*. 2001;25(8):1074-1078.
248. Yin H, He Q, Li T, Leong AS. Cytokeratin 20 and Ki-67 to distinguish carcinoma in situ from flat non-neoplastic urothelium. *Appl Immunohistochem Mol Morphol*. 2006;14:260-265.
249. Kunju LP, Lee CT, Montie J, Shah RB. Utility of cytokeratin 20 and Ki-67 as markers of urothelial dysplasia. *Pathol Int*. 2005;55:248-254.
250. Jimenez RE, Keane TE, Hardy HT, Amin MB. pT1 urothelial carcinoma of the bladder: criteria for diagnosis, pitfalls, and clinical implications. *Adv Anat Pathol*. 2000;7(1):13-25.
251. Bastacky S, Dhir R, Nangia AK, et al. Choriocarcinomatous differentiation in a high-grade urothelial carcinoma of the urinary bladder: case report and literature review. *J Urol Pathol*. 1997;6:223-234.
252. Shah VM, Newman J, Crocker J, et al. Ectopic beta-human chorionic gonadotropin production by bladder urothelial neoplasia. *Arch Pathol Lab Med*. 1986;110(2):107-111.
253. Ishikawa J, Nishimura R, Maeda S, et al. Primary choriocarcinoma of the urinary bladder. *Acta Pathol Jpn*. 1988;38(1):113-120.
254. Yokoyama S, Hayashida Y, Nagahama J, et al. Primary and metaplastic choriocarcinoma of the bladder. A report of two cases. *Acta Cytol*. 1992;36(2):176-182.
255. Kawamura J, Machida S, Yoshida O, et al. Bladder carcinoma associated with ectopic production of gonadotropin. *Cancer*. 1978;42(6):2773-2780.
256. Dirnhofer S, Koessler P, Ensinger C, et al. Production of trophoblastic hormones by transitional cell carcinoma of the bladder: association to tumor stage and grade. *Hum Pathol*. 1998;29(4):377-382.
257. Amin MB, Ro JY, el-Sharkawy T, et al. Micropapillary variant of transitional cell carcinoma of the urinary bladder. Histologic pattern resembling ovarian papillary serous

carcinoma. *Am J Surg Pathol*. 1994;18:1224-1232.
258. Sangoi AR, Beck AH, Amin MB, et al. Interobserver reproducibility in the diagnosis of invasive micropapillary carcinoma of the urinary tract among urologic pathologists. *Am J Surg Pathol*. 2010;34:1367-1376.
259. Johansson SL, Borghede G, Holmäng S. Micropapillary bladder carcinoma: a clinicopathological study of 20 cases. *J Urol*. 1999;161:1798-1802.
260. Alvarado-Cabrero I, Sierra-Santiesteban FI, Mantilla-Morales A, Hernández-Hernandez DM. Micropapillary carcinoma of the urothelial tract. A clinicopathologic study of 38 cases. *Ann Diagn Pathol*. 2005;9:1-5.
261. Compérat E, Roupret M, Yaxley J, et al. Micropapillary urothelial carcinoma of the urinary bladder: a clinicopathological analysis of 72 cases. *Pathology*. 2010;42:650-654.
262. Kamat AM, Gee JR, Dinney CP, et al. The case for early cystectomy in the treatment of nonmuscle invasive micropapillary bladder carcinoma. *J Urol*. 2006;175:881-885.
263. Amin A, Epstein JI. Noninvasive micropapillary urothelial carcinoma: a clinicopathologic study of 18 cases. *Hum Pathol*. 2012;43:2124-2128.
264. Shah TS, Kaag M, Raman JD, et al. Clinical significance of prominent retraction clefts in invasive urothelial carcinoma. *Hum Pathol*. 2017;61:90-96.
265. Sahin AA, Myhre M, Ro JY, et al. Plasmacytoid transitional cell carcinoma. Report of a case with initial presentation mimicking multiple myeloma. *Acta Cytol*. 1991;35:277-280.
266. Mai KT, Park PC, Yazdi HM, et al. Plasmacytoid urothelial carcinoma of the urinary bladder report of seven new cases. *Eur Urol*. 2006;50:1111-1114.
267. Ro JY, Shen SS, Lee HI, et al. Plasmacytoid transitional cell carcinoma of urinary bladder: a clinicopathologic study of 9 cases. *Am J Surg Pathol*. 2008;32:752-757.
268. Nigwekar P, Tamboli P, Amin MB, et al. Plasmacytoid urothelial carcinoma: detailed analysis of morphology with clinicopathologic correlation in 17 cases. *Am J Surg Pathol*. 2009;33:417-424.
269. Paner GP, Annaiah C, Gulmann C, et al. Immunohistochemical evaluation of novel and traditional markers associated with urothelial differentiation in a spectrum of variants of urothelial carcinoma of the urinary bladder. *Hum Pathol*. 2014;45:1473-1482.
270. Kaimakliotis HZ, Monn MF, Cheng L, et al. Plasmacytoid bladder cancer: variant histology with aggressive behavior and a new mode of invasion along fascial planes. *Urology*. 2014;83:1112-1116.
271. Ricardo-Gonzalez RR, Nguyen M, Gokden N, et al. Plasmacytoid carcinoma of the bladder: a urothelial carcinoma variant with a predilection for intraperitoneal spread. *J Urol*. 2012;187:852-855.
272. Al-Ahmadie HA, Iyer G, Lee BH, et al. Frequent somatic CDH1 loss-of-function mutations in plasmacytoid variant bladder cancer. *Nat Genet*. 2016;48:356-358.
273. Talbert ML, Young RH. Carcinomas of the urinary bladder with deceptively benign-appearing foci. A report of three cases. *Am J Surg Pathol*. 1989;13:374-381.
274. Murphy WM, Deana DG. The nested variant of transitional cell carcinoma: a neoplasm resembling proliferation of Brunn's nests. *Mod Pathol*. 1992;5:240-243.
275. Drew PA, Furman J, Civantos F, Murphy WM. The nested variant of transitional cell carcinoma: an aggressive neoplasm with innocuous histology. *Mod Pathol*. 1996;9:989-994.
276. Lin O, Cardillo M, Dalbagni G, et al. Nested variant of urothelial carcinoma: a clinicopathologic and immunohistochemical study of 12 cases. *Mod Pathol*. 2003;16:1289-1298.
277. Zhong M, Tian W, Zhuge J, et al. Distinguishing nested variants of urothelial carcinoma from benign mimickers by TERT promoter mutation. *Am J Surg Pathol*. 2015;39:127-131.
278. Amin MB, Ro JY, Lee KM, et al. Lymphoepithelioma-like carcinoma of the urinary bladder. *Am J Surg Pathol*. 1994;18(5):466-473.
279. Dinney CP, Ro JY, Babaian RJ, Johnson DE. Lymphoepithelioma of the bladder: a clinicopathological study of 3 cases. *J Urol*. 1993;149(4):840-841.
280. Young RH, Eble JN. Lymphoepithelioma-like carcinoma of the urinary bladder. *J Urol Pathol*. 1993;1:63-68.
281. Izquierdo-Garcia FM, Garcia-Diez F, Fernandez I, et al. Lymphoepithelioma-like carcinoma of the bladder: three cases with clinicopathological and p53 protein expression study. *Virchows Arch*. 2004;444(5):420-425.
282. Lopez-Beltran A, Luque RJ, Vicioso L, et al. Lymphoepithelioma-like carcinoma of the urinary bladder: a clinicopathologic study of 13 cases. *Virchows Arch*. 2001;438(6):552-557.
283. Tamas EF, Nielsen ME, Schoenberg MP, Epstein JI. Lymphoepithelioma-like carcinoma of the urinary tract: a clinicopathological study of 30 pure and mixed cases. *Mod Pathol*. 2007;20(8):828-834.
284. Holtz F, Fox JE, Abell MR. Carcinosarcoma of the urinary bladder. *Cancer*. 1972;29(2):294-304.
285. Ikegami H, Iwasaki H, Ohjimi Y, et al. Sarcomatoid carcinoma of the urinary bladder: a clinicopathologic and immunohistochemical analysis of 14 patients. *Hum Pathol*. 2000;31(3):332-340.
286. Perret L, Chaubert P, Hessler D, Guillou L. Primary heterologous carcinosarcoma (metaplastic carcinoma) of the urinary bladder: a clinicopathologic, immunohistochemical, and ultrastructural analysis of eight cases and a review of the literature. *Cancer*. 1998;82(8):1535-1549.
287. Reuter VE. Sarcomatoid lesions of the urogenital tract. *Semin Diagn Pathol*. 1993;10(2):188-201.
288. Young RH, Wick MR, Mills SE. Sarcomatoid carcinoma of the urinary bladder. A clinicopathologic analysis of 12 cases and review of the literature. *Am J Clin Pathol*. 1988;90(6):653-661.
289. Sanfrancesco J, McKenney JK, Leivo MZ, et al. Sarcomatoid urothelial carcinoma of the bladder: analysis of 28 cases with emphasis on clinicopathologic features and markers of epithelial-to-mesenchymal transition. *Arch Pathol Lab Med*. 2016;140:543-551.
290. Amir G, Rosenmann E. Osteoclast-like giant cell tumour of the urinary bladder. *Histopathology*. 1990;17(5):413-418.
291. Baydar D, Amin MB, Epstein JI. Osteoclast-rich undifferentiated carcinomas of the urinary tract. *Mod Pathol*. 2006;19(2):161-171.
292. Foschini MP, Pilato F, D'Aversa C, et al. Sarcomatoid carcinoma of the urinary bladder. *J Urol Pathol*. 1997;6:139-152.
293. Kitazawa M, Kobayashi H, Ohnishi Y, et al. Giant cell tumor of the bladder associated with transitional cell carcinoma. *J Urol*. 1985;133(3):472-475.
294. Lopez-Beltran A, Blanca A, Montironi R, et al. Pleomorphic giant cell carcinoma of the urinary bladder. *Hum Pathol*. 2009;40(10):1461-1466.
295. Shanks JH, Iczkowski KA. Spindle cell lesions of the bladder and urinary tract. *Histopathology*. 2009;55(5):491-504.
296. Zukerberg LR, Armin AR, Pisharodi L, Young RH. Transitional cell carcinoma of the urinary bladder with osteoclast-type giant cells: a report of two cases and review of the literature. *Histopathology*. 1990;17(5): 407-411.
297. Baschinsky DY, Chen JH, Vadmal MS, et al. Carcinosarcoma of the urinary bladder—an aggressive tumor with diverse histogenesis. A clinicopathologic study of 4 cases and review of the literature. *Arch Pathol Lab Med*. 2000;124(8):1172-1178.
298. Young RH, Rosenberg AE. Osteosarcoma of the urinary bladder. Report of a case and review of the literature. *Cancer*. 1987;59(1):174-178.
299. Bloxham CA, Bennett MK, Robinson MC. Bladder carcinosarcomas: three cases with diverse histogenesis. *Histopathology*. 1990;16(1):63-67.
300. Jao W, Soto JM, Gould VE. Squamous carcinoma of bladder with pseudosarcomatous stroma. *Arch Pathol*. 1975;99(9):461-466.
301. Bannach B, Grignon D, Shum D. Sarcomatoid transitional cell carcinoma vs pseudosarcomatous stromal reaction in bladder carcinoma. An immunohistochemical study. *J Urol Pathol*. 1993;1:105-120.
302. Torenbeek R, Blomjous CE, de Bruin PC, et al. Sarcomatoid carcinoma of the urinary bladder. Clinicopathologic analysis of 18 cases with immunohistochemical and electron microscopic findings. *Am J Surg Pathol*. 1994;18(3):241-249.
303. Wick MR, Brown BA, Young RH, Mills SE. Spindle-cell proliferations of the urinary tract. An immunohistochemical study. *Am J Surg Pathol*. 1988;12(5):379-389.
304. Mazzucchelli L, Kraft R, Gerber H, et al. Carcinosarcoma of the urinary bladder: a distinct variant characterized by small cell undifferentiated carcinoma with neuroendocrine features. *Virchows Arch A Pathol Anat Histopathol*. 1992;421(6):477-483.
305. Jones EC, Young RH. Myxoid and sclerosing sarcomatoid transitional cell carcinoma of the urinary bladder: a clinicopathologic and immunohistochemical study of 25 cases. *Mod Pathol*. 1997;10(9):908-916.
306. Fromowitz FB, Bard RH, Koss LG. The epithelial origin of a malignant mesodermal mixed tumor of the bladder: report of a case with long-term survival. *J Urol*. 1984;132(5):978-981.
307. Young RH, Wick MR. Transitional cell carcinoma of the urinary bladder with pseudosarcomatous stroma. *Am J Clin Pathol*. 1988;90(2):216-219.
308. Orsatti G, Corgan FJ, Goldberg SA. Carcinosarcoma of urothelial organs: sequential involvement of urinary bladder, ureter, and renal pelvis. *Urology*. 1993;41(3):289-291.
309. Smith JA Jr, Herr HW, Middleton RG. Bladder carcinosarcoma: histologic variation in metastatic lesions. *J Urol*. 1983;129(4):829-831.
310. Amin MB, Epstein JI, Ulbright TM, et al. Best practices recommendations in the application of immunohistochemistry in urologic pathology: report from the International Society of Urological Pathology consensus conference. *Am J Surg Pathol*. 2014;38:1017-1022.
311. Verduin L, Mentrikoski MJ, Heitz CT, Wick MR. The utility of GATA3 in the diagnosis of urothelial carcinomas with variant morphologic patterns. *Appl Immunohistochem Mol Morphol*. 2016;24:509-513.

312. Miettinen M, McCue PA, Sarlomo-Rikala M, et al. GATA3: a multispecific but potentially useful marker in surgical pathology: a systematic analysis of 2500 epithelial and nonepithelial tumors. *Am J Surg Pathol*. 2014;38:13-22.
313. Hoang LL, Tacha D, Bremer RE, et al. Uroplakin II (UPII), GATA3, and p40 are highly sensitive markers for the differential diagnosis of invasive urothelial carcinoma. *Appl Immunohistochem Mol Morphol*. 2015;23:711-716.
314. Tian W, Guner G, Miyamoto H, et al. Utility of uroplakin II expression as a marker of urothelial carcinoma. *Hum Pathol*. 2015;46:58-64.
315. Klopfer K, Delahunt B, Adamson M, Samaratunga H. Value of uroplakin III in distinguishing variants of primary bladder urothelial carcinoma from malignancy metastatic to the urinary bladder. *Anticancer Res*. 2014;34:6779-6784.
316. Li W, Liang Y, Deavers MT, et al. Uroplakin II is a more sensitive immunohistochemical marker than uroplakin III in urothelial carcinoma and its variants. *Am J Clin Pathol*. 2014;142:864-871.
317. Castillo-Martin M, Domingo-Domenech J, Karni-Schmidt O, et al. Molecular pathways of urothelial development and bladder tumorigenesis. *Urol Oncol*. 2010;28(4):401-408.
318. Goebell PJ, Knowles MA. Bladder cancer or bladder cancers? Genetically distinct malignant conditions of the urothelium. *Urol Oncol*. 2010;28(4):409-428.
319. McConkey DJ, Lee S, Choi W, et al. Molecular genetics of bladder cancer: Emerging mechanisms of tumor initiation and progression. *Urol Oncol*. 2010;28(4):429-440.
320. Mitra AP, Cote RJ. Molecular pathogenesis and diagnostics of bladder cancer. *Annu Rev Pathol*. 2009;4:251-285.
321. Pollard C, Smith SC, Theodorescu D. Molecular genesis of non-muscle-invasive urothelial carcinoma (NMIUC). *Expert Rev Mol Med*. 2010;12:e10.
322. Choi W, Czerniak B, Ochoa A, et al. Intrinsic basal and luminal subtypes of muscle-invasive bladder cancer. *Nat Rev Urol*. 2014;11:400-410.
323. Rampias T, Vgenopoulou P, Avgeris M, et al. A new tumor suppressor role for the Notch pathway in bladder cancer. *Nat Med*. 2014;20:1199-1205.
324. Allory Y, Beukers W, Sagrera A, et al. Telomerase reverse transcriptase promoter mutations in bladder cancer: high frequency across stages, detection in urine, and lack of association with outcome. *Eur Urol*. 2014;65:360-366.
325. National Bladder Cancer Collaborative Group A. Development of a strategy for a longitudinal study of patients with bladder cancer. National Bladder Cancer Collaborative Group A (NBCCGA). *Cancer Res*. 1977;37(8 Pt 2):2898-2906.
326. Amin MB, Delahunt B, Bochner BH, et al. Protocol for the examination of specimens from patients with carcinoma of the urinary bladder. *Coll Am Pathol*. 2013. cap.org/web/home/resources.
327. Tamas EF, Epstein JI. Detection of residual tumor cells in bladder biopsy specimens: pitfalls in the interpretation of cytokeratin stains. *Am J Surg Pathol*. 2007;31(3):390-397.
328. Bischoff CJ, Clark PE. Bladder cancer. *Curr Opin Oncol*. 2009;21(3):272-277.
329. Ghoneim MA, Abol-Enein H. Management of muscle-invasive bladder cancer: an update. *Nat Clin Pract Urol*. 2008;5(9):501-508.
330. Jacobs BL, Lee CT, Montie JE. Bladder cancer in 2010: how far have we come? *CA Cancer J Clin*. 2010;60(4):244-272.
331. Kaufman DS, Shipley WU, Feldman AS. Bladder cancer. *Lancet*. 2009;374:239-249.
332. Montie JE, Clark PE, Eisenberger MA, et al. Bladder cancer. *J Natl Compr Canc Netw*. 2009;7(1):8-39.
333. Raghavan D, Shipley WU, Garnick MB, et al. Biology and management of bladder cancer. *N Engl J Med*. 1990;322(16):1129-1138.
334. Pavone-Macaluso M, Tripi M, Ingargiola GB. Cooperative studies of chemoprophylaxis after transurethral resection of bladder tumors. *Cancer Chemother Pharmacol*. 1983;11(suppl):S 16-S21.
335. Fukui I, Yokokawa M, Sekine H, et al. Carcinoma in situ of the urinary bladder. Effect of associated neoplastic lesions on clinical course and treatment. *Cancer*. 1987;59(1):164-173.
336. Utz DC, Farrow GM, Rife CC, et al. Carcinoma in situ of the bladder. *Cancer*. 1980;45(7 suppl):1842-1848.
337. Soloway MS. Rationale for intensive intravesical chemotherapy for superficial bladder cancer. *J Urol*. 1980;123(4):461-466.
338. Cookson MS, Sarosdy MF. Management of stage T1 superficial bladder cancer with intravesical bacillus Calmette-Guerin therapy. *J Urol*. 1992;148(3):797-801.
339. Herr HW, Wartinger DD, Fair WR, Oettgen HF. Bacillus Calmette-Guerin therapy for superficial bladder cancer: a 10-year followup. *J Urol*. 1992;147(4):1020-1023.
340. Klein EA, Rogatko A, Herr HW. Management of local bacillus Calmette-Guerin failures in superficial bladder cancer. *J Urol*. 1992;147(3):601-605.
341. Lamm DL. Bacillus Calmette-Guerin immunotherapy for bladder cancer. *J Urol*. 1985;134(1):40-47.
342. Lage JM, Bauer WC, Kelley DR, et al. Histological parameters and pitfalls in the interpretation of bladder biopsies in bacillus Calmette-Guerin treatment of superficial bladder cancer. *J Urol*. 1986;135(5):916-919.
343. Huland H, Otto U, Droese M, Kloppel G. Long-term mitomycin C instillation after transurethral resection of superficial bladder carcinoma: influence on recurrence, progression and survival. *J Urol*. 1984;132(1):27-29.
344. Kaufman DS, Shipley WU, Griffin PP, et al. Selective bladder preservation by combination treatment of invasive bladder cancer. *N Engl J Med*. 1993;329(19):1377-1382.
345. Quilty PM, Duncan W. Treatment of superficial (T1) tumours of the bladder by radical radiotherapy. *Br J Urol*. 1986;58(2):147-152.
346. Soloway MS. The management of superficial bladder cancer. *Cancer*. 1980;45(7 suppl):1856-1865.
347. Amling CL, Thrasher JB, Frazier HA, et al. Radical cystectomy for stages Ta, Tis and T1 transitional cell carcinoma of the bladder. *J Urol*. 1994;151(1):31-35; discussion 5-6.
348. Mameghan H, Fisher RJ, Watt WH, et al. The management of invasive transitional cell carcinoma of the bladder. Results of definitive and preoperative radiation therapy in 390 patients treated at the Prince of Wales Hospital, Sydney, Australia. *Cancer*. 1992;69(11):2771-2778.
349. Shipley WU, Prout GR Jr, Kaufman DS. Bladder cancer. Advances in laboratory innovations and clinical management, with emphasis on innovations allowing bladder-sparing approaches for patients with invasive tumors. *Cancer*. 1990;65(3 suppl):675-683.
350. Wishnow KI, Levinson AK, Johnson DE, et al. Stage B (P2/3A/N0) transitional cell carcinoma of bladder highly curable by radical cystectomy. *Urology*. 1992;39(1):12-16.
351. Fossa SD, Waehre H, Aass N, et al. Bladder cancer definitive radiation therapy of muscle-invasive bladder cancer. A retrospective analysis of 317 patients. *Cancer*. 1993;72(10):3036-3043.
352. Yu WS, Sagerman RH, Chung CT, et al. Bladder carcinoma. Experience with radical and preoperative radiotherapy in 421 patients. *Cancer*. 1985;56(6):1293-1299.
353. Neumann MP, Limas C. Transitional cell carcinomas of the urinary bladder. Effects of preoperative irradiation on morphology. *Cancer*. 1986;58(12):2758-2763.
354. Coutts AG, Grigor KM, Fowler JW. Urethral dysplasia and bladder cancer in cystectomy specimens. *Br J Urol*. 1985;57(5):535-541.
355. Lerner SP, Skinner DG, Lieskovsky G, et al. The rationale for en bloc pelvic lymph node dissection for bladder cancer patients with nodal metastases: long-term results. *J Urol*. 1993;149(4):758-764; discussion 64-65.
356. Vieweg J, Whitmore WF Jr, Herr HW, et al. The role of pelvic lymphadenectomy and radical cystectomy for lymph node positive bladder cancer. The Memorial Sloan-Kettering Cancer Center experience. *Cancer*. 1994;73(12):3020-3028.
357. Grossman HB, Natale RB, Tangen CM, et al. Neoadjuvant chemotherapy plus cystectomy compared with cystectomy alone for locally advanced bladder cancer. *N Engl J Med*. 2003;349(9):859-866.
358. Powles T, Eder JP, Fine GD, et al. MPDL3280A (anti-PD-L1) treatment leads to clinical activity in metastatic bladder cancer. *Nature*. 2014;515:558-562.
359. Miller DC, Gang DL, Gavris V, et al. Villous adenoma of the urinary bladder: a morphologic or biologic entity? *Am J Clin Pathol*. 1983;79(6):728-731.
360. Adegboyega PA, Adesokan A. Tubulovillous adenoma of the urinary bladder. *Mod Pathol*. 1999;12(7):735-738.
361. Channer JL, Williams JL, Henry L. Villous adenoma of the bladder. *J Clin Pathol*. 1993;46(5):450-452.
362. Silver SA, Epstein JI. Adenocarcinoma of the colon simulating primary urinary bladder neoplasia. A report of nine cases. *Am J Surg Pathol*. 1993;17(2):171-178.
363. Cheng L, Montironi R, Bostwick DG. Villous adenoma of the urinary tract: a report of 23 cases, including 8 with coexistent adenocarcinoma. *Am J Surg Pathol*. 1999;23(7):764-771.
364. Seibel JL, Prasad S, Weiss RE, et al. Villous adenoma of the urinary tract: a lesion frequently associated with malignancy. *Hum Pathol*. 2002;33(2):236-241.
365. Chan TY, Epstein JI. In situ adenocarcinoma of the bladder. *Am J Surg Pathol*. 2001;25(7):892-899.
366. Miller JS, Epstein JI. Noninvasive urothelial carcinoma of the bladder with glandular differentiation: report of 24 cases. *Am J Surg Pathol*. 2009;33(8):1241-1248.
367. Grignon DJ, Ro JY, Ayala AG, et al. Primary adenocarcinoma of the urinary bladder. A clinicopathologic analysis of 72 cases. *Cancer*. 1991;67(8):2165-2172.
368. Ward AM. Glandular neoplasia within the urinary tract. The aetiology of adenocarcinoma of the urothelium with a review of the literature. I. Introduction: the origin of glandular epithelium in the renal pelvis, ureter and bladder. *Virchows Arch A Pathol Pathol Anat*. 1971;352(4):296-311.
369. Mostofi FK, Thomson RV, Dean AL Jr. Mucous adenocarcinoma of the urinary bladder. *Cancer*. 1955;8(4):741-758.

370. Nocks BN, Heney NM, Daly JJ. Primary adenocarcinoma of urinary bladder. *Urology*. 1983;21(1):26-29.
371. Thomas DG, Ward AM, Williams JL. A study of 52 cases of adenocarcinoma of the bladder. *Br J Urol*. 1971;43(1):4-15.
372. Anderstrom C, Johansson SL, von Schultz L. Primary adenocarcinoma of the urinary bladder. A clinicopathologic and prognostic study. *Cancer*. 1983;52(7):1273-1280.
373. Jacobs LB, Brooks JD, Epstein JI. Differentiation of colonic metaplasia from adenocarcinoma of urinary bladder. *Hum Pathol*. 1997;28(10):1152-1157.
374. Alroy J, Roganovic D, Banner BF, et al. Primary adenocarcinomas of the human urinary bladder: histochemical, immunological and ultrastructural studies. *Virchows Arch A Pathol Anat Histol*. 1981;393(2):165-181.
375. Hasegawa R, Fukushima S, Hirose M, et al. Histochemical demonstration of colonic type mucin in glandular metaplasia and adenocarcinoma of the human urinary bladder. *Acta Pathol Jpn*. 1987;37(7):1097-1103.
376. Newbould M, McWilliam LJ. A study of vesical adenocarcinoma, intestinal metaplasia and related lesions using mucin histochemistry. *Histopathology*. 1990;17(3):225-230.
377. Suh N, Yang XJ, Tretiakova MS, et al. Value of CDX2, villin, and alpha-methylacyl coenzyme A racemase immunostains in the distinction between primary adenocarcinoma of the bladder and secondary colorectal adenocarcinoma. *Mod Pathol*. 2005;18(9):1217-1222.
378. Wells M, Anderson K. Mucin histochemistry of cystitis glandularis and primary adenocarcinoma of the urinary bladder. *Arch Pathol Lab Med*. 1985;109(1):59-61.
379. Pallesen G. Neoplastic Paneth cells in adenocarcinoma of the urinary bladder: a first case report. *Cancer*. 1981;47(7):1834-1837.
380. Satake T, Takeda A, Matsuyama M. Argyrophil cells in the urachal epithelium and urachal adenocarcinoma. *Acta Pathol Jpn*. 1984;34(5):1193-1199.
381. Wang HL, Lu DW, Yerian LM, et al. Immunohistochemical distinction between primary adenocarcinoma of the bladder and secondary colorectal adenocarcinoma. *Am J Surg Pathol*. 2001;25(11):1380-1387.
382. Tamboli P, Mohsin SK, Hailemariam S, Amin MB. Colonic adenocarcinoma metastatic to the urinary tract versus primary tumors of the urinary tract with glandular differentiation: a report of 7 cases and investigation using a limited immunohistochemical panel. *Arch Pathol Lab Med*. 2002;126(9):1057-1063.
383. Humphrey PA. Clear cell neoplasms of the urinary tract and male reproductive system. *Semin Diagn Pathol*. 1997;14(4):240-252.
384. Ellis CL, Chang AG, Cimino-Mathews A, et al. GATA-3 immunohistochemistry in the differential diagnosis of adenocarcinoma of the urinary bladder. *Am J Surg Pathol*. 2013;37:1756-1760.
384a. Giannico GA, Gown AM, Epstein JI, et al. Role of SATB2 in distinguishing the site of origin in glandular lesions of the bladder/urinary tract. *Hum Pathol*. 2017 July [epub ahead of print].
385. Young RH, Scully RE. Clear cell adenocarcinoma of the bladder and urethra. A report of three cases and review of the literature. *Am J Surg Pathol*. 1985;9(11):816-826.
386. Young RH, Eble JN. Unusual forms of carcinoma of the urinary bladder. *Hum Pathol*. 1991;22(10):948-965.
387. Herawi M, Drew PA, Pan CC, Epstein JI. Clear cell adenocarcinoma of the bladder and urethra: cases diffusely mimicking nephrogenic adenoma. *Hum Pathol*. 2010;41:594-601.
388. Butterworth DM, Haboubi NY, Lupton EW. Mixed mesonephric adenocarcinoma and transitional cell carcinoma of the bladder. *Histopathology*. 1990;16(6):601-604.
389. Loy TS. Distribution of 66.4.C2 immunoreactivity in adenocarcinomas and transitional cell carcinomas: an immunohistochemical study of 506 cases. *Appl Immunohistochem Mol Morphol*. 1998;6:97-100.
390. Garavan F, Grainger R, Jeffers M. Endometrioid carcinoma of the urinary bladder complicating vesical Mullerianosis: a case report and review of the literature. *Virchows Arch*. 2004;444(6):587-589.
391. Tong GX, Weeden EM, Hamele-Bena D, et al. Expression of PAX8 in nephrogenic adenoma and clear cell adenocarcinoma of the lower urinary tract: evidence of related histogenesis? *Am J Surg Pathol*. 2008;32(9):1380-1387.
392. Grignon DJ, Cheville J, Ro JY, Tamboli P. Tumors of the urinary bladder. Glandular neoplasms. In: Moch H, Humphrey PA, Ulbright TM, Reuter VE, eds. *WHO Classification of Tumours of the Urinary System and Male Genital Organs*. IARC; 2016.
393. Choi H, Lamb S, Pintar K, Jacobs SC. Primary signet-ring cell carcinoma of the urinary bladder. *Cancer*. 1984;53(9):1985-1990.
394. Burgues O, Ferrer J, Navarro S, et al. Hepatoid adenocarcinoma of the urinary bladder. An unusual neoplasm. *Virchows Arch*. 1999;435(1):71-75.
395. Lopez-Beltran A, Luque RJ, Quintero A, et al. Hepatoid adenocarcinoma of the urinary bladder. *Virchows Arch*. 2003;442(4):381-387.
396. Sinard J, Macleay L Jr, Melamed J. Hepatoid adenocarcinoma in the urinary bladder. Unusual localization of a newly recognized tumor type. *Cancer*. 1994;73(7):1919-1925.
397. Davaris P, Petraki K, Arvanitis D, et al. Urinary bladder paraganglioma (U.B.P.). *Pathol Res Pract*. 1986;181(1):101-106.
398. Cheng L, Leibovich BC, Cheville JC, et al. Paraganglioma of the urinary bladder: can biologic potential be predicted? *Cancer*. 2000;88(4):844-852.
399. Moyana TN, Kontozoglou T. Urinary bladder paragangliomas. An immunohistochemical study. *Arch Pathol Lab Med*. 1988;112(1):70-72.
400. Zhou M, Epstein JI, Young RH. Paraganglioma of the urinary bladder: a lesion that may be misdiagnosed as urothelial carcinoma in transurethral resection specimens. *Am J Surg Pathol*. 2004;28(1):94-100.
401. Camassei FD, Bosman C, Corsi A, de Matteis A. Oncocytic paraganglioma of the urinary bladder. *J Urol Pathol*. 1998;8:157-166.
402. Lam KY, Loong F, Shek TW, Chu SM. Composite paraganglioma-ganglioneuroma of the urinary bladder: a clinicopathologic, immunohistochemical, and uitrastructural study of a case and review of the literature. *Endocr Pathol*. 1998;9(1):353-361.
403. Albores-Saavedra J, Maldonado ME, Ibarra J, Rodriguez HA. Pheochromocytoma of the urinary bladder. *Cancer*. 1969;23(5):1110-1118.
404. Mason EF, Sadow PM, Wagner AJ, et al. Identification of succinate dehydrogenase-deficient bladder paragangliomas. *Am J Surg Pathol*. 2013;37:1612-1618.
405. Giubellino A, Lara K, Martucci V, et al. Urinary bladder paragangliomas: how immunohistochemistry can assist to identify patients with SDHB germline and somatic mutations. *Am J Surg Pathol*. 2015;39:1488-1492.
406. Park S, Kang SY, Kwon GY, et al. Clinicopathologic characteristics and mutational status of succinate dehydrogenase genes in paraganglioma of the urinary bladder: a multi-institutional Korean study. *Arch Pathol Lab Med*. 2016; [Epub ahead of print].
407. Martucci VL, Lorenzo ZG, Weintraub M, et al. Association of urinary bladder paragangliomas with germline mutations in the SDHB and VHL genes. *Urol Oncol*. 2015;33:167.
408. Burgess NA, Lewis DC, Matthews PN. Primary carcinoid of the bladder. *Br J Urol*. 1992;69(2):213-214.
409. Murali R, Kneale K, Lalak N, Delprado W. Carcinoid tumors of the urinary tract and prostate. *Arch Pathol Lab Med*. 2006;130(11):1693-1706.
410. Walker BF, Someren A, Kennedy JC, Nicholas EM. Primary carcinoid tumor of the urinary bladder. *Arch Pathol Lab Med*. 1992;116(11):1217-1220.
411. Abrahams NA, Moran C, Reyes AO, et al. Small cell carcinoma of the bladder: a contemporary clinicopathological study of 51 cases. *Histopathology*. 2005;46(1):57-63.
412. Cheng L, Pan CX, Yang XJ, et al. Small cell carcinoma of the urinary bladder: a clinicopathologic analysis of 64 patients. *Cancer*. 2004;101(5):957-962.
413. Helpap B, Kloppel G. Neuroendocrine carcinomas of the prostate and urinary bladder: a diagnostic and therapeutic challenge. *Virchows Arch*. 2002;440(3):241-248.
414. Ordonez NG, Khorsand J, Ayala AG, Sneige N. Oat cell carcinoma of the urinary tract. An immunohistochemical and electron microscopic study. *Cancer*. 1986;58(11):2519-2530.
415. Soriano P, Navarro S, Gil M, Llombart-Bosch A. Small-cell carcinoma of the urinary bladder. A clinico-pathological study of ten cases. *Virchows Arch*. 2004;445(3):292-297.
416. Abenoza P, Manivel C, Sibley RK. Adenocarcinoma with neuroendocrine differentiation of the urinary bladder. Clinicopathologic, immunohistochemical, and ultrastructural study. *Arch Pathol Lab Med*. 1986;110(11):1062-1066.
417. Mills SE, Wolfe JT 3rd, Weiss MA, et al. Small cell undifferentiated carcinoma of the urinary bladder. A light-microscopic, immunocytochemical, and ultrastructural study of 12 cases. *Am J Surg Pathol*. 1987;11(8):606-617.
418. Blomjous CE, Vos W, De Voogt HJ, et al. Small cell carcinoma of the urinary bladder. A clinicopathologic, morphometric, immunohistochemical, and ultrastructural study of 18 cases. *Cancer*. 1989;64(6):1347-1357.
419. Grignon DJ, Ro JY, Ayala AG, et al. Small cell carcinoma of the urinary bladder. A clinicopathologic analysis of 22 cases. *Cancer*. 1992;69(2):527-536.
420. Iczkowski KA, Shanks JH, Allsbrook WC, et al. Small cell carcinoma of urinary bladder is differentiated from urothelial carcinoma by chromogranin expression, absence of CD44 variant 6 expression, a unique pattern of cytokeratin expression, and more intense gamma-enolase expression. *Histopathology*. 1999;35(2):150-156.
421. Jones TD, Kernek KM, Yang XJ, et al. Thyroid transcription factor 1 expression in small cell carcinoma of the urinary bladder: an immunohistochemical profile of 44 cases. *Hum Pathol*. 2005;36(7):718-723.
422. Buza N, Cohen PJ, Pei H, Parkash V. Inverse p16 and p63 expression in small cell carcinoma and high-grade urothelial cell carcinoma of the urinary bladder. *Int J Surg Pathol*. 2010;18(2):94-102.

423. Reyes CV, Soneru I. Small cell carcinoma of the urinary bladder with hypercalcemia. *Cancer*. 1985;56(10):2530-2533.
424. Partanen S, Asikainen U. Oat cell carcinoma of the urinary bladder with ectopic adrenocorticotropic hormone production. *Hum Pathol*. 1985;16(3):313-315.
425. Ali SZ, Reuter VE, Zakowski MF. Small cell neuroendocrine carcinoma of the urinary bladder. A clinicopathologic study with emphasis on cytologic features. *Cancer*. 1997;79(2):356-361.
426. Evans AJ, Al-Maghrabi J, Tsihlias J, et al. Primary large cell neuroendocrine carcinoma of the urinary bladder. *Arch Pathol Lab Med*. 2002;126(10):1229-1232.
427. Hailemariam S, Gaspert A, Komminoth P, et al. Primary, pure, large-cell neuroendocrine carcinoma of the urinary bladder. *Mod Pathol*. 1998;11(10):1016-1020.
428. Lee KH, Ryu SB, Lee MC, et al. Primary large cell neuroendocrine carcinoma of the urinary bladder. *Pathol Int*. 2006;56(11):688-693.
429. Del Mistro A, Koss LG, Braunstein J, et al. Condylomata acuminata of the urinary bladder. Natural history, viral typing, and DNA content. *Am J Surg Pathol*. 1988;12(3):205-215.
430. Cheng L, Leibovich BC, Cheville JC, et al. Squamous papilloma of the urinary tract is unrelated to condyloma acuminata. *Cancer*. 2000;88(7):1679-1686.
431. Widran J, Sanchez R, Gruhn J. Squamous metaplasia of the bladder: a study of 450 patients. *J Urol*. 1974;112(4):479-482.
432. Benson RC Jr, Swanson SK, Farrow GM. Relationship of leukoplakia to urothelial malignancy. *J Urol*. 1984;131(3):507-511.
433. O'Flynn JD, Mullaney J. Leukoplakia of the bladder. A report on 20 cases, including 2 cases progressing to squamous cell carcinoma. *Br J Urol*. 1967;39(4):461-471.
434. Lagwinski N, Thomas A, Stephenson AJ, et al. Squamous cell carcinoma of the bladder: a clinicopathologic analysis of 45 cases. *Am J Surg Pathol*. 2007;31(12):1777-1787.
435. DeKock ML, Anderson CK, Clark PB. Vesical leukoplakia progressing to squamous cell carcinoma in women. *Br J Urol*. 1981;53(4):316-317.
436. Guo CC, Gomez E, Tamboli P, et al. Squamous cell carcinoma of the urinary bladder: a clinicopathologic and immunohistochemical study of 16 cases. *Hum Pathol*. 2009;40(10):1448-1452.
437. Wall RL, Clausen KP. Carcinoma of the urinary bladder in patients receiving cyclophosphamide. *N Engl J Med*. 1975;293(6):271-273.
438. El-Bolkainy MN, Mokhtar NM, Ghoneim MA, Hussein MH. The impact of schistosomiasis on the pathology of bladder carcinoma. *Cancer*. 1981;48(12):2643-2648.
439. Ghoneim MA, Ashamalla A, Gaballa MA, Ibrahim EI. Cystectomy for carcinoma of the bilharzial bladder. 126 patients 10 years later. *Br J Urol*. 1985;57(3):303-305.
440. Sharfi AR, el Sir S, Beleil O. Squamous cell carcinoma of the urinary bladder. *Br J Urol*. 1992;69(4):369-371.
441. Sakamoto N, Tsuneyoshi M, Enjoji M. Urinary bladder carcinoma with a neoplastic squamous component: a mapping study of 31 cases. *Histopathology*. 1992;21(2):135-141.
442. Rundle JS, Hart AJ, McGeorge A, et al. Squamous cell carcinoma of bladder. A review of 114 patients. *Br J Urol*. 1982;54(5):522-526.
443. Cioffi-Lavina M, Chapman-Fredricks J, Gomez-Fernandez C, et al. P16 expression in squamous cell carcinomas of cervix and bladder. *Appl Immunohistochem Mol Morphol*. 2010;18(4):344-347.
444. Bessette PL, Abell MR, Herwig KR. A clinicopathologic study of squamous cell carcinoma of the bladder. *J Urol*. 1974;112(1):66-67.
445. Newman DM, Brown JR, Jay AC, Pontius EE. Squamous cell carcinoma of the bladder. *J Urol*. 1968;100(4):470-473.
446. Faysal MH. Squamous cell carcinoma of the bladder. *J Urol*. 1981;126(5):598-599.
447. Gonzalez-Zulueta M, Shibata A, Ohneseit PF, et al. High frequency of chromosome 9p allelic loss and CDKN2 tumor suppressor gene alterations in squamous cell carcinoma of the bladder. *J Natl Cancer Inst*. 1995;87(18):1383-1393.
448. Vakar-Lopez F, Abrams J. Basaloid squamous cell carcinoma occurring in the urinary bladder. *Arch Pathol Lab Med*. 2000;124(3):455-459.
449. Mahran MR, el-Baz M. Verrucous carcinoma of the bilharzial bladder. Impact of invasiveness on survival. *Scand J Urol Nephrol*. 1993;27(2):189-192.
450. Botella E, Burgues O, Navarro S, et al. Warty carcinoma arising in condyloma acuminatum of urinary bladder: a case report. *Int J Surg Pathol*. 2000;8(3):253-259.
451. Guo CC, Fine SW, Epstein JI. Noninvasive squamous lesions in the urinary bladder: a clinicopathologic analysis of 29 cases. *Am J Surg Pathol*. 2006;30(7):883-891.
452. McKenney JK. An approach to the classification of spindle cell proliferations in the urinary bladder. *Adv Anat Pathol*. 2005;12:312-323.
453. Proppe KH, Scully RE, Rosai J. Postoperative spindle cell nodules of genitourinary tract resembling sarcomas. A report of eight cases. *Am J Surg Pathol*. 1984;8(2):101-108.
454. Young RH. Pseudoneoplastic lesions of the urinary bladder and urethra: a selective review with emphasis on recent information. *Semin Diagn Pathol*. 1997;14(2):133-146.
455. Lundgren L, Aldenborg F, Angervall L, Kindblom LG. Pseudomalignant spindle cell proliferations of the urinary bladder. *Hum Pathol*. 1994;25(2):181-191.
456. Lott S, Lopez-Beltran A, Maclennan GT, et al. Soft tissue tumors of the urinary bladder, Part I: myofibroblastic proliferations, benign neoplasms, and tumors of uncertain malignant potential. *Hum Pathol*. 2007;38(6):807-823.
457. Albores-Saavedra J, Manivel JC, Essenfeld H, et al. Pseudosarcomatous myofibroblastic proliferations in the urinary bladder of children. *Cancer*. 1990;66(6):1234-1241.
458. Jones EC, Young RH. Nonneoplastic and neoplastic spindle cell proliferations and mixed tumors of the urinary bladder. *J Urol Pathol*. 1994;2:105-134.
459. Koirala TR, Hayashi K, Ohara N, et al. Inflammatory pseudotumor of the urinary bladder with an aberrant expression of cytokeratin. *Pathol Int*. 1994;44(1):73-79.
460. Lamovec J, Zidar A, Trsinar B, Jancar J. Sclerosing inflammatory pseudotumor of the urinary bladder in a child. *Am J Surg Pathol*. 1992;16(12):1233-1238.
461. Watanabe K, Baba K, Saito A, et al. Pseudosarcomatous myofibroblastic tumor and myosarcoma of the urogenital tract. *Arch Pathol Lab Med*. 2001;125(8):1070-1073.
462. Young RH, Scully RE. Pseudosarcomatous lesions of the urinary bladder, prostate gland, and urethra. A report of three cases and review of the literature. *Arch Pathol Lab Med*. 1987;111(4):354-358.
463. Iczkowski KA, Shanks JH, Gadaleanu V, et al. Inflammatory pseudotumor and sarcoma of urinary bladder: differential diagnosis and outcome in thirty-eight spindle cell neoplasms. *Mod Pathol*. 2001;14(10):1043-1051.
464. Montgomery EA, Shuster DD, Burkart AL, et al. Inflammatory myofibroblastic tumors of the urinary tract: a clinicopathologic study of 46 cases, including a malignant example inflammatory fibrosarcoma and a subset associated with high-grade urothelial carcinoma. *Am J Surg Pathol*. 2006;30(12):1502-1512.
465. Cheuk W, Chan JK. Timely topic: anaplastic lymphoma kinase (ALK) spreads its influence. *Pathology*. 2001;33(1):7-12.
466. Hirsch MS, Dal Cin P, Fletcher CD. ALK expression in pseudosarcomatous myofibroblastic proliferations of the genitourinary tract. *Histopathology*. 2006;48(5):569-578.
467. Tsuzuki T, Magi-Galluzzi C, Epstein JI. ALK-1 expression in inflammatory myofibroblastic tumor of the urinary bladder. *Am J Surg Pathol*. 2004;28(12):1609-1614.
468. Dehner LP. Inflammatory myofibroblastic tumor: the continued definition of one type of so-called inflammatory pseudotumor. *Am J Surg Pathol*. 2004;28(12):1652-1654.
469. Sukov WR, Cheville JC, Carlson AW, et al. Utility of ALK-1 protein expression and ALK rearrangements in distinguishing inflammatory myofibroblastic tumor from malignant spindle cell lesions of the urinary bladder. *Mod Pathol*. 2007;20(5):592-603.
470. Hughes DF, Biggart JD, Hayes D. Pseudosarcomatous lesions of the urinary bladder. *Histopathology*. 1991;18(1):67-71.
471. Mahadevia PS, Alexander JE, Rojas-Corona R, Koss LG. Pseudosarcomatous stromal reaction in primary and metastatic urothelial carcinoma. A source of diagnostic difficulty. *Am J Surg Pathol*. 1989;13(9):782-790.
472. Mills SE, Bova GS, Wick MR, Young RH. Leiomyosarcoma of the urinary bladder. A clinicopathologic and immunohistochemical study of 15 cases. *Am J Surg Pathol*. 1989;13(6):480-489.
473. Swartz DA, Johnson DE, Ayala AG, Watkins DL. Bladder leiomyosarcoma: a review of 10 cases with 5-year followup. *J Urol*. 1985;133(2):200-202.
474. Lee TK, Miyamoto H, Osunkoya AO, et al. Smooth muscle neoplasms of the urinary bladder: a clinicopathologic study of 51 cases. *Am J Surg Pathol*. 2010;34(4):502-509.
475. Martin SA, Sears DL, Sebo TJ, et al. Smooth muscle neoplasms of the urinary bladder: a clinicopathologic comparison of leiomyoma and leiomyosarcoma. *Am J Surg Pathol*. 2002;26(3):292-300.
476. Spiess PE, Tuziak T, Tibbs RF, et al. Pseudosarcomatous and sarcomatous proliferations of the bladder. *Hum Pathol*. 2007;38(5):753-761.
477. Young RH, Proppe KH, Dickersin GR, Scully RE. Myxoid leiomyosarcoma of the urinary bladder. *Arch Pathol Lab Med*. 1987;111(4):359-362.
478. Kinoshita T, Nakamura Y, Kinoshita M, et al. Bilateral cystic nephroblastomas and botryoid sarcoma in a child with Dandy-Walker syndrome. *Arch Pathol Lab Med*. 1986;110(2):150-152.
479. Hays DM, Raney RB Jr, Lawrence W Jr, et al. Bladder and prostatic tumors in the intergroup Rhabdomyosarcoma study (IRS-I): results of therapy. *Cancer*. 1982;50(8):1472-1482.
480. Leuschner I, Harms D, Mattke A, et al. Rhabdomyosarcoma of the urinary bladder and vagina: a clinicopathologic study with emphasis on recurrent disease: a report from the Kiel Pediatric Tumor Registry and the German CWS Study. *Am J Surg Pathol*. 2001;25(7):856-864.

481. Bainbridge TC, Singh RR, Mentzel T, Katenkamp D. Solitary fibrous tumor of urinary bladder: report of two cases. *Hum Pathol*. 1997;28(10):1204-1206.
482. Westra WH, Grenko RT, Epstein J. Solitary fibrous tumor of the lower urogenital tract: a report of five cases involving the seminal vesicles, urinary bladder, and prostate. *Hum Pathol*. 2000;31(1):63-68.
483. Govan AD. A case of solitary mucus-secreting cystadenoma of the urinary bladder. *J Pathol Bacteriol*. 1946;58:293-295.
484. Steele AA, Byrne AJ. Paramesonephric (mullerian) sinus of urinary bladder. *Am J Surg Pathol*. 1982;6(2):173-176.
485. McLucas B, Stein JJ. Bladder leiomyoma: a rare cause of pelvic pain. *Am J Obstet Gynecol*. 1985;153(8):896.
486. Cheng L, Nascimento AG, Neumann RM, et al. Hemangioma of the urinary bladder. *Cancer*. 1999;86(3):498-504.
487. Hendry WF, Vinnicombe J. Haemangioma of bladder in children and young adults. *Br J Urol*. 1971;43(3):309-316.
488. Sarma DP, Weiner M. Hemangioma of the urinary bladder. *J Surg Oncol*. 1983;24(2):142-144.
489. Tavora F, Montgomery E, Epstein JI. A series of vascular tumors and tumorlike lesions of the bladder. *Am J Surg Pathol*. 2008;32(8):1213-1219.
490. Nuovo GJ, Nagler HM, Fenoglio JJ Jr. Arteriovenous malformation of the bladder presenting as gross hematuria. *Hum Pathol*. 1986;17(1):94-97.
491. Bolkier M, Ginesin Y, Lichtig C, Levin DR. Lymphangioma of bladder. *J Urol*. 1983;129(5):1049-1050.
492. Pauwels CF, Van den Broecke C, Demeyer JM, De Potter CR. Chondroma of the bladder. *Virchows Arch*. 1998;432(3):299-300.
493. Fletcher MS, Aker M, Hill JT, et al. Granular cell myoblastoma of the bladder. *Br J Urol*. 1985;57(1):109-110.
494. Ng KJ, Sherif A, McClinton S, Ewen SW. Giant ancient schwannoma of the urinary bladder presenting as a pelvic mass. *Br J Urol*. 1993;72(4):513-514.
495. Wang W, Montgomery E, Epstein JI. Benign nerve sheath tumors on urinary bladder biopsy. *Am J Surg Pathol*. 2008;32(6):907-912.
496. Cheng L, Scheithauer BW, Leibovich BC, et al. Neurofibroma of the urinary bladder. *Cancer*. 1999;86(3):505-513.
497. Gersell DJ, Fulling KH. Localized neurofibromatosis of the female genitourinary tract. *Am J Surg Pathol*. 1989;13(10):873-878.
498. Scheithauer BW, Santi M, Richter ER, et al. Diffuse ganglioneuromatosis and plexiform neurofibroma of the urinary bladder: report of a pediatric example and literature review. *Hum Pathol*. 2008;39(11):1708-1712.
499. Winfield HN, Catalona WJ. An isolated plexiform neurofibroma of the bladder. *J Urol*. 1985;134(3):542-543.
500. Sukov WR, Cheville JC, Amin MB, et al. Perivascular epithelioid cell tumor (PEComa) of the urinary bladder: report of 3 cases and review of the literature. *Am J Surg Pathol*. 2009;33(2):304-308.
501. Huan Y, Dillon RW, Unger PD. Angiomyolipoma of the bladder. *Ann Diagn Pathol*. 2002;6(6):378-380.
502. Pan CC, Yu IT, Yang AH, Chiang H. Clear cell myomelanocytic tumor of the urinary bladder. *Am J Surg Pathol*. 2003;27(5):689-692.
503. Lott S, Lopez-Beltran A, Montironi R, et al. Soft tissue tumors of the urinary bladder Part II: malignant neoplasms. *Hum Pathol*. 2007;38(7):963-977.
504. Krumerman MS, Katatikarn V. Rhabdomyosarcoma of the urinary bladder with intraepithelial spread in an adult. *Arch Pathol Lab Med*. 1976;100(7):395-397.
505. Miettinen M. Rhabdomyosarcoma in patients older than 40 years of age. *Cancer*. 1988;62(9):2060-2065.
506. Carter RL, McCarthy KP, al-Sam SZ, et al. Malignant rhabdoid tumour of the bladder with immunohistochemical and ultrastructural evidence suggesting histiocytic origin. *Histopathology*. 1989;14(2):179-190.
507. Harris M, Eyden BP, Joglekar VM. Rhabdoid tumour of the bladder: a histological, ultrastructural and immunohistochemical study. *Histopathology*. 1987;11(10):1083-1092.
508. McBride JA, Ro JY, Hicks J, et al. Malignant rhabdoid tumor of the bladder in an adolescent. Case report and discussion of extrarenal rhabdoid tumor. *J Urol Pathol*. 1994;2:255-264.
509. Kulaga A, Yilmaz A, Wilkin RP, Trpkov K. Epithelioid angiosarcoma of the bladder after irradiation for endometrioid adenocarcinoma. *Virchows Arch*. 2007;450(2):245-246.
510. Seethala RR, Gomez JA, Vakar-Lopez F. Primary angiosarcoma of the bladder. *Arch Pathol Lab Med*. 2006;130(10):1543-1547.
511. Amin MB, Patel RM, Oliveira P, et al. Alveolar soft-part sarcoma of the urinary bladder with urethral recurrence: a unique case with emphasis on differential diagnoses and diagnostic utility of an immunohistochemical panel including TFE3. *Am J Surg Pathol*. 2006;30(10):1322-1325.
512. Liang M, Troncoso P, Czerniak BA, Guo CC. Rhabdomyosarcoma of the urinary bladder and prostate in adults: a clinicopathologic study of 11 cases. *Lab Invest*. 2009;89(suppl 1).
513. Goodman AJ, Greaney MG. Malignant fibrous histiocytoma of the bladder. *Br J Urol*. 1985;57(1):106-107.
514. Kunze E, Theuring F, Kruger G. Primary mesenchymal tumors of the urinary bladder. A histological and immunohistochemical study of 30 cases. *Pathol Res Pract*. 1994;190(4):311-332.
515. Henriksen OB, Mogensen P, Engelholm AJ. Inflammatory fibrous histiocytoma of the urinary bladder: clinicopathological report of a case. *Acta Pathol Microbiol Immunol Scand [A]*. 1982;90(5):333-337.
516. Oesterling JE, Epstein JI, Brendler CB. Myxoid malignant fibrous histiocytoma of the bladder. *Cancer*. 1990;66(8):1836-1842.
517. Berenson RJ, Flynn S, Freiha FS, et al. Primary osteogenic sarcoma of the bladder. Case report and review of the literature. *Cancer*. 1986;57(2):350-355.
518. De Pinieux G, Chatelain D, Vieillefond A, et al. Clear cell sarcoma of tendons and aponeuroses presenting as a bladder mass: a case report. *J Urol Pathol*. 1998;9:239-246.
519. Kalyanasundaram K, Parameswaran A, Mani R. Perivascular epithelioid tumor of urinary bladder and vagina. *Ann Diagn Pathol*. 2005;9(5):275-278.
520. Lasota J, Carlson JA, Miettinen M. Spindle cell tumor of urinary bladder serosa with phenotypic and genotypic features of gastrointestinal stromal tumor. *Arch Pathol Lab Med*. 2000;124(6):894-897.
521. Terada Y, Saito I, Morohoshi T, Niijima T. Malignant mesenchymoma of the bladder. *Cancer*. 1987;60(4):858-863.
522. Helpap B. Nonepithelial neoplasms of the urinary bladder. *Virchows Arch*. 2001;439(4):497-503.
523. Banerjee SS, Eyden BP, McVey RJ, et al. Primary peripheral primitive neuroectodermal tumour of urinary bladder. *Histopathology*. 1997;30(5):486-490.
524. Desai S, Lim SD, Jimenez RE, et al. Relationship of cytokeratin 20 and CD44 protein expression with WHO/ISUP grade in pTa and pT1 papillary urothelial neoplasia. *Mod Pathol*. 2000;13(12):1315-1323.
525. Ainsworth AM, Clark WH, Mastrangelo M, Conger KB. Primary malignant melanoma of the urinary bladder. *Cancer*. 1976;37(4):1928-1936.
526. Anichkov NM, Nikonov AA. Primary malignant melanomas of the bladder. *J Urol*. 1982;128(4):813-815.
527. Kojima T, Tanaka T, Yoshimi N, Mori H. Primary malignant melanoma of the urinary bladder. *Arch Pathol Lab Med*. 1992;116(11):1213-1216.
528. Meyer JE. Metastatic melanoma of the urinary bladder. *Cancer*. 1974;34(5):1822-1824.
529. Mourad WA, Mackay B, Ordonez NG, et al. Clear cell melanoma of the bladder. *Ultrastruct Pathol*. 1993;17(3-4):463-468.
530. Kempton CL, Kurtin PJ, Inwards DJ, et al. Malignant lymphoma of the bladder: evidence from 36 cases that low-grade lymphoma of the MALT-type is the most common primary bladder lymphoma. *Am J Surg Pathol*. 1997;21(11):1324-1333.
531. Maghrabi JA, Reid SK, Jewett M, et al. Primary low-grade B-cell lymphoma of mucosa-associated lymphoid tissue type arising in the urinary bladder: report of 4 cases with molecular genetic analysis. *Arch Pathol Lab Med*. 2001;125:332-336.
532. Pawade J, Banerjee SS, Harris M, et al. Lymphomas of mucosa-associated lymphoid tissue arising in the urinary bladder. *Histopathology*. 1993;23(2):147-151.
533. Ho DS, Patterson AL, Orozco RE, Murphy WM. Extramedullary plasmacytoma of the bladder: case report and review of the literature. *J Urol*. 1993;150(2 Pt 1):473-474.
534. Yang C, Motteram R, Sandeman TF. Extramedullary plasmacytoma of the bladder: a case report and review of literature. *Cancer*. 1982;50(1):146-149.
535. Weide R, Pfluger KH, Gorg C, et al. Multiple myeloma of the bladder and vagina. *Cancer*. 1990;66(5):989-991.
536. Mourad WA, Khalil S, Radwi A, et al. cell lymphoma of the urinary bladder. *Am J Surg Pathol*. 1998;22(3):373-377.
537. Bocian JJ, Flam MS, Mendoza CA. Hodgkin's disease involving the urinary bladder diagnosed by urinary cytology: a case report. *Cancer*. 1982;50(11):2482-2485.
538. Allory Y, Merabet Z, Copie-Bergman C, et al. Sarcomatoid variant of anaplastic large cell lymphoma mimics ALK-1-positive inflammatory myofibroblastic tumor in bladder. *Am J Surg Pathol*. 2005;29(6):838-839.
539. Murphy AJ, O'Neill P, O'Brien F, et al. Anaplastic large cell lymphoma: a unique presentation with urinary bladder involvement: a case report. *Int J Surg Pathol*. 2005;13(4):369-373.
540. Goldstein AG. Metastatic carcinoma to the bladder. *J Urol*. 1967;98(2):209-215.
541. Haid M, Ignatoff J, Khandekar JD, et al. Urinary bladder metastases from breast carcinoma. *Cancer*. 1980;46(1):229-232.
542. Perez-Mesa C, Pickren JW, Woodruff MN, Mohallatee A. Metastatic carcinoma of the urinary bladder from primary tumors in the mammary gland of female patients. *Surg Gynecol Obstet*. 1965;121(4):813-818.
543. Bates AW, Baithun SI. Secondary neoplasms of the bladder are histological mimics of nontransitional cell primary tumours: clinicopathological and histological features of 282 cases. *Histopathology*. 2000;36(1):32-40.
544. Chiang KS, Lamki N, Athey PA. Metastasis to the bladder from pancreatic adenocarcinoma presenting with hematuria. *Urol Radiol*. 1992;13(3):187-189.

545. Sim SJ, Ro JY, Ordonez NG, et al. Metastatic renal cell carcinoma to the bladder: a clinicopathologic and immunohistochemical study. *Mod Pathol*. 1999;12(4):351-355.
546. Young RH, Johnston WH. Serous adenocarcinoma of the uterus metastatic to the urinary bladder mimicking primary bladder neoplasia. A report of a case. *Am J Surg Pathol*. 1990;14(9):877-880.
547. Bates AW, Baithun SI. The significance of secondary neoplasms of the urinary and male genital tract. *Virchows Arch*. 2002;440(6):640-647.
548. Schwartz LE, Khani F, Bishop JA, et al. Carcinoma of the uterine cervix involving the genitourinary tract: a potential diagnostic dilemma. *Am J Surg Pathol*. 2016;40:27-35.
549. Chuang AY, DeMarzo AM, Veltri RW, et al. Immunohistochemical differentiation of high-grade prostate carcinoma from urothelial carcinoma. *Am J Surg Pathol*. 2007;31:1246-1255.
550. Mohanty SK, Smith SC, Chang E, et al. Evaluation of contemporary prostate and urothelial lineage biomarkers in a consecutive cohort of poorly differentiated bladder neck carcinomas. *Am J Clin Pathol*. 2014;142:173-183.

Prostate and Seminal Vesicles

26

Jesse K. McKenney

CHAPTER CONTENTS

Prostate, *1097*
Normal anatomy, *1097*
Ectopia, *1098*
Nodular hyperplasia, *1098*
Infarct, *1100*
Prostatitis, *1100*
Calculi, *1102*
Tumorlike conditions, *1102*
Carcinoma, *1104*
Other tumors (in infants and children), *1119*
Other tumors (in adults), *1119*
Prostatic urethra, *1121*
Seminal vesicles and Cowper's glands, *1121*

Prostate

Normal Anatomy

The prostate is a pear-shaped glandular organ that weighs up to 20 g in the normal adult male and that depends for its differentiation and subsequent growth on androgenic hormones synthesized in the testis, acting through a poorly understood mesenchymal–epithelial interaction.[1] It is most commonly divided into the anterior fibromuscular stroma and three distinct glandular zones as described by McNeal: peripheral zone, transition zone, central zone.[2-5] The transition zone envelops the urethra in the mid portion of the prostate and is the anatomic region enlarged by benign prostatic hyperplasia. The central zone (which together with the seminal vesicles is thought to be derived from the wolffian duct) is shaped like an inverted pyramid at the base of the prostate and contains the ejaculatory ducts as they course to the prostatic urethra at the verumontanum, a posterior prominence in the prostatic urethra. The prostatic glands of the central zone may have a unique morphology with more deeply eosinophilic cytoplasm and/or more complex intraluminal architecture consisting of papillary infolding or epithelial bridges (Fig. 26.1). The peripheral zone envelops the transition zone and extends caudally to comprise most of the apex. Finally, the anterior tissues consist of smooth muscle (extending from the base), skeletal muscle from the anterior fibromuscular sling (extending from the apex), and adipose tissue in the extraprostatic compartment. The prostate is enveloped by a fibromuscular layer usually referred to as a "capsule," but it has been pointed out that this is most definitely not a well-defined anatomic structure with constant features.[6]

The glandular component of the organ is traditionally divided into acini and ducts, the latter subdivided into large (primary, major, excretory) and peripheral (secondary, minor); however, unlike other organs, there is little morphologic difference between the two. Both acini and ducts contain luminal secretory cells, a surrounding outer layer of basal cells, and scattered neuroendocrine cells (which are often unrecognizable). The secretory cells, which are located in the luminal side of the gland, contribute a wide variety of products to the seminal fluid. Histologically, these cells form an undulating luminal surface and are characterized by relatively pale cytoplasm that contains minute closely packed vacuoles that may be difficult to appreciate. They produce prostate-specific acid phosphatase (PSAP) and prostate-specific antigen (PSA), both of which can be readily identified immunohistochemically and have been proved of great diagnostic utility because of their organ-related specificity. Secretory cells coexpress various keratins,[7,8] but they do not include high-molecular-weight types such as 34βE12, a fact of diagnostic significance. More recently, immunoreactivity for NKX3.1 (nuclear) and prostate-specific membrane antigen (PSMA; cytoplasmic) has been demonstrated in prostatic secretory cells, which may very useful diagnostically.[9-11] The normal prostatic secretion is a neutral mucosubstance. On occasion, one encounters scattered individual columnar mucin-secreting cells in non-neoplastic prostatic epithelium, particularly in areas of atrophy.[7,12,13]

The basal cells form a thin layer that separates the luminal secretory cells from the basement membrane. Morphologically, basal cells often appear as small inconspicuous, almost pyknotic nuclei at the base of the secretory cells. When prominent (such as in hyperplasia), they are more basophilic than secretory cells and commonly have large nuclei with open chromatin and small pin-point nucleoli. They characteristically express high-molecular-weight cytokeratin (e.g. 34βE12 and CK5/6) and p63, a fact that has been exploited in the differential diagnosis between well-differentiated carcinomas (in which basal cells are absent) and benign conditions that simulate it (in which they are generally present, although sometimes in a patchy discontinuous fashion).[14] Under

Abstract

This chapter covers the full spectrum of prostatic diseases that may be seen by the pathologist in the daily evaluation of biopsy and resection material. Normal histology, normal anatomy, and benign lesions are compared to inflammatory and neoplastic conditions. Prostatic adenocarcinoma is covered in detail to include clinical diagnosis, histology, variants, staging, grading, and molecular findings. Finally, rare lesions of the seminal vesicles and Cowper's glands are addressed.

Keywords

prostate carcinoma
benign prostatic hyperplasia
mimics

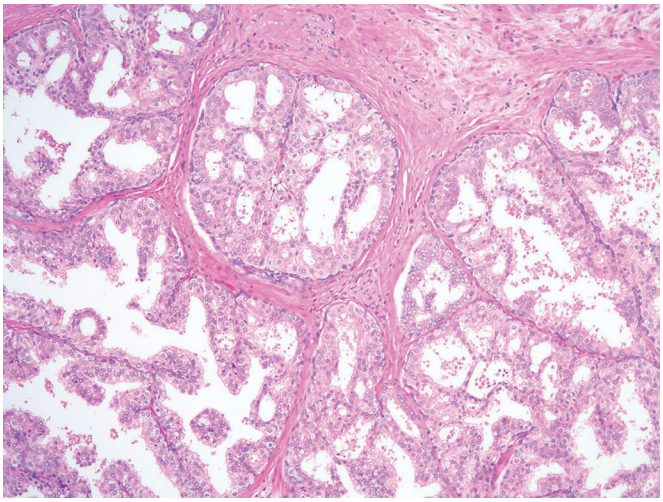

Figure 26.1 Normal central zone glands with typical "Roman bridge" formations and intraluminal papillary infolding.

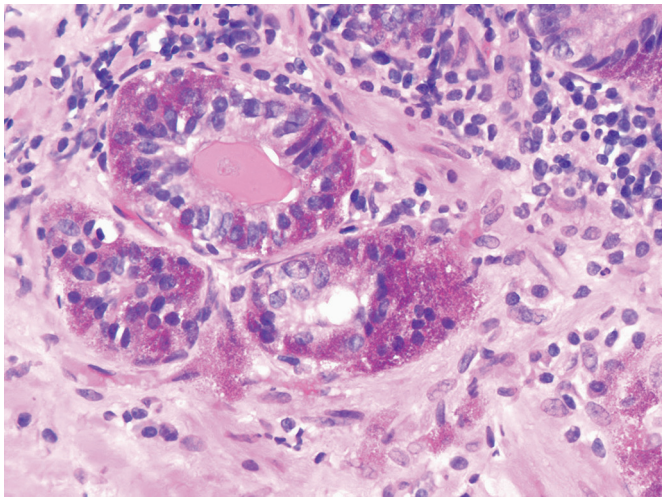

Figure 26.2 Eosinophilic Paneth-like neuroendocrine granules in benign prostatic glands.

normal conditions these basal cells do not have the phenotype of myoepithelial cells, in the sense that they lack immunoreactivity for S-100 protein or smooth muscle actin.[15,16] However, they can be viewed as being equivalent to the myoepithelial cells of the breast and other glandular organs. Support for this interpretation derives from the fact that they can undergo clear-cut myoepithelial metaplasia in conditions such as sclerosing adenosis.[17] They do not express PSA or PSAP, but they have been shown to exhibit strong immunoreactivity for androgen receptors focally.[18,19] They are thought to represent a multipotential population that gives rise to all epithelial lineages present in the normal, hyperplastic, and neoplastic prostate.[20]

The neuroendocrine cells express chromogranin A and B, secretogranin II, and various peptide hormones such as somatostatin, calcitonin, and bombesin[21,22]; they coexpress PSA, suggesting a common origin with the secretory cells.[23] However, they are negative for androgen receptors.[24] While often inconspicuous, occasional cells with red neuroendocrine granules may be seen (Fig. 26.2).

Near the urethra, the large prostatic ducts may be lined by urothelium that is continuous and indistinguishable from that lining the prostatic urethra. In contrast to bladder epithelium, its surface does not display umbrella cells, but rather a single layer of columnar cells that are immunoreactive for PSA and PSAP. On occasion, this epithelium undergoes squamous metaplastic changes; these were very common at the time estrogen therapy was widely employed for prostatic carcinoma.[25]

The prostatic stroma is notable because of its large content of smooth muscle fibers. It has been pointed out that the presence of this muscular stroma duplicates the function of myoepithelial cells in other organs, such as breast, and makes the presence of myoepithelial cells in the prostate superfluous. Prostatic stromal cells have been found to contain androgen receptors.

Peripheral nerves are evenly distributed in the apex, mid gland, and base[26]; they are of importance to pathologists because of the high frequency with which the loose connective space that surrounds them is involved by adenocarcinomas of this organ.

The prostatic lymph vessels drain into the pelvic lymph nodes and from there into the retroperitoneal chain.

Ectopia

Ectopia of prostatic tissue is a very rare event, save for the benign prostatic-type polyps discussed in Chapter 25 (Bladder). It has been described in the bladder (especially in the trigone and in association with urachal remnants),[27] root of the penis, epididymis,[28] testis, seminal vesicle,[29] retrovesical space, submucosa of the anal canal,[30] pericolic fat/pararectal space, uterine cervix and vagina,[31] and spleen.[32,33]

Nodular Hyperplasia

Benign prostatic hypertrophy is the usual name applied to a common benign disorder of the prostate that, when extensive, results in varying degrees of urinary obstruction, sometimes requiring surgical intervention. The term *nodular hyperplasia*, as proposed by Moore[34] in his classic study, is a more exact designation. The disease represents a nodular enlargement of the gland caused by hyperplasia of both glandular and stromal components. This results in an increase in the weight of the organ well beyond the 20 g regarded as normal for adult individuals. The clinical incidence of this disease is only 8% during the fourth decade, but it reaches 50% in the fifth decade and 75% in the eighth decade.

No predisposing or protecting factors (other than castration) have been identified. It has been established that prostatic nodular hyperplasia occurs only in individuals with intact testes and that it is an androgen-dependent disorder.[35,36] Specifically, it has been suggested that nodular hyperplasia may result from an initial activation of mesenchymal clones with embryonal functions that stimulate development of the glandular component.[37] In turn, this may result from dihydrotestosterone accumulation within the gland, resulting from decreased catabolism of the molecule and enhanced intracellular binding.[38] A peculiar immunohistochemical finding that may throw some light on this issue is the demonstration that p27 protein (a negative regulator of the cell cycle) is prominently expressed in the epithelial and stromal cells of the normal prostate, but is essentially negative in nodular hyperplasia.[39]

At autopsy the average weight of a prostate gland affected by nodular hyperplasia is 33 g ± 16 g. Specimens obtained surgically weigh 100 g on average, but on rare occasions weights of over 800 g have been recorded. Grossly, variously sized nodules with a gray to yellow color and a granular appearance are seen projecting above the cut surface (Fig. 26.3).

A cross section of an entire gland with early involvement clearly shows that nodular hyperplasia begins in the transition zone. This

Figure 26.3 Gross appearance of nodular hyperplasia in material obtained from suprapubic prostatectomy. Note the multinodular appearance and the admixture of solid and microcystic areas.

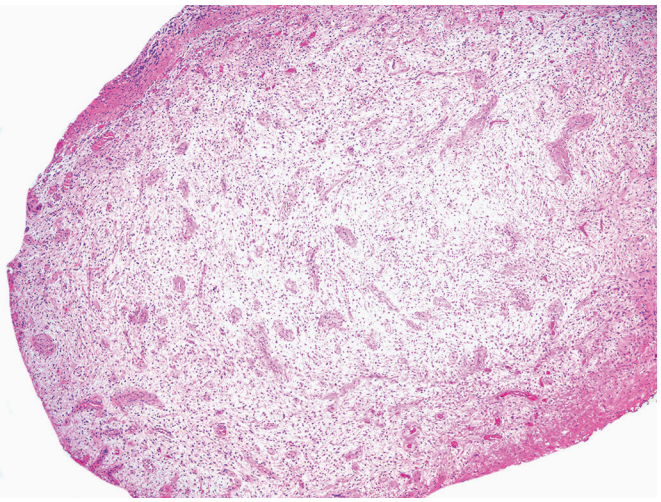

Figure 26.4 Stromal Nodule in Benign Prostatic Hyperplasia. The characteristic prominent blood vessels may be seen even at low power.

fact supports the interpretation that this zone of the gland reacts differently to hormonal stimuli than the outer zones. In most instances the nodules congregate on both sides of the urethra, causing compression and urinary obstruction. In others, the disease may result in a *midline dorsal nodule* at the bladder neck protruding into the bladder lumen, so-called "median-lobe hypertrophy." With increased growth, the peripheral zone of the organ is pushed aside and compressed; in florid examples, the transition zone may extend into and comprise much of the apex.

Microscopically, the earliest change is a stromal proliferation about small sinusoidal spaces in the periurethral regions and, to less degree, in the periductal and intralobular areas (Fig. 26.4). This stromal proliferation (which in the periductal areas may have a concentric or an eccentric quality) contains more smooth muscle

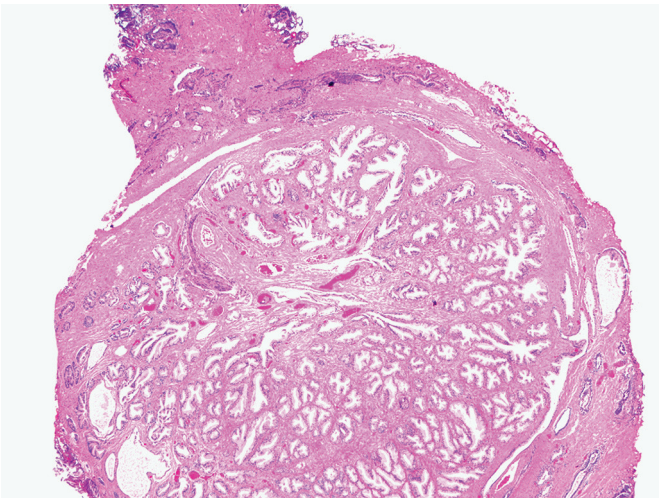

Figure 26.5 Nodular hyperplasia of prostate on TUR with detached well-circumscribed nodules of glands. *TUR*, Transurethral resection.

and less elastic tissue than the normal stroma. This is followed by hyperplasia of the glandular component, so that in the well-developed disease the nodules are composed of varying proportions of both elements.[40] These proportions are somewhat different in patients with symptomatic and those with asymptomatic nodular hyperplasia.[41] The glands are dilated or even cystic and often contain an inspissated secretion of glycoprotein nature (corpora amylacea), which is sometimes calcified.[42] The epithelium ranges from flat to columnar, sometimes facing each other in the same gland ("functional polarization"); the cytoplasm is pale, and the nuclei are regular and centrally located (Fig. 26.5). The nucleoli are inconspicuous. Papillary infoldings are common. A basal cell layer is seen immediately above a well-developed basement membrane.

Small clusters of lymphocytes are common in the interstitium and around the ducts. They are probably the result rather than the cause of the hyperplasia[43]; a diagnosis of chronic prostatitis is not warranted because of their mere presence.

Many morphologic variations of this basic theme exist, some of them resulting from the overgrowth of one component over the other and others form the emergence of distinctive patterns. It should be pointed out that there is little relation between a diagnosis of nodular hyperplasia made on a biopsy specimen and either the weight of the gland or the score system used to measure urinary obstructive symptoms.[44]

The treatment for nodular hyperplasia includes medical or surgical management.[45] Medical alternatives to surgery include various medications aimed at blocking the actions of androgens by preventing their secretion or their conversion to their tissue active form or at relaxing the stromal muscle cells.[46-51] Among these, the drug most widely used is finasteride, which works by inhibiting 5-α reductase, the enzyme that converts testosterone to the potent androgen dihydrotestosterone.[52] The morphologic changes induced by this compound in the prostate are thought to be relatively minor and nonspecific. The involved area may be excised by various techniques, such as transurethral resection (TUR), suprapubic prostatectomy, and laser enucleation.[53-55] It should be realized that these procedures remove *only the newly formed nodules.* The compressed peripheral portions of the gland remain; these expand by stromal growth to surround the prostatic urethra and may be the source of recurrent hyperplasia.[34] Not surprisingly, the chance of a patient undergoing a second operation for this disorder is substantially higher after a TUR than an open prostatectomy.[56]

Infarct

Infarct of the prostate occurs predominantly in large prostates affected by nodular hyperplasia.[55] Its reported incidence is probably related to the thoroughness of the microscopic examination. In the glands carefully studied by Moore,[34] it was found to be present in 18%–25% of cases. It has been traditionally reported in TUR specimens, but it can also be recognized in prostatic needle biopsies.[57] The size and number of the infarcts are directly related to the degree of prostatic hyperplasia. True infarcts occurring on a vascular basis should be distinguished from necrotic changes involving a gland or group of glands but sparing the stroma, a change sometimes seen in nodular hyperplasia.

The mechanism of infarct is unknown but may be related to the presence of prostatic infection or trauma resulting from an indwelling catheter, cystitis, or prostatitis, all of which may result in thrombosis of the intraprostatic portion of the urethral arteries.

Grossly, prostatic infarcts vary in size from a few millimeters up to 5 cm. They are speckled, gray-yellow, and often contain streaks of blood. The peripheral margins are usually sharp and hemorrhagic and may impinge on the urethra (Fig. 26.6). Microscopically, the infarcts are of ischemic type, with sharply outlined areas of coagulative necrosis involving glands *and stroma*. Prominent squamous metaplasia may develop in the ducts at the periphery of the infarct, a change that should not be confused with squamous cell carcinoma (Fig. 26.7). This metaplastic change is confined to the expanded ducts, keratinizes only rarely, and does not extend to the surrounding prostatic tissue.[58] It should be remembered that true squamous cell carcinomas of the prostate are exceptionally rare and are most often seen after radiation therapy.

Most prostatic infarcts are clinically silent. Occasionally, they cause acute urinary retention because of the accompanying edema.[59] Since they are often adjacent to the urethra, gross hematuria can also occur. Diffuse oozing of blood from the overlying mucosa may be seen cystoscopically. They may cause serum elevation of PSAP and PSA.[60] Removal of the infarcted area promptly returns these levels to normal; if it does not, further work-up is indicated.

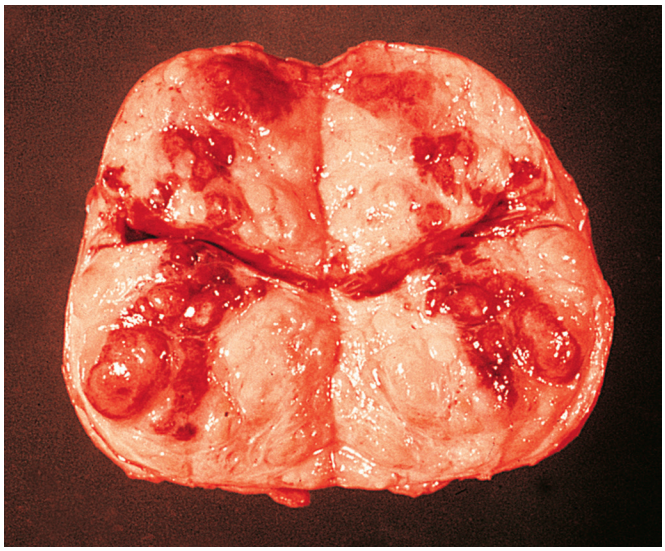

Figure 25.6 Gross Appearance of Infarct of Prostate. The lesion has a bright red color and bulges on the cut surface. Nodular hyperplasia is also present.

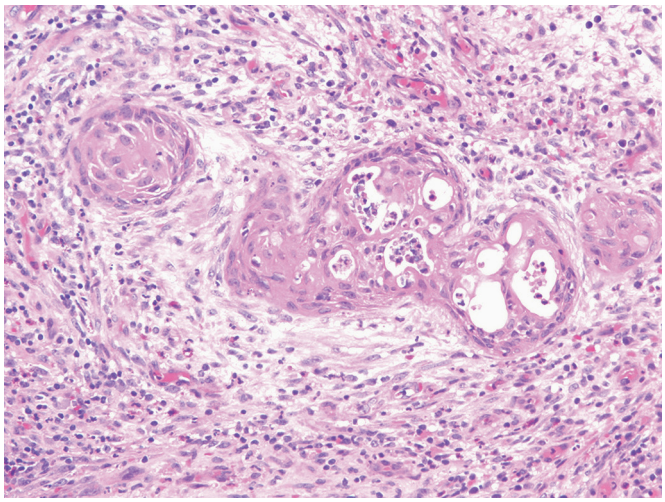

Figure 26.7 Prominent squamous metaplastic changes at the edge of a prostatic infarct. These are sometimes overdiagnosed as carcinoma.

Prostatitis

Acute prostatitis is rarely seen in surgical specimens. In general, prostatitis is a clinical, not a pathologic diagnosis. So-called *chronic prostatitis* is more common, but it is important to distinguish the true infectious processes of this organ from the inconsequential mononuclear infiltrates often seen in biopsies or accompanying nodular hyperplasia. While the latter phenomenon has been dignified by terms such as "chronic nonbacterial prostatitis" or "lymphocytic prostatitis," it is generally best to reserve the term "prostatitis" for clinical infections.[61,62] Therefore, we do not report the presence of chronic inflammation on biopsy unless it is quite marked and only with the descriptive term "marked chronic inflammation." In bacterial prostatitis, the route of infection remains uncertain in most cases. Some cases follow gonococcal or nongonococcal urethritis, and others result from periurethral infection associated with indwelling urethral catheterization. Gram-positive bacteria are the most common pathogens found in cultures from prostatic fluid.[63,64] *Adenovirus prostatitis*, as seen in immunosuppressed patients, can exhibit prominent necrotizing features.[65] While biopsy would be unusual for a clinically apparent infection, microscopically it usually appears as a *localized* process involving a small number of ducts or acini. The lumina are distended and filled with secretion mixed with inflammatory cells, among which neutrophils predominate. The stromal component, on the other hand, is mainly mononuclear and is composed of a mixture of lymphocytes, plasma cells, and histiocytes. In the presence of a monotonous infiltration of mature lymphocytes throughout the organ, the alternative diagnosis of involvement by chronic lymphocytic leukemia should be considered. We have seen rare prostate biopsies with CMV inclusions within epithelial and endothelial cells.

Prostatitis is often accompanied by elevation of serum PSA, particularly following a digital rectal examination, which should return quickly to normal following successful antibiotic treatment.[66,67]

Autoimmune prostatitis (IgG4-related sclerosing disease) has recently been proposed as a disease entity, characterized by elevated serum IgG4 levels and sometimes associated with systemic or multifocal lesions involving other organs.[68,69] In the histologically typical case, a mixed inflammatory infiltrate rich in plasma cells is seen, accompanied by fibrosis and obliterative phlebitis.[70]

Abscess

In the past, the majority of prostatic abscesses resulted from gonorrhea. At present, most have an obstructive etiology and are the

manifestation of secondary infection of the prostate from an infected pool of residual urine.[71] *Escherichia coli* is the organism usually responsible. In one series,[72] 36% presented with acute urinary retention and 31% with perineal or suprapubic pain. Prostatic fluctuation on digital rectal examination is the most characteristic sign, transrectal ultrasound is the most reliable diagnostic method, and transurethral drainage under antibiotic coverage is the treatment of choice.[73,74]

A relatively common form of prostatic abscess in east Asia and northern Australia is *melioidosis*, an infectious disease produced by the gram-negative bacterium *Burkholderia pseudomallei*.[75,76]

Tuberculosis and Bacillus Calmette–Guérin-Induced Granulomas

The prostate, epididymis, and testis are the organs most commonly involved in tuberculosis of the male genital system.[77] Of 105 autopsy cases included in the classic study by Auerbach,[78] the prostate was involved in 100, and in 35 it was the sole site in the system. In most cases, the infection is the result of hematogenous spread from the lungs (or, less often, from the skeletal system), but it may also result from direct invasion from the urethra.[79]

Early tuberculous lesions in the prostate are seldom detected on palpation. It is only when the disease is advanced that enlargement occurs and fluctuant, tender zones may be felt. Grossly, the lesions are usually bilateral. Confluent caseous zones occur with liquefaction and cavitation, until finally the prostate becomes an enlarged mass with multiple cavities. It may perforate into the urethra and extend into the urinary bladder. With still further spread, sinus tracts may form into the rectum, perineum, and peritoneal cavity. Healing with calcification may supervene, a change detectable by radiographic examination. In the late stages, the prostate becomes shrunken, fibrotic, and hard, to the point that it may simulate carcinoma on palpation.

Microscopically, the initial lesion is in the stroma but quickly spreads to the acini. Well-developed lesions show confluent foci of caseation with incomplete fibrous encapsulation. There is little tendency for the formation of typical tubercles.

Patients treated with intravesical bacillus Calmette–Guérin (BCG) for bladder carcinoma may develop granulomas in the prostate similar to those seen more often in the bladder itself (see Chapter 25).[80] These granulomas may be of noncaseating or caseating type.[81] They may be located along the periurethral or transitional zone or involve the gland diffusely. Stains for acid-fast organisms are usually negative, although occasionally a few organisms are visualized.

Other Specific Infections

The prostate can be involved by *blastomycosis*,[82] *coccidioidomycosis*,[83,84] *actinomycosis*,[85] *cryptococcosis*,[86-89] *histoplasmosis*,[90] *aspergillosis*,[91] *Cytomegalovirus* (CMV),[92] and *candidiasis*.[93,94] Many of these infections occur in the setting of immunosuppression resulting from AIDS or other disorders.[86,88,90]

Chlamydia trachomatis[62] and *Trichomonas vaginalis*[95] have been identified in the prostate gland, but their possible role as etiologic agents of prostatitis remains to be determined. The *Chlamydia* organism can be detected in tissue by immunohistochemical and in situ hybridization techniques.[96,97]

Granulomatous Prostatitis

Nonspecific granulomatous prostatitis, sometimes described as *"idiopathic,"* is applied to a rare prostatic disorder thought to represent an initially immune-mediated process accompanied by a reaction to the prostatic secretions released from obstructed ducts.[98-100] Most cases occur in glands affected by nodular hyperplasia in patients over 50 years of age. The clinical triad of high fever, symptoms of prostatitis, and a hard prostate on palpation is present in one-fifth of cases and may suggest the diagnosis.[101] A preoperative diagnosis of carcinoma is suspected in about 30% of cases because of the firmness of the lesion, caused by the dense fibrosis.

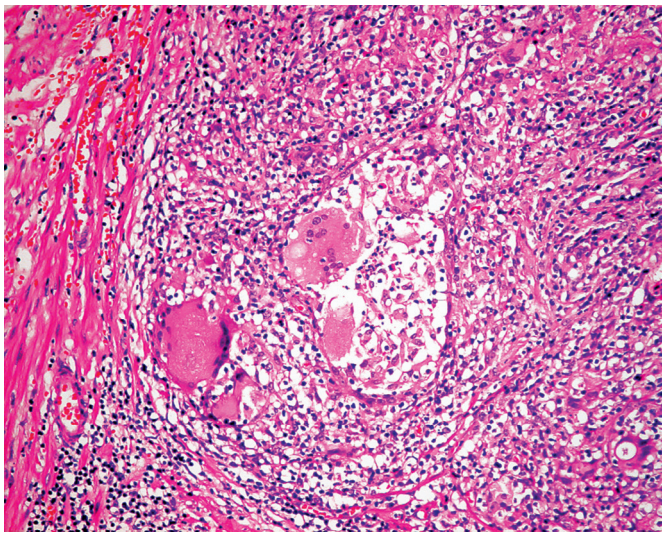

Figure 26.8 Nonspecific Granulomatous Prostatitis. The inflammatory infiltrate, which contains scattered multinucleated cells, is characteristically centered on a prostatic acinus.

Grossly, the gland is firm to stony hard. The cut surface shows obliteration of the architecture, with formation of yellow granular nodules. Microscopically, large nodular aggregates of histiocytes, epithelioid cells, lymphocytes, and plasma cells are seen. Characteristically, these granuloma-like formations are centered in the lobules (Fig. 26.8). A tubercle-like reaction with multinucleated giant cells, as well as collections of neutrophils, eosinophils, and detritus within the ducts, also may be seen. Microorganisms and caseation necrosis are absent. The microscopic changes can simulate carcinoma in needle biopsy specimens.[102] Immunohistochemical studies have shown a concentration of T cells in and around damaged ducts and glands.[103]

Prostatitis With Eosinophils

Most cases of prostatitis associated with a predominant eosinophilic infiltrate, sometimes intense, belong to one of the following categories[104,105]:

1. **Eosinophilic prostatitis** (allergic prostatitis, allergic granuloma of prostate), characterized by small stellate necrobiotic nodules surrounded by palisading epithelioid histiocytes and eosinophils, resembling rheumatoid nodules.[106,107] Vasculitis may be found. Patients often have a history of allergy and asthma and usually exhibit peripheral eosinophilia; in some cases, systemic vasculitis is present. Some of these cases have been thought to be a component of the Churg–Strauss syndrome.[108] Elevation of serum PSA levels may occur in this disorder.[109]
2. **Iatrogenic inflammation**, a morphologically similar condition in patients lacking these systemic symptoms that develops after a surgical procedure to the area, usually occurs in a TUR but sometimes a prostatic needle biopsy.[104,110-112] The interval between the surgical procedure and the appearance of the prostatitis ranges from less than 1 month to several years; eosinophils are more numerous when this interval is shorter. An associated

granulomatous response may represent a reaction to collagen altered as a result of the surgery or to metal deposition from the instruments themselves.[113] Some of these granulomas are elongated and tortuous, whereas others are wedge shaped, with their base facing the cauterized tissue.[104,114]

3. **Parasitic infestation** resulting from metazoa are rarely reported and, as in other sites, may be associated with an intense eosinophilic infiltrate.[115]

Other Inflammations

Malakoplakia can involve the prostate, usually in association with bladder disease (see Chapter 25).[116,117] As in the latter site, it should be viewed as a peculiar form of tissue reaction to bacterial infection. The infiltrate is usually located around prostatic ducts and has a mixed composition. The diagnosis is possible on needle biopsy specimens.[118] A similar condition but lacking Michaelis–Gutmann bodies has been described as **nodular histiocytic prostatitis**.[119] Reactive histiocytic infiltrates may closely mimic the morphologic appearance of prostatic adenocarcinoma after hormonal ablation. Malakoplakia may sonographically simulate prostatic carcinoma.[120] It can also be seen in prostates having carcinoma in other portions of the gland.[121]

Vasculitis of either necrotizing, fibrinoid, or granulomatous type can involve the prostate as an isolated event.[122,123]

Hair granuloma, described exceptionally in TUR specimens, is thought to result from hair from the perineal area being introduced into the prostate by an earlier perineal prostatic needle biopsy.[124]

Calculi

Prostatic calculi are seen in about 7% of prostates with nodular hyperplasia.[125] They should be distinguished from those found in the prostatic urethra, which may have their origin in the bladder, ureter, or renal pelvis.

The corpora amylacea seen in glands with nodular hyperplasia may act as the nucleus for stone formation as a result of improper drainage, infection of the acini, and calcium deposition. Blood clots, epithelial detritus, and bacteria are also present in the stone nucleus. The main inorganic elements are phosphated salts (calcium, magnesium, aminomagnesium, potassium), calcium carbonate, and calcium oxalate.

Because of their extreme hardness, large prostatic calculi may be erroneously diagnosed as carcinoma on palpation. They are radiopaque and easily detectable in plain-film x-rays. They are not associated with an increased risk for the development of prostatic carcinoma.[126] If they are extremely large and numerous, a prostatectomy may be required.

Tumorlike Conditions

The microscopic appearance of prostatic malignancy in general and of prostatic adenocarcinoma in particular can be simulated by a bewildering number of processes, all of benign nature, most of them not even neoplastic, and some simply representing examples of normal structures in an unexpected place.[127-130]

Normal tissue from ***seminal vesicle***, ***ejaculatory duct***, ***Cowper's glands***, and ***paraganglia*** can be found incidentally in prostatic resection specimens or biopsies and lead to diagnostic errors.[131-135] This is particularly true for the seminal vesicle because of its complex papillary arrangement and sometimes striking nuclear aberrations. A clue to the nature of this epithelium is the presence of abundant lipofuscin granules in the cytoplasm and/or the presence of scattered, large atypical epithelial cells (Fig. 26.9).[136] It should be noted, however, that a similar pigment can be occasionally found in benign and malignant prostatic epithelium[137] and that the distal seminal vesicle epithelium may show some immunoreactivity for PSA. Another clue is provided by the immunoreactivity of the seminal vesicle–ejaculatory duct epithelium for PAX-8, PAX-2, and GATA3.[138-140] **Rectal tissue** can be introduced in the prostate in the course of a needle biopsy[141]; when these glands are distorted, they can mimic prostatic cancer.[142] Finally, it should be kept in mind that normal and hyperplastic prostatic glands may be seen in a **perineurial location** and simulate perineurial invasion by carcinoma.[143-145]

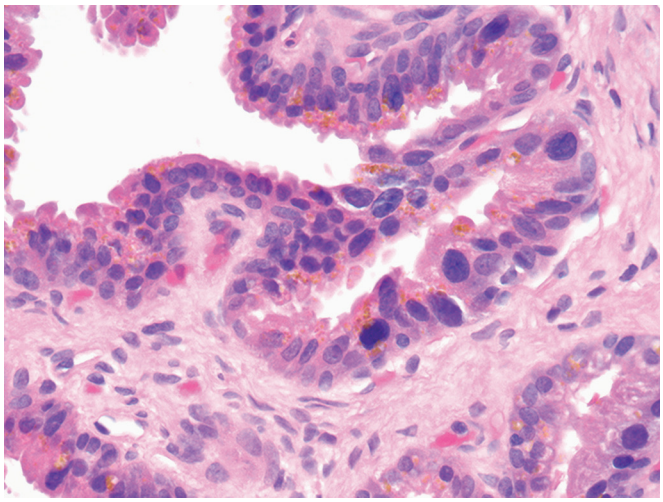

Figure 26.9 Benign Seminal Vesicle Epithelium Present in a Prostatic Needle Biopsy. The marked nuclear pleomorphism, which is characteristic, may prompt an overdiagnosis of carcinoma. Note the abundant intracytoplasmic pigment.

Microscopic Mimics of Prostatic Neoplasia

Florid hyperplasia of mesonephric remnants is extraordinarily rare but can involve the prostate and periprostatic tissues and mimic prostatic carcinoma.[146-149] They are most common in the anterior fibromuscular stroma and adjacent anterolateral periprostatic tissue or toward the base posteriorly and posterolaterally, either within or exterior to the prostate and around the seminal vesicle. As in other sites, these remnants are most commonly characterized by crowded small glands with a somewhat lobular arrangement, often with intraluminal eosinophilic secretions (Fig. 26.10). Rare cases may have ill-formed glands with infiltrative-like growth or some intraluminal papillary infoldings.

Foamy macrophages can appear in clusters ("xanthomas") and mimic high-grade prostatic carcinoma.[150,151]

Signet ring–like changes can develop in stromal cells and lymphocytes as a result of the effects of diathermy or other injuries and simulate signet ring adenocarcinoma. It is seen most often in TUR specimens, but it has also been described in prostatectomy specimens.[152]

Extramedullary hematopoiesis rarely involves the prostate in patients with myelofibrosis; the atypical megakaryocytes present in it should not be confused with malignant cells.[153]

Benign prostatic atrophy is an age-related phenomenon that occurs exclusively in the peripheral zone of the prostate.[154] A Working Group has proposed that prostatic atrophic lesions to be divided into the following subtypes: (1) *simple atrophy*; (2) *simple atrophy with cyst formation*; (3) *postatrophic hyperplasia*; and (4) *partial atrophy*.[155] Postatrophic hyperplasia may simulate carcinoma because of its complex arborization and surrounding fibrosis; however, the cytoplasm is scanty, and the lobular architecture is retained

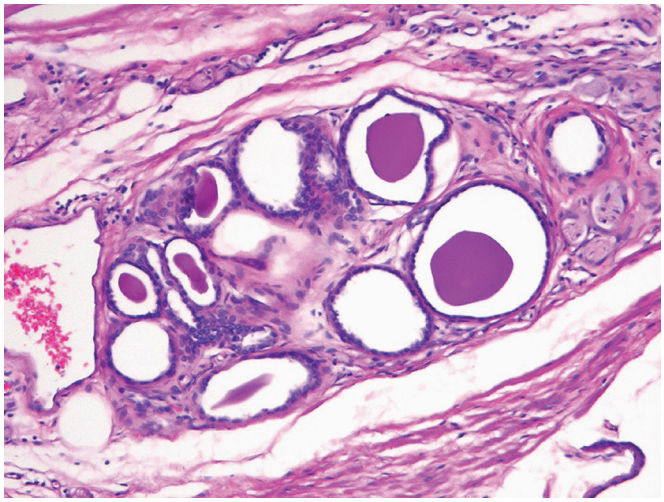

Figure 26.10 Mesonephric remnants within periprostatic stroma. (Courtesy of Dr. Samson Fine, Memorial Sloan Kettering Cancer Center, New York, NY.)

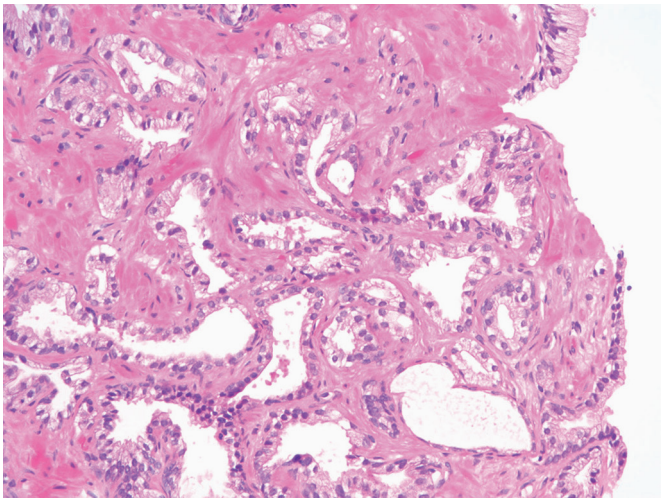

Figure 26.12 Partial atrophy, the most common mimic of prostatic carcinoma in routine practice, may be pseudoinfiltrative; however, the angulated/tapered shape of the glands and the loss of luminal cytoplasm are characteristic.

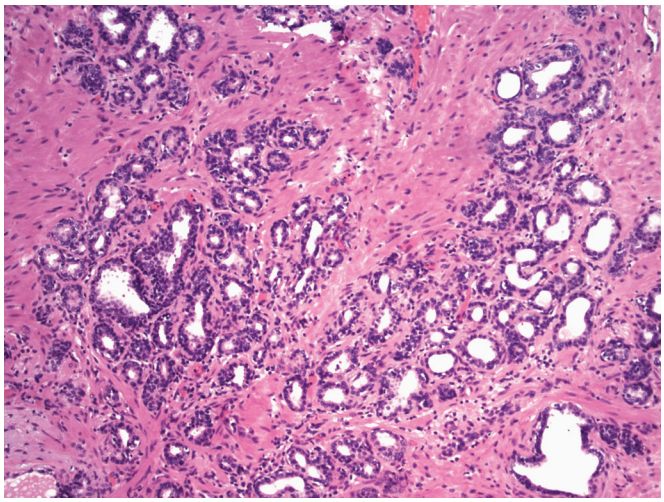

Figure 26.11 Postatrophic hyperplasia of the prostate retains its lobular architecture.

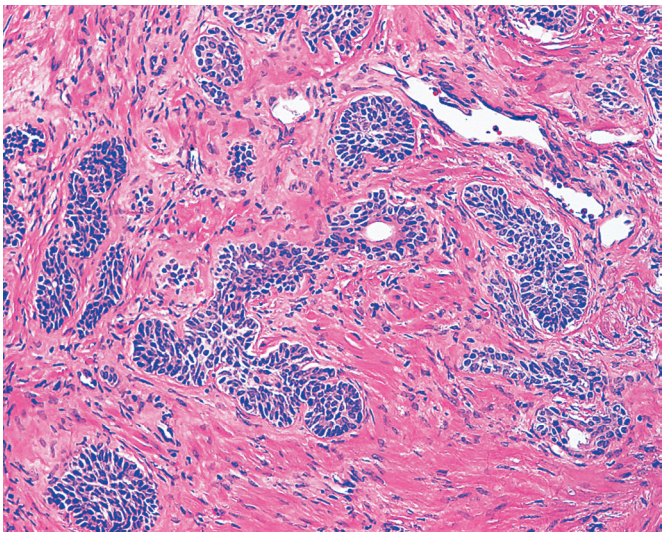

Figure 26.13 Basal cell hyperplasia often grows as solid nests or circumferential nodules of dark cells around residual prostatic secretory cells.

(Fig. 26.11).[156-159] Gland size and shape are typically variable, including round, oval, elongated, slit-like, and stellate forms. The individual cells have a very basophilic appearance because of the scant cytoplasm. The nuclei are regular and devoid of hyperchromasia,[160] but the nucleoli may be prominent.[161] The stroma may show elastosis in addition to fibrosis.[162] By immunohistochemistry, postatrophic hyperplasia glands are strongly immunoreactive for basal cell markers, making this a useful adjunct in difficult cases.

Partial atrophy is by far the most common benign mimicker of prostatic carcinoma on needle biopsy.[163] It is composed of crowded pseudoinfiltrative glands with reduced luminal cytoplasm. The glands are often angulated and preserved lateral cytoplasm is characteristic (Fig. 26.12). Nucleoli may be enlarged and some cases have visible nucleoli.[163] An association with fully developed atrophic changes of the simple or postatrophic hyperplasia type is a useful diagnostic feature.[164,165] Unfortunately, immunophenotypic analysis with basal cell markers and AMACR is problematic, as basal cells may be patchy or absent and luminal AMACR reactivity is common (reported in 30%–70% of cases).[163,166]

Squamous metaplasia can be seen at the periphery of infarcts, after TUR, as a result of hormonal manipulation, or sometimes with no obvious predisposing cause.

Basal cell hyperplasia is usually seen in the transition zone, but it may also occur in the peripheral portion of the gland.[167] It appears as small, generally solid nests of benign-appearing epithelial cells with minimal cytoplasm (Fig. 26.13). There is always an accompanying nodular hyperplasia of the usual type, with frequent merging of the two processes.[145] In *florid* basal cell hyperplasia, the proliferation is unduly complex.[168] Nuclear enlargement, hyperchromasia, and nucleolar prominence are seen in some cases and have been described as *atypical basal cell hyperplasia;* however, this seems to be of no clinical significance.[169] Other morphologic variations include the presence of intracytoplasmic globules (an allegedly diagnostic feature), psammomatous calcification, squamous changes, and a cribriform pattern of growth.[170,171] Basal cell hyperplasia may be the progenitor of the so-called adenoid basal cell tumor, which some

authors consider to be the extreme end of hyperplasia.[170] The proliferating basal cells are immunoreactive for high-molecular-weight keratin (34βE12) and p63 but not for actin.[172] The lesions are consistently negative for racemase.[173]

Urothelial "metaplasia" is characterized by the presence of a stratified epithelium composed of oval to spindled cells perpendicularly oriented to the lumina and having scanty pale eosinophilic to clear cytoplasm. The nuclei are elongated, vesicular, often with longitudinal grooves and inconspicuous nucleoli.[174] This is common in glands and ducts near the prostatic urethra and should be regarded as a normal finding.

Clear cell cribriform hyperplasia is an uncommon and controversial form of hyperplasia. The cytoplasm of the hyperplastic glandular cells often has a clear appearance, hence the original designation as *clear cell* cribriform hyperplasia (Fig. 26.14).[175] An important clue in the differential diagnosis with invasive carcinoma is the presence of a prominent row of basal cells at the periphery of the lesion, which are highlighted by the 34βE12 keratin stain.[176] In contrast to intraductal carcinoma (its closest mimic), nuclei are small, nucleoli are inconspicuous, and mitotic figures are absent.

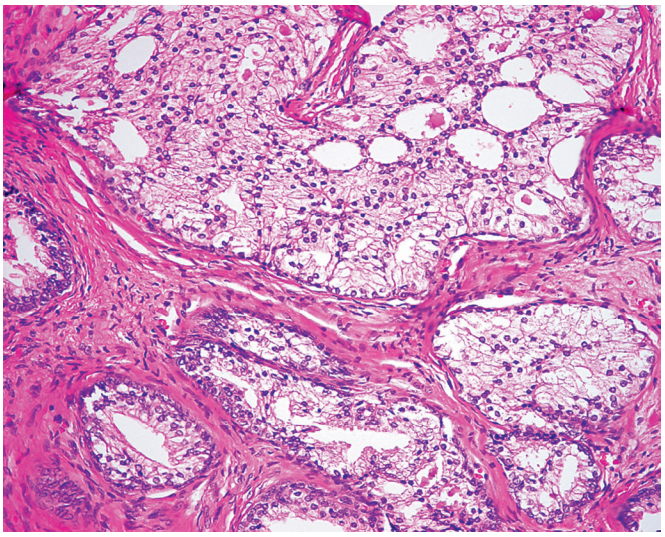

Figure 26.14 Clear cell hyperplasia of prostatic transition zone with a focally cribriform pattern of growth.

Sclerosing adenosis has an appearance similar to the homonymous lesion in the breast. It appears as a well-circumscribed nodule composed of variably sized and shaped (often compressed) glands and small clusters of epithelial cells embedded in a cellular, often myxoid stroma (Fig. 26.15). The clusters contain both a continuous basement membrane and a layer of basal cells. The latter are immunoreactive for keratin, S-100 protein, and smooth muscle actin, suggesting myoepithelial differentiation.[17,177,178] In some cases, there can be more pronounced cytologic atypia *(atypical sclerosing adenosis)* mimicking carcinoma.[179]

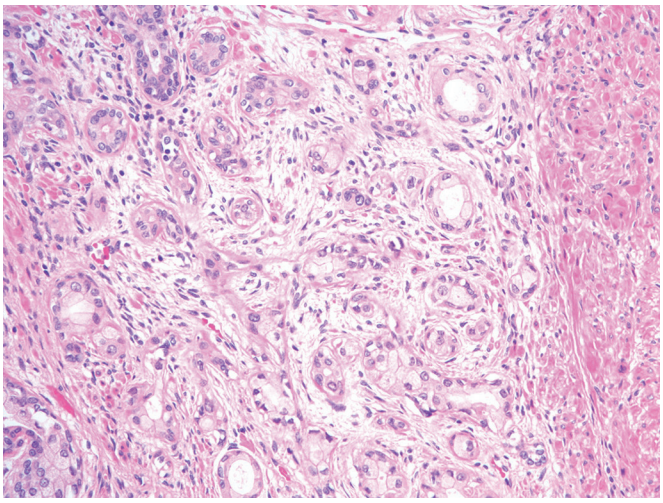

Figure 26.15 Sclerosing Adenosis of Prostate. The features are similar to those of its better-known mammary counterpart.

Adenosis (also known as *atypical adenomatous hyperplasia*) has a low-power appearance similar to that of well-differentiated adenocarcinoma in the sense of featuring a complex and disorderly cluster of crowded glands with an expansile margin but lacking prominent nucleoli or other nuclear abnormalities (Fig. 26.16).[176,180] It is usually an incidental microscopic finding in the transition zone, but it may rarely present as a mass lesion.[181,182] Acidic mucin is often present in the lumen of the glands.[183,184] While the relationship of adenosis to carcinoma has been debated, there are no strong data to support its role as a precursor; therefore, it is now simply considered a benign mimic.[185-188]

Lotan et al.[189] have described a variant of adenosis affecting younger patients, involving the peripheral zone of the prostate in a diffuse fashion (rather than localized to the transition zone), and possibly representing a risk factor for prostatic carcinoma; however, no subsequent validation studies have followed.

Radiation changes are characterized by cytologic atypia associated with retention of the lobular architecture, squamous metaplasia, stromal fibrosis, atypical fibroblasts, and vascular alterations. These changes can be very long lasting (up to 72 months in one series).[190] Radiated prostate glands often appear more angulated with small slit-like lumina, and they often have marked cytologic atypia (Fig. 26.17). After radiation, these cells typically have a basal immunophenotype, so basal cell markers are very useful in difficult cases. It should be noted that these radiated prostatic cells also commonly express GATA3 (a known basal cell marker), which could potentially lead to confusion with urothelial carcinoma.[191,192]

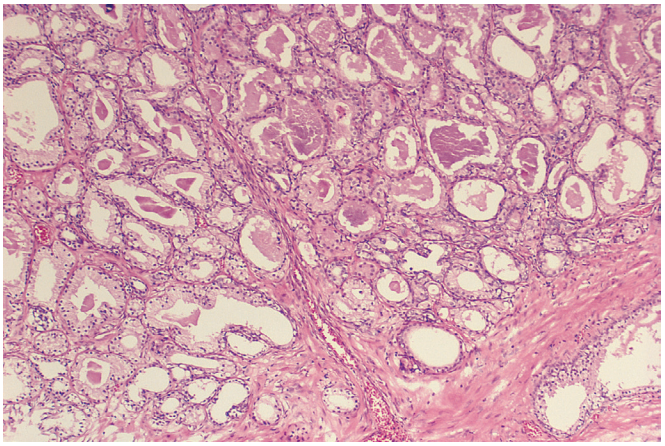

Figure 26.16 Adenosis of the prostate is characterized by crowded benign glands mimicking a well-differentiated adenocarcinoma.

Carcinoma

General Features

Carcinoma of the prostate is the most common internal malignancy among men in the United States and is responsible for 10% of

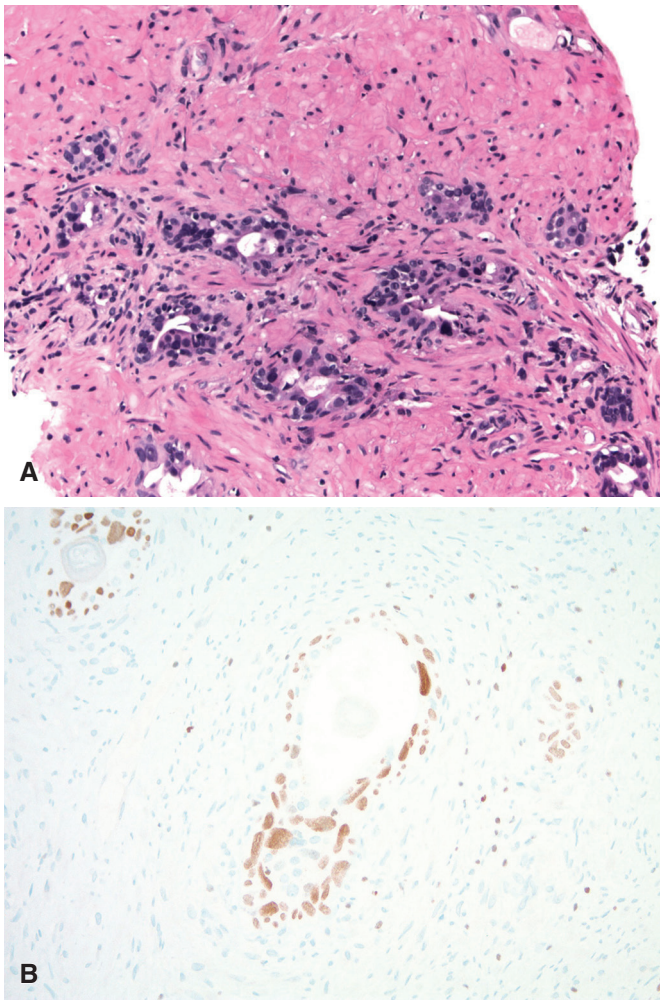

Figure 26.17 **A,** Radiation changes in prostate: the acini show marked nuclear pleomorphism. On low power, the lobular architecture was retained. **B,** Immunostain for GATA3 shows nuclear reactivity in the atypical cells, which may cause confusion with urothelial carcinoma.

cancer deaths in this population.[193] In the United States, an estimated 180,890 new cases of prostate cancer were diagnosed in 2016.[194] Rates among black males are one and a half those of white males.[195] The age-adjusted incidence is on the increase in most countries. Hormonal factors play a role in the development of prostatic carcinoma, a fact that has been dramatically highlighted with the statement that "essentially all men with circulating androgens will develop microscopic prostate cancer if they live long enough."[196] The disease does not occur in males castrated before puberty, and its incidence is low in patients with hyperestrogenism resulting from liver cirrhosis. It has been estimated that 5%–10% of prostatic carcinomas have a genetic link.

Almost 75% of the men diagnosed with prostatic cancer are age 65 or older, but the tumors can be seen in younger patients.[197] Their frequency increases with age, a fact well substantiated by careful observations at autopsy. The frequency with which incidental carcinoma is found at post mortem examination varies between 15% and 70%[198] and is directly related to the age of the patient and the thoroughness of the sampling. Similar figures have been obtained from the examination of cystoprostatectomy specimens performed for bladder carcinoma: in one such series, incidental prostatic adenocarcinoma was found in 42% of the specimens.[199]

Clinical Features

In general, most prostatic adenocarcinomas are now detected by serum PSA screening. Despite the recent controversy regarding PSA screening and the U.S. Preventive Services Task Force, the problem of overtreatment is evolving such that many men are now offered the option of active surveillance or watchful waiting.[200,201] PSA is secreted by all but the most undifferentiated prostatic tumors.[202] Gram for gram, the average prostatic carcinoma produces 10 times or more the amount of PSA produced by normal tissue, and this is reflected in the circulatory levels of this marker. The test, when performed over time, has a relatively high sensitivity and specificity, is rapid and inexpensive, and is minimally invasive.[203-205] Mild serum elevations of PSA can be seen with nodular hyperplasia, but levels above certain thresholds (such as 4 mg/mL) call for serial determination, with the performance of a biopsy if they continue to rise. Almost half of patients with prostatic carcinomas have levels over 10 mg/mL. Elevations of serum PSA also occur in prostatitis, prostatic infarct, and major trauma to the prostate, such as needle biopsy or TUR, but these elevations should be transitory and resolve with proper treatment.

Pathologic Features

Prostatic carcinomas can be divided into two major histologic categories: acinar and ductal. This morphologic distinction was initially based on the belief of a different site of origin for the two tumors; however, this histogenetic approach has been challenged by the observations that the two patterns are sometimes seen together in the same tumor and that the two types may coexist in the same prostate as anatomically separate lesions.[206,207] Therefore, the alternative proposal has been advanced that it is the *site* of the growth rather than the *origin* that governs the tumor architecture.[207] Even more problematic is the fact that histologic criteria for ductal subtype vary and interobserver reproducibility for the diagnosis is not high.[208] The large majority of the tumors are acinar, and most studies dealing with grading, staging, prognosis, and therapy of prostatic carcinoma refer exclusively to them.

Adenocarcinoma of Acinar Type

Most prostatic adenocarcinomas arise in the peripheral zone, which extends into the anterior regions of the prostate. However, a small percentage of tumors do actually arise in the prostatic transition zone or rarely central zone.[209]

Grossly, the tumor may be difficult to see but usually can be identified as a gray or yellowish, poorly delineated, firm area (Fig. 26.18). Early detection efforts are resulting in the identification of increasingly smaller tumors. As a matter of fact, residual carcinoma may be unidentifiable grossly or even microscopically in a radical prostatectomy specimen performed because of a positive biopsy (so-called vanishing cancer phenomenon or minimal residual cancer).[210] In such cases, a thorough reexamination to the point of compulsiveness (referred to as "methodically limited targeted approach") will unearth the carcinoma in about 75% of the cases.[211] The frequency of the "vanishing cancer phenomenon" is decreasing rapidly due to the increased use of active surveillance and the more frequent use of radical prostatectomy for larger, higher grade carcinomas. In our experience over the past few years, the only prostatectomies with no identifiable cancer were performed for Gleason score 3 + 3 = 6 carcinoma comprising 1 mm or less of a single biopsy.

Microscopically, prostatic adenocarcinomas exhibit a wide spectrum of appearances, ranging from highly differentiated neoplasms (Fig. 26.19) that are distinguished from the non-neoplastic

Figure 26.18 Gross Appearance of Prostatic Adenocarcinoma. The tumor appears as an irregularly shaped, yellow mass with punctate foci of necrosis in a gland that is also involved by nodular hyperplasia.

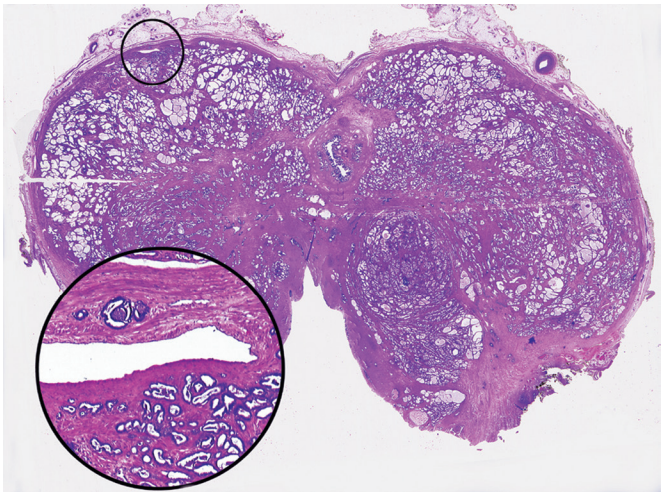

Figure 26.19 Whole mount of radical prostatectomy specimen showing involvement by an extremely small prostatic carcinoma located at the periphery of the organ and accompanied by perineurial invasion, the latter better seen in the inset.

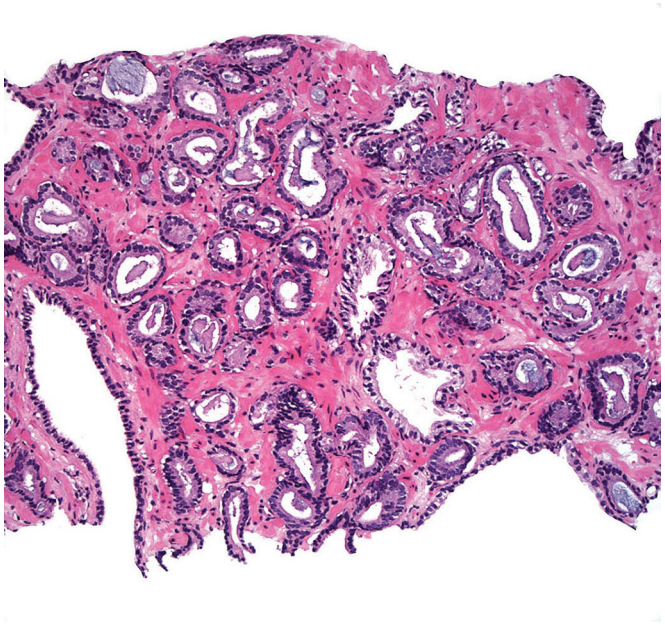

Figure 26.20 Microscopic Appearance of Prostatic Carcinoma. Well-differentiated Gleason score 3 + 3 = 6 adenocarcinoma composed of medium-sized glands. Note the irregular shape of the glands and presence of intraluminal basophilic secretion. The contrast with the non-neoplastic glands present in the field is obvious.

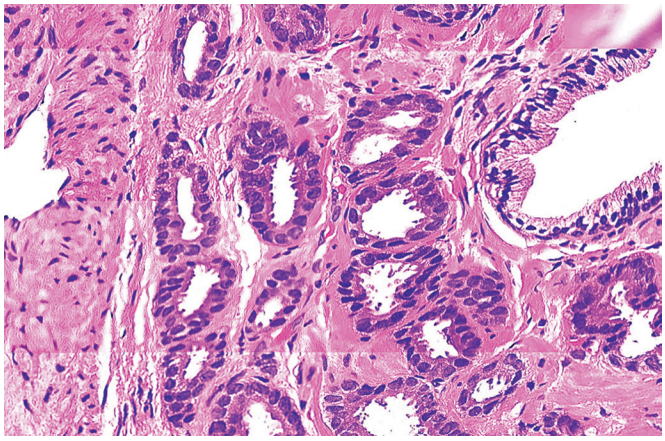

Figure 26.21 Gleason score 3 + 3 = 6 prostatic adenocarcinoma composed of small crowded glands.

gland only with great difficulty to rare anaplastic tumors.[212,213] The architectural patterns of prostate cancer can be quite varied, but the four major cytoarchitectural patterns described by Totten et al., and coauthored by Arthur Purdy Stout, still represent a useful framework for discussion.[159] These patterns are: medium-sized glands, small glands, diffuse individual cell infiltration, and cribriform. We would also add the pattern of small tumor nests (so-called poorly formed glands). Carcinomas composed of *medium-sized glands* are detected on low-power examination by virtue of the closely spaced arrangement of those glands, the prominent luminal cytoplasm with orientation of nuclei against the basement membrane, the smooth inner luminal surface, and the scanty intervening stroma (Fig. 26.20). Tumors made up of *small glands* appear as expansive nodules on low power or as an infiltrative population of individual glands that percolate between benign glands (Fig. 26.21). The individual glands have a regular round configuration and small size. Both of these architectural patterns (but particularly the latter) are accompanied by cytologic abnormalities in the form of nuclear enlargement, nuclear hyperchromasia, and prominent nucleoli ("macronucleoli," defined as measuring >1 μ in diameter).[214,215] Mitoses are also of significance, but they are rarely found in well-differentiated tumors composed of either medium-sized or small glands. The pattern of *diffuse cell infiltration* resembles somewhat that of invasive lobular carcinoma of the breast (Fig. 26.22), but this pattern is relatively rare. The *cribriform* pattern varies in the dimension of the epithelial aggregates, ranging from large expanses of anastomosing epithelium to small- or medium-caliber glands with complex intraluminal proliferations (Fig. 26.23). The gland-forming types of prostatic adenocarcinoma are usually lined by a single cell layer, but occasionally they exhibit a stratified epithelium that may simulate PIN.[216] An additional pattern of growth that has recently been described is that referred to as *glomeruloid*. It is characterized by the presence of intraluminal ball-like clusters of

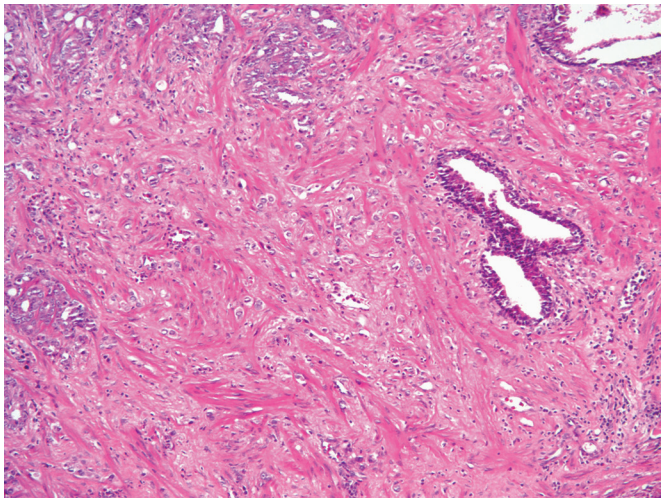

Figure 26.22 Poorly differentiated Gleason score 5 + 5 = 10 prostatic adenocarcinoma growing in a diffuse fashion. The appearance is reminiscent of that of invasive lobular carcinoma of breast.

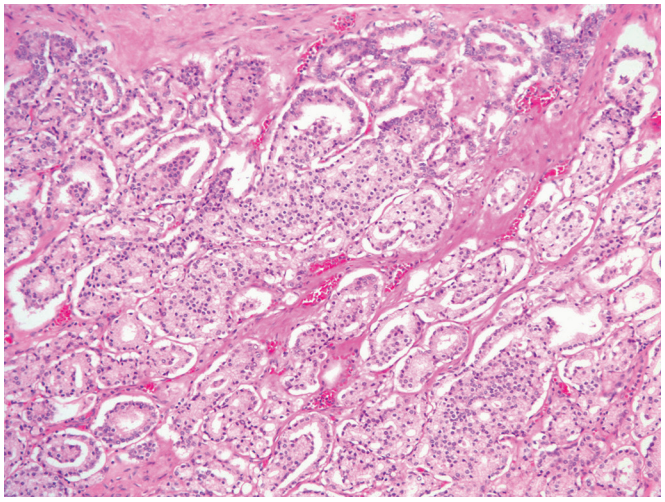

Figure 26.23 Prostatic adenocarcinoma with cribriform histology.

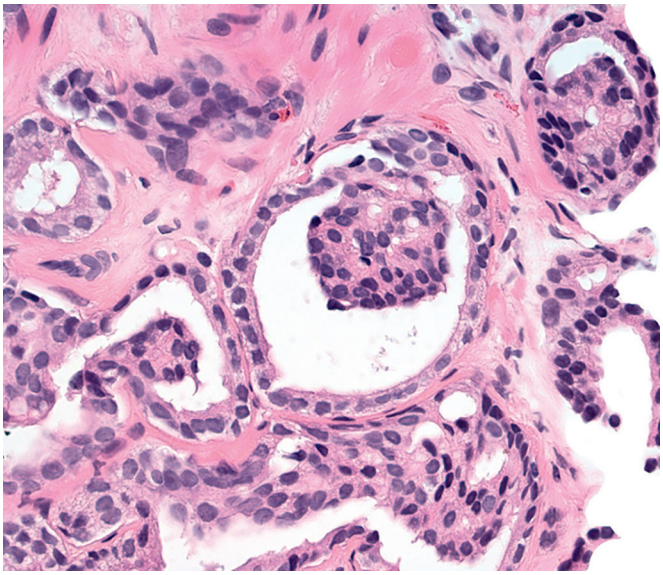

Figure 26.24 Prostatic adenocarcinoma with glomerulations is regarded as Gleason pattern 4.

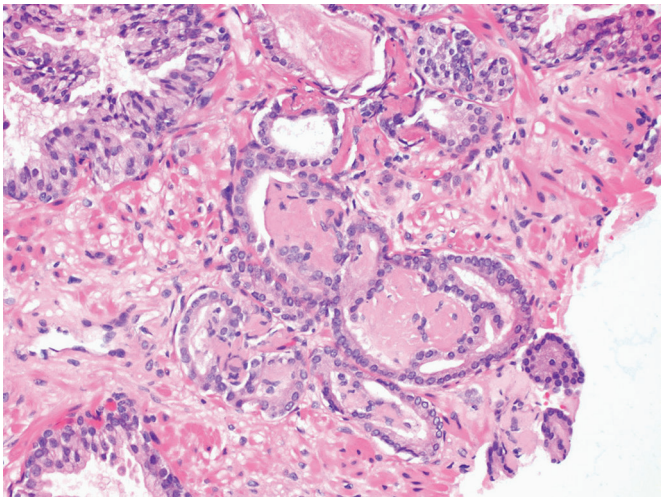

Figure 26.25 Prostatic adenocarcinoma with mucinous fibroplasia/collagenous micronodules.

tumor cells[217] and is regarded by many as a pathognomonic sign of malignancy (Fig. 26.24).[218]

The claim has been made that the rare prostatic adenocarcinomas arising in the transition zone have a distinct morphology, characterized by glands of variable size with tall columnar cells displaying basally located nuclei and clear to pale pink cytoplasm, but these features are neither specific nor consistent.[209]

Squamous metaplasia is an uncommon but well-documented finding in prostatic carcinoma (especially of the high-grade type). It is often, but not always, seen in the setting of prior hormonal or radiation therapy and is associated with a poor prognosis.[219]

The patterns just mentioned are often seen in combination, either synchronously or metachronously. For instance, a pattern of diffuse cell infiltration can be seen after the partial removal of a better differentiated neoplasm.[220] It should be mentioned here that it is on these patterns and their admixture, as seen on low-power examination, that the Gleason grading scheme (to be described later) is primarily based.

The presence of prostatic glands within perineurial spaces is common in these tumors.[221] This finding is a strong indicator of malignancy but is pathognomonic only when circumferential.[144]

The stroma surrounding the neoplastic glands may show a combination of hypercellularity and deposition of a basophilic ground substance (*"mucinous fibroplasia"* or *"collagenous micronodules"*), which has also been suggested as a pathognomonic feature of cancer (Fig. 26.25).[222,223]

Deeply eosinophilic protein crystalloid structures are seen in the glandular lumina of 10%–23% of prostatic carcinomas and are particularly common in tumors composed of medium-sized glands (Fig. 26.26).[224,225] Their presence usually indicates malignancy, but their occasional occurrence in benign glands has been documented.[226] When the latter is the case, their presence should not be viewed as indicating a significant risk factor for the subsequent development of cancer.[227,228] The intraluminal secretion of malignant glands often has a bluish hue ("wispy blue mucin"), indicative of a mucinous composition. The presence of corpora amylacea in the glandular lumen is not necessarily a sign of benignancy, as formerly believed; these formations can also be exceptionally found in association with malignant glands.[229,230]

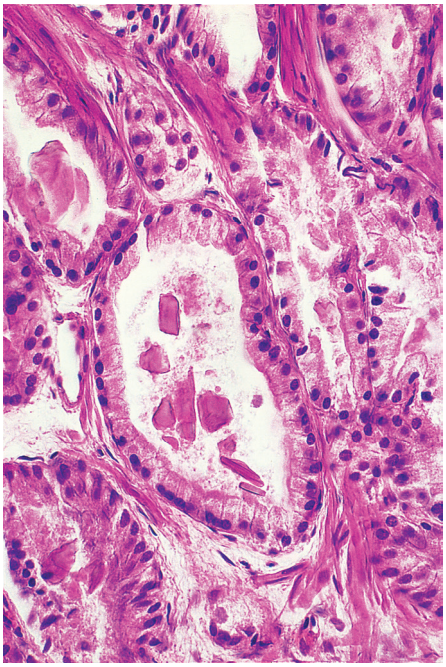

Figure 26.26 Well-differentiated prostatic adenocarcinoma showing intraluminal crystalloids.

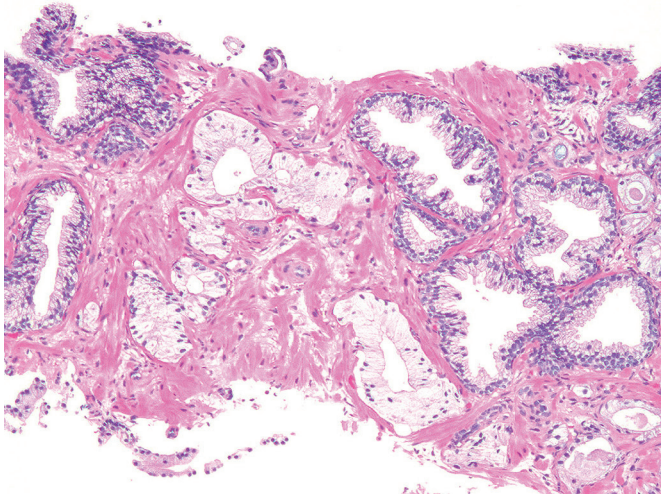

Figure 26.27 Prostatic adenocarcinoma with foamy gland features. The nuclei are often small and condensed in this specific variant.

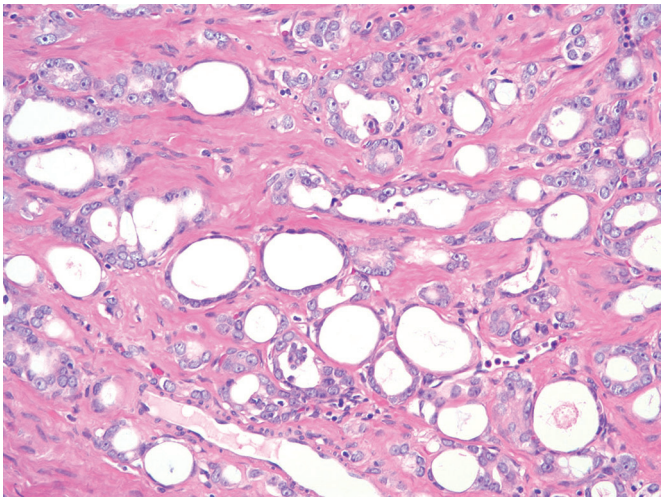

Figure 26.28 Prostatic adenocarcinoma with atrophic features. Despite the lack of cytoplasm, the glands were infiltrative and the nuclei maintained cytologic features of carcinoma.

Many variations of this already complex "basic" pattern have been described. Some are distinctive enough to be regarded as separate microscopic types, and are described later, in a section of their own. Others are variations of less degree, although still important because of the diagnostic errors they may engender. These treacherous variations of prostatic adenocarcinoma include:

1. *Foamy gland carcinoma*. The cytoplasm of the carcinoma cells usually has a nondescript, finely granular appearance, but on occasion it is clear or foamy ("xanthomatous") because of the massive accumulation of lipids (Fig. 26.27).[231] When this feature is prominent, the tumor is known as *foamy gland carcinoma*.[231] Its microscopic recognition can be difficult, particularly at metastatic sites.[232] The voluminous tumor cells are cuboidal to columnar, and the nuclei are small and often pyknotic. Nucleoli are not particularly conspicuous.[233] Most foamy gland carcinomas are assigned a low Gleason score (3 + 3 = 6), but a high-grade form of this variant exists.[234]
2. *Prostatic adenocarcinoma with atrophic features*. This variant, which mimics a benign hyperplastic change, is composed of tumor cells with an attenuated cytoplasm, such that the nuclei occupy almost the entire cell height (Fig. 26.28). These cells are identifiable as malignant because of their infiltrative pattern of growth, nuclear enlargement, macronucleoli, and most often the presence of adjacent carcinoma of the ordinary type.[235-237]
3. *Pseudohyperplastic prostatic adenocarcinoma*. As indicated by its name, this variant resembles many of the features of hyperplastic glands at the architectural level, including papillary infoldings and gland branching. On low power, the tumor has a deceptively bland microcystic appearance, a feature that it shares with the atrophic type.[238] Clues that identify the lesion as malignant are nuclear enlargement, orientation of nuclei at the basement membrane, macronucleoli, mitoses, and intraluminal crystalloids.[239,240]
4. *PIN-like adenocarcinoma*. Rare invasive prostatic adenocarcinomas may have medium- to large-caliber glands and a stratified epithelial lining, simulating high-grade prostatic intraepithelial neoplasia (PIN).[216,241] Unlike PIN, these carcinomas have a crowded arrangement beyond the normal anatomic distribution of normal glands (Fig. 26.29). In some cases, the neoplastic cells may appear pseudostratified columnar.[214] While the term "PIN-like ductal adenocarcinoma" has been applied to these later cases, we recommend avoiding use of the term "ductal" since these carcinomas behave similar to low grade acinar adenocarcinomas.
5. *Aberrant p63 expressing carcinoma*. A rare subset of prostatic adenocarcinomas express nuclear p63 in the neoplastic secretory cell population.[242,243] They lack a basal cell population, both by p63 and other high-molecular-weight keratins. These carcinomas often have a somewhat atrophic appearance with scant cytoplasm, slit-like luminal spaces, and occasional intraluminal eosinophilic secretions (Fig. 26.30A and B). This rare subset of carcinomas is also thought to be molecularly distinct.[244]

"Minimal Adenocarcinoma" and Atypical Small Acinar Proliferation

A particularly vexing and increasingly frequent problem in the handling of prostatic needle biopsies is represented by the foci of small atypical glands that are suspicious but not diagnostic

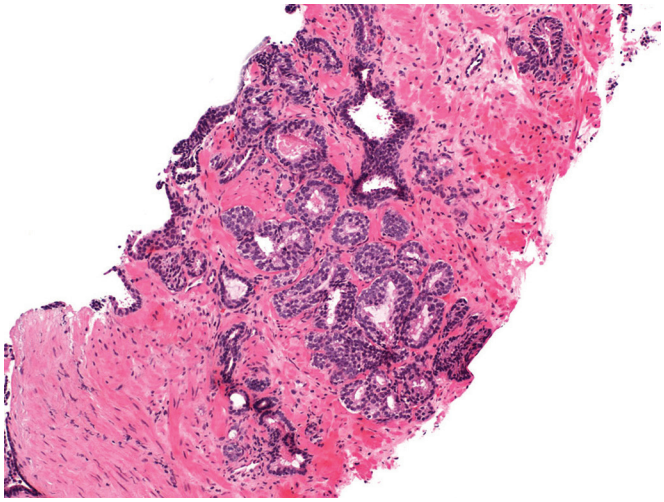

Figure 26.29 Prostatic adenocarcinoma with PIN-like features.

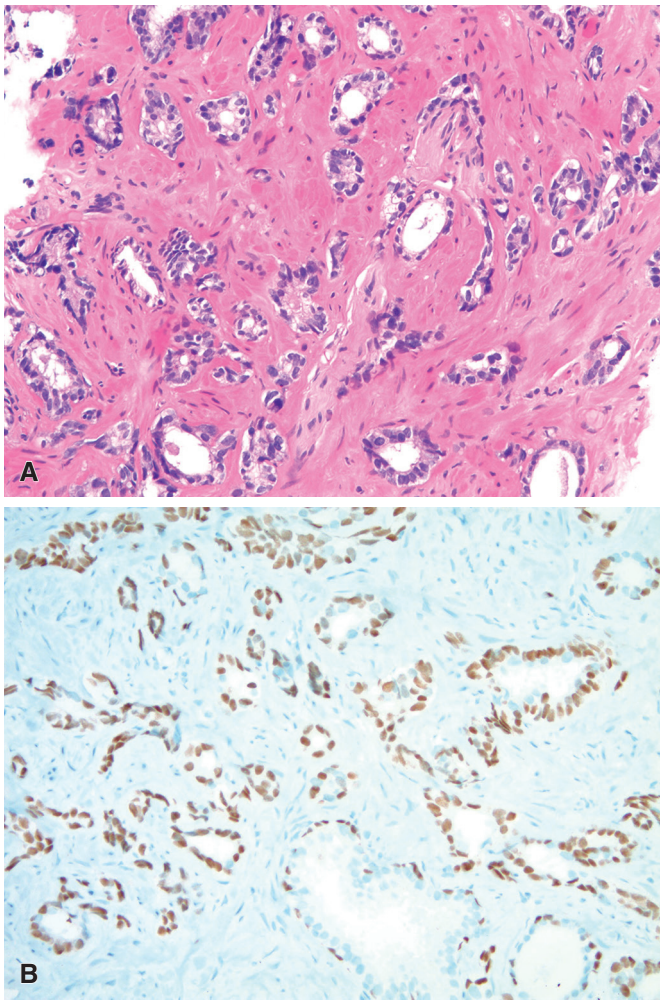

Figure 26.30 **A,** H&E section of an aberrant p63 expressing carcinoma showing somewhat atrophic features with paired p63 immunostaining **(B)**. Importantly, the nuclear staining is in a secretory cell pattern, not a basal cell pattern.

of carcinoma. Minimal criteria for the unequivocal diagnosis of malignancy have been presented.[245-247] These criteria have been particularly well spelled out and illustrated by Grignon.[248] For the cases in which the recommended threshold is not reached, terms such as "atypical glands suspicious of malignancy" and *"atypical small acinar proliferation (ASAP) suspicious of malignancy"* have been proposed.[249-252] However, no matter which criteria are employed, there is inevitable variability in the diagnosis as focal carcinoma versus "atypical suspicious."[253] Approximately 4%–6% of prostatic biopsies cannot be confidently placed into a benign or malignant category, either with morphology alone or after immunostaining with 34βE12 keratin and/or racemase.[254-256] It therefore seems to us wholly appropriate to express this uncertainty in the pathology report, whether using the ASAP acronym or with a descriptive "canned" text, as frustrating as this may be for the urologist and the patient.[257] One thing is certain: a patient with such a diagnosis warrants a second biopsy.[251,258]

Ductal Adenocarcinoma

The other major (but numerically less significant) type of prostatic carcinoma is the ductal subtype, which may be more commonly seen in a periurethral location (Fig. 26.31).[259-262] Cystoscopic examination may show a polypoid villous or an infiltrative urethral component. Microscopically, ductal carcinoma is characterized by papillary and cribriform architecture lined by columnar pseudostratified malignant epithelium (Fig. 26.32).[263] Many prostatic carcinomas presenting as macrocystic tumors (i.e. cystadenocarcinomas) have ductal features.[264] Rarely, the tumor is accompanied by pagetoid spread in the prostatic urethra.[265] Because ductal adenocarcinomas may show intraductal spread, intact basal cells may be identified by immunostains and should not alter a malignant diagnosis.[266] The tumors tend to have a more advanced stage at presentation and a higher short-term survival rate than typical acinar carcinomas, but not when controlled for grade, tumor volume, and stage.[267]

An important point for pathologists is that some prostatic ductal carcinomas may present as small prostatic urethral polyps identified by a transurethral evaluation. The morphologic findings may suggest a villous adenoma of the urothelial tract or a benign prostatic urethral polyp[268]; however, the presence of cribriform growth and/or lining by columnar cells should prompt careful consideration of prostatic adenocarcinoma (Fig. 26.33). Immunoreactivity with PSA and/or NKX3.1 can help with confirmation of prostatic epithelial

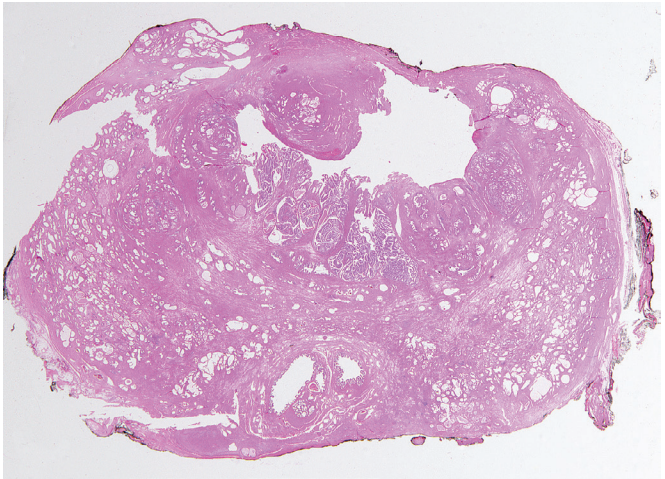

Figure 26.31 **Whole Mount of Ductal Adenocarcinoma.** The tumor is centrally located and has a distinctly papillary configuration.

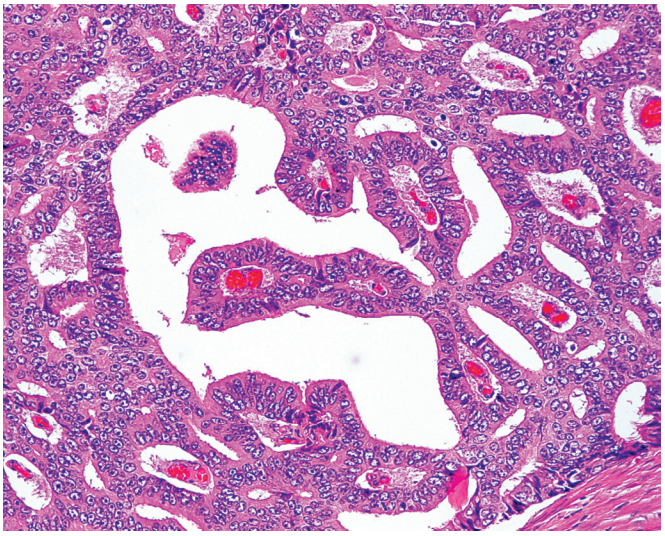

Figure 26.32 Ductal adenocarcinoma of prostate with papillary features.

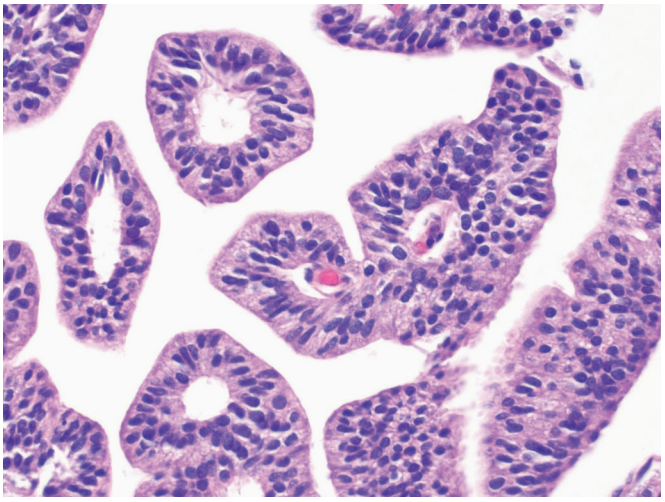

Figure 26.33 Ductal adenocarcinoma of the prostatic urethra mimicking a benign polyp or a papillary urothelial neoplasm.

origin. As in more typical forms of ductal adenocarcinoma, basal cell markers may show a patchy layer of preserved cells. Despite the morphologically subtle features, most of these tumors are high grade and high stage at radical prostatectomy. In approximately 10% of ductal carcinomas diagnosed on transurethral biopsy, no residual tumor is found at radical prostatectomy; therefore, some authors recommend transrectal prostate biopsies to assess extent of disease prior to definitive surgery.[269]

Immunohistochemical Features

Two immunohistochemical markers for prostatic epithelium demonstrable in routinely processed material with polyclonal or monoclonal antibody are PSAP and PSA.[270-273] They do not distinguish between benign and malignant processes in the prostate, but are of great use in identifying the prostatic origin of metastatic tumors, since they are positive in all but the most undifferentiated cases[274-276] and in occasional advanced cases following hormonal therapy.[277] NKX3.1 is a more recently described nuclear marker that has improved sensitivity and specificity over PSA and PSAP and is rapidly becoming the prostatic epithelial marker of choice in many departments.[9,11,278] A combination of these markers is useful in the differential diagnosis between poorly differentiated prostatic and urothelial tumors, especially if used as part of a panel together with high-molecular-weight cytokeratin, p63, and/or GATA3.[279,280]

Another prostate-related marker is so-called "PSMA."[281] This is a membrane-bound glycoprotein that is expressed in all types of prostatic adenocarcinoma. Curiously, this expression *increases* from benign epithelium to high-grade PIN to adenocarcinoma.[282]

The most promising marker to have appeared in recent times and claimed to be highly sensitive for prostatic carcinoma is P504S, a cytoplasmic protein that has been isolated through microarray screening.[283-285] It is an α-methylacyl-CoA racemase (referred to herein as *racemase*) that plays a role in the beta-oxidation of branched-chain fatty acid and fatty acid derivatives.[283] It is related to tumor differentiation,[286] it is not always present in carcinoma,[287] it can be expressed in a very heterogeneous fashion in the same case,[266] and can also be detected in atypical adenomatous hyperplasia, partial atrophy, some benign glands, and PIN.[288,289] The most specific pattern of immunoreactivity is strong circumferential luminal staining. While it can be useful for the detection of small foci of carcinoma in needle biopsies,[290,291] and for the confirmation of a diagnosis of malignancy in particularly difficult types of prostatic carcinoma (such as foamy gland and pseudohyperplastic), it must be used very cautiously with careful morphologic correlation.[292]

Prostatic carcinoma cells are often immunoreactive for androgen and progesterone receptors, but much less so for estrogen receptors.[293-296] The latter is related to the Gleason grade and score.[297] HER2/NEU protein is overexpressed in androgen-independent prostatic cancer, a situation somewhat analogous to that operating in breast carcinoma.[298] Exceptionally they show nuclear staining for CDX2, a potentially dangerous trap in the differential diagnosis with intestinal adenocarcinoma.[299]

Prostatic carcinoma cells are reactive for low-molecular-weight keratins.[300] In contrast to urothelial carcinoma, they stain only rarely for CK7 and CK20.[279,301] However, studies have shown the CK7/CK20 phenotype of prostatic adenocarcinoma is very heterogeneous in high-grade carcinomas, limiting its diagnostic utility.[302] Given the sensitivity and specificity of the NKX3.1 and GATA3 panel for the distinction of poorly differentiated prostatic versus urothelial origin, we would argue that CK7/CK20 profiling is no longer appropriate.

Antibody 34βE12 identifies the high-molecular-weight keratin present in the basal cells in the prostatic glands and is therefore of considerable diagnostic use, it is usually present (although sometimes discontinuously) in benign glands and absent in ordinary adenocarcinoma (of peripheral ducts and acini) regardless of grade.[303-305] Three caveats, however, are in order: (1) this marker is often present, either as a continuous or discontinuous layer, in ductal carcinoma[306]; (2) it may also be expressed, albeit exceptionally, in the carcinoma cells themselves (depending on the antibody clone utilized),[307] a point to remember in the differential diagnosis with urothelial carcinoma[243,308,309]; and (3) most importantly, it may be lacking in small foci of atypical glands, and therefore its absence is not necessarily diagnostic of carcinoma.[310,311] Useful measures proposed to optimize the detection of this important marker include the use of antigen retrieval[312] the systematic preparation of "intervening" unstained slides, in view of the fact that the lesion being evaluated may otherwise be no longer present in the residual block[313]; and the restaining of destained hematoxylin–eosin sections if the above procedure had not been carried out.[314] Other markers that are being used for the same purpose are keratin 5/6 and p63[315-317] or combinations thereof.[289]

A particularly powerful technique for the evaluation of small acinar proliferations is the use of an immunohistochemical multiplex

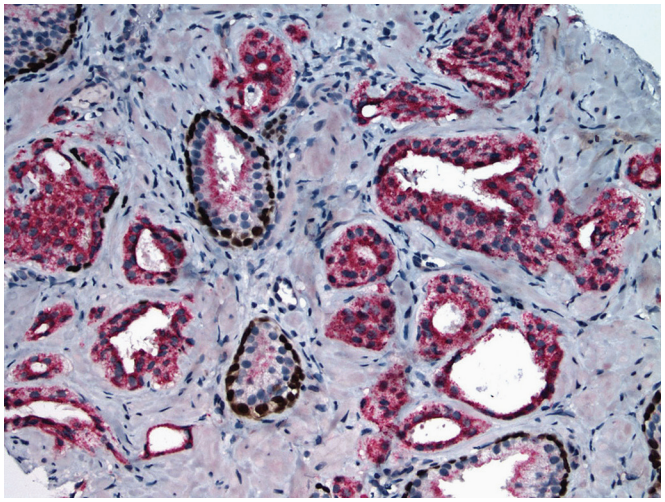

Figure 26.34 Immunohistochemical multiplex stain with HMWCK, p63, and P504S. The carcinoma cells show strong circumferential luminal staining for P504S with an absence of basal cells.

composed of racemase, 34βE12, and p63, or simply racemase and 34βE12.[318-321] Variations in the theme include cocktails made up of 34βE12 and p63,[322] and/or PSA, 34βE12 and/or p63.[323] In an ideal world, a malignant gland should show luminal reactivity for P504S in the luminal cells and absence of staining for the two basal cell markers, whereas the opposite should be true for benign glands (Fig. 26.34).[319] Most of the time it works this way, but the reader will not be surprised when told that exceptions occur with all three of the stains and, therefore, with the resulting pattern.[324,325] These stains should only be used in evaluating a focus suspicious for carcinoma by initial morphologic review and never in blind screening fashion.

Molecular Profile and Genetic Susceptibility

Many cytogenetic and molecular alterations have been described in prostatic adenocarcinoma.[326-329] Allelic loss has been found in about half of the cases,[330-332] and the suggestion has been made that chromosomes 8p, 10q, 13q, 16q, and 17p may be the sites of tumor suppressor genes.[330,333,334]

One of the most common genetic alterations in prostatic adenocarcinoma, found in approximately half of all cases, is fusion of the androgen-responsive serine protease gene *TMPRSS2* (21q22.2) with one of the *ETS* transcription factor gene family members.[334] The latter include *ERG* (21q22.2), *ETV1* (7p21.2), *ETV4* (17q21), and *ETV5* (3q27), with *ERG* accounting for >90% of cases. *TMPRSS2–ERG* fusion usually results from an interstitial deletion at 21q22.2–22.3, which causes juxtaposition of the two genes normally located 3 Mb apart. This molecular alteration appears to be an early event in the development of prostate adenocarcinoma. Interestingly, expression of the fusion transcript is bypassed and downregulated as tumor progresses to become androgen resistant.[335] There have been reports on the association of presence of *TMPRSS2–ERG*, certain gene fusion variants, or increased *ERG* copy number to be correlated with higher clinical stage and more aggressive disease,[334] but most reports have not found any correlation.[336]

Point mutations in *SPOP* are identified in approximately 10% of prostate cancers and are commonly associated with deletions of *CHD1*.[337,338] This *SPOP*/*CHD1*association and their mutual exclusivity with ETS rearrangement suggest a distinct molecular subtype.

Loss of the *PTEN* tumor suppressor gene is a common somatic event in prostate cancer, ranging from 10% to 70% in reported series, and correlates with high-grade and high-stage disease at radical prostatectomy.[339,340] Initial work studied deletions in the *PTEN* locus at 10q23 by FISH, showing that heterozygous *PTEN* deletion is more common than homozygous deletion.[341] Recent studies have shown that immunohistochemical evaluation for PTEN protein loss may serve as a sensitive surrogate for gene deletions.[342,343]

Mutations of *TP53* have been found in a subset of prostatic carcinomas characterized by a highly proliferative pattern and an aggressive behavior.[344] Conversely, alterations of *TP53* and *MDM2* genes are infrequent in clinically localized ordinary adenocarcinomas.[345,346] They are also seen more commonly in samples from metastatic sites than in those from primary tumors.[347] Alterations of the *RB* tumor suppressor gene occur in a significant fraction of prostatic adenocarcinomas.[348] *HER2* gene amplification is seen in about one-third of prostatic adenocarcinoma cases; it correlates with tumor grade, stage, and nondiploid DNA content.[349] It also seems to correlate with androgen independence of the tumor.

Prostatic carcinomas treated with androgen ablation therapy often eventually become androgen resistant. The latter phenomenon usually results from aberrant activation of the androgen receptor by gene amplification, mutation, phosphorylation, activation of coregulators, or androgen-independent activation.[334,350]

Positive family history of prostate cancer in a first-degree relative is an established risk factor for the disease (two- to three-fold risk).[351] While it is estimated that inherited factors account for 40%–50% of cases, it has been difficult to delineate specific genes. This is likely due to the high incidence of prostate cancer in in the general population and the fact that high- to moderate-penetrant gene variants tend to be rare, while more common genetic variants tend to have low penetrance.[352] *BRCA2* mutations have been associated with increased prostate cancer risk (and more aggressive prostate cancer), in addition to their more common breast and ovarian cancer risk.[353-355] *HOXB13* mutation also predisposes to prostate cancer, and a histologic and molecular correlation study demonstrated frequent "pseudo-hyperplastic morphology" as well as low prevalence of ERG fusion in this group.[356,357] Patients with mutations in mismatch repair gene (Lynch syndrome) also have an increased risk for prostate cancer.[358]

Other Microscopic Types

Several distinct morphologic types of prostatic carcinoma exist, most of them probably representing variants of acinar adenocarcinoma.[359,360] These include the following:

1. **Prostate adenocarcinoma with neuroendocrine differentiation.**

   This is a very difficult area in prostate pathology because of lack of consensus and poor reproducibility. One group of authors has proposed a morphologic classification that includes: usual prostate adenocarcinoma with neuroendocrine differentiation, adenocarcinoma with Paneth cell neuroendocrine differentiation, well-differentiated neuroendocrine tumor (carcinoid tumor), small cell carcinoma, large cell neuroendocrine carcinoma, and mixed neuroendocrine carcinoma-acinar adenocarcinoma.[361] This classification scheme has been recently adopted by 2016 WHO committee. A major problem is that many otherwise typical high-grade prostatic adenocarcinomas express neuroendocrine markers by immunohistochemistry (ranging from 10% to 100% in various series), but this finding has no proven clinical significance.[362] Therefore, immunohistochemistry for neuroendocrine markers is not recommended for cases of morphologically typical high-grade acinar adenocarcinoma.

   A rare subtype of **prostatic adenocarcinoma has Paneth cell–like neuroendocrine differentiation**, characterized by patchy or diffuse presence of cells with eosinophilic cytoplasmic granules. These carcinomas may grow in nests, cords, and single cells, but studies suggest they are clinically indolent and should not be

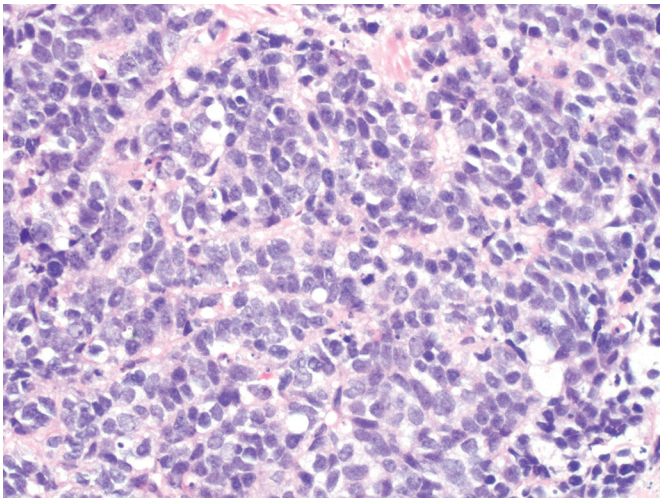

Figure 26.35 Small cell carcinoma of the prostate, morphologically identical to its lung counterpart.

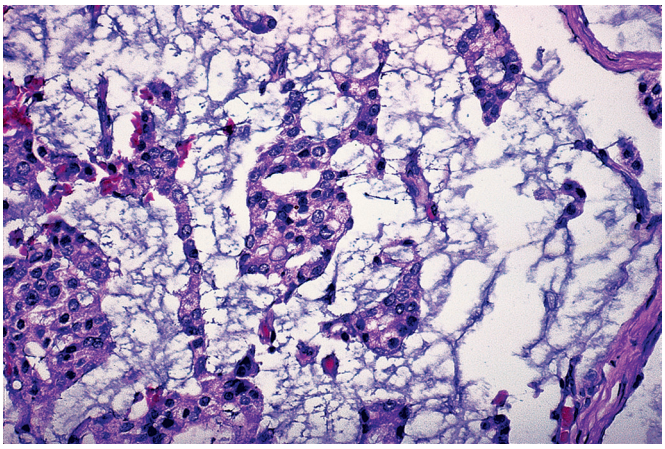

Figure 26.36 Mucinous Adenocarcinoma of Prostate. Most of the mucin is located extracellularly.

graded.[363,364] Primary **well-differentiated neuroendocrine tumor** ("carcinoid tumor") of the prostate gland is exceedingly rare and is morphologically identical to those occurring in other anatomic locations.[365] These may be more common in multiple neuroendocrine neoplasia syndromes.[366] As in other sites, well-differentiated neuroendocrine tumors often have a favorable prognosis.

Small cell carcinoma is morphologically similar to the homonymous lung tumor (Fig. 26.35).[367-369] This can present in a pure form or be associated with ordinary adenocarcinoma, either synchronously or metachronously.[368,370,371] Some of these tumors have resulted in Cushing syndrome[372] or inappropriate antidiuretic hormone secretion.[373] Features of endocrine differentiation are demonstrable immunohistochemically in some but not all of these cases.[374,375] In one large series, 88% of the tumors were positive for at least one neuroendocrine marker. PSA is positive in less than 20% of the cases, TTF-1 in about one-half, and CD44 reportedly in 100%.[368,376] These tumors feature a large number of apoptotic cells,[377] and their behavior is very aggressive.[367] On occasion, morphologically different forms of neuroendocrine differentiation (Paneth cell–like and small cell) are seen in the same neoplasm.[378] The main differential diagnosis is with high-grade (Gleason 5) prostatic adenocarcinoma.[379] In pure form, it may be difficult to determine if a small carcinoma is of prostatic or urothelial origin; however, that distinction has little relevance to treatment.

The last member of the neuroendocrine family to have been described in the prostate is **large cell neuroendocrine carcinoma**. Some of the reported cases have arisen after long-term hormonal therapy for prostatic adenocarcinoma.[380] This category is most problematic with regard to diagnostic criteria and reproducibility because of overlap with otherwise typical high-grade acinar adenocarcinomas.

2. **Mucinous (mucin-secreting) adenocarcinoma.** This tumor is accompanied by the formation of large amounts of intracellular and extracellular mucin, comprising 25% or more of the tumor (Fig. 26.36).[381,382] Its microscopic appearance is reminiscent of mucinous carcinoma of the breast. Microglandular, cribriform, "comedo," solid, and hypernephroid patterns may be present.[383] PSAP and PSA stains are usually positive. This tumor is said to differ from the ordinary prostatic adenocarcinoma by the rarity of bone metastases, the lack of hormone dependency, and less degree of response to radiation therapy. As a group, they do not seem to be more aggressive than garden-variety prostatic adenocarcinomas.[384] The differential diagnosis includes extension of mucinous carcinoma from the large bowel and Cowper's gland carcinoma.[385,386] Rare mucinous adenocarcinomas of urothelial origin are also described in the prostatic urethra and should be distinguished from those of prostatic origin.[387] Occasional mucin-secreting adenocarcinomas contain a population of neuroendocrine (including Paneth-like) cells.[388]
3. **Signet ring carcinoma.** This highly malignant neoplasm grows in a solid, acinar, or single file fashion and is composed primarily or exclusively of tumor cells with a signet ring configuration resulting from the intracellular accumulation of mucin.[389-392] Ultrastructurally, the cells have intracytoplasmic lumina lined by microvilli.[393] A treacherous artifact closely mimicking signet ring cells may be seen in the stromal cells and lymphocytes present in the stroma of TUR specimens.[394] The differential diagnosis includes involvement by either signet ring cell adenocarcinoma or plasmacytoid urothelial carcinoma of the urinary bladder or prostatic urethra.
4. **Adenosquamous carcinoma.** Some of these cases have been seen de novo, whereas others have occurred after radiation or hormonal therapy of ordinary adenocarcinomas (Fig. 26.37).[219,395-398]
5. **Squamous cell carcinoma.** Pure squamous cell carcinoma of the prostate is an extremely rare neoplasm. It can occur de novo or after hormonal therapy.[219,399-401] It has also been seen presenting as a well-circumscribed nodule in the prostatic transition zone.[402] It is closely related to adenosquamous carcinoma and in most cases probably represents the extreme manifestation of a similar metaplastic squamous change.
6. **Adenoid basal cell tumor**.[403,404] This process resembles adenoid cystic or basal cell carcinoma of the salivary gland. Some authors have regarded it as analogous to these carcinomas, while others classify it within the spectrum of basal cell hyperplasia.[170,263,405] The natural history of this tumor is much more indolent than that of the bona fide adenoid cystic carcinoma.[403,406] The key microscopic features are expansile pattern of growth, multinodularity, a cribriform architecture with luminal-basal lamina–like material, a surrounding fibromyxoid stroma (resembling stromal hyperplasia), common occurrence of squamous differentiation, and merging with foci of basal cell hyperplasia (Fig. 26.38). PSAP and PSA staining is negative or focally positive. The differential diagnosis includes acinar adenocarcinoma with cribriform pattern of growth, basaloid carcinoma (see immediately next), and true adenoid cystic carcinoma. As for the alternative term basal cell

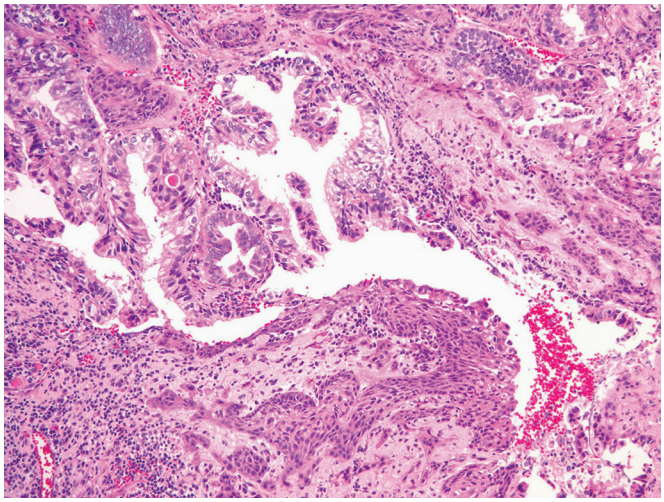

Figure 26.37 Adenosquamous carcinoma of the prostate gland, occurring after radiation therapy.

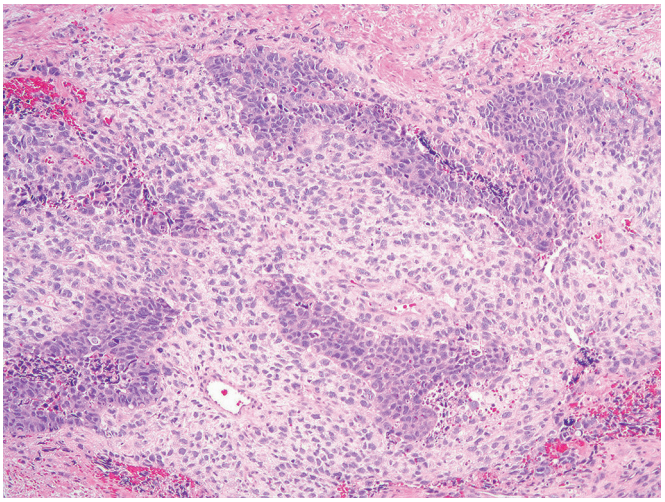

Figure 26.39 Sarcomatoid carcinoma of the prostate gland.

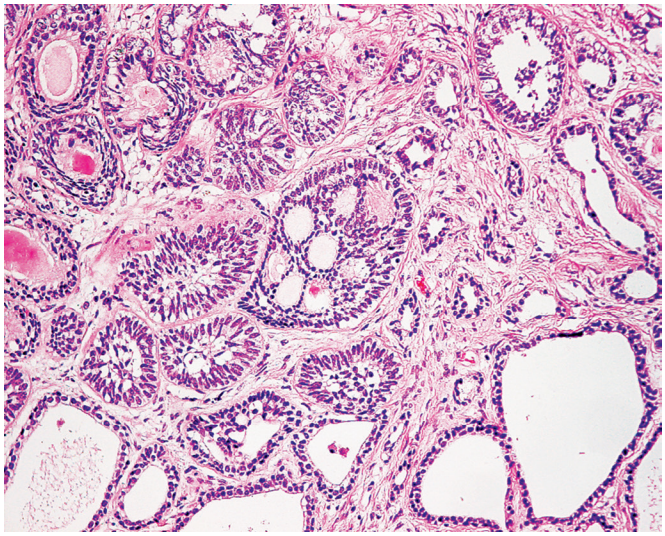

Figure 26.38 So-called adenoid basal cell tumor of prostate. The central tumor nest shows an appearance reminiscent of that seen in adenoid cystic carcinoma of salivary glands.

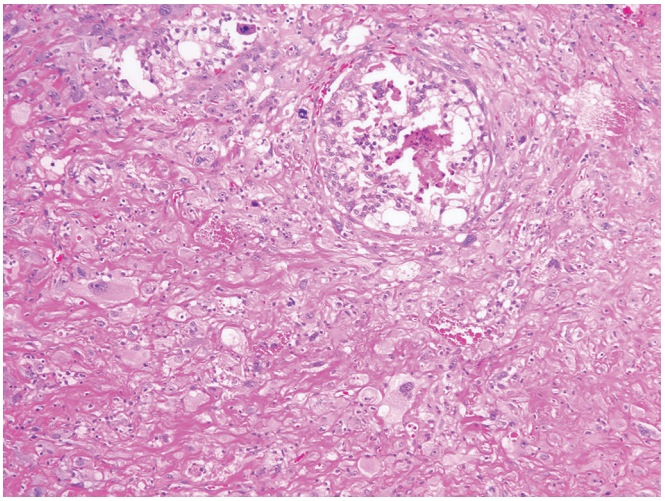

Figure 26.40 Pleomorphic giant cell carcinoma of the prostate gland.

carcinoma, in our opinion it should be avoided on morphologic and behavioral grounds.

7. **Basal cell carcinoma and adenoid cystic carcinoma.** While extremely rare, basal cell carcinoma is highly aggressive and has morphologic features comparable to those of basaloid (cloacogenic) carcinoma of the anal canal and basaloid squamous cell carcinoma of the upper aerodigestive tract[403,407] and should be clearly separated from adenoid basal cell tumor. Unfortunately, this is not always done and confusion ensues. Adenoid cystic carcinoma of the prostate is often reported under the term "basal cell carcinoma," but it has distinct morphology identical to its salivary gland counterpart.[170,408] Additionally, an identical *MYB* rearrangement is found in some cases, strongly supporting a unique neoplasm distinct from basal cell carcinoma.[408]
8. **Lymphoepithelioma-like carcinoma.** The appearance of this tumor is analogous to that of nasopharyngeal lymphoepithelioma.[409]
9. **Sarcomatoid carcinoma.** This tumor combines features of recognizable carcinoma with sarcomatoid elements, the latter having either nonspecific spindle cell or giant cell features, or showing divergent differentiation toward cartilage, bone, and/or skeletal muscle (Fig. 26.39).[410-413] The recently described *pleomorphic giant cell adenocarcinoma* can be regarded as a subtype of sarcomatoid carcinoma (Fig. 26.40).[414,415] The epithelial component is usually of adenocarcinoma type, but it may also have squamous features.[416] As in other sites, the distinction between carcinosarcoma and sarcomatoid carcinoma is arbitrary and probably unwarranted; most of the available evidence suggests that, whether a specific mesenchymal component is present or not, the tumor is in all likelihood of epithelial derivation.[410,417-419]

Intraepithelial Proliferative Lesions

PIN is the currently preferred term for a process involving prostatic ducts and acini, which has also been described as ductal–acinar dysplasia.[420,421] It is often multicentric and may be seen in all anatomic regions of the prostate gland. While originally divided into different "grades," only high-grade PIN is diagnosed and reported in modern practice. The reproducibility and clinical significance of lower-grade lesions is questionable at best. On scanning magnification, the glands of high-grade PIN appear more basophilic than surrounding glands due to the high nuclear to cytoplasmic ratio, nuclear crowding, and

more amphophilic cytoplasm. The presence of large nuclei with prominent nucleoli is the defining feature (Fig. 26.41). Importantly, to avoid overdiagnosis one should not need high-power magnification to see the nucleoli of high-grade PIN. The secretory cell nuclei near the basement membrane typically have the most pronounced cytologic atypia. Morphologic variations of PIN include *tufting*, *micropapillary*, *cribriform*, and *flat/atrophic* patterns at the architectural level, and *inverted (hobnail)* and *foamy* types at the cytologic level.[422-425] Of these, the cribriform pattern is the most difficult to distinguish from invasive tumors or intraductal carcinoma, particularly in biopsy specimens.[426] The presence of more than very focal cribriform architecture within a medium caliber gland should prompt consideration of intraductal carcinoma (see later).

Several studies have shown a statistical association between high-grade PIN and prostatic carcinoma, in the sense that PIN has been found in 59%–100% of step-sectioned radical prostatectomy specimens. It has also been shown that in prostates containing both PIN and adenocarcinoma, there is a good degree of concordance in the DNA ploidy pattern of both lesions.[427-429] These findings have led to the suggestion that PIN may have a high predictive value as a marker for carcinoma and to the recommendation to follow closely patients in whom PIN is identified in a prostatic biopsy.[430,431] It has also been shown that low-grade PIN is a relatively common finding in young male patients.[432]

In a study by Kronz et al.[433] repeat prostatic biopsy in patients with previous biopsy of high-grade PIN revealed invasive carcinoma in 32.2% of the cases. The incidence was 30.2% if only 1 or 2 cores had showed PIN, 40% with 3 cores, and 75% with >3 cores. If invasive cancer was not diagnosed on the first two follow-up biopsies, it was unlikely to develop later. If PIN was accompanied by the presence of adjacent small atypical glands, the risk of cancer on repeat biopsy was 46%.[434] Several more recent series have shown a much lesser degree of risk, to the point of raising questions at the predictive value of high-grade PIN.[435] However, Netto et al.[436] reestablished the prognostic significance of PIN by showing a 39% risk of finding prostatic carcinoma on repeat biopsies if the original biopsy had shown widespread (present in 4 or more biopsy cores) high-grade PIN. It would seem then as if the risk of cancer were directly related to the number of cores involved by PIN and not so much to the morphologic subtype.[437] Argument still persists as to the need for re-biopsy in men with only high-grade PIN on biopsy, regardless of extent. Particularly in the era of active surveillance, a few foci of high grade PIN often do not alter clinical follow-up strategies.

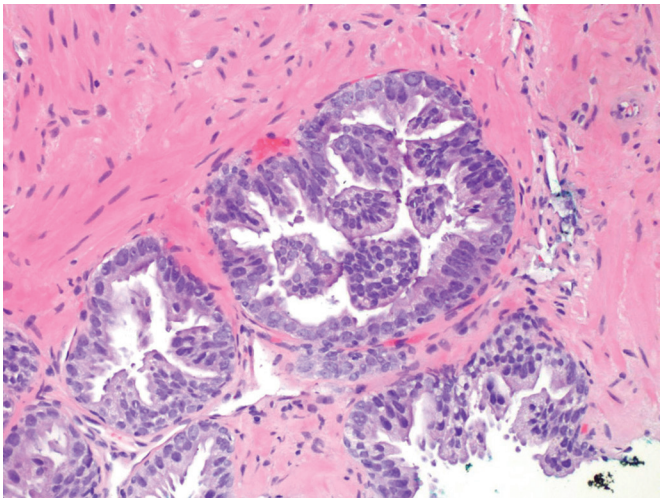

Figure 26.41 High-grade prostatic intraepithelial neoplasia.

Intraductal Carcinoma

While originally described in 1973,[438] intraductal carcinoma has become better recognized over the past decade and is now a distinct entity in the WHO Classification.[439] Numerous studies show the presence of intraductal carcinoma on biopsy is commonly associated with high-grade, high-stage disease at radical prostatectomy,[440-442] and predicts poor disease-specific survival.[443] Intraductal carcinoma is generally regarded as a late phase of intraductal spread by an aggressive carcinoma, but rare cases show only intraductal carcinoma, even at radical prostatectomy.[441]

Because intraductal carcinoma must be distinguished from PIN, precise histologic criteria are critical. Guo and Epstein defined intraductal carcinoma as malignant epithelial (i.e. prostatic secretory) cells filling large prostatic acini or ducts, with at least partial preservation of basal cells, forming either: (1) solid or dense cribriform patterns or (2) loose cribriform patterns or micropapillary patterns with either marked nuclear atypia (nuclear size 6× normal or larger) or nonfocal comedonecrosis. These malignant cells often involve and expand branching ducts and extend into adjacent acini (Fig. 26.42 A and B). Intraductal carcinoma is not factored into the Gleason grade but should be reported separately. Providing a comment discussing the prognostic significance with supporting references is often

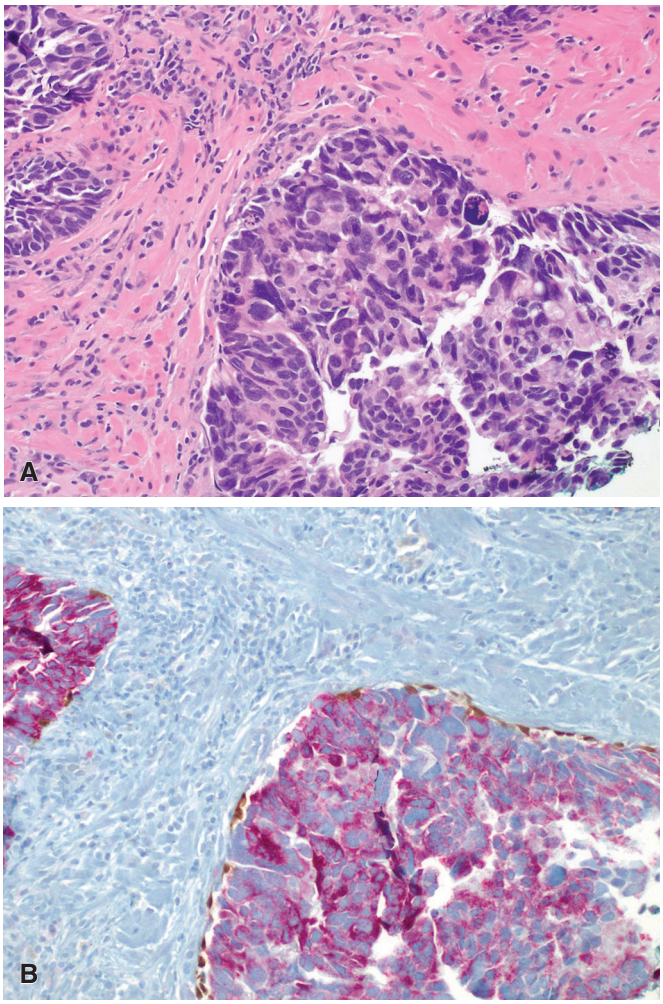

Figure 26.42 **A,** Intraductal carcinoma is characterized by a dense population of malignant cells filling the lumen. **B,** By definition, there is an intact basal cell layer (high molecular weight keratin, p63, and racemase stain).

helpful as varying levels of familiarity with this lesion are encountered.

Intraductal carcinoma may have histologic overlap with ductal adenocarcinoma, invasive acinar adenocarcinoma with cribriform architecture, and prostatic colonization by urothelial carcinoma. Ductal adenocarcinoma of the prostate often spreads within ducts (with retained basal cells), so the distinction from intraductal carcinoma may be difficult. Ductal carcinoma often has a true papillary architecture and neoplastic cells with a pseudostratified columnar morphology, compared to the typical cuboidal cells with relatively round nuclei in intraductal carcinoma. Invasive acinar adenocarcinoma with cribriform architecture typically has a more irregular distribution, other patterns of invasion, more variation in size and shape of the cribriform structures, and an absence of basal cells by immunohistochemistry. Urothelial carcinoma colonizing prostate glands may be distinguished by an absence of prostatic marker expression and reactivity for high-molecular-weight keratin, p63, and/or GATA3.

The distinction of high-grade PIN from intraductal carcinoma is critical for clinical management. Complex cribriform or solid architecture bridging the entire luminal space and extending into adjacent glands/ducts strongly argues for intraductal carcinoma. If the proliferation is not dense and/or does not bridge the entire space, then one must adhere to the nuclear pleomorphism criterion (i.e. 6× normal). Some cases are difficult to definitively classify, but given the implication of an intraductal carcinoma diagnosis, strict criteria must be followed. In borderline cases, a descriptive diagnosis such as "atypical intraductal proliferation" with an appropriate comment is justified to ensure re-biopsy. PTEN protein loss by immunohistochemistry has been suggested as surrogate marker to aid in the diagnosis of intraductal carcinoma, but its use is not widespread.[444,445]

Tissue Examination

Routine histologic evaluation of prostate tissue is generally based on initial transrectal biopsy or TUR specimens, and definitive radical prostatectomies. There is general agreement that adequate sampling of the core biopsy material entails cutting and staining three levels per core (step sections), with additional section(s) to be taken if atypical features are found.[446-449] Saving in-between unstained levels for possible immunohistochemistry is utilized at many centers and helps avoid loss of small atypical foci in deeper level sections. Specific recommendations on the amount of information to be included in the pathology reports of adenocarcinomas in core needle biopsy specimens are also available.[450,451]

The presence of tumor in a TUR specimen may signify extensive spread by conventional carcinoma from the peripheral portion of the gland or may be a manifestation of the rare type of carcinoma from the transition zone. The probability of detecting a carcinoma in a TUR specimen is directly related to the amount of sampling.[452] It has been estimated that if five blocks or 12 g of randomly selected chips are submitted, approximately 90% of the carcinomas will be detected.[453,454] With examination of eight blocks, the probability of detection rises to 98%.[455,456] The need for submission of remaining tissue in the cases in which incidental carcinoma is found depends on whether the lesion is a T1a (recommended) or T1b (not needed).[457]

Radical prostatectomy specimens can be examined by performing whole-mount sections or by accurately mapping the organ with standard-size sections.[458-461] The former produces material that is easier to evaluate and esthetically more pleasing but at a considerable investment of time and money. The mapping with standard-size sections, if properly done, provides roughly the same amount of information. For small, nonpalpable tumors, it has been recommended to sample the entire posterior region of the organ and to take an additional sections from the mid-anterior region of each lobe; if the latter is found to be positive, the entire ipsilateral region should be sampled.[461] The International Society of Urological Pathology (ISUP) has provided detailed recommendations for the evaluation and submission of radical prostatectomy specimens.[462]

Metastases

The most common sites of metastatic spread of prostatic carcinoma are the skeletal system and lymph nodes. Bone metastases are usually multiple but can be solitary.[463,464] They are characteristically osteoblastic and can radiographically simulate Paget disease or even osteosarcoma,[465] but they can also be mixed or entirely osteolytic. Sometimes, the appearance of a bone metastasis precedes by several years the urologic manifestations. Lumbar spine, sacrum, and pelvis are the most common locations, supposedly as a result of tumor spread via Batson's vertebral venous system.[466] However, any other bone can be involved through the systemic circulation.[467] Microscopically, clusters of malignant glands are seen surrounded by exuberant new bone formation. When the bone metastases are extensive, they can be accompanied by hypocalcemia, hypophosphatemia, and increased serum alkaline phosphatase levels.[468] Immunohistochemical reactions for PSAP, PSA, and NKX3.1 are usually positive, even after decalcification.

The most common pathway of nodal involvement is to the pelvic chains, from which the tumor spreads to the retroperitoneal nodes. However, in some instances, retroperitoneal node metastases may occur in the absence of pelvic node metastases; these patients are less likely to have metastases to bladder and rectum but more likely to have them in lungs and liver.[469] Rarely, metastases are also found in periprostatic/periseminal vesicle lymph nodes or in the perirectal lymph node basin.[470,471] The performance of surgical staging (including bilateral pelvic lymphadenectomy) has provided important information on the frequency of regional lymph node involvement and the pattern of spread of prostatic carcinoma.[472-475] Stage T1c tumors (nonpalpable, asymptomatic tumors) found because of serum PSA elevation have a very low incidence (<5%) of positive nodes. Latent prostatic carcinomas detected at autopsy are almost never accompanied by nodal metastases.[476]

Metastases can also occur in supradiaphragmatic lymph node groups.[477] Sometimes, involvement of a left supraclavicular[478,479] or a mediastinal node[480] is the first manifestation of the disease. Most of these tumors are poorly differentiated and not particularly suggestive of a prostatic origin on microscopic examination[481]; immunohistochemical staining is extremely valuable in establishing the prostatic origin of a metastatic adenocarcinoma.[482,483] In an older man, this possibility should always be considered when facing a poorly differentiated carcinoma of unknown primary site with relatively monomorphic round nuclei.

Lung metastases are not as rare as formerly believed; most of them exhibit a lymphangitic pattern of spread. Massive pleural effusion may be the initial symptom. On occasion, the process simulates primary lung carcinoma.[484] The pattern of growth may be microacinar, tubulopapillary, or carcinoid-like. Metastatic ductal adenocarcinoma may simulate metastatic colonic adenocarcinoma.[485]

Rarely, metastatic prostatic carcinoma is found unexpectedly in orchiectomy specimens.[486] Prostatic carcinoma also may metastasize to the breast, sometimes bilaterally, particularly in patients taking estrogens. This phenomenon is often confused clinically with gynecomastia and microscopically with primary breast carcinoma. In this regard, it is pertinent to note that several cases of primary breast carcinoma have been reported in patients treated with estrogen for prostatic carcinoma.

Other metastatic sites include liver, adrenal gland, central nervous system (including dura), eye, skin, and unusual locations such as

umbilicus ("Sister Mary Joseph nodule"), penis, and salivary gland.[486-498] In general, the degree of microscopic differentiation of the metastases and of PSA expression follows quite closely that of the primary tumor.[499,500] However, in almost half of the cases the Gleason score appears higher than in the primary tumor.[501]

Staging and Grading

Prostatic carcinoma spreads initially within the various compartments of the prostate itself, including ducts and acini, fibromuscular stroma, perineurial spaces, and blood vessels.[502,503] Extraprostatic invasion is common. Advanced tumor may extend into the seminal vesicles,[504,505] apex (distal aspect) of the gland, prostatic urethra (very rarely), and urinary bladder.[506]

The staging of prostatic adenocarcinoma in a radical prostatectomy specimen depends on histologic evaluation for extraprostatic extension. This may occur as infiltration of the carcinoma beyond the soft tissue plane at the prostatic interface with adipose tissue (Fig. 26.43), or less commonly beyond the contour of the prostate gland. Microscopic invasion of the smooth muscle taken at the bladder neck is also defined as extraprostatic extension (pT3a); however, this should be distinguished from direct invasion of the urinary bladder (pT4 disease), which generally requires macroscopic tumor involving the bladder with histologic confirmation, often by separate biopsy. In the interpretation of needle biopsies or radical prostatectomies, it should be remembered that there are normally bundles of striated muscle within the prostate gland, especially in the apex and anterior aspects; therefore the presence of prostatic glands adjacent to a skeletal muscle fiber is not necessarily evidence of carcinoma, nor is the presence of skeletal muscle adjacent to a carcinoma evidence that the tumor has extended outside the gland. Tumors should be listed as exhibiting seminal vesicle invasion (pT3b disease) only if the muscular wall of this organ is infiltrated by tumor.[507]

Rectal invasion is much less common, supposedly because of the resistance offered by the tough fibromuscular structure covering the posterior aspect of the prostate known as Denonvilliers fascia.[508] This invasion can manifest in the form of an anterior rectal mass (with an intact or ulcerated mucosa), an annular rectal stricture resulting from circumferential infiltration, or subserosal implants.[509] The diagnosis can be made from a colorectal biopsy, but only if the pathologist thinks of the possibility (a good example of Dr. Ackerman's "The man from Istanbul syndrome"!).[510,511]

The microscopic grading system developed by Gleason in conjunction with the Veterans' Administration Cooperative Urological Research Group[512,513] is currently preferred (with the modifications discussed later) to the other grading systems that have been proposed over the years.[514-518] It is based on the degree of glandular architectural differentiation and the growth pattern of the tumor in relation to the stroma as evaluated on low-power examination (Figs. 26.44–26.47; Table 26.1). The predominant tumor pattern (referred to as "primary") is graded from 1 to 5, and the "secondary" pattern (if present) is graded similarly, with the two numbers being added to obtain the Gleason *score* or *sum*. If the tumor has the same pattern throughout (i.e. it has only a "primary" pattern), the number is multiplied by 2 in order to obtain the final score.[519] Some tumors have a tertiary (or minor) pattern, which is reported only if it is of a higher grade.[520,521] In biopsies, the minor high-grade pattern is incorporated into the Gleason score. Gleason patterns 1 to 2 are not clinically meaningful in modern practice, so the grading system effectively begins at Gleason score 3 + 3 = 6.[451]

Criteria for Gleason pattern assignment have evolved over the past 50 years. Under the 2014 criteria, Gleason pattern 3 is comprised only of well-formed glands with central lumina.[451] Importantly, cribriform glands are no longer allowed in the pattern 3 category.

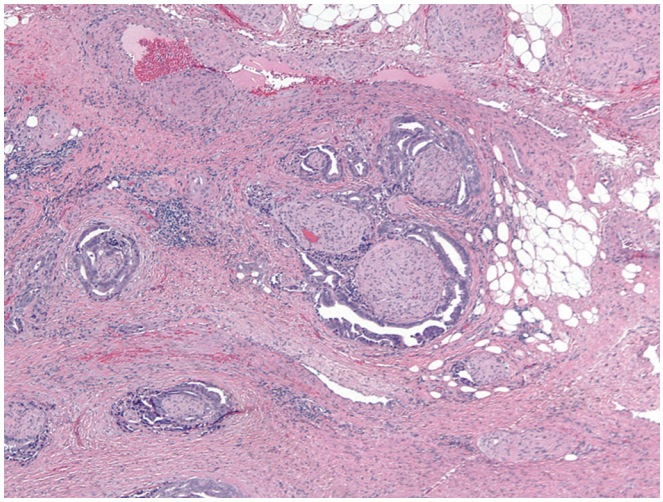

Figure 26.43 Extraprostatic extension as evidenced by prostatic adenocarcinoma extending into adipose tissue.

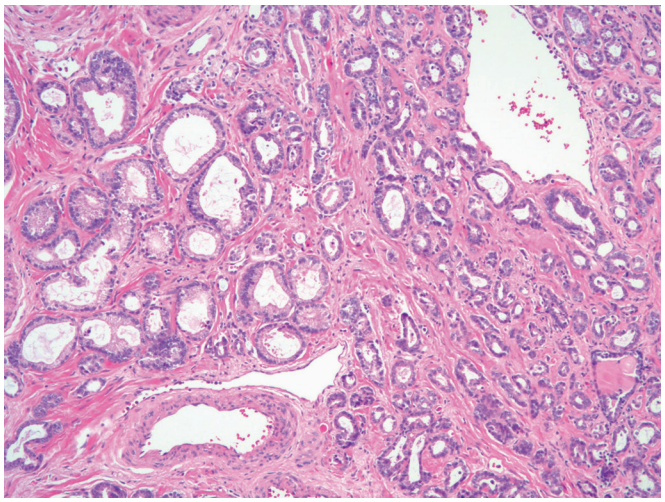

Figure 26.44 Prostatic adenocarcinoma, Gleason score 3 + 3 = 6/10 (Grade Group 1) characterized by distinct well-formed glands.

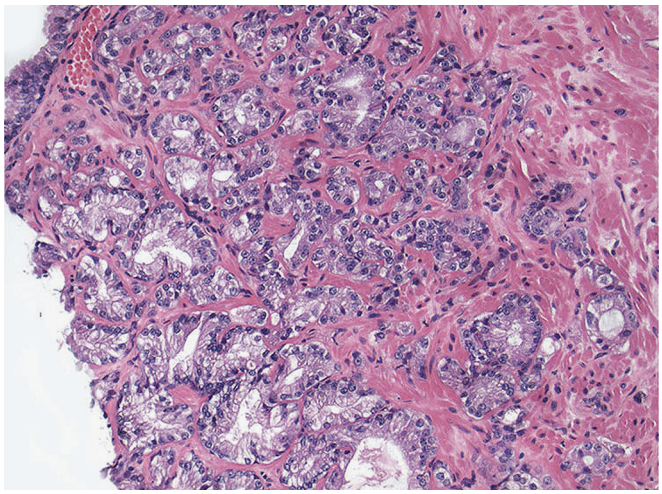

Figure 26.45 Prostatic adenocarcinoma, Gleason 3 + 4 = 7/10 (Grade Group 2). Pattern 4 is composed of "poorly formed glands."

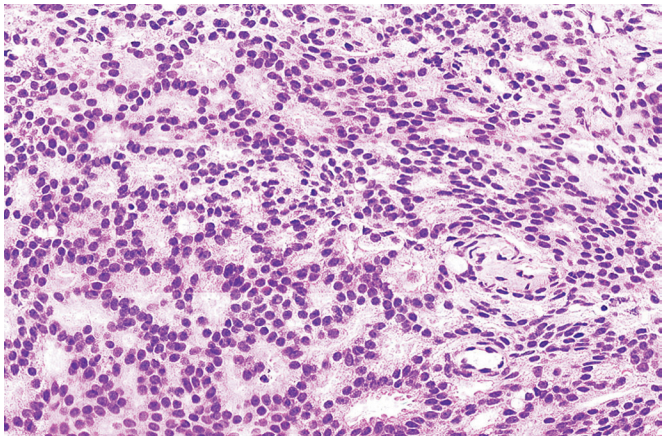

Figure 26.46 Gleason pattern 4 carcinoma characterized by cribriform glands.

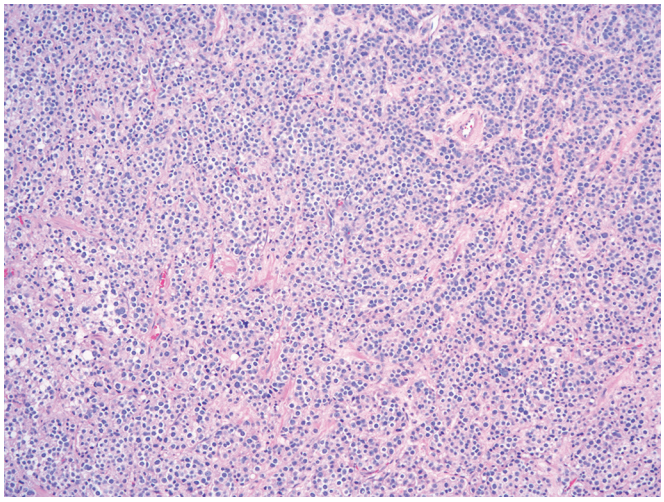

Figure 26.47 Gleason pattern 5 characterized by solid sheet-like growth.

Table 26.1 2014 modified Gleason grading and Grade Group comparison

GRADE GROUP	GLEASON SCORE	HISTOLOGIC FEATURES
1	≤3 + 3 = 6	Only individual discrete well-formed glands
2	3 + 4 = 7	Predominantly well-formed glands with lesser component of poorly formed glands, fused glands, glomerations, or cribriform glands
3	4 + 3 = 7	Predominantly poorly formed glands, fused glands, glomerations, or cribriform glands with lesser component of well-formed glands (if >5%)[a]
4	4 + 4 = 8 3 + 5 = 8 5 + 3 = 8	Only poorly formed glands, fused glands, glomerations, or cribriform glands[a] Predominantly well-formed glands with lesser component of sheets, cribriform glands with comedonecrosis, or single cells Predominantly sheets, cribriform glands with comedonecrosis, or single cells with lesser component of well-formed glands (if >5%)[a]
5	≥4 + 5 = 9	Only sheets, cribriform glands with comedonecrosis, or single cells[a]

[a]A lower-grade component, when less than 5% of the carcinoma, is not incorporated into the grade.

Gleason pattern 4 is heterogeneous and includes cribriform glands, glomerulations, "fused glands," and poorly formed glands. Pattern 5 carcinomas lack gland formation and are comprised by sheets, cribriform glands with central comedonecrosis, and single infiltrating cells mimicking lobular breast cancer. Subtle variants, such as pseudohyperplastic, atrophic, or "PIN-like" carcinoma, are graded by the same criteria but are typically Gleason score 3 + 3 = 6. Grading in the setting of mucinous fibroplasia is problematic, but the ISUP recommends to "subtract away" the mucinous fibroplasia and to grade based on underlying gland architecture.

As active surveillance has become more accepted, the threshold for distinguishing Gleason score 3 + 3 = 6 from 3 + 4 = 7 carcinomas has become more important. Historically, this has been the threshold for identifying aggressive cancer, an idea that is now being questioned as more men with 3 + 4 = 7 carcinomas are offered surveillance at some centers. The threshold for determining the presence of focal "poorly formed glands" varies and reproducibility for this decision is low[522]; therefore, the ISUP has suggested a conservative grading approach, such that difficult borderline cases are graded "down" to avoid potential for overtreatment.[451]

More recently, the Grade Group system has become adopted as a way to better report the Gleason score categories (see Table 26.1).[451,523-525] The Grade Group categories range from 1 to 5, such that low-risk tumors (Gleason score 3 + 3 = 6) are more appropriately designated as Grade Group 1. Additionally, it prevents collapsing of Gleason score categories, such as 3 + 4 = 7 and 4 + 3 = 7, which are more clearly separated as Grade Groups 2 and 3, respectively. This system also offers a framework for potential modifications, such as incorporating the presence of cribriform morphology.[526]

Microscopic grading of prostatic adenocarcinoma has been found to correlate well with PSAP and PSA levels,[527,528] clinical and pathologic staging,[529-531] incidence of lymph node and bone metastases,[532,533] survival rate, and response to therapy.[534-536]

Treatment

The management choices for localized prostatic carcinoma are radical prostatectomy, external radiation therapy, brachytherapy, evolving focal therapies (e.g. cryotherapy or high-intensity focused ultrasound [HIFU]), and active surveillance (or watchful waiting).[537]

Hormonal manipulation in the form of estrogens, luteinizing hormone–releasing hormone (LH-RH) analogues, and antiandrogens has mostly replaced orchiectomy as a palliative measure in locally advanced and metastatic tumor, particularly to relieve the severe pain sometimes associated with skeletal disease.[538-541] Marked tumor regression can occur as the result of apoptosis, manifested microscopically by vacuolization of the cytoplasm, rupture of cell membranes, pyknosis, naked nuclei, and decreased expression of racemase.[542-544] Combined endocrine therapy (LH-RH agonist and flutamide) results in a striking vacuolization of the tumor cells, which may appear as isolated elements with a hemangiopericytoma-like appearance.[545-551] Another alteration that has been described following neoadjuvant

androgen ablation therapy is a peculiar pseudomyxoma-like change in the prostatic stroma resulting from mucin extravasation.[552] These alterations may result in considerable difficulties in recognizing the tumor cells. In such instances, immunohistochemistry (particularly for PSMA) can be of diagnostic assistance.[553]

Systemic chemotherapy historically has had minimal benefit in hormone-refractory metastatic prostatic carcinoma; however, newer options are now available including chemotherapeutic agents (e.g. docetaxel and cabazitaxel) and next-generation hormonal therapies (e.g. abiraterone and enzalutamide).[554-557]

Prognosis

Many parameters have been evaluated for their ability to predict outcome in patients with prostatic carcinoma, and they are listed next. Because of the usually long natural history of the disease, the PSA-free survival and PSA recurrence have been used in some of the studies as surrogates for actual survival and recurrence, respectively.

1. *Clinical stage*. This is a very important prognostic determinant, and it has become even more so with the incorporation of newer technology.
2. *Pathologic stage*. This represents the ultimate indicator of tumor extent and, as such, the most accurate predictor of prognosis currently available.[558,559] Naturally, there is also a relationship between prognosis and the status of the individual factors that determine the stage, such as the prostatic capsule, the seminal vesicles, and the lymph nodes.[560] Thus, there is a strong association between the level of tumor invasion into or through the prostatic capsule and the grade, volume, and rate of recurrence of the tumor.[561] There is also an association between the radial distance of extraprostatic extension (as measured by an ocular micrometer) and PSA recurrence.[562] In cases with nodal metastases, the prognosis is worse when they are multiple rather than solitary, when they are detectable grossly rather than only microscopically, when their overall volume is large, and when they are accompanied by extracapsular extension.[563-566]
3. *Microscopic grading*. A direct correlation exists between clinical or pathologic staging and microscopic grading regardless of the grading system used.[567] In addition, there is convincing evidence that microscopic grading using the Gleason score system (or related Grade Group system) is superior to the others as an independent prognostic variable.[516,451,523-525] In a particularly impressive multivariate analysis of 185 cases of prostatic carcinoma treated by radical prostatectomy, Gleason score was by far the best predictor of progression. In another study involving 1143 consecutive patients who had radical prostatectomy for localized prostatic carcinoma, Gleason grade was found to be the only significant predictor of disease outcome.[568] There is some suggestion that the predictive power of the Gleason scheme could be increased even further by taking into account the tertiary pattern whenever present.[569]
4. *Surgical margins*. In a multivariate analysis of over 500 retropubic prostatectomy specimens, positive margins strongly correlated with progression.[570] Several other studies have confirmed the value of margin status as an indicator of an increased risk of tumor progression.[571-573] Positive margins indicative of extraprostatic extension should be distinguished from those resulting from *capsular incision*, in which the surgeon transects either benign or malignant prostatic tissue and leaves the edge of the prostate within the patient, a not particularly easy determination.[574]
5. *Tumor volume*. It has been shown that tumor volume, as measured in whole sections of prostatectomy specimens with morphometric techniques, correlates with Gleason score, capsular penetration, capsular margins of resection, seminal vesicle invasion, and lymph node metastases.[575] However, there is some question whether measurement of tumor volume provides additional prognostic information beyond that given by the parameters already listed (particularly the Gleason score), and it is therefore difficult to justify in routine practice the use of a technique that involves the performance of step sections of the whole specimen and the measurement of the tumor at 3-mm intervals with computer-assisted image analysis.[576] Some reasonable compromises have been proposed to make the determination more acceptable to the overwhelmed general surgical pathologist.[576-579] Common methods include visual estimate of percent gland involvement and/or providing the greatest (or two greatest) linear dimensions of tumor. While on the subject of tumor volume or surface, it could be mentioned that even the roughest estimations of tumor amount in core needle biopsy material—such as percentage of cancer or number of positive cores—bear a prognostic significance.[580] Therefore, it becomes important for the pathologist to provide a quantitative estimate of tumor amount in prostate needle biopsy specimens.[581,582] Providing the length of cancer in millimeters per biopsy core is favored at many centers.
6. *Race*. Men of African descent have a mortality from prostatic carcinoma that is almost twice that of white males. This is due, at least in part, to the fact that they are more likely to have a more advanced stage at presentation. When the disease is stratified for grade and stage, survival is similar in the two races.[583]
7. *PSA serum levels*. The serum level of PSA is related to prognosis in prostatic carcinoma, as an indirect indicator of tumor volume, tumor extension, and response to therapy.[584]
8. *Lymphovascular invasion*. Permeation of vascular channels as detected in whole-mount specimens of radical prostatectomy has been found to correlate with Gleason score, extraprostatic extension, seminal vesicle involvement, and likelihood of tumor progression.[585] Furthermore, peritumoral lymph vessel invasion is associated with an increased likelihood of regional lymph node metastases.[586]
9. *Neuroendocrine features*. Neuroendocrine features correlate with poor differentiation and poor prognosis in all types of prostatic carcinoma.[587,588] Furthermore, a relationship has been claimed to exist between the degree of neuroendocrine differentiation and tumor progression.[589] As discussed previously, criteria for designation as "neuroendocrine" are not precise.
10. *Prominent reactive stroma*. Tumors with abundant (grade 3) reactive stroma ("stromogenic") are more likely to recur, regardless of whether this feature is evaluated in radical prostatectomy specimens or in needle biopsies.[590,591]
11. *Androgen-receptor status*. High levels of androgen receptor as measured immunohistochemically are associated with aggressive clinicopathologic features and decreased PSA-free survival.[592] Mutations of the androgen-receptor gene have been detected in metastatic prostatic carcinoma and postulated to be the reason for the androgen independence of such tumors.[593]
12. *DNA ploidy*. Tumor aneuploidy, as determined by image or flow cytometry, correlates both with a higher Gleason score and with local and distant spread.[594-598] It also predicts an increased probability of grade shifting from the biopsy to the prostatectomy specimen.[599] However, there is still no agreement as to whether this technique provides independent prognostic information.[600-603] The Karolinska Institutet authors, who have obtained the most impressive results with this technique,[604] believe that the controversies related to its use are largely related to methodologic inadequacies.[605]
13. *Proliferation index*. The Ki-67 labeling index of prostatic carcinoma has been said to predict tumor-specific mortality both in cases

of limited disease and in cases associated with lymph node metastases.[606,607] The combined determination of Gleason score and proliferation index constitutes a particularly powerful prognostic tool but is not utilized in routine practice.[608]

14. *Chromosomal abnormalities*. Patients with clonal karyotypic abnormalities are said to have shorter survival rates than those with normal karyotypes.[609]
15. *P53 expression*. The *TP53* tumor suppressor gene has been found to be mutated in a subset of advanced-stage prostatic carcinomas.[610-613] It remains to be seen whether this finding is of value independent of stage and grade.
16. *PTEN* loss. *PTEN* inactivation is more common in advanced stage disease and has been suggested a marker of aggressive prostate cancer.[339,340,342,343]

The problem with these multitudinous markers, as in other areas of tumor pathology, is that most of them are indeed predictive of prognosis in an univariate analysis, but their power diminishes considerably or disappears altogether when corrected for other factors (particularly stage and grade), that is, when they are subjected to multivariate analysis.[614-617] Several attempts have been made to combine some of these factors to produce multiple and hopefully more powerful prognostic indices.[580] The most clinically relevant factors useful in clinical management remain: preoperative serum PSA level, TNM stage grouping, histologic grade as Gleason score (or Grade Group), and surgical margin status.[618]

Other Tumors (in Infants and Children)

Embryonal rhabdomyosarcoma is by far the most common malignant prostatic tumor in infancy and childhood (Fig. 26.48). It produces a firm, smooth enlargement of the prostate. Extraprostatic extension is the rule; nodal metastases are less common than in rhabdomyosarcoma of head and neck.[619] Microscopically, these tumors are very cellular, especially around blood vessels. These hypercellular foci alternate with areas of myxoid or edematous change and with foci of necrosis. Most of the tumor cells are small, varying in shape from round to oval to spindle. Occasional bizarre forms with a more abundant, brightly acidophilic cytoplasm are also found. The microscopic appearance is distinctive, even in the absence of cross striations, but supportive evidence should be sought through immunocytochemical markers (see Chapter 41). In a child or young adult, the diagnosis of rhabdomyosarcoma must be considered when faced with a spindle cell proliferation. The current therapy for this tumor, which consists of multidrug chemotherapy combined with limited surgery and radiation, has proved highly effective; pelvic exenteration is reserved for the few unresponsive cases.[620,621]

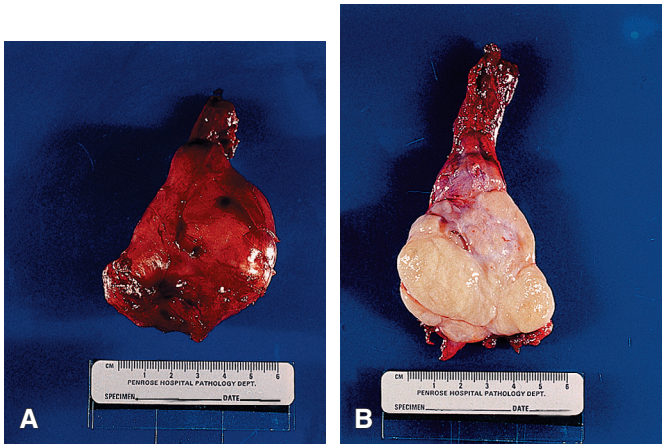

Figure 26.48 **A,** Outer aspect and **B,** cut surface of embryonal rhabdomyosarcoma of prostate in a child.

Other Tumors (in Adults)

Benign neoplasms of the adult prostate are exceptionally rare.

Melanosis of the prostate refers to the presence of melanin-containing elongated cells in the prostatic stroma. The microscopic appearance is analogous to that of *blue nevus*.[622,623] The pigmented spindle cells are immunoreactive for S-100 protein,[624] and melanosomes can be demonstrated ultrastructurally.[625] This condition should be distinguished from lipofuscin pigmentation of the prostatic epithelium, which is equivalent to that more often seen in the seminal vesicle.[626,627]

Cystadenoma of the prostate presents as a large, multilocular mass composed of glands and cysts lined by prostatic-type epithelium lying in a hypocellular fibrous stroma.[628,629] It may extend into the retroperitoneum and be attached to the prostate by a small pedicle.[630]

Leiomyoma has been described, sometimes featuring atypical bizarre giant cells.[631] However, it should be remembered that most cases so diagnosed are in reality foci of purely stromal overgrowth in nodular hyperplasia[632] or lesions belonging to the group listed immediately next.

Postoperative spindle cell nodules resembling sarcomas can develop as a result of an exuberant stromal reaction after a TUR procedure, the interval ranging from a few weeks to several months.[633,634] They present as friable reddish nodules in the prostatic bed and may be the source of postoperative bleeding. The superficial portion looks like granulation tissue, but the deep areas simulate sarcoma (particularly leiomyosarcoma) because of their extreme cellularity and high mitotic activity. Intersecting fascicles of spindle cells with extravasated red blood cells between are seen, but the nuclear chromatin remains fine. The proliferating cells, which in all likelihood are myofibroblastic, show immunohistochemically a strong and unexpected reactivity for keratin. They also express actin inconstantly and are EMA negative. The temporal relationship of these changes with a surgical procedure and their so far invariably benign evolution support a reactive pathogenesis.[634]

Inflammatory myofibroblastic tumor, similar in all regards to the more common homonymous lesion of the bladder (see Chapter 25), is sometimes seen in the prostate. Microscopically there is a proliferation of spindle cells of myoid (myofibroblastic) appearance in a well-vascularized and myxoid background.[625] As in the bladder and in other sites where it occurs, there are serious questions as to whether it really is a reactive pseudoneoplastic condition (as its original name *inflammatory pseudotumor* implies) or whether it should be regarded as a low-grade mesenchymal neoplasm, as most authors currently believe. If the latter, it would not belong to the category of "tumorlike lesions," but it was chosen to discuss it here because of the similarities and possible histogenetic commonality with postoperative spindle cell nodule.

Proliferative lesions of the specialized prostatic stroma comprise a number of entities with a wide range of morphologic appearances and clinical behavior.[635] They are grouped into two major categories: *prostatic stromal tumor of uncertain malignant potential (STUMP)* and *stromal sarcoma* (Figs. 26.49 and 26.50).[636,637] Four histologic patterns are identified in the STUMP category, ranging from scattered atypical stromal cells to lesions having a pattern of growth closely resembling ***phyllodes tumor*** of breast.[638,639] Prostatic stromal sarcoma shows greater cellularity, mitoses, necrosis, and stromal overgrowth. Immunohistochemically, these lesions are positive for CD34 and actin (the latter in less than half of the cases), and progesterone receptors (but only rarely estrogen receptors). STUMP lesions have a tendency to local recurrence, whereas stromal sarcomas have also

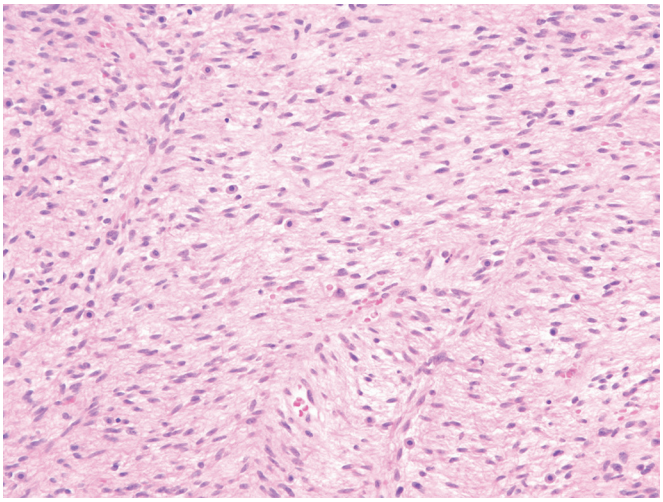

Figure 26.49 Prostatic stromal neoplasm of uncertain malignant potential with bland cytology.

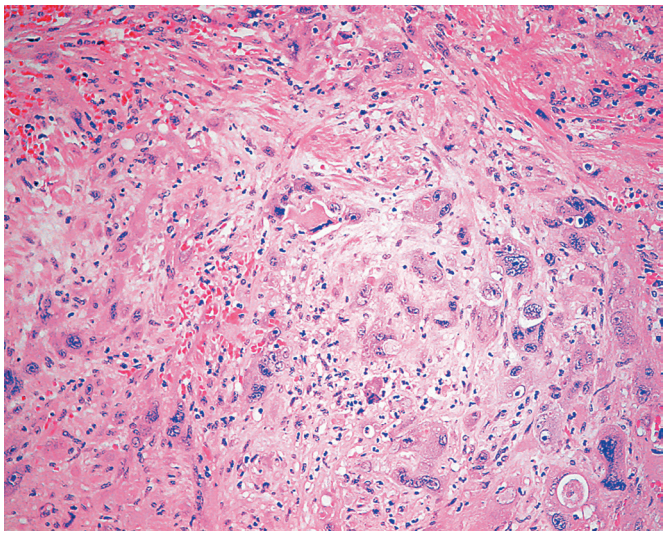

Figure 26.51 Angiosarcoma with epithelioid features involving the prostate. Note the cytoplasmic vacuolization. The diagnosis was confirmed immunohistochemically.

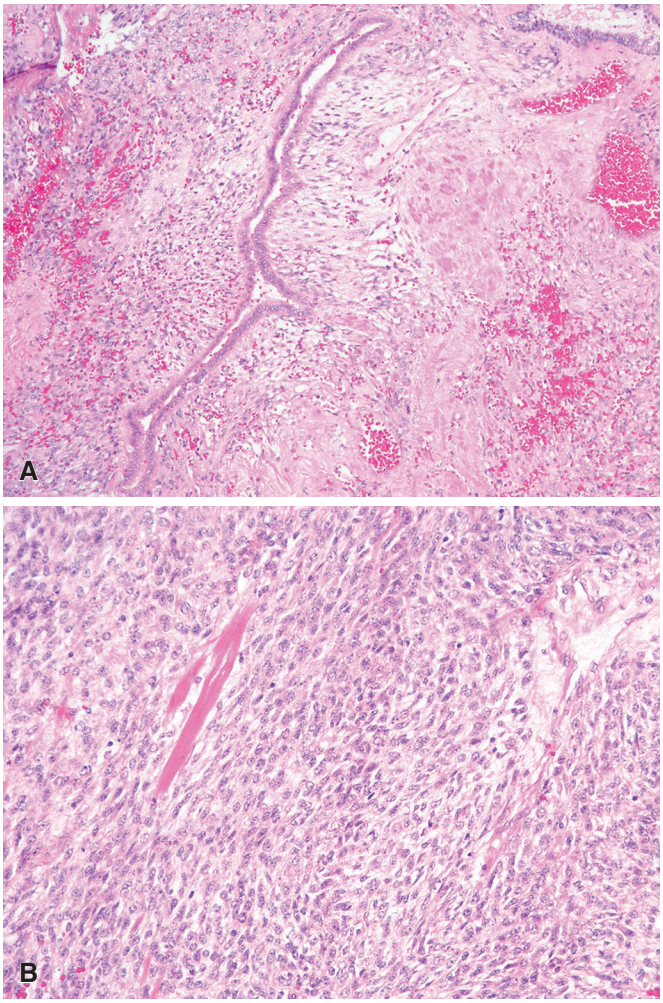

Figure 26.50 Prostatic stromal sarcoma with phyllodes-like pattern **(A)** showing marked cytologic atypia **(B)**.

the potential for distant metastases.[636] At resection, progression of STUMP to prostatic stromal sarcoma has been reported. STUMPs do not typically have the prominent blood vessels, some with surrounding hyalinization, seen in benign stromal hyperplasia.

Solitary fibrous tumor of the prostate, of which benign and malignant forms exist, shares many features with the previously described lesions (down to the positivity for progesterone but not for estrogen receptors), to the point of raising the question as to whether a separation among the two is warranted. However, the identification of the NAB2-STAT6 fusion in solitary fibrous tumor has made this distinction possible.[640] A novel STAT6 antibody provides a surrogate for the fusion and is very useful to confirming the diagnosis of solitary fibrous tumor.[641,642]

Other sarcomas of the adult prostate include **leiomyosarcoma** (to be distinguished primarily from postoperative spindle cell nodule, an exercise of crucial importance); **synovial sarcoma** (the existence of which in an intraprostatic location has been corroborated cytogenetically and molecularly[643-645]); **pleomorphic rhabdomyosarcoma; angiosarcoma** (Fig. 26.51); "**fibrosarcoma**"; and undifferentiated pleomorphic sarcoma.[646-649] The last two entities always remain diagnoses of exclusion in view of the lack of specific morphologic or other markers. Just as importantly, it is well to remember that—as in many other organs—one should consider the alternative and more likely possibility of sarcomatoid carcinoma/carcinosarcoma before making a diagnosis of primary sarcoma of one of those types. After radiation therapy, the possibility of a radiation induced sarcoma should also be considered.

Gastrointestinal stromal tumors (GISTs) can rarely involve the periprostatic region and be present in a prostatic needle biopsy. Most arise in the rectum and involve the prostate by direct extension.[650]

Malignant mixed tumor of salivary gland type, Wilms tumor, and **yolk sac tumor (endodermal sinus tumor)**, morphologically analogous to those seen in the salivary glands, kidney, and gonads, respectively, have been reported.[651-653]

Malignant lymphoma can involve the prostate. Most patients have previous or concurrent evidence of extraprostatic disease, but others are incidental findings.[654,655] The majority of the cases are small lymphocytic lymphomas, but other types can occur, including large B-cell lymphoma,[656] Hodgkin lymphoma,[657] and angiotropic

lymphoma.[658,659] Involvement of the prostate is seen in about 8% of the cases of leukemia.[660] This includes granulocytic sarcoma and chronic lymphocytic leukemia, the incidence in the latter reaching 20%.[73] Prostatic involvement by leukemia or lymphoma may result in acute urinary obstruction.

Secondary neoplastic involvement of the prostate occurs through direct extension by carcinoma of the bladder and urethra,[661] colorectum and anus,[662] and soft tissue tumors.[663,664] For bladder cancer treated with radical cystoprostatectomy, the incidence is as high as 32%–38%, this feature carrying a negative prognostic connotation.[665,666] Distant metastases have been seen from lung carcinomas, melanomas, renal cell carcinomas, and other tumor types.[663,667,668]

Prostatic Urethra

Because of its strategic location in relation to the prostate and bladder, the prostatic urethra is often involved secondarily in diseases of these two organs. Thus, direct extension of urothelial carcinoma of bladder and of carcinoma of prostate (particularly ductal) occurs with high frequency. In addition, there are some conditions that can affect primarily the urethra itself. They include the following:

1. **Postoperative spindle cell nodule** (see Chapter 25).
2. **Nephrogenic adenoma** similar to its more common bladder counterpart can occur in the prostatic urethra and can be mistaken for prostatic adenocarcinoma.[669,670] This lesion probably represents either a benign metaplastic response of the urothelium to injury or the result of mechanical implantation of renal tubules into the urethral mucosa (see Chapter 25). In keeping with the latter theory, nephrogenic adenoma has been found to be consistently positive for S-100A1, a calcium-binding protein normally expressed in renal tubular cells, as well as PAX2 and PAX8, both being renal transcription factors.[671-673] A potential pitfall is represented by the fact that the cells of nephrogenic adenomas often express racemase and may lack expression of basal cell markers.[674,675]
3. **Prostatic urethral polyps** composed of secretory cells of prostatic origin may be a source of hematuria in young adults.[676] They may have a villous configuration and tend to be found in the verumontanum but also along most of the posterior and lateral surfaces of the prostatic urethra.[677,678] They have traditionally been thought to arise from ectopic prostatic tissue located in the prostatic urethra but are more likely of hyperplastic–metaplastic nature.[679] They stain intensely for both PSAP, PSA, and also NKX3.1 in our experience.[680] These must be distinguished from subtle patterns of prostatic ductal carcinoma presenting as urethral polyps (see earlier). Most are cured by transurethral fulguration, but instances of local recurrence have been described.
4. **Inverted urothelial papilloma.** Their morphology and clinical significance are similar to those of their more common homonym in the bladder.[681]
5. **Urothelial carcinoma.** Very rarely, carcinoma of urothelial type is seen in the prostatic urethra in the absence of bladder or prostatic disease.

Seminal Vesicles and Cowper's Glands

The seminal vesicles have a thick muscular wall and highly complex mucosal folds. The epithelium is composed of columnar and basal cells. The cytoplasm of the former characteristically contains large amounts of lipofuscin pigment.

"Monstrous" cells are a common feature of the epithelium of this organ, particularly in older individuals. They are thought to represent an involutionary phenomenon and should not be confused with a malignant process.[136] The presence of lipofuscin pigment in the cytoplasm is the most important clue to their nature, even if it lacks specificity, in the sense that it can also be rarely seen in the prostate.

Hyaline globules are often found in the muscular wall of the organ; they are thought to be of degenerative nature and have no clinical significance.

Amyloidosis is detected in the form of subepithelial deposits in about 5%–10% of seminal vesicles.[682,683] The involvement is bilateral, subepithelial, of a nodular quality, and usually accompanied by involvement of the vasa deferentia and ejaculatory ducts.[684] It has been suggested that this abnormality may be more common in patients with hormonally treated prostatic adenocarcinoma.[685] This finding has no clinical significance and does not warrant a work-up for systemic amyloidosis.

Tuberculosis of the seminal vesicle is usually secondary to infection in the prostate; therefore the greatest amount of involvement is in the portion of the glands immediately adjacent to this organ.[78]

Cysts arising from the ducts of the seminal vesicle present as a soft cystic mass between the rectum and the base of the bladder. Congenital examples may be bilateral, associated with ipsilateral renal agenesis, ureteral anomalies, and oligospermia.[686,687] Acquired cysts result from obstruction secondary to chronic prostatitis.[688] Benign lesions of the seminal vesicles with a multilocular appearance and more cellular stroma have sometimes been designated as *cystadenomas*[689] or as *cystic epithelial–stromal tumors* (Fig. 26.52), but malignant examples also exist.[690,691]

Primary carcinomas of the seminal vesicle are pathologic curiosities.[692] Many of the reported cases probably represent secondary invasion from carcinoma originating in other sites, particularly the prostate. To make a diagnosis of primary carcinoma of the seminal vesicle, there must be no involvement of the prostate, and stains for PSA must be negative. They are instead immunoreactive for CA 125 and cytokeratin 7 (although not for cytokeratin 20).[693] Most cases have a prominent papillary configuration.[694]

Other reported types of primary malignant tumors of the seminal vesicles are **leiomyosarcoma**,[695] malignant mixed epithelial-stromal tumors (also reported as adenosarcoma and malignant phyllodes tumor),[691,696] **choriocarcinoma**,[697] **male adnexal tumor of probable wolffian origin**,[698] and **angiosarcoma**. In our experience, some of the latter have been of the epithelioid type.

Secondary involvement of seminal vesicles is common in prostatic carcinoma,[504] and it also occurs in in situ and invasive urothelial carcinoma of the bladder.[699]

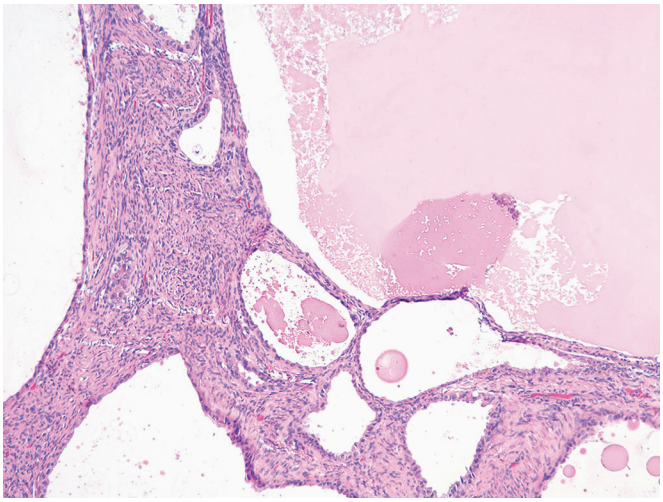

Figure 26.52 Mixed epithelial-stromal tumor of seminal vesicle.

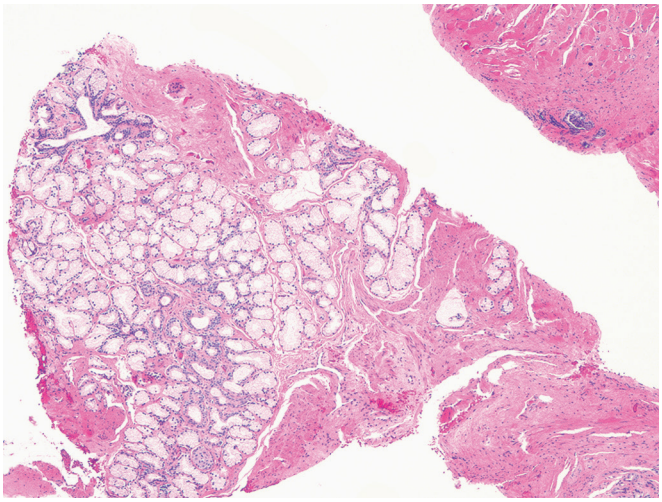

Figure 26.53 Normal benign Cowper's gland on needle core biopsy has features similar to minor salivary gland tissue.

Normal Cowper's glands are sometimes seen in specimens from prostatic resections or needle biopsies.[131] They form well-demarcated lobules composed of small, compact glands radiating from a central excretory duct lined by pseudostratified epithelium (Fig. 26.53). The best way to identify these glands is to remember that they have the appearance of mucinous minor salivary glands embedded within skeletal muscle.[131]

Adenocarcinomas of Cowper's gland are even less common than carcinomas of seminal vesicles, and the same care should be exercised in ruling out the alternative possibility of a prostatic origin.[700] They are mucin producing and may ulcerate through the skin of the scrotum. Rarely, carcinomas with salivary gland-like morphology may also occur at this site.[701]

References

1. Cunha GR. Role of mesenchymal-epithelial interactions in normal and abnormal development of the mammary gland and prostate. *Cancer*. 1994;74(3 suppl):1030-1044.
2. McNeal JE, Stamey TA, Hodge KK. The prostate gland: morphology, pathology, ultrasound anatomy. *Monogr Urol*. 1988;9:36-54.
3. McNeal JE. Anatomy of the prostate and morphogenesis of BPH. *Prog Clin Biol Res*. 1984;145:27-53.
4. McNeal JE. Regional morphology and pathology of the prostate. *Am J Clin Pathol*. 1968;49:347-357.
5. McNeal JE. The prostate and prostatic urethra—a morphologic synthesis. *J Urol*. 1972;107:1008-1016.
6. Ayala AG, Ro JY, Babaian R, et al. The prostatic capsule: does it exist? Its importance in the staging and treatment of prostatic carcinoma. *Am J Surg Pathol*. 1989;13(1):21-27.
7. Allsbrook WC Jr, Simms WW. Histochemistry of the prostate. *Hum Pathol*. 1992;23(3):297-305.
8. Leong AS, Gilham P, Milios J. Cytokeratin and vimentin intermediate filament proteins in benign and neoplastic prostatic epithelium. *Histopathology*. 1988;13(4):435-442.
9. Gurel B, Ali TZ, Montgomery EA, et al. NKX3.1 as a marker of prostatic origin in metastatic tumors. *Am J Surg Pathol*. 2010;34(8):1097-1105.
10. Wright GL, Haley C, Beckett ML, Schellhammer PF. Expression of prostate-specific membrane antigen in normal, benign, and malignant prostate tissues. *Urol Oncol*. 1995;1(1):18-28.
11. Gelmann EP. Expression of NKX3.1 in normal and malignant tissues. *Prostate*. 2003;55:111-117.
12. Grignon DJ, O'Malley FP. Mucinous metaplasia in the prostate gland. *Am J Surg Pathol*. 1993;17(3):287-290.
13. Shiraishi T, Kusano I, Watanabe M, et al. Mucous gland metaplasia of the prostate. *Am J Surg Pathol*. 1993;17(6):618-622.
14. Brawer MK, Peehl DM, Stamey TA, Bostwick DG. Keratin immunoreactivity in the benign and neoplastic human prostate. *Cancer Res*. 1985;45(8):3663-3667.
15. Okada H, Tsubura A, Okamura A, et al. Keratin profiles in normal/hyperplastic prostates and prostate carcinoma. *Virchows Arc A Pathol Anat Histopathol*. 1992;421(2):157-161.
16. Srigley JR, Dardick I, Hartwick RW, Klotz L. Basal epithelial cells of human prostate gland are not myoepithelial cells. A comparative immunohistochemical and ultrastructural study with the human salivary gland. *Am J Pathol*. 1990;136(4):957-966.
17. Grignon DJ, Ro JY, Srigley JR, et al. Sclerosing adenosis of the prostate gland. A lesion showing myoepithelial differentiation. *Am J Surg Pathol*. 1992;16(4):383-391.
18. Bonkhoff H, Remberger K. Widespread distribution of nuclear androgen receptors in the basal cell layer of the normal and hyperplastic human prostate. *Virchows Arc A Pathol Anat Histopathol*. 1993;422(1):35-38.
19. Chodak GW, Kranc DM, Puy LA, et al. Nuclear localization of androgen receptor in heterogeneous samples of normal, hyperplastic and neoplastic human prostate. *J Urol*. 1992;147(3 Pt 2):798-803.
20. Bonkhoff H, Stein U, Remberger K. Multidirectional differentiation in the normal, hyperplastic, and neoplastic human prostate: simultaneous demonstration of cell-specific epithelial markers. *Hum Pathol*. 1994;25(1):42-46.
21. di Sant'Agnese PA, de Mesy Jensen KL, Churukian CJ, Agarwal MM. Human prostatic endocrine-paracrine (APUD) cells. Distributional analysis with a comparison of serotonin and neuron-specific enolase immunoreactivity and silver stains. *Arch Pathol Lab Med*. 1985;109(7):607-612.
22. Schmid KW, Helpap B, Totsch M, et al. Immunohistochemical localization of chromogranins A and B and secretogranin II in normal, hyperplastic and neoplastic prostate. *Histopathology*. 1994;24(3):233-239.
23. Aprikian AG, Cordon-Cardo C, Fair WR, Reuter VE. Characterization of neuroendocrine differentiation in human benign prostate and prostatic adenocarcinoma. *Cancer*. 1993; 71(12):3952-3965.
24. Bonkhoff H, Stein U, Remberger K. Androgen receptor status in endocrine-paracrine cell types of the normal, hyperplastic, and neoplastic human prostate. *Virchows Arc A Pathol Anat Histopathol*. 1993;423(4): 291-294.
25. Lager DJ, Goeken JA, Kemp JD, Robinson RA. Squamous metaplasia of the prostate. An immunohistochemical study. *Am J Clin Pathol*. 1988;90(5):597-601.
26. Zhou M, Patel A, Rubin MA. Prevalence and location of peripheral nerve found on prostate needle biopsy. *Am J Clin Pathol*. 2001;115(1):39-43.
27. Bellezza G, Sidoni A, Cavaliere A. Ectopic prostatic tissue in the bladder. *Int J Urol*. 2005;12(12):1066-1068.
28. Lee LY, Tzeng J, Grosman M, Unger PD. Prostate gland-like epithelium in the epididymis: a case report and review of the literature. *Arch Pathol Lab Med*. 2004;128(4):e60-e62.
29. Lau SK, Chu PG. Prostatic tissue ectopia within the seminal vesicle: a potential source of confusion with seminal vesicle involvement by prostatic adenocarcinoma. *Virch Arch*. 2006;449(5):600-602.
30. Tekin K, Sungurtekin U, Aytekin FO, et al. Ectopic prostatic tissue of the anal canal presenting with rectal bleeding: report of a case. *Dis Colon Rectum*. 2002;45(7):979-980.
31. McCluggage WG, Ganesan R, Hirschowitz L, et al. Ectopic prostatic tissue in the uterine cervix and vagina: report of a series with a detailed immunohistochemical analysis. *Am J Surg Pathol*. 2006;30(2):209-215.
32. Gledhill A. Ectopic prostatic tissue. *J Urol*. 1985;133(1):110-111.
33. Kanomata N, Eble JN, Ohbayashi C, et al. Ectopic prostate in the retrovesical space. *J Urol Pathol*. 1997;7:121-126.
34. Moore RA. Benign hypertrophy of the prostate. A morphological study. *J Urol*. 1943;50:680-710.
35. Bonkhoff H, Remberger K. Morphogenetic concepts of normal and abnormal growth in the human prostate. *Virch Arch*. 1998;433(3):195-202.
36. Kyprianou N, Tu H, Jacobs SC. Apoptotic versus proliferative activities in human benign prostatic hyperplasia. *Hum Pathol*. 1996;27(7):668-675.
37. Algaba F. Bases morfológicas del desarrollo de la hiperplasia prostática. *Patología*. 1993;26:113-119.
38. Wilson JD. The pathogenesis of benign prostatic hyperplasia. *Am J Med*. 1980;68(5):745-756.

39. Cordon-Cardo C, Koff A, Drobnjak M, et al. Distinct altered patterns of p27KIP1 gene expression in benign prostatic hyperplasia and prostatic carcinoma. *J Natl Cancer Inst*. 1998;90(17):1284-1291.
40. Price H, McNeal JE, Stamey TA. Evolving patterns of tissue composition in benign prostatic hyperplasia as a function of specimen size. *Hum Pathol*. 1990;21(6): 578-585.
41. Shapiro E, Becich MJ, Hartanto V, Lepor H. The relative proportion of stromal and epithelial hyperplasia is related to the development of symptomatic benign prostate hyperplasia. *J Urol*. 1992;147(5):1293-1297.
42. Smith MJ. Prostatic corpora amylacea. *Monogr Surg Sci*. 1966;3(3):209-265.
43. Theyer G, Kramer G, Assmann I, et al. Phenotypic characterization of infiltrating leukocytes in benign prostatic hyperplasia. *Lab Invest*. 1992;66(1):96-107.
44. Viglione MP, Potter S, Partin AW, et al. Should the diagnosis of benign prostatic hyperplasia be made on prostate needle biopsy? *Hum Pathol*. 2002;33(8):796-800.
45. Brendler C, Schlegel P, Dowd J, et al. Surgical treatment for benign prostatic hyperplasia. *Cancer*. 1992;70(1 suppl):371-373.
46. Denis L, Lepor H, Dowd J, et al. Alternatives to surgery for benign prostatic hyperplasia. *Cancer*. 1992;70(1 suppl):374-378.
47. Eri LM, Tveter KJ. A prospective, placebo-controlled study of the luteinizing hormone-releasing hormone agonist leuprolide as treatment for patients with benign prostatic hyperplasia. *J Urol*. 1993;150(2 Pt 1):359-364.
48. Gormley GJ, Stoner E, Bruskewitz RC, et al. The effect of finasteride in men with benign prostatic hyperplasia. The Finasteride Study Group. *N Engl J Med*. 1992;327(17): 1185-1191.
49. Oesterling JE. Benign prostatic hyperplasia. Medical and minimally invasive treatment options. *N Engl J Med*. 1995;332(2):99-109.
50. Oyen RH, Van de Voorde WM, Van Poppel HP, et al. Benign hyperplastic nodules that originate in the peripheral zone of the prostate gland. *Radiology*. 1993;189(3):707-711.
51. Peters CA, Walsh PC. The effect of nafarelin acetate, a luteinizing-hormone-releasing hormone agonist, on benign prostatic hyperplasia. *N Engl J Med*. 1987;317(10): 599-604.
52. Lepor H. Advances in the medical treatment of benign prostatic hyperplasia. *Rev Urol*. 2009;11(4):181-184.
53. Bennett AH, Harrison JH. A comparison of operative approach for prostatectomy, 1948 and 1968. *Surg Gynecol Obstet*. 1969;128(5):969-974.
54. Krambeck AE, Handa SE, Lingeman JE. Experience with more than 1,000 holmium laser prostate enucleations for benign prostatic hyperplasia. *J Urol*. 2010;183(3):1105-1109.
55. Wasson JH, Reda DJ, Bruskewitz RC, et al. A comparison of transurethral surgery with watchful waiting for moderate symptoms of benign prostatic hyperplasia. The Veterans Affairs Cooperative Study Group on Transurethral Resection of the Prostate. *N Engl J Med*. 1995;332(2):75-79.
56. Roos NP, Wennberg JE, Malenka DJ, et al. Mortality and reoperation after open and transurethral resection of the prostate for benign prostatic hyperplasia. *N Engl J Med*. 1989;320(17):1120-1124.
57. Milord RA, Kahane H, Epstein JI. Infarct of the prostate gland: experience on needle biopsy specimens. *Am J Surg Pathol*. 2000;24(10):1378-1384.
58. Mostofi FK, Morse WH. Epithelial metaplasia in "prostatic infarction. *AMA Arch Pathol*. 1951;51(3):340-345.
59. Hubly JW, Thompson GJ. Infarction of the prostate and volumetric changes produced by the lesion. *J Urol Pathol*. 1940;43: 459-467.
60. Silber I, Rosai J, Cordonnier JJ. The incidence of elevated acid phosphatase in prostatic infarction. *J Urol*. 1970;103(6):765-766.
61. Blumenfeld W, Tucci S, Narayan P. Incidental lymphocytic prostatitis. Selective involvement with nonmalignant glands. *Am J Surg Pathol*. 1992;16(10):975-981.
62. Shortliffe LM, Sellers RG, Schachter J. The characterization of nonbacterial prostatitis: search for an etiology. *J Urol*. 1992;148(5):1461-1466.
63. de la Rosette JJ, Hubregtse MR, Meuleman EJ, et al. Diagnosis and treatment of 409 patients with prostatitis syndromes. *Urology*. 1993;41(4):301-307.
64. Nickel JC, Costerton JW. Coagulase-negative staphylococcus in chronic prostatitis. *J Urol*. 1992;147(2):398-400, discussion 401.
65. Dikov D, Chatelet FP, Dimitrakov J. Pathologic features of necrotizing adenoviral prostatitis in an AIDS patient. *Int J Surg Pathol*. 2005;13(2):227-231.
66. Neal DE Jr, Clejan S, Sarma D, Moon TD. Prostate specific antigen and prostatitis. I. Effect of prostatitis on serum PSA in the human and nonhuman primate. *Prostate*. 1992;20(2):105-111.
67. Thomson RD, Clejan S. Digital rectal examination-associated alterations in serum prostate-specific antigen. *Am J Clin Pathol*. 1992;97(4):528-534.
68. Stone JH, Khosroshahi A, Deshpande V, et al. Recommendations for the nomenclature of IgG4-related disease and its individual organ system manifestations. *Arthritis Rheum*. 2012;64(10):3061-3067.
69. Deshpande V, Zen Y, Chan JK, et al. Consensus statement on the pathology of IgG4-related disease. *Mod Pathol*. 2012;25(9):1181-1192.
70. Uehara T, Hamano H, Kawakami M, et al. Autoimmune pancreatitis-associated prostatitis: distinct clinicopathological entity. *Pathol Int*. 2008;58(2):118-125.
71. Jacobsen JD, Kvist E. Prostatic abscess. A review of literature and a presentation of 5 cases. *Scand J Urol Nephrol*. 1993;27(2):281-284.
72. Trapnell J, Roberts M. Prostatic abscess. *Br J Surg*. 1970;57(8):565-569.
73. Dajani YF, Burke M. Luekemic infiltration of the prostate: a case study and clinicopathological review. *Cancer*. 1976;38(6):2442-2446.
74. Granados EA, Riley G, Salvador J, Vincente J. Prostatic abscess: diagnosis and treatment. *J Urol*. 1992;148(1):80-82.
75. Morse LP, Moller CC, Harvey E, et al. Prostatic abscess due to Burkholderia pseudomallei: 81 cases from a 19-year prospective melioidosis study. *J Urol*. 2009;182(2):542-547, discussion 547.
76. White NJ. Melioidosis. *Lancet*. 2003;361(9370):1715-1722.
77. Wise GJ, Shteynshlyuger A. An update on lower urinary tract tuberculosis. *Curr Urol Rep*. 2008;9(4):305-313.
78. Auerbach O. Tuberculosis of the genital system. *Q Bull Sea View Hosp*. 1942;7:188-207.
79. Moore RA. Tuberculosis of the prostate gland. *J Urol Pathol*. 1937;37:372-384.
80. Miyashita H, Troncoso P, Babaian RJ. BCG-induced granulomatous prostatitis: a comparative ultrasound and pathologic study. *Urology*. 1992;39(4):364-367.
81. Mukamel E, Konichezky M, Engelstein D, et al. Clinical and pathological findings in prostates following intravesical bacillus Calmette-Guerin instillations. *J Urol*. 1990;144(6):1399-1400.
82. Bergner DM, Kraus SD, Duck GB, Lewis R. Systemic blastomycosis presenting with acute prostatic abscess. *J Urol*. 1981;126(1):132-133.
83. Chen KT, Schiff JJ. Coccidioidomycosis of prostate. *Urology*. 1985;25(1):82-84.
84. Haddad FS. Coccidioidomycosis of the genitourinary tract with special emphasis on the epididymis and the prostate: four case reports and review of the literature. *J Urol Pathol*. 1996;4:205-212.
85. de Souza E, Katz DA, Dworzack DL, Longo G. Actinomycosis of the prostate. *J Urol*. 1985;133(2):290-291.
86. Adams JR Jr, Mata JA, Culkin DJ, et al. Acquired immunodeficiency syndrome manifesting as prostate nodule secondary to cryptococcal infection. *Urology*. 1992;39(3):289-291.
87. Hinchey WW, Someren A. Cryptococcal prostatitis. *Am J Clin Pathol*. 1981;75(2):257-260.
88. Mamo GJ, Rivero MA, Jacobs SC. Cryptococcal prostatic abscess associated with the acquired immunodeficiency syndrome. *J Urol*. 1992;148(3):889-890.
89. Milchgrub S, Visconti E, Avellini J. Granulomatous prostatitis induced by capsule-deficient cryptococcal infection. *J Urol*. 1990;143(2):365-366.
90. Zighelboim J, Goldfarb RA, Mody D, et al. Prostatic abscess due to Histoplasma capsulatum in a patient with the acquired immunodeficiency syndrome. *J Urol*. 1992;147(1):166-168.
91. Campbell TB, Kaufman L, Cook JL. Aspergillosis of the prostate associated with an indwelling bladder catheter: case report and review. *Clin Infect Dis*. 1992;14(4):942-944.
92. Yoon GS, Nagar MS, Tavora F, Epstein JI. Cytomegalovirus prostatitis: a series of 4 cases. *Int J Surg Pathol*. 2010;18(1):55-59.
93. Indudhara R, Singh SK, Vaidyanathan S, Banerjee CK. Isolated invasive candidal prostatitis. *Urol Int*. 1992;48(3):362-364.
94. Yu S, Provet J. Prostatic abscess due to Candida tropicalis in a nonacquired immunodeficiency syndrome patient. *J Urol*. 1992;148(5):1536-1538.
95. Gardner WA Jr, Culberson DE, Bennett BD. Trichomonas vaginalis in the prostate gland. *Arch Pathol Lab Med*. 1986;110(5):430-432.
96. Abdelatif OM, Chandler FW, McGuire BS Jr. Chlamydia trachomatis in chronic abacterial prostatitis: demonstration by colorimetric in situ hybridization. *Hum Pathol*. 1991;22(1): 41-44.
97. Shurbaji MS, Gupta PK, Myers J. Immunohistochemical demonstration of Chlamydial antigens in association with prostatitis. *Mod Pathol*. 1988;1(5):348-351.
98. Dhundee J, Maciver AG. An immunohistological study of granulomatous prostatitis. *Histopathology*. 1991;18(5):435-441.
99. Tanner FH, McDonald JR. Granulomatous prostatitis. A histologic study of a group of granulomatous lesions collected from prostate glands. *Arch Pathol Lab Med*. 1943;36:358-370.
100. Uzoh CC, Uff JS, Okeke AA. Granulomatous prostatitis. *BJU Int*. 2007;99(3):510-512.
101. Kelalis PP, Greene LF, Harrison EG Jr. Granulomatous prostatitis. A mimic of carcinoma of the prostate. *JAMA*. 1965;191(4):287-289.
102. Oppenheimer JR, Kahane H, Epstein JI. Granulomatous prostatitis on needle biopsy. *Arch Pathol Lab Med*. 1997;121(7):724-729.
103. Bryan RL, Newman J, Campbell A, et al. Granulomatous prostatitis: a clinicopathological study. *Histopathology*. 1991;19(5):453-457.
104. Epstein JI, Hutchins GM. Granulomatous prostatitis: distinction among allergic, nonspecific, and post-transurethral resection lesions. *Hum Pathol*. 1984;15(9):818-825.

105. Towfighi J, Sadeghee S, Wheeler JE, Enterline HT. Granulomatous prostatitis with emphasis on the eosinophilic variety. *Am J Clin Pathol*. 1972;58(6):630-641.
106. Melicow MM. Allergic granulomas of the prostate gland. *J Urol*. 1951;65(2):288-296.
107. Stewart MJ, Wray S, Hall M. Allergic prostatitis in asthmatics. *J Pathol Bacteriol*. 1954;67(2):423-430.
108. Kiyokawa H, Koyama M, Kato H. Churg-Strauss syndrome presenting with eosinophilic prostatitis. *Int J Urol*. 2006;13(6):838-840.
109. Liu S, Miller PD, Holmes SA, et al. Eosinophilic prostatitis and prostatic specific antigen. *Br J Urol*. 1992;69(1):61-63.
110. Helpap B, Vogel J. TUR-prostatitis. Histological and immunohistochemical observations on a special type of granulomatous prostatitis. *Pathol Res Pract*. 1986;181(3):301-307.
111. Lee G, Shepherd N. Necrotising granulomata in prostatic resection specimens—a sequel to previous operation. *J Clin Pathol*. 1983;36(9):1067-1070.
112. Mies C, Balogh K, Stadecker M. Palisading prostate granulomas following surgery. *Am J Surg Pathol*. 1984;8(3):217-221.
113. Henry L, Wagner B, Faulkner MK, et al. Metal deposition in post-surgical granulomas of the urinary tract. *Histopathology*. 1993;22(5):457-465.
114. Sorensen FB, Marcussen N. Iatrogenic granulomas of the prostate and the urinary bladder. *Pathol Res Pract*. 1987;182(6):822-830.
115. Symmers WS. Two cases of eosinophilic prostatitis due to metazoan infestation. *J Pathol Bacteriol*. 1957;73:549-555.
116. Rach JF, Kandzari SJ. Unusual site for an unusual disease. Malacoplakia of the prostate. *W V Med J*. 1989;85(3):90-91.
117. Shimizu S, Takimoto Y, Niimura T, et al. A case of prostatic malacoplakia. *J Urol*. 1981;126(2):277-279.
118. Wagner D, Joseph J, Huang J, Xu H. Malakoplakia of the prostate on needle core biopsy: a case report and review of the literature. *Int J Surg Pathol*. 2007;15(1):86-89.
119. Fox H. Nodular histiocytic prostatitis. *J Urol*. 1966;96(3):372-374.
120. Chantelois AE, Parker SH, Sims JE, Horne DW. Malacoplakia of the prostate sonographically mimicking carcinoma. *Radiology*. 1990;177(1):193-195.
121. Sujka SK, Malin BT, Asirwatham JE. Prostatic malakoplakia associated with prostatic adenocarcinoma and multiple prostatic abscesses. *Urology*. 1989;34(3):159-161.
122. Val-Bernal JF, Garijo F. Isolated idiopathic granulomatous (giant cell) vasculitis of the prostate: a case report. *Int J Surg Pathol*. 1999;7:53-58.
123. Val-Bernal JF, Gonzalez-Vela C, Mayorga M, Garijo MF. Isolated fibrinoid arteritis of the prostate. *Int J Surg Pathol*. 1997;4:143-148.
124. Day DS, Carpenter HD Jr, Allsbrook WC Jr. Hair granuloma of the prostate. *Hum Pathol*. 1996;27(2):196-197.
125. Klimas R, Bennett B, Gardner WAJ. Prostatic calculi: a review. *Prostate*. 1985;7:91-96.
126. Hwang EC, Choi HS, Im CM, et al. Prostate calculi in cancer and BPH in a cohort of Korean men: presence of calculi did not correlate with cancer risk. *Asian J Androl*. 2010;12(2):215-220.
127. Berney DM, Fisher G, Kattan MW, et al. Pitfalls in the diagnosis of prostatic cancer: retrospective review of 1791 cases with clinical outcome. *Histopathology*. 2007;51(4):452-457.
128. Mostofi FK, Sesterhenn IA, Davis CJ Jr. Prostatic carcinoma: problems in the interpretation of prostatic biopsies. *Hum Pathol*. 1992;23(3):223-241.
129. Srigley JR. Benign mimickers of prostatic adenocarcinoma. *Mod Pathol*. 2004;17(3): 328-348.
130. Young RH. Tumor-like lesions of the urinary bladder and prostate. *Pathol Annu*. 1988;23(Pt 1):105-128.
131. Cina SJ, Silberman MA, Kahane H, Epstein JI. Diagnosis of Cowper's glands on prostate needle biopsy. *Am J Surg Pathol*. 1997;21(5):550-555.
132. Kawabata K. Paraganglion of the prostate in a needle biopsy: a potential diagnostic pitfall. *Arch Pathol Lab Med*. 1997;121(5):515-516.
133. Ostrowski ML, Wheeler TM. Paraganglia of the prostate. Location, frequency, and differentiation from prostatic adenocarcinoma. *Am J Surg Pathol*. 1994;18(4):412-420.
134. Rode J, Bentley A, Parkinson C. Paraganglial cells of urinary bladder and prostate: potential diagnostic problem. *J Clin Pathol*. 1990;43(1):13-16.
135. Saboorian MH, Huffman H, Ashfaq R, et al. Distinguishing Cowper's glands from neoplastic and pseudoneoplastic lesions of prostate: immunohistochemical and ultrastructural studies. *Am J Surg Pathol*. 1997;21(9):1069-1074.
136. Kuo T, Gomez LG. Monstrous epithelial cells in human epididymis and seminal vesicles. A pseudomalignant change. *Am J Surg Pathol*. 1981;5(5):483-490.
137. Amin MB, Bostwick DG. Pigment in prostatic epithelium and adenocarcinoma: a potential source of diagnostic confusion with seminal vesicular epithelium. *Mod Pathol*. 1996;9(7):791-795.
138. Quick CM, Gokden N, Sangoi AR, et al. The distribution of PAX-2 immunoreactivity in the prostate gland, seminal vesicle, and ejaculatory duct: comparison with prostatic adenocarcinoma and discussion of prostatic zonal embryogenesis. *Hum Pathol*. 2010;41: 1145-1149.
139. Ortiz-Rey JA, Juaneda-Benavides L, Peteiro-Cancelo Á, et al. Another application of PAX8: to confirm the presence of seminal vesicle epithelium in prostate needle biopsies. *Appl Immunohistochem Mol Morphol*. 2015;23:161-162.
140. Miettinen M, McCue PA, Sarlomo-Rikala M, et al. GATA3: a multispecific but potentially useful marker in surgical pathology: a systematic analysis of 2500 epithelial and nonepithelial tumors. *Am J Surg Pathol*. 2014;38:13-22.
141. Ashton-Sager A, Wu ML. Incidental rectal mucosa obtained via transrectal ultrasound-guided prostatic core biopsies. *Int J Surg Pathol*. 2007;15(1):26-30.
142. Schowinsky JT, Epstein JI. Distorted rectal tissue on prostate needle biopsy: a mimicker of prostate cancer. *Am J Surg Pathol*. 2006;30(7):866-870.
143. Ali TZ, Epstein JI. Perineural involvement by benign prostatic glands on needle biopsy. *Am J Surg Pathol*. 2005;29(9):1159-1163.
144. Carstens PH. Perineural glands in normal and hyperplastic prostates. *J Urol*. 1980;123(5):686-688.
145. Cleary KR, Choi HY, Ayala AG. Basal cell hyperplasia of the prostate. *Am J Clin Pathol*. 1983;80(6):850-854.
146. Bostwick DG, Qian J, Ma J, Muir TE. Mesonephric remnants of the prostate: incidence and histologic spectrum. *Mod Pathol*. 2003;16(7):630-635.
147. Gikas PW, Del Buono EA, Epstein JI. Florid hyperplasia of mesonephric remnants involving prostate and periprostatic tissue. Possible confusion with adenocarcinoma. *Am J Surg Pathol*. 1993;17(5):454-460.
148. Jimenez RE, Raval MFT, Spanta R, et al. Mesonephric remnants hyperplasia: a pitfall in the diagnosis of prostatic adenocarcinoma. *J Urol Pathol*. 1998;9:83-92.
149. Yacoub M, Milin S, Irani J, Fromont G. Mesonephric remnant hyperplasia: an unusual benign mimicker of prostate cancer. *Ann Diagn Pathol*. 2009;13(6):402-404.
150. Chuang AY, Epstein JI. Xanthoma of the prostate: a mimicker of high-grade prostate adenocarcinoma. *Am J Surg Pathol*. 2007;31(8):1225-1230.
151. Sebo TJ, Bostwick DG, Farrow GM, Eble JN. prostatic xanthoma: a mimic of prostatic adenocarcinoma. *Hum Pathol*. 1994;25(4):386-389.
152. Wang HL, Humphrey PA. Exaggerated signet-ring cell change in stromal nodule of prostate: a pseudoneoplastic proliferation. *Am J Surg Pathol*. 2002;26(8):1066-1070.
153. Humphrey PA, Vollmer RT. Extramedullary hematopoiesis in the prostate. *Am J Surg Pathol*. 1991;15(5):486-490.
154. Billis A. Prostatic atrophy: an autopsy study of a histologic mimic of adenocarcinoma. *Mod Pathol*. 1998;11(1):47-54.
155. De Marzo AM, Platz EA, Epstein JI, et al. A working group classification of focal prostate atrophy lesions. *Am J Surg Pathol*. 2006;30(10):1281-1291.
156. Cheville JC, Bostwick DG. Postatrophic hyperplasia of the prostate. A histologic mimic of prostatic adenocarcinoma. *Am J Surg Pathol*. 1995;19(9):1068-1076.
157. Gaudin PB, Reuter VE. Benign mimics of prostatic adenocarcinoma on needle biopsy. *Anat Pathol*. 1997;2:111-134.
158. Jones EC, Young RH. The differential diagnosis of prostatic carcinoma. Its distinction from premalignant and pseudocarcinomatous lesions of the prostate gland. *Am J Clin Pathol*. 1994;101(1):48-64.
159. Totten RS, Heinemann MW, Hudson PB, et al. Microscopic differential diagnosis of latent carcinoma of prostate. *AMA Arch Pathol*. 1953;55(2):131-141.
160. Amin MB, Tamboli P, Varma M, Srigley JR. Postatrophic hyperplasia of the prostate gland: a detailed analysis of its morphology in needle biopsy specimens. *Am J Surg Pathol*. 1999;23(8):925-931.
161. Ruska KM, Sauvageot J, Epstein JI. Histology and cellular kinetics of prostatic atrophy. *Am J Surg Pathol*. 1998;22(9):1073-1077.
162. Billis A, Magna LA. Prostate elastosis: a microscopic feature useful for the diagnosis of postatrophic hyperplasia. *Arch Pathol Lab Med*. 2000;124(9):1306-1309.
163. Wang W, Sun X, Epstein JI. Partial atrophy on prostate needle biopsy cores: a morphologic and immunohistochemical study. *Am J Surg Pathol*. 2008;32(6):851-857.
164. Oppenheimer JR, Wills ML, Epstein JI. Partial atrophy in prostate needle cores: another diagnostic pitfall for the surgical pathologist. *Am J Surg Pathol*. 1998;22(4):440-445.
165. Przybycin CG, Kunju LP, Wu AJ, Shah RB. Partial atrophy in prostate needle biopsies: a detailed analysis of its morphology, immunophenotype, and cellular kinetics. *Am J Surg Pathol*. 2008;32(1):58-64.
166. Adley BP, Yang XJ. Alpha-methylacyl coenzyme A racemase immunoreactivity in partial atrophy of the prostate. *Am J Clin Pathol*. 2006;126:849-855.
167. Thorson P, Swanson PE, Vollmer RT, Humphrey PA. Basal cell hyperplasia in the peripheral zone of the prostate. *Mod Pathol*. 2003;16(6):598-606.
168. van de Voorde W, Baldewijns M, Lauweryns J. Florid basal cell hyperplasia of the prostate. *Histopathology*. 1994;24(4):341-348.
169. Epstein JI, Armas OA. Atypical basal cell hyperplasia of the prostate. *Am J Surg Pathol*. 1992;16(12):1205-1214.

170. McKenney JK, Amin MB, Srigley JR, et al. Basal cell proliferations of the prostate other than usual basal cell hyperplasia: a clinicopathologic study of 23 cases, including four carcinomas, with a proposed classification. *Am J Surg Pathol*. 2004;28(10):1289-1298.
171. Rioux-Leclercq NC, Epstein JI. Unusual morphologic patterns of basal cell hyperplasia of the prostate. *Am J Surg Pathol*. 2002;26(2):237-243.
172. Yang XJ, Tretiakova MS, Sengupta E, et al. Florid basal cell hyperplasia of the prostate: a histological, ultrastructural, and immunohistochemical analysis. *Hum Pathol*. 2003;34(5):462-470.
173. Hosler GA, Epstein JI. Basal cell hyperplasia: an unusual diagnostic dilemma on prostate needle biopsies. *Hum Pathol*. 2005;36(5):480-485.
174. Yantiss RK, Young RH. Transitional cell 'metaplasia' in the prostate gland: a survey of its frequency and features based on 103 consecutive prostatic biopsy specimens. *J Urol Pathol*. 1997;7:71-80.
175. Ayala AG, Srigley JR, Ro JY, et al. Clear cell cribriform hyperplasia of prostate. Report of 10 cases. *Am J Surg Pathol*. 1986;10(10):665-671.
176. Eble JN. Variants of prostatic hyperplasia that resemble carcinoma. *J Urol Pathol*. 1998;8:3-20.
177. Jones EC, Clement PB, Young RH. Sclerosing adenosis of the prostate gland. A clinicopathological and immunohistochemical study of 11 cases. *Am J Surg Pathol*. 1991;15(12):1171-1180.
178. Sakamoto N, Tsuneyoshi M, Enjoji M. Sclerosing adenosis of the prostate. Histopathologic and immunohistochemical analysis. *Am J Surg Pathol*. 1991;15(7):660-667.
179. Cheng L, Bostwick DG. Atypical sclerosing adenosis of the prostate: a rare mimic of adenocarcinoma. *Histopathology*. 2010;56(5):627-631.
180. Gaudin PB, Epstein JI. Adenosis of the prostate. Histologic features in transurethral resection specimens. *Am J Surg Pathol*. 1994;18(9):863-870.
181. Humphrey PA, Zhu X, Crouch EC, et al. Mass-formative atypical adenomatous hyperplasia of prostate. *J Urol Pathol*. 1998; 9:73-82.
182. Muezzinoglu B, Erdamar S, Chakraborty S, Wheeler TM. Verumontanum mucosal gland hyperplasia is associated with atypical adenomatous hyperplasia of the prostate. *Arch Pathol Lab Med*. 2001;125(3):358-360.
183. Goldstein NS, Qian J, Bostwick DG. Mucin expression in atypical adenomatous hyperplasia of the prostate. *Hum Pathol*. 1995;26(8):887-891.
184. Epstein JI. Controversies in prostate pathology. Dysplasia and carcinoma in situ. *Monogr Pathol*. 1992;34:149-182.
185. Bostwick DG, Qian J. Atypical adenomatous hyperplasia of the prostate. Relationship with carcinoma in 217 whole-mount radical prostatectomies. *Am J Surg Pathol*. 1995;19(5):506-518.
186. Doll JA, Zhu X, Furman J, et al. Genetic analysis of prostatic atypical adenomatous hyperplasia (adenosis). *Am J Pathol*. 1999;155(3):967-971.
187. Haussler O, Epstein JI, Amin MB, et al. Cell proliferation, apoptosis, oncogene, and tumor suppressor gene status in adenosis with comparison to benign prostatic hyperplasia, prostatic intraepithelial neoplasia, and cancer. *Hum Pathol*. 1999;30(9):1077-1086.
188. Bostwick DG, Srigley J, Grignon D, et al. Atypical adenomatous hyperplasia of the prostate: morphologic criteria for its distinction from well-differentiated carcinoma. *Hum Pathol*. 1993;24(8):819-832.
189. Lotan TL, Epstein JI. Diffuse adenosis of the peripheral zone in prostate needle biopsy and prostatectomy specimens. *Am J Surg Pathol*. 2008;32(9):1360-1366.
190. Magi-Galluzzi C, Sanderson H, Epstein JI. Atypia in nonneoplastic prostate glands after radiotherapy for prostate cancer: duration of atypia and relation to type of radiotherapy. *Am J Surg Pathol*. 2003;27(2):206-212.
191. Wobker SE, Kharajian A, Epstein JI. GATA3 positivity in benign radiated prostate glands: a potential diagnostic pitfall. *Am J Surg Pathol*. 2017;41:557-563.
192. Tian W, Dorn D, Wei S, et al. GATA3 expression in benign prostate glands with radiation atypia: a diagnostic pitfall. *Histopathology*. 2017;[Epub ahead of print].
193. Nelson WG, de Marzo AM, Isaacs WB. Prostate cancer: mechanisms of disease. *N Engl J Med*. 2003;349:366-381.
194. Siegel RL, Miller KD, Jemal A. Cancer statistics, 2016. *CA Cancer J Clin*. 2016; 66:7-30.
195. Zaridze DG, Boyle P, Smans M. International trends in prostatic cancer. *Int J Cancer*. 1984;33(2):223-230.
196. Bostwick DG, Burke HB, Djakiew D, et al. *Hum Prostate* cancer risk factors. *Cancer*. 2004;101:2371-2490.
197. Shimada H, Misugi K, Sasaki Y, et al. Carcinoma of the prostate in childhood and adolescence: report of a case and review of the literature. *Cancer*. 1980;46(11):2534-2542.
198. Gittes RF. Carcinoma of the prostate. *N Engl J Med*. 1991;324(4):236-245.
199. Montironi R, Mazzucchelli R, Santinelli A, et al. Incidentally detected prostate cancer in cystoprostatectomies: pathological and morphometric comparison with clinically detected cancer in totally embedded specimens. *Hum Pathol*. 2005;36(6):646-654.
200. U.S. Preventative Services Task Force. https://screeningforprostatecancer.org/.
201. Messing EM, Albertsen P, Andriole GL Jr, et al. The Society of Urologic Oncology's reply to the US Preventative Services Task Force's recommendation on PSA testing. *Urol Oncol*. 2012;30:117-119.
202. Stamey TA, Yang N, Hay AR, et al. Prostate-specific antigen as a serum marker for adenocarcinoma of the prostate. *N Engl J Med*. 1987;317(15):909-916.
203. Barry MJ. Clinical practice. Prostate-specific-antigen testing for early diagnosis of prostate cancer. *N Engl J Med*. 2001;344(18): 1373-1377.
204. Bostwick DG. Prostate-specific antigen. Current role in diagnostic pathology of prostate cancer. *Am J Clin Pathol*. 1994;102(4 suppl 1):S31-S37.
205. Montironi R, Mazzucchelli R, Algaba F, et al. Prostate-specific antigen as a marker of prostate disease. *Virch Arch*. 2000;436(4):297-304.
206. Mai KT, Collins JP, Veinot JP. Prostatic adenocarcinoma with urothelial (transitional cell) carcinoma features. *Appl Immunohistochem Mol Morphol*. 2002;10:231-236.
207. Bock BJ, Bostwick DG. Does prostatic ductal adenocarcinoma exist? *Am J Surg Pathol*. 1999;23(7):781-785.
208. Seipel AH, Delahunt B, Samaratunga H, et al. Diagnostic criteria for ductal adenocarcinoma of the prostate: interobserver variability among 20 expert uropathologists. *Histopathology*. 2014;65:216-227.
209. Garcia JJ, Al-Ahmadie HA, Gopalan A, et al. Do prostatic transition zone tumors have a distinct morphology? *Am J Surg Pathol*. 2008;32(11):1709-1714.
210. Goldstein NS, Begin LR, Grody WW, et al. Minimal or no cancer in radical prostatectomy specimens. Report of 13 cases of the "vanishing cancer phenomenon. *Am J Surg Pathol*. 1995;19(9):1002-1009.
211. Duffield AS, Epstein JI. Detection of cancer in radical prostatectomy specimens with no residual carcinoma in the initial review of slides. *Am J Surg Pathol*. 2009;33(1):120-125.
212. Helpap B. Review of the morphology of prostatic carcinoma with special emphasis on subgrading and prognosis. *J Urol Pathol*. 1993;1:3-19.
213. Mostofi FK, Sesterhenn IA, Davis CJ Jr. A pathologist's view of prostatic carcinoma. *Cancer*. 1993;71(3 suppl):906-932.
214. Epstein JI. Diagnostic criteria of limited adenocarcinoma of the prostate on needle biopsy. *Hum Pathol*. 1995;26(2):223-229.
215. Kelemen PR, Buschmann RJ, Weisz-Carrington P. Nucleolar prominence as a diagnostic variable in prostatic carcinoma. *Cancer*. 1990;65(4):1017-1020.
216. Hameed O, Humphrey PA. Stratified epithelium in prostatic adenocarcinoma: a mimic of high-grade prostatic intraepithelial neoplasia. *Mod Pathol*. 2006;19(7):899-906.
217. Pacelli A, Lopez-Beltran A, Egan AJ, Bostwick DG. Prostatic adenocarcinoma with glomeruloid features. *Hum Pathol*. 1998;29(5):543-546.
218. Egevad L, Allsbrook WC Jr, Epstein JI. Current practice of diagnosis and reporting of prostate cancer on needle biopsy among genitourinary pathologists. *Hum Pathol*. 2006;37(3):292-297.
219. Parwani AV, Kronz JD, Genega EM, et al. Prostate carcinoma with squamous differentiation: an analysis of 33 cases. *Am J Surg Pathol*. 2004;28(5):651-657.
220. Brawn PN. The dedifferentiation of prostate carcinoma. *Cancer*. 1983;52(2):246-251.
221. Franks LM. Latent carcinoma of the prostate. *J Pathol Bacteriol*. 1954;68(2):603-616.
222. Arangelovich V, Tretiakova M, SenGupta E, et al. Pathogenesis and significance of collagenous micronodules of the prostate. *Appl Immunohistochem Mol Morphol*. 2003;11(1):15-19.
223. Baisden BL, Kahane H, Epstein JI. Perineural invasion, mucinous fibroplasia, and glomerulations: diagnostic features of limited cancer on prostate needle biopsy. *Am J Surg Pathol*. 1999;23(8):918-924.
224. Holmes EJ. Crystalloids of prostatic carcinoma: relationship to Bence-Jones crystals. *Cancer*. 1977;39(5):2073-2080.
225. Jensen PE, Gardner WA Jr, Piserchia PV. Prostatic crystalloids: association with adenocarcinoma. *Prostate*. 1980;1(1):25-30.
226. Bennett B, Gardner WA Jr. Crystalloids in prostatic hyperplasia. *Prostate*. 1980;1(1):31-35.
227. Anton RC, Chakraborty S, Wheeler TM. The significance of intraluminal prostatic crystalloids in benign needle biopsies. *Am J Surg Pathol*. 1998;22(4):446-449.
228. Henneberry JM, Kahane H, Humphrey PA, et al. The significance of intraluminal crystalloids in benign prostatic glands on needle biopsy. *Am J Surg Pathol*. 1997;21(6):725-728.
229. Christian JD, Lamm TC, Morrow JF, Bostwick DG. Corpora amylacea in adenocarcinoma of the prostate: incidence and histology within needle core biopsies. *Mod Pathol*. 2005;18(1):36-39.
230. Humphrey PA, Vollmer RT. Corpora amylacea in adenocarcinoma of the prostate. Prevalence in 100 prostatectomies and clinicopathologic correlations. *Surg Pathol*. 1990;3:133-141.
231. Nelson RS, Epstein JI. Prostatic carcinoma with abundant xanthomatous cytoplasm. Foamy gland carcinoma. *Am J Surg Pathol*. 1996;20(4):419-426.
232. Samaratunga H, Williamson R. Metastatic foamy gland carcinoma of the prostate: a

potential diagnostic pitfall. *J Urol Pathol*. 1998;9:155-162.
233. Arista-Nasr J, Martinez-Benitez B, Camorlinga-Tagle N, Albores-Saavedra J. Foamy gland microcarcinoma in needle prostatic biopsy. *Ann Diagn Pathol*. 2008;12(5):349-355.
234. Zhao J, Epstein JI. High-grade foamy gland prostatic adenocarcinoma on biopsy or transurethral resection: a morphologic study of 55 cases. *Am J Surg Pathol*. 2009;33(4):583-590.
235. Cina SJ, Epstein JI. Adenocarcinoma of the prostate with atrophic features. *Am J Surg Pathol*. 1997;21(3):289-295.
236. Egan AJ, Lopez-Beltran A, Bostwick DG. Prostatic adenocarcinoma with atrophic features: malignancy mimicking a benign process. *Am J Surg Pathol*. 1997;21(8): 931-935.
237. Kaleem Z, Swanson PE, Vollmer RT, Humphrey PA. Prostatic adenocarcinoma with atrophic features: a study of 202 consecutive completely embedded radical prostatectomy specimens. *Am J Clin Pathol*. 1998;109(6):695-703.
238. Yaskiv O, Cao D, Humphrey PA. Microcystic adenocarcinoma of the prostate: a variant of pseudohyperplastic and atrophic patterns. *Am J Surg Pathol*. 2010;34(4):556-561.
239. Humphrey PA, Kaleem Z, Swanson PE, Vollmer RT. Pseudohyperplastic prostatic adenocarcinoma. *Am J Surg Pathol*. 1998;22(10):1239-1246.
240. Levi AW, Epstein JI. Pseudohyperplastic prostatic adenocarcinoma on needle biopsy and simple prostatectomy. *Am J Surg Pathol*. 2000;24(8):1039-1046.
241. Tavora F, Epstein JI. High-grade prostatic intraepithelial neoplasialike ductal adenocarcinoma of the prostate: a clinicopathologic study of 28 cases. *Am J Surg Pathol*. 2008;32:1060-1067.
242. Giannico GA, Ross HM, Lotan T, Epstein JI. Aberrant expression of p63 in adenocarcinoma of the prostate: a radical prostatectomy study. *Am J Surg Pathol*. 2013;37:1401-1406.
243. Osunkoya AO, Hansel DE, Sun X, et al. Aberrant diffuse expression of p63 in adenocarcinoma of the prostate on needle biopsy and radical prostatectomy: report of 21 cases. *Am J Surg Pathol*. 2008;32(3):461-467.
244. Tan HL, Haffner MC, Esopi DM, et al. Prostate adenocarcinomas aberrantly expressing p63 are molecularly distinct from usual-type prostatic adenocarcinomas. *Mod Pathol*. 2015;28:446-456.
245. Grignon DJ, Sakr WA. Pathologic staging of prostate carcinoma. What are the issues? *Cancer*. 1996;78(2):337-340.
246. Iczkowski KA, Bostwick DG. Criteria for biopsy diagnosis of minimal volume prostatic adenocarcinoma: analytic comparison with nondiagnostic but suspicious atypical small acinar proliferation. *Arch Pathol Lab Med*. 2000;124(1):98-107.
247. Thorson P, Humphrey PA. Minimal adenocarcinoma in prostate needle biopsy tissue. *Am J Clin Pathol*. 2000;114(6):896-909.
248. Grignon DJ. Minimal diagnostic criteria for adenocarcinoma of the prostate. *J Urol Pathol*. 1998;8:31-44.
249. Cheville JC, Reznicek MJ, Bostwick DG. The focus of "atypical glands, suspicious for malignancy" in prostatic needle biopsy specimens: incidence, histologic features, and clinical follow-up of cases diagnosed in a community practice. *Am J Clin Pathol*. 1997;108(6):633-640.
250. Dundore PA. Atypical small acinar proliferations (ASAP) suspicious for malignancy in prostate needle biopsies. *J Urol Pathol*. 1998;8:21-30.
251. Iczkowski KA, MacLennan GT, Bostwick DG. Atypical small acinar proliferation suspicious for malignancy in prostate needle biopsies: clinical significance in 33 cases. *Am J Surg Pathol*. 1997;21(12):1489-1495.
252. Kambham N, Taylor JA, Troxel A, Rubin MA. Atypical small acinar proliferation in prostate needle biopsy: a clinically significant diagnostic category. *J Urol Pathol*. 1999;10:177-188.
253. Van der Kwast TH, Evans A, Lockwood G, et al. Variability in diagnostic opinion among pathologists for single small atypical foci in prostate biopsies. *Am J Surg Pathol*. 2010;34:169-177.
254. Halushka MK, Kahane H, Epstein JI. Negative 34betaE12 staining in a small focus of atypical glands on prostate needle biopsy: a follow-up study of 332 cases. *Hum Pathol*. 2004;35(1):43-46.
255. Herawi M, Parwani AV, Irie J, Epstein JI. Small glandular proliferations on needle biopsies: most common benign mimickers of prostatic adenocarcinoma sent in for expert second opinion. *Am J Surg Pathol*. 2005;29(7):874-880.
256. Novis DA, Zarbo RJ, Valenstein PA. Diagnostic uncertainty expressed in prostate needle biopsies. A College of American Pathologists Q-probes Study of 15,753 prostate needle biopsies in 332 institutions. *Arch Pathol Lab Med*. 1999;123(8):687-692.
257. Epstein JI. How should atypical prostate needle biopsies be reported? Controversies regarding the term "ASAP". *Hum Pathol*. 1999;30(12):1401-1402.
258. Bostwick DG, Meiers I. Atypical small acinar proliferation in the prostate: clinical significance in 2006. *Arch Pathol Lab Med*. 2006;130(7):952-957.
259. Dube VE, Farrow GM, Greene LF. Prostatic adenocarcinoma of ductal origin. *Cancer*. 1973;32(2):402-409.
260. Ende N, Woods LP, Shelley HS. Carcinoma originating in ducts surrounding the prostatic urethra. *Am J Clin Pathol*. 1963;40: 183-189.
261. Greene LF, Farrow GM, Ravits JM, Tomera FM. Prostatic adenocarcinoma of ductal origin. *J Urol*. 1979;121(3):303-305.
262. Kopelson G, Harisiadis L, Romas NA, et al. Periurethral prostatic duct carcinoma: clinical features and treatment results. *Cancer*. 1978;42(6):2894-2902.
263. Kuhajda FP, Gipson T, Mendelsohn G. Papillary adenocarcinomas of the prostate. An immunohistochemical study. *Cancer*. 1984;54(7):1328-1332.
264. Paner GP, Lopez-Beltran A, So JS, et al. Spectrum of Cystic Epithelial Tumors of the Prostate: Most Cystadenocarcinomas Are Ductal Type With Intracystic Papillary Pattern. *Am J Surg Pathol*. 2016;40:886-895.
265. Sleater JP, Ford MJ, Beers BB. Extramammary Paget's disease associated with prostate adenocarcinoma. *Hum Pathol*. 1994;25(6):615-617.
266. Herawi M, Epstein JI. Immunohistochemical antibody cocktail staining (p63/HMWCK/AMACR) of ductal adenocarcinoma and Gleason pattern 4 cribriform and noncribriform acinar adenocarcinomas of the prostate. *Am J Surg Pathol*. 2007;31(6):889-894.
267. Christensen WN, Steinberg G, Walsh PC, Epstein JI. Prostatic duct adenocarcinoma. Findings at radical prostatectomy. *Cancer*. 1991;67(8):2118-2124.
268. Samaratunga H, Letizia B. Prostatic ductal adenocarcinoma presenting as a urethral polyp: a clinicopathological study of eight cases of a lesion with the potential to be misdiagnosed as a benign prostatic urethral polyp. *Pathology*. 2007;39:476-481.
269. Aydin H, Zhang J, Samaratunga H, et al. Ductal adenocarcinoma of the prostate diagnosed on transurethral biopsy or resection is not always indicative of aggressive disease: implications for clinical management. *BJU Int*. 2010;105:476-480.
270. Nadji M, Tabei SZ, Castro A, et al. Prostatic-specific antigen: an immunohistologic marker for prostatic neoplasms. *Cancer*. 1981;48(5):1229-1232.
271. Papsidero LD, Croghan GA, Asirwatham J, et al. Immunohistochemical demonstration of prostate-specific antigen in metastases with the use of monoclonal antibody F5. *Am J Pathol*. 1985;121(3):451-454.
272. Shevchuk MM, Romas NA, Ng PY, et al. Acid phosphatase localization in prostatic carcinoma. A comparison of monoclonal antibody to heteroantisera. *Cancer*. 1983; 52(9):1642-1646.
273. Stein BS, Vangore S, Petersen RO, Kendall AR. Immunoperoxidase localization of prostate-specific antigen. *Am J Surg Pathol*. 1982;6(6):553-557.
274. Bentz MS, Cohen C, Demers LM, Budgeon LR. Immunohistochemical acid phosphatase level and tumor grade in prostatic carcinoma. *Arch Pathol Lab Med*. 1982;106(9): 476-480.
275. Feiner HD, Gonzalez R. Carcinoma of the prostate with atypical immunohistological features. Clinical and histologic correlates. *Am J Surg Pathol*. 1986;10(11):765-770.
276. Jobsis AC, De Vries GP, Anholt RR, Sanders GT. Demonstration of the prostatic origin of metastases: an immunohistochemical method for formalin-fixed embedded tissue. *Cancer*. 1978;41(5):1788-1793.
277. Mai KT, Commons AS, Perkins DG, et al. Absence of serum prostate-specific antigen and loss of tissue immunoreactive prostatic markers in advanced prostatic adenocarcinoma after hormonal therapy: a report of two cases. *Hum Pathol*. 1996;27(12): 1377-1381.
278. Chuang AY, DeMarzo AM, Veltri RW, et al. Immunohistochemical differentiation of high-grade prostate carcinoma from urothelial carcinoma. *Am J Surg Pathol*. 2007;31: 1246-1255.
279. Genega EM, Hutchinson B, Reuter VE, Gaudin PB. Immunophenotype of high-grade prostatic adenocarcinoma and urothelial carcinoma. *Mod Pathol*. 2000;13(11):1186-1191.
280. Lindeman N, Weidner N. Immunohistochemical profile of prostatic and urothelial carcinoma: impact of heat-induced epitope retrieval and presentation of tumors with intermediate features. *Appl Immunohistochem*. 1996;4:264-275.
281. Elgamal AA, Holmes EH, Su SL, et al. Prostate-specific membrane antigen (PSMA): current benefits and future value. *Semin Surg Oncol*. 2000;18(1):10-16.
282. Bostwick DG, Pacelli A, Blute M, et al. Prostate specific membrane antigen expression in prostatic intraepithelial neoplasia and adenocarcinoma: a study of 184 cases. *Cancer*. 1998;82(11):2256-2261.
283. Jiang Z, Woda BA, Rock KL, et al. P504S: a new molecular marker for the detection of prostate carcinoma. *Am J Surg Pathol*. 2001;25(11):1397-1404.
284. Jiang Z, Woda BA, Wu CL, Yang XJ. Discovery and clinical application of a novel prostate cancer marker: alpha-methylacyl CoA racemase (P504S). *Am J Clin Pathol*. 2004;122(2):275-289.
285. Varma M, Jasani B. Diagnostic utility of immunohistochemistry in morphologically difficult prostate cancer: review of current literature. *Histopathology*. 2005;47(1):1-16.
286. Kuefer R, Varambally S, Zhou M, et al. alpha-Methylacyl-CoA racemase: expression

levels of this novel cancer biomarker depend on tumor differentiation. *Am J Pathol*. 2002; 161(3):841-848.
287. Beach R, Gown AM, De Peralta-Venturina MN, et al. P504S immunohistochemical detection in 405 prostatic specimens including 376 18-gauge needle biopsies. *Am J Surg Pathol*. 2002;26(12):1588-1596.
288. Yang XJ, Wu CL, Woda BA, et al. Expression of alpha-Methylacyl-CoA racemase (P504S) in atypical adenomatous hyperplasia of the prostate. *Am J Surg Pathol*. 2002;26(7):921-925.
289. Zhou M, Shah R, Shen R, Rubin MA. Basal cell cocktail (34betaE12 + p63) improves the detection of prostate basal cells. *Am J Surg Pathol*. 2003;27(3):365-371.
290. Carswell BM, Woda BA, Wang X, et al. Detection of prostate cancer by alpha-methylacyl CoA racemase (P504S) in needle biopsy specimens previously reported as negative for malignancy. *Histopathology*. 2006;48(6):668-673.
291. Jiang Z, Wu CL, Woda BA, et al. P504S/ alpha-methylacyl-CoA racemase: a useful marker for diagnosis of small foci of prostatic carcinoma on needle biopsy. *Am J Surg Pathol*. 2002;26(9):1169-1174.
292. Zhou M, Chinnaiyan AM, Kleer CG, et al. Alpha-Methylacyl-CoA racemase: a novel tumor marker over-expressed in several human cancers and their precursor lesions. *Am J Surg Pathol*. 2002;26(7): 926-931.
293. Bonkhoff H, Fixemer T, Hunsicker I, Remberger K. Estrogen receptor expression in prostate cancer and premalignant prostatic lesions. *Am J Surg Pathol*. 1999;155(2):641-647.
294. Hiramatsu M, Maehara I, Orikasa S, Sasano H. Immunolocalization of oestrogen and progesterone receptors in prostatic hyperplasia and carcinoma. *Histopathology*. 1996;28(2):163-168.
295. Takeda H, Akakura K, Masai M, et al. Androgen receptor content of prostate carcinoma cells estimated by immunohistochemistry is related to prognosis of patients with stage D2 prostate carcinoma. *Cancer*. 1996;77(5):934-940.
296. Trapman J, Brinkmann AO. The androgen receptor in prostate cancer. *Pathol Res Pract*. 1996;192(7):752-760.
297. Torlakovic E, Lilleby W, Torlakovic G, et al. Prostate carcinoma expression of estrogen receptor-beta as detected by PPG5/10 antibody has positive association with primary Gleason grade and Gleason score. *Hum Pathol*. 2002; 33(6):646-651.
298. Osman I, Scher HI, Drobnjak M, et al. HER-2/ neu (p185neu) protein expression in the natural or treated history of prostate cancer. *Clin Cancer Res*. 2001;7(9):2643-2647.
299. Herawi M, De Marzo AM, Kristiansen G, Epstein JI. Expression of CDX2 in benign tissue and adenocarcinoma of the prostate. *Hum Pathol*. 2007;38(1):72-78.
300. Wernert N, Seitz G, Goebbels R, Dhom G. Immunohistochemical demonstration of cytokeratins in the human prostate. *Pathol Res Pract*. 1986;181(6):668-674.
301. Bassily NH, Vallorosi CJ, Akdas G, et al. Coordinate expression of cytokeratins 7 and 20 in prostate adenocarcinoma and bladder urothelial carcinoma. *Am J Clin Pathol*. 2000; 113(3):383-388.
302. Goldstein NS. Immunophenotypic characterization of 225 prostate adenocarcinomas with intermediate or high Gleason scores. *Am J Clin Pathol*. 2002;117:471-477.
303. Goldstein NS, Underhill J, Roszka J, Neill JS. Cytokeratin 34 beta E-12 immunoreactivity in benign prostatic acini. Quantitation, pattern assessment, and electron microscopic study. *Am J Clin Pathol*. 1999;112(1):69-74.
304. Googe PB, McGinley KM, Fitzgibbon JF. Anticytokeratin antibody 34 beta E12 staining in prostate carcinoma. *Am J Clin Pathol*. 1997;107(2):219-223.
305. Wojno KJ, Epstein JI. The utility of basal cell-specific anti-cytokeratin antibody (34 beta E12) in the diagnosis of prostate cancer. A review of 228 cases. *Am J Surg Pathol*. 1995;19(3):251-260.
306. Samaratunga H, Singh M. Distribution pattern of basal cells detected by cytokeratin 34 beta E12 in primary prostatic duct adenocarcinoma. *Am J Surg Pathol*. 1997;21(4):435-440.
307. Yang XJ, McEntee M, Epstein JI. Distinction of basaloid carcinoma of the prostate from benign basal cell lesions by using immunohistochemistry for bcl-2 and Ki-67. *Hum Pathol*. 1998;29(12):1447-1450.
308. Ali TZ, Epstein JI. False positive labeling of prostate cancer with high molecular weight cytokeratin: p63 a more specific immunomarker for basal cells. *Am J Surg Pathol*. 2008;32(12):1890-1895.
309. Chuang AY, DeMarzo AM, Veltri RW, et al. Immunohistochemical differentiation of high-grade prostate carcinoma from urothelial carcinoma. *Am J Surg Pathol*. 2007;31(8):1246-1255.
310. Epstein JI. Diagnosis and reporting of limited adenocarcinoma of the prostate on needle biopsy. *Mod Pathol*. 2004;17(3):307-315.
311. Hameed O, Humphrey PA. Immunohistochemistry in diagnostic surgical pathology of the prostate. *Semin Diagn Pathol*. 2005;22(1):88-104.
312. Iczkowski KA, Cheng L, Crawford BG, Bostwick DG. Steam heat with an EDTA buffer and protease digestion optimizes immunohistochemical expression of basal cell-specific antikeratin 34betaE12 to discriminate cancer in prostatic epithelium. *Mod Pathol*. 1999;12(1):1-4.
313. Green R, Epstein JI. Use of intervening unstained slides for immunohistochemical stains for high molecular weight cytokeratin on prostate needle biopsies. *Am J Surg Pathol*. 1999;23(5):567-570.
314. Dardik M, Epstein JI. Efficacy of restaining prostate needle biopsies with high-molecular weight cytokeratin. *Hum Pathol*. 2000;31(9):1155-1161.
315. Abrahams NA, Ormsby AH, Brainard J. Validation of cytokeratin 5/6 as an effective substitute for keratin 903 in the differentiation of benign from malignant glands in prostate needle biopsies. *Histopathology*. 2002;41(1):35-41.
316. Oliai BR, Kahane H, Epstein JI. Can basal cells be seen in adenocarcinoma of the prostate?: an immunohistochemical study using high molecular weight cytokeratin (clone 34betaE12) antibody. *Am J Surg Pathol*. 2002;26(9):1151-1160.
317. Shah RB, Zhou M, LeBlanc M, et al. Comparison of the basal cell-specific markers, 34betaE12 and p63, in the diagnosis of prostate cancer. *Am J Surg Pathol*. 2002;26(9):1161-1168.
318. Farinola MA, Epstein JI. Utility of immunohistochemistry for alpha-methylacyl-CoA racemase in distinguishing atrophic prostate cancer from benign atrophy. *Hum Pathol*. 2004;35(10):1272-1278.
319. Jiang Z, Li C, Fischer A, et al. Using an AMACR (P504S)/34betaE12/p63 cocktail for the detection of small focal prostate carcinoma in needle biopsy specimens. *Am J Clin Pathol*. 2005;123(2):231-236.
320. Sanderson SO, Sebo TJ, Murphy LM, et al. An analysis of the p63/alpha-methylacyl coenzyme A racemase immunohistochemical cocktail stain in prostate needle biopsy specimens and tissue microarrays. *Am J Clin Pathol*. 2004;121(2):220-225.
321. Trpkov K, Bartczak-McKay J, Yilmaz A. Usefulness of cytokeratin 5/6 and AMACR applied as double sequential immunostains for diagnostic assessment of problematic prostate specimens. *Am J Clin Pathol*. 2009;132(2):211-220, quiz 307.
322. Shah RB, Kunju LP, Shen R, et al. Usefulness of basal cell cocktail (34betaE12 + p63) in the diagnosis of atypical prostate glandular proliferations. *Am J Clin Pathol*. 2004;122(4):517-523.
323. Kunju LP, Mehra R, Snyder M, Shah RB. Prostate-specific antigen, high-molecular-weight cytokeratin (clone 34betaE12), and/or p63: an optimal immunohistochemical panel to distinguish poorly differentiated prostate adenocarcinoma from urothelial carcinoma. *Am J Clin Pathol*. 2006;125(5):675-681.
324. Murphy AJ, Hughes CA, Lannigan G, et al. Heterogeneous expression of alpha-methylacyl-CoA racemase in prostatic cancer correlates with Gleason score. *Histopathology*. 2007;50(2):243-251.
325. Zhou M, Aydin H, Kanane H, Epstein JI. How often does alpha-methylacyl-CoA-racemase contribute to resolving an atypical diagnosis on prostate needle biopsy beyond that provided by basal cell markers? *Am J Surg Pathol*. 2004;28(2):239-243.
326. Alers JC, Rochat J, Krijtenburg PJ, et al. Identification of genetic markers for prostatic cancer progression. *Lab Invest*. 2000;80(6):931-942.
327. Konig JJ, Teubel W, Romijn JC, et al. Gain and loss of chromosomes 1, 7, 8, 10, 18, and Y in 46 prostate cancers. *Hum Pathol*. 1996;27(7):720-727.
328. Konishi N, Cho M, Yamamoto K, Hiasa Y. Genetic changes in prostate cancer. *Pathol Int*. 1997;47(11):735-747.
329. Latil A, Lidereau R. Genetic aspects of prostate cancer. *Virch Arch*. 1998;432(5):389-406.
330. Carter BS, Ewing CM, Ward WS, et al. Allelic loss of chromosomes 16q and 10q in human prostate cancer. *Proc Natl Acad Sci USA*. 1990;87(22):8751-8755.
331. Lundgren R, Mandahl N, Heim S, et al. Cytogenetic analysis of 57 primary prostatic adenocarcinomas. *Genes Chromosomes Cancer*. 1992;4(1):16-24.
332. Sandberg AA. Chromosomal abnormalities and related events in prostate cancer. *Hum Pathol*. 1992;23(4):368-380.
333. Isaacs WB, Bova GS, Morton RA, et al. Molecular biology of prostate cancer. *Semin Oncol*. 1994;21(5):514-521.
334. Mackinnon AC, Yan BC, Joseph LJ, Al-Ahmadie HA. Molecular biology underlying the clinical heterogeneity of prostate cancer: an update. *Arch Pathol Lab Med*. 2009;133(7):1033-1040.
335. Hermans KG, van Marion R, van Dekken H, et al. TMPRSS2:ERG fusion by translocation or interstitial deletion is highly relevant in androgen-dependent prostate cancer, but is bypassed in late-stage androgen receptor-negative prostate cancer. *Cancer Res*. 2006;66(22):10658-10663.
336. Esgueva R, Perner S, J LaFargue C, et al. Prevalence of TMPRSS2-ERG and SLC45A3-ERG gene fusions in a large prostatectomy cohort. *Mod Pathol*. 2010;23(4):539-546.
337. Barbieri CE, Baca SC, Lawrence MS, et al. Exome sequencing identifies recurrent SPOP, FOXA1 and MED12 mutations in prostate cancer. *Nat Genet*. 2012;44:685-689.
338. Berger MF, Lawrence MS, Demichelis F, et al. The genomic complexity of primary human prostate cancer. *Nature*. 2011;470: 214-220.

339. Cairns P, Okami K, Halachmi S, et al. Frequent inactivation of PTEN/MMAC1 in primary prostate cancer. *Cancer Res*. 1997;57:4997-5000.
340. Feilotter HE, Nagai MA, Boag AH, et al. Analysis of PTEN and the 10q23 region in primary prostate carcinomas. *Oncogene*. 1998;17:1743-1748.
341. Verhagen PC, van Duijn PW, Hermans KG, et al. The PTEN gene in locally progressive prostate cancer is preferentially inactivated by bi-allelic gene deletion. *J Pathol*. 2006;208:699-707.
342. Lotan TL, Gurel B, Sutcliffe S, et al. PTEN protein loss by immunostaining: analytic validation and prognostic indicator for a high risk surgical cohort of prostate cancer patients. *Clin Cancer Res*. 2011;17:6563-6573.
343. Lotan TL, Wei W, Ludkovski O, et al. Analytic validation of a clinical-grade PTEN immunohistochemistry assay in prostate cancer by comparison with PTEN FISH. *Mod Pathol*. 2016;29:904-914.
344. Visakorpi T, Kallioniemi OP, Heikkinen A, et al. Small subgroup of aggressive, highly proliferative prostatic carcinomas defined by p53 accumulation. *J Natl Cancer Inst*. 1992;84(11):883-887.
345. Ittmann M, Wieczorek R, Heller P, et al. Alterations in the p53 and MDM-2 genes are infrequent in clinically localized, stage B prostate adenocarcinomas. *Am J Pathol*. 1994;145(2):287-293.
346. Losi L, Di Gregorio C, Brausi M, et al. Expression of p53 protein in prostate cancers of different histologic types. *Pathol Res Pract*. 1994;190(4):384-388.
347. Meyers FJ, Gumerlock PH, Chi SG, et al. Very frequent p53 mutations in metastatic prostate carcinoma and in matched primary tumors. *Cancer*. 1998;83(12):2534-2539.
348. Ittmann MM, Wieczorek R. Alterations of the retinoblastoma gene in clinically localized, stage B prostate adenocarcinomas. *Hum Pathol*. 1996;27(1):28-34.
349. Ross JS, Sheehan C, Hayner-Buchan AM, et al. HER-2/neu gene amplification status in prostate cancer by fluorescence in situ hybridization. *Hum Pathol*. 1997;28(7):827-833.
350. Wegiel B, Evans S, Hellsten R, et al. Molecular pathways in the progression of hormone-independent and metastatic prostate cancer. *Curr Cancer Drug Targets*. 2010;10(4):392-401.
351. Kicinski M, Vangronsveld J, Nawrot TS. An epidemiological reappraisal of the familial aggregation of prostate cancer: a meta-analysis. *PLoS ONE*. 2011;6(10):e27130.
352. Giri VN, Beebe-Dimmer JL. Familial prostate cancer. *Sem Oncol*. 2016;43:560-565.
353. Bancroft EK, Page EC, Castro E, et al. Targeted prostate cancer screening in BRCA1 and BRCA2 mutation carriers: results from the initial screening round of the IMPACT study. *Eur Urol*. 2014;66:489-499.
354. Easton DF, Steele L, Fields P, et al. Cancer risks in two large breast cancer families linked to BRCA2 on chromosome 13q12-13. *Am J Hum Genet*. 1997;61:120-129.
355. Kirchhoff T, Kauff ND, Mitra N, et al. BRCA mutations and risk of prostate cancer in Ashkenazi Jews. *Clin Cancer Res*. 2008;14:2918-2921.
356. Smith SC, Palanisamy N, Zuhlke KA, et al. HOXB13 G84E-related familial prostate cancers: a clinical, histologic, and molecular survey. *Am J Surg Pathol*. 2014;38:615-626.
357. Ewing CM, Ray AM, Lange EM, et al. Germline mutations in HOXB13 and prostate-cancer risk. *N Engl J Med*. 2012;366:141-149.
358. Haraldsdottir S, Hampel H, Wei L, et al. Prostate cancer incidence in males with Lynch syndrome. *Genet Med*. 2014;16:553-557.
359. Grignon DJ. Unusual subtypes of prostate cancer. *Mod Pathol*. 2004;17(3):316-327.
360. Randolph TL, Amin MB, Ro JY, Ayala AG. Histologic variants of adenocarcinoma and other carcinomas of prostate: pathologic criteria and clinical significance. *Mod Pathol*. 1997;10(6):612-629.
361. Epstein JI, Amin MB, Beltran H, et al. Proposed morphologic classification of prostate cancer with neuroendocrine differentiation. *Am J Surg Pathol*. 2014;38:756-767.
362. Abrahamsson PA. Neuroendocrine differentiation in prostatic carcinoma. *Prostate*. 1999;39:135-148.
363. So JS, Gordetsky J, Epstein JI. Variant of prostatic adenocarcinoma with Paneth cell-like neuroendocrine differentiation readily misdiagnosed as Gleason pattern 5. *Hum Pathol*. 2014;45:2388-2393.
364. Tamas EF, Epstein JI. Prognostic significance of paneth cell-like neuroendocrine differentiation in adenocarcinoma of the prostate. *Am J Surg Pathol*. 2006;30:980-985.
365. Giordano S, Tolonen T, Tolonen T, et al. A pure primary low-grade neuroendocrine carcinoma (carcinoid tumor) of the prostate. *Int Urol Nephrol*. 2010;42:683-687.
366. Goulet-Salmon B, Berthe E, Franc S, et al. Prostatic neuroendocrine tumor in multiple endocrine neoplasia Type 2B. *J Endocrinol Invest*. 2004;27:570-573.
367. Oesterling JE, Hauzeur CG, Farrow GM. Small cell anaplastic carcinoma of the prostate: a clinical, pathological and immunohistological study of 27 patients. *J Urol*. 1992;147(3 Pt 2):804-807.
368. Wang W, Epstein JI. Small cell carcinoma of the prostate. A morphologic and immunohistochemical study of 95 cases. *Am J Surg Pathol*. 2008;32(1):65-71.
369. Wenk RE, Bhagavan BS, Levy R, et al. Ectopic ACTH, prostatic oat cell carcinoma, and marked hypernatremia. *Cancer*. 1977;40(2):773-778.
370. Bleichner JC, Chun B, Klappenbach RS. Pure small-cell carcinoma of the prostate with fatal liver metastasis. *Arch Pathol Lab Med*. 1986;110(11):1041-1044.
371. Schron DS, Gipson T, Mendelsohn G. The histogenesis of small cell carcinoma of the prostate. An immunohistochemical study. *Cancer*. 1984;53(11):2478-2480.
372. Ghali VS, Garcia RL. Prostatic adenocarcinoma with carcinoidal features producing adrenocorticotropic syndrome. Immunohistochemical study and review of the literature. *Cancer*. 1984;54(6):1043-1048.
373. Ghandur-Mnaymneh L, Satterfield S, Block NL. Small cell carcinoma of the prostate gland with inappropriate antidiuretic hormone secretion: morphological, immunohistochemical and clinical expressions. *J Urol*. 1986;135(6):1263-1266.
374. Helpap B, Kollermann J. Undifferentiated carcinoma of the prostate with small cell features: immunohistochemical subtyping and reflections on histogenesis. *Virch Arch*. 1999;434(5):385-391.
375. Ro JY, Tetu B, Ayala AG, Ordonez NG. Small cell carcinoma of the prostate. II. Immunohistochemical and electron microscopic studies of 18 cases. *Cancer*. 1987;59(5):977-982.
376. Simon RA, di Sant'Agnese PA, Huang LS, et al. CD44 expression is a feature of prostatic small cell carcinoma and distinguishes it from its mimickers. *Hum Pathol*. 2009;40(2):252-258.
377. Gaffney EF. The extent of apoptosis in different types of high grade prostatic carcinoma. *Histopathology*. 1994;25(3):269-273.
378. Weaver MG, Abdul-Karim FW, Srigley JR. Paneth cell-like change and small cell carcinoma of the prostate. Two divergent forms of prostatic neuroendocrine differentiation. *Am J Surg Pathol*. 1992;16(10):1013-1016.
379. Yao JL, Madeb R, Bourne P, et al. Small cell carcinoma of the prostate: an immunohistochemical study. *Am J Surg Pathol*. 2006;30(6):705-712.
380. Evans AJ, Humphrey PA, Belani J, et al. Large cell neuroendocrine carcinoma of prostate: a clinicopathologic summary of 7 cases of a rare manifestation of advanced prostate cancer. *Am J Surg Pathol*. 2006;30(6):684-693.
381. Epstein JI, Lieberman PH. Mucinous adenocarcinoma of the prostate gland. *Am J Surg Pathol*. 1985;9(4):299-308.
382. McNeal JE, Alroy J, Villers A, et al. Mucinous differentiation in prostatic adenocarcinoma. *Hum Pathol*. 1991;22(10):979-988.
383. Ro JY, Grignon DJ, Ayala AG, et al. Mucinous adenocarcinoma of the prostate: histochemical and immunohistochemical studies. *Hum Pathol*. 1990;21(6):593-600.
384. Osunkoya AO, Nielsen ME, Epstein JI. Prognosis of mucinous adenocarcinoma of the prostate treated by radical prostatectomy: a study of 47 cases. *Am J Surg Pathol*. 2008;32(3):468-472.
385. Elbadawi A, Craig W, Linke CA, Cooper RA Jr. Prostatic mucinous carcinoma. *Urology*. 1979;13(6):658-666.
386. Proia AD, McCarty KS Jr, Woodard BH. Prostatic mucinous adenocarcinoma. A Cowper gland carcinoma mimicker. *Am J Surg Pathol*. 1981;5(7):701-706.
387. Osunkoya AO, Epstein JI. Primary mucin-producing urothelial-type adenocarcinoma of prostate: report of 15 cases. *Am J Surg Pathol*. 2007;31:1323-1329.
388. Van de Voorde W, Van Poppel H, Haustermans K, et al. Mucin-secreting adenocarcinoma of the prostate with neuroendocrine differentiation and Paneth-like cells. *Am J Surg Pathol*. 1994;18(2):200-207.
389. Das S, Brewer L, Bell S. Signet-ring cell carcinoma of the prostate. *J Urol Pathol*. 1996;5:149-156.
390. Kuroda N, Yamasaki I, Nakayama H, et al. Prostatic signet-ring cell carcinoma: case report and literature review. *Pathol Int*. 1999;49(5):457-461.
391. Leong FJ, Leong AS, Swift J. Signet-ring carcinoma of the prostate. *Pathol Res Pract*. 1997;192:1232-1238.
392. Torbenson M, Dhir R, Nangia A, et al. Prostatic carcinoma with signet ring cells: a clinicopathologic and immunohistochemical analysis of 12 cases, with review of the literature. *Mod Pathol*. 1998;11(6):552-559.
393. Guerin D, Hasan N, Keen CE. Signet ring cell differentiation in adenocarcinoma of the prostate: a study of five cases. *Histopathology*. 1993;22(4):367-371.
394. Alguacil-Garcia A. Artifactual changes mimicking signet ring cell carcinoma in transurethral prostatectomy specimens. *Am J Surg Pathol*. 1986;10(11):795-800.
395. Devaney DM, Dorman A, Leader M. Adenosquamous carcinoma of the prostate: a case report. *Hum Pathol*. 1991;22(10):1046-1050.
396. Gattuso P, Carson HJ, Candel A, Castelli MJ. Adenosquamous carcinoma of the prostate. *Hum Pathol*. 1995;26(1):123-126.
397. Moyana TN. Adenosquamous carcinoma of the prostate. *Am J Surg Pathol*. 1987;11(5):403-407.
398. Saito R, Davis BK, Ollapally EP. Adenosquamous carcinoma of the prostate. *Hum Pathol*. 1984;15(1):87-89.
399. Little NA, Wiener JS, Walther PJ, et al. Squamous cell carcinoma of the prostate: 2 cases of a rare malignancy and review of the literature. *J Urol*. 1993;149(1):137-139.

400. Wang I, Lin CS, Unger PD. Squamous cell carcinoma arising in hormonally treated adenocarcinoma of the prostate. *Int J Surg Pathol*. 1996;4:13-16.
401. Wernert N, Goebbels R, Bonkhoff H, Dhom G. Squamous cell carcinoma of the prostate. *Histopathology*. 1990;17(4):339-344.
402. Mai KT, Leahy CF. Squamous cell carcinoma occurring as a circumscribed nodule in the transition zone of the prostate: a case report and review of the literature. *J Urol Pathol*. 1996;5:85-92.
403. Ali TZ, Epstein JI. Basal cell carcinoma of the prostate: a clinicopathologic study of 29 cases. *Am J Surg Pathol*. 2007;31(5):697-705.
404. Begnami MD, Quezado M, Pinto P, et al. Adenoid cystic/basal cell carcinoma of the prostate: review and update. *Arch Pathol Lab Med*. 2007;131(4):637-640.
405. Frankel K, Craig JR. Adenoid cystic carcinoma of the prostate. Report of a case. *Am J Clin Pathol*. 1974;62(5):639-645.
406. Reed RJ. Consultation case: prostate (prostatectomy)–adenoid basal-cell tumor –multifocal basal-cell hyperplasia. *Am J Surg Pathol*. 1984;8(9):699-704.
407. Denholm SW, Webb JN, Howard GC, Chisholm GD. Basaloid carcinoma of the prostate gland: histogenesis and review of the literature. *Histopathology*. 1992;20(2): 151-155.
408. Bishop JA, Yonescu R, Epstein JI, Westra WH. A subset of prostatic basal cell carcinomas harbor the MYB rearrangement of adenoid cystic carcinoma. *Hum Pathol*. 2015;46:1204-1208.
409. Adlakha K, Bostwick DG. Lymphoepithelioma-like carcinoma of the prostate. A new histologic variant of prostatic adenocarcinoma. *J Urol Pathol*. 1994;2:319-326.
410. Lauwers GY, Schevchuk M, Armenakas N, Reuter VE. Carcinoma of the prostate. *Am J Surg Pathol*. 1993;17:342-349.
411. Ma TKF, Chapman WB, McLean M, Srigley J. Prostatic carcinosarcoma consisting of the unusual combination of ductal adenocarcinoma with osteogenic sarcoma: a report of a case and review of the literature. *J Urol Pathol*. 1998;8:111-120.
412. Mai KT, Burns BF, Morash C. Giant-cell carcinoma of the prostate. *J Urol Pathol*. 1996;5:167-174.
413. Ohtsuki Y, Ro JY, Ordonez NG, et al. Sarcomatoid carcinoma of the prostate with rhabdomyosarcomatous differentiation: case report and review of the literature. *J Urol Pathol*. 1996;5:157-166.
414. Lopez-Beltran A, Eble JN, Bostwick DG. Pleomorphic giant cell carcinoma of the prostate. *Arch Pathol Lab Med*. 2005;129(5):683-685.
415. Parwani AV, Herawi M, Epstein JI. Pleomorphic giant cell adenocarcinoma of the prostate: report of 6 cases. *Am J Surg Pathol*. 2006;30(10):1254-1259.
416. Berney DM, Ravi R, Baitum SI. Prostatic carcinosarcoma with squamous cell differentiation: a consequence of hormonal therapy? Report of two cases and review of the literature. *J Urol Pathol*. 1999;11: 123-132.
417. Reuter VE. Sarcomatoid lesions of the urogenital tract. *Semin Diagn Pathol*. 1993;10(2):188-201.
418. Shannon RL, Ro JY, Grignon DJ, et al. Sarcomatoid carcinoma of the prostate. A clinicopathologic study of 12 patients. *Cancer*. 1992;69(11):2676-2682.
419. Wick MR, Young RH, Malvesta R, et al. Prostatic carcinosarcomas. Clinical, histologic, and immunohistochemical data on two cases, with a review of the literature. *Am J Clin Pathol*. 1989;92(2):131-139.
420. Bostwick DG, Qian J. High-grade prostatic intraepithelial neoplasia. *Mod Pathol*. 2004;17(3):360-379.
421. Brawer MK. Prostatic intraepithelial neoplasia: a premalignant lesion. *Hum Pathol*. 1992;23(3):242-248.
422. Argani P, Epstein JI. Inverted (Hobnail) high-grade prostatic intraepithelial neoplasia (PIN): report of 15 cases of a previously undescribed pattern of high-grade PIN. *Am J Surg Pathol*. 2001;25(12):1534-1539.
423. Ayala AG, Ro JY. Prostatic intraepithelial neoplasia: recent advances. *Arch Pathol Lab Med*. 2007;131(8):1257-1266.
424. Berman DM, Yang J, Epstein JI. Foamy gland high-grade prostatic intraepithelial neoplasia. *Am J Surg Pathol*. 2000;24:140-144.
425. Reyes AO, Swanson PE, Carbone JM, Humphrey PA. Unusual histologic types of high-grade prostatic intraepithelial neoplasia. *Am J Surg Pathol*. 1997;21(10):1215-1222.
426. Kronz JD, Shaikh AA, Epstein JI. Atypical cribriform lesions on prostate biopsy. *Am J Surg Pathol*. 2001;25(2):147-155.
427. Crissman JD, Sakr WA, Hussein ME, Pontes JE. DNA quantitation of intraepithelial neoplasia and invasive carcinoma of the prostate. *Prostate*. 1993;22(2):155-162.
428. Baretton GB, Vogt T, Blasenbreu S, Lohrs U. Comparison of DNA ploidy in prostatic intraepithelial neoplasia and invasive carcinoma of the prostate: an image cytometric study. *Hum Pathol*. 1994;25(5):506-513.
429. Weinberg DS, Weidner N. Concordance of DNA content between prostatic intraepithelial neoplasia and concomitant invasive carcinoma. Evidence that prostatic intraepithelial neoplasia is a precursor of invasive prostatic carcinoma. *Arch Pathol Lab Med*. 1993;117(11):1132-1137.
430. Brawer MK, Bigler SA, Sohlberg OE, et al. Significance of prostatic intraepithelial neoplasia on prostate needle biopsy. *Urology*. 1991;38(2):103-107.
431. Weinstein MH, Epstein JI. Significance of high-grade prostatic intraepithelial neoplasia on needle biopsy. *Hum Pathol*. 1993;24(6):624-629.
432. Sakr WA, Haas GP, Cassin BF, et al. The frequency of carcinoma and intraepithelial neoplasia of the prostate in young male patients. *J Urol*. 1993;150(2 Pt 1):379-385.
433. Kronz JD, Allan CH, Shaikh AA, Epstein JI. Predicting cancer following a diagnosis of high-grade prostatic intraepithelial neoplasia on needle biopsy: data on men with more than one follow-up biopsy. *Am J Surg Pathol*. 2001;25(8):1079-1085.
434. Kronz JD, Shaikh AA, Epstein JI. High-grade prostatic intraepithelial neoplasia with adjacent small atypical glands on prostate biopsy. *Hum Pathol*. 2001;32(4):389-395.
435. Schlesinger C, Bostwick DG, Iczkowski KA. High-grade prostatic intraepithelial neoplasia and atypical small acinar proliferation: predictive value for cancer in current practice. *Am J Surg Pathol*. 2005;29(9):1201-1207.
436. Netto GJ, Epstein JI. Widespread high-grade prostatic intraepithelial neoplasia on prostatic needle biopsy: a significant likelihood of subsequently diagnosed adenocarcinoma. *Am J Surg Pathol*. 2006;30(9):1184-1188.
437. Bishara T, Ramnani DM, Epstein JI. High-grade prostatic intraepithelial neoplasia on needle biopsy: risk of cancer on repeat biopsy related to number of involved cores and morphologic pattern. *Am J Surg Pathol*. 2004;28(5):629-633.
438. Rhamy RK, Buchanan RD, Spalding MJ. Intraductal carcinoma of the prostate gland. *J Urol*. 1973;109:457-460.
439. Epstein JI, Oxley J, Ro JY, et al. Intraductal carcinoma. In: Moch H, Humphrey P, Ulbright T, Reuter V, eds. *WHO Classification of Tumours of the Urinary System and Male Genital Organs*. Lyon: IARC; 2016.
440. Guo CC, Epstein JI. Intraductal carcinoma of the prostate on needle biopsy: histologic features and clinical significance. *Mod Pathol*. 2006;19:1528-1535.
441. Robinson BD, Epstein JI. Intraductal carcinoma of the prostate without invasive carcinoma on needle biopsy: emphasis on radical prostatectomy findings. *J Urol*. 2010;184:1328-1333.
442. Khani F, Epstein JI. Prostate biopsy specimens with Gleason 3 + 3 = 6 and intraductal carcinoma: radical prostatectomy findings and clinical outcomes. *Am J Surg Pathol*. 2015;39:1383-1389.
443. Kweldam CF, Kümmerlin IP, Nieboer D, et al. Disease-specific survival of patients with invasive cribriform and intraductal prostate cancer at diagnostic biopsy. *Mod Pathol*. 2016;29:630-636.
444. Lotan TL, Gumuskaya B, Rahimi H, et al. Cytoplasmic PTEN protein loss distinguishes intraductal carcinoma of the prostate from high-grade prostatic intraepithelial neoplasia. *Mod Pathol*. 2013;26:587-603.
445. Morais CL, Han JS, Gordetsky J, et al. Utility of PTEN and ERG immunostaining for distinguishing high-grade PIN from intraductal carcinoma of the prostate on needle biopsy. *Am J Surg Pathol*. 2015;39: 169-178.
446. Brat DJ, Wills ML, Lecksell KL, Epstein JI. How often are diagnostic features missed with less extensive histologic sampling of prostate needle biopsy specimens? *Am J Surg Pathol*. 1999;23(3):257-262.
447. Lane RB Jr, Lane CG, Mangold KA, et al. Needle biopsies of the prostate: what constitutes adequate histologic sampling? *Arch Pathol Lab Med*. 1998;122(9):833-835.
448. Renshaw AA. Adequate tissue sampling of prostate core needle biopsies. *Am J Clin Pathol*. 1997;107(1):26-29.
449. Reyes AO, Humphrey PA. Diagnostic effect of complete histologic sampling of prostate needle biopsy specimens. *Am J Clin Pathol*. 1998;109(4):416-422.
450. Epstein JI. The diagnosis and reporting of adenocarcinoma of the prostate in core needle biopsy specimens. *Cancer*. 1996;78(2):350-356.
451. Epstein JI, Egevad L, Amin MB, et al. The 2014 International Society of Urological Pathology (ISUP) Consensus Conference on Gleason Grading of Prostatic Carcinoma: Definition of Grading Patterns and Proposal for a New Grading System. *Am J Surg Pathol*. 2016;40: 244-252.
452. Newman AJ Jr, Graham MA, Carlton CE Jr, Lieman S. Incidental carcinoma of the prostate at the time of transurethral resection: importance of evaluating every chip. *J Urol*. 1982;128(5):948-950.
453. Murphy WM, Dean PJ, Brasfield JA, Tatum L. Incidental carcinoma of the prostate. How much sampling is adequate? *Am J Surg Pathol*. 1986;10(3):170-174.
454. Vollmer RT. Prostate cancer and chip specimens: complete versus partial sampling. *Hum Pathol*. 1986;17(3):285-290.
455. Garborg I, Eide TJ. The probability of overlooking prostatic cancer in transurethrally resected material when different embedding practices are followed. *Acta Pathol Microbiol Immunol Scand [A]*. 1985;93(5):205-208.
456. Rohr LR. Incidental adenocarcinoma in transurethral resections of the prostate. Partial versus complete microscopic examination. *Am J Surg Pathol*. 1987;11(1):53-58.
457. McDowell PR, Fox WM, Epstein JI. Is submission of remaining tissue necessary when incidental carcinoma of the prostate is

found on transurethral resection? *Hum Pathol*. 1994;25(5):493-497.
458. Egevad L, Engstrom K, Busch C. A new method for handling radical prostatectomies enabling fresh tissue harvesting, whole mount sections, and landmarks for alignment of sections. *J Urol Pathol*. 1998;9:17-28.
459. Hoedemaeker RF, Ruijter ETG, Ruizeveld-de Winter JA, et al. Processing radical prostatectomy specimens: a comprehensive and standardized protocol. *J Urol Pathol*. 1998;9:211-222.
460. Montironi R, Mazzucchelli R, Kwast T. Morphological assessment of radical prostatectomy specimens. A protocol with clinical relevance. *Virch Arch*. 2003;442(3):211-217.
461. Sehdev AE, Pan CC, Epstein JI. Comparative analysis of sampling methods for grossing radical prostatectomy specimens performed for nonpalpable (stage T1c) prostatic adenocarcinoma. *Hum Pathol*. 2001;32(5):494-499.
462. Egevad L, Srigley JR, Delahunt B. International Society of Urological Pathology (ISUP) consensus conference on handling and staging of radical prostatectomy specimens: rationale and organization. *Mod Pathol*. 2011;24:1-5.
463. Carlin BI, Andriole GL. The natural history, skeletal complications, and management of bone metastases in patients with prostate carcinoma. *Cancer*. 2000;88(12 suppl):2989-2994.
464. Harada M, Iida M, Yamaguchi M, Shida K. Analysis of bone metastasis of prostatic adenocarcinoma in 137 autopsy cases. *Adv Exp Med Biol*. 1992;324:173-182.
465. Legier JF, Tauber LN. Solitary metastasis of occult prostatic carcinoma simulating osteogenic sarcoma. *Cancer*. 1968;22(1):168-172.
466. Harada M, Shimizu A, Nakamura Y, Nemoto R. Role of the vertebral venous system in metastatic spread of cancer cells to the bone. *Adv Exp Med Biol*. 1992;324:83-92.
467. Dodds PR, Caride VJ, Lytton B. The role of vertebral veins in the dissemination of prostatic carcinoma. *J Urol*. 1981;126(6):753-755.
468. Charhon SA, Chapuy MC, Delvin EE, et al. Histomorphometric analysis of sclerotic bone metastases from prostatic carcinoma special reference to osteomalacia. *Cancer*. 1983;51(5):918-924.
469. Saitoh H, Yoshida K, Uchijima Y, et al. Two different lymph node metastatic patterns of a prostatic cancer. *Cancer*. 1990;65(8):1843-1846.
470. Kothari PS, Scardino PT, Ohori M, et al. Incidence, location, and significance of periprostatic and periseminal vesicle lymph nodes in prostate cancer. *Am J Surg Pathol*. 2001;25(11):1429-1432.
471. Murray SK, Breau RH, Guha AK, Gupta R. Spread of prostate carcinoma to the perirectal lymph node basin: analysis of 112 rectal resections over a 10-year span for primary rectal adenocarcinoma. *Am J Surg Pathol*. 2004;28(9):1154-1162.
472. Benson RC Jr, Tomera KM, Zincke H, et al. Bilateral pelvic lymphadenectomy and radical retropubic prostatectomy for adenocarcinoma confined to the prostate. *J Urol*. 1984;131(6):1103-1106.
473. Olsson CA. Staging lymphadenectomy should be an antecedent to treatment in localized prostatic carcinoma. *Urology*. 1985;25(2 suppl):4-6.
474. Saltzstein SL, McLaughlin AP. Clinicopathologic features of unsuspected regional lymph node metastases in prostatic adenocarcinoma. *Cancer*. 1977;40(3):1212-1221.
475. Zincke H, Utz DC, Taylor WF. Bilateral pelvic lymphadenectomy and radical prostatectomy for clinical stage C prostatic cancer: role of adjuvant treatment for residual cancer and in disease progression. *J Urol*. 1986;135(6):1199-1205.
476. Brawn PN, Kuhl D, Speights VO, et al. The incidence of unsuspected metastases from clinically benign prostate glands with latent prostate carcinoma. *Arch Pathol Lab Med*. 1995;119(8):731-733.
477. Cho KR, Epstein JI. Metastatic prostatic carcinoma to supradiaphragmatic lymph nodes. A clinicopathologic and immunohistochemical study. *Am J Surg Pathol*. 1987;11(6):457-463.
478. Butler JJ, Howe CD, Johnson DE. Enlargement of the supraclavicular lymph nodes as the initial sign of prostatic carcinoma. *Cancer*. 1971;27(5):1055-1063.
479. Jones H, Anthony PP. Metastatic prostatic carcinoma presenting as left-sided cervical lymphadenopathy: a series of 11 cases. *Histopathology*. 1992;21(2):149-154.
480. Lindell MM, Doubleday LC, von Eschenbach AC, Libshitz HI. Mediastinal metastases from prostatic carcinoma. *J Urol*. 1982;128(2):331-334.
481. Brawn P. Histologic features of metastatic prostate cancer. *Hum Pathol*. 1992;23(3):267-272.
482. Gomella LG, White JL, McCue PA, et al. Screening for occult nodal metastasis in localized carcinoma of the prostate. *J Urol*. 1993;149(4):776-778.
483. Moul JW, Lewis DJ, Ross AA, et al. Immunohistologic detection of prostate cancer pelvic lymph node micrometastases: correlation to preoperative serum prostate-specific antigen. *Urology*. 1994;43(1):68-73.
484. Gentile PS, Carloss HW, Huang TY, et al. Disseminated prostatic carcinoma simulating primary lung cancer. Indications for immunodiagnostic studies. *Cancer*. 1988;62(4):711-715.
485. Copeland JN, Amin MB, Humphrey PA, et al. The morphologic spectrum of metastatic prostatic adenocarcinoma to the lung: special emphasis on histologic features overlapping with other pulmonary neoplasms. *Am J Clin Pathol*. 2002;117(4):552-557.
486. Tu SM, Reyes A, Maa A, et al. Prostate carcinoma with testicular or penile metastases. Clinical, pathologic, and immunohistochemical features. *Cancer*. 2002;94(10):2610-2617.
487. Ransom DT, Dinapoli RP, Richardson RL. Cranial nerve lesions due to base of the skull metastases in prostate carcinoma. *Cancer*. 1990;65(3):586-589.
488. Baumann MA, Holoye PY, Choi H. Adenocarcinoma of prostate presenting as brain metastasis. *Cancer*. 1984;54(8):1723-1725.
489. Bubendorf L, Schopfer A, Wagner U, et al. Metastatic patterns of prostate cancer: an autopsy study of 1589 patients. *Hum Pathol*. 2000;31(5):578-583.
490. de la Monte SM, Moore GW, Hutchins GM. Metastatic behavior of prostate cancer. Cluster analysis of patterns with respect to estrogen treatment. *Cancer*. 1986;58(4):985-993.
491. De Potter P, Shields CL, Shields JA, Tardio DJ. Uveal metastasis from prostate carcinoma. *Cancer*. 1993;71(9):2791-2796.
492. Hrebinko R, Taylor SR, Bahnson RR. Carcinoma of prostate metastatic to parotid gland. *Urology*. 1993;41(3):272-273.
493. Kasabian NG, Previte SR, Kaloustian HD, Ganem EJ. Adenocarcinoma of the prostate presenting initially as an intracerebral tumor. *Cancer*. 1992;70(8):2149-2151.
494. Pfister S, Kleinschmidt-DeMasters BK. Dural metastases from prostatic adenocarcinoma. Report of five cases and review of the literature. *J Urol Pathol*. 1995;3:119-128.
495. Powell FC, Venencie PY, Winkelmann RK. Metastatic prostate carcinoma manifesting as penile nodules. *Arch Dermatol*. 1984;120(12):1604-1606.
496. Simpson RH, Skalova A. Metastatic carcinoma of the prostate presenting as parotid tumour. *Histopathology*. 1997;30(1):70-74.
497. Stanko C, Grandinetti L, Baldassano M, et al. Epidermotropic metastatic prostate carcinoma presenting as an umbilical nodule-Sister Mary Joseph nodule. *Am J Dermatopathol*. 2007;29(3):290-292.
498. Tremont-Lukats IW, Bobustuc G, Lagos GK, et al. Brain metastasis from prostate carcinoma: the M. D. Anderson cancer center experience. *Cancer*. 2003;98(2):363-368.
499. Bovenberg SA, van der Zwet CJJ, van der Kwast TH, et al. Prostate-specific antigen expression in prostate cancer and its metastases. *J Urol Pathol*. 1993;1:55-61.
500. Kramer SA, Farnham R, Glenn JF, Paulson DF. Comparative morphology of primary and secondary deposits of prostatic adenocarcinoma. *Cancer*. 1981;48(2):271-273.
501. Cheng L, Slezak J, Bergstralh EJ, et al. Dedifferentiation in the metastatic progression of prostate carcinoma. *Cancer*. 1999;86(4):657-663.
502. McNeal JE, Yemoto CE. Spread of adenocarcinoma within prostatic ducts and acini. Morphologic and clinical correlations. *Am J Surg Pathol*. 1996;20(7):802-814.
503. McNeal JE, Yemoto CE. Significance of demonstrable vascular space invasion for the progression of prostatic adenocarcinoma. *Am J Surg Pathol*. 1996;20(11):1351-1360.
504. Ohori M, Scardino PT, Lapin SL, et al. The mechanisms and prognostic significance of seminal vesicle involvement by prostate cancer. *Am J Surg Pathol*. 1993;17(12):1252-1261.
505. Robinette MA, Robson CJ, Farrow GA, et al. Giant serial step sections of the prostate in assessment of the accuracy of clinical staging in patients with localized prostatic carcinoma [abstract]. *J Urol Pathol*. 1984;133(suppl):242A.
506. Mukamel E, deKernion JB, Hannah J, et al. The incidence and significance of seminal vesicle invasion in patients with adenocarcinoma of the prostate. *Cancer*. 1987;59(8):1535-1538.
507. Epstein JI, Carmichael M, Walsh PC. Adenocarcinoma of the prostate invading the seminal vesicle: definition and relation of tumor volume, grade and margins of resection to prognosis. *J Urol*. 1993;149(5):1040-1045.
508. Villers A, McNeal JE, Freiha FS, et al. Invasion of Denonvilliers' fascia in radical prostatectomy specimens. *J Urol*. 1993;149(4):793-798.
509. Gengler L, Baer J, Finby N. Rectal and sigmoid involvement secondary to carcinoma of the prostate. *Am J Roentgenol Radium Ther Nucl Med*. 1975;125(4):910-917.
510. Lane Z, Epstein JI, Ayub S, Netto GJ. Prostatic adenocarcinoma in colorectal biopsy: clinical and pathologic features. *Hum Pathol*. 2008;39(4):543-549.
511. Owens CL, Epstein JI, Netto GJ. Distinguishing prostatic from colorectal adenocarcinoma on biopsy samples: the role of morphology and immunohistochemistry. *Arch Pathol Lab Med*. 2007;131(4):599-603.
512. Gleason DF. Histologic grading of prostate cancer: a perspective. *Hum Pathol*. 1992;23(3):273-279.
513. Gleason DF, Mellinger GT. Prediction of prognosis for prostatic adenocarcinoma by

combined histological grading and clinical staging. *J Urol*. 1974;111(1):58-64.
514. Bain GO, Koch M, Hanson J. Feasibility of grading prostatic carcinomas. *Arch Pathol Lab Med*. 1982;106:265-267.
515. Humphrey PA. Gleason grading and prognostic factors in carcinoma of the prostate. *Mod Pathol*. 2004;17(3):292-306.
516. Lilleby W, Torlakovic G, Torlakovic E, et al. Prognostic significance of histologic grading in patients with prostate carcinoma who are assessed by the Gleason and World Health Organization grading systems in needle biopsies obtained prior to radiotherapy. *Cancer*. 2001;92(2):311-319.
517. Murphy GP, Whitmore WF Jr. A report of the workshops on the current status of the histologic grading of prostate cancer. *Cancer*. 1979;44(4):1490-1494.
518. Thomas R, Lewis RW, Sarma DP, et al. Aid to accurate clinical staging-histopathologic grading in prostatic cancer. *J Urol*. 1982;128(4):726-728.
519. Allsbrook WC, Mangold KAJ, Yang X, Epstein JI. The Gleason grading system: an overview. *J Urol Pathol*. 1999;10:141-158.
520. Mosse CA, Magi-Galluzzi C, Tsuzuki T, Epstein JI. The prognostic significance of tertiary Gleason pattern 5 in radical prostatectomy specimens. *Am J Surg Pathol*. 2004;28(3): 394-398.
521. Trpkov K, Zhang J, Chan M, et al. Prostate cancer with tertiary Gleason pattern 5 in prostate needle biopsy: clinicopathologic findings and disease progression. *Am J Surg Pathol*. 2009;33(2):233-240.
522. McKenney JK, Simko J, Bonham M, et al. The potential impact of reproducibility of Gleason grading in men with early stage prostate cancer managed by active surveillance: a multi-institutional study. *J Urol*. 2011;186: 465-469.
523. Pierorazo PM, Walsh PC, Partin AW, Epstein JI. Prognostic Gleason grade grouping: data based on the modified Gleason scoring system. *BJU Int*. 2013;111:753-760.
524. Epstein JI, Zelefsky MJ, Sjoberg DD, et al. A contemporary prostate cancer grading system: a validated alternative to the Gleason score. *Eur Urol*. 2016;69:428-435.
525. Berney DM, Beltran L, Fisher G, et al. Validation of a contemporary prostate cancer grading system using prostate cancer death as outcome. *Br J Cancer*. 2016;114:1078-1083.
526. Kweldam CF, Kümmerlin IP, Nieboer D, et al. Prostate cancer outcomes of men with biopsy Gleason score 6 and 7 without cribriform or intraductal carcinoma. *Eur J Cancer*. 2016;66:26-33.
527. Humphrey PA, Frazier HA, Vollmer RT, Paulson DF. Stratification of pathologic features in radical prostatectomy specimens that are predictive of elevated initial postoperative serum prostate-specific antigen levels. *Cancer*. 1993;71(5):1821-1827.
528. Pretlow TG 2nd, Harris BE, Bradley EL Jr, et al. Enzyme activities in prostatic carcinoma related to Gleason grades. *Cancer Res*. 1985;45(1):442-446.
529. Cantrell BB, DeKlerk DP, Eggleston JC, et al. Pathological factors that influence prognosis in stage A prostatic cancer: the influence of extent versus grade. *J Urol*. 1981;125(4):516-520.
530. Partin AW, Yoo J, Carter HB, et al. The use of prostate specific antigen, clinical stage and Gleason score to predict pathological stage in men with localized prostate cancer. *J Urol*. 1993;150(1):110-114.
531. Kallakury BV, Figge J, Ross JS, et al. Association of p53 immunoreactivity with high gleason tumor grade in prostatic adenocarcinoma. *Hum Pathol*. 1994;25(1):92-97.
532. Fan K, Peng CF. Predicting the probability of bone metastasis through histological grading of prostate carcinoma: a retrospective correlative analysis of 81 autopsy cases with antemortem transurethral resection specimen. *J Urol*. 1983;130(4):708-711.
533. Zincke H, Farrow GM, Myers RP, et al. Relationship between grade and stage of adenocarcinoma of the prostate and regional pelvic lymph node metastases. *J Urol*. 1982;128(3):498-501.
534. Gibbons RP, Correa RJ Jr, Brannen GE, Mason JT. Total prostatectomy for localized prostatic cancer. *J Urol*. 1984;131(1):73-76.
535. Perez CA, Bauer W, Garza R, Royce RK. Radiation therapy in the definitive treatment of localized carcinoma of the prostate. *Cancer*. 1977;40(4):1425-1433.
536. Utz DC, Farrow GM. Pathologic differentiation and prognosis of prostatic carcinoma. *JAMA*. 1969;209(11):1701-1703.
537. Whitmore WF Jr. Expectant management of clinically localized prostatic cancer. *Sem Oncol*. 1994;21(5):560-568.
538. Daneshgari F, Crawford ED. Endocrine therapy of advanced carcinoma of the prostate. *Cancer*. 1993;71(3 suppl):1089-1097.
539. Labrie F. Endocrine therapy for prostate cancer. *Endocrinol Metab Clin North Am*. 1991;20(4):845-872.
540. McLeod DG. Hormonal therapy in the treatment of carcinoma of the prostate. *Cancer Res*. 1995;75:1914-1919.
541. Samson DJ, Seidenfeld J, Schmitt B, et al. Systematic review and meta-analysis of monotherapy compared with combined androgen blockade for patients with advanced prostate carcinoma. *Cancer*. 2002;95(2):361-376.
542. Grignon DJ, Sakr WA. Histologic effects of radiation therapy and total androgen blockade on prostate cancer. *Cancer Res*. 1995;75:1837-1841.
543. Hellstrom M, Haggman M, Brandstedt S, et al. Histopathological changes in androgen-deprived localized prostatic cancer. A study in total prostatectomy specimens. *Eur Urol*. 1993;24(4):461-465.
544. Tang X, Serizawa A, Tokunaga M, et al. Variation of alpha-methylacyl-CoA racemase expression in prostate adenocarcinoma cases receiving hormonal therapy. *Hum Pathol*. 2006;37(9):1186-1192.
545. Armas OA, Aprikian AG, Melamed J, et al. Clinical and pathobiological effects of neoadjuvant total androgen ablation therapy on clinically localized prostatic adenocarcinoma. *Am J Surg Pathol*. 1994;18(10):979-991.
546. Civantos F, Soloway MS. Prostatic pathology after androgen blockade: effects on prostatic carcinoma and on nontumor prostate. *Adv Anat Pathol*. 1996;3:259-265.
547. Civantos F, Marcial MA, Banks ER, et al. Pathology of androgen deprivation therapy in prostate carcinoma. A comparative study of 173 patients. *Cancer*. 1995;75(7):1634-1641.
548. Gaudin PB, Zelefsky MJ, Leibel SA, et al. Histopathologic effects of three-dimensional conformal external beam radiation therapy on benign and malignant prostate tissues. *Am J Surg Pathol*. 1999;23(9):1021-1031.
549. Smith DM, Murphy WM. Histologic changes in prostate carcinomas treated with leuprolide (luteinizing hormone-releasing hormone effect). Distinction from poor tumor differentiation. *Cancer*. 1994;73(5):1472-1477.
550. Tetu B, Srigley JR, Boivin JC, et al. Effect of combination endocrine therapy (LHRH agonist and flutamide) on normal prostate and prostatic adenocarcinoma. A histopathologic and immunohistochemical study. *Am J Surg Pathol*. 1991;15(2):111-120.
551. Vailancourt L, Ttu B, Fradet Y, et al. Effect of neoadjuvant endocrine therapy (combined androgen blockade) on normal prostate and prostatic carcinoma. A randomized study. *Am J Surg Pathol*. 1996;20(1):86-93.
552. Tran TA, Jennings TA, Ross JS, Nazeer T. Pseudomyxoma ovariilike posttherapeutic alteration in prostatic adenocarcinoma: a distinctive pattern in patients receiving neoadjuvant androgen ablation therapy. *Am J Surg Pathol*. 1998;22(3):347-354.
553. Kusumi T, Koie T, Tanaka M, et al. Immunohistochemical detection of carcinoma in radical prostatectomy specimens following hormone therapy. *Pathol Int*. 2008;58(11):687-694.
554. Wozniak AJ, Blumenstein BA, Crawford ED, et al. Cyclophosphamide, methotrexate, and 5-fluorouracil in the treatment of metastatic prostate cancer. A Southwest Oncology Group study. *Cancer*. 1993;71(12):3975-3978.
555. Scher HI, Morris MJ, Stadler WM, et al. Trial design and objectives for castration-resistant prostate cancer: updated recommendations from the Prostate Cancer Clinical Trials Working Group 3. *J Clin Oncol*. 2016;34:1402-1418.
556. Ryan CJ, Smith MR, de Bono JS, et al. Abiraterone in metastatic prostate cancer without previous chemotherapy. *N Engl J Med*. 2012;368:138-148.
557. Scher HI, Fizazi K, Saad F, et al. Increased survival with enzalutamide in prostate cancer after chemotherapy. *N Engl J Med*. 2012;367:1187-1197.
558. Montie JE. Staging of prostate cancer: current TNM classification and future prospects for prognostic factors. *Cancer Res*. 1995;75:1814-1818.
559. Amin MB, ed. *AJCC Cancer Staging Manual*. 8th ed. Chicago: Springer; 2016.
560. Ahlering TE, Skarecky DW, McLaren CE, Weinberg AC. Seminal vesicle involvement in patients with D1 disease predicts early prostate specific antigen recurrence and metastasis after radical prostatectomy and early androgen ablation. *Cancer*. 2002;94(6):1648-1653.
561. Wheeler TM, Dillioglugil O, Kattan MW, et al. Clinical and pathological significance of the level and extent of capsular invasion in clinical stage T1-2 prostate cancer. *Hum Pathol*. 1998;29(8):856-862.
562. Sung MT, Lin H, Koch MO, et al. Radial distance of extraprostatic extension measured by ocular micrometer is an independent predictor of prostate-specific antigen recurrence: a new proposal for the substaging of pT3a prostate cancer. *Am J Surg Pathol*. 2007;31(2):311-318.
563. Cheng L, Bergstralh EJ, Cheville JC, et al. Cancer volume of lymph node metastasis predicts progression in prostate cancer. *Am J Surg Pathol*. 1998;22(12):1491-1500.
564. Cheng L, Pisansky TM, Ramnani DM, et al. Extranodal extension in lymph node-positive prostate cancer. *Mod Pathol*. 2000;13(2):113-118.
565. Griebling TL, Ozkutlu D, See WA, Cohen MB. Prognostic implications of extracapsular extension of lymph node metastases in prostate cancer. *Mod Pathol*. 1997;10(8):804-809.
566. Smith JA Jr, Middleton RG. Implications of volume of nodal metastasis in patients with adenocarcinoma of the prostate. *J Urol*. 1985;133(4):617-619.
567. Humphrey PA, Walther PJ. Adenocarcinoma of the prostate. Part II: tissue prognosticators. *Am J Clin Pathol*. 1993;100(3):256-269.
568. Zincke H, Bergstralh EJ, Blute ML, et al. Radical prostatectomy for clinically localized prostate cancer: long-term results of 1143

patients from a single institution. *J Clin Pathol*. 1994;12(11):2254-2263.
569. Pan CC, Potter SR, Partin AW, Epstein JI. The prognostic significance of tertiary Gleason patterns of higher grade in radical prostatectomy specimens: a proposal to modify the Gleason grading system. *Am J Surg Pathol*. 2000;24(4):563-569.
570. Epstein JI, Pizov G, Walsh PC. Correlation of pathologic findings with progression after radical retropubic prostatectomy. *Cancer*. 1993;71(11):3582-3593.
571. Blute ML, Bostwick DG, Seay TM, et al. Pathologic classification of prostate carcinoma: the impact of margin status. *Cancer*. 1998;82(5):902-908.
572. Cheng L, Darson MF, Bergstralh EJ, et al. Correlation of margin status and extraprostatic extension with progression of prostate carcinoma. *Cancer*. 1999;86(9):1775-1782.
573. Kausik SJ, Blute ML, Sebo TJ, et al. Prognostic significance of positive surgical margins in patients with extraprostatic carcinoma after radical prostatectomy. *Cancer*. 2002;95(6):1215-1219.
574. Chuang AY, Epstein JI. Positive surgical margins in areas of capsular incision in otherwise organ-confined disease at radical prostatectomy: histologic features and pitfalls. *Am J Surg Pathol*. 2008;32(8):1201-1206.
575. Schmid HP, McNeal JE. An abbreviated standard procedure for accurate tumor volume estimation in prostate cancer. *Am J Surg Pathol*. 1992;16(2):184-191.
576. Epstein JI, Carmichael M, Partin AW, Walsh PC. Is tumor volume an independent predictor of progression following radical prostatectomy? A multivariate analysis of 185 clinical stage B adenocarcinomas of the prostate with 5 years of followup. *J Urol*. 1993;149(6):1478-1481.
577. Humphrey PA, Vollmer RT. Percentage carcinoma as a measure of prostatic tumor size in radical prostatectomy tissues. *Mod Pathol*. 1997;10(4):326-333.
578. Renshaw AA, Chang H, D'Amico AV. Estimation of tumor volume in radical prostatectomy specimens in routine clinical practice. *Am J Clin Pathol*. 1997;107(6):704-708.
579. Renshaw AA, Richie JP, Loughlin KR, et al. Maximum diameter of prostatic carcinoma is a simple, inexpensive, and independent predictor of prostate-specific antigen failure in radical prostatectomy specimens. Validation in a cohort of 434 patients. *Am J Clin Pathol*. 1999;111(5):641-644.
580. Pisansky TM, Kahn MJ, Rasp GM, et al. A multiple prognostic index predictive of disease outcome after irradiation for clinically localized prostate carcinoma. *Cancer*. 1997;79(2):337-344.
581. Kunz GM Jr, Epstein JI. Should each core with prostate cancer be assigned a separate gleason score? *Hum Pathol*. 2003;34(9):911-914.
582. Lewis JS Jr, Vollmer RT, Humphrey PA. Carcinoma extent in prostate needle biopsy tissue in the prediction of whole gland tumor volume in a screening population. *Am J Clin Pathol*. 2002;118(3):442-450.
583. Brawn PN, Johnson EH, Kuhl DL, et al. Stage at presentation and survival of white and black patients with prostate carcinoma. *Cancer*. 1993;71(8):2569-2573.
584. Hammond ME, Sause WT, Martz KL, et al. Correlation of prostate-specific acid phosphatase and prostate-specific antigen immunocytochemistry with survival in prostate carcinoma. *Cancer*. 1989;63(3):461-466.
585. Herman CM, Wilcox GE, Kattan MW, et al. Lymphovascular invasion as a predictor of disease progression in prostate cancer. *Am J Surg Pathol*. 2000;24(6):859-863.
586. Roma AA, Magi-Galluzzi C, Kral MA, et al. Peritumoral lymphatic invasion is associated with regional lymph node metastases in prostate adenocarcinoma. *Mod Pathol*. 2006;19(3):392-398.
587. di Sant'Agnese PA. Neuroendocrine differentiation in carcinoma of the prostate. Diagnostic, prognostic, and therapeutic implications. *Cancer*. 1992;70(1 suppl):254-268.
588. Weinstein MH, Partin AW, Veltri RW, Epstein JI. Neuroendocrine differentiation in prostate cancer: enhanced prediction of progression after radical prostatectomy. *Hum Pathol*. 1996;27(7):683-687.
589. Abrahamsson PA, Falkmer S, Falt K, Grimelius L. The course of neuroendocrine differentiation in prostatic carcinomas. An immunohistochemical study testing chromogranin A as an "endocrine marker. *Pathol Res Pract*. 1989;185(3):373-380.
590. Yanagisawa N, Li R, Rowley D, et al. Stromogenic prostatic carcinoma pattern (carcinomas with reactive stromal grade 3) in needle biopsies predicts biochemical recurrence-free survival in patients after radical prostatectomy. *Hum Pathol*. 2007;38(11):1611-1620.
591. Mckenney JK, Wei W, Hawley S, et al. Histologic grading of prostatic adenocarcinoma can be further pptimized: analysis of the relative prognostic strength of individual architectural patterns in 1275 patients from the canary retrospective cohort. *Am J Surg Pathol*. 2016;40:1439-1456.
592. Li R, Wheeler T, Dai H, et al. High level of androgen receptor is associated with aggressive clinicopathologic features and decreased biochemical recurrence-free survival in prostate: cancer patients treated with radical prostatectomy. *Am J Surg Pathol*. 2004;28(7):928-934.
593. Taplin ME, Bubley GJ, Shuster TD, et al. Mutation of the androgen-receptor gene in metastatic androgen-independent prostate cancer. *N Engl J Med*. 1995;332(21):1393-1398.
594. Benson MC, Walsh PC. The application of flow cytometry to the assessment of tumor cell heterogeneity and the grading of human prostatic cancer: preliminary results. *J Urol*. 1986;135(6):1194-1198.
595. Frankfurt OS, Chin JL, Englander LS, et al. Relationship between DNA ploidy, glandular differentiation, and tumor spread in human prostate cancer. *Cancer Res*. 1985;45: 1418-1423.
596. McIntire TL, Murphy WM, Coon JS, et al. The prognostic value of DNA ploidy combined with histologic substaging for incidental carcinoma of the prostate gland. *Am J Clin Pathol*. 1988;89(3):370-373.
597. Muller JG, Demel S, Wirth MP, et al. DNA-ploidy, G2M-fractions and prognosis of stages B and C prostate carcinoma. *Virch Arch*. 1994;424(6):647-651.
598. Winkler HZ, Rainwater LM, Myers RP, et al. Stage D1 prostatic adenocarcinoma: significance of nuclear DNA ploidy patterns studied by flow cytometry. *Mayo Clin Proc*. 1988;63(2):103-112.
599. Ross JS, Sheehan CE, Ambros RA, et al. Needle biopsy DNA ploidy status predicts grade shifting in prostate cancer. *Am J Surg Pathol*. 1999;23(3):296-301.
600. Hussain MH, Powell I, Zaki N, et al. Flow cytometric DNA analysis of fresh prostatic resections. Correlation with conventional prognostic parameters in patients with prostate cancer. *Cancer*. 1993;72(10):3012-3019.
601. Lieber MM, Murtaugh PA, Farrow GM, et al. DNA ploidy and surgically treated prostate cancer. Important independent association with prognosis for patients with prostate carcinoma treated by radical prostatectomy. *Cancer*. 1995;752:1935-1943.
602. Mohler JL, Partin AW, Epstein JI, et al. Prediction of prognosis in untreated stage A2 prostatic carcinoma. *Cancer*. 1992;69(2):511-519.
603. Nativ O, Winkler HZ, Raz Y, et al. Stage C prostatic adenocarcinoma: flow cytometric nuclear DNA ploidy analysis. *Mayo Clin Proc*. 1989;64(8):911-919.
604. Forsslund G, Esposti PL, Nilsson B, Zetterberg A. The prognostic significance of nuclear DNA content in prostatic carcinoma. *Cancer*. 1992;69(6):1432-1439.
605. Falkmer UG. Methodologic sources of errors in image and flow cytometric DNA assessments of the malignancy potential of prostatic carcinoma. *Hum Pathol*. 1992;23(4):360-367.
606. Bubendorf L, Tapia C, Gasser TC, et al. Ki67 labeling index in core needle biopsies independently predicts tumor-specific survival in prostate cancer. *Hum Pathol*. 1998;29(9):949-954.
607. Masuda M, Takano Y, Iki M, et al. Prognostic significance of Ki-67, p53, and Bcl-2 expression in prostate cancer patients with lymph node metastases: a retrospective immunohistochemical analysis. *Pathol Int*. 1998;48(1):41-46.
608. Chiusa L, Galliano D, Formiconi A, et al. High and low risk prostate carcinoma determined by histologic grade and proliferative activity. *Cancer*. 1997;79(10):1956-1963.
609. Lundgren R, Heim S, Mandahl N, et al. Chromosome abnormalities are associated with unfavorable outcome in prostatic cancer patients. *J Urol*. 1992;147(3 Pt 2): 784-788.
610. Bookstein R, MacGrogan D, Hilsenbeck SG, et al. p53 is mutated in a subset of advanced-stage prostate cancers. *Cancer Res*. 1993;53(14):3369-3373.
611. Navone NM, Troncoso P, Pisters LL, et al. p53 protein accumulation and gene mutation in the progression of human prostate carcinoma. *J Natl Cancer Inst*. 1993;85(20):1657-1669.
612. Shurbaji MS, Kalbfleisch JH, Thurmond TS. Immunohistochemical detection of p53 protein as a prognostic indicator in prostate cancer. *Hum Pathol*. 1995;26(1):106-109.
613. Thomas DJ, Robinson M, King P, et al. p53 expression and clinical outcome in prostate cancer. *Br J Urol*. 1993;72(5 Pt 2):778-781.
614. Cheng L, Bergstralh EJ, Scherer BG, et al. Predictors of cancer progression in T1a prostate adenocarcinoma. *Cancer*. 1999;85(6):1300-1304.
615. Epstein JI, Partin AW, Sauvageot J, Walsh PC. Prediction of progression following radical prostatectomy. A multivariate analysis of 721 men with long-term follow-up. *Am J Surg Pathol*. 1996;20(3):286-292.
616. Murphy WM. Prognostic factors in the pathological assessment of prostate cancer. *Hum Pathol*. 1998;29(5):427-430.
617. Zagars GK, Pollack A, von Eschenbach AC. Prognostic factors for clinically localized prostate carcinoma: analysis of 938 patients irradiated in the prostate specific antigen era. *Cancer*. 1997;79(7):1370-1380.
618. Bostwick DG, Grignon DJ, Hammond ME, et al. Prognostic factors in prostate cancer. College of American Pathologists Consensus Statement 1999. *Arch Pathol Lab Med*. 2000;124(7):995-1000.
619. Loughlin KR, Retik AB, Weinstein HJ, et al. Genitourinary rhabdomyosarcoma in children. *Cancer*. 1989;63(8):1600-1606.
620. Fleischmann J, Perinetti EP, Catalona WJ. Embryonal rhabdomyosarcoma of the genitourinary organs. *J Urol*. 1980;124:389-391.

621. Kaplan WE, Firlit CF, Berger RM. Genitourinary rhabdomyosarcoma. *J Urol*. 1983;130(1):116-119.
622. Gardner WA Jr, Spitz WU. Melanosis of the prostate gland. *Am J Clin Pathol*. 1971;56(6):762-764.
623. Jao W, Fretzin DF, Christ ML, Prinz LM. Blue nevus of the prostate gland. *Arch Pathol*. 1971;91(2):187-191.
624. Lew S, Richter S, Jelin N, Siegal A. A blue naevus of the prostate: a light microscopic study including an investigation of S-100 protein positive cells in the normal and in the diseased gland. *Histopathology*. 1991;18(5):443-448.
625. Ro JY, el-Naggar AK, Amin MB, et al. Pseudosarcomatous fibromyxoid tumor of the urinary bladder and prostate: immunohistochemical, ultrastructural, and DNA flow cytometric analyses of nine cases. *Hum Pathol*. 1993;24(11):1203-1210.
626. Brennick JB, O'Connell JX, Dickersin GR, et al. Lipofuscin pigmentation (so-called "melanosis") of the prostate. *Am J Surg Pathol*. 1994;18(5):446-454.
627. Goldman RL. Melanogenic epithelium in the prostate gland. *Am J Clin Pathol*. 1968;49(1):75-78.
628. Levy DA, Gogate PA, Hampel N. Giant multilocular prostatic cystadenoma: a rare clinical entity and review of the literature. *J Urol*. 1993;150(6):1920-1922.
629. Lim DJ, Hayden RT, Murad T, et al. Multilocular prostatic cystadenoma presenting as a large complex pelvic cystic mass. *J Urol*. 1993;149(4):856-859.
630. Maluf HM, King ME, DeLuca FR, et al. Giant multilocular prostatic cystadenoma: a distinctive lesion of the retroperitoneum in men. A report of two cases. *Am J Surg Pathol*. 1991;15(2):131-135.
631. Hossain D, Meiers I, Qian J, et al. Prostatic stromal hyperplasia with atypia: follow-up study of 18 cases. *Arch Pathol Lab Med*. 2008;132(11):1729-1733.
632. Helpap B. Nonepithelial tumor-like lesions of the prostate: a never-ending diagnostic problem. *Virch Arch*. 2002;441(3):231-237.
633. Huang WL, Ro JY, Grignon DJ, et al. Postoperative spindle cell nodule of the prostate and bladder. *J Urol*. 1990;143(4):824-826.
634. Proppe KH, Scully RE, Rosai J. Postoperative spindle cell nodules of genitourinary tract resembling sarcomas. A report of eight cases. *Am J Surg Pathol*. 1984;8(2):101-108.
635. Hansel DE, Herawi M, Montgomery E, Epstein JI. Spindle cell lesions of the adult prostate. *Mod Pathol*. 2007;20(1):148-158.
636. Gaudin PB, Rosai J, Epstein JI. Sarcomas and related proliferative lesions of specialized prostatic stroma: a clinicopathologic study of 22 cases. *Am J Surg Pathol*. 1998;22(2):148-162.
637. Herawi M, Epstein JI. Specialized stromal tumors of the prostate: a clinicopathologic study of 50 cases. *Am J Surg Pathol*. 2006;30(6):694-704.
638. Bostwick DG, Hossain D, Qian J, et al. Phyllodes tumor of the prostate: long-term followup study of 23 cases. *J Urol*. 2004;172(3):894-899.
639. Wang X, Bostwick DG. Prostatic stromal hyperplasia with atypia: a study of 11 cases. *J Urol Pathol*. 1997;6:15-26.
640. Robinson DR, Wu YM, Kalyana-Sundaram S, et al. Identification of recurrent NAB2-STAT6 gene fusions in solitary fibrous tumor by integrative sequencing. *Nat Genet*. 2013;45:180-185.
641. Doyle LA, Vivero M, Fletcher CD, et al. Nuclear expression of STAT6 distinguishes solitary fibrous tumor from histologic mimics. *Mod Pathol*. 2014;27:390-395.
642. Cheah AL, Billings SD, Goldblum JR, et al. STAT6 rabbit monoclonal antibody is a robust diagnostic tool for the distinction of solitary fibrous tumour from its mimics. *Pathology*. 2014;46:389-395.
643. Fritsch M, Epstein JI, Perlman EJ, et al. Molecularly confirmed primary prostatic synovial sarcoma. *Hum Pathol*. 2000;31(2):246-250.
644. Iwasaki H, Ishiguro M, Ohjimi Y, et al. Synovial sarcoma of the prostate with t(X;18)(p11.2;q11.2). *Am J Surg Pathol*. 1999;23(2):220-226.
645. Jun L, Ke S, Zhaoming W, et al. Primary synovial sarcoma of the prostate: report of 2 cases and literature review. *Int J Surg Pathol*. 2008;16(3):329-334.
646. Chin W, Fay R, Ortega P. Malignant fibrous histiocytoma of prostate. *Urology*. 1986;27(4):363-365.
647. Hassan MO, Gogate PA, Hampel N. Malignant mesenchymoma of the prostate: immunohistochemical and ultrastructural observations. *Ultrastruct Pathol*. 1994;18(4):449-456.
648. Mackenzie AR, Whitmore WF Jr, Melamed MR. Myosarcomas of the bladder and prostate. *Cancer*. 1968;22(4):833-844.
649. Waring PM, Newland RC. Prostatic embryonal rhabdomyosarcoma in adults. A clinicopathologic review. *Cancer*. 1992;69(3):755-762.
650. Herawi M, Montgomery EA, Epstein JI. Gastrointestinal stromal tumors (GISTs) on prostate needle biopsy: a clinicopathologic study of 8 cases. *Am J Surg Pathol*. 2006;30(11):1389-1395.
651. Benson RC Jr, Segura JW, Carney JA. Primary yolk-sac (endodermal sinus) tumor of the prostate. *Cancer*. 1978;41(4):1395-1398.
652. Casiraghi O, Martinez-Madrigal F, Mostofi FK, et al. Primary prostatic Wilms' tumor. *Am J Surg Pathol*. 1991;15(9):885-890.
653. Manrique JJ, Albores-Saavedra J, Orantes A, Brandt H. Malignant mixed tumor of the salivary-gland type, primary in the prostate. *Am J Clin Pathol*. 1978;70(6):932-937.
654. Bostwick DG, Iczkowski KA, Amin MB, et al. Malignant lymphoma involving the prostate: report of 62 cases. *Cancer*. 1998;83(4):732-738.
655. Ferry JA, Young RH. Malignant lymphoma of the genitourinary tract. *Curr Diagn Pathol*. 1997;4:145-169.
656. Schniederjan SD, Osunkoya AO. Lymphoid neoplasms of the urinary tract and male genital organs: a clinicopathological study of 40 cases. *Mod Pathol*. 2009;22(8):1057-1065.
657. Klotz LH, Herr HW. Hodgkin's disease of the prostate: a detailed case report. *J Urol*. 1986;135(6):1261-1262.
658. Ben-Ezra J, Sheibani K, Kendrick FE, et al. Angiotropic large cell lymphoma of the prostate gland: an immunohistochemical study. *Hum Pathol*. 1986;17(9):964-967.
659. Chu PG, Huang Q, Weiss LM. Incidental and concurrent malignant lymphomas discovered at the time of prostatectomy and prostate biopsy: a study of 29 cases. *Am J Surg Pathol*. 2005;29(5):693-699.
660. Mitch WE Jr, Serpick AA. Leukemic infiltration of the prostate: a reversible form of urinary obstruction. *Cancer*. 1970;26(6):1361-1365.
661. Mahadevia PS, Koss LG, Tar IJ. Prostatic involvement in bladder cancer. Prostate mapping in 20 cystoprostatectomy specimens. *Cancer*. 1986;58(9):2096-2102.
662. Osunkoya AO, Netto GJ, Epstein JI. Colorectal adenocarcinoma involving the prostate: report of 9 cases. *Hum Pathol*. 2007;38(12):1836-1841.
663. Bates AW, Baithun SI. Secondary solid neoplasms of the prostate: a clinico-pathological series of 51 cases. *Virch Arch*. 2002;440(4):392-396.
664. Zein TA, Huben R, Lane W, et al. Secondary tumors of the prostate. *J Urol*. 1985;133(4):615-616.
665. Mazzucchelli R, Barbisan F, Santinelli A, et al. Prediction of prostatic involvement by urothelial carcinoma in radical cystoprostatectomy for bladder cancer. *Urology*. 2009;74(2):385-390.
666. Shen SS, Lerner SP, Muezzinoglu B, et al. Prostatic involvement by transitional cell carcinoma in patients with bladder cancer and its prognostic significance. *Hum Pathol*. 2006;37(6):726-734.
667. Grignon DJ, Ro JY, Ayala AG. Malignant melanoma with metastasis to adenocarcinoma of the prostate. *Cancer*. 1989;63(1):196-198.
668. Leung CS, Srigley JR, Robertson AR. Metastatic renal cell carcinoma presenting as solitary bleeding prostatic metastasis. *J Urol Pathol*. 1997;7:127-132.
669. Allan CH, Epstein JI. Nephrogenic adenoma of the prostatic urethra: a mimicker of prostate adenocarcinoma. *Am J Surg Pathol*. 2001;25(6):802-808.
670. Daroca PJJ, Martin AA, Reed RJ, et al. Urethral nephrogenic adenoma. A report of three cases, including a case with infiltration of the prostatic stroma. *J Urol Pathol*. 1993;2:157-172.
671. Cossu-Rocca P, Contini M, Brunelli M, et al. S-100A1 is a reliable marker in distinguishing nephrogenic adenoma from prostatic adenocarcinoma. *Am J Surg Pathol*. 2009;33(7):1031-1036.
672. Tong GX, Melamed J, Mansukhani M, et al. PAX2: a reliable marker for nephrogenic adenoma. *Mod Pathol*. 2006;19(3):356-363.
673. Tong GX, Weeden EM, Hamele-Bena D, et al. Expression of PAX8 in nephrogenic adenoma and clear cell adenocarcinoma of the lower urinary tract: evidence of related histogenesis? *Am J Surg Pathol*. 2008;32(9):1380-1387.
674. Skinnider BF, Oliva E, Young RH, Amin MB. Expression of alpha-methylacyl-CoA racemase (P504S) in nephrogenic adenoma: a significant immunohistochemical pitfall compounding the differential diagnosis with prostatic adenocarcinoma. *Am J Surg Pathol*. 2004;28(6):701-705.
675. McDaniel AS, Chinnaiyan AM, Siddiqui J, et al. Immunohistochemical staining characteristics of nephrogenic adenoma using the PIN-4 cocktail (p63, AMACR, and CK903) and GATA-3. *Am J Surg Pathol*. 2014;38:1664-1671.
676. Craig JR, Hart WR. Benign polyps with prostatic-type epithelium of the urethra. *Am J Clin Pathol*. 1975;63(3):343-347.
677. Butterick JD, Schnitzer B, Abell MR. Ectopic prostatic tissue in urethra: a clinocopathological entity and a significant cause of hematuria. *J Urol*. 1971;105(1):97-104.
678. Murad TM, Robinson LH, Bueschen AJ. Villous polyps of the urethra: a report of two cases. *Hum Pathol*. 1979;10(4):478-481.
679. Chan JK, Chow TC, Tsui MS. Prostatic-type polyps of the lower urinary tract: three histogenetic types? *Histopathology*. 1987;11(8):789-801.
680. Walker AN, Mills SE, Fechner RE, Perry JM. Epithelial polyps of the prostatic urethra. A light-microscopic and immunohistochemical study. *Am J Surg Pathol*. 1983;7(4):351-356.
681. Fine SW, Chan TY, Epstein JI. Inverted papillomas of the prostatic urethra. *Am J Surg Pathol*. 2006;30(8):975-979.
682. Coyne JD, Kealy WF. Seminal vesicle amyloidosis: morphological, histochemical and immunohistochemical observations. *Histopathology*. 1993;22(2):173-176.

683. Seidman JD, Shmookler BM, Connolly B, Lack EE. Localized amyloidosis of seminal vesicles: report of three cases in surgically obtained material. *Mod Pathol*. 1989;2(6): 671-675.
684. Kee KH, Lee MJ, Shen SS, et al. Amyloidosis of seminal vesicles and ejaculatory ducts: a histologic analysis of 21 cases among 447 prostatectomy specimens. *Ann Diagn Pathol*. 2008;12(4):235-238.
685. Unger PD, Wang Q, Gordon RE, et al. Localized amyloidosis of the seminal vesicle. Possible association with hormonally treated prostatic adenocarcinoma. *Arch Pathol Lab Med*. 1997;121(12):1265-1268.
686. Sharma TC, Dorman PS, Dorman HP. Bilateral seminal vesicular cysts. *J Urol*. 1969;102(6):741-744.
687. Sheih CP, Liao YJ, Li YW, Yang LY. Seminal vesicle cyst associated with ipsilateral renal malformation and hemivertebra: report of 2 cases. *J Urol*. 1993;150(4):1214-1215.
688. Conn IG, Peeling WB, Clements R. Complete resolution of a large seminal vesicle cyst–evidence for an obstructive aetiology. *Br J Urol*. 1992;69(6):636-639.
689. Peker KR, Hellman BH, McCammon KA, et al. Cystadenoma of the seminal vesicle: a case report and review of the literature. *J Urol Pathol*. 1997;6:213-222.
690. Mazur MT, Myers JL, Maddox WA. Cystic epithelial-stromal tumor of the seminal vesicle. *Am J Surg Pathol*. 1987;11(3): 210-217.
691. Reikie BA, Yilmaz A, Medlicott S, Trpkov K. Mixed epithelial-stromal tumor (MEST) of seminal vesicle: a proposal for unified nomenclature. *Adv Anat Pathol*. 2015;22:113-120.
692. Tanaka T, Takeuchi T, Oguchi K, et al. Primary adenocarcinoma of the seminal vesicle. *Hum Pathol*. 1987;18(2):200-202.
693. Ormsby AH, Haskell R, Jones D, Goldblum JR. Primary seminal vesicle carcinoma: an immunohistochemical analysis of four cases. *Mod Pathol*. 2000;13(1):46-51.
694. Awadalla O, Hunt AC, Miller A. Primary carcinoma of the seminal vesicle. *Br J Urol*. 1968;40(5):574-579.
695. Schned AR, Ledbetter JS, Selikowitz SM. Primary leiomyosarcoma of the seminal vesicle. *Cancer*. 1986;57(11):2202-2206.
696. Fain JS, Cosnow I, King BF, et al. Cystosarcoma phyllodes of the seminal vesicle. *Cancer*. 1993;71:2055-2061.
697. Fairey AE, Mead GM, Murphy D, Theaker J. Primary seminal vesicle choriocarcinoma. *Br J Urol*. 1993;71(6):756-757.
698. Middleton LP, Merino MJ, Popok SM, et al. Male adnexal tumour of probable Wolffian origin occurring in a seminal vesicle. *Histopathology*. 1998;33(3):269-274.
699. Ro JY, Ayala AG, el-Naggar A, Wishnow KI. Seminal vesicle involvement by in situ and invasive transitional cell carcinoma of the bladder. *Am J Surg Pathol*. 1987;11(12):951-958.
700. Keen MR, Golden RL, Richardson JF, Melicow MM. Carcinoma of Cowper's gland treated with chemotherapy. *J Urol*. 1970;104(6):854-859.
701. Zhang M, Pettaway C, Vikram R, Tamboli P. Adenoid cystic carcinoma of the urethra/Cowper's gland with concurrent high-grade prostatic adenocarcinoma: a detailed clinicopathologic case report and review of the literature. *Hum Pathol*. 2016;58:138-144.

Testis and Testicular Adnexa

27

Jesse K. McKenney

CHAPTER CONTENTS

Testis, *1135*
Normal embryology and anatomy, *1135*
Cryptorchidism, *1136*
Atrophy and infertility, *1136*
Other non-neoplastic lesions, *1138*
Tumors, *1139*

Testicular adnexa, *1157*
Normal anatomy, *1157*
Rete testis, *1158*
Epididymis, *1158*
Spermatic cord, *1162*

Testis

Normal Embryology and Anatomy

The growth and development of the human testis can be divided into three major phases: (1) static, from birth to age 4 years; (2) growth, from age 4 to 10 years; and (3) developmental (maturation), from age 10 years to puberty.[1,2] At birth, the seminiferous tubules are compactly filled with small undifferentiated cuboidal cells. Leydig cells are seen in the newborn because of the influence of maternal hormones, but then disappear to reappear only later. Increases in tubule and cell size are slow and gradual, with barely perceptible growth from age 4 to 10 years, increasing tortuosity, and lumen formation. At age 10 years, a definite spurt is noted, coinciding with the appearance of gonadotropins and 17-ketosteroids in urine. Mitotic figures appear in the tubular cells, and Leydig cells again become recognizable in the interstitium. At age 11 years, mitotic activity is pronounced, and primary and secondary spermatocytes appear. At age 12 years, spermatids are numerous. Finally, spermatozoa appear. The number of maturing tubules with active spermatogenesis increases gradually until the adult stage is reached. Because of the great variation in the age at which puberty normally occurs, the age of the individual cannot be determined by histologic study of the testis after the 12th year.[1]

The normal adult testis is a paired organ that lies within the scrotum suspended by the spermatic cord. The average weight of each testis is 15–19 g, the right usually being 10% heavier than the left.[3] The organ is covered by a capsule composed of three layers: the outer serosa or *tunica vaginalis* (covered by a flattened layer of mesothelial cells), the *tunica albuginea*, and the inner *tunica vasculosa*. The posterior portion of the capsule, called the mediastinum, contains blood and lymph vessels, nerves, and the mediastinal portion of the rete testis. The parenchyma is divided into approximately 250 lobules, each lobule containing up to four seminiferous tubules. The usual testicular biopsy is composed of three to five lobules together with portions of the septa (which should not be misinterpreted as areas of fibrosis). The seminiferous tubules are bound by a limiting membrane made up of basal lamina and alternating layers of myoid cells and collagen fibers. These tubules contain germ cells in various stages of development and Sertoli cells.[4]

The maturation of germ cells in man covers a period of about 70 days and follows these steps: spermatogonium (of which two types have been described, known respectively as A and B), primary spermatocyte (further subdivided depending on the stage of meiosis into preleptotene, leptotene, zygotene, pachytene, and diplotene), secondary spermatocyte, spermatid, and (mature) spermatozoon (Fig. 27.1).[4,5] Until spermatozoa are formed, all progeny of a spermatogonium are held together by a narrow cytoplasmic bridge. This maturation proceeds in an orderly overlapping helical pattern along the length of the tubule[6]; as a consequence, not all stages of differentiation of germ cells are seen in any one cross-sectional view of a seminiferous tubule. *This normal pattern should not be confused with a maturation arrest.*

Sertoli cells have a columnar shape, lie on the basement membrane of the tubule, and send cytoplasmic prolongations around the germ cell elements.[7] Their nuclei are irregularly shaped, are highly folded, and have a prominent nucleolus. The cytoplasm may contain Charcot–Bottcher crystalloids, which represent bundles of filaments. Immunohistochemically, the intermediate filament of Sertoli cells is vimentin, but coexpression of keratin and desmin is present in the fetal testis and can reappear in pathologic conditions.[8]

The interstitium contains stromal elements (including the already mentioned myoid cells) and Leydig cells. The latter occur either singly or in clusters and are often associated with nerve fibers.[9] Their cytoplasm contains lipid droplets, lipochrome pigment, and sometimes Reinke crystalloids, which appear ultrastructurally as hexagonal

Abstract

This chapter covers the spectrum of diseases that involve the testis and testicular adnexa. Inflammatory conditions, including common infectious etiologies, are addressed. Germ cell tumors are discussed in detail and are organized as suggested by the latest WHO 2016 classification, according to their association with germ cell neoplasia or not. The full spectrum of sex-cord stromal tumors is also addressed to include new molecular data and variants. Finally, rare diseases of the rete testis, epididymis, and spermatic cord are reviewed.

Keywords

testis
infection
germ cell
seminoma
germ cell neoplasia in situ
teratoma
embryonal
yolk sac
choriocarcinoma
Sertoli
Leydig
spermatocytic
adenomatoid

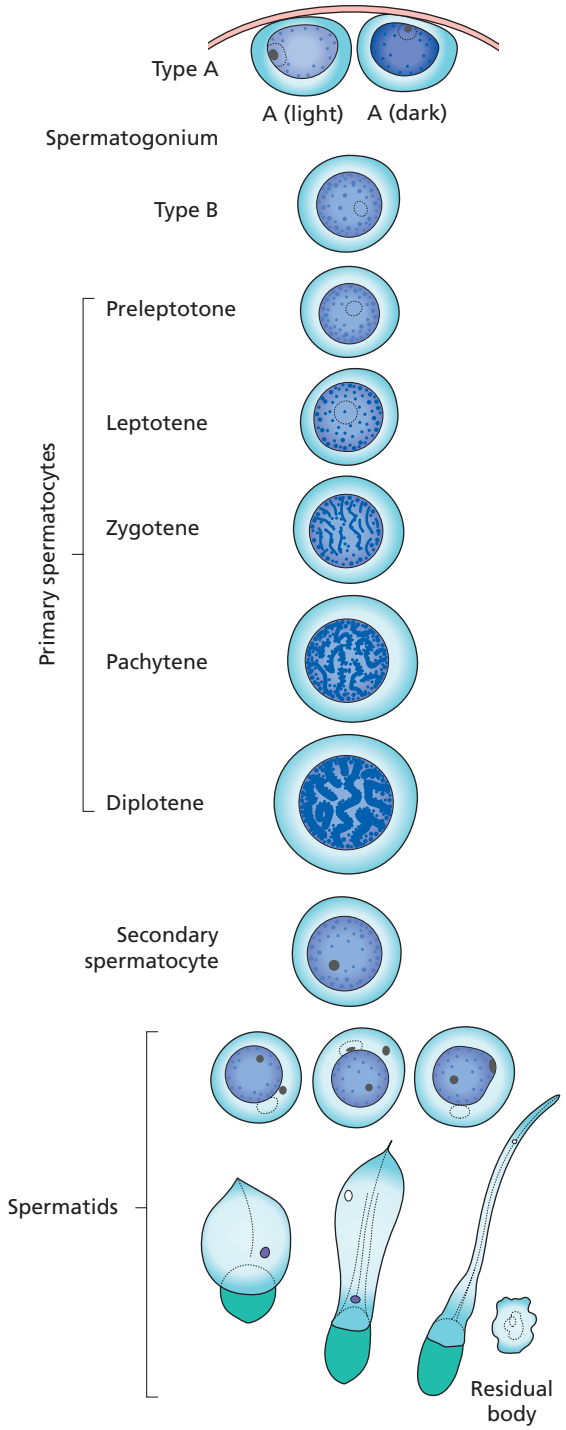

Figure 27.1 Steps in Spermatogenesis. (From Trainer TD. Testis and excretory duct system. In: Sternberg SS, ed. *Histology for Pathologists*. 2nd ed. New York: Lippincott–Raven; 1997:1022.)

prisms.[4] Immunohistochemically, there is reactivity for inhibin and Melan-A (Mart-1). Leydig cells gradually decrease in number with aging.

Cryptorchidism

In 1 out of every 10 males, the testis has not descended into the scrotum at the time of birth, but has remained in the inguinal region or abdomen, the former situation being about four times as common as the latter.[10,11] Most of these "retained" or "retractile" testes descend into the scrotum during the first year of life. In only 1 in 100 individuals will a permanent retention of the testis outside the scrotum occur, a condition known as cryptorchidism. The exact pathogenesis is unknown, but most evidence favors a role for testosterone under the influence of the hypothalamic–pituitary axis.[12] If by the age of 2 or 3 years the testis has not spontaneously descended into the scrotum (or sooner, if the abnormality is bilateral), an open or laparoscopic orchiopexy should be carried out; otherwise permanent anatomic alterations will occur.[11,13,14]

Cryptorchidism is unilateral in 80% of the cases. Of patients with bilateral cryptorchid testes in whom repair is performed before the age of 5 years, 50% are fertile and 31% are normospermic.[15] The microscopic appearance of the prepubertal testicle as seen in a small biopsy at the time of orchiopexy is a good predictor of the degree of post-pubertal spermatogenesis and, therefore, of fertility.[16]

Grossly, cryptorchid testes in adults are small and brown. The testicular tubules are atrophic, and their basement membrane is greatly thickened. The Leydig cells are prominent; some of them may be present inside the tubules.[17] Not infrequently, foci of hyperplastic Sertoli cells occur. They are usually multiple and may appear grossly as minute white nodules. In some instances, atypical germ cells are seen at the base of the tubules; these are indicative of germ cell neoplasia in situ (GCNIS, intratubular germ cell neoplasia [IGCN]) and are the forerunner of malignancy. Traditionally, the atrophy and infertility associated with cryptorchidism have been attributed to the higher intrascrotal temperature. However, the facts that boys with cryptorchidism have histologically abnormal seminiferous tubules also in the contralateral descended testis[18] and that men who had unilateral cryptorchidism corrected in childhood have lower sperm counts and higher serum concentrations of follicle-stimulating hormone as adults than do normal men[19] suggest that even unilateral cryptorchidism is associated with a bilateral testicular abnormality.

A cryptorchid testis is more likely to develop a germ cell tumor than is a normally placed organ. Of 7000 cases of testicular germ cell tumors reviewed in a classic study by Gilbert and Hamilton,[20] 10.9% occurred in cryptorchid organs. The incidence of malignancy is greater in the abdominal than in the inguinal testis. Seminoma is the most common type, but other germ cell tumors also occur.[21,22] The contralateral testis in patients with unilateral cryptorchidism also has an increased incidence of malignancy.[23,24] If a cryptorchid testis is surgically placed in the scrotum, it may still develop a germ cell neoplasm, especially if the operation has been done at a late age.[25] Dow and Mostofi[26] reported 14 cases of such tumors occurring in patients who had had orchiopexy between the ages of 11 and 36 years. In a large Swedish study, the relative risk of testicular cancer among cryptorchidic patients who underwent orchiopexy before reaching 13 years of age was 2.23 as compared to the Swedish general population, whereas for those treated at 13 years of age or older, the relative risk was 5.40.[27] Because of these findings, it has been recommended that high-positioned testes that have not been surgically placed into the scrotum before mid-adolescence be removed.[28]

Atrophy and Infertility

Atrophy of the testis may result from a large variety of causes: the already mentioned cryptorchidism; the orchitis of mumps, especially when the infection occurs at or after puberty[29]; liver cirrhosis, as a result of increased circulating endogenous estrogens not metabolized by the diseased liver[30]; administration of estrogens or gonadotropin-releasing hormone analogue in the treatment of prostatic carcinoma[31]; radiation exposure; chemotherapy, particularly cyclophosphamide[32,33];

and exposure to an environmental toxin, the nematocide dibromochloropropane.

In advanced testicular atrophy of any of these etiologies, the tubules are small, with thick basement membranes and few or no germ cells. The interstitial tissue shows varying degrees of fibrosis, and there may be an increased number of Leydig cells.

An extreme degree of testicular atrophy occurs in the testicular regression ("vanishing testis") syndrome, a condition characterized by a rudimentary epididymis and spermatic cord with no identifiable testicular tissue.[34] There is instead in this location a dense fibrovascular tissue ("nubbin") with foci of calcification and hemosiderin deposition.[35] The suggestion has been made that this condition results from testicular infarct, presumably caused by torsion occurring in utero.[36] It affects approximately 5% of patients with cryptorchidism.[34]

Various degrees of testicular atrophy occur frequently in AIDS-affected patients, the precise pathogenesis being unclear.[37,38]

The effect of vasectomy on testicular morphology is minimal but detectable; there is thickening of the tubular wall, reduction in the number of spermatids and Sertoli cells, and sometimes foci of interstitial fibrosis.[39]

The male factor is the primary or contributing cause of infertility in 40%–60% of the cases.[40] The causes of male infertility fall into one of three categories: pretesticular, testicular, and post-testicular.[41–43] The pretesticular causes are extragonadal endocrine disorders, usually originating in the pituitary or adrenal gland. The testicular causes are primary diseases of the testes, and little treatment is available at the present time. The post-testicular causes consist mainly of obstructions of the ducts leading away from the testes. These obstructions may be congenital, postinflammatory, or postsurgical and include Young syndrome, in which the obstructive azoospermia is combined with chronic sinopulmonary infections.[44] These obstructions have generally little or no adverse effect on spermatogenesis. Treatment consists of epididymovasostomy or vasovasostomy to bypass the obstruction. Impaired sperm mobility, presumably because of faulty maturation or storage of spermatozoa in the epididymis, and immunologic factors are included among the post-testicular causes of infertility.[45]

The evaluation of the infertile male includes a thorough clinical history and examination, semen analysis, quantitation of leukocytes in semen, and search for antisperm antibodies. Tests of sperm function include evaluation of cervical mucus interaction, ova penetration, and the hemizona assay. Additional tests, performed in selected cases, are transrectal ultrasonography, venography, and testicular biopsy.[46,47] The latter is particularly useful in the individual with azoospermia and normal endocrine findings.[48–51] Punch biopsy is not nearly as satisfactory as an open surgical biopsy. The material should be handled with extreme care.[52] Zenker and Bouin fixatives preserve cytologic features better than formalin; however, some hospitals no longer allow their use. Fine-needle aspiration cytology has been proposed as an alternative to testicular biopsy,[51] some studies showing a high correlation between the two methods.[53]

Biopsy specimens from infertile men with total lack of spermatozoa (azoospermia) usually show one of the following conditions[54]:

1. Germ cell aplasia (Sertoli cell-only syndrome) (29%), in which the tubules are populated by only Sertoli cells (Fig. 27.2), measure 100–150 µm in diameter, and may show some thickening of the tubular basement membrane; germ cells are completely absent.[55] Leydig cells are usually normal but on occasion are found to be reduced in size and number.
2. Spermatocytic arrest (26%), characterized by a halt of the maturation sequence (Fig. 27.3), usually at the stage of the primary spermatocyte (presumably at the end of the meiotic prophase at late pachytene)[56]; no spermatids or spermatozoa are present despite the presence of abundant cells in division; Leydig cells are normal.
3. Generalized fibrosis (18%).
4. Normal spermatogenesis (27%).

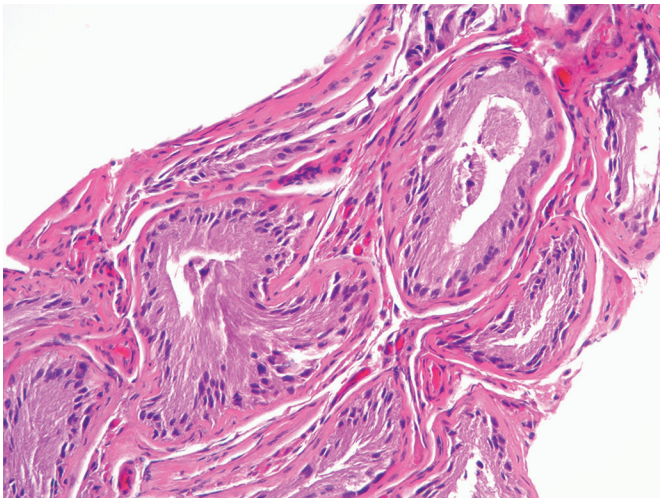

Figure 27.2 Testis biopsy showing Sertoli cell only syndrome.

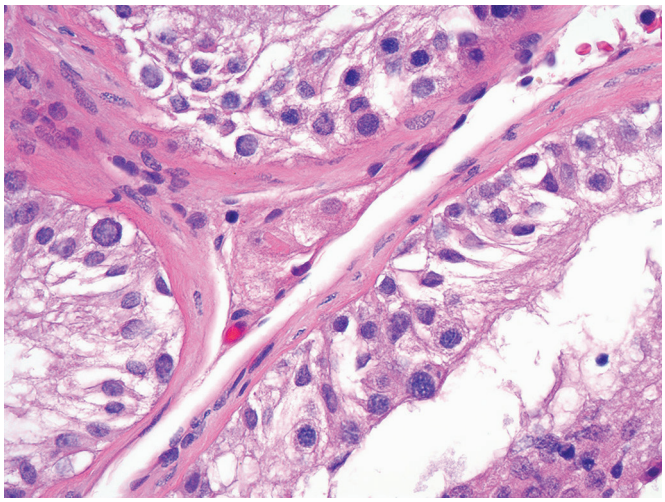

Figure 27.3 Testis biopsy showing maturation arrest at the spermatocyte phase.

The last finding suggests the diagnosis of obstructive azoospermia and implies the bilateral obstruction or absence of some part of the duct system.[57] In the series of Nistal et al., of patients with obstructive azoospermia of known etiology, over half had a normal testicular biopsy, whereas most of the others exhibited subtle alterations of the adluminal compartment of the seminiferous tubules (early or late sloughing of primary spermatocytes), possibly induced by the increase in hydrostatic pressure.[58]

In patients with a reduction in the number of spermatozoa (oligospermia), the following microscopic patterns are recognizable, often combined: (1) incomplete spermatocytic arrest, characterized by arrest of spermatogenesis in some of the tubules; (2) regional or incomplete fibrosis; (3) spermatogenic hypoplasia (hypospermatogenesis), characterized by tubules with a reduced population of germ cells and a poor order of spermatogenesis; (4) tubular hyalinization, a probably heterogeneous group that includes Klinefelter syndrome, in which the tubules have a small diameter and a markedly thickened basement membrane, and Leydig cells are often increased

in number; (5) mixed atrophy, that is, the synchronous occurrence of seminiferous tubules containing germ cells and tubules with Sertoli cells only; and (6) normal or essentially normal spermatogenesis, usually implying a partial occlusion of some part of the duct system.[59–61] Another pattern sometimes described is that of sloughing and disorganization, in which spermatogenesis has a disorderly appearance and the tubular lumina are filled with desquamated immature cells. We have found that this pattern is rather nonspecific, since it can be seen in spermatogenic hypoplasia as well as with testicular blockage; it also can be closely simulated by artifactual detachment of germ cells resulting from rough handling of the biopsy. The degree of spermatogenic hypoplasia, a very subjective evaluation, can be estimated with quantitative techniques.[7,62]

Multinucleated giant stromal cells of reactive nature have been observed in cases of testicular atrophy after estrogen therapy.[63]

In the series of over 800 cases of azoospermia studied via testicular biopsy by Girgis et al.,[64] the etiology was obstructive in about 55%. In more than half of these, epididymovasostomy proved beneficial. Patients with varicocele are often oligospermic and infertile. The most common patterns at biopsy are those of spermatogenic hypoplasia plus sloughing and disorganization.[65] The azoospermia commonly seen in patients with cystic fibrosis is obstructive, secondary to structural abnormalities of the epididymis and vas deferens.[66]

Biopsies are rarely done in patients with testicular failure involving primarily the endocrine function, since the diagnosis is usually established by hormonal determinations. Failure of pubertal maturation is the cardinal symptom if the disease is congenital or begins in childhood.[44] Three different patterns can be seen in testicular biopsies: (1) hypogonadotrophic eunuchoidism (60%), accompanied by low gonadotropin levels and characterized by small, infantile tubules with scattered spermatogonia and Sertoli cells but few or no Leydig cells; (2) Klinefelter syndrome (30%), with fibrosis of tubules, prominent thickening of the basement membrane, and Leydig cell hyperplasia[67]; and (3) testicular aplasia (10%), characterized by the absence of testicular tissue and elevation of urinary gonadotropin levels. Patients with Klinefelter syndrome have an increased incidence of breast carcinoma[68]; cases of Leydig cell tumor and testicular and extragonadal (mainly mediastinal) germ cell tumors also have been reported in this population.[69–71]

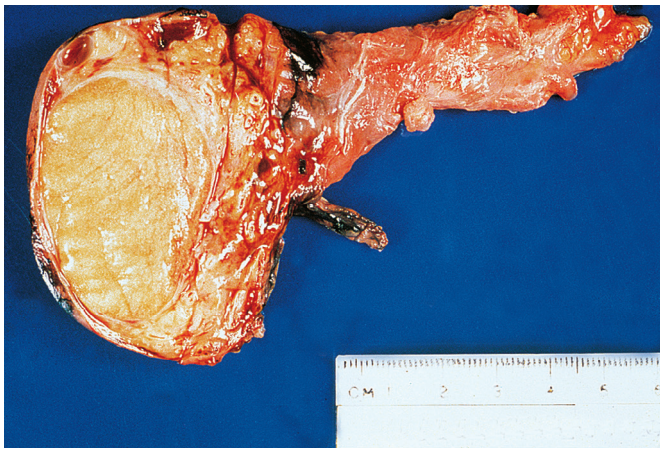

Figure 27.4 Gross Appearance of Granulomatous Orchitis. The testis has firmer consistency, and is enlarged and vaguely nodular.

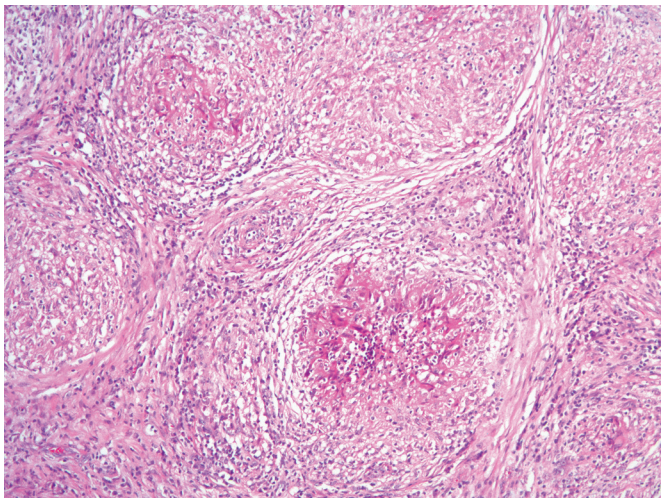

Figure 27.5 Microscopic appearance of granulomatous orchitis associated with tuberculosis.

Other Non-Neoplastic Lesions

Infarct of the testis is usually the result of torsion of the spermatic cord, but it may also be due to venous thrombosis secondary to pyogenic epididymo-orchitis (see later), a sequela of inguinal hernia repair,[72] or, rarely, vasculitis of various causes, such as that accompanying Crohn disease.[73] Intermittent torsion may cause histologic changes that mimic other etiologies.[74]

Viral-type orchitis can simulate testicular neoplasia at the microscopic level. The architecture is preserved, but there is hemorrhage, edema, and a patchy lymphohistiocytic infiltrate within and between the seminiferous tubules.[75]

Granulomatous orchitis is characterized grossly by a solid nodular enlargement of the testis (Fig. 27.4) and microscopically by granulomatous lesions centered in the seminiferous tubules, as described in the classic paper by Spjut and Thorpe.[76] Epithelioid cells, multinucleated giant cells, lymphocytes, and plasma cells are present. The granulomatous response is at least in part secondary to the products of disintegrated sperm. A history of trauma to the region is often obtained.[77] The clinical evolution is benign, but this should obviously be distinguished from infectious etiologies.[78,79]

Malakoplakia can affect the testis, either alone or accompanied by epididymal involvement.[80] It is associated with abscess formation, atrophy of tubules, and the characteristic Michaelis–Gutmann bodies. Thrombosed blood vessels are often found.[81] Bacteria (mainly coliform organisms) may be found on culture. Three other proliferative histiocytic disorders that occasionally involve the testis are juvenile xanthogranuloma,[82] Rosai–Dorfman disease (sinus histiocytosis with massive lymphadenopathy),[83] and xanthogranulomatous orchitis.[84,85]

Pyogenic epididymo-orchitis may be complicated by venous thrombosis and septic infarct of the testis.[86] *Escherichia coli* is the organism usually recovered. Microscopically, many similarities exist between this condition and granulomatous orchitis, suggesting a common ischemic background.

Tuberculosis, atypical mycobacteriosis,[87] leprosy, sarcoidosis,[88] syphilis, and Crohn disease can involve the testis (Fig. 27.5).[73,89] Clinically, a syphilitic gumma can resemble a neoplasm.

Other infectious agents responsible for orchitis are *Toxoplasma* (in immunosuppressed patients), fungi, parasites, and *Brucella*. These are rarely seen as surgical specimens.[90]

Multinucleated stromal giant cells are a relatively common and clinically insignificant finding in the testis. They seem to be age related and are said to be particularly common in cases of testicular atrophy due to estrogen therapy.[91]

Necrotizing vasculitis can involve the testis, either as a manifestation of polyarteritis nodosa or other systemic disease or as an isolated finding.[92,93]

Ectopic spleen in the scrotum (splenogonadal fusion syndrome) results from a congenital malformation occurring at a stage when the splenic and gonadal anlages are topographically close.[94] In the continuous variant, there is a fibrous or splenic tissue-containing cord that connects the spleen and the scrotal ectopic splenic tissue. In the discontinuous variant, the connection is lost, and the ectopic splenic tissue appears as a scrotal accessory spleen, which may clinically simulate a tumor. All of the reported cases have been on the left side.[95]

Cystic dysplasia of the testis is a rare congenital defect that results in the formation of numerous irregularly shaped cystic spaces within the mediastinum testis.[96] The cysts are lined by flattened cuboidal epithelium that morphologically and immunohistochemically resembles the epithelium of rete testis.[97] Thus this condition merges with those described in the section on rete testis.

Cysts located within the testicular parenchyma away from the rete testis are lined by a similar flattened cuboidal (non-ciliated) epithelium and may have a similar pathogenesis.[77]

Testicular implants (silicone gel-filled) can elicit a tissue reaction similar to that seen in breast implants. Microscopically, it is characterized by a fibrous capsule infiltrated by lymphocytes and foamy macrophages, and occasionally featuring a synovial-like cleft at the interphase.[98]

Tumors

Testicular tumors can be divided into five general categories: germ cell tumors (90%) arising from the germinal epithelium of the seminiferous tubules; sex cord–stromal tumors; mixed germ cell–sex cord–stromal tumors; primary tumors not specific to the testis; and metastatic tumors.

Germ Cell Tumors

Classification

This current classification of testicular neoplasia is based on the recent restructuring of terminology recommended by the WHO 2016 classification. In this system, germ cell tumors are divided into categories based on their relationship with germ cell neoplasia in situ (GCNIS), previously termed intratubular germ cell neoplasia, unclassified (ITGCN).[99] In addition, minor changes to the nomenclature of sex cord–stromal tumors are based on more recent molecular genetic data.

Germ Cell Tumors Associated With Germ Cell Neoplasia In Situ

Clinical Nomenclature. Although somewhat confusing when approached from a histologic perspective, urologists and oncologists divide testicular germ cell tumors into two categories: "seminoma" (pure classic seminoma) and "non-seminoma" (any other pure or mixed subtype, including those with an admixed seminoma component). The latter is often described as "non-seminomatous germ cell tumor" (NSGCT).

Incidence. Testicular germ cell tumors make up only a small percentage of all malignant neoplasms in men (approximately 1%), but are the most common malignant tumors in young men between 25 and 29 years of age. The worldwide incidence is 1.5 cases per 100,000, with rates highest in Norway and Switzerland. Their incidence seems to be increasing, at least for seminomas.[100]

Predisposing and Accompanying Factors. The main factors thought to predispose to testicular germ cell tumors are cryptorchidism, disorders of sex development, family history, testicular microliths in subfertility, and prior germ cell tumor. Hereditary forms are described, but almost all are related to low penetrance autosomal recessive susceptibility genes.[101–106] Specifically, the AZFc region (gr/gr microdeletion) of chromosome Y, 12q22 (KITLG), and 5q31 (RAS-ERK-MAPK pathway) are proposed as susceptibility loci, in some cases possibly due to interactions with c-KIT.[107–109] It is also suggested that PTEN hamartoma tumor syndrome, Li–Fraumeni syndrome, and neurofibromatosis type 1 may rarely be associated with germ cell tumors.

Age. There is a good correlation between age and the incidence of the different types of testicular tumor.[99] The median age at presentation is 35 years for seminoma, 25 years for non-seminoma, and 30 years from non-seminomas that include a seminomatous component. In individuals over 60 years of age, germ cell tumors are rare. Seminomas (and spermatocytic tumor described below with germ cell tumors unrelated to GCNIS) are the most common germ cell tumors in this age group, outnumbered only by malignant lymphomas.[110,111]

Presentation. Most testicular germ cell tumors present with progressive, painless enlargement of the testis. A small tumor may be found in a testis by palpation or ultrasonography. They may grow slowly or with appalling speed. Sometimes, the initial presentation is in the form of a metastatic deposit in the retroperitoneum, lung, or mediastinum. Presentation with significant clinical symptomatology is uncommon in seminoma, but relatively common for choriocarcinoma, in which the patient may have gynecomastia; large mediastinal, pulmonary, liver and/or brain metastases; and markedly increased levels of serum human chorionic gonadotropin (hCG).[112,113]

Bilaterality. Bilateral testicular involvement by germ cell tumors is seen in 1.0%–2.7% of the cases according to different series.[114–117] The risk of bilaterality rises to 15% if both testes are undescended. It can be seen as a synchronous or, more commonly, as a metachronous event. The tumors may have a different histology.[118] In the presence of bilateral testicular tumors in an elderly patient, the most likely diagnosis is malignant lymphoma.

Molecular Genetic Features. Germ cell tumors of adults and adolescents (almost always of the post-pubertal GCNIS-associated type) show one or more copies of an isochromosome of chromosome 12p (i(12p)) or other forms of 12p amplification. Since this genetic aberration is absent in isolated GCNIS, the gain of genes on 12p appears to be crucial for the development of invasive germ cell tumor.[119–121] 12p harbors multiple genes that promote cell growth.[122–125] Other common non-random genetic changes include loss of chromosome 1p, 11, 13, 18, or Y and gain of chromosome 21, 7, 8, or X.[126–132] *KIT* mutation and/or amplification (most commonly in seminoma) and *KRAS* mutation are also described in a small subset of cases.[133,134] In cases of NSGCT with an admixed seminoma component, in which the two components were evaluated separately from a genetic standpoint, some showed similar clonal abnormalities (suggesting an origin from the same stem cell), whereas others did not.[130,135,136]

Spermatocytic tumor shows completely different genetic features (with an absence of 12p abnormality), and are discussed separately.[121]

Spread and Metastases. It has been generally assumed that the first manifestation of local spread of testicular germ cell tumors is in the tunica albuginea, but invasion of the testicular hilum is actually a much more common event.[137] Since this may be grossly inapparent, microscopic sampling of this region is mandatory, as discussed in staging.[138,139]

In terms of lymph-borne metastases, testicular tumors spread first to periaortic and iliac lymph nodes and later to mediastinal and left supraclavicular nodes. Retroperitoneal lymph node metastases are on the side of the tumor in about 80%–86% of cases and bilateral in about 13%–20%. The presence of contralateral metastases in the absence of ipsilateral metastases is rare.[140,141] Characteristically, the first retroperitoneal metastases are highly placed, immediately below the renal vessels. In general, involvement of inguinal lymph nodes does not occur unless there is invasion of the skin of the scrotum, tumor recurrence in a cutaneous scar, or a history of previous operation in the area (such as correction of cryptorchidism, herniorrhaphy, or scrotal orchiectomy).[142] Blood-borne metastases occur most frequently in lungs, liver, brain, and bone.[143] There is a high incidence of brain metastases in choriocarcinoma and of bone metastases in seminoma.[144] Embryonal carcinoma frequently metastasizes early, and choriocarcinoma almost always has widespread metastases by the time the tumor is diagnosed. Teratoma occurring in the post-pubertal testis can be accompanied by metastases no matter how well-differentiated the primary tumor appears, which is why the mature/immature designation is no longer recommended.[99]

The microscopic appearance of the metastases may differ from that of the primary tumor. In general, classic seminoma metastasizes as classic seminoma, but it may also spread as other types.[144] In combined mixed germ cell tumors with admixed seminoma, the non-seminomatous component is the one most likely to metastasize. Late metastases of testicular germ cell tumors often have a teratomatous appearance.[145] Mixed germ cell tumors with focal choriocarcinoma tend to metastasize as pure choriocarcinomas. Surgical removal of the postchemotherapy residual tumors is recommended.[146–148] In some instances, total spontaneous regression of the primary tumor or of the metastatic foci has been observed.[149–151] Sometimes, tumor foci with a somatic-type malignancy (rather than germ cell) appearance develop in these metastases.

The microscopic appearance of the lung metastases after chemotherapy correlates well with prognosis. The presence of total necrosis or fully mature elements is indicative of a good prognosis[146,152,153]; viable non-teratomatous components are associated with a decreased survival, and the presence of sarcomatous elements is a particularly ominous sign.[154,155]

Treatment. The initial treatment for all testicular germ cell tumors is inguinal orchiectomy with high ligation of the spermatic cord ("radical orchiectomy").[156] The subsequent treatment of confirmed low-stage testicular germ cell tumors is evolving. Depending on the institution, orchiectomy may be followed by retroperitoneal lymphadenectomy, chemotherapy, or surveillance.[157–159] Radiation therapy is used less commonly. Many groups have recommended treating stage I seminoma or even NSGCT with orchiectomy alone, with further therapy for only those cases that show relapse on close monitoring.[160–164] Along similar lines, it has been suggested that stage II NSGCT could be treated with orchiectomy and retroperitoneal lymphadenectomy, with chemotherapy reserved for those patients who develop relapse.[165,166] The "surveillance only" approach is more controversial in patients with a predominance of the embryonal carcinoma or in tumors exhibiting blood vessel invasion because of the high probability of distant metastases under these circumstances; however, high-risk pathology is not an absolute contraindication in certain settings, given that therapies still have high cure rates for relapses.

Controversy exists as to whether patients undergoing orchiectomy for germ cell tumors should also have a biopsy of the contralateral testis searching for IGCN.[167] Most authors do not favor this approach, but the practice varies significantly by country.[168] We never receive such biopsies.

Prognosis. With current treatment protocols, testicular germ cell tumors represent the most curable solid cancer in men, even when metastatic spread is present. For stage I tumors, whether seminoma or non-seminoma, cure rates are close to 100%. With metastatic spread, cure rates remain high, but vary with prognostic groups as defined by the International Germ Cell Cancer Collaborative Group classification.[169] Even in this metastatic group, overall cure rates are over 80%, and salvage therapy may cure over half of the patients with initial treatment failures. Later relapses (defined as >2 years after initial treatment with complete remission) are less common, but may occur and portend an adverse prognosis, particularly when associated with secondary somatic malignancy.

Noninvasive Germ Cell Neoplasia

Germ Cell Neoplasia In Situ (Intratubular Germ Cell Neoplasia, Unclassified). The in situ stage of germ cell neoplasia has been variably designated as IGCN, in situ carcinoma, or testicular intraepithelial neoplasia.[170–172] The WHO 2016 classification (based on the consensus of an international panel) now promotes the diagnostic term *germ cell neoplasia in situ* (*GCNIS*).[99] It is most often seen in the residual testis in organs harboring an invasive germ cell malignancy, the frequency being higher than 80% in some series.[173,174] It is also seen in the contralateral testicle in approximately 5% of patients with testicular tumors.[175,176] Interestingly, the appearance of GCNIS is usually the same regardless of the nature of the invasive germ cell component. All types of post-pubertal germ cell tumor have been found to be associated with GCNIS.

Although usually restricted to the seminiferous tubules, GCNIS sometimes colonizes the rete testis, where it results in a pagetoid appearance that can be very confusing to the unwary (Fig. 27.6).[177]

Sometimes, GCNIS is found incidentally in the absence of an obvious tumor, occasionally in children or adolescents with various disorders of sex development,[178] but most often in the study of post-pubertal testicular biopsies performed for the study of infertility or in cases of current or corrected cryptorchidism.[179,180] It is important to recognize GCNIS in these settings because it is regarded as an almost obligate precursor to invasive disease; 50% progress within 5 years and longer progression intervals of up to 15–20 years are reported.

Histologically, GCNIS is characterized by atypical germ cells at the base of the seminiferous tubules (Fig. 27.7A). Spermatogenesis is typically absent or greatly reduced within involved tubules, but

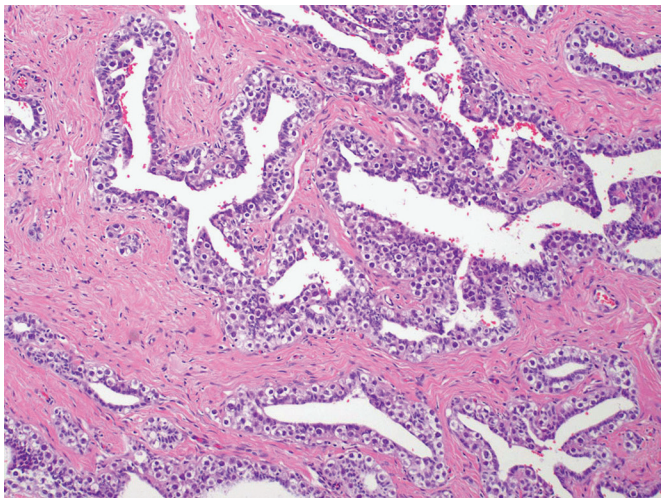

Figure 27.6 Pagetoid Extension of Seminoma Into Rete Testis. This should not be misinterpreted as a nonseminomatous component.

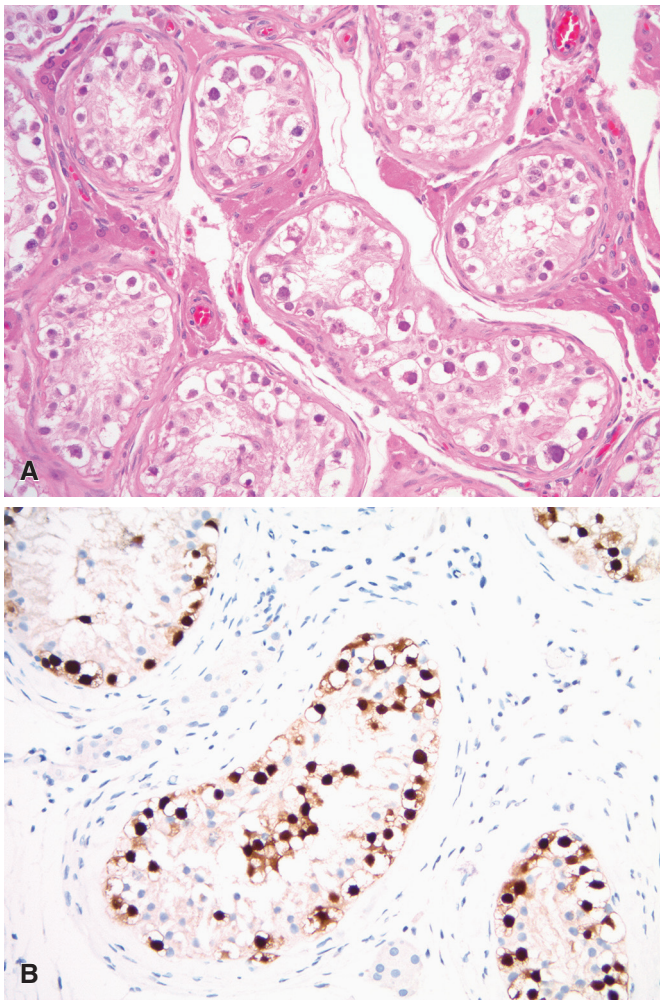

Figure 27.7 **A**, Microscopic appearance of germ cell neoplasia in situ (GCNIS) in routinely stained section. A row of atypical germ cells with clear cytoplasm is seen against a thickened basement membrane. No spermatogenesis is occurring in these tubules. **B**, Nuclear OCT3/4 expression in GCNIS.

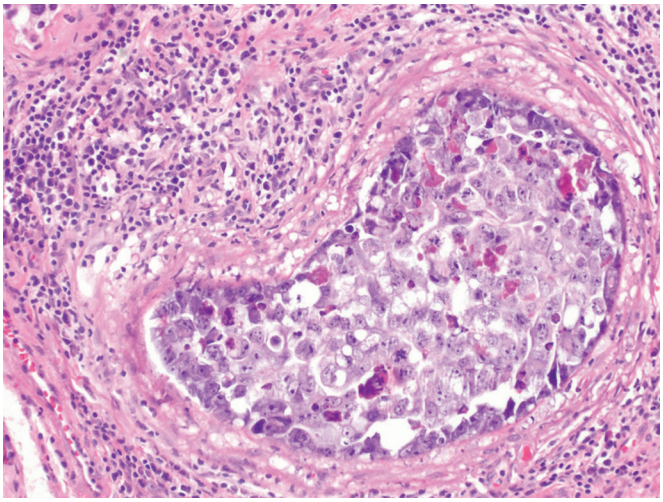

Figure 27.8 Intratubular Embryonal Carcinoma.

pagetoid spread to adjacent tubules creates a pattern with interspersed spermatogonia. Concomitant with the proliferation of atypical germ cells, the lamina propria of the tubule often becomes thickened and hyalinized. The atypical cells have a clear cytoplasm rich in glycogen and closely resemble classic seminoma. In some cases, intraluminal microliths or associated trophoblastic giant cells are seen.[181] Immunohistochemically, the neoplastic cells express markers of embryonic germ cells and seminoma, but placental alkaline phosphatase (PLAP), CD117 (c-KIT), OCT3/4, and podoplanin (D2-40) are most clinically useful because they are not expressed in normal spermatogonia (see Fig. 27.7B). GCNIS has a heterogeneous distribution from case to case, ranging from nearly 100% of seminiferous tubules to only focal[182–184]; it is least prominent in the region close to the epididymis. The differential diagnosis includes vacuolization of seminiferous tubule cells (a probable degenerative change), as well as maturation delayed gonocytes and maturation arrest at the stage of spermatogonia.[185] Exceptionally rare cases of metastatic carcinoma, melanoma, or even lymphoma may colonize seminiferous tubules.[186] Immunohistochemistry with OCT3/4 or other specific markers can resolve most difficult cases, so considering these other diagnostic possibilities is important. It is also important to screen for a subtle component of invasive seminoma (intertubular pattern), particularly when extensive GCNIS is identified in the absence of an obvious invasive component.[187]

Specific Forms of Intratubular Germ Cell Neoplasia. GCNIS is the most common histologic type of noninvasive germ cell neoplasia, but other types are rarely seen. When other types are present, associated GCNIS and invasive components are almost always present. In intratubular seminoma, atypical germ cells indistinguishable from those of seminoma are seen packing the tubules and totally replacing the normal Sertoli and germ cells.[188] An admixed intratubular syncytiotrophoblastic component may be present, but is nearly always accompanied by syncytiotrophoblasts within the invasive component of the tumor, whenever present.[181] In contrast to GCNIS, the invasive component of intratubular seminoma, if present, is nearly always a pure seminoma or a mixed germ cell tumor with a seminomatous component.

With intratubular embryonal carcinoma, the tubules contain highly malignant cells, identical to those seen in embryonal carcinoma (Fig. 27.8).[189] Foci of central necrosis and calcification are common in this lesion.[190,191] This finding is more common in smaller tumors, and, if needed, the diagnosis may be confirmed by documenting immunoreactivity for CD30.[189]

The possibility of other forms of germ cell neoplasia (i.e., yolk sac tumor, teratoma, or choriocarcinoma) being identified in an intratubular pattern exists, but the finding is extraordinarily rare.[192] On some occasions, all one sees is a collection of tubules with necrotic cells, often heavily calcified.[193]

Invasive Germ Cell Neoplasia

Seminoma. Seminomas make up 30%–40% of all testicular tumors (Fig. 27.9). While seminoma was historically divided into two types (classic and spermatocytic), the stark differences between these two tumors warrant their separation and use of the new terminology "spermatocytic tumor" for the latter; therefore, seminoma now refers only to the classic type.[99]

Seminoma has a characteristic gross appearance. It is usually solid, homogeneous, and light yellow to tan, and may contain sharply circumscribed zones of necrosis (Fig. 27.10). This macroscopic appearance may be similar to lymphoma or mesenchymal neoplasms. Areas of cystic change or hemorrhage are usually not seen, so their presence should raise the strong possibility of a nonseminomatous component and warrants thorough sampling of these foci.

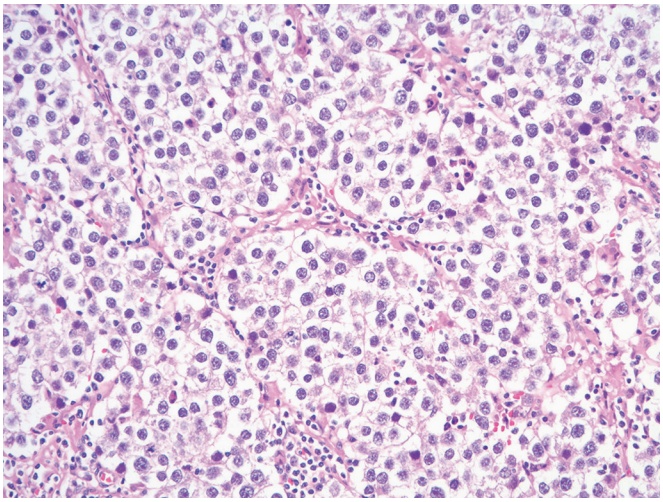

Figure 27.9 Classic Seminoma of Testis. Compact nests of large tumor cells are separated by fibrous septa heavily infiltrated by lymphocytes.

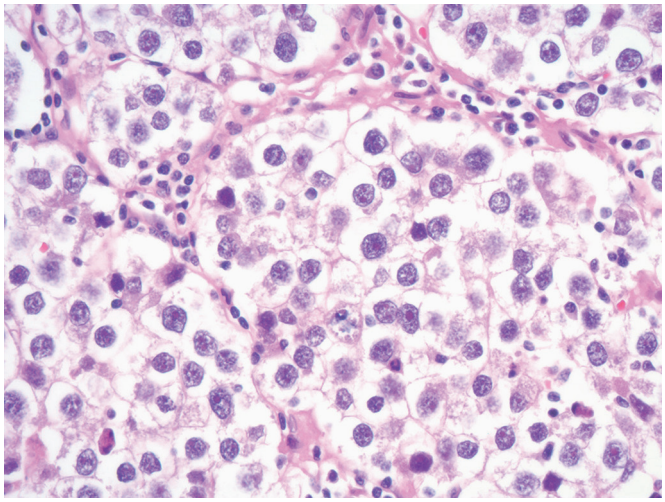

Figure 27.11 Seminoma, characterized by uniform cells with clear cytoplasm, sharp cell membranes, and centrally located nuclei, some with flattened edges.

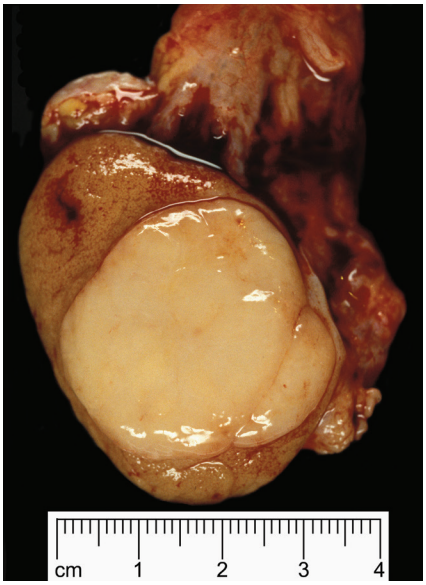

Figure 27.10 Typical tan, bulging homogeneous appearance of seminoma.

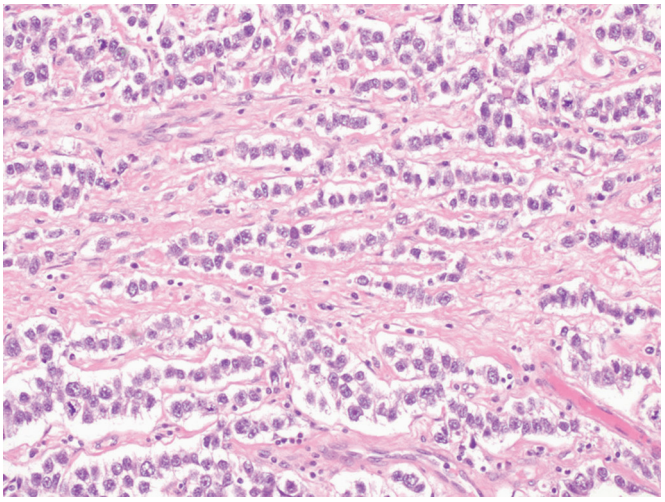

Figure 27.12 Seminoma With Cord-Like (Single File) Growth Pattern.

Microscopically, the individual tumor cells are uniform and relatively evenly spaced with abundant clear cytoplasm, sharply outlined cell membranes, and large centrally located nuclei with finely granular chromatin and flattened edges (Fig. 27.11). Central nucleoli are often prominent and may be multiple. The number of mitoses is highly variable. In some cases, the cells appear more crowded with denser cytoplasm that may impart a plasmacytoid appearance, more closely mimicking lymphoma. The tumor cells are typically arranged in nests outlined by fibrous bands; in 80% of the cases, these bands are infiltrated by lymphocytes (the large majority of T-cell type), plasma cells, and histiocytes.[194,195] Other morphologic patterns that are seen and may cause diagnostic difficulty include: cord-like (single file), tubular, trabecular, microcystic, intertubular, and signet ring–like vacuoles (Figs. 27.12 and 27.13).[187,196–200] A granulomatous reaction is not uncommon and ranges from focal collections of epithelioid histiocytes to well-formed granulomas obscuring much of the tumor (Fig. 27.14). Occasional Langhans-type multinucleated giant cells may also be present.

Seminoma cells contain variable, but usually abundant amounts of cytoplasmic glycogen, imparting the clear cytoplasmic appearance. Immunohistochemically, they exhibit reactivity for PLAP, CD117 (c-KIT), OCT 3/4, SALL4, SOX17, D2-40 (podoplanin), and NANOG, but are generally negative for high-molecular-weight keratin, epithelial membrane antigen (EMA), CD30, glypican-3, p63, and SOX2, features of importance in the differential diagnosis with embryonal carcinoma.[201–221] Some positivity for low-molecular-weight and wide-spectrum keratin is seen frequently, and may show a subtle dot-like pattern.[205,222] Rare cases with focal positivity for CD30 and EMA are reported in the litertaure,[223] but one must carefully consider the possibility of focal embryonal carcinoma in such cases.[209,224] Significantly, some of these immunomarkers are retained despite extensive tumor necrosis.[225,226] Despite the extensive literature on immunohistochemistry in germ cell tumors, it should be emphasized

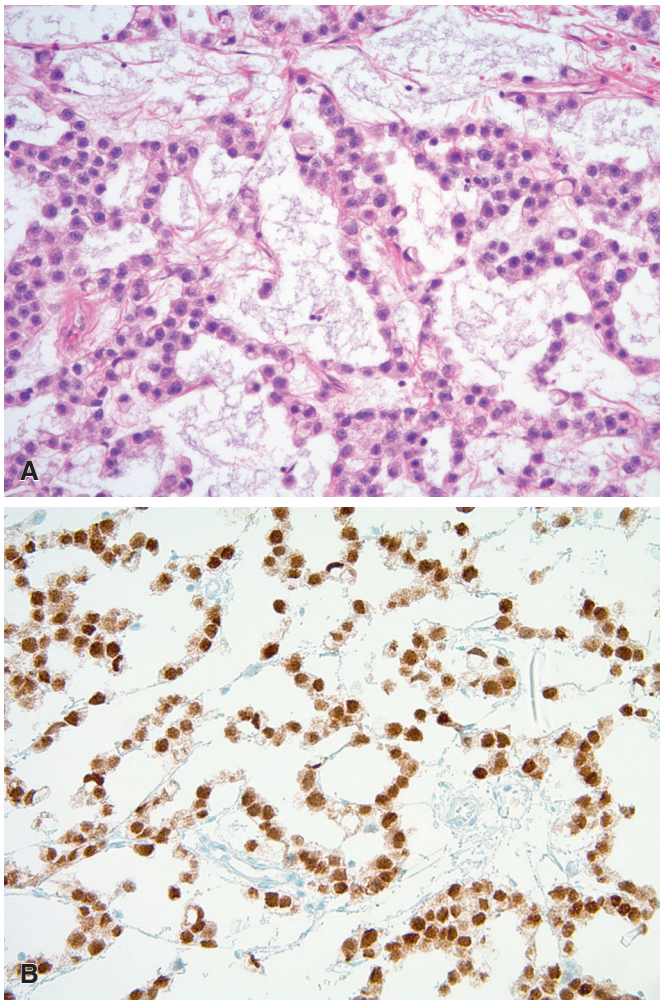

Figure 27.13 Seminoma With Microcystic Growth Pattern. **A,** Hematoxylin and eosin; **B,** OCT3/4 immunostain.

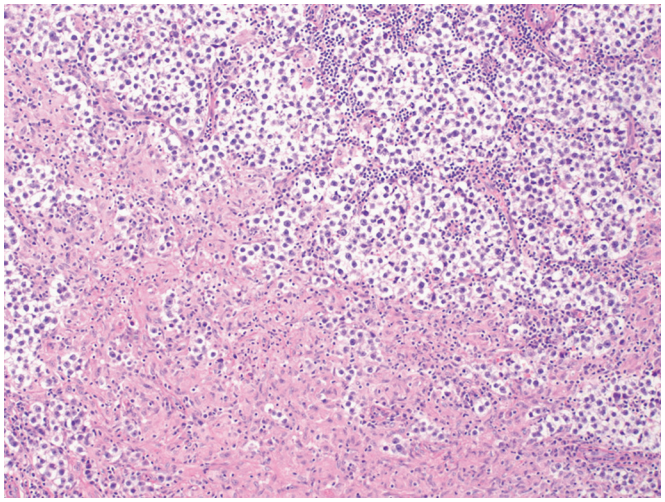

Figure 27.14 Seminoma Associated With Marked Granulomatous Reaction.

that morphology is sufficient for diagnosis in the vast majority of cases.

The concept of anaplastic seminoma was originally defined by Mostofi as a seminoma with features of the classic type having three or more mitoses per high-power field and characterized by a more aggressive clinical course.[192,227] In the era of modern chemotherapy, this distinction is not clinically relevant; therefore, use of that diagnostic category is no longer recommended.[99]

Seminoma with syncytiotrophoblastic giant cells constitutes 10%–20% of all seminomas. These multinucleated giant cells are either isolated, intimately admixed with the seminoma cells, or in the form of syncytial masses that are often associated with foci of hemorrhage (Fig. 27.15A). As in other sites, these cells express cytokeratin and hCG (see Fig. 27.15B); this latter finding explains why some seminoma patients have serum elevations of this hormone.[228] These clusters of syncytiotrophoblasts may be cytologically atypical and, when associated with hemorrhage, are often mistaken for choriocarcinoma. The diagnosis of testicular choriocarcinoma requires a distinct dimorphic population of associated cytotrophoblasts and syncytiotrophoblasts. The presence of intratumoral syncytiotrophoblasts should not alter the diagnosis as seminoma or the expected prognosis.

Embryonal Carcinoma. Embryonal carcinoma has a grossly more variegated appearance than seminoma (Fig. 27.16). It is mainly solid and gray or white, with foci of hemorrhage and necrosis. The latter may be so extensive as to render the diagnosis difficult. Microscopically, architectural patterns are heterogeneous but include solid sheets, papillary, glandular, and nested formations (Fig. 27.17).[191,229,230]

In the differential diagnosis with seminoma, the cells of embryonal carcinoma are more anaplastic, with numerous mitoses (often atypical) and apoptotic bodies, and exhibit prominent variation in size and shape. Multiple large nucleoli are present and overlapping of nuclei is typical.[230] Not uncommonly, a layer of ischemic or apoptotic cells with more eosinophilic cytoplasm may be present at the edges of the tumor imparting a biphasic appearance; this "appliqué" pattern should not be mistaken for choriocarcinoma (Fig. 27.18).[191,231] Immunohistochemically, embryonal carcinoma cells are reactive for keratin (including keratin 19 and high-molecular-weight forms), CD30, OCT 3/4, SALL4, NANOG, and SOX2 but not for CD117, glypican-3, or SOX17.[204,209,215,216,218,219,221,222,232–235] D2-40 staining is reported as more variable.[216] In general, CD30 is most useful for diagnostically challenging cases; however, the reactivity for CD30 may disappear following chemotherapy.[236] Reactivity for OCT3/4 tends to persist both in the primary tumor and in the metastases.[234]

Post-Pubertal Teratoma. Under the current WHO criteria, testicular teratomas should be divided into prepubertal and post-pubertal subtypes, which generally correspond to the patient's age in relation to puberty (but not always).[99] The terms "mature" and "immature" (which are applied in the ovary) or "malignant teratoma" no longer apply to testicular tumors because the terms have been used variably and serve only to confuse oncologists and urologists with regard to the well-recognized malignant potential of all post-pubertal type teratomas regardless of morphology.[147]

Pure post-pubertal teratomas represent approximately 5% of all germ cell tumors, but mixed germ cell tumors contain a component in approximately half of cases. Grossly, it is predominantly cystic and multiloculated (Fig. 27.19). Foci of cartilage are usually evident, whereas the presence of bone is infrequent.

All types of tissue can be seen microscopically in testicular post-pubertal teratoma, the most common being neural tissue, cartilage, and various types of epithelium (Fig. 27.20). The epithelial component can differentiate in the direction of gastrointestinal, respiratory,

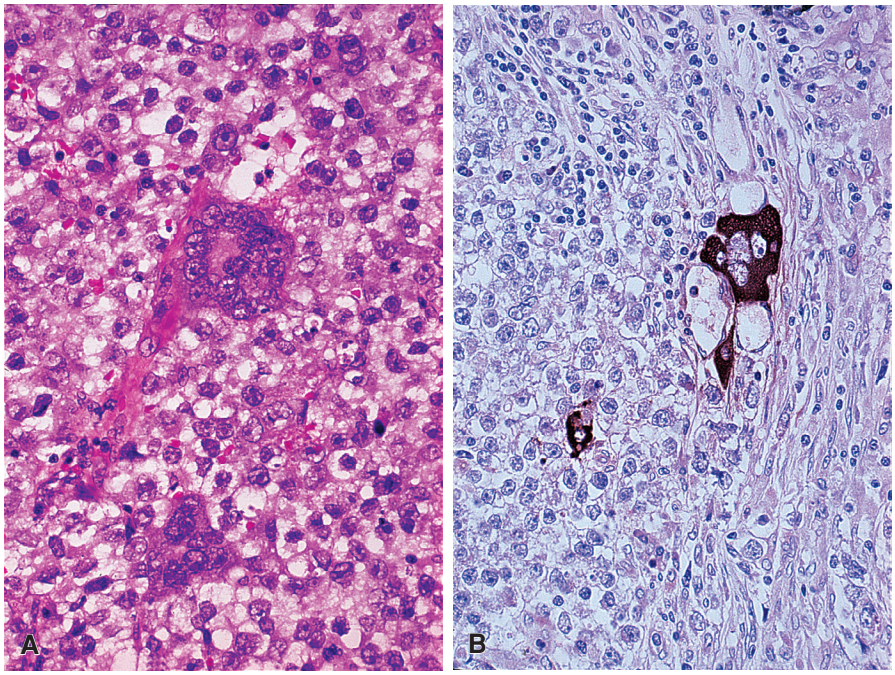

Figure 27.15 Seminoma With Trophoblastic Giant Cells. A, Hematoxylin and eosin; **B,** hCG immunostain.

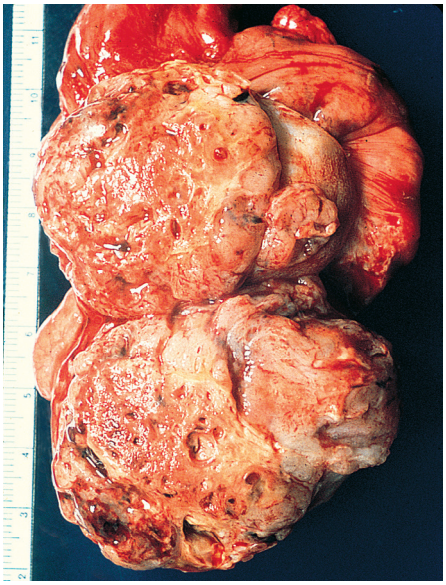

Figure 27.16 Embryonal carcinoma showing solid nodular cut surface with numerous areas of necrosis and hemorrhage.

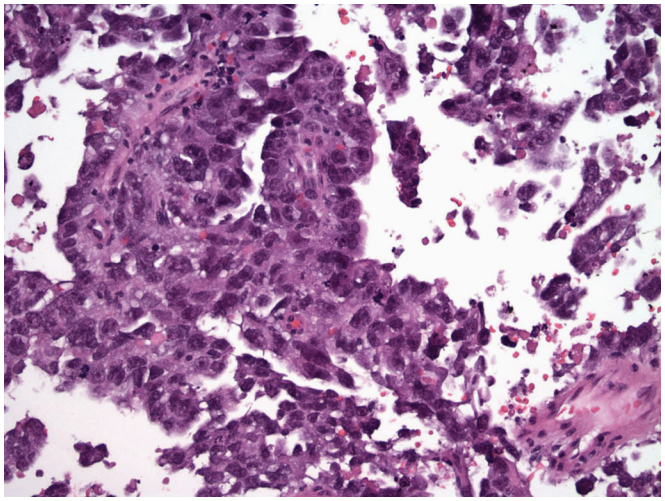

Figure 27.17 Embryonal Carcinoma With Papillary Growth Pattern.

cutaneous, or virtually any other tissue type. All of the cells normally present in the corresponding somatic structures may be identified, including neuroendocrine cells in the case of gastrointestinal epithelium, and meningothelial cells (to the point of forming meningioma-like structures) in the case of neural tissue.[237,238] Sometimes one of the components of the teratoma (such as cartilage) predominates to the near exclusion of the others.[239] Areas of cellular monomorphic spindle cells often show circumferential swirling growth around glands, another characteristic feature of post-pubertal teratoma.

A high proportion of post-pubertal teratomas exhibit some areas of tissue that in the past might be regarded as histologically "immature," a designation of poor reproducibility. The presence of these tissues, which may consist of stroma, epithelium, or neural components, does not change the overall prognosis or expected response to therapy; therefore, diagnosis as a post-pubertal type teratoma is sufficient.

Some post-pubertal teratomas have components of primitive neuroepithelial tissue with the appearance of neuroblastoma or peripheral neuroectodermal tumor (PNET).[240,241] In these cases, the criteria for somatic type malignancy must be applied in order to determine the minimal threshold required for classification as secondary somatic PNET (as discussed later). The distinction from dermoid cyst, epidermoid cyst, and related lesions are discussed under prepubertal-type teratoma.

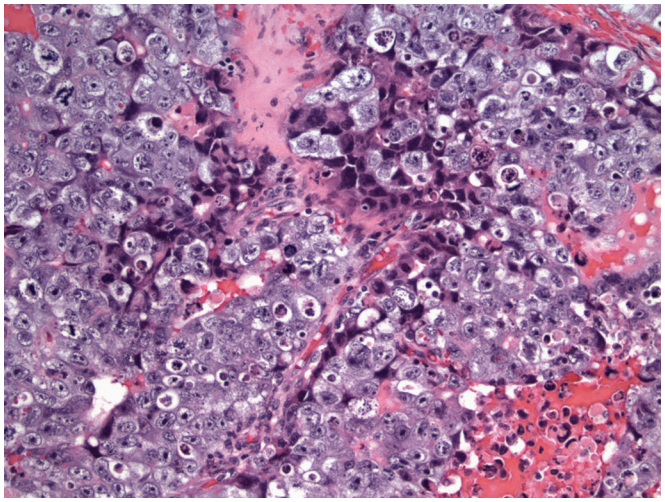

Figure 27.18 Embryonal Carcinoma With Overlapping Nuclei and Marked Pleomorphism. Mitotic activity and apoptotic cells are often abundant. Degenerative cells with eosinophilic cytoplasm create an "appliqué" pattern.

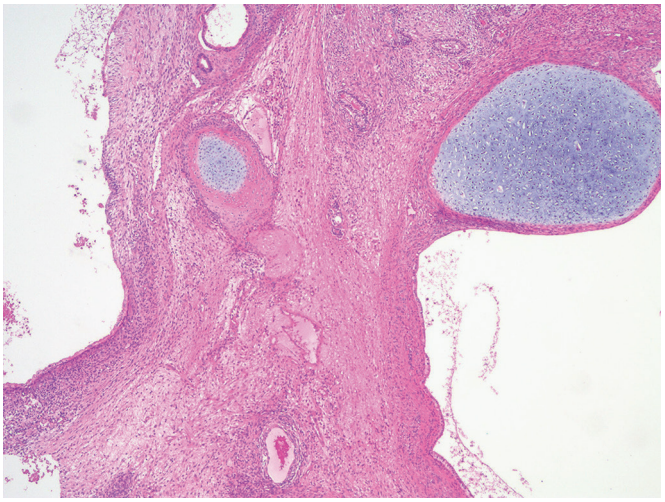

Figure 27.20 Post-Pubertal Teratoma With Glandular Epithelium and Cartilage.

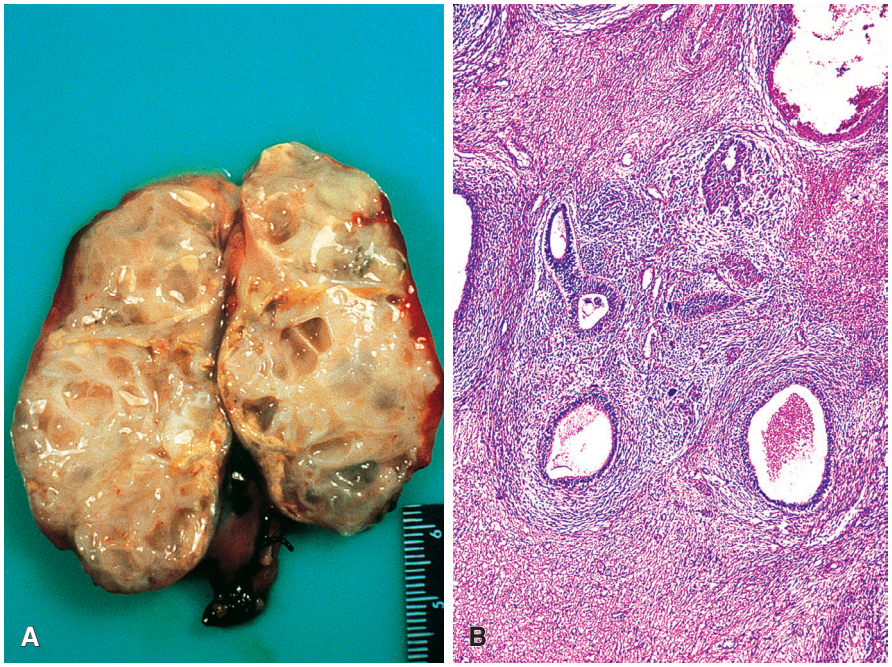

Figure 27.19 Post-Pubertal Teratoma. A, Gross appearance. **B,** Microscopic appearance. Hypercellular stroma is seen growing in a concentric fashion around glandular formations.

Yolk Sac Tumor. Although numerous names have been applied over the years, yolk sac tumor is the preferred term for this pattern of germ cell tumor that may recapitulate the yolk sac, allantoid, and extraembryonic mesenchyme.[242–250] In the post-pubertal setting, it is typically a component of a mixed germ cell tumor. Increased awareness of the different morphologic patterns that yolk sac differentiation may exhibit (as a result of correlative studies with immunocytochemical techniques) has led to an ever-increasing percentage of yolk sac elements being described in association with other germ cell components, particularly embryonal carcinoma.

Yolk sac elements in germ cell tumors of adults are difficult to discern on gross inspection. Microscopically, diagnosis depends on recognition of the full diversity of the histologic spectrum.[251] The microcystic reticular pattern is common and is characterized by collections of cells with intracytoplasmic vacuoles of varying size that create a sieve-like meshwork (Fig. 27.21). Associated areas with larger macrocysts may also be seen. Myxomatous patterns are underrecognized and often misinterpreted as stromal components, either reactive or teratomatous (Fig. 27.22). They consist of myxoid stroma with an admixed hypocellular population of bipolar to stellate spindle and/or epithelioid cells. Solid yolk sac tumor may closely mimic seminoma and recognition requires appreciation of the more varied cytology with scattered polygonal tumor cells and larger more pleomorphic cells (Fig. 27.23).[252] In contrast to seminoma, fibrous septa and lymphocytes are typically absent. Occasional examples of solid yolk sac tumor have less clear cytoplasm imparting a

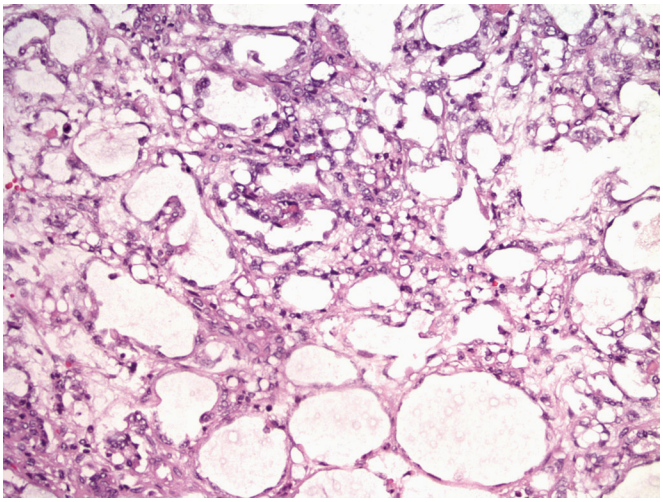

Figure 27.21 Yolk Sac Tumor With Reticular Pattern.

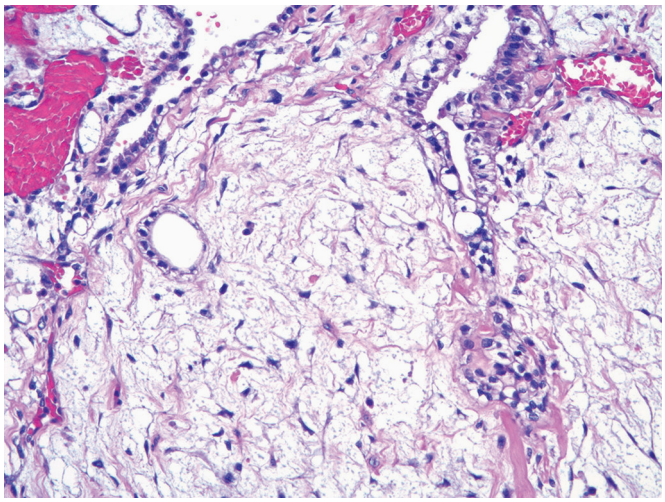

Figure 27.22 Yolk Sac Tumor With Myxoid Spindle Cell and Focal Glandular Patterns.

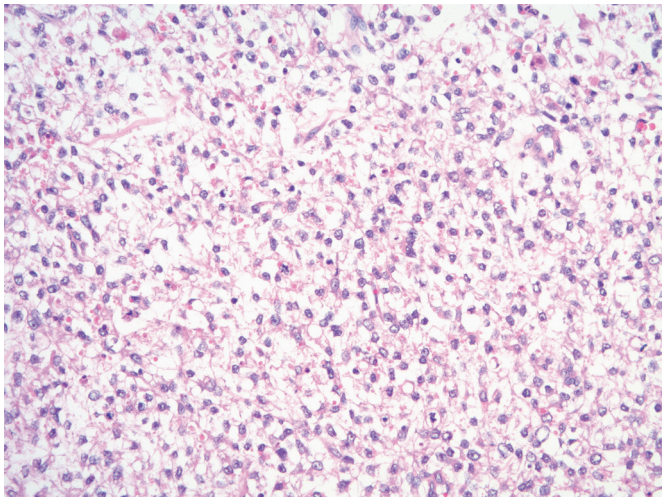

Figure 27.23 Solid yolk sac tumor may mimic seminoma, but cells are more variable in appearance.

"blastemal-like" appearance. Glandular patterns of yolk sac tumor may have enteric type features or subnuclear vacuoles reminiscent of secretory endometrium. The distinction from teratoma glands may be difficult, but yolk sac glands lack a smooth muscle layer or the cellular "encircling" stroma of teratoma; instead, they are typically intimately admixed with other yolk sac patterns. In this respect, the distinction of individual foci as either glandular yolk sac tumor or glandular teratoma may be somewhat subjective and is often based on "the company they keep." Some examples of yolk sac tumor create a pattern of interconnecting glands with a more alveolar pattern. Endodermal/perivascular patterns are characterized by a central blood vessel with supporting connective tissue and a surrounding layer of cuboidal tumor cells. Perivascular Schiller–Duval bodies are the one of the classical features of yolk sac tumor, but they are over-emphasized in education and not required for diagnosis. Hepatoid patterns consist of round epithelioid cells with eosinophilic cytoplasm growing in sheets or trabeculae, similar to normal hepatocytes with or without intracytoplasmic lipid. A spectrum of papillary patterns may be seen, with lining cells showing characteristic cytologic features of yolk sac tumor. Sarcomatoid/spindle cell patterns have close histologic overlap with secondary somatic sarcoma, but they are often seen in direct continuity to other patterns of yolk sac tumor, often with gradual transition to the myxomatous pattern. The parietal pattern is easy to overlook and is characterized by densely eosinophilic basement membrane like material surrounding a subtle, hypocellular population of tumor cells. The polyvesicular vitelline pattern is less common, but is composed of dilated gland-like spaces (with or without constrictions creating a "bead-like" pattern) lined by a flattened, atrophic epithelium.[253] These "vesicles" are often surrounded by a loose stroma.

Variants of yolk sac tumor that tend to be misinterpreted are those exhibiting a hepatoid pattern (featuring fetal-type liver cell cords), a solid pattern, or a well-differentiated glandular pattern (resembling fetal lung or intestine, the latter also referred to as primitive intestinal or enteric pattern).[252,254,255] Hyaline intracytoplasmic and extracytoplasmic round inclusions are commonly seen in yolk sac tumors.

The cells of yolk sac tumor are also consistently positive immunohistochemically for keratin.[256] A SALL4+, OCT3/4– immunophenotype is highly characteristic of yolk sac tumor,[204] and glypican-3 and CDX2 expression is also typical.[221,257–259] In our experience, AFP stains have high background and are difficult to interpret compared to some of the newer markers; therefore, as a matter of preference we rarely employ its use. It should also be emphasized that solid yolk sac tumor loses AFP reactivity in up to 38% of cases.[252]

Choriocarcinoma. Choriocarcinomas account for about 5% of testicular tumors. They are usually hemorrhagic and partially necrotic. Rarely the primary tumor may completely regress, leaving only a scar containing hemosiderin pigment. Microscopically, these tumors show giant syncytiotrophoblastic cells with large, atypical nuclei intermingled with cytotrophoblasts (Fig. 27.24).[112] The syncytiotrophoblastic cells are consistently immunoreactive for hCG and keratin.[260,261] It has been noted that keratin 7 stains trophoblastic cells (whether in a choriocarcinoma or in other germ cell tumors), but not any of the other tumor components in germ cell tumors.[262] As already mentioned, cells with the morphologic appearance of syncytiotrophoblasts can be seen in several other types of testicular germ cell tumor; however, their presence as isolated elements or even as syncytial clusters (with or without accompanying hemorrhage) in a testicular germ cell tumor is not sufficient for a diagnosis of choriocarcinoma (Fig. 27.25). It is only when these cells are intimately mixed with cytotrophoblastic elements in a biphasic pattern that the diagnosis of choriocarcinoma is justified.[263] Something similar can be said concerning serum levels of chorionic gonadotropins. Although classically elevated in choriocarcinomas, they also may

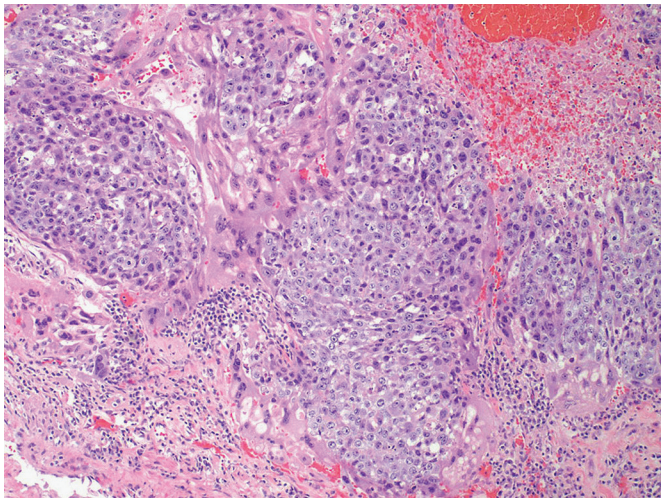

Figure 27.24 Microscopic Appearance of Testicular Choriocarcinoma. There is close intermingling of cytotrophoblast and syncytiotrophoblast, which recapitulates that seen in normal chorionic villi.

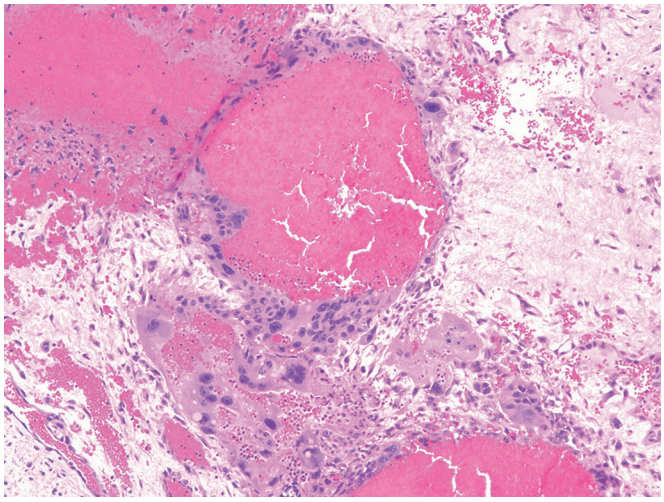

Figure 27.25 Clusters of atypical syncytiotrophoblasts with hemorrhage are NOT diagnostic of choriocarcinoma. The dimorphic relationship to cytotrophoblasts is needed. The background in this case is yolk sac tumor.

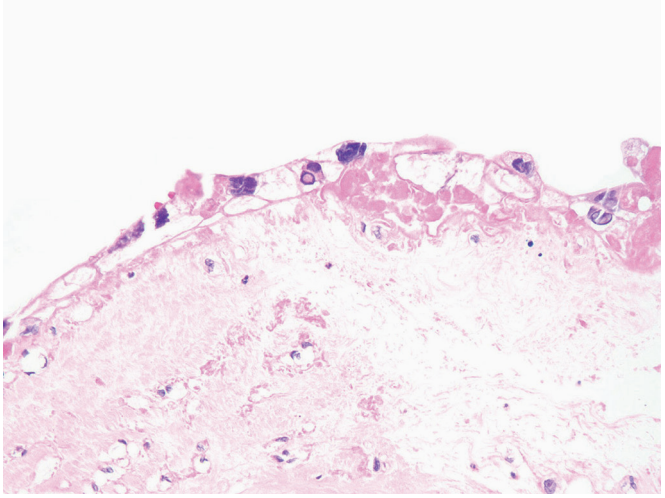

Figure 27.26 Cystic Trophoblastic Tumor.

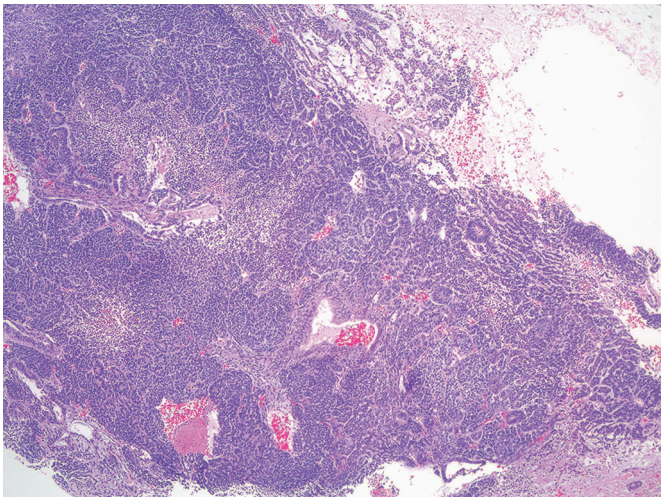

Figure 27.27 Somatic Type Malignancy in Teratoma. A low-power field is composed of primitive neuroectodermal tumor (resembling its central nervous system counterpart).

be increased in any other type of testicular germinal tumor, so the diagnosis of choriocarcinoma should be made on the basis of the microscopic pattern rather than on the basis of the hormone being produced. It should also be mentioned that in exceptional circumstances one can find a trophoblastic testicular tumor formed almost exclusively of cytotrophoblasts (so-called monophasic choriocarcinoma), but this is more common in the post-treatment setting.[264] A monophasic syncytiotrophoblastic form is not recognized.

Non-Choriocarcinomatous Trophoblastic Tumors. Other rare types of trophoblastic neoplasia are described in the testis, including *placental site trophoblastic tumor* and *epithelioid trophoblastic tumor*.[264] The morphology is identical to their gestational counterparts (fully described in Chapter 33). These rare tumors may also occur in recurrences.[265]

The *cystic trophoblastic tumor*, which may occur in the testis, is more commonly seen in the post-therapy setting within retroperitoneal lymph node dissection specimens.[266,267] They consist of multiple cysts lined by a variable layer of mononuclear trophoblastic cells characterized by eosinophilic cytoplasm, large nuclei with dark smudgy chromatin, only rare mitoses, and frequent intracytoplasmic lacunae (Fig. 27.26).[266,267] These may be associated with minor elevations in serum human chorion gonadotropin and evidence suggests that they represent "matured" forms of choriocarcinoma. Most importantly, for clinical management the cystic trophoblastic tumor should be regarded similarly to teratoma as it has no increased risk for disease progression and warrants no additional therapy.

Somatic-Type Malignancies in Germ Cell Tumors. Occasionally, testicular germ cell tumors develop malignancies—referred to as somatic type—having appearances analogous to those of conventional tumors of nongerm-cell nature. The malignant component is often in the form of sarcoma (such as rhabdomyosarcoma) or neuroepithelial type neoplasms similar to those in the central nervous system (primitive neuroectodermal tumor) (Fig. 27.27),[268,269] but it may also present in the form of epithelial malignancy (such as adenocarcinoma). This phenomenon is designated as somatic type malignancy; older terms such as "teratoma with malignant transformation" are not recommended.

By definition, the somatic-type malignancy should consist of a pure population of the atypical cells showing an expansile or infiltrative growth that occupies at least one low-power field (×4

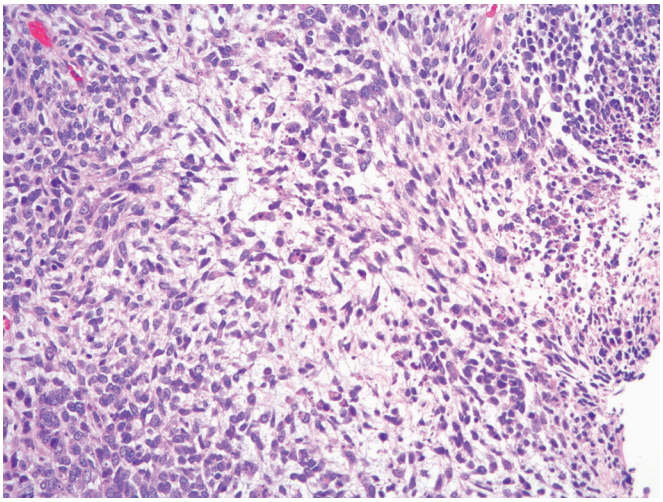

Figure 27.28 Sarcomatoid yolk sac tumor (expressed SALL4 and glypican-3) behaves similarly to somatic type sarcoma.

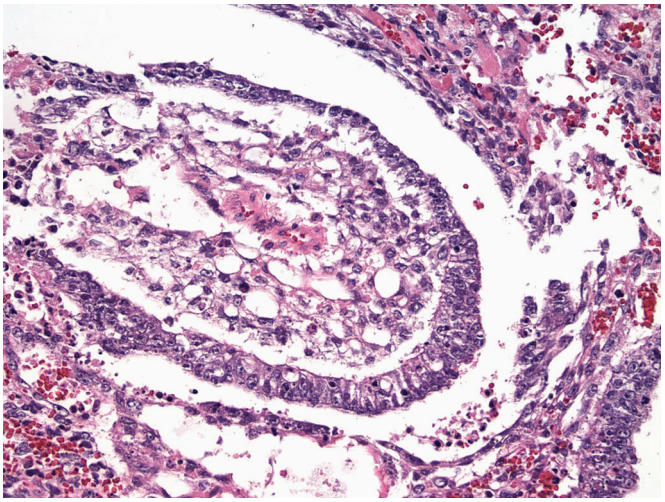

Figure 27.29 Embryoid body pattern of mixed yolk sac tumor and embryonal carcinoma.

objective, 5 mm in diameter). Similar cell populations admixed within the otherwise typical varied components of a post-pubertal teratoma do not have prognostic significance and, therefore, should not change the overall classification. Studies of clonality and 12p status have shown that in most cases the somatic-type neoplasms arise from the preexisting germ cell tumors[270,271]; as such, primitive neuroectodermal tumors do not have the EWSR1 rearrangement typical of Ewing sarcoma.[272] In general terms, the emergence of somatic malignancy in a testicular germ cell tumor represents a poor prognostic sign, at least when invading outside of the testis or when presenting at a metastatic site.[268,269] It has been shown that tumors with more mature skeletal muscle differentiation developing in the retroperitoneum after chemotherapy for metastatic germ cell tumor exhibit a clinical behavior more in keeping with a teratoma than with an adult-type rhabdomyosarcoma and should therefore be separated under the diagnostic term "differentiated rhabdomyomatous tumor."[273] While a subset of post-chemotherapy malignant spindle cell tumors may represent a sarcomatoid form of yolk sac tumor, they behave similar to other secondary somatic sarcomas; therefore, distinction may not be critical for clinical management (Fig. 27.28).[274,275]

Carcinomatous forms of somatic malignancy are most commonly enteric or mucinous type adenocarcinomas.[271,276–278] These carcinomas often lose markers of germ cell origin, but may retain SALL4 expression.[276] Glandular patterns of yolk sac tumor should be considered before a somatic carcinoma is diagnosed.[276]

Unlike mediastinal germ cell tumors, secondary somatic hematopoietic neoplasms would be extraordinarily uncommon in the testis.

Somatic type malignancies do not show the excellent response to cisplatin-based chemotherapies seen with germ cell tumors; therefore, treatment should be tailored to the specific histologic type of malignancy present.[271]

Specific Histologic Patterns of Mixed Germ Cell Tumor. Some germ cell tumors have a distinctive appearance resulting from their unique architectural admixture of yolk sac tumor and embryonal carcinoma and have been given descriptive names. Polyembryomas are characterized by the presence of multiple embryoid bodies throughout the neoplasm.[279] Histologically, they are characterized by a linear core of embryonal carcinoma directly adjacent to an "amniotic-like" space with an underlying yolk sac tumor competent with reticular or microcytic features (Fig. 27.29). Diffuse embryoma features an equal admixture of yolk sac tumor and embryonal carcinoma that are arranged in "stacked" linear arrays (Fig. 27.30).[280,281] The two components have a subtle but distinct cytologic difference with the yolk sac component having smaller nuclei. These almost never occur in a pure form, but rather as a component of a variety of mixed germ cell tumors.[282]

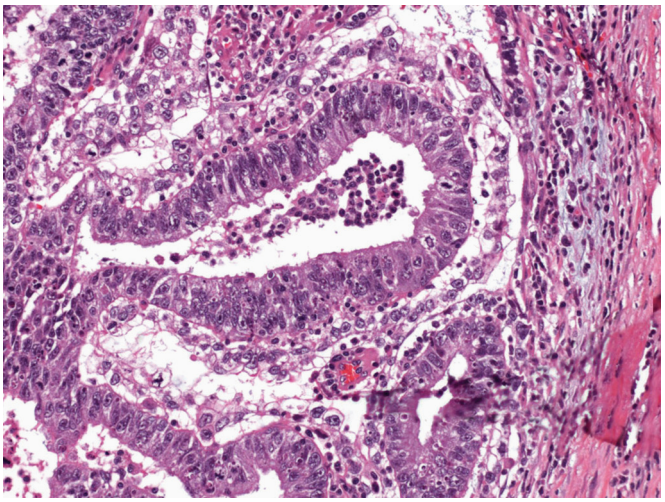

Figure 27.30 Diffuse embryoma pattern of mixed yolk sac tumor and embryonal carcinoma.

Regressed Germ Cell Tumors. It is well recognized that a small subset of testicular germ cell tumors undergoes partial or complete regression (<5%). These patients may present with retroperitoneal metastases, but only nonspecific findings on testicular ultrasound. Histologically, regression is characterized by a well-demarcated fibrotic scar with variable lymphoplasmacytic inflammation, ischemic "ghosts" of hyalinized tubules, increased numbers of small blood vessels, hemosiderin-laden macrophages, and coarse intratubular calcifications.[151] The identification of GCNIS in the adjacent testicular parenchyma is a strong corroborating finding.

Diagnosing Metastatic Germ Cell Neoplasia. It is not uncommon to receive biopsies of nodal or parenchymal-based lesions where the differential diagnosis of a germ cell tumor might be considered. Improved immunohistochemical germ cell markers are helpful

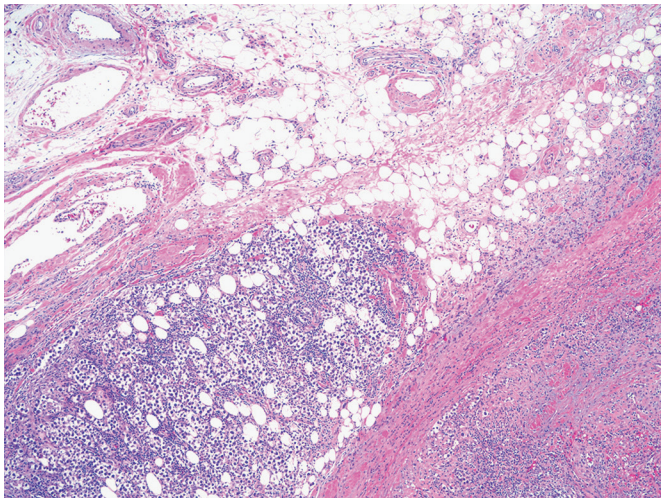

Figure 27.31 Seminoma infiltrating into the renal hilar tissue, indicating pT2 disease.

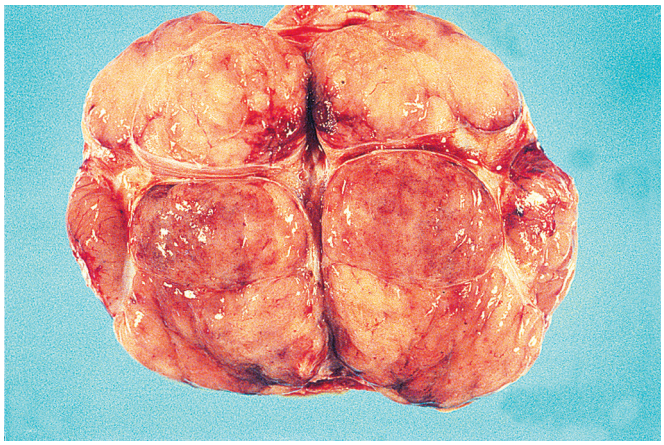

Figure 27.32 Gross Appearance of Spermatocytic Tumor. A large tumor of myxoid appearance bulges on the cut surface.

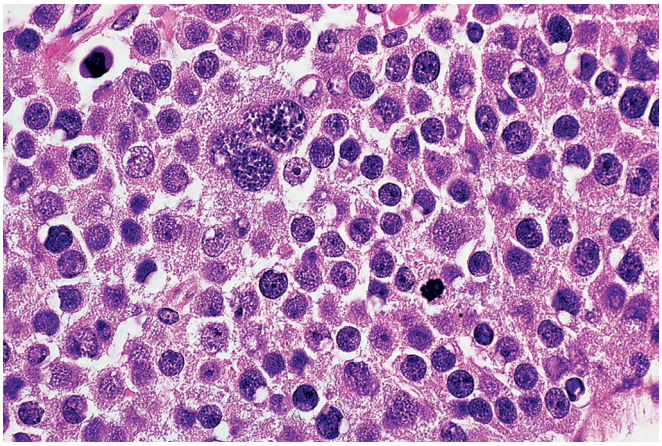

Figure 27.33 Spermatocytic tumor showing admixture of medium-sized cells (predominating), giant cells, and small lymphocyte-like cells.

(particularly SALL4 and OCT3/4), but close clinical and histologic correlation is essential as these markers are not entirely specific.[283,284] SALL4 is expressed in some high-grade serous carcinomas of the gynecologic tract, a subset of adenocarcinomas of the upper gastrointestinal tract that may have unusual "immature" or "fetal" features (particularly the esophagus and GE junction), urothelial carcinoma, rhabdoid tumors (kidney and extrarenal), blastemal tumors of children (e.g., Wilms tumor and hepatoblastoma), as well as rarely in other carcinomas from various sites.[285–287] OCT3/4 stains a subset of large cell lymphomas, is commonly expressed in medullary carcinoma of the kidney, and may rarely stain poorly differentiated carcinomas from various sites.[288,289] It should also be remembered that yolk sac tumor may express PAX-8. As mentioned previously, CD30 reactivity may be lost in metastatic embryonal carcinoma.[236] There is much less published experience with other novel markers of germ cell origin such as SOX17, NANOG, and MAGEA4, particularly with regard to expression in other carcinoma types.

Staging on Orchiectomy Specimens. The major keys to staging in the testis are identifying the extent of invasion beyond the testis and the presence of lymphovascular invasion. In latest version of the AJCC staging manual, invasion of testicular hilar soft tissue (Fig. 27.31) and tumor size are now emphasized. For pure seminoma limited to the testis, 3 cm is an important cutoff.[139]

Germ Cell Tumors Unrelated to Germ Cell Neoplasia In Situ

Overview. With the exception of spermatocytic tumor, this group of germ cell tumors typically occurs in the pediatric or prepubertal setting. In children, seminomas and embryonal carcinomas are practically nonexistent. Only yolk sac tumor and teratoma occur with any frequency, and they may be admixed.[290] The majority of pure yolk sac tumors occur in infants under 2 years of age.[249] Prepubertal type teratoma may occur only very rarely in post-pubertal patients.[291] Tumors developing in prepubertal gonads tend to be diploid and are not associated with i(12p) or with GCNIS.[121] Prepubertal type teratoma is the only testicular germ cell tumor lacking gross chromosomal aberrations.[292] Yolk sac tumor in infants and children commonly shows loss of 1p and 6q and gain of 1q, 20p, and 22. Teratoma of the prepubertal testis has never been shown to metastasize. Pure yolk sac tumors occurring in infants or children metastasize to periaortic or other lymph node groups only rarely.[249] The incidence of retroperitoneal spread in pure yolk sac tumors of infants is too low to justify a lymphadenectomy.[293] Similarly, teratomas occurring in infants or children should be treated by orchiectomy alone.

Spermatocytic tumor shows completely different genetic features from classic seminoma. Isochromosome 12p is not found. Numerical chromosomal aberrations are common and gain of chromosome 9 is characteristic; recent studies have identified that this corresponds to additional copies of the *DMRT1* gene.[294] Activating mutations in the *FGFR3* and *HRAS* genes are also reported in a smaller subset of spermatocytic tumors, typically in older patients.[295]

Spermatocytic Tumor. These rare tumors (previously called spermatocytic seminoma) should be clearly separated from classic seminoma and its variants. It comprises approximately 1% of testicular germ cell tumors and typically occurs in an older age group (mean, 52–59 years) compared to seminoma.[99,296] Grossly, it has a soft, gelatinous appearance (Fig. 27.32). Microscopically, it is composed of cells with round nuclei growing in sheets with or without a nodular pattern separated by scant fibrous stroma. Edema is frequent and may create a cystic appearance. The overall tinctorial quality is more amphophilic than classic seminoma because the cytoplasm is denser and lacks glycogen,[297] a useful clue to considering the possibility of spermatocytic tumor. Although variable, the prototypical morphology is a polymorphous population of three cell types: small round cells (lymphocyte-like), intermediate cells similar in size to classic seminoma, and giant cells that may be multinucleate (Fig. 27.33). Some

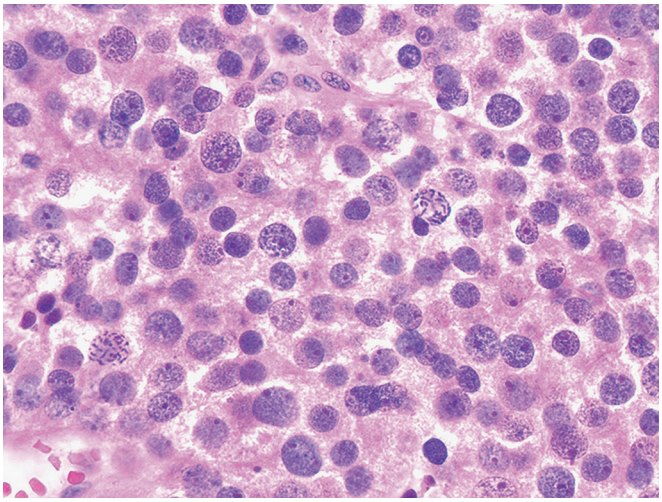

Figure 27.34 Typical chromatin pattern of spermatocytic tumor.

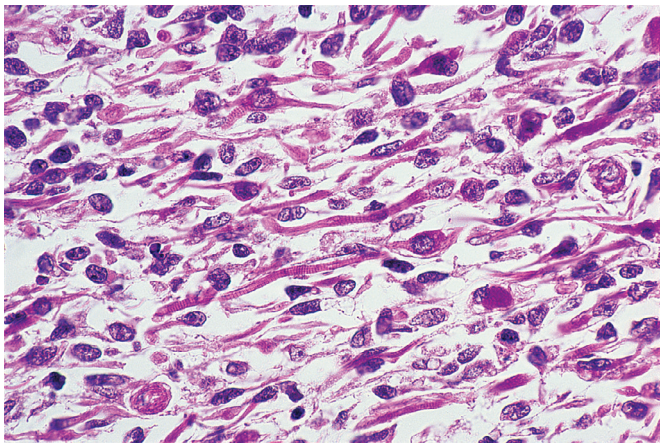

Figure 27.36 Sarcomatous focus in spermatocytic tumor of testis, exhibiting rhabdomyoblastic differentiation. This section is from a lung metastasis.

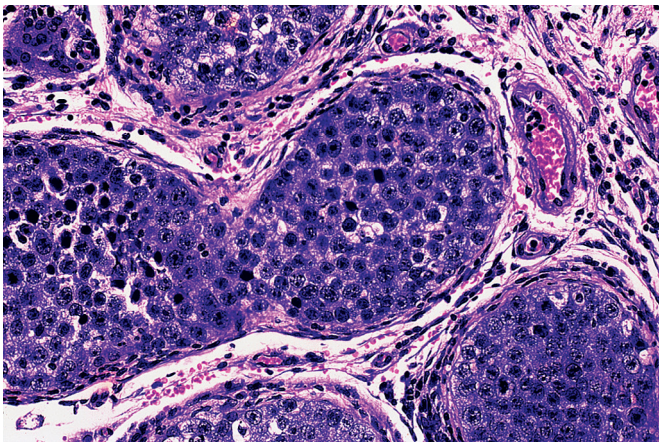

Figure 27.35 Extensive intratubular growth of spermatocytic tumor.

of the nuclei have a filamentous appearance (spireme-like chromatin) suggestive of an early stage of meiotic division (Fig. 27.34). Mitoses and apoptotic bodies may be numerous. Intratubular edema may also be present, inducing a "pseudoglandular" pattern. Prominent intratubular growth is often seen at the periphery (Fig. 27.35), but this should not be equated with GCNIS, which is not seen. Areas of lymphocytic infiltration and granuloma formation are typically absent.[298]

Rare cases of spermatocytic tumor have a more monomorphic population of intermediate size cells, often with prominent nucleoli. In the past, the term "anaplastic spermatocytic seminoma" has been used for this pattern. The few reported cases have so far behaved no differently than spermatocytic tumor without this feature; therefore, the term is not recommended.

In contrast to classic seminoma, immunoreactivity for PLAP and OCT3/4 is absent, which is very helpful in diagnosis.[299] Focal and inconstant positivity for keratin may be observed, as in classic seminoma.[299] SALL4, CD117, and DMRT1, as well as SAGE1, SSX, and OCT2 (germ cell tumor markers that are expressed in spermatogonia), are positive in spermatocytic tumor.[204,294,300,301]

In contrast to classic seminoma, spermatocytic tumor occurs only in the testicle and is never seen in combination with other admixed germ cell components. It is more commonly bilateral, and the prognosis is excellent. Metastases are extraordinarily rare, and therefore simple orchiectomy is considered sufficient therapy.[297,302] It is worth restating that, although spermatocytic tumor occurs moist commonly in men over age 50 years, the GCNIS-related classic seminoma is actually more common.

Spermatocytic tumor may be complicated by a secondary sarcoma, most commonly rhabdomyosarcoma or undifferentiated sarcoma (Fig. 27.36). This development is accompanied by frequent metastases and high mortality rate.[303–305]

Prepubertal Teratoma. Prepubertal type teratomas, which are clinically benign, by definition have no association with GCNIS, dysgenetic gonadal changes, 12p abnormalities, or adjacent regressed components. They have some major histologic differences when compared to their post-pubertal counterparts, including more organoid arrangement of the distinct elements into structures resembling normal tissue. For example, epithelial lined tubular structures are often surrounding by a muscular layer and secondary structures are often present, such as cutaneous adnexa in skin or minor mucinous glands in bronchial-like tissue. Significant cytologic atypia is usually absent. Special types include dermoid cyst and epidermoid cyst (Fig. 27.37).[99,306] In difficult cases, molecular studies evaluating for chromosome 12p abnormalities may be of great aid; moreover, one might consider this test required if the diagnosis is considered in a patient that is post-pubertal (or over 12 years of age).

The current WHO classification considers well-differentiated neuroendocrine tumors ("carcinoid tumors") (Fig. 27.38), which are extremely rare in the testis, as monodermal teratomas within the spectrum of prepubertal-type teratomas given that: (1) most lack associated GCNIS, (2) some are associated with other forms of prepubertal-type teratoma, and (3) absence of 12p abnormalities in most cases.[99] These tumors may be pure, associated with teratoma showing prepubertal features, or associated with either a dermoid or epidermoid cyst.[307–310] Importantly, the possibility of a metastasis from an extragonadal primary site (such as the gastrointestinal tract) must be excluded clinically before the diagnosis of a primary pure neuroendocrine neoplasm of the testis is accepted. While most of these tumors are benign regardless of their association with a teratomatous component or not, metastases are reported; however, metastases are more commonly seen in cases with more aggressive features (e.g., increased mitotic activity or necrosis).

Two seemingly contradictory points for pure primary testicular neuroendocrine neoplasms are that 12p abnormalities have been reported in at least some cases and that most cases occur in a much

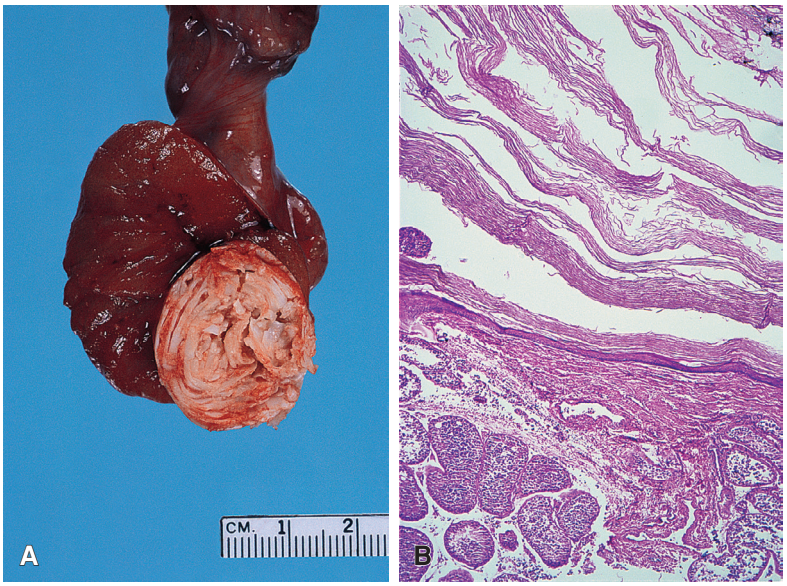

Figure 27.37 Epidermoid Cyst of Testis. A, The lesion is sharply outlined and contains laminated layers of keratin. **B**, Microscopic appearance of epidermoid cyst of testis. Keratin squames are laid down by well-differentiated squamous epithelium. There are no skin adnexal structures.

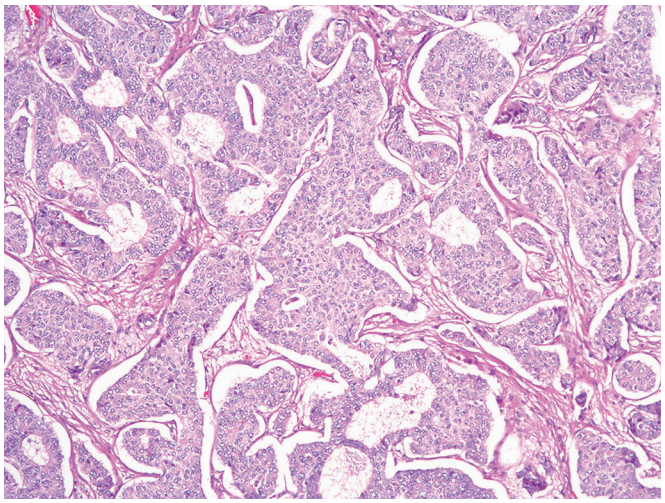

Figure 27.38 Intratesticular well-differentiated neuroendocrine tumor ("carcinoid tumor") showing the classic insular pattern.

Figure 27.39 Gross Appearance of Pure Yolk Sac Tumor in an Infant.

older age group than typical for prepubertal type germ cell tumors, suggesting biologic heterogeneity and the possibility that classification could evolve with more study.[311,312]

Mixed Teratoma and Yolk Sac Tumor, Prepubertal. Mixed tumors of the testis in the prepubertal setting are rare, but consist of admixed prepubertal-type teratoma and yolk sac tumor.[313] The yolk sac component may be focal. Although other types of germ cell tumor are not seen, exceptional cases may progress to primitive neuroectodermal tumor or other secondary somatic type malignancy.

Yolk Sac Tumor, Prepubertal. Prepubertal yolk sac tumors typically occur in young children (median age of 16–20 months).[314] These tumors have a similar spectrum of morphologic features and immunophenotype to their post-pubertal counterpart, but lack the isochromosome 12p. Grossly, the pure yolk sac tumor of infancy has a soft consistency and a microcystic appearance on cross section (Fig. 27.39). For pathologists used to classifying germ cell tumors in adults, the degree of cytologic atypia may suggest the possibility of an embryonal component, but that combination is essentially not seen in the pediatric age group. Juvenile granulosa cell tumor (described later) may be a close histologic mimic.

Sex Cord–Stromal Tumors

Leydig Cell Tumor and Related Lesions

Leydig cell tumors comprise between 1% and 3% of all testicular tumors. About 3% are bilateral, either synchronously or metachronously.[315] A few have been described in cryptorchid testes and others in patients with Klinefelter syndrome (where they may simply represent florid hyperplasia). There is also an uncommon association with hereditary leiomyomatosis and renal cell carcinoma syndrome

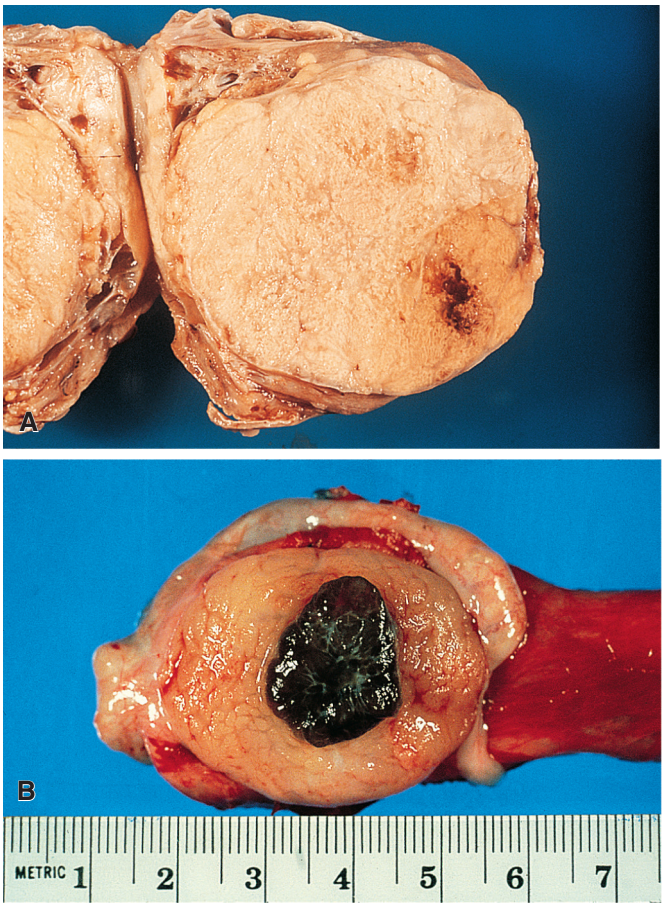

Figure 27.40 Gross Appearance of Leydig Cell Tumor. A, The tumor, which has replaced most of the testis, has a granular yellow appearance. **B,** This tumor, occurring in a child, is solid, well circumscribed, and dark brown.

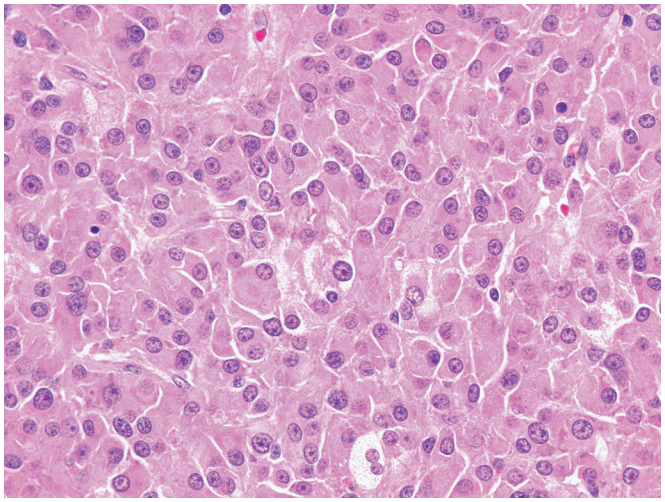

Figure 27.41 Leydig Cell Tumor of Testis. The neoplasm is characterized by solid growth of polygonal cells with abundant granular acidophilic cytoplasm.

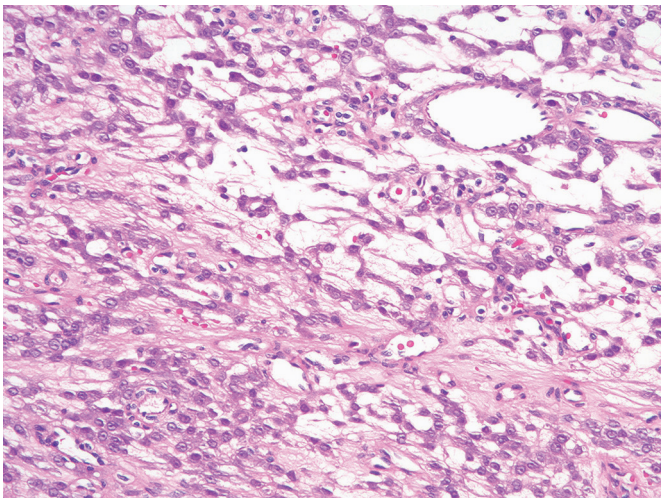

Figure 27.42 Leydig cell tumor with microcystic pattern, which may closely mimic yolk sac tumor.

(i.e., germline *FH* mutation).[316] In rare cases, they occur in patients with a germ cell tumor in the contralateral testis, either synchronously or metachronously.[317] They may produce endocrine changes because of increased production of androgens and/or estrogens.[318,319] Most occur in adults, with a palpable testicular mass and gynecomastia being the most common symptoms. The few that occur in childhood cause precocious pseudopuberty with growth of pubic hair and penis, but without spermatocytic maturation in the non-neoplastic testis (hence the prefix pseudo); these symptoms usually regress after removal of the tumor.[320]

Grossly, Leydig cell tumor presents as a generally small (average size, 3 cm), sharply delimited solid nodule embedded within the testicle (Fig. 27.40). The brown color it usually exhibits is one of its most distinguishing gross features. In rare cases, Leydig cell tumor or other gonadal stromal tumors are found outside the testis proper.[321]

Microscopically, the tumor cells have well-defined outlines, deeply acidophilic but occasionally clear cytoplasm, and a round or oval (occasionally grooved) nucleus (Fig. 27.41). Some of the cells have a plasmacytoid appearance. Lipochrome pigment and Reinke crystalloids are sometimes present, the latter well demonstrated with Masson trichrome stain. As with most other endocrine tumors, marked variation in the size and shape of the tumor cells may occur, with the presence of bizarre forms with giant nuclei. The pattern of growth is generally solid, but trabecular, myxoid, pseudofollicular, and microcystic formations can be present (Fig. 27.42).[322,323] Occasionally, there is prominent spindling of tumor cells, metaplastic ossification or adipose metaplasia.[324–327] On occasion, the ultrastructural appearance is reminiscent of fetal-type Leydig cells.[328]

The markers that have proved to be of the greatest utility for the evaluation of these tumors are inhibin, calretinin, SF-1, CD99, and Mart-1 (also known as Melan-A and detected with the antibody A103).[329–334] Expression of S-100 protein, synaptophysin, and cytokeratin is variable.[335–337] Nuclear β-catenin is absent.[337]

An activating mutation of the gene encoding the luteinizing hormone receptor has been detected in some cases of pediatric Leydig cell tumor.[338]

Most Leydig cell tumors behave in a benign fashion, but about 5% show evidence of malignant behavior in the form of metastatic disease, particularly to lymph nodes, lung, and liver.[339,340] Malignant Leydig cell tumors occur exclusively in adults, are usually unaccompanied by endocrine changes, are larger than the benign variety (average size, 7.5 cm), are more commonly infiltrative, and tend to exhibit necrosis, blood vessel invasion, nuclear atypia, numerous mitoses (>3 mitoses per 10 high-power fields), and lack of lipochrome pigment.[341] Sarcomatoid (spindle cell) changes can be present in

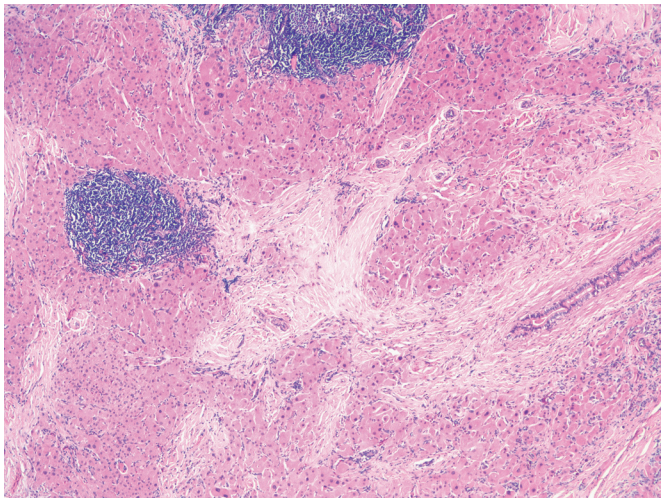

Figure 27.43 "Testicular Tumor" of the Adrenogenital Syndrome. Multiple nodules are present, divided by fibrous septa.

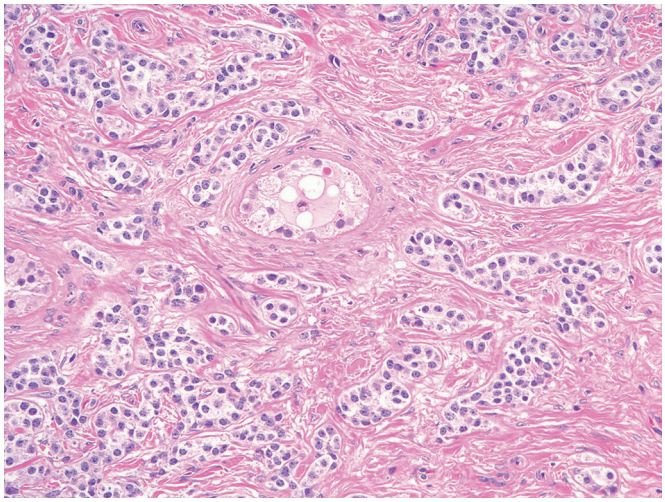

Figure 27.44 Microscopic appearance of Sertoli cell tumor, not otherwise specified.

the metastatic foci.[342] Metastasizing Leydig cell tumors have a higher MIB-1 index and a much higher incidence of aneuploidy than their nonmetastasizing counterparts.[343,344]

Leydig cell tumors are usually treated with simple orchiectomy. Malignant tumors may need retroperitoneal node dissection.

The differential diagnosis of Leydig cell tumor includes the following conditions:

1. Nodular Leydig cell hyperplasia, as seen in cryptorchid testes and other conditions. These lesions are typically smaller, often in a background of increased interstitial Leydig cells. Macroscopic Sertoli nodules are described, but are distinguished by their associated basement membrane material and tubules with fetal-type Sertoli cells and spermatogonia.[345a]
2. Large cell calcifying Sertoli cell tumor, which may have a component with a Leydig cell–like appearance (described later).
3. Testicular "tumor" of the adrenogenital syndrome. This perhaps constitutes the most important and difficult differential diagnosis. This lesion is usually discovered during early adult life as a palpable mass; examples in children tend to be smaller and found incidentally. The adrenogenital syndrome is of the "salt-forming type" in two-thirds of cases. The testicular masses are usually bilateral and located at the hilum. Grossly, they are well-circumscribed, brown–green masses that are separated into lobules by prominent fibrous bands.[345] Microscopically, there are sheets, nests, and cords of cells with abundant eosinophilic cytoplasm broken up by bands of fibrosis (Fig. 27.43); these cells often contain more prominent lipochrome pigment, and Reinke crystalloids are absent. Bilaterality of the lesions, associated clinical and laboratory features, and therapeutic response (decrease in size after corticosteroid therapy) are the most important features distinguishing these lesions—which may represent nodular hyperplasias of ectopic adrenal cortical cells rather than true neoplasms—from Leydig cell tumors.[345,346] Immunophenotypic studies suggest that expression of synaptophysin and lack of nuclear androgen receptor staining favor a tumor of adrenogenital syndrome, but novel markers such as DLK1 (FA1) may be more specific.[347–350]
4. Yolk sac tumor. This is true for the cases of Leydig cell tumors exhibiting a prominent microcystic pattern of growth.[322]

Tumors and Tumorlike Conditions of Sertoli Cells

Sertoli cell tumors and tumorlike conditions form a complex and poorly understood group of proliferative disorders composed of cells with morphologic features of Sertoli cells or related specialized gonadal stromal cells.[351]

Areas of Sertoli cell hyperplasia (also known as hypoplastic tubules, dysgenetic zones, tubular adenomas, and Sertoli cell nodules) are seen in half of patients with cryptorchid testes. However, they have also been found in 20% of non-neoplastic testes in patients with testicular tumors[352] and in about the same proportion in an autopsy study of scrotal, otherwise normal testes; the frequency of these foci decreases with age.[353] Exceptionally, these nodules have been reported within the epididymis rather than in the testis.[354]

Sertoli cell adenomas are not uncommon in patients with the testicular feminization (androgen insensitivity) syndrome.[355–357] Microscopically, they are composed of elongated tubules lined by Sertoli-like cells.

Sertoli cell tumors (not otherwise specified [NOS]) arise in the descended testis of normal individuals and are sometimes associated with gynecomastia.[358–360] Grossly, the tumors are well circumscribed, white or yellow, and firm, with focal cystic areas. Microscopically, the diagnostic feature is the presence of cord-like or tubular formations lined by elongated cells having the appearance of Sertoli cells (Fig. 27.44). In other areas, the tumor is solid and can be confused with seminoma (Fig. 27.45). The cytoplasm is moderate to abundant, with a pale to intense eosinophilic quality. Lipid vacuoles are present in some cases.[360] Exceptionally, Sertoli cell tumors are accompanied by a heterologous sarcomatous component.[361] Immunohistochemically, Sertoli cell tumors typically show reactivity for keratin, SF-1, CD99, calretinin, melan A, and WT1 but are negative for PLAP and CD117 (c-KIT).[331–334,362,363] Inhibin is positive in only 50% of tumors, while nuclear β-catenin is expressed in 60%–70%.[337,364]

About one-tenth of Sertoli cell tumors behave in a malignant fashion, the most common site of metastatic involvement being the iliac and para-aortic lymph nodes.[365] Features that should raise the suspicion of malignancy in Sertoli cell tumors include mitotic figures, pleomorphism, large tumor size, and necrosis, particularly when occurring together.[360] Parenthetically, misinterpretation of a Sertoli cell tumor as seminoma is more likely to occur in these malignant forms.[366] The treatment of Sertoli cell tumor is orchiectomy. Surgical excision of metastatic lesions—when present—is recommended, inasmuch as radiation therapy and chemotherapy have not proved particularly effective.[367]

Sclerosing Sertoli cell tumor represents a morphologic pattern within the spectrum of Sertoli cell tumor, NOS.[368] Grossly, they tend to be

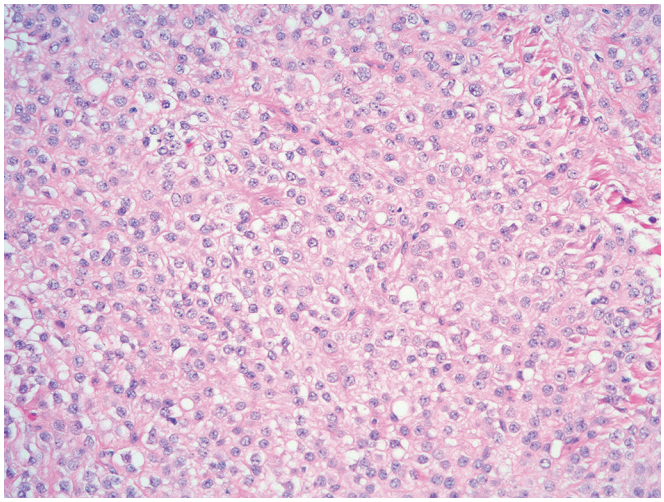

Figure 27.45 Sertoli cell tumor, NOS with solid growth, which may mimic seminoma.

Figure 27.47 Gross Appearance of Large Cell Calcifying Sertoli Cell Tumor of Testis. The tumor is distinctly multinodular. The dark nodules had a prominent component of Leydig cells.

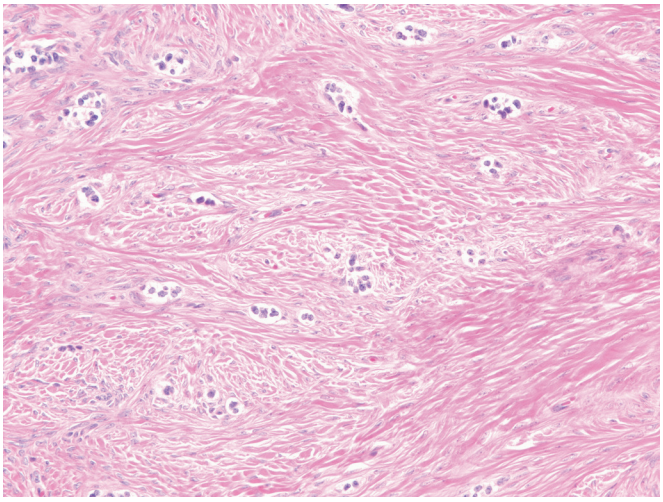

Figure 27.46 Sclerosing Sertoli Cell Tumor.

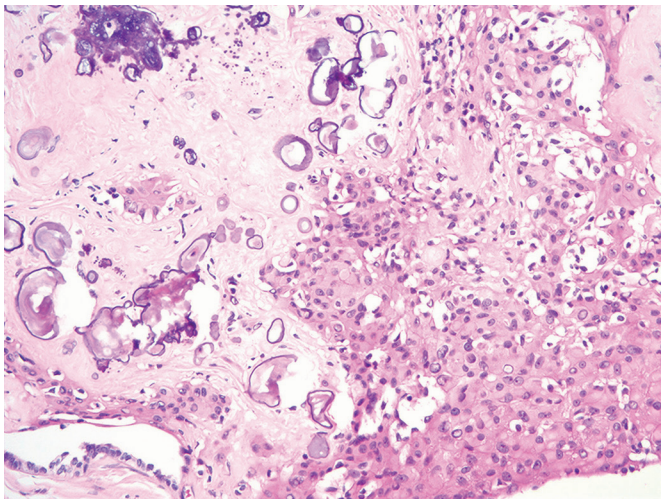

Figure 27.48 Large Cell Calcifying Sertoli Cell Tumor.

small, well demarcated, hard, and yellow–white to tan. Microscopically, they are formed of simple and anastomosing cords and rare tubules within a prominent densely sclerotic acellular stroma that, by definition, comprises greater than 50% of the tumor (Fig. 27.46).[368] Sclerosing Sertoli cell tumor was previously separated as distinct variant, but the shared *CTNNB1* mutation with non-sclerotic forms support a single subtype of diverse morphology; however, documentation of this pattern is recommend because it seems to have a lower metastatic rate when strictly defined.[369]

Large cell calcifying Sertoli cell tumor is usually seen in patients under 20 years of age and is often part of the Carney complex, which may also include testicular Leydig cell tumors, pituitary tumors, pigmented nodular hyperplasia of the adrenal cortex, cardiac myxomas, spotty pigmentation of skin, and other abnormalities; however, 60% are sporadic.[370,371] Both syndromic and non-syndromic forms may have a *PRKAR1A* mutation.[372] Bilaterality and multifocality are very common in syndromic forms, but sporadic tumors are commonly unilateral and unifocal (Fig. 27.47). Microscopically, this lesion is characterized by sheets, cords, and solid tubules of cells with abundant acidophilic cytoplasm, separated by abundant fibrous tissue that contains large areas of calcification (Fig. 27.48).[373] An intratubular component is commonly seen. Ultrastructurally, the features are those of Sertoli cells, including the presence of Charcot–Bottcher crystalloids.[374–376] Immunoreactivity for inhibin, S-100 protein, and SF-1 is common, while β-catenin expression is absent.[334,336,337,377] While most are benign, metastases do rarely occur and are often associated with large size, increased mitotic rate, extratesticular spread, necrosis, lymphovascular invasion, and more pronounced cytologic atypia.[378]

Another subtype, *intratubular large cell hyalinizing Sertoli cell neoplasia*, is seen in patients with the Peutz–Jeghers syndrome,[379–381] and are associated with germline *STK11* mutations.[382] These Sertoli cell proliferations typically present in prepubertal males with gynecomastia and they are often multicentric and bilateral. Histologically, randomly distributed seminiferous tubules are expanded by large Sertoli cells with bland cytologic features and pale eosinophilic cytoplasm, as well as associated globular deposits of eosinophilic basement membrane material (Fig. 27.49). In rare cases, an invasive component is present that has morphologic features resembling those of the Peutz–Jeghers syndrome associated ovarian tumor known as "sex-cord tumor with annular tubules." These tumors behave in a clinically benign fashion.

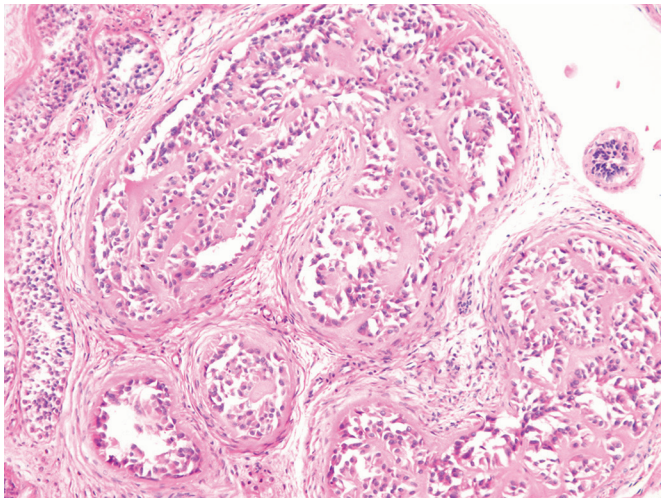

Figure 27.49 Intratubular hyalinizing Sertoli cell neoplasia may be seen in Peutz-Jeghers syndrome.

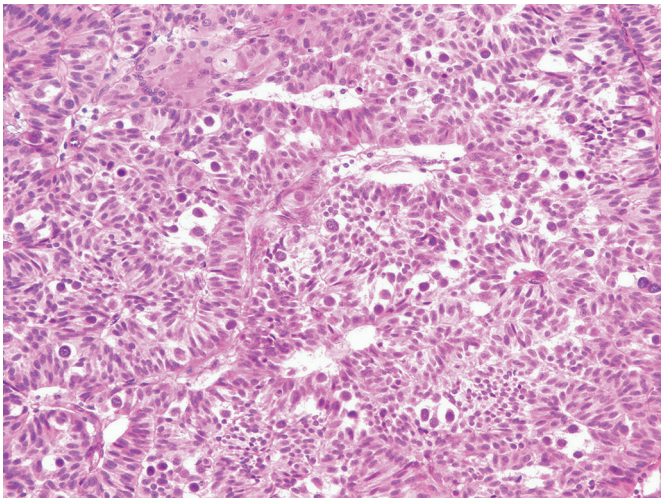

Figure 27.51 Rare mixed germ cell-sex cord-stromal tumor with Sertoli-like and spermatocytic tumorlike components. (Case courtesy of Dr. Michal Michal, Czech Republic.)

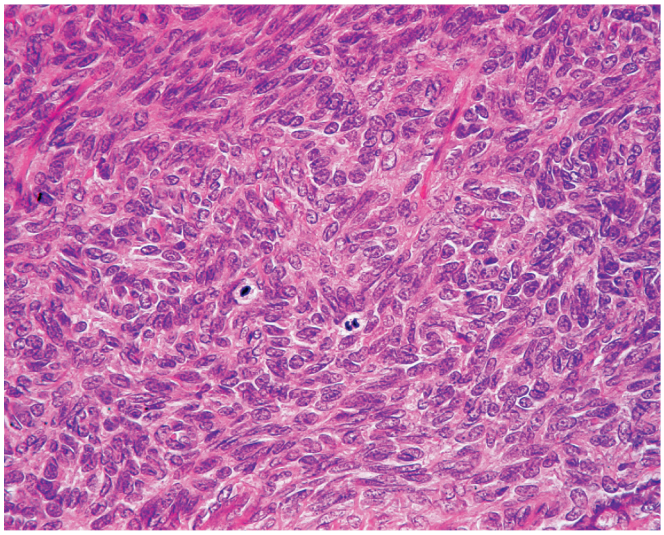

Figure 27.50 Adult form of granulosa cell tumor involving testis. Note the occasional longitudinal grooves, the oval to spindle shape of the tumor cells, and the high mitotic activity.

Other Sex Cord–Stromal Tumors

Some neoplasms belonging to this category have an appearance analogous to that of the adult or the juvenile forms of ovarian granulosa cell tumor.[383–386] The adult form, which is the more common, presents as a testicular mass without evidence of endocrine function, although isolated examples of gynecomastia are on record.[387] The pattern of growth may be admixtures of diffuse (most common), insular, spindled, trabecular, corded, "watered-silk," palisading, or pseudopapillary, as in the ovarian counterpart (Fig. 27.50).[386,388] Similarly, Call–Exner bodies may be present. Immunohistochemically, they are somewhat heterogeneous, but reactivity for inhibin, calretinin, Mart-1 (Melan-A), SF-1, S-100 protein, smooth muscle actin, CD99, FOXL2, and low-molecular-weight keratin (focal) is common, but not for EMA or nuclear β-catenin.[389] Metastases have occurred in about 10% of the reported cases and are more common in association with size greater than 4 cm, lymphovascular invasion, and infiltrative growth.[386,388]

The juvenile form is the most common testicular tumor in infants younger than 6 months of age and may even be congenital.[383,384,390–393] The morphology is identical to its ovarian counterpart and may closely mimic yolk sac tumor. SALL4 and glypican-3 are consistently negative, aiding in this distinction. The immunophenotype is similar to adult-type granulosa cell tumor. It is sometimes associated with cytogenetic abnormalities affecting the Y chromosome and with ambiguous genitalia.[394,395] Some of the tumors have developed in undescended testes.

Fibroma-thecoma of gonadal stromal origin with an appearance similar to that of its vastly more common ovarian counterpart can also occur in the testis.[396,397] Some of these tumors are grossly yellow–white, that is, akin to ovarian fibrothecomas. Still others are analogous to ovarian fibroma with minor sex-cord elements.[398] These tumors are clinically benign, even when increased mitotic activity is present.

Signet ring stromal tumor, an entity well known in the ovary, has now been also described in the testis.[399,400] A recent series of 13 cases suggests a close relationship to pancreatic solid pseudopapillary neoplasm, including *CTNNB1* mutations.[401] A novel tumor called myoid gonadal stromal tumor was also recently described.[402] Finally, mixed or unclassified forms of testicular sex cord–stromal neoplasia may also rarely occur.

Mixed Germ Cell–Sex Cord–Stromal Tumors

The better-known member of this group is gonadoblastoma, a tumor that arises nearly always in individuals with an underlying gonadal disorder, either pure or mixed gonadal dysgenesis, or male pseudohermaphroditism,[403] and which is fully discussed in Chapter 35. Only extraordinarily rare cases have developed in the testis of phenotypically and karyotypically normal males.[404]

One should be careful not to misinterpret sex cord–stromal tumors of the testis with entrapped germ cells as evidence of a mixed germ cell–sex cord–stromal tumor.[405] However, rare mixed germ cell–sex cord–stromal tumors with a morphology different from gonadoblastoma, as described by Talerman, also exist.[406,407] These consist of a sex cord–stromal component with either a granulosa cell tumor or Sertoli cell tumor appearance, intimately admixed with scattered cells showing histologic and immunophenotypic features of spermatocytic tumor (Fig. 27.51). After personally reviewing the cases published by Michal and colleagues, we agree that the distribution of the germ cells and their invasion into hilar tissues argue for the

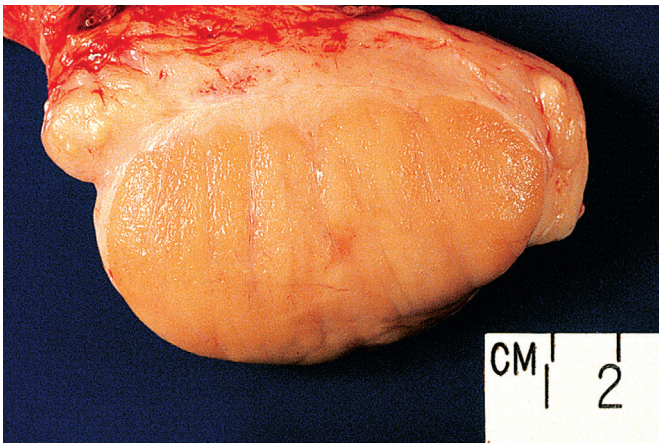

Figure 27.52 Gross appearance of malignant lymphoma of large cell type, which completely replaces the testis.

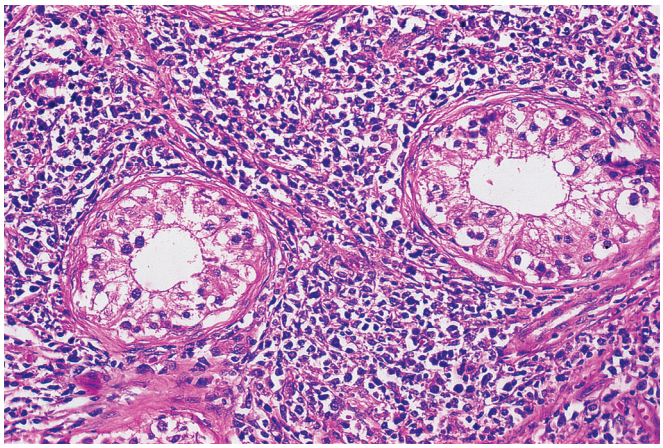

Figure 27.53 Malignant Lymphoma of Testis. There is diffuse infiltration of the interstitium by neoplastic lymphocytes, which surround and separate atrophic tubules.

existence of a distinct mixed lineage neoplasm.[407] To date, this rare tumor has followed a benign clinical course.

Malignant Lymphoma and Related Tumors

Malignant lymphoma comprises 5% of all testicular malignancies. It is the most common testicular tumor in elderly persons, but it can occur in any age group, including children.[408] It has a much greater tendency for bilaterality than germ cell tumors; as a matter of fact, about 50% of cases of bilateral testicular tumors are malignant lymphomas.[409]

Nearly all cases are of non-Hodgkin type. By far the most common variety is diffuse large B-cell lymphoma, but small lymphocytic lymphoma, follicular lymphoma (see later), anaplastic large cell lymphoma (including the neutrophil-rich variety of the latter), NK/T-cell lymphoma, and intravascular (angiotropic) lymphoma also occur.[410–416]

Grossly, large cell lymphoma results in a solid homogeneous replacement of the testicular parenchyma not too dissimilar from that of seminoma (Fig. 27.52). Microscopically, there is a predominantly interstitial proliferation of large tumor cells that surrounds and infiltrates the seminiferous tubules (Fig. 27.53).[417] The presence of scattered malignant cells within the tubular epithelium should not be confused with intratubular germ cell neoplasia. There is a high incidence of vascular invasion.[418] Testicular lymphomas are sometimes misdiagnosed as spermatocytic tumor or "anaplastic" seminoma, and anaplastic large cell lymphomas may be misinterpreted as embryonal carcinoma (Fig. 27.54).[414] Immunohistochemical (and, if needed, molecular) evaluation should establish the correct diagnosis without much difficulty.[419] Phenotypically, most testicular large B-cell lymphomas belong to the nongerminal center B-cell–like subgroup.[420] Immunophenotypically, one must be aware of OCT3/4 and SALL4 expression in a subset of diffuse large B cell lymphomas.[289] CD30 and EMA expression in anaplastic large cell lymphoma, which may overlap with embryonal carcinoma, is more commonly recognized.

Diffuse large cell lymphoma of the testis is treated with orchiectomy and chemotherapy, sometimes combined with radiation therapy.[421] Nearly half of the patients are found to have systemic disease at the time of diagnosis and their prognosis is poor.[422,423] A high proportion of relapses occur in the CNS or contralateral testis.[421,423,424]

Follicular lymphoma has been rarely described in the testis and epididymis both in adults and children. In contrast to conventional follicular lymphomas, the tumor is often localized and *BCL2* gene rearrangement is lacking. It typically runs a clinically indolent course.[425]

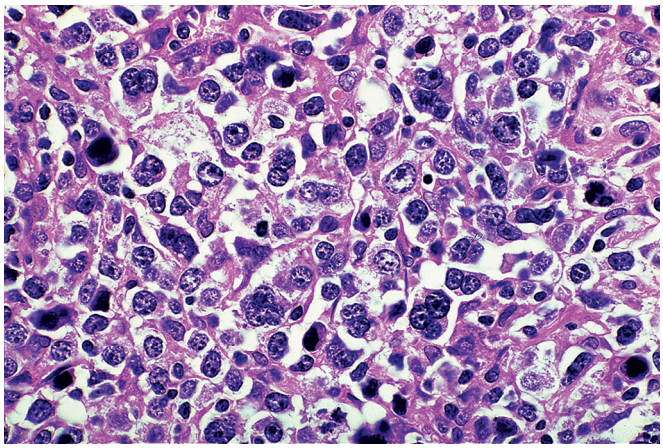

Figure 27.54 Cases of large B-cell lymphoma with pleomorphic features such as that depicted in this photograph can be misdiagnosed as seminoma, spermatocytic tumor, or embryonal carcinoma.

Plasmacytoma of testis may be seen as a manifestation of multiple myeloma or as an isolated lesion.[426] The latter is by far the most common situation, even if the testicular involvement may be the first clinical manifestation of the disease.[427,428]

Leukemic involvement of the testis is more commonly seen with lymphocytic leukemia, but it also may occur in the myeloid types.[429] It is not uncommon for the latter ("myeloid sarcoma") to be initially misdiagnosed as large cell lymphoma.[430,431] Children with acute lymphocytic leukemia develop clinical evidence of testicular involvement in about 8% of cases,[432] but the microscopic rate of involvement is over 20%.[433] Often the testis represents the first sign of relapse after bone marrow remission.[434] Assistance for the identification of residual disease can be obtained by the use of specific immunohistochemical markers.[435]

Other Primary Tumors

A spectrum of vascular malformations and neoplasms may involve the testis and paratestis,[436,437] and these should be distinguished from adenomatoid tumor.[438,439] A unique vascular lesion with predilection

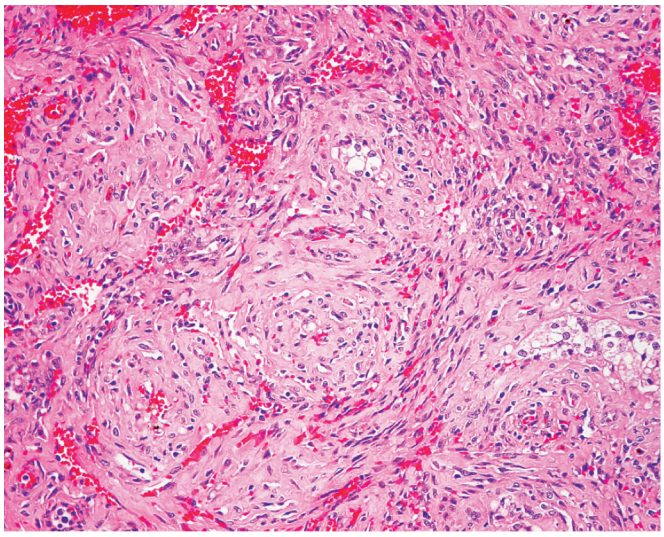

Figure 27.55 Kaposi sarcoma of the testis in an HIV-infected individual.

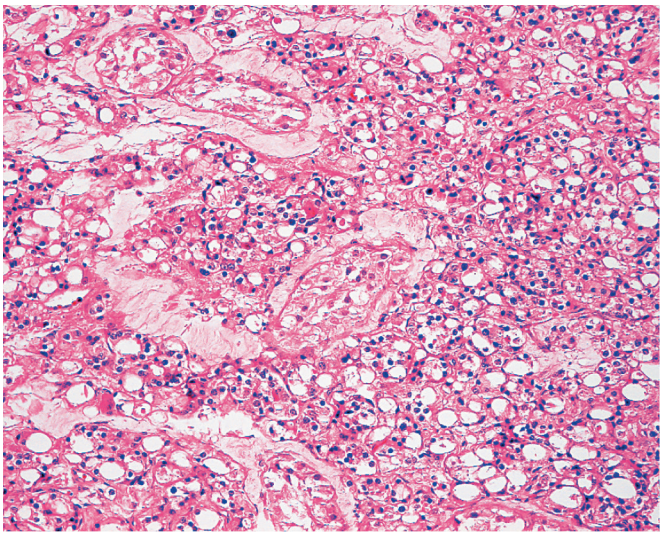

Figure 27.57 Prostatic Adenocarcinoma Metastatic to Testis. This not too rare occurrence is sometimes misdiagnosed as sex cord–stromal tumor.

Figure 27.56 Malignant Melanoma Metastatic to Testis. The black color of the tumor is due to massive melanin deposition.

for the testis (and kidney) has been described as "anastomosing hemangioma."[437,440] These tumors have a lobular architecture and consist of anastomosing sinusoidal capillary–sized vessels with a lining endothelial layer showing scattered hobnail arrangement.

Juvenile xanthogranuloma and myofibroma can present as intratesticular masses in children.[441–443]

Lipomatosis of the testicle has been documented by ultrasound and biopsy in individuals affected by Cowden syndrome.[444]

Primary sarcoma of the testis is rare, both in children and in adults. Cases of fibrosarcoma, leiomyosarcoma, Kaposi sarcoma, angiosarcoma, adenosarcoma, and Ewing sarcoma have been reported (Fig. 27.55).[445–449] In the presence of a tumor of sarcomatous appearance involving the testis, the possibility of a somatic-type malignancy in a germ cell tumor, a sarcomatous transformation of a spermatocytic seminoma, or a Sertoli cell tumor should be entertained (see corresponding sections).

Metastatic Tumors

Metastatic tumors in the testicle are most commonly from the lung, prostate, kidney, stomach, or skin (melanoma) (Fig. 27.56).[450–455] It is very rare for them to be the first clinical sign of disease.[452,456] When this is the case, the tumors tend to be unilateral and solitary, thus mimicking the presentation of a primary tumor.[186] Historically, the testicular metastases originating in the prostate have usually been incidental findings in orchiectomy specimens performed for hormonal ablation (Fig. 27.57).[457]

The microscopic diagnosis is usually easy, but sometimes the tumor simulates the appearance of a primary sex cord–stromal tumor, particularly Leydig cell tumor. The presence of conspicuous intrarete or intratubular growth can also be confusing.[186] Secondary prostatic carcinoma in the testis appears to be associated with a better prognosis than secondary prostatic carcinoma in the penis.[458] Metastatic Merkel cell tumors to the testis can be confused with malignant lymphoma.[459] Metastatic signet ring carcinoma from the gastrointestinal tract may acquire features analogous to those of ovarian Krukenberg tumor.[460]

In children, the testis can be involved by metastatic neuroblastoma from the adrenal or other sites.[461,462]

Testicular Adnexa

Normal Anatomy

The rete testis, located at the hilum of the testis, has a complex tubular architecture (particularly when undergoing reactive hyperplastic changes).[4,463] It receives the luminal contents of the seminiferous tubules and is divided into three components: septal, mediastinal or tunical, and extratesticular (bullae retis).[4] The rete testis empties into the ductuli efferentes, which consist of 12–15 tubules aggregated in the region of the head of the epididymis; they are lined by pseudostratified ciliated and nonciliated epithelium.[4,464,465]

The epididymis is a tubular structure connecting the ductuli efferentes to the vas deferens and is composed anatomically of three portions: head (caput), body (corpus), and tail (cauda).[4] The epididymal epithelium is composed of tall columnar (principal) cells; narrow, darker-staining columnar cells; basal cells; and clear cells. "Monstrous" pleomorphic epithelial cells similar to those commonly found in the seminal vesicles can be seen in the epididymis and should not be confused with a malignant process.[466,467] Prominent cilia are present in the tall columnar cells.[468] These cells may feature variously sized intranuclear eosinophilic periodic acid–Schiff (PAS)-positive inclusions, similar to those also found in the vas deferens

and seminal vesicles. They may also exhibit bright eosinophilic intracytoplasmic granules and globules, resulting in a Paneth cell–like appearance, which may also be seen in the ductuli efferentes.[464,469]

The vas deferens is a 30–40 cm tubular structure arising from the caudal portion of the epididymis. The distal portion joins the excretory duct of the seminal vesicle to form the ejaculatory duct, emptying into the prostatic urethra at the level of the verumontanum. The vas is lined by pseudostratified epithelium composed of ciliated columnar and basal cells.[4,470] Prominent intranuclear inclusions may be seen.[471] The muscle coat, which is extremely thick, is composed of inner and outer longitudinal coats and a middle oblique or circular zone.

Four small testicular appendages of vestigial nature exist.[4] Of these the most constant is the appendix testis or hydatid of Morgagni, which represents a remnant of the cranial portion of the müllerian duct. It is a round or oval, sessile or pedunculated, 1- to 10-mm structure attached to the tunica albuginea at the upper pole of the testis. The other appendages are the appendix epididymis (a remnant of the cranial portion of the mesonephric duct), the vas aberrans or organ of Haller (a remnant of mesonephric tubules), and the paradidymis or organ of Giraldes (also a remnant of mesonephric tubules).

Immunophenotypically, the adult excretory system has similar findings throughout its course.[472] The epithelium of the rete testis, ductus efferentes, epididymis, and vas deferens all typically express PAX-8, PAX-2, AR, and CK7.[472,473] The adult rete testis is unique in its reactivity for WT1 and calretinin. Immunoreactivity for CD10 in the epithelium of both the vas deferens and testicular/epididymal appendages has been used to support a wolffian (mesonephric) derivation.[474,475]

Rete Testis

Non-Neoplastic Lesions

Rete testis dysgenesis is a constant accompanying feature of cryptorchid testicles. Morphologically, it is characterized by underdevelopment of the rete, which is lined by columnar or large cuboidal cells.[476]

Calcifying nodules can be seen protruding into the rete testis channels; these probably represent dystrophic changes and are of no clinical significance.[477] They are different from the microlithiasis that can be seen in the rete testis, epididymis, and efferent ducts in an intraluminal, subepithelial (most frequent), or interstitial location.[478]

Cystic dilation (transformation) of the rete testis can occur as a result of obstruction of the epididymis or of the intratesticular excretory ducts secondary to varicocele.[479,480] Other cases have been seen in the absence of obstruction in patients with renal failure treated with hemodialysis,[481] sometimes associated with deposits of calcium oxalate crystals.[482] There may be an accompanying smooth muscle hyperplasia.[483]

Rete testis–associated steroid cell nests are described as nodules of eosinophilic cells growing in cords within or adjacent to the rete testis that are distinct from adnexal Leydig cells.[484]

Hyperplasia of rete testis (or adenomatous hyperplasia) may be confused with a malignant neoplasm. It may present in adult patients with a grossly evident solid or cystic mass in the testicular hilum. More commonly, the lesion is very small and detected as an incidental microscopic finding. Microscopically, there is a tubulopapillary and occasionally cribriform proliferation of rete testis epithelium with bland cytologic features.[485] Some cases of rete testis hyperplasia are accompanied by the deposition of hyaline globules, simulating the appearance of yolk sac tumor.[486] Immunohistochemically, there is reactivity for keratin and EMA, while actin, desmin, and S-100 protein are negative.[487] The behavior has been benign in all reported cases. The pathogenesis is unknown; in cases associated with germ cell tumor of the testis, it may represent a reaction to the invasion by the latter.[486]

Neoplasms

Very rare benign tumors of the rete testis now described under the term "adenoma" are likely all related and have been described as cystadenoma, benign papillary tumor, and adenofibroma of the rete testis. A unique subset sometimes exhibits sertoliform features and expresses inhibin, the "sertoliform cystadenoma."[479,488]

Adenocarcinoma of the rete testis is a very rare neoplasm, which may be difficult to distinguish from malignant mesothelioma of the tunica vaginalis.[489,490] Some of these tumors have a distinctly papillary appearance, while others are more tubuloglandular or consist of irregular anastomosing "retiform" glandular patterns.[491] Intratubular invasion of the testis may occur.[492] Cases have been described with a spindle cell (metaplastic) component,[493] and others having focal sertoliform differentiation similar to that seen in rete cystadenoma.[494] Diagnostic criteria include: (1) involvement centered in the hilum of the testis, (2) no features of another specific testicular/paratesticular tumor subtype, (3) lack of any other primary tumor (i.e., exclusion of metastasis), and (4) immunohistochemical exclusion of mesothelioma and ovarian type carcinoma.[489,495] Transitions from carcinoma to benign rete epithelium have been suggested as a corroborating feature of a primary rete adenocarcinoma, but this pattern may be closely mimicked by metastatic carcinomas. Because of their extreme rarity, rete primary carcinomas seem to have a nonspecific immunophenotype based on the findings in very few cases. Mesothelioma commonly expresses WT1, CK5/6, and calretinin (while negative for B72.3 and BerEP4), while high-grade serous type carcinomas are also often WT1 positive and have abnormal p53 staining patterns. Rete testis carcinomas may express PAX-8 (overlapping with gynecologic type carcinomas),[473] and their reactivity patterns with mesothelial markers are not fully evaluated. As noted, benign rete epithelium often expresses both WT1 and calretinin.

Secondary involvement of the rete testis by testicular germ cell tumors may occur in the form of pagetoid spread.[496] This relatively common event (particularly with seminoma) should not be confused with a primary tumor of the rete tetsis.[497]

Epididymis

Non-Neoplastic Lesions

Nonspecific epididymitis may be caused by *Neisseria gonorrhoeae*, *Chlamydia trachomatis*, *E. coli*, or other organisms (Fig. 27.58). It may lead to testicular necrosis secondary to hypoperfusion caused by ischemia.[498] Chlamydial epididymitis is mainly proliferative, whereas bacterial epididymitis tends to be destructive and abscess forming.[499]

Tuberculosis of the epididymis may result in confluent caseation of this organ, as described by Auerbach in his classic work on urogenital tuberculosis.[500] When extensive, the infection can spread into the testis and clinically simulate a malignant tumor.[501] The source of infection may be hematogenous or through the prostate, the former being the more common. When the infection is hematogenous, the process begins in the epididymal interstitial tissue and preferentially involves the head, often with sparing of the vas deferens. When it originates in the prostate, there is involvement of the tail of the epididymis and the vas.

Fungal infections that can involve the epididymis include coccidioidomycosis[502] and histoplasmosis.[503]

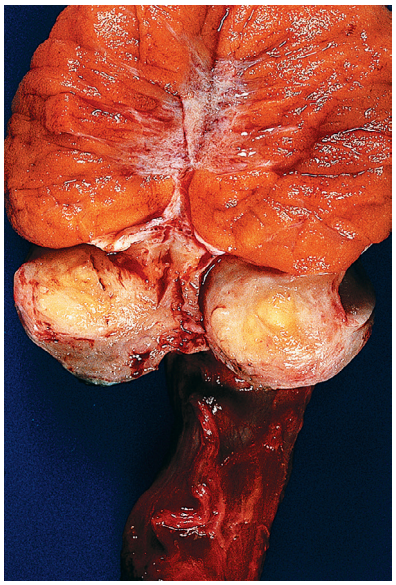

Figure 27.58 Acute and Chronic Epididymitis. The inflammation has not spread to the testicle.

Figure 27.59 Granulomatous Epididymitis With Focal Extension Into the Testis. Some of the granulomas have a necrotic center. No microorganisms were identified on special stains.

Granulomatous ischemic lesion is the term proposed by Nistal et al.[504] for a granulomatous process involving the head of the epididymis accompanied by partial necrosis of the ductal wall, which they interpreted as having a probable ischemic pathogenesis.[504]

Spermatic granuloma of the epididymis (epididymitis nodosa) presents grossly as a nodule measuring up to 3 cm in diameter, most often located in the head. Microscopically, a granulomatous reaction is seen around collections of spermatozoa. This lesion is thought to result from damage to the epithelium and basement membrane of epididymal ducts by inflammation or trauma,[505] with the subsequent spillage of sperm into the interstitium that elicits a granulomatous response.

Idiopathic granulomatous epididymitis is a diagnosis of exclusion, which is justified for cases of granulomatous inflammation lacking features that would place it in any of the specific categories mentioned in this section (Fig. 27.59).[506] Obviously, infection, germ cell tumor with granulomatous response, and vasculitis must be excluded. Necrotizing vasculitis can occur in the epididymis as an isolated finding or as a manifestation of a systemic disease; since there are no apparent morphologic differences between the two forms, clinical evaluation and follow-up of these patients are indicated.[507–509] The most common forms of systemic vasculitis are polyarteritis nodosum and "granulomatosis with polyangiitis (Wegener's)."[509]

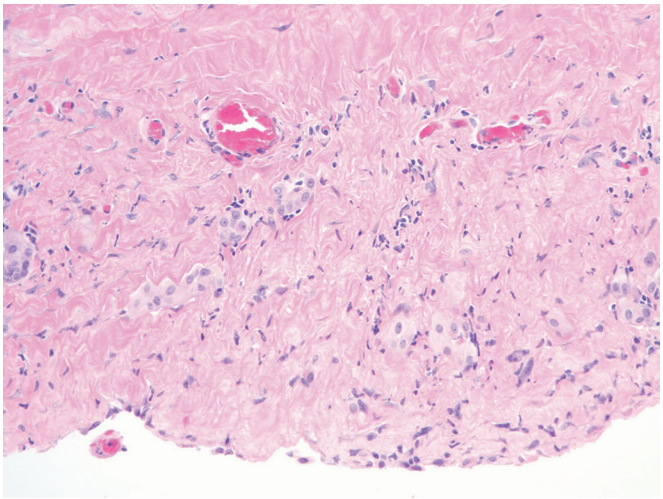

Figure 27.60 Reactive mesothelial cells in the fibrous wall of a hydrocele, mimicking a neoplasm.

Spermatocele represents a cystic dilation of efferent ducts, with their lumina filled with masses of sperm. The cysts are lined by ciliated tall columnar cells, and the wall is made up of loose connective tissue rather than smooth muscle. Secondary changes, such as cholesterol clefts and foreign body giant cell reaction, are common.

Cribriform hyperplasia of the epididymis has a pattern reminiscent of cribriform atypical ductal hyperplasia of the breast. Lack of mitotic activity or well-established marked cytologic atypia argues against carcinoma. Some degree of cytologic atypia, often with large pleomorphic, multinucleated cells, is common and should not be interpreted as malignancy. It is apparently not associated with adenomatous hyperplasia of the rete testis.[467,510]

A variety of nonspecific, non-neoplastic tumoral reactions, likely unrelated to inflammatory myofibroblastic tumor, have been described in the paratestis under various names including inflammatory pseudotumor, pseudosarcomatous myofibroblastic proliferation, fibrous pseudotumor, fibromatous periorchitis, and nodular periorchitis.[511] These have varied cellularity depending on the ratio of myofibroblasts to dense collagen; calcifications may be present. It is important to carefully exclude de-differentiated liposarcoma before diagnosing a non-neoplastic process in the paratestis, as some examples may have myofibroblastic features.[512]

Finally, hydrocele repair specimens are fairly common. While they typically consist of fibrous tissue with nonspecific chronic inflammation, occasional cases contain histologic features that may simulate a neoplastic process, including hyperplastic mesothelial cells (Fig. 27.60), florid nodular collections of histiocytes, and peculiar aggregates of incidental benign small blue cells of proposed sloughed rete epithelial origin (Fig. 27.61).[513–515]

Tumors

Adenomatoid Tumor and Mesothelioma

Adenomatoid tumor, a benign mesothelial tumor, is the most common neoplasm of the epididymis, typically occurring in patients

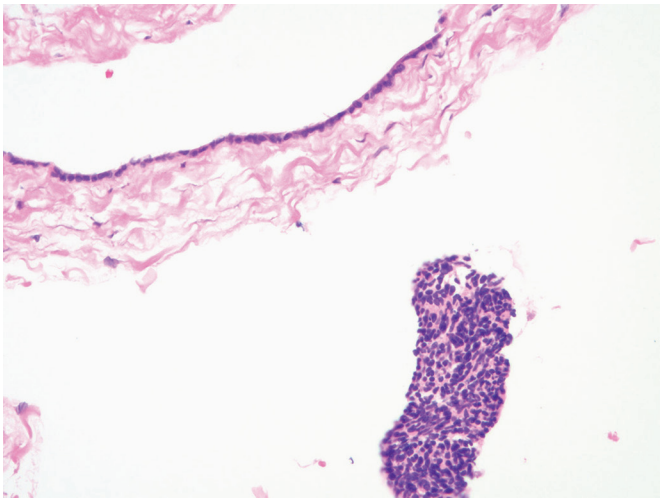

Figure 27.61 Spermatoceles or hydroceles rarely contain aggregates of small blue cells, likely of rete testis origin. They are of no clinical importance.

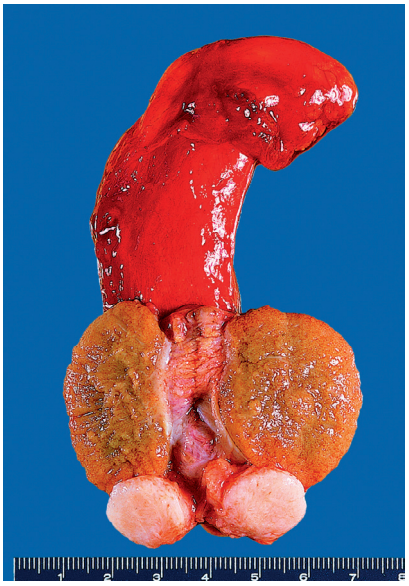

Figure 27.62 Typical gross appearance of adenomatoid tumor of epididymis.

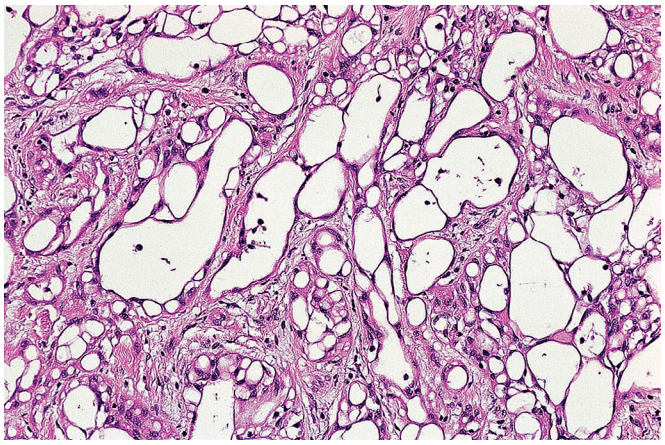

Figure 27.63 Adenomatoid tumor, showing typical conglomerate of cystically dilated spaces lined by cuboidal cells, whereas others are lined by flattened cells with the appearance of endothelial cells.

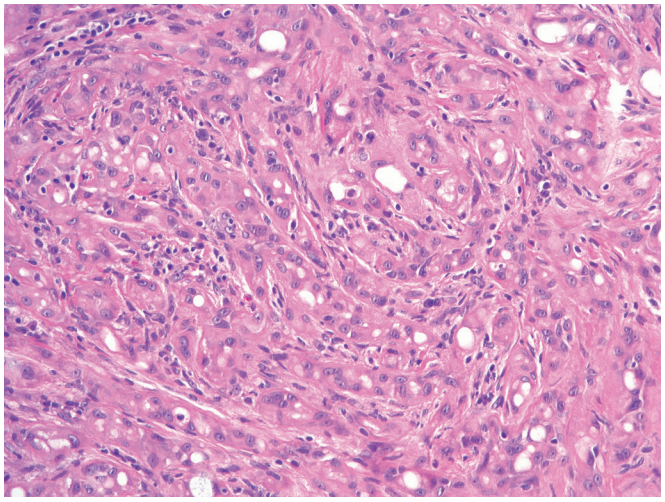

Figure 27.64 Adenomatoid Tumor With Epithelioid Features.

in the third or fourth decade of life.[516] This tumor also occurs in the testicular spermatic cord and ejaculatory duct in males and in the fallopian tube and uterus in females.[517–519] It presents clinically as a mass, sometimes associated with pain. Grossly, it appears as a small (average size, 2 cm), solid, firm, gray-white nodule and occasionally containing small cysts (Fig. 27.62). Microscopically, the lesion is unencapsulated and poorly circumscribed (in contrast with its female counterpart), and on rare occasions it may extend to the adjacent testis. There is a proliferation of cells ranging from cuboidal to flattened, which form solid cords with an epithelial appearance alternating with channels having dilated lumina simulating vascular structures (Fig. 27.63). The tumor cells may exhibit prominent cytoplasmic vacuolization. Tubular areas often have an atrophic lining and distinctive thread-like strands crossing the luminal space are common.[518] Examples with an oncocytic and epithelioid appearance may mimic carcinoma, mesothelioma, a vascular neoplasm, or a sex cord–stromal tumor (Fig. 27.64). The prominent intervening stroma may contain abundant smooth muscle and elastic fibers[520]; it may also have a reactive desmoplastic quality and be infiltrated by inflammatory cells. Rare cases may have extensive infarct-type necrosis with associated reactive atypia.[521] The behavior of adenomatoid tumor is invariably benign, even when extending into the testis.

Immunocytochemically, there is strong reactivity for pan-keratin, calretinin, D2-40, and WT1, while negative for CEA (Fig. 27.65).[517–519]

Adenomatoid tumor should be distinguished from true vascular tumors, which can also occur in this area. As expected, endothelial tumors are typically immunoreactive for ERG, CD34, and CD31; however, they may also coexpress keratin.

Mesothelioma of the usual type has also been described in this region, arising from the tunica vaginalis testis (Fig. 27.66).[522–525] Most cases are malignant, similar to those seen in the peritoneal cavity and—like them—occasionally associated with asbestos exposure.[526–528] They exhibit a wide age range of occurrence (with occasional examples in children), a wide differentiation spectrum, and a generally aggressive behavior (with potential for late recurrence or metastasis).[522,529,530] Like their more common counterparts in the

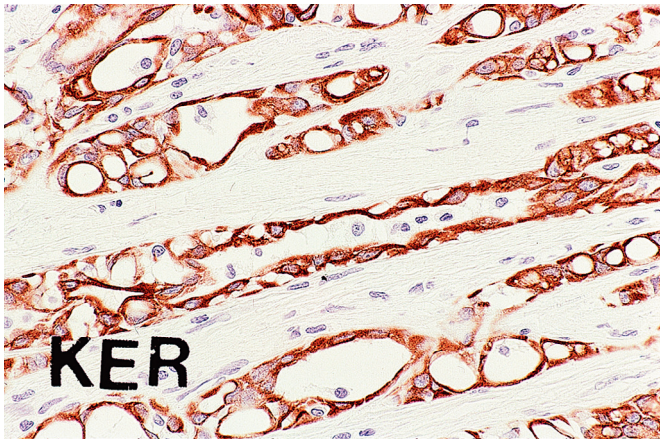

Figure 27.65 Adenomatoid Tumor With Typical Keratin Reactivity.

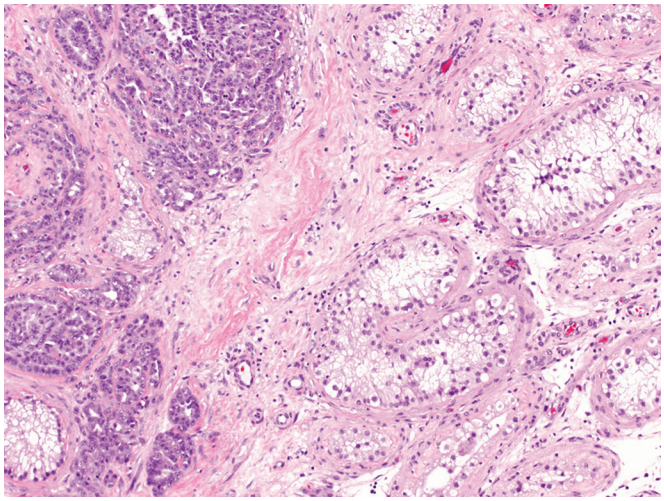

Figure 27.66 Mesothelioma infiltrating the testis with a tubular architecture.

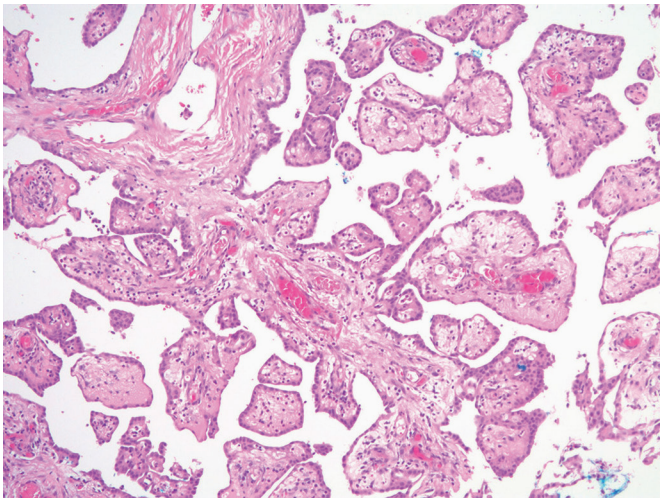

Figure 27.67 Well-differentiated papillary mesothelioma with a single, cytologically bland lining of cuboidal mesothelial cells.

Figure 27.68 Bilateral Clear Cell Papillary Cystadenoma.

main abdominal cavity and in the pleura, they are immunoreactive for pan-keratin, calretinin, D2-40, and CK7 and negative for CK20 and CEA.[525] Sarcomatoid mesotheliomas, which mimic a variety of spindle cell lesions, may also occur.

The classification of small localized low-grade papillary mesothelial lesions is problematic. Well-differentiated papillary mesotheliomas are similar to those described in the peritoneum of women.[531] In men, they are often found unexpectedly in a "hydrocele sac."[532,533] The diagnosis should be restricted to cases with papillae and tubules lined by a single layer of cytologically bland cuboidal to flattened mesothelial cells (Fig. 27.67). They often have little mitotic activity, and no invasion should be present. While long-term follow-up for such cases is limited, they seem to follow a much less aggressive course than typical mesothelioma (when diagnosed under these strict criteria).

Other Tumors and Tumorlike Conditions

(Clear cell) papillary cystadenoma of the epididymis may be unilateral or bilateral and exhibits a familial incidence.[534] It is regarded as the epididymal component of von Hippel–Lindau (VHL) disease and is often seen with other manifestations of the disease, especially when bilateral. Grossly, it measures 1–5 cm and is well circumscribed, either cystic or solid (Fig. 27.68). Microscopically, papillary infoldings lined by columnar cells with abundant clear cytoplasm are the distinctive feature (Fig. 27.69).[535] Immunohistochemically, they are reactive for pankeratin, keratin 7, and PAX-8.[536] It has been noted that the histology and immunophenotype of papillary cystadenoma of the epididymis, including the cup-like pattern of CA9 expression, are identical to the clear-cell papillary subtype of renal cell carcinoma.[537] Because patients with VHL disease may present with concomitant clear cell papillary cystadenoma of the epididymis and clear cell renal cell carcinoma of the kidney, distinction from metastasis is important; strong and diffuse CK7 expression would support clear cell papillary cystadenoma.[538] Allelic deletion of the VHL gene has been detected in these tumors,[539] as well as expression of vascular endothelial growth factor.[540]

Carcinoma of the epididymis is an extremely rare lesion; it has the microscopic appearance of either adenocarcinoma (more commonly) or undifferentiated carcinoma and is associated with a poor prognosis.[541] The pattern of growth of the adenocarcinoma can be

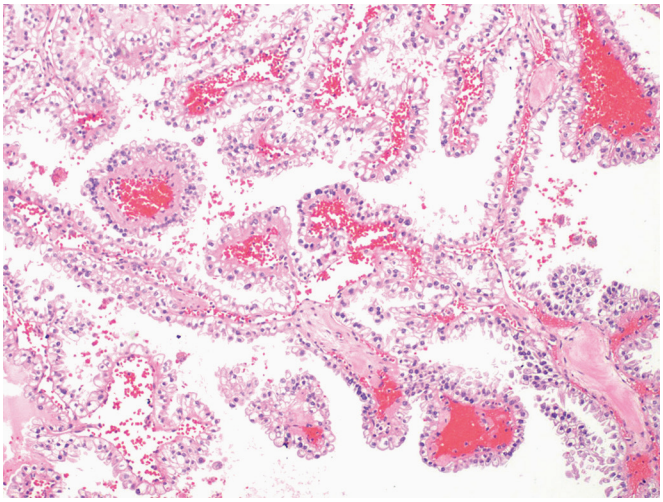

Figure 27.69 Clear cell papillary cystadenoma has a mixed papillary and tubular architecture with a lining of bland clear cells.

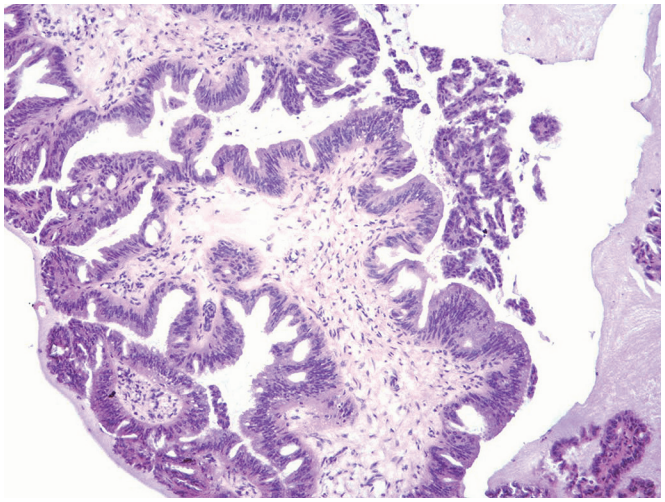

Figure 27.71 Müllerian type borderline tumor of the paratestis.

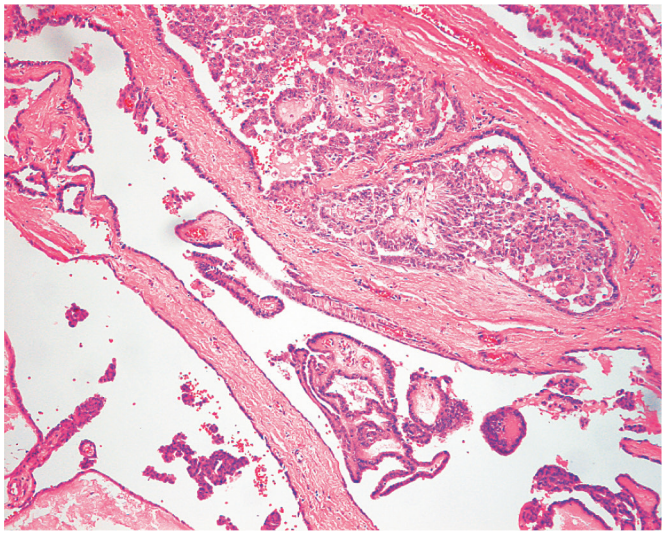

Figure 27.70 A rare adenocarcinoma of the epididymis.

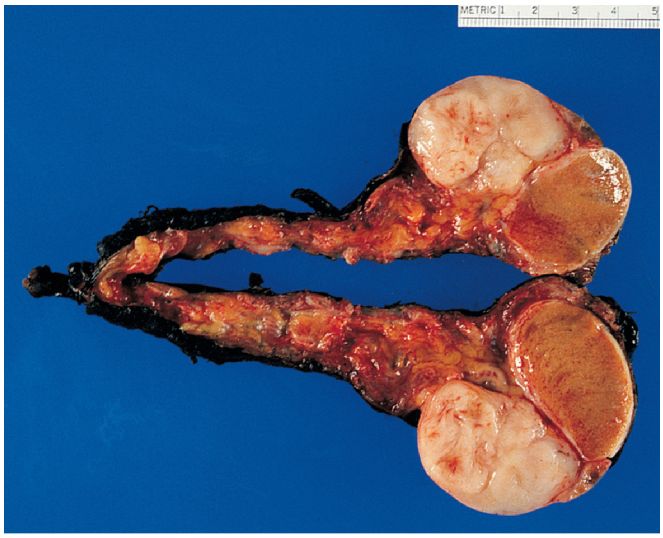

Figure 27.72 Leiomyosarcoma of the paratestis.

tubular, tubulocystic, or tubulopapillary, and there is often a conspicuous component of clear cells (Fig. 27.70).[542] Rare tumors combine epididymal-like cells and mucin-producing cells.[543]

Ovarian tumors of surface epithelial type, including serous, mucinous, endometrioid, clear cell, and Brenner varieties, may occur in the paratesticular region but are extremely rare.[544–547] They may be unilateral or bilateral.[548] Most have benign or borderline features (Fig. 27.71), but some have the appearance of serous carcinoma and can result in nodal and distant metastases.[549,550] The similarities with surface epithelial tumors of the female genital tract includes the expression of estrogen and progesterone receptors.[551] Another example of the analogy between the male and female genital tracts is provided by the isolated examples of endometriosis-like lesions in the paratesticular region of males treated with estrogens.[547]

Other tumors of this region include leiomyoma and leiomyosarcoma (Fig. 27.72),[552,553] hemangioma,[554] lymphangioma,[555] rhabdomyoma,[556] pigmented neuroectodermal tumor of infancy,[557] malignant lymphoma,[558,559] and plasmacytoma.[427] In some cases of the latter, the epididymal involvement represents the first clinical manifestation of the disease.[427]

Secondary tumors, in the majority of instances, represent a direct extension from testicular lesions. Prostate, lung, and kidney account for most of the others.[560]

Pseudotumors centered in the epididymis and composed of reactive myofibroblasts may be encountered in children after testicular torsion.[561] In children, an additional benign paratesticular lesion includes meconium periorchitis, which is related to in uteri bowel perforation, and may mimic a myxoid neoplasm (Fig. 27.73). It consists of mucin, heterotopic calcification, and fibrosis, and fetal squamous cells may also be present.[562]

Spermatic Cord

Torsion of the spermatic cord, if not treated promptly, may result in testicular infarct. Most cases occur in the first year of life, with a second peak toward puberty.[563] In 64% of the cases, the torsion is located in the intravaginal portion of the cord.[564] The adipose tissue around the cord may undergo fat necrosis, sometimes of the so-called lipomembranous type.[565] The treatment varies from untwisting of the torsion and fixation of the testis to orchiectomy, depending on

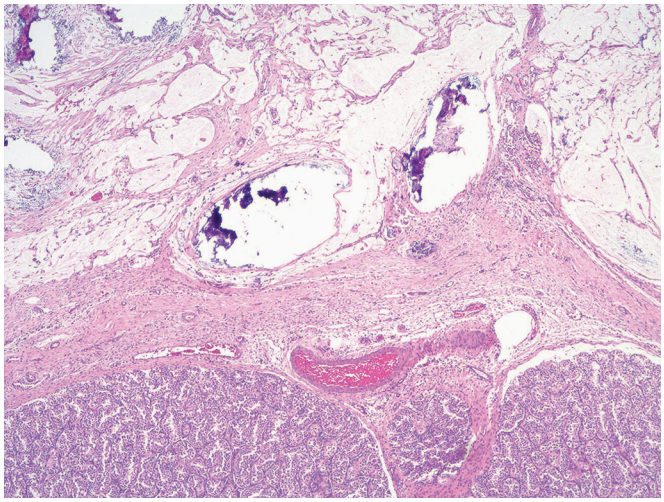

Figure 27.73 Meconium periorchitis in a child with cystic fibrosis.

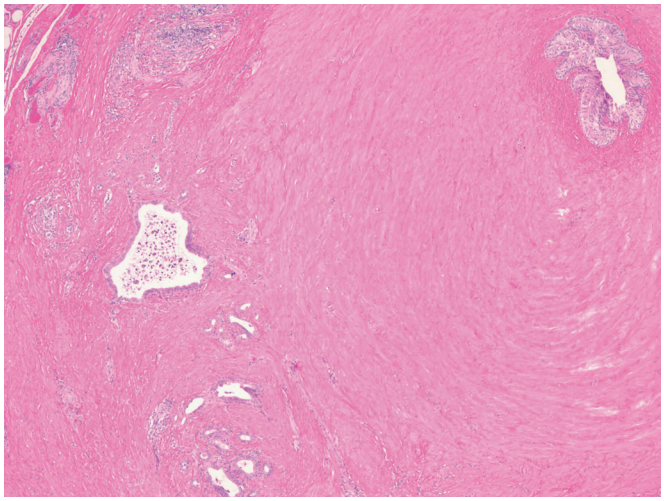

Figure 27.74 Vasitis nodosa with benign proliferating ductules deep in the wall of the vas deferens.

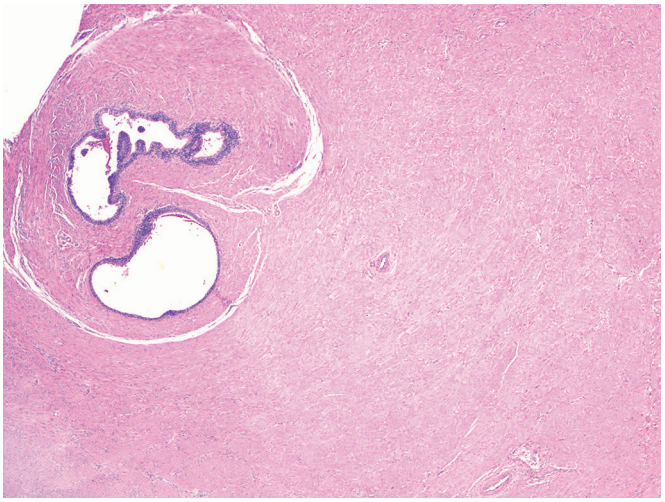

Figure 27.75 Smooth muscle hyperplasia of the testicular adnexa with dense sheets of benign smooth muscle cells encasing normal structures.

the viability of the testis as determined at surgery. Whatever procedure is carried out, the opposite testis should be fixed to the dartos musculature as a preventive measure.

The differential diagnosis of torsion of the spermatic cord includes torsion of a testicular appendage, a condition that results in a dramatic clinical picture out of proportion with the minute size and significance of this structure.[566,567] The appendix testis, a vestigial structure of müllerian derivation, is the one most often involved (92%). Parenthetically, tumors arising from this structure have been described.[568]

Giant cell vasculitis has been reported as an isolated event in the spermatic cord and presenting as a mass lesion.[569]

Vasitis nodosa is a granulomatous condition of the vas that resembles spermatic granuloma of the epididymis.[570] Most of the reported cases have appeared after vasectomy or herniorrhaphy.[571] The presence of proliferating ductules with a disorganized intramural location and perineural invasion may be found and should not be interpreted as a sign of malignancy (Fig. 27.74).[572]

Proliferative funiculitis is the name given to a pseudosarcomatous myofibroblastic proliferation of the spermatic cord.[573] Most of the reported cases have been incidental findings at inguinal herniorrhaphy. The microscopic appearance is similar to that of nodular fasciitis as seen in soft tissue. The pathogenesis is probably ischemic, sometimes resulting from torsion. These lesions are in all likelihood analogous to those sometimes seen under similar circumstances within the substance of the epididymis (see previous section).

Smooth muscle hyperplasia of testicular adnexa presents as a localized increase in mature smooth muscle of the spermatic cord or paratestis growing between or around vessels or efferent ducts (Fig. 27.75).[574] It can reach a diameter of 7 cm and may have an obstructive etiology.

Primary tumors of the spermatic cord can be of many types. Because of the intimate anatomic connection of the spermatic cord with the scrotum and the tunica vaginalis testis, it is often impossible to decide from which of these anatomic compartments these tumors have arisen. This is particularly true when the tumors in question are large, as is often the case. Indeed, one gets the impression that tumors are assigned into spermatic cord, tunica vaginalis, scrotal, epididymal, and paratesticular categories on a very arbitrary basis.[575,576] From a topographic and surgical standpoint, it would perhaps be more appropriate to simply divide them into those of the scrotum and those of the inguinal canal, without attributing them to a particular anatomic structure unless the gross and microscopic features of the case allow this to be done. In any event, the most common tumor of this region is the lipoma.[577] It is surrounded by tunica vaginalis and derives its blood supply from the vessels of the cord. The nodular collections of mature fatty tissue often seen in front of a hernia sac are not true lipomas.

The family of genital stromal tumors, identical to those in the vulvovaginal region, may also be seen in the paratestis, including cellular angiofibroma, aggressive angiomyxoma, and mammary-type myofibroblastoma. Nomenclature for these tumors has evolved over time, creating some confusion, but most neoplasms reported as "angiomyofibroblastoma-like tumor of the male genital tract" would now be classified as cellular angiofibroma.[578,579] These tumors are typically well circumscribed and consist of short, cytologically bland spindle cells set within a collagenous stroma and associated with variable thick-walled hyalinized blood vessels (Fig. 27.76). The cells show variable immunoreactivity for CD34 and smooth muscle actin, with less frequent staining for desmin; in addition, they harbor 13q rearrangements with *RB1* deletion/loss.[580] Aggressive angiomyxoma (deep angiomyxoma) may rarely occur in the spermatic cord or scrotum.[581] Compared to cellular angiofibroma, these lesions are

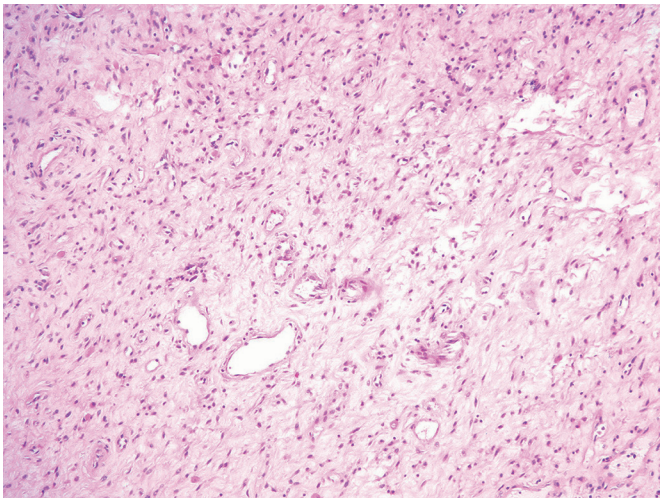

Figure 27.76 Cellular angiofibroma of the inguinal canal.

less cellular and have a more myxoid background, but associated blood vessels are variable. Additionally, aggressive angiomyxoma is often more infiltrative. Immunophenotypically there is varying expression of actin, CD34, and desmin. These lesions, which may recur locally, are characterized by *HMGA2* gene rearrangement on 12q14.3.[582] Protein expression of HMAG2 by immunohistochemistry is a sensitive marker of aggressive angiomyxoma, but is not specific as it is also expressed in smooth muscle tumors, adipocytic tumors, nodular fasciitis, and benign fibrous histiocytoma.[583,584] Mammary-type myofibroblastoma may also occur in the inguinal/spermatic cord or paratesticular region. Like their breast counterpart, these may have morphologic features very similar to a cellular spindle cell lipoma; however, they typically have rather diffuse expression of desmin. Similar to cellular angiofibroma, they have *RB1* deletion/loss.[585] Local recurrence is rare for both cellular angiofibroma and mammary-type myofibroblastoma. Rare cases of cellular angiofibroma show cytologic atypia or sarcomatous transformation, but these changes have not been associated with an aggressive course.[586] Neoplasms fitting the current strict definition of angiomyofibroblastoma are not well-documented at this site.

Papillary cystadenoma of the spermatic cord may present as an inguinal mass.[587] The morphologic resemblance it bears with borderline ovarian serous tumors suggests a müllerian derivation.[588]

Other reported primary tumors of this region include hemangioma, lymphangioma, leiomyoma, rhabdomyoma, solitary fibrous tumor, desmoid fibromatosis, fibrous hamartoma of infancy, and paraganglioma.[581,589–594]

The most common malignant tumor of this region in children is embryonal rhabdomyosarcoma, but the rare spindle cell/sclerosing variant may also occur.[553,595] In children and young adults, desmoplastic small round cell tumor should always be considered before a diagnosis of carcinoma is rendered.[596]

In adults, well-differentiated liposarcoma (atypical lipomatous tumor) or de-differentiated liposarcoma predominate, but cases of leiomyosarcoma, fibrosarcoma, epithelioid hemangioendothelioma, and undifferentiated pleomorphic sarcoma also occur.[597–602]

The standard treatment for the sarcomas occurring in adults consists of orchiectomy with high ligation of the cord.[603] Since local recurrence is very common after this procedure, the administration of postoperative radiation therapy has been advocated.[604,605]

Secondary involvement of the spermatic cord by testicular germ cell tumors may occur as a result of direct extension or vascular invasion. It is important to distinguish this prognostically significant finding from contamination induced at the time of the gross dissection, which is common. The latter occurrence, which is particularly common with seminoma (probably because of its very friable nature), can be minimized with meticulous handling and processing, specifically by taking spermatic cord sections prior to dissection of the main testis mass.[606]

References

1. Charny CW, Conston AS, Meranze DR. Development of the testis. *Fertil Steril*. 1952;3:461-479.
2. Vilar O. Histology of the human testis from neonatal period to adolescence. *Adv Exp Med Biol*. 1970;10:95-111.
3. Handelsman DJ, Stara S. Testicular size. The effects of aging, malnutrition, and illness. *J Androl*. 1985;6:144-151.
4. Trainer TD. Testis and excretory duct system. In: Mills SE, ed. *Histology for Pathologists*. 3rd ed. Philadelphia: Lippincott Williams & Wilkins; 2007.
5. Dym M. Spermatogonial stem cells of the testis [commentary]. *Proc Natl Acad Sci USA*. 1994;91:11287-11289.
6. Schulze W, Riemer M, Rehder U, Hohne K. Computer-aided three-dimensional reconstructions of the arrangement of primary spermatocytes in human seminiferous tubules. *Cell Tissue Res*. 1986;244:1-8.
7. Silber SJ, Rodriguez-Rigau LJ. Quantitative analysis of testicular biopsy. Determination of partial obstruction and prediction of sperm count after surgery for obstruction. *Fertil Steril*. 1981;36:480-485.
8. Rogatsch H, Jezek D, Hittmair A, et al. Expression of vimentin, cytokeratin, and desmin in Sertoli cells of human fetal, cryptorchid, and tumor-adjacent testicular tissue. *Virchows Arch*. 1996;427:497-502.
9. Schulze C. Sertoli cells and Leydig cells in man. *Adv Anat Embryol Cell Biol*. 1984;88:1-104.
10. Callaghan P. Undescended testis. *Pediatr Rev*. 2000;21:395.
11. Gill B, Kogan S. Cryptorchidism. Current concepts. *Pediatr Clin North Am*. 1997;44:1211-1227.
12. Rajfer J, Handelsman DJ, Swerdloff RS, et al. Hormonal therapy of cryptorchidism. A randomized, double-blind study comparing human chorionic gonadotropin and gonadotropin-releasing hormone. *N Engl J Med*. 1986;314:466-470.
13. Gross RE, Jewett TC Jr. Surgical experiences from 1,222 operations for undescended testis. *JAMA*. 1956;160:634-641.
14. Jordan GH. Laparoscopic management of the undescended testicle. *Urol Clin North Am*. 2001;28:23-29.
15. Fonkalsrud EW. Current concepts in the management of the undescended testis. *Surg Clin North Am*. 1970;50:847-852.
16. Nistal M, Paniagua R, Diez-Pardo JA. Histologic classification of undescended testes. *Hum Pathol*. 1980;11:666-674.
17. Mori H, Tamai M, Fushimi H, et al. Leydig cells within the aspermatogenic seminiferous tubules. *Hum Pathol*. 1987;18:1227-1231.
18. Mengel W, Hienz HA, Sippe WG II, Hecker WC. Studies on cryptorchidism. A comparison of histological findings in the germinative epithelium before and after the second year of life. *J Pediatr Surg*. 1974;9:445-450.
19. Lipschultz LI, Caminos-Torres R, Greenspan CS, Snyder PJ. Testicular function after orchiopexy for unilaterally undescended testis. *N Engl J Med*. 1976;295:15-18.
20. Gilbert JB, Hamilton JB. Studies in malignant testis tumors. *Surg Gynecol Obstet*. 1940;71:731-743.
21. Batata MA, Chu FCH, Hilaris BS, et al. Testicular cancer in cryptorchids. *Cancer*. 1982;49:1023-1030.
22. Batata MA, Whitmore WF Jr, Chu FCH, et al. Cryptorchidism and testicular cancer. *J Urol*. 1980;124:382-387.
23. Campbell HE. The incidence of malignant growth of the undescended testicle. A reply and re-evaluation. *J Urol*. 1959;81:663-668.
24. Palmer JM. The undescended testicle. *Endocrinol Metab Clin North Am*. 1991;20:231-240.
25. Hinman F Jr. The implications of testicular cytology in the treatment of cryptorchidism. *Am J Surg*. 1955;90:381-386.
26. Dow JA, Mostofi FK. Testicular tumors following orchiopexy. *South Med J*. 1967;60:193-195.
27. Pettersson A, Richiardi L, Nordenskjold A, et al. Age at surgery for undescended testis and risk of testicular cancer. *N Engl J Med*. 2007;356:1835-1841.

28. Fonkalsrud EW. Current management of the undescended testis. *Semin Pediatr Surg*. 1996;5:2-7.
29. Gall EA. The histopathology of acute mumps orchitis. *Am J Pathol*. 1947;23:637-652.
30. Bennett HS, Baggenstoss AH, Butt HR. The testis and prostate of men who die of cirrhosis of the liver. *Am J Clin Pathol*. 1950;20:814-828.
31. Smith JA Jr, Urry RL. Testicular histology after prolonged treatment with a gonadotropin-releasing hormone analogue. *J Urol*. 1985;133:612-614.
32. Fairley KF, Barrie JU, Johnson W. Sterility and testicular atrophy related to cyclophosphamide therapy. *Lancet*. 1972;1:568-569.
33. Lendon M, Hann IM, Palmer MK, et al. Testicular histology after combination chemotherapy in childhood for acute lymphoblastic leukaemia. *Lancet*. 1978;2:439-441.
34. Spires SE, Woolums CS, Pulito AR, Spires SM. Testicular regression syndrome: a clinical and pathologic study of 11 cases. *Arch Pathol Lab Med*. 2000;124:694-698.
35. Schned AR, Cendron M. Pathologic findings in the vanishing testis syndrome. *J Urol Pathol*. 1997;6:95-108.
36. Smith NM, Byard RW, Bourne AJ. Testicular regression syndrome—a pathological study of 77 cases. *Histopathology*. 1991;19:269-272.
37. De Paepe ME, Waxman M. Testicular atrophy in AIDS. A study of 57 autopsy cases. *Hum Pathol*. 1989;20:210-214.
38. Yoshikawa Y, Truong LD, Fraire AE, Kim HS. The spectrum of histopathology of the testis in acquired immunodeficiency syndrome. *Mod Pathol*. 1989;2:233-238.
39. Jarow JP, Budin RE, Dym M, et al. Quantitative pathologic changes in the human testis after vasectomy. A controlled study. *N Engl J Med*. 1985;313:1252-1256.
40. Schlegel PN. Evaluation of male infertility. *Minerva Ginecol*. 2009;61:261-283.
41. Wong TW, Straus FH II, Warner NE. Testicular biopsy in the study of male infertility. I. Testicular causes of infertility. *Arch Pathol*. 1973;95:151-159.
42. Wong TW, Straus FH II, Warner NE. Testicular biopsy in the study of male infertility. II. Posttesticular causes of infertility. *Arch Pathol*. 1973;95:160-164.
43. Wong TW, Straus FH II, Warner NE. Testicular biopsy in the study of male infertility. III. Pretesticular causes of infertility. *Arch Pathol*. 1974;98:1-8.
44. Handelman DJ, Conway AJ, Boylan LM, Turtle JR. Young's syndrome. Obstructive azoospermia and chronic sinopulmonary infections. *N Engl J Med*. 1984;310:3-9.
45. Lehmann D, Temminck B, Da Rugna D, et al. Role of immunological factors in male infertility. Immunohistochemical and serological evidence. *Lab Invest*. 1987;57:21-28.
46. Cerilli LA, Kuang W, Rogers D. A practical approach to testicular biopsy interpretation for male infertility. *Arch Pathol Lab Med*. 2010;134:1197-1204.
47. Fisch H, Lipshultz LI. Diagnosing male factors of infertility. *Arch Pathol Lab Med*. 1992;116:398-405.
48. Federman DD. The assessment of organ function—the testis. *N Engl J Med*. 1971;285:901-904.
49. Levin HS. Testicular biopsy in the study of male infertility. Its current usefulness, histologic techniques, and prospects for the future. *Hum Pathol*. 1979;10:569-584.
50. Pesce CM. The testicular biopsy in the evaluation of male infertility. *Semin Diagn Pathol*. 1987;4:264-274.
51. Piaton E, Fendler J-P, Berger N, et al. Clinical value of fine-needle aspiration cytology and biopsy in the evaluation of male infertility. A comparative study of 48 infertile patients. *Arch Pathol Lab Med*. 1995;119:722-726.
52. Rowley MJ, Heller CG. The testicular biopsy. Surgical procedure, fixation, and staining technics. *Fertil Steril*. 1966;17:177-186.
53. Meng MV, Cha I, Ljung BM, Turek PJ. Testicular fine-needle aspiration in infertile men: correlation of cytologic pattern with biopsy histology. *Am J Surg Pathol*. 2001;25:71-79.
54. Nelson WO. Testicular biopsy. In: Tyler ET, ed. *Sterility—Office Management of the Infertile Couple*. New York: McGraw-Hill; 1961.
55. Nistal M, Jimenez F, Paniagua R. Sertoli cell types in the Sertoli-cell-only syndrome. Relationships between Sertoli cell morphology and aetiology. *Histopathology*. 1990;16:173-180.
56. Söderström K-O, Suominen J. Histopathology and ultrastructure of meiotic arrest in human spermatogenesis. *Arch Pathol Lab Med*. 1980;104:476-482.
57. Jequier AM, Holmes SC. Aetiological factors in the production of obstructive azoospermia. *Br J Urol*. 1984;56:540-543.
58. Nistal M, Riestra ML, Galmes-Belmonte I, Paniagua R. Testicular biopsy in patients with obstructive azoospermia. *Am J Surg Pathol*. 1999;23:1546-1554.
59. Nistal M, Paniagua R, Riestra ML, et al. Bilateral prepubertal testicular biopsies predict significance of cryptorchidism-associated mixed testicular atrophy, and allow assessment of fertility. *Am J Surg Pathol*. 2007;31:1269-1276.
60. Sniffen RC. The testis. I. The normal testis. *Arch Pathol*. 1950;50:259-284.
61. Sniffen RC, Howard RP, Simmons FA. The testis. II. Abnormalities of spermatogenesis. Atresia of the excretory ducts. *Arch Pathol*. 1950;50:285-295.
62. Guarch R, Pesce C, Puras A, Lazaro J. A quantitative approach to the classification of hypospermatogenesis in testicular biopsies for infertility. *Hum Pathol*. 1992;23:1032-1037.
63. Schofield JB, Evans DJ. Multinucleate giant stromal cells in testicular atrophy following oestrogen therapy. *Histopathology*. 1990;16:200-201.
64. Girgis SM, Etriby A, Ibrahim AA, Kahil SA. Testicular biopsy in azoospermia. A review of the last ten years' experience of over 800 cases. *Fertil Steril*. 1969;20:467-477.
65. Durbin L, Hotchkiss RS. Testis biopsy in subfertile men with varicocele. *Fertil Steril*. 1969;20:50-57.
66. Landing BH, Wells TR, Wang C-I. Abnormality of the epididymis and vas deferens in cystic fibrosis. *Arch Pathol*. 1969;88:569-580.
67. Gordon DL, Krmpotic E, Thomas W, et al. Pathologic testicular findings in Klinefelter's syndrome. 47,XXY vs 46,XY–47,XXY. *Arch Intern Med*. 1972;130:726-729.
68. Jackson AW, Muldal S, Ockey CH, O'Connor PJ. Carcinoma of male breast in association with the Klinefelter syndrome. *BMJ*. 1965;1:223-225.
69. Dodge OG, Jackson AW, Muldal S. Breast cancer and interstitial cell tumor in a patient with Klinefelter's syndrome. *Cancer*. 1969;24:1027-1032.
70. Isurugi K, Imao S, Hirose K, Aoki H. Seminoma in Klinefelter's syndrome with 47,XXY, 15s+ karyotype. *Cancer*. 1977;39:2041-2047.
71. Sogge MR, McDonald SD, Cofold PB. The malignant potential of the dysgenetic germ cell in Klinefelter's syndrome. *Am J Med*. 1979;66:515-518.
72. Chu L, Averch TD, Jackman SV. Testicular infarction as a sequela of inguinal hernia repair. *Can J Urol*. 2009;16:4953-4954.
73. Palmer-Toy DE, McGovern F, Young RH. Granulomatous orchitis and vasculitis with testicular infarction complicating Crohn's disease: a hitherto undescribed tumor-like lesion of the testis. *J Urol Pathol*. 1999;11:143-150.
74. Kao CS, Zhang C, Ulbright TM. Testicular hemorrhage, necrosis, and vasculopathy: likely manifestations of intermittent torsion that clinically mimic a neoplasm. *Am J Surg Pathol*. 2014;38:34-44.
75. Braaten KM, Young RH, Ferry JA. Viral-type orchitis: a potential mimic of testicular neoplasia. *Am J Surg Pathol*. 2009;33:1477-1484.
76. Spjut HJ, Thorpe JD. Granulomatous orchitis. *Am J Clin Pathol*. 1956;26:136-145.
77. Nistal M, Iniguez L, Paniagua R. Cysts of the testicular parenchyma and tunica albuginea. *Arch Pathol Lab Med*. 1989;113:902-906.
78. Aitchison M, Mufti GR, Farrell J, et al. Granulomatous orchitis. Review of 15 cases. *Br J Urol*. 1990;66:312-314.
79. Wegner HE, Loy V, Dieckmann KP. Granulomatous orchitis—an analysis of clinical presentation, pathological anatomic features and possible etiologic factors. *Eur Urol*. 1994;26:56-60.
80. Diaz Gonzalez R, Leiva O, Navas Palacios JJ, et al. Testicular malacoplakia. *J Urol*. 1982;127:325-328.
81. Brown RC, Smith BH. Malacoplakia of the testis. *Am J Clin Pathol*. 1967;47:135-147.
82. Townell NH, Gledhill A, Robinson T, Hopewell P. Juvenile xanthogranuloma of the testis. *J Urol*. 1985;133:1054-1055.
83. Lossos IS, Okon E, Bogomolski-Yahalom V, et al. Sinus histiocytosis with massive lymphadenopathy (Rosai–Dorfman disease): report of a patient with isolated renotesticular involvement after cure of non-Hodgkin's lymphoma. *Ann Hematol*. 1997;74:41-44.
84. Nistal M, Gonzalez-Peramato P, Serrano A, Regadera J. Xanthogranulomatous funiculitis and orchiepididymitis: report of 2 cases with immunohistochemical study and literature review. *Arch Pathol Lab Med*. 2004;128: 911-914.
85. Yap RL, Jang TL, Gupta R, et al. Xanthogranulomatous orchitis. *Urology*. 2004;63:176-177.
86. Hourihane DO'B. Infected infarcts of the testis. A study of 18 cases preceded by pyogenic epididymoorchitis. *J Clin Pathol*. 1970;23:668-675.
87. Hepper NGG, Karlson AG, Leary FJ, Soule EH. Genitourinary infection due to Mycobacterium kansasii. *Mayo Clin Proc*. 1971;46:387-390.
88. Haas GP, Badalament R, Wonnell DM, Miles BJ. Testicular sarcoidosis. Case report and review of the literature. *J Urol*. 1986;135:1254-1256.
89. Akhtar M, Ali MA, Mackey DM. Lepromatous leprosy presenting as orchitis. *Am J Clin Pathol*. 1980;73:712-715.
90. Nistal M, Paniagua R. Inflammatory diseases of the epididymis and testis. In: Nistal M, Paniagua R, eds. *Testicular and Epididymal Pathology*. New York: Thieme-Stratton; 1984:263-277.
91. Coyne JD, Dervan PA. Multinucleated stromal giant cells of testis. *Histopathology*. 1997;31:381-383.
92. Natarajan V, Gaches CGC, Scott DGI, Ball RY. Isolated vasculitis of the testis: distinction from generalized polyarteritis nodosa. *J Urol Pathol*. 1996;4:167-174.
93. Shurbaji MS, Epstein JI. Testicular vasculitis. Implications for systemic disease. *Hum Pathol*. 1988;19:186-189.
94. Andrews RW, Copeland DD, Fried FA. Splenogonadal fusion. *J Urol*. 1985;133:1052-1053.
95. Mendez R, Morrow JW. Ectopic spleen simulating testicular tumor. *J Urol*. 1969;102:598-601.

96. Camassei FD, Francalanci P, Ferro F, et al. Cystic dysplasia of the rete testis: report of two cases and review of the literature. *Pediatr Dev Pathol*. 2002;5:206-210.
97. Glantz L, Hansen K, Caldamone A, Medeiros LJ. Cystic dysplasia of the testis. *Hum Pathol*. 1993;24:1142-1145.
98. Abbondanzo SL, Young VL, Wei MQ, Miller FW. Silicone gel-filled breast and testicular implant capsules: a histologic and immunophenotypic study. *Mod Pathol*. 1999;12:706-713.
99. Ulbright TM, Amin MB, Balzer B, et al. Germ cell tumors. In: Moch H, Humphrey PA, Ulbright TM, Reuter VE, eds. *WHO Classification of Tumours of the Urinary System and Male Genital Organs*. Lyon, France: IARC Press; 2016.
100. Mcglynn KA, Devesa SS, Sigurdson AJ, et al. Trends in the incidence of testicular germ cell tumors in the United States. *Cancer*. 2003;97:63-70.
101. Fuller DB, Plenk HP. Malignant germ cell tumors in a father and two sons. Case report and literature review. *Cancer*. 1986;58:955-958.
102. Goss PE, Bulbul MA. Familial testicular cancer in five members of a cancer-prone kindred. *Cancer*. 1990;66:2044-2046.
103. Patel SR, Kvols LK, Richardson RL. Familial testicular cancer. Report of six cases and review of the literature. *Mayo Clin Proc*. 1990;65:804-808.
104. Lutke Holzik MF, Sijmons RH, Sleijfer DT, et al. Syndromic aspects of testicular carcinoma. *Cancer*. 2003;97:984-992.
105. Czene K, Lichtenstein P, Hemminki K. Environmental and heritable causes of cancer among 9.6 million individuals in the Swedish Family-Cancer Database. *Int J Cancer*. 2002;99:260-266.
106. Chung CC, Kanetsky PA, Wang Z, et al. Meta-analysis identifies four new loci associated with testicular germ cell tumor. *Nat Genet*. 2013;45:680-685.
107. Greene MH, Mai PL, Loud JT, et al. Familial testicular germ cell tumors (FTGCT) - overview of a multidisciplinary etiologic study. *Andrology*. 2015;3:47-58.
108. Kanetsky PA, Mitra N, Vardhanabhuti S, et al. A second independent locus within DMRT1 is associated with testicular germ cell tumor susceptibility. *Hum Mol Genet*. 2011;20:3109-3117.
109. Kanetsky PA, Mitra N, Vardhanabhuti S, et al. Common variation in KITLG and at 5q31.3 predisposes to testicular germ cell cancer. *Nat Genet*. 2009;41:811-815.
110. Abell MR, Holtz F. Testicular and paratesticular neoplasms in patients 60 years of age and older. *Cancer*. 1968;21:852-870.
111. Berney DM, Warren AY, Verma M, et al. Malignant germ cell tumours in the elderly: a histopathological review of 50 cases in men aged 60 years or over. *Mod Pathol*. 2008;21:54-59.
112. Alvarado-Cabrero I, Hernández-Toriz N, Paner GP. Clinicopathologic analysis of choriocarcinoma as a pure or predominant component of germ cell tumor of the testis. *Am J Surg Pathol*. 2014;38:111-118.
113. Jiang F, Xiang Y, Feng FZ, et al. Clinical analysis of 13 males with primary choriocarcinoma and review of the literature. *Onco Targets Ther*. 2014;7:1135-1141.
114. Aristizabal S, Davis JR, Miller RC, et al. Bilateral primary germ cell testicular tumors. Report of four cases and review of the literature. *Cancer*. 1978;42:591-597.
115. Che M, Tamboli P, Ro JY, et al. Bilateral testicular germ cell tumors: twenty-year experience at M.D. Anderson Cancer Center. *Cancer*. 2002;95:1228-1233.
116. Kristainslund S, Fossa SD, Kjellevold K. Bilateral malignant testicular germ cell cancer. *Br J Urol*. 1986;58:60-63.
117. Patel SR, Richardson RL, Kvols L. Synchronous and metachronous bilateral testicular tumors. Mayo Clinic experience. *Cancer*. 1990;65:1-4.
118. Reinberg Y, Manivel JC, Zhang G, Reddy PK. Synchronous bilateral testicular germ cell tumors of different histologic type. Pathogenetic and practical implications of bilaterality in testicular germ cell tumors. *Cancer*. 1991;68:1082-1085.
119. Bosl GJ, Ilson DH, Rodriguez E, et al. Clinical relevance of the i(12p) marker chromosome in germ cell tumors. *J Natl Cancer Inst*. 1994;86:349-355.
120. Murty VV, Houldsworth J, Baldwin S, et al. Allelic deletions in the long arm of chromosome 12 identify sites of candidate tumor suppressor genes in male germ cell tumors. *Proc Natl Acad Sci USA*. 1992;89:11006-11010.
121. Reuter VE. Origins and molecular biology of testicular germ cell tumors. *Mod Pathol*. 2005;18(suppl 2):S51-S60.
122. Zafarana G, Gillis AJ, van Gurp RJ, et al. Coamplification of DAD-R, SOX5, and EKI1 in human testicular seminomas, with specific overexpression of DAD-R, correlates with reduced levels of apoptosis and earlier clinical manifestation. *Cancer Res*. 2002;62:1822-1831.
123. Korkola JE, Houldsworth J, Bosl GJ, Chaganti RS. Molecular events in germ cell tumours: linking chromosome-12 gain, acquisition of pluripotency and response to cisplatin. *BJU Int*. 2009;104(9 Pt B):1334-1338.
124. Looijenga LH, Gillis AJ, Stoop HJ, et al. Chromosomes and expression in human testicular germ-cell tumors: insight into their cell of origin and pathogenesis. *Ann N Y Acad Sci*. 2007;1120:187-214.
125. Rodriguez S, Jafer O, Goker H, et al. Expression profile of genes from 12p in testicular germ cell tumors of adolescents and adults associated with i(12p) and amplification at 12p11.2-p12.1. *Oncogene*. 2003;22:1880-1891.
126. Castedo SM, de Jong B, Oosterhuis JW, et al. Cytogenetic analysis of ten human seminomas. *Cancer Res*. 1989;49: 439-443.
127. Korn WM, Oide Weghuis DE, Suijkerbuijk RF, et al. Detection of chromosomal DNA gains and losses in testicular germ cell tumors by comparative genomic hybridization. *Genes Chromosomes Cancer*. 1996;17:78-87.
128. Mostert MM, van de Pol M, Olde Weghuis D, et al. Comparative genomic hybridization of germ cell tumors of the adult testis: confirmation of karyotypic findings and identification of a 12p-amplicon. *Cancer Genet Cytogenet*. 1996;89:146-152.
129. Ottesen AM, Kirchhoff M, De-Meyts ER, et al. Detection of chromosomal aberrations in seminomatous germ cell tumours using comparative genomic hybridization. *Genes Chromosomes Cancer*. 1997;20:412-418.
130. De Jong B, Oosterhuis JW, Castedo SMMJ, et al. Pathogenesis of adult testicular germ cell tumors. A cytogenetic model. *Cancer Genet Cytogenet*. 1990;48:143-167.
131. Korkola JE, Heck S, Olshen AB, et al. In vivo differentiation and genomic evolution in adult male germ cell tumors. *Genes Chromosomes Cancer*. 2008;47:43-55.
132. Oosterhuis JW, et al. Interphase cytogenetics of carcinoma in situ of the testis. Numeric analysis of the chromosomes 1, 12 and 15. *Eur Urol*. 1993;23:16-21.
133. McIntyre A, Gilbert D, Goddard N, et al. Genes, chromosomes and the development of testicular germ cell tumors of adolescents and adults. *Genes Chromosomes Cancer*. 2008;47:547-557.
134. McIntyre A, Summersgill B, Grygalewicz B, et al. Amplification and overexpression of the KIT gene is associated with progression in the seminoma subtype of testicular germ cell tumors of adolescents and adults. *Cancer Res*. 2005;65:8085-8089.
135. Kernek KM, Zhang S, Ulbright TM, et al. Identical allelic loss in mature teratoma and different histologic components of malignant mixed germ cell tumors of the testis [abstract]. *Mod Pathol*. 2003;16:157A.
136. van Echten J, Oosterhuis JW, Looijenga LHJ, et al. Mixed testicular germ cell tumors: monoclonal or polyclonal. *Mod Pathol*. 1996;9:371-374.
137. Yilmaz A, Cheng T, Elliott F, Trpkov K. How should hilar paratesticular soft tissue invasion be staged in germ cell tumors (GCT). *Lab Invest*. 2009;89:202A.
138. Dry SM, Renshaw AA. Extratesticular extension of germ cell tumors preferentially occurs at the hilum. *Am J Clin Pathol*. 1999;111:534-538.
139. Brimo F, Srigley JR, Ryan CJ, et al. Testis. In: Amin MB, ed. *AJCC Staging Manual*. 8th ed. New York: Springer; 2017.
140. Donohue JP, Zachary JM, Maynard BR. Distribution of nodal metastases in nonseminomatous testis cancer. *J Urol*. 1982;128:315-320.
141. Ray B, Hajdu SI, Whitmore WF Jr. Distribution of retroperitoneal lymph node metastases in testicular germinal tumors. *Cancer*. 1974;33:340-348.
142. Klein FA, Whitmore WF Jr, Sogani PC, et al. Inguinal lymph node metastases from germ cell testicular tumors. *J Urol*. 1984;131:497-500.
143. Raina V, Singh SP, Kamble N, et al. Brain metastasis as the site of relapse in germ cell tumor of testis. *Cancer*. 1993;72:2182-2185.
144. Bredael JJ, Vugrin D, Whitmore WF Jr. Autopsy findings in 154 patients with germ cell tumors of the testis. *Cancer*. 1982;50:548-551.
145. Michael H, Lucia J, Foster RS, Ulbright TM. The pathology of late recurrence of testicular germ cell tumors. *Am J Surg Pathol*. 2000;24:257-273.
146. Qvist HL, Fossa SD, Ous S, et al. Post-chemotherapy tumor residuals in patients with advanced nonseminomatous testicular cancer. Is it necessary to resect all residual masses? *J Urol*. 1991;145:300-302.
147. Sella A, el Naggar A, Ro JY, et al. Evidence of malignant features in histologically mature teratoma. *J Urol*. 1991;146:1025-1028.
148. Sonnevald DJ, Sleijfer DT, Koops HS, et al. Mature teratoma identified after postchemotherapy surgery in patients with disseminated nonseminomatous testicular germ cell tumors: a plea for an aggressive surgical approach. *Cancer*. 1998;82:1343-1351.
149. Birkhead BM, Scott RM. Spontaneous regression of metastatic testicular cancer. *Cancer*. 1973;32:125-129.
150. Ferlicot S, Paradis V, Ladouch A, et al. 'Burned out' testicular tumor: report of three cases. *J Urol Pathol*. 1999;11:171-180.
151. Balzer BL, Ulbright TM. Spontaneous regression of testicular germ cell tumors: an analysis of 42 cases. *Am J Surg Pathol*. 2006;30:858-865.
152. Madden M, Goldstraw P, Corrin B. Effect of chemotherapy on the histological appearances of testicular teratoma metastatic to the lung. Correlation with patient survival. *J Clin Pathol*. 1984;37:1212-1214.
153. Panicek DM, Toner GC, Heelan RT, Bosl GJ. Nonseminomatous germ cell tumors: enlarging masses despite chemotherapy. *Radiology*. 1990;175:499-502.
154. Ulbright TM, Roth LM. A pathologic analysis of lesions following modern chemotherapy for metastatic germ-cell tumors. *Pathol Annu*. 1990;25(Pt I):313-340.

155. Ulbright TM, Loehrer PJ, Roth LM, et al. The development of non-germ-cell malignancies within germ cell tumors. A clinicopathologic study of 11 cases. *Cancer*. 1984;54:1824-1833.
156. Sheinfeld J, Herr HW. Role of surgery in management of germ cell tumor. *Semin Oncol*. 1998;25:203-209.
157. Logothetis CJ, Samuels ML, Selig DE, et al. Primary chemotherapy followed by a selective retroperitoneal lymphadenectomy in the management of clinical stage II testicular carcinoma. A preliminary report. *J Urol*. 1985;134:1127-1130.
158. Sweeney CJ, Hermans BP, Heilman DK, et al. Results and outcome of retroperitoneal lymph node dissection for clinical stage 1 embryonal carcinoma-predominant testis cancer. *J Clin Oncol*. 2000;18:358-362.
159. Kovas E, Stephenson AJ. Management of Stage I Nonseminomatous Germ Cell Tumors. *Urol Clin North Am*. 2015;42:299-310.
160. Duchesne GM, Horwich A, Dearnaley DP, et al. Orchidectomy alone for stage I seminoma of the testis. *Cancer*. 1990;65:1115-1118.
161. Foster RS, Roth BJ. Clinical stage 1 nonseminoma: surgery versus surveillance. *Semin Oncol*. 1998;25:145-153.
162. Gelderman WAH, Koops HS, Sleijfer DTH, et al. Orchidectomy alone in stage I nonseminomatous testicular germ cell tumors. *Cancer*. 1987;59:578-580.
163. Peckham MJ, Barrett A, Horwich A, Hendry WF. Orchiectomy alone for stage I testicular nonseminoma. A progress report on the Royal Marsden Hospital Study. *Br J Urol*. 1983;55:754-759.
164. Stephenson AJ, Aprikian AG, Gilligan TD. Management of low-stage nonseminomatous germ cell tumors of testis: SIU/ICUD Consensus Meeting on Germ Cell Tumors (GCT), Shanghai 2009. *Urology*. 2011;78(4 sup pl):S444-S455.
165. Rorth M. Therapeutic alternatives in clinical stage I nonseminomatous disease. *Semin Oncol*. 1992;19:190-196.
166. Williams SD, Stablein DM, Einhorn LH, et al. Immediate adjuvant chemotherapy versus observation with treatment at relapse in pathological stage II testicular cancer. *N Engl J Med*. 1987;317:1433-1438.
167. Oldenburg J, Dieckmann KP. Contralateral biopsies in patients with testicular germ cell tumours: What is the rationale? *World J Urol*. 2016.
168. Heidenreich A. Contralateral testicular biopsy in testis cancer: current concepts and controversies. *BJU Int*. 2009;104:1346-1350.
169. Beyer J, Albers P, Altena R, et al. Maintaining success, reducing treatment, focusing on survivorship: highlights from the third European consensus conference on diagnosis and treatment of germ-cell cancer. *Ann Oncol*. 2013;24:878-888.
170. Giwercman A, Hopman AH, Ramaekers FC, Skakkebaek NE. Carcinoma in situ of the testis. Possible origin, clinical significance, and diagnostic methods. *Recent Results Cancer Res*. 1991;123:21-36.
171. Gondos B, Migliozzi JA. Intratubular germ cell neoplasia. *Semin Diagn Pathol*. 1987;4:292-303.
172. Loy V, Dieckmann KP. Carcinoma in situ of the testis. Intratubular germ cell neoplasia or testicular intraepithelial neoplasia? *Hum Pathol*. 1990;21:457-458.
173. Jacobsen GK, Henriksen OB, Der Maase HV. Carcinoma in situ of testicular tissue adjacent to malignant germ-cell tumors. A study of 105 cases. *Cancer*. 1981;47:2660-2662.
174. Klein FA, Melamed MR, Whitmore WF Jr. Intratubular malignant germ cells (carcinoma in situ) accompanying invasive testicular germ cell tumors. *J Urol*. 1985;133:413-415.
175. Berthelsen JG, Skakkebaek NE, Mogensen P, Sorensen BL. Incidence of carcinoma in situ of germ cells in contralateral testis of men with testicular tumours. *BMJ*. 1979;2:363-364.
176. Dieckmann KP, Loy V. Prevalence of contralateral testicular intraepithelial neoplasia in patients with testicular germ cell neoplasms. *J Clin Oncol*. 1996;14:3126-3132.
177. Perry A, Wiley EL, Albores-Saavedra J. Pagetoid spread of intratubular germ cell neoplasia into rete testis. A morphologic and histochemical study of 100 orchiectomy specimens with invasive germ cell tumors. *Hum Pathol*. 1994;25:235-239.
178. Ramani P, Yeung CK, Habeebu SS. Testicular intratubular germ cell neoplasia in children and adolescents with intersex. *Am J Surg Pathol*. 1993;17:1124-1133.
179. Lifschitz-Mercer B, Elliott DJ, Schreiber-Bramante L, et al. Intratubular germ cell neoplasia: associated infertility and review of the diagnostic modalities. *Int J Surg Pathol*. 2001;9:93-98.
180. Skakkebaek NE. Carcinoma in situ of the testis. Frequency and relationship to invasive germ cell tumours in infertile men. *Histopathology*. 1978;2:157-170.
181. Berney DM, Lee A, Shamash J, Oliver RT. The frequency and distribution of intratubular trophoblast in association with germ cell tumors of the testis. *Am J Surg Pathol*. 2005;29:1300-1303.
182. Loy V, Wigand I, Dieckmann KP. Incidence and distribution of carcinoma in situ in testes removed for germ cell tumour. Possible inadequacy of random testicular biopsy in detecting the condition. *Histopathology*. 1990;16:198-200.
183. Nistal M, Codesal J, Paniagua R. Carcinoma in situ of the testis in infertile men. A histological, immunocytochemical, and cytophotometric study of DNA content. *J Pathol*. 1989;159:205-210.
184. van Casteren NJ, Boellaard WP, Dohle GR, et al. Heterogeneous distribution of ITGCNU in an adult testis: consequences for biopsy-based diagnosis. *Int J Surg Pathol*. 2008;16:21-24.
185. Bruce E, Al-Talib RK, Cook IS, Theaker JM. Vacuolation of seminiferous tubule cells mimicking intratubular germ cell neoplasia (ITGCN). *Histopathology*. 2006;49:194-196.
186. Ulbright TM, Young RH. Metastatic carcinoma to the testis: a clinicopathologic analysis of 26 nonincidental cases with emphasis on deceptive features. *Am J Surg Pathol*. 2008;32:1683-1693.
187. Henley JD, Young RH, Wade CL, Ulbright TM. Seminomas with exclusive intertubular growth: a report of 12 clinically and grossly inconspicuous tumors. *Am J Surg Pathol*. 2004;28:1163-1168.
188. Berney DM, Lee A, Shamash J, Oliver RT. The association between intratubular seminoma and invasive germ cell tumors. *Hum Pathol*. 2006;37:458-461.
189. Berney DM, Lee A, Randle SJ, et al. The frequency of intratubular embryonal carcinoma: implications for the pathogenesis of germ cell tumours. *Histopathology*. 2004;45:155-161.
190. Rakheja D, Hoang MP, Sharma S, Albores-Saavedra J. Intratubular embryonal carcinoma. *Arch Pathol Lab Med*. 2002;126:487-490.
191. Kao CS, Ulbright TM, Young RH, Idrees MT. Testicular embryonal carcinoma: a morphologic study of 180 cases highlighting unusual and unemphasized aspects. *Am J Surg Pathol*. 2014;38:689-697.
192. Mostofi FK. Pathology of germ cell tumors of the testis. A progress report. *Cancer*. 1980;45:1735-1754.
193. Kang J-L, Raipert-De Meyts E, Giwercman A, Skakkebaek NE. The association of testicular carcinoma in situ with intratubular microcalcifications. *J Urol Pathol*. 1994;2:235-242.
194. Cope NJ, McCullagh P, Sarsfield PT. Tumour responding accessory cells in testicular seminoma: an immunohistochemical study. *Histopathology*. 1999;34:510-516.
195. Wei YQ, Hang ZB, Liu KF. In situ observation of inflammatory cell–tumor cell interaction in human seminomas (germinomas). Light, electron microscopic, and immunohistochemical study. *Hum Pathol*. 1992;23:421-428.
196. Rouse RV. Tubular seminoma: an addition to the short list of potentially confusing seminoma variants, with an addendum on the immunohistology of seminomas and dysgerminomas. *Adv Anat Pathol*. 1996;3:91-96.
197. Ulbright TM, Young RH. Seminoma with conspicuous signet ring cells: a rare, previously uncharacterized morphologic variant. *Am J Surg Pathol*. 2008;32:1175-1181.
198. Ulbright TM, Young RH. Seminoma with tubular, microcystic, and related patterns: a study of 28 cases of unusual morphologic variants that often cause confusion with yolk sac tumor. *Am J Surg Pathol*. 2005;29:500-505.
199. Ulbright TM. The most common, clinically significant misdiagnoses in testicular tumor pathology, and how to avoid them. *Adv Anat Pathol*. 2008;15:18-27.
200. Zavala-Pompa A, Ro JY, el Naggar AK, et al. Tubular seminoma. An immunohistochemical and DNA flow-cytometric study of four cases. *Am J Clin Pathol*. 1994;102:397-401.
201. Aubry F, Satie A-P, Rioux-Leclercq N, et al. MAGE-A4, a germ cell specific marker, is expressed differentially in testicular tumors. *Cancer*. 2001;92:2778-2785.
202. Battifora H, Sheibani K, Tubbs RR, et al. Antikeratin antibodies in tumor diagnosis. Distinction between seminoma and embryonal carcinoma. *Cancer*. 1984;54:843-848.
203. Beckstead JH. Alkaline phosphatase histochemistry in human germ cell neoplasms. *Am J Surg Pathol*. 1983;7:341-349.
204. Cao D, Li J, Guo CC, et al. SALL4 is a novel diagnostic marker for testicular germ cell tumors. *Am J Surg Pathol*. 2009;33:1065-1077.
205. Cheville JC, Rao S, Iczkowski KA, et al. Cytokeratin expression in seminoma of the human testis. *Am J Clin Pathol*. 2000;113:583-588.
206. Emanuel PO, Unger PD, Burstein DE. Immunohistochemical detection of p63 in testicular germ cell neoplasia. *Ann Diagn Pathol*. 2006;10:269-273.
207. Emerson RE, Ulbright TM. The use of immunohistochemistry in the differential diagnosis of tumors of the testis and paratestis. *Semin Diagn Pathol*. 2005;22:33-50.
208. Franke FE, Pauls K, Kerkman L, et al. Somatic isoform of angiotensin I-converting enzyme in the pathology of testicular germ cell tumors. *Hum Pathol*. 2000;31:1466-1476.
209. Gopalan A, Dhall D, Olgac S, et al. Testicular mixed germ cell tumors: a morphological and immunohistochemical study using stem cell markers, OCT3/4, SOX2 and GDF3, with emphasis on morphologically difficult-to-classify areas. *Mod Pathol*. 2009;22:1066-1074.
210. Hart AH, Hartley L, Parker K, et al. The pluripotency homeobox gene NANOG is expressed in human germ cell tumors. *Cancer*. 2005;104:2092-2098.
211. Hoei-Hansen CE, Almstrup K, Nielsen JE, et al. Stem cell pluripotency factor NANOG is expressed in human fetal gonocytes, testicular

carcinoma in situ and germ cell tumours. *Histopathology*. 2005;47:48-56.
212. Iczkowski KA, Butler SL, Shanks JH, et al. Trials of new germ cell immunohistochemical stains in 93 extragonadal and metastatic germ cell tumors. *Hum Pathol*. 2008;39:275-281.
213. Jacobsen GK, Norgaard-Pedersen B. Placental alkaline phosphatase in testicular germ cell tumours and in carcinoma-in-situ of the testis. An immunohistochemical study. *Acta Pathol Microbiol Immunol Scand [A]*. 1984;92:323-329.
214. Jacobsen GK, Jacobsen M, Clausen PP. Distribution of tumor-associated antigens in the various histologic components of germ cell tumors of the testis. *Am J Surg Pathol*. 1981;5:257-266.
215. Jones TD, Ulbright TM, Eble JN, et al. OCT4 staining in testicular tumors: a sensitive and specific marker for seminoma and embryonal carcinoma. *Am J Surg Pathol*. 2004;28:935-940.
216. Lau SK, Weiss LM, Chu PG. D2-40 immunohistochemistry in the differential diagnosis of seminoma and embryonal carcinoma: a comparative immunohistochemical study with KIT (CD117) and CD30. *Mod Pathol*. 2007;20:320-325.
217. Manivel JC, Jessurun J, Wick MR, Dehner LP. Placental alkaline phosphatase immunoreactivity in testicular germ-cell neoplasms. *Am J Surg Pathol*. 1987;11:21-29.
218. Nonaka D. Differential expression of SOX2 and SOX17 in testicular germ cell tumors. *Am J Clin Pathol*. 2009;131:731-736.
219. Ramaekers F, Feitz W, Moesker O, et al. Antibodies to cytokeratin and vimentin in testicular tumour diagnosis. *Virchows Arch A Pathol Anat Histopathol*. 1985;408:127-142.
220. Saint-Andre JP, Alhenc-Gelas F, Rohmer V, et al. Angiotensin-I-converting enzyme in germinomas. *Hum Pathol*. 1988;19:208-213.
221. Zynger DL, Dimov ND, Luan C, et al. Glypican 3: a novel marker in testicular germ cell tumors. *Am J Surg Pathol*. 2006;30:1570-1575.
222. Miettinen M, Virtanen I, Talerman A. Intermediate filament proteins in human testis and testicular germ-cell tumors. *Am J Pathol*. 1985;120:402-410.
223. Hittmair A, Rogatsch H, Hobisch A, et al. CD30 expression in seminoma. *Hum Pathol*. 1996;27:1166-1171.
224. Tickoo SK, Hutchinson B, Bacik J, et al. Testicular seminoma: a clinicopathologic and immunohistochemical study of 105 cases with special reference to seminomas with atypical features. *Int J Surg Pathol*. 2002;10:23-32.
225. Florentine BD, Roscher AA, Garrett J, Warner NE. Necrotic seminoma of the testis: establishing the diagnosis with masson trichrome stain and immunostains. *Arch Pathol Lab Med*. 2002;126:205-206.
226. Miller JS, Lee TK, Epstein JI, Ulbright TM. The utility of microscopic findings and immunohistochemistry in the classification of necrotic testicular tumors: a study of 11 cases. *Am J Surg Pathol*. 2009;33:1293-1298.
227. Mostofi FK. Testicular tumors. Epidemiologic, etiologic, and pathologic features. *Cancer*. 1973;32:1186-1201.
228. Javadpour N. Human chorionic gonadotropin in seminoma. *J Urol*. 1984;131:407.
229. Jacobsen GK. Histogenetic considerations concerning germ cell tumours. Morphological and immunohistochemical comparative investigation of the human embryo and testicular germ cell tumors. *Virchows Arch A Pathol Anat Histopathol*. 1986;408:509-525.
230. Pierce GB Jr, Abell MR. Embryonal carcinoma of the testis. *Pathol Annu*. 1970;5:27-60.
231. Friedman NB, Moore RA. Tumors of the testis; a report on 922 cases. *Mil Surg*. 1946;99:573-593.
232. Rinke de Wit TF, Wilson L, van den Elsen PJ, et al. Monoclonal antibodies to human embryonal carcinoma cells. Antigenic relationships of germ cell tumors. *Lab Invest*. 1991;65:180-191.
233. Santagata S, Ligon KL, Hornick JL. Embryonic stem cell transcription factor signatures in the diagnosis of primary and metastatic germ cell tumors. *Am J Surg Pathol*. 2007;31:836-845.
234. Sung MT, Jones TD, Beck SD, et al. OCT4 is superior to CD30 in the diagnosis of metastatic embryonal carcinomas after chemotherapy. *Hum Pathol*. 2006;37:662-667.
235. Bai S, Wei S, Pasha TL, et al. Immunohistochemical studies of metastatic germ-cell tumors in retroperitoneal dissection specimens: a sensitive and specific panel. *Int J Surg Pathol*. 2013;21:342-351.
236. Berney DM, Shamash J, Pieroni K, Oliver RT. Loss of CD30 expression in metastatic embryonal carcinoma: the effects of chemotherapy? *Histopathology*. 2001;39:382-385.
237. Allen EA, Burger PC, Epstein JI. Microcystic meningioma arising in a mixed germ cell tumor of the testis: a case report. *Am J Surg Pathol*. 1999;23:1131-1135.
238. Michal M. Meningeal nodules in teratoma of the testis. *Virchows Arch*. 2001;438:198-200.
239. Singh N, Cumming J, Theaker JM. Pure cartilaginous teratoma differentiated of the testis. *Histopathology*. 1997;30:373-374.
240. Michael H, Hull MT, Ulbright TM, et al. Primitive neuroectodermal tumors arising in testicular germ cell neoplasms. *Am J Surg Pathol*. 1997;21:896-904.
241. Serrano-Olmo J, Tang CK, Seidmon EJ, et al. Neuroblastoma as a prominent component of a mixed germ cell tumor of testis. *Cancer*. 1993;72:3271-3276.
242. Pierce GB Jr, Bullock WK, Huntington RW Jr. Yolk sac tumors of the testis. *Cancer*. 1970;25:644-658.
243. Talerman A. Yolk sac tumor associated with seminoma of the testis in adults. *Cancer*. 1974;33:1468-1473.
244. Talerman A. The incidence of yolk sac tumor (endodermal sinus tumor) elements in germ cell tumors of the testis in adults. *Cancer*. 1975;36:211-215.
245. Talerman A. Endodermal sinus (yolk sac) tumor elements in testicular germ cell tumors in adults. Comparison of prospective and retrospective studies. *Cancer*. 1980;46:1213-1217.
246. Teilum G. Endodermal sinus tumor of the ovary and testis. Comparative morphogenesis of the so-called mesonephroma ovarii (Schiller) and of extraembryonic (yolk sac-allantoic) structures of the rat's placenta. *Cancer*. 1959;12:1092-1105.
247. Teoh TB, Steward JK, Willis RA. The distinctive adenocarcinoma of the infant's testis. An account of 15 cases. *J Pathol Bacteriol*. 1960;80:147-156.
248. Woodtli W, Hedinger CE. Endodermal sinus tumor or orchioblastoma in children and adults. *Virchows Arch A Pathol Anat Histopathol*. 1974;364:93-110.
249. Young PG, Mount BM, Foote FW Jr, Whitmore WF Jr. Embryonal adenocarcinoma in the prepubertal testis. A clinicopathologic study of 18 cases. *Cancer*. 1970;26:1065-1075.
250. Young RH. The yolk sac tumor: reflections on a remarkable neoplasm and two of the many intrigued by it-Gunnar Teilum and Aleksander Talerman-and the bond it formed between them. *Int J Surg Pathol*. 2014;22:677-687.
251. Ulbright TM, Amin MB, Young RH. Tumors of the Testis, Adnexa, Spermatic Cord, and Scrotum. Atlas of Tumor Pathology. Thrid Series. Fascicle 25. *AFIP*, 1997.
252. Kao CS, Idrees MT, Young RH, Ulbright TM. Solid pattern yolk sac tumor: a morphologic and immunohistochemical study of 52 cases. *Am J Surg Pathol*. 2012;36:360-367.
253. Young RH, Ulbright TM, Policarpio-Nicolas ML. Yolk sac tumor with a prominent polyvesicular vitelline pattern: a report of three cases. *Am J Surg Pathol*. 2013;37:393-398.
254. Jacobsen GK, Jacobsen M. Possible liver cell differentiation in testicular germ cell tumours. *Histopathology*. 1983;7:537-548.
255. Ulbright TM, Roth LM, Brodhecker CA. Yolk sac differentiation in germ cell tumors. A morphologic study of 50 cases with emphasis on hepatic, enteric, and parietal yolk sac features. *Am J Surg Pathol*. 1986;10:151-164.
256. Eglen DE, Ulbright TM. The differential diagnosis of yolk sac tumor and seminoma. Usefulness of cytokeratin, alpha-fetoprotein, and alpha-1-antitrypsin immunoperoxidase reactions. *Am J Clin Pathol*. 1987;88:328-332.
257. Bing Z, Pasha T, Tomaszewski JE, Zhang P. CDX2 expression in yolk sac component of testicular germ cell tumors. *Int J Surg Pathol*. 2009;17:373-377.
258. Zynger DL, McCallum JC, Luan C, et al. Glypican 3 has a higher sensitivity than alpha-fetoprotein for testicular and ovarian yolk sac tumour: immunohistochemical investigation with analysis of histological growth patterns. *Histopathology*. 2010;56:750-757.
259. Osman H, Cheng L, Ulbright TM, Idrees MT. The utility of CDX2, GATA3, and DOG1 in the diagnosis of testicular neoplasms: an immunohistochemical study of 109 cases. *Hum Pathol*. 2016;48:18-24.
260. Kurman RJ, Scardino PT, McIntire KR, et al. Cellular localization of alpha-fetoprotein and human chorionic gonadotropin in germ cell tumors of the testis using an indirect immunoperoxidase technique. A new approach to classification utilizing tumor markers. *Cancer*. 1977;40:2136-2151.
261. Mostofi FK, Sesterhenn IA, Davis CJ Jr. Immunopathology of germ cell tumors of the testis. *Semin Diagn Pathol*. 1987;4:320-341.
262. Damjanov I, Osborn M, Miettinen M. Keratin 7 is a marker for a subset of trophoblastic cells in human germ cell tumors. *Arch Pathol Lab Med*. 1990;114:81-83.
263. Ulbright TM. Germ cell tumors of the gonads: a selective review emphasizing problems in differential diagnosis, newly appreciated, and controversial issues. *Mod Pathol*. 2005;18:S61-S79.
264. Ulbright TM, Young RH, Scully RE. Trophoblastic tumors of the testis other than classic choriocarcinoma: 'monophasic' choriocarcinoma and placental site trophoblastic tumor; a report of two cases. *Am J Surg Pathol*. 1997;21:282-288.
265. Suurmeijer AJ, Gietema JA, Hoekstra HJ. Placental site trophoblastic tumor in a late recurrence of a nonseminomatous germ cell tumor of the testis. *Am J Surg Pathol*. 2004;28:830-833.
266. Gondim DD, Ulbright TM, Cheng L, Idrees MT. Primary cystic trophoblastic tumor of the testis: a study of 14 cases. *Am J Surg Pathol*. 2017;41:788-794.
267. Ulbright TM, Henley JD, Cummings OW, et al. Cystic trophoblastic tumor: a nonaggressive lesion in postchemotherapy resections of patients with testicular germ cell tumors. *Am J Surg Pathol*. 2004;28:1212-1216.
268. Guo CC, Punar M, Contreras AL, et al. Testicular germ cell tumors with sarcomatous components: an analysis of 33 cases. *Am J Surg Pathol*. 2009;33:1173-1178.

269. Malagón HD, Valdez AM, Moran CA, Suster S. Germ cell tumors with sarcomatous components: a clinicopathologic and immunohistochemical study of 46 cases. *Am J Surg Pathol*. 2007;31:1356-1362.
270. Idrees MT, Kuhar M, Ulbright TM, et al. Clonal evidence for the progression of a testicular germ cell tumor to angiosarcoma. *Hum Pathol*. 2010;41:139-144.
271. Motzer RJ, Amsterdam A, Prieto V, et al. Teratoma with malignant transformation: diverse malignant histologies arising in men with germ cell tumors. *J Urol*. 1998;159:133-138.
272. Ulbright TM, Hattab EM, Zhang S, et al. Primitive neuroectodermal tumors in patients with testicular germ cell tumors usually resemble pediatric-type central nervous system embryonal neoplasms and lack chromosome 22 rearrangements. *Mod Pathol*. 2010;23:972-980.
273. Clevenger JA, Foster RS, Ulbright TM. Differentiated rhabdomyomatous tumors after chemotherapy for metastatic testicular germ-cell tumors: a clinicopathological study of seven cases mandating separation from rhabdomyosarcoma. *Mod Pathol*. 2009;22:1361-1366.
274. Howitt BE, Magers MJ, Rice KR, et al. *Am J Surg Pathol*. 2015;39:251-259.
275. Rice KR, Rice KR, Magers MJ, et al. Management of germ cell tumors with somatic type malignancy: pathological features, prognostic factors and survival outcomes. *J Urol*. 2014;192:1403-1409.
276. Magers MJ, Magers MJ1, Kao CS, et al. "Somatic-type" malignancies arising from testicular germ cell tumors: a clinicopathologic study of 124 cases with emphasis on glandular tumors supporting frequent yolk sac tumor origin. *Am J Surg Pathol*. 2014;38:1396-1409.
277. Ulbright TM, Goheen MP, Roth LM, Gillespie JJ. The differentiation of carcinomas of teratomatous origin from embryonal carcinoma. A light and electron microscopic study. *Cancer*. 1986;57:257-263.
278. Colecchia M, Necchi A, Paolini B, et al. Teratoma with somatic-type malignant components in germ cell tumors of the testis: a clinicopathologic analysis of 40 cases with outcome correlation. *Int J Surg Pathol*. 2011;19:321-327.
279. Stall JN, Young RH. Polyembryoma of the testis: a report of two cases dominant within mixed germ cell tumors and review of gonadal polyembryomas. *Mod Pathol*. 2017;30:908-918.
280. Cardoso de Almeida PC, Scully RE. Diffuse embryoma of the testis. A distinctive form of mixed germ cell tumor. *Am J Surg Pathol*. 1983;7:633-642.
281. de Peralta-Venturina MN, Ro JY, Ordóñez NG, Ayala AG. Diffuse embryoma of the testis. An immunohistochemical study of two cases. *Am J Clin Pathol*. 1994;101:402-405.
282. Young RH. Testicular tumors—some new and a few perennial problems. *Arch Pathol Lab Med*. 2008;132:548-564.
283. Cheng L. Establishing a germ cell origin for metastatic tumors using OCT4 immunohistochemistry. *Cancer*. 2004;101:2006-2010.
284. Cao D, Humphrey PA, Allan RW. SALL4 is a novel sensitive and specific marker for metastatic germ cell tumors, with particular utility in detection of metastatic yolk sac tumors. *Cancer*. 2009;115:2640-2651.
285. Ushiku T, Shinozaki A, Shibahara J. SALL4 represents fetal gut differentiation of gastric cancer, and is diagnostically useful in distinguishing hepatoid gastric carcinoma from hepatocellular carcinoma. *Am J Surg Pathol*. 2010;34:533-540.
286. Miettinen M, Wang Z, McCue PA. SALL4 expression in germ cell and non-germ cell tumors: a systematic immunohistochemical study of 3215 cases. *Am J Surg Pathol*. 2014;38:410-420.
287. Matsumoto K, Ueyama H, Matsumoto K, et al. Clinicopathological features of alpha-fetoprotein producing early gastric cancer with enteroblastic differentiation. *World J Gastroenterol*. 2016;22:8203-8210.
288. Rao P, Tannir NM, Tamboli P. Expression of OCT3/4 in renal medullary carcinoma represents a potential diagnostic pitfall. *Am J Surg Pathol*. 2012;36:583-588.
289. Williams AS, Shawwa A, Merrimen J, Dakin Haché K. Expression of OCT4 and SALL4 in diffuse large B-cell lymphoma: an analysis of 145 consecutive cases and testicular lymphomas. *Am J Surg Pathol*. 2016;40:950-957.
290. Abell MR, Holtz F. Testicular neoplasms in infants and children. I. Tumors of germ cell origin. *Cancer*. 1963;16:965-981.
291. Zhang C, Berney DM, Hirsch MS, et al. Evidence supporting the existence of benign teratomas of the postpubertal testis: a clinical, histopathologic, and molecular genetic analysis of 25 cases. *Am J Surg Pathol*. 2013;37:827-835.
292. Mostert M, Rosenberg C, Stoop H, et al. Comparative genomic and in situ hybridization of germ cell tumors of the infantile testis. *Lab Invest*. 2000;80: 1055-1064.
293. Carroll WL, Kempson RL, Govan DE, et al. Conservative management of testicular endodermal sinus tumors in childhood. *J Urol*. 1985;133:1011-1014.
294. Looijenga LH, Hersmus R, Gillis AJ, et al. Genomic and expression profiling of human spermatocytic seminomas: primary spermatocyte as tumorigenic precursor and DMRT1 as candidate chromosome 9 gene. *Cancer Res*. 2006;66:290-302.
295. Goriely A, Hansen RM, Taylor IB. Activating mutations in FGFR3 and HRAS reveal a shared genetic origin for congenital disorders and testicular tumors. *Nat Genet*. 2009;41:1247-1252.
296. Talerman A. Spermatocytic seminoma. Clinicopathologic study of 22 cases. *Cancer*. 1980;45:2169-2176.
297. Burke AP, Mostofi FK. Spermatocytic seminoma. A clinicopathologic study of 79 cases. *J Urol Pathol*. 1993;1:21-32.
298. Rosai J, Silber I, Khodadoust K. Spermatocytic seminoma. I. Clinicopathologic study of six cases and review of the literature. *Cancer*. 1969;24:92-102.
299. Cummings OW, Ulbright TM, Eble JN, Roth LM. Spermatocytic seminoma. An immunohistochemical study. *Hum Pathol*. 1994;25:54-59.
300. Lim J, Goriely A, Turner GD, et al. OCT2, SSX and SAGE1 reveal the phenotypic heterogeneity of spermatocytic seminoma reflecting distinct subpopulations of spermatogonia. *J Pathol*. 2011;224: 473-483.
301. Kraggerud SM, Berner A, Bryne M, et al. Spermatocytic seminoma as compared to classical seminoma: an immunohistochemical and DNA flow cytometric study. *APMIS*. 1999;107:297-302.
302. Eble JN. Spermatocytic seminoma. *Hum Pathol*. 1994;25:1035-1042.
303. Floyd C, Ayala AG, Logothetis CJ, Silva EG. Spermatocytic seminoma with associated sarcoma of the testis. *Cancer*. 1988;61: 409-414.
304. Matoska J, Talerman A. Spermatocytic seminoma associated with rhabdomyosarcoma. *Am J Clin Pathol*. 1990;94:89-95.
305. True LD, Otis CN, Delprado W, et al. Spermatocytic seminoma of testis with sarcomatous transformation. A report of five cases. *Am J Surg Pathol*. 1988;12: 75-82.
306. Ulbright TM, Srigley JR. Dermoid cyst of the testis: a study of five postpubertal cases, including a pilomatrixoma-like variant, with evidence supporting its separate classification from mature testicular teratoma. *Am J Surg Pathol*. 2001;25:788-793.
307. Wang WP, Guo C, Berney DM, et al. Primary carcinoid tumors of the testis: a clinicopathologic study of 29 cases. *Am J Surg Pathol*. 2010;34:519-524.
308. Berdijs C, Mostofi FK. Carcinoid tumors of the testis. *J Urol*. 1977;118:777-782.
309. Reyes A, Moran CA, Suster S, et al. Neuroendocrine carcinomas (carcinoid tumor) of the testis. A clinicopathologic and immunohistochemical study of ten cases. *Am J Clin Pathol*. 2003;120:182-187.
310. Herschorn S, Gajewski J, Schulz J, Corcos J. A population-based study of urinary symptoms and incontinence: the Canadian Urinary Bladder Survey. *BJU Int*. 2008;101:1101-1105.
311. Abbosh PH, Zhang S, Maclennan GT, et al. Germ cell origin of testicular carcinoid tumors. *Clin Cancer Res*. 2008;14:1393-1396.
312. Kato N, et al. Primary carcinoid tumor of the testis: immunohistochemical, ultrastructural and FISH analysis with review of the literature. *Pathol Int*. 2003;53:680-685.
313. Stang A, Trabert B, Wentzensen N, et al. Gonadal and extragonadal germ cell tumours in the United States, 1973–2007. *Int J Androl*. 2012;35:616-625.
314. Cornejo KM, Frazier L, Lee RS, et al. Yolk Sac Tumor of the testis in infants and children: a clinicopathologic analysis of 33 cases. *Am J Surg Pathol*. 2015;39:1121-1131.
315. Sugimura J, Suzuki Y, Tamura G, et al. Metachronous development of malignant Leydig cell tumor. *Hum Pathol*. 1997;28:1318-1320.
316. Carvajal-Carmona LG, Alam NA, Pollard PJ, et al. Adult leydig cell tumors of the testis caused by germline fumarate hydratase mutations. *J Clin Endocrinol Metab*. 2006;91:3071-3075.
317. Dieckmann KP, Loy V. Metachronous germ cell and Leydig cell tumors of the testis. Do testicular germ cell tumors and Leydig cell tumors share common etiologic factors? *Cancer*. 1993;72:1305-1307.
318. Freeman DA. Steroid hormone-producing tumors of the adrenal, ovary, and testes. *Endocrinol Metab Clin North Am*. 1991;20:751-766.
319. Gabrilove JL, Nicolis GL, Mitty HA, Sohval AR. Feminizing interstitial cell tumor of the testis. Personal observations and a review of the literature. *Cancer*. 1975;35:1184-1202.
320. Bercovici JP, Nahoul K, Ducasse M, et al. Leydig cell tumor with gynecomastia. Further studies—the recovery after unilateral orchidectomy. *J Clin Endocrinol Metab*. 1985;61:957-962.
321. Maurer R, Taylor CR, Schmucki O, Hedinger CE. Extratesticular gonadal stromal tumor of the testis. A case report with immunoperoxidase findings. *Cancer*. 1980;45:985-990.
322. Billings SD, Roth LM, Ulbright TM. Microcystic Leydig cell tumors mimicking yolk sac tumor: a report of four cases. *Am J Surg Pathol*. 1999;23:546-551.
323. Kim I, Young RH, Scully RE. Leydig cell tumors of the testis. A clinicopathological analysis of 40 cases and review of the literature. *Am J Surg Pathol*. 1985;9: 177-192.

324. Balsitis M, Sokal M. Ossifying malignant Leydig (interstitial) cell tumour of the testis. *Histopathology*. 1990;16:599-601.
325. Santonja C, Varona C, Burgos FJ, Nistal M. Leydig cell tumor of testis with adipose metaplasia. *Appl Pathol*. 1989;7:201-204.
326. Ulbright TM, Srigley JR, Hatzianastassiou DK, Young RH. Leydig cell tumors of the testis with unusual features: adipose differentiation, calcification with ossification, and spindle-shaped tumor cells. *Am J Surg Pathol*. 2002;26:1424-1433.
327. Sohval AR, Churg J, Gabrilove JL, et al. Ultrastructure of feminizing testicular Leydig cell tumors. *Ultrastruct Pathol*. 1982;3:335-345.
328. Ekfors TO, Martikainen P, Kuopio T, et al. Ultrastructure and immunohistochemistry of a fetal-type Leydig cell tumor. *Ultrastruct Pathol*. 1992;16:651-658.
329. Augusto D, Leteurtre E, de la Taille A, et al. Calretinin: a valuable marker of normal and neoplastic Leydig cells of the testis. *Appl Immunohistochem Mol Morphol*. 2002;10:159-162.
330. Busam KJ, Iversen K, Coplan KA, et al. Immunoreactivity for A103 and antibody to Melan-A (Mart-1) in adrenocortical and other steroid tumors. *Am J Surg Pathol*. 1998;22:57-63.
331. McCluggage WG, Shanks JH, Whiteside C, et al. Immunohistochemical study of testicular sex cord-stromal tumors, including staining with anti-inhibin antibody. *Am J Surg Pathol*. 1998;22:615-619.
332. Gordon MD, Corless C, Renshaw AA, Beckstead J. CD99, keratin, and vimentin staining of sex cord-stromal tumors, normal ovary, and testis. *Mod Pathol*. 1998;11:769-773.
333. Iczkowski KA, Bostwick DG, Roche PC, Cheville JC. Inhibin A is a sensitive and specific marker for testicular sex cord-stromal tumors. *Mod Pathol*. 1998;11:774-779.
334. Sangoi AR, McKenney JK, Brooks JD, Higgins JP. Evaluation of SF-1 expression in testicular germ cell tumors: a tissue microarray study of 127 cases. *Appl Immunohistochem Mol Morphol*. 2013;21:318-321.
335. McLaren K, Thomson D. Localization of S-100 protein in a Leydig and Sertoli cell tumour of testis. *Histopathology*. 1989;15:649-652.
336. Tanaka Y, Carney JA, Ijiri R, et al. Utility of immunostaining for S-100 protein subunits in gonadal sex cord-stromal tumors, with emphasis on the large-cell calcifying Sertoli cell tumor of the testis. *Hum Pathol*. 2002;33:285-289.
337. Zhang C, Ulbright TM. Nuclear localization of β-catenin in sertoli cell tumors and other sex cord-stromal tumors of the testis: an immunohistochemical study of 87 cases. *Am J Surg Pathol*. 2015;39:1390-1394.
338. Liu G, Duranteau L, Carel JC, et al. Leydig-cell tumors caused by an activating mutation of the gene encoding the luteinizing hormone receptor. *N Engl J Med*. 1999;341:1731-1736.
339. Mahon FB Jr, Gosset F, Trinity RG, Madsen PO. Malignant interstitial cell testicular tumor. *Cancer*. 1973;31:1208-1212.
340. Grem JL, Robins HI, Wilson KS, et al. Metastatic Leydig cell tumor of the testis. Report of three cases and review of the literature. *Cancer*. 1986;58:2116-2119.
341. Tavora F, Barton JH, Sesterhenn I. Leydig cell tumors of the testis, a clinicopathological series with malignant histological features. *Lab Invest*. 2009;89:196A.
342. Gulbahce HE, Lindeland AT, Engel W, Lillemoe TJ. Metastatic Leydig cell tumor with sarcomatoid differentiation. *Arch Pathol Lab Med*. 1999;123:1104-1107.
343. Cheville JC, Sebo TJ, Lager DJ, et al. Leydig cell tumor of the testis: a clinicopathologic, DNA content and MIB-1 comparison of nonmetastasizing and metastasizing tumors. *Am J Surg Pathol*. 1998;22:1361-1367.
344. McCluggage WG, Shanks JH, Arthur K, Banerjee SS. Cellular proliferation and nuclear ploidy assessments augment established prognostic factors in predicting malignancy in testicular Leydig cell tumours. *Histopathology*. 1998;33:361-368.
345. Rutgers JL, Young RH, Scully RE. The testicular 'tumor' of the adrenogenital syndrome. *Am J Surg Pathol*. 1988;12:503-513.
345a. Vallangeon BD, Eble JN, Ulbright TM. Macroscopic Sertoli cell nodule: a study of 6 cases that presented as testicular masses. *Am J Surg Pathol*. 2010;34:1874-1880.
346. Knudsen JL, Savage A, Mobb GE. The testicular 'tumour' of adrenogenital syndrome—a persistent diagnostic pitfall. *Histopathology*. 1991;19:468-470.
347. Ashley RA, McGee SM, Isotaolo PA, et al. Clinical and pathological features associated with the testicular tumor of the adrenogenital syndrome. *J Urol*. 2007;177:546-549.
348. Lottrup G, Nielsen JE, Skakkebæk NE, et al. Abundance of DLK1, differential expression of CYP11B1, CYP21A2 and MC2R, and lack of INSL3 distinguish testicular adrenal rest tumours from Leydig cell tumours. *Eur J Endocrinol*. 2015;172:491-499.
349. Lottrup G, Nielsen JE, Maroun LL, et al. Expression patterns of DLK1 and INSL3 identify stages of Leydig cell differentiation during normal development and in testicular pathologies, including testicular cancer and Klinefelter syndrome. *Hum Reprod*. 2014;29:1637-1650.
350. Wang Z, Yang S, Shi H, et al. Histopathological and immunophenotypic features of testicular tumour of the adrenogenital syndrome. *Histopathology*. 2011;58:1013-1018.
351. Young RH, Talerman A. Testicular tumors other than germ cell tumors. *Semin Diagn Pathol*. 1987;4:342-360.
352. Sohval AR. Testicular dysgenesis in relation to neoplasm of the testicle. *J Urol*. 1956;75:285-291.
353. Hedinger CE, Huber R, Weber E. Frequency of so-called hypoplastic or dysgenetic zones in scrotal and otherwise normal human testes. *Virchows Arch A Pathol Anat Histopathol*. 1967;342:165-168.
354. Harbaum L, Langner C. Epididymal Sertoli cell nodule—a diagnostic pitfall. *Histopathology*. 2009;55:465-488.
355. Manuel M, Katayama KP, Jones HW Jr. The age of occurrence of gonadal tumor in intersex patients with a Y chromosome. *Am J Obstet Gynecol*. 1976;124:293-300.
356. Neubecker RD, Theiss EA. Sertoli cell adenomas in patients with testicular feminization. *Am J Clin Pathol*. 1962;38:52-59.
357. O'Connell MJ, Ramsey HE, Whang-Peng J, Wiernik PH. Testicular feminization syndrome in three sibs. Emphasis on gonadal neoplasia. *Am J Med Sci*. 1973;265:321-333.
358. Higgins JP, Rouse RV. Testicular Sertoli cell tumors NOS, the final word? *Adv Anat Pathol*. 1999;6:103-113.
359. Hopkins GB, Parry HD. Metastasizing Sertoli-cell tumor (androblastoma). *Cancer*. 1969;23:463-467.
360. Young RH, Koelliker DD, Scully RE. Sertoli cell tumors of the testis, not otherwise specified: a clinicopathologic analysis of 60 cases. *Am J Surg Pathol*. 1998;22:709-721.
361. Gilcrease MZ, Delgado R, Albores-Saavedra J. Testicular Sertoli cell tumor with a heterologous sarcomatous component: immunohistochemical assessment of Sertoli cell differentiation. *Arch Pathol Lab Med*. 1998;122:907-911.
362. Comperat E, Tissier F, Boyé K, et al. Non-Leydig sex-cord tumors of the testis. The place of immunohistochemistry in diagnosis and prognosis. A study of twenty cases. *Virchows Arch*. 2004;444:567-571.
363. Kommoss F, Oliva E, Bittinger F, et al. Inhibin-alpha CD99, HEA125, PLAP, and chromogranin immunoreactivity in testicular neoplasms and the androgen insensitivity syndrome. *Hum Pathol*. 2000;31:1055-1061.
364. Perrone F, Bertolotti A, Montemurro G, et al. Frequent mutation and nuclear localization of β-catenin in sertoli cell tumors of the testis. *Am J Surg Pathol*. 2014;38:66-71.
365. Talerman A. Malignant Sertoli cell tumor of the testis. *Cancer*. 1971;28:446-455.
366. Henley JD, Young RH, Ulbright TM. Malignant Sertoli cell tumors of the testis: a study of 13 examples of a neoplasm frequently misinterpreted as a seminoma. *Am J Surg Pathol*. 2002;26:541-550.
367. Jacobsen GK. Malignant Sertoli cell tumors of the testis. *J Urol Pathol*. 1993;1:233-255.
368. Samaratunga H, Spork MR, Cooritz D. Sclerosing Sertoli cell tumor of the testis. *J Urol Pathol*. 2000;12:39-50.
369. Zukerberg LR, Young RH, Scully RE. Sclerosing Sertoli cell tumor of the testis. A report of 10 cases. *Am J Surg Pathol*. 1991;15:829-834.
370. Carney JA, Gordon H, Carpenter PC, et al. The complex of myxomas, spotty pigmentation, and endocrine overactivity. *Medicine (Baltimore)*. 1985;64:270-283.
371. Proppe KH, Scully RE. Large-cell calcifying Sertoli cell tumor of the testis. *Am J Clin Pathol*. 1980;74:607-619.
372. Gourgari E, Saloustros E, Stratakis CA. Large-cell calcifying Sertoli cell tumors of the testes in pediatrics. *Curr Opin Pediatr*. 2012;24:518-522.
373. Plata C, Algaba F, Andujar M, et al. Large cell calcifying Sertoli cell tumour of the testis. *Histopathology*. 1995;26:255-260.
374. Cano-Valdez AM, Chanona-Vilchis J, Dominguez-Malagon H. Large cell calcifying Sertoli cell tumor of the testis: a clinicopathological immunohistochemical, and ultrastructural study of two cases. *Ultrastruct Pathol*. 1999;23:259-265.
375. Proppe KH, Dickersin GR. Large-cell calcifying Sertoli cell tumor of the testis. Light microscopic and ultrastructural study. *Hum Pathol*. 1982;13:1109-1114.
376. Tetu B, Ro JY, Ayala AG. Large cell calcifying Sertoli cell tumor of the testis. A clinicopathologic, immunohistochemical, and ultrastructural study of two cases. *Am J Clin Pathol*. 1991;96:717-722.
377. Sato K, Ueda Y, Sakurai A, et al. Large cell calcifying Sertoli cell tumor of the testis: comparative immunohistochemical study with Leydig cell tumor. *Pathol Int*. 2005;55:366-371.
378. Peterson F, Bulimbasic S, Sima R, et al. Large cell calcifying Sertoli cell tumor: a clinicopathologic study of 1 malignant and 3 benign tumors using histomorphology, immunohistochemistry, ultrastructure, comparative genomic hybridization, and polymerase chain reaction analysis of the PRKAR1A gene. *Hum Pathol*. 2010;41:552-559.
379. Ramaswamy G, Jagadha V, Tcherkoff V. A testicular tumor resembling the sex cord with annular tubules in a case of the androgen insensitivity syndrome. *Cancer*. 1985;55:1607-1611.
380. Ulbright TM, Amin MB, Young RH. Intratubular large cell hyalinizing Sertoli cell neoplasia of the testis: a report of 8 cases of a distinctive lesion of the Peutz–Jeghers syndrome. *Am J Surg Pathol*. 2007;31:827-835.
381. Young S, Gooneratne S, Straus FH, et al. Feminizing Sertoli cell tumors in boys with Peutz–Jeghers syndrome. *Am J Surg Pathol*. 1995;19:50-58.

382. Wang ZJ, Churchman M, Avizienyte E, et al. Germline mutations of the LKB1 (STK11) gene in Peutz-Jeghers patients. *J Med Genet*. 1999;36:365-368.
383. Harms D, Kock LR. Testicular juvenile granulosa cell and Sertoli cell tumours: a clinicopathologic study of 29 cases from the Kiel Paediatric Tumour Registry. *Virchows Arch*. 1997;430:301-310.
384. Lawrence WD, Young RH, Scully RE. Juvenile granulosa cell tumor of the infantile testis. A report of 14 cases. *Am J Surg Pathol*. 1985;9:87-94.
385. Young RH. Sex cord–stromal tumors of the ovary and testis: their similarities and differences with consideration of selected problems. *Mod Pathol*. 2005;18:S81-S98.
386. Cornejo KM, Young RH. Adult granulosa cell tumors of the testis: a report of 32 cases. *Am J Surg Pathol*. 2014;38:1242-1250.
387. Matoska J, Ondrus D, Talerman A. Malignant granulosa cell tumor of the testis associated with gynecomastia and long survival. *Cancer*. 1992;69:1769-1772.
388. Jimenez-Quintero LP, Ro JY, Zavala-Pompa A, et al. Granulosa cell tumor of the adult testis. A clinicopathologic study of seven cases and a review of the literature. *Hum Pathol*. 1994;24:1120-1125.
389. Due W, Dieckmann KP, Niedobitek G, et al. Testicular sex cord stromal tumour with granulosa cell differentiation. Detection of steroid hormone receptors as a possible basis for tumour development and therapeutic management. *J Clin Pathol*. 1990;43: 732-737.
390. Alexiev BA, Alaish SM, Sun CC. Testicular juvenile granulosa cell tumor in a newborn: case report and review of the literature. *Int J Surg Pathol*. 2007;15:321-325.
391. Chan JK, Chan VS, Mak KL. Congenital juvenile granulosa cell tumour of the testis. Report of a case showing extensive degenerative changes. *Histopathology*. 1990;17:75-80.
392. Kos M, Nogales FF, Kos M, et al. Congenital juvenile granulosa cell tumor of the testis in a fetus showing full 69,XXY triploidy. *Int J Surg Pathol*. 2005;13:219-221.
393. Kao CS, Cornejo KM, Ulbright TM, Young RH. Juvenile granulosa cell tumors of the testis: a clinicopathologic study of 70 cases with emphasis on its wide morphologic spectrum. *Am J Surg Pathol*. 2015;39:1159-1169.
394. Tanaka Y, Sasaki Y, Tachibana K, et al. Testicular juvenile granulosa cell tumor in an infant with X/XY mosaicism clinically diagnosed as true hermaphroditism. *Am J Surg Pathol*. 1994;18:316-322.
395. Young RH, Lawrence WD, Scully RE. Juvenile granulosa cell tumor. Another neoplasm associated with abnormal chromosomes and ambiguous genitalia. A report of three cases. *Am J Surg Pathol*. 1985;9:737-743.
396. Jones MA, Young RH, Scully RE. Benign fibromatous tumors of the testis and paratesticular region: a report of 9 cases with a proposed classification of fibromatous tumors and tumor-like lesions. *Am J Surg Pathol*. 1997;21:296-305.
397. Zhang M, et al. Testicular fibrothecoma: a morphologic and immunohistochemical study of 16 cases. *Am J Surg Pathol*. 2013;37:1208-1214.
398. De Pinieux G, Glaser C, Chatelain D, et al. Testicular fibroma of gonadal stromal origin with minor sex cord elements: clinicopathologic and immunohistochemical study of 2 cases. *Arch Pathol Lab Med*. 1999;123:391-394.
399. Kuo CY, Wen MC, Wang J, Jan YJ. Signet-ring stromal tumor of the testis: a case report and literature review. *Hum Pathol*. 2009;40:584-587.
400. Michal M, Hes O, Kazakov DV. Primary signet-ring stromal tumor of the testis. *Virchows Arch*. 2005;447:107-110.
401. Michalova K, Michal M Jr, Kazakov DV, et al. Primary signet ring stromal tumor of the testis: a study of 13 cases indicating their phenotypic and genotypic analogy to pancreatic solid pseudopapillary neoplasm. *Hum Pathol*. 2017 (in press).
402. Kao CS, Ulbright TM. Myoid gonadal stromal tumor: a clinicopathologic study of three cases of a distinctive testicular tumor. *Am J Clin Pathol*. 2014;142:675-682.
403. Scully RE. Gonadoblastoma. A review of 74 cases. *Cancer*. 1970;25:1340-1356.
404. Chapman WH, Plymyer MR, Dresner ML. Gonadoblastoma in an anatomically normal Man: a case report and literature review. *J Urol*. 1990;144:1472-1474.
405. Ulbright TM, Srigley JR, Reuter VE, et al. Sex cord-stromal tumors of the testis with entrapped germ cells: a lesion mimicking unclassified mixed germ cell sex cord-stromal tumors. *Am J Surg Pathol*. 2000;24:535-542.
406. Bolen JW. Mixed germ cell–sex cord–stromal tumor. A gonadal tumor distinct from gonadoblastoma. *Am J Clin Pathol*. 1981;75:565-573.
407. Michal M, Vanecek T, Sima R, et al. Mixed germ cell sex cord–stromal tumors of the testis and ovary. Morphological, immunohistochemical, and molecular genetic study of seven cases. *Virchows Arch*. 2006;448:612-622.
408. Finn LS, Viswanatha DS, Belasco JB, et al. Primary follicular lymphoma of the testis in childhood. *Cancer*. 1999;85:1626-1635.
409. Kiely IM, Massey BD Jr, Harrison EG Jr, Utz DC. Lymphoma of the testis. *Cancer*. 1970;26:847-852.
410. Totonchi KF, Engel G, Weisenberg E, et al. Testicular natural killer/T-cell lymphoma, nasal type, of true natural killer-cell origin. *Arch Pathol Lab Med*. 2002;126:1527-1529.
411. Tranchida P, Bayerl M, Voelpel MJ, Palutke M. Testicular ischemia due to intravascular large B-cell lymphoma: a novel presentation in an immunosupressed individual. *Int J Surg Pathol*. 2003;11:319-324.
412. Aktah M, Al-Dayel F, Siegrist K, Ezzat A. Neutrophil-rich Ki-1-positive anaplastic large cell lymphoma presenting as a testicular mass. *Mod Pathol*. 1996;9:812-815.
413. Ferry JA, Harris NL, Young RH, et al. Malignant lymphoma of the testis, epididymis, and spermatic cord. A clinicopathologic study of 69 cases with immunophenotypic analysis. *Am J Surg Pathol*. 1994;18:376-390.
414. Ferry JA, Ulbright TM, Young RH. Anaplastic large-cell lymphoma presenting in the testis: a lesion that may be confused with embryonal carcinoma. *J Urol Pathol*. 1996;5:139-148.
415. Turner RR, Colby TV, MacKintosh FR. Testicular lymphomas. A clinicopathologic study of 35 cases. *Cancer*. 1981;48:2095-2102.
416. Wilkins BS, Williamson JM, O'Brien CJ. Morphological and immunohistological study of testicular lymphomas. *Histopathology*. 1989;15:147-156.
417. Al-Abbadi MA, Hattab EM, Tarawneh M, et al. Primary testicular and paratesticular lymphoma: a retrospective clinicopathologic study of 34 cases with emphasis on differential diagnosis. *Arch Pathol Lab Med*. 2007;131:1040-1046.
418. Paladugu RR, Bearman RM, Rappaport H. Malignant lymphoma with primary manifestation in the gonad. A clinicopathologic study of 38 patients. *Cancer*. 1980;45:561-571.
419. Hyland J, Lasota J, Jasinski M, et al. Molecular pathological analysis of testicular diffuse large cell lymphomas. *Hum Pathol*. 1998;29:1231-1239.
420. Al-Abbadi MA, Hattab EM, Tarawneh MS, et al. Primary testicular diffuse large B-cell lymphoma belongs to the nongerminal center B-cell-like subgroup: a study of 18 cases. *Mod Pathol*. 2006;19:1521-1527.
421. Fonseca R, Habermann TM, Colgan JP, et al. Testicular lymphoma is associated with a high incidence of extranodal recurrence. *Cancer*. 2000;88:154-161.
422. Shahab N, Doll DC. Testicular lymphoma. *Semin Oncol*. 1999;26:259-269.
423. Tondini C, Ferreri AJ, Siracusano L, et al. Diffuse large-cell lymphoma of the testis. *J Clin Oncol*. 1999;17:2854-2858.
424. Woolley PV III, Osborne CK, Levi JA, et al. Extranodal presentation of non-Hodgkin's lymphomas in the testis. *Cancer*. 1976;38:1026-1035.
425. Bacon CM, Ye H, Diss TC, et al. Primary follicular lymphoma of the testis and epididymis in adults. *Am J Surg Pathol*. 2007;31:1050-1058.
426. Oppenheim PI, Cohen S, Anders KH. Testicular plasmacytoma. A case report with immunohistochemical studies and literature review. *Arch Pathol Lab Med*. 1991;115:629-632.
427. Ferry JA, Young RH, Scully RE. Testicular and epididymal plasmacytoma: a report of 7 cases, including three that were the initial manifestation of plasma cell myeloma. *Am J Surg Pathol*. 1997;21:590-598.
428. Levin HS, Mostofi FK. Symptomatic plasmacytoma of the testis. *Cancer*. 1970;25:1193-1203.
429. Givler RL. Testicular involvement in leukemia and lymphoma. *Cancer*. 1969;23:1290-1295.
430. Ferry JA, Srigley JR, Young RH. Granulocytic sarcoma of the testis: a report of two cases of a neoplasm prone to misinterpretation. *Mod Pathol*. 1997;10:320-325.
431. Valbuena JR, Admirand JH, Lin P, Medeiros LJ. Myeloid sarcoma involving the testis. *Am J Clin Pathol*. 2005;124:445-452.
432. Stoffel TJ, Nesbit ME, Levitt SH. Extramedullary involvement of the testes in childhood leukemia. *Cancer*. 1975;35:1203-1211.
433. Kim TH, Hargreaves HK, Chan WC, et al. Sequential testicular biopsies in childhood acute lymphocytic leukemia. *Cancer*. 1986;57:1038-1041.
434. Nesbit ME Jr, Robison LL, Ortega JA, et al. Testicular relapse in childhood acute lymphoblastic leukemia. Association with pretreatment patient characteristics and treatment. A report for Children's Cancer Study Group. *Cancer*. 1980;45:2009-2016.
435. Brousset P, Imadalou K, Rubie H, et al. Paraffin-section immunohistochemistry of residual disease in the testis in patients with acute lymphoblastic leukemia using anti-mb-1/CD79a (JCB117) monoclonal antibody. *Appl Immunohistochem*. 1996;4:56-60.
436. Suriawinata A, Talerman A, Vapnek JM, Unger P. Hemangioma of the testis: report of unusual occurrences of cavernous hemangioma in a fetus and capillary hemangioma in an older man. *Ann Diagn Pathol*. 2001;5:80-83.
437. Kryvenko ON, Epstein JI. Testicular hemangioma: a series of 8 cases. *Am J Surg Pathol*. 2013;37:860-866.
438. Banks ER, Mills SE. Histiocytoid (epithelioid) hemangioma of the testis. The so-called vascular variant of 'adenomatoid tumor'. *Am J Surg Pathol*. 1990;14:584-589.
439. Hargreaves HK, Scully RE, Richie JP. Benign hemangioendothelioma of the testis. Case report with electron microscopic

documentation and review of the literature. *Am J Clin Pathol*. 1982;77:637-642.
440. Montgomery E, Epstein JI. Anastomosing hemangioma of the genitourinary tract: a lesion mimicking angiosarcoma. *Am J Surg Pathol*. 2009;33:1364-1369.
441. Fine SW, Davis NJ, Lykins LE, Montgomery E. Solitary testicular myofibroma: a case report and review of the literature. *Arch Pathol Lab Med*. 2005;129:1322-1325.
442. Senger C, Gonzalez-Crussi F. Testicular juvenile xanthogranuloma: a case report. *J Urol Pathol*. 1999;10:159-168.
443. Suson K, Mathews R, Goldstein JD, Dehner LP. Juvenile xanthogranuloma presenting as a testicular mass in infancy: a clinical and pathologic study of three cases. *Pediatr Dev Pathol*. 2010;13:39-45.
444. Woodhouse JB, Delahunt B, English SF, et al. Testicular lipomatosis in Cowden's syndrome. *Mod Pathol*. 2005;18:1151-1156.
445. Fleshman RL, Wasman JK, Bodner DG, et al. Mesodermal adenosarcoma of the testis. *Am J Surg Pathol*. 2005;29:420-423.
446. Heikaus S, Schaefer KL, Eucker J, et al. Primary peripheral primitive neuroectodermal tumor/Ewing's tumor of the testis in a 46-year-old man—differential diagnosis and review of the literature. *Hum Pathol*. 2009;40:893-897.
447. Masera A, Ovcak Z, Mikuz G. Angiosarcoma of the testis. *Virchows Arch*. 1999;434:351-353.
448. Washecka RM, Mariani AJ, Zuna RE, et al. Primary intratesticular sarcoma: immunohistochemical, ultrastructural and DNA flow cytometric study of three cases with a review of the literature. *Cancer*. 1996;77:1524-1528.
449. Zukerberg LR, Young RH. Primary testicular sarcoma. A report of two cases. *Hum Pathol*. 1990;21:932-935.
450. Bates AW, Baithun SI. The significance of secondary neoplasms of the urinary and male genital tract. *Virchows Arch*. 2002;440:640-647.
451. Datta MW, Young RH. Malignant melanoma metastatic to the testis: a report of three cases with clinically significant manifestations. *Int J Surg Pathol*. 2000;8:49-58.
452. Datta MW, Ulbright TM, Young RH. Renal cell carcinoma metastatic to the testis and its adnexa: a report of five cases including three that accounted for the initial clinical presentation. *Int J Surg Pathol*. 2001;9:49-56.
453. Nistal M, Gonzalez-Peramato P, Paniagua R. Secondary testicular tumors. *Eur Urol*. 1989;16:185-188.
454. Price EB Jr, Mostofi FK. Secondary carcinoma of the testis. *Cancer*. 1957;10:592-595.
455. Tiltman AJ. Metastatic tumours in the testis. *Histopathology*. 1979;3:31-37.
456. Haupt HM, Mann RB, Trump DL, Abeloff MD. Metastatic carcinoma involving the testis. Clinical and pathologic distinction from primary testicular neoplasms. *Cancer*. 1984;54:709-714.
457. Kay S, Hennigar GR, Hooper JW Jr. Carcinoma of the testes metastatic from carcinoma of the prostate. *Arch Pathol*. 1954;57:121-129.
458. Weitzner S. Survival of patients with secondary carcinoma of prostate in the testis. *Cancer*. 1973;32:447-449.
459. Ro JY, Ayala AG, Tetu B, et al. Merkel cell carcinoma metastatic to the testis. *Am J Clin Pathol*. 1990;94:384-389.
460. Zuk RJ, Trotter SE, Baithun SI. 'Krukenberg' tumour of the testis. *Histopathology*. 1989;14:214-216.
461. Dutt N, Bates AW, Baithun SI. Secondary neoplasms of the male genital tract with different patterns of involvement in adults and children. *Histopathology*. 2000;37:323-331.
462. Simon T, Hero B, Berthold F. Testicular and paratesticular involvement by metastatic neuroblastoma. *Cancer*. 2000;88:2636-2641.
463. Roosen-Runge EC, Holstein AF. The human rete testis. *Cell Tissue Res*. 1978;189:409-433.
464. Shah VI, Ro JY, Amin MB, et al. Histologic variations in the epididymis: findings in 167 orchiectomy specimens. *Am J Surg Pathol*. 1998;22:990-996.
465. Mai KT. Cytoplasmic eosinophilic granular change of the ductuli efferentes. A histological, immunohistochemical, and electron microscopic study. *J Urol Pathol*. 1994;2:273-282.
466. Kuo T-T, Gomez LG. Monstrous epithelial cells in human epididymis and seminal vesicles. A pseudomalignant change. *Am J Surg Pathol*. 1981;5:483-490.
467. Oliva E, Young RH. Paratesticular tumor-like lesions. *Semin Diagn Pathol*. 2000;17:340-358.
468. Maneely RB. Epididymal structure and function. A historical and critical review. *Acta Zool*. 1959;40:1-21.
469. Schned AR, Memoli VA. Coarse granular cytoplasmic change of the epididymis. An immunohistochemical and ultrastructural study. *J Urol Pathol*. 1994;2:213-222.
470. Paniagua R, Regadera J, Nistal M, Abaurrea MA. Histological, histochemical and ultrastructural variations along the length of the human vas deferens before and after puberty. *Acta Anat (Basel)*. 1981;111:190-203.
471. Madara JL, Haggitt RC, Federman M. Intranuclear inclusions of the human vas deferens. *Arch Pathol Lab Med*. 1978;102:648-650.
472. Magers MJ, Udager AM, Chinnaiyan AM, et al. Comprehensive Immunophenotypic Characterization of Adult and Fetal Testes, the Excretory Duct System, and Testicular and Epididymal Appendages. *Appl Immunohistochem Mol Morphol*. 2016;24:e50-e68.
473. Tong GX, Memeo L, Colarossi C, et al. PAX8 and PAX2 immunostaining facilitates the diagnosis of primary epithelial neoplasms of the male genital tract. *Am J Surg Pathol*. 2011;35:1473-1483.
474. Nistal M, González-Peramato P, Serrano A, et al. Paratesticular cysts with benign epithelial proliferations of wolffian origin. *Am J Clin Pathol*. 2005;124:245-251.
475. Sasaki K, Bastacky SI, Zynger DL, Parwani AV. Use of immunohistochemical markers to confirm the presence of vas deferens in vasectomy specimens. *Am J Clin Pathol*. 2009;132:893-898.
476. Nistal M, Jiménez-Heffernan JA. Rete testis dysgenesis: a characteristic lesion of undescended testes. *Arch Pathol Lab Med*. 1997;121:1259-1264.
477. Nistal M, Paniagua R. Nodular proliferation of calcifying connective tissue in the rete testis. A study of three cases. *Hum Pathol*. 1989;20:58-61.
478. Nistal M, García-Cabezas MA, Regadera J, Castillo MC. Microlithiasis of the epididymis and the rete testis. *Am J Surg Pathol*. 2004;28:514-522.
479. Jones EC, Murray SK, Young RH. Cysts and epithelial proliferations of the testicular collecting system (including rete testis). *Semin Diagn Pathol*. 2000;17:270-293.
480. Nistal M, Mate A, Paniagua R. Cystic transformation of the rete testis. *Am J Surg Pathol*. 1996;20:1231-1239.
481. Nistal M, Santamaria L, Paniagua R. Acquired cystic transformation of the rete testis secondary to renal failure. *Hum Pathol*. 1989;20:1065-1070.
482. Nistal M, Jiménez-Heffernan JA, Garcia-Viera M, Paniagua R. Cystic transformation and calcium oxalate deposits in rete testis and efferent ducts in dialysis patients. *Hum Pathol*. 1996;27:336-341.
483. Fridman E, Skarda J, Ofek-Moravsky E, Cordoba M. Complex multilocular cystic lesion of rete testis, accompanied by smooth muscle hyperplasia, mimicking intratesticular Leydig cell neoplasm. *Virchows Arch*. 2005;447:768-771.
484. Paner GP, Kristiansen G, McKenney JK, et al. Rete testis-associated nodular steroid cell nests: description of putative pluripotential testicular hilus steroid cells. *Am J Surg Pathol*. 2011;35:505-511.
485. Butterworth DM, Bisset DL. Cribriform intra-tubular epididymal change and adenomatous hyperplasia of the rete testis—a consequence of testicular atrophy? *Histopathology*. 1992;21:435-438.
486. Ulbright TM, Gersell DJ. Rete testis hyperplasia with hyaline globule formation. A lesion simulating yolk sac tumor. *Am J Surg Pathol*. 1991;15:66-74.
487. Hartwick RW, Ro JY, Srigley JR, et al. Adenomatous hyperplasia of the rete testis. A clinicopathologic study of nine cases. *Am J Surg Pathol*. 1991;15:350-357.
488. Jones MA, Young RH. Sertoliform cystadenoma of the rete testes: a report of two cases. *J Urol Pathol*. 1997;7:47-54.
489. Nochomovitz LE, Orenstein JM. Adenocarcinoma of the rete testis. Consolidation and analysis of 31 reported cases with a review of miscellaneous entities. *J Urol Pathol*. 1994;2:1-37.
490. Sarma DP, Weilbaecher TG. Adenocarcinoma of the rete testis. *J Surg Oncol*. 1985;30:67-71.
491. Fukunaga M, Aizawa S, Furusato M, et al. Papillary adenocarcinoma of the rete testis. A case report. *Cancer*. 1982;50:134-138.
492. Samaratunga H, Kanowski P, O'Loughlin B, et al. Adenocarcinoma of the rete testis with intratubular invasion of the testis. *J Urol Pathol*. 1994;2:291-300.
493. Visscher DW, Talerman A, Rivera LR, Mazur MT. Adenocarcinoma of the rete testis with a spindle cell component. A possible metaplastic carcinoma. *Cancer*. 1989;64:770-775.
494. Watson PH, Jacob VC. Adenocarcinoma of the rete testis with sertoliform differentiation. *Arch Pathol Lab Med*. 1989;113:1169-1171.
495. Amin MB. Tumors of the collecting duct and rete testis. In: Moch H, Humphrey PA, Ulbright TM, Reuter VE, eds. *WHO Classification of Tumours of the Urinary System and Male Genital Organs*. Lyon, France: IARC Press; 2016.
496. Lee AH, Theaker JM. Pagetoid spread into the rete testis by testicular tumours. *Histopathology*. 1994;24:385-389.
497. Mai KT, Yazdi HM, Rippstein P. Light and electron microscopy of the pagetoid spread of germ cell carcinoma in the rete testis: morphologic evidence suggestive of field effect as a mechanism of tumor spread. *Appl Immunohistochem Mol Morphol*. 2001;9:335-339.
498. Vordermark JS II, Favila MQ. Testicular necrosis. A preventable complication of epididymitis. *J Urol*. 1982;128:1322-1324.
499. Hori S, Tsutsumi Y. Histological differentiation between chlamydial and bacterial epididymitis. Nondestructive and proliferative versus destructive and abscess forming. Immunohistochemical and clinicopathological findings. *Hum Pathol*. 1995;26:402-407.
500. Auerbach O. The pathology of urogenital tuberculosis. *Int Clin*. 1940;3:21-61.
501. Ferrie SG, Rundle JSH. Tuberculous epididymo-orchitis. A review of 20 cases. *Br J Urol*. 1983;55:437-439.
502. Haddad FS. Coccidioidomycosis of the genitourinary tract with special emphasis on the epididymis and the prostate: four case

reports and review of the literature. *J Urol Pathol*. 1996;4:205-212.
503. Kanomata N, Eble JN. Fungal epididymitis caused by Histoplasma capsulatum: a case report. *J Urol Pathol*. 1996;5:229-234.
504. Nistal M, Mate A, Paniagua R. Granulomatous epididymal lesion of possible ischemic origin. *Am J Surg Pathol*. 1997;21:951-956.
505. Glassy FJ, Mostofi FK. Spermatic granulomas of the epididymis. *Am J Clin Pathol*. 1956;26:1303-1313.
506. Yantiss RK, Young RH. Idiopathic granulomatous epididymitis: report of a case and review of the literature. *J Urol Pathol*. 1998;8:171-179.
507. Levine TS. Testicular and epididymal vasculitides. Is morphology of help in classification and prognosis? *J Urol Pathol*. 1994;2:81-88.
508. Womack C, Ansell ID. Isolated arteritis of the epididymis. *J Clin Pathol*. 1985;38:797-800.
509. Hernandez-Rodriguez J, Tan CD, Koening CL, et al. Testicular vasculitis: findings differentiating isolated disease from systemic disease in 72 patients. *Medicine (Baltimore)*. 2012;91:75-85.
510. Sharp SC, Batt MA, Lennington WJ. Epididymal cribriform hyperplasia. A variant of normal epididymal histology. *Arch Pathol Lab Med*. 1994;118:1020-1022.
511. Khalil KH, Ball RY, Eardley I, Ashken MH. Inflammatory pseudotumor of the rete testis. *J Urol Pathol*. 1996;5:39-44.
512. Lucas DR, Shukla A, Thomas DG, et al. Dedifferentiated liposarcoma with inflammatory myofibroblastic tumor-like features. *Am J Surg Pathol*. 2010;34:844-851.
513. Lee S, Illei PB, Han JS, Epstein JI. Florid mesothelial hyperplasia of the tunica vaginalis mimicking malignant mesothelioma: a clinicopathologic study of 12 cases. *Am J Surg Pathol*. 2014;38:54-59.
514. Lane Z, Epstein JI. Small blue cells mimicking small cell carcinoma in spermatocele and hydrocele specimens: a report of 5 cases. *Hum Pathol*. 2010;41:88-93.
515. Michal M, Kazakov DV, Dundr P, et al. Histiocytosis with raisinoid nuclei: a unifying concept for lesions reported under different names as nodular mesothelial/histiocytic hyperplasia, mesothelial/monocytic incidental cardiac excrescences, intralymphatic histiocytosis, and others: a report of 50 cases. *Am J Surg Pathol*. 2016;40:1507-1516.
516. Berney DM, Agaimy A, Amin MB, et al. Tumours of the paratesticular system. In: Moch H, Humphrey PA, Ulbright TM, Reuter VE, eds. *WHO Classification of Tumours of the Urinary System and Male Genital Organs*. Lyon, France: IARC Press; 2016.
517. Said JW, Nash G, Lee M. Immunoperoxidase localization of keratin proteins, carcinoembryonic antigen, and factor VIII in adenomatoid tumors. Evidence for a mesothelial derivation. *Hum Pathol*. 1982;13:1106-1108.
518. Sangoi AR, McKenney JK, Schwartz EJ, et al. Adenomatoid tumors of the female and male genital tracts: a clinicopathological and immunohistochemical study of 44 cases. *Mod Pathol*. 2009;22:1228-1235.
519. Wachter DL, Wünsch PH, Hartmann A, Agaimy A. Adenomatoid tumors of the female and male genital tract. A comparative clinicopathologic and immunohistochemical analysis of 47 cases emphasizing their site-specific morphologic diversity. *Virchows Arch*. 2011;458:593-602.
520. Akhtar M, Reyes F, Young I. Elastogenesis in adenomatoid tumor. *Cancer*. 1976;37: 338-345.
521. Skinnider BF, Young RH. Infarcted adenomatoid tumor: a report of five cases of a facet of a benign neoplasm that may cause diagnostic difficulty. *Am J Surg Pathol*. 2004;28:77-83.
522. Jones MA, Young RH, Scully RE. Malignant mesothelioma of the tunica vaginalis. A clinicopathologic analysis of 11 cases with review of the literature. *Am J Surg Pathol*. 1995;19:815-825.
523. Kamiya M, Eimoto T. Malignant mesothelioma of the tunica vaginalis. *Pathol Res Pract*. 1990;186:680-684.
524. Kasdon EJ. Malignant mesothelioma of the tunica vaginalis propria testis. Report of two cases. *Cancer*. 1969;23:1144-1150.
525. Winstanley AM, Landon G, Berney D, et al. The immunohistochemical profile of malignant mesotheliomas of the tunica vaginalis: a study of 20 cases. *Am J Surg Pathol*. 2006;30:1-6.
526. Attanoos RL, Gibbs AR. Primary malignant gonadal mesotheliomas and asbestos. *Histopathology*. 2000;37:150-159.
527. Fligiel Z, Kaneko M. Malignant mesothelioma of the tunica vaginalis propria testis in a patient with asbestos exposure. A case report. *Cancer*. 1976;37:1478-1484.
528. Gorini G, Pinelli M, Sforza V, et al. Mesothelioma of the tunica vaginalis testis: report of 2 cases with asbestos occupational exposure. *Int J Surg Pathol*. 2005;13:211-214.
529. Perez-Ordonez B, Srigley JR. Mesothelial lesions of the paratesticular region. *Semin Diagn Pathol*. 2000;17:294-306.
530. Plas E, Riedl CR, Pfuger H. Malignant mesothelioma of the tunica vaginalis testis: review of the literature and assessment of prognostic parameters. *Cancer*. 1998;83:2437-2446.
531. Goldblum J, Hart WR. Localized and diffuse mesotheliomas of the genital tract and peritoneum in women. A clinicopathologic study of nineteen true mesothelial neoplasms, other than adenomatoid tumors, multicystic mesotheliomas, and localized fibrous tumors. *Am J Surg Pathol*. 1995;19:1124-1137.
532. Butnor KJ, Sporn TA, Hammar SP, Roggli VL. Well-differentiated papillary mesothelioma. *Am J Surg Pathol*. 2001;25:1304.
533. Brimo F, Illei PB, Epstein JI. Mesothelioma of the tunica vaginalis: a series of eight cases with uncertain malignant potential. *Mod Pathol*. 2010;23:1165-1172.
534. Tsuda H, Fukushima S, Takahashi M, et al. Familial bilateral papillary cystadenoma of the epididymis. Report of three cases in siblings. *Cancer*. 1976;37:1831-1839.
535. Price EB Jr. Papillary cystadenoma of the epididymis. *Arch Pathol*. 1971;91:456-470.
536. Calder CJ, Gregory J. Papillary cystadenoma of the epididymis. A report of two cases with an immunohistochemical study. *Histopathology*. 1993;23:89-91.
537. Cox R, Vang R, Epstein JI. Papillary cystadenoma of the epididymis and broad ligament: morphologic and immunohistochemical overlap with clear cell papillary renal cell carcinoma. *Am J Surg Pathol*. 2014;38:713-718.
538. Aydin H, Young RH, Ronnett BM, Epstein JI. Clear cell papillary cystadenoma of the epididymis and mesosalpinx: immunohistochemical differentiation from metastatic clear cell renal cell carcinoma. *Am J Surg Pathol*. 2005;29:520-523.
539. Shen T, Zhuang Z, Gersell DJ, Tavassoli FA. Allelic deletion of VHL gene detected in papillary tumors of the broad ligament, epididymis, and retroperitoneum in von Hippel–Lindau disease patients. *Int J Surg Pathol*. 2000;8:207-212.
540. Leung SY, Chan AS, Wong MP, et al. Expression of vascular endothelial growth factor in von Hippel–Lindau syndrome-associated papillary cystadenoma of the epididymis. *Hum Pathol*. 1998;29:1322-1323.
541. Salm R. Papillary carcinoma of the epididymis. *J Pathol*. 1969;97:253-259.
542. Jones MA, Young RH, Scully RE. Adenocarcinoma of the epididymis: a report of four cases and review of the literature. *Am J Surg Pathol*. 1997;21:1474-1480.
543. Mai KT, Carlier M, Lajeunesse C. Paratesticular composite tumour of epididymal-like and mucinous cells of low malignant potential. *Histopathology*. 1998;33:193-194.
544. De Nictolis M, Tommasoni S, Fabris G, Prat J. Intratesticular serous cystadenoma of borderline malignancy. A pathological, histochemical and DNA content study of a case with long-term follow-up. *Virchows Arch A Pathol Anat Histopathol*. 1993;423:221-225.
545. McClure RF, Keeney GL, Sebo TJ, Cheville JC. Serous borderline tumor of the paratestis: a report of seven cases. *Am J Surg Pathol*. 2001;25:373-378.
546. Ulbright TM, Young RH. Primary mucinous tumors of the testis and paratestis: a report of nine cases. *Am J Surg Pathol*. 2003;27:1221-1228.
547. Young RH, Scully RE. Testicular and paratesticular tumors and tumor-like lesions of ovarian common epithelial and müllerian types. A report of four cases and review of the literature. *Am J Clin Pathol*. 1986;86:146-152.
548. Nistal M, Revestido R, Paniagua R. Bilateral mucinous cystadenocarcinoma of the testis and epididymis. *Arch Pathol Lab Med*. 1992;116:1360-1363.
549. Blumberg HM, Hendrix LE. Serous papillary adenocarcinoma of the tunica vaginalis of the testis with metastasis. *Cancer*. 1991;67:1450-1453.
550. Jones MA, Young RH, Srigley JR, Scully RE. Paratesticular serous papillary carcinoma. A report of six cases. *Am J Surg Pathol*. 1995;19:1359-1365.
551. Carano KS, Soslow RA. Immunophenotypic analysis of ovarian and testicular mullerian papillary serous tumors. *Mod Pathol*. 1997;10:414-420.
552. Spark RP. Leiomyoma of epididymis. *Arch Pathol*. 1972;93:18-21.
553. Primer Trevino K, Chen S, Ulbright TM, Idrees MT. Paratesticular soft-tissue masses in orchiectomy specimens: a 17-year survey of primary and incidental cases from one institution. *Int J Surg Pathol*. 2017;25(6):480-487.
554. Chetty R. Epididymal cavernous haemangiomas. *Histopathology*. 1993;22:396-398.
555. Postius J, Manzano C, Concepcion T, et al. Epididymal lymphangioma. *J Urol*. 2000;163:550-551.
556. Wehner MS, Humphreys JL, Sharkey FE. Epididymal rhabdomyoma: a report of a case, including histologic and immunohistochemical findings. *Arch Pathol Lab Med*. 2000;124:1518-1519.
557. Ricketts RR, Majmudarr B. Epididymal melanotic neuroectodermal tumor of infancy. *Hum Pathol*. 1985;16:416-420.
558. McDermott MB, O'Briain DS, Shiels OM, Daly PA. Malignant lymphoma of the epididymis. A case report of bilateral involvement by a follicular large cell lymphoma. *Cancer*. 1995;75:2174-2179.
559. Novella G, Porcaro AB, Righetti R, et al. Primary lymphoma of the epididymis: case report and review of the literature. *Urol Int*. 2001;67:97-99.
560. Wachtel TL, Mehan DG. Metastatic tumors of the epididymis. *J Urol*. 1970;103:624-627.
561. Yamashina M, Honma T, Uchijima Y. Myofibroblastic pseudotumor mimicking epididymal sarcoma. A clinicopathologic

study of three cases. *Pathol Res Pract*. 1992;188:1054-1059.
562. Dehner LP, Scott D, Stocker JT. Meconium periorchitis: a clinicopathologic study of four cases with a review of the literature. *Hum Pathol*. 1986;17:807-812.
563. Skoglund RW, McRoberts JW, Ragde H. Torsion of the spermatic cord. A review of the literature and an analysis of 70 new cases. *J Urol*. 1970;104:604-607.
564. McFarland JB. Testicular strangulation in children. *Br J Surg*. 1966;53:110-114.
565. Nistal M, Gonzàlez-Peramato P, Paniagua R. Lipomembranous fat necrosis in three cases of testicular torsion. *Histopathology*. 2001;38:443-447.
566. Simon HB, Larkin PC. Torsion of the appendix testis. Report of 13 cases. *JAMA*. 1967;202:140-141.
567. Skoglund RW, McRoberts JW, Ragde H. Torsion of testicular appendages. Presentation of 43 new cases and a collective review. *J Urol*. 1970;104:598-600.
568. Kernohan NM, Coutts AG, Best PV. Cystadenocarcinoma of the appendix testis. *Histopathology*. 1990;17:147-154.
569. Corless CL, Daut D, Burke R. Localized giant cell vasculitis of the spermatic cord presenting as a mass lesion. *J Urol Pathol*. 1997;6:235-242.
570. Taxy JB. Vasitis nodosa. *Arch Pathol Lab Med*. 1978;102:643-647.
571. Olson AL. Vasitis nodosa. *Am J Clin Pathol*. 1971;55:364-368.
572. Balogh K, Travis WD. The frequency of perineurial ductules in vasitis nodosa. *Am J Clin Pathol*. 1984;82:710-713.
573. Hollowood K, Fletcher CD. Pseudosarcomatous myofibroblastic proliferations of the spermatic cord ('proliferative funiculitis'). Histologic and immunohistochemical analysis of a distinctive entity. *Am J Surg Pathol*. 1992;16:448-454.
574. Barton JH, Davis CJ Jr, Sesterhenn IA, Mostofi FK. Smooth muscle hyperplasia of the testicular adnexa clinically mimicking neoplasia: clinicopathologic study of sixteen cases. *Am J Surg Pathol*. 1999;23:903-909.
575. Henley JD, Ferry J, Ulbright TM. Miscellaneous rare paratesticular tumors. *Semin Diagn Pathol*. 2000;17:319-339.
576. Srigley JR. The paratesticular region: histoanatomic and general considerations. *Semin Diagn Pathol*. 2000;17:258-269.
577. Lilly MC, Arregui ME. Lipomas of the cord and round ligament. *Ann Surg*. 2002;235:586-589.
578. Laskin WB, Fetsch JF, Mostofi FK. Angiomyofibroblastomalike tumor of the male genital tract: analysis of 11 cases with comparison to female angiomyofibroblastoma and spindle cell lipoma. *Am J Surg Pathol*. 1998;22:6-16.
579. Iwasa Y, Fletcher CD. Cellular angiofibroma: clinicopathologic and immunohistochemical analysis of 51 cases. *Am J Surg Pathol*. 2004;28:1426-1435.
580. Flucke U, van Krieken JH, Mentzel T. Cellular angiofibroma: analysis of 25 cases emphasizing its relationship to spindle cell lipoma and mammary-type myofibroblastoma. *Mod Pathol*. 2011;24:82-89.
581. Idrees MT, Hoch BL, Wang BY, Unger PD. Aggressive angiomyxoma of male genital region. Report of 4 cases with immunohistochemical evaluation including hormone receptor status. *Ann Diagn Pathol*. 2006;10:197-204.
582. Nucci MR, Weremowicz S, Neskey DM, et al. Chromosomal translocation t(8;12) induces aberrant HMGIC expression in aggressive angiomyxoma of the vulva. *Genes Chromosomes Cancer*. 2001;32:172-176.
583. McCluggage WG, Connolly L, McBride HA. HMGA2 is a sensitive but not specific immunohistochemical marker of vulvovaginal aggressive angiomyxoma. *Am J Surg Pathol*. 2010;34:1037-1042.
584. Dreux N, Marty M, Chibon F, et al. Value and limitation of immunohistochemical expression of HMGA2 in mesenchymal tumors: about a series of 1052 cases. *Mod Pathol*. 2010;23:1657-1666.
585. Magro G, Righi A, Casorzo L, et al. Mammary and vaginal myofibroblastomas are genetically related lesions: fluorescence in situ hybridization analysis shows deletion of 13q14 region. *Hum Pathol*. 2012;43:1887-1893.
586. Chen E, Fletcher CD. Cellular angiofibroma with atypia or sarcomatous transformation: clinicopathologic analysis of 13 cases. *Am J Surg Pathol*. 2010;34:707-714.
587. Izhak OB. Solitary papillary cystadenoma of the spermatic cord presenting as an inguinal mass. *J Urol Pathol*. 1997;7:55-62.
588. McCluggage WG, Shah V, Nott C, et al. Cystadenoma of spermatic cord resembling ovarian serous epithelial tumour of low malignant potential: immunohistochemical study suggesting Mullerian differentiation. *Histopathology*. 1996;28:77-80.
589. Bacchi CE, Schmidt RA, Brandao M, et al. Paraganglioma of the spermatic cord. Report of a case with immunohistochemical and ultrastructural studies. *Arch Pathol Lab Med*. 1990;114:899-901.
590. Eusebi V, Massarelli G. Phaeochromocytoma of the spermatic cord. Report of a case. *J Pathol*. 1971;105:283-284.
591. Folpe AL, Weiss SW. Paratesticular soft tissue neoplasms. *Semin Diagn Pathol*. 2000;17:307-318.
592. Sarma DP, Weilbaecher TG. Leiomyoma of the spermatic cord. *J Surg Oncol*. 1985;28:318-320.
593. Shim JW, Ro JY, Yang I, et al. Solitary fibrous tumor: a case report arising in the scrotum. *J Urol Pathol*. 1999;10:229-238.
594. Tanda F, Rocca PC, Bosincu L, et al. Rhabdomyoma of the tunica vaginalis of the testis: a histologic, immunohistochemical, and ultrastructural study. *Mod Pathol*. 1997;10:608-611.
595. Yasui N, Yoshida A, Kawamoto H, et al. Clinicopathologic analysis of spindle cell/sclerosing rhabdomyosarcoma. *Pediatr Blood Cancer*. 2015;62:1011-1016.
596. Cummings OW, Ulbright TM, Young RH, et al. Desmoplastic small round cell tumors of the paratesticular region: a report of six cases. *Am J Surg Pathol*. 1997;21:219-225.
597. Arlen M, Grabstald H, Whitmore WF Jr. Malignant tumors of the spermatic cord. *Cancer*. 1969;23:525-532.
598. Fisher C, Goldblum JR, Epstein JI, Montgomery E. Leiomyosarcoma of the paratesticular region: a clinicopathologic study. *Am J Surg Pathol*. 2001;25:1143-1149.
599. Kinjo M, Hokamura K, Tanaka K, et al. Leiomyosarcoma of the spermatic cord. A case report and a brief review of literature. *Acta Pathol Jpn*. 1986;36:929-934.
600. Lin BT, Harvey DA, Medeiros LJ. Malignant fibrous histiocytoma of the spermatic cord: report of two cases and review of the literature. *Mod Pathol*. 2002;15:59-65.
601. McCluggage WG, Dolan S, Cameron CH, Russell CF. Epithelioid hemangioendothelioma of the spermatic cord. *Int J Surg Pathol*. 2000;8:75-78.
602. Montgomery E, Fisher C. Paratesticular liposarcoma: a clinicopathologic study. *Am J Surg Pathol*. 2003;27:40-47.
603. Blitzer PH, Dosoretz DE, Proppe KH, Shipley WU. Treatment of malignant tumors of the spermatic cord. A study of 10 cases and a review of the literature. *J Urol*. 1981;126:611-614.
604. Ballo MT, Zagars GK, Pisters PW, et al. Spermatic cord sarcoma: outcome, patterns of failure and management. *J Urol*. 2001;166:1306-1310.
605. Fagundes MA, Zietman AL, Althausen AF, et al. The management of spermatic cord sarcoma. *Cancer*. 1996;77:1873-1876.
606. Nazeer T, Ro JY, Kee KH, Ayala AG. Spermatic cord contamination in testicular cancer. *Mod Pathol*. 1996;9:762-766.

Penis and Scrotum

28

Jesse K. McKenney

CHAPTER CONTENTS

Penis, *1175*
Normal anatomy, *1175*
Non-neoplastic lesions, *1175*
Tumors, *1178*

Scrotum, *1184*
Normal anatomy, *1184*
Non-neoplastic lesions, *1184*
Tumors, *1185*

Penis

Normal Anatomy

The main anatomic components of the penis are the *corpus* (shaft), *glans*, and *prepuce* (foreskin). The corpus is composed of the *corpora cavernosa* (made up of a net of vascular spaces surrounded by the tunica albuginea) and the inferiorly located *corpus spongiosus*, in the center of which runs the penile urethra. All of these structures are covered by skin, a smooth discontinuous muscle layer known as *dartos*, and an elastic sheath designated as *Buck fascia*. The latter separates the penis into dorsal (corpora cavernosa) and ventral (corpus spongiosum) portions, a distinction highlighted by computed tomography (CT) and magnetic resonance imaging (MRI) techniques.[1]

The skin of the glans is made up of nonkeratinized stratified squamous epithelium, five to six cell layers thick; this becomes keratinized after circumcision.[2] The glans is separated from the shaft by the *balanopreputial sulcus* in the dorsal and lateral aspects and by the *frenulum* in the ventral region.

The male urethra is divided into three portions: *prostatic* (the short proximal segment surrounded by the prostate), *membranous* or *bulbomembranous* (extending from the lower pole of the prostate to the bulb of the corpus spongiosum), and *penile* (which passes longitudinally through the corpus spongiosum). The terminal enlarged portion of the penile urethra is known as the *fossa navicularis*.

Microscopically, the lining of the urethra is of urothelial type in the proximal (prostatic) portion, of stratified squamous type in the distal portion corresponding to the fossa navicularis, and of stratified or pseudostratified columnar ciliated epithelium in the rest of the canal.[1] Glandular structures associated with the urethra are the *intraepithelial glands* or Morgagni lacunae (one-layer cylindrical intraepithelial glands), *Littré glands* (tubuloacinar mucinous glands present along the full length of the corpus spongiosum), and the bulbourethral or *Cowper glands* (mucous acinar structures located deeply at the level of the membranous urethra).[1]

The lymphatic drainage of the penis is to the superficial and deep inguinal nodes. There are centrally located anastomoses between lymph vessels that result in bilateral drainage.

Non-Neoplastic Lesions

Small accessory urethral canals or periurethral ducts may open in or about the fossa navicularis and produce symptoms because of secondary inflammation.[3] The *median raphe cyst* that has been described in the central aspect of the glans in young men probably represents a cystic dilation of these structures (Fig. 28.1).[4]

Mucoid cyst can be found on the prepuce or glans penis. It has a lining of stratified columnar epithelium, often associated with intraepithelial mucous glands (Fig. 28.2).[5,6]

Mucinous metaplasia refers to the presence of mucin-producing cells in the surface epithelium in the prepuce or glans penis. It is seen in the elderly and appears to be a metaplastic change associated with severe chronic inflammation, particularly Zoon balanitis (see later).[7,8]

Inflammation of Littré glands can clinically simulate a penile tumor.[9]

Dermatoses of various types can involve the skin of the penis. These include eczematous dermatitis, seborrheic dermatitis, fixed drug eruption, psoriasis, lichen planus, lichen nitidus, and lichen sclerosus et atrophicus.

Lichen sclerosus has traditionally been known in this location as *balanitis xerotica obliterans*.[10] Evidence suggests that lichen sclerosus plays a role in the development of non-human papilloma virus (HPV)-related squamous cell carcinoma (Fig. 28.3A and B).[11]

An inflammatory condition clinically resembling Bowen disease is *balanitis circumscripta* (Zoon balanitis), characterized microscopically by epidermal atrophy and a dense inflammatory infiltrate rich in plasma cells.[12,13]

Abstract

This chapter covers the spectrum of diseases that involve the penis and scrotum. Inflammatory lesions, including those of infectious etiology, are reviewed in detail. The discussion of squamous cell carcinoma follows the latest WHO 2016 classification; therefore, both non-invasive (i.e. penile intraepithelial neoplasia) and invasive variants are divided into HPV and non-HPV types. Other rare mesenchymal tumors are also addressed, as are tumors that frequently involve the male urethra and scrotum.

Keywords

penis
scrotum
male urethra
squamous cell carcinoma
verrucous carcinoma
penile intraepithelial neoplasia
human papilloma virus

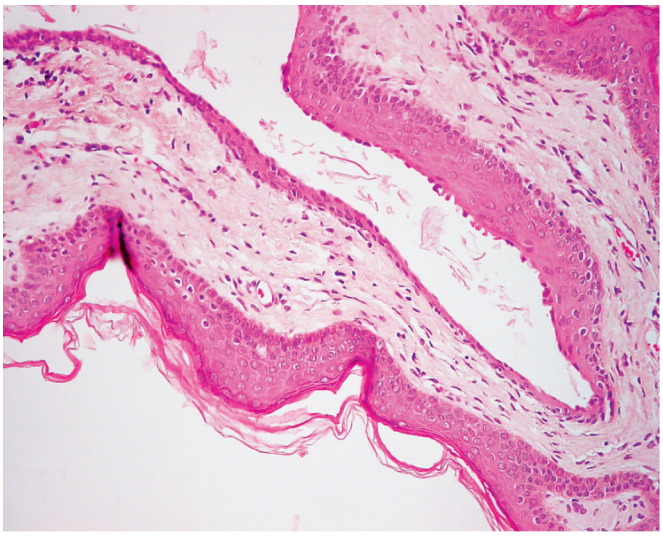

Figure 28.1 Median Raphe Cyst. This probably results from cystic dilation of accessory urethral canals or periurethral ducts.

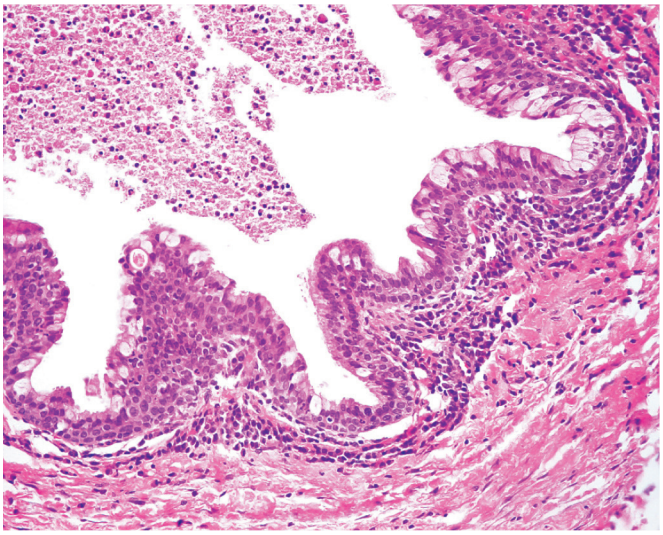

Figure 28.2 Mucoid Cyst of Penis. The lesion is lined by stratified columnar epithelium containing mucin-secreting cells.

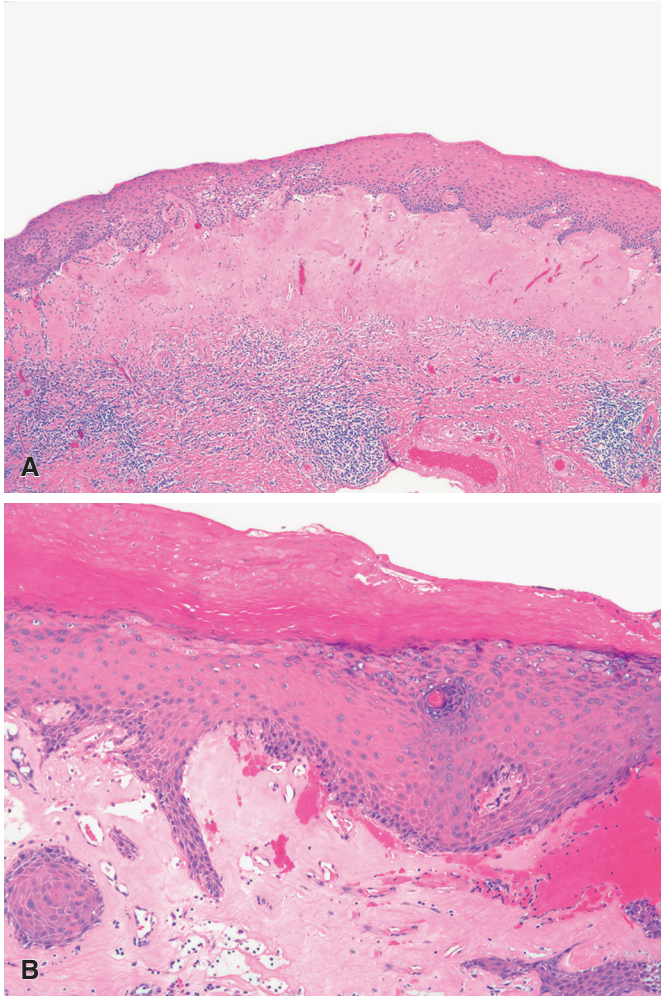

Figure 28.3 Lichen Sclerosus. A, The dense hyalinized band of dermal collagen, chronic lymphocytic inflammation, and loss of rete ridges is characteristic. **B,** Acanthosis and hyperkeratosis defines squamous hyperplasia, in this case associated with lichen sclerosus.

Deep *granuloma annulare* can be localized to the penis.[14]

Amyloidosis presenting as a localized mass in the shaft of the penis has been reported.[14]

Primary syphilis (chancre) consists microscopically of a thin and sometimes ulcerated epidermis accompanied by a dense dermal inflammatory infiltrate rich in plasma cells and lymphocytes (Fig. 28.4A). The blood vessels show marked endothelial cell swelling and proliferation, as well as infiltration of the wall by inflammatory cells ("endarteritis obliterans"). Spirochetes can be demonstrated with the Warthin–Starry silver stain or immunohistochemically, both in the epidermis and in the dermis (particularly in and around the proliferating vessels) (see Fig. 28.4B).

Chancroid, the most common cause of genital ulceration in Africa, is characterized microscopically by vasculitis in the deep dermis, manifested by perivascular and intramural lymphocytic and histiocytic infiltrates associated with swelling of endothelial cells, sometimes admixed with neutrophils and/or multinucleated giant cells.[15] The overlying epidermis shows psoriasiform hyperplasia and spongiosis, sometimes accompanied by neutrophils in the malpighian and horny parakeratotic layers.

Genital **herpes** is caused by the herpes simplex virus (HSV), most commonly HSV2. It presents as small skin vesicles that rupture to form small painful ulcers. Histologically, the edges of the ulcer show multinucleated keratinocytes with ground-glass nuclear inclusions and molding (Fig. 28.5). The diagnosis may be made by Tzanck preparations.

Tuberculosis and other granulomatous inflammations can on rare occasions present as penile nodules.[16]

Abscess and **gangrene** of the penis are described.[17]

Granulomatosis with polyangitis (Wegener's granulomatosis) can be localized to the penis and clinically simulate a carcinoma.[18]

Behçet disease is a symptom complex of oral and genital ulcers and iritis.[19,20] Microscopically, various types of vasculitis may be encountered.

Peyronie disease (plastic induration of the penis) is a progressive fibrous thickening arising in the connective tissue layer between the corpora cavernosa and the tunica albuginea. It causes pain and penile curvature toward the side of the lesion on penile erection.[21–23] Microscopically, the lesion is composed of hyalinized fibrous tissue, at times containing cartilage and bone (Fig. 28.6).[24] It may be

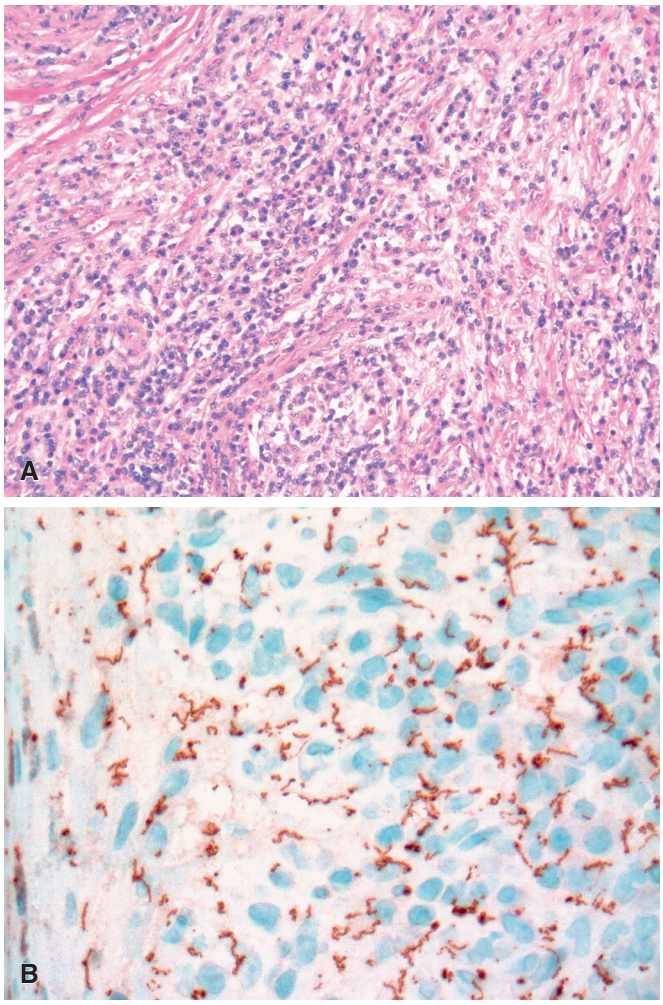

Figure 28.4 Syphilis. A, The dense plasma cell–rich inflammatory infiltrate, often around blood vessels, is characteristic. **B,** Immunostain for *Treponema pallidum*.

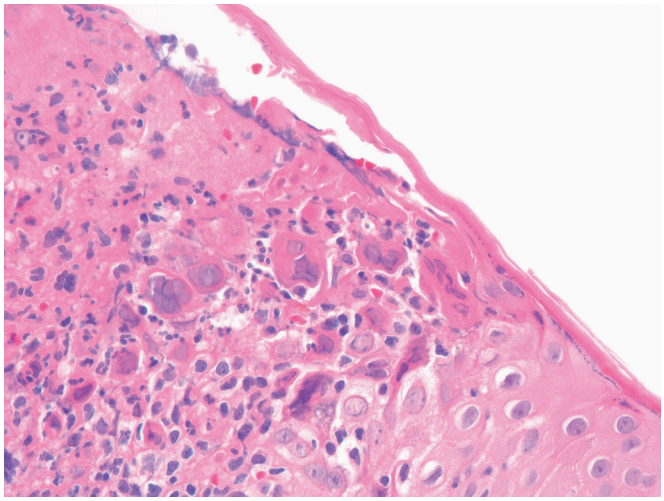

Figure 28.5 Herpes with prototypical viral cytopathic effect at the edge of the ulcer.

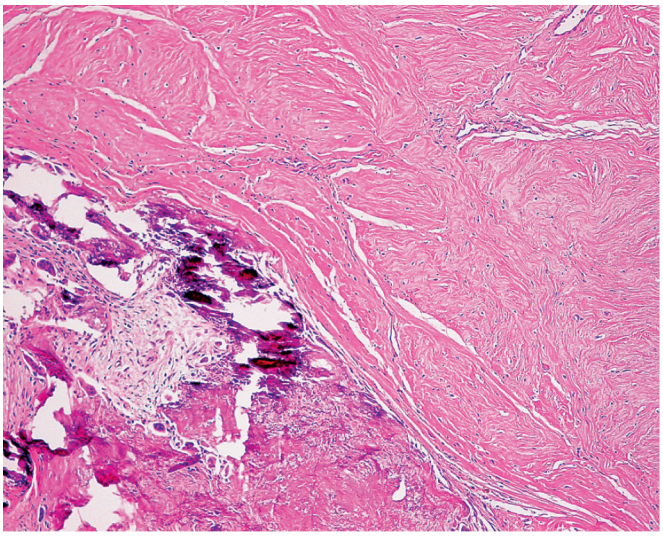

Figure 28.6 Peyronie Disease. The lesion is composed of densely hyalinized tissue that has undergone focal dystrophic calcification.

Figure 28.7 Large Lesions of Condyloma Acuminatum in an HIV-Infected Patient. The glans penis also shows herpesvirus infection.

associated with Dupuytren contracture[25] and may be treated by surgical techniques, topical therapy (including low intensity shock wave therapy), and intralesional injections of various agents.[26,27] Although older literature often regarded Peyronie disease as a form of "fibromatosis," current data argue strongly against any relationship to true desmoid tumor. It is most likely a sclerosing inflammatory process with an initial acute inflammatory response to microvascular trauma and a subsequent chronic fibrosing phase. TGF-β1 likely serves as a pro-fibrotic factor in the development of this condition.[28,29]

Condyloma acuminatum of the penis is a venereal disease caused by HPV and is most commonly seen between the ages of 20 and 40 years. It presents as a papillary growth at the penile meatus or fossa navicularis or in other regions of the glans (Fig. 28.7). Almost

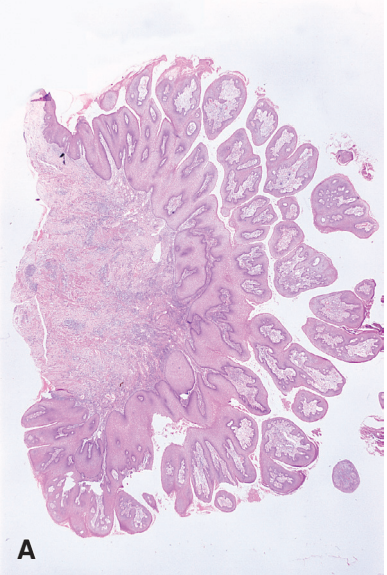

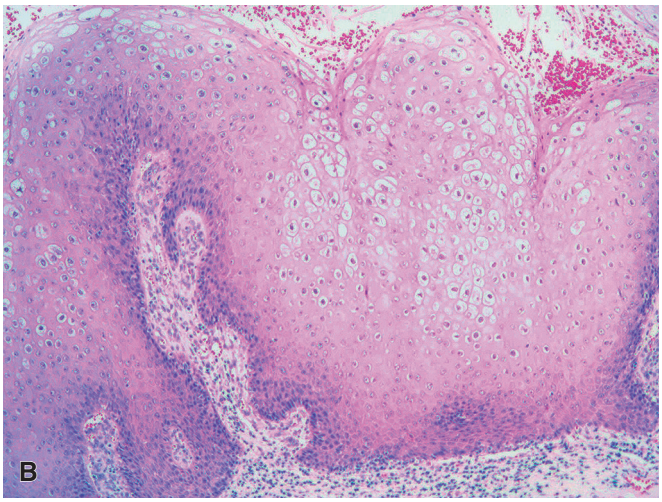

Figure 28.8 Condyloma Acuminatum. A, Complex papillary pattern composed of well-differentiated squamous epithelium is seen. **B,** Virus-induced cytopathic changes are present.

30% of the polypoid lesions of the male urethra are examples of this entity. Microscopically, there are complex papillary infoldings of squamous epithelium accompanied by vacuolization of keratinocytes and nuclear abnormalities ("koilocytosis") (Fig. 28.8A and B). The virus can be demonstrated by immunocytochemical and in situ hybridization techniques, but this is typically not necessary.[30,31] A subset of condylomas have a histologic appearance similar to seborrheic keratosis, and the distinction may be difficult without HPV evaluation (Fig. 28.9).

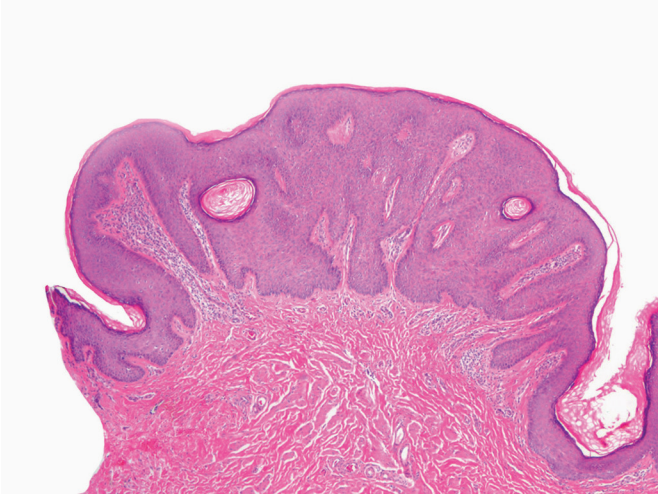

Figure 28.9 Some condylomas have a low-power appearance simulating seborrheic keratosis.

Tumors

Squamous Cell Carcinoma

The vast majority of malignant tumors arising in the penis are squamous cell carcinomas. They are relatively infrequent in the United States, accounting for fewer than 1% of all malignancies in males.[32] However, it is very common in some Asian, African, and Latin American countries, where it may constitute over 10% of all carcinomas.[33,34] It most commonly affects patients in their fourth to fifth decade.

If circumcision is done shortly after birth, carcinoma of the penis develops very rarely. If the operation is delayed until the age of 10 years, carcinoma is more likely to develop.[35] It is possible that carcinoma is related to personal hygiene and the carcinogenic effect of smegma, factors that might be enhanced by failure to circumcise.[36] In keeping with this assumption, an association has been found between penile cancer and long phimotic foreskins.[36,37]

Cases have also been reported in association with lichen sclerosus et atrophicus (balanitis xerotica obliterans)[38] and lichen planus.[39] In resection specimens for the well-differentiated spectrum of squamous cell carcinoma, lichen sclerosus is often seen together with squamous hyperplasia and the differentiated form of penile intraepithelial neoplasia (PeIN), suggesting a precancerous role for that condition.[40]

The association of penile carcinoma with HPV is well documented.[41,42] McCance et al.[43] found HPV-16 DNA sequences in 49% and HPV-18 DNA in 9% of 53 cases from Brazil. Recent data suggest that HPV-related carcinomas are decreasing in some countries, but are on the rise in the United States.[44] The association of HPV with various microscopic subtypes is also well established.[45–49] Based on these findings, the classification of penile squamous cell carcinoma has evolved to an HPV-based nomenclature as presented later.

Morphologic Features and Tumor Types

Most squamous cell carcinomas of the penis arise in the glans, prepuce, and coronal sulcus, in this order of frequency (Figs. 28.10 and 28.11). Their pattern of growth may be superficially spreading, predominantly exophytic (fungating, verruciform) or predominantly endophytic (infiltrative, ulcerating, vertical). Mixtures of these patterns occur, and there may be multicentricity.[50] In general, the exophytic tumors are better differentiated than their endophytic counterparts. At the microscopic level, penile squamous cell carcinomas are now broadly divided into HPV and non-HPV associated. The relative proportion of each group varies by geographic region, probably based largely on levels and types of HPV infection.

Precursor Lesions

Penile Intraepithelial Neoplasia

PeIN is an early neoplastic lesion of the squamous epithelium of the penis that retains an intact basement membrane (i.e., noninvasive

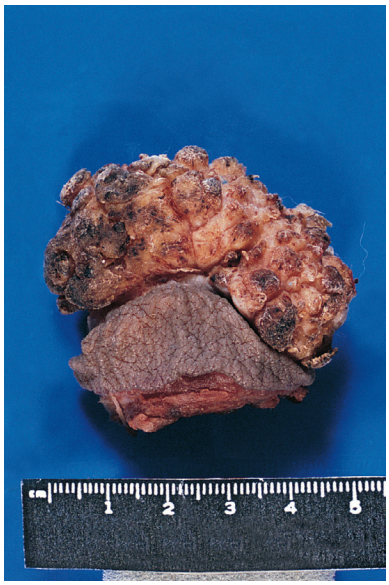

Figure 28.10 Outer aspect of squamous cell carcinoma of the glans penis showing a papillomatous pattern of growth.

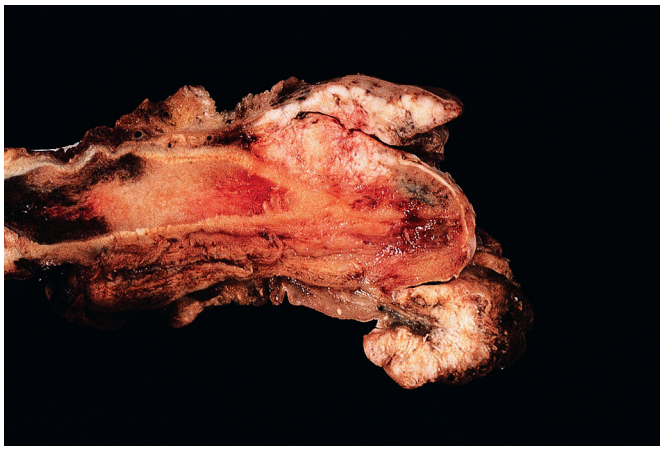

Figure 28.11 Penile squamous cell carcinoma with extensive involvement of the prepuce (foreskin).

lesion) and is the precursor to invasive squamous cell carcinoma. A variety of diagnostic names have been used in the past (such as Bowen disease, erythroplasia of Queyrat, dysplasia, and carcinoma in situ), but these have been replaced by the current PeIN terminology.[51,52] These lesions, like their invasive counterparts, can also be subdivided into HPV and non-HPV associated types.[48] Non-HPV–associated types generally occur in an older age group, compared to those associated with HPV.

Human Papilloma Virus Related (PeIN)

Basaloid (undifferentiated) PeIN typically involves the glans penis in young men. The morphologic features are similar to high-grade squamous intraepithelial lesions of the cervix with full-thickness involvement by small monotonous immature cells with high nuclear-to-cytoplasmic ratio (Fig. 28.12).[48] Mitotic activity and apoptotic bodies may be frequent, but squamous maturation is not characteristic. These lesions show diffuse staining for p16. Studies have shown a common association with HPV type 16.

Warty (Bowenoid) PeIN has more complex architecture than basaloid PeIN, with a papillomatous surface and more abundant

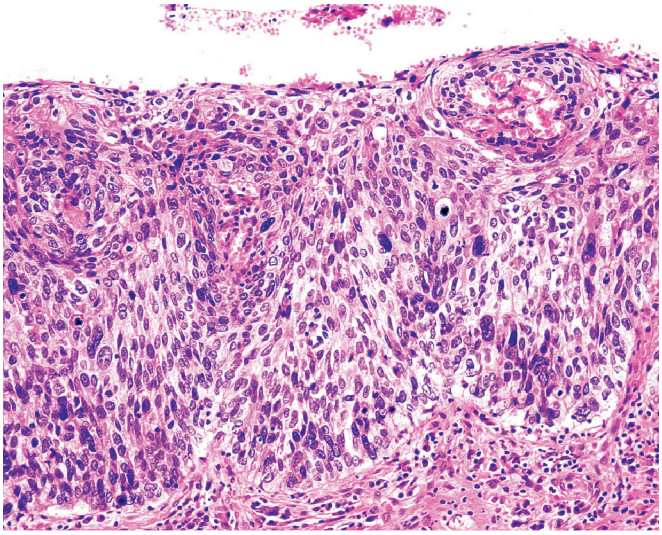

Figure 28.12 Basaloid penile intraepithelial neoplasia (PeIN).

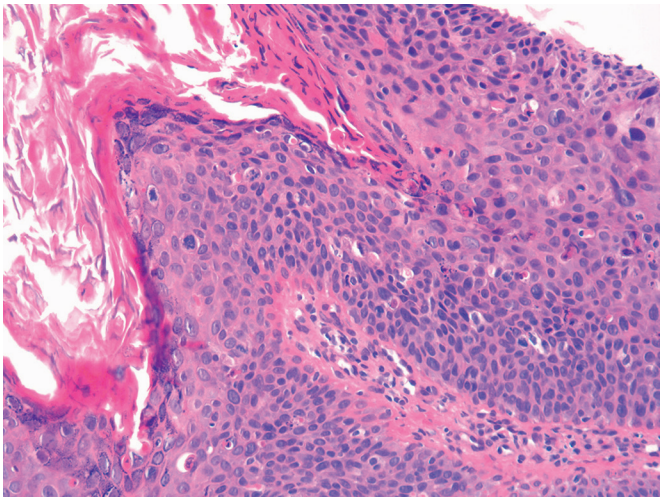

Figure 28.13 Warty-basaloid penile intraepithelial neoplasia (PeIN).

surface keratin. There is also more nuclear pleomorphism, and well-developed koilocytotic atypia is characteristic.[48] Another contrasting point with basaloid PeIN is frequent squamous maturation in the warty variant. This lesion also expresses strong p16, but the associated HPV type is more variable.

Warty-basaloid PeIN, as the name implies, shows an admixture of basaloid and warty features.[48,53] The surface may show papillations with koilocytotic atypia, while the basal half has a more uniform basaloid population of cells (Fig. 28.13). These lesions seem to have more overlap with basaloid PeIN, having a strong association with HPV-16.[46]

Human Papilloma Virus Unrelated (PeIN)

Differentiated PeIN has been associated with lichen sclerosus or other chronic inflammatory conditions.[11] In contrast to HPV-associated PeIN (such as basaloid PeIN that affects the glans penis), differentiated PeIN generally involves the foreskin. Clinically, these often have a plaque-like or raised macular growth. Microscopically, they are similar to their vulvar counterparts with thickened squamous epithelium and elongated rete ridges, which may show bridging. The degree of cytologic atypia varies, but the most subtle cases show only basal atypia, often with abnormal maturation/keratinization near the base

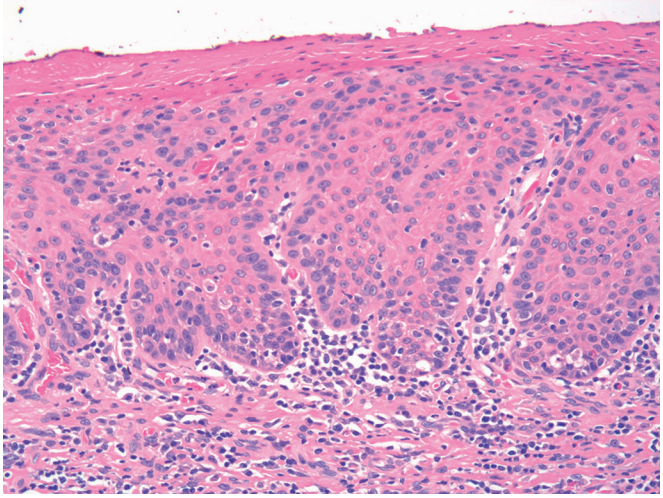

Figure 28.14 Differentiated penile intraepithelial neoplasia (PeIN).

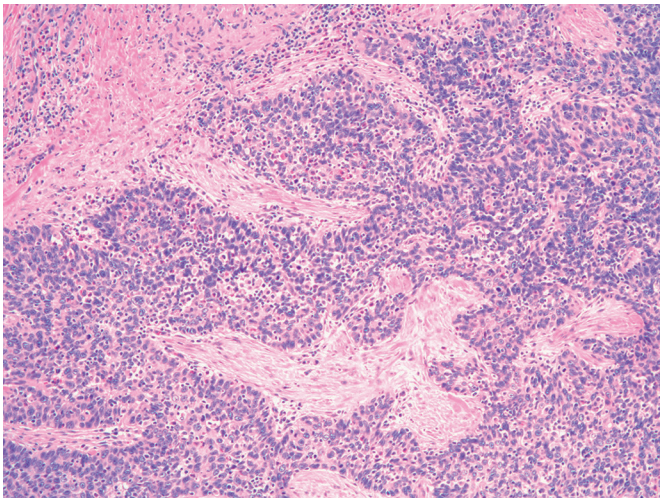

Figure 28.15 Invasive basaloid carcinoma of penis, an HPV-related variant of squamous cell carcinoma.

or in the rete ridges (Fig. 28.14). Because of the subtle histologic features, distinction from reactive epithelial changes may be difficult in some cases. Immunophenotypically, differentiated PeIN is typically p16 negative, but shows some increase in Ki-67 proliferation rate. p53 nuclear staining may be strong and diffuse, but is variable.[54] p16 immunostains have a high sensitivity and specificity for discriminating differentiated PeIN from basaloid, warty, and warty-basaloid PeIN.[55] When differentiated PeIN is associated with an invasive component, it is typically a keratinizing or well-differentiated variant.

Invasive Carcinoma

Human Papilloma Virus Related. Basaloid squamous carcinoma is a biologically aggressive form of penile carcinoma related to HPV-16 in most cases and typically arising on the glans. It is characterized by broad anastomosing sheets of basaloid cells with little cytoplasm that irregularly infiltrate the underlying stroma, sometimes with associated central necrosis (Fig. 28.15). Typically, numerous mitotic figures and apoptotic bodies are easily identified in a single high-power field. As expected, these tumors show strong and diffuse reactivity for p16. Occasional cases have an exophytic papillary component resembling the architecture of a urothelial neoplasm, which is described as "**papillary basaloid carcinoma.**"[56]

Warty carcinoma is a large slow-growing tumor with exophytic and papillomatous architecture, mimicking condyloma or verrucous carcinoma; however, its cytologic features are distinct. In contrast to other subtypes, warty carcinoma exhibit nuclear pleomorphism with perinuclear clearing and koilocytotic atypia (Fig. 28.16).[57] The invasive front has a burrowing pattern with irregular, jagged downgrowth. Some cases have mixed features of warty and basaloid carcinoma.[47] As with the precursor warty PeIN, the associated HPV type is variable.

Other rarer subtypes of HPV-related squamous cell carcinoma include lymphoepithelial-like, medullary, and clear cell carcinoma.[58–61] Some cases may also show neuroendocrine differentiation.

Non-Human Papilloma Virus Related. Squamous cell carcinoma of the "usual type" is the prototypical invasive carcinoma, similar to keratinizing carcinomas of the head and neck (Fig. 28.17A and B). It might be thought of as a "diagnosis of exclusion" after other subtypes are ruled out. It is graded similar to other sites, ranging from well to poorly differentiated based on nuclear pleomorphism and keratinization. Grade is typically based on the highest-grade component present, regardless of extent.

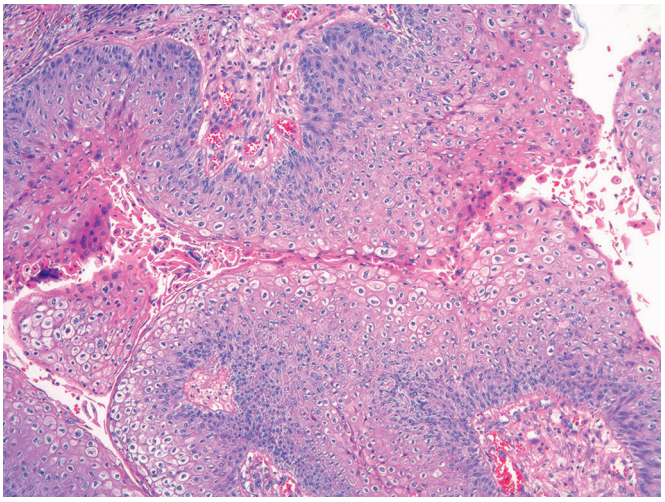

Figure 28.16 Invasive warty carcinoma is characterized by well-developed koilocytotic atypia.

Verrucous carcinoma, which constitutes 2% to 3% of all penile cancers, generally affects older men in their sixth to seventh decade. Microscopically, it is characterized by papillomatosis with hyperkeratosis and acanthosis. It has a more regular architecture than warty carcinoma, particularly at its base, where it features broad-based bulbous expansions of squamous epithelium lacking irregular stromal penetration (Fig. 28.18).[57,62,63] By definition, verrucous carcinoma is composed of cytologically bland cells with very little atypia, except for a subtle degree of nuclear enlargement near the base. It lacks koilocytotic atypia. Tumors combining features of squamous cell carcinoma of the usual and verrucous types are referred to as *hybrid tumors* and generally have an outcome based on the non-verrucous component.[62,64]

Other described subtypes of non-HPV–related squamous cell carcinoma include carcinoma cuniculatum (Fig. 28.19),[42] pseudohyperplastic (Fig. 28.20A and B),[65] pseudoglandular,[66] papillary,[67] adenosquamous,[68] sarcomatoid (Fig. 28.21),[69,70] and mixed types.

Molecular Genetic Features

The molecular pathogenesis of penile cancer is not as well developed as for many other carcinoma types. As suggested by the histologic

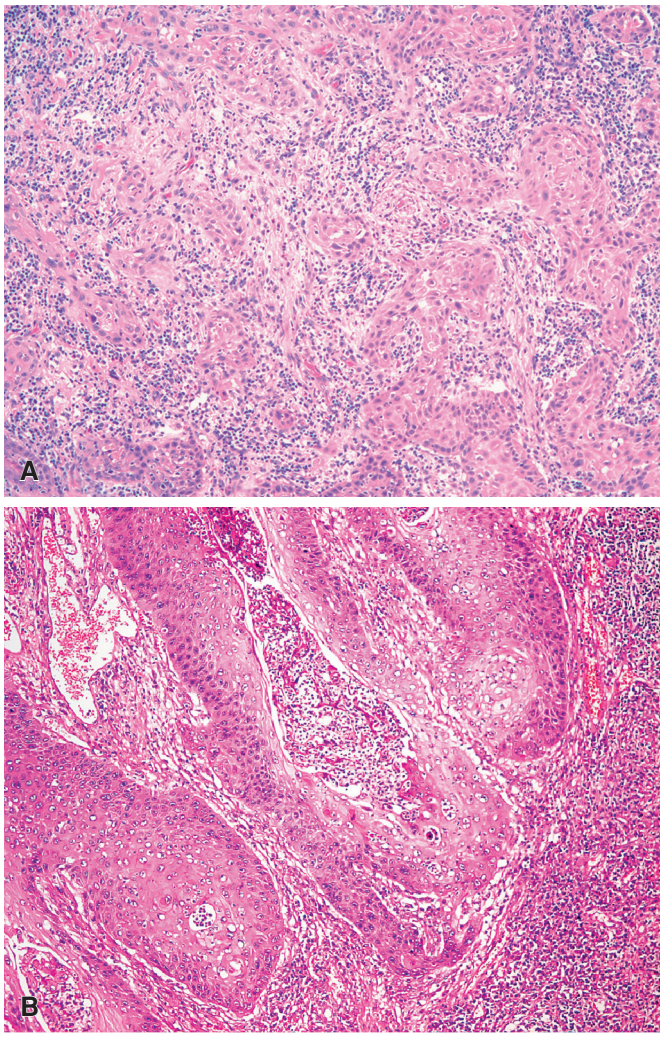

Figure 28.17 **A,** Invasive squamous cell carcinoma, usual type, shows irregular invasion of underlying stroma without features of other subtypes. **B**, Moderately differentiated invasive squamous cell carcinoma, usual type.

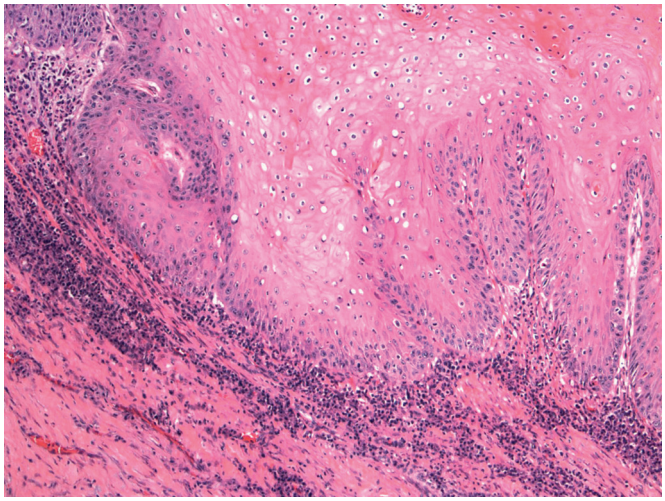

Figure 28.18 Verrucous carcinoma is characterized by a broad-based "pushing" interface with underlying stroma.

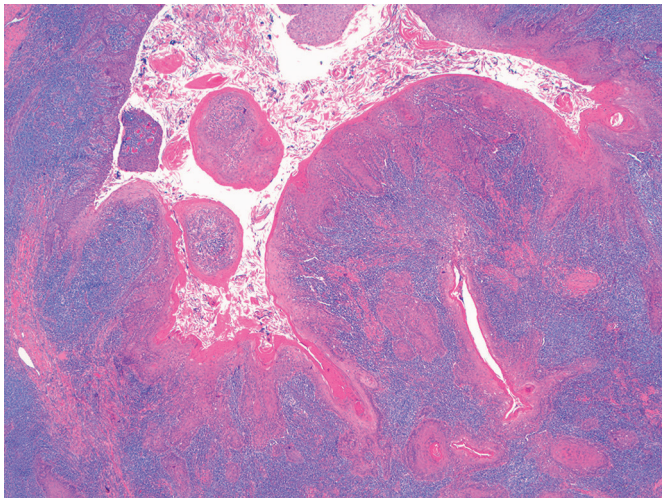

Figure 28.19 Carcinoma cuniculatum often has a central opening simulating a cyst.

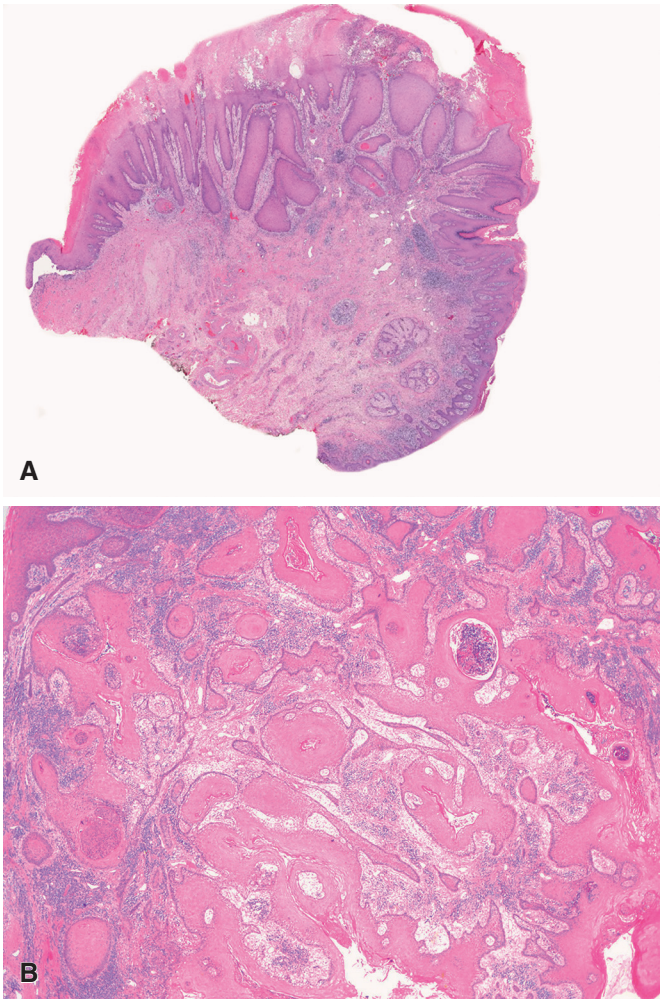

Figure 28.20 **Pseudohyperplastic Squamous Cell Carcinoma. A,** On low power, there are markedly irregular invaginations of squamous epithelium. **B,** The histologic features are extremely well differentiated.

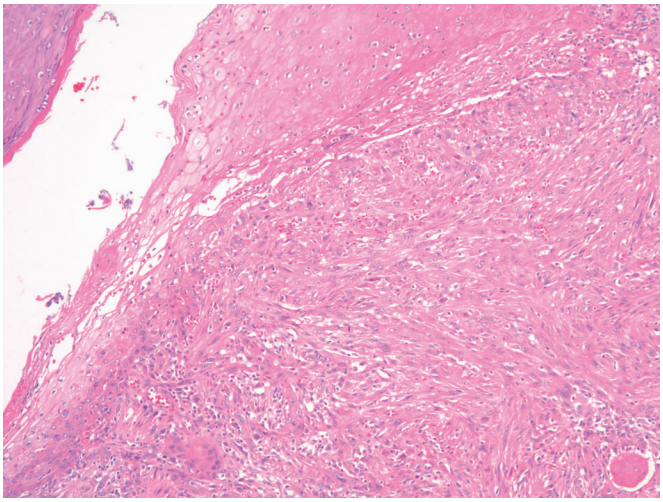

Figure 28.21 Squamous Cell Carcinoma of Penis With Spindle Cell (Sarcomatoid) Features. There is a blending of the carcinoma islands with the sarcoma-like component.

classification, studies support two main genetic pathways: high-risk HPV pathogenesis and non-HPV pathogenesis.[71] Abnormalities in the *Rb*/p16/p21 pathway are common in the HPV tumors, similar to those of the uterine cervix and head and neck region.[72] *TP53* mutations are not typical in the HPV-associated subset. For non-HPV–related squamous cell carcinoma of the penis, there seem to be two pathways: high chromosomal instability and *TP53* mutation.[73,74]

Spread and Metastases

Squamous cell carcinoma arising within a penile compartment (glans, prepuce, or coronal sulcus) often spreads to involve others. Early invasion of the Buck fascia is common in carcinomas of the coronal sulcus. Local spread into the urethra is also a common finding, especially among the deeply invasive tumors. Velazquez et al.[75] have listed the following five major routes of local spread of penile cancer: (1) horizontal superficial spread from one compartment to another; (2) following the penile fascia; (3) through spaces created by feeding vessels in the tunica albuginea; (4) vertical spread involving step-by-step different compartments; and (5) along the urethral epithelium.

The overall incidence of inguinal lymph node metastases is 15%. The first node usually involved ("sentinel node") belongs to the superficial epigastric group and is located medial to and above the epigastric–saphenous junction.[76] Because carcinomas are often associated with secondary infection, enlargement of inguinal nodes is very common and clinical appraisal is extremely inaccurate.[77] Lymph node metastases are uncommon in exophytic tumors; when present, they usually appear late in the evolution of the disease. Conversely, they are common in deeply invasive tumors, sometimes accompanied by spread to other lymph node groups. Metastases do not occur in verrucous carcinomas,[62] but may be present in hybrid carcinomas.[78] They are particularly common in basaloid and spindle cell carcinomas.[63] In the series of Cubilla et al.,[50] inguinal lymph node metastases were present in 82% of deeply invasive tumors with minimal or no in situ component, 42% of "superficially invasive" tumors, and 33% of multicentric tumors. Nodal metastases were very rare in tumors that invaded only the lamina propria, and relatively common in tumors that had invaded the urethra.

Treatment and Prognosis

Carcinoma of the penis can be treated by local resection or by partial or total penectomy, according to the size and location of the lesion and its microscopic type.[79–82] Local recurrence occurs in about one-third of the cases, usually due to insufficient surgery or positive margins.[83] It is extremely rare if all the surgical margins are negative, even if narrow (≤10 mm).[84] Controversy still exists as to the role of elective inguinal lymphadenectomy. Most authors advocate it except for very small and early lesions,[79,85,86] but others have questioned the need for this procedure, which is associated with significant morbidity.[87,88] Since lymph node metastases do not occur in verrucous carcinoma, this tumor is therefore treated with resection of the primary lesion only.[62] As in other sites, radiation therapy has been described in association with anaplastic transformation.[89]

The overall 5- and 10-year survival rates for squamous cell carcinoma of the penis are 77% and 71%, respectively.[90] The prognosis is related to the following factors:

1. *Stage*. As usual, this is the most important parameter.[91] However, it should be noted that there is a considerable difference between clinical and pathologic stage, which is attributable to the difficulty of assessing clinically corpora cavernosa invasion and inguinal lymph node metastases[92,93] and the fact that a biopsy alone is insufficient to stage this tumor accurately.[83] The close relationship that exists between the depth of invasion of the penile anatomic landmarks and prognosis renders essential an accurate anatomic dissection and sampling of the penectomy specimen.[94] If metastases are present in two or more nodes, the chances of cure are very small.[95]
2. *Local invasion*. Invasion of the corpora cavernosa or preputial skin is a significantly adverse prognostic factor.[96]
3. *Microscopic type*. Verrucous carcinoma is associated with a much better prognosis. Basaloid and sarcomatoid carcinomas are associated with high rate of nodal metastases and poor survival.[63,96]
4. *Microscopic grade*. The grade of the tumor shows a very good correlation with prognosis. Presence of a grade 3 component, regardless of its amount, is a sign of poor prognosis.[85,97–99]
5. *Vascular invasion*. This is an indicator of poor prognosis, which seems to retain its value independently of staging and microscopic grading.[85,98,100]
6. Perineurial invasion.[101]

Other Carcinoma Types

Primary **extramammary Paget disease** is less common in the penis than in the scrotum or perineum; it may be purely intraepidermal or associated with invasion of the dermis.[102,103] Rare cases are associated with an underlying sweat gland carcinoma. As in other sites, Paget disease may present clinically as a pink to red plaque, but early lesions may mimic benign inflammatory conditions. Histologically, there is a population of large atypical cells with abundant pale cytoplasm that are present within the epidermis, either singly or in clusters (Fig. 28.22A). Small gland-like lumina may be present, and the cells may colonize underlying adnexal structures.

The differential diagnosis includes mainly PeIN ("squamous cell carcinoma in situ") with a pagetoid growth, melanoma, and secondary involvement from an anatomically adjacent adenocarcinoma. Primary Paget disease must be carefully distinguished from secondary involvement by occult carcinomas from regional anatomic sites, most commonly urethra and bladder (but very rarely prostatic). When extending to involve perineal and perianal regions, rectal adenocarcinomas should be considered. While immunophenotypes may vary considerably, primary Paget disease often has a CK7+/CK20–, Her2+, BerEP4+, GCDFP15+, CEA+ phenotype (see Fig. 28.22B).[104,105] CDX2 and p63 are typically negative in primary Paget disease. It should be noted that Paget disease is positive for GATA-3, limiting its utility

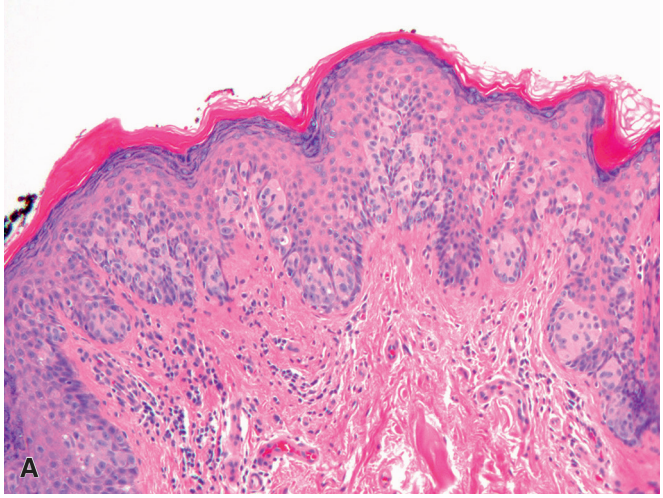

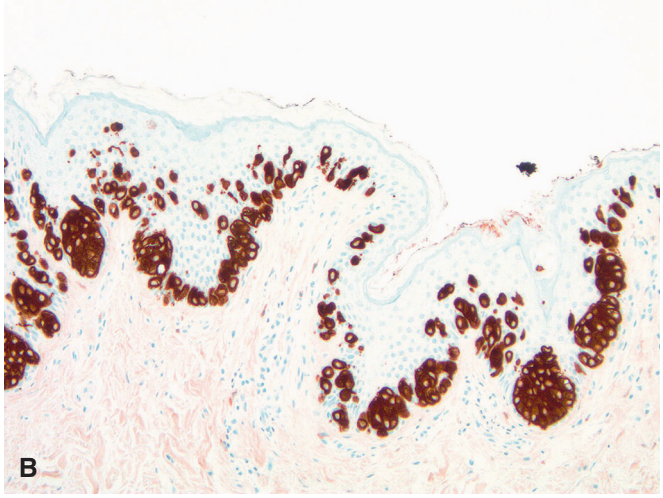

Figure 28.22 **Extramammary Paget Disease. A,** A population of atypical cells with clear cytoplasm, either as singe cells or clusters, involves the epidermis. **B,** Cytokeratin 7 shows strong cytoplasmic reactivity.

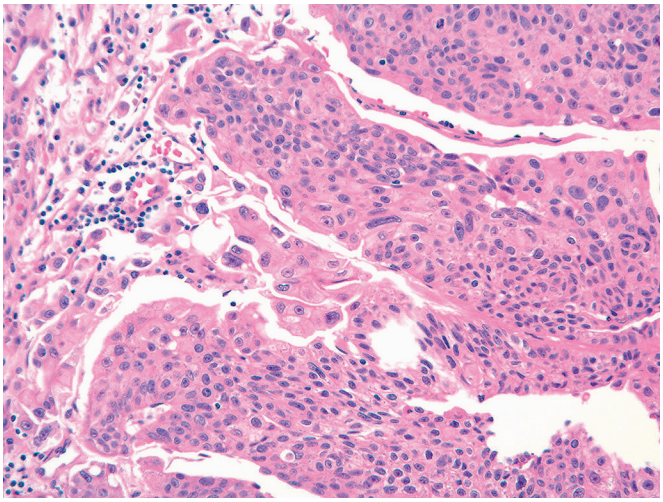

Figure 28.23 Urothelial carcinoma of penile urethra.

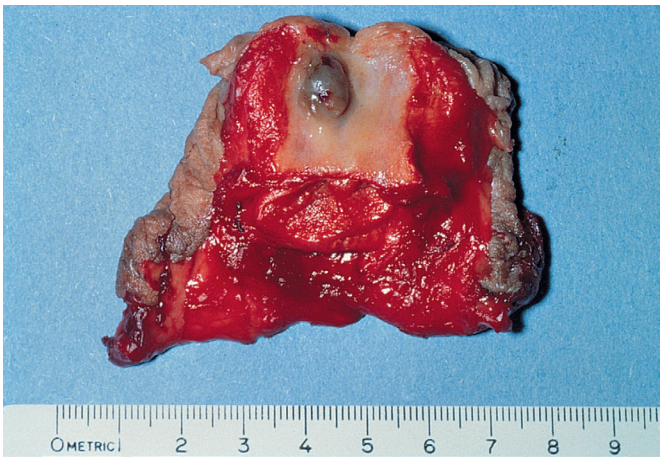

Figure 28.24 Malignant melanoma presenting as a polypoid blue-colored mass protruding from the urethra.

in distinction from urothelial origin[106,107]; however, expression of CK20 and uroplakin III (with absence of CEA) would support urothelial carcinoma.[108] Expression of CK5/6, other high-molecular-weight cytokeratins, and/or p63, and absence of GCDFP15 and CEA staining would support squamous lineage.[109] S-100, SOX-10, or HMB-45 reactivity, and absence of keratins, would support melanocytic origin.[110,111] Rectal adenocarcinomas often express CK20, CEA, and CDX2, but CK7 reactivity is more variable.[112,113]

Basal cell carcinoma of the penis is microscopically similar to its counterpart elsewhere in the skin; to the best of our knowledge, no instances of metastatic behavior have been reported.[114] Obviously, a sharp distinction should be made between this tumor and basaloid squamous cell carcinoma.

Tumors of Penile Urethra

Benign tumors of the penile urethra are extremely rare. Isolated cases of **inverted urothelial papilloma** similar to their bladder counterparts have been reported.[115] **Condyloma acuminatum** can extend into the distal portion of the urethra. **Leiomyoma** of the male urethra is much less common than in the female urethra, but its existence has been documented.[116]

Carcinoma of the male urethra is a rare disease. In some cases, it follows stricture produced by trauma or gonorrhea. In some series as many as 44% of the patients had a history of venereal disease.[117] The most common location of the tumor is the bulbomembranous portion, followed by the penile portion.[118] Microscopically, 75% of the tumors are *squamous cell carcinomas;* most of the others (usually located in the prostatic portion) are *urothelial carcinomas* (Fig. 28.23). A few cases of *adenocarcinoma* have also been reported[119]; possible sources for them are metaplastic urethral mucosa, bulbourethral (Cowper) glands, and periurethral (Littré) glands.[120] Some of these adenocarcinomas have been of mucinous (colloid) type.[121]

The prognosis and treatment of urethral carcinoma depend more on location and stage than on microscopic type or grade.[122] Anterior or distal lesions have a much better prognosis than posterior or proximal lesions. In general, the anterior lesions drain to inguinal nodes, whereas posterior lesions drain into pelvic nodes.[117] The treatment is primarily surgical.

Primary **malignant melanoma** of the urethra also occurs; the shape of these tumors is typically polypoid and their prognosis is exceedingly poor (Fig. 28.24).[123,124]

Malignant lymphoma presenting in the urethra is rare.[125]

Other Penile Tumors and Tumorlike Conditions

Hirsutoid papillomas (also known as papillomatosis corona penis or glans) appear as small, polypoid, 1–2 mm lesions in the corona of the glans, usually on its dorsal aspect. They can be solitary or multiple and have the microscopic appearance of fibroepithelial polyps.[126,127]

Lymphedematous fibroepithelial polyp of the glans and prepuce is a non-neoplastic lesion with a polypoid or cauliflower-like gross appearance that is usually secondary to chronic condom catheter use and which can reach a size of 7.5 cm (!).[128]

Adnexal tumors of sweat gland (such as *eruptive syringoma*), sebaceous, or hair follicle type rarely occur in the penile skin.[129–131]

Melanocytic lesions of the penis can be of benign or malignant nature. **Lentigo** of the common variety occurs most commonly in the glans as a relatively large (up to 2 cm), multifocal, irregularly shaped lesion of variegated pigmentation. It is also known as (atypical) melanotic macule and is characterized microscopically by basal cell hyperpigmentation, epithelial hyperplasia, and lack of melanocytic atypia.[132,133] **Nevi** of various types also occur, including *blue nevus*.[134] **Malignant melanoma** may arise in the glans or prepuce; metastases to lymph nodes are common.[135,136]

Soft tissue tumors of the penis are located for the most part in the shaft. Among the benign tumors, those of vascular, neural, and smooth muscle derivation are the most common.[137,138] These include, among others, hemangioma (including the epithelioid variety).[169,140] Fordyce angiokeratoma, lymphangioma,[90] schwannoma,[141] neurofibroma,[142,143] traumatic neuroma (secondary to trauma or circumcision[144]), granular cell tumor,[145–147] leiomyoma,[148] myofibroma,[149] and verruciform xanthoma.[150] The list of malignant soft tissue tumors includes angiosarcoma,[151,152] Kaposi sarcoma (some occurring in the setting of AIDS),[153–155] fibrosarcoma, malignant peripheral nerve sheath tumor, epithelioid sarcoma,[137,156] pleomorphic undifferentiated sarcoma,[157–159] clear cell sarcoma,[160] leiomyosarcoma,[139,161] and osteosarcoma.[162,163] *Myointimoma* is the term proposed by Fetsch et al.[164] for a peculiar vascular myointimal proliferation composed of cells with myoid features involving the corpus spongiosum of young men (Fig. 28.25), including adolescents and children.[165] The etiology is unknown and the evolution is benign; however, some have suggested that it represents intravascular fasciitis of the corpus spongiosum.

Malignant lymphoma of the penis usually represents secondary involvement by nodal lymphoma.[166,167] *Langerhans cell histiocytosis* can present in the male genitalia and lead to confusion microscopically with Paget disease.[168]

Metastatic carcinoma to the penis is rare.[169–171] Priapism is one of the forms of presentation.[172] The most common sources are prostate, bladder, rectum, kidney, testis, and lung, in that order of frequency.[173–175] Sometimes the tumor in the penile skin is epidermotropic and exhibits the features of extramammary Paget disease, whether arising from an underlying sweat gland carcinoma[176] or a distant site, such as the bladder.[177]

Scrotum

Normal Anatomy

The scrotal sac is a seven-layer structure that invests the testes, adnexa, and distal spermatic cord. The seven layers are the epidermis, dermis, tunica dartos (composed of smooth muscle bundles), the three layers of Colles fascia (intercrural, cremasteric, and infundibuliform), and the parietal layer of the tunica vaginalis. The latter consists of a flattened layer of mesothelial cells resting on a well-developed basement membrane.[178]

The scrotal lymphatics drain into the ipsilateral superficial inguinal lymph nodes. Anastomotic connections to the lymphatics of the contralateral network across the raphe occur.

Non-Neoplastic Lesions

Many paratesticular lesions are described in the chapter on paratestis and spermatic cord. We cover only lesions involving the epidermis and superficial tissue of the scrotum in this section.

Ectopic testicular parenchyma can be found within the tunica albuginea. Theoretically, it could be the source of extratesticular germ cell, Leydig cell, and Sertoli cell tumors.[179]

Idiopathic calcinosis of the scrotum is characterized by multiple asymptomatic nodules in the scrotal skin that begin in childhood or adolescence and tend to increase in size and number (Fig. 28.26). Occasionally, they break down through the skin and discharge a chalky content. Microscopically, amorphous basophilic masses are seen in the corium, often associated with a prominent foreign body reaction (Fig. 28.27).[180]

The pathogenesis is obscure, but the presence in some cases of a layer of squamous epithelium surrounding the calcium deposits suggests that this lesion may be the result of massive calcification of keratinous cysts derived from hair follicles.[181,182]

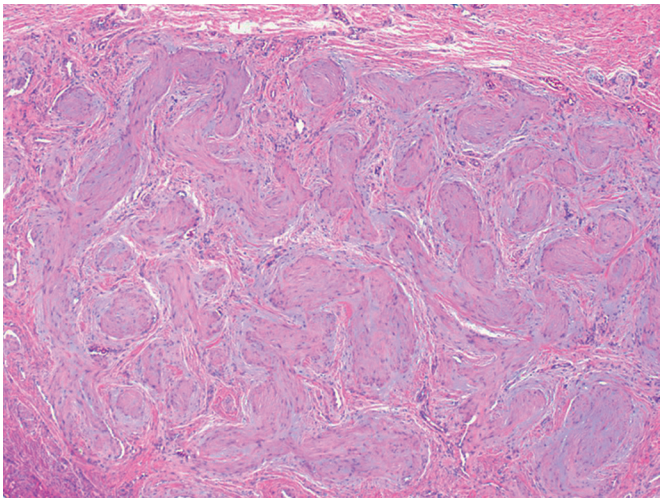

Figure 28.25 Myointimoma of the corpus spongiosum.

Figure 28.26 Idiopathic Calcinosis of Scrotum. (Courtesy of Dr. Juan J Segura, San José, Costa Rica.)

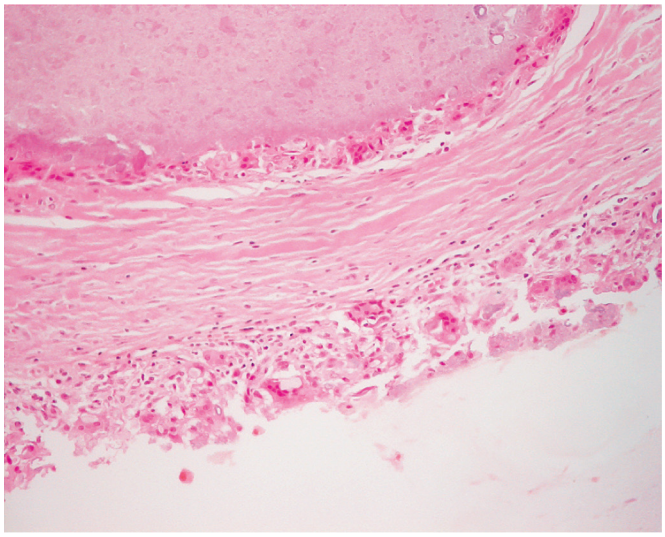

Figure 28.27 Idiopathic calcinosis of scrotum, with accompanying foreign body–type giant cell reaction.

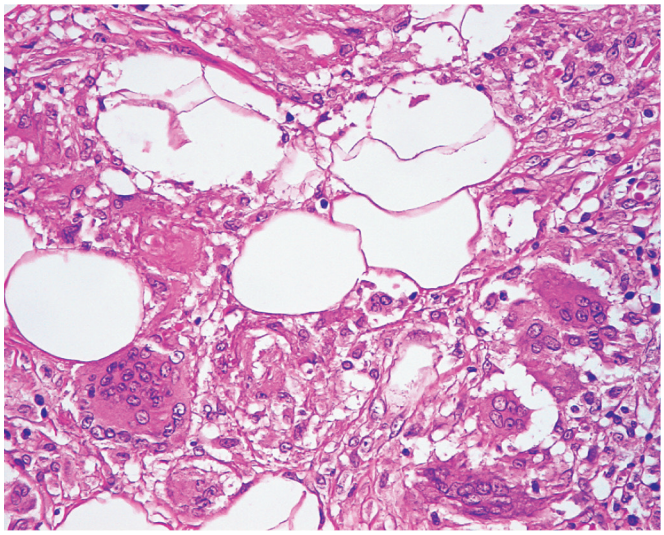

Figure 28.28 Sclerosing Lipogranuloma of Scrotum. Prominent histiocytic and multinucleated giant cell reaction around empty spaces, which presumably contained lipid material.

Sclerosing lipogranuloma is a rare condition of the penis and scrotum that affects adults and is usually painless. Microscopically, foci of fat necrosis are intermingled with collections of histiocytes, foamy macrophages, and multinucleated giant cells, accompanied by extensive areas of fibrosis and hyalinization (Fig. 28.28).[183] A history of trauma is present in a minority of the cases. Oertel and Johnson[184] made the startling suggestion that the lesion is usually a sequel to injections of exogenous material ("paraffinoma"), after their demonstration of paraffin hydrocarbons by infrared spectrophotometry in nearly all of their cases. The microscopic differential diagnosis includes adenomatoid tumor, lymphangioma, and atypical lipomatous tumor (sclerosing well-differentiated liposarcoma).

Scrotal fat necrosis can result from exposure to cold; it usually presents as bilateral masses below the testis, in the lower portion of the scrotum.[185]

Cysts of the tunica albuginea are lined by a single row of low cuboidal to columnar cells, which may be ciliated. The cavity contains clear fluid. The pathogenesis is unknown.[186,187]

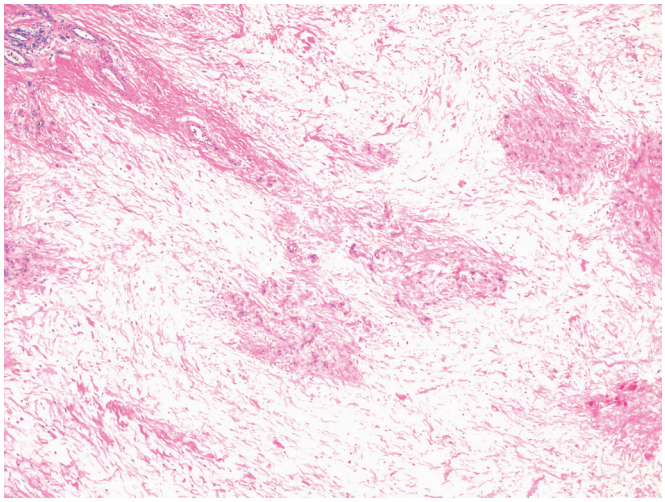

Figure 28.29 Massive Localized Lymphedema of the Scrotum. The lobular collections of capillary sized blood vessels are typical.

Accessory scrotum is the term generally used for the presence of a congenital perineal nodule adjacent to the scrotum composed of fat and smooth muscle. The condition is regarded by some authors as a hamartoma.[188]

Crohn disease can involve the scrotum in the form of an erythematous, nontender swelling.[189]

Fournier gangrene is a necrotizing subcutaneous (fascial) infection of the perineum and external genitalia.[190] It is usually characterized by an abrupt onset in previously healthy young males, but it can have an indolent onset and presents over a broad age range.[191,192] Some cases are idiopathic, others are secondary to urethral strictures with extravasation, and still others are seen as a complication of chemotherapy in patients with hematologic malignancies.[193]

Massive localized lymphedema, while more commonly described in the thigh, also occurs in the scrotum. This is a localized tumor-like collection of edema fluid due to lymphatic obstruction, most commonly associated with morbid obesity[194]; however, the etiology in younger patients is not well understood.[195] Histologically, the edema fluid is associated with loose connective tissue and intermixed lobular collections of small capillary-sized blood vessels (Fig. 28.29). Hyperplastic bundles of dartos muscle are also described.

Tumors

Both benign and malignant tumors of the scrotum are rare. Most of the benign tumors arise in the skin from cutaneous adnexa and have a morphologic appearance analogous to that of other cutaneous sites.

Leiomyoma is the most common benign mesenchymal tumor of this region (Figs. 28.30 and 28.31)[196]; some of them have bizarre (symplasmic) nuclear features.[197,198]

Squamous cell carcinoma is extremely rare in the general population, but is notorious in the oncology literature for being the first malignancy linked to occupational exposure (found in chimney sweeps, paraffin workers, tar workers, and cotton mill workers).[199] Wide local excision with bilateral ilioinguinal lymphadenectomy is the treatment of choice, with more limited surgery advocated in early cases.[200]

Other reported malignant tumors of the scrotal skin are **basal cell carcinoma**[201] and **Paget disease**.[202]

Sarcomas involving the scrotal wall are rare; most of the reported cases have been of smooth muscle derivation, that is, *leiomyosarcomas*.[196,203]

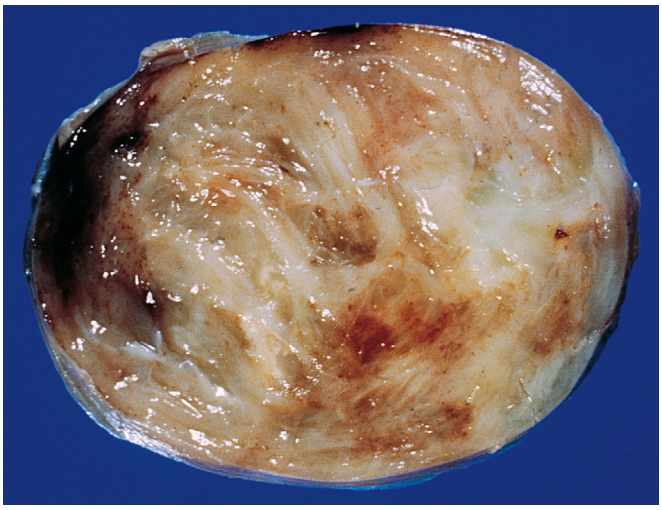

Figure 28.30 Gross appearance of vascular leiomyoma of scrotum.

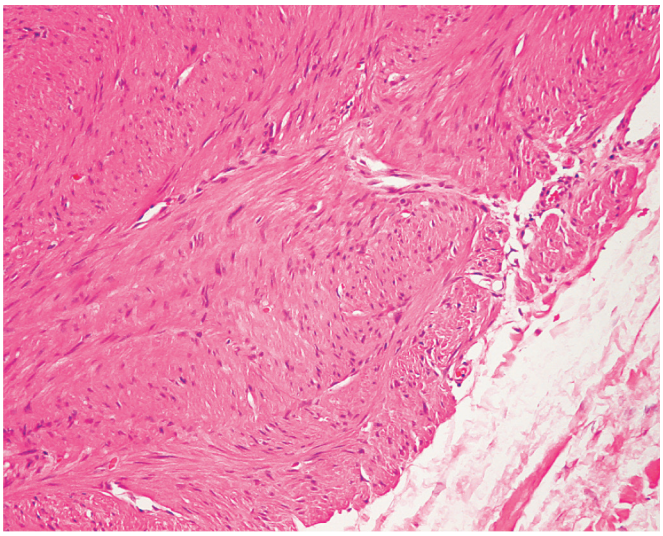

Figure 28.31 Leiomyoma of tunica dartos.

References

1. Hricak H, Marotti M, Gilbert TJ, et al. Normal penile anatomy and abnormal penile conditions: evaluation with MR imaging. *Radiology*. 1988;169(3):683-690.
2. Velazquez EF, Cold JC, Barreto JC, Cubilla AL. Penis and distal urethra. In: Mills SE, ed. *Histology for Pathologists*. 3rd ed. Philadelphia: Lippincott Williams & Wilkins; 2007.
3. Hinman F *American Pediatric Urology*. San Francisco: Norman Pub.; 1991.
4. Dini M, Baroni G, Colafranceschi M. Median raphe cyst of the penis: a report of two cases with immunohistochemical investigation. *Am J Dermatopathol*. 2001;23(4):320-324.
5. Cole LA, Helwig EB. Mucoid cysts of the penile skin. *J Urol*. 1976;115(4):397-400.
6. Shiraki IW. Parametal cysts of the glans penis: a report of 9 cases. *J Urol*. 1975;114(4):544-548.
7. Fang AW, Whittaker MA, Theaker JM. Mucinous metaplasia of the penis. *Histopathology*. 2002;40(2):177-179.
8. Val-Bernal JF, Hernandez-Nieto E. Benign mucinous metaplasia of the penis. A lesion resembling extramammary Paget's disease. *J Cutan Pathol*. 2000;27(2):76-79.
9. Krawitt LN, Schechterman L. Inflammation of the periurethral glands of Littre simulating tumor. *J Urol*. 1977;118(4):685.
10. Das S, Tunuguntla HS. Balanitis xerotica obliterans—a review. *World J Urol*. 2000;18(6):382-387.
11. Oertell J, Caballero C, Iglesias M, et al. Differentiated precursor lesions and low-grade variants of squamous cell carcinomas are frequent findings in foreskins of patients from a region of high penile cancer incidence. *Histopathology*. 2011;58:925-933.
12. Souteyrand P, Wong E, MacDonald DM. Zoon's balanitis (balanitis circumscripta plasmacellularis). *Br J Dermatol*. 1981;105(2):195-199.
13. Weyers W, Ende Y, Schalla W, Diaz-Cascajo C. Balanitis of Zoon: a clinicopathologic study of 45 cases. *Am J Dermatopathol*. 2002;24(6):459-467.
14. Kossard S, Collins AG, Wegman A, Hughes MR. Necrobiotic granulomas localised to the penis: a possible variant of subcutaneous granuloma annulare. *J Cuta Pathol*. 1990;17(2):101-104.
15. Magro CM, Crowson AN, Alfa M, et al. A morphological study of penile chancroid lesions in human immunodeficiency virus (HIV)-positive and -negative African men with a hypothesis concerning the role of chancroid in HIV transmission. *Hum Pathol*. 1996;27(10):1066-1070.
16. Baskin LS, Mee S. Tuberculosis of the penis presenting as a subcutaneous nodule. *J Urol*. 1989;141(6):1430-1431.
17. Haddad FS. Subcutaneous abscess and gangrene of the penis: report of four cases. *J Urol Pathol*. 1996;5:223-228.
18. Nielsen GP, Pilch BZ, Black-Schaffer WS, Young RH. Wegener's granulomatosis of the penis clinically simulating carcinoma: report of a case. *J Urol Pathol*. 1996;4:265-272.
19. Mendes D, Correia M, Barbedo M, et al. Behcet's disease—a contemporary review. *J Autoimmun*. 2009;32(3-4):178-188.
20. Yurdakul S, Yazici H. Behcet's syndrome. *Best Pract Res Clin Rheumatol*. 2008;22(5):793-809.
21. McRoberts JW. Peyronie's disease. *Surg Gynecol Obstet*. 1969;129(6):1291-1294.
22. Perimenis P, Athanasopoulos A, Gyftopoulos K, et al. Peyronie's disease: epidemiology and clinical presentation of 134 cases. *Int Urol Nephrol*. 2001;32(4):691-694.
23. Gholami SS, Lue TF. Peyronie's disease. *Urol Clin N Am*. 2001;28(2):377-390.
24. Smith BH. Peyronie's disease. *Am J Clin Pathol*. 1966;45(6):670-678.
25. Shindel AW, Sweet G, Thieu W, et al. Prevalence of Peyronie's disease-like symptoms in men presenting with Dupuytren contractures. *Sex Med*. 2017;pii: S2050-1161(17)30038-7.
26. Favilla V, Russo GI, Zucchi A, et al. Evaluation of intralesional injection of hyaluronic acid compared with verapamil in Peyronie's disease: preliminary results from a prospective, double-blinded, randomized study. *Andrology*. 2017;5:771-775.
27. Chung E, Ralph D, Kagioglu A, et al. Evidence-Based Management Guidelines on Peyronie's Disease. *J Sex Med*. 2016;13:905-923.
28. Al-Thakafi S, Al-Hathal N. Peyronie's disease: a literature review on epidemiology, genetics, pathophysiology, diagnosis and work-up. *Transl Androl Urol*. 2016;5:280-289.
29. El-Sakka AI, Hassoba HM, Pillarisetty RJ, et al. Peyronie's disease is associated with an increase in transforming growth factor-β protein expression. *J Urol*. 1997;158:1391-1396.
30. Del Mistro A, Braunstein JD, Halwer M, Koss LG. Identification of human papillomavirus types in male urethral condylomata acuminata by in situ hybridization. *Hum Pathol*. 1987;18(9):936-940.
31. Murphy WM, Fu YS, Lancaster WD, Jenson AB. Papillomavirus structural antigens in condyloma acuminatum of the male urethra. *J Urol*. 1983;130(1):84-85.
32. Lucia MS, Miller GJ. Histopathology of malignant lesions of the penis. *Urol Clin N Am*. 1992;19(2):227-246.
33. Merrin CE. Cancer of the penis. *Cancer*. 1980;45(7 suppl):1973-1979.
34. Riveros M, Lebron RF. Geographical pathology of cancer of the penis. *Cancer*. 1963;16:798-811.
35. Dillner J, von Krogh G, Horenblas S, Meijer CJ. Etiology of squamous cell carcinoma of the penis. *Scand J Urol Nephrol Suppl*. 2000;205:189-193.
36. Brinton LA, Li JY, Rong SD, et al. Risk factors for penile cancer: results from a case-control study in China. *Int J Cancer (J Int Cancer)*. 1991;47(4):504-509.
37. Velazquez EF, Bock A, Soskin A, et al. Preputial variability and preferential association of long phimotic foreskins with penile cancer: an anatomic comparative study of types of foreskin in a general population and cancer patients. *Am J Surg Pathol*. 2003;27(7):994-998.
38. Pride HB, Miller OF 3rd, Tyler WB. Penile squamous cell carcinoma arising from balanitis xerotica obliterans. *J Am Acad Dermatol*. 1993;29(3):469-473.
39. Bain L, Geronemus R. The association of lichen planus of the penis with squamous cell carcinoma in situ and with verrucous squamous carcinoma. *J Dermatol Surg Oncol*. 1989;15(4):413-417.
40. Velazquez EF, Cubilla AL. Lichen sclerosus in 68 patients with squamous cell carcinoma of the penis: frequent atypias and correlation with special carcinoma variants suggests a precancerous role. *Am J Surg Pathol*. 2003;27(11):1448-1453.

41. Varma VA, Sanchez-Lanier M, Unger ER, et al. Association of human papillomavirus with penile carcinoma: a study using polymerase chain reaction and in situ hybridization. *Hum Pathol*. 1991;22(9):908-913.
42. Weaver MG, Abdul-Karim FW, Dale G, et al. Detection and localization of human papillomavirus in penile condylomas and squamous cell carcinomas using in situ hybridization with biotinylated DNA viral probes. *Mod Pathol*. 1989;2(2):94-100.
43. McCance DJ, Kalache A, Ashdown K, et al. Human papillomavirus types 16 and 18 in carcinomas of the penis from Brazil. *Int J Cancer*. 1986;37(1):55-59.
44. Hernadez BY, Goodman MT, Unger ER, et al. Human papillomavirus genotype prevalence in invasive penile cancers from a registry-based United States population. *Front Oncol*. 2014;4:9.
45. Gregoire L, Cubilla AL, Reuter VE, et al. Preferential association of human papillomavirus with high-grade histologic variants of penile-invasive squamous cell carcinoma. *J Natl Cancer Inst*. 1995;87:1705-1709.
46. Fernandez-Nestosa MJ, Guimerà N, Sanchez DF, et al. Human Papillomavirus (HPV) Genotypes in Condylomas, Intraepithelial Neoplasia, and Invasive Carcinoma of the Penis Using Laser Capture Microdissection (LCM)-PCR: A Study of 191 Lesions in 43 Patients. *Am J Surg Pathol*. 2017;41:820-832.
47. Chaux A, Tamboli P, Ayala A, et al. Warty-basaloid carcinoma: clinicopathological features of a distinctive penile neoplasm. Report of 45 cases. *Mod Pathol*. 2010;23:896-904.
48. Chaux A, Velazquez EF, Amin A, et al. Distribution and characterization of subtypes of penile intraepithelial neoplasia and their association with invasive carcinomas: a pathological study of 139 lesions in 121 patients. *Hum Pathol*. 2012;43:102-107.
49. Rubin MA, Kleter B, Zhou M, et al. Detection and typing of human papillomavirus DNA in penile carcinoma: evidence for multiple independent pathways of penile carcinogenesis. *Am J Pathol*. 2001;159(4):1211-1218.
50. Cubilla AL, Barreto J, Caballero C, et al. Pathologic features of epidermoid carcinoma of the penis. A prospective study of 66 cases. *Am J Surg Pathol*. 1993;17(8):753-763.
51. Velazquez EF, Amin MB, Cubilla AL, et al. Precursor lesions. In: Moch H, Humphrey PA, Ulbright TM, Reuter VE, eds. *WHO Classification of Tumours of the Urinary System and Male Genital Organs*. Lyon: IARC; 2016.
52. Velazquez FE, Chaux A, Cubilla AL. Histologic classification of penile intraepithelial neoplasia. *Semin Diag Pathol*. 2012;29: 96-102.
53. Soskin A, Vieillefond A, Carlotti A, et al. Warty/basaloid penile intraepithelial neoplasia is more prevalent than differentiated penile intraepithelial neoplasia in nonendemic regions for penile cancer when compared with endemic areas: a comparative study between pathologic series from Paris and Paraguay. *Hum Pathol*. 2012;43:190-196.
54. Chaux A, Pfannl R, Rodríguez IM, et al. Distinctive immunohistochemical profile of penile intraepithelial lesions: a study of 74 cases. *Am J Surg Pathol*. 2011;35:553-562.
55. Chaux A, Pfannl R, Lloveras B, et al. Distinctive association of p16INK4a overexpression with penile intraepithelial neoplasia depicting warty and/or basaloid features: a study of 141 cases evaluating a new nomenclature. *Am J Surg Pathol*. 2010;34:385-392.
56. Chaux A, Velazquez EF, Barreto JE, et al. New pathologic entities in penile carcinomas: an update of the 2004 world health organization classification. *Am J Surg Pathol*. 2012;29:59-66.
57. Cubilla AL, Velazques EF, Reuter VE, et al. Warty (condylomatous) squamous cell carcinoma of the penis: a report of 11 cases and proposed classification of 'verruciform' penile tumors. *Am J Surg Pathol*. 2000;24(4):505-512.
58. Liegl B, Regauer S. Penile clear cell carcinoma: a report of 5 cases of a distinct entity. *Am J Surg Pathol*. 2004;28:1513-1517.
59. Canete-Portillo S, Clavero O, Sanchez DF, et al. Medullary carcinoma of the penis: a distinctive HPV-related neoplasm: A report of 12 cases. *Am J Surg Pathol*. 2017;41:535-540.
60. Sanchez DF, Rodriguez IM, Piris A, et al. Clear cell carcinoma of the penis: an HPV-related variant of squamous cell carcinoma: a report of 3 cases. *Am J Surg Pathol*. 2016;40:917-922.
61. Mentrikoski MJ, Frierson HF Jr, Stelow EB, Cathro HP. Lymphoepithelioma-like carcinoma of the penis: association with human papilloma virus infection. *Histopathology*. 2014;64:312-315.
62. Johnson DE, Lo RK, Srigley J, Ayala AG. Verrucous carcinoma of the penis. *J Urol*. 1985;133(2):216-218.
63. Cubilla AL, Reuter V, Velazquez E, et al. Histologic classification of penile carcinoma and its relation to outcome in 61 patients with primary resection. *Int J Surg Pathol*. 2001;9(2):111-120.
64. Masih AS, Stoler MH, Farrow GM, et al. Penile verrucous carcinoma: a clinicopathologic, human papillomavirus typing and flow cytometric analysis. *Mod Pathol*. 1992;5(1):48-55.
65. Cubilla AL, Velazquez EF, Young RH. Pseudohyperplastic squamous cell carcinoma of the penis associated with lichen sclerosus. An extremely well-differentiated, nonverruciform neoplasm that preferentially affects the foreskin and is frequently misdiagnosed: a report of 10 cases of a distinctive clinicopathologic entity. *Am J Surg Pathol*. 2004;28(7):895-900.
66. Cunha IW, Guimaraes GC, Soares F, et al. Pseudoglandular (adenoid, acantholytic) penile squamous cell carcinoma: a clinicopathologic and outcome study of 7 patients. *Am J Surg Pathol*. 2009;33:551-555.
67. Chaux A, Soares F, Rodríguez I, et al. Papillary squamous cell carcinoma, not otherwise specified (NOS) of the penis: clinicopathologic features, differential diagnosis, and outcome of 35 cases. *Am J Surg Pathol*. 2010;34:23-30.
68. Watanabe K, Mukawa A, Miyazaki K, Tsukahara K. Adenoid squamous cell carcinoma of the penis. Report of a surgical case clinically manifested with rapid lung metastasis. *Acta Pathol Japonica*. 1983;33(6):1243-1250.
69. Manglani KS, Manaligod JR, Ray B. Spindle cell carcinoma of the glans penis: a light and electron microscopic study. *Cancer*. 1980;46(10):2266-2272.
70. Velazquez EF, Melamed J, Barreto JE, et al. Sarcomatoid carcinoma of the penis: a clinicopathologic study of 15 cases. *Am J Surg Pathol*. 2005;29(9):1152-1158.
71. Stankiewicz E, Prowse DM, Ng M, et al. Alternative HER/PTEN/Akt pathway activation in HPV positive and negative penile carcinomas. *PLoS ONE*. 2011;6:e17517.
72. Stankiewicz E, Prowse DM, Ktori E, et al. The retinoblastoma protein/p16 INK4A pathway but not p53 is disrupted by human papillomavirus in penile squamous cell carcinoma. *Histopathology*. 2011;58: 433-439.
73. Roccha RM, Ignácio JA, Jordán J, et al. A clinical, pathologic, and molecular study of p53 and murine double minute 2 in penile carcinogenesis and its relation to prognosis. *Hum Pathol*. 2012;43:481-488.
74. Alves G, Heller A, Fiedler W, et al. Genetic imbalances in 26 cases of penile squamous cell carcinoma. *Genes Chromosomes Cancer*. 2001;31:48-53.
75. Velazquez EF, Soskin A, Bock A, et al. Positive resection margins in partial penectomies: sites of involvement and proposal of local routes of spread of penile squamous cell carcinoma. *Am J Surg Pathol*. 2004;28(3):384-389.
76. Cabanas RM. An approach for the treatment of penile carcinoma. *Cancer*. 1977;39(2):456-466.
77. Horenblas S, Van Tinteren H, Delemarre JF, et al. Squamous cell carcinoma of the penis: accuracy of tumor, nodes and metastasis classification system, and role of lymphangiography, computerized tomography scan and fine needle aspiration cytology. *J Urol*. 1991;146(5):1279-1283.
78. Kato N, Onozuka T, Yasukawa K, et al. Penile hybrid verrucous-squamous carcinoma associated with a superficial inguinal lymph node metastasis. *Am J Dermatopathol*. 2000;22(4):339-343.
79. Fraley EE, Zhang G, Sazama R, Lange PH. Cancer of the penis. Prognosis and treatment plans. *Cancer*. 1985;55(7):1618-1624.
80. Hanash KA, Furlow WL, Utz DC, Harrison EG Jr. Carcinoma of the penis: a clinicopathologic study. *J Urol*. 1970;104(2):291-297.
81. Narayana AS, Olney LE, Loening SA, et al. Carcinoma of the penis: analysis of 219 cases. *Cancer*. 1982;49(10):2185-2191.
82. Young MJ, Reda DJ, Waters WB. Penile carcinoma: a twenty-five-year experience. *Urology*. 1991;38(6):529-532.
83. Velazquez EF, Barreto JE, Rodriguez I, et al. Limitations in the interpretation of biopsies in patients with penile squamous cell carcinoma. *Int J Surg Pathol*. 2004;12(2):139-146.
84. Hoffman MA, Renshaw AA, Loughlin KR. Squamous cell carcinoma of the penis and microscopic pathologic margins: how much margin is needed for local cure? *Cancer*. 1999;85(7):1565-1568.
85. Fraley EE, Zhang G, Manivel C, Niehans GA. The role of ilioinguinal lymphadenectomy and significance of histological differentiation in treatment of carcinoma of the penis. *J Urol*. 1989;142(6):1478-1482.
86. Johnson DE, Lo RK. Management of regional lymph nodes in penile carcinoma. Five-year results following therapeutic groin dissections. *Urology*. 1984;24(4):308-311.
87. Ornellas AA, Seixas AL, de Moraes JR. Analyses of 200 lymphadenectomies in patients with penile carcinoma. *J Urol*. 1991;146(2):330-332.
88. Ravi R. Prophylactic lymphadenectomy vs observation vs inguinal biopsy in node-negative patients with invasive carcinoma of the penis. *Jpn J Clin Oncol*. 1993;23(1):53-58.
89. Fukunaga M, Yokoi K, Miyazawa Y, et al. Penile verrucous carcinoma with anaplastic transformation following radiotherapy. A case report with human papillomavirus typing and flow cytometric DNA studies. *Am J Surg Pathol*. 1994;18(5):501-505.
90. Hayashi T, Tsuda N, Shimada O, et al. A clinicopathologic study of tumors and tumor-like lesions of the penis. *Acta Pathol Japonica*. 1990;40(5):343-351.
91. Pettaway CA, Srigley JR, Brookland RK, et al. Penis. In: Amin MB, ed. *AJCC Cancer Staging Manual*. 8th ed. Springer; 2017.
92. Burgers JK, Badalament RA, Drago JR. Penile cancer. Clinical presentation, diagnosis, and staging. *Urol Clin N Am*. 1992;19(2):247-256.
93. Maiche AG, Pyrhonen S. Clinical staging of cancer of the penis: by size? By localization?

Or by depth of infiltration? *Eur Urol*. 1990;18(1):16-22.
94. Cubilla AL, Piris A, Pfannl R, et al. Anatomic levels: important landmarks in penectomy specimens: a detailed anatomic and histologic study based on examination of 44 cases. *Am J Surg Pathol*. 2001;25(8):1091-1094.
95. Baker BH, Spratt JS Jr, Perez-Mesa C, et al. Carcinoma of the penis. *J Urol*. 1976;116(4):458-461.
96. Chaux A, Reuter V, Lezcano C, et al. Comparison of morphologic features and outcome of resected recurrent and nonrecurrent squamous cell carcinoma of the penis: a study of 81 cases. *Am J Surg Pathol*. 2009;33(9):1299-1306.
97. Chaux A, Torres J, Pfannl R, et al. Histologic grade in penile squamous cell carcinoma: visual estimation versus digital measurement of proportions of grades, adverse prognosis with any proportion of grade 3 and correlation of a Gleason-like system with nodal metastasis. *Am J Surg Pathol*. 2009;33(7):1042-1048.
98. Emerson RE, Ulbright TM, Eble JN, et al. Predicting cancer progression in patients with penile squamous cell carcinoma: the importance of depth of invasion and vascular invasion. *Mod Pathol*. 2001;14(10):963-968.
99. Maiche AG, Pyrhonen S, Karkinen M. Histological grading of squamous cell carcinoma of the penis: a new scoring system. *Br J Urol*. 1991;67(5):522-526.
100. Cubilla AL. The role of pathologic prognostic factors in squamous cell carcinoma of the penis. *World J Urol*. 2009;27(2):169-177.
101. Velazquez EF, Ayala G, Liu H, et al. Histologic grade and perineural invasion are more important than tumor thickness as predictor of nodal metastasis in penile squamous cell carcinoma invading 5 to 10 mm. *Am J Surg Pathol*. 2008;32(7):974-979.
102. Kvist E, Osmundsen PE, Sjolin KE. Primary Paget's disease of the penis. Case report. *Scand J Urol Nephrol*. 1992;26(2):187-190.
103. Park S, Grossfeld GD, McAninch JW, Santucci R. Extramammary Paget's disease of the penis and scrotum: excision, reconstruction and evaluation of occult malignancy. *J Urol*. 2001;166(6):2112-2116, discussion 7.
104. Perotto J, Abbott JJ, Ceilley RI, Ahmed I. The role of immunohistochemistry in discriminating primary from secondary extramammary Paget disease. *Am J Dermatopathol*. 2010;32:137-143.
105. Mazoujian G, Pinkus GS, Haagensen DE Jr, et al. Extramammary Paget's disease—evidence for an apocrine origin. An immunoperoxidase study of gross cystic disease fluid protein-15, carcinoembryonic antigen, and keratin proteins. *Am J Surg Pathol*. 1984;8:43-50.
106. Zhao M, Zhao L, Sun L, et al. GATA3 is a sensitive marker for primary genital extramammary paget disease: an immunohistochemical study of 72 cases with comparison to gross cystic disease fluid protein 15. *Diagn Pathol*. 2017;12:51.
107. Morbeck D, Tregnago AC, Netto GB, et al. GATA3 expression in primary vulvar Paget disease: a potential pitfall leading to misdiagnosis of pagetoid urothelial intraepithelial neoplasia. *Histopathology*. 2017;70:435-441.
108. Brown HM, Wilkinson EJ. Uroplakin-III to distinguish primary vulvar Paget disease from Paget disease secondary to urothelial carcinoma. *Hum Pathol*. 2002;33:545-548.
109. Memezawa A, Memezawa A, Okuyama R, et al. p63 constitutes a useful histochemical marker for differentiation of pagetoid Bowen's disease from extramammary Paget's disease. *Acta Derm Venereol*. 2008;88:619-620.
110. Ramachandra S, Gillett CE, Millis RR. A comparative immunohistochemical study of mammary and extramammary Paget's disease and superficial spreading melanoma, with particular emphasis on melanocytic markers. *Virchows Arch*. 1996;429:371-376.
111. Bacchi CE, Goldfogel GA, Greer BE, Gown AM. Paget's disease and melanoma of the vulva. Use of a panel of monoclonal antibodies to identify cell type and to microscopically define adequacy of surgical margins. *Gynecol Oncol*. 1992;46(2):216-221.
112. Goldblum JR, Hart WR. Perianal Paget's disease: a histologic and immunohistochemical study of 11 cases with and without associated rectal adenocarcinoma. *Am J Surg Pathol*. 1998;22(2):170-179.
113. Zeng HA, Cartun R, Ricci A Jr. Potential diagnostic utility of CDX-2 immunophenotyping in extramammary Paget's disease. *Appl Immunohistochem Mol Morphol*. 2005;13:342-346.
114. Goldminz D, Scott G, Klaus S. Penile basal cell carcinoma. Report of a case and review of the literature. *J Am Acad Dermatol*. 1989;20(6):1094-1097.
115. Heaton ND, Kadow C, Yates-Bell AJ. Inverted papilloma of the penile urethra. *Br J Urol*. 1990;66(6):661-662.
116. Mira JL, Fan G. Leiomyoma of the male urethra: a case report and review of the literature. *Arch Pathol Lab Med*. 2000;124(2):302-303.
117. Levine RL. Urethral cancer. *Cancer*. 1980;45(7 suppl):1965-1972.
118. Vernon HK, Wilkins RD. Primary carcinoma of the male urethra. *Br J Urol*. 1950;21:232-236.
119. Dailey VL, Humphrey PA, Hameed O. Primary urethral adenocarcinomas: a clinicopathological review. *Lab Invest*. 2009;89(suppl 1):164A.
120. Bostwick DG, Lo R, Stamey TA. Papillary adenocarcinoma of the male urethra. Case report and review of the literature. *Cancer*. 1984;54(11):2556-2563.
121. Loo KT, Chan JK. Colloid adenocarcinoma of the urethra associated with mucosal in situ carcinoma. *Arch Pathol Lab Med*. 1992;116(9):976-977.
122. Bolduan JP, Farah RN. Primary urethral neoplasms: review of 30 cases. *J Urol*. 1981;125(2):198-200.
123. Begun FP, Grossman HB, Diokno AC, Sogani PC. Malignant melanoma of the penis and male urethra. *J Urol*. 1984;132(1):123-125.
124. Oliva E, Quinn TR, Amin MB, et al. Primary malignant melanoma of the urethra: a clinicopathologic analysis of 15 cases. *Am J Surg Pathol*. 2000;24(6):785-796.
125. Kahn DG, Rothman PJ, Weisman JD. Urethral T-cell lymphoma as the initial manifestation of the acquired immune deficiency syndrome. *Arch Pathol Lab Med*. 1991;115(11):1169-1170.
126. Tanenbaum MH, Becker SW. Papillae of the corona of the glans penis. *J Urol*. 1965;93:391-395.
127. Winer JH, Winer LH. Hirsutoid papillomas of coronal margin of glans penis. *J Urol*. 1955;74(3):375-378.
128. Fetsch JF, Davis CJ Jr, Hallman JR, et al. Lymphedematous fibroepithelial polyps of the glans penis and prepuce: a clinicopathologic study of 7 cases demonstrating a strong association with chronic condom catheter use. *Hum Pathol*. 2004;35(2):190-195.
129. Lo JS, Dijkstra JW, Bergfeld WF. Syringomas on the penis. *Int J Dermatol*. 1990;29(4):309-310.
130. Nomura M, Hata S. Sebaceous trichofolliculoma on scrotum and penis. *Dermatologica*. 1990;181(1):68-70.
131. Petersson F, Mjornberg PA, Kazakov DV, Bisceglia M. Eruptive syringoma of the penis. A report of 2 cases and a review of the literature. *Am J Dermatopathol*. 2009;31(5):436-438.
132. Barnhill RL, Albert LS, Shama SK, et al. Genital lentiginosis: a clinical and histopathologic study. *J Am Acad Dermatol*. 1990;22(3):453-460.
133. Leicht S, Youngberg G, Diaz-Miranda C. Atypical pigmented penile macules. *Arch Dermatol*. 1988;124(8):1267-1270.
134. Val-Berna lJF, Hernando M. Blue nevus of the penis. *J Urol Pathol*. 1997;6:61-66.
135. Oldbring J, Mikulowski P. Malignant melanoma of the penis and male urethra. Report of nine cases and review of the literature. *Cancer*. 1987;59(3):581-587.
136. Zurrida S, Bartoli C, Clemente C, De Palo G. Malignant melanoma of the penis. A report of four cases. *Tumori*. 1990;76(6):599-602.
137. Dehner LP, Smith BH. Soft tissue tumors of the penis. A clinicopathologic study of 46 cases. *Cancer*. 1970;25(6):1431-1447.
138. Fetsch JF, Sesterhenn IA, Davis CJ, Mostofi FK. Soft tissue tumors of the penis: a retrospective review of 114 cases [abstract]. *Mod Pathol*. 2003;16.
139. Fetsch JF, Sesterhenn IA, Miettinen M, Davis CJ Jr. Epithelioid hemangioma of the penis: a clinicopathologic and immunohistochemical analysis of 19 cases, with special reference to exuberant examples often confused with epithelioid hemangioendothelioma and epithelioid angiosarcoma. *Am J Surg Pathol*. 2004;28(4):523-533.
140. Srigley JR, Ayala AG, Ordonez NG, van Nostrand AW. Epithelioid hemangioma of the penis. A rare and distinctive vascular lesion. *Arch Pathol Lab Med*. 1985;109(1):51-54.
141. Kubota Y, Nakada T, Yaguchi H, et al. Schwannoma of the penis. *Urol Int*. 1993;51(2):111-113.
142. Dwosh J, Mininberg DT, Schlossberg S, Peterson P. Neurofibroma involving the penis in a child. *J Urol*. 1984;132(5):988-989.
143. Fethiere W, Carter HW, Sturim HS. Elephantiasis neuromatosa of the penis. Light and electron microscopical studies. *Arch Pathol*. 1974;97(5):326-330.
144. Salcedo E, Soldano AC, Chen L, et al. Traumatic neuromas of the penis: a clinical, histopathological and immunohistochemical study of 17 cases. *J Cutan Pathol*. 2009;36(2):229-233.
145. Carver BS, Venable DD, Eastham JA. Large granular cell tumor of the penis in a 53-year-old man with coexisting prostate cancer. *Urology*. 2002;59(4):602.
146. Laskin WB, Fetsch JF, Davis CJ Jr, Sesterhenn IA. Granular cell tumor of the penis: clinicopathologic evaluation of 9 cases. *Hum Pathol*. 2005;36(3):291-298.
147. Tanaka Y, Sasaki Y, Kobayashi T, Terashima K. Granular cell tumor of the corpus cavernosum of the penis. *J Urol*. 1991;146(6):1596-1597.
148. Bartoletti R, Gacci M, Nesi G, et al. Leiomyoma of the corona glans penis. *Urology*. 2002;59(3):445.
149. Val-Bernal JF, Garijo MF. Solitary cutaneous myofibroma of the glans penis. *Am J Dermatopathol*. 1996;18(3):317-321.
150. Kraemer BB, Schmidt WA, Foucar E, Rosen T. Verruciform xanthoma of the penis. *Arch Dermatol*. 1981;117(8):516-518.
151. Ghandur-Mnaymneh L, Gonzalez MS. Angiosarcoma of the penis with hepatic angiomas in a patient with low vinyl chloride exposure. *Cancer*. 1981;47(6):1318-1324.
152. Rasbridge SA, Parry JR. Angiosarcoma of the penis. *Br J Urol*. 1989;63(4):440-441.
153. Angulo JC, Lopez JI, Unda-Urzaiz M, et al. Kaposi's sarcoma of the penis as an initial urological manifestation of AIDS. A report of two cases. *Urol Int*. 1991;46(2):235-237.

154. Lowe FC, Lattimer DG, Metroka CE. Kaposi's sarcoma of the penis in patients with acquired immunodeficiency syndrome. *J Urol*. 1989;142(6):1475-1477.
155. Seftel AD, Sadick NS, Waldbaum RS. Kaposi's sarcoma of the penis in a patient with the acquired immune deficiency syndrome. *J Urol*. 1986;136(3):673-675.
156. Moore SW, Wheeler JE, Hefter LG. Epitheloid sarcoma masquerading as Peyronie's disease. *Cancer*. 1975;35(6):1706-1710.
157. Fletcher CD, Lowe D. Inflammatory fibrous histiocytoma of the penis. *Histopathology*. 1984;8(6):1079-1084.
158. Moran CA, Kaneko M. Malignant fibrous histiocytoma of the glans penis. *Am J Dermatopathol*. 1990;12(2):182-187.
159. Yantiss RK, Althausen AF, Young RH. Malignant fibrous histiocytoma of the penis: report of a case and review of the literature. *J Urol Pathol*. 1998;9:171-180.
160. Saw D, Tse CH, Chan J, et al. Clear cell sarcoma of the penis. *Hum Pathol*. 1986;17(4):423-425.
161. Isa SS, Almaraz R, Magovern J. Leiomyosarcoma of the penis. Case report and review of the literature. *Cancer*. 1984;54(5):939-942.
162. Bacetic D, Knezevic M, Stojsic Z, et al. Primary extraskeletal osteosarcoma of the penis with a malignant fibrous histiocytoma-like component. *Histopathology*. 1998;33(2):185-186.
163. Sacker AR, Oyama KK, Kessler S. Primary osteosarcoma of the penis. *Am J Dermatopathol*. 1994;16(3):285-287.
164. Fetsch JF, Brinsko RW, Davis CJ Jr, et al. A distinctive myointimal proliferation ('myointimoma') involving the corpus spongiosum of the glans penis: a clinicopathologic and immunohistochemical analysis of 10 cases. *Am J Surg Pathol*. 2000;24(11):1524-1530.
165. McKenney JK, Collins MH, Carretero AP, et al. Penile myointimoma in children and adolescents: a clinicopathologic study of 5 cases supporting a distinct entity. *Am J Surg Pathol*. 2007;31(10):1622-1626.
166. Gonzalez-Campora R, Nogales FF Jr, Lerma E, et al. Lymphoma of the penis. *J Urol*. 1981;126(2):270-271.
167. Yu GS, Nseyo UO, Carson JW. Primary penile lymphoma in a patient with Peyronie's disease. *J Urol*. 1989;142(4):1076-1077.
168. Meehan SA, Smoller BR. Cutaneous Langerhans cell histiocytosis of the genitalia in the elderly: a report of three cases. *J Cutan Pathol*. 1998;25(7):370-374.
169. Chaux A, Amin M, Cubilla AL, Young RH. Metastatic tumors to the penis: a report of 17 cases and review of the literature. *Int J Surg Pathol*. 2011;19(5):597-606.
170. Perez-Mesa C, Oxenhandler R. Metastatic tumors of the penis. *J Surg Oncol*. 1989;42(1):11-15.
171. Robey EL, Schellhammer PF. Four cases of metastases to the penis and a review of the literature. *J Urol*. 1984;132(5):992-994.
172. Belville WD, Cohen JA. Secondary penile malignancies: the spectrum of presentation. *J Surg Oncol*. 1992;51(2):134-137.
173. Daniels GF Jr, Schaeffer AJ. Renal cell carcinoma involving penis and testis: unusual initial presentations of metastatic disease. *Urology*. 1991;37(4):369-373.
174. Fujimoto N, Hiraki A, Ueoka H, Harada M. Metastasis to the penis in a patient with squamous cell carcinoma of the lung with a review of reported cases. *Lung Cancer*. 2001;34(1):149-152.
175. Kotake Y, Gohji K, Suzuki T, et al. Metastases to the penis from carcinoma of the prostate. *Int J Urol*. 2001;8(2):83-86.
176. Mitsudo S, Nakanishi I, Koss LG. Paget's disease of the penis and adjacent skin: its association with fatal sweat gland carcinoma. *Arch Pathol Lab Med*. 1981;105(10):518-520.
177. Metcalf JS, Lee RE, Maize JC. Epidermotropic urothelial carcinoma involving the glans penis. *Arch Dermatol*. 1985;121(4):532-534.
178. Trainer TD. Histology of the normal testis. *Am J Surg Pathol*. 1978;11:797-809.
179. Cajaiba MM, Garcia-Fernandez E, Reyes-Mugica M, Nistal M. The spectrum of persistence of testicular blastema and ectopic testicular parenchyma: a possible result of focal delay in gonadal development. *Virchows Archiv*. 2007;451(1):89-94.
180. Shapiro L, Platt N, Torres-Rodriguez VM. Idiopathic calcinosis of the scrotum. *Arch Dermatol*. 1970;102(2):199-204.
181. Gormally S, Dorman T, Powell FC. Calcinosis of the scrotum. *Int J Dermatol*. 1992;31(2):75-79.
182. Shah V, Shet T. Scrotal calcinosis results from calcification of cysts derived from hair follicles: a series of 20 cases evaluating the spectrum of changes resulting in scrotal calcinosis. *Am J Dermatopathol*. 2007;29(2):172-175.
183. Smetana HF, Bernhard W. Sclerosing lipogranuloma. *Arch Pathol (Chic)*. 1950;50(3):296-325.
184. Oertel YC, Johnson FB. Sclerosing lipogranuloma of male genitalia. Review of 23 cases. *Arch Pathol Lab Med*. 1977;101(6):321-326.
185. Hollander JB, Begun FP, Lee RD. Scrotal fat necrosis. *J Urol*. 1985;134(1):150-151.
186. Nistal M, Iniguez L, Paniagua R. Cysts of the testicular parenchyma and tunica albuginea. *Arch Pathol Lab Med*. 1989;113(8):902-906.
187. Warner KE, Noyes DT, Ross JS. Cysts of the tunica albuginea testis: a report of 3 cases with a review of the literature. *J Urol*. 1984;132(1):131-132.
188. Amann G, Berger A, Rokitansky A. Accessory scrotum or perineal collision-hamartoma. A case report to illustrate a misnomer. *Pathol Res Pract*. 1996;192(10):1039-1043, discussion 44.
189. Acker SM, Sahn EE, Rogers HC, et al. Genital cutaneous Crohn disease: two cases with unusual clinical and histopathologic features in young men. *Am J Dermatopathol*. 2000;22(5):443-446.
190. Spirnak JP, Resnick MI, Hampel N, Persky L. Fournier's gangrene: report of 20 patients. *J Urol*. 1984;131(2):289-291.
191. Bahlmann JC, Fourie IJ, Arndt TC. Fournier's gangrene: necrotising fasciitis of the male genitalia. *Br J Urol*. 1983;55(1):85-88.
192. Paty R, Smith AD. Gangrene and Fournier's gangrene. *Urol Clin N Am*. 1992;19(1):149-162.
193. Radaelli F, Della Volpe A, Colombi M, et al. Acute gangrene of the scrotum and penis in four hematologic patients. The usefulness of hyperbaric oxygen therapy in one case. *Cancer*. 1987;60(7):1462-1464.
194. Lee S, Han JS, Ross HM, Epstein JI. Massive localized lymphedema of the male external genitalia: a clinicopathologic study of 6 cases. *Hum Pathol*. 2013;44:277-281.
195. Schook CC, Kulungowski AM, Greene AK, Fishman SJ. Male genital lymphedema: clinical features and management in 25 pediatric patients. *J Pediatr Surg*. 2014;49:1647-1651.
196. Newman PL, Fletcher CD. Smooth muscle tumours of the external genitalia: clinicopathological analysis of a series. *Histopathology*. 1991;18(6):523-529.
197. Slone S, O'Connor D. Scrotal leiomyomas with bizarre nuclei: a report of three cases. *Mod Pathol*. 1998;11(3):282-287.
198. Matoso A, Chen S, Plaza JA, et al. Symplastic leiomyomas of the scrotum: a comparative study to usual leiomyomas and leiomyosarcomas. *Am J Surg Pathol*. 2014;38:1410-1417.
199. Castiglione FM Jr, Selikowitz SM, Dimond RL. Mule spinner's disease. *Arch Dermatol*. 1985;121(3):370-372.
200. Lowe FC. Squamous cell carcinoma of scrotum. *Urology*. 1985;25(1):63-65.
201. Greider HD, Vernon SE. Basal cell carcinoma of the scrotum: a case report and literature review. *J Urol*. 1982;127(1):145-146.
202. Perez MA, LaRossa DD, Tomaszewski JE. Paget's disease primarily involving the scrotum. *Cancer*. 1989;63(5):970-975.
203. Johnson S, Rundell M, Platt W. Leiomyosarcoma of the scrotum: a case report with electron microscopy. *Cancer*. 1978;41(5):1830-1835.

29 Adrenal Gland and Other Paraganglia

Jesse K. McKenney

CHAPTER CONTENTS

Normal anatomy, *1190*
Adrenal gland, *1190*
Paraganglion system, *1191*
Biopsy and cytology, *1192*
Lesions of adrenal cortex, *1192*
Adrenal adhesion and union, *1192*
Adrenal heterotopia, *1192*
Adrenal hyperplasia, *1193*
Adrenocortical neoplasms, *1194*
Lesions of adrenal medulla, *1200*
Neuroblastoma, *1200*
Adrenal medullary hyperplasia, *1204*
Pheochromocytoma, *1205*
Other adrenal lesions, *1207*
Tumors and tumorlike lesions of other paraganglia, *1209*
Generalities, *1209*
Morphologic features, *1210*
Electron microscopic and immunohistochemical features, *1210*
Treatment and prognosis, *1211*
Paraganglioma subtypes, *1211*

Normal Anatomy

Adrenal Gland

The adrenal gland is a composite of two endocrine organs, one mesodermally derived (cortex) and the other neuroectodermally derived (medulla).[1-3] The function of the adrenal cortex is to secrete several steroid hormones known as corticosteroids, all of which are produced by a series of complicated enzymatic steps from cholesterol (Fig. 29.1). They are classified into three groups—mineralocorticoids, glucocorticoids, and sex hormones (adrenal androgens)—depending on their biologic action. The enzymes responsible for their production can be assayed biochemically and detected immunohistochemically.[4]

The adrenal glands are located in the retroperitoneum, superomedial to the kidneys. The combined adrenal weight in normal adult individuals should not exceed 6 g; there are no apparent sex differences.

The adrenal cortex is divided into three zones, all of which are under the influence of adrenocorticotropic hormone (ACTH): glomerulosa, fasciculata, and reticularis (Fig. 29.2). The zona glomerulosa, which lies immediately beneath the capsule and is the site of mineralocorticoid (aldosterone) production, is composed of well-outlined cells aggregated into small clusters and short trabeculae. The zona fasciculata, which is the site of glucocorticoid and sex hormone production, forms a broad band made up of large cells with distinct membranes arranged in two cell-wide cords. The cytoplasm is characterized by the presence of innumerable small lipid-containing vacuoles, some of which indent the centrally located nucleus in a fashion similar to that seen in sebaceous cells and lipoblasts; these cells are sometimes referred to as spongiocytes or clear cells. The zona reticularis is also involved in the secretion of glucocorticoids and sex hormones (particularly the latter). Its cells, which are arranged in a haphazard fashion, are smaller than those in the zona fasciculata and have a cytoplasm that is granular and acidophilic, with little or no lipid (so-called compact cells). Some of these cells contain lipofuscin in their cytoplasm.[1]

The predominant cell type in the medulla is the pheochromocyte (medullary cell or chromaffin cell), which is admixed with scattered cortical cells and ganglion cells. The pheochromocyte is a rather large cell of polygonal shape and poorly outlined borders. Its abundant cytoplasm is distinctly granular and usually basophilic, although it may be amphophilic or even eosinophilic. Occasional cells feature cytoplasmic hyaline ("colloid") droplets, which are strongly positive with periodic acid–Schiff (PAS) stain.[1] A second cell population of the medullary region is represented by the sustentacular cells, which are located at the periphery of the nests and trabeculae; they are difficult to identify in routinely stained preparations but are readily demonstrated by immunostaining for S-100 protein.[1]

Ultrastructurally, the cells of the adrenal cortex share two important features that are common to all steroid-producing cells: abundant smooth endoplasmic reticulum and numerous mitochondria. The mitochondria have lamellar cristae in the zona glomerulosa and

Abstract

This chapter covers the features of normal adrenal gland and the full spectrum of benign and malignant alterations that may be encountered in routine practice. Adrenal cortical hyperplasia types, emphasizing newer molecular correlates, are detailed. The spectrum of adrenal cortical neoplasia (including adenoma, carcinoma, and borderline lesions) is addressed, and the adjunctive techniques useful in difficult cases are reviewed. Adrenal medullary lesions, pheochromocytoma, and medullary hyperplasia, are also discussed. Finally, the spectrum of rare intra-adrenal tumors and extra-adrenal paragangliomas are covered.

Keywords

adrenal
cortex
hyperplasia
adenoma
carcinoma
medulla
pheochromocytoma
paraganglioma

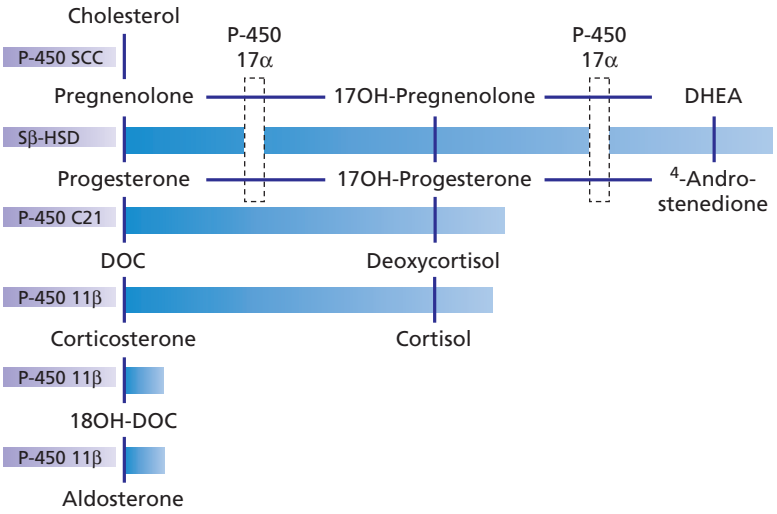

Figure 29.1 Pathways of corticosteroidogenesis.

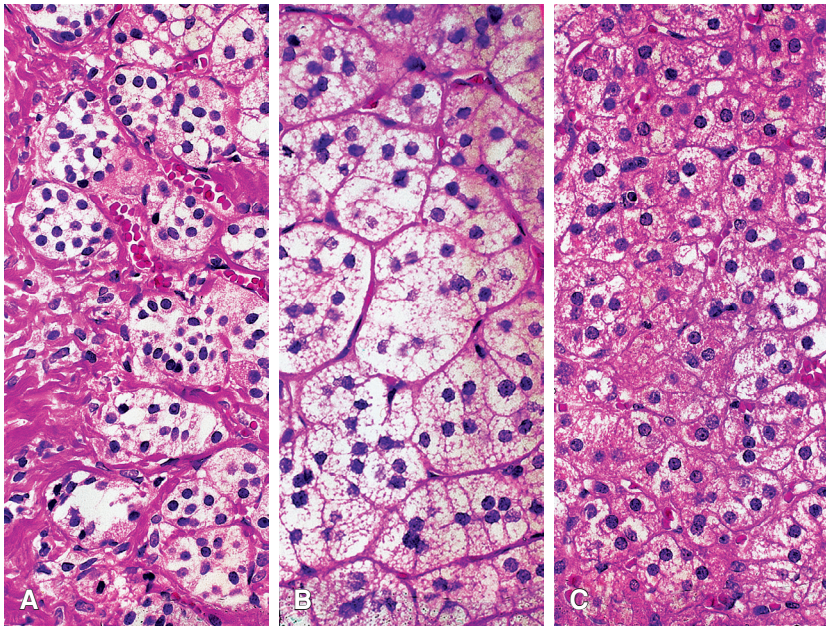

Figure 29.2 The three layers of the normal adrenal cortex: **A,** glomerulosa; **B,** fasciculata; **C,** reticularis.

tubulovesicular cristae in the zona fasciculata and reticularis.[5] The medullary cells can be divided into two types on the basis of the size of the cytoplasmic dense-core neurosecretory granules they contain: norepinephrine containing (electron opaque, often eccentrically located within a dilated sac, about 250 nm in diameter) and epinephrine containing (finely granular, filling the enclosing membrane, about 190 nm in diameter).

The immunohistochemical features of the cells are discussed in connection with the respective neoplasms.

Paraganglion System

The paraganglion system is formed by numerous collections of neuroepithelial cells ("chief cells") scattered throughout the body,[6] their common morphologic denominator being the presence of numerous cytoplasmic neurosecretory granules containing catecholamines.[7,8] Microscopically, all paraganglia have a similar morphologic appearance characterized by chief cells arranged in well-defined nests ("Zellballen") encircled by a thin layer of S-100 protein–positive sustentacular cells. The most conspicuous member of the paraganglion system is the already described adrenal medulla, a neuroeffector system connected with the orthosympathetic system. Extra-adrenal paraganglia can be divided into two broad categories: those related to the parasympathetic system (ninth, tenth, and possibly third and fifth nerves) and those connected with the orthosympathetic system. The former are usually nonchromaffin, are concentrated in the head, neck, and mediastinum, and are thought to have a chemoreceptor function. The latter are chromaffin, predominate in the retroperitoneum along the thoracolumbar para-aortic region, and probably represent lesser homologues of the adrenal medulla. Sometimes small paraganglia are found incidentally in sites such as the bladder, prostate, gallbladder, splenic capsule, and mesosigmoid[9]; special care should be exercised not to confuse them with foci of metastatic carcinoma (Fig. 29.3).[9,10]

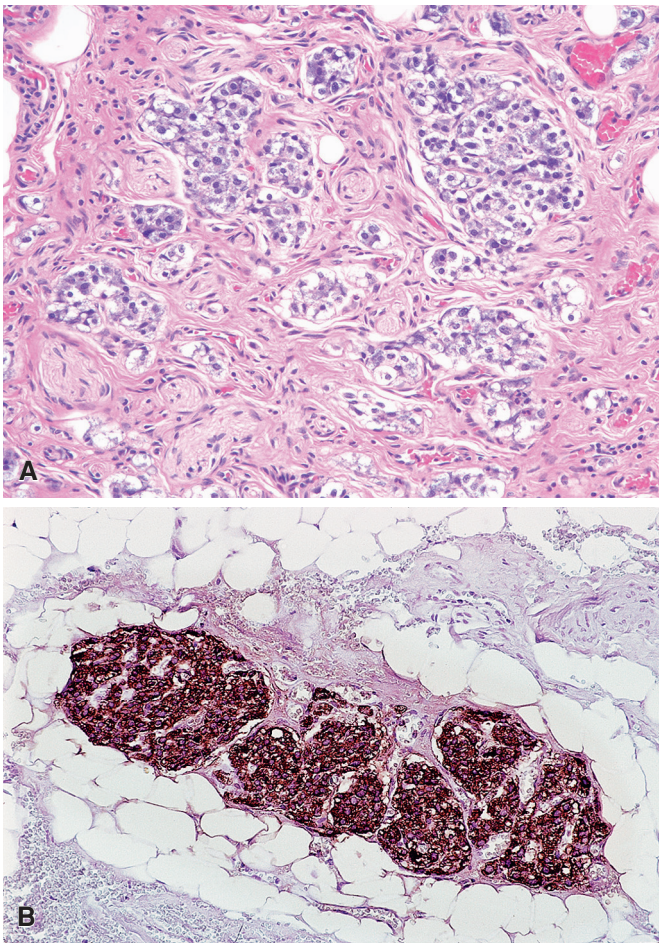

Figure 29.3 Normal paraganglion found incidentally in the retroperitoneal region. **A,** Hematoxylin–eosin; **B,** chromogranin.

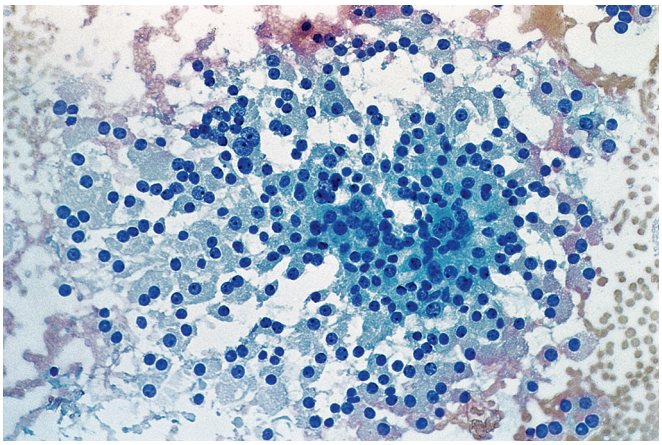

Figure 29.4 Fine-needle aspiration specimen from an adrenal cortical adenoma.

Biopsy and Cytology

The specimens from adrenal gland received in the laboratory usually consist of the entire organ, but in selected cases the diagnosis can be achieved through the performance of an ultrasonically or computed tomography (CT)-guided biopsy[11,12] or fine-needle aspiration cytology (Fig. 29.4).[13-15] The latter procedure is particularly useful for the diagnosis of metastatic tumors to this organ. In the series of Suen and Chan,[16] a success rate of 86% was achieved in obtaining cellular material for diagnosis. A high rate of diagnostic accuracy for adrenal core biopsy (an overall sensitivity for malignancy of 94.6% and a specificity of 95.3%) was reported in a recently concluded multi-institutional trial of 220 consecutive patients.[17]

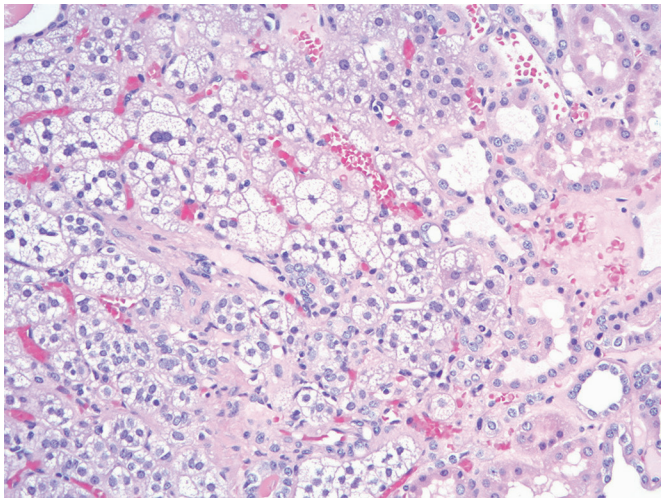

Figure 29.5 Adrenal renal fusion showing adrenal cortical tissue admixed with renal tubules *(on right)*.

Lesions of Adrenal Cortex

A variety of pathologic processes may arise from adrenal cortical tissue. These include malformations, heterotopias, hyperplasias, and neoplasms. Hyperplasias have been divided into clinical groups as diffuse, micronodular, and macronodular types, while neoplasms are classified as adenoma or carcinoma. Even more than in other organs, these diagnostic categories are not as discrete as might be assumed and classification based purely on histology may be impossible in a given case. The integration of the histologic and macroscopic features with endocrine findings, clinical history, and evolving molecular genetic "signatures" are likely to produce the most accurate diagnoses.

Adrenal Adhesion and Union

The adrenal gland may rarely have an abnormal connection to the liver or kidney.[18,19] When an intervening capsule is present (without intervening fat), this is referred to as *adhesion*. The term *union* (or fusion) is used when the two tissue types are intermingled (Fig. 29.5). Occasional biopsies of such lesions may be easily confused with renal cell carcinoma.

Adrenal Heterotopia

Heterotopic (accessory) adrenal cortical tissue has been reported in numerous locations, many of them resulting from some cells of the adrenocortical primordium becoming associated with and migrating alongside the gonads. The most common site is the retroperitoneal fat close to the adrenal gland. Other described sites include the region of the celiac plexus, the kidney (in an intrarenal location, to be distinguished from renal–adrenal fusion[18]), along the course of the spermatic and ovarian veins, the testis, adjacent to the tail of the epididymis, the broad ligament near the ovary, the ovary itself (but only exceptionally), the canal of Nuck, hernial and hydrocele

sacs, the mesoappendix, and the liver. It has also been rarely reported in distant sites such as lung, intradural space, and brain.[20-23] The epididymis associated with the ectopic adrenal tissue may show various types of malformation.[24] The ectopic cortical tissue is almost never accompanied by a medullary component.

These ectopic nests may undergo marked hyperplasia in patients with Nelson syndrome or other conditions associated with increased ACTH production,[25] and they occasionally give rise to ectopic adrenal cortical adenomas and carcinomas.[22,26-28]

Adrenal Hyperplasia

Congenital Adrenal Hyperplasia

Congenital adrenal hyperplasia, an inborn error of metabolism, is a family of autosomal recessive disorders that produce defects in adrenal steroid production.[29,30] It is responsible for the large majority of cases of adrenogenital syndrome developing within the first year of life, but it can also first present clinically during adulthood.[31] Specific symptoms and their severity are variable, depending on the specific mutation, the residual enzyme activity, and the sex of the patient.

In approximately 95% of the cases, the defect is an absence of the enzyme 21-hydroxylase, which results in the accumulation of 17OH-progesterone and its catabolite pregnanetriol and in a deficiency of cortisol.[32] The clinical picture may include pure virilizing syndrome, electrolyte disturbances (e.g. "salt losing" forms), or more mild symptoms.[33] The second most frequent form is due to a deficiency of 11β-hydroxylase and is characterized by virilization and hypertension. Several other variants, all exceptionally rare, have been described, including 17OH deficiency, 3 βHSD2 deficiency, P540 oxidoreductase deficiency, lipoid congenital adrenal hyperplasia (*STAR* mutation), and P540 cholesterol side chain cleavage enzyme deficiency.[30,34-36] The specific genes encoding each of the steroid biosynthetic enzymes have been cloned, and the common mutations (and their variants) in these genes are being determined.[37,38] The most important of these is the *CYP21A2* gene on chromosome 6p21.3, but over 100 separate mutations are reported even in this most common form.[39-41] The pathologic change is the same in all types and is characterized by diffuse cortical hyperplasia, especially of the zona reticularis. The treatment consists predominantly of hormone replacement, but a balance of measures to address normal development and later psychosocial, sexual, and fertility issues may be challenging.[36] The testicular "tumors" occurring in patients with adrenal cortical hyperplasia are discussed in Chapter 27.

Primary Pigmented Nodular Adrenal Cortical Hyperplasia

This morphologically distinct form of adrenal hyperplasia (sometimes referred to as "micronodular adrenal disease") may be isolated or a component of Carney complex[42] and is characterized by ACTH-independent Cushing syndrome typically in younger age groups. The adrenal glands, which may be small, normal sized, or slightly enlarged, show multiple pigmented cortical nodules with atrophy of the intervening cortex.[43,44] These nodules are primarily composed of eosinophilic, lipid-poor cells similar to those of the normal zona reticularis, and many cells contain lipofuscin/neuromelanin pigment (Fig. 29.6). The cells show intense immunoreactivity for all the steroidogenic enzymes.[45] Occasional additional features include microscopic foci of necrosis, mitoses, and a trabecular pattern of growth.[46] Some patients have germline mutations in *PRKAR1A*. Although rare, this etiology should be carefully considered in children who present with Cushing disease.[47] Other similar hyperplasias are rarely seen in patients with *PDE11A* or *PDE8B* mutations.[48,49]

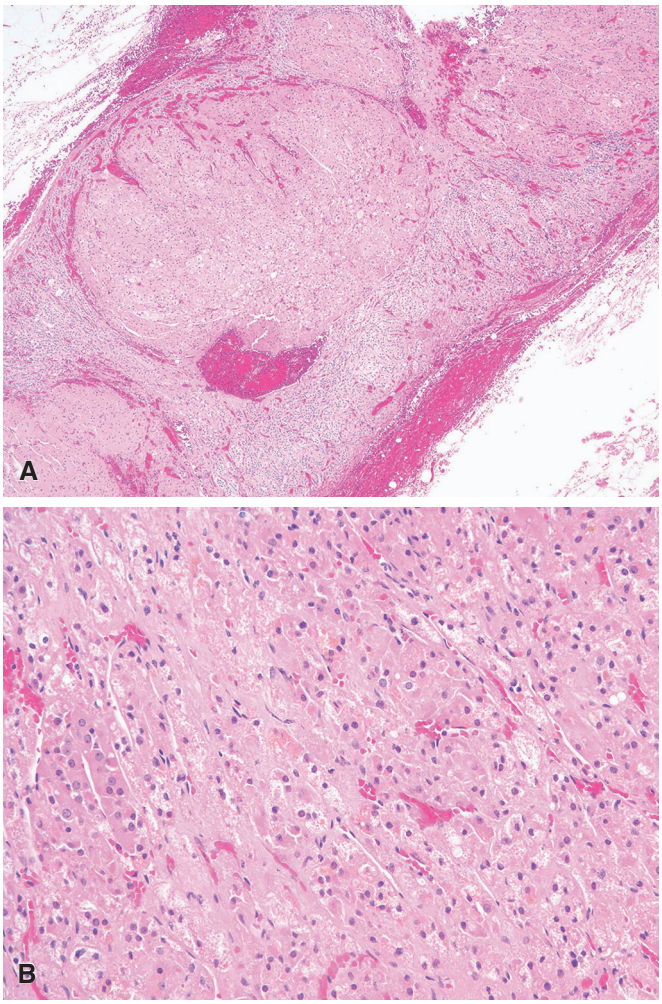

Figure 29.6 Primary pigmented nodular adrenal cortical hyperplasia. **A,** A micronodular pattern of growth is characteristic. **B,** Nodules are comprised of eosinophilic cells containing brown pigment.

Other Adrenocortical Hyperplasia

Acquired hyperplasia, which is always bilateral, may result in a diffuse or a nodular ("adenomatous" or "adenomatoid") enlargement of the adrenal gland (Fig. 29.7). An adrenal gland in an adult can be regarded as hyperplastic if it weighs over 6 g, provided that a careful dissection of the fat has been carried out. Most cases of *diffuse* cortical hyperplasia are due to ACTH hyperproduction by either the pituitary gland or an ACTH-producing neoplasm in the lung or some other organ. Thus they are referred to as ACTH dependent or—in the former instance—pituitary dependent. In some cases, however, the pathogenesis remains obscure.

Grossly, the cortical zone of the adrenal appears thickened. Microscopically, an increased thickness of the zona reticularis and fasciculata is observed, the relative proportions varying from case to case.[50] Occasionally, cells with large hyperchromatic nuclei are seen in some of the nodules. Many of the cells in the fasciculata layer appear compact and lipid depleted. Ultrastructurally, these cells have abundant smooth endoplasmic reticulum and long

Figure 29.7 Adrenal cortical hyperplasia showing multinodular pattern of growth.

microvilli that interdigitate with the microvilli of adjacent cells.[50] Flow cytometric and image analysis studies have shown the presence of aneuploid and polyploid cell populations.[50]

Most cases of ***macronodular cortical hyperplasia***, which are unrelated to ACTH production and are therefore referred to as ACTH independent or adrenal dependent, present with Cushing syndrome.[51] In some instances, they may represent a later stage of diffuse hyperplasia, in which the lesion has undergone a transition from pituitary dependent to adrenal dependent.[52,53] The bilateral adrenal glands can become massively enlarged, mimicking a neoplasm, and the cortex between cortical nodules is commonly atrophic. A rare subset of cases presents in children and may be associated with McCune–Albright syndrome (*GNAS* mutation).[54] Recent studies suggest the presence of germline or somatic mutations in *ARMC5*, particularly in cortisol secreting forms of the disease.[55,56]

Adrenocortical Neoplasms

Traditionally, adrenocortical neoplasms have been divided into adenomas and carcinomas. Many tumors can be easily placed into one category or another, but there is an intermediate ("borderline") group for which the distinction is difficult and to some extent arbitrary (further discussed in the differential diagnosis section).

Adrenocortical Adenoma

Clinical Features

Adrenal cortical adenomas represent the most common primary adrenal lesion seen in routine diagnostic practice. They may be functioning (producing aldosterone, cortisol, or sex hormones) or nonfunctioning. These are either detected by symptoms of a hormonal secretory product with subsequent identification on CT scan or incidentally at the time of imaging for other reasons.

Morphologic Features

Grossly, adenomas are usually solitary. Adenomas are characteristically small, rarely exceeding 5 cm in greatest diameter or 50 g in weight.[57] Adenomas are well circumscribed and typically encapsulated. The cut surface of an adenoma usually has a solid homogeneous yellow to tan appearance (Fig. 29.8). Larger tumors may have areas of central hemorrhage.

Microscopically, the adenomas may recapitulate the appearance of the zona fasciculata, the zona glomerulosa, or, more commonly,

Figure 29.8 Gross appearance of adrenal cortical adenoma with single nodule, well-circumscribed growth, and typical golden yellow color.

a combination of both (Fig. 29.9). Prototypically, the cells are clear to lightly eosinophilic and are filled with small lipid vacuoles. The cells are often organized in nests or cords that are associated with a rich capillary vasculature or sinusoidal network. Occasional bizarre nuclear forms can be seen, as in most other endocrine neoplasms. However, *mitoses are exceptionally rare or absent*.[58] Morphologic variants of adrenocortical adenomas include:

1. Adrenocortical adenoma containing foci of *myelolipoma* are reported but are of no clinical consequence.[59,60]
2. *Black adenoma*.[61] Occasionally, adenomas (as well as hyperplastic nodules) have a dark brown to black color because of the presence of pigment, representing either lipofuscin[62] or rarely neuromelanin.[63] Most of these "black adenomas" or "black nodules" are nonfunctioning and found incidentally at autopsy, but on occasion they have been associated with primary aldosteronism[64] or Cushing syndrome.[65] These nodules have a higher radiologic density than the ordinary yellow cortical tumors.[65]
3. *Adrenocortical oncocytic adenoma (oncocytoma)*. This is a neoplasm in which the tumor cells are packed with mitochondria (Fig. 29.10). Both benign (i.e. oncocytoma) and malignant forms exist, the former predominating.[66-70] Most are nonfunctioning.[71,72] Interestingly, at the ultrastructural level the mitochondria retain the tubulovesicular cristae that are typical of steroid-producing cells, and they may also contain peculiar cytoplasmic crystalline inclusions.[73,74] The typical prognostic features used to distinguish adenoma from carcinoma are not optimized for oncocytic tumors, so modified classifications have been adopted (see differential diagnosis later and Box 29.1).[68]
4. *Myxoid adrenocortical neoplasms.* Adrenocortical adenomas can rarely have prominent myxoid stroma. Myxoid tumors seem to behave more aggressively than would be predicted by the Weiss criteria; therefore, the diagnosis of myxoid adrenocortical adenoma should be made with extreme caution.[75-78]
5. *Lipoadenoma.* Cases have been reported of adrenocortical adenomas (as well as nodular cortical hyperplasias) containing abundant mature adipose tissue.[79-81]

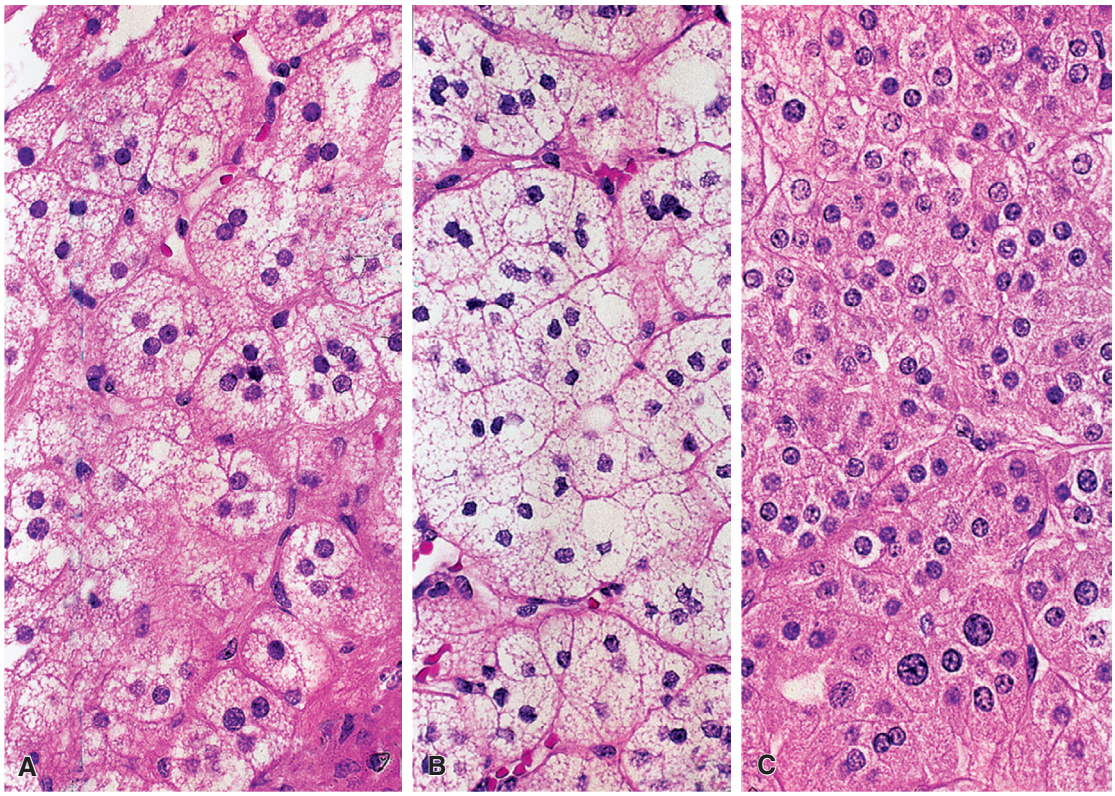

Figure 29.9 **A–C,** Various morphologic patterns within the same aldosterone-secreting adrenal cortical adenoma.

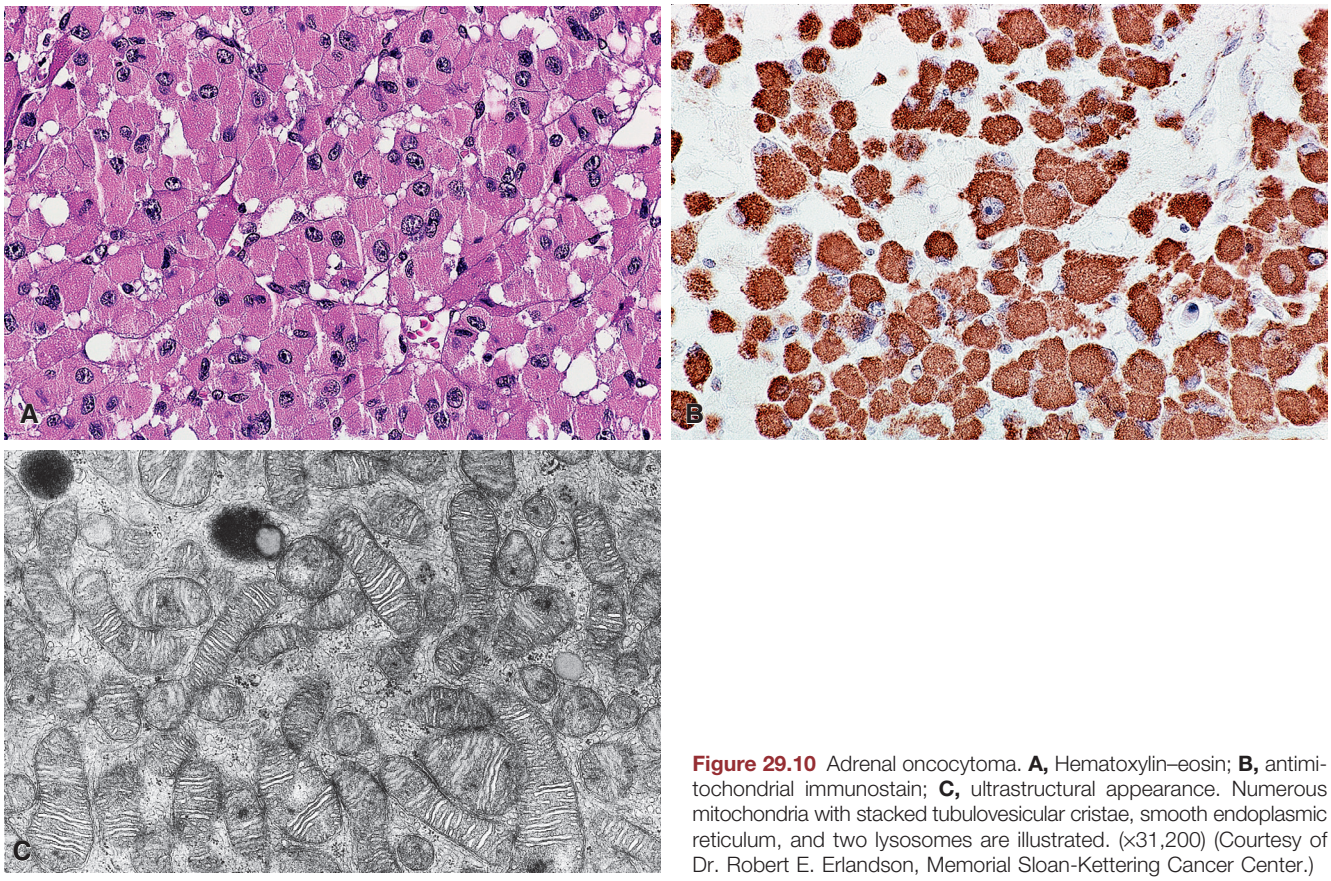

Figure 29.10 Adrenal oncocytoma. **A,** Hematoxylin–eosin; **B,** antimitochondrial immunostain; **C,** ultrastructural appearance. Numerous mitochondria with stacked tubulovesicular cristae, smooth endoplasmic reticulum, and two lysosomes are illustrated. (×31,200) (Courtesy of Dr. Robert E. Erlandson, Memorial Sloan-Kettering Cancer Center.)

Box 29.1 Weiss criteria for the classification of adrenal cortical neoplasms[a]

Tumor necrosis
Mitotic rate >5 mitoses per 50 high-power fields
Atypical mitoses
High nuclear grade (Fuhrman criteria for grade III or IV)
Diffuse architecture
<25% clear cells
Invasion of venous structures
Invasion of sinusoidal structures
Invasion through the capsule

[a]The presence of ≥3 of these criteria correlates with malignant potential.

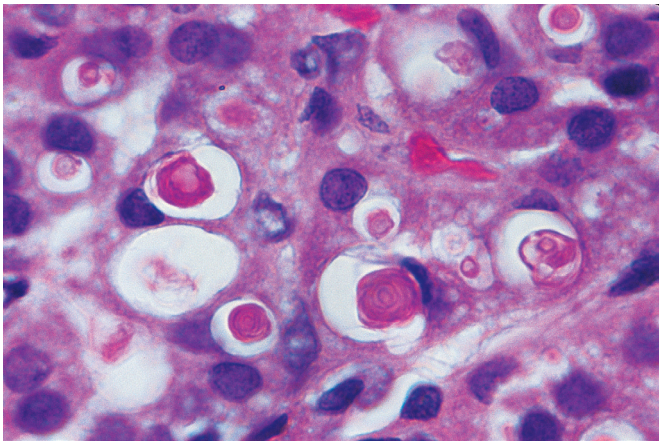

Figure 29.11 So-called spironolactone bodies. They appear as concentric laminated eosinophilic structures.

Hormone Production in Adenomas

Nonfunctioning Lesions. Whereas instances of cortical hyperplasia and adenomas are found commonly at post mortem examination of asymptomatic individuals,[82] most of the nonfunctioning adrenal cortical lesions seen in the past as surgical specimens were carcinomas.[83] This has changed markedly since the advent of ultrasonography, CT, and magnetic resonance imaging, which have allowed the detection of a large number of benign asymptomatic adrenocortical adenomas.[84-86]

Aldosterone-Producing Adenoma. In primary aldosteronism (Conn syndrome), the excessive amount of secreted aldosterone results in urinary loss of potassium, retention of sodium, suppressed renin levels, hypertension, and muscle weakness.[87-89]

Microscopically, one would expect these adenomas to have an appearance similar to that of the zona glomerulosa, since this is the area in which aldosterone is produced in the normal adrenal gland. Although this is sometimes the case, most of the tumor cells resemble those of the zona fasciculata or have characteristics intermediate between zona glomerulosa and zona fasciculata cells (so-called hybrid cells). The zona glomerulosa of the nontumoral gland is normal, hyperplastic, or atrophic.[90] In patients who have been treated with spironolactone, a characteristic cytoplasmic structure may appear in the tumor cells, as well as in the cells of the adjacent zona glomerulosa. It is a whorled, multilaminar collection of membranes, as large as 20 µm in diameter, and is thought to derive from the smooth endoplasmic reticulum (Fig. 29.11).[91,92] Typical evaluation of a patient suspected of having primary aldosteronism includes pharmacologic exploration of the renin–angiotensin–aldosterone system[87] and radiographic examination of the adrenal glands to distinguish primary aldosteronism from cases of renovascular and essential hypertension.

Cortisol-Producing Adenoma. Cushing syndrome is the result of hyperproduction of cortisol, often leading to characteristic external features (weight gain with central obesity, round face, skin striae, hirsutism), hypertension, hyperglycemia, poor wound healing, proximal muscle weakness, and increased risk for opportunistic infection.[93] It has a primary adrenal cause (i.e. ACTH independent) in only 20% of cases.[94-97] In rare cases the adrenal neoplasm associated with Cushing syndrome is not of cortical origin but rather a pheochromocytoma.[98] In cases of Cushing syndrome–associated adrenal cortical tumor, the remaining adrenal cortex often shows signs of atrophy. Diagnosis can be aided by various types of cortisol testing, including the dexamethasone suppression.

The presence of a large adrenal mass in a patient with Cushing syndrome is typically indicative of carcinoma. Similarly, cases of Cushing syndrome associated with obvious changes of virilization ("mixed" type) and markedly increased excretion of 17-ketosteroids are almost always the result of cortical carcinoma.[57,99]

Sex Hormone–Producing Adenoma. The most common cause of virilization in childhood is congenital adrenal hyperplasia; however, if an adrenal neoplasm is present, carcinomas are more common than adenomas.[100,101] The probability that an adrenal cortical tumor is of a malignant nature is about 70% if it results in virilization in an adult woman and even higher if the virilization is accompanied by Cushing syndrome.[102-104] In adult male patients with feminization, the incidence of malignancy approaches 100%.[105] In patients with adenomas, symptoms depend on the hormone secreted. Estrogen excess in men may produce gynecomastia or sexual dysfunction, while androgen excess in women causes variable hirsutism, virilization, and amenorrhea.

Other Functional Manifestations. Less common manifestations of adrenal cortical lesions (particularly carcinomas) include hypoglycemia,[106] polycythemia,[107] and inappropriate secretion of antidiuretic hormone.[108]

Electron Microscopic, Histochemical, Immunohistochemical, and Molecular Genetic Features

While most adrenocortical adenomas are recognizable by morphology alone, select cases may require immunophenotypic analysis. Immunohistochemically, the cells of adrenocortical neoplasms are immunoreactive for synaptophysin (but generally not chromogranin!), inhibin, Melan-A (Mart-1; A103), and SF-1 (Fig. 29.12).[109-115] They also stain for calretinin (usually in a focal fashion)[116] and keratin (about half of adenomas, but focally and erratically).[117]

The molecular mechanisms of adrenocortical adenomas continue to be elucidated. Many driver mutations are closely associated with specific hormone production and other clinicopathologic features.

Approximately 40% of sporadic aldosterone-secreting adenomas are associated with somatic mutations in *KCNJ5* and are more frequently seen in young women with more severe hyperaldosteronism. Other mutations in *ATP1A1*, *ATP2B3*, *CTNNB1*, and *CACNA1D* are also reported, but tumors with *KCNJ5* mutations tend to be larger.[118-121] In cortisol-producing adenomas, somatic mutations in *PRKACA* are common and are identified in approximately 35%–65% of cases with Cushing syndrome.[122,123] Nonfunctioning adenomas most commonly have mutations in *CTNNB1*, which encodes the β-catenin protein.[124] Adrenal cortical adenomas are also associated with some

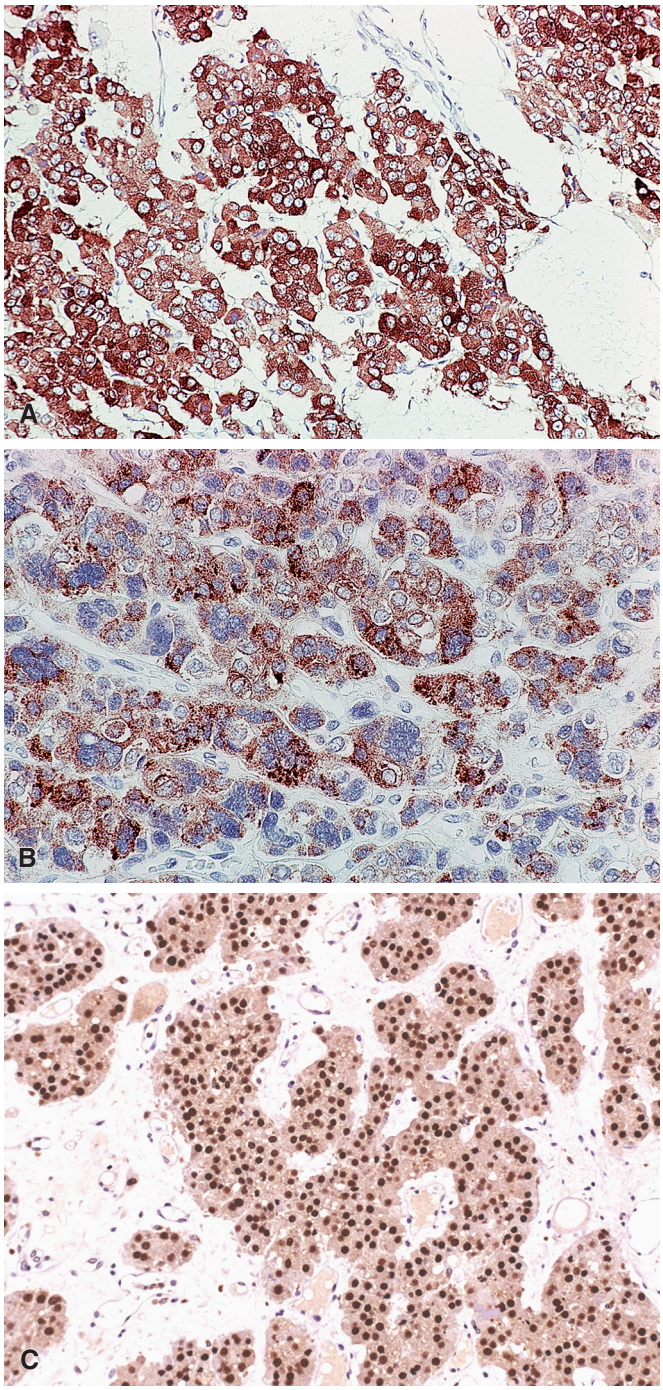

Figure 29.12 Immunohistochemical reactivity of adrenal cortical neoplasm. **A,** Inhibin; **B,** Melan A; and **C,** SF-1.

hereditary syndromes, including Carney complex, Li–Fraumeni, MEN type 1, Beckwith–Wiedemann, familial adenomatous polyposis, and McCune–Alright.[125]

Adrenocortical Carcinoma

Clinical Features

Cortical carcinomas are relatively uncommon. They have a bimodal age distribution, with peaks in the first and fifth decades of life.[126-133] Patients may present asymptomatically (incidental lesion detected at imaging), with symptoms related to local mass effect, with symptoms of metastatic disease, or with symptoms of excess steroid production. Highly necrotic carcinomas may result in fever and thus simulate an infectious disease clinically. Palpable adrenocortical neoplasms are malignant in practically every instance. CT scan is the most useful technique for the detection, pretreatment staging, and determination of resectability of these tumors.[134]

A diagnosis of adrenocortical carcinoma in children and young adults should prompt exclusion of Li–Fraumeni syndrome by molecular analysis for germline mutation in the *TP53* gene, since this association is found in more than half of the cases, regardless of family history.[135-137] Adrenocortical carcinomas also occur with increased frequency in patients with Beckwith–Wiedemann syndrome.[138]

Morphologic Features

Grossly, carcinomas are usually solitary. Most carcinomas weigh more than 10 g, and some may reach 1000 g or more before being discovered.[57] A capsule may be present around carcinomas, but this is often infiltrated by tumor. The cut surface of a carcinoma shows a variegated pattern, with soft and friable intratumoral nodules (Fig. 29.13). Areas of necrosis and hemorrhage are frequent in carcinomas. Invasion of major veins is a frequent finding in carcinoma and often leads to total occlusion, thrombosis, and embolism.

Microscopically, carcinomas exhibit a wide range of differentiation, from tumors that are so well differentiated as to be almost impossible to distinguish from adenoma to totally undifferentiated neoplasms composed of giant cells with abundant acidophilic cytoplasm and bizarre hyperchromatic nuclei, sometimes multiple (Figs. 29.14 and 29.15). Occasionally, the tumor is heavily infiltrated by neutrophils, with some of the latter located within the cytoplasm of the tumor cells.

The key distinguishing histologic features between adenoma and carcinoma are discussed in a later section. Morphologic variants of adrenocortical carcinoma include:

1. *Adrenocortical oncocytic carcinoma*. The typical prognostic features used to distinguish adenoma from carcinoma are not optimized for oncocytic tumors, so modified classifications have been proposed (see differential diagnosis later and Box 29.2).[68]
2. *Myxoid adrenocortical neoplasms* (Fig. 29.16). Optimized criteria remain to be determined for this rare group of tumors, but studies suggest more aggressive behavior than would be predicted by standard prognostic parameters (see differential diagnosis later).[75-78]
3. *Sarcomatoid carcinoma*, a self-explanatory designation. As in other sites, when the carcinomatous and the sarcoma-like elements are sharply segregated, the alternative term *carcinosarcoma* has been used.[104,139,140]

Electron Microscopic, Histochemical, Immunohistochemical, and Molecular Genetic Features

Immunohistochemically, carcinomas express the same cortical lineage markers as adenomas (i.e. inhibin, Melan-A, and SF-1) but with lower sensitivity.[109-115,141]

Knowledge of the molecular mechanisms of adrenocortical carcinomas in both children and adults, and their differences from adenomas, is expanding rapidly.[141-145] The most recent data show that adrenal cortical carcinomas have a number of different driver mutations (including *p53*, *ZNFR3*, *CTNNB1*, *PRKAR1A*, *CCNE1*, and *TERF2*), frequent IGF2 overexpression, and whole genome doubling as a mechanism of disease progression.[142] The Cancer Genome Atlas (TCGA) study also proposed a prognostic molecular subtype model based on DNA methylation signature.[142] These

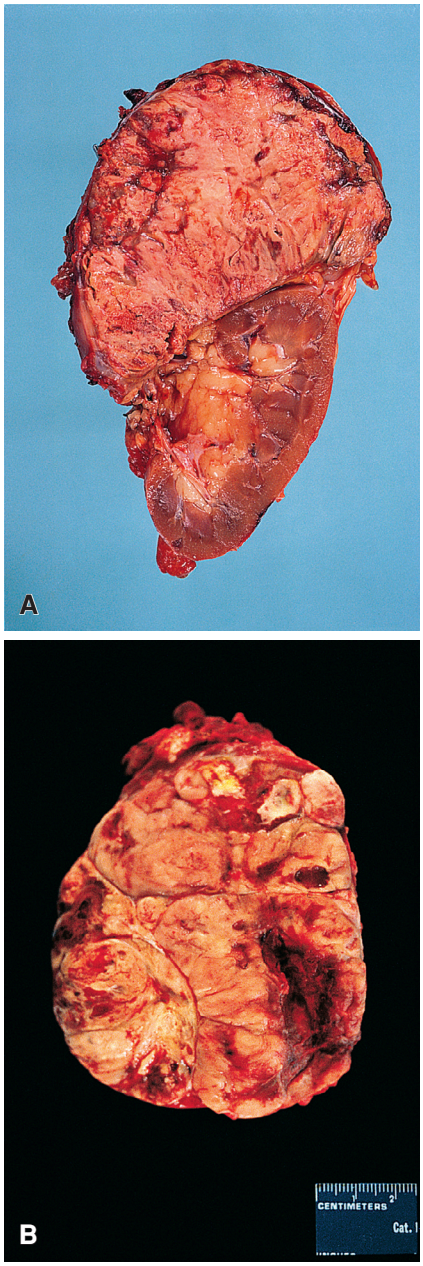

Figure 29.13 **A** and **B,** Gross appearance of adrenal cortical carcinoma. Both tumors are large and exhibit areas of hemorrhage and necrosis. The tumor shown in **A** has destroyed the upper pole of the kidney.

discoveries could lead to more integrated histologic/molecular classification in the near future.

Finally, as with adenomas, carcinomas may be associated with hereditary neoplasia syndromes, including Li–Fraumeni, Lynch (hereditary nonpolyposis colorectal cancer), MEN type 1, NF1, Beckwith–Wiedemann, familial adenomatous polyposis, and Carney complex.[125]

Differential Diagnosis

The principal differential diagnostic problems in this area are distinguishing: (1) between adrenocortical adenoma and carcinoma; (2) between adrenocortical carcinoma and renal cell carcinoma; and (3) between adrenocortical and adrenomedullary tumors.

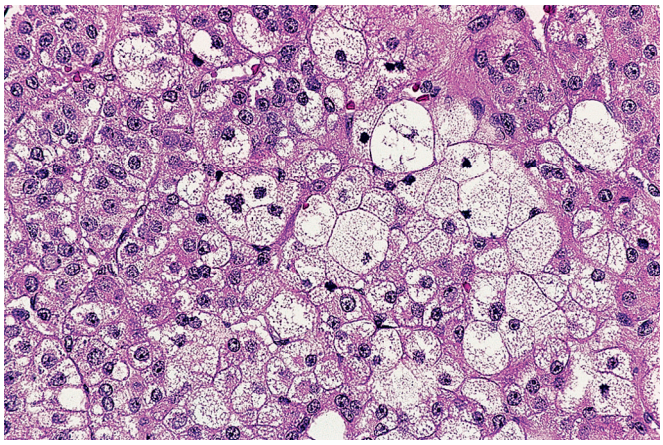

Figure 29.14 Adrenal cortical carcinoma with more intratumoral heterogeneity.

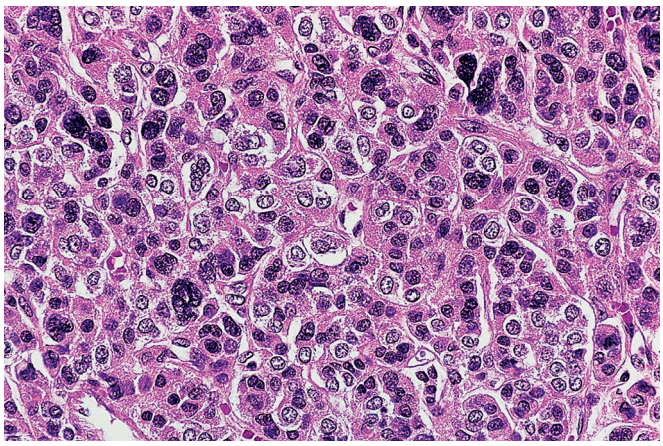

Figure 29.15 Adrenal cortical carcinoma. There is nuclear hyperchromasia, diffuse pattern of growth, and mitotic activity.

Box 29.2 Lin-Weiss-Bisceglia criteria for the classification of adrenal cortical neoplasms[a]

Major criteria

Invasion of venous structures
Mitotic rate >5 mitoses per 50 high-power fields
Atypical mitoses

Minor criteria

Size >10 cm and/or weight >200 g
Tumor necrosis
Invasion of sinusoidal structures
Invasion through the capsule

[a]The presence of one major criterion correlates with malignant potential (i.e. adrenal cortical carcinoma). The presence of 1–4 minor criteria has a weaker correlation, and the term "adrenal cortical neoplasm of uncertain malignant potential" has been suggested.

The majority of adrenocortical adenomas and carcinomas are fairly easy to diagnose; however, a subset of cases may present a true diagnostic challenge. Adenomas tend to be smaller, more homogeneous, and lacking hemorrhage and necrosis.[146,147] Specifically, lesions under 50 g are generally cured by excision, even if exceptions occur.[148] Microscopically, mitotic activity (especially if accompanied

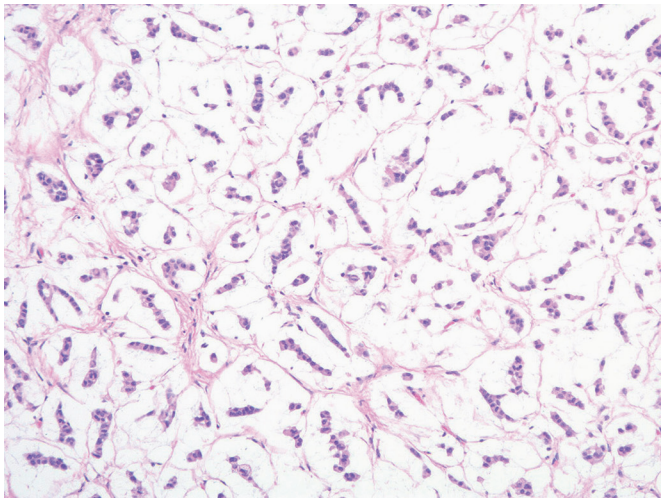

Figure 29.16 Myxoid adrenal cortical neoplasm with cord-like pattern of growth.

by atypical forms) and venous invasion correlate best with recurrence or metastasis.[58,147,149-151]

Weiss[150] proposed a prognostic model, which is the most widely utilized today, based on analysis of the following nine microscopic findings: nuclear grade III or IV, mitotic rate greater than 5 per 50 high-power fields (HPFs), atypical mitoses, less than 25% clear cells, diffuse architecture, necrosis, capsular invasion, venous invasion, and sinusoidal invasion (see Box 29.1). In general, tumors with 3 or more features are regarded as having malignant potential. The value of this approach has been proven by independent observers, both in adults[152,153] and in children.[154] This is also true for the slightly revised version proposed by Weiss.[155]

It must be emphasized, however, that these schemes may not be entirely applicable to adrenocortical tumors occurring in childhood, those of oncocytic type, and those with myxoid features. For oncocytic tumors, the WHO recommends the Lin-Weiss-Bisceglia criteria (see Box 29.2), which weights features into major (>5 mitoses per 50 HPFs, atypical mitotic figures, venous invasion) and minor (necrosis, sinusoidal invasion, capsular invasion, size >10 cm and/or weight >200 g) criteria.[68] In this system, the presence of any single major criterion within the tumor is sufficient for designation as malignant, while tumors with 1–4 of the minor criteria are designated as "uncertain malignant potential." Myxoid tumors are rare and the largest series to date is only 14 cases; therefore, optimal criteria for classification have not been developed.[75-78] In our experience and in several reported cases, very bland myxoid adrenocortical tumors may behave in a surprisingly malignant fashion.

It has been highlighted by Dehner that the Weiss criteria seem less predictive of aggressive behavior in the pediatric population (i.e. many tumors classified as "carcinoma" seem to be clinically indolent).[156] Several groups have proposed criteria for risk stratification specific to pediatric patients, often placing increased emphasis on tumor weight.[157-159]

Numerous special techniques have also been tested as possible ancillary aids to this differential diagnosis. At present, Ki-67 immunohistochemistry and reticulin stains are sometimes used in difficult cases. Ki-67 proliferation rates of adenomas are typically less than 5%.[160-163] In normal adrenal cortex and adenomas, reticulin stains highlight a network of reticulin fibers that encircle small nests of cells. In carcinomas, abnormal reticulin patterns are more commonly seen, characterized by larger confluent sheets of neoplastic cells with a patchy distribution of fragmented or thickened reticulin fibers.[164-166] Recently, two additional immunohistochemical markers have been described that reportedly stain most carcinomas, but very few adenomas: matrix metalloproteinase type 2[167] and insulin-like growth factor (IGF2); however, these have not been fully implemented into standard practice.[168,169] Incorporating some of the more robust adjunctive tests into histologic prognostic algorithms holds promise.[164,170]

The fact that so many parameters have been evaluated for this purpose provides indirect evidence that none—short of detection of metastases—discriminates in an absolute fashion between adenomas and carcinomas, particularly in pediatric cases.[128,158,171,172] A combined evaluation of clinical features, size or weight, microscopic appearance, and immunohistochemical/molecular genetic data is necessary.[147,150,173,174] Even so, the pathologist and the clinician should accept the fact that a sharp distinction between adenomas and carcinomas may be impossible at the practical level and unsound at the conceptual level. Except for the cases situated at the two extremes, it may be more honest and accurate to designate the tumors as *adrenocortical neoplasms*, followed by an estimate of the risk of the tumor recurring or metastasizing on the basis of all the evaluable parameters, a list which is rapidly expanding.[175] The alternative is to have an intermediate category designated as *borderline* or of *uncertain malignant potential*, as it is being increasingly done in other tumor types in spite of the initial disapproval and irritation of some.

The second important differential diagnosis is between adrenocortical neoplasia and renal cell carcinoma, which can invade the adrenal gland directly or metastasize to it, either ipsilaterally or contralaterally.[176] Microscopically, these two tumors resemble each other a great deal. In fact, Grawitz originally regarded clear cell renal cell carcinoma to be of adrenocortical origin![177] Two features favoring the diagnosis of renal cell carcinoma are the presence of glands (particularly if they contain numerous red blood cells) and abundant cytoplasmic glycogen, but neither is pathognomonic. Immunohistochemically, much is written with regard to immunoreactivity for cytokeratin, EMA, renal cell carcinoma marker, and CD10 as markers of renal cell carcinoma,[114,178] but for routine practice it is our experience that PAX-8 offers the highest level of sensitivity and specificity as a renal epithelial marker.[114,179] Positivity for SF-1, inhibin, Melan-A (Mart-1, A103), and synaptophysin favors adrenocortical lineage.[114] The nuclear reactivity pattern of SF-1 makes it easier to interpret and an ideal pair with PAX-8 in this differential diagnostic distinction. This also applies to fine-needle aspiration specimens.[180,181]

Regarding the differential diagnosis between adrenocortical and adrenomedullary tumors (which can be very difficult but for some reason is rarely mentioned), the former should be favored in the presence of inhibin, Melan-A, SF-1, and calretinin positivity, whereas the latter is more likely if chromogranin reactivity is present.[115,182] Synaptophysin is of no help since it stains both tumor types.[115,182] GATA3 shows nuclear expression in approximately 70% of pheochromocytomas, while only rarely positive in adrenal cortical carcinoma; however, it should be remembered that GATA3 reactivity is seen in many metastatic carcinomas.[183,184]

Spread and Metastases

Whereas adrenocortical adenoma is encapsulated, adrenocortical carcinoma often spreads to the retroperitoneum and infiltrates the kidney. Blood-borne metastases are frequent and are already present at the time of the diagnosis in half of the cases.[185] The most common sites of metastatic involvement are liver (60%), regional lymph nodes (40%), lungs (40%), peritoneal and pleural surfaces, and bone.[127,186] Poorly differentiated ("anaplastic") tumors may be more likely to metastasize to skin.[187] Some of these may masquerade as primary tumors in these metastatic sites.[188-190]

Treatment and Prognosis

The primary treatment of adrenocortical neoplasms is surgical excision.[191] Unfortunately, the carcinoma often recurs, and its radiosensitivity is usually poor.[192,193] Chemotherapy and/or mitotane therapy may be utilized with advanced disease.[190,194-197] Mitotane has very significant side effects; therefore, markers predictive of treatment response are being investigated.[198,199] In most series, half of the patients are dead within 2 years of the onset of the symptoms, and the 5-year survival rate is between 20% and 35%.[194]

Some correlation exists between microscopic degree of differentiation in adrenal cortical carcinoma and survival.[200] Proliferative activity—whether measured by counting mitoses or through other means—seems to be the pathologic feature of greatest prognostic significance and is utilized for grading in many centers.[155,160,201-203] In the two grade system, low-grade carcinomas have less than 20 mitotic figures per 50 HPFs, while high-grade carcinomas ≥20.[203] Proliferation rate as determined by Ki-67 and/or the combination of morphology (necrosis and mitotic count >5 per 50 HPFs) and Ki-67 have been validated as highly predictive of outcome in carcinomas.[170,204] However, improved Ki-67 scoring reproducibility is needed.[205]

Staging

Two major systems are utilized for the staging of adrenal cortical carcinoma: the AJCC/TNM and the European Network for the Study of Adrenal Tumours (ENSAT) staging systems[206]; however, the current WHO classification recommends the ENSAT system.[125] Both are based on conventional TNM categories that depend on tumor size (greater or less than 5 cm), infiltration outside of the adrenal gland (into fat or adjacent organs), any lymph node involvement, and distant metastasis. The ENSAT utilizes different TNM stage groupings for stage III and stage IV disease.[207,208] A modified European Network for the Study of Adrenal Tumours (mENSAT) staging system has been proposed that further incorporates tumor grade.[202]

Lesions of Adrenal Medulla

Tumors and tumorlike conditions of the adrenal medulla segregate into two distinct categories, acknowledging the existence of hybrid and transitional forms:

1. **Neuroblastic tumors**, which are characteristically seen in infants and children but can also present in adults (particularly ganglioneuroma).
2. **Adult neuroendocrine tumors and tumorlike conditions**, represented by pheochromocytoma and adrenal medullary hyperplasia. These are characteristically seen in adults, although they can also appear in children (particularly if part of a genetically determined syndrome).

Neuroblastoma

General and Clinical Features

The term neuroblastoma encompasses a spectrum of tumors showing variable degrees of differentiation, including neuroblastoma, ganglioneuroblastoma, and ganglioneuroma. Neuroblastomas are usually seen in young children; over 80% are detected in those under the age of 4 years, and the median age at diagnosis is 21 months. Typical examples in adults occur but are exceptional.[209,210] There is no sex predilection. Neuroblastomas can exhibit familial incidence (approximately 1% of cases)[211] and may be associated with the Beckwith–Wiedemann syndrome,[212] Hirschsprung disease,[213] and Turner syndrome (especially if the neuroblastoma itself is congenital).[214,215] Neuroblastoma can also occur in patients with neurofibromatosis type 1[216] or congenital central hypoventilation syndrome.[217,218] The usual presentation of neuroblastoma is in the form of an abdominal mass first noted by the parents. Rare cases have been reported associated with watery diarrhea (although not nearly as commonly as with ganglioneuroma), Cushing syndrome, heterochromia iridis and Horner syndrome (in cervical or mediastinal tumors), opsoclonus/myoclonus (a paraneoplastic autoimmune process), and several other manifestations.[219] About 70% of the neuroblastomas occur in the retroperitoneum, and the majority of these involve the adrenal gland; however, they can be found anywhere along the sympathetic chain, including the neck and mediastinum.

Synchronous or metachronous bilaterality is extremely unusual.[220] Many cases are diagnosed before biopsy, as neuroblastoma retains the ability to metabolize catecholamines, and often secretes homovanillic acid (HMA) and vanillylmandelic acid (VMA), both of which may be detected in the urine.[123] I-metaiodobenzyl guanidine (MIBG) scintigraphy commonly highlights the primary tumor and foci of metastases.

Morphologic Features

Grossly, neuroblastomas are usually large, soft, gray, and relatively well circumscribed; areas of hemorrhage, necrosis, and calcification are often present (Fig. 29.17). Sometimes the hemorrhage is so extensive as to mimic a hematoma. Cystic degeneration can also occur, to the point of simulating the appearance of an adrenal cyst. Multifocality is present in less than 10% of the cases.[221]

Microscopically, the pattern of growth is vaguely nodular or nested as a result of the presence of delicate, incomplete fibrovascular septa. Hemorrhage, which is common, occasionally leads to the formation of pseudovascular or alveolar structures. Calcification may be a prominent feature; it may appear as a dustlike basophilic stippling, as closely aggregated round concretions, or surrounding individual tumor cells in a "chicken-wire" fashion. Necrosis is also a rather constant feature, sometimes leaving viable tumor cells grouped around blood vessels. Typical neuroblasts are small and regular, with round, deeply staining nuclei slightly larger than lymphocytes. A small amount of pink cytoplasm is present, continuous with the intermixed neuropil. Neuropil appears as a lightly eosinophilic fibrillary material; it is composed of a tangled mass of neurites as revealed by silver stains, immunohistochemistry, or electron microscopy. Homer Wright rosettes are present in about a fourth to a third of the cases; they are characterized by collections of tumor cells not related to blood vessels, arranged around a central area filled with neuropil (Fig. 29.18).[222] In contrast to the structures formed by retinoblastomas, ependymomas, and carcinoid tumors, the rosettes of neuroblastomas *do not* have a central lumen. On occasion, the lobular pattern just described becomes prominent, the tumor nests being surrounded by elongated S-100 protein–positive cells in a "Zellballen" configuration reminiscent of that seen in paraganglia and paragangliomas.[223]

Based on the International Neuroblastoma Pathology Classification (INPC), the tumor cells show a spectrum of differentiation from primitive neuroblasts to ganglion cells and their classification depends on the relative amounts of these components (Table 29.1). This classification applies to untreated neuroblastomas; chemotherapy often induces maturation and/or nuclear anaplasia; therefore, post-chemotherapy neuroblastoma should be diagnosed only as "neuroblastoma with chemotherapy effect."

The most primitive neuroblast lacks discernable cytoplasm. Tumors comprised entirely of these primitive cells without any associated neuropil, termed "**undifferentiated neuroblastoma**," have significant morphologic overlap with lymphoma or other small round blue cell tumors (Fig. 29.19A). Neuroblast differentiation and Schwannian stroma development go hand in hand. When less than 5% of

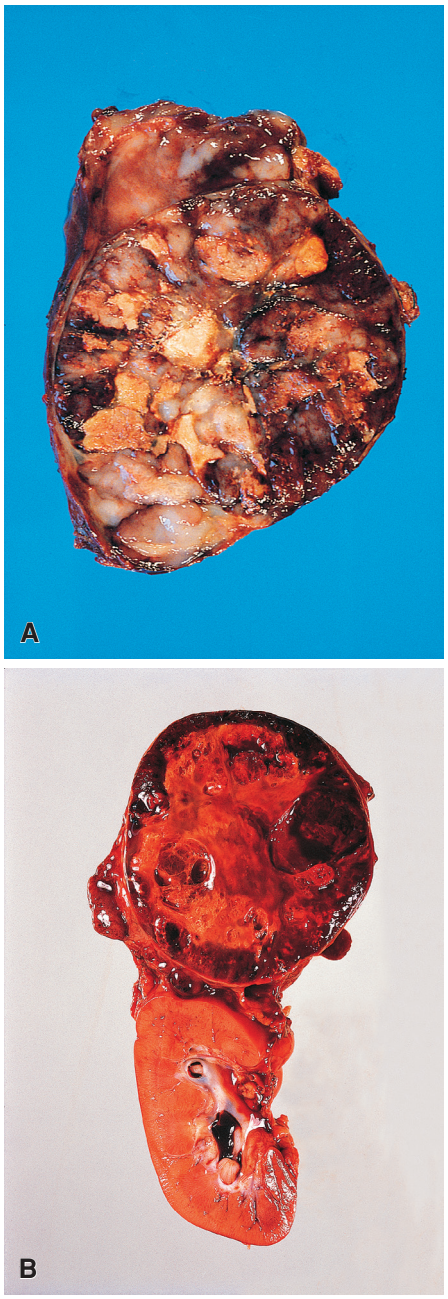

Figure 29.17 Gross appearance of adrenal neuroblastoma. **A,** The tumor exhibits a variegated appearance resulting from hemorrhage and necrosis. **B,** Suprarenal location strongly suggests the diagnosis of neuroblastoma in a child.

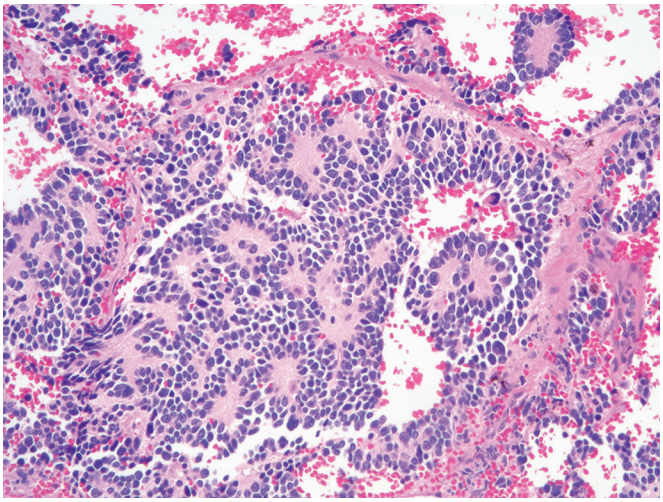

Figure 29.18 Homer Wright rosettes in neuroblastoma. Note the absence of a central lumen.

neuroblasts show ganglion cell differentiation (equal volumes of nucleus and cytoplasm, see Fig. 29.19B) the tumor is classified as "**poorly differentiated neuroblastoma**." Poorly differentiated neuroblastomas have a definite component of neuropil, which makes the diagnosis more straightforward than the undifferentiated form. When a tumor has greater than 5% ganglion cell differentiation, but is composed of less than 50% Schwannian stroma, the diagnosis is "**differentiating neuroblastoma**" (Fig. 29.20). When the Schwannian stroma represents greater than 50% of the tumor (which is always accompanied by greater than 5% ganglion cell differentiation), the term "**ganglioneuroblastoma, intermixed**" is applied. Finally, "**ganglioneuroma**" is diagnosed when the tumor is composed completely of Schwannian stroma and ganglion cells. In children, ganglioneuromas should be diagnosed with caution; they should be thoroughly sampled and should not show any persistent nests of neuroblastic cells and no recognizable neuropil.[224] Ganglioneuroma is further stratified in children. When clusters of maturing ganglion cells are present (without associated neuropil), the term "ganglioneuroma, maturing" is used. When ganglion cells are scattered throughout the Schwannian stroma individually (in association with surrounding sustentacular cells), the tumor is classified as "ganglioneuroblastoma, mature" (Fig. 29.21). In adults, ganglioneuromas are almost always mature.

A subset of neuroblastic tumors shows any type of Schwannian "stromal-rich" neuroblastic tumor (otherwise typical ganglioneuroma or ganglioneuroblastoma, intermixed) with a distinct grossly identifiable nodule composed of a more primitive "stromal-poor" histology (Fig. 29.22), which is most commonly poorly differentiated neuroblastoma or differentiating neuroblastoma. Such tumors are classified as "**ganglioneuroblastoma, nodular type**" and should include a separate classification for the nodular component, which drives the prognosis. It is critically important to carefully evaluate all gross specimens with thin sectioning to assess for such macroscopic nodules.

Finally, a rare pleomorphic (anaplastic) form of neuroblastoma characterized by the presence of bizarre giant tumor cells has been described; however, this diagnostic term should not be used in post-therapy specimens where chemotherapy induced atypia is not uncommon.[225,226]

Electron Microscopic, Histochemical, Immunohistochemical, and Molecular Genetic Features

Ultrastructurally, neuroblastoma cells are characterized by the presence of neurites, neurosecretory granules, and synaptic endings.[151,227] The neurites form a complex interdigitating meshwork in the center of the Homer Wright rosettes.

Immunohistochemically, neuroblastoma cells express NSE, chromogranin, synaptophysin, microtubule-associated proteins, and NB-84.[228-241] Recent studies strongly suggest that immunohistochemistry for PHOXB2 represents the most sensitive and specific marker for neuroblastoma.[242-244] These, together with molecular techniques, are of great use in the differential diagnosis between undifferentiated

Table 29.1 The International Neuroblastoma Pathology Classification

STROMA	HISTOLOGIC FEATURES	DIAGNOSIS
Schwannian stroma poor	• No Schwannian stroma/no neuropil • Requires adjunctive diagnostic tests	Neuroblastoma, Undifferentiated
	• Presence of neuropil allows for H&E diagnosis • Less than 5% differentiating neuroblasts	Neuroblastoma, Poorly Differentiated
	• More abundant neuropil • >5% differentiating neuroblasts	Neuroblastoma, Differentiating
Schwannian stroma rich (>50%)	• Schwannian stroma comprises >50% of the tumor • Microscopic foci of neuropil contain neuroblastic cells at varying stages of maturation • By definition, no macroscopic nodules present	Ganglioneuroblastoma, Intermixed
Schwannian stroma dominant	• Schwannian stroma is the predominant element of the tumor • Scattered ganglion cells are mature or maturing • No neuropil is present	Ganglioneuroma, Maturing
	• Schwannian stroma is the predominant element of the tumor • Scattered ganglion cells are mature with surrounding satellite cells • No neuropil is present	Ganglioneuroma, Mature
Composite stroma rich/dominant and stroma poor	• Grossly visible nodule consists of any type of stroma poor neuroblastoma • Background of ganglioneuroblastoma or ganglioneuroma • Nodular component should also be classified	Ganglioneuroblastoma, Nodular

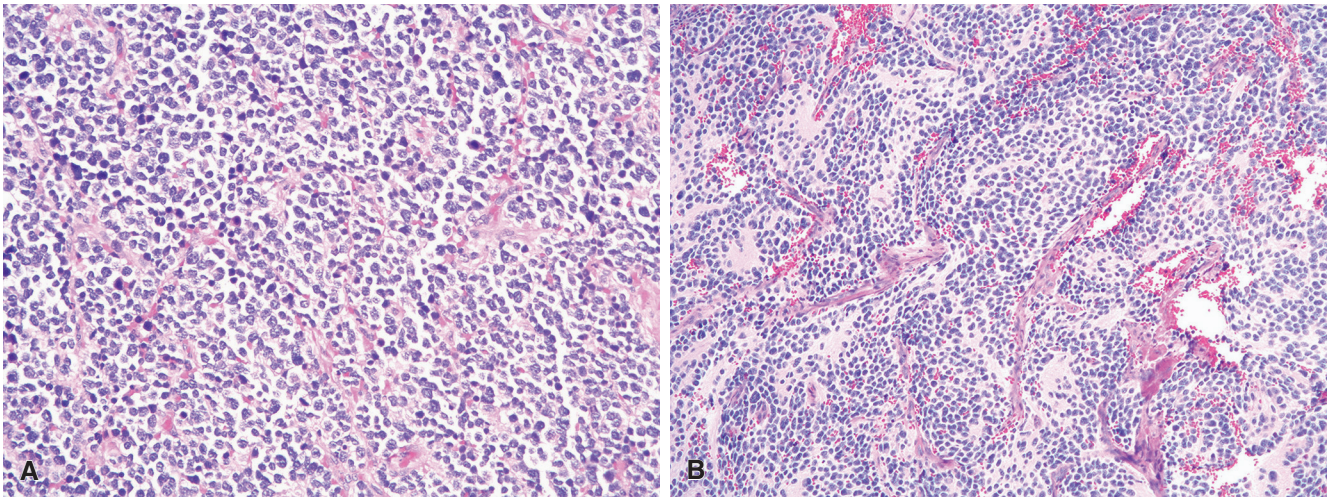

Figure 29.19 **A,** Undifferentiated neuroblastoma. There is no neuropil or cellular differentiation. Adjunctive diagnostic studies and clinical context are important in such cases. **B,** Poorly differentiated neuroblastoma is more lobular and associated with neuropil, the latter making diagnosis more straightforward.

neuroblastoma and other small round blue cell tumors of infancy, such as rhabdomyosarcoma, Ewing sarcoma, and malignant lymphoma.[236] When associated neuropil is present (as in poorly differentiated neuroblastoma), adjunctive studies are rarely needed for diagnosis. While sensitive, the antineuroblastoma antibody NB-84 has proved less than specific, in that it also stains several other types of small round blue cell tumors.[245,246] It should be emphasized that exclusion of other diagnostic possibilities and correlation with clinical setting and laboratory findings (e.g. child with intra-abdominal mass and elevated urine catecholamine metabolites) represent the optimal approach for diagnosing undifferentiated neuroblastoma.

Several genes involved in neural crest development also serve as oncogenes in neuroblastoma, including *MYCN*, *ALK*, and paired-like homeobox 2B *(PHBX2B)* genes. Neuroblastoma typically shows a complex karyotype, and the chromosomal translocation t(11;22) characteristic of Ewing sarcoma is not found.[247] The most common genetic alteration is gain of 17q (up to 80% of cases), either in the form of an unbalanced translocation or as whole chromosome gain; this feature is associated with an unfavorable outcome.[248] The well-known amplification of the *MYCN* oncogene, which is most commonly assessed by the fluorescence in situ hybridization (FISH) technique and defined as greater than 10 copies per diploid genome, occurs in approximately 25% of cases.[249-251] While this feature is an adverse prognostic factor, it is not specific to neuroblastoma. Low-risk neuroblastomas are often hyperploid. High-risk tumors more often have segmental chromosomal abnormalities, commonly in 1p, 1q, 3p, 11q, 14q, and 17p (including *MYCN* amplification). Germline mutations in *ALK* are a major cause of familial neuroblastoma.

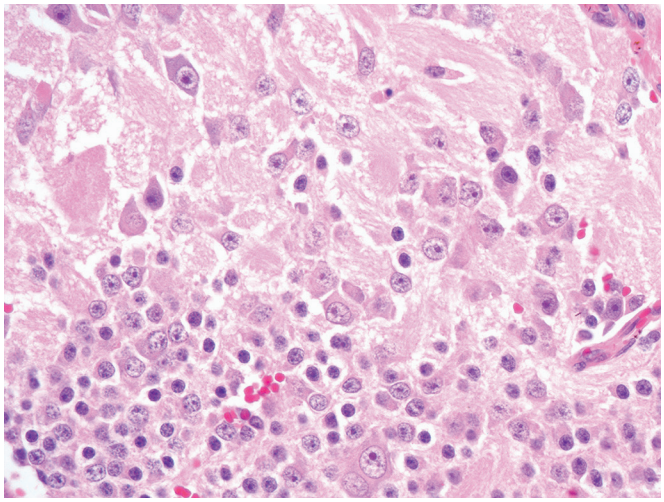

Figure 29.20 Differentiating neuroblastoma contains greater than 5% of cells with varying levels of maturation, typically acquiring a more ganglion-like appearance.

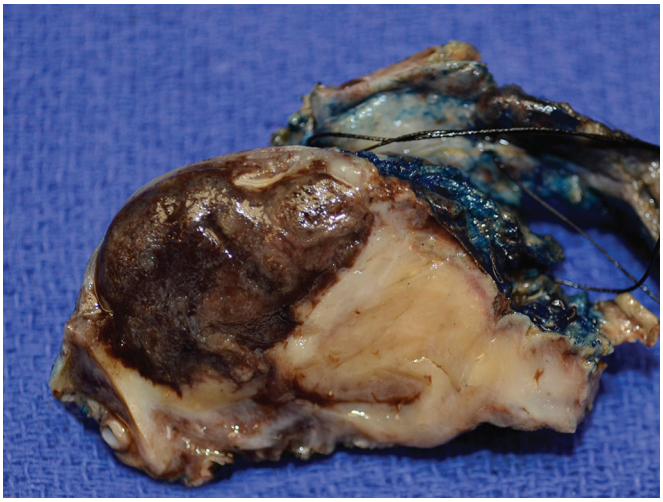

Figure 29.22 Ganglioneuroblastoma, nodular type, is characterized macroscopically by the tan ganglioneuromatous component that contains a dark nodule with stroma-poor neuroblastoma morphology. (Courtesy of Dr. Jason Jarzembowski, Medical College of Wisconsin.)

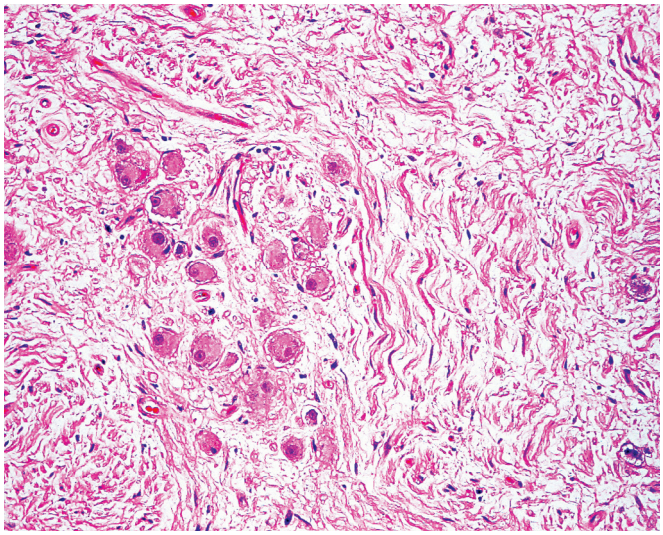

Figure 29.21 Ganglioneuroma of adrenal gland showing clusters of mature ganglion cells surrounded by fascicles of Schwann-like cells (i.e. Schwannian stroma). This diagnosis requires the absence of both neuropil and any nests of neuroblastic cells, which would warrant classification as ganglioneuroblastoma, intermixed.

An International Committee has recently published an authoritative report on the guidelines for the molecular diagnosis of neuroblastoma.[252]

The rare cases of familial neuroblastoma (1%–2%), which typically present at younger age and may have multifocal disease, are reported to have mutations in *ALK* (most common) and *PHOX2B*.[253] Familial neuroblastoma has also been linked to susceptibility alleles, including 16p12-13.

Spread and Metastases

Adrenal neuroblastomas locally invade the surrounding tissues. They may show intraspinal (dumbbell) extension[254] or spread into the kidney. The most common sites of distant metastases are lymph nodes, bone marrow, bone, liver, orbit, and dura.[255-257] Bone metastases are usually multiple and sometimes symmetrical, a point to remember in the differential diagnosis with Ewing sarcoma. Intracranial and pulmonary metastases are rare. Most recurrences and metastases develop within 2 years after excision of the primary tumor, but occasional instances of very late recurrences are on record.[258] The pattern of tumor metastasis is altered by therapy.[259]

Morphologic evaluation of bone marrow for neuroblastoma cells is a routine component of clinical staging and has been standardized for use in definitive diagnosis and risk stratification. The use of immunostains and PCR to increase the yield of detection has been advocated, particularly using the emerging marker PHOX2B.[260]

Therapy and Prognosis

The treatment of neuroblastoma depends on the risk of relapse. Low-risk patients may be observed only, while high-risk patients require multimodal therapy including varying combinations of surgery, chemotherapy, radiation, autologous bone marrow transplant, immunotherapy, and (more recently) targeted therapy.[261-264] Patient age, stage, histologic grading (including specific neuroblastoma diagnosis and mitosis–karyorrhexis index [MKI]), and MYCN amplification status are the backbone of risk stratification.

1. *International Neuroblastoma Pathology Classification (INPC)*.[265-269] The INPC histologic system is applicable to pretreatment specimens only (see Table 29.1). It provides further classification as "favorable" or "unfavorable" histology when combined with patient age and MKI (Table 29.2).[268,270,271] Combinations of patient age, tumor stage, MKI, and MYCN status determine the Children's Oncology Group (COG) neuroblastoma risk group system: low, intermediate, and high risk of disease recurrence.[271,272]
2. *Mitosis-karyorrhexis index (MKI)*.[269] The MKI is a count of all mitotic and karyorrhectic figures present per 5000 neuroblasts. The number of mitotic and karyorrhectic figures can vary across fields in a large pretreatment resection, but the reported MKI should be representative of all tumor represented on the slides (see MKI averaging method later). Once at least 5000 neuroblasts are exceeded in the denominator, one calculates the percentage for the MKI (mitotic + karyorrhectic figures / neuroblasts). This index is categorized as low (<100/5000; 2%), intermediate (100–200/5000; 2%–4%), or high (>200/5000; >4%). The following guidelines and tips may aid in appropriate MKI determination:

Table 29.2 International Neuroblastoma Pathology Classification: favorable and unfavorable histology groups[a]

AGE AT DIAGNOSIS	FAVORABLE HISTOLOGY	UNFAVORABLE HISTOLOGY
Any age	• Ganglioneuroblastoma, intermixed • Ganglioneuroma, mature or maturing	• Neuroblastoma, undifferentiated • Neuroblastoma of any subtype, with high MKI
<18 months	• Neuroblastoma, poorly differentiated, with low or intermediate MKI • Neuroblastoma, differentiating, with low or intermediate MKI	
18–60 months	• Neuroblastoma, differentiating, with low MKI	• Neuroblastoma, poorly differentiated • Neuroblastoma, differentiating, with intermediate MKI
>60 months	• None	• Neuroblastoma of any subtype

[a]For **Ganglioneuroblastoma, nodular subtype**, favorable versus unfavorable designation is based on the subtype of the Schwannian stroma poor neuroblastoma component using the same age and MKI-based criteria.
MKI, Mitosis–karyorrhexis index.

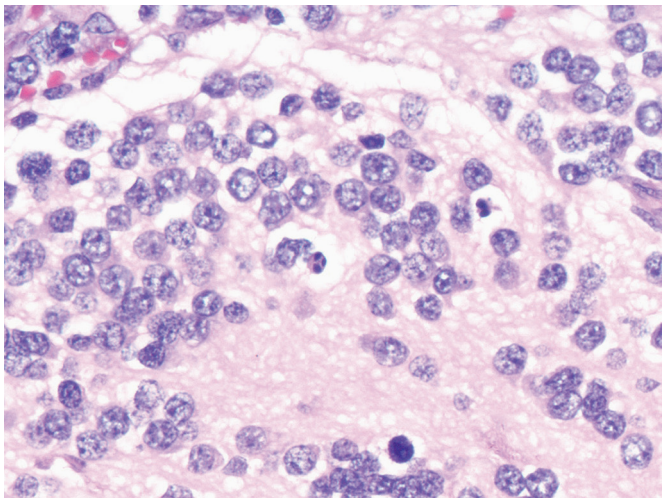

Figure 29.23 Karyorrhectic bodies have eosinophilic cytoplasm and condensed, fragmented nuclear chromatin.

a. *Karyorrhectic figures*. These are recognized by small pyknotic nuclei, which may appear crescentic, angulated, or round, and should have recognizable eosinophilic cytoplasm (Fig. 29.23). Caution should be exercised to avoid counting lymphocytes.
b. *MKI averaging method*. Unlike many mitotic count systems, MKI should be weighted and not determined by areas of highest count. Determine if the tumor is homogeneous or heterogeneous with respect to mitotic-karyorrhectic figures. If heterogeneous, determine regions that may be high, intermediate, or low. Count fields in those regions proportionally to their composition of the overall tumor.
c. *Counting and magnification*. The MKI should never be visually estimated! Ideally using a manual differential counter, count 40× fields to record the number of mitotic-karyorrhectic figures over the denominator of neuroblasts present. Most poorly differentiated neuroblastomas average 600-800 neuroblasts per 40× field, but differentiating neuroblastoma may be as low as 100–200. For the average poorly differentiated neuroblastoma, a count of ten 40× fields will yield greater than 5000 neuroblasts.
d. *Necrosis*. When counting MKI, areas of necrosis should be avoided.

3. *MYCN amplification*. Amplification of the *MYCN* oncogene, which occurs in approximately 25% of the cases, is associated with rapid clinical progression.[273-276] This also applies to stage IV cases[277] but not to stage IVS patients.[278] This amplification can be detected by FISH or PCR techniques.[279,280] Rare cases with genotype-phenotype discordance are reported (i.e. MYCN amplification with favorable histology). Two prognostic subgroups are identified in these discordant neuroblastomas with the poor prognostic group characterized by prominent nucleoli (i.e. "bull's eye" tumor).[281]
4. *Chromosomal abnormalities*. In patients without MYCN amplification, 11q deletion and 17q gain predict a worse prognosis. In the International Neuroblastoma Risk Group system, an unbalanced 11q aberration would place a child in the intermediate risk group when other factors are favorable.
5. *Flow cytometric DNA pattern*. A favorable clinical outcome has been found in association with an aneuploid stem line and a low percentage of tumor cells in the S, G_2, and M phases of the cell cycle.[282,283] The non-aneuploid tumors secrete higher levels of DOPA, dopamine, and HVA and are more likely to present in higher clinical stages.[284] Diploid tumors tend to exhibit an unfavorable histology and high proliferative activity.[285] While the proven clinical utility could be debated, it is our experience that flow cytometric testing may rarely be requested by pediatric oncologists when the constellation of findings closely straddles the border of two risk groups with possible therapeutic implications; however, fresh tissue is required. This is most useful in children less than 2 years of age.

Staging

There are two widely recognized staging systems for neuroblastoma, the International Neuroblastoma Staging System (INSS) and the International Risk Group Staging System (INRGSS).[286-288] The INSS is a surgical staging system, while the INRG is influenced by preoperative imaging. The INSS staging is described in Table 29.3 as it directly relates to surgical pathology. At the time of gross evaluation and sectioning, correct staging requires that lymph nodes attached to and removed with the primary tumor be evaluated separately from other submitted lymph nodes.

Adrenal Medullary Hyperplasia

Hyperplasia of the adrenal medulla may result in symptoms similar to those of pheochromocytoma, and its distinction form the latter

Table 29.3 International Neuroblastoma Staging System

STAGE	DEFINITION
Stage I	• Localized tumor with complete gross excision • Ipsilateral "non-adherent" lymph node negative microscopically • May include positive margins (microscopic residual disease) • May include positive lymph node if adherent to resected tumor
Stage IIA	• Localized tumor with incomplete gross excision • Ipsilateral "non-adherent" lymph node negative microscopically
Stage IIB	• Localized tumor with incomplete gross excision • Ipsilateral "non-adherent" lymph node positive microscopically • Any enlarged contralateral lymph node confirmed microscopically negative
Stage III	• Unresectable unilateral tumor crossing vertebral column with or without regional lymph node involvement • Localized unilateral tumor with contralateral lymph node involvement • Unresectable midline tumor with bilateral tumor infiltration or lymph node involvement
Stage IV	• Any primary tumor with distant metastasis to lymph node, bone, bone marrow, liver, skin or other organs not defined as stage IVS
Stage IVS	• Infant younger than 12 months • Localized primary tumor (stage I, IIA, or IIB) with dissemination limited to skin, liver, and/or bone marrow • Bone marrow involvement must have <10% cellularity • Bone marrow must be metaiodobenzyl guanidine scan negative

may be problematic.[289] It may be nodular or diffuse and is always bilateral. Diffuse hyperplasia may be characterized by extension of the medullary cells into the alae and tail. Ultrastructurally and immunohistochemically, the features are similar to those of normal medullary cells: chromogranin and synaptophysin reactivity can be consistently demonstrated.[290]

Advanced cases of medullary hyperplasia are easy to recognize, but earlier phases may need morphometric studies to detect minor increases in medullary volume and weight, inasmuch as random sectioning techniques are grossly inadequate for this purpose.[291,292] In most cases, the medullary hyperplasia is a component of multiple endocrine neoplasia (MEN 2A and 2B) and is the background against which pheochromocytomas (sometimes multiple and bilateral) develop in these patients.[293,294] It has also been reported in association with neurofibromatosis, cystic fibrosis, germline *SDHB* mutation, *MAX* mutation, and Beckwith–Wiedemann syndrome.[295-298]

Pheochromocytoma

General and Clinical Features

Pheochromocytomas are primary neoplasms of the adrenal chromaffin cells and are essentially sympathetic paragangliomas of the adrenal medulla. While the term *"extra-adrenal pheochromocytoma"* has been historically used for extra-adrenal paragangliomas that are either functioning and/or connected with the orthosympathetic system (such as those arising in the bladder or in the Zuckerkandl body), it is probably best to avoid that diagnostic term altogether. Both pheochromocytomas and paragangliomas secrete norepinephrine, but only the former have the capacity to also secrete epinephrine, since the adrenal cortex is necessary for the needed methylation step. Indeed, the pure norepinephrine-producing adrenal pheochromocytomas have been found to have a deficiency of phenylethanolamine *N*-methyltransferase.[299]

The clinical signs and symptoms of hormonally active pheochromocytomas derive from the catecholamines they secrete. Hypertensive episodes are usually intermittent, but at times may be sustained. They may be precipitated by drugs, anesthetic agents, parturition, surgery for an unrelated condition, or massaging of the tumor.[300] The complete symptomatic triad of sweating attacks, tachycardia, and headaches clinically suggests the presence of a pheochromocytoma, but is seen in less than one-fourth of patients. Rarely, pheochromocytoma and paraganglioma may be associated with a paraneoplastic syndrome secondary to other ectopic secretory products: Cushing syndrome (most common), diarrhea/hypokalemia/achlorhydria (typically in composite tumors with a component of ganglioneuroma or ganglioneuroblastoma), or polycythemia (with *EPAS1* or *EGLN1/2* mutations).[301-305]

Confirmation of the diagnosis is usually obtained by testing for evidence of catecholamine production, typically by plasma free metanephrines or urinary fractionated metanephrines.[306,307] Provocative pharmacologic tests are used only when the biochemical results are equivocal.[300] CT imaging for the preoperative detection is often reserved for patients with corroborative biochemical evidence of pheochromocytoma.

Morphologic Features

The weight of pheochromocytomas ranges from a few grams to over 2000 g, and they are typically 3–5 cm. They are often circumscribed, usually soft, and, on section, yellowish white to reddish brown (Fig. 29.24). The larger tumors often have areas of necrosis, hemorrhage, and cyst formation. The adrenal gland usually is compressed or incorporated within the tumor.[308]

Microscopically, the tumor cells are characteristically arranged in well-defined nests ("Zellballen") bound by a delicate fibrovascular stroma. Other patterns include more diffuse growth, trabecular arrangement, or prominent sclerosis.[308] The cells vary considerably in size and shape and have a finely granular basophilic or amphophilic cytoplasm (Fig. 29.25). The nuclei are usually round or oval with prominent nucleoli and may contain inclusion-like structures resulting from deep cytoplasmic invaginations.[309] Intracytoplasmic hyaline globules are common.[310] Lipid accumulation may develop in the cytoplasm and lead to confusion with adrenal cortical tumors on both gross and light microscopic examination.[311-313] Melanin pigment is occasionally present.[314,315] Nuclear gigantism and hyperchromasia are common and *are not* an expression of malignancy.

Exceptionally, the cells of pheochromocytomas are found to contain a large number of mitochondria (in addition to the neurosecretory granules) and thus acquire an oncocytic appearance.[316,317]

Isolated ganglion cells are sometimes found in pheochromocytoma. More rarely, a true composite tumor will be found to be composed of a mixture of pheochromocytoma and ganglioneuroma, ganglioneuroblastoma, or neuroblastoma, a finding not surprising in view of the close histogenetic relationship of the cell types.[318-321] Some of these combined tumors have occurred in the setting of MEN 2a.[322] Other combinations that have been described are

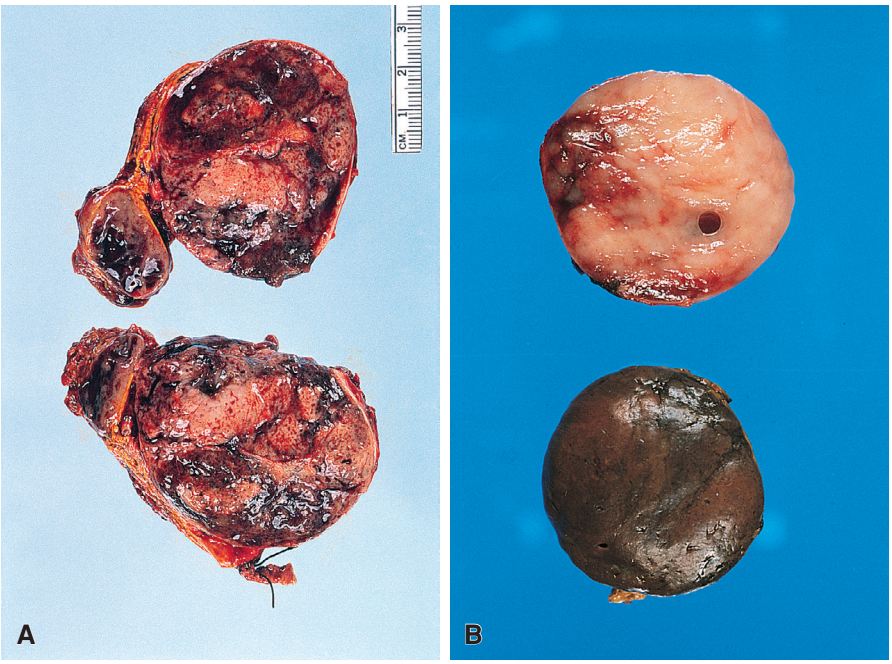

Figure 29.24 Gross appearance of adrenal pheochromocytoma. The tumor shown in **A** has a markedly variegated appearance. The lower half of the specimen shown in **B** was fixed in Zenker fluid and has acquired the typical dark brown color indicative of a positive chromaffin reaction.

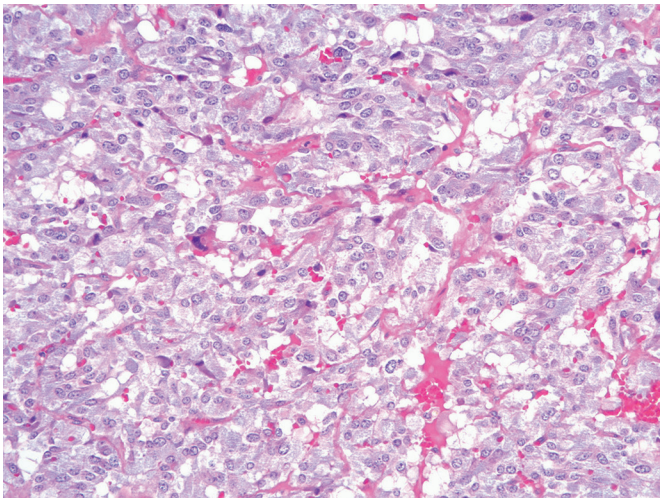

Figure 29.25 Adrenal pheochromocytoma shows the typical "Zellballen" configuration and abundant granular amphophilic cytoplasm of the tumor cells.

pheochromocytoma with spindle cell sarcoma,[323,324] some of possibly malignant peripheral nerve sheath nature,[325] pheochromocytoma with cortical adenoma, and pheochromocytoma with neuroendocrine carcinoma.[326]

Electron Microscopic, Histochemical, Immunohistochemical, and Molecular Genetic Features

Ultrastructurally, the cells of pheochromocytoma contain numerous dense-core granules of neurosecretory type; in the typical case they segregate into two size categories, corresponding to their respective content of norepinephrine and epinephrine.[7,327,328]

Immunohistochemically, pheochromocytoma cells are typically immunoreactive for chromogranin (strong and diffuse) and GATA-3 (nuclear).[115,182-184] PHOX2B expression by immunohistochemistry is recently reported in pheochromocytomas, but not as commonly in well-differentiated neuroendocrine neoplasms.[329] Cytokeratin expression is variably reported, but is typically negative; keratin staining is known to be most common in paragangliomas of the cauda equina.[330,331] Surrounding sustentacular cells, which form a peripheral coat around the "Zellballen," are strongly reactive for S-100 protein; however, they are present in variable numbers.[332-335] S-100 protein may also show weak cytoplasmic staining of the chromaffin cells. Immunostains for SDHB are being increasingly utilized as initial screening for SDH family mutations because other SDH mutations also result in loss of the SDHB protein due to a shared epitope.[336-339]

With recent progress in the molecular biology of adrenal pheochromocytoma, it is now apparent that at least 30% may be hereditary and germline mutations in well over 15 different known hereditary susceptibility genes are now described, including *SDH* family (most common), *NF1*, *VHL*, *RET*, *MAX*, *EPAS1*, and *FH*. Many patients present with a solitary tumor suggesting sporadic disease; however, between 8% and 24% of patients with apparently sporadic pheochromocytoma and no family history are carriers of germline mutations in one of these genes.[340-343] When compared with the sporadic examples, syndromic pheochromocytomas tend to occur in a younger age group, are more commonly bilateral, and are more frequently associated with other primary neoplasms.[344] Pheochromocytomas in children are less likely to be malignant, but more likely to be bilateral, or associated with MEN.[345,346]

Other common genetic changes, including allelic losses at 1p, 3q, 11q, 17p, and 22q, are frequent.[347-352] Alterations in chromosome 11 and losses at 6q and 17p are found more commonly in tumors with malignant behavior.[347,348]

Interestingly, somatic mutations in some of these same hereditary susceptibility genes are identified in sporadic tumors, with *NF1* being

most common.[353-363] Sporadic tumors may also harbor *HRAS* or *BRAF* mutations (~9% of cases), and *TP53* in 2%–3%.[364]

Spread, Metastases, Treatment, and Prognosis

We know of no reliable morphologic markers of malignancy for this tumor other than the presence of metastases. In fact, the current WHO classification no longer includes a "malignant pheochromocytoma" category.[365] As a group, however, pheochromocytomas associated with metastases are usually larger, have more necrosis, and are composed of smaller cells than their benign counterparts.[308] Although the statement is often made that only 10% of pheochromocytomas are malignant, several series in adults with long-term follow-up suggest that the real incidence is much higher since metastases may arise many years after initial diagnosis.[366,367]

Morphologic parameters such as proliferative activity, cytologic abnormalities (extreme pleomorphism, spindling, cellular monotony), diffuse architectural growth, necrosis, and invasion (vascular or capsular) have proven to be poor prognostic determinants in this tumor, at least when evaluated independently. While no prognostic system is uniformly adopted, combining histologic features into a scoring system in a way similar to the one that has been successfully employed for adrenocortical tumors has been proposed, including the Pheochromocytoma of the Adrenal Gland Scaled Score (PASS) and the Grading System for Adrenal Pheochromocytoma and Paraganglioma (GAPP).[368,369] The GAPP employs six criteria (histologic pattern, cellularity, coagulation necrosis, vascular/capsular invasion, MIB-1 immunoreactivity, and types of catecholamine produced) and divides the tumors accordingly into well, moderately, and poorly differentiated (with 10-year survival rates of 83%, 38%, and 0%, respectively).[369,370] More recently, SDHB protein loss by immunohistochemistry was shown to add additional prognostic information by predicting for higher risk of metastatic disease.[370-372]

Other reportedly unfavorable prognostic factors are high proliferative index (as measured with MIB-1 or topoisomerase alpha II staining)[373-377]; absence of S-100 protein–positive sustentacular cells[334]; increased expression of tenascin; and expression of the gene for human telomerase reverse transcriptase (*hTERT*).[378,379]

Metastatic pheochromocytomas most commonly involve local lymph nodes, bone, liver, and lung. Metastases should only be diagnosed at sites where normal chromaffin cells are absent to avoid misclassification of multifocal primaries (which are not uncommon in familial cases). The primary treatment of pheochromocytoma is surgical excision. Most patients with metastatic tumor die within 1 year of diagnosis, but long-term relapse-free survival is possible for locally invasive neoplasms.[334,366]

Staging

The 8th edition of the AJCC staging manual now includes pheochromocytoma.[364,380]

Other Adrenal Lesions

Adrenal hemorrhage of massive proportions can occur in infants within the first few days after delivery; it may present as an abdominal or retroperitoneal mass, septicemia, or adrenal insufficiency.[381] In the first instance, surgery is indicated to rule out the possibility of neuroblastoma.[382] This differential diagnosis also applies to the surgical and pathologic findings, since neuroblastoma can undergo marked hemorrhagic necrosis. Massive adrenal hemorrhage must also be distinguished from renal vein thrombosis. This hemorrhage can be unilateral (more commonly on the right side) or affect both glands; if the patient survives, calcification rapidly develops around its periphery (Fig. 29.26).[383] The postulated causes include fetal hypoxia, septicemia, thrombocytopenia, coagulopathies, and disseminated thromboembolic disease.

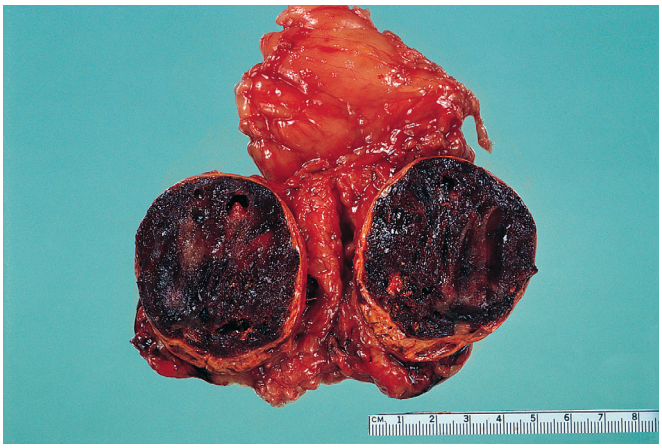

Figure 29.26 Adrenal gland massively replaced by hemorrhage. There was no evidence of a tumor in any of the many sections taken.

Adrenal cysts can be clinically confused with retroperitoneal neoplasms because of their occasionally large size of up to 30 cm in diameter (Fig. 29.27).[384] They are sometimes bilateral. Microscopically, the wall is composed of partially calcified fibrous tissue without an epithelial lining.[385] In some instances, intracystic mature adipose tissue or myelolipomatous metaplasia is encountered.[386] The content may be serous or blood-colored fluid. The mechanism of formation remains controversial. It would seem that two main variants exist.[387-389] The first, known as *endothelial (vascular) cyst*, contains serous fluid, is multiloculated, has an endothelial lining, and often contains adrenal cortex in the wall. The second, known as *hemorrhagic cyst* or *pseudocyst*, contains clotted blood and hyalinized thrombus with attenuated adrenal cortex in the outer fibrous wall.[390] It has been suggested that both cyst types arise on the basis of a vascular anomaly,[391] perhaps of lymphatic nature in the first instance and of blood vessel type in the second.[387] Hemorrhagic cysts can occur as a component of Beckwith–Wiedemann syndrome.[392,393] In rare cases, *epithelial-lined ("true") adrenal cysts* are seen; their histogenesis is probably similar to that of epithelial-lined cysts of the spleen and possibly derived from mesothelial structures.[394] These should be distinguished from *bronchogenic cysts*, which sometimes present as adrenal masses,[395,396] and with adrenal cortical and medullary neoplasms with marked secondary cystic changes.[397] It follows that thorough sampling of the specimen is crucial in making this distinction.

Adrenal cytomegaly refers to the presence in the adrenal cortex of foci of bizarre polyhedral cells with eosinophilic granular cytoplasm and large hyperchromatic nuclei with pseudoinclusions. This condition is usually detected in infancy, often as a component of Beckwith syndrome; it is not likely to be seen as a surgical specimen.[398]

Heterotopic tissue in the adrenal gland is highly unusual. This includes *liver tissue* (usually resulting from adrenohepatic fusion, but sometimes occurring as a separate nodule),[399] and *thyroid tissue*.[400]

Tuberculosis of the adrenal glands is one of the classic causes of Addison disease[401]; the glands are enlarged, calcified, and massively replaced by granulomatous inflammation.[402]

Malakoplakia involving the adrenal gland has been reported in infants[403] and adults.[404]

Myelolipoma is a lesion characterized by the presence within the adrenal gland of adult fat containing active bone marrow elements

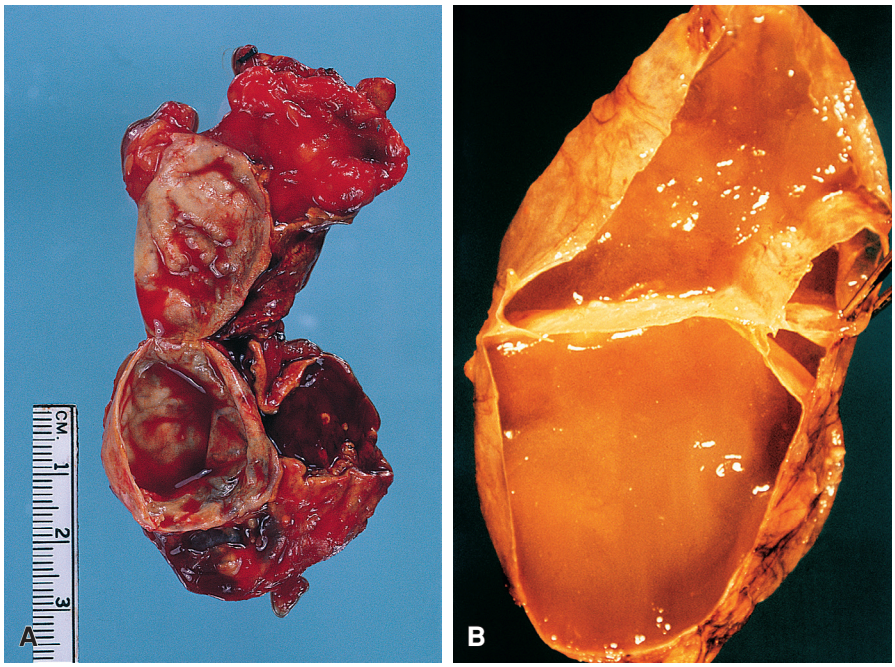

Figure 29.27 Gross appearance of adrenal cyst. The cyst shown in **A** has a unilocular appearance, whereas that shown in **B** is divided into two portions by a prominent septum.

Figure 29.28 Gross appearance of adrenal myelolipoma. *Yellow* areas with the appearance of adipose tissue alternate with hemorrhagic foci composed of bone marrow tissue.

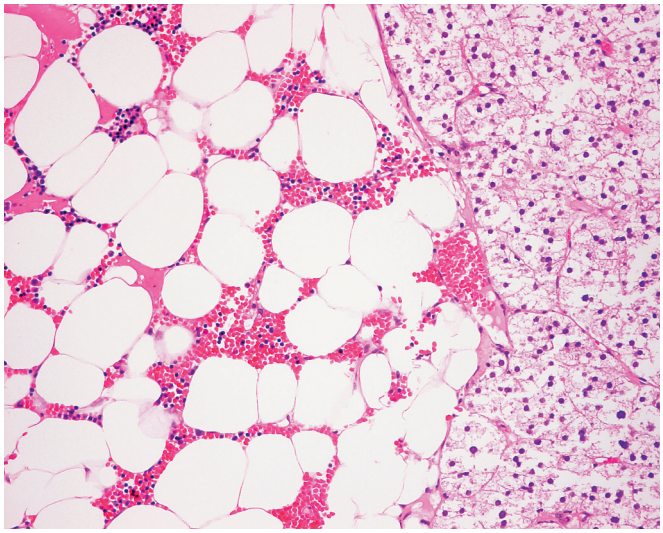

Figure 29.29 Adrenal myelolipoma composed of bone marrow elements and mature fat.

(Figs. 29.28 and 29.29).[405-407] There is a wide variation in cellularity. The bone marrow component shows normal trilineage hematopoiesis, but with a markedly increased number of megakaryocytes.[408] Most cases are found incidentally, either at autopsy or through CT scanning done for other reasons. Only occasionally will the lesion attain a size large enough to become clinically apparent.[409,410] Bilaterality is rare.[411] The tumors are hormonally inactive, most of the patients being obese adults. Traumatic rupture leading to hemoperitoneum may supervene.[412] Myelolipoma has been seen in association with adrenal cortical tumors accompanied by Cushing syndrome,[413] with congenital adrenal hyperplasia,[414] and with adrenal ganglioneuroma.[415] Cases of pure adrenal myelolipoma associated with Cushing disease have also been reported.[413,416] In contrast to other extramedullary foci of hematopoiesis in adults (which are usually the expression of a hematologic disease), adrenal myelolipoma is practically always accompanied by a normal bone marrow.[417] Recent cytogenetic studies have shown that adrenal myelolipoma is a clonal lesion.[408]

Benign mesenchymal tumors of the adrenal gland, all exceptionally rare, include lipoma, hemangioma, lymphangioma, leiomyoma, solitary fibrous tumor, calcifying fibrous tumor, and schwannoma.[418-425]

Adenomatoid tumor has been reported in a primary adrenal location (Fig. 29.30); as in other sites, its nature is in all likelihood mesothelial. The behavior is benign.[426-431]

Sex cord stromal tumors are rarely reported in the adrenal gland, including granulosa and Leydig cell tumors.[432-435] These have occurred in postmenopausal women, and the pathologic features are identical to those encountered in the gonads. Patients have often presented with symptoms of hormonal production.

Sarcomas primary in the adrenal gland are exceptionally rare. They include *leiomyosarcoma*[436] (some in association with HIV infection[437]), *malignant peripheral nerve sheath tumor*,[438,439] *synovial saarcoma*,[440] and *angiosarcoma* (often epithelioid).[441,442] There have also been isolated reports of *Ewing sarcoma* arising in the adrenal gland, to be distinguished from the considerably more common neuroblastomas,[443] and a case of an intra-adrenal neoplasm indistinguishable from renal *Wilms tumor*.[444]

Malignant lymphoma involving the adrenal gland is usually a manifestation of widespread disease. Only a few cases have been reported as having an apparently primary adrenal location.[445,446] Most of the cases have been of B-cell type,[447] and several of these were Epstein–Barr virus (EBV) associated.[448] Fibrin-associated EBV-positive large B-cell lymphoma is a subtle, yet distinct form of lymphoma with an indolent clinical behavior that has been described in adrenal cysts and may be cured by surgical excision.[449] There have also been cases of T-cell lymphoma,[448] anaplastic large cell lymphoma,[450] and intravascular lymphoma.[451] If the adrenal replacement is extensive bilaterally, adrenal insufficiency may result.[452,453]

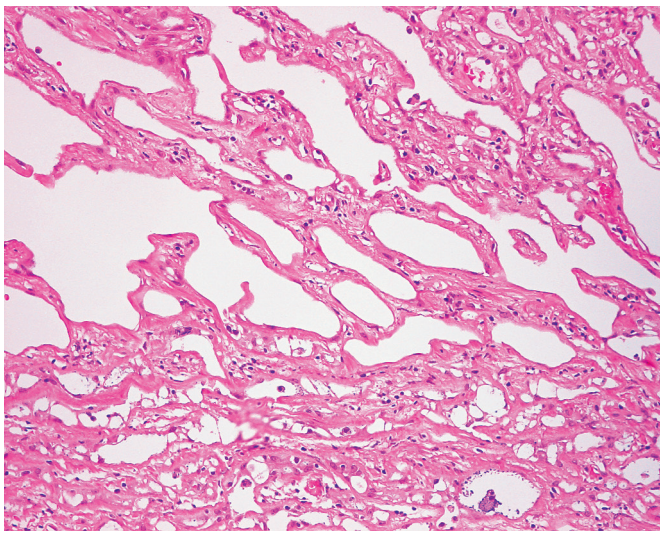

Figure 29.30 Adenomatoid tumor of adrenal gland. The appearance closely simulates that of a vascular tumor.

Malignant melanoma as a primary adrenal tumor is reported; however, the differential diagnosis includes melanotic pheochromocytoma and metastatic melanoma, both of which are considerably more common.[454]

Metastatic tumors to the adrenal glands are very common at autopsy but sometimes also present as surgical specimens simulating a primary adrenal neoplasm (Fig. 29.31). Bilaterality is the rule. CT scanning is the method of choice for their detection. If extensive enough, they may lead to Addison disease.[455,456] The most common sites of the primary tumor are lung, breast, gastric, skin (melanoma), pancreas, hepatobiliary, and kidney. Renal metastases can be contralateral and may grossly and microscopically simulate the appearance of adrenocortical carcinoma or adenoma (Fig. 29.32).[457]

Tumors and Tumorlike Lesions of Other Paraganglia

Generalities

Paraganglioma is the generic term applied to nonepithelial tumors of paraganglion cells regardless of location.[458,459] The only exception, largely on the basis of tradition, is the already discussed paraganglioma of the adrenal medulla, which is universally known as *pheochromocytoma*. Extra-adrenal paragangliomas may arise in the parasympathetic paraganglia (mostly of the head and neck) or the sympathetic paraganglia (found along the sympathetic nerve chain adjacent to the vertebral bodies in the abdomen, pelvis, and thorax and along sympathetic nerve fibers). Paragangliomas have been found in practically every site in which normal paraganglia are known to

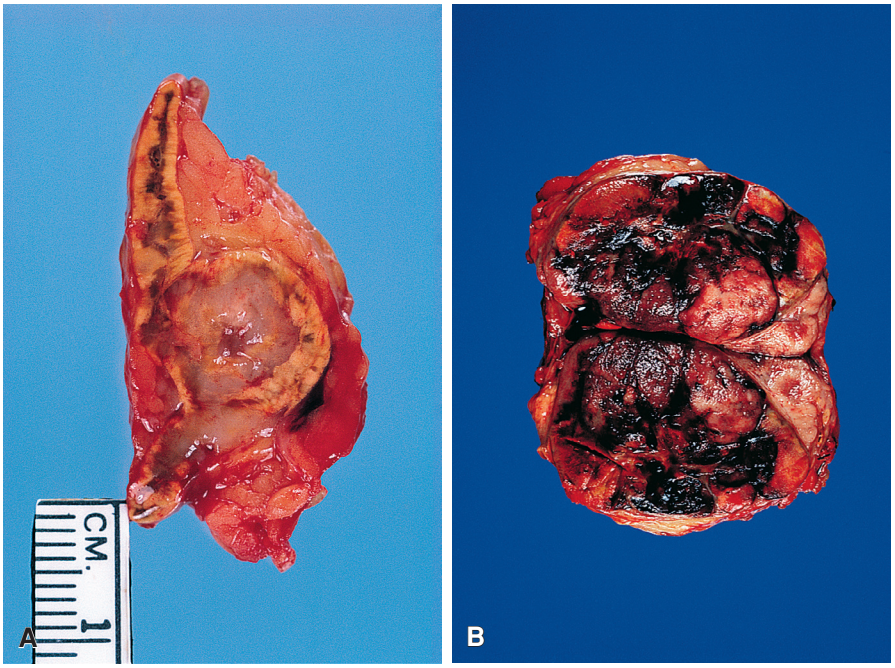

Figure 29.31 Metastatic carcinoma to adrenal gland. **A,** The whitish, ill-defined mass present in the center of the gland represents metastatic squamous cell carcinoma from the esophagus. **B,** Enlargement of the gland by a markedly hemorrhagic tumor representing metastatic breast carcinoma.

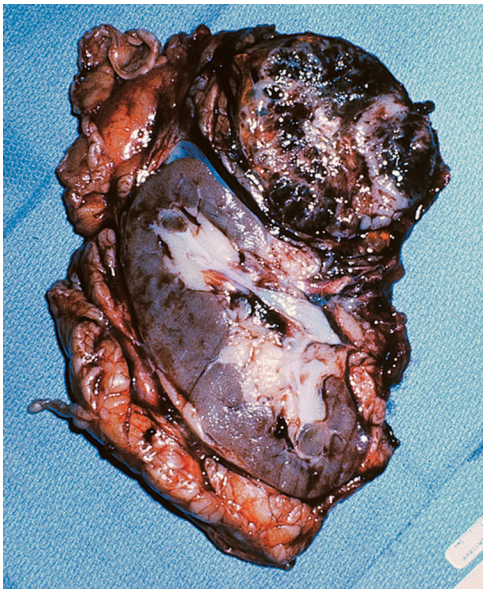

Figure 29.32 Renal cell carcinoma metastatic to contralateral adrenal gland and simulating a primary adrenal cortical tumor at the gross and microscopic level.

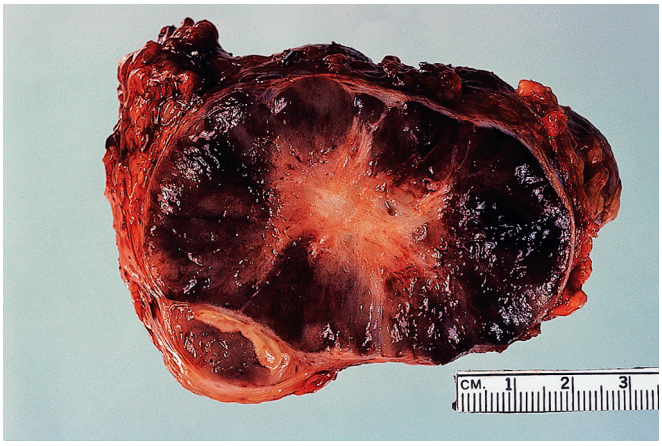

Figure 29.33 Gross appearance of paraganglioma. The brown appearance of the cut surface is characteristic. A large central scar is present.

occur, their description sometimes preceding that of the corresponding normal structure.

Morphologic Features

The gross and microscopic appearance of paragangliomas is practically the same regardless of location and indistinguishable from that of adrenal pheochromocytoma (Fig. 29.33); however, head and neck paragangliomas have been described as more cellular. Well-defined nests of cuboidal cells ("Zellballen") are separated by highly vascularized fibrous septa (Fig. 29.34). The individual cells have a moderately abundant granular basophilic cytoplasm. On occasion, a brown melanin-like pigment is present (*pigmented* or *black* paraganglioma).[460,461] As with many other endocrine tumors, bizarre nuclei and vascular invasion are sometimes found, neither of which should be taken as evidence of malignancy. Mitoses are exceptional, except in poorly differentiated tumors. The stroma can be very abundant; it often has a hyalinized quality and may undergo osseous metaplasia.[462] The sclerosing variant can be easily overdiagnosed as a

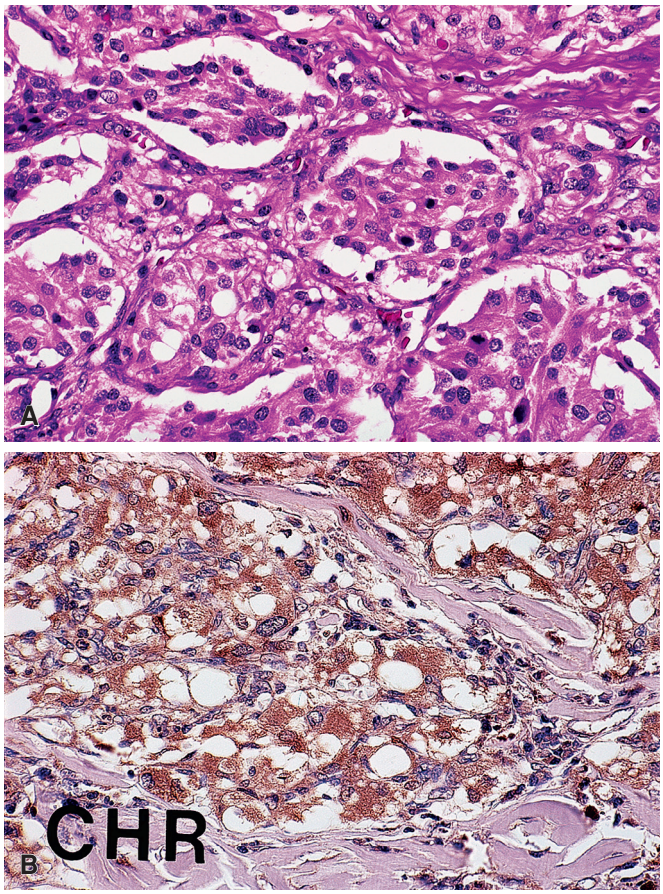

Figure 29.34 Paraganglioma. **A,** "Zellballen" formation in paraganglioma and **B** expression of chromogranin.

malignant tumor because of the pseudoinvasive appearance of the tumor nests.[463]

Electron Microscopic and Immunohistochemical Features

Ultrastructurally, the tumor ("chief") cells contain large numbers of cytoplasmic neurosecretory granules whose appearance is similar to those seen in normal paraganglia.[464,465] Giant mitochondria with paracrystalline inclusions may also be present.[466] The second cell type present in these tumors is the sustentacular cell, which wraps around the chief cells and lacks dense-core granules. Biochemical assays of the tumor have confirmed the presence of norepinephrine and sometimes also of epinephrine and dopamine.[467,468] Immunohistochemically, positivity has been found for NSE, chromogranin, synaptophysin, neurofilaments, opioid peptides, serotonin, somatostatin, and various other peptide hormones.[465,469-473] Interestingly, compared to other sites, head and neck paragangliomas are more frequently chromogranin negative.[474] Similar to pheochromocytoma, GATA3 and PHOX2B also show frequent immunoreactivity in extra-adrenal paragangliomas.[184,329,475] Keratin is almost always negative, but rare cases have focal staining (a fact of importance in the differential diagnosis with neuroendocrine carcinomas),[476] the curious exception being paraganglioma of the filum terminale in which stronger keratin reactivity is more common.[477] The sustentacular cells can be demonstrated with S-100 protein, another feature of importance in the differential diagnosis from other endocrine neoplasms (Fig. 29.35).[335,478]

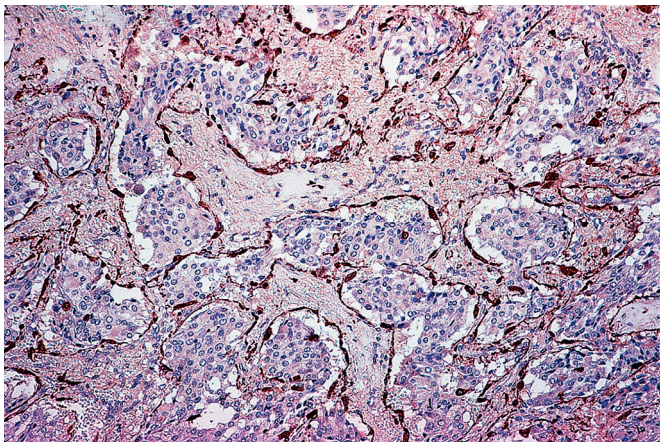

Figure 29.35 Sustentacular cells immunostained for S-100 protein at the periphery of the tumor nests of paraganglioma.

Figure 29.36 Typical location of carotid body tumor at the bifurcation of the carotid artery. (Courtesy of Dr. R.A. Cooke, Brisbane, Australia; From Cooke RA, Stewart B. *Colour Atlas of Anatomical Pathology*. Edinburgh: Churchill Livingstone; 2004.)

Treatment and Prognosis

Surgical excision is the standard treatment for paraganglioma. There are no reliable morphologic criteria by which to separate the benign from the malignant forms; therefore, risk assessment models (similar to gastrointestinal stromal tumors) have been proposed. Like pheochromocytoma, the GAPP may be applied to extra-adrenal paragangliomas for risk stratification.[368,369] Increasing tumor size (>5 cm), *SDHB* mutations, *MAX* mutations, and increasing Ki-67 proliferation rate are also risk factors for metastatic behavior.[370-372] Common sites of metastasis include bone, lymph nodes, lung, and liver.[479]

Paraganglioma Subtypes

Parasympathetic (Head and Neck) Paragangliomas

Most paragangliomas of the head and neck are nonfunctioning with only very rare cases secreting catecholamines. Paragangliomas of the head and neck (particularly carotid body tumors, Fig. 29.36) are about 10 times more frequent in persons living at high altitudes than in those at sea level[480,481]; these have been invariably benign.[482,483] While carotid body is most common,[484-487] other frequent sites of origin include middle ear, vagus nerve, and larynx.[488-496] Head and neck paragangliomas are commonly benign, but approximately 5% follow a malignant course. Metastatic paragangliomas of the head and neck are more commonly functioning, present at younger age, and have multifocal disease.[479]

The rate of germline mutations specifically in head and neck paragangliomas approaches at least 20%.[497] The most common mutations involve genes encoding the subunits of succinate dehydrogenase (i.e. hereditary paraganglioma syndrome), including *SDHD*, *SDHB*, *SDHA*, and *SDHC*.[498-500] Tumors with *SDHB* mutations have a high rate of developing metastasis (approximately 30%).[501] Other less common mutations described in the head and neck tumors include *VHL*, *TMEM127*, *RET*, and *NF1*.[502]

Sympathetic Paraganglioma

Sympathetic paragangliomas occur most commonly in the retroperitoneum, typically adjacent to the adrenal gland or kidney, but other sites include Zuckerkandl body,[503-505] heart,[506] gallbladder,[507] urinary bladder (one of the most frequent),[508] uterus,[509,510] and spinal cord (especially lumbar region and cauda equina) (Fig. 29.37).[511,512]

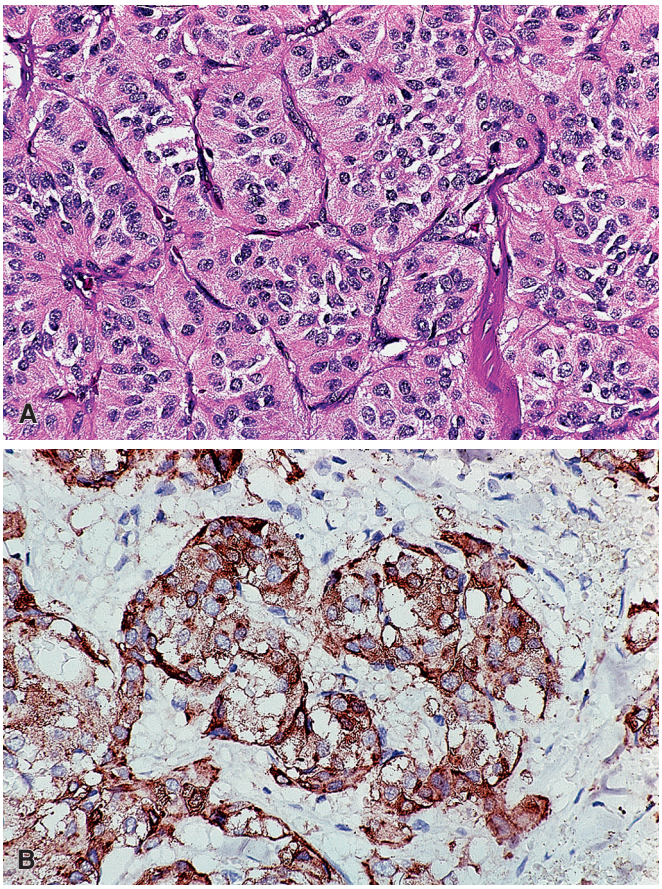

Figure 29.37 Paraganglioma of cauda equina. **A**, Hematoxylin–eosin; **B**, chromogranin.

As already mentioned, the latter are the only paragangliomas likely to show immunoreactivity for keratin. Some of these tumors are discussed with their respective organs. The sympathetic paraganglia are capable of catecholamine synthesis with production of norepinephrine alone or norepinephrine and dopamine.[513]

The molecular genetic profile of sympathetic paragangliomas is similar to that described for pheochromocytoma. Sympathetic paragangliomas are hereditary in up to 30% of cases, and should be strongly suspected in younger patients.[514]

References

1. Carney JA, Lloyd RV. Adrenal. In: Mills SE, ed. *Histology for Pathologists*. 3rd ed. Philadelphia: Lippincott Williams & Wilkins; 2007:1167-1188.
2. Cooper MJ, Hutchins GM, Israel MA. Histogenesis of the human adrenal medulla. An evaluation of the ontogeny of chromaffin and nonchromaffin lineages. *Am J Pathol*. 1990;137(3):605-615.
3. Symington T. *Functional Pathology of the Human Adrenal Gland*. Baltimore: Williams & Wilkins; 1969.
4. Sasano H. New approaches in human adrenocortical pathology. Assessment of adrenocortical function in surgical specimen of human adrenal glands. *Endocr Pathol*. 1992;3:4-13.
5. Belloni AS, Mazzocchi G, Mantero F, Nussdorfer GG. The human adrenal cortex: ultrastructure and base-line morphometric data. *J Submicrosc Cytol*. 1987;19(4):657-668.
6. Coupland RE. The chromaffin system. In: Blaschko H, Muschall E, eds. *Catecholamines. Handbook of Experimental Pharmacology*. New York: Springer-Verlag; 1972.
7. Bloom FE. Electron microscopy of catecholamine-containing structures. In: Blaschko H, Muschall E, eds. *Catecholamines. Handbook of Experimental Pharmacology*. New York: Springer-Verlag; 1972.
8. Tischler AS. Paraganglia. In: Mills SE, ed. *Histology for Pathologists*. 3rd ed. Philadelphia: Lippincott Williams & Wilkins; 2007:1211-1233.
9. Freedman SR, Goldman RL. Normal paraganglion in the mesosigmoid. *Hum Pathol*. 1981;12(11):1037-1038.
10. Makinen J, Nickels J. Paraganglion cells mimicking metastatic clear cell carcinoma. *Histopathology*. 1979;3(6):459-465.
11. Berkman WA, Bernardino ME, Sewell CW, et al. The computed tomography-guided adrenal biopsy. An alternative to surgery in adrenal mass diagnosis. *Cancer*. 1984;53(10):2098-2103.
12. Karstrup S, Torp-Pedersen S, Nolsoe C, et al. Ultrasonically guided fine-needle biopsies from adrenal tumors. *Scand J Urol Nephrol Suppl*. 1991;137:31-34.
13. Hoda SA, Zaman MB, Burt M. Aspiration cytology in the evaluation of adrenal masses. *Acta Cytol*. 1991;35.
14. Katz RL, Patel S, Mackay B, Zornoza J. Fine needle aspiration cytology of the adrenal gland. *Acta Cytol*. 1984;28(3):269-282.
15. Wadih GE, Nance KV, Silverman JF. Fine-needle aspiration cytology of the adrenal gland. Fifty biopsies in 48 patients. *Arch Pathol Lab Med*. 1992;116(8):841-846.
16. Suen KC, Chan NH. Fine needle aspiration biopsy of the adrenal gland. Cytological features and clinical applications. *Endocr Pathol*. 1992;3:173-181.
17. Saeger W, Fassnacht M, Chita R, et al. High diagnostic accuracy of adrenal core biopsy: results of the German and Austrian adrenal network multicenter trial in 220 consecutive patients. *Hum Pathol*. 2003;34(2):180-186.
18. Ye H, Yoon GS, Epstein JI. Intrarenal ectopic adrenal tissue and renal-adrenal fusion: a report of nine cases. *Mod Pathol*. 2009;22(2):175-181.
19. Honma K. Adreno-hepatic fusion. An autopsy study. *Zentralbl Pathol*. 1991;137:117-122.
20. Dahl EV, Bahn RC. Aberrant adrenal contical tissue near the testis in human infants. *Am J Pathol*. 1962;40:587-598.
21. Graham LS. Celiac accessory adrenal glands. *Cancer*. 1953;6(1):149-152.
22. Mitchell A, Scheithauer BW, Sasano H, et al. Symptomatic intradural adrenal adenoma of the spinal nerve root: report of two cases. *Neurosurgery*. 1993;32(4):658-661, discussion 61-2.
23. Vestfrid MA. Ectopic adrenal cortex in neonatal liver. *Histopathology*. 1980;4(6):669-672.
24. Habuchi T, Mizutani Y, Miyakawa M. Ectopic aberrant adrenals with epididymal abnormality. *Urology*. 1992;39(3):251-253.
25. Johnson RE, Scheithauer B. Massive hyperplasia of testicular adrenal rests in a patient with Nelson's syndrome. *Am J Clin Pathol*. 1982;77(4):501-507.
26. Kepes JJ, O'Boynick P, Jones S, et al. Adrenal cortical adenoma in the spinal canal of an 8-year-old girl. *Am J Surg Pathol*. 1990;14(5):481-484.
27. Nguyen GK, Vriend R, Ronaghan D, Lakey WH. Heterotopic adrenocortical oncocytoma. A case report with light and electron microscopic studies. *Cancer*. 1992;70(11):2681-2684.
28. Rodriguez FJ, Scheithauer BW, Erickson LA, et al. Ectopic low-grade adrenocortical carcinoma in the spinal region: immunohistochemical and molecular cytogenetic study of a pediatric case. *Am J Surg Pathol*. 2009;33(1):142-148.
29. Merke DP, Camacho CA. Novel basic and clinical aspects of congenital adrenal hyperplasia. *Rev Endocr Metab Disord*. 2001;2(3):289-296.
30. El-Maouche D, Arlt W, Merke DP. Congenital adrenal hyperplasia. *Lancet*. 2017.
31. Georgitis WJ. Clinically silent congenital adrenal hyperplasia masquerading as ectopic adrenocorticotropic hormone syndrome. *Am J Med*. 1986;80(4):703-708.
32. Merke DP, Bornstein SR. Congenital adrenal hyperplasia. *Lancet*. 2005;365(9477):2125-2136.
33. New MI. Congenital adrenal hyperplasia. *Pediatr Clin North Am*. 1968;15(2):395-407.
34. Lin-Su K, Nimkarn S, New MI. Congenital adrenal hyperplasia in adolescents: diagnosis and management. *Ann N Y Acad Sci*. 2008;1135:95-98.
35. Sasano H, Masuda T, Ojima M, et al. Congenital 17 alpha-hydroxylase deficiency: a clinicopathologic study. *Hum Pathol*. 1987;18(10):1002-1007.
36. Witchel SF. Congenital adrenal hyperplasia. *J Pediatr Adolesc Gynecol*. 2017.
37. Miller WL. Congenital adrenal hyperplasias. *Endocrinol Metab Clin North Am*. 1991;20(4):721-749.
38. Sutter JA, Grimberg A. Adrenocortical tumors and hyperplasias in childhood—etiology, genetics, clinical presentation and therapy. *Pediatr Endocrinol Rev*. 2006;4(1):32-39.
39. Dacou-Voutetakis C, Maniati-Christidi M, Dracopoulou-Vabouli M. Genetic aspects of congenital adrenal hyperplasia. *J Pediatr Endocrinol Metab*. 2001;14(suppl 5):1303-1308, discussion 17.
40. Lee HH. CYP21 mutations and congenital adrenal hyperplasia. *Clin Genet*. 2001;59(5):293-301.
41. Wang C, Pallan PS1, Zhang W, et al. Functional analysis of human cytochrome P450 21A2 variants involved in congenital adrenal hyperplasia. *J Biol Chem*. 2017;292:10767-10778.
42. Stratakis CA. Adrenocortical tumors, primary pigmented adrenocortical disease (PPNAD)/ Carney complex, and other bilateral hyperplasias: the NIH studies. *Horm Metab Res*. 2007;39(6):467-473.
43. Iseli BE, Hedinger CE. Histopathology and ultrastructure of primary adrenocortical nodular dysplasia with Cushing's syndrome. *Histopathology*. 1985;9(11):1171-1194.
44. Shenoy BV, Carpenter PC, Carney JA. Bilateral primary pigmented nodular adrenocortical disease. Rare cause of the Cushing syndrome. *Am J Surg Pathol*. 1984;8(5):335-344.
45. Sasano H, Miyazaki S, Sawai T, et al. Primary pigmented nodular adrenocortical disease (PPNAD): immunohistochemical and in situ hybridization analysis of steroidogenic enzymes in eight cases. *Mod Pathol*. 1992;5(1):23-29.
46. Travis WD, Tsokos M, Doppman JL, et al. Primary pigmented nodular adrenocortical disease. A light and electron microscopic study of eight cases. *Am J Surg Pathol*. 1989;13(11):921-930.
47. da Silva RM, Pinto E, Goldman SM, et al. Children with Cushing's syndrome: Primary Pigmented Nodular Adrenocortical Disease should always be suspected. *Pituitary*. 2011;14:61-67.
48. Almeida MQ, Stratakis CA. Carney complex and other conditions associated with micronodular adrenal hyperplasias. *Best Pract Res Clin Endocrinol Metab*. 2010;24:907-914.
49. Carney JA, Gaillard RC, Bertherat J, Stratakis CA. Familial micronodular adrenocortical disease, Cushing syndrome, and mutations of the gene encoding phosphodiesterase 11A4 (PDE11A). *Am J Surg Pathol*. 2010;34(4):547-555.
50. Li KH, Asa SL, Kovacs K, et al. The adrenal cortex in ectopic adrenocorticotropic hormone syndrome. A morphological study with histology, transmission and scanning electron microscopy, flow cytometry, and image analysis. *Endocr Pathol*. 1990;1:183-191.
51. Sasano H, Suzuki T, Nagura H. ACTH-independent macronodular adrenocortical hyperplasia: immunohistochemical and in situ hybridization studies of steroidogenic enzymes. *Mod Pathol*. 1994;7(2):215-219.
52. Hermus AR, Pieters GF, Smals AG, et al. Transition from pituitary-dependent to adrenal-dependent Cushing's syndrome. *N Engl J Med*. 1988;318(15):966-970.
53. Hocher B, Bahr V, Dorfmuller S, Oelkers W. Hypercortisolism with non-pigmented micronodular adrenal hyperplasia: transition from pituitary-dependent to adrenal-dependent Cushing's syndrome. *Acta Endocrinol (Copenh)*. 1993;128(2): 120-125.

54. Kirk JM, Brain CE, Carson DJ, et al. Cushing's syndrome caused by nodular adrenal hyperplasia in children with McCune-Albright syndrome. *J Pediatr*. 1999;134:789-792.
55. Albiger NM, Regazzo D, Rubin B, et al. A multicenter experience on the prevalence of ARMC5 mutations in patients with primary bilateral macronodular adrenal hyperplasia: from genetic characterization to clinical phenotype. *Endocrine*. 2017;55:959-968.
56. Bourdeau I, Oble S, Magne F, et al. ARMC5 mutations in a large French-Canadian family with cortisol-secreting β-adrenergic/vasopressin responsive bilateral macronodular adrenal hyperplasia. *Eur J Endocrinol*. 2016;174:85-96.
57. Schteingart DE, Oberman HA, Friedman BA, Conn JW. Adrenal cortical neoplasms producing cushing's syndrome. A clinicopathologic study. *Cancer*. 1968;22(5):1005-1013.
58. Evans HL, Vassilopoulou-Sellin R. Adrenal cortical neoplasms. A study of 56 cases. *Am J Clin Pathol*. 1996;105(1):76-86.
59. Al-Brahim N, Asa S. Myelolipoma with adrenocortical adenoma: an unusual combination that can resemble carcinoma. *Endocr Pathol*. 2007;18(2):103-105.
60. Vyberg M, Sestoft L. Combined adrenal myelolipoma and adenoma associated with Cushing's syndrome. *Am J Clin Pathol*. 1986;86(4):541-545.
61. Lam KY, Wat MS. Adrenal cortical black adenoma: report of two cases and review of the literature. *J Urol Pathol*. 1996;4:183-190.
62. Macadam RF. Black adenoma of the human adrenal cortex. *Cancer*. 1971;27(1):116-119.
63. Damron TA, Schelper RL, Sorensen L. Cytochemical demonstration of neuromelanin in black pigmented adrenal nodules. *Am J Clin Pathol*. 1987;87(3):334-341.
64. Sienkowski IK, Watkins RM, Anderson VE. Primary tumorous aldosteronism due to a black adrenal adenoma: a light and electron microscopic study. *J Clin Pathol*. 1984;37(2):143-149.
65. Komiya I, Takasu N, Aizawa T, et al. Black (or brown) adrenal cortical adenoma: its characteristic features on computed tomography and endocrine data. *J Clin Endocrinol Metab*. 1985;61(4):711-717.
66. Begin LR. Adrenocortical oncocytoma: case report with immunocytochemical and ultrastructural study. *Virchows Arch A Pathol Anat Histopathol*. 1992;421(6):533-537.
67. Bisceglia M, Ben-Dor D, Pasquinelli G. Oncocytic adrenocortical tumors. *Pathol Case Rev*. 2005;10:228-242.
68. Bisceglia M, Ludovico O, Di Mattia A, et al. Adrenocortical oncocytic tumors: report of 10 cases and review of the literature. *Int J Surg Pathol*. 2004;12(3):231-243.
69. el Naggar AK, Evans DB, Mackay B. Oncocytic adrenal cortical carcinoma. *Ultrastruct Pathol*. 1991;15(4-5):549-556.
70. Sasano H, Suzuki T, Sano T, et al. Adrenocortical oncocytoma. A true nonfunctioning adrenocortical tumor. *Am J Surg Pathol*. 1991;15(10):949-956.
71. Hoang MP, Ayala AG, Albores-Saavedra J. Oncocytic adrenocortical carcinoma: a morphologic, immunohistochemical and ultrastructural study of four cases. *Mod Pathol*. 2002;15(9):973-978.
72. Lin BT, Bonsib SM, Mierau GW, et al. Oncocytic adrenocortical neoplasms: a report of seven cases and review of the literature. *Am J Surg Pathol*. 1998;22(5):603-614.
73. Erlandson RA, Reuter VE. Oncocytic adrenal cortical adenoma. *Ultrastruct Pathol*. 1991;15(4-5):539-547.
74. Seo IS, Henley JD, Min KW. Peculiar cytoplasmic inclusions in oncocytic adrenal cortical tumors: an electron microscopic observation. *Ultrastruct Pathol*. 2002;26(4):229-235.
75. Brown FM, Gaffey TA, Wold LE, Lloyd RV. Myxoid neoplasms of the adrenal cortex: a rare histologic variant. *Am J Surg Pathol*. 2000;24(3):396-401.
76. Raparia K, Ayala AG, Sienko A, et al. Myxoid adrenal cortical neoplasms. *Ann Diagn Pathol*. 2008;12(5):344-348.
77. Papotti M, Volante M, Duregon E, et al. Adrenocortical tumors with myxoid features: a distinct morphologic and phenotypical variant exhibiting malignant behavior. *Am J Surg Pathol*. 2010;34(7):973-983.
78. Weissferdt A, Phan A, Suster S, Moran CA. Myxoid adrenocortical carcinoma: a clinicopathologic and immunohistochemical study of 7 cases, including 1 case with lipomatous metaplasia. *Am J Clin Pathol*. 2013;139:780-786.
79. Feldberg E, Guy M, Eisenkraft S, Czernobilsky B. Adrenal cortical adenoma with extensive fat cell metaplasia. *Pathol Res Pract*. 1996;192(1):62-65, discussion 6.
80. Finch C, Davis R, Truong LD. Extensive lipomatous metaplasia in bilateral macronodular adrenocortical hyperplasia. *Arch Pathol Lab Med*. 1999;123(2):167-169.
81. Papotti M, Sapino A, Mazza E, et al. Lipomatous changes in adrenocortical adenomas: report of two cases. *Endocr Pathol*. 1996;7(3):223-228.
82. Hedeland H, Ostberg G, Hokfelt B. On the prevalence of adrenocortical adenomas in an autopsy material in relation to hypertension and diabetes. *Acta Med Scand*. 1968;184(3):211-214.
83. Lewinsky BS, Grigor KM, Symington T, Neville AM. The clinical and pathologic features of "non-hormonal" adrenocortical tumors. Report of twenty new cases and review of the literature. *Cancer*. 1974;33(3):778-790.
84. Corsello SM, Della Casa S, Bollanti L, et al. Incidentally discovered adrenal masses: a functional and morphological study. *Exp Clin Endocrinol*. 1993;101(3):131-137.
85. Suzuki T, Sasano H, Sawai T, et al. Small adrenocortical tumors without apparent clinical endocrine abnormalities. Immunolocalization of steroidogenic enzymes. *Pathol Res Pract*. 1992;188(7):883-889.
86. Yamakita N, Saitoh M, Mercado-Asis LB, et al. Asymptomatic adrenal tumor; 386 cases in Japan including our 7 cases. *Endocrinol Jpn*. 1990;37(5):671-684.
87. Ganguly A. Primary aldosteronism. *N Engl J Med*. 1998;339(25):1828-1834.
88. Ganguly A, Donohue JP. Primary aldosteronism: pathophysiology, diagnosis and treatment. *J Urol*. 1983;129(2):241-247.
89. White PC. Disorders of aldosterone biosynthesis and action. *N Engl J Med*. 1994;331(4):250-258.
90. O'Neal LW, Kissane JM, Hartroft PM. The kidney in endocrine hypertension. Cushing's syndrome, pheochromocytoma, and aldosteronism. *Arch Surg*. 1970;100(4):498-505.
91. Aiba M, Suzuki H, Kageyama K, et al. Spironolactone bodies in aldosteromas and in the attached adrenals. Enzyme histochemical study of 19 cases of primary aldosteronism and a case of aldosteronism due to bilateral diffuse hyperplasia of the zona glomerulosa. *Am J Pathol*. 1981;103:404-410.
92. Shrago SS, Waisman J, Cooper PH. Spironolactone bodies in an adrenal adenoma. *Arch Pathol*. 1975;99(8):416-420.
93. Orth DN. Cushing's syndrome. *N Engl J Med*. 1995;332(12):791-803.
94. Perry RR, Nieman LK, Cutler GB Jr, et al. Primary adrenal causes of Cushing's syndrome. Diagnosis and surgical management. *Ann Surg*. 1989;210(1):59-68.
95. Gilbert MG, Cleveland WW. Cushing's syndrome in infancy. *Pediatrics*. 1970;46(2):217-229.
96. Neville AM, Symington T. Bilateral adrenocortical hyperplasia in children with Cushing's syndrome. *J Pathol*. 1972;107(2):95-106.
97. Thomas CG Jr, Smith AT, Griffith JM, Askin FB. Hyperadrenalism in childhood and adolescence. *Ann Surg*. 1984;199(5):538-548.
98. Hartmann CA, Gross U, Stein H. Cushing syndrome-associated pheochromocytoma and adrenal carcinoma. An immunohistological investigation. *Pathol Res Pract*. 1992;188(3):287-295.
99. Neville AM, Symington T. The pathology of the adrenal gland in Cushing's syndrome. *J Pathol Bacteriol*. 1967;93(1):19-35.
100. Burrington JD, Stephens CA. Virilizing tumors of the adrenal gland in childhood: report of eight cases. *J Pediatr Surg*. 1969;4(3):291-302.
101. Kenny FM, Hashida Y, Askari HA, et al. Virilizing tumors of the adrenal cortex. *Am J Dis Child*. 1968;115(4):445-458.
102. Derksen J, Nagesser SK, Meinders AE, et al. Identification of virilizing adrenal tumors in hirsute women. *N Engl J Med*. 1994;331(15):968-973.
103. Del Gaudio AD, Del Gaudio GA. Virilizing adrenocortical tumors in adult women. Report of 10 patients, 2 of whom each had a tumor secreting only testosterone. *Cancer*. 1993;72(6):1997-2003.
104. Fischler DF, Nunez C, Levin HS, et al. Adrenal carcinosarcoma presenting in a woman with clinical signs of virilization. A case report with immunohistochemical and ultrastructural findings. *Am J Surg Pathol*. 1992;16(6):626-631.
105. Gabrilove JL, Sharma DC, Wotiz HH, Dorfman RI. Feminizing adrenocortical tumors in the male. a review of 52 cases including a case report. *Medicine (Baltimore)*. 1965;44:37-79.
106. Williams R, Kellie AE, Wade AP, et al. Hypoglycaemia and abnormal steroid metabolism in adrenal tumours. *Q J Med*. 1961;30:269-284.
107. Lipsett MB, Hertz R, Ross GT. Clinical and pathophysiologic aspects of adrenocortical carcinoma. *Am J Med*. 1963;35:374-383.
108. Falchuk KR. Inappropriate antidiuretic hormone-like syndrome associated with an adrenocortical carcinoma. *Am J Med Sci*. 1973;266(5):393-395.
109. Busam KJ, Iversen K, Coplan KA, et al. Immunoreactivity for A103, an antibody to melan-A (Mart-1), in adrenocortical and other steroid tumors. *Am J Surg Pathol*. 1998;22(1):57-63.
110. Chivite A, Matias-Guiu X, Pons C, et al. Inhibin A expression in adrenal neoplasms: a new immunohistochemical marker for adrenocortical tumors. *Appl Immunohistochem*. 1998;6:42-49.
111. Cho EY, Ahn GH. Immunoexpression of inhibin alpha-subunit in adrenal neoplasms. *Appl Immunohistochem Mol Morphol*. 2001;9(3):222-228.
112. Loy TS, Phillips RW, Linder CL. A103 immunostaining in the diagnosis of adrenal cortical tumors: an immunohistochemical study of 316 cases. *Arch Pathol Lab Med*. 2002;126(2):170-172.
113. Enriquez ML, Lal P, Ziober A, et al. The use of immunohistochemical expression of SF-1 and EMA in distinguishing adrenocortical tumors from renal neoplasms. *Appl Immunohistochem Mol Morphol*. 2012;20:141-145.
114. Sangoi AR, Fujiwara M, West RB, et al. Immunohistochemical distinction of primary adrenal cortical lesions from metastatic clear

cell renal cell carcinoma: a study of 248 cases. *Am J Surg Pathol*. 2011;35(5):678-686.
115. Sangoi AR, McKenney JK. A tissue microarray-based comparative analysis of novel and traditional immunohistochemical markers in the distinction between adrenal cortical lesions and pheochromocytoma. *Am J Surg Pathol*. 2010;34(3):423-432.
116. Jorda M, De MB, Nadji M. Calretinin and inhibin are useful in separating adrenocortical neoplasms from pheochromocytomas. *Appl Immunohistochem Mol Morphol*. 2002;10(1):67-70.
117. Zhang H, Bu H, Chen H, et al. Comparison of immunohistochemical markers in the differential diagnosis of adrenocortical tumors: immunohistochemical analysis of adrenocortical tumors. *Appl Immunohistochem Mol Morphol*. 2008;16(1):32-39.
118. Williams TA, Monticone S, Schack VR, et al. Somatic ATP1A1, ATP2B3, and KCNJ5 mutations in aldosterone-producing adenomas. *Hypertension*. 2014;63:188-195.
119. Fernandes-Rosa FL, Williams TA, Riester A, et al. Genetic spectrum and clinical correlates of somatic mutations in aldosterone-producing adenoma. *Hypertension*. 2014;64:354-361.
120. Akerstrom T, Willenberg HS, Cupisti K, et al. Novel somatic mutations and distinct molecular signature in aldosterone-producing adenomas. *Endocr Relat Cancer*. 2015;22:735-744.
121. Akerstrom T, Maharjan R, Sven Willenberg H, et al. Activating mutations in CTNNB1 in aldosterone producing adenomas. *Sci Rep*. 2016;6:19546.
122. Sato Y, Maekawa S, Ishii R, et al. Recurrent somatic mutations underlie corticotropin-independent Cushing's syndrome. *Science*. 2014;344:917-920.
123. Thiel A, Reis AC, Haase M, et al. PRKACA mutations in cortisol-producing adenomas and adrenal hyperplasia: a single-center study of 60 cases. *Eur J Endocrinol*. 2015;172:677-685.
124. Bonnet S, Gaujoux S, Launay P, et al. Wnt/β-catenin pathway activation in adrenocortical adenomas is frequently due to somatic CTNNB1-activating mutations, which are associated with larger and nonsecreting tumors: a study in cortisol-secreting and -nonsecreting tumors. *J Clin Endocrinol Metab*. 2011;96:E416-E426.
125. Giordano TJ, Chrousos GP, Kawashima A, et al. Adrenal cortical adenoma. In: Lloyd RV, Osamura RY, Kloppel G, Rosai J, eds. *WHO Classification of Tumours of Endocrien Organs*. Lyon, France: IARC Press; 2017.
126. Icard P, Chapuis Y, Andreassian B, et al. Adrenocortical carcinoma in surgically treated patients: a retrospective study on 156 cases by the French Association of Endocrine Surgery. *Surgery*. 1992;112(6):972-979, discussion 9-80.
127. Nader S, Hickey RC, Sellin RV, Samaan NA. Adrenal cortical carcinoma. A study of 77 cases. *Cancer*. 1983;52(4):707-711.
128. Bergada I, Venara M, Maglio S, et al. Functional adrenal cortical tumors in pediatric patients: a clinicopathologic and immunohistochemical study of a long term follow-up series. *Cancer*. 1996;77(4):771-777.
129. Kay R, Schumacher OP, Tank ES. Adrenocortical carcinoma in children. *J Urol*. 1983;130(6):1130-1132.
130. Lack EE, Mulvihill JJ, Travis WD, Kozakewich HP. Adrenal cortical neoplasms in the pediatric and adolescent age group. Clinicopathologic study of 30 cases with emphasis on epidemiological and prognostic factors. *Pathol Annu*. 1992;27 (Pt 1):1-53.
131. Ribeiro RC, Sandrini Neto RS, Schell MJ, et al. Adrenocortical carcinoma in children: a study of 40 cases. *J Clin Oncol*. 1990;8(1):67-74.
132. Lam AK. Update on adrenal tumours in 2017 World Health Organization (WHO) of endocrine tumours. *Endocr Pathol*. 2017.
133. Ayala-Ramirez M, Jasim S, Feng L, et al. Adrenocortical carcinoma: clinical outcomes and prognosis of 330 patients at a tertiary care center. *Eur J Endocrinol*. 2013;169:891-899.
134. McClennan BL. Oncologic imaging. Staging and follow-up of renal and adrenal carcinoma. *Cancer*. 1991;67(4 suppl):1199-1208.
135. Gonzalez KD, Noltner KA, Buzin CH, et al. Beyond Li Fraumeni Syndrome: clinical characteristics of families with p53 germline mutations. *J Clin Oncol*. 2009;27(8):1250-1256.
136. Varley JM, McGown G, Thorncroft M, et al. Are there low-penetrance TP53 Alleles? evidence from childhood adrenocortical tumors. *Am J Hum Genet*. 1999;65(4):995-1006.
137. Wagner J, Portwine C, Rabin K, et al. High frequency of germline p53 mutations in childhood adrenocortical cancer. *J Natl Cancer Inst*. 1994;86(22):1707-1710.
138. Bertherat J, Bertagna X. Pathogenesis of adrenocortical cancer. *Best Pract Res Clin Endocrinol Metab*. 2009;23(2):261-271.
139. Barksdale SK, Marincola FM, Jaffe G. Carcinosarcoma of the adrenal cortex presenting with mineralocorticoid excess. *Am J Surg Pathol*. 1993;17(9):941-945.
140. Decorato JW, Gruber H, Petti M, Levowitz BS. Adrenal carcinosarcoma. *J Surg Oncol*. 1990;45(2):134-136.
141. Sbiera S, Schmull S, Assie G, et al. High diagnostic and prognostic value of steroidogenic factor-1 expression in adrenal tumors. *J Clin Endocrinol Metab*. 2010;95:E161-E171.
142. Zheng S, Cherniack AD, Dewal N, et al. Comprehensive pan-genomic characterization of adrenocortical carcinoma. *Cancer Cell*. 2016;29:723-736.
143. Pinto EM, Chen X, Easton J, et al. *Nat Commun*. 2015;6:6302.
144. Assie G, Letouzé E, Fassnacht M, et al. Integrated genomic characterization of adrenocortical carcinoma. *Nat Genet*. 2014;46(6):607-612.
145. Juhlin CC, Goh G, Healy JM, et al. Whole-exome sequencing characterizes the landscape of somatic mutations and copy number alterations in adrenocortical carcinoma. *J Clin Endocrinol Metab*. 2015;100(3):E493-E502.
146. Bugg MF, Ribeiro RC, Roberson PK, et al. Correlation of pathologic features with clinical outcome in pediatric adrenocortical neoplasia. A study of a Brazilian population. Brazilian Group for Treatment of Childhood Adrenocortical Tumors. *Am J Clin Pathol*. 1994;101(5):625-629.
147. van Slooten H, Schaberg A, Smeenk D, Moolenaar AJ. Morphologic characteristics of benign and malignant adrenocortical tumors. *Cancer*. 1985;55(4):766-773.
148. Gandour MJ, Grizzle WE. A small adrenocortical carcinoma with aggressive behavior. An evaluation of criteria for malignancy. *Arch Pathol Lab Med*. 1986;110(11):1076-1079.
149. Sasano H, Suzuki T, Moriya T. Discerning malignancy in resected adrenocortical neoplasms. *Endocr Pathol*. 2001;12(4):397-406.
150. Weiss LM. Comparative histologic study of 43 metastasizing and nonmetastasizing adrenocortical tumors. *Am J Surg Pathol*. 1984;8(3):163-169.
151. Kay S. Hyperplasia and neoplasia of the adrenal gland. *Pathol Annu*. 1976;11:103-139.
152. Aubert S, Wacrenier A, Leroy X, et al. Weiss system revisited: a clinicopathologic and immunohistochemical study of 49 adrenocortical tumors. *Am J Surg Pathol*. 2002;26(12):1612-1619.
153. Stojadinovic A, Brennan MF, Hoos A, et al. Adrenocortical adenoma and carcinoma: histopathological and molecular comparative analysis. *Mod Pathol*. 2003;16(8):742-751.
154. Wieneke JA, Thompson LD, Heffess CS. Adrenal cortical neoplasms in the pediatric population: a clinicopathologic and immunophenotypic analysis of 83 patients. *Am J Surg Pathol*. 2003;27(7):867-881.
155. Weiss LM, Medeiros LJ, Vickery AL Jr. Pathologic features of prognostic significance in adrenocortical carcinoma. *Am J Surg Pathol*. 1989;13(3):202-206.
156. Dehner LP. Pediatric adrenocortical neoplasms: on the road to some clarity. *Am J Surg Pathol*. 2003;27:1005-1007.
157. Dehner LP, Hill DA. Adrenal cortical neoplasms in children: why so many carcinomas and yet so many survivors? *Pediatr Dev Pathol*. 2009;12:284-291.
158. Cagle PT, Hough AJ, Pysher TJ, et al. Comparison of adrenal cortical tumors in children and adults. *Cancer*. 1986;57(11):2235-2237.
159. Weinenke JA, Thompson LD, Heffess CS. Adrenal cortical neoplasms in the pediatric population: a clinicopathologic and immunophenotypic analysis of 83 patients. *Am J Surg Pathol*. 2003;27:867-881.
160. McNicol AM, Struthers AL, Nolan CE, et al. Proliferation in adrenocortical tumors: correlation with clinical outcome and p53 status. *Endocr Pathol*. 1997;8(1):29-36.
161. Goldblum JR, Shannon R, Kaldjian EP, et al. Immunohistochemical assessment of proliferative activity in adrenocortical neoplasms. *Mod Pathol*. 1993;6:663-668.
162. Suzuki T, Sasano H, Nisikawa T, et al. Discerning malignancy in human adrenocortical neoplasms: utility of DNA flow cytometry and immunohistochemistry. *Mod Pathol*. 1992;5(3):224-231.
163. Iino K, Sasano H, Yabuki N, et al. DNA topoisomerase II alpha and Ki-67 in human adrenocortical neoplasms: a possible marker of differentiation between adenomas and carcinomas. *Mod Pathol*. 1997;10(9):901-907.
164. Duregon E, Fassina A, Volante M, et al. The reticulin algorithm for adrenocortical tumor diagnosis: a multicentric validation study on 245 unpublished cases. *Am J Surg Pathol*. 2013;37:1433-1440.
165. Duregon E, Volante M, Cappia S, et al. Oncocytic adrenocortical tumors: diagnostic algorithm and mitochondrial DNA profile in 27 cases. *Am J Surg Pathol*. 2011;35:1882-1893.
166. Volante M, Bollito E, Sperone P, et al. Clinicopathological study of a series of 92 adrenocortical carcinomas: from a proposal of simplified diagnostic algorithm to prognostic stratification. *Histopathology*. 2009;55(5):535-543.
167. Volante M, Sperone P, Bollito E, et al. Matrix metalloproteinase type 2 expression in malignant adrenocortical tumors: Diagnostic and prognostic significance in a series of 50 adrenocortical carcinomas. *Mod Pathol*. 2006;19(12):1563-1569.
168. Schmitt A, Saremaslani P, Schmid S, et al. IGFII and MIB1 immunohistochemistry is helpful for the differentiation of benign from malignant adrenocortical tumours. *Histopathology*. 2006;49(3):298-307.
169. Soon PS, Gill AJ, Benn DE, et al. Microarray gene expression and immunohistochemistry analyses of adrenocortical tumors identify IGF2 and Ki-67 as useful in differentiating carcinomas from adenomas. *Endocr Relat Cancer*. 2009;16(2):573-583.

170. Duregon E, Cappellesso R, Maffeis V, et al. Validation of the prognostic role of the "Helsinki Score" in 225 cases of adrenocortical carcinoma. *Hum Pathol*. 2017;62:1-7.
171. Medeiros LJ, Weiss LM. New developments in the pathologic diagnosis of adrenal cortical neoplasms. A review. *Am J Clin Pathol*. 1992;97(1):73-83.
172. Rosai J. The benign versus malignant paradigm in oncologic pathology: a critique. *Semin Diagn Pathol*. 2008;25(3):147-153.
173. Hough AJ, Hollifield JW, Page DL, Hartmann WH. Prognostic factors in adrenal cortical tumors. A mathematical analysis of clinical and morphologic data. *Am J Clin Pathol*. 1979;72(3):390-399.
174. Page DL, Hough AJ Jr, Gray GF Jr. Diagnosis and prognosis of adrenocortical neoplasms. *Arch Pathol Lab Med*. 1986;110(11):993-994.
175. Renshaw AA, Granter SR. A comparison of A103 and inhibin reactivity in adrenal cortical tumors: distinction from hepatocellular carcinoma and renal tumors. *Mod Pathol*. 1998;11(12):1160-1164.
176. Winter P, Miersch WD, Vogel J, Jaeger N. On the necessity of adrenal extirpation combined with radical nephrectomy. *J Urol*. 1990;144(4):842-843, discussion 4.
177. Grawitz PA. Die Enstehung von Nierentumoren aus Nebennierengewebe. *Arch Klin Chir*. 1884;30:824-834.
178. Wick MR, Cherwitz DL, McGlennen RC, Dehner LP. Adrenocortical carcinoma. An immunohistochemical comparison with renal cell carcinoma. *Am J Pathol*. 1986;122(2):343-352.
179. Gokden N, Gokden M, Phan DC, McKenney JK. The utility of PAX-2 in distinguishing metastatic clear cell renal cell carcinoma from its morphologic mimics: an immunohistochemical study with comparison to renal cell carcinoma marker. *Am J Surg Pathol*. 2008;32:1462-1467.
180. Fetsch PA, Powers CN, Zakowski MF, Abati A. Anti-alpha-inhibin: marker of choice for the consistent distinction between adrenocortical carcinoma and renal cell carcinoma in fine-needle aspiration. *Cancer*. 1999;87(3):168-172.
181. Shin SJ, Hoda RS, Ying L, DeLellis RA. Diagnostic utility of the monoclonal antibody A103 in fine-needle aspiration biopsies of the adrenal. *Am J Clin Pathol*. 2000;113(2):295-302.
182. Zhang PJ, Genega EM, Tomaszewski JE, et al. The role of calretinin, inhibin, melan-A, BCL-2, and C-kit in differentiating adrenal cortical and medullary tumors: an immunohistochemical study. *Mod Pathol*. 2003;16(6):591-597.
183. Perrino CM, Ho A, Dall CP, Zynger DL. Utility of GATA3 in the differential diagnosis of pheochromocytoma. *Histopathology*. 2017.
184. Miettinen M, McCue PA, Sarlomo-Rikala M, et al. GATA3: a multispecific but potentially useful marker in surgical pathology: a systematic analysis of 2500 epithelial and nonepithelial tumors. *Am J Surg Pathol*. 2014;38:13-22.
185. Grondal S, Cedermark B, Eriksson B, et al. Adrenocortical carcinoma. A retrospective study of a rare tumor with a poor prognosis. *Eur J Surg Oncol*. 1990;16(6):500-506.
186. Didolkar MS, Bescher RA, Elias EG, Moore RH. Natural history of adrenal cortical carcinoma: a clinicopathologic study of 42 patients. *Cancer*. 1981;47(9):2153-2161.
187. Hogan TF, Gilchrist KW, Westring DW, Citrin DL. A clinical and pathological study of adrenocortical carcinoma: therapeutic implications. *Cancer*. 1980;45(11):2880-2883.
188. McCartney AC. Metastatic adrenal carcinoma masquerading as primary bronchial carcinoma: report of two cases. *Thorax*. 1984;39(4):315-316.
189. Milchgrub S, Wiley EL. Adrenal carcinoma presenting as a lesion resembling cutaneous angiosarcoma. *Cancer*. 1991;67(12):3087-3092.
190. Pommier RF, Brennan MF. An eleven-year experience with adrenocortical carcinoma. *Surgery*. 1992;112(6):963-970, discussion 70-71.
191. Kasperlik-Zaluska AA, Migdalska BM, Zgliczynski S, Makowska AM. Adrenocortical carcinoma. A clinical study and treatment results of 52 patients. *Cancer*. 1995;75(10):2587-2591.
192. Brennan MF. Adrenocortical carcinoma. *CA Cancer J Clin*. 1987;37(6):348-365.
193. Markoe AM, Serber W, Micaily B, Brady LW. Radiation therapy for adjunctive treatment of adrenal cortical carcinoma. *Am J Clin Oncol*. 1991;14(2):170-174.
194. Luton JP, Cerdas S, Billaud L, et al. Clinical features of adrenocortical carcinoma, prognostic factors, and the effect of mitotane therapy. *N Engl J Med*. 1990;322(17):1195-1201.
195. Vassilopoulou-Sellin R, Guinee VF, Klein MJ, et al. Impact of adjuvant mitotane on the clinical course of patients with adrenocortical cancer. *Cancer*. 1993;71(10):3119-3123.
196. Ferrari L, Claps M, Grisanti S, Berruti A. Systemic therapy in locally advanced or metastatic adrenal cancers: a critical appraisal and clinical trial update. *Eur Urol Focus*. 2016;1:298-300.
197. Postlewait LM, Ethun CG, Tran TB. Outcomes of adjuvant mitotane after resection of adrenocortical carcinoma: a 13-institution study by the US Adrenocortical Carcinoma Group. *J Am Coll Surg*. 2016;222:480-490.
198. Volante M, Terzolo M, Fassnacht M, et al. Ribonucleotide reductase large subunit (RRM1) gene expression may predict efficacy of adjuvant mitotane in adrenocortical cancer. *Clin Cancer Res*. 2012;18:3452-3461.
199. Rochi CL, Sbiera S, Volante M, et al. *PLoS ONE*. 2014;9:e105855.
200. Karakousis CP, Rao U, Moore R. Adrenal adenocarcinomas: histologic grading and survival. *J Surg Oncol*. 1985;29(2):105-111.
201. Vargas MP, Vargas HI, Kleiner DE, Merino MJ. Adrenocortical neoplasms: role of prognostic markers MIB-1, P53, and RB. *Am J Surg Pathol*. 1997;21(5):556-562.
202. Miller BS, Gauger PG, Hammer GD, et al. Proposal for modification of the ENSAT staging system for adrenocortical carcinoma using tumor grade. *Langenbecks Arch Surg*. 2010;395:955-961.
203. Giordano TJ. The argument for mitotic rate-based grading for the prognostication of adrenocortical carcinoma. *Am J Surg Pathol*. 2011;35:471-473.
204. Duregon E, Molinaro L, Volante M, et al. Comparative diagnostic and prognostic performances of the hematoxylin-eosin and phospho-histone H3 mitotic count and Ki-67 index in adrenocortical carcinoma. *Mod Pathol*. 2014;27:1246-1254.
205. Papathomas TG, Pucci E, Giordano TJ, et al. An international Ki67 reproducibility study in adrenal cortical carcinoma. *Am J Surg Pathol*. 2016;40:569-576.
206. Phan AT, Grogan RH, Rohren E, Perrier ND. Adrenal cortical carcinoma. In: Amin MB, ed. *American Joint Committee on Cancer Staging Manual*. 8th ed. New York: Springer; 2017.
207. Libe R, Borget I, Ronchi CL, et al. Prognostic factors in stage III-IV adrenocortical carcinomas (ACC): an European Network for the Study of Adrenal Tumor (ENSAT) study. *Ann Oncol*. 2015;26:2119-2125.
208. Lughezzani G, Sun M, Perrotte P, et al. The European Network for the Study of Adrenal Tumors staging system is prognostically superior to the international union against cancer-staging system: a North American validation. *Eur J Cancer*. 2010;46:713-719.
209. Allan SG, Cornbleet MA, Carmichael J, et al. Adult neuroblastoma. Report of three cases and review of the literature. *Cancer*. 1986;57(12):2419-2421.
210. Kaye JA, Warhol MJ, Kretschmar C, et al. Neuroblastoma in adults. Three case reports and a review of the literature. *Cancer*. 1986;58(5):1149-1157.
211. Kushner BH, Gilbert F, Helson L. Familial neuroblastoma. Case reports, literature review, and etiologic considerations. *Cancer*. 1986;57(9):1887-1893.
212. Emery LG, Shields M, Shah NR, Garbes A. Neuroblastoma associated with Beckwith-Wiedemann syndrome. *Cancer*. 1983;52(1):176-179.
213. Gaisie G, Oh KS, Young LW. Coexistent neuroblastoma and Hirschsprung's disease—another manifestation of the neurocristopathy? *Pediatr Radiol*. 1979;8(3):161-163.
214. Andersen HJ, Hariri J. Congenital neuroblastoma in a fetus with multiple malformations. Metastasis in the umbilical cord as a cause of intrauterin death. *Virchows Arch A Pathol Anat Histopathol*. 1983;400(2):219-222.
215. Sy WM, Edmonson JH. The development defects associated with neuroblastoma—etiologic implications. *Cancer*. 1968;22(1):234-238.
216. Witzleben CL, Landy RA. Disseminated neuroblastoma in a child with von Recklinghausen's disease. *Cancer*. 1974;34(3):786-790.
217. Sherman S, Roizen N. Fetal hydantoin syndrome and neuroblastoma. *Lancet*. 1976;1(7984):517.
218. Trochet D, O'Brien LM, Gozal D, et al. PHOX2B genotype allows for prediction of tumor risk in congenital central hypoventilation syndrome. *Am J Hum Genet*. 2005;76:421-426.
219. Gambini C, Conte M, Bernini G, et al. Neuroblastic tumors associated with opsoclonus-myoclonus syndrome: histological, immunohistochemical and molecular features of 15 Italian cases. *Virchows Arch*. 2003;442(6):555-562.
220. Suzuki H, Honzumi M, Funada M, Tomiyama H. Metachronous bilateral adrenal neuroblastoma. *Cancer*. 1985;56(6):1490-1492.
221. Hiyama E, Yokoyama T, Hiyama K, et al. Multifocal neuroblastoma: biologic behavior and surgical aspects. *Cancer*. 2000;88(8):1955-1963.
222. Joshi VV, Silverman JF. Pathology of neuroblastic tumors. *Semin Diagn Pathol*. 1994;11(2):107-117.
223. Hachitanda Y, Tsuneyoshi M. Neuroblastoma with a distinct organoid pattern: a clinicopathologic, immunohistochemical, and ultrastructural study. *Hum Pathol*. 1994;25(1):67-72.
224. Okamatsu C, London WB, Naranjo A, et al. Clinicopathological characteristics of ganglioneuroma and ganglioneuroblastoma: a report from the CCG and COG. *Pediatr Blood Cancer*. 2009;53:563-569.
225. Abramowsky CR, Katzenstein HM, Alvarado CS, Shehata BM. Anaplastic large cell neuroblastoma. *Pediatr Dev Pathol*. 2009;12(1):1-5.
226. Cozzutto C, Carbone A. Pleomorphic (anaplastic) neuroblastoma. *Arch Pathol Lab Med*. 1988;112(6):621-625.
227. Hachitanda Y, Tsuneyoshi M, Enjoji M. An ultrastructural and immunohistochemical evaluation of cytodifferentiation in

neuroblastic tumors. *Mod Pathol*. 1989;2(1):13-19.
228. Artlieb U, Krepler R, Wiche G. Expression of microtubule-associated proteins, MAP-1 and MAP-2, in human neuroblastomas and differential diagnosis of immature neuroblasts. *Lab Invest*. 1985;53(6):684-691.
229. Foley J, Witte D, Chiu FC, Parysek LM. Expression of the neural intermediate filament proteins peripherin and neurofilament-66/alpha-internexin in neuroblastoma. *Lab Invest*. 1994;71(2):193-199.
230. Grossman DB, Jin L, Heidelberger KP, Lloyd RV. Expression of chromogranin A protein and messenger RNA and tyrosine hydroxylase protein in paraffin-embedded sections of neuroendocrine neoplasms. *Endocr Pathol*. 1991;2:148-154.
231. Kimura N, Nakamura M, Kimura I, Nagura H. Tissue localization of nerve growth factor receptors: trk A and low-affinity nerve growth factor receptor in neuroblastoma, pheochromocytoma, and retinoblastoma. *Endocr Pathol*. 1996;7(4):281-289.
232. Krishnan C, Higgins JP, West RB, et al. Microtubule-associated protein-2 is a sensitive marker of primary and metastatic neuroblastoma. *Am J Surg Pathol*. 2009;33(11):1695-1704.
233. Mendelsohn G, Eggleston JC, Olson JL, et al. Vasoactive intestinal peptide and its relationship to ganglion cell differentiation in neuroblastic tumors. *Lab Invest*. 1979;41(2):144-149.
234. Molenaar WM, Baker DL, Pleasure D, et al. The neuroendocrine and neural profiles of neuroblastomas, ganglioneuroblastomas, and ganglioneuromas. *Am J Pathol*. 1990;136(2):375-382.
235. Mukai M, Torikata C, Iri H, et al. Expression of neurofilament triplet proteins in human neural tumors. An immunohistochemical study of paraganglioma, ganglioneuroma, ganglioneuroblastoma, and neuroblastoma. *Am J Pathol*. 1986;122(1):28-35.
236. Oppedal BR, Brandtzaeg P, Kemshead JT. Immunohistochemical differentiation of neuroblastomas from other small round cell neoplasms of childhood using a panel of mono- and polyclonal antibodies. *Histopathology*. 1987;11(4):363-374.
237. Osborn M, Dirk T, Kaser H, et al. Immunohistochemical localization of neurofilaments and neuron-specific enolase in 29 cases of neuroblastoma. *Am J Pathol*. 1986;122(3):433-442.
238. Pagani A, Fischer-Colbrie R, Sanfilippo B, et al. Secretogranin II expression in Ewing's sarcomas and primitive neuroectodermal tumors. *Diagn Mol Pathol*. 1992;1(3):165-172.
239. Pagani A, Forni M, Tonini GP, et al. Expression of members of the chromogranin family in primary neuroblastomas. *Diagn Mol Pathol*. 1992;1(1):16-24.
240. Tsokos M, Linnoila RI, Chandra RS, Triche TJ. Neuron-specific enolase in the diagnosis of neuroblastoma and other small, round-cell tumors in children. *Hum Pathol*. 1984;15(6):575-584.
241. Wirnsberger GH, Becker H, Ziervogel K, Hofler H. Diagnostic immunohistochemistry of neuroblastic tumors. *Am J Surg Pathol*. 1992;16(1):49-57.
242. Hung YP, Lee JP, Bellizzi AM, Hornick JL. PHOX2B reliably distinguishes neuroblastoma among small round blue cell tumors. *Histopathology*. 2017.
243. Bielle F, Fréneaux P, Jeanne-Pasquier C, et al. PHOX2B immunolabeling: a novel tool for the diagnosis of undifferentiated neuroblastomas among childhood small round blue-cell tumors. *Am J Surg Pathol*. 2012;36:1141-1149.
244. Hata JL, Correa H, Krishnan C, et al. Diagnostic utility of PHOX2B in primary and treated neuroblastoma and in neuroblastoma metastatic to the bone marrow. *Arch Pathol Lab Med*. 2015;139:543-546.
245. Folpe AL, Patterson K, Gown AM. Antineuroblastoma antibody NB-84 also identifies a significant subset of other small blue round cell tumors. *Appl Immunohistochem*. 1997;5:239-245.
246. Miettinen M, Chatten J, Paetau A, Stevenson A. Monoclonal antibody NB84 in the differential diagnosis of neuroblastoma and other small round cell tumors. *Am J Surg Pathol*. 1998;22(3):327-332.
247. Betts DR, Cohen N, Leibundgut KE, et al. Characterization of karyotypic events and evolution in neuroblastoma. *Pediatr Blood Cancer*. 2005;44(2):147-157.
248. Bown N, Cotterill S, Lastowska M, et al. Gain of chromosome arm 17q and adverse outcome in patients with neuroblastoma. *N Engl J Med*. 1999;340(25):1954-1961.
249. Brodeur GM. Molecular pathology of human neuroblastomas. *Semin Diagn Pathol*. 1994;11(2):118-125.
250. Christiansen H, Schestag J, Christiansen NM, et al. Clinical impact of chromosome 1 aberrations in neuroblastoma: a metaphase and interphase cytogenetic study. *Genes Chromosomes Cancer*. 1992;5(2):141-149.
251. Hayashi Y, Kanda N, Inaba T, et al. Cytogenetic findings and prognosis in neuroblastoma with emphasis on marker chromosome 1. *Cancer*. 1989;63(1):126-132.
252. Ambros PF, Ambros IM, Brodeur GM, et al. International consensus for neuroblastoma molecular diagnostics: report from the International Neuroblastoma Risk Group (INRG) Biology Committee. *Br J Cancer*. 2009;100(9):1471-1482.
253. Tolbert VP, Coggins GE, Maris JM. Genetic susceptibility to neuroblastoma. *Curr Opin Genet Dev*. 2017;42:81-90.
254. Holgersen LO, Santulli TV, Schullinger JN, Berdon WE. Neuroblastoma with intraspinal (dumbbell) extension. *J Pediatr Surg*. 1983;18(4):406-411.
255. Kramer K, Kushner B, Heller G, Cheung NK. Neuroblastoma metastatic to the central nervous system. The Memorial Sloan-kettering Cancer Center experience and a literature review. *Cancer*. 2001;91(8):1510-1519.
256. Simon T, Hero B, Berthold F. Testicular and paratesticular involvement by metastatic neuroblastoma. *Cancer*. 2000;88(11):2636-2641.
257. Young RH, Kozakewich HP, Scully RE. Metastatic ovarian tumors in children: a report of 14 cases and review of the literature. *Int J Gynecol Pathol*. 1993;12(1):8-19.
258. Dannecker G, Leidig E, Treuner J, Niethammer D. Late recurrence of neuroblastoma: a reason for prolonged follow-up? *Am J Pediatr Hematol Oncol*. 1983;5(3):271-274.
259. de la Monte SM, Moore GW, Hutchins GM. Nonrandom distribution of metastases in neuroblastic tumors. *Cancer*. 1983;52(5):915-925.
260. Burchill SA, Beiske K, Shimada H, et al. Recommendations for the standardization of bone marrow disease assessment and reporting in children with neuroblastoma on behalf of the International Neuroblastoma Response Criteria Bone Marrow Working Group. *Cancer*. 2017;123:1095-1105.
261. Maris JM. Recent advances in neuroblastoma. *N Engl J Med*. 2010;362(23):2202-2211.
262. Azizkhan RG, Haase GM. Current biologic and therapeutic implications in the surgery of neuroblastoma. *Semin Surg Oncol*. 1993;9(6):493-501.
263. De Bernardi B, Conte M, Mancini A, et al. Localized resectable neuroblastoma: results of the second study of the Italian Cooperative Group for Neuroblastoma. *J Clin Oncol*. 1995;13(4):884-893.
264. Whittle SB, Smith V, Doherty E, et al. Overview and recent advances in the treatment of neuroblastoma. *Expert Rev Anticancer Ther*. 2017;17:369-386.
265. Shimada H, Ambros IM, Dehner LP, et al. The International Neuroblastoma Pathology Classification (the Shimada system). *Cancer*. 1999;86(2):364-372.
266. Shimada H, Ambros IM, Dehner LP, et al. Terminology and morphologic criteria of neuroblastic tumors: recommendations by the International Neuroblastoma Pathology Committee. *Cancer*. 1999;86(2):349-363.
267. Shimada H, Chatten J, Newton WA Jr, et al. Histopathologic prognostic factors in neuroblastic tumors: definition of subtypes of ganglioneuroblastoma and an age-linked classification of neuroblastomas. *J Natl Cancer Inst*. 1984;73(2):405-416.
268. Ambros IM, Hata J, Joshi VV, et al. Morphologic features of neuroblastoma (Schwannian stroma-poor tumors) in clinically favorable and unfavorable groups. *Cancer*. 2002;94(5):1574-1583.
269. Goto S, Umehara S, Gerbing RB, et al. Histopathology (International Neuroblastoma Pathology Classification) and MYCN status in patients with peripheral neuroblastic tumors: a report from the Children's Cancer Group. *Cancer*. 2001;92(10):2699-2708.
270. Peuchmaur M, d'Amore ES, Joshi VV, et al. Revision of the International Neuroblastoma Pathology Classification: confirmation of favorable and unfavorable prognostic subsets in ganglioneuroblastoma, nodular. *Cancer*. 2003;15(98):2274-2281.
271. Shimada H, DeLellis RA, Tissier F. Neuroblastic tumours of the adrenal gland. In: Lloyd RV, Osamura RY, Kloppel G, Rosai J, eds. *WHO Classification of Tumours of Endocrine Organs*. Lyon, France: IARC Press; 2017.
272. Children's Oncology Group. Accessed July, 2017. https://childrensoncologygroup.org/index.php/newly-diagnosed-with-neuroblastoma.
273. Maris JM, Matthay KK. Molecular biology of neuroblastoma. *J Clin Oncol*. 1999;17(7):2264-2279.
274. Bordow SB, Norris MD, Haber PS, et al. Prognostic significance of MYCN oncogene expression in childhood neuroblastoma. *J Clin Oncol*. 1998;16(10):3286-3294.
275. Seeger RC, Brodeur GM, Sather H, et al. Association of multiple copies of the N-myc oncogene with rapid progression of neuroblastomas. *N Engl J Med*. 1985;313(18):1111-1116.
276. Tsuda T, Obara M, Hirano H, et al. Analysis of N-myc amplification in relation to disease stage and histologic types in human neuroblastomas. *Cancer*. 1987;60(4):820-826.
277. Bourhis J, Dominici C, McDowell H, et al. N-myc genomic content and DNA ploidy in stage IVS neuroblastoma. *J Clin Oncol*. 1991;9(8):1371-1375.
278. Tonini GP, Boni L, Pession A, et al. MYCN oncogene amplification in neuroblastoma is associated with worse prognosis, except in stage 4s: the Italian experience with 295 children. *J Clin Oncol*. 1997;15(1):85-93.
279. Crabbe DC, Peters J, Seeger RC. Rapid detection of MYCN gene amplification in neuroblastomas using the polymerase chain reaction. *Diagn Mol Pathol*. 1992;1(4):229-234.
280. Shapiro DN, Valentine MB, Rowe ST, et al. Detection of N-myc gene amplification by fluorescence in situ hybridization. Diagnostic utility for neuroblastoma. *Am J Pathol*. 1993;142(5):1339-1346.
281. Suganuma R, Wang LL, Sano H, et al. Peripheral neuroblastic tumors with

genotype-phenotype discordance: a report from the Children's Oncology Group and the International Neuroblastoma Pathology Committee. *Pediatr Blood Cancer*. 2013;60:363-370.
282. Carlsen NL, Ornvold K, Christensen IJ, et al. Prognostic importance of DNA flow cytometrical, histopathological and immunohistochemical parameters in neuroblastomas. *Virchows Arch A Pathol Anat Histopathol*. 1992;420(5):411-418.
283. Gansler T, Chatten J, Varello M, et al. Flow cytometric DNA analysis of neuroblastoma. Correlation with histology and clinical outcome. *Cancer*. 1986;58(11): 2453-2458.
284. Abramowsky CR, Taylor SR, Anton AH, et al. Flow cytometry DNA ploidy analysis and catecholamine secretion profiles in neuroblastoma. *Cancer*. 1989;63(9):1752-1756.
285. Cohn SL, Rademaker AW, Salwen HR, et al. Analysis of DNA ploidy and proliferative activity in relation to histology and N-myc amplification in neuroblastoma. *Am J Pathol*. 1990;136(5):1043-1052.
286. Brodeur GM, Pritchard J, Berthold F, et al. Revisions of the international criteria for neuroblastoma diagnosis, staging, and response to treatment. *J Clin Oncol*. 1993;11:1466-1477.
287. Monclair T, Brodeur GM, Ambros PF, et al. The International Neuroblastoma Risk Group (INRG) staging system: an INRG Task Force report. *J Clin Oncol*. 2009;27:298-303.
288. Smith EI, Haase GM, Seeger RC, Brodeur GM. A surgical perspective on the current staging in neuroblastoma—the International Neuroblastoma Staging System proposal. *J Pediatr Surg*. 1989;24:386-390.
289. Visser JW, Axt R. Bilateral adrenal medullary hyperplasia: a clinicopathological entity. *J Clin Pathol*. 1975;28(4):298-304.
290. DeLellis RA, Tischler AS, Lee AK, et al. Leu-enkephalin-like immunoreactivity in proliferative lesions of the human adrenal medulla and extra-adrenal paraganglia. *Am J Surg Pathol*. 1983;7(1):29-37.
291. DeLellis RA, Wolfe HJ, Gagel RF, et al. Adrenal medullary hyperplasia. A morphometric analysis in patients with familial medullary thyroid carcinoma. *Am J Pathol*. 1976;83(1):177-196.
292. Kreiner E. Weight and shape of the human adrenal medulla in various age groups. *Virchows Arch A Pathol Anat Histol*. 1982;397(1):7-15.
293. Carney JA, Sizemore GW, Sheps SG. Adrenal medullary disease in multiple endocrine neoplasia, type 2: pheochromocytoma and its precursors. *Am J Clin Pathol*. 1976;66(2):279-290.
294. Kurihara K, Mizuseki K, Kondo T, et al. Adrenal medullary hyperplasia. Hyperplasia-pheochromocytoma sequence. *Acta Pathol Jpn*. 1990;40(9):683-686.
295. Yoshida A, Hatanaka S, Ohi Y, et al. von Recklinghausen's disease associated with somatostatin-rich duodenal carcinoid (somatostatinoma), medullary thyroid carcinoma and diffuse adrenal medullary hyperplasia. *Acta Pathol Jpn*. 1991;41(11):847-856.
296. Tischler AS, Semple J. Adrenal medullary nodules in Beckwith-Wiedemann Syndrome resemble extra-adrenal paraganglia. *Endocr Pathol*. 1996;7(4):265-272.
297. Grogan RH, Pacak K, Pasche L, et al. Bilateral adrenal medullary hyperplasia associated with an SDHB mutation. *J Clin Oncol*. 2011;29:e200-e202.
298. Romanet P, Guerin C, Pedini P, et al. Pathological and genetic characterization of bilateral adrenomedullary hyperplasia in a patient with Germline MAX mutation. *Endocr Pathol*. 2016.
299. Kimura N, Togo A, Sugimoto T, et al. Deficiency of phenylethanolamine N-methyltransferase in norepinephrine-producing pheochromocytoma. *Endocr Pathol*. 1996;7(2):131-136.
300. Bravo EL, Gifford RW Jr. Current concepts. Pheochromocytoma: diagnosis, localization and management. *N Engl J Med*. 1984;311(20):1298-1303.
301. Falhammar H, Calissendorff J, Höybye C. Frequency of Cushing's syndrome due to ACTH-secreting adrenal medullary lesions: a retrospective study over 10 years from a single center. *Endocrine*. 2017;55:296-302.
302. George DJ, Watermeyer GA, Levin D. Composite adrenal phaeochromocytoma-ganglioneuroma causing watery diarrhoea, hypokalaemia and achlorhydria syndrome. *Eur J Gastroenterol Hepatol*. 2010;22:632-634.
303. Jiang J, Zhang L, Wu Z, et al. A rare case of watery diarrhea, hypokalemia and achlorhydria syndrome caused by pheochromocytoma. *BMC Cancer*. 2014;14:553.
304. Liu Q, Wang Y, Tong D, et al. A somatic HIF2α mutation-induced multiple and recurrent pheochromocytoma/paraganglioma with polycythemia: clinical study with literature review. *Endocr Pathol*. 2017;28: 75-82.
305. Yang C, Zhuang Z, Fliedner SM, et al. Germ-line PHD1 and PHD2 mutations detected in patients with pheochromocytoma/paraganglioma-polycythemia. *J Mol Med*. 2015;93:93-104.
306. Samaan NA, Hickey RC. Pheochromocytoma. *Semin Oncol*. 1987;14(3):297-305.
307. Sheps SG, Jiang NS, Klee GG, van Heerden JA. Recent developments in the diagnosis and treatment of pheochromocytoma. *Mayo Clin Proc*. 1990;65(1):88-95.
308. Medeiros LJ, Wolf BC, Balogh K, Federman M. Adrenal pheochromocytoma: a clinicopathologic review of 60 cases. *Hum Pathol*. 1985;16(6):580-589.
309. DeLellis RA, Suchow E, Wolfe HJ. Ultrastructure of nuclear "inclusions" in pheochromocytoma and paraganglioma. *Hum Pathol*. 1980;11(2):205-207.
310. Linnoila RI, Keiser HR, Steinberg SM, Lack EE. Histopathology of benign versus malignant sympathoadrenal paragangliomas: clinicopathologic study of 120 cases including unusual histologic features. *Hum Pathol*. 1990;21(11):1168-1180.
311. McNichol AM. Differential diagnosis of pheochromocytomas and paragangliomas. *Endocr Pathol*. 2001;12(4):407-415.
312. Ramsay JA, Asa SL, van Nostrand AW, et al. Lipid degeneration in pheochromocytomas mimicking adrenal cortical tumors. *Am J Surg Pathol*. 1987;11(6):480-486.
313. Unger PD, Cohen JM, Thung SN, et al. Lipid degeneration in a pheochromocytoma histologically mimicking an adrenal cortical tumor. *Arch Pathol Lab Med*. 1990;114(8):892-894.
314. Chetty R, Clark SP, Taylor DA. Pigmented pheochromocytomas of the adrenal medulla. *Hum Pathol*. 1993;24(4):420-423.
315. Landas SK, Leigh C, Bonsib SM, Layne K. Occurrence of melanin in pheochromocytoma. *Mod Pathol*. 1993;6(2):175-178.
316. Li M, Wenig BM. Adrenal oncocytic pheochromocytoma. *Am J Surg Pathol*. 2000;24(11):1552-1557.
317. Wang BY, Gabrilove L, Pertsemlidis D, et al. Oncocytic pheochromocytoma with cytokeratin reactivity: a case report with immunohistochemical and ultrastructural studies. *Int J Surg Pathol*. 1997;5:61-67.
318. Chetty R, Duhig JD. Bilateral pheochromocytoma-ganglioneuroma of the adrenal in type 1 neurofibromatosis. *Am J Surg Pathol*. 1993;17(8):837-841.
319. Kimura N, Miura Y, Miura K, et al. Adrenal and retroperitoneal mixed neuroendocrine–neural tumors. *Endocr Pathol*. 1991;2:139-147.
320. Lam KY, Lo CY. Composite pheochromocytoma-ganglioneuroma of the adrenal gland: an uncommon entity with distinctive clinicopathologic features. *Endocr Pathol*. 1999;10(4):343-352.
321. Nakagawara A, Ikeda K, Tsuneyoshi M, et al. Malignant pheochromocytoma with ganglioneuroblastoma elements in a patient with von Recklinghausen's disease. *Cancer*. 1985;55(12):2794-2798.
322. Brady S, Lechan RM, Schwaitzberg SD, et al. Composite pheochromocytoma/ganglioneuroma of the adrenal gland associated with multiple endocrine neoplasia 2A: case report with immunohistochemical analysis. *Am J Surg Pathol*. 1997;21(1):102-108.
323. Harach HR, Laidler P. Combined spindle cell sarcoma/phaeochromocytoma of the adrenal. *Histopathology*. 1993;23(6):567-569.
324. Michal M, Havlicek F. Corticomedullary tumors of the adrenal glands. Report of two cases. Association of corticomedullary tumor with spindle cell sarcoma. *Pathol Res Pract*. 1996;192(11):1082-1089.
325. Sakaguchi N, Sano K, Ito M, et al. A case of von Recklinghausen's disease with bilateral pheochromocytoma-malignant peripheral nerve sheath tumors of the adrenal and gastrointestinal autonomic nerve tumors. *Am J Surg Pathol*. 1996;20(7):889-897.
326. Juarez D, Brown RW, Ostrowski M, et al. Pheochromocytoma associated with neuroendocrine carcinoma. A new type of composite pheochromocytoma. *Arch Pathol Lab Med*. 1999;123(12):1274-1279.
327. Gomez RR, Osborne BM, Ordonez NG, Mackay B. Pheochromocytoma. *Ultrastruct Pathol*. 1991;15(4-5):557-562.
328. Tannenbaum M. Ultrastructural pathology of adrenal medullary tumors. In: Sommers SC, ed. *Pathology Annual*. New York: Appleton-Century-Crofts; 1970:145-171.
329. Lee JP, Hung YP, O'Dorisio TM, et al. Examination of PHOX2B in adult neuroendocrine neoplasms reveals relatively frequent expression in phaeochromocytomas and paragangliomas. *Histopathology*. 2017.
330. Kimura N, Nakazato Y, Nagura H, Sasano N. Expression of intermediate filaments in neuroendocrine tumors. *Arch Pathol Lab Med*. 1990;114(5):506-510.
331. Chetty R, Pillay P, Jaichand V, et al. Cytokeratin expression in adrenal phaeochromocytomas and extra-adrenal paragangliomas. *J Clin Pathol*. 1998;51:477-478.
332. Tischler AS, Dayal Y, Balogh K, et al. The distribution of immunoreactive chromogranins, S-100 protein, and vasoactive intestinal peptide in compound tumors of the adrenal medulla. *Hum Pathol*. 1987;18(9):909-917.
333. Lloyd RV, Blaivas M, Wilson BS. Distribution of chromogranin and S100 protein in normal and abnormal adrenal medullary tissues. *Arch Pathol Lab Med*. 1985;109(7):633-635.
334. Unger P, Hoffman K, Pertsemlidis D, et al. S100 protein-positive sustentacular cells in malignant and locally aggressive adrenal pheochromocytomas. *Arch Pathol Lab Med*. 1991;115(5):484-487.
335. Schroder HD, Johannsen L. Demonstration of S-100 protein in sustentacular cells of phaeochromocytomas and paragangliomas. *Histopathology*. 1986;10(10):1023-1033.

336. van Nederveen FH, Gaal J, Favier J, et al. An immunohistochemical procedure to detect patients with paraganglioma and phaeochromocytoma with germline SDHB, SDHC, or SDHD gene mutations: a retrospective and prospective analysis. *Lancet Oncol*. 2009;10:764-771.
337. Menara M, Oudijk L, Badoual C, et al. SDHD immunohistochemistry: a new tool to validate SDHx mutations in pheochromocytoma/paraganglioma. *J Clin Endocrinol Metab*. 2015;100:E287-E291.
338. Papathomas TG, Oudijk L, Persu A, et al. SDHB/SDHA immunohistochemistry in pheochromocytomas and paragangliomas: a multicenter interobserver variation analysis using virtual microscopy: a Multinational Study of the European Network for the Study of Adrenal Tumors (ENS@T). *Mod Pathol*. 2015;28:807-821.
339. Gill AJ, Benn DE, Chou A, et al. Immunohistochemistry for SDHB triages genetic testing of SDHB, SDHC, and SDHD in paraganglioma-pheochromocytoma syndromes. *Hum Pathol*. 2010;41:805-814.
340. Bryant J, Farmer J, Kessler LJ, et al. Pheochromocytoma: the expanding genetic differential diagnosis. *J Natl Cancer Inst*. 2003;95(16):1196-1204.
341. Neumann HP, Bausch B, McWhinney SR, et al. Germ-line mutations in nonsyndromic pheochromocytoma. *N Engl J Med*. 2002;346(19):1459-1466.
342. Pigny P, Cardot-Bauters C. Genetics of pheochromocytoma and paraganglioma: new developments. *Ann Endocrinol (Paris)*. 2010;71(2):76-82.
343. Pigny P, Cardot-Bauters C, Do Cao C, et al. Should genetic testing be performed in each patient with sporadic pheochromocytoma at presentation? *Eur J Endocrinol*. 2009;160(2):227-231.
344. Wilson RA, Ibanez ML. A comparative study of 14 cases of familial and nonfamilial pheochromocytomas. *Hum Pathol*. 1978;9(2):181-188.
345. Caty MG, Coran AG, Geagen M, Thompson NW. Current diagnosis and treatment of pheochromocytoma in children. Experience with 22 consecutive tumors in 14 patients. *Arch Surg*. 1990;125(8):978-981.
346. Kaufman BH, Telander RL, van Heerden JA, et al. Pheochromocytoma in the pediatric age group: current status. *J Pediatr Surg*. 1983;18(6):879-884.
347. Dannenberg H, Speel EJ, Zhao J, et al. Losses of chromosomes 1p and 3q are early genetic events in the development of sporadic pheochromocytomas. *Am J Pathol*. 2000;157(2):353-359.
348. Edstrom E, Mahlamaki E, Nord B, et al. Comparative genomic hybridization reveals frequent losses of chromosomes 1p and 3q in pheochromocytomas and abdominal paragangliomas, suggesting a common genetic etiology. *Am J Pathol*. 2000;156(2):651-659.
349. Petri BJ, Speel EJ, Korpershoek E, et al. Frequent loss of 17p, but no p53 mutations or protein overexpression in benign and malignant pheochromocytomas. *Mod Pathol*. 2008;21(4):407-413.
350. Shin E, Fujita S, Takami K, et al. Deletion mapping of chromosome 1p and 22q in pheochromocytoma. *Jpn J Cancer Res*. 1993;84(4):402-408.
351. Tanaka N, Nishisho I, Yamamoto M, et al. Loss of heterozygosity on the long arm of chromosome 22 in pheochromocytoma. *Genes Chromosomes Cancer*. 1992;5(4):399-403.
352. Vargas MP, Zhuang Z, Wang C, et al. Loss of heterozygosity on the short arm of chromosomes 1 and 3 in sporadic pheochromocytoma and extra-adrenal paraganglioma. *Hum Pathol*. 1997;28(4):411-415.
353. Lamovec J, Frkovic-Grazio S, Bracko M. Nonsporadic cases and unusual morphological features in pheochromocytoma and paraganglioma. *Arch Pathol Lab Med*. 1998;122(1):63-68.
354. de Mendonca WC, Espat PA. Pheochromocytoma associated with arterial fibromuscular dysplasia. *Am J Clin Pathol*. 1981;75(5):749-754.
355. Melicow MM. One hundred cases of pheochromocytoma (107 tumors) at the Columbia-Presbyterian Medical Center, 1926-1976: a clinicopathological analysis. *Cancer*. 1977;40(5):1987-2004.
356. Sparagana M, Feldman JM, Molnar Z. An unusual pheochromocytoma associated with an androgen secreting adrenocortical adenoma. Evaluation of its polypeptide hormone, catecholamine, and enzyme characteristics. *Cancer*. 1987;60(2):223-231.
357. Neumann HP, Berger DP, Sigmund G, et al. Pheochromocytomas, multiple endocrine neoplasia type 2, and von Hippel-Lindau disease. *N Engl J Med*. 1993;329(21):1531-1538.
358. Nibbelink DW, Peters BH, McCormick WF. On the association of pheochromocytoma and cerebellar hemangioblastoma. *Neurology*. 1969;19(5):455-460.
359. Irvin GL 3rd, Fishman LM, Sher JA. Familial pheochromocytoma. *Surgery*. 1983;94(6):938-940.
360. Astuti D, Latif F, Dallol A, et al. Gene mutations in the succinate dehydrogenase subunit SDHB cause susceptibility to familial pheochromocytoma and to familial paraganglioma. *Am J Hum Genet*. 2001;69(1):49-54.
361. Eng C, Crossey PA, Mulligan LM, et al. Mutations in the RET proto-oncogene and the von Hippel-Lindau disease tumour suppressor gene in sporadic and syndromic phaeochromocytomas. *J Med Genet*. 1995;32(12):934-937.
362. Gimm O, Armanios M, Dziema H, et al. Somatic and occult germ-line mutations in SDHD, a mitochondrial complex II gene, in nonfamilial pheochromocytoma. *Cancer Res*. 2000;60(24):6822-6825.
363. Komminoth P, Kunz E, Hiort O, et al. Detection of RET proto-oncogene point mutations in paraffin-embedded pheochromocytoma specimens by nonradioactive single-strand conformation polymorphism analysis and direct sequencing. *Am J Pathol*. 1994;145(4):922-929.
364. Luchetti A, Walsh D, Rodger F, et al. Profiling of somatic mutations in phaeochromocytoma and paraganglioma by targeted next generation sequencing analysis. *Int J Endocrinol*. 2015;2015:138573.
365. Tischler AS, de Krijger RR, Gill A, et al. Phaeochromocytoma. In: Lloyd RV, Osamura RY, Kloppel G, Rosai J, eds. *WHO Classification of Tumours of Endocrine Organs*. Lyon, France: IARC Press; 2017.
366. Lewi HJ, Reid R, Mucci B, et al. Malignant phaeochromocytoma. *Br J Urol*. 1985;57(4):394-398.
367. Scott HW Jr, Halter SA. Oncologic aspects of pheochromocytoma: the importance of follow-up. *Surgery*. 1984;96(6):1061-1066.
368. Thompson LD. Pheochromocytoma of the Adrenal gland Scaled Score (PASS) to separate benign from malignant neoplasms: a clinicopathologic and immunophenotypic study of 100 cases. *Am J Surg Pathol*. 2002;26(5):551-566.
369. Kimura N, Watanabe T, Noshiro T, et al. Histological grading of adrenal and extra-adrenal pheochromocytomas and relationship to prognosis: a clinicopathological analysis of 116 adrenal pheochromocytomas and 30 extra-adrenal sympathetic paragangliomas including 38 malignant tumors. *Endocr Pathol*. 2005;16(1):23-32.
370. Kimura N, Takayanagi R, Takizawa N, et al. Pathological grading for predicting metastasis in phaeochromocytoma and paraganglioma. *Endocr Relat Cancer*. 2014;21(3):405-414.
371. Assadipour Y, Sadowski SM, Alimchandani M, et al. SDHB mutation status and tumor size but not tumor grade are important predictors of clinical outcome in pheochromocytoma and abdominal paraganglioma. *Surgery*. 2017;161:230-239.
372. Blank A, Schmitt AM, Korpershoek E, et al. SDHB loss predicts malignancy in pheochromocytomas/sympathethic paragangliomas, but not through hypoxia signalling. *Endocr Relat Cancer*. 2010;17:919-928.
373. Brown HM, Komorowski RA, Wilson SD, et al. Predicting metastasis of pheochromocytomas using DNA flow cytometry and immunohistochemical markers of cell proliferation: a positive correlation between MIB-1 staining and malignant tumor behavior. *Cancer*. 1999;86(8):1583-1589.
374. Clarke MR, Weyant RJ, Watson CG, Carty SE. Prognostic markers in pheochromocytoma. *Hum Pathol*. 1998;29(5):522-526.
375. Gupta D, Shidham V, Holden J, Layfield L. Prognostic value of immunohistochemical expression of topoisomerase alpha II, MIB-1, p53, E-cadherin, retinoblastoma gene protein product, and HER-2/neu in adrenal and extra-adrenal pheochromocytomas. *Appl Immunohistochem Mol Morphol*. 2000;8(4):267-274.
376. Nagura S, Katoh R, Kawaoi A, et al. Immunohistochemical estimations of growth activity to predict biological behavior of pheochromocytomas. *Mod Pathol*. 1999;12(12):1107-1111.
377. Salmenkivi K, Heikkila P, Haglund C, et al. Lack of histologically suspicious features, proliferative activity, and p53 expression suggests benign diagnosis in phaeochromocytomas. *Histopathology*. 2003;43(1):62-71.
378. Elder EE, Xu D, Hoog A, et al. KI-67 and hTERT expression can aid in the distinction between malignant and benign pheochromocytoma and paraganglioma. *Mod Pathol*. 2003;16(3):246-255.
379. Salmenkivi K, Haglund C, Arola J, Heikkila P. Increased expression of tenascin in pheochromocytomas correlates with malignancy. *Am J Surg Pathol*. 2001;25(11):1419-1423.
380. Jimenez C, Libutti SK, Landry CS, et al. Adrenal-neuroendocrine tumors. In: Amin MB, ed. *American Joint Committee on Cancer Staging Manual*. 8th ed. New York: Springer; 2017.
381. DeSa DJ, Nicholls S. Haemorrhagic necrosis of the adrenal gland in perinatal infants: a clinico-pathological study. *J Pathol*. 1972;106(3):133-149.
382. Gross M, Kottmeier PK, Waterhouse K. Diagnosis and treatment of neonatal adrenal hemorrhage. *J Pediatr Surg*. 1967;2(4):308-312.
383. Black J, Williams DI. Natural history of adrenal haemorrhage in the newborn. *Arch Dis Child*. 1973;48(3):183-190.
384. Cheema P, Cartagena R, Staubitz W. Adrenal cysts: diagnosis and treatment. *J Urol*. 1981;126(3):396-399.
385. Medeiros LJ, Lewandrowski KB, Vickery AL Jr. Adrenal pseudocyst: a clinical and pathologic study of eight cases. *Hum Pathol*. 1989;20(7):660-665.
386. Gaffey MJ, Mills SE, Medeiros LJ, Weiss LM. Unusual variants of adrenal pseudocysts with

intracystic fat, myelolipomatous metaplasia, and metastatic carcinoma. *Am J Clin Pathol*. 1990;94(6):706-713.
387. Gaffey MJ, Mills SE, Fechner RE, et al. Vascular adrenal cysts. A clinicopathologic and immunohistochemical study of endothelial and hemorrhagic (pseudocystic) variants. *Am J Surg Pathol*. 1989;13(9):740-747.
388. Groben PA, Roberson JB Jr, Anger SR, et al. Immunohistochemical evidence for the vascular origin of primary adrenal pseudocysts. *Arch Pathol Lab Med*. 1986;110(2):121-123.
389. Hodges FV, Ellis FR. Cystic lesions of the adrenal glands. *AMA Arch Pathol*. 1958;66(1):53-58.
390. Jennings TA, Ng B, Boguniewicz A, et al. Adrenal Pseudocysts: Evidence of Their Posthemorrhagic Nature. *Endocr Pathol*. 1998;9(1):353-361.
391. Torres C, Ro JY, Batt MA, et al. Vascular adrenal cysts: a clinicopathologic and immunohistochemical study of six cases and a review of the literature. *Mod Pathol*. 1997;10(6):530-536.
392. McCauley RG, Beckwith JB, Elias ER, et al. Benign hemorrhagic adrenocortical macrocysts in Beckwith-Wiedemann syndrome. *AJR Am J Roentgenol*. 1991;157(3):549-552.
393. Walton GR, Peng BC, Berdon WE, et al. Cystic adrenal masses in the neonate associated with hemihypertrophy and the relation to the Beckwith-Wiedemann syndrome. *J Urol*. 1991;146(2 Pt 2):580-582.
394. Medeiros LJ, Weiss LM, Vickery AL Jr. Epithelial-lined (true) cyst of the adrenal gland: a case report. *Hum Pathol*. 1989;20(5):491-492.
395. Meehan SM, Scully RE. Para-adrenal bronchogenic cyst: clinical dilemma, pathologic curiosity. *J Urol Pathol*. 1996;4:51-56.
396. Swanson SJ 3rd, Skoog SJ, Garcia V, Wahl RC. Pseudoadrenal mass: unusual presentation of bronchogenic cyst. *J Pediatr Surg*. 1991;26(12):1401-1403.
397. Erickson LA, Lloyd RV, Hartman R, Thompson G. Cystic adrenal neoplasms. *Cancer*. 2004;101(7):1537-1544.
398. Nakamura Y, Yano H, Nakashima T. False intranuclear inclusions in adrenal cytomegaly. *Arch Pathol Lab Med*. 1981;105(7):358-360.
399. Honore LH. Intra-adrenal hepatic heterotopia. *J Urol*. 1985;133(4):652-654.
400. Shiraishi T, Imai H, Fukutome K, et al. Ectopic thyroid in the adrenal gland. *Hum Pathol*. 1999;30(1):105-108.
401. Oelkers W. Adrenal insufficiency. *N Engl J Med*. 1996;335(16):1206-1212.
402. McMurry JF Jr, Long D, McClure R, Kotchen TA. Addison's disease with adrenal enlargement on computed tomographic scanning. Report on two cases of tuberculosis and review of the literature. *Am J Med*. 1984;77(2):365-368.
403. Sinclair-Smith C, Kahn LB, Cywes S. Malacoplakia in childhood. Case report with ultrastructural observations and review of the literature. *Arch Pathol*. 1975;99(4):198-203.
404. Benjamin E, Fox H. Malakoplakia of the adrenal gland. *J Clin Pathol*. 1981;34(6):606-611.
405. Lam KY. Lipomatous tumors of the adrenal gland. Clinicopathologic study of eight cases. *J Urol Pathol*. 1995;3:95-106.
406. Noble MJ, Montague DK, Levin HS. Myelolipoma: an unusual surgical lesion of the adrenal gland. *Cancer*. 1982;49(5):952-958.
407. O'Malley DP. Benign extramedullary myeloid proliferations. *Mod Pathol*. 2007;20(4):405-415.
408. Bishop E, Eble JN, Cheng L, et al. Adrenal myelolipomas show nonrandom X-chromosome inactivation in hematopoietic elements and fat: support for a clonal origin of myelolipomas. *Am J Surg Pathol*. 2006;30(7):838-843.
409. Boudreaux D, Waisman J, Skinner DG, Low R. Giant adrenal myelolipoma and testicular interstitial cell tumor in a man with congenital 21-hydroxylase deficiency. *Am J Surg Pathol*. 1979;3(2):109-123.
410. Wilhelmus JL, Schrodt GR, Alberhasky MT, Alcorn MO. Giant adrenal myelolipoma: case report and review of the literature. *Arch Pathol Lab Med*. 1981;105(10):532-535.
411. Kraimps JL, Marechaud R, Levillain P, et al. Bilateral symptomatic adrenal myelolipoma. *Surgery*. 1992;111(1):114-117.
412. Medeiros LJ, Wolf BC. Traumatic rupture of an adrenal myelolipoma. *Arch Pathol Lab Med*. 1983;107(9):500.
413. Bennett BD, McKenna TJ, Hough AJ, et al. Adrenal myelolipoma associated with Cushing's disease. *Am J Clin Pathol*. 1980;73(3):443-447.
414. Condom E, Villabona CM, Gomez JM, Carrera M. Adrenal myelolipoma in a woman with congenital 17-hydroxylase deficiency. *Arch Pathol Lab Med*. 1985;109(12):1116-1117.
415. Merchant SH, Herman CM, Amin MB, et al. Myelolipoma associated with adrenal ganglioneuroma. *Arch Pathol Lab Med*. 2002;126(6):736-737.
416. Boronat M, Moreno A, Ramon y Cajal S, et al. Subclinical Cushing's syndrome due to adrenal myelolipoma. *Arch Pathol Lab Med*. 1997;121(7):735-737.
417. Hunter SB, Schemankewitz EH, Patterson C, Varma VA. Extraadrenal myelolipoma. A report of two cases. *Am J Clin Pathol*. 1992;97(3):402-404.
418. Avinoach I, Robinson CR, Avinoah E, Peiser J. Adrenal lipoma: a rare tumour of the adrenal gland. *Histopathology*. 1989;15(2):195-196.
419. Banerjee P, Netto GJ. Adrenal lymphangiomas: clinicopathologic review of a rare lesion. *Lab Invest*. 2009;89(suppl 1):158A-159A.
420. Bedard YC, Horvath E, Kovacs K. Adrenal schwannoma with apparent uptake of immunoglobulins. *Ultrastruct Pathol*. 1986;10(6):505-513.
421. Bongiovanni M, Viberti L, Giraudo G, et al. Solitary fibrous tumour of the adrenal gland associated with pregnancy. *Virchows Arch*. 2000;437(4):445-449.
422. Lau SK, Spagnolo DV, Weiss LM. Schwannoma of the adrenal gland: report of two cases. *Am J Surg Pathol*. 2006;30(5):630-634.
423. Lau SK, Weiss LM. Calcifying fibrous tumor of the adrenal gland. *Hum Pathol*. 2007;38(4):656-659.
424. Lin J, Wasco MJ, Korobkin M, et al. Leiomyoma of the adrenal gland presenting as a non-functioning adrenal incidentaloma: case report and review of the literature. *Endocr Pathol*. 2007;18(4):239-243.
425. Prevot S, Penna C, Imbert JC, et al. Solitary fibrous tumor of the adrenal gland. *Mod Pathol*. 1996;9(12):1170-1174.
426. Garg K, Lee P, Ro JY, et al. Adenomatoid tumor of the adrenal gland: a clinicopathologic study of 3 cases. *Ann Diagn Pathol*. 2005;9(1):11-15.
427. Isotalo PA, Keeney GL, Sebo TJ, et al. Adenomatoid tumor of the adrenal gland: a clinicopathologic study of five cases and review of the literature. *Am J Surg Pathol*. 2003;27(7):969-977.
428. Raaf HN, Grant LD, Santoscoy C, et al. Adenomatoid tumor of the adrenal gland: a report of four new cases and a review of the literature. *Mod Pathol*. 1996;9(11):1046-1051.
429. Simpson PR. Adenomatoid tumor of the adrenal gland. *Arch Pathol Lab Med*. 1990;114(7):725-727.
430. Travis WD, Lack EE, Azumi N, et al. Adenomatoid tumor of the adrenal gland with ultrastructural and immunohistochemical demonstration of a mesothelial origin. *Arch Pathol Lab Med*. 1990;114(7):722-724.
431. Limbach AL, Ni Y, Huang J, et al. Adenomatoid tumour of the adrenal gland in a patient with germline SDHD mutation: a case report and review of the literature. *Pathology*. 2011;43:495-498.
432. Cheng JY, Gill AJ, Kumar SK. Granulosa cell tumour of the adrenal. *Pathology*. 2015;47:487-489.
433. Pollock WJ, McConnell CF, Hilton C, Lavine RL. Virilizing Leydig cell adenoma of adrenal gland. *Am J Surg Pathol*. 1986;10(11):816-822.
434. Trost BN, Koenig MP, Zimmermann A, et al. Virilization of a post-menopausal woman by a testosterone-secreting Leydig cell type adrenal adenoma. *Acta Endocrinol (Copenh)*. 1981;98:274-282.
435. Vasiloff J, Chideckel EW, Boyd CB, Foshag LJ. Testosterone-secreting adrenal adenoma containing crystalloids characteristic of Leydig cells. *Am J Med*. 1985;79:772-776.
436. Lack EE, Graham CW, Azumi N, et al. Primary leiomyosarcoma of adrenal gland. Case report with immunohistochemical and ultrastructural study. *Am J Surg Pathol*. 1991;15(9):899-905.
437. Dugan MC. Primary adrenal leiomyosarcoma in acquired immunodeficiency syndrome. *Arch Pathol Lab Med*. 1996;120(9):797-798.
438. Ayala GE, Ettinghausen SE, Epstein AH, et al. Primary malignant peripheral nerve sheath tumor of the adrenal gland. Case report and literature review. *J Urol Pathol*. 1994;2:265-272.
439. Harach HR, Laidler P. Adrenal spindle-cell sarcoma with features of malignant peripheral nerve sheath tumor. *Endocr Pathol*. 1993;4:222-225.
440. Just PA, Tissier F, Silvera S, et al. Unexpected diagnosis for an adrenal tumor: synovial sarcoma. *Ann Diagn Pathol*. 2010;14(1):56-59.
441. Ben-Izhak O, Auslander L, Rabinson S, et al. Epithelioid angiosarcoma of the adrenal gland with cytokeratin expression. Report of a case with accompanying mesenteric fibromatosis. *Cancer*. 1992;69(7):1808-1812.
442. Wenig BM, Abbondanzo SL, Heffess CS. Epithelioid angiosarcoma of the adrenal glands. A clinicopathologic study of nine cases with a discussion of the implications of finding "epithelial-specific" markers. *Am J Surg Pathol*. 1994;18:62-73.
443. Kato K, Kato Y, Ijiri R, et al. Ewing's sarcoma family of tumor arising in the adrenal gland—possible diagnostic pitfall in pediatric pathology: histologic, immunohistochemical, ultrastructural, and molecular study. *Hum Pathol*. 2001;32(9):1012-1016.
444. Santonja C, Diaz MA, Dehner LP. A unique dysembryonic neoplasm of the adrenal gland composed of nephrogenic rests in a child. *Am J Surg Pathol*. 1996;20(1):118-124.
445. Choi CH, Durishin M, Garbadawala ST, Richard J. Non-Hodgkin's lymphoma of the adrenal gland. *Arch Pathol Lab Med*. 1990;114(8):883-885.
446. Harris GJ, Tio FO, Von Hoff DD. Primary adrenal lymphoma. *Cancer*. 1989;63(4):799-803.
447. Mozos A, Ye H, Chuang WY, et al. Most primary adrenal lymphomas are diffuse large B-cell lymphomas with non-germinal center B-cell phenotype, BCL6 gene rearrangement and poor prognosis. *Mod Pathol*. 2009;22(9):1210-1217.
448. Ohsawa M, Tomita Y, Hashimoto M, et al. Malignant lymphoma of the adrenal gland: its possible correlation with the Epstein-Barr virus. *Mod Pathol*. 1996;9(5):534-543.
449. Boyer DF, McKelvie PA, de Leval L, et al. Fibrin-associated EBV-positive large B-cell

lymphoma: an indolent neoplasm with features distinct from diffuse large B-cell lymphoma associated with chronic inflammation. *Am J Surg Pathol*. 2017;41:299-312.
450. Frankel WL, Shapiro P, Weidner N. Primary anaplastic large cell lymphoma of the adrenal gland. *Ann Diagn Pathol*. 2000;4(3):158-164.
451. Srivasta S, Sharma J, Logani S. Intravascular lymphoma: an unusual diagnostic outcome of an incidentally detected adrenal mass. *Endocr Pract*. 2008;14:884-888.
452. Carey RW, Harris N, Kliman B. Addison's disease secondary to lymphomatous infiltration of the adrenal glands. Recovery of adrenocortical function after chemotherapy. *Cancer*. 1987;59(6):1087-1090.
453. Schnitzer B, Smid D, Lloyd RV, Primary T. cell lymphoma of the adrenal glands with adrenal insufficiency. *Hum Pathol*. 1986;17(6):634-636.
454. Dao AH, Page DL, Reynolds VH, Adkins RB Jr. Primary malignant melanoma of the adrenal gland. A report of two cases and review of the literature. *Am Surg*. 1990;56(4):199-203.
455. Kung AW, Pun KK, Lam K, et al. Addisonian crisis as presenting feature in malignancies. *Cancer*. 1990;65(1):177-179.
456. Seidenwurm DJ, Elmer EB, Kaplan LM, et al. Metastases to the adrenal glands and the development of Addison's disease. *Cancer*. 1984;54(3):552-557.
457. Huisman TK, Sands JP Jr. Renal cell carcinoma with solitary metachronous contralateral adrenal metastasis. Experience with 2 cases and review of the literature. *Urology*. 1991;38(4):364-368.
458. Abell MR, Hart WR, Olson JR. Tumors of the peripheral nervous system. *Hum Pathol*. 1970;1(4):503-551.
459. Kliewer KE, Cochran AJ. A review of the histology, ultrastructure, immunohistology, and molecular biology of extra-adrenal paragangliomas. *Arch Pathol Lab Med*. 1989;113(11):1209-1218.
460. Lack EE, Kim H, Reed K. Pigmented ("black") extraadrenal paraganglioma. *Am J Surg Pathol*. 1998;22(2):265-269.
461. Moran CA, Albores-Saavedra J, Wenig BM, Mena H. Pigmented extraadrenal paragangliomas. A clinicopathologic and immunohistochemical study of five cases. *Cancer*. 1997;79(2):398-402.
462. Reddy VB, Norris J, Waters B, Gattus P. Extraadrenal retroperitoneal paraganglioma with osseous metaplasia. *Int J Surg Pathol*. 1996–1997;4:193-196.
463. Plaza JA, Wakely PE Jr, Moran C, et al. Sclerosing paraganglioma: report of 19 cases of an unusual variant of neuroendocrine tumor that may be mistaken for an aggressive malignant neoplasm. *Am J Surg Pathol*. 2006;30(1):7-12.
464. Grimley PM, Glenner GG. Histology and ultrastructure of carotid body paragangliomas. Comparison with the normal gland. *Cancer*. 1967;20(9):1473-1488.
465. Warren WH, Lee I, Gould VE, et al. Paragangliomas of the head and neck: ultrastructural and immunohistochemical analysis. *Ultrastruct Pathol*. 1985;8(4):333-343.
466. Papadimitriou JC, Drachenberg CB. Giant mitochondria with paracrystalline inclusions in paraganglioma of the urinary bladder: correlation with mitochondrial abnormalities in paragangliomas of other sites. *Ultrastruct Pathol*. 1994;18(6):559-564.
467. Crowell WT, Grizzle WE, Siegel AL. Functional carotid paragangliomas. Biochemical, ultrastructural, and histochemical correlation with clinical symptoms. *Arch Pathol Lab Med*. 1982;106(12):599-603.
468. Pryse-Davies J, Dawson IM. Some morphologic, histochemical, and chemical observations on chemodectomas and the normal carotid body, including a study of the chromaffin reaction and possible ganglion cell elements. *Cancer*. 1964;17:185-202.
469. Hamid Q, Varndell IM, Ibrahim NB, et al. Extraadrenal paragangliomas. An immunocytochemical and ultrastructural report. *Cancer*. 1987;60(8):1776-1781.
470. Kliewer KE, Wen DR, Cancilla PA, Cochran AJ. Paragangliomas: assessment of prognosis by histologic, immunohistochemical, and ultrastructural techniques. *Hum Pathol*. 1989;20(1):29-39.
471. Martinez-Madrigal F, Bosq J, Micheau C, et al. Paragangliomas of the head and neck. Immunohistochemical analysis of 16 cases in comparison with neuro-endocrine carcinomas. *Pathol Res Pract*. 1991;187(7):814-823.
472. Saito H, Saito S, Sano T, et al. Immunoreactive somatostatin in catecholamine-producing extra-adrenal paraganglioma. *Cancer*. 1982;50(3):560-565.
473. Tadros TS, Strauss RM, Cohen C, Gal AA. Galanin immunoreactivity in paragangliomas but not in carcinoid tumors. *Appl Immunohistochem Mol Morphol*. 2003;11(3):250-252.
474. Schmid KW, Schröder S, Dockhorn-Dworniczak B, et al. Immunohistochemical demonstration of chromogranin A, chromogranin B, and secretogranin II in extra-adrenal paragangliomas. *Mod Pathol*. 1994;7:347-353.
475. So JS, Epstein JI. GATA3 expression in paragangliomas: a pitfall potentially leading to misdiagnosis of urothelial carcinoma. *Mod Pathol*. 2013;26:1365-1370.
476. Johnson TL, Zarbo RJ, Lloyd RV, Crissman JD. Paragangliomas of the head and neck: immunohistochemical neuroendocrine and intermediate filament typing. *Mod Pathol*. 1988;1:216-223.
477. Pytel P, Krausz T, Wollmann R, Utset MF. Ganglioneuromatous paraganglioma of the cauda equina—a pathological case study. *Hum Pathol*. 2005;36(4):444-446.
478. Min KW. Diagnostic usefulness of sustentacular cells in paragangliomas: immunocytochemical and ultrastructural investigation. *Ultrastruct Pathol*. 1998;22(5):369-376.
479. Hamidi O, Young WF Jr, Iñiguez-Ariza NM, et al. Malignant pheochromocytoma and paraganglioma: 272 patients over 55 years. *J Clin Endocrinol Metab*. 2017.
480. Rodriguez-Cuevas H, Lau I, Rodriguez HP. High-altitude paragangliomas diagnostic and therapeutic considerations. *Cancer*. 1986;57(3):672-676.
481. Saldana MJ, Salem LE, Travezan R. High altitude hypoxia and chemodectomas. *Hum Pathol*. 1973;4(2):251-263.
482. Arias-Stella J, Valcarcel J. Chief cell hyperplasia in the human carotid body at high altitudes; physiologic and pathologic significance. *Hum Pathol*. 1976;7(4):361-373.
483. Lack EE. Hyperplasia of vagal and carotid body paraganglia in patients with chronic hypoxemia. *Am J Pathol*. 1978;91(3):497-516.
484. Farr HW. Carotid body tumors. A thirty year experience at Memorial Hospital. *Am J Surg*. 1967;114(4):614-619.
485. Lack EE, Cubilla AL, Woodruff JM. Paragangliomas of the head and neck region. A pathologic study of tumors from 71 patients. *Hum Pathol*. 1979;10(2):191-218.
486. Oberman HA, Holtz F, Sheffer LA, Magielski JE. Chemodectomas (nonchromaffin paragangliomas) of the head and neck. A clinicopathologic study. *Cancer*. 1968;21(5):838-851.
487. Shamblin WR, ReMine WH, Sheps SG, Harrison EG Jr. Carotid body tumor (chemodectoma). Clinicopathologic analysis of ninety cases. *Am J Surg*. 1971;122(6):732-739.
488. Johnstone PA, Foss RD, Desilets DJ. Malignant jugulotympanic paraganglioma. *Arch Pathol Lab Med*. 1990;114(9):976-979.
489. Rosenwasser H. Glomus jugulare tumors. I. Historical background. *Arch Otolaryngol*. 1968;88(1):1-40.
490. Schermer KL, Pontius EE, Dziabis MD, McQuiston RJ. Tumors of the glomus jugulare and glomus tympanicum. *Cancer*. 1966;19(9):1273-1280.
491. Eriksen C, Girdhar-Gopal H, Lowry LD. Vagal paragangliomas: a report of nine cases. *Am J Otolaryngol*. 1991;12(5):278-287.
492. Heinrich MC, Harris AE, Bell WR. Metastatic intravagal paraganglioma. Case report and review of the literature. *Am J Med*. 1985;78(6 Pt 1):1017-1024.
493. Kahn LB. Vagal body tumor (nonchromaffin paraganglioma, chemodectoma, and carotid body-like tumor) with cervical node metastasis and familial association: ultrastructural study and review. *Cancer*. 1976;38(6):2367-2377.
494. Murphy TE, Huvos AG, Frazell EL. Chemodectomas of the glomus intravagale: vagal body tumors, nonchromaffin paragangliomas of the nodose ganglion of the vagus nerve. *Ann Surg*. 1970;172(2):246-255.
495. Lack EE, Cubilla AL, Woodruff JM, Farr HW. Paragangliomas of the head and neck region: a clinical study of 69 patients. *Cancer*. 1977;39(2):397-409.
496. Zeman MS. Carotid body tumor of the trachea: glomus jugularis tumor, tympanic body tumor, nonchromaffin paraganglioma. *Ann Otol Rhinol Laryngol*. 1956;65(4):960-962.
497. Boedeker CC, Hensen EF, Neumann HP, et al. Genetics of hereditary head and neck paragangliomas. *Head Neck*. 2014;36:907-916.
498. Bayley JP, van Minderhout I, Weiss MM, et al. Mutation analysis of SDHB and SDHC: novel germline mutations in sporadic head and neck paraganglioma and familial paraganglioma and/or pheochromocytoma. *BMC Med Genet*. 2006;7:1.
499. Hao HX, Khalimonchuk O, Schraders M, et al. SDH5, a gene required for flavination of succinate dehydrogenase, is mutated in paraganglioma. *Science*. 2009;325(5944):1139-1142.
500. Niemeijer ND, Rijken JA, Eijkelenkamp K, et al. The phenotype of SDHB germline mutation carriers: a nationwide study. *Eur J Endocrinol*. 2017;117:115-125.
501. Amar L, Baudin E, Burnichon N, et al. Succinate dehydrogenase B gene mutations predict survival in patients with malignant pheochromocytomas or paragangliomas. *J Clin Endocrinol Metab*. 2007;92:3822-3828.
502. Gimenez-Roquelo AP, Dahia PL, Robledo M. An update on the genetics of paraganglioma, pheochromocytoma, and associated hereditary syndromes. *Horm Metab Res*. 2012;44:328-333.
503. Altergott R, Barbato A, Lawrence A, et al. Spectrum of catecholamine-secreting tumors of the organ of Zuckerkandl. *Surgery*. 1985;98(6):1121-1126.
504. Glenn F, Gray GF. Functional tumors of the organ of Zuckerkandl. *Ann Surg*. 1976;183(5):578-586.
505. Ober WB. Emil Zuckerkandl and his delightful little organ. *Pathol Annu*. 1983;18(Pt 1):103-119.
506. Johnson TL, Shapiro B, Beierwaltes WH, et al. Cardiac paragangliomas. A clinicopathologic and immunohistochemical study of four cases. *Am J Surg Pathol*. 1985;9(11):827-834.
507. Miller TA, Weber TR, Appelman HD. Paraganglioma of the gallbladder. *Arch Surg*. 1972;105(4):637-639.
508. Grignon DJ, Ro JY, Mackay B, et al. Paraganglioma of the urinary bladder:

immunohistochemical, ultrastructural, and DNA flow cytometric studies. *Hum Pathol*. 1991;22(11):1162-1169.
509. Beham A, Schmid C, Fletcher CD, et al. Malignant paraganglioma of the uterus. *Virchows Arch A Pathol Anat Histopathol*. 1992;420(5):453-457.
510. Young TW, Thrasher TV. Nonchromaffin paraganglioma of the uterus. A case report. *Arch Pathol Lab Med*. 1982;106(12):608-609.
511. Horoupian DS, Kerson LA, Sainotz H, Valsamis M. Paraganglioma of cauda equina. Clinicopathologic and ultrastructural studies of an unusual case. *Cancer*. 1974;33(5):1337-1348.
512. Moran CA, Rush W, Mena H. Primary spinal paragangliomas: a clinicopathological and immunohistochemical study of 30 cases. *Histopathology*. 1997;31(2):167-173.
513. Plouin PF, Gimenez-Roqueplo AP. Pheochromocytomas and secreting paragangliomas. *Orphanet J Rare Dis*. 2006;1:49.
514. Babic B, Patel D, Aufforth R, et al. Pediatric patients with pheochromocytoma and paraganglioma should have routine preoperative genetic testing for common susceptibility genes in addition to imaging to detect extra-adrenal and metastatic tumors. *Surgery*. 2017;161:220-227.

30 Vulva

Blake Gilks

CHAPTER CONTENTS

Normal anatomy, *1224*
Mammary-like glands of the vulva and related lesions, *1224*
Inflammatory diseases, *1225*
Spongiotic and lichenoid reactions of the vulvar skin, *1225*
Human papilloma virus and vulvar pathology, *1227*
Condyloma and seborrheic keratosis, *1227*
Squamous intraepithelial lesions, *1229*
Human papilloma virus-associated squamous intraepithelial neoplasia: HSIL (VIN2/3), *1229*
Human papilloma virus-independent squamous intraepithelial neoplasia: differentiated VIN (dVIN), *1230*
Invasive squamous cell carcinoma, *1230*
Superficially invasive squamous cell carcinoma, *1232*
Paget disease, *1234*
Other epithelial tumors, *1236*
Melanocytic tumors, *1237*
Aggressive angiomyxoma and related lesions, *1238*
Other tumors and tumorlike conditions, *1239*
Lesions of Bartholin glands and related structures, *1240*
Lesions of the female urethra, *1240*

Normal Anatomy

The vulva is composed of the following anatomic structures: mons pubis, clitoris, labia minora, labia majora, vulvar vestibule and vestibulovaginal bulbs, urethral meatus, hymen, Bartholin and Skene glands and ducts, and vaginal introitus.[1,2]

The *labia majora* are lined by keratinized skin containing all the cutaneous adnexa: hair follicles, sebaceous glands, apocrine glands, and sweat (eccrine) glands.[3] The *labia minora* are covered by nonkeratinized stratified squamous epithelium on their vestibular surfaces but have a thin keratinized layer on their lateral side. Skin adnexa are usually absent in them, but on occasion, one encounters both sweat and sebaceous glands.

The *Bartholin gland* is the major vestibular gland and has a tubuloalveolar structure. It is made up of acini composed of mucus-secreting columnar cells and a duct lined with transitional epithelium.[4] *Minor vestibular glands* are of simple tubular type and are lined with a mucus-secreting columnar epithelium that merges with the stratified squamous epithelium of the vestibule.

Skene or *periurethral glands* are analogous to the male prostate gland; they are lined by a pseudostratified mucus-secreting columnar epithelium that merges with the transitional-type epithelium of the ducts, which in turn joins with the stratified squamous epithelium of the vestibule.

The *hymen* is lined by nonkeratinized stratified squamous epithelium on both surfaces.

The *clitoris* contains erectile tissue similar to that present in the corpora cavernosa of the penis.

Most of the vulvar lymph vessels drain to the superficial inguinal nodes, but those in the clitoris empty directly into the deep chain.

Mammary-Like Glands of the Vulva and Related Lesions

Mammary-like glands of the vulva, formerly thought to be ectopic breast tissue related to the "milk line," are now recognized as a normal finding in the vulva,[5] and are found primarily in the sulcus between the labium minus and labium majus. These glands consist of ducts, variably with associated acini, lined by glandular epithelium identical to that of the breast. The ducts draining these glands empty through the skin. Clear cells (Toker cells) may be found singly or in clusters where these ducts traverse the epidermis. This tissue is subject to many of the physiologic and pathologic changes that occur in the normally situated breast and some that seem peculiar to this location. These include swelling and secretion of milk during pregnancy, cysts,[6] peculiar hyperplastic changes,[7] so-called pseudoangiomatous stromal hyperplasia (PASH; see Chapter 36),[8] fibroadenoma (including the juvenile type),[8–10] (Fig. 30.1) phyllodes tumor,[11,12] and carcinoma.[6,13–15] Most of the latter have been of ductal type, but any histotype/molecular subtype, i.e. luminal, basal-like, HER2, may be encountered.[16–18] In addition, it is likely that ectopic mammary tissue is the source of the common benign vulvar tumor known as papillary hidradenoma.

For personal use only. No other uses without permission. Copyright ©2017. Elsevier Inc. All rights reserved.

Abstract

Vulvar pathology encompasses a wide range of inflammatory and neoplastic conditions. Although generalized dermatopathies can involve the vulvar skin, we will focus on those specific conditions that involve the vulva preferentially or exclusively. Most neoplasms of the vulva arise from the squamous epithelium; unlike squamous cell neoplasia of sun-exposed skin, vulvar squamous cell carcinoma can metastasize and is associated with significant mortality. Vulvar squamous carcinoma can arise from human papilloma virus (HPV)–independent or HPV-associated pathways, and these differ with respect to age at onset, molecular events during pathogenesis, risk factors, precursor lesions, and prognosis. Neoplasms other than squamous cell carcinoma can arise from specialized epithelia (e.g., Bartholin gland or mammary-like glands of the vulva) or hormone receptor–expressing mesenchymal cells of the vulva.

Keywords

Vulva, VIN,
lichenoid inflammation,
lichen sclerosus,
squamous cell carcinoma,
HPV

For personal use only. No other uses without permission. Copyright ©2017. Elsevier Inc. All rights reserved.

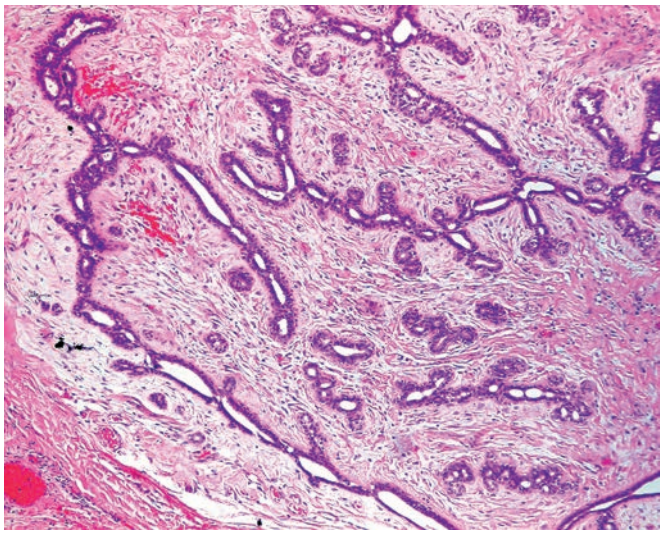

Figure 30.1 Fibroadenoma of vulva arising from ectopic breast tissue.

Inflammatory Diseases

Syphilis in women often manifests itself initially in the vulvar region. The fully developed syphilitic chancre is composed microscopically of plasma cells, lymphocytes, and histiocytes, and is covered by a zone of ulceration infiltrated by neutrophils and necrotic debris. The microscopic appearance is not specific, but the combination of numerous plasma cells and endarteritis should alert to the diagnosis. Your diagnostic report can suggest the possibility of syphilis, based on the histopathologic findings, indicating to the clinician the need to exclude this possibility with appropriate serologic testing on the patient. Additionally, immunostains for *Treponema pallidum* are now available and allow for easy confirmation of the causative organisms.[19] Sometimes, the possibility of syphilis is first suggested on the basis of the microscopic examination of an enlarged inguinal lymph node if this node shows a combination of capsular and pericapsular fibrosis, follicular hyperplasia, plasma cell infiltration, and endarteritis. The latter feature, which represents the most useful clue to the diagnosis, is particularly well seen in or outside the nodal capsule (see Chapter 37).

Granuloma inguinale (donovanosis) is a chronic infection caused by *Klebsiella* (*Calymmatobacterium*) *granulomatis*, a gram-negative, nonmotile, encapsulated bacillus.[20–22] It begins as a soft elevated granulomatous area that enlarges very slowly by peripheral extension and ulcerates. Microscopically, there is a dense dermal inflammatory infiltrate composed of histiocytes and plasma cells, with a scattering of small abscesses.[23] The diagnosis rests on the demonstration of Donovan bodies, which appear as small round encapsulated bodies inside the cytoplasm of the histiocytes. They can be seen in hematoxylin-eosin (H&E) sections but are best demonstrated with Giemsa or Warthin-Starry stains. Pronounced pseudoepitheliomatous hyperplasia, which may accompany chronic lesions, should be distinguished from the very rare squamous cell carcinoma that may arise in such areas.[24] The infection can spread to the retroperitoneum and simulate a soft tissue neoplasm.[25]

Lymphogranuloma venereum (LGV) is a venereal disease produced by *Chlamydia trachomatis* organisms (specifically L-serovars).[26–28] It mainly affects lymph vessels and lymphoid tissue. The initial small ulcer at a site of venereal contact often goes unnoticed. The first clinical manifestation is swelling of inguinal lymph nodes caused by stellate abscesses surrounded by pale epithelioid cells.[29] There is extensive scarring as the disease progresses, often leading to fistulas and strictures of the urethra, vagina, and rectum. It is increasing in incidence, especially in homosexual men.[30] The diagnosis can be confirmed by submission of swabs for nucleic acid amplification, with LGV genotyping on samples positive for *Chlamydia*.[30] Rainey[31] reported 11 cases of squamous cell carcinoma or adenocarcinoma arising from lymphogranulomatous strictures. Most of the tumors were located in the anorectal area.

Crohn disease can involve the vulvar region.[32–35] In some cases, the vulvar lesions are associated with perineal disease and fistula formation, whereas in others they are separated from the anal lesions by normal tissue. Grossly, erythematous areas appear that later ulcerate. Microscopically, noncaseating granulomas may be found. The process reported as *vulvitis granulomatosa* is probably related to Crohn disease, in that some of the patients have subsequently developed either intestinal Crohn disease or cheilitis granulomatosa.[36]

Behçet disease can, rarely, involve the vulvar region, where it presents as a microscopically nonspecific ulceration.[37,38]

Necrotizing fasciitis of the vulva may be seen in diabetic women. It is associated with a high mortality rate; wide excision of the diseased tissue is the treatment of choice.[39]

Vulvar vestibulitis is a disorder characterized microscopically by a nonspecific chronic inflammatory infiltrate predominantly involving the mucosal lamina propria and the periglandular/periductal connective tissue of the vestibular region.[40] It is unrelated to human papilloma virus (HPV).[41]

Plasma cell vulvitis (of Zoon) is an uncommon condition of uncertain etiology. It typically presents as a solitary, asymptomatic, sharply defined red/brown patch. Microscopically, there is a dense band-like mononuclear inflammatory infiltrate in the superficial dermis, consisting predominantly (>50%) of plasma cells.[42] The differential diagnosis includes secondary syphilis and lichenoid drug reaction, but neither of these conditions present as a solitary lesion resembling those of plasma cell vulvitis.

Spongiotic and Lichenoid Reactions of the Vulvar Skin

There exists a group of vulvar diseases that are pathogenetically unrelated but that have several features in common at the clinical level. They typically present as a long-standing lesion consisting of irregular areas of thickened skin, often accompanied by severe pruritus. The color is usually white, in which case the clinically descriptive term *leukoplakia* has been used (note that this is not an acceptable histopathologic diagnosis!). In other instances, the lesions are red or a mixture of both colors. They are easily traumatized and excoriated. In some of these lesions the vulvar soft tissues are atrophied and shrunken, in which case the clinical term *kraurosis vulvae* has been employed.

In the presence of a lesion with some of these clinical features, it is essential to reach a specific diagnosis, and this often necessitates the performance of a biopsy.[43] Multiple biopsies may be necessary if the lesion is large or varies in appearance from place to place. Although a key function of the biopsy is to exclude neoplasia, it is important to reach a specific diagnosis as this will guide subsequent management, and the former practice of diagnosing benign "vulvar dystrophy" or "squamous hyperplasia" is not acceptable.[44,45] What follows is a list of the most commonly encountered inflammatory conditions of the vulva; this list is by no means exhaustive but will be sufficient to handle most vulvar biopsies taken for a non-neoplastic inflammatory process that will be encountered in general surgical pathology practice, focusing on those entities that chiefly involve the vulva. The vulvar skin can be secondarily involved in a wide range of inflammatory dermatopathies and the reader is referred to Chapter 2 for a full discussion of these conditions.

For personal use only. No other uses without permission. Copyright ©2017. Elsevier Inc. All rights reserved.

Spongiotic dermatitis (eczematous reaction) is a nonspecific pattern of cutaneous inflammation, familiar to those whose practice includes a significant dermatopathology component. It is characterized histologically by intercellular edema in the epidermis (spongiosis) with intraepithelial lymphocytes, and less commonly neutrophils and/or eosinophils. Pure acute spongiotic reactions are rarely encountered in vulvar biopsies, but spongiotic dermatitis is not uncommonly seen admixed with a chronic process, especially lichen simplex chronicus (discussed below), so awareness of the histopathologic features is important. Eczematous reactions confined to the vulva are most commonly attributable to allergic or irritant contact reactions, with drug reaction and atopic reaction less common. In patients with allergic contact reaction, the precipitant may be difficult to identify, clinically, as the reaction can persist for variable periods of time after removal of the irritant. Management consists of scrupulous avoidance of irritants/allergens.[46] When longstanding, there is progression to lichen simplex chronicus and it is our impression that many cases of lichen simplex chronicus start as an acute spongiotic dermatitis.

Lichen simplex chronicus is probably the most common diagnosis rendered on vulvar biopsies. It can affect nonvulvar sites or be limited to the vulva, where it manifests as pruritic scaly plaques.[46] The microscopic findings reflect chronic irritation, and the diagnosis of lichen simplex chronicus does not indicate a single disease entity but instead reflects chronic irritation of vulvar skin from any cause. On histopathologic examination there is hyperkeratosis (predominantly orthokeratosis, with parakeratosis focally present, for example, as sites of excoriation) with epidermal hyperplasia and a patchy, predominantly lymphocytic inflammatory infiltrate in the superficial dermis (Fig. 30.2). Because lichen simplex chronicus reflects trauma, and can appear secondary to many different primary dermatopathic conditions, it is important to search for an underlying disease process that has precipitated the lichen simplex chronicus. That being said, in most cases no underlying condition can be identified. Cutaneous fungal infections can result in changes of lichen simplex chronicus but can be ruled out with periodic acid–Schiff–diastase (PAS-D) stain. The differential diagnosis of lichen simplex chronicus, especially for the clinician, is vulvar intraepithelial neoplasia (VIN), but lichen simplex chronicus lacks the atypia of VIN (differential diagnosis discussed in more detail later, in the section on differentiated VIN [dVIN]).

Lichen planus is an idiopathic inflammatory dermatopathy characterized by pruritic red/purple papules.[46] While there is usually extragenital involvement, vulvar lesions may be the only finding at presentation. The lesions resolve after 12–18 months in most patients. The histopathologic findings are a band-like infiltrate in the superficial dermis, with damage to basal keratinocytes, resulting in apoptotic keratinocytes (Civatte bodies). The inflammatory infiltrate does not extend into the suprabasal keratinocytes. Hyperkeratosis with wedge-shaped hypergranulosis is a common finding. Lichen planus is considerably less common than lichen simplex chronicus or lichen sclerosus. The absence of basal keratinocyte degenerative changes aids in the distinction of lichen simplex chronicus from lichen planus. Lichen planus involves mucosal membranes and other extragenital sites, which is a clinical finding that can also serve to distinguish lichen planus from lichen sclerosus. The histopathologic features useful in differential diagnosis between lichen planus and lichen sclerosus are discussed in the following paragraphs.

Lichen sclerosus (also spelled sclerosis) of the vulva may occur in any age group, including children (Fig. 30.3).[47] In the latter group, the vulvar region represents the most common location, and there is a high incidence of spontaneous involution at the time of puberty.[48] The microscopic features are similar but not identical to those seen in this disorder when it occurs elsewhere in the skin (see Chapter 2) (Fig. 30.4). It has been stated that the minimal histologic criteria for the microscopic diagnosis of lichen sclerosus (LS) are the presence

Figure 30.3 Clinical appearance of vulvar lichen sclerosus.

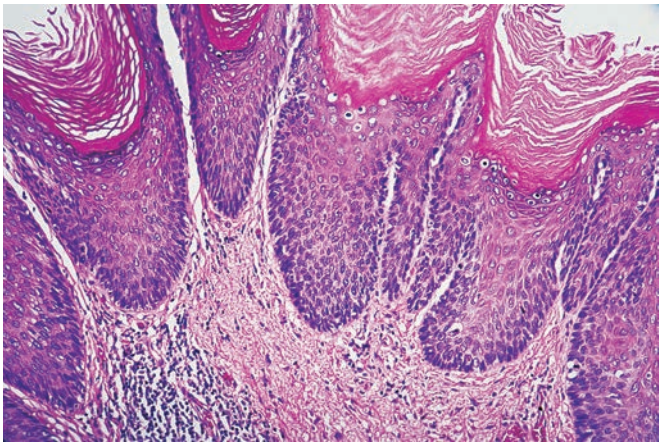

Figure 30.2 Lichen simplex chronicus, with hyperkeratosis, epidermal hyperplasia, and chronic inflammation of the underlying stroma. There is no significant atypia.

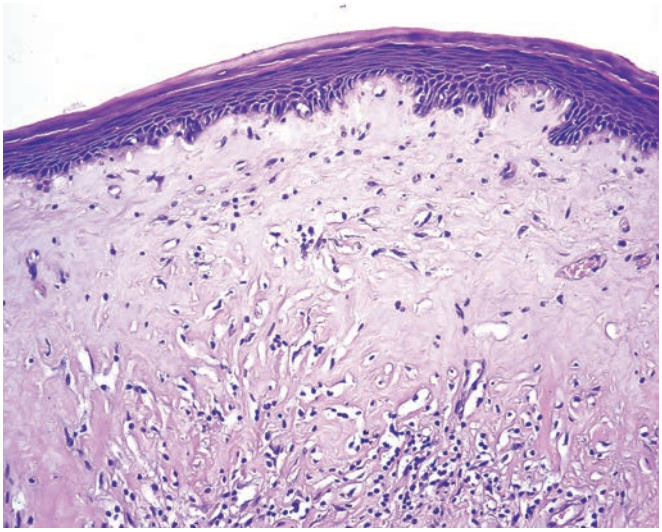

Figure 30.4 Lichen sclerosus of vulva. A thick hypocellular edematous layer is bounded by atrophic epidermis on one side and inflamed stroma on the other.

For personal use only. No other uses without permission. Copyright ©2017. Elsevier Inc. All rights reserved.

of a vacuolar interface reaction pattern in conjunction with dermal sclerosis (homogenized and hyalinized eosinophilic collagen bundles) of any thickness in between the inflammatory infiltrate and the epithelium and/or vessel walls.[49] In the early stages, LS may be difficult to diagnose as it may be indistinguishable from lichen planus.[50] In such cases, the differential diagnosis should be noted, and it can be indicated in the pathology report that with follow-up it will declare itself to be either lichen planus or LS, as in LS the pathognomonic superficial hyalinized collagen will appear. The diagnostic alterations of early LS may be very subtle and often are more prominent in adnexal structures than in the interfollicular skin.[51] The overlying epidermis is characteristically atrophic, but on occasion it may show foci of hyperplasia[52]; however, the presence of hyperplasia in LS, especially as a focal finding, forming a clinically recognizable discrete lesion with an abrupt change from the adjacent atrophic epithelium, should always raise the differential diagnosis of dVIN arising in LS. The presence of basal atypia and altered maturation (loss of the granular cell layer) in the hyperplastic focus is evidence supporting a diagnosis of dVIN.

It is now accepted that LS is a precancerous condition, associated with an increased risk of developing dVIN and HPV-independent squamous cell carcinoma. The risk, however, is relatively small. In one series, squamous cell carcinoma developed in only one of 92 patients,[53] and in another it was found in 12 (4%) of 290 patients followed for a mean period of 12.5 years.[54] In a large (n = 507) prospective study of patients with LS, 0 of 357 patients who were compliant with treatment recommendations developed invasive squamous cell carcinoma or VIN, compared to 7 of 150 patients who were not fully compliant.[55] While many invasive HPV-independent vulvar squamous cell carcinomas are seen in a background of LS at the time of diagnosis, newly diagnosed LS (in the absence of neoplasia) can be managed medically with a relatively low risk of progression. The designation "atypical LS" has been used for cases of LS where there is basal atypia of the atrophic epithelium, greater than would be expected in usual LS.[56] Atypical LS has been reported to show overexpression of p53,[56,57] and atypical LS may well be a step in the pathway towards development of dVIN, but we do not have the ability to render the diagnosis of atypical LS reproducibly, nor do we understand its clinical significance; therefore, it cannot be considered to be a robust clinically relevant diagnosis. In practice, the presence of basal atypia in LS should be documented in the Comment field of the surgical pathology diagnostic report, indicating that it may be associated with increased likelihood of malignant transformation, with recommendation for close follow-up.

Human Papilloma Virus and Vulvar Pathology

The role of HPV in vulvar pathology is analogous to the one it plays in the vagina and cervix, and is discussed in detail in connection with the latter (see Chapter 32). In the vulva, this includes condyloma (acuminatum and flat), as well as high-grade squamous intraepithelial lesion (HSIL) VIN2/3 and HPV-associated invasive squamous cell carcinoma. The vulva differs from the cervix in that there are a significant number of HPV-independent squamous cell carcinomas, unlike in cervix, where virtually all squamous cell carcinomas are HPV-associated. It is becoming apparent that the HPV-independent intraepithelial and invasive squamous cell neoplasms are more aggressive than their HPV-associated counterparts in the vulva.[58–60] Accordingly, attention will be paid to the differences (histopathologic and natural history) between these two subtypes of vulvar squamous neoplasia, which are summarized in Table 30.1. With respect to diagnosis, immunostaining for p16INK4a has emerged as a sensitive and specific surrogate for detection of HPV-associated versus HPV-independent vulvar squamous neoplasia, with sensitivity of 100% and specificity of 98%–99%.[61,62]

Table 30.1 Human Papilloma Virus-dependent and Human Papilloma Virus-independent Vulvar Intraepithelial Neoplasia and Vulvar Squamous Cell Carcinoma

	HPV-ASSOCIATED	HPV-INDEPENDENT
Prevalence in VIN without invasive carcinoma	87%	13%
Prevalence in invasive squamous cell carcinoma	29%	71%
Age (peak incidence)	Sixth decade	Eighth decade
Histologic features of precursor	HSIL (VIN2/3)	Differentiated VIN (dVIN)
Histologic type of invasive carcinoma	Warty/basaloid	Well-differentiated keratinizing
Lichen sclerosus	Generally absent	Often present
Nonsurgical treatment of VIN	Imiquimod and other antiviral/ immunomodulatory treatments effective	No role for antiviral treatment
Survival/prognosis	Less aggressive	Significantly higher recurrence rates and mortality

dVIN, Differentiated vulvar intraepithelial neoplasia; *HPV*, human papilloma virus; *HSIL*, high-grade squamous intraepithelial lesion; *VIN*, vulvar intraepithelial neoplasia.

Staining is most reliably performed on intraepithelial lesions or early invasive carcinomas, as p16 expression can be lost during tumor progression. Polymerase chain reaction (PCR) for HPV DNA allows for viral genotyping and is highly sensitive, but lacks specificity.[60] In situ hybridization for HPV is highly specific, but is more expensive than immunostaining and has a longer turnaround time; however, it can be valuable in establishing HPV status for those cases where the clinical, histomorphologic, and p16 immunostaining data are not concordant.[62] Detection of mRNA of HPV oncogene E6 can be used to establish an etiologic role for HPV by demonstrating that the virus genome is being transcribed. However, such testing is not widely available, and p16 immunostaining is currently the most important surrogate test of HPV status.

Condyloma and Seborrheic Keratosis

Vulvar **condyloma** is a venereal disease caused by HPV, usually type 6. Although according to the 2012 Lower Anogenital Squamous Terminology (LAST) recommendations, these lesions should be diagnosed as (VIN1) (low-grade squamous intraepithelial lesion [LSIL]),[63] the diagnosis of condyloma is well established, while a diagnosis of LSIL may lead to confusion. The diagnosis of VIN1 was not used for vulvar lesions for the 8 years prior to the LAST recommendations, as the 2004 International Society for the Study of Vulvar Diseases had dropped it from recommended terminology as it was generally accepted to not have a specific meaning. It was instead viewed as a collection of different conditions, including low-risk HPV infection.[64] While we are able to endorse LSIL (CIN1) for cervical

For personal use only. No other uses without permission. Copyright ©2017. Elsevier Inc. All rights reserved.

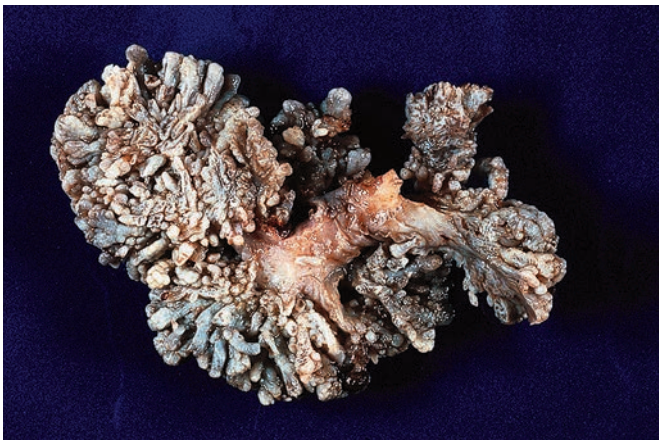

Figure 30.5 Large condyloma of vulva.

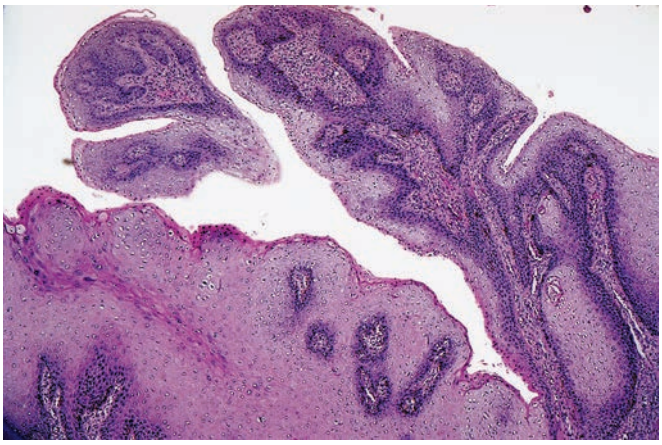

Figure 30.7 Papillomatous shape of vulvar condyloma.

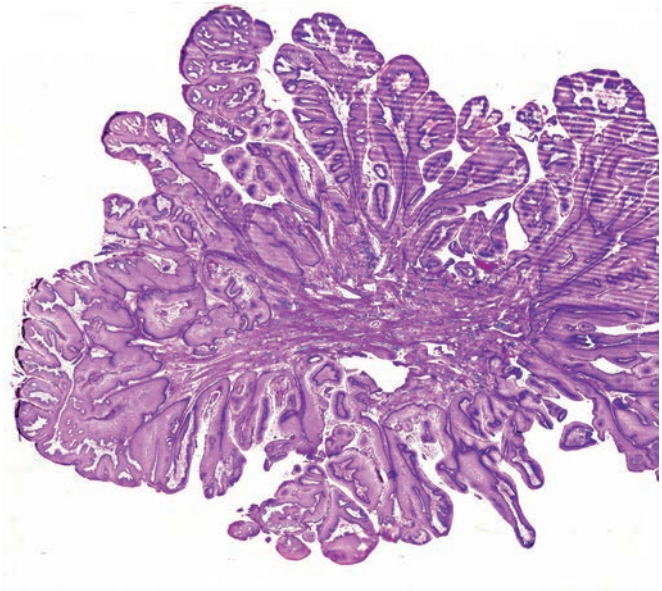

Figure 30.6 Whole mount of condyloma acuminatum of vulva.

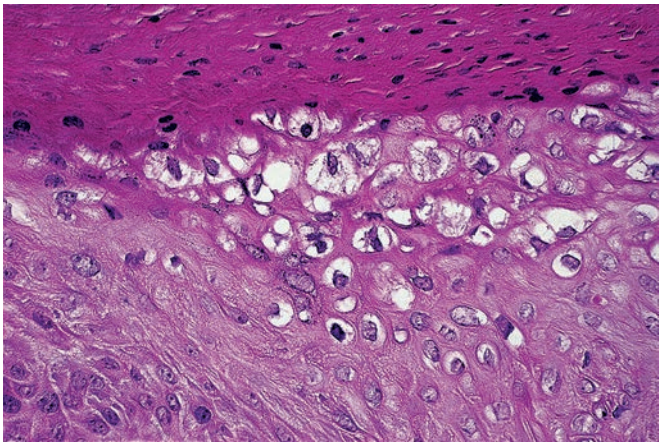

Figure 30.8 Prominent koilocytotic changes in vulvar epithelium.

lesions, we do not recommend adopting this terminology for condylomatous vulvar lesions, and recommend, instead, the diagnosis of "condyloma." The better-known form of condyloma is **condyloma acuminatum,** which is characterized grossly by one or several soft elevated masses of variable size (Fig. 30.5). Microscopically there is a complicated papillary arrangement of well-differentiated undulating squamous epithelium supported by delicate, well-vascularized connective tissue stalks containing mononuclear inflammatory cells (mainly CD4+ and CD8+ cells) (Figs. 30.6 and 30.7).[65] The other form of condyloma, which is actually much more common, is the **flat condyloma** (not to be confused with the *condyloma latum* of syphilis). The cytologic features are similar in both forms. Koilocytosis of the malpighian epithelium and lymphocytic infiltration of the stroma are regular features (Fig. 30.8). Koilocytosis refers to the combination of perinuclear cytoplasmic clearing and wrinkling of the nuclear membrane (nuclear "raisins"). As a rule, this change is not as florid in vulvar condylomas as it tends to be in condylomas of the cervix. A typical condyloma shows minimal basal or parabasal cell atypia, orderly maturation, and a smooth transition to koilocytotic intermediate and superficial cells; mitoses may be numerous but are all typical.[66,67] In contrast, the lesions of VIN2/3 exhibit abnormal mitoses and nuclear pleomorphism, enlargement, and hyperchromasia in the basal and parabasal cell layers, as well as "block positivity" on p16 immunostaining, with strong nuclear and cytoplasmic immunoreactivity in all cells of at least the basal third of the epithelium, but with positivity usually extending into the upper half (see later section). The increased proliferative activity of condyloma (in contrast to fibroepithelial polyp and squamous papilloma) can be easily appreciated with the Ki-67 stain.[68] The DNA content of condylomas is diploid and polyploid (including tetraploidy and octaploidy), in contrast to the aneuploid pattern seen in most cases of VIN2/3.[69]

Sometimes one sees verrucopapillary vulvar lesions that lack the viral cytopathic effects (koilocytic change) of condyloma; these are often referred to as *squamous papillomas* and usually contain genital HPV types by PCR.[70] Conversely, there may be multinucleated atypia of the epithelial squamous cells associated with reactive conditions in the absence of HPV infection.[71] A final consideration in the diagnosis of condyloma in children is that verruca vulgaris, due to HPV2, can occur on the vulva of children and be morphologically indistinguishable from condyloma.[72] It is therefore important to exercise caution in diagnosing condyloma in children (with the implication of a venereal infection/sexual abuse). We recommend that HPV testing to document genital-type HPV be required to support a diagnosis of condyloma in this setting. Another vulvar lesion which needs to be discussed here is the process morphologically indistinguishable from cutaneous seborrheic keratosis, which in this particular

For personal use only. No other uses without permission. Copyright ©2017. Elsevier Inc. All rights reserved.

location is usually associated with HPV infection.[73] The differential diagnosis of condyloma also includes a lesion characterized by *epidermolytic hyperkeratosis*, which could be related to Darier disease or represent a form of Hailey–Hailey disease.[74] The acantholysis is usually suprabasal, but we have also seen it at the level of the granular layer. A final important differential diagnosis is verrucous carcinoma. Despite the name, verrucous carcinoma is not associated with HPV and is part of the spectrum of non-HPV-associated vulvar squamous neoplasia; it is distinguished from condyloma by examination of the epidermal/dermal junction. Verrucous carcinoma is characterized by a distinctive pattern of bulbous downgrowths with pushing margins, and will be discussed in greater detail later in this chapter.

The traditional therapy for condyloma consisted of podophyllin application. Microscopically, this results in epidermal pallor, necrosis of keratinocytes, and marked increase in mitosis; these changes wane after 72 hours and are essentially gone in 1 week.[75] Occasionally, similar microscopic changes are seen in the absence of podophyllin therapy.[76] The treatment of choice for these lesions at present is carbon dioxide laser.[77]

Squamous Intraepithelial Lesions

It is now appreciated that squamous neoplasia of the vulva can be subclassified into HPV-associated and HPV-independent forms, which differ with respect to etiology, age at diagnosis, natural history, and morphology (i.e., they are different diseases). These differences are summarized in Table 30.1. In North America, most preinvasive lesions (VIN) are HPV-associated (HSIL) (VIN2/3) rather than dVIN, while most invasive squamous cell carcinomas are HPV-independent; this is thought to reflect the more rapid progression of dVIN to invasive carcinoma.[60] The presence of an admixture of HPV-associated and HPV-independent squamous neoplasia in the vulva is in contrast to the uterine cervix or vagina, where virtually all squamous neoplasia is HPV-associated. Because of the histopathologic differences between HPV-associated and HPV-independent squamous neoplasia (both intraepithelial and invasive), they will be considered separately in the following sections. It is important to acknowledge that clinical and morphologic features (based on examination of H&E stained slides) cannot distinguish between HPV-associated and HPV-independent squamous neoplasia in every case; however p16 immunostaining is a sensitive (100%) and specific (>98%) marker of HPV-associated squamous neoplasia in the vulva.[61,62] Interpretation of p16 immunostaining, as for cervical lesions, is based on the presence or absence of "block" positivity, defined as intense nuclear and cytoplasmic staining of *every* cell in the basal third of the epithelium (Fig. 30.9). p16 positivity, so defined, is evidence of HPV-associated VIN or invasive squamous cell carcinoma. Note that p16 staining intensity often decreases in the superficial layers of HSIL (VIN2/3), as the neoplastic squamous epithelium undergoes maturation.

Human Papilloma Virus-Associated Squamous Intraepithelial Neoplasia: High-Grade Squamous Intraepithelial Lesion (VIN2/3)

The in situ or pre-invasive lesion of HPV-associated vulvar squamous neoplasia is, as noted previously, referred to as HSIL or high-grade vulvar intraepithelial neoplasia (VIN2/3) and is entirely analogous to equivalent lesions in the vagina (VaIN2/3), cervix (CIN2/3), or anal mucosa (AIN2/3).[63] The recommended terminology for preinvasive lesions associated with oncogenic HPV (most commonly HPV16 or 18, but a number of other oncogenic HPV genotypes have also been reported), according to the LAST recommendations, is HSIL (VIN2 or VIN3).[63] In practice, it is not possible to reproducibly distinguish between VIN2 and VIN3, nor is the distinction clinically relevant. It has been proposed that VIN2 be used for cases where the "dysplasia" does not extend into the upper third of the squamous epithelium, while VIN3 be diagnosed in cases with full-thickness or near-full-thickness dysplasia; biologically this is a curious proposition, as all cells in VIN2/3 are neoplastic and transformed by oncogenic HPV (i.e., the full thickness of the epithelium is replaced by a clonal neoplastic proliferation, irrespective of whether there is some degree of flattening or maturation of the superficial cells). Any distinction between VIN2 and VIN3, accordingly, is arbitrary, and one may simply call all such cases VIN3 or VIN2/3, in practice. If this seems a touch iconoclastic, it is worth noting that according to the 2004 recommendations of the International Society for the Study of Vulvovaginal Disease, the diagnosis of "high-grade VIN" was used for all lesions that would be diagnosed as VIN2 or VIN3 according to the LAST criteria,[64] and many of us used this simplified system for almost a decade and found it entirely satisfactory.

HSIL (VIN2/3) usually presents as a slightly elevated, plaque-like lesion with a red velvety appearance.[78] It is typically centered in the labia majora, and it may extend to the perineum and anus. Microscopically, there is hyperkeratosis and parakeratosis, acanthosis, and a variable number of multinucleated dyskeratotic cells and abnormal mitoses involving the entire thickness of the epidermis (Fig. 30.10). The acrotrichium (intraepidermal portion of the hair follicle) is often involved, whereas the acrosyringium (intraepidermal portion of the sweat gland) is usually spared.[79,80] On occasion, the tumor cells are arranged in a nested pattern and/or have a clear cytoplasm, thus simulating Paget disease.[81,82] The lesions of HSIL (VIN2/3) may be uniformly composed of cells with high N:C ratio (basaloid pattern VIN2/3) or there may be maturation as the cells move toward the

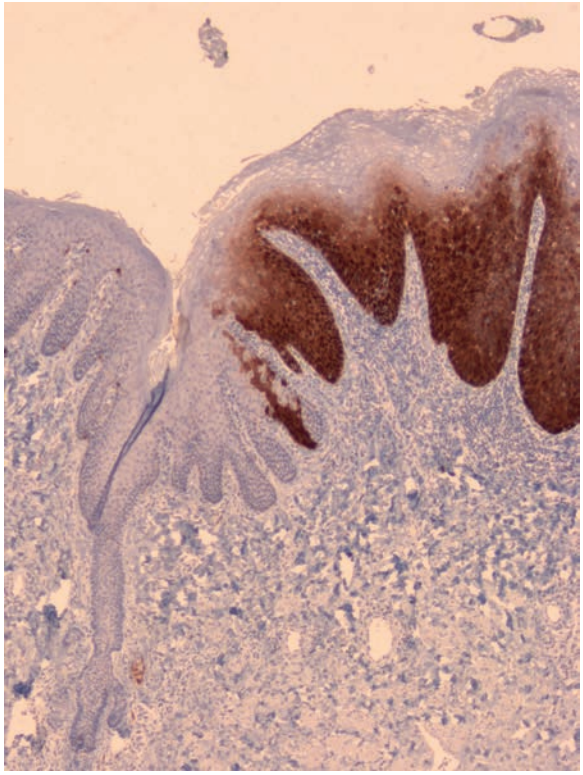

Figure 30.9 "Block" immunoreactivity for p16, with strong nuclear and cytoplasmic staining of all cells of at least the basal third of the epithelium, in HSIL (VIN2/3), as a surrogate test for the presence of oncogenic HPV.

For personal use only. No other uses without permission. Copyright ©2017. Elsevier Inc. All rights reserved.

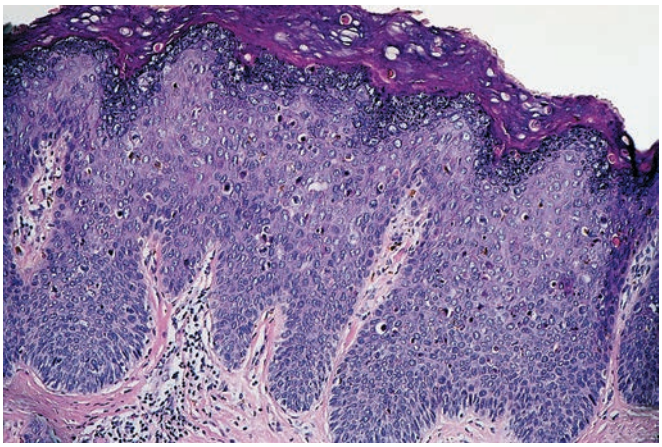

Figure 30.10 Typical microscopic appearance of HSIL (VIN2/3).

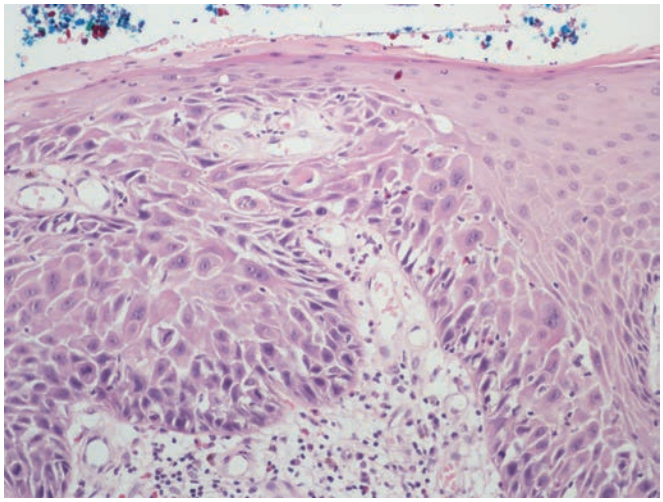

Figure 30.11 Differentiated VIN (dVIN), showing basal epithelial atypia.

surface, with epithelial hyperplasia and koilocytic change (warty pattern VIN2/3). This latter pattern can mimic condyloma but shows greater atypia, as well as block p16 positivity.

The type of HSIL (VIN2/3) that was, historically, designated as *bowenoid papulosis* presents as multiple, often pigmented, papules in or near the vulva of young patients. Clinically, they resemble verrucae, small condylomas, or nevi, but microscopically they show striking cytologic atypia, similar to that of Bowen disease/usual HSIL.[83] It is important to note that the terms Bowen disease and Bowenoid papulosis may be used clinically but the pathologic diagnosis is HSIL (VIN2/3) for both, as there are no histopathologic features for reliably distinguishing between them. The designations of "warty" or "basaloid" VIN similarly are not routinely used in practice, as they are not of clinical significance.

It has been stated that, if left untreated, HSIL (VIN2/3) will progress into invasive carcinoma in approximately 10% of cases, but the rate of transformation varies widely among the different series.[84] The therapy for HSIL (VIN2/3) depends on the age of the patient and the size, configuration, and distribution of the lesions.[84] Localized lesions can be treated by wide local excision, skinning vulvectomy, laser, or topical therapy.[85] Imiquimod, an immune-response modulator, can be used to treat HSIL (VIN2/3), with many lesions showing a response, sometimes a complete response.[86]

It is anticipated that with increasingly widespread use of vaccination against HPV, cases of HSIL (VIN2/3) will start to decrease in the coming years. It has been increasing, especially in younger women. The frequent history of an abnormal cervical smear is important, and all patients with a past history of HSIL or HPV-associated squamous cell carcinoma elsewhere in the lower anogenital tract are at increased risk for vulvar disease.

Human Papilloma Virus-Independent Squamous Intraepithelial Neoplasia: Differentiated Vulvar Intraepithelial Neoplasia

VIN of differentiated type (dVIN) is consistently negative for HPV, arises in elderly women, is frequently associated with squamous hyperplasia and LS, and is related to invasive squamous cell carcinoma of keratinizing type.[56,87–89] Microscopically, it is characterized by (1) epidermal hyperplasia with parakeratosis and elongated and anastomosing rete ridges, (2) significant basal cytologic atypia, and (3) cells with abundant eosinophilic cytoplasm (Fig. 30.11).[89] It is increasingly appreciated that dVIN is under-recognized in clinical practice, as the aforementioned changes may not all be present or may be subtle.[90,91] Immunostaining is of limited use as a diagnostic adjunct, as Ki-67 staining intensity overlaps with that of reactive conditions in the differential diagnosis, and there is a variable pattern of p53 expression; while some cases show complete loss or convincing overexpression of p53, consistent with underlying *TP53* mutations, this is not a consistent finding.[89,92–94] p16 immunostaining is consistently negative (i.e., lacking the block positivity associated with oncogenic HPV-associated VIN). It is important to note that HPV-independent VIN may be higher grade and may even mimic the basaloid pattern seen in HSIL (VIN2/3).[95] This variant of HPV-independent VIN can be distinguished from HPV-associated HSIL (VIN2/3) by p16 immunostaining; as well, it typically shows abnormal p53 immunoreactivity (complete absence or strong diffuse positivity), in our experience. What to call such a lesion is another matter, as it is not adequately addressed in current classification systems. Poorly differentiated dVIN presents itself as a potential designation (to join other oxymoronic diagnoses such as large cell variant of small cell carcinoma or oxyphilic variant of clear cell carcinoma), but it may be preferable to simply diagnose it as an HPV-independent high-grade squamous intraepithelial lesion and explain the unconventional terminology in the comment field of your report. dVIN is infrequently diagnosed in the absence of invasive squamous cell carcinoma, suggesting that it progresses rapidly to invasion. This view is supported by a small case series of dVIN without invasive carcinoma, where most patients developed invasive carcinoma, with a median interval between diagnosis of dVIN and invasive carcinoma of 1.9 years, a significantly worse outcome than for HSIL (VIN2/3).[60]

Vulvar acanthosis with altered differentiation (VAAD) is characterized by marked acanthosis, a variable verruciform architecture, loss of the granular layer, cytoplasmic pallor at the surface, and multilayered parakeratosis. It has been suggested that VAAD (which is consistently negative for HPV) may be a precursor or a risk factor for verrucous carcinoma.[96]

Invasive Squamous Cell Carcinoma

General Features

Squamous cell carcinoma accounts for approximately 95% of the malignant tumors of this organ.

For personal use only. No other uses without permission. Copyright ©2017. Elsevier Inc. All rights reserved.

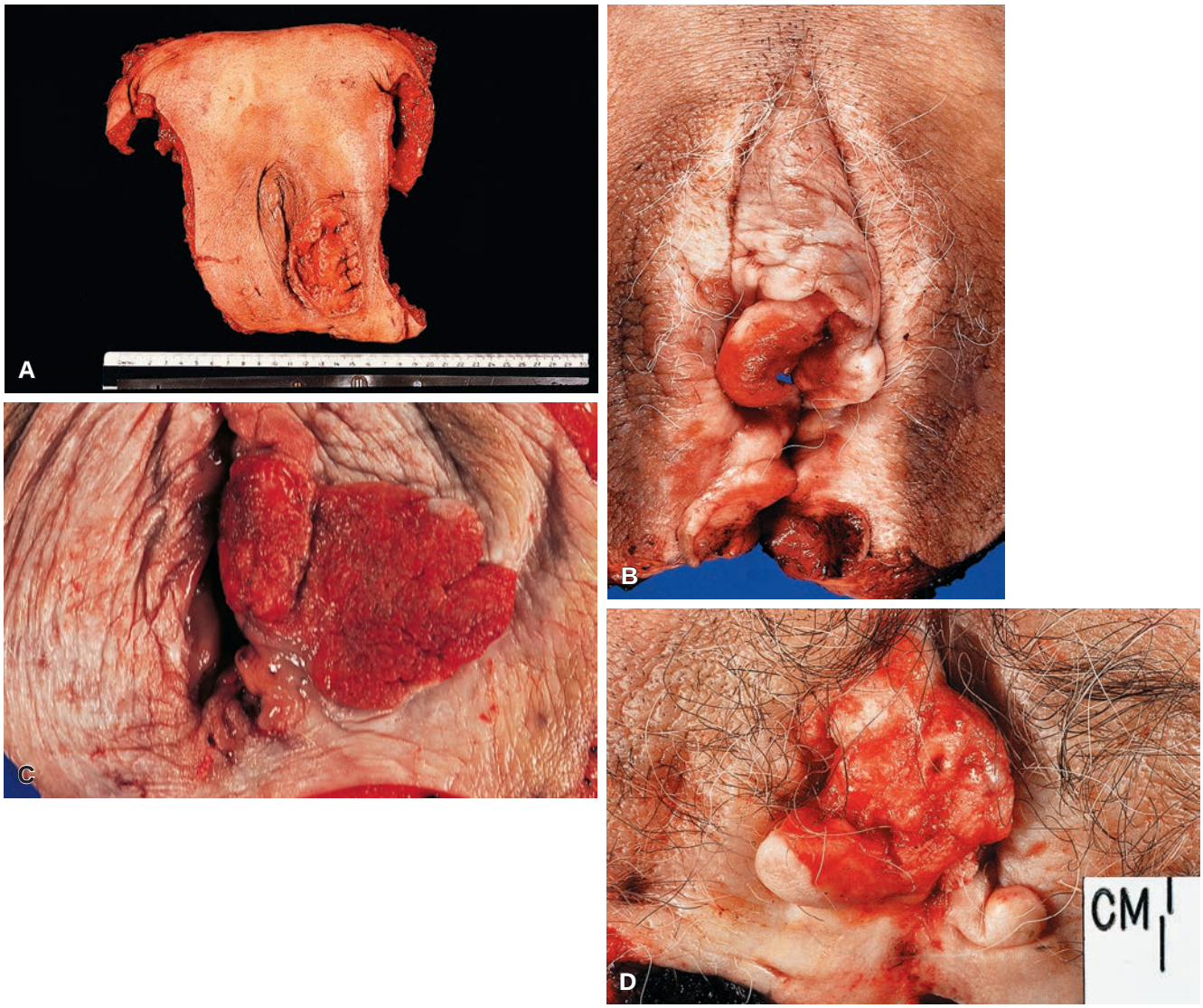

Figure 30.12 Gross Appearance of Invasive Squamous Cell Carcinoma of Vulva. A, Tumor of labium majus. **B**, Tumor of clitoris. **C**, Tumor involving both labia. **D**, Huge tumor mass involving all vulvar structures.

Invasive squamous cell carcinoma of the vulva arises most commonly on the labia majora but may be found on the labia minora or in the region of the clitoris (Fig. 30.12).[97] The immunohistochemical features of vulvar squamous cell carcinoma are not distinctive.

Human Papilloma Virus-Associated Invasive Squamous Cell Carcinoma

HPV-associated invasive squamous cell carcinomas are less common than HPV-independent carcinomas of the vulva.[98,99] Patients with HPV-associated disease are, on average, a decade or more younger than those with HPV-independent tumors, and they often have a history of prior cervical cytology abnormality, cervical intraepithelial neoplasia (CIN), or cervical carcinoma. It is curious that the vulvar squamous cell carcinomas that develop after a successfully treated cervical squamous cell carcinoma appear to be derived from the same malignant clone, but behave more like an independent primary vulvar carcinoma than a metastasis.[100] HPV-associated squamous cell carcinomas are more common in patients who are immunocompromised. Morphologically, most HPV-associated carcinomas are of basaloid or warty pattern (Fig. 30.13); however a significant minority are well or moderately differentiated keratinizing carcinomas,[62] and thus are morphologically indistinguishable from HPV-independent carcinomas. Warty-pattern carcinoma[101] should not be confused with verrucous carcinoma, despite the fact that the gross appearance of the latter has sometimes been described as "warty." The term "warty pattern carcinoma," if used at all, should be reserved for the squamous cell carcinomas in which the tumor cells display marked pleomorphism, enlargement, atypia, and multinucleation. These features are often associated with koilocytotic atypia in the adjacent epithelium. Basaloid-pattern carcinoma[101] has an appearance analogous to its counterpart in the upper aerodigestive tract and penis. Peripheral palisading is prominent (see Fig. 30.13). Typical HSIL (VIN2/3) may be found adjacent to the invasive carcinoma, and is strong evidence that the carcinoma is HPV-associated.

For personal use only. No other uses without permission. Copyright ©2017. Elsevier Inc. All rights reserved.

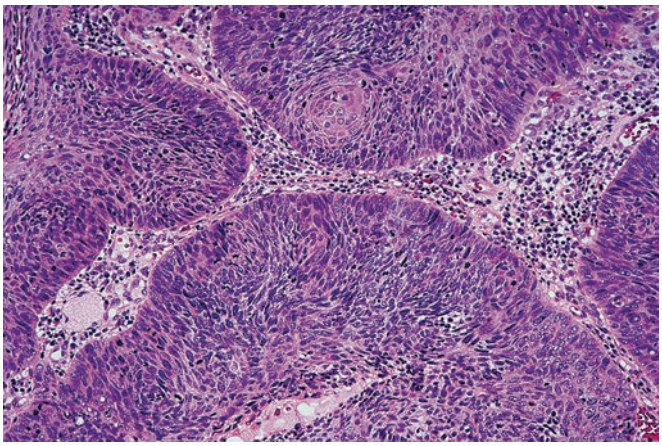

Figure 30.13 Basaloid-pattern invasive squamous cell carcinoma of vulva, a pattern typical of HPV-associated vulvar squamous cell carcinoma. Note the peripheral palisading and deep basophilic staining pattern.

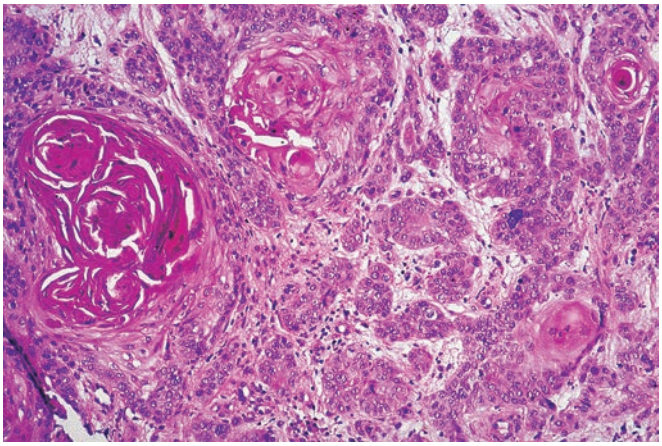

Figure 30.14 Microscopic appearance of invasive well-differentiated keratinizing squamous cell carcinoma of vulva. Such tumors are typically HPV-independent.

Human Papilloma Virus-Independent Invasive Squamous Cell Carcinoma

HPV-independent vulvar squamous cell carcinoma occurs in older women and often is in the setting of lichen sclerosus. Most HPV-independent squamous cell carcinomas are well or moderately differentiated keratinizing squamous cell carcinomas (Fig. 30.14). dVIN may be present at the edge of the lesion, a finding that supports the interpretation that you are dealing with an HPV-independent squamous cell carcinoma. HPV-independent squamous cell carcinoma may be high-grade and, rarely, sarcomatoid, either at presentation or with progression from a more differentiated carcinoma, in the course of recurrence(s). Verrucous carcinoma is a distinctive variant of HPV-independent carcinoma, and will be discussed in a later section.

Spread and Metastases

Regional lymph node metastases occur in approximately 20% of cases.[102] Tumors of the labia spread first to inguinal lymph nodes, whereas those located in the clitoris may metastasize directly into the deep nodes. It should be noted that ulceration and inflammation in vulvar carcinoma often lead to reactive enlargement of inguinal lymph nodes, which may be confused clinically with metastatic disease, so clinical assessment of nodal status is unreliable.

The technique of sentinel lymph node biopsy is used as a staging criterion and therapeutic guide for vulvar carcinoma,[103] and this procedure is highly accurate in predicting the inguinofemoral lymph node status of those patients.[104] The optimal protocol for handling sentinel nodes upon receipt in the laboratory, and the significance of micrometastases or isolated tumor cells, specifically with respect to sentinel nodes associated with vulvar squamous cell carcinoma, remain to be determined; however, the eighth edition of the American Joint Committee on Cancer's *AJCC Cancer Staging Manual* now includes a pN0(i+) category for isolated tumor cells (Table 30.2).[105]

Therapy

The usual treatment of invasive carcinoma is radical vulvectomy with bilateral radical inguinal lymph node dissection.[106] Iliac lymphadenectomy and pelvic exenteration are reserved for advanced cases.[107] Conversely, early cases can be treated with a more conservative approach in the form of wide local excision;[108] it has been shown that leaving a 1-cm tumor-free surgical margin results in a high rate of local control.[109] Alternative methods include radiation therapy (either alone or together with chemotherapy[110]) and the combination of wide local excision and radiation therapy.[111,112]

Prognosis

The overall 5-year survival rate in patients treated for vulvar squamous cell carcinoma has been in the 50%–75% range in most large series.[112–114]

1. *Stage*. The most important prognostic factors are included in the staging system and are represented by *tumor diameter*, *depth of invasion*, and *lymph node status*.[109,113,114,115–117] The latter is by far the most significant parameter.[118,119]
2. *Extracapsular nodal spread*. In cases with involved nodes, the presence of extracapsular spread and large size of the metastatic focus are poor prognostic indicators.[120,121]
3. *HPV status.* As noted previously, HPV-associated vulvar carcinomas are associated with a more favorable prognosis, as has also been seen for squamous cell carcinomas of the head and neck. Infiltrative margins,[122,123] fibromyxoid stromal response,[124] and abnormal p53 immunostaining[125,126] are all features that are reported to be prognostic indicators, but also are associated with HPV-independent carcinomas, so it is not clear whether their prognostic significance is independent of HPV status.

Superficially Invasive Squamous Cell Carcinoma

The term *superficially invasive squamous cell carcinoma* is a "Histologic Type" designation in the widely used 2016 update to the College of American Pathologists Protocol for Examination of Specimens from Patients with Carcinoma of the Vulva.[127] This refers to those carcinomas in which the depth of penetration is less than 1 mm (see Fig. 30.13). **Depth of invasion in vulvar carcinoma is the measurement in millimeters from the epithelial-stromal junction of the adjacent, most superficial dermal papilla to the deepest point of invasion.** It should be noted, with humility, that there is suboptimal reproducibility in pathologists' assessments of whether there is invasion, and in measuring the depth of invasion; when 11 pathologists reviewed 50 cases, the number considered to show invasive squamous cell carcinoma ranged from 21 to 44, depending

For personal use only. No other uses without permission. Copyright ©2017. Elsevier Inc. All rights reserved.

Table 30.2 Definitions of American Joint Committee on Cancer TNM: Vulva

DEFINITION OF PRIMARY TUMOR (T)		
T CATEGORY	**FIGO STAGE**	**T CRITERIA**
TX		Primary tumor cannot be assessed
T0		No evidence of primary tumor
T1	1	Tumor confined to the vulva and/or perineum Multifocal lesions should be designated as such. The largest lesion or the lesion with the greatest depth of invasion will be the target lesion identified to address the highest pT stage. Depth of invasion is defined as the measurement of the tumor from the epithelial-stromal junction of the adjacent most superficial dermal papilla to the deepest point of invasion.
T1a	IA	Lesions 2 cm or less, confined to the vulva and/or perineum, and with stromal invasion of 1.0 mm or less.
T1b	IB	Lesions >2 cm, or any size with stromal invasions of >1.0 mm, confined to the vulva and/or perineum
T2	II	Tumor of any size with extension to adjacent perineal structures (lower/distal third of the urethra, lower/distal third of the vagina, anal involvement)
T3	IVA	Tumor of any size with extension to any of the following—upper/proximal two-thirds of the urethra, upper/proximal two-thirds of the vagina, bladder mucosa, or rectal mucosa—or fixed to pelvic bone
DEFINITION OF REGIONAL LYMPH NODE (N)		
N CATEGORY	**FIGO STAGE**	**N CRITERIA**
NX		Regional lymph nodes cannot be assessed
N0		No regional lymph node metastasis
N0(i+)		Isolated tumor cells in regional lymph node(s) no >0.2 mm
N1	III	Regional lymph node metastasis with one or two lymph node metastases each <5 mm, or one lymph node metastasis ≥ 5 mm
N1a[a]	IIIA	One or two lymph node metastases, each <5 mm
N1b	IIIA	One lymph node metastasis = 5 mm
N2		Regional lymph node metastasis with three or more lymph node metastases, each <5 mm, or two or more lymph node metastases = 5 mm, or lymph node(s) with extranodal extension
N2a[a]	IIIB	Three or more lymph node metastases, each <5 mm
N2b	IIIB	Two or more lymph node metastases ≥ 5 mm
N2c	IIIC	Lymph node(s) with extranodal extension
N3	IVA	Fixed or ulcerated regional lymph node metastasis
DEFINITION OF DISTANT METASTASIS (M)		
M CATEGORY	**FIGO STAGE**	**M CRITERIA**
M0		No distant metastasis (no pathologic M0; use clinical M to complete stage group)
M1	IVB	Distant metastasis (including pelvic lymph node metastasis)

[a]Includes micrometastasis, N1mi and N2mi.
Note: The site, size, and laterality of lymph node metastases should be recorded.
From Amin MB, Edge S, Greene F, et al. eds.. *AJCC Cancer Staging Manual.* vol. 8. New York: Springer; 2017.

For personal use only. No other uses without permission. Copyright ©2017. Elsevier Inc. All rights reserved.

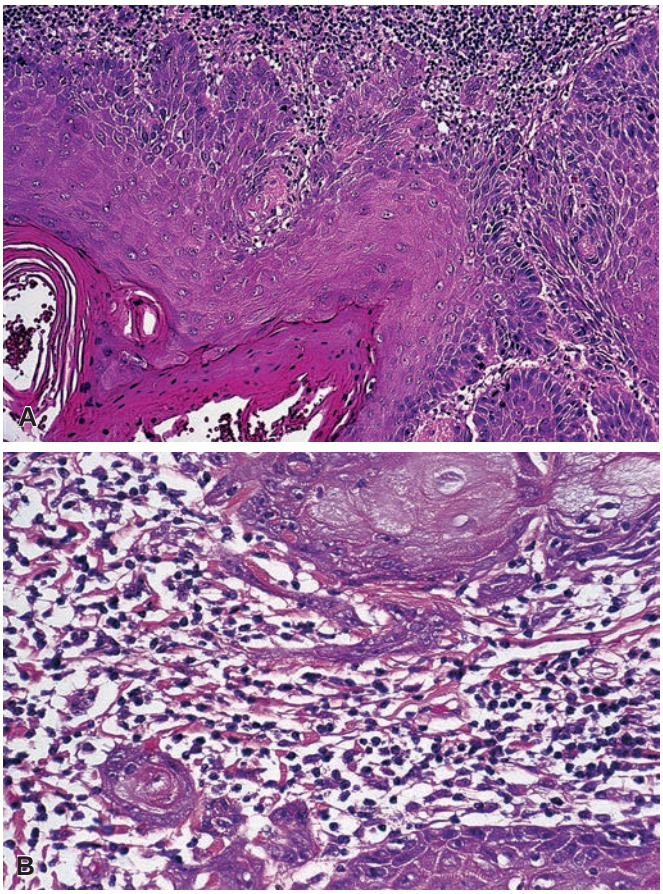

Figure 30.15 Superficial Invasive Squamous Cell Carcinoma. **A**, Low-power appearance. **B**, High-power view, showing small clusters of tumor cells detaching from the in situ component and invading a heavily inflamed stroma. All invasive cells are present within 1 mm of the overlying epidermal-dermal junction.

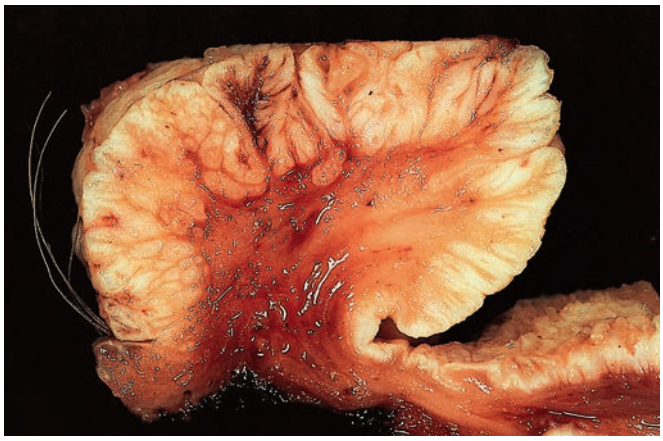

Figure 30.16 Cut surface of verrucous carcinoma of vulva. (Courtesy of Dr Pedro J Grases Galofré; from Grases Galofré PJ. Patología ginecológica. *Bases para el diagnóstico morfológico.* Barcelona: Masson; 2002)

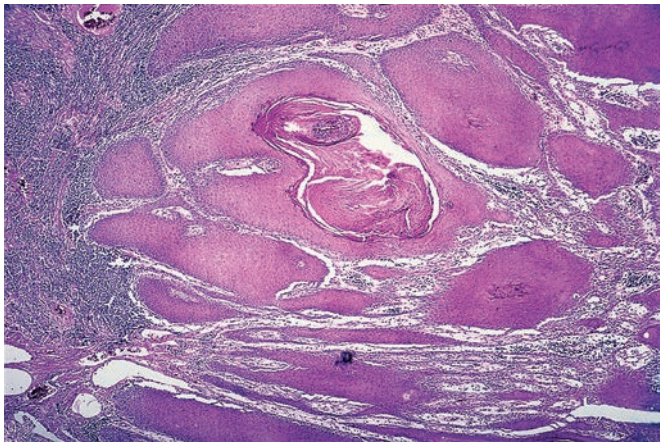

Figure 30.17 Bulbous pegs of well-differentiated squamous cells infiltrate the stroma in vulvar verrucous carcinoma.

on the reviewing pathologist.[128] This limitation notwithstanding, in those tumors where depth of invasion is considered to be less than 1 mm (Fig. 30.15), consideration can be given to forgoing lymph node sampling, although some oncologists would offer even these patients sentinel lymph node biopsy.

Verrucous carcinoma is a reasonably distinctive type of squamous cell carcinoma of the vulva, similar to its more common counterpart in the upper aerodigestive tract. It may grow to quite large dimensions, has a typical exophytic appearance, and infiltrates locally (Figs. 30.16 and 30.17). Metastases are practically nonexistent,[129,130] and therefore inguinal lymphadenectomy is not indicated.

The differential diagnosis of verrucous carcinoma includes condyloma acuminatum and conventional squamous cell carcinoma. It is distinguished from the former by its generally larger size and the presence of club-shaped fingers of epithelium invading the underlying stroma in a well-circumscribed ("pushing") fashion.[131] The distinction from squamous cell carcinoma rests entirely on two criteria, which often go together: the presence in the latter of cytologic atypia and/or a clearly infiltrative pattern of growth. The occurrence of either of these features removes the lesion from the verrucous carcinoma category and puts it into the squamous cell category. Immunohistochemically, staining for keratin is more uniform and homogeneous in verrucous carcinoma than in squamous cell carcinoma.[132]

Paget Disease

Paget disease is a malignant tumor of the vulva that can be subclassified as primary Paget disease, or secondary Paget disease when it represents spread from an underlying carcinoma of rectum, bladder, or endocervix. The former is far more common in practice, and will be the focus of the following discussion. Paget disease is a vulvar adenocarcinoma of uncertain histogenesis. It could be viewed as a sweat gland carcinoma arising primarily from the intraepidermal portion of the glands (acrosyringium),[133] as a carcinoma of multipotential (adnexal stem cells) residing in the infundibulo-sebaceous unit of the hair follicles and other adnexal structures that differentiate along glandular (sweat gland) lines,[134] or as being derived from a population of CK7-positive clear cells associated with the openings of the ducts of the mammary-like glands of the vulva, known as Toker cells.[135]

Clinically, Paget disease presents as a crusting, elevated scaling erythematous rash in the labia majora, labia minora, and/or perineal skin of adult and elderly patients (Fig. 30.18). Microscopically, the epidermis contains large pale tumor cells that form solid nests, glandular spaces, or a continuous layer along the epidermal basement membrane and also in pilosebaceous structures and sweat ducts

For personal use only. No other uses without permission. Copyright ©2017. Elsevier Inc. All rights reserved.

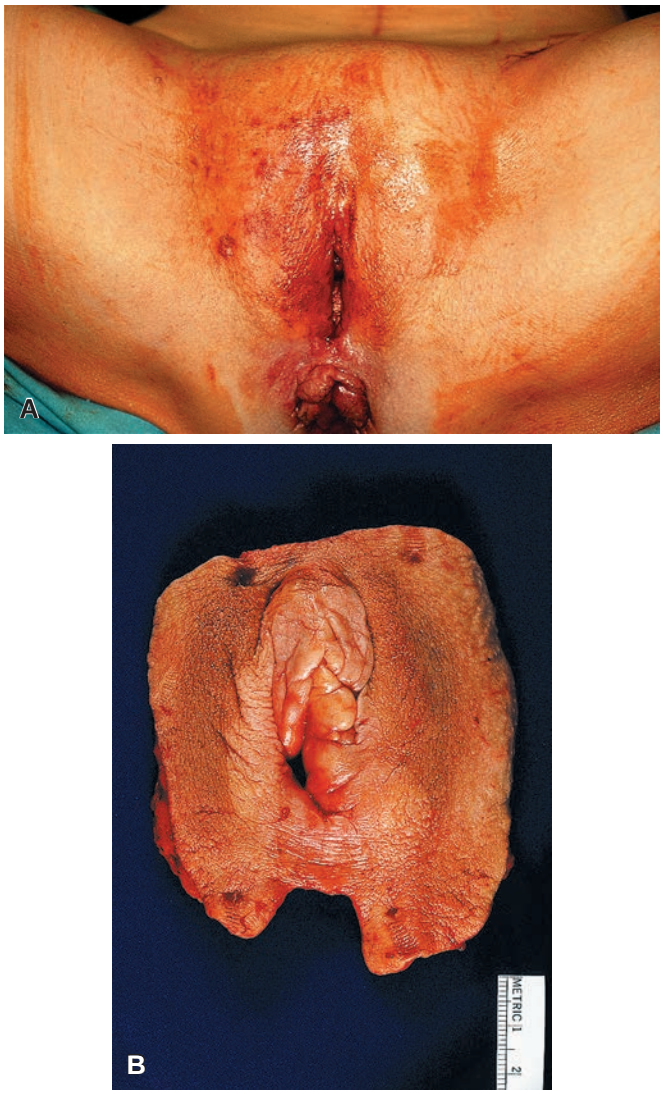

Figure 30.18 **A** and **B**, Clinical and gross appearance of vulvar Paget disease. In both cases the disease is very extensive.

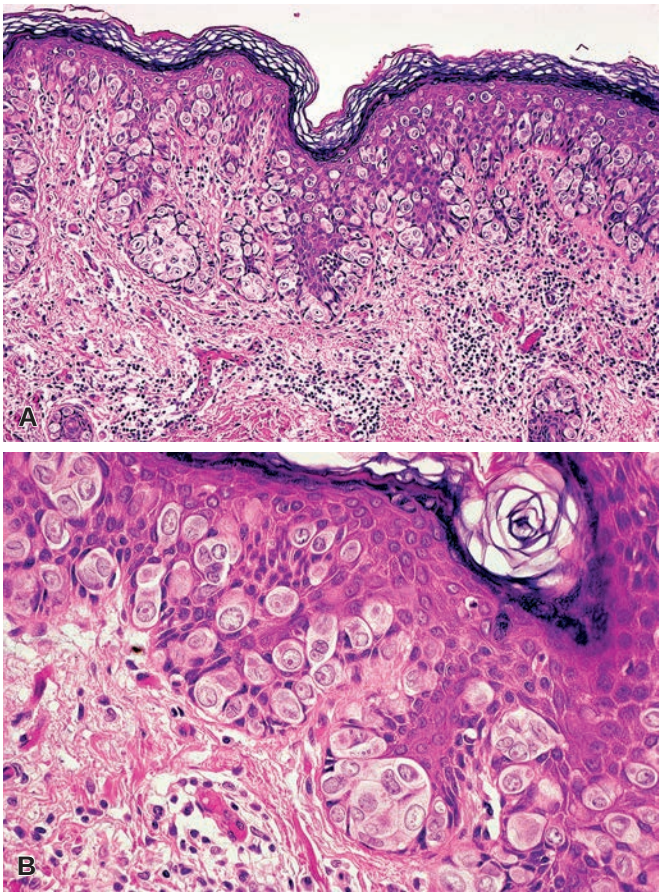

Figure 30.19 **A** and **B**, Low- and medium-power appearances of vulvar Paget disease. The large clear tumor cells are distinct from the malpighian layer.

(Fig. 30.19). A cleft often develops between the row of malignant cells and the overlying keratinocytes, resulting in a low-power appearance sometimes reminiscent of an acantholytic suprabasal bulla. Paget disease can also be misinterpreted as malignant melanoma. It should be noted that the presence of melanin granules in some tumor cells *does not* rule out the diagnosis of Paget disease. Histochemically, some or all of the tumor cells contain acidic mucin, as evidenced by their positivity for Mayer mucicarmine and aldehyde fuchsin stains.[136] Immunohistochemically, these mucins are positive for MUC1 and MUC5AC, the latter in striking contrast with Paget disease of the breast.[137,138] They are also reactive for HGM-45, a marker associated with gastric surface mucous cells.[139] Vulvar Paget disease also expresses pankeratin, cytokeratin 7 (CK7), epithelial membrane antigen (EMA), carcinoembryonic antigen (CEA), B72.3, and GCDFP-15 (a marker of apocrine differentiation) (Fig. 30.20).[140–144] S-100 protein is positive in up to one-third of the cases, depending on the immunostaining protocol used, and HMB-45 and Melan-A are negative.[145,146] There is also negativity for CDX-2, in contrast to a secondary Paget disease associated with rectal carcinoma.[147] Vulvar Paget disease variably expresses estrogen and progesterone receptors and frequently expresses androgen receptor.[148,149]

Regarding the keratins, the usual profile of primary vulvar Paget disease is CK7+/CK20–.[150,151] If it is instead CK20+ (and GCDFP-15 negative), the possibility of secondary Paget disease (especially of rectal or urothelial nature) should be suspected.[150,152] Confirmation of the latter can be obtained with uroplakin-III immunostains.[153] A recent study has reported that nuclear GATA3 expression is typical of primary vulvar Paget disease, a potential diagnostic pitfall when considering secondary urothelial carcinoma.[154] Overexpression and amplification of HER2 is found in a subset of cases.[155]

As already indicated, Paget disease of the vulva differs in several respects from Paget disease of the breast. The latter is nearly always associated with an underlying carcinoma, which may be intraductal or invasive, and the intraepidermal malignant cells are more often than not mucin-negative. In contrast, the majority of the cases (about 90%) of vulvar Paget disease are not associated with an invasive carcinoma[156] and are usually (although not always) positive for mucin stains, as previously noted.[157–159] The incidence of invasive carcinoma ("invasive Paget disease") in primary vulvar Paget disease ranges from 0%–30% depending on the series,[160–162] with some of the invasive cases being in the microinvasive or minimally invasive (>1 mm) category, a finding not associated with lymph node or distant metastases, based on a limited number of reported cases.[163]

If no invasive component is found in the resected specimen, the prognosis is good. Metastases do not occur under these circumstances, although local recurrence is common (about 30%), sometimes in the form of invasive carcinoma.[156,163,164] Therefore, excision should include a margin of normal skin and the underlying subcutaneous

For personal use only. No other uses without permission. Copyright ©2017. Elsevier Inc. All rights reserved.

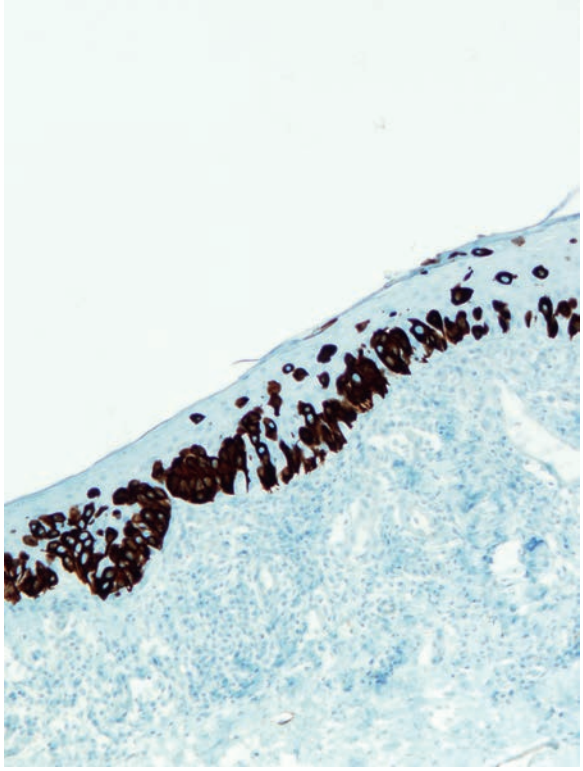

Figure 30.20 Cytokeratin 7 expression in vulvar Paget disease.

tissue. Unfortunately, the microscopic extent of the disease is often greater than that suspected from clinical examination, and this should be taken into account at the time of surgery.[165] The status of resection margins is only minimally related to the incidence of local recurrence.[163] In some instances local recurrence has been seen in the vulvar split-thickness skin graft.[166] Cases of Paget disease with an invasive component beyond the microinvasive stage have a high likelihood of nodal involvement.[163]

Other Epithelial Tumors

Hidradenoma papilliferum is a benign vulvar tumor that usually presents as a small, well-circumscribed nodule covered by normal skin. Occasionally, it ulcerates through the skin and clinically may simulate carcinoma. Microscopically, it has a complex papillary glandular pattern, with stratification and some degree of pleomorphism and mitotic activity, sometimes brisk.[167] A myoepithelial layer is always apparent (Fig. 30.21). Traditionally, this tumor has been regarded as being of sweat gland origin. However, its close morphologic and immunohistochemical similarity to intraductal papilloma of the breast and nipple adenoma suggests an origin from vulvar mammary-like tissue. All acceptable examples of this tumor have behaved in a benign fashion.[168,169] However, a case of intraductal carcinoma of mammary-type apocrine epithelium has been reported as arising from this tumor.[170]

Benign lesions of epidermal or skin adnexal type occur in the vulva. These include *verruca vulgaris*,[72] *syringoma*,[171] *chondroid syringoma* (benign mixed tumor),[172] *myoepithelioma*,[173] *pigmented apocrine hamartoma*,[174] *adenolipoma*,[175] *benign pilar tumor*,[176] *other trichogenic tumors*,[177] *warty dyskeratoma*,[178] and *inverted follicular keratosis*.[179] Although not necessarily a benign skin adnexal tumor, we thought of mentioning here also the occasional occurrence of vulvar *keratoacanthoma*.[180,181]

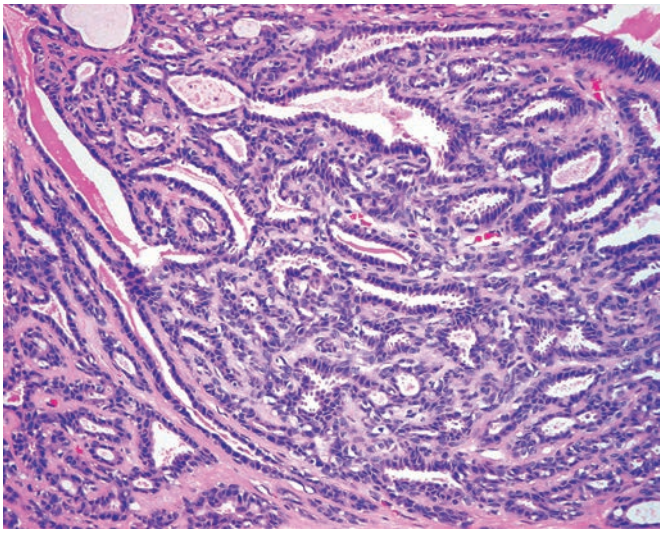

Figure 30.21 Hidradenoma papilliferum of vulva. This tumor probably arises from ectopic breast tissue.

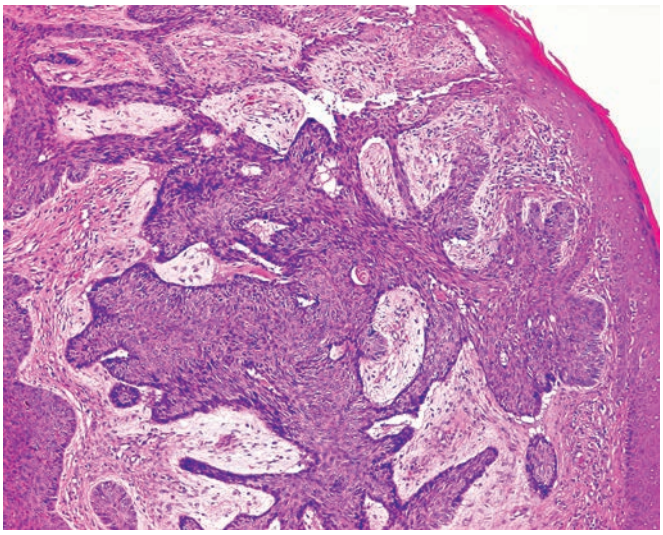

Figure 30.22 Basal cell carcinoma of vulva. It is important to distinguish this tumor from squamous cell carcinoma, especially the basaloid variant of the latter.

Basal cell carcinoma of the vulva usually presents as a nodular mass in the labia majora of elderly patients; it may grow very large and ulcerate.[182,183] Its microscopic appearance and behavior are the same as those of basal cell carcinomas elsewhere in the skin, and solid, keratotic, and adenoid types have been described (Fig. 30.22). The differential diagnosis includes HPV-associated squamous cell carcinoma with a basaloid pattern.[101] It should be remembered that, as elsewhere in the skin, basal cell carcinoma may exhibit abrupt squamous differentiation of possible follicular type, a change that does not affect the natural history of the lesion; such tumors should not be referred to as basosquamous carcinomas.

The incidence of nodal metastases in vulvar basal cell carcinoma is extremely low and is largely restricted to deeply invasive lesions.[183]

Merkel cell carcinoma has been reported in the vulva, sometimes in association with HPV-associated squamous neoplasia (invasive or intraepithelial).[184,185] Its behavior has been very aggressive.[186]

For personal use only. No other uses without permission. Copyright ©2017. Elsevier Inc. All rights reserved.

In a single case tested, there was no evidence of Merkel cell polyomavirus.[185]

Sweat gland carcinoma of the vulva is exceptional; it may present with a variety of morphologic patterns and should be distinguished from metastatic adenocarcinoma.[187] A case has been described showing *mucinous and neuroendocrine* features,[188] another with features of *malignant myoepithelioma*,[189] and another resembling *polymorphous low-grade adenocarcinoma* of the salivary glands[190] (see also under Bartholin gland).

Sebaceous carcinoma can occur in the vulva; its appearance is similar to that of its more common counterpart in the head and neck region.[191]

Melanocytic Tumors

Melanocytic nevi occur in the vulva, particularly in the labia majora. Those seen in adults are nearly always of intradermal or compound type. Sometimes, a prominent junctional component is seen in nevi of younger women, in which the enlarged junctional nests vary in size, shape, and position, and may lead to an overdiagnosis of malignant melanoma.[192,193] The term (*atypical*) *genital nevus* is sometimes employed for this microscopically troublesome lesion, which may exhibit a striking degree of cytologic and architectural atypia.[194,195] Benign lentigo (lentigo simplex) may also occur on the vulva. Genital melanotic macules are typically larger (up to 1.5 cm) than a lentigo; while they show similar basal hyperpigmentation to lentigo, there is typically less epidermal hyperplasia. There may be dermal melanophages present.

Melanoma is the second most common malignant tumor of the vulva, following squamous cell carcinoma and representing roughly 5% of all malignant tumors at this site.[196,197] The large majority of the patients are older than 50 years at the time of diagnosis, a fact of great importance in the differential diagnosis with genital nevus.[198,199] Most lesions are advanced (Clark level III or IV) at the time of diagnosis (Fig. 30.23).[200] The microscopic appearance is similar to that of cutaneous melanoma (see Chapter 3) (Fig. 30.24A).

Figure 30.23 Gross appearance of vulvar malignant melanoma. The tumor is large, polypoid, deeply pigmented, and ulcerated.

An important differential diagnosis is with Paget disease, a situation complicated by the fact that on occasion the two tumors coexist.[201] Sometimes the melanoma is formed of spindle cells growing in fascicles and simulating sarcoma (see Fig. 30.24B).

The usual treatment is radical vulvectomy with bilateral inguinal lymph node dissection, but small lesions with depths of ≤1.75 mm may be treated with wide local excision.[202–204] The overall 5-year survival rate is approximately 35%.[205,206] Lymph node status, level or thickness of the primary tumor, and ulceration are the most important prognostic parameters.[206–210] There is some suggestion that the DNA ploidy pattern may also provide prognostic information.[211] Vulvar melanomas may have c-KIT or NRAS mutations more frequently than melanomas arising at other anatomic sites, but BRAF mutations are rare.[212–214]

Malignant blue nevus of the vulva leading to ovarian metastases has been recorded.[215]

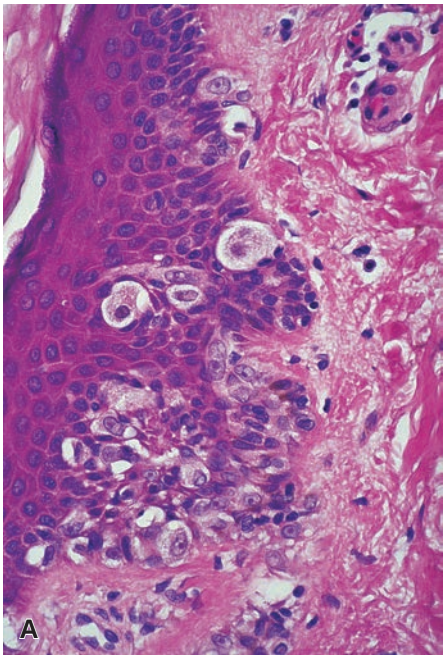

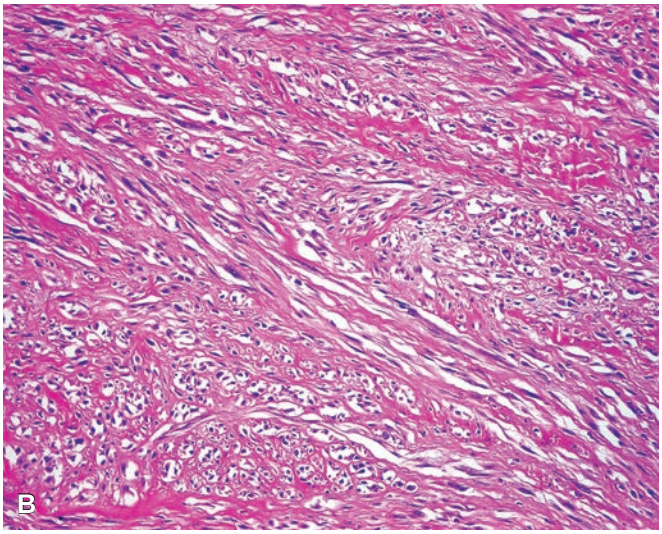

Figure 30.24 **Malignant Melanoma of Vulva. A**, Superficially spreading type, showing typical intraepidermal growth of pagetoid cells. **B**, Melanoma growing in the form of fascicles of spindle cells and simulating a mesenchymal neoplasm.

For personal use only. No other uses without permission. Copyright ©2017. Elsevier Inc. All rights reserved.

Figure 30.25 Aggressive angiomyxoma protruding in a polypoid fashion through one of the labia.

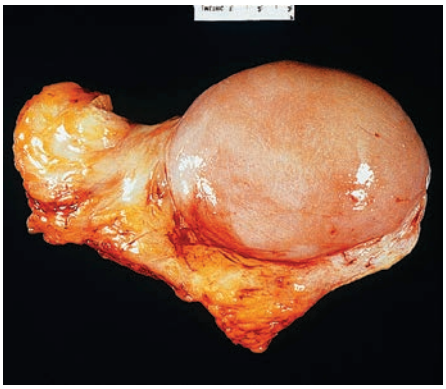

Figure 30.26 Cut surface of vulvar aggressive angiomyxoma. The tumor is soft, gelatinous, and appears encapsulated.

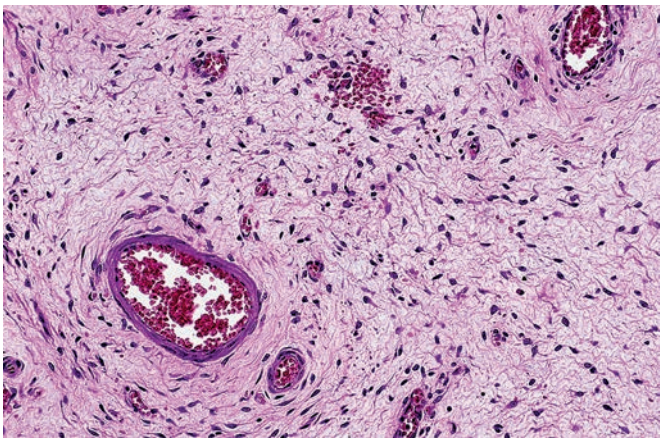

Figure 30.27 Microscopic appearance of aggressive angiomyxoma. The lesion is hypocellular and features large-sized vessels.

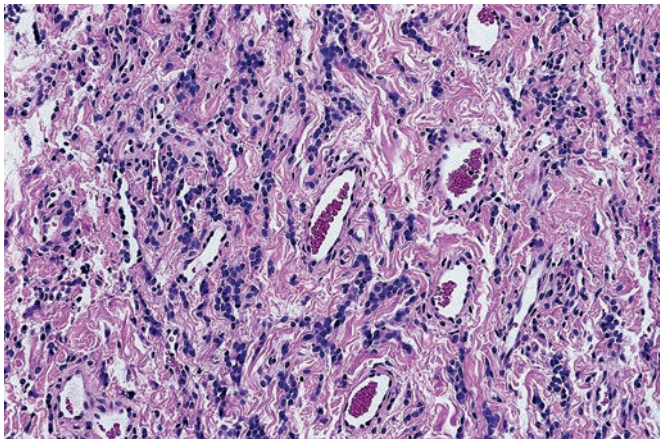

Figure 30.28 Vulvar angiomyofibroblastoma. Rows of small oval cells are separated by fibrous strands.

Aggressive Angiomyxoma and Related Lesions

Aggressive angiomyxoma is a soft tissue neoplasm that usually arises within the perineum. It often presents as a vulvar mass and clinically simulates a Bartholin gland cyst (Fig. 30.25).[216,217] Most patients are in the second or third decade of life, but cases have also been reported in children.[217,218] A similar tumor has been described in the scrotal region in males.[219]

Grossly, the appearance is edematous and ill-defined (Fig. 30.26). Microscopically, a hypocellular stroma devoid of atypicality or mitotic activity is seen intermingling with sizable vessels having dilated lumina and frequent hyaline thickening of the adventitia (Fig. 30.27). This tumor is distinguished from the more common and innocuous fibroepithelial polyp described below because of its larger size, deeper location, and lack of bizarre stromal cells. The differential diagnosis also includes angiomyofibroblastoma, cellular angiofibroma, and massive vulvar edema (see later). Superficial angiomyxoma is a closely related tumor that, as its name implies, has a more superficial location (frequently exophytic) and also differs from aggressive angiomyxoma in being well circumscribed.[220] The ultrastructural and immunohistochemical features of aggressive angiomyxoma are those of primitive mesenchymal cells focally exhibiting myoid traits.[221,222] Stains for acidic mucins are only weakly positive, suggesting that the stroma is more edematous than myxoid. Immunohistochemically, there is positivity for desmin (less so in the male counterpart of this lesion), smooth muscle actin (about half of the cases), CD34 (about half), and estrogen and progesterone receptors (100%, irrespective of gender).[223,224] One-fourth of the cases also show keratin AE1/AE3 positivity.[225] Some cases analyzed cytogenetically have shown a chromosomal translocation involving the region 12q14–15,[226] where the high mobility group AT-hook 2 gene *HMGA2* is translocated, resulting in overexpression of this molecule.[227–229] It should be noted that HMGA2 overexpression is not specific for aggressive angiomyxoma and can be seen in other neoplasms, including leiomyoma.[229] One case of aggressive angiomyxoma was found to have a t(5;8)(p15;q22) translocation.[230]

Recurrence in the ischiorectal and retroperitoneal spaces is common, probably because of the difficulties encountered in achieving a complete surgical excision.[231] In addition, two typical cases have been reported in association with lung metastases.[232,233] Dramatic response to therapy targeting the hormone receptors on the tumor cells has been reported.[234]

Angiomyofibroblastoma is a benign vulvar tumor characterized by alternating hypercellular and hypocellular areas admixed with small blood vessels.[235–237] Spindle and plump stromal cells aggregate around the vessels (Fig. 30.28). These cells are immunoreactive for

For personal use only. No other uses without permission. Copyright ©2017. Elsevier Inc. All rights reserved.

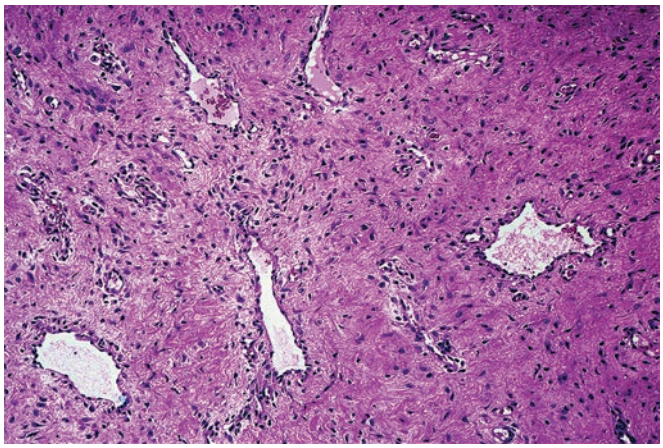

Figure 30.29 Angiofibroma of vulva. The microscopic appearance is reminiscent of nasopharyngeal angiofibroma. (Slide courtesy of Dr. Robert E Scully, Boston, MA)

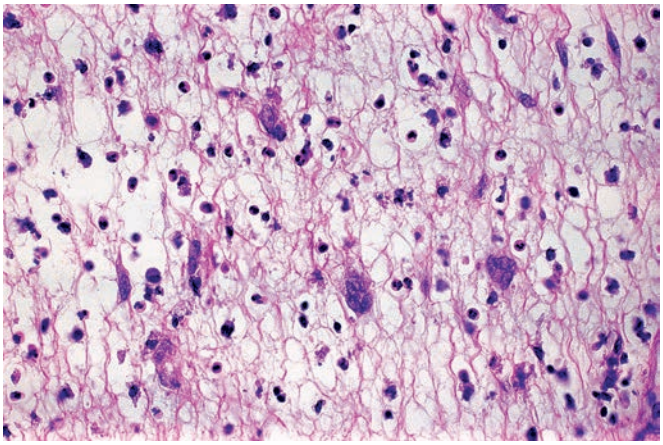

Figure 30.30 Vulvar polyp containing reactive stromal cells, some of which are multinucleated.

vimentin, desmin, and hormone receptors, but usually not for actin or keratin.[238,239] There may be a component of mature adipose tissue; when abundant, the tumor is referred to as the *lipomatous variant*.[240] The behavior is benign, with an extremely low rate of local recurrence, but a case with sarcomatous transformation ("angiomyofibrosarcoma") has been reported.[241] A relationship between angiomyofibroblastoma and tamoxifen therapy has been suggested.[242]

The typical example of angiomyofibroblastoma differs from aggressive angiomyxoma by virtue of its circumscribed borders, higher cellularity, abundance of blood vessels, plump stromal cells, minimal stromal mucin, and rarity of red blood cell extravasation.[235,243] However, enough common features and transitions occur between it and aggressive angiomyxoma to suggest that they are closely related entities.[222,244–246]

Cellular angiofibroma has well-circumscribed margins, like angiomyofibroblastoma. Microscopically, it is composed of uniform, bland, spindle-shaped mesenchymal cells accompanied by numerous thick-walled vessels and inconspicuous islands of mature fat (Fig. 30.29).[247] The tumor is cellular and can be mitotically active.[248] Once again, it is hard to escape the suspicion that this tumor is histogenetically related to the others described in this section, their common denominator being an origin from the specialized hormone receptor–positive mesenchymal tissue within the lower female genital tract.[99,223]

Other Tumors and Tumorlike Conditions

Asymmetric labium majus enlargement in the pre- and early pubertal age may clinically mimic a neoplasm.[249] It tends to regress spontaneously and probably represents an asymmetric physiologic enlargement in response to the normal hormonal surges in this age group.

Massive vulvar edema may be seen secondary to obesity and immobilization.[250] It is similar if not identical to the condition described as *vulvar hypertrophy with lymphedema (or massive localized lymphedema)*.[251] It can simulate aggressive angiomyxoma, but the clinical features should alert the gynecologist and the pathologist to the correct diagnosis.

Fibroepithelial polyp is a superficially located lesion composed of a loose myxoid stroma covered by normal squamous epithelium. Bizarre, stellate, frequently multinucleated cells may be present (Fig. 30.30).[252–254] Some lesions are moderately hypercellular. The combination of hypercellularity and bizarre tumor cells may result in overdiagnosis.[255] As in other sites where this lesion occurs, desmin immunoreactivity may be present.[256]

Prepubertal vulvar fibroma is a controversial entity and some authors regard it as a non-neoplastic hormonally driven lesion identical to **asymmetric labium majus enlargement**.[249,257] It presents at a median age of 8 years. It is grossly ill-defined and is microscopically composed of bland spindle-shaped cells in a variably collagenous to edematous or myxoid stroma lacking atypia and mitotic activity. It may recur locally after excision.[258]

Smooth muscle tumors of both benign and malignant types occur.[259] The leiomyomas include a myxoid variety that can simulate aggressive angiomyxoma,[260] and the leiomyosarcomas include epithelioid and myxoid variants.[261,262] Nielsen et al.[259] evaluated the tumors on the basis of size (≥5 cm), infiltrative margins, mitoses (≥5/10 HPF), and moderate to severe cytologic atypia. Tumors that had three or all four of these features were regarded as leiomyosarcomas, tumors that had none or one of the features were called leiomyomas, and tumors that had two features were designated atypical leiomyomas.

Nonepithelial tumors and tumorlike conditions of many other types have been described in the vulva and its surroundings, most of them of soft tissue type.[263,264] They include *endometriosis*, *varices*,[265] *hemangioma* and *hemangiomatosis* (sometimes as a component of Maffucci syndrome),[266] *lymphangioma* (which may clinically simulate warts),[267] *angiokeratoma*,[268] *epithelioid hemangioendothelioma*,[269] *glomus tumor*[270,271] and *glomangiomyoma*,[272] *angiosarcoma*[273] (including the *postradiation epithelioid type*),[274] *solitary fibrous tumor*[271] (Fig. 30.31), benign and malignant *granular cell tumors* (some with accompanying pseudoepitheliomatous hyperplasia)[275–277] (Fig. 30.32), *schwannoma*,[278] *neurofibroma*(*tosis*),[279,280] *malignant peripheral nerve sheath tumor*,[281,282] *sclerosing lipogranuloma*,[283] *yolk sac tumor*,[284] *rhabdomyosarcoma*[285,286] (usually occurring in children and belonging to the embryonal/botryoid variety), *benign lymphoid hyperplasia*,[287] *verruciform xanthoma*,[288] *Langerhans cell histiocytosis*,[289–291] *nodular fasciitis*,[292] *postoperative spindle cell nodule*,[293] undifferentiated pleomorphic sarcoma,[294] *dermatofibrosarcoma protuberans*[295–297] (including cases with fibrosarcomatous transformation[298]), *Ewing sarcoma/PNET*,[299] *synovial sarcoma*[300] (including the monophasic type[301]), *fibromatosis/desmoid tumor* (sometimes associated with pregnancy),[302,303] *atypical lipomatous tumor*,[304] a lesion resembling *lipoblastoma*,[305] *malignant lymphoma*,[306,307] *paraganglioma*,[308] *alveolar soft part sarcoma*,[309] and *epithelioid sarcoma*.[310]

Epithelioid sarcoma is of importance because of its relatively high frequency at this site and the fact that it tends to run a more

For personal use only. No other uses without permission. Copyright ©2017. Elsevier Inc. All rights reserved.

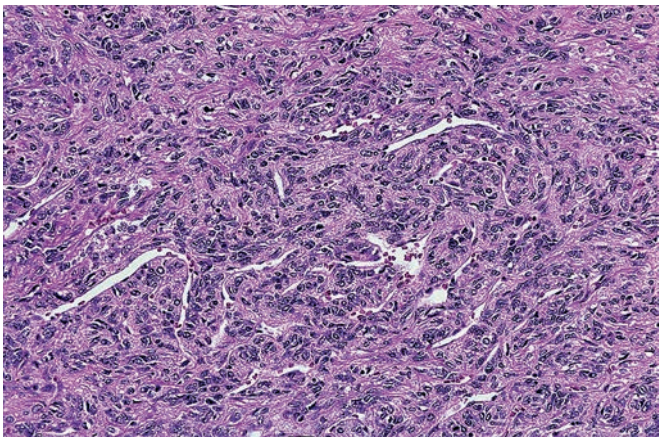

Figure 30.31 A rare example of solitary fibrous tumor involving soft tissues of vulva.

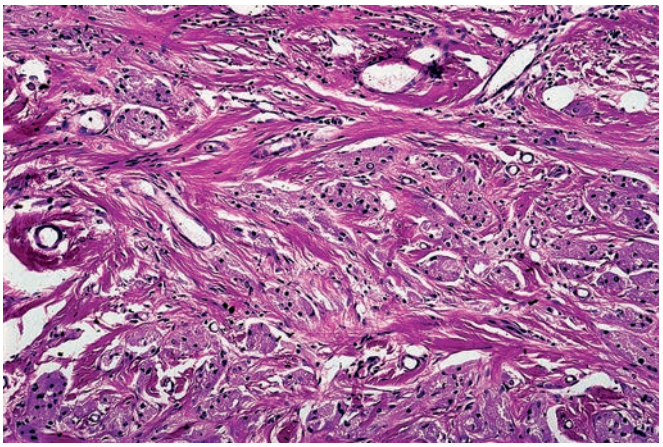

Figure 30.32 Granular cell tumor of vulva.

aggressive course here than in its usual location in the distal extremities. This may at least partially result from the fact that this tumor, when located in the vulva, often exhibits rhabdoid features, known to be associated with an aggressive course.[311] As a matter of fact, it may be difficult to decide whether to designate a vulvar tumor with these features as an epithelioid sarcoma or as a malignant rhabdoid tumor.[312,313] The overlap between these two entities extends to the molecular level as both may show loss of SMARCB1 (INI1) expression.[314] The term proximal-type epithelioid sarcoma has been employed for this particular situation, of which the vulva is a prime example (see Chapter 41).

Metastases to the vulva usually originate from the cervix (almost 50%), endometrium, kidney, or gastrointestinal tract.[315] Most are expressions of generalized disease.[316] The labium majus is the most common location.[317]

Lesions of Bartholin Glands and Related Structures

Cysts and abscesses of the Bartholin glands are the result of chronic bacterial inflammation. The lining of the cyst, which is usually of transitional or squamous type, can be destroyed partially or totally by the inflammatory infiltrate. The nature of the cyst can be established by the presence of residual mucinous glands in the fibrotic and inflamed connective tissue that forms the cyst wall. The secretion product is a nonsulfated sialomucin.[4] Sometimes, extravasation of this mucus into the stroma may induce changes similar to those seen in "mucocele" of the oral cavity.[318] The cyst may be treated by excision or marsupialization.[319] Exceptionally, the inflammatory infiltrate is found to have the features of *malakoplakia*.[320]

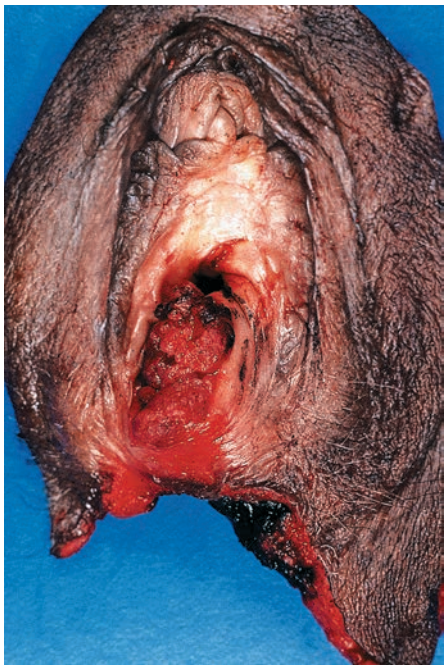

Figure 30.33 Large carcinoma arising from the Bartholin gland.

Mucous cysts of the *vulvar vestibule* are usually solitary and lined by mucin-producing columnar cells.[321]

Benign tumors and tumorlike conditions of this area include adenoma of minor vestibular glands[322] (which may well represent focal hyperplastic changes secondary to trauma and inflammation), nodular hyperplasia, adenomyoma,[323] mucinous cystadenoma,[324] and papilloma.[325]

Carcinomas of the Bartholin gland[326–329] may take the form of squamous cell carcinoma (the most common) (Fig. 30.33), adenocarcinoma,[330] urothelial (transitional cell) carcinoma, a variant of HPV-associated squamous cell carcinoma (Fig. 30.34), salivary gland–type basal cell and epithelial-myoepithelial adenocarcinoma,[331,332] small cell (neuroendocrine) carcinoma,[333] and adenoid cystic carcinoma (including the tubular variety) (Fig. 30.35).[334–336] Lymph node metastases are common. HPV is often found in the squamous cell carcinoma type,[337] as well as in the transitional cell carcinoma type.[338] The adenoid cystic carcinomas can have the NF1B gene rearrangements, similar to those commonly seen in salivary gland adenoid cystic carcinomas.[339] The overall survival rate is in the neighborhood of 60%.[324,340]

Lesions of the Female Urethra

Urethral caruncle has the appearance of a small raspberry protruding from the meatus; it bleeds easily and may become infected. It occurs only in the female urethra and is not a true neoplasm but rather a reactive polypoid lesion. Microscopically, chronic inflammatory cells, dilated vessels, and hyperplastic epithelium are seen in varying proportions. Mistaken diagnoses of malignancy can result from overinterpretation of islands of reactive epithelium or scattered bizarre stromal or lymphoid cells.[341] There is a tendency for these lesions to recur following excision, probably because of persistence of the original inciting factors.

For personal use only. No other uses without permission. Copyright ©2017. Elsevier Inc. All rights reserved.

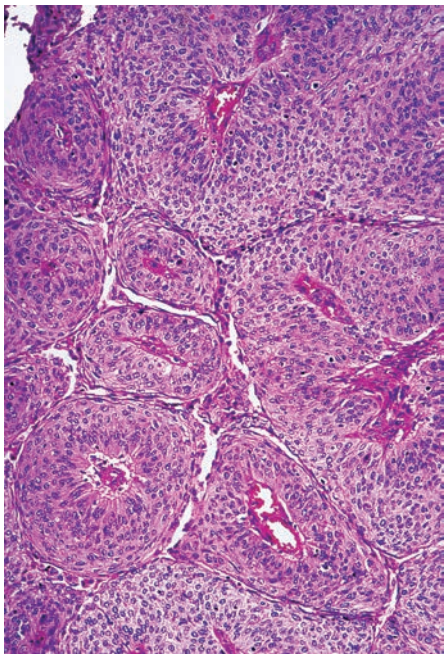

Figure 30.34 Bartholin gland carcinoma of transitional type, a variant of HPV-associated squamous cell carcinoma.

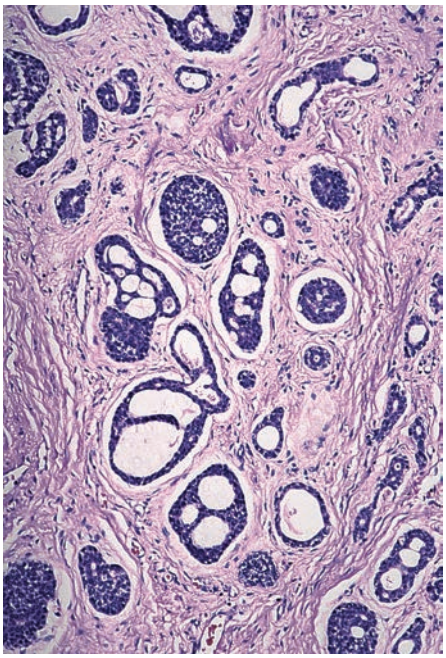

Figure 30.35 Bartholin gland carcinoma of adenoid cystic type.

Prolapse of the urethral mucosa can occur in childhood and clinically simulate a vulvovaginal neoplasm.[342]

So-called **nephrogenic (mesonephric) adenoma** has been traditionally regarded as a metaplastic change resulting from inflammation rather than a true neoplasm. It is microscopically similar to the more common lesions located in the bladder neck.[343,344] Similarly, an occurrence in the urethra of mucinous epithelium of *colonic* type can also be explained on a metaplastic basis, although a congenital origin is also possible.[345]

Villous adenoma has been reported in the urethra in association with tubulovillous adenoma and adenocarcinoma of the rectum.[346]

Urethral carcinoma occurs in elderly patients and presents with bleeding or dysuria.[347,348] The majority of the cases arise from the meatus, at the junction of the transitional and squamous epithelium. In a series of 35 cases, 19 were anterior (vulvourethral), 4 were posterior (vesicoureteral), and 12 involved the entire urethra.[349]

Microscopically, most urethral carcinomas are of squamous cell type.[350,351] Other types include urothelial (transitional cell) carcinoma, columnar/mucinous adenocarcinoma,[352] signet ring adenocarcinoma,[353] and clear cell adenocarcinoma.[354,355] Interestingly, nearly half of the carcinomas reported as arising in urethral diverticula have been adenocarcinomas of either conventional or clear cell type.[356,357] Some of the urethral adenocarcinomas have been associated with adenomatous hyperplasia of the periurethral glands.[358] HPV has been detected by PCR techniques in a high proportion of urethral carcinomas.[359]

The prognosis of urethral carcinoma is relatively poor, except when the disease is limited to the anterior portion of the urethra.[360] In one large series, the 5-, 10-, and 15-year actuarial survival rates were 41%, 31%, and 22%, respectively.[361] The usual treatment is radiation therapy,[361–363] but depending on their size and location, they can also be treated by surgery alone or surgery plus irradiation.[364,365]

Leiomyoma of the urethra, although extremely unusual, is the most common type of benign mesenchymal tumor at this site.[366]

Melanoma of the urethra is a highly aggressive neoplasm that is treated by total urethrectomy with bilateral inguinal lymph node dissection.[367–368]

Malignant lymphoma can exceptionally present as a urethral tumor.[369]

Metastatic tumors in the urethra usually originate in other portions of the female genital tract, particularly endometrium.[351]

References

1. McLean JM. Anatomy and physiology of the vulvar area. In: Ridley CM, ed. *The Vulva*. New York: Churchill Livingstone; 1988.
2. Wilkinson EJ, Hardt NS. Vulva. In: Mills SE, ed. *Histology for Pathologists*. 3rd ed. Philadelphia: Lippincott Williams and Wilkins; 2007:983-998.
3. van der Putte SC. Anogenital 'sweat' glands. Histology and pathology of a gland that may mimic mammary glands. *Am J Dermatopathol*. 1991;13:557-567.
4. Rorat E, Ferenczy A, Richart RM. Human Bartholin gland, duct, and duct cyst. *Arch Pathol*. 1975;99:367-374.
5. Kazakov DV, Spagnolo DV, Kacerovska D, Michal M. Lesions of anogenital mammary-like glands: an update. *Adv Anat Pathol*. 2011;18:1-28.
6. van der Putte SC. Mammary-like glands of the vulva and their disorders. *Int J Gynecol Pathol*. 1994;13:150-160.
7. Kazakov DV, Hügel H, Vanecek T, Michal M. Unusual hyperplasia of anogenital mammary-like glands. *Am J Dermatopathol*. 2006;28:134-137.
8. Kazakov DV, Spagnolo DV, Stewart CJ, et al. Fibroadenoma and phyllodes tumors of anogenital mammary-like glands: a series of 13 neoplasms in 12 cases, including mammary-type juvenile fibroadenoma, fibroadenoma with lactation changes, and neurofibromatosis-associated pseudoangiomatous stromal hyperplasia with multinucleated giant cells. *Am J Surg Pathol*. 2010;34:95-103.
9. Burger RA, Marcuse PM. Fibroadenoma of the vulva. *Am J Clin Pathol*. 1954;24:965-968.
10. Sington JD, Manek S, Hollowood K. Fibroadenoma of the mammary-like glands of the vulva. *Histopathology*. 2002;41:563-565.
11. Chulia MT, Paya A, Niveiro M, et al. Phyllodes tumor in ectopic breast tissue of the vulva. *Int J Surg Pathol*. 2001;9:81-83.
12. Tbakhi A, Cowan DF, Kumar D, Kyle D. Recurring phyllodes tumor in aberrant breast tissue of the vulva. *Am J Surg Pathol*. 1993;17:946-950.

For personal use only. No other uses without permission. Copyright ©2017. Elsevier Inc. All rights reserved.

13. Di Bonito L, Patriarca S, Falconieri G. Aggressive 'breast-like' adenocarcinoma of vulva. *Pathol Res Pract*. 1992;188:211-214.
14. Rose PG, Roman LD, Reale FR, et al. Primary adenocarcinoma of the breast arising in the vulva. *Obstet Gynecol*. 1990;76:537-539.
15. Simon KE, Dutcher JP, Runowicz CD, Wiernik PH. Adenocarcinoma arising in vulvar breast tissue. *Cancer*. 1988;62:2234-2238.
16. Abbott JJ, Ahmed I. Adenocarcinoma of mammary-like glands of the vulva: report of a case and review of the literature. *Am J Dermatopathol*. 2006;28:127-133.
17. Chung-Park M, Zheng Liu C, Giampoli EJ, et al. Mucinous adenocarcinoma of ectopic breast tissue of the vulva. *Arch Pathol Lab Med*. 2002;126:1216-1218.
18. Kazakov DV, Belousova IE, Sima R, Michal M. Mammary type tubulolobular carcinoma of the anogenital area: report of a case of a unique tumor presumably originating in anogenital mammarylike glands. *Am J Surg Pathol*. 2006;30:1193-1196.
19. Martin-Ezquerra G, et al. Treponema pallidum distribution patterns in mucocutaneous lesions of primary and secondary syphilis: an immunohistochemical and ultrastructural study. *Hum Pathol*. 2009;40(5):624-630.
20. Bassa AG, Hoosen AA, Moodley J, Bramdev A. Granuloma inguinale (donovanosis) in women. An analysis of 61 cases from Durban, South Africa. *Sex Transm Dis*. 1993;20:164-167.
21. O'Farrell N. Donovanosis. *Sex Transm Infect*. 2002;78:452-457.
22. Velho PE, Souza EM, Belda Junior W. Donovanosis. *Braz J Infect Dis*. 2008;12:521-525.
23. Ramdial PK, Kharsany AB, Reddy R, Chetty R. Transepithelial elimination of cutaneous vulval granuloma inguinale. *J Cutan Pathol*. 2000;27:493-499.
24. Alexander LJ, Shields TL. Squamous cell carcinoma of the vulva secondary to granuloma inguinale. *Arch Dermatol*. 1953;67:395-402.
25. Barnes R, Masood S, Lammert N, Young RH. Extragenital granuloma inguinale mimicking a soft-tissue neoplasm. A case report and review of the literature. *Hum Pathol*. 1990;21:559-561.
26. Mabey D, Peeling RW. Lymphogranuloma venereum. *Sex Transm Infect*. 2002;78:90-92.
27. Oriel JD. Infective conditions of the vulva. In: Ridley CM, Neill SM, eds. *The Vulva*. 2nd ed. Oxford: Blackwell Science; 1999:71-120.
28. White JA. Manifestations and management of lymphogranuloma venereum. *Curr Opin Infect Dis*. 2009;22:57-66.
29. Koteen H. Lymphogranuloma venereum. *Medicine (Baltimore)*. 1945;24:1-69.
30. O'Byrne P, MacPherson P, DeLaplante S, et al. Approach to lymphogranuloma venereum. *Can Fam Physician*. 2016;62:554-558.
31. Rainey R. The association of lymphogranuloma inguinale and cancer. *Surgery*. 1954;35:221-235.
32. Andreani SM, Ratnasingham K, Dang HH, et al. Crohn's disease of the vulva. *Int J Surg*. 2010;8:2-5.
33. Kremer M, Nussenson E, Steinfeld M, Zuckerman P. Crohn's disease of the vulva. *Am J Gastroenterol*. 1984;79:376-378.
34. Lavery HA, Pinkerton JHM, Sloan J. Crohn's disease of the vulva. Two further cases. *Br J Dermatol*. 1985;113:359-363.
35. Vettraino IM, Merritt DF. Crohn's disease of the vulva. *Am J Dermatopathol*. 1995;17:410-413.
36. Guerrieri C, Ohlsson E, Rydén G, Westermark P. Vulvitis granulomatosa. A cryptogenic chronic inflammatory hypertrophy of vulvar labia related to cheilitis granulomatosa and Crohn's disease. *Int J Gynecol Pathol*. 1995;14:352-359.
37. Haidopoulos D, Rodalakis A, Stefanidis K, et al. Behçet's disease: part of the differential diagnosis of the ulcerative vulva. *Clin Exp Obstet Gynecol*. 2002;29:219-221.
38. Sakane T, Takeno M, Suzuki N, Inaba G. Behçet's disease. *N Engl J Med*. 1999;341:1284-1291.
39. Roberts DB. Necrotizing fascitis of the vulva. *Am J Obstet Gynecol*. 1987;157:568-571.
40. Prayson RA, Stoler MH, Hart WR. Vulvar vestibulitis. A histopathologic study of 36 cases, including human papillomavirus in situ hybridization analysis. *Am J Surg Pathol*. 1995;19:154-160.
41. Chadha S, Gianotten WL, Drogendijk AC, et al. Histopathologic features of vulvar vestibulitis. *Int J Gynecol Pathol*. 1998;17:7-11.
42. Virgili A, Levratti A, Marzola A, Corassa M. Retrospective histopathologic reevaluation of 18 cases of plasma cell vulvitis. *J Reprod Med*. 2005;50:3-7.
43. Kiryu H, Ackerman AB. A critique of current classification of vulvar diseases. *Am J Dermatopathol*. 1990;12:377-392.
44. Ambros RA, Malfetano JH, Carlson JA, Mihm MC. Non-neoplastic epithelial alterations of the vulva: recognition assessment and comparisons of terminologies used among the various specialities. *Mod Pathol*. 1997;10:401-408.
45. Lawrence WD. Non-neoplastic epithelial disorders of the vulva (vulvar dystrophies). Historical and current perspectives. *Pathol Annu*. 1993;28(Pt 2):23-51.
46. Guerrero A, Venkatesan A. Inflammatory vulvar dermatoses. *Clin Obstet Gynecol*. 2015;58:464-475.
47. Janovski NA, Ames S. Lichen sclerosus et atrophicus of the vulva. A poorly understood disease entity. *Obstet Gynecol*. 1963;22:697-708.
48. Laseano EF, Montes LF, Mazzini MA. Lichen sclerosus et atrophicus in childhood. Report of 6 cases. *Obstet Gynecol*. 1964;24:872-877.
49. Carlson JA, Lamb P, Malfetano J, et al. Clinicopathologic comparison of vulvar and extragenital lichen sclerosus: histologic variants, evolving lesions, and etiology of 141 cases. *Mod Pathol*. 1998;11:844-854.
50. Fung MA, LeBoit PE. Light microscopic criteria for the diagnosis of early vulvar lichen sclerosus: a comparison with lichen planus. *Am J Surg Pathol*. 1998;22:473-478.
51. Regauer S, Liegl B, Reich O. Early vulvar lichen sclerosus: a histopathological challenge. *Histopathology*. 2005;47:340-347.
52. Lee ES, Allen D, Scurry J. Pseudoepitheliomatous hyperplasia in lichen sclerosus of the vulva. *Int J Gynecol Pathol*. 2002;22:57-62.
53. Hart WR, Norris JH, Helwig EB. Relation of lichen sclerosus et atrophicus of the vulva to development of carcinoma. *Obstet Gynecol*. 1975;45:369-377.
54. Wallace HJ. Lichen sclerosus et atrophicus. *Trans St Johns Hosp Dermatol Soc*. 1971;57:9-30.
55. Lee A, Bradford J, Fisher G. Long-term management of adult vulvar lichen sclerosus: a prospective cohort study of 507 women. *JAMA Dermatol*. 2015;151:1061-1067.
56. Chiessa-Vottero A, Dvoretsky PM, Hart WR. Histopathologic study of thin vulvar squamous cell carcinomas and associated cutaneous lesions: a correlative study of 48 tumors in 44 patients with analysis of adjacent vulvar intraepithelial neoplasia type and lichen sclerosus. *Am J Surg Pathol*. 2006;30:310-318.
57. Carlson JA, Ambros R, Malfetano J, et al. Vulvar lichen sclerosus and squamous cell carcinoma: a cohort, case control, and investigational study with historical perspective; implications for chronic inflammation and sclerosis in the development of neoplasia. *Hum Pathol*. 1998;29:932-948.
58. McAlpine JN, Leung SCY, Cheng A, et al. Human papillomavirus (HPV)-independent vulvar squamous cell carcinoma has a worse prognosis than HPV-associated disease: a retrospective cohort study. *Histopathology*. 2017 [Epub ahead of print].
59. Lee LJ, Howitt B, Catalanod P, et al. Prognostic importance of human papilloma virus (HPV) and p16 positivity in squamous cell carcinoma of the vulva treated with radiotherapy. *Gynecol Oncol*. 2016;142:293-298.
60. McAlpine JM, Kim SY, Akbari A, et al. HPV-independent differentiated vulvar intraepithelial neoplasia (dVIN) is associated with an aggressive clinical course. *Int J Gynecol Pathol*. 2016;in press.
61. Santos M, Landolfi S, Olivella A, et al. p16 overexpression identifies HPV-positive vulvar squamous cell carcinomas. *Am J Surg Pathol*. 2006;30:1347-1356.
62. Cheng AS, Karnezis AN, Jordan S, et al. p16 immunostaining allows for accurate subclassification of vulvar squamous cell carcinoma into HPV-associated and HPV-independent cases. *Int J Gynecol Pathol*. 2016;35:385-393.
63. Darragh TM, Colgan TJ, Cox T, et al. The lower anogenital squamous terminology standardization project for HPV-associated lesions: background and consensus recommendations from the College of American Pathologists and the American Society for Colposcopy and Cervical Pathology. *Int J Gynecol Pathol*. 2013;32:76-115.
64. Sideri M, Jones RW, Wilkinson EJ, et al. Squamous vulvar intraepithelial neoplasia: 2004 modified terminology, ISSVD Vulvar Oncology Subcommittee. *J Reprod Med*. 2005;50:807-810.
65. McMillan A, Bishop PE, Fletcher S. An immunohistological study of condylomata acuminata. *Histopathology*. 1990;17:45-52.
66. Crum CP, Fu YS, Levine RU, et al. Intraepithelial squamous lesions of the vulva. Biologic and histologic criteria for the distinction of condylomas from vulvar intraepithelial neoplasia. *Am J Obstet Gynecol*. 1982;144:77-83.
67. Nuovo GJ, O'Connell M, Blanco JS, et al. Correlation of histology and human papillomavirus DNA detection in condyloma acuminatum and condyloma-like vulvar lesions. *Am J Surg Pathol*. 1989;13:700-706.
68. Pirog EC, Chen YT, Isacson C. MIB-1 immunostaining is a beneficial adjunct test for accurate diagnosis of vulvar condyloma acuminatum. *Am J Surg Pathol*. 2000;24:1393-1399.
69. Shevchuk MM, Richart RM. DNA content of condyloma acuminatum. *Cancer*. 1982;49:489-492.
70. McLachlin CM, Kozakewich H, Craighill M, et al. Histologic correlates of vulvar human papillomavirus infection in children and young adults. *Am J Surg Pathol*. 1994;18:728-735.
71. McLachlin CM, Mutter GL, Crum CP. Multinucleated atypia of the vulva. Report of a distinct entity not associated with human papillomavirus. *Am J Surg Pathol*. 1994;18:1233-1239.
72. Aguillera-Barrantes I, Magro C, Nuovo GJ. Verruca vulgaris of the vulva in children and adults: a non-venereal type of vulvar wart. *Am J Surg Pathol*. 2007;31:529-535.
73. Hongwei B, Cviko A, Granter S, et al. Immunophenotypic and viral (human papillomavirus) correlates of vulvar seborrheic keratosis. *Hum Pathol*. 2003;34:559-564.

For personal use only. No other uses without permission. Copyright ©2017. Elsevier Inc. All rights reserved.

74. Quinn TR, Young RH. Epidermolytic hyperkeratosis in the lower female genital tract: an uncommon simulant of mucocutaneous papillomavirus infection—a report of two cases. *Int J Gynecol Pathol*. 1997;16:163-168.
75. Wade TR, Ackerman AB. The effects of resin of podophyllin on condyloma acuminatum. *Am J Dermatopathol*. 1984;6:109-122.
76. Nucci MR, Genest DR, Tate JE, et al. Pseudobowenoid change of the vulva: a histologic variant of untreated condyloma acuminatum. *Mod Pathol*. 1996;9:375-379.
77. Ferenczy A. Laser treatment of patients with condylomata and squamous carcinoma precursors of the lower female genital tract. *CA Cancer J Clin*. 1987;37:334-347.
78. Abell MR, Gosling JRG. Intraepithelial and infiltrating carcinoma of the vulva. Bowen's type. *Cancer*. 1961;14:318-329.
79. Patterson JW, Kao GF, Graham JH, Helwig EB. Bowenoid papulosis. A clinicopathologic study with ultrastructural observations. *Cancer*. 1986;57:823-836.
80. Shatz P, Bergeron C, Wilkinson EJ, et al. Vulvar intraepithelial neoplasia and skin appendage involvement. *Obstet Gynecol*. 1989;74:769-774.
81. Armes JE, Lourie R, Bowlay G, Tabrizi S. Pagetoid squamous cell carcinoma in situ of the vulva: comparison with extramammary Paget disease and nonpagetoid squamous cell neoplasia. *Int J Gynecol Pathol*. 2008;27:118-124.
82. Raju RR, Goldblum JR, Hart WR. Pagetoid squamous cell carcinoma in situ (pagetoid Bowen disease) of the external genitalia. *Int J Gynecol Pathol*. 2003;22:127-135.
83. Kimura A. Condylomata acuminata with pigmented papular lesions. *Dermatologica*. 1980;160:390-397.
84. Sykes P, Smith N, McCormick P, Frizelle FA. High-grade vulval intraepithelial neoplasia (VIN 3): a retrospective analysis of patient characteristics, management outcome and relationship to squamous cell carcinoma of the vulva 1989–1999. *Aust N Z J Obstet Gynaecol*. 2002;42:69-74.
85. Forney JP, Morrow CP, Townsend DE, DiSaia PJ. Management of carcinoma in situ of the vulva. *Am J Obstet Gynecol*. 1977;127:801-806.
86. van Seters M, van Beurden M, ten Kate FJ, et al. Treatment of vulvar intraepithelial neoplasia with topical imiquimod. *N Engl J Med*. 2008;358:1465-1473.
87. Hart WR. Vulvar intraepithelial neoplasia: historical aspects and current status. *Int J Gynecol Pathol*. 2001;20:16-30.
88. Mulvany NJ, Allen DG. Differentiated intraepithelial neoplasia of the vulva. *Int J Gynecol Pathol*. 2008;27:125-135.
89. Yang B, Hart WR. Vulvar intraepithelial neoplasia of the simplex (differentiated) type: a clinicopathologic study including analysis of HPV and p53 expression. *Am J Surg Pathol*. 2000;24:429-441.
90. van de Nieuwenhof HP, Bulten J, Hollema H, et al. Differentiated vulvar intraepithelial neoplasia is often found in lesions, previously diagnosed as lichen sclerosus, which have progressed to vulvar squamous cell carcinoma. *Mod Pathol*. 2011;24:297-305.
91. Singh N, Leen SL, Han G, et al. Expanding the morphologic spectrum of differentiated VIN (dVIN) through detailed mapping of cases with p53 loss. *Am J Surg Pathol*. 2015;39:52-60.
92. Kaefner HK, Tate JE, McLachlin CM, Crum CP. Vulvar intraepithelial neoplasia. Morphological phenotype, papillomavirus DNA, and coexisting invasive carcinoma. *Hum Pathol*. 1995;26:147-154.
93. Pinto AP, Miron A, Yassin Y, et al. Differentiated vulvar intraepithelial neoplasia contains Tp53 mutations and is genetically linked to vulvar squamous cell carcinoma. *Mod Pathol*. 2010;23:404-412.
94. van der Avoort IA, van der Laak JA, Paffen A, et al. MIB1 expression in basal cell layer: a diagnostic tool to identify premalignancies of the vulva. *Mod Pathol*. 2007;20:770-778.
95. Ordi J, Alejo M, Fuste V, et al. HPV-negative vulvar intraepithelial neoplasia (VIN) with basaloid histologic pattern: an unrecognized variant of simplex (differentiated) VIN. *Am J Surg Pathol*. 2009;33:1659-1665.
96. Nascimento AF, Granter SR, Cviko A, et al. Vulvar acanthosis with altered differentiation: a precursor to verrucous carcinoma? *Am J Surg Pathol*. 2004;28:638-643.
97. Dvoretsky PM, Bonfiglio TA. The pathology of vulvar squamous cell carcinoma and verrucous carcinoma. *Pathol Annu*. 1986;21(Pt 2):23-45.
98. McCluggage WG. Recent developments in vulvovaginal pathology. *Histopathology*. 2009;54:156-173.
99. Del Pino M, Rodriguez-Carunchio L, Ordi J. Pathways of vulvar intraepithelial neoplasia and squamous cell carcinoma. *Histopathology*. 2013;62:392-399.
100. Vinokurova S, Wentzensen N, Einekel J, et al. Clonal history of papillomavirus-induced dysplasia in the female lower genital tract. *J Natl Cancer Inst*. 2005;97:1816-1821.
101. Kurman RJ, Toki T, Schiffman MH. Basaloid and warty carcinomas of the vulva. Distinctive types of squamous cell carcinoma frequently associated with human papillomaviruses. *Am J Surg Pathol*. 1993;17:133-145.
102. Figge DC, Tamimi HK, Greer BE. Lymphatic spread in carcinoma of the vulva. *Am J Obstet Gynecol*. 1985;152:387-394.
103. Cady B. Sentinel lymph node procedure in squamous cell carcinoma of the vulva. *J Clin Oncol*. 2000;18:2795-2797.
104. de Hullu JA, Hollema H, Piers DA, et al. Sentinel lymph node procedure is highly accurate in squamous cell carcinoma of the vulva. *J Clin Oncol*. 2000;18:2811-2816.
105. Gibb RK, et al. Vulva. In: Mahul B, ed. *AJCC Cancer Staging Manual*. 8th ed. Amin: Chicago, IL; 2016.
106. Creasman WT, Phillips JL, Menck HR. The National Cancer Data Base Report on early stage invasive vulvar carcinoma. The American College of Surgeons Commission on Cancer and the American Cancer Society. *Cancer*. 1997;80:505-513.
107. Hopkins MP, Morley GW. Pelvic exenteration for the treatment of vulvar cancer. *Cancer*. 1992;70:2835-2838.
108. Hacker NF, Van der Velden J. Conservative management of early vulvar cancer. *Cancer*. 1993;71:1673-1677.
109. Heaps JM, Fu YS, Montz FJ, et al. Surgical–pathologic variables predictive of local recurrence in squamous cell carcinoma of the vulva. *Gynecol Oncol*. 1990;38:309-314.
110. Moore DH. Chemotherapy and radiation therapy in the treatment of squamous cell carcinoma of the vulva: are two therapies better than one? *Gynecol Oncol*. 2009;113:379-383.
111. Coleman RL, Santoso JT. Vulvar carcinoma. *Curr Treat Options Oncol*. 2000;1:177-190.
112. Perez CA, Grigsby PW, Galakatos A, et al. Radiation therapy in management of carcinoma of the vulva with emphasis on conservation therapy. *Cancer*. 1993;71:3707-3716.
113. Donaldson ES, Powell DE, Hanson MB, van Nagell JR. Prognostic parameters in invasive vulvar cancer. *Gynecol Oncol*. 1981;11:184-190.
114. Homesley HD, Bundy BN, Sedlis A, et al. Assessment of current International Federation of Gynecology and Obstetrics staging of vulvar carcinoma relative to prognostic factors for survival (a Gynecologic Oncology Group study). *Am J Obstet Gynecol*. 1991;164:997-1003.
115. Homesley HD, Bundy BN, Sedlis A, et al. Prognostic factors for groin node metastasis in squamous cell carcinoma of the vulva (a Gynecologic Oncology Group study). *Gynecol Oncol*. 1993;49:279-283.
116. Husseinzadeh N, Zaino R, Nahhas WA, Mortel R. The significance of histologic findings in predicting nodal metastases in invasive squamous cell carcinoma of the vulva. *Gynecol Oncol*. 1983;16:105-111.
117. Kunschner A, Kanbour AI, David B. Early vulvar carcinoma. *Am J Obstet Gynecol*. 1978;132:599-606.
118. Blecharz P, Karolewski K, Bieda T, et al. Prognostic factors in patients with carcinoma of the vulva—our own experience and literature review. *Eur J Gynaecol Oncol*. 2008;29:260-263.
119. Woelber L, Mahner S, Voelker K, et al. Clinicopathological prognostic factors and patterns of recurrence in vulvar cancer. *Anticancer Res*. 2009;29:545-552.
120. Homesley HD. Lymph node findings and outcome in squamous cell carcinoma of the vulva [editorial]. *Cancer*. 1994;74: 2399-2402.
121. Paladini D, Cross P, Lopes A, Monaghan JM. Prognostic significance of lymph node variables in squamous cell carcinoma of the vulva. *Cancer*. 1994;74:2491-2496.
122. Binder SW, Huang I, Fu YS, et al. Risk factors for the development of lymph node metastasis in vulvar squamous cell carcinoma. *Gynecol Oncol*. 1990;37:9-16.
123. Ross MJ, Ehrmann RL. Histologic prognosticators in stage I squamous cell carcinoma of the vulva. *Obstet Gynecol*. 1987;70:774-784.
124. Ambros RA, Melfetano JH, Mihm MC. Clinicopathologic features of vulvar squamous cell carcinomas exhibiting prominent fibromyxoid stromal response. *Int J Gynecol Pathol*. 1996;15:137-145.
125. Kagie MJ, Kenter GG, Tollenaar RA, et al. p53 protein overexpression, a frequent observation in squamous cell carcinoma of the vulva and in various synchronous vulvar epithelia, has no value as a prognostic parameter. *Int J Gynecol Pathol*. 1997;16:124-130.
126. Kojiro S, Growdon WB, Orezzoli JP, et al. Expression of p16, p53 and EGFR in squamous cell carcinoma (SCC) of the vulva: a study of 96 cases. *Lab Invest*. 2009;89(suppl 1):221A.
127. College of American Pathologists. Cancer protocol templates. http://www.cap.org/web/oracle/webcenter/portalapp/pagehierarchy/cancer_protocol_templates.jspx?_adf.ctrl-state=sj65ljtfp_4&_afrLoop=886554031265311#!.
128. Abdel-Mesih A, Daya D, Onuma K, Sur M. Interobserver agreement for assessing invasion in stage 1A vulvar squamous cell carcinoma. *Am J Surg Pathol*. 2013;37:1336-1341.
129. Japaze H, Van Dinh T, Woodruff JD. Verrucous carcinoma of the vulva. Study of 24 cases. *Obstet Gynecol*. 1982;60:462-466.
130. Kraus FT, Perez-Mesa C. Verrucous carcinoma. Clinical and pathologic study of 105 cases involving oral cavity, larynx and genitalia. *Cancer*. 1966;19:26-38.
131. Partridge EE, Murad T, Shingleton HM, et al. Verrucous lesions of the female genital tract. I. Giant condyloma. *Am J Obstet Gynecol*. 1980;137:412-418.
132. Brisigotti M, Moreno A, Murcia C, et al. Verrucous carcinoma of the vulva. A clinicopathologic and immunohistochemical study of five cases. *Int J Gynecol Pathol*. 1989;8:1-7.
133. Liegl B, Leibl S, Gogg-Kamerer M, et al. Mammary and extramammary Paget's disease:

For personal use only. No other uses without permission. Copyright ©2017. Elsevier Inc. All rights reserved.

an immunohistochemical study of 83 cases. *Histopathology*. 2007;50:439-447.
134. Regauer S. Extramammary Paget's disease—a proliferation of adnexal origin? *Histopathology*. 2006;48:723-729.
135. Willman JH, Golitz LE, Fitzpatrick JE. Vulvar clear cells of Toker: precursors of extramammary Paget's disease. *Am J Dermatopathol*. 2005;27:185-188.
136. Helm KF, Goellner JR, Peters MS. Immunohistochemical stains in extramammary Paget's disease. *Am J Dermatopathol*. 1992;14:402-407.
137. Kuan SF, Montag AG, Hart J, et al. Differential expression of mucin genes in mammary and extramammary Paget's disease. *Am J Surg Pathol*. 2001;25:1469-1477.
138. Yoshii N, Kitajima S, Yonezawa S, et al. Expression of mucin core proteins in extramammary Paget's disease. *Pathol Int*. 2002;52:390-399.
139. Kondo Y, Kashima K, Daa T, et al. The ectopic expression of gastric mucin in extramammary and mammary Paget's disease. *Am J Surg Pathol*. 2002;26:617-623.
140. Kohler S, Smoller BR. Gross cystic disease fluid protein-15 reactivity in extramammary Paget's disease with and without associated internal malignancy. *Am J Dermatopathol*. 1996;18:118-123.
141. Nadji M, Morales AR, Girtanner RE, et al. Paget's disease of the skin. A unifying concept of histogenesis. *Cancer*. 1982;50:2203-2206.
142. Olson DJ, Fujimura M, Swanson P, Okagaki T. Immunohistochemical features of Paget's disease of the vulva with and without adenocarcinoma. *Int J Gynecol Pathol*. 1991;10:285-295.
143. Urabe A, Matsukuma A, Shimizu N, et al. Extramammary Paget's disease. Comparative histopathologic studies of intraductal carcinoma of the breast and apocrine adenocarcinoma. *J Cutan Pathol*. 1990;17:257-265.
144. Watanabe S, Ohnishi T, Takahashi H, Ishibashi Y. A comparative study of cytokeratin expression in Paget cells located at various sites. *Cancer*. 1993;72:3323-3330.
145. Guarner J, Cohen C, De Rose PB. Histogenesis of extramammary and mammary Paget cells. An immunohistochemical study. *Am J Dermatopathol*. 1989;11:313-318.
146. Reed W, Oppedal BR, Eeg Larsen T. Immunohistology is valuable in distinguishing between Paget's disease, Bowen's disease and superficial spreading malignant melanoma. *Histopathology*. 1990;16:583-588.
147. Zeng HA, Cartun R, Ricci A Jr. Potential diagnostic utility of CDX-2 immunophenotyping in extramammary Paget's disease. *Appl Immunohistochem Mol Morphol*. 2005;13:342-346.
148. Diaz de Leon E, Carcangiu ML, Prieto VG, et al. Extramammary Paget's disease is characterized by the consistent lack of estrogen and progesterone receptors but frequently expresses androgen receptor. *Am J Clin Pathol*. 2000;113:572-575.
149. Fujimoto A, Takata M, Hatta N, Takehara K. Expression of structurally unaltered androgen receptor in extramammary Paget's disease. *Lab Invest*. 2000;80:1465-1471.
150. Goldblum JR, Hart WR. Vulvar Paget's disease: a clinicopathologic and immunohistochemical study of 19 cases. *Am J Surg Pathol*. 1997;21:1178-1187.
151. Smith KJ, Tuur S, Corvette D, et al. Cytokeratin 7 staining in mammary and extramammary Paget's disease. *Mod Pathol*. 1997;10:1069-1074.
152. Wilkinson EJ, Brown HM. Vulvar Paget disease of urothelial origin: a report of three cases and a proposed classification of vulvar Paget disease. *Hum Pathol*. 2002;33:549-554.
153. Brown HM, Wilkinson EJ. Uroplakin-III to distinguish primary vulvar Paget disease from Paget disease secondary to urothelial carcinoma. *Hum Pathol*. 2002;33:545-548.
154. Morbeck D, et al. GATA3 expression in primary vulvar Paget disease: a potential pitfall leading to misdiagnosis of pagetoid urothelial intraepithelial neoplasia. *Histopathology*. 2016;70(3):435-441.
155. Plaza JA, Torres-Cabala C, Ivan D, Preito VG. Her-2/neu expression in extramammary Paget disease: immunohistochemical study of 47 cases with and without underlying malignancy. *J Cutan Pathol*. 2009;36:729-733.
156. Shaco-Levy R, Bean SM, Vollmer RT, et al. Paget disease of the vulva: a histologic study of 56 cases correlating pathologic features and disease course. *Int J Gynecol Pathol*. 2010;29:69-78.
157. Alguacil-Garcia A, O'Connor R. Mucin-negative biopsy in extra-mammary Paget's disease. A diagnostic problem. *Histopathology*. 1989;15:429-431.
158. Helwig EB, Graham JH. Anogenital (extramammary) Paget's disease. A clinicopathological study. *Cancer*. 1963;16:387-403.
159. Jones RE Jr, Austin C, Ackerman AB. Extramammary Paget's disease. A critical reexamination. *Am J Dermatopathol*. 1979;1:101-132.
160. Curtin JP, Rubin SC, Jones WB, et al. Paget's disease of the vulva. *Gynecol Oncol*. 1990;39:374-377.
161. Fenn ME, Morley GW, Abell MR. Paget's disease of vulva. *Obstet Gynecol*. 1971;38:660-670.
162. Lee SC, Roth LM, Ehrlich C, Hall JA. Extramammary Paget's disease of the vulva. A clinicopathologic study of 13 cases. *Cancer*. 1977;39:2540-2549.
163. Crawford D, Nimmo M, Clement PB, et al. Prognostic factors in Paget's disease of the vulva: a study of 21 cases. *Int J Gynecol Pathol*. 1999;18:351-359.
164. Hart WR, Millman JB. Progression of intraepithelial Paget's disease of the vulva to invasive carcinoma. *Cancer*. 1977;40:2333-2337.
165. Gunn RA, Gallager HS. Vulvar Paget's disease. A topographic study. *Cancer*. 1980;46:590-594.
166. Misas JE, Larson JE, Podezaski E, et al. Recurrent Paget disease of the vulva in a split-thickness graft. *Obstet Gynecol*. 1990;76:543-544.
167. Sington J, Chandrapala R, Manek S, Hollowood K. Mitotic count is not predictive of clinical behavior in hidradenoma papilliferum of the vulva: a clinicopathologic study of 19 cases. *Am J Dermatopathol*. 2006;28:322-326.
168. Meeker JH, Neubecker RD, Helwig EF. Hidradenoma papilliferum. *Am J Clin Pathol*. 1962;37:182-195.
169. Woodworth H Jr, Dockerty MB, Wilson RB, Pratt JH. Papillary hidradenoma of the vulva. A clinicopathologic study of 69 cases. *Am J Obstet Gynecol*. 1971;110:501-508.
170. Pelosi G, Martignoni G, Bonetti F. Intraductal carcinoma of mammary-type apocrine epithelium arising within a papillary hydradenoma of the vulva. Report of a case and review of the literature. *Arch Pathol Lab Med*. 1991;115:1249-1254.
171. Carneiro SJ, Gardner HL, Knox JM. Syringoma. Three cases with vulvar involvement. *Obstet Gynecol*. 1972;39:95-99.
172. Rorat E, Wallach RC. Mixed tumors of the vulva. Clinical outcome and pathology. *Int J Gynecol Pathol*. 1984;3:323-328.
173. Meenakshi M, McCluggage WG. Myoepithelial neoplasms involving the vulva and vagina: report of 4 cases. *Hum Pathol*. 2009;40:1747-1753.
174. Chen KT. Pigmented apocrine hamartoma of the vulva: a report of two cases. *Int J Gynecol Pathol*. 2005;24:85-87.
175. Pantanowitz L, Henneberry JM, Otis CN, Zakhary M. Adenolipoma of the external female genitalia. *Int J Gynecol Pathol*. 2008;27:297-300.
176. Avinoach I, Zirkin HJ, Glezerman M. Proliferating trichilemmal tumor of the vulva. Case report and review of the literature. *Int J Gynecol Pathol*. 1989;8:163-168.
177. Regauer S, Nogales FF. Vulvar trichogenic tumors: a comparative study with vulvar basal cell carcinoma. *Am J Surg Pathol*. 2005;29:479-484.
178. Duray PH, Merino MJ, Axiotis C. Warty dyskeratoma of the vulva. *Int J Gynecol Pathol*. 1983;2:286-293.
179. Roth LM, Look KY. Inverted follicular keratosis of the vulvar skin: a lesion that can be confused with squamous cell carcinoma. *Int J Gynecol Pathol*. 2001;19:369-373.
180. Chen W, Koenig C. Vulvar keratoacanthoma: a report of two cases. *Int J Gynecol Pathol*. 2004;23:284-286.
181. Rhatigan RM, Nuss RC. Keratoacanthoma of the vulva. *Gynecol Oncol*. 1985;21:118-123.
182. Cruz-Jimenez PR, Abell MR. Cutaneous basal cell carcinoma of vulva. *Cancer*. 1975;36:1860-1868.
183. Perrone T, Twiggs LB, Adcock LL, Dehner LP. Vulvar basal cell carcinoma. An infrequently metastasizing neoplasm. *Int J Gynecol Pathol*. 1987;6:152-165.
184. Chen KTK. Merkel's cell (neuroendocrine) carcinoma of the vulva. *Cancer*. 1994;73:2186-2191.
185. Chien CH, Wu YY, Kuo KT, et al. Combined squamous cell carcinoma and Merkel cell carcinoma of the vulva: Role of human papillomavirus and Merkel cell polyomavirus. *JAAD Case Rep*. 2015;4:196-199.
186. Loret de Mola JR, Hudock PA, Steinetz C, et al. Merkel cell carcinoma of the vulva. *Gynecol Oncol*. 1993;51: 272-276.
187. Wick MR, Goellner JR, Wolfe JT III, Su WPD. Vulvar sweat gland carcinomas. *Arch Pathol Lab Med*. 1985;109:43-47.
188. Rahilly MA, Beattie GJ, Lessells AM. Mucinous eccrine carcinoma of the vulva with neuroendocrine differentiation. *Histopathology*. 1995;27:82-86.
189. Hinze P, Feyler S, Berndt J, et al. Malignant myoepithelioma of the vulva resembling a rhabdoid tumour. *Histopathology*. 1999;35:50-54.
190. Young S, Leon M, Talerman A, et al. Polymorphous low-grade adenocarcinoma of the vulva and vagina: a tumor resembling adenoid cystic carcinoma. *Int J Surg Pathol*. 2003;11:43-49.
191. Escalonilla P, Grilli R, Canamero M, et al. Sebaceous carcinoma of the vulva. *Am J Dermatopathol*. 1999;21:468-472.
192. Christensen WN, Friedman KJ, Woodruff JD, Hood AF. Histologic characteristics of vulvar nevocellular nevi. *J Cutan Pathol*. 1987;14:87-91.
193. Rock B. Pigmented lesions of the vulva. *Dermatol Clin*. 1992;10:361-370.
194. Clark WH Jr, Hood AF, Tucker MA, Jampel RM. Atypical melanocytic nevi of the genital type with a discussion of reciprocal parenchymal–stromal interactions in the biology of neoplasia. *Hum Pathol*. 1998;29:S1-S24.
195. Gleason BC, Hirsch MS, Nucci MR, et al. Atypical genital nevi. A clinicopathologic analysis of 56 cases. *Am J Surg Pathol*. 2008;32:51-57.
196. Jaramillo BA, Ganjei P, Averette HE, et al. Malignant melanoma of the vulva. *Obstet Gynecol*. 1985;66:398-401.

For personal use only. No other uses without permission. Copyright ©2017. Elsevier Inc. All rights reserved.

197. Panizzon RG. Vulvar melanoma. *Semin Dermatol*. 1996;15:67-70.
198. Ragnarsson-Olding B, Johansson H, Rutqvist LE, Ringborg U. Malignant melanoma of the vulva and vagina. Trends in incidence, age distribution, and long-term survival among 245 consecutive cases in Sweden 1960–1984. *Cancer*. 1993;71:1893-1897.
199. Ragnarsson-Olding BK, Kanter-Lewensohn LR, Lagerlof B, et al. Malignant melanoma of the vulva in a nationwide, 25-year study of 219 Swedish females: clinical observations and histopathologic features. *Cancer*. 1999;86:1273-1284.
200. Ronan SG, Eng AM, Briele HA, et al. Malignant melanoma of the female genitalia. *J Am Acad Dermatol*. 1990;22:428-435.
201. Hill SJ, Berkowitz R, Granter SR, Hirsch MS. Pagetoid lesions of the vulva: a collision between malignant melanoma and extramammary Paget disease. *Int J Gynecol Pathol*. 2008;27:292-296.
202. Dunton CJ, Kautzky M, Hanau C. Malignant melanoma of the vulva: a review. *Obstet Gynecol Surv*. 1995;50:739-746.
203. Irvin WP Jr, Legallo RL, Stoler MH, et al. Vulvar melanoma: a retrospective analysis and literature review. *Gynecol Oncol*. 2001;83:457-465.
204. Look KY, Roth LM, Sutton GP. Vulvar melanoma reconsidered. *Cancer*. 1993;72:143-146.
205. Bradgate MG, Rollason TP, McConkey CC, Powell J. Malignant melanoma of the vulva. A clinicopathological study of 50 women. *Br J Obstet Gynaecol*. 1990;97:124-133.
206. Raber G, Mempel V, Jackisch C, et al. Malignant melanoma of the vulva: report of 89 patients. *Cancer*. 1996;78:2353-2358.
207. Johnson TL, Kumar NB, White CD, Morley GW. Prognostic features of vulvar melanoma. A clinicopathologic analysis. *Int J Gynecol Pathol*. 1986;5:110-118.
208. Podratz KC, Symmonds RE, Taylor WF, Williams TJ. Carcinoma of the vulva. Analysis of treatment and survival. *Obstet Gynecol*. 1983;61:63-74.
209. Ragnarsson-Olding BK, Nilsson BR, Kanter-Lewensohn LR, et al. Malignant melanoma of the vulva in a nationwide, 25-year study of 219 Swedish females: predictors of survival. *Cancer*. 1999;86:1285-1293.
210. Tasseron EW, van der Esch EP, Hart AA, et al. A clinicopathological study of 30 melanomas of the vulva. *Gynecol Oncol*. 1992;46: 170-175.
211. Scheistroen M, Trope C, Koern J, et al. Malignant melanoma of the vulva. Evaluation of prognostic factors with emphasis on DNA ploidy in 75 patients. *Cancer*. 1995;75:72-80.
212. Rouzbahman M, et al. Malignant melanoma of vulva and vagina: a histomorphological review and mutation analysis–a single-center study. *J Low Genit Tract Dis*. 2015;19(4):350-353.
213. van Engen-van Grunsven AC, et al. NRAS mutations are more prevalent than KIT mutations in melanoma of the female urogenital tracty—a study of 24 cases from the Netherlands. *Gynecol Oncol*. 2014;134(1):10-14.
214. Aulmann S, Sinn HP, Penzel R, et al. Comparison of molecular abnormalities in vulvar and vaginal melanomas. *Mod Pathol*. 2013;27:1386-1393.
215. Spatz A, Zimmermann U, Bachollet B, et al. Malignant blue nevus of the vulva with late ovarian metastasis. *Am J Dermatopathol*. 1998;20:408-412.
216. Bégin LR, Clement PB, Kirk ME, et al. Aggressive angiomyxoma of pelvic soft parts. A clinicopathologic study of nine cases. *Hum Pathol*. 1985;16:621-628.
217. Steeper TA, Rosai J. Aggressive angiomyxoma of the female pelvis and perineum. Report of nine cases of a distinctive type of gynecologic soft tissue neoplasm. *Am J Surg Pathol*. 1983;7:463-475.
218. White J, Chan YF. Aggressive angiomyxoma of the vulva in an 11-year-old girl. *Pediatr Pathol*. 1994;14:27-37.
219. Iezzoni JC, Fechner RE, Wong LS, Rosai J. Aggressive angiomyxoma in males. A report of four cases. *Am J Clin Pathol*. 1995;104:391-396.
220. Fetsch JF, Laskin WB, Tavassoli FA. Superficial angiomyxoma (cutaneous myxoma): a clinicopathologic study of 17 cases arising in the genital region. *Int J Gynecol Pathol*. 1998;16:325-334.
221. Martinez MA, Ballestin C, Carabias E, Lois CG. Aggressive angiomyxoma: an ultrastructural study of four cases. *Ultrastruct Pathol*. 2003;27:227-233.
222. Skalova A, Michal M, Husek K, et al. Aggressive angiomyxoma of the pelvioperineal region. Immunohistological and ultrastructural study of seven cases. *Am J Dermatopathol*. 1993;15:446-451.
223. McCluggage WG, Ganesan R, Hirschowitz L, Rollason TP. Cellular angiofibroma and related fibromatous lesions of the vulva: report of a series of cases with a morphological spectrum wider than previously described. *Histopathology*. 2004;45:360-368.
224. Rotmensch EJ, Kasznica J, Hamid MA. Immunohistochemical analysis of hormone receptors and proliferating cell nuclear antigen in aggressive angiomyxoma of the vulva. *Int J Gynaecol Obstet*. 1993;41:171-179.
225. van Roggen JF, van Unnik JA, Briaire-de Bruijn IH, Hogendoorn PC. Aggressive angiomyxoma: a clinicopathological and immunohistochemical study of 11 cases with long-term follow-up. *Virchows Arch*. 2005;446:157-163.
226. Kazmierczak B, Wanschura S, Meyer-Bolte K, et al. Cytogenetic and molecular analysis of an aggressive angiomyxoma. *Am J Pathol*. 1995;147:580-585.
227. Micci F, Panagopoulos I, Bjerkehagen B, Heim S. Deregulation of HMGA2 in an aggressive angiomyxoma with t(11;12)(q23;q15). *Virchows Arch*. 2006;448:838-842.
228. Rabban JT, Dal Cin P, Oliva E. HMGA2 rearrangement in a case of vulvar aggressive angiomyxoma. *Int J Gynecol Pathol*. 2006;25:403-407.
229. McCluggage WG, Connoly L, McBride HA. HMGA2 is a sensitive but not specific immunohistochemical marker of vulvovaginal aggressive angiomyxoma. *Am J Surg Pathol*. 2010;34:1037-1042.
230. Tsuji T, Yoshinaga M, Inomoto Y, et al. Aggressive angiomyxoma of the vulva with a sole t(5;8)(p15;q22) chromosome change. *Int J Gynecol Pathol*. 2007;26:494-496.
231. Fetsch JF, Laskin WB, Lefkowitz M, et al. Aggressive angiomyxoma: a clinicopathologic study of 29 female patients. *Cancer*. 1996;78:79-90.
232. Blandamura S, Cruz J, Vergara LF, et al. Aggressive angiomyxoma: a second case of metastasis with patient's death. *Hum Pathol*. 2003;34:1072-1074.
233. Siassi R, Papadopoulos T, Matzel KE. Metastasizing aggressive angiomyxoma [letter to the editor]. *N Engl J Med*. 1999;341:1772.
234. McCluggage EG, Jamieson T, Dobbs SP, Grey A. Aggressive angiomyxoma of the vulva: dramatic response to gonadotropin-releasing hormone agonist therapy. *Gynecol Oncol*. 2006;100:623-625.
235. Fletcher CD, Tsang WY, Fisher C, et al. Angiomyofibroblastoma of the vulva. A benign neoplasm distinct from aggressive angiomyxoma. *Am J Surg Pathol*. 1992;16:373-382.
236. Fukunaga M, Nomura K, Matsumoto K, et al. Vulval angiomyofibroblastoma. Clinicopathologic analysis of six cases. *Am J Clin Pathol*. 1997;107:45-51.
237. Vasquez MD, Ro JY, Park YW, et al. Angiomyofibroblastoma: a clinicopathologic study of eight cases and review of the literature. *Int J Surg Pathol*. 1999;7:161-170.
238. Laskin WB, Fetsch JF, Tavassoli FA. Angiomyofibroblastoma of the female genital tract: analysis of 17 cases including a lipomatous variant. *Hum Pathol*. 1997;28:1046-1055.
239. Nielsen GP, Rosenberg AE, Young RH, et al. Angiomyofibroblastoma of the vulva and vagina. *Mod Pathol*. 1996;9:284-291.
240. Cao D, Srodon M, Montgomery EA, Kurman RJ. Lipomatous variant of angiomyofibroblastoma: report of two cases and review of the literature. *Int J Gynecol Pathol*. 2005;24:196-200.
241. Nielsen GP, Young RH, Dickersin GR, Rosenberg AE. Angiomyofibroblastoma of the vulva with sarcomatous transformation ('angiomyofibrosarcoma'). *Am J Surg Pathol*. 1997;21:1104-1108.
242. Ganesan R, McCluggage WG, Hirschowitz L, Rollason TP. Superficial myofibroblastoma of the lower female genital tract: report of a series including tumours with a vulval location. *Histopathology*. 2005;46:137-143.
243. Hisaoka M, Kouho H, Aoki T, et al. Angiomyofibroblastoma of the vulva. A clinicopathologic study of seven cases. *Pathol Int*. 1995;45:487-492.
244. Alameda F, Munné A, Baró T, et al. Vulvar angiomyxoma, aggressive angiomyxoma, and angiomyofibroblastoma: an immunohistochemical and ultrastructural study. *Ultrastruct Pathol*. 2006;30:193-205.
245. Granter SR, Nucci MR, Fletcher CD. Aggressive angiomyxoma: reappraisal of its relationship to angiomyofibroblastoma in a series of 16 cases. *Histopathology*. 1997;30:3-10.
246. Ockner DM, Sayadi H, Swanson PE, et al. Genital angiomyofibroblastoma. Comparison with aggressive angiomyxoma and other myxoid neoplasms of skin and soft tissue. *Am J Clin Pathol*. 1997;107:36-44.
247. Iwasa Y, Fletcher CD. Cellular angiofibroma: clinicopathologic and immunohistochemical analysis of 51 cases. *Am J Surg Pathol*. 2004;28:1426-1435.
248. Nucci MR, Granter SR, Fletcher CD. Cellular angiofibroma: a benign neoplasm distinct from angiomyofibroblastoma and spindle cell lipoma. *Am J Surg Pathol*. 1997;21: 636-644.
249. Vargas SO, Kozakewich HP, Boyd TK, et al. Childhood asymmetric labium majus enlargement: mimicking a neoplasm. *Am J Surg Pathol*. 2005;29:1007-1016.
250. McCluggage WG, Nielsen GP, Young RH. Massive vulval edema secondary to obesity and immobilization: a potential mimic of aggressive angiomyxoma. *Int J Gynecol Pathol*. 2008;27:447-452.
251. Vang R, Connelly JH, Hammill HA, Shannon RL. Vulvar hypertrophy with lymphedema: a mimicker of aggressive angiomyxoma. *Arch Pathol Lab Med*. 2000;124:1697-1699.
252. Abdul-Karim FW, Cohen RE. Atypical stromal cells of lower female genital tract. *Histopathology*. 1990;17:249-253.
253. Elliott GB, Elliott JDA. Superficial stromal reactions of lower genital tract. *Arch Pathol*. 1973;95:100-101.
254. Ostor AG, Fortune DW, Riley CB. Fibroepithelial polyps with atypical stromal cells (pseudosarcoma botryoides) of vulva and vagina. A report of 13 cases. *Int J Gynecol Pathol*. 1988;7:351-360.

For personal use only. No other uses without permission. Copyright ©2017. Elsevier Inc. All rights reserved.

255. Nucci MR, Young RH, Fletcher CD. Cellular pseudosarcomatous fibroepithelial stromal polyps of the lower female genital tract: an underrecognized lesion often misdiagnosed as sarcoma. *Am J Surg Pathol*. 2000;24:231-240.
256. Mucitelli DR, Charles EZ, Kraus FT. Vulvovaginal polyps. Histologic appearance, ultrastructure, immunocytochemical characteristics, and clinicopathologic correlations. *Int J Gynecol Pathol*. 1990;9:20-40.
257. Goldrat O, et al. Prepubertal vulvar fibroma: neoplasm or physiological condition? *J Pediatr Adolesc Gynecol*. 2016;e67-e70.
258. Iwasa Y, Fletcher CD. Distinctive prepubertal vulval fibroma: a hitherto unrecognized mesenchymal tumor of prepubertal girls: analysis of 11 cases. *Am J Surg Pathol*. 2004;28:1601-1608.
259. Nielsen GP, Rosenberg AE, Koerner FC, et al. Smooth-muscle tumors of the vulva: a clinicopathological study of 25 cases and review of the literature. *Am J Surg Pathol*. 1996;20:779-793.
260. Nemoto T, Shinoda M, Komatsuzaki K, et al. Myxoid leiomyoma of the vulva mimicking aggressive angiomyxoma. *Pathol Int*. 1994;44:454-459.
261. Newman PL, Fletcher CD. Smooth muscle tumours of the external genitalia. Clinicopathological analysis of a series. *Histopathology*. 1991;18:523-529.
262. Tavassoli FA, Norris HJ. Smooth muscle tumors of the vulva. *Obstet Gynecol*. 1979;53:213-217.
263. Nielsen GP, Young RH. Mesenchymal tumors and tumor-like lesions of the female genital tract: a selective review with emphasis on recently described entities. *Int J Gynecol Pathol*. 2001;20:105-127.
264. Nucci MR, Fletcher CD. Vulvovaginal soft tissue tumors: update and review. *Histopathology*. 2000;36:97-108.
265. Bell D, Kane PB, Liang S, et al. Vulvar varices: an uncommon entity in surgical pathology. *Int J Gynecol Pathol*. 2007;26:99-101.
266. Fernández-Aguilar S, Fayt I, Noël JC. Spindle cell vulvar hemangiomatosis associated with enchondromatosis: a rare variant of Maffucci's syndrome. *Int J Gynecol Pathol*. 2004;23: 68-70.
267. Mu XC, Tran TA, Dupree M, Carslon JA. Acquired vulvar lymphangioma mimicking genital warts. A case report and review of the literature. *J Cutan Pathol*. 1999;26:150-154.
268. McNeely TB. Angiokeratoma of the clitoris. *Arch Pathol Lab Med*. 1992;116:880-881.
269. Strayer SA, Yum MN, Sutton GP. Epithelioid hemangioendothelioma of the clitoris. A case report with immunohistochemical and ultrastructural findings. *Int J Gynecol Pathol*. 1992;11:234-239.
270. Katz VL, Askin FB, Bosch BD. Glomus tumor of the vulva. A case report. *Obstet Gynecol*. 1986;67:43S-45S.
271. Sonobe H, Ro JY, Ramos M, et al. Glomus tumor of the female external genitalia. A report of two cases. *Int J Gynecol Pathol*. 1994;13:359-364.
272. Blandamura S, Florea G, Brotto M, et al. Periurethral glomangiomyoma in women: case report and review of the literature [letter]. *Histopathology*. 2000;36:571-572.
273. Nirenberg A, Ostor AG, Slavin J, et al. Primary vulvar sarcomas. *Int J Gynecol Pathol*. 1995;14:55-62.
274. Guirguis A, Kanbour-Shakir A, Kelley J. Epithelioid angiosarcoma of the mons after chemoradiation for vulvar cancer. *Int J Gynecol Pathol*. 2007;26:265-268.
275. Papalas JA, Shaco-Levy R, Robboy SJ, Selim MA. Isolated and synchronous vulvar granular cell tumors: a clinicopathologic study of 17 cases in 13 patients. *Int J Gynecol Pathol*. 2010;29:173-180.
276. Robertson AJ, McIntosh W, Lamont P, Guthrie W. Malignant granular cell tumour (myoblastoma) of the vulva. Report of a case and review of the literature. *Histopathology*. 1981;5:69-79.
277. Wolber RA, Talerman A, Wilkinson EJ, Clement PB. Vulvar granular cell tumors with pseudocarcinomatous hyperplasia. A comparative analysis with well-differentiated squamous carcinoma. *Int J Gynecol Pathol*. 1991;10:59-66.
278. Huang HJ, Yamabe T, Tagawa H. A solitary neurilemmoma of the clitoris. *Gynecol Oncol*. 1983;15:103-110.
279. Gersell DJ, Fulling KH. Localized neurofibromatosis of the female genitourinary tract. *Am J Surg Pathol*. 1989;13:873-878.
280. Hood AF, Lumadue J. Benign vulvar tumors. *Dermatol Clin*. 1992;10:371-385.
281. Terada KY, Schmidt RW, Roberts JA. Malignant schwannoma of the vulva. A case report. *J Reprod Med*. 1988;33:969-972.
282. Thomas WJ, Bevan HE, Hooper DG, Downey EJ. Malignant schwannoma of the clitoris in a 1-year-old child. *Cancer*. 1989;63:2216-2219.
283. Kempson RL, Sherman AI. Sclerosing lipogranuloma of the vulva. Report of a case. *Obstet Gynecol*. 1968;101:854-856.
284. Dudley AG, Young RH, Lawrence WD, Scully RE. Endodermal sinus tumor of the vulva in an infant. *Obstet Gynecol*. 1983;61:76S-78S.
285. Hays DM, Raney RB Jr, Lawrence W Jr, et al. Rhabdomyosarcoma of the female urogenital tract. *J Pediatr Surg*. 1981;16:828-834.
286. Hays DM, Shimada H, Raney RB Jr, et al. Clinical staging and treatment results in rhabdomyosarcoma of the female genital tract among children and adolescents. *Cancer*. 1988;61:1893-1903.
287. Kernen JA, Morgan ML. Benign lymphoid hamartoma of the vulva. Report of a case. *Obstet Gynecol*. 1970;35:290-292.
288. Santa Cruz J, Martin SA. Verruciform xanthoma of the vulva. *Am J Clin Pathol*. 1979;71:224-228.
289. Axiotis CA, Merino MJ, Duray PH. Langerhans cell histiocytosis of the female genital tract. *Cancer*. 1991;67:1650-1660.
290. Meehan SA, Smoller BR. Cutaneous Langerhans cell histiocytosis of the genitalia in the elderly: a report of three cases. *J Cutan Pathol*. 1998;25:370-374.
291. Padula A, Medeiros LJ, Silva EG, Deavers MT. Isolated vulvar Langerhans cell histiocytosis: report of two cases. *Int J Gynecol Pathol*. 2004;23:278-283.
292. O'Connell JX, Young RH, Nielsen GP, et al. Nodular fasciitis of the vulva: study of six cases and literature review. *Int J Gynecol Pathol*. 1997;16:117-123.
293. Manson CM, Hirsch PJ, Coyne JD. Post-operative spindle cell nodule of the vulva. *Histopathology*. 1995;26:571-574.
294. Taylor RN, Bottles K, Miller TR, Braga CA. Malignant fibrous histiocytoma of the vulva. *Obstet Gynecol*. 1985;66:145-148.
295. Barnhill DR, Boling R, Nobles W, et al. Vulvar dermatofibrosarcoma protuberans. *Gynecol Oncol*. 1988;30:149-152.
296. Bock JE, Andreasson B, Thorn A, Holck S. Dermatofibrosarcoma protuberans of the vulva. *Gynecol Oncol*. 1985;20:129-135.
297. Edelweiss M, Malpica A. Dermatofibrosarcoma protuberans of the vulva: a clinicopathologic and immunohistochemical study of 13 cases. *Am J Surg Pathol*. 2010;34:393-400.
298. Ghorbani RP, Malpica A, Ayala AG. Dermatofibrosarcoma protuberans of the vulva: clinicopathologic and immununohistochemical analysis of four cases, one with fibrosarcomatous change, and review of the literature. *Int J Gynecol Pathol*. 1999;18:366-373.
299. Vang R, Taubenberger JK, Mannion CM, et al. Primary vulvar and vaginal extraosseous Ewing's sarcoma/peripheral neuroectodermal tumor: diagnostic confirmation with CD99 immunostaining and reverse transcriptase-polymerase chain reaction. *Int J Gynecol Pathol*. 2000;19:103-109.
300. Nielsen GP, Shaw PA, Rosenberg AE, et al. Synovial sarcoma of the vulva: a report of two cases. *Mod Pathol*. 1997;9:970-974.
301. White BE, Kaplan A, Lopez-Terrada DH, et al. Monophasic synovial sarcoma arising in the vulva: a case report and review of the literature. *Arch Pathol Lab Med*. 2008;132:698-702.
302. Allen MV, Novotny DB. Desmoid tumor of the vulva associated with pregnancy. *Arch Pathol Lab Med*. 1997;121:512-514.
303. Nielsen GP, Young RH. Fibromatosis of soft tissue type involving the female genital tract: a report of two cases. *Int J Gynecol Pathol*. 1998;16:383-386.
304. Nucci MR, Fletcher CD. Liposarcoma (atypical lipomatous tumors) of the vulva: a clinicopathologic study of six cases. *Int J Gynecol Pathol*. 1998;17:17-23.
305. Lae ME, Pereira PF, Keeney GL, Nascimento AG. Lipoblastoma-like tumour of the vulva: report of three cases of a distinctive mesenchymal neoplasm of adipocytic differentiation. *Histopathology*. 2002;40:505-509.
306. Kaplan MA, Jacobson JO, Ferry JA, Harris NL. T-cell lymphoma of the vulva in a renal allograft recipient with associated hemophagocytosis. *Am J Surg Pathol*. 1993;17:842-849.
307. Vang R, Medeiros LJ, Malpica A, et al. Non-Hodgkin's lymphoma involving the vulva. *Int J Gynecol Pathol*. 2000;19: 236-242.
308. Colgan TJ, Dardick I, O'Connell G. Paraganglioma of the vulva. *Int J Gynecol Pathol*. 1991;10:203-208.
309. Shen J-T, D'Ablaing G, Morro CP. Alveolar soft part sarcoma of the vulva. Report of first case and review of literature. *Gynecol Oncol*. 1982;13:120-128.
310. Ulbright TM, Brokaw SA, Stehman FB, Roth LM. Epithelioid sarcoma of the vulva. Evidence suggesting a more aggressive behavior than extra-genital epithelioid sarcoma. *Cancer*. 1983;52:1462-1469.
311. Weissmann D, Amenta PS, Kantor GR. Vulvar epithelioid sarcoma metastatic to the scalp. A case report and review of the literature. *Am J Dermatopathol*. 1990;12:462-468.
312. Matias C, Nunes JF, Vicente LF, Almeida MO. Primary malignant rhabdoid tumour of the vulva. *Histopathology*. 1990;17:576-578.
313. Perrone T, Swanson PE, Twiggs L, et al. Malignant rhabdoid tumor of the vulva. Is distinction from epithelioid sarcoma possible? A pathologic and immunohistochemical study. *Am J Surg Pathol*. 1989;13:848-858.
314. Folpe AL, Schoolmeester JK, McCluggage WG, et al. SMARCB1 deficient vulvar neoplasms: a clinicopathologic, immunohistochemical and molecular genetic study of 14 cases. *Am J Surg Pathol*. 2015;39:836-849.
315. Dehner LP. Metastatic and secondary tumors of the vulva. *Obstet Gynecol*. 1973;42:47-57.
316. Mazur MT, Hsueh S, Gersell DJ. Metastases to the female genital tract. Analysis of 325 cases. *Cancer*. 1984;53:1978-1984.
317. Neto AG, Deavers MT, Silva EG, Malpica A. Metastatic tumors of the vulva. A clinicopathologic study of 66 cases. *Am J Surg Pathol*. 2003;27:799-804.
318. Freedman SR, Goldman RL. Mucocele-like changes in Bartholin's glands. *Hum Pathol*. 1978;9:111-114.
319. Andersen G, Christensen S, Detlefsen GU, Kern-Hansen P. Treatment of Bartholin's

For personal use only. No other uses without permission. Copyright ©2017. Elsevier Inc. All rights reserved.

abscess. Marsupialization versus incision, curettage and suture under antibiotic cover. A randomized trial with a 6-months follow-up. *Acta Obstet Gynecol Scand*. 1992;71:59-62.
320. Paquin ML, Davis JR, Weiner S. Malacoplakia of Bartholin's gland. *Arch Pathol Lab Med*. 1986;110:757-758.
321. Friedrich EG Jr, Wilkinson EJ. Mucous cysts of the vulvar vestibule. *Obstet Gynecol*. 1973;42:407-414.
322. Axe S, Parmley T, Woodruff JD, Hlopak B. Adenomas in minor vestibular glands. *Obstet Gynecol*. 1986;68:16-18.
323. Koenig C, Tavassoli FA. Nodular hyperplasia, adenoma, and adenomyoma of Bartholin's gland. *Int J Gynecol Pathol*. 1998;17:289-294.
324. Chapman GW Jr, Hassan N, Page D, et al. Mucinous cystadenoma of Bartholin's gland. A case report. *J Reprod Med*. 1987;32:939-941.
325. Enghardt MH, Valente PT, Day DH. Papilloma of Bartholin's gland duct cyst. First report of a case. *Int J Gynecol Pathol*. 1993;12:86-92.
326. Balat O, Edwards CL, Delclos L. Advanced primary carcinoma of the Bartholin gland: report of 18 patients. *Eur J Gynaecol Oncol*. 2001;22:46-49.
327. Copeland LJ, Sneige N, Gershenson DM, et al. Bartholin gland carcinoma. *Obstet Gynecol*. 1986;67:794-801.
328. Leuchter RS, Hacker NF, Voet RL, et al. Primary carcinoma of the Bartholin gland. A report of 14 cases and review of the literature. *Obstet Gynecol*. 1982;60:361-368.
329. Wheelock JB, Goplerud DR, Dunn LJ, Oates JF III. Primary carcinoma of the Bartholin gland. A report of ten cases. *Obstet Gynecol*. 1984;63:820-824.
330. Mossler JA, Woodard BH, Addison A, McArty KS. Adenocarcinoma of Bartholin's gland. *Arch Pathol Lab Med*. 1980;104:523-526.
331. Felix A, Nunes JF, Soares J. Salivary gland-type basal cell adenocarcinoma of presumed Bartholin's gland origin: a case report. *Int J Gynecol Pathol*. 2002;21:194-197.
332. McCluggage WG, Aydin NE, Wong NA, Cooper K. Low-grade epithelial–myoepithelial carcinoma of Bartholin gland: report of 2 cases of a distinctive neoplasm arising in the vulvovaginal region. *Int J Gynecol Pathol*. 2009;28:286-291.
333. Jones MA, Mann EW, Caldwell CL, et al. Small cell neuroendocrine carcinoma of Bartholin's gland. *Am J Clin Pathol*. 1990;94:439-442.
334. Copeland LJ, Sneige N, Gershenson DM, et al. Adenoid cystic carcinoma of Bartholin gland. *Obstet Gynecol*. 1986;67:115-120.
335. Milchgrub S, Wiley EL, Vuitch F, Albores-Saavedra J. The tubular variant of adenoid cystic carcinoma of the Bartholin's gland. *Am J Clin Pathol*. 1994;101:204-208.
336. Rosenberg P, Simonsen E, Risberg B. Adenoid cystic carcinoma of Bartholin's gland. A report of five new cases treated with surgery and radiotherapy. *Gynecol Oncol*. 1989;34:145-147.
337. Felix JC, Cote RJ, Kramer EE, et al. Carcinomas of Bartholin's gland. Histogenesis and the etiological role of human papillomavirus. *Am J Pathol*. 1993;142:925-933.
338. Scinicariello F, Rady P, Hannigan E, et al. Human papillomavirus type 16 found in primary transitional cell carcinoma of the Bartholin's gland and in a lymph node metastasis. *Gynecol Oncol*. 1992;47: 263-266.
339. Xing D, Bakhsh S, Melnyk N, et al. Frequent NFB1-associated gene rearrangement in adenoid cystic carcinoma of the vulva. *Int J Gynecol Pathol*. 2016;in press.
340. Cardosi RJ, Speights A, Fiorica JV, et al. Bartholin's gland carcinoma: a 15-year experience. *Gynecol Oncol*. 2001;82:247-251.
341. Young RH, Oliva E, Saenz Garcia JA, et al. Urethral caruncle with atypical stromal cells simulating lymphoma or sarcoma—a distinctive pseudoneoplastic lesion of females: a report of six cases. *Am J Surg Pathol*. 1996;20:1190-1195.
342. Capraro VJ, Bayonet-Rivera NP, Magoss I. Vulvar tumor in children due to prolapse of urethral mucosa. *Am J Obstet Gynecol*. 1970;108:572-575.
343. Furusato M, Takaki K, Joh K, et al. Nephrogenic adenoma in female urethra. *Acta Pathol Jpn*. 1983;33:1009-1015.
344. Odze R, Begin LR. Tubular adenomatous metaplasia (nephrogenic adenoma) of the female urethra. *Int J Gynecol Pathol*. 1989;8:374-380.
345. Jarvi OH, Marin S, de Boer WG. Further studies of intestinal heterotopia in urethral caruncle. *Acta Pathol Microbiol Immunol Scand [A]*. 1984;92:469-474.
346. Morgan DR, Dixon MF, Harnden P. Villous adenoma of urethra associated with tubulovillous adenoma and adenocarcinoma of rectum. *Histopathology*. 1998;32:87-89.
347. Benson RC, Tunca JC, Buchler DA, Uehling DT. Primary carcinoma of the female urethra. *Gynecol Oncol*. 1982;14:313-318.
348. Johnson DE, O'Connell JR. Primary carcinoma of female urethra. *Urology*. 1983;21:42-44.
349. Rogers RE, Burns B. Carcinoma of the female urethra. *Obstet Gynecol*. 1969;33:54-57.
350. Amin MB, Young RH. Primary carcinomas of the urethra. *Semin Diagn Pathol*. 1997;14:147-160.
351. Mostofi FK, David CJ Jr, Sesterhenn IA. Carcinoma of the male and female urethra. *Urol Clin North Am*. 1992;19:347-358.
352. Meis JM, Ayala AG, Johnson DE. Adenocarcinoma of the urethra in women. A clinicopathologic study. *Cancer*. 1987;60:1038-1052.
353. Suzuki K, Morita T, Tokue A. Primary signet ring cell carcinoma of female urethra. *Int J Urol*. 2001;8:509-512.
354. Oliva E, Young RH. Clear cell adenocarcinoma of the urethra: a clinicopathologic analysis of 19 cases. *Mod Pathol*. 1997;9:513-520.
355. Young RH, Scully RE. Clear cell adenocarcinoma of the bladder and urethra. A report of three cases and review of the literature. *Am J Surg Pathol*. 1985;9:816-826.
356. Clayton M, Siami P, Guinan P. Urethral diverticular carcinoma. *Cancer*. 1992;70:665-670.
357. Evans KJ, McCarthy MP, Sands JP. Adenocarcinoma of a female urethral diverticulum. Case report and review of the literature. *J Urol*. 1981;126:124-126.
358. Baxendine-Jones JA, Wedderburn AW, Smart CJ, Theaker JM. Primary adenocarcinoma of the female urethra associated with adenomatous hyperplasia of the periurethral glands. *J Urol Pathol*. 1998;9:233-239.
359. Wiener JS, Walther PJ. A high association of oncogenic human papillomaviruses with carcinomas of the female urethra. Polymerase chain reaction-based analysis of multiple histological types. *J Urol*. 1994;151:49-53.
360. Mayer R, Fowler JE Jr, Clayton M. Localized urethral cancer in women. *Cancer*. 1987;60:1548-1551.
361. Garden AS, Zagars GK, Delclos L. Primary carcinoma of the female urethra. Results of radiation therapy. *Cancer*. 1993;71:3102-3108.
362. Prempee T, Amornmarn R, Patanaphan V. Radiation therapy in primary carcinoma of the female urethra. Part II. An update on results. *Cancer*. 1984;54:729-733.
363. Wegnaupt K, Gerstner GJ, Kucera H. Radiation therapy for primary carcinoma of the female urethra. A survey over 25 years. *Gynecol Oncol*. 1984;17:58-63.
364. Grigsby PW, Corn BW. Localized urethral tumors in women. Indications for conservative versus exenterative therapies. *J Urol*. 1992;147:1516-1520.
365. Narayan P, Konety B. Surgical treatment of female urethral carcinoma. *Urol Clin North Am*. 1992;19:373-382.
366. Saad AG, Kaouk JH, Kaspar HG, Khauli RB. Leiomyoma of the urethra: report of three cases of a rare entity. *Int J Surg Pathol*. 2003;11:123-126.
367. Kim CJ, Pak K, Hamaguchi A, et al. Primary malignant melanoma of the female urethra. *Cancer*. 1993;71:448-451.
368. Oliva E, Quinn TR, Amin MB, et al. Primary malignant melanoma of the urethra: a clinicopathologic analysis of 15 cases. *Am J Surg Pathol*. 2000;24:785-796.
369. Ohsawa M, Mishima K, Suzuki A, et al. Malignant lymphoma of the urethra. Report of a case with detection of Epstein–Barr virus genome in the tumor cells. *Histopathology*. 1994;24:525-529.

For personal use only. No other uses without permission. Copyright ©2017. Elsevier Inc. All rights reserved.

31 Vagina

Blake Gilks

CHAPTER CONTENTS

Normal anatomy, 1248
Adenosis and related lesions, 1248
Other non-neoplastic lesions, 1249
Benign epithelial tumors, 1250
Squamous intraepithelial lesions, 1250
Invasive squamous cell carcinoma, 1251
Clear cell carcinoma, 1252
Other carcinoma types, 1253
Mesenchymal tumors and tumorlike conditions, 1253
Melanocytic tumors, 1256
Other primary tumors, 1256
Metastatic tumors, 1257

Normal Anatomy

The vagina is a tubular structure derived from the paired müllerian ducts that extend from the vestibule of the vulva to the uterus.[1–6] It is composed of three main layers: mucosa, muscularis, and adventitia. The mucosa is composed of stratified squamous epithelium resting on loose connective tissue stroma. The squamous epithelium is responsive to steroid hormones, its appearance depending on the age of the individual and the time of the menstrual cycle.[5]

The subepithelial stroma or lamina propria contains elastic fibers and a rich venous and lymphatic network. Polygonal to stellate stromal cells—some multinucleated—may be present. These cells are immunoreactive for desmin and hormone receptors.

The wolffian (mesonephric) duct in the vagina is represented by *Gartner's duct*,[6] which runs deeply along the lateral vaginal walls. Microscopically, this usually appears in the form of a small single duct, sometimes surrounded by a cluster of small glands, all of them lined by a simple cuboidal epithelium. The presence of inspissated eosinophilic secretion in the lumen is a characteristic feature of these remnants. These cells are immunoreactive for GATA3 and CD10.[7]

Ectopic tissues exceptionally found in the vagina include *prostatic glands*[5] and *sebaceous glands*.[1]

The lymphatic drainage of the vagina is rather complex. The vessels in the upper anterior wall join those of the cervix and terminate in the medial chain of the external iliac nodes (interiliac nodes). Those in the posterior vagina drain into deep pelvic, rectal, and para-aortic nodes. Some of those of the lower vagina (including the hymenal portion) go to the interiliac nodes; others traverse the paravesical spaces and drain into the inferior gluteal nodes. Finally, the vessels that anastomose with those from the vulva drain to the femoral nodes.[2,3]

Adenosis and Related Lesions

Adenosis of the vagina was originally described as a partial or complete conversion of the vaginal mucosa from squamous to endocervical-type glandular epithelium (Fig. 31.1),[8] but the concept was later expanded to embrace the presence of any müllerian-type glandular epithelium in the vagina. Sandberg[9] found occult vaginal adenosis in 9 (41%) of 22 vaginas from postpubertal girls obtained at autopsy but in none of 13 prepubertal patients. Kurman and Scully[10] obtained similar results, suggesting that vaginal adenosis can arise on a congenital basis but that steroid hormones probably play a stimulatory role in their development. Excess mucous discharge is the most common complaint in symptomatic cases. Grossly, adenosis appears as red granular spots or patches that do not stain with Lugol solution. Microscopically, the glands may be mucin-secreting and similar to those of the endocervix (most commonly) or have a lining resembling tubal or endometrial mucosa (Fig. 31.2).[11] Depending on the predominant epithelial component, *mucinous (endocervical)* and *tuboendometrial* forms of vaginal adenosis have been described. The glandular-type epithelium of vaginal adenosis may be in the lamina propria or it may line the surface of the vagina. Chronic inflammation and squamous metaplasia (mature, immature, or atypical) are common accompanying features (Fig. 31.3). The latter, which is poor in cytoplasmic glycogen, can obliterate the glandular lumen and appear as a peg continuous with the surface, a feature that may be misinterpreted as high-grade squamous intraepithelial lesion (HSIL)/vaginal intraepithelial neoplasia 2/3 (VaIN2/3) or even as invasive squamous cell carcinoma.[12] One should be aware, however, that lesions with the features of HSIL (VaIN2/3) can superimpose themselves on foci of adenosis; the identifying features are the same as those described for similar lesions in the chapter on the uterine cervix.

For personal use only. No other uses without permission. Copyright ©2017. Elsevier Inc. All rights reserved.

Abstract

The vagina is the least likely part of the female reproductive tract to be sampled for diagnostic purposes, and most pathologic conditions involving the vagina are more commonly encountered in the vulva or cervix. There are exceptions, however, ranging from congenital abnormalities like transverse vaginal septum through to vaginal adenosis, mixed tumor of vagina, and prolapsed fallopian tube at the vaginal apex occurring after hysterectomy. Most neoplasms of the vagina are squamous intraepithelial neoplasia/invasive squamous cell carcinoma secondary to oncogenic HPV. The vagina can also be secondarily involved by tumors arising elsewhere in the reproductive tract, or from extragenital sites.

Keywords

Vagina,
VaIN,
Squamous cell carcinoma,
Fibroepithelial polyp,
Rhabdomyosarcoma,
Mixed tumor

For personal use only. No other uses without permission. Copyright ©2017. Elsevier Inc. All rights reserved.

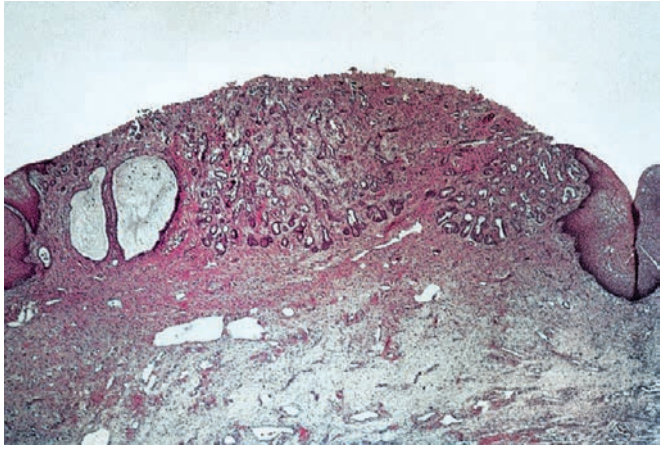

Figure 31.1 Vaginal adenosis with the surface squamous epithelium replaced by glandular epithelium and glands extending down into the superficial lamina propria.

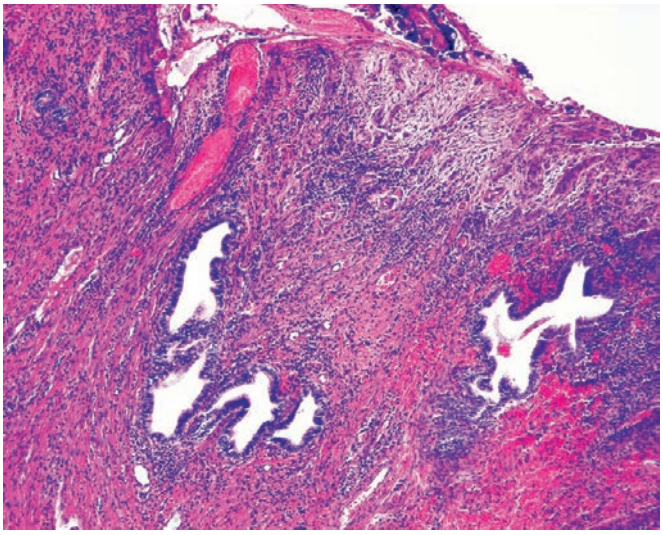

Figure 31.2 Vaginal adenosis of tuboendometrial type beneath an ulcerated surface. Other areas of this specimen showed adenocarcinoma arising from the adenosis.

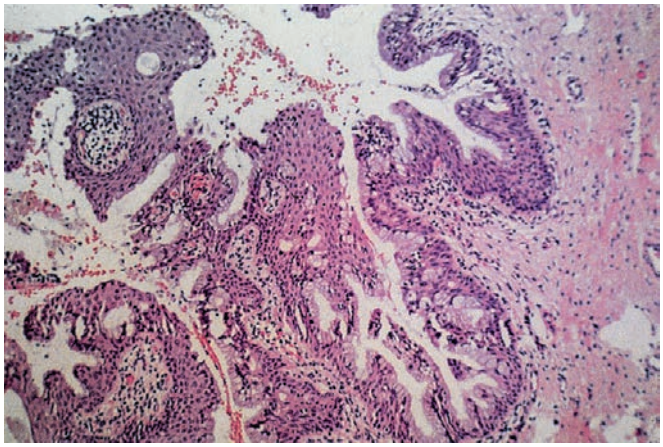

Figure 31.3 Extensive squamous metaplasia in vaginal adenosis.

Sometimes the squamous metaplasia is so extensive that the only evidence of a preexisting adenosis is found in the form of rare intercellular pools or intracellular droplets of mucin, as shown by mucicarmine or other mucin stains. It has been suggested that, as these women grow older, vaginal adenosis regresses by the process of squamous metaplasia.[13]

Microglandular hyperplasia can develop within lesions of vaginal adenosis. It is important not to confuse this benign lesion with adenocarcinoma.[14]

A footnote of historical interest relates to the causal relationship between vaginal adenosis and exposure in utero to diethylstilbestrol (DES). The reported incidence of adenosis in the exposed population has varied from 35% to more than 90% in the different series.[15] It has been shown that the incidence of vaginal adenosis and related colposcopic abnormalities is close to 100% if the drug was begun during or before the eighth week of pregnancy and only 6% if it was begun during the fifteenth week or later.[16] The microscopic features of adenosis in women exposed in utero to DES are identical to those seen in unexposed women.[17,18] **Transverse ridges** and other structural anomalies are also related to DES administration.[19,20] They are found in the upper vagina or cervix in about one-fourth of the exposed population, and microscopically the ridge is composed of a core of fibrous tissue lined by mucinous epithelium, metaplastic squamous epithelium, or, rarely, tubal or endometrial epithelium.

Other Non-Neoplastic Lesions

Transverse vaginal septum is a congenital malformation that occurs as a result of failure of fusion of the distal müllerian duct and the anogenital sinus. It can completely obstruct the vagina and present with primary amenorrhea. Histologically it is characterized by central smooth muscle (not seen in the hymen) and may show adenosis of the epithelium on the proximal side of the septum. It is distinct from the longitudinal vaginal septum associated with duplication (complete or partial) of the genital tract, and it may be associated with other anomalies.[21]

Condylomas can occur in the vagina and show similar papillomatous architecture and viral cytopathic effect (koilocytic change, with large nuclei showing irregular nuclear contours) as condyloma occurring at other body sites, for example, vulva or penis. Indolent infections caused by *Trichomonas vaginalis* and *Candida albicans* are relatively common, especially during pregnancy.[22] **Lymphogranuloma venereum** can involve the vagina during the late stage of the disease and result in stricture. **Xanthogranulomatous reactions**[23] and **malakoplakia**[24] may occur as a result of unusual bacterial infections and lead to pseudotumor formation or strictures (Fig. 31.4). The use of *tampons*, especially if left in place long term, can result in gross vaginal ulcers, as can pessaries.[25]

Occasionally, following vaginal hysterectomy, the **tubal fimbria** may become entrapped in the healing vaginal apex, a finding that must not be confused with a neoplastic process.[26] The clinical presentation is that of a mass grossly resembling "granulation tissue" at the vaginal apex, usually appearing within 6 months following a hysterectomy.[27] Occasionally, the tubal prolapse is associated with an exuberant stromal response with an angiomyofibroblastic appearance, a feature which adds to the diagnostic difficulty.[28]

Endometriosis and the related condition known as **endocervicosis** occur in the vagina, but less commonly than in other genital tract sites.[29] Most cases are seen in connection with episiotomy scars.

Cysts of the vagina can be of several different types.[30] The most common is the *epithelial inclusion cyst*, lined by squamous epithelium and sometimes resulting from surgery or trauma. Another common type is characterized by a simple lining of mucin-secreting, tall columnar, nonciliated epithelium of endocervical type, sometimes

For personal use only. No other uses without permission. Copyright ©2017. Elsevier Inc. All rights reserved.

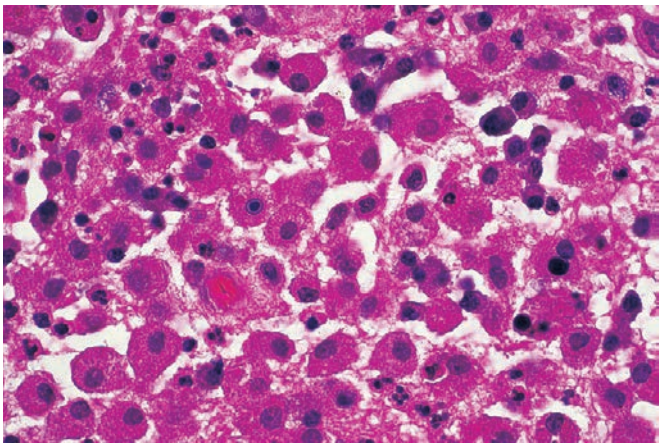

Figure 31.4 Malakoplakia of Vagina. This periodic acid–Schiff stain shows numerous histiocytes containing particulate material in their cytoplasm.

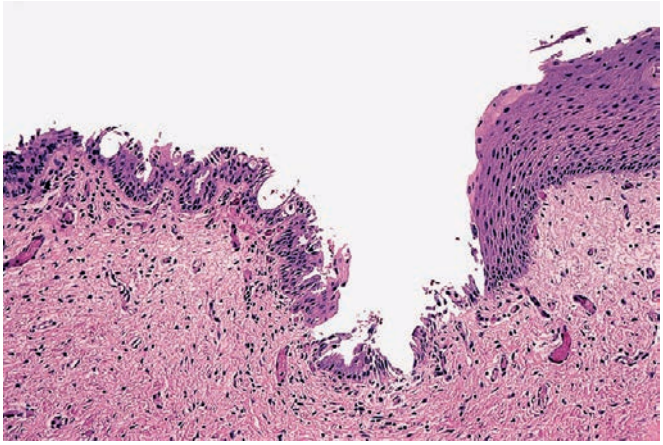

Figure 31.5 Vaginal cyst lined by müllerian epithelium connecting with surface squamous epithelium.

associated with focal squamous metaplasia; this has been designated *müllerian cyst* and can be found anywhere in the vagina (Fig. 31.5). *Mesonephric (Gartner duct) cyst* is rare; it is located in the anterolateral or lateral vaginal wall and is lined by low cuboidal epithelial cells, sometimes ciliated, that do not secrete mucin. Other rare cystic lesions of the vagina include *urothelial cysts* (located in the suburethral portion and probably arising from paraurethral glands and Skene ducts), *emphysematous vaginitis*,[30,31] and the already mentioned *endometriosis*.

Benign Epithelial Tumors

Müllerian papilloma, having a branching configuration and a lining of a single layer of cuboidal cells, has been rarely described in children. It may present on the mucosal surface as polyps or intramurally. *Papillary müllerian cystadenofibroma* of the vagina is probably a histogenetically closely related tumor.[32]

Squamous papilloma may be seen in the adult vagina as a solitary lesion or as multiple small projections (micropapillomatosis). Both variants are unrelated to HPV in most cases.

Tubulovillous adenoma and villous adenoma of the vagina, morphologically similar but immunohistochemically distinct (i.e., positive for ER and CK7 expression) to their colorectal counterparts, have been described.[33,34] They are unrelated to HPV, and their histogenesis is poorly understood at this time but may represent the vaginal counterpart to the HPV-independent adenocarcinoma in situ of the cervix, given that association with invasive adenocarcinoma has been described.

Mixed tumor (spindle cell epithelioma) is usually located in or near the hymenal ring. It is composed of small stromal-type spindle cells intermixed with mature squamous cells and glands lined by mucinous epithelium (Fig. 31.6).[32,35] Ultrastructural and immunohistochemical studies support an epithelial nature.[36] There may also be immunoreactivity for CD34, ER, PR, h-caldesmon, and CD10.[35,37] The lesion is benign, but it may recur locally if incompletely excised.[36,38]

Tubulosquamous polyp is a recently described distinctive vaginal lesion characterized microscopically by the presence of well-circumscribed expansile nests of epithelial cells embedded in a hypocellular fibrous stroma. The epithelial component is generally of both squamous and glandular type, the former predominating.[39] They may be solid/polypoid or cystic, with the former being more commonly located in the upper vagina and the latter in the lower third. Prostatic-type tissue can sometimes be found within this polyp, and the glandular tissue may stain positively for prostate-specific antigen (PSA).[40]

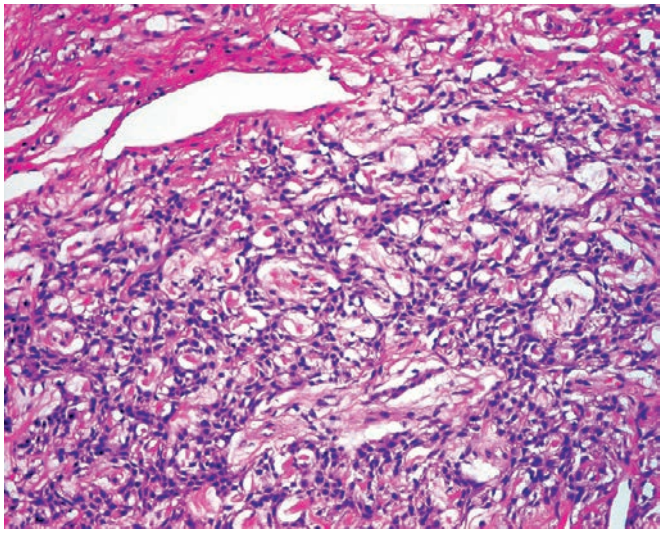

Figure 31.6 Mixed Tumor of Vagina. The plexiform pattern of growth seen in this field is characteristic of the entity.

Squamous Intraepithelial Lesions

Atypical premalignant squamous epithelial lesions of the vagina are designated **HSIL (VaIN2/3)**, using the terminology proposed by LAST (Lower Anogenital Squamous Terminology Standardization Project) for squamous intraepithelial neoplasia associated with anogenital HPV infection (Fig. 31.7).[41] It should be noted that the vaginal lesions usually arise from native squamous epithelium, in contrast to most cervical cases, which originate from *metaplastic* squamous epithelium. HSIL (VaIN2/3) is multifocal in about half of cases and very frequently associated with concomitant, subsequent, or prior (in situ or invasive) neoplasms elsewhere in the lower genital tract, especially the cervix.[42–44] The upper third of the vagina is the most common site, in which case the vaginal and cervical lesions may be confluent.[45] The HPV genotype distribution in HSIL (VaIN2/3) is similar to that of HSIL elsewhere in the genital tract.[46] The type of treatment depends largely on the extent of the disease and may

For personal use only. No other uses without permission. Copyright ©2017. Elsevier Inc. All rights reserved.

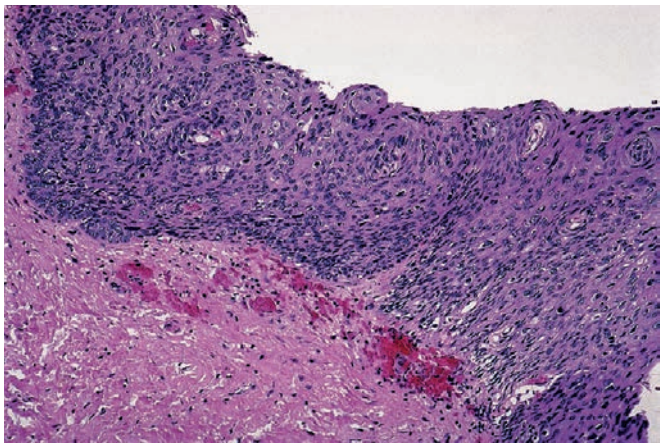

Figure 31.7 High-grade squamous intraepithelial lesions/vaginal intraepithelial neoplasia (HSIL/VaIN3).

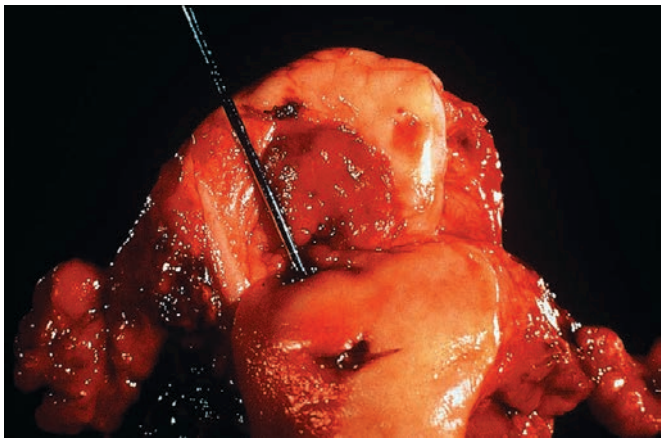

Figure 31.8 Invasive squamous cell carcinoma resulting in a large ulcerated mass.

consist of local excision, partial or total vaginectomy, CO_2 laser therapy, or administration of topical 5-fluorouracil.[42,43,47]

It is important not to overdiagnose transitional cell metaplasia as HSIL (VaIN2/3), the criteria for the differential diagnosis being the same as for the uterine cervix.[48] Additionally, vaginal atrophy may closely mimic squamous intraepithelial neoplasia because of the high nuclear-to-cytoplasmic ratio.

Invasive Squamous Cell Carcinoma

Primary carcinoma of the vagina is much less common than carcinoma of the vulva or cervix and often presents in patients with a prior diagnosis of HSIL or invasive carcinoma of cervix or vulva.[49–51] It is HPV-associated in a large majority of cases and is largely a disease of the elderly.[52,53] As with vulvar squamous cell carcinomas, the HPV-independent tumors are associated with a worse prognosis than the more common HPV-associated squamous cell carcinoma.[54] Since most carcinomas involving the upper vagina represent direct extension from cervical carcinomas, only vaginal tumors that spare the uterine cervix are regarded as primary. Those involving both areas are classified as cervical carcinomas with vaginal extension, regardless of the relative proportion of involvement. The same reasoning holds true for carcinomas involving vulva and distal vagina; these are considered to be vulvar carcinomas with vaginal extension, by convention.

Most primary vaginal carcinomas are grossly nodular or ulcerative (Fig. 31.8).[55] The upper third and the anterior or lateral walls are the most common sites of origin.[56] A few cases have arisen in surgically constructed neovaginas.[57,58]

Microscopically, the morphologic appearance of vaginal squamous cell carcinomas duplicates that of their vulvar counterparts and can be well-differentiated keratinizing type (Fig. 31.9) or can show basaloid or warty morphology (Fig. 31.10).

Vaginal carcinoma is usually treated by a combination of external and intracavitary radiation[59–61]; local excision can be employed for small tumors and radical surgery for selected cases located in the upper vaginal third or posterior wall.[62] The overall 5-year survival rate is between 40% and 50% but is significantly higher (~75%) for patients with stage I disease (Table 31.1).[63] The prognosis is similar whether the patient has a previously treated cervical carcinoma or not.[64] Most recurrences occur within 1 year of therapy and carry an ominous prognosis. Upper lesions tend to recur locally, whereas lower lesions are more commonly associated with pelvic sidewall and distal recurrence.[65]

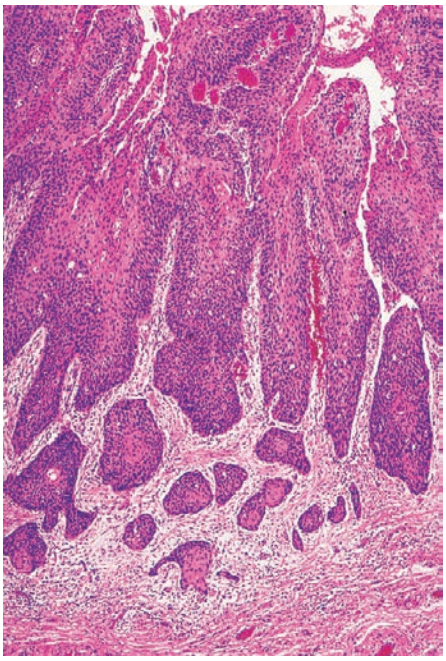

Figure 31.9 Well-differentiated keratinizing squamous cell carcinoma of vagina invading the superficial stroma.

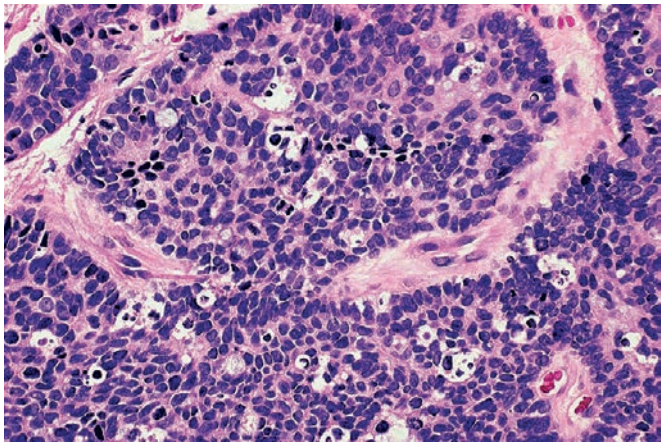

Figure 31.10 Squamous cell carcinoma of the vagina with a more basaloid morphology.

For personal use only. No other uses without permission. Copyright ©2017. Elsevier Inc. All rights reserved.

Table 31.1 Definitions of AJCC TNM: vagina

DEFINITION OF PRIMARY TUMOR (T)		
T CATEGORY	**FIGO STAGE**	**T CRITERIA**
TX		Primary tumor cannot be assessed
T0		No evidence of primary tumor
T1	I	Tumor confined to the vagina
T1a	I	Tumor confined to the vagina, measuring ≤2.0 cm
T1b	I	Tumor confined to the vagina, measuring >2.0 cm
T2	II	Tumor invading paravaginal tissues but not to pelvic sidewall
T2a	II	Tumor invading paravaginal tissues but not to pelvic wall, measuring ≤2.0 cm
T2b	II	Tumor invading paravaginal tissues but not to pelvic wall, measuring >2.0 cm
T3	III	Tumor extending to the pelvic sidewall[a] and/or involving the lower third of the vagina and/or causing hydronephrosis or nonfunctioning kidney
T4	IVA	Tumor invading the mucosa of the bladder or rectum and/or extending beyond the true pelvis (bullous edema is not sufficient evidence to classify a tumor as T4)
DEFINITION OF REGIONAL LYMPH NODE (N)		
N CATEGORY	**FIGO STAGE**	**N CRITERIA**
NX		Regional lymph nodes cannot be assessed
N0		No regional lymph node metastasis
N0(i+)		Isolated tumor cells in regional lymph node(s) no greater than 0.2 mm
N1	III	Pelvic or inguinal lymph node metastasis
DEFINITION OF DISTANT METASTASIS (M)		
M CATEGORY	**FIGO STAGE**	**M CRITERIA**
M0		No distant metastasis
M1	IVB	Distant metastasis

[a]*Pelvic sidewall* is defined as the muscle, fascia, neurovascular structures, or skeletal portions of the bony pelvis. On rectal examination, there is no cancer-free space between the tumor and pelvic sidewall.
From Amin M, Edge S, Greene F, et al., eds. *AJCC Cancer Staging Manual*. Vol 8. New York, NY: Springer; 2017.

The existence of *microinvasive (superficially or minimally invasive) carcinoma* as a distinct clinical entity in the vagina has been proposed, but the concept faces the same theoretic and practical difficulties for a precise definition as in the vulva and cervix, a problem exacerbated by the rarity of vaginal carcinoma.[66] The College of American Pathologists checklist for vaginal tumors does include a category of superficial invasive squamous cell carcinoma, defined as 3 mm or less invasion with no lymphovascular invasion, which identifies a group of patients with reduced (but not negligible) chance of lymph node metastases.[66]

Clear Cell Carcinoma

Clear cell (adeno)carcinoma characteristically occurs in the anterior or lateral wall of the upper vagina or in the uterine cervix. Formerly it was most often encountered in children, adolescents, and young adults post in utero exposure to DES.[12,56] Since DES stopped being used during pregnancy, it has become a very rare form of vaginal carcinoma. Microscopically, there are tubules and cysts lined by clear cells alternating with more solid areas and papillary formations (Fig. 31.11).[67] Mitotic figures are variable but usually scanty. The tumor cells have abundant clear cytoplasm because of the presence of glycogen. Intracytoplasmic mucin is either absent or scanty. Hobnail-shaped cells are frequently seen protruding into the glandular lumen. The microscopic differential diagnosis needs to be made primarily with microglandular hyperplasia, which can occur in areas of vaginal adenosis, and the Arias-Stella reaction related to pregnancy or progestational agents. Yolk sac tumor is theoretically in the differential diagnosis but occurs almost exclusively in infancy and early childhood (<4 years old). The immunohistochemical profile of these tumors is not well characterized but appears to be similar to that of the more common clear cell carcinomas of endometrium and ovary.[68]

The prognosis is relatively favorable; small, asymptomatic tumors usually are cured by surgery. Tumors that are large, that are close to the resection margins, or that have penetrated more than 3 mm into the wall tend to recur locally.[69]

For personal use only. No other uses without permission. Copyright ©2017. Elsevier Inc. All rights reserved.

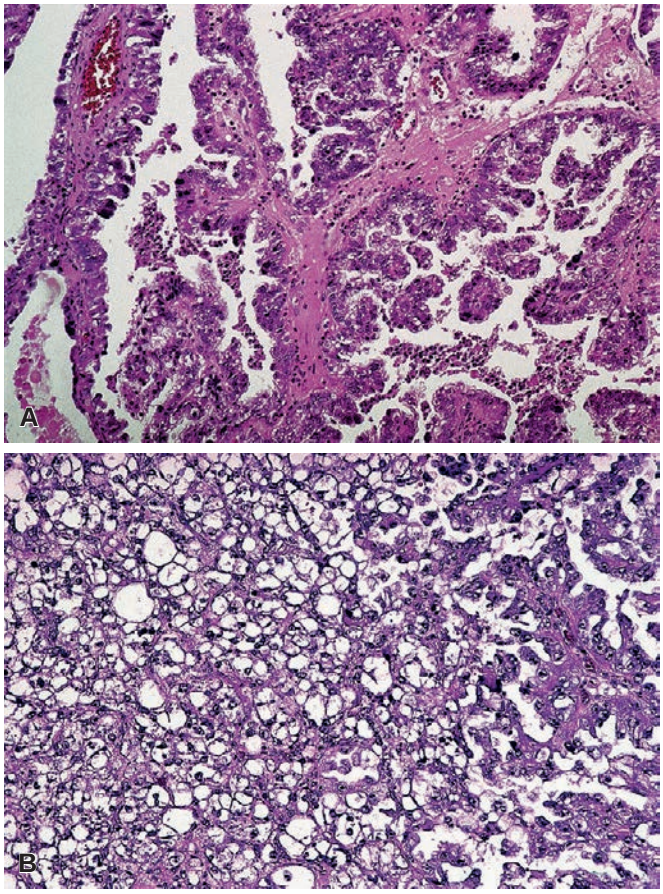

Figure 31.11 Clear Cell Carcinoma of Vagina. A, Papillary pattern; **B,** prominent clear cell features.

Other Carcinoma Types

Verrucous carcinoma is an extremely well-differentiated variant of squamous cell carcinoma. Like its vulvar and cervical counterparts, it invades locally but is practically never associated with lymph node metastases. The local spread can be quite extensive and reach the rectum and coccyx.[70] It should be distinguished from condyloma acuminatum, which may rarely involve the vagina; the criteria are the same as those described in the section on the vulva. Most verrucous carcinomas are unrelated to HPV.[71]

Endometrioid adenocarcinoma can occur in the vagina, and most cases are located at the vaginal apex.[72] It is thought to arise on the basis of vaginal endometriosis.[73] The presence of the latter is important in supporting a primary vaginal tumor as opposed to secondary spread from the endometrium. The combination of p16 and ER immunostaining, most commonly used to distinguish HPV-associated cervical adenocarcinoma (diffuse p16 reactivity, ER–) from endometrioid adenocarcinoma of the endometrium (patchy p16 reactivity, ER+) can shed light on the pathogenesis of an adenocarcinoma present in a vaginal biopsy, but cannot distinguish between a primary vaginal adenocarcinoma of endometrioid type arising from endometriosis versus secondary vaginal involvement from an endometrioid carcinoma of endometrium, or primary vaginal adenocarcinoma of HPV-associated type versus secondary involvement by an endocervical adenocarcinoma. Note that metastatic involvement of the vagina is more common than primary vaginal adenocarcinoma, and a primary endometrial or cervical adenocarcinoma must be excluded on clinical grounds as there are no primary site-specific immunomarkers. Endometriosis is also the presumed origin for most cases of adenocarcinoma located in the rectovaginal septum and having no mucosal involvement of either the vagina or rectum.[74,75]

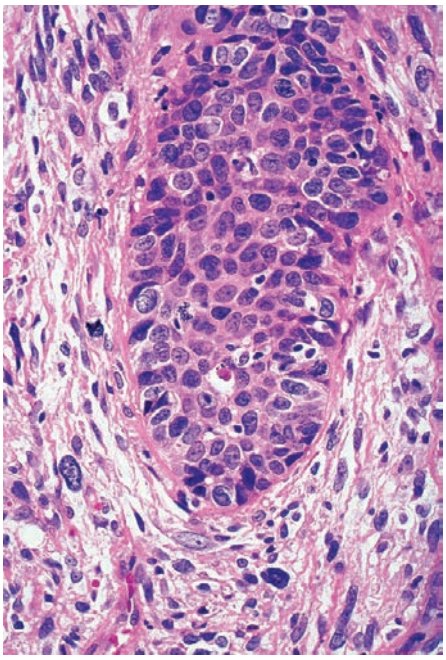

Figure 31.12 Spindle cell (sarcomatoid) carcinoma of vagina. Elongated cells with a mesenchymal-like appearance surround a well-defined nest having a clear-cut epithelial appearance.

Mesonephric (wolffian) adenocarcinoma is an exceptionally rare tumor located paravaginally, along the course of the wolffian-derived ducts of Gartner.[76,77] They morphologically and immunophenotypically resemble the more common mesonephric adenocarcinomas of the cervix and uterine corpus. They may be biphasic, with a spindle cell component.[76]

Sarcomatoid carcinoma (carcinosarcoma) of the vagina is equivalent to the more common sarcomatoid carcinomas of the upper aerodigestive tract (Fig. 31.12).[78,79]

Mucinous adenocarcinoma of vagina has been described in middle-aged and elderly patients, occasionally arising on the basis of endocervicosis.[80] Its microscopic features are indistinguishable from those of its more common endocervical counterpart.[81] In a few reported cases, the appearance has been reminiscent of enteric epithelium.[33,82] Its relationship with HPV is not known at this time.

High-grade (neuroendocrine) carcinoma can occur in the vagina, either in a pure form or associated with squamous or glandular elements.[80,83–85] They can be either small cell or large cell type. Most cases have been treated by a combination of radiation therapy and chemotherapy.[84] A case of neuroendocrine carcinoma of the vagina with a *Merkel cell* phenotype has also been reported.[86]

Other carcinoma types that have been described in the vagina are *urothelial (transitional cell) carcinoma*[87] (including a pagetoid form[88] and a variant described as *papillary squamotransitional*[89]), *lymphoepithelioma-like carcinoma*,[90,91] *basaloid carcinoma*,[92] adenoid basal carcinoma, and adenosquamous carcinoma.

Mesenchymal Tumors and Tumorlike Conditions

Fibroepithelial polyps may be seen in adult women (especially during pregnancy) or in neonates.[93,94] They are probably not true neoplasms but rather manifestations of hormone-induced localized hyperplasia of the loose subepithelial connective tissue zone[95]; others

For personal use only. No other uses without permission. Copyright ©2017. Elsevier Inc. All rights reserved.

Figure 31.13 Curious mushroom-like appearance of vaginal fibroepithelial polyp. (Courtesy of Dr. Pedro J. Grases Galofré; from Grases Galofré PJ. *Patología ginecológica. Bases para el diagnóstico morfológico*. Barcelona: Masson; 2002.)

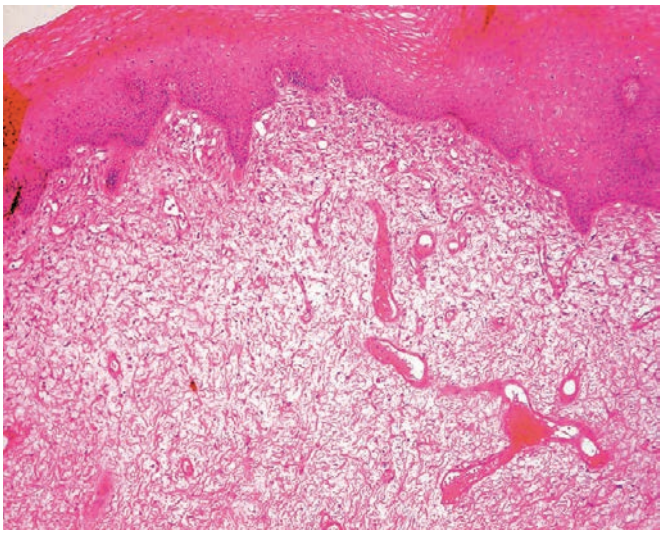

Figure 31.14 Fibroepithelial polyp of vagina showing loose fibrovascular stroma covered by slightly thickened but otherwise unremarkable squamous epithelium.

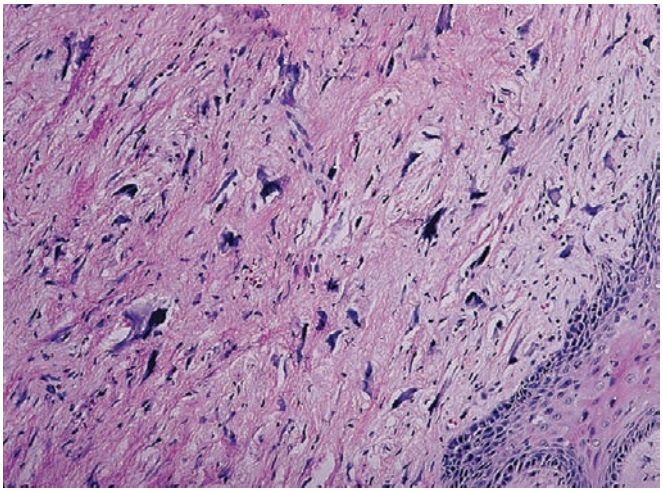

Figure 31.15 Atypical benign stromal cells in a vaginal polyp.

may represent the end stage of granulation tissue (Fig. 31.13).[96] Microscopically, they are formed of a central fibrovascular core and a covering of normal-appearing squamous epithelium (Fig. 31.14). Sometimes the stroma is markedly edematous[95]; in other instances it is hypercellular and/or contains scattered highly atypical stromal cells of stellate shape (Fig. 31.15).[97–100] These stromal cells are commonly immunoreactive for desmin and steroid receptors but usually not for actin.[101,102] The clinical appearance, nuclear atypia, and desmin immunoreactivity may lead to a mistaken diagnosis of embryonal rhabdomyosarcoma or other types of malignant tumor.[94,103] The slow pace of growth at the clinical level and the fact that a cambium layer, epithelial invasion, and cross striations are absent are among the distinguishing features; they also lack expression of the myoblastic markers myogenin and MyoD1 on immunostaining.

Aggressive angiomyxoma can present as a protruding intravaginal mass and extend through the paravaginal soft tissue.[104]

Angiomyofibroblastoma, superficial myofibroblastoma, and **solitary fibrous tumor** are other types of benign mesenchymal neoplasms of fibroblastic/myofibroblastic nature that have been reported in the vagina.[105–107] The angiomyofibroblastoma has an appearance identical to that of its vulvar counterpart, and the superficial myofibroblastoma represents a minor variation on the theme of benign polypoid tumors of the hormonally responsive mesenchymal cells of the region.[108] Solitary fibrous tumor, as in other sites, can be confirmed with *STAT6* nuclear expression by immunohistochemistry.

Postoperative spindle cell nodule is a pseudosarcomatous vaginal lesion that occurs a few weeks following hysterectomy or some other surgical procedure in the region and which presents as a small friable reddish mass in the vaginal vault.[109,110] Microscopically, it shows ulceration, granulation tissue, and a very hypercellular spindle cell proliferation characterized by a fascicular pattern of growth, many mitotic figures, and numerous extravasated red blood cells, resulting in a Kaposi sarcoma-like appearance (Fig. 31.16).[109] It can also be confused with sarcoma (particularly leiomyosarcoma) and sarcomatoid carcinoma. Immunohistochemically, there may be reactivity for low-molecular-weight keratin, which may contribute to the misinterpretation of the lesion. Clues to its recognition are the distinctly fascicular pattern, the Kaposi sarcoma-like areas, fine nuclear chromatin, the absence of pleomorphism, the fact that the mitoses—although abundant—are all typical, and, most important, the history of a recent operation in the area.

Leiomyoma is the most common benign mesenchymal tumor of the vagina.[108,111] The patients are adults, and any region of the vagina can be affected. A peculiar case has been seen containing paraganglioma-like tissue within.[112]

Leiomyosarcoma can attain a large size and ulcerate.[113] The majority of the cases manifest their malignancy only through local recurrence. The criteria of malignancy used by Tavassoli and Norris[111] were the presence of moderate to marked atypia and five or more mitotic figures per 10 high-power fields. Poorly differentiated tumors are associated with a high mortality rate.[114]

Rhabdomyoma presents as a polypoid mass.[115] All of the reported cases have occurred in adult patients, an important differential point with botryoid rhabdomyosarcoma, discussed later. Microscopically, the lesion consists of interweaving and haphazardly oriented

For personal use only. No other uses without permission. Copyright ©2017. Elsevier Inc. All rights reserved.

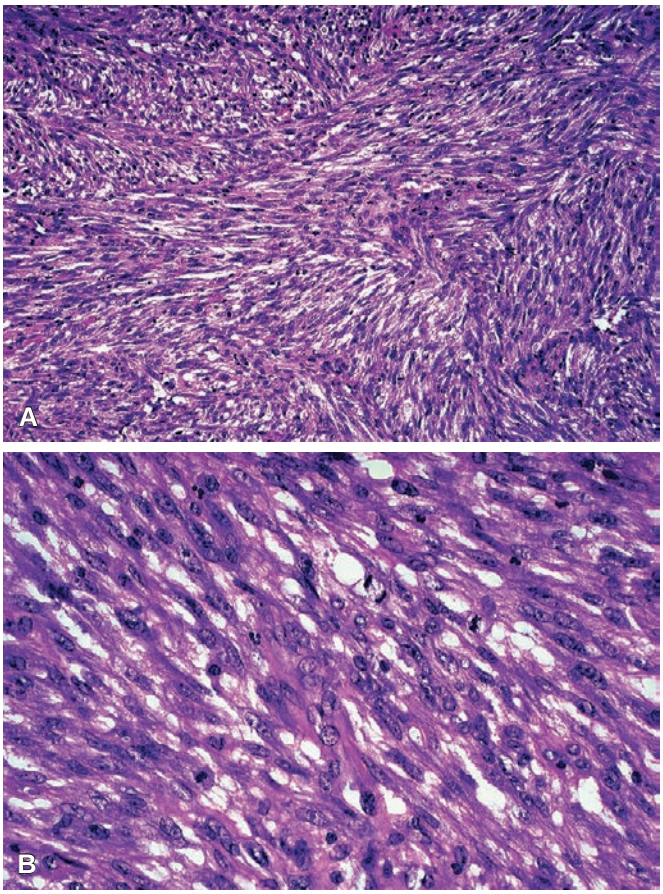

Figure 31.16 **A** and **B,** Medium- and high-power views of postoperative spindle cell nodule. The lesion is extremely cellular and mitotically active, but there is little pleomorphism.

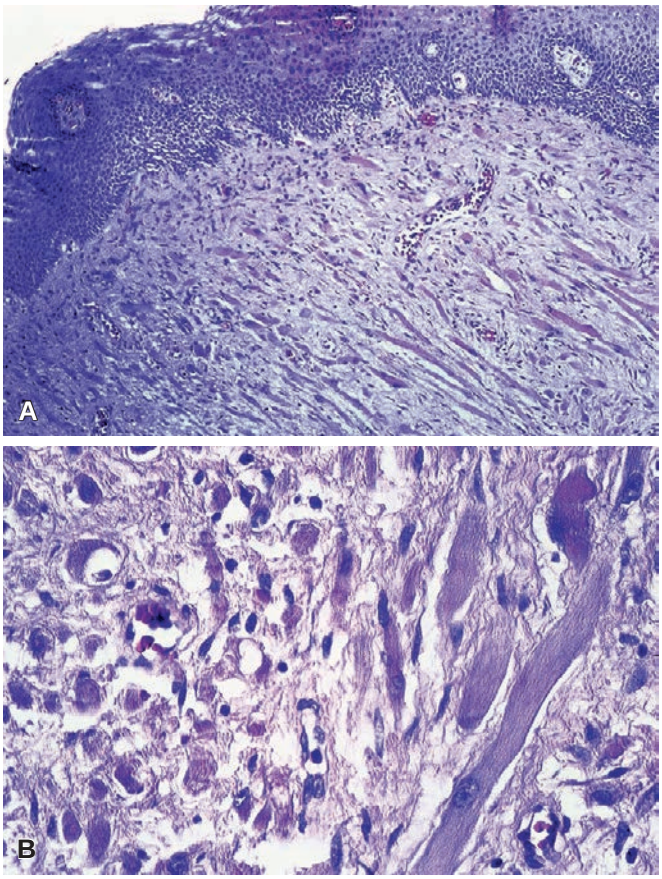

Figure 31.17 **A** and **B,** Vaginal rhabdomyoma composed of bundles of mature skeletal muscle cells scattered in the stroma beneath normal squamous epithelium.

bundles of spindle- to strap-shaped cells, some with cross striations (Fig. 31.17).[116] Mitoses are scanty or absent, and there is no concentration of neoplastic cells beneath the epithelium.

Other benign mesenchymal tumors that have been reported in the vagina are *hemangioma, hemangiopericytoma,*[117] *glomus tumor,*[118] *benign "triton" tumor,*[119] *angiomyolipoma,*[120] *(cellular) schwannoma,*[121] and *neurofibroma.*[122]

Embryonal rhabdomyosarcoma (sarcoma botryoides) is a rare polypoid invasive tumor that usually arises from the anterior vaginal wall (Fig. 31.18).[123] Approximately 90% of cases occur in girls under 5 years of age, with close to two-thirds appearing during the first 2 years. Grossly, it presents as a conglomerate of soft polypoid masses resembling a bunch of grapes—hence its designation as "botyroid."

Microscopically, a myxoid stroma is seen containing a mixture of fusiform, round, or spindle cells (Fig. 31.19). Some of these cells contain a bright eosinophilic granular cytoplasm suggestive of rhabdomyoblastic differentiation. Their racquet- or strap-shaped form mimics that of the cells seen during normal muscle embryogenesis. Cross striations may or may not be present. An important diagnostic feature is the crowding of the tumor cells around blood vessels and, most important, beneath the squamous epithelium. The latter results in a distinctive subepithelial dense zone (the "cambium layer" of Nicholson) (Fig. 31.20). Invasion of the overlying epithelium can be seen. Foci of neoplastic cartilage may be found; these tend to occur in older patients and/or in tumors located higher in the vagina or cervix, and they are said to be associated with a better prognosis. Botryoid tumors are currently regarded as a variation

Figure 31.18 **Botryoid Embryonal Rhabdomyosarcoma of Vagina.** The grape-like configuration of this lesion is characteristic.

in the growth pattern of embryonal rhabdomyosarcoma, due to their location immediately beneath an expansile epithelial lining. They cause death more often by direct extension than by distant metastases.[124] Of the 15 autopsied cases reviewed by Hilgers et al.,[125] the tumor was confined to the pelvis in about half.

The treatment of this tumor, traditionally consisting of radical surgery,[126,127] is now primarily based on chemotherapy, which can

For personal use only. No other uses without permission. Copyright ©2017. Elsevier Inc. All rights reserved.

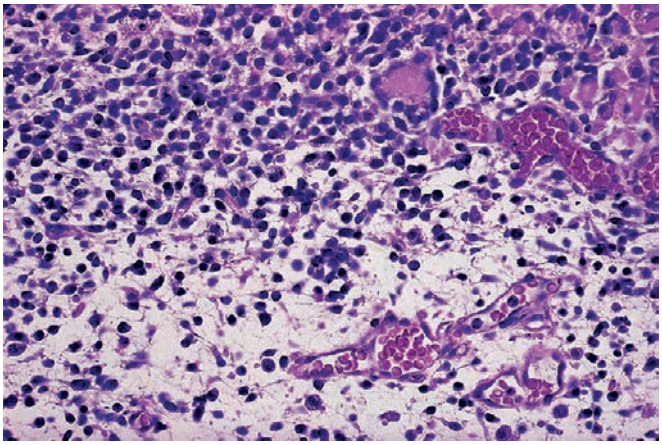

Figure 31.19 Microscopic Appearance of Embryonal Rhabdomyosarcoma. The differential diagnosis is that of small round cell tumors.

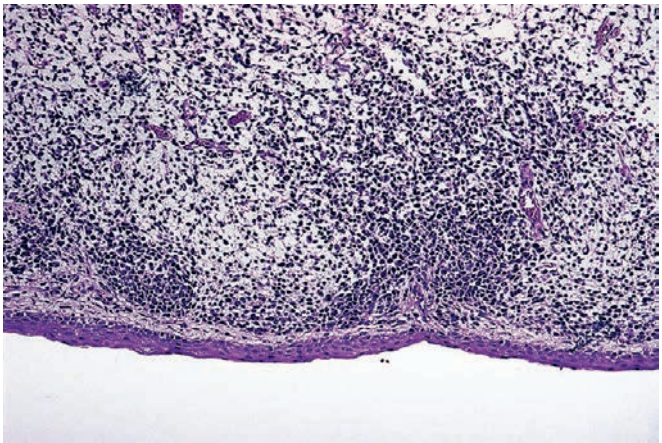

Figure 31.20 So-called cambium layer beneath non-neoplastic epithelium in embryonal rhabdomyosarcoma.

be combined with radiation therapy and/or surgery depending on the circumstances.[128]

Other primary sarcomas that have been reported in the vagina are *stromal sarcoma* of endometrial type,[129] *malignant peripheral nerve sheath tumor*,[129] *angiosarcoma*[130] (sometimes arising as a complication of radiation therapy[131]), *alveolar soft part sarcoma*,[132–134] synovial sarcoma,[135] and Ewing sarcoma/PNET.[136] Confirmation of the characteristic molecular abnormalities, where available (e.g., EWS translocation in Ewing sarcoma), is key to accurate diagnosis of these rare sarcomas.

Melanocytic Tumors

Melanoma can occur as a primary vaginal tumor in elderly patients.[137–140] It presents as a soft polypoid mass, blue or black, and frequently ulcerated (Fig. 31.21).[141] Most cases are located in the lower one-third and in the anterolateral aspect.[142] Microscopically, the appearance is similar to that of the cutaneous melanomas, although they tend to show greater anaplasia and pleomorphism (Fig. 31.22). An intraepithelial component of lentiginous appearance should be looked for to substantiate a local origin, although this feature can be destroyed by the tumor ulceration. The prognosis is extremely poor.[138,143,144] BRAF and KIT mutations were not identified in a series of primary vaginal melanomas, but 12% of cases had

Figure 31.21 Malignant Melanoma of Vagina. (From Norris HJ, Taylor HB. Melanomas of the vagina. *Am J Clin Pathol*. 1966;46:420–426.)

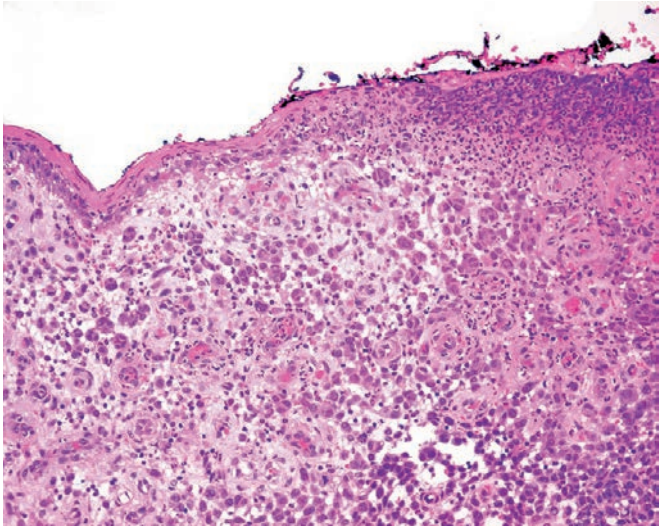

Figure 31.22 Malignant Melanoma of Vagina. The tumor has an undifferentiated appearance, is largely amelanotic, and has an ulcerated surface.

NRAS mutations and another 12% had KIT amplification.[145] The melanocytes that have been identified in 3% of normal vaginas[139] most likely represent the cell of origin of this neoplasm, sometimes through a preceding stage of melanosis or atypical melanocytic hyperplasia.[146,147]

Blue nevus of the ordinary type can present as a primary vaginal lesion.[141]

Other Primary Tumors

Yolk sac tumor (endodermal sinus tumor) typically affects infants under 2 years of age and is more commonly located in either the posterior wall or the fornices.[148,149] Clinically, it can simulate rhabdomyosarcoma.[150] Microscopically, the most important differential diagnosis is with clear cell (adeno)carcinoma, a tumor with which it has been confused in the past. Immunohistochemically, reactivity for SALL4 and alpha-fetoprotein favors yolk sac tumor, and reactivity

For personal use only. No other uses without permission. Copyright ©2017. Elsevier Inc. All rights reserved.

for Leu-M1 favors clear cell carcinoma.[151] In early series, most patients with vaginal yolk sac tumor died with generalized metastases,[152] but the combination of surgical excision and multidrug chemotherapy (sometimes with the addition of radiation therapy) has resulted in many long-term cures.[129,153]

Malignant lymphoma can affect the vagina secondarily or sometimes as the only site of involvement; nearly all cases are of non-Hodgkin type.[154–156] The largest group is represented by diffuse large B-cell lymphomas.[157] A case has been reported in association with malakoplakia.[158] Vaginal involvement can also occur in *acute myeloid leukemias* (granulocytic sarcoma).[159]

Other primary tumors of the vagina or paravaginal region, all exceptionally rare, are *Brenner tumor*,[160,161] *female adnexal tumor of probable wolffian origin*,[162] *PEComa*,[155] *myoepithelioma*,[163] and *gastrointestinal stromal tumor* (presenting in the vaginal wall or in the rectovaginal septum).[164,165]

Metastatic Tumors

Metastatic carcinoma to the vagina arises most commonly in the uterine cervix and endometrium, followed by the ovary, large bowel, and kidney.[166–168] Some cases represent direct extension, and others are distant metastases. The metastases from endometrial adenocarcinoma are often submucosal and located in the upper third of the organ.

Other tumors that can metastasize to vagina are melanoma[169] and malignant trophoblastic neoplasms, including epithelioid trophoblastic tumor.[170]

References

1. Belousova IE, Kazakov DV, Michal M. Ectopic sebaceous glands in the vagina. *Int J Gynecol Pathol*. 2005;24:193-195.
2. Hafez ES, Evans TN, eds. *The Human Vagina*. New York, NY: North-Holland; 1978.
3. Krantz KE. The gross and microscopic anatomy of the human vagina. *Ann N Y Acad Sci*. 1959;83:89-104.
4. McCluggage WG, Ganesan R, Hirschowitz L, et al. Ectopic prostatic tissue in the uterine cervix and vagina: report of a series with a detailed immunohistochemical analysis. *Am J Surg Pathol*. 2006;30:209-215.
5. Robboy SJ, Bently RC. Vagina. In: Mills SE, ed. *Histology for Pathologists*. 3rd ed. Philadelphia, PA: Lippincott Williams and Wilkins; 2007:999-1010.
6. Ulfelder H, Robboy SJ. The embryological development of the human vagina. *Am J Obstet Gynecol*. 1976;126:769-776.
7. Howitt BE, Emori M, Drapkin R, et al. GATA3 is a sensitive and specific marker of benign and malignant mesonephric lesions in the lower female genital tract. *Am J Surg Pathol*. 2015;39:1411-1419.
8. Siders DB, Parrott MH, Abell MR. Gland cell prosoplasia (adenosis) of vagina. *Am J Obstet Gynecol*. 1965;91:190-203.
9. Sandberg EC. The incidence of distribution of occult vaginal adenosis. *Trans Pac Coast Obstet Gynecol Soc*. 1967;35:36-48.
10. Kurman RJ, Scully RE. The incidence and histogenesis of vaginal adenosis. An autopsy study. *Hum Pathol*. 1974;5:265-276.
11. Hart WR, Townsend DE, Aldrich JO, et al. Histopathologic spectrum of vaginal adenosis and related changes in stilbestrol-exposed females. *Cancer*. 1976;37:763-775.
12. Robboy SJ, Scully RE, Welch WR, Herbst AL. Intrauterine diethylstilbestrol exposure and its consequences. Pathologic characteristics of vaginal adenosis, clear cell adenocarcinoma, and related lesions. *Arch Pathol Lab Med*. 1977;101:1-5.
13. Robboy SJ, Szyfelbein WM, Goellner JR, et al. Dysplasia and cytologic findings in 4589 young women enrolled in the Diethylstilbestrol Adenosis (DESAD) Project. *Am J Obstet Gynecol*. 1981;140:579-586.
14. Robboy SJ, Welch WR. Microglandular hyperplasia in vaginal adenosis associated with oral contraceptives and prenatal diethylstilbestrol exposure. *Obstet Gynecol*. 1977;49:430-434.
15. Antonioli DA, Burke L. Vaginal adenosis. Analysis of 325 biopsy specimens from 100 patients. *Am J Clin Pathol*. 1975;64:625-638.
16. Sonek M, Bibbo M, Wied GL. Colposcopic findings in offspring of DES-treated mothers as related to onset of therapy. *J Reprod Med*. 1976;16:65-71.
17. Chattopadhyay I, Cruickshan DJ, Packer M. Non diethylstilbesterol induced vaginal adenosis—a case series and review of literature. *Eur J Gynecol Oncol*. 2001;22:260-262.
18. Robboy SJ, Hill EC, Sandberg EC, Czernobilsky B. Vaginal adenosis in women born prior to the diethylstilbestrol era. *Hum Pathol*. 1986;17:488-492.
19. Herbst AL, Poskanzer DC, Robboy SJ, et al. Prenatal exposure to stilbestrol. A prospective comparison of exposed female offspring with unexposed controls. *N Engl J Med*. 1975;292:334-339.
20. Jefferies JA, Robboy SJ, O'Brien PC, et al. Structural anomalies of the cervix and vagina in women enrolled in the Diethylstilbestrol Adenosis (DESAD) Project. *Am J Obstet Gynecol*. 1984;148:59-66.
21. Amer MI, Ahmed Mel-S, Ali AH. Congenital urethrovaginal fistula with transverse vaginal septum. *J Obstet Gynaecol Res*. 2016;42:1042-1045.
22. Sobel JD. Vaginal infections in adult women. *Med Clin North Am*. 1990;74:1573-1602.
23. Strate SM, Taylor WE, Forney JP, Silva FG. Xanthogranulomatous pseudotumor of the vagina. Evidence of a local response to an unusual bacterium (mucoid *Escherichia coli*). *Am J Clin Pathol*. 1983;79:637-643.
24. Chalvardjan A, Picard L, Shaw R, et al. Malacoplakia of the female genital tract. *Am J Obstet Gynecol*. 1980;138:391-394.
25. Danielson RW. Vaginal ulcers caused by tampons. *Am J Obstet Gynecol*. 1983;146:547-548.
26. Bilodeau B. Intravaginal prolapse of the fallopian tube following vaginal hysterectomy. *Am J Obstet Gynecol*. 1982;143:970-971.
27. Silverberg SG, Frable WJ. Prolapse of fallopian tube into vaginal vault after hysterectomy. Histopathology, cytopathology, and differential diagnosis. *Arch Pathol*. 1974;97:100-103.
28. Michal M, Rokyta Z, Mejchar B, et al. Prolapse of the fallopian tube after hysterectomy associated with exuberant angiomyofibroblastic stroma response: a diagnostic pitfall. *Virchows Arch*. 2000;437:436-439.
29. Martinka M, Allaire C, Clement PB. Endocervicosis presenting as a painful vaginal mass: a case report. *Int J Gynecol Pathol*. 2002;18:274-276.
30. Deppisch LM. Cysts of the vagina. Classification and clinical correlations. *Obstet Gynecol*. 1975;45:632-637.
31. Kramer K, Tobón H. Vaginitis emphysematosa. *Arch Pathol Lab Med*. 1987;111:746-749.
32. Kerner H, Munichor M. Papillary mullerian cystadenofibroma of the vagina. *Histopathology*. 1997;30:84-86.
33. Fox H, Wells M, Harris M, et al. Enteric tumours of the lower female genital tract. A report of three cases. *Histopathology*. 1988;12:167-176.
34. Pena-Fernandez M, Abdulkader-Nalib I, Novo-Dominguez A, et al. Vaginal tubulovillous adenoma: a clinicopathologic and molecular study with review of the literature. *Int J Gynecol Pathol*. 2013;32:131-136.
35. Sirota RL, Dickersin GR, Scully RE. Mixed tumors of the vagina. *Am J Surg Pathol*. 1981;5:413-422.
36. Branton PA, Tavassoli FA. Spindle cell epithelioma, the so-called mixed tumor of the vagina. A clinicopathologic, immunohistochemical, and ultrastructural analysis of 28 cases. *Am J Surg Pathol*. 1993;17:509-515.
37. Oliva E, Gonzalez L, Dionigi A, Young RH. Mixed tumors of the vagina: an immunohistochemical study of 13 cases with emphasis on the cell of origin and potential aid in differential diagnosis. *Mod Pathol*. 2004;17:1243-1250.
38. Wright RG, Buntine DW, Forbes KL. Recurrent benign mixed tumor of the vagina. *Gynecol Oncol*. 1991;40:84-86.
39. McCluggage WG, Young RH. Tubulo-squamous polyp: a report of ten cases of a distinctive hitherto uncharacterized vaginal polyp. *Am J Surg Pathol*. 2007;31:1013-1019.
40. Kazakov DV, Stewart CJ, Kacerovska D, et al. Prostatic-type tissue in the lower female genital tract: a morphologic spectrum, including vaginal tubulosquamous polyp, adenomyomatous hyperplasia of paraurethral Skene glands (female prostate), and ectopic lesion in the vulva. *Am J Surg Pathol*. 2010;34:950-955.
41. Darragh TM, Colgan TJ, Cox T, et al. The lower anogenital squamous terminology standardization project for HPV-associated lesions: background and consensus recommendations from the College of American Pathologists and the American Society for Colposcopy and Cervical Pathology. *Int J Gynecol Pathol*. 2013;32:76-115.
42. Aho M, Vesterinen E, Meyer B, et al. Natural history of vaginal intraepithelial neoplasia. *Cancer*. 1991;68:195-197.
43. Benedet JL, Sanders BH. Carcinoma in situ of the vagina. *Am J Obstet Gynecol*. 1984;148:695-700.
44. Kanbour AI, Klionsky B, Murphy AI. Carcinoma of the vagina following cervical cancer. *Cancer*. 1974;34:1838-1841.
45. Nwabineli NJ, Monaghan JM. Vaginal epithelial abnormalities in patients with CIN.

For personal use only. No other uses without permission. Copyright ©2017. Elsevier Inc. All rights reserved.

Clinical and pathological features and management. *Br J Obstet Gynaecol*. 1991;98:25-29.
46. Srodon M, Stoler MH, Baber GB, Kurman RJ. The distribution of low and high-risk HPV types in vulvar and vaginal intraepithelial neoplasia (VIN and VaIN). *Am J Surg Pathol*. 2006;30:1513-1518.
47. Audet-Lapointe P, Body G, Vauclair R, et al. Vaginal intraepithelial neoplasia. *Gynecol Oncol*. 1990;36:232-239.
48. Weir MM, Bell DA, Young RH. Transitional cell metaplasia of the uterine cervix and vagina: an underrecognized lesion that may be confused with high-grade dysplasia: a report of 59 cases. *Am J Surg Pathol*. 1997;21:510-517.
49. Benedet JL. Vaginal malignancy. *Curr Opin Obstet Gynecol*. 1991;3:73-77.
50. Manetta A, Gutrecht EL, Berman ML, Di Saia PJ. Primary invasive carcinoma of the vagina. *Obstet Gynecol*. 1990;76:639-642.
51. Piura B, Rabinovich A, Cohen Y, Glezerman M. Primary squamous cell carcinoma of the vagina: report of four cases and review of the literature. *Eur J Gynecol Oncol*. 1998;19:60-63.
52. Ikenberg H, Runge M, Goppinger A, Pfeiderer A. Human papillomavirus DNA in invasive carcinoma of the vagina. *Obstet Gynecol*. 1990;76:432-438.
53. Merino MJ. Vaginal cancer. The role of infectious and environmental factors. *Am J Obstet Gynecol*. 1991;165:1255-1262.
54. Alonso I, Felix A, Torne A, et al. Human Papilloma Virus as a favourable prognostic biomarker in squamous cell carcinoma of the vagina. *Gynecol Oncol*. 2012;125:194-199.
55. Whelton J, Kottmeier HL. Primary carcinoma of the vagina. A study of a Radiumhemmet series of 145 cases. *Acta Obstet Gynecol Scand*. 1962;41:22-40.
56. Robboy SJ, Young RH, Welch WR, et al. Atypical vaginal adenosis and cervical ectropion. Association with clear cell adenocarcinoma in diethylstilbestrol-exposed offspring. *Cancer*. 1984;54:869-875.
57. Rotmensch J, Rosenshein N, Dillon M, et al. Carcinoma arising in the neovagina. Case report and review of the literature. *Obstet Gynecol*. 1983;61:534-538.
58. Steiner E, Woernle F, Kuhn W, et al. Carcinoma of the neovagina: case report and review of the literature. *Gynecol Oncol*. 2002;84:171-175.
59. Kucera H, Vavra N. Radiation management of primary carcinoma of the vagina. Clinical and histopathological variables associated with survival. *Gynecol Oncol*. 1991;40:12-16.
60. Reddy S, Lee MS, Graham JE, et al. Radiation therapy in primary carcinoma of the vagina. *Gynecol Oncol*. 1987;26:19-24.
61. Spirtos NM, Doshi BP, Kapp DS, Teng N. Radiation therapy for primary squamous cell carcinoma of the vagina. Standford University experience. *Gynecol Oncol*. 1989;35:20-26.
62. Davis KP, Stanhope CR, Garton GR, et al. Invasive vaginal carcinoma. Analysis of early-stage disease. *Gynecol Oncol*. 1991;42:131-136.
63. Hellman K, Lundell M, Silverwood C, et al. Clinical and histopathologic factors related to prognosis in primary squamous cell carcinoma of the vulva. *Int J Gynecol Cancer*. 2006;16:1201-1211.
64. Perez CA, Arneson AN, Galakatos A, Samanth HK. Malignant tumors of the vagina. *Cancer*. 1973;31:36-44.
65. Tarraza MH Jr, Muntz H, Decain M, et al. Patterns of recurrence of primary carcinoma of the vagina. *Eur J Gynaecol Oncol*. 1991;12:89-92.
66. Peters WA III, Kumar NB, Morley GW. Microinvasive carcinoma of the vagina. A distinct clinical entity? *Am J Obstet Gynecol*. 1985;153:505-507.
67. Nordqvist SRB, Fidler WJ Jr, Woodruff JM, Lewis JL. Clear cell adenocarcinoma of the cervix and vagina. A clinicopathologic study of 21 cases with and without a history of maternal ingestion of estrogens. *Cancer*. 1976;37:858-871.
68. Vang R, Whitaker BP, Farhood AI, et al. Immunohistochemical analysis of clear cell carcinoma of the gynaecologic tract. *Int J Gynecol Pathol*. 2001;20:252-259.
69. Robboy SJ, Herbst AL, Scully RE. Clear-cell adenocarcinoma of the vagina and cervix in young females. Analysis of 37 tumors that persisted or recurred after primary therapy. *Cancer*. 1974;34:606-614.
70. Ramzy I, Smout MS, Collins JA. Verrucous carcinoma of the vagina. *Am J Clin Pathol*. 1976;65:644-653.
71. del Pino M, Bleeker MC, Quint WG, et al. Comprehensive analysis of human papillomavirus prevalence and the potential role of low-risk types in verrucous carcinoma. *Mod Pathol*. 2012;25:1354-1363.
72. Staats PN, Clement PB, Young RH. Primary endometrioid adenocarcinoma of the vagina: a clinicopathologic study of 18 cases. *Am J Surg Pathol*. 2007;31:1490-1501.
73. Haskel S, Chen SS, Spiegel G. Vaginal endometrioid adenocarcinoma arising in vaginal endometriosis. A case report and literature review. *Gynecol Oncol*. 1989;34:232-236.
74. Granai CO, Walters MD, Safaii H, et al. Malignant transformation of vaginal endometriosis. *Obstet Gynecol*. 1984;64:592-595.
75. Young EE, Gamble CH. Primary adenocarcinoma of the rectovaginal septum arising from endometriosis. Report of a case. *Cancer*. 1969;24:597-601.
76. Bagué S, Rodríguez IM, Prat J. Malignant mesonephric tumors of the female genital tract: a clinicopathologic study of 9 cases. *Am J Surg Pathol*. 2004;28:601-607.
77. Hinchey WW, Silva EG, Guarda LA, et al. Paravaginal Wolffian duct (mesonephros) adenocarcinoma. A light and electron microscopic study. *Am J Clin Pathol*. 1983;80:539-544.
78. Raptis S, Haber G, Ferenczy A. Vaginal squamous cell carcinoma with sarcomatoid spindle cell features. *Gynecol Oncol*. 1993;49:100-106.
79. Steeper TA, Piscioli F, Rosai J. Squamous cell carcinoma with sarcoma-like stroma of the female genital tract. Clinicopathologic study of four cases. *Cancer*. 1983;52:890-898.
80. McCluggage WG, Price JH, Dobbs SP. Primary adenocarcinoma of the vagina arising in endocervicosis. *Int J Gynecol Pathol*. 2001;20:399-402.
81. Ebrahim S, Daponte A, Smith TH, et al. Primary mucinous adenocarcinomas of the vagina. *Gynecol Oncol*. 2001;80:89-92.
82. Yaghsezian H, Palazzo JP, Finkel GC, et al. Primary vaginal adenocarcinoma of the intestinal type associated with adenosis. *Gynecol Oncol*. 1992;45:62-65.
83. Chafe W. Neuroepithelial small cell carcinoma of the vagina. *Cancer*. 1989;64: 1948-1951.
84. Hopkins MP, Kumar NB, Lichter AS, et al. Small cell carcinoma of the vagina with neuroendocrine features. A report of three cases. *J Reprod Med*. 1989;34:486-491.
85. Kaminski JM, Anderson PR, Han AC, et al. Primary small cell carcinoma of the vagina. *Gynecol Oncol*. 2003;88:451-455.
86. Coleman NM, Smith-Zagone MJ, Tanyi J, et al. Primary neuroendocrine carcinoma of the vagina with Merkel cell carcinoma phenotype. *Am J Surg Pathol*. 2006;30:405-410.
87. Bass PS, Birch B, Smart C, et al. Low-grade transitional cell carcinoma of the vagina. An unusual cause of vaginal bleeding. *Histopathology*. 1994;24:581-583.
88. Singer G, Hohl MK, Hering F, Anabitarte M. Transitional cell carcinoma of the vagina with pagetoid spread pattern. *Hum Pathol*. 1998;29:299-301.
89. Rose PG, Stoler MH, Abdul-Karin FW. Papillary squamotransitional cell carcinoma of the vagina. *Int J Gynecol Pathol*. 1998;17:372-375.
90. Dietl J, Horny HP, Kaiserling E. Lymphoepithelioma-like carcinoma of the vagina. A case report with special reference to the immunophenotype of the tumor cells and tumor-infiltrating lymphoreticular cells. *Int J Gynecol Pathol*. 1994;13:186-189.
91. McCluggage WG. Lymphoepithelioma-like carcinoma of the vagina. *J Clin Pathol*. 2001;54:964-965.
92. Li H, Heller DS, Sama J, et al. Basaloid squamous cell carcinoma of the vagina metastasizing to the lung. A case report. *J Reprod Med*. 2000;45:841-843.
93. McCluggage WG. A review and update of morphologically bland vulvovaginal mesenchymal lesions. *Int J Gynecol Pathol*. 2005;24:26-38.
94. Norris HJ, Taylor HB. Polyps of the vagina. *Cancer*. 1966;19:227-232.
95. al-Nafussi AI, Rebello G, Hughes D, Blessing K. Benign vaginal polyp. A histological, histochemical and immunohistochemical study of 20 polyps with comparison to normal vaginal subepithelial layer. *Histopathology*. 1992;20:145-150.
96. Halvorsen TB, Johannesen E. Fibroepithelial polyps of the vagina. Are they old granulation tissue polyps? *J Clin Pathol*. 1992;45:235-240.
97. Abdul-Karim FW, Cohen RE. Atypical stromal cells of lower female genital tract. *Histopathology*. 1990;17:249-253.
98. Chirayil SJ, Tobon H. Polyps of the vagina. A clinico-pathologic study of 18 cases. *Cancer*. 1981;47:2904-2907.
99. Miettinen M, Wahlstrom T, Vesterinen E, Saksela E. Vaginal polyps with pseudosarcomatous features. A clinicopathologic study of seven cases. *Cancer*. 1983;51:1148-1151.
100. Ostor AG, Fortune DW, Riley CB. Fibroepithelial polyps with atypical stromal cells (pseudosarcoma botryoides) of vulva and vagina. A report of 13 cases. *Int J Gynecol Pathol*. 1988;7:351-360.
101. Hartmann CA, Sperling M, Stein H. So-called fibroepithelial polyps of the vagina exhibiting an unusual but uniform antigen profile characterized by expression of desmin and steroid hormone receptors but no muscle-specific actin or macrophage markers. *Am J Clin Pathol*. 1990;93:604-608.
102. Mucitelli DR, Charles EZ, Kraus FT. Vulvovaginal polyps. Histologic appearance, ultrastructure, immunocytochemical characteristics, and clinicopathologic correlations. *Int J Gynecol Pathol*. 1990;9: 20-40.
103. Nucci MR, Young RH, Fletcher CD. Cellular pseudosarcomatous fibroepithelial stromal polyps of the lower female genital tract: an underrecognized lesion often misdiagnosed as sarcoma. *Am J Surg Pathol*. 2000;24: 231-240.
104. Steeper TA, Rosai J. Aggressive angiomyxoma of the female pelvis and perineum. Report of nine cases of a distinctive type of gynecologic soft tissue neoplasm. *Am J Surg Pathol*. 1983;7:463-475.
105. Laskin WB, Fetsch JF, Tavassoli FA. Superficial cervicovaginal myofibroblastoma: fourteen cases of a distinctive mesenchymal tumor arising from the specialised subepithelial stroma of the lower female genital tract. *Hum Pathol*. 2001;32:715-725.

For personal use only. No other uses without permission. Copyright ©2017. Elsevier Inc. All rights reserved.

106. Nielsen GP, Rosenberg AE, Young RH, et al. Angiomyofibroblastoma of the vulva and vagina. *Mod Pathol*. 1996;9:284-291.
107. Vadmal MS, Pellegrini AE. Solitary fibrous tumor of the vagina. *Am J Dermatopathol*. 2000;22:83-86.
108. Nucci MR, Fletcher CD. Vulvovaginal soft tissue tumors: update and review. *Histopathology*. 2000;36:97-108.
109. Proppe KH, Scully RE, Rosai J. Postoperative spindle cell nodules of genitourinary tract resembling sarcomas. A report of eight cases. *Am J Surg Pathol*. 1984;8:101-108.
110. Young RH, Clement PB. Pseudoneoplastic lesions of the lower female genital tract. *Pathol Annu*. 1989;24(Pt 2):189-226.
111. Tavassoli FA, Norris HJ. Smooth muscle tumors of the vagina. *Obstet Gynecol*. 1979;53:689-693.
112. Naidoo P. Vaginal leiomyoma with heterologous paragangliomatous elements. *Int J Surg Pathol*. 2001;8:359-365.
113. Ciaravino G, Kapp DS, Vela AM, et al. Primary leiomyosarcoma of the vagina. A case report and literature review. *Int J Gynecol Cancer*. 2000;10:340-347.
114. Rastogi BL, Bergman B, Angervall L. Primary leiomyosarcoma of the vagina. A study of five cases. *Gynecol Oncol*. 1984;18:77-86.
115. Chabrel CM, Beilby JOW. Vaginal rhabdomyoma. *Histopathology*. 1980;4:645-651.
116. Gold JH, Bossen EH. Benign vaginal rhabdomyoma. A light and electron microscopic study. *Cancer*. 1976;37:2283-2294.
117. Hiura M, Nogawa T, Nagai N, et al. Vaginal hemangiopericytoma. A light microscopic and ultrastructural study. *Gynecol Oncol*. 1985;21:376-384.
118. Spitzer M, Molho L, Seltzer VL, Lipper S. Vaginal glomus tumor. Case presentation and ultrastructural findings. *Obstet Gynecol*. 1985;66:86S-88S.
119. Azzopardi JG, Eusebi V, Tison V, Betts CM. Neurofibroma with rhabdomyomatous differentiation. Benign 'triton' tumour of the vagina. *Histopathology*. 1983;7:561-572.
120. Chen KT. Angiomyolipoma of the vagina. *Gynecol Oncol*. 1990;37:302-304.
121. Ellison DW, MacKenzie IZ, McGee JO. Cellular schwannoma of the vagina. *Gynecol Oncol*. 1992;46:119-121.
122. Gersell DJ, Fulling KH. Localized neurofibromatosis of the female genitourinary tract. *Am J Surg Pathol*. 1989;13:873-878.
123. Hays DM, Shimada H, Raney RB Jr, et al. Sarcomas of the vagina and uterus. The Intergroup Rhabdomyosarcoma Study. *J Pediatr Surg*. 1985;20:718-724.
124. Leuschner I, Harms D, Mattke A, et al. Rhabdomyosarcoma of the urinary bladder and vagina: a clinicopathologic study with emphasis on recurrent disease: a report from the Kiel Pediatric Tumor Registry and the German CWS study. *Am J Surg Pathol*. 2001;25:856-864.
125. Hilgers R, Malkasian GD Jr, Soule EH. Embryonal rhabdomyosarcoma (botryoid type) of the vagina. A clinicopathologic review. *Am J Obstet Gynecol*. 1970;107:484-502.
126. Hilgers RD. Pelvic exenteration for vaginal embryonal rhabdomyosarcoma. A review. *Obstet Gynecol*. 1975;45:175-180.
127. Rutledge F, Sullivan MP. Sarcoma botryoides. *Ann N Y Acad Sci*. 1967;142:694-708.
128. Hays DM, Shimada H, Raney RB Jr, et al. Clinical staging and treatment results in rhabdomyosarcoma of the female genital tract among children and adolescents. *Cancer*. 1988;61:1893-1903.
129. Peters WA III, Kumar NB, Anderson WA, Morley GW. Primary sarcoma of the adult vagina. A clinicopathologic study. *Obstet Gynecol*. 1985;63:699-704.
130. Prempree T, Tang C-K, Hatef A, Forster S. Angiosarcoma of the vagina. A clinicopathologic report. A reappraisal of the radiation treatment of angiosarcomas of the female genital tract. *Cancer*. 1983;51:618-622.
131. Chan WW, Sen Gupta SK. Postirradiation angiosarcoma of the vaginal vault. *Arch Pathol Lab Med*. 1991;115:527-528.
132. Carinelli SG, Giudici MN, Brioschi D, Cefis F. Alveolar soft part sarcoma of the vagina. *Tumori*. 1990;76:77-80.
133. Chapman GW, Genda J, Williams T. Alveolar soft-part sarcoma of the vagina. *Gynecol Oncol*. 1984;18:125-129.
134. Nielsen GP, Oliva E, Young RH, et al. Alveolar soft-part sarcoma of the female genital tract. A report of nine cases and review of the literature. *Int J Gynecol Pathol*. 1995;14:283-292.
135. Pelosi G, Luzzatto F, Landoni F, et al. Poorly differentiated synovial sarcoma of the vagina: first reported case with immunohistochemical, molecular and ultrastructural data. *Histopathology*. 2007;50:808-810.
136. Vang R, Taubenberger JK, Mannion CM, et al. Primary vulvar and vaginal extraosseous Ewing's sarcoma/peripheral neuroectodermal tumor: diagnostic confirmation with CD99 immunostaining and reverse transcriptase-polymerase chain reaction. *Int J Gynecol Pathol*. 2000;19:103-109.
137. Chung AF, Casey MJ, Flannery JT, et al. Malignant melanoma of the vagina. Report of 19 cases. *Obstet Gynecol*. 1980;55:720-727.
138. Neven P, Shepherd JH, Masotina A, et al. Malignant melanoma of the vulva and vagina: a report of 23 cases presenting in 10-year period. *Int J Gynecol Cancer*. 1994;4:379-383.
139. Nigogosyan G, De La Pava S, Pickren JW. Melanoblasts in the vaginal mucosa. Origin for primary malignant melanoma. *Cancer*. 1964;17:912-913.
140. Ragnarsson-Olding B, Johansson H, Rutqvist LE, Ringborg U. Malignant melanoma of the vulva and vagina. Trends in incidence, age distribution, and long-term survival among 245 consecutive cases in Sweden 1960–1984. *Cancer*. 1993;71:1893-1897.
141. Schmidt M, Honig A, Schwab M, et al. Primary vaginal melanoma: a case report and literature review. *Eur J Gynaecol Oncol*. 2008;29:285-288.
142. Borazjani G, Prem KA, Okagaki T, et al. Primary malignant melanoma of the vagina. A clinicopathological analysis of 10 cases. *Gynecol Oncol*. 1990;37:264-267.
143. Gupta D, Neto AG, Deavers MT, et al. Metastatic melanoma of the vagina: clinicopathologic and immunohistochemical study of three cases and literature review. *Int J Gynecol Pathol*. 2003;22:136-140.
144. Hasumi K, Sakamoto G, Sugano H, et al. Primary malignant melanoma of the vagina. Study of four autopsy cases with ultrastructural findings. *Cancer*. 1978;42:2675-2686.
145. Aulmann S, Sinn HP, Penzel R, et al. Comparison of molecular abnormalities in vulvar and vaginal melanomas. *Mod Pathol*. 2013;27:1386-1393.
146. Bottles K, Lacey CG, Miller TR. Atypical melanocytic hyperplasia of the vagina. *Gynecol Oncol*. 1984;19:226-230.
147. Kerley SW, Blute ML, Keeney GL. Multifocal malignant melanoma arising in vesicovaginal melanosis. *Arch Pathol Lab Med*. 1991;115:950-952.
148. Copeland LJ, Sneige N, Ordonex NG, et al. Endodermal sinus tumor of the vagina and cervix. *Cancer*. 1985;55:2558-2565.
149. Young RH, Scully RE. Endodermal sinus tumor of the vagina. A report of nine cases and review of the literature. *Gynecol Oncol*. 1984;18:380-392.
150. Lopes LF, Chazan R, Sredni ST, de Camargo B. Endodermal sinus tumor of the vagina in children. *Med Pediatr Oncol*. 1999;32:377-381.
151. Zirker TA, Silva EG, Morris M, Ordonez NG. Immunohistochemical differentiation of clear-cell carcinoma of the female genital tract and endodermal sinus tumor with the use of alpha-fetoprotein and Leu-M1. *Am J Clin Pathol*. 1989;91:511-514.
152. Norris HJ, Bagley GP, Taylor HB. Carcinoma of the infant vagina. A distinctive tumor. *Arch Pathol*. 1970;90:473-479.
153. Kohorn EI, McIntosh S, Lytton B, et al. Endodermal sinus tumor of the infant vagina. *Gynecol Oncol*. 1985;20:196-203.
154. Chorlton I, Karnei RF Jr, Norris HJ. Primary malignant reticuloendothelial disease involving the vagina, cervix, and corpus uteri. *Obstet Gynecol*. 1974;44:735-748.
155. Kalyanasundaram K, Parameswaran A, Mani R. Perivascular epithelioid tumor of urinary bladder and vagina. *Ann Diagn Pathol*. 2005;9:275-278.
156. Perren T, Farrant M, McCarthy K, et al. Lymphomas of the cervix and upper vagina. A report of five cases and a review of the literature. *Gynecol Oncol*. 1992;44:87-95.
157. Vang R, Medeiros LJ, Silva EG, et al. Non-Hodgkin's lymphoma involving the vagina: a clinicopathologic analysis of 14 patients. *Am J Surg Pathol*. 2000;24:719-725.
158. Skinnider BF, Clement PB, MacPherson N, et al. Primary non-Hodgkin's lymphoma and malakoplakia of the vagina: a case report. *Hum Pathol*. 1999;30:871-874.
159. Harris NL, Scully RE. Malignant lymphoma and granulocytic sarcoma of the uterus and vagina. A clinicopathologic analysis of 27 cases. *Cancer*. 1984;53:2530-2545.
160. Ben-Izhak O, Munichor M, Malkin L, Kerner H. Brenner tumor of the vagina. *Int J Gynecol Pathol*. 1998;17:79-82.
161. Chen KTK. Brenner tumor of the vagina. *Diagn Gynecol Obstet*. 1981;3:255-258.
162. Daya D, Murphy J, Simon G. Paravaginal female adnexal tumor of probable wolffian origin. *Am J Clin Pathol*. 1994;101:275-278.
163. Meenakshi M, McCluggage WG. Myoepithelial neoplasms involving the vulva and vagina: report of 4 cases. *Hum Pathol*. 2009;40:1747-1753.
164. Lam MM, Corless CL, Goldblum JR, et al. Extragastrointestinal stromal tumors presenting as vulvovaginal/rectovaginal septal masses: a diagnostic pitfall. *Int J Gynecol Pathol*. 2006;25:288-292.
165. McCluggage WG. Recent developments in vulvovaginal pathology. *Histopathology*. 2009;54:156-173.
166. Mazur MT, Hsueh S, Gersell DJ. Metastases to the female genital tract. Analysis of 325 cases. *Cancer*. 1984;53:1978-1984.
167. Nerdrum TA. Vaginal metastasis of hypernephroma. Report of three cases. *Acta Obstet Gynecol Scand*. 1966;45:515-524.
168. Stander RW. Vaginal metastases following treatment of endometrial carcinoma. *Am J Obstet Gynecol*. 1956;71:776-779.
169. Gupta D, Malpica A, Deavers MT, Silva EG. Vaginal melanoma: a clinicopathologic and immunohistochemical study of 26 cases. *Am J Surg Pathol*. 2002;26:1450-1457.
170. Ohira S, Yamazaki T, Hatano H, et al. Epithelioid trophoblastic tumor metastatic to the vagina: an immunohistochemical and ultrastructural study. *Int J Gynecol Pathol*. 2001;19:381-386.

For personal use only. No other uses without permission. Copyright ©2017. Elsevier Inc. All rights reserved.

32 Uterus: Cervix

Blake Gilks

CHAPTER CONTENTS

Normal anatomy, 1260
Remnants and ectopias, 1260
Squamous and other metaplasias, 1261
Inflammatory lesions, 1263
Non-neoplastic glandular lesions, 1263
Non-neoplastic stromal lesions (including endometriosis and related processes), 1265
Human papilloma virus and the lower female genital tract, 1266
Tumors, 1267
Squamous cell carcinoma and its precursors, 1267
Adenocarcinoma, 1274
Neuroendocrine carcinoma, 1280
Other tumors and tumorlike conditions, 1283

Normal Anatomy

The cervix is the lower portion of the uterus which connects this organ to the vagina through the endocervical canal. It is divided into a portion that protrudes into the vagina *(portio vaginalis)* and one that lies above the vaginal vault *(supravaginal portion)*. The outer surface of the portio vaginalis is known as the exocervix or ectocervix, and the portion related to the endocervical canal corresponds to the endocervix. The opening of the endocervical canal onto the exocervix is known as the *external os*, whereas the grossly indistinct upper limit of the endocervical canal is designated the *internal os*.[1]

Most of the exocervix is covered by nonkeratinizing squamous epithelium that in childbearing age is composed of three layers: basal cell, midzone (stratum spongiosum), and superficial. The portion of the midzone immediately above the basal layer is referred to as the *suprabasal layer*. The morphologic appearance of the various layers varies with age; in the postmenopausal period, the cells are atrophic and exhibit a high nuclear-to-cytoplasmic ratio. These changes should not be misinterpreted as evidence of squamous intraepithelial lesions (SILs)/cervical intraepithelial neoplasia (CIN).

Histochemically, the cells above the basal layer show variable amounts of glycogen, readily appreciated in sections with a periodic acid–Schiff (PAS) stain and clinically by the application of the iodine (Lugol or Schiller) test. Immunohistochemically, the cells of the basal layer are positive for low-molecular-weight keratin and tissue polypeptide antigen (TPA) but not for high-molecular-weight (epidermal type) keratin or for involucrin.[2–6] The latter two markers become positive in the cells above the basal layer. Basal cells are also immunoreactive for estrogen receptors.[7]

The glandular mucosa of the endocervix is formed by a layer of columnar mucus-secreting cells, the histochemical reactivity for the mucin depending on the time of the menstrual cycle.[8] These cells rest on a normally inconspicuous layer of subcolumnar "reserve" cells, which are also positive for TPA.[2] These "reserve" cells (in particular, those located at or near the squamocolumnar junction) are primarily involved in the processes of squamous metaplasia, high-grade squamous intraepithelial lesion (HSIL) (CIN2/3), and carcinoma. The glandular epithelium is immunoreactive for estrogen receptors.[7] In addition to lining the surface, it invaginates into the stroma to produce elongated clefts (usually <5 mm deep but sometimes as deep as 1 cm or more), forming the endocervical glands.

The area where the squamous and glandular epithelia meet is known as the *squamocolumnar junction* (Fig. 32.1). It should be noted that this junction is not located in the anatomic external os but rather in the adjacent exocervix, a fact that renders it easily accessible to the colposcope. The portion of endocervical mucosa covering the exocervix is sometimes referred to as *ectropion* and, inaccurately, as *erosion*. This is a very unstable region, in which replacement of one epithelium for another repeatedly occurs, a process that Robert Meyer allegorically referred to as "the fight of the epithelia." Today, this area is more prosaically known as the *transformation zone*.

Scattered endocrine cells are found in both the normal endocervix and exocervix,[9,10] and melanocytes are occasionally detected along the exocervical basal layer.[11]

The stroma of the cervix is mainly made up of fibrous tissue admixed with elastic fibers and scattered smooth muscle fibers. It has a dominant CD34 immunophenotype, whereas the endometrial stroma has a dominant CD10 phenotype.[12]

Remnants and Ectopias

Mesonephric rests are remnants of the wolffian ducts that are found surrounded by the endocervical stroma in about a third of women.

For personal use only. No other uses without permission. Copyright ©2017. Elsevier Inc. All rights reserved.

Abstract

Diseases of the uterine cervix account for a burden of human suffering and mortality that is disproportionate to its size, due to the susceptibility of the epithelium of the cervical transformation zone to infection by oncogenic human papilloma virus (HPV). Despite the introduction of cervical screening programs, cancer of the cervix remains one of the most common cancers. With the introduction of vaccination against HPV it can be anticipated that there will be a decrease in the number of surgical pathology specimens taken for evaluation of primary diseases of the cervix, but this is years off and in the near term, the pathology of the cervix will be important in any general surgical pathology practice.

Keywords

cervix,
HPV,
HSIL,
LSIL,
CIN,
squamous cell carcinoma,
adenocarcinoma

For personal use only. No other uses without permission. Copyright ©2017. Elsevier Inc. All rights reserved.

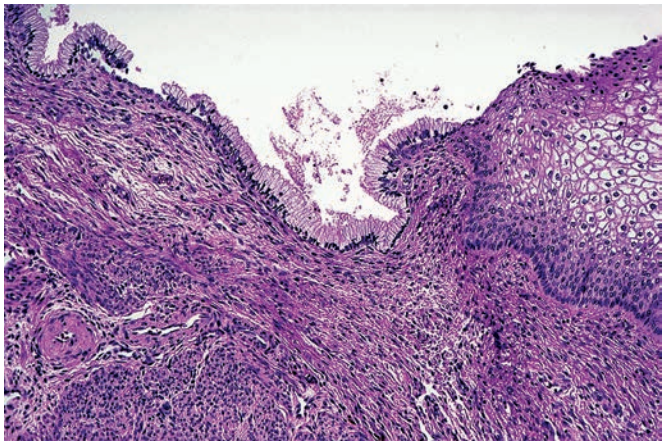

Figure 32.1 Transition zone of uterine cervix between exocervical squamous cells and endocervical mucin-producing glandular epithelium.

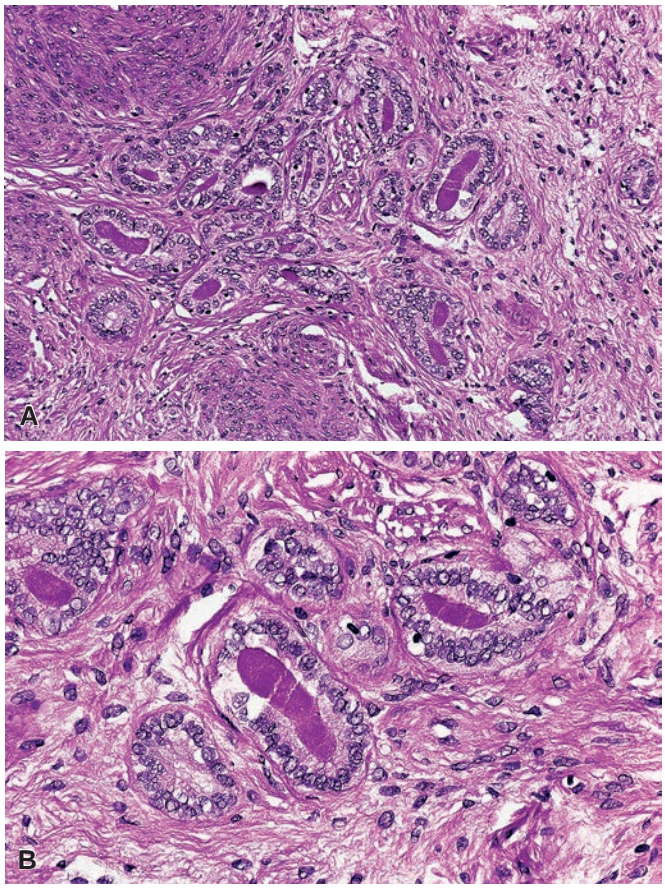

Figure 32.2 **A** and **B**, Florid mesonephric rests in endocervix. Note the eosinophilic inspissated secretion in the glandular lumen, an important diagnostic clue.

They are composed of tubules lined by a single row of cuboidal cells; they typically contain an inspissated deeply eosinophilic secretion in the lumen (Fig. 32.2). They are immunoreactive for PAX8, PAX2, and GATA3, a fact potentially useful for their distinction from endocervical adenocarcinoma and other glandular proliferations of the cervix.[13,14]

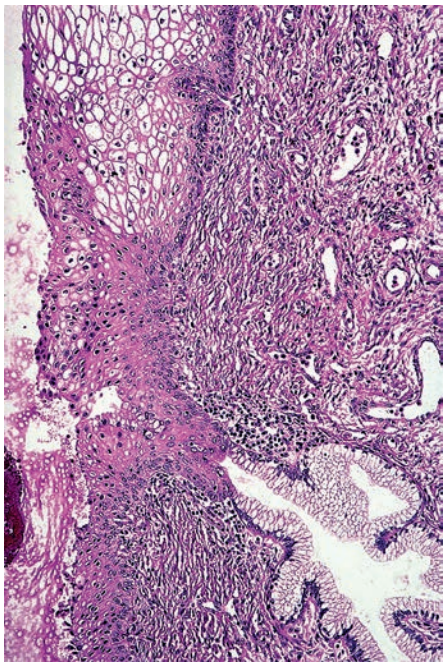

Figure 32.3 Squamous metaplasia of endocervix involving surface epithelium and glandular opening.

Ectopic tissues sometimes found in the cervix include *cutaneous adnexa* (sebaceous glands and hair follicles),[15] *prostatic tissue* (sometimes referred to as "female prostate"),[16–18] and *mature cartilage islands*.[19] The latter (which may be metaplastic rather than ectopic) should not be confused with the cartilaginous component of a carcinoma or a rhabdomyosarcoma.

Squamous and Other Metaplasias

Various types of metaplastic change of the cervical epithelium occur, their appearance being related to the type of mucosa affected. Squamous metaplasia, by far the most common (to the point that some regard it as a normal finding) is centered on the transformation zone; transitional metaplasia involves the exocervical squamous epithelium; and tubal, tuboendometrial, and intestinal metaplasia affect the glandular epithelium of the endocervix.

The term **squamous metaplasia** is used to designate the focal or extensive replacement of the mucus-secreting glandular epithelium by stratified squamous epithelium, which, in its late stage, is morphologically indistinguishable from the epithelium normally lining the exocervical portion (Fig. 32.3). The pathogenesis of this process, also known as *prosoplasia*, has been a subject of a heated controversy over the years. It is now generally agreed that it most commonly arises on the basis of proliferation and metaplasia of reserve cells. It is possible that in other instances it results from direct ingrowth of mature native squamous epithelium into the endocervical mucosa from the exocervix, possibly as a healing mechanism of a true cervical erosion.[20] Strictly speaking, the latter is not a metaplastic process but rather one of "squamous epithelialization." However, it is common usage to employ the term squamous metaplasia regardless of the presumed mechanism for the change.

Some degree of squamous metaplasia is present in almost every uterine cervix during the childbearing years. Most commonly, the process involves only the superficial epithelium and is recognized by the presence of squamous epithelium overlying endocervical glands. In other instances, it involves the glandular component as

For personal use only. No other uses without permission. Copyright ©2017. Elsevier Inc. All rights reserved.

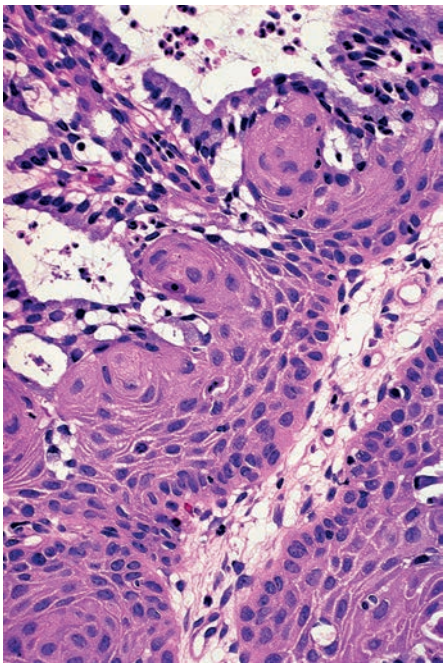

Figure 32.4 Complex pattern resulting from cervical squamous metaplasia. It may result in an overdiagnosis of squamous cell carcinoma.

well, resulting in a complex microscopic appearance that can be confused with invasive carcinoma by the inexperienced (Fig. 32.4).

Ultrastructural and immunohistochemical markers of squamous epithelium appear *pari passu* with the morphologic changes.[21,22] Variations on this theme, probably representing various stages within a continuum, have been described as *reserve cell hyperplasia* and as *immature, intermediate*, and *mature squamous metaplasia*.[23] The presence of cytologic atypia in immature squamous metaplasia raises the possibility of SIL/CIN; p16 immunostaining can be used to establish a diagnosis of HSIL (CIN2/3), but there remains significant overlap in the morphologic features between atypical immature metaplasia and low-grade squamous intraepithelial lesion (LSIL), with resulting interobserver variability in distinguishing between these two possibilities.[23–28] The diagnosis of SIL is discussed in more detail later in this chapter.

All of the above changes are characterized by a flat architecture and are, therefore, different from the condyloma and other papillary processes, including so-called papillary immature metaplasia (immature condyloma).

Although most cervical carcinomas arise in areas of the cervix that sometime in the past had been involved by squamous metaplasia, the latter process has no premalignant connotations per se. Actually, it is so common and insignificant that, unless quite extensive and/or involving the glandular component, we tend to ignore it altogether in our pathology reports.

A somewhat different appearance is seen often in the cervix of prolapsed uteri. The clinical appearance is usually referred to as "leukoplakic." Microscopically, the process involves mainly the exocervical portion and is characterized by the appearance of granular and horny layers in the epithelium. This process, which is also unrelated to carcinoma, is best designated as *keratosis*. Sometimes this epithelium contains scattered large pale cells, a change that has been dignified by the term *pagetoid dyskeratosis*.[29]

Transitional metaplasia is seen in the exocervix of older women, and it is often associated with atrophy. It morphologically resembles transitional (urothelial) epithelium, and it involves the entire thickness

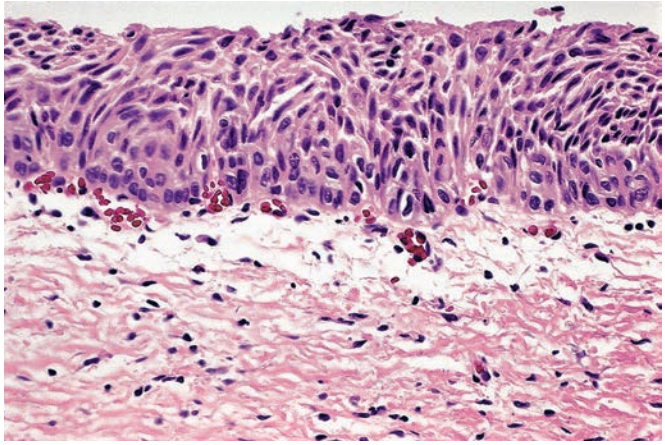

Figure 32.5 Typical appearance of transitional metaplasia, which lacks the nuclear atypia of HSIL (CIN2/3).

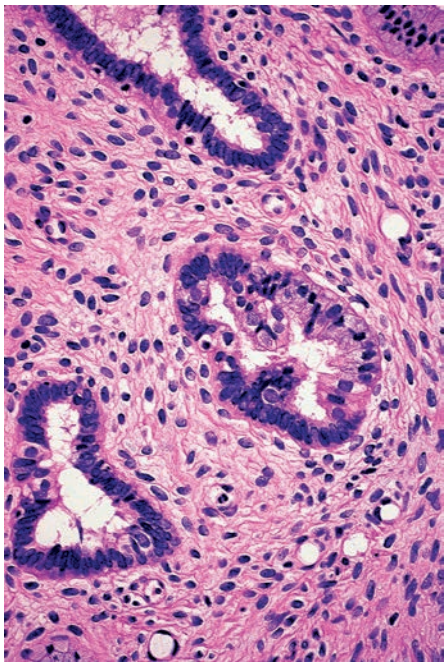

Figure 32.6 Tubal metaplasia of endocervix. Some of the lining cells are ciliated.

of the mucosa, without evidence of normal squamous maturation. The nuclei are oval and devoid of atypical features. Their long axes, which are arranged perpendicularly to the surface, often exhibit longitudinal grooves (Fig. 32.5).[30,31] Immunohistochemically, there is positivity for CK13, CK17, and CK18 but not for CK20.[32] Its phenotypic profile is very similar to that of senile atrophy.[33] Although this entity has engendered some controversy in the past, with respect to its relationship to SIL,[34] it is now regarded as an entirely benign metaplastic change that differs from atrophy only in consisting of a greater number of cellular layers.[35,36]

Tubal metaplasia is diagnosed when a specimen from the endocervix (usually from the upper portion) is found to contain all three cell types found in the normal fallopian tube (i.e., ciliated, secretory, and intercalated; Fig. 32.6).[37,38] In many instances, the appearance of the metaplastic epithelium combines features of tubal and endometrial mucosa, in which case the term *tuboendometrial*

For personal use only. No other uses without permission. Copyright ©2017. Elsevier Inc. All rights reserved.

(tuboendometrioid) metaplasia is employed.[39–41] Diagnostic difficulties may result from the fact that these glands may be deeply seated, irregularly shaped, cystically dilated, and/or accompanied by a hypercellular, edematous, or myxoid stroma.[42] The condition can be identified in cytologic preparations.[43]

Combined staining for Ki-67 and p16 is of help in the differential diagnosis from in situ and invasive endocervical adenocarcinoma, as tubal metaplasia shows a lower proliferative index and lacks the strong, diffuse, block positivity for p16 seen in human papilloma virus (HPV)-associated adenocarcinomas.[40,44] Tubal metaplasia is often found after conization, and it has therefore been suggested that it represents aberrant differentiation following injury.[45]

A *pseudoinvasive* form of the condition has been described in women with a history of in utero diethylstilbestrol (DES) exposure, suggesting that it may be a form of DES-related adenosis.[46]

Intestinal metaplasia is a vanishingly rare condition, which may be accompanied by extravasation of mucin into the stroma.[47] The presence of goblet cells in the endocervix should prompt a search for dysplastic change/adenocarcinoma in situ; this may be HPV associated or HPV independent.

Oxyphilic (eosinophilic) metaplasia is characterized by the presence of large cuboidal or polygonal epithelial cells with dense eosinophilic, focally vacuolated cytoplasm and variable nuclear atypia in the endocervical glands.[48,49] The differential diagnosis includes HSIL (CIN2/3) with eosinophilic cells, which can be recognized based on the presence of mitotic activity and p16 immunoreactivity.[49]

Inflammatory Lesions

Chronic cervicitis is an extremely common condition in adult females, at least at the microscopic level. It affects preferentially the squamocolumnar junction and endocervix, and it may be accompanied by hyperemia, edema, fibrosis, and metaplastic changes in the epithelium. The etiology is variable.[50] In most cases the disease is asymptomatic. Given that the presence of inflammatory cells at the squamocolumnar junction is normal (this being the junction between the sterile endometrial cavity/endocervix and the exocervix/vagina), it is a highly subjective distinction between "normal cervix" and a degree of inflammation that merits designation as "chronic cervicitis."

Herpes simplex infection of the cervix is now recognized as a relatively common occurrence. The microscopic appearance at the time of biopsy is usually that of an intense nonspecific inflammation with ulceration (Fig. 32.7A). Only rarely are diagnostic multinucleated squamous cells with intranuclear inclusions encountered (see Fig. 32.7B).[51] The diagnosis can be confirmed by immunocytochemical demonstration of the viral antigen.[52,53]

***Chlamydia trachomatis* infection** is now recognized as the most common venereal disease in the Western world. The microscopic appearance in the cervix is that of a chronic nonspecific inflammation, with reactive epithelial atypia and sometimes prominent formation of lymphoid follicles.[54,55] The organisms are not visible in routine histologic slides and only with difficulty in cytologic preparations, but they can be detected by immunocytochemical techniques.[55] Culture isolation is regarded as the standard for diagnosis of active infection. Chlamydial cervicitis can be associated with CIN, but there is no evidence of a causal relationship.[56]

Syphilis can affect the cervix, usually in the form of a primary chancre.[57]

Amebiasis may produce a polypoid and ulcerated mass in the cervix clinically simulating carcinoma, and it may also engraft itself upon a preexisting cervical carcinoma.[58,59]

Actinomycosis of the cervix occurs, but it needs to be distinguished from the more common pseudoactinomycotic radiate granules that may form around microorganisms or biologically inert substances.[60]

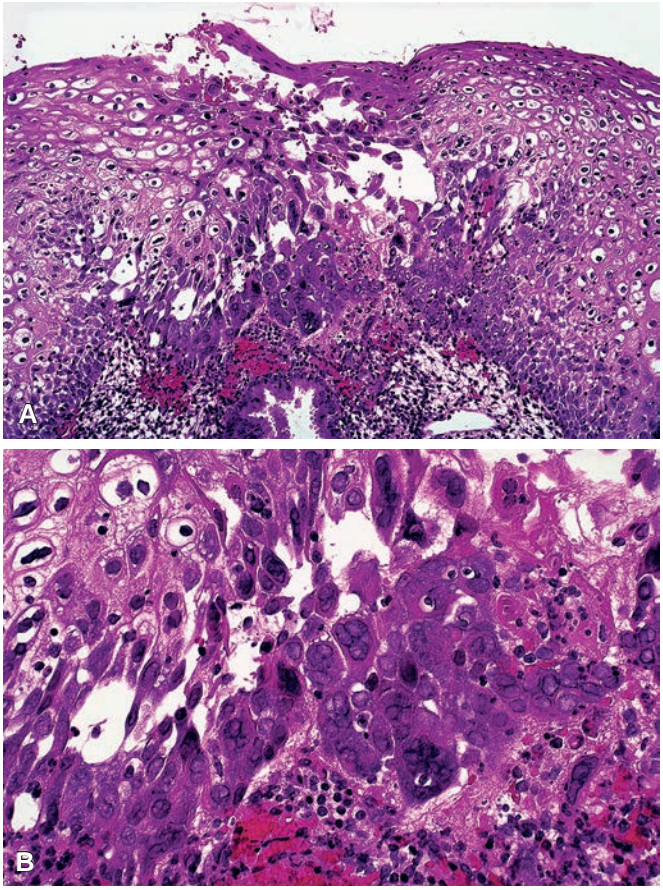

Figure 32.7 **A** and **B**, Low- and high-power appearance of herpes simplex infection of cervix. Multinucleated epithelial cells and intranuclear inclusions are evident in the high-power view.

Bilharziasis (schistosomiasis), common in Africa and Central America, can involve any portion of the female genital tract, including the cervix.[61]

Malakoplakia occurs rarely in the cervix, sometimes in association with disease in the uterine corpus, renal pelvis, or kidney.[62]

Ceroid granuloma of the type more commonly seen in the gallbladder has, exceptionally, been found to involve the cervix.[63,64]

Localized arteritis of the cervix has been described, accompanied by inflammation and ulceration, and apparently restricted to this anatomic site.[65,66] The cervix can also be involved in cases of granulomatosis with polyangiitis (formerly known as Wegener granulomatosis).[67]

Non-Neoplastic Glandular Lesions

Endocervical polyps are not true neoplasms but are probably the result of chronic inflammatory changes ("chronic polypoid cervicitis"). They are usually small but may reach several centimeters in diameter. Microscopically, dilated endocervical glands are seen in an edematous, inflamed, and fibrotic stroma. HSIL (CIN2/3) is an occasional incidental finding in a polyp. Occasionally, the configuration of these polyps is that of a branching papillary structure, in which case the term *papillary endocervicitis* is employed (Fig. 32.8).[47] This lesion is to be distinguished from so-called superficial cervicovaginal myofibroblastoma, which is equally benign and perhaps histogenetically related.[68] Exceptionally, cells with the morphology of signet

For personal use only. No other uses without permission. Copyright ©2017. Elsevier Inc. All rights reserved.

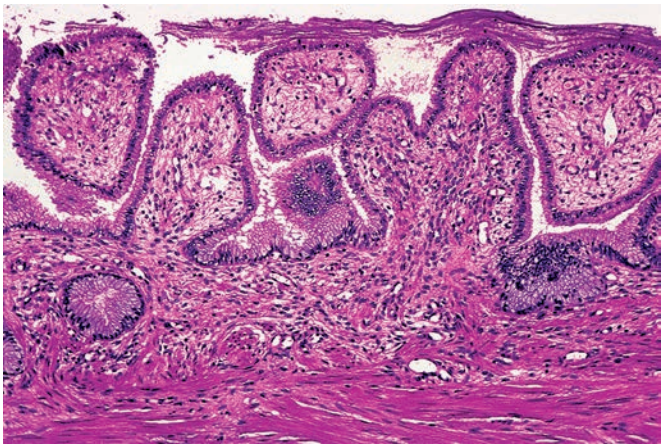

Figure 32.8 Chronic endocervicitis resulting in a papillary configuration at the surface. This pattern is sometimes referred to as papillary endocervicitis.

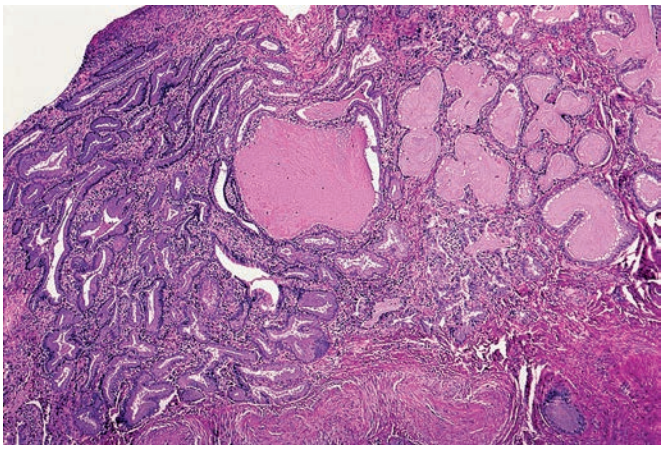

Figure 32.9 Cervical tunnel clusters of predominantly cystic type.

ring cells are seen within an ulcerated endocervical polyp; they are probably the result of ischemia and should not be overdiagnosed as signet ring cell carcinoma.[69]

Nabothian cysts are thought to develop from blockage of the endocervical glands secondarily to inflammation and associated changes; they appear grossly as cystic spaces filled with mucoid material and microscopically as cystically dilated glands lined by a flattened epithelium, sometimes focally absent. Occasionally they extend deeply into the cervical wall, a phenomenon that should not be mistaken for malignancy.[70]

Tunnel clusters, as originally described by Fluhmann, are the result of localized proliferation of endocervical glands (clefts), with side channels growing out from them. This may be accompanied by dilation resulting from the accumulation of inspissated, deeply eosinophilic secretion in the lumen (Fig. 32.9).[71]

Microglandular hyperplasia of the endocervical epithelium was originally described in women using oral contraceptive drugs and, less frequently, during pregnancy.[72,73] However, it can also be seen in the absence of these conditions and even in postmenopausal patients.[74] The relationship between microglandular hyperplasia and oral contraception or other hormonal perturbations has been questioned.[75] Microscopically, the typical case is characterized by a complex proliferation of small glands lined by flat epithelial cells with little or no atypia (Fig. 32.10). The condition usually evolves

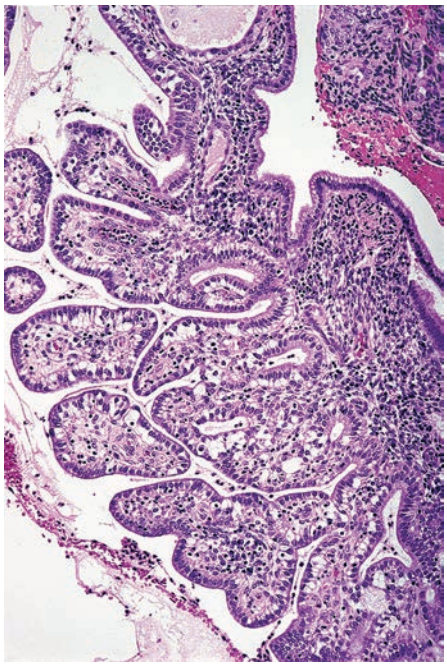

Figure 32.10 Microglandular Hyperplasia of Cervix. The papillary configuration seen here is common in this condition.

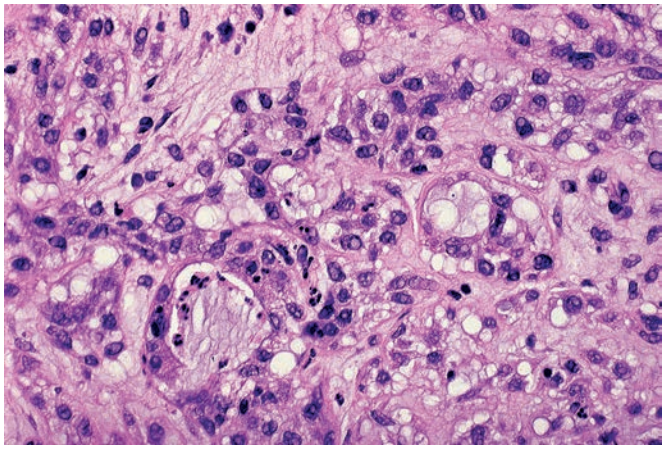

Figure 32.11 Predominantly Solid Form of Microglandular Hyperplasia. This variety is particularly likely to be overdiagnosed as a malignant process.

into squamous metaplasia, resulting in a complex microscopic picture that may be confused with carcinoma (Fig. 32.11). Additional features that may lead to overdiagnosis include areas of solid proliferation, pseudoinfiltrative pattern, signet ring cells, focal atypia, and occasional mitotic figures.[76] The intervening stroma invariably shows chronic inflammation. There is usually no immunocytochemical reactivity for carcinoembryonic antigen (CEA), a useful feature in the differential diagnosis with endocervical adenocarcinoma.[77] Microglandular hyperplasia must be distinguished from endometrial adenocarcinomas with microglandular hyperplasia-like features[78]; these carcinomas are seen in older patients, predominantly within the endometrial biopsy/curettings rather than the endocervical curettings, are often associated with atypical endometrial hyperplasia, and lack the p63 expressing reserve cells present in microglandular hyperplasia.

The **Arias–Stella reaction,** as seen during pregnancy, can involve the endocervical glands. The nuclear abnormalities are similar to

For personal use only. No other uses without permission. Copyright ©2017. Elsevier Inc. All rights reserved.

those seen more commonly in the endometrial mucosa and should not be confused with malignancy.[79–81] The microscopic appearance is quite variable and includes cells with vacuolated clear cytoplasm, intraglandular tufts, hobnail cells, oxyphilic cytoplasm, filiform papillae, nuclear pseudoinclusions, and cribriform intraglandular growth.[82] In contrast to clear cell carcinoma, the Arias–Stella reaction does not form a mass lesion, lacks a desmoplastic stromal response, and does not have an infiltrative pattern.[82]

Atypical reactive proliferation of the endocervical mucosal surface can be seen following endometrial sampling for endometrial carcinoma or other diseases. It shows nuclear stratification, short micropapillary processes, squamous metaplasia, hobnail cells, and mild cytologic atypia (i.e., many of the features that are associated with microglandular hyperplasia). It should not be interpreted as endocervical involvement by an endometrial carcinoma.[83]

Diffuse laminar endocervical glandular hyperplasia (DLEGH) is a non-neoplastic condition characterized by a proliferation of medium-sized, evenly spaced, well-differentiated glands within the inner third of the cervical wall, sharply separated from the underlying stroma, and often accompanied by chronic inflammation (Fig. 32.12)[84]; it should not be confused with adenoma malignum, from which it is distinguishable because of the fact that stromal infiltration, desmoplastic stromal response, and cytologic atypia are absent.[80]

Lobular endocervical glandular hyperplasia (LEGH) is characterized by a distinctly lobular proliferation of small- to medium-sized glands, often centered around a larger central gland.[85] The mucin secreted by some of these lesions is of gastric type.[86] In contrast to adenoma malignum, LEGH lacks irregular stromal infiltration, desmoplastic stromal response, and significant cytologic atypia. Interestingly, the phenotype of this process is similar to that of pyloric glands.[87] A possible pathogenetic relationship between the two conditions (and with HPV-independent mucinous adenocarcinomas of the cervix) has been suggested on the basis of some immunohistochemical and molecular genetic similarities,[87,88] as well as their occasional association.[86,89]

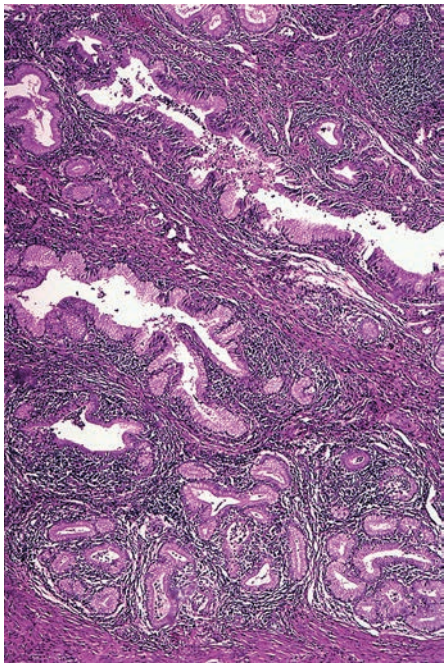

Figure 32.12 Diffuse Laminar Endocervical Hyperplasia. The glands are medium sized, evenly spaced, and well differentiated.

Mesonephric duct rests can undergo cystic dilation or be affected by florid and even atypical hyperplastic changes (Fig. 32.13).[90–92] This hyperplasia may have a lobular, diffuse, or ductal pattern (Fig. 32.14).[93] Rare malignant tumors arising from these structures also occur. Mesonephric remnants are also rarely involved by HSIL (CIN2/3).[94] It is doubtful whether the rare benign polypoid lesion found in the cervix and vagina of young children and described as *mesonephric papilloma* is related to these remnants.[95,96] Microscopically, it is a superficially located lesion composed of delicate connective tissue stalks covered by a layer of cuboidal cells and is probably of müllerian derivation.

Non-Neoplastic Stromal Lesions (Including Endometriosis and Related Processes)

Multinucleated stromal giant cells can be present beneath the cervical epithelium and be mistaken for a malignancy. They are often accompanied by edema and may result in a vaguely polypoid-appearing lesion.[97,98] These cells are of a reactive fibroblastic/myofibroblastic nature and analogous to those seen in other sites covered by mucosal membranes, such as vulva, vagina, anus, oral cavity, and nasal cavity.[99,100]

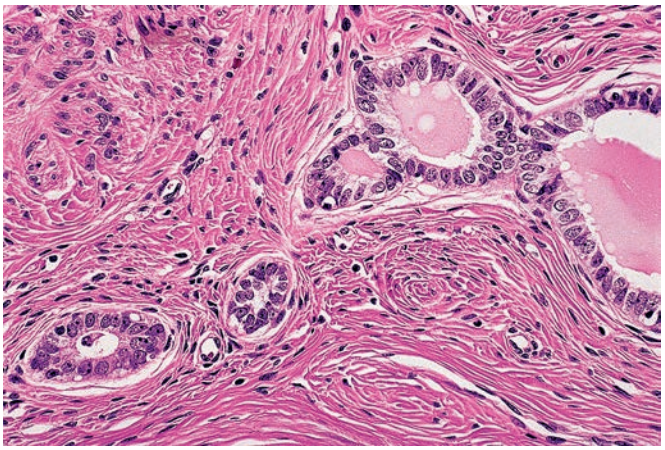

Figure 32.13 Hyperplastic mesonephric rests with mild atypia.

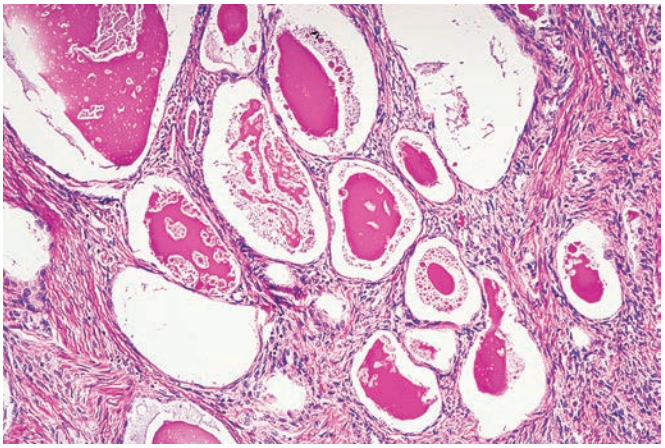

Figure 32.14 Mesonephric glands embedded within the stroma of the uterine cervix exhibiting cystic dilation. The presence of a dense eosinophilic secretion is characteristic.

For personal use only. No other uses without permission. Copyright ©2017. Elsevier Inc. All rights reserved.

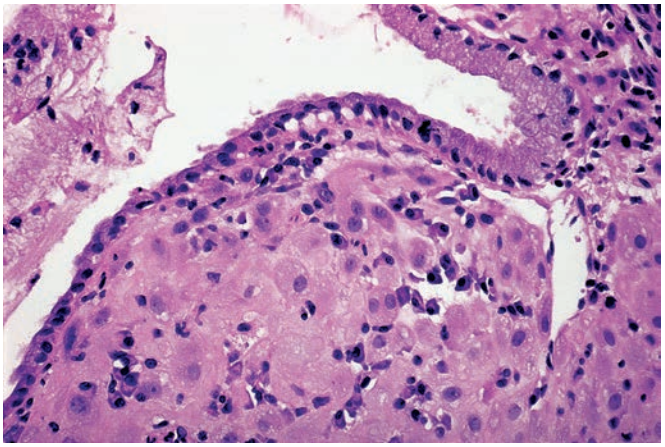

Figure 32.15 Focus of ectopic cervical decidual reaction.

Decidual reaction in the cervix during pregnancy usually presents as multiple, small, yellowish or red elevations of the cervical mucosa. They are soft and friable and bleed easily with trauma. Rarely, they develop into fungating masses difficult to distinguish grossly from carcinoma.[101] Microscopically, the decidual cells are characterized by abundant pale granular cytoplasm and bland nuclei (Fig. 32.15). Immunostains for keratin are negative.

Placental site nodule appears as a well-defined hyalinized lesion located immediately beneath the mucosa.[102] It is composed of intermediate trophoblasts exhibiting cytoplasmic vacuolization.[103,104] Some nuclear atypia may be present. This lesion can be confused with carcinoma and with neoplastic cartilage. Immunohistochemically, the trophoblastic cells are reactive for keratin (another factor that may lead to a mistaken diagnosis of malignancy) but also for human placental lactogen.

Endometriosis of the cervix presents as blue or reddish nodules and may result in abnormal uterine bleeding. Both endometrial glands and stroma are needed to establish the diagnosis. However, the proportion of the two components may vary greatly from case to case. On occasion, the process is composed exclusively of endometrial stroma ("stromal endometriosis") and may be confused with a neoplasm.[105] Another source of confusion arises when the endometriosis is superficial, in which case it may be overinterpreted as endocervical glandular dysplasia or adenocarcinoma in situ, one of the reasons being that it may be mitotically active.[106] It differs from tuboendometrial metaplasia of the endocervix because of the concomitant presence of endometrial-type stroma, however scarce. A lesion with an appearance resembling a miniature uterus in the cervix ("uterus-like mass") has been interpreted as a form of superficial endometriosis with florid smooth muscle metaplasia.[107] A bizarre variation on the theme is represented by **endocervicosis**, which can present as a deep-seated cervical mass simulating endocervical adenocarcinoma.[108]

Necrobiotic granulomas resembling tuberculosis or rheumatoid nodules have been seen following cervical surgery.[109] They are probably histologically and pathogenetically analogous to those described postoperatively in the prostate (see Chapter 26).

Florid mesenchymal reactions can develop from the cervical stroma as a result of various surgical interventions and lead to confusion with sarcoma.[110] Some of these have a nodular fasciitis-like appearance and may be looked upon as the genitourinary equivalent of this soft tissue lesion.

Myxoid changes of probable degenerative nature can sometimes be seen in the cervical stroma (and in the myometrium) in the absence of any other pathology.[111]

Human Papilloma Virus and the Lower Female Genital Tract

The role of HPV in the pathogenesis of both condyloma and carcinoma is so well established that it is easy to forget that relatively recently this relationship was completely unsuspected. It has now been demonstrated that greater than 99% of cervical carcinomas are associated with oncogenic HPV,[112] and the molecular mechanisms of virus-mediated oncogenesis are understood in considerable detail. zur Hausen deservedly won the Nobel prize in 2008 for his work establishing the link between HPV and cervical cancer, and we now see the circle closing, with both primary HPV screening to detect premalignant lesions, and HPV immunization to prevent such lesions increasingly being adopted. Against that background we should acknowledge that this is a rapidly advancing field, and what you read in this section will undoubtedly be out of date prior to the next edition of this text. It is possible to envision a world where the burden of disease due to HPV is dramatically reduced, but that is years away, and for the foreseeable future we will be contending with biopsies and resection specimens where the diagnostic issue is the presence or absence of HPV-associated premalignant changes or malignancy. In the following section we will focus on the biology of HPV, so that we can relate it to histopathologic changes described later.

HPV is a DNA virus and is classified based on the viral genome into different genotypes, each designated by a number (e.g., HPV-6).[113] HPV-2 is the most common cause of verruca vulgaris, but the focus of the following discussion are the genital HPV genotypes, transmitted by sexual contact and associated with either condyloma, in the case of the low-risk HPV genotypes such as 6 and 11, or cervical carcinoma, in the case of the high-risk genotypes (also referred to as oncogenic genotypes, later), of which HPV-16 and 18 are the most important. Other HPV genotypes considered to be oncogenic include 31, 33, 35, 39, 45, 51, 52, 56, 58, and 59.[114] Other genotypes are considered to be possibly oncogenic, of uncertain oncogenic potential (i.e., insufficient information to classify), or non-oncogenic; HPV-6 and 11 are in the latter group. Among the oncogenic HPV genotypes, the risk varies, with some being more likely to be associated with malignant transformation.

The genital HPVs are epitheliotropic and the high-risk HPV types, in particular, have a tropism for the metaplastic squamous cells at the squamocolumnar junction.[115,116] This has very important consequences for cytologic screening as most precursor lesions and carcinomas arise at this site, which is amenable to sampling with a brush or spatula. For example, if the lesions of HPV-associated neoplasia of the genital tract were randomly distributed within the squamous mucosa of the vagina and ectocervix, screening would have failed as it has in the oral cavity.

Potentially infectious virus particles must reach the proliferating basal cells for productive infection to take place, and it is thought that a micro-injury to the squamous epithelium is required for this to happen.[117] In the case of glandular epithelium, in which there is a single layer of cells, the proliferating stem cell compartment should, in theory, be more accessible; however, it remains that infection of squamous cells is more likely than the cervical glandular epithelial cells for reasons that are not well understood. Once the virus particles are taken up by the basal epithelial cells the infection may become silent (e.g., through methylation of the viral genome, so that episomic viral DNA remains in the cell but is not transcribed or translated), or productive infection may result. Such an infection may result in orderly expression of viral genes as the host squamous cells mature, with assembly and release of infectious virus particles at the epithelial surface. This is typically associated with koilocytic change, a viral cytopathic effect in which the E4 protein encoded by the viral genome

For personal use only. No other uses without permission. Copyright ©2017. Elsevier Inc. All rights reserved.

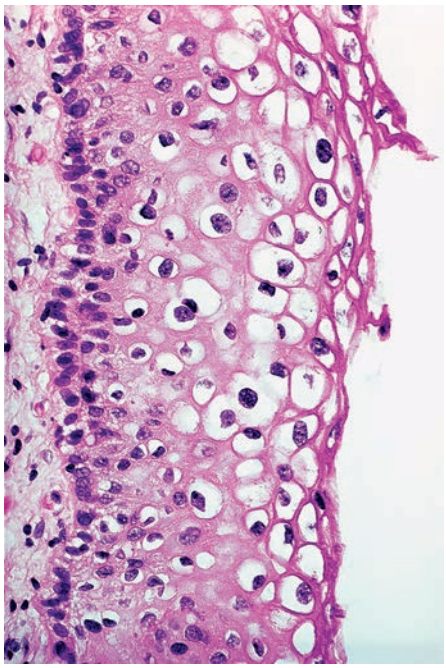

Figure 32.16 Koilocytotic changes in cervical squamous epithelium involved by LSIL (CIN1). These are diagnostic of HPV infection.

causes disruption in the cytoplasmic keratin matrix. The resulting koilocyte is a superficial or intermediate mature squamous cell characterized by a sharply outlined perinuclear vacuolation, dense- and irregular-staining peripheral cytoplasm, and an enlarged nucleus with an undulating (raisin- or prune-like) nuclear membrane and a rope-like chromatin pattern (Fig. 32.16).[118] Binucleation and multinucleation can occur.[119] It is important that these nuclear changes—which may be accompanied by either a diploid or polyploid nuclear DNA distribution[120]—be present somewhere in the lesion for the diagnosis of koilocytosis (and, by inference, HPV infection) to be made, or else other forms of cytoplasmic clearing (notably those related to glycogen accumulation) will be mistakenly included in this category.[121,122] This orderly expression of the viral genome as the squamous cells mature and move to the surface results in LSIL, discussed in more detail later. There may also be, in the case of high-risk/oncogenic HPV infection, deregulated expression of the viral genome. The E6 and E7 proteins encoded by the genomes of these HPV genotypes bind and inactivate the proteins encoded by the *TP53* and *RB* anti-oncogenes, resulting in unfettered proliferation of the host cell. This leads to decreased E4 expression and virion production, and decreased or absent koilocytic change, and increases the likelihood of integration of the viral genome into the host genome, acquisition of other genetic abnormalities in the host cell, and malignant transformation. Not all viral infections lead to transformation and most are cleared by the immune system of the host, through cell-mediated immunity.

HPV can be detected by electron microscopy (as intranuclear crystalline and occasionally filamentous inclusions), but its specific identification depends on nucleic acid hybridization, which can be done with or without amplification, from DNA or RNA, in either a liquid-based or *in situ* analysis.[123–127] Before talking about specific techniques for HPV detection, it is important to reiterate that the presence of HPV DNA may reflect (1) virus particles on the surface of the epithelium secondary to recent exposure, without infection, (2) productive infection that will be cleared completely by the host, (3) a latent infection, or (4) oncogenic HPV DNA that is integrated into the host genome. If the productive infection is by low-risk HPV (6 or 11), it leads to LSIL/condyloma, with viral cytopathic effects, while productive infection with high-risk HPV, most commonly 16 or 18, can lead to LSIL or can progress to HSIL or invasive squamous cell carcinoma. Thus identification of the specific genotype of HPV is of import, but even the identification of high-risk HPV does not mean that there is premalignant change or malignancy, and especially in the young, HPV may be cleared by the host. The Hybrid Capture HPV test, a signal-amplified hybridization microplate-based array designed to detect multiple HPV genotypes, is an example of a liquid based nucleic acid detection technique.[128] These assays are the most sensitive, providing more sensitivity than in situ hybridization techniques. However, they can be too sensitive and may detect virus that has not infected the host or is in the process of being cleared by normal immune mechanisms. Critically for surgical pathology practice, p16 immunohistochemistry has emerged as a highly sensitive and specific surrogate test for infection by high-risk HPV.[129,130] The p16 antioncogene is expressed at high levels in cells due to absence of the normal downregulation of p16 expression by phosphorylated RB protein; in cells infected by high-risk HPV this occurs through inactivation of the RB protein by the viral E7 protein. This results in high-level expression of p16, seen as strong nuclear and cytoplasmic immunoreactivity. There must be "block" positivity for p16 immunostaining to be indicative of high-risk HPV infection (i.e., strong nuclear and cytoplasmic staining of every cell in the basal third of the epithelium), with this staining typically extending into the middle and upper thirds. Correct interpretation of p16 immunostaining is only possible if the staining protocol has been properly validated, and appropriate controls run. There are a number of antibody clones specific for p16, and it is incumbent on each lab to optimize the staining for the clone they have chosen, a responsibility that is sometimes neglected. Immunoreactivity for p16 is not specific for HPV and other tumor types, unrelated to HPV, that have dysregulation of RB can show strong p16 staining (e.g., high-grade serous carcinoma of tubo-ovarian or endometrial origin). p16 expression can be lost through mutation, as cervical cancer progresses, but this appears to be rare in the in situ lesions of HSIL or in situ adenocarcinoma, so that p16 can serve as a very useful surrogate test for high-risk HPV in the cervix. The indications for use of p16 are covered in greater detail later in this chapter. Expression of the viral E5 oncoprotein mRNA is considered a better marker of HPV having a causative role in oncogenesis, in a given case (as HPV DNA may be present as a bystander if there is no transcription of the viral oncogenes), but such testing is currently not widely available in clinical laboratories.

Tumors

Squamous Cell Carcinoma and Its Precursors

Squamous Intraepithelial Lesions/Cervical Intraepithelial Neoplasia

We recommend use of the Bethesda terminology for cytology specimens[131–134] and the diagnostic terminology proposed by the LAST committee,[133] which is based on the Bethesda classification, for surgical pathology specimens. SIL terminology has gained wide acceptance, but there are still holdouts for the CIN terminology and we will adopt the practice, permitted under the LAST recommendations, of providing a two-part diagnosis, with SIL first and the equivalent CIN in parenthesis thereafter. LSIL will thus appear as "LSIL (CIN1)." CIN2 and CIN3 are both considered HSIL, and the distinction between CIN2 and CIN3 is arbitrary and not clinically relevant. Subtle differences in natural history have been reported

For personal use only. No other uses without permission. Copyright ©2017. Elsevier Inc. All rights reserved.

for CIN2 versus CIN3, but we would attribute these to inclusion in the former group of some cases better classified as CIN1, rather than being an indication that CIN2 and CIN3 are distinct diseases. Accordingly, we will not make an effort to distinguish between CIN2 and CIN3, instead using the terminology HSIL (CIN2/3) for all high-grade lesions.

Most SIL are initially detected cytologically, which leads to colposcopic biopsy. Occasionally SIL will be an incidental finding, sometimes appearing in endometrial biopsy specimens. It is anticipated that there will be a decline in SIL with widespread HPV vaccination, but this has not impacted on practice yet. With primary HPV testing rather than cytologic screening, as discussed in the Cytology section later in this chapter, there will be more patients referred for colposcopic examination, so familiarity with SIL and its mimics will be important for those practicing general surgical pathology for the foreseeable future.

LSIL (CIN1) is inclusive of condyloma in the LAST criteria.[133] The former practice of attempting to determine whether there is or is not dysplasia within condyloma (i.e., condyloma ± CIN1) has mercifully been brought to an end. Koilocytic viral cytopathic effect (see Fig. 32.16) is the pathognomonic feature of condyloma; it is doubtful whether LSIL (CIN1), as an indicator of HPV infection, can be reproducibly diagnosed in the absence of koilocytic change. Condyloma can be exophytic or flat. The former, **condyloma acuminatum**, are considerably less common than the latter and are visible grossly as a polypoid lesion characterized microscopically by papillomatosis, acanthosis, koilocytosis, and a variable degree of inflammatory infiltration of the stroma. An undulating appearance of the epithelium is a characteristic feature on low-power examination. A mild degree of atypia in the squamous component is common and need not be mentioned; if more severe, it should be evaluated and graded as for the flat SIL (i.e., is there HSIL [CIN2/3] present).

Condyloma acuminatum is associated with HPV-6 or HPV-11 in 70%–90% of the cases, but occasionally other types—such as HPV-16—are encountered. When the latter is the case, high-grade cytologic atypia may be found. The differential diagnosis of condyloma acuminatum includes verrucous carcinoma, discussed in more detail later. **Inverted transitional cell (urothelial) papilloma**, similar to its more common bladder counterpart, has been described in the cervix.[127,135] It is probably not related to HPV and is included here only because it enters into the differential diagnosis with the other polypoid benign lesions of this region. Papillary transitional lesions can mimic condyloma acuminatum at low power, but there is no koilocytic change and the cells have very uniform nuclear features, with even chromatin and nuclear grooves. Squamous papilloma is the diagnosis that has been suggested for lesions that architecturally resemble condyloma acuminatum, are composed of benign squamous cells, without dysplasia, but lack koilocytic change. These may be related to condyloma but have cleared the HPV infection, but this is speculative. They are not considered to have premalignant potential.

Flat condyloma, so-called, is more commonly encountered than condyloma acuminatum, and is the classic lesion of LSIL (CIN1). It is typically not recognizable grossly. Microscopically, there is a relatively normal basal cell layer, expanded or hyperplastic parabasal cell layer, orderly maturation, mitotic activity confined to the lower third of the epithelium (but few or no abnormal mitoses), and koilocytosis (Fig. 32.17). A degree of dysplasia of the lower third of the epithelium is acceptable within the spectrum of LSIL, although the distinction between "dysplasia" and reactive expansion of the parabasal layer due to increased proliferation is highly subjective. This lack of ability to distinguish between koilocytic change (HPV effect) with or without dysplasia contributed to them being combined as LSIL in the Bethesda classification. At this point we would most emphatically recommend that the old chestnut that mild, moderate,

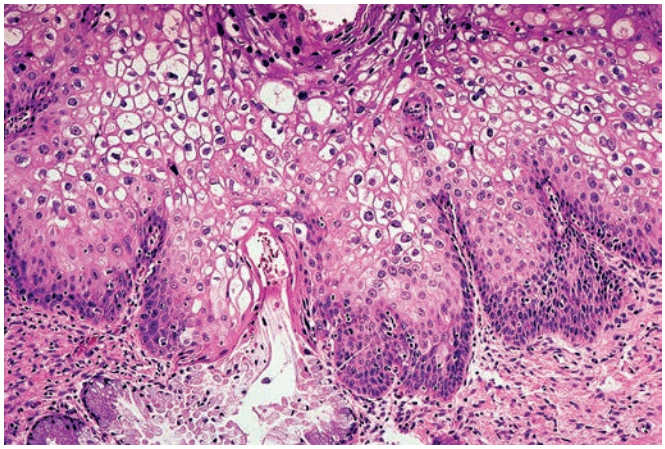

Figure 32.17 HPV-induced LSIL (CIN1) lesion characterized by acanthosis, papillomatosis, and koilocytotic changes.

and severe cervical dysplasia (CIN1-3), respectively, are distinguished by dysplasia in the lower third, lower two thirds, and full thickness of the squamous epithelium be relegated to the bin reserved for medical trivia of historical interest only. This observation is still repeated to trainees and has no underlying mechanistic basis. The Bethesda classification reflects the biology of in situ squamous neoplasia of the cervix, especially as it relates to HPV, with a bipartite LSIL/HSIL system.[134] The proliferation rate of LSIL (CIN1) is higher than that of inflamed or metaplastic cervical squamous epithelium. Most LSIL, apart from condyloma acuminatum, is associated with high-risk HPV types.

The natural history of LSIL is that most will clear spontaneously and relatively few will progress to HSIL (CIN2/3). Risk factors for progression include the presence of high-risk HPV, but, as noted previously, high-risk HPV are present in most LSIL. Cytokeratin 7, a marker of squamous cells of the transformation zone, has been proposed as a marker of LSIL that is more likely to progress.[115] This is based on the observation that LSIL/condyloma can arise on the ectocervix or elsewhere in the lower female genital tract and at these other sites there is little risk of progression to HSIL.[115,116] In contrast, the metaplastic squamous epithelium of the transformation zone is especially susceptible to progression when infected by high-risk HPV. CK7 is a marker of these metaplastic cells and, while it shows promise of being a marker of increased likelihood of progression from LSIL to HSIL, further validation is required before it enters routine practice.[136]

HSIL (CIN2/3) may be seen macroscopically, when extensive (Fig. 32.18), but is best appreciated colposcopically. On microscopic examination, it is characterized by a high N:C ratio in all layers of the epithelium, not just the basal and parabasal layers, but most importantly by striking nuclear atypia (Fig. 32.19). There is prominent mitotic activity, with atypical mitoses typically present, and mitotic figures are found in the upper layers of the epithelium. There are cases where the differential diagnosis rests between LSIL and HSIL and the recommendation is that in such lesions p16 immunostaining be used as an adjunct; if there is strong and diffuse block positivity, a diagnosis of HSIL (CIN2/3) can be rendered. It is important to note that diagnosis of LSIL or HSIL is made primarily based on H&E, with use of p16 immunostaining only in selected borderline cases.[129]

At a practical level, HSIL can be safely treated by conization, electrodiathermy, cryosurgery, laser, or loop electrosurgical excision, all of them done under colposcopic guidance.[137–141] In making the final decision regarding the timing and type of therapy for this group

For personal use only. No other uses without permission. Copyright ©2017. Elsevier Inc. All rights reserved.

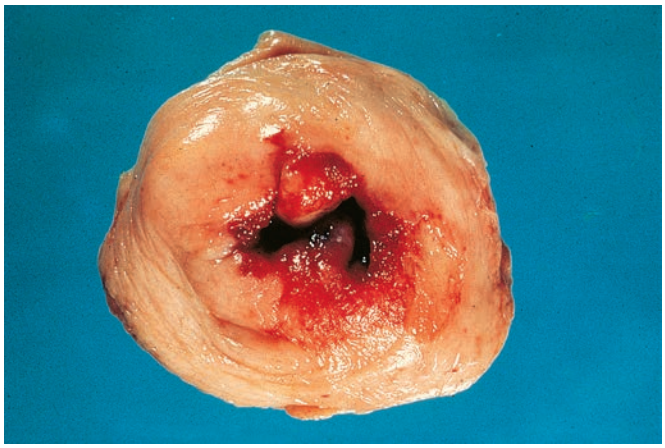

Figure 32.18 Gross appearance of HSIL (CIN2/3) extensively involving the uterine cervix. (Courtesy of Dr Hector Rodriguez-Martinez, Mexico City.)

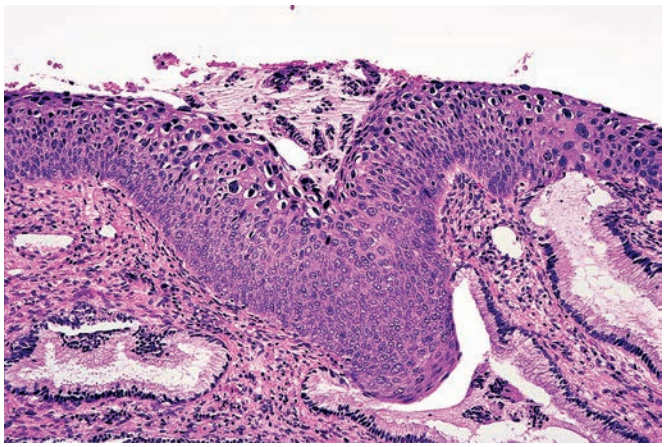

Figure 32.20 Extensive involvement by HSIL (CIN2/3) of surface epithelium and glands of endocervix.

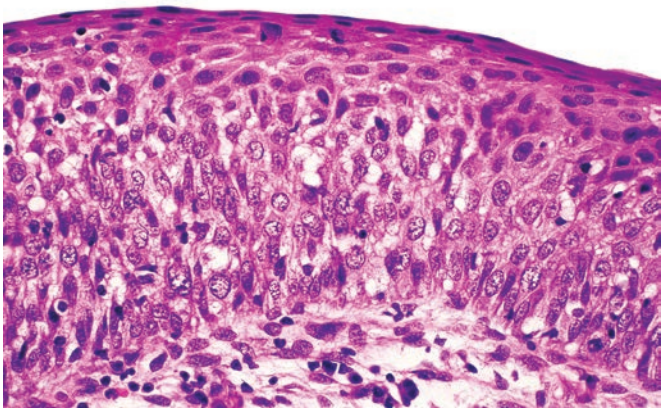

Figure 32.19 HSIL (CIN 2/3). There is proliferation and atypia, with increased N:C ratio and loss of normal maturation.

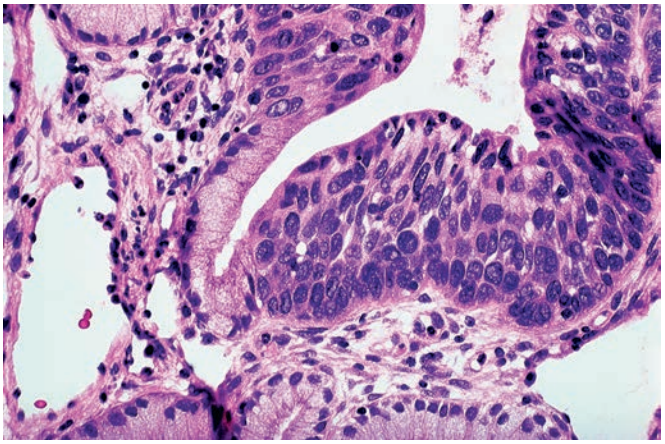

Figure 32.21 Partial replacement of endocervical glandular epithelium by HSIL (CIN2/3).

of lesions, the microscopic diagnosis is only one of the factors to be considered, albeit a very important one. The extension of the lesion, age of the patient, parity, and the desire to have more children all have to be considered. Both the surface and the possible depth of involvement also have to be taken into account, as extension of HSIL (CIN2/3) into endocervical glands is common. (Figs. 32.20 and 32.21) Anderson and Hartley[142] calculated that destruction of tissue to a depth of 2.92 mm would eradicate all involved glands in 95% of the patients, whereas destruction to a depth of 3.8 mm would eradicate 99.7%. Positive margins and glandular involvement by HSIL (CIN2/3) are independent predictors of residual or recurrent disease.[143–145]

Once the pathologist has made the diagnosis of HSIL (CIN2/3) in a cervical biopsy, it is the responsibility of the gynecologist to determine the presence or absence of invasive carcinoma. Thorough cervical sampling and the proper sectioning of tissue should establish whether or not invasive carcinoma exists. If the latter is found, conventional methods of therapy may be instituted. Whenever the therapy is conservative, long-term follow-up (longer than 5 years) is imperative. In one series, patients with continuing abnormal cytology after initial treatment of HSIL (CIN2/3) were found to be 25 times more likely to develop invasive carcinomas than women with normal follow-up cytology.[146]

The differential diagnosis of HSIL (CIN2/3) includes florid squamous metaplasia and transitional metaplasia. It should also be mentioned that the iodine test, used to delineate the extent of cervical disease prior to conization, can induce shrinkage, cytoplasmic eosinophilia and vacuolization, and pyknosis in the epithelial cells (particularly when they are abnormal to begin with).[147]

Superficial Invasive Squamous Cell Carcinoma

Invasive squamous cell carcinomas in which the depth of stromal invasion is minimal (3 mm or less, and <7 mm in breadth, Stage Ia1) have been segregated from the others and designated as "superficial invasive carcinoma" (Fig. 32.22 and Table 32.1).[148–151]

The justification for the recognition of this as a distinct entity is that the natural history of the lesion is quite different from that of ordinary invasive carcinoma and more akin to that of HSIL (CIN2/3).[151–153] Accordingly, the treatment can be generally conservative, although it needs to be individualized.[148,154,155] The common occurrence of pleomorphism, cellular differentiation, presence of conspicuous nucleoli, and individual cell keratinization in the areas of microinvasion has been emphasized (Fig. 32.23).[150] Since these features are rarely seen together in HSIL (CIN2/3), their presence in an apparently intraepidermal cervical lesion should stimulate the

For personal use only. No other uses without permission. Copyright ©2017. Elsevier Inc. All rights reserved.

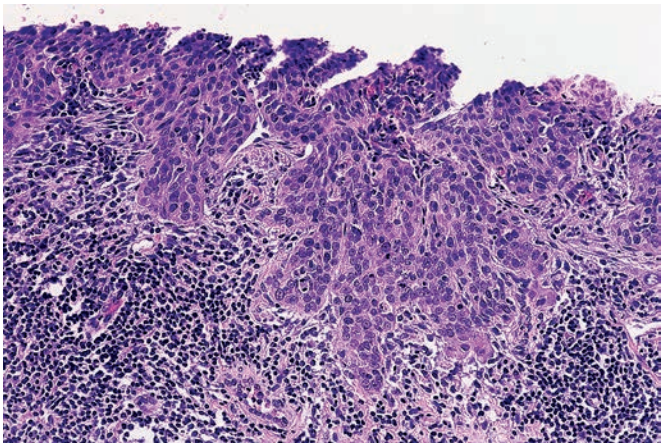

Figure 32.22 Low-power appearance of superficial invasive squamous cell carcinoma of cervix.

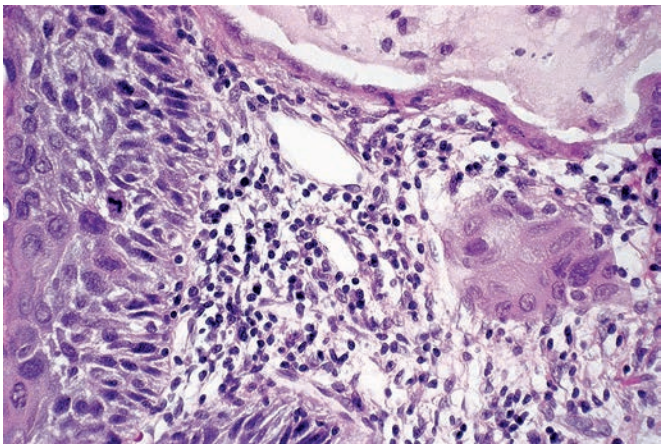

Figure 32.23 Small focus of invasion underlying HSIL (CIN2/3). Note the greater degree of squamous differentiation in the microinvasive component.

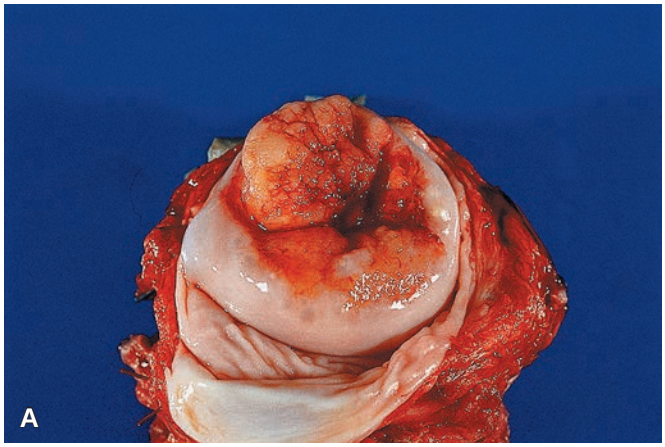

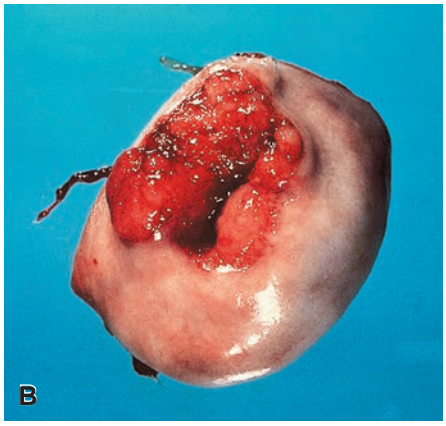

Figure 32.24 **A and B,** Gross appearance of invasive squamous cell carcinoma of cervix.

search for areas of invasion.[156] Another feature that should raise the suspicion of early stromal invasion is the presence of a desmoplastic stroma rich in acid mucosubstances and characterized by metachromatic staining properties.[157] In the area of invasion, there is a breach of the basement membrane. Hasumi et al.[158] found that one (0.9%) of 106 patients with invasion up to 3 mm had lymph node metastases, whereas four (13.19%) of 29 patients with invasion of 3.1–5 mm had nodal metastases. This study served as the original basis for the definition of superficial invasion as 3 mm or less depth of invasion, with conservative surgery (as for HSIL [CIN2/3]) as treatment of choice, in contrast to the radical surgery, with parametrial and lymph node resection, used for more deeply invasive carcinomas.

Invasive Squamous Cell Carcinoma

General Features

Invasive squamous cell carcinoma of the cervix is still the most common malignant tumor of the female genital tract in most countries and the most frequent neoplasm among women in many of them.[159,160] As noted previously, almost all are HPV associated, but rare HPV-independent squamous cell carcinomas do occur,[161] especially verrucous carcinoma. Accordingly, risk factors for the development of cervical squamous cell carcinoma reflect increased likelihood of HPV exposure, such as age at first intercourse, early marriage, multiparity, and low socioeconomic level,[162–164] as well as cigarette smoking.

Host immune response factors contribute to the persistence of HPV infection and progression to HSIL (CIN2/3). Genes in the human leukocyte antigen (HLA) region of chromosome 6 are associated with increased susceptibility to the transforming properties of high-risk HPV. Impaired immune function, such as immunosuppressant therapy in organ transplantation recipients and HIV infection, is associated with a 5- to 10-fold increased risk of cervical neoplasia.[165]

Squamous cell carcinoma can be associated with microscopically similar tumors in the lower and upper genital tracts. In some of these cases, the same clonal pattern has been demonstrated, consistent with a cervical origin of the tumor followed by migration to other areas.[166] Despite this molecular evidence of clonality and therefore metastatic behavior, these metachronous tumors (that usually involve first cervix, and later vulva) behave like independent primary tumors.

Morphologic Features

Grossly, cervical carcinoma may be polypoid or deeply infiltrative (Fig. 32.24). The bulky carcinomas that grow out of the cervix are less likely to invade surrounding structures than are the infiltrating ones. The general truism that exophytic tumors are less aggressive than endophytic tumors thus holds true for cervical squamous cell carcinoma.

Some tumors are either clinically inapparent or simply missed by the examiner and are first discovered on pathologic examination

For personal use only. No other uses without permission. Copyright ©2017. Elsevier Inc. All rights reserved.

Table 32.1 Definitions of AJCC TNM for cervical carcinoma

Primary Tumor (T)		
T CATEGORY	**FIGO STAGE**	**T CRITERIA**
TX		Primary tumor cannot be assessed
T0		No evidence of primary tumor
T1	I	Cervical carcinoma confined to the uterus (extension to corpus should be disregarded)
T1a	IA	Invasive carcinoma diagnosed only by microscopy. Stromal invasion with a maximum depth of 5.0 mm measured from the base of the epithelium and a horizontal spread of 7.0 mm or less. Vascular space involvement, venous or lymphatic, does not affect classification
T1a1	IA1	Measured stromal invasion of 3.0 mm or less in depth and 7.0 mm or less in horizontal spread
T1a2	IA2	Measured stromal invasion of more than 3.0 mm and not more than 5.0 mm, with a horizontal spread of 7.0 mm or less
T1b	IB	Clinically visible lesion confined to the cervix or microscopic lesion greater than T1a/IA2. Includes all macroscopically visible lesions, even those with superficial invasion.
T1b1	IB1	Clinically visible lesion 4.0 cm or less in greatest dimension
T1b2	IB2	Clinically visible lesion more than 4.0 cm in greatest dimension
T2	II	Cervical carcinoma invading beyond the uterus but not to the pelvic wall or to lower third of the vagina
T2a	IIA	Tumor without parametrial invasion
T2a1	IIA1	Clinically visible lesion 4.0 cm or less in greatest dimension
T2a2	IIA2	Clinically visible lesion more than 4.0 cm in greatest dimension
T2b	IIB	Tumor with parametrial invasion
T3	III	Tumor extending to the pelvic sidewall* and/or involving the lower third of the vagina and/or causing hydronephrosis or nonfunctioning kidney
T3a	IIIA	Tumor involving the lower third of the vagina but not extending to the pelvic wall
T3b	IIIB	Tumor extending to the pelvic wall and/or causing hydronephrosis or nonfunctioning kidney
T4	IVA	Tumor invading the mucosa of the bladder or rectum and/or extending beyond the true pelvis (bullous edema is not sufficient to classify a tumor as T4)
Regional Lymph Node (N)		
N CATEGORY	**FIGO STAGE**	**N CRITERIA**
NX		Regional lymph nodes cannot be assessed
N0		No regional lymph node metastasis
N0(i+)		Isolated tumor cells in regional lymph node(s) no greater than 0.2 mm
N1		Regional lymph node metastasis
Distant Metastasis (M)		
M CATEGORY	**FIGO STAGE**	**M CRITERIA**
M0		No distant metastasis
M1	IVB	Distant metastasis (including peritoneal spread or involvement of the supraclavicular, mediastinal, or distant lymph nodes; lung; liver; or bone)

*The pelvic sidewall is defined as the muscle, fascia, neurovascular structures, and skeletal portions of the bony pelvis. On rectal examinations, there is no cancer-free space between the tumor and pelvic sidewall.
From Amin M, Edge S, Greene F, et al. (eds.). AJCC Cancer Staging Manual. 8th ed. New York: Springer; 2017.

of a uterus removed for a benign condition.[167] Still others develop in the cervical stump left from a supracervical hysterectomy.[168]

Microscopically, three cellular variants of cervical squamous cell carcinoma exist, although admixtures and intermediate forms abound: *large cell nonkeratinizing*, *keratinizing* (Fig. 32.25), and *small cell*.[169–171] The latter should be distinguished from small cell neuroendocrine carcinoma, a tumor morphologically similar to small cell carcinoma of the lung and exhibiting features of neuroendocrine differentiation; immunohistochemistry may be necessary for this purpose. Although these patterns can be morphologically distinctive, they are not clinically relevant, in terms of planning treatment or prognosis.[172,173]

Some cervical squamous cell carcinomas have a distinctly papillary pattern of growth; these need to be distinguished from verrucous carcinoma.[174]

Other squamous cell carcinomas are accompanied by acantholysis, which may result in a pseudoglandular pattern.[175] Amyloid deposition

For personal use only. No other uses without permission. Copyright ©2017. Elsevier Inc. All rights reserved.

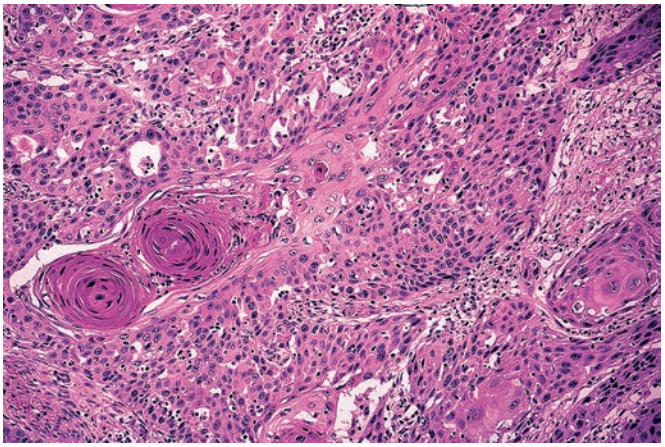

Figure 32.25 Microscopic appearance of invasive squamous cell carcinoma of cervix of large cell keratinizing type.

in the stroma has been documented in some other cases.[176,177] On occasion, cervical squamous cell carcinoma is found to be associated with intense infiltration by mature eosinophils, with or without accompanying peripheral blood eosinophilia; production of eosinotactic and eosinopoietic substances by the tumor cells has been suggested as the pathogenetic mechanism.[178,179]

Mucicarmine stains will demonstrate the presence of scattered droplets of cytoplasmic mucin in a minority of cases having the morphologic features of squamous cell carcinoma in routinely stained sections, a finding analogous to that sometimes encountered in carcinomas of the lung and other sites.[180] Their behavior seems to be the same as that of squamous cell carcinomas lacking mucin secretion.[180]

The exceptional occurrence of sebaceous differentiation in cervical carcinoma has also been documented.[181]

Immunohistochemical and Molecular Genetic Features

Immunohistochemically, squamous cell carcinomas of the cervix express keratins (nearly 100% of the cases), CEA (90%),[182] p63 (a homologue of p53 preferentially expressed in basal and immature cervical squamous epithelium),[183] and p40. The range of keratins found in the tumor varies somewhat depending on the subtype, but it is very wide.[184] There may also be reactivity for β-human chorionic gonadotrophin (β-hCG),[185] and for parathyroid hormone–related gene (although these tumors rarely give rise to hypercalcemia).[186]

In contrast to the situation in many other human malignancies, the *TP53* gene is rarely mutated in cervical squamous cell carcinoma; this is also true for the biologically related *MDM2* gene.[187] Despite the lack of mutation in *TP53*, the function of the gene is inactivated due to the effect of HPV-associated E6 protein, which binds to p53 protein, causing its rapid degradation.[165] The *RB* gene function is similarly inactivated due to binding of HPV-associated E7 protein with RB protein.[165]

Spread and Metastases

Cervical carcinoma spreads characteristically by direct extension to the vagina, corpus (endometrium and myometrial wall), parametrium, lower urinary tract, and uterosacral ligaments (Fig. 32.26).[188,189]

Lymph node metastases are also common. The pattern of involvement generally proceeds in a sequential fashion. The first station is represented by the paracervical, hypogastric, obturator, and external iliac groups and the second by the sacral, common iliac, aortic, and inguinal groups.[190] The incidence of nodal involvement is directly related to the stage of the disease. Hematogenous metastases were rare in older series, but with better control of the local lesion, they have increased in frequency.[189] Lung (9%) and bone (4%) are the most common sites.[191–193] Ovarian metastases are less common than with endometrial adenocarcinoma, but they do occur.[194]

The differential diagnosis between primary pulmonary squamous cell carcinoma and a pulmonary metastasis from a cervical carcinoma, which can be very difficult on morphologic grounds, is greatly aided by the detection of HPV in the latter by in situ hybridization, PCR, or immunostaining for p16.[195,196]

Treatment

Invasive carcinomas of the cervix that are more advanced than stage Ia1 can be treated with curative intent by surgery or irradiation with or without chemosensitization.[197–200] The choice depends on the extent of the tumor, the general condition of the patient, and the expertise available at the institution where the patient is treated. Early lesions can be treated just as effectively with hysterectomy or intracavitary radiation with platinum chemotherapy to radiosensitize the tumor cells[198,201,202]; for stage IIa lesions, irradiation alone and a combination of irradiation and surgery have yielded equivalent results in randomized studies.[203] As a rule, however, one is looking to use either surgery OR radiation therapy as the primary treatment modality, and not both, which results in the patient experiencing the morbidity and mortality of both procedures. Surgery is generally preferred for early carcinomas as the patients are typically young and surgery does not have the complication of late (>10 years) development of secondary malignancies in the radiated field. In some centers sentinel lymph node(s) are sent for frozen section at the start of the procedure, and if positive, radical hysterectomy is not performed since radiation therapy is indicated based on the positive node. If the sentinel node(s) frozen section is negative, surgery proceeds as planned, with the understanding that frozen section is not completely sensitive and that on permanent sections occasional micrometastases will be detected that were not present on frozen section examination.[204]

Early lesions can be treated conservatively with radical vaginal trachelectomy, a fertility-preserving procedure where the cervix is excised at the level of the upper endocervix or lower uterine segment along with a vaginal cuff and parametria, and pelvic lymph nodes.

In cases of central pelvic relapse of cervical carcinoma, pelvic exenteration should be seriously considered because a considerable number of the patients will have tumor confined to the pelvis.[205] This operation removes all pelvic viscera and lateral pelvic lymph node–bearing tissue. The bladder (anterior exenteration), rectum (posterior exenteration), or both may be removed, depending on the location of the tumor. At laparotomy, the surgeon should examine the upper abdomen carefully, particularly the periaortic area, for evidence of spread outside the pelvis. Any suspicious lymph nodes or liver nodules should be submitted to the pathologist for frozen section before the operative procedure is begun. Gross appraisal of enlarged extrapelvic nodes is unreliable, whereas frozen section examination is a highly accurate procedure.[206] The study of the surgical specimen should include a careful examination of the lymph nodes, the lateral edges of the resection, and the local extent of the tumor. Microscopically, the nodes, vessels, and adjacent organs should be examined for evidence of tumor. The finding of greatest prognostic relevance in the pathologic evaluation of pelvic exenteration specimens is the presence or absence of lymph node metastases.[207]

The microscopic examination of postradiochemotherapy specimens can be difficult due to the extent of regressive changes manifested in the tumor cells by cytoplasmic eosinophilia, vacuolization, and foamy degeneration. Prognostically, the most important feature to look for in these specimens is tumor embolism.[208]

For personal use only. No other uses without permission. Copyright ©2017. Elsevier Inc. All rights reserved.

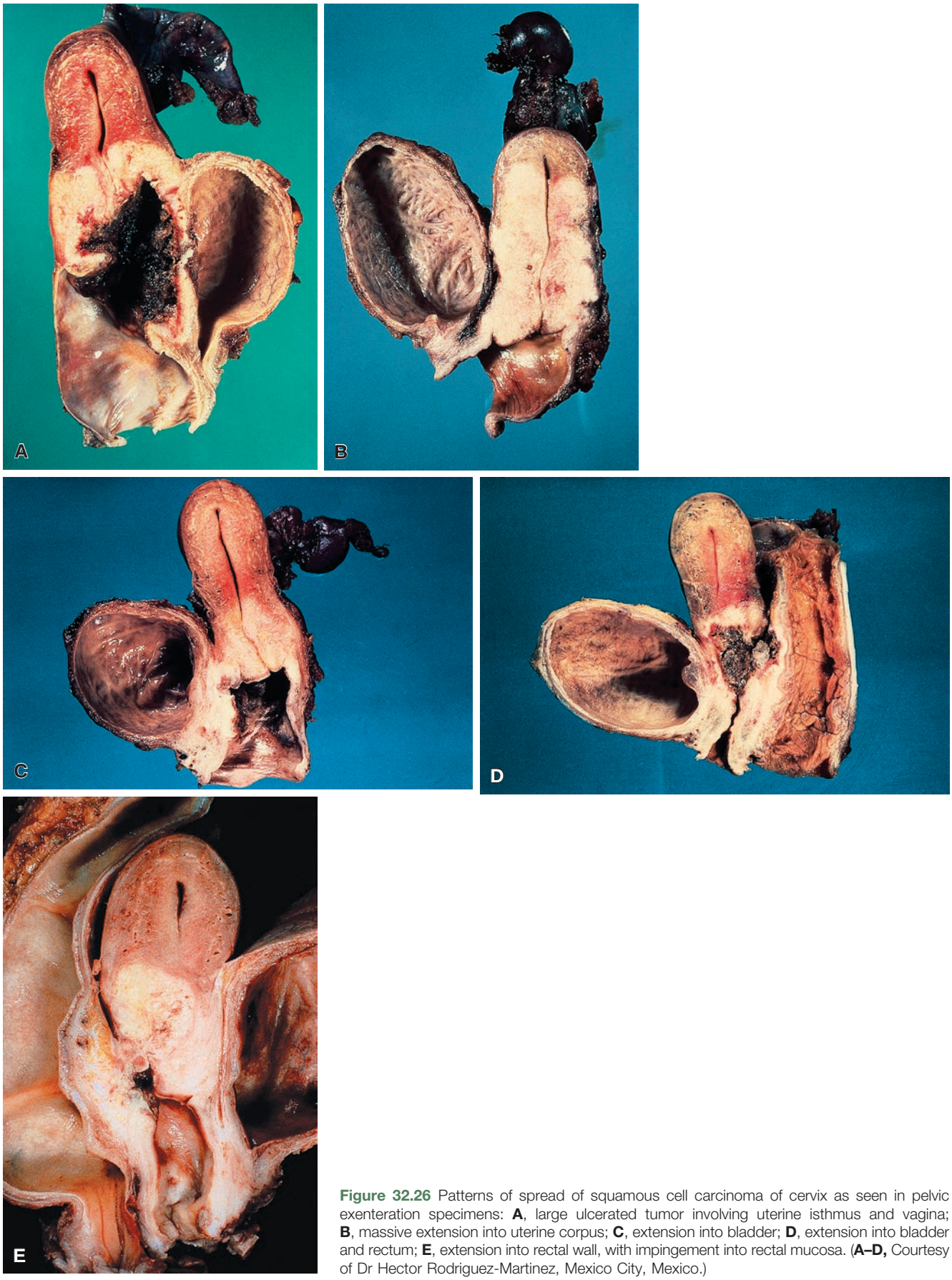

Figure 32.26 Patterns of spread of squamous cell carcinoma of cervix as seen in pelvic exenteration specimens: **A**, large ulcerated tumor involving uterine isthmus and vagina; **B**, massive extension into uterine corpus; **C**, extension into bladder; **D**, extension into bladder and rectum; **E**, extension into rectal wall, with impingement into rectal mucosa. (**A–D,** Courtesy of Dr Hector Rodriguez-Martinez, Mexico City, Mexico.)

For personal use only. No other uses without permission. Copyright ©2017. Elsevier Inc. All rights reserved.

Prognosis

The prognosis of cervical carcinoma is related to the following parameters:

1. *Clinical stage*. As for most other human malignancies, stage is the most important prognostic determinator.[209] It should be noted that clinical staging (FIGO) is used for cervical cancer, unlike for other organs. TNM staging is possible, but only for patients treated surgically; many patients are treated primarily by radiotherapy, and surgical pathology staging is not possible in these cases.
2. *Nodal status*. This is another crucial predictor, which is incorporated into the staging scheme.[210,211]
3. *Size* of the largest involved node[212] and *number* of positive nodes.[213]
4. *Size of the primary tumor*, as determined by measurement of the tumor's greatest diameter[214,215] or by volumetric techniques.[216]
5. *Depth of invasion*.[217–219]
6. *Endometrial extension*. The presence of this feature decreases the survival rate by 10%–20%.[220]
7. *Parametrial involvement*, as detected microscopically.[221]
8. *Blood vessel invasion*.[222–225]

Microscopic grade is not of prognostic significance, whether one uses the Reagan–Ng or the Broders method of grading.[225,226] This is in contrast to most other carcinomas. Our persistence in assigning a grade in pathology reports for cervical squamous cell carcinoma is a curiosity and will presumably stop in the near future, given that it is a useless practice. A similar comment applies to cell type (e.g., large cell nonkeratinizing) of squamous cell carcinoma; as noted previously, it is also not of prognostic significance.[172,173]

Other Microscopic Types

Verrucous carcinoma is a highly differentiated variant of squamous cell carcinoma with a polypoid pattern of growth, an extremely well-differentiated cytologic appearance, and a capacity for local invasion but not for metastatic spread. Some cases have been found to extend into the endometrial cavity.[227] Verrucous carcinoma should be distinguished both from condyloma acuminatum and from ordinary squamous cell carcinoma with a prominent papillary pattern of growth.[228,229] The general gross and microscopic features of this tumor are described in Chapter 30.

Spindle cell carcinoma (sarcomatoid carcinoma; squamous cell carcinoma with sarcoma-like stroma; carcinosarcoma) is morphologically analogous to the homonymous tumor in the upper aerodigestive tract.[230] It may contain osteoclast-like giant cells,[231] and there is often evidence of HPV infection.[232] The recognizable epithelial component of this tumor, when present, is of squamous type; this is in contrast with the malignant mixed müllerian tumor, in which that component is usually glandular. It is advisable to keep these tumors (both of which can occur in the cervix) in separate categories, although both of them probably represent carcinomas with a sarcoma-like component.

Basaloid (squamous cell) carcinoma is characterized by prominent peripheral palisading, an infiltrative growth pattern, and minimal stromal reaction (Fig. 32.27).[233] The behavior of this tumor is aggressive, as is also the case with the homonymous neoplasm in the upper aerodigestive tract. It is, therefore, very important to clearly separate this tumor from adenoid cystic carcinomas and adenoid basal carcinomas.[234]

Lymphoepithelioma-like carcinoma resembles its more common counterpart in the upper respiratory tract by virtue of the large size of the tumor cells, vesicular nuclei with prominent nucleoli, syncytial appearance, and heavy lymphocytic infiltration.[235–237] Some cases have been found to secrete β-hCG, as is also occasionally the case with conventional squamous cell carcinoma.[238] The possible association of this tumor with either EBV or HPV remains controversial.[239–241] This tumor type shows considerable overlap with the *circumscribed* type of cervical carcinoma that has been described.[242]

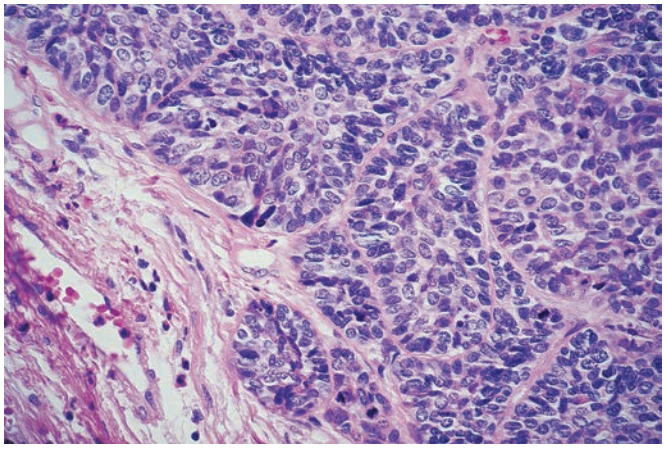

Figure 32.27 Basaloid Squamous Cell Carcinoma of Uterine Cervix. The tumor grows in the form of well-defined nests showing peripheral palisading.

Adenocarcinoma

Background

Adenocarcinomas account for approximately 20% of all cervical cancers.[243,244] They appear to be relatively more common in those areas where cervical screening programs have reduced the incidence of invasive squamous cell carcinoma, as cervical screening is relatively less successful in detecting precursor lesions of adenocarcinoma.[245] Cervical adenocarcinomas have traditionally been subclassified based on tumor cell type, but this is slowly giving way to a classification mirroring that of vulvar squamous cell carcinoma (i.e., HPV associated versus HPV independent. The basis for this shift is the recognition that the morphologic features and prognosis are significantly different for tumors in these two major categories.[246–259] This is a recent development, and there remains much to be learned about the HPV-independent cervical adenocarcinomas in particular, but in recognition of this emergent trend the HPV-dependent and HPV-independent variants will be considered separately, later. As for other lower genital tract carcinomas, p16 immunostaining can serve as a surrogate test for HPV status, with "block positivity" indicating an HPV-associated tumor.[250–252] p16 immunostaining is not perfect, as p16 expression can be seen in any tumor with loss of p53 function and dysregulation of RB signaling, and has been described as an uncommon finding in HPV-independent cervical adenocarcinoma.[253] Conversely, p16 expression can be lost through mutation during progression of an HPV-associated tumor; therefore, when staining a large carcinoma one should preferentially select a block with adenocarcinoma in situ, which is almost invariably positive for p16 in HPV-associated cervical adenocarcinoma. In practice, if the morphologic features and p16 staining result are concordant, a tumor can be confidently classified as HPV associated or HPV independent. If there are discordant features, molecular testing for HPV nucleic acid can be used to determine HPV status, just as in vulvar squamous cell carcinomas.[247]

For personal use only. No other uses without permission. Copyright ©2017. Elsevier Inc. All rights reserved.

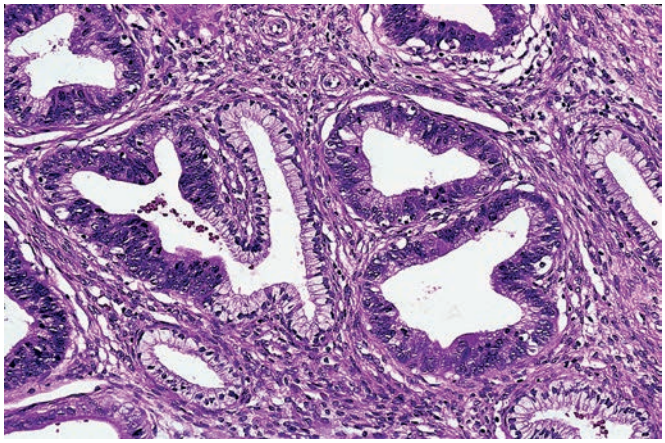

Figure 32.28 Adenocarcinoma in situ with partial preservation of endocervical glands.

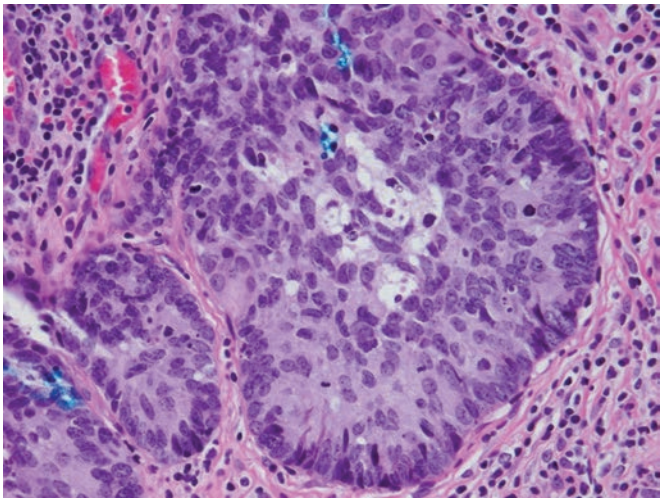

Figure 32.29 SMILE, a morphologically subtle variant of adenocarcinoma in situ/adenosquamous carcinoma in situ. (Courtesy of Dr Lien Hoang, Vancouver, Canada.)

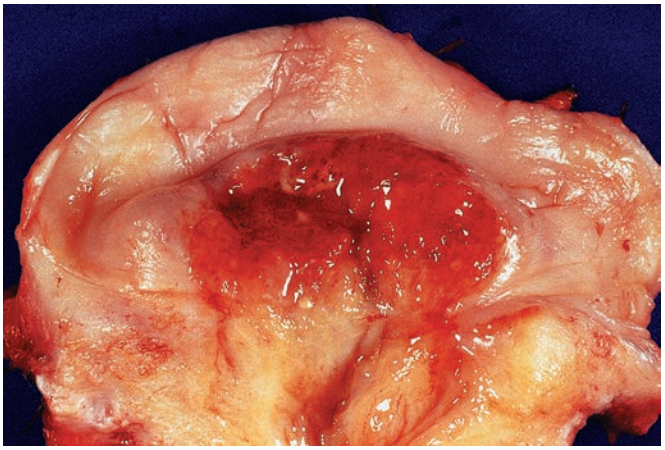

Figure 32.30 Gross appearance of endocervical adenocarcinoma.

In situ Adenocarcinoma

The documentation of the existence of an in situ stage of cervical adenocarcinoma lagged behind that of squamous cell carcinoma but is well established, at least for the HPV-associated cervical adenocarcinomas.[254,255] Cytologic atypia (manifested by nuclear hyperchromasia and pleomorphism) and increased mitotic figures are the two most important identifying features (Fig. 32.28). The presence of numerous apoptotic bodies is another diagnostic clue.[256] This combination of increased mitotic activity and numerous apoptotic bodies is characteristic of lesions induced by oncogenic HPV. The changes can be very subtle and limited to the endocervical surface.[257]

The mucins secreted by the in situ malignant glands may be similar to those of the normal endocervical mucosa or may resemble the pattern of intestinal goblet cells.[258] The latter, which is referred to as intestinal-type cervical adenocarcinoma in situ, shows consistent expression of CDX2.[259] Most in situ cervical adenocarcinomas are positive for CEA.[260] The cell proliferative index (as measured by Ki-67 immunostaining) is increased, there is an abnormal expression of cell cycle–related molecules, and the expression of hormone receptors is either decreased or absent.[261] Strong nuclear cytoplasmic positivity for p16, as a result of the association with HPV, is characteristic.[262] Glandular dysplasia short of that seen in carcinoma in situ has been described[263–268] but has not emerged as a well-defined diagnostic entity and is not a recommended category for routine diagnostic practice.

An important differential diagnosis of in situ cervical adenocarcinoma is with tubal or tubal–endometrial metaplasia.[269] The cells of tubal or tuboendometrial metaplasia can have increased N:C ratio but lack the stratification, nuclear atypia, numerous apoptotic bodies, or increased mitotic activity of adenocarcinoma in situ. Patchy p16 positivity may be seen in tubal or tuboendometrial metaplasia, but they lack the strong diffuse "block" positivity of adenocarcinoma in situ.

Almost half of the invasive HPV-associated cervical adenocarcinomas and approximately 75% of their in situ counterparts have an associated HSIL (CIN2/3) of the overlying epithelium.[270–272]

Stratified mucin-producing intraepithelial lesions (SMILEs) are uncommon intraepithelial lesions that may be seen in association with adenocarcinoma or adenosquamous carcinoma of the cervix.[273,274] More typical HSIL (CIN2/3) or adenocarcinoma in situ may also coexist. SMILE consists of stratified epithelial cells with nuclear atypia and a high proliferation index/strong diffuse p16 positivity that differs from HSIL in there being abundant intracellular mucin (Fig. 32.29). It is considered to be an uncommon variant of adenocarcinoma in situ or adenosquamous carcinoma in situ.[273]

Conization or LEEP is the treatment of choice for in situ adenocarcinoma of the cervix.[275] The circumferential extent of tumor is a marker of residual/recurrent disease, and it is therefore important to include this information in the pathology report.[276,277]

Human Papilloma Virus–Associated Cervical Adenocarcinoma

General Features

The HPV-associated tumors account for a large majority of cervical adenocarcinomas. These tumors present no distinguishing gross characteristics compared to their squamous cell counterparts (Fig. 32.30). Microscopically, the most common pattern is that of a well-differentiated glandular pattern with mucin secretion, some of which can leak into the stroma (Fig. 32.31).[278–282] However, the degree of differentiation varies, and poorly differentiated forms exist. Most HPV-associated cervical adenocarcinomas are of "usual type," as per the 2014 WHO classification of cervical adenocarcinomas, but other cell types can be seen and are described later. These morphologic variants may coexist in a given case, and there is considerable

For personal use only. No other uses without permission. Copyright ©2017. Elsevier Inc. All rights reserved.

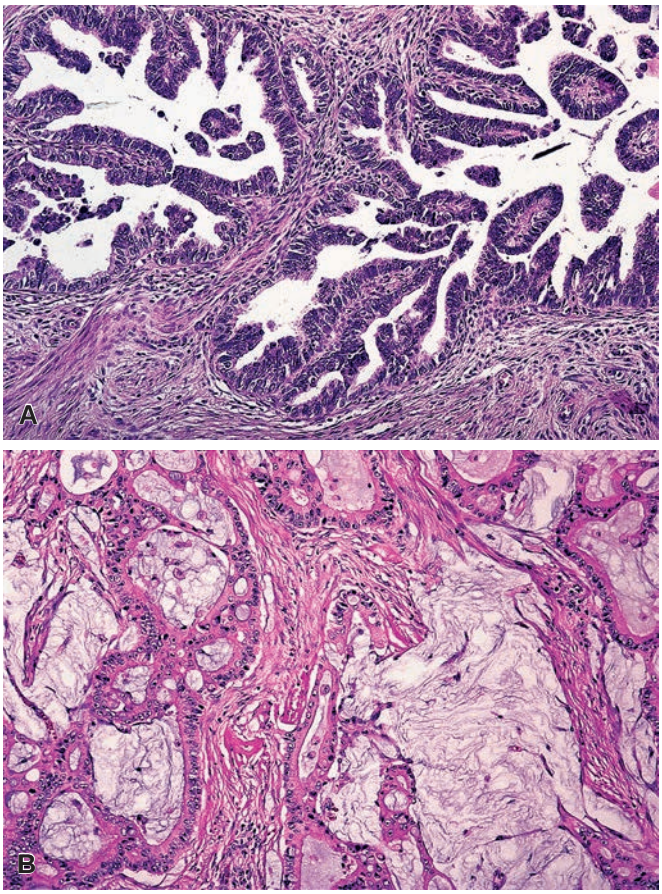

Figure 32.31 Microscopic appearance of HPV-associated adenocarcinoma of usual type. Note the variable amounts of mucin in **A** compared with **B**.

inter-observer variation in their application. Moreover, they are of doubtful significance as meaningful subcategories of HPV-associated cervical adenocarcinoma as they do not impact on patient management.

Histochemically, alcian blue– and mucicarmine-positive material is found intracellularly in nearly all cases of conventional cervical adenocarcinoma.[283] Among the mucins, there is positivity for MUC1 in nearly 100%, MUC2 in 40%, MUC4 in 75%, and MUC5AC "in most."[284] Keratins, EMA, and CEA are consistently expressed, whereas vimentin is not.[285–288] Estrogen and progesterone receptors are expressed in only one-fourth of the cases.[289] About one-fourth of endocervical adenocarcinomas are positive for CDX2, CK20, or both; this profile usually (but not always) correlates with intestinal differentiation.[290,291] It should be noted that intestinal differentiation, with goblet cells, can be encountered in HPV-associated tumors but is also commonly seen in HPV-independent tumors. Cervical adenocarcinomas have also been shown to contain argyrophilic (presumably neuroendocrine) cells,[292] a variety of peptide hormones,[293] and mammaglobin (although not as commonly as endometrial adenocarcinoma).[294]

A pattern-based classification of cervical adenocarcinoma that can be applied irrespective of histotype/HPV status has been proposed by Roma et al.[295] Invasive adenocarcinomas are subclassified as category A, B, or C. Category A is characterized by well-demarcated glands with rounded contours, with no destructive invasion (i.e., no single cell infiltration or lymphovascular invasion); this category includes tumors that would be considered to be entirely in situ by some observers. Category B shows limited destructive invasion, while category C shows diffuse destructive invasion. The most interesting finding is that none of the patients with A pattern invasion in their tumors had nodal metastasis.[295] In a follow-up study, it was demonstrated that the interobserver agreement in assignment of invasive category was superior to that of diagnosis of invasive versus noninvasive by typical criteria.[296] The main drawback to application of the classification is that, while the reproducibility is good ($\kappa = 0.65$), there are significant numbers of cases where pathologists cannot agree on the category,[296] making it difficult to make treatment decisions (i.e., whether to do radical surgery with lymph node dissection) based on this feature. An important practical point that has come out of this classification is confirmation that in those too frequent cases where the differential diagnosis rests between in situ adenocarcinoma and the subtle category A pattern of invasion, the distinction is not clinically important because both groups have an excellent prognosis with minimal chance of nodal metastasis. One final observation is that it in our experience category C pattern of invasion appears to be more commonly encountered in HPV-independent gastric-type adenocarcinomas; it will be interesting to see if this is a significant association and, if so, whether the pattern of invasion or HPV status is the more important prognostic indicator.

Cervical adenocarcinoma spreads directly to endometrium and vagina and metastasizes to the regional nodes, with a distribution pattern similar to that of cervical squamous cell carcinoma (see earlier). It can also metastasize to the ovaries, especially when extending to the lower uterine segment.[297,298] Those reported cases of combined endocervical adenocarcinoma and ovarian mucinous adenocarcinoma (and occasionally even tubal adenocarcinoma)[299,300] that were formerly considered to be independent primary tumors represent metastases of the cervical tumor to these organs.[297,298] p16 immunostaining or HPV testing of the ovarian tumor is useful in confirming the metastatic nature of these lesions.

The preferred therapies for cervical adenocarcinoma are surgery (especially for early lesions), chemo/radiation, or a combination of radiation and surgery.[301–303] The incidence of residual tumor in the hysterectomy specimens after intracavitary treatment is much higher than for squamous cell carcinoma.[304] The prognosis depends on the clinical stage, amount of tumor (as determined by tumor volume), microscopic grade, and nodal status.[305–310] In most series, the overall prognosis has been less favorable than for the squamous cell counterpart, but the more aggresive HPV-independent cervical adenocarcinomas have not been excluded from these analyses and it's possible that they acccount for the subtle differences seen between adenocarcinomas and squamous cell carcinomas.[307,311,312] There is not much difference among the various histologic subtypes of HPV-associated cervical adenocarcinoma.[313] The presence of nodal metastases is an ominous prognostic sign.[314]

Morphologic Variants of Human Papilloma Virus–Associated Cervical Adenocarcinoma

Most endocervical adenocarcinomas diagnosed as **endometrioid adenocarcinoma** of cervix in the past are better diagnosed as usual type (HPV-associated) adenocarcinoma as they show the high mitotic rate, numerous apoptotic bodies, and strong diffuse p16 positivity, as well as frequent admixture with more conventional appearing HPV-associated cervical adenocarcinoma. The differential diagnosis includes endometrioid adenocarcinoma of the endometrium, which can be accompanied by a very deceptive pattern of cervical spread,[315] which is discussed further later.

Serous (papillary) carcinoma is analogous in appearance to the homonymous uterine and ovarian neoplasm, including the common occurrence of psammoma bodies.[316,317] It may be seen in association with usual type endocervical adenocarcinoma.

For personal use only. No other uses without permission. Copyright ©2017. Elsevier Inc. All rights reserved.

Villoglandular (papillary) adenocarcinoma presents as an exophytic polypoid lesion with papillae lined by endocervical, endometrial, or intestinal-type epithelium showing only mild atypia (Fig. 32.31). The appearance of the superficial portion is similar to that of colorectal villous adenoma.[318] At the base they show Silva pattern A,[295] with smooth contoured glands, without infiltrative features, and these may be in situ lesions. Most cases are associated with adenocarcinoma in situ and/or HSIL (CIN2/3).[319,320] The prognosis is excellent[321] but only if strict architectural and cytologic criteria (exophytic growth, smooth border with underlying stroma, bland appearance of the nuclei) are applied.[322] This diagnosis should NOT be made based on a small biopsy as there may be conventional invasive cervical adenocarcinoma underlying and a diagnosis of "well-differentiated villoglandular adenocarcinoma" will suggest a very favorable prognosis that does not reflect the underlying infiltrative component.

Adenosquamous (mixed) carcinoma combines adenocarcinoma with a well-defined squamous component.[323] Adenosquamous carcinoma should be distinguished from squamous cell carcinoma without glandular formations but with histochemically demonstrable intracellular mucin.[324] When compared grade by grade and stage by stage with adenocarcinomas and squamous cell carcinomas, no prognostic differences are found.[325,326]

Glassy cell carcinoma has been described as a distinct type of poorly differentiated adenosquamous carcinoma.[327] It occurs in a younger age group (mean age, 41 years) than other cervical neoplasms and often has been associated with pregnancy. The tumor cells have a moderate amount of cytoplasm with a ground-glass or finely granular appearance, a prominent eosinophilic and PAS-positive cell membrane, and large nuclei with prominent nucleoli. Mitoses are numerous. A prominent inflammatory infiltrate, often rich in eosinophils, is regularly seen in the adjacent stroma, and this may be accompanied by peripheral blood eosinophilia.

In pure cases of glassy cell carcinoma, glandular or squamous differentiation is absent, although it can be consistently detected by ultrastructural examination.[328] Other cases show an admixture with mucin-producing adenocarcinoma and/or clear-cut squamous foci, raising the question whether it is justified to regard glassy cell carcinoma as a distinct entity.[329,330] It is likely that there is significant interobserver variation in use of this diagnosis. The prognosis is poor.[331,332]

Adenoid cystic carcinoma is a specific variant of cervical adenocarcinoma that tends to occur in elderly multigravid women of African descent[333] and is associated with a particularly poor prognosis.[334,335] The morphologic appearance is similar to that of the homonymous tumors of salivary glands. Like the former, it may be cribriform (the most common pattern) or grow in a predominantly solid fashion.[336] Adenoid cystic differentiation may be present admixed with other patterns of HPV-associated cervical adenocarcinoma.[337]

Adenoid basal carcinoma (tumor; epithelioma) should be distinguished both from adenoid cystic carcinoma and from basaloid (squamous cell) carcinoma. Although it shares many phenotypic features with adenoid cystic carcinoma,[338] it is a very low-grade lesion, in contrast with the two neoplasms with which it can be confused. It is usually discovered incidentally, it does not produce a mass lesion, and—when pure—it does not result in metastases.[339,340] The consistent presence of oncogenic HPV has been documented.[341] The lesion blends with the process that has been called *adenoid basal hyperplasia*. Brainard and Hart[339] have proposed grouping these two conditions under the term *adenoid basal epithelioma* to emphasize their indolent nature. Adenoid basal carcinoma can be associated with frankly invasive carcinoma, which can show a range of morphologic features (e.g., squamous cell, adenoid cystic, or small cell neuroendocrine carcinoma); the behavior in these cases reflects the aggressive component.[342]

Other variants of endocervical adenocarcinoma, all of them exceedingly rare, are a microcystic type,[343] a signet ring type,[344,345] a small intestinal (enteric) type,[346,347] and a type with choriocarcinomatous and hepatoid differentiation.[348] The HPV status of these rare cervical adenocarcinoma variants remains to be elucidated.

HPV-Independent Cervical Adenocarcinomas

General Features

Only approximately 10% of cervical adenocarcinomas (and thus 2% of cervical carcinomas overall) are HPV independent,[349,350] and this is not a homogeneous group of neoplasms, as noted in the discussion of the different variants below. What they do seem to have in common is that they are not as likely to be identified on cytology smears, are more likely to present at advanced stage, and are associated with a worse prognosis compared to HPV-associated carcinomas.[247–250,253] The difficulties in cytologic detection probably reflects both the bland cytologic features of many of these tumors, as well as their location being more often in the upper endocervical canal, while usual type HPV-associated adenocarcinomas are characteristically at the squamocolumnar junction (like their HPV-associated squamous counterparts). At this time our understanding of these rare tumors is incomplete, but with accurate histopathologic diagnosis we will rapidly learn more about them, and it can be hoped that this will lead to improved management/patient outcomes. Indeed, unless pathologists accurately recognize these tumors, there is unlikely to be progress as clinical research starts with diagnosis.

Morphologic Variants of Human Papilloma Virus–Independent Cervical Adenocarcinoma

Gastric-type adenocarcinoma is a subcategory under "Mucinous carcinoma" in the 2014 WHO classification, along with intestinal type and signet ring type. This is an unfortunate grouping, as it combines tumors of radically different pathogenesis (i.e., HPV-independent and HPV associated). Gastric-type adenocarcinoma of the endocervix remains an ill-defined concept, but it is starting to be more widely recognized and routinely diagnosed.[247–250,253] It is characterized by well-formed glands lined by cells with voluminous clear or eosinophilic cytoplasm and distinct cell borders (Fig. 32.32).[247,248] They lack the high mitotic rate and numerous

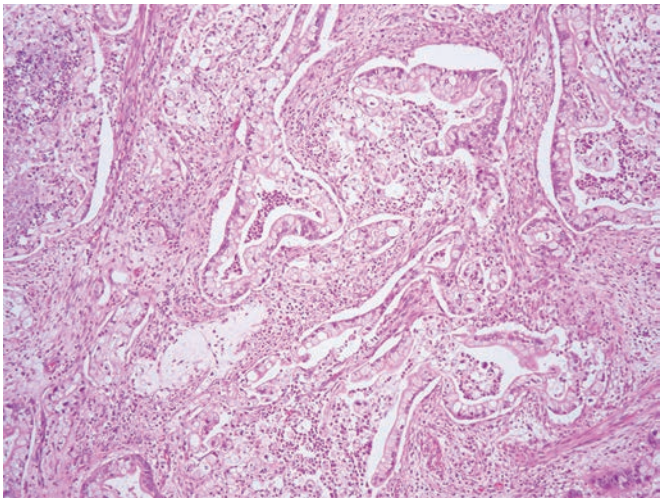

Figure 32.32 Gastric-type adenocarcinoma of cervix.

For personal use only. No other uses without permission. Copyright ©2017. Elsevier Inc. All rights reserved.

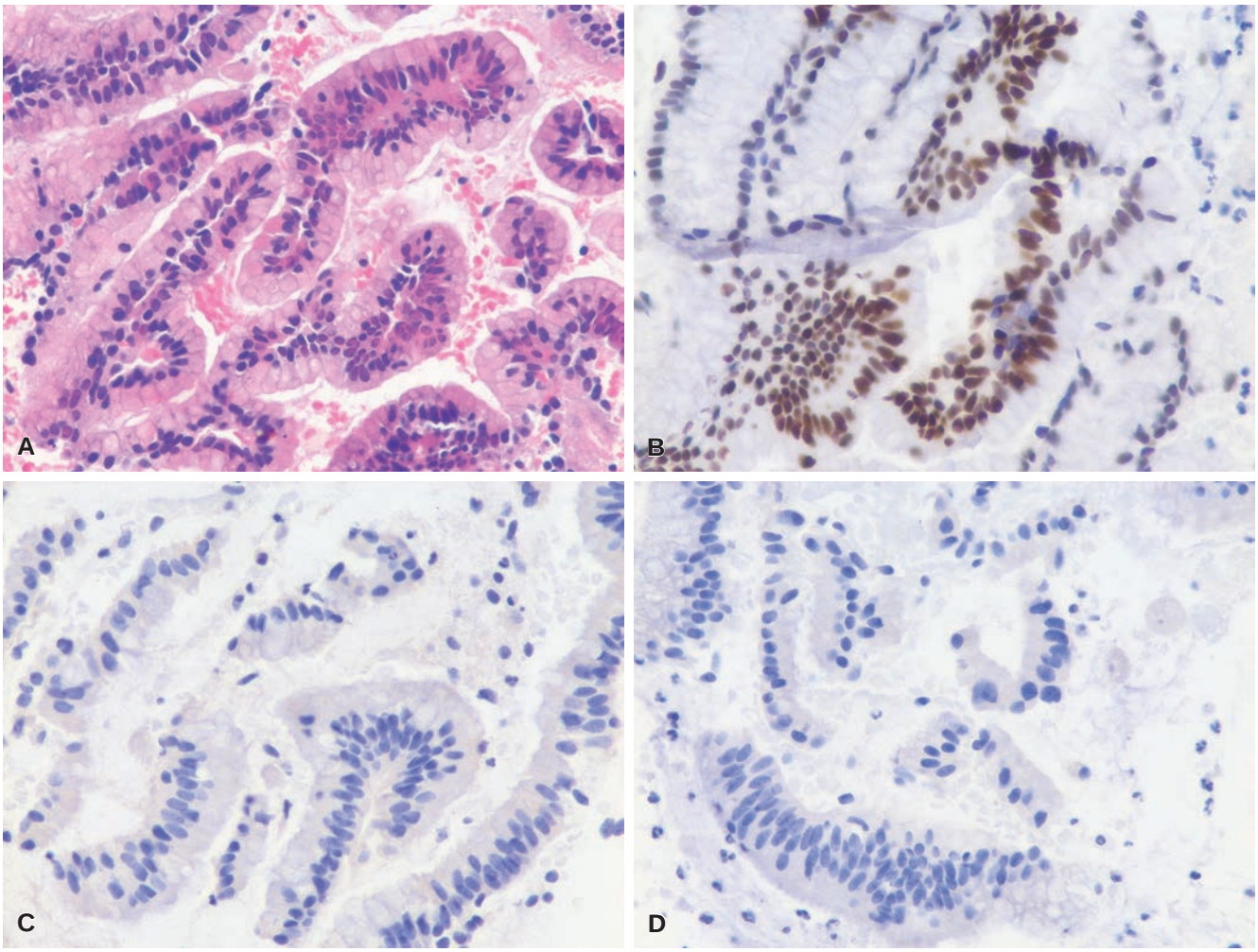

Figure 32.33 **A,** Endocervical curettings of a low-grade gastric-type adenocarcinoma of cervix. The cells show focal positivity for CDX2 **(B)** and are negative for ER **(C)** and p16 **(D)** expression.

apoptotic bodies of HPV-associated cervical adenocarcinoma. p16 immunostaining is helpful in distinguishing between gastric-type cervical adenocarcinoma and usual type HPV-associated adenocarcinoma, as the former typically shows no or only focal staining. There can be increased p16 immunostaining in a gastric-type adenocarcinoma that undergoes tumor progression to a higher-grade tumor (e.g., with *TP53* mutation), but this is uncommon.[253] CEA positivity can be used in the differential diagnosis with benign lesions such as microglandular hyperplasia that are CEA negative. The cells of gastric-type adenocarcinoma are usually completely negative for ER expression, an important consideration in distinguishing them from normal endocervical glandular epithelium or endometrioid carcinoma of endometrium; CDX2 expression is seen in approximately half of gastric-type adenocarcinomas (Fig. 32.33).[253] There can be considerable intratumoral variability in morphology, and although cells with abundant intracytoplasmic mucin are characteristic, there can be tumor progression and areas with less differentiated features and higher-grade nuclei. Goblet cells can be seen in approximately 25% of cases. At the advancing edge of the tumor, single cell invasion and/or signet ring cells may be identified. Most gastric-type adenocarcinomas are stage II–IV at presentation, in contrast to HPV-associated cervical adenocarcinoma where most are stage I.[249,254]

Adenoma malignum (minimal deviation adenocarcinoma) is a designation applied to particularly well-differentiated gastric-type cervical adenocarcinomas. It can be so well differentiated architecturally and cytologically that it can be diagnosed only as malignant because of the presence of distorted glands with irregular outlines deeply positioned in the cervix, and the fact that a portion of the infiltrating tumor is associated with a stromal response (Fig. 32.34).[351–354] Indeed, it is this very well-differentiated appearance that sets adenoma malignum apart from gastric-type adenocarcinoma, but it should be acknowledged that this distinction is artificial and adenoma malignum is best thought of as being within the category of gastric-type adenocarcinoma. It is not uncommon for a patient with adenoma malignum to have multiple superficial biopsies before a diagnosis of malignancy is made, because of the very bland cytologic features. About half of the cases have small foci with a less well-differentiated appearance; by definition this should comprise less than 10% of the tumor. Vascular and perineural invasion may be present. The fact that these tumors, like the more obvious adenocarcinomas, are CEA positive is of importance in the differential diagnosis with benign lesions such as microglandular hyperplasia.[355,356] HIK1083 has been introduced as a putative new marker for adenoma malignum, but this has not entered wide usage.[357] The differential diagnosis also includes endocervical-type *cervical adenomyoma*[358] and

For personal use only. No other uses without permission. Copyright ©2017. Elsevier Inc. All rights reserved.

the condition known as *florid deep glands*,[359] in which atypia, architectural disarray, and desmoplastic stromal reaction are lacking. Curiously, **LEGH** is seen in association with 20% of adenoma malignum but less than 5% of non-adenoma malignum gastric-type adenocarcinoma.[247] Even though well differentiated, adenoma malignum is associated with advanced stage at presentation and poor prognosis, similar to that of less differentiated gastric-type adenocarcinomas.[247] Approximately one-third of gastric-like adenocarcinomas may be designated as adenoma malignum.[247] Some cases are associated with Peutz–Jeghers syndrome,[351,360] and mutations of the *STK11* gene (a tumor suppressor gene responsible for this syndrome and located at 19p13.3) have been found in over half of the cases of adenoma malignum.[361]

Clear cell carcinoma (formerly called *mesonephric carcinoma*) of the cervix is of müllerian rather than of mesonephric origin.[362] Glands lined by large cells with abundant clear cytoplasm are characteristic (Fig. 32.35). "Hobnail" cells are common, as are intraglandular papillary projections. Grossly, the tumor is usually exophytic. This tumor type is rare now, but there was a cluster of cases in young women associated with DES exposure in utero. At this time, most cases are encountered in older women.[363]

Mesonephric (adeno)carcinoma is a very rare tumor. Most of the cases that have been reported as such in the past probably represent müllerian-type adenocarcinomas or yolk sac tumors. True mesonephric carcinomas are often found adjacent to mesonephric hyperplasia (sometimes florid and atypical) and may exhibit a variety of patterns, such as ductal (resembling endometrioid adenocarcinoma), small tubular, retiform, solid, sex cord–like, and spindle (Fig. 32.36).[364–366] The immunohistochemical profile is similar to that of mesonephric rests and includes positivity for CD10, GATA3, and calretinin.[357] Tumors in which the epithelial component is admixed with either a homologous or a heterologous sarcoma-like component have been referred to as **malignant mixed mesonephric tumors**.[367]

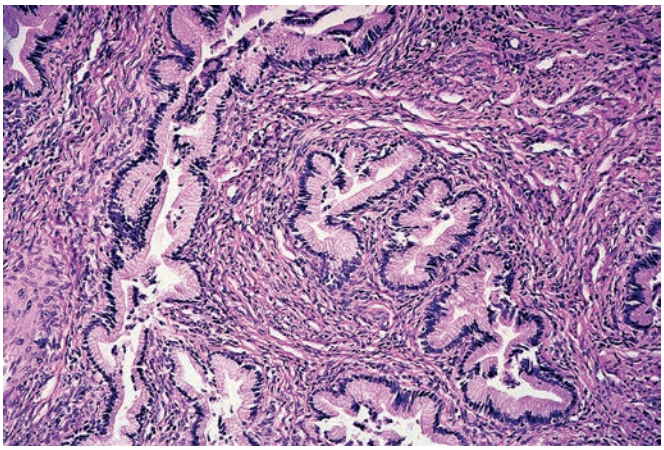

Figure 32.34 Adenoma malignum (minimal deviation adenocarcinoma), the very well-differentiated variant of gastric-type HPV-independent adenocarcinoma of cervix.

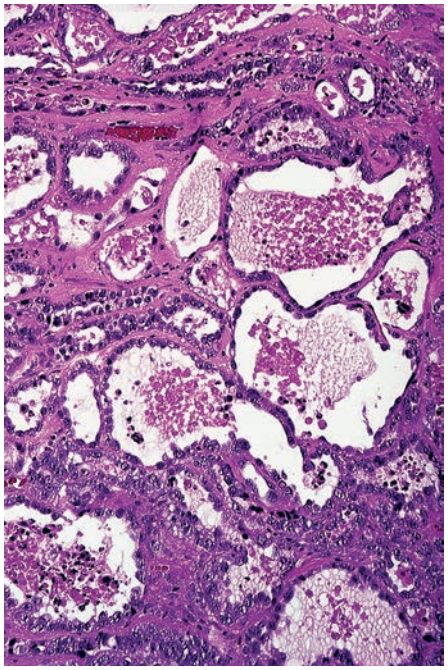

Figure 32.35 Clear cell adenocarcinoma of cervix showing tubular, microcystic, and tubulocystic features.

Early Invasive Adenocarcinoma

Although early invasive adenocarcinoma is included in the College of American Pathologists checklist for reporting cervical adenocarcinoma, no definition is provided and it is preferable to simply measure depth of invasion and assign stage accordingly, exactly as described for squamous cell carcinoma of the cervix earlier in this chapter. That being said it must be acknowledged that it is considerably more difficult to both recognize and, when present, measure depth of invasive cervical adenocarcinoma.[296] Irregular nests of tumor cells and individual tumor cells are relatively uncommon, especially in HPV-associated cervical adenocarcinoma and adenoma malignum variant of HPV-independent adenocarcinoma. Invasion may only be recognized when glands with smooth contours are present in the outer half of the wall of the cervix (deeper than normal endocervical glands) or neoplastic glands are present in close proximity to thick-wall blood vessels (as defined by the distance from the closest gland to a thick-wall vessel being less or equal to the thickness of the vessel wall).[368] The prognosis for patients with equivocal or at most superficially invasive adenocarcinoma is favorable. For example, Ostor reported on 219 cases where there was invasion to a depth of 5 mm or less, and only 5 (2%) had nodal metastases.[369] Interestingly, 73 patients whose tumors showed Silva pattern A invasion (i.e., rounded glandular contour) were all alive and well on follow-up. These findings, from disparate studies, indicate that superficially

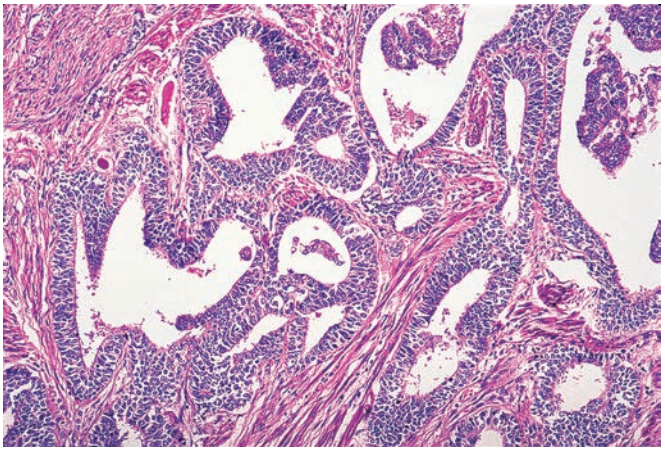

Figure 32.36 Mesonephric adenocarcinoma of cervix.

For personal use only. No other uses without permission. Copyright ©2017. Elsevier Inc. All rights reserved.

invasive cervical adenocarcinoma, especially if there is no destructive invasion, have a very favorable prognosis. In view of the generally indolent behavior of adenocarcinomas with equivocal or at most superficial invasion, a conservative type of surgery is advisable for most cases.[370]

Differential Diagnosis With Endometrial Adenocarcinoma

The differential diagnosis between endocervical and endometrial adenocarcinoma can be very difficult. The differential diagnosis is most commonly between usual type HPV-associated cervical adenocarcinoma and endometrial adenocarcinoma of endometrioid type, and it is this differential diagnosis that we will focus on. It should be noted that the guidelines do not apply if one is dealing with an HPV-independent cervical adenocarcinoma. We have encountered cases of gastric-type and mesonephric adenocarcinoma of the cervix where p16 negativity led to an erroneous diagnosis of endometrial carcinoma in a curetting specimen, so it is important to be mindful of the histologic features on H&E and not rush into immunostains.

Features that favor a primary endocervical origin are the following:

1. Presence of in situ adenocarcinoma in the cervical glands.
2. Negativity for vimentin.[371]
3. Negativity or only weak positivity for estrogen or progesterone receptor expression.[372,373]
4. Presence of HPV nucleic acid by in situ hybridization or PCR.[373]
5. Block positive immunoreactivity for p16.[374]

With regard to p16 immunostaining, it is important to note that up to 80% of the cells of some endometrioid carcinomas of endometrium can be p16 positive, but these tumors consistently lack the strong nuclear and cytoplasmic positivity characteristic of most HPV-associated endocervical adenocarcinomas of usual type. It is possible that a true endometrioid carcinoma could arise from cervical endometriosis; such a tumor would be HPV independent and immunophenotypically indistinguishable from endometrioid carcinoma arising in the uterine corpus or lower uterine segment; if these occur, they are rare. Tumors of the lower uterine segment are most commonly of endometrial-cell origin and indistinguishable from their counterparts arising in the uterine corpus rather than being related to endocervical adenocarcinomas.

Neuroendocrine Carcinoma

A small number of cervical carcinomas exhibit clear-cut evidence of neuroendocrine differentiation, as detected by ultrastructural, histochemical, and/or immunohistochemical criteria. These tumors have been variously called (atypical) carcinoid tumor, argyrophil cell carcinoma, (extrapulmonary) small cell carcinoma, (neuro) endocrine carcinoma, and carcinoma with (neuro)endocrine differentiation, the choice in terminology depending on the degree of differentiation of the tumor, the extent of endocrine features present, and the observer's bias.[375,376] It is preferable to use terms similar to those employed at other sites, as recommended in the 2014 WHO Classification, that is, low-grade neuroendocrine tumor (carcinoid or atypical carcinoid) or high-grade neuroendocrine carcinoma (small cell neuroendocrine carcinoma or large cell neuroendocrine carcinoma). It is important to remember that one can find neuroendocrine marker expression in cervical carcinomas of conventional type, a fact that should not result in a change of their designation; a diagnosis of neuroendocrine tumor can only be made in the presence of features of neuroendocrine differentiation recognizable on H&E.[377]

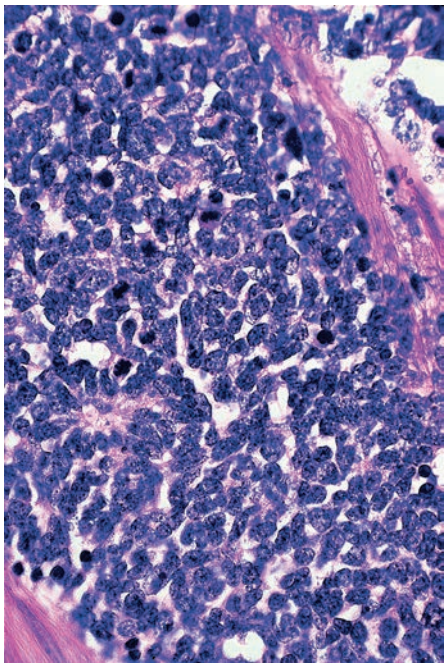

Figure 32.37 High-grade small cell neuroendocrine carcinoma of cervix.

Low-grade neuroendocrine tumors of the cervix are vanishingly rare, so we are left with small cell and large cell neuroendocrine carcinomas. The age distribution of patients with neuroendocrine carcinomas of the cervix is the same as for squamous cell carcinoma. They also show a similar association with HPV.[378–380] The carcinoid syndrome is invariably absent, but some cases have been seen in association with Cushing syndrome[381] and with inappropriate secretion of antidiuretic hormone (ADH).[382] In contrast to squamous cell carcinoma, HSIL (CIN2/3) changes in the adjacent epithelium are rare.[380,383] The histologic features of these tumors are identical to those of their more common counterparts occurring at other body sites. The large cell neuroendocrine carcinomas show variable organoid arrangement, with trabecular, insular, glandular, and spindle patterns of growth, while small cell neuroendocrine carcinomas are composed of monomorphic small cells with scant cytoplasm and hyperchromatic nuclei (Fig. 32.37). Most cases are pure, but others are combined with squamous cell carcinoma[384] or adenocarcinoma.[385–387] Immunohistochemically, positivity may be found for CD56,[388] chromogranin (but only in the better differentiated examples), and/or synaptophysin, but some tumors may be negative for all three markers. Generic neuroendocrine markers[389,390] and a variety of peptide hormones may be expressed (Fig. 32.38).[391] TTF-1 expression may be seen, so it does not aid in distinction from a lung primary.[392] p16 expression suggests HPV participation in the genesis of these tumors, which may be further confirmed at the molecular level.[393–396]

The large majority of these cervical neoplasms are histologically and clinically aggressive. The treatment, especially for high-grade lesions, usually consists of a combination of surgery, radiation therapy, and chemotherapy.[396] The prognosis is generally poor.[378,397–399] Naturally, there is also a close relationship between clinical stage and prognosis.[400] Both small cell and large cell neuroendocrine carcinomas with a polypoid shape or arising in polyps may be associated with a more favorable prognosis.[401]

Cytology

The broadest and most successful application of clinical cytology has been in the diagnosis of invasive carcinoma of the uterine cervix

For personal use only. No other uses without permission. Copyright ©2017. Elsevier Inc. All rights reserved.

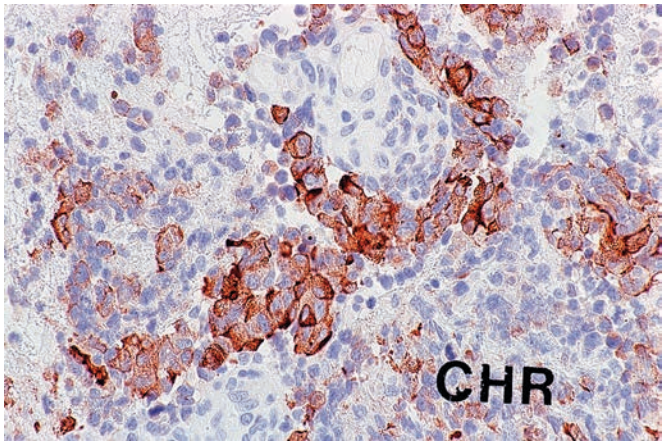

Figure 32.38 Strong focal immunoreactivity for chromogranin in neuroendocrine carcinoma of cervix.

and precursor lesions through the technique. Only a brief overview of cervical cytology can be provided in this chapter, and readers are referred to reference materials dedicated to cervical cytology, such as the excellent Bethesda 2014 website, for more detail on cytopathologic diagnosis of cervical smears.[402] There is a looming transition in which primary testing for HPV will have a place of more prominence, but there will also undoubtedly be large numbers of cervical cytology smears in need of skilled interpretation over the coming years, so that cervical cytology is undoubtedly going to be an important component of anatomic pathology practice. Cervical cytology was first described by Aureli Babès, a Romanian pathologist, further developed by George Papanicolaou at Cornell University, and is universally known as the Pap test[403,404] (Fig. 32.39). Today, it is widely used worldwide as a screening test in asymptomatic populations.[405,406]

Mass cytologic screening has shifted the presentation of cervical carcinoma from the clinical to the preclinical stage, saving many lives. In an often quoted article, Christopherson and Scott[407] reported a 70% decrease in mortality from carcinoma of the uterine cervix between 1970/1971 and 1955/1956 in women younger than 60 years of age. It should be emphasized that cervical cytology is a screening test, and the sensitivity is less than 100%. The success of cervical cancer screening programs in reducing mortality due to cervical cancer has led some to have unrealistic expectations for the performance of cervical smears in detection of premalignant and malignant lesions of the cervix.

Special techniques are applicable to cytology smears, including immunohistochemistry and in situ hybridization.[408] For instance, it has been shown that Ki-67 staining of cervical smears can improve the diagnostic accuracy of cervical LSIL,[409,410] while immunostaining for p16 is also of value in detection of HSIL.[411] The most important development, however, is development of sensitive automated HPV testing, with the previously described Hybrid Capture test being a leading example of the technology used. HPV testing was initially deployed as a triage test for patients with atypical cells that fell short of being diagnosable as SIL; results of HPV testing were used to guide referral for colposcopic examination in this setting. More recently there has been a move towards either co-testing (i.e., performing both conventional cervical smear cytologic examination and HPV testing) or primary HPV screening, where only HPV testing is performed as a screening test with no cervical smear cytology examination. The basis for the increasing use of HPV testing is that it is more sensitive than cervical cytology.[412–415] In the ATHENA study of more than 45,000 women, HPV testing had a sensitivity of 85%–90% in the four participating laboratories, while the sensitivity of cervical screening was both less, and showed more interlaboratory variation (42%–73%).[413–415] Given the added cost of co-testing, with little improvement in sensitivity, it is likely that there will be a move to primary HPV screening over the coming years. One such approach would stratify patients based on their HPV test results as follows: (1) women with negative tests will have no further testing done and return for HPV screening at regular intervals; (2) when testing is positive for HPV-16 or 18, there is reflex referral for colposcopic examination; and (3) with detection of other HPV genotypes, cervical cytology smears are prepared to guide referral to colposcopic examination (and if those smears are negative repeat testing is done in 12 months, which is at an accelerated interval). Primary HPV screening has already been instituted in some parts of the world (e.g., Mexico and Turkey).

The reader has undoubtedly noted that this is an area in transition. The uncertainty and change is also impacted by the emergence of patients at the age for initiation of screening (starting no earlier than at age 25) who were vaccinated against HPV as children or young adults. There are predictable effects of these highly effective vaccines on screening programs, in that there will be less HSIL in this population and this lower prevalence will lead to further decreases in both the sensitivity and specificity of cervical cytology screening, which is likely to disappear as a primary screening modality in immunized patients. HPV testing in this population will suffer from decreased specificity (although sensitivity should remain high) and more of the positive tests will be associated with transient infections that will be cleared by the immunized patients rather than progress to SIL. As well, there will be a higher proportion of non-HPV-16 and non-HPV-18 detected, and in these patients the risk of progression to HSIL is less.

The recommended terminology to be used in cervicovaginal cytology is that of the 2014 Bethesda classification.[428] There has been very significant evolution of diagnostic terminology within the memory of many senior practitioners, which we will briefly review. Papanicolaou's original system had five "classes" of increasing atypia. Although this nomenclature fulfilled a very important role in the establishment of the technique, it was eventually abandoned because of the vagueness of the information provided. A "class III" smear, for instance, could represent anything from a moderate dysplasia to an invasive carcinoma. Therefore, it was progressively replaced in the 1960s by the nomenclature then in vogue among histopathologists (i.e., negative, benign atypia, dysplasia [mild, moderate, or severe], carcinoma in situ, and invasive carcinoma).[416,417] During the 1970s, many institutions switched to the CIN system for both cytologic and histologic specimens. In 1988, at the initial Bethesda meeting, it was recommended to classify SIL in the following categories: (1) atypical squamous cells of undetermined significance (ASCUS); (2) low-grade SIL; (3) high-grade SIL; and (4) squamous cell carcinoma.[418–420] This classification was criticized on several grounds, one of them being the claim that it leads to overtreatment of many individuals whose smears are placed in the low-grade SIL category.[421,422] Partly as a response to these criticisms, the system was revised in 2001 in order to facilitate triage of women for more intensive screening only when a strong suspicion of a high-grade lesion is present.[423,424] The current classification (Bethesda 2014) includes the following categories for squamous cell abnormalities:

1. Atypical squamous cells:
   a. Of unknown significance (ASCUS)
   b. Cannot exclude high-grade squamous intraepithelial lesion (ASC-H)
2. Low-grade squamous intraepithelial lesion (LSIL)
3. High-grade squamous intraepithelial lesion (HSIL)
4. Squamous cell carcinoma

The recommendation is for women with ASCUS to be managed using a program of two repeat cytology tests, immediate colposcopy,

For personal use only. No other uses without permission. Copyright ©2017. Elsevier Inc. All rights reserved.

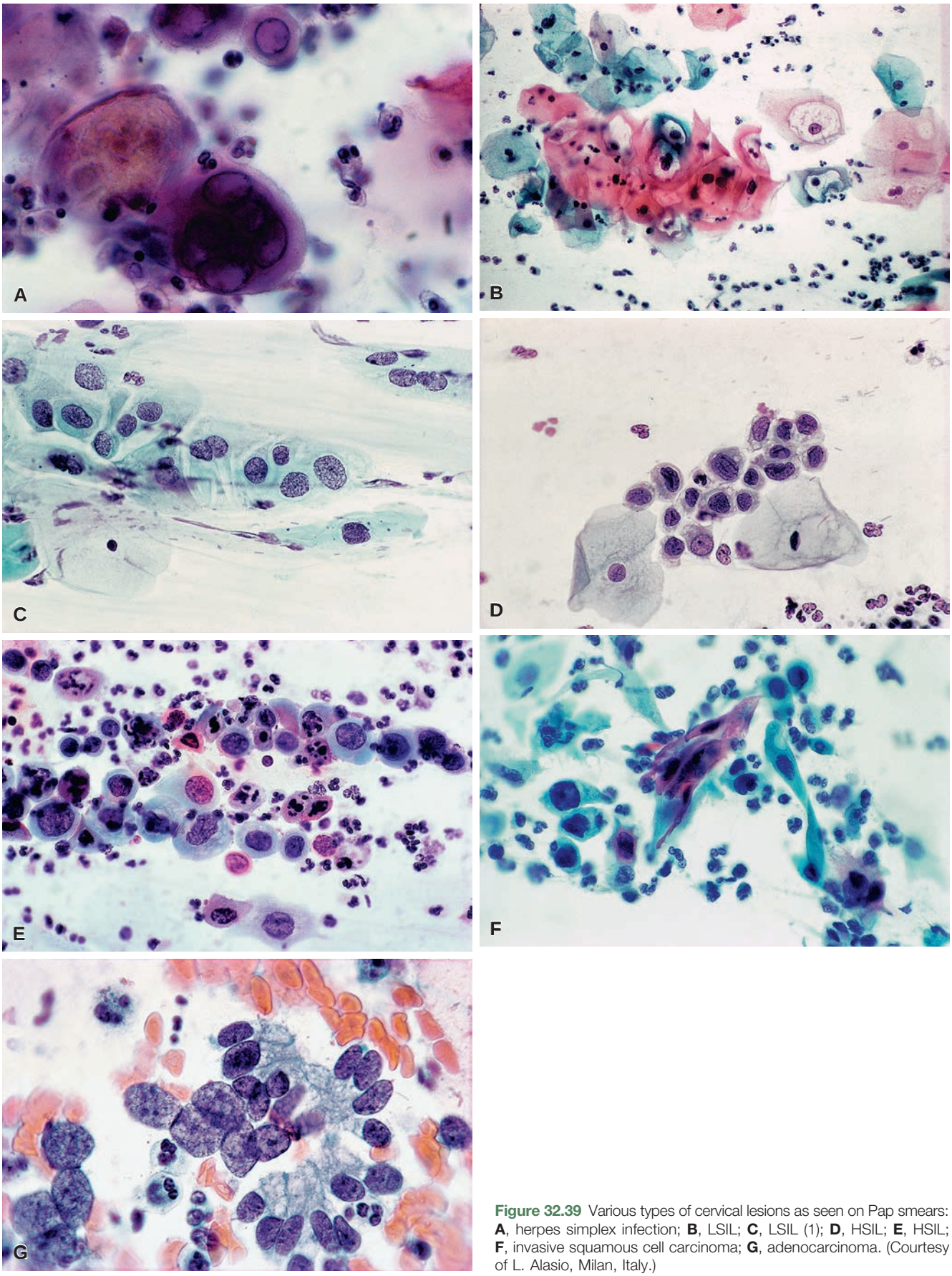

Figure 32.39 Various types of cervical lesions as seen on Pap smears: **A**, herpes simplex infection; **B**, LSIL; **C**, LSIL (1); **D**, HSIL; **E**, HSIL; **F**, invasive squamous cell carcinoma; **G**, adenocarcinoma. (Courtesy of L. Alasio, Milan, Italy.)

For personal use only. No other uses without permission. Copyright ©2017. Elsevier Inc. All rights reserved.

Figure 32.40 Embryonal (botryoid) rhabdomyosarcoma of cervix protruding in the form of grapelike masses.

or DNA testing for high-risk types of HPV, while patients with LSIL or HSIL are reflexly referred for colposcopic examinaiton.[425]

Whether there is co-testing or primary HPV screening, and even if the uptake of the vaccine is 100%, there will still be cervical cancer and cervical cancer deaths. There remain pockets of patient resistance to vaccination, based on pseudoscience and despite demonstration that HPV is so ubiquitous that 80% of sexually active women will be exposed by age 50. Furthermore, not all cervical cancers are related to HPV; in the previous section we discussed the HPV-independent cervical adenocarcinomas (e.g., gastric type or clear cell carcinomas) and these will not be detected by HPV testing and are suboptimally detected by cervical screening.

Other Tumors and Tumorlike Conditions

Carcinomas of one type or another comprise approximately 99% of all primary cervical malignancies. The remaining 1% is made up of a large variety of neoplasms.

Embryonal (botryoid) rhabdomyosarcoma presents in children and adolescents as a myxoid polypoid mass covered by attenuated epithelium.[426–428] The appearance is generally similar to that of the homonymous vaginal tumor. However, some of the cervical cases occurring in older patients have been seen to contain cartilage and to be associated with a better prognosis, (Fig. 32.40).[429] **Alveolar rhabdomyosarcoma** has also been reported.[430]

Carcinosarcomas (malignant mixed müllerian tumors) also present as polypoid masses but generally occur in much older patients, the average age in one series being 65 years.[431] Some tumors look identical to their more common uterine counterparts, but in others the recognizable epithelial component has an adenoid basal or squamous appearance.[431,432] When the latter is the case, the appearance blends with that of spindle cell (sarcomatoid) carcinoma.

Müllerian adenosarcoma[433,434] and **stromal sarcoma** of endometrial type also occur in the cervix (Fig. 32.41), the former sometimes featuring foci of ovarian sex cord–like structures.[435] **Smooth muscle tumors**, both benign and malignant, also occur in the cervix (Fig. 32.42).[436] The diagnostic criteria are the same as for those in the uterine corpus, but the ratio may be slightly different (comparatively more leiomyosarcomas are found in the cervix). Some of the reported leiomyosarcomas have been of the myxoid variety,[437] and others have had a xanthomatous appearance.[438]

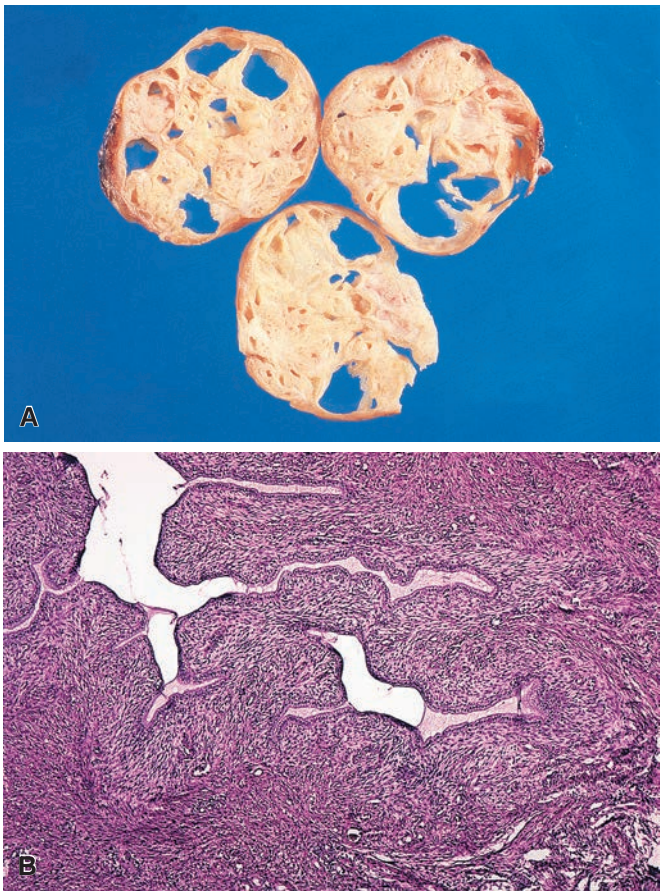

Figure 32.41 **A** and **B**, Müllerian adenosarcoma of cervix. **A**, Gross appearance. **B**, Microscopic appearance of typical adenosarcoma, with an appearance reminiscent of phylloides tumor of breast. (**A**, Courtesy of Dr Juan José Segura, San José, Costa Rica.)

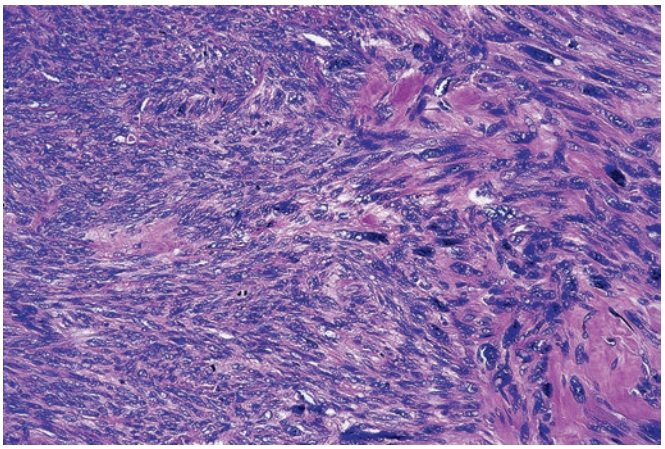

Figure 32.42 Poorly differentiated leiomyosarcoma of cervix.

Other primary cervical tumors and tumorlike conditions include *teratoma*,[439,440] *glial polyp (glial heterotopia, glioma)* of probable fetal origin,[441] and *ganglioneuroma*[442]; *yolk sac (endodermal sinus) tumor* (closely simulating the clinical appearance of embryonal rhabdomyosarcoma)[443]; *choriocarcinoma*[444]; *sebaceous carcinoma*[445]; *extrarenal Wilms tumor*[446]; *traumatic (amputation) neuroma*[447] (some occurring postpartum)[448]; *neurofibroma*[449]; *schwannoma*[450] (including the pigmented variety)[451]; *malignant peripheral nerve sheath tumor*[452,453]; *solitary*

For personal use only. No other uses without permission. Copyright ©2017. Elsevier Inc. All rights reserved.

Figure 32.43 Gross appearance of blue nevus of cervix. (Courtesy of Dr Luis Spitale, Córdoba, Argentina.)

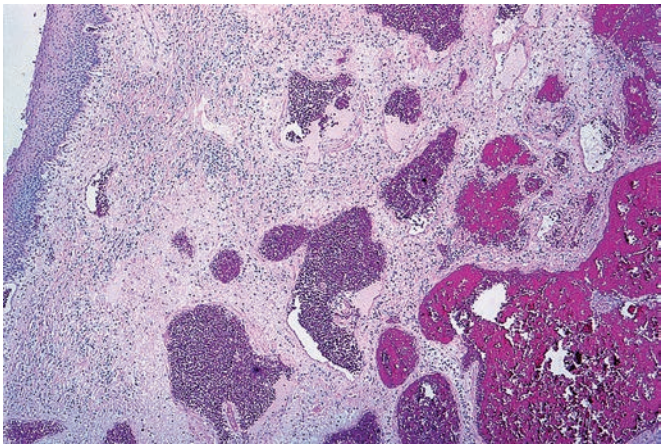

Figure 32.44 Cavernous hemangioma of cervix, a most unusual occurrence.

fibrous tumor[454]; *pigmented neuroectodermal tumor of infancy*[455]; *melanosis* (sometimes developing after cryotherapy for SIL)[456–458]; *blue nevus*[459–461] (Fig. 32.43); *cellular blue nevus*; *malignant melanoma*[462,463] (including the desmoplastic variety[464] and a type simulating malignant peripheral nerve sheath tumor[465]); *benign mesenchymoma*[466]; *hemangioma*[467] (Fig. 32.44); *glomus tumor*[468]; *angiosarcoma*[469]; *osteosarcoma*[470]; *alveolar soft part sarcoma*[471–473]; and *Ewing sarcoma/PNET*[474–476]).

Malignant lymphomas of the cervix present with vaginal bleeding and a subepithelial mass without obvious ulceration.[477] Most are diffuse large B-cell lymphomas and many are accompanied by extensive fibrosis (Fig. 32.45).[475,478–481] An important differential diagnosis is with **lymphoma-like lesions** resulting from focally florid lymphoid proliferation associated with chronic cervicitis or as an expression of infectious mononucleosis[482,483]; these are identified by

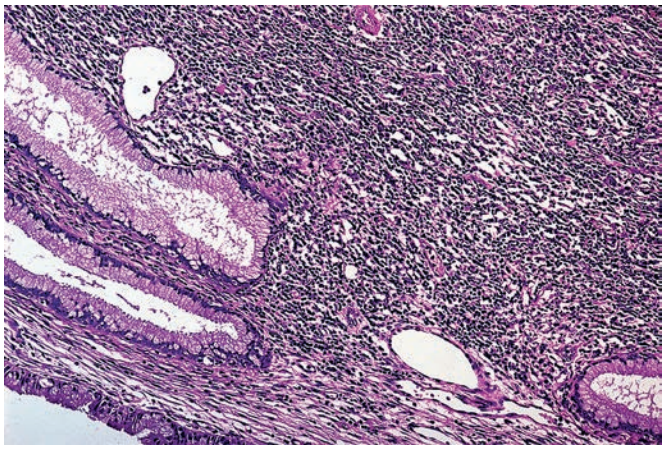

Figure 32.45 Diffuse large B-cell lymphoma of cervix growing between normal endocervical glands.

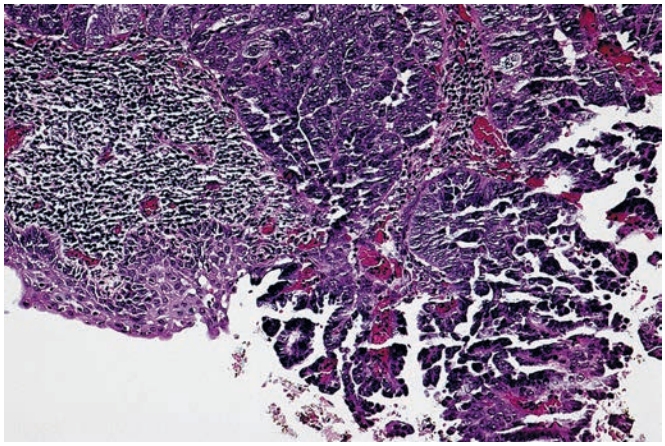

Figure 32.46 High-grade serous carcinoma of ovary metastatic to cervix.

the polymorphic nature of the infiltrate (including mature plasma cells, small lymphocytes, and neutrophils), surface ulceration, and minimal or no sclerosis. Despite the occasional detection of clonality in some cases, the disease has so far followed a benign clinical course.[484] *Granulocytic sarcoma (chloroma)*,[485–487] *Hodgkin lymphoma*, *inflammatory pseudotumor*,[488] localized *amyloidosis*,[457] and *Rosai–Dorfman disease* (sinus histiocytosis with massive lymphadenopathy)[489] can also present initially as a cervical mass.

Metastatic carcinomas to the cervix (excluding direct invasion from endometrial carcinoma) can originate from genital or extragenital organs; the most common sites are the ovary, large bowel, stomach, breast, and kidney (Fig. 32.46).[490,491] Some of them clinically and pathologically simulate the appearance of primary cervical carcinoma, including invasive and in situ cervical adenocarcinoma.[492] Knowledge of the clinical findings may make this mistake avoidable.

An exceptional event is represented by replacement of the endocervical (and endometrial) mucosa by metastatic mucinous tumor of the appendix.[479]

References

1. Hendrickson MR, Atkins KA, Kempson RL. Uterus and fallopian tubes. In: Mills SE, ed. *Histology for Pathologists*. 3rd ed. Philadelphia: Lippincott Williams and Wilkins; 2007:1011-1062.
2. Loning T, Kuhler C, Caselitz J, Stegner HE. Keratin and tissue polypeptide antigen profiles of the cervical mucosa. *Int J Gynecol Pathol*. 1983;2:105-112.
3. Malecha MJ, Miettinen M. Patterns of keratin subsets in normal and abnormal uterine cervical tissues. An immunohistochemical study. *Int J Gynecol Pathol*. 1992;11:24-29.
4. Smedts F, Ramaekers F, Troyanovsky S, et al. Basal-cell keratins in cervical reserve cells and a comparison to their expression in cervical intraepithelial neoplasia. *Am J Pathol*. 1992;140:601-612.
5. Warhol MJ, Antonioli DA, Pinkus GS, et al. Immunoperoxidase staining for involucrin. A

For personal use only. No other uses without permission. Copyright ©2017. Elsevier Inc. All rights reserved.

potential diagnostic aid in cervicovaginal pathology. *Hum Pathol*. 1982;13:1095-1099.
6. Whittaker JR, Samy AM, Sunter JP, et al. Cytokeratin expression in cervical epithelium. An immunohistological study of normal, wart virus-infected and neoplastic tissue. *Histopathology*. 1989;14:151-160.
7. Nonogaki H, Fujii S, Konishi I, et al. Estrogen receptor localization in normal and neoplastic epithelium of the uterine cervix. *Cancer*. 1990;66:2620-2627.
8. Gilks CB, Reid PE, Clement PB, Owen DA. Histochemical changes in cervical mucus-secreting epithelium during the normal menstrual cycle. *Fertil Steril*. 1989;5:286-291.
9. Fetissof F, Serres G, Arbeille B, et al. Argyrophilic cells and ectocervical epithelium. *Int J Gynecol Pathol*. 1991;10:177-190.
10. Remadi S, MacGee W, Mégevand E, et al. Resident neuroendocrine cells in the normal ectoendocervical epithelium: an immunohistochemical study of 100 cases using a microwave heating technique. *Int J Surg Pathol*. 1997;5:19-24.
11. Osamura RY, Watanabe K, Oh M. Melanin-containing cells in the uterine cervix. Histochemical and electron-microscopic studies of two cases. *Am J Clin Pathol*. 1980;74:239-242.
12. Barroeta JE, Pasha TL, Acs G, Zhang PJ. Immunoprofile of endocervical and endometrial stromal cells and its potential application in localization of tumor involvement. *Int J Gynecol Pathol*. 2007;26:76-82.
13. Howitt BE, Emori M, Drapkin R, et al. GATA3 Is a sensitive and specific marker of benign and malignant mesonephric lesions in the lower female genital tract. *Am J Surg Pathol*. 2015;39:1411-1419.
14. Rabban JT, McAlhany S, Lerwill MF, et al. PAX2 distinguishes benign mesonephric and mullerian glandular lesions of the cervix from endocervical adenocarcinoma, including minimal deviation adenocarcinoma. *Am J Surg Pathol*. 2010;34:137-146.
15. Robledo M, Vazquez J, Contreras-Mejuto F, Lopez-Garcia G. Sebaceous glands and hair follicles in the cervix uteri. *Histopathology*. 1992;21:278-279.
16. McCluggage WG, Ganesan R, Hirschowitz L, et al. Ectopic prostatic tissue in the uterine cervix and vagina: report of a series with a detailed immunohistochemical analysis. *Am J Surg Pathol*. 2006;30:209-215.
17. Nucci MR, Ferry JA, Young PR. Ectopic prostatic tissue in the uterine cervix: a report of four cases and review of ectopic prostatic tissue. *Am J Surg Pathol*. 2000;24:1224-1230.
18. Rath-Wolfson L, Koren R, Amiel A, et al. The 'female prostrate' in cervix uteri: a case report. *Appl Immunohistochem Mol Morphol*. 1998;6:50-53.
19. Roth E, Taylor HB. Heterotopic cartilage in the uterus. *Obstet Gynecol*. 1966;27:838-844.
20. Johnson LD, Easterday CL, Gore H, Hertig AT. Histogenesis of carcinoma in situ of the uterine cervix. A preliminary report of the origin of carcinoma in situ in subcylindrical cell anaplasia. *Cancer*. 1964;17:213-229.
21. Feldman D, Romney SL, Edgcomb J, Valentine T. Ultrastructure of normal, metaplastic, and abnormal human uterine cervix. Use of montages to study the topographical relationship of epithelial cells. *Am J Obstet Gynecol*. 1984;150:573-688.
22. Puts JJG, Moesker O, Kenemans P, et al. Expression of cytokeratins in early neoplastic epithelial lesions of the uterine cervix. *Int J Gynecol Pathol*. 1985;4:300-313.
23. Crum CP, Egawa K, Fu YS, et al. Atypical immature metaplasia (AIM). A subset of human papilloma virus infection of the cervix. *Cancer*. 1983;51:2214-2219.
24. Duggan MA, Akbari M, Magliocco AM. Atypical immature cervical metaplasia: immunoprofiling and longitudinal outcome. *Hum Pathol*. 2006;37:1473-1481.
25. Geng L, Connolly DC, Isaacson C, et al. Atypical immature metaplasia (AIM) of the cervix: is it related to high-grade squamous intraepithelial lesion (HSIL). *Hum Pathol*. 1999;30:345-351.
26. Kong CS, Balzer BL, Troxell ML, et al. p16INK4A immunohistochemistry is superior to HPV in situ hybridization for the detection of high-risk HPV in atypical squamous metaplasia. *Am J Surg Pathol*. 2007;31:33-43.
27. Miyatake T, Ueda Y, Yoshino K, et al. Clonality analysis and human papillomavirus infection in squamous metaplasia and atypical immature metaplasia of uterine cervix: is atypical immature metaplasia a precursor to cervical intraepithelial neoplasia 3? *Int J Gynecol Pathol*. 2007;26:180-187.
28. Park JJ, Genest DR, Sun D, Crum CP. Atypical immature metaplastic-like proliferations of the cervix: diagnostic reproducibility and viral (HPV) correlates. *Hum Pathol*. 1999;30:1161-1165.
29. Val-Bernal JF, Pinto J, Garijo MF, Gomez MS. Pagetoid dyskeratosis of the cervix: an incidental histologic finding in uterine prolapse. *Am J Surg Pathol*. 2000;24:1518-1523.
30. Egan AJM, Russell P. Transitional (urothelial) cell metaplasia of the uterine cervix: morphological assessment of 31 cases. *Int J Gynecol Pathol*. 1997;16:89-98.
31. Weir MM, Bell DA, Young RH. Transitional cell metaplasia of the uterine cervix and vagina: an underrecognized lesion that may be confused with high-grade dysplasia: a report of 59 cases. *Am J Surg Pathol*. 1997;21:510-517.
32. Harnden P, Kennedy W, Andrew AC, Southgate J. Immunophenotype of transitional metaplasia of the uterine cervix. *Int J Gynecol Pathol*. 1999;18:125-129.
33. Park SH, Lee YH, Kim KR. The immunoexpressions of biomarkers (p16, Ki67, and PreExTMC) are beneficial for the differential diagnosis of transitional cell metaplasia from high grade cervical intraepithelial neoplasia of the uterine cervix in perimenopausal and postmenopausal women. *Lab Invest*. 2009;89(suppl 1):231A.
34. Koss LG. Transitional cell metaplasia of cervix: a misnomer. *Am J Surg Pathol*. 1998;22:774-776.
35. Jones MA. Transitional cell metaplasia and neoplasia in the female genital tract: an update. *Adv Anat Pathol*. 1999;5:106-113.
36. Mittal K, Mesia A, Demopoulos RI. MIB-1 expression is useful in distinguishing dysplasia from atrophy in elderly women. *Int J Gynecol Pathol*. 1999;18:122-124.
37. Jonasson JG, Wang HH, Antonioli DA, Ducatman BS. Tubal metaplasia of the uterine cervix. A prevalence study in patients with gynecologic pathologic findings. *Int J Gynecol Pathol*. 1992;11:89-95.
38. Suh KS, Silverberg SG. Tubal metaplasia of the uterine cervix. *Int J Gynecol Pathol*. 1990;9:122-128.
39. al-Nafussi A, Rahilly M. The prevalence of tubo-endometrial metaplasia and adenomatoid proliferation. *Histopathology*. 1993;22:177-179.
40. McCluggage WG, Maxwell P, McBride HA, et al. Monoclonal antibodies Ki-67 and M1B1 in the distinction of tuboendometrial metaplasia from endocervical adenocarcinoma and adenocarcinoma in situ in formalin-fixed material. *Int J Gynecol Pathol*. 1995;14:209-216.
41. Yeh IT, Bronner M, Li Volsi VA. Endometrial metaplasia of the uterine endocervix. *Arch Pathol Lab Med*. 1993;117:734-735.
42. Oliva E, Clement PB, Young RH. Tubal and tubo-endometrioid metaplasia of the uterine cervix. Unemphasized features that may cause problems in differential diagnosis – a report of 25 cases. *Am J Clin Pathol*. 1995;103:618-623.
43. Ducatman BS, Wang HH, Jonasson JG, et al. Tubal metaplasia. A cytologic study with comparison to other neoplastic and non-neoplastic conditions of the endocervix. *Diagn Cytopathol*. 1993;9:95-103.
44. Samarawardana PN, Shroyer KR. Co-localization of p16INK4a and MIB-1 distinguishes high grade premalignant lesions from tuboendometrial metaplasia in cervical mucosa. *Lab Invest*. 2009;89(suppl 1):235A.
45. Ismail SM. Cone biopsy causes cervical endometriosis and tubo-endometrioid metaplasia. *Histopathology*. 1991;18:107-114.
46. Vang R, Vinh TN, Burks RT, et al. Pseudoinfiltrative tubal metaplasia of the endocervix: a potential form of in utero diethylstilbestrol exposure-related adenosis simulating minimal deviation adenocarcinoma. *Int J Gynecol Pathol*. 2005;24:391-398.
47. Young RH, Clement PB. Pseudoneoplastic glandular lesions of the uterine cervix. *Semin Diagn Pathol*. 1991;8:234-249.
48. Jones MA, Young RH. Atypical oxyphilic metaplasia of the endocervical epithelium: a report of six cases. *Int J Gynecol Pathol*. 1997;16:99-102.
49. Ma L, Fisk JM, Zhang RR, et al. Eosinophilic dysplasia of the cervix: a newly recognized variant of cervical squamous intraepithelial neoplasia. *Am J Surg Pathol*. 2004;28:1474-1484.
50. Paavonen J, Critchlow CW, DeRouen T, et al. Etiology of cervical inflammation. *Am J Obstet Gynecol*. 1986;154:556-564.
51. Naib ZM, Nahmias AJ, Josey WE. Cytology and histopathology of cervical herpes simplex infection. *Cancer*. 1966;19:1026-1031.
52. Adams RL, Springall DR, Levene MM. The immunocytochemical detection of herpes simplex virus in cervical smears. A valuable technique for routine use. *J Pathol*. 1984;143:241-247.
53. Marsella RC, Buckner SB, Bratthauer GL, et al. Identification of genital herpes simplex virus infection by immunoperoxidase staining. *Appl Immunohistochem Mol Morphol*. 1995;3:184-189.
54. Kiviat NB, Paavonen JA, Wolner-Hanssen P, et al. Histopathology of endocervical infection caused by *Chlamydia trachomatis*, herpes simplex virus, *Trichomonas vaginalis*, and *Neisseria gonorrhoeae*. *Hum Pathol*. 1990;21:831-837.
55. Winkler B, Crum CP. *Chlamydia trachomatis* infection of the female genital tract. Pathogenetic and clinicopathologic correlations. *Pathol Annu*. 1987;22(Pt 1):193-223.
56. Mitao M, Reumann W, Winkler B, et al. Chlamydial cervicitis and cervical intraepithelial neoplasia. An immunohistochemical analysis. *Gynecol Oncol*. 1984;19:90-97.
57. Tchertkoff V, Ober WB. Primary chancre of cervix uteri. *N Y State J Med*. 1966;66:1921-1924.
58. Albores-Saavedra J, Rosas-Uribe A, Altramirano-Dimas M, Brandt H. Cancer with superimposed amebiasis. *Am J Clin Pathol*. 1968;49:677-682.
59. Cohen C. Three cases of amoebiasis of the cervix uteri. *J Obstet Gynaecol Br Commonw*. 1973;80:476-479.

For personal use only. No other uses without permission. Copyright ©2017. Elsevier Inc. All rights reserved.

60. Bhagavan BS, Ruffier J, Shinn B. Pseudoactinomycotic radiate granules in the lower female genital tract. Relationship to the Splendore–Hoeppli phenomenon. *Hum Pathol*. 1982;13:898-904.
61. Berry A. A cytopathological and histopathological study of bilharziasis of the female genital tract. *J Pathol Bacteriol*. 1966;91:325-338.
62. Chen KTK, Hendricks EJ. Malakoplakia of the female genital tract. *Obstet Gynecol*. 1985;65:84S-87S.
63. al Nafussi AI, Hughes D, Rebello G. Ceroid granuloma of the uterine cervix. *Histopathology*. 1992;21:282-284.
64. Pikarsky E, Maly B, Maly A. Ceroid granuloma of the uterine cervix. *Int J Gynecol Pathol*. 2002;21:191-193.
65. Crow J, McWhinney N. Isolated arteritis of the cervix uteri. *Br J Obstet Gynaecol*. 1979;86:393-398.
66. Marrogi AJ, Gersell DJ, Kraus FT. Localized asymptomatic giant cell arteritis of the female genital tract. *Int J Gynecol Pathol*. 1991;10:51-58.
67. Bean SM, Conner MG. Wegener's granulomatosis of the uterine cervix: a case report and review of the literature. *Int J Gynecol Pathol*. 2007;26:95-98.
68. Laskin WB, Fetsch JF, Tavassoli FA. Superficial cervicovaginal myofibroblastoma: fourteen cases of a distinctive mesenchymal tumor arising from a specialized subepithelial stroma of the lower female genital tract. *Hum Pathol*. 2001;32:715-725.
69. Ragazzi M, Carbonara C, Rosai J. Nonneoplastic signet-ring cells in the gallbladder and uterine cervix. A potential source of overdiagnosis. *Hum Pathol*. 2009;40:326-331.
70. Clement PB, Young RH. Deep nabothian cysts of the uterine cervix. A possible source of confusion with minimal-deviation adenocarcinoma (adenoma malignum). *Int J Gynecol Pathol*. 1989;8:340-348.
71. Segal GH, Hart WR. Cystic endocervical tunnel clusters. A clinicopathologic study of 29 cases of so-called adenomatous hyperplasia. *Am J Surg Pathol*. 1990;14:895-903.
72. Kyriakos M, Kempson RL, Konikov NF. A clinical and pathologic study of endocervical lesions associated with oral contraceptives. *Cancer*. 1968;22:99-110.
73. Taylor HB, Irey NS, Norris HJ. Atypical endocervical hyperplasia in women taking oral contraceptives. *JAMA*. 1967;202:637-639.
74. Chumas JC, Nelson B, Mann WJ, et al. Microglandular hyperplasia of the uterine cervix. *Obstet Gynecol*. 1985;66:406-409.
75. Greeley C, Schroeder S, Silverberg SG. Microglandular hyperplasia of the cervix. A true 'pill' lesion? *Int J Gynecol Pathol*. 1995;14:50-54.
76. Young RH, Scully RE. Atypical forms of microglandular hyperplasia of the cervix simulating carcinoma. A report of five cases and review of the literature. *Am J Surg Pathol*. 1989;13:50-56.
77. Speers WC, Picaso LG, Silverberg SG. Immunohistochemical localization of carcinoembryonic antigen in microglandular hyperplasia and adenocarcinoma of the endocervix. *Am J Clin Pathol*. 1983;79:105-107.
78. Young RH, Scully RE. Uterine carcinomas simulating microglandular hyperplasia: A report of six cases. *Am J Surg Pathol*. 1992;16:1092-1097.
79. Cove H. The Arias-Stella reaction occurring in the endocervix in pregnancy. Recognition and comparison with an adenocarcinoma of the cervix. *Am J Surg Pathol*. 1979;3:567-568.
80. Nucci MR. Tumor-like glandular lesions of the uterine cervix. *Int J Gynecol Pathol*. 2002;21:347-359.
81. Rhatigan RM. Endocervical gland atypia secondary to Arias-Stella change. *Arch Pathol Lab Med*. 1992;116:943-946.
82. Nucci MR, Young RH. Arias-Stella reaction of the endocervix: a report of 18 cases with emphasis on its varied histology and differential diagnosis. *Am J Surg Pathol*. 2004;28:608-612.
83. Scott M, Lyness RW, McCluggage WG. Atypical reactive proliferation of endocervix: a common lesion associated with endometrial carcinoma and likely related to prior endometrial sampling. *Mod Pathol*. 2006;19:470-474.
84. Jones MA, Young RH, Scully RE. Diffuse laminar endocervical glandular hyperplasia. A benign lesion often confused with adenoma malignum (minimal deviation adenocarcinoma). *Am J Surg Pathol*. 1991;15:1123-1129.
85. Nucci MR, Clement PB, Young RH. Lobular endocervical glandular hyperplasia, not otherwise specified: a clinicopathologic analysis of thirteen cases of a distinctive pseudoneoplastic lesion and comparison with fourteen cases of adenoma malignum. *Am J Surg Pathol*. 1999;23:886-891.
86. Kondo T, Hashi A, Murata S, et al. Endocervical adenocarcinomas associated with lobular endocervical glandular hyperplasia: a report of four cases with histochemical and immunohistochemical analyses. *Mod Pathol*. 2005;18:1199-1210.
87. Mikami Y, Hata S, Melamed J, et al. Lobular endocervical glandular hyperplasia is a metaplastic process with a pyloric gland phenotype. *Histopathology*. 2001;39: 364-372.
88. Kawauchi S, Kusuda T, Liu XP, et al. Is lobular endocervical glandular hyperplasia a cancerous precursor of minimal deviation adenocarcinoma?: a comparative molecular-genetic and immunohistochemical study. *Am J Surg Pathol*. 2008;32:1807-1815.
89. Tsuda H, Mikami Y, Kaku T, et al. Reproducible and clinically meaningful differential diagnosis is possible between lobular endocervical glandular hyperplasia and 'adenoma malignum' based on common histopathological criteria. *Pathol Int*. 2005;55:412-418.
90. Inai K, Arihiro K, Tokuoka S, et al. Mesonephric duct hyperplasia of the uterus. Report of two cases and three other cases of mesonephric duct remnant with findings of mucin histochemistry and lectin binding immunohistochemistry. *Acta Pathol Jpn*. 1989;39:457-464.
91. Jones MA, Andrews J, Tarraza HM. Mesonephric remnant hyperplasia of the cervix. A clinicopathologic analysis of 14 cases. *Gynecol Oncol*. 1993;49:41-47.
92. Seidman JD, Tavassoli FA. Mesonephric hyperplasia of the uterine cervix. A clinicopathologic study of 51 cases. *Int J Gynecol Pathol*. 1995;14:293-299.
93. Ferry JA, Scully RE. Mesonephric remnants, hyperplasia, and neoplasia in the uterine cervix. A study of 49 cases. *Am J Surg Pathol*. 1990;14:1100-1111.
94. Samaratunga H, Beresford A, Davison A. Squamous cell carcinoma in situ involving mesonephric remnants. A potential diagnostic pitfall. *Am J Surg Pathol*. 1994;18:1265-1269.
95. Janovski NA, Kasdon EJ. Benign mesonephric papillary and polypoid tumors of the cervix in childhood. *J Pediatr*. 1963;63:211-216.
96. Selzer I, Nelson HM. Benign papilloma (polypoid tumor) of the cervix uteri in children. Report of 2 cases. *Am J Obstet Gynecol*. 1962;84:165-169.
97. Clement PB. Multinucleated stromal giant cells of the uterine cervix. *Arch Pathol Lab Med*. 1985;109:200-202.
98. Elliott GB, Elliott JDA. Superficial stromal reactions of lower genital tract. *Arch Pathol*. 1973;95:100-101.
99. Abdul-Karim FW, Cohen RE. Atypical stromal cells of lower female genital tract. *Histopathology*. 1990;17:249-253.
100. Hariri J, Ingemanssen JL. Multinucleated stromal giant cells of the uterine cervix. *Int J Gynecol Pathol*. 1993;12:228-234.
101. Clement PB, Young RH, Scully RE. Nontrophoblastic pathology of the female genital tract and peritoneum associated with pregnancy. *Semin Diagn Pathol*. 1989;6:372-406.
102. Van Dorpe J, Moerman P. Placental site nodule of the uterine cervix. *Histopathology*. 1997;29:379-382.
103. Huettner PC, Gersell DJ. Placental site nodule. A clinicopathologic study of 38 cases. *Int J Gynecol Pathol*. 1994;13:191-198.
104. Young RH, Kurman RJ, Scully RE. Placental site nodules and plaques. A clinicopathologic analysis of 20 cases. *Am J Surg Pathol*. 1990;14:1001-1009.
105. Clement PB, Young RH, Scully RE. Stromal endometriosis of the uterine cervix. A variant of endometriosis that may simulate a sarcoma. *Am J Surg Pathol*. 1990;14: 449-455.
106. Baker PM, Clement PB, Bell DA, Young RH. Superficial endometriosis of the uterine cervix: a report of 20 cases of a process that may be confused with endocervical glandular dysplasia or adenocarcinoma in situ. *Int J Gynecol Pathol*. 2002;18:198-205.
107. Fukunaga M. Uterus-like mass in the uterine cervix: superficial cervical endometriosis with florid smooth muscle metaplasia? *Virchows Arch*. 2001;438:302-305.
108. Young RH, Clement PB. Endocervicosis involving the uterine cervix: a report of four cases of a benign process that may be confused with deeply invasive endocervical adenocarcinoma. *Int J Gynecol Pathol*. 2001;19:322-328.
109. Evans CS, Goldman RL, Klein HZ, Kohout ND. Necrobiotic granulomas of the uterine cervix. A probable postoperative reaction. *Am J Surg Pathol*. 1984;8:841-844.
110. Kay S, Schneider V. Reactive spindle cell nodule of the endocervix simulating uterine sarcoma. *Int J Gynecol Pathol*. 1985;4:255-257.
111. McCluggage WG, Young RH. Myxoid change of the myometrium and cervical stroma: description of a hitherto unreported non-neoplastic phenomenon with discussion of myxoid uterine lesions. *Int J Gynecol Pathol*. 2010;29:351-357.
112. Walboomers JM, Jacobs MV, Manos MM, et al. Human papillomavirus is a necessary cause of invasive cervical cancer worldwide. *J Pathol*. 1999;189:12-49.
113. Bzhalava D, Eklund C, Dillner J. International standardization and classification of human papillomavirus types. *Virology*. 2015;476:341-344.
114. Doorbar J, Quint W, Banks S, et al. The biology and life cycle of human papilloma viruses. *Vaccine*. 2012;30(suppl 5):F55-F70.
115. Herfs M, Yamamoto Y, Laury A, et al. A discrete population of squamocolumnar junction cells implicated in the pathogenesis of cervical cancer. *Proc Natl Acad Sci USA*. 2012;109:10516-10521.
116. Herfs M, Parra-Herran C, Howitt BE, et al. Cervical squamocolumnar junction-specific markers define distinct, clinically relevant subsets of low-grade squamous intraepithelial lesions. *Am J Surg Pathol*. 2013;37:1311-1318.
117. Kurman RJ, Carcangiu ML, Herrington CS, Young RH, eds. *WHO Classification of Tumors of the Female Reproductive Organs*. IARC Lyon: 2014.

For personal use only. No other uses without permission. Copyright ©2017. Elsevier Inc. All rights reserved.

118. Lee KR, Minter LJ, Crum CP. Koilocytotic atypia in Papanicolaou smears: reproducibility and biopsy correlations. *Cancer*. 1997;81:10-15.
119. Prasad CJ, Sheets E, Selig AM, et al. The binucleate squamous cell. Histologic spectrum and relationship to low-grade squamous intraepithelial lesions. *Mod Pathol*. 1993;6:313-317.
120. Johnson TL, Kim W, Plieth DA, Sarkar FH. Detection of HPV 16/18 DNA in cervical adenocarcinoma using polymerase chain reaction (PCR) methodology. *Mod Pathol*. 1992;5:35-40.
121. Mittal KR, Chan W, Demopoulos RI. Sensitivity and specificity of various morphological features of cervical condylomas. An in situ hybridization study. *Arch Pathol Lab Med*. 1990;114:1038-1041.
122. Ward BE, Burkett B, Petersen C, et al. Cytologic correlates of cervical papillomavirus infection. *Int J Gynecol Pathol*. 1990;9: 297-305.
123. Delvenne P, Fontaine M, Delvenne C, et al. Detection of human papillomaviruses in paraffin-embedded biopsies of cervical intraepithelial lesions. Analysis by immunohistochemistry, in situ hybridization, and the polymerase chain reaction. *Mod Pathol*. 1994;7:113-119.
124. Vallejos H, Delmistro AD, Kleinhaus S, et al. Characterization of human papilloma virus types in condylomata acuminata in children by in situ hybridization. *Lab Invest*. 1987;56:611-615.
125. Nagai N, Nuovo G, Freidman D, Crum CP. Detection of papillomavirus nucleic acids in genital precancers with the in situ hybridization technique. *Int J Gynecol Pathol*. 1987;6:366-379.
126. Poljak M, Seme K, Gale N. Detection of human papillomaviruses in tissue specimens. *Adv Anat Pathol*. 1999;5:216-234.
127. Zehbe I, Rylander E, Edlund K, et al. Detection of human papillomavirus in cervical intraepithelial neoplasia, using in situ hybridisation and various polymerase chain reaction techniques. *Virchows Arch*. 1996;428:151-157.
128. Jenkins D. Diagnosing human papillomaviruses: recent advances. *Curr Opin Infect Dis*. 2001;14:53-62.
129. Darragh TM, Colgan TJ, Cox T, et al. The lower anogenital squamous terminology standardization project for HPV-associated lesions: background and consensus recommendations from the College of American Pathologists and the American Society for Colposcopy and Cervical Pathology. *Int J Gynecol Pathol*. 2013;32:76-115.
130. Klaes R, Benner A, Friedrich T, et al. p16INK4a immunohistochemistry improves interobserver agreement in the diagnosis of cervical intraepithelial neoplasia. *Am J Surg Pathol*. 2002;11:1389-1399.
131. Crum CP. Symposium part 1: should the Bethesda system terminology be used in diagnostic surgical pathology? *Int J Gynecol Pathol*. 2002;22:5-12.
132. Joste NE, Rushing L, Granados R, et al. Bethesda classification of cervicovaginal smears: reproducibility and viral correlates. *Hum Pathol*. 1996;27:581-585.
133. Kalof AN, Evans MF, Simmons-Arnold L, et al. p16INK4A immunoexpression and HPV in situ hybridization signal patterns: potential markers of high-grade cervical intraepithelial neoplasia. *Am J Surg Pathol*. 2005;29:674-679.
134. Wilbur DC, Nayar R. Bethesda 2014: improving on a paradigm shift. *Cytopathology*. 2015;26(6):339-342.
135. Albores-Saavedra J, Young RH. Transitional cell neoplasms (carcinomas and inverted papillomas) of the uterine cervix. A report of four cases. *Am J Surg Pathol*. 1995;19:1138-1145.
136. Mills AM, Paquette C, Terzic T, et al. CK7 Immunohistochemistry as a Predictor of CIN1 progression: a retrospective study of patients from the quadrivalent HPV vaccine trials. *Am J Surg Pathol*. 2017;41(2):143-152.
137. Coppleson M, Pixley E, Reid B. Colposcopy. In: *A Scientific and Practical Approach to the Cervix in Health and Disease*. Springfield, IL: Charles C Thomas; 1971.
138. Kolstad P, Stafl A. *Atlas of Colposcopy*. Baltimore: University Park Press; 1972.
139. Matseoane S, Williams SB, Navarro C, et al. Diagnostic value of conization of the uterine cervix in the management of cervical neoplasia: a review of 756 consecutive patients. *Gynecol Oncol*. 1992;47:287-291.
140. McIndoe GA, Robson MS, Tidy JA, et al. Laser excision rather than vaporization. The treatment of choice for cervical intraepithelial neoplasia. *Obstet Gynecol*. 1989;74:165-168.
141. Walton LA, Edelman DA, Fowler WC Jr, Photropulos GJ. Cryosurgery for the treatment of cervical intraepithelial neoplasm during the reproductive years. *Obstet Gynecol*. 1980;55:353-357.
142. Anderson MC, Hartley RB. Cervical crypt involvement by intraepithelial neoplasia. *Obstet Gynecol*. 1980;55:546-550.
143. Demopoulos RI, Horowitz LF, Vamvakas EC. Endocervical gland involvement by cervical intraepithelial neoplasia grade III. Predictive value for residual and/or recurrent disease. *Cancer*. 1991;68:1932-1936.
144. Livasy CA, Maygarden SJ, Rajaratnam CT, Novotny DB. Predictors of recurrent dysplasia after a cervical loop electrocautery excision procedure for CIN-3: a study of margin, endocervical gland, and quadrant involvement. *Mod Pathol*. 1999;12:233-238.
145. Paterson-Brown S, Chappatte OA, Clark SK, et al. The significance of cone biopsy resection margins. *Gynecol Oncol*. 1992;46:182-185.
146. McIndoe WA, McLean MR, Jones RW, Mullins PR. The invasive potential of carcinoma in situ of the cervix. *Obstet Gynecol*. 1984;64:451-458.
147. Benda JA, Lamoreaux J, Johnson SR. Artifact associated with the use of strong iodine solution (Lugol's) in cone biopsies. *Am J Surg Pathol*. 1987;11:367-374.
148. Copeland LJ, Silva EG, Gershenson DM, et al. Superficially invasive squamous cell carcinoma of the cervix. *Gynecol Oncol*. 1992;45:307-312.
149. Margulis RR, Ely CW Jr, Ladd JE. Diagnosis and management of stage IA (microinvasive) carcinoma of cervix. *Obstet Gynecol*. 1967;29:529-538.
150. Ng ABP, Reagan JW. Microinvasive carcinoma of the uterine cervix. *Am J Clin Pathol*. 1969;52:511-529.
151. Ostor AG. Studies on 200 cases of early squamous cell carcinoma of the cervix. *Int J Gynecol Pathol*. 1993;12:193-207.
152. Brudenell M, Cox BS, Taylor CW. The management of dysplasia, carcinoma in situ and microcarcinoma of the cervix. *J Obstet Gynaecol Br Commonw*. 1973;80:673-679.
153. Jones WB, Mercer GO, Lewis JL Jr, et al. Early invasive carcinoma of the cervix. *Gynecol Oncol*. 1993;51:26-32.
154. Burghardt E, Girardi F, Lahousen M, et al. Microinvasive carcinoma of the uterine cervix (International Federation of Gynecology and Obstetrics Stage IA). *Cancer*. 1991;67:1037-1045.
155. Christopherson WM, Gray LA, Parker JE. Microinvasive carcinoma of the uterine cervix. A long-term follow-up study of eighty cases. *Cancer*. 1976;38:629-632.
156. Genadry R, Olson J, Parmley T, Woodruff JD. The morphology of the earliest invasive cell in low genital tract epidermoid neoplasia. *Obstet Gynecol*. 1978;51:718-722.
157. Hartveit F, Sandstad E. Stromal metachromasia. A marker for areas of infiltrating tumour growth? *Histopathology*. 1982;6:423-428.
158. Hasumi K, Sakamoto A, Sugano H. Microinvasive carcinoma of the uterine cervix. *Cancer*. 1980;45:928-931.
159. Cannistra SA, Niloff JM. Cancer of the uterine cervix. *N Engl J Med*. 1996;334:1030-1038.
160. Piver MS. Invasive cervical cancer in the 1990s. *Semin Surg Oncol*. 1990;6:359-363.
161. Casey S, Harley I, Jamison J, et al. A rare case of HPV-negative cervical squamous cell carcinoma. *Int J Gynecol Pathol*. 2015;34:208-212.
162. Devesa SS. Descriptive epidemiology of cancer of the uterine cervix. *Obstet Gynecol*. 1984.
163. Herrero R, Brinton LA, Reeves WC, et al. Sexual behavior, venereal diseases, hygiene practices, and invasive cervical cancer in a high-risk population. *Cancer*. 1990;65:380-386.
164. La Vecchia C, Franceschi S, Decarli A, et al. Sexual factors, venereal diseases, and the risk of intraepithelial and invasive cervical neoplasia. *Cancer*. 1986;58:935-941.
165. Pfeifer JD. *Molecular Genetic Testing in Surgical Pathology*. Philadelphia: Lippincott Williams and Wilkins; 2006.
166. Kushima M, Fujii H, Murakami K, et al. Simultaneous squamous cell carcinomas of the uterine cervix and upper genital tract: loss heterozygosity analysis demonstrates clonal neoplasms of cervical origin. *Int J Gynecol Pathol*. 2001;20:353-358.
167. Heller PB, Barnhill DR, Mayer AR, et al. Cervical carcinoma found incidentally in a uterus removed for benign indications. *Obstet Gynecol*. 1986;67:187-190.
168. Miller BE, Copeland LJ, Hamberger AD, et al. Carcinoma of the cervical stump. *Gynecol Oncol*. 1984;18:100-108.
169. Benda JA. Pathology of cervical carcinoma and its prognostic implications. *Semin Oncol*. 1994;21:3-11.
170. Clement PB, Scully RE. Carcinoma of the cervix. Histologic types. *Semin Oncol*. 1982;9:251-264.
171. Ng ABP, Atkin NB. Histological cell type and DNA value in the prognosis of squamous cell cancer of uterine cervix. *Br J Cancer*. 1973;28:322-331.
172. Goellner JR. Carcinoma of the cervix. Clinicopathologic correlation of 196 cases. *Am J Clin Pathol*. 1976;66:775-785.
173. Gunderson LL, Weems WS, Hebertson RM, Plenk HP. Correlation of histopathology with clinical results following radiation therapy for carcinoma of the cervix. *Am J Roentgenol Radium Ther Nucl Med*. 1974;120:74-87.
174. Brinck U, Jakob C, Bau O, Fuzesi L. Papillary squamous cell carcinoma of the uterine cervix: report of three cases and a review of its classification. *Int J Gynecol Pathol*. 2000;19:231-235.
175. Aho HJ, Talve L, Maenpaa J. Acantholytic squamous cell carcinoma of the uterine cervix with amyloid deposition. *Int J Gynecol Pathol*. 1992;11:150-155.
176. Gondo T, Ishihara T, Kawano H, et al. Localized amyloidosis in squamous cell carcinoma of uterine cervix. Electron microscopic features of nodular and star-like amyloid deposits. *Virchows Arch A Pathol Anat Histopathol*. 1993;422:225-231.
177. Tsang WY, Chan JK. Amyloid-producing squamous cell carcinoma of the uterine cervix. *Arch Pathol Lab Med*. 1993;117:199-201.
178. Bostrom SG, Hart WR. Carcinomas of the cervix with intense stromal eosinophilia. *Cancer*. 1981;47:2887-2893.

For personal use only. No other uses without permission. Copyright ©2017. Elsevier Inc. All rights reserved.

179. Kapp DS, LiVolsi VA. Intense eosinophilic stromal infiltration in carcinoma of the uterine cervix. A clinicopathologic study of 14 cases. *Gynecol Oncol*. 1983;16:19-30.
180. Samlal RA, Ten Kate FJ, Hart AA, Lammes FB. Do mucin-secreting squamous cell carcinomas of the uterine cervix metastasise more frequently to pelvic lymph nodes? A case-control study. *Int J Gynecol Pathol*. 1998;17:201-204.
181. Rizzardi C, Perin T, Schneider M, et al. Carcinoma of the uterine cervix with squamous and sebaceous differentiation. *Int J Gynecol Pathol*. 2009;28:292-295.
182. Bychkov V, Rothman M, Bardawil WA. Immunocytochemical localization of carcinoembryonic antigen (CEA), alpha-fetoprotein (AFP), and human chorionic gonadotropin (HCG) in cervical neoplasia. *Am J Clin Pathol*. 1983;79:414-420.
183. Wang TY, Chen BF, Yang YC, et al. Histologic and immunophenotypic classification of cervical carcinomas by expression of the p53 homologue p63: a study of 250 cases. *Hum Pathol*. 2001;32:479-486.
184. Smedts F, Ramaekers F, Link M, et al. Detection of keratin subtypes in routinely processed cervical tissue. Implications for tumour classification and the study of cervix cancer aetiology. *Virchows Arch*. 1994;425:145-155.
185. Hameed A, Miller DS, Muller CY, et al. Frequent expression of beta-human chorionic gonadotropin (beta-hCG) in squamous cell carcinoma of the cervix. *Int J Gynecol Pathol*. 1999;18:381-386.
186. Dunne FP, Rollason T, Ratcliff WA, et al. Parathyroid hormone-related protein gene expression in invasive cervical tumors. *Cancer*. 1994;74:83-89.
187. Kessis TD, Slebos RJ, Han SM, et al. p53 gene mutations and MDM2 amplification are uncommon in primary carcinomas of the uterine cervix. *Am J Pathol*. 1993;143:1398-1405.
188. Benedetti-Panici P, Maneschi F, D'Andrea G, et al. Early cervical carcinoma: the natural history of lymph node involvement redefined on the basis of thorough parametrectomy and giant section study. *Cancer*. 2000;88:2267-2274.
189. Uqmakli A, Bonney WA Jr, Palladino A. The nonlymphatic metastases of carcinoma of the uterine cervix. A prospective analysis based on laparotomy. *Cancer*. 1978;41:1027-1033.
190. Henriksen E. The lymphatic spread of carcinoma of the cervix and the body of the uterus. *Am J Obstet Gynecol*. 1949;58:924-942.
191. Barmeir E, Langer O, Levy JI, et al. Unusual skeletal metastases in carcinoma of the cervix. *Gynecol Oncol*. 1985;20:307-316.
192. Ratanatharathorn V, Powers WE, Steverson N, et al. Bone metastasis from cervical cancer. *Cancer*. 1994;73:2372-2379.
193. Tellis CJ, Beechler CR. Pulmonary metastasis of carcinoma of the cervix. A retrospective study. *Cancer*. 1982;49:1705-1709.
194. Young RH, Gersell DJ, Roth LM, Scully RE. Ovarian metastases from cervical carcinomas other than pure adenocarcinomas. A report of 12 cases. *Cancer*. 1993;71:407-418.
195. Plaza JA, Ramirez NC, Nuovo GJ. Utility of HPV analysis for evaluation of possible metastatic disease in women with cervical cancer. *Int J Gynecol Pathol*. 2004;23:7-12.
196. Wang CW, Wu TI, Yu CT, et al. Usefulness of p16 for differentiating primary pulmonary squamous cell carcinoma from cervical squamous cell carcinoma metastatic to the lung. *Am J Clin Pathol*. 2009;131:715-722.
197. Holtz DO, Dunton C. Traditional management of invasive cervical cancer. *Obstet Gynecol Clin North Am*. 2002;29:645-657.
198. Keys HM, Bundy BN, Stehman FB, et al. Cisplatin, radiation, and adjuvant hysterectomy compared with radiation and adjuvant hysterectomy for bulky stage IB cervical carcinoma. *N Engl J Med*. 1999;340:1154-1161.
199. Morgan LS, Nelson JH. Surgical treatment of early cervical cancer. *Semin Oncol*. 1982;9:312-330.
200. Thar TL, Million RR, Daly JW. Radiation treatment of carcinoma of the cervix. *Semin Oncol*. 1982;9:299-311.
201. Hamberger AD, Fletcher GH, Wharton JT. Results of treatment of early stage I carcinoma of the uterine cervix with intracavitary radium alone. *Cancer*. 1978;41:980-985.
202. Hopkins MP, Morley GW. Radical hysterectomy versus radiation therapy for stage IB squamous cell cancer of the cervix. *Cancer*. 1991;68:272-277.
203. Perez CA, Camel HM, Kao MS, Hederman MA. Randomized study of preoperative radiation and surgery or irradiation alone in the treatment of stage IB and IIA carcinoma of the uterine cervix. Final report. *Gynecol Oncol*. 1987;27:129-140.
204. Roy M, Bouchard-Fortier G, Popa I, et al. Value of sentinel node mapping in cancer of the cervix. *Gynecol Oncol*. 2011;122:269-274.
205. Morley GW. Pelvic exenterative therapy and the treatment of recurrent carcinoma of the cervix. *Semin Oncol*. 1982;9:331-340.
206. Bjornsson BL, Nelson BE, Reale FR, Rose PG. Accuracy of frozen section for lymph node metastasis in patients undergoing radical hysterectomy for carcinoma of the cervix. *Gynecol Oncol*. 1993;51:50-53.
207. Perez-Mesa C, Spjut HJ. Persistent postirradiation carcinoma of cervix uteri. A pathologic study of 83 pelvic exenteration specimens. *Arch Pathol*. 1963;75:462-474.
208. Zannoni GF, Vellone VG, Carbone A. morphological effects of radiochemotherapy on cervical carcinoma: a morphological study of 50 cases of hysterectomy specimens after neoadjuvant treatment. *Int J Gynecol Pathol*. 2008;27:274-281.
209. Baltzer J, Lohe KJ. What's new in prognosis of uterine cancer? *Pathol Res Pract*. 1984;178:635-641.
210. Hopkins MP, Morley GW. Prognostic factors in advanced stage squamous cell cancer of the cervix. *Cancer*. 1993;72:2389-2393.
211. Noguchi H, Shiozawa I, Sakai Y, et al. Pelvic lymph node metastasis of uterine cervical cancer. *Gynecol Oncol*. 1987;27:150-158.
212. Inoue T, Chihara T, Morita K. The prognostic significance of the size of the largest nodes in metastatic carcinoma from the uterine cervix. *Gynecol Oncol*. 1984;19:187-193.
213. Inoue T, Morita K. The prognostic significance of number of positive nodes in cervical carcinoma stages IB, IIA, and IIB. *Cancer*. 1990;65:1923-1927.
214. Kamura T, Tsukamoto N, Tsuruchi N, et al. Multivariate analysis of the histopathologic prognostic factors of cervical cancer in patients undergoing radical hysterectomy. *Cancer*. 1992;69:181-186.
215. Perez CA, Grigsby PW, Nene SM, et al. Effect of tumor size on the prognosis of carcinoma of the uterine cervix treated with irradiation alone. *Cancer*. 1992;69:2796-2806.
216. Burghardt E, Baltzer J, Tulusan AH, Haas J. Results of surgical treatment of 1028 cervical cancers studied with volumetry. *Cancer*. 1992;70:648-655.
217. Inoue T. Prognostic significance of the depth of invasion relating to nodal metastases, parametrial extension, and cell types. A study of 628 cases with stage IB, IIA, and IIB cervical carcinoma. *Cancer*. 1984;54:3035-3042.
218. Robert ME, Fu YS. Squamous cell carcinoma of the uterine cervix – a review with emphasis on prognostic factors and unusual variants. *Semin Diagn Pathol*. 1990;7:173-189.
219. Samlal RA, van der Velden J, Ten Kate FJ, et al. Surgical pathology factors that predict recurrence in stage IB and IIA cervical carcinoma patients with negative pelvic lymph nodes. *Cancer*. 1997;80:1234-1240.
220. Perez CA, Camel HM, Askin F, Breaux S. Endometrial extension of carcinoma of the uterine cervix. A prognostic factor that may modify staging. *Cancer*. 1981;48:170-180.
221. Inoue T, Okumura M. Prognostic significance of parametrial extension in patients with cervical carcinoma stages IB, IIA, and IIB. A study of 628 cases treated by radical hysterectomy and lymphadenectomy with or without postoperative irradiation. *Cancer*. 1984;54:1714-1719.
222. Boyce JG, Fruchter RG, Nicastri AD, et al. Vascular invasion in stage I carcinoma of the cervix. *Cancer*. 1984;53:1175-1180.
223. Obermair A, Wanner C, Bilgi S, et al. The influence of vascular space involvement on the prognosis of patients with stage IB cervical carcinoma: correlation of results from hematoxylin and eosin staining with results from immunostaining for factor VIII-related antigen. *Cancer*. 1998;82:689-696.
224. Sakuragi N, Takeda N, Hareyama H, et al. A multivariate analysis of blood vessel invasion as predictor of ovarian and lymph node metastases in patients with cervical carcinoma. *Cancer*. 2000;88:2578-2583.
225. Zaino RJ, Ward S, Delgado G, et al. Histopathologic predictors of the behavior of surgically treated stage IB squamous cell carcinoma of the cervix. A gynecologic oncology group study. *Cancer*. 1992;69:1750-1758.
226. Stock RJ, Zaino R, Bundy BN, et al. Evaluation and comparison of histopathologic grading systems of epithelial carcinoma of the uterine cervix; Gynecologic Oncology Group studies. *Int J Gynecol Pathol*. 1994;13:99-108.
227. Tiltman AJ, Atad J. Verrucous carcinoma of the cervix with endometrial involvement. *Int J Gynecol Pathol*. 1982;1:221-226.
228. Brinck U, Jakob C, Bau O, Fuzesi L. Papillary squamous cell carcinoma of the uterine cervix: report of three cases and a review of its classification. *Int J Gynecol Pathol*. 2000;19:231-235.
229. Randall ME, Andersen WA, Mills SE, Kim JAC. Papillary squamous cell carcinoma of the uterine cervix. A clinicopathologic study of nine cases. *Int J Gynecol Pathol*. 1986;5:1-10.
230. Steeper TA, Piscioli F, Rosai J. Squamous cell carcinoma with sarcoma-like stroma of the female genital tract. *Cancer*. 1983;52:890-898.
231. Pang LC. Sarcomatoid squamous cell carcinoma of the uterine cervix with osteoclast-like giant cells: report of two cases. *Int J Gynecol Pathol*. 1998;17:174-177.
232. Grayson W, Taylor LF, Cooper K. Carcinosarcoma of the uterine cervix: a report of eight cases with immunohistochemical analysis and evaluation of human papillomavirus status. *Am J Surg Pathol*. 2001;25:338-347.
233. Daroca PJ Jr, Dhorandhar HN. Basaloid carcinoma of uterine cervix. *Am J Surg Pathol*. 1980;4:235-239.
234. Grayson W, Cooper K. A reappraisal of 'basaloid carcinoma' of the cervix, and the differential diagnosis of basaloid cervical neoplasms. *Adv Anat Pathol*. 2002;9:290-300.
235. Halpin TF, Hunter RE, Cohen MB. Lymphoepithelioma of the uterine cervix. *Gynecol Oncol*. 1989;34:101-105.
236. Mills SE, Austin MB, Randall ME. Lymphoepithelioma-like carcinoma of the uterine cervix. A distinctive, undifferentiated

For personal use only. No other uses without permission. Copyright ©2017. Elsevier Inc. All rights reserved.

carcinoma with inflammatory stroma. *Am J Surg Pathol*. 1985;9:883-889.
237. Weinberg E, Hoisington S, Eastman AY, et al. Uterine cervical lymphoepithelial-like carcinoma. Absence of Epstein–Barr virus genomes. *Am J Clin Pathol*. 1993;99:195-199.
238. Coleman RL, Lindberg G, Muller CY, et al. Ectopic production and localization of beta-human chorionic gonadatropin in lymphoepithelioma-like carcinoma of the cervix: a case report. *Int J Gynecol Pathol*. 2000;19:179-182.
239. Matorell MA, Julian JM, Calabuig C, et al. Lymphoepithelioma-like carcinoma of the uterine cervix. *Arch Pathol Lab Med*. 2002;126:1501-1505.
240. Song JS, Choi J, Lee YH, Kim KR. Lymphoepithelioma-like carcinomas in the uterine cervix and endometrium: a clinicopathologic study of 6 cases with evaluation of Epstein–Barr virus and human papilloma virus genomes. *Lab Invest*. 2009;89(suppl 1):238A.
241. Tseng CJ, Pao CC, Tseng LH, et al. Lymphoepithelioma-like carcinoma of the uterine cervix: association with Epstein–Barr virus and human papillomavirus. *Cancer*. 1997;80:91-97.
242. Hasumi K, Sugano H, Sakamoto G, et al. Circumscribed carcinoma of the uterine cervix, with marked lymphocytic infiltration. *Cancer*. 1977;39:2503-2507.
243. Arraiz GA, Wigle DT, Mao Y. Is cervical cancer increasing among young women in Canada? *Can J Public Health*. 1990;81:396-397.
244. Smith HO, Tiffany MF, Qualls CR, Key CR. The rising incidence of adenocarcinoma relative to squamous cell carcinoma of the uterine cervix in the United States—a 24-year population-based study. *Gynecol Oncol*. 2000;78:97-105.
245. Kalir T, Simsir A, Demopoulos HB, Demopoulos RI. Obstacles to the early detection of endocervical adenocarcinoma. *Int J Gynecol Pathol*. 2005;24:399-403.
246. Cheng AS, Karnezis AN, Jordan S, et al. p16 Immunostaining allows for accurate subclassification of vulvar squamous cell carcinoma into HPV-associated and HPV-independent cases. *Int J Gynecol Pathol*. 2016;35:385-393.
247. Karamurzin YS, Kiyokawa T, Parkash V, et al. Gastric-type endocervical adenocarcinoma: an aggressive tumor with unusual metastatic patterns and poor prognosis. *Am J Surg Pathol*. 2015;39:1449-1457.
248. Kawakami F, Mikami Y, Kojima A, et al. Diagnostic reproducibility in gastric-type mucinous adenocarcinoma of the uterine cervix: validation of novel diagnostic criteria. *Histopathology*. 2010;56:551-553.
249. Kojima A, Mikami Y, Sudo T, et al. Gastric morphology and immunophenotype predict poor outcome in mucinous adenocarcinoma of the uterine cervix. *Am J Surg Pathol*. 2007;31:664-672.
250. Kusanagi Y, Kojima A, Mikami Y, et al. Absence of high-risk human papillomavirus (HPV) detection in endocervical adenocarcinoma with gastric morphology and phenotype. *Am J Pathol*. 2010;177:2169-2175.
251. Negri G, Egarter-Vigl E, Kasal A, et al. P16 INK4a is a useful marker for the diagnosis of adenocarcinoma of the cervix uteri and its precursors: an immunohistochemical study with immunocytochemical correlations. *Am J Surg Pathol*. 2003;27:187-193.
252. Yemelyanova A, Ji H, Shih IeM, et al. Utility of p16 expression for distinction of uterine serous carcinomas from endometrial endometrioid and endocervical adenocarcinomas: immunohistochemical analysis of 201 cases. *Am J Surg Pathol*. 2009;33:1504-1514.
253. Carleton C, Hoang L, Sah S, et al. A detailed immunohistochemical analysis of a large series of cervical and vaginal gastric-type adenocarcinomas. *Am J Surg Pathol*. 2016;40:636-644.
254. Jones MW, Silverberg SG. Cervical adenocarcinoma in young women. Possible relationship to microglandular hyperplasia and use of oral contraceptives. *Obstet Gynecol*. 1989;73:984-989.
255. Muntz HG, Bell DA, Lage JM, et al. Adenocarcinoma in situ of the uterine cervix. *Obstet Gynecol*. 1992;80:935-939.
256. Biscotti CV, Hart WR. Apoptotic bodies: a consistent morphologic feature of endocervical adenocarcinoma in situ. *Am J Surg Pathol*. 1998;22:434-439.
257. Witkiewicz A, Lee KR, Brodsky G, et al. Superficial (early) endocervical adenocarcinoma in situ: a study of 12 cases and comparison to conventional AIS. *Am J Surg Pathol*. 2005;29:1609-1614.
258. Gloor E, Hurlimann J. Cervical intraepithelial glandular neoplasia (adenocarcinoma in situ and glandular dysplasia). A correlative study of 23 cases with histologic grading, histochemical analysis of mucins, and immunohistochemical determination of the affinity for four lectins. *Cancer*. 1986;58:1272-1280.
259. McCluggage WG, Shah R, Connolly LE, McBride HA. Intestinal-type cervical adenocarcinoma in situ and adenocarcinoma exhibit a partial enteric immunophenotype with consistent expression of CDX2. *Int J Gynecol Pathol*. 2008;27:92-100.
260. Hurlimann J, Gloor E. Adenocarcinoma in situ and invasive adenocarcinoma of the uterine cervix. An immunohistologic study with antibodies specific for several epithelial markers. *Cancer*. 1984;54:103-109.
261. Lu X, Shiozawa T, Nakayama K, et al. Abnormal expression of sex steroid receptors and cell cycle-related molecules in adenocarcinoma in situ of the uterine cervix. *Int J Gynecol Pathol*. 1999;18: 109-114.
262. Riethdorf L, Riethdorf S, Lee KR, et al. Human papillomavirus, expression of p16INK4A, and early endocervical glandular neoplasia. *Hum Pathol*. 2002;33:899-904.
263. Jaworski RC. Endocervical glandular dysplasia, adenocarcinoma in situ, and early invasive (microinvasive) adenocarcinoma of the uterine cervix. *Semin Diagn Pathol*. 1990;7:190-204.
264. Jaworski RC, Pacey NF, Greenberg ML, Osborn RA. The histologic diagnosis of adenocarcinoma in situ and related lesions of the cervix uteri. Adenocarcinoma in situ. *Cancer*. 1988;61:1171-1181.
265. Lee KR, Flynn CE. Early invasive adenocarcinoma of the cervix. *Cancer*. 2000;89:1048-1055.
266. Lee KR, Sun D, Crum CP. Endocervical intraepithelial glandular atypia (dysplasia): a histopathologic, human papillomavirus, and MIB-1 analysis of 25 cases. *Hum Pathol*. 2000;31:656-664.
267. Park KJ, Soslow RA. Current concepts in cervical pathology. *Arch Pathol Lab Med*. 2009;133:729-738.
268. Zaino RJ. Adenocarcinoma in situ, glandular dysplasia, and early invasive adenocarcinoma of the uterine cervix. *Int J Gynecol Pathol*. 2002;21:314-326.
269. Schlesinger C, Silverberg SG. Endocervical adenocarcinoma in situ of tubal type and its relation to atypical tubal metaplasia. *Int J Gynecol Pathol*. 1999;18:1-4.
270. Colgan TJ, Lickrish GM. The topography and invasive potential of cervical adenocarcinoma in situ, with and without associated dysplasia. *Gynecol Oncol*. 1990;36:246-249.
271. Maier RC, Norris HJ. Coexistence of cervical intraepithelial neoplasia with primaadenocarcinoma of the endocervix. *Obstet Gynecol*. 1980;56:361-364.
272. Weisbrot IM, Stabinsky C, Davis AM. Adenocarcinoma in situ of the uterine cervix. *Cancer*. 1972;29:225-233.
273. Boyle DP, McCluggage WG. Stratified mucin-producing intraepithelial lesion (SMILE): report of a case series with associated pathological findings. *Histopathology*. 2015;66:658-663.
274. Onishi J, Sato Y, Sawaguchi A, et al. Stratified mucin-producing intraepithelial lesion with invasive carcinoma: 12 cases with immunohistochemical and ultrastructural findings. *Hum Pathol*. 2016;55:174-181.
275. Andersen ES, Arffmann E. Adenocarcinoma in situ of the uterine cervix. A clinico-pathologic study of 36 cases. *Gynecol Oncol*. 1989;35:1-7.
276. Goldstein NS, Mani A. The status and distance of cone biopsy margins as a predictor of excision adequacy for endocervical adenocarcinoma in situ. *Am J Clin Pathol*. 1998;109:727-732.
277. Plotkin A, Khalifa MA, Ismiil N, et al. The circumferential extent of disease should be reported in vervical adenocarcinoma in situ (AIS) excised by LEEP and cone biopsies. *Lab Invest*. 2009;89(suppl 1):232A.
278. Konishi I, Fujii S, Nanbu Y, et al. Mucin leakage into the cervical stroma may increase lymph node metastasis in mucin-producing cervical adenocarcinomas. *Cancer*. 1990;65:229-237.
279. Nguyen GK, Daya D. Cervical adenocarcinoma and related lesions. Cytodiagnostic criteria and pitfalls. *Pathol Annu*. 1993;28(Pt 2): 53-75.
280. Young RH, Clement PB. Endocervical adenocarcinoma and its variants: their morphology and differential diagnosis. *Histopathology*. 2002;41:185-207.
281. Young RH, Scully RE. Invasive adenocarcinoma and related tumors of the uterine cervix. *Semin Diagn Pathol*. 1990;7:205-227.
282. Zaino RJ. Glandular lesions of the uterine cervix. *Mod Pathol*. 2000;13:261-274.
283. Sorvari TE. A histochemical study of epithelial mucosubstances in endometrial and cervical adenocarcinomas. With reference to normal endometrium and cervical mucosa. *Acta Pathol Microbiol Scand*. 1969;207(suppl):1-85.
284. Baker AC, Eltoum I, Curry RO, et al. Mucinous expression in benign and neoplastic glandular lesions of the uterine cervix. *Arch Pathol Lab Med*. 2006;130:1510-1515.
285. Cohen C, Shulman G, Budgeon LR. Endocervical and endometrial adenocarcinoma. An immunoperoxidase and histochemical study. *Am J Surg Pathol*. 1982;6:151-157.
286. Cooper P, Russell G, Wilson B. Adenocarcinoma of the endocervix. A histochemical study. *Histopathology*. 1987;11:1321-1330.
287. Dabbs DJ, Geisinger KR, Norris HT. Intermediate filaments in endometrial and endocervical carcinomas. The diagnostic utility of vimentin patterns. *Am J Surg Pathol*. 1986;10:568-576.
288. Kudo R, Sasano H, Koizumi M, et al. Immunohistochemical comparison of new monoclonal antibody 1C5 and carcinoembryonic antigen in the differential diagnosis of adenocarcinoma of the uterine cervix. *Int J Gynecol Pathol*. 1990;9:325-336.
289. Fujiwara H, Tortolero-Luna G, Mitchell MF, et al. Adenocarcinoma of the cervix: expression and clinical significance of estrogen and progesterone receptors. *Cancer*. 1997;79:505-512.

For personal use only. No other uses without permission. Copyright ©2017. Elsevier Inc. All rights reserved.

290. Park KJ, Bramlage MP, Ellenson LH, Pirog EC. Immunoprofile of adenocarcinomas of the endometrium, endocervix, and ovary with mucinous differentiation. *Appl Immunohistochem Mol Morphol*. 2009; 17:8-11.
291. Sullivan LM, Smolkin ME, Frierson HF Jr, Galgano MT. Comprehensive evaluation of CDX2 in invasive cervical adenocarcinomas: immunopositivity in the absence of overt colorectal morphology. *Am J Surg Pathol*. 2008;32:1608-1612.
292. Lee SJ, Rollason TP. Argyrophilic cells in cervical intraepithelial glandular neoplasia. *Int J Gynecol Pathol*. 1994;13:131-132.
293. Ueda G, Yamasaki M, Inoue M, et al. Immunohistochemical demonstration of peptide hormones in cervical adenocarcinomas with argyrophil cells. *Int J Gynecol Pathol*. 1984;2:373-379.
294. Onuma K, Dabbs DJ, Bhargava R. Mammaglobin expression in the female genital tract: immunohistochemical analysis in benign and neoplastic endocervix and endometrium. *Int J Gynecol Pathol*. 2008;27:418-425.
295. Roma AA, Diaz De Vivar A, Park KJ, et al. Invasive endocervical adenocarcinoma: a new pattern-based classification system with important clinical significance. *Am J Surg Pathol*. 2015;39:667-672.
296. Parra-Herran C, Taljaard M, Djordjevic B, et al. Pattern-based classification of invasive endocervical adenocarcinoma, depth of invasion measurement and distinction from adenocarcinoma in situ: interobserver variation among gynecologic pathologists. *Mod Pathol*. 2016;29:879-892.
297. Elishaev E, Gilks CB, Miller D, et al. Synchronous and metachronous endocervical and ovarian neoplasms: evidence supporting interpretation of the ovarian neoplasms as metastatic endocervical adenocarcinomas simulating primary ovarian surface epithelial neoplasms. *Am J Surg Pathol*. 2005;29: 281-294.
298. Ronnett BM, Yemelyanova AV, Vang R, et al. Endocervical adenocarcinomas with ovarian metastases: analysis of 29 cases with emphasis on minimally invasive cervical tumors and the ability of the metastases to simulate primary ovarian neoplasms. *Am J Surg Pathol*. 2008;32:1835-1853.
299. Jackson-York GL, Ramzy I. Synchronous papillary mucinous adenocarcinoma of the endocervix and fallopian tubes. *Int J Gynecol Pathol*. 1992;11:63-67.
300. LiVolsi VA, Merino MJ, Schwartz PE. Coexistent endocervical adenocarcinoma and mucinous adenocarcinoma of ovary. A clinicopathologic study of four cases. *Int J Gynecol Pathol*. 1983;1:391-402.
301. Eifel PJ, Burke TW, Delclos L, et al. Early stage I adenocarcinoma of the uterine cervix. Treatment results in patients with tumors less than or equal to 4 cm in diameter. *Gynecol Oncol*. 1991;41:199-205.
302. Greer BE, Figge DC, Tamimi HK, Cain JM. Stage IB adenocarcinoma of the cervix treated by radical hysterectomy and pelvic lymph node dissection. *Am J Obstet Gynecol*. 1989;160:1509-1513.
303. Hopkins MP, Schmidt RW, Roberts JA, Morley GW. The prognosis and treatment of stage I adenocarcinoma of the cervix. *Obstet Gynecol*. 1988;72:915-921.
304. Kjorstad KE, Bond B. Stage IB adenocarcinoma of the cervix. Metastatic potential and patterns of dissemination. *Am J Obstet Gynecol*. 1984;150:297-299.
305. Angel C, Du Beshter B, Lin JY. Clinical presentation and management of stage I cervical adenocarcinoma. A 25 year experience. *Gynecol Oncol*. 1992;44:71-78.
306. Eifel PJ, Morris M, Oswald MJ, et al. Adenocarcinoma of the uterine cervix. Prognosis and patterns of failure in 367 cases. *Cancer*. 1990;65:2507-2514.
307. Hopkins MP, Sutton P, Roberts JA. Prognostic features and treatment of endocervical adenocarcinoma of the cervix. *Gynecol Oncol*. 1987;27:69-75.
308. Kaspar HG, Dinh TV, Doherty MG, et al. Clinical implications of tumor volume measurement in stage I adenocarcinoma of the cervix. *Obstet Gynecol*. 1993;81:296-300.
309. Kleine W, Rau K, Schwoeorer D, Pfleiderer A. Prognosis of the adenocarcinoma of the cervix uteri: a comparative study. *Gynecol Oncol*. 1989;35:145-149.
310. Matthews CM, Burke TW, Tornos C, et al. Stage I cervical adenocarcinoma. Prognostic evaluation of surgically treated patients. *Gynecol Oncol*. 1993;49:19-23.
311. Korhonen MO. Adenocarcinoma of the uterine cervix. Prognosis and prognostic significance of histology. *Cancer*. 1984;53:1760-1763.
312. Moberg PJ, Einhorn N, Silfversward C, Soderberg G. Adenocarcinoma of the uterine cervix. *Cancer*. 1986;57:407-410.
313. Alfsen GC, Thorensen S, Kristensen GB, et al. Histopathological subtyping of cervical adenocarcinoma reveals increasing incidence rates of endometrioid tumors in all age groups: a population based study with review of all nonsquamous cervical carcinomas in Norway from 1966 to 1970, 1976 to 1980, and 1986 to 1990. *Cancer*. 2000;89:1291-1299.
314. Berek JS, Hacker NF, Fu Y-S, et al. Adenocarcinoma of the uterine cervix. Histologic variables associated with lymph node metastasis and survival. *Obstet Gynecol*. 1985;65:46-52.
315. Tambouret R, Clement PB, Young RH. Endometrial endometrioid adenocarcinoma with a deceptive pattern of spread to the uterine cervix. A manifestation of stage IIB endometrial carcinoma liable to be misinterpreted as an independent carcinoma or a benign lesion. *Am J Surg Pathol*. 2003;27:1080-1088.
316. Shintaku M, Ueda H. Serous papillary adenocarcinoma of the uterine cervix. *Histopathology*. 1993;22:506-507.
317. Zhou C, Gilks CB, Hayes M, Clement PB. Papillary serous carcinoma of the uterine cervix: a clinicopathologic study of 17 cases. *Am J Surg Pathol*. 1998;22:113-120.
318. Hart WR. Symposium Part II: special types of adenocarcinoma of the uterine cervix. *Int J Gynecol Pathol*. 2002;21:327-346.
319. Jones MW, Silverberg SG, Kurman RJ. Well-differentiated villoglandular adenocarcinoma of the uterine cervix. A clinicopathological study of 24 cases. *Int J Gynecol Pathol*. 1993;12:1-7.
320. Jones MW, Kounelis S, Papadaki H, et al. Well-differentiated villoglandular adenocarcinoma of the uterine cervix: oncogene/tumor suppressor gene alterations and human papillomavirus genotyping. *Int J Gynecol Pathol*. 2000;124:110-117.
321. Young RH, Scully RE. Villoglandular papillary adenocarcinoma of the uterine cervix. A clinicopathologic analysis of 13 cases. *Cancer*. 1989;63:1773-1779.
322. Heatley MK. Villoglandular adenocarcinoma of the uterine cervix – a systematic review of the literature. *Histopathology*. 2007;51: 268-269.
323. Choo YC, Naylor B. Coexistent squamous cell carcinoma and adenocarcinoma of the uterine cervix. *Gynecol Oncol*. 1984;17:168-174.
324. Thelmo WL, Nicastri AD, Fruchter R, et al. Mucoepidermoid carcinoma of uterine cervix stage IB. Long-term follow-up, histochemical and immunohistochemical study. *Int J Gynecol Pathol*. 1990;9:316-324.
325. Costa MJ, Kenny MB, Judd R. Adenocarcinoma and adenosquamous carcinoma of the uterine cervix. Histologic and immunohistochemical features with clinical correlation. *Int J Surg Pathol*. 1994;1:181-190.
326. Harrison TA, Sevin BU, Koechli O, et al. Adenosquamous carcinoma of the cervix. Prognosis in early stage disease treated by radical hysterectomy. *Gynecol Oncol*. 1993;50:310-315.
327. Glücksmann A, Cherry CP. Incidence, histology, and response to radiation of mixed carcinomas (adenocanthomas) of the uterine cervix. *Cancer*. 1956;9:971-979.
328. Ulbright TM, Gersell DJ. Glassy cell carcinoma of the uterine cervix. A light and electron microscopic study of five cases. *Cancer*. 1983;51:2255-2263.
329. Costa MJ, Kenny MB, Hewan-Lowe K, Judd R. Glassy cell features in adenosquamous carcinoma of the uterine cervix. Histologic, ultrastructural, immunohistochemical, and clinical findings. *Am J Clin Pathol*. 1991;96:520-528.
330. Maier RC, Norris HJ. Glassy cell carcinoma of the cervix. *Obstet Gynecol*. 1982;60:219-224.
331. Littman P, Clement PB, Henriksen B, et al. Glassy cell carcinoma of the cervix. *Cancer*. 1976;37:2238-2246.
332. Pak HY, Yokota SB, Paladugu RR, Agliozzo CM. Glassy cell carcinoma of the cervix. Cytologic and clinicopathologic analysis. *Cancer*. 1983;52:307-312.
333. Gallager HS, Simpson CB, Ayala AG. Adenoid cystic carcinoma of the uterine cervix. Report of 4 cases. *Cancer*. 1971;27:1398-1402.
334. Fowler WC Jr, Miles PA, Surwit EA, et al. Adenoid cystic carcinoma of the cervix. *Obstet Gynecol*. 1978;52:337-342.
335. Hoskins WJ, Averette HE, Ng ABP, Yon JL. Adenoid cystic carcinoma of the cervix uteri. Report of six cases and review of literature. *Gynecol Oncol*. 1979;7:371-384.
336. Albores-Saavedra J, Manivel C, Mora A, et al. The solid variant of adenoid cystic carcinoma of the cervix. *Int J Gynecol Pathol*. 1992;11:2-10.
337. Xing D, Bakhsh S, Melnyk N, et al. Frequent NFB1-associated gene rearrangement in adenoid cystic carcinoma of the vulva. *Int J Gynecol Pathol*. 2016 Sep 22;[Epub ahead of print].
338. Grayson W, Taylor LF, Cooper K. Adenoid cystic and adenoid basal carcinoma of the uterine cervix: comparative morphologic, mucin, and immunohistochemical profile of two rare neoplasms of putative 'reserve cell' origin. *Am J Surg Pathol*. 1999;23:448-458.
339. Brainard JA, Hart WR. Adenoid basal epitheliomas of the uterine cervix: a reevaluation of distinctive cervical basaloid lesions currently classified as adenoid basal carcinoma and adenoid basal hyperplasia. *Am J Surg Pathol*. 1998;22:965-975.
340. Ferry JA, Scully RE. Adenoid cystic' carcinoma and adenoid basal carcinoma of the uterine cervix. A study of 28 cases. *Am J Surg Pathol*. 1988;12:134-144.
341. Jones MW, Kounelis S, Papadaki H, et al. The origin and molecular characterization of adenoid basal carcinoma of the uterine cervix. *Int J Gynecol Pathol*. 1998;16:301-306.
342. Parwani AV, Smith Sehdev AE, Kurman RJ, Ronnett BM. Cervical adenoid basal tumors comprised of adenoid basal epithelioma associated with various types of invasive carcinoma: clinicopathologic features, human papillomavirus DNA detection, and P16 expression. *Hum Pathol*. 2005;36:82-90.
343. Tambouret R, Bell DA, Young RH. Microcystic endocervical adenocarcinomas: a report of

For personal use only. No other uses without permission. Copyright ©2017. Elsevier Inc. All rights reserved.

eight cases. *Am J Surg Pathol*. 2000;24:369-374.
344. Mayorga M, Garcia-Valtuille A, Fernàndez F, et al. Adenocarcinoma of the uterine cervix with massive signet-ring cell differentiation. *Int J Surg Pathol*. 1997;5:95-100.
345. Suárez-Peñaranda JM, Abdulkader I, Barón-Duarte FJ, et al. Signet-ring cell carcinoma presenting in the uterine cervix: report of a primary and 2 metastatic cases. *Int J Gynecol Pathol*. 2007;26:254-258.
346. Lee KR, Trainer TD. Adenocarcinoma of the uterine cervix of small intestinal type containing numerous Paneth cells. *Arch Pathol Lab Med*. 1990;114:731-733.
347. Savargaonkar PR, Hale RJ, Pope R, et al. Enteric differentiation in cervical adenocarcinomas and its prognostic significance. *Histopathology*. 1993;23: 275-277.
348. Shintaku M, Kariya M, Shime H, Ishikura H. Adenocarcinoma of the uterus cervix with choriocarcinomatous and hepatoid differentiation: report of a case. *Int J Gynecol Pathol*. 2000;19:174-178.
349. Andersson S, Rylander E, Larsson B, et al. The role of human papillomavirus in cervical adenocarcinoma carcinogenesis. *Eur J Cancer*. 2001;37:246-250.
350. Quint KD, de Koning MN, Geraets DT, et al. Comprehensive analysis of Human Papillomavirus and Chlamydia trachomatis in in-situ and invasive cervical adenocarcinoma. *Gynecol Oncol*. 2009;114:390-394.
351. Gilks CB, Young RH, Aguirre P, et al. Adenoma malignum (minimal deviation adenocarcinoma) of the uterine cervix. A clinicopathological and immunohistochemical analysis of 26 cases. *Am J Surg Pathol*. 1989;13:717-729.
352. Kaku T, Enjoji M. Extremely well-differentiated adenocarcinoma ('adenoma malignum') of the cervix. *Int J Gynecol Pathol*. 1983;2:28-41.
353. Kaminski PF, Norris HJ. Minimal deviation carcinoma (adenoma malignum) of the cervix. *Int J Gynecol Pathol*. 1983;2:141-152.
354. Norris HJ, McCauley KM. Unusual forms of adenocarcinoma of the cervix. An update. *Pathol Annu*. 1993;28(Pt 1):73-95.
355. Michael H, Grawe L, Kraus FT. Minimal deviation endocervical adenocarcinoma. Clinical and histologic features, immunohistochemical staining for carcino-embryonic antigen, and differentiation from confusing benign lesions. *Int J Gynecol Pathol*. 1984;3:261-276.
356. Steeper TA, Wick MR. Minimal deviation adenocarcinoma of the uterine cervix ('adenoma malignum'). An immunohistochemical comparison with microglandular endocervical hyperplasia and conventional endocervical adenocarcinoma. *Cancer*. 1986;58:1131-1138.
357. McCluggage WG. Immunohistochemistry as a diagnostic aid in cervical pathology. *Pathology*. 2007;39:97-111.
358. Gilks CB, Young RH, Clement PB, et al. Adenomyomas of the uterine cervix of endocervical type: a report of ten cases of a benign cervical tumor that may be confused with adenoma malignum [corrected]. *Mod Pathol*. 1996;9:220-224.
359. Daya D, Young RH. Florid deep glands of the uterine cervix. Another mimic of adenoma malignum. *Am J Clin Pathol*. 1995;103:614-617.
360. Young RH, Welch WR, Dickersin GR, Scully RE. Ovarian sex-cord tumor with annular tubules. *Cancer*. 1982;50:1384-1402.
361. Kuragaki C, Enomoto T, Ueno Y, et al. Mutations in the STK11 gene characterize minimal deviation adenocarcinoma of the uterine cervix. *Lab Invest*. 2003;83:35-45.
362. Matias-Guiu X, Lerma E, Prat J. Clear cell tumors of the female genital tract. *Semin Diagn Pathol*. 1998;14:233-239.
363. Kaminski PF, Maier RC. Clear cell adenocarcinoma of the cervix unrelated to diethylstilbestrol exposure. *Obstet Gynecol*. 1983;62:720-727.
364. Clement PB, Young RH, Keh P, et al. Malignant mesonephric neoplasms of the uterine cervix. A report of eight cases, including four with a malignant spindle cell component. *Am J Surg Pathol*. 1995;19:1158-1171.
365. Lang G, Dallenbach-Hellweg G. The histogenetic origin of cervical mesonephric hyperplasia6and mesonephric adenocarcinoma of the uterine cervix studied with immunohistochemical methods. *Int J Gynecol Pathol*. 1990;9:145-157.
366. Rosen Y, Dolan TE. Carcinoma of the cervix with cylindromatous features believed to arise in mesonephric duct. *Cancer*. 1975;36:1739-1747.
367. Bagué S, Rodríguez IM, Prat J. Malignant mesonephric tumors of the female genital tract: a clinicopathologic study of 9 cases. *Am J Surg Pathol*. 2004;28:601-607.
368. Wheeler DT, Kurman RJ. The relationship of glands to thick-wall blood vessels as a marker of invasion in endocervical adenocarcinoma. *Int J Gynecol Pathol*. 2005;24:125-130.
369. Ostor AG. Early invasive adenocarcinoma of the uterine cervix. *Int J Gynecol Pathol*. 2000;19:29-38.
370. Ceballos KM, Shaw D, Daya D. Microinvasive cervical adenocarcinoma (FIGO stage 1A tumors): results of surgical staging and outcome analysis. *Am J Surg Pathol*. 2006;30:370-374.
371. Castrilon DH, Lee KR, Nucci MR. Distinction between endometrial and endocervical adenocarcinoma: an immunohistochemical study. *Int J Gynecol Pathol*. 2002;21:4-10.
372. McCluggage WG, Sumathi VP, McBride HA, Patterson A. A panel of immunohistochemical stains, including carcinoembryonic antigen, vimentin, and estrogen receptor, aids the distinction between primary endometrial and endocervical adenocarcinomas. *Int J Gynecol Pathol*. 2002;21:11-15.
373. Staebler A, Sherman ME, Zaino RJ, Ronnett BM. Hormone receptor immunohistochemistry and human papillomavirus in situ hybridisation are useful for distinguishing endocervical and endometrial adenocarcinomas. *Am J Surg Pathol*. 2002;26:998-1006.
374. Ansari-Lari MA, Staebler A, Zaino RJ, et al. Distinction of endocervical and endometrial adenocarcinomas: immunohistochemical p16 expression correlated with human papillomavirus (HPV) DNA detection. *Am J Surg Pathol*. 2004;28:160-167.
375. Ibrahim NBN, Briggs JC, Corbishley CM. Extrapulmonary oat cell carcinoma. *Cancer*. 1984;54:1645-1661.
376. Tateishi R, Wada A, Hayakawa K, et al. Argyrophil cell carcinomas (apudomas) of the uterine cervix. Light and electron microscopic observations of 5 cases. *Virchows Arch A Pathol Anat Histol*. 1975;366:257-274.
377. Chavez-Bianco A, Taja-Chayeb L, Cetina L, et al. Neuroendocrine marker expression in cervical carcinomas of non-small cell type. *Int J Gynecol Pathol*. 2002;21:368-374.
378. Abeler VM, Holm R, Nesland JM, Kjorstad KE. Small cell carcinoma of the cervix. A clinicopathologic study of 26 patients. *Cancer*. 1994;73:672-677.
379. Mannion C, Park WS, Man YG, et al. Endocrine tumors of the cervix: morphologic assessment, expression of human papillomavirus, and evaluation for loss of heterozygosity on 1p, 3p, 11q and 17p. *Cancer*. 1998;83:1391-1400.
380. Stoler MH, Mills SE, Gersell DJ, Walker AN. Small-cell neuroendocrine carcinoma of the cervix. A human papillomavirus type 18-associated cancer. *Am J Surg Pathol*. 1991;15:28-32.
381. Jones HW III, Plymate S, Gluck FB, et al. Small cell non-keratinizing carcinoma of the cervix associated with ACTH production. *Cancer*. 1976;38:1629-1635.
382. Ishibashi-Ueda H, Imakita M, Yutani C, et al. Small cell carcinoma of the uterine cervix with syndrome of inappropriate antidiuretic hormone secretion. *Mod Pathol*. 1996;9:397-400.
383. Ambros RA, Park JS, Shah KV, Kurman RJ. Evaluation of histologic, morphometric, and immunohistochemical criteria in the differential diagnosis of small cell carcinomas of the cervix with particular reference to human papillomavirus types 16 and 18. *Mod Pathol*. 1991;4:586-593.
384. Stahl R, Demopoulos RI, Bigelow B. Carcinoid tumor within a squamous cell carcinoma of the cervix. *Gynecol Oncol*. 1981;11:387-392.
385. Husain AN, Gattuso P, Abraham K, Castelli MJ. Synchronous adenocarcinoma and carcinoid of the uterine cervix. Immunohistochemical study of a case and review of literature. *Gynecol Oncol*. 1990;33:125-128.
386. Mullins JD, Hilliard GD. Cervical carcinoid ('argyrophil cell' carcinoma) associated with an endocervical adenocarcinoma. A light and ultrastructural study. *Cancer*. 1981;47:785-790.
387. Silva EG, Kott MM, Ordonez NG. Endocrine carcinoma intermediate cell type of the uterine cervix. *Cancer*. 1984;54:1705-1713.
388. Albores-Saavedra J, Latif S, Carrick KS, et al. CD56 reactivity in small cell carcinoma of the uterine cervix. *Int J Gynecol Pathol*. 2005;24:113-117.
389. Ueda G, Shimizu C, Shimizu H, et al. An immunohistochemical study of small-cell and poorly differentiated carcinomas of the cervix using neuroendocrine markers. *Gynecol Oncol*. 1989;34:164-169.
390. Ueda G, Yamasaki M, Inoue M, et al. Immunohistochemical demonstration of HNK-1-defined antigen in gynecologic tumors with argyrophilia. *Int J Gynecol Pathol*. 1986;5:143-150.
391. Ulich TR, Liao S-Y, Layfield L, et al. Endocrine and tumor differentiation markers in poorly differentiated small cell carcinoids of the cervix and vagina. *Arch Pathol Lab Med*. 1986;110:1054-1057.
392. McCluggage WG, Kennedy K, Busam KJ. An immunohistochemical study of cervical neuroendocrine carcinomas: neoplasms that are commonly TTF1 positive and which may express CK20 and P63. *Am J Surg Pathol*. 2010;34:525-532.
393. Horn LC, Lindner K, Szepankiewicz G, et al. p16, p14, p53, and Cyclin D1 expression and HPV analysis in small cell carcinomas of the uterine cervix. *Int J Gynecol Pathol*. 2006;25:182-186.
394. Ishida GM, Kato N, Hayasaka T, et al. Small cell neuroendocrine carcinomas of the uterine cervix: a histological, immunohistochemical, and molecular genetic study. *Int J Gynecol Pathol*. 2004;23:366-372.
395. Wang HL, Lu DW. Detection of human papillomavirus DNA and expression of p16, Rb, and p53 proteins in small cell carcinomas of the uterine cervix. *Am J Surg Pathol*. 2004;28:901-908.
396. Sevin BU, Method MW, Nadji M, et al. Efficacy of radical hysterectomy as treatment for patients with small cell carcinoma of the cervix. *Cancer*. 1996;77:1489-1493.

For personal use only. No other uses without permission. Copyright ©2017. Elsevier Inc. All rights reserved.

397. Gersell DJ, Mazoujian G, Mutch DG, Rudloff MA. Small-cell undifferentiated carcinoma of the cervix. A clinicopathologic, ultrastructural, and immunocytochemical study of 15 cases. *Am J Surg Pathol*. 1988;12:684-698.
398. Johannessen JV, Capella C, Solcia E, et al. Endocrine cell carcinoma of the uterine cervix. *Diagn Gynecol Obstet*. 1980;2:127-134.
399. Miller B, Dockter M, el Torky M, Photopulos G. Small cell carcinoma of the cervix: a clinical and flow-cytometric study. *Gynecol Oncol*. 1991;42:27-33.
400. Chan JK, Loizzi V, Burger RA, et al. Prognostic factors in neuroendocrine small cell cervical carcinoma: a multivariate analysis. *Cancer*. 2003;97:568-574.
401. Albores-Saavedra J, Martinez-Benitez B, Luevano E. Small cell carcinomas and large cell neuroendocrine carcinomas of the endometrium and cervix: polypoid tumors and those arising in polyps may have a favorable prognosis. *Int J Gynecol Pathol*. 2008;27:333-339.
402. http://nih.techriver.net.
403. Koss LG. *Diagnostic Cytology and its Histopathologic Bases*. 3rd ed. Philadelphia: J.B. Lippincott; 1979.
404. Schneider V, Henry MR, Jimenez-Ayala M, et al. Cervical cancer screening, screening errors, and reporting. *Acta Cytol*. 2001;45:493-498.
405. Ducatman BS, Wang HH. *The PAP Smear: Controversies in Practice*. London: Arnold; 2002.
406. Nguyen GK, Nguyen-Ho P, Husain M, Husain EM. Cervical squamous cell carcinoma and its precursor lesions: cytodiagnostic criteria and pitfalls. *Anat Pathol*. 1998;1:139-164.
407. Christopherson WM, Scott MA. Trends in mortality from uterine cancer in relation to mass screening. *Acta Cytol*. 1977;21:5-9.
408. Davey DD, Gallion H, Jennings CD. DNA cytometry in postirradiation cervical-vaginal smears. *Hum Pathol*. 1992;23:1027-1031.
409. Pirog EC, Baergen RN, Soslow RA, et al. Diagnostic accuracy of cervical low-grade squamous intraepithelial lesions is improved with MIB-1 immunostaining. *Am J Surg Pathol*. 2001;26:70-75.
410. Zeng Z, Del Priore G, Cohen JM, Mittal K. MIB-1 expression in cervical Papanicolau tests correlates with dysplasia in subsequent cervical biopsies. *Appl Immunohistochem Mol Morphol*. 2002;10:15-19.
411. Schledermann D, Andersen BT, Bisgaard K, et al. Are adjunctive markers useful in routine cervical cancer screening? Application of p16(INK4a) and HPV-PCR on ThinPrep samples with histological follow-up. *Diagn Cytopathol*. 2008;36:453-459.
412. Kinney W, Stoler MH, Castle PE. Special commentary: patient safety and the next generation of HPV DNA tests. *Am J Clin Pathol*. 2010;134:193-199.
413. Wright TC Jr, Stoler MH, Sharma A, et al. Evaluation of HPV-16 and HPV-18 genotyping for the triage of women with high-risk HPV+ cytology-negative results. *Am J Clin Pathol*. 2011;36:578-586.
414. Wright TC Jr, Stoler MH, Behrens CM, et al. Interlaboratory variation in the performance of liquid-based cytology: insights from the ATHENA trial. *Int J Cancer*. 2014;134:1835-1843.
415. Wright TC, Stoler MH, Behrens CM, et al. Primary cervical cancer screening with human papillomavirus: end of study results from the ATHENA study using HPV as the first-line screening test. *Gynecol Oncol*. 2015;136:189-197.
416. Seybolt JF. Thoughts on 'the numbers game. *Acta Cytol*. 1968;12:271-273.
417. Seybolt JF, Johnson WD. Cervical cytodiagnostic problems. A survey. *Am J Obstet Gynecol*. 1971;109:1089-1103.
418. Luff RD. The Bethesda System for reporting cervical/vaginal cytologic diagnoses. Report of the 1991 Bethesda workshop. The Bethesda System Editorial Committee. *Hum Pathol*. 1992;23:719-721.
419. Solomon D. The Bethesda Sytem for reporting cervical/vaginal cytologic diagnosis. An overview. *Int J Gynecol Pathol*. 1991;10:323-325.
420. The Bethesda System for reporting cervical/vaginal cytologic diagnosis: revised after the second National Cancer Institute Workshop, April 29–30, 1991. *Acta Cytol*. 1993;37:115-124.
421. Bonfiglio TA. Atypical squamous cell of undetermined significance: a continuing controversy. *Cancer*. 2002;96:125-127.
422. Herbst AL. The Bethesda System for cervical/vaginal cytologic diagnoses. A note of caution [editorial]. *Obstet Gynecol*. 1990;76:449-450.
423. Smith JH. Bethesda 2001. *Cytopathology*. 2002;13:4-10.
424. Solomon D, Davey D, Kurman R, et al. The 2001 Bethesda System: terminology for reporting results of cervical cytology. *JAMA*. 2002;287:2114-2119.
425. Wright TC Jr, Cox JT, Massad LS, et al. 2001 Consensus Guidelines for the management of women with cervical cytological abnormalities. *JAMA*. 2002;287:2120-2129.
426. Brand E, Berek JS, Nieberg RK, Hacker NF. Rhabdomyosarcoma of the uterine cervix. Sarcoma botryoides. *Cancer*. 1987;60:1552-1560.
427. Copeland LJ, Gershenson DM, Saul PB, et al. Sarcoma botryoides of the female genital tract. *Obstet Gynecol*. 1985;66:262-266.
428. Loughlin KR, Retik AB, Weinstein HJ, et al. Genitourinary rhabdomyosarcoma in children. *Cancer*. 1989;63:1600-1606.
429. Daya DA, Scully RE. Sarcoma botryoides of the uterine cervix in young women: a clinicopathological study of 13 cases. *Gynecol Oncol*. 1988;29:290-304.
430. Rivasi F, Botticelli L, Bettelli SR, Masellis G. Alveolar rhabdomyosarcoma of the uterine cervix. A case report confirmed by FKHR break-apart rearrangement using a fluorescence in situ hybridization probe on paraffin-embedded tissues. *Int J Gynecol Pathol*. 2008;27:442-446.
431. Clement PB, Zubovits JT, Young RH, Scully RE. Malignant mullerian mixed tumors of the uterine cervix: a report of nine cases of a neoplasm with morphology often different from its counterpart in the corpus. *Int J Gynecol Pathol*. 1998;17:211-222.
432. Mathoulin-Portier MP, Pernault-Llorca F, Labit-Bouvier C, et al. Malignant mullerian mixed tumor of the uterine cervix and adenoid cystic component. *Int J Gynecol Pathol*. 1998;17:91-92.
433. Gallardo A, Prat J. Mullerian adenosarcoma: a clinicopathologic and immunohistochemical study of 55 cases challenging the existence of adenofibroma. *Am J Surg Pathol*. 2009;33:278-288.
434. Jones MW, Lefkowitz M. Adenosarcoma of the uterine cervix. A clinicopathological study of 12 cases. *Int J Gynecol Pathol*. 1995;14:223-229.
435. Hirschfield L, Kahn LB, Chen S, et al. Müllerian adenosarcoma with ovarian sex cord-like differentiation. *Cancer*. 1986;57:1197-1200.
436. Tiltman AJ. Leiomyomas of the uterine cervix: a study of frequency. *Int J Gynecol Pathol*. 1998;17:231-234.
437. Fraga M, Prieto O, Garcia-Caballero T, et al. Myxoid leiomyosarcoma of the uterine cervix. *Histopathology*. 1994;25:381-383.
438. Grayson W, Fourie J, Tiltman AJ. Xanthomatous leiomyosarcoma of the uterine cervix. *Int J Gynecol Pathol*. 1998;17:89-90.
439. Hanai J, Tsuji M. Uterine teratoma with lymphoid hyperplasia. *Acta Pathol Jpn*. 1981;31:153-159.
440. Khoor A, Fleming MV, Purcell CA, et al. Mature teratoma of the uterine cervix with pulmonary differentiation. *Arch Pathol Lab Med*. 1995;119:848-850.
441. Siddon A, Hui P. Glial heterotopia of the uterine cervix: DNA genotyping confirmation of its fetal origin. *Int J Gynecol Pathol*. 2010;29:394-397.
442. Luevano-Flores E, Sotelo J, Tena-Suck M. Glial polyp (glioma) of the uterine cervix. Report of a case with demonstration of glial fibrillary acidic protein. *Gynecol Oncol*. 1985;21:385-390.
443. Copeland LJ, Sneige N, Ordonez NG, et al. Endodermal sinus tumor of the vagina and cervix. *Cancer*. 1985;55:2558-2565.
444. Lee JD, Chang TC, Lai YM, et al. Choriocarcinoma of the cervix. *Acta Obstet Gynecol Scand*. 1992;71:479-481.
445. Yamazawa K, Ishikura H, Matsui H, et al. Sebaceous carcinoma of the uterine cervix: a case report. *Int J Gynecol Pathol*. 2002;22:92-94.
446. Bell DA, Shimm DS, Gang DL. Wilms' tumor of the endocervix. *Arch Pathol Lab Med*. 1985;109:371-373.
447. Barua R. Post-cone biopsy traumatic neuroma of the uterine cervix. *Arch Pathol Lab Med*. 1989;113:945-947.
448. Tiltman AJ, Duffield MS. Postpartum microneuromas of the uterine cervix. *Histopathology*. 1996;28:153-156.
449. Gersell DJ, Fulling KH. Localized neurofibromatosis of the female genitourinary tract. *Am J Surg Pathol*. 1989;13:873-878.
450. Gwavava NJ, Traub AL. A neurilemmoma of the cervix. *Br J Obstet Gynaecol*. 1980;87:444-446.
451. Terzakis JA, Opher E, Melamed J, et al. Pigmented melanocytic schwannoma of the uterine cervix. *Ultrastruct Pathol*. 1990;14:357-366.
452. Bernstein HB, Broman JH, Apicelli A, Kredentser DC. Primary malignant schwannoma of the uterine cervix: a case report and literature review. *Gynecol Oncol*. 1999;74:288-292.
453. Keel SB, Clement PB, Prat J, Young RH. Malignant schwannoma of the uterine cervix: a study of three cases. *Int J Gynecol Pathol*. 1998;17:223-230.
454. Rahimi K, Shaw PA, Chetty R. Solitary fibrous tumor of the uterine cervix. *Int J Gynecol Pathol*. 2010;29:189-192.
455. Sobel N, Carcangiu ML. Primary pigmented neuroectodermal tumor of the uterine cervix. *Int J Surg Pathol*. 1994;2:31-36.
456. Deppisch LM. Cervical melanosis. *Obstet Gynecol*. 1983;62:525-526.
457. Gibbons D, Lindberg GM, Ashfaq R, Saboorian MH. Localized amyloidosis of the uterine cervix. *Int J Gynecol Pathol*. 1998;17:368-371.
458. Yilmaz AG, Chandler P, Hahm GK, et al. Melanosis of the uterine cervix: a report of two cases and discussion of pigmented cervical lesions. *Int J Gynecol Pathol*. 1999;18:73-76.
459. Patel DS, Bhagavan BS. Blue nevus of the uterine cervix. *Hum Pathol*. 1985;16:79-86.
460. Uehara T, Izumo T, Kishi K, et al. Stromal melanocytic foci ('blue nevus') in step sections of the uterine cervix. *Acta Pathol Jpn*. 1991;41:751-756.
461. Zevallos-Giampietri EA, Barrionuevo C. Common blue nevus of the uterine cervix: case report and review. *Appl Immunohistochem Mol Morphol*. 2004;12:79-82.

For personal use only. No other uses without permission. Copyright ©2017. Elsevier Inc. All rights reserved.

462. Clark KC, Butz WR, Hapke MR. Primary malignant melanoma of the uterine cervix: case report with world literature review. *Int J Gynecol Pathol*. 2002;18:265-273.
463. Kristiansen SB, Anderson R, Cohen DM. Primary malignant melanoma of the cervix and review of the literature. *Gynecol Oncol*. 1992;47:398-403.
464. Ishikura H, Kojo T, Ichimura H, Yoshiki T. Desmoplastic malignant melanoma of a uterine cervix: a rare primary malignancy in the uterus mimicking a sarcoma. *Histopathology*. 1998;33:93-94.
465. Pusceddu S, Bajetta E, Buzzoni R, et al. Primary uterine cervix melanoma resembling malignant peripheral nerve sheath tumor: a case report. *Int J Gynecol Pathol*. 2008;27:596-600.
466. Volpe R, Canzonieri V, Gloghini A, Carbone A. 'Lipoleiomyoma with metaplastic cartilage' (benign mesenchymoma) of the uterine cervix. *Pathol Res Pract*. 1992;188:799-801.
467. Kondi-Pafiti A, Kairi-Vassilatou E, Spanidou-Carvouni H, et al. Vascular tumors of the female genital tract: a clinicopathological study of nine cases. *Eur J Gynaecol Oncol*. 2003;24:48-50.
468. Albores-Saavedra J, Gilcrease M. Glomus tumor of the uterine cervix. *Int J Gynecol Pathol*. 1999;18:69-72.
469. Clement PB. Miscellaneous primary tumors and metastatic tumors of the uterine cervix. *Semin Diagn Pathol*. 1990;7:228-248.
470. Bloch T, Roth LM, Stehman FB, et al. Osteosarcoma of the uterine cervix associated with hyperplastic and atypical mesonephric rests. *Cancer*. 1988;62:1594-1600.
471. Foschini MP, Eusebi V, Tison V. Alveolar soft part sarcoma of the cervix uteri. A case report. *Pathol Res Pract*. 1989;184:354-358.
472. Nielsen GP, Oliva E, Young RH, et al. Alveolar soft-part sarcoma of the female genital tract. A report of nine cases and review of the literature. *Int J Gynecol Pathol*. 1995;14:283-292.
473. Sahin AA, Silva EG, Ordonez NG. Alveolar soft part sarcoma of the uterine cervix. *Mod Pathol*. 1989;2:676-680.
474. Cenacchi G, Pasquinelli G, Montanaro L, et al. Primary endocervical extaosseous Ewing's sarcoma/ PNET. *Int J Gynecol Pathol*. 1998;17:83-88.
475. Ferry JA, Young RH. Malignant lymphoma, pseudolymphoma, and hematopoietic disorders of the female genital tract. *Pathol Annu*. 1991;26(Pt 1):227-263.
476. Malpica A, Moran CA. Primitive neuroectodermal tumor of the cervix: a clinicopathologic and immunohistochemical study of two cases. *Ann Diagn Pathol*. 2002;6:281-287.
477. Lagoo AS, Robboy SJ. Lymphoma of the female genital tract: current status. *Int J Gynecol Pathol*. 2006;25:1-21.
478. Aozasa K, Saeki K, Ohsawa M, et al. Malignant lymphoma of the uterus. Report of seven cases with immunohistochemical study. *Cancer*. 1993;72:1959-1964.
479. Moore WF, Bentley RC, Kim KR, et al. Goblet-cell mucinous epithelium lining the endometrium and endocervix: evidence of a metastasis from an appendiceal primary tumor through the use of cytokeratin-7 and -20 immunostains. *Int J Gynecol Pathol*. 1998;17:363-367.
480. Kosari F, Daneshbod Y, Parwaresch R, et al. Lymphomas of the female genital tract: a study of 186 cases and review of the literature. *Am J Surg Pathol*. 2005;29:1512-1520.
481. Perren T, Farrant M, McCarthy K, et al. Lymphomas of the cervix and upper vagina: a report of five cases and a review of the literature. *Gynecol Oncol*. 1992;44:87-95.
482. Ma J, Shi QL, Zhou XJ, et al. Lymphoma-like lesion of the uterine cervix: report of 12 cases of a rare entity. *Int J Gynecol Pathol*. 2007;26:194-198.
483. Young RH, Harris NL, Scully RE. Lymphoma-like lesions of the lower female genital tract. A report of 16 cases. *Int J Gynecol Pathol*. 1985;4:289-299.
484. Geyer JT, Ferry JA, Harris NL, et al. Florid reactive lymphoid hyperplasia of the lower female genital tract (lymphoma-like lesions): a benign condition that frequently harbors clonal immunoglobulin heavy chain gene rearrangements. *Am J Surg Pathol*. 2010;34:161-168.
485. Abeler V, Kjorstad KE, Langholm R, Marton PF. Granulocytic sarcoma (chloroma) of the uterine cervix. Report of two cases. *Int J Gynecol Pathol*. 1983;2:88-92.
486. Garcia MG, Deavers MT, Knoblock RJ, et al. Myeloid sarcoma involving the gynecologic tract: a report of 11 cases and review of the literature. *Am J Clin Pathol*. 2006;125: 783-790.
487. Seo IS, Hull MT, Pak HY. Granulocytic sarcoma of the cervix as a primary manifestation. Case without overt leukemic features for 26 months. *Cancer*. 1977;40:3030-3037.
488. Abenoza P, Shek Y, Perrone T. Inflammatory pseudotumor of the cervix. *Int J Gynecol Pathol*. 1994;13:80-86.
489. Murray J, Fox H. Rosai–Dorfman disease of the uterine cervix. *Int J Gynecol Pathol*. 1991;10:209-213.
490. Imachi M, Tsukamoto N, Amagase H, et al. Metastatic adenocarcinoma to the uterine cervix from gastric cancer. A clinicopathologic analysis of 16 cases. *Cancer*. 1993;71:3472-3477.
491. Lemoine NR, Hall PA. Epithelial tumors metastatic to the uterine cervix. A study of 33 cases and review of the literature. *Cancer*. 1986;57:2002-2005.
492. McCluggage WG, Hurrell DP, Kennedy K. Metastatic carcinomas in the cervix mimicking primary cervical adenocarcinoma and adenocarcinoma in situ: report of a series of cases. *Am J Surg Pathol*. 2010;34:735-741.

For personal use only. No other uses without permission. Copyright ©2017. Elsevier Inc. All rights reserved.

33 Uterus: Corpus

Blake Gilks

CHAPTER CONTENTS

Normal anatomy, *1294*
Effects of hormone administration, *1296*
Estrogen therapy, *1296*
Progestational agents, *1296*
Tamoxifen, *1297*
Endometritis, *1297*
Metaplasia, *1298*
Adenomyosis and endometriosis, *1300*
Dysfunctional uterine bleeding, *1302*
Endometrial hyperplasia without atypia, atypical hyperplasia, and variants, *1303*
Curettage and biopsy, *1305*
Tumors, *1306*
Endometrial polyps, *1306*
Endometrial carcinoma, *1306*
Endometrial stromal tumors, *1318*
Müllerian adenosarcoma and related tumors, *1322*
Leiomyoma, *1323*
Leiomyosarcoma, *1328*
PEComa, *1331*
Inflammatory myofibroblastic tumor, *1331*
Gestational trophoblastic neoplasia, *1332*
Other tumors and tumorlike conditions, *1338*

Normal Anatomy

The adult nulliparous uterus is a hollow, pear-shaped organ that weighs 40–80 g and measures 7–8 cm along its longest axis. It is divided into the *cervix* (discussed in Chapter 32) and the *corpus*. The portion of the corpus cephalad to a line connecting the insertion of the fallopian tubes is the *fundus*. The two lateral regions of the fundus associated with the intramural portion of the fallopian tubes are referred to as the *cornua*. The portion of the corpus that connects with the cervix is called the *isthmus* or *lower uterine segment*.

The uterine cavity has a triangular shape and a length of approximately 6 cm. It is lined by the endometrial mucosa, which constitutes the inner layer (endometrium) of the organ. It is surrounded by a thick muscular layer (myometrium) and a serosal covering, the latter extending to the point of peritoneal reflection. Two useful clues to distinguish the anterior from the posterior side of a hysterectomy specimen at time of gross examination are: (1) the fact that the point of peritoneal reflection is *lower* on the posterior side; and (2) the fact that the uterine insertion of the fallopian tube is *posterior* to the insertion of the round ligament.[1]

The uterine lymph vessels drain to a rich network of lymph nodes, the main groups being parametrial and paracervical; internal (hypogastric), external, and common iliac; periaortic; and inguinal.

The endometrial mucosa is made up of glands and stroma. It is divided into a deeply seated *basal* layer and a superficial *functional* layer. The basal layer is the equivalent of the reserve cell layer of other epithelia and is responsible for the regeneration of the endometrium following menstruation. It is made up of weakly proliferative glands and spindled stroma. The functional layer is subdivided into two strata, the *compactum* (toward the surface) and the *spongiosum* (close to the basalis). The stroma is mainly composed of endometrial stromal cells (whose appearance changes considerably during the menstrual cycle, see later section) and vessels (of which the spiral arterioles are the most distinctive). Also present are stromal granulocytes. The immunohistochemical profile of endometrial stromal cells is "CD10 dominant" in relation to CD34, whereas the reverse is true for the endocervical stroma.[2] The phenotypic profile of the endometrial glands will be discussed in connection with the various pathologic conditions that affect that tissue[3,4]; suffice to warn the reader that two markers associated with breast and lung/thyroid—that is, mammaglobin and thyroid transcription factor-1 (TTF-1), respectively—can be expressed by endometrial cells.[5,6]

During childbearing age, the normal endometrium undergoes a series of sequential changes in the course of the ovulatory cycle that prepare it to receive the ovum (Fig. 33.1).[7] If the ovum is not fertilized, the proliferative endometrium is cast off by menstruation, and the cycle repeats itself. A normal endometrial cycle is associated with changes in both endometrial glands and stroma that allow the pathologist to diagnose microscopically the phase of the menstrual cycle.[8] In a series of classic articles, Noyes and colleagues.[9,10] set forth specific criteria by which a relatively accurate dating of the endometrium was made possible (Fig. 33.2). At one time it was common for pathologists to be asked to "date" endometrial biopsy specimens (i.e. assess the development of the endometrial glands and stroma, relative to the time of ovulation) that were taken for investigation of infertility, but such requests have dramatically decreased over the

For personal use only. No other uses without permission. Copyright ©2017. Elsevier Inc. All rights reserved.

Abstract

Endometrial biopsy and curetting specimens are among the most commonly encountered in general surgical pathology practice and can show a wide range of pathologic alterations. Many relate to perturbations in the normal hormonal environment, secondary exogenous hormones or shifts in endogenous hormone levels, for example, during the perimenopausal period. Endometrial carcinoma is the most common malignancy of the female reproductive organs and recent insights into the genomic subtypes of endometrial cancer have changed our understanding of the pathogenesis of endometrial carcinoma. As well as carcinomas, a range of sarcomas and biphasic tumors, such as adenosarcoma, also occur in the uterine corpus, and these are reviewed.

Keywords

Endometrium
hyperplasia
carcinoma
leiomyosarcoma
endometrial stromal sarcoma
The cancer genome atlas

For personal use only. No other uses without permission. Copyright ©2017. Elsevier Inc. All rights reserved.

past decade; nevertheless all surgical pathologists should be familiar with the normal cyclical changes in the endometrium.

In general, the changes are quite uniform throughout the functional endometrium.[9] The surface epithelium is less responsive to the hormonal influences than the glandular epithelium. For subnuclear vacuolation to be regarded as evidence of ovulation, it should be present in at least 50% of the functional glands present in the section, as patchy development of subnuclear vacuoles is a common finding in endometrium subject to prolonged unopposed estrogenic stimulation (so-called disordered proliferative endometrium). Neutrophils, which are seen in large numbers in areas of tissue degradation (beginning on day 26) are very rare during the other days of the cycle; they should be distinguished from the already mentioned stromal granulocytes, which do not stain for chloroacetate esterase.[11]

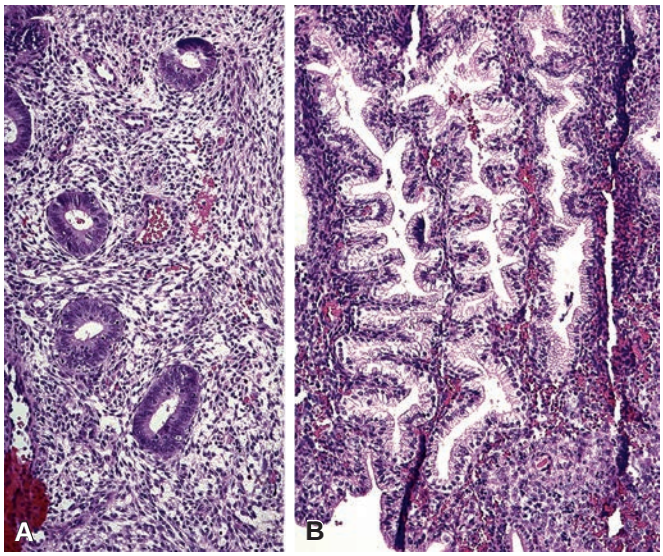

Figure 33.1 Normal Endometrium. A, Proliferative; **B,** secretory.

The cellular condensation with nuclear crowding, squamoid appearance, and focal cytoplasmic eosinophilia seen in menstrual specimens should not be confused with a malignant or other pathologic process. The possibility of overdiagnosis is even greater in the rare instances in which the menstrual endometrium is seen within the lumen of blood vessels.[12] It should be noted that endometrial tissue can also be found in myometrial vessels independently from menstruation.[13]

The basal layer of the endometrium is not subject to the influence of progesterone. Similarly, the mucosa of the lower uterine segment responds only sluggishly to the hormonal stimulation and can appear different from sampled functionalis.[14] This mucosa gradually merges with that of the endocervix; the hybrid endometrial–endocervical appearance of both glands and stroma allows its recognition in endometrial sampling (either biopsy or dilation and curettage [D&C] specimens).

The reappearance of glandular secretion and stromal edema once predecidual reaction is established—leading to the simultaneous presence of these three features in an endometrial specimen—is evidence that a fertilized ovum has implanted. An exaggerated expression of this pregnancy-related phenomenon is the ***Arias-Stella reaction***, as originally described by the Peruvian pathologist Javier Arias-Stella.[15] In this condition, secretory or proliferative changes in the endometrial glands are accompanied by prominent nuclear changes, manifested by hyperchromasia and marked enlargement (Fig. 33.3). Normal and abnormal mitoses may also be present.[16] These changes are almost always focal and may also occur in the cervix, endocervical polyps, adenomyosis, and endometriosis.[17] They are more often seen in postabortion curettings (present in 20%–70% of cases and persisting for weeks), but they are also seen in normal orthotopic or ectopic pregnancies, hydatidiform mole, choriocarcinoma, and (very rarely) following the administration of exogenous hormones.[18,20] In hydatidiform mole and choriocarcinoma, the nuclei of the endometrial cells may attain gigantic sizes. The most important

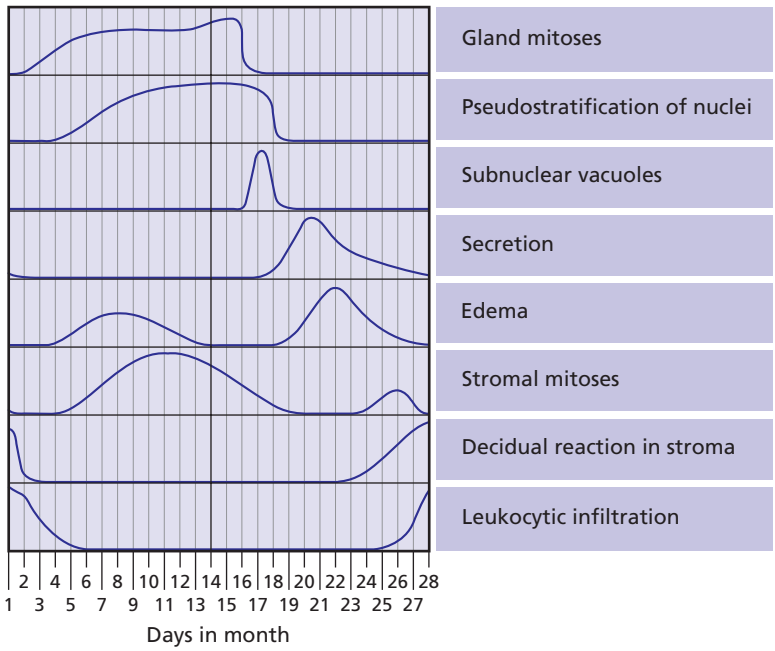

Figure 33.2 Cyclic Changes in Endometrium. Approximate relationship of microscopic changes. (From American Society for Reproductive Medicine. Noyes RW, Hertig AT, Rock J. Dating the endometrial biopsy. *Fertil Steril*. 1950;1:3–25).

For personal use only. No other uses without permission. Copyright ©2017. Elsevier Inc. All rights reserved.

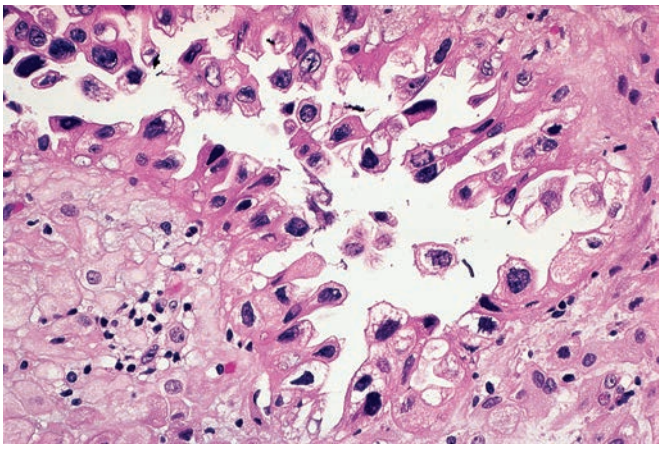

Figure 33.3 Arias-Stella Reaction in Endometrial Mucosa. This is not to be confused with a malignant condition.

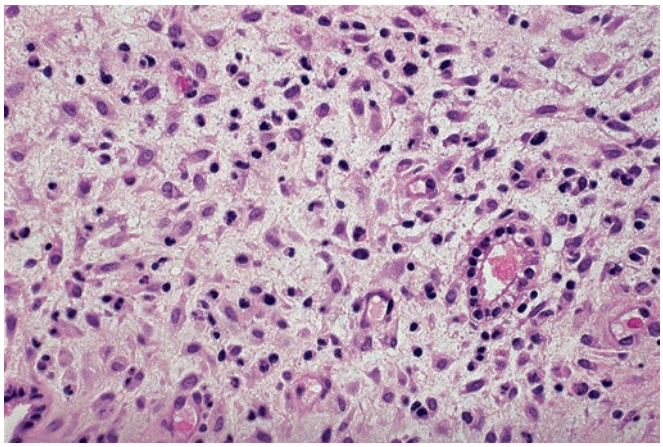

Figure 33.4 Typical appearance of endometrium after long-term administration of contraceptive pills. The glands are sparse and atrophic, whereas the stroma is prominent and has deciduoid features, reflecting the predominant progestin effect.

differential diagnosis is with serous and clear cell types of endometrial adenocarcinoma. Immunostains for Ki-67 and p53 are helpful in this regard, their being usually low and wild type–pattern, respectively, in the Arias-Stella reaction.[21]

Another interesting pregnancy-related endometrial alteration (often associated with the Arias-Stella reaction) is the focal appearance of optically clear nuclei in the glandular cells, simulating viral inclusions; these are due to the replacement of normal chromatin by a fine filamentous network that is immunoreactive for biotin.[22–24]

Exceptionally, an "idiopathic" decidual reaction is seen in the postmenopausal endometrium in the absence of an exogenous or endogenous source of progesterone excess.[25]

After the menopause the endometrium becomes inactive (simple glands lined by metabolically inactive, non-mitotic cuboidal epithelial cells and associated stroma) or atrophic (strips of inactive surface epithelial cells with no or minimal stroma). These glands may become cystically dilated (cystic atrophy), but the lining cells have an atrophic appearance, in contrast to the proliferative columnar cells lining cystic glands in endometrial hyperplasia without atypia. Although a distinction can be made between inactive and atrophic endometrium histologically, based on the presence or absence of endometrial stroma, it is not clinically relevant. Endometrial biopsy for postmenopausal bleeding is one of the most common specimens encountered in practice, with most such specimens showing the expected inactive/atrophic endometrium. In most series, approximately 5%–15% of the cases of postmenopausal bleeding are due to endometrial carcinoma and a similar proportion to endometrial polyps.[26,27] Degenerative and other changes in the endometrial blood vessels have been suggested as a possible etiology in the majority of cases where no significant pathology is identified (i.e. there is only the expected inactive/atrophic endometrium).[28,29]

The myometrium has a rich network of thick-walled vessels in its midportion, a landmark that can be recognized grossly. A peculiar vascular architecture sometimes encountered in the myometrium is that of arteries apparently free-floating within cleft-like spaces, which have been interpreted as venous channels.[30]

Effects of Hormone Administration

Estrogen Therapy

Exogenous administration of estrogen preparations exposes the cycling or postmenopausal endometrium to a potent stimulus.[31] Endometrial hyperplasia is a frequent development in women taking unopposed estrogen, and this can progress to atypical hyperplasia and adenocarcinoma.[32,33] The large majority of tumors arising secondary to unopposed estrogen are well differentiated and superficial and are associated with an excellent prognosis.[34]

Progestational Agents

Owing to the widespread use of progestational agents for therapeutic and contraceptive purposes, endometrial changes secondary to progestational effects are commonly encountered in practice.[35–37] The effects of exogenous progestins are seen primarily in the stroma, which predominates and shows striking pseudodecidual changes (Fig. 33.4).[38] In contrast to the prominent stromal development, the glands are small, widely separated by stroma, and atrophic appearing.

In endometrium from patients taking oral contraceptive pills, the effects in the endometrium reflect the progesterone predominance and variably show the features described previously, that is, stromal predominance, with pseudodecidual changes, and small atrophic glands.[39] On very rare occasions, focal glandular changes of the Arias-Stella type may appear in patients taking contraceptive pills. In most cases, discontinuation of the hormones results in a restoration of a normal endometrial pattern in a matter of weeks.

Patients receiving hormone replacement therapy for postmenopausal symptoms will typically be on low-dose combination (estrogen and progestin) therapy; the goal is to relieve symptoms but to not have stimulation of the endometrium. Thus, the endometrium should appear inactive or atrophic. If a patient on postmenopausal hormone replacement therapy presents with bleeding and the biopsy shows proliferative changes, this reflects excessive estrogenic stimulation of the endometrium; if the dosage is not altered, continued bleeding is likely.

Endometrial changes secondary to treatment of endometrial hyperplasia with high-dose progestin therapy will be covered later, in the section on endometrial hyperplasia.

The **Mirena coil (levonorgestrel)**, increasingly used for the treatment of menorrhagia/endometrial hyperplasia, can induce a large variety of alterations in the endometrial mucosa, including pseudodecidualization, mucinous changes, ulceration, inflammatory infiltrates, stromal hyaline nodules, superficial micropapillary changes, infarcted decidua, dystrophic calcification, and others.[40]

For personal use only. No other uses without permission. Copyright ©2017. Elsevier Inc. All rights reserved.

Progesterone receptor modulators used in the management of endometriosis and uterine leiomyomas most commonly cause only minimal and inconsistent changes in the endometrial mucosa but can cause cystic dilated glands that raise the differential diagnosis of endometrial hyperplasia.[41] These changes can be distinguished from hyperplasia by the appearance of the epithelial cells lining the cysts, which appear inactive and may contain abortive subnuclear vacuoles.[42] Abnormal stromal vessels are commonly seen.

Tamoxifen

Tamoxifen is a synthetic anti-estrogen used in the treatment and prophylaxis of breast carcinoma. Not only does it have an anti-estrogenic effect on the endometrium when competing with ovarian estrogen secretion, it also has a paradoxical estrogenic effect in the absence of ovarian estrogen secretion.[43–45] It is associated with an increased frequency of proliferative endometrial lesions, including hyperplasias, polyps, and malignant tumors,[46,47] but the latter are not seen often enough to justify routine endometrial biopsies in this population.[48] None of the changes associated with tamoxifen are pathognomonic[49] and, accordingly, biopsies taken from women receiving tamoxifen therapy are diagnosed using terminology and diagnostic criteria identical to those used for patients not on tamoxifen. With respect to endometrial carcinomas developing in patients on tamoxifen, in two reported series a significant number of the cases were high-grade tumors associated with a poor prognosis,[50–52] but in others there was a great predominance of low-grade endometrioid adenocarcinomas,[53] and the former studies may reflect some selection bias.

Endometritis

Acute endometritis is usually seen in association with abortion, the postpartum state, or instrumentation. Gonococcal endometritis is rarely seen by the pathologist because of its very transient nature. Before making a diagnosis of acute endometritis, the pathologist should remember that neutrophils are normally present in the endometrium on days 26, 27, and 28.[54]

Chronic endometritis, characterized by an infiltrate of lymphocytes and plasma cells (often with an additional minor component of eosinophils[55]), may follow pregnancy or abortion, be the result of an intrauterine device (IUD), be associated with a submucosal leiomyoma, or be accompanied by mucopurulent cervicitis and/or pelvic inflammatory disease (PID).[56,57] The presence of chronic endometritis is associated with infertility/recurrent implantation failure. There, is some evidence that antibiotic therapy in these patients can result in improved outcomes in subsequent in vitro fertilization cycles, thus it is an important and clinically actionable diagnosis.[58] The most common symptoms are vaginal bleeding and pelvic pain, but most patients are asymptomatic.[57] It should be emphasized that lymphoid follicles, with or without germinal centers, are a normal occurrence in the functional layers of the endometrial mucosa and, therefore, should not be considered as evidence of chronic endometritis.[59] Therefore, identification of plasma cells constitutes the most important criterion for the diagnosis of chronic endometritis, whether by conventional criteria or—as suggested by some—by immunostaining the sections for immunoglobulins,[60] CD38,[61] VS38,[61] or syndecan-1 (Fig. 33.5).[62] However, it should be kept in mind that scattered plasma cells can be found in the absence of endometritis[63] and the demonstration of rare plasma cells with immunostains should not lead to overdiagnosis of endometritis. Clearly there remains important work to be done in refining the diagnostic criteria for chronic endometritis. The possibility of inflammation should be suspected—and plasma cells searched for—whenever there is an abnormal cyclic pattern, a focal mononuclear infiltrate, inflammatory cells in the glandular lumina, dense stroma, a stellate stromal pattern of proliferation, or foci of necrosis or calcification (Fig. 33.6). Glandular alterations commonly accompany the inflammatory reaction. The presence of neutrophils in the endometrial surface is a good predictor of PID, especially if combined with plasma cells in the endometrial stroma.[64]

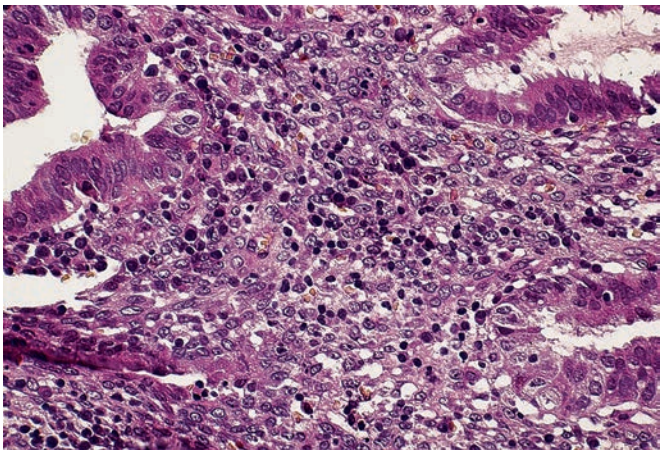

Figure 33.5 Chronic endometritis showing an inflammatory infiltrate rich in lymphocytes and plasma cells.

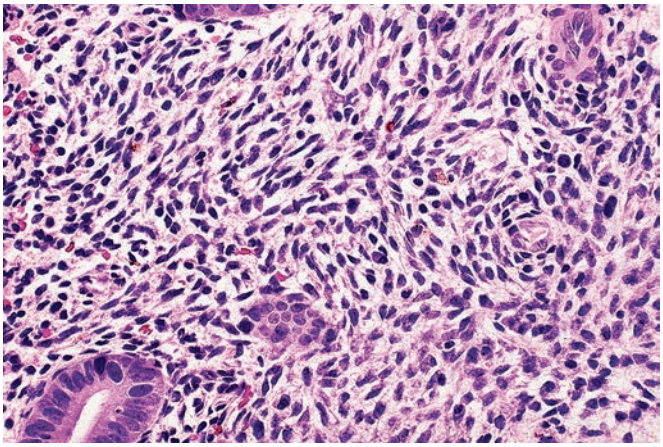

Figure 33.6 The oval to spindle and occasionally stellate shape of endometrial stromal cells is a clue to the diagnosis of chronic endometritis.

The myometrium is usually spared in most types of endometritis (sarcoidosis excluded, see later) unless the inflammation is very severe.

IUDs inserted for the purpose of contraception result in many biologic changes.[65,66] The most common change is focal or extensive chronic endometritis, which may be accompanied by necrosis and squamous metaplasia.[67,68] On occasion, the inflammation spreads through the fallopian tubes to produce PID and sometimes tubo-ovarian abscesses.[69,70] One of the agents involved in the inflammatory process is *Actinomyces* (Fig. 33.7).[71–73] The organisms can be detected in microscopic sections or in cytology preparations,[74] but care should be exercised in distinguishing them from pseudoactinomycotic radiate granules; the latter lack central branching filaments and diphtheroid forms.[75] The changes that can develop following the insertion of the Mirena coil were described in the previous section.

For personal use only. No other uses without permission. Copyright ©2017. Elsevier Inc. All rights reserved.

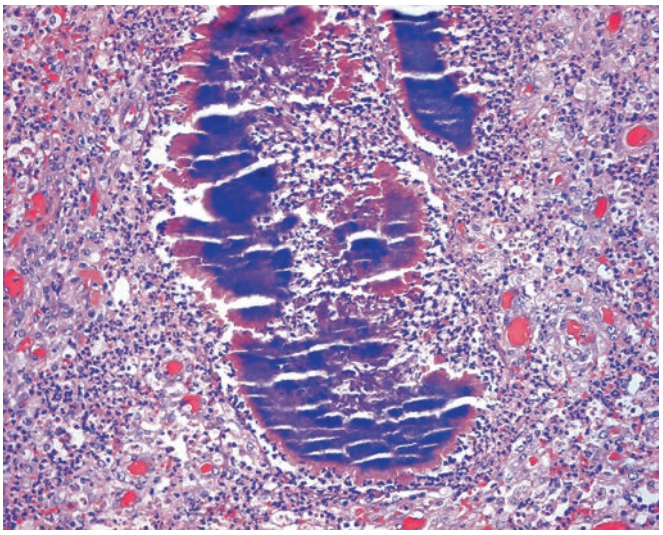

Figure 33.7 IUD-Related Uterine Actinomycosis. The disease had spread to the pelvic cavity.

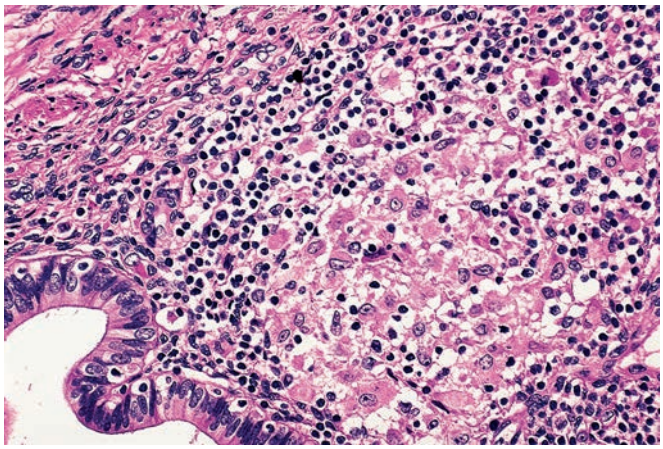

Figure 33.8 Noncaseating granuloma in endometrial mucosa consistent with sarcoidosis.

Pyometra refers to the accumulation of pus within the endometrial cavity. It is the consequence of the combined effect of obstruction and infection. Whiteley and Hamlett[76] reviewed 35 cases in postmenopausal patients. Only five were secondary to carcinoma; the remaining 30 were the result of benign cervical stricture originating from senile atresia, surgery, or cauterization.

Hematometra is the accumulation of blood within the endometrial cavity, usually as a result of cervical occlusion. This may lead to the disappearance of the endometrial mucosa and its replacement by sheets of lipid-containing histiocytic cells, a process known as *histiocytic* or *xanthogranulomatous endometritis* when diffuse and as *nodular histiocytic hyperplasia* when localized.[77,78] Sometimes the histiocytes are found to contain a yellowish-brown cytoplasmic pigment, in which case the term *ceroid-containing histiocytic granuloma* has been used.[79]

Endometrial tuberculosis is rare in the United States but still common in other parts of the world. Menstrual disturbances are common. The microscopic diagnosis is based on the demonstration of acid-fast bacilli in tubercles or culture. The presence of plasma cells and leukocytes probably results from secondary infection.[80] Tubercles may be missed unless multiple levels of curettings are examined. Since the granulomas tend to concentrate in the superficial functional layers of the endometrium, it is recommended that the biopsy be taken during the late secretory phase, and tissue should be submitted for culture as well as histopathologic examination.

Chlamydial infection has been identified through the immunohistochemical demonstration of chlamydial antigens in endometrial epithelial cells[81,82] or by polymerase chain reaction (PCR).[83] These cases are associated with severe acute and/or chronic inflammation. Plasma cells tend to be very numerous; as a matter of fact, it has been proposed that the presence of these cells is linked to *Chlamydia* infection.[84]

Viral infection of the endometrium is probably more common than generally suspected. Cytomegalovirus endometritis and diffuse papillomatosis (condyloma) have both been documented[85,86]; the former can have a granulomatous quality.[87]

Coccidioidomycosis of the uterus has been reported in the United States in a few cases as a localized infection; it probably results from a clinically inapparent and completely resolved primary lung infection.[88,89]

Postoperative granulomas of the endometrium have been described following endometrial ablation procedures; they may be thought of as the female counterpart of those seen in the prostate or bladder following transurethral resection (TUR).[90,91]

Malakoplakia of the endometrium has been reported, sometimes in a recurrent fashion and occasionally in association with endometrial adenocarcinoma.[92]

Sarcoidosis of the uterus occurs, but it remains a diagnosis of exclusion (Fig. 33.8).[93] In contrast to tuberculosis, the granulomatous reaction usually spreads to the myometrium.[94] Granulomatous endometritis can also follow hysteroscopic resection of the endometrium.[95]

Giant cell arteritis may involve the uterus and other genital organs of elderly women, either as an isolated finding (i.e. no systemic symptoms and normal acute phase reactants) or as part of a generalized process.[96–98] The former event is more frequent than the latter,[98] but sometimes female genital tract disease is the first manifestation of systemic periarteritis nodosa.[99] Over 90% of patients with isolated vasculitis of the myometrium have a nongranulomatous histology.[100]

Metaplasia

The endometrial glands and stroma are subject to a variety of metaplastic changes, many of them hormonally induced. They are often accompanied by hyperplastic changes in the endometrial glands but can occur independently from them and, therefore, need to be evaluated separately. They should not be regarded by themselves as evidence for the existence of a neoplastic process, but the presence of squamous metaplasia and mucinous metaplasia, in particular, should heighten awareness of the possibility of coexistent hyperplasia. Papillary syncytial and ciliated cell metaplasia are much less likely to be associated with hyperplasia. The endometrial metaplasias include:

1. **Squamous (morular) metaplasia**. This is most commonly encountered in hyperplastic endometrium but can be seen in association with leiomyoma or uterine polyps.[101] Frank keratinization is very rare *(ichthyosis uteri)*. A more common finding is the presence of nonkeratinizing squamoid cells occurring either diffusely (adenoacanthosis)[102] or in the form of berry-like aggregates (morules or morular metaplasia; Fig. 33.9).[103] Most are seen in premenopausal women, in those receiving exogenous hormones, or in association with polycystic ovary syndrome

For personal use only. No other uses without permission. Copyright ©2017. Elsevier Inc. All rights reserved.

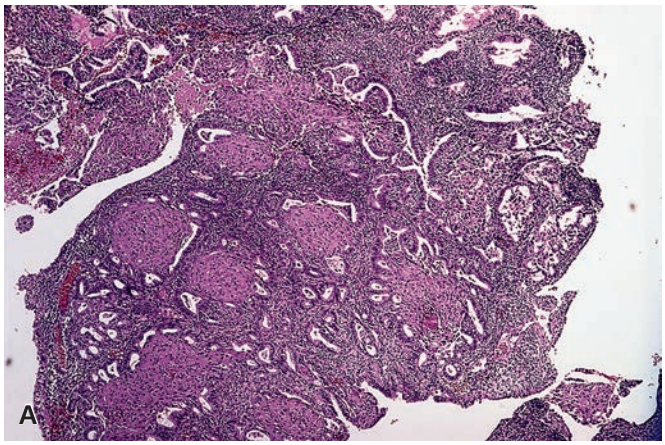

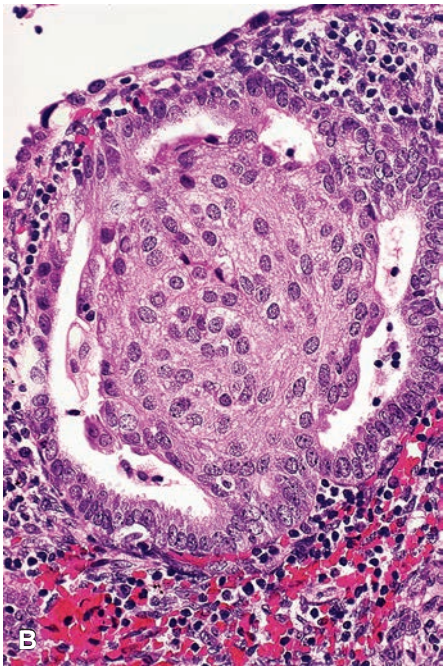

Figure 33.9 **A** and **B,** Squamous metaplasia of endometrium with morule formation.

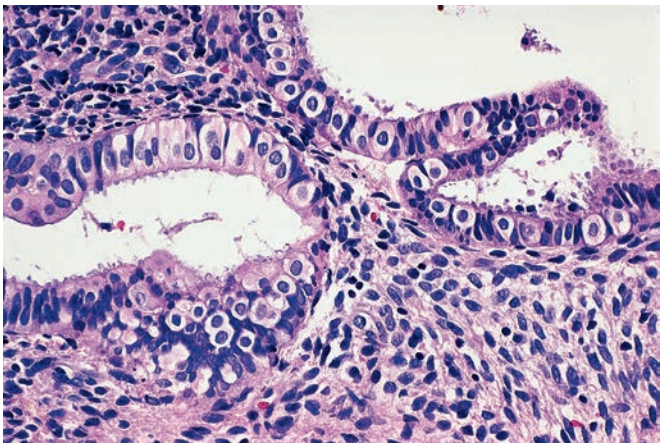

Figure 33.10 **Tubal Metaplasia of Endometrial Mucosa.** All three cell types that make up the normal mucosa of the fallopian tube can be recognized.

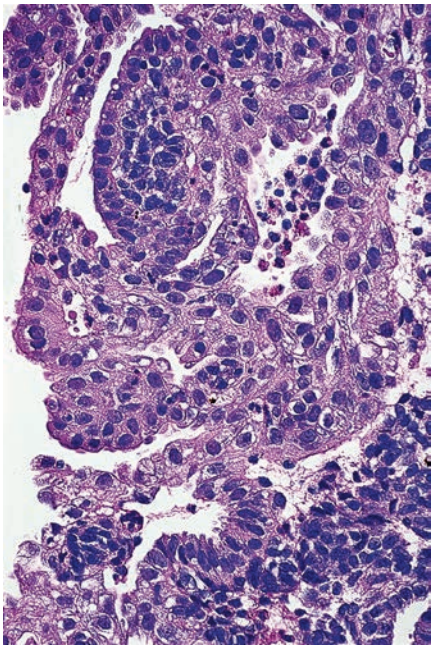

Figure 33.11 Papillary (syncytial) metaplasia of endometrium.

(PCOS).[104,105] This change is distinguished from well-differentiated endometrial adenocarcinoma with squamous metaplasia because of the benign appearance of the glandular elements, without glandular crowding or atypia. The morules represent a functionally inert tissue, in the sense of being devoid of sex hormone receptors and having an extremely low proliferation rate.[106] Surprisingly, they are immunoreactive for the intestinal transcription factor CDX2.[107]

2. **Ciliated cell (tubal) metaplasia**. Scattered ciliated cells are normally present in the endometrial mucosa; when markedly increased in number, the appearance resembles that of a fallopian tube, and the term listed earlier is used (Fig. 33.10).[108] Ciliated cell metaplasia is common in atrophic endometrium, to the point where it need not be commented on this setting. Occasionally the condition is associated with atypical nuclear features *("atypical tubal metaplasia")*, but even under these circumstances it does not seem to constitute a factor of significant risk for the development of endometrial adenocarcinoma.[109]
3. **Papillary syncytial metaplasia** (papillary syncytial change). This alteration is characterized by the presence of syncytial to papillary aggregates of eosinophilic cells along the surface epithelium (Fig. 33.11). It is often seen in association with endometrial breakdown.[110]
4. **Mucinous metaplasia**. In this condition, the endometrial mucosa reverts to a pattern morphologically, histochemically, and ultrastructurally similar to that of the endocervical mucosa (Fig. 33.12).[111,112] It is particularly common in endometrial polyps. The main differential diagnosis is with normal cervix or atypical mucinous proliferation of the endometrium/mucinous variant of endometrial adenocarcinoma.[113] With regards to the differential diagnosis with normal cervix, mucinous metaplasia can be recognized by its involvement of endometrial tissue (i.e. association with endometrial stromal cells and non-metaplastic endometrial glandular epithelium), and by the absence of reserve cells. Mucinous metaplasia should be focal, bland, and without glandular architectural features; in their presence a diagnosis of

For personal use only. No other uses without permission. Copyright ©2017. Elsevier Inc. All rights reserved.

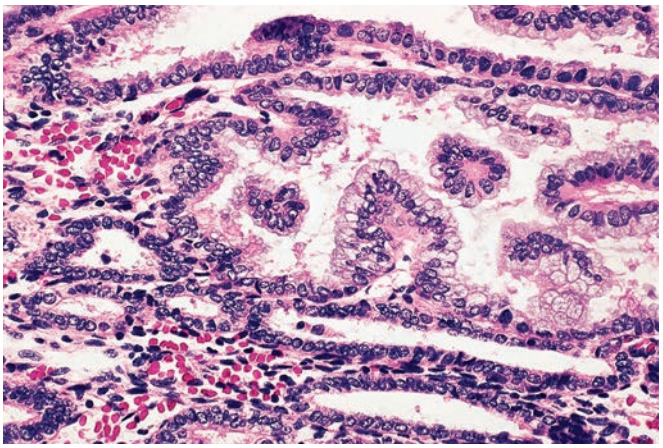

Figure 33.12 Mucinous Metaplasia of Endometrium. Note the basal location of the nuclei and the mucin-containing cytoplasm of the columnar cells.

Figure 33.14 Gross Appearance of Uterus Involved by Adenomyosis. The wall is irregularly thickened and contains small hemorrhagic foci.

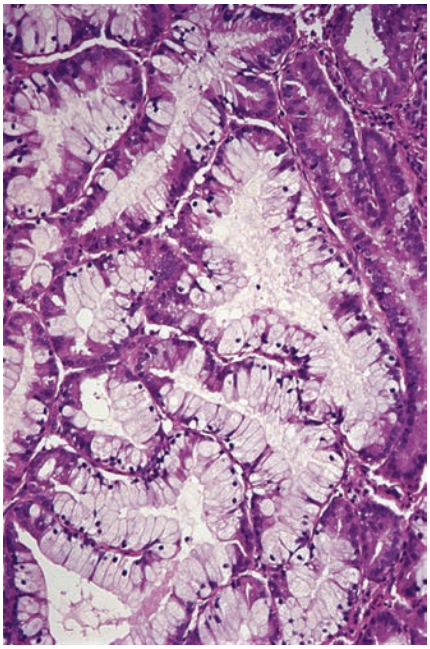

Figure 33.13 Clear Cell Metaplasia of Endometrium. The cytoplasm has a finely granular quality.

atypical mucinous glandular proliferation (discussed later) should be entertained.

5. **Eosinophilic (oxyphilic; oncocytic) metaplasia**. This is characterized by cells with abundant eosinophilic cytoplasm.[114] It is distinguished from atypical endometrial hyperplasia and the exceptionally rare oncocytic carcinoma by the absence of glandular crowding and atypical nuclear features.[115,116]
6. **Hobnail and clear cell metaplasia**. In these closely related metaplastic changes, the epithelium is clear, with tall cells having apically located nuclei (Fig. 33.13). The differential diagnosis is with clear cell (mesonephroid) adenocarcinoma.[115]
7. **Arias-Stella reaction.** See under Normal anatomy.
8. **Stromal metaplasia**. This includes the formation within the endometrial stroma of islands of smooth muscle,[117] cartilage,[118] and bone.[119] It should be noted that in most instances the presence of cartilage or bone is the result of retained fetal parts.[120]

Adenomyosis and Endometriosis

Adenomyosis refers to the presence of islands of endometrial glands and stroma deep within the myometrium, whereas *endometriosis* is the term employed for the occurrence of endometrial tissue outside the uterus.[121] These two disorders are usually regarded as closely related, but their microscopic appearance is somewhat different. In most cases, adenomyosis is made up of the nonfunctional (basal) layer of the endometrium and is frequently connected with the mucosa. Endometriosis, on the other hand, is composed of the functional layers of the endometrium. As such, it may go through proliferative, secretory, and menstrual stages similar to those of its orthotopic counterpart. However, studies using conventional morphologic techniques, immunohistochemistry, and cell proliferation markers have shown that the endometriotic lesions are consistently more proliferative than the normally located endometrium, both during childbearing years and in postmenopause.[122–124] Adenomyosis is rare in postmenopausal women, except for the tamoxifen-associated cases, which tend to show stromal fibrosis, glandular dilation, and various metaplastic changes.[125]

Many pathogenetic theories have been proposed over the years for endometriosis: origin from congenital müllerian or wolffian rests, implantation of endometrium, lymphatic or hematogenous spread, and serosal metaplasia.[126,127] The finding of clonality, both within and a single endometriotic focus,[121,128] and across multiple foci from the same patient,[129] as well as the demonstration of oncogenic mutations in the epithelium of endometriosis,[130] lend support to the implantation theory but it should be noted that more than one pathogenetic mechanism may be involved.

Both endometriosis and adenomyosis may result in pelvic pain, characteristically associated with the menstrual period. Between 30% and 40% of women with endometriosis are infertile, the exact mechanism being still obscure. Exceptionally, adenomyosis may lead to rupture at the time of pregnancy.

Adenomyosis results grossly in an enlarged and globular uterus because of the myometrial hypertrophy that regularly accompanies it.[131,132] This enlargement is often asymmetrical. The diagnosis may be suspected on cut section in the presence of depressed small cystic lesions in obvious but ill-defined bulging zones of muscle hypertrophy (Fig. 33.14). Adenomyosis may form nodules, grossly, in which case the designation adenomyoma or adenomyotic nodule can be used.[133] Leiomyomas in utero with adenomyosis may themselves be involved by the process; distinction between leiomyoma with adenomyosis and adenomyoma/adenomyotic nodule is subjective but is made

For personal use only. No other uses without permission. Copyright ©2017. Elsevier Inc. All rights reserved.

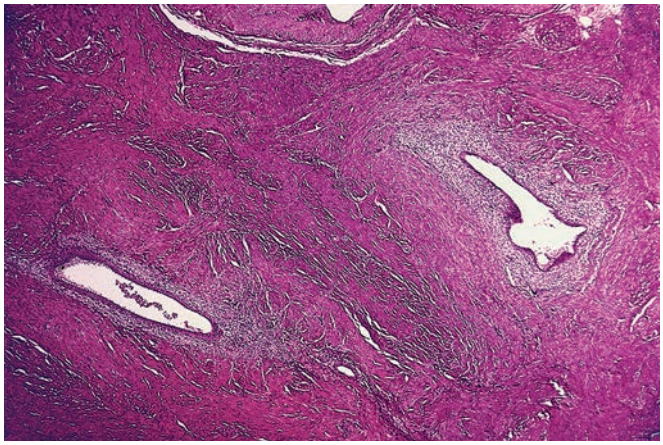

Figure 33.15 Intramyometrial foci of endometrial glands and stroma in adenomyosis.

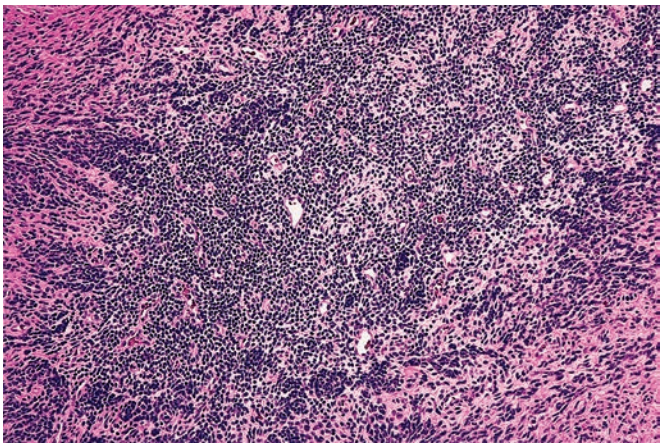

Figure 33.16 **So-Called Stromal Adenomyosis.** An ill-defined island of endometrial stroma is deeply embedded within the myometrium.

based on the endometrial glands and stromal being only at the periphery of the nodule in the former while they are present throughout the latter.

Microscopically, the diagnosis of adenomyosis depends on the thresholds used by the individual pathologist, some of which are very liberal indeed.[134] The interface between endometrium and myometrium is normally an irregular one, without interposition of a submucosal layer; invaginations of the endometrial basal layer into the superficial portions of the myometrium should be regarded as a normal finding. By convention, the diagnosis of adenomyosis should be reserved for those cases in which endometrial glands and stroma are seen in the myometrium at a distance of at least one low-power field from the endometrial–myometrial junction (Fig. 33.15).

Microscopically, the endometrium of adenomyosis usually has a proliferative appearance, consistent with its basal layer nature. When the normally located endometrium is in the secretory phase, this is also true for one-fourth of the foci of adenomyosis.[135] These foci can be involved by any of the diseases affecting the orthotopic endometrium, including hyperplasia and adenocarcinoma.[136] It is important to recognize this phenomenon, lest a case of in situ or superficial endometrial adenocarcinoma associated with similar changes in the foci of adenomyosis be misinterpreted as a deeply invasive malignancy.[137] Involvement of adenomyosis by endometrial adenocarcinoma does not seem to affect outcome.[138]

Vascular involvement may be present and should not be over-interpreted as a sign of malignancy.[139]

Some small islands of adenomyosis are made up predominantly of endometrial stroma (*stromal adenomyosis*, *incomplete adenomyosis* or *adenomyosis with sparse glands*; Fig. 33.16)[140]; however, any sizable intramyometrial focus composed entirely of endometrial stroma is likely to represent an endometrial stromal sarcoma.[141]

Endometriosis, which is thought to occur in 1%–7% of women in the United States,[142,143] is a major cause of pelvic pain and subfertility.[144] It can be located in the cervix, vagina, vulva, rectovaginal septum, ovary, fallopian tubes, uterine ligaments, appendix, small and large bowel, bladder and ureters, pelvic peritoneum, hernia sacs, lymph nodes, kidney, and skin, and even within skeletal muscles, peripheral nerves, pleura, lung, and nasal cavity (Figs. 33.17 and 33.18). The specific features as they pertain to the various sites are discussed in the respective chapters. Spontaneous cutaneous endometriosis is limited to the umbilicus and inguinal area.[145] In other locations, such as the lower abdominal wall, it practically always arises in surgical scars (particularly those from cesarean sections).

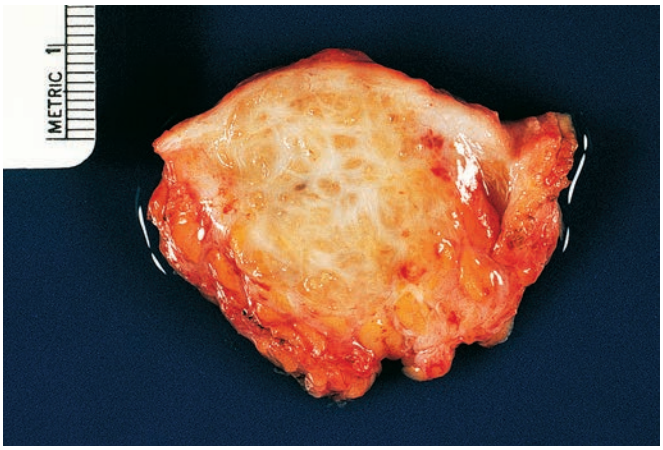

Figure 33.17 Gross appearance of endometriosis involving the anterior abdominal wall.

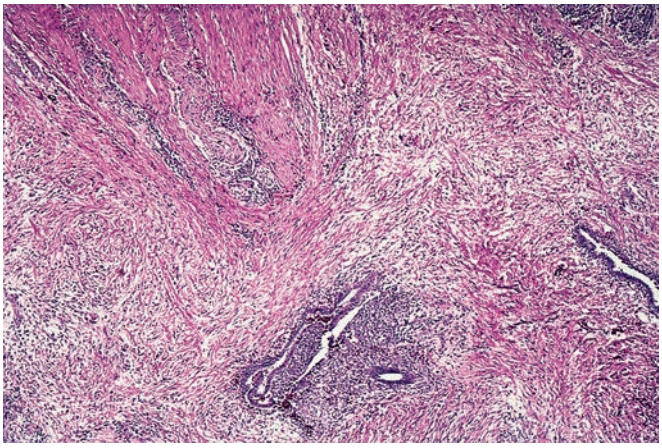

Figure 33.18 Endometriosis involving the umbilical region.

Grossly, endometriosis appears as bluish cystic nodules, often surrounded by fibrosis. Exceptionally, it may present as multiple polypoid masses grossly simulating a neoplastic process (*polypoid endometriosis* or *endometriotic polyposis*).[146,147] These masses can be located in the colon, ovary, uterine serosa, ureter, fallopian tubes, and several other sites.[147]

For personal use only. No other uses without permission. Copyright ©2017. Elsevier Inc. All rights reserved.

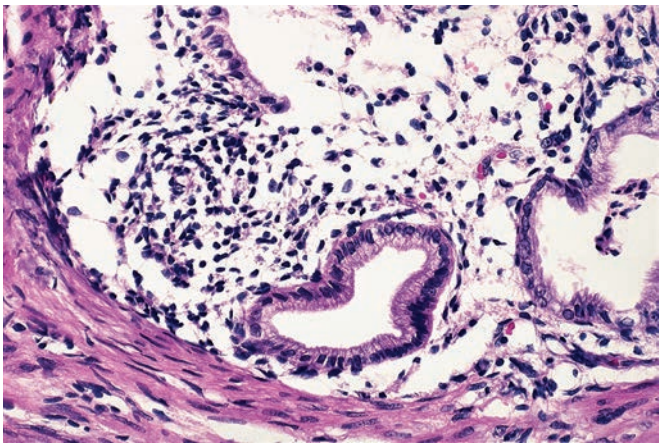

Figure 33.19 So-Called Endocervicosis. The stroma has an endometrium-like quality, but the glands are of endocervical type.

Microscopically, endometrial glands and stroma are seen, often embedded in a dense fibrous mass exhibiting signs of fresh and old hemorrhage.[148] The stromal component of endometriosis can undergo smooth muscle metaplasia.[149] Along those lines, it is still being argued whether the nodular lesion resembling a miniature uterus, which can be found in several places within the peritoneal cavity (ovary, small bowel, etc.), is a peculiar variant of endometriosis with smooth muscle metaplasia of the stroma or a malformation of the müllerian ducts.[131,150,151]

Other morphologic variations in the theme of endometriosis, some of which can be of confusing interpretation, include the presence of stromal micronodules, stromal elastosis, prominent myxoid changes, perineurial invasion, and regeneration of the surrounding skeletal muscle.[152–155] Endometriotic foci can undergo prominent mucinous metaplasia, a change that can result in a mistaken diagnosis of well-differentiated mucinous adenocarcinomas. Such change has been interpreted as a metaplasia toward endocervical-type epithelium and designated as *endocervicosis* (Fig. 33.19).[148]

Although well-documented cases of endometriosis of lymph nodes exist, most cases so designated are made up of glands lined by ciliated or nonciliated cuboidal epithelium unaccompanied by stroma, limited to the capsule or cortical area of the node[156]; as such, they are more reminiscent of fallopian tube than endometrial epithelium and are better designated as *endosalpingiosis*. They have been found in approximately 14% of nodes in females but practically never in males.[157]

Endosalpingiosis is particularly frequent in the pelvic peritoneum in connection with low-grade ovarian serous tumors. It can also present in the form of a florid cystic mass and involve the uterine wall in a transmural fashion.[158,159]

The combination of endometriosis with endocervicosis and/or endosalpingiosis is sometimes referred to as müllerianosis.[160]

Endometriosis, like adenomyosis, is subject to any of the metaplastic, hyperplastic, and atypical changes that may supervene in the orthotopic endometrium.[162] More importantly, it may undergo malignant transformation.[163,164] The most common forms are endometrioid and clear cell carcinoma,[146,165–167] but endometrial stromal sarcoma, carcinosarcoma, and adenosarcoma have also been reported.[168] Benign and borderline tumors of either serous or endometrioid nature can also develop, both from conventional endometriosis and from endosalpingiosis.[169–172] The most common site for endometriosis-related neoplasms is within endometriotic cysts of the ovary, with pelvic peritoneum, rectovaginal septum, intestinal wall, and other sites being much less common.[167,173]

The treatment of endometriosis may be hormonal or surgical depending on the circumstances.[174] It is believed that the laparoscopic ablation of minimal and mild endometriosis enhances fecundity in infertile women.[175]

Dysfunctional Uterine Bleeding

Bleeding not associated with an organic cause in women of childbearing age belongs to the large and somewhat nebulous category known as **dysfunctional uterine bleeding**. Examination of specimens obtained on D&C or endometrial biopsy from patients with dysfunctional uterine bleeding is done primarily to exclude neoplasia/preneoplastic changes, or other pathology that may be causing the abnormal bleeding, such as an endometrial polyp. A wide range of changes can be seen in the endometrium that differ from normal proliferative or secretory endometrium, but attempts by pathologists to classify these changes into categories that can guide treatment have been largely unsuccessful. On a personal note, it was a disheartening experience as a senior surgical pathologist to talk to a group of younger gynecologists and find out how little clinical value there was in my carefully crafted reports describing minor morphologic changes in the endometrium associated with dysfunctional uterine bleeding! What follows is a description of some of the histologic abnormalities that may be encountered in endometria sampled for dysfunctional uterine bleeding, but the suggested diagnostic terminology is provided in the upcoming section on "Curettage and biopsy."

The presence of fibrin clumps in the endometrial stroma (a finding not usually present in the normal menstrual endometrium),[123] the identification of fragmented pieces with dense stromal cellularity (a process known as *stromal crumbling*), and the presence of an increased number of apoptotic bodies at the base of the glands (so-called Benirschke granules)[176] may all be seen. Another type of defect seen in the ovulatory group of bleeders is known as *irregular shedding of the endometrium*. The term refers to a regularly recurring menorrhagia in which the bleeding phase of the cycle requires 7 days or more for completion, without subsequent prolongation of the cycle. This is due to a lag in the shedding of the secretory endometrium, which is normally completed by the fourth day of menstruation.[177] Tissue obtained five or more days after the onset of menstrual bleeding shows retained secretory endometrium in addition to fragmented menstrual and/or early proliferative endometrium.

The term *membranous dysmenorrhea* has been used for a rare condition characterized by the painful passage of an endometrial cast of the uterus during the first few days of menstruation. This cast has the microscopic appearance of decidua. The disease is thought to result from a hyperprogestational response and may be induced by the administration of high doses of progesterone.[177]

Anovulatory cycles result in exuberant *disordered proliferative endometrium*, recognized by irregularity of glandular outlines, with more complexity of gland profiles than is encountered in normal proliferative phase. There is not sufficient glandular crowding to warrant a diagnosis of endometrial hyperplasia. The glandular epithelial cells lack atypia and show nuclear features similar to those of normal proliferative glands. There may be abortive subnuclear vacuoles and apoptotic bodies within glands. Anovulatory cycles are common in PCOS but also very common at puberty and in the perimenopausal period. Distinction between disordered proliferative endometrium and normal proliferative endometrium, on one hand, and endometrial hyperplasia without atypia on the other, is subjective. The general rule of diagnosing an abnormal state only when changes are clear-cut can be applied in this situation; only diagnose disordered proliferative endometrium when the architecture of the glands is too abnormal to fit into the spectrum of

For personal use only. No other uses without permission. Copyright ©2017. Elsevier Inc. All rights reserved.

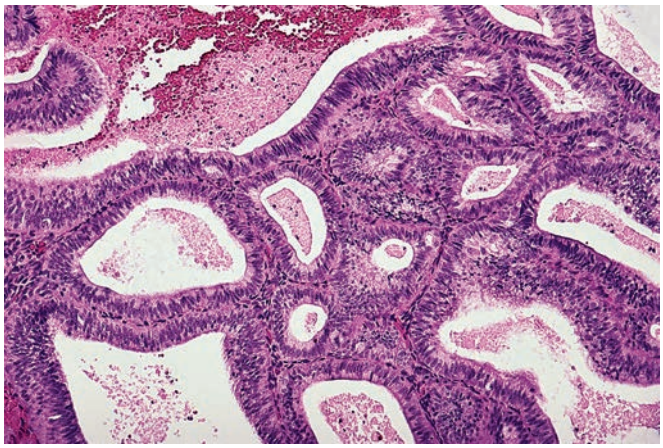

Figure 33.20 Endometrial Hyperplasia Without Atypia. There is mild irregularity of glandular architecture, and crowding.

normal proliferative endometrium. Distinction between disordered proliferative endometrium and hyperplasia without atypia will be discussed next.

Endometrial Hyperplasia Without Atypia, Atypical Hyperplasia, and Variants

Endometrial hyperplasia is recognized by increased gland-to-stroma ratio and glandular architectural irregularity and complexity. There have been many classifications of endometrial hyperplasia over the years, but the one in current use is the one put forward by the World Health Organization (WHO) in 2014.[124]

Endometrial hyperplasia without atypia occurs as a result of unopposed estrogenic stimulation of the endometrium and is on a continuum with disordered proliferative endometrium. There is glandular branching, irregularity, and crowding (Fig. 33.20). The diagnostic threshold for diagnosis of endometrial hyperplasia without atypia, rather than disordered proliferative endometrium, is highly subjective, but at the point where glands predominate over stroma, a diagnosis of endometrial hyperplasia without atypia is appropriate. In the past, endometrial hyperplasia was subdivided into simple and complex hyperplasia, based on the degree of glandular architectural complexity; this is no longer done as it is not a clinically relevant subclassification. The risk of progression to carcinoma with endometrial hyperplasia without atypia is low (1%–3%).[178] The chief differential diagnosis is with atypical hyperplasia, and this is based on the assessment of cytologic atypia; the criteria for recognition of atypia are presented in the next section.

Atypical hyperplasia is the precursor lesion of low-grade endometrioid adenocarcinoma. It shows glandular crowding and irregularity in addition to cytologic atypia. The nuclear atypia is characterized by enlargement, rounding, pleomorphism, and presence of nucleoli. Quite apart from these descriptive terms, the presence of cytologic atypia is most reliably recognized by comparison of the cytologic features in the hyperplastic focus to those of proliferative endometrial glandular epithelial cells outside the area of hyperplasia (Fig. 33.21).[124,179] This approach to diagnosis of cytologic atypia, proposed by Mutter and colleagues, has enhanced the reproducibility of the diagnosis of atypical hyperplasia.[126,180] It is exactly equivalent to the way we evaluate colonic biopsies for adenomatous change and, as is the case for colonic adenomas, the cytologic atypia within the atypical hyperplasia reflects a clonal proliferation of cells with some but not all the mutations necessary for transformation

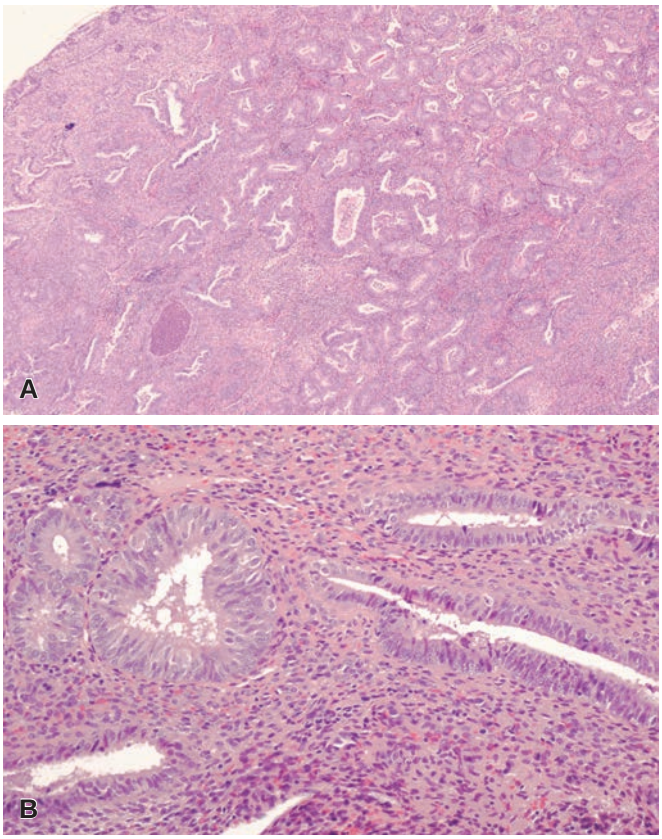

Figure 33.21 A, Endometrial hyperplasia with atypia, in a polyp; **B,** low-power, showing the glandular crowding, and **C,** high-power, from the edge of the hyperplastic focus, showing the cytologic difference between the atypical epithelium (on the left) and non-atypical epithelium.

to carcinoma. One cautionary note is warranted on using this approach to diagnose cytologic atypia; if there is coexistence of proliferative endometrium and inactive endometrium, there are going to be differences between the nuclei in the two areas, but this does not reflect premalignant change. The recognition of atypia is based on cytologic differences between the endometrium in the hyperplastic focus and proliferative endometrium in non-hyperplastic endometrium.

The presence of metaplastic changes complicates the interpretation of cytologic features, and we can offer no easy to solution to this vexing, recurrent problem: is this atypical hyperplasia or hyperplasia without atypia, but with metaplastic changes? This is further complicated by the frequent coexistence of metaplasia and atypical hyperplasia. As a practical guideline, the greater the degree of glandular crowding, the more likely it is that the cytologic changes are atypical.

Endometrioid intraepithelial neoplasia (EIN) is an alternative diagnostic term for atypical hyperplasia. The EIN terminology was proposed by Mutter, who developed the much improved diagnostic criteria for recognition of premalignant change in the endometrium.[134,179,181] What has happened is that there has been universal adoption of the new criteria for diagnosis of endometrial premalignancy, but less uniform adoption of EIN terminology. Thus, at this time, atypical hyperplasia and EIN are completely synonymous diagnostic terms, reflecting the same diagnostic criteria.

The incidence of carcinoma in women with atypical hyperplasia has been in the neighborhood of 15% and has reached 30% in

For personal use only. No other uses without permission. Copyright ©2017. Elsevier Inc. All rights reserved.

some series.[125,178,182,183] A significant minority of women who have a diagnosis of atypical hyperplasia made on biopsy or curettings will have adenocarcinoma (almost invariably low grade and minimally or non-myoinvasive) diagnosed on the subsequent hysterectomy specimen.[184]

The distinction between a case of atypical hyperplasia with severe architectural and cytologic atypia and a well-differentiated adenocarcinoma can be very difficult, largely because of the fact that endometrial hyperplasia and carcinoma represent different points in a disease continuum at the morphologic, ultrastructural, immunocytochemical, and molecular genetic levels.[139,185,186] A careful reading of the landmark study by Longacre and colleagues is recommended.[187] Although more than 20 years have passed since the publication of this paper, it remains a beautiful example of good study design, and the data produced continue to inform everyday practice. The presence of confluence of glands, such there are no longer small glands surrounded by stroma, or a papillary/villoglandular architecture are features supporting a diagnosis of well-differentiated adenocarcinoma. On biopsy or curettings it has been recommended that the diagnosis of "atypical hyperplasia, cannot exclude low-grade adenocarcinoma" be used for those cases where the features are intermediate between atypical hyperplasia and grade 1 endometrioid adenocarcinoma, and we endorse this view. We do not recommend the use of this terminology for hysterectomy specimens.

There is an increasing trend to treat atypical hyperplasia or even low-grade adenocarcinoma with high-dose progestin therapy,[188] so as to avoid hysterectomy and preserve fertility. The interpretation of findings in follow-up biopsies is complicated by prominent progestational effects, including squamous and mucinous metaplasia of the epithelium and stromal decidual reaction. In our experience, there are three possible diagnostic results for these follow-up specimens: either 1. There is no evidence of residual hyperplasia, 2. There is residual hyperplasia with treatment effects (metaplasia and decidual change), or 3. There is residual hyperplasia that shows no treatment effects, and may even show more severe atypia or progression to frank carcinoma, when compared to the pretreatment biopsy.

Atypical mucinous glandular proliferation of the endometrium is considered to be a precursor of mucinous carcinoma. It is recognized based on glandular crowding and complexity with prominent mucinous metaplasia of the glandular lining cells, but these cells can show minimal cytologic atypia.[124] We have previously acknowledged the difficulty in distinguishing between atypical hyperplasia and carcinoma, but it is even more difficult for mucinous proliferations. The likelihood of adenocarcinoma in the hysterectomy after a diagnosis of atypical mucinous glandular proliferation was 45% in a recent study.[189] Atypical mucinous glandular proliferation of the endometrium should therefore be considered to be a premalignant lesion with significant chance of progression or coexistent carcinoma, with hysterectomy being the preferred treatment. Awareness of atypical mucinous proliferation of the endometrium is important as we have seen this premalignant change misdiagnosed as normal endocervical tissue.

Papillary proliferation of the endometrium (PPE) was first described by Lehman and Hart[190] and is characterized by a prominent papillary architecture, with papillae covered by epithelial cells with minimal cytologic atypia (Fig. 33.22). There is a variation from small foci of simple papillae with short nonbranching stalks to extensive complex papillae with elongated stalks and branches. The absence of significant nuclear atypia separates this from carcinoma. The lining epithelium consists of a single layer cells with pale eosinophilic or mucinous cytoplasm, sometimes ciliated. Papillary proliferation frequently involves an endometrial polyp. PPE has

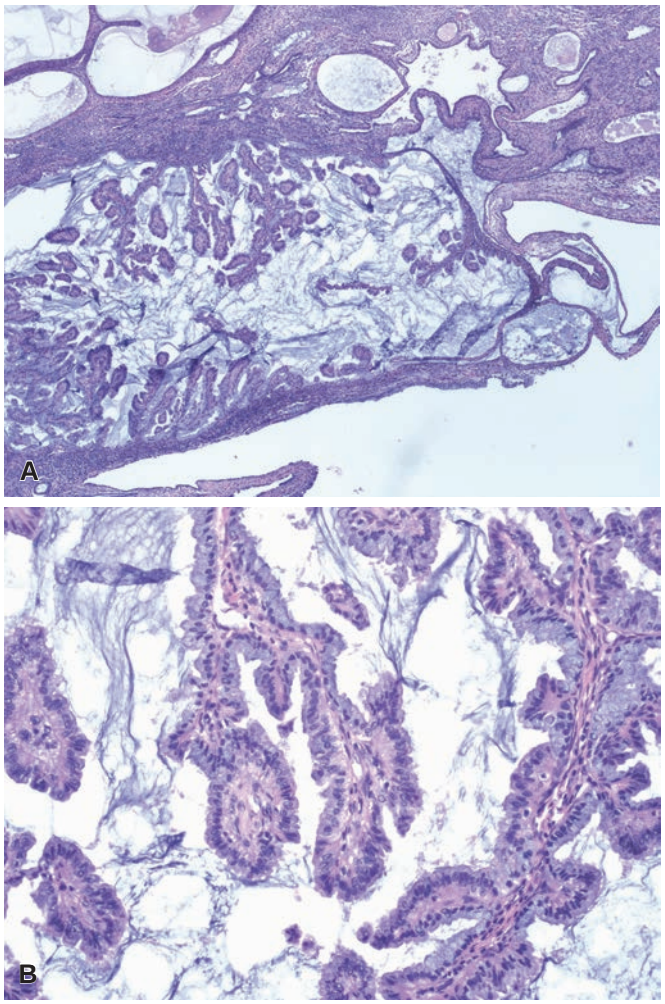

Figure 33.22 Papillary Proliferation of the Endometrium (PPE). A, PPE in an endometrial polyp; **B,** bland mucinous epithelial cells cover the papillae. This single focus, confined to a polyp, is simple PPE.

subsequently been subdivided into simple and complex forms, by Ip et al.[191] Simple PPE is characterized by short, predominantly nonbranching stalks (occasional secondary branches may be seen) localized to 1 or 2 foci involving the surface of polyps, non-polypoid endometrium, or within cystically dilated glands, or involvement of <50% of a polyp. Complex PPE consists of complex papillae (short or long stalks with frequent secondary and complex branching) and/or diffuse involvement (three or more foci within a specimen, or involvement of >50% of polyp). Complex PPE, in particular, often coexists with conventional atypical hyperplasia or even carcinoma. The clinical significance of simple PPE is considered equivalent to that of hyperplasia without atypia, while complex PPE is equivalent to atypical hyperplasia, based on a limited number of reported cases.[191]

The term **(atypical) secretory hyperplasia** has been applied to a pattern of architectural abnormalities and cellular atypia within a secretory endometrium, with the atypical glands resembling those seen in the sixteenth to the seventeenth day of the normal cycle.[128,132,192] This change should be distinguished from the Arias-Stella reaction and from hormonally treated conventional endometrial hyperplasia. The natural history of this condition is not well known, but involution appears to be relatively common when the background endometrium also shows secretory changes.[192] Normal secretory endometrium

For personal use only. No other uses without permission. Copyright ©2017. Elsevier Inc. All rights reserved.

appears relatively crowded, and it is best to be conservative in diagnosis of hyperplasia in the setting of secretory endometrium.

Curettage and Biopsy

Tissue from the endometrial cavity taken for diagnostic purposes was traditionally obtained by *dilation* of the cervical canal and *curettage* of the endometrial cavity (D&C). Information about endocervical extension of an endometrial neoplasm can be obtained by performing a *fractional curettage* (i.e. a separate sampling from the endometrial and endocervical cavities during the same procedure). The endocervical specimen should be obtained first so as to minimize contamination from the endometrium. However, even when this precaution is taken, small isolated tumor fragments may be found in endocervical curetting specimens in cases where there is no infiltration of the cervix by tumor. Therefore, the presence of endocervical extension of a tumor can only be diagnosed if cancer and normal endocervical glands are seen *in the same tissue fragment*. Otherwise, simply record the presence of carcinoma in the material submitted from the endocervix and let the clinician decide whether this is significant on the basis of the findings at the time of curettage.

Endometrial biopsy has emerged as an alternative to D&C for the evaluation of the endometrium.[127] It can be performed safely in the office (but causes significant discomfort and pathologists should not be cavalier in recommending resampling of the endometrium). Biopsy may also be carried out under hysteroscopic guidance.[121] A meta-analysis study with the use of the Pipelle showed a detection rate for endometrial adenocarcinoma of 99.6% in postmenopausal women and 91% in the premenopausal group.[136] Another issue is the accuracy of the grading of endometrial carcinoma done in a biopsy when compared with that seen in the hysterectomy specimen. In one study, the concordance was 45% for grade I, 63.3% for grade II, and 75.6% for grade III, the overall concordance being 64.5%.[193] Even comparing the diagnosis of low-grade (grade I or II) versus high-grade (grade 3) carcinoma in biopsy/curettings versus hysterectomy, there remains distressing variation, but with some improvement (kappa—0.7).[194] Histotype diagnosis (i.e. endometrioid, serous, clear cell, etc.) shows only moderate agreement between biopsy/curettings and hysterectomy (kappa—0.44).[194]

A curious artifact that can be seen in hysteroscopically assessed tissue is *pseudolipomatosis*, a condition analogous to its more common counterpart in the gastrointestinal tract. It results from air or gas entering into the endometrial mucosa and simulating fatty infiltration.[195]

An exceptionally rare occurrence is the failure to find tumor in a hysterectomy specimen following a diagnosis of adenocarcinoma in an endometrial biopsy. This distressing event, which has been referred to as *vanishing endometrial carcinoma* (in analogy to the same phenomenon as described in the prostate) is probably explained by the very minute size of the tumor, most or all of which has been removed by the biopsy procedure.[196]

The language used in reporting on endometrial biopsies where there are only benign findings is highly variable from pathologist to pathologist, in contrast to the standardized language and formatting we use for cancer specimens. There remain pathologists who believe that they are being called upon to determine whether ovulation has occurred, even though this has not been an expectation for more than a decade, while other pathologists report in great morphologic detail on biopsies taken for infertility when their clinical colleagues only want reassurance that there is no polyp, endometritis, or hyperplasia/carcinoma. Please do discuss with clinicians their needs, so that you can better serve your patients by providing clinically relevant information in your surgical pathology reports. We do believe, however, that more uniform reporting of benign endometrial biopsy specimens will enhance the value of our reports, improving their comprehensibility. A guideline for uniform diagnostic categories to use in reporting endometrial biopsies has been proposed by the Canadian Gynecological Pathology Special Interest Group (Box 33.1); when trialed in practice, more than 90% of cases could be reported using this template, in a range of practice scenarios.

Box 33.1 Suggested terminology for signing out benign endometrial biopsy or curetting specimens

Diagnosis (choose one or more)

- Non-diagnostic sample (no endometrial tissue present)
- Scant fragments of inactive endometrial surface epithelium and/or stroma; this is a suboptimal specimen for histopathological assessment and may not be representative*
- Inactive/atrophic endometrium
- Proliferative endometrium
  - Normal proliferative
  - Weakly proliferative
  - Disordered proliferative
- Secretory endometrium
  - Normal secretory
    - Date ___
    - Polypoid secretory endometrium
  - Irregular secretory
- Menstrual endometrium
- Endometrial polyp(s)
- Endometrial hyperplasia without atypia
- Chronic endometritis
- Changes consistent with exogenous hormonal therapy
  - Progestin
  - Progesterone receptor selective agonist
  - Oral contraceptive
- Products of conception
  - Chorionic villi
  - Chorionic plate
  - Chorionic membranes
  - Implantation site trophoblast
  - Exaggerated implantation site
  - Embryonic/fetal tissue
- Pregnancy-related endometrial changes
- Pregnancy-related endometrial changes only; no products of conception identified
- Placental site nodule/remote implantation site
- Adipose tissue, mesothelium—lined tissue or other extrauterine tissues present

*Fewer than 10 strips of epithelium in an endometrial biopsy or curettage specimen is suboptimal and is associated with decreased sensitivity and negative predictive value.[197]

A final comment is called for on the criteria for insufficiency in an endometrial biopsy or curetting. Remember that the expected finding in a postmenopausal woman is scant inactive or atrophic endometrium. The presence of strips of atrophic endometrium is normal in this clinical scenario and should not be considered insufficient for diagnosis, a diagnosis that should be reserved for instances where there is no endometrial tissue sampled. Sakhdari et al. have suggested that the presence of 10 or more endometrial strips constitutes an adequate sample, while fewer than 10 strips is suboptimal (negative predictive values in the group with an adequate sample was >99% versus approximately 80% in the group with a suboptimal sample).[197] This finding should be validated independently, but it appears that there are three categories of samples: adequate, benign but suboptimal because of their scanty nature (<10 strips of endometrial epithelium), and insufficient for diagnosis (no endometrial tissue sampled).

For personal use only. No other uses without permission. Copyright ©2017. Elsevier Inc. All rights reserved.

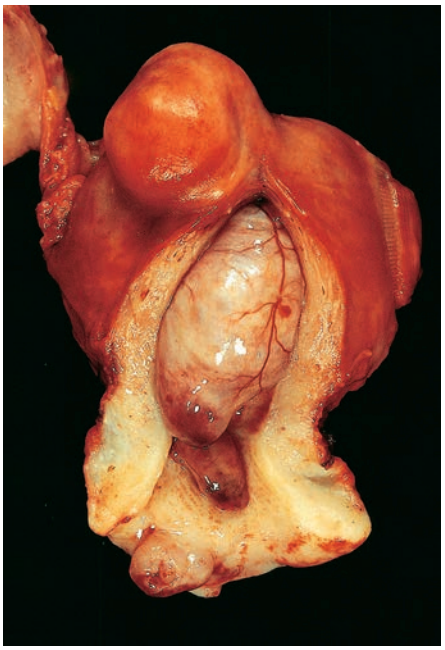

Figure 33.23 Huge Endometrial Polyp Filling the Endometrial Cavity. There is also a smaller endocervical polyp and a subserosal leiomyoma. (Courtesy Dr. Pedro J Grases Galofrè; from Grases Galofrè PJ. *Patologia ginecològica. Bases para el diagnòstico morfològico*. Barcelona: Masson; 2002.)

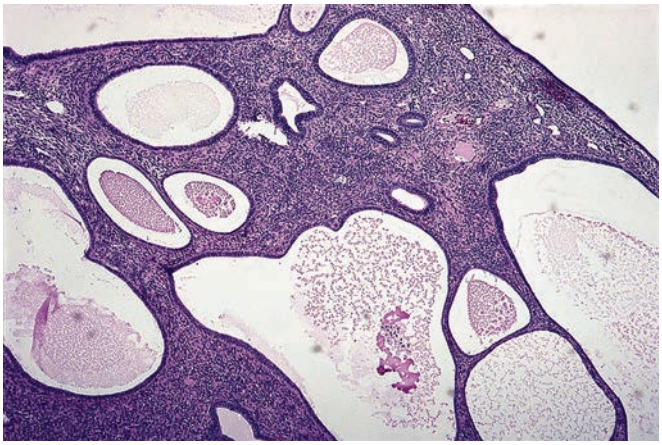

Figure 33.24 Low-power appearance of endometrial polyp showing cystically dilated glands and a fibrous stroma with thick-walled vessels.

Tumors

Endometrial Polyps

Endometrial polyps protrude into the endometrial cavity and often exhibit changes secondary to vascular insufficiency or prolapse (Fig. 33.23). They consist of epithelial and stromal components, and a key to recognition in fragmented specimens, e.g. endometrial curettings, is the altered cellularity of the stroma compared to normal endometrium, with the polyp stroma usually showing reduced cellularity with a more "fibrous" appearing and spindle cell stroma, compared to normal endometrial stroma. The glands usually show some degree of cystic change. They may be lined by an active pseudostratified epithelium containing mitotic figures or, in the postmenopausal patient, by a flat, inactive epithelium (Fig. 33.24). The abnormal glandular architecture may raise the possibility of endometrial hyperplasia, but the absence of glandular crowding excludes the diagnosis of hyperplasia. Note that hyperplasia (without atypia or atypical) or carcinoma may be present in an endometrial polyp and are diagnosed using the same criteria as are used in the absence of a polyp.

The glands and stroma of the polyp are unresponsive to progesterone stimulation and retain their integrity throughout the menstrual cycle. The frequent coexistence of endometrial polyps and endometrial hyperplasia points to a shared pathogenesis for these two lesions. The clinical significance and management of atypical hyperplasia are the same irrespective of whether it involves or is confined to an endometrial polyp.[198]

Exceptionally, the stroma of endometrial polyps contains scattered atypical (bizarre) cells.[199,200]

Endometrial polyps occur with increased frequency after tamoxifen exposure. These are characteristically multiple, large, and fibrotic and may exhibit stromal decidualization and mucinous metaplasia.[201–203]

With the increasing use of hysteroscopy, we frequently receive endometrial biopsies of polypoid endometrium that microscopically is seen to be normal secretory endometrium. Unfortunately there is no uniform diagnosis used for this relatively common scenario, and proposed diagnoses include "polypoid secretory endometrium" or "secretory pseudopolyp."

Endometrial polyps having smooth muscle fibers (not connected with blood vessel walls) in addition to the customary glands and stroma are designated as **adenomyomatous polyps** (polypoid adenomyomas) (Fig. 33.25).[204] In order to make this diagnosis, the smooth muscle should be integral to the polyp; benign endometrial polyps when they start to prolapse often draw smooth muscle into the polyp stalk, and this phenomenon does not warrant diagnosis as adenomyomatous polyp. They have a characteristic hard consistency and a grayish color.

An important variation on the theme is the **atypical polypoid adenomyoma**.[205–208] These tend to occur in premenopausal women (average age, 40 years) and present with abnormal uterine bleeding (Fig. 33.26). Some are associated with Turner syndrome.[209] Microscopically, they are identified by the fact that the glands occurring between the endometrial stroma and smooth muscle exhibit varying degrees of hyperplasia and atypia (often with squamous morular metaplasia), sometimes approaching the appearance of low-grade carcinoma (Fig. 33.27).[210] Recognition is important to avoid misdiagnosis as adenocarcinomas with myometrial invasion. The behavior reflects the degree of complexity and atypia of the epithelial component, which can range from atypia without hyperplasia, to atypical hyperplasia and, on occasion, frank carcinoma of low-grade endometrioid type.

At the molecular level, atypical polypoid adenomyomas share several alterations with hyperplasias.[211]

Endometrial Carcinoma

General and Clinical Features, Including Molecular Subtypes

Carcinoma of the endometrium is the most common gynecologic malignancy in developed countries.[212] The highest incidence rates are in the United States and Canada, but in recent years there has been a decline in incidence and mortality. It typically occurs in elderly individuals, 80% of the patients being postmenopausal at the time of diagnosis.[213] However, it can occur in any age group and has even been reported in association with intrauterine pregnancy.[214] Most endometrial adenocarcinomas occurring in women aged 40 years or younger are of endometrioid type, well to moderately differentiated, and early stage disease.[215] Conversely, tumors of elderly patients are more likely to be grade 2 or 3 and to have more advanced disease at the time of diagnosis.[216]

For personal use only. No other uses without permission. Copyright ©2017. Elsevier Inc. All rights reserved.

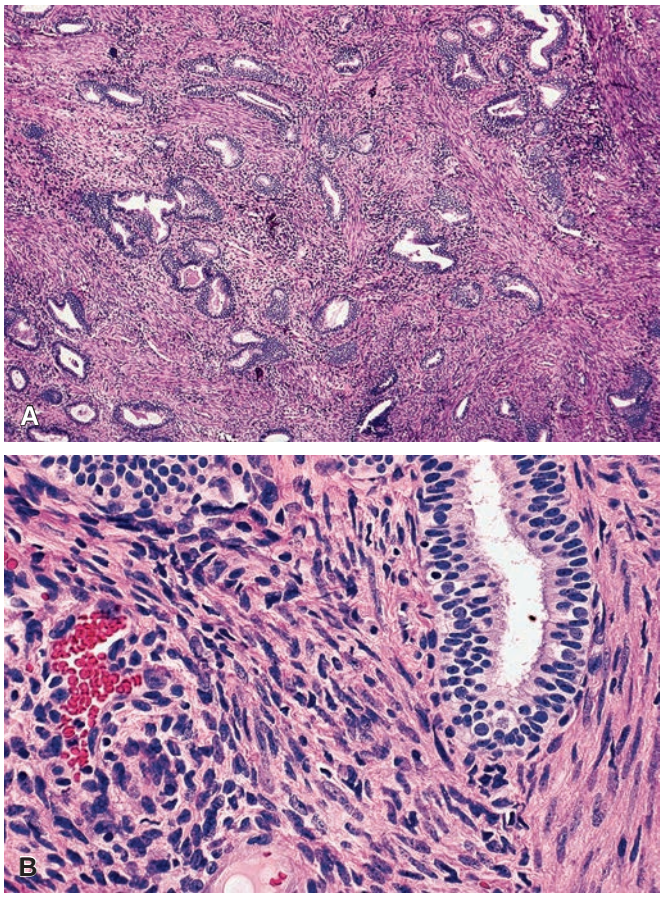

Figure 33.25 **A** and **B,** Low- and high-power appearance of adenomyomatous polyp.

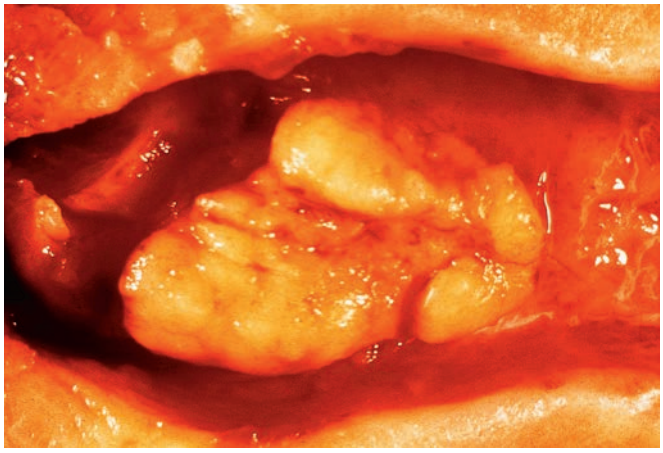

Figure 33.26 **Atypical Polypoid Adenomyoma.** The gross appearance is not substantially different from that of an ordinary polyp.

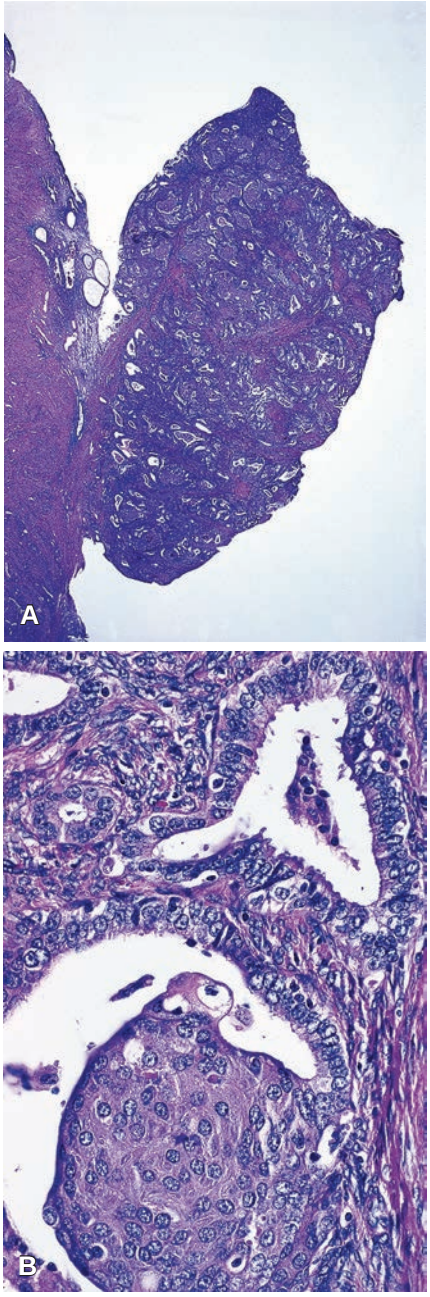

Figure 33.27 **A** and **B,** Whole-mount and high-power appearance of atypical polypoid adenomyoma. Note the glandular architectural complexity, metaplastic changes, and atypia.

Bokhman proposed that endometrial carcinoma be divided into two types, type I and type II, on the basis of their pathogenesis: one—by far the more common—occurring as a result of excess estrogenic stimulation and developing against a background of endometrial hyperplasia, and the other developing de novo, independent of estrogen stimulation, in older women.[217–219] The prototype for type I endometrial carcinoma is low-grade endometrioid carcinoma, while the prototype for type II endometrial carcinoma is serous carcinoma.

Patients at high risk for the first category include the obese, diabetic, hypertensive, and infertile; those with failure of ovulation (including PCOS) and dysfunctional bleeding; longstanding estrogen users; breast cancer patients treated with tamoxifen (see later); those with severe degrees of endometrial hyperplasia; and—to a much lesser degree—those with functioning granulosa cell tumors and thecomas.[220–222] Tumors in this category are typically low grade and the prognosis is favorable; treatment with progestins is an option, especially if preservation of fertility is desired.

There are no well-defined risk factors for patients with type II carcinomas. Occasional cases have been reported in patients with BRCA germline mutations,[215] but this is uncommon and certainly

For personal use only. No other uses without permission. Copyright ©2017. Elsevier Inc. All rights reserved.

much less frequently encountered than with high-grade serous carcinoma of tubo-ovarian origin.[223] The prognosis of patients with type II carcinomas is much worse than that of patients with type I carcinomas.

The Cancer Genome Atlas (TCGA) study of 373 endometrial carcinomas opened important new windows onto the molecular subclassification of endometrial carcinoma.[223] As well as confirming the presence of type I and type II subtypes, which are characterized by low numbers of somatic copy number alterations (CN low)/wild-type expression pattern of p53, and high numbers of somatic copy number alterations in the genome (CN high)/abnormal expression of p53, respectively, two additional endometrial carcinoma molecular subtypes were identified, based on their mutation profiles: hypermutated endometrial carcinomas and ultramutated endometrial carcinomas. Together these latter two subtypes account for approximately one-third of endometrial carcinomas. The clinical significance of identification of these subtypes is still being explored but could prove to be dramatic, impacting on surgical and adjuvant treatment decisions.[224-232]

Hypermutated endometrial carcinomas are characterized by microsatellite instability (MSI) secondary to dysfunction of one of the enzymes that repairs DNA sequence abnormalities by the post-replicative DNA mismatch repair pathway. A surrogate test for identification of tumors in this category is immunohistochemistry for mismatch repair enzymes (MLH1, PMS2, MSH2, MSH6), which is increasingly preferred to MSI testing (Fig. 33.28). Because of dimerization of MMR proteins, screening for MMR deficiency (MMR-D) can be done by immunostaining for just two of the proteins, MSH6 and PMS2; if both are expressed the tumor is MMR intact. 3%–4% of endometrial carcinomas arise in patients with Lynch syndrome, and these tumors are MMR-D. The endometrial carcinomas in Lynch syndrome patients often present at a young age.[233–235] MMR-D endometrial carcinomas tend to be higher grade and associated with peritumoral and intratumoral lymphocytic infiltrates.[233,234] Although most are endometrioid, they may be nonendometrioid histology.[233] Most MMR-D endometrial carcinomas are not associated with Lynch syndrome; the MMR-D phenotype in these cases is secondary to somatic events, most commonly promoter methylation of *MLH1*, with loss of protein expression. Compared to MMR-D endometrial carcinomas in patients with Lynch syndrome, those with somatic *MLH1* promoter methylation arise in older patients and are more likely to be endometrioid type, show mucinous differentiation, and have tumor infiltrating lymphocytes.[236]

Ultramutated endometrial carcinomas have 10-fold more mutations than the hypermutated tumors, and the molecular basis for this is mutations, almost invariably somatic, in the polymerase-epsilon (POLE) gene, resulting in loss of the exonuclease proofreading function and increased mutation rates. The tumors associated with POLE exonuclease domain mutations (POLE EDMs) are associated with a very favorable prognosis, even though they are often higher grade.[224–226,237] They are typically of endometrioid histotype and, like the MMR-D tumors, are commonly associated with prominent lymphoid infiltrates (Fig. 33.29).[227]

The clinical, molecular, and pathologic features associated with each of the major molecular subtypes of endometrial carcinoma (type I/CN low/p53 wildtype, type II/CN high/p53 abn, MMR-D, POLE EDM) are summarized in Table 33.1, and the differences in prognosis are shown in Figure 33.30. The conventional histopathologic features of endometrial carcinoma, such as grade and histotype, correlate imperfectly with the molecular subtypes, so for the foreseeable future we will include these findings in our pathology reports. Accordingly, the remainder of this section will focus on the histopathologic assessment of endometrial carcinoma.

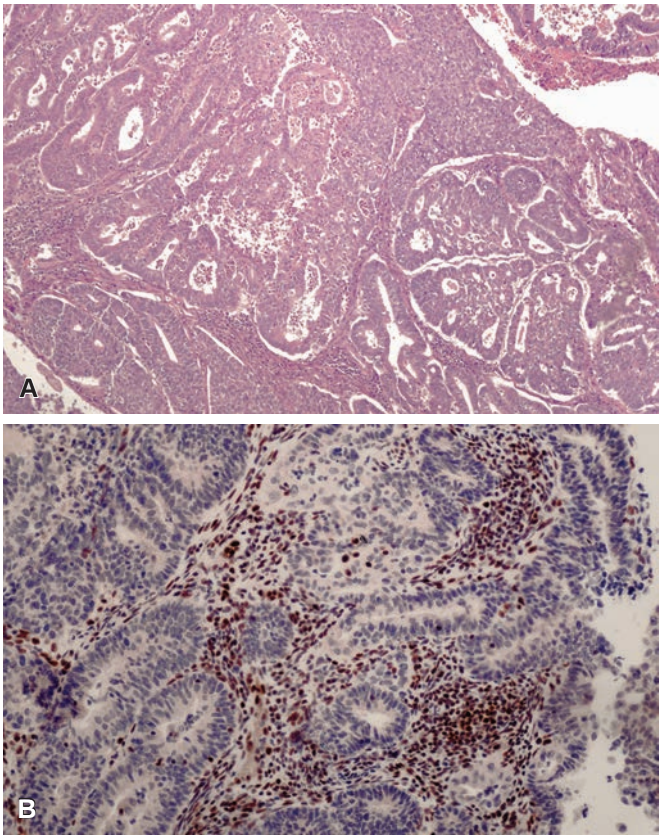

Figure 33.28 Hypermutated/Mismatch Repair Deficient Endometrial Carcinoma. There is heterogeneity in the appearance of the tumor, with more solid areas alternating with glandular areas (**A**) and a prominent lymphoid infiltrate. Immunostaining shows loss of expression of MLH1 in the tumor cells, with retained expression in lymphocytes and stromal cells (**B**).

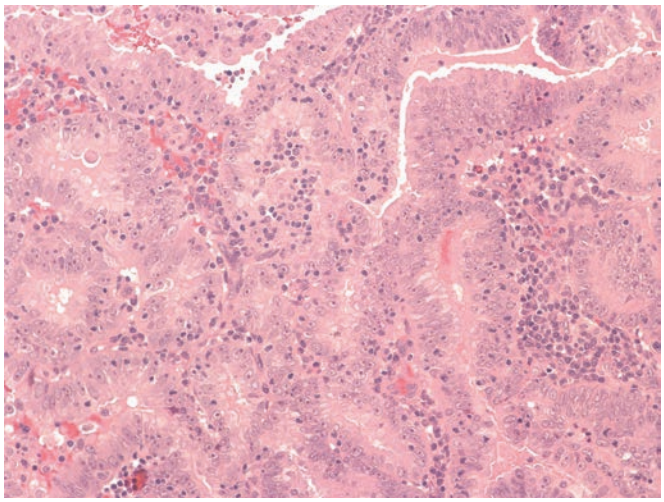

Figure 33.29 Ultramutated/Polymerase Epsilon Exonuclease Domain Mutated (POLE EDM) Endometrial Carcinoma. The cells of this endometrioid carcinoma show high-grade nuclear features, and there is a prominent lymphoid infiltrate, features associated with POLE EDM tumors.

For personal use only. No other uses without permission. Copyright ©2017. Elsevier Inc. All rights reserved.

Table 33.1 Genomic-based endometrial carcinoma subtypes

TCGA CATEGORY[223]	GENOMIC ALTERATION	SURROGATE MARKER	FORMER DESIGNATION[229]	AGE[217]	PROGNOSIS	HISTOTYPE
CN low	Few mutations, low # of somatic copy number alterations	Absence of POLE EDM, MMR-D and p53 abn	Type I	65 years	Intermediate	Endometrioid (usually grade 1 or 2)
CN high	Few mutations, low # of somatic copy number alterations	p53 abn	Type II	72 years	Poor	Serous and some grade 3 endometrioid
Hypermutated	Many mutations	MMR-D	NA	66 years	Intermediate	Mostly endometrioid, may be high grade
Ultramutated	Very many mutations	POLE EDM	NA	62 years	Favorable	Endometrioid, may be high grade

CN high, High numbers of somatic copy number abnormalities; *CN low*, low numbers of somatic copy number abnormalities; *MMR-D*, mismatch repair deficient; *NA*, not applicable; *p53 abn*, abnormal p53 expression by immunohistochemistry that is either complete absence of expression or strong diffuse overexpression; *POLE EDM*, mutations in the POLE exonuclease domain; *TCGA*, The Cancer Genome Atlas.

Pathologic Features

Grossly, carcinoma of the endometrium may form broad-based polypoid masses or infiltrate diffusely into the myometrium (Fig. 33.31). In general, extensive myometrial invasion is accompanied by clinically detectable uterine enlargement. However, notable exceptions occur; sometimes deep myometrial extension is accompanied by a normal-sized uterus, the pattern of growth resembling that of adenoma malignum of cervix.[223]

Endometrial carcinoma can develop in any anatomic region of the mucosa. Tumors developing in younger women have a greater tendency to involve the lower uterine segment (isthmus).[238] Most tumors thought to have arisen in the isthmus are best included among the endometrial rather than the cervical carcinomas, based on the clinical and biomarker expression profiles.[239] Small carcinomas restricted to a cornu can be missed by a biopsy or D&C.

Microscopically, approximately 80% of endometrial malignant epithelial tumors are conventional adenocarcinomas, which are usually divided into well (grade 1, 50%), moderately (grade 2, 35%), and poorly differentiated (grade 3, 15%) tumors (Fig. 33.32A–C). The FIGO three-grade system is primarily based on the growth pattern (relative proportion of glandular and solid areas), with grade 1 having 5% or less solid growth, grade 2 5%–50% solid growth, and grade 3 >50% solid growth, but it also makes provisions for nuclear atypia, with grade increased by one in the presence of notable nuclear atypia, defined as grade 3 nuclei in more than 50% of the tumor.[223,240] Because there are minimal prognostic differences between grade 1 and grade 2, and they are treated identically with respect to adjuvant chemotherapy and radiation therapy, it has also been proposed that grade 1 and 2 be combined as "low grade."

The better differentiated tumors closely recapitulate the light and electron microscopic features of the non-neoplastic endometrium,[241,242] hence the term "endometrioid" that is used for them. Over one-fourth of the endometrioid carcinomas have papillary (villoglandular) foci, either on the surface or in the invasive areas (see Fig. 33.32D).[243] These tumors should be sharply separated from the much more aggressive serous carcinomas.[244–246] A further variation on the theme is represented by endometrioid adenocarcinomas containing small nonvillous papillae. These papillae can arise either from an otherwise unremarkable endometrioid carcinoma or from the villous projections of the villoglandular variant of this tumor.[247] It should also be noted that the most superficial portions of endometrial adenocarcinomas can exhibit patterns closely simulating various hyperplastic and metaplastic conditions of the endometrial mucosa.[248]

The stroma of endometrial adenocarcinoma may contain collections of foamy cells, probably the result of tumor necrosis.[249] However, these cells can also be seen in hyperplasia and in the absence of proliferative epithelial changes. Their immunophenotype corresponds to that of histiocytes rather than endometrial stromal cells.[250]

The non-neoplastic endometrium of a uterus harboring an endometrioid adenocarcinoma is often hyperplastic and only exceptionally exhibits a normal secretory pattern.[251]

The frequency and extent of myometrial invasion by carcinoma correlate with the microscopic grade of the tumor.[187] High-grade tumors are significantly associated with cervical involvement and lymphovascular invasion.[253] Care should be exercised to distinguish true myometrial extension by carcinoma from expansion of the endometrial–myometrial junction and from atypical or malignant changes involving preexisting foci of adenomyosis[254]; the latter condition is recognized by the presence of endometrial stroma around the intramyometrial proliferating glandular foci.[255] It has been proposed that CD10 immunostaining can help in this distinction by highlighting the endometrial stroma associated with the adenomyosis when present.[256] However, a warning has been sounded to the effect that CD10 immunoreactivity can also be found around foci of invasive adenocarcinoma,[257] and we do not recommend immunostaining in the assessment of myometrial invasion. If there is doubt about the presence of myometrial invasion, it can be communicated in the surgical pathology report by indicating that "no definite myometrial invasion" is identified.

Extension of the endometrial carcinoma into the cervix occurs in over 10% of cases, usually by direct invasion,[258,259] but can also be discontinuous with the endometrial tumor (presumably by mucosal "drop" implantation or via lymphatic spread). This extension may be grossly evident or become apparent only on microscopic examination. It is important, for staging purposes, to distinguish between surface/mucosal involvement only, which does not impact on stage, and invasion of the cervical stroma, which does result in a tumor being stage II.[223,259] Assessment of cervical stromal invasion is challenging, and there is considerable interobserver variability in assessment of this important feature and, consequently, tumor stage.[260]

With respect to the molecular subtype of endometrioid carcinomas, the low-grade (grade 1 or grade 2) tumors consist of type I/CN low/p53 wild type, MMR-D and POLE mutant tumors, while high-grade

For personal use only. No other uses without permission. Copyright ©2017. Elsevier Inc. All rights reserved.

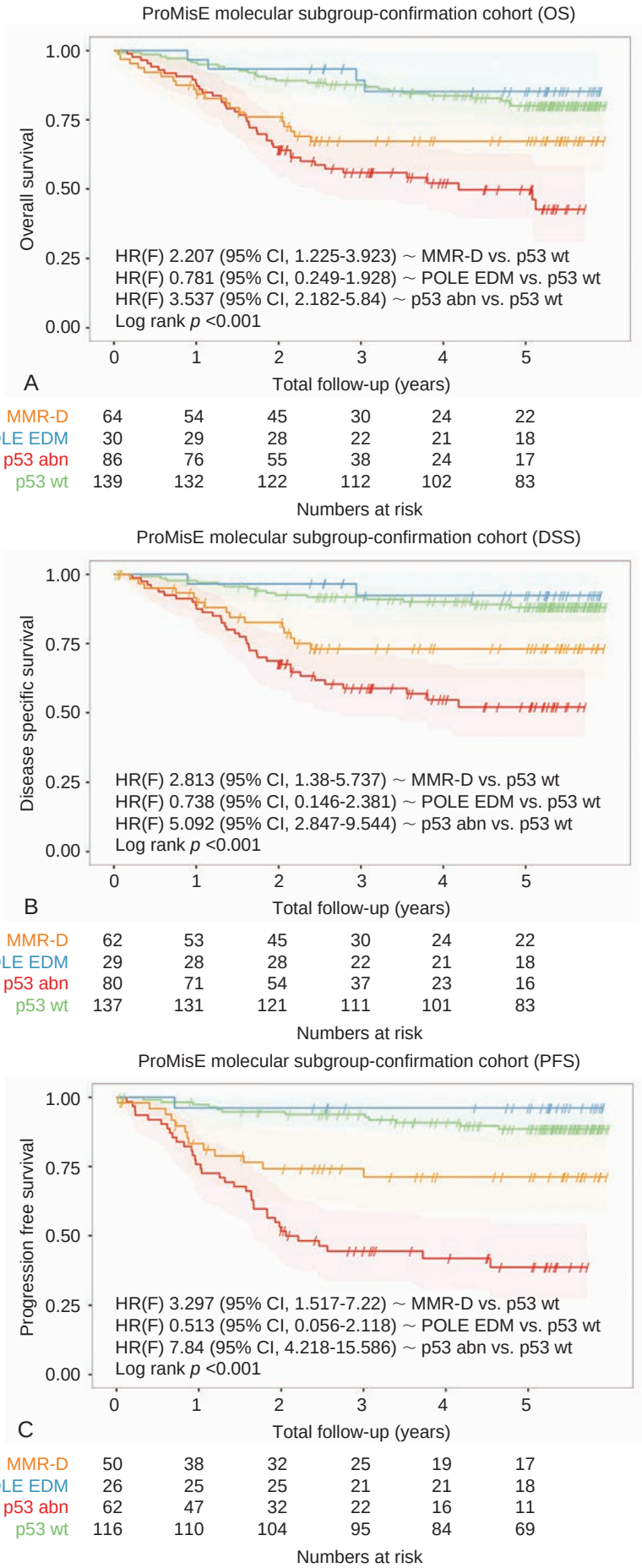

Figure 33.30 Outcomes of patients with the four genomic subtypes of endometrial carcinoma (POLE exonuclease domain mutation [POLE EDM], CN low/p53 wildtype, mismatch repair deficient [MMR-D], and CN high/p53 abnormal, from best to worst prognosis). **A,** Overall survival. **B,** Disease-specific survival. **C,** Progression-free survival. (From Talhouk A, McConechy MK, Leung S, et al. Confirmation of ProMisE: A simple genomics-based clinical classifier for endometrial cancer. *Cancer* 2017;123:802–813.)

For personal use only. No other uses without permission. Copyright ©2017. Elsevier Inc. All rights reserved.

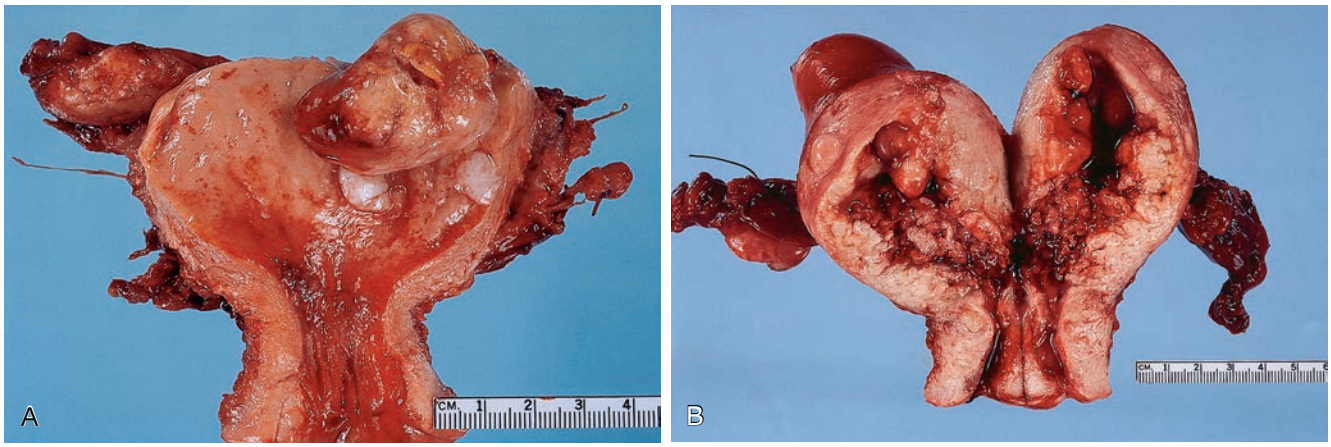

Figure 33.31 **A** and **B,** Gross appearances of endometrioid adenocarcinoma. The tumor shown in **A** is polypoid, whereas that depicted in **B** is highly infiltrating.

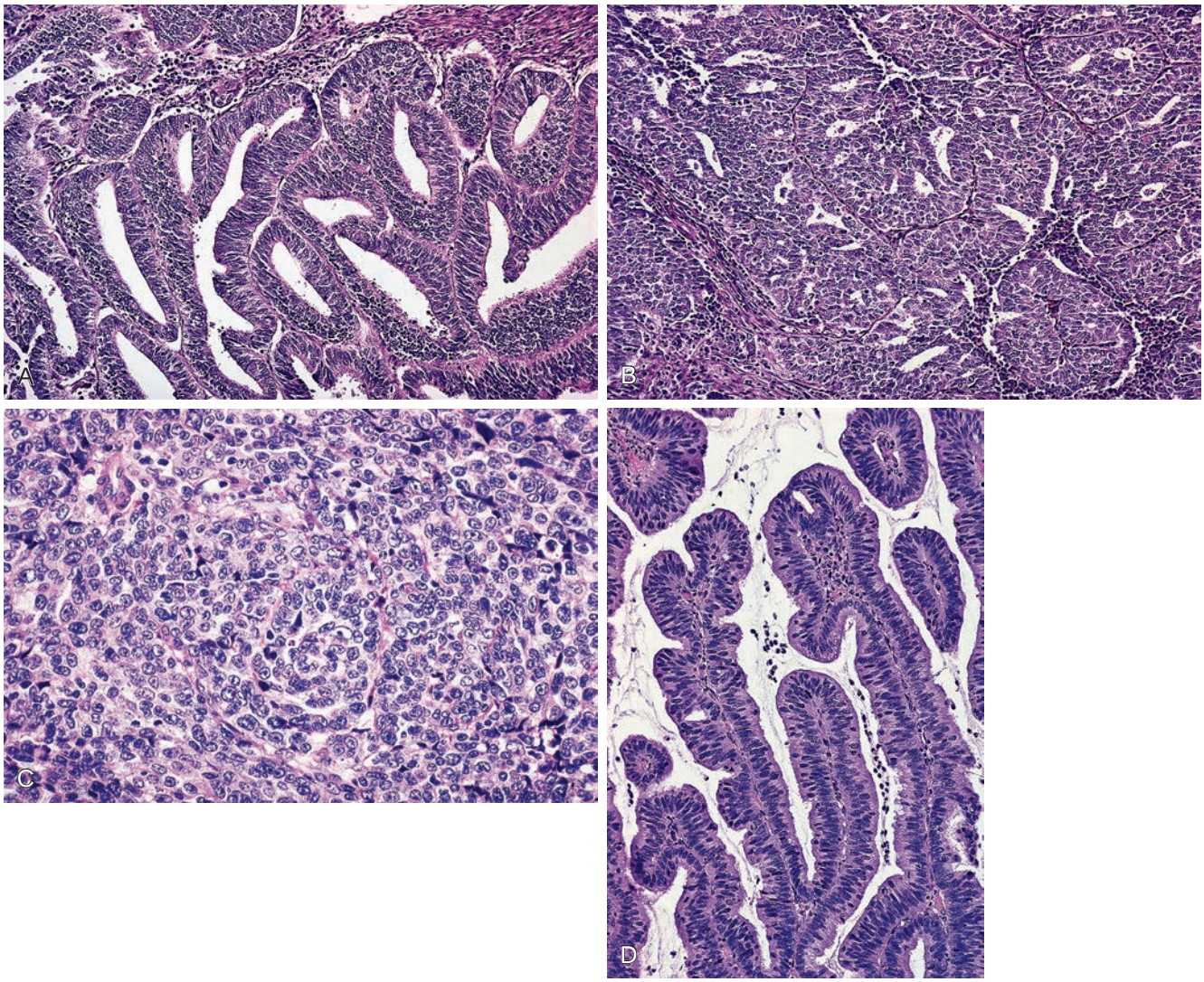

Figure 33.32 **Endometrioid Endometrial Adenocarcinoma. A,** Grade 1; **B,** grade 2; **C,** grade 3; **D,** with villoglandular pattern of growth.

For personal use only. No other uses without permission. Copyright ©2017. Elsevier Inc. All rights reserved.

(grade 3) endometrioid carcinomas can be any of the four molecular subtypes.

The differential diagnosis between endometrial and endocervical carcinoma is discussed elsewhere.

Variants of Endometrioid Carcinoma and Other Endometrial Carcinoma Histotypes

Numerous morphologic forms of endometrial adenocarcinoma have been described. Some, such as adenocarcinoma with squamous differentiation, mucinous carcinoma, and secretory carcinoma, are thought to represent variants of ordinary ("endometrioid") adenocarcinoma. Others, notably serous carcinoma, carcinosarcoma, and clear cell carcinoma, are regarded as being of nonendometrioid type, although any of them can be seen coexisting with endometrioid adenocarcinoma.

Adenocarcinoma with squamous differentiation (formerly known as adenoacanthoma if low grade and adenosquamous carcinoma if high grade) refers to endometrioid adenocarcinoma containing squamous elements derived from metaplasia of the tumor glands (Figs. 33.33 and 33.34). Its natural history closely parallels that of the ordinary endometrioid adenocarcinoma of a similar degree of differentiation lacking squamous changes.[261] **Glassy cell carcinoma** is a variant of endometrioid carcinoma with squamous differentiation that has occasionally been reported in the endometrium; its appearance is similar to that of its more common cervical counterpart.[262,263]

Corded and hyalinized endometrioid carcinoma (CHEC) is characterized by epithelial cells in cords separated by hyalinized stroma. Spindled epithelial cells are also commonly encountered.[264] The nuclei are grade 1 or 2, which serves to separate these low-grade variants of endometrioid carcinoma with carcinosarcoma, with which they are often confused.

The **microcystic, elongated, and fragmented** (MELF) pattern of invasive endometrioid adenocarcinoma is recognized for its subtle histologic features that may be easily overlooked (particularly at the time of frozen section analysis for depth of myoinvasion) and its possible staging implications.[265] MELF is characterized by small pockets of a fibromyxoid stromal reaction that contain varying patterns of admixed eosinophilic carcinoma cells: small glands with attenuated epithelium (i.e. microcysts), elongated glands with a flattened lining mimicking endothelial cells, or clusters of detached cells or individual cells. Associated lymphocytes and neutrophils are common. Lymphovascular invasion in the myometrium and lymph node metastases are commonly identified, and often have a very subtle "histiocyte-like" appearance.[266–268] Data on the long-term clinical significance of this pattern of endometrial cancer are still emerging.

Secretory carcinoma is characterized by neoplastic glands having subnuclear vacuolization resembling that of a normal 17-day secretory

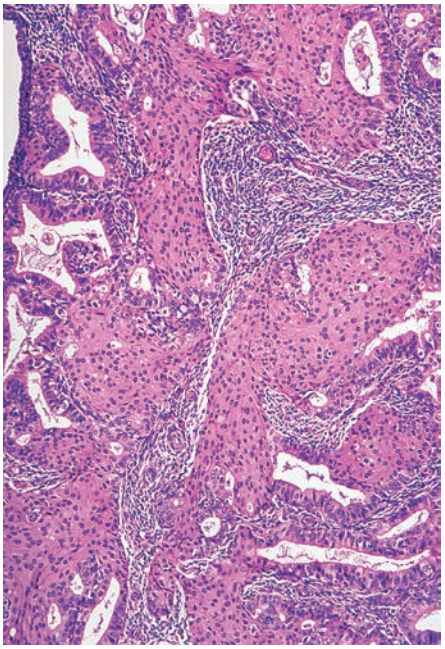

Figure 33.33 Well-differentiated endometrioid adenocarcinoma with squamous metaplasia.

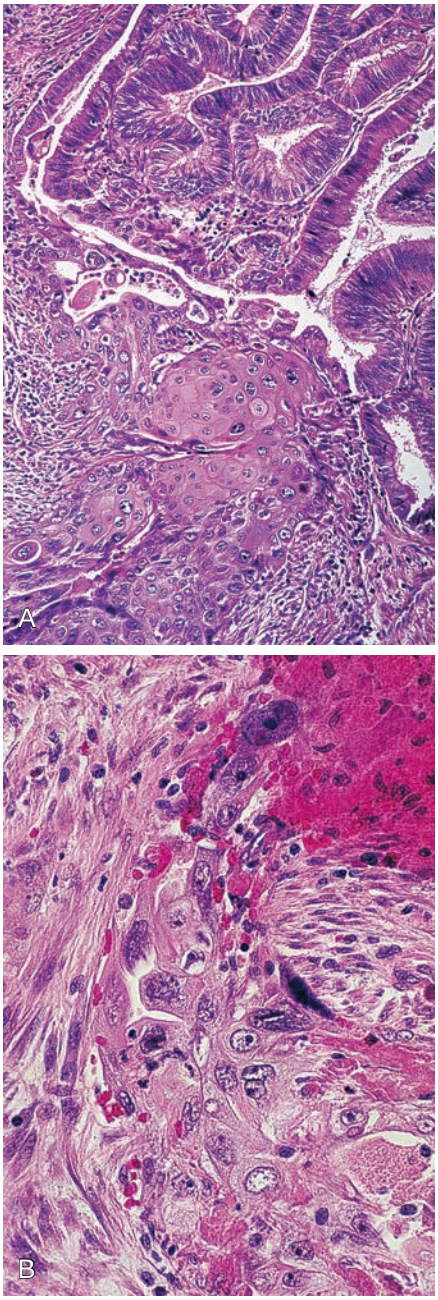

Figure 33.34 **A** and **B,** Endometrial adenocarcinoma of endometrioid type with squamous metaplasia. In contrast to the case shown in Fig. 33.36, the squamous component has markedly atypical cytologic features.

For personal use only. No other uses without permission. Copyright ©2017. Elsevier Inc. All rights reserved.

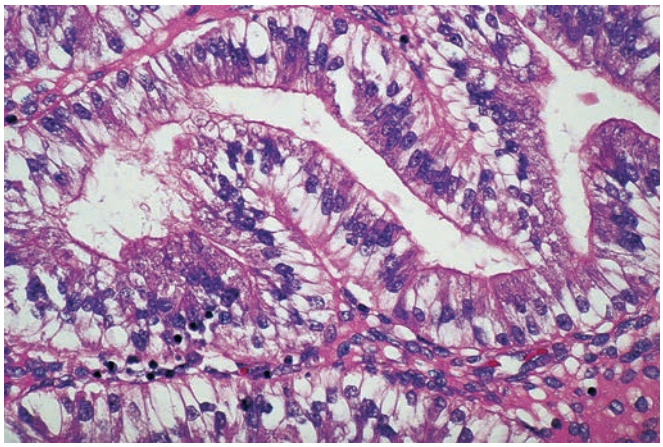

Figure 33.35 Secretory Carcinoma of Endometrium. This well-differentiated lesion is a variant of endometrioid adenocarcinoma and is composed of cells with abundant clear to finely granular cytoplasm. It should be distinguished from clear cell carcinoma.

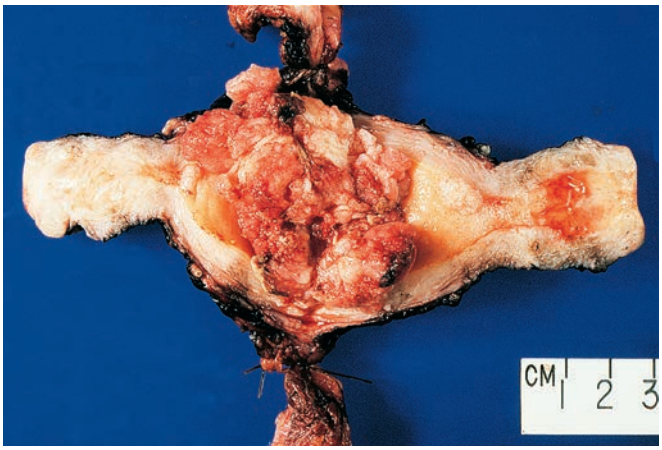

Figure 33.36 Gross appearance of serous carcinoma of endometrium. The neoplasm fills the endometrial cavity.

endometrium and accompanied by a late secretory pattern in the adjacent noninvolved endometrium (Fig. 33.35).[269] This tumor is believed to be the expression of a pattern that may be present diffusely or focally in a well-differentiated endometrioid carcinoma, usually as a result of progesterone stimulation. It should be distinguished from clear cell carcinoma, described later.[270–272]

Mucinous adenocarcinoma is a tumor subtype characterized by abundant intracellular mucin within the tumor cells.[273] Areas of mucinous differentiation are relatively common in usual endometrioid adenocarcinoma and is not of clinical significance. By definition, mucinous adenocarcinoma must consist predominantly (i.e. >50%) of tumor cells showing mucinous differentiation, and when so defined, this is a rare variant of endometrial adenocarcinoma. It is distinguished from atypical mucinous glandular proliferation of the endometrium (the mucinous equivalent of atypical hyperplasia) by increased glandular architectural complexity. Cytologic atypia is of limited help in this differential diagnosis as it is often minimal, even in mucinous carcinoma. There is often a prominent neutrophilic infiltrate in the epithelium of mucinous carcinoma of the endometrium. The distinction between endometrial mucinous adenocarcinoma and primary endocervical adenocarcinoma can be made based on immunostains, with the former showing strong diffuse ER and PR positivity, in most instances, and lacking block p16 positivity, while cervical mucinous carcinomas show block p16 positivity if HPV-associated, or are ER/PR negative if HPV-independent adenocarcinomas of gastric type.[274,275] On occasion, endometrial adenocarcinomas of mucinous or mixed mucinous–endometrioid type exhibit a conspicuous *microglandular* pattern associated with eosinophilic mucinous intraluminal secretion and prominent acute inflammation, the overall picture simulating the appearance of endocervical microglandular hyperplasia.[276,277]

Serous carcinoma is a highly aggressive form of endometrial adenocarcinoma closely resembling tubo-ovarian high-grade serous carcinoma (Fig. 33.36).[278-280] It is characterized by a complex papillary pattern of growth, a high degree of cytologic atypia (pleomorphism, hyperchromasia, giant nucleoli), numerous mitoses, extensive necrosis, psammoma bodies (30% of the cases), and prominent myometrial invasion (Fig. 33.37). It should be distinguished from the already mentioned (and much more common) endometrial adenocarcinoma with a villoglandular pattern of growth, with which it shares several architectural features.[281] A key aspect in this regard is the consistently high-grade nature of its cytologic features.[282] Conversely, papillae

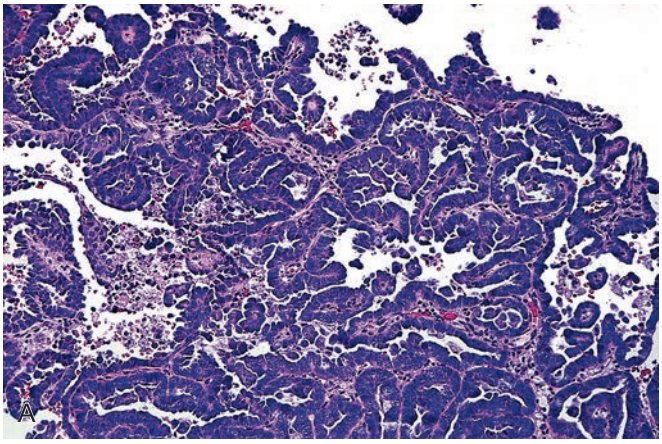

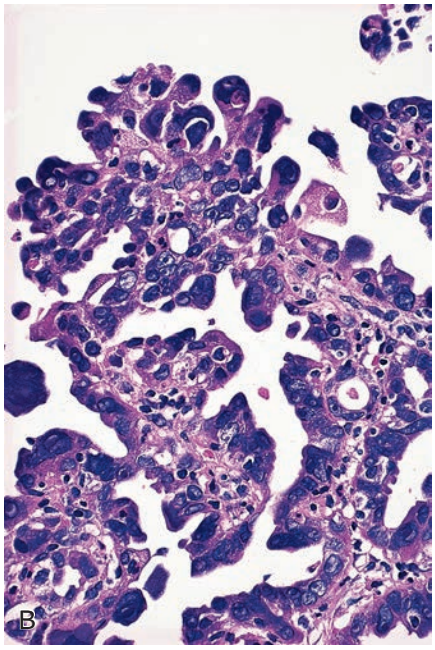

Figure 33.37 A and **B,** Low- and high-power appearance of serous carcinoma. Note the high nuclear grade.

For personal use only. No other uses without permission. Copyright ©2017. Elsevier Inc. All rights reserved.

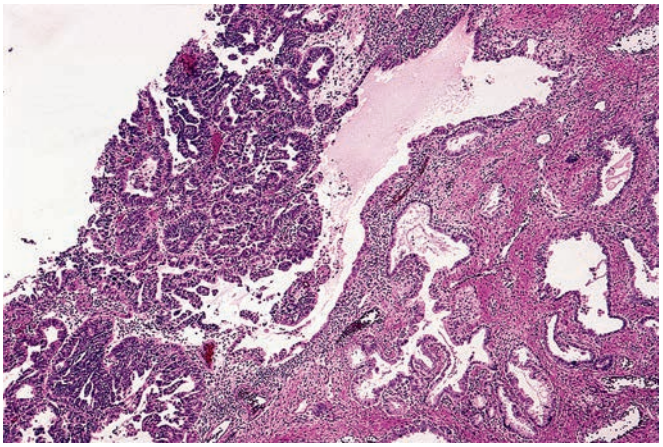

Figure 33.38 Serous carcinoma limited to the superficial portion of an endometrial polyp.

may be scanty, the tumor growing predominantly in the form of tubuloglandular structures with angulated outlines and compressed lumens, raising a differential diagnosis with endometrioid carcinoma.[283] The glandular luminal margin in serous carcinoma with glandular differentiation appears ragged, in contrast to the smooth margin typical of endometrioid adenocarcinoma. It should be mentioned here that psammoma bodies are not necessarily indicative of a serous-type tumor, since occasionally they are also seen in endometrioid carcinomas.[241]

Uterine serous carcinoma can coexist with endometrioid adenocarcinoma of the uterus,[284] be confined to an endometrial polyp, or be entirely intramucosal ("minimal serous carcinoma") (Fig. 33.38).[242,284–291] Even when confined to a polyp there can occasionally be extra-uterine spread, presumably by a transtubal route.[292,293] A putative precursor of serous carcinoma has been described under the term *endometrial glandular dysplasia*.[277,294,295] In patients with widespread involvement by high-grade serous carcinoma in which there is endometrial involvement, most such tumors are endometrial primary tumors.[292] WT1 is less commonly positive in endometrial serous carcinoma than in tubo-ovarian serous carcinoma, but it is not a reliable marker in an individual case. When there is extensive serous carcinoma with significant endometrial involvement, it is our practice to stage it as an endometrial primary tumor and not do immunostains.[293]

Immunohistochemically, abnormal immunostaining for p53 (either strong and diffuse staining or complete absence of staining) is characteristic of serous carcinoma, although not every serous carcinoma will show abnormal p53 staining, and approximately 30% of high-grade endometrioid carcinomas show abnormal p53 immunoreactivity. Thus staining for p53 does not help in distinguishing between serous carcinoma and high-grade endometrioid carcinoma, but it can be useful in cases of glandular tumors with greater atypia than is expected for a low-grade endometrioid carcinoma, but lacking unequivocal high-grade cytologic features of serous carcinoma. Abnormal p53 immunostaining in these so-called "ambiguous" cases supports a diagnosis of serous carcinoma.[296] By molecular classification, the serous carcinomas are almost all type II/CN high/p53 abn subtype.

Carcinosarcoma (formerly referred to as malignant mixed müllerian tumor) was for many years considered to be a variant of uterine sarcoma but is now, based on a number of lines of evidence, classified as an endometrial carcinoma with metaplastic sarcomatous differentiation. Carcinosarcomas are practically always seen in postmenopausal patients, although exceptions occur.[297] Grossly, they

Figure 33.39 Carcinosarcoma of uterus resulting in a huge polypoid mass.

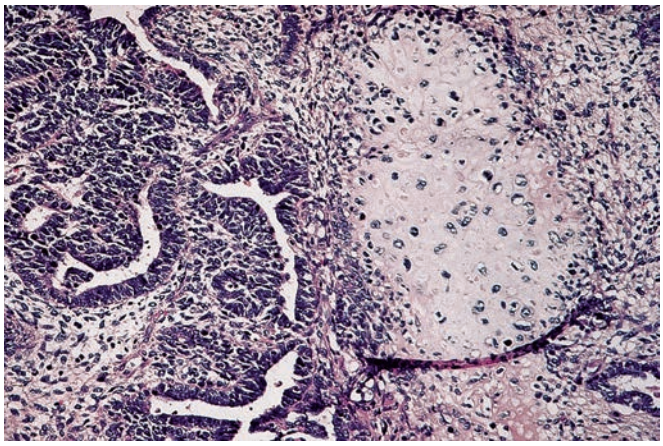

Figure 33.40 Glandular and mesenchymal components of carcinosarcoma. Heterologous elements in the form of cartilage are present.

present as large, soft, polypoid growths involving the endometrium and myometrium, sometimes protruding from the cervix (Fig. 33.39). Foci of necrosis and hemorrhage are common.

Microscopically, the distinctive feature of carcinosarcomas is the *admixture of carcinomatous and sarcoma-like elements*, resulting in a characteristic biphasic appearance (Fig. 33.40). The transition between carcinoma and sarcoma should be abrupt; if it is not, consider one of the mimics of carcinosarcoma, such as dedifferentiated carcinoma or endometrioid carcinoma with corded and hyalinized (CHEC) pattern. The carcinomatous component is usually of glandular type, whether endometrioid, clear cell, or papillary serous (particularly the latter).[298] As a rule, it has a poorly differentiated appearance and is of a high-grade nature; therefore, a careful search for sarcomatous elements should be carried out whenever such patterns are found in an endometrial biopsy, particularly if accompanied by extensive necrosis and hemorrhage. Squamous cell, undifferentiated, and

For personal use only. No other uses without permission. Copyright ©2017. Elsevier Inc. All rights reserved.

primitive neuroectodermal patterns may also be seen.[299,300] Cases have also been described with melanocytic[301] and yolk sac differentiation.[302]

The appearance of the sarcomatous component is the basis for the time-honored division of these neoplasms into a *homologous* and a *heterologous* variety. In the former, the malignant stroma is composed either of round cells resembling those of the endometrial stroma or of spindle cells resembling leiomyosarcoma or fibrosarcoma. In the latter, specific heterologous mesenchymal elements (such as skeletal muscle, cartilage, bone, or adipose tissue) are also present (see Fig. 33.40). Identification of cross striations, or of skeletal muscle markers by immunocytochemistry (e.g. myogenin), is required to document the presence of a rhabdomyosarcomatous component. In some cases this component is so prominent as to overgrow the epithelial elements and to mimic a pure rhabdomyosarcoma.[281] Conversely, the sarcoma-like component may be very inconspicuous. The metastases are most commonly purely epithelial but may be mixed or purely sarcomatous. Exceptionally, a rhabdoid component is present.[303]

Keratin expression is always detectable in the epithelial areas but is also present, albeit reduced, in the sarcomatous component in most cases.[304] Carcinosarcomas can show genetic changes of a type I endometrial carcinoma with progression (i.e. both *PTEN* and/or *ARID1A* mutations AND mutation in *TP53*), or those of a type II endometrial carcinoma (*TP53* mutations without *PTEN* or *ARID1A* mutations), and carcinosarcoma may be an end result of tumor progression in both pathways.[305] Carcinosarcomas are rare among the hypermutated/MMR-D or ultramutated/POLE mutant tumors but there is relatively little data available regarding this point at the time of writing.

Carcinosarcomas are easily distinguished from teratomas by their occurrence in an older age group and by the absence of skin appendages, glia, thyroid, and other tissues; however, as already noted, they may exceptionally contain neuroectodermal elements.[299] They should also be clearly separated from embryonal rhabdomyosarcoma (sarcoma botryoides). The latter term should be reserved for the tumor of childhood or adolescence arising from the cervix or vagina that exhibits skeletal muscle differentiation but lacks a carcinomatous component.

Carcinosarcomas are highly aggressive neoplasms, perhaps more so than even the higher grades and the more unfavorable histotypes of endometrial carcinoma.[306] Extension into the pelvis, lymphatic and vascular permeation, and distant lymph-borne and blood-borne metastases are all common. If the tumor has extended to the serosa of the uterus or beyond at the time of surgery, the prognosis is very poor. In several series, tumors having only homologous stromal elements have been found to have a better prognosis than those with heterologous elements.[307–310] It should be pointed out, however, that the difference between the two is generally small, in some series absent altogether, and far outweighed by the stage of the disease.[311–313]

Carcinosarcomas are the most common uterine tumors to arise in the uterus after irradiation, typically for cervical carcinoma; these postirradiation tumors start to appear 8–10 years after radiation therapy and are associated with a particularly poor prognosis.[314,315]

Clear cell carcinoma is composed of large clear cells with distinct cellular margins containing variable but usually large amounts of glycogen (Figs. 33.41 and 33.42).[271,316] The papillary formations and "hobnail" cells found in this variant of adenocarcinoma resemble those seen in the ovarian, cervical, and vaginal tumors that carry the same name. The ultrastructural and immunohistochemical features of this tumor support their being of müllerian origin, and not mesonephric as was originally believed.[317–320] Most patients are postmenopausal.

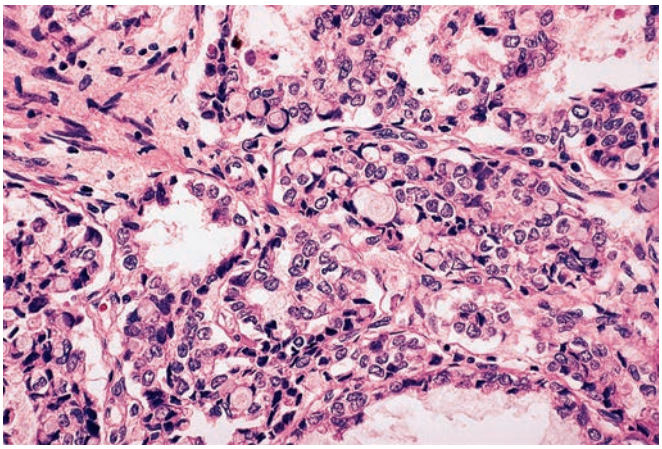

Figure 33.41 Clear cell carcinoma of endometrium.

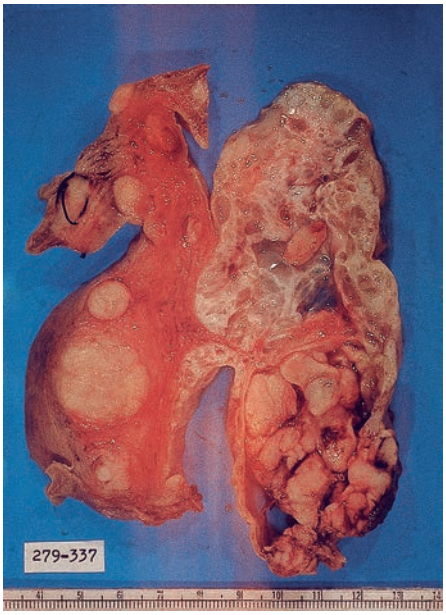

Figure 33.42 Gross appearance of a clear cell carcinoma involving a large endometrial polyp. (Courtesy Dr. Juan José Segura, San José, Costa Rica.)

A rare variant of clear cell carcinoma is characterized by a predominant or exclusive component of large eosinophilic (oxyphilic) cells.[321] Unlike serous carcinomas, most clear cell carcinomas express p53 in a wild type pattern. They are typically negative for ER and PR expression. A putative precursor lesion has been described, characterized by endometrial cells with clear and/or eosinophilic cytoplasm and varying degrees of nuclear atypia.[322]

Undifferentiated carcinoma and the closely related **dedifferentiated carcinoma**, where there is a component of low-grade endometrioid carcinoma present,[323] have emerged as a distinct entity. It grows in the form of solid sheets of cells without any signs of differentiation (Fig. 33.43).[323,324] Epithelial differentiation is inconspicuous and the differential diagnosis may include sarcoma or hematopoietic malignancy. It is important to distinguish it from a grade 3 endometrioid adenocarcinoma because of its worse prognosis.[325] Some of the reported cases of undifferentiated carcinoma have occurred in young women and have pursued a fulminant clinical course.[326] Undifferentiated and dedifferentiated carcinoma are characterized by mutations in genes in the SWI/SNF chromatin

For personal use only. No other uses without permission. Copyright ©2017. Elsevier Inc. All rights reserved.

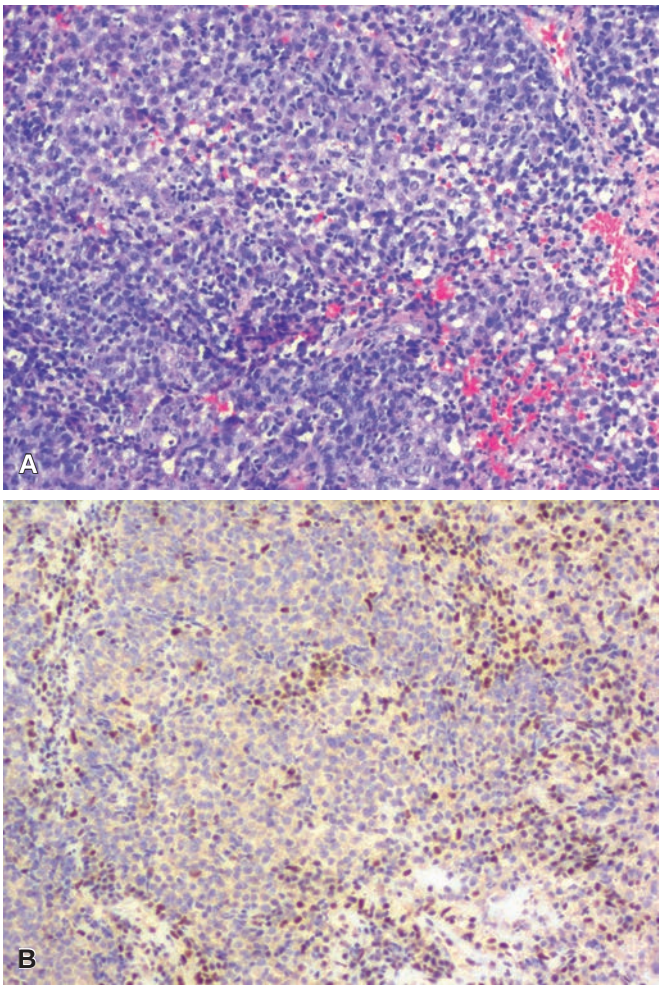

Figure 33.43 Undifferentiated carcinoma (**A**), with loss of MLH1 expression in the tumor cells (**B**).

remodeling complex (the same gene family mutated in ovarian small cell carcinoma of hypercalcemic type) and they typically show weak/focal expression of keratins, loss of PAX8 expression and wild type p53 expression, with frequent loss of expression of mismatch repair proteins (see Fig. 33.43B).[327–329]

Small cell (neuroendocrine) carcinoma usually presents grossly as bulky (sometimes polypoid), ill-defined, and invasive tumor. In rare instances it is seen confined to an endometrial polyp.[330] Microscopically, its appearance is similar to that of its more common cervical counterpart. It may be associated with areas of ordinary endometrioid or serous adenocarcinoma or be seen as a component of carcinosarcoma.[331–333] Immunohistochemically, there is usually reactivity for neuron-specific enolase (NSE) and low-molecular-weight keratin and sometimes also for chromogranin and synaptophysin. Dense-core secretory granules can be detected ultrastructurally. The behavior is very aggressive.[334] As in the lung, cervix, and other sites, tumors with similar high-grade neuroendocrine features but composed of cells of intermediate or large size exist, either pure or admixed with endometrioid adenocarcinoma.[324,335] In this context, it should be noted that a minor population of endocrine cells—as detected with argyrophilic stains—is present in 25%–50% of otherwise typical endometrial adenocarcinomas.[336,337] Some of these cells have been found to contain chromogranin, NSE, 5-hydroxytryptamine (5-HT; serotonin), somatostatin, adrenocorticotropic hormone (ACTH), and indolamines.[338,339]

Squamous cell carcinoma occurring in the endometrium in a pure form is extremely rare,[340,341] and it is, therefore, particularly important to rule out the alternative possibility of extension of a cervical carcinoma.[342] Some cases have developed in elderly patients with pyometra, presumably on the basis of a preexisting endometrial squamous metaplasia.[343] One reported case was associated with *spindle cell (sarcomatoid)* changes,[344] and another was of the *verrucous type*.[345]

Giant cell carcinoma is a rare pleomorphic form of high-grade endometrial adenocarcinoma featuring poorly cohesive sheets and nests of bizarre multinucleated giant cells.[346,347] It may be combined with better differentiated areas showing endometrioid or clear cell carcinoma features.[347]

Endometrial carcinoma with trophoblastic (choriocarcinomatous) or yolk sac differentiation should be distinguished from the giant cell carcinoma (just described), as well as malignant germ tumor, and gestational choriocarcinoma.[348] The multinucleated syncytiotrophoblast-like cells present in the choriocarcinomatous differentiation are strongly immunoreactive for human chorionic gonadotropin (hCG), while yolk sac differentiation is associated with expression of alpha-fetoprotein.[349–351] The conventional endometrial adenocarcinoma areas are more likely to have a serous than an endometrioid morphology.

Endometrioid carcinoma with sertoliform (sex cord–like) differentiation similar to that more commonly seen in ovarian endometrioid tumors has been reported.[352,353] This phenomenon is to be distinguished from the uterine tumors resembling ovarian sex-cord tumors (UTROSCTs). The term *corded and hyalinized endometrioid carcinoma* (so called CHEC pattern) is probably a variant of this sex cord–like differentiation, and it is important to distinguish it from carcinosarcoma, a more aggressive neoplasm.[264]

Hepatoid adenocarcinoma has been reported as arising from the endometrium, in association with alpha-fetoprotein production.[354]

Signet ring cell adenocarcinoma has been described as a primary uterine tumor.[355] Before making this diagnosis, all attempts should be made to rule out the alternative possibilities of metastasis (particularly from breast and stomach) and of vacuolated decidual cells and stromal histiocytes simulating signet ring cells.[356]

Lymphoepithelioma-like carcinoma looks like its homonym in other sites. The few reported cases have not shown evidence of Epstein–Barr virus infection.[357]

Rhabdoid tumor of the uterus represents, in at least some of the cases, a dedifferentiated form of endometrial adenocarcinoma, as is strongly suggested by its occasional coexistence with a conventional adenocarcinoma appearance.[358]

Mesonephric (adeno)carcinoma of the endometrium, that is, a tumor truly derived from wolffian remnants and, therefore, unrelated to the clear cell carcinoma described earlier (which in the past was inaccurately called mesonephric), has been described, presenting as a myometrial mass.[359–361] It may be more common than is generally appreciated, as it can resemble low-grade endometrioid carcinoma and many such tumors have undoubtedly been signed out as such in the past. The expression of TTF-1, CD10, and GATA3 and absence of ER and PR expression are helpful diagnostic features.

Histochemical and Immunohistochemical Features

Immunohistochemically, endometrial adenocarcinomas of the conventional (endometrioid) type are positive for keratin (especially keratins 7, 8, 18, and 19),[362,363] vimentin,[364,365] and PAX8.[366] Coexpression of keratin and vimentin is the norm.[367] Some tumor cells have also been found to contain glial fibrillary acidic protein.[363]

Estrogen and progesterone receptors are present in most cases of endometrial adenocarcinoma of endometrioid type, with

For personal use only. No other uses without permission. Copyright ©2017. Elsevier Inc. All rights reserved.

low-grade tumors being almost invariably positive.[368–370] Expression of ER and PR is variable in high-grade endometrioid and serous carcinomas and uncommon in clear cell carcinoma.[371] A finding of diagnostic significance is that WT1, which is nearly always positive in serous tumor of the tube and ovary and its metastases, is generally negative or only weakly expressed in serous carcinoma of the endometrium,[372–374] as well as in other types of primary endometrial carcinoma.[375] A potential pitfall is represented by TTF-1, a marker classically associated with lung and thyroid carcinoma but which can be also be expressed in endometrial (and endocervical) adenocarcinoma.[376,377]

Note that there are no immunomarkers that are completely sensitive or specific for histotype, and the diagnosis of endometrial carcinoma histotype should be based on evaluation of H&E-stained slides. As mentioned previously, in the specific instance of a glandular neoplasm with "ambiguous features" (i.e. nuclear atypia that exceeds what is usually seen in low-grade endometrioid carcinoma but is insufficient to confidently diagnose serous carcinoma), p53 immunostaining can be used to help in the differential diagnosis between low-grade endometrioid and serous, with wild type p53 expression supporting the former diagnosis.[296]

Molecular Genetic Features

Earlier in this section we described how TCGA identified four subtypes of endometrial carcinoma, based on genomic features: type I/low somatic copy number abnormalities/p53 wild type (endometrioid, typically low grade); type II/high somatic copy number abnormalities/p53 abnormal (mostly serous with a few high-grade endometrioid); hypermutated/MMR deficient (mostly endometrioid); ultramutated/POLE exonuclease domain mutated (endometrioid, often high grade).[228–230,232] Up until now we have attempted to understand the molecular genetic features of endometrial carcinoma in the context of histotype, but in the future all molecular studies should take into account the four genomic subtypes.

The major genetic abnormalities that have been detected in endometrioid adenocarcinomas are mutations in the *PTEN* gene (most cases) and frequent mutations in *PIK3CA*, *KRAS*, *ARID1A*, and *CTNNB1*, whereas serous carcinomas have *TP53* mutations (>90% of cases).[382–389] Mutations in *PPP2R1A* are a feature of endometrial serous carcinomas but not serous carcinomas of tube and ovary.[390]

DNA aneuploidy is present in approximately one-fourth of endometrial carcinomas; positive tumors tend to be of advanced surgical stage and higher microscopic grade, associated with deeper myometrial invasion, and accompanied by lymph node metastases. As expected, aneuploidy is the rule in serous carcinoma but can also be seen in a minority of endometrioid carcinomas.[391,392]

Spread and Metastases

The two obvious sites of direct spread of endometrial carcinoma are the myometrium and the cervix, both of these having important prognostic connotations.[393] For staging purposes, myometrial invasion is divided into two stages: up to 50% of the myometrial thickness or invasion to 50% or more of the myometrial thickness. This apparently straightforward determination is actually fraught with many potential inaccuracies.[394] The arcuate vascular plexus of the myometrium has been used as a guideline for this measurement, in the sense that carcinomatous infiltration into or through this plexus can be taken as surrogate evidence that the tumor has invaded over 50% of the myometrium.[393] This can be a useful approach when the uterine corpus is distorted by leiomyomas, for example, making measurement of depth of invasion difficult. A particularly difficult situation arises if there is coexistent adenomyosis. On the one hand, involvement of adenomyosis foci by carcinoma can be overinterpreted as deep myometrial invasion; on the other, it has been claimed that involvement of adenomyosis by carcinoma is an indicator of the likely presence of true myometrial invasion elsewhere in the myometrium.[395]

Invasion of the endocervix by endometrial carcinoma is relatively common, and the histologic features were discussed previously.

Lymphovascular invasion is the most important route of spread of endometrial cancer. It has recently been shown that "substantial" rather than minimal or focal lymphovascular invasion is of prognostic significance; the prognosis of patients with one or two lymphatic channels containing tumors is indistinguishable from that of patients without lymphovascular invasion.[396] A warning here is in order. We are referring to the artifact known as *vascular pseudoinvasion* sometimes seen in laparoscopic hysterectomy specimens and characterized by conspicuous tumor fragments in the lumen of thick-walled vessels in the outer myometrium or in ectatic vessels anywhere in the myometrium. These tumor fragments are detached from the vascular wall, lack an inflammatory perivascular infiltrate, and are accompanied by tumor fragments in myometrial clefts.

The most common sites of extrauterine spread in endometrial adenocarcinoma of the endometrioid type are the pelvic and paraaortic lymph nodes and the ovaries (see next section). Nodal metastases occur in approximately 5%–25% of clinically stage I tumors and are more likely to occur in invasive high-grade tumors (even if such tumors are superficial), in large sized and/or deeply invasive tumors regardless of grade, in tumors with cervical extension, and in tumors with vascular invasion.[397–399]

Serous carcinoma has a particular propensity for lymph vessel permeation. Involvement of peritoneal surfaces (particularly in the pelvis) occurs early in the disease and can be present even at the intraepithelial stage.[400] In these cases, molecular analysis has shown that the disease is clonal, indicating origin at a single site with secondary early spread.[393,399,401] An additional route of spread of endometrial carcinoma is transtubal,[293,403] but another warning is in order. On occasion, the keratin present in endometrial carcinoma with squamous metaplasia desquamates into the uterine cavity and from there travels via the fallopian tube to produce implants on the peritoneal surface, leading to the formation of foreign body granulomas.[404] This finding should not be regarded as evidence of metastatic disease *in the absence of viable neoplastic cells.* Follow-up data on these patients suggest that these keratin granulomas have no prognostic significance.[405]

The most common sites of recurrence of endometrial carcinoma are the vaginal vault and pelvis. Serous carcinoma characteristically spreads throughout the abdominal cavity in a fashion similar to that of tubo-ovarian serous carcinoma. Metastases of endometrial carcinoma in the bladder can simulate a primary neoplasm of this organ.[406]

Distant metastases of endometrial carcinoma are more common in the lung, liver, bone, central nervous system, and skin. The latter tend to occur in the head and neck region, particularly the scalp.

Coexistent Uterine and Other Genital Tract Carcinomas

Approximately 8% of endometrial carcinomas are accompanied by a simultaneous **ovarian carcinoma.** When they are of similar microscopic types—which is usually the case—it has been difficult to decide whether there are two independent tumors or whether one of the sites represents a metastasis.[407] Features in the endometrial tumor that are considered to favor an independent primary are stage Ia, grade 1 or 2, without lymphovascular invasion, while the ovarian tumor should similarly be organ confined and low grade.[408] There is ample evidence, based on large case series, that these tumors

For personal use only. No other uses without permission. Copyright ©2017. Elsevier Inc. All rights reserved.

behave as independent stage I primary tumors rather than as stage II ovarian carcinoma or stage III endometrial carcinoma.[407,409] High-grade tumors should be considered metastatic (almost always from endometrium to ovary, as discussed previously) until proven otherwise.[407] Other features considered to favor a metastatic nature for the synchronous ovarian tumor include the following: bilateral involvement, multinodular pattern of growth, presence of associated surface implants, and prominent lymphatic or vascular invasion within the ovarian stroma.[410] The clinical outcome data make interpretation of whole genome or whole exome sequencing data challenging, as these clearly indicate a clonal origin for synchronous ovarian and endometrial tumors in a large majority of cases.[411,412] The empirical evidence supports the practice of using the older clinicopathologic criteria in staging, as they result in the appropriately conservative treatment, and in this circumstance molecular testing results should not enter into the decision on whether to stage as independent primary tumors. Please note that in taking this pragmatic approach we are not suggesting that the synchronous tumors have risen independently; this would be akin to suggesting that, based on available evidence, the world is flat. We are simply advocating an approach to staging that is supported by clinical outcome data and will not lead to overtreatment of patients.

Endometrioid carcinomas have been described involving simultaneously the uterine corpus and the fallopian tube; in about half of them the fallopian tube tumors were located in the distal or fimbriated end, and some of the tumors were in situ.[413] Approximately 20% of serous carcinomas of endometrium are associated with metastatic tubal mucosal involvement.[293] We undoubtedly are seeing more cases of endometrial carcinoma with involvement of the fallopian tube mucosa since the introduction of more extensive sampling of tubal fimbria, but we do not yet know the clinical significance of this finding.

Treatment

The usual treatment of endometrial carcinoma is total abdominal hysterectomy with bilateral salpingo-oophorectomy. Whenever feasible, this should be supplemented by surgical staging (including biopsies of pelvic and para-aortic lymph nodes) if any of the following is present: greater than 50% myometrial invasion, grade III tumor, cervical involvement, extrauterine spread, unfavorable histologic component (serous, clear cell, or undifferentiated), or palpably enlarged nodes.[415] Radiation therapy, which was administered routinely in conjunction with surgery (either preoperatively or postoperatively), is no longer favored, except for patients with poor prognostic factors that put them at a high risk of recurrence.[416] This has largely been the result of randomized clinical trials showing that radiation therapy decreases local recurrences but does not influence disease specific or overall survival.[417]

Progestational agents can be curative for early stage, low-grade tumors, and in more advanced tumors, although usually not curative, occasionally induce striking temporary regressions in the primary tumor as well as in the metastases.[418,419] Well-differentiated carcinomas treated with progestins show a decreased gland-to-stroma ratio, decreased glandular cellularity, decreased or absent mitotic activity, loss of cytologic atypia, and a variety of cytoplasmic changes, including mucinous, secretory, squamous, and eosinophilic metaplasia.[420]

The treatment of serous carcinoma consists of hysterectomy with bilateral salpingo-oophorectomy, omentectomy, and surgical staging, the latter including peritoneal cytology and pelvic and para-aortic lymph node sampling. This is usually followed by adjuvant therapy, except for the minimally invasive tumors.[421–425]

Tumor relapse may appear in the form of local recrudescence (50%), distant metastases (28%), or both (21%); the median interval is between 1 and 2 years.[426] Local recurrences can be treated successfully with aggressive radiation therapy.[427]

Prognosis

Factors of prognostic importance in endometrial adenocarcinoma are the following:

1. *Tumor stage*, as defined by the FIGO system.[428] As for most of the common epithelial malignancies, stage is the strongest prognostic indicator and all biomarkers must be evaluated for significance independent of stage.
2. Level of *infiltration* of the myometrial wall, as incorporated into the FIGO staging system.[461] Tumors with invasion of over onehalf of the myometrium fare worse than those invading less than one-half.[429–432] Among the latter (stage Ia tumors), there is no significant difference between those that invade up to one-third and those that invade greater than one-third but less than one-half.[433]
3. *Microscopic grade* of differentiation, as defined by the FIGO system.[431,434,435] As already stated, originally this system was primarily based on architectural rather than nuclear features, except for the serous and clear cell types, which are by definition high-grade tumors.[436] The addition of a nuclear parameter to the FIGO system has improved its prognostic significance.[437] High-grade tumors have a worse prognosis regardless of their histologic subtype.[438]
4. *Age*. Patient age has consistently been an important prognostic factor, with advanced patient age associated with worse outcomes, but this has recently been questioned; Haley et al., in a large series, showed no significance for age as a prognostic factor in patients with early stage endometrial carcinoma, when carefully matched for tumor grade/histotype and other pathologic variables.[439] This illustrates the difficulty in assessing the relative strength of prognostic markers, when they co-vary, as age does with type II/serous/advanced stage.
5. *Histotype*. Among high-grade tumors (grade III endometrioid, serous, and clear cell) some studies show that histotype is of prognostic significance while other studies do not; the likely explanation is that the grade III endometrioid carcinomas are a heterogeneous group, and include all four molecular subgroups (i.e. copy number low, copy number high, ultramutated and hypermutated), and the subgroups of grade III endometrioid as defined based on the genomic abnormalities have very different prognoses.[440]
6. *Lymph vessel invasion*. Tumor permeation of lymph vessels is a poor prognostic sign,[441,442] particularly if extensive.[396,444]
7. *Molecular subtypes:* The four molecular subtypes of endometrial cancer, identified based on TCGA study, were discussed previously in this section and have emerged as important prognostic subgroups of endometrial carcinoma (see Table 33.1).
8. *Others*. Parameters said to be indicative of favorable outcome are absence of L1CAM expression,[229] absence of β-catenin mutation,[229,446] and diploid cellular DNA content.[392,448]

Endometrial Stromal Tumors

Tumors composed of endometrial stroma tend to occur in middle-aged women (average age, 45 years) and often present with vaginal bleeding.[449]

Microscopically, the low-grade endometrial stromal neoplasms are composed of uniform, predominantly oval, small cells, very closely resembling those of the endometrial stroma, individually enveloped by reticulin fibers, which characteristically encircle small vessels that resemble spiral arterioles (Fig. 33.44).

For personal use only. No other uses without permission. Copyright ©2017. Elsevier Inc. All rights reserved.

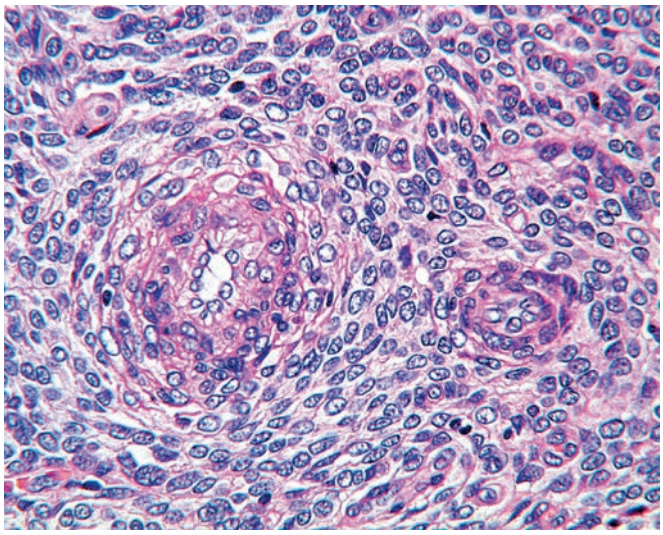

Figure 33.44 Typical microscopic appearance of low-grade endometrial stromal tumor, showing bland oval cells arranged concentrically around spiral arterioles.

Figure 33.45 **Endometrial Stromal Nodule.** The lesion is characteristically well circumscribed and has a yellow color.

Endometrial stromal tumors are divided into low-grade and high-grade stromal neoplasms; the former are further subdivided according to the type of margins into: (1) a benign category (endometrial stromal nodule) having pushing margins; and (2) a malignant category (low-grade endometrial stromal sarcoma) having infiltrating margins.[450–452] Distinction between endometrial stromal nodule and low-grade endometrial stromal sarcoma is made solely based on the margin between the tumor and myometrium, and it follows that this distinction is not possible based on endometrial biopsy/curettings. Endometrial stromal neoplasia is recognized in a biopsy/curetting by the presence of confluent areas of stroma measuring more than 5 mm, without glands; in such a case, one can only diagnose "low-grade stromal neoplasm" and defer definitive classification to the hysterectomy specimen.

Endometrial stromal nodules appear grossly as solitary sharply circumscribed masses of soft consistency and a characteristic yellow-to-orange color (Fig. 33.45). They do not invade veins, lymphatics, or the myometrium. The prognosis is excellent; recurrence did not occur in any of the 60 cases studied by Tavassoli and Norris,[430] even when some irregularities in the margin, high mitotic counts, or glandular foci were present. Cases in which the irregularities at the margins are pronounced but which lack the typical, usually extensive infiltration of the endometrial stromal sarcomas listed later have been referred to as *endometrial stromal tumors with limited infiltration*.[453] Their behavior seems to be as favorable as that of the conventional stromal nodules. Genetically, endometrial stromal nodule is characterized by t(7;17), which results in *JAZF1–JJAZ1* fusion.[454–456] The differential diagnosis is with cellular leiomyoma and markers of importance in this context are CD10 (consistently positive), h-caldesmon (consistently negative), and HDAC8 (consistently negative); note that desmin and smooth muscle actin may show weak immunoreactivity in low-grade endometrial stromal neoplasms.[457–461]

Low-grade endometrial stromal sarcomas infiltrate the myometrium and have a particular tendency to permeate lymph vessels (Figs. 33.46 and 33.47). The latter feature sometimes can be detected grossly by the presence of yellowish, ropy, or ball-like masses filling dilated channels. They may also present as polypoid masses (Fig. 33.48). The local invasion may extend into the broad ligament, tubes, and ovaries. Their low-power appearance is very distinctive,

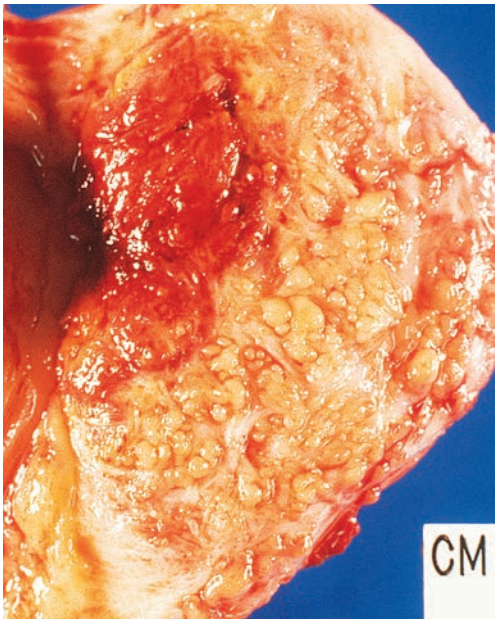

Figure 33.46 Low-grade endometrial stromal sarcoma showing diffuse permeation of the myometrium in the form of small nodules bulging on the cut surface.

in the sense of showing extensive myometrial permeation by sharply defined tumor islands with pointed edges, somewhat reminiscent of those seen (in an altogether different context) in thymoma. Other commonly encountered features in low-grade endometrial stromal sarcomas include foci of hyalinization and scattered foamy cells.[462] Morphologic variations (other than those described in greater detail later) include the presence of a prominent fibrous or myxoid component,[463] adipose metaplasia,[464] a component of epithelioid cells with abundant eosinophilic cytoplasm,[465] scattered tumor cells

For personal use only. No other uses without permission. Copyright ©2017. Elsevier Inc. All rights reserved.

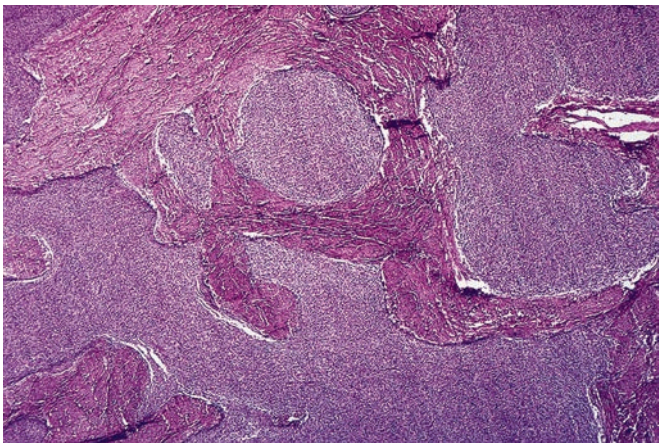

Figure 33.47 Typical low-power appearance of endometrial stromal sarcoma.

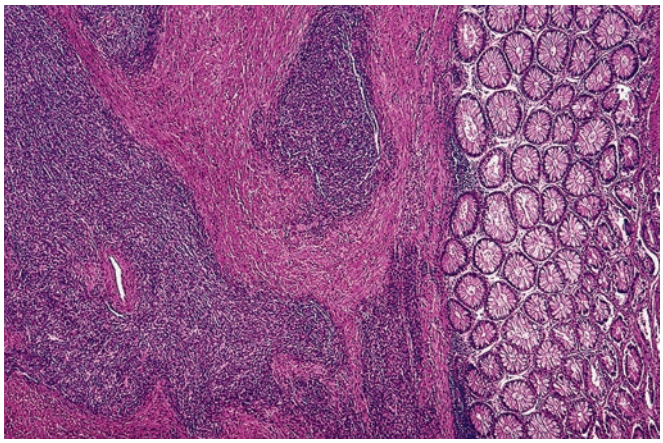

Figure 33.49 Low-grade endometrial stromal sarcoma metastatic to wall of large bowel.

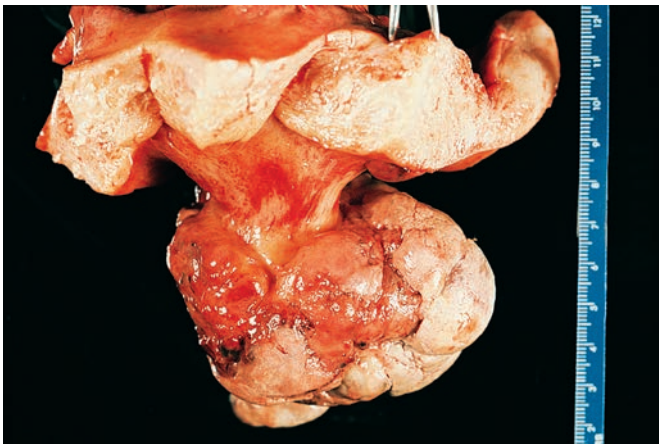

Figure 33.48 Low-grade endometrial stromal sarcoma presenting as a huge polypoid mass within the endometrial cavity. This pattern of growth is unusual in this tumor type.

with "symplastic" nuclei,[464,466] and papillary/pseudopapillary formations.[467]

The natural history of low-grade endometrial stromal sarcoma is characterized by slow clinical progression, repeated local recurrences (in the pelvis, ovary, intestinal wall, other intra-abdominal sites, and anterior abdominal wall), and occasional metastases (Figs. 33.49 and 33.50).[468]

Size of the tumor and extrauterine extension are important prognostic features. Low-grade stromal neoplasms less than 4 cm in diameter practically never recur, and tumors confined to the uterus at the time of the initial surgery infrequently do so.

The tumor cells contain estrogen and progesterone receptors, and the tumors respond to administration of progestins.[469,470] Genetically, about 50% of cases show t(7;17) with *JAZF1–SUZ12 (JJAZ1)* fusion (identical to that seen in endometrial stromal nodule, but differ in showing concurrent silencing of the unrearranged *SUZ12* allele). Other less common genetic abnormalities include t(6;7) with *JAZF1–PHF1* fusion, t(6 : 10) (*EPC1-PHF1*) and t(1 : 6) (*MEAF6-PHF1*).[454–456] These genetic findings may be utilized to aid in the diagnosis of endometrial stromal sarcoma by using fluorescence in situ hybridization (FISH) or reverse transcriptase-polymerase chain reaction (RT-PCR). It should be noted that as well as the translocations described previously, a significant minority of low-grade endometrial stromal sarcomas have rearrangement of JAZF1 or PHF1 by FISH, without identification of the fusion partner.[471]

The differential diagnosis between low-grade endometrial stromal neoplasm and a smooth muscle tumor was discussed previously, but a related issue is the phenomenon of tumors that show both endometrial stromal and smooth muscle differentiation, based on both light microscopic examination and immunostaining. If the smooth muscle differentiation is present in the form of an inconspicuous focus in the midst of an otherwise typical endometrial stromal tumor, it can be ignored for diagnostic purposes.[472] A distinct histologic pattern is the presence of relatively discrete nodules of small epithelioid tumor cells, which stain strongly with desmin, embedded in hyalinized collagen, the so-called "starburst" pattern.[473] If sizable (one-third or more of the tumor mass), the neoplasm is referred to as **combined smooth muscle–stromal tumor.**[474,473] These combined tumors often show the t(7;17) with *JAZF1–SUZ12* fusion characteristic of low-grade endometrial stromal neoplasms and behaviorally seem to be closer to endometrial stromal tumors than to smooth muscle tumors, and—on the whole—are very indolent; therefore, the diagnostic term *endometrial stromal sarcoma with smooth muscle differentiation* is commonly used.[474]

Epithelial-like formations may appear in endometrial stromal tumors in the form of solid masses, glandular structures, or anastomosing cords. Some of these formations have been likened to those of ovarian sex-cord neoplasms (particularly granulosa cell tumors) and the tumors containing them have been referred to as **uterine tumors resembling ovarian sex-cord tumors** (**UTROSCTs;** Fig. 33.51).[455,475] Some cases feature an epithelial retiform component resembling rete ovarii.[476] Their immunohistochemical and ultrastructural profile has varied considerably in the reported series, ranging from myogenous to epithelial.[477] However, at least some of the cases have shown a phenotype consistent indeed with a sex-cord line of differentiation, including reactivity for inhibin, CD99, and Melan-A.[478–481] Uterine tumors in which these structures predominate to almost the exclusion of others have generally behaved in a benign fashion,[475] but occasional metastasizing examples are on record.[482]

The uterine neoplasm known as **plexiform tumor** or **tumorlet** is an occasional incidental finding in a hysterectomy specimen. They are typically less than 1 cm and invariably benign. Their histogenesis is controversial, and they have been claimed to be of endometrial stromal,[483] myofibroblastic,[484] and smooth muscle derivation.[485,486]

A different type of epithelium-like formation that can be seen in endometrial stromal tumor is represented by **endometrioid**

For personal use only. No other uses without permission. Copyright ©2017. Elsevier Inc. All rights reserved.

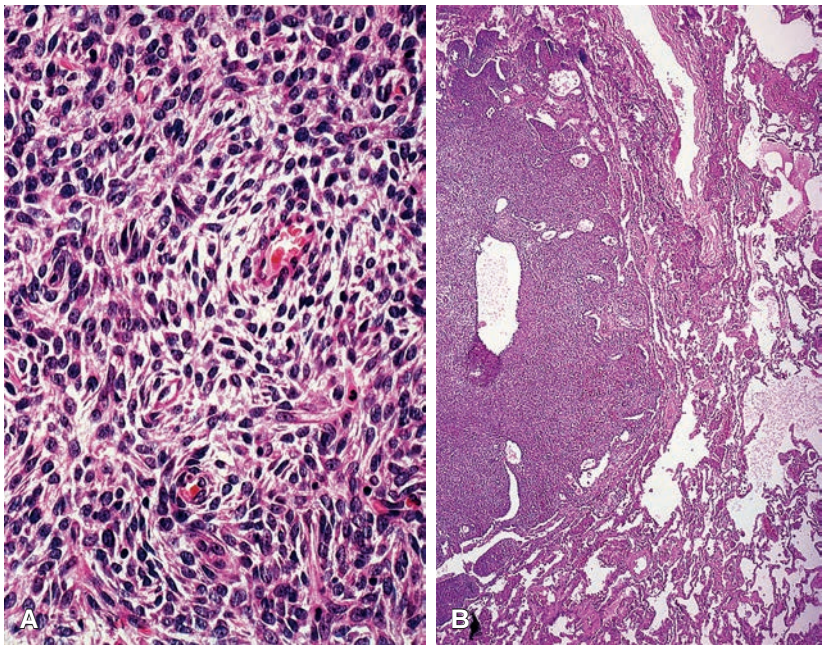

Figure 33.50 **A** and **B,** Low- and high-power appearance of low-grade endometrial stromal sarcoma metastatic to lung. This lesion may be misdiagnosed as spindle carcinoid tumor, hemangiopericytoma, or solitary fibrous tumor.

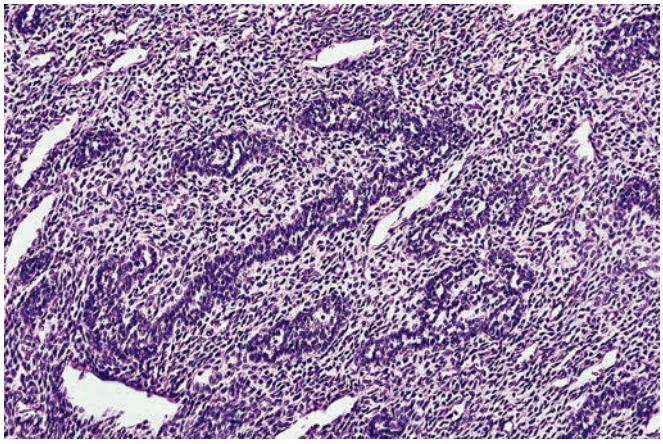

Figure 33.51 Low-grade endometrial stromal sarcoma with structures resembling ovarian sex cord tumors.

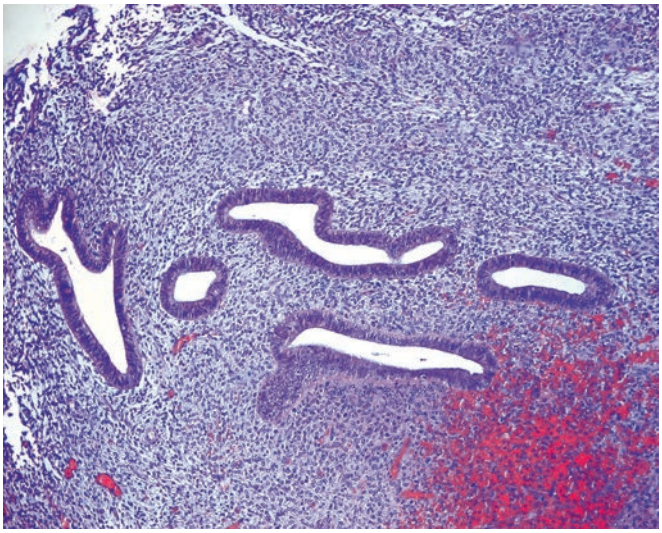

Figure 33.52 Peritoneal metastasis from endometrial stromal sarcoma accompanied by benign endometrioid glands.

glandular foci having a benign, atypical, or carcinomatous appearance (Fig. 33.52).[487,488]

Tumors with the appearance of low-grade endometrial stromal neoplasms may be found in the cervix,[489] ovary, pelvis, and retroperitoneum.[490] Some of these are seen in association with endometriosis, from which presumably they have arisen.[491] These extrauterine tumors may have any of the morphologic features and variations described in connection with the uterine neoplasms, including ovarian sex cord–like structures and endometrioid glandular proliferation.[492] A note of caution is in order. Before making a diagnosis of primary extrauterine low-grade endometrial stromal tumor, one should make an effort to rule out a metastasis from a uterine lesion, knowing that these metastases are often solitary and that they can occur years or decades after the excision of the original tumor, which (to complicate things further) might have been misdiagnosed as a peculiar-looking smooth muscle tumor.[493,494]

High-grade endometrial stromal sarcoma is a rare tumor; however, as it was only recently described, the true incidence is unknown. On low power it infiltrates the myometrium in a manner similar to that of low-grade endometrial stromal sarcoma.[495] The microscopic appearance is variable, ranging from low-grade spindle cell areas to a high-grade uniform small round cell component (Fig. 33.53).[496] It lacks conspicuous pleomorphism, which sets it apart from undifferentiated uterine sarcoma (see later). The mitotic activity is typically greater than 10 MF/10 HPF, in contrast to low-grade endometrial stromal sarcoma. The high-grade component of these tumors is negative for ER, PR, and CD10 but positive for expression of cyclin D1 (which unfortunately is not a specific marker of this tumor) and also express c-kit/CD117.[497] The low-grade

For personal use only. No other uses without permission. Copyright ©2017. Elsevier Inc. All rights reserved.

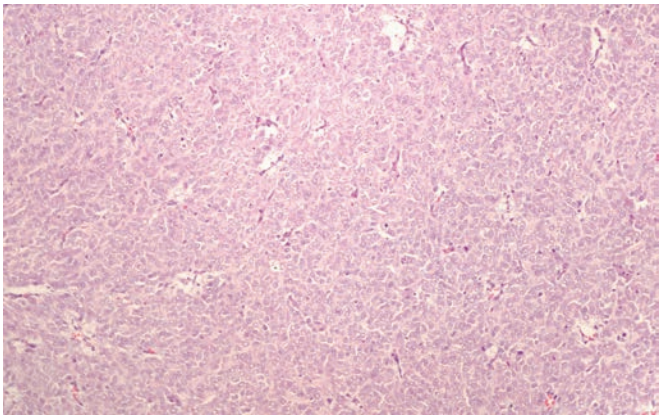

Figure 33.53 High-grade endometrial stromal sarcoma with t(10:17) *YWHAE-NUTM2* translocation. The nuclei are higher grade than in low-grade endometrial stromal sarcoma. (Courtesy Dr. Lien Hoang, Vancouver.)

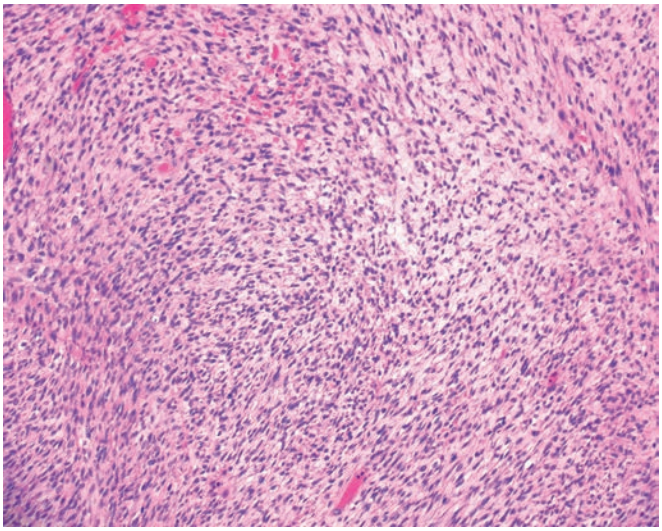

Figure 33.54 Myxoid high-grade endometrial stromal sarcoma with *Z3H7B-BCOR* translocation. (Courtesy Dr. Lien Hoang, Vancouver.)

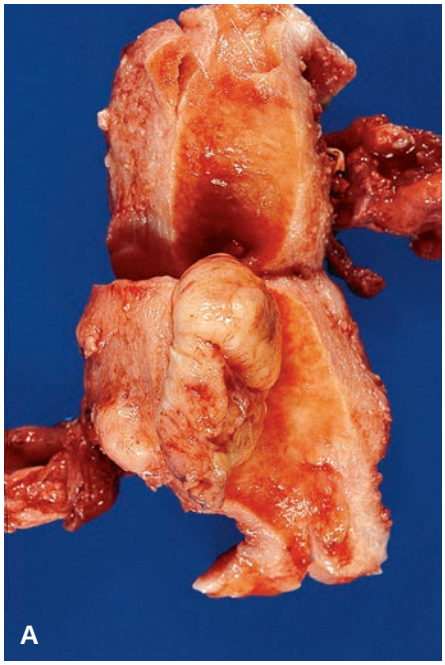

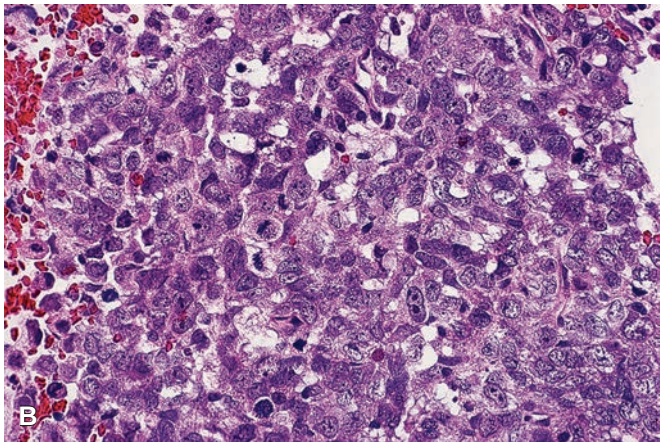

Figure 33.55 **A** and **B,** Gross and microscopic appearance of undifferentiated uterine sarcoma.

spindle cell component shows a more conventional endometrial stromal cell immunophenotype (ER, PR and CD10 positive). These tumors are characterized by t(10:17) with fusion of *YWHAE* and *NUTM2* (formerly known as *FAM22*). Genetic testing, for example, FISH, is an important diagnostic adjunct.[498] The prognosis of high-grade endometrial stromal sarcoma is intermediate between that of low-grade endometrial stromal sarcoma and undifferentiated uterine sarcoma. Responses to anthracycline chemotherapy have been reported and accurate diagnosis is important in guiding management.[499]

A second variant of high-grade endometrial stromal sarcoma has been described, characterized by spindled cells with abundant myxoid stroma and brisk mitotic activity, an appearance mimicking that of myxoid leiomyosarcoma (Fig. 33.54).[500] These tumors have *ZC3H7B-BCOR* gene fusion and follow an aggressive clinical course.

Recent studies suggest that BCOR immunohistochemical staining may serve as a sensitive and specific surrogate for identifying high-grade endometrial stromal sarcomas, regardless of the underlying genetic alteration (i.e. tumors with *BCOR* and *YWHAE* alterations are both immunoreactive).[501]

Undifferentiated uterine sarcoma shows a marked degree of nuclear pleomorphism and atypicality and lacks the vascular pattern and other distinctive features of endometrial stromal sarcoma (Fig. 33.55). It is an altogether different neoplasm from the lower grade, translocation-driven sarcomas described previously and behaves in a very aggressive manner. It is may prove to be a mixed group, histogenetically, with some being of endometrial stromal cell or smooth muscle cell origin, and others being monophasic carcinosarcoma, which it resembles morphologically.

Müllerian Adenosarcoma and Related Tumors

Müllerian adenosarcoma is a distinctive type of uterine tumor, consisting of sarcomatous stroma, typically low grade, and benign glandular elements.[502–504] It usually presents in elderly individuals as a bulky polypoid growth filling the endometrial cavity, less commonly as an intramural nodule (Fig. 33.56). Microscopically, it can bear a striking similarity to phyllodes tumor of the breast (Fig. 33.57). The stromal elements usually resemble endometrial stroma by light and electron microscopic examination but are more

For personal use only. No other uses without permission. Copyright ©2017. Elsevier Inc. All rights reserved.

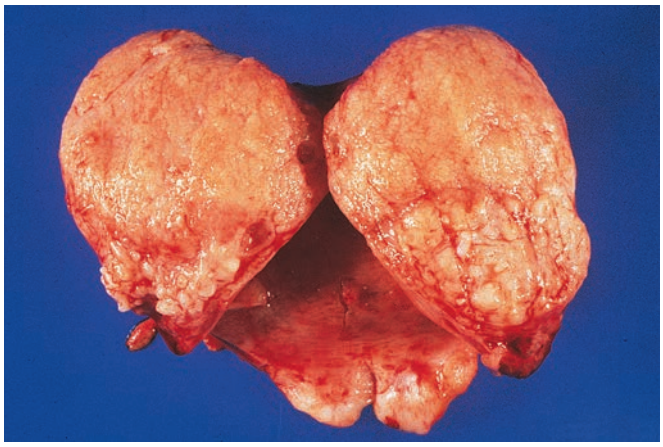

Figure 33.56 Müllerian Adenosarcoma. The tumor shows less degree of necrosis and hemorrhage than the usual malignant mixed müllerian tumor.

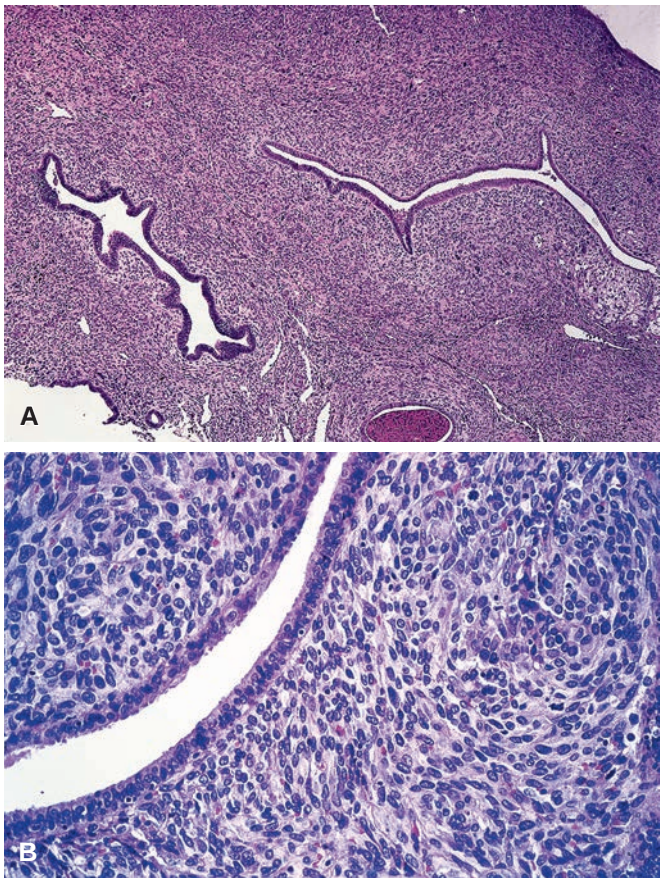

Figure 33.57 A and **B,** Low- and high-power view of müllerian adenosarcoma. The resemblance to phyllodes tumor of breast is obvious.

spindled.[505,506] As a rule, they do not appear as bizarre and undifferentiated as in the classic MMMT, although multinucleated giant cells and heterologous elements occur in approximately 20% of cases. The latter are usually of skeletal muscle type, but peculiar components such as angiosarcoma have also been observed.[507,508] Extensive areas of stromal fibrosis may result in a deceptively benign appearance.[503]

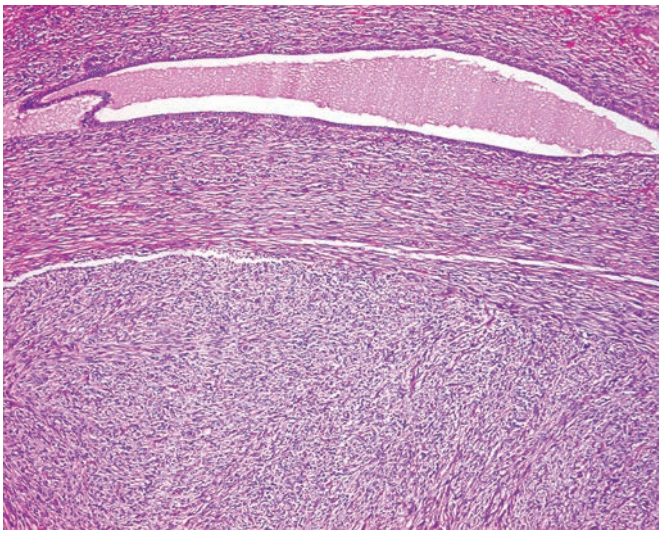

Figure 33.58 Müllerian adenosarcoma *(top)* with sarcomatous overgrowth *(bottom)*.

Like phyllodes tumor of the breast, müllerian adenosarcomas can show overgrowth by a pure sarcoma having a higher grade and exhibiting a greater mitotic rate than the sarcomatous component of the associated adenosarcoma (Fig. 33.58). These *müllerian adenosarcomas with sarcomatous overgrowth* behave in an aggressive fashion and are often associated with postoperative recurrence or metastases and a fatal outcome, in contrast to the usually indolent behavior of usual adenosarcoma.[504,509] The presence of high-grade cytologic features and sarcomatous overgrowth occur together and the prognostic significance of just high-grade cytologic features OR sarcomatous overgrowth in a low-grade tumor is not clear, as very few cases have been reported.

In the past, **uterine adenofibroma** was recognized as a benign counterpart of adenosarcoma.[510–513] The dividing line between the two groups was never sharp,[514] and it is clear that tumors with the characteristic features of uterine "adenofibroma" have occasionally been found to invade myometrium and pelvic veins, so it is now recommended that all such tumors be diagnosed as adenosarcoma.[515] Cases have been reported of adenosarcoma involved by adenocarcinoma.[516]

Leiomyoma

Leiomyomas of the uterus are extremely common neoplasms. The overall incidence is between 4% and 11%, but it rises to nearly 40% in women over the age of 50 years. Clinically apparent lesions are less common in parous than nulliparous women and premenopausal than postmenopausal women.[517] They are known to shrink after menopause; this is associated both with fibrosis and with a reduction in the size of the individual tumor cells.[518,519] The normal myometrium of leiomyoma-containing uteri expresses higher levels of estrogen receptors, a fact that may be related to their pathogenesis.[520] Leiomyomas are much more common in black women, in whom they have a tendency to be very numerous (Fig. 33.59).

Many of these tumors are small and go undetected; a systematic and meticulous study of 100 consecutive hysterectomy specimens revealed leiomyomas in 77 of them, 84% of the tumors being multicentric.[521]

These tumors occur subserosally, intramurally, or submucosally (Fig. 33.60) and produce symptoms referable to their size and location. The conventional teaching (which, like most conventional

For personal use only. No other uses without permission. Copyright ©2017. Elsevier Inc. All rights reserved.

Figure 33.59 Multiple uterine leiomyomas.

Figure 33.60 Large uterine leiomyoma with intramural and subserous involvement.

teachings, is only partially true) is that the submucous tumors produce metrorrhagia, sometimes massive, (because of endometrial ulceration), the intramural ones result in menorrhagia (because they interfere with myometrial contraction), and the subserosal ones usually remain asymptomatic. They may become large enough to block the ureters, interfere with pregnancy, or cause inflammatory complications. In rare instances, uterine leiomyomas have been associated with polycythemia, which regressed after the tumor was excised ("myomatous erythrocytosis syndrome").[522] These tumors, which are usually very large, have been shown to be the source of erythropoietin.[523]

Submucosal tumors often result in secondary endometrial changes that range from gland distortion to atrophy and ulceration. They may fill the endometrial cavity and emerge from the cervical canal as polypoid growths ("myoma nascens"). Under these circumstances,

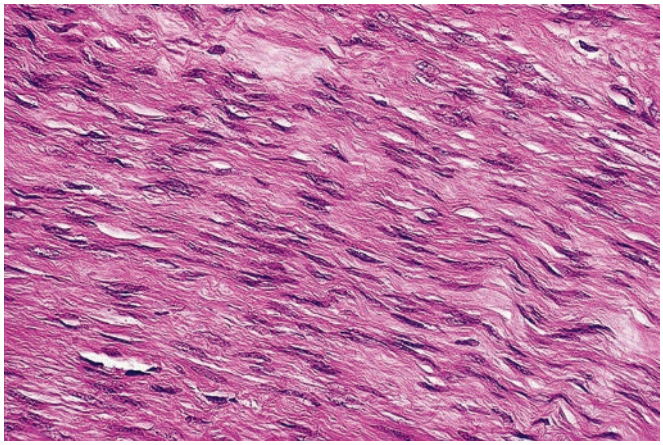

Figure 33.61 Elongated spindle cells with fibrillary acidophilic cytoplasm in the usual type of uterine leiomyoma.

their surface is usually ulcerated and infected, the gross appearance thus simulating that of a malignant neoplasm.

It may be difficult to make a diagnosis of leiomyoma when only a few small fragments of smooth muscle are present in a curettage specimen. Unless these fragments show an obvious increase in cellularity or decreased cellularity/hyaline changes, one is unable to decide whether they originated in a submucosal leiomyoma or whether they represent normal superficial myometrium.

Grossly, the cut surface of a typical leiomyoma has a white whorled appearance that has been likened to raw silk. Microscopically, the tumor is formed by interlacing bundles of smooth muscle cells separated by a greater or lesser amount of well-vascularized connective tissue (Fig. 33.61). Ultrastructurally, the features are those of smooth muscle cells with varying degrees of differentiation.[524] Exceptionally, the tumors may contain skeletal muscle–like cells (which, however, lack cross striations and are myogenin negative; see also under Leiomyoma variants) and rhabdoid cells.[525] The stroma may contain a scattering of lymphocytes. Mast cells are often conspicuous, in contrast with leiomyomas of other sites.[526,527] On average, they are more numerous in cellular leiomyomas and leiomyomas with bizarre nuclei than in either ordinary leiomyomas or leiomyosarcomas.[522]

Cytogenetic alterations are common in uterine leiomyomas. The most consistent are rearrangements of 6p (involving the *HMGA1* gene), del(7q), +12 (involving the *HMGA2* gene), and t(12;14) (involving the *HMGA2* gene).[528-532] These have led to the discovery that disruptions or dysregulations of the high-mobility group proteins HMGA1 and HMGA2 contribute to the development of these tumors.[410,533] Mutations in *MED12* are present in most conventional leiomyomas but are less common in some leiomyoma variants.[534,535]

The treatment of uterine leiomyomas (including that of most of the many variants listed later) varies depending on the size and number of lesions, the age of the patient, and her desire to have children. Most asymptomatic leiomyomas need not be excised. Symptomatic neoplasms can be treated by hysterectomy or, in the case of patients who desire to become pregnant, by myomectomy.[536] Medical therapy includes administration of gonadotropin-releasing hormone analogs, such as leuprolide acetate depot. This may result in a decrease in the size of the leiomyoma—probably as a result of ischemic injury and cellular atrophy—but it does not result in significant pleomorphism or increased mitotic activity.[537–541] The decrease in cell size and increase in collagenization have also been documented at the ultrastructural level.[542] Other authors have reported tumor infiltration by lymphocytes of predominantly T-cell type[543,544]

For personal use only. No other uses without permission. Copyright ©2017. Elsevier Inc. All rights reserved.

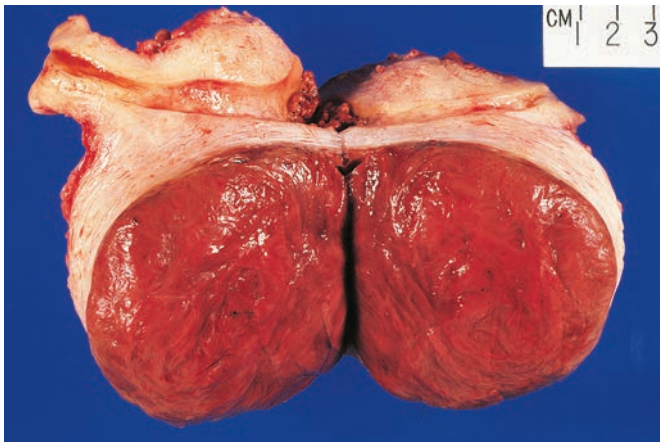

Figure 33.62 This uterine leiomyoma has undergone massive so-called red degeneration.

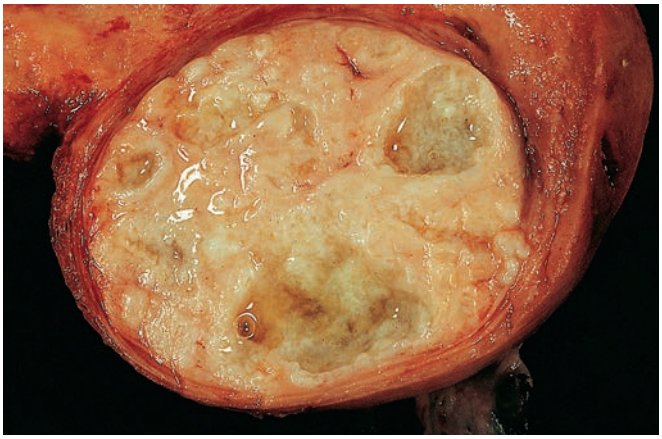

Figure 33.63 Leiomyoma with edematous (hydropic) changes leading to the formation of cystic cavities. (Courtesy Dr. Pedro J. Grases Galofré; from Grases Galofré PJ. *Patología ginecológica. Bases para el diagnóstico morfológico*. Barcelona: Masson; 2002.)

and vasculitis.[545] Immunohistochemically, leuprolide-treated leiomyomas show a decrease in cell proliferation indices and in hormone receptor expression.[546] Selective progesterone receptor modulators are increasingly used to treat symptomatic leiomyomas, as they have been shown to be effective for both a single course of therapy and repeated treatments.[547] Pathologists should be aware of the effects of these agents on the endometrium, described earlier in this section.

Another treatment modality for uterine leiomyoma is arterial embolization with tris-acryl gelatin microspheres.[548] This results in massive necrosis, sometimes accompanied by calcification, thrombosis, and a foreign body-type reaction to the injected material.[549,550] Infarct-type necrosis has also been observed in uterine leiomyomas of women treated with tranexamic acid, an antifibrinolytic agent.[551]

Leiomyoma Variants

Many variations on the basic theme previously described exist. Most of these are the result of secondary changes and are detectable in approximately 65% of cases. These include hyaline degeneration (63%), myxoid changes (19%), calcification (8%), cystic changes (4%), and fatty metamorphosis (3%). There is no relation between symptomatology and the presence of these changes.[552]

Red degeneration (present in 3% of cases) can result in abdominal pain, vomiting, and fever. This change is characterized grossly by a bulging surface and a homogeneous dark red appearance and microscopically by extensive coagulative necrosis. It may be associated with pregnancy or the use of contraceptive drugs (Fig. 33.62).

Apoplectic leiomyoma is pathogenetically related to red degeneration and is characterized by stellate zones of recent hemorrhage within nodules of hypercellular smooth muscle, with few or no mitotic figures.[553] Many variations on this basic theme exist, some of which can simulate malignancy.[554]

Hydropic degeneration is characterized by the accumulation of edema fluid, often associated with collagen deposition. It may have a diffuse, perinodular, or other patterns (Figs. 33.63 and 33.64).[555,556] The appearance may simulate intravenous leiomyomatosis or myxoid leiomyosarcoma.[555] Regarding the latter, leiomyomas with hydropic degeneration have a delicate filigree pattern rather than thick fascicles, and the extracellular material is edema fluid rather than mucopolysaccharides. Also, the presence of medium- to large-caliber blood vessels "floating" in the extracellular material is more characteristic of hydropic change.

Myxoid leiomyoma must be distinguished from both hydropic degeneration and myxoid leiomyosarcoma. The latter is recognized

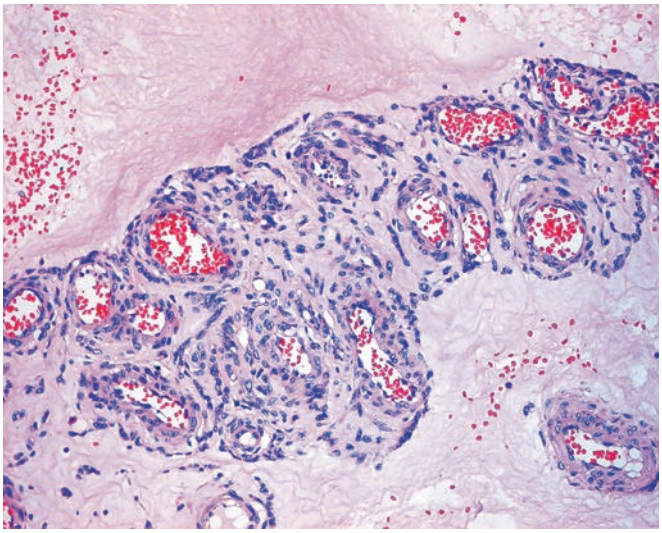

Figure 33.64 So-called perinodular hydropic degeneration in uterine leiomyoma.

because of the presence of destructive myometrial invasion and the conventional features of malignancy.[557]

Leiomyoma with lymphoid infiltration may simulate a malignant lymphoma because of the massiveness of the inflammatory component, which is made up of small lymphocytes, immunoblasts, and plasma cells.[558] Germinal centers may be present. The surrounding myometrium is relatively unaffected.[559,560] A variation on the theme is represented by the leiomyomas with a heavy infiltration by eosinophils.[561]

Cellular leiomyoma is a term reserved for those tumors having markedly increased cellularity but no coagulative necrosis, atypia, or an excessive number of mitotic figures (Fig. 33.65). It is a diagnosis that should be used sparingly; many leiomyomas can be more cellular than the surrounding myometrium, but the designation of cellular leiomyoma should be made only for tumors at the upper end of this spectrum of increased cellularity. Their natural history is the same as for the ordinary leiomyoma. The differential diagnosis includes leiomyosarcoma and endometrial stromal neoplasms.[562] At the cytogenetic level, cellular leiomyoma has been

For personal use only. No other uses without permission. Copyright ©2017. Elsevier Inc. All rights reserved.

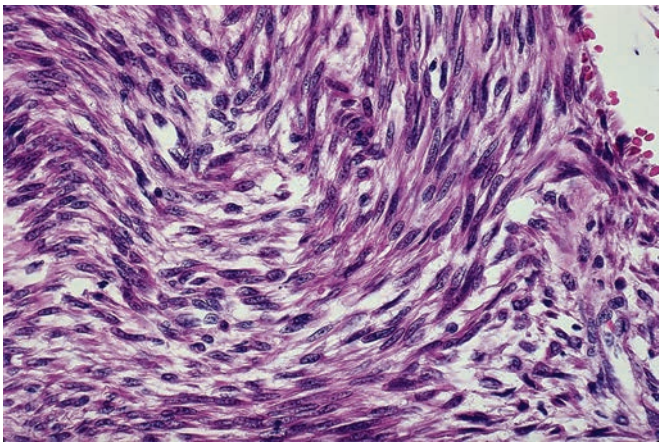

Figure 33.65 Cellular leiomyoma. There is no pleomorphism, undue mitotic activity, or necrosis.

found to be accompanied by loss of almost the entire short arm of chromosome 1.[563]

Leiomyoma with bizarre nuclei (also referred to in the past as atypical, bizarre, symplastic, or pleomorphic leiomyoma**)** contains foci with bizarre tumor cells showing variation in size and shape, hyperchromatic nuclei, and multinucleated forms but no infiltration of myometrium, coagulative necrosis, or increased mitotic activity (Fig. 33.66).[564] Rarely, the entire tumor is composed of such cells. The usual assumption has been that the symplastic cells represent a degenerative phenomenon, but they have been shown to be actively proliferating.[565] There should be no more than an occasional mitotic figure or the designation of smooth muscle tumor of uncertain malignant potential (STUMP) should be used (see later).

Mitotically active leiomyoma refers to tumors having from 5 to 15 mitotic figures per 10 HPF but lacking coagulative necrosis or cytologic atypia (Fig. 33.67).[566,567]

Leiomyolipoma (lipoleiomyoma) contains an admixture of smooth muscle and mature adipose tissue (Fig. 33.68).[568-571] It is believed that some of these tumors and the even rarer **lipomas** result from adipose metaplasia in leiomyomas.[569,572] The differential diagnosis includes lipid-rich angiomyolipomas (PEComas), which are HMB-45 positive (see later).[573] **Palisaded leiomyoma** is characterized by a degree of nuclear palisading such as to simulate a schwannoma.[574]

Epithelioid leiomyoma is partially or totally composed of rounded or polygonal cells (Fig. 33.69). Mixtures of epithelioid, clear cell, and plexiform patterns occur frequently enough to suggest that they represent variants of a single entity.[575,576] A transition to typical smooth muscle is sometimes observed. Morphologically similar tumors occur in the round ligament.[577]

Cotyledonoid dissecting leiomyoma is so designated because its gross appearance resembles that of placental tissue. The tumor is exophytic, bulky, and extends from the uterine wall into the broad ligament and pelvic cavity.[578,579] Microscopically, the appearance is that of a leiomyoma with extensive degenerative changes (Fig. 33.70). Despite its dissecting pattern, it lacks vascular invasion and is benign. Variations exist of leiomyomas that are cotyledonoid but not dissecting,[580] and dissecting but not cotyledonoid.[581,582] Believe it or not, there is also a cotyledonoid hydropic intravenous leiomyomatosis.[583]

Parasitic leiomyoma is the term given to the uterine leiomyoma that has become separate from the uterus and has acquired vascular connections with the omentum, pelvic wall, or other intra-abdominal sites, such as the cecal wall. The low-lying retroperitoneal smooth

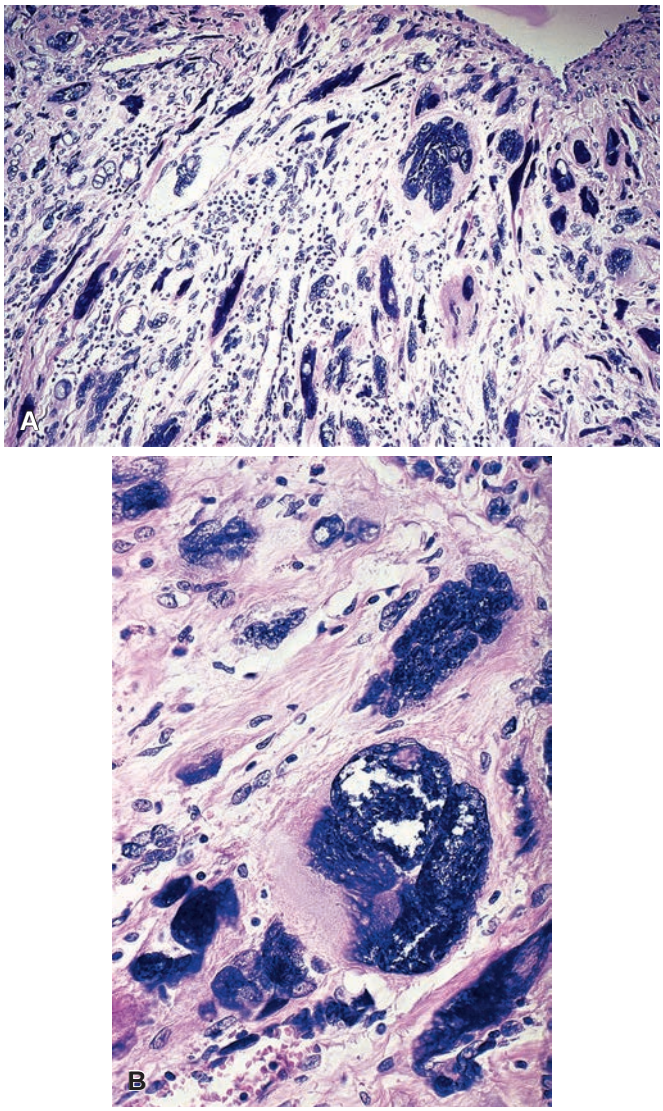

Figure 33.66 A and **B,** Two views of leiomyoma with bizarre nuclei. The size of some of the tumor cell nuclei makes them almost visible to the naked eye.

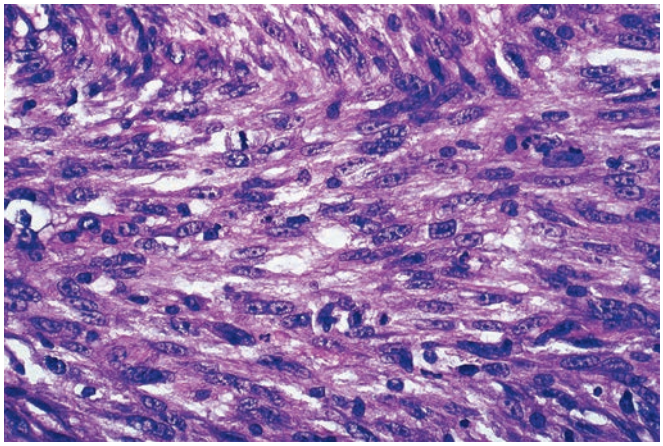

Figure 33.67 Mitotically Active Leiomyoma. There is also hypercellularity but no pleomorphism or necrosis.

For personal use only. No other uses without permission. Copyright ©2017. Elsevier Inc. All rights reserved.

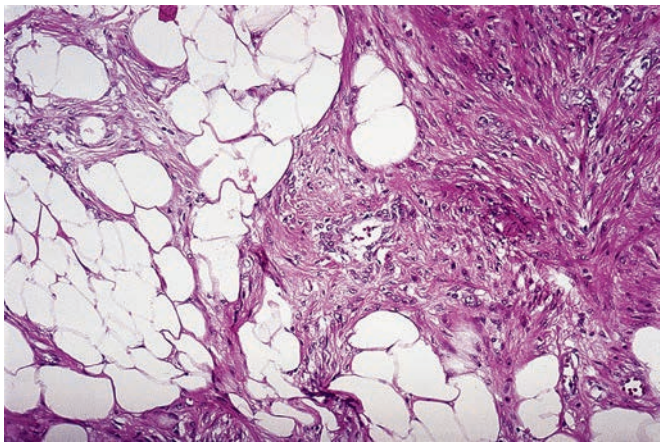

Figure 33.68 Admixture of mature smooth muscle and adipose tissue in leiomyolipoma.

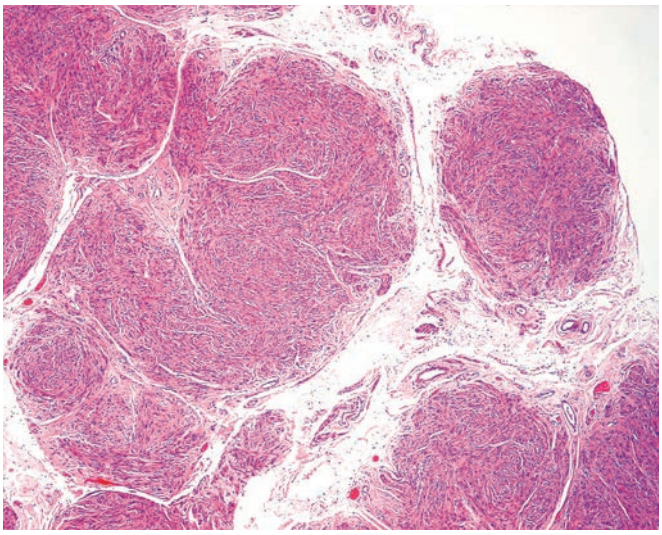

Figure 33.70 Micronodular microscopic appearance of uterine leiomyoma having the gross appearance of so-called cotyledonoid dissecting type.

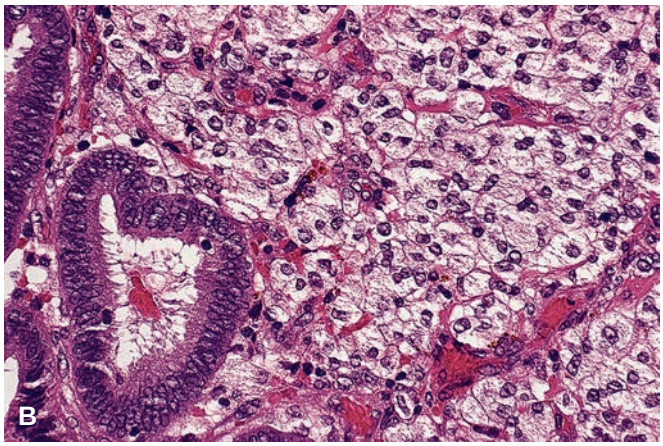

Figure 33.69 **Epithelioid Leiomyoma. A,** Gross appearance; **B,** microscopic appearance. The tumor cells have a round shape and an artifactually clear cytoplasm.

muscle tumors occurring in females and behaving in a benign fashion probably belong to this category, in the sense of being composed of myometrium-type smooth muscle, whether they actually arise from the myometrial wall or not.[584] Expression of estrogen receptor is a feature of smooth muscle tumors of the female reproductive tract; ER is rarely expressed in non-gynecologic smooth muscle tumors.[585]

Leiomyoma with skeletal muscle differentiation has been reported as an exceptional event.[586,587]

Angioleiomyoma (vascular leiomyoma) is a variant of uterine leiomyoma characterized by a swirling of the spindle cells around myometrial vessels, similar to that seen in the homonymous tumor of soft tissues. This tumor is thought to arise not from the parenchymal myometrial cells (as all other uterine leiomyomas are presumed to), but rather from the smooth muscle cells of the vessel walls.[588]

Diffuse leiomyomatosis is the term given to involvement of almost the entire myometrium by innumerable, ill-defined leiomyomas, many of microscopic size.[589,590] Clonality analysis done in a case of this condition supports the interpretation that these minute leiomyomas are independent tumors.[591] This extremely rare condition, which is probably analogous to so-called *seedling leiomyomas*,[592] should be distinguished from the nebulous *primary myometrial hypertrophy* or *myometrial hyperplasia*, defined as a uterus weighing over 120 g in the absence of any mass-like myometrial lesion.[593,594]

Hereditary leiomyomatosis and renal cancer syndrome is a rare autosomal dominant condition in which there is a germline mutation in the fumarate hydratase gene. Patients with this syndrome typically have multiple leiomyomas at an early age and the tumors are characterized by atypical nuclei with prominent nucleoli and occasional multinucleate forms.[595,596] While other histologic features have been described in the uterine tumors, such as perinucleolar halos (as also seen in the kidney tumors), hemangiopericytomatous vasculature, and brightly eosinophilic globules,[596,597] it is not possible to reliably recognize the syndromic leiomyomas based on H&E; immunostaining for overexpression of S-(2-succinyl) cysteine (2-SC) can serve to identify those tumors associated with the syndrome.[598]

Intravenous leiomyomatosis is an extremely rare condition characterized by the growth of mature smooth muscle inside the

For personal use only. No other uses without permission. Copyright ©2017. Elsevier Inc. All rights reserved.

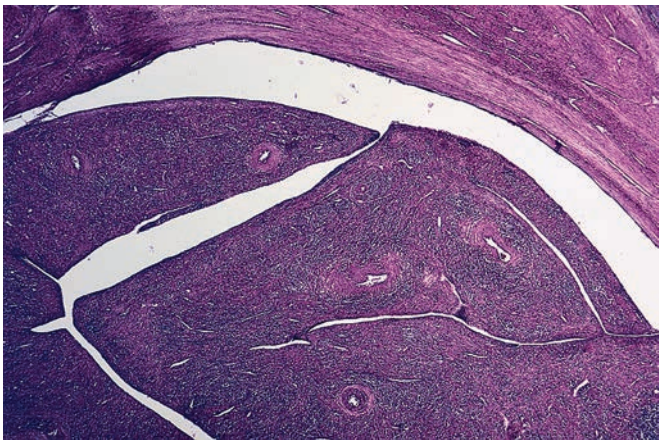

Figure 33.71 Large plugs of mature smooth muscle filling the vascular lumina in intravenous leiomyomatosis.

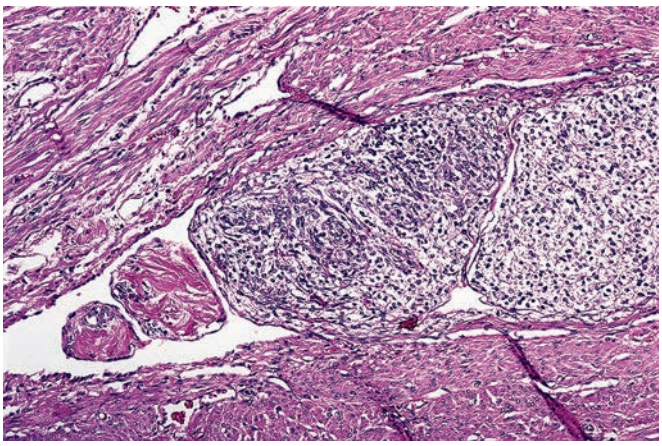

Figure 33.72 Intravenous leiomyomatosis composed of clear smooth muscle cells.

lumen of uterine and pelvic veins (Figs. 33.71 and 33.72).[599,600] It is often associated with typical uterine leiomyomas.[601] The clinical and gross features are similar to those of low-grade endometrial stromal sarcoma, but grossly apparent involvement of veins is more prominent. At the microscopic level, intravenous leiomyomatosis is composed of elongated smooth muscle cells, whereas endometrial stromal sarcoma is made up of round or oval endometrial stromal cells. Mitotic figures are rare or absent. The vessel permeation often extends to vessels in the broad ligament and in uterine and iliac veins; from there, it can proceed along the vena cava and even reach the right atrium.[602] However, distant metastases are exceptionally rare, and the long-term prognosis is excellent.[603] Cases have been described in which the microscopic appearance of the intravenous masses was that of lipoleiomyomas,[604] and others in which the intravenous leiomyomatosis was associated with a benign metastasizing leiomyoma in the lung.[605]

Benign metastasizing leiomyoma is the name given to the uterine tumor having the typical features of a leiomyoma (sometimes on the cellular side but invariably lacking coagulative necrosis, increased mitotic activity, and significant atypia) which is accompanied by nodules in the lung, regional lymph nodes, or other sites having a similar appearance and presumably representing metastases from it.[606] The extrauterine nodules may be just as bland-looking as the original uterine tumor or show features of leiomyosarcoma or STUMP.[607] The interval between hysterectomy and the appearance of the lung nodules is, on average, 15 years. The nodules tend to be multiple, and they have an average size of approximately 2 cm. The patients tend to be younger than those with conventional leiomyosarcoma, and the clinical course is much more indolent, with a median survival of 94 months after the excision of the metastases.[608] Some of these occurrences may be explained on the basis of inadequate sampling of the original tumor, but the fact that in many instances the extrauterine foci have a microscopic appearance that is just as bland suggests that this cannot be the explanation for the entire category. Parenthetically, the similarities with ordinary leiomyomas also apply to their hormone receptor profile (high) and proliferative activity (low).[608,609] They also can show deletion of the long arm of chromosomes 19 and 22.[610] Another possibility that has been advanced is that the extrauterine foci represent independent neoplasms.[611] However, the fact that they have been found to be clonally related speaks in favor of metastasis from a uterine neoplasm.[612,613]

Although this occurrence is unsettling, it is entirely credible. Other examples of tumors that generally behave in a benign fashion but once in a great while result in metastases having the same "benign" appearance certainly exist, benign mixed tumor of the salivary gland being a prime example. We simply have to accept the fact that tumors do not need to have the conventional morphologic attributes of malignancy to be able to metastasize. As to whether the particular neoplasm discussed in this section should be called a metastasizing leiomyoma or a low-grade leiomyosarcoma mimicking a leiomyoma depends on whether one wishes to designate tumors according to their morphology (in which case it would be a leiomyoma) or their behavior (in which case it would be a leiomyosarcoma). We favor the designation of low-grade leiomyosarcoma, once these bland tumors have been found to metastasize and thus declared their biological potential; in this regard, it may be opportune to quote here Julian Huxley—the famous biologist, zoologist, humanist, and popular writer—who, in his lecture on "Biological aspects of cancer," given at the Sloan Kettering Institute in 1955, stated when discussing the policy for designating lesions solely on the basis of their morphology: "This seems a regrettable example of specialist scholasticism. Cancer (malignancy) must be defined operatively in terms of what the tumor cells do, not what they look like; otherwise the term ceases to have biological meaning."[614]

Leiomyosarcoma

Clinical and Gross Features

Leiomyosarcomas occur in an older average age group than leiomyomas (median age, 54 years), although they can also occur in younger patients. Some of the epidemiologic findings in patients with leiomyosarcoma parallel those from studies in endometrial carcinoma and suggest a role for unopposed estrogen stimulation.[615] Some leiomyosarcomas are grossly similar to ordinary leiomyomas, but the majority are soft or fleshy, with necrotic or hemorrhagic areas and signs of invasiveness (Fig. 33.73).[616]

Microscopic Features

Microscopically, typical leiomyosarcomas are hypercellular, with nuclear atypia and pleomorphism, mitotically active (with some of the mitoses being atypical), and with areas of necrosis (Fig. 33.74).[617] Alas, not all leiomyosarcomas will exhibit simultaneously all of these features, whereas some leiomyomas can display one or several of them.[564] The relative importance of these criteria for the differential diagnosis between leiomyoma and leiomyosarcoma is the subject of a special section later.

For personal use only. No other uses without permission. Copyright ©2017. Elsevier Inc. All rights reserved.

Figure 33.73 Leiomyosarcoma resulting in a large intramural and submucous mass. There are foci of hemorrhage and necrosis.

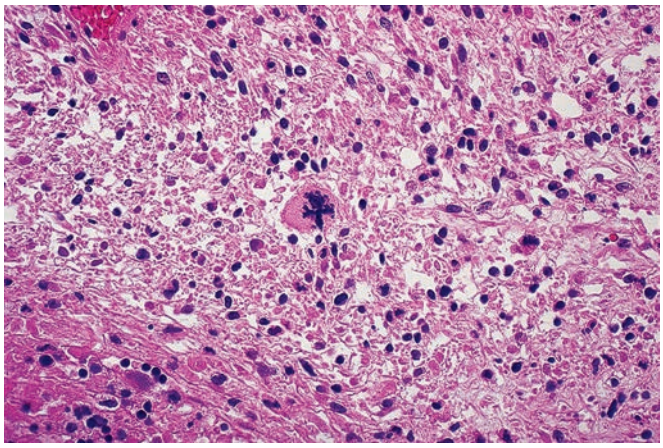

Figure 33.74 Leiomyosarcoma showing hypercellularity, pleomorphism, atypical mitoses, and necrosis.

Electron Microscopic, Immunohistochemical, and Molecular Genetic Features

Ultrastructurally and immunohistochemically, the features of leiomyosarcoma are those of smooth muscle cells.[619,620] There is consistent immunoreactivity for smooth and common muscle actin, desmin, calponin, h-caldesmon, and vimentin.[621] There is also common reactivity for low-molecular-weight keratin (as identified with CAM 5.2) and epithelial membrane antigen,[622] a feature that may lead to a mistaken interpretation, particularly if the tumor cells have an epithelioid appearance.[623] Estrogen and progesterone receptors are expressed, although with less degree of intensity than in leiomyomas.[624,625] The immunohistochemical profile of uterine leiomyosarcomas is somewhat different from that of leiomyosarcomas arising outside the female reproductive tract, probably due at least in part to the estrogen dependency of the former.[585,627]

At the molecular genetic level, there is no evidence of progression from leiomyoma to leiomyosarcoma.[456] Leiomyosarcomas are characterized by complex karyotypes comparable to their soft tissue counterparts. Breakpoint clusters have been mapped to 1q32 and 10q22.[456] In contrast to leiomyoma, there is commonly *TP53* mutation, which usually results in overexpression of p53.[625,629,630]

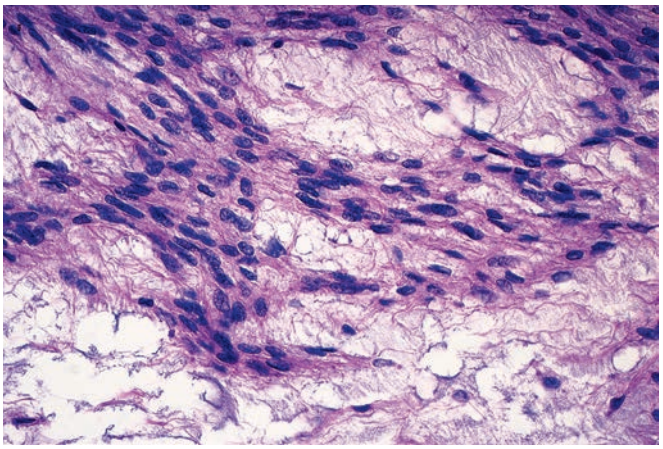

Figure 33.75 Uterine myxoid leiomyosarcoma. (Courtesy Dr. Robert E Scully, Boston.)

Leiomyosarcoma Variants

Epithelioid leiomyosarcoma are rare and must be distinguished from their benign counterpart (i.e. epithelioid leiomyoma).[631–633] General criteria apply (see earlier), such as marked atypia, larger size, infiltrating margins, mitotic activity, and presence of necrosis, and also absence of hyalinization.[631–633] Because of the rarity of epithelioid smooth muscle tumors, the criteria for distinction between benign and malignant are not as well developed as for the more common spindle cell smooth muscle tumors, and the designation of STUMP can be used for tumors with one or two concerning features, where an unequivocal diagnosis of leiomyosarcoma cannot be made. The differential diagnosis also includes endometrial stromal tumors, metastatic carcinoma,[634] and uterine gastrointestinal stromal tumor (GIST), which stain with GIST markers CD117 and DOG-1.[635]

Myxoid leiomyosarcoma can arise in the uterine wall, broad ligament, and other pelvic sites.[636] Grossly, it has a gelatinous appearance and deceptively well-circumscribed borders. Microscopically, however, it is invasive. The stroma is highly myxoid and the tumor cells are arranged as bundles of typical smooth muscle cells alternating with nondescript mesenchymal cells (Fig. 33.75). The main differential diagnosis (an important one) is with leiomyoma with hydropic degeneration. Regarding this differential, it is important to point out that the mitotic count criteria used for the usual leiomyosarcoma (see later) do not apply, in the sense that myxoid leiomyosarcomas tend to recur and metastasize whether mitoses are scanty (which is the usual situation) or numerous.[636,637]

Leiomyosarcoma with osteoclast-like giant cells occurs more frequently in the uterus than in any of the other places where malignant smooth muscle tumors can develop. The smooth muscle nature of the tumor cells—as confirmed immunohistochemically—distinguishes this entity from so-called "malignant giant cell tumor."[638]

Intravenous leiomyosarcomatosis, an exceptionally rare condition, can be viewed as the malignant counterpart of intravenous leiomyomatosis.[639]

Leiomyosarcoma with skeletal muscle differentiation is a vanishingly rare phenomenon similar to that sometimes seen in endometrial stromal sarcoma.[640]

For personal use only. No other uses without permission. Copyright ©2017. Elsevier Inc. All rights reserved.

Spread, Metastases, Treatment, and Prognosis

Uterine leiomyosarcoma usually spreads within the pelvis and in the form of distant metastases to the lung, bone, and other sites.[641] It is an aggressive neoplasm and most patients, even with Stage I tumors, die of disease; a curious phenomenon has occurred, attributable to more accurate diagnosis of benign leiomyoma variants that mimic leiomyosarcoma in current practice, that is, the outcomes of patients with stage I leiomyosarcoma in recent series appear worse than in the past.[642] Lymph node metastases are exceptional. The standard treatment is total abdominal hysterectomy with bilateral salpingo-oophorectomy. Prognostic factors include the following:

1. *Tumor stage.* Extension outside the confines of the uterus is a finding of ominous prognosis.[643] In one series of 20 patients in whom this occurred, there were no survivors beyond 29 months.[644]
2. *Tumor size.* This is a significant prognostic factor for tumors confined to the uterus.[645]
3. *Microscopic grade.* There is no accepted grading system for uterine leiomyosarcomas, and no consistent correlation has been found between survival and the histologic grade of the tumor. Specifically, the grading system used for sarcomas of the somatic soft tissue is not applicable.[646] Nonetheless, occasional leiomyosarcomas with more uniform nuclear features, lower mitotic rate, and apparently better outcomes do occur, [647] but we lack criteria to consistently recognize them in practice (except in retrospect).

Relationship Between Morphology and Behavior of Uterine Smooth Muscle Tumors

The majority of uterine smooth muscle tumors are readily classifiable into benign or malignant.[124,648] There are some lesions, however, for which that placement is very difficult, sometimes excruciatingly so.[650] The morphologic reasons for this, which at the same time represent the main criteria upon which to base a decision, are the following:

1. *Necrosis.* Two patterns of necrosis have been identified in smooth muscle tumors, respectively, named coagulative tumor cell necrosis and hyaline ischemic-type. In the former there is an abrupt transition between the necrotic and the viable cells. On low power, the typical appearance is that of a cuff of preserved tumor cells around large vessels surrounded by large expanses of necrotic tumor. On high power, two of the classic morphologic forms of nuclear necrosis (pyknosis and karyorrhexis) are evident. In hyaline/ischemic-type necrosis, there is a distinct zonal pattern reminiscent of an evolving infarct: a center of "bland" necrosis (i.e. one in which nuclear debris is difficult to see), a periphery of granulation tissue, and a layer of hyalinized collagen in between. Coagulative tumor cell necrosis, as defined previously, is currently regarded as the most important criterion of malignancy in these tumors. Unfortunately (but predictably) there is considerable interobserver variation in assessment of coagulative tumor cell necrosis.[651]
2. *Mitotic activity.* This remains another important criterion despite the admittedly imprecise fashion in which it is measured in terms of lack of standardization and poor reproducibility,[652–654] in the sense of being influenced by the thickness of the slide, microscope magnification factor, size of tumor cells, proportion of tumor cells to stroma, and observer criteria.[655] Regarding the latter, a common mistake among neophytes is to count the pyknotic nuclei often seen scattered around in smooth muscle tumors (whether from lymphocytes, mast cells, or smooth muscle cells) as mitotic figures. Another theoretical source of variation is the interval between excision and fixation, but this seems not to be important. Some practical measures can be taken to improve accuracy. One is to scan the sections for the *most active area*, do the mitotic count in 10 *consecutive fields* in that area, and repeat the procedure a minimum of *four times.* Another obvious measure is to sample the tumor adequately. Kempson[652] recommends a total of *at least 10 sections or one section for each centimeter of diameter, whichever is greater.* Note that this guideline applies to tumors with atypical gross or microscopic features, and not the majority of usual benign leiomyomas. HPF usually means the combination of a 10× eyepiece and a 40× objective. If the operator is using a 15× eyepiece and/or a 63× objective, adjustments should be made. The criteria for identifying mitotic figures should be strict. The members of the Multicenter Morphometric Mammary Carcinoma Project proposed the following:[656]
   1. The nuclear membrane must be absent, so cells must have passed the prophase.
   2. Clear, hairy extensions of nuclear material (condensed chromosomes) must be present, and clotted (beginning metaphase), in a plane (metaphase/anaphase), or in separate clots (telophase). Regular extensions with an empty central zone favor a nonmitosis.
   3. *Atypia.* This refers to the combination of pleomorphism (meaning marked differences in size and shape) and nuclear hyperchromasia, and should already be evident on low-power examination. It is classified as focal or extensive, and graded (acknowledging the subjectivity of the exercise) as mild, moderate, or severe.
   4. *Cellularity.* The term is self-explanatory and the determination just as subjective. This is one of the least important parameters in this exercise.
   5. *Tumor borders*, that is, the relationship of the tumor with the surrounding myometrium.

The evaluation of these criteria, alone and in combination, allows a fairly accurate *but not infallible* prediction of tumor behavior. The points worth stressing are the following:

1. The weight of the morphologic factors, in order of significance, is coagulative tumor cell necrosis, high mitotic activity, pleomorphism, and cellularity (remembering that most leiomyosarcomas are evidently malignant at presentation, based on macroscopic evidence of invasiveness and metastasis, so that very detailed histomorphologic assessment is not necessary).
2. Tumors that are hypercellular but lack the other criteria are to be regarded as benign cellular leiomyomas.
3. Noninfiltrative tumors with atypia (even if marked and diffuse) should not be regarded as malignant if they lack coagulative tumor cell necrosis and mitotic activity is less than 10/10 HPF. Rather, they belong to the category of *leiomyoma with bizarre nuclei* if mitoses are rare (<2/10 HPF) and to the category of STUMP if mitotic activity is 2–10/10 HPF.
4. Tumors with increased mitotic activity (up to 15 mitoses per 10 HPF) but lacking coagulative tumor cell necrosis and atypia are to be regarded as *mitotically active leiomyomas*.
5. Tumors with coagulative necrosis and diffuse atypia and/or increased mitotic activity (>10 per 10 HPF) should be regarded as leiomyosarcomas.
6. Tumors with coagulative necrosis but neither atypia nor increased mitotic activity should be diagnosed as STUMP.
7. Tumors with diffuse moderate-to-severe atypia *and* 10 or more mitoses per 10 HPF should be called leiomyosarcoma even if they lack coagulative tumor cell necrosis.

These recommendations are primarily based on the careful and painstaking work done by Richard Kempson and colleagues over a 35-year period.[648,655,657–661] Some modifications are made, based on the 2014 WHO guidelines,[662] and this approach to diagnosis is illustrated in a simplified form for the benefit of the reader in Table 33.2. Although Kempson and colleagues did not propose a "STUMP"

For personal use only. No other uses without permission. Copyright ©2017. Elsevier Inc. All rights reserved.

Table 33.2 Criteria and diagnostic terms for uterine smooth muscle tumors

COAGULATIVE TUMOR CELL NECROSIS	MITOTIC COUNT PER 10 HPF	ATYPIA		DIAGNOSIS
Present	Greater than 10	Moderate to severe (focal or diffuse)		Leiomyosarcoma
		None to mild		Leiomyosarcoma
	Equal to or less than 10	Moderate to severe (focal or diffuse)		Leiomyosarcoma
		None to mild		STUMP
Absent	Greater than 10	Moderate to severe	Diffuse	Leiomyosarcoma
			Focal	STUMP
		None to mild		Mitotically active leiomyoma (up to 15 mitoses/10 HPF are allowed)
	1 to 10	Moderate to severe	Diffuse	STUMP
			Focal	STUMP
		None to mild		Mitotically Active Leiomyoma

Data from Kempson RL, Hendrickson MR. Smooth muscle, endometrial stromal, and mixed Mullerian tumors of the uterus. *Mod Pathol*. 2000;13:328–342.

category, it has been retained in this table, in keeping with the WHO classification.[662]

In our opinion, one would serve the patient and the clinician better (and would also be closer to expressing the truth) by doing away with the traditional binary classification of these tumors into benign and malignant (i.e. leiomyoma versus leiomyosarcoma), which is improved only slightly by the addition of a STUMP category, and by switching to a nomenclature that would simply identify these neoplasms as smooth muscle tumors, followed by an estimation (ideally expressed in percentages) of the probability of the tumor recurring or metastasizing, based on a careful evaluation of all the parameters discussed in this section and any others that may be found of help in this regard. Until and unless such a radical change in nosology takes place, and as long as we subject ourselves to the current Manicheist approach, the above recommendations will have to do.

Two additional comments are in order. These considerations have been devised for the conventional type of uterine smooth muscle tumor and cannot be applied unchanged to the variants. For instance, myxoid leiomyosarcoma is to be diagnosed as such even if in most cases it lacks coagulative necrosis, increased mitotic activity, and severe atypia.

The other comment applies to the hope that the abundant information that is being obtained regarding the genotypic features of these tumors will provide assistance to the pathologist in terms of an accurate prognostic assessment and a precise therapeutic recommendation. The most promising modality to date is comparative genomic hybridization with determination of a genomic index; this can separate leiomyomas, with minimal genomic perturbation, from leiomyosarcomas, and identifies STUMPs with high versus low risk of recurrence but is some ways off from being sufficiently validated for everyday use.[663] It is fair to say that the decision to place a uterine smooth muscle tumor into a given prognostic category remains for now largely dependent on the time-honored morphologic criteria.

PEComa

Perivascular epithelioid cell tumors (PEComas) are tumors showing both melanocytic and smooth muscle differentiation.[664] They occur at non-gynecologic sites, and their recognition in the uterus was delayed because of their rarity and the overwhelming number and variety of uterine smooth muscle tumors; undoubtedly in the past these were diagnosed as smooth muscle tumors, especially of the epithelioid variant. Some of these tumors are associated with pelvic lymphangiomyomatosis and/or have developed in patients with tuberous sclerosis.[665-668] They can be benign or malignant; because there are few reported cases, the criteria for diagnosis of malignancy are not well established.[664,669] The uterine corpus is the most common location of PEComas of the female reproductive organs; grossly they resemble smooth muscle tumors. Microscopically they consist of epithelioid cells or a mixture of epithelioid and spindle cells. Conspicuous sclerosis is present in some tumors. Necrosis is present in almost half, as is significant nuclear atypia. Mitotic activity is variable, from undetectable to brisk. The tumor cells consistently stain for HMB-45, with a minority of case showing immunoreactivity for Melan-A or MiTF.[664,670] Smooth muscle markers (smooth muscle actin, desmin, caldesmon) are expressed in approximately 2/3 of cases.[664] Features associated with malignancy include size greater than 5 cm, infiltrative margin, high nuclear grade, increased cellularity, mitotic rate >1/50 HPF, vascular invasion, and necrosis.[669] The absence of ALL these features is associated with benign behavior, while it has been suggested that the presence of one feature should lead to designation as "uncertain malignant potential," and two or more of these features is associated with malignant behavior in most cases.[664,669]

There are case reports of PEComatosis, with multiple PEComas variously involving the female reproductive organs, bowel wall, omentum, and lymph nodes.[671]

Both syndromic (tuberous sclerosis complex) and sporadic PEComas are associated with TSC1 or TSC2 inactivation.[672] TFE-3 translocations have been identified in a subset of PEComas.[560,673]

Inflammatory Myofibroblastic Tumor

Inflammatory myofibroblastic tumor is similar to PEComa in that it can occur at many sites in the body but when it was present in the uterus it has often been mistaken for a smooth muscle tumor. Inflammatory myofibroblastic tumors of the uterus can occur at any age, including in childhood.[675–677] They can appear ill-defined grossly but tend to resemble leiomyomas. The microscopic appearance is identical to inflammatory myofibroblastic tumors occurring elsewhere in the body; the plump spindle cells can be separated by edematous stroma, grown in fascicles, or there can be stromal hyalinization (Fig. 33.76).[677] The myxoid areas can raise the differential diagnosis of myxoid leiomyosarcoma or a myxoid pattern of endometrial stromal sarcoma, such as the subtype with *BCOR* alteration.[676] A

For personal use only. No other uses without permission. Copyright ©2017. Elsevier Inc. All rights reserved.

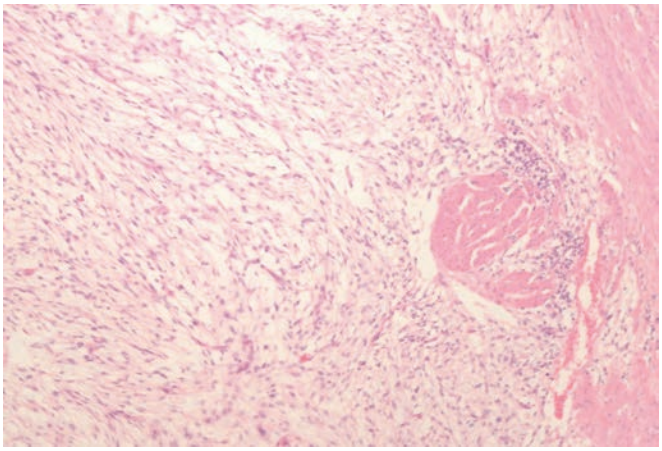

Figure 33.76 Inflammatory myofibroblastic tumor.

Figure 33.77 **Complete Mole.** All villi are markedly swollen. (Courtesy Dr. Pedro J Grases Galofrè; from Grases Galofrè PJ. *Patologia ginecològica. Bases para el diagnòstico morfològico*. Barcelona: Masson; 2002.)

mononuclear inflammatory infiltrate rich in plasma cells is invariably present but may be sparse in areas. ALK immunoreactivity is an important diagnostic adjunct, distinguishing inflammatory myofibroblastic tumor from smooth muscle neoplasms.[677] Some have pursued an aggressive course.[676]

Gestational Trophoblastic Neoplasia

There is a group of diseases related to normal or abnormal gestation that have as a common denominator the proliferation of trophoblast and that are generically designated as *(gestational) trophoblastic neoplasia*. The individual disorders differ remarkably in appearance and clinical significance. The major ones are hydatidiform mole (complete, partial, or invasive), placental site trophoblastic tumor, and choriocarcinoma.[678] The pathogenesis of these remains poorly understood, but genomic imprinting is believed to play a key role in the formation of hydatidiform moles.[679-681]

Hydatidiform Mole

In hydatidiform moles, the trophoblastic proliferation is associated with swelling of the villi. They are subdivided into complete and partial types, and either type can be invasive.

Complete Mole

Complete hydatidiform mole is caused by abnormal gametogenesis and fertilization. The nuclei of the trophoblastic cells in this disease contain only paternal chromosomes and are, therefore, androgenetic in origin.[682,683] In most cases the chromosomal number is normal; 85% of cases are 46,XX and 15% are 46,XY. In a minority of cases, the DNA pattern is tetraploid, these generally occurring in an older age group.[656]

There is a striking geographic variation in the frequency of complete mole. In Southeast Asia, the reported incidence is at least 4 to 5 times greater than in the United States.[684,685] Yet higher incidences have been reported from Mexico (1:200), the Philippines (1:173), India (1:160), Taiwan (1:125), and Indonesia (1:82).[686] A history of previous term birth reduces the risk of molar pregnancy, whereas a history of a previous mole greatly increases the probability of developing another.[685,687,688] "Repetitive" moles are usually of complete type, but they can be of partial type, or a complete mole may be followed by a partial mole.[689]

Clinically, the uterus involved by a complete mole is disproportionately large for the stage of pregnancy.[690] Serum hCG levels continue to rise after the 14th week, as opposed to the drop typically seen in the course of normal gestation. Evidence of toxemia of pregnancy (hypertension, edema, albuminuria) is frequently found, and this typically occurs during the early stages of the pregnancy. Exceptionally, hyperthyroidism develops as a result of a thyroid stimulator secreted by the molar tissue, perhaps residing in the hCG molecule itself.[691–693] At the time of the medical consultation there may be vaginal bleeding, a sign that the mole has begun to abort spontaneously.

Grossly, the complete mole has been typically described as a "bunch of grapes," with all or nearly all the villi showing hydropic degeneration. The individual vesicles measure anywhere from 1 to 30 mm in diameter, and the total weight is usually over 200 g. In a hysterectomy specimen, these swollen villi are seen to fill and distend the uterus (Fig. 33.77). Characteristically, there are no identifiable embryo, cord, or amniotic membranes. The exceptional cases of bona fide complete mole in which an embryo is present almost invariably represent a twin gestation.[694,695]

Microscopically, the two constant features of a complete mole are *trophoblastic hyperplasia* and *vesicular swelling*, the latter probably representing a secondary phenomenon. The severity of the changes varies considerably from case to case and from villus to villus and may be difficult to appreciate in very early cases, as evidenced by the high degree of interobserver and intraobserver diagnostic variability.[696–698] Some of the villi are surrounded by an attenuated layer of degenerating trophoblast. In others, the trophoblast forms large hyperplastic sheets of cells (Fig. 33.78). The distended core of the villus is traversed by widely separated, broken strands of fibrillar material ("cistern" formation). Vessels seem absent or very scanty in hematoxylin–eosin-stained sections, even though they do not seem very diminished in number in CD34-stained preparations.[699] The stromal changes of molar villi, which include stromal mucin and stromal nuclear debris (apoptosis), appear very early and represent a diagnostic clue.[700–702] The trophoblastic hyperplasia characteristically has a circumferential but haphazard arrangement around the individual villi, as opposed to the polar proliferation seen in normal first-trimester villi. The plexiform pattern of intermixed syncytiotrophoblast and cytotrophoblast seen in choriocarcinoma does not occur. Trophoblastic hyperplasia with atypia also occurs at the implantation site, to a much greater degree than in hydropic villi of abortion or partial moles.[703]

For personal use only. No other uses without permission. Copyright ©2017. Elsevier Inc. All rights reserved.

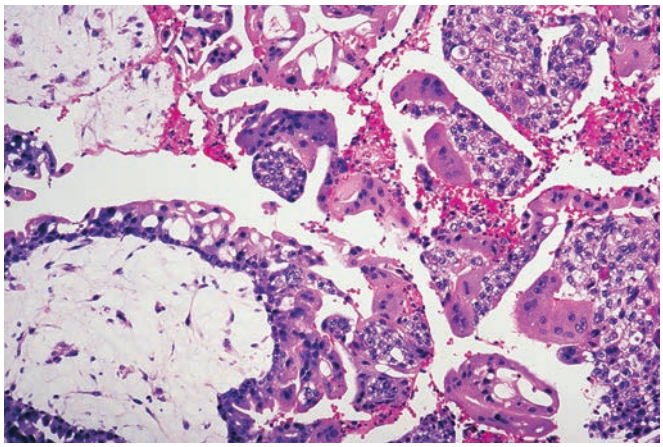

Figure 33.78 Complete mole showing large villi with stromal edema and marked trophoblastic proliferation.

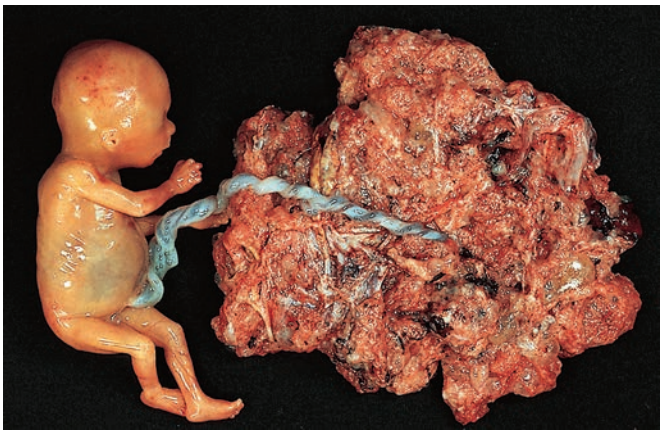

Figure 33.79 Partial Mole With Attached Fetus. The fetus showed no abnormality and was connected to the mole by a normal umbilical cord. (Courtesy Dr. Pedro J Grases Galofré; from Grases Galofré PJ. *Patología ginecológica. Bases para el diagnóstico morfológico*. Barcelona: Masson; 2002.)

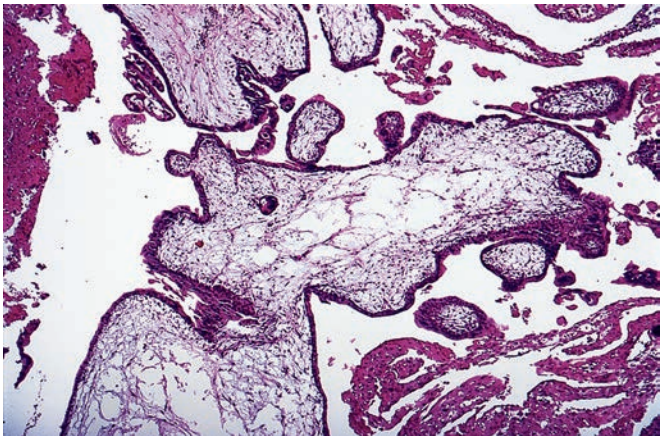

Figure 33.80 Partial mole showing scalloping of villi and isolated trophoblastic cells embedded in the stroma.

Ultrastructurally, the molar trophoblast closely resembles that seen during the first trimester of a normal pregnancy.[704]

Immunohistochemically, hCG is widely distributed and PLAP is patchily distributed in the molar syncytiotrophoblast regardless of gestational age, whereas hPL tends to increase with increased gestational age.[705,706] Both the α- and β-subunits of inhibin are evident in the molar syncytiotrophoblast.[707,708] A very useful marker for the differential diagnosis of complete mole is $p57^{kip2}$ protein, a cell cycle inhibitor and tumor suppressor encoded by a strongly paternally imprinted gene. It is expressed in the cytotrophoblast and villous mesenchyme of normal pregnancy, spontaneous abortions, and partial moles but absent or very markedly decreased in complete moles because both copies of the *TP57* gene are of paternal origin.[709–712]

By flow cytometry, complete moles are most commonly diploid, with the non-diploid being tetraploid in a most instances.[713] Heterozygous (dispermic) moles, including dispermic heterozygous XY moles, are associated with a higher incidence of persistent trophoblastic disease than homozygous (monospermic) moles.[714]

The initial therapy of complete mole consists of evacuation of the uterus by curettage.[715] This is followed by sequential quantitative determination of the β-subunit of hCG.[716,717] The standard recommendation has been to measure the serum level of hCG at 10, 20, 30, 45, and 60 days after termination of the molar gestation. In approximately 80% of cases, normal levels will be reached by day 60. If there is rising titer between day 45 and day 60 or the level is still elevated by day 60, chemotherapy is administered; this is necessary in approximately 20% of cases.[718] With this approach, the cure rate is close to 100%.[719] Unfortunately, the use of etoposide has been found to be associated with an increased risk of development of second tumors.[720]

Other authors recommend the administration of chemotherapy to those patients who have a plateau of three high values of hCG over a 2-week period after evacuation of the mole (approximately 20%–30% of cases). Still others recommend waiting for 4 weeks or even 2 months before initiating chemotherapy, especially if the hCG levels are low.[721]

In a series of 738 patients with mole, spontaneous regression occurred in 81%. Of the remaining patients, 17% developed an invasive mole, and 2% developed choriocarcinoma.[722] The presence of villi or atypical trophoblast following the evacuation of a molar pregnancy indicates "persistent trophoblastic disease," but the decision of whether to give chemotherapy or not still largely depends on the hCG levels.

Partial Mole

Approximately 15%–35% of all moles are of the partial type. In contrast to complete mole, the condition is often associated with the presence of an embryo, although this is usually abnormal ("blighted ovum"). The volume of placental tissue is relatively normal, and the grossly vesicular villi are mixed with normal-appearing ones (Fig. 33.79). The former often show focal edema leading to central "cisternal" formation and stromal inclusions of trophoblast (Fig. 33.80). Many of the villi have an irregular, scalloped outline and contain vessels with fetal (nucleated) red blood cells. Fibrosis of the villous stroma is common. Trophoblastic proliferation is present, although generally to less degree than in complete mole; cytoplasmic vacuolization of the syncytiotrophoblast is prominent.[723]

Most partial moles are triploid (69,XXX or 69,XXY) and a few show trisomy 16.[724–726] The extra material is of paternal derivation (so-called "diandric triploidy").[727]

Because of the generally small size of the lesion, the uterine size is nearly always small or appropriate for the gestational age. Serum hCG levels—although elevated—tend to be relatively low, and the ovarian theca-lutein cysts that commonly accompany complete moles do not occur.[728] The risk for the development of choriocarcinoma

For personal use only. No other uses without permission. Copyright ©2017. Elsevier Inc. All rights reserved.

following a partial mole is very low, but a few well-documented cases are on record.[729,730] Furthermore, some series document a 5%–10% incidence of persistent disease (lower in those evacuated early),[731] indicating that follow-up of these patients is mandatory.[732–734] Some of the recurrences have been in the form of invasive mole[735–737] and some in the form of lung metastases.[738]

As already pointed out, not all placentas of triploid conceptuses show partial molar transformation; some (perhaps the majority) have a normal morphologic appearance.[739] The triploid fetuses in both groups tend to die at about 8 weeks menstrual age.[740]

Partial moles should be distinguished on one hand from complete moles and on the other from the hydropic villi seen in 15%–40% of spontaneous abortions and with rare conditions such as placental stem villous hydrops, mesenchymal dysplasia, and Beckwith–Wiedemann syndrome.[741] As noted previously, the pattern of p57 immunostaining, with expression in cytotrophoblast and villous mesenchyme, serves to distinguish between complete and partial mole but is not helpful in the distinction between partial mole and hydropic abortion. With regard to the differential diagnosis between partial mole and hydropic abortion, in the latter gross villous swelling and cistern formation are not present. As already stated, the villous trophoblast in spontaneous abortions either is attenuated or—if proliferating—has a polar distribution. Furthermore, trophoblastic atypia is absent or minimal. Flow cytometry studies are of great assistance in the evaluation of this problem, with triploidy favoring a diagnosis of partial mole, being mindful that triploid spontaneous abortions do occur, but lack histologic features of partial mole.[727,732,742] Flow cytometry for ploidy assessment is not widely available and FISH for HER2, which is, can serve as a surrogate test, as trisomy for chromosome 17, as determined with the HER2 and centromeric probes used for breast and gastric cancer HER2 FISH, is an indicator of triploidy.[743] The "gold standard," however, in the diagnosis of mole is genotypic analysis using the technology developed for DNA fingerprinting/forensic identification, as it allows determination of copy number and parent of origin of the DNA, improving diagnostic accuracy.[744] This approach is not widely available and is relatively expensive, so the diagnosis of molar pregnancy is still based largely on routine histology with liberal use of p57 immunostaining.

Invasive Mole

The term *invasive mole* refers to a hydatidiform mole (nearly always of the complete type but occasionally of the partial type) in which villi penetrate deeply the myometrium and/or its blood vessels (Figs. 33.81–33.83).[745,746] This phenomenon, which occurs in 16% of all complete moles, is an exaggerated expression of the capacity of normal trophoblast for invasion, a necessary property for implantation.

The myometrial permeation in invasive mole may be extensive and may lead to persistent hemorrhage, but the serosa is usually intact. However, uterine perforation may occur. The vascular invasion may result in trophoblastic nodules in sites outside the uterus, such as the vagina, lung, brain, and spinal cord.[747,748] The lung nodules have a characteristic radiographic appearance[749,750]; they continue to produce hCG and have a similar tendency for hemorrhagic complications. The clinical manifestations depend on the site involved: a sizable mass in the lung may regress spontaneously without ever causing symptoms, whereas a deposit in the brain may produce fatal hemorrhage.[751,752]

It should be mentioned that invasive mole is distinguished from the usual mole by its invasiveness and from choriocarcinoma by the presence of villi, which are also present in the "metastatic" foci. The degree of trophoblastic proliferation in invasive mole does not differ significantly from that of its ordinary counterpart. Patients

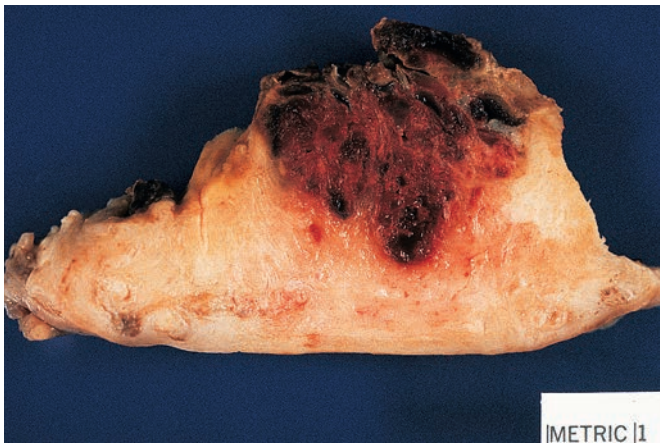

Figure 33.81 Gross Appearance of Invasive Mole. A hemorrhagic mass has permeated half of the thickness of the myometrial wall.

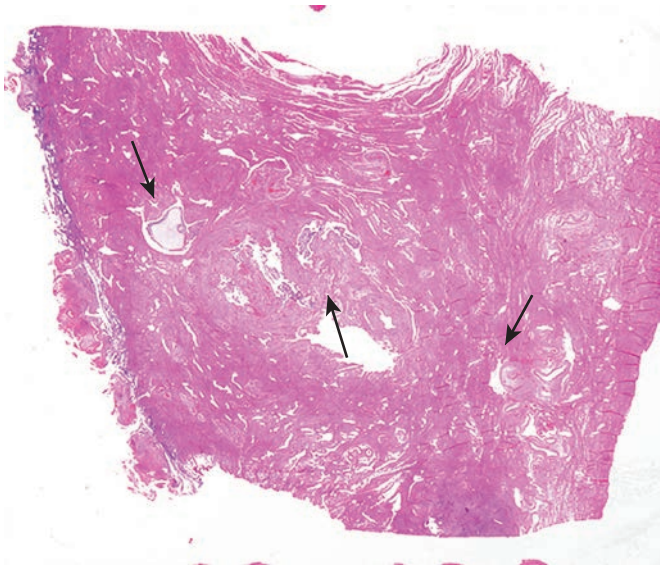

Figure 33.82 Whole-Mount View of Invasive Mole. Abnormal villi are seen permeating the thickened myometrium *(arrows)*.

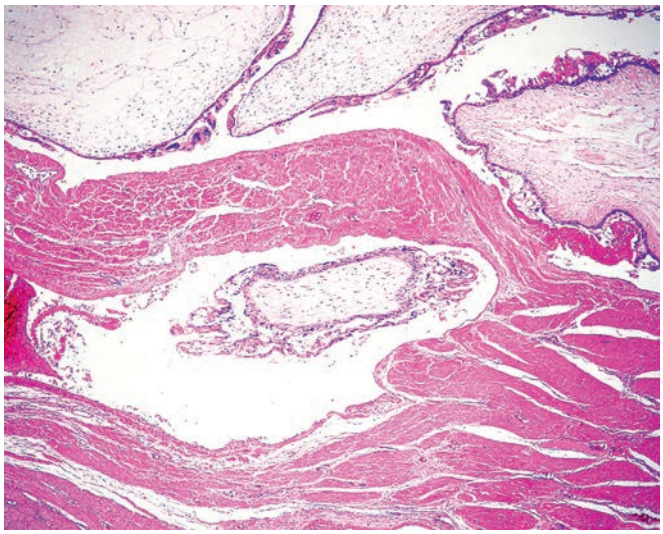

Figure 33.83 Hydropic villi covered by proliferating trophoblast are seen permeating the myometrium in this invasive mole.

For personal use only. No other uses without permission. Copyright ©2017. Elsevier Inc. All rights reserved.

with invasive mole are primarily treated with chemotherapy, but hysterectomy may be indicated in some circumstances.[746,753]

Choriocarcinoma

Choriocarcinoma, when untreated, is the most aggressive form of gestational trophoblastic neoplasia. Most cases occur following a complete hydatidiform mole; consequently, this malignant tumor is more common in areas of the world in which hydatidiform mole is prevalent. It has been estimated that 1%–2% of complete moles are followed by choriocarcinoma.[754]

Choriocarcinoma can also be preceded by a partial mole (a very unusual event), ectopic pregnancy, nonmolar intrauterine abortion, or term pregnancy.[755–757] In the latter instance, which is exceptionally rare, the tumor may appear as one or more masses in an otherwise normal placenta or develop following the delivery.[758–760] In addition, cases of "in-situ" choriocarcinoma arising from the trophoblast of stem villi in the first trimester of pregnancy have been described.[761]

In cases of choriocarcinoma following abortion—whether molar or not—the latent period is almost always less than 1 year, although it can be considerably longer ("latent choriocarcinoma").[762] At the time of the diagnosis of the malignancy, the average age of the patient is 29 years.

Grossly, choriocarcinoma characteristically forms soft, dark red, hemorrhagic, round nodular tumor masses (Fig. 33.84). Microscopically, the tumor is composed of clusters of cytotrophoblast separated by streaming masses of syncytiotrophoblast, resulting in a characteristic dimorphic plexiform pattern (Fig. 33.85).[763] Hemorrhage and necrosis are usually present but have no real diagnostic significance, since they are also commonly found in spontaneous abortions. Villi are characteristically absent; as a matter of fact, their presence is said to rule out the diagnosis of choriocarcinoma no matter how atypical the trophoblastic cells may be.[764]

Immunohistochemically, choriocarcinoma cells are positive for hCG and keratin. There may also be reactivity for hPL, SP1, and CEA.[765] There can be a minor component of intermediate trophoblastic cells immunoreactive for hPL, CD146 (Mel-CAM), HLA-G, and inhibin.

The natural history of untreated choriocarcinoma is characterized by the development of early hematogenous metastases, the most common sites being the lung, brain, liver, kidney, and bowel.[766–768] They can be clinically solitary, may occur in the most unusual places, and often present with massive hemorrhage.[769] Interestingly, the fetus is rarely involved, even in cases of widespread metastatic disease.[770] Residual tumor in the uterus of patients dying of disseminated choriocarcinoma may be inconspicuous or altogether absent.[771]

Many of the morphologic changes seen in other organs in patients with choriocarcinoma are the result of increased secretion of hCG and other hormones by the tumor cells. These include hyperplasia of endocervical glands, decidual reaction (both endometrial and ectopic), Arias-Stella phenomenon, bilateral enlargement of the ovaries by theca-lutein cysts ("hyperreactio luteinalis"), and hyperplasia of mammary lobules. The detection of ovarian theca-lutein cysts long after a case of choriocarcinoma has been treated is usually a sign of persistent disease.[772] In the endometrial decidual reaction of patients with choriocarcinoma, the spiral arterioles fail to develop as they do in the normal cycle, the appearance of the mucosa being similar to that seen after the administration of progestogens.[771]

The evolution of the treatment of choriocarcinoma (and of gestational trophoblastic neoplasia in general) is one of the greatest success stories in medical oncology.[773] When treated by surgery alone, the cure rate was only 40% for tumors apparently restricted to the uterus and less than 20% for those accompanied by metastases.[774] With the use of chemotherapy, the survival rate is close to 100% for cases restricted to the uterus and approximately 83% for patients with metastatic disease.[775,776] Low- and high-risk patient groups have

Figure 33.84 **A** and **B,** Uterine choriocarcinoma showing typical highly hemorrhagic appearance.

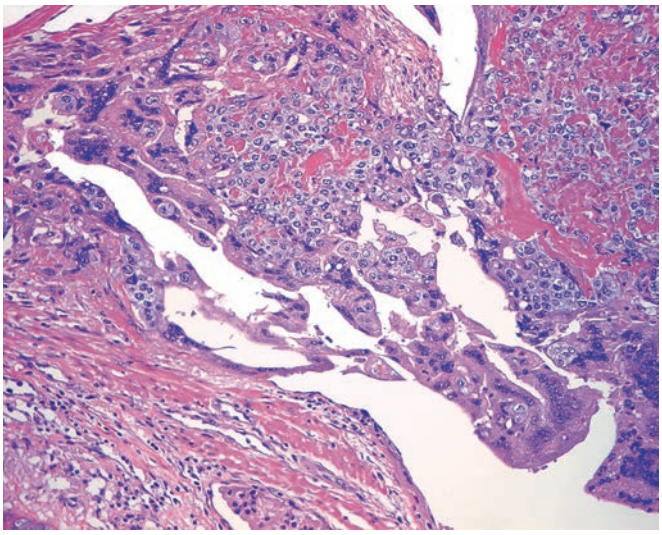

Figure 33.85 Intimate admixture of syncytiotrophoblast and cytotrophoblast in choriocarcinoma.

For personal use only. No other uses without permission. Copyright ©2017. Elsevier Inc. All rights reserved.

Table 33.3 FIGO/WHO Prognostic Index Score for gestational trophoblastic neoplasia

PROGNOSTIC FACTOR	SCORE[a] 0	1	2	4
Age (years)	≤39	>39	—	—
Antecedent pregnancy	Hydatidiform mole	Abortion	Term	—
Interval (months)[b]	4	4–6	7–12	>12
β-hCG (IU/L)	$<10^3$	10^3–10^4	10^4–10^5	$>10^5$
Largest tumor, including uterine tumor	<3 cm	3–5 cm	>5 cm	–
Site of metastases	Lung	Spleen, kidney	Gastrointestinal tract	Brain, liver
Number of metastases identified	—	1–4	5–8	>8
Prior chemotherapy	—	—	Single drug	Two or more drugs

[a]The total score for a patient is obtained by adding the individual scores for each prognostic factor: low risk, 0–6; high risk, ≥7.
[b]Interval is time between end of antecedent pregnancy and start of chemotherapy.
From Kurman RJ, Carcangiu ML, Herrington CS, Young RH, eds. *WHO Classification of Tumors of the Female Reproductive Organs*. Lyon: IARC; 2014.

been identified on the basis of location of metastases, hCG, and duration of the disease (Table 33.3).[777]

In most cases the uterus can be retained. Hysterectomy is performed in those patients in whom preservation of the reproductive function is not desired and/or who are unresponsive to chemotherapy alone. Surgery also remains useful in controlling life-threatening hemorrhage from metastatic lesions.[778,779]

The importance of early diagnosis, prompt institution of therapy, and monitoring of the effects of treatment with sequential quantitative determination of hCG production cannot be overemphasized. In regard to the latter, it should be mentioned that hCG secretion is by no means restricted to gestational choriocarcinomas. It can also occur in nongestational choriocarcinoma; other ovarian and testicular germ cell tumors; melanoma; malignant lymphoma; and carcinomas of the esophagus, stomach, pancreas, kidney, liver, lung, urinary bladder, uterus, adrenal gland, breast, and other sites. A feature common to many of these tumors is the presence of tumor giant cells shown to contain hCG by immunocytochemical techniques.[780]

Genetic studies using the same technique used to aid in diagnosis of molar pregnancy, described previously, and distinguish gestational from nongestational choriocarcinoma by identification of paternal DNA.[744]

Placental Site Trophoblastic Tumor and Related Lesions of Intermediate Trophoblast

Placental site trophoblastic tumor is a rare form of trophoblastic disease.[782–784] About 75% of cases follow a normal pregnancy, with only 5% of the reported patients having had a preceding molar pregnancy.[785] A paternally derived X chromosome and the absence of a Y chromosome may be necessary for its formation, consistent with an origin from the trophectoderm of a female conceptum.[786,787] It presents grossly as a myometrial mass that can be well localized or ill defined (Fig. 33.86A). Hemorrhage is not as conspicuous as in invasive mole or choriocarcinoma. The uterine penetration may be deep, and perforation may result, either spontaneously or following curettage.

Microscopically, large trophoblastic cells with abundant eosinophilic cytoplasm and nuclear pleomorphism are seen invading the myometrium and vessel lumina (see Fig. 33.86B). The morphologic, ultrastructural, and immunohistochemical features of these cells correspond to those of intermediate trophoblast.[788–791] As such, the immunoreactivity for hPL is strong and widespread, whereas that for hCG tends to be focal.[792,793] There is also positivity for keratin, CD66a (CEACAM1), CD146 (Mel-CAM), pregnancy-associated major basic protein, HLA-G, and inhibin.[794–796] The DNA pattern, as determined by flow cytometry, is usually diploid,[797,798] and this seems to also be the case in the rare examples with malignant behavior.[799] The Ki-67 labeling index is higher than in exaggerated placental site reaction but lower than in choriocarcinoma.[800] There is no expression of p63, an useful feature in the differential diagnosis with epithelioid trophoblastic tumor (see later).[801]

Although this condition was initially considered to be an exuberant form of syncytial endometritis,[782] additional experience has shown that it is instead a neoplastic process with a 10%–20% mortality rate if not treated properly.[802] Some cases have resulted in widespread metastases;[797,803] these have generally shown a high mitotic count in the primary tumor, extensive necrosis, and/or a preponderance of cells with clear cytoplasm.[783]

Serum hCG levels in placental site trophoblastic tumor are usually not as high as in choriocarcinoma and may not accurately reflect the extent of the disease. Sometimes the tumor is totally resistant to chemotherapy.[804,805] A distinctive renal glomerular lesion accompanied by proteinuria and hematuria and characterized by occlusive eosinophilic deposits in the glomerular capillary lumina has been observed in connection with this neoplasm.[806]

The differential diagnosis of placental site trophoblastic tumor includes other gestational trophoblastic diseases, as well as nonneoplastic placental proliferations of intermediate trophoblast, especially placental site nodule. In contrast to placental site nodule, placental site trophoblastic tumor shows confluent growth of intermediate trophoblast and Ki-67 labeling index of greater than 10%. The distinction with choriocarcinoma is made because of a lack of a dimorphic population of cytotrophoblast and syncytiotrophoblast (although scattered multinucleated cells may be present), lack or paucity of hemorrhage, and the presence of an interdigitating pattern of muscle invasion.

Epithelioid Trophoblastic Tumor

Epithelioid trophoblastic tumor, the latest entry into the gestational trophoblastic disease family, was originally described as a peculiar

For personal use only. No other uses without permission. Copyright ©2017. Elsevier Inc. All rights reserved.

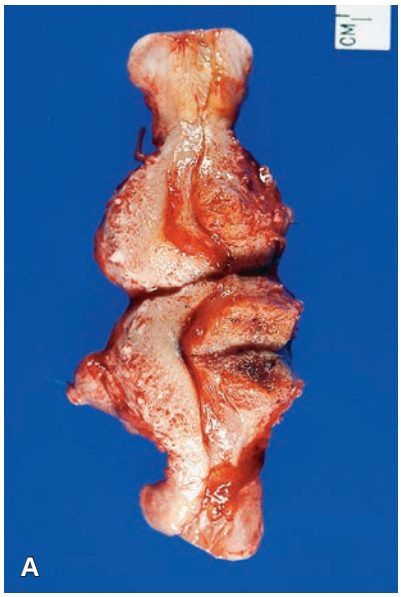

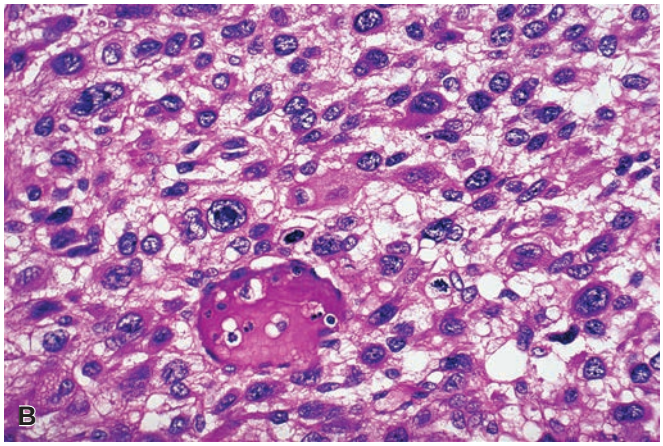

Figure 33.86 A and **B,** Placental site trophoblastic tumor. **A,** Gross appearance. A solid hemorrhagic nodule is seen distending the myometrium and protruding into the endometrial cavity. **B,** Microscopic appearance. Medium-sized cells of intermediate trophoblastic type are seen growing in a diffuse fashion into the myometrium. The biphasic pattern resulting from the admixture of cytotrophoblast and syncytiotrophoblast, which is typical of choriocarcinoma, is absent.

change in the metastatic foci of choriocarcinoma surgically excised following chemotherapy[807] but is now known to also occur de novo. Like the other members of the family, it usually occurs in the reproductive age group (although it can be seen after menopause),[808] and it presents with abnormal vaginal bleeding. The primary tumor most commonly occurs in the endomyometrium but can sometimes be centered in the uterine cervix,[809] develop outside the uterus in places such as the broad ligament,[810] or even present as a primary lung tumor, simulating microscopically squamous and pleomorphic carcinomas of this organ.[811] hCG levels are usually elevated. Grossly, it is solid and cystic, discrete, and hemorrhagic. Microscopically, it is composed of a relatively uniform population of intermediate trophoblastic cells forming nests and solid masses. Necrosis is extensive, and there is a hyaline matrix with a geographic configuration (Fig. 33.87). The appearance closely simulates that of a carcinoma. Immunohistochemically, there is diffuse reactivity for keratin, α-inhibin, EMA, p63, HLA-G, and E-cadherin but only focal reactivity

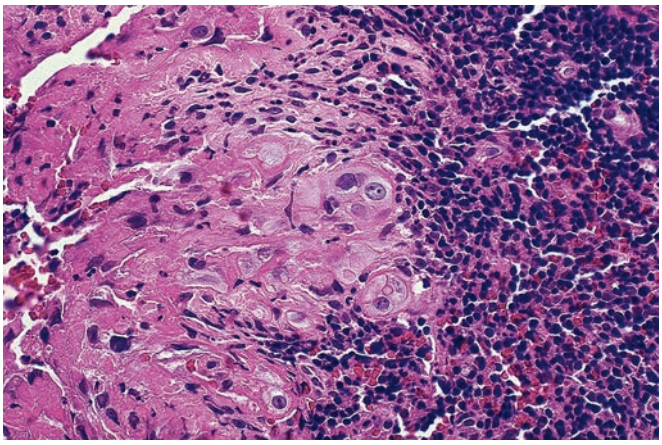

Figure 33.87 Epithelioid Trophoblastic Tumor. The microscopic appearance closely simulates carcinoma of either squamous or glassy cell type.

for hPL, hCG, PLAP, and CD116 (Mel-CAM).[812] Positivity for cyclin E helps in the differential diagnosis with placental site trophoblastic tumor, and lack of reactivity for p16 is useful in the differential diagnosis with cervical and other types of carcinoma.[813] Shih and Kurman[814] believe that the tumor is composed of chorion laeve-type intermediate trophoblast. Molecular genetic analysis has confirmed its trophoblastic origin by demonstrating a Y-chromosomal locus and/or new (paternal) alleles not present in the adjacent normal uterine tissue.[815] It behaves as a malignant tumor, with metastases to lung and other sites.[814]

Tumorlike Conditions of Intermediate Trophoblast. Non-neoplastic proliferations of intermediate trophoblast that can create serious problems in the differential diagnosis with malignant trophoblastic tumors are exaggerated placental site reaction, placental site nodule, and placental site plaque.[816]

Exaggerated placental site reaction was called syncytial endometritis in the past, but this was a double misnomer since the lesion is not primarily of inflammatory nature and is not composed of syncytiotrophoblast. As the currently preferred name indicates, it is believed to be the result of excessive but otherwise normal infiltration of the implantation site by intermediate trophoblast (Fig. 33.88). Its distinction from placental site trophoblastic tumor can be difficult because the cytologic and immunohistochemical features are very similar. Exaggerated placental site is to be favored when the lesion is microscopic in size, lacks mitotic activity, contains a hyaline material between the trophoblastic cells, and is admixed with decidua and villi.

Placental site nodules and plaques appear as single or multiple, mostly well-circumscribed, variably cellular round or flat lesions (nodules and plaques, respectively) that tend to be extensively hyalinized (Fig. 33.89).[817,818] Most cells have abundant amphophilic or acidophilic cytoplasm, irregularly shaped nuclei, and very scanty mitotic activity, but others have a glycogen-rich clear cytoplasm.[819] Mallory bodies (representing abnormal cytoplasmic aggregates of keratin filaments) may be present.[820] These nodules and plaques, which can also occur in the cervix, fallopian tube, and other sites,[821,822] are distinguished from placental site trophoblastic tumor because of their smaller size, better circumscription, extensive hyalinization, degenerative appearance, and paucity of mitotic activity.[823,824] It has been pointed out that placental site nodules and plaques closely resemble the intermediate trophoblast of the chorion laeve rather than that at the implantation site. As such, they are diffusely positive

For personal use only. No other uses without permission. Copyright ©2017. Elsevier Inc. All rights reserved.

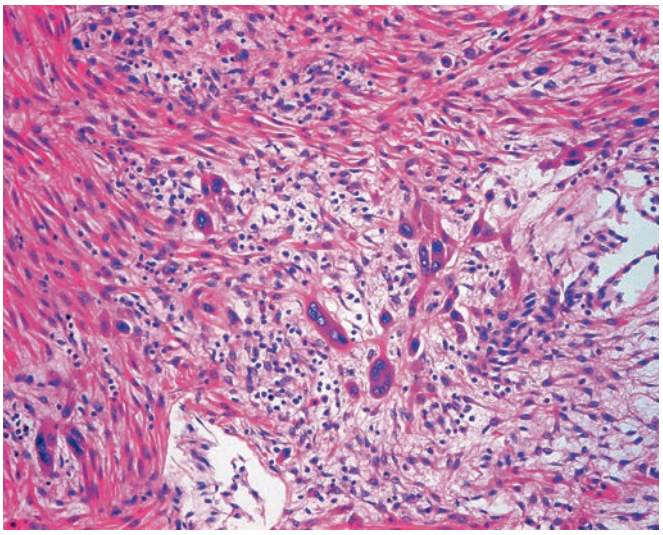

Figure 33.88 Trophoblastic cells infiltrating the myometrium in a tumorlike fashion in exaggerated placental site reaction.

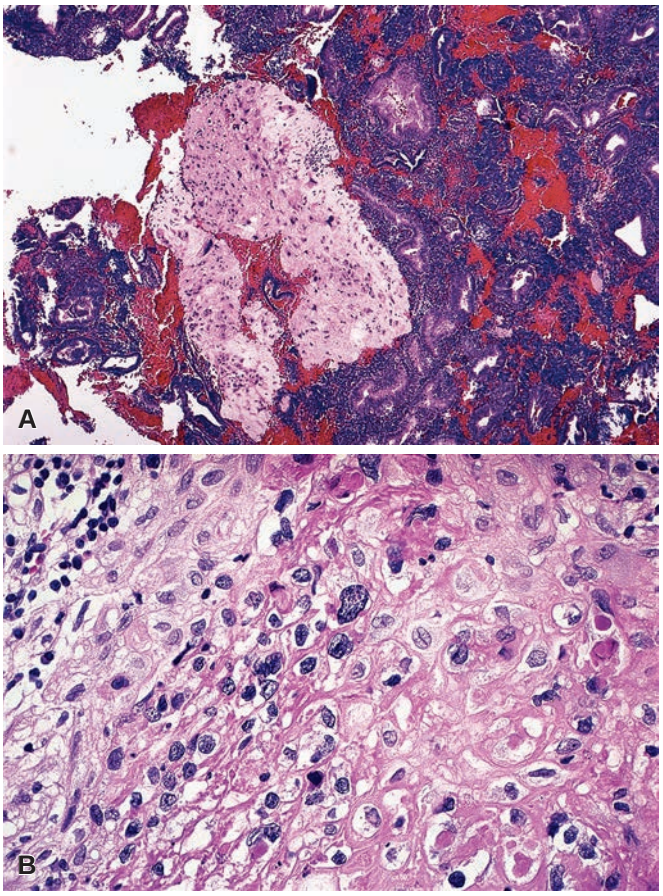

Figure 33.89 **A** and **B,** Low- and medium-power appearance of placental site nodule. The appearance is vaguely chondroid and can be easily misinterpreted.

for PLAP but only focally positive or negative for hPL and CD146 (Mel-CAM).[819]

The differential diagnosis between placental site trophoblastic tumor and the non-neoplastic proliferations previously mentioned may not be always possible in a curettage specimen. In such cases, subsequent curettings and monitoring of serum levels of hCG and hPL become imperative.

Other Tumors and Tumorlike Conditions

Postoperative spindle cell nodules similar to those occurring in the vagina have been observed in the endometrium.[825]

Idiopathic granulomas similar to those more commonly seen in the ovary (and known there as idiopathic ovarian cortical granulomas) have been occasionally seen in the uterus. Most of them were multiple and located in the myometrium.[826]

Extramedullary hematopoiesis can occur in the uterus in the absence of any hematologic disorder or systemic disease (but see Granulocytic [myeloid] sarcoma later).[827] Most of the reported cases have been located in endometrial polyps or leiomyomas and have been associated with chronic anemia.[828]

Myxoid changes can occur in the myometrium in the absence of any other pathology.[829]

Adenomatoid tumors identical to those more commonly seen in the fallopian tube are sometimes found in the uterine wall, usually beneath the serosa and close to the cornua.[830,831] Exceptionally, they will be apparent in a curetting specimen. These tumors are usually small (mean diameter, 2 cm) and macroscopically are usually mistaken for leiomyomas. They are characterized microscopically by adenoid, angiomatoid, solid, and cystic patterns occurring singly or in combination (Fig. 33.90).[832,833] The most cystic examples can simulate lymphangiomas. Their mesothelial nature has been established on the basis of ultrastructural and immunohistochemical findings (including reactivity for calretinin, WT1, and D2-40).[834–839]

Arteriovenous fistula in the wall of the uterus may produce large pulsating masses. The vascular connections are demonstrable by angiography.[840]

Benign mesenchymal tumors other than those already described are extremely rare. They include *hemangioma* of the endometrium,[841] *solitary fibrous tumor* (some associated with hypoglycemia),[842,843] and *lipoma.* The latter may result, at least in some instances, from adipose metaplasia of leiomyomas.[569,570]

Sarcomas of types other than those already described can arise in the uterus. They include *chondrosarcoma,*[846] *osteosarcoma,*[847] *rhabdomyosarcoma,*[848–851] *malignant peripheral nerve sheath tumor,*[852] *angiosarcoma,*[853–855] so-called *malignant fibrous histiocytoma,*[856] *malignant mesenchymoma* (one arising in a leiomyoma),[857] *alveolar soft part sarcoma,*[858] GIST,[859] so-called *rhabdoid sarcoma,*[860] *Ewing sarcoma/PNET,*[861–863] and *tumors with neuroectodermal differentiation* but lacking the *EWSR1* gene rearrangement (Fig. 33.91).[864,865] Some of these sarcomas have developed following radiation therapy for cervical carcinoma or other malignancies.[866] Some of the angiosarcomas have been of epithelioid type, immunoreactive for keratin, and apparently arising within leiomyomas.[867]

Before making a diagnosis of uterine sarcoma (particularly if the tumor is very pleomorphic and/or with heterologous elements), the more likely possibility of an MMMT with predominance of the sarcoma-like component should be ruled out with thorough sampling.[868]

Malignant lymphomas can present initially in the endometrium (including an endometrial polyp[869]), myometrium, or both.[870–873] The patients typically complain of bleeding and a mass. Most tumors are of diffuse large B-cell type.[874–876] Cases of low-grade B-cell lymphoma (including marginal zone B-cell lymphoma),[876,877] T-cell lymphoma,[878] Hodgkin lymphoma,[879] angiotropic lymphoma,[880] and intravascular large B-cell lymphoma[881] with primary uterine involvement have also been described. Malignant lymphomas should be distinguished from florid but reactive lymphoid proliferations involving the endometrium (lymphoma-like lesion),[882,883] and massive lymphoid infiltration of leiomyomas (see earlier). In these benign conditions,

For personal use only. No other uses without permission. Copyright ©2017. Elsevier Inc. All rights reserved.

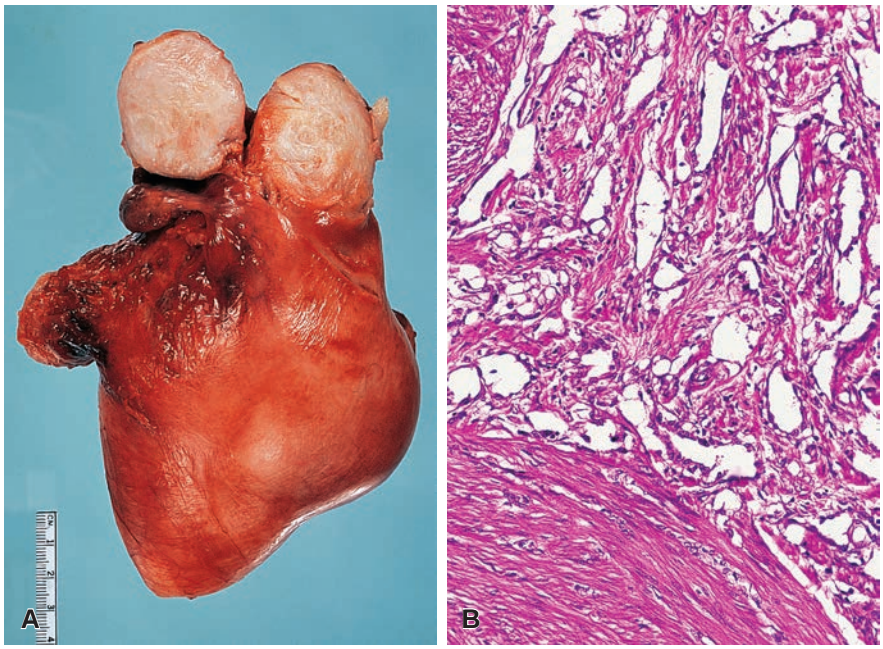

Figure 33.90 **A** and **B,** Adenomatoid tumor of uterus. **A,** Gross appearance. The location at one of the cornua is characteristic. **B,** Microscopic appearance showing tubular formations lined by flattened mesothelial cells.

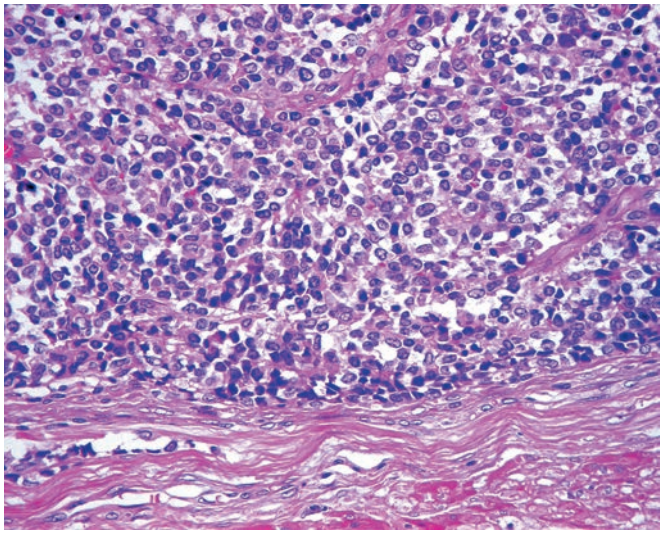

Figure 33.91 Ewing sarcoma/primitive neuroectodermal tumor presenting as a uterine mass, a most unusual occurrence.

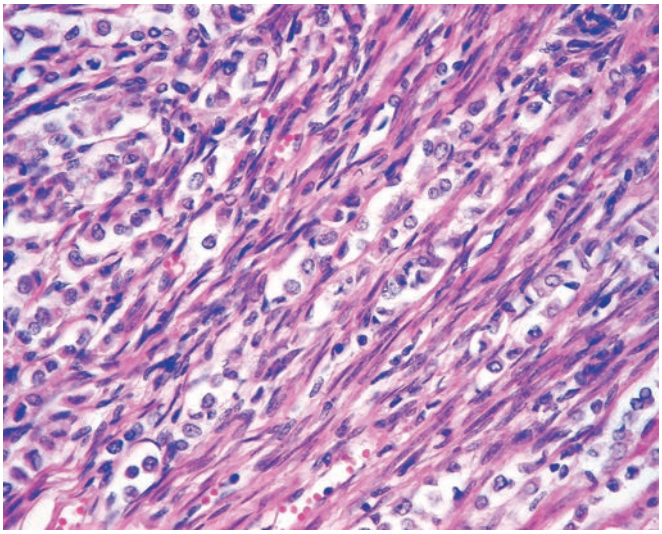

Figure 33.92 Lobular breast carcinoma metastatic to myometrium. Note the Indian file pattern of growth.

the large lymphoid cells are usually accompanied by plasma cells, small lymphocytes, and/or neutrophils.[884] **Granulocytic (myeloid) sarcoma** and **plasmacytoma/myeloma** can also involve the uterus, occasionally as the first manifestation of the disease.[871,885–887]

Other exceptionally rare primary uterine tumors include **Brenner tumor**[888] (microscopically identical to its ovarian counterpart and sometimes having a polypoid configuration),[889] **extrarenal Wilms tumor** (with or without teratoid features),[890,891] **desmoplastic small cell tumor**, **glioma**,[892] **carcinoid tumor**,[893] **paraganglioma**[894] (including a pigmented variant[895]), and **yolk sac (endodermal sinus) tumor**.[896]

Metastatic carcinoma from extrapelvic sites may metastasize to the uterus and cause uterine bleeding as the presenting symptom. The breast, gastrointestinal tract, kidney, and skin (melanoma) are the most frequent primary sites.[897–899] The myometrium is more often involved than the endometrium (Fig. 33.92) and sometimes the leiomyomas present contain metastatic tumor; however, it is not rare for the malignancy to be present in material from endometrial curettings, especially in cases of lobular carcinoma of the breast,[900] and also with neuroendocrine carcinomas and other neoplasms.[901] Exceptionally, a well-differentiated mucinous neoplasm of the appendix will coat the endometrial surface in a pseudomyxomatous fashion.[902] On occasion, a metastatic breast lobular carcinoma has been seen involving a tamoxifen-associated endometrial polyp,[903] and a melanoma has been seen to metastasize into a uterine adenomyoma.[904]

For personal use only. No other uses without permission. Copyright ©2017. Elsevier Inc. All rights reserved.

References

1. Young ES, Diaz-Arrastia C, Castro CY. The hysterectomy. *Ann Diagn Pathol*. 2005;9:202-208.
2. Barroeta JE, Pasha TL, Acs G, Zhang PJ. Immunoprofile of endocervical and endometrial stromal cells and its potential application in localization of tumor involvement. *Int J Gynecol Pathol*. 2007;26:76-82.
3. McElin TW, Bird CC, Reeves BD, Scott RC. Diagnostic dilation and curettage. A 20-year survey. *Obstet Gynecol*. 1969;33:807-812.
4. Mittal K, Soslow R, McCluggage WG. Application of immunohistochemistry to gynecologic pathology. *Arch Pathol Lab Med*. 2008;132:402-423.
5. Niu HL, Pasha TL, Pawel BR, et al. Thyroid transcription factor-1 expression in normal gynecologic tissues and its potential significance. *Int J Gynecol Pathol*. 2009;28:301-307.
6. Onuma K, Dabbs DJ, Bhargava R. Mammaglobin expression in the female genital tract: immunohistochemical analysis in benign and neoplastic endocervix and endometrium. *Int J Gynecol Pathol*. 2008;27:418-425.
7. Hendrickson MR, Atkins KA, Kempson RL. Uterus and fallopian tubes. In: Mills SE, ed. *Histology for Pathologists*. 3rd ed. Philadelphia: Lippincott Williams and Wilkins; 2007:1011-1062.
8. Norris HJ, Hertig AT, Abell MR. *The Uterus*. Baltimore: Williams and Wilkins; 1973.
9. Noyes RW. Uniformity of secretory endometrium. Study of multiple sections from 100 uteri removed at operation. *Fertil Steril*. 1956;7:103-109.
10. Noyes RW, Hertig AT, Rock J. Dating the endometrial biopsy. *Fertil Steril*. 1950;1:3-25.
11. Poropatich C, Rojas M, Silverberg SG. Polymorphonuclear leukocytes in the endometrium during the normal menstrual cycle. *Int J Gynecol Pathol*. 1987;6:230-234.
12. Banks ER, Mills SE, Frierson HF Jr. Uterine intravascular menstrual endometrium simulating malignancy. *Am J Surg Pathol*. 1991;15:407-412.
13. Sahin AA, Silva EG, Landon G, et al. Endometrial tissue in myometrial vessels not associated with menstruation. *Int J Gynecol Pathol*. 1989;8:139-146.
14. Ferenczy A, Bertrand G, Gelfand MM. Proliferation kinetics of human endometrium during the normal menstrual cycle. *Am J Obstet Gynecol*. 1979;133:859-867.
15. Arias-Stella J. *Historia de un descubrimiento cientifico en un pais en desarrollo*. Lima, Peru: Universidad Peruana Cayetano Heredia; 2009.
16. Arias-Stella J Jr, Arias-Velasquez A, Arias-Stella J. Normal and abnormal mitoses in the atypical endometrial change associated with chorionic tissue effect. *Am J Surg Pathol*. 1994;18:694-701.
17. Arias-Stella J. Atypical endometrial changes produced by chorionic tissue. *Hum Pathol*. 1972;3:450-453.
18. Azzopardi JC, Zayid I. Synthetic progestogen-oestrogen therapy and uterine changes. *J Clin Pathol*. 1967;20:731-738.
19. Reference deleted in proofs.
20. Huettner PC, Gersell DJ. Arias-Stella reaction in nonpregnant women. A clinicopathologic study of nine cases. *Int Gynecol Pathol*. 1994;13:241-247.
21. Vang R, Barner R, Wheeler DT, Strauss BL. Immunohistochemical staining for Ki-67 and p53 helps distinguish endometrial Arias-Stella reaction from high-grade carcinoma, including clear cell carcinoma. *Int J Gynecol Pathol*. 2004;23:223-233.
22. McCluggage WG. Immunohistochemical and functional biomarkers of value in female genital tract lesions. *Int J Gynecol Pathol*. 2006;25:101-120.
23. Sickel JZ, di Sant'Agnese PA. Anomalous immunostaining of 'optically clear' nuclei in gestational endometrium. A potential pitfall in the diagnosis of pregnancy-related herpesvirus infection. *Arch Pathol Lab Med*. 1994;118:831-833.
24. Yokoyama S, Kashima K, Inoue S, et al. Biotin-containing intranuclear inclusions in endometrial glands during gestation and puerperium. *Am J Clin Pathol*. 1993;99:13-17.
25. Clement PB, Scully RE. Idiopathic postmenopausal decidual reaction of the endometrium. A clinicopathologic analysis of four cases. *Int J Gynecol Pathol*. 1988;7:152-161.
26. Mazur MT, Hendrickson MR, Kempson RL. Optically clear nuclei. An alteration of endometrial epithelium in the presence of trophoblast. *Am J Surg Pathol*. 1983;7:415-423.
27. Pacheco JC, Kempers RD. Etiology of postmenopausal bleeding. *Obstet Gynecol*. 1968;32:40-46.
28. Loghavi S, Silva EG. Abnormal myometrial vasculature explains some cases of menorrhagia. *Lab Invest*. 2009;89(suppl 1):225A.
29. Meyer WC, Malkasian GD, Dockerty MB, Decker DG. Postmenopausal bleeding from atrophic endometrium. *Obstet Gynecol*. 1971;38:731-738.
30. Merchant S, Malpica A, Deavers MT, et al. Vessels within vessels in the myometrium. *Am J Surg Pathol*. 2002;26:232-236.
31. Whitehead MI, Townsend PT, Pryse-Davies J, et al. Effects of estrogens and progestins on the biochemistry and morphology of the post-menopausal endometrium. *N Engl J Med*. 1981;305:1599-1605.
32. Smith DC, Prentice R, Thompson DJ, Herrmann WL. Association of exogenous estrogen and endometrial carcinoma. *N Engl J Med*. 1975;293:1164-1166.
33. Ziel HK, Finkle WD. Increased risk of endometrial carcinoma among users of conjugated estrogens. *N Engl J Med*. 1975;293:1167-1170.
34. Silverberg SG, Mullen D, Faraci JA, et al. Endometrial carcinoma. Clinical–pathologic comparison of cases in post-menopausal women receiving and not receiving exogenous estrogens. *Cancer*. 1980;45:3018-3026.
35. Deligdisch L. Effects of hormone therapy on the endometrium. *Mod Pathol*. 1993; 6:94-106.
36. Ober WB. Effects of oral and intrauterine administration of contraceptives on the uterus. *Hum Pathol*. 1977;8:513-527.
37. Rice-Wray E, Aranda-Rosell A, Maqueo M, Goldzieher JW. Comparison of the long-term endometrial effects of synthetic progestins used in fertility control. *Am J Obstet Gynecol*. 1963;87:429-433.
38. Azzopardi JG, Zayid I. Synthetic progestogen–oestrogen therapy and uterine changes. *J Clin Pathol*. 1967;20:731-738.
39. Ober WB. Synthetic progestogen-oestrogen preparations and endometrial morphology. *J Clin Pathol*. 1966;19:138-147.
40. Hejmadi RK, Chaudhri S, Ganesan R, Rollason TP. Morphologic changes in the endometrium associated with the use of the mirena coil: a retrospective study of 106 cases. *Int J Surg Pathol*. 2007;15:148-154.
41. Mutter GL, Bergeron C, Deligdisch L, et al. The spectrum of endometrial pathology induced by progesterone receptor modulators. *Mod Pathol*. 2008;21:591-598.
42. Williams AR, Bergeron C, Barlow DH, Ferenczy A. Endometrial morphology after treatment of uterine fibroids with the selective progesterone receptor modulator, ulipristal acetate. *Int J Gynecol Pathol*. 2012;31:556-569.
43. Hachisuga T, Hideshima T, Kawarabayashi T, et al. Expression of steroid receptors, Ki-67, and epidermal growth factor receptor in tamoxifen-treated endometrium. *Int J Gynecol Pathol*. 1999;18:297-303.
44. Leslie KK, Walter SA, Torkko K, et al. Effect of tamoxifen on endometrial histology, hormone receptors, and cervical cytology: a prospective study with follow-up. *Appl Immunohistochem Mol Morphol*. 2007;15:284-293.
45. Seidman JD, Kurman RJ. Tamoxifen and the endometrium. *Int J Gynecol Pathol*. 1999;18:293-296.
46. Carcangiu ML. Uterine pathology in tamoxifen-treated patients with breast cancer. *Anat Pathol*. 1998;2:53-70.
47. Ismail SM. Endometrial pathology associated with prolonged tamoxifen therapy: a review. *Adv Anat Pathol*. 1996;3:266-271.
48. Barakat RR, Goóewski TA, Almadrones L, et al. Effect of adjuvant tamoxifen on the endometrium in women with breast cancer: a prospective study using office endometrial biopsy. *J Clin Oncol*. 2000;18:3459-3463.
49. Kennedy MM, Baigrie CF, Manek S. Tamoxifen and the endometrium: review of 102 cases and comparison with HRT-related and non-HRT related endometrial pathology. *Int J Gynecol Pathol*. 1999;18:130-137.
50. Deligdisch L, Kalir T, Cohen CJ, et al. Endometrial histopathology in 700 patients treated with tamoxifen for breast cancer. *Gynecol Oncol*. 2000;78:181-186.
51. Magriples U, Naftolin F, Schwartz PE, Carcangiu ML. High-grade endometrial carcinoma in tamoxifen-treated breast cancer patients. *J Clin Oncol*. 1993;11:485-490.
52. Silva EG, Tornos CS, Follen-Mitchell M. Malignant neoplasms of the uterine corpus in patients treated for breast carcinoma. The effects of tamoxifen. *Int J Gynecol Pathol*. 1994;13:248-258.
53. Turbiner J, Moreno-Bueno G, Dahiya S, et al. Clinicopathological and molecular analysis of endometrial carcinoma associated with tamoxifen. *Mod Pathol*. 2008;21:925-936.
54. Risse EKJ, Beerthuizen RJCM, Vooijs GP. Cytologic and histologic findings in women using an IUD. *Obstet Gynecol*. 1981;58:569-573.
55. Adegboyega PA, Pei Y, McLarty J. Relationship between eosinophils and chronic endometritis. *Hum Pathol*. 2010;41:33-37.
56. Park HJ, Kim YS, Yoon TK, Lee WS. Chronic endometritis and infertility. *Clin Exp Reprod Med*. 2016;43:185-192.
57. Schmidt WA. IUDs, inflammation, and infection. Assessment after two decades of IUD use. *Hum Pathol*. 1982;13:878-881.
58. Paukku M, Puolakkainen M, Paavonen T, Paavonen J. Plasma cell endometritis is associated with *Chlamydia trachomatis* infection. *Am J Clin Pathol*. 1999;112:211-215.
59. Shintaku M, Sasaki M, Baba Y. Ceroid-containing histiocytic granuloma of the endometrium. *Histopathology*. 1991;18:169-172.
60. Crum CP, Egawa K, Fenoglio CM, Richart RM. Chronic endometritis. The role of immunohistochemistry in the detection of plasma cells. *Am J Obstet Gynecol*. 1983;147:812-815.
61. Lombard CM, Moore MH, Seifer DB. Diagnosis of systemic polyarteritis nodosa following total abdominal hysterectomy and

For personal use only. No other uses without permission. Copyright ©2017. Elsevier Inc. All rights reserved.

bilateral salpingo-oophorectomy. A case report. *Int J Gynecol Pathol*. 1986;5:63-68.
62. Bayer-Garner IB, Nickell JA, Korourian S. Routine syndecan-1 immunohistochemistry aids in the diagnosis of chronic endometritis. *Arch Pathol Lab Med*. 2004;128:1000-1003.
63. Gilmore H, Fleischhacker D, Hecht JL. Diagnosis of chronic endometritis in biopsies with stromal breakdown. *Hum Pathol*. 2007;38:581-584.
64. Leong AS, Vinyuvat S, Leong FW, Suthipintawong C. Anti-CD38 and VS38 antibodies for the detection of plasma cells in the diagnosis of chronic endometritis. *Appl Immunohistochem*. 1997;5:189-193.
65. Corfman PA, Segal SJ. Biologic effects of intrauterine devices. *Am J Obstet Gynecol*. 1968;100:448-459.
66. Silvernagel SW, Harshbarger KE, Shevlin DW. Postoperative granulomas of the endometrium: histological features after endometrial ablation. *Ann Diagn Pathol*. 1999;1:82-90.
67. Rotterdam H. Chronic endometritis. A clinicopathologic study. *Pathol Annu*. 1978;13(Pt 2):209-231.
68. Sen DK, Fox H. The lymphoid tissue of the endometrium. *Gynaecologia*. 1967;163:371-378.
69. Venkataseshan VS, Woo TH. Diffuse viral papillomatosis (condyloma) of the uterine cavity. *Int J Gynecol Pathol*. 1985;4:370-377.
70. Whiteley PF, Hamlett JD. Pyometra—a reappraisal. *Am J Obstet Gynecol*. 1971;109:108-112.
71. Bhagavan BS, Gupta PK. Genital actinomyosis and intrauterine contraceptive devices. Cytopathologic diagnosis and clinical significance. *Hum Pathol*. 1978;9:567-578.
72. Burkman R, Schlesselman S, McCaffrey L, et al. The relationship of genital tract *Actinomyces* and the development of pelvic inflammatory disease. *Am J Obstet Gynecol*. 1982;143:585-589.
73. Paavonen J, Aine R, Teisala K, et al. Comparison of endometrial biopsy and peritoneal fluid cytologic testing with laparoscopy in the diagnosis of acute pelvic inflammatory disease. *Am J Obstet Gynecol*. 1985;151:645-650.
74. Gupta PK. Intrauterine contraceptive devices. Vaginal cytology, pathologic changes and clinical implications. *Acta Cytol*. 1982;26:571-613.
75. Bhagavan BS, Ruffier J, Shinn B. Pseudoactinomycotic radiate granules in the lower female genital tract. Relationship to the Splendore–Hoeppli phenomenon. *Hum Pathol*. 1982;13:898-904.
76. Winkler B, Reumann W, Mitao M, et al. Chlamydial endometritis. A histological and immunohistochemical analysis. *Am J Surg Pathol*. 1984;8:771-778.
77. Buckley CH, Fox H. Histiocytic endometritis. *Histopathology*. 1980;4:105-110.
78. Kiviat NB, Wolner-Hanssen P, Eschenbach DA, et al. Endometrial histopathology in patients with culture-proved upper genital tract infection and laparoscopically diagnosed acute salpingitis. *Am J Surg Pathol*. 1990;14:167-175.
79. Silverberg SG, Haukkamaa M, Arko H, et al. Endometrial morphology during long-term use of levonorgestrel-releasing intrauterine devices. *Int J Gynecol Pathol*. 1986;5:235-241.
80. Govan ADT. Tuberculous endometritis. *J Pathol Bacteriol*. 1962;83:363-372.
81. Paavonen J, Kiviat N, Brunham RC, et al. Prevalence and manifestations of endometritis among women with cervicitis. *Am J Obstet Gynecol*. 1985;152:280-286.
82. Abell MR. Endometrial biopsy. Normal and abnormal diagnostic characteristics. In: Gold JJ, ed. *Gynecologic Endocrinology*. New York: Harper and Row; 1975:156-190.
83. Taylor ES, McMillan JH, Greer BE, et al. The intrauterine device and tubo-ovarian abscess. *Am J Obstet Gynecol*. 1975;123:338-347.
84. Kiviat NB, Wolner-Hanssen P, Eschenbach DA, et al. Endometrial histopathology in patients with culture-proven upper genital tract infection and laparascopically diagnosed acute salpingitis. *Am J Surg Pathol*. 1990;14:167-175.
85. Dehner LP, Askin FB. Cytomegalovirus endometritis. *Obstet Gynecol*. 1975;45:211-214.
86. Westrom L, Bengtsson LP, Mardh P. The risk of pelvic inflammatory disease in women using intrauterine contraceptive devices as compared to non-users. *Lancet*. 1976;2:221-224.
87. Frank TS, Himebaugh KS, Wilson MD. Granulomatous endometritis associated with histologically occult cytomegalovirus in a healthy patient. *Am J Surg Pathol*. 1992;16:716-720.
88. Bylund DJ, Nanfro JJ, Marsh WL. Coccidioidomycosis of the female genital tract. *Arch Pathol Lab Med*. 1986;110:232-235.
89. Hart WR, Prins RP, Tsai JC. Isolated coccidioidomycosis of the uterus. *Hum Pathol*. 1976;7:235-239.
90. Almoujahed MO, Briski LE, Prysak M, et al. Uterine granulomas. Clinical and pathologic features. *Am J Clin Pathol*. 2002;117:771-775.
91. Stern RA, Svoboda-Newman SM, Frank TS. Analysis of chronic endometritis for *Chlamydia trachomatis* by polymerase chain reaction. *Hum Pathol*. 1996;27:1085-1088.
92. Müller-Holzner E, Ruth NR, Abfalter E, et al. IUD-associated pelvic actinomycosis. A report of five cases. *Int J Gynecol Pathol*. 1995;14:70-74.
93. Kim KR, Lee YH, Ro JY. Nodular histocytic hyperplasia of the endometrium. *Int J Gyncol Pathol*. 2002;21:141-146.
94. Di Carlo FJ Jr, Di Carlo JP, Robboy SJ, Lyons MM. Sarcoidosis of the uterus. *Arch Pathol Lab Med*. 1989;113:941-943.
95. Ashworth MT, Moss CI, Kenyon WE. Granulomatous endometritis following hysteroscopic resection of the endometrium. *Histopathology*. 1991;18:185-187.
96. Bell DA, Mondschein M, Scully RE. Giant cell arteritis of the female genital tract. A report of three cases. *Am J Surg Pathol*. 1986;10:696-701.
97. Francke ML, Mihaescu A, Chaubert P. Isolated necrotizing arteritis of the female genital tract: a clinicopathologic and immunohistochemical study of 11 cases. *Int J Gynecol Pathol*. 1998;17:193-200.
98. Ganesan R, Ferryman SR, Meier L, Rollason TP. Vasculitis of the female genital tract with clinicopathologic correlation: a study of 46 cases with follow-up. *Int J Gynecol Pathol*. 2000;19:258-265.
99. Molnar JJ, Poliak A. Recurrent endometrial malakoplakia. *Am J Clin Pathol*. 1983;80:762-764.
100. Hernández-Rodríguez J, Tan CD, Rodríguez ER, Hoffman GS. Gynecologic vasculitis: an analysis of 163 patients. *Medicine (Baltimore)*. 2009;88(3):169-181.
101. Crum CP, Richart RM, Fenoglio CM. Adenoacanthosis of the endometrium. A clinicopathologic study in premenopausal women. *Am J Surg Pathol*. 1981;5:15-20.
102. Demopoulos RI, Greco MA. Mucinous metaplasia of the endometrium. Ultrastructural and histochemical characteristics. *Int J Gynecol Pathol*. 1983;1:383-390.
103. Hendrickson MR, Kempson RL. Endometrial epithelial metaplasias. Proliferations frequently misdiagnosed as adenocarcinoma. Report of 89 cases and proposed classification. *Am J Surg Pathol*. 1980;4:525-542.
104. Bomze EJ, Friedman NB. Squamous metaplasia and adenoacanthosis of the endometrium. *Obstet Gynecol*. 1967;30:619-625.
105. Nucci MR, Prasad CJ, Crum CP, Mutter GL. Mucinous endometrial epithelial proliferations: a morphologic spectrum of changes with diverse clinical significance. *Mod Pathol*. 2000;12:1137-1142.
106. Miranda MC, Mazur MT. Endometrial squamous metaplasia. An unusual response to progestin therapy of hyperplasia. *Arch Pathol Lab Med*. 1995;119:458-460.
107. Lin MC, Lomo L, Baak JP, et al. Squamous morules are functionally inert elements of premalignant endometrial neoplasia. *Mod Pathol*. 2009;22:167-174.
108. Shah SS, Mazur MT. Endometrial eosinophilic syncytial change related to breakdown: immunohistochemical evidence suggests a regressive process. *Int J Gynecol Pathol*. 2008;27:534-538.
109. Silver SA, Cheung AN, Tavassoli FA. Oncocytic metaplasia and carcinoma of the endometrium: an immunohistochemical and ultrastructural study. *Int J Gynecol Pathol*. 1999;18:12-19.
110. Simon RA, Peng SL, Liu F, et al. Tubal metaplasia of the endometrium with cytologic atypia: analysis of p53, Ki-67, TERT, and long-term follow-up. *Mod Pathol*. 2011;24(9):1254-1261.
111. Dutra FR. Intraglandular morules of the endometrium. *Am J Clin Pathol*. 1959;31:60-65.
112. Schueller EF. Ciliated epithelia of the human uterine mucosa. *Obstet Gynecol*. 1968;31:215-223.
113. Roth E, Taylor HB. Heterotopic cartilage in the uterus. *Obstet Gynecol*. 1966;27:838-844.
114. Bhatia NN, Hoshiko MG. Uterine osseous metaplasia. *Obstet Gynecol*. 1982;60:256-259.
115. Houghton O, Connolly LE, McCluggage WG. Morules in endometrioid proliferations of the uterus and ovary consistently express the intestinal transcription factor CDX2. *Histopathology*. 2008;53:156-165.
116. Tyagi SP, Saxena K, Rizvi R, Langley FA. Foetal remnants in the uterus and their relation to other uterine heterotopia. *Histopathology*. 1979;3:339-345.
117. Blaustein A. Morular metaplasia misdiagnosed as adenoacanthoma in young women with polycystic ovarian disease. *Am J Surg Pathol*. 1982;6:223-228.
118. Salm R. Mucin production of the normal and abnormal endometrium. *Arch Pathol*. 1962;73:30-39.
119. Bird CC, Willis RA. The production of smooth muscle by the endometrial stroma of the adult human uterus. *J Pathol Bacteriol*. 1965;90:75-81.
120. Ahmed AA, Swan RW, Owen A, et al. Uterus-like mass arising in broad ligament: a metaplasia or mullerian duct anomaly? *Int J Gynecol Pathol*. 1998;16:279-281.
121. Chambers JT, Chambers SK. Endometrial sampling. When? Where? Why? With what? *Clin Obstet Gynecol*. 1992;35:28-39.
122. Meenakshi M, McCluggage WG. Vascular involvement in adenomyosis: report of a large series of a common phenomenon with observations on the pathogenesis of adenomyosis. *Int J Gynecol Pathol*. 2010;29:117-121.
123. Picoff RC, Luginbuhl WH. Fibrin in the endometrial stroma. Its relation to uterine bleeding. *Am J Obstet Gynecol*. 1964;88:642-646.
124. Kurman RJ, Carcangiu ML, Herrington CS, Young RH, eds. *WHO Classification of Tumors of the Female Reproductive Organs*. Lyon: IARC; 2014.
125. Dietel M. The histological diagnosis of endometrial hyperplasia: is there a need to simplify? *Virchows Arch*. 2001;439:604-608.

For personal use only. No other uses without permission. Copyright ©2017. Elsevier Inc. All rights reserved.

126. Baak JP, Mutter GL, Robboy S, et al. The molecular genetics and morphometry-based endometrial intraepithelial neoplasia classification system predicts disease progression in endometrial hyperplasia more accurately than the 1994 World Health Organization classification system. *Cancer*. 2005;103:2304-2312.
127. Hofmeister FJ, Vondrak B, Barbo DM. The value of the endometrial biopsy. A study of 14,655 office endometrial biopsies. *Am J Obstet Gynecol*. 1966;95:91-98.
128. Welch WR, Scully RE. Precancerous lesions of the endometrium. *Hum Pathol*. 1977;8:503-512.
129. Anglesio MS, Papadopoulos N, Ayhan A, et al. Cancer-associated mutations in endometriosis without cancer. *N Engl J Med*. 2017;376:1835-1848.
130. Barbieri RL. Etiology and epidemiology of endometriosis. *Am J Obstet Gynecol*. 1990;162:565-567.
131. Shutter J. Uterus-like ovarian mass presenting near menarche. *Int J Gynecol Pathol*. 2005;24:382-384.
132. Bell CD, Ostrezega E. The significance of secretory features and coincident hyperplastic changes in endometrial biopsy specimens. *Hum Pathol*. 1987;18:830-838.
133. Giudice LC. Endometriosis. *N Engl J Med*. 2010;362:2389-2398.
134. Mutter GL. Histopathology of genetically defined endometrial precancers. *Int J Gynecol Pathol*. 2001;19:301-309.
135. Fox H, Buckley CH. The endometrial hyperplasias and their relationship to endometrial neoplasia. *Histopathology*. 1982;6:493-510.
136. Dijkhuizen FP, Mol BW, Brolmann HA, Heintz AP. The accuracy of endometrial sampling in the diagnosis of patients with endometrial carcinoma and hyperplasia: a meta-analysis. *Cancer*. 2000;89:1765-1772.
137. Toki T, Horiuchi A, Li SF, et al. Proliferative activity of postmenopausal endometriosis: a histopathologic and immunocytochemical study. *Int J Gynecol Pathol*. 1996;15:45-53.
138. Wells M. Recent advances in endometriosis with emphasis on pathogenesis, molecular pathology, and neoplastic transformation. *Int J Gynecol Pathol*. 2004;23:316-320.
139. Fenoglio CM, Crum CP, Ferenczy A. Endometrial hyperplasia and carcinoma. Are ultrastructural, biochemical and immunocytochemical studies useful in distinguishing between them? *Pathol Res Pract*. 1982;174:257-284.
140. Molitor JJ. Adenomyosis. A clinical and pathological appraisal. *Am J Obstet Gynecol*. 1971;110:275-284.
141. Tamura M, Fukaya T, Murakami T, et al. Analysis of clonality in human endometriotic cysts based on evaluation of X chromosome inactivation in archival formalin-fixed, paraffin-embedded tissue. *Lab Invest*. 1998;78:213-218.
142. Brooks JJ, Wheeler JE. Malignancy arising in extragonadal endometriosis. A case report and summary of the world literature. *Cancer*. 1977;40:3065-3073.
143. Chumas JC, Thanning L, Mann WJ. Malignant mixed müllerian tumor arising in extragenital endometriosis. Report of a case and review of the literature. *Gynecol Oncol*. 1986;23:227-233.
144. Heaps JM, Nieberg RK, Berek JS. Malignant neoplasms arising in endometriosis. *Obstet Gynecol*. 1990;75:1023-1028.
145. Steck WD, Helwig EB. Cutaneous endometriosis. *JAMA*. 1965;191:167-170.
146. Mostoufizadeh M, Scully RE. Malignant tumors arising in endometriosis. *Clin Obstet Gynecol*. 1980;23:951-963.
147. Parker RL, Dadmanesh F, Young RH, Clement PB. Polypoid endometriosis: a clinicopathologic analysis of 24 cases and a review of the literature. *Am J Surg Pathol*. 2004;28:285-297.
148. Clement PB, Granai CO, Young RH, Scully RE. Endometriosis with myxoid change. A case simulating pseudomyxoma peritonei. *Am J Surg Pathol*. 1994;18:849-853.
149. Fukunaga M, Ushigome S. Epithelial metaplastic changes in ovarian endometriosis. *Mod Pathol*. 1998;11:784-788.
150. Ahn GH, Scully RE. Clear cell carcinoma of the inguinal region arising from endometriosis. *Cancer*. 1991;67:116-120.
151. Karp LA, Czernobilsky B. Glandular inclusions in pelvic and abdominal paraaortic lymph nodes. *Am J Clin Pathol*. 1969;52:212-218.
152. Clement PB, Young RH. Florid cystic endosalpingiosis with tumor-like manifestations: a report of four cases including the first reported cases of transmural endosalpingiosis of the uterus. *Am J Surg Pathol*. 1999;23:166-175.
153. Colella R, Mameli MG, Bellezza G, et al. Endometriosis-associated skeletal muscle regeneration: a hitherto undescribed entity and a potential diagnostic pitfall. *Am J Surg Pathol*. 2010;34:10-17.
154. Ferguson BR, Bennington JL, Haber SL. Histochemistry of mucosubstances and histology of mixed müllerian pelvic lymph node glandular inclusions. Evidence for histogenesis by müllerian metaplasia of coelomic epithelium. *Obstet Gynecol*. 1969;33:617-625.
155. Roth LM. Endometriosis with perineural involvement. *Am J Clin Pathol*. 1973;59:807-809.
156. Fukunaga M. Smooth muscle metaplasia in ovarian endometriosis. *Histopathology*. 2000;36:348-352.
157. Leiman G. Carcinoma ex endometriosis: the jury is still out. *Adv Anat Pathol*. 1996;3:362-366.
158. Clement PB, Young RH. Two previously unemphasized features of endometriosis: micronodular stromal endometriosis and endometriosis with stromal elastosis. *Int J Surg Pathol*. 2001;8:223-227.
159. Youssef AH, Ganesan R, Rollason TP. Florid cystic endosalpingiosis of the uterus. *Histopathology*. 2006;49:546-548.
160. Sinkre P, Hoang MP, Albores-Saavedra J. Mullerianosis of inguinal lymph nodes: report of a case. *Int J Gynecol Pathol*. 2002;21:60-64.
161. Reference deleted in proofs.
162. Seidman JD. Prognostic importance of hyperplasia and atypia in endometriosis. *Int J Gynecol Pathol*. 1996;15:1-9.
163. Jung WY, Shin BK, Kim I. Uterine adenomyoma with uterus-like features: a report of two cases. *Int J Surg Pathol*. 2002;10:163-166.
164. Lu PY, Ory SJ. Endometriosis. Current management. *Mayo Clin Proc*. 1995;70:453-463.
165. Anglesio MS, Bashashati A, Wang YK, et al. Multifocal endometriotic lesions associated with cancer are clonal and carry a high mutation burden. *J Pathol*. 2015;236:201-209.
166. Bulun SE. Endometriosis. *N Engl J Med*. 2009;360:268-279.
167. Stern RC, Dash R, Bentley RC, et al. Malignancy in endometriosis: frequency and comparison of ovarian and extraovarian types. *Int J Gynecol Pathol*. 2001;20:133-139.
168. Clement PB. Pathology of endometriosis. *Pathol Annu*. 1990;25(Pt 1):245-295.
169. McCluggage WG, Bryson C, Lamki H, Boyle DD. Benign, borderline, and malignant endometrioid neoplasia arising in endometriosis in association with tamoxifen therapy. *Int J Gynecol Pathol*. 2000;19:276-279.
170. Nagai Y, Kishimoto T, Nikaido T, et al. Squamous predominance in mixed-epithelial papillary cystadenomas of borderline malignancy of Mullerian type arising in endometriotic cysts: a study of four cases. *Am J Surg Pathol*. 2003;27:242-247.
171. Nuovo M, Bayani E, Gerold T, et al. Endometrioid cystadenofibroma developing in juxtahepatic endometriosis: a case report. *Int J Surg Pathol*. 1998;6:109-112.
172. Prade M, Spatz A, Bentledy R, et al. Borderline and malignant serous tumor arising in pelvic lymph nodes. Evidence of origin in benign glandular inclusions. *Int J Gynecol Pathol*. 1995;14:87-91.
173. Slavin RE, Krum R, Van Dinh T. Endometriosis-associated intestinal tumors: a clinical and pathologic study of 6 cases and review of the literature. *Hum Pathol*. 2000;31:456-463.
174. Ho K-L. Sarcoidosis of the uterus. *Hum Pathol*. 1978;10:219-222.
175. Marcoux S, Maheux R, Berube S. Laparoscopic surgery in infertile women with minimal or mild endometriosis. Canadian Collaborative Group on Endometriosis. *N Engl J Med*. 1997;337:217-222.
176. Stewart CJ, Campbell-Brown M, Critchley HO, Farquharson MA. Endometrial apoptosis in patients with dysfunctional uterine bleeding. *Histopathology*. 1999;34:99-105.
177. Greenblatt RB, Hammond DO, Clark SL. Membranous dysmenorrhea. Studies in etiology and treatment. *Am J Obstet Gynecol*. 1954;68:835-844.
178. Kurman RJ, Kaminski PF, Norris HJ. The behavior of endometrial hyperplasia. A long-term study of 'untreated' hyperplasia in 170 patients. *Cancer*. 1985;56:403-412.
179. Jarboe EA, Mutter GL. Endometrial intraepithelial neoplasia. *Semin Diagn Pathol*. 2010;27:215-225.
180. Usubutun A, Mutter GL, Saglam A, et al. Reproducibility of endometrial intraepithelial neoplasia diagnosis is good, but influenced by the diagnostic style of pathologists. *Mod Pathol*. 2012;25:877-884.
181. Mutter GL. Endometrial intraepithelial neoplasia (EIN): will it bring order to chaos? The Endometrial Collaborative Group. *Gynecol Oncol*. 2000;76:287-290.
182. Chamlian LD, Taylor HB. Endometrial hyperplasia in young women. *Obstet Gynecol*. 1970;36:659-666.
183. Gusberg SB, Kaplan AL. Precursors of corpus cancer. IV. Adenomatous hyperplasia as stage 0 carcinoma of the endometrium. *Am J Obstet Gynecol*. 1963;87:662-667.
184. Trimble CL, Kauderer J, Zaino R, et al. Concurrent endometrial carcinoma in women with a biopsy diagnosis of atypical endometrial hyperplasia: a Gynecologic Oncology Group study. *Cancer*. 2006;106:812-819.
185. Baloglu H, Cannizzaro LA, Jones J, Koss LG. Atypical endometrial hyperplasia shares genomic abnormalities with endometrioid carcinoma by comparative genomic hybridisation. *Hum Pathol*. 2001;32:615-622.
186. Gordon MD, Ireland K. Pathology of hyperplasia and carcinoma of the endometrium. *Semin Oncol*. 1994;21:64-70.
187. Longacre TA, Chung MH, Jensen DN, Hendrickson MR. Proposed criteria for the diagnosis of well-differentiated endometrial carcinoma. A diagnostic test for myoinvasion. *Am J Surg Pathol*. 1995;19:371-406.
188. Trimble CL, Method M, Leitao M, et al. Society of Gynecologic Oncology Clinical Practice Committee.. Management of endometrial precancers. *Obstet Gynecol*. 2012;120:1160-1175.
189. Rawish KR, Desouki MM, Fadare O. Atypical mucinous glandular proliferations in

For personal use only. No other uses without permission. Copyright ©2017. Elsevier Inc. All rights reserved.

endometrial samplings: follow-up and other clinicopathologic findings in 41 cases. *Hum Pathol*. 2017;63:53-62.
190. Lehman MB, Hart WR. Simple and complex hyperplastic papillary proliferations of the endometrium: a clinicopathologic study of nine cases of apparently localized papillary lesions with fibrovascular stromal cores and epithelial metaplasia. *Am J Surg Pathol*. 2001;25:1347-1354.
191. Ip PP, Irving JA, McCluggage WG, et al. Papillary proliferation of the endometrium: a clinicopathologic study of 59 cases of simple and complex papillae without cytologic atypia. *Am J Surg Pathol*. 2013;37:167-177.
192. Parra-Herran CE, Monte NM, Mutter GL. Endometrial intraepithelial neoplasia with secretory differentiation: diagnostic features and underlying mechanisms. *Mod Pathol*. 2013;26:68-73.
193. Mitchard J, Hirschowitz L. Concordance of FIGO grade of endometrial adenocarcinomas in biopsy and hysterectomy specimens. *Histopathology*. 2003;42:372-378.
194. Talhouk A, Hoang LN, McConechy MK, et al. Molecular classification of endometrial carcinoma on diagnostic specimens is highly concordant with final hysterectomy: Earlier prognostic information to guide treatment. *Gynecol Oncol*. 2016;143:46-53.
195. Unger ZM, Gonzalez JL, Hanissian PD, Schned AR. Pseudolipomatosis in hysteroscopically resected tissues from the gynecologic tract: pathologic description and frequency. *Am J Surg Pathol*. 2009;33:1187-1190.
196. Dubé V, Macdonald D, Allingham-Hawkins DJ, et al. Vanishing endometrial carcinoma. *Int J Gynecol Pathol*. 2007;26:271-277.
197. Sakhdari A, Moghaddam PA, Liu Y. Endometrial samples from postmenopausal women: a proposal for adequacy criteria. *Int J Gynecol Pathol*. 2016;35:525-530.
198. Mittal K, Da Costa D. Endometrial hyperplasia and carcinoma in endometrial polyps: clinicopathologic and follow-up findings. *Int J Gynecol Pathol*. 2008;27:45-48.
199. Creagh TM, Krausz T, Flanagan AM. Atypical stromal cells in a hyperplastic endometrial polyp. *Histopathology*. 1995;27:386-387.
200. Tai LH, Tavassoli FA. Endometrial polyps with atypical (bizarre) stromal cells. *Am J Surg Pathol*. 2002;26:505-509.
201. Corley D, Rowe J, Curtis MT, et al. Postmenopausal bleeding from unusual endometrial polyps in women on chronic tamoxifen therapy. *Obstet Gynecol*. 1992;79:111-116.
202. Reference deleted in proofs.
203. Schlesinger C, Kamoi S, Ascher SM, et al. Endometrial polyps: a comparison study of patients receiving tamoxifen with two control groups. *Int J Gynecol Pathol*. 1998;17:302-311.
204. Gilks CB, Clement PB, Hart WR, Young RH. Uterine adenomyomas excluding atypical polypoid adenomyomas and adenomyomas of endocervical type: a clinicopathologic study of 30 cases of an underemphasized lesion that may cause diagnostic problems with brief consideration of adenomyomas of other female genital tract sites. *Int J Gynecol Pathol*. 2000;19:195-205.
205. Heatley MK. Atypical polypoid adenomyoma: a systematic review of the English literature. *Histopathology*. 2006;48:609-610.
206. Mazur MT. Atypical polypoid adenomyomas of the endometrium. *Am J Surg Pathol*. 1981;5:473-482.
207. Tahlan A, Nanda A, Mohan H. Uterine adenomyoma: a clinicopathologic review of 26 cases and a review of the literature. *Int J Gynecol Pathol*. 2006;25:361-365.
208. Young RH, Treger T, Scully RE. Atypical polypoid adenomyoma of the uterus. A report of 27 cases. *Am J Clin Pathol*. 1986;86:139-145.
209. Clement PB, Young RH. Atypical polypoid adenomyoma of the uterus associated with Turner's syndrome. A report of three cases, including a review of 'estrogen-associated' endometrial neoplasms and neoplasms associated with Turner's syndrome. *Int J Gynecol Pathol*. 1987;6:104-113.
210. Longacre TA, Chung MH, Rouse RV, Hendrickson MR. Atypical polypoid adenomyofibromas (atypical polypoid adenomyomas) of the uterus: a clinicopathologic study of 55 cases. *Am J Surg Pathol*. 1996;20:1-20.
211. Ota S, Catasus L, Matius-Guiu X, et al. Molecular pathology of atypical polypoid adenomyoma of the uterus. *Hum Pathol*. 2003;34:784-788.
212. Voigt LF, Weiss NS. Epidemiology of endometrial cancer. *Cancer Treat Res*. 1989;49:1-21.
213. Rose PG. Endometrial carcinoma. *N Engl J Med*. 1996;335:640-649.
214. Schammel DP, Mittal KR, Kaplan K, et al. Endometrial adenocarcinoma associated with intrauterine pregnancy: a report of five cases and a review of the literature. *Int J Gynecol Pathol*. 1998;17:327-335.
215. de Jonge MM, Mooyaart AL, Vreeswijk MP, et al. Linking uterine serous carcinoma to BRCA1/2-associated cancer syndrome: a meta-analysis and case report. *Eur J Cancer*. 2017;72:215-225.
216. Hafezi S, Nofech-Mozes S, Ismiil N, et al. Endometrioid endometrial adenocarcinoma (EEA) in elderly women: a clinic-pathologic study. *Lab Invest*. 2009;89(suppl 1): 216A.
217. Bokhman JV. Two pathogenetic types of endometrial carcinoma. *Gynecol Oncol*. 1983;15:10-17.
218. Gusberg SB. The changing nature of endometrial cancer. *N Engl J Med*. 1980;302:709-732.
219. Silverberg SG. The endometrium. *Arch Pathol Lab Med*. 2007;131:372-382.
220. Geisler HE, Huber CP, Rogers S. Carcinoma of the endometrium in premenopausal women. *Am J Obstet Gynecol*. 1969;104:657-663.
221. Robboy SJ, Miller AW III, Kurman RJ. The pathologic features and behavior of endometrial carcinoma associated with exogenous estrogen administration. *Pathol Res Pract*. 1982;174:237-256.
222. Shapiro S, Kelly JP, Rosenberg L, et al. Risk of localized and widespread endometrial cancer in relation to recent and discontinued use of conjugated estrogens. *N Engl J Med*. 1985;313:969-972.
223. The Cancer Genome Atlas Research, N, Kandoth C, Schultz N, et al. Integrated genomic characterization of endometrial carcinoma. *Nature*. 2013;497:67-73.
224. Church DN, Stelloo E, Nout RA, et al. Prognostic significance of POLE proofreading mutations in endometrial cancer. *J Natl Cancer Inst*. 2015;107:402.
225. Hussein YR, Weigelt B, Levine DA, et al. Clinicopathological analysis of endometrial carcinomas harboring somatic POLE exonuclease domain mutations. *Mod Pathol*. 2015;28:505-514.
226. Meng B, Hoang LN, McIntyre JB, et al. POLE exonuclease domain mutation predicts long progression-free survival in grade 3 endometrioid carcinoma of the endometrium. *Gynecol Oncol*. 2014;134:15-19.
227. Stelloo E, Nout RA, Naves LC, et al. High concordance of molecular tumor alterations between pre-operative curettage and hysterectomy specimens in patients with endometrial carcinoma. *Gynecol Oncol*. 2014;133:197-204.
228. Stelloo E, Bosse T, Nout RA, et al. Refining prognosis and identifying targetable pathways for high-risk endometrial cancer; a TransPORTEC initiative. *Mod Pathol*. 2015;28:836-844.
229. Stelloo E, Nout RA, Osse EM, et al. Improved risk assessment by integrating molecular and clinicopathological factors in early-stage endometrial cancer-combined analysis of the PORTEC cohorts. *Clin Cancer Res*. 2016;22:4215-4524.
230. Talhouk A, McConechy MK, Leung S, et al. A clinically applicable molecular-based classification for endometrial cancers. *Br J Cancer*. 2015;113:299-310.
231. Reference deleted in proofs.
232. Talhouk A, McConechy MK, Leung S, et al. Confirmation of ProMisE: A simple, genomics-based clinical classifier for endometrial cancer. *Cancer*. 2017;123:802-813.
233. Carcangiu ML, Radice P, Casalini P, et al. Lynch syndrome—related endometrial carcinomas show a high frequency of nonendometrioid types and of high FIGO grade endometrioid types. *Int J Surg Pathol*. 2010;18:21-26.
234. Chui MH, Ryan P, Radigan J, et al. The histomorphology of Lynch syndrome-associated ovarian carcinomas: toward a subtype-specific screening strategy. *Am J Surg Pathol*. 2014;38:1173-1181.
235. Garg K, Soslow RA. Lynch syndrome (hereditary non-polyposis colorectal cancer) and endometrial carcinoma. *J Clin Pathol*. 2009;62:679-684.
236. Sloan EA, Moskaluk CA, Mills AM. Mucinous differentiation with tumor infiltrating lymphocytes is a feature of sporadically methylated endometrial carcinomas. *Int J Gynecol Pathol*. 2016;[Epub ahead of print].
237. Bakhsh S, Kinloch M, Hoang LN, et al. Histopathological features of endometrial carcinomas associated with POLE mutations: implications for decisions about adjuvant therapy. *Histopathology*. 2016;68:916-924.
238. Hachisuga T, Fukuda K, Iwasaka T, et al. Endometrial adenocarcinomas of the uterine corpus in women younger than 50 years of age can be divided into two distinct clinical and pathologic entities based on anatomic location. *Cancer*. 2001;92:2578-2584.
239. Jacques SM, Qureshi F, Ramirez NC, et al. Tumors of uterine isthmus: clinicopathologic features and immunohistochemical characterization of p53 expression and hormone receptors. *Int J Gynecol Pathol*. 1997;16:38-44.
240. Zaino RJ, Kurman RJ, Diana KL, Morrow CP. The utility of the revised International Federation of Gynecology and Obstetrics histologic grading of endometrial adenocarcinoma using a defined nuclear grading system. A Gynecologic Oncology Group study. *Cancer*. 1995;75:81-86.
241. Parkash V, Carcangiu ML. Endometrioid endometrial adenocarcinoma with psammoma bodies. *Am J Surg Pathol*. 1997;21:399-406.
242. Rabban JT, Zaloudek CJ. Minimal uterine serous carcinoma: current concepts in diagnosis and prognosis. *Pathology*. 2007;39:125-133.
243. Gospel C. Ultrastructure of endometrial carcinoma. Review of fourteen cases. *Cancer*. 1971;28:745-754.
244. Clement PB, Young RH. Endometrioid carcinomas of the uterine corpus: a review of its pathology with emphasis on recent advances and problematic aspects. *Adv Anat Pathol*. 2002;9:145-184.
245. Esteller M, Garcia A, Martinez-Palones JM, et al. Clinicopathologic features and genetic

For personal use only. No other uses without permission. Copyright ©2017. Elsevier Inc. All rights reserved.

alterations in endometrioid carcinoma of the uterus with villoglandular differentiation. *Am J Clin Pathol*. 1999;111:336-342.
246. Zaino RJ, Kurman RJ, Brunetto VL, et al. Villoglandular adenocarcinoma of the endometrium: a clinicopathologic study of 61 cases: a Gynecologic Oncology Group Study. *Am J Surg Pathol*. 1998;22:1379-1385.
247. Murray SK, Young RH, Scully RE. Uterine endometrioid carcinoma with small nonvillous papillae: an analysis of 26 cases of a favourable-prognosis tumor to be distinguished from serous carcinoma. *Int J Surg Pathol*. *2001*;8:279-289.
248. Jacques SM, Qureshi F, Lawrence WD. Surface epithelial changes in endometrial adenocarcinoma. Diagnostic pitfalls in curettage specimens. *Int J Gynecol Pathol*. 1995;14:191-197.
249. Isaacson PG, Pilot LM Jr. Gooselaw JG. Foam cells in the stroma in carcinoma of the endometrium. *Obstet Gynecol*. 1964;23:9-11.
250. Silver SA, Sherman ME. Morphologic and immunophenotypic characterization of foam cells in endometrial lesions. *Int J Gynecol Pathol*. 1998;17:140-145.
251. Risberg B, Grontoft O, Westholm B. Origin of carcinoma in secretory endometrium—a study using a whole-organ sectioning technique. *Gynecol Oncol*. 1983;15:32-41.
252. Reference deleted in proofs.
253. Nofech-Mozes S, Ghorab Z, Ismiil N, et al. Endometrial endometrioid adenocarcinoma: a pathologic analysis of 827 consecutive cases. *Am J Clin Pathol*. 2008;129:110-114.
254. Jacques SM, Lawrence WD. Endometrial adenocarcinoma with variable-level myometrial involvement limited to adenomyosis. A clinicopathologic study of 23 cases. *Gynecol Oncol*. 1990;37:401-407.
255. Hall JB, Young RH, Nelson JH. The prognostic significance of adenomyosis in endometrial carcinoma. *Gynecol Oncol*. 1984;17:32-40.
256. Nascimento AF, Hirsch MS, Cviko A, et al. The role of CD10 staining in distinguishing invasive endometrial adenocarcinoma from adenocarcinoma involving adenomyosis. *Mod Pathol*. 2003;16:22-27.
257. Srodon M, Klein WM, Kurman RJ. CD10 immunostaining does not distinguish endometrial carcinoma invading myometrium from carcinoma involving adenomyosis. *Am J Surg Pathol*. 2003;27:786-789.
258. Frauenhoffer EE, Zaino RJ, Wolff TV, Whitney CE. Value of endocervical curettage in the staging of endometrial carcinoma. *Int J Gynecol Pathol*. 1987;6:195-202.
259. Larson DM, Copeland LJ, Gallagher HS, et al. Nature of cervical involvement in endometrial carcinoma. *Cancer*. 1987;59:959-962.
260. Zaino RJ, Abendroth C, Yemelyanova A, et al. Endocervical involvement in endometrial adenocarcinoma is not prognostically significant and the pathologic assessment of the pattern of involvement is not reproducible. *Gynecol Oncol*. 2013;128:83-87.
261. Zaino RJ, Kurman R, Herbold D, et al. The significance of squamous differentiation in endometrial carcinoma. Data from a Gynecologic Oncology Group study. *Cancer*. 1991;68:2293-2302.
262. Christopherson WM, Alberhasky RC, Connelly PJ. Glassy cell carcinoma of the endometrium. *Hum Pathol*. 1982;13:418-421.
263. Hachisuga T, Sugimori H, Kaku T, et al. Glassy cell carcinoma of the endometrium. *Gynecol Oncol*. 1990;36:134-138.
264. Murray SK, Clement PB, Young RH. Endometrioid carcinomas of the uterine corpus with sex cord-like formations, hyalinization, and other unusual morphologic features: a report of 31 cases of a neoplasm that may be confused with carcinosarcoma and other uterine neoplasms. *Am J Surg Pathol*. 2005;29:157-166.
265. Murray SK, Young RH, Scully RE. Unusual epithelial and stromal changes in myoinvasive endometrioid adenocarcinoma: a study of their frequency, associated diagnostic problems, and prognostic significance. *Int J Gynecol Pathol*. 2003 Oct;22(4):324-333.
266. Altunpulluk MD, Kir G, Topal CS, et al. The association of the microcystic, elongated and fragmented (MELF) invasion pattern in endometrial carcinomas with deep myometrial invasion, lymphovascular space invasion and lymph node metastasis. *J Obstet Gynaecol*. 2014;35(4):397-402.
267. McKenney JK, Kong CS, Longacre TA. Endometrial adenocarcinoma associated with subtle lymph-vascular space invasion and lymph node metastasis: a histologic pattern mimicking intravascular and sinusoidal histiocytes. *Int J Gynecol Pathol*. 2005;24(1):73-78.
268. Hertel JD, Huettner PC, Pfeifer JD. Lymphovascular space invasion in microcystic elongated and fragmented (MELF)-pattern well-differentiated endometrioid adenocarcinoma is associated with a higher rate of lymph node metastasis. *Int J Gynecol Pathol*. 2014;33(2):127-134.
269. Tobon H, Watkins GJ. Secretory adenocarcinoma of the endometrium. *Int J Gynecol Pathol*. 1985;4:328-335.
270. Christopherson WM, Alberhasky RC, Connelly PJ. Carcinoma of the endometrium. I. A clinicopathologic study of clear cell carcinoma and secretory carcinoma. *Cancer*. 1982;49:1511-1523.
271. Kurman RJ, Scully RE. Clear cell carcinoma of the endometrium. An analysis of 21 cases. *Cancer*. 1976;37:872-882.
272. Silva EG, Young RH. Endometrioid neoplasms with clear cells: a report of 21 cases in which the alteration is not of typical secretory type. *Am J Surg Pathol*. 2007;31:1203-1208.
273. Melhem MF, Tobon H. Mucinous adenocarcinoma of the endometrium. A clinico-pathological review of 18 cases. *Int J Gynecol Pathol*. 1987;6:347-355.
274. Alkushi A, Irving J, Hsu F, et al. Immunoprofile of cervical and endometrial adenocarcinomas using a tissue microarray. *Virchows Arch*. 2003;442:271-277.
275. Ansari-Lari MA, Staebler A, Zaino RJ, et al. Distinction of endocervical and endometrial adenocarcinomas: immunohistochemical p16 expression correlated with human papillomavirus (HPV) DNA detection. *Am J Surg Pathol*. 2004;28:160-167.
276. Zaloudek C, Hayashi GM, Ryan IP, et al. Microglandular adenocarcinoma of the endometrium: a form of mucinous adenocarcinoma that may be confused with microglandular hyperplasia of the cervix. *Int J Gynecol Pathol*. 1997;16:52-59.
277. Zheng W, Liang SX, Yu H, et al. Endometrial glandular dysplasia: a newly defined precursor lesion of uterine papillary serous carcinoma. Part I: morphologic features. *Int J Surg Pathol*. 2004;12:207-223.
278. Gitsch G, Friedlander ML, Wain GV, Hacker NF. Uterine papillary serous carcinoma. A clinical study. *Cancer*. 1995;75:2239-2243.
279. Hendrickson M, Ross J, Eifel P, et al. Uterine papillary serous carcinoma. A highly malignant form of endometrial adenocarcinoma. *Am J Surg Pathol*. 1982;6:93-108.
280. Jeffrey JF, Krepart GV, Lotocki RJ. Papillary serous adenocarcinoma of the endometrium. *Obstet Gynecol*. 1986;67:670-674.
281. Deligdisch L, Gil J, Heller D, Cohen CJ. Two types of endometrial papillary neoplasm. A morphometric study. *Pathol Res Pract*. 1992;188:473-477.
282. Kuebler DL, Nikrui N, Bell DA. Cytologic features of endometrial papillary serous carcinoma. *Acta Cytol*. 1989;33:120-126.
283. Darvishian F, Hummer AJ, Thaler HT, et al. Serous endometrial cancers that mimic endometrioid adenocarcinomas: a clinicopathologic and immunohistochemical study of a group of problematic cases. *Am J Surg Pathol*. 2004;28:1568-1578.
284. Carcangiu ML, Chambers JT. Uterine papillary serous carcinoma. A study on 108 cases with emphasis on the prognostic significance of associated endometrioid carcinoma, absence of invasion, and concomitant ovarian carcinoma. *Gynecol Oncol*. 1992;47:298-305.
285. Carcangiu ML, Tan LK, Chambers JT. Stage 1A uterine serous carcinoma: a study of 13 cases. *Am J Surg Pathol*. 1998;21:1507-1514.
286. Dotto J, Tavassoli FA. Serous intraepithelial carcinoma arising in an endometrial polyp: a proposal for modification of terminology. *Int J Surg Pathol*. 2008;16:8-10.
287. Hui P, Kelly M, O'Malley DM, et al. Minimal uterine serous carcinoma: a clinicopathological study of 40 cases. *Mod Pathol*. 2005;18:75-82.
288. Sherman ME, Bitterman P, Rosenshein NB, et al. Uterine serous carcinoma. A morphologically diverse neoplasm with unifying clinicopathologic features. *Am J Surg Pathol*. 1992;16:600-610.
289. Silva EG, Jenkins R. Serous carcinoma in endometrial polyps. *Mod Pathol*. 1990;3:120-128.
290. Trahan S, Têtu B, Raymond PE. Serous papillary carcinoma of the endometrium arising from endometrial polyps: a clinical, histological, and immunohistochemical study of 13 cases. *Hum Pathol*. 2005;36:1316-1321.
291. Wheeler DT, Bell KA, Kurman RJ, Sherman ME. Minimal uterine serous carcinoma: diagnosis and clinicopathologic correlation. *Am J Surg Pathol*. 2000;24:797-806.
292. Euscher ED, Malpica A, Deavers MT, Silva EG. Differential expression of WT-1 in serous carcinomas in the peritoneum with or without associated serous carcinoma in endometrial polyps. *Am J Surg Pathol*. 2005;29:1074-1078.
293. Kommoss F, Faruqi A, Gilks CB, et al. Uterine serous carcinomas frequently metastasize to the fallopian tube and can mimic serous tubal intraepithelial carcinoma. *Am J Surg Pathol*. 2017;41:161-170.
294. Liang SX, Chambers SK, Cheng L, et al. Endometrial glandular dysplasia: a putative precursor lesion of uterine papillary serous carcinoma. Part II: molecular features. *Int J Surg Pathol*. 2004;12:319-331.
295. Zheng W, Liang SX, Yi X, et al. Occurrence of endometrial glandular dysplasia precedes uterine papillary serous carcinoma. *Int J Gynecol Pathol*. 2007;26:38-52.
296. Garg K, Leitao MM Jr, Wynveen CA, et al. p53 overexpression in morphologically ambiguous endometrial carcinomas correlates with adverse clinical outcomes. *Mod Pathol*. 2010;23:80-92.
297. Chumas JC, Mann WJ, Tseng L. Malignant mixed müllerian tumor of the endometrium in a young woman with polycystic ovaries. *Cancer*. 1983;52:1478-1481.
298. Silverberg SG, Major FJ, Blessing JA, et al. Carcinosarcoma (malignant mixed mesodermal tumor) of the uterus. A Gynecologic Oncology Group pathologic study of 203 cases. *Int J Gynecol Pathol*. 1990;9:1-19.
299. Gersell DJ, Duncan DA, Fulling KH. Malignant mixed müllerian tumor of the uterus with neuroectodermal differentiation. *Int J Gynecol Pathol*. 1989;8:169-178.
300. Yorokoglu K, Aktas S, Gore O, Ozen E. Malignant mixed mullerian tumor of the

For personal use only. No other uses without permission. Copyright ©2017. Elsevier Inc. All rights reserved.

uterus with prominent neuroectodermal differentiation: a case report. *Int J Surg Pathol*. 1998;6:155-158, 375.
301. Amant F, Moerman P, Davel GH, et al. Uterine carcinosarcoma with melanocytic differentiation. *Int J Gynecol Pathol*. 2001;20:186-190.
302. Shokeir MO, Noel SM, Clement PB. Malignant Müllerian mixed tumor of the uterus with a prominent alpha-fetoprotein-producing component of yolk sac tumor. *Mod Pathol*. 1996;9:647-651.
303. Mount SL, Lee KR, Taatjes DJ. Carcinosarcoma (malignant mixed müllerian tumor) of the uterus with a rhabdoid tumor component. An immunohistochemical, ultrastructural, and immunoelectron microscopic case study. *Am J Clin Pathol*. 1995;103:235-239.
304. George E, Manivel JC, Dehner LP, Wick MR. Malignant mixed müllerian tumors. An immunohistochemical study of 47 cases, with histogenetic considerations and clinical correlation. *Hum Pathol*. 1991;22:215-223.
305. McConechy MK, Ding J, Cheang MC, et al. Use of mutation profiles to refine the classification of endometrial carcinomas. *J Pathol*. 2012;228:20-30.
306. George E, Lillemoe TJ, Twiggs LB, Perrone T. Malignant mixed müllerian tumor versus high-grade endometrial carcinoma and aggressive variants of endometrial carcinoma. A comparative analysis of survival. *Int J Gynecol Pathol*. 1995;14:39-44.
307. Ferguson SE, Tornos C, Hummer A, et al. Prognostic features of surgical stage I uterine carcinosarcoma. *Am J Surg Pathol*. 2007;31:1653-1661.
308. Norris HJ, Roth E, Taylor HB. Mesenchymal tumors of the uterus. II. A clinical and pathologic study of 31 mixed mesodermal tumors. *Obstet Gynecol*. 1966;28:57-63.
309. Norris NJ, Taylor HB. Mesenchymal tumors of the uterus. III. A clinical and pathologic study of 31 carcinosarcomas. *Cancer*. 1966;19:1459-1465.
310. Schaepman-van Geuns EJ. Mixed tumors and carcinosarcomas of the uterus evaluated five years after treatment. *Cancer*. 1970;25:72-77.
311. Chuang JT, Van Velden DJJ, Graham JB. Carcinosarcoma and mixed mesodermal tumor of the uterine corpus. Review of 49 cases. *Obstet Gynecol*. 1970;35:769-780.
312. Gagne E, Tetu B, Blondeau L, et al. Morphologic prognostic factors of malignant mixed müllerian tumor of the uterus. A clinicopathologic study of 58 cases. *Mod Pathol*. 1989;2:433-438.
313. Spanos WJ, Wharton JT, Gomez L, et al. Malignant mixed müllerian tumors of the uterus. *Cancer*. 1984;53:311-316.
314. Norris HJ, Taylor HB. Postirradiation sarcomas of the uterus. *Obstet Gynecol*. 1965;26:689-694.
315. Varela-Duran J, Nochomovitz LE, Prem KA, Dehner LP. Postirradiation mixed müllerian tumors of the uterus. A comparative clinicopathologic study. *Cancer*. 1980;45:1625-1631.
316. Matias-Guiu X, Lerma E, Prat J. Clear cell tumors of the female genital tract. *Semin Diagn Pathol*. 1998;14:233-239.
317. Lax SF, Pizer ES, Ronnett BM, Kurman RJ. Clear cell carcinoma of the endometrium is characterized by a distinctive profile of p53, Ki-67, estrogen, and progesterone receptor expression. *Hum Pathol*. 1998;29:551-558.
318. Rorat E, Ferenczy A, Richart RM. The ultrastructure of clear cell adenocarcinoma of endometrium. *Cancer*. 1974;33:880-887.
319. Roth LM. Clear-cell adenocarcinoma of the female genital tract. A light and electron microscopic study. *Cancer*. 1974;33:990-1001.
320. Vang R, Whitaker BP, Farhood AI, et al. Immunohistochemical analysis of clear cell carcinoma of the gynecologic tract. *Int J Gynecol Pathol*. 2001;20:252-259.
321. Pitman MB, Young RH, Clement PB, et al. Endometrioid carcinoma of the ovary and endometrium, oxyphilic cell type. A report of nine cases. *Int J Gynecol Pathol*. 1994;13:290-301.
322. Fadare O, Liang SX, Ulukus EC, et al. Precursors of endometrial clear cell carcinoma. *Am J Surg Pathol*. 2006;30:1519-1530.
323. Silva EG, Deavers MT, Malpica A. Undifferentiated carcinoma of the endometrium: a review. *Pathology*. 2007;39:134-138.
324. Abeler VM, Kjorstad KE, Nesland JM. Undifferentiated carcinoma of the endometrium. A histopathologic and clinical study of 31 cases. *Cancer*. 1991;68:98-105.
325. Altrabulsi B, Malpica A, Deavers MT, et al. Undifferentiated carcinoma of the endometrium. *Am J Surg Pathol*. 2005;29:1316-1321.
326. Tafe LJ, Garg K, Chew I, et al. Endometrial and ovarian carcinomas with undifferentiated components: clinically aggressive and frequently underrecognized neoplasms. *Mod Pathol*. 2010;23:781-789.
327. Coatham M, Li X, Karnezis AN, et al. Concurrent ARID1A and ARID1B inactivation in endometrial and ovarian dedifferentiated carcinomas. *Mod Pathol*. 2016;29:1586-1593.
328. Hoang LN, Lee YS, Karnezis AN, et al. Immunophenotypic features of dedifferentiated endometrial carcinoma—insights from BRG1/INI1-deficient tumours. *Histopathology*. 2016;69:560-569.
329. Karnezis AN, Hoang LN, Coatham M, et al. Loss of switch/sucrose non-fermenting complex protein expression is associated with dedifferentiation in endometrial carcinomas. *Mod Pathol*. 2016;29:302-314.
330. Albores-Saavedra J, Martinez-Benitez B, Luevano E. Small cell carcinomas and large cell neuroendocrine carcinomas of the endometrium and cervix: polypoid tumors and those arising in polyps may have a favorable prognosis. *Int J Gynecol Pathol*. 2008;27:333-339.
331. Huntsman DG, Clement PB, Gilks CB, Scully RE. Small-cell carcinoma of the endometrium. A clinicopathological study of sixteen cases. *Am J Surg Pathol*. 1994;18:364-375.
332. Paz RA, Frigerio B, Sundblad AS, Eusebi V. Small-cell (oat cell) carcinoma of the endometrium. *Arch Pathol Lab Med*. 1985;109:270-272.
333. Shaco-Levy R, Manor E, Piura B, Ariel I. An unusual composite endometrial tumor combining papillary serous carcinoma and small cell carcinoma. *Am J Surg Pathol*. 2004;28:1103-1106.
334. van Hoeven KH, Hudock JA, Woodruff JM, Suhrland MJ. Small cell neuroendocrine carcinoma of the endometrium. *Int J Gynecol Pathol*. 1995;14:21-29.
335. Mulvany NJ, Allen DG. Combined large cell neuroendocrine and endometrioid carcinoma of the endometrium. *Int J Gynecol Pathol*. 2008;27:49-57.
336. Bannatyne P, Russell P, Wills EJ. Argyrophilia and endometrial carcinoma. *Int J Gynecol Pathol*. 1983;2:235-254.
337. Sivridis E, Buckley CH, Fox H. Argyrophil cells in normal, hyperplastic, and neoplastic endometrium. *J Clin Pathol*. 1984;37:378-381.
338. Aguirre P, Scully RE, Wolfe HJ, DeLellis RA. Endometrial carcinoma with argyrophil cells. A histochemical and immunohistochemical analysis. *Hum Pathol*. 1984;15:210-217.
339. Inoue M, DeLellis RA, Scully RE. Immunohistochemical demonstration of chromogranin in endometrial carcinomas with argyrophil cells. *Hum Pathol*. 1986;17:841-847.
340. Abeler V, Kjorstad KE. Endometrial squamous cell carcinoma. Report of three cases and review of the literature. *Gynecol Oncol*. 1990;36:321-326.
341. Jeffers MD, McDonald GS, McGuinness EP. Primary squamous cell carcinoma of the endometrium. *Histopathology*. 1991;19:177-179.
342. Peison B, Benisch B, Fox H. Invasive keratinising squamous cell carcinoma of the endometrium as extension of invasive cervical squamous cell carcinoma. *Int J Surg Pathol*. 1997;4:189-192.
343. Hopkin ID, Harlow RA, Stevens PJ. Squamous carcinoma of the body of the uterus. *Br J Cancer*. 1970;24:71-76.
344. Yamashina M, Kobara TY. Primary squamous cell carcinoma with its spindle cell variant in the endometrium. A case report and review of literature. *Cancer*. 1986;57:340-345.
345. Ryder DE. Verrucous carcinoma of the endometrium—a unique neoplasm with long survival. *Obstet Gynecol*. 1982;59:78S-80S.
346. Jones MA, Young RH, Scully RE. Endometrial adenocarcinoma with a component of giant cell carcinoma. *Int J Gynecol Pathol*. 1991;10:260-270.
347. Mulligan AM, Plotkin A, Rouzbahman M, et al. Endometrial giant cell carcinoma: a case series and review of the spectrum of endometrial neoplasms containing giant cells. *Am J Surg Pathol*. 2010;34:1132-1138.
348. Kalir T, Seijo L, Deligdisch L, Cohen C. Endometrial adenocarcinoma with choriocarcinomatous differentiation in an elderly virginal woman. *Int J Gynecol Pathol*. 1995;14:266-269.
349. McNamee T, Damato S, McCluggage WG. Yolk sac tumours of the female genital tract in older adults derive commonly from somatic epithelial neoplasms: somatically derived yolk sac tumours. *Histopathology*. 2016;69:739-751.
350. Pesce C, Merino MJ, Chambers JT, Nogales F. Endometrial carcinoma with trophoblastic differentiation. An aggressive form of uterine cancer. *Cancer*. 1991;68:1799-1802.
351. Tran TA, Ortiz HB, Holloway RW, et al. Alpha-fetoprotein-producing serous carcinoma of the uterus metastasizing to the ovaries, mimicking primary ovarian yolk sac tumor: a case report and review of the literature. *Int J Gynecol Pathol*. 2007;26:66-70.
352. Eichhorn JH, Young RH, Clement PB. Sertoliform endometrial adenocarcinoma: a study of four cases. *Int J Gynecol Pathol*. 1996;15:119-126.
353. Usadi RS, Bentley RC. Endometrioid carcinoma of the endometrium with sertoliform differentiation. *Int J Gynecol Pathol*. 1995;14:360-364.
354. Hoshida Y, Nagakawa T, Mano S, et al. Hepatoid adenocarcinoma of the endometrium associated with alpha-fetoprotein production. *Int J Gynecol Pathol*. 1997;15:266-269.
355. Mooney EE, Robboy SJ, Hammond CB, et al. Signet-ring cell carcinoma of the endometrium: a primary tumor masquerading as a metastasis. *Int J Gynecol Pathol*. 1997;16:169-172.
356. Iezzoni GC, Mills SE. Nonneoplastic endometrial signet-ring cells. Vacuolated decidual cells and stromal histiocytes mimicking adenocarcinoma. *Am J Clin Pathol*. 2001;115:249-255.
357. Vargas MP, Merino MJ. Lymphoepitheliomalike carcinoma: an usual variant of endometrial cancer; a report of two cases. *Int J Gynecol Pathol*. 1998;17:272-276.

For personal use only. No other uses without permission. Copyright ©2017. Elsevier Inc. All rights reserved.

358. Gaertner EM, Farley JH, Taylor RR, Silver SA. Collision of uterine rhaboid tumor and endometrial adenocarcinoma: a case report and review of the literature. *Int J Gynecol Pathol*. 1999;18:396-401.
359. McFarland M, Quick CM, McCluggage WG. Hormone receptor-negative, thyroid transcription factor 1-positive uterine and ovarian adenocarcinomas: report of a series of mesonephric-like adenocarcinomas. *Histopathology*. 2016;68:1013-1020.
360. Ordi J, Nogales FF, Palacin A, et al. Mesonephric adenocarcinoma of the uterine corpus: CD10 expression as evidence of mesonephric differentiation. *Am J Surg Pathol*. 2001;25:1540-1545.
361. Wani Y, Notohara K, Tsukayama C. Mesonephric adenocarcinoma of the uterine corpus: a case report and review of the literature. *Int J Gynecol Pathol*. 2008;27:346-352.
362. Moll R, Levy R, Czernobilsky B, et al. Cytokeratins of normal epithelia and some neoplasms of the female genital tract. *Lab Invest*. 1983;49:599-610.
363. Moll R, Pitz S, Levy R, et al. Complexity of expression of intermediate filament proteins, including glial filament protein, in endometrial and ovarian adenocarcinomas. *Hum Pathol*. 1991;22:989-1001.
364. Dabbs DJ, Geisinger KR, Norris HT. Intermediate filaments in endometrial and endocervical carcinomas. The diagnostic utility of vimentin patterns. *Am J Surg Pathol*. 1986;10:568-576.
365. Dabbs DJ, Sturtz K, Zaino RJ. The immunohistochemical discrimination of endometrioid adenocarcinomas. *Hum Pathol*. 1996;27:172-177.
366. Tong GX, Devaraj K, Hamele-Bena D, et al. PAX8: a marker for carcinoma of Müllerian origin in serous effusions. *Diagn Cytopathol*. 2011;39(8):567-574.
367. Puts JJG, Moesker O, Aldeweireldt J, et al. Application of antibodies to intermediate filament proteins in simple and complex tumors of the female genital tract. *Int J Gynecol Pathol*. 1987;6:257-274.
368. Brustein S, Fruchter R, Greene GL, Pertschuk LP. Immunocytochemical assay of progesterone receptors in paraffin-embedded specimens of endometrial carcinoma and hyperplasia. A preliminary evaluation. *Mod Pathol*. 1989;2:449-455.
369. Reference deleted in proofs.
370. Reid-Nicholson M, Iyengar P, Hummer AJ, et al. Immunophenotypic diversity of endometrial adenocarcinomas: implications for differential diagnosis. *Mod Pathol*. 2006;19:1091-1100.
371. Demopoulos RI, Mesia AF, Mittal K, Vamvakas E. Immunohistochemical comparison of uterine papillary serous and papillary endometrioid carcinoma: clues to pathogenesis. *Int J Gynecol Pathol*. 2002;18:233-237.
372. Al-Hussaini M, Stockman A, Foster H, McCluggage WG. WT-1 assists in distinguishing ovarian from uterine serous carcinoma and in distinguishing between serous and endometrioid ovarian carcinoma. *Histopathology*. 2004;44:109-115.
373. Goldstein NS, Uzieblo A. WT1 immunoreactivity in uterine papillary serous carcinomas is different from ovarian serous carcinomas. *Am J Clin Pathol*. 2002;117:541-545.
374. McCluggage WG. WT1 is of value in ascertaining the site of origin of serous carcinomas within the female genital tract. *Int J Gynecol Pathol*. 2004;23:97-99.
375. Zhang PJ, Williams E, Pasha T, Acs G. WT1 is expressed in serous, but not in endometrioid, clear cell or mucinous carcinomas of the peritoneum, fallopian tube, ovaries and endometrium [abstract]. *Mod Pathol*. 2003;16:216a. (See also *Int J Gynecol Pathol* 2004;23:110-118).
376. Siami K, McCluggage WG, Ordonez NG, et al. Thyroid transcription factor-1 expression in endometrial and endocervical adenocarcinomas. *Am J Surg Pathol*. 2007;31:1759-1763.
377. Zhang PJ, Gao HG, Pasha TL, et al. TTF-1 expression in ovarian and uterine epithelial neoplasia and its potential significance, an immunohistochemical assessment with multiple monoclonal antibodies and different secondary detection systems. *Int J Gynecol Pathol*. 2009;28:10-18.
378. Reference deleted in proofs.
379. Reference deleted in proofs.
380. Reference deleted in proofs.
381. Reference deleted in proofs.
382. Ali IU. Gatekeeper for endometrium: the PTEN tumor suppressor gene. *J Natl Cancer Inst*. 2000;92:861-863.
383. Bussaglia E, del Rio E, Matias-Guiu X, Prat J. PTEN mutations in endometrial carcinomas: a molecular and clinicopathologic analysis of 38 cases. *Hum Pathol*. 2000;31:312-317.
384. Machin P, Catasus L, Pons C, et al. CTNNB1 mutations and beta-catenin expression in endometrial carcinoma. *Hum Pathol*. 2002;33:206-212.
385. Matias-Guiu X, Catasus L, Bussaglia E, et al. Molecular pathology of endometrial hyperplasia and carcinoma. *Hum Pathol*. 2001;32:569-577.
386. Tashiro H, Lax SF, Gaudin PB, et al. Microsatellite instability is uncommon in uterine serous carcinoma. *Am J Pathol*. 1997;150:75-79.
387. Reference deleted in proofs.
388. Tritz D, Pieretti M, Turner S, Powell D. Loss of heterozygosity in usual and special variant carcinomas of the endometrium. *Hum Pathol*. 1997;28:607-612.
389. Watanabe Y, Nakajima H, Nozaki K, et al. Clinicopathologic and immunohistochemical features and microsatellite status of endometrial cancer of the uterine isthmus. *Int J Gynecol Pathol*. 2001;20:368-373.
390. McConechy MK, Anglesio MS, Kalloger SE, et al. Subtype-specific mutation of PPP2R1A in endometrial and ovarian carcinomas. *J Pathol*. 2011;223:567-573.
391. Williams JW, Hirschowitz L. Assessment of uterine wall thickness and position of the vascular plexus in the deep myometrium: implications for the measurement of depth of myometrial invasion of endometrial carcinomas. *Int J Gynecol Pathol*. 2006;25:59-64.
392. Danielsen HE, Pradhan M, Novelli M. Revisiting tumour aneuploidy—the place of ploidy assessment in the molecular era. *Nat Rev Clin Oncol*. 2016;13:291-304.
393. Tambouret R, Clement PB, Young RH. Endometrial endometrioid adenocarcinoma with a deceptive pattern of spread to the uterine cervix. A manifestation of stage IIB endometrial carcinoma liable to be misinterpreted as an independent carcinoma or a benign lesion. *Am J Surg Pathol*. 2003;27:1080-1088.
394. Ali A, Black D, Soslow RA. Difficulties in assessing the depth of myometrial invasion in endometrial carcinoma. *Int J Gynecol Pathol*. 2007;26:115-123.
395. Ismiil N, Rasty G, Ghorab Z, et al. Adenomyosis involved by endometrial adenocarcinoma is a significant risk factor for deep myometrial invasion. *Ann Diagn Pathol*. 2007;11:252-257.
396. Bosse T, Peters EE, Creutzberg CL, et al. Substantial lymph-vascular space invasion (LVSI) is a significant risk factor for recurrence in endometrial cancer—a pooled analysis of PORTEC 1 and 2 trials. *Eur J Cancer*. 2015;51:1742-1750.
397. Boronow RC, Morrow CP, Creasman WT, et al. Surgical staging in endometrial cancer. Clinical–pathologic findings of a prospective study. *Obstet Gynecol*. 1984;63:825-832.
398. Creasman WI, Morrow CP, Bundy BN, et al. Surgical pathologic spread patterns of endometrial cancer. *Cancer*. 1987;60:2035-2041.
399. Kupryjanczyk J, Thor AD, Beauchamp R, et al. Ovarian, peritoneal, and endometrial serous carcinoma: clonal origin of multifocal disease. *Mod Pathol*. 1996;9:166-173.
400. Soslow RA, Pirog E, Isaacson C. Endometrial intraepithelial carcinoma with associated peritoneal carcinomatosis. *Am J Surg Pathol*. 2000;24:726-732.
401. Baergen RN, Warren CD, Isaacson C, Ellenson LH. Early uterine serous carcinoma: clonal origin of extrauterine disease. *Int J Gynecol Pathol*. 2001;20:214-219.
402. Reference deleted in proofs.
403. Snyder MJ, Bentley R, Robboy SJ. Transtubal spread of serous adenocarcinoma of the endometrium: an underrecognized mechanism of metastasis. *Int J Gynecol Pathol*. 2006;25:155-160.
404. Chen KTK, Kostich ND, Rosai J. Peritoneal foreign body granulomas to keratin in uterine adenoacanthoma. *Arch Pathol Lab Med*. 1978;102:174-177.
405. Kim KR, Scully RE. Peritoneal keratin granulomas with carcinomas of endometrium and ovary and atypical polypoid adenomyoma of endometrium. A clinicopathological analysis of 22 cases. *Am J Surg Pathol*. 1990;14:925-932.
406. Young RH, Johnston WH. Serous adenocarcinoma of the uterus metastatic to the urinary bladder mimicking primary bladder neoplasia. A report of a case. *Am J Surg Pathol*. 1990;14:877-880.
407. Singh N. Synchronous tumours of the female genital tract. *Histopathology*. 2010;56:277-285.
408. Scully RE, Young RH, Clement PB. *Tumors of the Ovary, Maldeveloped Gonads, Fallopian Tube and Broad Ligament. Atlas of Tumor Pathology*. Bethesda, MD: Armed Forces Institute of Pathology; 1998.
409. Heitz F, Amant F, Fotopoulou C, et al. Synchronous ovarian and endometrial cancer—an international multicenter case-control study. *Int J Gynecol Cancer*. 2014;24:54-60.
410. Ligon AH, Morton CC. Genetics of uterine leiomyomata. *Genes Chromosomes Cancer*. 2000;28:235-245.
411. Anglesio MS, Wang YK, Maassen M, et al. Synchronous endometrial and ovarian carcinomas: evidence of clonality. *J Natl Cancer Inst*. 2016;108:djv428.
412. Schultheis AM, Ng CK, De Filippo MR, et al. Massively parallel sequencing-based clonality analysis of synchronous endometrioid endometrial and ovarian carcinomas. *J Natl Cancer Inst*. 2016;108:djv427.
413. Culton LK, Deavers MT, Silva EG, et al. Endometrioid carcinoma simultaneously involving the uterus and the fallopian tube: a clinicopathologic study of 13 cases. *Am J Surg Pathol*. 2006;30:844-849.
414. Reference deleted in proofs.
415. Sonoda Y. Optimal therapy and management of endometrial cancer. *Expert Rev Anticancer Ther*. 2003;3:37-47.
416. Tewari KS, DiSaia PJ. Radiation therapy for gynecologic cancer. *J Obstet Gynaecol Res*. 2003;28:123-140.
417. Kong A, Johnson N, Kitchener HC, Lawrie TA. Adjuvant radiotherapy for stage I endometrial

For personal use only. No other uses without permission. Copyright ©2017. Elsevier Inc. All rights reserved.

cancer. *Cochrane Database Syst Rev*. 2012;(18):CD003916.
418. Baekelandt M. Hormonal treatment of endometrial carcinoma. *Expert Rev Anticancer Ther*. 2002;2:106-112.
419. Kim YB, Holschneider CH, Ghosh K, et al. Progestin alone as primary treatment of endometrial carcinoma in premenopausal women: report of seven cases and review of the literature. *Cancer*. 1997;79:320-327.
420. Wheeler DT, Bristow RE, Kurman RJ. Histologic alterations in endometrial hyperplasia and well-differentiated carcinoma treated with progestins. *Am J Surg Pathol*. 2007;31:988-998.
421. Frank AH, Tseng PC, Haffty BG, et al. Adjuvant whole-abdominal radiation therapy in uterine papillary serous carcinoma. *Cancer*. 1991;68:1516-1519.
422. Levine DA, Hoskins WJ. Update in the management of endometrial cancer. *Cancer J*. 2002;8:S31-S40.
423. Lim P, Al Kushi A, Gilks B, et al. Early stage uterine papillary serous carcinoma of the endometrium: effect of adjuvant whole abdominal radiotherapy and pathologic parameters and outcome. *Cancer*. 2001;91:752-757.
424. Price FV, Chambers SK, Carcangiu ML, et al. Intravenous cisplatin, doxorubicin, and cyclophosphamide in the treatment of uterine papillary serous carcinoma (UPSC). *Gynecol Oncol*. 1993;51:383-389.
425. Trope C, Kristensen GB, Abeler VM. Clear-cell and papillary serous cancer: treatment options. *Best Pract Res Clin Obstet Gynaecol*. 2001;15:433-446.
426. Aalders JG, Abeler V, Kolstad P. Recurrent adenocarcinoma of the endometrium. A clinical and histopathological study of 379 patients. *Gynecol Oncol*. 1984;17:85-103.
427. Sears JD, Greven KM, Hoen HM, Randall ME. Prognostic factors and treatment outcome for patients with locally recurrent endometrial cancer. *Cancer*. 1994;74:1303-1308.
428. Pecorelli S. Revised FIGO staging for carcinoma of the vulva, cervix, and endometrium. *Int J Gynaecol Obstet*. 2009;105:103-104.
429. Christopherson WM, Connelly PJ, Alberhasky RC. Carcinoma of the endometrium. V. An analysis of prognosticators in patients with favorable subtypes and stage I disease. *Cancer*. 1983;51:1705-1709.
430. Greven KM, Lanciano RM, Corn B, et al. Pathologic stage III endometrial carcinoma. Prognostic factors and patterns of recurrence. *Cancer*. 1993;71:3697-3702.
431. Hendrickson M, Ross J, Eifel PJ, et al. Adenocarcinoma of the endometrium. Analysis of 256 cases with carcinoma limited to the uterine corpus. Pathology review and analysis of prognostic variables. *Gynecol Oncol*. 1982;13:373-392.
432. Homesley HD, Zaino R. Endometrial cancer. Prognostic factors. *Semin Oncol*. 1994;21:71-78.
433. Ambros RA, Vigna PA, Figge J, et al. Observations on tumor and metastatic suppressor gene status in endometrial carcinoma with particular emphasis on. *Cancer*. 1994;73.
434. Sidawy MK, Silverberg SG. Endometrial carcinoma. Pathologic factors of therapeutic and prognostic significance. *Pathol Annu*. 1992;27:153-185.
435. Zaino RJ. Pathologic indicators of prognosis in endometrial adenocarcinoma. Selected aspects emphasizing the GOG experience. Gynecologic Oncology Group. *Pathol Annu*. 1995;30(Pt 1):1-28.
436. Zaino RJ, Silverberg SG, Norris HJ, et al. The prognostic value of nuclear versus architectural grading in endometrial adenocarcinoma. A Gynecologic Oncology Group study. *Int J Gynecol Pathol*. 1994;13:29-36.
437. Ayhan A, Taskiran C, Yuce K, Kucukali T. The prognostic value of nuclear grading and the revised FIGO grading of endometrial adenocarcinoma. *Int J Gynecol Pathol*. 2002;22:71-74.
438. Soslow RA, Bissonnette JP, Wilton A, et al. Clinicopathologic analysis of 187 high-grade endometrial carcinomas of different histologic subtypes: similar outcomes belie distinctive biologic differences. *Am J Surg Pathol*. 2007;31:979-987.
439. Haley L, Burmeister C, Buekers T, Elshaikh MA. Is older age a real adverse prognostic factor in women with early-stage endometrial carcinoma? A matched analysis. *Int J Gynecol Cancer*. 2017;27:479-485.
440. Tjalling Bosse T, Nout R, McAlpine JN, et al. Molecular classification of grade 3 endometrioid endometrial cancers identifies distinct prognostic subgroups. *Mod Pathol*. 2017;30(suppl 2):277A.
441. Hanson MB, Van Nagell JR, Powell DE, et al. The prognostic significance of lymph-vascular space invasion in stage I endometrial cancer. *Cancer*. 1985;55:1753-1757.
442. Mannelqvist M, Stefansson I, Salvesen HB, Akslen LA. Importance of tumour cell invasion in blood and lymphatic vasculature among patients with endometrial carcinoma. *Histopathology*. 2009;54:174-183.
443. Reference deleted in proofs.
444. Hachisuga T, Kaku T, Fukuda K, et al. The grading in lymphovascular space invasion in endometrial carcinoma. *Cancer*. 2000;86:2090-2097.
445. Reference deleted in proofs.
446. Liu Y, Patel L, Mills GB, et al. Clinical significance of CTNNB1 mutation and Wnt pathway activation in endometrioid endometrial carcinoma. *J Natl Cancer Inst*. 2014;106:dju245.
447. Reference deleted in proofs.
448. Zaino RJ, Davis AT, Ohlsson-Wilhelm BM, Brunetto VL. DNA content is an independent prognostic indicator in endometrial adenocarcinoma: a Gynecologic Oncology Group study. *Int J Gynecol Pathol*. 1998;17:312-319.
449. Fekete PS, Vellios F. The clinical and histologic spectrum of endometrial stromal neoplasms. A report of 41 cases. *Int J Gynecol Pathol*. 1984;3:198-212.
450. Kempson RL, Hendrickson MR. Smooth muscle, endometrial stromal, and mixed Mullerian tumors of the uterus. *Mod Pathol*. 2000;13:328-342.
451. Norris HJ, Taylor HB. Mesenchymal tumors of the uterus. I, A clinical and pathological study of 53 endometrial stromal tumors. *Cancer*. 1966;19:755-766.
452. Oliva E, Clement PB, Young RH. Endometrial stromal tumors: an update on a group of tumors with a protean phenotype. *Adv Anat Pathol*. 2000;7:257-281.
453. Dionigi A, Oliva E, Clement PB, Young RH. Endometrial stromal nodules and endometrial stromal tumors with limited infiltration: a clinicopathologic study of 50 cases. *Am J Surg Pathol*. 2002;26:567-581.
454. Czernobilsky B. Uterine tumors resembling ovarian sex cord tumors: an update. *Int J Gynecol Pathol*. 2008;27:229-235.
455. Dal Cin P. Cytogenetics of mesenchymal tumors of the female genital tract. *Surg Pathol Clin*. 2009;2:813-821.
456. Lee CH, Ali R, Gilks CB. Molecular genetics of mesenchymal tumors of the female genital tract. *Surg Pathol Clin*. 2009;2:823-834.
457. Chu PG, Arber DA, Weiss LM, Chang KL. Utility of CD10 in distinguishing between endometrial stromal sarcoma and uterine smooth muscle tumors: an immunohistochemical comparison of 34 cases. *Mod Pathol*. 2001;14:465-471.
458. deLeval L, Waltregny D, Boniver J, et al. Use of histone deacetylase 8 (HDAC8), a new marker of smooth muscle differentiation, in the classification of mesenchymal tumors of the uterus. *Am J Surg Pathol*. 2006;30:319-327.
459. McCluggage WG, Sumathi VP, Maxwell P. CD10 is a sensitive and diagnostically useful immunohistochemical marker of normal endometrial stroma and of endometrial stromal neoplasms. *Histopathology*. 2001;39:273-278.
460. Nucci MR, O'Connell JT, Heuttner PC, et al. H-Caldesmon expression effectively distinguishes endometrial stromal tumors from uterine smooth muscle tumors. *Am J Surg Pathol*. 2001;25:455-463.
461. Rush DS, Tan J, Baergen RN, Soslow RA. h-Caldesmon, a novel smooth muscle-specific antibody, distinguishes between cellular leiomyoma and endometrial stromal sarcoma. *Am J Surg Pathol*. 2001;25:253-258.
462. Suarez Vilela D, Izquierdo Garcia FM. Foam cells and histiocytes in endometrial stromal tumours. *Histopathology*. 1998;32:568-569.
463. Oliva E, Young RH, Clement PB, Scully RE. Myxoid and fibrous endometrial stromal tumors of the uterus: a report of 10 cases. *Int J Gynecol Pathol*. 1999;18:310-319.
464. Baker PM, Moch H, Oliva E. Unusual morphologic features of endometrial stromal tumors: a report of 2 cases. *Am J Surg Pathol*. 2005;29:1394-1398.
465. Oliva E, Clement PB, Young RH. Epithelioid endometrial and endometrioid stromal tumors: a report of four cases emphasising their distinction from epithelioid smooth muscle tumors and other oxyphilic uterine and extrauterine tumors. *Int J Gynecol Pathol*. 2002;21:48-55.
466. Shah R, McCluggage WG. Symplastic atypia in neoplastic and non-neoplastic endometrial stroma: report of 3 cases with a review of atypical symplastic cells within the female genital tract. *Int J Gynecol Pathol*. 2009;28:334-337.
467. McCluggage WG, Young RH. Endometrial stromal sarcomas with true papillae and pseudopapillae. *Int J Gynecol Pathol*. 2008;27:555-561.
468. Abrams J, Talcott J, Corson JM. Pulmonary metastases in patients with low-grade endometrial stromal sarcoma. Clinicopathologic findings with immunohistochemical characterization. *Am J Surg Pathol*. 1989;13:133-140.
469. Sabini G, Chumas JC, Mann WJ. Steroid hormone receptors in endometrial stromal sarcomas. A biochemical and immunohistochemical study. *Am J Clin Pathol*. 1992;97:381-386.
470. Tsukamoto N, Kamura T, Matsukuma K, et al. Endolymphatic stromal myosis. A case with positive estrogen and progesterone receptors and good response to progestins. *Gynecol Oncol*. 1985;20:120-128.
471. Chiang S, Ali R, Melnyk N, et al. Frequency of known gene rearrangements in endometrial stromal tumors. *Am J Surg Pathol*. 2011;35:1364-1372.
472. Yilmaz A, Rush DS, Soslow RA. Endometrial stromal sarcomas with unusual histologic features: a report of 24 primary and metastatic tumors emphasizing fibroblastic and smooth muscle differentiation. *Am J Surg Pathol*. 2002;26:1142-1150.
473. Oliva E, Clement PB, Young RH, Scully RE. Mixed endometrial stromal and smooth

For personal use only. No other uses without permission. Copyright ©2017. Elsevier Inc. All rights reserved.

muscle tumors of the uterus: a clinicopathologic study of 15 cases. *Am J Surg Pathol*. 1998;22:997-1005.
474. Tavassoli FA, Norris HJ. Mesenchymal tumours of the uterus. VII. A clinicopathological study of 60 endometrial stromal nodules. *Histopathology*. 1981;5:1-10.
475. Clement PB, Scully RE. Uterine tumors resembling ovarian sex-cord tumors. A clinicopathologic analysis of fourteen cases. *Am J Clin Pathol*. 1976;66:512-525.
476. Nogales FF, Stolnicu S, Harilal KR, et al. Retiform uterine tumours resembling ovarian sex cord tumours. A comparative immunohistochemical study with retiform structures of the female genital tract. *Histopathology*. 2009;54:471-477.
477. Lillemoe TJ, Perrone T, Norris HJ, Dehner LP. Myogenous phenotype of epithelial-like areas in endometrial stromal sarcomas. *Arch Pathol Lab Med*. 1991;115:215-219.
478. Baker RJ, Hildebrandt RH, Rouse RV, et al. Inhibin and CD99 (MIC2) expression in uterine stromal neoplasms with sex-cord-like elements. *Hum Pathol*. 1999;30:671-679.
479. Czernobilsky B, Mamet Y, David MB, et al. Uterine retiform Sertoli–Leydig cell tumor: report of a case providing additional evidence that uterine tumors resembling ovarian sex cord tumors have a histologic and immunohistochemical phenotype of genuine sex cord tumors. *Int J Gynecol Pathol*. 2005;24:335-340.
480. Irving JA, Carinelli S, Prat J. Uterine tumors resembling ovarian sex cord tumors are polyphenotypic neoplasms with true sex cord differentiation. *Mod Pathol*. 2006;19:17-24.
481. Krishnamurthy S, Jungbluth AA, Busam KJ, Rosai J. Uterine tumors resembling ovarian sex-cord tumors have an immunophenotype consistent with true sex-cord differentiation. *Am J Surg Pathol*. 1998;22:1078-1082.
482. Biermann K, Heukamp LC, Büttner R, Zhou H. Uterine tumor resembling an ovarian sex cord tumor associated with metastasis. *Int J Gynecol Pathol*. 2008;27:58-60.
483. Larbig GG, Clemmer JJ, Koss LG, Foote FW. Plexiform tumorlets of endometrial stromal origin. *Am J Clin Pathol*. 1965;44:32-35.
484. Fisher ER, Paulson JD, Gregorio RM. The myofibroblastic nature of the uterine plexiform tumor. *Arch Pathol Lab Med*. 1978;102:477-480.
485. Goodhue WW, Susin M, Kramer EE. Smooth muscle origin of uterine plexiform tumors. Ultrastructural and histochemical evidence. *Arch Pathol*. 1974;97:263-268.
486. Kaminski PF, Tavassoli FA. Plexiform tumorlet. A clinical and pathologic study of 15 cases with ultrastructural observations. *Int J Gynecol Pathol*. 1984;3:124-134.
487. Clement PB, Scully RE. Endometrial stromal sarcomas of the uterus with extensive endometrioid glandular differentiation. A report of three cases that caused problems in differential diagnosis. *Int J Gynecol Pathol*. 1992;11:163-173.
488. McCluggage WG, Ganesan R, Herrington CS. Endometrial stromal sarcomas with extensive endometrioid glandular differentiation: report of a series with emphasis on the potential for misdiagnosis and discussion of the differential diagnosis. *Histopathology*. 2009;54:365-373.
489. Mazur MT, Askin FB. Endolymphatic stromal myosis. Unique presentation and ultrastructural study. *Cancer*. 1978;42:2661-2667.
490. Ulbright TM, Kraus FT. Endometrial stromal tumors of extra-uterine tissue. *Am J Clin Pathol*. 1981;76:371-377.
491. Shiraki M, Otis CN, Powell JL. Endometrial stromal sarcoma arising from ovarian and extraovarian endometriosis—report of two cases and review of the literature. *Surg Pathol*. 1991;4:333-343.
492. Lee CH, Ali RH, Rouzbahman M, et al. Cyclin D1 as a diagnostic immunomarker for endometrial stromal sarcoma with YWHAE-FAM22 rearrangement. *Am J Surg Pathol*. 2012;36:1562-1570.
493. Aubry MC, Myers JL, Colby TV, et al. Endometrial stromal sarcoma metastatic to the lung: a detailed analysis of 16 patients. *Am J Surg Pathol*. 2002;26:440-449.
494. Kolda TF, Ro JY, Ordonez NG, et al. Endometrial stromal sarcoma presenting as extrauterine metastases: a morphologic and immunohistochemical approach to diagnosis. *Int J Surg Pathol*. 1997;5:105-110.
495. Lee CH, Mariño-Enriquez A, Ou W, et al. The clinicopathologic features of YWHAE-FAM22 endometrial stromal sarcomas: a histologically high-grade and clinically aggressive tumor. *Am J Surg Pathol*. 2012;36:641-653.
496. Kurihara S, Oda Y, Ohishi Y, et al. Endometrial stromal sarcomas and related high-grade sarcomas: immunohistochemical and molecular genetic study of 31 cases. *Am J Surg Pathol*. 2008;32:1228-1238.
497. Levine PH, Abou-Nassar S, Mittal K. Extrauterine low-grade endometrial stromal sarcoma with florid endometrioid glandular differentiation. *Int J Gynecol Pathol*. 2001;20:395-398.
498. Isphording A, Ali RH, Irving J, et al. YWHAE-FAM22 endometrial stromal sarcoma: diagnosis by reverse transcription-polymerase chain reaction in formalin-fixed, paraffin-embedded tumor. *Hum Pathol*. 2013;44:837-843.
499. Hemming ML, Wagner AJ, Nucci MR, et al. YWHAE-rearranged high-grade endometrial stromal sarcoma: two-center case series and response to chemotherapy. *Gynecol Oncol*. 2017;145:531-535.
500. Hoang LN, Aneja A, Conlon N, et al. Novel high-grade endometrial stromal sarcoma: a morphologic mimicker of myxoid leiomyosarcoma. *Am J Surg Pathol*. 2017;41:12-24.
501. Chiang S, Lee CH, Stewart C, et al. BCOR is a robust diagnostic immunohistochemical marker of genetically diverse high-grade endometrial stromal sarcoma, including tumors exhibiting variant morphology. *Mod Pathol*. 2017;PMID: 28621321. epub ahead of print.
502. Clement PB, Scully RE. Müllerian adenosarcoma of the uterus. A clinicopathologic analysis of ten cases of a distinctive type of müllerian mixed tumor. *Cancer*. 1974;34:1138-1149.
503. Clement PB, Scully RE. Müllerian adenosarcoma of the uterus. A clinicopathologic analysis of 100 cases with a review of the literature. *Hum Pathol*. 1990;21:363-381.
504. Kaku T, Silverberg SG, Major FJ, et al. Adenosarcoma of the uterus. A Gynecologic Oncology Group clinicopathologic study of 31 cases. *Int J Gynecol Pathol*. 1992;11:75-88.
505. Gloor E. Müllerian adenosarcoma of the uterus. *Am J Surg Pathol*. 1979;3:203-209.
506. Katzenstein AA, Askin FB, Feldman PS. Müllerian adenosarcoma of the uterus. An ultrastructural study of four cases. *Cancer*. 1977;40:2233-2242.
507. Chen KTK. Rhabdomyosarcomatous uterine adenosarcoma. *Int J Gynecol Pathol*. 1985;4:146-152.
508. Lack EE, Bitterman P, Sundeen JT. Müllerian adenosarcoma of the uterus with pure angiosarcoma. Case report. *Hum Pathol*. 1991;22:1289-1291.
509. Clement PB. Müllerian adenosarcomas of the uterus with sarcomatous overgrowth. A clinicopathological analysis of 10 cases. *Am J Surg Pathol*. 1989;13:28-38.
510. Grimalt M, Arguelles M, Ferenczy A. Papillary cyst-adenofibroma of endometrium. A histochemical and ultrastructural study. *Cancer*. 1975;36:137-144.
511. Silverberg SG. Adenomyomatosis of endometrium and endocervix. A hamartoma? *Am J Clin Pathol*. 1975;64:192-199.
512. Vellios F, Ng ABP, Reagan JW. Papillary adenofibroma of the uterus. A benign mesodermal mixed tumor of müllerian origin. *Am J Clin Pathol*. 1973;60:543-551.
513. Zaloudek CJ, Norris HJ. Adenofibroma and adenosarcoma of the uterus. A clinicopathologic study of 35 cases. *Cancer*. 1981;48:354-366.
514. Gallardo A, Prat J. Mullerian adenosarcoma: a clinicopathologic and immunohistochemical study of 55 cases challenging the existence of adenofibroma. *Am J Surg Pathol*. 2009;33:278-288.
515. Clement PB, Scully RE. Müllerian adenofibroma of the uterus with invasion of myometrium and pelvic veins. *Int J Gynecol Pathol*. 1990;9:363-371.
516. Miller KN, McClure SP. Papillary adenofibroma of the uterus. Report of a case involved by adenocarcinoma and review of the literature. *Am J Clin Pathol*. 1992;97:806-809.
517. Parazzini F, La Vecchia C, Negri E, et al. Epidemiologic characteristics of women with uterine fibroids. A case-control study. *Obstet Gynecol*. 1988;72:853-857.
518. Cramer SF, Horiszny J, Patel A, Sigrist S. The relation of fibrous degeneration to menopausal status in small uterine leiomyomas with evidence for postmenopausal origin of seeding myomas. *Mod Pathol*. 1997;9:774-780.
519. Cramer SF, Marchetti C, Freedman J, Padela A. Relationships of myoma cell size and menopausal status in small uterine leiomyomas. *Arch Pathol Lab Med*. 2000;124:1448-1453.
520. Richards PA, Tiltman AJ. Anatomical variation of the oestrogen receptor in the non-neoplastic myometrium of fibromyomatous uteri. *Virchows Arch*. 1996;428:347-351.
521. Cramer SF, Patel A. The frequency of uterine leiomyomas. *Am J Clin Pathol*. 1990;94:435-438.
522. Nedwich A, Frumin A, Meranze DR. Erythrocytosis associated with uterine myomas. *Am J Obstet Gynecol*. 1962;84:174-178.
523. Pollio F, Staibano S, Mansueto G, et al. Erythropoietin and erythropoietin receptor system in a large uterine myoma of a patient with myomatous erythrocytosis syndrome: possible relationship with the pathogenesis of unusual tumor size. *Hum Pathol*. 2005;36:120-127.
524. Konishi I, Fujii S, Ban C, et al. Ultrastructural study of minute uterine leiomyomas. *Int J Gynecol Pathol*. 1983;2:113-120.
525. Parker RL, Young RH, Clement PB. Skeletal muscle-like and rhabdoid cells in uterine leiomyomas. *Int J Gynecol Pathol*. 2005;24:319-325.
526. Lascano EF. Mast cells in human tumors. *Cancer*. 1958;11:1110-1114.
527. Mäkinen N, Kämpjärvi K, Frizzell N, et al. Characterization of MED12, HMGA2, and FH alterations reveals molecular variability in uterine smooth muscle tumors. *Mol Cancer*. 2017;6:101.
528. Orii A, Mori A, Zhai YL, et al. Mast cells in smooth muscle tumors of the uterus. *Int J Gynecol Pathol*. 1998;17:336-342.

For personal use only. No other uses without permission. Copyright ©2017. Elsevier Inc. All rights reserved.

529. Reference deleted in proofs.
530. Hu J, Surti U. Subgroups of uterine leiomyomas based on cytogenetic analysis. *Hum Pathol*. 1991;22:1009-1016.
531. Reference deleted in proofs.
532. Nilbert M, Heim S, Mandahl N, et al. Karyotypic rearrangements in 20 uterine leiomyomas. *Cytogenet Cell Genet*. 1988;49:300-304.
533. Klotzbucher M, Wasserfall A, Fuhrmann U. Misexpresson of wild-type and truncated isoforms of the high-mobility group I proteins HMBI-C and HMGI(Y) in uterine leiomyomas. *Am J Pathol*. 1999;155:1535-1542.
534. Heinonen HR, Sarvilinna NS, Sjöberg J, et al. MED12 mutation frequency in unselected sporadic uterine leiomyomas. *Fertil Steril*. 2014;102:1137-1142.
535. Maluf HM, Gersell DJ. Uterine leiomyomas with high content of mast cells. *Arch Pathol Lab Med*. 1994;118:712-714.
536. Brown JM, Malkasian GD Jr, Symmonds RE. Abdominal myomectomy. *Am J Obstet Gynecol*. 1967;99:126-129.
537. Colgan TJ, Pendergast S, Le Blanc M. The histopathology of uterine leiomyomas following treatment with gonadotropin-releasing hormone analogues. *Hum Pathol*. 1993;24:1073-1077.
538. Demopoulus RI, Jones KY, Mittal KR, Vamvakas EC. Histology of leiomyomata in patients treated with leuprolide acetate. *Int J Gynecol Pathol*. 1997;16:131-137.
539. Friedman AJ, Hoffman DI, Comite F, et al. Treatment of leiomyomata uteri with leuprolide acetate depot. A double-blind, placebo-controlled, multicenter study. The Leuprolide Study Group. *Obstet Gynecol*. 1991;77:720-725.
540. Gutmann JN, Thornton KL, Diamond MP, Carcangiu ML. Evaluation of leuprolide acetate treatment on histopathology of uterine myomata. *Fertil Steril*. 1994;61:622-626.
541. Sreenan JJ, Prayson RA, Biscotti CV, et al. Histopathologic findings in 107 uterine leiomyomas treated with leuprolide acetate compared with 126 controls. *Am J Surg Pathol*. 1996;20:427-432.
542. Kalir T, Goldstein M, Dottino P, et al. Morphometric and electron-microscopic analyses of the effects of gonadotropin-releasing hormone agonists on uterine leiomyomas. *Arch Pathol Lab Med*. 1998;122:442-446.
543. Bardsley V, Cooper P, Peat DS. Massive lymphocytic infiltration of uterine leiomyomas associated with GnRH agonist treatment. *Histopathology*. 1998;33:80-82.
544. Laforga JB, Aranda FI. Uterine leiomyomas with T-cell infiltration associated with GnRH agonist goserelin. *Histopathology*. 1999;34:471-472.
545. McClean G, McCluggage WG. Unusual morphologic features of uterine leiomyomas treated with gonadotropin-releasing hormone agonists: massive lymphoid infiltration and vasculitis. *Int J Surg Pathol*. 2003;11:339-344.
546. Vu K, Greenspan DL, Wu TC, et al. Cellular proliferation, estrogen receptor, progesterone receptor, and bcl-2 expression in GnRH agonist-treated uterine leiomyomas. *Hum Pathol*. 1998;29:359-363.
547. Donnez J, Vázquez F, Tomaszewski J, et al. Long-term treatment of uterine fibroids with ulipristal acetate. *Fertil Steril*. 2014;101:1565-1573.
548. Weichert W, Denkert C, Gauruder-Burmester A, et al. Uterine arterial embolization with tris-acryl gelatin microspheres: a histopathologic evaluation. *Am J Surg Pathol*. 2005;29:955-961.
549. Colgan TJ, Pron G, Mocarski EJM, et al. Pathologic features of uteri and leiomyomas following uterine artery embolization for leiomyomas. *Am J Surg Pathol*. 2003;27:167-177.
550. McCluggage WG, Ellis PK, McClure N, et al. Pathologic features of uterine leiomyomas following uterine artery embolization. *Int J Gynecol Pathol*. 2000;19:342-347.
551. Ip PP, Lam KW, Cheung CL, et al. Tranexamic acid-associated necrosis and intralesional thrombosis of uterine leiomyomas: a clinicopathologic study of 147 cases emphasizing the importance of drug-induced necrosis and early infarcts in leiomyomas. *Am J Surg Pathol*. 2007;31:1215-1224.
552. Persaud V, Arjoon PD. Uterine leiomyoma. Incidence of degenerative change and a correlation of associated symptoms. *Obstet Gynecol*. 1970;35:432-436.
553. Myles JL, Hart HR. Apoplectic leiomyomas of the uterus. *Am J Surg Pathol*. 1985;9:798-805.
554. Lamb CA, Young RH. Apoplectic change in uterine leiomyomas: an analysis of 70 cases highlighting previously underemphasized aspects. *Lab Invest*. 2009;89(suppl 1):223A.
555. Clement PB, Young RH, Scully RE. Diffuse, perinodular, and other patterns of hydropic degeneration within and adjacent to uterine leiomyomas. Problems in differential diagnosis. *Am J Surg Pathol*. 1992;16:26-32.
556. Coad JE, Sulaiman RA, Das K, Staley N. Perinodular hydropic degeneration of a uterine leiomyoma: a diagnostic challenge. *Hum Pathol*. 1997;28:249-251.
557. Lamb CA, Young RH. Myxoid leiomyomas of the uterus: a report of 14 cases. *Lab Invest*. 2009;89(suppl 1):223A.
558. Botsis D, Koliopoulos C, Kondi-Pafitis A, Creatsas G. Frequency, histological, and immunohistochemical properties of massive inflammatory lymphocytic infiltration of leiomyomas of the uterus: an entity causing diagnostic difficulties. *Int J Gynecol Pathol*. 2005;24:326-329.
559. Ferry JA, Harris NL, Scully RE. Uterine leiomyomas with lymphoid infiltration simulating lymphoma. A report of seven cases. *Int J Gynecol Pathol*. 1989;8:263-270.
560. Gilks CB, Taylor GP, Clement PB. Inflammatory pseudotumor of the uterus. *Int J Gynecol Pathol*. 1987;6:275-286.
561. Vang R, Medeiros LJ, Samoszuk M, Deavers MT. Uterine leiomyomas with eosinophils: a clinicopathologic study of 3 cases. *Int J Gynecol Pathol*. 2001;20:239-243.
562. Oliva E, Young RH, Clement PB, et al. Cellular benign mesenchymal tumors of the uterus. A comparative morphologic and immunohistochemical analysis of 33 highly cellular leiomyomas and six endometrial stromal nodules, two frequently confused tumors. *Am J Surg Pathol*. 1995;19:769-774.
563. Dal Cin P, Christacos N, Morton CC, Quade BJ. Cellular leiomyoma: a genetically distinct entity among benign uterine tumors [abstract]. *Mod Pathol*. 2003;16:187a.
564. Downes KA, Hart WR. Bizarre leiomyomas of the uterus: a comprehensive pathologic study of 24 cases with long-term follow-up. *Am J Surg Pathol*. 1997;21:1261-1270.
565. Sun X, Mittal K. MIB-1 (Ki-67), estrogen receptor, progesterone receptor, and p53 expression in atypical cells in uterine symplastic leiomyomas. *Int J Gynecol Pathol*. 2009;29:51-54.
566. O'Connor DM, Norris HJ. Mitotically active leiomyomas of the uterus. *Hum Pathol*. 1990;21:223-227.
567. Prayson RA, Hart WR. Mitotically active leiomyomas of the uterus. *Am J Clin Pathol*. 1992;97:14-20.
568. Jacobs DS, Cohen H, Johnson JS. Lipoleiomyomas of the uterus. *Am J Clin Pathol*. 1965;44:45-51.
569. Pounder DJ. Fatty tumours of the uterus. *J Clin Pathol*. 1982;35:1380-1383.
570. Resta L, Maiorano E, Piscitelli D, Botticella MA. Lipomatous tumors of the uterus. Clinico-pathological features of 10 cases with immunocytochemical study of histogenesis. *Pathol Res Pract*. 1994;190:378-383.
571. Wang X, Kumar D, Seidman JD. Uterine lipoleiomyomas: a clinicopathologic study of 50 cases. *Int J Gynecol Pathol*. 2006;25:239-242.
572. Shintaku M. Lipoleiomyomatous tumors of the uterus: a heterogeneous group? Histopathological study of five cases. *Pathol Int*. 1997;46:498-502.
573. Aung T, Goto M, Nomoto M, et al. Uterine lipoleiomyoma: a histopathological review of 17 cases. *Pathol Int*. 2004;54:751-758.
574. Clement PB. The pathology of uterine smooth muscle tumors and mixed endometrial stromal-smooth muscle tumors: a selective review with emphasis on recent advances. *Int J Gynecol Pathol*. 2000;19:39-55.
575. Hyde KE, Geisinger KR, Marshall RB, Jones TL. The clear-cell variant of uterine epithelioid leiomyoma. An immunohistologic and ultrastructural study. *Arch Pathol Lab Med*. 1989;113:551-553.
576. Kurman RJ, Norris HJ. Mesenchymal tumors of the uterus. VI. Epithelioid smooth muscle tumors including leiomyoblastoma and clear-cell leiomyoma. A clinical and pathologic analysis of 26 cases. *Cancer*. 1976;37:1853-1865.
577. Bakotic BW, Cabello-Inchausti B, Willis IH, Suster S. Clear-cell epithelioid leiomyoma of the round ligament. *Mod Pathol*. 1999;12:912-918.
578. Cheuk W, Chan JK, Liu JY. Cotyledonoid leiomyoma: a benign uterine tumor with alarming gross appearance. *Arch Pathol Lab Med*. 2002;126:210-213.
579. Roth LM, Reed RJ, Sternberg WH. Cotyledonoid dissecting leiomyoma of the uterus: the Sternberg tumor. *Am J Surg Pathol*. 1996;20:1455-1461.
580. Roth LM, Reed RJ. Cotyledonoid leiomyoma of the uterus: report of a case. *Int J Gynecol Pathol*. 2000;19:272-275.
581. Fukunaga M, Ushigome S. Dissecting leiomyoma of the uterus with extrauterine extension. *Histopathology*. 1998;32:160-164.
582. Roth LM, Reed RJ. Dissecting leiomyomas of the uterus other than cotyledonoid dissecting leiomyomas: a report of eight cases. *Am J Surg Pathol*. 1999;23:1032-1039.
583. Jordan LB, Al-Nafussi A, Beattie G. Cotyledonoid hydropic intravenous leiomyomatosis: a new variant leiomyoma. *Histopathology*. 2002;40:245-252.
584. Billings SD, Folpe AL, Weiss SW. Do leiomyomas of deep soft tissue exist? An analysis of highly differentiated smooth muscle tumors of deep soft tissue supporting two distinct subtypes. *Am J Surg Pathol*. 2001;25:1134-1142.
585. Lee CH, Turbin DA, Sung YC, et al. A panel of antibodies to determine site of origin and malignancy in smooth muscle tumors. *Mod Pathol*. 2009;22:1519-1531.
586. Fornelli A, Pasquinelli G, Eusebi V. Leiomyoma of the uterus showing skeletal muscle differentiation: a case report. *Hum Pathol*. 1999;30:356-359.
587. Martin-Reay DG, Christ ML, La Pata RE. Uterine leiomyoma with skeletal-muscle differentiation. Report of a case. *Am J Clin Pathol*. 1991;96:344-347.
588. McCluggage WG, Boyde A. Uterine angioleiomyomas: a report of 3 cases of a

For personal use only. No other uses without permission. Copyright ©2017. Elsevier Inc. All rights reserved.

distinctive benign leiomyoma variant. *Int J Surg Pathol*. 2007;15:262-265.
589. Clement PB, Young RH. Diffuse leiomyomatosis of the uterus. A report of four cases. *Int J Gynecol Pathol*. 1987;6:322-330.
590. Mulvany NJ, Ostör AG, Ross I. Diffuse leiomyomatosis of the uterus. *Histopathology*. 1995;27:175-179.
591. Baschinsky DY, Isa A, Niemann TH, et al. Diffuse leiomyomatosis of the uterus: a case report with clonality analysis. *Hum Pathol*. 2000;31:1429-1432.
592. Cramer SF, Mann L, Calianese E, et al. Association of seedling myomas with myometrial hyperplasia. *Hum Pathol*. 2009;40:218-225.
593. Cramer SF, Patel A. Myometrial hyperplasia. Proposed criteria for a discrete morphological entity. *Mod Pathol*. 1995;8:71-77.
594. Lemis PL, Lee ABH, Easler RE. Myometrial hypertrophy. A clinical pathologic study and review of the literature. *Am J Obstet Gynecol*. 1962;84:1032-1041.
595. Sanz-Ortega J, Vocke C, Stratton P, et al. Morphologic and molecular characteristics of uterine leiomyomas in hereditary leiomyomatosis and renal cancer (HLRCC) syndrome. *Am J Surg Pathol*. 2013;37:74-80.
596. Joseph NM1, Solomon DA, Frizzell N, et al. Morphology and immunohistochemistry for 2SC and FH aid in detection of fumarate hydratase gene aberrations in uterine leiomyomas from young patients. *Am J Surg Pathol*. 2015;39(11):1529-1539.
597. Reyes C, Karamurzin Y, Frizzell N, et al. Uterine smooth muscle tumors with features suggesting fumarate hydratase aberration: detailed morphologic analysis and correlation with S-(2-succino)-cysteine immunohistochemistry. *Mod Pathol*. 2014;27(7):1020-1027.
598. Alsolami S, El-Bahrawy M, Kalloger SE, et al. Current morphologic criteria perform poorly in identifying hereditary leiomyomatosis and renal cell carcinoma syndrome-associated uterine leiomyomas. *Int J Gynecol Pathol*. 2014;33:560-567.
599. Harper RS, Scully RE. Intravenous leiomyomatosis of the uterus. *Am J Clin Pathol*. 1965;4:45-51.
600. Norris HJ, Parmley T. Mesenchymal tumors of the uterus. V. Intravenous leiomyomatosis. A clinical and pathologic study of 14 cases. *Cancer*. 1975;36:2164-2178.
601. Nogales FF, Novano N, Martinez de Victoria JM, et al. Uterine intravascular leiomyomatosis. An update and report of seven cases. *Int J Gynecol Pathol*. 1987;6:331-339.
602. Canzonieri V, D'Amore ES, Bartoloni G, et al. Leiomyomatosis with vascular invasion. A unified pathogenesis regarding leiomyoma with vascular microinvasion, benign metastasizing leiomyoma and intravenous leiomyomatosis. *Virchows Arch*. 1994;425:541-545.
603. Mulvany NJ, Slavin JL, Ostor AG, Fortune DW. Intravenous leiomyomatosis of the uterus. A clinicopathologic study of 22 cases. *Int J Gynecol Pathol*. 1994;13:1-9.
604. Brescia RJ, Tazelaar HD, Hobbs J, Miller AW. Intravascular lipoleiomyomatosis. A report of two cases. *Hum Pathol*. 1989;20:252-256.
605. Lee HJ, Choi J, Kim KR. Pulmonary benign metastasizing leiomyoma associated with intravenous leiomyomatosis of the uterus: clinical behavior and genomic changes supporting a transportation theory. *Int J Gynecol Pathol*. 2008;27:340-345.
606. Abell MR, Littler ER. Benign metastasizing uterine leiomyoma. Multiple lymph nodal metastases. *Cancer*. 1975;36:2206-2213.
607. Esteban JM, Allen WM, Schaerf RH. Benign metastasising leiomyoma of the uterus: histologic and immunohistochemical characterization of primary and metastatic lesions. *Arch Pathol Lab Med*. 1999;123:960-962.
608. Kayser K, Zink S, Schneider T, et al. Benign metastasising leiomyoma of the uterus: documentation of clinical, immunohistochemical and lectin-histochemical data of ten cases. *Virchows Arch*. 2000;437:284-292.
609. Jautzke G, Muller-Ruchholtz E, Thalmann U. Immunohistological detection of estrogen and progesterone receptors in multiple and well differentiated leiomyomatous lung tumors in women with uterine leiomyomas (so-called benign metastasising leiomyomas). A report on 5 cases. *Pathol Res Pract*. 1997;192:215-223.
610. Nucci MR, Drapkin R, Dal Cin P, et al. Distinctive cytogenetic profile in benign metastasizing leiomyoma: pathogenetic implications. *Am J Surg Pathol*. 2007;31:737-743.
611. Cho KR, Woodruff JD, Epstein JI. Leiomyoma of the uterus with multiple extrauterine smooth muscle tumors: a case report suggesting multifocal origin. *Hum Pathol*. 1989;20:80-82.
612. Patton KT, Cheng L, Papavero V, et al. Benign metastasizing leiomyoma: clonality, telomere length and clinicopathologic analysis. *Mod Pathol*. 2006;19:130-140.
613. Tietze L, Gunther K, Horbe A, et al. Benign metastasising leiomyoma: a cytogenetically balanced but clonal disease. *Hum Pathol*. 2000;31:126-128.
614. Huxley J. *Biological Aspects of Cancer*. New York: Harcourt, Brace; 1958:14.
615. Schwartz SM, Weiss NS, Daling JR, et al. Exogenous sex hormone use, correlates of endogenous hormone levels, and the incidence of histologic types of sarcoma of the uterus. *Cancer*. 1996;77:717-724.
616. Christopherson WM, Williamson EO, Gray LA. Leiomyosarcoma of the uterus. *Cancer*. 1972;29:70-75.
617. Moinfar F, Azodi M, Tavassoli FA. Uterine sarcomas. *Pathology*. 2007;39:55-71.
618. Reference deleted in proofs.
619. Dickersin GR, Selig MK, Park YN. The many faces of smooth muscle neoplasms in a gynaecological sampling: an ultrastructural study. *Ultrastruct Pathol*. 1997;21:109-134.
620. Marshall RJ, Braye SG. Alpha-1-antitrypsin, alpha-1-antichymotrypsin, actin, and myosin in uterine sarcomas. *Int J Gynecol Pathol*. 1985;4:346-354.
621. Watanabe K, Tajino T, Sekiguchi M, Suzuki T. h-caldesmon as a specific marker for smooth muscle tumors. Comparison with other smooth muscle markers in bone tumors. *Am J Clin Pathol*. 2000;113:663-668.
622. Iwata J, Fletcher CM. Immunohistochemical detection of cytokeratin and epithelial membrane antigen in leiomyosarcoma: a systematic study of 100 cases. *Pathol Int*. 2000;50:7-14.
623. Rizeq MN, van de Rijn M, Hendrickson MR, Rouse RV. A comparative immunohistochemical study of uterine smooth muscle neoplasms with emphasis on the epithelioid variant. *Hum Pathol*. 1994;25:671-677.
624. Mittal K, Iovine RI. MIB-1 (Ki-67), p53, estrogen receptor, and progesterone receptor expression in uterine smooth muscle tumors. *Hum Pathol*. 2001;32:984-987.
625. Zhai YL, Kobayashi Y, Mori A, et al. Expression of steroid receptors, Ki-67, and p53 in uterine leiomyosarcoma. *Int J Gynecol Pathol*. 1999;18:20-28.
626. Reference deleted in proofs.
627. Rao UN, Finkelstein SD, Jones MW. Comparative immunohistochemical and molecular analysis of uterine and extrauterine leiomyosarcomas. *Mod Pathol*. 1999;12:1001-1009.
628. Reference deleted in proofs.
629. Reference deleted in proofs.
630. Niemann TH, Raab SS, Lenel JC, et al. p53 protein over-expression in smooth muscle tumors of the uterus. *Hum Pathol*. 1995;26:375-379.
631. Buscema J, Carpenter SE, Rosenshein NB, Woodruff JD. Epithelioid leiomyosarcoma of the uterus. *Cancer*. 1986;7:1192-1196.
632. Reference deleted in proofs.
633. Prayson RA, Goldblum JR, Hart WR. Epithelioid smooth-muscle tumors of the uterus: a clinicopathologic study of 18 patients. *Am J Surg Pathol*. 1997;21:383-391.
634. Seidman JD, Yetter RA, Papadimitriou JC. Epithelioid component of uterine leiomyosarcoma simulating metastatic carcinoma. *Arch Pathol Lab Med*. 1992;116:287-290.
635. Wingen CB, Pauwels PA, Debiec-Rychter M, et al. Uterine gastrointestinal stromal tumour (GIST). *Gynecol Oncol*. 2005;97:970-972.
636. King E, Dickersin GR, Scully RE. Myxoid leiomyosarcoma of the uterus. *Am J Surg Pathol*. 1982;6:589-598.
637. Pounder DJ, Iyer PV. Uterine leiomyosarcoma with myxoid stroma. *Arch Pathol Lab Med*. 1985;109:762-764.
638. Watanabe K, Hiraki H, Ohishi M, et al. Uterine leiomyosarcoma with osteoclast-like giant cells. Histopathological and cytological observations. *Pathol Int*. 1997;46:656-660.
639. Coard KC, Fletcher HM. Leiomyosarcoma of the uterus with a florid intravascular component ('intravenous leiomyosarcomatosis. *Int J Gynecol Pathol*. 2002;21:182-185.
640. Shintaku M, Sekiyama K. Leiomyosarcoma of the uterus with focal rhabdomyosarcomatous differentiation. *Int J Gynecol Pathol*. 2004;23:188-192.
641. Lucas DR, Kolodziej P, Gross ML, et al. Metastatic uterine leiomyosarcoma to bone: a clinicopathologic study. *Int J Surg Pathol*. 1997;4:159-168.
642. D'Angelo E, Spagnoli LG, Prat J. Comparative clinicopathologic and immunohistochemical analysis of uterine sarcomas diagnosed using the World Health Organization classification system. *Hum Pathol*. 2009;40:1571-1585.
643. Salazar OM, Bonfiglio TA, Patten SF, et al. Uterine sarcomas. Natural history, treatment and prognosis. *Cancer*. 1978;42:1152-1160.
644. Bartsich EG, Bowe ET, Moore JG. Leiomyosarcoma of the uterus. A 50-year review of 42 cases. *Obstet Gynecol*. 1968;32:101-106.
645. Abeler VM, Røyne O, Thoresen S, et al. Uterine sarcomas in Norway. A histopathological and prognostic survey of a total population from 1970 to 2000 including 419 patients. *Histopathology*. 2009;54:355-364.
646. Pautier P, Genestie C, Rey A, et al. Analysis of clinicopathologic prognostic factors for 157 uterine sarcomas and evaluation of a grading score validated for soft tissue sarcoma. *Cancer*. 2000;88:1425-1431.
647. D'Angelo E, Espinosa I, Ali R, et al. Uterine leiomyosarcomas: tumor size, mitotic index, and biomarkers Ki67, and Bcl-2 identify two groups with different prognosis. *Gynecol Oncol*. 2011;121:328-333.
648. Longacre TA, Hendrickson MR, Kempson RL. Predicting clinical outcome for uterine smooth muscle neoplasms with a reasonable degree of certainty. *Adv Anat Pathol*. 1997;4:95-104.
649. Reference deleted in proofs.

For personal use only. No other uses without permission. Copyright ©2017. Elsevier Inc. All rights reserved.

650. Toledo G, Oliva E. Smooth muscle tumors of the uterus: a practical approach. *Arch Pathol Lab Med*. 2008;132:595-605.
651. Lim D, Alvarez T, Nucci MR, et al. Interobserver variability in the interpretation of tumor cell necrosis in uterine leiomyosarcoma. *Am J Surg Pathol*. 2013;37:650-658.
652. Editorials. Mitosis counting—I. (Scully RE et al) Mitosis counting—II. (Kempson RL) Mitosis counting—III. (Norris HJ). *Hum Pathol*. 1976;7:481-484.
653. Silverberg SG. Reproducibility of the mitosis count in the histologic diagnosis of smooth muscle tumors of the uterus. *Hum Pathol*. 1976;7:451-454.
654. Thunnissen FBJM, Ambergen AW, Koss M, et al. Mitotic counting in surgical pathology: sampling bias, heterogeneity and statistical uncertainty. *Histopathology*. 2001;39:1-8.
655. Donhuijsen K. Mitosis counts. Reproducibility and significance in grading of malignancy. *Hum Pathol*. 1986;17:1122-1125.
656. Bewtra C, Frankforter S, Marcus JN. Clinicopathologic differences between diploid and tetraploid complete hydatidiform moles. *Int J Gynecol Pathol*. 1998;16:239-244.
657. van Diest PJ, Baak JP, Matze-Cok P, et al. Reproducibility of mitosis counting in 2,469 breast cancer specimens; results from the Multicenter Morphometric Mammary Carcinoma Project. *Hum Pathol*. 1992;23:603-607.
658. Bell SW, Kempson RL, Hendrickson MR. Problematic uterine smooth muscle neoplasms. A clinicopathologic study of 213 cases. *Am J Surg Pathol*. 1994;18:535-558.
659. Hart WR. Problematic uterine smooth muscle neoplasms. *Am J Surg Pathol*. 1997;21:252-255.
660. Reference deleted in proofs.
661. Kempson RL, Hendrickson MR. Smooth muscle, endometrial stromal, and mixed Mullerian tumors of the uterus. *Mod Pathol*. 2000;13:328-342.
662. Wilkinson N, Rollason TP. Recent advances in the pathology of smooth muscle tumors of the uterus. *Histopathology*. 2001;39:331-341.
663. Croce S, Ribeiro A, Brulard C, et al. Uterine smooth muscle tumor analysis by comparative genomic hybridization: a useful diagnostic tool in challenging lesions. *Mod Pathol*. 2015;28:1001-1010.
664. Conlon N, Soslow RA, Murali R. Perivascular epithelioid tumours (PEComas) of the gynaecological tract. *J Clin Pathol*. 2015;68:418-426.
665. Gyure KA, Hart WR, Kennedy AW. Lymphangiomyomatosis of the uterus associated with tuberous sclerosis and malignant neoplasia of the female genital tract. A report of two cases. *Int J Gynecol Pathol*. 1995;14:344-351.
666. Jameson CF. Angiomyoma of the uterus in a patient with tuberous sclerosis. *Histopathology*. 1990;16:202-203.
667. Liang SX, Pearl M, Liu J, et al. Malignant' uterine perivascular epithelioid cell tumor, pelvic lymph node lymphangioleiomyomatosis, and gynecological pecomatosis in a patient with tuberous sclerosis: a case report and review of the literature. *Int J Gynecol Pathol*. 2008;27:86-90.
668. Yavuz E, Cakr C, Tuzlal S, et al. Uterine perivascular epithelioid cell tumor coexisting with pulmonary lymphangioleiomyomatosis and renal angiomyolipoma: a case report. *Appl Immunohistochem Mol Morphol*. 2008;16:405-409.
669. Folpe AL, Mentzel T, Lehr HA, et al. Perivascular epithelioid cell neoplasms of soft tissue and gynecologic origin: a clinicopathologic study of 26 cases and review of the literature. *Am J Surg Pathol*. 2005;29:1558-1575.
670. Fadare O, Parkash V, Yilmaz Y, et al. Perivascular epithelioid cell tumor (PEComa) of the uterine cervix associated with intraabdominal "PEComatosis": A clinicopathological study with comparative genomic hybridization analysis. *World J Surg Oncol*. 2004;2:35.
671. Michal M, Zamecnik M. Hyalinized uterine mesenchymal neoplasms with HMB-45-positive epithelioid cells: epithelioid leiomyomas or angiomyolipomas? Report of four cases. *Int J Surg Pathol*. 2000;8:323-328.
672. Argani P, Aulmann S, Illei PB, et al. A distinctive subset of PEComas harbors TFE3 gene fusions. *Am J Surg Pathol*. 2010;34:1395-1406.
673. Martignoni G, Pea M, Reghellin D, et al. Molecular pathology of lymphangioleiomyomatosis and other perivascular epithelioid cell tumors. *Arch Pathol Lab Med*. 2010;134:33-40.
674. Reference deleted in proofs.
675. Gilks CB, Taylor GP, Clement PB. Inflammatory pseudotumor of the uterus. *Int J Gynecol Pathol*. 1987;6:275-286.
676. Parra-Herran C, Quick CM, Howitt BE, et al. Inflammatory myofibroblastic tumor of the uterus: clinical and pathologic review of 10 cases including a subset with aggressive clinical course. *Am J Surg Pathol*. 2015;39:157-168.
677. Rabban JT, Zaloudek CJ, Shekitka KM, Tavassoli FA. Inflammatory myofibroblastic tumor of the uterus: a clinicopathologic study of 6 cases emphasizing distinction from aggressive mesenchymal tumors. *Am J Surg Pathol*. 2005;29:1348-1355.
678. Shih IeM. Gestational trophoblastic neoplasia—pathogenesis and potential therapeutic targets. *Lancet Oncol*. 2007;8:642-650.
679. Berkowitz RS, Goldstein DP. Chorionic tumors. *N Engl J Med*. 1996;335:1740-1748.
680. Li HW, Tsao SW, Cheung AN. Current understandings of the molecular genetics of gestational trophoblastic diseases. *Placenta*. 2002;23:20-31.
681. Shih IM, Kurman RJ. Molecular basis of gestational trophoblastic diseases. *Curr Mol Med*. 2002;2:1-12.
682. Fulop V, Mok SC, Gati I, Berkowitz RS. Recent advances in molecular biology of gestational trophoblastic diseases. A review. *J Reprod Med*. 2002;47:369-379.
683. Kajii T, Ohama K. Androgenetic origin of hydatidiform mole. *Nature*. 1977;268:633-634.
684. Hsu CT, Chen TY, Chiu WH, et al. Some aspects of trophoblastic diseases peculiar to Taiwan. *Am J Obstet Gynecol*. 1964;90:308-316.
685. Joint Project for Study of Choriocarcinoma and Hydatidiform Mole in Asia. Geographic variation in the occurrence of hydatidiform mole and choriocarcinoma. *Ann N Y Acad Sci*. 1959;80:178-195.
686. Park WW. *Choriocarcinoma. A Study of its Pathology*. Philadelphia: F.A. Davis; 1971.
687. Sand PK, Lurain JR, Brewer JI. Repeat gestational trophoblastic disease. *Obstet Gynecol*. 1984;63:140-144.
688. Shapter AP, McLellan R. Gestational trophoblastic disease. *Obstet Gynecol Clin North Am*. 2001;28:805-817.
689. Rice LW, Lage JM, Berkowitz RS, et al. Repetitive complete and partial hydatidiform mole. *Obstet Gynecol*. 1989;74:217-219.
690. Atrash HK, Hogue CJR, Grimes DA. Epidemiology of hydatidiform mole during early gestation. *Am J Obstet Gynecol*. 1986;154:906-909.
691. Cave WT Jr, Dunn JT. Choriocarcinoma with hyperthyroidism. Probable identity of the thyrotropin with human chorionic gonadotropin. *Ann Intern Med*. 1976;85:60-63.
692. Hershman JM, Higgins HP. Hydatidiform mole—a cause of clinical hyperthyroidism. Report of two cases with evidence that the molar tissue secreted a thyroid stimulator. *N Engl J Med*. 1971;284:573-577.
693. Narasimhan KL, Ghobrial MW, Ruby EB. Hyperthyroidism in the setting of gestational trophoblastic disease. *Am J Med Sci*. 2002;323:285-287.
694. Baergen RN, Kelly T, McGinnis MJ, et al. Complete hydatidiform mole with a coexistent embryo. *Hum Pathol*. 1996;27:731-734.
695. Van de Kaa CA, Robben JC, Hopman AH, et al. Complete hydatidiform mole in twin pregnancy. Differentiation from partial mole with interphase cytogenetic and DNA cytometric analyses on paraffin embedded tissues. *Histopathology*. 1995;26:123-129.
696. Deavers MT, Kalhor N, Silva EG. Diagnostic problems with trophoblastic lesions. *Arch Pathol Lab Med*. 2008;132:168-174.
697. Fukunaga M, Katabuchi H, Nagasaka T, et al. Interobserver and intraobserver variability in the diagnosis of hydatidiform mole. *Am J Surg Pathol*. 2005;29:942-947.
698. Keep D, Zaragoza MV, Hassold T, Redline RW. Very early complete hydatidiform mole. *Hum Pathol*. 1996;27:708-713.
699. Qiao S, Nagasaka T, Nakashima N. Numerous vessels detected by CD34 in the villous stroma of complete hydatidiform moles. *Int J Gynecol Pathol*. 1998;16:233-238.
700. Kim KR, Park BH, Hong YO, et al. The villous stromal constituents of complete hydatidiform mole differ histologically in very early pregnancy from the normally developing placenta. *Am J Surg Pathol*. 2009;33:176-185.
701. Kim MJ, Kim KR, Ro JY, et al. Diagnostic and pathogenetic significance of increased stromal apoptosis and incomplete vasculogenesis in complete hydatidiform moles in very early pregnancy periods. *Am J Surg Pathol*. 2006;30:362-369.
702. Wells M. The pathology of gestational trophoblastic disease: recent advances. *Pathology*. 2007;39:88-96.
703. Montes M, Roberts D, Berkowitz RS, Genest DR. Prevalence and significance of implantation site trophoblastic atypia in hydatidiform moles and spontaneous abortions. *Am J Clin Pathol*. 1996;105:411-416.
704. Okudaira Y, Strauss L. Ultrastructure of molar trophoblast. Observations on hydatidiform mole and chorioadenoma destruens. *Obstet Gynecol*. 1967;30:172-187.
705. Brescia RJ, Kurman RJ, Main CS, et al. Immunocytochemical localization of chorionic gonadotropin, placental lactogen, and placental alkaline phosphatase in the diagnosis of complete and partial hydatidiform moles. *Int J Gynecol Pathol*. 1987;6:213-229.
706. Fukunaga M, Miyazawa Y, Sugishita M, Ushigome S. Immunohistochemistry of molar and non-molar placentas with special reference to their differential diagnosis. *Acta Pathol Jpn*. 1993;43:683-689.
707. Kommoss F, Schmidt D, Coerdt W, et al. Immunohistochemical expression analysis of inhibin-alpha and -beta subunits in partial and complete moles, trophoblastic tumors, and endometrial decidua. *Int J Gynecol Pathol*. 2001;20:380-385.
708. Pelkey TJ, Frierson HF, Mills SE, Stoler MH. Detection of the alpha-subunit of inhibin in trophoblastic neoplasia. *Hum Pathol*. 1999;30:26-31.
709. Castrillon DH, Sun D, Weremowicz S, et al. Discrimination of complete hydatidiform mole from its mimics by

For personal use only. No other uses without permission. Copyright ©2017. Elsevier Inc. All rights reserved.

immunohistochemistry of the paternally imprinted gene product p57KIP2. *Am J Surg Pathol*. 2001;25:1225-1230.
710. Crisp H, Burton JL, Stewart R, Wells M. Refining the diagnosis of hydatidiform mole: image ploidy analysis and p57KIP2 immunohistochemistry. *Histopathology*. 2003;43:363-373.
711. Fukunaga M. Immunohistochemical characterization of p57KIP2 expression in early hydatidiform moles. *Hum Pathol*. 2003;33:1188-1192.
712. Jun S-Y, Ro JY, Kim K-R. P57KIP2 is useful in the classification and differential diagnosis of complete and partial hydatidiform moles. *Histopathology*. 2003;43:17-25.
713. Lage JM, Popek EJ. The role of DNA flow cytometry in evaluation of partial and complete hydatidiform moles and hydropic abortions. *Semin Diagn Pathol*. 1993;10:267-274.
714. Baasanjav B, Usui H, Kihara M, et al. The risk of post-molar gestational trophoblastic neoplasia is higher in heterozygous than in homozygous complete hydatidiform moles. *Hum Reprod*. 2010;25:1183-1191.
715. Rose PG. Hydatidiform mole. Diagnosis and management. *Semin Oncol*. 1995;22:149-156.
716. Berkowitz RS, Goldstein DP. Clinical practice. Molar pregnancy. *N Engl J Med*. 2009;360:1639-1645.
717. Tyrey L. Human chorionic gonadotropin. Structural, biologic, and immunologic aspects. *Semin Oncol*. 1982;9:163-173.
718. Lewis JL Jr. Diagnosis and management of gestational trophoblastic disease. *Cancer*. 1993;71:1639-1647.
719. Hancock BW, Tidy JA. Current management of molar pregnancy. *J Reprod Med*. 2002;47:347-354.
720. Schorge JO, Goldstein DP, Bernstrein MR, Berkowitz RS. Recent advances in gestational trophoblastic disease. *J Reprod Med*. 2000;45:692-700.
721. Kohorn EI. Criteria toward the definition of nonmetastatic gestational trophoblastic disease after hydatidiform mole. *Am J Obstet Gynecol*. 1982;142:416-419.
722. Lurain JR, Brewer JI, Torok EE, Halpern B. Natural history of hydatidiform mole after primary evacuation. *Am J Obstet Gynecol*. 1983;145:591-595.
723. Chew SH, Periman EJ, Williams R, et al. Morphology and DNA content analysis in the evaluation of first trimester placentas for partial hydatidiform mole (PHM). *Hum Pathol*. 2000;31:914-924.
724. Boue J, Boue A. Chromosomal anomalies in early spontaneous abortion. In: Gropp A, Benirschke K, eds. *Current Topics in Pathology. 62. Developmental Biology and Pathology*. Berlin: Springer-Verlag; 1977.
725. Vejerslev LO, Fisher RA, Surti U, Walke N. Hydatidiform mole. Cytogenetically unusual cases and their implications for the present classification. *Am J Obstet Gynecol*. 1987;157:180-184.
726. Wolf NG, Lage JM. Genetic analysis of gestational trophoblastic disease. A review. *Semin Oncol*. 1995;22:113-120.
727. Genest DR. Partial hydatidiform mole: clinicopathological features, differential diagnosis, ploidy and molecular studies, and gold standards for diagnosis. *Int J Gynecol Pathol*. 2001;20:315-322.
728. Berkowitz RS, Goldstein DP, Bernstein MR. Natural history of partial molar pregnancy. *Obstet Gynecol*. 1983;66:677-681.
729. Gardner HA, Lage JM. Choriocarcinoma following a partial hydatidiform mole. A case report. *Hum Pathol*. 1992;23:468-471.
730. Szulman AE, Surti U. The clinicopathologic profile of the partial hydatidiform mole. *Obstet Gynecol*. 1982;59:597-602.
731. Fukunaga M. Early partial hydatidiform mole: prevalence, histopathology, DNA ploidy, and persistence rate. *Virchows Arch*. 2000;437:180-184.
732. Jeffers MD, O'Dwyer P, Curran B, et al. Partial hydatidiform mole. A common but underdiagnosed condition. A 3-year retrospective clinicopathological and DNA flow cytometric analysis. *Int J Gynecol Pathol*. 1993;12:315-323.
733. Lage JM, Berkowitz RS, Rice LW, et al. Flow cytometric analysis of DNA content in partial hydatidiform moles with persistent gestational trophoblastic tumor. *Obstet Gynecol*. 1991;77:111-115.
734. Mostoufi-zadeh M, Berkowitz RS, Driscoll SG. Persistence of partial mole. *Am J Clin Pathol*. 1987;87:377-380.
735. Gaber LW, Redline RW, Mostoufi-zadeh M, Driscoll SG. Invasive partial mole. *Am J Clin Pathol*. 1986;85:722-724.
736. Goto S, Yamada A, Ishizuka T, Tomoda Y. Development of postmolar trophoblastic disease after partial molar pregnancy. *Gynecol Oncol*. 1993;48:165-170.
737. Rice LW, Berkowitz RS, Lage JM, et al. Persistent gestational trophoblastic tumor after partial hydatidiform mole. *Gynecol Oncol*. 1990;36:358-362.
738. Cheung AN, Khoo US, Lai CY, et al. Metastatic trophoblastic disease after an initial diagnosis of partial hydatidiform mole: genotyping and chromosome in situ hybridization analysis. *Cancer*. 2004;100:1411-1417.
739. Doshi N, Surti U, Szulman AE. Morphologic anomalies in triploid liveborn fetuses. *Hum Pathol*. 1983;14:716-723.
740. Szulman AE, Philippe E, Boue JG, Boue A. Human triploidy. Association with partial hydatidiform moles and nonmolar conceptuses. *Hum Pathol*. 1981;12:1016-1021.
741. Paradinas FJ, Sebire NJ, Fisher RA, et al. Pseudo-partial moles: placental stem vessel hydrops and the association with Beckwith–Wiedemann syndrome and complete moles. *Histopathology*. 2001;39:447-454.
742. Koenig C, Demopoulos RI, Vamvakas EC, et al. Flow cytometric DNA ploidy and quantitative histopathology in partial moles. *Int J Gynecol Pathol*. 1993;12:235-240.
743. LeGallo RD, Stelow EB, Ramirez NC, Atkins KA. Diagnosis of hydatidiform moles using p57 immunohistochemistry and HER2 fluorescent in situ hybridization. *Am J Clin Pathol*. 2008;129:749-755.
744. Vang R, Gupta M, Wu LS, et al. Diagnostic reproducibility of hydatidiform moles: ancillary techniques (p57 immunohistochemistry and molecular genotyping) improve morphologic diagnosis. *Am J Surg Pathol*. 2012;36:443-453.
745. Kurman RJ. Pathology of trophoblast. *Monogr Pathol*. 1991;33:195-227.
746. Lurain JR, Brewer JI. Invasive mole. *Semin Oncol*. 1982;9:174-180.
747. Haines M. Hydatidiform mole and vaginal nodules. *J Obstet Gynaecol Br Emp*. 1955;62:6-11.
748. Ring AM. The concept of benign metastasizing hydatidiform moles. *Am J Clin Pathol*. 1972;58:111-117.
749. Bagshawe KD, Garnett ES. Radiological changes in the lungs of patients with trophoblastic tumours. *Br J Radiol*. 1963;36:673-679.
750. Evans KT, Cockshott WP, de Hendrickse P V. Pulmonary changes in malignant trophoblastic disease. *Br J Radiol*. 1965;38:161-171.
751. Greene RR. Chorioadenoma destruens. *Ann N Y Acad Sci*. 1959;80:143-148.
752. Wilson RB, Hunter JS Jr, Dockerty MB. Chorioadenoma destruens. *Am J Obstet Gynecol*. 1961;81:546-559.
753. Takeuchi S. Nature of invasive mole and its rational management. *Semin Oncol*. 1982;9:181-186.
754. Benirschke K, Kaufmann P. *Pathology of the Human Placenta*. New York: Springer; 2000.
755. Berkowitz RS, Goldstein DP, Bernstein MR. Choriocarcinoma following term gestation. *Gynecol Oncol*. 1984;17:52-57.
756. Medeiros F, Callahan MJ, Elvin JA, et al. Intraplacental choriocarcinoma arising in a second trimester placenta with partial hydatidiform mole. *Int J Gynecol Pathol*. 2008;27:247-251.
757. Olive DL, Lurain JR, Brewer JI. Choriocarcinoma associated with term gestation. *Am J Obstet Gynecol*. 1984;148:711-716.
758. Barghorn A, Bannwart F, Stallmach T. Incidental choriocarcinoma confined to a near-term placenta. *Virchows Arch*. 1998;433:89-91.
759. Brewer JI, Mazur MT. Gestational choriocarcinoma. Its origin in the placenta during seemingly normal pregnancy. *Am J Surg Pathol*. 1981;5:267-277.
760. Lage J, Roberts DJ. Choriocarcinoma in a term placenta. Pathologic diagnosis of tumor in an asymptomatic patient with metastatic disease. *Int J Gynecol Pathol*. 1993;12:80-85.
761. Fukunaga M, Nomura K, Ushigome S. Choriocarcinoma in situ of a first trimester: report of two cases indicating an origin of trophoblast of a stem villus. *Virchows Arch*. 1996;429:185-188.
762. Dyke PC, Fink LM. Latent choriocarcinoma. *Cancer*. 1967;20:150-154.
763. Redline RW, Abdul-Karim FW. Pathology of gestational trophoblastic disease. *Semin Oncol*. 1995;22:96-108.
764. Elston CW, Bagshawe KD. The diagnosis of trophoblastic tumours from uterine curettings. *J Clin Pathol*. 1972;25:111-118.
765. Lind HM, Haghighi P. Carcinoembryonic antigen staining in choriocarcinoma. *Am J Clin Pathol*. 1986;86:538-540.
766. Ishizuka T, Tomoda Y, Kaseki S, et al. Intracranial metastasis of choriocarcinoma. A clinicopathologic study. *Cancer*. 1983;52:1896-1903.
767. Mazur MT, Lurain JR, Brewer JI. Fatal gestational choriocarcinoma. Clinicopathologic study of patients treated at a trophoblastic disease center. *Cancer*. 1982;50:1833-1846.
768. Soper JT, Mutch DG, Chin N, et al. Renal metastases of gestational trophoblastic disease. A report of eight cases. *Obstet Gynecol*. 1988;72:796-798.
769. Heaton GE, Matthews TH, Christopherson WM. Malignant trophoblastic tumors with massive hemorrhage presenting as liver primary. A report of two cases. *Am J Surg Pathol*. 1986;10:342-347.
770. Tsukamoto N, Matsumura M, Matsukuma K, et al. Choriocarcinoma in mother and fetus. *Gynecol Oncol*. 1986;24:113-119.
771. Ober WB, Edgcomb JH, Price EB Jr. The pathology of choriocarcinoma. *Ann N Y Acad Sci*. 1971;172:299-321.
772. Kohorn EI. Theca lutein ovarian cyst may be pathognomonic for trophoblastic neoplasia. *Obstet Gynecol*. 1983;62:80S-81S.
773. Ostor A. God's first cancer and man's first cure': milestones in gestational trophoblastic disease. *Anat Pathol*. 1998;1:165-178.
774. Brewer JI, Smith RT, Pratt GB. Choriocarcinoma. Absolute 5-year survival rates of 122 patients treated by hysterectomy. *Am J Obstet Gynecol*. 1963;85:841-843.
775. Kaseki S. Prognosis and treatment of trophoblastic diseases. *Excerpta Medica (International Congress Series)*. 1980;512:566-570.

For personal use only. No other uses without permission. Copyright ©2017. Elsevier Inc. All rights reserved.

776. Lurain JR, Brewer JI, Torok EE, Halpern B. Gestational trophoblastic disease. Treatment results at the Brewer Trophoblastic Disease Center. *Obstet Gynecol*. 1982;60:354-360.
777. Mortakis AE, Braga CA. 'Poor prognosis' metastatic gestational trophoblastic disease. The prognostic significance of the scoring system in predicting chemotherapy failures. *Obstet Gynecol*. 1990;76:272-277.
778. Clayton LA, Barnard DE, Weed JC Jr, Hammond CB. The role of surgery in the management of gestational trophoblastic disease. *Semin Oncol*. 1982;9:213-220.
779. Lewis J, Ketcham AS, Hertz R. Surgical intervention during chemotherapy of gestational trophoblastic neoplasms. *Cancer*. 1966;19:1517-1522.
780. Civantos F, Rywlin AM. Carcinomas with trophoblastic differentiation and secretion of chorionic gonadotrophins. *Cancer*. 1972;29:789-798.
781. Reference deleted in proofs.
782. Kurman RJ, Scully RE, Norris HJ. Trophoblastic pseudotumor of the uterus. An exaggerated form of 'syncytial endometritis' simulating a malignant tumor. *Cancer*. 1976;38:1214-1226.
783. Scully RE, Young RH. Trophoblastic pseudotumor. A reappraisal. *Am J Surg Pathol*. 1981;5:75-76.
784. Young RH, Scully RE. Placental-site trophoblastic tumor. Current status. *Clin Obstet Gynecol*. 1984;27:248-258.
785. Silva EG, Tornos C, Lage J, et al. Multiple nodules of intermediate trophoblast following hydatidiform moles. *Int J Gynecol Pathol*. 1993;12:324-332.
786. Hui P, Parkash V, Perkins AS, Carcangiu ML. Pathogenesis of placental site trophoblastic tumor may require the presence of a paternally derived X chromosome. *Lab Invest*. 2000;80:965-972.
787. Hui P, Wang HL, Chu P, et al. Absence of Y chromosome in human placental site trophoblastic tumor. *Mod Pathol*. 2007;20:1055-1060.
788. Duncan DA, Mazur MT. Trophoblastic tumors. Ultrastructural comparison of choriocarcinoma and placental-site trophoblastic tumor. *Hum Pathol*. 1989;20:370-381.
789. Kurman RJ. The morphology, biology, and pathology of intermediate trophoblast. A look back to the present. *Hum Pathol*. 1991;22:847-855.
790. Motoyama T, Ohta T, Ajioka Y, Watanabe H. Neoplastic and non-neoplastic intermediate trophoblasts. An immunohistochemical and ultrastructural study. *Pathol Int*. 1994;44:57-65.
791. Yeh IT, O'Connor DM, Kurman RJ. Intermediate trophoblast. Further immunocytochemical characterization. *Mod Pathol*. 1990;3:282-287.
792. Berger G, Verbaere J, Feroldi J. Placental site trophoblastic tumor of the uterus. An ultrastructural and immunohistochemical study. *Ultrastruct Pathol*. 1984;6:319-329.
793. Kurman RJ, Young RH, Norris HJ, et al. Immunocytochemical localization of placental lactogen and chorionic gonadotropin in the normal placenta and trophoblastic tumors, with emphasis on intermediate trophoblast and the placental site trophoblastic tumor. *Int J Gynecol Pathol*. 1984;3:101-121.
794. Bamberger AM, Sudhal S, Wagener C, Loning T. Expression pattern of the adhesion molecule CEACAM1 (C-CAM, CD66a, BGP) in gestational trophoblastic lesions. *Int J Gynecol Pathol*. 2001;20:160-165.
795. Rhoton-Vlasak A, Wagner JM, Rutgers JL, et al. Placental site trophoblastic tumor: human placental lactogen and pregnancy-associated major basic protein ad immunohistologic markers. *Hum Pathol*. 1998;29:280-288.
796. Singer G, Kurman RJ, McMaster MT, Shih IeM. HLA-G immunoreactivity is specific for intermediate trophoblast in gestational trophoblastic disease and can serve as a useful marker in differential diagnosis. *Am J Surg Pathol*. 2002;26:914-920.
797. Fukunaga M, Ushigome S. Metastasizing placental site trophoblastic tumor. An immunohistochemical and flow cytometric study of two cases. *Am J Surg Pathol*. 1993;17:1003-1010.
798. Kotylo PK, Michael H, Davis TE, et al. Flow cytometric DNA analysis of placental-site trophoblastic tumors. *Int J Gynecol Pathol*. 1992;11:245-252.
799. Xue WC, Guan XY, Ngam HY, et al. Malignant placental site trophoblastic tumor: a cytogenetic study using comparative genomic hybridisation and chromosome in situ hybridisation. *Cancer*. 2002;94:2288-2294.
800. Shih IM, Kurman RJ. Ki-67 labeling index in the differential diagnosis of exaggerated placental site, placental site trophoblastic tumor, and choriocarcinoma: a double immunohistochemical staining technique using Ki-67 and MEL-CAM antibodies. *Hum Pathol*. 1998;29:27-33.
801. Shih IM, Kurman RJ. p63 expression is useful in the distinction of epithelioid trophoblastic and placental site trophoblastic tumors by profiling trophoblastic subpopulations. *Am J Surg Pathol*. 2004;28:1177-1183.
802. Lathrop JC, Lauchlan S, Nayak R, Ambler M. Clinical characteristics of placental site trophoblastic tumor (PSTT). *Gynecol Oncol*. 1988;31:32-42.
803. Orrell JM, Sanders DS. A particularly aggressive placental site trophoblastic tumour. *Histopathology*. 1991;18:559-561.
804. Eckstein RP, Paradinas FJ, Bagshawe KD. Placental site trophoblastic tumour (trophoblastic pseudotumour). A study of four cases requiring hysterectomy including one fatal case. *Histopathology*. 1982;6:211-226.
805. Gloor E, Dialdas J, Hurlimann J, et al. Placental site trophoblastic tumor (trophoblastic pseudotumor) of the uterus with metastases and fetal outcome. Clinical and autopsy observations of a case. *Am J Surg Pathol*. 1983;7:483-486.
806. Young RH, Scully RE, McCluskey RT. A distinctive glomerular lesion complicating placental site trophoblastic tumor. Report of two cases. *Hum Pathol*. 1985;16:35-42.
807. Mazur MT. Metastatic gestational choriocarcinoma. Unusual pathologic variant following therapy. *Cancer*. 1989;63:1370-1377.
808. Coulson LE, Kong CS, Zaloudek C. Epithelioid trophoblastic tumor of the uterus in postmenpausal women: a case report and review of the literature. *Am J Surg Pathol*. 2000;24:1558-1562.
809. Fadare O, Parkash V, Carcangiu ML, Hui P. Epithelioid trophoblastic tumor: clinicopathological features with an emphasis on uterine cervical involvement. *Mod Pathol*. 2006;19:75-82.
810. Kuo KT, Chen MJ, Lin MC. Epithelioid trophoblastic tumor of the broad ligament: a case report and review of the literature. *Am J Surg Pathol*. 2004;28:405-409.
811. Lewin SN, Aghajanian C, Moreira AL, Soslow RA. Extrauterine epithelioid trophoblastic tumors presenting as primary lung carcinomas: morphologic and immunohistochemical features to resolve a diagnostic dilemma. *Am J Surg Pathol*. 2009;33:1809-1814.
812. Hamazaki S, Nakamoto S, Okino T, et al. Epithelioid trophoblastic tumor: morphological and immunohistochemical study of three lung lesions. *Hum Pathol*. 1999;30:1321-1327.
813. Mao TL, Seidman JD, Kurman RJ, Shih IeM. Cyclin E and p16 immunoreactivity in epithelioid trophoblastic tumor—an aid in differential diagnosis. *Am J Surg Pathol*. 2006;30:1105-1110.
814. Shih IM, Kurman RJ. Epithelioid trophoblastic tumor: a neoplasm distinct from choriocarcinoma and placental site trophoblastic tumor simulating carcinoma. *Am J Surg Pathol*. 1998;22:1393-1403.
815. Oldt RJ III, Kurman RJ, Shih IM. Molecular genetic analysis of placental site trophoblastic tumors and epithelioid trophoblastic tumors confirms their trophoblastic origin. *Am J Pathol*. 2002;161:1033-1037.
816. Shih IM, Kurman RJ. The pathology of intermediate trophoblastic tumors and tumor-like lesions. *Int J Gynecol Pathol*. 2001;20:31-47.
817. Huettner PC, Gersell DJ. Placental site nodules. A clinicopathologic study of 38 cases. *Int J Gynecol Pathol*. 1994;13:191-198.
818. Shitabata PK, Rutgers JL. The placental site nodule. An immunohistochemical study. *Hum Pathol*. 1994;25:1295-1301.
819. Shih IM, Seidman JD, Kurman RJ. Placental site nodule and characterization of distinctive type of intermediate trophoblast. *Hum Pathol*. 1999;30:687-694.
820. Tsang WY, Chum NP, Tang SK, et al. Mallory's bodies in placental site nodule. *Arch Pathol Lab Med*. 1993;117:547-550.
821. Campello TR, Fittipaldi H, O'Valle F, et al. Extrauterine (tubal) placental site nodule. *Histopathology*. 1998;32:562-565.
822. El Hag IA, Ramesh K, Kollur SM, Salem M. Extrauterine placental site trophoblastic tumour in association with a lithopedion. *Histopathology*. 2002;41:446-449.
823. Lee KC, Chan JK. Placental site nodule. *Histopathology*. 1988;16:193-195.
824. Young RH, Kurman RJ, Scully RE. Placental site nodules and plaques. A clinicopathologic analysis of 20 cases. *Am J Surg Pathol*. 1990;14:1001-1009.
825. Davey DD, Munn R, Smith LW, Cibull ML. Angiotropic lymphoma. Presentation in uterine vessels with cytogenetic studies. *Arch Pathol Lab Med*. 1990;114:879-882.
826. Kelly P, McCluggage WG. Idiopathic uterine granulomas: report of a series with morphological similarities to idiopathic ovarian cortical granulomas. *Int J Gynecol Pathol*. 2006;25:243-246.
827. Sirgi KE, Swanson PE, Gersell DJ. Extramedullary hematopoiesis in the endometrium. Report of four cases and review of the literature. *Am J Clin Pathol*. 1994;101:643-646.
828. Gru AA, Hassan A, Pfeifer JD, Huettner PC. Uterine extramedullary hematopoiesis: what is the clinical significance? *Int J Gynecol Pathol*. 2010;29:366-373.
829. McCluggage WG, Young RH. Myxoid change of the myometrium and cervical stroma: description of a hitherto unreported non-neoplastic phenomenon with discussion of myxoid uterine lesions. *Int J Gynecol Pathol*. 2010;29:351-357.
830. Nogales FF, Isaac A, Hardisson D, et al. Adenomatoid tumors of the uterus: an analysis of 60 cases. *Int J Gynecol Pathol*. 2002;21:34-40.
831. Tiltman AJ. Adenomatoid tumours of the uterus. *Histopathology*. 1980;4:437-443.
832. Palacios J, Suarez Manrique A, Ruiz Villaespesa A, et al. Cystic adenomatoid tumor of the uterus. *Int J Gynecol Pathol*. 1991;10:296-301.
833. Quigley JC, Hart WR. Adenomatoid tumors of the uterus. *Am J Clin Pathol*. 1981;76:627-635.
834. McAlhany SJ, Rabban JT. Expression of D2-40, a marker of mesothelial and lymphatic

For personal use only. No other uses without permission. Copyright ©2017. Elsevier Inc. All rights reserved.

endothelial differentiation, in adenomatoid tumors: a potential diagnostic pitfall in distinguishing from lymphatic tumors. *Lab Invest*. 2009;89(suppl 1):227A.
835. Otis CN. Uterine adenomatoid tumors: immunohistochemical characteristics with emphasis on Ber-EP4 immunoreactivity and distinction from adenocarcinoma. *Int J Gynecol Pathol*. 1996;15:146-151.
836. Sangoi AR, McKenney JK, Schwartz EJ, et al. Adenomatoid tumors of the female and male genital tracts: a clinicopathological and immunohistochemical study of 44 cases. *Mod Pathol*. 2009;22:1228-1235.
837. Shintaku M, Sasaki M, Honda T. Thrombomodulin immunoreactivity in adenomatoid tumour of the uterus. *Histopathology*. 1997;28:375-377.
838. Stephenson TJ, Mill PM. Adenomatoid tumours. An immunohistochemical and ultrastructural appraisal of their histogenesis. *J Pathol*. 1986;148:327-335.
839. Suzuki T, Yoshida Y, Kaku T, et al. Adenomatoid tumor of the uterus. Ultrastructural, histochemical, and immunohistochemical analysis. *Arch Pathol Lab Med*. 1985;109:1049-1051.
840. Liggins GC. Uterine arteriovenous fistula. *Obstet Gynecol*. 1964;23:214-217.
841. Johnson C, Reid-Nicholson M, Deligdisch L, et al. Capillary hemangioma of the endometrium: a case report and review of the literature. *Arch Pathol Lab Med*. 2005;129:1326-1329.
842. Thaung C, Shanks J, Eyden B, Fitzmaurice R. Solitary fibrous tumour of the uterus. *Histopathology*. 2006;49:199-201.
843. Wakami K, Tateyama H, Kawashima H, et al. Solitary fibrous tumor of the uterus producing high-molecular-weight insulin-like growth factor II and associated with hypoglycemia. *Int J Gynecol Pathol*. 2005;24:79-84.
844. Reference deleted in proofs.
845. Reference deleted in proofs.
846. Clement PB. Postoperative spindle-cell nodule of the endometrium. *Arch Pathol Lab Med*. 1988;112:566-568.
847. Di Tommaso L, Rahal D, Bresciani G, Roncalli M. Cutaneous melanoma metastatic to uterine adenomyoma: report of a case. *Int J Surg Pathol*. 2005;13:223-225.
848. Fadare O, Bonvicino A, Martel M, et al. Pleomorphic rhabdomyosarcoma of the uterine corpus: a clinicopathologic study of 4 cases and a review of the literature. *Int J Gynecol Pathol*. 2010;29:122-134.
849. Ferguson SE, Gerald W, Barakat RR, et al. Clinicopathologic features of rhabdomyosarcoma of gynecologic origin in adults. *Am J Surg Pathol*. 2007;31:382-389.
850. Ordi J, Stamatakos MD, Tavassoli FA. Pure pleomorphic rhabdomyosarcomas of the uterus. *Int J Gynecol Pathol*. 1998;16:369-377.
851. Podczaski E, Sees J, Kaminski P, et al. Rhabdomyosarcoma of the uterus in a postmenopausal patient. *Gynecol Oncol*. 1990;37:439-442.
852. den Bakker MA, Hegt VN, Sleddens HB, et al. Malignant mesenchymona of the uterus, arising in a leiomyoma. *Histopathology*. 2002;40:65-70.
853. Cardinale L, Mirra M, Galli C, et al. Angiosarcoma of the uterus: report of 2 new cases with deviant clinicopathologic features and review of the literature. *Ann Diagn Pathol*. 2008;12:217-221.
854. Milne DS, Hinshaw K, Malcolm AJ, Hilton P. Primary angiosarcoma of the uterus. A case report. *Histopathology*. 1994;16:203-205.
855. Schammel DP, Tavassoli FA. Uterine angiosarcomas: a morphologic and immunohistochemcial study of four cases. *Am J Surg Pathol*. 1998;22:246-250.
856. Chou S-T, Fortune D, Beischer NA, et al. Primary malignant fibrous histiocytoma of the uterus—ultrastructural and immunocytochemical studies of two cases. *Pathology*. 1985;17:36-40.
857. De Young B, Bitterman P, Lack EE. Primary osteosarcoma of the uterus. Report of a case with immunohistochemical study. *Mod Pathol*. 1992;5:212-215.
858. Gray GF, Glick AD, Kurtin PJ, Jones HWIII. Alveolar soft part sarcoma of the uterus. *Hum Pathol*. 1986;17:297-300.
859. Terada T. Gastrointestinal stromal tumor of the uterus: a case report with genetic analyses of c-kit and PDGFRA genes. *Int J Gynecol Pathol*. 2009;28:29-34.
860. Al-Hussaini M, Hirschowitz L, McCluggage WG. Uterine neoplasms composed of rhabdoid cells do not exhibit loss of INI1 immunoreactivity and are not related to childhood malignant rhabdoid tumor. *Int J Gynecol Pathol*. 2008;27:236-242.
861. de A Focchi GR, Cuatrecasas M, Prat J. Malignant peripheral nerve sheath tumor of the uterine corpus: a case report. *Int J Gynecol Pathol*. 2007;26:437-440.
862. Hendrickson MR, Scheithauer BW. Primitive neuroectodermal tumor of the endometrium. Report of two cases, one with electron microscopic observations. *Int J Gynecol Pathol*. 1986;5:249-259.
863. Varghese L, Arnesen M, Boente M. Primitive neuroectodermal tumor of the uterus: a case report and review of literature. *Int J Gynecol Pathol*. 2006;25:373-377.
864. Clement PB. Chondrosarcoma of the uterus. Report of a case and review of the literature. *Hum Pathol*. 1978;9:726-732.
865. Fraggetta F, Magro G, Vasquez E. Primitive neuroectodermal tumor of the uterus with focal cartilaginous differentiation. *Histopathology*. 1997;30:483-485.
866. Morrel B, Mulder AF, Chadha S, et al. Angiosarcoma of the uterus following radiotherapy for squamous cell carcinoma of the cervix. *Eur J Obstet Gynecol Reprod Biol*. 1993;49:193-197.
867. Tallini G, Price FV, Carcangiu ML. Epithelioid angiosarcoma arising in uterine leiomyomas. *Am J Clin Pathol*. 1993;100:514-518.
868. Euscher ED, Deavers MT, Lopez-Terrada D, et al. Uterine tumors with neuroectodermal differentiation: a series of 17 cases and review of the literature. *Am J Surg Pathol*. 2008;32:219-228.
869. Rittenbach J, Cao JD, Weiss LM, et al. Primary diffuse large B-cell lymphoma of the uterus presenting solely as an endometrial polyp. *Int J Gynecol Pathol*. 2005;24:347-351.
870. Ferry JA, Young RH. Malignant lymphoma of the genitourinary tract. *Curr Diagn Pathol*. 1997;4:145-169.
871. Harris NL, Scully RE. Malignant lymphoma and granulocytic sarcoma of the uterus and vagina. *Cancer*. 1984;53:2530-2545.
872. Lagoo AS, Robboy SJ. Lymphoma of the female genital tract: current status. *Int J Gynecol Pathol*. 2006;25:1-21.
873. Vang R, Medeiros LJ, Ha CS, Deavers S. Non-Hodgkin's lymphoma involving the uterus: a clinicopathologic analysis of 26 cases. *Mod Pathol*. 2000;13:19-28.
874. Aozasa K, Saeki K, Ohsawa M, et al. Malignant lymphoma of the uterus. Report of seven cases with immunohistochemical study. *Cancer*. 1993;72:1959-1964.
875. Kosari F, Daneshbod Y, Parwaresch R, et al. Lymphomas of the female genital tract: a study of 186 cases and review of the literature. *Am J Surg Pathol*. 2005;29:1512-1520.
876. Heeren JH, Croonen AM, Pijnenborg JM. Primary extranodal marginal zone B-cell lymphoma of the female genital tract: a case report and literature review. *Int J Gynecol Pathol*. 2008;27:243-246.
877. van de Rijn M, Kamel OW, Chang PP, et al. Primary low-grade endometrial B-cell lymphoma. *Am J Surg Pathol*. 1997;21:187-194.
878. Masunaga A, Abe M, Tsuji E, et al. Primary uterine T-cell lymphoma. *Int J Gynecol Pathol*. 1998;17:376-379.
879. Hung LHY, Kurtz DM. Hodgkin's disease of the endometrium. *Arch Pathol Lab Med*. 1985;109:952-953.
880. Daya D, Lukka H, Clement PB. Primitive neuroectodermal tumors of the uterus. A report of four cases. *Hum Pathol*. 1992;23:1120-1129.
881. Sur M, Ross C, Moens F, Daya D. Intravascular large B-cell lymphoma of the uterus: a diagnostic challenge. *Int J Gynecol Pathol*. 2005;24:201-203.
882. Geyer JT, Ferry JA, Harris NL, et al. Florid reactive lymphoid hyperplasia of the lower female genital tract (lymphoma-like lesion): a benign condition that frequently harbors clonal immunoglobulin heavy chain gene rearrangements. *Am J Surg Pathol*. 2010;34:161-168.
883. Young RH, Harris NL, Scully RE. Lymphoma-like lesions of the lower female genital tract. A report of 16 cases. *Int J Gynecol Pathol*. 1985;4:289-299.
884. Ferry JA, Young RH. Malignant lymphoma, pseudolymphoma, and hematopoietic disorders of the female genital tract. *Pathol Annu*. 1991;26:227-263.
885. Garcia MG, Deavers MT, Knoblock RJ, et al. Myeloid sarcoma involving the gynecologic tract: a report of 11 cases and review of the literature. *Am J Clin Pathol*. 2006;125:783-790.
886. Oliva E, Ferry JA, Young RH, et al. Granulocytic sarcoma of the female genital tract: a clinicopathologic study of 11 cases. *Am J Surg Pathol*. 1997;21:1156-1165.
887. Smith NL, Baird DB, Strausbauch PH. Endometrial involvement by multiple myeloma. *Int J Gynecol Pathol*. 1997;16:173-175.
888. Arhelger RB, Bocian JJ. Brenner tumor of the uterus. *Cancer*. 1976;38:1741-1743.
889. Angeles-Angeles A, Gutierrez-Villalobos LG, Lome-Maldonado C, Jimenez-Moreno A. Polypoid brenner tumor of the uterus. *Int J Gynecol Pathol*. 2002;21:86-87.
890. García-Galvis OF, Stolnicu S, Muñoz E, et al. Adult extrarenal Wilms tumor of the uterus with teratoid features. *Hum Pathol*. 2009;40:418-424.
891. Muc RS, Grayson W, Grobbelaar JJ. Adult extrarenal Wilms tumor occurring in the uterus. *Arch Pathol Lab Med*. 2001;125:1081-1083.
892. Young RH, Kleinman GM, Scully RE. Glioma of the uterus. *Am J Surg Pathol*. 1981;5:695-699.
893. Chetty R, Clark SP, Bhathal PS. Carcinoid tumor of the uterine corpus. *Virchows Arch A Pathol Anat Histopathol*. 1993;422:93-95.
894. Young TW, Thrasher TV. Nonchromaffin paraganglioma of the uterus. *Arch Pathol Lab Med*. 1982;106:608-609.
895. Tavassoli FA. Melanotic paraganglioma of the uterus. *Cancer*. 1986;58:942-948.
896. Joseph MG, Fellows FG, Hearn SA. Primary endodermal sinus tumor of the endometrium. A clinicopathologic, immunocytochemical, and ultrastructural study. *Cancer*. 1990;65:297-302.
897. Kumar NB, Hart WR. Metastases to the uterine corpus from extragenital cancers. *Cancer*. 1982;50:2163-2169.

For personal use only. No other uses without permission. Copyright ©2017. Elsevier Inc. All rights reserved.

898. Mazur MT, Hsueh S, Gersell DJ. Metastases to the female genital tract. *Cancer*. 1984;53:1978-1984.
899. Stemmermann GN. Extrapelvic carcinoma metastatic to the uterus. *Am J Obstet Gynecol*. 1961;82:1261-1266.
900. Taxy JB, Trujillo YP. Breast cancer metastatic to the uterus. Clinical manifestations of a rare event. *Arch Pathol Lab Med*. 1994;118:819-821.
901. Jordan CD, Andrews SJ, Memoli VA. Well-differentiated pulmonary neuroendocrine carcinoma metastatic to the endometrium: a case report. *Mod Pathol*. 1997;9:1066-1070.
902. Moore WF, Bentley RC, Kim KR, et al. Goblet-cell mucinous epithelium lining the endometrium and endocervix: evidence of a metastasis from an appendiceal primary tumor through the use of cytokeratin-7 and -20 immunostains. *Int J Gynecol Pathol*. 1998;17:363-367.
903. Houghton JP, Ioffe OB, Silverberg SG, et al. Metastatic breast lobular carcinoma involving tamoxifen-associated endometrial polyps: report of two cases and review of tamoxifen-associated polypoid uterine lesions. *Mod Pathol*. 2003;16:395-398.
904. Donner LR. Uterine carcinosarcoma with complete sarcomatous overgrowth mimicking pure embryonal rhabdomyosarcoma. *Int J Gynecol Pathol*. 2002;22:89-91.

For personal use only. No other uses without permission. Copyright ©2017. Elsevier Inc. All rights reserved.

34 Fallopian Tube

Blake Gilks

CHAPTER CONTENTS

Normal anatomy, 1356
Inflammation, 1356
Torsion, 1359
Tubal pregnancy, 1359
Other non-neoplastic processes, 1359
Proliferative epithelial lesions, 1360
Carcinoma, 1361
Serous tubal intraepithelial carcinoma, 1362
High-grade serous carcinoma, 1362
Other carcinomas, 1363
Other tumors, 1363
Tumors and tumorlike conditions of broad and round ligaments, 1364

Normal Anatomy

The **fallopian tube** or salpinx is a tubular hollow structure measuring 11–12 cm in length that runs throughout the apex of the broad ligament and spans the distance between the uterine cornus and the ovary. It is divided into four segments: *intramural* (inside the uterine wall), *isthmus* (2–3 cm, thick-walled), *ampulla* (a thin-walled expanded area), and *infundibulum* (a trumpet-shaped ending that opens into the peritoneal cavity through the ostium and is fringed by the *fimbriae*). One of the latter structures, known as the *ovarian fimbria*, attaches the tube to the ovary.

The inner aspect of the tube is lined by mucosa arranged in the shape of longitudinal, branching folds (known as *plicae*), which merge with the fimbriae. There is good correlation between the microscopic features of this mucosa and its salpingoscopic appearance.[1] Microscopically, the epithelium is composed of three distinct cell types: *secretory*, *ciliated*, and *intercalated (peg)*.[2] Amylase is secreted by the epithelium, and its presence can be demonstrated immunohistochemically.[3] Endocrine cells have been found only exceptionally. A low degree of proliferative activity takes place normally in the tubal epithelium, more so during proliferative/follicular phase of the menstrual cycle, compared to the secretory/luteal phase.[4] At the time of menstruation, as well as a few days postpartum, the tubal mucosa may be normally infiltrated by neutrophils, probably as a reaction to blood and necrotic debris (*"physiologic salpingitis"*); it is accompanied by negative cultures and should not be confused with a bacterial or other infectious salpingitis.[5,6]

The muscular wall *(myosalpinx)* is composed of an inner circular layer and an outer longitudinal layer; the isthmus near the uterotubal junction also possesses an inner longitudinal layer.

The lymphatics of the fallopian tube leave the tubal wall within the mesosalpinx, where they join efferent lymphatics from the ovary and uterus and follow the ovarian vessels to terminate in the aortic lymph nodes. Other lymphatics course within the broad ligament and drain into the interiliac nodes; a separate lymphatic channel from the ampulla of the tube follows the broad ligament to terminate in the superior gluteal lymph nodes.

The **broad ligament** is the peritoneal fold that supports the uterus on either side, extending from this organ to the pelvic wall. It comprises the mesovarium, mesometrium, and mesosalpinx. The broad ligament and the adjacent areas contain a variety of tubular structures related to the müllerian and wolffian systems that may give rise to grossly evident cysts.[7] Most of these are lined by müllerian-type epithelium and have been variously referred to—depending on their specific location and presumed histogenesis—as *parovarian cyst*, *paratubal cyst (hydatid of Morgagni)*, *subserosal müllerian cyst*, *Kobelt cyst (appendix vesiculosa)*, *paroöphoron cyst*, *epoöphoron cyst*, and *rete ovarii cyst*.[8] *Walthard cell nests*, which can also be cystic, are of a different (probably mesothelial) nature.

The **round ligament** is a fibrous cord attached to the superior lateral border of the uterus that passes over the external iliac vessels and the inguinal ligament to leave the abdominal cavity through the deep inguinal ring. From there, it follows the inguinal canal to anchor itself in the labium majus. It serves to orient the uterus by the fact that its insertion is *anterior* to that of the fallopian tube.

Inflammation

Bacterial infection of the fallopian tube is a common disease, and its incidence keeps increasing. It may follow invasive procedures (such

For personal use only. No other uses without permission. Copyright ©2017. Elsevier Inc. All rights reserved.

Abstract

The fallopian tube has received increasing attention in this millennium, leading to the recognition that most extra-uterine high-grade serous carcinomas arise in the tube rather than the ovary. With more careful examination of the fallopian tube, increasing numbers of incidental findings are being identified by surgical pathologists; while most are not clinically significant, some do have implications for patient care, and accurate diagnosis is critically important. In addition to neoplastic changes, inflammatory/infectious processes involving the tube are relatively common; although they usually do not lead to surgery, they can do and it is important to for pathologists to be familiar with the spectrum of inflammatory changes in the tube.

Keywords

Fallopian tube;
infection;
inflammation;
carcinoma;
STIC

For personal use only. No other uses without permission. Copyright ©2017. Elsevier Inc. All rights reserved.

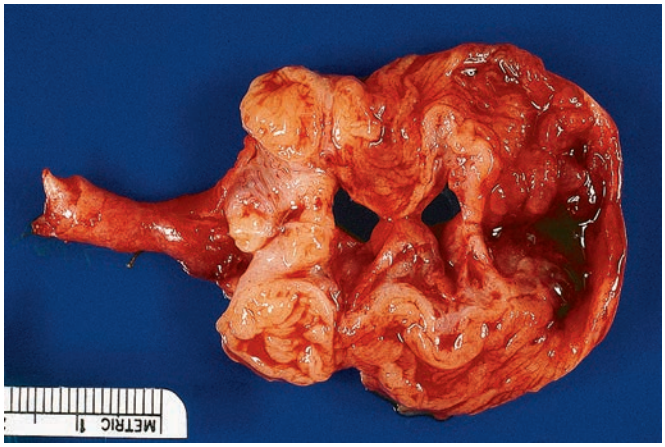

Figure 34.1 Gross appearance of chronic salpingitis with superimposed acute changes.

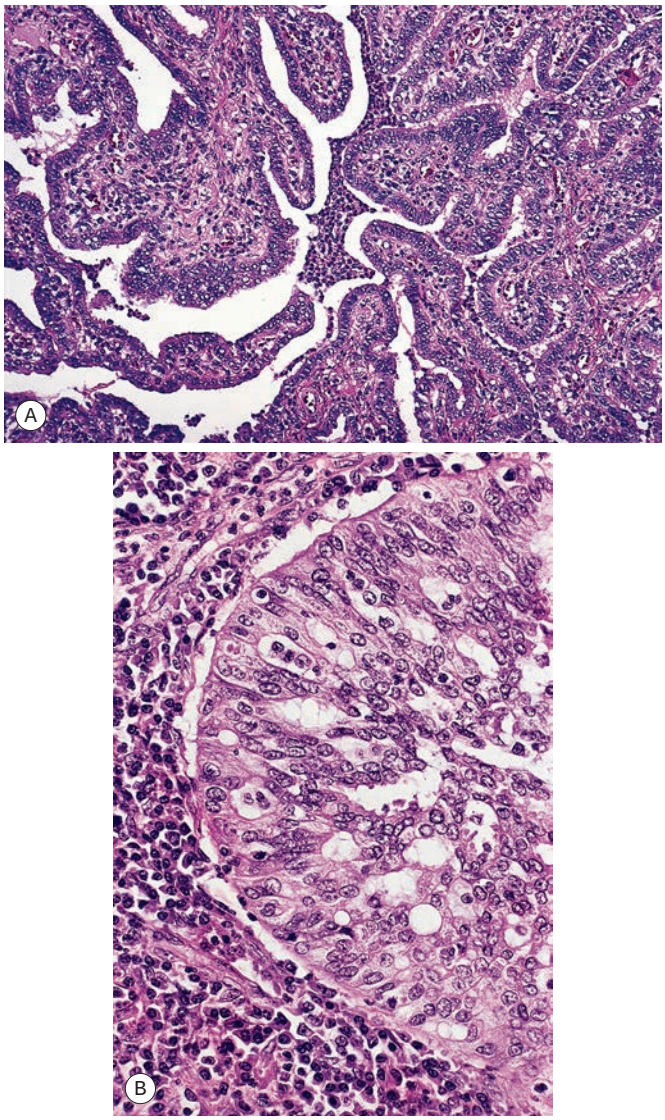

Figure 34.2 **Chronic Salpingitis. A**, Blunting of villi due to heavy inflammatory infiltrate. **B**, Marked secondary reactive hyperplasia of the mucosa, which may simulate a malignant process.

as curettage or the insertion of intrauterine devices[9]), and it may accompany endometriosis,[10] but in most cases it is due to an ascending infection, often sexually transmitted (Fig. 34.1).[11] The inflammation may result in fusion of tubal plicae and obliteration of the ostium (Fig. 34.2A). Obstruction of the fimbriated end and, less commonly, of the intramural or isthmic portion leads to tubal infertility.[12] Microscopically, the trapped epithelial spaces produce a complicated gland-like pattern that can simulate malignancy (see Fig. 34.2B).[13]

The lumen is often distended and filled with secretions or pus (**pyosalpinx**) (Fig. 34.3). Massive intraluminal hemorrhage may lead to the formation of **hematosalpinx**, a rare condition that needs to be distinguished from the much more common form secondary to ruptured tubal pregnancy. In chronic inflammatory cases, the tubal wall is markedly fibrotic, and serosal adhesions are prominent. The inflammatory exudate often spreads to the ovary, resulting in the formation of a **tubo-ovarian abscess** and obliteration of the pelvic anatomic relationships (Fig. 34.4). The rupture of such an abscess may lead to localized or generalized peritonitis,[14] and it is recommended that fluid collections of greater than 3 cm be drained laparascopically.[15] **Hydrosalpinx** is generally regarded as the end stage of a purulent salpingitis in which pus has been reabsorbed and replaced by a transudate of plasma.[16] The external gross appearance has been likened to that of a retort (Fig. 34.5). Exceptionally, the involvement is limited to the intramural portion of the tube. The wall is thin and fibrotic, with atrophy or even disappearance of the smooth muscle wall. The epithelium is flat and focally absent.

Pelvic inflammatory disease (PID) is the generic term used for inflammatory processes of this region in which the fallopian tube is the epicenter of the inflammation.[17–19] *Neisseria gonorrhoeae* and chlamydia account for most cases.[20–22] Polymicrobial tuboperitoneal infection (resulting from *Bacteroides fragilis*, peptostreptococci, peptococci, and other organisms) is responsible for most of the remaining cases. In established tubo-ovarian abscesses, the most common agents recovered are coliform organisms. *N. gonorrhoeae* was isolated only once in a series of 93 cases by Mickal et al.[14] This finding, however, does not rule out its role as a possible initiating factor before superinfection has occurred, in view of the fact that isolation of *N. gonorrhoeae* is inversely proportional to the number of episodes of salpingitis.[23]

Tuberculosis of the tube develops by the hematogenous route. Most patients are young, and infertility is common.[24,25] In advanced cases, both tubes are replaced by caseous tuberculous masses (Fig. 34.6). There is often extreme proliferation of the tubal mucosa in association with granulomatous inflammation, and this may lead to a mistaken diagnosis of carcinoma. The endometrium is concomitantly involved in approximately 80% of cases.[26]

Granulomatous inflammation of the tubes can also be produced by *Schistosoma*, *Oxyuris vermicularis*, *Actinomyces*, *Coccidioides immitis*, and other organisms.[27] *Sarcoidosis* and *Crohn disease* may be accompanied by tubal involvement.

Foreign bodies introduced for diagnostic or therapeutic measures can induce a bizarre granulomatous response (Fig. 34.7). Reaction to the *lipiodol* that used to be introduced in the Rubin test may be so proliferative as to resemble a neoplasm. The push of a uterine sound may drive lubricant into the tube, causing *lipoid granulomas*.[28]

Xanthogranulomatous (pseudoxanthomatous) salpingitis is characterized by an expansion of the tubal plicae by an infiltrate of foamy histiocytes (Fig. 34.8). The distinction some authors make between xanthogranulomatous and pseudoxanthomatous salpingitis is probably unwarranted.[29] Some cases may be due to endometriosis, and, therefore, the term "salpingitis" may be inaccurate.[30] Accordingly, some authors refer to it as *pseudoxanthomatous salpingiosis*.[31]

For personal use only. No other uses without permission. Copyright ©2017. Elsevier Inc. All rights reserved.

Figure 34.3 **A** and **B**, Outer aspect and cut surface of pyosalpinx. (**A**, Courtesy of Dr RA Cooke, Brisbane, Australia; from Cooke RA, Stewart B. *Colour Atlas of Anatomical Pathology*. Edinburgh: Churchill Livingstone; 2004; **B**, Courtesy of Dr Pedro J Grases Galofrè; from Grases Galofrè PJ. *Patologia ginecològica. Bases para el diagnòstico morfològico*. Barcelona: Masson; 2002).

Figure 34.4 Fusion of fallopian tube and ovary into a tubo-ovarian abscess.

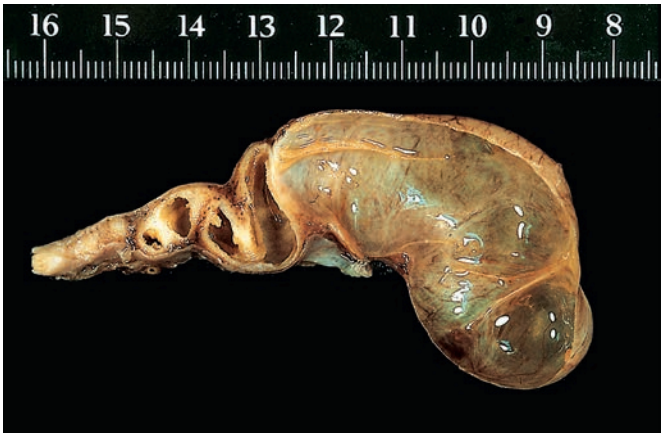

Figure 34.5 Gross appearance of hydrosalpinx showing the typical retort-type appearance. (Courtesy of Dr Pedro J Grases Galofré; from Grases Galofré PJ. *Patología ginecológica. Bases para el diagnóstico morfológico*. Barcelona: Masson; 2002).

Figure 34.6 Large caseating nodules in tuberculous salpingitis. (Courtesy of Dr Pedro J Grases Galofré; from Grases Galofré PJ. *Patología ginecológica. Bases para el diagnóstico morfológico*. Barcelona: Masson; 2002).

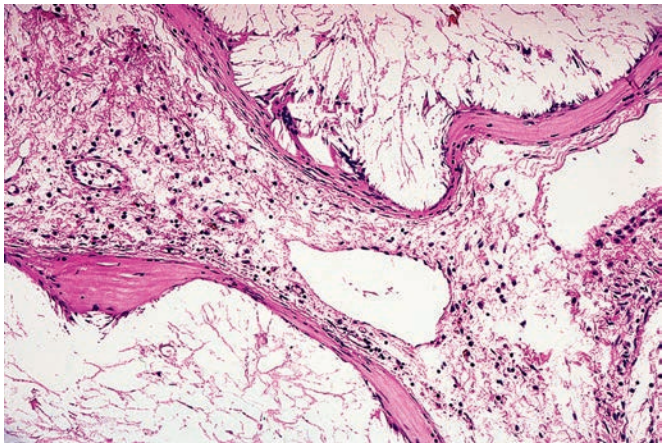

Figure 34.7 Granulomatous reaction to contrast material injected into the fallopian tube.

For personal use only. No other uses without permission. Copyright ©2017. Elsevier Inc. All rights reserved.

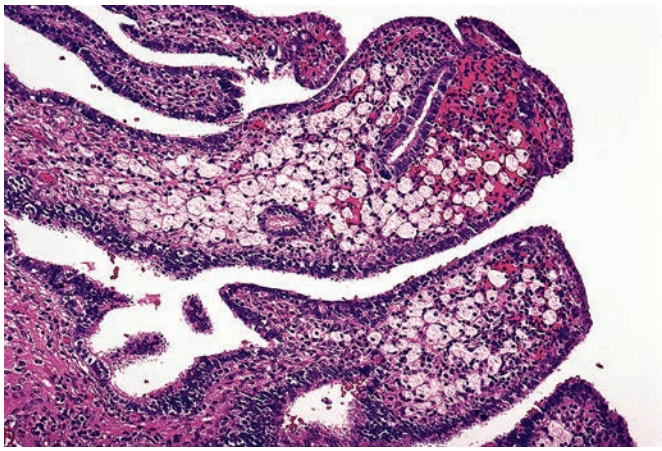

Figure 34.8 Xanthogranulomatous salpingitis.

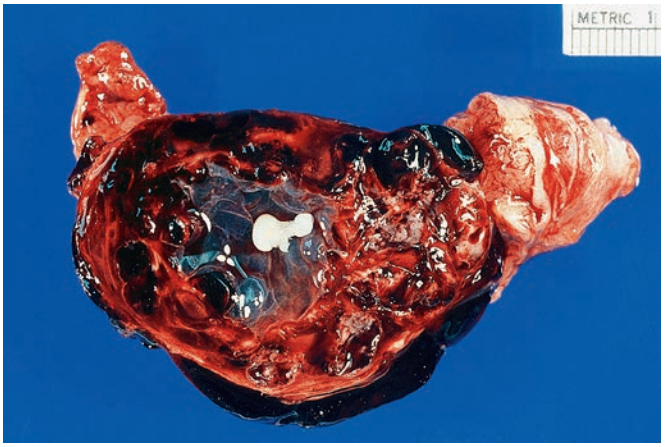

Figure 34.9 Ruptured tubal pregnancy with marked hemorrhage (hematosalpinx). The tiny embryo is identifiable in the center of the clot.

Giant cell arteritis is occasionally found in the tubes, ovaries, and uterus of postmenopausal patients, either as an isolated finding (most frequently) or as a manifestation of a generalized immune-mediated disease.[18,32,33]

Torsion

Torsion of the fallopian tube and ovary is usually secondary to inflammation or tumor, but occasionally it develops in a previously normal organ, the appearance at surgery being that of a hemorrhagic infarct. This phenomenon can occur in adults,[34] as well as in infants and children.[35,36] In children, torsion of the normal adnexa is about one-third as common as torsion of an ovarian cyst or tumor.[37] If the operation (which can be carried out laparoscopically) is done early enough, untwisting of the adnexa may lead to full recovery. Without surgical intervention, cases may resolve spontaneously or result in a necrotic and calcified mass, which may later detach from the uterus. It has been suggested that this complication, when occurring in previously normal adnexa, is due to the fact that the infundibulopelvic ligament extends along the edge of the ovarian ligament so that the tube and ovary hang on a very narrow stalk.

Tubal Pregnancy

The incidence of tubal pregnancy has increased in recent times.[38] It is often the consequence of chronic salpingitis, which leads to inflammatory destruction of the lining folds and retention of the ovum.[39,40] Congenital tubal abnormalities, functional tubal disturbances, and salpingitis isthmica nodosa are responsible for a minority of the cases.[39,41] A history of infertility is associated with an increased risk of tubal pregnancy.[42]

In tubal pregnancy the gestational sac is completely made up of tubal tissue, with no participation from the ovarian or intraligamentary tissues. Following implantation of the ovum in the tubal epithelium (usually in the ampullo-isthmic or midtubal portion), chorionic villi and extravillous (intermediate) trophoblasts can grow predominantly intraluminally[43] or penetrate into the wall, just as they do in the uterus,[39,44] except that the wall here is much thinner. Trophoblastic invasion of muscle and vessels is a common finding of no clinical significance. Hydropic changes and polar trophoblastic proliferation can occur; they should not be overdiagnosed as hydatidiform mole.[45] Changes resembling atherosclerosis may be seen in tubal arteries at the site of implantation, analogous to those occurring in the uterus in orthotopic pregnancy.[46] The fallopian tube epithelium may undergo clear cell hyperplasia.[47] Although a few tubal pregnancies have gone to term,[48] the usual outcome is abortion. The maternal vessels rupture into the gestational sac and cause hematosalpinx (Fig. 34.9). In the presence of a large hematosalpinx, it may be difficult to identify the products of gestation; numerous blocks *from the intratubal blood clot* should be taken for this purpose. Tubal rupture can occur (usually near the end of the second month) because of destruction of the tubal wall by the invading trophoblast, and this may result in severe intra-abdominal hemorrhage. This rupture may result in a brisk reactive proliferation of the mesothelium, with formation of papillae and psammoma bodies. These changes should be recognized as reactive and not misinterpreted as metastases or implants from an ovarian serous neoplasm. The necrotic trophoblastic tissue may be retained for a long time and appear as hyalinized ghost outlines of chorionic villi.[49] On occasion, the appearance of these retained tissues corresponds to that of so-called *placental site nodule*, as described in the uterine corpus.[50,51]

The usual treatment for tubal pregnancy is salpingectomy or laparoscopic salpingostomy (evacuation of the tubal implantation with preservation of the tube).[43,52,53] Conservative laparoscopic procedures for tubal ectopic pregnancy can result in extratubal trophoblastic implants accompanied by persistent beta human chorionic gonadotropin (β-hCG) postoperative serum titers.[54] Exceptionally, omental deposits of fetal parts are seen as a sequela of salpingectomy for ruptured ectopic pregnancy.[55]

Uterine curettings in the presence of a *viable* tubal pregnancy show gestational endometrium, sometimes associated with the Arias-Stella reaction. When trophoblastic elements are not obvious in routinely stained sections from the curettings, some authors have suggested the utility of immunohistochemical stains for hCG, human placental lactogen (hPL), and keratin in the confirmation of an intrauterine pregnancy; however, we have not found this useful in routine practice.[56,57] After death of the embryo or fetus there may be expulsion of the endometrial decidual cast, regeneration of the epithelium, and reestablishment of the cyclic pattern. Therefore, the presence of a proliferative, secretory, or menstrual endometrium in a patient with an adnexal mass does not rule out the possibility of an ectopic pregnancy.

Other Non-Neoplastic Processes

Walthard cell nests are small, glistening, round collections of flat to cuboidal cells with the appearance of urothelium located on the tubal serosa,[58] sometimes accompanied by cystic changes. They are probably of mesothelial rather than müllerian or wolffian nature.[58]

For personal use only. No other uses without permission. Copyright ©2017. Elsevier Inc. All rights reserved.

Figure 34.10 Ectopic decidual reaction in the fallopian tube. This is a very common finding during pregnancy.

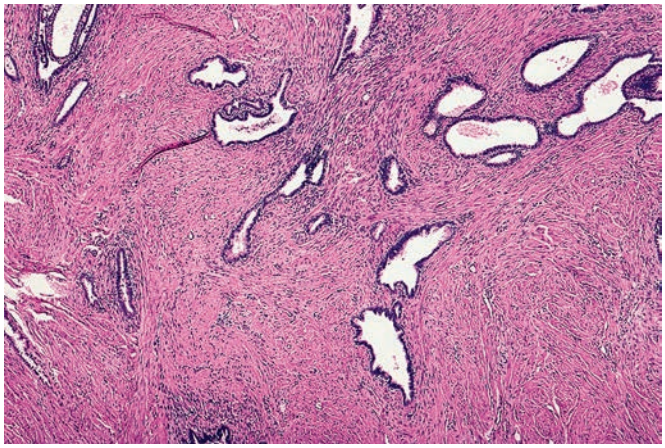

Figure 34.11 Low-power view of salpingitis isthmica nodosa.

They should not be mistaken for serosal implants in patients with ovarian neoplasms.

Paratubal cysts, traditionally known as *hydatids of Morgagni*, are commonly seen as small round cysts attached by a pedicle to the fimbriated end of the tube. Their wall is paper-thin and their content is clear. Occasionally, they attain a large size and may undergo torsion.[59] Most are lined by tubal columnar epithelium containing both ciliated and secretory cells, sometimes projecting in a papillary fashion into the lumen and covered by a thin layer of smooth muscle.[60] Their appearance is consistent with origin from müllerian-type structures. Other paratubal cysts, lined by flat cells and surrounded by a thin fibrous wall, are regarded as of mesothelial origin.[61]

Endometriosis frequently involves the tube in the form of nodules located in the wall or serosa.[62] In this context, it should be mentioned that the most common manifestation of ectopic endometrium in the tube is focal replacement of tubal epithelium by uterine mucosa[63]; however, it is doubtful whether this mucosal colonization of the isthmus by endometrial epithelium and stroma is related to conventional endometriosis; it may, however, be associated with infertility.

Cases have also been reported of the pathogenetically related *müllerianosis* (endometriosis plus endosalpingiosis plus endocervicosis) in the mesosalpinx.[64]

Endosalpingiosis is a term used for the presence of ectopic tubal epithelium beyond the anatomic confines of the tube.[65] It is usually located in the peritoneum but also lymph node and other sites in the pelvis and consists of small cystic structures lined by an epithelium of tubal type cells (secretory, intercalated, and ciliated cells). Since this disorder is often associated with ovarian low-grade serous tumors, it is discussed in more detail in the next chapter.

Decidual reaction of the tubal mucosa is a common finding in specimens of tubal ligation obtained at the time of cesarean section; it appears as small nodular collections of decidual cells covered by a flattened, sometimes inflamed epithelium (Fig. 34.10). Similar changes have been documented following hormonal therapy.[66]

Arias-Stella reaction can occur in the fallopian tube epithelium in association with either orthotopic or tubal pregnancy.[67]

Salpingitis isthmica nodosa is a usually bilateral lesion that presents grossly as a well-delimited nodular enlargement of the isthmic portion of the tube.[65] Microscopically, cystically dilated gland-like formations are seen surrounded by hypertrophic muscle (Fig. 34.11). Radiographic and tridimensional reconstructive studies have shown that the cystic formations are connected to the lumen of the tube. Although classically regarded as the result of inflammation (hence its name), convincing evidence has been presented that its pathogenesis is analogous to that of uterine adenomyosis.[68] It is accompanied by infertility in approximately half of patients, and it may also lead to ectopic pregnancy.[69]

Tubal sterilization procedures can lead to a sequence of morphologic alterations, which include proximal luminal dilation, plical attenuation, chronic inflammation with pseudopolyp formation, and plical thickening in the distal segment.[70] The appearance varies depending on the length of time that has elapsed from the sterilization procedure.[71]

Metaplastic changes of several types can develop in the fallopian tube mucosa. *Transitional cell (urothelial) metaplasia* is usually located in the fimbriae, where it may mimic serous tubal intraepithelial carcinoma (STIC). It is distinguished from it because of the uniformity in cell size and shape, low nucleocytoplasmic ratio, lack of nuclear atypia, presence of nuclear grooves, lack of mitoses, and absence of abnormal p53 expression or increased staining for Ki-67.[72,73] *Eosinophilic metaplasia* (sometimes accompanied by mucinous changes) presenting as a sharply outlined papillary lesion is occasionally encountered; the initial descriptions were in tubes removed in the immediate postpartum period (Fig. 34.12).[74,75] Their behavior is benign. This lesion, which has been called *metaplastic papillary tumor*, is morphologically similar to "papillary tubal hyperplasia," discussed in more detail later. It is an interesting lesion but is not of clinical significance, in that no further treatment is indicated. *Mucinous changes*, probably of metaplastic nature, have also been described in fallopian tubes.[76] When associated with appendiceal and ovarian mucinous tumors, however, we suspect that this is secondary spread to the fallopian tube mucosa, having encountered a case with HER2 amplification in both the primary tumor and fallopian tube mucinous epithelium. It has been described in a patient with Peutz-Jeghers syndrome who had both ovarian mucinous neoplasms and mucinous epithelium in tube and endometrium.[77]

Papillary endothelial hyperplasia can develop in tubal vessels and simulate an angiosarcoma; as in other sites, it is the expression of organization and recanalization of thrombi.[78]

Fallopian tube prolapse into the vaginal apex following vaginal hysterectomy can simulate the microscopic appearance of recurrent endometrial adenocarcinoma or, if the stroma predominates, an aggressive angiomyxoma.[79]

Proliferative Epithelial Lesions

Proliferative epithelial lesions may be found during the microscopic examination of a specimen from tubal ligation or salpingectomy.

For personal use only. No other uses without permission. Copyright ©2017. Elsevier Inc. All rights reserved.

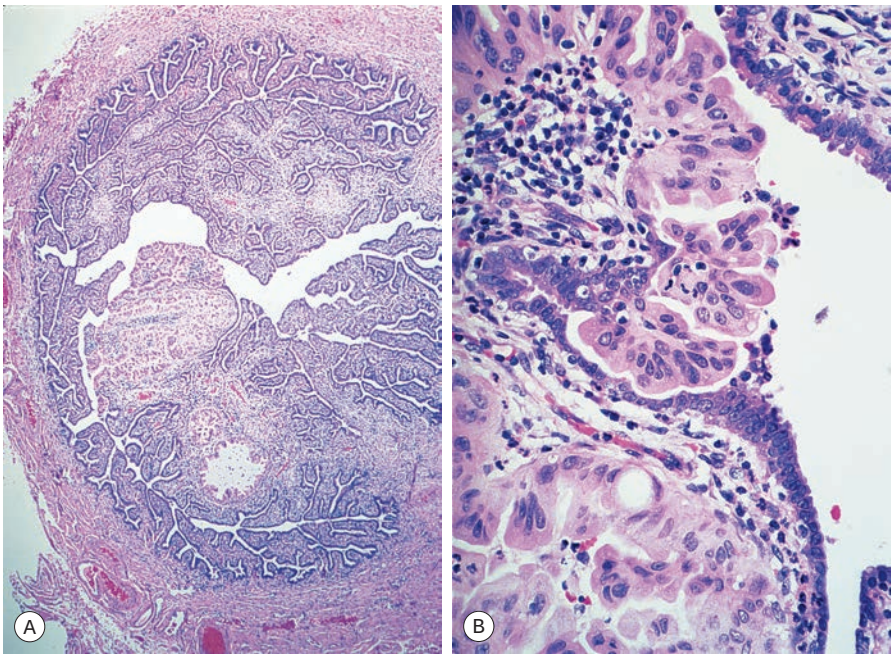

Figure 34.12 **A** and **B**, So-called metaplastic papillary tumor of fallopian tube. This lesion is characterized by a papillary proliferation of acidophilic epithelium. This process is probably the same as "papillary tubal hyperplasia."

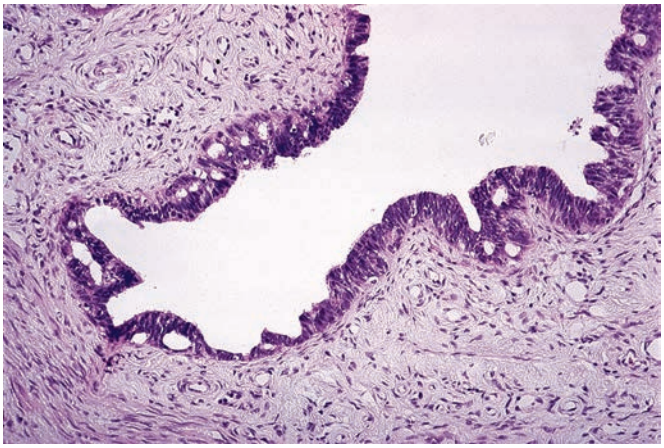

Figure 34.13 Hyperplasia of the tubal epithelium; this is a common incidental finding of no clinical significance and must be distinguished from STIC.

They may show one or more of the following features: nuclear crowding, stratification, loss of polarity, mild to at most moderate atypia, occasional mitoses, acidophilic metaplasia, and papillary formations (Fig. 34.13).[80] Mild degrees of this change are extremely common; in one study, they were found in 83% of all tubes examined and are benign.[81]

Some of the above changes have been found in association with other lesions or situations, such as salpingitis and exogenous or endogenous estrogen stimulation; such florid reactive proliferations have in the past been confused with STIC, but lack the high-grade nuclear atypia of STIC and are completely benign.[81–85]

The term **papillary tubal hyperplasia** has been proposed for a papillary lesion composed of rounded papillary clusters of bland tubal epithelial cells that project into the tubal lumen. They can be seen as an incidental finding in salpingectomy specimens from women with serous borderline tumors, or unassociated with any ovarian pathology, and Kurman et al. have suggested that they are precursors of serous borderline tumor and endosalpingiosis.[86] Such a relationship is highly speculative, as they are not seen in association with most serous borderline tumors. In one case *RAS* mutations were found in an ovarian serous borderline and in papillary tubal hyperplasia present in both fallopian tubes, suggesting a clonal relationship.[87] Morphologically, papillary tubal hyperplasia appears to be the same as the metaplastic papillary tumor, described originally by Scully and colleagues as a rare incidental and benign finding in the fallopian tube. It is likely that papillary tubal hyperplasia is more commonly encountered now that fallopian tubes are being more carefully examined, but they remain distinctly uncommon and their relationship, if any, low-grade serous neoplasia remains to be elucidated.

Carcinoma

Traditionally, primary carcinoma of the fallopian tube has been regarded as very rare, accounting for approximately 1% of primary genital tract malignancies.[88] This figure, however, was based on diagnostic criteria that reserved the diagnosis of primary fallopian tube carcinoma for cases where there was minimal ovarian involvement; the presence of ovarian mass(es) resulted in tumors being designated as primary ovarian carcinoma.[89] These criteria are based on the so-called dominant mass theory, which has been thoroughly discredited. For example, ovarian involvement associated with mucinous appendiceal neoplasms, gastric carcinoma, colorectal carcinoma, and cervical adenocarcinoma is frequently larger that the primary tumor, and while the associated ovarian tumors were mistakenly considered to be independent primary tumors in the past, they have been convincingly demonstrated to be metastasis. A superior approach to identification of primary site is to characterize the anatomic site of unifocal lesions of high-grade serous carcinoma (HGSC), before there is metastatic spread and involvement of multiple sites. In both sporadic and hereditary cases of HGSC the earliest,

For personal use only. No other uses without permission. Copyright ©2017. Elsevier Inc. All rights reserved.

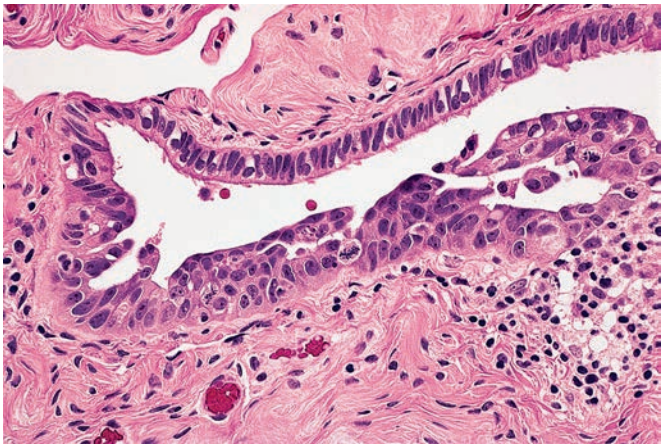

Figure 34.14 Serous Tubal Intraepithelial Carcinoma. Note the abrupt transition from benign tubal epithelium to cells with pleomorphic nuclei. Abnormal p53 immunostaining and a high (>10%) Ki-67 labeling index can help confirm the diagnosis.

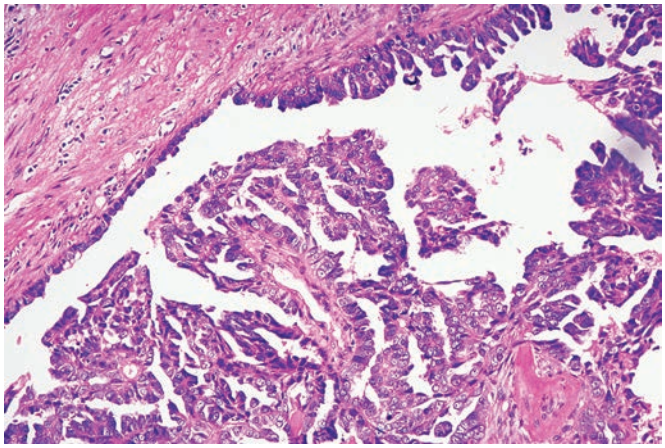

Figure 34.15 High-power view showing the complex papillary architecture that is characteristic of high-grade serous carcinoma.

unifocal lesions are almost always in the fallopian tube.[89,90] There are certainly cases of HGSC where the fallopian tube is normal, even after careful examination, but these are a minority.[90]

Serous Tubal Intraepithelial Carcinoma

The earliest fully malignant lesion of HGSC is STIC. It most commonly, but not exclusively, involves the fimbriae and is characterized by increased nucleus to cytoplasm ratio with rounded nuclei, loss of cell polarity, coarsely clumped chromatin, prominent nucleoli, and the presence of mitotic activity involving non-ciliated (i.e., secretory) cells (Fig. 34.14). The cells are morphologically identical to those seen in HGSC, and the immunophenotype is also the same with WT1 expression, high (usually >50%) Ki-67 labeling index, and abnormal p53 staining. The diagnostic criteria for STIC have since evolved and guidelines for diagnosis have been published, which include the use of p53 and Ki-67 immunostaining[91–93]; high-grade nuclear atypia, together with abnormal p53 staining and a Ki-67 labeling index greater than 10% allow for a reproducible diagnosis of STIC.[93] Adherence to these criteria results in a high degree of interobserver diagnostic agreement. In practice, immunohistochemistry can be reserved for those cases where morphology alone is insufficient for unequivocal diagnosis; a diagnosis of STIC in a patient with advanced stage HGSC can usually be made without resorting to immunostains.

Fallopian tube epithelial lesions with atypia that do not meet all the criteria for STIC are variously referred to as tubal intraepithelial lesion in transition (TILT) or serous tubal intraepithelial lesion (STIL).[94–97] These lesions are of uncertain significance and, in our opinion, these diagnostic terms should not be used in routine practice; additional research is required to determine the clinical significance, if any, of such lesions. Similarly p53 signatures should not be reported. These take the form of small foci of intense p53 nuclear staining involving consecutive secretory cells, most commonly but not exclusively in the fimbriae, in the absence of cytologic atypia.[98] p53 signatures are common in normal fallopian tube and should not be commented on in a diagnostic surgical pathology report.

STIC, if unassociated with invasion or extratubal disease, will usually follow a benign course.[99,100] Exceptions have been reported. As is the case with serous carcinoma of endometrium confined to a polyp, the favorable prognosis of STIC is only true if there has been an adequate staging procedure, as apparently noninvasive STICs have been associated with trans-coelomic spread and stage III disease. Thus, only when there has been confirmation of no extratubal disease should observation be elected in patients with incidentally diagnosed STIC.

Figure 34.16 Fallopian tube filled by high-grade serous carcinoma. This uncommon finding is seen in association with obstruction of the fimbrial end of the tube.

High-Grade Serous Carcinoma

The clinical and pathologic features of HGSC are the same, whether the tumor is considered to have arisen in fallopian tube, ovary, or peritoneum (Fig. 34.15). There has been a shift in our understanding of where most HGSC originate,[89] but it has not impacted significantly on management our outcomes. In keeping with tradition, we will leave a more comprehensive discussion of HGSC for the section on ovarian carcinoma, later in this chapter, even though there is evidence that most arise in the fallopian tube.[89,90] Although most patients with HGSC present with ascites and an adnexal mass, the nature of the adnexal involvement can vary. In patients with predominantly tubal involvement, a history and/or morphologic evidence of coexisting or preceding salpingitis is common, and reduced access by tumor cells to the peritoneal cavity may explain the unusual tumor distribution (Fig. 34.16). Staging of HGSC is the same, whether the tumor is considered to have arisen from fallopian tube and ovary.

For personal use only. No other uses without permission. Copyright ©2017. Elsevier Inc. All rights reserved.

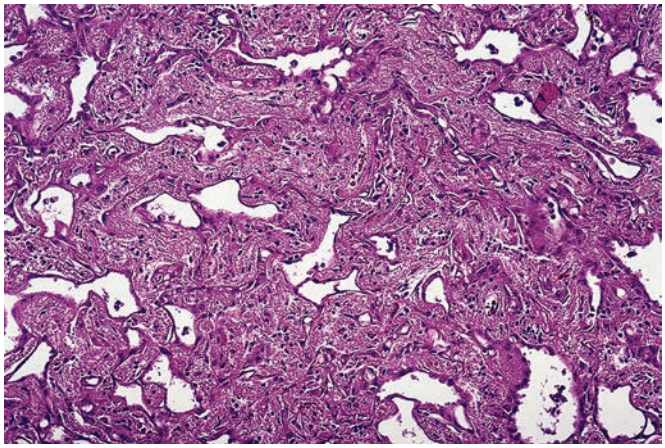

Figure 34.17 Adenomatoid tumor of fallopian tube accompanied by smooth muscle hyperplasia.

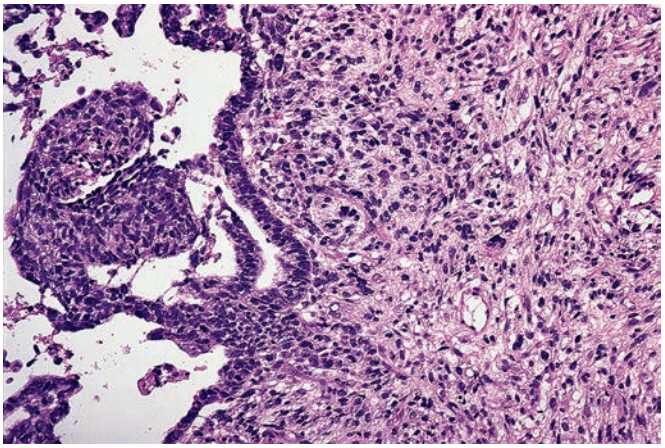

Figure 34.18 Carcinosarcoma (malignant mixed müllerian tumor) of fallopian tube, showing the typical biphasic pattern.

Other Carcinomas

Although HGSC is most common, all carcinomas reported in the ovary can occur in the fallopian tube, including endometrioid (the second most common type, including spindle cell, oxyphilic, adenoacanthomatous, adenosquamous, and squamous types), mucinous, seromucinous, clear cell, and hepatoid.[11,101–107] The endometrioid carcinomas typically present as intraluminal masses and may microscopically simulate a neoplasm of wolffian origin.[108]

A carcinoma extensively involving both endometrium and tube should be classified as a primary endometrial tumor; serous carcinoma of the endometrium involves the fallopian tube in 20% of cases when the fallopian tube is carefully examined.[109] Such tumors stain as would be expected of endometrial serous carcinoma, with weak or negative WT1 staining, in contrast to the strong WT1 positivity characteristic of tubo-ovarian HGSC.

Borderline epithelial neoplasms have also been described in the fallopian tube. As in the ovary, they can be of serous, endometrioid, or mucinous type.[110,111]

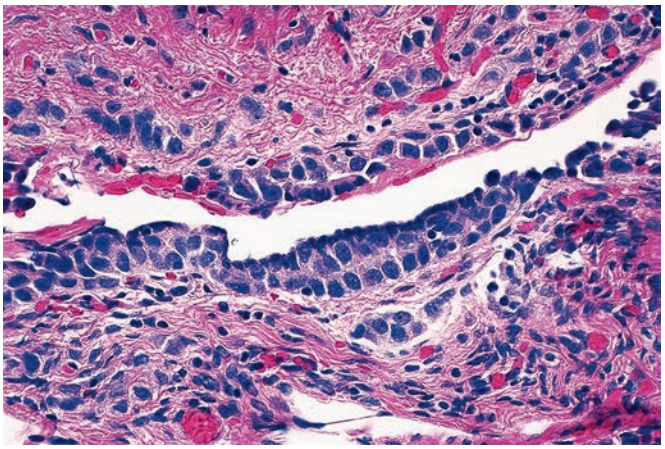

Figure 34.19 Metastatic lobular carcinoma of breast growing beneath tubal epithelium.

Other Tumors

Adenomatoid tumor is a benign, usually small lesion that may be found within the wall of the tube or beneath the uterine serosa near a cornu.[112] The gross and microscopic features are identical to those of its epididymal counterpart (see Chapter 27). The ill-defined, seemingly infiltrating margins may lead to a mistaken diagnosis of carcinoma.[113] A marked degree of smooth muscle hyperplasia may be present and obscure the true nature of the lesion (Fig. 34.17). There is now agreement on the basis of ultrastructural and immunohistochemical findings (the latter including positivity for calretinin, WT1, CK5/6, and D2-40[112,114]) that this entity is of mesothelial (rather than wolffian, müllerian, or endothelial) derivation and that it represents a unique variant of benign mesothelioma largely restricted to the genital region,[115,116] as originally postulated by Pierre Masson.

Papillary cystadenoma of the mesosalpinx has been seen in patients with von Hippel–Lindau disease.[88] Allelic deletions of the *VHL* gene have been detected in these cases.[117]

Mucinous lesions of the fallopian tubes comprise a wide variety of processes, which include mucinous metaplasia (see earlier), mucinous cystadenoma, "mucinous borderline tumor," and mucinous adenocarcinoma. Some of these lesions have occurred in patients with Peutz-Jeghers syndrome, others in association with in situ or invasive adenocarcinoma of other portions of the female genital tract (such as endocervix), and still others in conjunction with mucinous neoplasms of the appendix.[118,119] It is likely that the latter are tubal metastases or implants of appendiceal primaries.

Approximately 50 cases of tubal **teratomas** have been published, nearly all cystic and benign[120]; one of them contained a *carcinoid tumor* and another was entirely composed of mature thyroid tissue *(struma salpingis)*.[121] Other reported benign tubal tumors, all very rare, are **leiomyoma, hemangioma, adenofibroma,**[122–124] **sex-cord tumor with annular tubules** (associated with endometriosis),[125] and **papilloma**.[121] The latter should be distinguished from the more common papillary hyperplasia associated with inflammation and hyperestrinism.

Malignant tumors other than carcinoma include **carcinosarcoma (malignant mixed müllerian tumor)**[88,124,126–128] (some bilateral[129]) (Fig. 34.18), **leiomyosarcoma**, **gestational choriocarcinoma**,[130] and **synovial sarcoma**.[131] The first three tumor types resemble, grossly and microscopically, their more common uterine counterparts; tubal extension from the latter should always be considered in the differential diagnosis. Tubal involvement by **malignant lymphoma** is always the expression of systemic disease. Most **metastases** to the tube originate from other genital organs (Fig. 34.19).[111]

For personal use only. No other uses without permission. Copyright ©2017. Elsevier Inc. All rights reserved.

Tumors and Tumorlike Conditions of Broad and Round Ligaments

The **round and broad ligaments** are only rarely the site of primary disease.[107,132] **Striated muscle heteroplasia** is an inconsequential incidental finding, thought to represent aberrant persistence of gubernacular rhabdomyoblasts.[133]

Cystic formations derived from müllerian or mesonephric (wolffian) rests can be found in or around the broad ligament.

Wolffian tumor (female adnexal tumor of probable wolffian origin) is a distinctive lesion originally described in the broad ligament and subsequently also recognized in the ovary. In its most typical form, it is seen within the leaves of the broad ligament or hanging on a pedicle from it or the fallopian tube. Grossly, it is predominantly solid. Microscopically, it is composed of epithelial cells growing in diffuse, trabecular, and tubular patterns (Fig. 34.20). Mitotic activity and capsular invasion may be present, but the prognosis is generally good.[134,135] The differential diagnosis of wolffian tumor includes endometrioid carcinoma and sex cord–stromal tumor. The presence in the broad ligament is a finding in favor of wolffian tumor. Caution must be used in interpretation of immunostains as there is often expression of sex cord–stromal markers, and inconsistent expression of markers of mesonephric differentiation, such as GATA3.

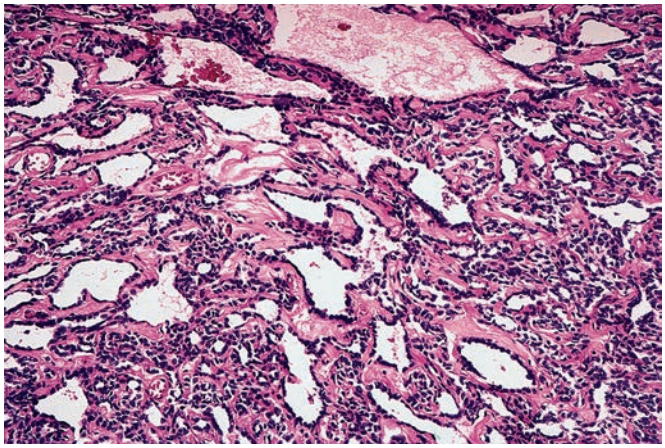

Figure 34.20 Wolffian tumor of the broad ligament. The sieve-like low-power appearance is characteristic.

Other tumors and tumorlike conditions that can be found in the broad ligament unassociated with either uterine or ovarian disease are *endometriosis* (including the possibly related condition known as uterus-like mass)[136]; *borderline serous tumors*[137]; *serous*, *endometrioid*, *clear cell*, and *mucinous carcinomas*[138,139]; *papillary cystadenomas* and other neoplasms associated with von Hippel–Lindau disease[140,141]; *ependymoma*[142]; *smooth muscle tumors*; and other types of *mesenchymal neoplasm*. Some of the carcinomas of this region are thought to arise from foci of endometriosis.[139]

References

1. Hershlag A, Seifer DB, Carcangiu ML, et al. Salpingoscopy. Light microscopic and electron microscopic correlations (published erratum appears in Obstet Gynecol 1991 May; 77: 809–810). *Obstet Gynecol*. 1991;77: 399-405.
2. Hendrickson MR, Atkins KA, Kempson RL. Uterus and fallopian tubes. In: Mills SE, ed. *Histology for Pathologists*. 3rd ed. Philadelphia: Lippincott Williams and Wilkins; 2007:1011-1062.
3. Bruns DE, Mills SE, Savory J. Amylase in fallopian tube and serous ovarian neoplasms. Immunohistochemical localization. *Arch Pathol Lab Med*. 1982;106:17-20.
4. George SH, Milea A, Shaw PA. Proliferation in the normal FTE is a hallmark of the follicular phase, not BRCA mutation status. *Clin Cancer Res*. 2012;18:6199-6207.
5. Nassberg S, McKay DG, Hertig AT. Physiologic salpingitis. *Am J Obstet Gynecol*. 1954;67:130-137.
6. Rubin A, Czernobilsky B. Tubal ligation. A bacteriologic, histologic and clinical study. *Obstet Gynecol*. 1970;36:199-203.
7. Hunt JL, Lynn AA. Histologic features of surgically removed fallopian tubes. *Arch Pathol Lab Med*. 2002;126:951-955.
8. Gardner GH, Greene RR, Peckham B. Normal and cystic structures of the broad ligament. *Am J Obstet Gynecol*. 1948;55:917-939.
9. Charonis G, Larsson PG. Prolonged use of intrauterine contraceptive device as a risk factor for tubo-ovarian abscess. *Acta Obstet Gynecol Scand*. 2009;88:680-684.
10. Seidman JD, Sherman ME, Bell KA, et al. Salpingitis, salpingoliths, and serous tumors of the ovaries: is there a connection? *Int J Gynecol Pathol*. 2002;21:101-107.
11. Thor AD, Young RH, Clement PB. Pathology of the fallopian tube, broad ligament, peritoneum, and pelvic soft tissues. *Hum Pathol*. 1991;22:856-867.
12. Fortier KJ, Haney AF. The pathologic spectrum of uterotubal junction obstruction. *Obstet Gynecol*. 1985;65:93-98.
13. Cheung ANY, Young RH, Scully RE. Pseudocarcinomatous hyperplasia of the fallopian tube associated with salpingitis. A report of 14 cases. *Am J Surg Pathol*. 1994;18:1125-1130.
14. Mickal A, Sellmann AH, Beebe JL. Ruptured tuboovarian abscess. *Am J Obstet Gynecol*. 1968;100:432-436.
15. Brun JL, Graesslin O, Fauconnier A, et al. Updated French guidelines for diagnosis and management of pelvic inflammatory disease. *Int J Gynaecol Obstet*. 2016;134:121-125.
16. David A, Garcia C-S, Czernobilsky B. Human hydrosalpinx. Histologic study and chemical composition of fluid. *Am J Obstet Gynecol*. 1969;105:400-411.
17. McCormack WM. Pelvic inflammatory disease. *N Engl J Med*. 1994;330:115-119.
18. Onuma K, Chu CT, Dabbs GJ. Asymptomatic giant-cell (temporal) arteritis involving the bilateral adnexa: case report and literature review. *Int J Gynecol Pathol*. 2007;26: 352-355.
19. Washington AE, Aral SO, Wolner-Hanssen P, et al. Assessing risk for pelvic inflammatory disease and its sequelae. *JAMA*. 1991;266:2581-2586.
20. Eschenbach DA, Buchanan TM, Pollock HM, et al. Polymicrobial etiology of acute pelvic inflammatory disease. *N Engl J Med*. 1975;29:166-171.
21. Wallace TM, Hart WR. Acute chlamydial salpingitis with ascites and adnexal mass simulating a malignant neoplasm. *Int J Gynecol Pathol*. 1991;10:394-401.
22. Winkler B, Reumann W, Mitao M, et al. Immunoperoxidase localization of chlamydial antigens in acute salpingiris. *Am J Obstet Gynecol*. 1985;152:275-278.
23. Sweet RL, Draper DL, Hadley WK. Etiology of acute salpingitis. Influence of episode number and duration of symptoms. *Obstet Gynecol*. 1981;58:62-68.
24. Francis WAJ. Female genital tuberculosis. A review of 135 cases. *J Obstet Gynaecol Br Commonw*. 1964;71:418-428.
25. Henderson DN, Harkins JL, Stitt JF. Pelvic tuberculosis. *Am J Obstet Gynecol*. 1966;94:630-633.
26. Nogales-Ortiz F, Tarancón I, Nogales FF Jr. The pathology of female genital tuberculosis. *Obstet Gynecol*. 1979;53:422-428.
27. Erthan Y, Zekioglu O, Ozdemir N, Sen S. Unilateral salpingitis due to enterobious vermicularis. *Int J Gynecol Pathol*. 2000;19:188-189.
28. Elliott GB, Brody H, Elliott KA. Implications of "lipoid salpingitis". *Fertil Steril*. 1965;16:541-548.
29. Kostopoulou E, Daponte A, Kallitsaris A, et al. Xanthogranulomatous salpingitis: report of three cases and comparison with a case of pseudoxanthomatous salpingitis. *Clin Exp Obstet Gynecol*. 2008;35:291-294.
30. Furuya M, Murakami T, Sato O, et al. Pseudoxanthomatous salpingitis of the fallopian tube: a report of four cases and a literature review. *Int J Gynecol Pathol*. 2002;21:56-59.
31. Seidman JD, Oberer S, Bitterman P, Aisner SC. Pathogenesis of pseudoxanthomatous salpingiosis. *Mod Pathol*. 1993;6:53-55.
32. Bell DA, Mondschein M, Scully RE. Giant cell arteritis of the female genital tract. A report of three cases. *Am J Surg Pathol*. 1986;10:696-701.
33. Ganesan R, Ferryman SR, Meier L, Rollason TP. Vasculitis of the female genital tract with clinicopathologic correlation: a study of 46 cases with follow-up. *Int J Gynecol Pathol*. 2000;19:258-265.
34. Hansen OH. Isolated torsion of the fallopian tube. *Acta Obstet Gynecol Scand*. 1970;49:3-6.
35. Grosfeld JL. Torsion of normal ovary in the first two years of life. *Am J Surg*. 1969;117:726-727.

For personal use only. No other uses without permission. Copyright ©2017. Elsevier Inc. All rights reserved.

36. James DF, Barber HRK, Graber EA. Torsion of normal uterine adnexa in children. Report of three cases. *Obstet Gynecol*. 1970;35:226-230.
37. Breech LL, Hillard PJ. Adnexal torsion in pediatric and adolescent girls. *Curr Opin Obstet Gynecol*. 2005;17:483-489.
38. Barnhart KT. Ectopic pregnancy. *N Engl J Med*. 2009;361:379-387.
39. Green LK, Kott ML. Histopathologic findings in ectopic tubal pregnancy. *Int J Gynecol*. 1989;8:255-262.
40. Pauerstein CJ, Croxatto HB, Eddy CA, et al. Anatomy and pathology of tubal pregnancy. *Obstet Gynecol*. 1986;67:301-308.
41. Majmudar B, Henderson PH, Semple E. Salpingitis isthmica nodosa. A high-risk for tubal pregnancy. *Obstet Gynecol*. 1983;62:73-78.
42. Yang CP, Chow WH, Daling JR, et al. Does prior infertility increase the risk of tubal pregnancy? *Fertil Steril*. 1987;48:62-66.
43. Stock RJ. Tubal pregnancy. Associated histopathology. *Obstet Gynecol Clin North Am*. 1991;18:73-94.
44. Randall S, Buckley CH, Fox H. Placentation in the fallopian tube. *Int J Gynecol Pathol*. 1987;6:132-139.
45. Burton JL, Lidbury EA, Gillespie AM, et al. Over-diagnosis of hydatidiform mole in early tubal ectopic pregnancy. *Histopathology*. 2001;38:409-417.
46. Blaustein A, Shenker L. Vascular lesions of the uterine tube in ectopic pregnancy. *Obstet Gynecol*. 1967;30:551-555.
47. Tziortziotis DV, Bouros AC, Ziogas VS, Young RH. Clear cell hyperplasia of the fallopian tube epithelium associated with ectopic pregnancy: report of a case. *Int J Gynecol Pathol*. 1997;16:79-80.
48. Chokroverty M, Caballes RL, Gear PE. An unruptured tubal pregnancy at term. *Arch Pathol Lab Med*. 1986;110:250-251.
49. Jacques SM, Qureshi F, Ramirez NC, Lawrence WD. Retained trophoblastic tissue in fallopian tubes: a consequence of unsuspected ectopic pregnancies. *Int J Gynecol Pathol*. 1998;16:219-224.
50. Campello TR, Fittipaldi H, O'Valle F, et al. Extrauterine (tubal) placental site nodule. *Histopathology*. 1998;32:562-565.
51. Nayar R, Snell J, Silverberg SG, Lage JM. Placental site nodule occurring in a fallopian tube. *Hum Pathol*. 1997;27: 1243-1245.
52. Goldrath MH, Platt LD. Treatment of ectopic tubal pregnancies by laparoscopy. *J Am Assoc Gynecol Laparosc*. 2002;9:409-413.
53. Mol F, Mol BW, Ankum WM, et al. Current evidence on surgery, systemic methotrexate and expectant management in the treatment of tubal ectopic pregnancy: a systematic review and meta-analysis. *Hum Reprod Update*. 2008;14:309-319.
54. Doss BJ, Jacques SM, Qureshi F, et al. Extratubal secondary trophoblastic implants: clinicopathologic correlation and review of the literature. *Hum Pathol*. 1998;29: 184-187.
55. Deheragoda MG, Baithun S. Omental deposits of fetal parts as a sequal to salpingectomy for ruptured ectopic pregnancy. *Histopathology*. 2006;49:426.
56. Angel E, Davis JR, Nagle RB. Immunohistochemical demonstration of placental hormones in the diagnosis of uterine versus ectopic pregnancy. *Am J Clin Pathol*. 1985;84:705-709.
57. O'Connor DM, Kurman RJ. Intermediate trophoblast in uterine curettings in the diagnosis of ectopic pregnancy. *Obstet Gynecol*. 1988;72:665-670.
58. Teoh TB. The structure and development of Walthard nests. *J Pathol Bacteriol*. 1953;66:433-439.
59. Wittich AC. Hydatid of Morgagni with torsion diagnosed during cesarean delivery. A case report. *J Reprod Med*. 2002;47:680-682.
60. Bransilver BR, Ferenczy A, Richart RM. Female genital tract remnants. An ultrastructural comparison of hydatid of Morgagni and mesonephric ducts and tubules. *Arch Pathol*. 1973;96:255-261.
61. Samaha M, Woodruff JD. Paratubal cysts. Frequency, histogenesis, and associated clinical features. *Obstet Gynecol*. 1985;65:691-694.
62. Sheldon RS, Wilson RB, Dockerty MB. Serosal endometriosis of fallopian tubes. *Am J Obstet Gynecol*. 1967;99:882-884.
63. Rubin IC, Lisa JR, Trinidad S. Further observations of ectopic endometrium of fallopian tube. *Surg Gynecol Obstet*. 1956;103:469-474.
64. Lim S, Kim JY, Park K, et al. Mullerianosis of the mesosalpinx: a case report. *Int J Gynecol Pathol*. 2003;22:209-212.
65. Jenkins CS, Williams SR, Schmidt GE. Salpingitis isthmica nodosa: a review of the literature, discussion of clinical significance, and consideration of patient management. *Fertil Steril*. 1993;60:599-607.
66. Mills SE, Fechner RE. Stromal and epithelial changes in the fallopian tube following hormonal therapy. *Hum Pathol*. 1980;11:583-584.
67. Milchgrub S, Sandstad J. Arias-Stella reaction in fallopian tube epithelium. A light and electron microscopic study with a review of the literature. *Am J Clin Pathol*. 1991;95:892-895.
68. Benjamin CL, Beaver DC. Pathogenesis of salpingitis isthmica nodosa. *Am J Clin Pathol*. 1951;21:212-222.
69. Majmudar B, Henderson PH, Semple E. Salpingitis isthmica nodosa. A high-risk for tubal pregnancy. *Obstet Gynecol*. 1983;62:73-78.
70. Rubin A, Czernobilsky B. Tubal ligation. A bacteriologic, histologic and clinical study. *Obstet Gynecol*. 1970;36:199-203.
71. Stock RJ. Histopathologic changes in fallopian tubes subsequent to sterilization procedures. *Int J Gynecol Pathol*. 1983;2:13-27.
72. Egan AJM, Russell P. Transitional (urothelial) cell metaplasia of the fallopian tube mucosa: morphological assessment of three cases. *Int J Gynecol Pathol*. 1996;15:72-76.
73. Rabban JT, Crawford B, Chen LM, et al. Transitional cell metaplasia of fallopian tube fimbriae: a potential mimic of early tubal carcinoma in risk reduction salpingo-oophorectomies from women with BRCA mutations. *Am J Surg Pathol*. 2009;33:111-119.
74. Bartnik J, Powell WS, Moriber-Katz S, Amenta PS. Metaplastic papillary tumor of the fallopian tube. Case report, immunohistochemical features, and review of the literature. *Arch Pathol Lab Med*. 1989;113:545-547.
75. Saffos RO, Rhatigan RM, Scully RE. Metaplastic papillary tumor of the fallopian tube – a distinctive lesion of pregnancy. *Am J Clin Pathol*. 1980;74:232-236.
76. Wong AK, Seidman JD, Barbuto DA, et al. Mucinous metaplasia of the fallopian tube: a diagnostic pitfall mimicking metastasis. *Int J Gynecol Pathol*. 2011;30:36-40.
77. Song SH, Lee JK, Saw HS, et al. Peutz-Jeghers Syndrome with multiple genital tract tumors and breast cancer: a case report with a review of literatures. *J Korean Med Sci*. 2006;21:752-757.
78. Safneck JR, Alguacil-Garcia A, Paraskevas M. Papillary endothelial hyperplasia of adnexal vasculature. *Histopathology*. 1996;28:157-161.
79. Varnholt H, Otis CN, Nucci MR, Johari VP. Fallopian tube prolapse mimicking aggressive angiomyxoma. *Int J Gynecol Pathol*. 2005;24:292-294.
80. Moore SW, Enterline HT. Significance of proliferative epithelial lesions of the uterine tube. *Obstet Gynecol*. 1975;45:385-390.
81. Yanai-Inbar I, Siriaunkgul S, Silverberg SG. Mucosal epithelial proliferation of the fallopian tube. A particular association with ovarian serous tumor of low malignant potential? *Int J Gynecol Pathol*. 1995;14:107-113.
82. Colgan TJ. Challenges in the early diagnosis and staging of fallopian-tube carcinomas associated with BRCA mutations. *Int J Gynecol Pathol*. 2003;22:109-120.
83. Piek JM, van Diest PJ, Zweemer RP, et al. Dysplastic changes in prophylactically removed fallopian tubes of women predisposed to developing ovarian cancer. *J Pathol*. 2001;195:451-456.
84. Robey SS, Silva EG. Epithelial hyperplasia of the fallopian tube. Its association with serous borderline tumors of the ovary. *Int J Gynecol Pathol*. 1989;8:214-220.
85. Yanai-Inbar I, Silverberg SG. Mucosal epithelial proliferation of the fallopian tube: prevalence, clinical associations, and optimal strategy for histopathologic assessment. *Int J Gynecol Pathol*. 2000;19:139-144.
86. Kurman RJ, Vang R, Junge J, et al. Papillary tubal hyperplasia: the putative precursor of ovarian atypical proliferative (borderline) serous tumors, noninvasive implants, and endosalpingiosis. *Am J Surg Pathol*. 2011;35:1605-1614.
87. Huang WC, Tsai CC, Wei MC, Kuo KT. Mutation analysis of papillary tubal hyperplasia associated with ovarian atypical proliferative serous tumor and low-grade serous carcinoma. *Am J Obstet Gynecol*. 2013;209:e6-e8.
88. Gersell DJ, King TC. Papillary cystadenoma of the mesosalpinx in von Hippel–Lindau disease. *Am J Surg Pathol*. 1988;12:145-149.
89. Singh N, Gilks CB, Wilkinson N, McCluggage WG. The secondary Mullerian system, field effect, BRCA, and tubal fimbria: our evolving understanding of the origin of tubo-ovarian high-grade serous carcinoma and why assignment of primary site matters. *Pathology*. 2015;47(5):423-431.
90. Singh N, Gilks CB, Wilkinson N, McCluggage WG. Assessment of a new system for primary site assignment in high-grade serous carcinoma of the fallopian tube, ovary, and peritoneum. *Histopathology*. 2015;67(3):331-337.
91. Carlson JW, Jarboe EA, Kindelberger D, et al. Serous tubal intraepithelial carcinoma: diagnostic reproducibility and its implications. *Int J Gynecol Pathol*. 2010;29(4):310-314.
92. Vang R, Visvanathan K, Gross A, et al. Validation of an algorithm for the diagnosis of serous tubal intraepithelial carcinoma. *Int J Gynecol Pathol*. 2012;31(3):243-253.
93. Visvanathan K, Vang R, Shaw P, et al. Diagnosis of serous tubal intraepithelial carcinoma based on morphologic and immunohistochemical features: a reproducibility study. *Am J Surg Pathol*. 2011;35(12):1766-1775.
94. Mehra K, Mehrad M, Ning G, et al. STICS, SCOUTs and p53 signatures; a new language for pelvic serous carcinogenesis. *Front Biosci (Elite Ed)*. 2011;3:625-634.
95. Morrison JC, Blanco LZ Jr, Vang R, Ronnett BM. Incidental serous tubal intraepithelial carcinoma and early invasive serous carcinoma in the nonprophylactic setting: analysis of a case series. *Am J Surg Pathol*. 2015;39(4):442-453.
96. Mehrad M, Ning G, Chen EY, et al. A pathologist's road map to benign, precancerous, and malignant intraepithelial

For personal use only. No other uses without permission. Copyright ©2017. Elsevier Inc. All rights reserved.

proliferations in the fallopian tube. *Adv Anat Pathol*. 2010;17(5):293-302.
97. Vang R, Shih IeM, Kurman RJ. Fallopian tube precursors of ovarian low- and high-grade serous neoplasms. *Histopathology*. 2013;62(1):44-58.
98. Folkins AK, Jarboe EA, Saleemuddin A, et al. A candidate precursor to pelvic serous cancer (p53 signature) and its prevalence in ovaries and fallopian tubes from women with BRCA mutations. *Gynecol Oncol*. 2008;109(2):168-173.
99. Chay WY, McCluggage WG, Lee CH, et al. Outcomes of Incidental Fallopian Tube High-Grade Serous Carcinoma and Serous Tubal Intraepithelial Carcinoma in Women at Low Risk of Hereditary Breast and Ovarian Cancer. *Int J Gynecol Cancer*. 2016;26(3):431-436.
100. Wethington SL, Park KJ, Soslow RA, et al. Clinical outcome of isolated serous tubal intraepithelial carcinomas (STIC). *Int J Gynecol Cancer*. 2013;23(9):1603-1611.
101. Cheung A, So K, Ngan H, Wong L. Primary squamous cell carcinoma of fallopian tube. *Int J Gynecol Pathol*. 1994;13:92-95.
102. De la Torre FJ, Rojo F, Garcia A. Clear cells carcinoma of fallopian tubes associated with tubal endometriosis. Case report and review. *Arch Gynecol Obstet*. 2002;266:172-174.
103. Fukunaga M, Fujiwara Y, Naito Z. Hepatoid carcinoma with serous component of the fallopian tube: a case report with immunohistochemical and ultrastructural studies. *Int J Gynecol Pathol*. 2006;25:233-237.
104. Gilks CB, Irving J, Kobel M, et al. Incidental nonuterine high-grade serous carcinomas arise in the fallopian tube in most cases: further evidence for the tubal origin of high-grade serous carcinomas. *Am J Surg Pathol*. 2015;39(3):357-364.
105. Navani SS, Alvarado-Cabrero I, Young RH, Scully RE. Endometrioid carcinoma of the fallopian tube: a clinicopathologic analysis of 26 cases. *Gynecol Oncol*. 1996;63:371-378.
106. Voet RL, Lifshitz S. Primary clear cell adenocarcinoma of the fallopian tube. Light microscopic and ultrastructural findings. *Int J Gynecol Pathol*. 1982;1:292-298.
107. Young RH. Neoplasms of the fallopian tube and broad ligament: a selective survey including historical perspective and emphasising recent developments. *Pathology*. 2007;39:112-124.
108. Daya D, Young RH, Scully RE. Endometrioid carcinoma of the fallopian tube resembling an adnexal tumor of probable wolffian origin. A report of six cases. *Int J Gynecol Pathol*. 1992;11:122-130.
109. Kommoss F, Faruqi A, Gilks CB, et al. Uterine Serous Carcinomas Frequently Metastasize to the Fallopian Tube and Can Mimic Serous Tubal Intraepithelial Carcinoma. *Am J Surg Pathol*. 2017;41(2):161-170.
110. Zheng W, Wolf S, Kramer EE, et al. Borderline papillary serous tumor of the fallopian tube. *Am J Surg Pathol*. 1996;20:30-35.
111. Mazur MT, Hsueh S, Gersell DJ. Metastases to the female genital tract. Analysis of 325 cases. *Cancer*. 1984;53:1978-1984.
112. Sangoi AR, McKenney JK, Schwartz EJ, et al. Adenomatoid tumors of the female and male genital tracts: a clinicopathological and immunohistochemical study of 44 cases. *Mod Pathol*. 2009;22:1228-1235.
113. Youngs LA, Taylor HB. Adenomatoid tumors of the uterus and fallopian tube. *Am J Clin Pathol*. 1967;48:537-545.
114. Schwartz EJ, Longacre TA. Adenomatoid tumors of the female and male genital tracts express WT1. *Int J Gynecol Pathol*. 2004;23:123-128.
115. Mackay B, Bennington JL, Skoglund RW. The adenomatoid tumor. Fine structural evidence for a mesothelial origin. *Cancer*. 1971;27:109-115.
116. Salazar H, Kanbour A, Burgess F. Ultrastructure and observations on the histogenesis of mesotheliomas "adenomatoid tumors" of the female genital tract. *Cancer*. 1972;29:141-152.
117. Shen T, Zhuang Z, Gersell DJ, Tavassoli FA. Allelic deletion of VHL gene detected in papillary tumors of the broad ligament, epididymis, and retroperitoneum in von Hippel–Lindau disease patients. *Int J Surg Pathol*. 2001;8:207-212.
118. Kanbour AL, Burgess F, Salazar H. Intramural adenofibroma of the fallopian tube light and electron microscopy. *Cancer*. 1973;31:1433-1439.
119. Seidman JD. Mucinous lesions of the fallopian tube. A report of seven cases. *Am J Surg Pathol*. 1994;18:1205-1212.
120. Imachi M, Tsukamoto N, Shigematsu T, et al. Malignant mixed Mullerian tumor of the fallopian tube. Report of two cases and review of literature. *Gynecol Oncol*. 1992;47:114-124.
121. Horn T, Jao W, Keh PC. Benign cystic teratoma of the fallopian tube [letter to the Editor]. *Arch Pathol Lab Med*. 1983;107:48.
122. Bossuyt V, Medeiros F, Drapkin R, et al. Adenofibroma of the fimbria: a common entity that is indistinguishable from ovarian adenofibroma. *Int J Gynecol Pathol*. 2008;27:390-397.
123. Carlson J, Ackerman B, Wheeler J. Malignant mixed mullerian tumor of the fallopian tube. *Cancer*. 1993;71:187-192.
124. Li S, Zimmerman RL, LiVolsi VA. Mixed malignant germ cell tumor of the fallopian tube. *Int J Gynecol Pathol*. 1999;18:183-185.
125. Hoda SA, Huvos AG. Struma salpingis associated with struma ovarii. *Am J Surg Pathol*. 1993;17:1187-1189.
126. Jackson-York GL, Ramzy I. Synchronous papillary mucinous adenocarcinoma of the endocervix and fallopian tubes. *Int J Gynecol Pathol*. 1991;10:394-401.
127. Manes JL, Taylor HB. Carcinosarcoma and mixed müllerian tumors of the fallopian tube. Report of four cases. *Cancer*. 1976;38:1687-1693.
128. Muntz HG, Rutgers JL, Tarraza HM, Fuller AF Jr. Carcinosarcomas and mixed Mullerian tumors of the fallopian tube. *Gynecol Oncol*. 1989;34:109-115.
129. van Dijk CM, Kooijman CD, van Lindert AC. Malignant mixed mullerian tumor of the fallopian tube. *Histopathology*. 1990;16:300-302.
130. Riggs JA, Wainer AS, Hahn GA, Farell MD. Extrauterine tubal choriocarcinoma. *Am J Obstet Gynecol*. 1964;88:637-641.
131. Mitsuhashi A, Nagai Y, Suzuka K, et al. Primary synovial sarcoma in fallopian tube: case report and literature review. *Int J Gynecol Pathol*. 2007;26:34-37.
132. Gardner GH, Greene RR, Peckham B. Tumors of the broad ligament. *Am J Obstet Gynecol*. 1957;73:536-555.
133. Honore LH, Manickavel V. Striated muscle heteroplasia in the uterine round ligament. A report of 30 cases. *Arch Pathol Lab Med*. 1991;115:223-225.
134. Kariminejad MH, Scully RE. Female adnexal tumor of probable wolffian origin. A distinctive pathologic entity. *Cancer*. 1973;31:671-677.
135. Rahilly MA, Williams AR, Krausz T, al Nafussi A. Female adnexal tumour of probable Wolffian origin. A clinicopathological and immunohistochemical study of three cases. *Histopathology*. 1995;26:69-74.
136. Ahmed AA, Swan RW, Owen A, et al. Uterus-like mass arising in the broad ligament: a metaplasia or mullerian duct anomaly? *Int J Gynecol Pathol*. 1998;16:279-281.
137. Aslani M, Ahn GH, Scully RE. Serous papillary cystadenoma of borderline malignancy of broad ligament. A report of 25 cases. *Int J Gynecol Pathol*. 1988;7:131-138.
138. Altaras MM, Jaffe R, Corduba M, et al. Primary paraovarian cystadenocarcinoma. Clinical and management aspects and literature review. *Gynecol Oncol*. 1990;38:268-272.
139. Aslani M, Scully RE. Primary carcinoma of the broad ligament. Report of four cases and review of the literature. *Cancer*. 1989;64:1540-1545.
140. Korn WT, Schatzki SC, Di Sciullo AJ, Scully RE. Papillary cystadenoma of the broad ligament in von Hippel–Lindau disease. *Am J Obstet Gynecol*. 1990;163:596-598.
141. Werness BA, Guccion JG. Tumor of the broad ligament in von Hippel–Lindau disease of probable mullerian origin. *Int J Gynecol Pathol*. 1998;16:282-285.
142. Bell DA, Woodruff JM, Scully RE. Ependymoma of the broad ligament. A report of two cases. *Am J Surg Pathol*. 1984;8:203-209.

For personal use only. No other uses without permission. Copyright ©2017. Elsevier Inc. All rights reserved.

Ovary

35

Blake Gilks

CHAPTER CONTENTS

Normal anatomy, *1367*
Gonadal dysgenesis, *1368*
Cysts, stromal hyperplasia, and other non-neoplastic lesions, *1369*
Inflammation, *1373*
Endometriosis, *1374*
Tumors, *1374*
Classification, *1374*
Epithelial tumors, *1375*
Serous tumors, *1377*
Mucinous tumors, *1382*
Seromucinous tumors, *1385*
Endometrioid tumors, *1385*
Clear cell tumors, *1387*
Brenner tumors, *1389*
Carcinosarcoma and adenosarcoma, *1390*
Mixed and other epithelial tumors, *1390*
Ovarian carcinoma, *1391*
Germ cell tumors, *1392*
Sex cord–stromal tumors, *1401*
Germ cell–sex cord–stromal tumors, *1411*
Tumors not specific to ovary, *1412*
Other primary tumors, *1413*
Metastatic tumors, *1413*

Normal Anatomy

The ovaries are paired pelvic organs located on the sides of the uterus close to the lateral pelvic wall, behind the broad ligament and anterior to the rectum. They are connected to the broad ligament by the mesovarium (a double fold of peritoneum), to the uterine cornu by the ovarian (or utero-ovarian) ligament, and to the lateral pelvic wall by the infundibulopelvic (or suspensory) ligament. During the reproductive period, their average size is $4 \times 2 \times 1$ cm and their average weight is 5–8 g; after menopause, they shrink to one half or less of this size.

The ovarian lymph vessels drain to large trunks that form a plexus at the hilus, from which they travel through the mesovarium to drain into the para-aortic nodes; others drain into the internal iliac, external iliac, interaortic, common iliac, and inguinal nodes.

The ovary is covered by a single layer of modified mesothelium known as *ovarian surface epithelium* or OSE. This epithelium is immunoreactive for keratin, epithelial membrane antigen (EMA), Ber-EP4, CA 125, vimentin, estrogen and progesterone receptors (ER and PR), and follicle-stimulating hormone.[1,2] Epithelial inclusion glands/cysts are commonly found in the cortex. Interestingly, although the OSE is negative for PAX8, the lining cells of the epithelial inclusion cysts are typically PAX8 positive.[3]

The *ovarian stroma* is divided into a cortical and a medullary region, but the boundaries between them are indistinct. It is composed mainly of spindle-shaped stromal cells resembling fibroblasts, typically arranged in whorls or a storiform pattern. The cells may contain cytoplasmic lipid and are surrounded by a dense network of reticulin fibers. They are immunoreactive for FOXL2, ER, and PR.[1] Some of these cells have myoid ("myofibroblastic") features and exhibit immunoreactivity for smooth muscle actin and desmin.[4,5] Foci of smooth muscle hyperplasia may be found, most often in perimenopausal or postmenopausal women.[4] Metaplastic bone formation can also occur.[6] Other cells that may be found in the ovarian stroma are luteinized stromal cells (singly or in small nests, mainly in the medulla), decidual cells, nests of cells resembling endometrial stromal cells, mature fat cells, and neuroendocrine cells.[1,6,7]

The life cycle of the *ovarian follicle* includes primordial, maturing (primary, secondary, tertiary, and graafian), and atretic forms, together with corpora lutea and corpora albicantia for those that have reached full maturation. Primordial follicles contain germ cells that have originated from the yolk sac endoderm and migrated into the ovary, where they develop into oogonia and oocytes.[1] The maturing follicle is composed of the oocyte, the granulosa layer, and the two theca layers. *Granulosa cells* lack a reticulum around them and are immunoreactive for vimentin, FOXL2, and ER and show variable/weak immunoreactivity for keratin.[1] They feature small rosettelike formations known as Call–Exner bodies, which contain at their center a deeply eosinophilic filamentous material consisting of excess basal lamina. The stroma-derived *theca cells* form an internal layer (which is typically luteinized) and an external layer (which is very cellular and can simulate a neoplastic process

For personal use only. No other uses without permission. Copyright ©2017. Elsevier Inc. All rights reserved.

Abstract

A broad range of pathologic conditions are encountered in the ovary in routine surgical pathology practice. Indeed, there is no organ in the body that can lay claim to a greater variety of primary neoplasms. This reflects the complex function of the ovary in reproduction, as site of germ cells and their supporting sex cord–stromal cells; both cell types can give rise to benign or malignant tumors. The most common ovarian neoplasms, however, are epithelial. Although the histogenesis of epithelial ovarian tumors of different cell types (histotypes) remains controversial, recent years have seen significant advances and these have solidified the important concept that the different histotypes of epithelial ovarian cancer are distinct diseases. This, in turn, has led to an emphasis on accurate histotype diagnosis by surgical pathologists.

Keywords

Ovary,
neoplasia,
borderline,
carcinoma,
sex cord–stromal,
germ cell.

For personal use only. No other uses without permission. Copyright ©2017. Elsevier Inc. All rights reserved.

when cut tangentially). Internal theca cells are an important site of sex steroid production, as determined indirectly by the immunohistochemical detection of enzymes involved in steroid hormone biosynthesis.[8,9]

The mature *corpus luteum* is a 1.5–2.5-cm round yellow structure with lobulated outlines and a cystic center. Both the granulosa and the theca cells that form it show prominent luteinization. Morphologic criteria for the dating of the corpus luteum have been established.[10] The corpus luteum of pregnancy is characterized by its larger size, bright yellow color, prominent central cavity, and the presence of hyaline droplets and calcification.[1]

At the ovarian hilus, there are clusters of cells analogous to testicular Leydig cells known as *ovarian hilus cells*. They are closely associated with large hilar veins and lymph vessels and may form nodular protrusions within their lumina. They also exhibit an intimate relationship with the nerves of the region.[1,11] They may contain Reinke crystalloids, lipids, and lipochrome pigment. Hyperplasia of these cells is found following the administration of chorionic gonadotropin, in pregnancy, and in the presence of choriocarcinoma.[1]

The *rete ovarii*, present in the ovarian hilus, represents the ovarian counterpart of the rete testis. It consists of a network of clefts, tubules, cysts, and papillae lined by an epithelium of variable height and surrounded by a cuff of spindle cell stroma. This epithelium is immunoreactive for keratin and CA 125.[12]

Walthard cell nests may be cystic or solid. They are located in the mesovarium, in the adjacent mesosalpinx, or within the ovarian hilus and have a lining of transitional/urothelial appearance (sometimes mucin producing), which is probably of mesothelial nature.

The previous description mainly pertains to the fully developed ovary in women of childbearing age. The many modifications exhibited by the prepubertal and postmenopausal ovary are beyond the scope of this chapter. It should be mentioned, however, that prominent cystic follicles are normally seen during the first few months of life and at puberty and that the shrunken postmenopausal ovary ("ovarium gyratum") has thick-walled medullary and hilar vessels (which should not be mistaken for hemangiomas). These atrophic ovaries may also contain clinically inconsequential granulomas and hyaline scars.[1]

The immunohistochemical profiles of the various cell components of the ovary are discussed further in connection with the tumors of the respective structures.

Gonadal Dysgenesis

Patients with gonadal dysgenesis have abnormally developed gonads and infantile sexual development. The conditions mentioned here are mainly those associated with an abnormal sex chromosome constitution ("abnormalities in sex determination"), to be distinguished from those such as male and female pseudohermaphroditism, persistent müllerian duct syndrome (due to a defect in the müllerian inhibiting substance system), and end-organ defects[13] ("abnormalities in genital differentiation").[14,15]

Sometimes, gonadal tissue is biopsied or removed in the course of evaluation of these malformations.[16,17]

Klinefelter syndrome is usually characterized by the karyotype 47,XXY and is further discussed in Chapter 27.

In patients with **gonadal dysgenesis**, either "**pure**" (with a 46,XX or 46,XY karyotype) or associated with the somatic features of **Turner syndrome** (with a 45,XO karyotype), both gonads are represented by a streak of fibrous tissue that resembles ovarian stroma (Fig. 35.1).[18–20] These patients do not seem to have an increased incidence of gonadal tumors (in the absence of Y chromosome specific sequences),[21] but various types of nongonadal neoplasm (such as

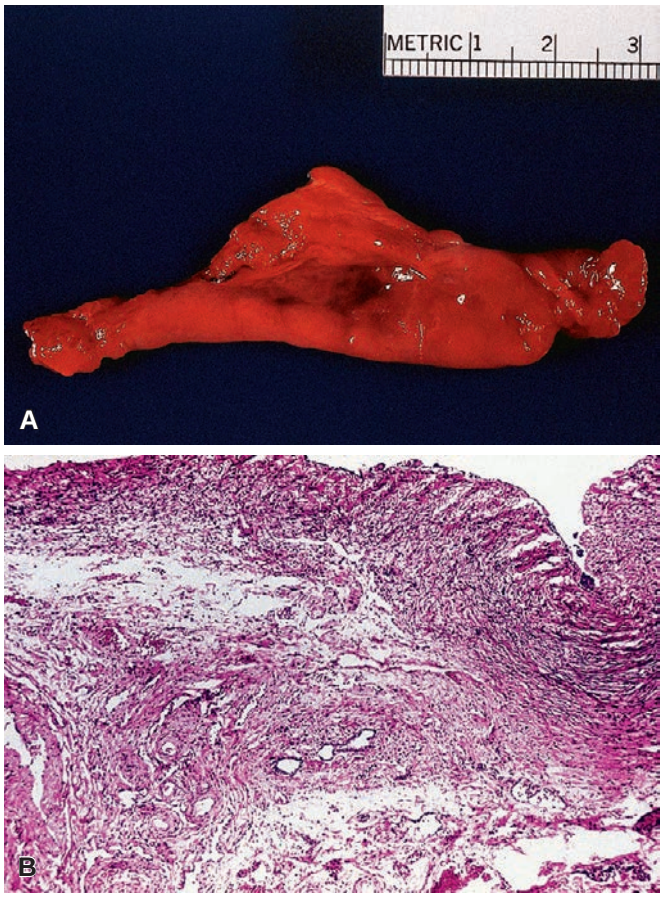

Figure 35.1 Streak Gonad in Turner Syndrome. A, Gross appearance; **B**, microscopic appearance.

atypical polypoid adenomyoma of uterus, leukemia, and soft tissue tumors) have been reported in patients with the syndrome.[22,23] Also, several cases of Turner syndrome have been reported in association with endometrial adenocarcinoma; in some of these, prolonged estrogen therapy had been administered.[24]

In **mixed gonadal dysgenesis** (usually characterized by a 45,X/46,XY mosaicism or 46,XY phenotype), one gonad is represented by a streak gonad or streak testis and a contralateral testis (that is typically cryptorchid) or bilateral streak testis.[25] Individuals with this condition are particularly prone to the development of gonadoblastomas, a complication prevented by early removal of the gonads.[26] The tumors may totally obliterate the testicular elements and thus lead to an incorrect typing of the dysgenesis.

True hermaphrodites may have ovotestes containing both ova and immature seminiferous tubules or other combinations of ovary and testis (Fig. 35.2). [27–29] The most common karyotypes are 46,XX (60%), 46,XY (12%), and mosaic (28%). Multiple tumors can occur in these gonads.[30]

The familial syndrome of **testicular feminization** is the most common type of male pseudohermaphroditism. It occurs in individuals with a normal male chromosome constitution with an end-organ defect (androgen insensibility). It is characterized by the presence of several well-developed female secondary sex characteristics. These patients consult a gynecologist because of amenorrhea or sterility. They are found to have a vagina, no uterus, and bilateral cryptorchid testes. The latter often contain nodular masses of immature tubules that should not be confused with Sertoli–Leydig cell tumor (Fig. 35.3).[31,32] The syndrome is of further clinical importance because

For personal use only. No other uses without permission. Copyright ©2017. Elsevier Inc. All rights reserved.

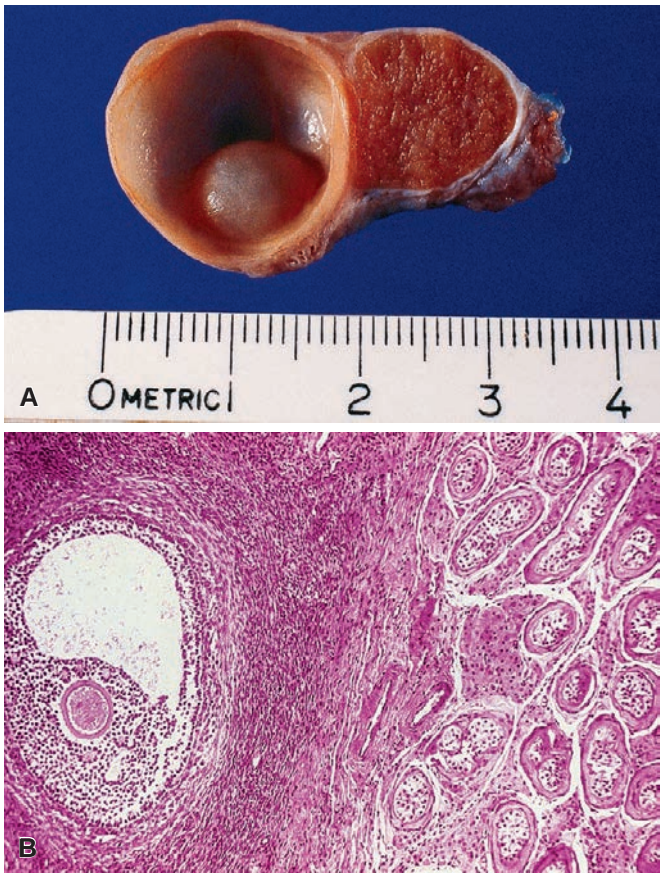

Figure 35.2 Ovotestis in True Hermaphroditism. A, Gross appearance. The testicular component is represented by the solid nodule, whereas the ovarian component has a largely cystic appearance. **B**, Microscopic appearance of the two components.

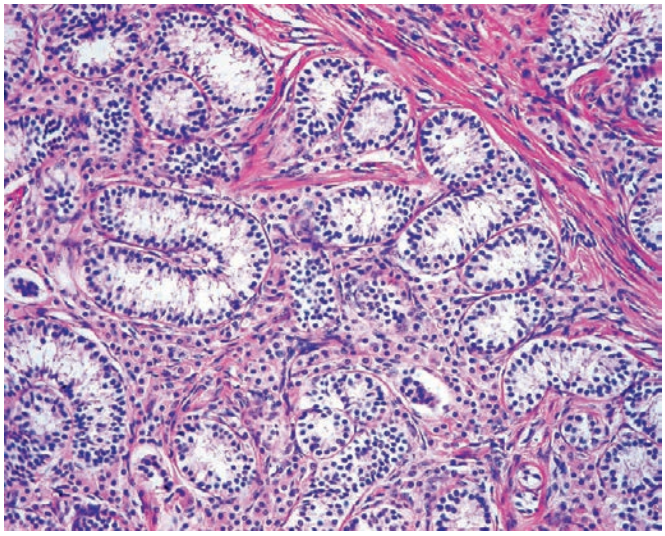

Figure 35.3 Immature testicular tubules in testicular feminization syndrome.

of the eventual occurrence of malignant tumors in the cryptorchid testes of approximately 9% of these patients. For this reason, the testes should be removed after puberty and supplemental estrogen therapy given. A classification of disorders of sexual development is presented in Table 35.1.

Cysts, Stromal Hyperplasia, and Other Non-Neoplastic Lesions

Ovarian diseases of surgical importance can be broadly divided into non-neoplastic cysts, inflammations, and neoplasms. Non-neoplastic cysts are sufficiently common as to be the norm during the reproductive years; cysts up to 6 cm, detected by ultrasound, can be followed and most will resolve spontaneously, reflecting their functional nature.

Inclusion cysts ("cortical inclusion cysts") are common in older women; they are generally small and multiple and have no clinical significance. Most of them probably arise from invaginations of the surface epithelium, with subsequent loss of the connection with the surface (Fig. 35.4A).[33] Microscopically, they are lined by a flattened, cuboidal, or columnar epithelium; tubal metaplasia is frequent (see Fig. 35.4B). Psammoma bodies may be seen in their lumen or in the adjacent stroma. By definition cortical inclusion cysts are less than 1 cm and if larger they are considered to be serous cystadenomas, if there is tubal epithelium, or benign simple cysts if lined by nondescript flattened or cuboidal epithelium. This rule need not be firmly adhered to; in general, if a cyst is clinically evident it can be designated a cystadenoma or benign simple cyst, while a small cyst that is an incidental finding can be designated an inclusion cyst. This practice reflects the arbitrary nature of the definitions, with a continuum existing between inclusion cyst and serous cystadenoma.

Follicular cysts form by distention of developing or atretic follicles and usually do not exceed 10 cm in diameter (Fig. 35.5). It has been proposed that cystic follicular structures be designated as (normal) *cystic follicles* when measuring less than 2.5 cm and as *follicular cysts* when exceeding this diameter. The latter may occur at any age from infancy to menopause and are asymptomatic in the majority of cases. Occasionally, twisting of the pedicle occurs, with resulting hemorrhagic infarction of the ovary. In children, the cysts may be seen in conjunction with precocious puberty.[34,35] During reproductive life, they may be associated with endometrial hyperplasia and metrorrhagia.[36] The cyst fluid may contain estrogens.

The cyst wall is lined by theca, with or without an inner granulosa layer (Fig. 35.6). The theca layer is frequently luteinized. The granulosa layer may be luteinized after puberty but not before. **Multiple luteinized follicular cysts** (theca–lutein cysts; hyperreactio luteinalis) are common in cases of hydatidiform mole and choriocarcinoma but also have been seen in twin pregnancies and, exceptionally, in uncomplicated single pregnancies (Fig. 35.7).[37] **Large solitary luteinized follicular cyst** is a rare lesion presenting during pregnancy and puerperium, unaccompanied by endocrine abnormalities. The median diameter of this type of cyst is 25 cm.[38] Marked focal atypia is often seen in the luteinized cells of this lesion.[39]

Polycystic (sclerocystic) ovaries are characterized by multiple follicular cysts or cystic follicles with varying degrees of luteinization of the theca interna, and dense fibrosis of the superficial cortex. Evidence of previous ovulation (i.e. corpora lutea or albicantia) is sparse or absent (Fig. 35.8).[40,41] Various clinical manifestations may develop in patients with polycystic ovaries, including amenorrhea and sterility, endometrial hyperplasia, and frank virilism; these fall under the collective designation of polycystic ovary syndrome (PCOS), formerly (and still occasionally) referred to as Stein–Leventhal syndrome. The pathogenesis of PCOS is poorly understood.[38,42–43] These patients have "masculinizing" pituitary and ovarian responses to stimulation by the specific gonadotropin-releasing hormone agonist nafarelin, suggesting that the regulation of the ovarian 17-hydroxylase and C-17,20-lyase activities is abnormal.[44] Dysregulation of 11β-hydroxysteroid dehydrogenase, causing increased oxidation of cortisol to cortisone, has also been documented.[45]

For personal use only. No other uses without permission. Copyright ©2017. Elsevier Inc. All rights reserved.

Table 35.1 Disorders of sexual development

SYNDROME	GONAD	DUCTS	EXTERNAL GENITALIA	PUBERTY	BARR	CHROMOSOMES	HORMONES FSH	HORMONES 17-KS	HORMONES ESTROGEN	REMARKS
Klinefelter	Testis with hyalinized sclerotic tubules and clumped Leydig cells	Male	Male	Normal penis with small testes; partial androgen lack	"True" are chromatin positive, a few are 2+ or 3+	All chromatin positive have 2 Xs and a Y in at least some cells. Chromatin negative are 46,YY	↑↑	N or ↑	N	Affects 1:400 newborn males
Turner	Streak gonad with whorled stroma	Female	Female	No pubertal development; rare cases show mild virilization	50% chromatin negative	Second sex chromosome missing or abnormal in some or all of the cells	↑↑	↓	↓	1:7000 newborns, more common in abortuses; short stature
True hermaphrodite	Ovary and testis	All have uterus, most have tubes too, a few have vasa	Ambiguous but 80% favor the male	80% have gynecomastia, 50% menstruate	80% chromatin positive	60% are 46,XX in blood cells only; Y present in most of the others	N	N	N	—
Mixed gonadal dysgenesis	Streak plus testis or tumor	Female; vas found occasionally	Vary from female (often with clitoromegaly) to male with hypospadias to normal male	Virilization, sometimes complete; breast development only with tumors	Chromatin negative	Almost all are mosaics including XO stem; many have Y-bearing stem as well	↑	N	?	—
Dysgenetic male pseudohermaphroditism	Dysgenetic testis	Mixed male and/or female	Variable virilized	Rarely patients may be fertile	Chromatin negative	Some are XO/XY	↑	N	?	—
Familial male pseudohermaphroditism that ranges from testicular feminization to	Immature infertile testis	No uterus, ± rudimentary vas	Female with short, blind vagina	Breasts develop but sexual hair is missing	Chromatin negative	46,XY	↑ or N	↑ or N	N	Sex-linked recessive or sex-limited autosomal dominant
Reifenstein syndrome	Infertile testis	Male	Male with hypospadias ± cleft scrotum	Androgen lack is evident in incomplete virilization	Chromatin negative	46,XY	↑ or N	↑ or N	?	
Female Pseudohermaphroditism										
1. Congenital adrenal hyperplasia	Ovary	Female	Variably virilized	Amenorrhea with virilization	Chromatin positive	46,XX	N	↑↑	N	Autosomal recessive
2. Nonadrenal	Ovary	Female	Variably virilized	Normal	Chromatin positive	46,XX	N	N	N	Consider maternal exposure to progestins or androgens

↑, Increased; ↑↑, markedly increased; ↓, decreased; *N,* normal.
The summaries under the several headings are necessarily brief; the text should be consulted for details, qualifications, and crucial exceptions.
From Federman DD. *Abnormal Sexual Development. A Genetic and Endocrine Approach to Differential Diagnosis*. Philadelphia: WB Saunders; 1967.

For personal use only. No other uses without permission. Copyright ©2017. Elsevier Inc. All rights reserved.

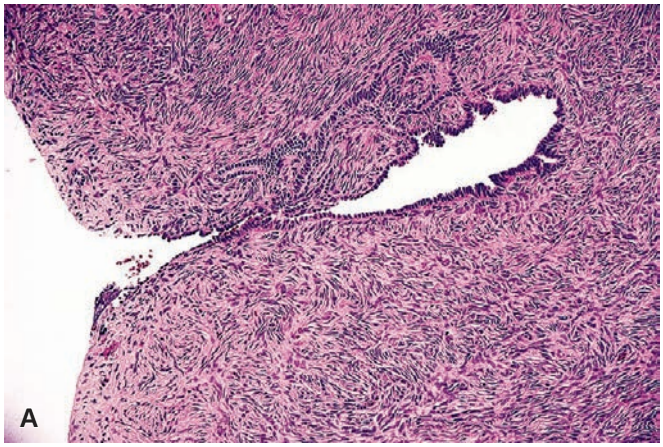

Figure 35.4 Ovarian Inclusion Cysts. A, Cyst being formed through invagination of the surface epithelium. **B**, Multiple inclusion cysts within ovarian cortex. The lining is similar to that of the surface epithelium but tends to be taller and more prominent.

Figure 35.5 Outer appearance of bilateral ovarian follicular cysts.

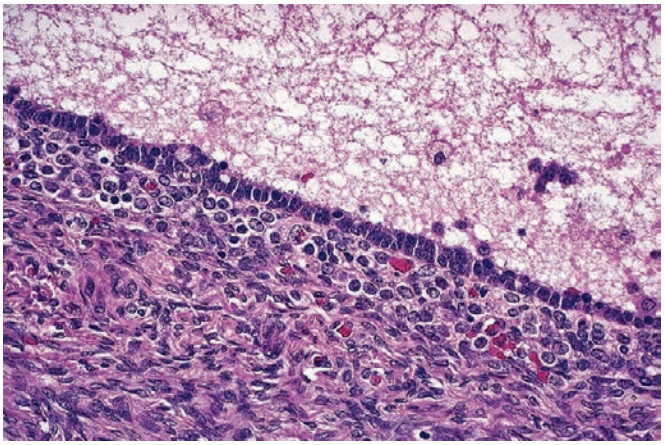

Figure 35.6 Microscopic Appearance of Follicular Cyst. A single layer of granulosa cells is resting on a thick theca layer.

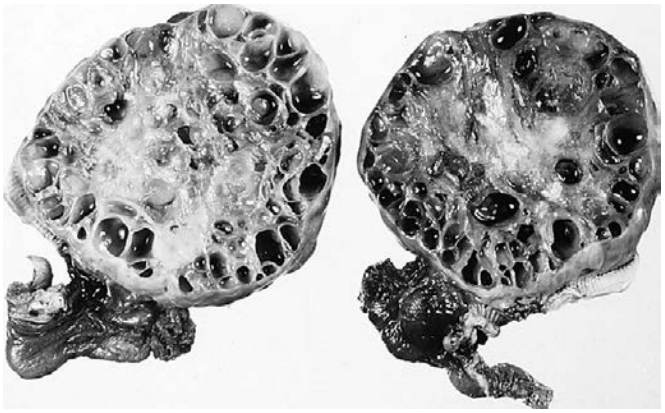

Figure 35.7 Marked bilateral ovarian enlargement due to multiple theca–lutein cysts associated with normal pregnancy. The changes were misinterpreted as representing neoplasms and both ovaries were excised.

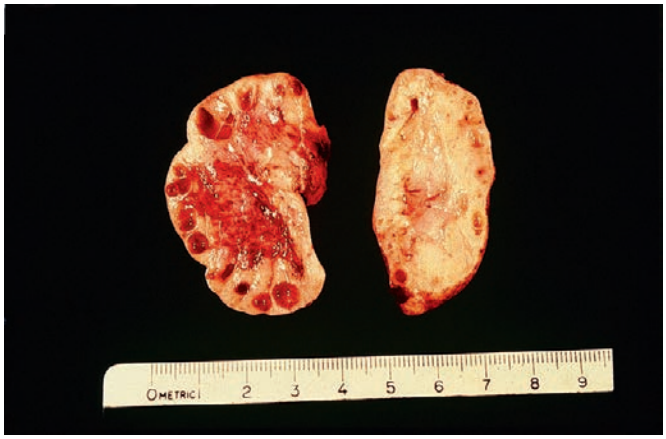

Figure 35.8 Outer aspect and cut surface of ovary in a patient with polycystic ovary syndrome. Note the numerous follicular cysts beneath the ovarian surface and the absence of corpus luteum.

In general, the ovaries of patients with PCOS have the macroscopic and microscopic features of polycystic ovaries just described. The histologic appearance does not correlate well with clinical manifestations in a given patient, and sclerocystic changes can be seen as an incidental finding in asymptomatic patients whose ovaries are removed for unrelated reasons. Polycystic ovaries have also been observed in association with primary hypothyroidism.[46]

Most patients with PCOS will respond favorably, with restoration of the menstrual cycle, to medical treatment, typically metformin (an oral hypoglycemic agent) and an aromatase inhibitor such as letrazole.[47,48] The endometrium of patients with PCOS may become hyperplastic, and endometrial carcinoma may develop against this

For personal use only. No other uses without permission. Copyright ©2017. Elsevier Inc. All rights reserved.

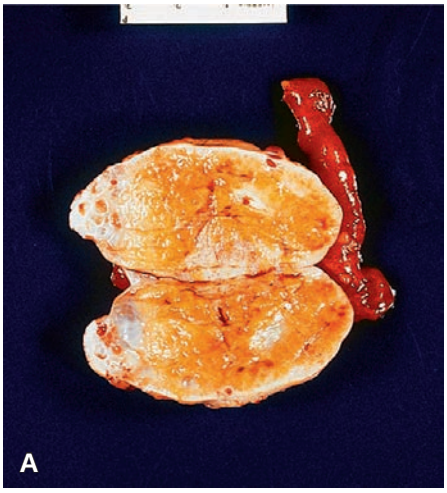

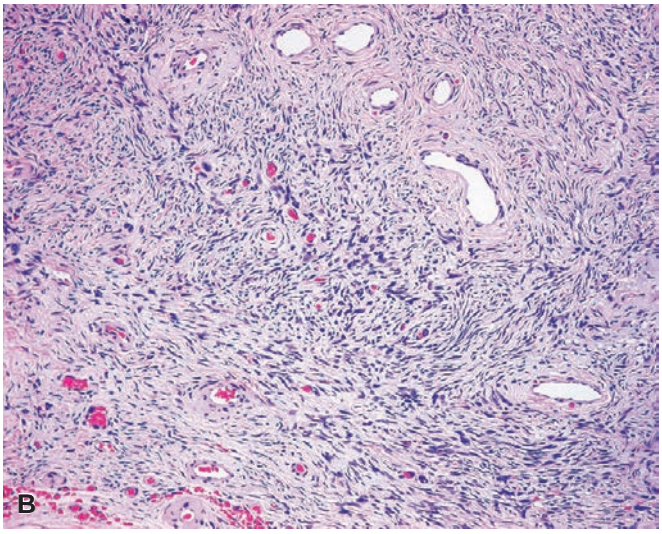

Figure 35.9 Ovarian Stromal Hyperplasia. A, Gross appearance. The cut surface is solid and has a yellowish hue. **B**, Microscopic appearance. The ovarian stroma is hypercellular.

Figure 35.10 Ovary showing a combination of multiple follicular cysts and stromal hyperplasia, providing support for a pathogenetic link between the two processes.

Figure 35.11 Gross Appearance of Corpus Luteum Cyst. The luminal content is typically hemorrhagic.

background, the tumor typically being well differentiated and superficial.[49,50]

Stromal hyperplasia and hyperthecosis is characterized by a diffuse or nodular proliferation of plump ovarian cortical stromal cells encroaching on the medulla (Fig. 35.9).[7] Ovaries involved by stromal hyperplasia typically measure more than 5 cm in greatest dimension. Patchy luteinization of these cells may be present, a finding termed *stromal hyperthecosis*. Stromal hyperplasia and hyperthecosis may be associated with estrogenic or androgenic effects, obesity, hypertension, and an abnormal glucose tolerance test or even frank diabetes. The onset of symptoms may be abrupt, thus simulating a virilizing ovarian tumor. Immunohistochemical studies have shown androgen production by the luteinized stromal cells, suggesting that estrogenic effects in these cases are mediated through peripheral aromatization of these androgens.[51]

The boundaries between polycystic disease and stromal hyperplasia are ill-defined (Fig. 35.10)[41,52]; however, typical stromal hyperplasia lacks cysts and is usually more refractory to therapy.

Corpus luteum cysts are single and usually less than 6 cm in diameter. They may develop at the end of the menstrual cycle or may occur in pregnancy (Fig. 35.11). The cyst wall is composed of luteinized granulosa and theca cell layers. Hyaline bodies and foci of calcification may be found in the cysts associated with pregnancy. The fluid content is often bloody. If the cyst ruptures, hemorrhage into the peritoneal cavity occurs (sometimes over 500 mL), and an erroneous diagnosis of ruptured ectopic pregnancy may be made.[53] It should be remembered that the corpus luteum is normally a cystic structure. The arbitrary diameter of 2.5 cm has been proposed to distinguish the (normal) *cystic corpus luteum* from a *corpus luteum cyst*, in a manner analogous to that employed for follicle-related cystic formations. Distinction between a corpus luteum cyst and a luteinized follicular cyst can be arbitrary; the former diagnosis is favored when the degree of luteinization is similar to that of the cells in a normal corpus luteum.

Ectopic decidual reaction can occur in the ovary during pregnancy and occasionally even in the absence of current or recent pregnancy.

So-called **luteomas of pregnancy** are yellow or orange solid nodules that may reach sizable proportions (Fig. 35.12).[39] They have been typically encountered during cesarean section in multiparous women, sometimes accompanied by a mild degree of virilization.[54,55] If left undisturbed, they will regress after delivery.[56] Microscopically, the lesions are composed of masses of uniform theca–lutein cells (Fig. 35.13). Occasionally, there is an associated granulosa cell proliferation.[57] All of the reported lesions have been benign. It is reasonable to regard them as nodular hyperplasias of theca–lutein

For personal use only. No other uses without permission. Copyright ©2017. Elsevier Inc. All rights reserved.

Figure 35.12 Bilateral pregnancy luteomas in a 29-year-old woman that were discovered incidentally at the time of cesarean section performed for cord prolapse. The tumors bled excessively on manipulation by the surgeon and had to be removed.

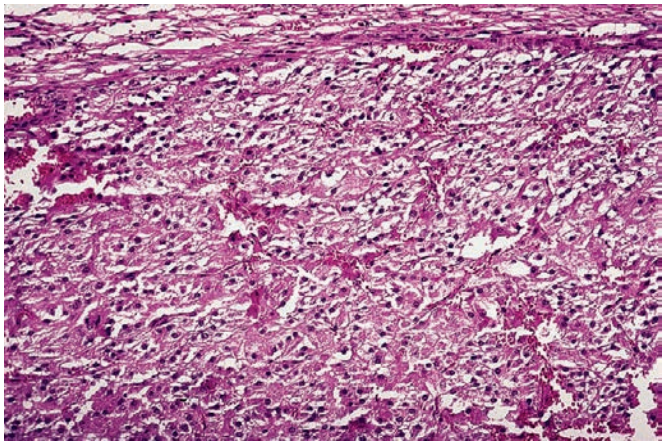

Figure 35.13 Solid growth pattern of pregnancy luteoma.

cells rather than true neoplasms.[55] If pregnancy luteoma is correctly identified by frozen section, no further surgery is necessary. A steroid cell tumor should not be diagnosed based on frozen section of an ovarian mass performed at the time of C-section as it is more likely to be a luteoma of pregnancy, and an incorrect diagnosis of steroid cell tumor may lead to an unnecessary oophorectomy. This scenario illustrates, as well as any example, the importance of having adequate clinical history at the time of intraoperative consultation/frozen section.

Developmental cysts derived from wolffian (mesonephric) and müllerian (paramesonephric) remnants are common in the region of the ovarian hilus. Suffice it to say here that, according to some authors, it is possible to distinguish these two types of tissue—and sometimes the cysts derived from them—on microscopic grounds.[58] Wolffian structures are lined by cuboidal, predominantly nonciliated epithelium resting on a well-developed basement membrane; müllerian formations are lined by generally taller, ciliated and nonciliated epithelium with larger nuclei and resting on an inconspicuous basement membrane. Such a distinction is not clinically important and may not be possible in some cases, and the designation of "Benign parovarian (or paratubal) cyst" may be used. Both may have a smooth muscle coat. According to these criteria and some ultrastructural differences,[59] **hydatids of Morgagni** (pedunculated cysts at the fimbriated end of the fallopian tube) are believed to be of müllerian origin, whereas most **parovarian** and **paratubal cysts** (in the tubo-ovarian ligament) and **Gartner duct cysts** (in the vaginal wall) are thought to arise from wolffian remnants.

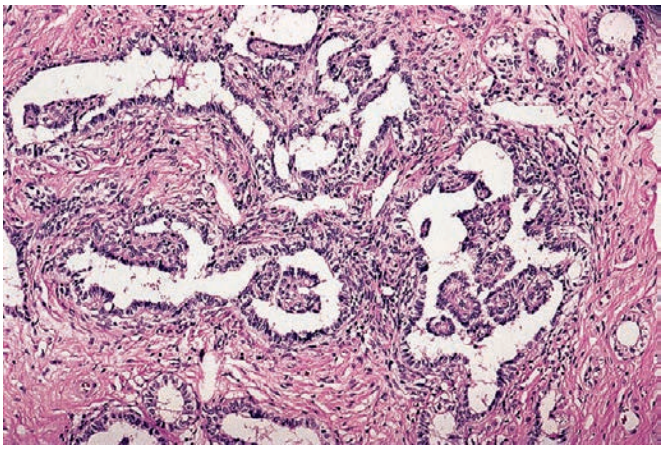

Figure 35.14 Benign hyperplastic changes in rete ovarii. This alteration is of no clinical significance.

Cysts of the rete ovarii are characterized by a hilar position, an epithelial lining of variable height that is usually nonciliated, crevices along the inner surfaces, and a fibromuscular wall that often contains hyperplastic hilus cells.[50] The rete ovarii may also be the site of benign proliferative lesions that have been variously reported as adenomatous hyperplasia[60] and adenoma (Fig. 35.14).[61]

Epidermoid cysts, lined by benign squamous epithelium without evidence of skin adnexal structures or other teratomatous elements, are exceptionally rare and are of uncertain histogenesis.[62–64]

Squamous metaplasia of the OSE accompanied by subjacent fibrosis has been described in patients on long-term peritoneal dialysis.[65]

Amyloidosis can exceptionally present in the form of bilateral ovarian masses.[66]

Supernumerary ovaries are extremely rare.[67] Most of the reported cases have measured less than 1 cm. They should be distinguished from **accessory ovaries**, which are small portions of ovarian tissue situated near—and sometimes connected to—the normally placed organ.[68]

Inflammation

Nonspecific inflammation of the ovary usually spreads from the endometrium and is practically always associated with tubal involvement. A large, loculated cystic mass filled with pus or secretion is often the result, the ovarian stroma forming part of the cystic wall (tubo-ovarian abscess or cyst). Exceptionally, a solid mass rich in foamy macrophages develops in long-standing cases *("xanthogranulomatous oophoritis")*.[69,70]

Granulomatous infections such as tuberculosis occur in the ovary. Invariably this is hematogenous in origin and often also involves the tube and endometrium. In time, the infection may subside and leave a large tubo-ovarian cystic mass. Other infectious agents responsible for granulomatous oophoritis are *Actinomyces* (particularly common after the introduction of intrauterine devices), *Schistosoma*, and *Enterobius vermicularis*. Rarely, *sarcoidosis* and *Crohn disease* involve the ovary, the latter as a result of direct extension from the bowel. *Foreign body granulomas* can occur in the ovarian surface secondarily to talc, cornstarch, carbon pigment (at the site of fulguration surgery),[71] other foreign materials,[72] and keratin; the latter may originate from a ruptured ovarian cystic teratoma or may have spilled through the fallopian tube from an endometrial

For personal use only. No other uses without permission. Copyright ©2017. Elsevier Inc. All rights reserved.

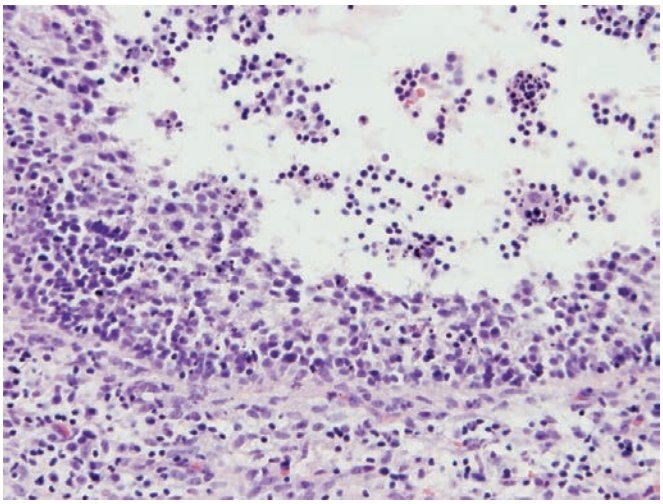

Figure 35.15 Lymphocytic and plasmacytic infiltrate of a developing follicle in autoimmune oophoritis.

Figure 35.16 Inner surface of cyst in a case of ovarian endometriosis. The color is typically brown.

adenocarcinoma of endometrioid type, with squamous differentiation.[73] *Palisading granulomas* of unknown etiology have also been reported, most of them in patients with a history of previous pelvic surgery.[74]

Autoimmune oophoritis is a poorly understood cause of premature ovarian failure characterized microscopically by lymphocytic and plasma cell infiltration in relation to developing follicles but not primordial follicles (Fig. 35.15).[71,75] It results in primary ovarian failure with either primary or secondary amenorrhea.[76,77] Many of the reported cases have been associated with adrenal failure (Addison disease), hypothyroidism, or both conditions.[76,78]

Eosinophilic perifolliculitis is characterized by a predominantly eosinophilic infiltrate around the follicles; it is not clear how this rare disorder relates to autoimmune oophoritis.[79]

Giant cell arteritis occasionally involves the ovary of elderly women; it may occur as an isolated finding (most frequently) or as a component of generalized giant cell arteritis.[80]

Endometriosis

The ovary is the most common site of endometriosis, as defined by the presence of endometrial glands *and* stroma outside the uterus.[81] The pathogenesis of endometriosis remains incompletely understood; suffice it to say that endometriosis shows evidence of clonality and in a minority of cases the epithelium has an activating KRAS mutation.[82,83] Ovarian endometriosis is usually associated with infertility, and it remains active during the childbearing years.[84,85] Pain associated with the menstrual cycle is the most common symptom; infrequently, the disease is complicated by massive ascites or perforation into the peritoneal cavity.[86] Grossly, it usually presents as small, slightly raised, blueberry-like spots on the ovarian surface, often accompanied by fibrous adhesions. In cases with extensive involvement, the entire ovary may be converted into a "chocolate cyst" as a result of repeated hemorrhages (Fig. 35.16). Microscopically, the typical lesions are composed of endometrial glands, endometrial stroma, and fresh and old (hemosiderin-containing) hemorrhagic foci (Fig. 35.17).[87] The endometrial stroma is responsible for the bleeding; it has cells with a "naked nucleus" surrounded by reticulin and typical spiral arterioles, in conjunction with old and recent hemorrhage. Unfortunately, this diagnostic combination of findings is not always present. The more advanced the endometriotic lesion, the more difficult the diagnosis and the greater the number of sections required to make it. Not infrequently, the repeated hemorrhages have totally destroyed the endometrial tissue, the cyst being lined by several layers of hemosiderin-laden macrophages with a thick fibrous wall. Under these circumstances, the most the pathologist can do is to report the case as a hemorrhagic cyst and comment that the changes are "consistent" with those of endometriosis. Sometimes, the lesion is entirely composed of *necrotic pseudoxanthomatous nodules*, to be distinguished from infectious granulomas and necrotic neoplasms (Fig. 35.18).[88] Other morphologic variations of endometriosis include the formation of Liesegang rings,[89] stromal elastosis,[90] and smooth muscle hyperplasia,[91] the latter sometimes resulting in the formation of uterus-like masses.[92]

The ectopic endometrial tissue of endometriosis is subject to most of the influences that affect the intrauterine endometrium. Ovarian endometriosis more often undergoes malignant transformation than endometriotic foci elsewhere in the pelvis. Somewhat confusingly, two different premalignant changes have been described within ovarian endometriosis, and both have been termed "atypical endometriosis." The first consists of cells that do not show significant stratification but which have prominent nuclear atypia (Fig. 35.19).[93–96] These cells are thought to be a precursor of clear cell carcinoma and can have ARID1A mutations and show an immunophenotype intermediate between endometriosis and clear cell carcinoma.[97] The other premalignant change seen in ovarian endometriosis is morphologically identical to atypical endometrial hyperplasia, with glandular crowding and atypia.[98] This is thought to be the precursor of endometrioid carcinoma. Although clear cell and endometrioid carcinomas account for most malignancies arising in endometriosis, a wide range of other malignancies may also be encountered in association with ovarian endometriosis (e.g. carcinosarcoma, adenosarcoma, endometrial stromal sarcoma, seromucinous borderline tumor, and, rarely, serous borderline tumor or low-grade serous carcinoma).

Tumors

Classification

The classification of ovarian tumors is primarily morphologic and based on the cytologic features of the tumor cells. This approach has served us well over the years, with recent molecular studies, for the most part, supporting this morphology-based classification system and demonstrating that it accurately reflects both histogenesis/cell of origin, and the underlying molecular abnormalities of the different

For personal use only. No other uses without permission. Copyright ©2017. Elsevier Inc. All rights reserved.

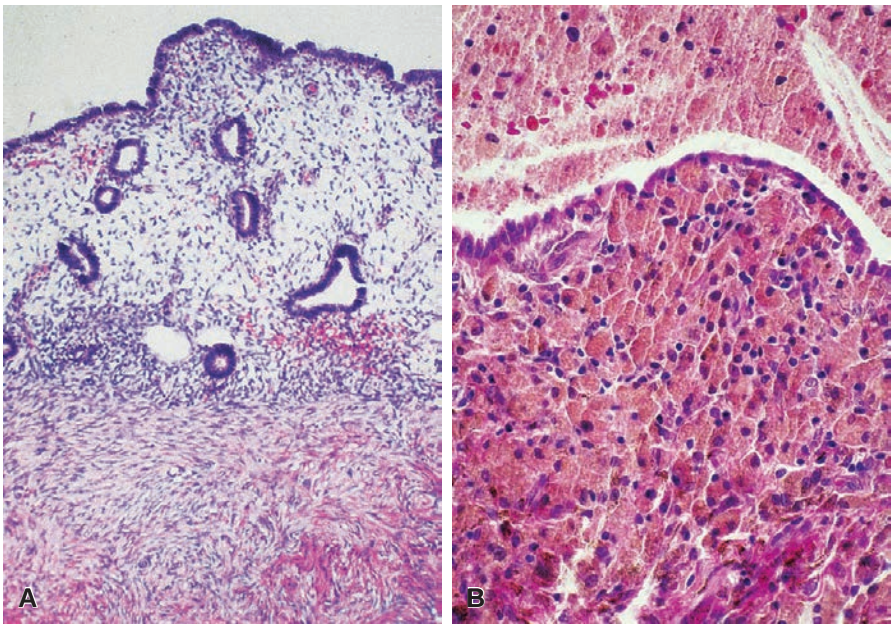

Figure 35.17 **Ovarian Endometriosis. A,** In this area endometrial tissue faithfully reproduces the appearance of normal endometrium, in terms of both glands and stroma. **B,** A more common appearance resulting from repeated hemorrhage and accumulation of hemosiderin-laden macrophages.

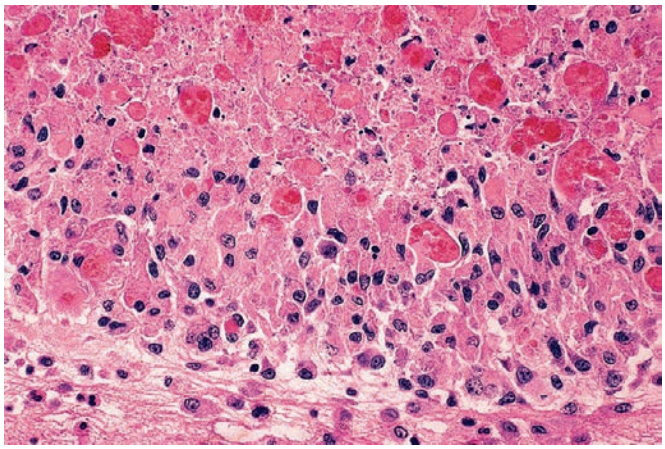

Figure 35.18 Necrotic nodule surrounded by histiocytes in pelvic endometriosis.

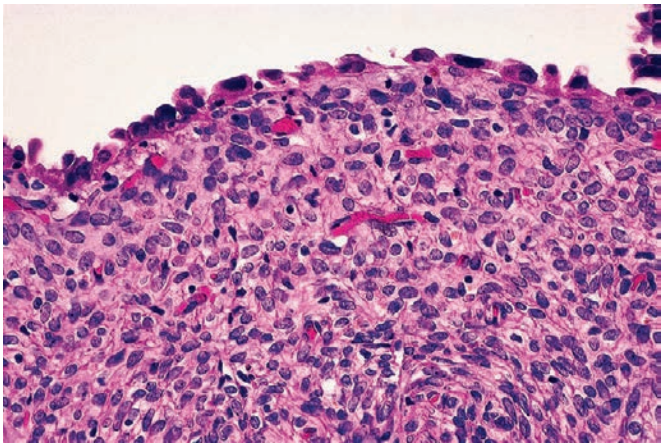

Figure 35.19 Atypia of the cells lining an ovarian endometriotic cyst, a change referred to as atypical endometriosis.

ovarian tumor subtypes.[99] While there have been some minor adjustments made, reflected in the 2014 WHO classification system,[100] the fundamental premise that the ovary contains four major types of tissue, all of which can give rise to a variety of neoplasms, has remained unchanged for decades. These four tissue types are:

1. Epithelium
2. Germ cells
3. Sex cords
4. Ovarian stroma, specialized and nonspecific.

Epithelial Tumors

Overview

Epithelial tumors, numerically the most important group of neoplasms, have traditionally been thought to derive from the OSE[101] and were thus referred to as "surface epithelial" tumors. It is now appreciated that the epithelial tumors of the ovary are of diverse origins, histogenetically, and the cell of origin of each histotype will be discussed in the section devoted to that specific histotype, later in this chapter.

Epithelial ovarian tumors are subclassified based on cell type as **serous, endometrioid, clear cell, mucinous, seromucinous,** or **transitional (Brenner)**.[100] It is now appreciated that the histotype reflects differences in cell of origin and molecular abnormalities, and subclassification based on cell type, or histotype, has taken on increased importance in recent years.[100]

Within each histotype, tumors are further subclassified as **benign, borderline,** or **malignant.** Benign tumors are characterized by epithelium with benign nuclear features and differentiated cytoplasm; for example, the benign serous tumors feature cells with cilia, morphologically identical to the normal ciliated cells of the fallopian tube. Benign epithelial tumors can be further subclassified based on whether they are predominantly cystic, cystic and solid, or

For personal use only. No other uses without permission. Copyright ©2017. Elsevier Inc. All rights reserved.

predominantly solid with fibromatous stroma, as cystadenoma, cystadenofibroma, and adenofibroma, respectively.[99] There is an arbitrary cutoff between cystadenoma and cystadenofibroma, with the latter having at least 25% solid component. This subclassification based on the gross appearance of the tumor is not clinically relevant, beyond allowing correlation with radiologic findings.

The borderline category is characterized by cytologic atypia, but without evidence of invasion, and its existence as a diagnostic entity has been controversial. Although it has been stated that this category is unique to ovarian tumors, other "borderline" tumors do exist, such as low-grade mucinous neoplasm of the vermiform appendix. Attempts have been made to eliminate the borderline category of ovarian epithelial tumors, so that tumors are classified as either benign or malignant[102,103]; however, the borderline category has survived these attempts. The key to the survival of "borderline" as a diagnostic entity can probably be found in its history as a subcategory of ovarian epithelial tumors[104]; it was recognized that there were advanced-stage tumors that did not behave like usual high-stage ovarian carcinoma, and in these patients adjuvant treatment did more harm than good. Creation of a borderline designation for these unusual tumors allowed for a more conservative management to emerge. This is true specifically for serous and seromucinous borderline tumors, where a significant minority of cases (15%–40%) are associated with extra-ovarian implants (i.e. stage II or III), and yet there is a favorable prognosis. Although the borderline category has been extended to the other ovarian histotypes (e.g. clear cell, endometrioid), such tumors are invariably stage I and can be expected to behave in a benign fashion when diagnosed using strict criteria.

The distinction between borderline and malignant is based on the presence of "invasion" in the latter; the criteria for invasion differ from histotype to histotype, and histotype-specific discussions are provided later in this chapter. The malignant epithelial tumors ("carcinomas") show other striking differences between histotypes, which are summarized in Table 35.2,[105] and described in more detail in the histotype-specific sections of this chapter, later. It is important to recognize that although histotype of ovarian carcinoma was considered to not be diagnostically reproducible or clinically relevant in the past, that has changed, and ovarian carcinoma histotype can be diagnosed with very high interobserver agreement[106–108] and increasing clinical significance. There remain 1%–2% of ovarian carcinomas that show unusual morphologic features and defy histotype assignment, but in most tumors the diagnosis of histotype is straightforward on routine H&E stains. The importance of histotype in ovarian carcinoma can be illustrated by consideration of two aspects of ovarian carcinoma: stage at presentation and association with hereditary cancer susceptibility syndromes.

The stage at presentation of ovarian carcinoma of different histotypes are shown in in Table 35.3.[109] For patients presenting with high-stage disease (i.e. stage III or IV), the large majority are high-grade serous, while patients presenting with tumors confined to the adnexa are more likely to have a tumor other than high-grade serous carcinoma (HGSC), which account for a minority of such cases. The histotype of organ confined ovarian carcinomas, e.g. presenting at the time of frozen section for an adnexal mass that was thought to be an endometriotic cyst preoperatively, are very different than those diagnosed in patients with ascites and omental involvement.

Familial Ovarian Cancer Syndromes

There are two common autosomal dominant hereditary cancer syndromes: hereditary breast and ovarian cancer syndrome (HBOCS) and Lynch syndrome, with the former first described by Henry Lynch and the latter named after him for his pioneering work in establishing

Table 35.2 Features of the five major histologic types of ovarian carcinoma.

	HGSC	CCC	EC	LGSC	MC
Mean age	63	55	58	53	45
5-Year survival (stage III only)	40	23	66	71	NA
Origin	Fallopian tube	Endometriosis	Endometriosis	Cystadenoma	Germ cell, transitional epithelium
Molecular abnormalities	Genomic instability; TP53 mutation; homologous recombination DNA damage repair defects; CCNE1, NOTCH3 activation; Rb, NF1 inactivation	Wnt-catenin activation; ARID1A-chromatin remodeling complex inactivation; PI3K activation; PTEN inactivation, MMR abnormalities		KRAS/BRAF/MEK pathway activation	ERBB2/KRAS/BRAF/MEK pathway activation
Inherited syndromes	HBOC	LS	LS	?LS	?LS
Sensitivity to platinum-based chemotherapy	Sensitive	Relatively resistant	Relatively resistant	Relatively resistant	Relatively resistant
Adjuvant/targeted therapies licensed or in trial	PARPi; immune checkpoint inhibitors	Radiotherapy; Sunitinib	mTOR inhibitors	Selumetinib (MEK1/2 inhibitors)	Trastuzumab

CCC, Clear cell carcinoma; *EC*, endometrioid carcinoma; *HBOC*, hereditary breast and ovarian cancer syndrome; *HGSC*, high-grade serous carcinoma; *LGSC*, low-grade serous carcinoma; *MC*, mucinous carcinoma; *LS*, Lynch syndrome; *NA*, not applicable.
From Singh N, Gilks CB. The changing landscape of gynaecological cancer diagnosis: implications for histopathological practice in the 21st century. *Histopathology*. 2017;70:56–69.

For personal use only. No other uses without permission. Copyright ©2017. Elsevier Inc. All rights reserved.

Table 35.3 Low-stage (I/II) versus high-stage (III/IV) distribution of histotypes of epithelial ovarian cancer

OVARIAN CARCINOMA HISTOTYPE	PERCENTAGE (ALL STAGES) (%)	PERCENTAGE (STAGE III/IV) (%)	STAGE I/II: STAGE III/IV
High-grade serous	68.1	87.7	20:80
Clear cell	12.2	4.5	82:18
Endometrioid	11.3	2.5	88:12
Mucinous	3.4	1.2	82:18
Low-grade serous	3.4	5.3	18:82

From Singh N, McCluggage WG, Gilks CB. High-grade serous carcinoma of tubo-ovarian origin: recent developments. *Histopathology*. 2017 May 6. [Epub ahead of print].

the importance of these hereditary cancer syndromes; both are associated with an increased risk of ovarian carcinoma, but the histotypes of the carcinomas encountered in these syndromes are completely different. Germline mutations in BRCA1 or BRCA2, which encode proteins involved in high-fidelity repair of double-strand (DS) DNA breaks, account for 95% of cases of HBOCS, and these patients have an estimated 45% lifetime risk of developing ovarian carcinoma, although the risk varies depending on the specific mutation, being higher in patients with BRCA1 mutations than those with BRCA2 mutations.[110,111] In HBOCS, patients are at increased risk of developing HGSC but not at significantly increased risk of developing other histotypes of ovarian carcinoma, borderline tumors, germ cell tumors or sex cord–stromal tumors.[112,113] Of patients newly diagnosed with HGSC, 15%–20% will have a germline BRCA1 or BRCA2 mutation; consideration should therefore be given to genetic counseling and testing for HBOC in all such patients.[114]

Lynch syndrome, secondary to mutations in genes involved in another DNA repair pathway that is, mismatch repair, is associated with an 8%–10% lifetime risk of developing ovarian carcinoma,[115,116] and the carcinomas that arise in patients with Lynch syndrome are of those histotypes associated with endometriosis (i.e. endometrioid and clear cell).[117,118] The likelihood of a clear cell or endometrioid carcinoma of the ovary being associated with Lynch syndrome appears to be the same as that of colorectal carcinoma or endometrial carcinoma (i.e. 3%–5%). Therefore, if screening for Lynch syndrome mutations through immunostaining for mismatch repair enzymes in newly diagnosed carcinomas is being done, it has been suggested that it should be inclusive of not just colorectal and endometrial carcinoma, but the 20% of ovarian carcinomas of endometrioid or clear cell type.[118]

Serous Tumors

Serous tumors make up about one-fourth of all ovarian tumors and most occur in adults. A critical advance in our understanding of ovarian neoplasia is the recent recognition that low-grade serous neoplasms are a different disease than HGSC.[119–124] In the past it was thought that HGSCs arose through progression of low-grade serous neoplasms, but it is now recognized that, despite the shared "serous" or fallopian tube cell type, the low-grade and high-grade serous tumors are not closely related. Differences include cell and site of origin, molecular events during pathogenesis and response to chemotherapy, among others. Accordingly the low-grade and high-grade serous tumors will be discussed separately.

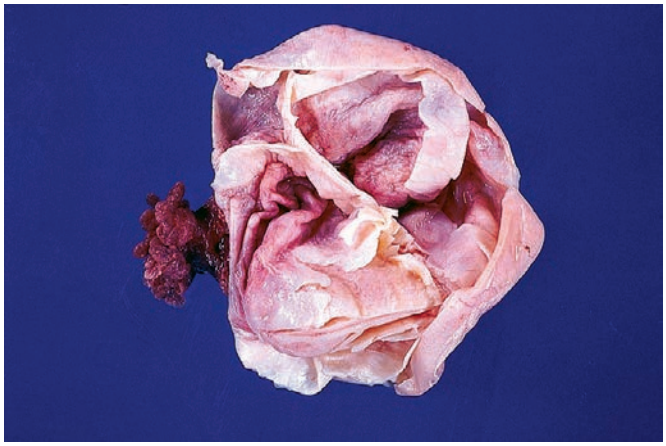

Figure 35.20 Smooth outer and inner surfaces of the cystic formations in a case of ovarian serous cystadenoma.

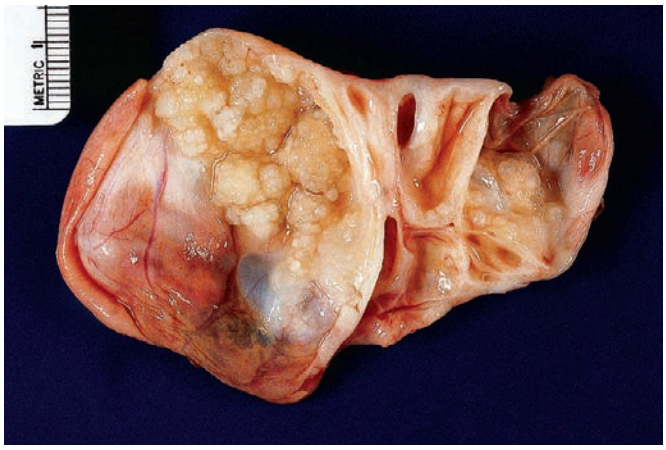

Figure 35.21 Inner aspect of serous cystadenoma showing papillary structures protruding within.

Low-Grade Serous Neoplasia

This category is inclusive of benign and borderline serous tumors and low-grade serous carcinoma. Grossly, these tumors typically consist of cystic masses, usually unilocular, containing a clear but sometimes viscous fluid (Fig. 35.20). Papillary formations are often present, most of them protruding into the cavity but some occasionally occur on the outer surface (Fig. 35.21). In serous borderline tumors the papillae lining cysts are more delicate than the predominantly stromal papillae of benign serous tumors (Fig. 35.22). The low-grade serous carcinomas tend to be solid but lack conspicuous areas of necrosis and hemorrhage.

Microscopically, cuboidal to columnar cells are seen lining the wall of the cysts and the papillae (Fig. 35.23). They are similar to normal tubal epithelium at both a light and electron microscopic level.[125] Hobnail cells can be present, not to be taken as evidence of the presence of a clear cell carcinoma component.[126] In borderline tumors and low-grade serous carcinomas, calcific concretions with concentric laminations (psammoma bodies) are often present.

A morphologic spectrum of proliferation exists in these tumors. At one end is the benign **serous cystadenoma**, in which the cysts

For personal use only. No other uses without permission. Copyright ©2017. Elsevier Inc. All rights reserved.

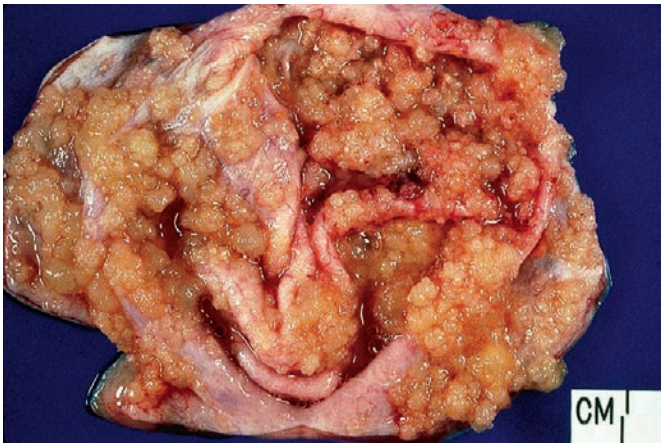

Figure 35.22 Inner aspect of an ovarian serous borderline tumor. Numerous fine papillary projections can be appreciated.

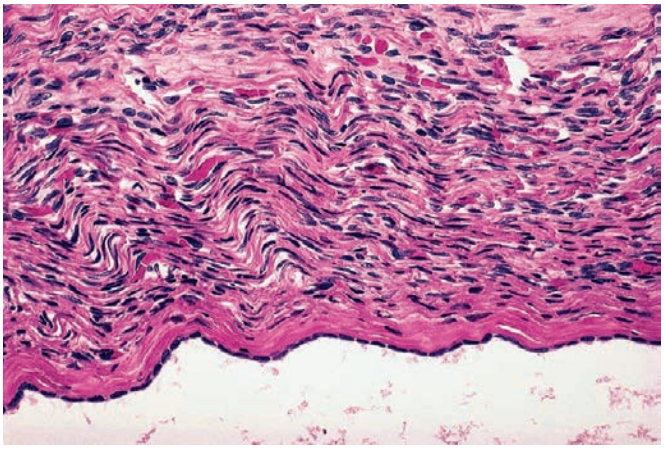

Figure 35.23 Single layer of bland-looking epithelial cells lining one of the cystic structures of a serous cystadenoma.

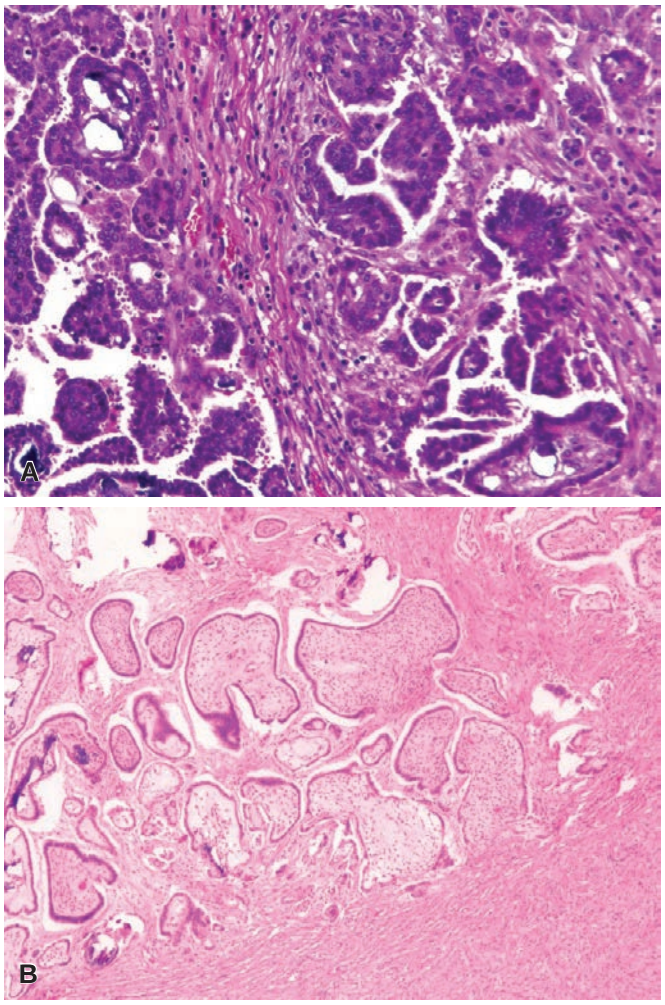

Figure 35.24 Low-Grade Serous Carcinoma. Invasion is evident as micropapillae and individual cells infiltrating the stroma **(A)** and as macropapillae, with broad central cores, also infiltrating the stroma **(B)**; note the clear space surrounding the invasive cell clusters.

and the papillae (if present) are lined by a single layer of cells, without atypia, architectural complexity, or invasion (see Fig. 35.23). At the other end is low-grade serous carcinoma, characterized by low-grade nuclear atypia, mitotic activity, stratification, glandular complexity, branching papillary fronds, and *stromal invasion* (Fig. 35.24). Stromal invasion in low-grade serous carcinoma can show a number of patterns, which may be admixed in a single tumor,[127] and include: A. single cells and small, compact, irregular nests of cells, B. micropapillae and complex papillary forms (see Fig. 35.24A), C. inverted macropapillae, in which the neoplastic epithelium covers broad fibrovascular stromal stalks (this is the least common pattern; see Fig. 35.24B), D. cribriform, E, glandular or cystic, and F. solid sheets with slit-like spaces. In all of these patterns there is typically a clear space surrounding the neoplastic cells. **Serous psammocarcinoma**, so called, is a rare variant of low-grade serous carcinoma characterized by massive psammoma body formation (Fig. 35.25).[128] In between these two ends of the spectrum are serous borderline tumors, characterized by cellular stratification, detached cell clusters, atypia and occasional mitotic figures, but lacking stromal invasion (Fig. 35.26).[129,130] Borderline tumors account for approximately 15% of all serous tumors.[131–135] Ciliated cells are invariably present in benign serous tumors, less common in serous borderline tumors and uncommon in low-grade serous carcinoma.

In summary, benign serous tumors (serous cystadenoma, serous cystadenofibroma, or serous adenofibroma) are distinguished from

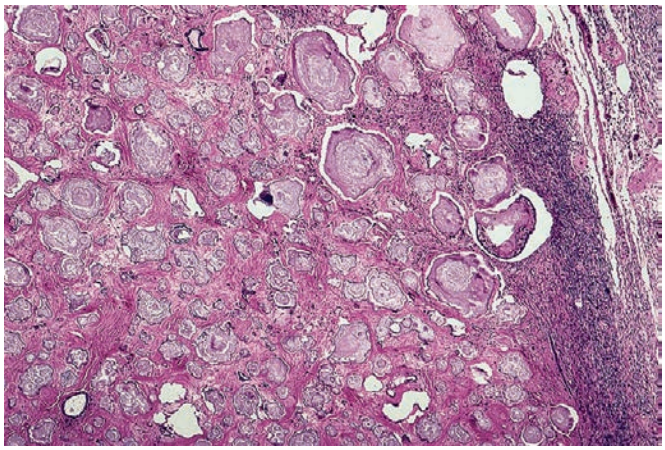

Figure 35.25 Low-grade serous carcinoma with innumerable psammoma bodies, so-called serous psammocarcinoma.

For personal use only. No other uses without permission. Copyright ©2017. Elsevier Inc. All rights reserved.

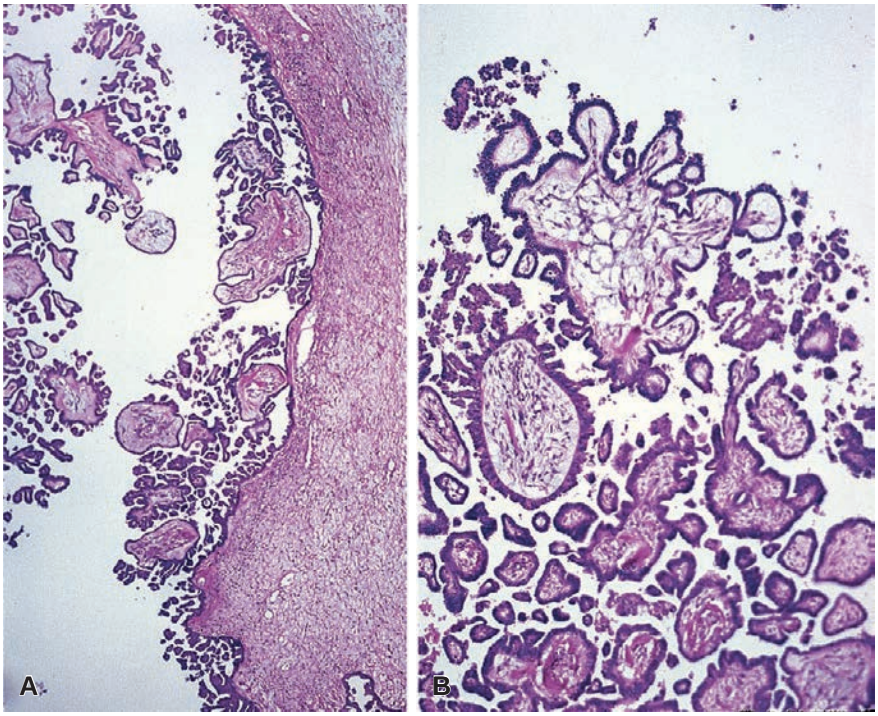

Figure 35.26 Low-power **(A)** and medium-power **(B)** appearance of ovarian borderline serous neoplasm. The growth is entirely exophytic.

serous borderline tumor by the absence of cellular stratification and atypia. The finding of detached clusters of epithelial cells is important evidence of cellular stratification; epithelial pseudostratification with apparent multilayered epithelium can be seen due to tangential sectioning, but this never leads to the presence of detached cell clusters. When the "borderline" features are present only focally (i.e. account for less than 10% of the cyst lining) in an otherwise benign tumor, the designation *"cystadenomas with focal proliferation or focal atypia"* can be used and these tumors also have a benign course.[131,136]

Borderline serous tumors are distinguished from low-grade serous carcinoma by the absence of stromal invasion. It should also be noted that microinvasion in serous borderline tumors, defined as one or more invasive foci measuring less than 5 mm in greatest dimension, is a relatively common finding in serous borderline tumor, seen in 10%–15% of cases, and is not of prognostic significance (Fig. 35.27).[100,137,138] The microinvasive foci typically appear as individual cells or clusters of cells with abundant eosinophilic cytoplasm ("eosinophilic metaplastic cells") that show a low Ki67 labeling index.[139,140] It should be noted that in 50% or more of low-grade serous carcinomas there is a coexisting borderline component, from which the low-grade serous carcinoma has presumably arisen. A special circumstance is when there is a serous borderline tumor of the ovary and invasive low-grade serous carcinoma in the extra-ovarian implants (a situation that in the past would have led to a diagnosis of "serous borderline tumor with invasive implants). Recognition of invasive carcinoma in extra-ovarian implants is based on the criteria proposed by Bell et al.[141]: the presence of a haphazard infiltrative growth pattern that destroys the architecture of the invaded tissues. Surface peritoneal involvement does NOT constitute evidence of invasion in extra-ovarian implants; there must be invasion into underlying tissue. The presence of invasion at extra-ovarian sites should lead to a diagnosis of low-grade serous carcinoma, even if the ovarian tumor is entirely borderline.[100,142]

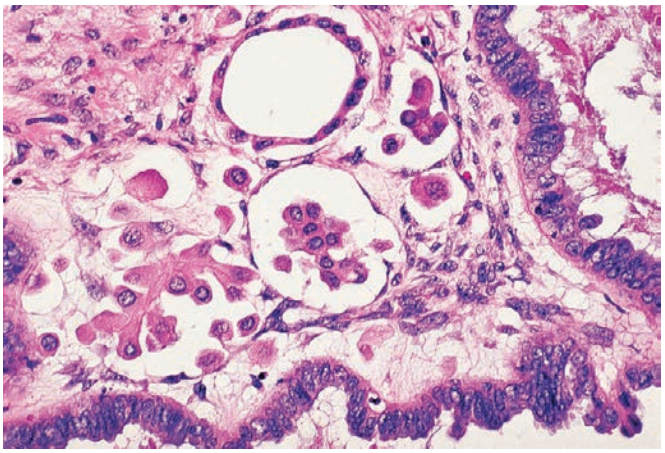

Figure 35.27 Serous borderline tumor with focal microinvasion represented by clusters of cells with abundant eosinophilic cytoplasm.

Low-grade serous carcinomas are distinguished from the much more common HGSCs by their frequent association with serous borderline tumor and a lesser degree of nuclear pleomorphism (less than threefold variation in nuclear size). In cases where there remains difficulty in deciding between these two possibilities, the low-grade serous carcinomas have a much lower mitotic rate than HGSCs (12 or fewer MF per 10 HPF),[119–121] and p53 immunostaining shows a normal pattern, compared to the abnormal staining (so-called all or nothing patterns) present in 95% of HGSCs.

Prognosis

The benign serous tumors are invariably benign, while the prognosis of serous borderline tumors is dependent primarily on stage. Stage Ia tumors, without surface involvement, positive washings or

For personal use only. No other uses without permission. Copyright ©2017. Elsevier Inc. All rights reserved.

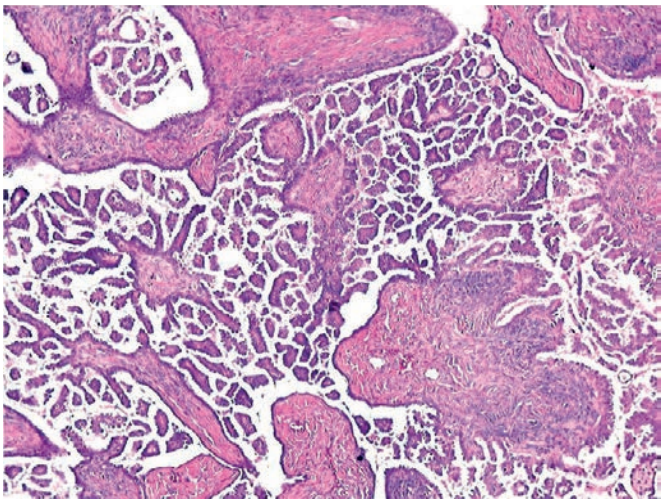

Figure 35.28 Ovarian serous borderline tumor with a micropapillary pattern of growth.

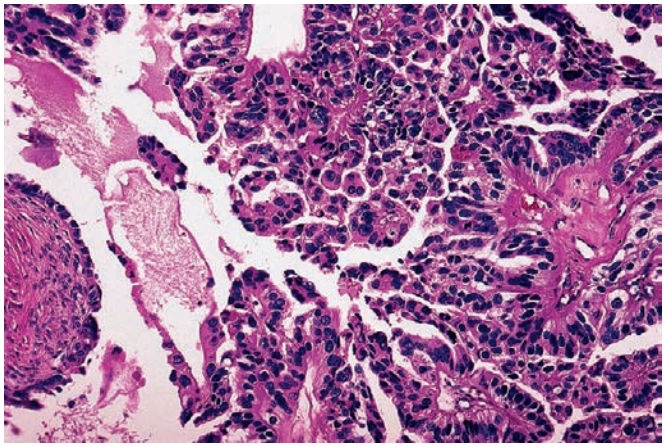

Figure 35.29 High-grade serous carcinoma with papillary architecture.

extra-ovarian implants, are associated with an excellent prognosis. Curiously the presence of nodal involvement is not associated with an adverse outcome in patients with serous borderline tumor. Micropapillary architecture is associated with a worse prognosis in patients with serous borderline tumor, but it is not established whether this is independent of the well-known association of micropapillarity with higher stage and a component of invasive low-grade serous carcinoma (either within the ovary or at extra-ovarian sites).[143–146] Micropapillary architecture is defined as nonhierarchical branching of elongate filiform papillae and/or a cribriform architecture, with the latter being considerably less common than the former. The papillae should be at least 5 times as long as wide (Fig. 35.28), and the micropapillary focus must be confluent for at least 5 mm. Kurman and colleagues have suggested that serous borderline tumor with micropapillary features should be diagnosed as noninvasive low-grade serous carcinoma; micropapillarity in a stage Ia tumor is not associated with a different prognosis than in a stage Ia conventional serous borderline tumor,[145] and it is therefore not justified, in our opinion, to introduce a new diagnostic term for these patients (i.e. noninvasive low-grade serous carcinoma), especially when the diagnostic criteria have not been shown to be highly reproducible. The borderline category was introduced in the 1950s to clearly indicate that there is a different natural history for patients with these tumors, compared to those with usual carcinoma, and this rationale is still applicable and constitutes an argument against use of the terminology of "noninvasive low-grade serous carcinoma." As noted previously, micropapillary architecture is more likely to be associated with either higher stage disease (ovarian surface involvement or extra-ovarian implants), or the presence of invasive low-grade serous carcinoma, and recurrence as carcinoma is also more common in these tumors, so when micropapillarity is present it should be documented in the pathology report and a careful search for evidence of higher stage or invasion is warranted, but that is the only action we would currently recommend based on the presence of micropapillary variant of serous borderline tumor.

The prognosis of low-grade serous carcinoma is highly dependent on stage. For stage Ia disease the prognosis is excellent, but in most reported cases there is extra-ovarian spread at the time of diagnosis and these patients have a poor prognosis, similar to that of patients with HGSC.[126,147] With recurrence and tumor progression, low-grade serous carcinomas can become higher grade, with increased mitotic activity. These tumors differ from usual HGSC in lacking *TP53* mutations[124] (i.e. they are not examples of "progression" from low-grade serous carcinoma to HGSC of the usual type).[148]

Immunohistochemistry and Molecular Pathology

Immunohistochemically, the typical keratin profile of low-grade serous tumors is CK7+/CK20–.[149] They also express CK8, 18, and 19, EMA, B72.3,[150–152] vimentin,[153] glial fibrillary acidic protein (GFAP) (occasionally),[152] the β-subunit of human chorionic gonadotropin (hCG) (in a minority of cases),[154] and receptors for estrogen and progesterone.[155,156] A small minority (around 10%) of serous tumors stain for calretinin and/or inhibin, a potentially confusing finding in the differential diagnosis with sex cord–stromal tumors.[157] WT1 and PAX8 stain most low-grade ovarian serous tumors.[158–160] Serous borderline tumors and low-grade serous carcinoma have relatively few mutations and are typically diploid. The most common mutations are in *KRAS* and *BRAF*.[100,123]

High-Grade Serous Carcinoma

Most HGSCs show bilateral ovarian involvement. Tubal fimbrial involvement is often noted on gross examination and is usually unilateral. On sectioning the ovarian masses are solid and cystic, with conspicuous hemorrhage and necrosis. Microscopically, HGSC is characterized by morphologic heterogeneity, and there is often an admixture of different architectural patterns including papillary, micropapillary, slit-like, glandular, microcystic/ microglandular, solid, and transitional-like patterns. While papillary elements and slit-like spaces are characteristic of HGSC (Figs. 35.29 and 35.30), well-formed rounded glands are also common, resulting in a pseudoendometrioid appearance (Fig. 35.31). The tumor cells usually have scant to moderate amounts of cytoplasm, but occasionally there is abundant eosinophilic or clear cytoplasm, or cells with vacuoles and intracytoplasmic mucin, resulting in a signet ring appearance. The neoplastic cells consistently show high-grade nuclear features, with significant pleomorphism and a high mitotic rate with frequent abnormal mitotic figures. As a rule, high-power microscopic fields with multiple mitoses are easily found, and individual bizarre tumor giant cells are also often present, features that are helpful in ruling out low-grade serous carcinoma. Areas of necrosis are common, but psammoma bodies are less frequently encountered than in low-grade serous carcinoma.

Prognosis

When there is a general discussion of "ovarian carcinoma" it is usually concerned with HGSC, as it accounts for 70% of all cases

For personal use only. No other uses without permission. Copyright ©2017. Elsevier Inc. All rights reserved.

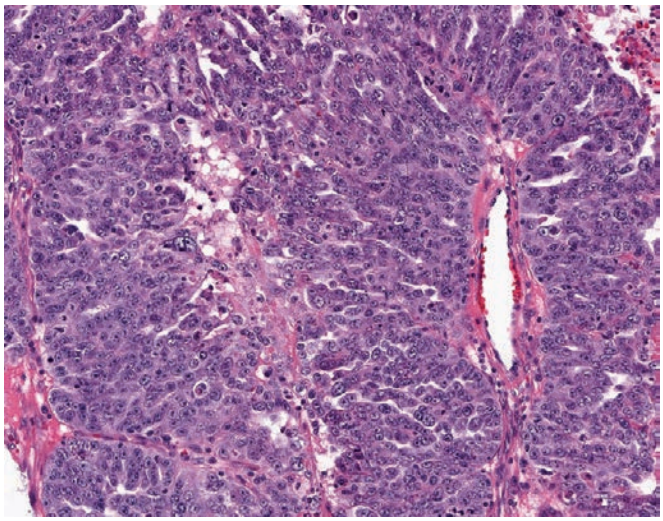

Figure 35.30 High-grade serous carcinoma with slit-like spaces.

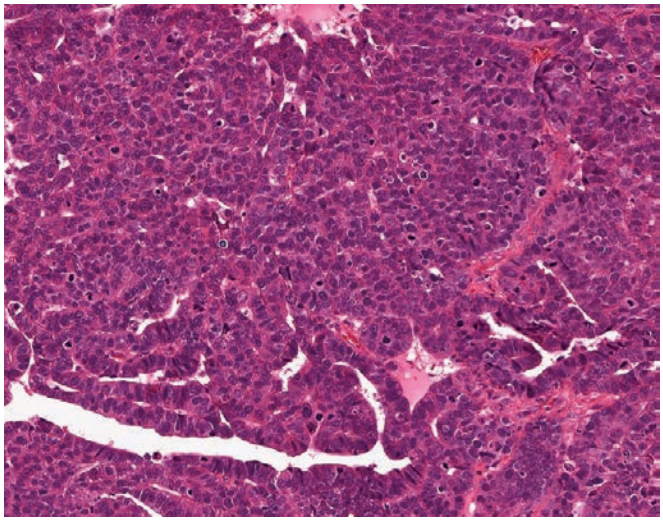

Figure 35.31 High-Grade Serous Carcinoma With Gland Formation. This is a common finding in high-grade serous carcinoma and is not evidence of a component of endometrioid carcinoma.

(see Table 35.2) and a disproportionate number of the deaths due to disease. The latter is attributable to these tumors being high-stage at diagnosis, which is itself attributable to most of them originating in the tubal fimbria (discussed later). There has unfortunately been little progress in treatment of HGSC. Although most patients experience a remission, recurrence and death due to progressive disease are usual. Treatments targeting the molecular abnormalities of HGSC, such as PARP inhibitors, show great promise,[161] but they have not yet entered practice as adjuvant treatment, where they would be given with curative intent. Nonetheless, the activity they show against recurrent HGSC is impressive and they will undoubtedly become more widely used over the coming years.

Site of Origin

There is now irrefutable evidence that most extrauterine HGSCs arise from the fallopian tube (most commonly the fimbrial end) from a precursor lesion referred to as serous tubal intraepithelial carcinoma (STIC).[162–167] It was first recognized that the fimbrial end of the fallopian tube is the site of origin of a large majority of HGSCs in patients with a germline BRCA1 or BRCA2 mutations, based on the fimbrial location of early carcinomas identified in risk-reducing salpingo-oophorectomy specimens.[166,168–170] This observation became possible only with more detailed and systematic examination of the fallopian tubes; introduction of the **S**ectioning and **E**xtensively **E**xamining the **FIM**bria (SEE-FIM) protocol[166] resulted in a dramatic increase in the number of STICs and small invasive HGSCs detected. It is now clear that STIC and small tubal mucosal HGSCs are found in sporadic "ovarian" HGSCs at comparable frequency to what is seen in high-risk patients with HBOCS. Adding to the cases with STIC those where the fimbrial end of the tube is overgrown and incorporated into an adnexal mass, one is left with fewer than 20% of HGSCs where there is not tubal involvement. It is also clear that the tubal lesions usually precede the disease in the ovaries and other extratubal sites.[170] Four recent studies have reported on HGSC diagnosed as an incidental finding at surgery carried out for unrelated reasons; these occurred in women who were not at high risk for ovarian cancer.[171–174] The tubal mucosa was involved in 100% (48 of 48) of cases and STIC, with or without an invasive mucosal carcinoma, was identified in 98% (47 of 48).

It should be remembered that fallopian tube mucosal involvement and ovarian involvement by uterine or nongynecological primary tumors can occur and can mimic STIC. Most cases with both endometrial serous carcinoma (either intraepithelial or invasive) and concomitant unilateral or bilateral HGSC in the ovary (and/or STIC or HGSC in the fallopian tube) represent adnexal metastases from an endometrial primary.[161] WT1 may be of value in these cases, as most tubal HGSCs exhibit diffuse nuclear positivity with WT1, while most uterine serous carcinomas are negative. Unfortunately, there is some overlap in that a proportion of uterine serous carcinomas are WT1 positive (the percentage has varied between studies, but may be up to 30%) and a small percentage of tubal HGSCs are WT1 negative.[175]

While the assignment of primary site in HGSC does not change management, it is often a requirement for tumor registries, and a uniform approach to site assignment is desirable. The following guidelines take into account recent advances in our understanding of the histogenesis of HGSC, described previously[176]: A. Primary site should be assigned as tubal in the presence of STIC or invasive mucosal HGSC in either fallopian tube, or when either tube is partly or fully incorporated into and inseparable from a tubo-ovarian mass. B. Primary site should be assigned as ovarian only when there is ovarian involvement and the fallopian tubes are clearly visible, have been dissected away from the surface of the ovaries, fully examined by a standardized SEE-FIM protocol and neither STIC nor invasive mucosal carcinoma is present in either tube. C. Primary site should be assigned as peritoneal only when both tubes and both ovaries are grossly and microscopically normal; primary peritoneal HGSC should only be diagnosed in a specimen from primary surgery (as neoadjuvant chemotherapy can impact on the ability to assign primary site by changing the disease distribution) and only after complete examination of both tubes and both ovaries using a standard protocol.

Differential Diagnosis

The differential diagnosis between HGSC and low-grade serous carcinoma was discussed in the preceding section. The differential diagnosis also includes endometrioid carcinoma, clear cell carcinoma, and undifferentiated carcinoma (Fig. 35.32). As endometrioid-like glandular formation, clear cell change or solid undifferentiated architecture are rarely present throughout a well-sampled tumor, the presence of typical HGSC will establish the diagnosis. In problematic cases (e.g. a small biopsy with limited tissue available to seek different architectural patterns), immunostaining may

For personal use only. No other uses without permission. Copyright ©2017. Elsevier Inc. All rights reserved.

help (Table 35.4). For a diagnosis of undifferentiated carcinoma, it should be undifferentiated throughout; by definition, even a minor component showing differentiation excludes a diagnosis of undifferentiated carcinoma. Similarly, one should resist the urge to diagnose mixed HGSC and endometrioid carcinoma, or HGSC and clear cell carcinoma. True admixtures of these components are rare, and most purported examples are, based on clinical and immunohistochemical features, HGSC with glandular architecture, or clear cells, respectively.[177,178]

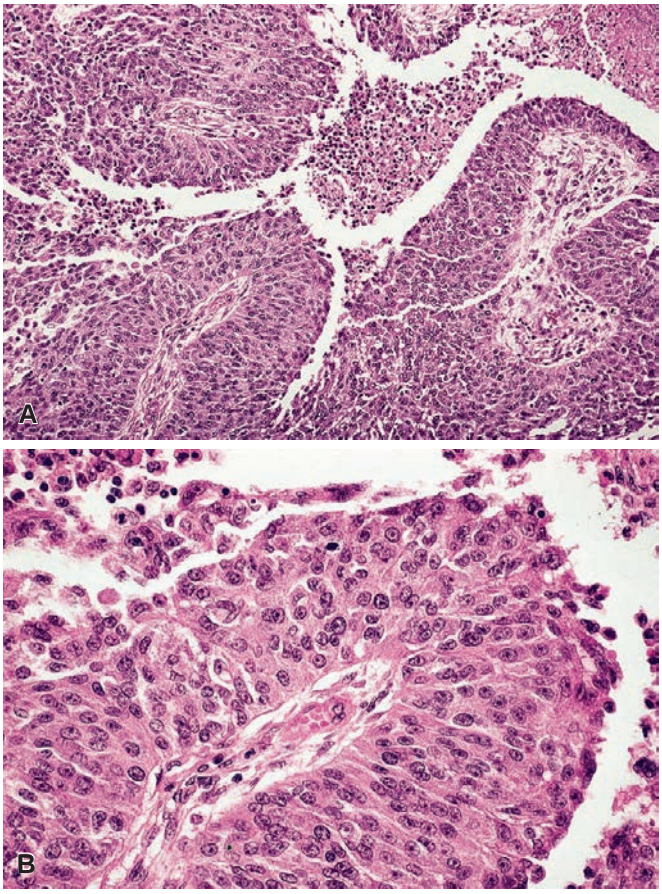

Figure 35.32 **A** and **B,** High-grade serous carcinoma with solid and transitional-like architecture.

Immunohistochemistry and Molecular Morphology

The immunoprofile of HGSC, compared to other ovarian carcinomas, is show in Table 35.4. With regard to the differential diagnosis with mesothelioma, MOC31, Ber-EP4, PAX8, and hormone receptors are more likely to be expressed by serous carcinoma, whereas calretinin, thrombomodulin, and CK5/6 are more likely to be seen in mesothelioma.[179–182] The Cancer Genome Atlas (TCGA) study, with sequencing of more than 300 tubo-ovarian HGSCs,[183] confirmed the ubiquity of *TP53* mutations and also highlighted the fact that apart from *TP53*, *BRCA1*, and *BRCA2*, there are few *recurrent* mutations in HGSC, in contrast to many other tumor types. It is, instead, characterized by aneuploidy and large numbers of somatic copy number alterations, rather than recurrent mutations. The mechanism accounting for this phenotype is the presence of defects in cellular mechanisms that allow for high-fidelity repair of DNA double strand breaks, which leads to mutation-prone repair mechanisms and resultant aneuploidy/copy number abnormalities. Genetic abnormalities accrue rapidly within the dividing tumor cells, leading to dramatic intratumoral heterogeneity at both the genetic and morphologic level. In a study of advanced-stage HGSC where tumor from multiple anatomic sites in the same patient was compared, fewer than 50% of mutations were present in all sampled specimens.[184] Thus, loss of the ability to repair DNA double strand breaks is as an early event in HGSC, followed by accrual of large numbers of copy number abnormalities that result in striking inter- and intra-tumoral heterogeneity. A minority of HGSCs have amplification of cyclin E1 (CCNE1), a molecular abnormality that is mutually exclusive of BRCA mutation and is associated with a worse prognosis/platinum resistance, compared to HGSCs without CCNE amplification.[185–187] CCNE amplification often coexists with AKT amplification, and treatment directed against cyclin-dependent kinase-2 (CDK2) and AKT, with small molecule kinase inhibitors, is a potential approach to targeted treatment of these platinum resistant HGSCs.[188]

Mucinous Tumors

Mucinous neoplasms are less common than serous neoplasms and are bilateral in less than 10% of cases.[189] As with their serous counterparts, ovarian mucinous tumors have been divided into *benign* **(mucinous cystadenoma)**, *borderline*, and *malignant* **(mucinous carcinoma);** most mucinous tumors are benign or borderline. Grossly, they tend to grow larger than the serous types and are partially or completely cystic, often multiloculated and have a smooth surface. A fluid to viscous material of mucoid nature is present in the lumen (Figs. 35.33–35.35).

Table 35.4 Markers of value in histotype diagnosis of ovarian carcinoma

	HGSC	LGSC	ENDOMETRIOID	CLEAR CELL	MUCINOUS
WT1	Diffuse positive	Diffuse positive	Negative	Negative	Negative
p53	Mutation type	Wild type	Wild type or mutation type	Wild type	Wild type or mutation type
p16	Diffuse positive	Focal positive	Focal positive	Variable	Variable
ER	Diffuse or focal positive or negative	Diffuse positive	Diffuse positive	Negative	Negative or focal positive
HNF-1β	Negative	Negative	Negative	Diffuse or focal positive	Variable
Napsin A	Negative	Negative	Negative	Diffuse or focal positive	Negative

From Singh N, McCluggage WG, Gilks CB. High-grade serous carcinoma of tubo-ovarian origin: recent developments. *Histopathology*. 2017 May 6. [Epub ahead of print]

Note: These are the most common staining patterns, but exceptions may occur with all of the markers.

ER, Estrogen receptor; *HGSC*, high-grade serous carcinoma; *HNF-1β*, hepatocyte nuclear factor-1β; *LGSC*, low-grade serous carcinoma

For personal use only. No other uses without permission. Copyright ©2017. Elsevier Inc. All rights reserved.

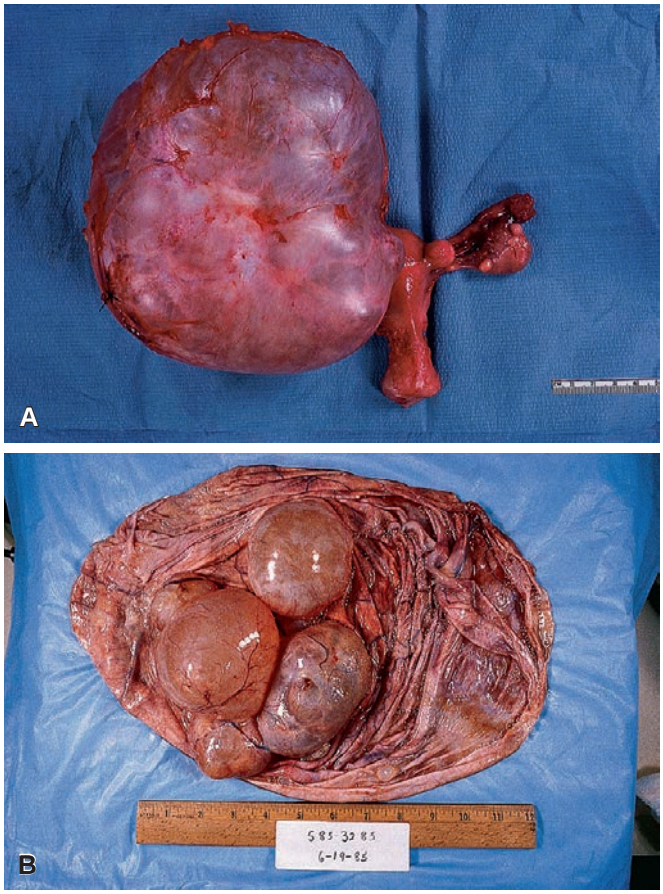

Figure 35.33 A and **B,** Outer and inner aspect of mucinous cystadenoma.

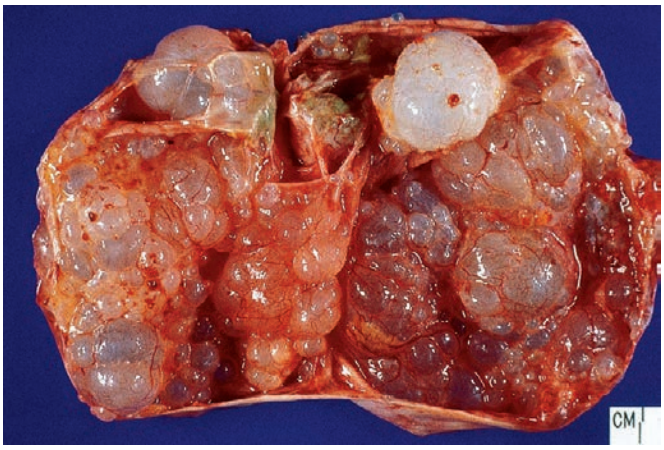

Figure 35.34 Gross appearance of a mucinous ovarian neoplasm that had borderline features at the microscopic level.

Figure 35.35 Gross Appearance of Mucinous Cystadenocarcinoma. The neoplasm is predominantly solid, but some mucin-containing cystic spaces can still be appreciated.

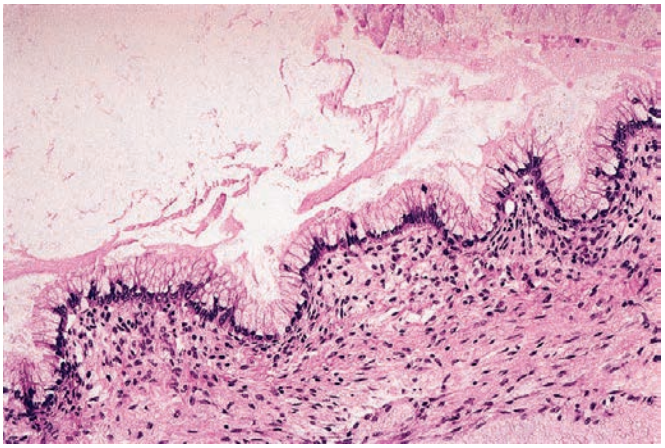

Figure 35.36 Lining of Mucinous Cystadenoma. Goblet cells are evident.

The epithelium is referred to as *intestinal* (in contrast to the endocervical-like epithelium of seromucinous tumors, described in the next section) and is characterized by an epithelial lining with a "picket fence" appearance, goblet cells, Paneth cells, endocrine cells, the secretion of gastrointestinal or pancreatobiliary type mucin,[190] and the production of intestinal enzymes such as lipase, trypsin, amylase, and sucrase (Fig. 35.36).[191] The endocrine cells, which are more common in the borderline category, are argyrophil and sometimes argentaffin.[192] 5-Hydroxytryptamine (serotonin, 5-HT), ACTH, gastrin, somatostatin, and other peptide hormones have been detected in this endocrine cell population by immunohistochemistry.[193–196] There is usually no clinical evidence of hormone excess, but cases associated with Zollinger–Ellison syndrome have been described.[197] Exceptionally, there is a focal component of signet ring cells, which may lead to a mistaken diagnosis of Krukenberg tumor,[198] but it should be noted that the presence of signet ring cells usually is an indication that you are dealing with a metastasis to the ovary.[199]

Occasionally, mucinous tumors of intestinal type are found in association with a teratoma or carcinoid tumor in the same ovary.[200] These uncommon mucinous neoplasms associated with teratomatous elements are of germ cell origin, based on the frequent finding of homozygosity, with genotypic concordance between the mucinous neoplasm and the teratoma.[201,202] Those mucinous tumors lacking a teratomatous component have a normal heterozygous genotype, indicating that they are most probably of somatic cell origin. The mucinous tumors of germ cell origin are more likely to be associated with mucin dissection through the ovarian stroma (pseudomyxoma ovarii). Importantly, the mucinous tumors of germ cell origin, which can be benign, borderline, or malignant, have a fully intestinal immunophenotype (i.e. CK20+, CK7−, unlike the mixed intestinal/müllerian immunophenotype typical of mucinous tumors without a teratomatous component [CK20 and CK7+]).

For personal use only. No other uses without permission. Copyright ©2017. Elsevier Inc. All rights reserved.

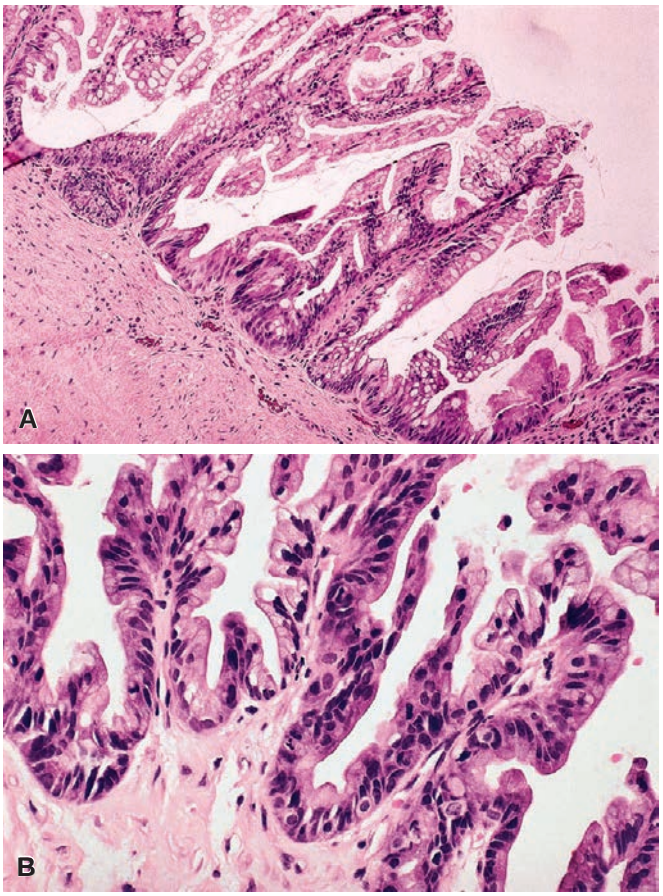

Figure 35.37 **A** and **B,** Mucinous borderline tumor of intestinal type, with focal intraepithelial carcinoma.

The distinction between benign and borderline mucinous tumor is based on the presence of cytologic atypia and stratification in the latter (Fig. 35.37), which is absent in the former. It is easy to understand how this distinction can be highly subjective. If borderline change is focal, occupying less than 10% of the cyst lining, which is otherwise benign, the designation of mucinous cystadenoma with focal atypia or focal proliferation has been suggested, and all such tumors have been benign on follow-up.[203] Almost all mucinous borderline tumors of intestinal type have been associated with a benign clinical course, but very rare exceptions have been reported.[204] The distinction between mucinous borderline tumor and carcinoma is based on the presence of invasion, and two patterns of invasion are recognized in mucinous tumors. The most common is expansile pattern, in which there is marked complexity of the glandular architecture. There is minimal or no intervening stroma between the glands, which show cribriform or labyrinthine patterns (Fig. 35.38). The contours of the gland margins are smooth, unlike what is seen with infiltrative or destructive pattern of invasion. The architecturally complex glands are invariably lined by atypical cells, showing increased layering and papillae (e.g. budding, bridging, and/or appearance of solid foci; see Fig. 35.38).[199,205] Infiltrative pattern of invasion (also referred to as "destructive invasion") is recognized by the presence of single cells or irregular cell clusters in stroma that may show desmoplasia. This pattern of invasion is less common and may be associated with a worse prognosis than purely expansile pattern of invasion; however, it should be noted that tumors with only expansile pattern of invasion are fully malignant and may metastatsize.[199,205]

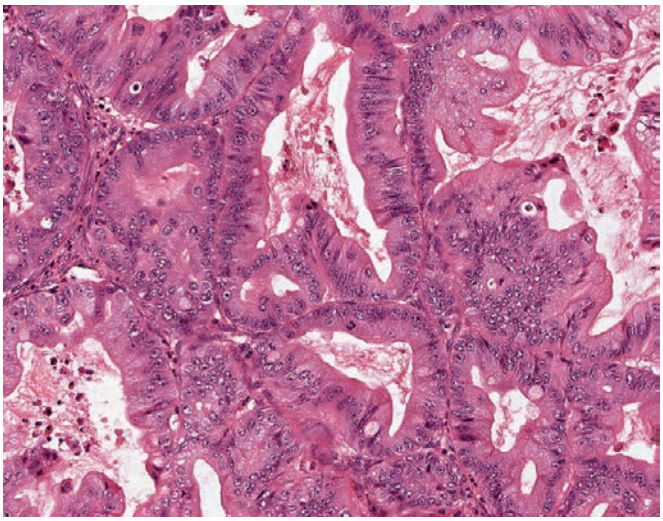

Figure 35.38 Mucinous carcinoma with expansile pattern of invasion; there is minimal stroma between the closely packed glands.

Within the borderline category we also recognize mucinous borderline tumor with focal intraepithelial carcinoma (see Fig. 35.37B).[199] The degree of cytologic atypia is greater than what is encountered in a usual mucinous borderline tumor; it is analogous to adenomatous polyps of the colon with high-grade dysplasia, featuring malignant-appearing epithelial cells showing increased stratification and sometimes cribriform architecture. Clinically, the outcome for patients with mucinous borderline tumor with intraepithelial carcinoma is usually favorable, but occasional patients have experienced a fatal recurrence.[199,206] Mucinous borderline tumors with microinvasion (<5 mm) should be distinguished from frankly invasive (≥5 mm) carcinoma; microinvasion is usually associated with an excellent prognosis.[199,207,208]

There is a subgroup of mucinous tumors in which the stromal component is particularly prominent. These have been designated *mucinous adenofibroma* or *cystadenofibroma* if benign and *mucinous adenocarcinofibroma* and *cystadenocarcinofibroma* if malignant. The benign ones are sometimes misinterpreted as malignant and even as metastatic because of the irregularly shaped glands in a "desmoplastic" stroma,[209] or as microinvasive because of the presence of micronests of cells.[210]

Exceptionally, ovarian mucinous tumors have been found to contain foci of: (1) *sarcoma-like nodules*, with a configuration and cytologic composition similar to those of giant cell tumor of soft parts,[211] characterized by a lack of reactivity for keratin[212]; (2) *sarcoma*, usually spindle shaped, sometimes with heterologous features,[213,214] and also unreactive for keratin; and (3) *anaplastic carcinoma*, with pleomorphic round to spindle cells that are immunoreactive for keratin.[215,216] The distinction between the latter two lesions is very tenuous, both on microscopic and histogenetic grounds (as it is in the pancreas or thyroid under similar circumstances), and both are associated with a poor prognosis unless they present as stage I lesions.[217] Actually, we favor the interpretation that the sarcoma-like nodules themselves are not a reactive phenomenon,[218] but rather are of neoplastic nature and related histogenetically to the other two processes, a possibility also expressed by others[219] and supported by the occasional overlap and coexistence of these various lesions.[217] However, it is important to consider the sarcoma-like nodules separately because of their better prognosis.[211,216,218,220] On occasion, the appearance of the mural nodule is that of a benign leiomyomatous growth.[221]

For personal use only. No other uses without permission. Copyright ©2017. Elsevier Inc. All rights reserved.

Immunohistochemically, the tumor cells of ovarian mucinous tumors express CEA (more so the intestinal types and/or malignant tumors),[222] keratin, EMA (particularly if malignant),[223] MUC5AC (a gastrin mucin gene), DPC4 (a nuclear transcription factor inactivated in about half of pancreatic adenocarcinomas),[224] hepatocyte nuclear factor 1,[225] and hepatocyte nuclear factor 4 alpha.[226] Importantly, the tumor cells express markers of gastrointestinal type differentiation such as CK20, SATB2 (very rarely), and CDX2,[224,227–230] as well as CK7, which is more strongly expressed than the intestinal markers in most cases.[230] As noted previously, mucinous tumors of germ cell origin have a more purely intestinal immunophenotype (strong diffuse CK20, SATB2 and CDX2, with negative CK7). In contrast to other types of ovarian epithelial tumor, PAX8 is often negative, as are WT1 and ER.[161]

Only rarely is a mucinous tumor arising from the ovary accompanied by extensive deposits of intra-abdominal mucin (pseudomyxoma peritonei); a large majority of these tumors are metastatic to the ovary and peritoneal cavity from an appendiceal origin, and are, therefore, discussed in Chapter 16.

The chief differential diagnosis is with metastatic carcinoma. A simple algorithmic approach has been advocated for the distinction between primary and metastatic mucinous tumors of the ovary, relying in size and laterality. Tumors that are unilateral, smooth surfaced and more than 13 cm, without mucinous ascites, are highly likely to be primary ovarian mucinous neoplasms.[231] The differential diagnosis also includes high-grade serous or endometrioid carcinoma, especially in those mucinous carcinomas where there is loss of intracellular mucin with increasing grade. The presence of a lower grade or borderline area can support the diagnosis of mucinous carcinoma, as can the absence of WT1 immunoreactivity and negative (or only focally positive) immunostaining for ER (see Table 35.4).

Seromucinous Tumors

Formerly considered a variant of mucinous tumor, the seromucinous neoplasms have been recognized as a distinct tumor type in the 2014 WHO classification. They differ from mucinous tumors of intestinal type morphologically and clinically, and such a distinction is therefore justified. They have also been referred to as *endocervical*, *endocervical-like*, or *müllerian*, and are characterized by a papillary architecture similar to that of serous tumor but with a lining of tall nonciliated cells with basally located nuclei and abundant intracellular mucin (Fig. 35.39). The stroma of the papillae is typically edematous and infiltrated by neutrophils. Seromucinous tumors express müllerian-type markers (such as hormone receptors, CA 125, and mesothelin) and resemble endocervical epithelium both at the light and electron microscopic level.[232] It has been pointed out that the seromucinous tumors share more morphologic and immunohistochemical features with the endometrioid or serous (or even clear cell) carcinomas than they do with mucinous tumors of intestinal type.[233–235] Seromucinous borderline tumors frequently have *ARID1A* mutation and show loss of ARID1A protein expression, at a frequency similar to that of endometrioid tumors.[236] In addition to the mucinous component, there are often admixed serous and, occasionally, squamous or clear cell components, leading to a proposal that a more apt designation for the seromucinous group of neoplasms would be "mixed müllerian" tumors. Having only just set these tumors apart as a separate entity in the 2014 WHO classification, it is difficult to muster enthusiasm for a name change so soon.

Most seromucinous tumors are benign or borderline, and only a handful of carcinomas have been reported. The borderline tumors are associated with a favorable prognosis, even when extra-ovarian implants are present.

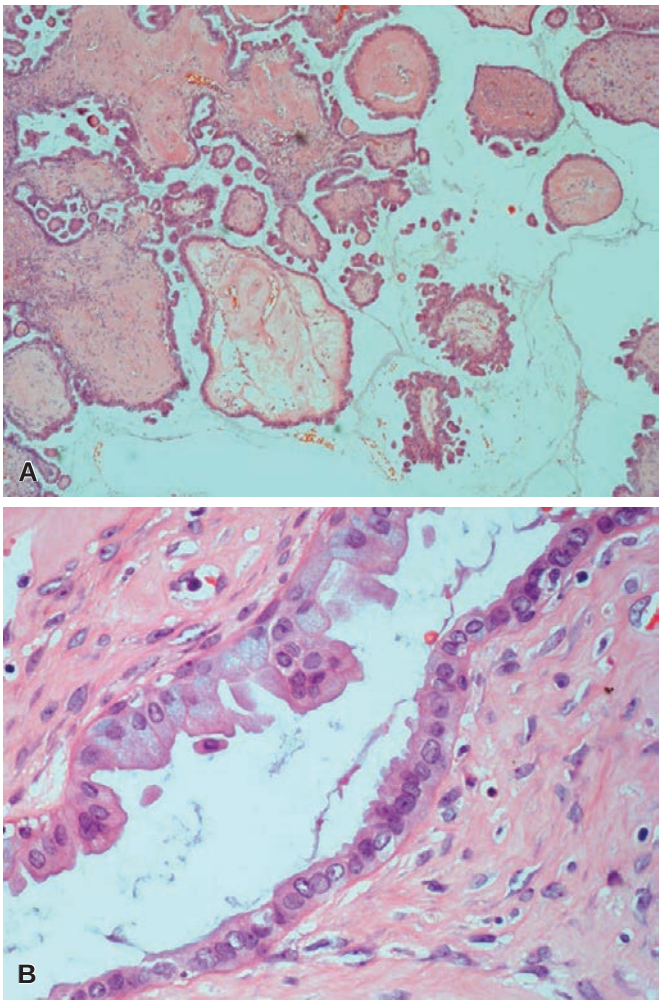

Figure 35.39 Seromucinous Borderline Tumor. At lower magnification **(A)** it resembles serous borderline tumor, but with prominent edema of the stroma in papillae. At higher magnification there is prominent intracellular mucin in some of the cells **(B)**.

The differential diagnosis for a benign seromucinous tumor includes a benign mucinous tumor of intestinal type. In practice, it is not clinically relevant to subtype a benign mucinous tumor, and a diagnosis of "mucinous cystadenoma" (or adenofibroma), without further qualification, can be made based on H&E as it would be an inappropriate use of resources to apply special stains in this setting. The seromucinous borderline tumors are sufficiently distinctive such that there is usually no doubt about the diagnosis on routine H&E stains alone. The presence of conspicuous intracellular mucin sets them apart from serous borderline tumor, the tumor they most resemble. Although seromucinous carcinoma has been reported, it is not entirely clear how they differ from the more commonly diagnosed endometrioid carcinoma with mucinous differentiation.

Endometrioid Tumors

Endometrioid carcinoma comprises 10% of all primary ovarian carcinomas (see Table 35.3). Coexistent endometriosis can often be demonstrated,[237] and some of the tumors can be seen arising from these endometriotic foci. However, the identification of endometriosis is not a prerequisite for the diagnosis of endometrioid carcinoma.

For personal use only. No other uses without permission. Copyright ©2017. Elsevier Inc. All rights reserved.

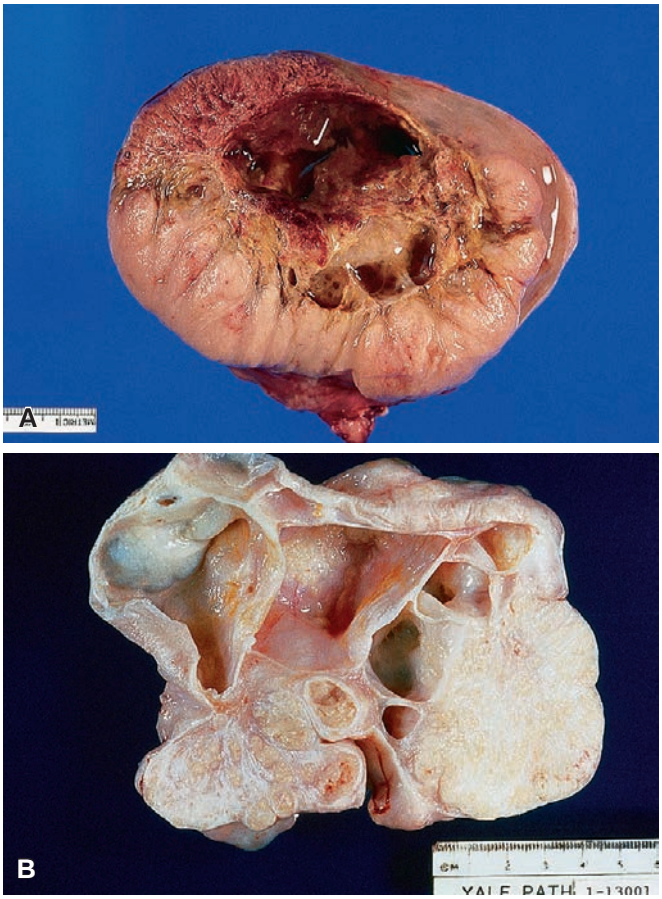

Figure 35.40 **A** and **B,** Gross appearances of ovarian endometrioid carcinoma. Both tumors show a combination of solid and cystic appearances.

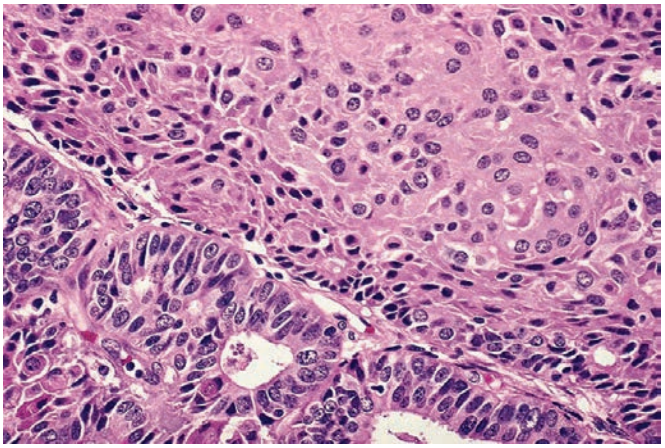

Figure 35.41 Well-differentiated endometrioid ovarian carcinoma with extensive squamous differentiation.

Grossly, endometrioid carcinoma may present as a cystic or solid mass (Fig. 35.40). The content tends to be hemorrhagic rather than serous or mucinous. Visible papillary formations are usually absent or inconspicuous. Microscopically, the tumors strongly resemble the appearance of the ordinary type of endometrial adenocarcinoma—hence their name (Fig. 35.41).[238,239] Most are well differentiated (grade 1 or 2, according to the FIGO grading system used for endometrial carcinomas of endometrioid type), with or without papillary formations. Half of the tumors have foci of squamous metaplasia (see Fig. 35.43).[240] Morules may express CDX2 and β-catenin (nuclear translocation).[241] In contrast to serous tumors, psammoma bodies are exceptional. Approximately 10% of endometrioid carcinomas have a component of non-neoplastic luteinized stromal cells.

The keratin produced by these ovarian neoplasms can result in the formation of peritoneal keratin granulomas.[74] It seems likely that at least some of the reported cases of primary **squamous cell carcinomas** of the ovary represent the extreme expression of this metaplastic tendency of endometrioid carcinoma.[242–245] Parenthetically, the other large category of ovarian squamous cell carcinoma is that associated with benign cystic teratomas (i.e. secondary somatic transformation).[246]

Histochemically, mucin may be found within the glandular lumina and in the apical border of the tumor cells. Some tumors show mucinous metaplasia, just as can be seen in endometrioid carcinomas of the endometrium; these tumors lack goblet cells and strongly express ER, which serves to distinguish them from mucinous tumors of intestinal type (see Table 35.4). Scattered argyrophil cells are seen in almost half of cases.[247]

Immunohistochemically, the tumor cells are positive for keratin, EMA, vimentin, and PAX8, whereas CEA is usually negative or weak.[248] There can also be positivity for CA 19-9 and hPL.[249,250]

Mutations leading to β-catenin deregulation are found in nearly half of ovarian endometrioid adenocarcinomas.[251] Many endometrioid and clear cell carcinomas (i.e. ovarian tumors related to endometriosis) have mutations of *ARID1A*, a tumor suppressor gene, in stark contrast with serous carcinomas, which do not have this mutation.[98]

In some endometrioid carcinomas, the neoplastic glands are small and tubular or solid and elongated, simulating the pattern of sex cord–stromal tumors, particularly of Sertoli–Leydig cell type.[252,253] These are referred to as endometrioid carcinoma resembling sex cord–stromal tumors.[254] Features that favor a diagnosis of endometrioid carcinoma in such cases are the older age of the patients, the usual absence of endocrine manifestations, and the occurrence elsewhere in the tumor of larger tubular glands, foci of squamous metaplasia, luminal mucin accumulation, adenofibromatous components, immunoreactivity for keratin (including CK7) and EMA, and negativity for inhibin.[255,256] Other endometrioid carcinomas simulate the appearance of granulosa cell tumors, from which they can be distinguished on immunohistochemical grounds.[257]

Other morphologic variations of endometrioid carcinoma include presence of yolk sac elements,[258,259] tumors composed of ciliated cells,[260] tumors composed of oxyphilic (oncocytic) epithelium,[261,262] and tumors containing foci of collagenous spherulosis that simulate squamous metaplasia.[263] Endometrioid carcinomas containing foci of hepatoid differentiation have also been described.[264] Just as for endometrial endometrioid tumors, there can be de-differentiation with emergence of undifferentiated carcinoma from a low-grade endometrioid tumor.[265] This is associated with loss of expression of one or more proteins of the SWI/SNF chromatin remodeling complex (BRG1, INI1, ARID1A, ARID1B) and mutation of the corresponding gene(s) in most cases.[266]

Benign and borderline types of endometrioid ovarian tumors exist, in addition to the malignant ones.[261,267–269] Most of the benign endometrioid tumors, which are rare, have a prominent stromal component and have been designated as adenofibromas or cystadenofibromas, depending on the degree of cystic change (Fig. 35.42). Sometimes, benign and malignant areas coexist in the same case.[270,271] In the borderline category, the epithelial changes are equivalent in all respects to those of atypical endometrial hyperplasia (Fig. 35.43). The distinction between borderline endometrioid tumor and low-grade endometrial carcinoma is made based on the same criteria

For personal use only. No other uses without permission. Copyright ©2017. Elsevier Inc. All rights reserved.

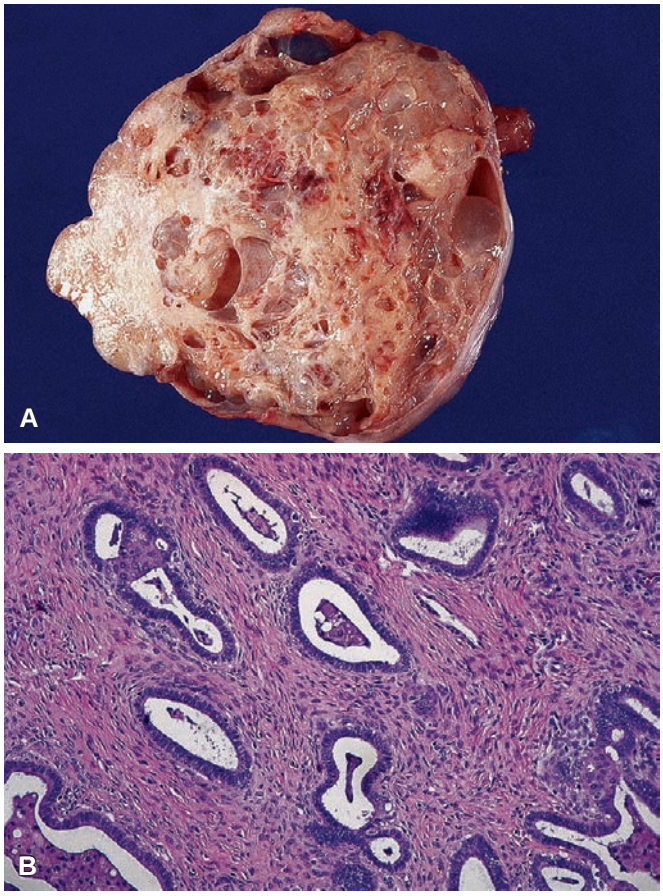

Figure 35.42 **A** and **B**, Gross and microscopic appearance of endometrioid adenofibroma.

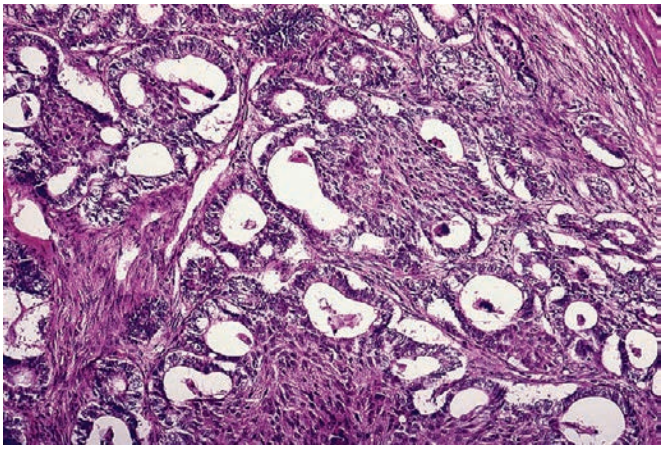

Figure 35.43 Ovarian endometrioid borderline tumor, with glandular architectural complexity.

(i.e. primarily based on architectural complexity, but with the additional requirement of associated cytological atypia) as are used in the uterus.

Some patients with endometrioid carcinoma of the ovary have either endometrial hyperplasia or a synchronous endometrial adenocarcinoma, which is often well differentiated and superficial.[272] There is a wide disparity in the reported incidence of the latter occurrence (largely because of different diagnostic criteria used for diagnosis

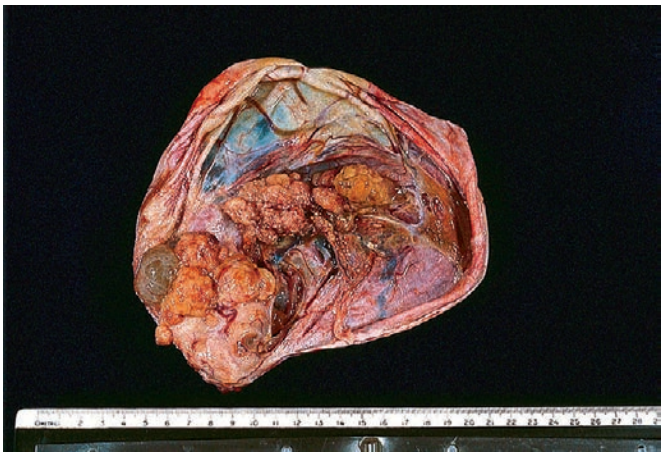

Figure 35.44 **Gross Appearance of Clear Cell Carcinoma of Ovary.** The tumor is predominantly cystic, but it contains several mural nodules.

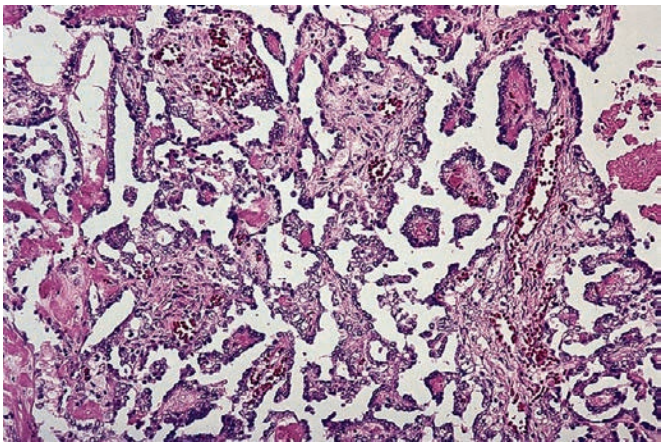

Figure 35.45 A highly papillary configuration is seen in this low-power view of ovarian clear cell carcinoma.

of endometrioid carcinoma in the past), with most series ranging from 15% to 45%. This incidence is higher in recent years due to more accurate diagnosis of endometrioid histotype in the ovary (i.e. there are fewer HGSCs misdiagnosed as endometrioid).[239,272,119] It is frequent enough, in our opinion, that if an endometrial biopsy has not been done previously, it would be warranted to obtain one in any patient with an ovarian endometrioid carcinoma.

The differential diagnosis of endometrioid carcinoma includes serous carcinoma (WT1 positive), mucinous carcinoma of intestinal type (negative or only weakly ER positive), and, in rare instances, sex cord–stromal tumors (negative for EMA and positive for inhibin).

Clear Cell Tumors

Clear cell carcinoma accounts for 10% of ovarian carcinomas (see Table 35.2) and is a distinctive ovarian tumor with a grossly spongy, often cystic appearance (Fig. 35.44), which microscopically can grow in tubulo–cystic, papillary, and solid-sheet patterns (Fig. 35.45).[273,274] Stroma-rich variants of clear cell carcinoma, with a prominent adenofibromatous component, are also common. In contrast to serous carcinomas, the papillae of clear cell carcinoma have a nonhierarchically branched pattern and lack epithelial stratification.[275]

For personal use only. No other uses without permission. Copyright ©2017. Elsevier Inc. All rights reserved.

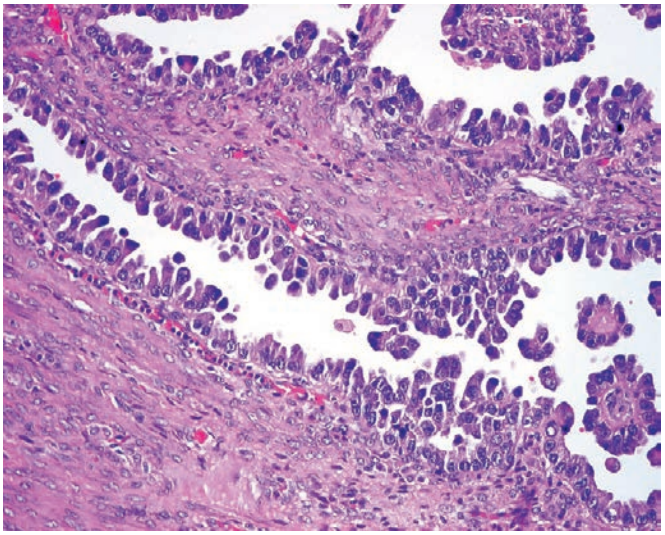

Figure 35.46 Clear Cell Carcinoma of Ovary. Note the high nuclear grade and the hobnail configuration.

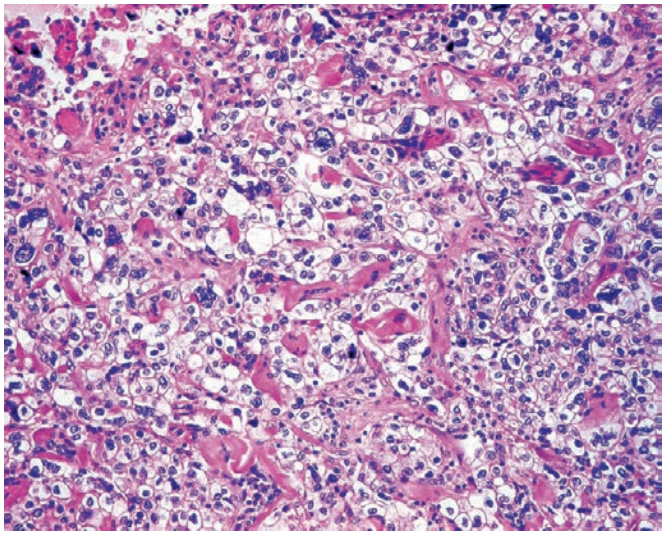

Figure 35.48 Clear cell carcinoma of ovary showing short papillae with hyalinized cores lined by highly atypical cells.

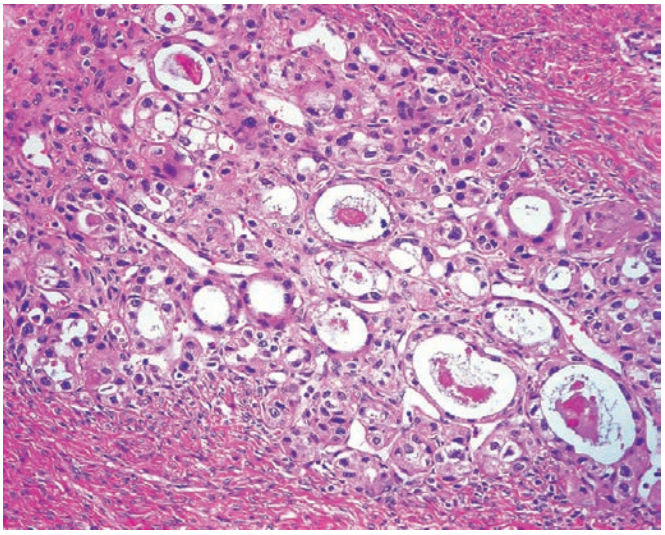

Figure 35.47 Oxyphilic variant of clear cell carcinoma.

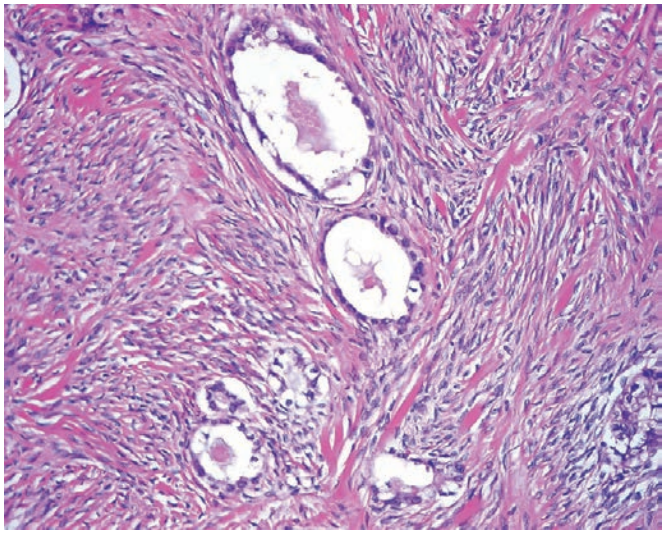

Figure 35.49 Clear cell borderline tumor; the epithelial cells of this adenofibroma show mild to moderate nuclear atypia.

The tumor cells are large and some of the nuclei protrude into the lumina, resulting in a "hobnail" configuration (Fig. 35.46). Their cytoplasm is clear; it often contains glycogen, mucin, and fat, and it may exhibit periodic acid–Schiff (PAS)-positive, diastase-resistant hyaline globules, which are negative for alpha-fetoprotein. In some of the tumor cells, the cytoplasm may appear oxyphilic rather than clear (Fig. 35.47).[268,276] Stromal hyalinization is a common and distinctive feature of clear cell carcinoma, with the stroma of papillae distended by basement membrane material (Fig. 35.48). Immunohistochemically, the tumor cells are always reactive for keratin (CK7, CK5/6, CAM 5.2, 34βE12), EMA, CD15 (Leu-M1), Ber-EP4, vimentin, and PAX8. ER and PR are usually negative or, at most, only focally positive, while p53 shows wild-type staining. Napsin A and hepatocyte nuclear factor-1β (HNF-1β, a transcription factor involved with liver differentiation), are usually expressed.[249,277]

Clear cell carcinoma is frequently associated with pelvic endometriosis, arising in some cases from endometriotic cysts.[278,279] The lining cells of endometriotic cysts may show marked cytological atypia, a finding designated "atypical endometriosis," which is thought to be the precursor of clear cell carcinoma.[98] At the electron microscopic level, the cytoplasmic clearing is seen to be largely due to the accumulation of glycogen.[280]

Benign and **borderline** ovarian clear cell tumors are rare. They can be "pure" or be associated with obviously malignant clear cell carcinomas.[281] Their growth pattern is most commonly that of an adenofibroma.[248] The borderline tumors are identified because of moderate to marked degrees of epithelial proliferation and atypia in the absence of recognizable stromal invasion (Fig. 35.49).[282]

The differential diagnosis of ovarian clear cell carcinoma includes:

- *Metastatic renal cell carcinoma*, which is negative for keratin 34βE12 and positive for CD10, whereas primary clear cell ovarian carcinoma usually (but not always) shows the opposite results.[283]
- *Ovarian yolk sac tumor*, which is characteristically positive for SALL4.[284] It is also positive for glypican-3,[285] but this is also true for about 40% of clear cell carcinomas.[286]

For personal use only. No other uses without permission. Copyright ©2017. Elsevier Inc. All rights reserved.

- *Ovarian serous carcinoma*, as a result of the fact that clear cell carcinomas can have a highly papillary pattern of growth,[287] and that serous carcinomas can contain clear cells.[178] An immunohistochemical panel consisting of WT1, estrogen receptor, and HNF-1β is useful in making the distinction.[288]

Brenner Tumor

Brenner tumors constitute between 1% and 2% of all ovarian neoplasms.[289] The average age at presentation is approximately 50 years, about 70% of the patients being over 40 years of age. Some cases are accompanied by signs of hyperestrinism, such as uterine bleeding from endometrial hyperplasia in a postmenopausal woman. The rate of growth is slow, and ascites is rare. Grossly, these tumors vary greatly in size; they are usually unilateral, firm, and white or yellowish white (Fig. 35.50). They closely resemble fibromas or thecomas, except for the frequent presence of small cystic areas filled with opaque, viscous, yellowish-brown fluid. Microscopically, they consist of solid and cystic nests of epithelial cells resembling transitional epithelium (urothelium) surrounded by an abundant stromal component of dense, fibroblastic nature (Fig. 35.51). The epithelial cells have sharply defined outlines; those lining the cysts may be flattened, cuboidal, or columnar. The nuclei of the tumor cells are oval, with a small but distinct nucleolus and longitudinal grooves similar to those seen in granulosa cell tumors (Fig. 35.52). The cytoplasm is clear and immunoreactive for keratin, EMA, and CEA (the latter also present in the lumen of the cysts); nuclear GATA3 reactivity is also common.[290] Scattered argyrophilic cells are present in about one-third of cases; they are positive for chromogranin and 5-HT, have dense-core granules at the ultrastructural level, and are similar to those seen in normal urothelium.[250,291] Steroidogenic enzymes as detected immunohistochemically are usually absent.[292]

Sometimes the cystic formations within the tumor are unduly prominent and accompanied by florid mucinous change.[293] If there is architectural complexity (crowding, stratification of the epithelium) and nuclear atypia but no evidence of invasion, a diagnosis of borderline Brenner tumor is indicated; all such tumors have followed a benign course (Figs. 35.53 and 35.54). *Malignant Brenner tumors* are rare. Some of these have been bilateral.[294,295] They are recognized through the association of the malignant epithelial component with

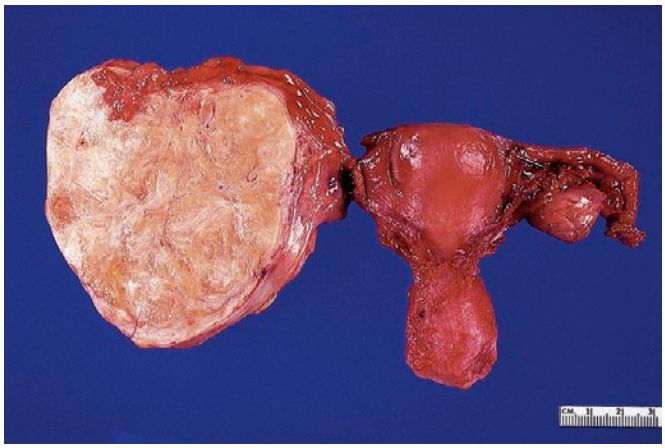

Figure 35.50 Large Brenner Tumor Involving the Right Ovary. The gross appearance of this neoplasm is very similar to that of fibroma or thecoma.

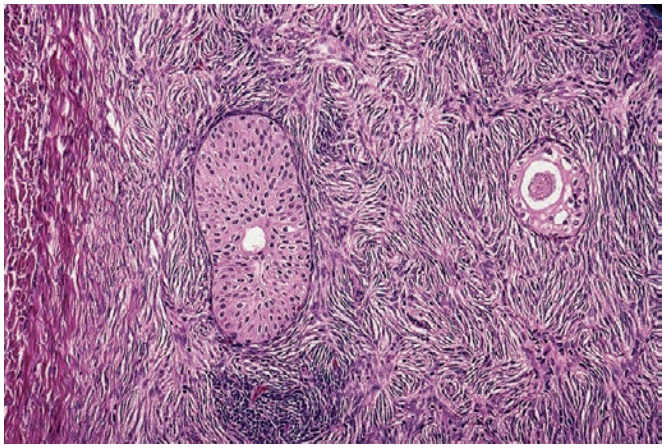

Figure 35.51 Brenner tumor of ovary showing solid and cystic epithelial cell nests embedded within fibrous tissue.

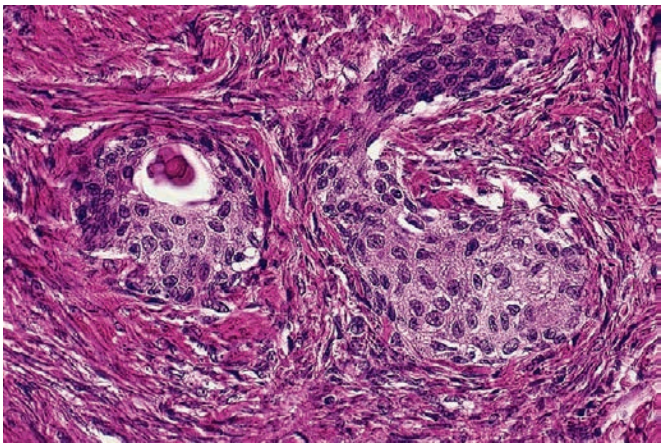

Figure 35.52 The epithelial nests of Brenner tumor are composed of cells with oval nuclei, many of which exhibit longitudinal grooves.

Figure 35.53 Borderline Brenner Tumor.

For personal use only. No other uses without permission. Copyright ©2017. Elsevier Inc. All rights reserved.

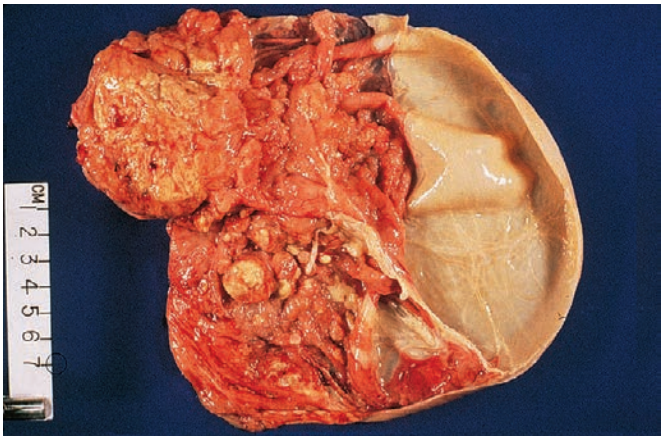

Figure 35.54 Borderline Brenner tumor showing solid area with papillary formations, associated with a large cystic space.

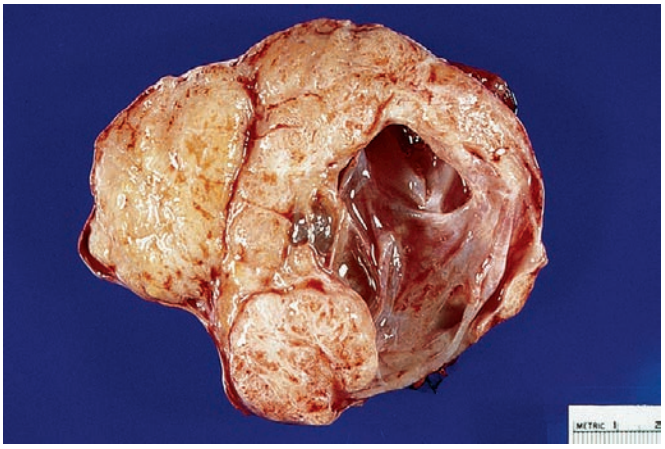

Figure 35.55 Brenner tumor with typical solid appearance coexisting with mucinous cystadenoma. This is a well-recognized combination.

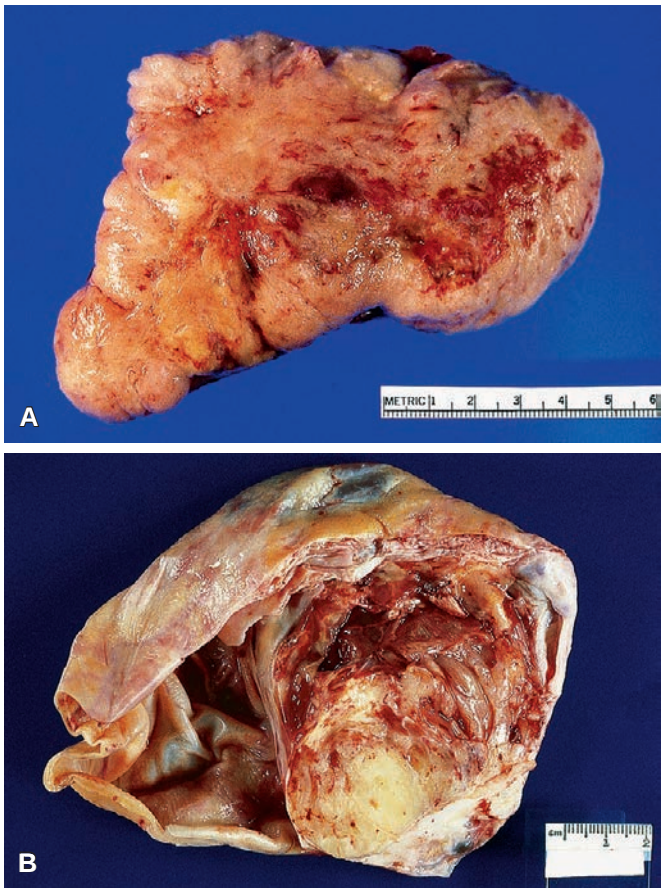

Figure 35.56 **A** and **B,** Gross appearances of carcinosarcoma of ovary. The neoplasms are large, variegated, solid and cystic, with hemorrhagic and necrotic areas.

a typical benign or borderline component.[296] The appearance of the malignant epithelium may be that of a transitional cell, squamous, glandular, or undifferentiated carcinoma, or an admixture of these.[296]

The tumors formerly referred to as **transitional cell carcinomas** (non-Brenner type),[292,297] unassociated with a benign or borderline Brenner tumor (see Fig. 35.32), are now recognized to be variants of HGSC (i.e. they are not related to Brenner tumors). Their immunophenotype is typical of HGSC (WT1 and ER expression).[298]

Brenner tumors show a strong association with mucinous tumors (Fig. 35.55)[299] and are sometimes seen together with struma ovarii.[300] Brenner tumors have exceptionally been seen to occur in accessory ovaries[301] or in other female genital tract sites, including vagina.

Carcinosarcoma and Adenosarcoma

Carcinosarcoma (malignant mixed müllerian tumor or MMMT) of the ovary resembles grossly and microscopically in every respect its more common uterine counterpart (Fig. 35.56). Thus a *homologous* variety (with nonspecific malignant stroma) and a *heterologous* variety (with malignant heterologous elements) occur.[302] The carcinomatous component may be of serous, endometrioid, squamous, or clear cell type. The sarcoma-like elements may have the appearance of chondrosarcoma (the most common), osteosarcoma, rhabdomyosarcoma, or angiosarcoma (Fig. 35.57). Hyaline droplets containing α1-antitrypsin are often present in the cytoplasm of the tumor cells.[303] Although some response to chemotherapy has been noted,[161] the overall prognosis is extremely poor,[304] with some outstanding exceptions.[305] The most reliable prognostic criterion is the initial tumor stage.[208,306–308] Unfortunately, most tumors have already extended outside the ovary at the time of surgery.[309] The most important differential diagnosis is with immature teratoma and adenosarcoma with heterologous elements. Almost all carcinosarcomas are seen in postmenopausal patients, whereas immature teratomas are typically tumors of children and adolescents. Furthermore, the former usually lack the neural and other germ cell elements of teratomas. However, cases of carcinosarcoma featuring prominent neuroectodermal differentiation have been described.[247,310,311]

Müllerian adenosarcoma, more commonly seen in the endometrium and cervix, also can occur in the ovary.[306,312–314] The morphologic appearance and behavior are again similar to those of its uterine counterpart, including the occurrence of sex cordlike elements, sarcomatous overgrowth, and heterologous elements.[313] The subject was discussed previously (see Chapter 33).

Mixed and Other Epithelial Tumors

Carcinomas composed of an admixture of two or more of the five common histotypes of ovarian carcinoma account for fewer than 1% of cases and most commonly consist of an admixture of those histotypes that are associated with endometriosis (e.g. clear cell and

For personal use only. No other uses without permission. Copyright ©2017. Elsevier Inc. All rights reserved.

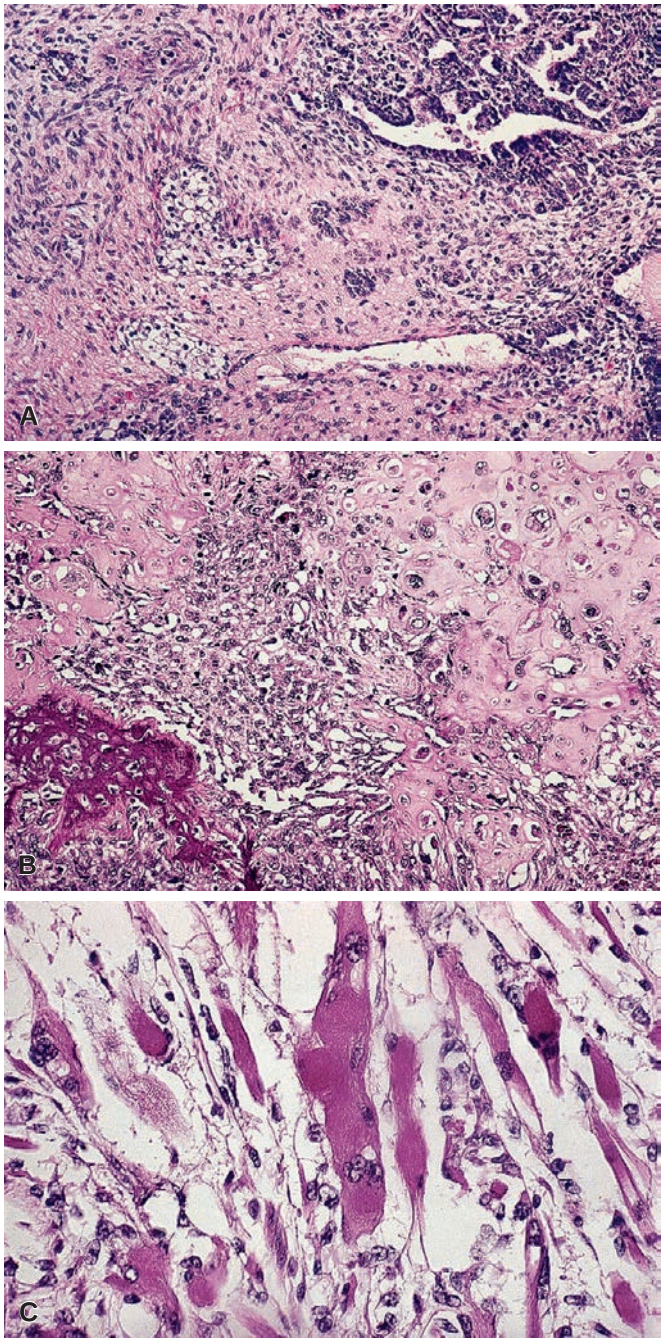

Figure 35.57 Carcinosarcoma of Ovary. The tumor shown in **A** is of the so-called homologous type, whereas the others exhibit heterologous foci in the form of bone and cartilage **(B)** or skeletal muscle **(C)**.

endometrioid carcinoma).[179] A diagnosis of mixed carcinoma should only be made when there is clear evidence of more than one histotype present, preferably supported by the appropriate immunostains (although they need not be done in an unequivocal case).

There are also approximately 1% of ovarian carcinomas that defy histotype classification; we refer to these as "adenocarcinoma NOS." Undifferentiated carcinoma is a diagnosis reserved for tumors that are undifferentiated throughout. Any component of HGSC, or even expression of the serous marker WT1, is sufficient to classify such a tumor as high-grade serous. Undifferentiated carcinoma, when seen in association with low-grade endometrioid carcinoma, is a de-differentiated carcinoma, following the practice for endometrial tumors.[265] Exceptionally, carcinomas of the ovary show a pattern resembling that of salivary gland carcinomas of adenoid cystic type or that of cutaneous basal cell carcinomas.[284,315,316] These may be seen in pure form or in association with conventional serous, endometrioid, or clear cell patterns. The tumors with an adenoid cystic carcinoma-like appearance are more aggressive than the basaloid neoplasms.[284]

Ovarian Carcinoma

Ovarian Tumors in Children

Germ cell tumors are the most common tumors in children, accounting for 60%–70% of all ovarian tumors in this age group.[317–319] Whereas mature cystic teratomas predominate, the proportion of malignant germ cell tumors (especially immature teratomas, yolk sac tumors, and dysgerminomas) is much greater than in adults.[320–324]

Sex cord–stromal tumors constitute 10%–25% of cases and are largely represented by juvenile granulosa cell tumor and fibrothecomas.[325] Epithelial tumors represent only 15%–20% of ovarian tumors in children, and the vast majority are benign.[326] Indisputable cases of carcinoma occur, particularly of the mucinous type; however, some cases reported as serous carcinomas actually represent yolk sac tumors or retiform Sertoli–Leydig cell tumors with a prominent papillary component, and when one encounters a malignant ovarian neoplasm in the first two decades of life, it is most probably NOT an ovarian carcinoma.

As in adults, primary malignant ovarian tumors in children need to be distinguished from metastatic neoplasms. The latter include neuroblastoma, adrenal cortical carcinoma, rhabdomyosarcoma, Ewing sarcoma, and intra-abdominal desmoplastic small cell tumor.[327]

Coexistence of Ovarian and Endometrial Carcinoma

The simultaneous presence of carcinoma in the ovary and uterus is an uncommon but well-recognized event.[328–330] The two tumors may have a similar appearance (usually endometrioid but sometimes serous or clear cell) or may be of different histologic types.[328] Theoretically, this phenomenon could be the result of: (1) metastasis from an endometrial carcinoma into the ovary; (2) two independent primary tumors; or (3) metastasis from an ovarian carcinoma to the endometrium.[329] Historically, ovarian metastasis from an endometrial tumor was favored in the presence of high-grade (especially serous), advanced stage, bilaterality, and/or very small size of the ovarian tumor, involvement of the tubal lumen, and presence of deep myometrial invasion and/or vascular invasion in the uterine tumor.[328] It was thought that most neoplasms with a low-grade endometrioid appearance in both sites were probably independent neoplasms, as they are associated with little or no myometrial invasion in the uterus, extrauterine disease confined to the ovary (without ovarian surface involvement or trans-coelomic spread), and often endometriosis. These patients have an excellent prognosis, even without adjuvant therapy, as would be expected for synchronous stage Ia tumors. It was surprising, then, to find that based on sequencing of tumor DNA, the endometrial and ovarian tumors in a large majority of such cases are derived from a single clone.[331,332] The compelling molecular evidence that these tumors are clonally related does not, of course, change the excellent prognosis and it is therefore reasonable to continue with the previous practice of staging such low-grade organ-confined tumors as independent primary tumors, as that reflects their behavior. A further interesting point is that patients with synchronous endometrial and ovarian carcinoma have Lynch syndrome in only 7% of cases.[333]

For personal use only. No other uses without permission. Copyright ©2017. Elsevier Inc. All rights reserved.

Cytology

The main role of diagnostic cytology in ovarian carcinoma is the identification of malignant cells in the peritoneal cavity. The value of peritoneal washing cytology to detect the microscopic spread of ovarian carcinoma has been acknowledged by the fact that the FIGO staging system incorporates the results of cytological examination of the washings in its scheme. Serous carcinomas are more often positive than carcinomas of other types, and high-grade tumors more than low-grade tumors.[334] Specifically, a high positive rate is related to advanced stage of disease, involvement of the ovarian surface, a moderate to large amount of fluid, and nonbloody serous ascites.[335]

The interpretation of peritoneal washings can be made difficult by the admixture of reactive mesothelial cells as well as the differential diagnosis with peritoneal malignant mesothelioma. Calretinin is a good positive marker of mesothelioma, while BerEP4 is consistently positive in carcinomas, but also stains occasional mesotheliomas.[336,337] It should be noted that the "epithelial/carcinoma" markers such as BerEP4 and MOC31 do not allow distinction between carcinoma and benign epithelium (e.g. derived from endometriosis) as both can stain positively. Heterozygous loss of 9p21 is specific for mesothelioma, but not completely sensitive.[336]

Therapy

The primary form of therapy of epithelial tumors is surgical.[338–340] Benign tumors are cured by a conservative operation in the form of unilateral salpingo-oophorectomy. Although the uninvolved portion of the ovary can be preserved for some small benign tumors, the majority require the excision of the entire gonad. Most borderline tumors in young females can also be treated conservatively with safety, the results following salpingo-oophorectomy being equivalent to those seen following more extensive procedures.[341,342] As a matter of fact, some cases have been treated with cystectomy only, the overall outcome being excellent; however, recurrences in the ipsilateral ovary are relatively common and close follow-up is necessary.[343]

Carcinomas were traditionally treated initially by bilateral salpingo-oophorectomy with total abdominal hysterectomy and omentectomy, peritoneal washings, peritoneal biopsies, and lymph node dissection (so-called complete surgical staging), irrespective of histotype. There has been some move away this more extensive surgical staging as it is clear that patients with "apparently" low stage (stage Ia) mucinous and endometrioid carcinomas do exceptionally well, even without extensive staging or adjuvant therapy. Avoiding the morbidity of more extensive surgery and chemotherapy for these two subtypes does not significantly impact on their excellent prognosis (>95% disease-free survival at 5 years).[344] On the other hand, patients with HGSC have such a guarded prognosis that, to date, it has not been possible to identify a group where chemotherapy would not be offered, in the absence of medical contraindications. Thus, more extensive surgery, including node dissection, is not needed to guide treatment for these patients as all will receive platinum/taxane chemotherapy (with intraperitoneal delivery in some patients)[338] irrespective of nodal status. At the present time, most patients with ovarian carcinoma have something less than complete surgical staging.

A recent trend is towards neoadjuvant chemotherapy for patients with advanced stage ovarian carcinoma. As noted previously, most such tumors are HGSC. A large international randomized clinical trial found that neoadjuvant chemotherapy followed by surgery, rather than surgery first, resulted in comparable survival rates and less morbidity.[345] This approach is becoming more widely accepted; only those patients who experience a response to chemotherapy go on to surgery, and in this interval debulking specimen there is the opportunity to assign a chemotherapy response score (CRS), as an indication of response to neoadjuvant chemotherapy.[346] CRS is assigned based on examination of the omentum, as follows: CRS1: mainly viable tumor with no or minimal regression-associated fibroinflammatory changes limited to a few foci, CRS2: appreciable tumor response amidst viable tumor, CRS3: no residual tumor OR minimal irregularly scattered tumor foci seen as individual cells, cell groups or nodules up to 2 mm in maximum size. Only CRS3 is prognostically significant, and these patients, as one would expect, are more likely to be long-term survivors.[346]

Prognosis

The overall prognosis of ovarian carcinoma remains poor. HGSC accounts for most cases, most of which are advanced stage at presentation, and a large majority of these patients will die of disease. Stage and histotype are of independent prognostic significance (even though they co-vary, as noted in Table 35.2). Assignment of grade in ovarian carcinoma is done in a histotype-specific way.[347] Grade is not assigned in HGSC, low-grade serous carcinoma or clear cell carcinoma. Grading systems for the latter have been proposed but have not been independently validated to be of prognostic significance independent of stage. Endometrioid carcinomas are typically graded using the FIGO system in use for endometrial carcinomas of endometrioid type, while mucinous carcinomas are most commonly graded using the WHO system, which does not provide specific criteria for grading.

Germ Cell Tumors

Germ cell tumors constitute approximately 20% of all ovarian neoplasms. Most of them are seen in children and young adults, and approximately 95% are benign cystic teratomas; the younger the patient, the more likely the germ cell tumor will be malignant.[328,348]

Significant advances have been made in the understanding of these tumors,[349,350] many of them fueled by the description of new immunohistochemical markers having a high degree of specificity for germ cell tumors in general and for some of the individual types.[351–353]

In the sections that follow, the tumors are discussed as individual types; however, it should be recognized that a combination of various elements occurs in approximately 8% of cases. These are referred to as *mixed germ cell tumors*[354,355]; the most common combination is that of dysgerminoma with yolk sac tumor, but many others occur,[356] including some with a predominance of the polyembryoma component.[348]

One of the greatest achievements in oncology is represented by the therapy of malignant germ cell tumors. Chemotherapeutic regimens consisting of a combination of bleomycin, etoposide, and cisplatin have resulted in overall disease-free survival rates greater than 95%.[357,358]

Dysgerminoma

Dysgerminoma constitutes less than 1% of all ovarian tumors.[359] Most patients are young. In Santesson's series of nearly 300 cases, 81% were under 30 years of age and 44% were under 20 years of age.[360] Dysgerminoma made up 6% of 188 childhood ovarian neoplasms collected by Abell et al.[361] Approximately 5% of dysgerminomas arise in abnormal gonads: pure or mixed gonadal dysgenesis (from a gonadoblastoma) or testicular feminization (androgen insensitivity) syndrome. Exceptionally, the tumor is associated with hypercalcemia.[362]

Dysgerminoma is somewhat more common on the right side and is bilateral in 15% of cases.[360] It is often large (it may reach

For personal use only. No other uses without permission. Copyright ©2017. Elsevier Inc. All rights reserved.

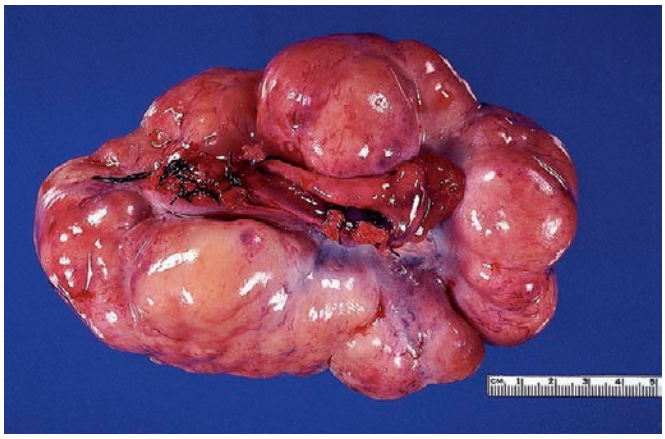

Figure 35.58 Typical lobulated outer aspect of ovarian dysgerminoma.

Figure 35.59 Cut Surface of Ovarian Dysgerminoma. The multinodular solid quality and the tan color are characteristic features.

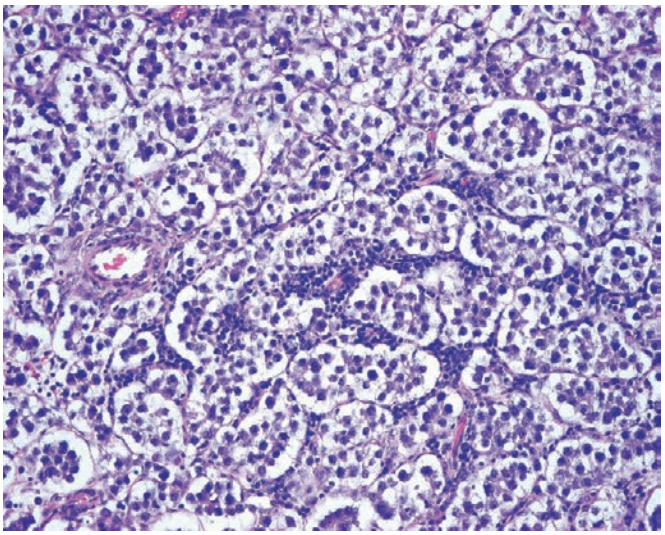

Figure 35.60 Typical nesting appearance of ovarian dysgerminoma. The septa contain numerous inflammatory cells.

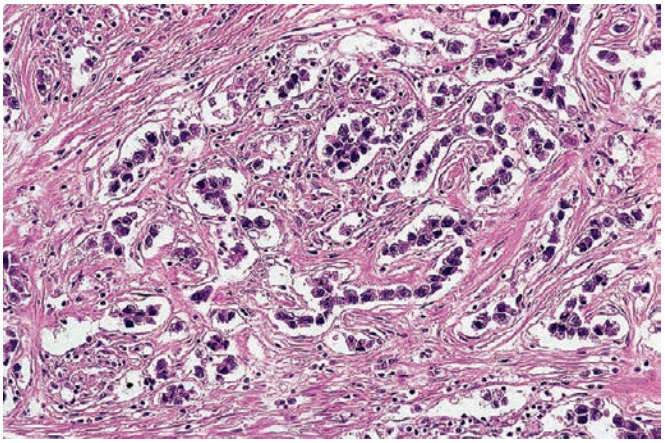

Figure 35.61 The thin trabecular pattern that dysgerminomas sometimes exhibit may be the source of diagnostic errors.

over 1000 g) and encapsulated, with a smooth, often bosselated surface (Fig. 35.58). The cut surface is solid and gray; foci of hemorrhage and necrosis can occur, but they are not as common or prominent as in other malignant germ cell tumors (Fig. 35.59). Microscopically, the tumor cells usually group themselves in well-defined nests separated by fibrous strands infiltrated by lymphocytes (most of which are T cells[363]; Fig. 35.60). Occasionally, a pseudotubular, alveolar, or cordlike arrangement may be seen (the latter particularly at the tumor periphery), which may be quite confusing (Fig. 35.61).[364] Focal necrosis, hyaline changes in vessels, germinal centers, and granulomatous foci may be present. The individual tumor cells are uniform and have large "squared-off" nuclei, *one or more prominent elongated purple nucleoli*, and abundant clear to finely granular cytoplasm that contains glycogen and sometimes fine droplets of fat. The cell membrane is prominent.

Immunohistochemically, the tumor cells are consistently reactive for PLAP and CD117, variably for keratin (erratically and focally), and sometimes for GFAP and desmin but not for CD30.[365–368] OCT4, a transcription factor involved in the regulation of pluripotency during embryonic development, stains the cells of dysgerminoma, the germ cell component of gonadoblastoma, and embryonal carcinoma, but not yolk sac tumor.[369] SALL4 is typically positive.[370]

The microscopic pattern, ultrastructural appearance, immunohistochemical and cytogenetic profiles, clinical behavior, and probable histogenesis (from indifferent or primordial germ cells) of ovarian dysgerminoma are the same as for classic seminoma of the testis.[371–373] It also commonly shows cytogenetic abnormalities involving chromosome 12p. Like testicular seminoma, ovarian dysgerminoma may exhibit signs of early differentiation toward other types of germ cell elements. These include:

1. Scattered hCG-positive syncytiotrophoblastic cells, often in close proximity to blood vessels or to hemorrhagic foci (Fig. 35.62).[374] This change, seen in approximately 3% of all dysgerminomas, may be accompanied by serum elevation of hCG and tissue immunoreactivity for this marker.
2. Abortive yolk sac elements, accompanied by serum elevation of alpha-fetoprotein and tissue immunoreactivity for this marker (Fig. 35.63).[375]

As with the equivalent testicular examples, it is not clear whether these changes alter the prognosis of dysgerminoma, and it is, therefore, important to distinguish them from dysgerminoma admixed with choriocarcinoma, embryonal carcinoma, or yolk sac tumor, a phenomenon that occurs in approximately 8% of cases and that affects prognosis significantly.

Metastases of dysgerminoma occur more commonly in the contralateral ovary, retroperitoneal nodes, and peritoneal cavity.

For personal use only. No other uses without permission. Copyright ©2017. Elsevier Inc. All rights reserved.

The survival rate of pure dysgerminoma is 95%. The initial treatment of unilateral dysgerminoma is oophorectomy. Chemotherapy is the treatment of choice for this tumor when it has spread beyond the ovary.

Yolk Sac Tumor and Embryonal Carcinoma

The history of these two germ cell neoplasms of the ovary is replete with confusing, contradictory, and sometimes erroneous statements as to their origin, relationship, and natural history. Yolk sac tumor was included in Schiller's original description of mesonephroma,[376] together with the ovarian tumor presently designated as clear cell carcinoma.[377] Once it was realized that the latter has a different histogenesis, morphologic appearance, and natural history, the analogy became no longer tenable. The next generation of articles on the subject clearly separated these two neoplasms but used more or less interchangeably the terms *yolk sac tumor* and *embryonal carcinoma*. Since both of these neoplasms are of germ cell derivation, share many morphologic features, and are closely related histogenetically, this is not entirely inappropriate.[378] However, enough differences exist between the two to justify their separation.

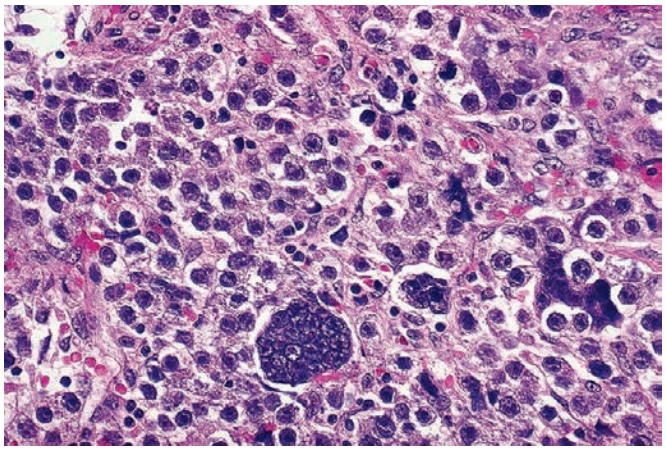

Figure 35.62 Isolated multinucleated cells of trophoblastic type in ovarian dysgerminoma.

Yolk sac tumor (endodermal sinus tumor) is generally a neoplasm of children and young adults (median age, 19 years).[379] In the series of Kurman and Norris,[380] 23% of the patients were prepubertal at the time of diagnosis. None of the patients presented with precocious puberty, amenorrhea, or hirsutism. Vaginal bleeding occurred in only 1%. The serum alpha-fetoprotein level was invariably elevated, whereas the chorionic gonadotropin levels were normal, resulting in consistently negative pregnancy tests. Grossly, the tumors had an average diameter of 15 cm, a smooth and glistening external surface, and a variegated cut surface, partially cystic and often containing large foci of hemorrhage and necrosis (Fig. 35.64). A component of benign cystic teratoma was identified in 10 of the 71 cases.

Exceptionally, a yolk sac tumor will be found in the pelvis (in close proximity to the uterus), omentum, or mesentery, unattached to the ovary.[381–383]

Microscopically, the appearance of yolk sac tumors is extremely variable.[384] There are reticular or microcystic areas formed by a loose meshwork lined by flat or cuboidal cells (Fig. 35.65), rounded or festooning pseudopapillary processes with central vessels (Schiller–Duval bodies), and solid areas. The mesenchyme-like component of these tumors has pluripotential properties; it usually presents in the form of spindle cells in a well-vascularized myxoid background, but it exhibits keratin immunoreactivity as a sign of early epithelial differentiation and may contain heterologous elements such as skeletal muscle.[385]

Intracytoplasmic and extracellular PAS-positive hyaline droplets are nearly always present. Their chemical composition is heterogeneous; they usually stain for alpha-fetoprotein, but they may also

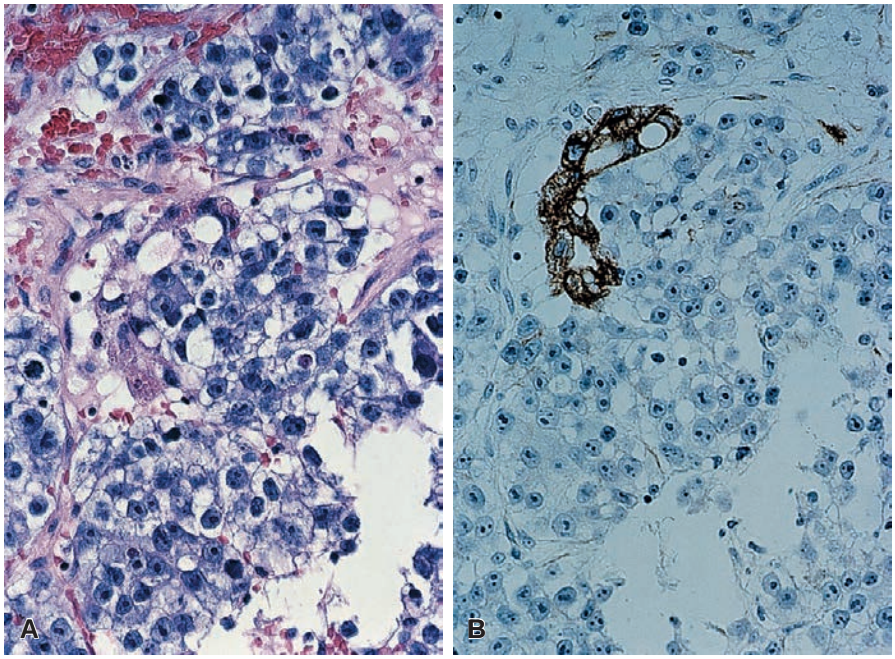

Figure 35.63 Ovarian Dysgerminoma With Early Yolk Sac Differentiation. A, H&E appearance. The foci of early yolk sac differentiation are represented by the small gland-like structures near the center. **B,** This formation is strongly immunoreactive for keratin, in contrast with the rest of the neoplasm. (Courtesy of Dr. Vinita Parash, New Haven, CT.)

For personal use only. No other uses without permission. Copyright ©2017. Elsevier Inc. All rights reserved.

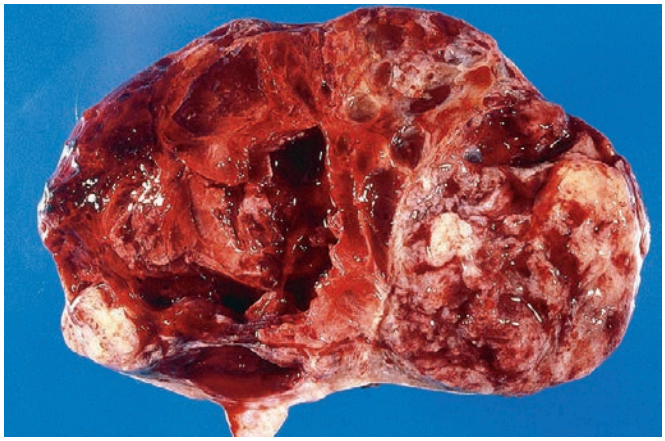

Figure 35.64 Gross appearance of yolk sac tumor. The cut surface is remarkably heterogeneous due to extensive hemorrhage, necrosis, and cystic degeneration.

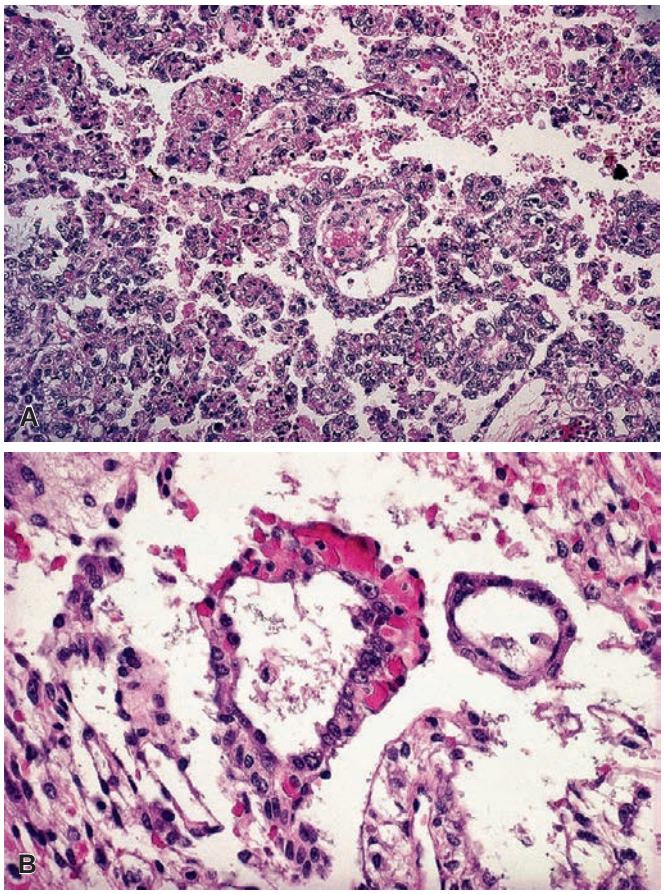

Figure 35.65 **A** and **B,** Low- and high-power views of ovarian yolk sac tumor. Numerous hyaline globules are seen in the cytoplasm of the tumor cells lining the papillae.

contain α1-antitrypsin and basement membrane components (type IV collagen and laminin).[386] Yolk sac tumor also stains for pankeratin but not for keratin 7 or EMA (in contrast with endometrioid and clear cell ovarian carcinoma), or for WT1 (in contrast with serous ovarian carcinoma).[387] They also exhibit positivity for SALL4 and glypican 3,[388] a property they share with testicular and extragonadal yolk sac tumors.[389] However, OCT4 is typically negative. DNA ploidy

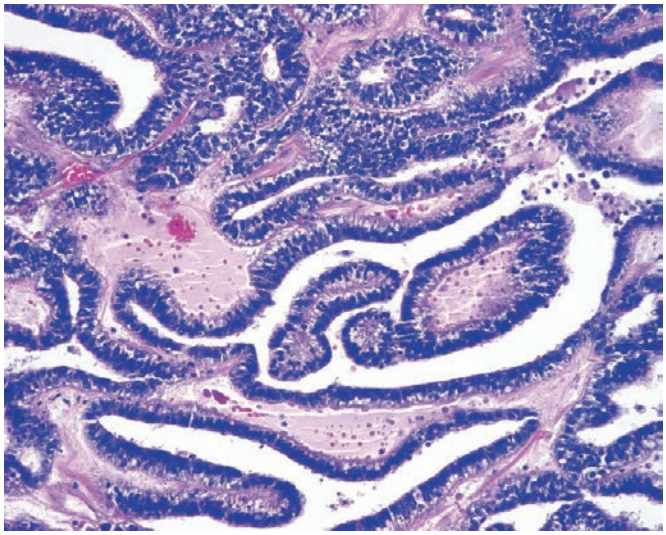

Figure 35.66 Yolk sac tumor with endometrioid features.

studies have shown that yolk sac tumors are almost invariably aneuploid.[390]

A fourth of the yolk sac tumors have vesicular structures with eccentric constrictions surrounded by a dense spindle cell stroma; this has been referred to as a *polyvesicular vitelline pattern* and is said to be associated with a good prognosis when present in a pure form.[391] Others show a scattered hCG-positive syncytiotrophoblast component. Still others exhibit evidence of differentiation toward hepatic, intestinal, and parietal yolk sac structures.[392] The latter are recognized by the presence of thick layers of intercellular basement membrane.[393] The *hepatoid* component, which can predominate almost to the exclusion of the others, is composed of masses, nests, and broad bands of large polyhedral cells with occasional glandular formations and numerous hyaline bodies. Their immunohistochemical profile is similar to that of hepatocellular carcinoma, including reactivity for α1-antitrypsin and a canalicular staining pattern with polyclonal CEA.[394,395] These hepatoid yolk sac tumors are to be distinguished from *hepatoid ovarian carcinomas*, rare tumors of epithelial origin.[396] In some yolk sac tumors, the presence of *glandular* formations may simulate the appearance of endometrioid carcinoma (Fig. 35.66).[397] An exceptional event in ovarian yolk sac tumor is the presence of mucinous carcinoid tumor as a manifestation of endodermal differentiation.[398]

Areas of luteinized stromal cells may be present and may sometimes be responsible for virilization.

An important phenomenon in the differential diagnosis of yolk sac tumor of germ cell origin is the occurrence of typical yolk sac tumor in older women, sometimes in association with an epithelial malignancy such as clear cell carcinoma.[399] These yolk sac tumors of presumed somatic cell origin are analogous to the well-known phenomenon of choriocarcinomatous differentiation in poorly differentiated carcinomas from a number of different primary sites[400] and should be distinguished from yolk sac tumors of germ cell origin. The patient's age can usually serve to make this distinction as those of somatic cell origin arise in the elderly.

Teilum's brilliant hypothesis that this tumor recapitulates normal yolk sac elements[377] has been amply confirmed by histochemical and ultrastructural studies,[401–403] including the detection of GATA4, a transcription factor that regulates the differentiation and function of murine yolk sac endoderm.[404]

In the series of Kurman and Norris,[380] from more than 40 years ago, the actuarial survival at 3 years was only 13%; although 71%

For personal use only. No other uses without permission. Copyright ©2017. Elsevier Inc. All rights reserved.

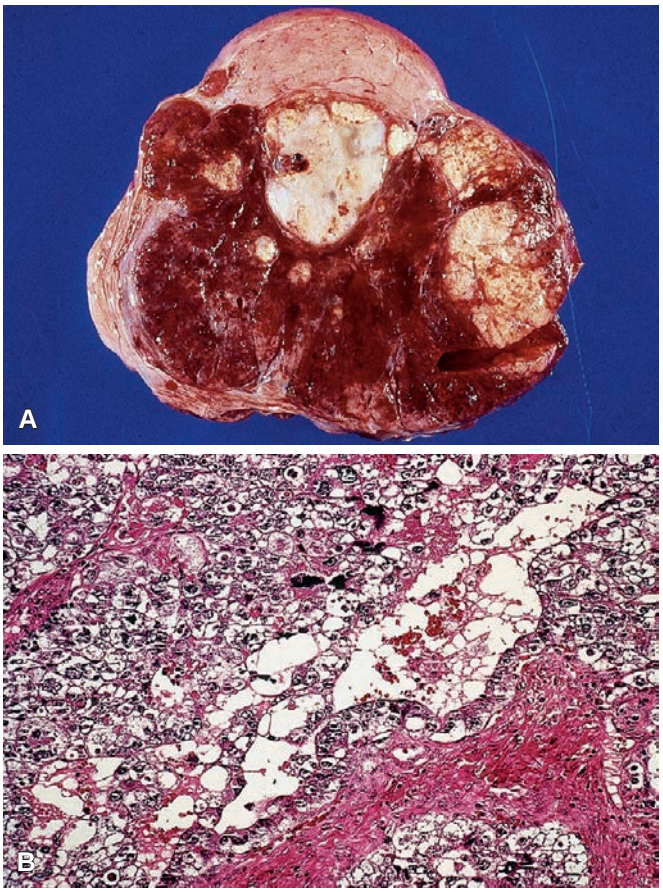

Figure 35.67 **A** and **B**, Gross and microscopic appearance of embryonal carcinoma of ovary.

of the patients were thought to have stage I tumors, subclinical metastases were present in 84%. The introduction of multidrug chemotherapy has dramatically improved survival rates.[405] As usual, clinical stage is the most important prognostic indicator.[385,406] Serial determinations of serum alpha-fetoprotein are useful in monitoring the tumor course.[407,408]

Embryonal carcinoma also occurs in a young age group (median age, 15 years). In one series, 47% of the patients were prepubertal at the time of diagnosis, and 43% of them presented with precocious puberty.[409] Vaginal bleeding was recorded in 33%, amenorrhea in 7%, and hirsutism in 7%. Serum chorionic gonadotropin levels are invariably high, to a level that may result in consistently positive pregnancy tests.

Grossly, the median diameter of these neoplasms is 17 cm, on average. Their external surface is smooth and glistening, and their cut surface is predominantly solid and variegated, with extensive areas of necrosis and hemorrhage (Fig. 35.67). Microscopically, this tumor has a similar appearance to the embryonal carcinoma of the adult testis. As such, it is composed of solid sheets and nests of large primitive cells, occasionally forming papillae and abortive glandular structures (see Fig. 35.67). Syncytiotrophoblast-like tumor cells are frequently seen scattered among the smaller cells; these are immunoreactive for hCG. Embryonal carcinoma shows immunoreactivity for pan-keratin, CD30, OCT4, and SALL4.[410] In the Kurman and Norris series,[421] the prognosis was somewhat better than for yolk sac tumor, but current multidrug chemotherapeutic regimens have erased these differences.[380,411]

Embryonal carcinomas largely composed of embryoid bodies are referred to as *polyembryomas*.[360]

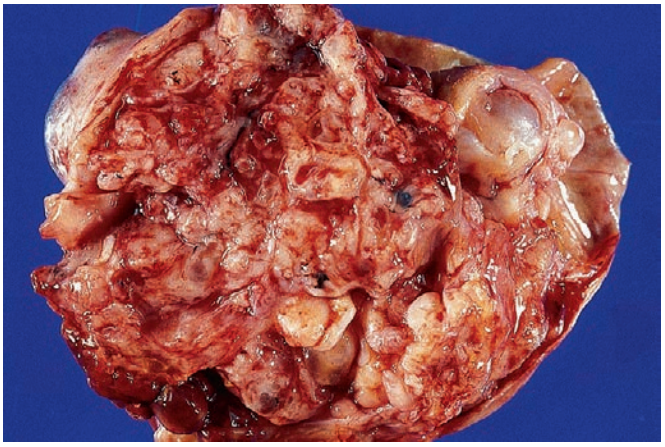

Figure 35.68 Gross appearance of ovarian immature teratoma.

Choriocarcinoma

Most choriocarcinomas involving the ovary represent metastases from uterine tumors. The exceedingly rare primary ovarian choriocarcinomas can develop from an ovarian pregnancy (gestational type, which is the most common) or as a form of germ cell neoplasm (nongestational).[412] The latter can be pure or, more frequently, a component of a mixed germ cell tumor. If pure, DNA typing may be required to distinguish between a gestational choriocarcinoma, containing paternal DNA, and nongestational choriocarcinoma of maternal germ cell origin. Microscopically, they show the typical admixture solid cytotrophoblastic elements enveloped by a rim of syncytiotrophoblast, often in a necrotic and hemorrhagic background. This should be distinguished from aggregates of syncytiotrophoblasts admixed with other germ cell elements (e.g. yolk sac tumor or embryonal carcinoma), which should not alter the diagnosis. Immunohistochemical reactivity for hCG is the rule.

Ovarian choriocarcinomas of either gestational or nongestational type should be distinguished from the exceptionally rare ovarian carcinomas of epithelial origin exhibiting choriocarcinomatous differentiation, a phenomenon analogous to that sometimes seen in carcinomas of the lung, breast, endometrium, gallbladder, and other sites.[413] Patients with choriocarcinomatous differentiation arising in an epithelial malignancy are typically considerably older than those with ovarian choriocarcinoma of either germ cell or gestational origin.

Ovarian gestational choriocarcinomas have a better prognosis than their nongestational counterparts.[400]

Immature Teratoma

Immature teratoma is the currently preferred term for the malignant ovarian teratoma usually seen in children and adolescents and composed of a mixture of embryonal and adult tissues derived from all three germ layers, regardless of its gross appearance (Fig. 35.68). Any type of tissue may be represented. The main component is usually neuroepithelial, but mesodermal elements are also common (Fig. 35.69).[414] Some tumors are predominantly composed of endodermal derivatives, including esophagus, liver, and intestinal structures.[415]

Staining for GFAP is helpful in the identification of mature and immature glial tissue.[416] It should be noted, however, that GFAP is also detectable in chondrocytes.[417]

Grossly, immature teratoma may be solid throughout, solid with multiple minute cysts, or predominantly cystic. Grading of immature

For personal use only. No other uses without permission. Copyright ©2017. Elsevier Inc. All rights reserved.

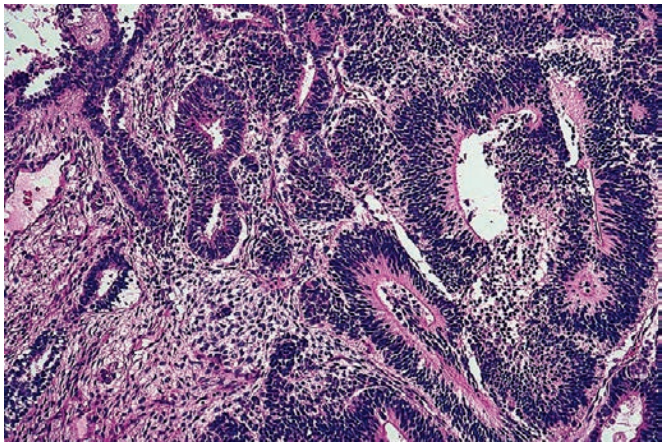

Figure 35.69 Ovarian immature teratoma with predominance of primitive neuroepithelial elements.

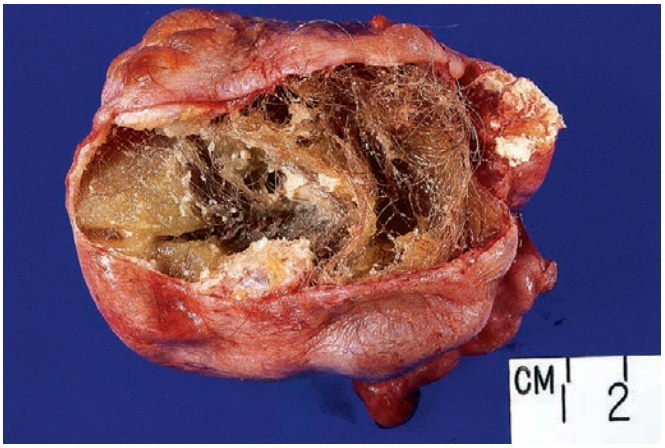

Figure 35.70 Admixture of sebum and hair within the cavity of an ovarian mature cystic teratoma.

teratomas is done based on the WHO 2014 recommendations; grade 1 immature teratomas behave in a benign fashion, while grade 2 and 3 immature teratomas are malignant and can be referred to collectively as "high-grade" immature teratoma. The grading system is as follows:

Grade I, Rare foci of immature neuroepithelial tissue (<1 low power field in any slide)
Grade II, Occasional foci of immature neuroepithelium with mitoses, *not exceeding* three low power fields in any one slide
Grade III, Few or no mature tissues; numerous neuroepithelial elements, merging with a cellular stroma *occupying* four or more low power fields per slide.

Obviously, a thorough tumor sampling is necessary for this grading system to be accurate.

It is important to separate from this group the teratomas that also have yolk sac or embryonal carcinoma patterns.[418] On occasion, an ovarian immature teratoma can be predominantly or exclusively composed of one type of tissue. Neoplasms with an exclusive or almost exclusive malignant neuroectodermal composition are designated **malignant neuroectodermal tumor** and are generally regarded as a form of monodermal teratoma.[419,420] A variation on the theme is the ovarian **ependymoma**, in which this neuroectodermal component is made up entirely of primitive ependymal structures.[420–422] Other teratomas have a prominent component of renal (metanephrogenic),[423] retinal anlage,[424] or skeletal muscle (rhabdomyosarcomatous) nature.[425]

A sometimes confusing pattern seen in teratomas, usually in connection with the neuroectodermal component, is the presence of florid vascular proliferation,[426] a phenomenon possibly due to the secretion of angiogenic factors by the tumor cells and which has also been recorded at other sites.[427]

Another peculiar morphologic change sometimes encountered in these tumors is membranous fat necrosis, perhaps secondary to torsion and ischemia.[428]

The treatment of immature teratoma consists of surgery plus multidrug chemotherapy for grade 2 or grade 3 tumors[429–431]; sometimes, only mature tissue is found in metastatic sites following chemotherapy, a sign of excellent prognosis.[416] It is interesting, however, that the abnormal karyotype of the original immature teratoma is maintained in the area of chemotherapy-induced maturation.[432] This mature tissue may continue to grow (the growing teratoma syndrome, more commonly observed with testicular germ cell tumors), but the growth is self-limited if all tissues are mature and masses formed can be observed, without further treatment.[433]

Mature Solid Teratoma

Mature solid teratoma has a predominantly solid gross appearance, but multiple small cystic areas also are present. By definition, the tumor should be *composed entirely of adult tissues* derived from all three germ layers.[434,435]

Clearly, extensive sampling is needed to separate this tumor from a grade 1 immature teratoma. The two tumors are closely related, and the distinction is somewhat subjective; as a matter of fact, some authors refer to mature solid teratoma as "grade 0" immature teratoma.

This rare neoplasm occurs in young women, predominantly in the second decade. The prognosis is excellent, even if peritoneal implants (also mature and for the most part glial in composition) are present.[436]

Mature Cystic Teratoma

Mature cystic teratomas make up almost 20% of all ovarian neoplasms. They constitute the most common ovarian tumor in childhood.[332] They are unilateral in 88% of cases and typically provoke only symptoms relating to the mass. Occasionally, however, they are accompanied by hemolytic anemia,[437,438] virilization,[439,440] or paraneoplastic encephalitis.[441] The latter is often associated with autoantibodies against N-methyl-D-aspartate (NMDA) receptor; teratoma (mature or immature) is the most common neoplasm found in association with this particular paraneoplastic syndrome, and resolution of symptoms, consisting of psychiatric manifestations and/or neurological deficits, occurs in most patients after removal of the teratoma. A moving account of this condition, from the patient's perspective, is provided in the memoir "Brain on Fire" by Susannah Cahalan. Grossly, they are usually multiloculated. The cystic content is greasy, largely composed of keratin, sebum, and hairs (Fig. 35.70). Teeth are often present (Fig. 35.71).[442] Sometimes the tumor contains an imperfectly formed mandible or even a partial human body-like structure (homunculus); the latter are referred to as *fetiform teratomas*.[443] The teeth tend to be located in a well-defined nipple-like structure covered with hair, known as *Rokitansky's protuberance*. This structure should be selected for microscopic examination (even if

For personal use only. No other uses without permission. Copyright ©2017. Elsevier Inc. All rights reserved.

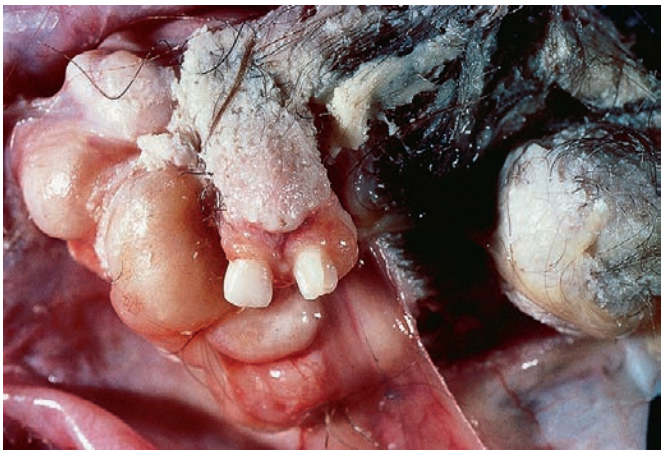

Figure 35.71 Well-developed teeth in ovarian mature cystic teratoma.

decalcification may be required) because it will exhibit the greatest variety of tissue types.

In a classic microscopic study, Blackwell et al.[444] found ectodermal derivatives in 100% of the tumors, mesodermal structures in 93%, and endodermal derivatives in 71%. The cystic cavities are lined by mature epidermis. Skin appendages and neural (particularly glial) tissue are extremely common. The latter may feature meningothelial proliferations and Wagner–Meissner corpuscles and be accompanied by florid vascular proliferation.[445,446] Other common tissue types present are cartilage, respiratory tissue, and gastrointestinal tract tissue (Fig. 35.72). The gastric mucosa can be very well developed anatomically, to the point of containing interstitial cells of Cajal[447]; sometimes it is complicated by peptic ulcer formation.[448] Other tissues include thyroid (10% of cases), various types of melanin-containing tissue (particularly patients with dark skin),[449] anterior pituitary,[450] various types of neuroendocrine cells,[451] prostate,[452,453] pancreas, and cavernous blood vessels. Prominent lymphoid infiltration of glial elements, with germinal center formation, is a feature of teratomas associated with NMDA receptor paraneoplastic syndrome; occasionally the syndrome becomes manifest after removal of the teratoma.[441]

Because of the usual predominance of skin and skin adnexal structures, and also on historical grounds, some authors still prefer the old term dermoid cyst for ovarian mature cystic teratoma. Time-honored considerations aside, we feel that this term is pathogenetically not very informative and that it does not do justice to the plethora of other tissue types that can be present in these tumors.

By definition, all of the components present in mature cystic teratomas should appear histologically mature. However, on occasions one sees microscopic foci of immature (to be distinguished from malignant, see later) tissue in them. The behavior of these tumors, which can be considered to be grade 1 immature teratomas, is usually benign, with no further treatment required beyond surgical removal.[454]

Mature cystic teratomas may coexist with Brenner tumor and thecoma.[455,456]

On occasion, teratomas rupture into the abdominal cavity; when this occurs, the keratin and sebum present in the lumen may provoke a prominent foreign body reaction that can look like metastatic cancer to the surgeon, who may be incredulous when the surgical pathologist goes back to him or her with a benign diagnosis (but not incredulous enough to accept a risky bet about it; Fig. 35.73).[457,458]

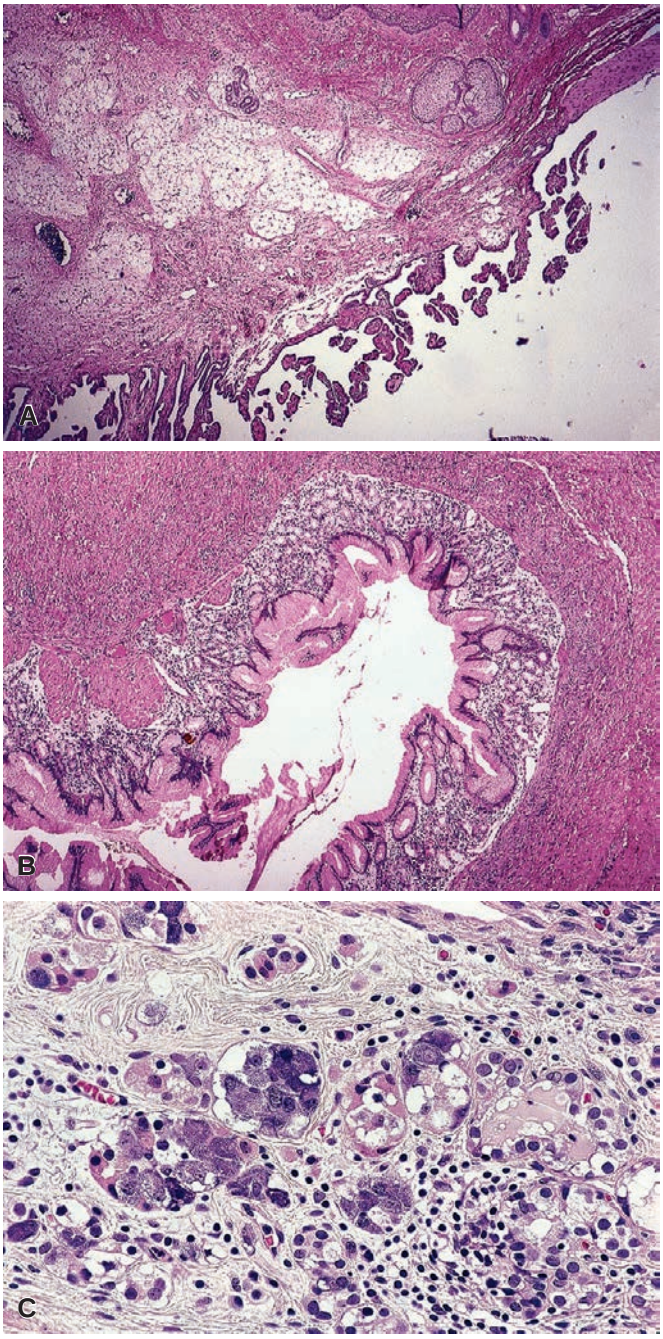

Figure 35.72 Various Tissue Components of Mature Cystic Teratoma of Ovary. A, Skin adnexa, glial tissue, and choroid plexus; **B,** gastric mucosa of pyloric type; **C,** anterior pituitary gland.

In other instances, mature ovarian teratomas of either the cystic or solid variety—as well as immature teratomas—may be accompanied by peritoneal nodules exclusively composed of mature glial and neuronal tissue, a condition known as *gliomatosis peritonei* (Fig. 35.74).[459–462] These nodules appear grossly as miliary grayish-white nodules in the peritoneal surface or omentum and may be accompanied by fibrosis and chronic inflammation. This is a benign process, as long as the glial tissue is entirely mature and unaccompanied by other teratomatous elements (Fig. 35.75).[463–465] Another teratoma-related process is peritoneal "melanosis," which can also follow the rupture of a cystic teratoma.[466]

For personal use only. No other uses without permission. Copyright ©2017. Elsevier Inc. All rights reserved.

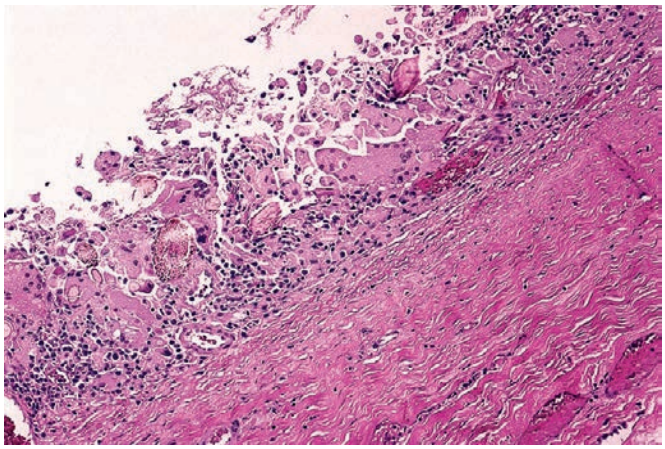

Figure 35.73 Exuberant foreign body-type giant cell response to contents of ruptured ovarian mature cystic teratoma. These changes may simulate grossly the appearance of tuberculous peritonitis or metastatic carcinoma.

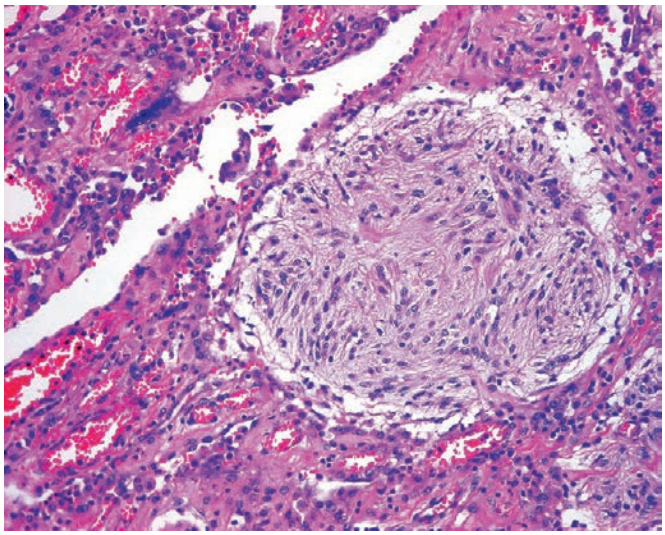

Figure 35.74 Peritoneal implant of mature glial tissue associated with an ovarian teratoma (so-called gliomatosis peritonei).

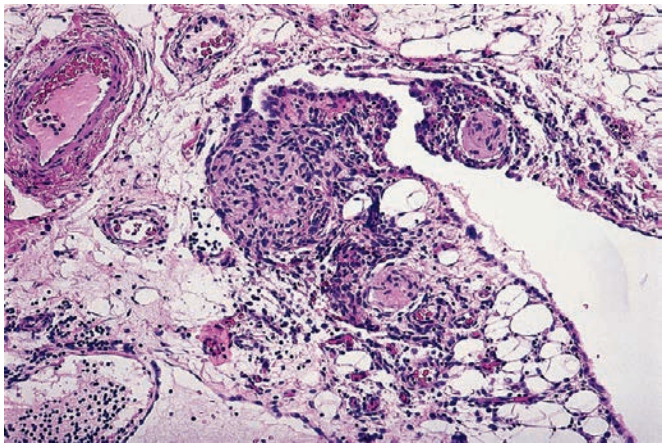

Figure 35.75 Peritoneal implants secondary to immature ovarian teratoma. When the appearance of the implants is immature, as shown here, the prognosis is more guarded than in gliomatosis peritonei (compare with Fig. 35.74).

"Somatic-type" Tumors Developing in Mature Cystic Teratoma

Emergence of a benign or a malignant neoplasm with somatic-type features is an uncommon event in mature cystic teratoma, occurring in approximately 2% of all cases.

The most common malignant change in cystic teratoma is squamous cell carcinoma (possibly arising from metaplastic columnar epithelium),[467] followed by carcinoid tumor and adenocarcinoma.[468–471] These ovarian squamous cell carcinomas typically present in the 5th or 6th decade, suggesting that transformation requires prolonged contact between the epithelium and the cyst contents. The prognosis of squamous cell carcinoma arising from a teratoma is guarded and these tumors are characterized by aggressive locally invasive growth.[469] Other types include malignant melanoma,[472,473] Paget disease,[474]sarcomas of various types, carcinosarcoma, glioblastoma multiforme,[475] central-type neurocytoma,[476] and neuroblastoma/PNET.[477,478] This malignant transformation is accompanied by complex chromosomal aberrations.[479] An interesting twist is the occurrence of mucinous borderline tumors and adenocarcinomas similar to appendiceal neoplasms and resulting in pseudomyxoma peritonei.[480–482] These mucinous tumors arising in association with teratoma have a complete intestinal immunophenotype, indistinguishable from that of colorectal neoplasms. In an elegant study by Kerr et al., they were able to demonstrate, by DNA typing, that these mucinous neoplasms associated with a teratoma are of germ cell origin, while those without a teratomatous component are of somatic origin.[201] The teratoma component may be inconspicuous or consist of a monodermal component such as a carcinoid tumor.

Benign tumors have also been described, such as blue nevus,[483,484] sebaceous adenoma,[485] sweat gland tumors,[486] glomus tumor,[487] epithelioid (histiocytoid) hemangioma,[488] and various types of pituitary adenoma.[489,490]

Epidermoid Cyst

The rare **epidermoid cyst** of the ovary possibly arises from epithelial cell nests, of the type encountered in Brenner tumors.[65] It is distinguished from mature cystic teratoma on thorough sampling by the absence of skin adnexa and other tissues. It is discussed here not only in the light of this differential diagnosis but also because of the distinct possibility that some of these lesions were mature cystic teratomas in which the skin adnexal components were either missed or absent.

Struma Ovarii

Struma ovarii is the expression of the dominant growth of thyroid tissue in a teratoma, sometimes to the exclusion of other components (Fig. 35.76).[491] Grossly, the mass has the color and consistency of thyroid tissue, but it is often cystic (Fig. 35.77). These cystic changes can be very prominent and obscure the diagnosis, and result in a misdiagnosis of serous cystadenoma.[492,493] The thyroid nature of the lesion has been fully documented with biologic and immunohistochemical studies for TTF-1 and thyroid hormones.[494] The tissue may show any of the pathologic changes seen in a normally placed gland, including diffuse or nodular hyperplasia (which may lead to hyperthyroidism[495]), thyroiditis, papillary carcinoma (including the follicular or microcarcinoma variants[496] and featuring either *RAS* or *BRAF* mutation),[497,498] follicular carcinoma (sometimes resulting in peritoneal spread, so-called peritoneal strumosis),[499,500] and malignant lymphoma.[494,501] Some of the carcinomas are extremely well differentiated,[498,499,502] whereas others have a predominantly solid or trabecular pattern.[493]

For personal use only. No other uses without permission. Copyright ©2017. Elsevier Inc. All rights reserved.

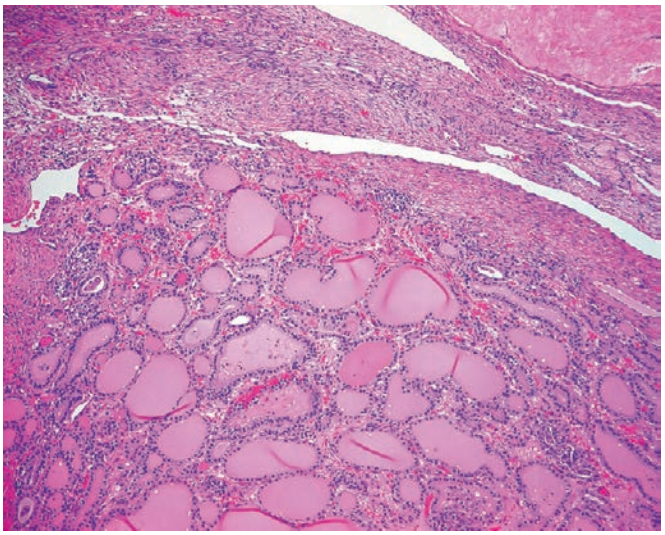

Figure 35.76 Struma Ovarii. The thyroid tissue, which has a microscopically unremarkable appearance, is sharply delimited from the ovarian stroma.

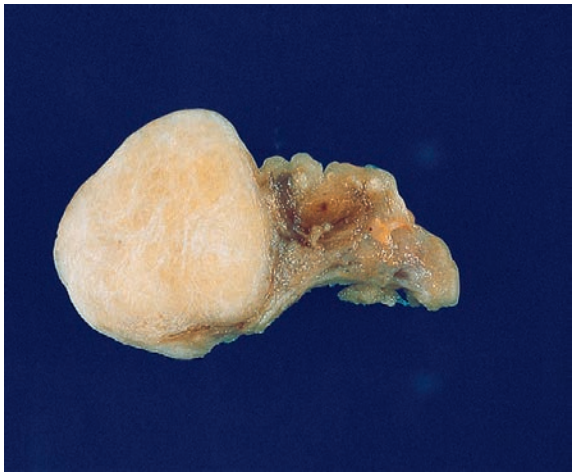

Figure 35.78 Cut surface of carcinoid tumor of ovary showing typical solid appearance and white to yellowish color.

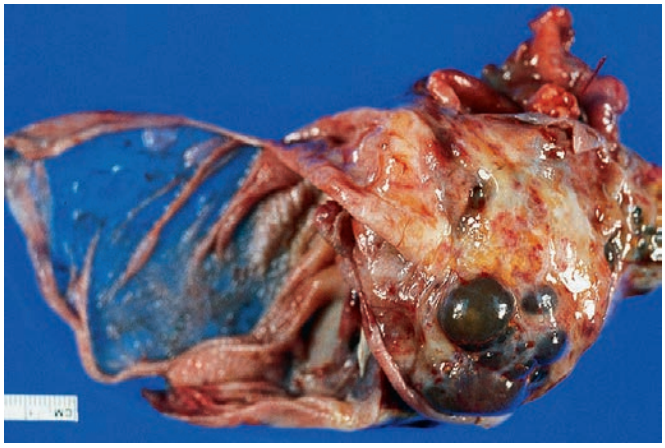

Figure 35.77 Gross Appearance of Struma Ovarii. The thyroid tissue is represented by the solid areas.

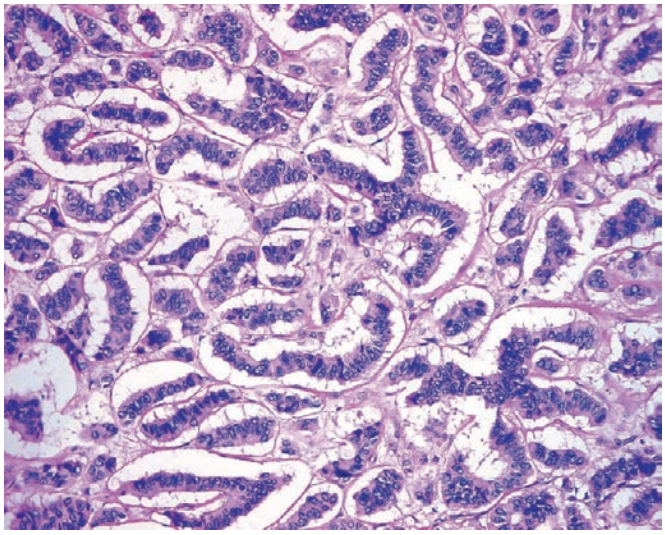

Figure 35.79 Primary Ovarian Carcinoid Tumor With a Trabecular Pattern of Growth. There is a close resemblance to carcinoid tumors of lung and rectum.

Struma ovarii can be seen combined with mucinous cystadenoma, Brenner tumor, or carcinoid tumor. The latter combination, known as strumal carcinoid, is discussed in the following section.

Carcinoid Tumor and Strumal Carcinoid

Carcinoid tumor can be seen in the ovary as a metastasis of a primary tumor located in the gastrointestinal tract or elsewhere,[503] as a component of adult cystic teratoma, or as a primary pure neoplasm of this organ. Approximately one-third of the latter are associated with the carcinoid syndrome, even in the absence of liver metastases[504]; the larger the tumor, the more likely that the carcinoid syndrome will develop. Some cases present with severe constipation, presumably because of secretion of peptide YY.[505] Small tumors arising in cystic teratomas are nearly always asymptomatic. The large majority of primary ovarian carcinoid tumors are unilateral, but in 16% of cases the contralateral ovary is involved by a cystic teratoma or a mucinous neoplasm.[506] In contrast, most metastatic carcinoid tumors to the ovary are bilateral and associated with peritoneal metastases. The prognosis in primary ovarian carcinoid tumors (whether pure or as a component of cystic teratoma) is very good, whereas metastatic carcinoids have a poor outcome.

Grossly, pure primary carcinoid tumors have a mean diameter of 10 cm; their external surface is smooth or bosselated, and the cut surface is predominantly solid, firm, tan to yellow, and homogeneous (Fig. 35.78). Microscopically, the appearance is similar to that of carcinoid tumors elsewhere, in that they recapitulate the various patterns of this well-differentiated neuroendocrine tumor as seen in various sites. Thus, there are tumors with an *insular* pattern of growth similar to those seen in the appendix and small bowel, tumors with a *trabecular* appearance similar to those seen in the rectum (Fig. 35.79), and tumors with a *mucinous* (goblet cell) appearance similar to those seen primarily in the appendix.[507–509] The similarities also apply to the occasional presence of pleomorphic forms,[510] to their histochemical features (argentaffinity or argyrophilia depending on the type), and to the consistent presence of neurosecretory granules at the electron microscopic level.[511]

Neuron-specific enolase (NSE), chromogranin, 5-HT, and a large variety of peptide hormones (including peptide YY) have been

For personal use only. No other uses without permission. Copyright ©2017. Elsevier Inc. All rights reserved.

demonstrated immunohistochemically, particularly in tumors of the trabecular type.[505,512]

It is not possible to separate primary from metastatic carcinoid tumors on morphologic grounds; however, if the ovarian carcinoid is admixed with areas of teratoma, the chances are overwhelming that it is of primary origin. Conversely, tumors with goblet cell carcinoid-like features and signet ring patterns (traditionally known as goblet cell carcinoid tumors, see Chapter 16) are likely to be metastases from the appendix.[513] A potential pitfall should be mentioned here: primary ovarian carcinoid tumors and those metastatic from the gastrointestinal tract show identical immunoprofiles (e.g. expression of CDX2),[514] so immunohistochemistry is not helpful in distinguishing primary from metastatic carcinoid tumor.

Excision of a primary ovarian carcinoid of insular or trabecular type is usually curative. As in the appendix, the behavior of the mucinous type is more aggressive, particularly if the tumor contains a clear-cut carcinomatous component.[507]

Strumal carcinoid is an ovarian neoplasm combining the features of carcinoid tumor and struma ovarii (Fig. 35.80).[515] There was some question about the thyroidal nature of the latter element on the basis of ultrastructural studies, but the immunohistochemical demonstration of thyroglobulin and TTF-1,[516,517] and the occasional occurrence of thyroid-type papillary microcarcinomas[518] have settled the issue. The interesting suggestion has been made that the carcinoid-like component represents a medullary carcinoma arising from thyroid C cells,[519] but the morphologic appearance and immunohistochemical profile of the tumor are more akin to those of a trabecular carcinoid of hindgut derivation[520,521]; specifically, calcitonin and amyloid are only rarely demonstrable.[522] It is of interest that these tumors also exhibit immunoreactivity for prostatic acid phosphatase in the carcinoid component, as further evidence of their similarity to rectal (hindgut-type) carcinoids.[523] The occasional occurrence of severe constipation, presumably due to secretion of peptide YY,[511] and of carcinoid heart disease[524] also link it with pure ovarian carcinoid tumor. Exceptionally, the carcinoid component is of mucinous type.[525]

Other teratomatous elements are found in over 50% of the cases of strumal carcinoid.[504] This lesion has also been observed in association with multiple endocrine neoplasia type 2a.[526]

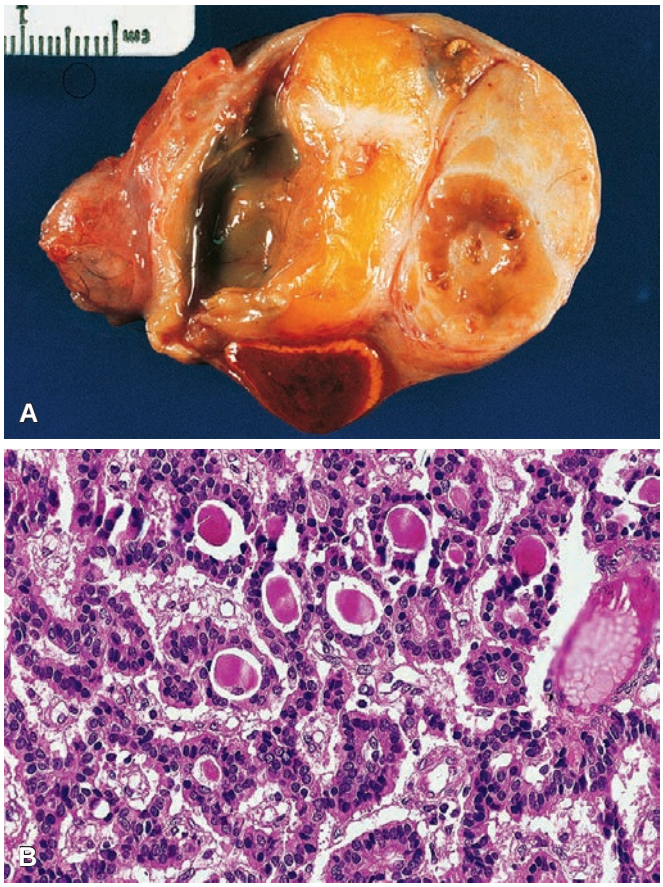

Figure 35.80 **A**, Gross appearance of strumal carcinoid showing a variegated appearance resulting from the admixture of carcinoid tumor and struma ovarii. **B**, Microscopic appearance, showing intimate admixture of thyroid follicles and carcinoid trabecula.

Sex Cord–Stromal Tumors

Sex cord–stromal tumors, which comprise approximately 5% of all ovarian neoplasms, are tumors that differentiate in the direction of sex cords and/or the specialized ovarian stroma.[527] This includes female-type cells (granulosa and theca cells), male-type cells (Sertoli and Leydig cells), and indifferent elements.[528,529] These various elements can occur in combination[530] and exhibit a wide range of differentiation, which often seems to recapitulate the patterns produced during embryogenesis of both the ovary and testis, as proposed many years ago by Gunnar Teilum.[531] Secondary changes, such as luteinization, may also develop. As a result, a wide array of tumor types may be seen, some of which do not fit easily into a rigid classification system. In general, a relationship exists between the morphologic appearance of the tumor and the presence and type of clinically evident hormonal activity.[532–534] However, there may be no demonstrable endocrine effects, and rare examples of hormonal effects opposite to those expected from the morphologic features also occur.[535,536]

Recently, a number of immunohistochemical markers have become available that are of considerable assistance in the identification of these tumors.[537,538] *Inhibin* has emerged as one of the most useful.[539] The α-subunit of the molecule seems to have a greater degree of specificity than the β-subunit.[540,541] It stains all types of sex cord–stromal tumors, the sex-cordlike elements of other gynecologic neoplasms, and most trophoblastic tumors.[542,543] It is also useful for the identification of steroid hormone-secreting cells in the non-neoplastic stroma component of epithelial, germ cell, and other types of ovarian tumor.[544] It has been reported to stain some carcinomas at other sites,[545] but this seems to be due at least in part to endogenous biotin, in older studies where avidin-biotin detection systems were used.[546] It should be also pointed out that negativity for inhibin does not rule out a diagnosis of sex cord–stromal tumor (following the general rule that a negative stain never rules out anything).

Molecules functionally related to inhibin that also stain sex cord–stromal tumors are activin (a molecule biochemically similar to inhibin but with an opposite function, and composed of two βA-subunits), müllerian inhibiting substance (anti-müllerian hormone), and relaxin-like factor.[537,547,548]

Calretinin is more sensitive but less specific than inhibin, in the sense that it often stains sex cord–stromal tumors that are inhibin negative, such as fibromas.[549–551] However, it also stains a good number of surface epithelial neoplasms.

Melan-A is consistently expressed in sex cord–stromal tumors and other types of steroid-producing cells, such as those of ovarian steroid cell tumor and adrenal cortical neoplasms.[552] Like calretinin, however, it lacks specificity as a marker of sex-cord stromal differentiation.

FOXL2 is a transcription factor, expressed in the nuclei of tumor cells; this can be an advantage in staining cells with scant cytoplasm

For personal use only. No other uses without permission. Copyright ©2017. Elsevier Inc. All rights reserved.

(e.g. adult granulosa cell tumors and fibromas), where cytoplasmic stains such as inhibin may not be positive.[549] It is a very sensitive marker of sex cord-stromal tumors with the exception of Sertoli–Leydig cell tumors (only 50% stain) and steroid cell tumors (most are negative).

SF-1 (steroidogenic factor 1) is a sensitive sex cord–stromal marker.[553]

WT1, present in normal granulosa cells, is also expressed by a majority of ovarian sex cord–stromal tumors.[542]

Sex cord–stromal tumors of ovarian type are exceptionally encountered in extraovarian locations, such as the broad ligament.[554]

Granulosa Cell Tumor

Granulosa cell tumor is a sex cord–stromal ovarian neoplasm showing differentiation toward follicular granulosa cells. Two distinct types exist, known respectively as adult and juvenile.

Adult granulosa cell tumor is usually diagnosed during childbearing age, but it can occur after menopause and sometimes (despite its name) before puberty. Three-fourths of cases are associated with hyperestrinism; the excessive production of estrogens can lead to isosexual precocious puberty in children[555] and to metrorrhagia in adults, including postmenopausal patients.[556] Some of the cases are hormonally inactive at the clinical level, and a very few are androgenic.[557,558]

Grossly, adult granulosa cell tumors have a smooth, lobulated outline and a predominantly solid cut surface (Fig. 35.81). The color is usually gray, but it may be yellow in areas of luteinization (Fig. 35.82). Cysts filled with straw-colored or mucoid fluid may be present (Fig. 35.83). Sometimes the cysts are so prominent as to simulate grossly the appearance of a cystadenoma (Fig. 35.84). Interestingly, a disproportionate number of androgenic granulosa cell tumors are large and cystic, either unilocular or multilocular.[558,559] The microscopic appearance of granulosa cell tumors is extremely variable, even within the same neoplasm. Patterns of growth include microfollicular (with Call–Exner bodies), macrofollicular, trabecular, insular, watered-silk, solid, pseudopapillary, and diffuse (sarcomatoid) (Fig. 35.85).[560,561] A theca cell component may also be present. Focal luteinization of either the granulosa or the theca cell component may occur[562]; it is particularly prominent in those tumors associated with pregnancy, together with edema and disorderly arrangement.[563] An important diagnostic feature is the presence of folds or grooves in the nuclei, resulting in a "coffee-bean" appearance (Fig. 35.86). Occasionally, bizarre nuclei and multinucleated giant cells (some of the "floret" type) are seen; this change is not a sign of malignancy, but rather of a degenerative nature.[564] Rare cases of granulosa cell tumor have been reported exhibiting hepatocytic differentiation[565,566] and others are associated with mucinous cystadenoma.[567]

Consistent immunohistochemical markers of granulosa cell tumors include vimentin, FOXL2, and SF-1 (see preceding section; Fig. 35.87).[549,556,568–571] Inhibin expression may be weak or absent in

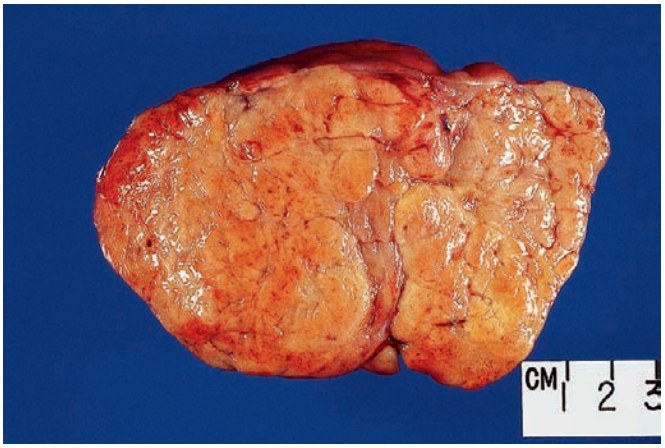

Figure 35.81 Adult granulosa cell tumor with solid cut surface.

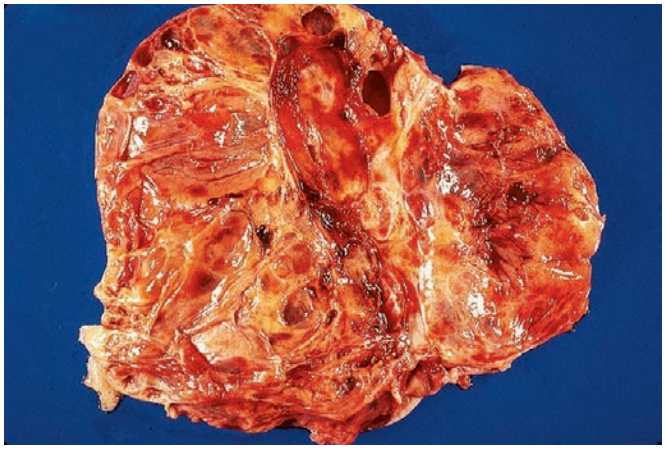

Figure 35.82 Adult granulosa cell tumor showing admixture of solid and cystic areas.

Figure 35.83 Predominantly cystic adult granulosa cell tumor.

Figure 35.84 Adult granulosa cell tumor with an entirely cystic gross appearance.

For personal use only. No other uses without permission. Copyright ©2017. Elsevier Inc. All rights reserved.

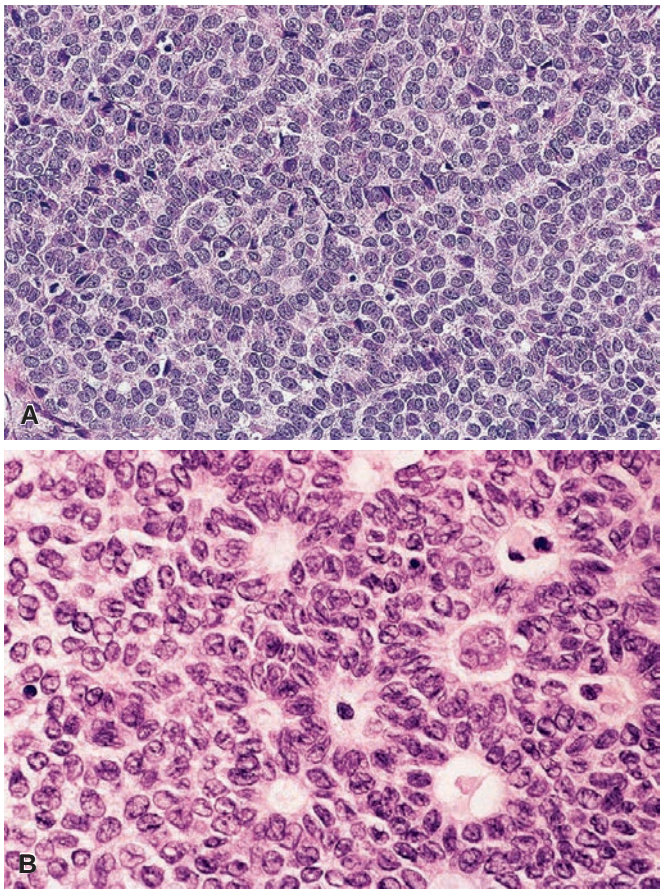

Figure 35.85 **A** and **B,** Microscopic appearance of adult granulosa cell tumor. Call–Exner bodies are seen in **B**.

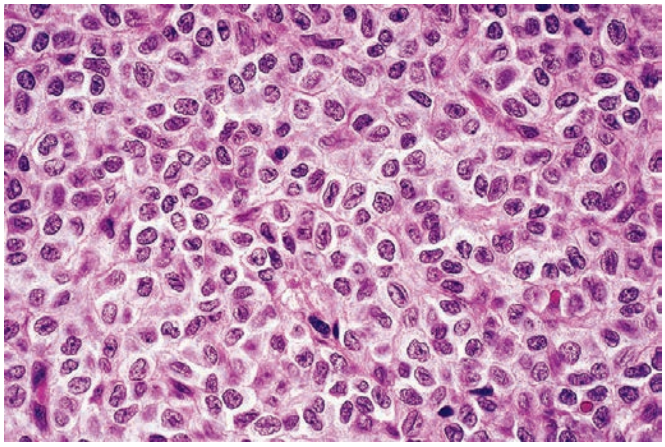

Figure 35.86 Coffee-bean nuclei in adult granulosa cell tumor.

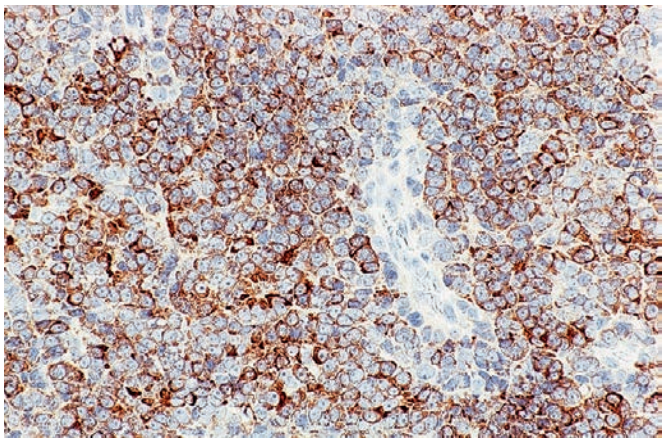

Figure 35.87 Strong immunoreactivity for inhibin in adult granulosa cell tumor.

Figure 35.88 Gross appearance of juvenile granulosa cell tumor.

tumors where the cells have very scant cytoplasm, and this is a frequent source of diagnostic confusion. Keratin expression is present in one-third to one-half of cases; it has a typical dot-like distribution and consists mainly of CK8 and CK18 types.[572] Approximately 50% of cases are reactive for S-100 protein, whereas none are immunoreactive for EMA.[573] Estrogen and progesterone receptors are usually expressed.[574] The peptide hormone inhibin and follicle regulatory proteins, two substances normally produced by ovarian granulosa cells, have been found to be elevated in the serum of patients with granulosa cell tumor.[575] Curiously, granulosa cell tumors have also been found to be often immunoreactive for CD99, a marker associated with Ewing sarcoma.[568]

Recently, it has been shown that almost all cases of adult granulosa cell tumor show somatic mutation in the *FOXL2* gene (402C→G),[567,576,577] and this has emerged as a useful diagnostic marker. Except for occasional well- or moderately differentiated Sertoli–Leydig cell tumors, *FOXL2* mutation is specific for adult granulosa cell tumor. Mutational status need not be assessed in a typical adult granulosa cell tumor, but in diagnostically challenging cases, *FOXL2* mutation testing can be invaluable in confirming/excluding adult granulosa cell tumor.[577]

Juvenile granulosa cell tumor is diagnosed in nearly 80% of cases during the first two decades of life, most patients presenting with isosexual precocity (Fig. 35.88). A few cases have been associated with enchondromatosis (Ollier disease)[578] or Maffucci syndrome.[579] Typical morphologic features of this subtype include diffuse or macrofollicular patterns of growth (the former predominating), mucin-positive intrafollicular secretion, larger tumor cells with extensive luteinization, paucity of nuclear grooves, presence of a thecal component, nuclear atypia, and variable but often high mitotic activity (Fig. 35.89).[580,581] Like their adult counterpart, they may exhibit pseudopapillary features.[560] They also show consistent trisomy for chromosome 12.[582]

The differential diagnosis of granulosa cell tumor (particularly of the adult variety) includes poorly differentiated (predominantly

For personal use only. No other uses without permission. Copyright ©2017. Elsevier Inc. All rights reserved.

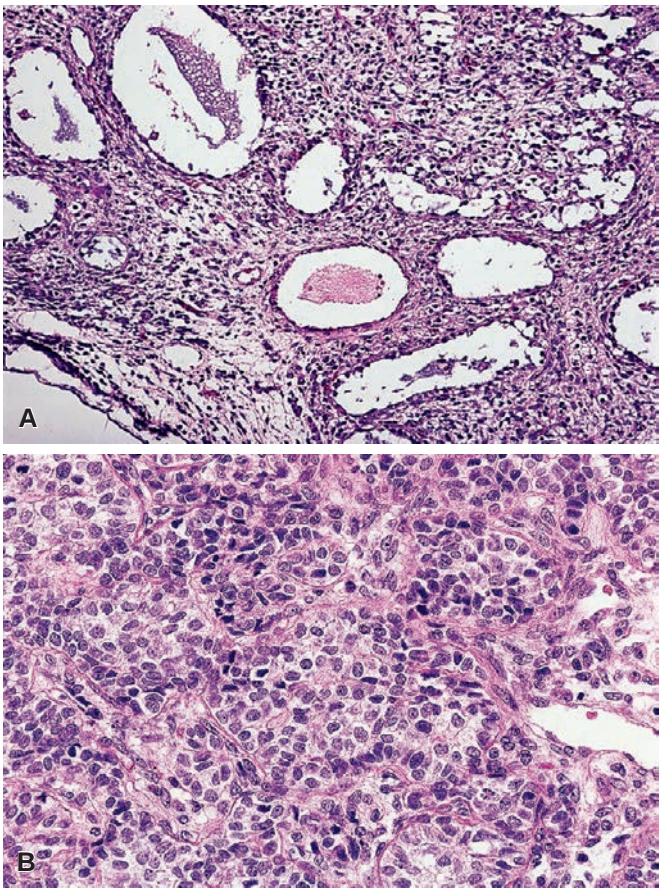

Figure 35.89 Juvenile Granulosa Cell Tumor. The follicle-like spaces seen on low-power examination **(A)** are a common feature of this neoplasm. On high power **(B)** the tumor cells are seen to lack the coffee bean nuclei seen in the adult type.

Figure 35.90 Cut surface of thecoma showing a predominance of yellow areas alternating with whitish foci.

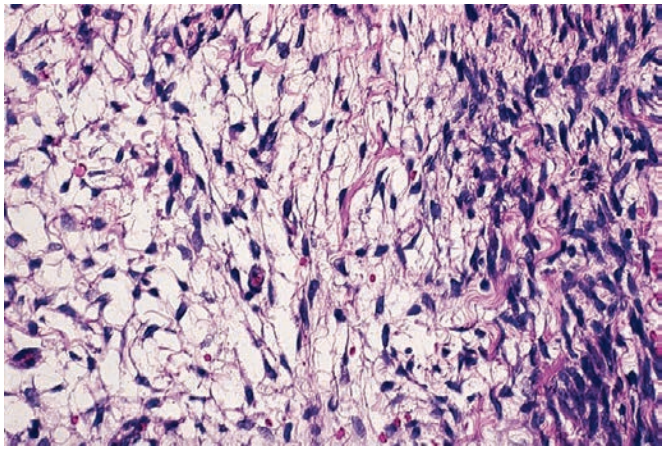

Figure 35.91 Bland microscopic appearance of thecoma, with some variability in cellularity.

solid) carcinoma of surface epithelial origin, carcinoid tumor, and the rare tumors of endometrial stromal type.[542] The nuclear features are of crucial importance in this regard. Some early series describing a poor prognosis for granulosa cell tumors are contaminated with solid-pattern ovarian carcinomas (i.e. tumors of epithelial rather than sex-cord origin).[583] Strong and widespread positivity for keratin should point toward the direction of carcinoma in a controversial case, especially if this positivity is diffuse cytoplasmic rather than dot-like. The differential diagnosis also includes the *ovarian granulosa cell proliferations of pregnancy*; this change is usually microscopic, multiple, and associated with atretic follicles.[584]

The prognosis of granulosa cell tumors is largely dependent on the clinical stage and resectability of the tumor. Adult granulosa cell tumors are indolent, and the prognosis is little different from age matched controls[583]; however, pelvic or upper abdominal metastases do occur, especially in cases with intraoperative tumor rupture. Importantly, these clinical relapses may occur 10 or even 20 years after initial surgery. Juvenile granulosa cell tumors are also associated with a favorable prognosis, especially when confined to the ovary at diagnosis, as is true in most patients.

Thecoma, Fibroma, and Related Tumors

Fibroma and thecoma are closely related tumors, but distinction between them is possible in most cases (although some recommend a diagnosis of *fibrothecoma* for all tumors in this category).

Thecoma presents after menopause in 65% of patients. It is usually unilateral and varies considerably in size. It has a well-defined capsule and a firm consistency. The cut surface is largely or entirely solid, but cysts may be present. It has a yellow color, an important feature in the differential diagnosis with fibroma (Fig. 35.90). Microscopically, it is composed of fascicles of spindle cells with ill-defined borders, centrally placed nuclei, and a moderate amount of pale grayish-pink cytoplasm (Fig. 35.91). The intervening tissue may show considerable collagen deposition and focal hyaline plaque formation. The degree of cellularity varies considerably. Some tumors in young women are heavily calcified.[585]

With oil red O, the cells of thecoma show abundant intracytoplasmic neutral fat, and silver stains usually demonstrate reticulin fibers surrounding individual cells (as opposed to granulosa cell tumor, in which the reticulin surrounds clusters of cells). The differential diagnosis with a luteinized adult granulosa cell tumor can be challenging; *FOXL2* mutational analysis can be of use in such cases, with the presence of a mutation supporting the diagnosis of adult granulosa cell tumor.[577]

For personal use only. No other uses without permission. Copyright ©2017. Elsevier Inc. All rights reserved.

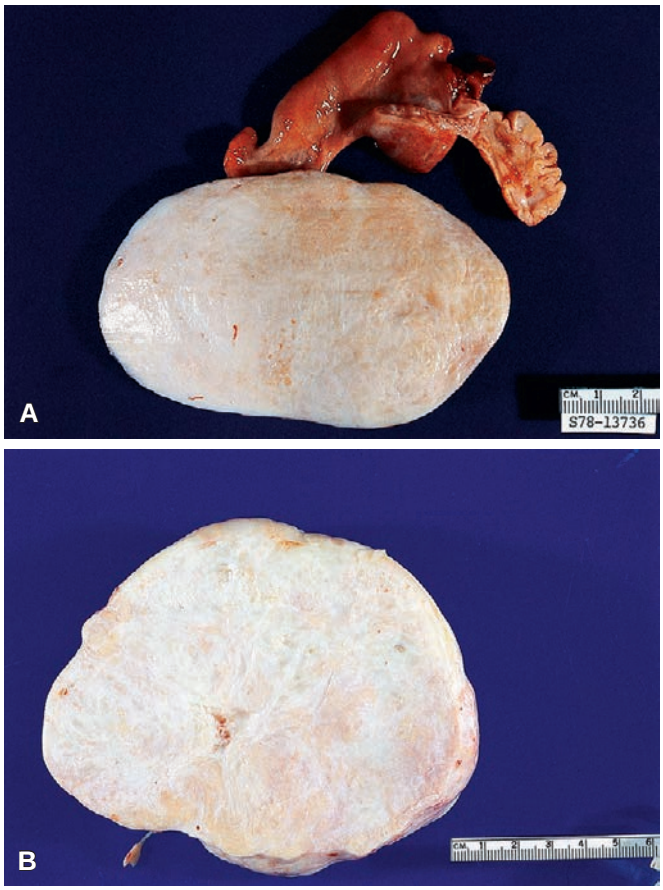

Figure 35.92 **A** and **B,** Outer aspect and cut surface of ovarian fibroma. The white color contrasts with the yellow hue of thecoma (compare with Fig. 35.90).

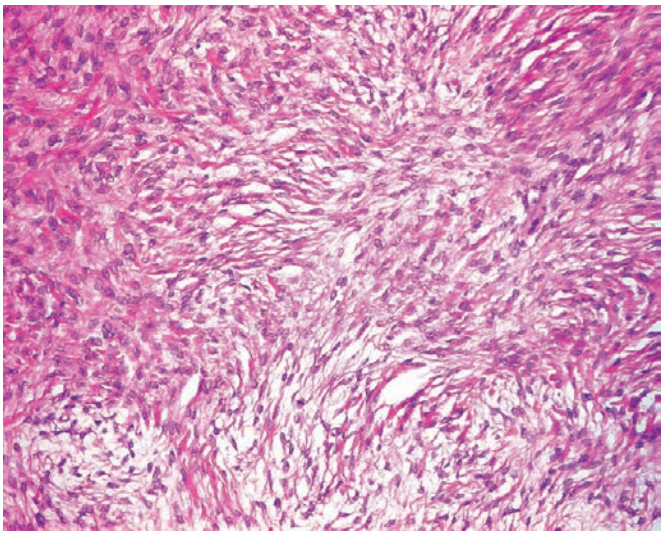

Figure 35.93 Ovarian fibroma showing, bland nuclear features, and a suggestion of a storiform pattern of growth.

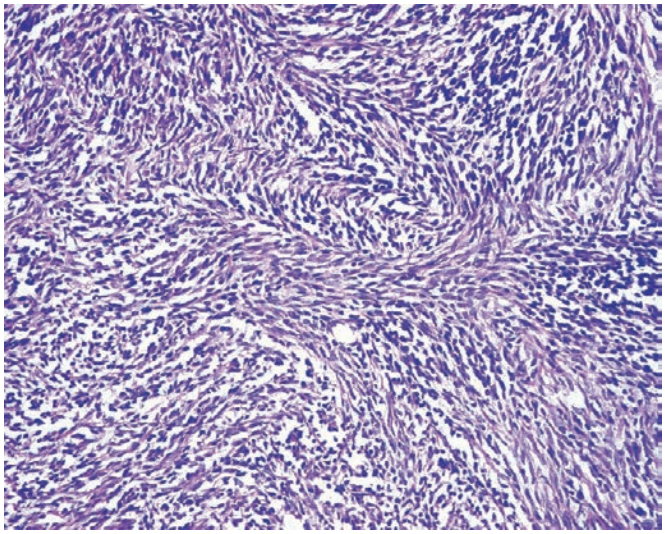

Figure 35.94 Cellular fibroma. The tumor is hypercellular, but pleomorphism and mitotic activity are minimal.

Thecomas may be associated with prominent stromal hyperplasia, particularly in postmenopausal patients. Thecomas are typically associated with estrogenic manifestations, although some (particularly those containing steroid cells, as just indicated) may be androgenic. They are nearly always benign, but a few malignant examples have been documented.[586] Some ovarian tumors with the overall appearance of thecoma with luteinized stromal cells have been found to be associated with a peculiar form of *sclerosing peritonitis;* in this context they have been referred to as stromal luteomas.[587–589]

Fibromas are common ovarian tumors, usually unilateral, which occur almost invariably after puberty.[590] They are solid, lobulated, firm, uniformly white, and usually not accompanied by adhesions (Fig. 35.92). The average diameter is 6 cm. Myxoid or edematous changes may be seen, sometimes resulting in cystic degeneration. Grossly, fibromas may have an appearance similar to thecoma, Brenner tumor, and Krukenberg tumor.

Microscopically, fibromas are composed of closely packed spindle stromal cells arranged in a "feather-stitched" or storiform pattern (Fig. 35.93). Hyaline bands, edema, and hyaline globules may be present.[591] Some fibromas occur in young women with the basal cell nevus (Gorlin) syndrome; these are calcified, usually bilateral, and often multinodular.[592] Fibromas exhibiting a high degree of cellularity can be referred to as *cellular fibromas* (Fig. 35.94). Some cellular fibromas can have conspicuous mitotic activity, and these may be diagnosed as *mitotically active cellular fibroma*, but the diagnosis of *fibrosarcoma*[593] should be reserved for tumors with moderate to severe atypia, with or without necrosis (Fig. 35.95).[594] Differences between ovarian fibroma and fibrosarcoma have also been described at the DNA ploidy, genetic, and cell proliferation levels.[595]

Some otherwise typical fibromas have a minor component of sex cord elements.[596]

Cytogenetically, both thecomas and fibromas have been found to exhibit trisomy of chromosome 12 in a minority of the tumor cells.[597,598] Loss of heterozygosity at both the *PTCH* gene (implicated in Gorlin syndrome) and the *STK11* gene (implicated in Peutz–Jeghers syndrome) is relatively frequent in cellular fibromas.[599]

Fibromas are distinguished from thecoma by their gross appearance (white rather than yellow), the absence of significant cytoplasm in the tumor cells, and the lack of evidence of hormone production (e.g. endometrial hyperplasia or carcinoma).

Ovarian fibroma (especially if large) can be associated with ascites, sometimes in combination with right-sided pleural effusion (Meigs syndrome).[600,601] This may lead to a mistaken impression of inoperable ovarian neoplasm, but removal of the tumor leads to the disappearance of these manifestations. The mechanism for the pleural effusion

For personal use only. No other uses without permission. Copyright ©2017. Elsevier Inc. All rights reserved.

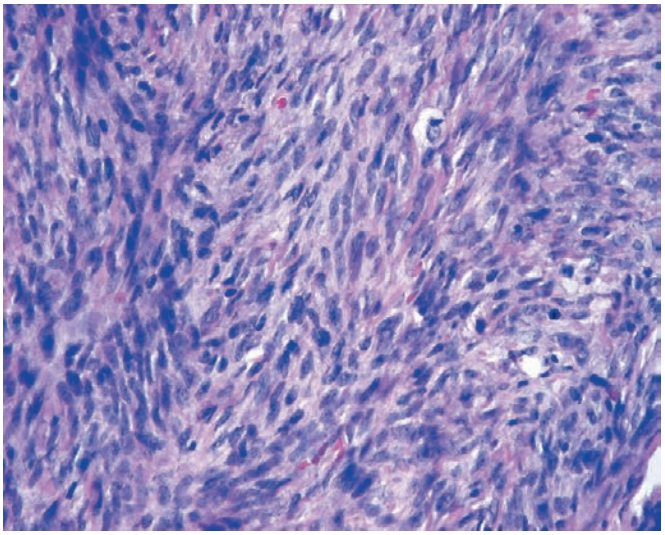

Figure 35.95 Fibrosarcoma of Ovary. Hypercellularity, nuclear hyperchromasia, and brisk mitotic activity are present. The latter is the most important feature in the differential diagnosis with cellular fibroma.

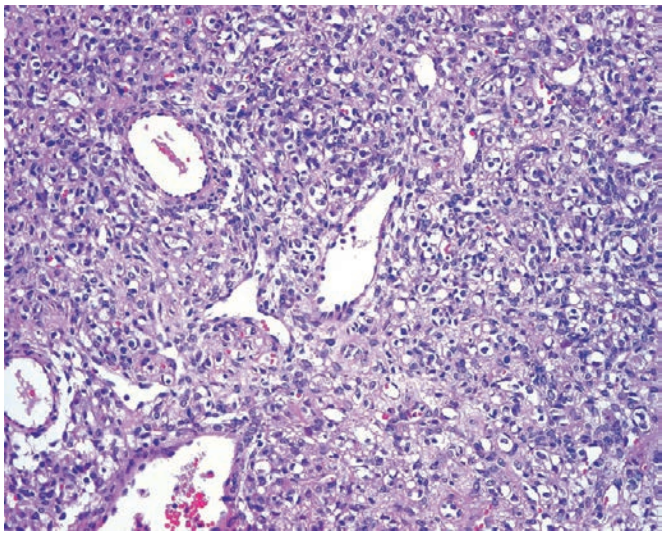

Figure 35.97 Sclerosing Stromal Tumor of Ovary. The hemangiopericytoma-like foci and the alternation of hypocellular and hypercellular areas are important diagnostic clues.

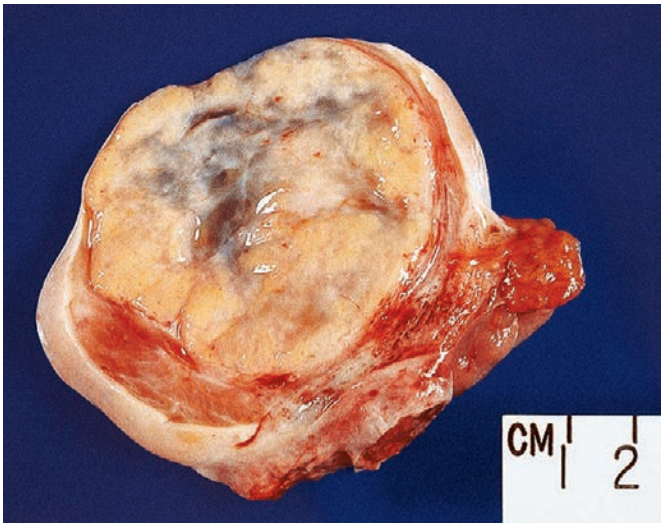

Figure 35.96 Multinodular quality of cut surface of sclerosing stromal tumor.

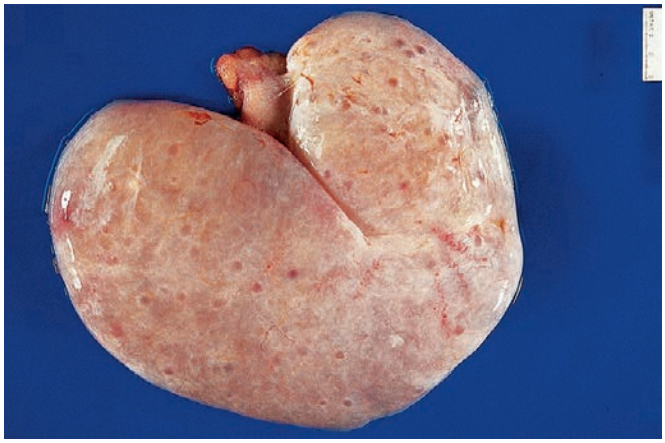

Figure 35.98 Bulging cut surface of ovary involved by massive edema.

is said to be related to intrathoracic negative pressure and transdiaphragmatic passage of fluid through peritoneal "pores" or lymphatics. Meigs syndrome can also occur in association with other ovarian tumors.[602]

Fibromas are benign, and oophorectomy is curative. However, cellular fibromas may recur or be associated with peritoneal implants.[593]

Sclerosing stromal tumor is a benign ovarian neoplasm that shares many features with fibroma and thecoma. However, it occurs in a younger age group, has a less homogeneous gross appearance (Fig. 35.96), and is characterized microscopically by a lobular pattern of growth, interlobular fibrosis, marked vascularity, and the presence of a dual cell population: collagen-producing spindle cells and lipid-containing round or oval cells (Fig. 35.97). Some of the latter may have a signet ring appearance and thus simulate a Krukenberg tumor.[603] Endocrine manifestations are rarely present.[604] The tumor cells are immunoreactive for smooth muscle actin and sometimes for desmin.[605,606] Cytogenetically, this tumor shares the tendency for trisomy 12 that is also a feature of fibromas and thecomas.[607]

Massive edema of the ovary is probably not a neoplasm but is a tumorlike condition discussed here because of its gross similarities with fibroma. Most patients present with pain, abdominal mass, and/or menstrual irregularities; virilization, precocious puberty, and Meigs syndrome have also been described.[608,609] Partial torsion of the meso-ovarium with interference in the venous and lymphatic drainage has been suggested as the pathogenetic mechanism.[609] The cut surface has been described as watery (Fig. 35.98). Microscopically, there is marked edema of the stroma surrounding follicles and other structures (Fig. 35.99).[610] Clusters of luteinized cells are often present.[611] The presence of follicles and other normal ovarian structures distinguishes massive edema and fibromatosis from fibroma.

Fibromatosis is the term proposed by Young and Scully[612] for a disorder that they proposed to be related to massive edema. The patients usually present because of menstrual irregularities. Grossly, the ovaries show a firm, white, cut surface. Microscopically, a diffuse proliferation of spindle cells separated by dense collagen is seen surrounding normal follicular structures. Luteinized cells may be

For personal use only. No other uses without permission. Copyright ©2017. Elsevier Inc. All rights reserved.

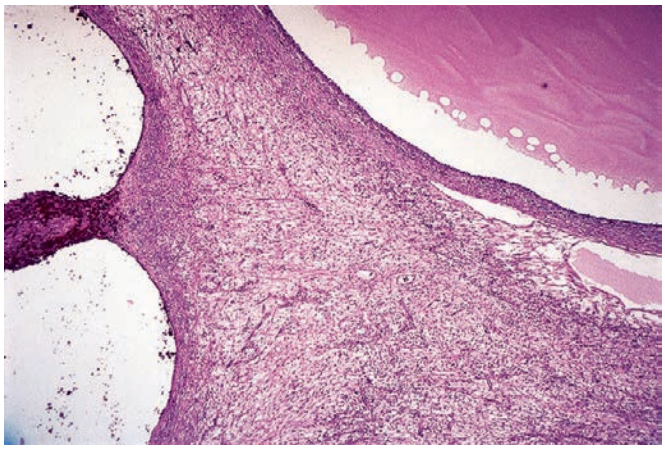

Figure 35.99 Massive edema of ovary typically surrounding dilated follicles.

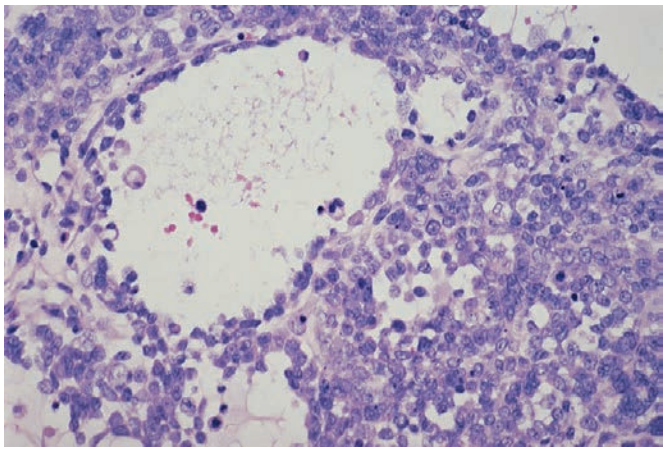

Figure 35.101 Small Cell Carcinoma, Hypercalcemic Type. The presence of follicle-like formations is an important diagnostic feature.

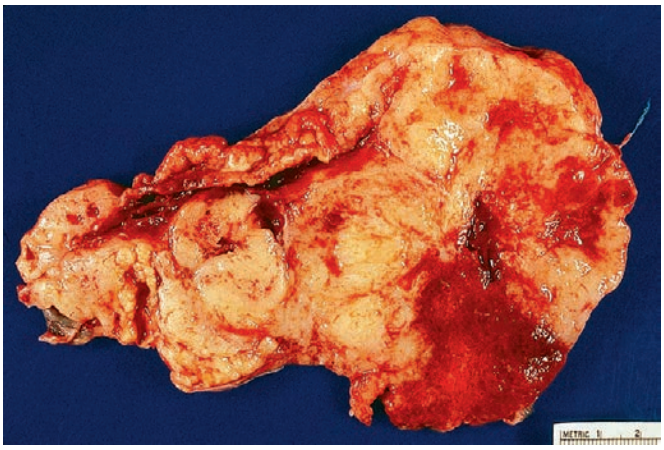

Figure 35.100 Solid cut surface with hemorrhagic foci in ovarian small cell carcinoma of hypercalcemic type.

present. The fact that some cases of massive ovarian edema are accompanied by small cellular foci of fibromatosis lends support to their interpretation. The term *fibromatosis*, although descriptively correct, should not be equated with the similarly named lesion of soft tissues (i.e. desmoid tumor), which under exceptional circumstances can involve the ovary.[613]

Myxoma of ovary presents as a solid and cystic mass, some of the cysts being occasionally filled with blood. Microscopically, scattered cells with fibroblastic/myofibroblastic features are seen in a well-vascularized myxoid background.[614,615] Some authors regard this as a distinct type of ovarian neoplasm, whereas others view it as part of the spectrum of differentiation in the fibrothecoma group.[616,617]

Small Cell Carcinoma of Hypercalcemic Type

Small cell carcinoma of hypercalcemic type is a high-grade ovarian malignancy that may be confused with granulosa cell tumor.[618–620] It occurs in young females (average age, 23 years) and is often bilateral. Familial cases have been reported.[621] The tumor is associated with hypercalcemia in up to two-thirds of cases, which disappears following removal of the tumor.[622] Grossly, the tumor is large and solid, with areas of necrosis and hemorrhage (Fig. 35.100). Microscopically, a diffuse proliferation of small, closely packed cells of carcinomatous appearance with scant cytoplasm and small nuclei is seen (Fig. 35.101). Clusters of larger and more pleomorphic rhabdoid cells are present in approximately half of cases. Cytoplasmic hyaline globules may also be seen. Tumors containing a large number of these larger cells have been referred to, tongue-in-cheek, as the "large cell variant" of small cell carcinoma. There may also be islands, cords, trabeculae, mucinous glands, and *follicle-like structures*. The latter are an important clue to the diagnosis.

The tumor cells usually express keratin, vimentin, EMA, and WT1 but not S-100 protein, chromogranin, inhibin, CD117, or OCT4.[623,624] The genetic basis of these tumors, whether sporadic or familial, has recently been elucidated[625–628]; most have mutations in the *SMARCA4* gene, which encodes the BRG1 protein, a component of the SWI/SNF chromatin remodeling complex. Loss of expression of both BRG1 and BRM (another SWI/SNF protein encoded by the *SMARCA2* gene) in an ovarian tumor appears to be completely specific for small cell carcinoma of hypercalcemic type.[629] The prognosis is very poor. The histogenesis remains obscure, but the occasional association with a germ cell tumor (mature or immature teratoma, or yolk sac tumor) has led to suggestions that it is a primitive germ cell tumor. The differential diagnosis of small cell carcinoma of hypercalcemic type includes **pulmonary-type small cell carcinoma,** which resembles the homonymous lung tumor (Fig. 35.102).[630] It may be pure or associated with endometrioid carcinoma or other patterns. Immunohistochemically, there is reactivity for keratin, EMA, NSE, and (rarely) for chromogranin and Leu7 (CD57). The prognosis is poor. They occur in older patients than small cell carcinoma of hypercalcemic type and are thought to represent dedifferentiation in an epithelial malignancy.

Sertoli–Leydig Cell Tumor

As the name indicates, Sertoli–Leydig cell tumors are composed of a mixture in variable proportions of cells morphologically resembling male Sertoli and Leydig cells; the Sertoli cell elements predominate with a variable, often inconspicuous Leydig cell component. This term replaces the old designations arrhenoblastoma and androblastoma and should be regarded as synonymous with Sertoli–stromal cell tumor. Pure Sertoli cell tumors are also included in this group, but pure Leydig cell tumors are included with the steroid cell tumors.[631] The interesting point has been made that the only neoplastic component of this tumor may be represented by the Sertoli cells, as the Leydig cell component has been shown to be polyclonal, in at least some cases.[632,633]

For personal use only. No other uses without permission. Copyright ©2017. Elsevier Inc. All rights reserved.

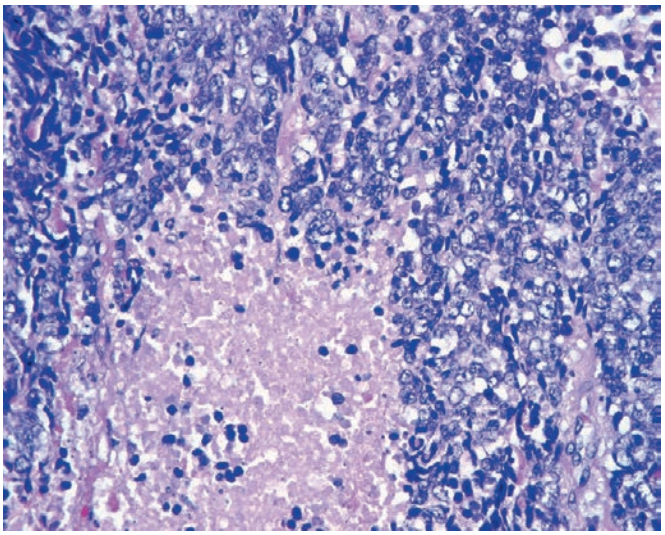

Figure 35.102 Small Cell Carcinoma of Pulmonary Type. The sharply outlined foci of necrosis are a common feature of this tumor, which has a microscopic appearance very similar to its pulmonary counterpart.

Figure 35.103 Variegated appearance of cut surface of ovarian Sertoli–Leydig cell tumor.

Sertoli–Leydig cell tumors are rare, comprising less than 0.1% of ovarian neoplasms. Grossly they are predominantly solid, but cystic areas may also be present (Fig. 35.103).

The microscopic pattern is extremely variable. Several major patterns have been described, which may coexist in the same tumor:

1. *Well differentiated* (11%). Composed of tubules lined by Sertoli-like cells separated by variable numbers of Leydig-like cells (Fig. 35.104).[634] Sometimes those tubules have a hollow "pseudoendometrioid" appearance, the tumor thus simulating a borderline or malignant endometrioid neoplasm.[635] The opposite phenomenon, endometrioid adenocarcinoma simulating Sertoli–Leydig cell tumor, also occurs (and is more common), immunohistochemical evaluation being sometimes necessary to arrive at a correct diagnosis.[636]
2. *Moderately differentiated (intermediate grade)* (54%). Characterized by the formation of cords, sheets, and aggregates of Sertoli-like cells, separated by spindle stromal cells and recognizable Leydig cells (Fig. 35.105).
3. *Poorly differentiated (sarcomatoid; undifferentiated)* (13%). Composed of masses of spindle-shaped cells arranged in a "sarcomatoid" pattern (Fig. 35.106).

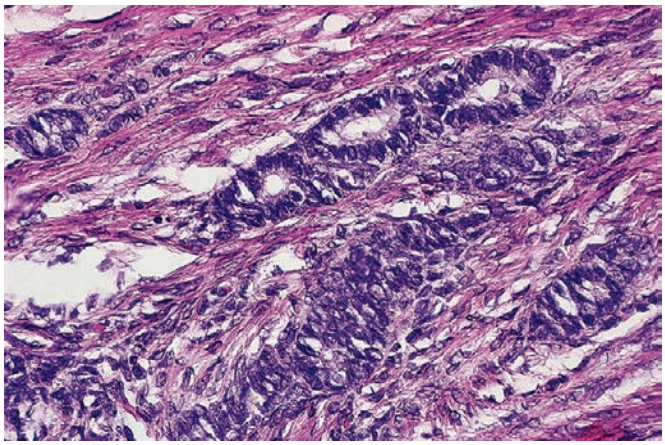

Figure 35.104 Well-differentiated Sertoli–Leydig cell tumor.

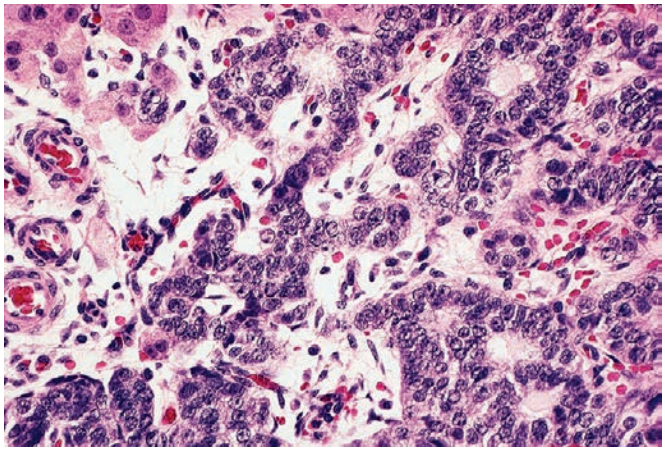

Figure 35.105 Moderately differentiated Sertoli–Leydig cell tumor.

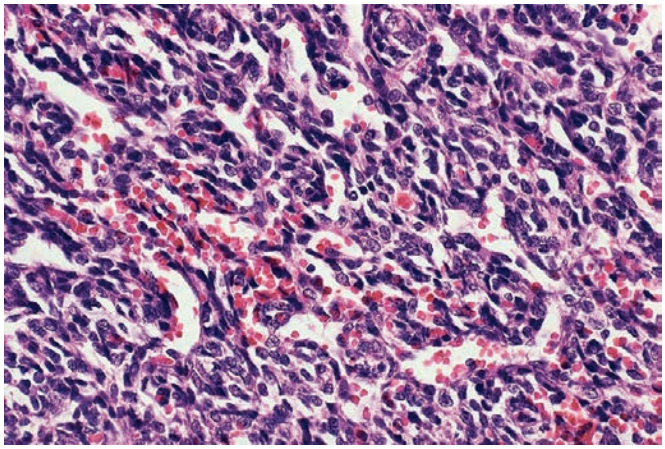

Figure 35.106 Poorly differentiated Sertoli–Leydig cell tumor.

4. *Pure Sertoli cell tumors.* Essentially identical to well-differentiated Sertoli–Leydig cell tumors but lacking Leydig cells and primitive stromal elements.[637,638] Abundant lipid may be present in the cytoplasm. The microscopic pattern can be tubular or follicle-like.[639] Amyloid-like material can be present, and cytoplasmic crystalline structures have been found by electron microscopy.[640] Some Sertoli cell tumors are composed of cells with oxyphilic cytoplasm.[641]

For personal use only. No other uses without permission. Copyright ©2017. Elsevier Inc. All rights reserved.

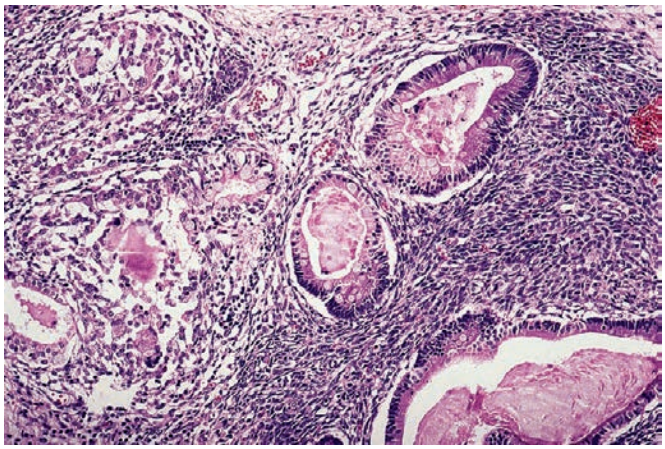

Figure 35.107 Sertoli–Leydig cell tumor with heterologous elements represented by well-differentiated mucin-secreting glands.

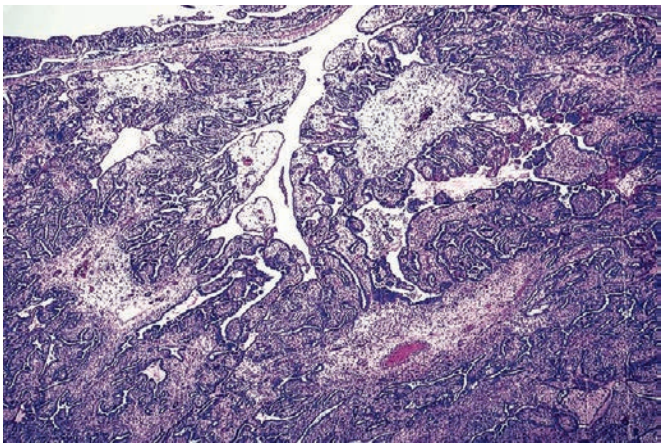

Figure 35.109 Retiform variant of Sertoli–Leydig cell tumor as seen on low-power examination. The retiform areas are represented by the micropapillary foci.

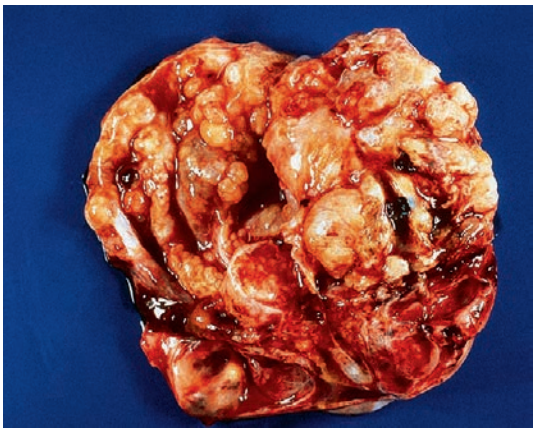

Figure 35.108 Gross appearance of Sertoli–Leydig cell tumor of the retiform variant.

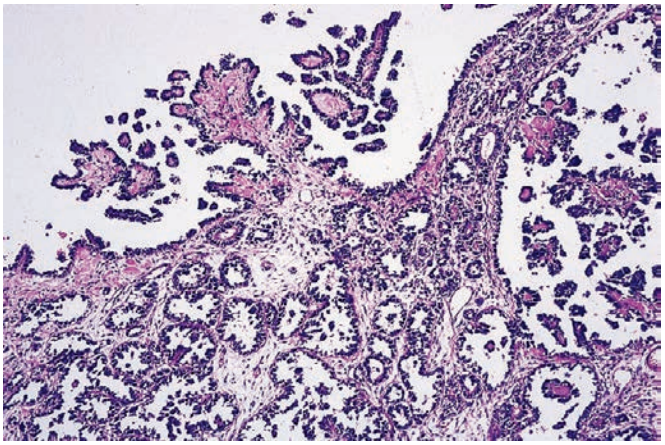

Figure 35.110 When the retiform type of Sertoli–Leydig cell tumor is made up predominantly or exclusively of retiform elements without conventional foci of Sertoli–Leydig cells, as seen here, the diagnosis can be easily missed.

5. *With heterologous elements* (22%). Rare cases are associated with tissues such as mucinous epithelium of gastrointestinal type, liver,[642] skeletal muscle, or cartilage (Fig. 35.107).[643,644] The epithelial component of this neoplasm contains a variety of endocrine cells[645] and can give rise to microscopic carcinoid tumors.[576,646]
6. *Retiform* (15%). In this category, typical elements of Sertoli–Leydig cell tumors coexist with formations resembling the rete of the ovary or testis (Figs. 35.108 and 35.109). These appear as irregular cleft-like spaces lined by low cuboidal cells; blunt papillae with hyalinized or edematous cores are often present. Sometimes the retiform formations predominate almost to the exclusion of the Sertoli–Leydig cell component (Fig. 35.110).[647,648] In other instances there is a hepatocytic component in the tumor, which may be difficult to distinguish from Leydig cells without immunostains.[649]

As in the case of granulosa cell tumor, the cells of a few Sertoli–Leydig cell tumors may contain bizarre and/or multiple nuclei, a change of no apparent prognostic significance.[579]

Immunohistochemically, testosterone and estradiol are found in both Sertoli and Leydig cells and less frequently in primitive stromal cells.[650] The areas of Sertoli cell differentiation stain for keratin and Sox-9 (but not for EMA, PLAP, CEA, or S-100 protein).[651] Positivity for inhibin, calretinin, and WT1 is seen in most tumors.[652,653]

Mutations in *DICER1*, which encodes an endoribonuclease involved in miRNA processing, are found in most Sertoli–Leydig cell tumors[654]; mutations are associated with young age at diagnosis, as well as higher-grade, heterologous elements, or retiform pattern. The *DICER1* mutations may be germline, in which case there is a hereditary predisposition not just to Sertoli–Leydig cell tumor but also pleuropulmonary blastoma and embryonal rhabdomyosarcoma.[655] A small number of low-grade Sertoli cell or Sertoli–Leydig cell tumors harbor a somatic FOXL2 mutation identical to that seen in 95% of adult granulosa cell tumors; these tumors are typically in patients who are older than the usual age of patients with Sertoli–Leydig cell tumor (i.e. postmenopausal), and their relationship to adult granulosa cell tumor remains to be determined.

Most Sertoli–Leydig cell tumors are seen in young patients (average age, 25 years) and they are relatively rare after menopause. Some are diagnosed during pregnancy.[578] These tend to exhibit prominent intercellular edema. Bilateral involvement is seen in less than 2% of cases. Cases have been reported in association with mature cystic teratoma.[656] Nearly half are accompanied by signs of androgen excess. This is manifested first by *defeminization* (amenorrhea, breast atrophy, loss of subcutaneous tissue deposits) and later by *masculinization*

For personal use only. No other uses without permission. Copyright ©2017. Elsevier Inc. All rights reserved.

(clitoral hypertrophy, deepening of the voice, hirsutism). Usually prompt return of feminine characteristics follows excision of the tumor, but the manifestations of masculinization disappear more slowly.

Some Sertoli–Leydig cell tumors do not have demonstrable endocrine effect, whereas others are accompanied by secretion of estrogen or progesterone. The latter is often the case for pure Sertoli cell tumors.[657] It is opportune to mention again that the diagnosis of these neoplasms should be based on their morphologic appearance rather than on the nature of their hormonal manifestations. Curiously, some cases of Sertoli–Leydig cell tumor have been associated with serum elevation of alpha-fetoprotein[658–660]; this marker has been detected immunohistochemically in areas of hepatocytic differentiation[642] and in the more conventional Leydig and Sertoli cell-like component.

The prognosis of Sertoli–Leydig cell tumor, which is usually good, correlates with the stage and degree of differentiation of the tumor.[661,662] The overall incidence of clinical malignancy in one large series was 18%; all the well-differentiated tumors were benign, but 11% of those with intermediate differentiation, 59% of those with poor differentiation, and 19% of those with heterologous elements were malignant.[642] In one series of 28 cases of pure Sertoli cell tumor, there were two recurrences.[640] Conservative surgery is indicated in young women for Sertoli–Leydig cell tumors grossly confined to the ovary.[639,662]

Steroid Cell Tumor

A small group of ovarian tumors is composed entirely of cells with morphologic features indicative of steroid hormone secretion. These are manifested by an abundant eosinophilic or vacuolated cytoplasm that is often positive for fat stains and that, at the ultrastructural level, is shown to contain well-developed smooth endoplasmic reticulum and mitochondria with tubulovesicular cristae.[663] Normal steroid hormone-secreting cells can be of lutein (thecal or stromal), Leydig (hilus), and adrenal cortical type.[664] Theoretically, these tumors could arise from any of these sources. In the few cases in which Reinke crystalloids are found, the tumor can be categorized as **Leydig cell tumor**.[664–666] The exact origin of this tumor remains undecided; the descriptive terms **lipid, lipoid**, and—more recently—**steroid cell tumor** have therefore been proposed for the entire group, with the subcategory of Leydig cell tumor recognized for those tumors with Reinke crystalloids or arising in the hilus, with associated hilus cell hyperplasia.

Steroid cell tumors are usually unilateral and are composed of yellow or yellowish-brown nodules separated by fibrous trabeculae (Fig. 35.111). Microscopically, they are characterized by masses of large rounded or polyhedral cells with the morphologic and ultrastructural features previously described for their normal counterparts (Fig. 35.112). Immunohistochemically, there is reactivity for vimentin in three-fourths of cases, for keratin in one-half, and for actin in about one-third.[667] There is also consistent reactivity for inhibin and Melan-A.[668]

This neoplasm can occur at any age. Most are associated with a virilizing syndrome (with defeminization and amenorrhea), and a few cases meet the criteria for Cushing syndrome. Some of the tumors are biologically inactive, at least at the clinical level, and others are associated with estrogenic or progestogenic manifestations. A few cases have been associated with endometrioid carcinoma.[669] The incidence of clinical malignancy is approximately 25%.[670] Malignant tumors tend to be larger (7 cm in diameter or greater), with foci of necrosis and hemorrhage, and often exhibit nuclear atypia and mitotic activity.[670] Tumors containing Reinke crystalloids are almost invariably benign.[665]

Figure 35.111 Cut Surface of Ovarian Steroid Cell Tumor. The deep brown color is reminiscent of a renal or thyroid oncocytoma.

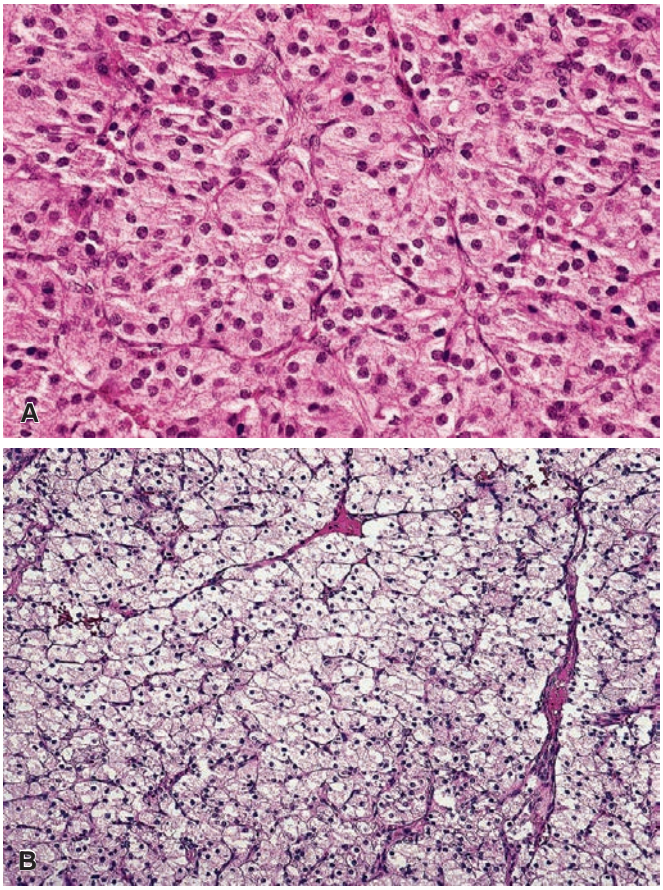

Figure 35.112 Two cases of steroid cell tumor showing acidophilic **(A)** and clear **(B)** appearances of the cytoplasm of the tumor cells.

Steroid cell tumors should be distinguished from lesions in which acquisition of cells with features of steroid hormone–producing cells occurs as a secondary event. These include luteinized granulosa cell tumor (particularly the juvenile type), fibrothecoma, and the relatively common finding of proliferation of non-neoplastic steroid cells that may be seen at the periphery of other tumors, such as struma ovarii, strumal carcinoid, epithelial tumors, and metastatic carcinoma.[671]

For personal use only. No other uses without permission. Copyright ©2017. Elsevier Inc. All rights reserved.

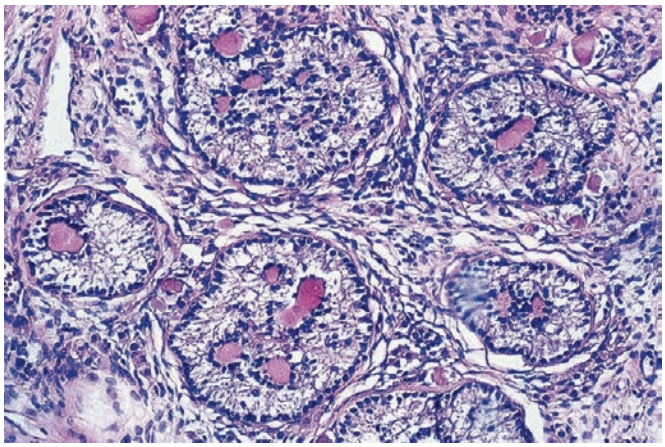

Figure 35.113 Sex Cord Tumor With Annular Tubules. The patient was affected by Peutz–Jeghers syndrome.

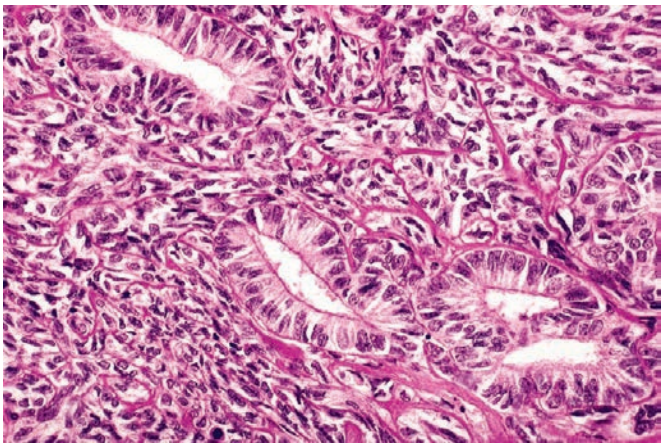

Figure 35.114 Wolffian Tumor of Ovary. Elongated glandular structures are admixed with solid foci composed of oval to spindle cells.

Other Types

Gynandroblastoma is the term used for the sex cord–stromal tumor composed of a mixture *in similar amounts* of clearly identifiable granulosa cell and Sertoli–Leydig cell elements.[672] When thus defined, this entity is extremely rare. On occasion the granulosa cell component is of the juvenile rather than the adult type.[673,674] Reported cases of this entity have been accompanied by androgenic, estrogenic, or no hormonal effects.[675,676] Examples of late recurrence following excision are on record.[677] Mutations in *DICER1* can be found in gynandroblastomas, in particular those where the granulosa cell component is of juvenile type.[678]

Sex cord tumor with annular tubules is a distinctive ovarian tumor that is associated in one-third of the cases with the Peutz–Jeghers syndrome.[679,680] This lesion combines features suggestive of a granulosa cell tumor with a pattern of growth reminiscent of Sertoli cells.[681] Its morphologic hallmark is the presence of simple and complex annular tubules containing eosinophilic hyaline bodies, often calcified (Fig. 35.113). The appearance is similar to that of gonadoblastoma, from which it differs because of the clinical/genetic background and the presence of a germ cell component in the latter.

The ambiguous or biphasic nature of the tumor cells is also apparent on ultrastructural examination: features consistent with granulosa cell or nonspecialized ovarian stroma[682,683] alternate with features indicative of Sertoli cell differentiation, notably the presence of Charcot–Bottcher filaments.[684] Symptoms suggestive of hyperestrinism have been described in approximately 50% of cases. Tumors associated with the Peutz–Jeghers syndrome are typically multifocal, bilateral, small (or even microscopic), calcified, and usually benign, although exceptions occur.[685] Those unassociated with the syndrome are unilateral, often large, and clinically malignant in approximately 22% of cases.[686,687]

It should be mentioned here that Peutz–Jeghers syndrome can be associated with other neoplasms of the female genital tract, such as other sex cord–stromal ovarian tumors,[688] mucinous ovarian tumors, and HPV-independent well-differentiated adenocarcinoma of the cervix of gastric type (adenoma malignum).

Wolffian tumor is the designation for the tumor entity first named *ovarian tumor of probable wolffian origin or female adnexal tumor of probable wolffian origin* (the latter designation reflecting its more frequent occurrence in the broad ligament, compared to the ovary).[689–691] It is thought to be of wolffian (mesonephric) derivation. Although it is not thought to be sex cord–stromal in nature, they are discussed here because of their resemblance to them and the fact that their immunophenotype overlaps with that of tumors in the sex cord-stromal category. Grossly, they may be either solid or solid and cystic. Microscopically, epithelial cells are seen growing in the form of cystic structures, solid or hollow tubules, and diffuse sheets (Fig. 35.114). The sieve-like appearance on low-power examination is a useful diagnostic feature. Conversely, the presence of a predominant spindle cell component can be confusing.[692] PAS-positive basement membranes are prominent around the epithelial aggregates. These tumors lack stromal cells of steroid hormone–secreting type and are unaccompanied by hormonal manifestations. Mucin stains are negative. Immunohistochemically, the tumor is positive for keratin (CK7 but not CK20), androgen receptor (three-fourths of cases), estrogen and progesterone receptors (one-fourth), inhibin (over half), FOXL2, calretinin (almost all), and vimentin (always). Surprisingly, given its putative wolffian origin, most cases are negative for GATA3.[693] It is negative for CEA. The behavior is generally benign, but a few have recurred or metastasized.[691,694,695]

Signet ring stromal tumor of the ovary is a very rare type but of great practical importance because of the fact that it can be easily mistaken for Krukenberg tumor. Some of the examples may be variants of sclerosing stromal tumor. The tumor cells are negative for keratin, PAS, and mucin. Their behavior is benign.[696]

Microcystic stromal tumor is the latest addition to the group of sex cord–stromal ovarian neoplasms.[697] It is usually unilateral and nonfunctioning. Microscopically, its most distinctive feature is the presence of small round to oval cystic spaces, in areas coalescing to form larger irregular channels, combined with lobulated cellular masses with intervening fibrous or fibrohyaline stroma. Mutations in β-catenin, with associated nuclear immunoreactivity, are a feature of this tumor.[698,699]

Sex cord–stromal tumor NOS (indeterminate or unclassified type) is a justifiable designation for ovarian tumors in which the cytologic and/or architectural features are consistent with a sex cord–stromal origin but which cannot be assigned to any specific category. These tumors are decidedly uncommon. Their behavior is similar to that of granulosa cell tumor and Sertoli–Leydig cell tumor, with a generally favorable prognosis when confined to the ovaries at presentation.[699,700]

Germ Cell–Sex Cord–Stromal Tumors

The most distinctive member of the group of tumors composed of a combination of germ cells and sex cord–stromal cells is **gonadoblastoma**.[701] This tumor occurs practically always in sexually abnormal

For personal use only. No other uses without permission. Copyright ©2017. Elsevier Inc. All rights reserved.

individuals, most commonly affected by gonadal dysgenesis and carrying all or part of the Y chromosome (i.e. XY gonadal dysgenesis and XO-XY mosaicism but not XX gonadal dysgenesis). The testis-specific protein Y-encoded gene is the putative gene for the gonadoblastoma locus on the Y chromosome.[702]

The risk of neoplasia in these dysgenetic gonads is estimated to be 25%. However, gonadoblastomas have also been documented in phenotypically and chromosomally normal females, even during pregnancy.[703,704] They have also been seen in association with ataxia–telangiectasia.[705] It is often impossible to determine the nature of the gonad bearing the tumor. In some cases it has been identified as a streak and in others as a cryptorchid testis, but never as a normal ovary.

Approximately 36% of the tumors are bilateral. They are usually small, and many become apparent only on microscopic examination (Fig. 35.115).[706] The key microscopic feature is the admixture of primitive germ cells (resembling those of dysgerminoma) with sex cord–stromal cells resembling morphologically and immunohistochemically immature Sertoli and granulosa cells (Fig. 35.116).[707–709] Steroid hormone–producing cells may also be present, especially after puberty; their capacity for steroidogenesis has been demonstrated by their in vitro production of androgens and estrogens.[710] Hyalinization and calcification are common. The hyaline material reacts strongly with anti-laminin antibodies, indicating basement membrane deposition.[711]

An interesting analogy has been made between gonadoblastoma and intratubular germ cell neoplasia of the testis on the basis of the morphology and the immunohistochemical profile, the implication being that gonadoblastoma is an in situ germ cell malignancy arising in a dysgenetic gonad.[709]

The germ cell component of gonadoblastoma may overgrow the stromal elements and result in the formation of a germinoma (i.e. a tumor that would be diagnosed as a seminoma if arising in the testis or dysgerminoma if arising in the ovary) or, exceptionally, another type of germ cell tumor.[712,713] Only under these circumstances is the tumor endowed with a malignant potential. Much more unusual is the overgrowth of the sex cord–stromal component, which may acquire the features of a Sertoli cell tumor.[714]

Microscopic structures resembling gonadoblastoma and sex cord tumor with annular tubules are sometimes found incidentally in the ovaries of *normal* infants and children in association with follicular cysts; it has been suggested that they represent the precursor of these tumors.[715]

Rare *germ cell–sex cord–stromal tumors* not fulfilling the diagnostic criteria for gonadoblastoma have been described in genetically normal females,[716,506] some of them containing retiform structures.[717] The germ cell component of these tumors—like that of gonadoblastomas—is positive for PLAP, OCT4, and CD117.[718] These tumors can be hormonally active and clinically malignant.[719] Like gonadoblastoma, they can be accompanied by dysgerminoma or other germ cell tumors.

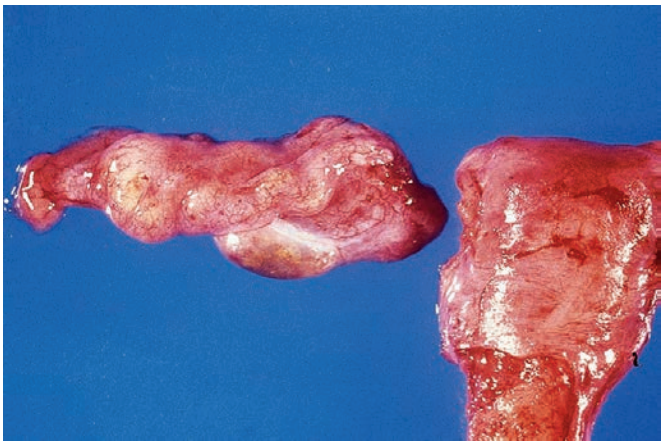

Figure 35.115 Streak gonad microscopically shown to contain gonadoblastoma. The tumor was barely apparent grossly.

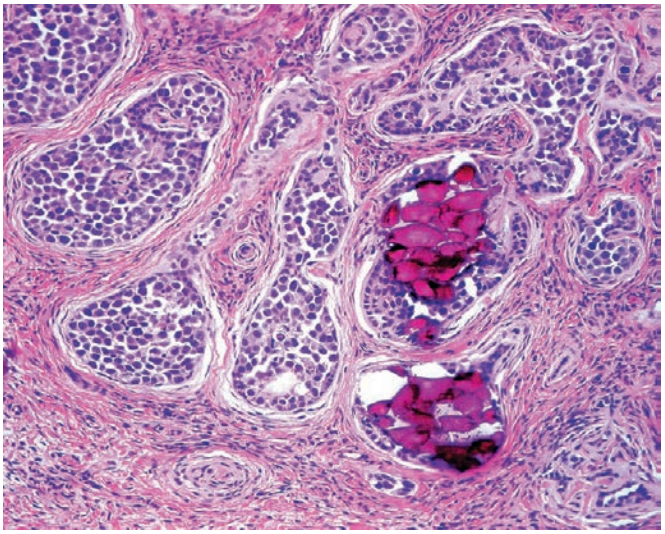

Figure 35.116 Ovarian Gonadoblastoma. Note the sharply outlined tumor nests and the heavy calcification.

Tumors Not Specific to Ovary

Malignant Lymphoma and Leukemia

Secondary ovarian involvement by generalized lymphoma or leukemia is well recognized.[720,721] Much more rarely, malignant lymphoma involves the ovaries as the primary manifestation of the disease (Fig. 35.117).[721–725] This is also true for *granulocytic sarcoma*.[726,727]

Nearly all ovarian lymphomas are of non-Hodgkin type.[728] In children, Burkitt lymphomas predominate; in adults, most are diffuse large B-cell lymphomas.[728,729] Immunophenotypically, practically all cases are of B-cell nature.[728,730] In the series of Osborne and Robboy,[731]

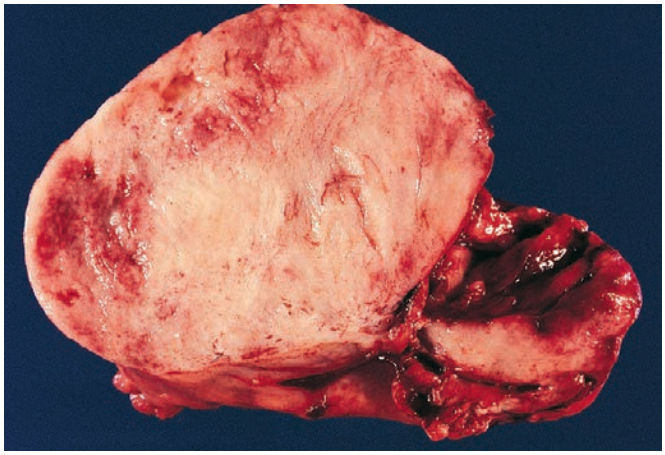

Figure 35.117 Malignant lymphoma of Burkitt type with massive ovarian involvement.

For personal use only. No other uses without permission. Copyright ©2017. Elsevier Inc. All rights reserved.

55% were bilateral, and 64% also involved extragonadal sites (usually the omentum, fallopian tubes, or lymph nodes); only 9 of their 42 patients survived more than 5 years, and 2 subsequently died of lymphoma.

Exceptionally, ovarian lymphoma has been found to coexist with a borderline serous tumor.[732]

Sarcoma

Primary sarcomas of the ovary are extremely rare. They need to be distinguished from undifferentiated carcinomas, carcinosarcomas/MMMTs, "sarcomatoid" forms of sex cord–stromal tumors, Krukenberg tumors associated with brisk stromal reaction, and cellular fibromas.

Fibrosarcomas are separated from cellular fibromas mainly on the basis of their mitotic activity (4 or more per 10 high-power fields) plus moderate to severe cytologic atypia; hemorrhage and necrosis are also common (see Figs. 35.94 and 35.95). They tend to be large, solid, and accompanied by adhesions. The clinical course is aggressive.[610] One case has been diagnosed in the context of the nevoid basal cell carcinoma syndrome.[733]

Endometrial (endometrioid) stromal sarcomas can present as primary ovarian neoplasms; they can closely simulate the pattern of growth of the diffuse type of granulosa tumor[734] but are recognized because of the presence of plump oval cells arranged around vessels of the spiral arteriole type.[735] Immunohistochemically, they are reactive for CD10 but negative for inhibin and FOXL2.

Müllerian adenosarcoma is discussed elsewhere, although it is probably more closely related to endometrial stromal sarcoma than to MMMT.

Other sarcomas of the adult ovary, all exceptionally rare, are *leiomyosarcoma*[736,737] (some of the myxoid type and some in patients with the nevoid basal cell carcinoma syndrome),[738,739] *chondrosarcoma*,[740] *osteosarcoma*,[741–743] *malignant peripheral nerve sheath tumor*,[744] *angiosarcoma*,[745] *rhabdomyosarcoma*,[746] *low-grade fibromyxoid sarcoma*,[747] and *Ewing sarcoma*.[748,749] The rhabdomyosarcomas are usually of the embryonal type, but they can also be of the alveolar variety[750]; a case has been reported in association with clear cell carcinoma.[751] The angiosarcomas show a wide morphologic spectrum and can be associated with mature cystic teratoma.[752,753]

The treatment of ovarian sarcoma is surgical excision ("cytoreduction") followed by chemotherapy.[754]

Other Primary Tumors

Hemangiomas of the ovary are usually small, found incidentally, unilateral, and cavernous in type.[755] Rarely, they are bilateral and/or associated with hemangiomas elsewhere in the body. Ovarian hemangiomas should be distinguished from the normal prominent hilar vasculature, lipid cell tumors having a prominent vascular component, and from the florid non-neoplastic vascular proliferation that sometimes accompanies the primitive neuroectodermal component of ovarian germ cell tumors.[439] Other types of vascular tumors that have been reported in the ovary are *infantile hemangioendothelioma*,[756] *lymphangioma* (which can be bilateral),[757] and *glomus tumor*.[758,759] *Leiomyomas* can exceptionally develop in the ovary, usually in association with uterine leiomyomas[760]; some are mitotically active and need to be distinguished from leiomyosarcomas.[761–763] The criteria for making this distinction are similar to those employed for their infinitely more common uterine counterparts (and just as frustrating).[758]

Isolated examples of ovarian myofibroblastoma,[764] epithelioid angiomyolipoma/PEComa,[765] nephroblastoma (Wilms tumor),[766] desmoplastic small cell tumor,[767] pheochromocytoma/paraganglioma,[768,769] and hydatidiform mole[770] have also been described. Adenomatoid tumor can occur in an intra- or juxta-ovarian location; it can simulate the appearance of yolk sac tumor,[771] and it can be predominantly composed of oxyphilic cells.[772]

The great majority of cases of *melanoma* involving the ovary are metastatic, but cases thought to be primary in the ovary have been described, the most convincing examples being those arising within a mature cystic teratoma or a struma ovarii.[773] Pancreatic-type solid and pseudopapillary neoplasm can also occur in the ovary.[774]

Metastatic Tumors

The ovary is a common site of involvement for metastases.[775–778] Approximately 7% of lesions presenting clinically as primary ovarian tumors are of metastatic origin. Over half are bilateral. The most common sources are stomach, large bowel, appendix, breast, uterus (corpus and cervix),[779] lung,[780,781] and skin (melanoma).[782–785] The difficult situation resulting from the simultaneous presence of carcinoma in ovary and uterus is discussed elsewhere. At the time when therapeutic oophorectomies were done in patients with breast carcinoma, it was not unusual to find small and sometimes microscopic (occult) metastases. Their pattern of growth could be either diffuse (with single file formations, suggestive of a lobular nature) or glandular, more in keeping with a ductal type. Immunoreactivity for GCDFP-15 and GATA3 is the rule, a fact of importance in the differential diagnosis with primary ovarian carcinoma, which is generally negative.[786,787] The reverse is true for WT1 and PAX8, which tend to be positive in ovarian carcinomas but negative in breast carcinoma.[161,788]

Adenocarcinomas of the large bowel are particularly important because of their relatively high frequency and their ability to simulate primary ovarian carcinomas, mainly of the mucinous and endometrioid types but sometimes also of the clear cell type (Fig. 35.118).[784,789–791] The primary tumors are usually advanced but sometimes are small and clinically occult.[792] The ovarian metastases tend to be cystic, well differentiated, mucin-producing, and associated with necrosis and hemorrhage. In some cases (particularly those of cecal origin), the ovarian metastases are associated with luteinization of the surrounding stroma, which may lead to masculinization and other endocrine changes.[793]

Features favoring metastasis from large bowel are bilaterality, surface involvement by tumor cells, infiltrative or nodular pattern of invasion, ovarian hilar involvement, single cell invasion, signet ring cells, garland and cribriform growth pattern, "dirty" necrosis, segmental destruction of glands, lack of squamous metaplasia, and vascular invasion (Fig. 35.119).[789,794–796] Features favoring a primary ovarian tumor are an expansile (pushing) pattern of invasion, a complex papillary architecture, size over 13 cm, a smooth external surface, and the presence of benign- and borderline-appearing foci.[795] This combination of primarily architectural features should allow the differential diagnosis to be made in the large majority of cases with the H&E sections. Unfortunately, exceptions to each and every one of these criteria exist.[797] Immunohistochemical stains can be of great assistance, although they also fall short of being pathognomonic. Metastatic large bowel carcinoma is characteristically CK7–/CK20+, CDX2+, and SATB2+. By contrast, primary ovarian mucinous carcinomas are nearly always CK7+ and variably CK20+, SATB2+, and CDX2+.[798–800] Hormone receptors are of no help, being negative in both metastatic carcinoma from the colon and the usual type of primary ovarian mucinous carcinoma.[801]

It should be realized that these distinctions apply specifically to the large bowel. Ovarian metastases from gastric, biliary, or pancreatic primaries have different phenotypic features (Fig. 35.120).[225,802–804] Of note, pancreaticobiliary adenocarcinomas often have bland foci

For personal use only. No other uses without permission. Copyright ©2017. Elsevier Inc. All rights reserved.

Figure 35.118 **A** and **B,** Colonic carcinoma metastatic to ovary. This may be misdiagnosed as a primary ovarian tumor both grossly and microscopically.

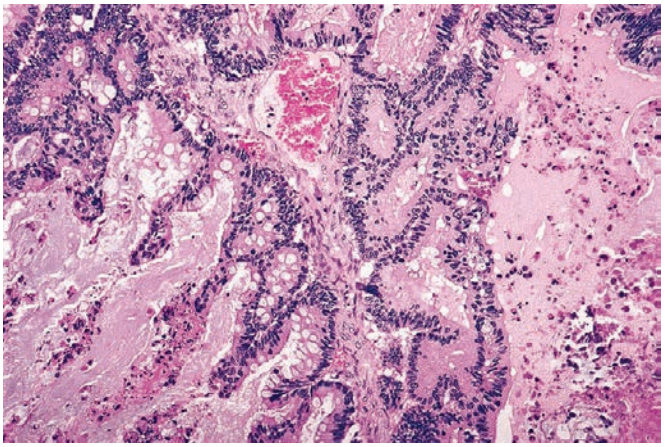

Figure 35.119 Colonic carcinoma metastatic to ovary.

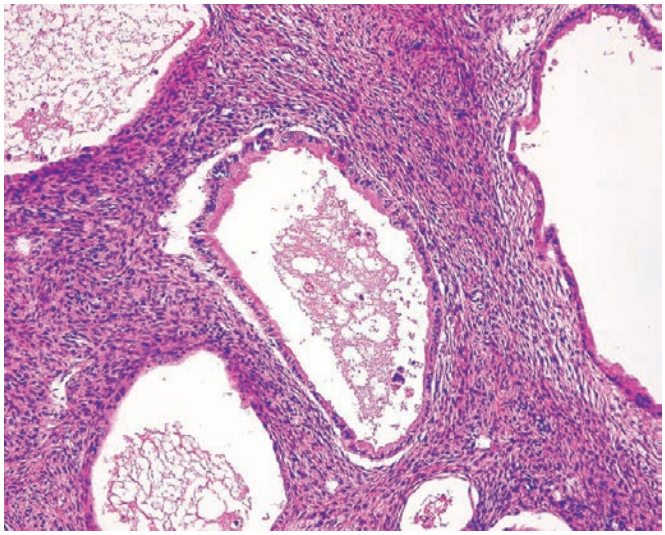

Figure 35.120 **Ovarian Metastasis From Pancreatic Adenocarcinoma.** As in the primary tumor, this ovarian metastasis shows the disparity between the extremely well-differentiated architecture and the high degree of nuclear atypia that is characteristic of pancreatobiliary neoplasms.

that simulate a benign or borderline ovarian mucinous tumor. The peculiar situation concerning the relationship of ovarian mucinous tumors and pseudomyxoma peritonei has been mentioned earlier in this chapter. Briefly, the current consensus—based on a combination of clinical, morphologic, immunohistochemical, and molecular observations—is that the overwhelming majority of these tumors are primary appendiceal neoplasms that have implanted on the peritoneal surface and on the ovaries.[805,806] However, that may not be true for all cases (e.g. the rare appendiceal-type ovarian mucinous adenocarcinomas arising from benign cystic teratomas).[482]

Metastatic carcinoid tumors to the ovary are discussed elsewhere. Small cell (neuroendocrine) carcinomas from the lung, gastrointestinal tract, thymus, and other sites can metastasize to the ovary; these should be distinguished from both the hypercalcemic and the pulmonary type of primary ovarian small cell carcinoma,[807] the latter being a more difficult task.

The eponym **Krukenberg tumor** is used to designate an ovarian neoplasm, usually bilateral and nearly always of metastatic origin, characterized grossly by moderate solid multinodular enlargement of the ovaries and microscopically by a diffuse infiltration by signet ring cells containing abundant neutral and acidic (sialo) mucins[808–811] (Figs. 35.121 and 35.122). Tumor emboli are found in over half of the cases.[812] Marked stromal proliferation with a storiform pattern of growth and a variable degree of luteinization are common and may obscure the diagnosis.[811] Another difficult problem is represented by the variant of this tumor referred to as *tubular*, in which a prominent tubular pattern, stromal luteinization, and

For personal use only. No other uses without permission. Copyright ©2017. Elsevier Inc. All rights reserved.

Figure 35.121 Typical Gross Appearance of Krukenberg Tumors of Ovary. The involvement is bilateral and the tumors are characterized by a multinodular outer appearance. (Courtesy of Dr. RA Cooke, Brisbane, Australia; from Cooke RA, Stewart B. *Colour Atlas of Anatomical Pathology*. Edinburgh: Churchill Livingstone; 2004.)

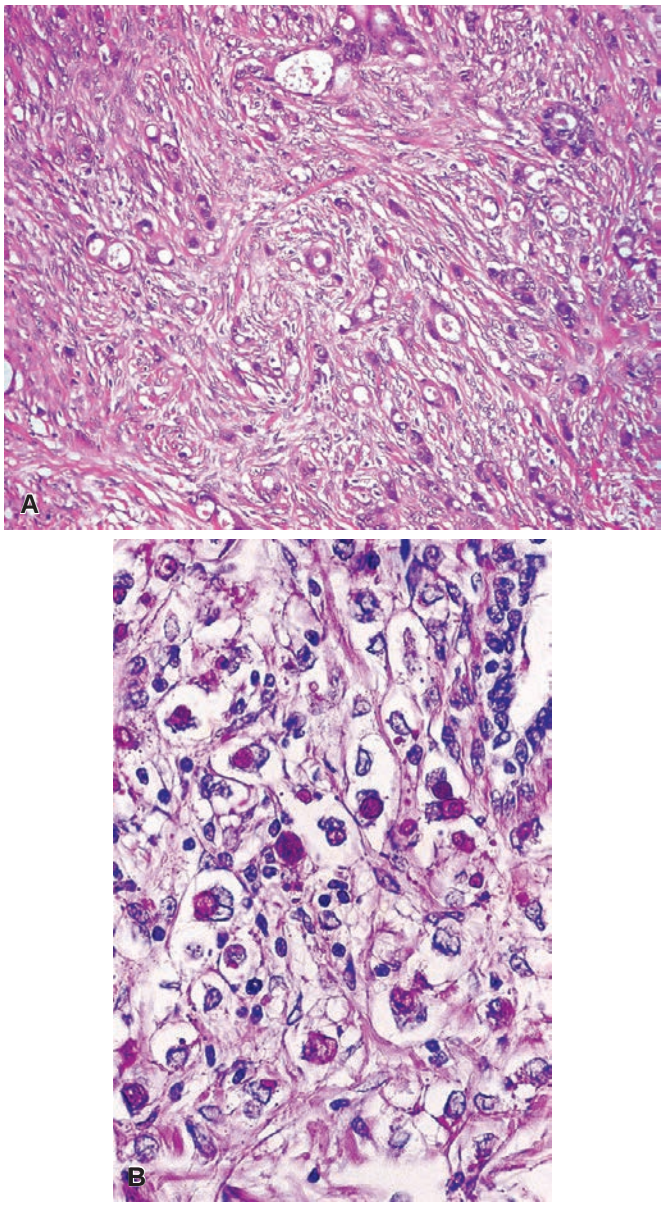

Figure 35.122 Krukenberg Tumor of Ovary. A, Microscopic appearance. Numerous signet ring cells are present in a highly fibrous stroma, either individually or in small nests. **B,** Presence of intracellular mucin evidenced by Meyer mucicarmine stain.

occasional associated virilization may lead to a mistaken diagnosis of Sertoli–Leydig cell tumor (Fig. 35.123)[812]; the presence of typical mucin-positive signet ring cells should point toward the correct diagnosis.

Most examples of Krukenberg tumors occur after the age of 40 years, but younger patients can also be affected. In the latter instance, a mistaken diagnosis of granulosa cell tumor or steroid cell tumor may be made.

The usual primary sources of Krukenberg tumor are stomach, large bowel, appendix, and breast (Fig. 35.124).[812–815] Of these, diffuse gastric carcinoma ("linitis plastic") used to be the most common, but at present there is a preponderance of cases originating from the breast, at least in the United States. The ovarian deposits can be accompanied by retroperitoneal lymph node metastases and peritoneal implants. A rarer phenomenon is ovarian metastasis from gastric carcinoma of intestinal type.[816]

Exceptionally, an extra-ovarian primary tumor is not found at autopsy in a patient harboring a Krukenberg tumor. In such an instance, the lesion is assumed to be primary in the ovary.[817] Before such an occurrence is accepted, a meticulous study of the gastrointestinal tract, breast, and other organs should be carried out.[812] It should be emphasized here that the diagnosis of Krukenberg tumor requires the histochemical identification of intracytoplasmic mucin, and the immunohistochemical detection of epithelial markers, inasmuch as mucin negative signet ring cells are occasionally seen in other ovarian conditions.[818]

Other tumors that can metastasize to the ovary and give rise to difficult diagnostic problems are pancreatobiliary ductal adenocarcinoma (which can simulate primary ovarian mucinous tumors and which can arise in the pancreas, gallbladder or extrahepatic or intrahepatic bile ducts),[819–822] pancreatic acinar cell carcinoma,[823] renal cell carcinoma (which mimics ovarian clear cell adenocarcinoma),[824,825] carcinoma of the renal pelvis,[826] thyroid carcinoma (which can be confused with struma ovarii),[827] hepatocellular carcinoma and hepatoblastoma (not to be mistaken for hepatoid yolk sac tumor or hepatoid carcinoma, all of which are Hep Par1 positive[828]),[829,830] intra-abdominal desmoplastic small cell tumor (of which the ovary can be the only manifestation),[831,832] and a variety of sarcomas, including rhabdomyosarcoma,[777] leiomyosarcoma, osteosarcoma,[833] gastrointestinal stromal tumor (GIST),[834] soft tissue–type clear cell sarcoma,[835] and chordoma.[778,836,837] We have also seen ovarian metastases from malignant thymoma.

Malignant melanomas are usually easy to recognize because of their pigmentation, nodular pattern of growth, and cytologic features; however, some can be confused with primary ovarian tumors (particularly juvenile granulosa cell tumor and the hypercalcemic type of small cell carcinoma) because of their tendency to form follicle-like spaces (Figs. 35.125 and 35.126).[785] Positivity for S-100 protein, SOX-10, Melan-A, and HMB-45 should remove whatever doubts may remain after examination of H&E-stained sections.[838] Metastatic melanoma should be distinguished from the much rarer primary ovarian melanoma.

Not surprisingly, carcinoma metastatic to the ovary is generally associated with a very poor prognosis.

For personal use only. No other uses without permission. Copyright ©2017. Elsevier Inc. All rights reserved.

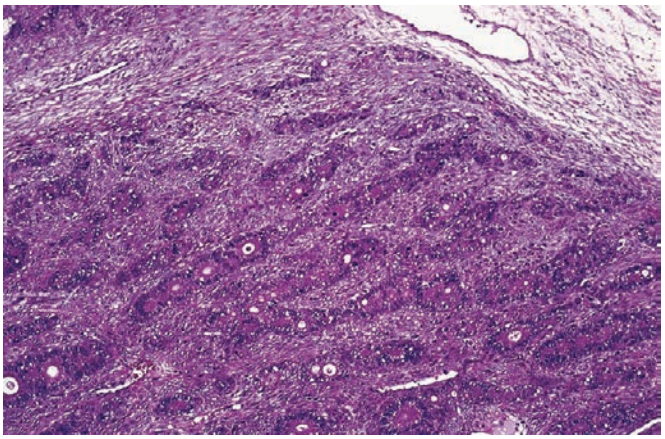

Figure 35.123 Tubular variant of Krukenberg cell tumor.

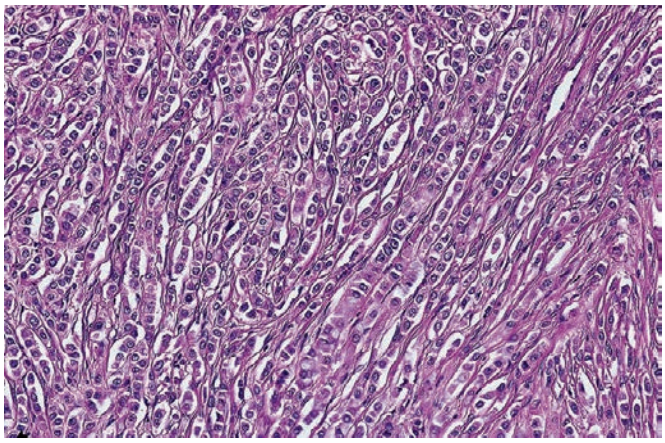

Figure 35.124 Ovarian metastasis of lobular carcinoma of breast.

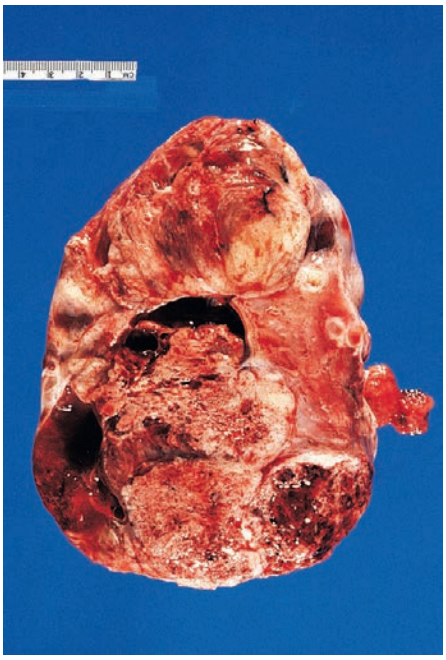

Figure 35.125 Gross appearance of ovarian metastasis of a malignant melanoma.

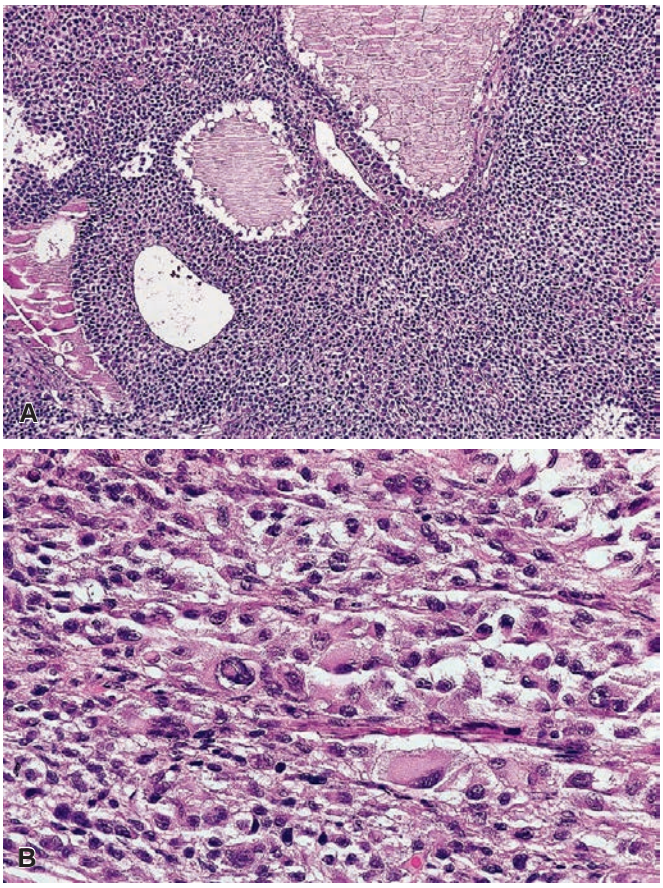

Figure 35.126 **A** and **B,** Low- and high-power appearances of ovarian metastasis from malignant melanoma. The follicle-like formations seen in **A** may result in a misdiagnosis of juvenile granulosa cell tumor or hypercalcemic-type small cell carcinoma.

For personal use only. No other uses without permission. Copyright ©2017. Elsevier Inc. All rights reserved.

References

1. Gilks CB, Clement PB. Ovary. In: Mills SE, ed. *Histology for Pathologists*. 4th ed. Philadelphia: Lippincott Williams and Wilkins; 2012:1119-1148.
2. Zheng W, Magid MS, Kramer EE, Chen YT. Follicle-stimulating hormone receptor is expressed in human ovarian surface epithelium and fallopian tube. *Am J Pathol*. 1996;148:47-53.
3. Bowen NJ, Logani S, Dickerson EB, et al. Emerging roles for PAX8 in ovarian cancer and endosalpingeal development. *Gynecol Oncol*. 2007;104:331-337.
4. Czernobilsky B, Shezen E, Lifschitz-Mercer B, et al. Alpha smooth muscle actin (alpha-SM actin) in normal human ovaries, in ovarian stromal hyperplasia and in ovarian neoplasms. *Virchows Arch [Cell Pathol]*. 1989;57:55-61.
5. Lastarria D, Sachdev RK, Babury RA, et al. Immunohistochemical analysis for desmin in normal and neoplastic ovarian stromal tissue. *Arch Pathol Lab Med*. 1990;114:502-505.
6. Fetissof F, Dubois MP, Heitz PU, et al. Endocrine cells in the female genital tract. *Int J Gynecol Pathol*. 1986;5:75-87.
7. Boss JH, Scully RE, Wegner KH, Cohen RB. Structural variations in the adult ovary. Clinical significance. *Obstet Gynecol*. 1965;25:747-764.
8. Sasano H, Sasano N. What's new in the localization of sex steroids in the human ovary and its tumors? *Pathol Res Pract*. 1989;185:942-948.
9. Sasano H, Okamoto M, Mason JI, et al. Immunolocalization of aromatase, 17 alpha-hydroxylase and side-chain cleavage cytochromes P-450 in the human ovary. *J Reprod Fertil*. 1989;85:163-169.
10. Visfeldt J, Starup J. Dating of the human corpus luteum of menstruation using histological parameters. *Acta Pathol Microbiol Scand [A]*. 1974;82:137-144.
11. Laffargue P, Benkoël L, Laffargue F, et al. Ultrastructural and enzyme histochemical study of ovarian hilar cells in women and their relationships with sympathetic nerves. *Hum Pathol*. 1978;9:649-659.
12. Woolnough E, Russo L, Khan MS, Heatley MK. An immunohistochemical study of the rete ovarii and epoophoron. *Pathology*. 2000;32:77-83.
13. Robboy SJ, Bentley RC, Russell P. Embryology of the female genital tract and disorders of abnormal sexual development. In: Kurman RJ, ed. *Blaustein's Pathology of the Female Genital Tract*. ed 5. New York: Springer-Verlag; 2002:3-36.
14. MacLaughlin DT, Donahoe PK. Sex determination and differentiation. *N Engl J Med*. 2004;350:367-378.
15. Robboy SJ, Jaubert F. Neoplasms and pathology of sexual developmental disorders (intersex). *Pathology*. 2007;39:147-163.
16. Rutgers JL. Advances in the pathology of intersex conditions. *Hum Pathol*. 1991;22:884-891.
17. Scully RE. Gonadal pathology of genetically determined diseases. *Monogr Pathol*. 1991;33:257-285.
18. Jones HW, Ferguson-Smith MA, Heller RH. The pathology and cytogenetics of gonadal agenesis. *Am J Obstet Gynecol*. 1963;87:578-600.
19. Sohval AR. The syndrome of pure gonadal dysgenesis. *Am J Med*. 1965;38:615-625.
20. Sybert VP, McCauley E. Turner's syndrome. *N Engl J Med*. 2004;351:1227-1238.
21. Taylor H, Barter RH, Jacobson CB. Neoplasms of dysgenetic gonads. *Am J Obstet Gynecol*. 1966;96:816-823.
22. Clement PB, Young RH. Atypical polypoid adenomyoma of the uterus associated with Turner's syndrome. A report of three cases, including a review of 'estrogen-associated' endometrial neoplasms and neoplasms associated with Turner's syndrome. *Int J Gynecol Pathol*. 1987;6:104-113.
23. Males JL, Lain KC. Epithelioid sarcoma in XO/XX Turner's syndrome. *Arch Pathol*. 1972;94:214-216.
24. McCarty KS Jr, Barton TK, Peete CH Jr, Creasman WT. Gonadal dysgenesis with adenocarcinoma of the endometrium. An electron microscopic and steroid receptor analyses with a review of the literature. *Cancer*. 1978;42:512-520.
25. Calabrese F, Valente M. Mixed gonadal dysgenesis: histological and ultrastructural finding in two cases. *Int J Gynecol Pathol*. 1996;15:270-277.
26. Robboy SJ, Miller T, Donahoe PK, et al. Dysgenesis of testicular and streak gonads in the syndrome of mixed gonadal dysgenesis. Perspective derived from a clinicopathologic analysis of twenty-one cases. *Hum Pathol*. 1982;13:700-716.
27. Federman DD. *Abnormal Sexual Development. A Genetic and Endocrine Approach to Differential Diagnosis*. Philadelphia: WB Saunders; 1967.
28. Jones HW, Ferguson-Smith MA, Heller RH. Pathologic and cytogenetic findings in true hermaphroditism. Report of 6 cases and review of 23 cases from the literature. *Obstet Gynecol*. 1965;25:435-447.
29. Kim KR, Kwon Y, Young Joung J, et al. True hermaphroditism and mixed gonadal dysgenesis in young children: a clinicopathologic study of 10 cases. *Mod Pathol*. 2002;15:1013-1019.
30. Radhakrishnan S, Sivaraman L, Natarajan PS. True hermaphrodite with multiple gonadal neoplasms. Report of a case with cytogenetic study. *Cancer*. 1978;42:2726-2732.
31. Ferenczy A, Richart RM. The fine structure of the gonads in the complete form of testicular feminization syndrome. *Am J Obstet Gynecol*. 1972;113:399-409.
32. Neubecker RD, Theiss EA. Sertoli cell adenomas in patients with testicular feminization. *Am J Clin Pathol*. 1962;38:52-59.
33. Blaustein A. Surface cells and inclusion cysts in fetal ovaries. *Gynecol Oncol*. 1981;12:222-233.
34. Adelman S, Benson CD, Hertzler JH. Surgical lesions of the ovary in infancy and childhood. *Surg Gynecol Obstet*. 1975;141:219-222.
35. Towne BH, Mahour GH, Woolley MM, Isaacs H. Ovarian cysts and tumors in infancy and childhood. *J Pediatr Surg*. 1975;10:311-320.
36. Morris JM, Scully RE. *Endocrine Pathology of the Ovary*. St Louis: CV Mosby; 1958.
37. Wajda KJ, Lucas JG, Marsh WL Jr. Hyperreactio luteinalis. Benign disorder masquerading as an ovarian neoplasm. *Arch Pathol Lab Med*. 1989;113:921-925.
38. Legro RS, Strauss JF. Molecular progress in infertility: polycystic ovary syndrome. *Fertil Steril*. 2002;78:569-576.
39. Clement PB. Tumor-like lesions of the ovary associated with pregnancy. *Int J Gynecol Pathol*. 1993;12:108-115.
40. Goldzieher JW, Green JA. The polycystic ovary. I. Clinical and histologic features. *J Clin Endocrinol*. 1962;22:325-338.
41. Sommers SC. Polycystic ovaries revisited. In: Fenoglio CM, Wolfe M, eds. *Progress in Surgical Pathology*. New York: Masson; 1980:221-232.
42. Balen A, Michelmore K. What is polycystic ovary syndrome? Are national views important? *Hum Reprod*. 2002;17:2219-2227.
43. Insler V, Lunenfeld B. Pathophysiology of polycystic ovarian disease. New insights. *Hum Reprod*. 1991;6:1025-1029.
44. Barnes RB, Rosenfield RL, Burstein S, Ehrmann DA. Pituitary-ovarian responses to nafarelin testing in the polycystic ovary syndrome. *N Engl J Med*. 1989;320:559-565.
45. Rodin A, Thakkar H, Taylor N, Clayton R. Hyperandrogenism in polycystic ovary syndrome. Evidence of dysregulation of 11β-hydroxysteroid dehydrogenase. *N Engl J Med*. 1994;330:460-465.
46. Lindsay AN, Voorhess ML, MacGillivray MH. Multicystic ovaries in primary hypothyroidism. *Obstet Gynecol*. 1983;61:433-437.
47. Awartani KA, Cheung AP. Metformin and polycystic ovary syndrome: a literature review. *J Obstet Gynaecol Can*. 2002;24:393-401.
48. Franik S, Kremer JA, Nelen WL, Farquhar C. Aromatase inhibitors for subfertile women with polycystic ovary syndrome. *Cochrane Database Syst Rev*. 2014;(2):CD010287.
49. Fechner RE, Kaufman RH. Endometrial adenocarcinoma in Stein–Leventhal syndrome. *Cancer*. 1974;34:444-452.
50. Smyczek-Gargya B, Geppert M. Endometrial cancer associated with polycystic ovaries in young women. *Pathol Res Pract*. 1992;188:946-948.
51. Sasano H, Fukunaga M, Rojas M, Silverberg SG. Hyperthecosis of the ovary. Clinicopathologic study of 19 cases with immunohistochemical analysis of steroidogenic enzymes. *Int J Gynecol Pathol*. 1989;8:311-320.
52. Judd HL, Scully RE, Herbst AL, et al. Familial hyperthecosis. Comparison of endocrinologic and histologic findings with polycystic ovarian disease. *Am J Obstet Gynecol*. 1973;117:976-982.
53. Hallatt JG, Steele CH Jr, Snyder M. Ruptured corpus luteum with hemoperitoneum. A study of 173 surgical cases. *Am J Obstet Gynecol*. 1984;149:5-9.
54. Garcia-Bunuel R, Berek JS, Woodruff JD. Luteomas of pregnancy. *Obstet Gynecol*. 1975;45:407-414.
55. Norris HJ, Taylor HB. Nodular theca-lutein hyperplasia of pregnancy (so-called 'pregnancy luteoma'). *Am J Clin Pathol*. 1967;47:557-566.
56. Sternberg WH, Barclay DL. Luteoma of pregnancy. *Am J Obstet Gynecol*. 1966;95:165-184.
57. Piana S, Nogales FF, Corrado S, et al. Pregnancy luteoma with granulosa cell proliferation: an unusual hyperplastic lesion arising in pregnancy and mimicking an ovarian neoplasia. *Pathol Res Pract*. 1999;195:859-863.
58. Gardner GH, Greene RR, Peckham B. Normal and cystic structures of broad ligament. *Am J Obstet Gynecol*. 1948;55:917-939.
59. Bransilver BR, Ferenczy A, Richart RM. Female genital tract remnants. An ultrastructural comparison of hydatid of Morgagni and mesonephric ducts and tubules. *Arch Pathol*. 1973;96:255-261.
60. Heatley MK. Adenomatous hyperplasia of the rete ovarii. *Histopathology*. 2000;36:383-384.
61. Nogales FF, Carvia RE, Donne C, et al. Adenomas of the rete ovarii. *Hum Pathol*. 1998;28:1428-1433.
62. Fan LD, Zang HY, Zhang XS. Ovarian epidermoid cyst: report of eight cases. *Int J Gynecol Pathol*. 1996;15:69-71.
63. Nogales FF, Silverberg SG. Epidermoid cysts of the ovary. A report of five cases with histogenetic considerations and ultrastructural findings. *Am J Obstet Gynecol*. 1976;124:523-528.
64. Young RH, Prat J, Scully RE. Epidermoid cyst of the ovary. A report of three cases with comments on histogenesis. *Am J Clin Pathol*. 1980;73:272-276.

For personal use only. No other uses without permission. Copyright ©2017. Elsevier Inc. All rights reserved.

65. Hosfield EM, Rabban JT, Chen LM, Zaloudek CJ. Squamous metaplasia of the ovarian surface epithelium and subsurface fibrosis: distinctive pathologic findings in the ovaries and fallopian tubes of patients on peritoneal dialysis. *Int J Gynecol Pathol*. 2008;27:465-474.
66. Mount SL, Eltabbakh GH, Hardin NJ. Beta-2 microglobulin amyloidosis presenting as bilateral ovarian masses: a case report and review of the literature. *Am J Surg Pathol*. 2001;26:130-133.
67. Kamiyama K, Moromizato H, Toma T, et al. Two cases of supernumerary ovary: one with large fibroma with Meig's syndrome and the other with endometriosis and cystic change. *Pathol Res Pract*. 2001;197:847-851.
68. Lee B, Gore BZ. A case of supernumerary ovary. *Obstet Gynecol*. 1984;64:738-740.
69. Gray Y, Libbey P. Xanthogranulomatous salpingitis and oophoritis: a case report and review of the literature. *Arch Pathol Lab Med*. 2001;125:260-263.
70. Pace EH, Voet RL, Melancon JT. Xanthogranulomatous oophoritis. An inflammatory pseudotumor of the ovary. *Int J Gynecol Pathol*. 1984;3:398-402.
71. Tatum ET, Beattie JF, Bryson K. Postoperative carbon pigment granuloma: a report of eight cases involving the ovary. *Hum Pathol*. 1996;27:1008-1011.
72. Mostafa SAM, Bargeron CB, Flower RW, et al. Foreign body granulomas in normal ovaries. *Obstet Gynecol*. 1985;66:701-702.
73. Kim KR, Scully RE. Peritoneal keratin granulomas with carcinomas of endometrium and ovary and atypical polypoid adenomyoma of endometrium: a clinicopathological analysis of 22 cases. *Am J Surg Pathol*. 1990;14:925-932.
74. Herbold DR, Frable WJ, Kraus FT. Isolated noninfectious granulomas of the ovary. *Int J Gynecol Pathol*. 1984;2:380-391.
75. Gloor E, Hurlimann J. Autoimmune oophoritis. *Am J Clin Pathol*. 1984;81:105-109.
76. Bannatyne P, Russell P, Shearman RP. Autoimmune oophoritis. A clinicopathologic assessment of 12 cases. *Int J Gynecol Pathol*. 1990;9:191-207.
77. Silva CA, Yamakami LY, Aikawa NE, et al. Autoimmune primary ovarian insufficiency. *Autoimmun Rev*. 2014;13:427-430.
78. Irvine WJ, Barnes EW. Addison's disease and autoimmune ovarian failure. *J Reprod Fertil*. 1974;21(suppl):1-31.
79. Lewis J. Eosinophilic perifolliculitis. A variant of autoimmune oophoritis. *Int J Gynecol Pathol*. 1993;12:360-364.
80. Francke ML, Mihaescu A, Chaubert P. Isolated necrotizing arteritis of the female genital tract: a clinicopathologic and immunohistochemical study of 11 Cases. *Int J Gynecol Pathol*. 1998;17:193-200.
81. Olive DL, Schwartz LB. Endometriosis. *N Engl J Med*. 1993;328:1759-1769.
82. Anglesio MS, Bashashati A, Wang YK, et al. Multifocal endometriotic lesions associated with cancer are clonal and carry a high mutation burden. *J Pathol*. 2015;236:201-209.
83. Jimbo H, Hitomi Y, Yoshikawa H, et al. Evidence for monoclonal expansion of epithelial cells in ovarian endometrial cysts. *Am J Pathol*. 1997;150:1173-1178.
84. Devereux WP. Endometriosis. Long-term observation with particular reference to incidence of pregnancy. *Obstet Gynecol*. 1963;22:444-450.
85. Young RH, Scully RE. Ovarian pathology of infertility. *Monogr Pathol*. 1991;33:104-139.
86. Pratt JH, Shamblin WR. Spontaneous rupture of endometrial cysts of the ovary presenting as an acute abdominal emergency. *Am J Obstet Gynecol*. 1970;108:56-62.
87. Clement PB. Pathology of endometriosis. *Pathol Annu*. 1990;25:245-295.
88. Clement PB, Young RH, Scully RE. Necrotic pseudoxanthomatous nodules of ovary and peritoneum in endometriosis. *Am J Surg Pathol*. 1988;12:390-397.
89. Perotta PL, Ginsburg FW, Siderides CI, Parkash V. Liesegang rings and endometriosis. *Int J Gynecol Pathol*. 1998;17:358-362.
90. Clement PB, Young RH. Two previously unemphasized features of endometriosis: micronodular stromal endometriosis and endometriosis with stromal elastosis. *Int J Surg Pathol*. 2001;8:223-227.
91. Fukunaga M. Smooth muscle metaplasia in ovarian endometriosis. *Histopathology*. 2000;36:348-352.
92. Pai SA, Desai SB, Borges AM. Uteruslike masses of the ovary associated with breast cancer and raised serum CA 125. *Am J Surg Pathol*. 1998;22:333-337.
93. Ballouk F, Ross JS, Wolf BC. Ovarian endometriotic cysts. An analysis of cytologic atypia and DNA ploidy patterns. *Am J Clin Pathol*. 1994;102:415-419.
94. Czernobilsky B, Morris WJ. A histologic study of ovarian endometriosis with emphasis on hyperplastic and atypical changes. *Obstet Gynecol*. 1979;53:318-323.
95. Fukunaga M, Nomura K, Ishikawa E, Ushigome S. Ovarian atypical endometriosis. Its close association with malignant epithelial tumors. *Histopathology*. 1997;30:249-255.
96. La Grenade A, Silverberg SG. Ovarian tumors associated with atypical endometriosis. *Hum Pathol*. 1988;19:1080-1084.
97. Wiegand KC, Shah SP, Al-Agha OM, et al. ARID1A mutations in endometriosis-associated ovarian carcinomas. *N Engl J Med*. 2010;363:1532-1543.
98. Fukunaga M, Ushigome S. Epithelial metaplastic changes in ovarian endometriosis. *Mod Pathol*. 1998;11:784-788.
99. Scully RE, Young RH, Clement PB. *Tumors of the Ovary, Maldeveloped Gonads, Fallopian Tube, and Broad Ligament. Atlas of Tumor Pathology, Series 3, Fascicle 23*. Washington, DC: Armed Forces Institute of Pathology; 1998:527.
100. Kurman RJ, Carcandiu ML, Herrington SC, Young RH, eds. *WHO Classification of Tumours of the Female Reproductive Organs*. Lyon: IARC; 2014.
101. Bell DA. Ovarian surface epithelial–stromal tumors. *Hum Pathol*. 1991;22:750-762.
102. Seidman JD, Kurman RJ. Subclassification of serous borderline tumors of the ovary into benign and malignant types: a clinicopathologic study of 65 advanced stage cases. *Am J Surg Pathol*. 1996;20:1331-1345.
103. Smith Sehdev AE, Sehdev PS, Kurman RJ. Noninvasive and invasive micropapillary (low-grade) serous carcinoma of the ovary. A clinicopathologic analysis of 135 cases. *Am J Surg Pathol*. 2003;27:725-736.
104. Scully RE. One pathologist's reminiscences of the 20th century and random thoughts about the 21st: reflections at the millennium. *Int J Surg Pathol*. 2002;10:8-13.
105. Singh N, Gilks CB. The changing landscape of gynaecological cancer diagnosis: implications for histopathological practice in the 21st century. *Histopathology*. 2017;70:56-69.
106. Kobel M, Kalloger SE, Baker PM, et al. Diagnosis of ovarian carcinoma cell type is highly reproducible: a transcanadian study. *Am J Surg Pathol*. 2010;34:984-993.
107. Kobel M, Bak J, Bertelsen BI, et al. Ovarian carcinoma histotype determination is highly reproducible, and is improved through the use of immunohistochemistry. *Histopathology*. 2014;4:1004-1013.
108. Kommoss SG, Gilks CB, du Bois A, Kommoss F. Ovarian carcinoma diagnosis: the clinical impact of 15 years of change. *Br J Cancer*. 2016;115:993-999.
109. Singh N, McCluggage WG, Gilks CB. High-grade serous carcinoma of tubo-ovarian origin: recent developments. *Histopathology*. 2017 May 6;[Epub ahead of print].
110. Girolimetti G, Perrone AM, Santini D, et al. BRCA-associated ovarian cancer: from molecular genetics to risk management. *Biomed Res Int*. 2014;2014:787143.
111. Lynch HT, Snyder C, Casey MJ. Hereditary ovarian and breast cancer: what have we learned? *Ann Oncol*. 2013;24(suppl 8):viii8 3-viii95.
112. McAlpine JN, Porter H, Köbel M, et al. BRCA1 and BRCA2 mutations correlate with TP53 abnormalities and presence of immune cell infiltrates in ovarian high-grade serous carcinoma. *Mod Pathol*. 2012;25:740-750.
113. Risch HA, McLaughlin JR, Cole DE, et al. Prevalence and penetrance of germline BRCA1 and BRCA2 mutations in a population series of 649 women with ovarian cancer. *Am J Hum Genet*. 2001;68:700-710.
114. Schrader KA, Hurlburt J, Kalloger SE, et al. Germline BRCA1 and BRCA2 mutations in ovarian cancer: utility of a histology-based referral strategy. *Obstet Gynecol*. 2012;120:235-240.
115. Aarnio M, Sankila R, Pukkala E, et al. Cancer risk in mutation carriers of DNA-mismatch-repair genes. *Int J Cancer*. 1999;81:214-218.
116. Watson P, Vasen HF, Mecklin J-PP, et al. The risk of extra-colonic, extra-endometrial cancer in the Lynch syndrome. *Int J Cancer*. 2008;123:444-449.
117. Chui MH, Gilks CB, Cooper K, et al. Identifying Lynch syndrome in patients with ovarian carcinoma: the significance of tumor subtype. *Adv Anat Pathol*. 2013;20:378-386.
118. Chui MH, Ryan P, Radigan J, et al. The histomorphology of Lynch syndrome-associated ovarian carcinomas: toward a subtype-specific screening strategy. *Am J Surg Pathol*. 2014;38:1173-1181.
119. Malpica A, Deavers MT, Lu K, et al. Grading ovarian serous carcinoma using a two-tier system. *Am J Surg Pathol*. 2004;28:496-504.
120. Malpica A, Deavers MT, Tornos C, et al. Interobserver and intraobserver variability of a two-tier system for grading ovarian serous carcinoma. *Am J Surg Pathol*. 2007;31:1168-1174.
121. O'Neill CJ, Deavers MT, Malpica A, et al. An immunohistochemical comparison between low-grade and high-grade ovarian serous carcinomas: significantly higher expression of p53, MIB1, BCL2, HER-2/neu, and C-KIT in high-grade neoplasms. *Am J Surg Pathol*. 2005;29:1034-1041.
122. Singer G, Kurman RJ, Chang HW, et al. Diverse tumorigenic pathways in ovarian serous carcinoma. *Am J Pathol*. 2002;160:1223-1228.
123. Singer G, Shih IeM, Truskinovsky A, et al. Mutational analysis of K-ras segregates ovarian serous carcinomas into two types: invasive MPSC (low-grade tumor) and conventional serous carcinoma (high-grade tumor). *Int J Gynecol Pathol*. 2003;22:37-41.
124. Singer G, Stohr R, Cope L, et al. Patterns of p53 mutations separate ovarian serous borderline tumors and low- and high-grade carcinomas and provide support for a new model of ovarian carcinogenesis: a mutational analysis with immunohistochemical correlation. *Am J Surg Pathol*. 2005;29:218-224.
125. Fenoglio CM. Ultrastructural features of the common epithelial tumors of the ovary. *Ultrastruct Pathol*. 1980;1:419-444.
126. Ohishi Y, Oda Y, Kurihara S, et al. Hobnail-like cells in serous borderline tumor do not represent concomitant incipient clear cell neoplasms. *Hum Pathol*. 2009;40:1168-1175.

For personal use only. No other uses without permission. Copyright ©2017. Elsevier Inc. All rights reserved.

127. Ahn G, Folkins AK, McKenney JK, Longacre TA. Low-grade serous carcinoma of the ovary: clinicopathologic analysis of 52 invasive cases and identification of a possible noninvasive intermediate lesion. *Am J Surg Pathol*. 2016;40:1165-1176.
128. Gilks CB, Bell DA, Scully RE. Serous psammocarcinoma of the ovary and peritoneum. *Int J Gynecol Pathol*. 1990;9:110-121.
129. Colgan TJ, Norris HJ. Ovarian epithelial tumors of low malignant potential: a review. *Int J Gynecol Pathol*. 1983;1:367-382.
130. Ulbright TM, Roth LM. Common epithelial tumors of the ovary. Proliferating and of low malignant potential. *Semin Diagn Pathol*. 1985;2:2-15.
131. Bell DA, Longacre TA, Prat J, et al. Serous borderline (low malignant potential, atypical proliferative) ovarian tumors: workshop perspectives. *Hum Pathol*. 2004;35:934-948.
132. Dietel M, Hauptmann S. Serous tumors of low malignant potential of the ovary. 1. Diagnostic pathology. *Virchows Arch*. 2000;436:403-412.
133. Hart WR. Borderline epithelial tumors of the ovary. *Mod Pathol*. 2005;18(suppl 2):S33-S50.
134. Kurman RJ, Seidman JD, Shih IeM. Serous borderline tumours of the ovary. *Histopathology*. 2005;47:310-315.
135. Silva EG, Kurman RJ, Russell P, Scully RE. Symposium: ovarian tumors of borderline malignancy. *Int J Gynecol Pathol*. 1996;15:281-307.
136. Katzenstein AL, Mazur MT, Morgan TE, Kao MS. Proliferative serous tumors of the ovary. Histologic features and prognosis. *Am J Surg Pathol*. 1978;2:339-355.
137. Bell DA, Scully RE. Ovarian serous borderline tumors with stromal microinvasion. A report of 21 cases. *Hum Pathol*. 1990;21:397-403.
138. Nayar R, Siriaunkgul S, Robbins KM, et al. Microinvasion of low malignant potential tumors of the ovary. *Hum Pathol*. 1996;27:521-527.
139. McKenney JK, Balzer BL, Longacre TA. Patterns of stromal invasion in ovarian serous tumors of low malignant potential (borderline tumors): a reevaluation of the concept of stromal microinvasion. *Am J Surg Pathol*. 2006;30:1209-1221.
140. Yemelyanova A, Mao TL, Nakayama N, et al. Low-grade serous carcinoma of the ovary displaying a macropapillary pattern of invasion. *Am J Surg Pathol*. 2008;32:1800-1806.
141. Bell DA, Weinstock MA, Scully RE. Peritoneal implants of ovarian serous borderline tumors. Histologic features and prognosis. *Cancer*. 1988;62:2212-2222.
142. McKenney JK, Gilks CB, Kalloger S, Longacre TA. Classification of extraovarian implants in patients with ovarian serous borderline tumors (tumors of low malignant potential) based on clinical outcome. *Am J Surg Pathol*. 2016;40:1155-1164.
143. Burks RT, Sherman ME, Kurman RJ. Micropapillary serous carcinoma of the ovary: a distinctive low-grade carcinoma related to serous borderline tumors. *Am J Surg Pathol*. 1996;20:1319-1330.
144. Eichhorn JH, Bell DA, Young RH, Scully RE. Ovarian serous borderline tumors with micropapillary and cribriform patterns: a study of 40 cases and comparison with 44 cases without these patterns. *Am J Surg Pathol*. 1999;23:397-409.
145. Hannibal CG, Vang R, Junge J, et al. A nationwide study of serous "borderline" ovarian tumors in Denmark 1978–2002: centralized pathology review and overall survival compared with the general population. *Gynecol Oncol*. 2014(134):267-273.
146. Hannibal CG, Vang R, Junge J, et al. A nationwide study of ovarian serous borderline tumors in Denmark 1978–2002. Risk of recurrence, and development of ovarian serous carcinoma. *Gynecol Oncol*. 2017(144):174-180.
147. Ali RH, Kalloger SE, Santos JL, et al. Stage II to IV low-grade serous carcinoma of the ovary is associated with a poor prognosis: a clinicopathologic study of 32 patients from a population-based tumor registry. *Int J Gynecol Pathol*. 2013;32:529-535.
148. Boyd C, McCluggage WG. Low-grade ovarian serous neoplasms (low-grade serous carcinoma and serous borderline tumor) associated with high-grade serous carcinoma or undifferentiated carcinoma: report of a series of cases of an unusual phenomenon. *Am J Surg Pathol*. 2012;36:368-375.
149. Cathro HP, Stoler MH. Expression of cytokeratins 7 and 20 in ovarian neoplasia. *Am J Clin Pathol*. 2002;117:944-951.
150. Cajigas HE, Fariza E, Scully RE, Thor AD. Enhancement of tumor-associated glycoprotein-72 antigen expression in hormone-related ovarian serous borderline tumors. *Cancer*. 1991;68:348-354.
151. Hanselaar AG, Vooijs GP, Mayall B, et al. Epithelial markers to detect occult microinvasion in serous ovarian tumors. *Int J Gynecol Pathol*. 1993;12:20-27.
152. Moll R, Pitz S, Levy R, et al. Complexity of expression of intermediate filament proteins, including glial filament protein, in endometrial and ovarian adenocarcinomas. *Hum Pathol*. 1991;22:989-1001.
153. Miettinen M, Lehto V-P, Virtanen I. Expression of intermediate filaments in normal ovaries and ovarian epithelial, sex cord-stromal, and germinal tumors. *Int J Gynecol Pathol*. 1983;2:64-71.
154. Mohabeer J, Buckley CH, Fox H. An immunohistochemical study of the incidence and significance of human chorionic gonadotrophin synthesis by epithelial ovarian neoplasms. *Gynecol Oncol*. 1983;16:78-84.
155. Chadha S, Rao BR, Slotman BJ, et al. An immunohistochemical evaluation of androgen and progesterone receptors in ovarian tumors. *Hum Pathol*. 1993;24:90-95.
156. Harding M, Cowan S, Hole D, et al. Estrogen and progesterone receptors in ovarian cancer. *Cancer*. 1990;65:486-491.
157. Cathro HP, Stoler MH. The utility of calretinin, inhibin, and WT1 immunohistochemical staining in the differential diagnosis of ovarian tumors. *Hum Pathol*. 2005;36:195-201.
158. Hwang H, Quenneville L, Yaziji H, Gown AM. Wilms tumor gene product: sensitive and contextually specific marker of serous carcinomas of ovarian surface epithelial origin. *Appl Immunohistochem Mol Morphol*. 2004;12:122-126.
159. Laury AR, Hornick JL, Perets R, et al. PAX8 reliably distinguishes ovarian serous tumors from malignant mesothelioma. *Am J Surg Pathol*. 2010;34:627-635.
160. Nonaka D, Chiriboga L, Soslow RA. Expression of pax8 as a useful marker in distinguishing ovarian carcinomas from mammary carcinomas. *Am J Surg Pathol*. 2008;32:1566-1571.
161. Konecny GE, Kristeleit RS. PARP inhibitors for BRCA1/2-mutated and sporadic ovarian cancer: current practice and future directions. *Br J Cancer*. 2016;115:1157-1173.
162. Herrington CS, McCluggage WG. The emerging role of the distal fallopian tube and p53 in pelvic serous carcinogenesis. *J Pathol*. 2010;220:5-6.
163. Kindelberger DW, Lee Y, Miron A, et al. Intraepithelial carcinoma of the fimbria and pelvic serous carcinoma: evidence for a causal relationship. *Am J Surg Pathol*. 2007;31:161-169.
164. Lee Y, Miron A, Drapkin R, et al. A candidate precursor to serous carcinoma that originates in the distal fallopian tube. *J Pathol*. 2007;211:26-35.
165. Lee Y, Medeiros F, Kindelberger D, et al. Advances in the recognition of tubal intraepithelial carcinoma: applications to cancer screening and the pathogenesis of ovarian cancer. *Adv Anat Pathol*. 2006;13:1-7.
166. Medeiros F, Muto MG, Lee Y, et al. The tubal fimbria is a preferred site for early adenocarcinoma in women with familial ovarian cancer syndrome. *Am J Surg Pathol*. 2006;30:230-236.
167. Przybycin CG, Kurman RJ, Ronnett BM, et al. Are all pelvic (nonuterine) serous carcinomas of tubal origin? *Am J Surg Pathol*. 2010;34:1407-1416.
168. Piek JM, van Diest PJ, Zweemer RP, et al. Dysplastic changes in prophylactically removed fallopian tubes of women predisposed to developing ovarian cancer. *J Pathol*. 2001;195:451-456.
169. Piek JM, Verheijen RH, Kenemans P, et al. BRCA1/2-related ovarian cancers are of tubal origin: a hypothesis. *Gynecol Oncol*. 2003;90:491.
170. Singh N, Gilks CB, Wilkinson N, McCluggage WG. The secondary mullerian system, field effect, BRCA, and tubal fimbria: our evolving understanding of the origin of tubo-ovarian high-grade serous carcinoma and why assignment of primary site matters. *Pathology*. 2015;47:423-431.
171. Gilks CB, Irving J, Kobel M, et al. Incidental nonuterine high-grade serous carcinomas arise in the fallopian tube in most cases: further evidence for the tubal origin of high-grade serous carcinomas. *Am J Surg Pathol*. 2015;39(3):357-364.
172. Morrison JC, Blanco LZ Jr, Vang R, Ronnett BM. Incidental serous tubal intraepithelial carcinoma and early invasive serous carcinoma in the nonprophylactic setting: analysis of a case series. *Am J Surg Pathol*. 2015;39:442-453.
173. Rabban JT, Garg K, Crawford B, et al. Early detection of high-grade tubal serous carcinoma in women at low risk for hereditary breast and ovarian cancer syndrome by systematic examination of fallopian tubes incidentally removed during benign surgery. *Am J Surg Pathol*. 2014;38:729-742.
174. Semmel DR, Folkins AK, Hirsch MS, et al. Intercepting early pelvic serous carcinoma by routine pathological examination of the fimbria. *Mod Pathol*. 2009;22:985-988.
175. Al-Hussaini M, Stockman A, Foster H, McCluggage WG. WT-1 assists in distinguishing ovarian from uterine serous carcinoma and in distinguishing between serous and endometrioid ovarian carcinoma. *Histopathology*. 2004;44:109-115.
176. Singh N, Gilks CB, Hirshowitz L, et al. Adopting a uniform approach to site assignment in tubo-ovarian high-grade serous carcinoma: the time has come. *Int J Gynecol Pathol*. 2016;35(3):230-237.
177. Han G, Gilks CB, Leung S, et al. Mixed ovarian epithelial carcinomas with clear cell and serous components are variants of high-grade serous carcinoma: an interobserver correlative and immunohistochemical study of 32 cases. *Am J Surg Pathol*. 2008;32:955-964.
178. Mackenzie R, Talhouk A, Eshragh S, et al. Morphologic and molecular characteristics of mixed epithelial ovarian cancers. *Am J Surg Pathol*. 2015;39:1548-1557.
179. Attanoos RL, Webb RL, Dojcinov SD, Gibbs AR. Value of mesothelial and epithelial antibodies in distinguishing diffuse peritoneal

For personal use only. No other uses without permission. Copyright ©2017. Elsevier Inc. All rights reserved.

mesothelioma in females from serous papillary carcinoma of the ovary and peritoneum. *Histopathology*. 2002;40:237-244.
180. Bollinger DJ, Wick MR, Dehner LP, et al. Peritoneal malignant mesothelioma versus serous-papillary adenocarcinoma. A histochemical and immunohistochemical comparison. *Am J Surg Pathol*. 1989;13:659-670.
181. Halperin R, Zehavi S, Hadas E, et al. Immunohistochemical comparison of primary ovarian serous papillary carcinoma. *Int J Gynecol Pathol*. 2001;20:341-345.
182. Khoury N, Raju U, Crissman JD, et al. A comparative immunohistochemical study of peritoneal and ovarian serous tumors, and mesotheliomas. *Hum Pathol*. 1990;21:811-819.
183. Cancer Genome Atlas Research Network. Integrated genomic analyses of ovarian carcinoma. *Nature*. 2011;474:609-615.
184. Bashashati A, Ha G, Tone A, et al. Distinct evolutionary trajectories of primary high-grade serous ovarian cancers revealed through spatial mutational profiling. *J Pathol*. 2013;231:21-34.
185. Etemadmoghadam D, Weir BA, Au-Yeung G, et al. Synthetic lethality between CCNE1 amplification and loss of BRCA1. *Proc Natl Acad Sci USA*. 2013;110:19489-19494.
186. Nakayama N, Nakayama K, Shamima Y, et al. Gene amplification CCNE1 is related to poor survival and potential therapeutic target in ovarian cancer. *Cancer*. 2010;116:2621-2634.
187. Patch AM, Christie EL, Etemadmoghadam D, et al. Whole-genome characterization of chemoresistant ovarian cancer. *Nature*. 2015;521:489-494.
188. Au-Yeung G, Lang F, Azar WJ, et al. Selective targeting of Cyclin E1 amplified high grade serous ovarian cancer by cyclin-dependent kinase 2 and AKT inhibition. *Clin Cancer Res*. 2016, Sept 23;[Epub ahead of print].
189. Yemelyanova AV, Vang R, Judson K, et al. Distinction of primary and metastatic mucinous tumors involving the ovary: analysis of size and laterality data by primary site with reevaluation of an algorithm for tumor classification. *Am J Surg Pathol*. 2008;32:128-138.
190. Shiohara S, Shiozawa T, Shimizu M, et al. Histochemical analysis of estrogen and progesterone receptors and gastric-type mucin in mucinous ovarian tumors with reference to their pathogenesis. *Cancer*. 1997;80:908-916.
191. Shiozawa T, Tsukahara Y, Ishii K, et al. Histochemical demonstration of gastrointestinal mucins in ovarian mucinous cystadenoma. *Acta Pathol Jpn*. 1992;42:104-110.
192. Klemi PJ. Pathology of mucinous ovarian cystadenomas. I. Argyrophil and argentaffin cells and epithelial mucosubstances. *Acta Pathol Microbiol Scand [A]*. 1978;86:465-470.
193. Aguirre P, Scully RE, Dayal Y, DeLellis RA. Mucinous tumors of the ovary with argyrophil cells. An immunohistochemical analysis. *Am J Surg Pathol*. 1984;8:345-356.
194. Louwerens JK, Schaberg A, Bosman FT. Neuroendocrine cells in cystic mucinous tumours of the ovary. *Histopathology*. 1983;7:389-398.
195. Sasaki E, Sasano N, Kimura N, et al. Demonstration of neuroendocrine cells in ovarian mucinous tumors. *Int J Gynecol Pathol*. 1989;8:189-200.
196. Sporrong B, Alumets J, Clase L, et al. Neurohormonal peptide immunoreactive cells in mucinous cystadenomas and cystadenocarcinomas of the ovary. *Virchows Arch [A]*. 1981;392:271-280.
197. Bhagavan BS, Slavin RE, Goldberg J, Rao RN. Ectopic gastrinoma and Zollinger-Ellison syndrome. *Hum Pathol*. 1986;17:584-592.
198. McCluggage WG, Young RH. Primary ovarian mucinous tumors with signet ring cells: report of 3 cases with discussion of so-called primary Krukenberg tumor. *Am J Surg Pathol*. 2008;32:1373-1379.
199. Lee KR, Scully RE. Mucinous tumors of the ovary: a clinicopathologic study of 196 borderline tumors (of intestinal type) and carcinomas, including an evaluation of 11 cases with 'pseudomyxoma peritonei. *Am J Surg Pathol*. 2000;24:1447-1464.
200. Robboy SJ. Insular carcinoid of ovary associated with malignant mucinous tumors. *Cancer*. 1984;54:2273-2276.
201. Kerr SE, Flotte AB, McFalls MJ, et al. Matching maternal isodisomy in mucinous carcinomas and associated ovarian teratomas provides evidence of germ cell derivation for some mucinous ovarian tumors. *Am J Surg Pathol*. 2013;37:1229-1235.
202. Snir OL, Buza N, Hui P. Mucinous epithelial tumours arising from ovarian mature teratomas: a tissue genotyping study. *Histopathology*. 2016;69:383-392.
203. Ronnett BM, Kajdacsy-Balla A, Gilks CB, et al. Mucinous borderline ovarian tumors: points of general agreement and persistent controversies regarding nomenclature, diagnostic criteria, and behavior. *Hum Pathol*. 2004;35:949-960.
204. Chiesa AG, Deavers MT, Veras E, et al. Ovarian intestinal type mucinous borderline tumors: are we ready for a nomenclature change? *Int J Gynecol Pathol*. 2010;29:108-112.
205. Tabrizi AD, Kalloger SE, Köbel M, et al. Primary ovarian mucinous carcinoma of intestinal type: significance of pattern of invasion and immunohistochemical expression profile in a series of 31 cases. *Int J Gynecol Pathol*. 2010;29:99-107.
206. Rodriguez IM, Prat J. Mucinous tumors of the ovary: a clinicopathologic analysis of 75 borderline tumors (of intestinal type) and carcinomas. *Am J Surg Pathol*. 2002;26:139-152.
207. Khunamornpong S, Russell P, Dalrymple JC. Proliferating (LMP) mucinous tumors of the ovaries with microinvasion: morphologic assessment of 13 cases. *Int J Gynecol Pathol*. 2002;18:238-246.
208. Nomura K, Aizawa S. Noninvasive, microinvasive and invasive mucinous carcinomas of the ovary: a clinicopathologic analysis of 40 cases. *Cancer*. 2000;89:1541-1546.
209. Bell DA. Mucinous adenofibromas of the ovary. A report of 10 cases. *Am J Surg Pathol*. 1991;15:227-232.
210. Ishikura H, Shibata M, Yoshiki T. Endocrine cell micronests in an ovarian mucinous cystadenofibroma: a mimic of microinvasion. *Int J Gynecol Pathol*. 1999;18:392-395.
211. Prat J, Scully RE. Ovarian mucinous tumors with sarcoma-like nodules. A report of seven cases. *Cancer*. 1979;44:1332-1344.
212. Matias-Guiu X, Aranda I, Prat J. Immunohistochemical study of sarcoma-like mural nodules in a mucinous cystadenocarcinoma of the ovary. *Virchows Arch [A]*. 1991;419:89-92.
213. Prat J, Scully RE. Sarcomas in ovarian mucinous tumors. A report of two cases. *Cancer*. 1979;44:1327-1331.
214. Tsujimura T, Kawano K. Rhabdomyosarcoma coexistent with ovarian mucinous cystadenocarcinoma. A case report. *Int J Gynecol Pathol*. 1992;11:58-62.
215. Nichols GE, Mills SE, Ulbright TM, et al. Spindle cell mural nodules in cystic ovarian mucinous tumors. A clinicopathologic and immunohistochemical study of five cases. *Am J Surg Pathol*. 1991;15:1055-1062.
216. Prat J, Young RH, Scully RE. Ovarian mucinous tumors with foci of anaplastic carcinoma. *Cancer*. 1982;50:300-304.
217. Provenza C, Young RH, Prat J. Anaplastic carcinoma in mucinous ovarian tumors: a clinicopathologic study of 34 cases emphasizing the crucial impact of stage on prognosis, their histologic spectrum, and overlap with sarcomalike mural nodules. *Am J Surg Pathol*. 2008;32:383-389.
218. Baguè S, Rodriguez IM, Prat J. Sarcoma-like mural nodules in mucinous cystic tumors of the ovary revisited: a clinicopathologic analysis of 10 additional cases. *Am J Surg Pathol*. 2002;26:1467-1476.
219. Czernobilsky B, Dgani R, Roth LM. Ovarian mucinous cystadenocarcinoma with mural nodule of carcinomatous derivation. A light and electron microscopic study. *Cancer*. 1983;51:141-148.
220. Baergen RN, Rutgers JL. Mural nodules in common epithelial tumors of the ovary. *Int J Gynecol Pathol*. 1994;13:62-72.
221. Lifschitz-Mercer B, Dgani R, Jacob N, et al. Ovarian mucinous cystadenoma with leiomyomatous mural nodule. *Int J Gynecol Pathol*. 1990;9:80-85.
222. Charpin C, Bhan AK, Zurawski VR, Scully RE. Carcinoembryonic antigen (CEA) and carbohydrate determinant 19-9 (CA 19-9) localization in 121 primary and metastatic ovarian tumors. An immunohistochemical study with the use of monoclonal antibodies. *Int J Gynecol Pathol*. 1982;1:231-245.
223. Rutgers JL, Bell DA. Immunohistochemical characterization of ovarian borderline tumors of intestinal and mullerian types. *Mod Pathol*. 1992;5:367-371.
224. Ji H, Isacson C, Seidman JD, et al. Cytokeratins 7 and 20, Dpc4, and MUC5AC in the distinction of metastatic mucinous carcinomas in the ovary from primary ovarian mucinous tumors: Dpc4 assists in identifying metastatic pancreatic carcinomas. *Int J Gynecol Pathol*. 2002;21:391-400.
225. Tsuchiya A, Sakamoto M, Yasuda J, et al. Expression profiling in ovarian clear cell carcinoma: identification of hepatocyte nuclear factor-1 as a molecular marker and a possible molecular target for therapy of ovarian clear cell carcinoma. *Am J Pathol*. 2003;163:2503-2512.
226. Sugai M, Umezu H, Yamamoto T, et al. Expression of hepatocyte nuclear factor 4 alpha in primary ovarian mucinous tumors. *Pathol Int*. 2008;58:681-686.
227. Moh M, Krings G, Ates D, et al. SATB2 expression distinguishes ovarian metastases of colorectal and appendiceal origin from primary ovarian tumors of mucinous or endometrioid type. *Am J Surg Pathol*. 2016;40:419-432.
228. Park KJ, Bramlage MP, Ellenson LH, Pirog EC. Immunoprofile of adenocarcinomas of the endometrium, endocervix, and ovary with mucinous differentiation. *Appl Immunohistochem Mol Morphol*. 2009;17:8-11.
229. Vang R, Gown AM, Wu LS, et al. Immunohistochemical expression of CDX2 in primary ovarian mucinous tumors and metastatic mucinous carcinomas involving the ovary: comparison with CK20 and correlation with coordinate expression of CK7. *Mod Pathol*. 2006;19:1421-1428.
230. Vang R, Gown AM, Barry TS, et al. Ovarian atypical proliferative (borderline) mucinous tumors: gastrointestinal and seromucinous (endocervical-like) types are immunophenotypically distinctive. *Int J Gynecol Pathol*. 2006;25:83-89.
231. Plaxe SC, Dottino PR, Goodman HM, et al. Clinical features of advanced ovarian mixed mesodermal tumors and treatment with doxorubicin-and *cis*-platinum-based chemotherapy. *Gynecol Oncol*. 1990;37:244-249.

For personal use only. No other uses without permission. Copyright ©2017. Elsevier Inc. All rights reserved.

232. Dubé V, Roy M, Plante M, et al. Mucinous ovarian tumors of Mullerian-type: an analysis of 17 cases including borderline tumors and intraepithelial, microinvasive, and invasive carcinomas. *Int J Gynecol Pathol*. 2005;24:138-146.
233. Kurman RJ, Shih IeM. Seromucinous tumors of the ovary. What's in a name? *Int J Gynecol Pathol*. 2016;35:78-81.
234. Rutgers JL, Scully RE. Ovarian mullerian mucinous papillary cystadenomas of borderline malignancy. A clinicopathologic analysis. *Cancer*. 1988;61:340-348.
235. Shappell HW, Riopel MA, Smith Sehdev AE, et al. Diagnostic criteria and behavior of ovarian seromucinous (endocervical-type mucinous and mixed cell-type) tumors: atypical proliferative (borderline) tumors, intraepithelial, microinvasive, and invasive carcinomas. *Am J Surg Pathol*. 2002;26:1529-1541.
236. Wu CH, Mao TL, Vang R, et al. Endocervical-type mucinous borderline tumors are related to endometrioid tumors based on mutation and loss of expression of ARID1A. *Int J Gynecol Pathol*. 2012;31:297-303.
237. Mostoufizadeh M, Scully RE. Malignant tumors arising in endometriosis. *Clin Obstet Gynecol*. 1980;23:951-963.
238. Czernobilsky B. Endometrioid neoplasia of the ovary. A reappraisal. *Int J Gynecol Pathol*. 1982;1:203-210.
239. Czernobilsky B, Silverman BB, Mikuta JJ. Endometrioid carcinoma of the ovary. A clinicopathologic study of 75 cases. *Cancer*. 1970;26:1141-1152.
240. Kistner RW, Hertig AT. Primary adenoacanthoma of the ovary. *Cancer*. 1952;5:1134-1145.
241. Houghton O, Connolly LE, McCluggage WG. Morules in endometrioid proliferations of the uterus and ovary consistently express the intestinal transcription factor CDX2. *Histopathology*. 2008;53:156-165.
242. Macko MB, Johnson LA. Primary squamous ovarian carcinoma. A case report and review of the literature. *Cancer*. 1983;52:1117-1119.
243. Park JY, Song JS, Choi G, et al. Pure primary squamous cell carcinoma of the ovary: a report of two cases and review of the literature. *Int J Gynecol Pathol*. 2010;29:328-334.
244. Tetu B, Silva EG, Gershenson DM. Squamous cell carcinoma of the ovary. *Arch Pathol Lab Med*. 1987;111:864-866.
245. Yetman TJ, Dudzinski MR. Primary squamous carcinoma of the ovary. A case report and review of the literature. *Gynecol Oncol*. 1989;34:240-243.
246. Pins MR, Young RH, Daly WJ, Scully RE. Primary squamous cell carcinoma of the ovary: report of 37 cases. *Am J Surg Pathol*. 1996;20:823-833.
247. Ehrmann RL, Weidner N, Welch WR, Gleiberman I. Malignant mixed mullerian tumor of the ovary with prominent neuroectodermal differentiation (teratoid carcinosarcoma). *Int J Gynecol Pathol*. 1990;9:272-282.
248. Zhao C, Barner R, Kurman R, et al. Clinicopathologic analysis of ovarian clear cell carcinoma: comparison of cases with and without adenofibromatous components and implications for pathogenesis. *Lab Invest*. 2009;89(suppl 1):242A.
249. Yamamoto S, Tsuda H, Aida S, et al. Immunohistochemical detection of hepatocyte nuclear factor 1beta in ovarian and endometrial clear-cell adenocarcinomas and nonneoplastic endometrium. *Hum Pathol*. 2007;38:1074-1080.
250. Euscher ED, Malpica A. Neuroendocrine cells as a component of ovarian Brenner tumor: the source rare ovarian carcinoid tumors associated with these neoplasms. *Lab Invest*. 2009;89(suppl 1):212A-213A.
251. Zhai Y, Wu R, Schwartz DR, et al. Role of beta-caterin/T-cell factor-regulated genes in ovarian endometrioid adenocarcinomas. *Am J Pathol*. 2002;160:1229-1238.
252. Roth LM, Liban E, Czernobilsky B. Ovarian endometrioid tumors mimicking Sertoli and Sertoli-Leydig cell tumors. Sertoliform variant of endometrioid carcinoma. *Cancer*. 1984;50:1322-1331.
253. Young RH, Prat J, Scully RE. Ovarian endometrioid carcinomas resembling sex cord-stromal tumors. A clinicopathological analysis of 13 cases. *Am J Surg Pathol*. 1982;6:513-522.
254. Ordi J, Schammel DP, Rasekh L, Tavassoli FA. Sertoliform endometrioid carcinomas of the ovary: a clinicopathologic and immunohistochemical study of 13 cases. *Mod Pathol*. 1999;12:933-940.
255. Aguirre P, Thor AD, Scully RE. Ovarian endometrioid carcinomas resembling sex cord–stromal tumors. An immunohistochemical study. *Int J Gynecol Pathol*. 1989;8:364-373.
256. Guerrieri C, Franlund B, Malmstrom H, Boeryd B. Ovarian endometrioid carcinomas simulating sex cord–stromal tumors: a study using inhibin and cytokeratin 7. *Int J Gynecol Pathol*. 1998;17:266-271.
257. Fujibayashi M, Aiba M, Iizuka E, et al. Granulosa cell tumor-like variant of endometrioid carcinoma of the ovary exhibiting nuclear clearing with biotin activity: a subtype showing close macroscopic, cytologic, and histologic similarity to adult granulosa cell tumor. *Arch Pathol Lab Med*. 2005;129:1288-1294.
258. Nogales FF, Carvia RE, Bergeron C, et al. Ovarian endometrioid tumors with yolk sac tumor component, an unusual form of ovarian neoplasm: analysis of six cases. *Am J Surg Pathol*. 1996;20:1056-1066.
259. Rutgers JL, Young RH, Scully RE. Ovarian yolk sac tumor arising from an endometrioid carcinoma. *Hum Pathol*. 1987;18:1296-1299.
260. Eichhorn JH, Scully RE. Endometrioid ciliated-cell tumors of the ovary: a report of five cases. *Int J Gynecol Pathol*. 1997;15:248-256.
261. Pitman MB, Young RH, Clement PB, et al. Endometrioid carcinoma of the ovary and endometrium, oxyphilic cell type. A report of nine cases. *Int J Gynecol Pathol*. 1994;13:290-301.
262. Young RH, Scully RE. Oxyphilic tumors of the female and male genital tracts. *Semin Diagn Pathol*. 1999;16:146-161.
263. Treilleux l, Godeneche J, Duvillard P, et al. Collagenous spherulosis mimicking keratinizing squamous metaplasia in a borderline endometrioid tumor of the ovary. *Histopathology*. 1999;35:271-276.
264. Stolnicu S, Preda O, Dohan M, et al. Pseudoglandular hepatoid differentiation in endometrioid carcinoma of the ovary simulates oxyphilic cell change. *Int J Gynecol Pathol*. 2008;27:521-525.
265. Silva EG, Deavers MT, Bodurka DC, Malpica A. Association of low-grade endometrioid carcinoma of the uterus and ovary with undifferentiated carcinoma: a new type of dedifferentiated carcinoma? *Int J Gynecol Pathol*. 2006;25:52-58.
266. Coatham M, Li X, Karnezis AN, et al. Concurrent ARID1A and ARID1B inactivation in endometrial and ovarian dedifferentiated carcinomas. *Mod Pathol*. 2016;29: 1586-1593.
267. Bell DA, Scully RE. Atypical and borderline endometrioid adenofibromas of the ovary. A report of 27 cases. *Am J Surg Pathol*. 1985;9:205-214.
268. Bell KA, Kurman RJ. A clinicopathologic analysis of atypical proliferative (borderline) tumors and well-differentiated endometrioid adenocarcinomas of the ovary. *Am J Surg Pathol*. 2000;24:1465-1479.
269. Roth LM, Emerson RE, Ulbright TM. Ovarian endometrioid tumors of low malignant potential. A clinicopathologic study of 30 cases with comparison to well-differentiated endometrioid adenocarcinoma. *Am J Surg Pathol*. 2003;27:1253-1259.
270. Hughesdon PE. Benign endometrioid tumours of the ovary and the müllerian concept of ovarian epithelial tumours. *Histopathology*. 1984;8:977-990.
271. Roth LM, Czernobilsky B, Langley FA. Ovarian endometrioid adenofibromatous and cystadenofibromatous tumors. Benign, proliferating, and malignant. *Cancer*. 1981;48:1838-1845.
272. Zaino RJ, Unger ER, Whitney C. Synchronous carcinomas of the uterine corpus and ovary. *Gynecol Oncol*. 1984;19:329-335.
273. Matias-Guiu X, Lerma E, Prat J. Clear cell tumors of the female genital tract. *Semin Diagn Pathol*. 1998;14:233-239.
274. Montag AG, Jenison EL, Griffiths CT, et al. Ovarian clear cell carcinoma. A clinicopathologic analysis of 44 cases. *Int J Gynecol Pathol*. 1989;8:85-96.
275. DeLair D, Olvia E, Köbel M, et al. Morphologic spectrum of immunohistochemically characterized clear cell carcinoma of the ovary: a study of 155 cases. *Am J Surg Pathol*. 2011;35:36-44.
276. Young RH, Scully RE. Oxyphilic clear cell carcinoma of the ovary. A report of nine cases. *Am J Surg Pathol*. 1987;11:661-667.
277. Kato N, Sasou S, Motoyama T. Expression of hepatocyte nuclear factor-1beta (HNF-1beta) in clear cell tumors and endometriosis of the ovary. *Mod Pathol*. 2006;19:83-89.
278. Brescia RJ, Dubin N, Demopoulos RI. Endometrioid and clear cell carcinoma of the ovary. Factors affecting survival. *Int J Gynecol Pathol*. 1989;8:132-138.
279. Scully RE, Barlow JF. Mesonephroma of the ovary. Tumor of müllerian nature related to the endometrioid carcinoma. *Cancer*. 1967;20:1405-1417.
280. Kwon TJ, Ro JY, Mackay B. Clear-cell carcinoma: an ultrastructural study of 57 tumors from various sites. *Ultrastruct Pathol*. 1997;20:519-527.
281. Yamamoto S, Tsuda H, Yoshikawa T, et al. Clear cell adenocarcinoma associated with clear cell adenofibromatous components: a subgroup of ovarian clear cell adenocarcinoma with distinct clinicopathologic characteristics. *Am J Surg Pathol*. 2007;31:999-1006.
282. Roth LM, Langley FA, Fox H, et al. Ovarian clear cell adenofibromatous tumors. Benign, of low malignant potential, and associated with invasive clear cell carcinoma. *Cancer*. 1984;53:1156-1163.
283. Nolan LP, Heatley MK. The value of immunohistochemistry in distinguishing between clear cell carcinoma of the kidney and ovary. *Int J Gynecol Pathol*. 2001;20:155-159.
284. Eichhorn JH, Scully RE. "Adenoid cystic" and basaloid carcinomas of the ovary. Evidence for a surface epithelial lineage. A report of 12 cases. *Mod Pathol*. 1995;8:731-740.
285. Esheba GE, Pate LL, Longacre TA. Oncofetal protein glypican-3 distinguishes yolk sac tumor from clear cell carcinoma of the ovary. *Am J Surg Pathol*. 2008;32:600-607.
286. Maeda D, Ota S, Takazawa Y, et al. Glypican-3 expression in clear cell adenocarcinoma of the ovary. *Mod Pathol*. 2009;22:824-832.
287. Sangoi AR, Soslow RA, Teng NN, Longacre TA. Ovarian clear cell carcinoma with papillary features: a potential mimic of serous tumor of

For personal use only. No other uses without permission. Copyright ©2017. Elsevier Inc. All rights reserved.

low malignant potential. *Am J Surg Pathol*. 2008;32:269-274.
288. Köbel M, Kalloger SE, Carrick J, et al. A limited panel of immunomarkers can reliably distinguish between clear cell and high-grade serous carcinoma of the ovary. *Am J Surg Pathol*. 2009;33:14-21.
289. Silverberg SG. Brenner tumor of the ovary. A clinicopathologic study of 60 tumors in 54 women. *Cancer*. 1971;28:588-596.
290. Ganjei P, Nadji M, Penneys NS, et al. Immunoreactive prekeratin in Brenner tumors of the ovary. *Int J Gynecol Pathol*. 1983;1:353-358.
291. Aguirre P, Scully RE, Wolfe HJ, DeLellis RA. Argyrophil cells in Brenner tumors. Histochemical and immunohistochemical analysis. *Int J Gynecol Pathol*. 1986;5:223-234.
292. Sasano H, Wargotz ES, Silverberg SG, et al. Brenner tumor of the ovary. Immunoanalysis of steroidogenic enzymes in 23 cases. *Hum Pathol*. 1989;20:1103-1107.
293. Roth LM, Dallenbach-Hellweg G, Czernobilsky B. Ovarian Brenner tumors. I. Metaplastic, proliferating, and of low malignant potential. *Cancer*. 1985;56:582-591.
294. Hallgrimsson J, Scully RE. Borderline and malignant Brenner tumors of the ovary. A report of 15 cases. *Acta Pathol Microbiol Scand*. 1972;233(suppl):56-66.
295. Seldenrijk CA, Willig AP, Baak JPA, et al. Malignant Brenner tumor. A histologic, morphometrical, immunohistochemical, and ultrastructural study. *Cancer*. 1986;58:754-760.
296. Roth LM, Czernobilsky B. Ovarian Brenner tumors. II. Malignant. *Cancer*. 1985;56:592-601.
297. Eichhorn JH, Young RH. Transitional cell carcinoma of the ovary: a morphologic study of 100 cases with emphasis on differential diagnosis. *Am J Surg Pathol*. 2004;28:453-463.
298. Ali RH, Seidman JD, Luk M, et al. Transitional cell carcinoma of the ovary is related to high-grade serous carcinoma and is distinct from malignant brenner tumor. *Int J Gynecol Pathol*. 2012;31:499-506.
299. Seidman JD, Khedmati F. Exploring the histogenesis of ovarian mucinous and transitional cell (Brenner) neoplasms and their relationship with Walthard cell nests: a study of 120 tumors. *Arch Pathol Lab Med*. 2008;132:1753-1760.
300. Moon S, Waxman M. Mixed ovarian tumor composed of Brenner and thyroid elements. Cancer 1976, 38: 1997–2001. *Virchows Arch*. 2001;438:181-191.
301. Heller DS, Harpaz N, Breakstone B. Neoplasms arising in ectopic ovaries. A case of Brenner tumor in an accessory ovary. *Int J Gynecol Pathol*. 1990;9:185-189.
302. Dictor M. Malignant mixed mesodermal tumor of the ovary. A report of 22 cases. *Obstet Gynecol*. 1985;65:720-724.
303. Dictor M. Ovarian malignant mixed mesodermal tumor. The occurrence of hyaline droplets containing alpha-1-antitrypsin. *Hum Pathol*. 1982;13:930-933.
304. Dehner LP, Norris HJ, Taylor HB. Carcinosarcomas and mixed mesodermal tumors of the ovary. *Cancer*. 1971;27:207-216.
305. Dass KK, Biscoti CV, Webster K, Saxton JP. Malignant mixed mullerian tumors of the ovary. An analysis of two long-term survivors. *Am J Clin Oncol*. 1993;16:346-349.
306. Ariyoshi K, Kawauchi S, Kaku T, et al. Prognostic factors in ovarian carcinosarcoma: a clinicopathological and immunohistochemical analysis of 23 cases. *Histopathology*. 2000;37:427-436.
307. Boucher D, Tetu B. Morphologic prognostic factors of malignant mixed mullerian tumors of the ovary. A clinicopathologic study of 15 cases. *Int J Gynecol Pathol*. 1994;13:22-28.
308. Morrow CP, d'Ablaing G, Brady LW, et al. A clinical and pathologic study of 30 cases of malignant mixed müllerian epithelial and mesenchymal ovarian tumors. A gynecologic oncology group study. *Gynecol Oncol*. 1984;18:278-292.
309. Fenn ME, Abell MR. Carcinosarcoma of the ovary. *Am J Obstet Gynecol*. 1971;110:1066-1074.
310. García-Galvis OF, Cabrera-Ozoria C, Fernández JA, et al. Malignant Müllerian mixed tumor of the ovary associated with yolk sac tumor, neuroepithelial and trophoblastic differentiation (teratoid carcinosarcoma). *Int J Gynecol Pathol*. 2008;27:515-520.
311. Tanimoto A, Arima N, Hayashi R, et al. Teratoid carcinosarcoma of the ovary with prominent neuroectodermal differentiation. *Pathol Int*. 2002;51:829-832.
312. Clement PB, Scully RE. Extrauterine mesodermal (müllerian) adenosarcoma. A clinicopathologic analysis of five cases. *Am J Clin Pathol*. 1978;69:276-283.
313. Eichhorn JH, Young RH, Clement PB, Scully RE. Mesodermal (mullerian) adenosarcoma of the ovary: a clinicopathologic analysis of 40 cases and a review of the literature. *Am J Surg Pathol*. 2002;26:1243-1258.
314. Fukunaga M, Nomura K, Endo Y, et al. Ovarian adenosarcoma. *Histopathology*. 1997;30:283-287.
315. Feczko JD, Jentz LD, Roth LM. Adenoid cystic ovarian carcinoma compared with other adenoid cystic carcinomas of the female genital tract. *Mod Pathol*. 1996;9:413-417.
316. Zamecnik M, Michal M, Curik R. Adenoid cystic carcinoma of the ovary. *Arch Pathol Lab Med*. 2000;124:1529-1531.
317. Hawkins EP. Germ cell tumors. *Am J Clin Pathol*. 1998;109:S82-S88.
318. Lack EE, Young RH, Scully RE. Pathology of ovarian neoplasms in childhood and adolescence. *Pathol Annu*. 1992;27(Pt 2):281-356.
319. Young RH. Ovarian tumors of the young. *Int J Surg Pathol*. 2010;18(suppl):155S-161S.
320. Breen JL, Neubecker RD. Ovarian malignancy in children with special reference to the germ cell tumors. *Ann N Y Acad Sci*. 1967;142:658-674.
321. Ein SH, Darte JMM, Stephens CA. Cystic and solid ovarian tumors in children. A 44-year review. *J Pediatr Surg*. 1970;5:148-156.
322. Morris HB, La Vecchia C, Draper GJ. Endodermal sinus tumor and embryonal carcinoma of the ovary in children. *Gynecol Obstet*. 1985;21:7-17.
323. Norris HJ, Jensen RD. Relative frequency of ovarian neoplasms in children and adolescents. *Cancer*. 1972;30:713-719.
324. Wollner N, Exelby PR, Woodruff JM, et al. Malignant ovarian tumors in childhood. Prognosis in relation to initial therapy. *Cancer*. 1976;37:1953-1964.
325. Zaloudek C, Norris HJ. Granulosa tumors of the ovary in children. A clinical and pathologic study of 32 cases. *Am J Surg Pathol*. 1982;6:513-522.
326. Morris HB, La Vecchia C, Draper GJ. Malignant epithelial tumors of the ovary in childhood. A clinicopathological study of 13 cases in Great Britain 1962–1978. *Gynecol Oncol*. 1984;19:290-297.
327. Young RH, Kozakewich HP, Scully RE. Metastatic ovarian tumors in children. A report of 14 cases and review of the literature. *Int J Gynecol Pathol*. 1993;12:8-19.
328. Eifel P, Hendrickson M, Ross J, et al. Simultaneous presentation of carcinoma involving the ovary and the uterine corpus. *Cancer*. 1982;50:163-170.
329. Press MF. Are synchronous uterine and ovarian carcinomas independent primary tumors? *Adv Anat Pathol*. 1997;4:370-372.
330. Robboy SJ, Datto MB. Synchronous endometrial and ovarian tumors: metastatic disease or independent primaries? *Hum Pathol*. 2005;36:597-599.
331. Anglesio MS, Wang YK, Maassen M, et al. Synchronous endometrial and ovarian carcinomas: evidence of clonality. *J Natl Cancer Inst*. 2016;108:djv428.
332. Schultheis AM, Ng CK, De Filippo MR, et al. Massively parallel sequencing-based clonality analysis of synchronous endometrioid endometrial and ovarian carcinomas. *J Natl Cancer Inst*. 2016;108:djv427.
333. Soliman PT, Broaddus RR, Schmeler KM, et al. Women with synchronous primary cancers of the endometrium and ovary: do they have Lynch syndrome? *J Clin Oncol*. 2005;23:9344-9350.
334. Yoshimura S, Scully RE, Taft PD, Herrington JB. Peritoneal fluid cytology in patients with ovarian cancer. *Gynecol Oncol*. 1984;17:161-167.
335. Yoshimura S, Scully RE, Bell DA, Taft PD. Correlation of ascitic fluid cytology with histologic findings before and after treatment of ovarian cancer. *Am J Obstet Gynecol*. 1984;148:716-721.
336. Kawai T, Tominaga S, Hiroi S, et al. Peritoneal malignant mesothelioma (PMM), and primary peritoneal serous carcinoma (PPSC) and reactive mesothelial hyperplasia (RMH) of the peritoneum. Immunohistochemical and fluorescence in situ hybridisation (FISH) analyses. *J Clin Pathol*. 2016;69:706-712.
337. Yaziji H, Battifora H, Barry TS, et al. Evaluation of 12 antibodies for distinguishing epithelioid mesothelioma from adenocarcinoma: identification of a three-antibody immunohistochemical panel with maximal sensitivity and specificity. *Mod Pathol*. 2006;19:514-523.
338. Armstrong DK, Bundy B, Wenzel L, et al. Gynecologic Oncology Group. Intraperitoneal cisplatin and paclitaxel in ovarian cancer. *N Engl J Med*. 2006;354:34-43.
339. Fields AL, Runowicz CD. Current therapies in ovarian cancer. *Cancer Invest*. 2003;21: 148-156.
340. McGuire WP. Primary treatment of epithelial ovarian malignancies. *Cancer*. 1993;71:1541-1550.
341. Tazelaar HD, Bostwick DG, Ballon SC, et al. Conservative treatment of borderline ovarian tumors. *Obstet Gynecol*. 1985;66:417-422.
342. Tropé C, Davidson B, Paulsen T, et al. Diagnosis and treatment of borderline ovarian neoplasms: "the state of the art". *Eur J Gynaecol Oncol*. 2009;30:471-482.
343. Lim-Tan SK, Cajigas HE, Scully RE. Ovarian cystectomy for serous borderline tumors. A follow-up study of 35 cases. *Obstet Gynecol*. 1988;72:775-781.
344. Köbel M, Kalloger SE, Santos JL, et al. Tumor type and substage predict survival in stage I and II ovarian carcinoma: insights and implications. *Gynecol Oncol*. 2010;116:50-56.
345. Vergote I, Tropé CG, Amant F, et al. Neoadjuvant chemotherapy or primary surgery in stage IIIC or IV ovarian cancer. *N Engl J Med*. 2010;363:943-953.
346. Böhm S, Faruqi A, Said I, et al. Chemotherapy response score: development and validation of a system to quantify histopathologic response to neoadjuvant chemotherapy in tubo-ovarian high-grade serous carcinoma. *J Clin Oncol*. 2015;33:2457-2463.
347. Malpica A. Grading of ovarian cancer: a histotype-specific approach. *Int J Gynecol Pathol*. 2008;27:175-181.
348. Jondle DM, Shahin MS, Sorosky J, Benda JA. Ovarian mixed germ cell tumor with predominance of polyembryoma: a case report with literature review. *Int J Gynecol Pathol*. 2002;21:78-81.

For personal use only. No other uses without permission. Copyright ©2017. Elsevier Inc. All rights reserved.

349. Roth LM, Talerman A. Recent advances in the pathology and classification of ovarian germ cell tumors. *Int J Gynecol Pathol*. 2006;25:305-320.
350. Ulbright TM. Germ cell tumors of the gonads: a selective review emphasizing problems in differential diagnosis, newly appreciated, and controversial issues. *Mod Pathol*. 2005;18(suppl 2):S61-S79.
351. Chang MC, Vargas SO, Hornick JL, et al. Embryonic stem cell transcription factors and D2-40 (podoplanin) as diagnostic immunohistochemical markers in ovarian germ cell tumors. *Int J Gynecol Pathol*. 2009;28:347-355.
352. Hart AH, Hartley L, Parker K, et al. The pluripotency homeobox gene NANOG is expressed in human germ cell tumors. *Cancer*. 2005;104:2092-2098.
353. Iczkowski KA, Butler SL, Shanks JH, et al. Trials of new germ cell immunohistochemical stains in 93 extragonadal and metastatic germ cell tumors. *Hum Pathol*. 2008;39:275-281.
354. Gershenson DM, Del Junco G, Copeland LJ, Rutledge FN. Mixed germ cell tumors of the ovary. *Obstet Gynecol*. 1984;64:200-206.
355. Kurman RJ, Norris HJ. Malignant mixed germ cell tumors of the ovary. A clinical and pathologic analysis of 30 cases. *Obstet Gynecol*. 1976;48:579-589.
356. Young RH. New and unusual aspects of ovarian germ cell tumors. *Am J Surg Pathol*. 1993;17:1210-1224.
357. Gershenson DM. Update on malignant ovarian germ cell tumors. *Cancer*. 1993;71:1581-1590.
358. Pfleiderer A. Therapy of ovarian malignant germ cell tumors and granulosa tumors. *Int J Gynecol Pathol*. 1993;12:162-165.
359. Creasman WT, Fetter BF, Hammond CB, Parker RT. Germ cell malignancies of the ovary. *Obstet Gynecol*. 1979;53:226-230.
360. Santesson L. Clinical and pathological survey of ovarian tumors treated at the Radium-hemmet. *Acta Radiol (Stockh)*. 1947;28:643-668.
361. Abell MR, Johnson VJ, Holtz F. Ovarian neoplasms in childhood and adolescence. *Am J Obstet Gynecol*. 1965;92:1059-1081.
362. Fleischhacker DS, Young RH. Dysgerminoma of the ovary associated with hypercalcemia. *Gynecol Oncol*. 1994;52:87-90.
363. Dietl J, Horny HP, Ruck P, Kaiserling E. Dysgerminoma of the ovary. An immunohistochemical study of tumor-infiltrating lymphoreticular cells and tumor cells. *Cancer*. 1993;71:2562-2568.
364. Asadourian LA, Taylor HB. Dysgerminoma. An analysis of 105 cases. *Obstet Gynecol*. 1969;33:370-379.
365. Beckstead JH. Alkaline phosphatase histochemistry in human germ cell neoplasms. *Am J Surg Pathol*. 1983;7:341-349.
366. Cossu-Rocca P, Jones TD, Roth LM, et al. Cytokeratin and CD30 expression in dysgerminoma. *Hum Pathol*. 2006;37:1015-1021.
367. Lifshitz-Mercer B, Walt H, Kushnir I, et al. Differentiation potential of ovarian dysgerminoma. An immunohistochemical study of 15 cases. *Hum Pathol*. 1995;26:62-66.
368. Sever M, Jones TD, Roth LM, et al. Expression of CD117 (c-kit) receptor in dysgerminoma of the ovary: diagnostic and therapeutic implications. *Mod Pathol*. 2005;18:1411-1416.
369. Cheng L, Thomas A, Roth LM, et al. OCT4: a novel biomarker for dysgerminoma of the ovary. *Am J Surg Pathol*. 2004;28:1341-1346.
370. Cao D, Guo S, Allan RW, et al. SALL4 is a novel sensitive and specific marker of ovarian primitive germ cell tumors and is particularly useful in distinguishing yolk sac tumor from clear cell carcinoma. *Am J Surg Pathol*. 2009;33:894-904.
371. Freel JH, Cassir JF, Pierce VK, et al. Dysgerminoma of the ovary. *Cancer*. 1979;43:798-805.
372. Gibas Z, Talerman A. Analysis of chromosome aneuploidy in ovarian dysgerminoma by flow cytometry and fluorescence in situ hybridization. *Diagn Mol Pathol*. 1993;2:50-56.
373. Gondos B. Comparative studies of normal and neoplastic ovarian germ cells. II. Ultrastructure and pathogenesis of dysgerminoma. *Int J Gynecol Pathol*. 1987;6:124-131.
374. Zaloudek CJ, Tavassoli FA, Norris HJ. Dysgerminoma with syncytiotrophoblastic giant cells. A histologically and clinically distinctive subtype of dysgerminoma. *Am J Surg Pathol*. 1981;5:361-367.
375. Parkash V, Carcangiu ML. Transformation of ovarian dysgerminoma to yolk sac tumor. Evidence for a histogenetic continuum. *Mod Pathol*. 1995;8:881-887.
376. Schiller W. Mesonephroma ovarii. *Am J Cancer*. 1939;35:1-21.
377. Teilum G. Endodermal sinus tumors of the ovary and testis. Comparative morphogenesis of the so-called mesonephroma ovarii (Schiller) and extraembryonic (yolk sac-allantoic) structures of the rat's placenta. *Cancer*. 1959;12:1092-1105.
378. Langley FA, Govan ADT, Anderson MC, et al. Yolk sac and allied tumours of the ovary. *Histopathology*. 1981;5:389-401.
379. Oh C, Kendler A, Hernandez E. Ovarian endodermal sinus tumor in a postmenopausal woman. *Gynecol Oncol*. 2001;82:392-394.
380. Kurman RJ, Norris HJ. Endodermal sinus tumor of the ovary. A clinical and pathologic analysis of 71 cases. *Cancer*. 1976;38:2404-2419.
381. Clement PB, Young RH, Scully RE. Extraovarian pelvic yolk sac tumors. *Cancer*. 1988;62:620-626.
382. Jones MA, Clement PB, Young RH. Primary yolk sac tumors of the mesentery. A report of two cases. *Am J Clin Pathol*. 1994;101:42-47.
383. Park NH, Ryu SY, Park IA, et al. Primary endodermal sinus tumor of the omentum. *Gynecol Oncol*. 1999;72:427-430.
384. Gonzalez-Crussi F. The human yolk sac and yolk sac (endodermal sinus) tumors. A review. *Persp Pediatr Pathol*. 1979;5:179-215.
385. Nawa A, Obata N, Kikkawa F, et al. Prognostic factors of patients with yolk sac tumors of the ovary. *Am J Obstet Gynecol*. 2001;184:1182-1188.
386. Barsky SH, Hannah JB. Extracellular hyaline bodies are basement membrane accumulations. *Am J Clin Pathol*. 1987;87:455-460.
387. Ramalingam P, Malpica A, Silva EG, et al. The use of cytokeratin 7 and EMA in differentiating ovarian yolk sac tumors from endometrioid and clear cell carcinomas. *Am J Surg Pathol*. 2004;28:1499-1505.
388. Zynger DL, McCallum JC, Luan C, et al. Glypican 3 has a higher sensitivity than alpha-fetoprotein for testicular and ovarian yolk sac tumour: immunohistochemical investigation with analysis of histological growth patterns. *Histopathology*. 2010;56:750-757.
389. Wang F, Liu A, Peng Y, et al. Diagnostic utility of SALL4 in extragonadal yolk sac tumors: an immunohistochemical study of 59 cases with comparison to placental-like alkaline phosphatase, alpha-fetoprotein, and glypican-3. *Am J Surg Pathol*. 2009;33:1529-1539.
390. Kommoss F, Bibbo M, Talerman A. Nuclear deoxyribonucleic acid content (ploidy) of endodermal sinus (yolk sac) tumor. *Lab Invest*. 1990;62:223-231.
391. Nogales FF Jr, Matilla A, Nogales-Ortiz F, Galera-Davidson HL. Yolk sac tumors with pure and mixed polyvesicular vitelline patterns. *Hum Pathol*. 1978;9:553-566.
392. Cohen MB, Friend DS, Molnar JJ. Gonadal endodermal sinus (yolk sac) tumor with pure intestinal differentiation. A new histologic type. *Pathol Res Pract*. 1987;182:609-616.
393. Ulbright TM, Roth LM, Brodhecker CA. Yolk sac differentiation in germ cell tumors. A morphologic study of 50 cases with emphasis on hepatic, enteric, and parietal yolk sac features. *Am J Surg Pathol*. 1986;10:151-164.
394. Devouassoux-Shisheboran M, Schammel DP, Tavassoli FA. Ovarian hepatoid yolk sac tumors: morphological, immunohistochemical and ultrastructural features. *Histopathology*. 1999;34:462-469.
395. Prat J, Bhan AK, Dickersin GR, et al. Hepatoid yolk sac tumor of the ovary (endodermal sinus tumor with hepatoid differentiation). A light microscopic, ultrastructural and immunohistochemical study of seven cases. *Cancer*. 1982;50:2355-2368.
396. Ishikura H, Scully RE. Hepatoid carcinoma of the ovary. A newly described tumor. *Cancer*. 1987;60:2775-2784.
397. Clement PB, Young RH, Scully RE. Endometrioid-like variant of ovarian yolk sac tumor. A clinicopathological analysis of eight cases. *Am J Surg Pathol*. 1987;11:767-778.
398. Nogales FF, Buriticá C, Regauer S, González T. Mucinous carcinoid as an unusual manifestation of endodermal differentiation in ovarian yolk sac tumors. *Am J Surg Pathol*. 2005;29:1247-1251.
399. McNamee T, Damato S, McCluggage WG. Yolk sac tumours of the female genital tract in older adults derive commonly from somatic epithelial neoplasms: somatically derived yolk sac tumours. *Histopathology*. 2016;69:739-751.
400. Vance RP, Geisinger KR. Pure nongestational choriocarcinoma of the ovary. Report of a case. *Cancer*. 1985;56:2321-2325.
401. Nogales FF. Embryologic clues to human yolk sac tumors. A review. *Int J Gynecol Pathol*. 1993;12:101-107.
402. Nogales FF, Beltran E, Pavcovich M, Bustos M. Ectopic somatic endoderm in secondary human yolk sac. *Hum Pathol*. 1992;23:921-924.
403. Nogales-Fernandez G, Silverberg SG, Bloustein PA, et al. Yolk sac carcinoma (endodermal sinus tumor). Ultrastructure and histogenesis of gonadal and extragonadal tumors in comparison with normal human yolk sac. *Cancer*. 1977;39:1462-1474.
404. Siltanen S, Anttonen M, Heikkila P, et al. Transcription factor GATA-4 is expressed in pediatric yolk sac tumors. *Am J Pathol*. 1999;155:1823-1829.
405. Gershenson DM, Del Junco G, Herson J, Rutledge FN. Endodermal sinus tumor of the ovary. The M.D. Anderson experience. *Obstet Gynecol*. 1983;61:194-202.
406. Kawai M, Kano T, Furuhashi Y, et al. Prognostic factors in yolk sac tumors of the ovary. A clinicopathologic analysis of 29 cases. *Cancer*. 1991;67:184-192.
407. Kawai M, Furuhashi Y, Kano T, et al. Alpha-fetoprotein in malignant germ cell tumors of the ovary. *Gynecol Oncol*. 1990;39:160-166.
408. Talerman A, Haije WG, Baggerman L. Serum alphafetoprotein (AFP) in diagnosis and management of endodermal sinus (yolk sac) tumor and mixed germ cell tumor of the ovary. *Cancer*. 1978;41:272-278.
409. Kurman RJ, Norris HJ. Embryonal carcinoma of the ovary. A clinicopathologic entity distinct from endodermal sinus tumor resembling embryonal carcinoma of the adult testis. *Cancer*. 1976;38:2420-2433.
410. Cheng L, Zhang S, Talerman A, Roth LM. Morphologic, immunohistochemical, and fluorescence in situ hybridization study of

For personal use only. No other uses without permission. Copyright ©2017. Elsevier Inc. All rights reserved.

ovarian embryonal carcinoma with comparison to solid variant of yolk sac tumor and immature teratoma. *Hum Pathol*. 2010;41:716-723.
411. Abu-Rustum NR, Aghajanian C. Management of malignant germ cell tumors of the ovary. *Semin Oncol*. 1998;25:235-242.
412. Gerbie MV, Brewer JI. Tamini H. Primary choriocarcinoma of the ovary. *Obstet Gynecol*. 1975;46:720-723.
413. Oliva E, Andrada E, Pezzica E, Prat J. Ovarian carcinomas with choriocarcinomatous differentiation. *Cancer*. 1993;72:2441-2446.
414. Nogales FF Jr, Favara BE, Major FJ, Silverberg SG. Immature teratoma of the ovary with a neural component ('solid' teratoma). *Hum Pathol*. 1976;7:625-642.
415. Nogales FF, Ruiz Avila I, Concha A, del Moral E. Immature endodermal teratoma of the ovary. Embryologic correlations and immunohistochemistry. *Hum Pathol*. 1993;24:364-370.
416. Schwartz PE, Merino MJ, LiVolsi VA. Immature ovarian teratomas. Maturation following chemotherapy. *Am J Diagn Gynecol Obstet*. 1979;1:361-366.
417. Notohara K, Hsueh CL, Awai M. Glial fibrillary acidic protein immunoreactivity of chondrocytes in immature and mature teratomas. *Acta Pathol Jpn*. 1990;40:335-342.
418. Heifetz SA, Cushing B, Giller R, et al. Immature teratomas in children: pathologic considerations: a report from the combined pediatric oncology group/children's cancer group. *Am J Surg Pathol*. 1998;22:1115-1124.
419. Aguirre P, Scully RE. Malignant neuroectodermal tumor of the ovary, a distinctive form of monodermal teratoma. Report of five cases. *Am J Surg Pathol*. 1982;6:283-292.
420. Kleinman GM, Young RH, Scully RE. Primary neuroectodermal tumors of the ovary. A report of 25 cases. *Am J Surg Pathol*. 1993;17:764-778.
421. Guerrieri C, Jarlsfelt I. Ependymoma of the ovary. A case report with immunohistochemical, ultrastructural, and DNA cytometric findings, as well as histogenetic considerations. *Am J Surg Pathol*. 1993;17:623-632.
422. Kleinman GM, Young RH, Scully RE. Ependymoma of the ovary. Report of three cases. *Hum Pathol*. 1984;15:632-638.
423. Nogales FF Jr, Ortega I, Rivera F, Armas JR. Metanephrogenic tissue in immature ovarian teratoma. *Am J Surg Pathol*. 1980;4:297-299.
424. King ME, Micha JP, Allen SL, et al. Immature teratoma of the ovary with predominant malignant retinal anlage component. A parthenogenically derived tumor. *Am J Surg Pathol*. 1985;9:221-231.
425. Yanai H, Matsuura H, Kawasaki M, et al. Immature teratoma of the ovary with a minor rhabdomyosarcomatous component and fatal rhabdomyosarcomatous metastases: the first case in a child. *Int J Gynecol Pathol*. 2002;21:82-85.
426. Baker PM, Rosai J, Young RH. Ovarian teratomas with florid benign vascular proliferation: a distinctive finding associated with the neural component of teratomas that may be confused with a vascular neoplasm. *Int J Gynecol Pathol*. 2002;21:16-21.
427. Gaudin PB, Rosai J. Florid vascular proliferation associated with neural and neuroendocrine neoplasms. A diagnostic clue and potential pitfall. *Am J Surg Pathol*. 1995;19:642-652.
428. Ramdial PK, Bagratee JS. Membranous fat necrosis in mature cystic teratomas of the ovary. *Int J Gynecol Pathol*. 1998;17:120-122.
429. Culine S, Lhomme C, Kattan J, et al. Pure malignant immature teratoma of the ovary: the role of chemotherapy and second-look surgery. *Int J Gynecol Cancer*. 1995;5:432-437.
430. Kawai M, Kano T, Furuhashi Y, et al. Immature teratoma of the ovary. *Gynecol Oncol*. 1991;40:133-137.
431. Koulos JP, Hoffman JS, Steinhoff MM. Immature teratoma of the ovary. *Gynecol Oncol*. 1989;34:46-49.
432. Gibas Z, Talerman A, Faruqi S, et al. Cytogenetic analysis of an immature teratoma of the ovary and its metastasis after chemotherapy-induced maturation. *Int J Gynecol Pathol*. 1993;12:276-280.
433. Merard R, Ganesan R, Hirschowitz L. Growing teratoma syndrome: a report of 2 cases and review of the literature. *Int J Gynecol Pathol*. 2015;34:465-472.
434. Peterson WF. Solid, histologically benign teratomas of the ovary. A report of four cases and review of the literature. *Am J Obstet Gynecol*. 1956;72:1094-1102.
435. Thurlbeck WM, Scully RE. Solid teratoma of the ovary. A clinicopathological analysis of 9 cases. *Cancer*. 1960;13:804-811.
436. Benirschke K, Easterday C, Abramson D. Malignant solid teratoma of the ovary. Report of three cases. *Obstet Gynecol*. 1960;15:512-521.
437. Cobo F, Pereira A, Nomdedeu B, et al. Ovarian dermoid cyst-associated autoimmune hemolytic anemia. A case report with emphasis on pathogenic mechanisms. *Am J Clin Pathol*. 1996;105:567-571.
438. Payne D, Muss HB, Homesley HD, et al. Autoimmune hemolytic anemia and ovarian dermoid cysts. Case report and review of the literature. *Cancer*. 1981;48:721-724.
439. Boman F, Vantyghem MC, Querleu D, Sasano H. Virilizing ovarian dermoid cyst with peripheral steroid cells: a case study with immunohistochemical study of steroidogenesis. *Int J Gynecol Pathol*. 1999;18:174-177.
440. López-Beltrán A, Calañas AS, Jimena P, et al. Virilizing mature ovarian cystic teratomas. *Virchows Arch*. 1997;431:149-151.
441. Mann AP, Grebenciucova E, Lukas RV. Anti-*N*-methyl-D-aspartate-receptor encephalitis: diagnosis, optimal management, and challenges. *Ther Clin Risk Manag*. 2014;10:517-525.
442. Dick HM, Honoré LH. Dental structures in benign ovarian cystic teratomas (dermoid cysts). A study of ten cases with a review of the literature. *Oral Surg*. 1985;60:299-307.
443. Miyake J, Ireland K. Ovarian mature teratoma with homunculus coexisting with an intrauterine pregnancy. *Arch Pathol Lab Med*. 1986;110:1192-1194.
444. Blackwell WJ, Dockerty MB, Masson JC, Mussey RD. Dermoid cysts of the ovary. Their clinical and pathologic significance. *Am J Obstet Gynecol*. 1946;51:151-172.
445. Chen E, Fletcher CDM, Nucci MR. Meningothelial proliferations in mature cystic teratoma of the ovary: evidence for the common presence of cranially derived tissues paralleling anterior embryonic plate development. An analysis of 25 consecutive cases. *Am J Surg Pathol*. 2010;34:1014-1018.
446. Fellegara G, Young RH, Kuhn E, Rosai J. Ovarian mature cystic teratoma with florid vascular proliferation and Wagner-Meissner-like corpuscles. *Int J Surg Pathol*. 2008;16:320-323.
447. Agaimy A, Lindner M, Wuensch PH. Interstitial cells of Cajal (ICC) in mature cystic teratoma of the ovary. *Histopathology*. 2006;48:208-209.
448. Sahin AA, Ro JY, Chen J, Ayala AG. Spindle cell nodule and peptic ulcer arising in a fully developed gastric wall in a mature cystic teratoma. *Arch Pathol Lab Med*. 1990;114:529-531.
449. Lewis MG. Melanin-pigmented components in ovarian teratomas in Ugandan Africans. *J Pathol Bacteriol*. 1968;95:405-409.
450. McKeel DW Jr, Askin FB. Ectopic hypophyseal hormonal cells in benign cystic teratoma of the ovary. Light microscopic histochemical dye staining and immunoperoxidase cytochemistry. *Arch Pathol Lab Med*. 1978;102:122-128.
451. Calame J, Bosman FT, Schaberg A, Louwerens JWK. Immunocytochemical localization of neuroendocrine hormones and oncofetal antigens in ovarian teratomas. *Int J Gynecol Pathol*. 1984;3:92-100.
452. McLachlin CM, Srigley JR. Prostatic tissue in mature cystic teratomas of the ovary. *Am J Surg Pathol*. 1992;16:780-784.
453. Vadmal M, Hadju SI. Prostatic tissue in benign cystic ovarian teratomas. *Hum Pathol*. 1996;27:428-429.
454. Yanai-Inbar I, Scully RE. Relation of ovarian dermoid cysts and immature teratomas. An analysis of 350 cases of immature teratoma and 10 cases of dermoid cyst with microscopic foci of immature tissue. *Int J Gynecol Pathol*. 1987;6:203-212.
455. Burg J, Kommoss F, Bittinger F, et al. Mature cystic teratoma of the ovary with struma and benign Brenner tumor: a case report with immunohistochemical characterization. *Int J Gynecol Pathol*. 2002;21:74-77.
456. Morimitsu Y, Nakashima O, Kage M, et al. Coexistence of mature teratoma and thecoma in an ovary. A report of two cases. *Acta Pathol Jpn*. 1991;41:922-926.
457. Ackerman LV. Autobiographical notes. In: Rosai J, ed. *Guiding the Surgeon's Hand. The History of American Surgical Pathology*. Washington, DC: The American Registry of Pathology/Armed Forces Institute of Pathology; 1997:284.
458. Auer EA, Dockerty MB, Mayo CW. Ruptured dermoid cyst of the ovary simulating abdominal carcinomatosis. *Mayo Clin Proc*. 1951;26:489-497.
459. Harms D, Janig U, Gobel U. Gliomatosis peritonei in childhood and adolescence. Clinicopathological study of 13 cases including immunohistochemical findings. *Pathol Res Pract*. 1989;184:422-430.
460. Huang AY, Bolen AW, Zaloudek CJ. Neuronal elements within gliomatosis peritonei: immunohistochemical evidence of an under-recognized feature. *Lab Invest*. 2009;89(suppl 1):218A.
461. Robboy SJ, Scully RE. Ovarian teratoma with glial implants on the peritoneum. An analysis of 12 cases. *Hum Pathol*. 1970;1:644-653.
462. Wheeler JE. Extraovarian teratoma with peritoneal gliomatosis. *Hum Pathol*. 1978;9:232-234.
463. Fortt RW, Mathie IK. Gliomatosis peritonei caused by ovarian teratoma. *J Clin Pathol*. 1969;22:348-353.
464. Nielsen SNJ, Scheithauer BW, Gaffey TA. Gliomatosis peritonei. *Cancer*. 1985;56:2499-2503.
465. Truong LD, Jurco S III, McGavran MH. Gliomatosis peritonei. Report of two cases and review of literature. *Am J Surg Pathol*. 1982;6:443-449.
466. Jaworski RC, Boable R, Greg J, Cocks P. Peritoneal 'melanosis' associated with a ruptured ovarian dermoid cyst: report of a case with electron-probe energy dispersive X-ray analysis. *Int J Gynecol Pathol*. 2001;20:386-389.
467. Climie ARW, Heath LP. Malignant degeneration of benign cystic teratomas of the ovary. Review of the literature and report of a chondrosarcoma and carcinoid tumor. *Cancer*. 1968;22:824-832.

For personal use only. No other uses without permission. Copyright ©2017. Elsevier Inc. All rights reserved.

468. Ronnett BM, Seidman JD. Mucinous tumors arising in ovarian mature cystic teratomas. *Am J Surg Pathol*. 2003;27:650-657.
469. Hirakawa T, Tsuneyoshi M, Enjoji M. Squamous cell carcinoma arising in mature cystic teratoma of the ovary. Clinicopathologic and topographic analysis. *Am J Surg Pathol*. 1989;13:397-405.
470. Kelley RR, Scully RE. Cancer developing in dermoid cysts of the ovary. *Cancer*. 1961;14:989-1000.
471. Peterson WF. Malignant degeneration of benign cystic teratomas of the ovary. A collective review of the literature. *Obstet Gynecol Survey*. 1957;12:793-830.
472. Davis GL. Malignant melanoma arising in mature ovarian cystic teratoma (dermoid cyst). Report of two cases and literature analysis. *Int J Gynecol Pathol*. 1997;15:356-362.
473. Ueda Y, Kimura A, Kawahara E, et al. Malignant melanoma arising in a dermoid cyst of the ovary. *Cancer*. 1991;67:3141-3145.
474. Shimizu S, Kobayashi H, Suchi T, et al. Extramammary Paget's disease arising in mature cystic teratoma of the ovary. *Am J Surg Pathol*. 1991;15:1002-1006.
475. Yadav A, Lellouch-Tubiana A, Fournet JC, et al. Glioblastoma multiforme in a mature ovarian teratoma with recurring brain tumors. *Histopathology*. 1999;35:170-173.
476. Hirschowitz L, Ansari A, Cahill DJ, et al. Central neurocytoma arising within a mature cystic teratoma of the ovary. *Int J Gynecol Pathol*. 1997;16:176-179.
477. Kanbour-Shakir A, Sawaday J, Kanbour AI, et al. Primitive neuroectodermal tumor arising in an ovarian mature cystic teratoma. Immunohistochemical and electron microscopic studies. *Int J Gynecol Pathol*. 1993;12:270-275.
478. Reid H, van der Walt JD, Fox H. Neuroblastoma arising in a mature cystic teratoma of the ovary. *J Clin Pathol*. 1983;36:68-73.
479. Shen DH, Khoo US, Xue WC, Cheung AN. Ovarian mature cystic teratoma with malignant transformation: an interphase cytogenetic study. *Int J Gynecol Pathol*. 1998;17:351-357.
480. Iwasa A, Oda Y, Kaneki E, et al. Squamous cell carcinoma arising in mature cystic teratoma of the ovary: an immunohistochemical analysis of its tumorigenesis. *Histopathology*. 2007;51:98-104.
481. Hwang JH, So KA, Modi G, et al. Borderline-like mucinous tumor arising in mature cystic teratoma of the ovary associated with pseudomyxoma peritonei. *Int J Gynecol Pathol*. 2009;28:376-380.
482. Stewart CJ, Junckerstorff R, Tsukamoto T. Ovarian mucinous tumor arising in mature cystic teratoma associated with pseudomyxoma peritonei: a case with possible respiratory epithelial differentiation. *Int J Gynecol Pathol*. 2008;27:41-43.
483. Kudo M. The nature of "blue nevus" in cystic teratomas of the ovary. An ultrastructural evidence for Schwann cell origin. *Acta Pathol Jpn*. 1985;35:693-698.
484. Tsang P, Berman L, Kasznica J. Adnexal tumor and a pigmented nevoid lesion in a benign cystic ovarian teratoma. *Arch Pathol Lab Med*. 1993;117:846-847.
485. Chumas JC, Scully RE. Sebaceous tumors arising in ovarian dermoid cysts. *Int J Gynecol Pathol*. 1991;10:356-363.
486. Morimitsu Y, Nakashima O, Nakashima Y, et al. Apocrine adenocarcinoma arising in cystic teratoma of the ovary. *Arch Pathol Lab Med*. 1993;117:647-649.
487. Silver SA, Tavassoli FA. Glomus tumor arising in a mature teratoma of the ovary: report of a case simulating a metastasis from cervical squamous carcinoma. *Arch Pathol Lab Med*. 2000;124:1373-1375.
488. Madison JF, Cooper PH. A histiocytoid (epithelioid) vascular tumor of the ovary. Occurrence within a benign cystic teratoma. *Mod Pathol*. 1989;2:55-58.
489. Palmer PE, Bogojavlensky S, Bhan AK, Scully RE. Prolactinoma in wall of ovarian dermoid cyst with hyperprolactinemia. *Obstet Gynecol*. 1990;75:540-543.
490. Waugh MS, Soler AP, Robboy SJ. Silent corticotroph cell pituitary adenoma in a struma ovarii. *Int J Gynecol Pathol*. 2007;26:26-29.
491. Talerman A, Roth LM. Recent advances in the pathology and classification of gonadal neoplasms composed of germ cells and sex cord derivatives. *Int J Gynecol Pathol*. 2007;26:313-321.
492. Szyfelbein WM, Young RH, Scully RE. Cystic struma ovarii. A frequently unrecognized tumor. A report of 20 cases. *Am J Surg Pathol*. 1994;18:785-788.
493. Szyfelbein WM, Young RH, Scully RE. Struma ovarii simulating ovarian tumors of other types. A report of 30 cases. *Am J Surg Pathol*. 1995;19:21-29.
494. Hasleton PS, Kelehan P, Wittaker JS, et al. Benign and malignant struma ovarii. *Arch Pathol Lab Med*. 1978;102:180-184.
495. Roth LM, Talerman A. The enigma of struma ovarii. *Pathology*. 2007;39:139-146.
496. Boutross-Tadross O, Saleh R, Asa SL. Follicular variant papillary thyroid carcinoma arising in struma ovarii. *Endocr Pathol*. 2007;18:182-186.
497. Coyne C, Nikiforov YE. RAS mutation-positive follicular variant of papillary thyroid carcinoma arising in a struma ovarii. *Endocr Pathol*. 2010;21:144-147.
498. Schmidt J, Derr V, Heinrich MC, et al. BRAF in papillary thyroid carcinoma of ovary (struma ovarii). *Am J Surg Pathol*. 2007;31:1337-1343.
499. Garg K, Soslow RA, Rivera M, et al. Histologically bland 'extremely well differentiated' thyroid carcinomas arising in struma ovarii can recur and metastasize. *Int J Gynecol Pathol*. 2009;28:222-230.
500. Roth LM, Karseladze AI. Highly differentiated follicular carcinoma arising from struma ovarii: a report of 3 cases, a review of the literature, and a reassessment of so-called peritoneal strumosis. *Int J Gynecol Pathol*. 2008;27:213-222.
501. Seifer DB, Weiss LM, Kempson RL. Malignant lymphoma arising within thyroid tissue in a mature cystic teratoma. *Cancer*. 1986;58:2459-2461.
502. Roth LM, Miller AW 3rd, Talerman A. Typical thyroid-type carcinoma arising in struma ovarii: a report of 4 cases and review of the literature. *Int J Gynecol Pathol*. 2008;27:496-506.
503. Robboy SJ, Scully RE, Norris HJ. Carcinoid metastatic to ovary. A clinicopathologic analysis of 35 cases. *Cancer*. 1974;33: 798-811.
504. Robboy SJ, Scully RE. Strumal carcinoid of the ovary. An analysis of 50 cases of a distinctive tumor composed of thyroid tissue and carcinoid. *Cancer*. 1980;46:2019-2034.
505. Motoyama T, Katayama Y, Watanabe H, et al. Functioning ovarian carcinoids induce severe constipation. *Cancer*. 1992;70:513-518.
506. Robboy SJ, Norris HJ, Scully RE. Insular carcinoid primary in ovary—a clinicopathologic analysis of 48 cases. *Cancer*. 1975;36:406-420.
507. Baker PM, Oliva E, Young RH, et al. Ovarian mucinous carcinoids including some with a carcinomatous component: a report of 17 cases. *Am J Surg Pathol*. 2001;25:557-568.
508. Robboy SJ, Scully RE, Norris HJ. Primary trabecular carcinoid of the ovary. *Obstet Gynecol*. 1977;49:202-207.
509. Serratoni FT, Robboy SJ. Ultrastructure of primary and metastatic ovarian carcinoids. Analysis of 11 cases. *Cancer*. 1975;36:157-160.
510. Czernobilsky B, Segal M, Dgani R. Primary ovarian carcinoid with marked heterogeneity of microscopic features. *Cancer*. 1984;54:585-589.
511. Shigeta H, Taga M, Kurogi K, et al. Ovarian strumal carcinoid with severe constipation: immunohistochemical and mRNA analyses of peptide YY. *Hum Pathol*. 1999;30:242-246.
512. Sporrong B, Falkmer S, Robboy SJ, et al. Neurohormonal peptides in ovarian carcinoids. An immunohistochemical study of 81 primary carcinoids and of intraovarian metastases from six mid-gut carcinoids. *Cancer*. 1982;49:68-74.
513. Hristov AC, Young RH, Vang R, et al. Ovarian metastases of appendiceal tumors with goblet cell carcinoidlike and signet ring cell patterns: a report of 30 cases. *Am J Surg Pathol*. 2007;31:1502-1511.
514. Rabban JT, Lerwill MF, McCluggage WG, et al. Primary ovarian carcinoid tumors may express CDX-2: a potential pitfall in distinction from metastatic intestinal carcinoid tumors involving the ovary. *Int J Gynecol Pathol*. 2009;28:41-48.
515. Talerman A. Carcinoid tumors of the ovary. *J Cancer Res Clin Oncol*. 1984;107:125-135.
516. Hamazaki S, Okino T, Tsukayama C, Okada S. Expression of thyroid transcription factor-1 in strumal carcinoid and struma ovarii: an immunohistochemical study. *Pathol Int*. 2002;52:458-462.
517. Ulbright TM, Roth LM, Ehrlich CE. Ovarian strumal carcinoid. An immunocytochemical and ultrastructural study of two cases. *Am J Clin Pathol*. 1982;77:622-631.
518. Pelosi G, Sonzogni A, Rosai J. Thyroid-type papillary microcarcinoma in ovarian strumal carcinoid. *Int J Surg Pathol*. 2008;16:435-437.
519. Arhelger RB, Kelly B. Strumal carcinoid. Report of a case with electron microscopical observations. *Arch Pathol*. 1974;97:323-325.
520. Snyder RR, Tavassoli FA. Ovarian strumal carcinoid. Immunohistochemical, ultrastructural, and clinicopathologic observations. *Int J Gynecol Pathol*. 1986;3:187-201.
521. Stagno PA, Petras RE, Hart WR. Strumal carcinoids of the ovary. An immunohistologic and ultrastructural study. *Arch Pathol Lab Med*. 1987;111:440-446.
522. Dayal Y, Tashjian H Jr, Wolfe HJ. Immunocytochemical localization of calcitonin-producing cells in a strumal carcinoid with amyloid stroma. *Cancer*. 1979;43:1331-1338.
523. Sidhu J, Sanchez RL. Prostatic acid phosphatase in strumal carcinoids of the ovary. An immunohistochemical study. *Cancer*. 1993;72:1673-1678.
524. Brunaud L, Antunes L, Sebbag H, et al. Ovarian strumal carcinoid tumor responsible for carcinoid heart disease. *Eur J Obstet Gynecol Reprod Biol*. 2001;98:124-126.
525. Matias-Guiu X, Forteza J, Prat J. Mixed strumal and mucinous carcinoid tumor of the ovary. *Int J Gynecol Pathol*. 1995;14:179-183.
526. Tamsen A, Mazur MT. Ovarian strumal carcinoid in association with multiple endocrine neoplasia, type IIA. *Arch Pathol Lab Med*. 1992;116:200-203.
527. Young RH, Scully RE. Ovarian sex cord–stromal tumors. Problems in differential diagnosis. *Pathol Annu*. 1988;23(Pt 1):273-296.
528. Young RH, Scully RE. Ovarian sex cord–stromal tumors. Recent progress. *Int J Gynecol Pathol*. 1982;1:101-123.
529. Young RH. Sex cord–stromal tumors of the ovary and testis: their similarities and differences with consideration of selected

For personal use only. No other uses without permission. Copyright ©2017. Elsevier Inc. All rights reserved.

problems. *Mod Pathol*. 2005;18(suppl 2):S81-S98.
530. Vang R, Herrmann ME, Tavassoli FA. Comparative immunohistochemical analysis of granulosa and sertoli components in ovarian sex cord–stromal tumors with mixed differentiation: potential implications for derivation of sertoli differentiation in ovarian tumors. *Int J Gynecol Pathol*. 2004;23:151-161.
531. Teilum G. Estrogen-producing Sertoli cell tumors (androblastoma tubular lipoides) of the human testis and ovary. Homologous ovarian and testicular tumors. *J Clin Endocrinol*. 1949;9:301-318.
532. Roth LM, Billings SD. Hormonally functional ovarian neoplasms. *Endocrine Pathol*. 2002;11:1-17.
533. Sasano H. Functional pathology of human ovarian steroidogenesis. Normal cycling ovary and steroid-producing neoplasms. *Endocr Pathol*. 1994;5:81-89.
534. Tavassoli FA. Ovarian tumors with functioning manifestations. *Endocr Pathol*. 1994;5:137-148.
535. Freeman DA. Steroid hormone-producing tumors of the adrenal, ovary, and testes. *Endocrinol Metab Clin North Am*. 1991;20:751-766.
536. Lobo RA. Ovarian hyperandrogenism and androgen-producing tumors. *Endocrinol Metab Clin North Am*. 1991;20:773-805.
537. McCluggage WG. Recent advances in immunohistochemistry in gynecological pathology. *Histopathology*. 2002;40:309-326.
538. Yaziji H, Gown AM. Immunohistochemical analysis of gynecologic tumors. *Int J Gynecol Pathol*. 2000;20:64-78.
539. Roth LM. Recent advances in the pathology and classification of ovarian sex cord–stromal tumors. *Int J Gynecol Pathol*. 2006;25:199-215.
540. Choi YL, Kim HS, Ahn G. Immunoexpression of inhibin alfa subunit, inhibin/activin beta A subunit and CD99 in ovarian tumors. *Arch Pathol Lab Med*. 2000;124:563-569.
541. Iczkowski KA, Bostwick DG, Roche PC, Cheville JC. Inhibin A is a sensitive and specific marker for testicular sex cord–stromal tumors. *Mod Pathol*. 1998;11:774-779.
542. Deavers MT, Malpica A, Liu J, et al. Ovarian sex cord–stromal tumors: an immunohistochemical study including a comparison of calretinin and inhibin. *Mod Pathol*. 2003;16:584-590.
543. Pelkey TJ, Frierson HF Jr, Mills SE, Stoler MH. Detection of the alpha-subunit of inhibin in trophoblastic neoplasia. *Hum Pathol*. 1999;30:26-31.
544. Kommoss F, Oliva E, Bhan AK, et al. Inhibin expression in ovarian tumors and tumor-like lesions: an immunohistochemical study. *Mod Pathol*. 1998;11:656-664.
545. McCluggage WG, Maxwell P. Adenocarcinomas of various sites may exhibit immunoreactivity with anti-inhibin antibodies. *Histopathology*. 1999;35:216-220.
546. Iezzoni JC, Mills SE, Pelkey TJ, Stoler MH. Inhibin is not an immunohistochemical marker for hepatocellular carcinoma. An example of the potential pitfall diagnostic immunohistochemistry caused by endogenous biotin. *Am J Clin Pathol*. 1999;111:229-234.
547. Bamberger AM, Ivell R, Balvers M, et al. Relaxin-like factor (RLF): a new specific marker for Leydig cells in the ovary. *Int J Gynecol Pathol*. 1999;18:163-168.
548. Rey R, Sabourin JC, Venara M, et al. Anti-Mullerian hormone is a specific marker of Sertoli- and granulosa-cell origin in gonadal tumors. *Hum Pathol*. 2000;31:1202-1208.
549. Al-Agha OM, Huwait HF, Chow C, et al. FOXL2 is a sensitive and specific marker for sex cord–stromal tumors of the ovary. *Am J Surg Pathol*. 2011;35:484-494.
550. Cao QJ, Jones JG, Li M. Expression of calretinin in human ovary, testis and ovarian sex cord–stromal tumors. *Int J Gynecol Pathol*. 2001;20:346-352.
551. Movahedi-Lankarani S, Kurman RJ. Calretinin, a more sensitive but less specific marker than alpha-inhibin for ovarian sex cord–stromal neoplasms: an immunohistochemical study of 215 cases. *Am J Surg Pathol*. 2002;26:1477-1483.
552. Busam KJ, Iversen K, Coplan KA, et al. Immunoreactivity for A103, and antibody to Melan-A (Mart-1), in adrenocortical and other steroid tumors. *Am J Surg Pathol*. 1998;22:57-63.
553. Zhao C, Vinh TN, McManus K, et al. Identification of the most sensitive and robust immunohistochemical markers in different categories of ovarian sex cord–stromal tumors. *Am J Surg Pathol*. 2009;33:354-366.
554. Keitoku M, Konishi I, Nanbu K, et al. Extraovarian sex cord–stromal tumor: case report and review of the literature. *Int J Gynecol Pathol*. 1997;16:180-185.
555. Lack EE, Perez-Atayde AR, Murthy ASK, et al. Granulosa theca cell tumors in premenarchal girls. A clinical and pathologic study of ten cases. *Cancer*. 1981;48:1846-1854.
556. Evans AT III, Gaffey TA, Malkasian GD Jr, Annegers JF. Clinicopathologic review of 118 granulosa and 82 theca cell tumors. *Obstet Gynecol*. 1980;55:231-238.
557. Castro CY, Malpica A, Hearne RH, et al. Androgenic adult granulosa cell tumor in a 13-year-old prepubertal patient: a case report and review of the literature. *Int J Gynecol Pathol*. 2000;19:266-271.
558. Nakashima N, Young RH, Scully RE. Androgenic granulosa cell tumors of the ovary. A clinicopathologic analysis of 17 cases and review of the literature. *Arch Pathol Lab Med*. 1984;108:786-791.
559. Norris HJ, Taylor HB. Virilization associated with cystic granulosa tumors. *Obstet Gynecol*. 1969;34:629-635.
560. Irving JA, Young RH. Granulosa cell tumors of the ovary with a pseudopapillary pattern: a study of 14 cases of an unusual morphologic variant emphasizing their distinction from transitional cell neoplasms and other papillary ovarian tumors. *Am J Surg Pathol*. 2008;32:581-586.
561. Scully RE. Ovarian tumors. A review. *Am J Pathol*. 1977;87:686-720.
562. Young RH, Oliva E, Scully RE. Luteinized adult granulosa cell tumors of the ovary. A report of four cases. *Int J Gynecol Pathol*. 1994;13:302-310.
563. Young RH, Dudley AG, Scully RE. Granulosa cell, Sertoli-Leydig cell, and unclassified sex cord–stromal tumors associated with pregnancy. A clinico-pathological analysis of thirty-six cases. *Gynecol Oncol*. 1984;18:181-205.
564. Young RH, Scully RE. Ovarian sex cord–stromal tumors with bizarre nuclei. A clinicopathologic analysis of 17 cases. *Int J Gynecol Pathol*. 1983;1:325-335.
565. Ahmed E, Young RH, Scully RE. Adult granulosa cell tumor of the ovary with foci of hepatic cell differentiation: a report of four cases and comparison with two cases of granulosa cell tumor with Leydig cells. *Am J Surg Pathol*. 1999;23:1089-1093.
566. Nogales FF, Concha A, Plata C, Ruiz-Avila I. Granulosa cell tumor of the ovary with diffuse true hepatic differentation simulating stromal luteinization. *Am J Surg Pathol*. 1993;17:85-90.
567. Shah SP, Kobel M, Senz J, et al. Mutation of FOXL2 in granulosa-cell tumors of the ovary. *N Engl J Med*. 2009;360:2719-2729.
568. Loo KT, Leung AKF, Chan JKC. Immunohistochemical staining of ovarian granulosa cell tumours with MIC2 antibody. *Histopathology*. 1995;27:388-390.
569. McCluggage WG, Maxwell P, Sloan JM. Immunohistochemical staining of ovarian granulosa cell tumors with monoclonal antibody against inhibin. *Hum Pathol*. 1997;28:1034-1038.
570. Miettinen M, Wahlstrom T, Virtanen I, et al. Cellular differentiation in ovarian sex cord–stromal and germ-cell tumors studied with antibodies to intermediate-filament proteins. *Am J Surg Pathol*. 1985;9:640-651.
571. Rodgers KE, Marks JF, Ellefson DD, et al. Follicle regulatory protein. A novel marker for granulosa cell cancer patients. *Gynecol Oncol*. 1990;37:381-387.
572. Otis CN, Powell JL, Barbuto D, Carcangiu ML. Intermediate filamentous proteins in adult granulosa cell tumors. An immunohistochemical study of 25 cases. *Am J Surg Pathol*. 1992;16:962-968.
573. Costa MJ, De Rose PB, Roth LM, et al. Immunohistochemical phenotype of ovarian granulosa cell tumors. Absence of epithelial membrane antigen has diagnostic value. *Hum Pathol*. 1994;25:60-66.
574. Farinola MA, Gown AM, Judson K, et al. Estrogen receptor alpha and progesterone receptor expression in ovarian adult granulosa cell tumors and Sertoli-Leydig cell tumors. *Int J Gynecol Pathol*. 2007;26:375-382.
575. Flemming P, Wellmann A, Maschjek H, et al. Monoclonal antibodies against inhibin represent key markers of adult granulosa cell tumors of the ovary even in their metastases. A report of three cases with late metastasis, being previously misinterpreted as hemangiopericytoma. *Am J Surg Pathol*. 1995;19:927-933.
576. Jamieson S, Butzow R, Andersson N, et al. The FOXL2 C134W mutation is characteristic of adult granulosa cell tumors of the ovary. *Mod Pathol*. 2010;23:1477-1485.
577. Kommoss S, Gilks CB, Penzel R, et al. A current perspective on the pathological assessment of FOXL2 in adult-type granulosa cell tumours of the ovary. *Histopathology*. 2014;64:380-388.
578. Tamimi HK, Bolen JW. Enchondromatosis (Ollier's disease) and ovarian juvenile granulosa cell tumor. A case report and review of the literature. *Cancer*. 1984;53:1605-1608.
579. Tanaka Y, Sasaki Y, Nishihira H, et al. Ovarian juvenile granulosa cell tumor associated with Maffucci's syndrome. *Am J Clin Pathol*. 1992;97:523-527.
580. Roth LM, Nicholas TR, Ehrlich CE. Juvenile granulosa cell tumor. A clinicopathologic study of three cases with ultrastructural observations. *Cancer*. 1979;44:2194-2205.
581. Young RH, Dickersin GR, Scully RE. Juvenile granulosa cell tumor of the ovary. A clinicopathologic analysis of 125 cases. *Am J Surg Pathol*. 1984;8:575-596.
582. Schofield DE, Fletcher JA. Trisomy 12 in pediatric granulosa-stromal cell tumors. Demonstration by a modified method of fluorescence in situ hybridization on paraffin-embedded material. *Am J Pathol*. 1992;141:1265-1269.
583. McConechy MK, Färkkilä A, Horlings HM, et al. Molecularly defined adult granulosa cell tumor of the ovary: the clinical phenotype. *J Natl Cancer Inst*. 2016;108(11).
584. Clement PB, Young RH, Scully RE. Ovarian granulosa cell proliferations of pregnancy. A report of nine cases. *Hum Pathol*. 1988;19:657-662.
585. Young RH, Clement PB, Scully RE. Calcified thecomas in young women. A report of four cases. *Int J Gynecol Pathol*. 1988;7:343-350.
586. Waxman M, Vuletin JC, Urcuyo R, Belling CG. Ovarian low-grade stromal sarcoma with thecomatous features. A critical reappraisal of

For personal use only. No other uses without permission. Copyright ©2017. Elsevier Inc. All rights reserved.

the so-called 'malignant thecoma. *Cancer*. 1979;44:2206-2217.
587. Clement PB, Young RH, Hanna W, Scully RE. Sclerosing peritonitis associated with luteinized thecomas of the ovary. A clinicopathological analysis of six cases. *Am J Surg Pathol*. 1994;18:1-13.
588. Iwasa Y, Minamiguchi S, Konishi I, et al. Sclerosing peritonitis associated with luteinized thecoma of the ovary. *Pathol Int*. 1996;46:510-514.
589. Werness BA. Luteinized thecoma with sclerosing peritonitis. *Arch Pathol Lab Med*. 1996;120:303-306.
590. Fox H. Sex cord–stromal tumours of the ovary. *J Pathol*. 1985;145:127-148.
591. Michal M, Kacerovska D, Mukensnabl P, et al. Ovarian fibromas with heavy deposition of hyaline globules: a diagnostic pitfall. *Int J Gynecol Pathol*. 2009;28:356-361.
592. Raggio M, Kaplan AL, Harberg JF. Recurrent ovarian fibromas with basal cell nevus syndrome (Gorlin syndrome). *Obstet Gynecol*. 1983;61:95S-96S.
593. Prat J, Scully RE. Cellular fibromas and fibrosarcomas of the ovary. A comparative clinicopathologic analysis of seventeen cases. *Cancer*. 1981;47:2663-2670.
594. Irving JA, Alkushi A, Young RH, Clement PB. Cellular fibromas of the ovary: a study of 75 cases including 40 mitotically active tumors emphasizing their distinction from fibrosarcoma. *Am J Surg Pathol*. 2006;30:929-938.
595. Tsuji T, Kawauchi S, Utsunomiya T, et al. Fibrosarcoma versus cellular fibroma of the ovary: a comparative study of their proliferative activity and chromosome aberrations using MIB-1 immunostaining, DNA flow cytometry, and fluorescence in situ hybridisation. *Am J Surg Pathol*. 1997;21:52-59.
596. Young RH, Scully RE. Ovarian stromal tumors with minor sex-cord elements. A report of seven cases. *Int J Gynecol Pathol*. 1983;2:227-234.
597. Persons DL, Hartmann LC, Herath JF, et al. Fluorescence in situ hybridization analysis of trisomy 12 in ovarian tumors. *Am J Clin Pathol*. 1994;102:775-779.
598. Taruscio D, Carcangiu ML, Ward DC. Detection of trisomy 12 on ovarian sex cord stromal tumors by fluorescence in situ hybridization. *Diagn Mol Pathol*. 1993;2:94-98.
599. Tsuji T, Catasus L, Prat J. Is loss of heterozygosity at 9q22.3 (PTCH gene) and 19p13.3 (STK11 gene) involved in the pathogenesis of ovarian stromal tumors? *Hum Pathol*. 2005;36:792-796.
600. Samanth KK, Black WCIII. Benign ovarian stromal tumors associated with free peritoneal fluid. *Am J Obstet Gynecol*. 1970;107:538-545.
601. Young RH. Meigs' syndrome: Dr. Richard Cabot's hidden first American case. *Int J Surg Pathol*. 2001;8:165-168.
602. Meigs JV. Pelvic tumors other than fibromas of the ovary with ascites and hydrothorax. *Obstet Gynecol*. 1954;3:471-486.
603. Chalvardjian A, Scully RE. Sclerosing stromal tumors of the ovary. *Cancer*. 1973;31:664-670.
604. Tiltman AJ. Sclerosing stromal tumor of the ovary. Demonstration of ligandin in three cases. *Int J Gynecol Pathol*. 1985;4:362-369.
605. Saitoh A, Tsutsumi Y, Osamura RY, Watanabe K. Sclerosing stromal tumor of the ovary. Immunohistochemical and electron-microscopic demonstration of smooth-muscle differentiation. *Arch Pathol Lab Med*. 1989;113:372-376.
606. Tiltman AJ, Haffajee Z. Sclerosing stromal tumors, thecomas, and fibromas of the ovary: an immunohistochemical profile. *Int J Gynecol Pathol*. 2002;18:254-258.
607. Kawauchi S, Tsuji T, Kaku T, et al. Sclerosing stromal tumor of the ovary: A clinicopathologic, immunohistochemical, ultrastructural, and cytogenetic analysis with special reference to its vasculature. *Am J Surg Pathol*. 1998;22:83-92.
608. Lacson AG, Alrabeeah A, Gillis DA, et al. Secondary massive ovarian edema with Meigs' syndrome. *Am J Clin Pathol*. 1989;91:597-603.
609. Roth LM, Deaton RL, Sternberg WH. Massive ovarian edema. A clinicopathologic study of five cases including ultrastructural observations and review of the literature. *Am J Surg Pathol*. 1979;3:11-21.
610. Nogales FF, Martin-Sances L, Mendoza-Garcia E, et al. Massive ovarian oedema. *Histopathology*. 1997;28:229-234.
611. Kanbour AI, Salazar H, Tobon H. Massive ovarian edema. A non-neoplastic pelvic mass of young women. *Arch Pathol Lab Med*. 1979;103:42-45.
612. Young RH, Scully RE. Fibromatosis and massive edema of the ovary, possibly related entities. A report of 14 cases of fibromatosis and 11 cases of massive edema. *Int J Gynecol Pathol*. 1984;3:153-178.
613. Nielsen GP, Young RH. Fibromatosis of soft tissue type involving the female genital tract: a report of two cases. *Int J Gynecol Pathol*. 1998;16:383-386.
614. Eichhorn JH, Scully RE. Ovarian myxoma. Clinicopathologic and immunocytologic analysis of five cases and a review of the literature. *Int J Gynecol Pathol*. 1991;10:156-169.
615. Tetu B, Bonenfant JL. Ovarian myxoma. A study of two cases with long-term follow-up. *Am J Clin Pathol*. 1991;95:340-346.
616. Costa MJ, Morris R, De Rose PB, Cohen C. Histologic and immunohistochemical evidence for considering ovarian myxoma as a variant of the thecomafibroma group of ovarian stromal tumors. *Arch Pathol Lab Med*. 1993;117:802-808.
617. Costa MJ, Thomas W, Majmudar B, Hewan-Lowe K. Ovarian myxoma. Ultrastructural and immunohistochemical findings. *Ultrastruct Pathol*. 1992;16:429-438.
618. Dickersin GR, Kline IW, Scully RE. Small cell carcinoma of the ovary with hypercalcemia. A report of eleven cases. *Cancer*. 1982;49:188-197.
619. Scully RE. Small cell carcinoma of hypercalcemic type. *Int J Gynecol Pathol*. 1993;12:148-152.
620. Young RH, Oliva E, Scully RE. Small cell carcinoma of the ovary, hypercalcemic type. A clinicopathological analysis of 150 cases. *Am J Surg Pathol*. 1994;18:1102-1116.
621. Lamovec J, Bracko M, Cerar O. Familial occurrence of small-cell carcinoma of the ovary. *Arch Pathol Lab Med*. 1995;119:551-554.
622. Clement PB. Selected miscellaneous ovarian lesions: small cell carcinomas, mesothelial lesions, mesenchymal and mixed neoplasms, and non-neoplastic lesions. *Mod Pathol*. 2005;18(suppl 2):S113-S129.
623. Carlson JW, Nucci MR, Brodsky J, et al. Biomarker-assisted diagnosis of ovarian, cervical and pulmonary small cell carcinomas: the role of TTF-1, WT-1 and HPV analysis. *Histopathology*. 2007;51:305-312.
624. Ulbright TM, Roth LM, Stehman FB, et al. Poorly differentiated (small cell) carcinoma of the ovary in young women. Evidence supporting a germ cell origin. *Hum Pathol*. 1987;18:175-184.
625. Jelinic P, Mueller JJ, Olvera N, et al. Recurrent SMARCA4 mutations in small cell carcinoma of the ovary. *Nat Genet*. 2014;46:424-426.
626. Kupryjańczyk J, Dansonka-Mieszkowska A, Moes-Sosnowska J, et al. Ovarian small cell carcinoma of hypercalcemic type - evidence of germline origin and SMARCA4 gene inactivation. A pilot study. *Pol J Pathol*. 2013;64:238-246.
627. Ramos P, Karnezis AN, Craig DW, et al. Small cell carcinoma of the ovary, hypercalcemic type, displays frequent inactivating germline and somatic mutations in SMARCA4. *Nat Genet*. 2014;46:427-429.
628. Witkowski L, Carrot-Zhang J, Albrecht S, et al. Germline and somatic SMARCA4 mutations characterize small cell carcinoma of the ovary, hypercalcemic type. *Nat Genet*. 2014;46:438-443.
629. Karnezis AN, Wang Y, Ramos P, et al. Dual loss of the SWI/SNF complex ATPases SMARCA4/BRG1 and SMARCA2/BRM is highly sensitive and specific for small cell carcinoma of the ovary, hypercalcaemic type. *J Pathol*. 2016;238:389-400.
630. Eichhorn JH, Young RH, Scully RE. Primary ovarian small cell carcinoma of pulmonary type. A clinicopathologic, immunohistologic, and flow cytometric analysis of 11 cases. *Am J Surg Pathol*. 1992;16:926-938.
631. Fox H, Langley FA. *Tumours of the Ovary*. London: Heinemann; 1976:156-157.
632. Emerson RE, Wang M, Roth LM, et al. Molecular genetic evidence supporting the neoplastic nature of the Leydig cell component of ovarian Sertoli-Leydig cell tumors. *Int J Gynecol Pathol*. 2007;26:368-374.
633. Mooney EE, Man YG, Bratthauer GL, Tavassoli FA. Evidence that Leydig cells in Sertoli-Leydig cell tumors have a reactive rather then a neoplastic profile. *Cancer*. 2000;86:2312-2319.
634. Young RH, Scully RE. Well-differentiated ovarian Sertoli-Leydig cell tumors. A clinicopathological analysis of 23 cases. *Int J Gynecol*. 1984;3:277-290.
635. McCluggage WG, Young RH. Ovarian Sertoli-Leydig cell tumors with pseudoendometrioid tubules (pseudoendometrioid Sertoli-Leydig cell tumors). *Am J Surg Pathol*. 2007;31:592-597.
636. Zhao C, Bratthauer GL, Barner R, Vang R. Comparative analysis of alternative and traditional immunohistochemical markers for the distinction of ovarian Sertoli cell tumor from endometrioid tumors and carcinoid tumor: a study of 160 cases. *Am J Surg Pathol*. 2007;31:255-266.
637. Oliva E, Alvarez T, Young RH. Sertoli cell tumors of the ovary: a clinicopathologic and immunohistochemical study of 54 cases. *Am J Surg Pathol*. 2005;29:143-156.
638. Young RH, Scully RE. Ovarian Sertoli cell tumors. A report of 10 cases. *Int J Gynecol Pathol*. 1984;2:349-363.
639. Young RH, Scully RE. Ovarian Sertoli-Leydig cell tumors. A clinicopathological analysis of 207 cases. *Am J Surg Pathol*. 1985;9:543-569.
640. Tavassoli FA, Norris HJ. Sertoli tumors of the ovary. A clinicopathologic study of 28 cases with ultrastructural observations. *Cancer*. 1980;46:2281-2297.
641. Ferry JA, Young RH, Engel G, Scully RE. Oxyphilic Sertoli cell tumor of the ovary. A report of three cases, two in patients with the Peutz-Jeghers syndrome. *Int J Gynecol Pathol*. 1994;13:259-266.
642. Young RH, Perez-Atayde AR, Scully RE. Ovarian Sertoli-Leydig cell tumor with retiform and heterologous components. Report of a case with hepatocytic differentiation and elevated serum alpha-fetoprotein. *Am J Surg Pathol*. 1984;8:709-718.
643. Prat J, Young RH, Scully RE. Ovarian Sertoli-Leydig cell tumors with heterologous elements. II. Cartilage and skeletal muscle. A clinicopathologic analysis of twelve cases. *Cancer*. 1982;50:2465-2475.
644. Roth LM, Cleary RE, Rosenfield RL. Sertoli-Leydig cell tumor of the ovary, with an associated mucinous cystadenoma. An

For personal use only. No other uses without permission. Copyright ©2017. Elsevier Inc. All rights reserved.

ultrastructural and endocrine study. *Lab Invest*. 1974;31:648-657.
645. Aguirre P, Scully RE, DeLellis RA. Ovarian heterologous Sertoli-Leydig cell tumors with gastrointestinal-type epithelium. An immunohistochemical analysis. *Arch Pathol Lab Med*. 1986;110:528-533.
646. Young RH, Prat J, Scully RE. Ovarian Sertoli-Leydig cell tumors with heterologous elements. I. Gastrointestinal epithelium and carcinoid. A clinicopathologic analysis of thirty-six cases. *Cancer*. 1982;50:2448-2456.
647. Roth LM, Slayton RE, Brady LW, et al. Retiform differentiation in ovarian Sertoli-Leydig cell tumors. A clinicopathologic study of six cases from a gynecologic oncology group study. *Cancer*. 1985;55:1093-1098.
648. Young RH, Scully RE. Ovarian Sertoli-Leydig cell tumors with a retiform pattern. A problem in histopathologic diagnosis. A report of 25 cases. *Am J Surg Pathol*. 1983;7:755-771.
649. Mooney EE, Nogales FF, Tavassoli FA. Hepatocytic differentiation in retiform Sertoli-Leydig cell tumors: distinguishing a heterologous element from Leydig cells. *Hum Pathol*. 1999;30:611-617.
650. Kurman RJ, Ganjei P, Nadji M. Contributions of immunocytochemistry to the diagnosis and study of ovarian neoplasms. *Int J Gynecol Pathol*. 1984;3:3-26.
651. Zhao C, Bratthauer GL, Barner R, Vang R. Immunohistochemical analysis of sox9 in ovarian Sertoli cell tumors and other tumors in the differential diagnosis. *Int J Gynecol Pathol*. 2007;26:1-9.
652. Mooney EE, Nogales FF, Bergeron C, Tavassoli FA. Retiform Sertoli-Leydig cell tumors: clinical, morphological and immunohistochemical findings. *Histopathology*. 2002;41:110-117.
653. Zhao C, Bratthauer GL, Barner R, Vang R. Diagnostic utility of WT1 immunostaining in ovarian sertoli cell tumor. *Am J Surg Pathol*. 2007;31:1378-1386.
654. Heravi-Moussavi A, Anglesio MS, Cheng SW, et al. Recurrent somatic DICER1 mutations in nonepithelial ovarian cancers. *N Engl J Med*. 2012;366:234-242.
655. Foulkes WD, Priest JR, Duchaine TF. DICER1: mutations, microRNAs and mechanisms. *Nat Rev Cancer*. 2014;14:662-672.
656. Seidman JD, Patterson JA, Bitterman P. Sertoli-Leydig cell tumor associated with a mature cystic teratoma in a single ovary. *Mod Pathol*. 1989;2:687-692.
657. Tracy SL, Askin FB, Reddick RL, et al. Progesterone-secreting Sertoli cell tumor of the ovary. *Gynecol Oncol*. 1985;22:85-96.
658. Chadha S, Honnebier WJ, Schaberg A. Raised serum alphafetoprotein in Sertoli-Leydig cell tumor (androblastoma) of ovary. Report of two cases. *Int J Gynecol Pathol*. 1987;6:82-88.
659. Gagnon S, Tetu B, Silva EG, McCaughey WT. Frequency of alpha-fetoprotein production by Sertoli-Leydig cell tumors of the ovary. An immunohistochemical study of eight cases. *Mod Pathol*. 1989;2:63-67.
660. Motoyama I, Watanabe H, Gotoh A, et al. Ovarian Sertoli-Leydig cell tumor with elevated serum alpha-fetoprotein. *Cancer*. 1989;63:2047-2053.
661. Roth LM, Anderson MC, Govan ADT, et al. Sertoli-Leydig cell tumors. A clinicopathologic study of 34 cases. *Cancer*. 1981;48:187-197.
662. Zaloudek C, Norris HJ. Sertoli-Leydig tumors of the ovary. A clinicopathologic study of 64 intermediate and poorly differentiated neoplasms. *Am J Surg Pathol*. 1984;8: 405-418.
663. Ishida T, Okagaki T, Tagatz GE, et al. Lipid cell tumor of the ovary. An ultrastructural study. *Cancer*. 1977;40:234-243.
664. Roth LM, Sternberg WH. Ovarian stromal tumors containing Leydig cells. II. Pure Leydig cell tumor, nonhilar type. *Cancer*. 1973;32:952-960.
665. Paraskevas M, Scully RE. Hilus cell tumor of the ovary. A clinicopathological analysis of 12 Reinke crystal-positive and nine crystal-negative cases. *Int J Gynecol Pathol*. 1989;8:299-310.
666. Salm R. Ovarian hilus-cell tumours. Their varying presentations. *J Pathol*. 1974;113:117-127.
667. Seidman JD, Abbondanzo SL, Bratthauer GL. Lipid cell (steroid cell) tumor of the ovary. Immunophenotype with analysis of potential pitfall due to endogenous biotin-like activity. *Int J Gynecol Pathol*. 1995;14:331-338.
668. Jones MW, Harri R, Dabbs DJ, Carter GJ. Immunohistochemical profile of steroid cell tumor of the ovary: a study of 14 cases and a review of the literature. *Int J Gynecol Pathol*. 2010;29:315-320.
669. Ichinohasama R, Teshima S, Kishi K, et al. Leydig cell tumor of the ovary associated with endometrial carcinoma and containing 17 beta-hydroxysteroid dehydrogenase. *Int J Gynecol Pathol*. 1989;8:64-71.
670. Hayes MC, Scully RE. Ovarian steroid cell tumors (not otherwise specified). A clinicopathological analysis of 63 cases. *Am J Surg Pathol*. 1987;11:835-845.
671. Rutgers JL, Scully RE. Functioning ovarian tumors with peripheral steroid cell proliferation. A report of twenty-four cases. *Int J Gynecol Pathol*. 1986;5:319-337.
672. Fukunaga M, Endo Y, Ushigome S. Gynandroblastoma of the ovary: a case report with an immunohistochemical and ultrastructural study. *Virchows Arch*. 1997;430:77-82.
673. Broshears JR, Roth LM. Gynandroblastoma with elements resembling juvenile granulosa cell tumor. *Int J Gynecol Pathol*. 1998;16:387-391.
674. McCluggage WG, Sloan JM, Murnaghan M, White R. Gynandroblastoma of ovary with juvenile granulosa cell component and heterologous intestinal type glands. *Histopathology*. 1997;29:253-257.
675. Neubecker RD, Breen JL. Gynandroblastoma. A report of five cases, with a discussion of the histogenesis and classification of ovarian tumors. *Am J Clin Pathol*. 1962;38:60-69.
676. Novak ER. Gynandroblastoma of the ovary. Review of 8 cases from the Ovarian Tumor Registry. *Obstet Gynecol*. 1967;30:709-715.
677. Chivukula M, Hunt J, Carter G, et al. Recurrent gynandroblastoma of ovary—a case report: a molecular and immunohistochemical analysis. *Int J Gynecol Pathol*. 2007;26:30-33.
678. Oparka R, Cassidy A, Reilly S, et al. The C134W (402 C>G) FOXL2 mutation is absent in ovarian gynandroblastoma: insights into the genesis of an unusual tumour. *Histopathology*. 2012;60:838-842.
679. Hart WR, Kumar N, Crissman JD. Ovarian neoplasms resembling sex cord tumors with annular tubules. *Cancer*. 1980;45:2352-2363.
680. Scully RE. The prolonged gestation, birth, and early life of the sex cord tumor with annular tubules and how it joined a syndrome. *Int J Surg Pathol*. 2001;8:233-238.
681. Anderson MC, Govan ADT, Langley FA, et al. Ovarian sex cord tumours with annular tubules. *Histopathology*. 1980;4:137-145.
682. Crissman JD, Hart WR. Ovarian sex cord tumors with annular tubules. An ultrastructural study of three cases. *Am J Clin Pathol*. 1981;75:11-17.
683. Hertel BF, Kempson RL. Ovarian sex cord tumors with annular tubules. An ultrastructural study. *Am J Surg Pathol*. 1977;1:145-153.
684. Ahn GH, Chi JG, Lee SK. Ovarian sex cord tumor with annular tubules. *Cancer*. 1986;57:1066-1073.
685. Lele SM, Sawh RN, Zaharopoulos P, et al. Malignant ovarian sex cord tumor with annular tubules in a patient with Peutz-Jeghers syndrome: a case report. *Mod Pathol*. 2000;13:466-470.
686. Gloor E. Ovarian sex-cord tumor with annular tubules. Clinicopathologic report of two benign and one malignant cases with long follow-ups. *Virchows Arch [A]*. 1979;384:185-193.
687. Young RH, Welch WR, Dickersin GR, Scully RE. Ovarian sex cord tumor with annular tubules. Review of 74 cases including 27 with Peutz-Jeghers syndrome and four with adenoma malignum of the cervix. *Cancer*. 1982;50:1384-1402.
688. Young RH, Dickersin GR, Scully RE. A distinctive ovarian sex cord–stromal tumor causing sexual precocity in the Peutz-Jeghers syndrome. *Am J Surg Pathol*. 1983;7:233-243.
689. Kariminejad MH, Scully RE. Female adnexal tumor of probable wolffian origin—a distinctive pathological entity. *Cancer*. 1973;31:671-677.
690. Rahilly MA, Williams ARW, Krausz T, al Nafussi A. Female adnexal tumour of probable Wolffian origin. A clinicopathological and immunohistochemical study of three cases. *Histopathology*. 1995;26:69-74.
691. Young RH, Scully RE. Ovarian tumors of probable wolffian origin. A report of 11 cases. *Am J Surg Pathol*. 1983;7:125-135.
692. Fanghong LI, Szallasi A, Young RH. Wolffian tumor of the ovary with a prominent spindle cell component: report of a case with brief discussion of unusual problems in differential diagnosis, and literature review. *Int J Surg Pathol*. 2008;16:222-225.
693. Goyal A, Masand RP, Roma AA. Value of PAX-8 and SF-1 Immunohistochemistry in the distinction between female adnexal tumor of probable Wolffian origin and its mimics. *Int J Gynecol Pathol*. 2016;35:167-175.
694. Brescia RJ, Cardoso De Almeida PC, Fuller AF, et al. Female adnexal tumor of probable wolffian origin with multiple recurrences over 16 years. *Cancer*. 1985;56:1456-1461.
695. Sheyn I, Mira JL, Bejarano PA, Husseinzadeh N. Metastatic female adnexal tumor of probable Wolffian origin: a case report and review of the literature. *Arch Pathol Lab Med*. 2000;124:431-434.
696. Vang R, Bagué S, Tavassoli FA, Prat J. Signet-ring stromal tumor of the ovary: clinicopathologic analysis and comparison with Krukenberg tumor. *Int J Gynecol Pathol*. 2004;23:45-51.
697. Irving JA, Young RH. Microcystic stromal tumor of the ovary: report of 16 cases of a hitherto uncharacterized distinctive ovarian neoplasm. *Am J Surg Pathol*. 2009;33:367-375.
698. Bi R, Bai QM, Yang F, et al. Microcystic stromal tumour of the ovary: frequent mutations of β-catenin (CTNNB1) in six cases. *Histopathology*. 2015;67:872-879.
699. Seidman JD. Unclassified ovarian gonadal stromal tumors: a clinicopathologic study of 32 cases. *Am J Surg Pathol*. 1996;20:699-706.
700. Simpson JL, Michael H, Roth LM. Unclassified sex cord–stromal tumors of the ovary: a report of eight cases. *Arch Pathol Lab Med*. 1998;122:52-55.
701. Teter J. The mixed germ tumours with hormonal activity. *Acta Pathol Microbiol Scand [A]*. 1963;58:306-320.
702. Li Y, Tabatabai ZL, Lee TL, et al. The Y-encoded TSPY protein: a significant marker potentially plays a role in the pathogenesis of testicular germ cell tumors. *Hum Pathol*. 2007;38:1470-1481.
703. Nakashima N, Nagasaka T, Fukata S, et al. Ovarian gonadoblastoma with dysgerminoma in a woman with two normal children. *Hum Pathol*. 1989;20:814-816.

For personal use only. No other uses without permission. Copyright ©2017. Elsevier Inc. All rights reserved.

704. Pratt-Thomas HR, Cooper JM. Gonadoblastoma with tubal pregnancy. *Am J Clin Pathol*. 1976;65:121-125.
705. Goldsmith CI, Hart WR. Ataxia-telangiectasia with ovarian gonadoblastoma and contralateral dysgerminoma. *Cancer*. 1975;36:1838-1842.
706. Scully RE. Gonadoblastoma. A review of 74 cases. *Cancer*. 1970;25:1340-1356.
707. Hou-Jensen K, Kempson RL. The ultrastructure of gonadoblastoma and dysgerminoma. *Hum Pathol*. 1974;5:79-91.
708. Hussong J, Crussi FG, Chou PM. Gonadoblastoma: immunohistochemical localization of Mullerian-inhibiting substance, inhibin, WT-1, and. *Mod Pathol*. 1997;10(1101-1105):p53.
709. Kersemaekers AM, Honecker F, Stoop H, et al. Identification of germ cells at risk for neoplastic transformation in gonadoblastoma: an immunohistochemical study for OCT3/4 and TSPY. *Hum Pathol*. 2005;36:512-521.
710. Mackay AM, Pettigrew N, Symington T, Neville AM. Tumors of dysgenetic gonads (gonadoblastoma). Ultrastructural and steroidogenic aspects. *Cancer*. 1974;34:1108-1125.
711. Roth LM, Eglen DE. Gonadoblastoma. Immunohistochemical and ultrastructural observations. *Int J Gynecol Pathol*. 1989;8:72-81.
712. Govan ADT, Woodcock AS, Gowing NFC, et al. A clinico-pathological study of gonadoblastoma. *Br J Obstet Gynecol*. 1977;84:222-228.
713. Hart WR, Burkons DM. Germ cell neoplasms arising in gonadoblastomas. *Cancer*. 1979;43:669-678.
714. Nomura K, Matsui T, Aizawa S. Gonadoblastoma with proliferation resembling sertoli cell tumor. *Int J Gynecol Pathol*. 1999;18:91-93.
715. Safneck JR, deSa DJ. Structures mimicking sex cord–stromal tumours and gonadoblastomas in the ovaries of normal infants and children. *Histopathology*. 1986;10:909-920.
716. Talerman A, van der Harten JJ. A mixed germ cell–sex cord–stromal tumor of the ovary associated with isosexual precocious puberty in a normal girl. *Cancer*. 1977;40:889-894.
717. Tokuoka S, Aoki Y, Hayashi Y, et al. A mixed germ cell–sex cord–stromal tumor of the ovary with retiform tubular structure. A case report. *Int J Gynecol Pathol*. 1985;4:161-170.
718. Michal M, Vanecek T, Sima R, et al. Mixed germ cell sex cord–stromal tumors of the testis and ovary. Morphological, immunohistochemical, and molecular genetic study of seven cases. *Virchows Arch*. 2006;448:612-622.
719. Lacson AG, Gillis DA, Shawwa A. Malignant mixed germ-cell–sex cord–stromal tumors of the ovary associated with isosexual precocious puberty. *Cancer*. 1988;61:2122-2133.
720. Ferry JA, Young RH. Malignant lymphoma, pseudolymphoma, and hematopoietic disorders of the female genital tract. *Pathol Annu*. 1991;26(Pt 1):227-263.
721. Ferry JA, Young RH. Malignant lymphoma of the genitourinary tract. *Curr Diagn Pathol*. 1997;4:145-169.
722. Chorlton I, Norris HJ, King FM. Malignant reticuloendothelial disease involving the ovary as a primary manifestation. A series of 19 lymphomas and 1 granulocytic sarcoma. *Cancer*. 1974;34:397-407.
723. Lagoo AS, Robboy SJ. Lymphoma of the female genital tract: current status. *Int J Gynecol Pathol*. 2006;25:1-21.
724. Paladugu RR, Bearman RM, Rappaport H. Malignant lymphoma with primary manifestation in the gonad. A clinicopathologic study of 38 patients. *Cancer*. 1980;45:561-571.
725. Rotmensch J, Woodruff JD. Lymphoma of the ovary. Report of twenty new cases and update of previous series. *Am J Obstet Gynecol*. 1982;143:870-875.
726. Oliva E, Ferry JA, Young RH, et al. Granulocytic sarcoma of the female genital tract: a clinicopathologic study of 11 cases. *Am J Surg Pathol*. 1997;21:1156-1165.
727. Pressler H, Horny HP, Wolf A, Kaiserling E. Isolated granulocytic sarcoma of the ovary. Histologic, electron microscopic, and immunohistochemical findings. *Int J Gynecol Pathol*. 1992;11:68-74.
728. Monterroso V, Jaffe ES, Merino MJ, Medeiros LJ. Malignant lymphomas involving the ovary. A clinicopathologic analysis of 39 cases. *Am J Surg Pathol*. 1992;17:154-170.
729. Vang R, Medeiros J, Warnke RA, et al. Ovarian non-Hodgkin's lymphoma: a clinicopathologic study of eight primary cases. *Mod Pathol*. 2001;14:1093-1099.
730. Kosari F, Daneshbod Y, Parwaresch R, et al. Lymphomas of the female genital tract: a study of 186 cases and review of the literature. *Am J Surg Pathol*. 2005;29:1512-1520.
731. Osborne BM, Robboy SJ. Lymphomas or leukemias presenting as ovarian tumors. An analysis of 42 cases. *Cancer*. 1983;52:1933-1943.
732. Skodras G, Fields V, Kragel PJ. Ovarian lymphoma and serous carcinoma of low malignant potential arising in the same ovary. A case report with literature review of 14 primary ovarian lymphomas. *Arch Pathol Lab Med*. 1994;118:647-650.
733. Kraemer BB, Silva EG, Sneige N. Fibrosarcoma of ovary. A new component in the nevoid basal-cell carcinoma syndrome. *Am J Surg Pathol*. 1984;8:231-236.
734. Young RH, Prat J, Scully RE. Endometrioid stromal sarcomas of the ovary. A clinicopathologic analysis of 23 cases. *Cancer*. 1984;53:1143-1155.
735. Silverberg SG, Fernandez FN. Endolymphatic stromal myosis of the ovary. A report of three cases and literature review. *Gynecol Oncol*. 1981;12:129-138.
736. Lerwill MF, Sung R, Oliva E, et al. Smooth muscle tumors of the ovary: a clinicopathologic study of 54 cases emphasizing prognostic criteria, histologic variants, and differential diagnosis. *Am J Surg Pathol*. 2004;28:1436-1451.
737. Nasu M, Inoue J, Matsui M, et al. Ovarian leiomyosarcoma: an autopsy case report. *Pathol Int*. 2000;50:162-165.
738. Nogales FF, Ayala A, Ruiz-Avila I, Sirvent JJ. Myxoid leiomyosarcoma of the ovary. Analysis of three cases. *Hum Pathol*. 1991;22:1268-1273.
739. Seracchioli R, Colombo FM, Bagnoli A, et al. Primary ovarian leiomyosarcoma as a new component in the nevoid basal cell carcinoma syndrome: a case report. *Am J Obstet Gynecol*. 2003;188:1093-1095.
740. Talerman A, Auerbach WM, Van Meurs AJ. Primary chondrosarcoma of the ovary. *Histopathology*. 1981;5:319-324.
741. Fadare O, Bossuyt V, Martel M, Parkash V. Primary osteosarcoma of the ovary: a case report and literature review. *Int J Gynecol Pathol*. 2007;26:21-25.
742. Hines JF, Compton DM, Stacy CC, Potter ME. Pure primary osteosarcoma of the ovary presenting as an extensively calcified adnexal mass. A case report and review of the literature. *Gynecol Oncol*. 1990;39: 259-263.
743. Sakata H, Hirahara T, Ryu A, et al. Primary osteosarcoma of the ovary. A case report. *Acta Pathol Jpn*. 1991;41:311-317.
744. Stone GC, Bell DA, Fuller A, et al. Malignant schwannoma of the ovary. Report of a case. *Cancer*. 1986;58:1575-1582.
745. Ongkasuwan C, Taylor JE, Tang C-K, Prempree T. Angiosarcomas of the uterus and ovary. Clinicopathologic report. *Cancer*. 1982;49:1469-1475.
746. Guerard MJ, Arguelles MA, Ferenczy A. Rhabdomyosarcoma of the ovary. Ultrastructural study of a case and review of literature. *Gynecol Oncol*. 1983;15:325-339.
747. Winfield HL, De Las Casas LE, Greenfield WW, et al. Low-grade fibromyxoid sarcoma presenting clinically as a primary ovarian neoplasm: a case report. *Int J Gynecol Pathol*. 2007;26:173-176.
748. Kawauchi S, Fukuda T, Miyamoto S, et al. Peripheral primitive neuroectodermal tumor of the ovary confirmed by CD99 immunostaining, karyotypic analysis, and RT-PCR for EWS/FLI-1 chimeric mRNA. *Am J Surg Pathol*. 1998;22:1417-1422.
749. Kojiro S, Quer A, Snuderl M, et al. Primitive neuroectodermal tumors (PNETs) of the female genital tract (FGT): a morphologic, immunohistochemical, and molecular study of 18 cases. *Lab Invest*. 2009;89(suppl 1):222A.
750. Nielsen GP, Oliva E, Young RH, et al. Primary ovarian rhabdomyosarcoma: a report of 13 cases. *Int J Gynecol Pathol*. 1998;17:113-119.
751. Sant'Ambrogoio S, Malpica A, Schroeder B, Silva EG. Primary ovarian rhabdomyosarcoma associated with clear cell carcinoma of the ovary: a case report and review of the literature. *Int J Gynecol Pathol*. 2000;19:169-173.
752. Nielsen GP, Young RH, Prat J, Scully RE. Primary angiosarcoma of the ovary: A report of seven cases and review of the literature. *Int J Gynecol Pathol*. 1998;16:378-382.
753. Nucci MR, Krausz T, Lifschitz-Mercer B, et al. Angiosarcoma of the ovary: clinicopathologic and immunohistochemical analysis of four cases with a broad morphologic spectrum. *Am J Surg Pathol*. 1998;22:620-630.
754. Sood AK, Sorosky JI, Gelder MS, et al. Primary ovarian sarcoma: analysis of prognostic variables and the role of surgical cytoreduction. *Cancer*. 1998;82:1731-1737.
755. Alvarez M, Cerezo L. Ovarian cavernous hemangioma. *Arch Pathol Lab Med*. 1986;110:77-78.
756. Prus D, Rosenburg AE, Blumenfeld A, et al. Infantile hemangioendothelioma of the ovary: a monodermal teratoma or a neoplasm of ovarian somatic cells? *Am J Surg Pathol*. 1997;21:1231-1235.
757. Evans A, Lytwyn A, Urbach G, Chapman W. Bilateral lymphangiomas of the ovary: an immunohistochemical characterization and review of the literature. *Int J Gynecol Pathol*. 1999;18:87-90.
758. Gokten N, Peterdy G, Philpott T, Maluf HM. Glomus tumor of the ovary: report of a case with immunohistochemical and ultrastructural observations. *Int J Gynecol Pathol*. 2001;20:390-394.
759. Slone SP, Moore GD, Parker LP, et al. Glomus tumor of the ovary masquerading as granulosa cell tumor: case report. *Int J Gynecol Pathol*. 2010;29:24-26.
760. Doss BJ, Wanek SM, Jacques SM, et al. Ovarian leiomyomas: clinicopathologic features in fifteen cases. *Int J Gynecol Pathol*. 1999;18:63-68.
761. Friedman HD, Mazur MT. Primary ovarian leiomyosarcoma. An immunohistochemical and ultrastructural study. *Arch Pathol Lab Med*. 1991;115:941-945.
762. Kandalaft PL, Esteban JM. Bilateral massive ovarian leiomyomata in a young woman. A case report with review of the literature. *Mod Pathol*. 1992;5:586-589.
763. Prayson RA, Hart WR. Primary smooth-muscle tumors of the ovary. A clinicopathologic study of four leiomyomas and two mitotically active

For personal use only. No other uses without permission. Copyright ©2017. Elsevier Inc. All rights reserved.

leiomyomas. *Arch Pathol Lab Med*. 1992;116:1068-1071.
764. Rhoades CP, McMahon JT, Goldblum JR. Myofibroblastoma of the ovary: report of a case. *Mod Pathol*. 1999;12:907-911.
765. Anderson AE, Yang X, Young RH. Epithelioid angiomyolipoma of the ovary: a case report and literature review. *Int J Gynecol Pathol*. 2002;21:69-73.
766. Isaac MA, Vijayalakshmi S, Madhu CS, et al. Pure cystic nephroblastoma of the ovary with a review of extrarenal Wilms' tumors. *Hum Pathol*. 2000;31:761-764.
767. Fang X, Rodabaugh K, Penetrante R, et al. Desmoplastic small round cell tumor (DSRCT) with ovarian involvement in 2 young women. *Appl Immunohistochem Mol Morphol*. 2008;16:94-99.
768. Fawcett FJ, Kimbell NKB. Phaeochromocytoma of the ovary. *J Obstet Gynaecol Br Commonw*. 1971;78:458-459.
769. McCluggage WG, Young RH. Paraganglioma of the ovary: report of three cases of a rare ovarian neoplasm, including two exhibiting inhibin positivity. *Am J Surg Pathol*. 2006;30:600-605.
770. Yenen E, Inanc FA, Babuna C. Primary ovarian hydatidiform mole. Report of a case. *Obstet Gynecol*. 1966;26:721-724.
771. Young RH, Silva EG, Scully RE. Ovarian and juxtaovarian adenomatoid tumors. A report of six cases. *Int J Gynecol Pathol*. 1991;10:364-371.
772. Phillips V, McCluggage WG, Young RH. Oxyphilic adenomatoid tumor of the ovary: a case report with discussion of the differential diagnosis of ovarian tumors with vacuoles and related spaces. *Int J Gynecol Pathol*. 2007;26:16-20.
773. McCluggage WG, Bissonnette JP, Young RH. Primary malignant melanoma of the ovary: a report of 9 definite or probable cases with emphasis on their morphologic diversity and mimicry of other primary and secondary ovarian neoplasms. *Int J Gynecol Pathol*. 2006;25:321-329.
774. Deshpande V, Oliva E, Young RH. Solid pseudopapillary neoplasm of the ovary: a report of 3 primary ovarian tumors resembling those of the pancreas. *Am J Surg Pathol*. 2010;34:1514-1520.
775. Demopoulos RI, Touger L, Dubin N. Secondary ovarian carcinoma. A clinical and pathological evaluation. *Int J Gynecol Pathol*. 1987;6:166-175.
776. McCluggage WG, Wilkinson N. Metastatic neoplasms involving the ovary: a review with an emphasis on morphological and immunohistochemical features. *Histopathology*. 2005;47:231-247.
777. Mazur MT, Hsueh S, Gersell DJ. Metastases to the female genital tract. Analysis of 325 cases. *Cancer*. 1984;53:1978-1984.
778. Young RH, Scully RE. Metastatic tumors in the ovary. A problem-oriented approach and review of the recent literature. *Semin Diagn Pathol*. 1991;8:250-276.
779. Ronnett BM, Yemelyanova AV, Vang R, et al. Endocervical adenocarcinomas with ovarian metastases: analysis of 29 cases with emphasis on minimally invasive cervical tumors and the ability of the metastases to simulate primary ovarian neoplasms. *Am J Surg Pathol*. 2008;32:1835-1853.
780. Irving JA, Young RH. Lung carcinoma metastatic to the ovary: a clinicopathologic study of 32 cases emphasizing their morphologic spectrum and problems in differential diagnosis. *Am J Surg Pathol*. 2005;29:997-1006.
781. Young RH, Scully RE. Ovarian metastases from cancer of the lung. Problems in interpretation—a report of seven cases. *Gynecol Oncol*. 1985;21:337-350.
782. Fitzgibbons PL, Martin SE, Simmons TJ. Malignant melanoma metastatic to the ovary. *Am J Surg Pathol*. 1987;11:959-964.
783. Ulbright TM, Roth LM, Stehman FB. Secondary ovarian neoplasia. A clinicopathologic study of 35 cases. *Cancer*. 1984;53:1164-1174.
784. Yazigi R, Sandstad J. Ovarian involvement in extragenital cancer. *Gynecol Oncol*. 1989;34:84-87.
785. Young RH, Scully RE. Malignant melanoma metastatic to the ovary. A clinicopathologic analysis of 20 cases. *Am J Surg Pathol*. 1991;15:849-860.
786. Monteagudo C, Merino MJ, La Porte N, Neumann RD. Value of gross cystic disease fluid protein-15 in distinguishing metastatic breast carcinomas among poorly differentiated neoplasms involving the ovary. *Hum Pathol*. 1991;22:368-372.
787. Yang Y, Lu S, Zeng W, et al. GATA3 expression in clinically useful groups of breast carcinoma: a comparison with GCDFP15 and mammaglobin for identifying paired primary and metastatic tumors. *Ann Diagn Pathol*. 2017;26:1-5.
788. Tornos C, Soslow R, Chen S, et al. Expression of WT1, CA 125, and GCDFP-15 as useful markers in the differential diagnosis of primary ovarian carcinomas versus metastatic breast cancer to the ovary. *Am J Surg Pathol*. 2005;29:1482-1489.
789. Daya D, Nazerali L, Frank GL. Metastatic ovarian carcinoma of large intestinal origin simulating primary ovarian carcinoma. A clinicopathologic study of 25 cases. *Am J Clin Pathol*. 1992;97:751-758.
790. Hart WR. Diagnostic challenge of secondary (metastatic) ovarian tumors simulating primary endometroid and mucinous neoplasms. *Pathol Int*. 2005;55:231-243.
791. Young RH, Hart WR. Metastatic intestinal carcinomas simulating primary ovarian clear cell carcinoma and secretory endometrioid carcinoma: clinicopathologic and immunohistochemical study of five cases. *Am J Surg Pathol*. 1998;22:805-815.
792. Judson K, McCormick C, Vang R, et al. Women with undiagnosed colorectal adenocarcinomas presenting with ovarian metastases: clinicopathologic features and comparison with women having known colorectal adenocarcinomas and ovarian involvement. *Int J Gynecol Pathol*. 2008;27:182-190.
793. Scully RE, Richardson GS. Luteinization of the stroma of metastatic cancer involving the ovary and its endocrine significance. *Cancer*. 1961;14:827-840.
794. Lash RH, Hart WR. Intestinal adenocarcinomas metastatic to the ovaries. A clinicopathologic evaluation of 22 cases. *Am J Surg Pathol*. 1987;11:114-121.
795. Lee KR, Young RH. The distinction between primary and metastatic mucinous carcinomas of the ovary: gross and histologic findings in 50 cases. *Am J Surg Pathol*. 2003;27:281-292.
796. Seidman JD, Kurman RJ, Ronnett BM. Primary and metastatic mucinous adenocarcinomas in the ovaries. Incidence of routine practice with a new approach to improve intraoperative diagnosis. *Am J Surg Pathol*. 2003;27:985-993.
797. Lewis MR, Deavers MT, Silva EG, Malpica A. Ovarian involvement by metastatic colorectal adenocarcinoma: still a diagnostic challenge. *Am J Surg Pathol*. 2006;30:177-184.
798. Albarracin CT, Jafri J, Montag AG, et al. Differential expression of MUC2 and MUC5AC mucin genes in primary ovarian and metastatic colonic carcinoma. *Hum Pathol*. 2000;31:672-677.
799. Groisman GM, Meir A, Sabo E. The value of Cdx2 immunostaining in differentiating primary ovarian carcinomas from colonic carcinomas metastatic to the ovaries. *Int J Gynecol Pathol*. 2004;23:52-57.
800. Lagendijk JH, Mullink H, Van Diest PJ, et al. Tracing the origin of adenocarcinomas with unknown primary. Using immunohistochemistry: differential diagnosis between colonic and ovarian carcinomas as primary sites. *Hum Pathol*. 1998;29:491-497.
801. Vang R, Gown AM, Barry TS, et al. Immunohistochemistry for estrogen and progesterone receptors in the distinction of primary and metastatic mucinous tumors in the ovary: an analysis of 124 cases. *Mod Pathol*. 2006;19:97-105.
802. Abadeer RA, Malpica A. Metastatic pancreatic adenocarcinoma to the ovary: a clinicopathologic review of twenty nine cases. *Lab Invest*. 2009;89(suppl 1):204A-205A.
803. Park SY, Kim HS, Hong EK, Kim WH. Expression of cytokeratins 7 and 20 in primary carcinomas of the stomach and colorectum and their value in the differential diagnosis of metastatic carcinomas of the ovary. *Hum Pathol*. 2002;33:1078-1085.
804. Vang R, Gown AM, Barry TS, et al. Cytokeratins 7 and 20 in primary and secondary mucinous tumors of the ovary: analysis of coordinate immunohistochemical expression profiles and staining distribution in 179 cases. *Am J Surg Pathol*. 2006;30:1130-1139.
805. Ronnett BM, Kurman RJ, Shmookler BM, et al. The morphologic spectrum of ovarian metastases of appendiceal: a clinicopathologic immunohistochemical analysis of tumors often misinterpreted as primary ovarian tumors or metastatic tumors from other gastrointestinal sites. *Am J Surg Pathol*. 1997;21:1144-1155.
806. Szych C, Staebler A, Connolly DC, et al. Molecular genetic evidence supporting the clonality and appendiceal origin of pseudomyxoma peritonei in women. *Am J Pathol*. 1999;154:1849-1855.
807. Eichhorn JH, Young RH, Scully RE. Nonpulmonary small cell carcinomas of extragenital origin metastatic to the ovary. *Cancer*. 1993;71:177-186.
808. Al-Agha OM, Nicastri AD. An in-depth look at Krukenberg tumor: an overview. *Arch Pathol Lab Med*. 2006;130:1725-1730.
809. Kiyokawa T, Young RH, Scully RE. Krukenberg tumors of the ovary: a clinicopathologic analysis of 120 cases with emphasis on their variable pathologic manifestations. *Am J Surg Pathol*. 2006;30:277-299.
810. Wong PC, Ferenczy A, Fan L-D, McCaughey E. Krukenberg tumors of the ovary. Ultrastructural, histochemical, and immunohistochemical studies of 15 cases. *Cancer*. 1986;57:751-760.
811. Woodruff JD, Novak ER. The Krukenberg tumor. Study of 48 cases from the Ovarian Tumor Registry. *Obstet Gynecol*. 1960;15:351-360.
812. Bullon A Jr, Arseneau J, Prat J, et al. Tubular Krukenberg tumor. A problem in histopathologic diagnosis. *Am J Surg Pathol*. 1981;5:225-232.
813. Holtz F, Hart WR. Krukenberg tumors of the ovary. A clinicopathologic analysis of 27 cases. *Cancer*. 1982;50:2438-2447.
814. Klein EA, Rosen MH. Bilateral Krukenberg tumors due to appendiceal mucinous carcinoid. *Int J Gynecol Pathol*. 1996;15:85-88.
815. Warren S, Macomber WB. Tumor metastasis. IV. Ovarian metastasis of carcinoma. *Arch Pathol*. 1935;19:75-82.
816. Lerwill MF, Young RH. Ovarian metastases of intestinal-type gastric carcinoma: a clinicopathologic study of 4 cases with contrasting features to those of the Krukenberg tumor. *Am J Surg Pathol*. 2006;30:1382-1388.

For personal use only. No other uses without permission. Copyright ©2017. Elsevier Inc. All rights reserved.

817. Joshi VV. Primary Krukenberg tumor of ovary. Review of literature and case report. *Cancer*. 1968;22:1199-1207.
818. Ramzy I. Signet-ring stromal tumor of ovary. Histochemical, light, and electron microscopic study. *Cancer*. 1976;38:166-172.
819. Khunamornpong S, Lerwill MF, Siriaunkgul S, et al. Carcinoma of extrahepatic bile ducts and gallbladder metastatic to the ovary: a report of 16 cases. *Int J Gynecol Pathol*. 2008;27:366-379.
820. Khunamornpong S, Siriaunkgul S, Suprasert P, et al. Intrahepatic cholangiocarcinoma metastatic to the ovary: a report of 16 cases of an underemphasized form of secondary tumor in the ovary that may mimic primary neoplasia. *Am J Surg Pathol*. 2007;31:1788-1799.
821. Young RH, Hart WR. Metastases from carcinomas of the pancreas simulating primary mucinous tumors of the ovary. A report of seven cases. *Am J Surg Pathol*. 1989;13:748-756.
822. Young RH, Scully RE. Ovarian metastases from carcinoma of the gallbladder and extrahepatic bile ducts simulating primary tumors of the ovary. A report of six cases. *Int J Gynecol Pathol*. 1990;9:60-72.
823. Vakiani E, Young RH, Carcangiu ML, Klimstra DS. Acinar cell carcinoma of the pancreas metastatic to the ovary: a report of 4 cases. *Am J Surg Pathol*. 2008;32:1540-1545.
824. Insabato L, De Rosa G, Franco R, et al. Ovarian metatasis from renal cell carcinoma: a report of three cases. *Int J Surg Pathol*. 2003;11:309-312.
825. Young RH, Hart WR. Renal cell carcinoma metastatic to the ovary. A report of three cases emphasizing possible confusion with ovarian clear cell adenocarcinoma. *Int J Gynecol Pathol*. 1992;11:96-104.
826. Irving JA, Vasques DR, McGuinness TB, Young RH. Krukenberg tumor of renal pelvic origin: report of a case with selected comments on ovarian tumors metastatic from the urinary tract. *Int J Gynecol Pathol*. 2006;25:147-150.
827. Young RH, Jackson A, Wells M. Ovarian metastasis from thyroid carcinoma 12 years after partial thyroidectomy mimicking struma ovarii. Report of a case. *Int J Gynecol Pathol*. 1994;13:181-185.
828. Pitman MB, Triratanachat S, Young RH, Oliva E. Hepatocyte paraffin 1 antibody does not distinguish primary ovarian tumors with hepatoid differentiation from metastatic hepatocellular carcinoma. *Int J Gynecol Pathol*. 2004;23:58-64.
829. Green LK, Silva EG. Hepatoblastoma in an adult with metastasis to the ovaries. *Am J Clin Pathol*. 1989;92:110-115.
830. Young RH, Gersell DJ, Clement PB, Scully RE. Hepatocellular carcinoma metastatic to the ovary. A report of three cases discovered during life with discussion of the differential diagnosis of hepatoid tumors of the ovary. *Hum Pathol*. 1992;23:574-580.
831. Young RH, Eichhorn JH, Dickersin GR, Scully RE. Ovarian involvement by the intra-abdominal desmoplastic small round cell tumor with divergent differentiation. A report of three cases. *Hum Pathol*. 1992;23:454-464.
832. Zaloudek C, Miller TR, Stern JL. Desmoplastic small cell tumor of the ovary. A unique polyphenotypic tumor with an unfavorable prognosis. *Int J Gynecol Pathol*. 1995;14:260-265.
833. Eltabbakh GH, Belinson JL, Biscotti CV. Osteosarcoma metastatic to the ovary: a case report and review of the literature. *Int J Gynecol Pathol*. 1997;16:76-78.
834. Irving JA, Lerwill MF, Young RH. Gastrointestinal stromal tumors metastatic to the ovary: a report of five cases. *Am J Surg Pathol*. 2005;29:920-926.
835. Nugent SL, Dim DC, Bridge JA, Ioffe OB. Clear cell sarcoma of soft tissue metastatic to the ovaries: a heretofore unreported occurrence. *Int J Gynecol Pathol*. 2009;28:234-238.
836. Young RH, Scully RE. Sarcomas metastatic to the ovary. A report of 21 cases. *Int J Gynecol Pathol*. 1990;9:231-252.
837. Zukerberg LR, Young RH. Chordoma metastatic to the ovary. *Arch Pathol Lab Med*. 1990;114:208-210.
838. Gupta D, Deavers MT, Silva EG, Malpica A. Malignanat melanoma involving the ovary: a clinicopathologic and immunohistochemical study of 23 cases. *Am J Surg Pathol*. 2004;28:771-780.

For personal use only. No other uses without permission. Copyright ©2017. Elsevier Inc. All rights reserved.

36 Breast

Laura C. Collins

CHAPTER CONTENTS

Normal anatomy, *1434*
Ectopia, *1436*
Inflammatory and related lesions, *1437*
Mammary duct ectasia, *1437*
Fat necrosis, *1438*
Lymphocytic mastopathy, *1438*
Idiopathic granulomatous mastitis, *1439*
Cystic neutrophilic granulomatous mastitis, *1439*
Other inflammatory diseases, *1439*
Benign breast disease, *1440*
Intraductal proliferative lesions and nonproliferative changes, *1440*
Nonproliferative changes, *1440*
Intraductal proliferative lesions, *1441*
Fibroepithelial lesions, *1447*
Fibroadenoma, *1447*
Phyllodes tumor, *1449*
Adenosis and sclerosing lesions, *1451*
Adenosis, *1451*
Radial scar and complex sclerosing lesions, *1453*
Papillary lesions, *1456*
Intraductal papilloma, *1456*
Papillary ductal carcinoma in situ, *1458*
Encapsulated papillary carcinoma, *1459*
Solid papillary carcinoma, *1460*
Solid papillary carcinoma with reverse polarity, *1461*
Invasive papillary carcinoma, *1462*
Nipple lesions, *1462*
Nipple adenoma, *1462*
Squamous metaplasia of lactiferous ducts, *1462*
Paget disease, *1462*
Carcinoma, *1464*
General features, *1464*
Diagnosis, *1468*
Carcinoma in situ, *1472*
Invasive carcinoma, *1478*
Hormone receptors, *1492*
Molecular genetics and molecular classification of breast cancer, *1494*
Extent, local recurrence, and metastases, *1496*
Occult breast carcinoma, *1496*
Sentinel lymph node, *1497*
Staging of breast carcinoma, *1497*
Therapy for breast carcinoma, *1499*
Prognosis, *1501*
Salivary gland and skin adnexal-type tumors (including myoepithelial tumors), *1503*
Stromal and vascular tumors and tumorlike conditions, *1504*
Other malignant stromal tumors, *1506*
Lymphoid tumors and tumorlike conditions, *1506*
Other primary tumors and tumorlike conditions, *1507*
Metastatic tumors, *1509*
Breast diseases in children and adolescents, *1510*
Breast diseases in males, *1511*
Gynecomastia, *1511*
Myofibroblastoma, *1511*
Carcinoma, *1511*
Other lesions, *1512*

Normal Anatomy

The breast or mammary gland is covered by skin and subcutaneous tissue and rests on the pectoralis muscle, from which it is separated by a fascial layer. The morphofunctional unit of the breast is a complex branching structure that is topographically arranged into *lobes* and which is made up of two major components: the *terminal duct–lobular unit (TDLU)* and the *large duct system*.[1] The TDLU is formed by the *lobule*, which in turn is made up of acini, and the *terminal ductule* and represents the secretory portion of the gland. It connects with the *subsegmental duct*, which in turn leads to the *segmental duct*, and this to the *collecting* (*lactiferous*) *duct*, which empties into the nipple. A fusiform dilation located beneath the nipple between the collecting and segmental ducts is known as the *lactiferous sinus* (Fig. 36.1).

The TDLU is recognized by its distinctly lobular architecture, the presence of a mantle of specialized, myxoid-appearing hormone-responsive connective tissue, and the absence of elastic fibers. The development of the breast is dependent on the close interaction of these specialized epithelial and mesenchymal tissues.[2] The large ducts have less specialized stroma and are enveloped by a continuous and well-developed layer of elastic tissue. The entire ductal–lobular system of the breast is lined by a specialized *inner epithelial cell layer* with secretory and absorptive functions (often simply called epithelium)

For personal use only. No other uses without permission. Copyright ©2017. Elsevier Inc. All rights reserved.

Abstract

Breast pathology encompasses a wide range of benign, atypical, and malignant lesions. This chapter reviews both neoplastic and non-neoplastic lesions of the breast with discussion of differential diagnoses and appropriate adjunctive studies. Consideration is given to challenges that may be encountered with particular specimen types, such as core needle biopsies. Risk factors and molecular alterations are discussed as they pertain to the entities described.

Keywords

Breast,
carcinoma,
benign breast disease,
fibroepithelial lesions,
papillary lesions,
adenosis,
nipple lesions

For personal use only. No other uses without permission. Copyright ©2017. Elsevier Inc. All rights reserved.

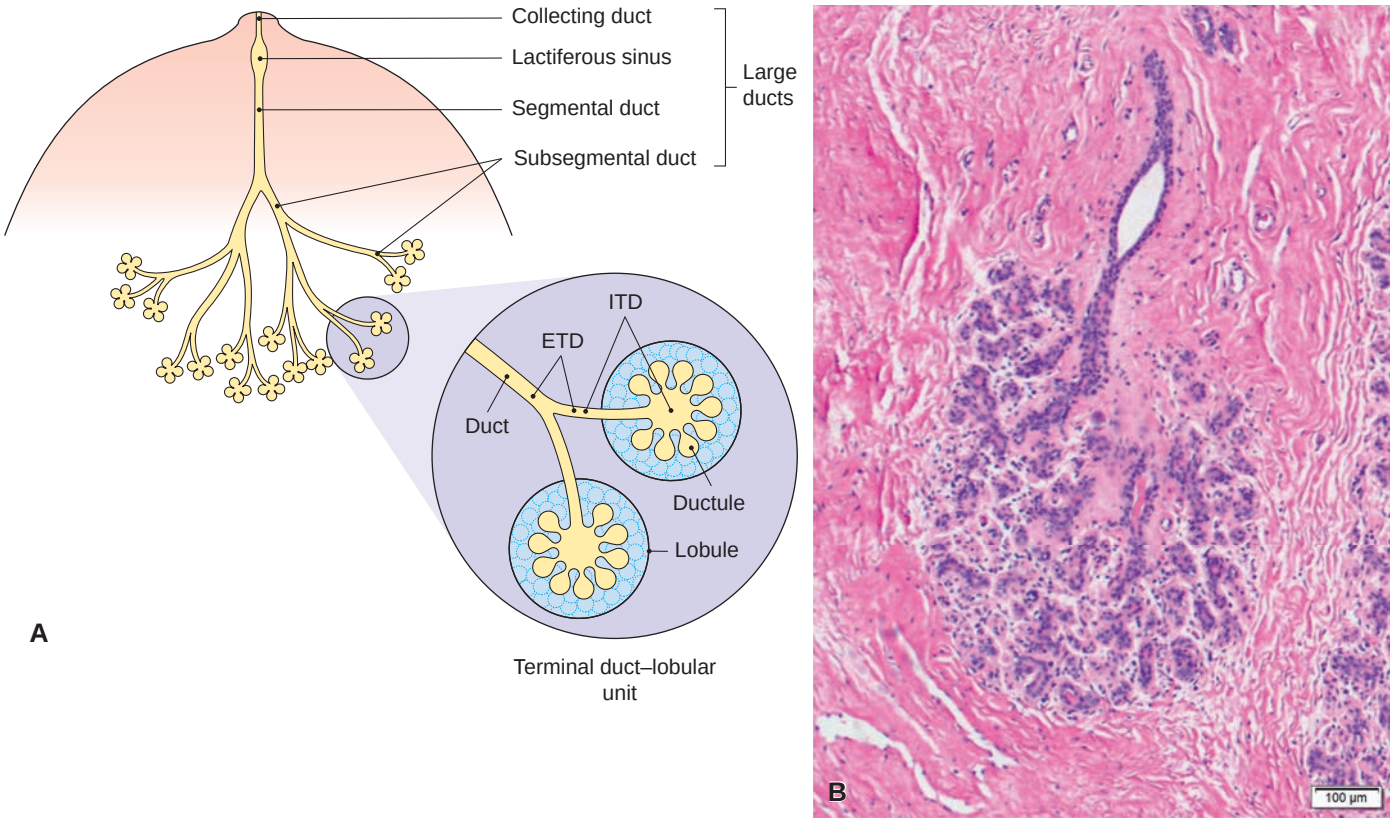

Figure 36.1 Terminal Duct–Lobular Unit. A, Diagrammatic representation of this structure. **B,** Photomicrograph of this unit as seen in a normal adult female. *ETD*, Extralobular terminal duct; *ITD*, intralobular terminal duct.

and is surrounded by an outer *myoepithelial cell layer*. These two cell types have distinctive immunohistochemical features. The most reliable markers for the epithelial cells are the various cytokeratins (see later), epithelial membrane antigen (EMA), mammaglobin (Fig. 36.2A), GCDFP-15, and GATA3. Myoepithelial cells react with high-molecular-weight (HMW) cytokeratins, smooth muscle actin (SMA), calponin, smooth muscle myosin heavy chain (see Fig. 36.2B), maspin, and caldesmon (the latter only in the ductal portion). They also show nuclear reactivity for p63 (a member of the *TP53* gene family) and p75 neurotrophin receptor (p75NTR).

EMA reacts strongly with the apical region of active secretory cells but may be faint or negative in other epithelial cells. Pankeratin antibodies react with both epithelial and myoepithelial cells. Cytokeratins (CK) 8, 18, and 19 react with the epithelial cells throughout the TDLU but not with the myoepithelial cells, whereas the converse is true for CK14. Other immunohistochemical features of mammary epithelial cells are discussed in the section on invasive carcinoma. A sparse population of endocrine cells has been demonstrated in the normal breast with the use of chromogranin stain.[3]

It has been proposed that the two basic cell lineages of the breast—epithelial and myoepithelial—derive from a common cell that displays the phenotypic features of a committed stem cell (progenitor cell). This cell expresses CK5 in the absence of CK8, 18, and 19 and SMA. These progenitor cells are postulated to differentiate through an intermediary cell type that is CK5+ and either CK8/18+ or SMA+.[4,5]

The entire glandular system rests on a continuous basement membrane. This can be demonstrated with reticulin stains or with immunohistochemical reactions for laminin or type IV collagen.

The nipple has a very characteristic microscopic appearance. In addition to the large collecting ducts, which open onto the surface through five to nine orifices arranged as a central and a peripheral group,[6] it contains numerous sebaceous glands that open independently of hair follicles, and a dense fibrous stroma in which erectile smooth muscle tissue is embedded. *Montgomery tubercles* are areolar protuberances, usually between 10 and 20 in number, which become prominent during pregnancy; microscopically, they are formed by the association of a collecting (lactiferous) duct with sebaceous glands. The epidermis of the nipple and areola resembles that of the skin elsewhere, except for an increase in melanin content in the basal layer and the occasional presence of clear cells known as *Toker cells*, which can be mistaken for the cells of Paget disease.[7,8] The irregular corrugated appearance of the lactiferous sinus should not be confused with a pathologic condition. In approximately 15% of individuals, normal breast lobules are present in the nipple region.[9]

Breast tissue responds to hormonal and other influences throughout life, and, as a result, it may display a wide range of "normal" appearances: the immature and largely resting breast before puberty; the developed breast of reproductive life, which exhibits changes depending on the point in the menstrual cycle[10]; the actively secreting breast of lactation (Fig. 36.3); and the involuted postmenopausal breast. In the resting breast, cellular proliferation is largely confined to epithelial cells[11]; during pregnancy and lactation, all cell types show a high level of proliferative activity.[12] Nodularity and leakage of milk into the stroma can occur; exaggerated expressions of these phenomena have been designated *lactating adenoma* and *milk granuloma*, respectively.[13,14]

Mild, transient changes may be seen with initiation of contraceptive therapy. Microscopically, the only definite mammary change that can be ascribed to the medication is the development of true acini resembling those seen in the lactating breast.[15]

For personal use only. No other uses without permission. Copyright ©2017. Elsevier Inc. All rights reserved.

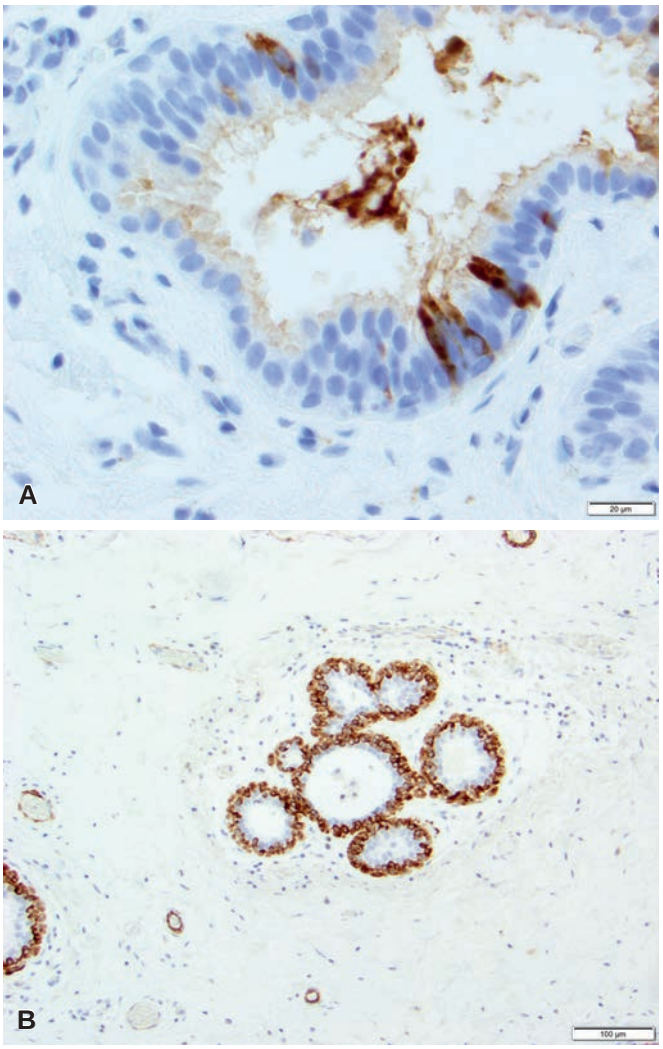

Figure 36.2 Immunohistochemical Markers of Mammary Lobule. A, Mammaglobin, showing positivity in scattered secretory epithelial cells and material in the glandular lumen. **B,** Smooth muscle myosin heavy chain, showing positivity in the outer myoepithelial cell component. Smooth muscle cells present in adjacent vessel walls serve as internal controls.

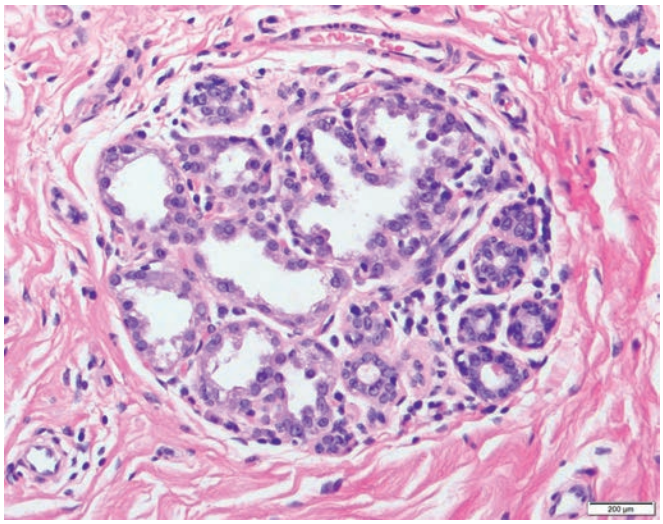

Figure 36.3 Lactational or Secretory Changes in Mammary Lobule. Some of the acini of this lobule demonstrate cytoplasmic vacuolization and protrusion as well as nuclear enlargement in keeping with lactation or secretory change.

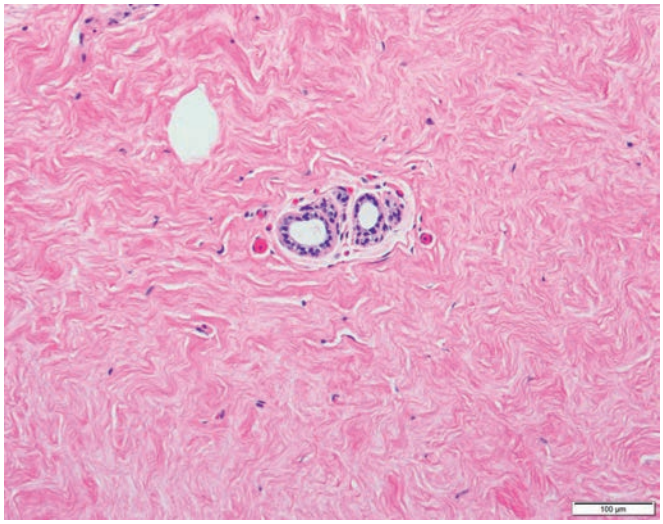

Figure 36.4 Postmenopausal Breast Tissue. The TDLU undergoes involution leaving few atrophic acini.

The process of normal *postmenopausal involution* is most apparent in the TDLU and involves both epithelium and specialized stroma (Fig. 36.4); it may acquire a microcystic quality. Deposits of elastic tissue around the ducts *(elastosis)* have been reported in nearly half of all women over 50 years of age.[16]

There are two morphologic curiosities of the breast worth knowing about, not because of their clinical significance, but because they can simulate other conditions of greater consequence. One is the *pregnancy-like change* seen in one or several lobules in the absence of pregnancy or hormonal manipulation.[17,18] The cells have abundant vacuolated cytoplasm, the nuclei are large and sometimes apically located (giving the lesion an appearance that resembles the Arias-Stella reaction), and the lumina are dilated (Fig. 36.5). Pregnancy-like change may be seen in association with *cystic hypersecretory hyperplasia (CHH)*, though the exact relationship of these two lesions is unknown at present.[19] The other process is *clear cell change* of the ductal or lobular epithelium, in which the cytoplasm acquires a finely granular, finely vacuolated, or totally clear appearance (Fig. 36.6).[17,20] The mechanism of these two changes is unknown.

The main importance of the division of the mammary gland unit into two major portions (ducts and lobules) resides in its relation to diseases of this organ. As Wellings et al.[21] convincingly showed and Azzopardi[22] strongly emphasized, the site of origin of benign breast disease, and most carcinomas (including those of so-called ductal type) is the TDLU and not the large duct system. The latter is instead the primary site of most single solitary papillomas and of duct ectasia.

Ectopia

The mammary gland is not a sharply demarcated organ; as a result, isolated mammary lobules can sometimes be seen outside the standard anatomic confines of the breast parenchyma, such as in the nipple or axilla.[9,23] The latter may explain the occurrence of some seemingly primary breast carcinomas in the axilla. Ectopic breast tissue has also been reported within axillary lymph nodes[24,25] and along the

For personal use only. No other uses without permission. Copyright ©2017. Elsevier Inc. All rights reserved.

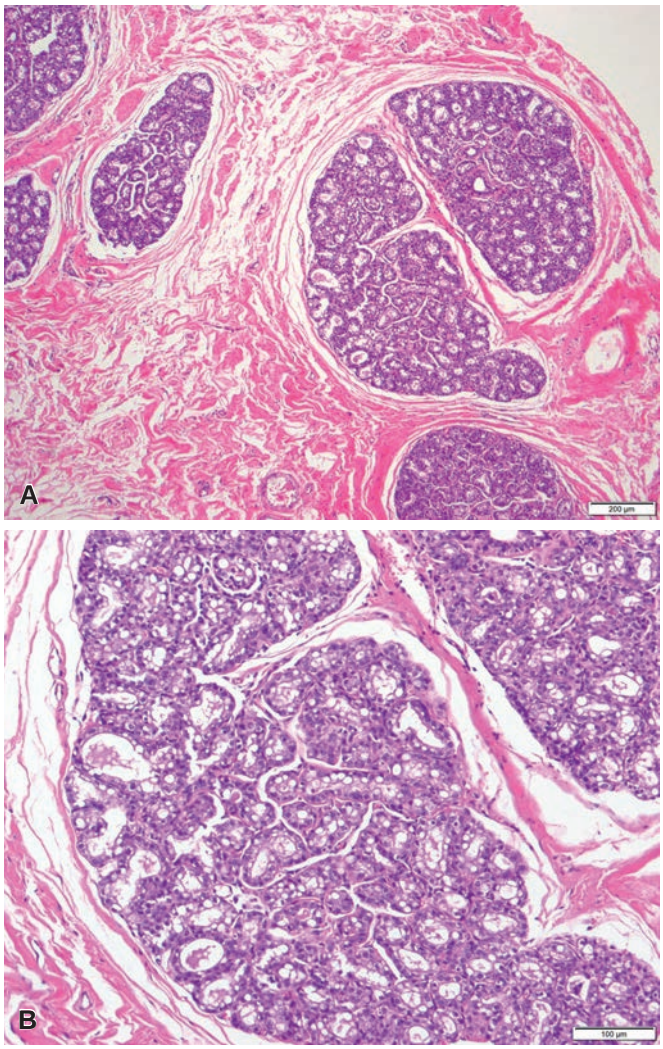

Figure 36.5 Pregnancy-Like Change in Mammary Lobule. A, Low-power view. **B,** Higher-power view.

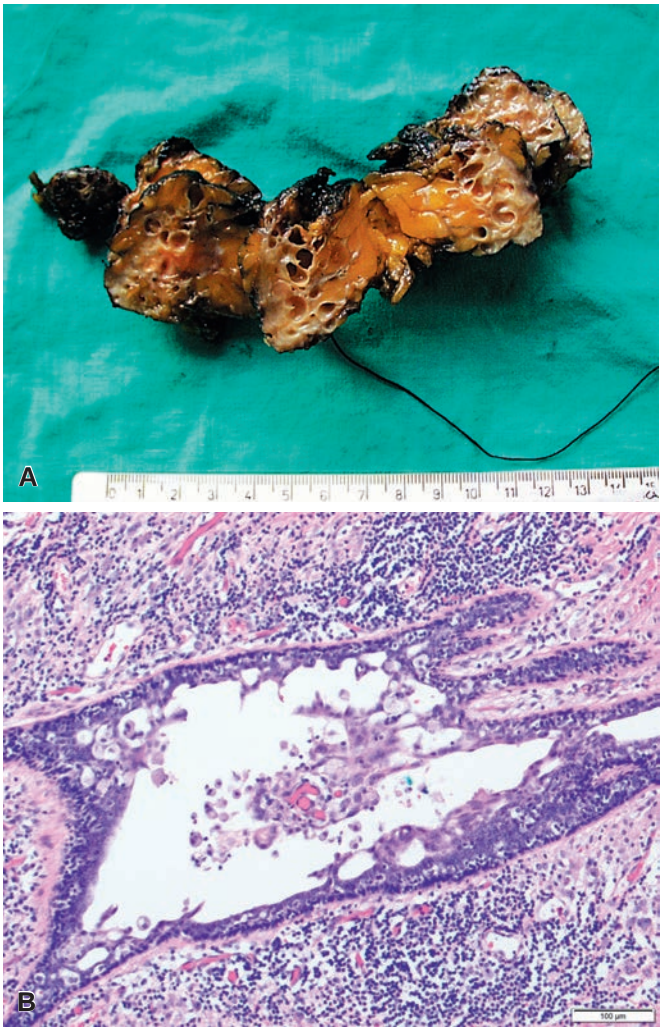

Figure 36.7 Gross and Microscopic Appearance of Mammary Duct Ectasia. A, Some of the dilated ducts contain a thick dark material. **B,** Inflammatory stage of duct ectasia in which there is dilation of a large duct, with accumulation of lipid-rich detritus in the lumen and a florid inflammatory reaction rich in macrophages and plasma cells.

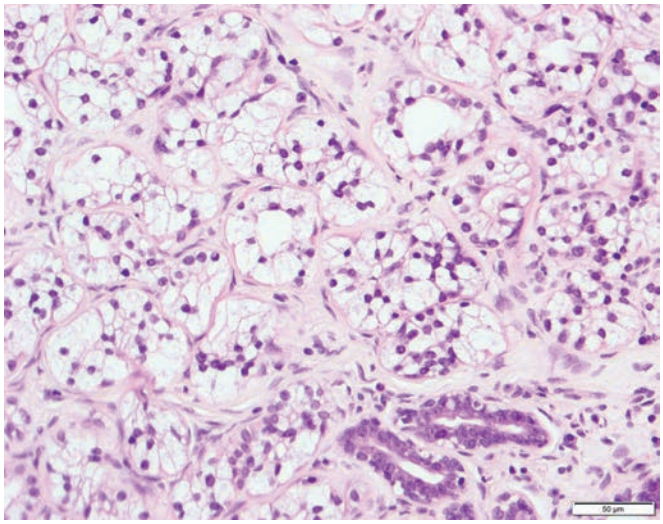

Figure 36.6 Clear cell change.

"milk line" that runs from the axilla to the inguinal region, the most common sites being the chest wall and the vulva.[26]

Ectopic breast parenchyma is subject to changes similar to those of the orthotopic organ, including lactational changes, benign neoplasms, and carcinomas.[26,27] There is considerable overlap between ectopic breast tissue and breast-like metaplasias of sweat glands, a fact that renders precise histogenetic identification of some of these lesions almost impossible.[28]

Inflammatory and Related Lesions

Mammary Duct Ectasia

Mammary duct ectasia has also been referred to as periductal mastitis and mastitis obliterans (Fig. 36.7).[29] Most cases are seen in premenopausal women and may represent a localized response to stagnant secretions. While the pathogenesis remains unknown, some studies have shown an association with smoking.[30] As beautifully described and illustrated in the classic article by Haagensen,[31] the disease may produce retraction or inversion of the nipple and thus clinically and radiologically may simulate invasive carcinoma.

For personal use only. No other uses without permission. Copyright ©2017. Elsevier Inc. All rights reserved.

Calcification is common, producing tubular, annular, and linear shadowing on mammographic examination. Nipple discharge is present in 20% of cases. Microscopically, there is dilation of large ducts, with accumulation of lipid-rich detritus in the lumen and fibrous thickening of the wall, which contains an increased amount of elastic fibers. There is usually no accompanying epithelial hyperplasia or apocrine metaplasia. If the luminal material escapes from the duct, a florid inflammatory reaction rich in macrophages and plasma cells may ensue. In advanced stages, fibrous obliteration of the ducts can occur. Some authors have suggested that the inflammatory stage ("periductal mastitis") and the later fibrotic stage ("duct ectasia") represent two different disease processes, given the younger age and greater association with smoking in the former.[30,32]

Fat Necrosis

A process with the microscopic features of fat necrosis (i.e., foamy macrophages infiltrating partially necrotic adipose tissue) can be seen in the breast under two disparate circumstances. One is as a secondary and relatively minor event in mammary duct ectasia and—to lesser extent—with large cyst formation. In these cases, rupture of the dilated duct or cystic structures leads to extravasation of luminal contents, some degree of tissue necrosis, and a secondary inflammatory reaction in which foamy macrophages can be numerous. In particularly florid examples of this phenomenon, the term *xanthogranulomatous mastitis* has been used.[33] Parenthetically, small collections of foamy cells are seen not infrequently within duct lumina or in cohesive masses along duct walls; their immunohistochemical profile is that of histiocytes rather than epithelial cells.[34]

The other circumstance, which perhaps is the one that deserves to be called fat necrosis, is the traumatic (either accidental or surgical) type. This usually involves the superficial subcutaneous tissue rather than the breast parenchyma itself in accidental trauma (Fig. 36.8). A history of trauma, usually 1 to 2 weeks before diagnosis, can be elicited in about half the cases. The process can simulate carcinoma clinically because of skin retraction (Fig. 36.9), and also on imaging studies.[35] In long-standing cases, the nodule is harder and more fibrotic and has an orange–brown color because of the deposition of hemoglobin-derived pigments. The microscopic diagnosis is usually straightforward on core needle or excisional biopsy.

Cases of mammary fat necrosis have also been reported following radiation therapy for breast carcinoma[36] and as a local manifestation of Weber–Christian disease. Exceptionally, the fat necrosis acquires the morphologic features of the so-called membranous type, which is of variably sized cystic spaces with eosinophilic membranes, particularly in postradiation therapy cases.[37]

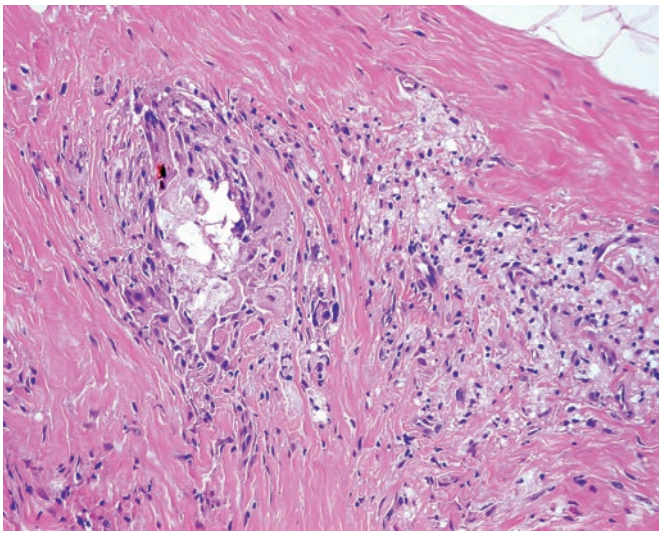

Figure 36.8 Post-traumatic fat necrosis involving breast.

Lymphocytic Mastopathy

Lymphocytic mastopathy is an unusual breast lesion of probable immune-mediated pathogenesis consisting microscopically of dense perilobular, and perivascular lymphocytic infiltrates associated with lobular atrophy and keloid-like fibrosis (Fig. 36.10).[41,42] The lymphocytes are mainly of the B-cell type. Often, the lymphocytic infiltrate is accompanied by stromal epithelioid myofibroblasts that can lead to a mistaken diagnosis of invasive carcinoma, granular cell tumor, or Rosai–Dorfman disease.[43,44] Lymphocytic mastopathy can result clinically in a palpable mass; cases can be seen in association with diabetes (hence the synonym *diabetic mastopathy*[45–47]) but may also occur in the absence of this disease or in the presence of other

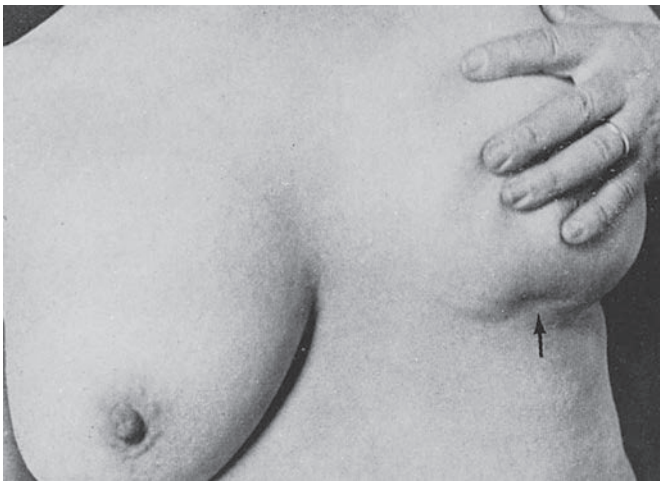

Figure 36.9 Retraction of skin in a patient with fat necrosis *(arrow)*, as seen in a photograph taken from a well-seasoned paper. (From Lee BJ, Adair F. Traumatic fat necrosis of the female breast and its differentiation from carcinoma. *Ann Surg.* 1924;80:670–691.)

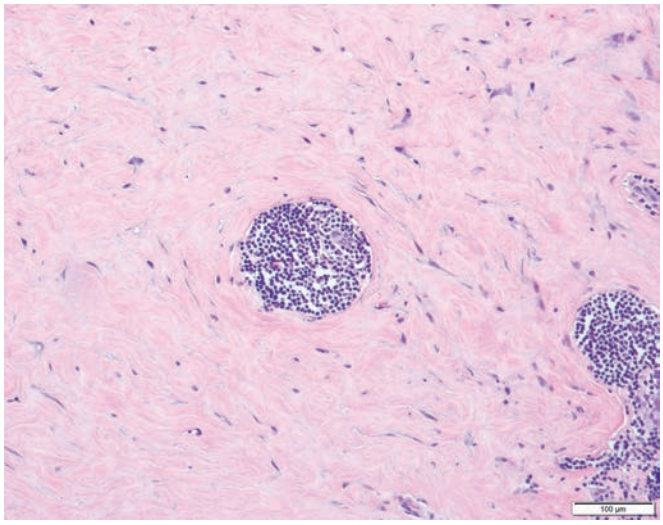

Figure 36.10 **Lymphocytic Mastopathy.** This process is characterized by periductal and perivascular lymphocytic infiltrates, fibrosis, and epithelioid myofibroblasts present in the stroma.

For personal use only. No other uses without permission. Copyright ©2017. Elsevier Inc. All rights reserved.

autoimmune diseases.[48] There is no increased risk for malignancy associated with a diagnosis of lymphocytic mastopathy though coexistent carcinoma has been reported.[49]

Core needle biopsy specimens of lymphocytic mastopathy may go underrecognized due to the subtle stromal changes and a tendency to overlook benign inflammatory cells. In an apparently nondiagnostic core needle biopsy of a targeted mass, the constellation of perilobular and perivascular lymphocytic infiltrates, keloidal collagen and epithelioid myofibroblasts should be examined for, before rendering a diagnosis of normal or unremarkable breast tissue.

Idiopathic granulomatous mastitis

Idiopathic granulomatous mastitis is a term applied to a granulomatous inflammatory process of the breast characterized by the presence of non-necrotizing granulomas confined to breast lobules, in which no microorganisms are identified. The suggestion has been made that the disease may be immunologically mediated and, therefore, analogous to granulomatous thyroiditis or granulomatous orchitis.[50,51] It can simulate malignancy clinically and on imaging studies.[52] Microscopically, lobulocentric granulomatous inflammation is present, usually with admixed neutrophils. It has been postulated that some cases of granulomatous mastitis may belong to the family of IgG4-related diseases[53,54] or be cases of cystic neutrophilic granulomatous mastitis (CNGM) (see next). Idiopathic granulomatous mastitis is a diagnosis of exclusion.

Cystic Neutrophilic Granulomatous Mastitis

CNGM is a relatively newly recognized entity that presents as mastitis in parous or lactating women.[55–58] It has also been described in nulliparous women with hyperprolactinemia.[59] Patients are often febrile and have a leukocytosis. Nipple inversion or retraction is common and fistulas can occur.

Histologically, this lesion is characterized by lobulocentric granulomas that often contain neutrophils or areas of microabscess formation similar to that described for idiopathic granulomatous mastitis. The feature distinguishing CNGM from idiopathic granulomatous mastitis is the presence of empty "cystic" spaces consistent with dissolved lipid (Fig. 36.11). These spaces are surrounded by neutrophils; giant cells may also be present. With careful searching, faint rod-like structures may be identified within some of these "cystic" spaces. The bacteria are more easily identified on a Gram stain as gram-positive rods morphologically consistent with *Corynebacteria*. Microbiologic identification has shown that the lipophilic bacteria *Corynebacterium kroppenstedtii* is the species most commonly present.[55,56,58] It is hypothesized that women who have been unable to breastfeed from one breast (due to nipple inversion, for example) may have stasis of lipid-rich milk secretions predisposing to the development of CNGM in that breast. It is possible that some (if not all) cases of idiopathic granulomatous mastitis represent CNGM in which the bacteria have not been recognized/identified. Note that these organisms are difficult to grow in the laboratory, requiring special culture media and prolonged incubation times. Treatment often includes antibiotic therapy (though to date this likely has not been specific to *Corynebacterium* spp.), excision and sometimes steroids. As this is an underrecognized entity, the most appropriate therapeutic algorithm has not yet been established.[55,56,60,61]

Other Inflammatory Diseases

Abscess of the breast usually results from rupture of mammary ducts, occurring most often during lactation but also independently of it.[38] It may be located deep within the parenchyma or in the periareolar region.[39] Microscopically, a central cavity filled with neutrophils and secretion is surrounded by mixed inflammatory cells and, eventually, fibrosis, with obliteration of the lobular pattern. Clinically, a localized abscess may simulate carcinoma. Periareolar abscess associated with squamous metaplasia of lactiferous ducts (SMOLD) is referred to as such or as *Zuska disease* (see later).[39,40]

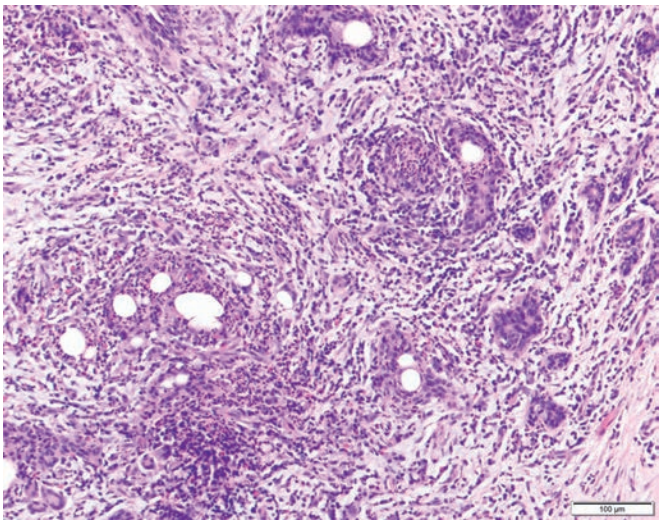

Figure 36.11 Cystic Neutrophilic Granulomatous Mastitis. In this field note the presence of "cystic" spaces cuffed by neutrophils and a background of lymphocytes, histiocytes, and giant cells (bottom left of field).

Tuberculosis of the breast may be secondary either to bloodstream dissemination or direct extension from an adjacent tuberculous process.[62] Grossly, multiple sinuses and areas of caseous necrosis occur. Microscopically, typical necrotizing granulomas are identified in most cases. The lesion may be mistaken clinically for advanced breast carcinoma. Regional nodes are often involved; occasionally, these tuberculous nodes are in an intramammary location.[63]

Actinomycosis, coccidiomycosis, and **histoplasmosis** of the breast can cause necrotizing granulomatous masses and multiple sinus tracts.[64,65]

Sarcoidosis can begin in the breast and remain localized in this organ for long periods.[66,67] Alternatively, breast involvement may be seen as a component of systemic disease.[68] The morphologic features are the same as those described for sarcoidosis elsewhere in the body.

Foreign body reaction to the polyvinyl plastic or silicone used for mammoplasty in the past or that is occasionally injected directly into the breast by unorthodox practitioners sometimes resulted in tumorlike masses and sinus tracts (Fig. 36.12) (see later for discussion of malignancy associated with implants).[69]

Breast infarct can complicate a large variety of conditions, including intraductal papilloma, fibroadenoma, phyllodes tumor, hyperplastic lobules during pregnancy, syphilis, and granulomatosis with polyangiitis.[70,71] It also has been reported in association with anticoagulant therapy, postpartum abscess, thrombophlebitis migrans disseminata, and mitral stenosis with heart failure.[72]

Mondor disease is the eponymous term given to a peculiar thrombophlebitis involving the breast and contiguous thoracoabdominal wall.[73] The condition, which may simulate clinically a malignant neoplasm, often has a sudden onset and appears as a firm, slightly nodular cord beneath the skin. Ecchymosis may or may not be present. Microscopically, the process is one of phlebitis with thrombosis. With time, the thrombus recanalizes completely. The condition is self-limited and practically never recurs. It may be related to mechanical injury, as suggested by the fact that in 8 of

For personal use only. No other uses without permission. Copyright ©2017. Elsevier Inc. All rights reserved.

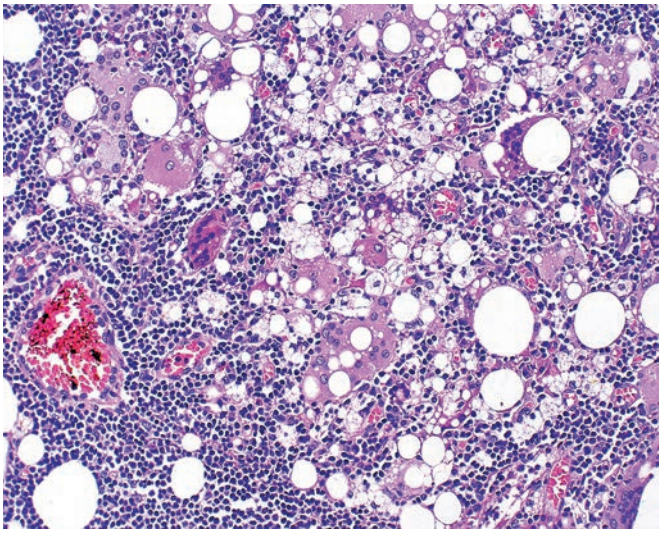

Figure 36.12 Florid Granulomatous Reaction to Silicone. Foamy macrophages, foreign body–type multinucleated giant cells, and lymphocytes are present.

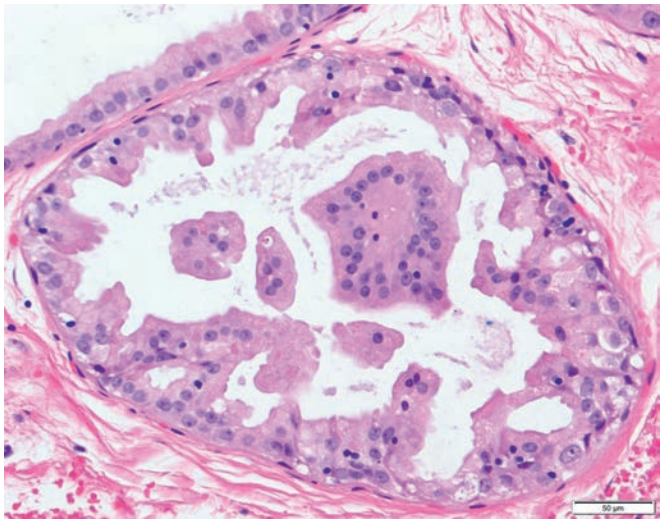

Figure 36.13 Apocrine Metaplasia. The cells have abundant granular eosinophilic cytoplasm, often with an apical "apocrine snout." The nuclei are round, of medium size and have prominent nucleoli.

the 15 cases reported by Herrmann[74] the disease appeared a few months after radical mastectomy. A few cases have been found to be associated with untreated breast carcinoma.[75]

Rheumatoid nodules, periarteritis nodosa, lupus profundus, and **granulomatosis with polyangiitis (Wegener granulomatosis)** may present as single or multiple breast masses.[70,76–82]

Benign Breast Disease

Benign breast disease is the term used to describe collectively an interrelated group of proliferative disorders of the breast parenchyma, many of which are not true neoplasms but, rather, hormone-induced hyperplastic processes.[83]

Intraductal Proliferative Lesions and Nonproliferative Changes

Fibrocystic change was the term introduced by the College of American Pathologists (CAP) for the collective description of nonproliferative and proliferative changes of the breast.[84] It was the term preferred over "fibrocystic disease," and was to be followed by specification of the component lesions in the body of the pathology report or in the diagnosis, but neither of these terms is widely used in reports today, rather the component lesions are listed a priori. Benign breast lesions form an extremely important group because of their high frequency, the ability of some of the lesions to simulate the clinical, radiographic, gross, and microscopic appearance of carcinoma, and the relationship of some of the lesions to carcinoma.[85]

Nonproliferative and intraductal proliferative lesions are most frequently seen, at least at the clinical level, between the ages of 25 and 45 years. Proliferative lesions of the breast are more common in Anglo-Saxon than in Latin American, Native American, or Japanese women.[86] The real incidence is difficult to estimate because the diagnosis depends a great deal on definitions used by the individual clinician, radiologist, or pathologist.[87] The cumulative incidence of biopsy-proven benign breast disease is approximately 9% among women below the age of 65 years, which compares with a rate of between 50% and 60% from autopsy series.[87,88] Hormones play a role in the development of proliferative lesions of the breast, but the exact pathogenesis remains obscure.[89] There is no definitive evidence that administration of oral contraceptives increases the degree of epithelial proliferation.[90] Epidemiologic evidence suggests a modest relationship between alcohol consumption and the development of benign breast disease and ultimately to subsequent breast cancer risk, with an inverse relationship being found for coffee consumers.[91,92]

It is important to realize that nonproliferative and proliferative breast lesions primarily affect the TDLU, although epithelial hyperplasia can also extend to larger ducts. The basic morphologic changes are the following:

Nonproliferative Changes

1. **Cysts.** These can be microscopic or grossly visible and sometimes reach large proportions. They usually contain a cloudy yellow or clear fluid. Some of these cysts have a bluish cast ("blue dome cysts" of Bloodgood). Occasionally, numerous small thin-walled cysts are seen in the breast parenchyma surrounding a large cyst. Microscopically, the epithelial lining of most cysts, especially the larger ones, is flattened or absent, the cyst having only a thick fibrous wall. Frequently cysts rupture and elicit an inflammatory response in the stroma, with abundant foamy macrophages and cholesterol clefts. Azzopardi has observed that cysts—no matter how large—arise from the TDLU rather than from ducts.[22]
2. **Apocrine metaplasia.** This is a very common change. It is most often seen in dilated and cystic structures, but it may appear in normal-sized lobules as well. The individual cells have abundant granular eosinophilic cytoplasm, often with supranuclear vacuoles and yellow–brown pigment, some of which contains iron. The apical portion of the cytoplasm shows the typical "apocrine snout." The nucleus is round and medium sized, and the nucleolus can be very prominent (Fig. 36.13). Periodic acid–Schiff (PAS) stain shows a crescent of coarse glycolipid granules on the luminal side. Immunohistochemical stain for GCDFP-15 shows strong cytoplasmic reactivity, and there is strong nuclear reactivity for androgen receptor.[93] Clusters of apocrine cysts may be detected on imaging studies as a "mass lesion" or as an area of calcifications, prompting core needle biopsy. Typically the calcifications take the form of calcium oxalate crystals, which may be overlooked on routine histologic examination. Viewing the cysts through polarized light will reveal the translucent crystals.

For personal use only. No other uses without permission. Copyright ©2017. Elsevier Inc. All rights reserved.

3. **Fibrosis.** "Fibrosis" is often present, but its degree varies markedly and thus deciding when it is pathologic can be a challenge. It is probably most often seen as an event secondary to cyst rupture, and it may proceed to hyalinization. The terms *fibrous disease* of the breast and *fibrous mastopathy* have been used by some authors to designate a breast condition in which the main change seems to be a more or less localized stromal fibrosis; however, it is not clear that this represents a distinct clinicopathologic entity, and since it is difficult to determine an individual woman's degree of "fibrosis," particularly on a core needle biopsy, use of the term is discouraged.
4. **Calcification.** Chemically, calcification may be composed of calcium phosphate or calcium oxalate. On mammography, calcium oxalate is amorphous, of low-to-medium density and is nearly always associated with benign disease. The crystals can be easily missed on routine sections; they are better seen with polarized lenses (because of their birefringent quality). As mentioned previously, calcium oxalate is frequently associated with apocrine cysts, and searching for the crystals with that knowledge in mind can be fruitful. Calcium phosphate is of medium-to-high density on imaging studies and is readily detectable on hematoxylin–eosin (H&E) stained sections.
5. **Chronic inflammation.** This is another common but secondary feature present in benign breast biopsies. It is usually related to cyst rupture, with release of secretion into the stroma. Lymphocytes, plasma cells, and foamy histiocytes are the predominant elements. Cysts with associated intense chronic inflammation should not be confused with mammary duct ectasia.

Intraductal Proliferative Lesions

Usual Ductal Hyperplasia

Usual ductal hyperplasia (UDH) is the preferred term of the WHO Working Group. The degree of proliferation may be commented upon if desired: *mild* (when made up of three or four epithelial cells in thickness) or *moderate to florid* (when more pronounced). In florid UDH, the entire lumen is filled by the epithelial proliferation. The features most helpful in recognizing the benign nature of the proliferation are the following:

1. Nuclei that are oval (rather than round, except when cut transversely), normochromatic (rather than hyperchromatic), with nuclear grooves, and with slight overlap; small, single, indistinct nucleoli; occasional intranuclear inclusions; scant or no mitotic activity (Fig. 36.14).
2. Cytoplasm that is eosinophilic rather than pale and homogeneous.
3. Indistinct cytoplasmic borders, so that the nuclei seem to lie in a syncytial mass rather than within sharply outlined cell membranes.
4. Streaming effect, induced by the oval cells being vaguely arranged in parallel bundles (Fig. 36.15).
5. "Tufts" and "mounds" projecting into the lumen.
6. Presence of peripheral elongated clefts, bound on one side by a single layer of basally located cells and on the other by a solid intraluminal formation; sometimes this cleft spans almost the entirety of the circumference, with the retracted solid ball of epithelial cells hanging from the wall like the vascular tuft of a renal glomerulus. The intercellular lumina of UDH tend to be irregular in size, shape (elongated rather than round), and location (predominating at the periphery) rather than regular in all three parameters as seen in the cribriform pattern of ductal carcinoma in situ (DCIS). Notably, there is an absence of cellular polarization around the clefts.

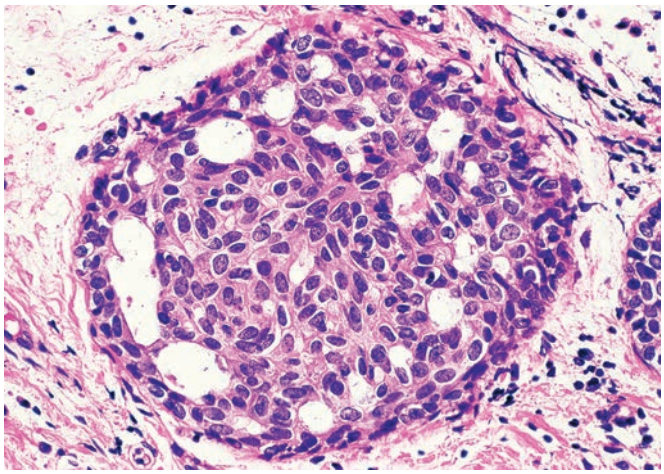

Figure 36.14 Usual Ductal Hyperplasia. In this proliferation note the presence of oval nuclei that are normochromatic, with slight overlap giving the cells a streaming appearance. The clefts are preferentially located at the periphery of the duct and there is a lack polarization of cells around the spaces.

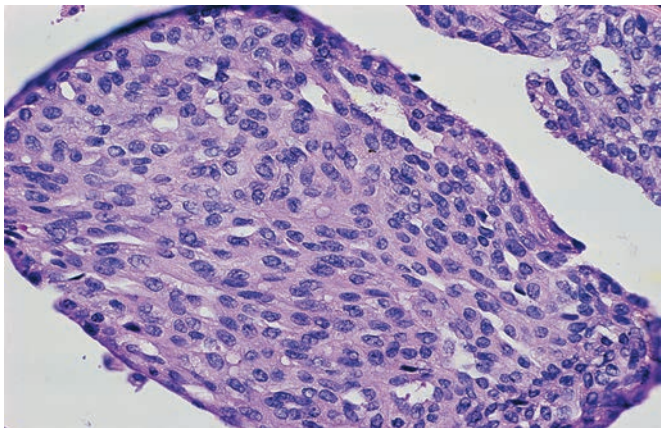

Figure 36.15 Usual Ductal Hyperplasia. Note the oval shape of the nuclei and the parallel arrangement, resulting in a "streaming" effect.

7. Presence of irregularly shaped bridges connecting opposite portions of the wall. The cells in these bridges have oval nuclei arranged parallel to the long axis of the bridge. Their appearance is very different from that seen in the rigid trabecular bars and Roman bridges of low nuclear grade DCIS.
8. Complete or incomplete apocrine metaplasia.
9. Presence of a peripheral layer of myoepithelial cells, with clear or eosinophilic cytoplasm, or elongated and smooth muscle-like ("myoid").
10. Presence of foamy macrophages, both in the lumen and intimately admixed with the proliferating epithelial cells.[94]
11. Occasional intraluminal or stromal calcifications.
12. Absence of necrosis (though see below).

As important as these features are, none of them is diagnostic by itself. They need to be weighed against each other, sometimes modified depending on the nature of the case, and occasionally ignored altogether. For instance, focal necrosis may be found in UDH, particularly in the setting of UDH in a nipple adenoma. Furthermore, proliferative benign breast disease and carcinoma can coexist, which means that an area may be diagnostic of DCIS even

For personal use only. No other uses without permission. Copyright ©2017. Elsevier Inc. All rights reserved.

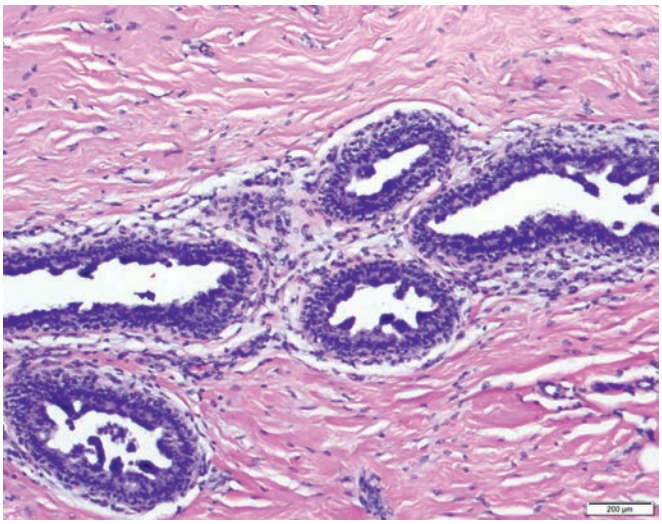

Figure 36.16 Gynecomastoid Hyperplasia. A form of UDH characterized by micropapillary tufting of the lining epithelium; the micropapillae have broader bases and narrow pinched tips. The nuclei are also smaller and more hyperchromatic at the tips than at the bases of the micropapillae.

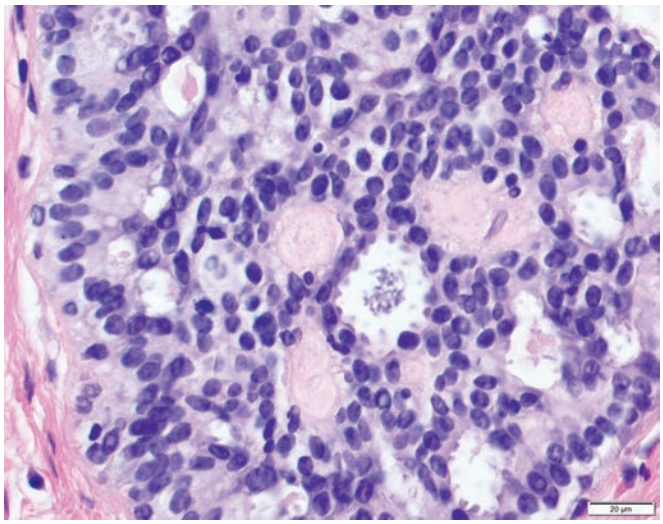

Figure 36.17 Collagenous Spherulosis. The round spaces contain eosinophilic or sometimes basophilic collagen-rich spherules composed of basement membrane material. Note the more spindled nuclei of the myoepithelial cells surrounding the spaces containing the eosinophilic basement membrane material.

if the immediately surrounding glands show features indicative of benign disease.

Immunohistochemically, UDH is characterized by a heterogeneous or "mosaic" pattern of immunoreactivity for HMW cytokeratin antibodies, in particular for CK 5/6 (which is preferred over 34βE12).[95] This is of importance in the differential diagnosis with atypical ductal hyperplasia (ADH) and low and intermediate nuclear grade DCIS, which lack reactivity for HMW cytokeratins. The combination of CK 5/6 with estrogen receptor (ER), which also shows a heterogeneous pattern of staining in UDH whereas strong, diffuse nuclear staining is seen in ADH and DCIS, can be particularly helpful in this differential diagnosis.

Other benign intraductal proliferations, or variants of UDH, of note include the following:

Gynecomastoid hyperplasia is a form of UDH of the female breast that resembles gynecomastia of the male breast and is characterized by micropapillary tufting of the lining epithelium. The micropapillae have broad bases and narrow pinched tips with nuclei that are larger at the base than at the tip of the micropapillae (Fig. 36.16).

The special variant of ductal hyperplasia known as *juvenile papillomatosis* or "Swiss cheese" disease is discussed later in this chapter.

Collagenous spherulosis is characterized by the presence of intraluminal eosinophilic but sometimes basophilic, collagen-rich spherules that arise within spaces surrounded by myoepithelial cells (Fig. 36.17).[96] Ultrastructurally, the spherules show a variable composition of basement membrane material, banded collagen, and mineral deposition.[97] This curious entity can be confused with adenoid cystic carcinoma, signet ring carcinoma, and cribriform pattern DCIS. It should be noted that collagenous spherulosis can be seen in association with intraductal papilloma, sclerosing adenosis and lobular carcinoma in situ (LCIS).[98] The latter can be a particular pitfall in the distinction with cribriform pattern DCIS due to the monomorphic appearance of the LCIS cells in combination with the cribriform appearance of collagenous spherulosis (Fig. 36.18).[99]

Cystic hypersecretory hyperplasia is characterized by the presence of cystically dilated ducts containing a bright pink colloid-like material lined by cells that have relatively abundant vacuolated or secretory cytoplasm (Fig. 36.19A); this lesion needs to be distinguished from cystic hypersecretory carcinoma, not always an easy task.[100] CHH can become atypical (CHH with atypia or DCIS), which is recognized by an increase in architectural and nuclear atypia (see Fig. 36.19B).[101]

Having discussed benign *ductal* proliferations, specifically UDH, it should be noted that the term lobular hyperplasia should never be used unless qualified as atypical lobular hyperplasia (ALH) (see next).

Atypical Ductal Hyperplasia and Atypical Lobular Hyperplasia

As already mentioned, there is a wide range in the degree of epithelial proliferation in benign breast disease. It has been demonstrated that there is a correlation between proliferative breast disease and the risk of development of invasive carcinoma.[102–105] Dupont and Page[103] proposed the terms *ADH* and *ALH* for proliferative lesions in which some but not all of the features of DCIS or LCIS, respectively, are present. Using these criteria in a retrospective study of women with benign breast disease, they diagnosed atypical hyperplasia (ADH and/or ALH) in 3.6% of the cases and demonstrated that these patients had a relative risk for the subsequent development of invasive breast carcinoma that was 4 to 5 times that of the general population (i.e. about half of that of DCIS or LCIS). Largely on the basis of that study, the recommended grouping of patients with benign breast disease (previously "fibrocystic change") is into the following three categories[106]:

1. No or mild UDH (**nonproliferative changes**): no increased risk for subsequent invasive carcinoma.
2. Moderate or florid UDH (**proliferative disease without atypia**): 1.5–2 times the risk.
3. ADH or ALH (**atypical hyperplasia**): 4–5 times the risk.

   For completeness and comparison purposes, Page[107] added to this list the following category:
4. DCIS or LCIS: 8–10 times the risk.

The Page–Dupont studies represent an extremely important contribution to the study of benign breast disease vis-à-vis breast carcinoma, as well as the standardization of nomenclature and criteria in the diagnosis of benign breast disease, which in turn have had a

For personal use only. No other uses without permission. Copyright ©2017. Elsevier Inc. All rights reserved.

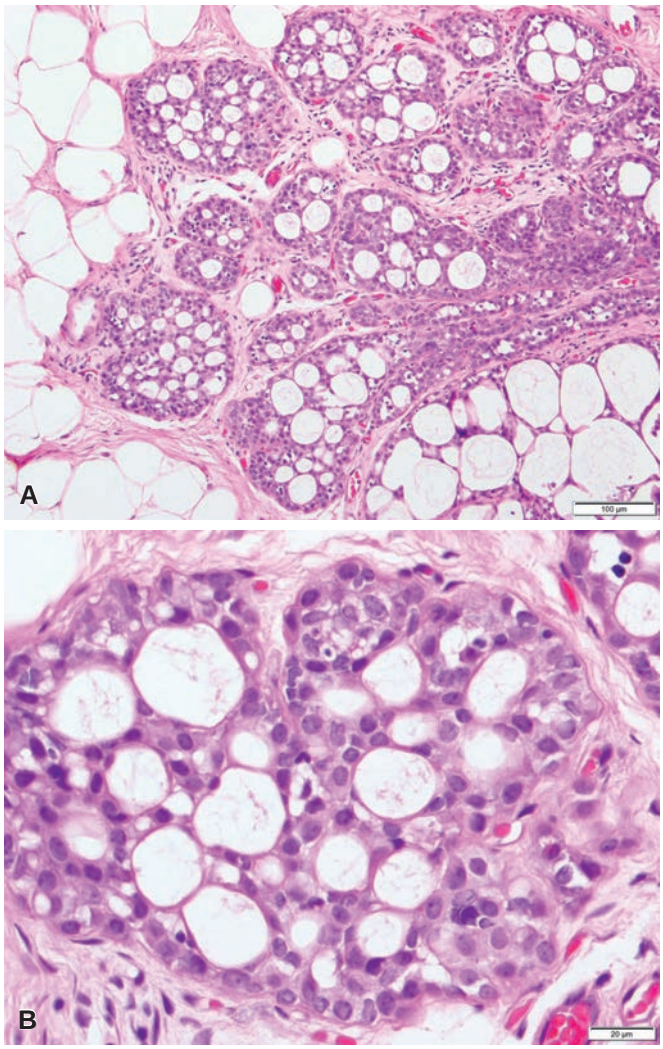

Figure 36.18 Lobular Carcinoma In Situ Involving Collagenous Spherulosis. The monomorphic appearance of the LCIS cells in combination with the cribriform appearance of the collagenous spherulosis can be a mimic for ductal carcinoma in situ at low power **(A)**. At high power **(B)**, the cytologic atypia and cellular dyshesion of the LCIS is better appreciated. Again, note the presence of myoepithelial cells surrounding the spaces containing the eosinophilic basement membrane material.

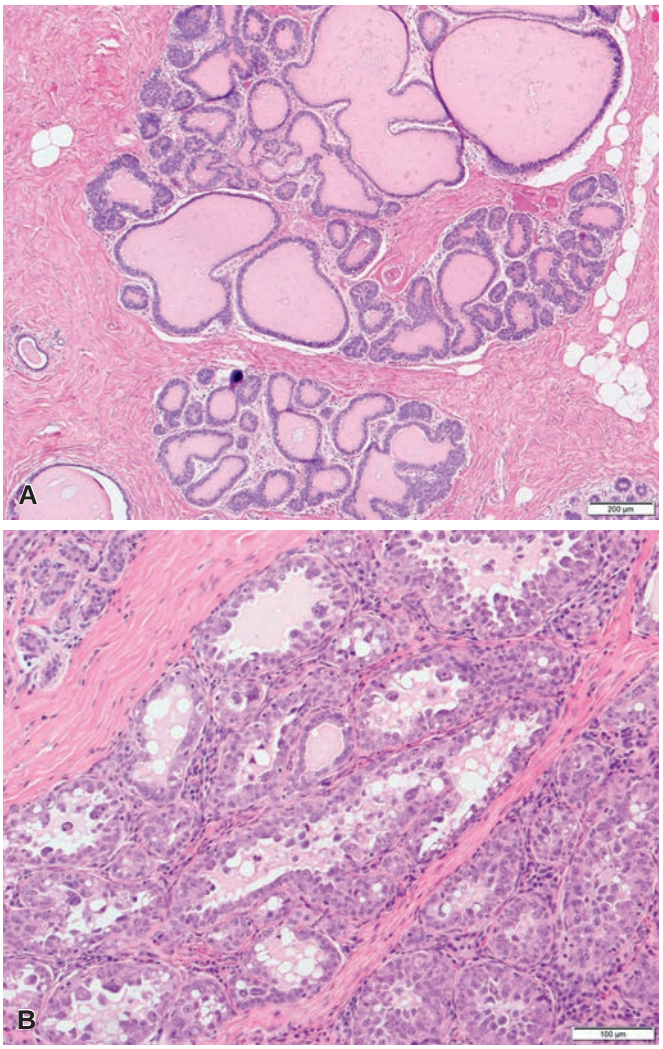

Figure 36.19 A and **B,** Cystic hypersecretory hyperplasia (CHH) is characterized by the presence of cystically dilated spaces containing a bright pink colloid-like material lined by cells that have relatively abundant vacuolated or secretory cytoplasm **(A)**. The lesion can demonstrate areas of architectural and cytologic atypia **(B)**, in this case sufficient for a diagnosis of ductal carcinoma in situ.

great impact on patients, clinicians, and pathologists. The currently accepted definition of *ADH* is that of a lesion with cytologic and architectural features indistinguishable from those of low-grade DCIS, that is, monomorphic cells with ovoid to rounded nuclei and the formation of micropapillae, tufts, fronds, bridges, solid, and/or cribriform patterns within the involved space (Figs. 36.20–36.22), *but* either (1) intimately admixed with UDH or (2) showing only partial involvement of the TDLU. Quantitative requirements have been proposed for when there is complete involvement of the space(s) involved (namely to be ≤2 mm or to be present in fewer than two adjacent spaces; the corollary being that a diagnosis of low-grade DCIS would be rendered if these same cells involved two or more spaces or measured >2 mm); the most recent WHO Working Group did not recommend one size/extent approach over another.[108]

ALH is defined as a monomorphic proliferation of atypical epithelial cells with round nuclei and indistinct nucleoli. The cells are dyshesive and often have intracytoplasmic lumina (Figs. 36.23 and 36.24). ALH is said to be present when less than 50% of the TDLU is expanded by the atypical proliferation, with LCIS being defined as greater than 50% of the TDLU expanded by the atypical proliferation. Pagetoid extension along the ducts may also be seen in ALH.

There are no special techniques (e.g., morphometry, DNA ploidy studies, immunohistochemical stains, or genetic molecular tests) that are able to separate ADH and ALH from low nuclear grade DCIS and LCIS, respectively.[109,110]

Columnar Cell Lesions and Flat Epithelial Atypia

A further variation on the theme of mammary ductal hyperplasia, the identification of which has increased through screening mammography because of the association with microcalcifications, is the group of lesions collectively referred to as columnar cell lesions. The lesions that make up this group are columnar cell change, columnar cell hyperplasia, and flat epithelial atypia (FEA), which is the terminology preferred by the WHO Working Group.[111]

For personal use only. No other uses without permission. Copyright ©2017. Elsevier Inc. All rights reserved.

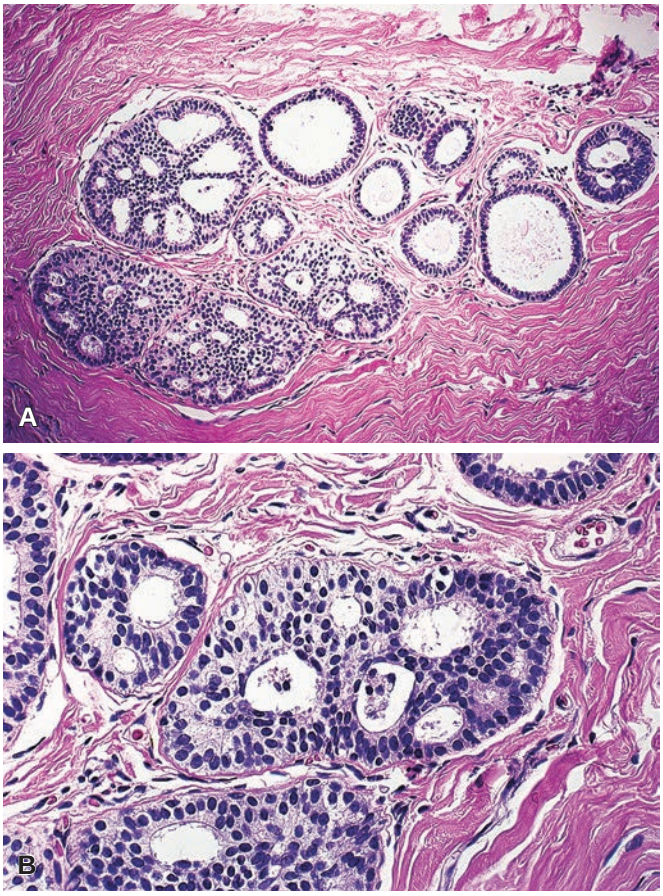

Figure 36.20 **A** and **B,** Atypical ductal hyperplasia. Proliferative ductal lesion with monomorphic cells and cribriform architectural pattern diagnosed as atypical ductal hyperplasia on account of these cytoarchitectural features and small lesion size.

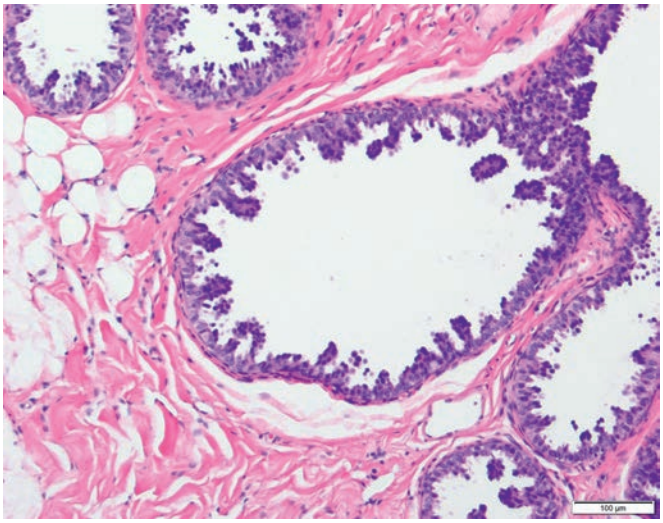

Figure 36.21 **Atypical Ductal Hyperplasia.** This micropapillary proliferation demonstrates bulbous micropapillations with enlarged atypical nuclei present both at the base and the tip of the micropapillations.

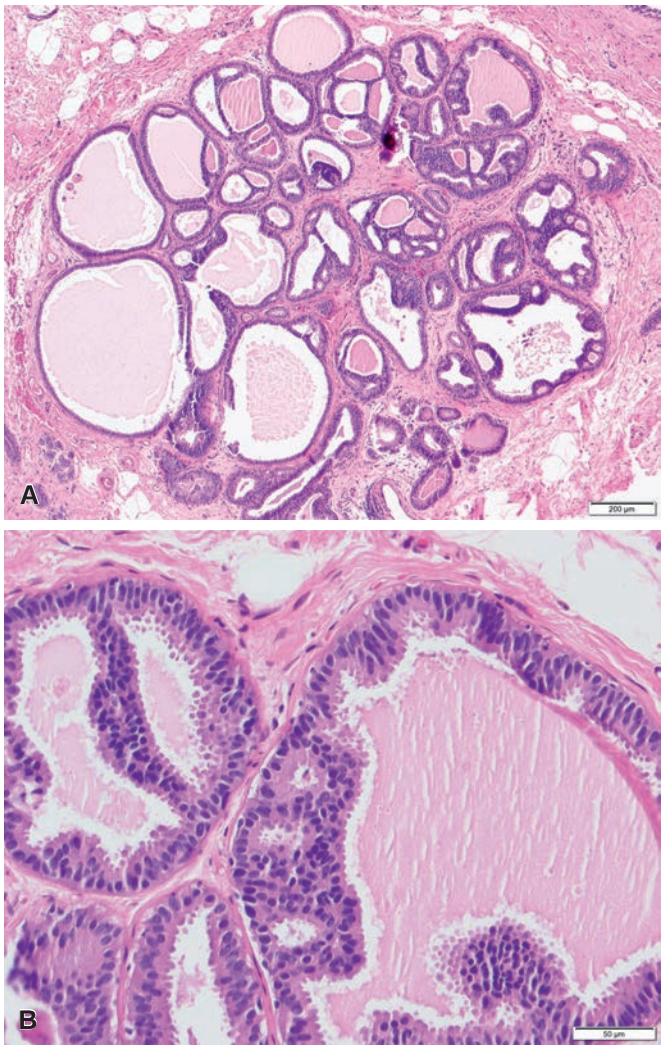

Figure 36.22 **Atypical Ductal Hyperplasia. A,** A TDLU with a predominantly cribriform proliferation of monomorphic epithelial cells; some rigid bridges and bars are also present. **B,** At high power note the low-grade nuclear atypia and the polarization around the cribriform spaces.

Unfortunately, the literature is awash with other names for these lesions. For example, early terms for FEA included low-grade (monomorphic) clinging carcinoma, atypical cystic lobules, atypical columnar change, columnar cell hyperplasia and columnar cell change with atypia.

FEA is characterized by a single or stratified layer of columnar to cuboidal cells with low nuclear grade cytologic atypia and loss of polarization with respect to the basement membrane. There is variable dilatation of the acini of the affected TDLUs, with smooth, rather than irregular, contours (Figs. 36.25 and 36.26). Apical snouts can be prominent. The lumens of the acini contain granular secretions and/or calcifications.[112] It may seem paradoxical that a lesion can be flat and columnar at the same time; the explanation is that "flat" refers to the "architectural" appearance of the involved acini, whereas "columnar" refers to the shape of the lining epithelial cells.

In contrast to FEA, *columnar cell change* and *columnar cell hyperplasia* refer to these same architecturally "flat" lesions but without the cytologic atypia. It is these two lesions in which the lining epithelial cells are most recognizably columnar with elongated nuclei oriented perpendicular to the basement membrane, whereas in FEA the lining epithelial cells tend to have a more cuboidal appearance. In columnar

For personal use only. No other uses without permission. Copyright ©2017. Elsevier Inc. All rights reserved.

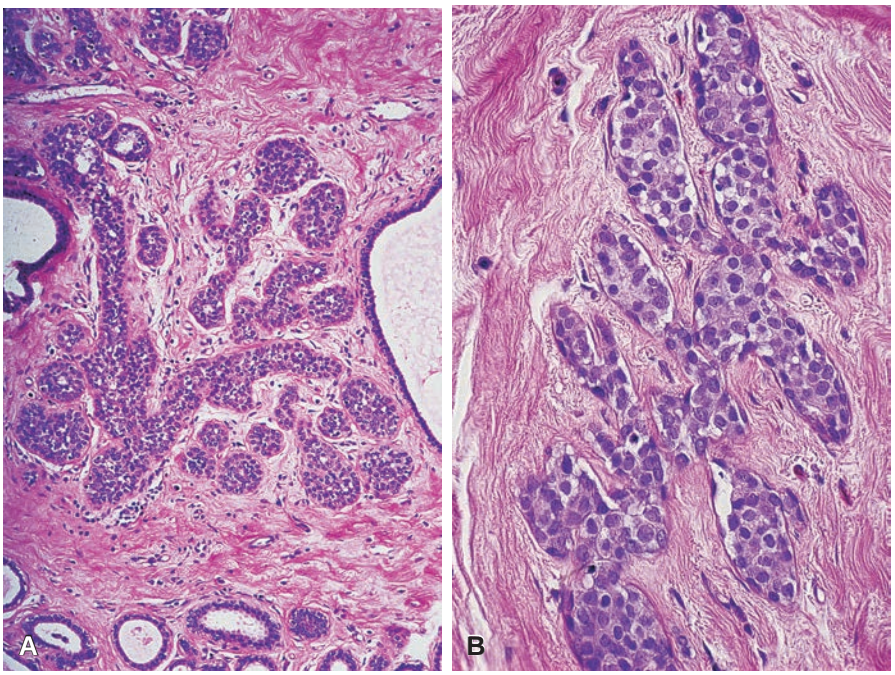

Figure 36.23 Atypical Lobular Hyperplasia. A, There is expansion of the lobules by a monomorphic proliferation of atypical epithelial cells with round nuclei and indistinct nucleoli. **B,** The cells are dyshesive and often have intracytoplasmic lumina, which can be appreciated at higher power.

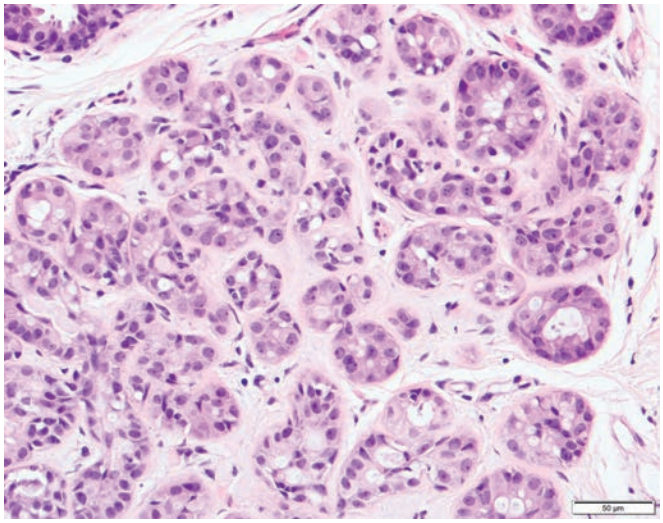

Figure 36.24 Atypical Lobular Hyperplasia. There is expansion of the lobules by a monomorphic proliferation of atypical epithelial cells with enlarged nuclei and small nucleoli. The cells are dyshesive and many have intracytoplasmic vacuoles.

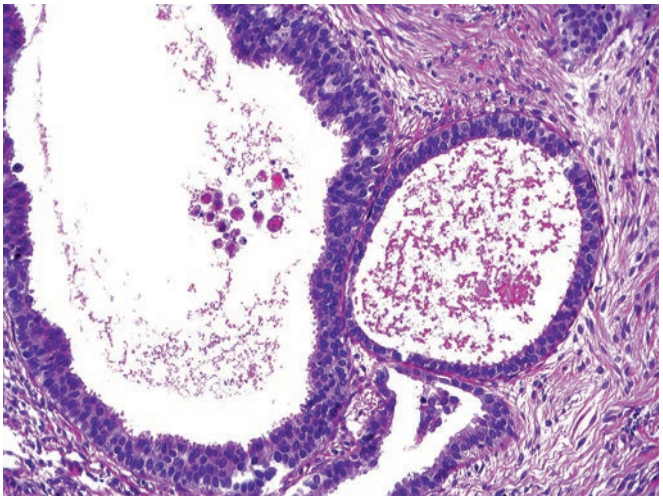

Figure 36.25 Flat Epithelial Atypia. The spaces are dilated and lined by a stratified layer of cuboidal cells with low-grade cytologic atypia.

cell hyperplasia, there is stratification of the lining epithelial cells with some tufting but no true micropapillations. Other features of these lesions include variably dilated acini with irregular acinar contours, prominent apical snouts, luminal secretions, and calcifications (Figs. 36.27 and 36.28).[111] ER is strongly positive, CK5/6 is negative, and there is an increased expression of MIB-1 in all columnar cell lesions.[113]

The biologic significance of FEA is still being elucidated, but it is generally thought to be the earliest step in the low-grade breast neoplasia pathway (perhaps the precursor to ADH),[114] with a subsequent breast cancer risk similar to proliferative lesions without atypia (i.e., 1.5- to 2-fold risk), though it may be that there is no increase in risk over and above that of any associated proliferative lesion present.[115–117] In several studies, columnar cell lesions have been found to be frequently associated with low-grade DCIS, LCIS, and pure and/or mixed forms of tubular carcinoma.[118–121]

Nomenclature of Proliferative Ductal and Lobular Lesions

While the nomenclature first suggested by Page et al. and endorsed by the CAP is the preferred term of the WHO Working Group,[122] other terminology has been suggested, such as mammary intraepithelial neoplasia (MIN) of either ductal or lobular type, followed

For personal use only. No other uses without permission. Copyright ©2017. Elsevier Inc. All rights reserved.

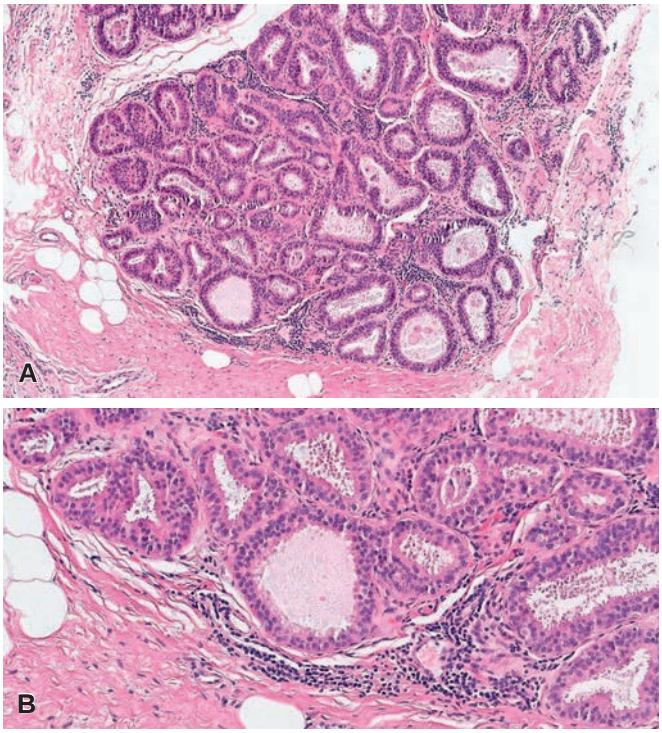

Figure 36.26 Flat Epithelial Atypia. A, The acini of the terminal duct lobular unit are variably dilated and the spaces lined by a stratified layer of monomorphic cuboidal cells. **B,** At higher power the low-grade cytologic atypia is appreciated as well as the apical snouts and secretions.

by a grading system[123] in accordance with the trend at many other sites, such as cervix (CIN), prostate (PIN), and gastrointestinal tract. Tavassoli and her group have further developed this nomenclature, according to the scheme shown in Table 36.1.[124–126]

The proposal has some merit; in point of fact, many of the arguments that have been raised against its adoption apply to other organ sites just as well, yet they have not prevented a terminology change taking place in those sites. There is one issue, however, that deserves comment. The ductal intraepithelial neoplasia (DIN) numerical terminology implies a continuum of changes, which may or may not exist. The alternative view, masterfully articulated by Azzopardi[22] and currently supported by many experts, is that proliferative breast disease can be divided into distinct categories: the "usual" hyperplasia category and the intraductal carcinoma category, which may be further subdivided into a low-grade and a high-grade pathway.[127] In this scheme, ADH and likely FEA are the nonobligate precursors to low nuclear grade DCIS. Given this, linking these conditions (i.e., low- and high-grade DCIS) in a grading system that presupposes a nosologic unity might be misleading. In practice, the MIN schema has not been widely adopted in the United States, and this terminology was not included in the 2012 edition of the WHO publication on Tumors of the Breast.[128]

Relationship With Carcinoma and Management

A relationship between benign breast disease and breast carcinoma has been suggested over the years on the basis of the following evidence:

1. The observation that breast tissue excised for carcinoma usually also exhibits changes of benign breast disease[129] and that there is a greater degree of epithelial proliferation than is found in a population without carcinoma.[130]

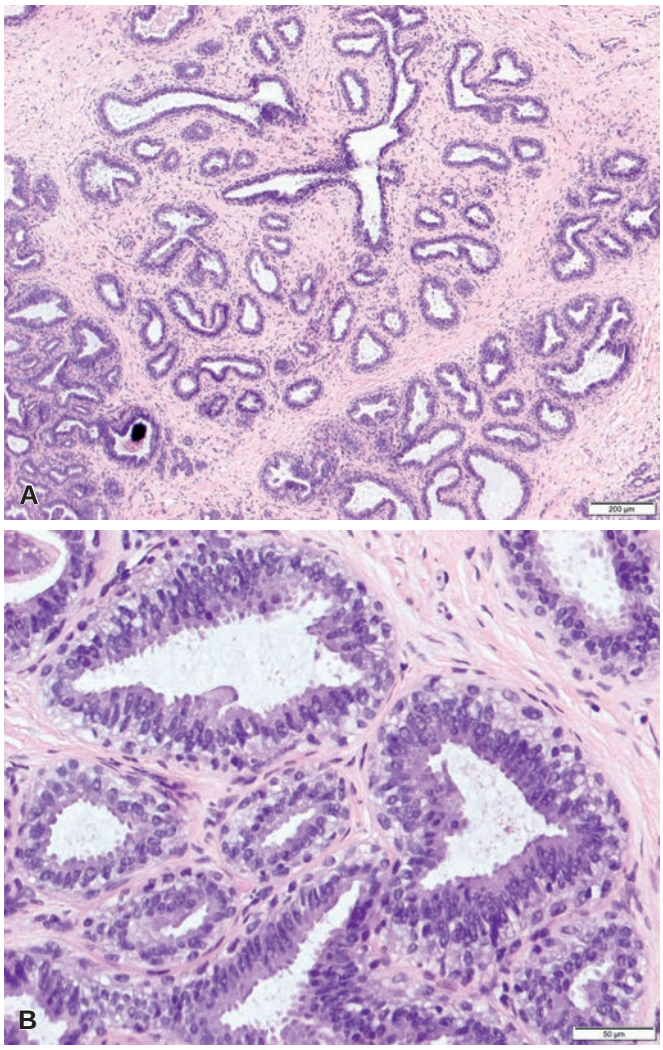

Figure 36.27 Columnar Cell Change. A, The acini of the terminal duct lobular unit are variably dilated and the spaces lined by a layer of columnar epithelial cells; a calcification is present in the lower left of the field. **B,** At higher power the columnar cells are seen to be arrayed perpendicular to the basement membrane; apical snouts are present.

2. The fact that retrospectively studied breast biopsies in patients who subsequently developed invasive carcinoma often show proliferative disease without atypia or atypical hyperplasia rather than nonproliferative changes.[131,132]
3. The parallelism in incidence of breast carcinoma and benign proliferative breast lesions in various populations,[133] including the fact that kindreds susceptible to breast carcinoma also inherit a predisposition to proliferative breast disease.[134]
4. The presence of molecular alterations in atypical hyperplasias that parallel those of breast carcinoma.[114,135–138]
5. The observation that patients with benign breast disease are found to develop invasive carcinoma at a higher rate than a control population.[139–141] Parenthetically, the breast carcinomas that develop in patients with a previous diagnosis of benign breast disease do not differ depending on the histologic category of the latter.[142]

A quantitative leap was made once it was demonstrated that it is not benign breast disease per se but rather the presence and type of epithelial proliferation that determines the risk for subsequent carcinoma and that this risk seems to range from one to five times

For personal use only. No other uses without permission. Copyright ©2017. Elsevier Inc. All rights reserved.

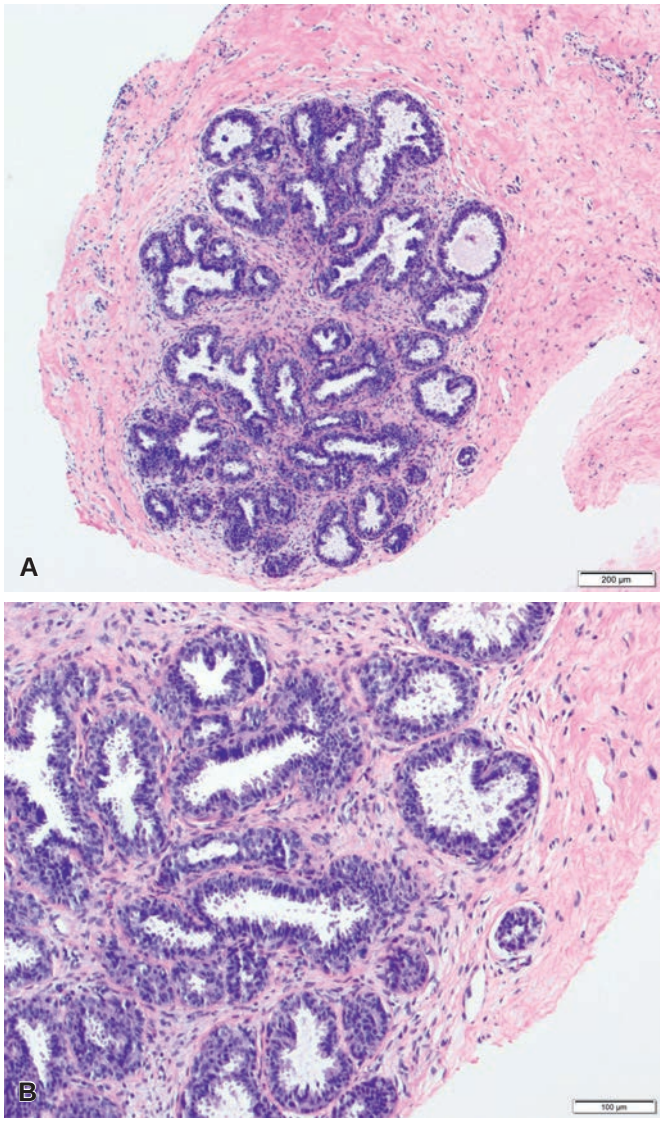

Figure 36.28 Columnar Cell Hyperplasia. A, The acini of the terminal duct lobular unit are variably dilated and the spaces lined by a layer of columnar epithelial cells with some multilayering and tufting; calcifications are present in some acini (*upper part* of field). **B,** At higher power the columnar nature of the cells is appreciated as well as the apical snouts.

Figure 36.29 Gross Appearance of a Fibroadenoma. The lesion is sharply circumscribed and has a bulging cut surface with slit-like spaces. (Photograph courtesy of Dr. M. DiStasio).

Table 36.1 Alternate nomenclature of proliferative ductal and lobular lesions

TRADITIONAL TERMINOLOGY	MIN TERMINOLOGY
Usual ductal hyperplasia	(No DIN equivalent)
Flat epithelial atypia	DIN1A
Atypical ductal hyperplasia	DIN1B
DCIS low nuclear grade	DIN1C
DCIS intermediate nuclear grade	DIN2
DCIS high nuclear grade	DIN3
Lesions in the ALH/lobular CIS spectrum	LIN 1, 2, and 3
Proliferative epithelial lesions not easily placed into either a ductal or a lobular category	MIN

ALH, Atypical lobular hyperplasia; *CIS*, carcinoma in situ; *DCIS*, ductal carcinoma in situ; *DIN*, ductal intraepithelial neoplasia; *LIN*, lobular intraepithelial neoplasia; *MIN*, mammary intraepithelial neoplasia.

that of the control population, as indicated in the section on atypical hyperplasia.[107,143] This fact, which has been confirmed in independent studies,[139,140] indicates that evaluation of epithelial hyperplasia is an important gauge in deciding on the best approach to ongoing management for these patients. Naturally, several other factors need to be taken into consideration, such as the length of time since the diagnosis of atypical hyperplasia was made and the type of atypical hyperplasia (ADH vs. ALH).[144–147] In general, a conservative approach to benign breast disease is amply justified.[148]

Fibroepithelial Lesions

Fibroadenoma

Fibroadenoma is a very common benign neoplasm typically occurring in patients between the ages of 20 and 35 years. It increases in size during pregnancy and tends to regress with age. It is usually single, but in 20% of cases there are multiple lesions in the same breast or bilaterally.

Grossly, the typical fibroadenoma is a sharply demarcated, firm mass, usually no more than 3 cm in diameter. The cut surface is solid, grayish white, and bulging, with a whorled pattern and slit-like spaces (Fig. 36.29). Necrosis is absent.

Microscopically, fibroadenomas vary in appearance from case to case, depending on the relative amounts of glandular and fibrous tissue and the configuration of the former (Fig. 36.30). They are labeled *intracanalicular* when the connective tissue invaginates into the glandular spaces so that it appears to be within them, and *pericanalicular* when the regular round or oval configuration of the glands is preserved. Often, both growth patterns are seen in the same lesion and the distinction has no clinical connotations. The glands are composed of cuboidal or low columnar cells with round, regular nuclei resting on a myoepithelial cell layer. The stroma is usually made up of loose connective tissue rich in acid mucopolysaccharides, but it may be partially or completely composed of a dense

For personal use only. No other uses without permission. Copyright ©2017. Elsevier Inc. All rights reserved.

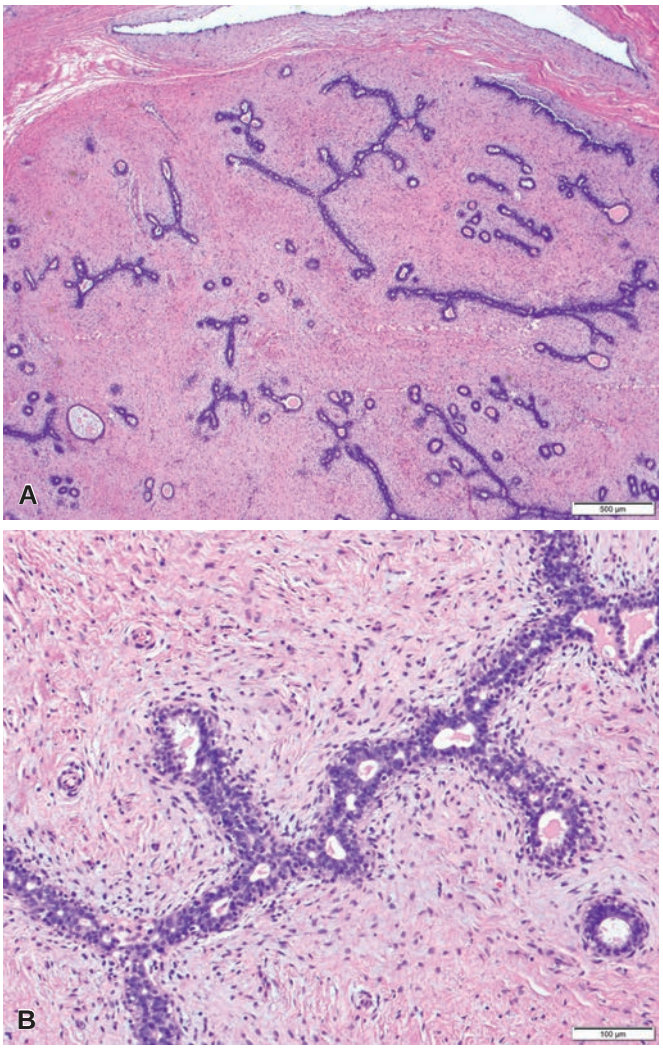

Figure 36.30 Microscopic Appearance of Fibroadenoma. A, Low-power image showing the circumscribed border, mixed glandular and stromal growth. **B,** On higher power, the bland nature of the stromal spindle cells is appreciated as well as the presence of mild epithelial hyperplasia.

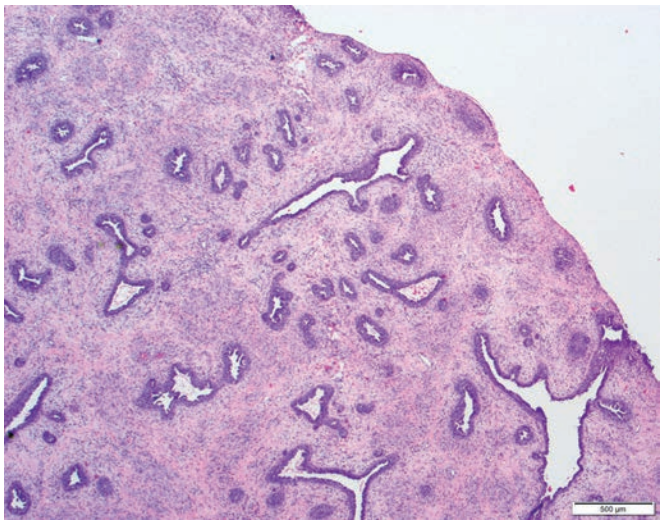

Figure 36.31 Juvenile Fibroadenoma. In this particular lesion the pericanalicular growth pattern predominates; florid hyperplasia is often seen as part of the epithelial component.

fibrous-type stroma. The spindle cells are predominantly CD34-positive fibroblasts.[149] Elastic tissue is absent, in keeping with the presumed TDLU origin of the lesion. The cellularity of the stroma varies from case to case, but in any unduly hypercellular lesion the alternative diagnosis of phyllodes tumor should be considered (see later).

Morphologic variations in fibroadenoma are plentiful, some of greater significance than others:

1. Hyalinization, calcification, and/or ossification of the stroma. These changes are more commonly seen in older patients and can be appreciated radiographically.
2. Presence in the stroma of multinucleated giant cells of reactive nature, similar to those seen in polypoid lesions of nasal cavity and other sites.[150,151]
3. Presence in the stroma of mature adipose tissue, smooth muscle, or metaplastic cartilage.[152] Some of the lesions described as hamartoma or choristoma of the breast probably belong to this category.[153]
4. Prominent myxoid changes. Most of these fibroadenomas are not otherwise different from the others. However, whenever multiple, highly myxoid fibroadenomas are found, the possibility that they are a component of Carney complex, which also includes endocrine hyperactivity, cardiac myxoma, cutaneous hyperpigmentation, and other abnormalities should be investigated. Parenthetically, other breast abnormalities that can be seen in this syndrome are myxoma and ductal adenoma with tubular features.[154]
5. Hypercellular stroma. On occasion, fibroadenomas will have an increase in stromal cellularity raising the differential diagnostic consideration of *cellular fibroadenoma* versus benign phyllodes tumor.
6. Hemorrhagic infarct. Fibroadenomas with this complication show a bulging, red appearance grossly that can be quite perplexing. This complication is more likely to occur during pregnancy.
7. Ill-defined edge blending with the surrounding breast parenchyma. This appearance is usually referred to as *fibroadenomatous change*.
8. Sclerosing adenosis. This occurs in less than 10% of cases.[22] Fibroadenomas with cysts larger than 3 mm, sclerosing adenosis, calcifications, or papillary apocrine change are referred to as "complex fibroadenomas."[155]
9. Squamous metaplasia. This is a rare finding; its presence in abundance should suggest the alternative possibility of phyllodes tumor.
10. Lactational changes. These are manifested by an increase in the amount of cytoplasm in the epithelial cells, which appear vacuolated, and by dilation of the glandular lumina by secretion.[26] It has been suggested that lactation adenomas in actuality represent this phenomenon rather than a distinct entity.
11. Young patients, large tumor size, and hypercellularity. There is a reasonably distinct type of fibroadenoma that tends to occur in adolescents (often in African-Americans and sometimes involving both breasts), reach a large size (over 10 cm), and show hypercellularity of glands and/or stroma.[156] A plethora of names exists to designate these lesions, depending on which feature predominates or which has impressed the writer the most. There are age-related terms, such as *juvenile fibroadenoma*;[157,158] size-related terms, such as giant or massive fibroadenoma; and cellularity-related terms, such *cellular fibroadenoma*.[158] In juvenile fibroadenoma the cellularity is mainly florid UDH and a pericanalicular growth pattern predominates (Fig. 36.31).[157] What

For personal use only. No other uses without permission. Copyright ©2017. Elsevier Inc. All rights reserved.

matters most is to recognize the lesion as a fibroadenoma and not to confuse it with virginal hypertrophy or, more importantly, phyllodes tumor. The epithelial hypercellularity can be dismissed as clinically inconsequential (unless it has the cytoarchitectural features of DCIS). Stromal hypercellularity and stromal cell atypia should be evaluated more carefully in terms of degree; it is good to remember, however, that it is rare for phyllodes tumors to occur in young patients (although they certainly can).

Fibroadenomas removed from patients taking oral contraceptives occasionally demonstrate formation of acini.[159]

Fibroadenomas express progesterone receptor (PR) almost universally and ER in approximately a quarter of cases.[160] Interestingly, the stromal cells of fibroadenomas express ER beta rather than ER alpha, this expression being related to the expression of smooth muscle markers.[161]

Cytogenetically, approximately 20% of fibroadenomas have been found to have clonal chromosome aberrations.[162] A lineage-restricted analysis has shown that these clonal aberrations are present in the stromal component, suggesting that fibroadenoma is a benign neoplasm of the specialized stroma of the breast with an accompanying epithelial component.[163] A recent large-scale epidemiologic study has confirmed that fibroadenoma represents a low, long-term risk for the development of breast carcinoma (1.5–2-fold; i.e., similar to proliferative lesions without atypia) and that there is no further increase in risk in women with complex fibroadenomas[164] nor is the risk further increased if the fibroadenoma contains foci of atypical hyperplasia.[165]

Malignant Changes

Malignant changes in fibroadenomas are found in only 0.1% of cases.[166,167] The malignant change usually involves the epithelial component, and the large majority are in situ lesions (Fig. 36.32).[168] In some cases the malignant tumor is entirely within the confines of the fibroadenoma, but in others it involves the surrounding breast parenchyma as well. The latter may simply represent extension into the fibroadenoma by a carcinoma originating elsewhere in the breast.[168]

Phyllodes Tumor

Phyllodes tumor is the term for the biphasic neoplasm originally named cystosarcoma phyllodes by Johannes Müller in 1838, a term that is to be avoided because of its malignant connotations. Phyllodes tumor occurs in middle-aged and older women. Very few patients are younger than 25 years of age, which is in striking contrast with the age distribution of fibroadenoma. However, phyllodes tumor can certainly occur in young adults and even in adolescents,[169] and, therefore, the diagnosis cannot be excluded on the basis of age. Of note, in Asian populations the average age is 41 years.[170] The interesting observation has been made that phyllodes tumors are more common in Hispanics than in other ethnic groups and that this risk is higher among Hispanics born in Latin America than those born in the United States.[171]

Figure 36.32 Fibroadenoma with focal involvement by low-grade ductal carcinoma in situ.

Grossly, the typical phyllodes tumor is round, relatively well circumscribed, and firm. The nipple may be flattened, but the overlying skin is almost never attached. The cut surface is solid and gray–white and shows the cleft-like spaces that give the tumor its name (Fig. 36.33A). Areas of necrosis, cystic degeneration, and hemorrhage may be present (see Fig. 36.33B). Rarely, the entire tumor undergoes hemorrhagic infarction. Many phyllodes tumors are large, and some reach huge dimensions, but others measure less than 5 cm in diameter. It follows, then, that the diagnosis of phyllodes tumor can be neither made nor ruled out by size alone. A lesion with the microscopic appearance of fibroadenoma should still be diagnosed as such, after appropriate sampling, even if large.

Microscopically, the two key features of phyllodes tumor are stromal hypercellularity and the presence of benign glandular elements as an integral component of the neoplasm (Fig. 36.34). It is the amount and appearance of the stromal component that determine whether a breast neoplasm should be called a fibroadenoma or a phyllodes tumor and, in the latter instance, what the chances are of the tumor behaving clinically in an aggressive fashion. Three histologic categories of phyllodes tumor have been defined, although there is considerable overlap in the features such that a sharp distinction between benign and borderline and to lesser extent between borderline and malignant forms of phyllodes tumor is not always possible.[172] Furthermore, at the benign end of the spectrum it can be difficult to reliably distinguish cellular fibroadenoma from benign phyllodes tumor.

Tumors with the configuration of fibroadenomas but with a hypercellular stroma and some imbalance of the gland to stroma ratio are on the "benign" end of the spectrum; the stromal component has a fibroblastic appearance with little or mild stromal cell atypia and few mitoses (<5 per 10 high-power fields). Malignant phyllodes tumors have a high degree of stromal cellularity, marked stromal cell nuclear atypia, numerous mitoses (≥10 per 10 high-power fields), and a greater imbalance in the distribution of glands in the stroma. An important diagnostic criterion of malignancy is overgrowth of the glands by the malignant stroma such that low-power views (4× microscopic field) of the tumor show stroma only, without epithelial elements ("stromal overgrowth").[172] The neoplastic stromal component may be monomorphic or highly pleomorphic, and its appearance is most often reminiscent of fibrosarcoma, but liposarcomatous differentiation (Fig. 36.35) may also be seen; heterologous elements such as metaplastic cartilage, bone, or, exceptionally, skeletal muscle may be encountered. Phyllodes tumors with heterologous stromal elements are more aggressive. Tumor necrosis is also associated with poor prognosis.[173] It goes without saying that borderline tumors have features intermediate between benign and malignant phyllodes tumors with moderately cellular stroma, mild to moderate stromal cell atypia, 5–9 mitoses per 10 high-power fields and no (or very focal) stromal overgrowth. The border of the tumor is another feature used to help categorize phyllodes tumors: benign phyllodes tumor has a well-defined border, and malignant phyllodes tumor has an infiltrative or permeative tumor border. Borderline phyllodes tumor usually has a well-defined border, but it may be focally permeative. The epithelial component, although not neoplastic, can have a

For personal use only. No other uses without permission. Copyright ©2017. Elsevier Inc. All rights reserved.

Figure 36.33 Gross Appearance of Phyllodes Tumor. The tumor shown in **(A)** exhibits the typical appearance of the cut surface. The tumor illustrated in **(B)** has undergone extensive infarction.

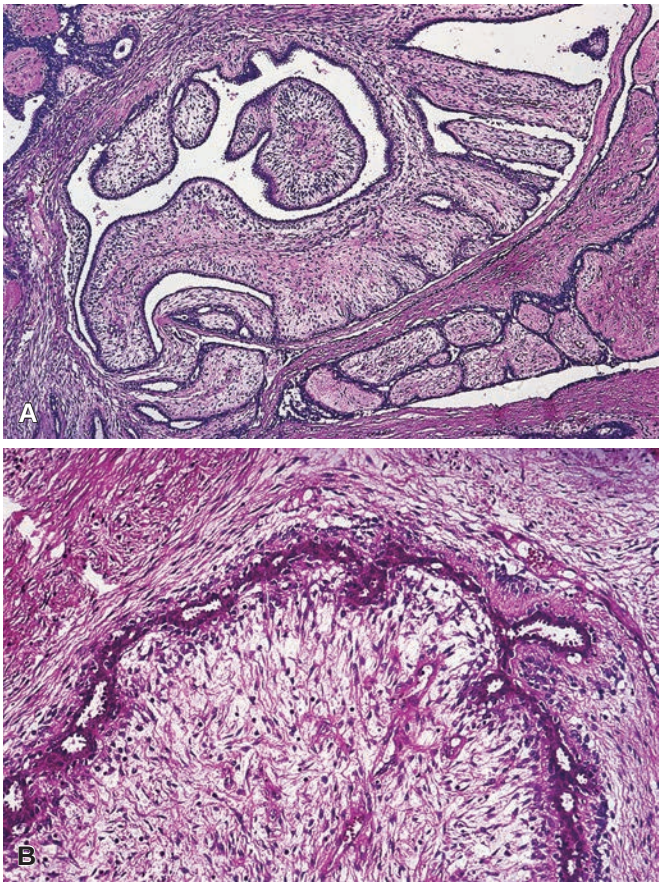

Figure 36.34 **A** and **B,** Two views of benign phyllodes tumor, showing cleft-like spaces and condensation of stromal cells under the epithelium.

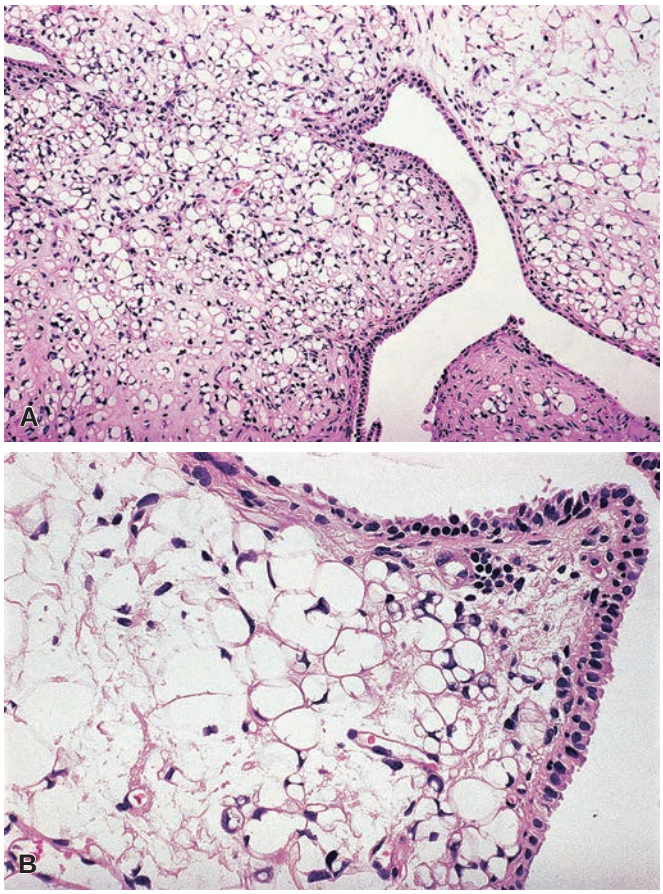

Figure 36.35 **A** and **B,** Malignant phyllodes tumor with liposarcomatous differentiation of the neoplastic stromal component.

For personal use only. No other uses without permission. Copyright ©2017. Elsevier Inc. All rights reserved.

markedly proliferative appearance, as it sometimes does in fibroadenoma, a finding of no clinical significance. On rare occasions, the features of carcinoma in situ of either ductal or lobular type may be present.[174–176]

Immunohistochemically, there is frequent expression of CD34 and bcl2, similar to other stromal tumors of the breast and in contrast to spindle cell metaplastic carcinomas, a feature of significance in the differential diagnosis.[161,177] Of note, recent reports have demonstrated staining with both p63 and cytokeratin in the stromal cells of phyllodes tumors,[178,179] albeit focal and weak in the majority of cases, a finding that may be problematic when working up a core needle biopsy of an apparently pure spindle cell lesion. Whenever the diagnosis of a spindle cell metaplastic carcinoma is being considered on a core needle biopsy, bear in mind that such specimens may represent sampling of the stromal component of a malignant phyllodes tumor. CD117 is expressed in about a third of all phyllodes tumors and over half of malignant ones.[180] ER beta and PR are expressed in the stromal cells of nearly all cases.[160] There is overexpression of p53 in a variable number of histologically malignant and borderline cases but very rarely in those with bland microscopic features; however, there is insufficient discrimination for this marker to prove clinically useful.

Fibroepithelial lesions have been shown to harbor *MED12* mutations with slightly greater prevalence in phyllodes tumor compared with fibroadenoma (62.5% vs. 59%).[181] Phyllodes tumors on the malignant end of the spectrum have a higher complexity of alterations, with recent array-based comparative genomic hybridization (CGH) data demonstrating interstitial deletion of 9p21 involving the *CDKN2A* locus.[182,183]

The behavior of benign phyllodes tumors is characterized by a potential for local recurrence but an extreme rarity of distant metastases.[172] If an enucleation has been performed under the clinical impression of fibroadenoma, the patient can be safely followed for the possibility of recurrence. If the latter develops or if this type of phyllodes tumor is recognized at the time of initial surgery, local excision with a wide margin of normal tissue is the treatment of choice.[184] Recurrent phyllodes tumor may still be managed with wide local excision.

The cytologically malignant tumors have the potential for metastasis, with the incidence of metastases ranging from 3% to 12% in various series, though local recurrence is still the more common event. Axillary lymph node metastases are exceptional. The most common sites of distant involvement are lung and bone.[185,186] The metastases are of the stromal component, although entrapment of normal structures in the lung may simulate a biphasic composition.

Wide local excision with an adequate margin of normal breast tissue is sufficient therapy for most cytologically malignant phyllodes tumors,[184] but if there is any question of invasion of the fascia, the tumor should be removed together with the underlying muscle. There is no need for removal of the axillary nodes, except for the exceptional instances in which they are clinically involved.

If both the benign epithelial component and the stromal component are sampled, the diagnosis of phyllodes tumor is generally straightforward (tumor grading notwithstanding). The main differential diagnosis of malignant phyllodes tumors is with spindle cell metaplastic carcinoma (as discussed previously) and far less likely with other types of sarcoma (again largely depending on the presence or absence of a non-neoplastic epithelial component). Benign phyllodes tumors need to be distinguished mainly from cellular fibroadenomas, both of which will have increased stromal cellularity, but the latter is more likely to have a pericanalicular growth pattern and will have an even balance in the gland distribution within the stroma. It should be acknowledged that in some instances this may not be possible at a practical level or justified at a conceptual level, in which case the term "benign fibroepithelial neoplasm" has been proposed by the WHO.[172]

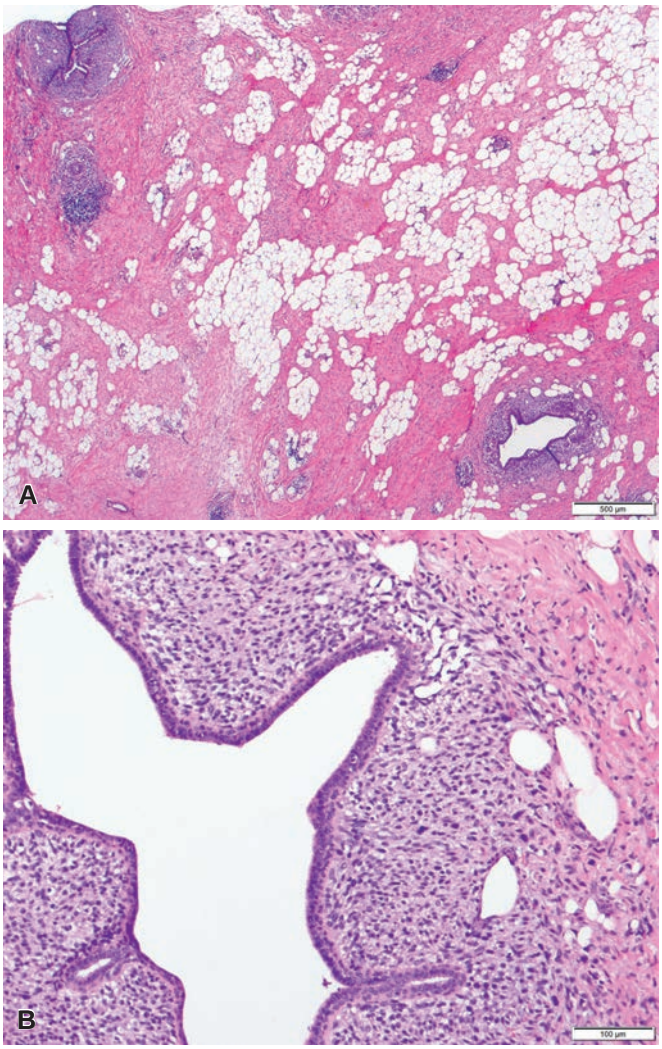

Figure 36.36 Periductal Stromal Tumor. A, This fibroepithelial tumor lacks the circumscription of fibroadenoma or phyllodes tumor and instead is seen as dispersed nodules. **B,** Higher power view reveals the hypercellular stroma surrounding a benign epithelial element.

The neoplasm described as *periductal stromal tumor*[187] contains epithelial structures like those of fibroepithelial lesions, but the stromal component lacks the phyllodes architecture and tumor circumscription and instead is seen as dispersed nodules (Fig. 36.36). Stromal cell cytologic atypia and mitoses may be present.

Adenosis and Sclerosing Lesions

Adenosis

The term adenosis can be applied to any hyperplastic process that primarily involves the glandular component of the breast; it should, therefore, be used with a qualifier in order to acquire a specific clinicopathologic connotation.

Blunt Duct Adenosis

This is a term that has been applied variably in the literature and as such its use is no longer recommended. The WHO Classification

For personal use only. No other uses without permission. Copyright ©2017. Elsevier Inc. All rights reserved.

of Tumors of the Breast refers to this term as a synonym of columnar cell change.[122]

Sclerosing Adenosis

Sclerosing adenosis is the best known form of adenosis because of its relative frequency and the potential for misdiagnosis as carcinoma. Most often, sclerosing adenosis is an incidental microscopic finding; however, in some instances it may present as an image-detected breast mass or as mammographically detected microcalcifications. The gross appearance can be of a small mass with a disk-like, somewhat multinodular configuration that cuts with increased resistance. In some cases, the overall gross appearance may be quite reminiscent of invasive carcinoma.

Microscopically, the most important diagnostic feature of the lesion is its architecture, as seen at low magnification. Sclerosing adenosis retains a rounded, lobulocentric configuration and is more cellular centrally than peripherally (Figs. 36.37 and 36.38). The elongated and compressed proliferating tubules are lined by epithelial cells and have a peripheral myoepithelial cell layer. The myoepithelial component predominates in some lesions and may even acquire spindle-shaped "myoid" features. Atypia in the form of cribriform areas, nuclear pleomorphism, and necrosis is absent. The stroma is dense and may show foci of elastosis, although not as commonly as in radial scar or invasive carcinoma. Microcalcifications may be present.

The involvement of myoepithelial cells in the process can be demonstrated with various immunohistochemical stains (see Figs. 36.37C and 36.38C) (smooth muscle myosin heavy chain, calponin, p63, or, less commonly now, actin), and the presence of basement membrane around the tubules with stains for laminin or type IV collagen, although the latter are not commonly used in clinical practice.

Morphologic variations of sclerosing adenosis that further complicate interpretation are the florid changes that may accompany pregnancy, the presence of apocrine metaplasia (which is accompanied by nuclear and nucleolar enlargement), the occasional occurrence of perineural invasion (Fig. 36.39),[188] and permeation of the walls of veins.[189]

The risk of subsequent invasive carcinoma in patients with sclerosing adenosis is the same as for proliferative disease without atypia.[190]

On occasion, foci of sclerosing adenosis may be secondarily involved by LCIS or even DCIS (Fig. 36.40).[191] In these cases, the distortion already present because of the sclerosing adenosis may result in a mistaken diagnosis of invasive carcinoma. The low-power impression is critical to arriving at the correct diagnosis; foci of sclerosing adenosis (with or without CIS) have dilated ductules peripherally and narrow ones centrally, whereas invasive lobular carcinoma has no overall organization.[192] Immunohistochemical evaluation demonstrating the presence of myoepithelial cells can be of assistance in recognizing the underlying benign lesion.

Nodular adenosis and **adenosis tumor** refer to sclerosing adenosis lesions that form a palpable or mammographic mass. The proliferating glands are better circumscribed forming a more discrete mass than in sclerosing adenosis.

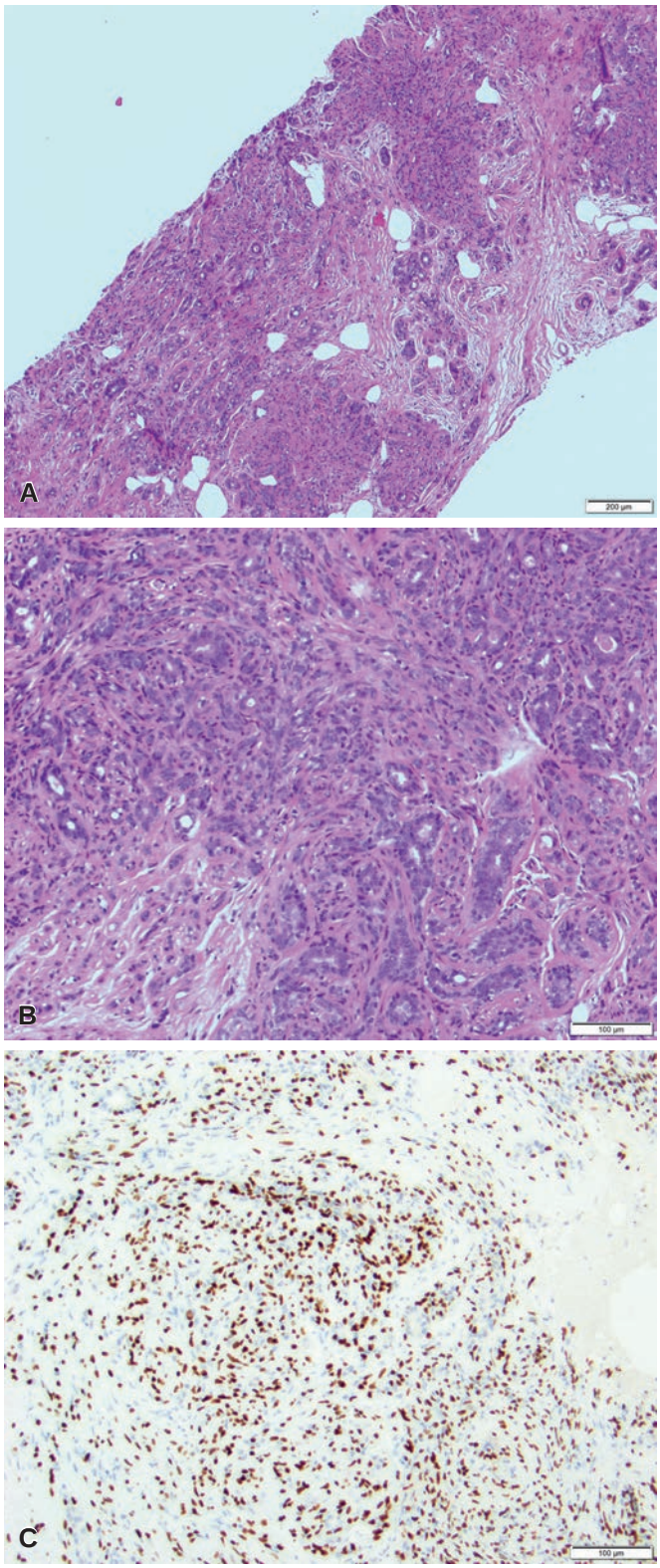

Figure 36.37 Sclerosing Adenosis. A, Low-power view. The lobular configuration of the small glandular proliferation is readily apparent even on this core needle biopsy specimen. **B,** Medium-power view. Note the spindle shape of the myoepithelial cells present. **C,** Immunohistochemical stain for p63 showing strong immunoreactivity in the myoepithelial cell component.

Microglandular Adenosis

Microglandular adenosis is a rare form of adenosis in which small, uniform glands with open lumina containing eosinophilic secretions are distributed in a haphazard fashion within the fibrous tissue or fat (Fig. 36.41).[193–195] The glands are composed of a single layer of small, uniform cuboidal cells with vacuolated or granular cytoplasm, lacking apocrine-type "snouts." In contrast to other forms of adenosis,

For personal use only. No other uses without permission. Copyright ©2017. Elsevier Inc. All rights reserved.

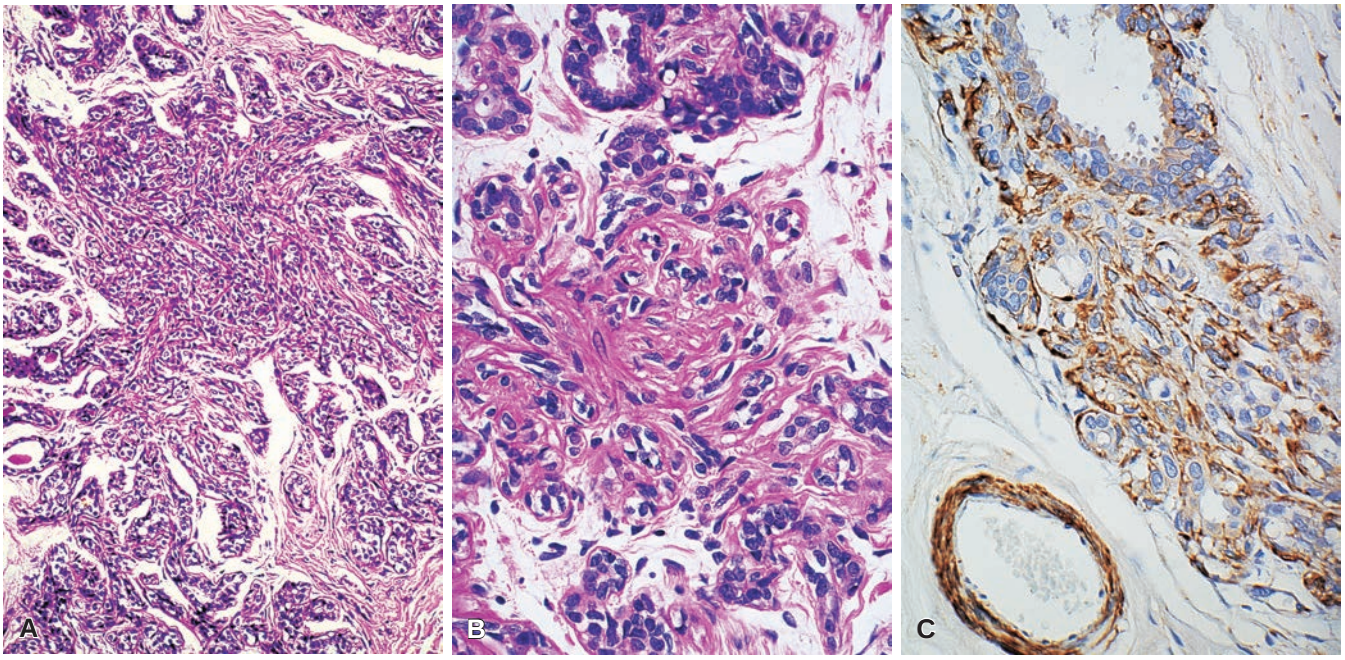

Figure 36.38 Sclerosing Adenosis. A, Low-power view. The lobular configuration of the lesion is obvious. **B,** Medium-power view of the myoepithelial cells in the center of the TDLU. **C,** Actin immunostain showing strong reactivity in the myoepithelial cell component.

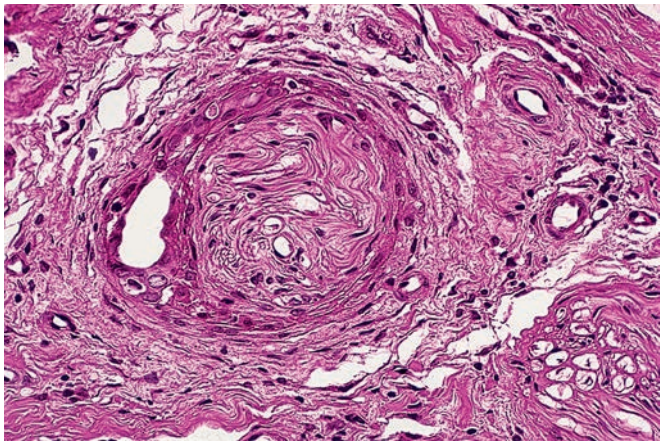

Figure 36.39 Benign "perineural invasion" in a breast lesion that had elsewhere the typical features of sclerosing adenosis.

the myoepithelial layer is absent.[193,196] However, there is a basement membrane that can be appreciated immunohistochemically and ultrastructurally.[195] The stroma may be hyalinized but is not cellular or elastotic. Microglandular adenosis is ER, PR, and HER2 negative and strongly and diffusely positive for S-100 protein. The main differential diagnosis of this lesion is with tubular carcinoma, which also lacks a myoepithelial cell layer but is uniformly ER positive.[193]

Atypical microglandular adenosis should be diagnosed when the glands begin to coalesce, forming small nests either solid or cribriform in architecture, often with cytologic atypia (Fig. 36.42). Luminal secretions are less prominent in atypical microglandular adenosis.

It is unclear whether microglandular adenosis is a benign process or whether it may be a precursor lesion[197]; enough cases have been reported in continuity with carcinoma to suggest that the lesion may evolve into malignancy in some patients.[197–199] Interestingly, a high percentage of these carcinomas in one series have been of the adenoid cystic type.[198] Actually, this frequently occurring spatial relationship with an easily recognizable carcinoma, and the fact that microglandular adenosis is the only "benign" epithelial breast lesion devoid of myoepithelial cells, makes one wonder whether it represents an indolent form of invasive ductal carcinoma. Indeed recurrent losses of chromosome 5q and gains of 8q as well as mutations in *TP53* have been reported in microglandular adenosis, particularly in cases with coexistent atypical microglandular adenosis and invasive carcinoma, specifically triple negative breast carcinomas.[200–202] Given the uncertainty about the role of microglandular adenosis as a precursor lesion, the need for excision to clear margins is controversial; diagnosis on a core needle biopsy should prompt an excision.

Apocrine Adenosis

Apocrine adenosis is a form of adenosis in which the glands are larger, the lining epithelium is apocrine in nature, and myoepithelial cells are present (Fig. 36.43).[203,204] Occasionally nuclear atypia and nucleolar prominence are noted; when at least threefold variation in nuclear and nucleolar size is seen, *atypical apocrine adenosis* is said to be present. The subsequent breast cancer risk associated with apocrine adenosis and atypical apocrine adenosis is uncertain.[205,206]

Tubular Adenosis

Tubular adenosis is an unusual form of adenosis, which is characterized by elongated, tubular, and branching glands arranged in a somewhat haphazard pattern. A myoepithelial cell layer is present, which is of value in distinguishing this lesion from invasive carcinoma, of which it can be a mimic (Fig. 36.44).[207]

Radial Scar and Complex Sclerosing Lesions

This is a group of breast lesions characterized by a generally small size, stellate shape, and a central fibroelastotic core, with variable degree of epithelial proliferation and distortion.[208,209] They have been variously designated as radial scar, complex sclerosing lesion,

For personal use only. No other uses without permission. Copyright ©2017. Elsevier Inc. All rights reserved.

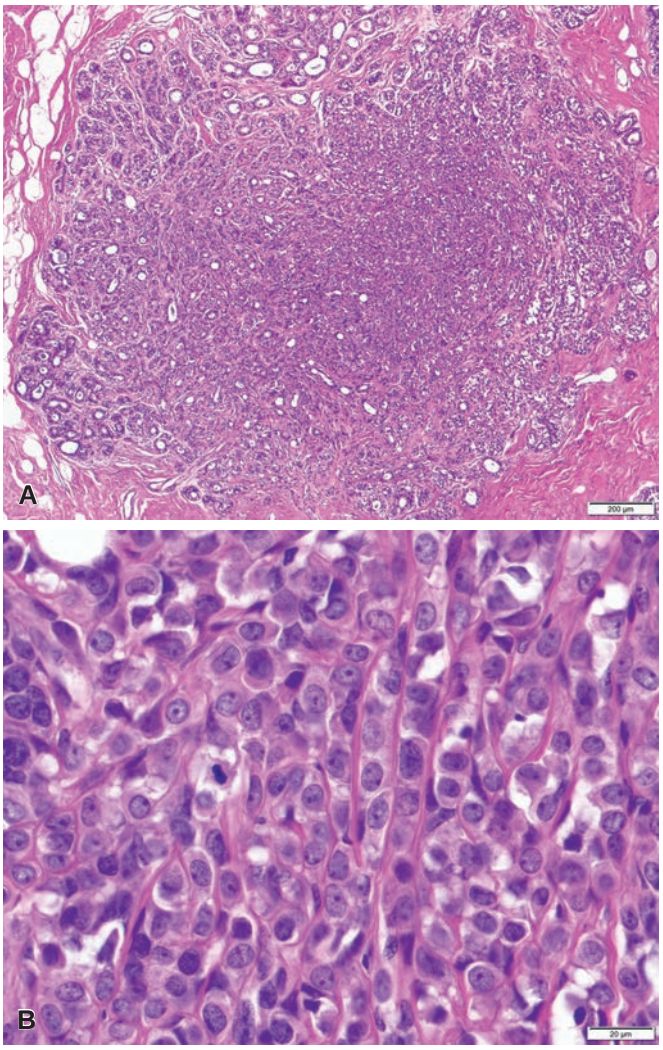

Figure 36.40 Sclerosing Adenosis With Lobular Carcinoma In Situ. A, Note the absence of infiltrative features at the border of the proliferation on low power. **B,** High power confirming the presence of LCIS in adenosis.

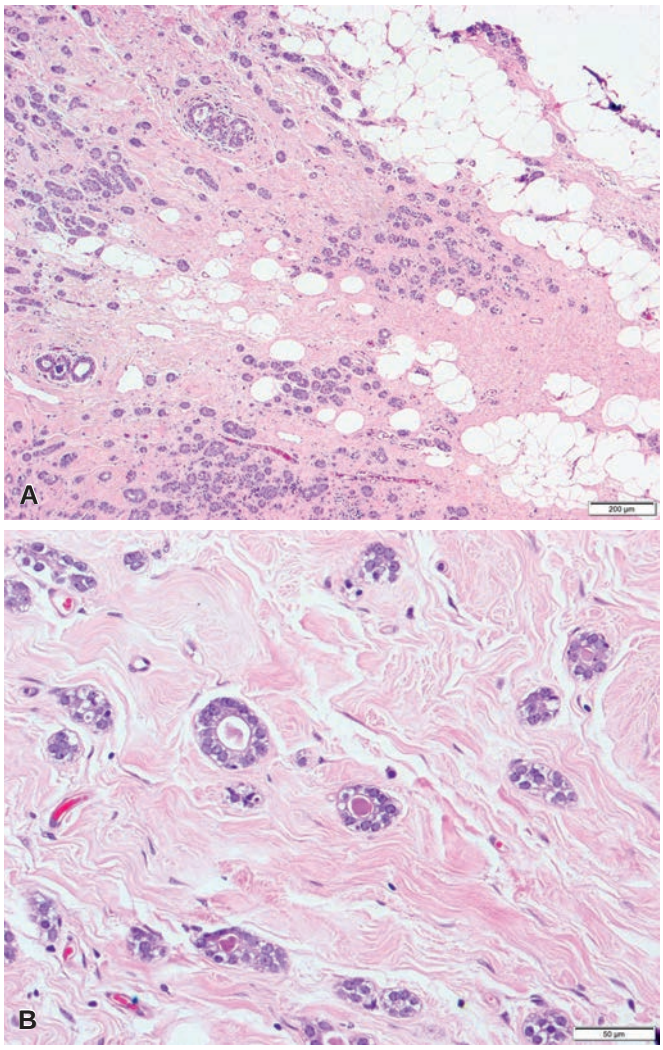

Figure 36.41 Microglandular Adenosis. A, Low-power appearance, showing haphazardly scattered small round glands. **B,** On high power, the glands are open and contain bright eosinophilic luminal secretion. There is no myoepithelial cell layer.

and infiltrating epitheliosis.[210] On mammography and gross examination, the irregular, stellate shape confers a resemblance to invasive ductal carcinoma (Fig. 36.45). Microscopically, the connective tissue center is densely fibrotic or fibroelastotic (Fig. 36.46). Basophilic elastic tissue may be seen in the walls of obliterated ducts and the stroma, sometimes in abundance. Embedded within the stroma are small ducts and glands that appear disorganized due to the distortion caused by the fibrosis, but which are still composed of both epithelial and myoepithelial cells; at the periphery of the "radial spokes" are larger duct-like structures that may be dilated and/or may exhibit UDH.

The terms radial scar and complex sclerosing lesion are used somewhat interchangeably, with some authors making the distinction on size (<1 cm for the former vs. >1 cm for the latter) and others making the distinction based on the degree to which the lesion is organized around a central scar. The most important aspect of radial scars/complex sclerosing lesions is the differential diagnosis with invasive ductal carcinoma, a problem that may be compounded if the radial scar is involved by DCIS or LCIS (Fig. 36.47). The diagnostic criteria for the identification of carcinoma should be the same whether a central scar is present or not. They include the cytoarchitectural criteria as seen in H&E-stained sections, as well as evaluation for the presence of a myoepithelial cell layer, using immunohistochemistry if necessary. Note that reduction in staining has been reported with some myoepithelial cell markers in this setting, thus a panel of immunohistochemical stains is recommended.[211]

There is no evidence to suggest radial scars are a direct precursor lesion to invasive breast carcinoma; any risk associated with this lesion is related to the presence of proliferative disease within the lesion.[208] Studies have demonstrated that women with radial scars have a risk for breast cancer that is almost twice that of women without radial scars, regardless of the histologic type of benign breast disease present[212,213]; however others contend that there is no increase in breast cancer risk above and beyond that conferred by the histologic type of benign breast disease present in the background breast tissue.[214,215] The management of mammographically detected radial scar is usually core needle biopsy with follow-up conservative excision to exclude a worse lesion, though with greater sampling by large gauge and vacuum-assisted core biopsy needles, excision may not be necessary in every case.[216]

Tubular adenoma presents in young adults as a solitary, well-circumscribed, firm, tan–yellow mass composed microscopically of closely packed uniform small tubules lined by a single layer of epithelial cells and an attenuated layer of myoepithelial cells; the

For personal use only. No other uses without permission. Copyright ©2017. Elsevier Inc. All rights reserved.

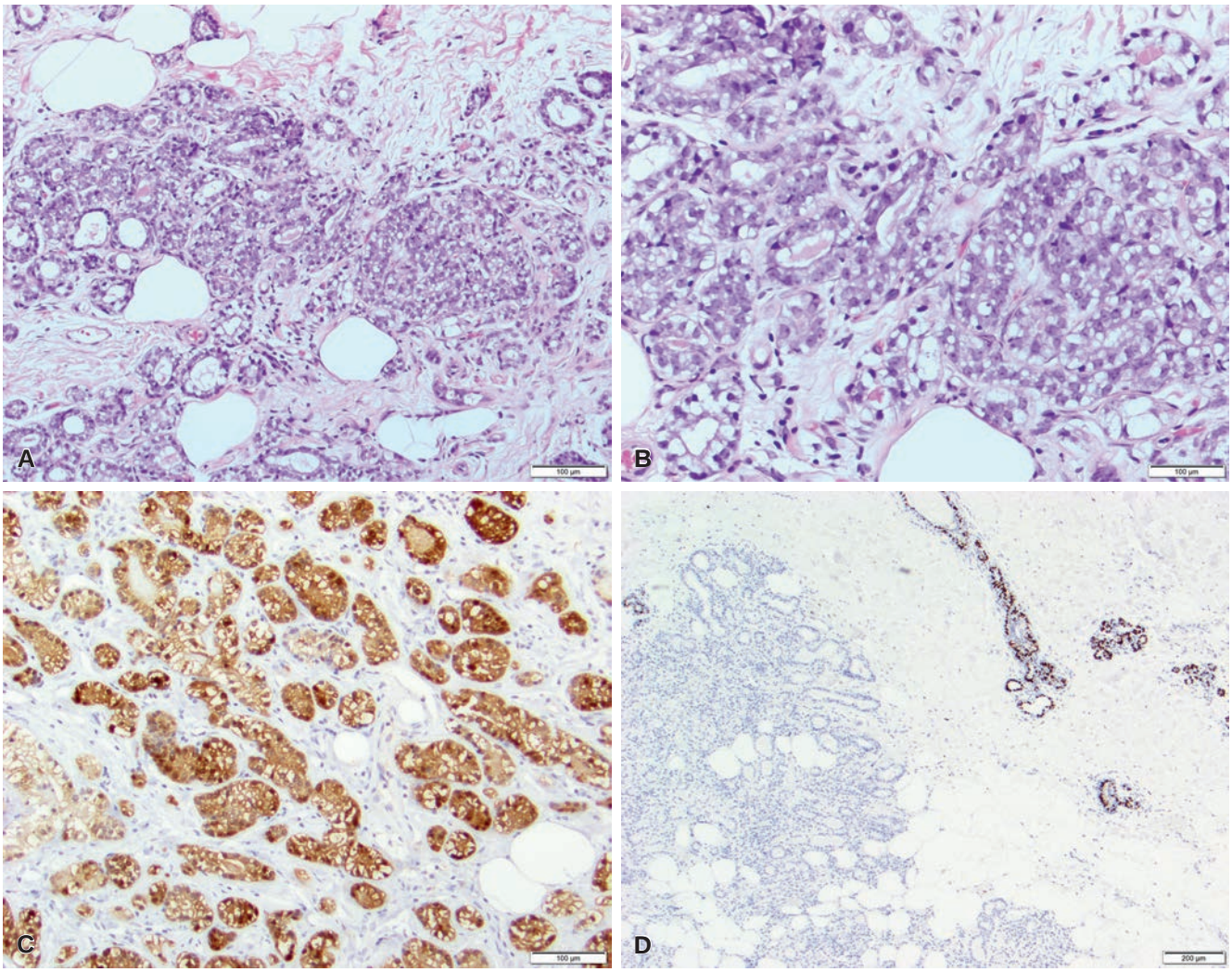

Figure 36.42 Atypical Microglandular Adenosis. A, Intermediate-power appearance, showing haphazardly arranged small round glands peripherally, with solid nests centrally. **B,** On high power, the cytologic atypia is appreciated; some luminal secretions are retained (*top right* of field). **C,** An S-100 protein immunostain is strongly positive. **D,** Estrogen receptor immunostain is negative in microglandular adenosis with good internal control in an adjacent normal duct.

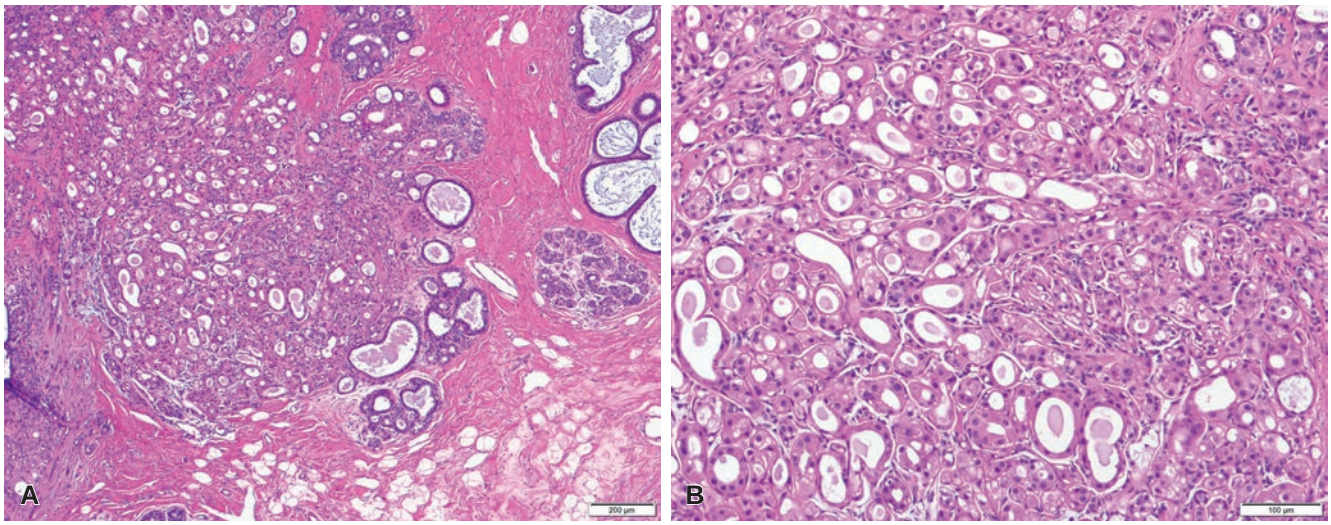

Figure 36.43 Apocrine Adenosis. A, This low-power image shows the lobulocentric architecture of adenosis; apocrine features are present. **B,** At higher power, the apocrine cells can be evaluated. The nuclei are round with large nucleoli, but there is no significant nuclear enlargement or variability.

For personal use only. No other uses without permission. Copyright ©2017. Elsevier Inc. All rights reserved.

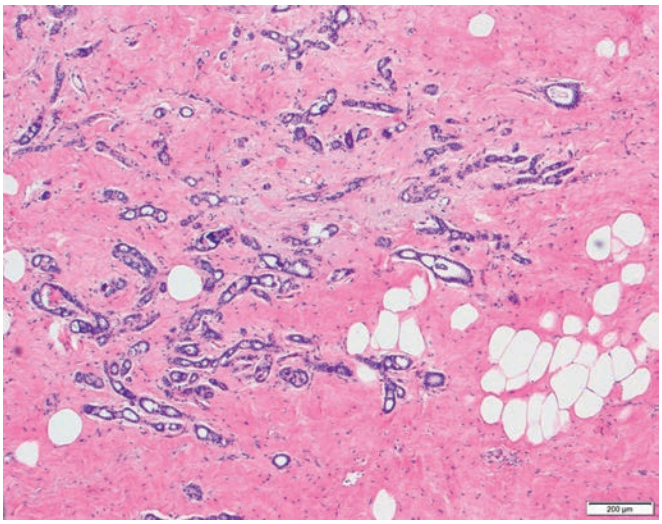

Figure 36.44 Tubular Adenosis. This low-power image shows the characteristic elongated, tubular, and branching glands of tubular adenosis arranged in a somewhat haphazard pattern.

Figure 36.45 Gross appearance of radial scar.

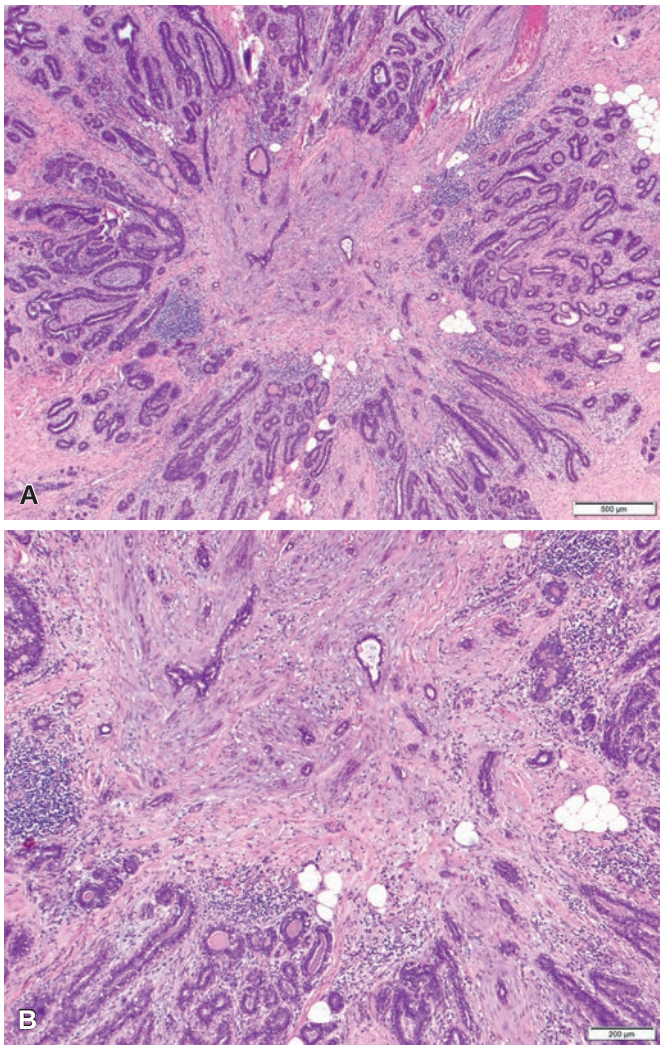

Figure 36.46 Radial Scar. A, Typical stellate shape of radial scar as seen on low power. **B,** Benign ductular structures are entrapped in the central fibroelastotic stroma.

stroma is sparse. It is not clear whether this is a separate entity or a pattern of fibroadenoma.[217]

Lactating adenoma presents as a solitary or multiple freely mobile breast masses during pregnancy or the puerperium. The lesion is more likely a localized focus of hyperplasia in the lactating breast, which may also develop in ectopic locations such as the axilla, chest wall, or vulva.[26,217] Grossly, the lesion is well circumscribed and lobulated. The cut surface is gray or tan, in contrast to the white color of fibroadenoma (Fig. 36.48). Areas of infarction may be seen. Microscopically, hyperplastic lobules are present lined by actively secreting cuboidal cells (Fig. 36.49). This lesion may be confused with the proliferative and secretory changes brought on by pregnancy in a preexisting fibroadenoma, a distinction that is likely of no clinical consequence.[26]

Papillary Lesions

Intraductal Papilloma

Intraductal papilloma of the breast occurs most commonly between the ages of 30 and 50 years. It can arise in large or small ducts; consequently, it can be identified grossly as a polypoid intraductal mass or be found only on microscopic examination. Intraductal papilloma can give rise to bloody nipple discharge and may be palpable in the subareolar location, but its diameter rarely exceeds 3 cm. The lesion is soft and friable and may have areas of hemorrhage. The duct that contains the papilloma may be dilated (Fig. 36.50). Approximately 90% of cases are solitary. Multiple papillomas are seen in slightly younger patients, arise in smaller, more peripherally located ducts, are usually not associated with nipple discharge, and are bilateral in one-quarter of cases.

Microscopically, papillomas are complex, cellular, and often intricately arborescent (Fig. 36.51A). Features favoring benignity in a papillary breast lesion are a hyalinized stroma in broad papillary

For personal use only. No other uses without permission. Copyright ©2017. Elsevier Inc. All rights reserved.

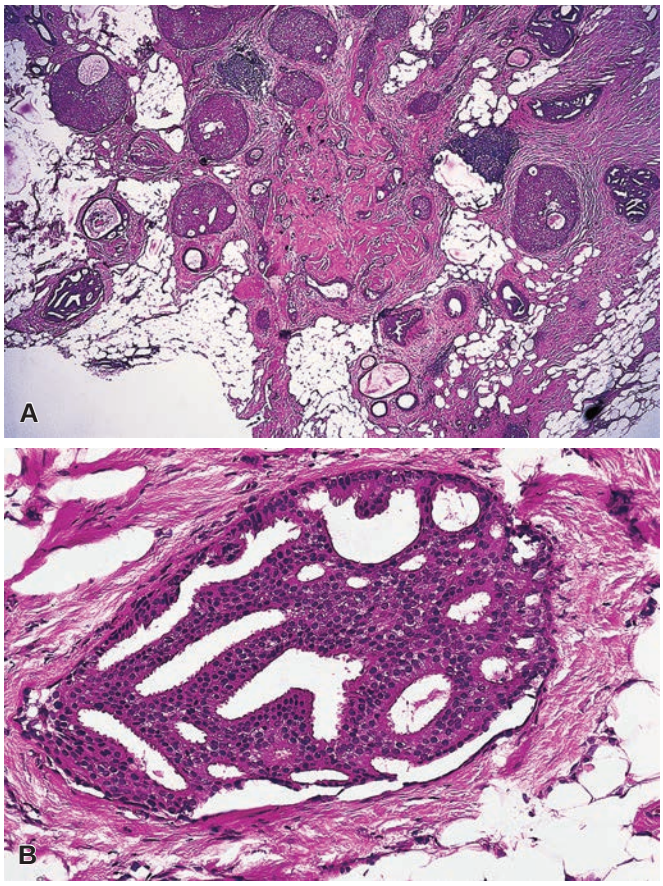

Figure 36.47 **A** and **B,** Radial scar with associated low-grade ductal carcinoma in situ.

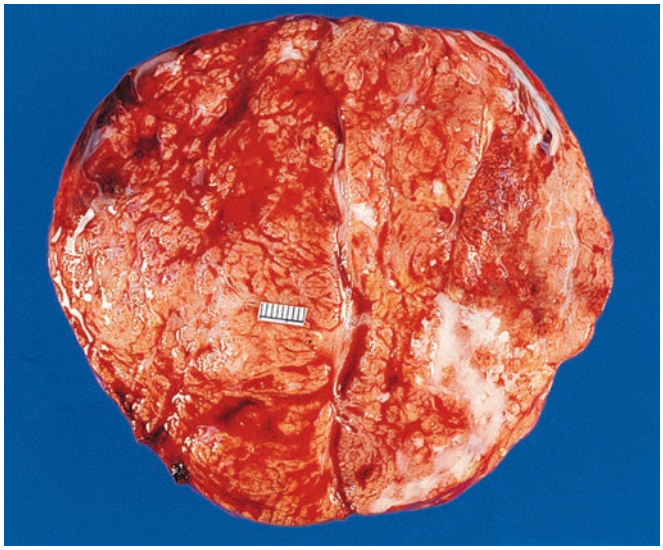

Figure 36.48 **Gross Appearance of a Lactating Adenoma.** The mass has a distinct lobular configuration, yellowish color, and marked vascularization.

fibrovascular cores, the presence of two cell types (epithelial and myoepithelial) (see Fig. 36.51B), normochromatic often oval epithelial cell nuclei, scanty mitotic activity, the presence of foci of apocrine metaplasia, and lack of a cribriform pattern.[218] Necrosis is nearly always absent (but see later). The presence of a myoepithelial cell

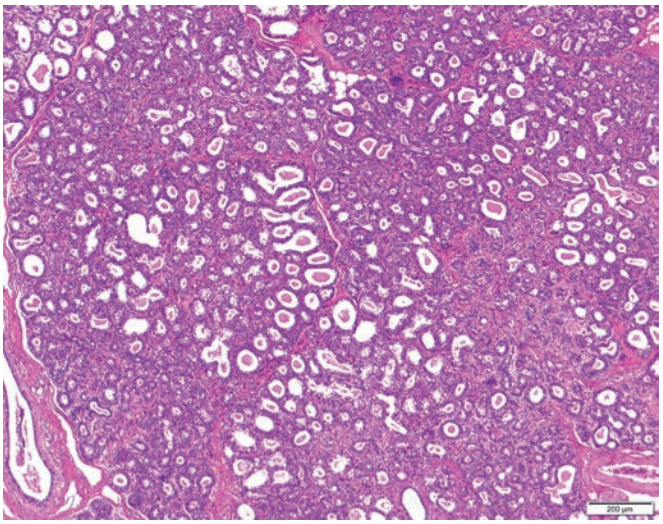

Figure 36.49 **So-called Lactating Adenoma.** The hyperplastic lobules show secretory change.

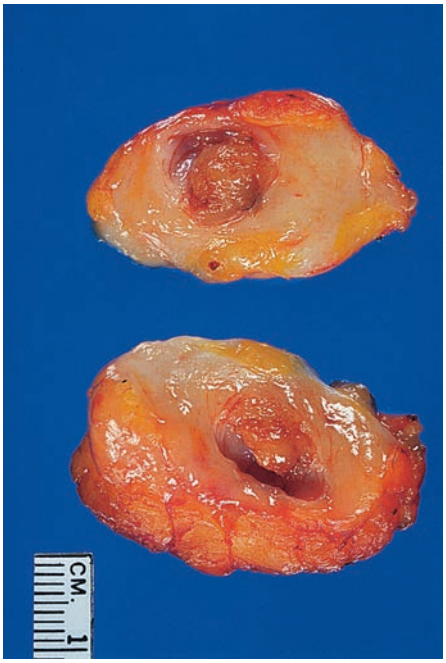

Figure 36.50 **Gross Appearance of an Intraductal Papilloma.** A polypoid mass is seen protruding within the lumen of a markedly dilated duct.

component can be highlighted with various immunostains, such as p63, calponin, and smooth muscle myosin heavy chain. Clonal analysis has shown that intraductal papilloma is a clonal lesion, a finding that supports its neoplastic nature.[219]

Morphologic variations sometimes encountered in intraductal papilloma include:

1. Partial or total hemorrhagic infarct. This change, which is probably caused by interruption of the blood supply, is entirely different from the tumor necrosis seen in carcinoma, and is most commonly seen following a fine-needle aspiration (FNA) or core needle biopsy procedure.
2. Necrosis. Necrosis has been described in papillomas involved by florid UDH; its presence should not lead to a misdiagnosis of DCIS.[220] The necrosis is most often focal in nature.

For personal use only. No other uses without permission. Copyright ©2017. Elsevier Inc. All rights reserved.

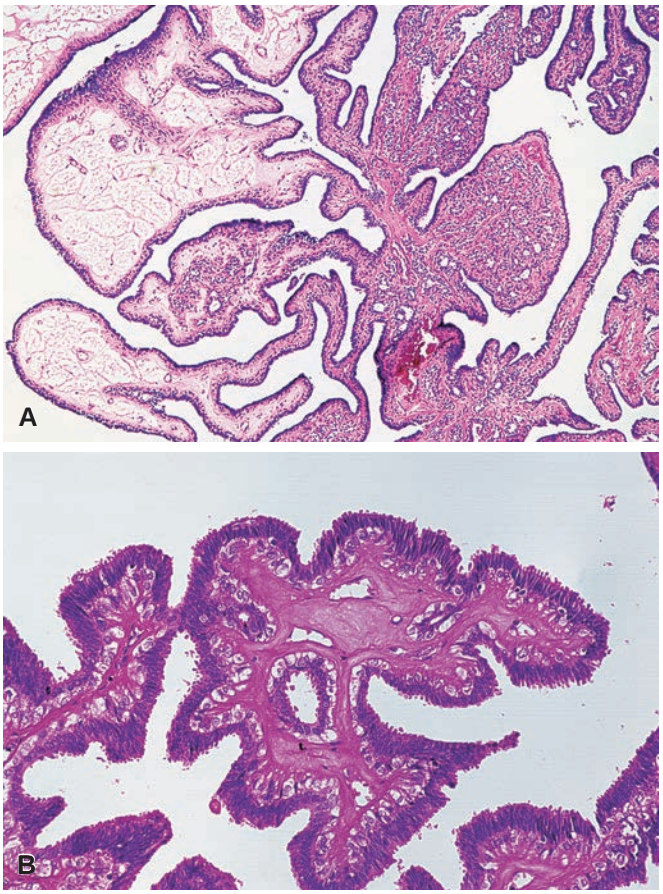

Figure 36.51 Intraductal Papilloma. A, Low-power appearance showing complex arborizing architecture. **B,** High-power view showing dual cell composition, with a well-defined row of myoepithelial cells.

3. Squamous metaplasia. This change is probably secondary to focal necrosis and is uncommon.
4. Entrapped glands within or adjacent to the papilloma. This is the most problematic change in terms of possible overinterpretation. It is the result of sclerosis (perhaps sometimes secondary to infarction), which leads to marked distortion of the glandular component and sometimes to the presence of isolated tubules embedded in dense fibrous tissue. When pronounced throughout the lesion, use of the diagnosis "sclerosed papilloma" is appropriate (Fig. 36.52). Preservation of the two-cell layer, as well as accompanying hemosiderin deposits and cholesterol clefts, are supportive diagnostic features. Immunohistochemical stains for myoepithelial cells, such as p63 or smooth muscle myosin heavy chain, are often helpful in cases where the two-cell layer is difficult to appreciate on H&E stained sections.
5. Superimposed florid UDH. In cases in which distinction between usual (florid) ductal hyperplasia and carcinoma in situ is problematic, the combination of ER and HMW cytokeratin stains (e.g., CK5/6) can be very useful. The former will demonstrate a heterogeneous pattern of staining with both ER and CK5/6; atypical ductal proliferations and DCIS will show strong, diffuse staining with ER and an absence of staining with CK5/6.
6. ***Ductal adenoma***. This lesion lacks the arborescent papillary quality of the typical papilloma, but its intraductal location with a dense fibrotic capsule and the distorted epithelial proliferation composed of two cell types (as confirmed immunohistochemically) embedded in a sclerotic stroma suggest that these lesions likely represent highly sclerotic variants of intraductal papilloma.[221,222] Ductal adenoma with tubular features can be seen as a component of Carney syndrome.[223]
7. Sebaceous metaplasia. This is an exceptionally rare but well-documented event.[224]
8. ***ADH and DCIS*** arising in an intraductal papilloma. The cytologic criteria for the recognition of these alterations are no different from those employed when a papilloma is not present (see later).[225, 226] The absence of myoepithelial cells in the areas of atypia may be confirmed with immunohistochemical stains (e.g. p63, SMMHC); of greater utility is the combined use of ER and CK5/6 (see previous discussion for use of these immunostains in the differential diagnosis with UDH). The recommendation of the WHO Classification of Tumors of the Breast Working Group is that foci of low nuclear grade atypia measuring less than 3 mm in extent arising in a papilloma be classified as intraductal papilloma with ADH; those with ≥3 mm of atypia merit a diagnosis of DCIS involving an intraductal papilloma (Fig. 36.53).[122]
9. Post-biopsy or FNA with benign epithelial displacement/implantation. Excision specimens of benign intraductal papilloma that have had a prior needling procedure can have small irregular nests and single epithelial cells with degenerative features distributed haphazardly within the biopsy site, which can be a mimic for invasive carcinoma. (Fig. 36.54).[227]

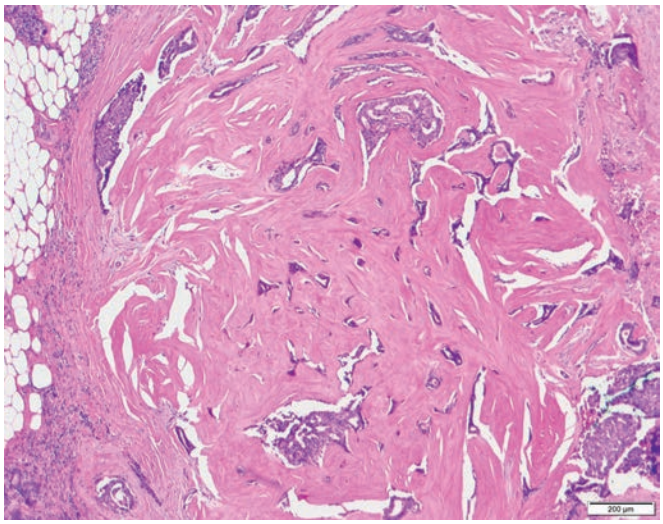

Figure 36.52 Sclerosed papilloma of breast showing entrapment of epithelial structures by fibrotic stroma, resulting in a pseudoinvasive appearance.

Solitary intraductal papilloma is a benign lesion that is curable by local excision. Management following core biopsy is evolving; however, most patients are still referred for surgical consultation. The subsequent breast cancer risk is similar to that of other proliferative lesions without atypia (1.5–2 fold).[228,229] Multiple papillomas have been found to be associated with a higher risk.[229–231] Some authors have reported that papillomas with foci of atypical hyperplasia ("atypical papillomas") are associated with a substantially increased risk for carcinoma largely restricted to the anatomic region of the original papilloma,[232] whereas others report that the risk is the same as when the atypical hyperplasia is unrelated to a papilloma and furthermore that the risk is conferred equally on both breasts.[229]

Papillary Ductal Carcinoma In Situ

A lesion considered to be distinct from papilloma with DCIS, as explained later, is papillary DCIS.[233] In contrast to the dual population of epithelial and myoepithelial cells seen in intraductal papilloma,

For personal use only. No other uses without permission. Copyright ©2017. Elsevier Inc. All rights reserved.

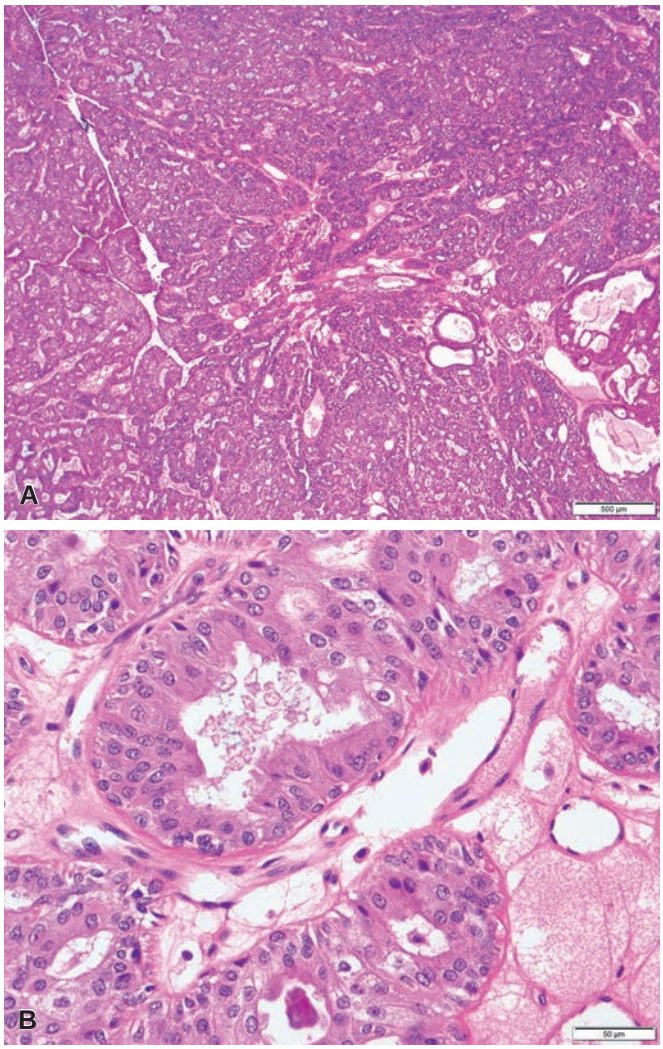

Figure 36.53 Intraductal Papilloma Involved by Ductal Carcinoma In Situ. A, Low-power appearance showing complex arborizing architecture with fibrovascular cores (particularly prominent in the *lower left* of field) and epithelial proliferation. **B,** High-power view showing monomorphic epithelial cells with areas of cribriforming; note the presence of scattered myoepithelial cells juxtaposed to the fibrovascular cores.

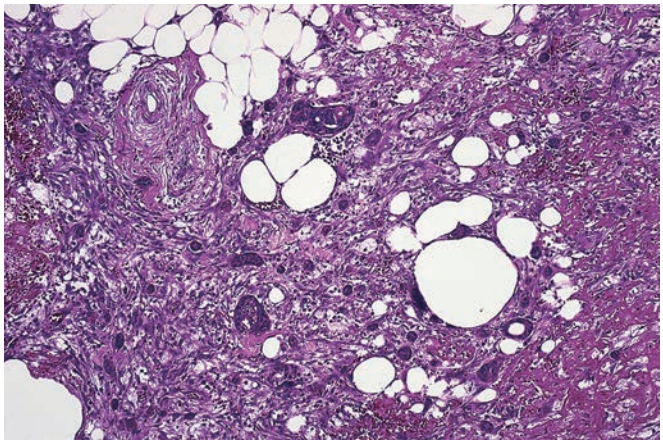

Figure 36.54 Displaced epithelium following core needle biopsy of a benign intraductal papilloma. The presence of nests and single squamoid-appearing cells embedded in a reactive stroma are characteristic of displaced epithelium.

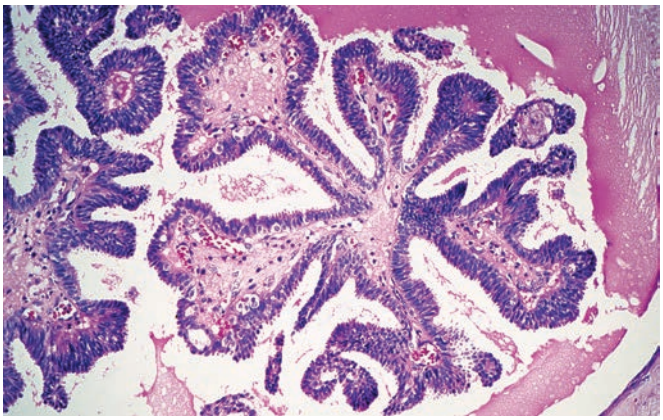

Figure 36.55 Papillary Ductal Carcinoma In Situ. The arborizing nature of this tumor and the prominent fibrovascular core in this example are not too different from those of a benign papilloma. The absence of a myoepithelial cell layer along the fibrovascular core along with the nuclear atypia clinch the diagnosis.

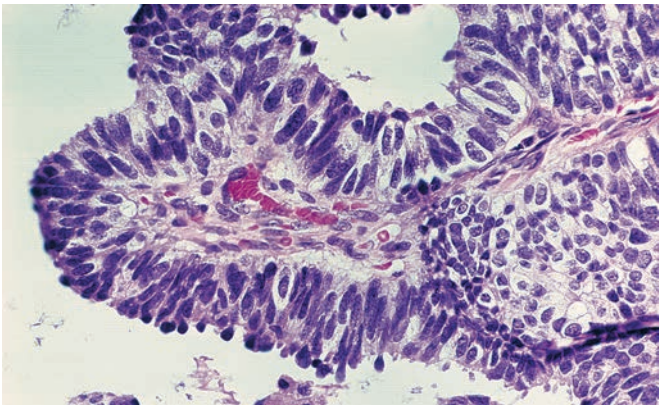

Figure 36.56 High-Power View of Papillary Ductal Carcinoma In Situ. Note the multi layering of cells, loss of nuclear polarity, marked hyperchromasia, and lack of a myoepithelial cell layer along the fibrovascular cores.

papillary DCIS is characterized by a single, uniform population of atypical epithelial cells, usually of low or intermediate nuclear grade (Figs. 36.55 and 36.56). The cells are arranged perpendicular to the delicate fibrovascular cores that typify papillary carcinomas (see following sections).[218] Notably, there are no myoepithelial cells lining the fibrovascular cores, supporting the premise that the papillae arise de novo as part of the neoplastic process,[233] whereas in DCIS involving a papilloma, the identification of a myoepithelial cell layer along the fibrovascular cores indicates the presence of an underlying benign papilloma. A myoepithelial cell layer is present at the periphery of spaces involved by papillary DCIS, consistent with the in situ nature of the disease. Helpful clues to the diagnosis of papillary DCIS are the presence of other patterns of DCIS in adjacent ducts and the absence of apocrine metaplasia within the papillary proliferation. A potential diagnostic trap is the occasional presence of scattered large pale eosinophilic cells, known as globoid cells, concentrated along the basal layer, which can be mistaken for myoepithelial cells (Fig. 36.57).[218]

Encapsulated Papillary Carcinoma

Encapsulated papillary carcinoma is a well-circumscribed papillary tumor surrounded by a thick fibrous capsule (Fig. 36.58). This tumor

For personal use only. No other uses without permission. Copyright ©2017. Elsevier Inc. All rights reserved.

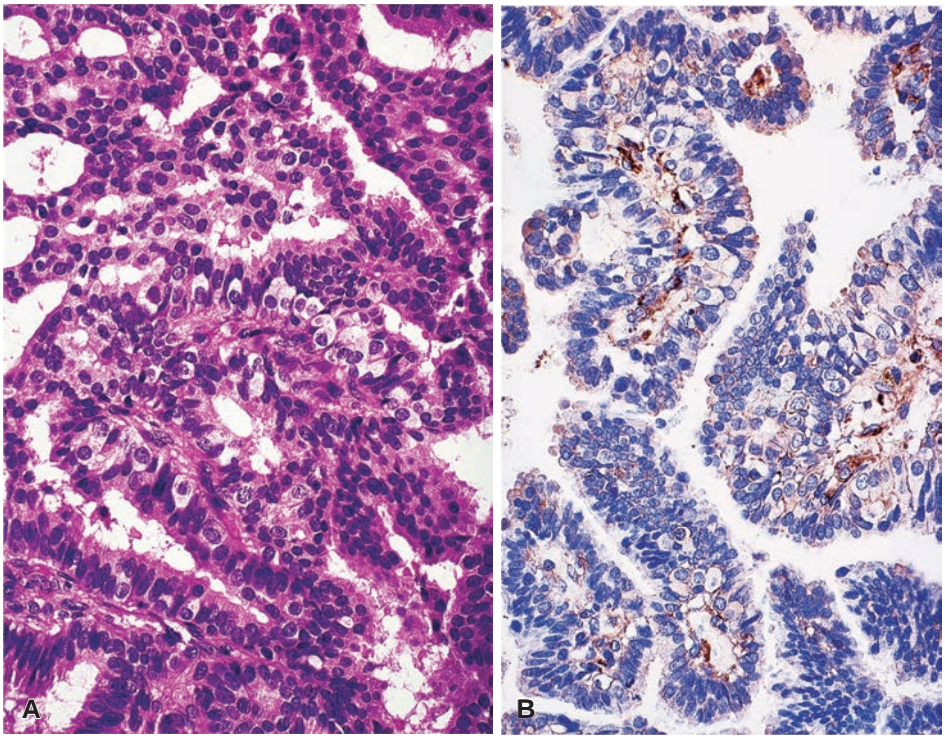

Figure 36.57 **A** and **B,** Papillary ductal carcinoma in situ with "globoid" cells. These cells, which are immunoreactive for GCDFP-15 and cytokeratin, should not be confused with myoepithelial cells. **B,** The globoid cells are negative for myoepithelial cell markers, as is demonstrated with this smooth muscle actin immunostain.

Figure 36.58 **Encapsulated Papillary Carcinoma of the Breast.** The papillary configuration of the tumor is grossly evident.

arises in older women, is centrally located, and often presents as a breast mass with or without bloody nipple discharge. On microscopic examination, the tumor gives the appearance of arising within a duct or "cyst" and had traditionally been considered to be an in situ or "intracystic" lesion. The fibrovascular cores are delicate and are surmounted by a monotonous proliferation of atypical epithelial cells that may, in addition to the papillary pattern, have areas of solid or cribriform architecture (Fig. 36.59). As with papillary DCIS, there is an absence of myoepithelial cells along the fibrovascular cores, but in contradistinction to the aforementioned DCIS, there is also an absence of myoepithelial cells at the periphery of most encapsulated papillary carcinomas,[234–236] raising the possibility that these tumors may be low-grade invasive carcinomas rather than in situ lesions.[237,238] Further evidence of the potential invasive nature of encapsulated papillary carcinoma is the rare occurrence of axillary lymph node metastases, even in the absence of conventional invasive carcinoma.[239] It is important to evaluate for areas of unequivocal conventional invasive carcinoma, as this will influence how the patient is staged and treated. This can be more challenging than might be imagined as the majority of patients have undergone a core needle biopsy procedure with the consequent displacement of epithelial nests into the biopsy site and fibrous capsule. Therefore, it is prudent to restrict diagnosis of associated invasive carcinoma to foci clearly away from the biopsy site. As far as tumor staging, it is the recommendation of the WHO Working Group that encapsulated papillary carcinomas be staged and managed as in situ lesions (Tis); any associated microinvasive or invasive carcinoma should be reported and staged according to the size of the largest focus of conventional invasive carcinoma.[237] Encapsulated papillary carcinomas are typically ER and PR positive and HER2 negative. The vast majority of encapsulated papillary carcinomas have low- or intermediate-grade nuclei and behave in an indolent manner; however, there are rare cases of encapsulated papillary carcinoma that have high-grade nuclei and a brisk mitotic rate.[240] Recent data indicate that these particular tumors, which represent approximately 3% of encapsulated papillary carcinomas, behave in a more aggressive manner and as such should be staged and managed as conventional invasive carcinoma of similar size.[240]

Solid Papillary Carcinoma

Solid papillary carcinoma presents in older women, often as an image-detected breast mass. Microscopically the tumor is composed of multiple, solid nests of neoplastic epithelial cells, within which is a fine fibrovascular network conferring the papillary architecture (Fig. 36.60). The epithelial cells may be spindled and have a streaming

For personal use only. No other uses without permission. Copyright ©2017. Elsevier Inc. All rights reserved.

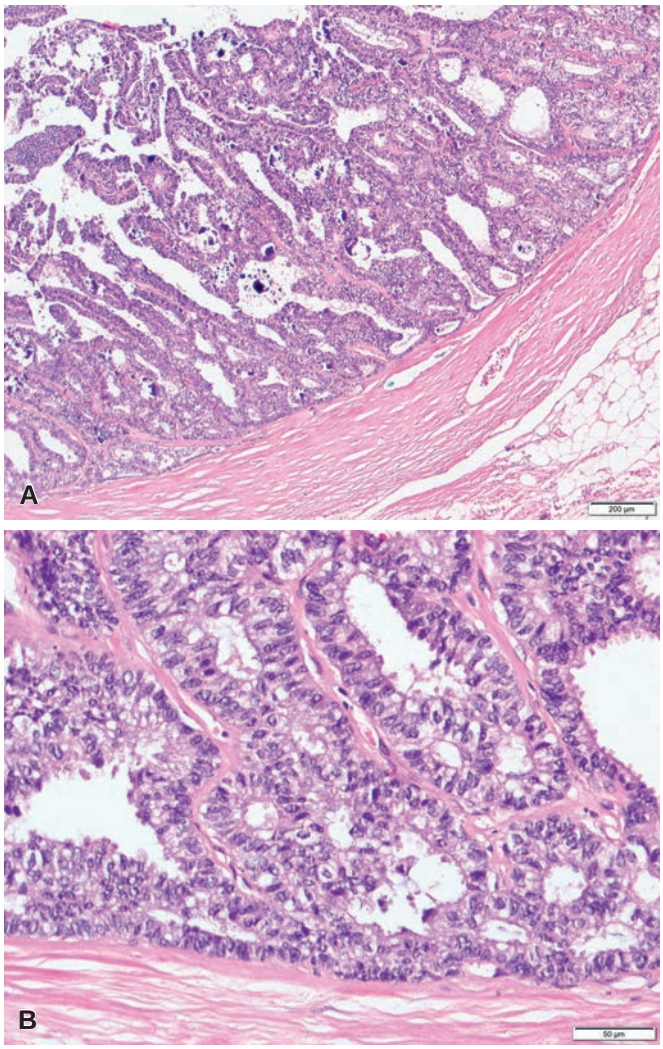

Figure 36.59 Encapsulated Papillary Carcinoma. A, Low-power view showing the fibrous capsule surrounding an encapsulated papillary carcinoma. At this power, the papillary architecture is apparent. **B,** At higher power the monotonous neoplastic epithelial cell population is better appreciated; in addition, note the cribriform architecture, the absence of myoepithelial cells at the periphery of the EPC (*lower left* of field), and the absence of myoepithelial cells running along the fibrovascular cores.

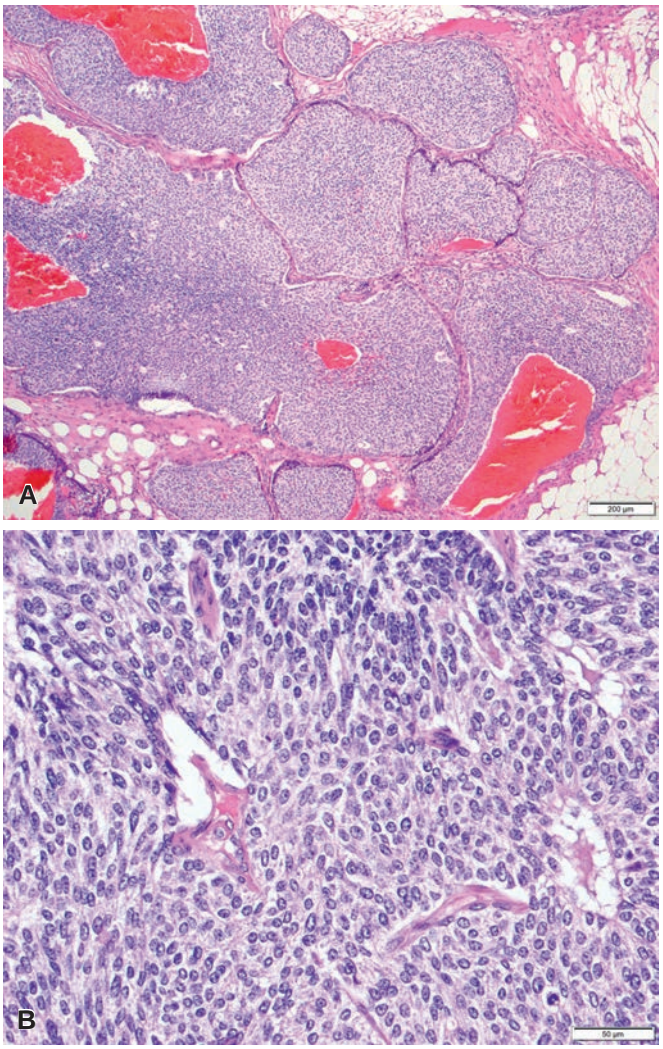

Figure 36.60 Solid Papillary Carcinoma. A, Low-power view showing multiple solid nests of neoplastic epithelial cells. **B,** High-power view reveals the fibrovascular network not readily appreciated at low power. The cells have a streaming appearance in areas but are monotonous with cytologic atypia.

appearance mimicking usual ductal hyperplasia. They may also have granular eosinophilic cytoplasm and fine nuclear chromatin consistent with endocrine differentiation. Mucin production is commonly seen in solid papillary carcinoma. As with papillary DCIS and encapsulated papillary carcinoma, there is an absence of myoepithelial cells within the neoplastic nodules. Studies have reported an absence of myoepithelial cells at the periphery of at least some cases of solid papillary carcinoma.[241] Thus, like encapsulated papillary carcinoma, this tumor may be an indolent, invasive carcinoma rather than an in situ lesion.[242] The WHO Working Group provides recommendations to aid in categorization of solid papillary carcinoma as in situ or invasive disease:[242]

Tumors with rounded nests and a complete or partial myoepithelial cell layer should be classified as DCIS, solid papillary pattern.

Tumors composed of nests with irregular borders and a geographic, jigsaw growth pattern and an absent myoepithelial cell layer may be considered invasive disease.

Tumors in which some but not all nests lack a myoepithelial cell layer are more difficult to classify. The recommendation is that if there is uncertainty about invasion, the lesion should be reported as in situ carcinoma for staging and management purposes.

The major differential diagnostic consideration is with UDH. Recognition of the fine fibrovascular network is the first step to separating these two entities. Other features favoring solid papillary carcinoma over UDH include a very monotonous appearance to the epithelial cells, cellular polarization around the fibrovascular cores, mucin production, and mitotic activity. In problematic cases, the combination of ER and CK5/6 can aid in diagnosis. ER is strongly and diffusely positive and CK5/6 is negative in solid papillary carcinoma.[243]

Solid Papillary Carcinoma With Reverse Polarity

Solid papillary carcinoma with reverse polarity (SPCRP) is a relatively recently described entity that is characterized by, as the name implies, solid papillary nests of bland columnar epithelial cells in which

For personal use only. No other uses without permission. Copyright ©2017. Elsevier Inc. All rights reserved.

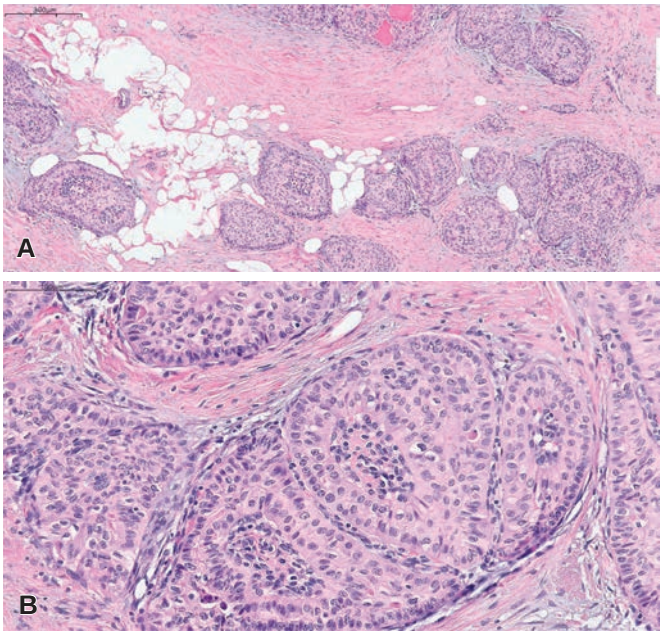

Figure 36.61 Solid Papillary Carcinoma with Reverse Polarity. A, Low-power view showing solid papillary nests of neoplastic epithelial cells infiltrating through the breast parenchyma. **B,** Higher-power demonstrating the fibrovascular core and the characteristic reverse polarization of the tumor cells.

nuclei of low or intermediate grade are apically rather than basally located ("reverse polarity"). Foamy histocytes are often present in the papillary cores.[243a] The tumor cell nests infiltrate through the breast parenchyma and adiopose tissue in a haphazard pattern, and lack a surrounding myoepithelial cell layer (Fig. 36.61). The morphology of these tumors is so striking, that once encountered, subsequent cases are readily recognized. The tumor cells are typically ER, PR and HER2 negative (though ER and/or PR positivity is reported); interestingly both low and high molecular weight cytokeratins are expressed by the epithelial cells.[243a] Earlier reports describing a "breast tumor resembling tall cell variant of papillary thyroid carcinoma"[243b,243c] bear some similarities to SPCRP, but because SPCRPs express breast markers (GCDFP-15, mammaglobin) and lack expression of thyroid markers (TTF-1 and thyroglobulin) this term better describes the lesions. Molecular analysis of these tumors has demonstrated recurrent *IDH2* as well as *PIK3CA* and *PIK3R1* mutations.[243a,243d] While little clinical follow-up is available for these rare tumors, they appear to behave in an indolent manner.

Invasive Papillary Carcinoma

Invasive papillary carcinoma is a very rare entity.[244] Papillary DCIS, encapsulated papillary carcinoma, and/or solid papillary carcinoma with associated invasive ductal or mucinous carcinoma should be categorized as such and not as invasive papillary carcinoma. Metastasis to the breast, such as from the ovary or lung, should be considered in cases of apparent invasive papillary carcinoma before rendering a diagnosis of primary papillary carcinoma of the breast.

Nipple Lesions

Nipple Adenoma

Nipple adenoma, also known as florid papillomatosis of the nipple ducts and erosive adenomatosis, is a benign proliferation of glands embedded in a fibrotic stroma (Fig. 36.62). It usually occurs in the fourth or fifth decade, is nearly always unilateral, and is often accompanied by serous or bloody discharge from the nipple. Clinically, the nipple may appear eroded, and the disease may be confused with Paget disease.

Microscopically, the most common pattern seen is of marked papillomatous changes, often associated with distortion induced by the dense stroma present. The latter is referred to by Rosen and Caicco[245] as the sclerosing papillomatosis pattern, the other patterns being papillomatosis (without sclerosis) and adenosis (the least common of the three). The features used to identify this lesion as benign are to a large extent analogous to those seen in intraductal papilloma and UDH. They include the presence of a dual population of epithelial and myoepithelial cells (confirmed if needed by immunohistochemical evaluation), an oval nuclear shape, lack of atypia, "streaming," the formation of peripheral clefts, and the absence of a cribriform pattern. Features of which to be aware in this lesion relate to the close interaction of the glandular epithelium of the mammary ducts with the squamous epithelium from the epidermis (Fig. 36.62), resulting in formation of adenosquamous nests that may be overinterpreted. Otherwise typical nipple adenomas can exhibit small foci of necrosis in the center of the proliferating ducts (Fig. 36.63).[245]

A note of warning is in order; just because an intraductal papillary lesion is located in or close to the nipple, it does not necessarily mean that it is a nipple adenoma and, therefore, benign. Papillary DCIS and invasive ductal carcinomas can also occur in this location, some occasionally even arising within a nipple adenoma.[245,246]

The treatment of uncomplicated nipple adenoma is local excision.[245,247]

Squamous Metaplasia of Lactiferous Ducts

SMOLD presents clinically as recurrent abscess with or without fistula formation.[248] As the name implies, the lesion is characterized by extension of the squamous epithelium of the nipple further than the usual 1–2 mm down the lactiferous ducts. The resulting accumulation of keratinaceous debris leads to duct rupture with consequent inflammatory response (Fig. 36.64). Patients are often managed with incision and drainage on the presumption of mastitis with abscess formation. By the time tissue samples reach the pathology department, the inflammatory response is often quite severe and specimens are sent piecemeal, making recognition of the underlying squamous metaplasia of the lactiferous ducts difficult. The diagnosis should be considered in this clinicopathologic scenario so that the patient may be directed to appropriate management, namely wide excision of the involved duct often with a wedge resection of the nipple to facilitate eradication of the process.

Paget Disease

Paget disease is the name given to a crusted lesion of the nipple caused by breast carcinoma in the nipple epithelium, as originally described by Sir James Paget in 1874. It is accompanied in nearly all instances (>95%) by an underlying breast carcinoma, typically high-grade DCIS, with or without associated stromal invasion. In this regard, the presence of Paget disease is a secondary, albeit dramatic, feature of the tumor. The management and prognosis depend largely on the in situ versus invasive nature of the underlying carcinoma, and on the presence or absence of axillary lymph node involvement, rather than on the presence or appearance of the intraepidermal component in the nipple.

For personal use only. No other uses without permission. Copyright ©2017. Elsevier Inc. All rights reserved.

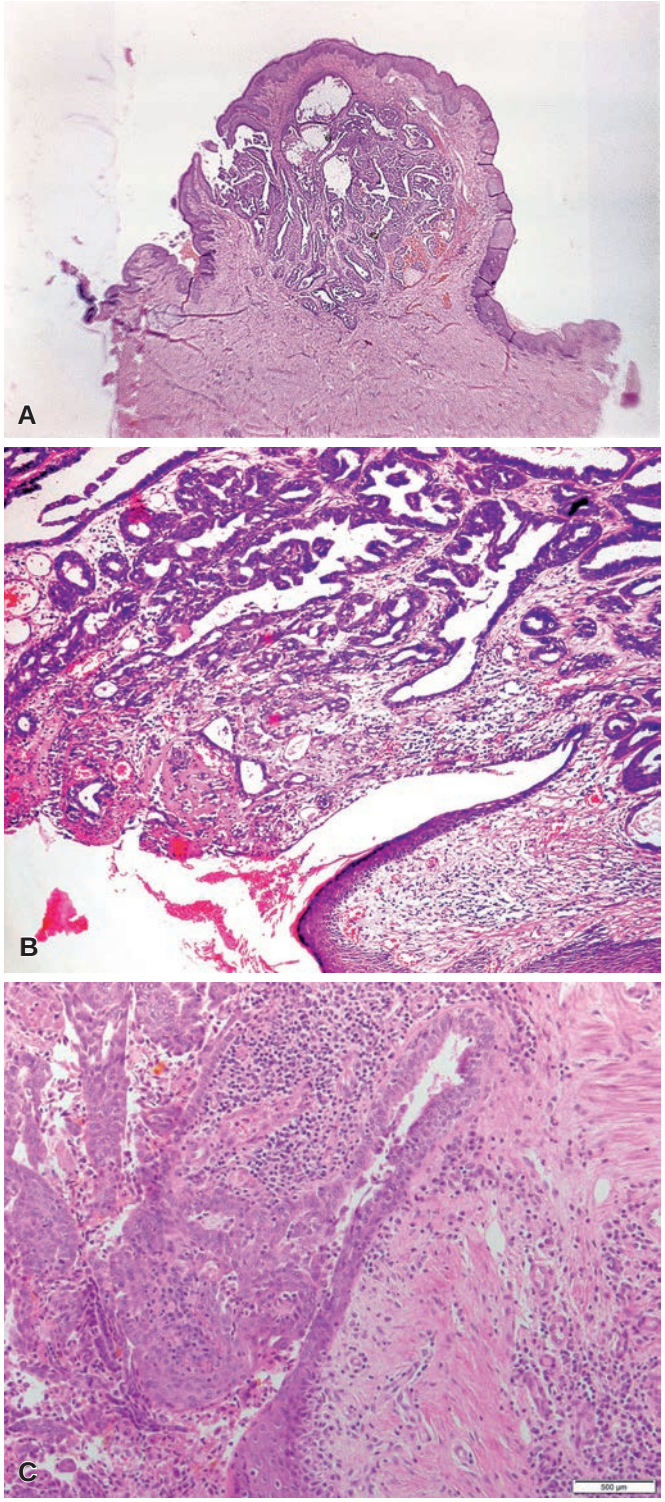

Figure 36.62 **A,** Typical polypoid shape of nipple adenoma, as seen in a whole mount section. **B,** The complex architectural arrangement can lead to overdiagnosis. **C,** The continuity with the squamous epithelium of the skin is a characteristic feature of this entity.

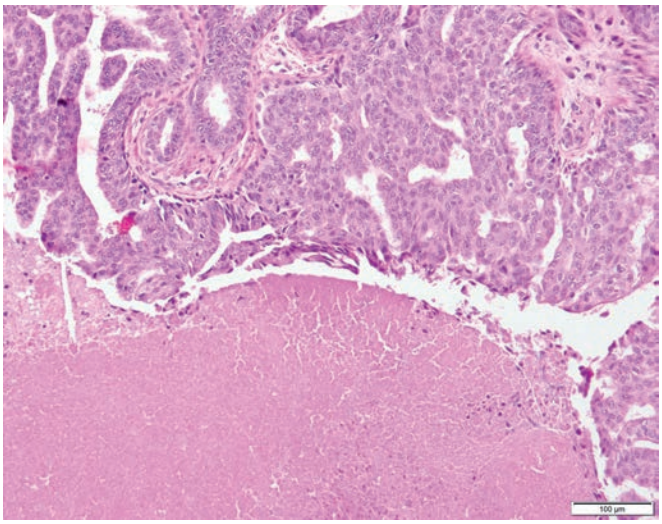

Figure 36.63 **Nipple Adenoma.** High-power view showing usual ductal hyperplasia and necrosis present in a nipple adenoma.

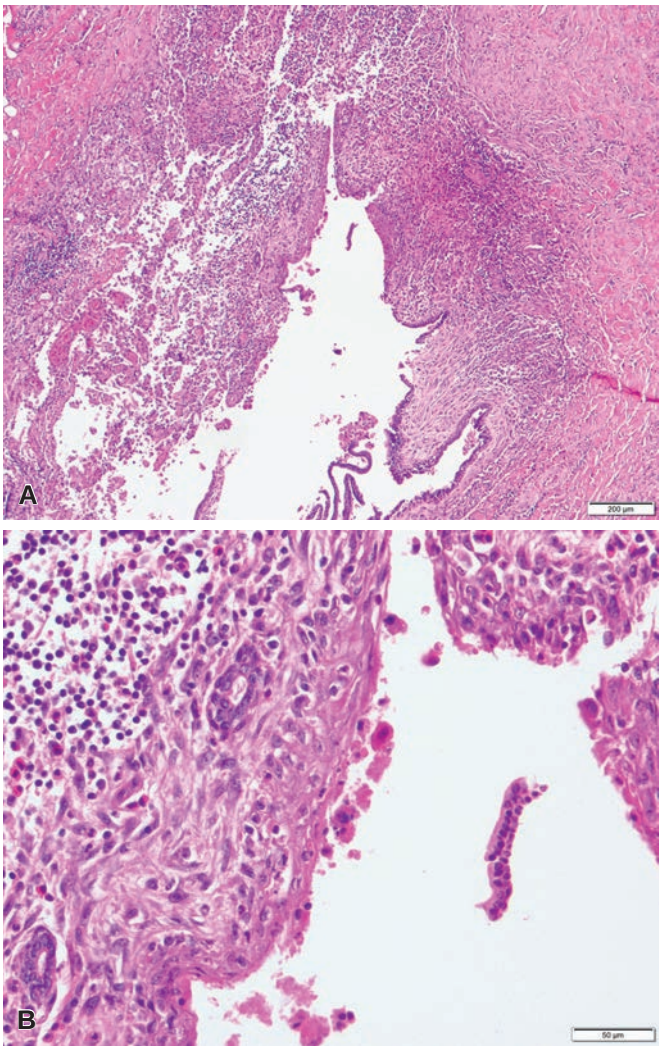

Figure 36.64 **Squamous Metaplasia of Lactiferous Ducts. A,** Low-power view of a dilated nipple duct partially lined by squamous epithelium, with surrounding inflammation. **B,** High-power view of the squamous epithelial lining.

For personal use only. No other uses without permission. Copyright ©2017. Elsevier Inc. All rights reserved.

Figure 36.65 Eczematous hyperemic and eroded clinical appearance of Paget disease. (Courtesy of Dr RA Cooke, Brisbane, Australia. From Cooke RA, Stewart B. *Colour Atlas of Anatomical Pathology*. Edinburgh: Churchill Livingstone; 2004.)

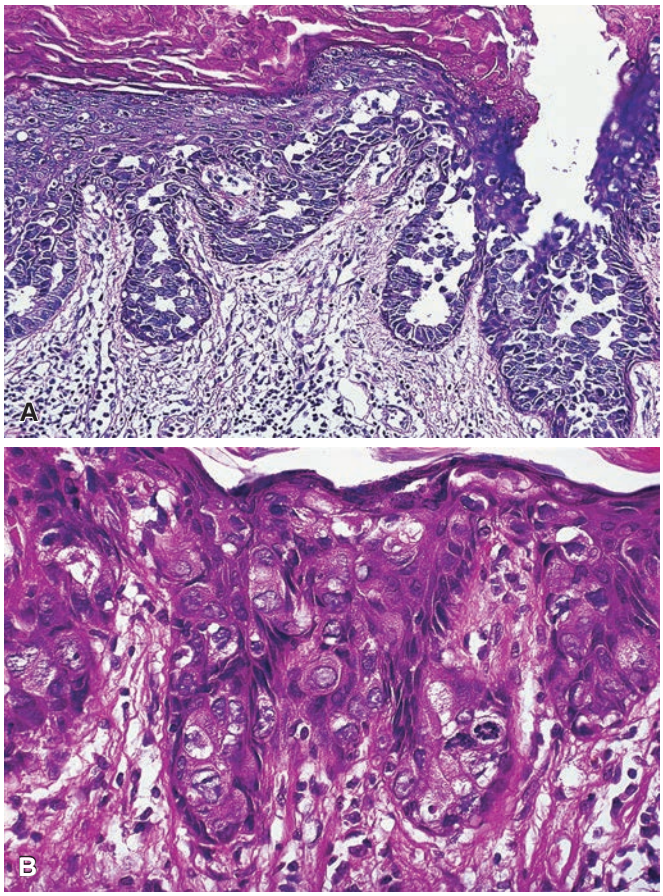

Figure 36.66 **A** and **B,** Low- and high-power views of Paget disease. **A,** The cleft-like separation between the tumor cells and the overlying squamous epithelium is characteristic. **B,** At high power, striking cytologic atypia in the tumor cells is readily apparent.

Clinically, these weeping, eczematous lesions are centered on the nipple (Fig. 36.65). Later the areola and surrounding skin may become involved over an area of a few centimeters. Microscopically, large clear cells with highly atypical nuclei are seen within the epidermis, usually concentrated along the basal layer but also spreading up through the epidermal layers (pagetoid growth pattern) (Fig. 36.66). The cells can be isolated or present in clusters, and sometimes they form small glandular structures.[249] Occasionally, intracytoplasmic melanin granules are present, a feature that may result in a mistaken diagnosis of malignant melanoma.[250]

The underlying breast carcinoma is practically always of high-grade ductal type and is composed of cells similar to those present within the epidermis. Mucin stains are usually positive. Immunohistochemically, Paget cells show reactivity for EMA, polyclonal CEA, low-molecular-weight cytokeratin (including CK7), HER2 and, in some cases, GCDFP-15 (Fig. 36.67). In general, they are negative for HMW cytokeratins and S-100 protein. ER may be positive or negative.

The main differential diagnostic considerations are Bowen disease, malignant melanoma, and Toker cells. Immunohistochemical stains are often necessary to help differentiate these entities in the absence of a readily identifiable breast carcinoma or in a small biopsy of the nipple (Table 36.2).

It is thought that Paget cells in the nipple epidermis have migrated there from a carcinoma present in deeper ductal structures. The similarities in immunohistochemical profile between Paget cells and any underlying high-grade carcinoma present (such as HER2 positivity, ER negativity) support this hypothesis. On the other hand, the existence of rare cases of Paget disease without underlying ductal carcinoma have led to the suggestion that in some cases the cell of origin is the Toker cell or keratinocytes at the squamocolumnar junction.[251,252] In this regard, the observation made by Toker[8] about the presence of clear cells in nipples without clinical evidence of Paget disease and without microscopic evidence of breast carcinoma is of great interest. These cells have some immunohistochemical similarities with Paget cells (positivity for CK7 and EMA, and negativity for p63)[7,253] and may exhibit mild nuclear atypia, suggesting the possibility of a dysplastic or "pre-Paget" change.[254,255] From a practical standpoint, Toker cells are distinguished from the cells of Paget disease because of the lack of clinical changes, the absence of cytologic features of malignancy (Fig. 36.68), and some histochemical and immunohistochemical differences, such as negativity for mucin and GCDFP-15.

Carcinoma

General Features

Age

The large majority of breast cancers are detected during the postmenopausal years. However, breast cancer can develop at any age, from childhood to old age.

Incidence

Breast carcinoma is the most common malignant tumor and the second most common cause of carcinoma death in women, with more than 1.7 million cases occurring worldwide annually.[256] In the United States, approximately 230,000 new cases are diagnosed annually and approximately 40,000 patients die from the disease each year.[257] The incidence is high in North America and northern Europe (92 new cases per 100,000 women/year), intermediate in southern European and Latin American countries, and low in most Asian and African countries (but rising rapidly in recent years in some of these countries). In the United States, there has been a sharp increase in the detection of breast carcinoma, largely due

For personal use only. No other uses without permission. Copyright ©2017. Elsevier Inc. All rights reserved.

to the widespread use of mammography.[258] Most of these cases have been early stage, measuring less than 2 cm in diameter and/or DCIS.[259] Initially, this increase in the number of smaller tumors did not translate into an improved survival rate. As a matter of fact, the mortality rate for breast carcinoma changed very little from the 1930s to the early 1990s.[259] However, in some regions of the world (North America, Western Europe, and Australia) breast cancer mortality is now declining, which has been attributed to the combined effects of earlier diagnosis and improved therapy.[260,261]

The incidence of clinically occult carcinoma can be inferred to a degree from examination of reduction mammoplasty specimens. In a study of 2498 cases, Desouki et al. found invasive carcinoma and DCIS to be extraordinarily rarely present (0.2%); by comparison, atypical proliferative lesions were identified in 4.3% of cases; the most common lesion being lobular neoplasia (2.2%).[262]

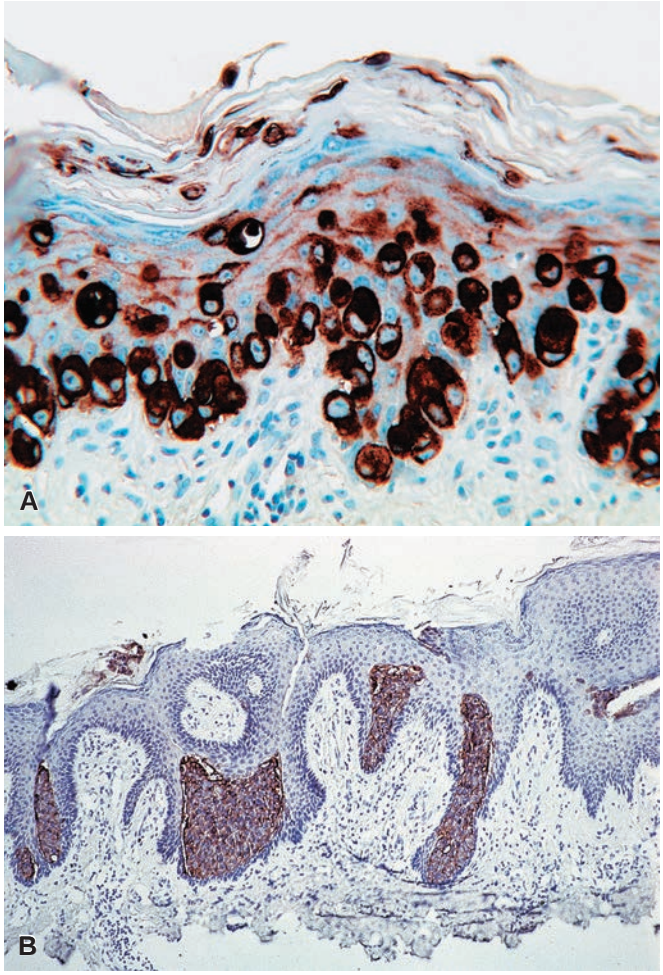

Figure 36.67 Immunohistochemical demonstration of malignant intraepidermal cells in Paget disease. **A,** EMA immunostain. **B,** HER2 immunostain.

Risk Factors

Several risk factors for the development of breast carcinoma have been established, whereas many others remain questionable. It has been hypothesized that the common denominator for most of these factors is strong and/or prolonged estrogen stimulation operating on a genetically susceptible background.

1. *Country of birth*. This has already been touched upon above.
2. *Family history*. Women who have a first-degree relative with breast carcinoma have a risk 2 or 3 times that of the general population, a risk further increased if the relative was affected at an early age and/or had bilateral disease.[263] The aspects related to discovery

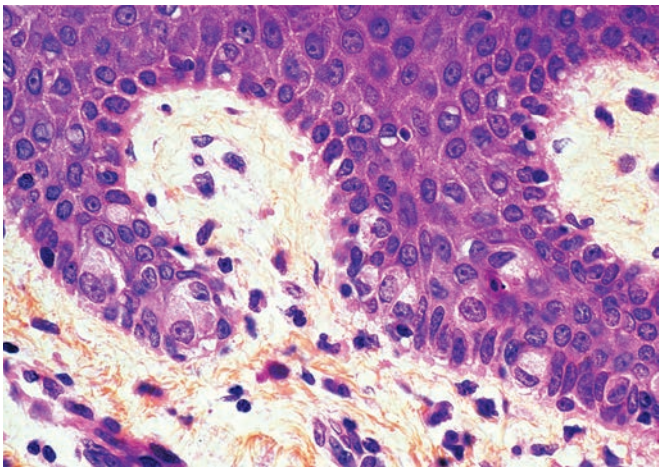

Figure 36.68 Biopsy of nipple showing scattered clear cells without nuclear atypia in the basal layer ("Toker cells").

Table 36.2 Differential histochemical and immunohistochemical staining patterns of epidermal lesions of the nipple (reported as proportion of cases expressing marker)

	PAGET DISEASE	MALIGNANT MELANOMA	SQUAMOUS CELL CARCINOMA IN SITU	TOKER CELLS
Mucin	High	Negative	Negative	Negative
Cytokeratin 7	Positive	Low	Low	Positive
HER2	High	Negative	Low	Negative
ER/PR	Low	Negative	Negative	High
GCDFP	Moderate	Negative	Negative	Low
S100	Low	Positive	Low	Negative
HMB45	Negative	Positive	Negative	Negative

Key: Positive >90% of cases, high 60%–90% of cases, moderate 40%–60% of cases, low 10%–30% of cases, negative <10% of cases express the marker.
From Dillon D, Lester S. Lesions of the nipple. In: Collins LC ed. *Current Concepts in Breast Pathology*. Philadelphia PA: Saunders; 2009:391–412.

For personal use only. No other uses without permission. Copyright ©2017. Elsevier Inc. All rights reserved.

of the genes responsible for predisposition to breast carcinoma are discussed in the next section.

3. *Menstrual and reproductive history.* Increased risk is correlated with early menarche, nulliparity, late age at first birth, and late menopause.[264] Breast carcinoma is rare in women who have undergone bilateral oophorectomy; risk-reducing salpingo-oophorectomy before 35 years of age reduces the risk by about one half.[265,266] Younger age at first pregnancy is associated with a lower lifetime risk of breast cancer. Note though, that there is a dual effect associated with pregnancy: an early transient increase in breast cancer risk followed by a prolonged protective effect.[267] A reduction in the risk of breast carcinoma among parous women who have breastfed for at least 4 months has been documented.[268] Breast carcinoma risk is increased in postmenopausal women with a hyperandrogenic plasma hormone profile.[269,270]
4. *Intraductal proliferative lesions*. The relationship between intraductal proliferative lesions without atypia and breast carcinoma has been discussed in earlier sections.
5. *Exogenous estrogens.* The influence of exogenous hormones on breast cancer risk is complex and varies with duration of therapy and combination of agents used. In brief, the risk appears greater with longer duration of use/current use and with use of estrogen combined with progestins compared with use of estrogen alone.[264]
6. *Contraceptive agents*. The various epidemiologic studies that have been conducted have shown no increased risk, or at most a very low increase among young long-term users.[271]
7. *Ionizing radiation*. An increased risk of breast carcinoma has been documented with exposure to ionizing radiation, particularly if this exposure occurred at the time of breast development, such as in young women receiving mantle irradiation for Hodgkin disease or atomic bomb survivors who were younger than 10 years of age at exposure.[272–274]
8. *Breast augmentation*. Breast implants do not result in an increase in breast cancer risk. Re-analysis of a previously published linkage study that had reported an elevated risk has shown that the incidence of breast carcinoma in that cohort was neither higher nor lower than that among the general population (see later section for discussion of other malignancies related to breast implants).[275,276]
9. *Others*. A peculiar association between breast carcinoma and meningioma has been repeatedly noted, with the even more peculiar observation that sometimes the breast carcinoma is found to metastasize to the meningioma. However, a recent study evaluating over 12,000 patients with breast cancer found no increased risk of meningioma, with a 10-year cumulative incidence of just 0.37%.[277]

Genetic Predisposition

Approximately 5%–10% of all breast cancers are familial.[278,279] An epochal event in the study of breast carcinoma was the discovery of two high-penetrance susceptibility genes which, when affected by germline mutations, are associated with a high lifetime risk for development of breast cancer, as well as some other cancers, in particular ovarian cancer.[278] Originally, mutations in these genes were thought to be responsible for a high proportion of familial breast carcinomas, but they are now found to be responsible for only about 16% of them.[279–281] These are *BRCA1*, located on chromosome 17q21, and *BRCA2*, located on chromosome 13q12.3 (Table 36.3).[282–284] Mutations of these genes are present in approximately 2% of the Ashkenazi Jewish population; it has been estimated that the risk for breast carcinoma among carriers is up to 70%–80% by the age of 70 years.[285–287] The finding of a positive test for the mutation can lead to an agonizing decision on the part of the affected individual, the main choices being close follow-up or bilateral prophylactic mastectomy.[288]

The *BRCA1*-encoded protein has many functions, including repair of DNA damage through homologous recombination, cell cycle checkpoint control, ubiquitylation, chromatin remodeling, and DNA decatenation.[279] The protein encoded by *BRCA2* is involved in DNA repair, cytokinesis, and meiosis.[279] That is, both *BRCA1* and *BRCA2* are essential for accurate repair of DNA double-strand breaks through homologous recombination.[279] Loss of such function in the associated cancers has been exploited to develop novel therapies—for example, poly-adenosine diphosphate (ADP)-ribose polymerase (PARP) inhibitors which block repair of DNA damage via alternate pathways in tumor cells deficient in DNA repair through homologous recombination—a process that has been referred to as "synthetic lethality".[289,290]

Analysis of breast carcinomas developing in carriers of *BRCA1* mutations has shown a higher percentage of tumors with the basal-like gene expression profile (see later discussion) and that tend to be high grade, mitotically very active, with a syncytial growth pattern, pushing margins, confluent necrosis, negativity for hormone receptors and HER2 ("triple negative"), and associated with *TP53* mutation.[279,291–293] On the other hand, *BRCA2*-associated cancers are a heterogeneous group without specific morphology or phenotype and are commonly positive for hormone receptors.[291,293]

In addition to *BRCA1* and *BRCA2*, several other genes (e.g., *CHEK2*, *CDH1*, *RAD50*, and *PALB2*) confer a low to moderate increased risk for the development of breast cancer.[294] Hereditary breast cancer can also occur in the setting of multiple cancer syndromes,[279] such as Lynch syndrome (e.g., *MLH1*), Li–Fraumeni syndrome *(TP53)*, ataxia–telangiectasia syndrome *(ATM)*, and Cowden syndrome *(PTEN)*, as summarized in Table 36.3.[279,295]

Location

The location of breast carcinoma is usually indicated in relation to the breast quadrants. Approximately 33% are in the upper outer quadrant, 9% in the upper inner quadrant, 6% in the lower outer quadrant, 5% in the lower inner quadrant, 7% in the central region (within 1 cm of the areola), and 40% occur in overlapping quadrants (or location not specified).[296] Several studies have also documented the peculiar fact that breast carcinoma is slightly more frequent in the left breast than in the right ("laterality ratio"). In one recent series, the excess for the left side varied by age, quadrant, and place of birth.[296] Preliminary studies in mouse models indicate that there may be baseline differences in gene expression that are left-right independently regulated during pubertal development, which may play a role in this observation.[297]

Multicentricity and Multifocality

Multicentricity, defined as the presence of carcinoma in a breast quadrant other than the one containing the dominant mass, was described as early as 1920 and later reported by others.[298,299] Multifocality is defined as the presence of additional foci of carcinoma in the same quadrant as the index carcinoma. Among a contemporary population of 1495 patients with invasive carcinoma, 82.3% of tumors were unifocal, 11.3% were multifocal, and 6.4% were multicentric. Multicentricity was more common in lobular than in ductal carcinomas; patients were more likely to be younger with larger tumors, to have lymphovascular space invasion and positive lymph nodes. Multifocality was more commonly seen with invasive ductal carcinomas that had an extensive intraductal component and were

For personal use only. No other uses without permission. Copyright ©2017. Elsevier Inc. All rights reserved.

Table 36.3 Summary of the syndromes associated with hereditary breast cancer

SYNDROME (OMIM)	GENE INVOLVED AND CYTOBAND	CLINICAL FEATURES
Hereditary breast cancer and ovarian cancer syndrome (113705)	*BRCA1* (17q21)	Breast cancer, high risk (50%–80%) Ovarian cancer, high risk (40%–50%)
Hereditary breast cancer and ovarian cancer syndrome (600185)	*BRCA2* (13q12.3)	Breast cancer, high risk (50%–70%) Ovarian cancer, intermediate risk (10%) Prostate cancer Pancreatic cancer Melanoma
CHEK2 mutations (Li–Fraumeni 2 syndrome?)	*CHEK2* (22q 12.1)	Breast cancer, intermediate risk (~twofold) Sarcomas Brain tumors
Other FANC genes (114480, 610355, 607139, 600901, 605882)	*PALB2/FANCN* (16p12)*FANCA* (16q24.3)*FANCE* (6p22–p21)*BRIP1/FANCJ* (17q22)	*PALB2/FANCN* and *BRIP1/FANCJ*: moderate risk of breast cancer development Other FANC genes: low risk of breast cancer development
Familial linitis plastica type gastric cancer and lobular breast carcinoma syndrome (192090)	*CDH1* (16q22.1)	Gastric cancer Lobular breast cancer
Louis–Bar syndrome (208900)	*ATM* (11q22.3)	Lymphoma Cerebellar ataxia Immune deficiency Glioma Medulloblastoma Breast cancer
Li–Fraumeni syndrome (151623)	*TP53* (17p13.1)	High penetrance for breast cancers at young age Risk of soft tissue sarcomas and osteosarcomas, brain tumors, leukemia, and adrenocortical carcinoma
Cowden syndrome (158350)	*PTEN* (10q23.31)	Increased risk of developing neoplasms (breast cancer, thyroid carcinoma, endometrial carcinoma and others) Hamartomatous polyps of the gastrointestinal tract Mucocutaneous lesions
Bannayan–Riley–Ruvalcaba syndrome (153480)	*PTEN* (10q23.31)	Breast cancer Meningioma Follicular cell tumors of the thyroid
Peutz–Jeghers syndrome (175200)	*STK11* (19p13.3)	Melanocytic macules of the lips, buccal mucosa, and digits Multiple gastrointestinal hamartomatous polyps Increased risk of various neoplasms (breast, testis, pancreas, and cervix)
Lynch cancer family syndrome II (114400)	*MSH2* (2p22–p21), *MSH3* (5q11–q12), *MSH6* (2p16), *MLH1* (3p21.3), *PMS1* (2q31–q33), *PMS2* (7p22)	Increased risk of endometrial carcinoma and colorectal carcinoma High risk of multiple primary malignant neoplasms, including breast, ovarian, gastrointestinal, and genitourinary carcinomas, sarcomas, glioblastoma, and leukemia

FANC, Fanconi anemia.
From Tan DSP, Marchio C, Reis-Filho JS. Hereditary breast cancer: from molecular pathology to tailored therapies. *J Clin Pathol.* 2008;61:1073–1082.

For personal use only. No other uses without permission. Copyright ©2017. Elsevier Inc. All rights reserved.

ER, PR, and HER2 positive.[299] Not surprisingly, a higher incidence of multicentricity and multifocality is reported in patients undergoing preoperative MRI and mastectomy.[299] Theoretically, multiple breast carcinomas can result from either intramammary spread of a single lesion or from independent events.[300] Clonal studies suggest that both mechanisms play a role.[301,302] If aggregate diameters are used, unifocal and multifocal carcinomas are similar with respect to the frequency of regional lymph node involvement,[303] but other studies have shown that the single largest tumor diameter, as is recommended by the AJCC TNM staging system, even in patients with multiple tumor foci, is an accurate method for staging patients.[299,304]

Bilaterality

The chance that a patient with invasive breast carcinoma will develop a carcinoma in the contralateral breast is estimated to be about 1% per year and is even higher if there is a family history of breast carcinoma and in cases of invasive lobular carcinoma.[305] The use of adjuvant estrogen blockade with or without chemotherapy significantly decreases the risk of metachronous contralateral breast carcinoma.[305,306] Annual screening mammography is the current surveillance practice for these patients, unless the lifetime risk is greater than 20%–25%, in which case adjunctive screening with MRI is recommended.[307]

Synchronous bilateral invasive breast carcinomas are being detected more frequently because of the use of MRI in the work-up of patients with a confirmed diagnosis of breast cancer, ostensibly for surgical planning purposes. An unfortunate corollary of this practice is the rising number of contralateral mastectomies being performed in patients found to have benign or atypical (nonmalignant) pathology on core needle biopsies of areas of radiologic concern in the contralateral breast.[308,309] No significant difference in overall survival has been reported for patients with bilateral breast carcinoma when appropriately matched to women with unilateral breast cancer.[310]

Diagnosis

Clinical Examination

Clinical examination is the time-honored method for the detection and evaluation of breast disease. It remains an extremely useful and practical technique, whether carried out by the physician or by the patient herself. However, both its sensitivity and discriminatory power are limited. Today, the majority of breast cancers are detected through imaging studies, with only 10% of the tumors being detected solely by palpation.[311] The clinical impression is incorrect in approximately 15% of the cases thought to be benign and approximately 10% of those thought to be malignant. The clinical evaluation of axillary lymph nodes is also fraught with error; determination of lymph node status requires microscopic examination.[312]

Mammography

The widespread use of screening mammography has led to an increase in the detection of breast cancers at an earlier stage and of smaller size, primarily based on the presence of microcalcifications, nonpalpable masses, or architectural distortion.[313] The incidence of calcification in breast carcinoma is approximately 50%–60%, and the incidence in benign breast disease is 20%.[314] There are also important qualitative differences in the appearance of the microcalcifications, with pleomorphic or heterogeneous calcifications that are fine, linear, branching, or casting (conforming to the pattern of a duct) being more frequently predictive of malignant disease on histology. In a study of 2545 women enrolled in a breast screening program found to have microcalcifications alone on imaging, 47.9% were subsequently shown to be associated with malignancy (31.8% DCIS and 16.1% invasive carcinoma, mostly with associated DCIS) and 52.1% of cases were associated with nonmalignant lesions.[315] In the United States, mammographic findings are universally reported using the Breast Imaging Reporting and Data System (BI-RADS), which allows the radiologist to convey the degree of suspicion, with 1 being negative and 5 being highly suspicious for malignancy.[316] The majority of core biopsy samples will be from patients with BI-RADS category 4 lesions. This category is very broad, with the likelihood of cancer being diagnosed on biopsy ranging from 2% to 94%. Consequently, subcategories were created to better convey the level of concern: BIRADS 4A (2%–9% chance of malignancy), 4B (10%–49% chance of malignancy), and 4C (50%–94% chance of malignancy).

It should be kept in mind that a negative mammogram does not rule out the possibility of the presence of carcinoma, since approximately 15% of palpable tumors are not detectable with this technique.[317] Ultrasound may be the better modality for palpable masses. The proper management of breast lesions detected by mammography requires close cooperation between radiologist, surgeon, and pathologist. Mammographically detected nonpalpable lesions usually require preoperative wire localization, if excision is necessary, to guide the surgeon to the suspicious area within the breast. Today, most patients have undergone a core needle biopsy procedure prior to excision with placement of a radio-opaque clip, and it is this clip, along with tissue landmarks, that is used to guide wire-localization by the radiologist. Once the appropriate area is excised, the margins should be marked by the surgeon with sutures (typically superior and lateral margins, short and long sutures, respectively by convention) and an x-ray study of the specimen performed to confirm removal of the target area and biopsy clip. If no lesion/calcification or clip is seen, the surgeon should obtain additional tissue, if feasible. If the abnormal area is present in the specimen, the specimen should be inked with six different colored inks according to the orientation given by the surgeon and the specimen sliced and processed in the pathology laboratory. As mentioned above, the vast majority of patients have undergone a core needle biopsy procedure prior to definitive surgery; therefore the pathologic diagnosis from that earlier procedure can be used to guide tissue processing. The highest yield is obtained from histologic examination of the areas with radiographic calcification and fibrous parenchyma.[318]

X-ray studies can be taken of the paraffin blocks to document the fact that the microcalcifications seen in the mammogram have been embedded (Fig. 36.69). An important source of discrepancy between mammographic targeting of calcifications and microscopic findings are calcium oxalate crystals, which can be easily identified radiographically but may be missed on histologic examination.[319] Every attempt should be made to identify, in the microscopic sections, the imaging target regarded by the radiologist as "suspicious" for carcinoma.

Breast ultrasonography is a valuable examination tool, particularly for determining whether a mass lesion is cystic or solid, and whether it is circumscribed and "wider than tall," which are features of benignity, or conversely whether it is hypoechoic with irregular borders, "taller than wide" and has posterior shadowing, which are features favoring a malignant diagnosis.[320]

MRI is unlikely to replace mammography as the imaging modality of choice, although contrast-enhanced techniques have rendered it more informative and potentially more useful. It is more sensitive but has lower specificity, resulting in greater numbers of false-positive call backs and unnecessary biopsies. There is greater application for

For personal use only. No other uses without permission. Copyright ©2017. Elsevier Inc. All rights reserved.

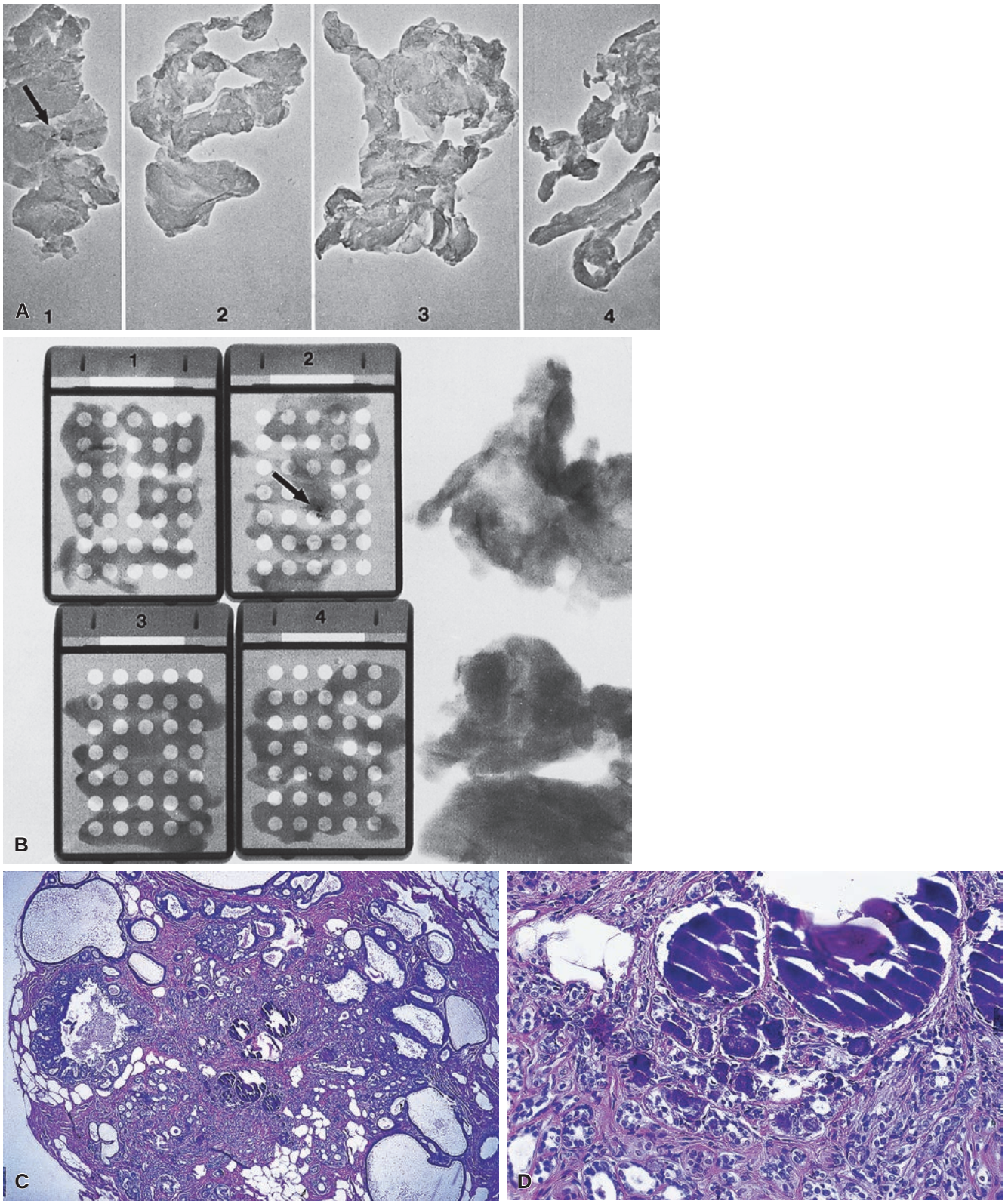

Figure 36.69 Demonstration of the Use of Specimen Radiography. A mammographically detected breast lesion was excised. **A,** The specimen was sliced into four portions and a radiograph taken. A pattern of calcification identical to that seen in original mammogram was detected in slice 1 *(arrow).* **B,** The portion corresponding to this area of calcification was further divided into four fragments, and all four were embedded in paraffin. A radiograph of the cassettes shows that the suspicious area is in cassette 2 *(arrow).* The remainder of the slice (two fragments at right) shows no calcification. **C** and **D,** Low- and high-power views of the corresponding microscopic specimen demonstrating the microcalcifications.

For personal use only. No other uses without permission. Copyright ©2017. Elsevier Inc. All rights reserved.

use of MRI in patients at high risk (>20% lifetime risk) for the development of breast cancer.[321]

Where adopted for screening purposes, the National Cancer Institute has traditionally recommended mammography be done on an annual basis from the age of 40 years onwards. Great controversy has recently arisen following the revised recommendations from the US Preventive Services Task Force, which calls for mammograms to be done biennially from the ages of 50 to 74, with the decision to begin screening at 40 years being an individual one depending on a woman's risk factors.[322]

Cytology

The two methods that have been used to obtain cytologic material from breast lesions are collection of nipple discharge (often directly onto a glass slide) and aspiration of a palpable lesion using a fine needle.

Nipple secretion cytology is of limited use, whether for the diagnosis of a clinically or mammographically detectable breast lesion or for screening purposes. Some carcinomas may be found, but the ability to provide a definitive interpretation from these often bloody, degenerated specimens is limited, rendering this technique of only marginal value. The situation with FNA is different, as shown in the pioneer attempts at Memorial Sloan Kettering Cancer Center in the 1930s. In experienced hands the technique is highly reliable (Fig. 36.70).[323,324] The average sensitivity is approximately 87%, the specificity close to 100%, the predictive value of a positive diagnosis nearly 100%, and the predictive value of a negative diagnosis between 60% and 90%.[323,325] Most benign lesions misinterpreted cytologically as possibly malignant are usually fibroadenomas or intraductal papillomas with marked epithelial proliferation.[326] At the malignant end of the spectrum however, it is not possible to distinguish between in situ and invasive carcinoma on FNA cytology,[327] for these reasons core needle biopsy has largely superseded FNA cytology as the diagnostic procedure of choice in the United States. There remains a role in the evaluation of clinically positive axillary lymph nodes, particularly in the neoadjuvant setting to document lymph node metastasis prior to initiation of chemotherapy.

Core Needle Biopsy

In recent years, core needle biopsy (image-guided and with or without vacuum assistance) has become the gold standard for the diagnosis of image-detected nonpalpable and palpable breast lesions. Core needle biopsy is favored over FNA for the preoperative diagnosis of breast carcinoma. As mentioned previously, core needle biopsy allows for evaluation of both cytologic *and* architectural features, thereby permitting definitive diagnosis of invasive carcinoma when present. Conversely a benign lesion, such as fibroadenoma, can be readily recognized, and core needle biopsy allows for easier sampling and identification of microcalcifications. Furthermore, it reduces the number of inadequate samples and does not require cytopathology expertise. In order to obtain maximum information from the procedure, the pathologist should be provided with complete a clinical history, including radiographic signs and the site of the biopsies. In cases with microcalcifications, the core biopsy specimens should be x-rayed and the cores with calcifications submitted separately from those without, in the event additional levels are needed.[328] The use of site-marking devices at the time of the core biopsy is helpful for the radiologist, to guide placement of a localization wire should an excision be required, and in determining whether the subsequent surgical specimen includes the radiographically abnormal area.

Per American Society of Clinical Oncology (ASCO)/ College of American Pathologists (CAP) published guidelines, breast specimens should be fixed for a minimum of 6 hours and a maximum of 72 hours to permit accurate biomarker testing, should that be required[329]; a minimum of three levels should be obtained initially on all core needle biopsy specimens, with additional levels and immunostains performed when necessary.[330] A definitive diagnosis on the basis of a core biopsy and triage for patient management is possible in the majority of cases.[331] However, there are some diagnoses that are not malignant that have warranted surgical excision because of the frequency with which a worse lesion has been found upon excision of the area of concern (i.e., the "upgrade" or "underestimation" rate). Unfortunately, many of these recommendations for excision were based on data from small studies, often with radiologic-pathologic discordance and selection bias with regard to which patients underwent excision. Newer studies have taken care to address the imaging findings, ensure radiologic-pathologic correlation, and provide data on upgrade rates for incidental cases of atypia.[216] The following is a standard management algorithm:

1. All cases showing DCIS or invasive carcinoma should undergo excision.
2. Cases showing ADH or atypical ductal proliferations with features bordering on DCIS should undergo excision.[216]
3. The management of LCIS and ALH is evolving. In the past, most authors recommended surgical excision,[332,333] but more recent studies, in which there is good radiologic-pathologic correlation and the lobular neoplasia is determined to be incidental to the targeted lesion, are recommending observation over excision (if the targeted lesion is benign and does not itself require excision), with the exception of cases of nonclassical or pleomorphic LCIS.[334,335]
4. Columnar cell lesions without atypia (i.e., columnar cell change and columnar cell hyperplasia) do not require excision. The management of FEA identified on core needle biopsy remains controversial. The WHO recommendation is for radiologic-pathologic correlation with consideration of excision in patients in whom there are residual calcifications on a post-biopsy mammogram or for whom there is radiologic-pathologic discordance.[112]
5. In most cases, papillomas can be distinguished from papillary carcinomas on core needle biopsies.[336] A diagnosis of papillary carcinoma or papilloma with atypia warrants excisional biopsy, whereas a diagnosis of papilloma may be managed with clinical follow-up if imaging findings are concordant, though many centers still excise radiologically targeted papillomas.[216]
6. The presence of stromal pools of mucin associated with mucocele-like lesion had been an indication for surgical excision because of the concern for undersampled mucinous carcinoma, but in patients in whom there is no atypia and no imaging findings of concern, observation may be acceptable.[216]

Complications of the core needle biopsy procedure include hemorrhage, reactive spindle cell nodules, and epidermal inclusion cysts.[337,338] A different type of complication, also seen in connection with the FNA procedure but more likely with the core biopsy technique, is the mechanical displacement of epithelial cells into the stroma or even inside vessel lumina (see Fig. 36.54).[339,340] This phenomenon is more common with both benign and malignant papillary lesions, presumably because of their greater friability.[341] It is doubtful whether this finding is of any clinical significance. The greater importance lies in recognition of this phenomenon as a procedural artifact and not as a focus of invasive carcinoma for which it may be mistaken. The displaced epithelial cells may appear as small nests or single cells with atypical, "squamoid," or degenerated features. Identification of

For personal use only. No other uses without permission. Copyright ©2017. Elsevier Inc. All rights reserved.

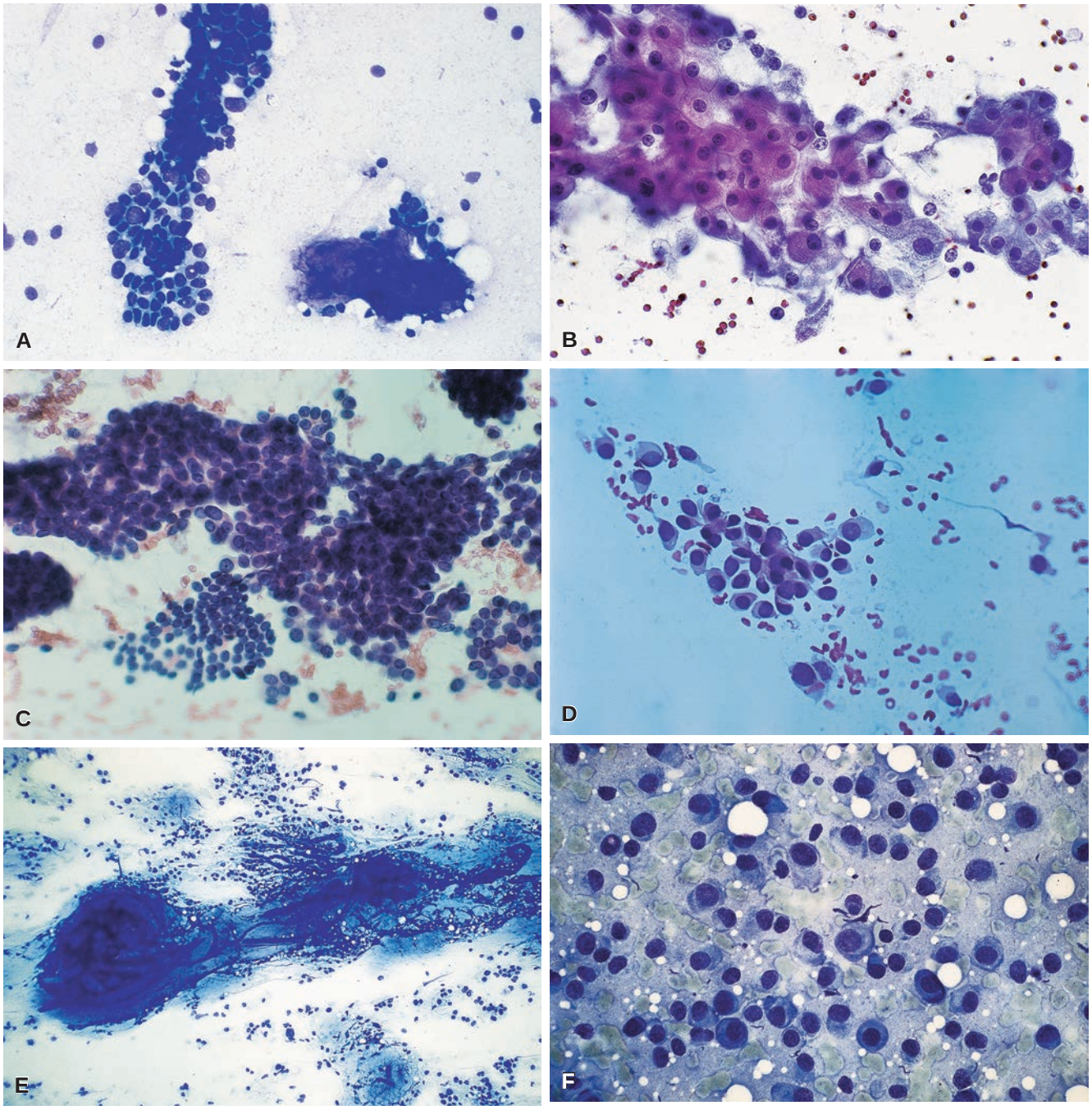

Figure 36.70 Cytologic features of various types of breast lesion as seen in FNA specimens: **(A)** fibroadenoma; **(B)** apocrine metaplasia; **(C** and **D)** invasive ductal carcinoma; **(E)** mucinous carcinoma; **(F)** invasive lobular carcinoma.

biopsy site changes such as granulation tissue and hemosiderin-laden macrophages will help prevent an erroneous diagnosis. Note that myoepithelial cells are often absent, as such IHC is not helpful.

Frozen Section

Intraoperative evaluation by frozen section has limited applicability in current practice. Some centers perform intraoperative evaluation of the specimen margins with a view to immediate reexcision of involved margins. These can be technically challenging specimens to freeze because they are often composed entirely of adipose tissue, and they can be challenging to interpret, resulting in well-documented false-positive and false-negative rates.[342]

A few centers still perform intraoperative frozen section evaluation of sentinel lymph nodes. The need for this is largely obsolete[343] given the results of the American College of Surgeons Oncology Group (ACSOG) Z0011 randomized clinical trial demonstrating an absence of clinical benefit for completion axillary dissection even in patients with 1–3 positive sentinel lymph nodes.[344] On occasion, request is made for frozen section in the setting of mastectomy, where completion dissection may be performed if the sentinel lymph node is positive.

For personal use only. No other uses without permission. Copyright ©2017. Elsevier Inc. All rights reserved.

Histologic Types

Two key determinations to make in the morphologic study of breast carcinoma are: (1) whether the tumor is confined to the ductolobular system (carcinoma in situ) or has invaded the stroma (invasive carcinoma), and (2) whether it is of ductal or lobular type. The first criterion, the prognostic significance of which far outweighs that of the second, is self-explanatory, but it may be appropriate to elaborate on the second. The term "ductal carcinoma" may be taken to imply that the tumor is either arising from or involving a duct, and an analogous assumption could be made about lobular carcinoma in relation to the lobule. The evidence obtained from the classic study of Wellings et al.[21] and several others indicates instead that both tumor types (and, for that matter, most benign proliferative breast diseases) arise from the same segment of the mammary gland, that is, the TDLU. As far as location is concerned, it is certainly true that many ductal carcinomas in situ preferentially involve structures with the appearance of ducts and that most lobular carcinomas in situ preferentially involve lobules. However, numerous exceptions in both directions exist. It has been hypothesized that these cases represent—respectively—ductal carcinomas in situ with secondary extension into lobules ("lobular cancerization"—an obsolete term), or lobular carcinomas in situ with secondary extension into ducts.[345] Be that as it may, it should be made clear that it is the type of tumor as defined by cytoarchitectural features that establishes its placement into one of these two diagnostic categories rather than its precise location within the breast. Therefore, it may be more accurate and less confusing to refer to these tumors as *ductal type* and *lobular type*, respectively. For the sake of brevity and tradition however, the conventional nomenclature of ductal and lobular will be used in this chapter.

Carcinoma In Situ

Ductal Carcinoma In Situ

DCIS is defined by the presence of neoplastic epithelial cells confined to the ductolobular system. Many architectural variants of DCIS exist, such as papillary, solid, cribriform, and micropapillary; in addition, there is nuclear variability ranging from low- to high-grade types. DCIS is believed to originate in the TDLU (although often extending into larger ducts) and had been historically divided into high-grade comedocarcinoma (characterized by large pleomorphic cells associated with necrosis) and a low-grade solid/cribriform/micropapillary group (composed of smaller uniform cells unassociated with necrosis). Contemporary classification schemes divide DCIS into a three-grade system largely on the basis of *nuclear pleomorphism* with or without the inclusion of *comedo necrosis*. These criteria apply irrespective of the architectural pattern. They may also apply independently of the presence or absence of necrosis, depending on the classification scheme employed.[346–348] Unfortunately, there is still no international consensus on a classification scheme for DCIS, but if nuclear grade, the presence or absence of comedo necrosis, architectural pattern, and some estimate of size is reported, any of the myriad classification schemes can be used to categorize a given DCIS lesion.[349,350]

Nowadays, the vast majority of DCIS is detected through screening mammography as clustered microcalcifications. Linear, branching calcifications raise the most concern for DCIS, but other patterns exist and are indeterminate with regard to the degree of certainty with which they can be distinguished from benign lesions associated with microcalcifications on radiologic studies. When sufficient concern exists, a core needle biopsy is performed to allow for pathologic diagnosis.

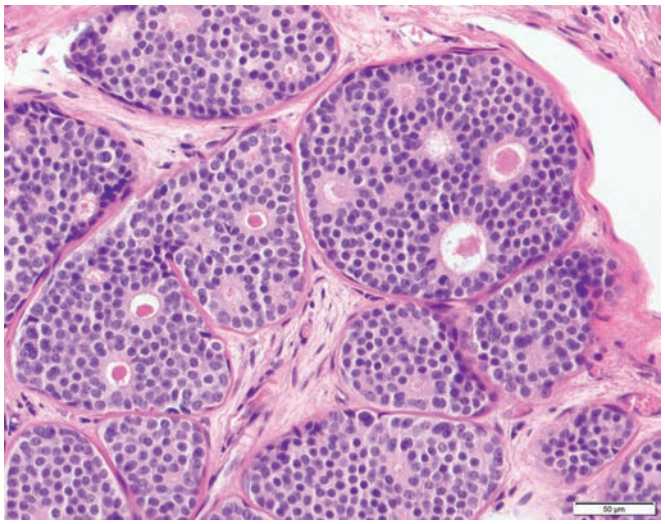

Figure 36.71 Ductal carcinoma in situ, low nuclear grade, cribriform pattern.

A small minority of DCIS lesions present as a palpable mass or with nipple discharge. It has been shown that DCIS occurring in younger women is more often symptomatic, more extensive, and more often accompanied by involvement of lobules than DCIS in older women.[351]

Low Nuclear Grade Ductal Carcinoma In Situ

Low nuclear grade DCIS is characterized by a neoplastic proliferation of monomorphic epithelial cells growing in solid, cribriform, papillary, or micropapillary patterns (Fig. 36.71). Microacini and/or areas of cellular polarization may be apparent in the solid pattern; a feature that aids in the distinction from LCIS. The cells have round, regular nuclei with even chromatin and inconspicuous nucleoli. Mitoses are rare. Punctate or even comedo necrosis may be seen but is unusual. Microcalcifications are often present.

Intermediate Nuclear Grade Ductal Carcinoma In Situ

Intermediate nuclear grade DCIS is characterized by cells with slightly more nuclear variability than low nuclear grade DCIS. The cells are larger and less evenly spaced within the involved TDLU. Polarization is still observed, though is less pronounced (Fig. 36.72). Calcification, mitoses, and necrosis may be present.

High Nuclear Grade Ductal Carcinoma In Situ

High nuclear grade DCIS is characterized by a neoplastic proliferation of highly atypical epithelial cells with large pleomorphic nuclei, coarse clumped chromatin, and prominent nucleoli. The proliferation may be solid, cribriform, or micropapillary in architectural pattern, but the cells are poorly organized and polarization is not usually evident (Fig. 36.73). Mitoses are abundant, and necrosis is a common, though not a required, feature. Comedo necrosis is said to be present when approximately half of the involved space has abundant necrotic material and is surrounded by DCIS cells. A less common pattern of high nuclear grade DCIS is the clinging pattern, in which a single layer of highly atypical cells lines the involved space (see later).

DCIS is not usually detectable on gross examination, with the possible exception of large areas of high-grade DCIS with comedo necrosis that induce a desmoplastic stroma. In this scenario, a mass may be palpable and on cut surface clusters of thick-walled ducts may be seen. When these ducts are compressed, plugs of necrotic

For personal use only. No other uses without permission. Copyright ©2017. Elsevier Inc. All rights reserved.

Figure 36.72 Ductal carcinoma in situ, intermediate nuclear grade, cribriform pattern with necrosis. There is greater nuclear variability compared with that seen in low-grade DCIS.

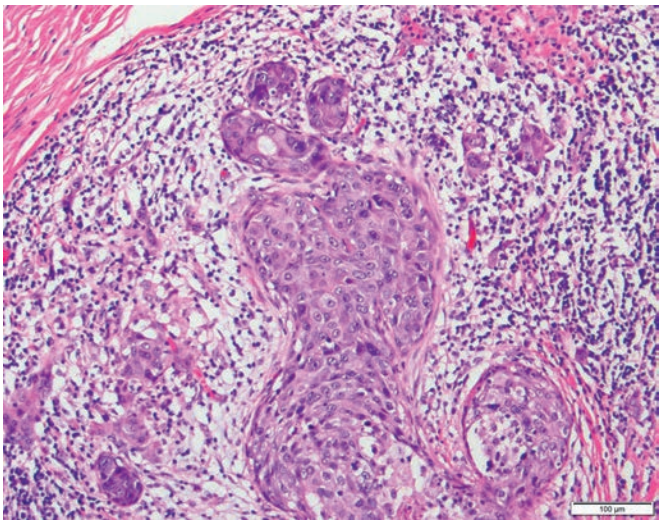

Figure 36.74 Microinvasive carcinoma associated with high-grade ductal carcinoma in situ. Notice the clusters and single highly atypical epithelial cells present in the stroma surrounding the high-grade DCIS. A dense lymphocytic infiltrate is often present.

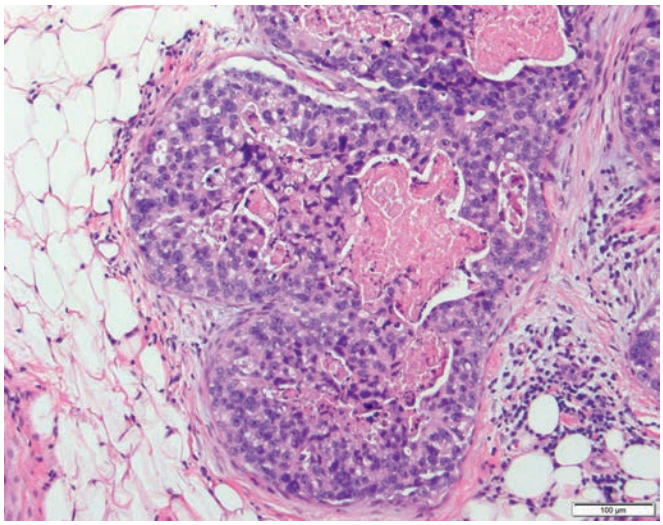

Figure 36.73 Ductal carcinoma in situ, high nuclear grade, solid pattern with necrosis.

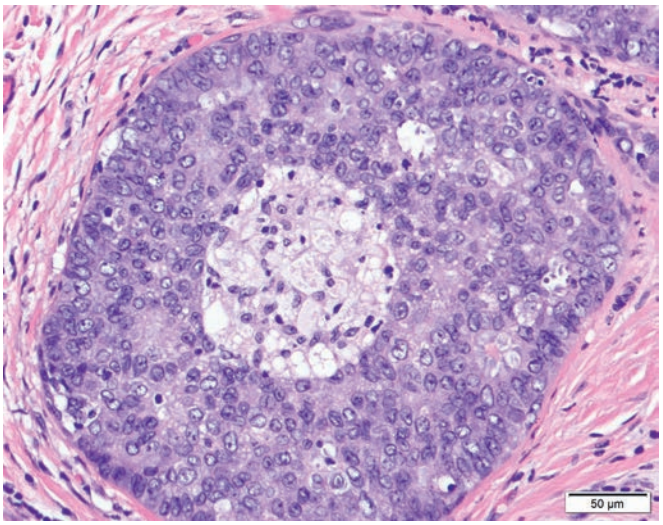

Figure 36.75 Ductal Carcinoma In Situ, Intermediate Nuclear Grade. Note how even in the absence of well-formed cribriform spaces, the cells are arranged in rosettes or microacinar structures.

tumor extrude from them, reminiscent of comedones, hence the historic appellation "comedocarcinoma."

Once the diagnosis of DCIS has been established, two additional important determinations need to be made. The first is the extent of the lesion, which in some cases may be very extensive and even reach the nipple, resulting in Paget disease. The other is to search for areas of definite stromal invasion and, if these are present, to report the size of the largest focus of invasion. Even if no definite invasion is detected in the sections examined, the possibility always exists, especially with extensive high nuclear grade DCIS, that a minute focus of invasion is present somewhere in the specimen (Fig. 36.74).[352] This accounts for the observation that up to 15% of patients have tumor cells present in the axillary lymph nodes (especially with cytokeratin immunohistochemical examination) in the absence of an identifiable invasive component in the breast.[353–355]

Architectural Patterns of Ductal Carcinoma In Situ

In the *solid* form of DCIS, the acini of the TDLU are filled by a proliferation of medium-sized cells, which are larger than those of LCIS, often with low-grade monomorphic nuclei, though any nuclear grade may be seen. Azzopardi[22] pointed out the sharp cell edges (as opposed to a "syncytial" quality) and the pallor of the cytoplasm (as opposed to prominent eosinophilia) often exhibited by these cells compared with the cells of UDH. Even in the absence of true lumen formation, the cells in solid pattern DCIS attempt to polarize, creating a rosette or microacinar pattern within the solid proliferation (Fig. 36.75). It is this feature that is most helpful in distinguishing low nuclear grade, solid pattern DCIS from LCIS.

In the *cribriform* pattern, round regular spaces are formed within the involved acini of the TDLU (see Figs. 36.71 and 36.72); in DCIS

For personal use only. No other uses without permission. Copyright ©2017. Elsevier Inc. All rights reserved.

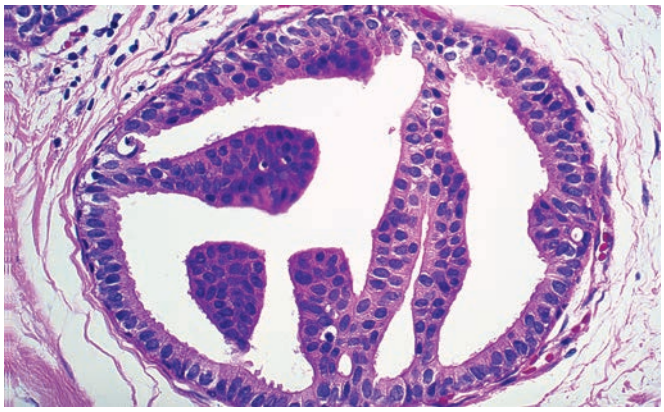

Figure 36.76 Trabecular Bars in Atypical Ductal Hyperplasia. Note the perpendicular arrangement of the nuclei in relation to the long axis of the bars.

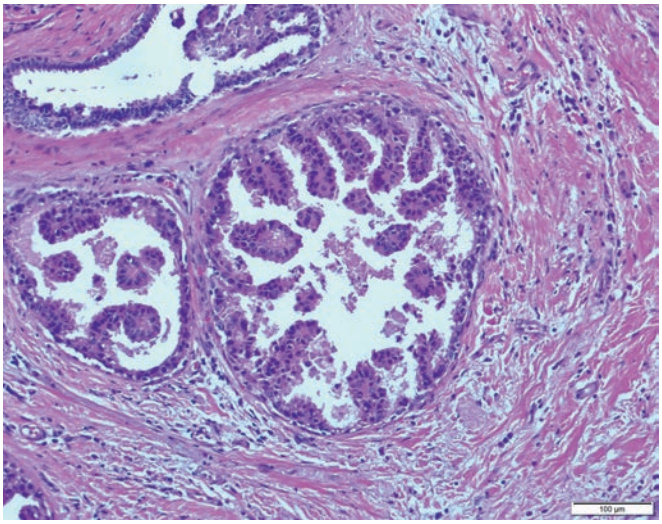

Figure 36.77 Ductal carcinoma in situ, micropapillary pattern.

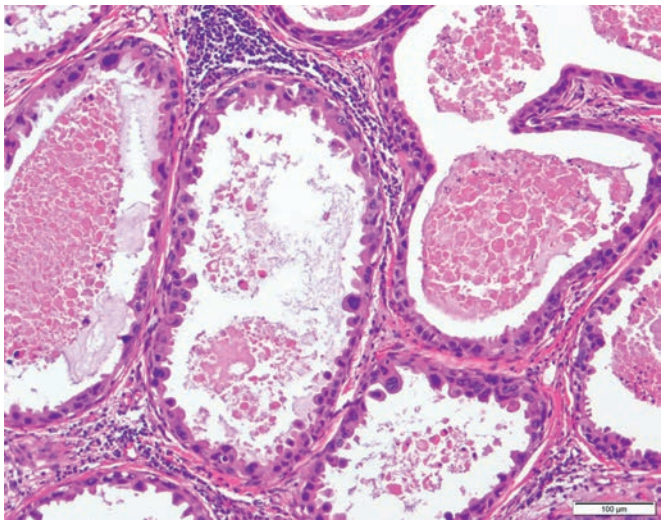

Figure 36.78 Ductal Carcinoma In Situ, Clinging Pattern. One or two layers of highly atypical cells line dilated glandular structures containing necrosis.

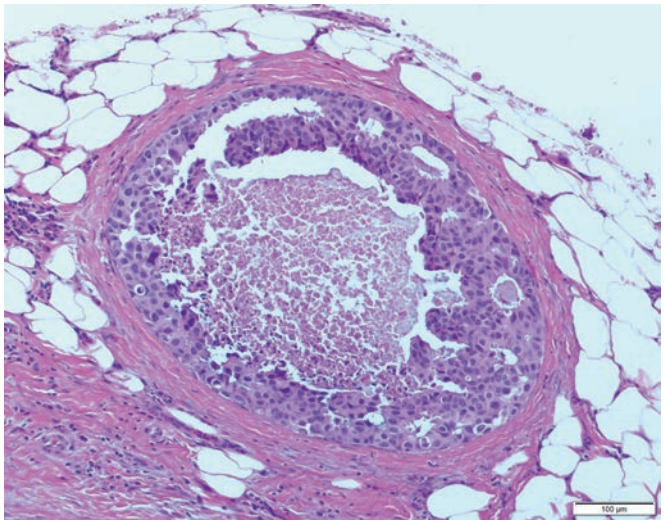

Figure 36.79 Ductal carcinoma in situ, with comedo necrosis.

the spaces are more regular in terms of distribution, size, and shape, as opposed to UDH in which the spaces are irregular and slit-like (see Figs. 36.36 and 36.37). Cribriform DCIS is often seen in association with two formations of similar pathogenesis, designated by Azzopardi[22] as trabecular bars and Roman bridges, respectively. Trabecular bars are rigid rows of cells with their long axes arranged more or less perpendicular (or at least not parallel) to the long axis of the bar, features that are more readily appreciated in examples of ADH (Fig. 36.76). Roman bridges are curvilinear trabecular bars connecting two portions of the epithelial lining. Collagenous spherulosis and adenoid cystic carcinoma can be mimics for the cribriform pattern of DCIS.

The *micropapillary* pattern shows epithelial micropapillations projecting into the ductular lumen; these lack connective tissue support and often show a bulbous expansion at the tip (Fig. 36.77). This variant is more likely than others to involve multiple quadrants of the breast.[356]

Papillary DCIS is another architectural pattern characterized by papillary projections with fibrovascular cores (see previous discussion).

Clinging pattern DCIS shows one or two layers of neoplastic epithelial cells lining a space often with an empty lumen, though necrosis may be seen.[22,357] The lining cells are large, highly atypical, and associated with apoptosis (Fig. 36.78). In the United States the term clinging carcinoma is restricted to the aforementioned high nuclear grade lesion. In Europe, reference is made to a pattern of DCIS referred to as clinging carcinoma of the monomorphic type,[22] but this lesion is now classified as FEA.

Comedo DCIS really refers to a pattern of necrosis, rather than an architectural pattern of DCIS, in which the involved space is lined by several layers of neoplastic epithelial cells with approximately half the space involved by necrosis (Fig. 36.79).

There are occasions when the acini or lobules involved by DCIS remain small, a phenomenon formerly known as lobular cancerization; nowadays the term "lobular involvement" or "involvement of lobules" by DCIS is preferred. (Fig. 36.80). Available evidence suggests that this phenomenon represents instead a variation in the growth pattern of DCIS in which the structure involved is still easily recognizable as belonging to a lobule.[345]

Rare additional morphologic variations of DCIS include cases with *signet ring cells* (see Fig. 36.62),[358] with *apocrine cytology* (Fig. 36.81),[359] with *squamous features,*[360] and with evidence of *(neuro)*

For personal use only. No other uses without permission. Copyright ©2017. Elsevier Inc. All rights reserved.

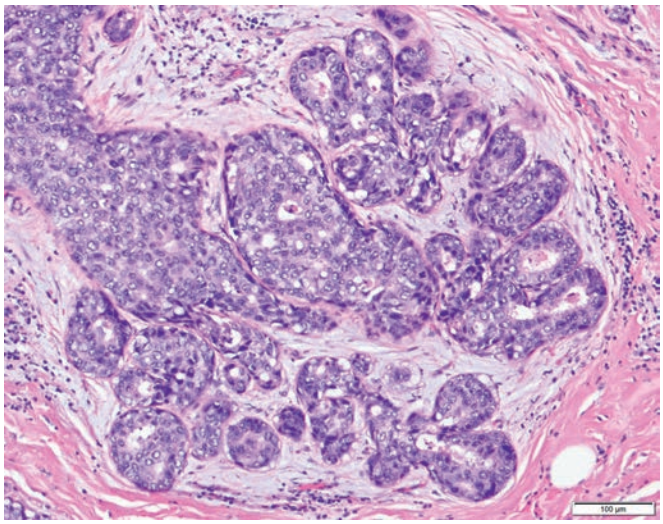

Figure 36.80 Ductal Carcinoma In Situ Involving Lobules. The terminal duct lobular unit is markedly expanded and composed of relatively large DCIS cells.

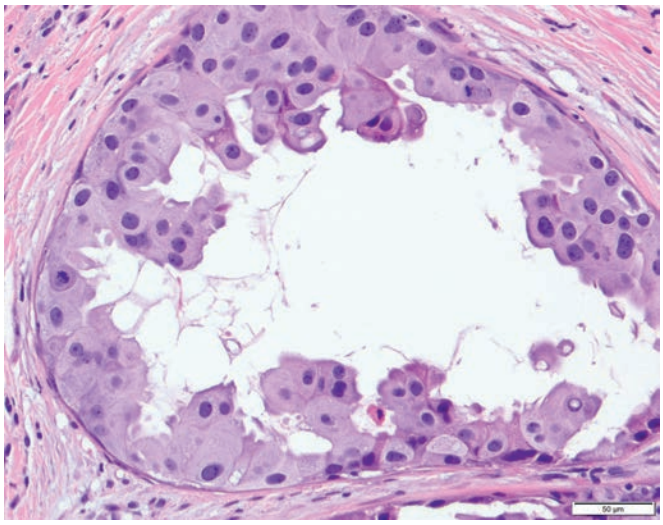

Figure 36.81 Ductal carcinoma in situ with apocrine features.

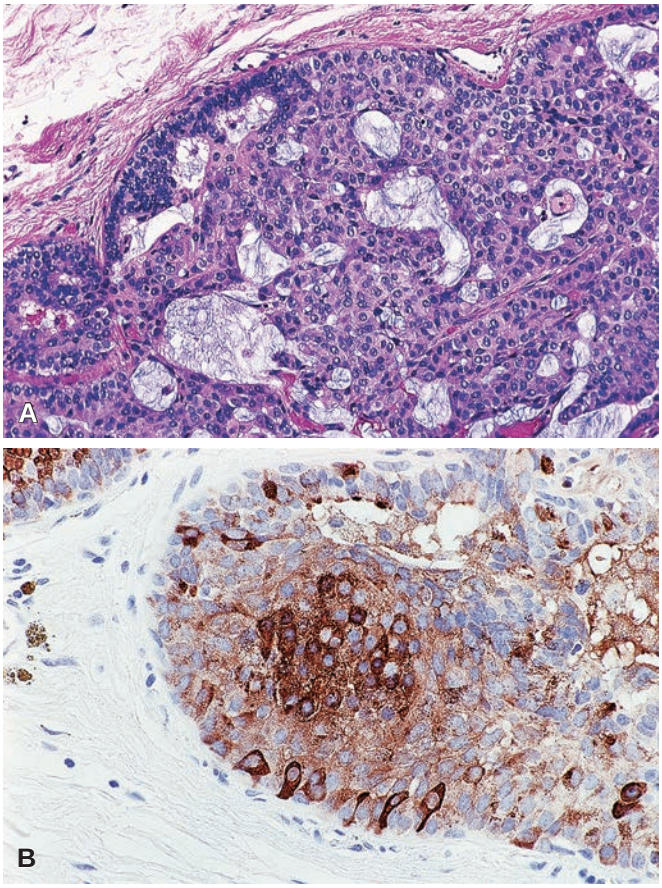

Figure 36.82 Ductal Carcinoma In Situ With Endocrine Features. A, Hematoxylin–eosin stain. **B,** Chromogranin immunostain.

endocrine differentiation (Fig. 36.82).[361] The latter tumor, known as *(neuro)endocrine DCIS (E-DCIS)*, is often seen in association with solid papillary carcinoma.[362] Sometimes these tumors are accompanied by an invasive component, which is also of neuroendocrine type. This tumor is probably closely related to the lesion that has been described as *spindle cell DCIS*.[363]

The two major differential diagnostic considerations of DCIS are LCIS (with low nuclear grade DCIS) and UDH (with intermediate nuclear grade DCIS), both of which can be separated on morphologic grounds supplemented by immunohistochemistry where needed.

Solid pattern, low nuclear grade DCIS is composed of cells that are cohesive and attempt to polarize (microacinar or rosette formation). In contrast, LCIS cells are dyshesive, often have intracytoplasmic vacuoles, and lack polarization. Immunostains for E-cadherin, β-catenin, and p120 catenin will show a strong membranous pattern of staining in DCIS. In general, LCIS cells have an absence of staining with E-cadherin and β-catenin and show a cytoplasmic pattern of staining with p120 catenin (but see discussion under LCIS for aberrant expression patterns).

Intermediate nuclear grade DCIS can be separated from UDH by recognizing the monotony of the atypical cells, even if showing a streaming pattern mimicking UDH. Some areas of polarization may be apparent even in intermediate nuclear grade DCIS. The cells of UDH are more variable in size, shape, and quality of chromatin. Immunohistochemically, DCIS will show an absence of staining with CK5/6 and strong, diffuse staining with ER, whereas UDH will have a heterogeneous pattern of expression with both markers.

Molecular genetic analyses in DCIS and ADH indicate that there is a low-grade pathway of neoplasia in which loss of 16q is identified in lesions as early in the progression pathway as FEA. These same genetic aberrations are present in ADH and low-grade DCIS, as well as in the lobular neoplasia pathway, suggesting that lobular lesions and low-grade ductal lesions are closely related.[118] High-grade DCIS has a different and greater set of molecular genetic alterations, which includes 17q loss, compared with low-grade lesions.[364] Needless to say intermediate-grade lesions are heterogeneous with regard to their molecular genetic alterations.[365]

Evolution

The implication of the diagnosis of DCIS is that, if left untreated, the lesion may progress to an invasive carcinoma of similar morphologic features. Evidence that DCIS is a nonobligate precursor lesion is as follows:

1. The transformation to an invasive phenotype does not occur in all cases, at least during the normal life span of an individual.[366]
2. When such a transformation occurs, the process usually evolves over a period of years if not decades.[366]

For personal use only. No other uses without permission. Copyright ©2017. Elsevier Inc. All rights reserved.

3. There is a substantial difference in the frequency with which this phenomenon occurs depending on the type of DCIS, with more rapid progression occurring in high nuclear grade DCIS and a more protracted course with low and intermediate nuclear grade DCIS.[367–370]
4. There is a relationship between the grade (and to some extent, microscopic type) of DCIS and the concurrent invasive component; however, numerous exceptions occur.[371]
5. The molecular alterations present in DCIS are more similar to invasive carcinomas of the same grade than they are to DCIS of a differing grade (e.g., low nuclear grade DCIS has a gene expression pattern more similar to low-grade invasive carcinoma than it does to high nuclear grade DCIS and vice versa).[372]

Not all invasive breast carcinomas go through the sequence just described; some have a very short intraductal stage and become invasive before being detectable by any imaging modality. It is this very fact that takes some of the value away from screening techniques such as mammography, which are much more likely to detect slow-growing carcinomas with a prolonged in situ stage. The goal of treatment is complete eradication of DCIS, through local (breast-conserving) surgery with or without irradiation, followed by anti-estrogen therapy in those with ER-positive DCIS.[373,374] There are some patients for whom mastectomy is indicated because of the extent of DCIS.

Lobular Carcinoma In Situ

LCIS has no distinguishing features on gross examination and is usually found incidentally in breast biopsies or excisions performed for other reasons. On occasion the term "lobular neoplasia" is used, particularly when referring to both ALH and LCIS. LCIS is multicentric in 60%–80% of cases and bilateral in approximately 30%–40%.[375]

Microscopically, the lobules are distended and completely filled by relatively uniform, round, small-to-medium-sized neoplastic epithelial cells with round and normochromatic or only mildly hyperchromatic nuclei.[376] In the typical case, there is a lack of cohesiveness among the tumor cells; intracytoplasmic vacuoles may be seen; and pleomorphism, mitotic activity, and necrosis are minimal or absent (Figs. 36.83 and 36.84).[375] LCIS cells may form a continuous row beneath the ductal epithelium, a pattern referred to as *pagetoid* (Fig. 36.85). Any of the following minor morphologic variations can occur, singly or in combination: moderate nuclear pleomorphism, larger nuclear size, appreciable mitotic activity, scattered signet ring cells (relatively common), apocrine changes (exceptional), and focal necrosis.[377] When the tumor cells are of medium-to-large size, with more marked nuclear pleomorphism, often prominent nucleoli, and moderate-to-abundant cytoplasm, the lesion is referred to as *pleomorphic LCIS* (Fig. 36.86).[378] Another variant form of LCIS is *florid LCIS with comedo necrosis* (Fig. 36.87), in which the involved TDLU is greatly expanded by a proliferation of LCIS cells, usually with classical cytologic features but accompanied by comedo necrosis and calcifications.[379]

LCIS can also involve fibroepithelial lesions (Fig. 36.88), sclerosing adenosis (see Fig. 36.40), a pattern that can be a mimic for invasive lobular carcinoma, or collagenous spherulosis (Fig. 36.89 and see Fig. 36.18), a pattern that can be a mimic for cribriform DCIS. The diagnosis of LCIS should be made only in those cases in which the cellular proliferation has resulted in the formation of solid nests that have expanded the lobules by greater than 50%, whereas the designation of ALH is to be given to those lesions in which the expansion of the lobules is of a lesser degree. LCIS also needs to be distinguished from solid pattern DCIS.

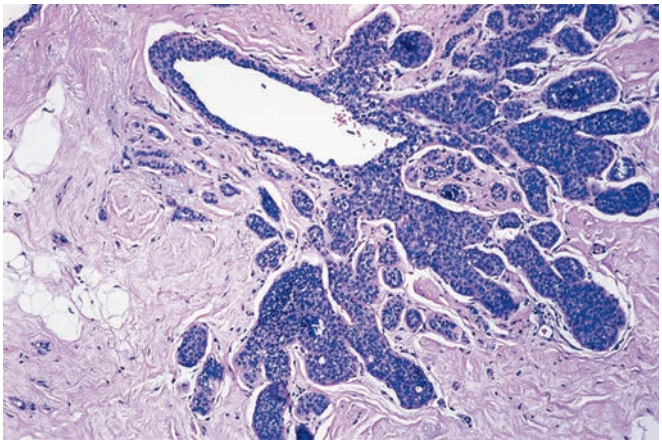

Figure 36.83 Typical pattern of involvement of terminal duct–lobular unit by lobular carcinoma in situ.

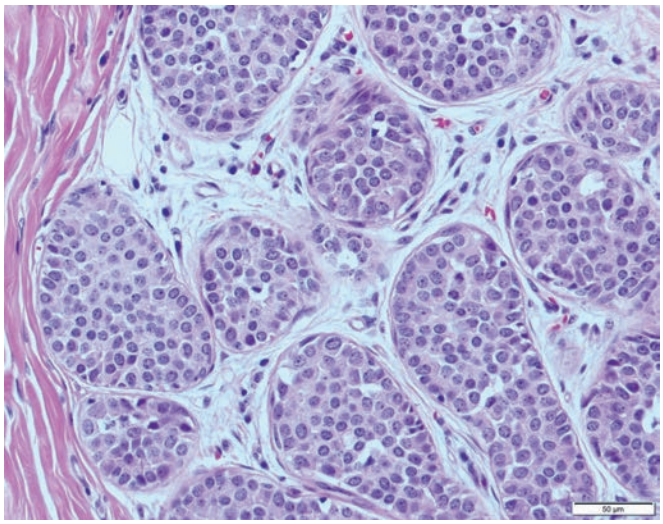

Figure 36.84 Marked expansion of a lobular unit by lobular carcinoma in situ.

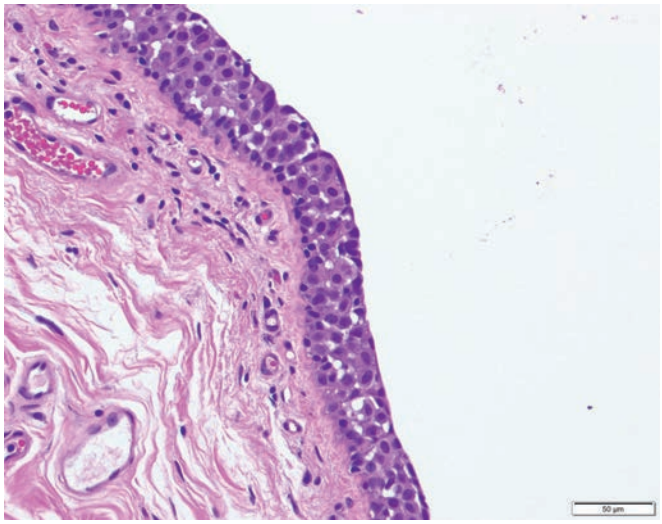

Figure 36.85 Pagetoid Involvement of Duct by Lobular Carcinoma In Situ. Note the presence of a monomorphic population of dyshesive cells underlying the attenuated layer of native ductal epithelium.

For personal use only. No other uses without permission. Copyright ©2017. Elsevier Inc. All rights reserved.

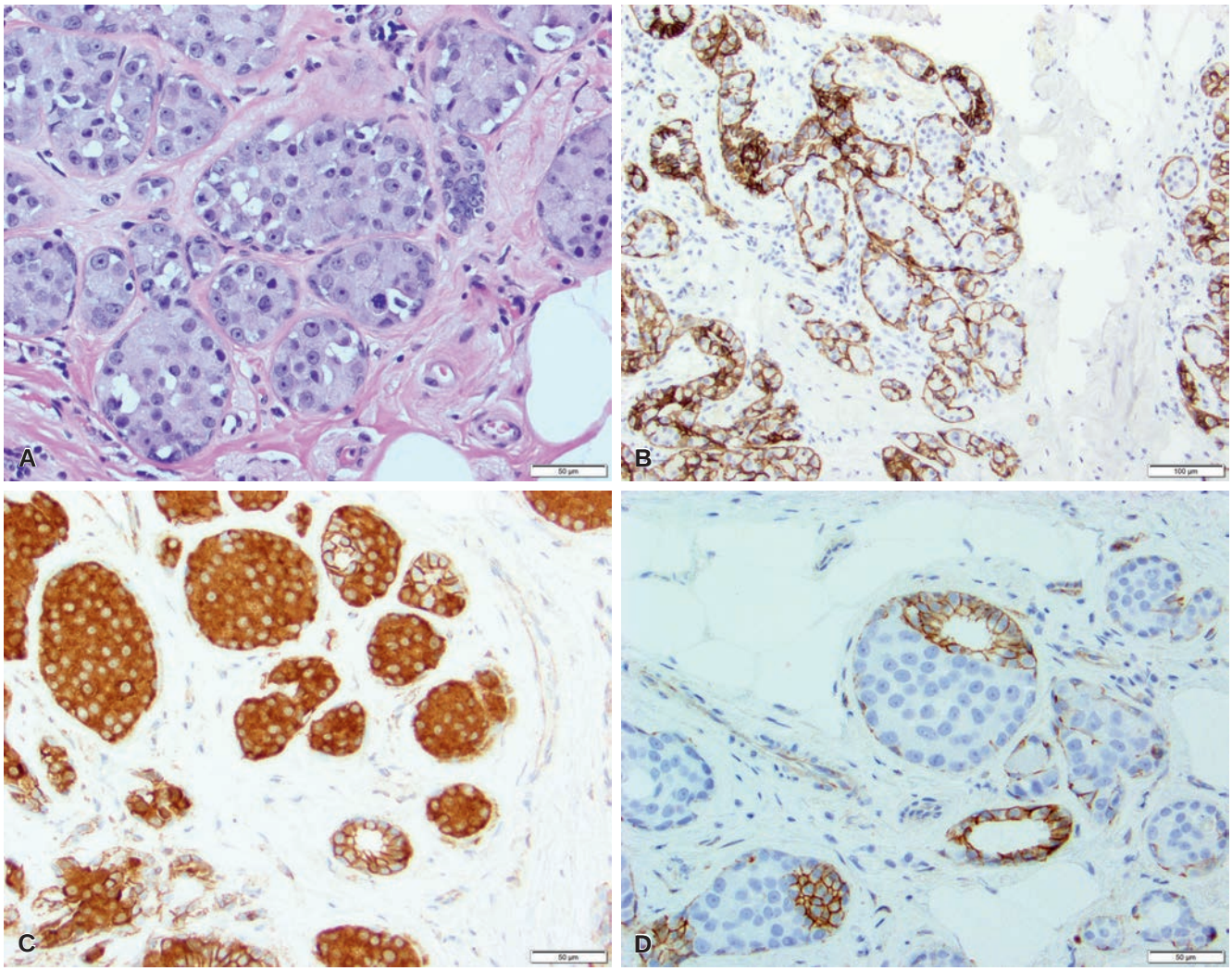

Figure 36.86 Pleomorphic Lobular Carcinoma In Situ. A, A lobule involved by pleomorphic LCIS. The cells are large with abundant eosinophilic cytoplasm and have pleomorphic nuclei with prominent nucleoli. **B,** E-cadherin immunostain. There is absence of staining in the LCIS cells. Myoepithelial cells and adjacent normal ductal epithelium show a membranous staining pattern. **C,** p120 catenin immunostain. There is cytoplasmic staining in the LCIS cells. Myoepithelial cells and adjacent normal ductal epithelium show a membranous staining pattern. **D,** β-Catenin immunostain. Like E-cadherin, there is absence of staining in the LCIS cells with myoepithelial cells and adjacent normal ductal epithelium showing a membranous staining pattern.

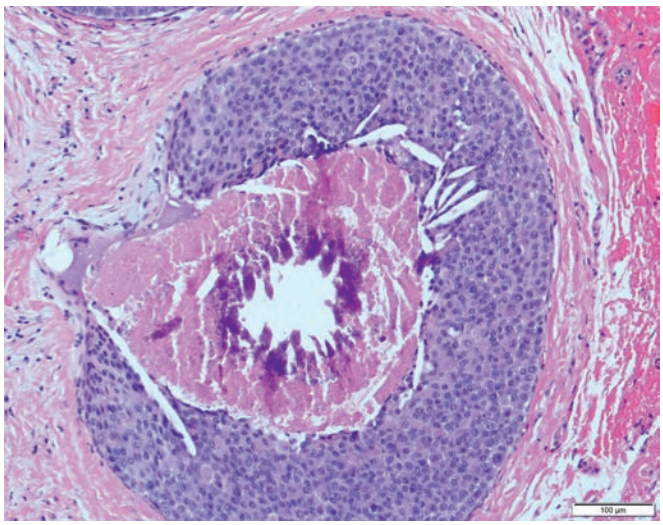

Figure 36.87 Lobular Carcinoma In Situ With Comedo Necrosis. The space is expanded by a monotonous proliferation of dyshesive epithelial cells (most pronounced in the lower right of the field); there is an absence of polarization of the cells. Comedo necrosis and calcifications are present in the center of the space.

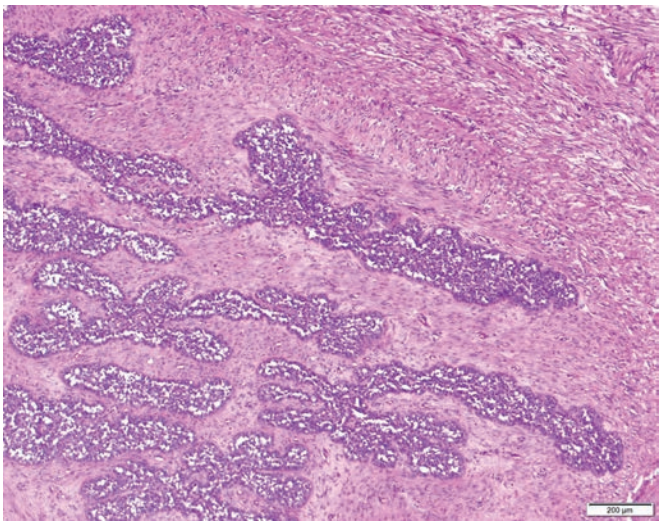

Figure 36.88 Lobular Carcinoma In Situ Involving a Benign Phyllodes Tumor. The ducts are expanded by a monotonous proliferation of dyshesive LCIS cells.

For personal use only. No other uses without permission. Copyright ©2017. Elsevier Inc. All rights reserved.

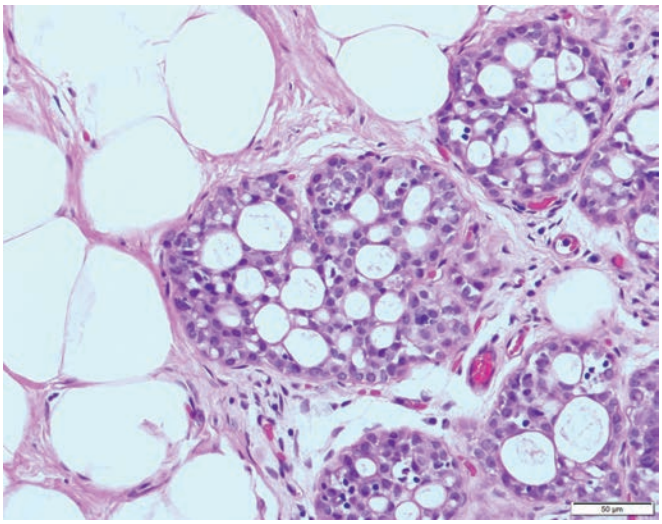

Figure 36.89 Lobular Carcinoma In Situ Involving Collagenous Spherulosis. The cribriform pattern conferred by this process can be a mimic for ductal carcinoma in situ.

From the point of view of the differential diagnosis with DCIS, morphologic features favoring a diagnosis of LCIS are cellular dyshesion, the presence of intracytoplasmic vacuoles, and an absence of polarization around the periphery of the involved space or of any attempt at microacinar formation; pagetoid involvement of ducts is also more characteristic of LCIS. Important immunohistochemical features of LCIS are an absence of expression with E-cadherin (see Fig. 36.86B and D) and β-catenin, and cytoplasmic positivity for p120 catenin (see Fig. 36.86C). By contrast, DCIS is consistently positive for all three markers, with a membranous pattern of expression.[380,381] As might be expected, some cases of LCIS show hybrid immunohistochemical features, manifested as aberrant, weak expression with E-cadherin; helpfully, p120 catenin tends to maintain the characteristic cytoplasmic staining pattern in lesions with a lobular phenotype.[381] The molecular correlate for loss of E-cadherin expression in LCIS is alteration of the *CDH1* gene; it is speculated that aberrant expression may be a function of the type of inactivation present.[382–384]

Evolution

One of the most controversial aspects of breast pathology is the nature of LCIS, specifically in regard to the probability of development of invasive carcinoma following a biopsy diagnosis of LCIS without additional therapy. Although the figures obtained in the various reported series[385–389] are not exactly superimposable, it is reasonable to conclude from them that: (1) approximately 20%–30% of patients will develop invasive carcinoma, a risk about 8–10 times higher than for a control population; (2) the risk seems greater in well-developed LCIS than in ALH; (3) the risk is about the same regardless of the amount of LCIS; (4) this increased risk applies to both breasts, although it is slightly greater on the side of the biopsy; (5) the invasive carcinoma may be of either lobular or ductal type, though there is a preponderance of invasive lobular carcinoma; and (6) if a patient with a biopsy diagnosis of LCIS is examined periodically, the chances of death from breast carcinoma are minimal. There are very limited data on the subsequent breast cancer risk associated with the nonclassical or variant forms of LCIS.

Most investigators agree that careful lifelong follow-up appears to be a safe and rational option for patients with LCIS.[387,390,391] Greater risk reduction is achieved with ER blockade with selective ER modulators (SERMs; such as with tamoxifen) or an aromatase inhibitor (e.g., anastrozole).[392,393] While an uncommon strategy today, the performance of simple mastectomy may be considered in the presence of a strong family history of carcinoma or if prolonged follow-up evaluation cannot be ensured, though given the bilateral nature of the risk conferred by LCIS, bilateral mastectomy would be the more appropriate surgical management.

Invasive Carcinoma

Tumors included in this category are all those in which stromal invasion is detectable, whether an in situ component is identifiable or not, and regardless of the relative proportion of the two components; in other words, it also includes "microinvasive carcinoma." Like in situ lesions, most invasive tumors can be divided into two major categories—ductal type and lobular type—acknowledging the existence of mixed forms. It should be mentioned that the type of invasive carcinoma ought to be determined from its own appearance, rather than deduced from the type of in situ component present, if any, since the two do not always correspond.

The classification of invasive breast carcinoma has evolved over a long period of time and, as a result, has had incorporated into it a wide range of criteria, such as cell type (as in apocrine carcinoma), type and amount of secretion (as in mucinous carcinoma), architectural features (as in papillary carcinoma), and pattern of spread (as in inflammatory carcinoma, which strictly speaking is a clinical and not a pathologic definition).

Microinvasive Breast Carcinoma

Once the concept of "microinvasive carcinoma" was entrenched in the gynecologic literature, it was only natural that it would be proposed at other sites, including the breast. Alas, its application at this site was not as straightforward, one of the reasons being that the mammary epithelium is not separated from the stroma by a sharp, straight line as it is in the cervix.[394] Be that as it may, microinvasive carcinoma is defined as any breast carcinoma showing stromal invasion not exceeding 1 mm in extent.[395] The term is applicable to both ductal and lobular lesions, but the former is more frequent. There may be a single focus of microinvasion or multifocal microinvasion may be identified. The mean number of foci reported is two.[396] Features of DCIS associated with microinvasion include greater extent, high nuclear grade, solid pattern, comedo necrosis, and periductal lymphoid infiltrates (see Fig. 36.74).[393] Note though that microinvasion may be seen with other grades and patterns of DCIS and with LCIS. Immunohistochemical evaluation with myoepithelial cell markers, in combination with cytokeratin if possible to highlight the microinvasive epithelial component, may be needed to confirm the diagnosis.[395,397] Patients with microinvasive carcinoma are at risk for nodal metastases,[398] but their survival rate is better than for patients with T1 invasive carcinoma[399] and the extent of microinvasive carcinoma does not appear to be correlated with likelihood of lymph node metastases.[400,401]

Invasive Ductal Carcinoma

This lesion represents the prototypic expression of breast carcinoma and is the tumor type usually implied when the terms "breast carcinoma" or "breast cancer" are used without further qualification. The size, shape, and tumor border are highly variable. Grossly, the typical case is firm and poorly circumscribed, cuts with a resistant gritty sensation, and shows a yellowish–gray cut surface, with trabeculae radiating through the surrounding parenchyma into the fat, resulting in the notorious stellate or crab-like configuration, from which the word "cancer" originated (Fig. 36.90). Areas of necrosis,

For personal use only. No other uses without permission. Copyright ©2017. Elsevier Inc. All rights reserved.

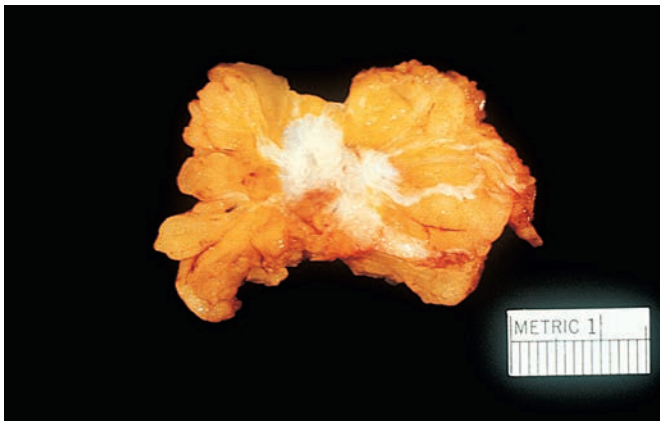

Figure 36.90 Typical Gross Appearance of Invasive Ductal Carcinoma. Note the irregular (crab-like) shape of the tumor, white fibrous appearance, and chalky streaks.

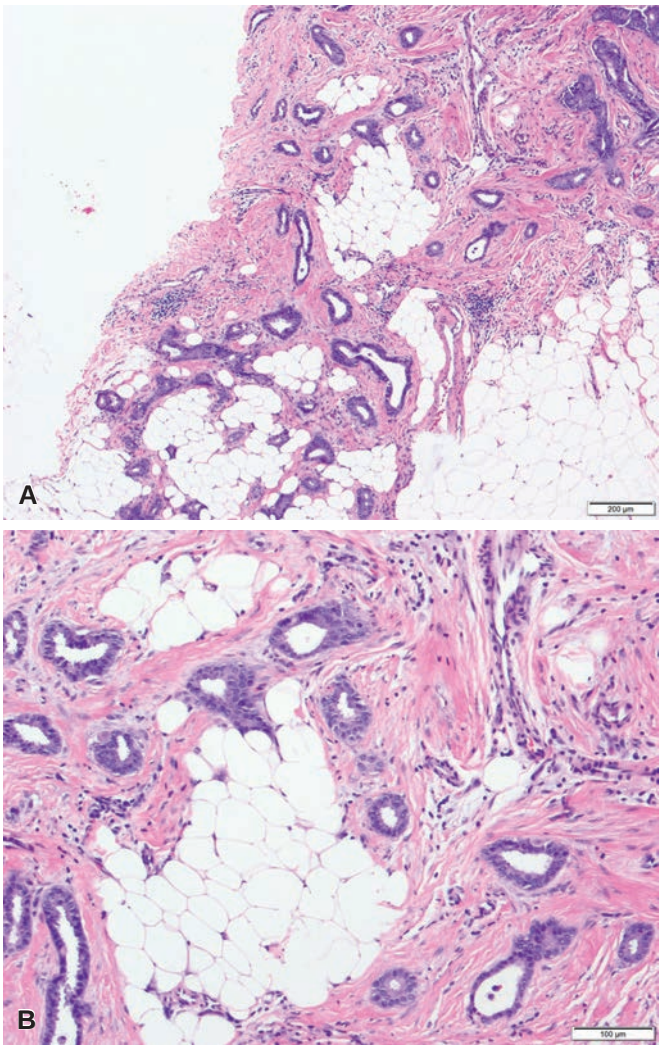

Figure 36.91 Prototypical Invasive Ductal Carcinoma. A, Irregularly shaped glands infiltrate through the stroma in a haphazard pattern. **B,** There is cytologic atypia present and myoepithelials cell are absent.

hemorrhage, and cystic degeneration are unusual but may be present, particularly in larger neoplasms. The tumor may invade the overlying skin or the underlying fascia and pectoralis muscle. Tumors that are particularly hard because of the large amounts of desmoplastic stroma were traditionally referred to as "scirrhous carcinomas." It is common for these neoplasms to exhibit "chalky streaks" on the cut surface, a feature caused by duct elastosis.[402] When this occurs, the appearance of the lesion has an uncanny resemblance to an unripe pear, further accentuated by the consistency felt while cutting it.

Microscopically, the variations are also legion. The tumor can grow in diffuse sheets, well-defined nests, cords, or as individual cells. Glandular/tubular differentiation may be well developed (Fig. 36.91), barely detectable, or altogether absent. The tumor cells vary in size and shape, the nuclei are large with varying degrees of pleomorphism, and nucleoli may be prominent. Mitotic figures vary from infrequent to more numerous. Areas of necrosis are unusual but may be identified in some cases. The amount of stroma ranges from none to abundant, and its appearance from densely fibrotic to cellular ("desmoplastic"). In cases with abundant stroma, it may be difficult to identify the tumor cells. Areas of "elastosis" may be present, which can involve the wall of the ducts and the vessels (mainly veins).[402] Calcification has been reported in approximately 60% of cases, either as coarse or fine deposits or, rarely, as psammoma bodies; most often the calcifications are identified within the associated in situ component.[315,403] A mononuclear inflammatory infiltrate of variable intensity may be present at the interface between tumor and stroma. Granulomatous inflammation is rarely seen.

Definite invasion of the perineural spaces, lymphatic vessels, and blood vessels was reported by Fisher et al.[403] in 28%, 33%, and 5% of cases, respectively. Lymphatic vessel invasion may be difficult to distinguish from artifactual tissue retraction. Features used to document the presence of lymphatic tumor emboli are the following: (1) the occurrence of the area in question outside the margin of the carcinoma, (2) the fact that the tumor emboli do not conform exactly to the space in which they lie, (3) the presence of an endothelial cell lining, and (4) the presence of blood vessels in the immediate vicinity.[404] If doubts persist, a stain with D2-40 or other endothelial cell markers might prove helpful (Fig. 36.92). Note that D2-40 crossreacts with myoepithelial cells;[405] thus it is prudent to include a myoepithelial cell marker in the panel also. These reactions can be carried out in the H&E-stained preparations after removing the coverslip and decolorizing the slide, if necessary.[406]

The term "extensive intraductal carcinoma" (EIC) applies to tumors in which the intraductal component comprises 25% or more of the area encompassed by the infiltrating tumor and is also present in the surrounding breast tissue.[407] The identification of EIC was of importance in predicting the likelihood of residual carcinoma in women undergoing reexcision; however, in contemporary practice, where greater attention is given to margin evaluation, this pathologic feature has become less critical.

Immunohistochemically, breast carcinoma cells show reactivity for low-molecular-weight cytokeratins (particularly types 8, 18, and 19) and EMA.[408] Some tumors (particularly high-grade tumors with a solid growth pattern and those with foci of squamous metaplasia) are also immunoreactive for HMW cytokeratin (CK5/6).[409] Three useful breast-related markers are mammaglobin, GCDFP-15, and GATA3. Each has varying degrees of sensitivity and specificity that can be improved by using them in combination where determination of breast origin is needed.[410–412]

Breast carcinomas can be immunoreactive for S-100 protein, the proportion ranging from 10% to 45% in the various reported series.[413,414] This is a fact to remember in the differential diagnosis of metastatic tumors to axillary nodes, lest a breast carcinoma be mislabeled as metastatic melanoma. Even more treacherous is the fact that some breast carcinomas may show positivity for HMB-45.[415]

For personal use only. No other uses without permission. Copyright ©2017. Elsevier Inc. All rights reserved.

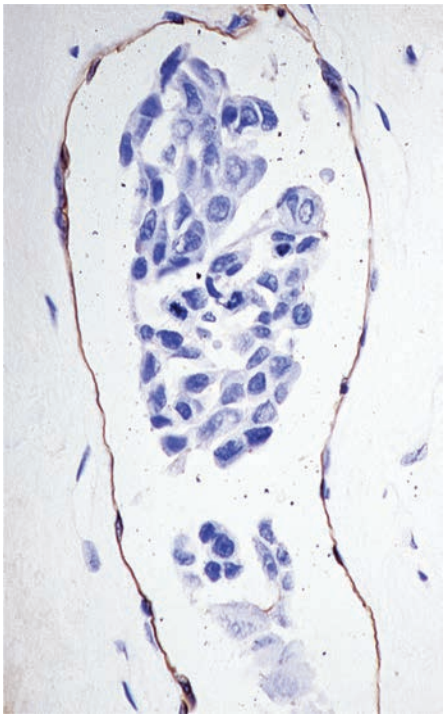

Figure 36.92 Vascular invasion by breast carcinoma demonstrated by positivity of endothelial cells for Ulex europaeus lectin I.

TTF-1 positivity has also been documented, a point to be remembered in the evaluation of core needle biopsies of a lung mass in a patient with a history of breast carcinoma.[416] While not often used in clinical practice, increased expression of the bone matrix proteins osteonectin and osteopontin has been documented, with the added suggestion that this may play a role in the bone homing of breast carcinoma metastases.[417,418] The basement membrane components laminin and collagen IV show a discontinuous linear pattern or are altogether absent, in contrast to the continuous pattern exhibited in intraductal lesions.[419,420] Smooth muscle myosin heavy chain, calponin, p63, and other myoepithelial cell markers are negative in invasive carcinomas, confirming the absence of myoepithelial cells around the tumor nests.

Ultrastructurally, breast carcinoma cells exhibit, in greater or lesser degree, features of glandular differentiation such as microvilli and terminal bars on their luminal side.[421] A particularly characteristic feature, although not as specific for breast carcinoma as originally suggested, is the presence of intracytoplasmic lumina bordered by microvilli.[422,423] These formations, when sufficiently large, appear as "bulls eyes" at the light microscopic level and are different from the formations seen in signet ring cells, which are intracytoplasmic vacuoles. The desmoplastic stroma accompanying breast carcinomas is formed by cells having the ultrastructural features of fibroblasts and myofibroblasts.[424]

Invasive Lobular Carcinoma

Classic type. In its most typical form, invasive lobular carcinoma is characterized by the presence of small and relatively uniform tumor cells growing in single file and in a targetoid fashion around ducts (Figs. 36.93–36.95). Gland formation is not a feature of invasive lobular carcinoma. The stroma is usually abundant, of dense fibrous type, with areas of periductal and perivenous elastosis. Rarely, a lymphocytic infiltrate may be present.

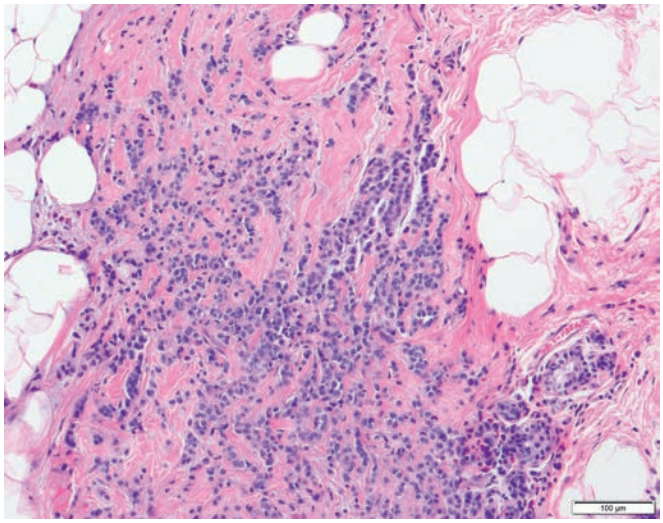

Figure 36.93 **Invasive Lobular Carcinoma.** The tumor cells are small and uniform with round nuclei and grow in single file fashion.

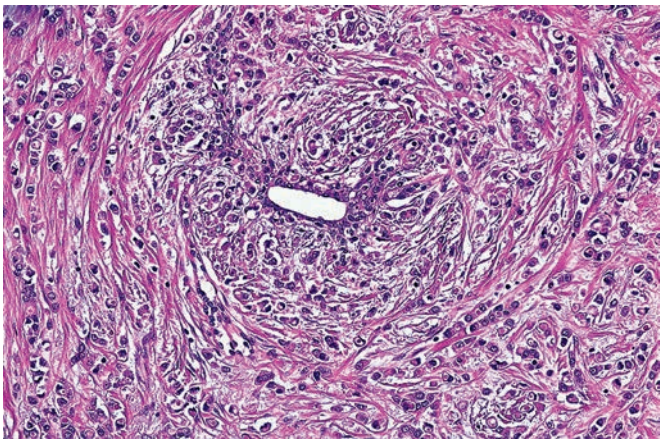

Figure 36.94 Typical target-like growth of tumor cells around an uninvolved duct in invasive lobular carcinoma.

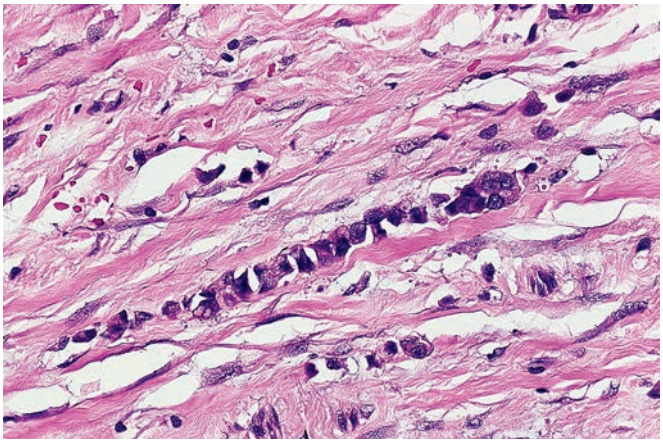

Figure 36.95 Single file pattern of growth of invasive lobular carcinoma.

For personal use only. No other uses without permission. Copyright ©2017. Elsevier Inc. All rights reserved.

The immunohistochemical features of invasive lobular carcinoma are analogous to those described for its in situ counterpart. This includes the presence of low-molecular-weight cytokeratins, an absence of E-cadherin expression, and a cytoplasmic staining pattern with p120 catenin.[380] While loss of E-cadherin expression is the hallmark of lobular carcinoma, positive immunostaining for E-cadherin does not preclude this diagnosis when the morphologic features are compatible. As a matter of fact, up to 16% of cases of invasive lobular carcinomas show immunoreactivity for E-cadherin, but these cases typically exhibit abnormal expression of one or more of the catenin complex members, most commonly diffuse cytoplasmic expression of p120 catenin.[382,426] That said, the diagnosis of invasive lobular carcinoma should be made on morphologic grounds; use of E-cadherin is not indicated in histologic typing of invasive carcinomas.[381]

The genetic basis for the loss of E-cadherin expression in lobular carcinoma includes: (1) inactivating mutation of the E-cadherin gene *CDH1*, usually attributable to loss of heterozygosity on chromosome 16q or homozygous deletions of *CDH1*; (2) *CDH1* promoter hypermethylation; (3) truncating mutation in *CDH1*; and (4) transcriptional inactivation.[426]

The main differential diagnosis of invasive lobular carcinoma is with invasive carcinoma with ductal and lobular features. The small size and uniformity of the cells and their lack of cohesiveness are the most important distinguishing features. It should be remarked, however, that in some cases the distinction is difficult and to a large extent subjective, as borne out by the fact that the incidence of invasive lobular carcinoma ranges from 0.7% to 20% in the published series.[427] As discussed earlier, LCIS involving adenosis can be a mimic of invasive lobular carcinoma. Myoepithelial cell markers are helpful in such cases. Other entities that can be confused with invasive lobular carcinoma are carcinoma with neuroendocrine features and malignant lymphoma. The latter possibility arises more often when invasive lobular carcinoma metastasizes to axillary nodes and other sites, particularly the orbit.[428] In those situations cases may be misdiagnosed as large cell lymphoma or malignant histiocytosis because of the diffuse pattern of growth and the histiocyte-like appearance of the tumor cells. Immunoreactivity for cytokeratins and histochemical positivity with mucicarmine should eliminate any problems not resolved by the examination of the routinely stained slides.

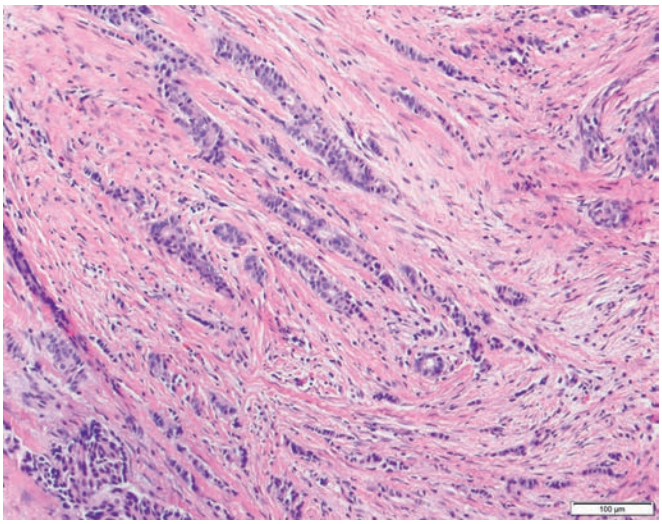

Figure 36.96 Invasive carcinoma with ductal and lobular features; in some areas there is gland formation, while in others, the tumor cells align in a single file (*lower portion* of field).

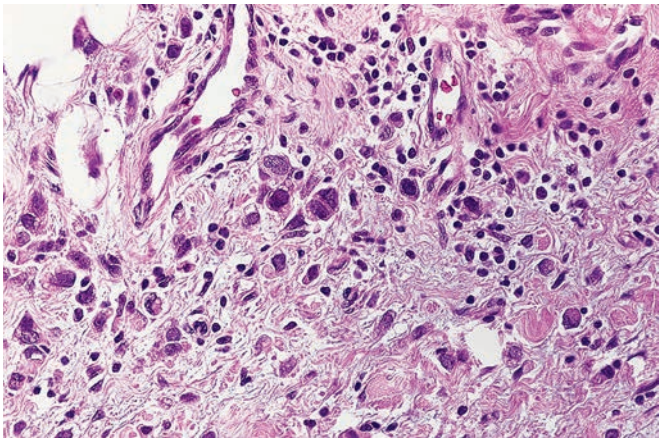

Figure 36.97 Pleomorphic variant of invasive lobular carcinoma.

Invasive Carcinoma With Ductal and Lobular Features

Carcinomas composed in part of a component with definite features of invasive ductal carcinoma and in part of a component with definite features of invasive lobular carcinoma do occur; more commonly seen are tumors with features neither definitively lobular nor definitively ductal (Fig. 36.96). It is acceptable to classify these tumors as invasive carcinoma with ductal and lobular features. They should be distinguished from cases in which two separate neoplasms of different microscopic appearances are present in the same breast. They should also be distinguished from so-called tubulo-lobular carcinoma, which has a reasonably distinct morphologic appearance (see next section).

Variants of Invasive Lobular Carcinoma

Pleomorphic invasive lobular carcinoma. This form of invasive breast carcinoma has the growth pattern of a classic breast carcinoma but exhibits a marked degree of nuclear pleomorphism (Fig. 36.97).[429] Apocrine differentiation and focal signet ring morphology may also be seen. Pleomorphic invasive lobular carcinoma more frequently demonstrates a lack of hormone receptors and shows expression of HER2 and p53, while still demonstrating an absence of E-cadherin staining, as well as loss of the long arm of chromosome 16, in keeping with the lobular phenotype.[383,384,430]

Signet ring carcinoma. Signet ring carcinoma is a type of breast carcinoma in which a significant number of tumor cells show intracytoplasmic mucin accumulation, resulting in the typical signet ring appearance (Fig. 36.98). It is important to separate this tumor from mucinous carcinoma (in which the mucin is extracellular) because of their differing prognoses.

Most cases of signet ring carcinoma show cytoarchitectural features (such as small cell size, uniformity, and cellular dyshesion) similar to those of classic invasive lobular carcinoma and sometimes coexist with it. Furthermore, it is not rare for LCIS or invasive lobular carcinoma to contain scattered signet ring cells. For these reasons, most cases of signet ring carcinoma are regarded as variants of invasive lobular carcinoma.[431]

Immunohistochemically, signet ring carcinoma is positive for CK7 and MUC1 and usually negative for E-cadherin.[432]

Care must be taken with the challenging differential diagnosis of gastric signet ring adenocarcinoma, as invasive lobular carcinomas with signet ring cell features are known to metastasize to the stomach.

For personal use only. No other uses without permission. Copyright ©2017. Elsevier Inc. All rights reserved.

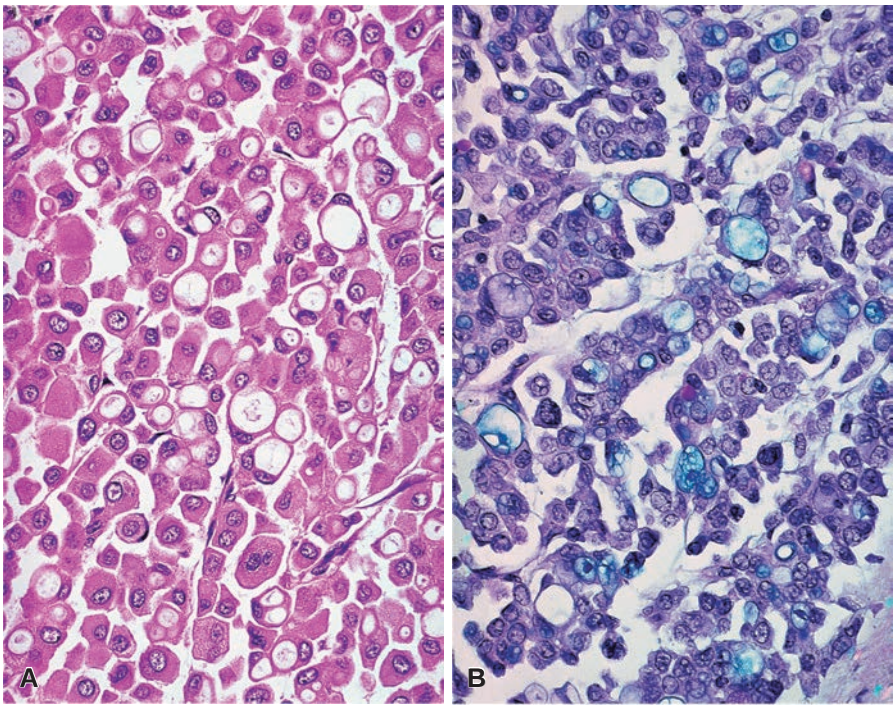

Figure 36.98 A, and B, Signet Ring Carcinoma of the Breast. This is regarded as a variant of lobular carcinoma. **B,** Alcian blue-PAS stain.

Rarely the converse of gastric metastasis to the breast has been reported.[433,434]

Histiocytoid carcinoma. Histiocytoid carcinoma is characterized by a diffuse pattern of growth of bland tumor cells displaying abundant granular, foamy cytoplasm.[435] It may simulate the appearance of an inflammatory process or of granular cell tumor.[436,437] Histiocytoid carcinoma is viewed as a variant of invasive lobular carcinoma exhibiting apocrine differentiation, as evidenced by immunohistochemical reactivity for GCDFP-15 and absence of E-cadherin expression.[436–438]

Histiocytoid carcinoma should also be distinguished from *lipid-rich carcinoma*. The latter is simply a form of breast carcinoma showing lipid accumulation in the cytoplasm of greater than 90% of the tumor cells (Fig. 36.99).[439–441]

Other types. As long as the relatively bland and homogeneous cytologic appearance is maintained, cases having closely aggregated cells, solid pattern, trabecular pattern, and loose alveolar pattern have been accepted as invasive lobular carcinoma. Perhaps the most distinctive of these forms is the *alveolar variant*, in which the tumor cells are arranged in sharply outlined groups separated by fibrous tissue sometimes containing osteoclast-like giant cells.[442] The cytologic and/or architectural similarities between these various forms and classic invasive lobular carcinoma are undeniable. The problem, however, is that the more the concept of invasive lobular carcinoma is widened, and to some extent diluted, the less distinct the entity becomes and the less significant (or at least the less uniform) its clinical connotations.[443]

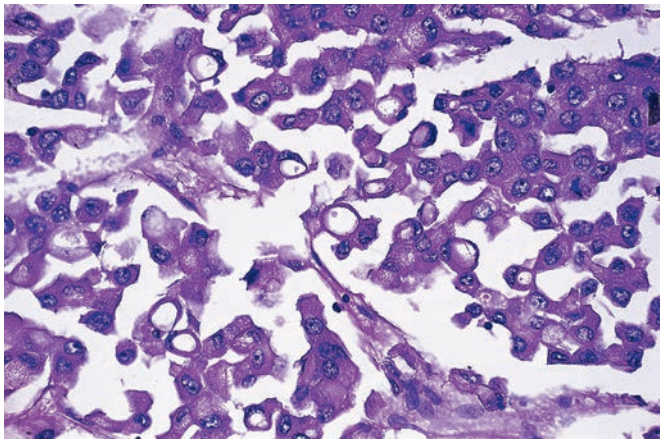

Figure 36.99 Lipid-Rich Carcinoma of the Breast. The cells show cytoplasmic vacuolation with nuclear displacement due to lipid accumulation. **A,** Intermediate power. **B,** High power.

Tubular Carcinoma

Tubular carcinoma is a well-differentiated tumor more common among older women. Grossly, tubular carcinoma suggests malignancy by virtue of its poorly circumscribed margins and hard consistency similar to invasive ductal carcinomas of no special type. It is characteristically small, with a mean diameter of about 1 cm.[444,445] Microscopically, it simulates a benign condition (particularly radial scar but also microglandular adenosis) because of the well-differentiated nature of the glands, absence of necrosis or mitoses, and scanty pleomorphism. Clues to the diagnosis are the haphazard arrangement of the glands in the stroma with absence of any lobular configuration; frequent invasion of fat at the periphery of the lesion; cellular (but often also elastotic[446]) nature of the stroma; irregular and often angulated contours of the glands (Fig. 36.100); open lumina sometimes with basophilic secretion; apical "snouts" in the cytoplasm; lack of a myoepithelial cell component (well appreciated in immunostained preparations with myoepithelial cell antibodies such as p63 and SMMHC); lack of basement membrane; and occurrence

For personal use only. No other uses without permission. Copyright ©2017. Elsevier Inc. All rights reserved.

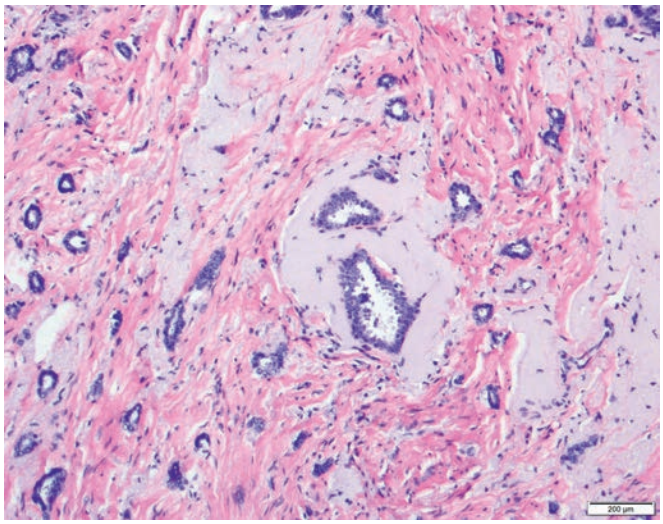

Figure 36.100 Tubular Carcinoma of Breast. The angulated shape of the glands percolating haphazardly through the cellular stroma are characteristic of this lesion. In this particular case, there is prominent stromal elastosis.

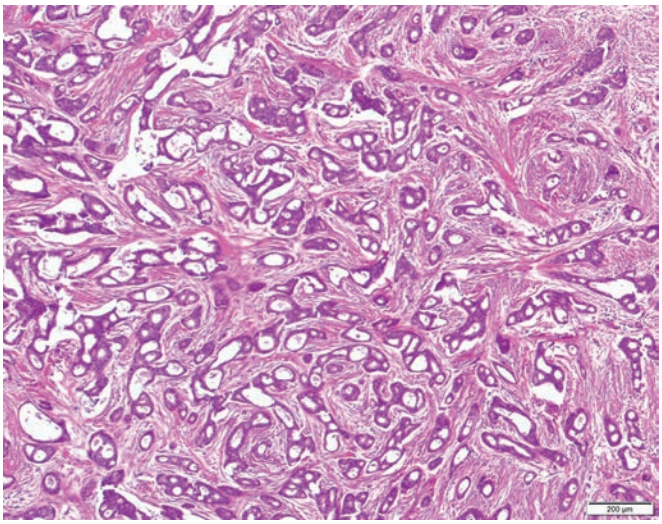

Figure 36.101 Invasive Cribriform Carcinoma. In this example, all the nests have a cribriform pattern. The irregular contour of the nests and the infiltrative growth pattern help distinguish this lesion from cribriform pattern DCIS.

in two-thirds of cases or more of low nuclear grade DCIS, often micropapillary or cribriform pattern.[444] FEA also is frequently found in cases of tubular carcinoma. In fact, low-grade DCIS, ADH, and FEA are considered to be nonobligate precursor lesions of low-grade invasive carcinomas and tubular carcinomas in particular.[118,447,448]

Because of the marked degree of cellular differentiation, it is not unusual for these tumors to be underdiagnosed as fibroadenoma or some other benign process on FNA material.[449] They are more readily recognized in core needle biopsy specimens.

Metastases to axillary lymph nodes occur in approximately 10% of cases,[444] but this does not appear to affect outcome, even in the absence of systemic chemotherapy.[450–452] In a series by Rakha et al.,[452] only 7% of their 102 patients developed recurrent or metastatic disease during a median follow-up period of 127 months and these events were all found to be associated with an intervening recurrence of breast carcinoma of different histologic type and/or grade. Thus tubular carcinoma can be considered a special-type breast cancer with an exceptionally favorable prognosis.[452]

Sometimes, a tubular carcinoma pattern is seen in association with an ordinary invasive ductal carcinoma; however, the diagnosis of tubular carcinoma should be reserved for those tumors in which the tubular component makes up more than 90% of the tumor.

Tubulolobular carcinoma. This variant is characterized by the admixture of small tubular formations with cords of tumor cells growing in a lobular configuration.[453] The in situ component, if present, may be of either lobular, ductal or both types.[454] The immunohistochemical profile is intermediate between those of ductal and lobular carcinoma, in that it may show positivity for E-cadherin.[454] This tumor is associated with a higher incidence of multifocality and positive axillary nodes than pure tubular carcinoma.[455,456]

Invasive Cribriform Carcinoma

Invasive cribriform carcinoma is another special-type breast carcinoma, which, similar to tubular carcinoma, has an excellent prognosis.[457,458] As the name indicates, the tumor has a cribriform appearance similar to that seen in the more common in situ counterpart, but it exhibits stromal invasion and lacks a myoepithelial cell layer (Fig. 36.101). This pattern is often seen in association with tubular carcinoma, the relative proportion of the two elements determining the term used.[458] The most important aspect of this particular tumor is the recognition that a cribriform lesion can be invasive, a potential diagnostic pitfall. In many cases, cribriform pattern DCIS is also present, but it is the size of the invasive component that should be reported for staging purposes. The invasive component can be recognized by the more infiltrative growth pattern extending between and around ducts and lobules, the irregular contour of some of the tumor cell nests and the presence of a desmoplastic-appearing stroma. DCIS, in contrast, has a growth pattern that conforms to the normal ductolobular architecture and more rounded contours to the nests; stromal changes are usually absent. If necessary, immunohistochemistry for myoepithelial cells can be used to separate the relative proportions of DCIS versus invasive cribriform carcinoma.

Mucinous Carcinoma

Mucinous carcinoma occurs over a wide age range (25–85 years), but the median age of 71 years is greater than that for invasive ductal carcinoma of no special type.[459] Grossly, it is well circumscribed, fluctuant to palpation, and formed by a gelatinous mass held together by delicate septa (Fig. 36.102). Foci of hemorrhage may be seen. Microscopically, the classic and often quoted description is that of small clusters of tumor cells "floating in pools of mucin" (Fig. 36.103). These clusters may be solid, exhibit acinar formations, or form micropapillary structures.[460] The mucin is almost entirely extracellular, and it may be of acid or neutral type.[461] Occasionally, mucinous carcinoma will consist almost entirely of mucin, and thorough sampling will be necessary to detect the neoplastic epithelium. An easily recognizable in situ component may be absent or inconspicuous (but see later section). Immunohistochemically, there is strong MUC2 cytoplasmic immunoreactivity and decreased MUC1 immunoreactivity compared with invasive ductal carcinoma of no special type.[462,463] Both pure and mixed mucinous carcinomas of the breast often express WT1, a potential diagnostic trap with ovarian carcinoma.[464] Hormone receptors are invariably positive, while HER2 is almost always negative.[465]

Interestingly, about a quarter to nearly one-half of mucinous carcinomas show features consistent with endocrine differentiation,

For personal use only. No other uses without permission. Copyright ©2017. Elsevier Inc. All rights reserved.

Figure 36.102 Typical Gelatinous Gross Appearance of Pure Mucinous Carcinoma. Note the sharply circumscribed quality of the tumor. (Courtesy of Dr RA Cooke, Brisbane, Australia. From Cooke RA, Stewart B. *Colour Atlas of Anatomical Pathology*. Edinburgh: Churchill Livingstone; 2004.)

such as synaptophysin and chromogranin immunoreactivity, and the presence of dense-core secretory granules by ultrastructural examination.[466,467] This unexpected finding has raised the possibility of a link between mucinous carcinoma and neuroendocrine carcinoma.[468] Some authors have suggested the existence of two types of mucinous carcinoma on the basis of being paucicellular or hypercellular and the absence or presence of endocrine differentiation, designated as type A and B, respectively (Fig. 36.103A, B and C, D respectively).[466] There appears to be no influence of this separation on survival.[469]

On analysis of array-based CGH assays, pure mucinous carcinomas are a homogeneous group and cluster together, separately from invasive ductal carcinoma of no special type.[465,468] They less frequently harbor gains of 1q and 16p and losses of 16q and 22q than grade- and ER-matched invasive ductal carcinomas of no special type. Gene expression profiling has shown that type B mucinous carcinomas and neuroendocrine carcinomas are part of a spectrum of lesions, whereas type A mucinous carcinoma is a discrete entity.[468]

It is important for prognostic reasons, and perhaps useful histogenetically, to restrict the term mucinous carcinoma to breast neoplasms exhibiting this feature throughout the tumor ("pure" mucinous carcinomas) and to exclude: (1) "mixed" tumors in which the mucinous pattern is admixed with an invasive ductal carcinoma (these having a prognosis analogous to the latter)[465]; and (2) signet ring carcinomas, even if technically speaking these are also "mucinous" tumors. The distinctiveness of signet ring carcinoma resides in the fact that the mucin remains within the cell, and the uniqueness of mucinous carcinoma is that most of the mucin is extracellular.

Pure mucinous carcinoma is associated with a very low incidence (2%–4%) of nodal metastases.[451,459,470] The higher incidence reported in some series is probably attributable to the inclusion of "mixed" mucinous tumors. Consequently, the pure form of mucinous carcinoma carries an excellent short-term prognosis. However, it has been shown that deaths from this tumor can occur greater than 25 years after therapy, indicating the need for long-term follow-up.[451,471] As already indicated, several groups found no prognostic difference between mucinous carcinomas with endocrine-like features and those without,[470] although others claim that the former are associated with favorable histologic and immunohistochemical parameters.[472]

A diagnostic challenge of which to be aware when encountering a mucinous lesion is the occurrence of extravasated mucin in association with benign or atypical lesions. "**Mucocele-like lesion**"[473] is the occurrence of a cystically dilated duct filled with mucin that may rupture, resulting in extravasation of mucin into the stroma (Fig. 36.104). In many cases, the lining epithelium is attenuated, but in some mucocele-like lesions the lining epithelium is proliferative, with morphologic changes including UDH, ADH, and even DCIS. On occasion, this proliferative epithelium may become detached and "float" in the stromal mucin pools, mimicking mucinous carcinoma. The distinction can be challenging, particularly if the detached epithelium is from DCIS. Features favoring a mucocele-like lesion with detached epithelium over mucinous carcinoma are the linear arrangement of the epithelial fragments that have detached from the duct wall and the presence of myoepithelial cells.

On core needle biopsy specimens, mucinous lesions can be particularly difficult to categorize, given the knowledge that some mucinous carcinomas are hypocellular with abundant mucin. Most practitioners have recommended excision for mucinous lesions on core needle biopsy regardless of the identification of atypia[474]; however, more recent publications have moved toward recommending a more conservative approach to management for mucocele-like lesions without epithelial atypia that are radiologically concordant.[475,476]

A further variation on the theme is represented by *mucinous cystadenocarcinoma*, an exceptionally rare tumor composed predominantly of tall columnar cells with abundant intracytoplasmic mucin and a multicystic gross quality similar to that of its ovarian counterpart.[477]

Carcinoma with Medullary Features

It is the recommendation of the WHO consensus panel convened in 2011 for the Classification of Tumors of the Breast that medullary carcinoma and atypical medullary carcinoma be included together under the descriptor "carcinoma with medullary features."[478] These tumors tend to occur in younger women, with the average age reported to range from 42 to 52 years. It has also been reported that patients with *BRCA1* mutations are particularly likely to have carcinomas with medullary features.[479] Grossly, carcinoma with medullary features is well circumscribed and may become large; as such it can be mistaken clinically, radiologically, and grossly for a fibroadenoma, but it lacks the trabeculation or whorling of the latter. Rather, the cut surface is solid, homogeneous, and gray, sometimes exhibiting small foci of necrosis (Fig. 36.105). Rare examples are partially or predominantly cystic.[480] Microscopically, the borders are of the "pushing" type. The pattern of growth is diffuse, with minimal or no glandular differentiation. The tumor cells are large, with enlarged, pleomorphic nuclei, prominent nucleoli, and abundant mitoses (some of them atypical). The cell borders are indistinct, giving the tumor a syncytial or sheet-like appearance somewhat reminiscent of a germ cell tumor of the embryonal carcinoma type. This is accentuated by the observation that the tumor cells located at the periphery are more elongated and have a denser, more acidophilic cytoplasm, acquiring a vague resemblance to syncytiotrophoblast. Spindle cell morphology, bizarre tumor giant cells, extensive necrosis, and the absence of calcification

For personal use only. No other uses without permission. Copyright ©2017. Elsevier Inc. All rights reserved.

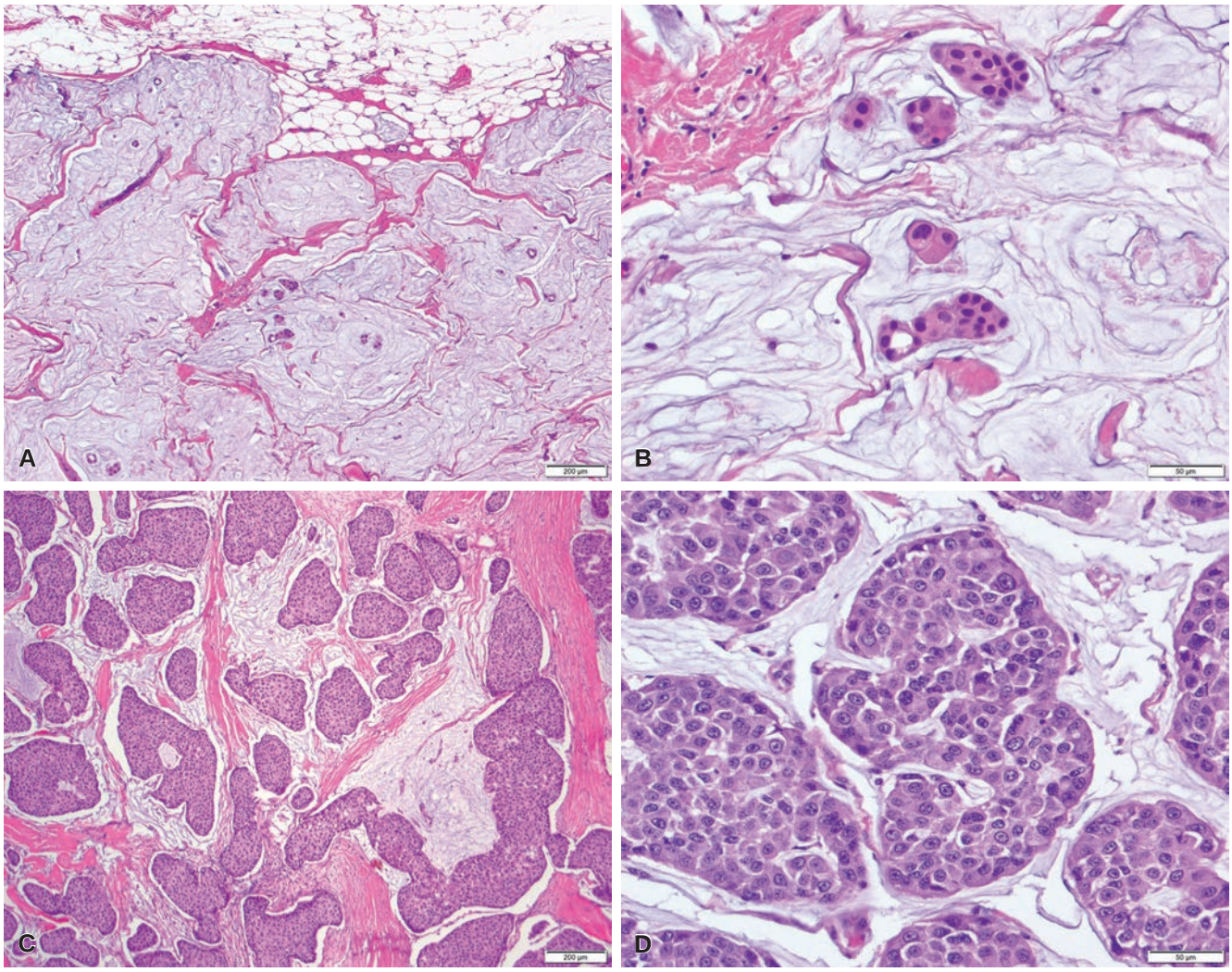

Figure 36.103 Mucinous Carcinoma of the Breast. Clusters of well-differentiated tumor cells are seen floating in a sea of mucin. Hypocellular variant, at low power **(A)** and high power **(B)**. Hypercellular variant, at low power **(C)** and high power **(D)**.

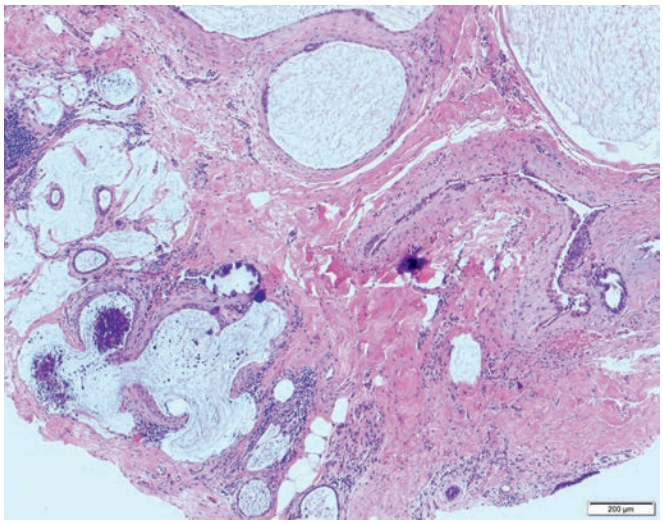

Figure 36.104 Mucocele-Like Lesion. Cystically dilated ducts are lined by an attenuated epithelium which are filled with mucin. Focally there is rupture with extravasation of mucin into the stroma. Note the association with calcifications in this case.

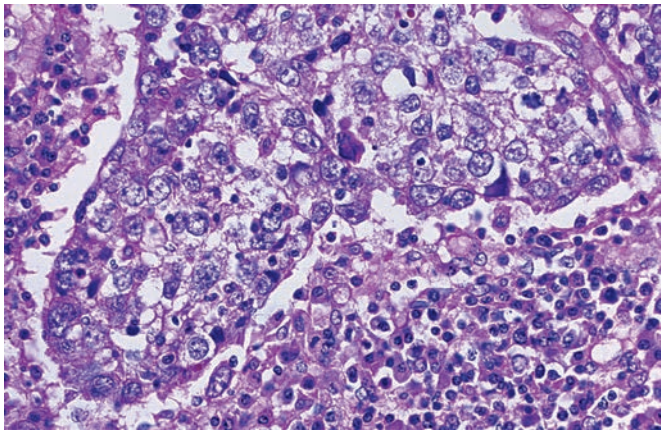

Figure 36.105 Carcinoma With Medullary Features. The large tumor cells grow in a "syncytial" fashion and are sharply separated from the surrounding stroma, which is heavily infiltrated by lymphocytes and plasma cells.

For personal use only. No other uses without permission. Copyright ©2017. Elsevier Inc. All rights reserved.

are other common features. A constant component is a prominent lymphoplasmacytic infiltrate, which is thought to represent a reaction of the host to the neoplasm. DCIS is usually minimal or absent.

Immunohistochemically, carcinomas with medullary features share the markers of ordinary invasive ductal carcinoma. They typically express CK7, often vimentin, S-100 protein, and p53, as well as HMW (basal) cytokeratins, and caveolin-1.[478] They are almost invariably negative for hormone receptors, as well as HER2 ("triple negative" phenotype).[478]

Genetically, carcinomas with medullary features commonly show *TP53* gene mutation.[481] Although the gene expression profile of carcinoma with medullary features is considered to represent part of the basal-like carcinoma spectrum (see later)[482] and it shares genetic changes such as 1q and 8q gains and X losses with basal-like carcinomas not otherwise specified, it does show distinct molecular features, including higher numbers of gains and losses on array CGH analysis, as well as recurrent 10p, 9p, and 16q gains, 4p losses, and 1q, 8p, 10p, and 12p amplicons.[481]

Axillary lymph node metastases are common, but they are usually few and limited to the low axillary group. The prognosis for "medullary carcinoma" is reported to be better than for the ordinary invasive ductal carcinoma, but given the low level of interobserver reproducibility for the diagnosis and the use of more descriptive terms for tumors with the aforementioned features, clinicians are increasingly treating these patients with the aggressive therapies used for patients with triple negative breast carcinoma.[478] Newer gene expression profiling studies reveal immune signatures that appear to correlate with a better outcome in patients with triple negative breast carcinomas that have a prominent lymphoplasmacytic infiltrate.[483]

Invasive Micropapillary Carcinoma

Invasive micropapillary carcinoma is a distinct variant of invasive ductal carcinoma with important prognostic correlates.[484,485] Microscopically, it bears close similarity to micropapillary carcinoma of other organs, most notably ovary, and bladder.[486] It is characterized by the formation of pseudopapillary structures lacking a fibrovascular core and by tubular structures free-floating in clear empty spaces (Fig. 36.106). Some of these spaces have been demonstrated to be lymphatic vessels, but the majority are newly formed clefts resulting from the inversion of polarity of the tumor cells (as evidenced by MUC1 and EMA staining).[487,488] The nuclear grade is often high.[489] Psammoma bodies are present in about one-half of the cases.[484] Immunohistochemically, invasive micropapillary carcinoma is usually positive for ER and breast markers (mammaglobin, GCDFP-15, and GATA3) and negative for PAX8 and WT1, a panel that will facilitate distinction from metastatic serous carcinoma from the ovary.[490,491] HER2 positivity is unusual, with fewer than 10% of cases showing overexpression/amplification.[485] Lymph node metastases are the rule (their frequency being directly related to the presence of lymphatic vessel invasion[492]), local recurrence is high, but the survival rate is no different than that for stage- and grade-matched conventional invasive ductal carcinoma.[493,494]

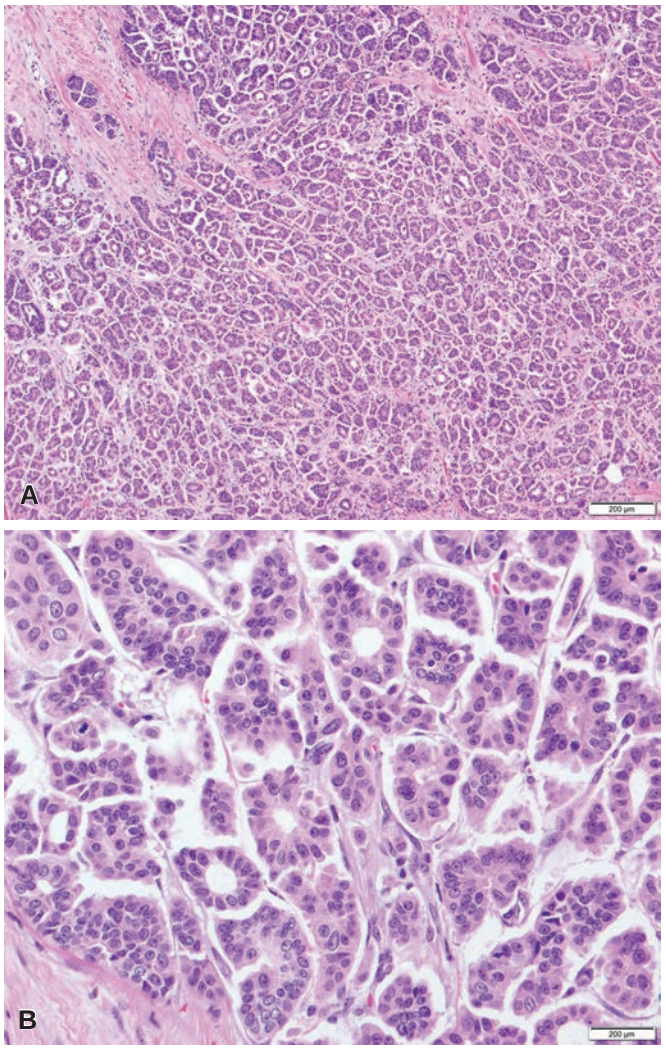

Figure 36.106 Invasive Micropapillary Carcinoma. A, At low power the tumor is characterized by the formation of micropapillary structures lacking a fibrovascular core and by tubular structures free-floating in clear empty spaces. **B,** At higher power the reverse polarity of the tumor cells can be appreciated.

Carcinomas with Apocrine Differentiation

Carcinoma with apocrine differentiation is a rare form of breast malignancy (ranging from 1% to 4% of all cases), at least when defined as composed entirely or predominantly of apocrine-type epithelium.[495,496] The large tumor cells have abundant eosinophilic, somewhat granular cytoplasm, which may contain eosinophilic or golden brown granules that are strongly PAS positive. The nuclei are vesicular, and nucleoli are prominent. Glandular differentiation is usually found, and the luminal aspect of the epithelial cells often have a characteristic bulbous expansion ("apocrine snout") (Fig. 36.107). Ultrastructurally, the cells of carcinoma with apocrine differentiation show prominent mitochondria (some with abnormal cristae).[497] Immunohistochemically, there is diffuse reactivity for GCDFP-15 and androgen receptor.[498] The gene coding for GCDFP-15 is located on chromosome 7q and is identical to the gene of prolactin-inducible protein (PIP); the expression of this gene in carcinomas with apocrine differentiation has been demonstrated with in situ hybridization techniques.[499] Carcinoma with apocrine differentiation is usually ER negative; HER2 overexpression is common.

Since apocrine changes in the breast are usually indicative of benignity, even when the cells exhibit prominent nucleolar enlargement, the diagnosis of carcinoma with apocrine differentiation should be made only when the architectural features are clearly those of a carcinoma; a distinction more problematic for in situ than invasive apocrine lesions. It is also important to limit the diagnosis to malignant tumors in which the apocrine change is widespread, in view of the fact that focal apocrine differentiation can be detected in close to 10% of ordinary carcinomas.[498] Finally, it should be noted that although carcinoma with apocrine differentiation is usually a

For personal use only. No other uses without permission. Copyright ©2017. Elsevier Inc. All rights reserved.

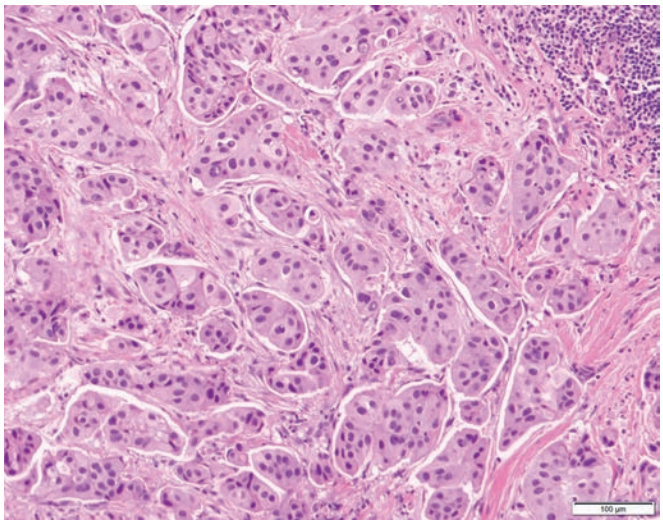

Figure 36.107 Carcinoma With Apocrine Differentiation. The large tumor cells have abundant eosinophilic, somewhat granular cytoplasm, which may contain eosinophilic or golden brown granules that are strongly PAS positive. The nuclei are vesicular and nucleoli are readily seen.

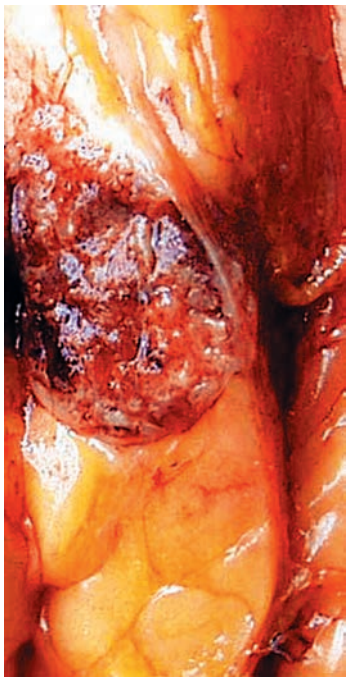

Figure 36.108 Gross Appearance of Secretory Carcinoma. The tumor is well circumscribed and shows a variegated cut surface.

variant of either DCIS or invasive ductal carcinoma, apocrine differentiation has also been described in LCIS and invasive lobular carcinoma.[500]

Secretory Carcinoma

This rare form of breast carcinoma is seen primarily in children, but it can also occur in adults.[501,502] Grossly, it is well circumscribed, with an average reported size of 3 cm (Fig. 36.108).[503] The margins of the tumor are of the "pushing" type, and prominent hyalinization is often present in the central portion. The microscopic appearance

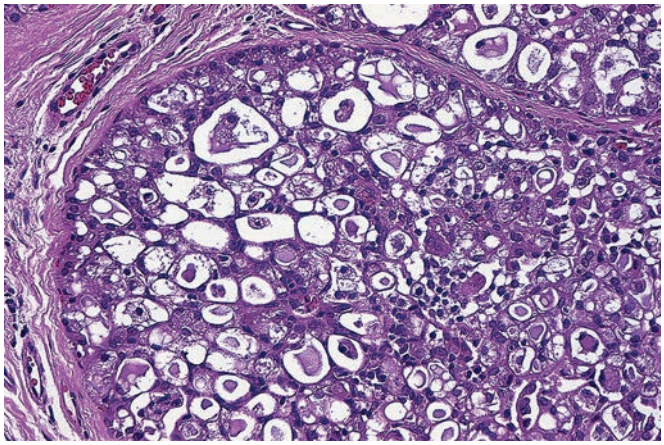

Figure 36.109 Secretory Carcinoma. The small uniform glands are filled by a secretory material.

is distinctive (Fig. 36.109). Tubular, microcystic and solid patterns are variably present forming lumina filled with an eosinophilic, PAS-positive secretion surrounded by cells with vacuolated (sometimes "hypernephroid"), granular cytoplasm.[502–504] Nucleoli may be prominent, but mitoses are scanty. Ultrastructurally, the tumor cells contain numerous membrane-bound intracytoplasmic secretory vacuoles.[505]

Immunohistochemically, there is strong reactivity for α-lactalbumin and S-100 protein, accompanied by variable expression of GCDFP-15 and CEA.[506] Secretory carcinoma is typically triple negative (ER, PR, and HER2 negative). It has been hypothesized that there may be a histogenetic link between secretory carcinoma and a type of salivary gland tumor historically placed among the acinic cell carcinomas, a subset of which have more recently been recategorized as a mammary analogue secretory carcinoma due to the identification of a similar molecular genetic abnormality,[507] namely a recurrent balanced chromosomal translocation, t(12;15)(p13;q25), which leads to fusion of the *ETV6* and *NTRK3* genes as is found in secretory carcinoma of the breast.[508,509] In fact, it is the identification of this gene fusion product that allows distinction of secretory carcinoma from acinic cell carcinoma of the breast.[509]

The overall prognosis is excellent, especially in younger patients, with most series quoting a 5-year survival rate close to 100%.[502–504] Local recurrences and nodal metastases can develop, sometimes very late in the course of the disease.[502–504] Death resulting from disseminated tumor has been recorded only exceptionally.[502] Secretory carcinoma has also been reported to occur in the axillary skin in the absence of a breast primary.[510]

Carcinomas with Neuroendocrine Features

(including so-called carcinoid tumor). The clinical presentation of carcinoma with neuroendocrine features is no different from that of ordinary breast carcinoma. Specifically, none of the patients has had carcinoid syndrome, even in the presence of widespread disease. There are no distinctive gross features. Carcinomas with neuroendocrine features occur in older women and constitute less than 1% of all breast carcinomas.

Microscopically, the tumor cells are small, arranged in solid nests separated by delicate bands of fibrous tissue (Fig. 36.110). Ribbons and rosette-like formations are not typically seen in carcinoma with neuroendocrine features arising in the breast. Mitoses are generally rare. Mucin secretion may be present. The microscopic differential diagnosis includes the alveolar variant of invasive lobular carcinoma

For personal use only. No other uses without permission. Copyright ©2017. Elsevier Inc. All rights reserved.

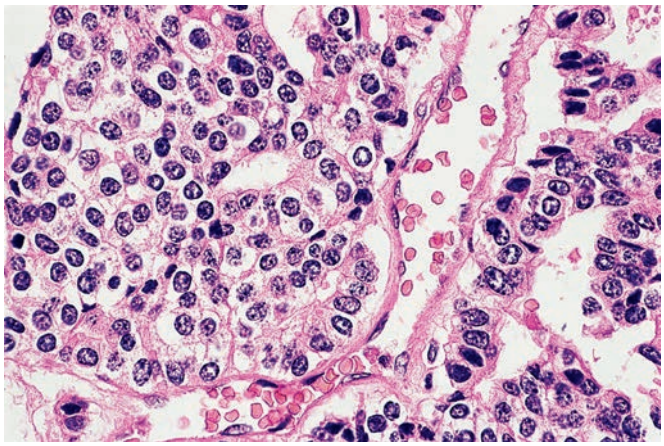

Figure 36.110 Breast carcinoma with neuroendocrine features.

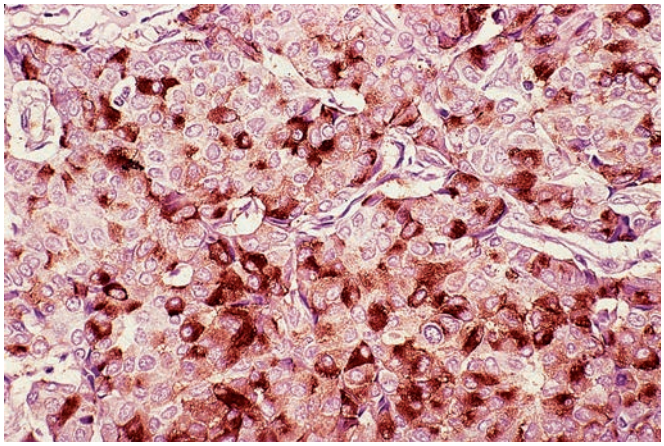

Figure 36.111 Strong reactivity for chromogranin in breast carcinoma with neuroendocrine differentiation.

and a metastasis to the breast of a neuroendocrine tumor located elsewhere. Identification of an intraductal component aids in establishing breast origin.

Of historical interest the tumor cells of neuroendocrine carcinoma of the breast are argyrophilic but not argentaffin positive and are found to contain dense-core secretory granules of various types ultrastructurally.[511,512] The tumor cells demonstrate immunohistochemical positivity for chromogranin, synaptophysin, NSE, and CD56[513–515] and in some instances for specific hormone peptides,[516] indicative of endocrine differentiation (Fig. 36.111).

It should be mentioned here that there are breast carcinomas of other morphologic patterns in which neuroendocrine features have been found.[517] Since markers of neuroendocrine differentiation are not routinely performed in breast pathology, the true incidence of this tumor is not known,[513,518] though a recent report found between 10% and 30% of invasive ductal carcinomas of no special type expressed neuroendocrine markers.[519]

Metaplastic Carcinoma

Metaplastic carcinoma is a generic term for breast carcinoma in which there is differentiation of the epithelial component into non-glandular elements. These include squamous differentiation and/or differentiation into mesenchymal elements.[520,521] Given that the designation is so broad, the diagnosis is best used with a qualifier.

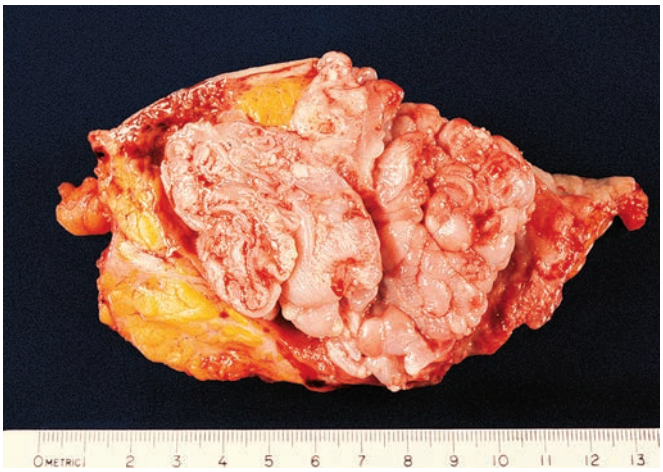

Figure 36.112 Gross Appearance of Metaplastic Carcinoma. A large, fleshy mass is seen protruding inside a cavity. Microscopically, this tumor showed an admixture of squamous and spindle cell elements.

The following categories, which overlap considerably with each other, are included:

1. *Metaplastic carcinoma with mesenchymal differentiation*. Grossly, this tumor tends to be well circumscribed (Fig. 36.112). Microscopically, the mesenchymal component may appear relatively well differentiated with minimal spindle cell atypia or may resemble its sarcomatous counterpart with areas of a chondrosarcoma, osteosarcoma, rhabdomyosarcoma, angiosarcoma, or a combination thereof.[522] There may be a gradual transition from carcinomatous to mesenchymal elements, or the separation between them can be abrupt. Tumors having overt carcinoma with abrupt transition to a cartilaginous and/or osseous matrix without an intervening spindle cell zone or osteoclastic giant cells have been referred to as *matrix-producing carcinomas*.[522–524]

   Immunohistochemically, the mesenchymal elements of these tumors have usually acquired vimentin positivity and other features of a mesenchymal nature ("phenotypic switch") but still retain epithelial markers, albeit focal and variable, a fact best demonstrated by employing several wide-spectrum cytokeratin antibodies.[525]

   As in other sites, molecular studies support the interpretation that the recognizable epithelial and the mesenchymal components originate from the same stem cell.[526,527]
2. *Spindle cell carcinoma*. The overt carcinomatous component of these tumors, when present, may be invasive ductal carcinoma or DCIS or it may be entirely squamous.[528] The spindle cell component is composed of atypical spindle cells within a fibrocollagenous stroma with feathered, myxoid, angioid, and storiform patterns (Fig. 36.113).[529,530] Merging of areas between the epithelial and the spindle components is common. The spindle cells are immunoreactive for cytokeratins and p63, albeit focal and variable in some cases.[531, 532]
3. *Fibromatosis-like metaplastic carcinoma*. These tumors are characterized by bland spindle cells with little to no cytologic atypia, resembling, as the name suggests, fibromatosis (Fig. 36.114). The spindle cells are arranged in fascicles that infiltrate into the surrounding fat and between ducts and lobules. On occasion, a central scar-like area may be present. Some of these tumors arise in connection with complex sclerosing lesions, sclerosing papillary lesions, or adenomyoepitheliomas.[522,533]
4. *Metaplastic carcinoma with osteoclast-like giant cells*.[534] When these cells appear in conjunction with mesenchymal elements, the

For personal use only. No other uses without permission. Copyright ©2017. Elsevier Inc. All rights reserved.

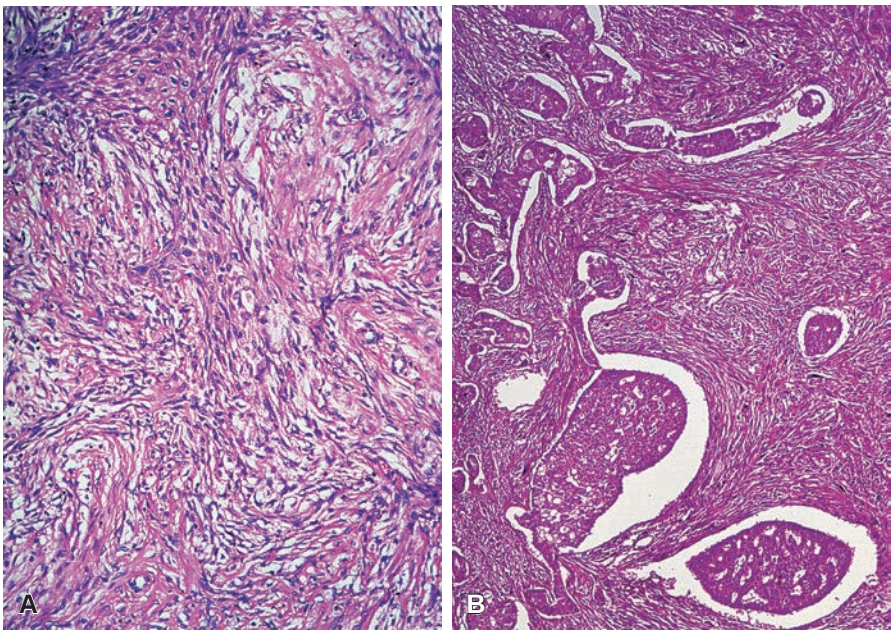

Figure 36.113 Metaplastic Carcinoma. The tumor shown in **(A)** exhibits a blending of the epithelial and spindle cell components making it more difficult to recognize this as a carcinoma, whereas that depicted in **(B)** has more readily recognizable epithelial elements admixed with the malignant spindle cell component.

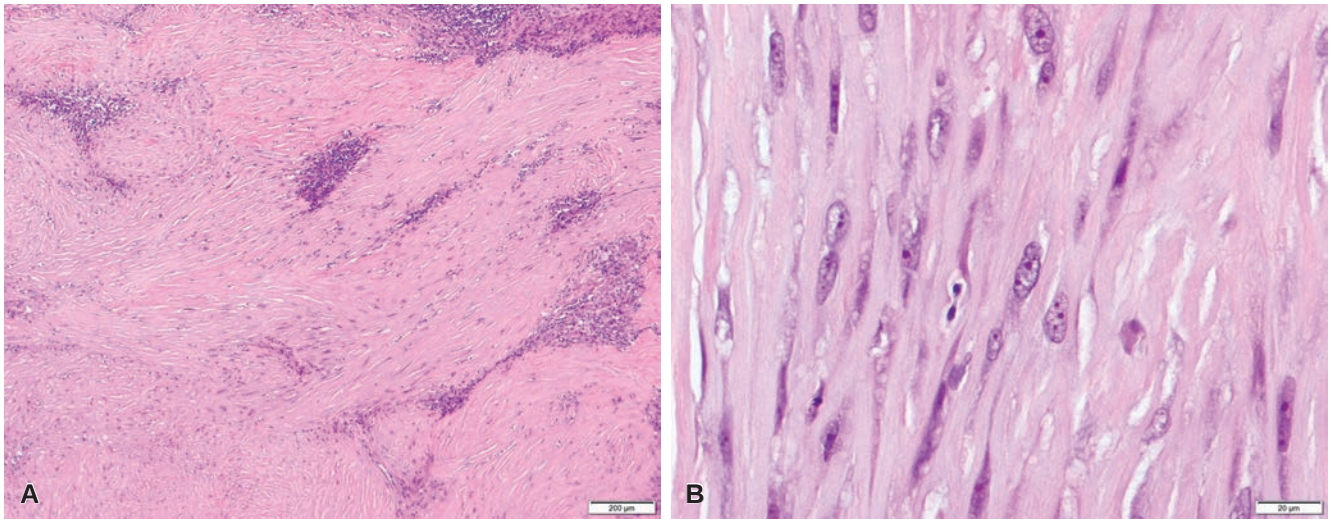

Figure 36.114 Low-grade Fibromatosis-like Metaplastic Carcinoma. A, At low power the tumor appears to be composed of bland spindle cells embedded in dense collagen resembling a scar. **B,** At high power the cytologic atypia of the spindle cells can be appreciated. The tumor cells were positive for cytokeratin (MNF116).

tumor should be regarded as a variant of metaplastic carcinoma. When osteoclast-like giant cells are seen in the stroma of what is otherwise a typical carcinoma lacking mesenchymal differentiation, the tumor is better classified as *invasive ductal carcinoma with osteoclast-like giant cells*. Interestingly, this particular tumor tends to have a reddish-brown appearance grossly and extravasated red blood cells on microscopic examination. All available evidence suggests that the osteoclast-like elements are of a non-neoplastic histiocytic nature and that they form from fusion of mononuclear precursors.[535,536]

5. *Squamous cell carcinoma*. Squamous cell carcinoma is a rare variant of metaplastic carcinoma.[522,537] Tumors of cutaneous origin and those in which the squamous component is a portion of an otherwise typical phyllodes tumor should be excluded. It is also important not to misinterpret the syncytial areas of carcinoma with medullary features or the partial apocrine changes sometimes seen in other tumors as representing squamous change. The gross appearance of squamous cell carcinoma differs little from that of conventional breast carcinomas, although sometimes a large central cyst filled with keratin can be identified. Microscopically, most cases seem to represent instances of squamous metaplasia in invasive ductal carcinoma, indicating that squamous cell carcinoma is a special type of metaplastic carcinoma (Fig. 36.115).[538] Occasionally, the tumor is accompanied by a prominent myxoid stroma.[539]

For personal use only. No other uses without permission. Copyright ©2017. Elsevier Inc. All rights reserved.

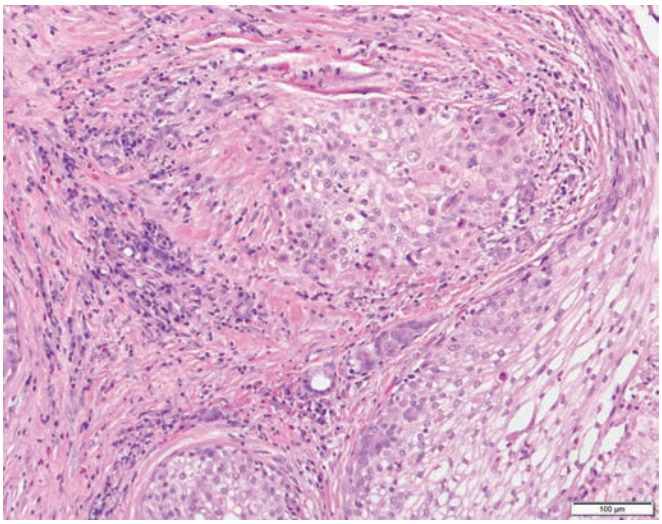

Figure 36.115 Metaplastic carcinoma, squamous cell type.

Two further variants are *acantholytic squamous cell carcinoma*, in which the lack of tumor cell cohesiveness results in a pseudovascular or pseudoglandular appearance (Fig. 36.116),[540] and *low-grade adenosquamous carcinoma* (see next).

6. *Low-grade adenosquamous carcinoma.* Low-grade adenosquamous carcinoma is a well-differentiated tumor with dual glandular and squamous differentiation with squamous pearl or cyst formation infiltrating through a cellular stroma (Fig. 36.117). Local recurrence is common following conservative surgery, but nodal and distant metastases are exceptional.[541] Like fibromatosis-like metaplastic carcinoma, low-grade adenosquamous carcinoma may arise in association with adenomyoepithelioma and benign sclerosing lesions.[533,541–544]

The differential diagnosis of metaplastic carcinoma includes phyllodes tumor, fibromatosis or scar, and less likely primary breast sarcoma. A broad panel of cytokeratin stains along with p63 is often necessary to aid in diagnosis of these challenging cases. As mentioned previously, metaplastic carcinomas vary with regard to which cytokeratin will be expressed and with regard to the extent of tumor cell positivity. In a well-sampled pure spindle cell lesion, unequivocal staining with cytokeratin or p63 is considered sufficient for the diagnosis of metaplastic carcinoma,[522] though it should be noted that it has been recently demonstrated that the stromal component of phyllodes tumor, particularly malignant phyllodes tumor may show focal staining with p63 (and/or p40) and/or cytokeratin immunostains.[178,179] As such, caution should be exercised in rendering a definitive diagnosis based on the interpretation of these immunostains on core needle biopsy specimens of pure spindle cell lesions.

The behavior of metaplastic carcinoma compared with that of invasive ductal-type carcinoma of no special type is not well defined, though fibromatosis-like metaplastic carcinoma and low-grade adenosquamous carcinoma do appear to have a more indolent course.[530] Metastases tend to occur via hematogenous spread rather than to lymph nodes.[530]

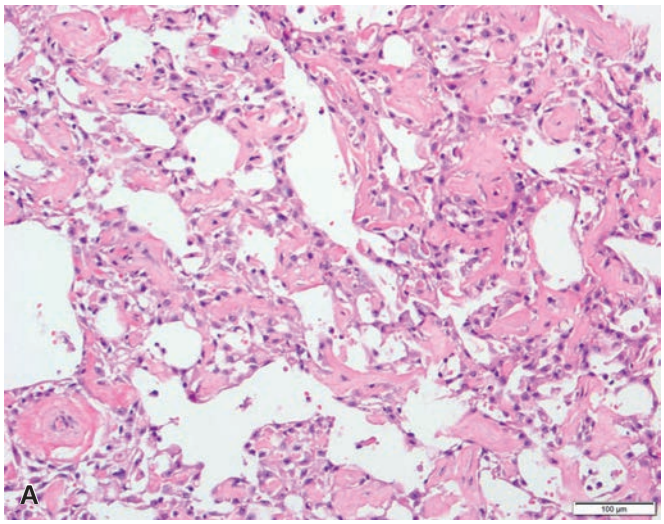

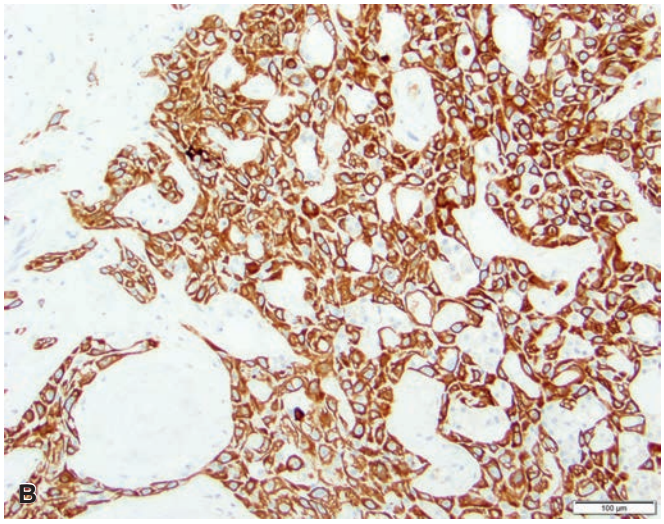

Figure 36.116 **A,** Metaplastic carcinoma, squamous cell type with acantholytic pattern mimicking angiosarcoma. **B,** Cytokeratin 903 immunostain.

Inflammatory Carcinoma

The term "inflammatory carcinoma" is used in a clinical context for a type of breast carcinoma in which the breast is reddened and warm, with widespread edema of the skin, simulating the appearance of mastitis.[545] A discrete breast mass is not always palpable. The clinical appearance is due to widespread carcinomatous emboli involving the dermal lymphatic vessels (Fig. 36.118). However, patients may have inflammatory carcinoma clinically in the absence of pathologically identifiable dermal lymphatic involvement, at least on small punch biopsies of the skin; conversely, widespread permeation of dermal lymphatics can be seen in the absence of the clinical features of inflammatory carcinoma (so-called occult inflammatory carcinoma[546]). The underlying carcinoma is usually a high-grade invasive ductal carcinoma of no special type. Inflammatory carcinoma is staged as T4d. From a prognostic standpoint, the presence of dermal lymphatic permeation on microscopic examination is an ominous sign, whether the clinical appearance is that of an inflammatory carcinoma or not, though there is some improvement in survival outcome with the use of neoadjuvant chemotherapy.[546,547]

Adenoid Cystic Carcinoma

Adenoid cystic carcinoma is similar to tumors of the same name occurring in the salivary gland and lung. It is important not to confuse this uncommon neoplasm with the much more common DCIS with cribriform pattern, with invasive cribriform carcinoma, or with collagenous spherulosis.[548,549] Adenoid cystic carcinoma of

For personal use only. No other uses without permission. Copyright ©2017. Elsevier Inc. All rights reserved.

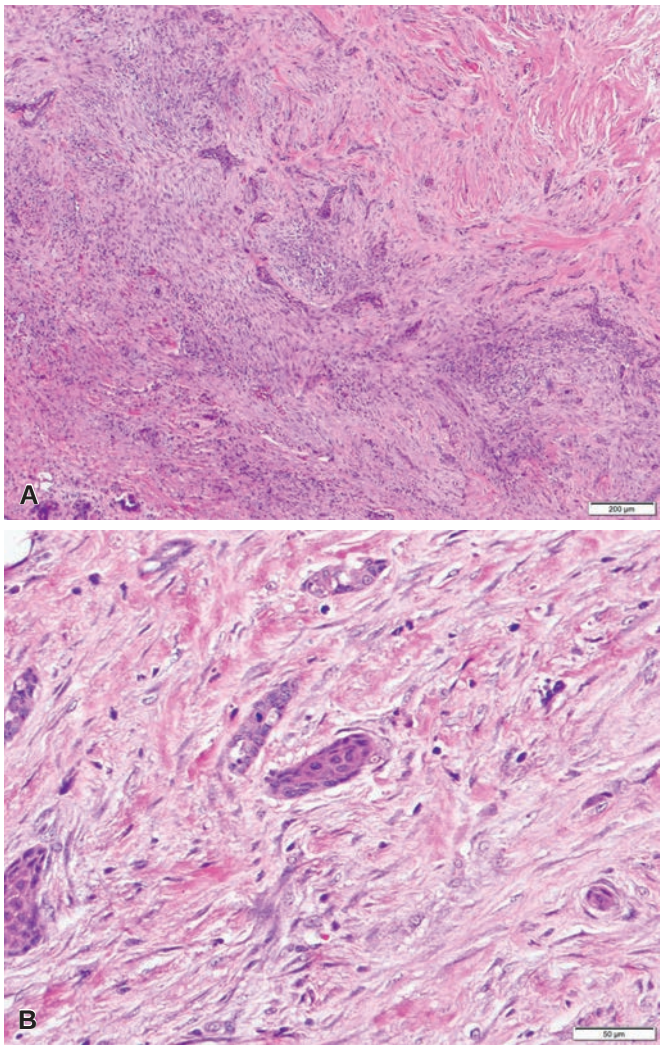

Figure 36.117 Low-grade Adenosquamous Carcinoma. A, At low power glands and squamous nests can be seen infiltrating haphazardly in a variably cellular and dense collagenous stroma. **B,** At high power the cytologic atypia and mitotic activity of the tumor cells is readily apparent.

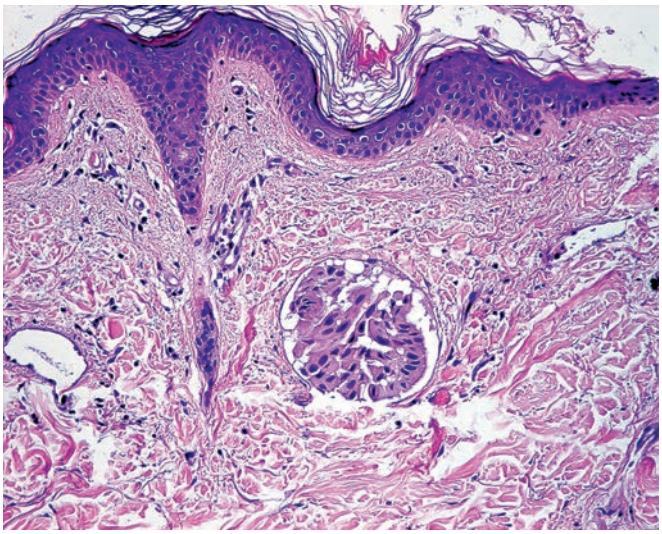

Figure 36.118 Large tumor embolus in a dermal lymph vessel in a case with the clinical appearance of inflammatory carcinoma.

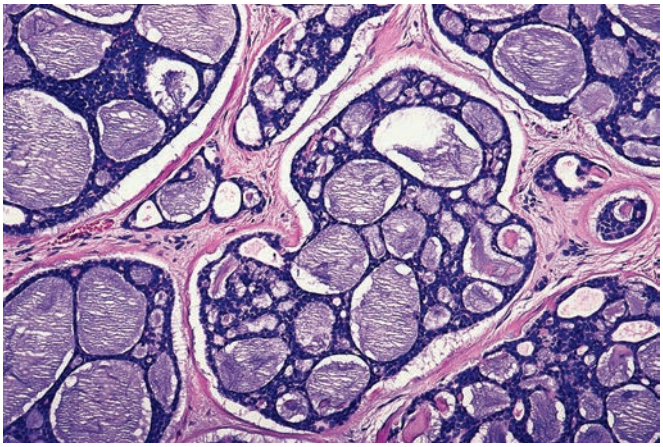

Figure 36.119 Adenoid Cystic Carcinoma. The appearance is similar to that of its more common homologue in salivary glands. The tumor is characterized by two types of cavity formation; true glandular lumina and pseudolumens containing basement membrane material surrounded by basal-myoepithelial cells, a feature that is more pronounced in this image.

the breast shows, as in the salivary glands, two types of lumen formation: true glandular lumina lined by cells which are positive for CK7 and 8/18, and pseudolumens containing eosinophilic basement membrane material and/or basophilic mucin surrounded by basal-myoepithelial cells which may express myoepithelial markers and basal cytokeratins (Fig. 36.119).[550] Foci of sebaceous differentiation may also be seen.[551] Perineural involvement may be present. Adenoid cystic carcinomas are typically ER, PR, and HER2 negative (i.e., they are "triple negative" tumors,[552] although they should not be equated with mammary carcinomas now bearing that catchy designation).[553] CD117 is usually expressed, mirroring the pattern of salivary gland adenoid cystic carcinoma; CD117 staining is not present in the previously mentioned simulators.[554,555] Like the homologous tumor occurring in the salivary gland, a distinctive chromosomal translocation, t(6;9) resulting in *MYB–NFIB* gene fusion is commonly found and the presence of nuclear MYB staining with IHC can be used to confirm the diagnosis in histologically ambiguous cases.[556,556a] Axillary lymph node metastases are extremely rare.[557,558] Some patients have developed local recurrence or pulmonary metastases many years after initial therapy,[557,559] but the prognosis for this tumor as a group is remarkably good.[560] The relationship between microscopic grading and prognosis is controversial.[557,561,562]

A solid variant of adenoid cystic carcinoma with basaloid features has been described in which the glandular lumens and pseudolumens with basement membrane material are more subtle. The tumor cell nuclei are usually higher grade, and mitoses and necrosis may be present (Fig. 36.120). The prognosis for these tumors appears to be less favorable, albeit with limited data.[561,562] As already mentioned, some cases of adenoid cystic carcinoma are seen in association with microglandular adenosis.[198]

Acinic Cell Carcinoma

As the name indicates, acinic cell carcinoma is highly reminiscent of the homologous tumor of the salivary gland with variable growth patterns, which include microcystic, microglandular, and solid, occasionally with comedo necrosis. The cells have abundant granular eosinophilic or clear cytoplasm with round nuclei and prominent

For personal use only. No other uses without permission. Copyright ©2017. Elsevier Inc. All rights reserved.

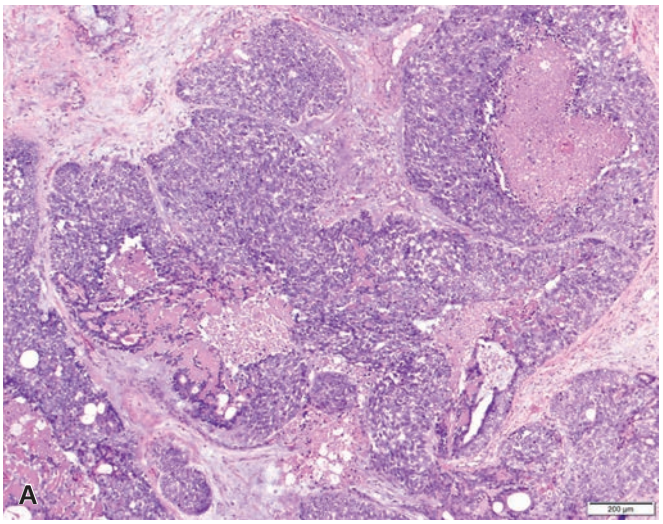

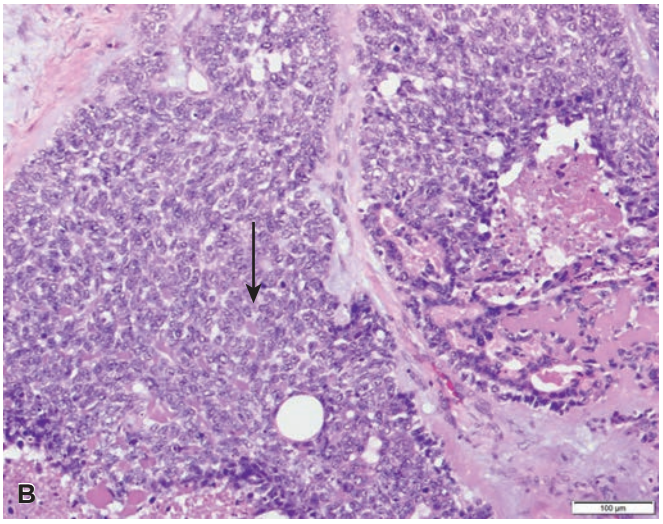

Figure 36.120 Solid Variant of Adenoid Cystic Carcinoma With Basaloid Features. A, At low power, solid nests of high-grade tumor cells with basaloid features and abundant necrosis are appreciated. Basement membrane material is also present at the lower left portion of the field. **B,** At higher power, pseudolumens with basement membrane material are confirmed to be present. The identification of true glandular lumens can be more challenging *(arrow).*

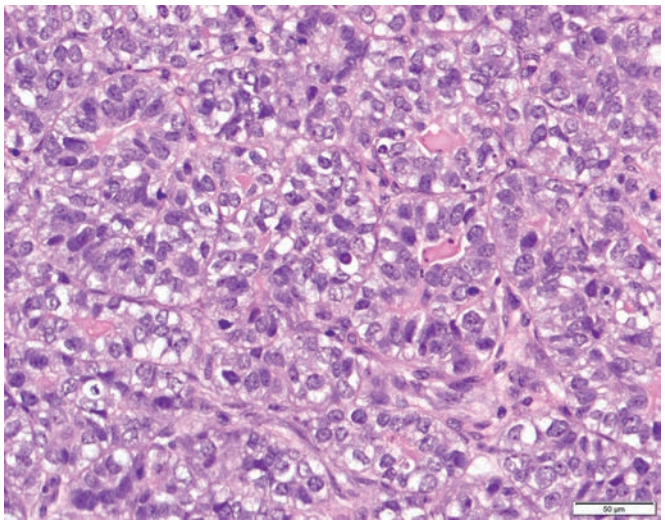

Figure 36.121 Acinic Cell Carcinoma of Breast. The cells have abundant eosinophilic or clear cytoplasm with round nuclei and prominent nucleoli. Coarse eosinophilic cytoplasmic granules can usually be identified.

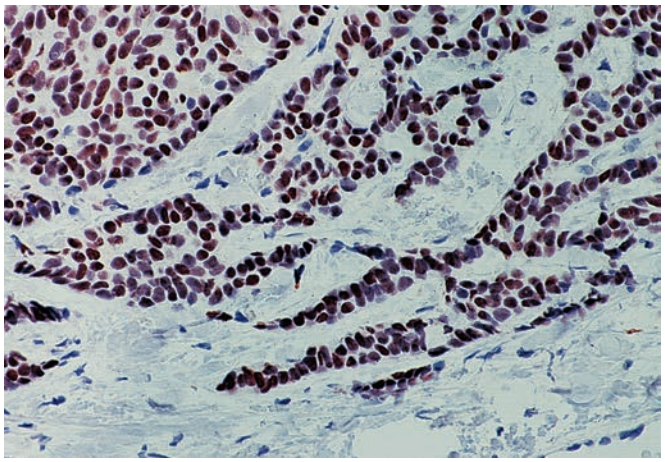

Figure 36.122 Immunostain for Estrogen Receptor in Invasive Ductal Carcinoma. Strong nuclear positivity of the tumor cells is shown.

nucleoli (Fig. 36.121). The cytoplasmic granules are coarse and bright pink. The similarities extend to the ultrastructural and immunohistochemical features, which include positivity with α1-antichymotrypsin, salivary gland amylase, and lysozyme.[563,564] Like secretory carcinomas, for which they can be a mimic, acinic cell carcinomas are triple negative and positive for S-100 protein. Notably acinic cell carcinomas do not show the t(12:15) *ETV6-NTRK3* rearrangement characteristic of secretory carcinoma.[565,566]

Other rare malignant breast tumors with similar counterparts in the salivary gland are **mucoepidermoid carcinoma,**[567] **polymorphous (low-grade) adenocarcinoma,**[568] **sebaceous carcinoma,**[569] **oncocytic carcinoma,**[570] and **basaloid carcinoma.**[571]

Glycogen-rich (clear cell) carcinoma is composed of large clear cells, which are found to contain abundant glycogen.[572–576] The differential diagnosis includes other breast tumors with clear cytoplasm, including adenomyoepithelioma, lipid-rich carcinoma, histiocytoid carcinoma, metastatic renal cell carcinoma, and the exceptionally rare tumors of perivascular epithelioid cells (PEComa).[572]

Hormone Receptors

A crucial development in the treatment of breast carcinoma was the recognition that the presence of hormone (estrogen and progesterone) receptors in the tumor tissue correlates well with response to hormone therapy and chemotherapy.[577] As a matter of fact, ER status is regarded as one of the most powerful predictive markers in breast cancer management.[578] ER and PR are codependent variables, PR being a weaker predictor of response to endocrine therapy than ER.[579] Initially, these hormone receptors were measured by the dextran-coated charcoal and sucrose gradient assay, but this has been replaced by the immunohistochemical method, on the grounds that it offers several important advantages (it does not require fresh tissue, it can be done with minute amounts of tumor, the location of the hormone receptor positivity can be visualized, etc.) (Fig. 36.122), correlation between the two methods is very good,[580,581] and technical ease of the immunohistochemical assay. Efforts have been made to semiquantitate the immunohistochemical method by standardizing the technical procedure and reporting and by using appropriate controls.[329,582,583] Delay in fixation has been reported to affect the results, whereas fixation time within reasonable boundaries

For personal use only. No other uses without permission. Copyright ©2017. Elsevier Inc. All rights reserved.

appears not to.[584] The ASCO and CAP have published guideline recommendations for immunohistochemical testing of ER and PR in breast specimens.[329,585] The guidelines have facilitated standardization of assay performance and reporting across laboratories in North America. Some of the more salient points of this document are the following:

- The pathologist must report the percentage of invasive tumor cells that are immunoreactive.
- Tumors having 1% or more invasive cancer cells staining are regarded as positive.
- The average intensity of the stain must be included (weak, moderate or strong).
- The pathologist must give an interpretation as to whether the sample is positive or negative.
- The use of a composite score based on percentage plus intensity (Allred, H, or Quick scores) is optional.
- Specimens should be placed in 10% neutral buffered formalin no later than 1 hour (but ideally much sooner) after being removed from the patient (cold ischemic time).
- Fixation time should be at least 6 hours and not longer than 72 hours.
- Normal breast cells in the sample should be used as internal positive controls and a comment about the adequacy of staining in the internal control provided.

Hormone receptors can also be evaluated in paraffin-embedded breast tissue by the in situ hybridization technique and by PCR.[586,587]

About 80% of breast cancers are ER positive, so that an ER-negative rate of greater than 30% suggests that some problems exist with the assay which need to be investigated and resolved.

ER-positive breast carcinomas tend to be better differentiated tumors; conversely ER-negative breast carcinomas tend to have grade 3 histology, the exception being some special type tumors, such as adenoid cystic carcinoma and secretory carcinoma. Most carcinomas with medullary features, metaplastic, and apocrine carcinomas are ER negative, whereas mucinous, tubular, and lobular carcinomas have a high rate of ER positivity. In DCIS, high nuclear grade is the best morphologic predictor of ER-negative status.[588,589] The positivity in LCIS is particularly strong, although this is not tested or reported in clinical practice.[590] It is very unusual for an ER-negative cancer to become ER-positive at the time of recurrence or metastasis, whereas the reverse is more common, especially if there has been intervening tamoxifen therapy.

Hormone receptor positivity also correlates with bcl2 immunoreactivity[591] and absence of *TP53* mutations[592] and correlates inversely with the presence of epidermal growth factor receptors (such as HER2).[593]

It should be pointed out that most breast carcinoma cells also have receptors for androgens, and that these may be found in the absence of estrogen and PR, a finding that is being exploited as a therapeutic option for patients with triple negative breast cancers.[594]

HER2

HER2 (c-*erb*B-2) is an oncogene that encodes a transmembrane glycoprotein with tyrosine kinase activity known as p185, which belongs to the family of epidermal growth factor receptors.[595] Approximately 15% of invasive breast cancers show HER2 gene amplification and protein overexpression.[596] Identification of HER2+ tumors is critically important in selecting patients for HER2-targeted therapies, such as trastuzumab. HER2 overexpression and amplification can be measured by immunohistochemistry or fluorescent in situ hybridization (FISH) (or its chromogenic equivalent), respectively,[597] and a good correlation exists between these methods (Fig. 36.123).[598]

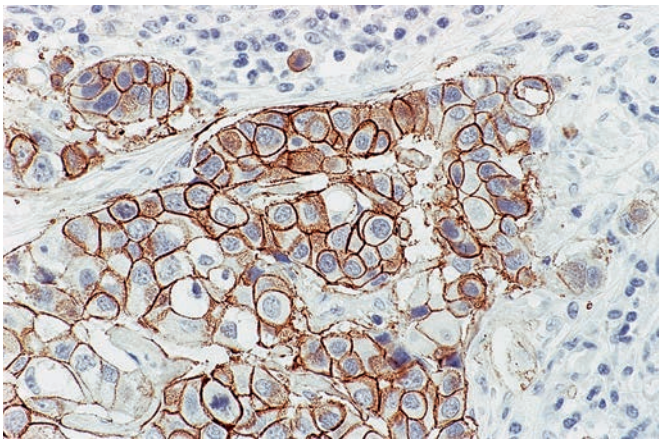

Figure 36.123 HER2-positive (3+) immunostain in high-grade invasive ductal carcinoma showing the required strong, complete, membranous pattern of staining in >10% of tumor cells.

The ASCO/CAP has published and updated guideline recommendations for HER2 testing in breast cancer.[599,600] According to this joint document, a *positive* HER2 result is:

- immunohistochemical staining of 3+ (uniform, intense membrane staining of greater than 10% of invasive tumor cells), or
- a FISH result of more than six *HER2* gene copies, or
- a FISH ratio (*HER2* gene signals to chromosome 17 signals) of greater than 2.0.

A *negative* HER2 result is:

- immunohistochemical staining of 0 or 1+, or
- a FISH result of less than 4.0 HER2 copies per nucleus, or
- a FISH ratio of less than 2.0.

An *equivocal* HER2 result is:

- immunohistochemical staining of 2+ (weak and moderate membrane staining in greater than 10% of tumor cells), or
- a FISH ratio of less than 2.0 *and* a FISH result of ≥4.0 and less than 6.0 copies per nucleus.

In the event of an equivocal IHC result, reflex testing to FISH is recommended. If the FISH test is equivocal, either reflex test to IHC using the same specimen, test with an alternative ISH chromosome 17 probe, or order a new test (new specimen if available, ISH or IHC).

Many laboratory directors have concluded that the best approach to HER2 testing from the point of view of cost effectiveness is to start with the immunohistochemical procedure, which is scored according to the ASCO/CAP guideline summarized in Table 36.4.[599] If the results are either 3+ or 0/1+, the determination can safely stop there, since the correlation with gene amplification or lack of it, respectively, as measured by FISH, is nearly 100%. If the IHC is 2+ (equivocal), the performance of FISH is recommended, and the result obtained tends to be regarded as the definitive result. Other laboratories perform both IHC and FISH on all cases because of the small possibility of a patient being HER2 positive by one or other of the tests.[601]

HER2 positivity by either technique is a very good predictor of response to trastuzumab. HER2-positive tumors are typically high-grade tumors. *HER2* amplification correlates inversely with estrogen and progesterone expression, though some hormone receptor positive tumors are also HER2 positive (~10% of all invasive breast carcinomas).[596]

HER2 heterogeneity is of sufficient importance that a CAP Expert Panel developed criteria to define it.[602] In 2009, this Expert

For personal use only. No other uses without permission. Copyright ©2017. Elsevier Inc. All rights reserved.

Table 36.4 Scoring of the immunohistochemical staining for HER2 overexpression

STAINING PATTERN	SCORE	HER2 PROTEIN OVEREXPRESSION ASSESSMENT
No staining is observed or faint, incomplete membrane staining is observed in ≤ 10% of tumor cells	0	Negative
Incomplete membrane staining that is faint/barely perceptible and within > 10% of tumor cells	1+	Negative
Weak and moderate complete membrane staining in >10% of tumor cells	2+	Equivocal
Circumferential membrane staining that is complete, intense, and within >10% of tumor cells	3+	Positive

Data from Wolff AC, Hammond ME, Hicks DG, et al. Recommendations for human epidermal growth factor receptor 2 testing in breast cancer: American Society of Clinical Oncology/College of American Pathologists clinical practice guideline update. *J Clin Oncol*. 2013;31(31):3997–4013.

Panel defined HER2 genetic heterogeneity as greater than 5% but less than 50% of invasive tumor cells, with an elevated ratio (then >2.2, now >2.0) in a dual probe ISH assay.[602] Approximately 20%–30% of cases are reported to be heterogeneous for HER2 amplification.[603,604]

Before leaving the topic of ER, PR, and HER2 in breast carcinoma, a few words need to be said about tumors that are negative for all three markers which are referred to as **triple negative tumors**.[605,606] Triple negative cancers overlap considerably with basal-like cancer (a tumor defined through gene-expression profiling studies, more fully discussed in the next section) and breast carcinomas arising in *BRCA1* mutation carriers. However, triple negative cancers are not synonymous with basal-like cancers—only 70%–80% of cases classified by gene expression profiling as basal-like show a triple negative phenotype, and conversely a similar, though not necessarily the same, proportion of triple negative cancers exhibit a basal-like gene expression profile.[607] Triple negative breast cancers represent a heterogeneous group of tumors, which most characteristically exhibit the following features: morphologically usually high-grade invasive ductal carcinoma of no special type, high degree of aneuploidy, and greater tendency to metastasize to lungs and brain.[605,606]

Molecular Genetics and Molecular Classification of Breast Cancer

Molecular Genetics

The development of invasive breast carcinoma involves multiple genetic alterations, as with other carcinomas of various anatomic sites. The genes most commonly affected, and consistently identified in breast cancer include: *PIK3CA*, *PTEN*, *AKT1*, *TP53*, *GATA3*, *CDH1*, *RB1*, *MLL3*, *MAP3K1*, and *CDKN1B*.[608] In addition, some types of breast carcinoma, such as secretory carcinoma, lobular carcinoma, and adenoid cystic carcinoma, exhibit distinctive genetic changes, as described in the respective sections.

Molecular Classification

The pioneering efforts of Perou and colleagues in 2000 to segregate breast cancers into distinct subgroups based on similarities in the gene expression profiles using a microarray platform has been enthusiastically embraced by the medical and scientific community, with the hope that this approach will provide new insights into the biology of breast cancers and impact therapeutic strategies.[609,610] The subtyping reported by this group has evolved into a molecular classification of breast cancer.

The subtypes of breast cancers most widely recognized by their gene expression signature include: luminal (type A and B), HER2 enriched, basal-like, and normal breast-like. The last subtype may represent an artifact rather than a genuine subtype of breast cancer, resulting from lack or paucity of tumor in the tissue samples used for the microarray analysis. The main features of the four molecular subtypes are summarized in Table 36.5. Among the various subtypes, the basal-like subtype is associated with the worst prognosis.[610] Since the different molecular subtypes of breast cancers exhibit specific characteristics, it is thought that more specific and targeted forms of therapy could be developed. Efforts have been made to use immunohistochemistry as a surrogate (such as a panel including antibodies to ER, PR, HER2, cytokeratin 5/6, EGFR, Ki-67) to assign tumors to the various molecular subtypes (Table 36.6),[611–614] but discordance is not uncommon, and there are currently no widely agreed upon criteria to define immunostain positivity for this purpose (particularly for Ki-67).

The current molecular classification of breast cancers still has drawbacks. The molecular subtypes were defined based on a relatively small number of cases, and some of the less common distinctive types of breast cancer (such as secretory carcinoma) were not included as part of the original analyses.[468,615] The basal-like subtype is highly heterogeneous and encompasses some tumors with a favorable prognosis, such as secretory carcinoma and adenoid cystic carcinoma, necessitating the creation of a "low-grade" category of basal-like carcinoma.[615] It is too simplistic to try to subsume the many different types of breast carcinoma into a few molecular categories, ignoring the known distinctive types with characteristic morphology and biologic features (such as invasive lobular carcinoma and secretory carcinoma).[616] In fact, additional molecular subtypes have since been identified, such as molecular apocrine, or luminal androgen receptor and claudin-low.[617–619]

Issues with standardization of analytic approaches, replication, attaining adequate sample size, and the evaluation of the clinical utility in heterogeneous populations apply to gene expression profiling studies as much as to any clinical trial with a component of pathologic testing and classification. In addition, how gene expression profiling can be applied to routine diagnosis and prognostication has yet to be fully determined. Further, although nearly every published microarray-based system can recognize molecular subtypes with similar survival and can also identify the basal-like subtype fairly consistently, the systems do not reliably assign the same patients to the same molecular groups for nonbasal-like tumors.[620]

Despite all the interest surrounding the molecular classification of breast cancers, currently the clinical value of characterizing invasive breast cancers beyond routine histologic type, histologic grade, and ER/PR/HER2 status has not been established; in fact it is these very characteristics that determine therapy.[614] Thus assignment of breast cancer cases to a molecular subtype is not a requirement at present,

For personal use only. No other uses without permission. Copyright ©2017. Elsevier Inc. All rights reserved.

Table 36.5 Major molecular subtypes of breast cancer determined by gene expression profiling

	MOLECULAR SUBTYPE			
	LUMINAL A-LIKE	**LUMINAL B-LIKE**	**HER2-ENRICHED**	**BASAL-LIKE[a]**
Gene expression pattern	Expression of luminal (low-molecular-weight) cytokeratins, and high expression of hormone receptors and associated genes	Expression of luminal (low-molecular-weight) cytokeratins and moderate to weak expression of progesterone receptor and associated genes	High expression of *HER2* and other genes in amplicon on 17q12 Low expression of ER and associated genes	High expression of basal epithelial genes, basal cytokeratins Low expression of ER and associated genes Low expression of HER2 related genes
Clinical and biologic features	~60% of invasive breast cancers ER/PR positive HER2 negative Low proliferation rate	~10% of invasive breast cancers ER positive, PR low positive HER2 expression variable (positive or negative) Intermediate or high proliferation rate (Ki-67 high) Luminal B tends to be higher histologic grade than luminal A	~15% of invasive breast cancers ER/PR negative HER2 positive (though not all HER2 enriched by molecular subtype are HER2+ by clinical definition) High proliferation rate *TP53* mutation common More likely to be high grade and node positive	~15% of invasive breast cancers Most ER/PR and HER2 negative ("triple negative") High proliferation rate *TP53* mutation common; *BRCA1* dysfunction (germline, sporadic) Particularly common in African–American women
Histologic correlation	Tubular carcinoma Cribriform carcinoma Low grade invasive ductal carcinoma NST[b] Classic lobular carcinoma	Invasive ductal carcinoma NST Micropapillary carcinoma	High-grade invasive ductal carcinoma NST	High-grade invasive ductal carcinoma NST Metaplastic carcinoma Carcinoma with medullary features
Treatment response and outcome	Respond to endocrine therapy	Respond to endocrine therapy (tamoxifen and aromatase inhibitors) Response may not be as good as for luminal A	Respond to trastuzumab (Herceptin)	No response to endocrine therapy or trastuzumab (Herceptin)
	Chemotherapy generally not indicated	Response to chemotherapy variable (greater than luminal A)	Respond to anthracycline-based chemotherapy	Appear to be sensitive to platinum-based chemotherapy and PARP inhibitors
	Good prognosis	Prognosis not as good as for luminal A	Generally poor prognosis, but better with HER2-targeted therapies	Generally poor prognosis (but not uniformly poor)

ER, Estrogen receptor; *PARP*, poly-adenosine diphosphate-ribose polymerase; *PR*, progesterone receptor; *NST*, no special type.
[a]There is a low-grade group of basal-like tumors that similarly express basal-type (high-molecular-weight) cytokeratin and have a triple negative phenotype, but with low proliferation (e.g., adenoid cystic carcinoma, secretory carcinoma).
[b]While classic lobular carcinoma usually exhibits luminal A features, pleomorphic lobular carcinoma often exhibits features of other molecular subtypes.

Table 36.6 Use of immunohistochemistry as surrogate marker for the molecular subtypes of breast cancer

	MOLECULAR SUBTYPE			
IMMUNOPROFILE	**LUMINAL A**	**LUMINAL B**	**HER2 ENRICHED**	**BASAL-LIKE**
ER, PR	ER+ and PR high+	ER+ and PR low or intermediate+	ER–, PR–	ER–, PR–
HER2	HER2–	HER2+ or HER2–	HER2+	HER2–
Others	Low Ki-67 (<14%)	Ki-67 ≥14%		CK5/6 and/or EGFR+

EGFR, Epidermal growth factor receptor; *ER*, estrogen receptor; *PR*, progesterone receptor.
Modified from Coates AS, Winer EP, Goldhirsch A, et al. Tailoring therapies—improving the management of early breast cancer: St Gallen International Expert Consensus on the Primary Therapy of Early Breast Cancer 2015. *Ann Oncol*. 2015;26(8):1533–1546.

For personal use only. No other uses without permission. Copyright ©2017. Elsevier Inc. All rights reserved.

though oncologists likely use the information provided in the pathology report to categorize tumors into their surrogate molecular subtypes.[621]

Oncologists treating patients with luminal-type breast cancers, that is, those with hormone receptor positive tumors, may opt for one of the genomic prognostic tests (e.g., Oncotype Dx, MammaPrint, PAM50, see later) to determine the need for adjuvant chemotherapy. Despite the relatively high cost of these tests, the human and economic benefits derived from a decision to avoid chemotherapy when the test result indicates a low risk of recurrence are enormous.[613,622–624]

Extent, Local Recurrence, and Metastases

Breast carcinoma spreads by direct invasion, by the lymphatic route, and by the hematogenous route. Some of these metastases are already present at the time of diagnosis, and others become manifest clinically months, years, or decades after initial diagnosis and treatment. Local invasion can occur into the nipple, skin, pectoralis fascia and muscle, or other structures of the chest wall.

The frequency of microscopic extension beyond the gross confines of the tumor was evaluated by Rosen et al. by performing a simulated "local excision" with a 2-cm gross margin in mastectomy specimens. Of 18 mastectomies performed for carcinoma measuring less than 1 cm, residual invasive carcinoma was found in 11% and residual DCIS in an additional 22%; this is particularly so for invasive lobular carcinoma.[625,626] The importance of a thorough pathologic evaluation of extent of breast carcinoma and the status of the margins is paramount because of the large number of conservative surgical procedures being performed.[627,628]

A somewhat related problem is that of microscopic involvement of the nipple by DCIS, since this structure is left in place when a local excision is carried out. Nipple involvement has been found in about 12% of all clinically detectable invasive carcinomas,[629] which is increasingly relevant in an era of nipple-sparing mastectomy. Evaluation of the shaved resection margin below the nipple is indicated in this procedure.[630]

Local recurrence following mastectomy appears as superficial nodules in or near the surgical scar or as subcutaneous parasternal nodules. Their malignant nature should always be documented by biopsy because the condition can be closely simulated by foreign body granulomas and infectious processes.

Tumor recurrence following local excision usually develops in the same breast quadrant, a fact that led some authors to recommend a primary excision technique that removes en bloc the tumor mass and the associated duct system.[631] However, contemporary excisions are more conservative because of the frequent use of adjuvant radiation therapy.

The two lymph node stations typically involved by metastatic breast carcinoma are the axilla and the internal mammary chain, with the supraclavicular area representing an extension of the former. It should be remembered that it is not too unusual also to find lymph nodes within the substance of the mammary gland ("intramammary lymph nodes"). Axillary lymph node metastases are present in approximately 30% of cases [632] and are divided into levels according to their topographic relation with the insertion of the pectoralis minor muscle: low or proximal, medium, and high or distal. When extensively involved by metastatic carcinoma, the axillary lymph nodes are palpable, but the margin of error with clinical examination is high. Careful dissection and microscopic examination of the submitted lymph nodes by the pathologist is important for accurate staging of the patient. Supraclavicular lymph node involvement is reported to be present in close to 20% of patients with axillary lymph node involvement but is almost zero in cases with negative axillae.[633]

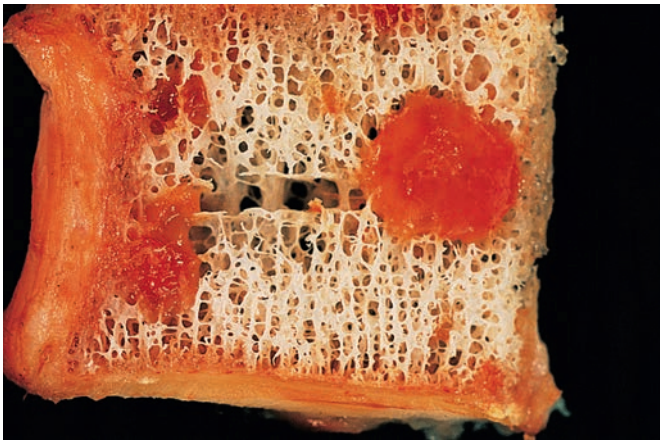

Figure 36.124 Breast Carcinoma Metastatic to Vertebra. The normal bone marrow has been flushed out by placing a thin slice of tissue under a strong jet of water.

The second major lymph node drainage area is to the internal mammary chain, which lies at the anterior ends of the intercostal spaces by the side of the internal thoracic artery. The overall incidence of metastatic involvement of this chain in patients with clinically detectable axillary lymph node metastases is approximately 20%.[634] Rarely, a metastatic lymph node will appear entirely necrotic and may simulate an infectious process; immunostains for keratin may be useful in aiding detection of necrotic tumor cells.

Distant metastases are seen most commonly in the skeletal system (Fig. 36.124), lung and pleura, liver, ovary, adrenal gland, and central nervous system (including leptomeninges and eyes)[635, 636] and vary according to breast cancer subtype, with the hormone receptor–positive, HER2-negative subtype having a higher rate of lymph node metastasis at diagnosis than the triple negative subtype.[637] Invasive lobular carcinoma (including the signet ring variant) has a propensity to metastasize to the abdominal cavity, particularly to the gastrointestinal tract (Fig. 36.125), ovaries, and serosal surfaces.[638,639]

In the presence of metastatic deposits of unknown source to lung and other sites, immunoreactivity for breast markers GCDFP-15, mammaglobin, GATA3, as well as hormone receptors, strongly suggests a breast primary.[412,640–642] Metastases of breast carcinoma to the ovary are likely to be positive for the aforementioned breast markers and negative for WT1, CA125, and PAX8, whereas the reverse is true, with the exception of ER, for primary ovarian carcinoma.[412,643,644]

The pattern of metastatic spread of breast carcinoma as evaluated by Fisher et al.[645] in a large randomized series of patients treated with various modalities brought them to the following conclusions: there is no orderly pattern of tumor dissemination; regional nodes are ineffective as barriers to tumor spread and, when positive, are more an indicator of a particular host–tumor relationship than the instigator of distant metastases; hematogenous spread is of considerable importance in tumor dissemination; complex host–tumor interrelationships affect every facet of the disease; operable breast carcinoma is a systemic disease; and variations in local–regional therapy are unlikely to substantially affect survival.[646]

Occult Breast Carcinoma

Sometimes a single enlarged axillary lymph node in an adult female is found to be involved by metastatic nonlymphoid tumor in the presence of a clinically and radiographically normal breast, with no evidence of tumor elsewhere. When this situation arises, the diagnosis will be metastatic breast carcinoma or metastatic malignant melanoma

For personal use only. No other uses without permission. Copyright ©2017. Elsevier Inc. All rights reserved.

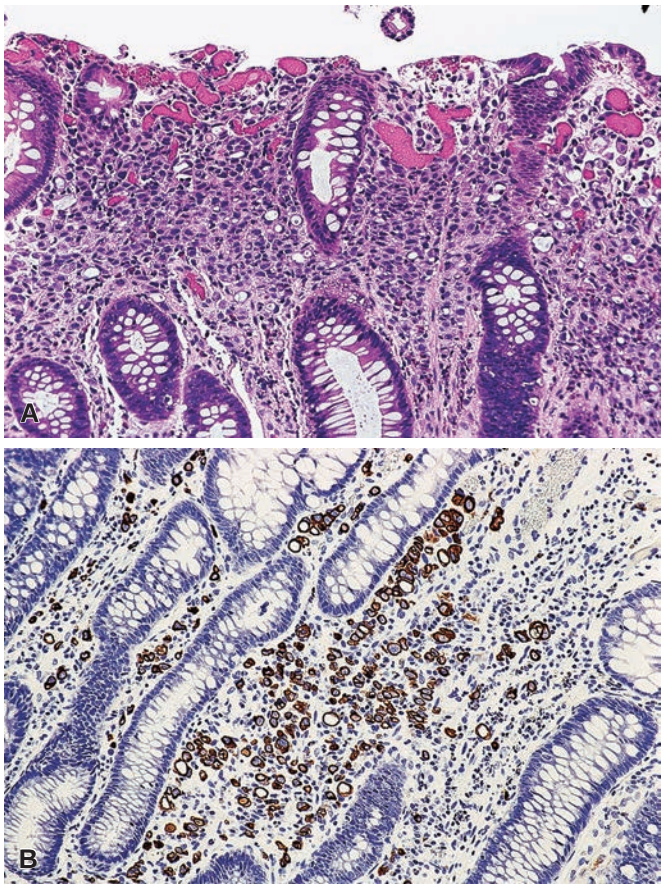

Figure 36.125 **A** and **B,** Metastasis of mammary lobular carcinoma to lamina propria of large bowel mucosa. **B,** Cytokeratin 7 immunostain.

in over 90% of cases. Making the distinction between carcinoma and melanoma should be possible in nearly every case from the combination of morphologic features and immunohistochemical stains, including cytokeratins, GCDFP-15, mammaglobin, GATA3, S-100 protein, HMB-45, and other markers. A note of caution is in order regarding the interpretation of the immunostains, since S-100 protein (originally thought to be very distinctive of melanoma in this situation) is now known to stain a high number of breast carcinomas and, some melanomas may show aberrant expression of cytokeratin. MRI is indicated to attempt to establish the location of the tumor. If the combined approach has shown that: (1) the tumor is a carcinoma rather than a melanoma; (2) the appearance of this carcinoma is compatible with breast origin; and (3) there is no clinicoradiographic evidence of tumor elsewhere, treatment options include ipsilateral mastectomy, whole breast irradiation, and even chemotherapy.[647–649] A primary tumor, which can be extremely small, will be found in most cases.[647–649] It appears from the limited data available that those women who undergo mastectomy fare better than those who elect to have breast irradiation.[647,649]

Occasionally, occult carcinomas are found on routine microscopic examination of a reduction mammoplasty specimen.[262] As already pointed out, these are almost always in situ rather than invasive tumors.

Sentinel Lymph Node

First pioneered in the early 1990s, the technique of sentinel lymph node biopsy for the evaluation and management of breast carcinoma has gained enormous popularity and has become the standard of care.[650] The procedure is based on the concept that if the sentinel node is negative, the other nodes of that group will also be negative in nearly all instances, whereas if it is positive, the chance that there will be additional metastases in that nodal group is about one-third.[344,651,652] In most substantial series the size of the primary tumor and the presence of lymphovascular invasion have been found to be significant predictors of positive sentinel lymph nodes.[653,654] The goal of sentinel lymph node examination is to identify macrometastases (>2 mm), which can be achieved by sectioning the lymph nodes at 2-mm intervals and examining one H&E section.[655] The use of enhanced techniques, such as step-sectioning or performing immunostains for cytokeratin to identify occult metastases, are not routinely indicated, as their identification does not translate into additional clinical benefit.[656,657] Molecular evaluation with RT-PCR (searching for the mammaglobin genes *MGB1* and *MGB2* or CK19 mRNA) offers an alternate method for identifying lymph node metastases[658]; however, these techniques have not been widely adopted in the United States, for the reasons stated previously.

Pitfalls in the interpretation of lymph nodes include keratin-positive reticulum cells indigenous in the lymph node (which may become quite hyperplastic and which have a typical dendritic morphology; use of AE1/AE3 and avoiding CAM5.2 will prevent this error), benign glandular inclusions, endosalpingiosis and other epithelial tissue, as well as traumatic displacement of breast epithelium.[27,659,660] Of these various traps, the one that presents the greatest challenge is that of *mechanical transport*, that is, the possibility that the biopsy procedure may push either normal or neoplastic epithelial cells into mammary lymphatic spaces, from which they could find their way into the sentinel lymph node.[659,660] This phenomenon likely does occur, as supported by the fact that it is seen more commonly in those patients in whom such instrumentation procedures were carried out.[661] It is also credible that it may involve both tumor and normal cells. Alas, it is also too evident that the distinction between normal and neoplastic epithelial cells for these isolated nodal-based epithelial cells is anything but easy.[662,663] Suffice it to say that, for practical purposes, it has been recommended that the term *micrometastases* be applied to a cluster of tumor cells greater than 0.2 mm (>200 cells) but ≤2 mm and that the term *isolated tumor cells* be used for the presence of single cells interpreted as malignant totaling fewer than 200 cells or ≤0.2 mm in greatest dimension. Cells that appear degenerated and that are associated with hemosiderin-laden macrophages are favored to be displaced.

As mentioned previously, the identification of isolated tumor cells and even micrometastases has little impact on patient management; further, the management of the axilla in patients with 1–3 lymph nodes with macrometastases and no extranodal extension has evolved to become less invasive. The ACSOG Z0011 trial demonstrated no significant differences in outcome for patients with the aforementioned findings undergoing completion axillary dissection versus those managed with wide local excision, whole breast irradiation, and sentinel lymph node biopsy alone.[344] This has translated into fewer intraoperative sentinel lymph node evaluations and fewer completion axillary dissections.[664,665]

Staging of Breast Carcinoma

The most widely used clinical staging system for breast carcinoma is the one adopted by both the International Union for Cancer Control (UICC) and the American Joint Commission on Cancer (AJCC). It is based on the TNM system (T, tumor; N, nodes; M, metastases) and is shown in (Table 36.7).[666] There are two stage group tables: the anatomic stage group table and the prognostic

For personal use only. No other uses without permission. Copyright ©2017. Elsevier Inc. All rights reserved.

Table 36.7 Definitions of AJCC TNM for breast carcinoma

Definition of Primary Tumor (T) — Clinical and Pathological

T CATEGORY	T CRITERIA
TX	Primary tumor cannot be assessed
T0	No evidence of primary tumor
Tis (DCIS)*	Ductal carcinoma in situ
Tis (Paget)	Paget disease of the nipple NOT associated with invasive carcinoma and/or carcinoma in situ (DCIS) in the underlying breast parenchyma. Carcinomas in the breast parenchyma associated with Paget disease are categorized based on the size and characteristics of the parenchymal disease, although the presence of Paget disease should still be noted.
T1	Tumor ≤ 20 mm in greatest dimension
T1mi	Tumor ≤ 1 mm in greatest dimension
T1a	Tumor > 1 mm but ≤ 5 mm in greatest dimension (round any measurement 1.0-1.9 mm to 2 mm)
T1b	Tumor > 5 mm but ≤ 10 mm in greatest dimension
T1c	Tumor > 10 mm but ≤ 20 mm in greatest dimension
T2	Tumor > 20 mm but ≤ 50 mm in greatest dimension
T3	Tumor > 50 mm in greatest dimension
T4	Tumor of any size with direct extension to the chest wall and/or to the skin (ulceration or macroscopic nodules); invasion of the dermis alone does not qualify as T4
T4a	Extension to the chest wall; invasion or adherence to pectoralis muscle in the absence of invasion of chest wall structures does not qualify as T4
T4b	Ulceration and/or ipsilateral macroscopic satellite nodules and/or edema (including peau d'orange) of the skin that does not meet the criterial for inflammatory carcinoma
T4c	Both T4a and T4b are present
T4d	Inflammatory carcinoma

Definition of Regional Lymph Nodes — Clinical (cN)†

cN CATEGORY	cN CRITERIA
cNX‡	Regional lymph nodes cannot be assessed (e.g., previously removed)
cN0	No regional lymph node metastases (by imaging or clinical examination)
cN1	Metastases to movable ipsilateral Level I, II, axillary lymph node(s)
cN1mi§	Micrometastases (approximately 200 cells, larger than 0.2 mm, but none larger than 2.0 mm)

Definition of Regional Lymph Nodes — Clinical (cN)†

CN CATEGORY	CN CRITERIA
cN2	Metastases in ipsilateral Level I, II axillary lymph nodes that are clinically fixed or matted; *or* in ipsilateral internal mammary nodes in the absence of axillary lymph node metastases
cN2a	Metastases in ipsilateral Level I, II axillary lymph nodes fixed to one another (matted) or to other structures
cN2b	Metastases only in ipsilateral internal mammary nodes in the absence of axillary lymph node metastases
cN3	Metastases in ipsilateral infraclavicular (Level III axillary) lymph node(s) with or without Level I, II axillary lymph node involvement; *or* in ipsilateral internal mammary lymph node(s) with Level I, II axillary lymph node metastases; *or* metastases in ipsilateral supraclavicular lymph node(s) with or without axillary or internal mammary lymph node involvement
cN3a	Metastases in ipsilateral infraclavicular lymph node(s)
cN3b	Metastases in ipsilateral internal mammary lymph node(s) and axillary lymph node(s)
cN3c	Metastases in ipsilateral supraclavicular lymph node(s)

Definition of Regional Lymph Nodes — Pathological (pN)¶

pN CATEGORY	pN CRITERIA
pNX	Regional lymph nodes cannot be assessed (e.g., not removed for pathological study or previously removed)
pN0	No regional lymph node metastasis identified or ITCs only
pN0(i+)	ITCs only (malignant cell clusters no larger than 0.2 mm) in regional lymph node(s)
pN0(mol+)	Positive molecular findings by reverse transcriptase polymerase chain reaction (RT-PCR); no ITCs detected
pN1	Micrometastases; or metastases in 1-3 axillary lymph nodes; and/or clinically negative internal mammary nodes with micrometastases by sentinel node biopsy
pN1mi	Micrometastases (approximately 200 cells, larger than 0.2 mm, but none larger than 2.0 mm)
pN1a	Metastases in 1-3 axillary lymph nodes, at least one metastasis larger than 2.0 mm
pN1b	Metastases in ipsilateral internal mammary sentinel nodes, excluding ITCs
pN1c	pN1a and pN1b combined

For personal use only. No other uses without permission. Copyright ©2017. Elsevier Inc. All rights reserved.

Table 36.7 Definitions of AJCC TNM for breast carcinoma—cont'd

Definition of Regional Lymph Nodes — Pathological (pN)¶	
pN CATEGORY	**pN CRITERIA**
pN2	Metastases in 4-9 axillary lymph nodes; or positive ipsilateral internal mammary lymph nodes by imaging in the absence of axillary lymph node metastases
pN2a	Metastases in 4-9 axillary lymph nodes (at least one tumor deposit larger than 2.0 mm)
pN2b	Metastases in clinically detected internal mammary lymph nodes with or without microscopic confirmation; with pathologically negative axillary nodes
pN3	Metastases in 10 or more axillary lymph nodes; *or* in infraclavicular (Level III axillary) lymph nodes; or positive ipsilateral internal mammary lymph nodes by imaging in the presence of one or more positive Level I, II axillary lymph nodes; *or* in more than three axillary lymph nodes and micrometastases or macrometastases by sentinel lymph node biopsy in clinically negative ipsilateral internal mammary lymph nodes; *or* in ipsilateral supraclavicular lymph nodes
pN3a	Metastases in 10 or more axillary lymph nodes (at least one tumor deposit larger than 2.0 mm); *or* metastases to the infraclavicular (Level III axillary lymph) nodes
pN3b	pN1a or pN2a in the presence of cN2b (positive internal mammary nodes by imaging); *or* pN2a in the presence of pN1b
pN3c	Metastases in ipsilateral supraclavicular lymph nodes

Definition of Distant Metastasis (M)	
M CATEGORY	**M CRITERIA**
M0	No clinical or radiographic evidence of distant metastases**
cM0(i+)	No clinical or radiographic evidence of distant metastases in the presence of tumor cells or deposits no larger than 0.2 mm detected microscopically or by molecular techniques in circulating blood, bone marrow, or other nonregional nodal tissue in a patient without symptoms or signs of metastases
M1	Distant metastases detected by clinical and radiographic means (cM) and/or histologically proven metastases larger than 0.2 mm (pM)

From Amin M, Edge S, Greene F, et al. (Eds.). AJCC Cancer Staging Manual. Ed. 8. New York: Springer; 2017.
*Note: Lobular carcinoma in situ (LCIS) is a benign entity and is removed from TNM staging in the AJCC Cancer Staging Manual, 8th edition.
†Note: (sn) and (f) suffixes should be added to the N category to denote confirmation of metastasis by sentinel node biopsy or fine needle aspiration/core needle biopsy respectively.
‡The cNX category is used sparingly in cases where regional lymph nodes have previously been surgically removed or where there is no documentation of physical examination of the axilla.
§cN1mi is rarely used but may be appropriate in cases where sentinel node biopsy is performed before tumor resection, most likely to occur in cases treated with neoadjuvant therapy.
¶Note: (sn) and (f) suffixes should be added to the N category to denote confirmation of metastasis by sentinel node biopsy or FNA/core needle biopsy respectively; with NO further resection.
**Note that imaging studies are not required to assign the cM0 category.

stage group table. Cancer registries and U.S. physicians must use the prognostic stage group table for reporting. Pathology synoptic reports need only report the biomarker status so that the prognostic stage group table may be appropriately assigned.

Therapy for Breast Carcinoma

Therapy for breast carcinoma includes surgery, radiation therapy, hormonal therapy, chemotherapy, and targeted therapy, depending on the type and extent of the disease.[667]

Surgical therapy, historically synonymous with Halsted's radical mastectomy, now includes a wide variety of options, such as partial mastectomy (lumpectomy, segmentectomy, or quadrantectomy, i.e., breast-conserving surgeries) and total (simple) mastectomy. The procedure selected is influenced by many factors, including tumor stage, patient preference and breast size, the surgeon's practice, whether or not reconstructive surgery is available, and geographic region.[668–670]

Radiation therapy is often employed as a postoperative adjunct (especially in more limited operations), as well as for control of locally recurrent disease.[671,672]

Microscopic evaluation of all surgical margins in breast-conserving surgery and of the deep margin in mastectomy is critical to determining the need for additional surgery and/or radiation therapy. A recent meta-analysis has endorsed the definition of ink on tumor (either invasive or DCIS) as being required for a positive margin in patients with invasive carcinoma being treated with breast-conserving surgery and whole breast irradiation. Anything less should be reported as a negative margin and the distance in millimeters reported.[673] Several studies have shown that patients with positive margins are more likely to develop local recurrence, as well as distant failure.[674–676] For margin-negative cases, the likelihood of ipsilateral breast failure and distant metastases is related to the amount of carcinoma near the margins.[677] Margin width is also a factor influencing recurrence among women with DCIS, particularly among those who forgo radiation

For personal use only. No other uses without permission. Copyright ©2017. Elsevier Inc. All rights reserved.

therapy.[678] A recent meta-analysis indicates that a 2-mm margin is desirable for patients with DCIS.[679] There is no requirement to report the margin status for classical LCIS, though reporting of margin status is recommended for the variant forms of LCIS, such as pleomorphic LCIS.

Endocrine therapy is the standard of care for all patients with ER-positive breast cancer.[680] At present, administration of a selective estrogen receptor modulator (SERM, e.g., tamoxifen) or an aromatase inhibitor in postmenopausal women (e.g., anastrazole) is the standard of care for early-stage, hormone receptor–positive breast carcinoma, usually combined with irradiation, with or without adjuvant chemotherapy, depending on the patient's age and other parameters.[680] Hormonal therapy, which had historically included the options of bilateral oophorectomy, adrenalectomy, and hypophysectomy, is now largely dependent on the aforementioned antiestrogen drugs.

Trastuzumab (Herceptin), a humanized monoclonal antibody against the HER2 receptor, is a form of targeted therapy that is effective for breast cancers that are HER2 positive (score 3+ by immunohistochemistry or *HER2* amplified by FISH studies). Although originally used only for patients with metastatic disease, the drug is now standard of care as an adjuvant agent for early-stage breast cancer as well.[681] Furthermore, newer agents against HER2 and its related receptors are becoming increasingly available either as alternate therapeutic options or as second-line therapy at the time of recurrence or metastasis.

Chemotherapy has had a significant impact on the survival of patients with metastatic breast carcinoma, the best results having been obtained with combination regimens. In addition, chemotherapy is currently used as an adjunct following local treatment, with curative intent, in patients with positive axillary nodes. The interested reader should refer to clinical texts for further information.[682] The value of platinum-based chemotherapeutic agents and of PARP inhibitors for treatment of breast cancers with specific DNA repair defects, including those arising in carriers of *BRCA1* or *BRCA2* mutation and basal-type breast cancers, have also shown promise.[683]

Effects of Therapy on the Tumor and on Normal Breast

Radiation therapy of breast carcinoma may result in bizarre nuclear changes, formation of giant tumor cells, naked nuclei, and abnormal mitotic figures. Extensive tumor necrosis may develop, which can become surrounded by a thick fibrous wall. It is important to remember that morphologic viability is not necessarily equivalent to biologic viability (i.e., the capacity of the tumor cell to replicate). In the non-neoplastic breast, the most characteristic irradiation effect is atypia of epithelial cells in the terminal ductules, associated with lobular sclerosis and atrophy (Fig. 36.126).[684] These postradiation changes can persist for years.[685]

Treatment of ER-positive tumors with endocrine therapy leads to prominent stromal fibrosis and hyalinization, an increase in the amount of elastic tissue, and degenerative changes in the tumor cells. The latter are manifested by cytoplasmic vacuolization, rupture of cell membranes, nuclear aberrations, and eventual necrosis. These changes may occur both in the primary tumor and in the metastases, and can be very patchy, in the sense of showing morphologically unaffected cells lying side by side with highly altered cells.

Chemotherapy can also induce striking morphologic changes in the tumor cells (Fig. 36.127), including such a degree of vacuolization as to simulate histiocytes. It also results in atrophy of the TDLU, with occasional atypia of the normal epithelial cells.[686] In most instances, treatment with neoadjuvant chemotherapy does not affect the histologic grading of the carcinoma; however, in some cases the tumor may appear to be higher grade (due to greater nuclear pleomorphism) or even lower grade (due to the identification of fewer mitoses).[687] The microscopic features of the treated tumor correlate poorly with patient outcome.[687] In some cases the residual tumor is present exclusively or predominantly as lymphatic emboli, a prognostically unfavorable feature.[688]

Guidelines have been published detailing appropriate gross examination, sampling, and reporting of breast carcinomas after neoadjuvant therapy.[687] In such patients, careful examination of the tumor bed, which is characterized by a hyalinized vascular stroma with fibroelastosis and edema infiltrated by histiocytes (Fig. 36.128), is critical to confirming the degree of pathologic response, particularly in the absence of any residual foci of invasive carcinoma. There are a variety of classification schemes in use to score the degree of tumor response with the two best known being the Residual Cancer Burden score and the Miller-Payne grade (Table 36.8).[689,690]

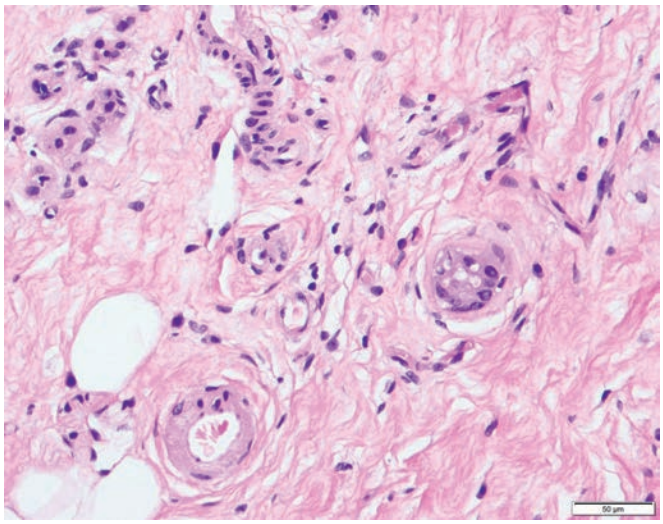

Figure 36.126 Radiation Effect in Non-Neoplastic Breast. The epithelial cells of the lobules show cytomegaly with smudgy nuclear features and cytoplasmic vacuolation associated with lobular sclerosis and atrophy. Note the absence of any epithelial proliferation.

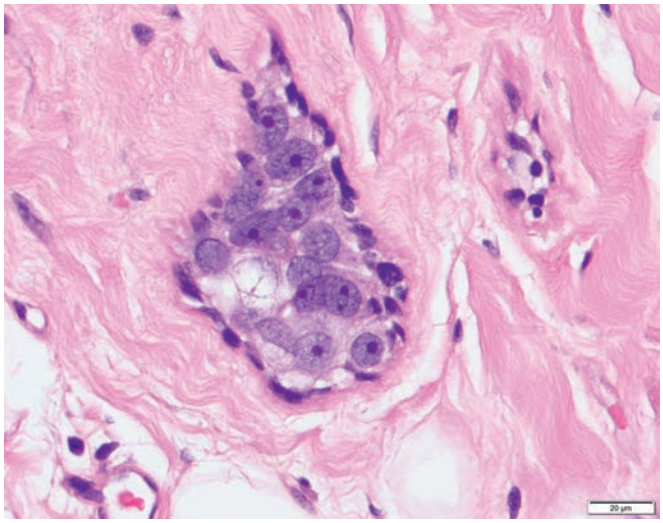

Figure 36.127 Chemotherapy Effect. Residual ductal carcinoma showing the effects of chemotherapy: nuclear enlargement, prominent nucleoli, and cellular vacuolization.

For personal use only. No other uses without permission. Copyright ©2017. Elsevier Inc. All rights reserved.

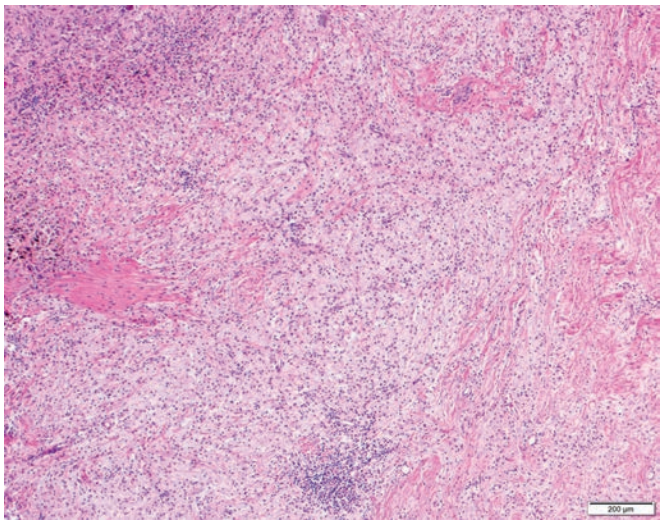

Figure 36.128 Tumor bed which is characterized by a hyalinized vascular stroma with fibroelastosis and edema infiltrated by histiocytes. Lymphocytes and hemosiderin are also noted in this field.

Table 36.8 Classification of neoadjuvant-treated breast cancers

Residual Cancer Burden (RCB)[689] Used in conjunction with MD Anderson Website Calculator (http://www3.mdanderson.org/app/medcalc/index.cfm?pagename=jsconvert3)

CATEGORY	DEFINITION
RCB-0 (pCR)	No carcinoma in breast or lymph nodes
RCB-I	Partial response
RCB-II	Partial response
RCB-III	Chemoresistant
Miller-Payne System	
GRADE	**DESCRIPTION OF RESPONSE**
Grade 1	No change or some alteration to individual malignant cells, but no reduction in overall cellularity
Grade 2	A minor loss of tumor cells but overall cellularity remains high; up to 30% loss
Grade 3	Between an estimated 30% and 90% reduction in tumor cell volume
Grade 4	A marked disappearance of tumor cells (>90% reduction); only small clusters or widely dispersed individual cells remain
Grade 5	No malignant cells identifiable; only tumor bed present. May have DCIS or LVI present

DCIS, Ductal carcinoma in situ; *LVI*, lymphovascular space invasion.
Data from Symmans WF, Peintinger F, Hatzis C, et al. Measurement of residual breast cancer burden to predict survival after neoadjuvant chemotherapy. *J Clin Oncol*. 2007;25(28):4414–4422; and Ogston KN, Miller ID, Payne S, et al. A new histological grading system to assess response of breast cancers to primary chemotherapy: prognostic significance and survival. *Breast*. 2003;12(5):320–327.

Another "treatment-related" effect worthy of comment relates to the use of breast implants for reconstructive purposes. The implants frequently develop a fibrous capsule around them, and the inside surface of this capsule has a tendency to undergo *synovial metaplasia*, which on occasion may become quite hyperplastic. Sometimes, the capsule is surrounded by benign squamous epithelium,[691] and, very rarely, implant-associated anaplastic lymphoma may occur (see later).[692,693]

Prognosis

The prognosis of breast carcinoma is related to a huge number of clinical and pathologic features, some of which are discussed later, often with conflicting reports as to the level of risk associated with any particular putative prognostic factor.

Patient age. Older, postmenopausal women have the best prognosis as these patients tend to have the better differentiated, ER-positive, screen-detected tumors presenting at a lower stage, though, of course, this age group will have competing morbidities that will affect survival data. As far as tumors occurring in young women (≤35 or <40 years of age), studies have shown young age to be an independent risk factor associated with a propensity for recurrence and distant metastases despite more aggressive therapies, related to the fact that these patients tend to have adverse histologic features, often have had delays in diagnosis, and thus present at a later/higher stage.[694–697]

BRCA. Early studies suggested that breast carcinomas developing in *BRCA1* mutation carriers were associated with worse overall survival if adjuvant therapy was not given, but a large study of Israeli women carriers of *BRCA1* and *BRCA2* mutations showed that their breast cancer–specific death rates were similar to those of noncarriers.[698] At this time, mutation status is not considered to be an independent predictor of clinical outcome.[666]

Pregnancy and oral contraceptives. There is general agreement that carcinoma of the breast manifesting during pregnancy or lactation is generally an aggressive tumor with low expression of hormone receptors and high expression of HER2 and that it is associated with an overall poorer prognosis.[699,700] However, it has been found that this difference does not reach statistical significance when evaluated stage for stage.[701,702]

No convincing evidence has been found that prior use of oral contraceptive agents has an effect on the evolution or survival of patients with breast carcinoma.[703]

Early diagnosis. The relative 5-, 10-, and 20-year survival rates for asymptomatic breast carcinomas detected in a large screening project (Breast Cancer Demonstration Detection Project) were 87%, 79%, and 78.2%, respectively.[311,704] These figures are much higher than those for clinically detectable carcinoma and relate to the fact that the tumors were small in most cases, were usually devoid of axillary metastases, and included a high percentage of microscopically favorable types.

Size. The diameter of the primary tumor shows a good correlation with the incidence of nodal metastases and with survival rate, with the notable exception of basal-like carcinomas which do not follow the "size–node rule," that is, small triple negative cancers may be lymph node positive and vice versa.[605,611,705,706] As a matter of fact, this easily, quickly, and cheaply determined parameter has been found to be one of the strongest predictors of dissemination and rate of relapse in node-negative breast carcinomas.[707] It should be noted that in tumors having both DCIS and an invasive component, the size of the latter, as measured microscopically, is a better predictor than is the total tumor size, hence the staging guideline for reporting microscopic size of the invasive component as the T-stage.[666,706,708]

For personal use only. No other uses without permission. Copyright ©2017. Elsevier Inc. All rights reserved.

Site. No relationship has been found in most studies between prognosis and the quadrant location of the primary tumor. However, in one large study, it was found that medial location of the tumor was associated with a risk of tumor-related death when compared with lateral location but not with local tumor control.[709–711]

Histologic type. There is no significant prognostic difference between ordinary invasive ductal and invasive lobular carcinoma.[712] Morphologic variants of invasive ductal carcinoma with a more favorable prognosis are tubular carcinoma, invasive cribriform carcinoma, pure mucinous carcinoma, adenoid cystic carcinoma, and secretory carcinoma.[210,713] A variant of invasive lobular (and sometimes ductal) carcinoma associated with a poor prognosis is signet ring carcinoma and the prognosis of inflammatory carcinoma (as defined microscopically, see next) is also particularly ominous. Metaplastic carcinomas show similar survival rates to invasive carcinomas of no special type.[210]

Microscopic grade. Since both architecture and cytology have been found to correlate with prognosis, Elston and Ellis championed a modification of the original Bloom and Richardson[714] and Black et al.[715] grading schemes, which were based on tubule formation and degree of nuclear atypia, respectively. This has come to be known as the Nottingham modification of the Bloom–Richardson system; it also incorporates evaluation of mitotic activity.[716] In this scheme, the grade is obtained by adding up the scores for tubule formation, nuclear pleomorphism, and mitotic count, each of which is given 1, 2, or 3 points. This is translated into the final grade by formulae outlined in Box 36.1 and Tables 36.9 and 36.10. The utility of this and related grading systems has been convincingly and repeatedly proven[717,718] to the point that incorporation of this information into the routine pathology report has become a requirement.[666] Further, an acceptable degree of interobserver reproducibility has been achieved when the criteria are applied.[719,720] The system was largely conceived for invasive ductal carcinoma NST, but it can also be applied to the special types of ductal carcinoma and to invasive lobular carcinoma.[721]

Box 36.1 Microscopic grading of breast carcinoma: Nottingham modification of the Bloom–Richardson system

Tubule formation

1 point: Tubule formation in >75% of the tumor
2 points: Tubule formation in 10%–75% of the tumor
3 points: Tubule formation in <10% of the tumor

Nuclear pleomorphism

1 point: Nuclei with minimal variation in size and shape
2 points: Nuclei with moderate variation in size and shape
3 points: Nuclei with marked variation in size and shape

Mitotic count

1, 2, or 3 points, according to Table 36.9.

Table 36.9 Assignment of points for mitotic counts according to the field diameter

Field diameter (mm)	0.44	0.59	0.63
Mitotic count			
1 point	0–5	0–9	0–11
2 points	6–10	10–19	12–22
3 points	>11	>20	>23

Tumor-infiltrating lymphocytes (TILs). Emerging data indicate that patients with breast carcinomas demonstrating a prominent lymphocytic reaction, particularly triple negative and HER2-positive tumors, have a better response to neoadjuvant chemotherapy than those tumors without.[722] Similarly, patients with triple negative or HER2-positive tumors and a prominent lymphocytic reaction receiving adjuvant chemotherapy appear to have a survival advantage over those without TILs.[722,723] No significant differences are noted for patients with hormone receptor–positive, HER2-negative disease according to TIL status.[722] At this point in time, however, there are no agreed-upon criteria for counting TILs or on how to report an "immune-score."

HER2. As already stated, overexpression or amplification of HER2 as determined either by immunohistochemistry or by FISH is an excellent predictor of response to trastuzumab (or other HER2-targeted therapies). Although it identifies a subset of patients with poor prognosis, HER2 status correlates closely with tumor grade and as such loses much of its independent prognostic significance in multivariate analysis.[724,725]

Skin invasion. Breast carcinomas in which invasion of the overlying skin has occurred are associated with a decreased survival rate.[726] Invasion of dermal lymphatic vessels as a determinant of the "inflammatory carcinoma" picture is a particularly ominous prognostic sign.

Lymphatic tumor emboli. The presence of tumor emboli in lymphatic vessels within the breast is associated with an increased risk of distant recurrence; an association made stronger with immunohistochemical confirmation of the lymphatic nature of the involved spaces (e.g. with D2-40).[727,728]

Blood vessel emboli. This finding shows a high correlation with tumor size, histologic grade, tumor type, lymph node status, development of distant metastases, and poor prognosis.[729]

Paget disease. The presence or absence of Paget disease in invasive ductal carcinoma is of no prognostic relevance.[730]

ER. Patients with ER-positive tumors have a longer disease-free survival than others.

DNA ploidy. Despite numerous studies evaluating DNA ploidy with flow cytometry, it is yet unclear whether this parameter adds *independent* information of therapeutic or prognostic value once the size of the tumor, microscopic grading, lymph node status, and hormone-receptor status have been taken into account; this ancillary information is not provided in routine clinical practice.[731–733]

Cell proliferation. This parameter, whether measured by the old-fashioned mitotic count, by MIB-1 (Ki-67) or analogous immunostain, by determination of S-phase fraction by flow cytometry, or by molecular-based testing such as PCR or gene expression profiling, has emerged as a very important prognostic determinant, particularly for ER-positive cases, hence its inclusion in the combined grading scheme espoused by Elston.[716] Many view it as the most important component of that system, which is being supported by evidence from innumerable gene expression profiling panels which all

Table 36.10 Final grading score

SUM OF POINTS	FINAL GRADE
3–5	1
6–7	2
8–9	3

For personal use only. No other uses without permission. Copyright ©2017. Elsevier Inc. All rights reserved.

demonstrate that proliferation-related genes are the main drivers in each of the gene signatures.[734,735]

Axillary lymph node metastases. This is one of the most important prognostic parameters. Not only is there a sharp difference in survival rates between patients with positive and negative nodes, but the survival rate also depends on the level of axillary node involved (low, medium, or high), the absolute number (fewer than four versus four or more), the amount of metastatic tumor and the presence or absence of extranodal extension.[655] There is no clinical significance to the presence of "micrometastases" (>0.2 to ≤2 mm) or "isolated tumor cells" (≤0.2 mm) as demonstrated in the NSABP (National Surgical Adjuvant Breast and Bowel Project) B32 trial.[736] For prognostic purposes, the best grouping seems to be the following: negative nodes, one to three positive nodes, and four or more positive nodes.

Internal mammary lymph node metastases. Survival in patients with involvement of this lymph node group is lower than in those without such involvement, especially if only patients with one to three positive axillary nodes are evaluated.[737]

Circulating tumor cells. There is increasing evidence that the presence and number of tumor cells in the bloodstream provide independent prognostic information on progression-free and overall survival in patients with early-stage and metastatic breast cancer.[738]

Local recurrence. Early studies showed this to be a sign of ominous prognosis. However, more recent data on larger series indicate that risk of death after local recurrence is related to the stage at initial breast cancer diagnosis.[739]

Type of therapy. This is too complex and multifactorial an issue to be adequately addressed here. Available evidence suggests that the outcome in breast carcinoma depends on both the nature of the individual tumor and on the type of therapy given, in addition to those factors discussed previously. A complicating factor in evaluating therapeutic results is the marked variation in the natural history of the disease among individuals, which renders imperative the use of carefully randomized studies.[740,741] The results of six large prospective randomized clinical trials have clearly demonstrated that the combination of breast-conserving surgery and radiation therapy provides survival rates equivalent to those following mastectomy.[742]

Surgical margins. Microscopically positive surgical margins in specimens from conservative breast excisions are associated with a higher risk of ipsilateral tumor recurrence.[628,673,743] Definitions of "positive" and "close" margins have varied in the literature, but a recent guideline statement by a multidisciplinary group of experts recommends use of "ink on tumor" as the definition of a positive margin in patients with invasive breast carcinoma. All else should be reported as a negative margin, with the distance to the margin reported in millimeters.[673] It is anticipated that standardizing the definition of a positive margin will result in less arbitrary decision-making regarding the need for reexcision. Early indications are that there has been a change in surgical practice with a reduction in reexcision rates reported.[744] Some surgeons excise multiple separate "cavity margins" (from the wall of the residual cavity during the same surgical procedure) and regard them as the "final margins" that supersede the initial margins from the excised specimen.[745]

Gene expression profiling. There are many studies reporting the use of microarray analysis to select tumor gene signatures for separating patients into meaningful prognostic/predictive groups that will potentially help with selection of therapy.[609,746–749] Two popular commercially available tests are: (1) MammaPrint (70-gene expression analysis by microarray); and (2) Oncotype DX (analysis of expression of 16 cancer-related genes and 5 reference genes by reverse transcription quantitative PCR). Both may be performed on formalin-fixed paraffin-embedded tissue.[750] A third test, PAM50 Prosigna assay, has recently come to market; it utilizes nanostring technology, as well as providing prognostic and predictive information, the test also classifies the tumor according to its intrinsic molecular subtype. This test will be available for laboratories to perform themselves, in contrast to the Onocotype Dx and MammaPrint assays, which are performed in single, commercial laboratories. It should be noted that almost all the gene signatures are applicable to hormone receptor–positive tumors with the decision point being whether or not to give the patient chemotherapy in addition to antiestrogen therapy.[623,749,751] Recent data from two prospective clinical trials indicate that chemotherapy may be safely omitted in patients with a low recurrence score on Oncotype Dx or a good prognosis signature on testing by MammaPrint.[623] Results guiding management of patients in the intermediate risk group have not yet been reported.

Salivary Gland and Skin Adnexal-Type Tumors (Including Myoepithelial Tumors)

A small proportion of benign and malignant tumors of the breast have an appearance analogous to, or at least reminiscent of, that more commonly seen in salivary glands or skin adnexa, particularly sweat glands.[752] This should not be too surprising, since the breast is a modified sweat gland and a close analogy exists between sweat gland tumors and salivary gland neoplasms. Some of the malignant tumors in this category share many of the features of ordinary breast carcinoma and therefore have been discussed in the preceding section. However, they could have been included here because of the histogenetic link they seem to have (at least at the conceptual level) with benign tumors of salivary gland and/or their skin adnexal-type morphology.

The benign tumors in this category include **eccrine spiradenoma** (which, as in the skin, may undergo malignant transformation), **syringomatous squamous tumors** (to be distinguished from low-grade adenosquamous carcinoma), **papillary syringocystadenoma**, dermal-type **cylindroma** (not to be equated with adenoid cystic carcinoma), **eccrine acrospiroma** (including nodular, solid–cystic, and clear cell hidradenoma), and **pleomorphic adenoma.** The latter, which is very rare in humans but relatively common in female dogs, has been interpreted by some as a variant of intraductal papilloma, but its appearance is quite similar to that of pleomorphic adenoma of salivary glands (benign mixed tumor) or of cutaneous sweat glands (chondroid syringoma) (Fig. 36.129). This tumor can arise as single or multiple nodules sometimes in a background of usual ductal hyperplasia, or in association (possibly coincidental) with breast carcinoma. An association with metaplastic carcinoma has not been well defined.[753,754]

A more complicated issue is represented by breast tumors of probable myoepithelial nature. First, it should be recognized that myoepithelial participation is an integral component of benign proliferative breast diseases (such as sclerosing adenosis, UDH, intraductal papilloma, and nipple adenoma) and that, in some instances, it dominates the histologic picture. Second, myoepithelial cells are a normal constituent of ducts and lobules, and therefore one might question whether these neoplasms should even be regarded as of salivary or sweat gland type. They are discussed here because the morphologic variations they exhibit and classification problems they elicit are very similar to those they pose in the salivary glands (see Chapter 12). **Adenomyoepithelioma** is a small (average diameter 1 cm), firm, well-circumscribed, often multilobulated tumor composed microscopically of cells of polygonal shape and optically clear to eosinophilic cytoplasm, arranged in nests within which

For personal use only. No other uses without permission. Copyright ©2017. Elsevier Inc. All rights reserved.

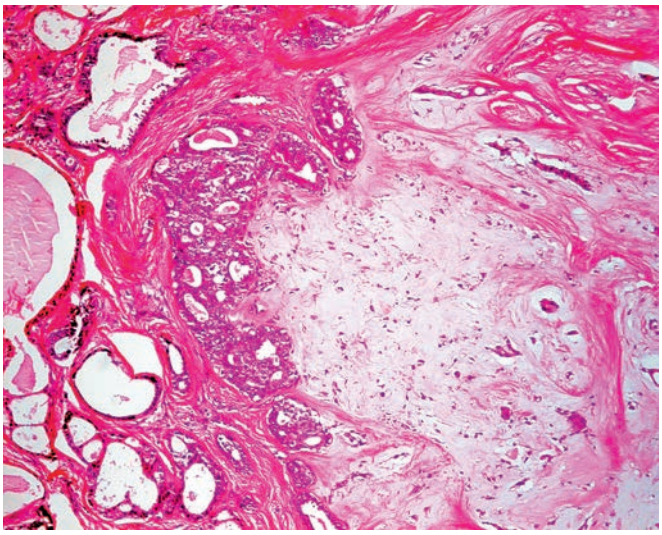

Figure 36.129 Pleomorphic Adenoma/Benign Mixed Tumor of the Breast. A prominent myxochondroid stroma is interspersed among the glandular structures.

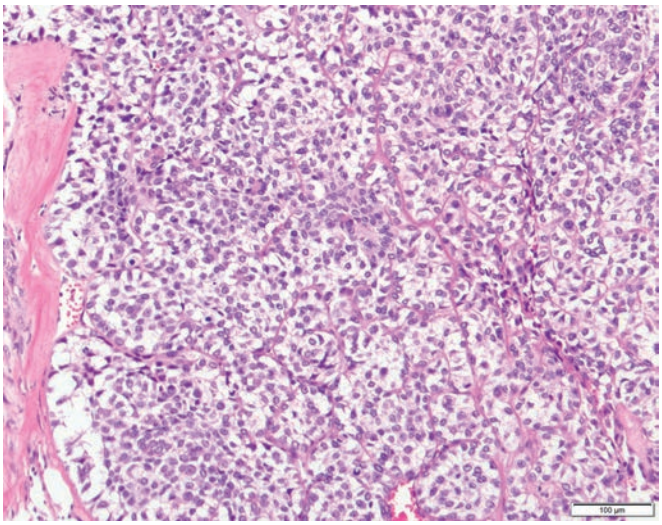

Figure 36.130 Adenomyoepithelioma. This well-circumscribed, multilobulated tumor is composed of polygonal cells with optically clear cytoplasm, arranged in nests. The gland-forming epithelial cells, with more eosinophilic cytoplasm, are harder to appreciate.

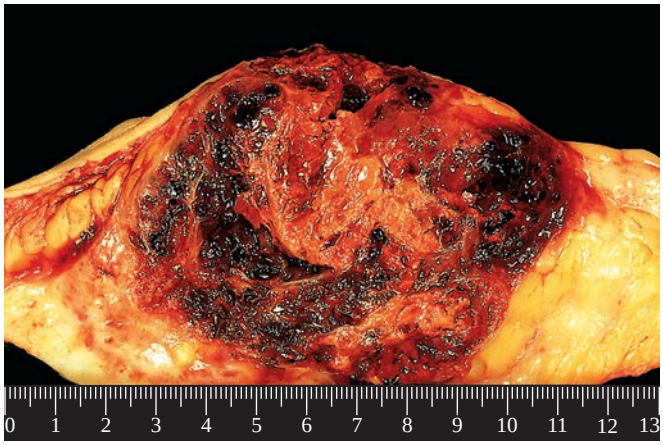

Figure 36.131 Typical Hemorrhagic Gross Appearance of Angiosarcoma of Breast. (Courtesy of Dr Pedro J Grases Galofrè. From Grases Galofrè P. *Patologìa ginecològica, Bases para el diagnòstico morfològico*. Barcelona: Masson; 2002.)

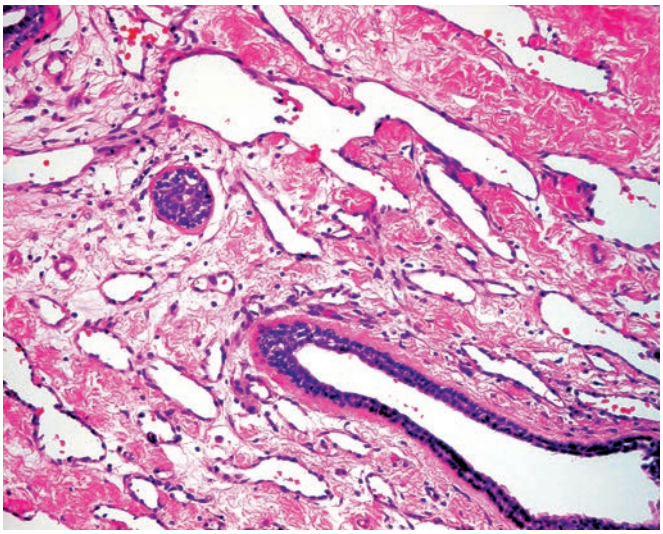

Figure 36.132 Well-Differentiated Angiosarcoma of Breast.

gland-forming epithelial cells may be appreciated.[755] The patterns of growth may be spindle cell (myoid), tubular, or lobulated (Fig. 36.130).[755–757] The behavior is generally benign, with local recurrence reported but no instances of metastatic spread.[756,758] Fully malignant myoepithelial tumors arising in association with adenomyoepithelioma (malignant myoepithelioma and/or myoepithelial carcinoma) are better classified as metaplastic carcinomas given the considerable overlap in expression of myoepithelial and epithelial markers in these tumors; a classification change that is largely semantic.[210]

Stromal and Vascular Tumors and Tumorlike Conditions

Primary angiosarcoma of the breast is an extremely rare tumor of young to middle-aged women.[759] Mammographically, it presents as a solitary mass without associated calcifications.[760] Grossly, the tumor is soft, spongy, and hemorrhagic (Fig. 36.131). Microscopically, the diagnostic areas are characterized by anastomosing vascular channels lined by atypical endothelial cells infiltrating through the breast parenchyma (Fig. 36.132). The appearance may vary, even in the same tumor, from that of a highly undifferentiated solid neoplasm to one that is extremely bland cytologically. However, close examination will usually reveal that even the better differentiated areas exhibit the telltale sign of angiosarcoma (i.e., inter-anastomosing vascular channels and endothelial cell atypia) (Figs. 36.133 and 36.134; see also Fig. 36.132). The tumor is thought to be of blood vessel rather than lymphatic vessel nature. Occasionally, the tumor is more epithelioid appearing and may mimic a high-grade invasive ductal carcinoma; a pitfall that may be compounded by aberrant keratin expression.[761] Curiously, some cases of breast angiosarcoma have been found to express ER.[762] The differential diagnosis of angiosarcoma includes metaplastic carcinoma, in particular, the acantholytic variant of squamous cell carcinoma (see Fig. 36.116), hemangioma (see following discussion), and pseudoangiomatous stromal

For personal use only. No other uses without permission. Copyright ©2017. Elsevier Inc. All rights reserved.

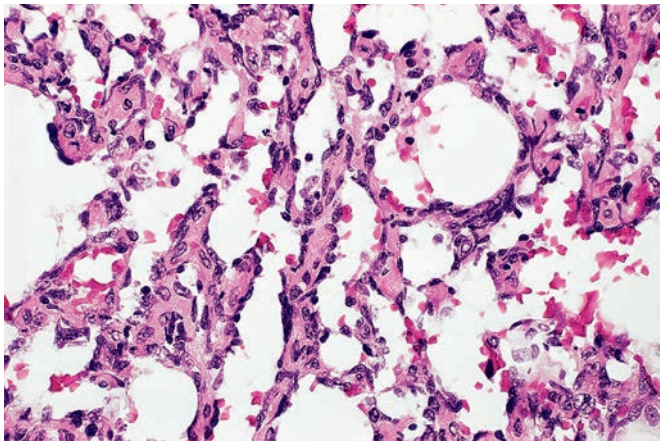

Figure 36.133 Complex anastomosing vascular pattern in angiosarcoma of breast.

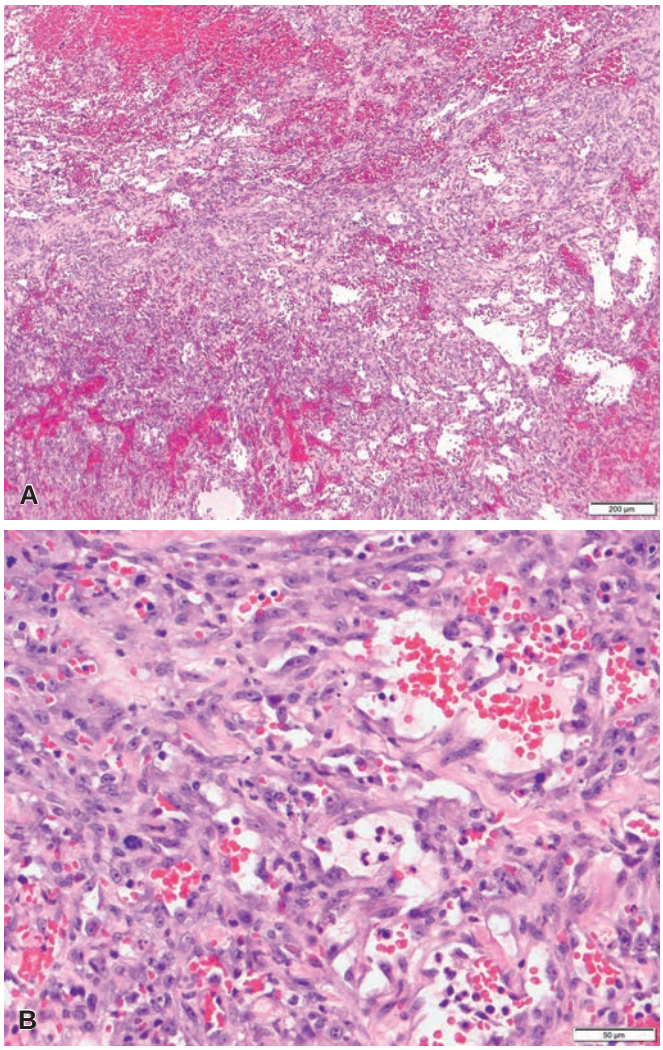

Figure 36.134 **Poorly Differentiated Angiosarcoma of Breast. A,** At low power, the interanastomosing vascular channels are apparent, as well as areas of solid growth and "blood lakes." **B,** High power, showing the significant endothelial cell atypia and brisk mitotic activity.

hyperplasia (PASH). Immunostaining for MIB-1 (Ki-67) is said to be of utility in distinguishing the better differentiated angiosarcomas from hemangiomas.[763]

A useful immunohistochemical panel for angiosarcoma should include vascular markers, such as ERG, CD34, and CD31, as well as cytokeratins and, on occasion p63, if the differential diagnosis includes metaplastic carcinoma and/or high-grade invasive ductal carcinoma. Note that some angiosarcomas, particularly the epithelioid variant, may show aberrant cytokeratin expression.

The overall prognosis of angiosarcoma is poor, with most patients developing metastases via hematogenous dissemination.[764] Donnell et al.[765] demonstrated that good correlation exists between microscopic grade and outcome. In their series, the 5-year disease-free survival was 33%; 10 of their 13 patients with grade I lesions were alive and well. The relationship of grading with prognosis has been confirmed in some, but not all, series.[766–768]

Post-mastectomy; post-lymphedema lymphangiosarcoma was a rare dreadful complication developing in the soft tissues of the upper extremity as a result of longstanding lymphedema following radical mastectomy or, exceptionally, segmental mastectomy[769] (Stewart–Treves syndrome). This is hardly seen now, though it has been replaced by another type of iatrogenic process, this time following radiation therapy for carcinoma of the breast, as described in the following paragraph.

Post-radiation vascular proliferations. Following the administration of radiation therapy to patients with breast carcinoma who have been treated with conservative surgery, the overlying skin can develop a variety of vascular proliferative lesions, which range from lymphangioma-like nodules to angiosarcoma,[770] with intermediate forms that have been descriptively named *atypical vascular lesions*.[771–777] Atypical vascular lesions are characterized by a proliferation of vascular channels located in the dermis and arrayed in a wedge-like manner. There is little if any endothelial cell atypia and they tend to run a benign clinical course, at least on a short-term basis. Some reports indicate that these lesions may evolve into angiosarcomas.[778]

Recent work has demonstrated that *post-radiation angiosarcomas* frequently show *MYC* amplification which potentially could be used to distinguish these lesions from primary angiosarcomas and atypical vascular lesions, which do not demonstrate amplification of this oncogene.[779–782] Post-radiation angiosarcomas, too, are preferentially located in the skin rather than the breast parenchyma itself.[783] The histologic features are as described for primary angiosarcomas, and the prognosis is poor. In contrast to angiosarcoma of the Stewart–Treves type, the interval between the radiation and the development of this tumor is short and lymphedema is minimal or absent.[784]

Benign vascular tumors can also develop within the breast parenchyma, contradicting the old adage that virtually all vascular tumors of the breast are malignant. Although the bland microscopic appearance of some angiosarcomas of the breast cannot be overemphasized, it is also true that a number of perfectly benign vascular tumors can occur in the breast. To begin with, hemangiomas of various types that share the features of those seen elsewhere in the body can develop in the overlying skin and subcutaneous fat. The most likely to be overdiagnosed is *angiolipoma* because sometimes it can be very cellular and the adipose tissue component can be inconspicuous.[785,786] The presence of fibrin thrombi in the vessels and absence of breast parenchyma indicating location in the subcutaneous tissue are important diagnostic clues on core needle biopsy[787]; encapsulation is often subtle in these specimens.

Perilobular hemangioma is usually an incidental microscopic finding; it is characterized by dilated capillary-sized vessels in a perilobular location, without anastomoses or cellular atypia.[788] Autopsy studies have shown that it is a relatively common lesion, having been found in 11% of all breasts.[789] Other *hemangiomas* are not perilobular in

For personal use only. No other uses without permission. Copyright ©2017. Elsevier Inc. All rights reserved.

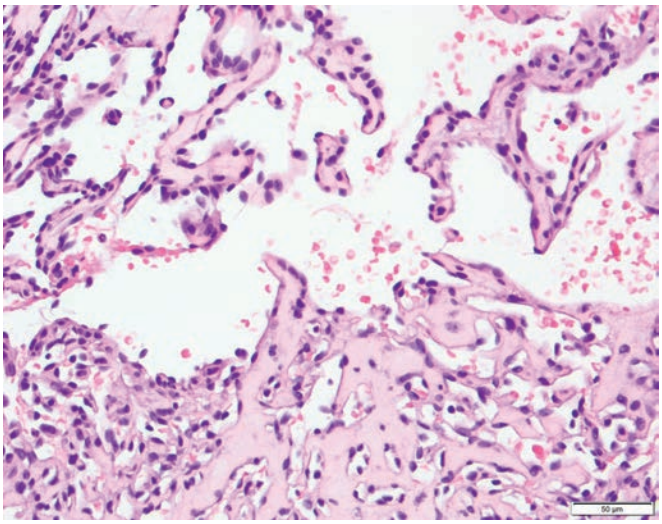

Figure 36.135 Papillary Endothelial Hyperplasia. High-power view showing a pattern of vascular anastomosis and prominent endothelial cells, which may be a mimic for low-grade angiosarcoma.

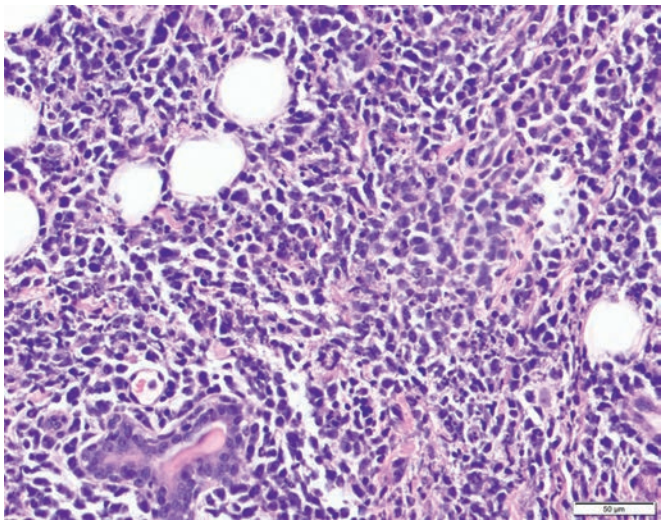

Figure 36.136 Diffuse Large B-cell Lymphoma of Breast. The breast parenchyma is infiltrated by a population of abnormal lymphoid cells which are medium and large in size, with irregular nuclear contours. Numerous apoptotic cells are seen.

location; they also tend to be small but can reach a diameter of 2 cm.[790] There are also *venous hemangiomas*.[791] Hemangiomas having a diffuse quality (although without anastomosing channels) have been referred to as *angiomatosis*.[792] *Epithelioid hemangioma* and *intravascular papillary endothelial hyperplasia (Masson tumor)* can also be located within the breast parenchyma (Fig. 36.135); the latter can be a mimic for low-grade angiosarcoma.

Other Malignant Stromal Tumors

Primary breast sarcoma is an extremely rare tumor. In fact, with the exception of angiosarcoma, any sarcomatous appearing tumor of the breast should be thoroughly worked up to exclude metaplastic carcinoma or the stromal component of a malignant phyllodes tumor before the diagnosis is rendered. Grossly, primary breast sarcomas appear solid, grayish white, and homogeneous. Necrosis may be present. Microscopically, most of them have the features of fibrosarcoma; focal osseous metaplasia can occur. Infiltrative margins and severe atypia indicate a greater tendency for local recurrence and distant metastases.[793] Many of these sarcomas do not match precisely the appearance of those arising in the usual soft tissue locations, probably owing to the fact that they are composed of a specialized type of stroma. Reported cases of CD10-positive mammary sarcomas are examples of this phenomenon.[794] Having said that, it ought to be acknowledged that tumors with an appearance equivalent to that of various types of sarcomas of somatic soft tissues do exist.[795] They include but are not limited to *liposarcoma*, *leiomyosarcoma*, *rhabdomyosarcoma* (though most such tumors are metastatic), *fibrosarcoma*, *chondrosarcoma*, and *osteosarcoma*.

Lymphoid Tumors and Tumorlike Conditions

Malignant lymphoma can present as a primary mammary neoplasm or involve the breast as part of a systemic process.[796] Lymphoma can also occur in association with breast implants (see below).[692,693] Grossly, lymphoma of the breast is fleshy and tan–white in color. It is not accompanied by skin retraction or nipple discharge. Multiple nodules are sometimes encountered. The involvement is bilateral in 10% of patients. In adult patients, primary lymphomas of the breast

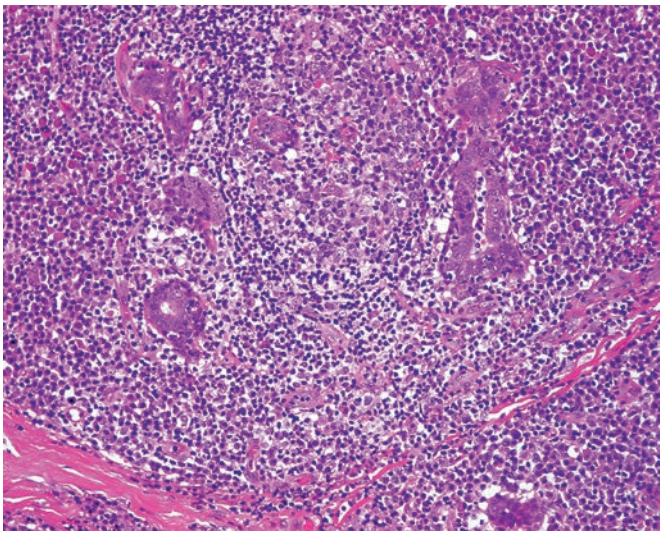

Figure 36.137 Extranodal Marginal Zone Lymphoma of Mucosa-Associated Lymphoid Tissue (MALT Lymphoma) of Breast. Some of the neoplastic lymphocytes infiltrate the glandular structures.

are nearly always of non-Hodgkin type and are usually composed of B cells,[796] although examples of T-cell lymphoma are also on record.[797,798] The B-cell lymphomas can be composed of either large or small cells[799,800] and usually show a nongerminal center phenotype.[801] Most primary breast lymphomas are of the diffuse large B-cell type (Fig. 36.136); other types include extranodal marginal zone lymphoma of mucosa-associated lymphoid tissue (MALT lymphoma) and follicular lymphoma (Fig. 36.137).[796] Rare types of lymphoma include Burkitt lymphoma, lymphoblastic lymphoma, and implant-associated anaplastic large cell lymphoma (see later). Extranodal marginal zone lymphoma of mucosa-associated lymphoid tissue (MALT lymphoma) shows the typical tendency to surround and invade the wall and lumina of the epithelial structures, resulting in the so-called "lymphoepithelial lesion." Immunohistochemical studies demonstrate the characteristic profile of the lymphoma as found at other sites.[800] Be aware that the targetoid pattern sometimes seen around the ducts in extranodal

For personal use only. No other uses without permission. Copyright ©2017. Elsevier Inc. All rights reserved.

marginal zone lymphoma of mucosa-associated lymphoid tissue may simulate the appearance of invasive lobular carcinoma; in such cases, stains for CD45, CD20, and cytokeratin should solve the diagnostic dilemma. The survival of patients with breast lymphoma is related to stage and microscopic type.[796,799]

"Pseudolymphoma" has been described in the breast. As in other organs, its position in relation to extranodal marginal zone lymphoma of mucosa-associated lymphoid tissue has become fuzzy. Some cases seem clearly reactive on morphologic and immunohistochemical grounds, perhaps representing an exuberant local reaction to injury.[802–804] Some cases may represent part of the spectrum of IgG4-related disease.[53,54] Other cases, instead, are composed of a monotonous small lymphocytic population and not easily separable from low-grade lymphomas. In some instances, the noncommittal diagnosis of *small lymphocytic proliferation* may be the best approach, followed by a recommendation for no further therapy if no systemic evidence of lymphoma is encountered. As far as the term pseudolymphoma is concerned, it is probably better to avoid it altogether.

Involvement of the breast by **Burkitt lymphoma** in African children has resulted in the formation of huge bilateral masses. Bilateral Burkitt-type lymphoma has also been seen in young women during pregnancy.[805]

Hodgkin lymphoma primary in the breast is exceptional. Most cases of Hodgkin lymphoma involving the breast represent secondary involvement in stage IV disease.

Plasmacytoma has been seen presenting as a primary breast mass, sometimes associated with a serum monoclonal protein.[806]

Intravascular lymphoma can involve the breast and bear an uncanny resemblance to high-grade DCIS, as Dr. Rosai admitted learning the hard way at a seminar in which he participated many years ago.[807,808]

Anaplastic large cell lymphoma can also involve the breast.[809] Notably, the majority of the reported cases have developed around a breast prosthesis ("implant-associated"). **Implant-associated anaplastic large cell lymphoma** is a recently reported distinct entity, very different from systemic ALK-negative anaplastic large cell lymphoma. There appears to be no relation to the indication for the implant, or the duration since the implant was placed; recent data indicate a significant association with textured implants. Limited data indicate a relatively indolent course, managed with implant removal and observation, unless associated with a mass-forming lesion, in which case a more aggressive course may ensue.[692,693,809]

Myelocytic leukemia of either acute or chronic type can present as a localized mass (granulocytic or myeloid sarcoma) in the breast and be microscopically confused with large cell lymphoma (Fig. 36.138).[810] The most important clue to the diagnosis in H&E sections is the presence of eosinophilic myelocytes and metamyelocytes, identified by their round or slightly indented nucleus and bright eosinophilic cytoplasmic granules. The diagnosis can be confirmed with immunostains for myeloperoxidase or CD117.[811]

Extramedullary hematopoiesis can exceptionally present in the form of a mass lesion in the breast in patients with idiopathic myelofibrosis or following neoadjuvant chemotherapy.[812,813]

Other Primary Tumors and Tumorlike Conditions

Basal cell carcinomas, squamous cell carcinomas, keratinous cysts, and **sweat gland tumors** may arise in the skin of the nipple or other sites in the breast, but they are not considered primary breast tumors.

Mammary hamartoma is defined as combination of ducts, lobules, collagenous stroma, and adipose tissue present as a relatively circumscribed lesion. Its identification is said to depend on the combination of clinical, radiologic, and pathologic criteria.[814,815] Morphologically, lesions that have been thought to be hamartomas on mammography may exhibit a wide diversity of appearances, the common denominator, by definition, being the admixture of epithelial and stromal elements, the latter including fat (Figs. 36.139 and 36.140).[816–818] A reproducible immunohistochemical profile has not been reported.[819] *Myoid hamartoma*[817,820] (which can contain epithelioid smooth muscle cells[821]) and *chondrolipoma* (a benign lesion composed of an admixture of fat, cartilage, and sometimes bone) are two other processes straddling the fence between malformation and benign neoplasia.

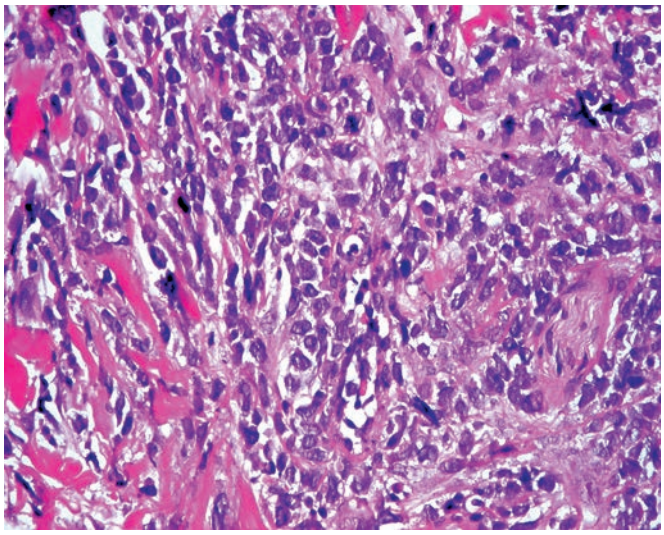

Figure 36.138 Granulocytic Sarcoma of Breast. It is easy to misdiagnose this lesion as a large cell lymphoma.

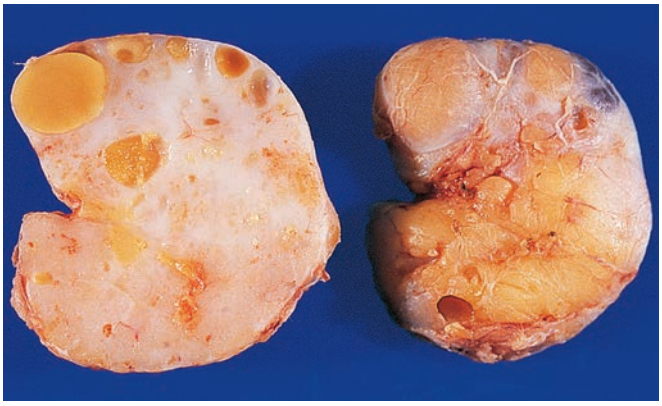

Figure 36.139 Gross Appearance of So-Called Hamartoma. There is a combination of cystic dilation of ducts, fibrosis, and entrapment of adipose tissue. This lesion is more distinctive and impressive grossly than microscopically.

Granular cell tumor is important because of its ability to simulate grossly the appearance of invasive carcinoma.[822–824] It is usually small, but it may reach a size of 10 cm or more. On cut section, it is firm, homogeneous, and white or grayish yellow. As a rule, it is not attached to the overlying skin, but it may be fixed to the underlying fascia. The behavior is benign, and the treatment is local excision.[822,825]

Myofibroblastoma is a benign mesenchymal tumor originally described in the male breast but also occurring in the female organ.[826,827] Grossly, it is well circumscribed and usually small,

For personal use only. No other uses without permission. Copyright ©2017. Elsevier Inc. All rights reserved.

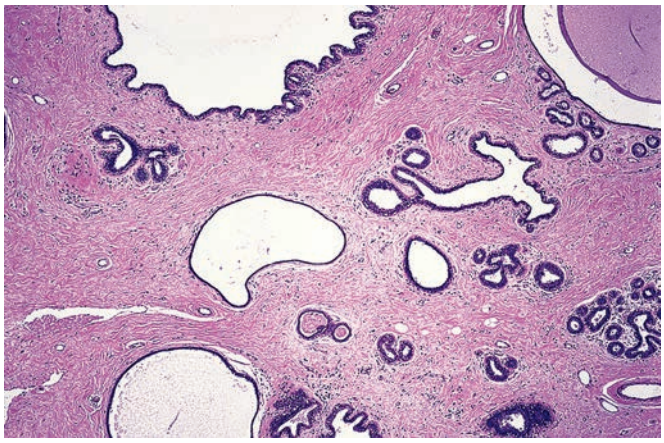

Figure 36.140 Glandular epithelium and fibrous stroma with distorted arrangement in hamartoma of breast.

although on occasion it can reach a large size. Microscopically, uniform, bland-looking spindle cells are arranged in short fascicles separated by broad bands of hyalinized collagen (Fig. 36.141).[826–828] Focally, there may be smooth muscle, cartilaginous, or adipose metaplasia. The appearance is very reminiscent of both solitary fibrous tumor and spindle cell lipoma, the suggestion having been made that there is a close histogenetic link between these neoplasms.[828–830] This hypothesis is further supported by the finding of genetic rearrangement or deletion of 13q14 and loss of Rb expression by immunohistochemistry in this group of lesions.[828,831,832] Immunoreactivity for desmin and CD34 is reported in the majority of cases.[828] ER and bcl-2 are also strongly expressed.[826]

There are several variants described, for example, *epithelioid* and the *deciduoid* myofibroblastoma. The former may be a mimic for invasive lobular carcinoma, particularly on core needle biopsy; an error that may be compounded by ER expression of the lesional cells.

Solitary fibrous tumor has been reported in the breast. Its morphologic and immunohistochemical features are the same as those reported for solitary fibrous tumor occurring at other sites and blend with those of spindle cell lipoma and myofibroblastoma.[833] Immunoreactivity for CD34, bcl-2, and especially STAT6 are helpful in confirming the diagnosis.[833]

Leiomyoma usually involves the nipple and is often painful[834]; occasionally, it is seen within the breast substance.[835] Some have been reported as having epithelioid features and granular changes.[836]

Benign peripheral nerve tumors of both *schwannoma* and *perineurioma* types have been described. *Traumatic neuromas with granular cell changes* have been observed in mastectomy scars.[837]

Perivascular epithelioid cell neoplasm (PEComa; clear cell ["sugar"] tumor) has been reported in the breast.[838] This a neoplasm characterized by HMB45-positive epithelioid smooth muscle cells.

Nodular fasciitis is rarely seen within the breast, its appearance and behavior being similar to those of its more common soft tissue counterpart. It should be included in the differential diagnostic consideration of spindle cell lesions of the breast.

Fibromatosis (extra-abdominal desmoid tumor) can also be found within the substance of the breast (Fig. 36.142). Morphologically it is composed of long, sweeping fascicles of bland spindle cells that entrap the native ducts and lobules. Lymphoid infiltrates are commonly seen at the periphery of the lesion (Fig. 36.143). It shares with its homologue in the somatic soft tissue a tendency for infiltration, local aggressiveness, and local recurrence.[839] This is also true at the molecular level, in that they have a similar spectrum of

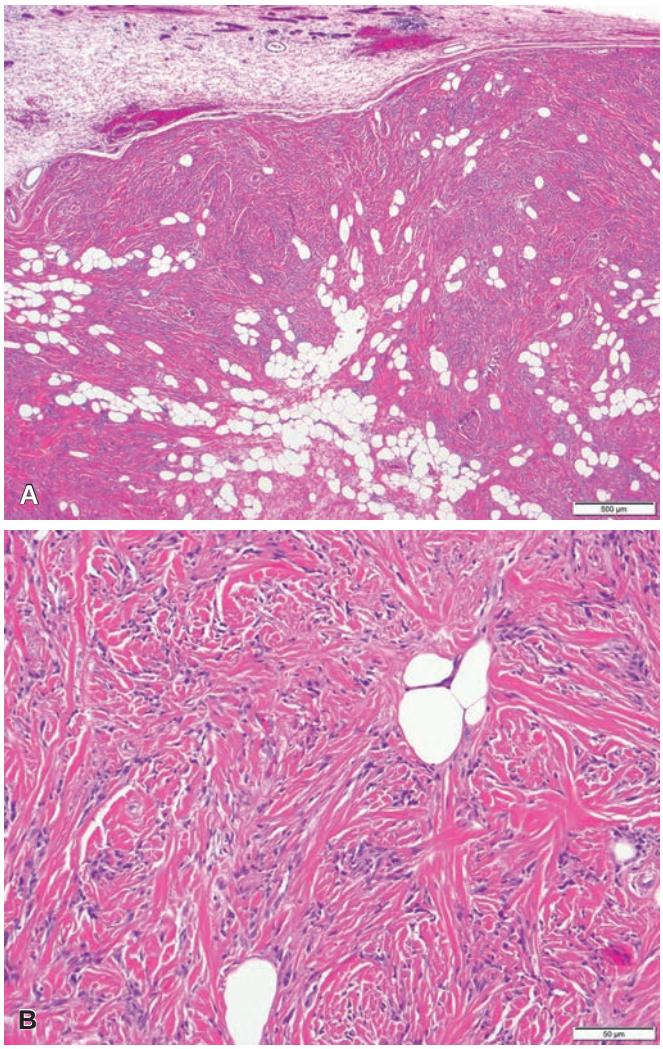

Figure 36.141 **Myofibroblastoma. A,** At low power, the well-circumscribed margin of this bland spindle cell tumor is appreciated. **B,** At high power, the spindle cells are bland, arranged in short fascicles separated by broad bands of collagen.

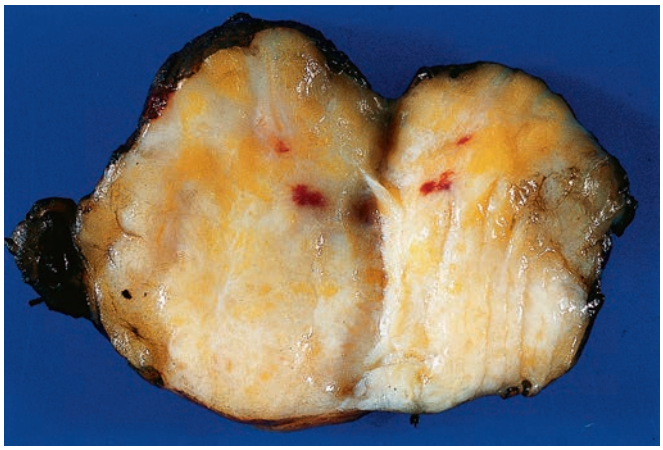

Figure 36.142 Gross appearance of fibromatosis involving breast. The mass is solid and ill defined.

For personal use only. No other uses without permission. Copyright ©2017. Elsevier Inc. All rights reserved.

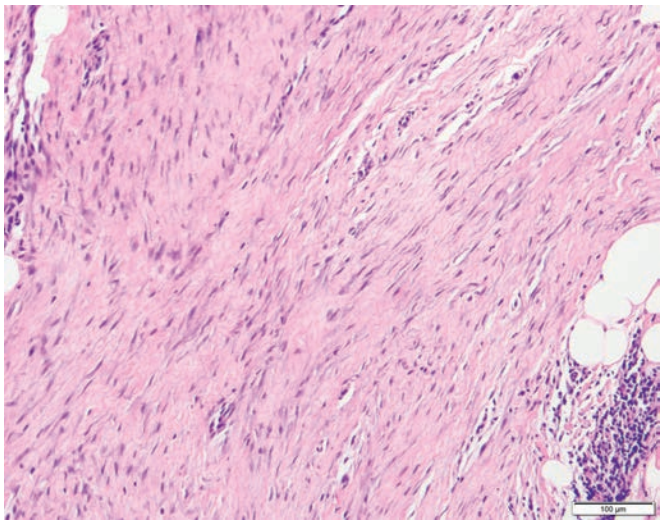

Figure 36.143 Fibromatosis. The lesion is composed of long, sweeping fascicles of bland spindle cells that entrap the native ducts and lobules. Lymphoid infiltrates are commonly seen at the periphery of the lesion.

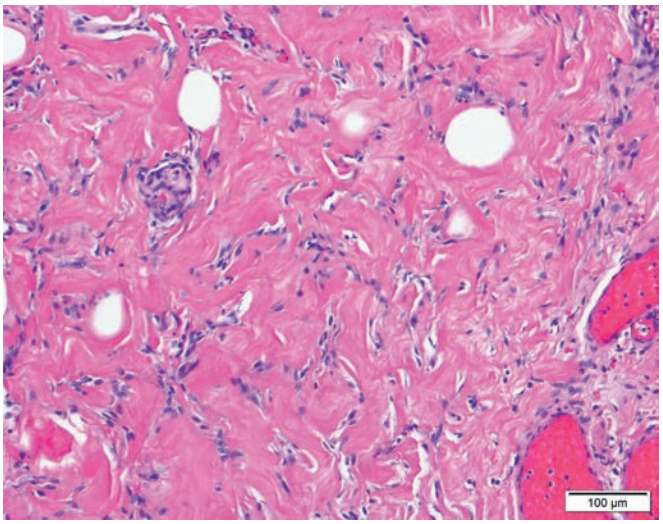

Figure 36.144 Pseudoangiomatous Stromal Hyperplasia. Thin channels lined by spindle cells are seen scattered within a hyalinized stroma.

CTNNB1 (β-catenin) and *APC* gene alterations.[840] Reports of mammary fibromatosis occurring in or around the capsule of a grossly intact implant have not been able to establish a significant pathogenetic relationship.[841]

Cases of mammary fibromatosis occurring during childbearing age are, in general, more cellular than those seen after menopause,[842] being infiltrative, aggressive, and prone to local recurrence.[839] Fibromatosis should be distinguished from low-grade fibromatosis-like metaplastic carcinoma and scarring secondary to (surgical) trauma. Nuclear staining with β-catenin may be useful in confirming the diagnosis of fibromatosis, though it should be noted that this is not specific for the lesion as phyllodes tumor and metaplastic carcinoma may also stain with β-catenin.

Pseudoangiomatous stromal hyperplasia (PASH) is characterized by a proliferation of stromal spindle cells of fibroblastic/myofibroblastic nature associated with the formation of clefts that simulate vascular channels (Fig. 36.144).[843,844] It is a common finding identified in nearly one-third of breast biopsies. PASH may present as a mass on mammographic and ultrasound studies; on MRI it is more likely to present as an area of non-mass-like enhancement. It is prudent to rule out other possible pathologies before diagnosing PASH as the imaging correlate for a targeted mass. Occasionally, the myofibroblasts may aggregate into fascicles; this appearance has been referred to as fascicular PASH. The spindle cells are immunoreactive for vimentin and CD34 and negative for vascular markers, such as ERG and CD31. In addition, they show intense positivity for PR. The latter finding suggests that PASH represents a localized form of stromal overgrowth with a hormonal (primarily progestogenic) pathogenesis.[845]

Multinucleated giant cells of reactive appearance are sometimes found incidentally in the normal mammary stroma or in the stroma of fibroadenomas[150,846]; they are of no clinical significance and are probably analogous to those seen in non-neoplastic polypoid stromal lesions located beneath mucosal membranes, such as the nasal cavity, oral cavity, anus, and lower female genital tract (Fig. 36.145).[846] Recognition of these cells for what they are and not mistaking them for a malignant process is the reason for mentioning them here.

Inflammatory myofibroblastic tumor may involve the breast, its microscopic features being analogous to those seen in other, more common sites.[847,848]

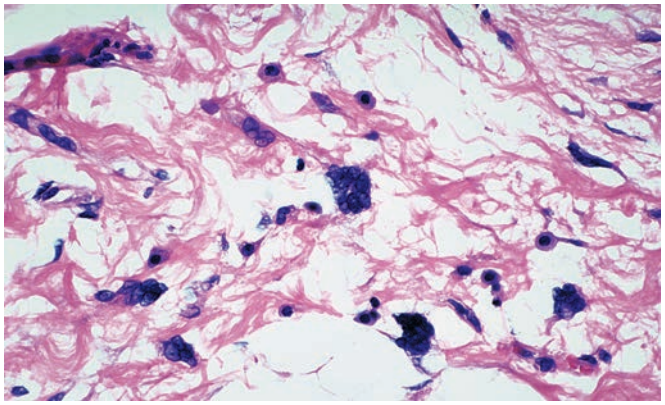

Figure 36.145 Bizarre Multinucleated Cells in Mammary Stroma. This non-neoplastic change is analogous to that more often seen in the stroma of the upper aerodigestive tract and in the genital tract.

Amyloidosis can appear as a solitary nodule within the breast parenchyma (so-called amyloid tumor).[849,850]

Rosai–Dorfman disease and **Erdheim–Chester disease** can also present under exceptional circumstances as breast masses, the former either as an isolated event or as a component of systemic disease.[851,852]

Juvenile xanthogranuloma can affect the breast of children and, exceptionally, of adult patients.[853]

Nodular mucinosis presents as a circumscribed area of myxoid stromal change near the nipple.[854] It should be distinguished from mucinous carcinoma and mucocele-like lesion.

Metastatic Tumors

Metastatic malignant tumors rarely affect the breast except when widely disseminated.[855] They typically appear as superficial, well-defined multinodular masses. Malignant melanoma and carcinoma of the lung, ovary, kidney, and stomach are the most common sources.[856,857] Most of the lung tumors are of the small cell neuroendocrine type. Breast metastases have also been documented from better differentiated neuroendocrine tumors, such as from the bronchus or small bowel, pancreatic (neuro)endocrine tumor, thyroid

For personal use only. No other uses without permission. Copyright ©2017. Elsevier Inc. All rights reserved.

medullary carcinoma, and even carcinoid tumor arising from a tailgut cyst.[858–862]

One should not forget in this listing the metastases from contralateral breast carcinoma, which is not an infrequent finding in autopsy series.[855] Azzopardi has made the interesting observation that the presence of elastosis has not been documented in association with metastatic disease of the breast.[22]

Metastatic carcinomas to the breast can simulate primary malignant tumors of this organ; exceptionally, they greatly mimic the appearance of DCIS.[863] In an era of increasing use of neoadjuvant chemotherapy, it is important to consider metastasis when encountering a tumor of the breast with unusual morphology, extensive lymphovascular invasion in the presence of a small "invasive" component, an absence of an in situ component and/or a triple negative immunophenotype. If doubt exists as to whether the tumor represents a breast primary, a panel of breast markers (GCDFP-15, mammaglobin, GATA3) may be appropriate. Of course, eliciting a history of prior malignancy at another site and comparing the morphology may be the most helpful tool.

In children, the most common malignant tumor to metastasize to the breast (hematolymphoid malignancies excluded) is rhabdomyosarcoma, particularly of the alveolar type.[864–866]

Breast Diseases in Children and Adolescents

The most common breast "mass" for which clinical consultation is sought in this age group is actually not a pathologic condition at all but rather precocious, sometimes predominantly unilateral, breast development.[867] Should such a "mass" be inadvertently removed, no development of the breast will occur.

Fibroadenoma is the most common pathologic condition of the breast between puberty and 20 years of age but is exceptional before puberty.[867]

Virginal hypertrophy (gigantomastia; macromastia) may result in massive unilateral or bilateral enlargement.[867] Microscopically, it is characterized by a combined proliferation of ducts and stroma with little, if any, lobular participation (Fig. 36.146).[866]

Pseudoangiomatous stromal hyperplasia is generally a disorder of adult life, but cases have been documented in adolescents and children (including a 3-year-old boy).[868]

So called fibrocystic change is practically never seen in this age group. However, highly proliferative epithelial lesions can develop, such as papillomas and usual duct hyperplasia, similar to those seen in the adult breast, with or without associated sclerosis and ductular distortion.[869] Wilson et al.[870] studied 74 patients with a process they termed *papillary duct hyperplasia*, which they distinguish from the juvenile papillomatosis described later. They found that 28% of the patients had a family history of breast carcinoma but that none of the patients had developed carcinoma at the time of the last follow-up.

Juvenile papillomatosis ("Swiss cheese" disease) is usually seen in young individuals (average age 19 years) but occurring in a wide age range (10–44 years). Clinically, the localized, multinodular masses simulate the appearance of fibroadenoma. Grossly, the clustering of cysts results in a cut surface appearance reminiscent of Swiss cheese—hence the alternative designation for this entity (Fig. 36.147). Microscopically, there is florid epithelial hyperplasia (sometimes with atypia and/or focal necrosis), cysts with or without apocrine metaplasia, duct stasis, and sclerosing adenosis (Fig. 36.148).[871,872] A family history of breast carcinoma is reported in 58% of cases, and 10% of the patients subsequently develop breast carcinoma.[872,873]

Figure 36.147 Juvenile Papillomatosis (Swiss Cheese Disease). The gross appearance is that of clustered cystic formations.

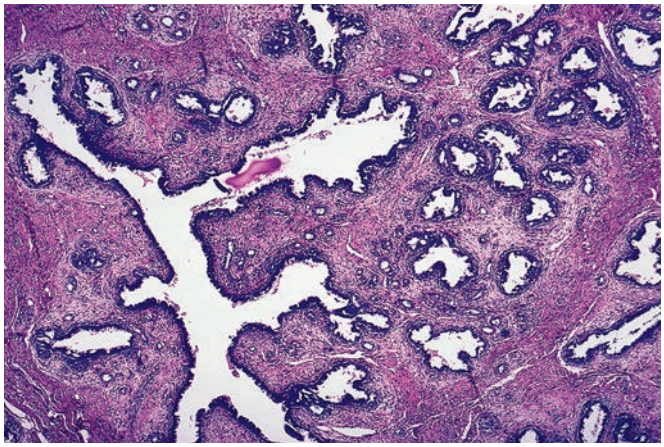

Figure 36.146 So-called "virginal hypertrophy" of breast, showing proliferative changes in epithelium and stroma.

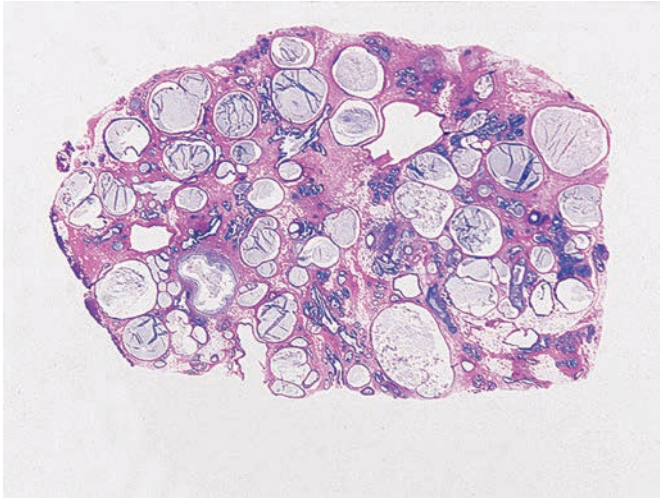

Figure 36.148 Juvenile Papillomatosis (Swiss Cheese Disease). Whole-mount view showing variously sized cystic formations, alternating with solid epithelial proliferations.

For personal use only. No other uses without permission. Copyright ©2017. Elsevier Inc. All rights reserved.

Carcinoma of the pre-pubertal breast is very rare; most cases are of the so-called secretory type (see earlier description). A few tumors have the appearance of ordinary invasive ductal carcinomas.

In the presence of a high-grade malignant round cell tumor of the breast in a child or adolescent, the possibility should be considered that it may be a solid variant of alveolar rhabdomyosarcoma, whether primary or metastatic.[156]

Breast Diseases in Males

Gynecomastia

Gynecomastia is defined as the enlargement of the male breast resulting from hypertrophy and hyperplasia of both glandular and stromal components. It may result from numerous causes, which share a background of relative increase in estrogenic activity (whether endogenous or exogenous), decrease in androgenic activity, or both.[874,875] Development of gynecomastia before 25 years of age is usually related to hormonal pubertal changes, whereas development in later years may be caused by hormonally active tumors (Leydig cell tumor of testis, hCG-secreting germ cell tumors, lung carcinoma, or others), cirrhosis, or medications (digitalis, reserpine, phenytoin, and others).[876] Cases have also been reported in type 1 neurofibromatosis.[877] Clinical gynecomastia developing in diabetic patients may have the features of diabetic or lymphocytic mastopathy, as seen in females.[878] Many cases are idiopathic.

Clinically, gynecomastia is usually centered behind the nipple, an important point in the differential diagnosis with carcinoma, which tends to be located eccentrically.[874] It may be unilateral (at least at the clinical level, the left breast being more commonly involved than the right) or bilateral. Pubertal and hormone-induced gynecomastias tend to be bilateral, whereas idiopathic and nonhormonal drug-induced gynecomastias are usually unilateral.

On ultrasound examination, gynecomastia may appear as a hypoechoic or hyperechoic mass or be of mixed echogenicity.[879] Mammographic examination reveals a round, retroareolar density with stranded extensions into the deeper adipose tissue.[879] The gross appearance is characteristic. The mass is oval, disk shaped, of elastic consistency, and with well-circumscribed borders. Microscopically, the ducts show a variable and sometimes very prominent degree of epithelial hyperplasia and are surrounded by a prominent edematous stroma, which results in a typical "halo" effect (Fig. 36.149). This stroma contains large amounts of acid mucopolysaccharides (mainly hyaluronic acid) of a type similar to that seen in fibroadenoma of the female breast.[880] The immunophenotype parallels that of normal breast stroma.[881] There may be PASH and focal squamous metaplasia; formation of lobules may be observed.[874,882] Exceptionally, a population of clear or globoid cells immunoreactive for GCDFP-15 may be present within the ducts.[883]

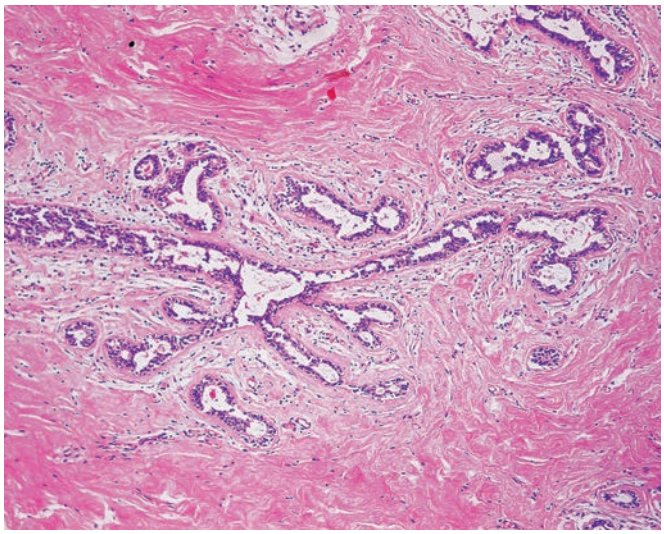

Figure 36.149 Epithelial proliferation surrounded by a hypocellular myxoid halo in gynecomastia.

The microscopic changes are related to the duration of the gynecomastia. Cases of short duration tend to have a prominent hyperplastic epithelial component, often with micropapillary ("gynecomastoid") architecture, and stromal edema, whereas those of long duration have prominent stromal fibrosis.[884] Occasionally ADH may be present; however, the clinical significance of the diagnosis in this setting is unknown.[885] The possible relationship between gynecomastia and carcinoma is discussed later. Changes morphologically similar to those of gynecomastia can be seen in the female breast ("gynecomastoid hyperplasia").

Myofibroblastoma

Myofibroblastoma is the term used for a benign stromal neoplasm composed of myofibroblasts and collagen first described by Toker et al.[886] Originally thought to involve primarily the male breast, it is now known to occur in the female breast with a higher frequency.[887]

Carcinoma

In the United States, only 1% of all breast carcinomas occur in males, but in some Arab countries the incidence rises to nearly 10%.[888–891] An increased incidence of breast carcinoma is seen in patients with Klinefelter syndrome.[892] Familial cases have also been recorded, particularly among *BRCA2* mutation carriers.[893,894] Cases of primary breast carcinoma have occurred in patients with prostatic carcinoma treated with estrogens.[875,895] A definitive relationship between gynecomastia and breast carcinoma has not been demonstrated.

Clinically, most breast carcinomas present in elderly men as breast masses, with or without associated nipple abnormalities.[896] Nipple discharge in an adult male, especially if bloody, should arouse a strong suspicion of carcinoma. Skin involvement by direct extension and Paget disease are much more common in males.

Imaging studies demonstrate findings as described earlier for the radiographic identification of breast cancer in female patients; namely a spiculated mass on mammography and a hypoechoic mass, taller-than-wide, with posterior shadowing on ultrasound examination.[879] Similarly, grossly, microscopically, and immunohistochemically, carcinomas of the male breast are like those seen in females. As such, they can be in situ or invasive, low grade, or high grade. All of the microscopic types and molecular subtypes identified in the female breast have been encountered in males. The incidence of papillary carcinoma is higher than in females.[889,897] The least common of the major categories is invasive lobular carcinoma, only a few cases having been described.[897,898]

Breast carcinoma is diagnosed on core needle biopsy in most patients, with the most important differential diagnosis for a breast mass in a male patient being gynecomastia. The incidence of positivity for ER is higher than in females.[899]

The overall survival rate is lower than for breast carcinoma occurring in females but, as is often the case, the differences tend to disappear when the tumors are compared stage by stage.[888,889] Indeed, the prognosis of breast cancer in males, like that in females, is heavily influenced by clinical stage, histologic grade, and receptor status. It also correlates with mitotic activity, DNA ploidy, and p53 status.[900,901]

For personal use only. No other uses without permission. Copyright ©2017. Elsevier Inc. All rights reserved.

Other Lesions

Mammary duct ectasia and **sclerosing adenosis** can occur in the male breast. Fibroadenoma (sometimes bilateral), phyllodes tumor, PASH, and nodular fasciitis have also been reported.[902,903] **Nipple adenoma** and **intraductal papilloma** have been seen on several occasions. There are also reports of **leiomyoma** and **leiomyosarcoma** of the nipple[904] and **neurofibromatosis** in a child whose condition simulated gynecomastia.[905]

Metastatic carcinoma to the male breast commonly originates from the prostate, is often bilateral, and is almost always seen following estrogen therapy.[895] As such, it occurs against a background of gynecomastia. Some of these cases have been confused with primary breast carcinoma. Immunohistochemical stains for PSA and prostatic acid phosphatase are helpful in the differential diagnosis. The matter is complicated by the fact that the normal mammary duct epithelium of males and the hyperplastic epithelium of gynecomastia are often immunoreactive for PSA (but not for prostatic acid phosphatase). Male breast carcinoma is typically negative for both markers; though PSA positivity has been reported in an FNA specimen from a primary breast carcinoma.[906,907]

The most common type of nonepithelial tumor to metastasize to the male breast is malignant melanoma.[897]

References

1. Collins LC, Schnitt SJ. *Breast*. 4th ed. Philadelphia: Lippincott Williams & Wilkins; 2012.
2. Cunha GR. Role of mesenchymal-epithelial interactions in normal and abnormal development of the mammary gland and prostate. *Cancer*. 1994;74(3 suppl):1030-1044.
3. Bussolati G, Gugliotta P, Sapino A, et al. Chromogranin-reactive endocrine cells in argyrophilic carcinomas ("carcinoids") and normal tissue of the breast. *Am J Pathol*. 1985;120(2):186-192.
4. Boecker W, Buerger H. Evidence of progenitor cells of glandular and myoepithelial cell lineages in the human adult female breast epithelium: a new progenitor (adult stem) cell concept. *Cell Prolif*. 2003;36(suppl 1):73-84.
5. Bocker W, Moll R, Poremba C, et al. Common adult stem cells in the human breast give rise to glandular and myoepithelial cell lineages: a new cell biological concept. *Lab Invest*. 2002;82(6):737-746.
6. Love SM, Barsky SH. Anatomy of the nipple and breast ducts revisited. *Cancer*. 2004;101(9):1947-1957.
7. Di Tommaso L, Franchi G, Destro A, et al. Toker cells of the breast. Morphological and immunohistochemical characterization of 40 cases. *Hum Pathol*. 2008;39(9):1295-1300.
8. Toker C. Clear cells of the nipple epidermis. *Cancer*. 1970;25(3):601-610.
9. Rosen PP, Tench W. Lobules in the nipple. Frequency and significance for breast cancer treatment. *Pathol Annu*. 1985;20(Pt 2):317-322.
10. McCarty KS, Nath M. Breast. In: Sternberg SS, ed. *Histology for Pathologists*. Philadelphia: Lippincott-Raven; 1997:71-82.
11. Joshi K, Smith JA, Perusinghe N, Monoghan P. Cell proliferation in the human mammary epithelium. Differential contribution by epithelial and myoepithelial cells. *Am J Pathol*. 1986;124(2):199-206.
12. Battersby S, Anderson TJ. Histological changes in breast tissue that characterize recent pregnancy. *Histopathology*. 1989;15(4):415-419.
13. Rytina ER, Coady AT, Millis RR. Milk granuloma: an unusual appearance in lactational breast tissue. *Histopathology*. 1990;17(5):466-468.
14. Slavin JL, Billson VR, Ostor AG. Nodular breast lesions during pregnancy and lactation. *Histopathology*. 1993;22(5):481-485.
15. Fechner RE. The surgical pathology of the reproductive system and breast during oral contraceptive therapy. *Pathol Annu*. 1971;6:299-319.
16. Farahmand S, Cowan DF. Elastosis in the normal aging breast. A histopathologic study of 140 cases. *Arch Pathol Lab Med*. 1991;115(12):1241-1246.
17. Tavassoli FA, Yeh IT. Lactational and clear cell changes of the breast in nonlactating, nonpregnant women. *Am J Clin Pathol*. 1987;87(1):23-29.
18. Kiaer HW, Andersen JA. Focal pregnancy-like changes in the breast. *Acta Pathol Microbiol Scand A*. 1977;85(6):931-941.
19. Shin SJ, Rosen PP. Carcinoma arising from preexisting pregnancy-like and cystic hypersecretory hyperplasia lesions of the breast: a clinicopathologic study of 9 patients. *Am J Surg Pathol*. 2004;28(6):789-793.
20. Barwick KW, Kashgarian M, Rosen PP. "Clear-cell" change within duct and lobular epithelium of the human breast. *Pathol Annu*. 1982;17(Pt 1):319-328.
21. Wellings SR, Jensen HM, Marcum RG. An atlas of subgross pathology of the human breast with special reference to possible precancerous lesions. *J Natl Cancer Inst*. 1975;55(2):231-273.
22. Azzopardi JG. *Problems in Breast Pathology*. Philadelphia: WB Saunders; 1979.
23. Jordan K, Laumann A, Conrad S, Medenica M. Axillary mass in a 20-year-old woman. Diagnosis: axillary accessory breast tissue. *Arch Dermatol*. 2001;137(10):1367-1372.
24. Edlow DW, Carter D. Heterotopic epithelium in axillary lymph nodes: report of a case and review of the literature. *Am J Clin Pathol*. 1973;59(5):666-673.
25. Turner DR, Millis RR. Breast tissue inclusions in axillary lymph nodes. *Histopathology*. 1980;4(6):631-636.
26. O'Hara MF, Page DL. Adenomas of the breast and ectopic breast under lactational influences. *Hum Pathol*. 1985;16(7): 707-712.
27. Boulos FI, Granja NM, Simpson JF, et al. Intranodal papillary epithelial proliferations: a local process with a spectrum of morphologies and frequent association with papillomas in the breast. *Am J Surg Pathol*. 2014;38(3):383-388.
28. Pfeifer JD, Barr RJ, Wick MR. Ectopic breast tissue and breast-like sweat gland metaplasias: an overlapping spectrum of lesions. *J Cutan Pathol*. 1999;26(4):190-196.
29. Webb AJ. Mammary duct ectasia—periductal mastitis complex. *Br J Surg*. 1995;82(10):1300-1302.
30. Dixon JM, Ravisekar O, Chetty U, Anderson TJ. Periductal mastitis and duct ectasia: different conditions with different aetiologies. *Br J Surg*. 1996;83(6):820-822.
31. Haagensen CD. Mammary-duct ectasia; a disease that may simulate carcinoma. *Cancer*. 1951;4(4):749-761.
32. Furlong AJ, al-Nakib L, Knox WF, et al. Periductal inflammation and cigarette smoke. *J Am Coll Surg*. 1994;179(4):417-420.
33. Koo JS, Jung W. Xanthogranulomatous mastitis: clinicopathology and pathological implications. *Pathol Int*. 2009;59(4): 234-240.
34. Dabbs DJ. Mammary ductal foam cells: macrophage immunophenotype. *Hum Pathol*. 1993;24(9):977-981.
35. Kinoshita T, Yashiro N, Yoshigi J, et al. Fat necrosis of breast: a potential pitfall in breast MRI. *Clin Imaging*. 2002;26(4):250-253.
36. Clarke D, Curtis JL, Martinez A, et al. Fat necrosis of the breast simulating recurrent carcinoma after primary radiotherapy in the management of early stage breast carcinoma. *Cancer*. 1983;52(3):442-445.
37. Coyne JD, Parkinson D, Baildam AD. Membranous fat necrosis of the breast. *Histopathology*. 1996;28(1):61-64.
38. Dener C, Inan A. Breast abscesses in lactating women. *World J Surg*. 2003;27(2):130-133.
39. Watt-Boolsen S, Rasmussen NR, Blichert-Toft M. Primary periareolar abscess in the nonlactating breast: risk of recurrence. *Am J Surg*. 1987;153(6):571-573.
40. Passaro ME, Broughan TA, Sebek BA, Esselstyn CB Jr. Lactiferous fistula. *J Am Coll Surg*. 1994;178(1):29-32.
41. Schwartz IS, Strauchen JA. Lymphocytic mastopathy. An autoimmune disease of the breast? *Am J Clin Pathol*. 1990;93(6):725-730.
42. Lammie GA, Bobrow LG, Staunton MD, et al. Sclerosing lymphocytic lobulitis of the breast—evidence for an autoimmune pathogenesis. *Histopathology*. 1991;19(1):13-20.
43. Ely KA, Tse G, Simpson JF, et al. Diabetic mastopathy. A clinicopathologic review. *Am J Clin Pathol*. 2000;113(4):541-545.
44. Fong D, Lann MA, Finlayson C, et al. Diabetic (lymphocytic) mastopathy with exuberant lymphohistiocytic and granulomatous response: a case report with review of the literature. *Am J Surg Pathol*. 2006;30(10):1330-1336.
45. Morgan MC, Weaver MG, Crowe JP, Abdul-Karim FW. Diabetic mastopathy: a clinicopathologic study in palpable and nonpalpable breast lesions. *Mod Pathol*. 1995;8(4):349-354.
46. Seidman JD, Schnaper LA, Phillips LE. Mastopathy in insulin-requiring diabetes mellitus. *Hum Pathol*. 1994;25(8):819-824.
47. Tomaszewski JE, Brooks JS, Hicks D, Livolsi VA. Diabetic mastopathy: a distinctive clinicopathologic entity. *Hum Pathol*. 1992;23(7):780-786.
48. Ashton MA, Lefkowitz M, Tavassoli FA. Epithelioid stromal cells in lymphocytic mastitis—a source of confusion with invasive carcinoma. *Mod Pathol*. 1994;7(1):49-54.
49. Valdez R, Thorson J, Finn WG, et al. Lymphocytic mastitis and diabetic mastopathy: a molecular, immunophenotypic, and clinicopathologic evaluation of 11 cases. *Mod Pathol*. 2003;16(3):223-228.
50. Fletcher A, Magrath IM, Riddell RH, Talbot IC. Granulomatous mastitis: a report of seven cases. *J Clin Pathol*. 1982;35(9):941-945.

For personal use only. No other uses without permission. Copyright ©2017. Elsevier Inc. All rights reserved.

51. Kessler EI, Katzav JA. Lobular granulomatous mastitis. *Surg Pathol*. 1990;3:115-120.
52. Khamapirad T, Hennan K, Leonard M Jr, et al. Granulomatous lobular mastitis: two case reports with focus on radiologic and histopathologic features. *Ann Diagn Pathol*. 2007;11(2):109-112.
53. Ogura K, Matsumoto T, Aoki Y, et al. IgG4-related tumour-forming mastitis with histological appearances of granulomatous lobular mastitis: comparison with other types of tumour-forming mastitis. *Histopathology*. 2010;57(1):39-45.
54. Cheuk W, Chan AC, Lam WL, et al. IgG4-related sclerosing mastitis: description of a new member of the IgG4-related sclerosing diseases. *Am J Surg Pathol*. 2009;33(7):1058-1064.
55. Paviour S, Musaad S, Roberts S, et al. Corynebacterium species isolated from patients with mastitis. *Clin Infect Dis*. 2002;35(11):1434-1440.
56. Taylor GB, Paviour SD, Musaad S, et al. A clinicopathological review of 34 cases of inflammatory breast disease showing an association between corynebacteria infection and granulomatous mastitis. *Pathology*. 2003;35(2):109-119.
57. D'Alfonso TM, Moo TA, Arleo EK, et al. Cystic Neutrophilic Granulomatous Mastitis: Further Characterization of a Distinctive Histopathologic Entity Not Always Demonstrably Attributable to Corynebacterium Infection. *Am J Surg Pathol*. 2015;39(10):1440-1447.
58. Troxell ML, Gordon NT, Doggett JS, et al. Cystic neutrophilic granulomatous mastitis: association with gram-positive bacilli and corynebacterium. *Am J Clin Pathol*. 2016;145(5):635-645.
59. Kutsuna S, Mezaki K, Nagamatsu M, et al. Two cases of granulomatous mastitis caused by corynebacterium kroppenstedtii infection in nulliparous young women with hyperprolactinemia. *Intern Med*. 2015;54(14):1815-1818.
60. Renshaw AA, Derhagopian RP, Gould EW. Cystic neutrophilic granulomatous mastitis: an underappreciated pattern strongly associated with gram-positive bacilli. *Am J Clin Pathol*. 2011;136(3):424-427.
61. Dobinson HC, Anderson TP, Chambers ST, et al. Antimicrobial treatment options for granulomatous mastitis caused by Corynebacterium species. *J Clin Microbiol*. 2015;53:2895-2899.
62. Khanna R, Prasanna GV, Gupta P, et al. Mammary tuberculosis: report on 52 cases. *Postgrad Med J*. 2002;78(921):422-424.
63. Arnaout AH, Shousha S, Metaxas N, Husain OA. Intramammary tuberculous lymphadenitis. *Histopathology*. 1990;17(1):91-93.
64. Bocian JJ, Fahmy RN, Michas CA. A rare case of 'coccidioidoma' of the breast. *Arch Pathol Lab Med*. 1991;115(10):1064-1067.
65. Osborne BM. Granulomatous mastitis caused by histoplasma and mimicking inflammatory breast carcinoma. *Hum Pathol*. 1989;20(1):47-52.
66. Banik S, Bishop PW, Ormerod LP, O'Brien TE. Sarcoidosis of the breast. *J Clin Pathol*. 1986;39(4):446-448.
67. Fitzgibbons PL, Smiley DF, Kern WH. Sarcoidosis presenting initially as breast mass: report of two cases. *Hum Pathol*. 1985;16(8):851-852.
68. Lower EE, Hawkins HH, Baughman RP. Breast disease in sarcoidosis. *Sarcoidosis Vasc Diffuse Lung Dis*. 2001;18(3):301-306.
69. Symmers WS. Silicone mastitis in "topless" waitresses and some other varieties of foreign-body mastitis. *Br Med J*. 1968;3(5609):19-22.
70. Jordan JM, Rowe WT, Allen NB. Wegener's granulomatosis involving the breast. Report of three cases and review of the literature. *Am J Med*. 1987;83(1):159-164.
71. Rickert RR, Rajan S. Localized breast infarcts associated with pregnancy. *Arch Pathol*. 1974;97(3):159-161.
72. Nudelman HL, Kempson RL. Necrosis of the breast: a rare complication of anticoagulant therapy. *Am J Surg*. 1966;111(5):728-733.
73. Farrow JH. Thrombophlebitis of the superficial veins of the breast and anterior chest wall (Mondor's disease). *Surg Gynecol Obstet*. 1955;101(1):63-68.
74. Herrmann JB. Thrombophlebitis of breast and contiguous thoracicoabdominal wall (Mondor's disease). *N Y State J Med*. 1966;66(24):3146-3152.
75. Catania S, Zurrida S, Veronesi P, et al. Mondor's disease and breast cancer. *Cancer*. 1992;69(9):2267-2270.
76. Allende DS, Booth CN. Wegener's granulomatosis of the breast: a rare entity with daily clinical relevance. *Ann Diagn Pathol*. 2009;13(5):351-357.
77. Cooper NE. Rheumatoid nodule in the breast. *Histopathology*. 1991;19(2):193-194.
78. Kariv R, Sidi Y, Gur H. Systemic vasculitis presenting as a tumorlike lesion. Four case reports and an analysis of 79 reported cases. *Medicine (Baltimore)*. 2000;79(6):349-359.
79. Kinonen C, Gattuso P, Reddy VB. Lupus mastitis: an uncommon complication of systemic or discoid lupus. *Am J Surg Pathol*. 2010;34(6):901-906.
80. Ng WF, Chow LT, Lam PW. Localized polyarteritis nodosa of breast—report of two cases and a review of the literature. *Histopathology*. 1993;23(6):535-539.
81. Nigar E, Contractor K, Singhal H, Matin RN. Lupus mastitis—a cause of recurrent breast lumps. *Histopathology*. 2007;51(6):847-849.
82. Trueb RM, Scheidegger EP, Pericin M, et al. Periarteritis nodosa presenting as a breast lesion: report of a case and review of the literature. *Br J Dermatol*. 1999;141(6):1117-1121.
83. Santen RJ, Mansel R. Benign breast disorders. *N Engl J Med*. 2005;353(3):275-285.
84. Conference C. Is 'fibrocystic disease' of the breast precancerous? *Arch Pathol Lab Med*. 1986;110(3):171-173.
85. Connolly JL, Schnitt SJ. Benign breast disease. Resolved and unresolved issues. *Cancer*. 1993;71(4):1187-1189.
86. Bartow SA, Black WC, Waeckerlin RW, Mettler FA. Fibrocystic disease: a continuing enigma. *Pathol Annu*. 1982;17(Pt 2):93-111.
87. Love SM, Gelman RS, Silen W. Sounding board. Fibrocystic "disease" of the breast—a nondisease? *N Engl J Med*. 1982;307(16):1010-1014.
88. Goehring C, Morabia A. Epidemiology of benign breast disease, with special attention to histologic types. *Epidemiol Rev*. 1997;19(2):310-327.
89. Rohan TE, Miller AB. Hormone replacement therapy and risk of benign proliferative epithelial disorders of the breast. *Eur J Cancer Prev*. 1999;8(2):123-130.
90. Fechner RE. Fibrocystic disease in women receiving oral contraceptive hormones. *Cancer*. 1970;25(6):1332-1339.
91. Oh JK, Sandin S, Strom P, et al. Prospective study of breast cancer in relation to coffee, tea and caffeine in Sweden. *Int J Cancer*. 2015;137(8):1979-1989.
92. Liu Y, Nguyen N, Colditz GA. Links between alcohol consumption and breast cancer: a look at the evidence. *Womens Health (Lond)*. 2015;11(1):65-77.
93. Mazoujian G, Pinkus GS, Davis S, Haagensen DE Jr. Immunohistochemistry of a gross cystic disease fluid protein (GCDFP-15) of the breast. A marker of apocrine epithelium and breast carcinomas with apocrine features. *Am J Pathol*. 1983;110(2):105-112.
94. Damiani S, Cattani MG, Buonamici L, Eusebi V. Mammary foam cells. Characterization by immunohistochemistry and in situ hybridization. *Virchows Arch*. 1998;432(5):433-440.
95. Raju U, Crissman JD, Zarbo RJ, Gottlieb C. Epitheliosis of the breast. An immunohistochemical characterization and comparison to malignant intraductal proliferations of the breast. *Am J Surg Pathol*. 1990;14(10):939-947.
96. Clement PB, Young RH, Azzopardi JG. Collagenous spherulosis of the breast. *Am J Surg Pathol*. 1987;11(6):411-417.
97. Maluf HM, Koerner FC, Dickersin GR. Collagenous spherulosis: an ultrastructural study. *Ultrastruct Pathol*. 1998;22(3):239-248.
98. Resetkova E, Albarracin C, Sneige N. Collagenous spherulosis of breast: morphologic study of 59 cases and review of the literature. *Am J Surg Pathol*. 2006;30(1):20-27.
99. Sgroi D, Koerner FC. Involvement of collagenous spherulosis by lobular carcinoma in situ. Potential confusion with cribriform ductal carcinoma in situ. *Am J Surg Pathol*. 1995;19(12):1366-1370.
100. Guerry P, Erlandson RA, Rosen PP. Cystic hypersecretory hyperplasia and cystic hypersecretory duct carcinoma of the breast. Pathology, therapy, and follow-up of 39 patients. *Cancer*. 1988;61(8):1611-1620.
101. Kasami M, Jensen RA, Simpson JF, Page DL. Lobulocentricity of breast hypersecretory hyperplasia with cytologic atypia: infrequent association with carcinoma in situ. *Am J Clin Pathol*. 2004;122(5):714-720.
102. Walker RA. The pathology of "precancerous" breast disease. *Pathol Annu*. 1994;29(Pt 2):75-97.
103. Dupont WD, Page DL. Risk factors for breast cancer in women with proliferative breast disease. *N Engl J Med*. 1985;312(3):146-151.
104. Page DL, Dupont WD, Rogers LW, Rados MS. Atypical hyperplastic lesions of the female breast. A long-term follow-up study. *Cancer*. 1985;55(11):2698-2708.
105. Page DL, Kidd TE Jr, Dupont WD, et al. Lobular neoplasia of the breast: higher risk for subsequent invasive cancer predicted by more extensive disease. *Hum Pathol*. 1991;22(12):1232-1239.
106. Fitzgibbons PL, Henson DE, Hutter RV. Benign breast changes and the risk for subsequent breast cancer: an update of the 1985 consensus statement. Cancer Committee of the College of American Pathologists. *Arch Pathol Lab Med*. 1998;122(12):1053-1055.
107. Page DL. Cancer risk assessment in benign breast biopsies. *Hum Pathol*. 1986;17(9):871-874.
108. Simpson J, Schnitt S, Visscher D, et al. Atypical ductal hyperplasia. In: Lakhani S, Ellis IO, Schnitt SJ, et al, eds. *WHO Classification of Tumours of the Breast*. Lyon: IARC press; 2012:88-89.
109. Putti TC, Pinder SE, Elston CW, et al. Breast pathology practice: most common problems in a consultation service. *Histopathology*. 2005;47(5):445-457.
110. Yeh IT, Mies C. Application of immunohistochemistry to breast lesions. *Arch Pathol Lab Med*. 2008;132(3):349-358.
111. Hanby A, Ellis IO, Schnitt SJ. Colunmar cell change and hyperplasia. In: Lakhani SREI, Schnitt SJ, Tan PH, van de Vijver MJ, eds. *WHO Classification of Tumors of the Breast*. Lyon: IARC; 2012:86-87.
112. Schnitt S, Collins LC, Lakhani SR, et al. Flat epithelial atypia. In: Lakhani SR, Ellis IO,

For personal use only. No other uses without permission. Copyright ©2017. Elsevier Inc. All rights reserved.

Schnitt SJ, et al, eds. *WHO Classification of Tumours of the Breast*. Lyon: IARC press; 2012:87.
113. Dabbs DJ, Kessinger RL, McManus K, Johnson R. Biology of columnar cell lesions in core biopsies of the breat. *Mod Pathol*. 2003;16:26A.
114. Abdel-Fatah TM, Powe DG, Hodi Z, et al. Morphologic and molecular evolutionary pathways of low nuclear grade invasive breast cancers and their putative precursor lesions: further evidence to support the concept of low nuclear grade breast neoplasia family. *Am J Surg Pathol*. 2008;32(4):513-523.
115. Boulos FI, Dupont WD, Simpson JF, et al. Histologic associations and long-term cancer risk in columnar cell lesions of the breast: a retrospective cohort and a nested case-control study. *Cancer*. 2008;113(9):2415-2421.
116. Aroner SA, Collins LC, Schnitt SJ, et al. Columnar cell lesions and subsequent breast cancer risk: a nested case-control study. *Breast Cancer Res*. 2010;12(4):R61.
117. Said SM, Visscher DW, Nassar A, et al. Flat epithelial atypia and risk of breast cancer: a Mayo cohort study. *Cancer*. 2015;121(10):1548-1555.
118. Abdel-Fatah TM, Powe DG, Hodi Z, et al. High frequency of coexistence of columnar cell lesions, lobular neoplasia, and low grade ductal carcinoma in situ with invasive tubular carcinoma and invasive lobular carcinoma. *Am J Surg Pathol*. 2007;31(3):417-426.
119. Collins LC, Achacoso NA, Nekhlyudov L, et al. Clinical and pathologic features of ductal carcinoma in situ associated with the presence of flat epithelial atypia: an analysis of 543 patients. *Mod Pathol*. 2007;20(11):1149-1155.
120. Leibl S, Regitnig P, Moinfar F. Flat epithelial atypia (DIN 1a, atypical columnar change): an underdiagnosed entity very frequently coexisting with lobular neoplasia. *Histopathology*. 2007;50(7):859-865.
121. Noske A, Pahl S, Fallenberg E, et al. Flat epithelial atypia is a common subtype of B3 breast lesions and is associated with noninvasive cancer but not with invasive cancer in final excision histology. *Hum Pathol*. 2010;41(4):522-527.
122. Lakhani SR, Ellis IO, Schnitt SJ, et al. *WHO Classification of Tumours of the Breast*. 4th ed. Lyon: IARC Press; 2012.
123. Rosai J. Borderline epithelial lesions of the breast. *Am J Surg Pathol*. 1991;15(3):209-221.
124. Bratthauer GL, Tavassoli FA. Lobular intraepithelial neoplasia: previously unexplored aspects assessed in 775 cases and their clinical implications. *Virchows Arch*. 2002;440(2):134-138.
125. Tavassoli FA. Ductal carcinoma in situ: introduction of the concept of ductal intraepithelial neoplasia. *Mod Pathol*. 1998;11(2):140-154.
126. Tavassoli FA, Hoefler H, Rosai J, et al. Intraductal proliferative lesions. In: Tavassoli FA, Devilee P, eds. *Pathology and Genetics: Tumours of the Breast and Female Genital Organs*. Lyon: IARC Press; 2003:63-73.
127. Lopez-Garcia MA, Geyer FC, Lacroix-Triki M, et al. Breast cancer precursors revisited: molecular features and progression pathways. *Histopathology*. 2010;57(2):171-192.
128. Schnitt S, Ellis I, van de Vijver MJ, et al. Intraductal proliferative lesions: Introduction and overview. In: Lakhani S, Ellis IO, Schnitt SJ, et al, eds. *WHO Classification of Tumours of the Breast*. Lyon: IARC press; 2012:82-83.
129. McDivitt RW. Breast carcinoma. *Hum Pathol*. 1978;9(1):3-21.
130. Frantz VK, Pickren JW, Melcher GW, Auchincloss H. Incidence of chronic cystic disease in so-called normal breasts: A study based on 225 post mortem examinations. *Cancer*. 1951;4:762.
131. Kern WH, Brooks RN. Atypical epithelial hyperplasia associated with breast cancer and fibrocystic disease. *Cancer*. 1969;24(4):668-675.
132. Steinhoff NG, Black WC. Florid cystic disease preceding mammary cancer. *Ann Surg*. 1970;171(4):501-508.
133. Schnitt SJ, Jimi A, Kojiro M. The increasing prevalence of benign proliferative breast lesions in Japanese women. *Cancer*. 1993;71(8):2528-2531.
134. Skolnick MH, Cannon-Albright LA, Goldgar DE, et al. Inheritance of proliferative breast disease in breast cancer kindreds. *Science*. 1990;250(4988):1715-1720.
135. Aubele MM, Cummings MC, Mattis AE, et al. Accumulation of chromosomal imbalances from intraductal proliferative lesions to adjacent in situ and invasive ductal breast cancer. *Diagn Mol Pathol*. 2000;9(1):14-19.
136. Millikan R, Hulka B, Thor A, et al. p53 mutations in benign breast tissue. *J Clin Oncol*. 1995;13(9):2293-2300.
137. Washington C, Dalbegue F, Abreo F, et al. Loss of heterozygosity in fibrocystic change of the breast: genetic relationship between benign proliferative lesions and associated carcinomas. *Am J Pathol*. 2000;157(1):323-329.
138. Younes M, Lebovitz RM, Bommer KE, et al. p53 accumulation in benign breast biopsy specimens. *Hum Pathol*. 1995;26(2): 155-158.
139. Byrne C, Connolly JL, Colditz GA, Schnitt SJ. Biopsy confirmed benign breast disease, postmenopausal use of exogenous female hormones, and breast carcinoma risk. *Cancer*. 2000;89(10):2046-2052.
140. Hartmann LC, Sellers TA, Frost MH, et al. Benign breast disease and the risk of breast cancer. *N Engl J Med*. 2005;353(3):229-237.
141. Page DL, Dupont WD. Histopathologic risk factors for breast cancer in women with benign breast disease. *Semin Surg Oncol*. 1988;4(4):213-217.
142. Jacobs TW, Byrne C, Colditz G, et al. Pathologic features of breast cancers in women with previous benign breast disease. *Am J Clin Pathol*. 2001;115(3):362-369.
143. Dupont WD, Parl FF, Hartmann WH, et al. Breast cancer risk associated with proliferative breast disease and atypical hyperplasia. *Cancer*. 1993;71(4):1258-1265.
144. Schnitt SJ. Benign breast disease and breast cancer risk: morphology and beyond. *Am J Surg Pathol*. 2003;27(6):836-841.
145. Collins LC, Baer HJ, Tamimi RM, et al. Magnitude and laterality of breast cancer risk according to histologic type of atypical hyperplasia: results from the Nurses' Health Study. *Cancer*. 2007;109(2):180-187.
146. Hartmann LC, Radisky DC, Frost MH, et al. Understanding the premalignant potential of atypical hyperplasia through its natural history: a longitudinal cohort study. *Cancer Prev Res (Phila)*. 2014;7(2):211-217.
147. Dupont WD, Page DL. Relative risk of breast cancer varies with time since diagnosis of atypical hyperplasia. *Hum Pathol*. 1989;20(8):723-725.
148. Rosen PP. Proliferative breast "disease". An unresolved diagnostic dilemma [comment]. *Cancer*. 1993;71(12):3798-3807.
149. Moore T, Lee AH. Expression of CD34 and bcl-2 in phyllodes tumours, fibroadenomas and spindle cell lesions of the breast. *Histopathology*. 2001;38(1):62-67.
150. Berean K, Tron VA, Churg A, Clement PB. Mammary fibroadenoma with multinucleated stromal giant cells. *Am J Surg Pathol*. 1986;10(11):823-827.
151. Huo L, Gilcrease MZ. Fibroepithelial lesions of the breast with pleomorphic stromal giant cells: a clinicopathologic study of 4 cases and review of the literature. *Ann Diagn Pathol*. 2009;13(4):226-232.
152. Goodman ZD, Taxy JB. Fibroadenomas of the breast with prominent smooth muscle. *Am J Surg Pathol*. 1981;5(1):99-101.
153. Petrik PK. Mammary hamartoma. *Am J Surg Pathol*. 1987;11(3):234-235.
154. Carney JA, Toorkey BC. Myxoid fibroadenoma and allied conditions (myxomatosis) of the breast. A heritable disorder with special associations including cardiac and cutaneous myxomas. *Am J Surg Pathol*. 1991;15(8):713-721.
155. Kuijper A, Mommers EC, van der Wall E, van Diest PJ. Histopathology of fibroadenoma of the breast. *Am J Clin Pathol*. 2001;115(5):736-742.
156. Dehner LP, Hill DA, Deschryver K. Pathology of the breast in children, adolescents, and young adults. *Semin Diagn Pathol*. 1999;16(3):235-247.
157. Mies C, Rosen PP. Juvenile fibroadenoma with atypical epithelial hyperplasia. *Am J Surg Pathol*. 1987;11(3):184-190.
158. Pike AM, Oberman HA. Juvenile (cellular) adenofibromas. A clinicopathologic study. *Am J Surg Pathol*. 1985;9(10):730-736.
159. Fechner RE. Fibroadenomas in patients receiving oral contraceptives: a clinical and pathologic study. *Am J Clin Pathol*. 1970;53(6):857-864.
160. Umekita Y, Yoshida H. Immunohistochemical study of hormone receptor and hormone-regulated protein expression in phyllodes tumour: comparison with fibroadenoma. *Virchows Arch*. 1998;433(4):311-314.
161. Sapino A, Bosco M, Cassoni P, et al. Estrogen receptor-beta is expressed in stromal cells of fibroadenoma and phyllodes tumors of the breast. *Mod Pathol*. 2006;19(4):599-606.
162. Petersson C, Pandis N, Rizou H, et al. Karyotypic abnormalities in fibroadenomas of the breast. *Int J Cancer*. 1997;70(3):282-286.
163. Fletcher JA, Pinkus GS, Weidner N, Morton CC. Lineage-restricted clonality in biphasic solid tumors. *Am J Pathol*. 1991;138(5):1199-1207.
164. Nassar A, Visscher DW, Degnim AC, et al. Complex fibroadenoma and breast cancer risk: a Mayo Clinic Benign Breast Disease Cohort Study. *Breast Cancer Res Treat*. 2015;153(2):397-405.
165. Carter BA, Page DL, Schuyler P, et al. No elevation in long-term breast carcinoma risk for women with fibroadenomas that contain atypical hyperplasia. *Cancer*. 2001;92(1):30-36.
166. Buzanowski-Konakry K, Harrison EG Jr, Payne WS. Lobular carcinoma arising in fibroadenoma of the breast. *Cancer*. 1975;35(2):450-456.
167. McDivitt RW, Farrow JH, Stewart FW. Breast carcinoma arising in solitary fibroadenomas. *Surg Gynecol Obstet*. 1967;125(3):572-576.
168. Diaz NM, Palmer JO, McDivitt RW. Carcinoma arising within fibroadenomas of the breast. A clinicopathologic study of 105 patients. *Am J Clin Pathol*. 1991;95(5):614-622.
169. Rajan PB, Cranor ML, Rosen PP. Cystosarcoma phyllodes in adolescent girls and young women: a study of 45 patients. *Am J Surg Pathol*. 1998;22(1):64-69.
170. Tan PH. 2005 Galloway Memorial Lecture: Breast phyllodes tumours—morphology and beyond. *Ann Acad Med Singapore*. 2005;34(11):671-677.
171. Bernstein L, Deapen D, Ross RK. The descriptive epidemiology of malignant cystosarcoma phyllodes tumors of the breast. *Cancer*. 1993;71(10):3020-3024.
172. Tan PH, Tse G, Lee A, et al. Fibroepithelial tumours. In: Lakhani SR, Ellis IO, Schnitt SJ, et al, eds. *WHO Classification of Tumours of the Breast*. Lyon: IARC press; 2012:142-147.

For personal use only. No other uses without permission. Copyright ©2017. Elsevier Inc. All rights reserved.

173. Cohn-Cedermark G, Rutqvist LE, Rosendahl I, Silfversward C. Prognostic factors in cystosarcoma phyllodes. A clinicopathologic study of 77 patients. *Cancer*. 1991;68(9):2017-2022.
174. Macher-Goeppinger S, Marme F, Goeppert B, et al. Invasive ductal breast cancer within a malignant phyllodes tumor: case report and assessment of clonality. *Hum Pathol*. 2010;41(2):293-296.
175. Knudsen PJ, Ostergaard J. Cystosarcoma phylloides with lobular and ductal carcinoma in situ. *Arch Pathol Lab Med*. 1987;111(9):873-875.
176. Nishimura R, Hasebe T, Imoto S, Mukai K. Malignant phyllodes tumour with a noninvasive ductal carcinoma component. *Virchows Arch*. 1998;432(1):89-93.
177. Lee AH. Recent developments in the histological diagnosis of spindle cell carcinoma, fibromatosis and phyllodes tumour of the breast. *Histopathology*. 2008;52(1):45-57.
178. Cimino-Mathews A, Sharma R, Illei PB, et al. A subset of malignant phyllodes tumors express p63 and p40: a diagnostic pitfall in breast core needle biopsies. *Am J Surg Pathol*. 2014;38(12):1689-1696.
179. Chia Y, Thike AA, Cheok PY, et al. Stromal keratin expression in phyllodes tumours of the breast: a comparison with other spindle cell breast lesions. *J Clin Pathol*. 2012;65(4):339-347.
180. Tan PH, Jayabaskar T, Yip G, et al. p53 and c-kit (CD117) protein expression as prognostic indicators in breast phyllodes tumors: a tissue microarray study. *Mod Pathol*. 2005;18(12):1527-1534.
181. Ng CC, Tan J, Ong CK, et al. MED12 is frequently mutated in breast phyllodes tumours: a study of 112 cases. *J Clin Pathol*. 2015;68(9):685-691.
182. Jones AM, Mitter R, Springall R, et al. A comprehensive genetic profile of phyllodes tumours of the breast detects important mutations, intra-tumoral genetic heterogeneity and new genetic changes on recurrence. *J Pathol*. 2008;214(5):533-544.
183. Tan WJ, Lai JC, Thike AA, et al. Novel genetic aberrations in breast phyllodes tumours: comparison between prognostically distinct groups. *Breast Cancer Res Treat*. 2014;145(3):635-645.
184. Reinfuss M, Mitus J, Duda K, et al. The treatment and prognosis of patients with phyllodes tumor of the breast: an analysis of 170 cases. *Cancer*. 1996;77(5):910-916.
185. Schwentner L, Kurzeder C, Kreienberg R, Wockel A. Focus on haematogenous dissemination of the malignant cystosarcoma phylloides: institutional experience. *Arch Gynecol Obstet*. 2011;283(3):591-596.
186. Tan PH, Thike AA, Tan WJ, et al. Predicting clinical behaviour of breast phyllodes tumours: a nomogram based on histological criteria and surgical margins. *J Clin Pathol*. 2012;65(1):69-76.
187. Burga AM, Tavassoli FA. Periductal stromal tumor: a rare lesion with low-grade sarcomatous behavior. *Am J Surg Pathol*. 2003;27(3):343-348.
188. Taylor HB, Norris HJ. Epithelial invasion of nerves in benign diseases of the breast. *Cancer*. 1967;20(12):2245-2249.
189. Eusebi V, Azzopardi JG. Vascular infiltration in benign breast disease. *J Pathol*. 1976;118(1):9-16.
190. Jensen RA, Page DL, Dupont WD, Rogers LW. Invasive breast cancer risk in women with sclerosing adenosis. *Cancer*. 1989;64(10):1977-1983.
191. Oberman HA, Markey BA. Noninvasive carcinoma of the breast presenting in adenosis. *Mod Pathol*. 1991;4(1):31-35.
192. Fechner RE. Lobular carcinoma in situ in sclerosing adenosis. A potential source of confusion with invasive carcinoma. *Am J Surg Pathol*. 1981;5(3):233-239.
193. Clement PB, Azzopardi JG. Microglandular adenosis of the breast—a lesion simulating tubular carcinoma. *Histopathology*. 1983;7(2):169-180.
194. Rosen PP. Microglandular adenosis. A benign lesion simulating invasive mammary carcinoma. *Am J Surg Pathol*. 1983;7(2):137-144.
195. Tavassoli FA, Norris HJ. Microglandular adenosis of the breast. A clinicopathologic study of 11 cases with ultrastructural observations. *Am J Surg Pathol*. 1983;7(8):731-737.
196. Millis RR. Microglandular adenosis of the breast. *Adv Anat Pathol*. 1995;2:10.
197. Koenig C, Dadmanesh F, Bratthauer GL, Tavassoli FA. Carcinoma arising in microglandular adenosis: an immunohistochemical analysis of 20 intraepithelial and invasive neoplasms. *Int J Surg Pathol*. 2000;8(4):303-315.
198. Acs G, Simpson JF, Bleiweiss IJ, et al. Microglandular adenosis with transition into adenoid cystic carcinoma of the breast. *Am J Surg Pathol*. 2003;27(8):1052-1060.
199. Khalifeh IM, Albarracin C, Diaz LK, et al. Clinical, histopathologic, and immunohistochemical features of microglandular adenosis and transition into in situ and invasive carcinoma. *Am J Surg Pathol*. 2008;32(4):544-552.
200. Geyer FC, Lacroix-Triki M, Colombo PE, et al. Molecular evidence in support of the neoplastic and precursor nature of microglandular adenosis. *Histopathology*. 2012;60(6B):E115-E130.
201. Shin SJ, Simpson PT, Da Silva L, et al. Molecular evidence for progression of microglandular adenosis (MGA) to invasive carcinoma. *Am J Surg Pathol*. 2009;33(4):496-504.
202. Guerini-Rocco E, Piscuoglio S, Ng CK, et al. Microglandular adenosis associated with triple-negative breast cancer is a neoplastic lesion of triple-negative phenotype harbouring TP53 somatic mutations. *J Pathol*. 2016;238(5):677-688.
203. O'Malley FP. Non-invasive apocrine lesions of the breast. *Curr Diagn Pathol*. 2004;10:211-219.
204. Eusebi V, Damiani S, Losi L, Millis RR. Apocrine differentiation in breast epithelium. *Adv Anat Pathol*. 1997;4:139.
205. Seidman JD, Ashton M, Lefkowitz M. Atypical apocrine adenosis of the breast: a clinicopathologic study of 37 patients with 8.7-year follow-up. *Cancer*. 1996;77(12):2529-2537.
206. Fuehrer N, Hartmann L, Degnim A, et al. Atypical apocrine adenosis of the breast: long-term follow-up in 37 patients. *Arch Pathol Lab Med*. 2012;136(2):179-182.
207. Lee KC, Chan JK, Gwi E. Tubular adenosis of the breast. A distinctive benign lesion mimicking invasive carcinoma. *Am J Surg Pathol*. 1996;20(1):46-54.
208. Andersen JA, Carter D, Linell F. A symposium on sclerosing duct lesions of the breast. *Pathol Annu*. 1986;21(Pt 2):145-179.
209. Rabban JT, Sgroi DC. Sclerosing lesions of the breast. *Semin Diagn Pathol*. 2004;21(1):42-47.
210. Lakhani SREI, Schnitt SJ, Tan PH, van de Vijver MJ, eds. *WHO Classification of Tumors of the Breast*. Lyon: IARC press; 2012.
211. Hilson JB, Schnitt SJ, Collins LC. Phenotypic alterations in myoepithelial cells associated with benign sclerosing lesions of the breast. *Am J Surg Pathol*. 2010;34(6):896-900.
212. Jacobs TW, Byrne C, Colditz G, et al. Radial scars in benign breast-biopsy specimens and the risk of breast cancer. *N Engl J Med*. 1999;340(6):430-436.
213. Aroner SA, Collins LC, Connolly JL, et al. Radial scars and subsequent breast cancer risk: results from the Nurses' Health Studies. *Breast Cancer Res Treat*. 2013;139(1):277-285.
214. Sanders ME, Page DL, Simpson JF, et al. Interdependence of radial scar and proliferative disease with respect to invasive breast carcinoma risk in patients with benign breast biopsies. *Cancer*. 2006;106(7):1453-1461.
215. Berg JC, Visscher DW, Vierkant RA, et al. Breast cancer risk in women with radial scars in benign breast biopsies. *Breast Cancer Res Treat*. 2008;108(2):167-174.
216. Calhoun B, Collins L. Recommendations for excision following core needle biopsy of the breast: a contemporary evaluation of the literature. *Histopathology*. 2016; 68(1):138-151.
217. Hertel BF, Zaloudek C, Kempson RL. Breast adenomas. *Cancer*. 1976;37(6):2891-2905.
218. Kraus FT, Neubecker RD. The differential diagnosis of papillary tumors of the breast. *Cancer*. 1962;15:444-455.
219. Noguchi S, Motomura K, Inaji H, et al. Clonal analysis of solitary intraductal papilloma of the breast by means of polymerase chain reaction. *Am J Pathol*. 1994;144(6):1320-1325.
220. Jaffer S, Bleiweiss IJ. Intraductal papilloma with "comedo-like" necrosis, a diagnostic pitfall. *Ann Diagn Pathol*. 2004;8(5):276-279.
221. Lammie GA, Millis RR. Ductal adenoma of the breast—a review of fifteen cases. *Hum Pathol*. 1989;20(9):903-908.
222. Azzopardi JG, Salm R. Ductal adenoma of the breast: a lesion which can mimic carcinoma. *J Pathol*. 1984;144(1):15-23.
223. Carney JA, Toorkey BC. Ductal adenoma of the breast with tubular features. A probable component of the complex of myxomas, spotty pigmentation, endocrine overactivity, and schwannomas. *Am J Surg Pathol*. 1991;15(8):722-731.
224. Jiao YF, Nakamura S, Oikawa T, et al. Sebaceous gland metaplasia in intraductal papilloma of the breast. *Virchows Arch*. 2001;438(5):505-508.
225. MacGrogan G, Tavassoli FA. Central atypical papillomas of the breast: a clinicopathological study of 119 cases. *Virchows Arch*. 2003;443(5):609-617.
226. Raju U, Vertes D. Breast papillomas with atypical ductal hyperplasia: a clinicopathologic study. *Hum Pathol*. 1996;27(11):1231-1238.
227. Lee KC, Chan JK, Ho LC. Histologic changes in the breast after fine-needle aspiration. *Am J Surg Pathol*. 1994;18(10):1039-1047.
228. Rosen PP. Arthur Purdy Stout and papilloma of the breast. Comments on the occasion of his 100th birthday. *Am J Surg Pathol*. 1986;10(suppl 1):100-107.
229. Lewis JT, Hartmann LC, Vierkant RA, et al. An analysis of breast cancer risk in women with single, multiple, and atypical papilloma. *Am J Surg Pathol*. 2006;30(6):665-672.
230. Papotti M, Gugliotta P, Ghiringhello B, Bussolati G. Association of breast carcinoma and multiple intraductal papillomas: an histological and immunohistochemical investigation. *Histopathology*. 1984;8(6):963-975.
231. Ali-Fehmi R, Carolin K, Wallis T, Visscher DW. Clinicopathologic analysis of breast lesions associated with multiple papillomas. *Hum Pathol*. 2003;34(3):234-239.
232. Page DL, Salhany KE, Jensen RA, Dupont WD. Subsequent breast carcinoma risk after biopsy with atypia in a breast papilloma. *Cancer*. 1996;78(2):258-266.
233. Collins LC, Schnitt SJ. Papillary lesions of the breast: selected diagnostic and management issues. *Histopathology*. 2008;52(1):20-29.

For personal use only. No other uses without permission. Copyright ©2017. Elsevier Inc. All rights reserved.

234. Collins LC, Carlo VP, Hwang H, et al. Intracystic papillary carcinomas of the breast: a reevaluation using a panel of myoepithelial cell markers. *Am J Surg Pathol*. 2006;30(8):1002-1007.
235. Esposito NN, Dabbs DJ, Bhargava R. Are encapsulated papillary carcinomas of the breast in situ or invasive? A basement membrane study of 27 cases. *Am J Clin Pathol*. 2009;131(2):228-242.
236. Wynveen CA, Nehhozina T, Akram M, et al. Intracystic papillary carcinoma of the breast: an in situ or invasive tumor? results of immunohistochemical analysis and clinical follow-up. *Am J Surg Pathol*. 2011;35(1):1-14.
237. Collins L, O'Malley F, Visscher D, et al. Encapsulated papillary carcinoma. In: Lakhani SR, Ellis IO, Schnitt SJ, et al, eds. *WHO Classification of Tumours of the Breast*. Lyon: IARC press; 2012.
238. Rakha EA, Gandhi N, Climent F, et al. Encapsulated papillary carcinoma of the breast: an invasive tumor with excellent prognosis. *Am J Surg Pathol*. 2011;35(8):1093-1103.
239. Mulligan AM, O'Malley FP. Metastatic potential of encapsulated (intracystic) papillary carcinoma of the breast: a report of 2 cases with axillary lymph node micrometastases. *Int J Surg Pathol*. 2007;15(2):143-147.
240. Rakha EA, Varga Z, Elsheik S, Ellis IO. High-grade encapsulated papillary carcinoma of the breast: an under-recognized entity. *Histopathology*. 2015;66(5):740-746.
241. Nassar H, Qureshi H, Volkanadsay N, Visscher D. Clinicopathologic analysis of solid papillary carcinoma of the breast and associated invasive carcinomas. *Am J Surg Pathol*. 2006;30(4):501-507.
242. Visscher D, Colllins L, O'Malley F, et al. Solid papillary carcinoma. In: Lakhani SR, Ellis IO, Schnitt SJ, et al, eds. *WHO Classification of Tumors of the Breast*. Lyon, France: IARC; 2012:108-109.
243. Rabban JT, Koerner FC, Lerwill MF. Solid papillary ductal carcinoma in situ versus usual ductal hyperplasia in the breast: a potentially difficult distinction resolved by cytokeratin 5/6. *Hum Pathol*. 2006;37(7):787-793.
243a. Chiang S, Weigelt B, Wen HC, et al. IDH2 Mutations define a unique subtype of breast cancer with altered nuclear polarity. *Cancer Res*. 2016;76(24):7118-7129.
243b. Eusebi V, Damiani S, Ellis IO, et al. Breast tumor resembling the tall cell variant of papillary thyroid carcinoma: report of 5 cases. *Am J Surg Pathol*. 2003;27(8):1114-1118.
243c. Foschini MP, Asioli S, Foreid S, et al. Solid papillary breast carcinomas resembling the tall cell variant of papillary thyroid neoplasms: a unique invasive tumor with indolent behavior. *Am J Surg Pathol*. 2017;41(7):887-895.
243d. Bhargava R, Florea AV, Pelmus M, et al. Breast tumor resembling tall cell variant of papillary thyroid carcinoma: a solid papillary neoplasm with characteristic immunohistochemical profile and few recurrent mutations. *Am J Clin Pathol*. 2017;147(4):399-410.
244. Tse G, Moriya T, Niu Y. Invasive papillary carcinoma. In: Lakhani SR, Ellis IO, Schnitt SJ, et al, eds. *WHO Classification of Tumours of the Breast*. Lyon, France: IARC; 2012:64.
245. Rosen PP, Caicco JA. Florid papillomatosis of the nipple. A study of 51 patients, including nine with mammary carcinoma. *Am J Surg Pathol*. 1986;10(2):87-101.
246. Jones MW, Tavassoli FA. Coexistence of nipple duct adenoma and breast carcinoma: a clinicopathologic study of five cases and review of the literature. *Mod Pathol*. 1995;8(6):633-636.
247. Perzin KH, Lattes R. Papillary adenoma of the nipple (florid papillomatosis, adenoma, adenomatosis). A clinicopathologic study. *Cancer*. 1972;29(4):996-1009.
248. Lester S. Subareolar abscess (Zuska's Disease): a specific disease entity with specific treatment and prevention strategies. *Pathol Case Rev*. 1999;4(5):189-193.
249. Shousha S. Glandular Paget's disease of the nipple. *Histopathology*. 2007;50(6):812-814.
250. Tang X, Umemura S, Kumaki N, et al. A case report of pigmented mammary Paget's disease mimicking nevus of the nipple. *Breast Cancer*. 2014;21(3):370-374.
251. Kuan SF, Montag AG, Hart J, et al. Differential expression of mucin genes in mammary and extramammary Paget's disease. *Am J Surg Pathol*. 2001;25(12):1469-1477.
252. Yao DX, Hoda SA, Chiu A, et al. Intraepidermal cytokeratin 7 immunoreactive cells in the non-neoplastic nipple may represent interepithelial extension of lactiferous duct cells. *Histopathology*. 2002;40(3):230-236.
253. Lundquist K, Kohler S, Rouse RV. Intraepidermal cytokeratin 7 expression is not restricted to Paget cells but is also seen in Toker cells and Merkel cells. *Am J Surg Pathol*. 1999;23(2):212-219.
254. Fernandez-Flores A. Toker-cell pathology as a unifying concept. *Histopathology*. 2008;52(7):889-891, author reply 91-2.
255. Marucci G, Betts CM, Golouh R, et al. Toker cells are probably precursors of Paget cell carcinoma: a morphological and ultrastructural description. *Virchows Arch*. 2002;441(2):117-123.
256. U.S. Cancer Statistics Working Group. United States Cancer Statistics: 1999–2014 Incidence and Mortality Web-based Report. Atlanta (GA): Department of Health and Human Services, Centers for Disease Control and Prevention, and National Cancer Institute; 2017. Available at: http://www.cdc.gov/uscs.
257. American Cancer Society. *Cancer Facts and Figures 2015*. Atlanta, Georgia: American Cancer Society; 2015.
258. Sondik EJ. Breast cancer trends. Incidence, mortality, and survival. *Cancer*. 1994;74(3 suppl):995-999.
259. Garfinkel L, Boring CC, Heath CW Jr. Changing trends. An overview of breast cancer incidence and mortality. *Cancer*. 1994;74(1 suppl):222-227.
260. Jatoi I, Miller AB. Why is breast-cancer mortality declining? *Lancet Oncol*. 2003;4(4):251-254.
261. Peto R, Boreham J, Clarke M, et al. UK and USA breast cancer deaths down 25% in year 2000 at ages 20-69 years. *Lancet*. 2000;355(9217):1822.
262. Desouki MM, Li Z, Hameed O, et al. Incidental atypical proliferative lesions in reduction mammoplasty specimens: analysis of 2498 cases from 2 tertiary women's health centers. *Hum Pathol*. 2013;44(9):1877-1881.
263. Skolnick MH, Cannon-Albright LA. Genetic predisposition to breast cancer. *Cancer*. 1992;70(6 suppl):1747-1754.
264. Willett WC, Tamimi RM, Hankinson SE, et al. Nongenetic factors in the causation of breast cancer. In: Harris JR, Lippman ME, Morrow M, Osborne CK, eds. *Diseases of the Breast*. 4th ed. Philadelphia: Lippincott Williams & Wilkins; 2010:248-290.
265. Kauff ND, Domchek SM, Friebel TM, et al. Risk-reducing salpingo-oophorectomy for the prevention of BRCA1- and BRCA2-associated breast and gynecologic cancer: a multicenter, prospective study. *J Clin Oncol*. 2008;26(8):1331-1337.
266. Eisen A, Lubinski J, Klijn J, et al. Breast cancer risk following bilateral oophorectomy in BRCA1 and BRCA2 mutation carriers: an international case-control study. *J Clin Oncol*. 2005;23(30):7491-7496.
267. Lambe M, Hsieh C, Trichopoulos D, et al. Transient increase in the risk of breast cancer after giving birth. *N Engl J Med*. 1994;331(1):5-9.
268. Cancer CGoHFiB. Breast cancer and breastfeeding: collaborative reanalysis of individual data from 47 epidemiological studies in 30 countries, including 50 302 women with breast cancer and 96 973 women without the disease. *Lancet*. 2002;360:187-195.
269. Key T, Appleby P, Barnes I, Reeves G. Endogenous sex hormones and breast cancer in postmenopausal women: reanalysis of nine prospective studies. *J Natl Cancer Inst*. 2002;94(8):606-616.
270. Kaaks R, Rinaldi S, Key TJ, et al. Postmenopausal serum androgens, oestrogens and breast cancer risk: the European prospective investigation into cancer and nutrition. *Endocr Relat Cancer*. 2005;12(4):1071-1082.
271. Collaborative Group on Hormonal Factors in Breast C. Breast cancer and hormonal contraceptives: collaborative reanalysis of individual data on 53 297 women with breast cancer and 100 239 women without breast cancer from 54 epidemiological studies. *Lancet*. 1996;347(9017):1713-1727.
272. Goss PE, Sierra S. Current perspectives on radiation-induced breast cancer. *J Clin Oncol*. 1998;16(1):338-347.
273. Tokunaga M, Land CE, Tokuoka S, et al. Incidence of female breast cancer among atomic bomb survivors, 1950-1985. *Radiat Res*. 1994;138(2):209-223.
274. Hancock SL, Tucker MA, Hoppe RT. Breast cancer after treatment of Hodgkin's disease. *J Natl Cancer Inst*. 1993;85(1):25-31.
275. Berkel H, Birdsell DC, Jenkins H. Breast augmentation: a risk factor for breast cancer? *N Engl J Med*. 1992;326(25):1649-1653.
276. Bryant H, Brasher P. Breast implants and breast cancer—reanalysis of a linkage study. *N Engl J Med*. 1995;332(23):1535-1539.
277. Criscitiello C, Disalvatore D, Santangelo M, et al. No link between breast cancer and meningioma: results from a large monoinstitutional retrospective analysis. *Cancer Epidemiol Biomarkers Prev*. 2014;23(1):215-217.
278. Wooster R, Weber BL. Breast and ovarian cancer. *N Engl J Med*. 2003;348(23):2339-2347.
279. Tan DS, Marchio C, Reis-Filho JS. Hereditary breast cancer: from molecular pathology to tailored therapies. *J Clin Pathol*. 2008;61(10):1073-1082.
280. Prevalence and penetrance of BRCA1 and BRCA2 mutations in a population-based series of breast cancer cases. Anglian Breast Cancer Study Group. *Br J Cancer*. 2000;83(10):1301-1308.
281. Ponder B. Breast cancer genes. Searches begin and end. *Nature*. 1994;371(6495):279.
282. Blackwood MA, Weber BL. BRCA1 and BRCA2: from molecular genetics to clinical medicine. *J Clin Oncol*. 1998;16(5):1969-1977.
283. Futreal PA, Liu Q, Shattuck-Eidens D, et al. BRCA1 mutations in primary breast and ovarian carcinomas. *Science*. 1994;266(5182):120-122.
284. Wooster R, Neuhausen SL, Mangion J, et al. Localization of a breast cancer susceptibility gene, BRCA2, to chromosome 13q12-13. *Science*. 1994;265(5181):2088-2090.
285. Narod SA, Foulkes WD. BRCA1 and BRCA2: 1994 and beyond. *Nat Rev Cancer*. 2004;4(9):665-676.
286. Hartge P, Struewing JP, Wacholder S, et al. The prevalence of common BRCA1 and BRCA2 mutations among Ashkenazi Jews. *Am J Hum Genet*. 1999;64(4):963-970.

For personal use only. No other uses without permission. Copyright ©2017. Elsevier Inc. All rights reserved.

287. Struewing JP, Hartge P, Wacholder S, et al. The risk of cancer associated with specific mutations of BRCA1 and BRCA2 among Ashkenazi Jews. *N Engl J Med*. 1997;336(20):1401-1408.
288. Robson M, Offit K. Clinical practice. Management of an inherited predisposition to breast cancer. *N Engl J Med*. 2007;357(2):154-162.
289. Fong PC, Boss DS, Yap TA, et al. Inhibition of poly(ADP-ribose) polymerase in tumors from BRCA mutation carriers. *N Engl J Med*. 2009;361(2):123-134.
290. Ashworth A. A synthetic lethal therapeutic approach: poly(ADP) ribose polymerase inhibitors for the treatment of cancers deficient in DNA double-strand break repair. *J Clin Oncol*. 2008;26(22):3785-3790.
291. Da Silva L, Lakhani SR. Pathology of hereditary breast cancer. *Mod Pathol*. 2010;23(suppl 2):S46-S51.
292. Adem C, Reynolds C, Soderberg CL, et al. Pathologic characteristics of breast parenchyma in patients with hereditary breast carcinoma, including BRCA1 and BRCA2 mutation carriers. *Cancer*. 2003;97(1):1-11.
293. Palacios J, Robles-Frias MJ, Castilla MA, et al. The molecular pathology of hereditary breast cancer. *Pathobiology*. 2008;75(2):85-94.
294. Sheikh A, Hussain SA, Ghori Q, et al. The spectrum of genetic mutations in breast cancer. *Asian Pac J Cancer Prev*. 2015;16(6):2177-2185.
295. Stuckey AR, Onstad MA. Hereditary breast cancer: an update on risk assessment and genetic testing in 2015. *Am J Obstet Gynecol*. 2015;213(2):161-165.
296. Sughrue T, Brody JP. Breast tumor laterality in the United States depends upon the country of birth, but not race. *PLoS ONE*. 2014;9(8):e103313.
297. Robichaux JP, Hallett RM, Fuseler JW, et al. Mammary glands exhibit molecular laterality and undergo left-right asymmetric ductal epithelial growth in MMTV-cNeu mice. *Oncogene*. 2015;34(15):2003-2010.
298. Qualheim RE, Gall EA. Breast carcinoma with multiple sites of origin. *Cancer*. 1957;10(3):460-468.
299. Kanumuri P, Hayse B, Killelea BK, et al. Characteristics of Multifocal and Multicentric Breast Cancers. *Ann Surg Oncol*. 2015;22(8):2475-2482.
300. Dawson PJ, Baekey PA, Clark RA. Mechanisms of multifocal breast cancer: an immunocytochemical study. *Hum Pathol*. 1995;26(9):965-969.
301. Middleton LP, Vlastos G, Mirza NQ, et al. Multicentric mammary carcinoma: evidence of monoclonal proliferation. *Cancer*. 2002;94(7):1910-1916.
302. Volante M, Sapino A, Croce S, Bussolati G. Heterogeneous versus homogeneous genetic nature of multiple foci of in situ carcinoma of the breast. *Hum Pathol*. 2003;34(11):1163-1169.
303. Andea AA, Bouwman D, Wallis T, Visscher DW. Correlation of tumor volume and surface area with lymph node status in patients with multifocal/multicentric breast carcinoma. *Cancer*. 2004;100(1):20-27.
304. Hilton JF, Bouganim N, Dong B, et al. Do alternative methods of measuring tumor size, including consideration of multicentric/multifocal disease, enhance prognostic information beyond TNM staging in women with early stage breast cancer: an analysis of the NCIC CTG MA.5 and MA.12 clinical trials. *Breast Cancer Res Treat*. 2013;142(1):143-151.
305. Broet P, de la Rochefordiere A, Scholl SM, et al. Contralateral breast cancer: annual incidence and risk parameters. *J Clin Oncol*. 1995;13(7):1578-1583.
306. Early Breast Cancer Trialists' Collaborative G. Aromatase inhibitors versus tamoxifen in early breast cancer: patient-level meta-analysis of the randomised trials. *Lancet*. 2015;386(10001):1341-1352.
307. Saslow D, Boetes C, Burke W, et al. American Cancer Society guidelines for breast screening with MRI as an adjunct to mammography. *CA Cancer J Clin*. 2007;57(2):75-89.
308. Hawley ST, Jagsi R, Morrow M, et al. Social and clinical determinants of contralateral prophylactic mastectomy. *JAMA Surg*. 2014;149(6):582-589.
309. Kummerow KL, Du L, Penson DF, et al. Nationwide trends in mastectomy for early-stage breast cancer. *JAMA Surg*. 2015;150(1):9-16.
310. Nichol AM, Yerushalmi R, Tyldesley S, et al. A case-match study comparing unilateral with synchronous bilateral breast cancer outcomes. *J Clin Oncol*. 2011;29(36):4763-4768.
311. Smart CR, Byrne C, Smith RA, et al. Twenty-year follow-up of the breast cancers diagnosed during the Breast Cancer Detection Demonstration Project. *CA Cancer J Clin*. 1997;47(3):134-149.
312. Specht MC, Fey JV, Borgen PI, Cody HS 3rd. Is the clinically positive axilla in breast cancer really a contraindication to sentinel lymph node biopsy? *J Am Coll Surg*. 2005;200(1):10-14.
313. Gajdos C, Tartter PI, Bleiweiss IJ, et al. Mammographic appearance of nonpalpable breast cancer reflects pathologic characteristics. *Ann Surg*. 2002;235(2):246-251.
314. Millis RR, Davis R, Stacey AJ. The detection and significance of calcifications in the breast: a radiological and pathological study. *Br J Radiol*. 1976;49(577):12-26.
315. Farshid G, Sullivan T, Downey P, et al. Independent predictors of breast malignancy in screen-detected microcalcifications: biopsy results in 2545 cases. *Br J Cancer*. 2011;105(11):1669-1675.
316. D'Orsi C, Sickles E, Mendelson E, Morris EA. *ACR BI-RADS Atlas, Breast Imaging Reporting and Data System*. Reston, VA: American College of Radiology; 2013.
317. Barlow WE, Lehman CD, Zheng Y, et al. Performance of diagnostic mammography for women with signs or symptoms of breast cancer. *J Natl Cancer Inst*. 2002;94(15):1151-1159.
318. Owings DV, Hann L, Schnitt SJ. How thoroughly should needle localization breast biopsies be sampled for microscopic examination? A prospective mammographic/pathologic correlative study. *Am J Surg Pathol*. 1990;14(6):578-583.
319. Gonzalez JE, Caldwell RG, Valaitis J. Calcium oxalate crystals in the breast. Pathology and significance. *Am J Surg Pathol*. 1991;15(6):586-591.
320. Gisvold JJ. Imaging of the breast: techniques and results. *Mayo Clin Proc*. 1990;65(1):56-66.
321. Gillman J, Toth HK, Moy L. The role of dynamic contrast-enhanced screening breast MRI in populations at increased risk for breast cancer. *Women's health*. 2014;10(6):609-622.
322. Force USPST. Screening for breast cancer: U.S. Preventive Services Task Force recommendation statement. *Ann Intern Med*. 2009;151(10):716-726, W-236.
323. Arisio R, Cuccorese C, Accinelli G, et al. Role of fine-needle aspiration biopsy in breast lesions: analysis of a series of 4,110 cases. *Diagn Cytopathol*. 1998;18(6):462-467.
324. Kline TS, Joshi LP, Neal HS. Fine-needle aspiration of the breast: diagnoses and pitfalls. A review of 3545 cases. *Cancer*. 1979;44(4):1458-1464.
325. Norton LW, Davis JR, Wiens JL, et al. Accuracy of aspiration cytology in detecting breast cancer. *Surgery*. 1984;96(4):806-814.
326. Kline TS. Masquerades of malignancy: a review of 4,241 aspirates from the breast. *Acta Cytol*. 1981;25(3):263-266.
327. Abendroth CS, Wang HH, Ducatman BS. Comparative features of carcinoma in situ and atypical ductal hyperplasia of the breast on fine-needle aspiration biopsy specimens. *Am J Clin Pathol*. 1991;96(5):654-659.
328. Chandrasoma PT. Microcalcification in the breast and the pathologist. *Am J Surg Pathol*. 2002;26(1):135-136.
329. Hammond ME, Hayes DF, Dowsett M, et al. American Society of Clinical Oncology/College Of American Pathologists guideline recommendations for immunohistochemical testing of estrogen and progesterone receptors in breast cancer. *J Clin Oncol*. 2010;28(16):2784-2795.
330. Renshaw AA. Adequate histologic sampling of breast core needle biopsies. *Arch Pathol Lab Med*. 2001;125(8):1055-1057.
331. Collins LC, Connolly JL, Page DL, et al. Diagnostic agreement in the evaluation of image-guided breast core needle biopsies: results from a randomized clinical trial. *Am J Surg Pathol*. 2004;28(1):126-131.
332. Elsheikh TM, Silverman JF. Follow-up surgical excision is indicated when breast core needle biopsies show atypical lobular hyperplasia or lobular carcinoma in situ: a correlative study of 33 patients with review of the literature. *Am J Surg Pathol*. 2005;29(4):534-543.
333. Cangiarella J, Guth A, Axelrod D, et al. Is surgical excision necessary for the management of atypical lobular hyperplasia and lobular carcinoma in situ diagnosed on core needle biopsy?: a report of 38 cases and review of the literature. *Arch Pathol Lab Med*. 2008;132(6):979-983.
334. Murray MP, Luedtke C, Liberman L, et al. Classic lobular carcinoma in situ and atypical lobular hyperplasia at percutaneous breast core biopsy: Outcomes of prospective excision. *Cancer*. 2013;119(5):1073-1079.
335. Rendi MH, Dintzis SM, Lehman CD, et al. Lobular in-situ neoplasia on breast core needle biopsy: imaging indication and pathologic extent can identify which patients require excisional biopsy. *Ann Surg Oncol*. 2012;19(3):914-921.
336. Carder PJ, Garvican J, Haigh I, Liston JC. Needle core biopsy can reliably distinguish between benign and malignant papillary lesions of the breast. *Histopathology*. 2005;46(3):320-327.
337. Davies JD, Nonni A, D'Costa HF. Mammary epidermoid inclusion cysts after wide-core needle biopsies. *Histopathology*. 1997;31(6):549-551.
338. Gobbi H, Tse G, Page DL, et al. Reactive spindle cell nodules of the breast after core biopsy or fine-needle aspiration. *Am J Clin Pathol*. 2000;113(2):288-294.
339. Youngson BJ, Liberman L, Rosen PP. Displacement of carcinomatous epithelium in surgical breast specimens following stereotaxic core biopsy. *Am J Clin Pathol*. 1995;103(5):598-602.
340. Koo JS, Jung WH, Kim H. Epithelial displacement into the lymphovascular space can be seen in breast core needle biopsy specimens. *Am J Clin Pathol*. 2010;133(5):781-787.
341. Nagi C, Bleiweiss I, Jaffer S. Epithelial displacement in breast lesions: a papillary phenomenon. *Arch Pathol Lab Med*. 2005;129(11):1465-1469.
342. Sauter ER, Hoffman JP, Ottery FD, et al. Is frozen section analysis of reexcision lumpectomy margins worthwhile? Margin analysis in breast reexcisions. *Cancer*. 1994;73(10):2607-2612.
343. Bishop JA, Sun J, Ajkay N, Sanders MA. Decline in frozen section diagnosis for axillary

For personal use only. No other uses without permission. Copyright ©2017. Elsevier Inc. All rights reserved.

sentinel lymph nodes as a result of the American College of Surgeons Oncology Group Z0011 trial. *Arch Pathol Lab Med*. 2016;140(8):830-835.
344. Giuliano AE, McCall L, Beitsch P, et al. Locoregional recurrence after sentinel lymph node dissection with or without axillary dissection in patients with sentinel lymph node metastases: the American College of Surgeons Oncology Group Z0011 randomized trial. *Ann Surg*. 2010;252(3):426-432, discussion 432-433.
345. Kerner H, Lichtig C. Lobular cancerization: incidence and differential diagnosis with lobular carcinoma in situ of breast. *Histopathology*. 1986;10(6):621-629.
346. Badve S, A'Hern RP, Ward AM, et al. Prediction of local recurrence of ductal carcinoma in situ of the breast using five histological classifications: a comparative study with long follow-up. *Hum Pathol*. 1998;29(9):915-923.
347. Douglas-Jones AG, Gupta SK, Attanoos RL, et al. A critical appraisal of six modern classifications of ductal carcinoma in situ of the breast (DCIS): correlation with grade of associated invasive carcinoma. *Histopathology*. 1996;29(5):397-409.
348. Ellis IO, Pinder SE, Lee AH, Elston CW. A critical appraisal of existing classification systems of epithelial hyperplasia and in situ neoplasia of the breast with proposals for future methods of categorization: where are we going? *Semin Diagn Pathol*. 1999;16(3):202-208.
349. Consensus Conference on the classification of ductal carcinoma in situ. The Consensus Conference Committee. *Cancer*. 1997;80(9):1798-1802.
350. Lester SC, Connolly JL, Amin MB. College of American Pathologists protocol for the reporting of ductal carcinoma in situ. *Arch Pathol Lab Med*. 2009;133(1):13-14.
351. Collins LC, Achacoso N, Nekhlyudov L, et al. Relationship between clinical and pathologic features of ductal carcinoma in situ and patient age: an analysis of 657 patients. *Am J Surg Pathol*. 2009;33(12):1802-1808.
352. Carter D, Smith RR. Carcinoma in situ of the breast. *Cancer*. 1977;40(3):1189-1193.
353. Lara JF, Young SM, Velilla RE, et al. The relevance of occult axillary micrometastasis in ductal carcinoma in situ: a clinicopathologic study with long-term follow-up. *Cancer*. 2003;98(10):2105-2113.
354. Rosen PP. Axillary lymph node metastases in patients with occult noninvasive breast carcinoma. *Cancer*. 1980;46(5):1298-1306.
355. O'Sullivan MJ, Morrow M. Ductal carcinoma in situ—current management. *Surg Clin North Am*. 2007;87(2):333-351, viii.
356. Bellamy CO, McDonald C, Salter DM, et al. Noninvasive ductal carcinoma of the breast: the relevance of histologic categorization. *Hum Pathol*. 1993;24(1):16-23.
357. Schnitt SJ. Clinging carcinoma: an American perspective. *Semin Diagn Pathol*. 2010;27(1):31-36.
358. Fisher ER, Brown R. Intraductal signet ring carcinoma. A hitherto undescribed form of intraductal carcinoma of the breast. *Cancer*. 1985;55(11):2533-2537.
359. Leal C, Henrique R, Monteiro P, et al. Apocrine ductal carcinoma in situ of the breast: histologic classification and expression of biologic markers. *Hum Pathol*. 2001;32(5):487-493.
360. Hayes MM, Peterse JL, Yavuz E, et al. Squamous cell carcinoma in situ of the breast: a light microscopic and immunohistochemical study of a previously undescribed lesion. *Am J Surg Pathol*. 2007;31(9):1414-1419.
361. Cross AS, Azzopardi JG, Krausz T, et al. A morphological and immunocytochemical study of a distinctive variant of ductal carcinoma in-situ of the breast. *Histopathology*. 1985;9(1):21-37.
362. Tsang WY, Chan JK. Endocrine ductal carcinoma in situ (E-DCIS) of the breast: a form of low-grade DCIS with distinctive clinicopathologic and biologic characteristics. *Am J Surg Pathol*. 1996;20(8):921-943.
363. Farshid G, Moinfar F, Meredith DJ, et al. Spindle cell ductal carcinoma in situ. An unusual variant of ductal intra-epithelial neoplasia that simulates ductal hyperplasia or a myoepithelial proliferation. *Virchows Arch*. 2001;439(1):70-77.
364. Bombonati A, Sgroi DC. The molecular pathology of breast cancer progression. *J Pathol*. 2011;223(2):307-317.
365. Sotiriou C, Wirapati P, Loi S, et al. Gene expression profiling in breast cancer: understanding the molecular basis of histologic grade to improve prognosis. *J Natl Cancer Inst*. 2006;98(4):262-272.
366. Rosen PP, Braun DW Jr, Kinne DE. The clinical significance of pre-invasive breast carcinoma. *Cancer*. 1980;46(4 suppl):919-925.
367. Collins LC, Tamimi RM, Baer HJ, et al. Outcome of patients with ductal carcinoma in situ untreated after diagnostic biopsy: results from the Nurses' Health Study. *Cancer*. 2005;103(9):1778-1784.
368. Eusebi V, Foschini MP, Cook MG, et al. Long-term follow-up of in situ carcinoma of the breast with special emphasis on clinging carcinoma. *Semin Diagn Pathol*. 1989;6(2):165-173.
369. Sanders ME, Schuyler PA, Dupont WD, Page DL. The natural history of low-grade ductal carcinoma in situ of the breast in women treated by biopsy only revealed over 30 years of long-term follow-up. *Cancer*. 2005;103(12):2481-2484.
370. Sanders ME, Schuyler PA, Simpson JE, et al. Continued observation of the natural history of low-grade ductal carcinoma in situ reaffirms proclivity for local recurrence even after more than 30 years of follow-up. *Mod Pathol*. 2015;28(5):662-669.
371. Lampejo OT, Barnes DM, Smith P, Millis RR. Evaluation of infiltrating ductal carcinomas with a DCIS component: correlation of the histologic type of the in situ component with grade of the infiltrating component. *Semin Diagn Pathol*. 1994;11(3):215-222.
372. Ma XJ, Salunga R, Tuggle JT, et al. Gene expression profiles of human breast cancer progression. *Proc Natl Acad Sci USA*. 2003;100(10):5974-5979.
373. Morrow M, Schnitt SJ, Norton L. Current management of lesions associated with an increased risk of breast cancer. *Nat Rev Clin Oncol*. 2015;12(4):227-238.
374. Morrow M, Strom EA, Bassett LW, et al. Standard for the management of ductal carcinoma in situ of the breast (DCIS). *CA Cancer J Clin*. 2002;52(5):256-276.
375. Schnitt SJ, Morrow M. Lobular carcinoma in situ: current concepts and controversies. *Semin Diagn Pathol*. 1999;16(3):209-223.
376. Hanby AM, Hughes TA. In situ and invasive lobular neoplasia of the breast. *Histopathology*. 2008;52(1):58-66.
377. Fadare O, Dadmanesh F, Alvarado-Cabrero I, et al. Lobular intraepithelial neoplasia [lobular carcinoma in situ] with comedo-type necrosis: a clinicopathologic study of 18 cases. *Am J Surg Pathol*. 2006;30(11):1445-1453.
378. Sneige N, Wang J, Baker BA, et al. Clinical, histopathologic, and biologic features of pleomorphic lobular (ductal-lobular) carcinoma in situ of the breast: a report of 24 cases. *Mod Pathol*. 2002;15(10):1044-1050.
379. Shin SJ, Lal A, De Vries S, et al. Florid lobular carcinoma in situ: molecular profiling and comparison to classic lobular carcinoma in situ and pleomorphic lobular carcinoma in situ. *Hum Pathol*. 2013;44(10):1998-2009.
380. Dabbs DJ, Bhargava R, Chivukula M. Lobular versus ductal breast neoplasms: the diagnostic utility of p120 catenin. *Am J Surg Pathol*. 2007;31(3):427-437.
381. Canas-Marques R, Schnitt SJ. E-cadherin immunohistochemistry in breast pathology: uses and pitfalls. *Histopathology*. 2016;68(1):57-69.
382. Da Silva L, Parry S, Reid L, et al. Aberrant expression of E-cadherin in lobular carcinomas of the breast. *Am J Surg Pathol*. 2008;32(5):773-783.
383. Middleton LP, Palacios DM, Bryant BR, et al. Pleomorphic lobular carcinoma: morphology, immunohistochemistry, and molecular analysis. *Am J Surg Pathol*. 2000;24(12):1650-1656.
384. Palacios J, Sarrio D, Garcia-Macias MC, et al. Frequent E-cadherin gene inactivation by loss of heterozygosity in pleomorphic lobular carcinoma of the breast. *Mod Pathol*. 2003;16(7):674-678.
385. Andersen JA. Lobular carcinoma in situ. A long-term follow-up in 52 cases. *Acta Pathol Microbiol Scand [A]*. 1974;82(4):519-533.
386. Fisher ER, Land SR, Fisher B, et al. Pathologic findings from the National Surgical Adjuvant Breast and Bowel Project: twelve-year observations concerning lobular carcinoma in situ. *Cancer*. 2004;100(2):238-244.
387. Haagensen CD, Lane N, Lattes R, Bodian C. Lobular neoplasia (so-called lobular carcinoma in situ) of the breast. *Cancer*. 1978;42(2):737-769.
388. Ottesen GL, Graversen HP, Blichert-Toft M, et al. Lobular carcinoma in situ of the female breast. Short-term results of a prospective nationwide study. The Danish Breast Cancer Cooperative Group. *Am J Surg Pathol*. 1993;17(1):14-21.
389. Wheeler JE, Enterline HT, Roseman JM, et al. Lobular carcinoma in situ of the breast. Long-term followup. *Cancer*. 1974;34(3):554-563.
390. Andersen JA. Lobular carcinoma in situ of the breast. An approach to rational treatment. *Cancer*. 1977;39(6):2597-2602.
391. Fisher ER, Costantino J, Fisher B, et al. Pathologic findings from the National Surgical Adjuvant Breast Project (NSABP) Protocol B-17. Five-year observations concerning lobular carcinoma in situ. *Cancer*. 1996;78(7):1403-1416.
392. Fisher B, Costantino JP, Wickerham DL, et al. Tamoxifen for prevention of breast cancer: report of the National Surgical Adjuvant Breast and Bowel Project P-1 Study. *J Natl Cancer Inst*. 1998;90(18):1371-1388.
393. Sue GR, Lannin DR, Killelea B, Chagpar AB. Predictors of microinvasion and its prognostic role in ductal carcinoma in situ. *Am J Surg*. 2013;206(4):478-481.
394. Schnitt SJ. Microinvasive carcinoma of the breast: a diagnosis in search of a definition. *Adv Anat Pathol*. 1998;5(6):367-372.
395. Hoda SA, Prasad ML, Moore A, et al. Microinvasive carcinoma of the breast: can it be diagnosed reliably and is it clinically significant? *Histopathology*. 1999;35(5):468-470.
396. Prasad ML, Osborne MP, Giri DD, Hoda SA. Microinvasive carcinoma (T1mic) of the breast: clinicopathologic profile of 21 cases. *Am J Surg Pathol*. 2000;24(3):422-428.
397. Werling RW, Hwang H, Yaziji H, Gown AM. Immunohistochemical distinction of invasive from noninvasive breast lesions: a comparative study of p63 versus calponin and smooth muscle myosin heavy chain. *Am J Surg Pathol*. 2003;27(1):82-90.

For personal use only. No other uses without permission. Copyright ©2017. Elsevier Inc. All rights reserved.

398. Zavotsky J, Hansen N, Brennan MB, et al. Lymph node metastasis from ductal carcinoma in situ with microinvasion. *Cancer*. 1999;85(11):2439-2443.
399. Padmore RF, Fowble B, Hoffman J, et al. Microinvasive breast carcinoma: clinicopathologic analysis of a single institution experience. *Cancer*. 2000;88(6):1403-1409.
400. de Mascarel I, MacGrogan G, Mathoulin-Pelissier S, et al. Breast ductal carcinoma in situ with microinvasion: a definition supported by a long-term study of 1248 serially sectioned ductal carcinomas. *Cancer*. 2002;94(8):2134-2142.
401. Matsen CB, Hirsch A, Eaton A, et al. Extent of microinvasion in ductal carcinoma in situ is not associated with sentinel lymph node metastases. *Ann Surg Oncol*. 2014;21(10):3330-3335.
402. Azzopardi JG, Laurini RN. Elastosis in breast cancer. *Cancer*. 1974;33(1):174-183.
403. Fisher ER, Gregorio RM, Fisher B, et al. The pathology of invasive breast cancer. A syllabus derived from findings of the National Surgical Adjuvant Breast Project (protocol no. 4). *Cancer*. 1975;36(1):1-85.
404. Rosen PP. Tumor emboli in intramammary lymphatics in breast carcinoma: pathologic criteria for diagnosis and clinical significance. *Pathol Annu*. 1983;18(Pt 2):215-232.
405. Rabban JT, Chen YY. D2-40 expression by breast myoepithelium: potential pitfalls in distinguishing intralymphatic carcinoma from in situ carcinoma. *Hum Pathol*. 2008;39(2):175-183.
406. Ordonez NG, Brooks T, Thompson S, Batsakis JG. Use of Ulex europaeus agglutinin I in the identification of lymphatic and blood vessel invasion in previously stained microscopic slides. *Am J Surg Pathol*. 1987;11(7):543-550.
407. Schnitt SJ, Connolly JL, Khettry U, et al. Pathologic findings on re-excision of the primary site in breast cancer patients considered for treatment by primary radiation therapy. *Cancer*. 1987;59(4):675-681.
408. Jarasch ED, Nagle RB, Kaufmann M, et al. Differential diagnosis of benign epithelial proliferations and carcinomas of the breast using antibodies to cytokeratins. *Hum Pathol*. 1988;19(3):276-289.
409. Collins LC, Martyniak AJ, Kandel MJ, et al. Basal cytokeratin and epidermal growth factor receptor expression are not predictive of BRCA1 mutation status in women with triple-negative breast cancers. *Am J Surg Pathol*. 2009;33:1093-1097.
410. Bhargava R, Beriwal S, Dabbs DJ. Mammaglobin vs GCDFP-15: an immunohistologic validation survey for sensitivity and specificity. *Am J Clin Pathol*. 2007;127(1):103-113.
411. Mazoujian G, Bodian C, Haagensen DE Jr, Haagensen CD. Expression of GCDFP-15 in breast carcinomas. Relationship to pathologic and clinical factors. *Cancer*. 1989;63(11):2156-2161.
412. Miettinen M, McCue PA, Sarlomo-Rikala M, et al. GATA3: a multispecific but potentially useful marker in surgical pathology: a systematic analysis of 2500 epithelial and nonepithelial tumors. *Am J Surg Pathol*. 2014;38(1):13-22.
413. Dwarakanath S, Lee AK, Delellis RA, et al. S-100 protein positivity in breast carcinomas: a potential pitfall in diagnostic immunohistochemistry. *Hum Pathol*. 1987;18(11):1144-1148.
414. Lunde S, Nesland JM, Holm R, Johannessen JV. Breast carcinomas with protein S-100 immunoreactivity. An immunocytochemical and ultrastructural study. *Pathol Res Pract*. 1987;182(5):627-631.
415. Bonetti F, Colombari R, Manfrin E, et al. Breast carcinoma with positive results for melanoma marker (HMB-45). HMB-45 immunoreactivity in normal and neoplastic breast. *Am J Clin Pathol*. 1989;92(4):491-495.
416. Robens J, Goldstein L, Gown AM, Schnitt SJ. Thyroid transcription factor-1 expression in breast carcinomas. *Am J Surg Pathol*. 2010;34(12):1881-1885.
417. Bellahcene A, Castronovo V. Increased expression of osteonectin and osteopontin, two bone matrix proteins, in human breast cancer. *Am J Pathol*. 1995;146(1):95-100.
418. Hirota S, Ito A, Nagoshi J, et al. Expression of bone matrix protein messenger ribonucleic acids in human breast cancers. Possible involvement of osteopontin in development of calcifying foci. *Lab Invest*. 1995;72(1):64-69.
419. Wetzels RH, Holland R, van Haelst UJ, et al. Detection of basement membrane components and basal cell keratin 14 in noninvasive and invasive carcinomas of the breast. *Am J Pathol*. 1989;134(3):571-579.
420. Willebrand D, Bosman FT, de Goeij AF. Patterns of basement membrane deposition in benign and malignant breast tumours. *Histopathology*. 1986;10(12):1231-1241.
421. Fisher ER. Ultrastructure of the human breast and its disorders. *Am J Clin Pathol*. 1976;66(2):291-375.
422. Battifora H. Intracytoplasmic lumina in breast carcinoma: a helpful histopathologic feature. *Arch Pathol*. 1975;99(11):614-617.
423. Sobrinho-Simoes M, Johannessen JV, Gould VE. The diagnostic significance of intracytoplasmic lumina in metastatic neoplasms. *Ultrastruct Pathol*. 1981;2(4):327-335.
424. Ohtani H, Sasano N. Myofibroblasts and myoepithelial cells in human breast carcinoma. An ultrastructural study. *Virchows Arch A Pathol Anat Histol*. 1980;385(3):247-261.
425. de Deus Moura R, Wludarski SC, Carvalho FM, Bacchi CE. Immunohistochemistry applied to the differential diagnosis between ductal and lobular carcinoma of the breast. *Appl Immunohistochem Mol Morphol*. 2013;21:1-12.
426. Rakha EA, Ellis IO. Lobular breast carcinoma and its variants. *Semin Diagn Pathol*. 2010;27(1):49-61.
427. Martinez V, Azzopardi JG. Invasive lobular carcinoma of the breast: incidence and variants. *Histopathology*. 1979;3(6):467-488.
428. Raap M, Antonopoulos W, Dammrich M, et al. High frequency of lobular breast cancer in distant metastases to the orbit. *Cancer Med*. 2015;4(1):104-111.
429. Weidner N, Semple JP. Pleomorphic variant of invasive lobular carcinoma of the breast. *Hum Pathol*. 1992;23(10):1167-1171.
430. Chen YY, Hwang ES, Roy R, et al. Genetic and phenotypic characteristics of pleomorphic lobular carcinoma in situ of the breast. *Am J Surg Pathol*. 2009;33(11):1683-1694.
431. Steinbrecher JS, Silverberg SG. Signet-ring cell carcinoma of the breast. The mucinous variant of infiltrating lobular carcinoma? *Cancer*. 1976;37(2):828-840.
432. Chu PG, Weiss LM. Immunohistochemical characterization of signet-ring cell carcinomas of the stomach, breast, and colon. *Am J Clin Pathol*. 2004;121(6):884-892.
433. Mahmud N, Ford JM, Longacre TA, et al. Metastatic lobular breast carcinoma mimicking primary signet ring adenocarcinoma in a patient with a suspected CDH1 mutation. *J Clin Oncol*. 2015;33(4):e19-e21.
434. Iesato A, Oba T, Ono M, et al. Breast metastases of gastric signet-ring cell carcinoma: a report of two cases and review of the literature. *Onco Targets Ther*. 2015;8:91-97.
435. Shimizu S, Kitamura H, Ito T, et al. Histiocytoid breast carcinoma: histological, immunohistochemical, ultrastructural, cytological and clinicopathological studies. *Pathol Int*. 1998;48(7):549-556.
436. Tan PH, Harada O, Thike AA, Tse GM. Histiocytoid breast carcinoma: an enigmatic lobular entity. *J Clin Pathol*. 2011;64(8):654-659.
437. Eusebi V, Foschini MP, Bussolati G, Rosen PP. Myoblastomatoid (histiocytoid) carcinoma of the breast. A type of apocrine carcinoma. *Am J Surg Pathol*. 1995;19(5):553-562.
438. Walford N, ten Velden J. Histiocytoid breast carcinoma: an apocrine variant of lobular carcinoma. *Histopathology*. 1989;14(5):515-522.
439. Ramos CV, Taylor HB. Lipid-rich carcinoma of the breast. A clinicopathologic analysis of 13 examples. *Cancer*. 1974;33(3):812-819.
440. van Bogaert LJ, Maldague P. Histologic variants of lipid-secreting carcinoma of the breast. *Virchows Arch A Pathol Anat Histol*. 1977;375(4):345-353.
441. Guan B, Wang H, Cao S, et al. Lipid-rich carcinoma of the breast clinicopathologic analysis of 17 cases. *Ann Diagn Pathol*. 2011;15(4):225-232.
442. Shousha S, Backhous CM, Alaghband-Zadeh J, Burn I. Alveolar variant of invasive lobular carcinoma of the breast. A tumor rich in estrogen receptors. *Am J Clin Pathol*. 1986;85(1):1-5.
443. Dixon JM, Anderson TJ, Page DL, et al. Infiltrating lobular carcinoma of the breast. *Histopathology*. 1982;6(2):149-161.
444. McDivitt RW, Boyce W, Gersell D. Tubular carcinoma of the breast. Clinical and pathological observations concerning 135 cases. *Am J Surg Pathol*. 1982;6(5):401-411.
445. Peters GN, Wolff M, Haagensen CD. Tubular carcinoma of the breast. Clinical pathologic correlations based on 100 cases. *Ann Surg*. 1981;193(2):138-149.
446. Tremblay G. Elastosis in tubular carcinoma of the breast. *Arch Pathol*. 1974;98(5):302-307.
447. Aulmann S, Elsawaf Z, Penzel R, et al. Invasive tubular carcinoma of the breast frequently is clonally related to flat epithelial atypia and low-grade ductal carcinoma in situ. *Am J Surg Pathol*. 2009;33(11):1646-1653.
448. Kunju LP, Ding Y, Kleer CG. Tubular carcinoma and grade 1 (well-differentiated) invasive ductal carcinoma: comparison of flat epithelial atypia and other intra-epithelial lesions. *Pathol Int*. 2008;58(10):620-625.
449. Dawson AE, Logan-Young W, Mulford DK. Aspiration cytology of tubular carcinoma. Diagnostic features with mammographic correlation. *Am J Clin Pathol*. 1994;101(4):488-492.
450. Winchester DJ, Sahin AA, Tucker SL, Singletary SE. Tubular carcinoma of the breast. Predicting axillary nodal metastases and recurrence. *Ann Surg*. 1996;223(3):342-347.
451. Diab SG, Clark GM, Osborne CK, et al. Tumor characteristics and clinical outcome of tubular and mucinous breast carcinomas. *J Clin Oncol*. 1999;17(5):1442-1448.
452. Rakha EA, Lee AH, Evans AJ, et al. Tubular carcinoma of the breast: further evidence to support its excellent prognosis. *J Clin Oncol*. 2010;28(1):99-104.
453. Fisher ER, Gregorio RM, Redmond C, Fisher B. Tubulolobular invasive breast cancer: a variant of lobular invasive cancer. *Hum Pathol*. 1977;8(6):679-683.
454. Wheeler DT, Tai LH, Bratthauer GL, et al. Tubulolobular carcinoma of the breast: an analysis of 27 cases of a tumor with a hybrid morphology and immunoprofile. *Am J Surg Pathol*. 2004;28(12):1587-1593.
455. Esposito NN, Chivukula M, Dabbs DJ. The ductal phenotypic expression of the

For personal use only. No other uses without permission. Copyright ©2017. Elsevier Inc. All rights reserved.

E-cadherin/catenin complex in tubulolobular carcinoma of the breast: an immunohistochemical and clinicopathologic study. *Mod Pathol*. 2007;20(1):130-138.
456. Green I, McCormick B, Cranor M, Rosen PP. A comparative study of pure tubular and tubulolobular carcinoma of the breast. *Am J Surg Pathol*. 1997;21(6):653-657.
457. Venable JG, Schwartz AM, Silverberg SG. Infiltrating cribriform carcinoma of the breast: a distinctive clinicopathologic entity. *Hum Pathol*. 1990;21(3):333-338.
458. Page DL, Dixon JM, Anderson TJ, et al. Invasive cribriform carcinoma of the breast. *Histopathology*. 1983;7(4):525-536.
459. Di Saverio S, Gutierrez J, Avisar E. A retrospective review with long term follow up of 11,400 cases of pure mucinous breast carcinoma. *Breast Cancer Res Treat*. 2008;111(3):541-547.
460. Bal A, Joshi K, Sharma SC, et al. Prognostic significance of micropapillary pattern in pure mucinous carcinoma of the breast. *Int J Surg Pathol*. 2008;16(3):251-256.
461. Walker RA. Mucoid carcinomas of the breast: a study using mucin histochemistry and peanut lectin. *Histopathology*. 1982;6(5):571-579.
462. O'Connell JT, Shao ZM, Drori E, et al. Altered mucin expression is a field change that accompanies mucinous (colloid) breast carcinoma histogenesis. *Hum Pathol*. 1998;29(12):1517-1523.
463. Matsukita S, Nomoto M, Kitajima S, et al. Expression of mucins (MUC1, MUC2, MUC5AC and MUC6) in mucinous carcinoma of the breast: comparison with invasive ductal carcinoma. *Histopathology*. 2003;42(1):26-36.
464. Domfeh AB, Carley AL, Striebel JM, et al. WT1 immunoreactivity in breast carcinoma: selective expression in pure and mixed mucinous subtypes. *Mod Pathol*. 2008;21(10):1217-1223.
465. Lacroix-Triki M, Suarez PH, MacKay A, et al. Mucinous carcinoma of the breast is genomically distinct from invasive ductal carcinomas of no special type. *J Pathol*. 2010;222(3):282-298.
466. Capella C, Eusebi V, Mann B, Azzopardi JG. Endocrine differentiation in mucoid carcinoma of the breast. *Histopathology*. 1980;4(6):613-630.
467. Rasmussen BB, Rose C, Thorpe SM, et al. Argyrophilic cells in 202 human mucinous breast carcinomas. Relation to histopathologic and clinical factors. *Am J Clin Pathol*. 1985;84(6):737-740.
468. Weigelt B, Geyer FC, Horlings HM, et al. Mucinous and neuroendocrine breast carcinomas are transcriptionally distinct from invasive ductal carcinomas of no special type. *Mod Pathol*. 2009;22(11):1401-1414.
469. Scopsi L, Andreola S, Pilotti S, et al. Mucinous carcinoma of the breast. A clinicopathologic, histochemical, and immunocytochemical study with special reference to neuroendocrine differentiation. *Am J Surg Pathol*. 1994;18(7):702-711.
470. Rasmussen BB, Rose C, Christensen IB. Prognostic factors in primary mucinous breast carcinoma. *Am J Clin Pathol*. 1987;87(2):155-160.
471. Bussolati G, Sapino A. Mucinous carcinoma and caricnomas with signet ring cell differentiation. In: Lakhani SR, Ellis IO, Schnitt SJ, et al, eds. *WHO Classification of Tumours of the Breast*. Lyon: IARC Press; 2012.
472. Tse GM, Ma TK, Chu WC, et al. Neuroendocrine differentiation in pure type mammary mucinous carcinoma is associated with favorable histologic and immunohistochemical parameters. *Mod Pathol*. 2004;17(5):568-572.
473. Rosen PP. Mucocele-like tumors of the breast. *Am J Surg Pathol*. 1986;10(7):464-469.
474. Carder PJ, Murphy CE, Liston JC. Surgical excision is warranted following a core biopsy diagnosis of mucocoele-like lesion of the breast. *Histopathology*. 2004;45(2):148-154.
475. Rakha EA, Shaaban AM, Haider SA, et al. Outcome of pure mucocele-like lesions diagnosed on breast core biopsy. *Histopathology*. 2013;62(6):894-898.
476. Sutton B, Davion S, Feldman M, et al. Mucocele-like lesions diagnosed on breast core biopsy: assessment of upgrade rate and need for surgical excision. *Am J Clin Pathol*. 2012;138(6):783-788.
477. Koenig C, Tavassoli FA. Mucinous cystadenocarcinoma of the breast. *Am J Surg Pathol*. 1998;22(6):698-703.
478. Jacquemier J, Reis-Filho JS, Lakhani S, Rakha E. Carcinomas with medullary features. In: Lakhani S, Ellis IO, Schnitt SJ, et al, eds. *WHO Classification of Tumors of the Breast*. Lyon: IARC press; 2012.
479. Farshid G, Balleine RL, Cummings M, Waring P. Morphology of breast cancer as a means of triage of patients for BRCA1 genetic testing. *Am J Surg Pathol*. 2006;30(11):1357-1366.
480. Howell LP, Kline TS. Medullary carcinoma of the breast. An unusual cytologic finding in cyst fluid aspirates. *Cancer*. 1990;65(2):277-282.
481. Vincent-Salomon A, Gruel N, Lucchesi C, et al. Identification of typical medullary breast carcinoma as a genomic sub-group of basal-like carcinomas, a heterogeneous new molecular entity. *Breast Cancer Res Treat*. 2007;9:R24.
482. Bertucci F, Finetti P, Cervera N, et al. Gene expression profiling shows medullary breast cancer is a subgroup of basal breast cancers. *Cancer Res*. 2006;66(9):4636-4644.
483. Sabatier R, Finetti P, Cervera N, et al. A gene expression signature identifies two prognostic subgroups of basal breast cancer. *Breast Cancer Res Treat*. 2011;126(2):407-420.
484. Pettinato G, Manivel CJ, Panico L, et al. Invasive micropapillary carcinoma of the breast: clinicopathologic study of 62 cases of a poorly recognized variant with highly aggressive behavior. *Am J Clin Pathol*. 2004;121(6):857-866.
485. Reis-Filho JS, Ellis I. Invasive micropapillary carcinoma. In: Lakhani S, Ellis IO, Schnitt SJ, et al, eds. *WHO Classification of Tumors of the Breast*. Lyon: IARC press; 2012.
486. Moritani S, Ichihara S, Hasegawa M, et al. Serous papillary adenocarcinoma of the female genital organs and invasive micropapillary carcinoma of the breast. Are WT1, CA125, and GCDFP-15 useful in differential diagnosis? *Hum Pathol*. 2008;39(5):666-671.
487. Acs G, Esposito NN, Rakosy Z, et al. Invasive ductal carcinomas of the breast showing partial reversed cell polarity are associated with lymphatic tumor spread and may represent part of a spectrum of invasive micropapillary carcinoma. *Am J Surg Pathol*. 2010;34(11):1637-1646.
488. Nassar H, Pansare V, Zhang H, et al. Pathogenesis of invasive micropapillary carcinoma: role of MUC1 glycoprotein. *Mod Pathol*. 2004;17(9):1045-1050.
489. De la Cruz C, Moriya T, Endoh M, et al. Invasive micropapillary carcinoma of the breast: clinicopathological and immunohistochemical study. *Pathol Int*. 2004;54(2):90-96.
490. Lee AH, Paish EC, Marchio C, et al. The expression of Wilms' tumour-1 and Ca125 in invasive micropapillary carcinoma of the breast. *Histopathology*. 2007;51(6):824-828.
491. Lotan TL, Ye H, Melamed J, et al. Immunohistochemical panel to identify the primary site of invasive micropapillary carcinoma. *Am J Surg Pathol*. 2009;33(7):1037-1041.
492. Acs G, Paragh G, Chuang ST, et al. The presence of micropapillary features and retraction artifact in core needle biopsy material predicts lymph node metastasis in breast carcinoma. *Am J Surg Pathol*. 2009;33(2):202-210.
493. Nassar H, Wallis T, Andea A, et al. Clinicopathologic analysis of invasive micropapillary differentiation in breast carcinoma. *Mod Pathol*. 2001;14(9):836-841.
494. Paterakos M, Watkin WG, Edgerton SM, et al. Invasive micropapillary carcinoma of the breast: a prognostic study. *Hum Pathol*. 1999;30(12):1459-1463.
495. Abati AD, Kimmel M, Rosen PP. Apocrine mammary carcinoma. A clinicopathologic study of 72 cases. *Am J Clin Pathol*. 1990;94(4):371-377.
496. O'Malley FP, Bane A. An update on apocrine lesions of the breast. *Histopathology*. 2008;52(1):3-10.
497. Mossler JA, Barton TK, Brinkhous AD, et al. Apocrine differentiation in human mammary carcinoma. *Cancer*. 1980;46(11):2463-2471.
498. Eusebi V, Millis RR, Cattani MG, et al. Apocrine carcinoma of the breast. A morphologic and immunocytochemical study. *Am J Pathol*. 1986;123(3):532-541.
499. Pagani A, Sapino A, Eusebi V, et al. PIP/GCDFP-15 gene expression and apocrine differentiation in carcinomas of the breast. *Virchows Arch*. 1994;425(5):459-465.
500. Eusebi V, Betts C, Haagensen DE Jr, et al. Apocrine differentiation in lobular carcinoma of the breast: a morphologic, immunologic, and ultrastructural study. *Hum Pathol*. 1984;15(2):134-140.
501. Krausz T, Jenkins D, Grontoft O, et al. Secretory carcinoma of the breast in adults: emphasis on late recurrence and metastasis. *Histopathology*. 1989;14(1):25-36.
502. Tavassoli FA, Norris HJ. Secretory carcinoma of the breast. *Cancer*. 1980;45(9):2404-2413.
503. McDivitt RW, Stewart FW. Breast carcinoma in children. *JAMA*. 1966;195(5):388-390.
504. Rosen PP, Cranor ML. Secretory carcinoma of the breast. *Arch Pathol Lab Med*. 1991;115(2):141-144.
505. Akhtar M, Robinson C, Ali MA, Godwin JT. Secretory carcinoma of the breast in adults. Light and electron microscopic study of three cases with review of the literature. *Cancer*. 1983;51(12):2245-2254.
506. Lamovec J, Bracko M. Secretory carcinoma of the breast: light microscopical, immunohistochemical and flow cytometric study. *Mod Pathol*. 1994;7(4):475-479.
507. Skalova A, Vanecek T, Sima R, et al. Mammary analogue secretory carcinoma of salivary glands, containing the ETV6-NTRK3 fusion gene: a hitherto undescribed salivary gland tumor entity. *Am J Surg Pathol*. 2010;34(5):599-608.
508. Del Castillo M, Chibon F, Arnould L, et al. Secretory breast carcinoma: a histopathologic and genomic spectrum characterized by a joint specific ETV6-NTRK3 gene fusion. *Am J Surg Pathol*. 2015;39(11):1458-1467.
509. Tognon C, Knezevich SR, Huntsman D, et al. Expression of the ETV6-NTRK3 gene fusion as a primary event in human secretory breast carcinoma. *Cancer Cell*. 2002;2(5):367-376.
510. Brandt SM, Swistel AJ, Rosen PP. Secretory carcinoma in the axilla: probable origin from axillary skin appendage glands in a young girl. *Am J Surg Pathol*. 2009;33(6):950-953.
511. Maluf HM, Zukerberg LR, Dickersin GR, Koerner FC. Spindle-cell argyrophilic

For personal use only. No other uses without permission. Copyright ©2017. Elsevier Inc. All rights reserved.

mucin-producing carcinoma of the breast. Histological, ultrastructural, and immunohistochemical studies of two cases. *Am J Surg Pathol*. 1991;15(7):677-686.
512. Capella C, Usellini L, Papotti M, et al. Ultrastructural features of neuroendocrine differentiated carcinomas of the breast. *Ultrastruct Pathol*. 1990;14(4):321-334.
513. Bussolati G, Badve S. Carcinomas with neuroendocrine features. In: Lakhani S, Ellis IO, Schnitt SJ, et al, eds. *WHO Classification of Tumors of the Breast*. Lyon: IARC press; 2012.
514. Bussolati G, Papotti M, Sapino A, et al. Endocrine markers in argyrophilic carcinomas of the breast. *Am J Surg Pathol*. 1987;11(4):248-256.
515. Papotti M, Macri L, Finzi G, et al. Neuroendocrine differentiation in carcinomas of the breast: a study of 51 cases. *Semin Diagn Pathol*. 1989;6(2):174-188.
516. Scopsi L, Andreola S, Pilotti S, et al. Argyrophilia and granin (chromogranin/secretogranin) expression in female breast carcinomas. Their relationship to survival and other disease parameters. *Am J Surg Pathol*. 1992;16(6):561-576.
517. Righi L, Sapino A, Marchio C, et al. Neuroendocrine differentiation in breast cancer: established facts and unresolved problems. *Semin Diagn Pathol*. 2010;27(1):69-76.
518. Sapino A, Bussolati G. Is detection of endocrine cells in breast adenocarcinoma of diagnostic and clinical significance? *Histopathology*. 2002;40(3):211-214.
519. Bogina G, Munari E, Brunelli M, et al. Neuroendocrine differentiation in breast carcinoma: clinicopathological features and outcome. *Histopathology*. 2016;68(3):422-432.
520. Yamaguchi R, Horii R, Maeda I, et al. Clinicopathologic study of 53 metaplastic breast carcinomas: their elements and prognostic implications. *Hum Pathol*. 2010;41(5):679-685.
521. Okada N, Hasebe T, Iwasaki M, et al. Metaplastic carcinoma of the breast. *Hum Pathol*. 2010;41(7):960-970.
522. Reis-Filho JS, Lakhani S, Gobbi H, Sneige N. Metaplastic carcinoma. In: Lakhani S, Ellis IO, Schnitt SJ, et al, eds. *WHO Classification of Tumors of the Breast*. Lyon: IARC press; 2012.
523. Downs-Kelly E, Nayeemuddin KM, Albarracin C, et al. Matrix-producing carcinoma of the breast: an aggressive subtype of metaplastic carcinoma. *Am J Surg Pathol*. 2009;33(4):534-541.
524. Wargotz ES, Norris HJ. Metaplastic carcinomas of the breast. I. Matrix-producing carcinoma. *Hum Pathol*. 1989;20(7):628-635.
525. Adem C, Reynolds C, Adlakha H, et al. Wide spectrum screening keratin as a marker of metaplastic spindle cell carcinoma of the breast: an immunohistochemical study of 24 patients. *Histopathology*. 2002;40(6):556-562.
526. Geyer FC, Weigelt B, Natrajan R, et al. Molecular analysis reveals a genetic basis for the phenotypic diversity of metaplastic breast carcinomas. *J Pathol*. 2010;220(5):562-573.
527. Zhuang Z, Lininger RA, Man YG, et al. Identical clonality of both components of mammary carcinosarcoma with differential loss of heterozygosity. *Mod Pathol*. 1997;10(4):354-362.
528. Wargotz ES, Deos PH, Norris HJ. Metaplastic carcinomas of the breast. II. Spindle cell carcinoma. *Hum Pathol*. 1989;20(8):732-740.
529. Brogi E. Benign and malignant spindle cell lesions of the breast. *Semin Diagn Pathol*. 2004;21(1):57-64.
530. Carter MR, Hornick JL, Lester S, Fletcher CD. Spindle cell (sarcomatoid) carcinoma of the breast: a clinicopathologic and immunohistochemical analysis of 29 cases. *Am J Surg Pathol*. 2006;30(3):300-309.
531. Koker MM, Kleer CG. p63 expression in breast cancer: a highly sensitive and specific marker of metaplastic carcinoma. *Am J Surg Pathol*. 2004;28(11):1506-1512.
532. Raju GC, Wee A. Spindle cell carcinoma of the breast. *Histopathology*. 1990;16(5):497-499.
533. Gobbi H, Simpson JF, Jensen RA, et al. Metaplastic spindle cell breast tumors arising within papillomas, complex sclerosing lesions, and nipple adenomas. *Mod Pathol*. 2003;16(9):893-901.
534. Wargotz ES, Norris HJ. Metaplastic carcinomas of the breast: V. Metaplastic carcinoma with osteoclastic giant cells. *Hum Pathol*. 1990;21(11):1142-1150.
535. Holland R, van Haelst UJ. Mammary carcinoma with osteoclast-like giant cells. Additional observations on six cases. *Cancer*. 1984;53(9):1963-1973.
536. Nielsen BB, Kiaer HW. Carcinoma of the breast with stromal multinucleated giant cells. *Histopathology*. 1985;9(2):183-193.
537. Wargotz ES, Norris HJ. Metaplastic carcinomas of the breast. IV. Squamous cell carcinoma of ductal origin. *Cancer*. 1990;65(2):272-276.
538. Oberman HA. Metaplastic carcinoma of the breast. A clinicopathologic study of 29 patients. *Am J Surg Pathol*. 1987;11(12):918-929.
539. Foschini MP, Fulcheri E, Baracchini P, et al. Squamous cell carcinoma with prominent myxoid stroma. *Hum Pathol*. 1990;21(8):859-865.
540. Eusebi V, Lamovec J, Cattani MG, et al. Acantholytic variant of squamous-cell carcinoma of the breast. *Am J Surg Pathol*. 1986;10(12):855-861.
541. Van Hoeven KH, Drudis T, Cranor ML, et al. Low-grade adenosquamous carcinoma of the breast. A clinocopathologic study of 32 cases with ultrastructural analysis. *Am J Surg Pathol*. 1993;17(3):248-258.
542. Foschini MP, Pizzicannella G, Peterse JL, Eusebi V. Adenomyoepithelioma of the breast associated with low-grade adenosquamous and sarcomatoid carcinomas. *Virchows Arch*. 1995;427(3):243-250.
543. Drudis T, Arroyo C, Van Hoeven K, et al. The pathology of low-grade adenosquamous carcinoma of the breast. An immunohistochemical study. *Pathol Annu*. 1994;29(Pt 2):181-197.
544. Drudis T, Arroyo C, Van Hoeven KH, et al. The pathology of low grade adenosquamous carcinoma of the breast. An immunohistochemical study. *Pathol Annu*. 1994;29(Pt 2):181-197.
545. Robertson FM, Bondy M, Yang W, et al. Inflammatory breast cancer: the disease, the biology, the treatment. *CA Cancer J Clin*. 2010;60(6):351-375.
546. Saltzstein SL. Clinically occult inflammatory carcinoma of the breast. *Cancer*. 1974;34(2):382-388.
547. Charafe-Jauffret E, Tsuda H, Rutgers EJ. Inflammatory carcinoma. In: Lakhani S, Ellis IO, Schnitt SJ, et al, eds. *WHO Classification of Tumors of the Breast*. Lyon: IARC press; 2012.
548. Harris M. Pseudoadenoid cystic carcinoma of the breast. *Arch Pathol Lab Med*. 1977;101(6):307-309.
549. Rosen PP. Adenoid cystic carcinoma of the breast. A morphologically heterogeneous neoplasm. *Pathol Annu*. 1989;24(Pt 2):237-254.
550. Kasami M, Olson SJ, Simpson JF, Page DL. Maintenance of polarity and a dual cell population in adenoid cystic carcinoma of the breast: an immunohistochemical study. *Histopathology*. 1998;32(3):232-238.
551. Tavassoli FA, Norris HJ. Mammary adenoid cystic carcinoma with sebaceous differentiation. A morphologic study of the cell types. *Arch Pathol Lab Med*. 1986;110(11):1045-1053.
552. Trendell-Smith NJ, Peston D, Shousha S. Adenoid cystic carcinoma of the breast: a tumour commonly devoid of oestrogen receptors and related proteins. *Histopathology*. 1999;35(3):241-248.
553. Foschini MP, Krausz T. Salivary gland-type tumors of the breast: a spectrum of benign and malignant tumors including "triple negative carcinomas" of low malignant potential. *Semin Diagn Pathol*. 2010;27(1):77-90.
554. Crisi GM, Marconi SA, Makari-Judson G, Goulart RA. Expression of c-kit in adenoid cystic carcinoma of the breast. *Am J Clin Pathol*. 2005;124(5):733-739.
555. Azoulay S, Lae M, Freneaux P, et al. KIT is highly expressed in adenoid cystic carcinoma of the breast, a basal-like carcinoma associated with a favorable outcome. *Mod Pathol*. 2005;18(12):1623-1631.
556. Persson M, Andren Y, Mark J, et al. Recurrent fusion of MYB and NFIB transcription factor genes in carcinomas of the breast and head and neck. *Proc Natl Acad Sci USA*. 2009;106(44):18740-18744.
556a. Poling J, Yonescu R, Sharma R, et al. MYB Labeling by Immunohistochemistry Is More Sensitive and Specific for Breast Adenoid Cystic Carcinoma than MYB Labeling by FISH. *Am J Surg Pathol*. 2017;41(7):973-979.
557. Ro JY, Silva EG, Gallager HS. Adenoid cystic carcinoma of the breast. *Hum Pathol*. 1987;18(12):1276-1281.
558. Wells CA, Nicoll S, Ferguson DJ. Adenoid cystic carcinoma of the breast: a case with axillary lymph node metastasis. *Histopathology*. 1986;10(4):415-424.
559. Cavanzo FJ, Taylor HB. Adenoid cystic carcinoma of the breast. An analysis of 21 cases. *Cancer*. 1969;24(4):740-745.
560. Arpino G, Clark GM, Mohsin S, et al. Adenoid cystic carcinoma of the breast: molecular markers, treatment, and clinical outcome. *Cancer*. 2002;94(8):2119-2127.
561. Kleer CG, Oberman HA. Adenoid cystic carcinoma of the breast: value of histologic grading and proliferative activity. *Am J Surg Pathol*. 1998;22(5):569-575.
562. Shin SJ, Rosen PP. Solid variant of mammary adenoid cystic carcinoma with basaloid features: a study of nine cases. *Am J Surg Pathol*. 2002;26(4):413-420.
563. Damiani S, Pasquinelli G, Lamovec J, et al. Acinic cell carcinoma of the breast: an immunohistochemical and ultrastructural study. *Virchows Arch*. 2000;437(1):74-81.
564. Roncaroli F, Lamovec J, Zidar A, Eusebi V. Acinic cell-like carcinoma of the breast. *Virchows Arch*. 1996;429(1):69-74.
565. Piscuoglio S, Hodi Z, Katabi N, et al. Are acinic cell carcinomas of the breast and salivary glands distinct diseases? *Histopathology*. 2015;67(4):529-537.
566. Guerini-Rocco E, Hodi Z, Piscuoglio S, et al. The repertoire of somatic genetic alterations of acinic cell carcinomas of the breast: an exploratory, hypothesis-generating study. *J Pathol*. 2015;237(2):166-178.
567. Di Tommaso L, Foschini MP, Ragazzini T, et al. Mucoepidermoid carcinoma of the breast. *Virchows Arch*. 2004;444(1):13-19.
568. Asioli S, Marucci G, Ficarra G, et al. Polymorphous adenocarcinoma of the breast. Report of three cases. *Virchows Arch*. 2006;448(1):29-34.
569. Hisaoka M, Takamatsu Y, Hirano Y, et al. Sebaceous carcinoma of the breast: case report and review of the literature. *Virchows Arch*. 2006;449(4):484-488.
570. Damiani S, Eusebi V, Losi L, et al. Oncocytic carcinoma (malignant oncocytoma) of the breast. *Am J Surg Pathol*. 1998;22(2):221-230.

For personal use only. No other uses without permission. Copyright ©2017. Elsevier Inc. All rights reserved.

571. Lamovec J, Falconieri G, Salviato T, Pizzolitto S. Basaloid carcinoma of the breast: a review of 9 cases, with delineation of a possible clinicopathologic entity. *Ann Diagn Pathol*. 2008;12(1):4-11.
572. Dina R, Eusebi V. Clear cell tumors of the breast. *Semin Diagn Pathol*. 1997;14(3):175-182.
573. Fisher ER, Tavares J, Bulatao IS, et al. Glycogen-rich, clear cell breast cancer: with comments concerning other clear cell variants. *Hum Pathol*. 1985;16(11):1085-1090.
574. Hayes MM, Seidman JD, Ashton MA. Glycogen-rich clear cell carcinoma of the breast. A clinicopathologic study of 21 cases. *Am J Surg Pathol*. 1995;19(8):904-911.
575. Hull MT, Warfel KA. Glycogen-rich clear cell carcinomas of the breast. A clinicopathologic and ultrastructural study. *Am J Surg Pathol*. 1986;10(8):553-559.
576. Sorensen FB, Paulsen SM. Glycogen-rich clear cell carcinoma of the breast: a solid variant with mucus. A light microscopic, immunohistochemical and ultrastructural study of a case. *Histopathology*. 1987;11(8):857-869.
577. Barnes DM, Hanby AM. Oestrogen and progesterone receptors in breast cancer: past, present and future. *Histopathology*. 2001;38(3):271-274.
578. Payne SJ, Bowen RL, Jones JL, Wells CA. Predictive markers in breast cancer—the present. *Histopathology*. 2008;52(1):82-90.
579. Mohsin SK, Weiss H, Havighurst T, et al. Progesterone receptor by immunohistochemistry and clinical outcome in breast cancer: a validation study. *Mod Pathol*. 2004;17(12):1545-1554.
580. Battifora H, Mehta P, Ahn C, Esteban JM. Estrogen receptor immunohistochemical assay in paraffin-embedded tissue. A better gold standard? *Appl Immunohistochem*. 1993;1(1):39-45.
581. Zafrani B, Aubriot MH, Mouret E, et al. High sensitivity and specificity of immunohistochemistry for the detection of hormone receptors in breast carcinoma: comparison with biochemical determination in a prospective study of 793 cases. *Histopathology*. 2000;37(6):536-545.
582. Allred DC, Harvey JM, Berardo M, Clark GM. Prognostic and predictive factors in breast cancer by immunohistochemical analysis. *Mod Pathol*. 1998;11(2):155-168.
583. Yaziji H, Taylor CR, Goldstein NS, et al. Consensus recommendations on estrogen receptor testing in breast cancer by immunohistochemistry. *Appl Immunohistochem Mol Morphol*. 2008;16(6):513-520.
584. Ibarra JA, Rogers LW, Kyshtoobayeva A, Bloom K. Fixation time does not affect the expression of estrogen receptor. *Am J Clin Pathol*. 2010;133(5):747-755.
585. Fitzgibbons PL, Murphy DA, Hammond ME, et al. Recommendations for validating estrogen and progesterone receptor immunohistochemistry assays. *Arch Pathol Lab Med*. 2010;134(6):930-935.
586. Badve SS, Baehner FL, Gray RP, et al. Estrogen- and progesterone-receptor status in ECOG 2197: comparison of immunohistochemistry by local and central laboratories and quantitative reverse transcription polymerase chain reaction by central laboratory. *J Clin Oncol*. 2008;26(15):2473-2481.
587. Graham DM, Jin L, Lloyd RV. Detection of estrogen receptor in paraffin-embedded sections of breast carcinoma by immunohistochemistry and in situ hybridization. *Am J Surg Pathol*. 1991;15(5):475-485.
588. Bur ME, Zimarowski MJ, Schnitt SJ, et al. Estrogen receptor immunohistochemistry in carcinoma in situ of the breast. *Cancer*. 1992;69(5):1174-1181.
589. Bryan BB, Schnitt SJ, Collins LC. Ductal carcinoma in situ with basal-like phenotype: a possible precursor to invasive basal-like breast cancer. *Mod Pathol*. 2006;19(5):617-621.
590. Middleton LP, Perkins GH, Tucker SL, et al. Expression of ERalpha and ERbeta in lobular carcinoma in situ. *Histopathology*. 2007;50(7):875-880.
591. Bhargava V, Kell DL, van de Rijn M, Warnke RA. Bcl-2 immunoreactivity in breast carcinoma correlates with hormone receptor positivity. *Am J Pathol*. 1994;145(3):535-540.
592. Caleffi M, Teague MW, Jensen RA, et al. p53 gene mutations and steroid receptor status in breast cancer. Clinicopathologic correlations and prognostic assessment. *Cancer*. 1994;73(8):2147-2156.
593. van Agthoven T, Timmermans M, Foekens JA, et al. Differential expression of estrogen, progesterone, and epidermal growth factor receptors in normal, benign, and malignant human breast tissues using dual staining immunohistochemistry. *Am J Pathol*. 1994;144(6):1238-1246.
594. Agoff SN, Swanson PE, Linden H, et al. Androgen receptor expression in estrogen receptor-negative breast cancer. Immunohistochemical, clinical, and prognostic associations. *Am J Clin Pathol*. 2003;120(5):725-731.
595. Hung MC, Lau YK. Basic science of HER-2/neu: a review. *Semin Oncol*. 1999;26(4 suppl 12):51-59.
596. Lal P, Tan LK, Chen B. Correlation of HER-2 status with estrogen and progesterone receptors and histologic features in 3,655 invasive breast carcinomas. *Am J Clin Pathol*. 2005;123(4):541-546.
597. Lewis F, Jackson P, Lane S, et al. Testing for HER2 in breast cancer. *Histopathology*. 2004;45(3):207-217.
598. Rhodes A, Jasani B, Anderson E, et al. Evaluation of HER-2/neu immunohistochemical assay sensitivity and scoring on formalin-fixed and paraffin-processed cell lines and breast tumors: a comparative study involving results from laboratories in 21 countries. *Am J Clin Pathol*. 2002;118(3):408-417.
599. Wolff AC, Hammond ME, Hicks DG, et al. Recommendations for human epidermal growth factor receptor 2 testing in breast cancer: American Society of Clinical Oncology/College of American Pathologists clinical practice guideline update. *J Clin Oncol*. 2013;31(31):3997-4013.
600. Wolff AC, Hammond ME, Schwartz JN, et al. American Society of Clinical Oncology/College of American Pathologists guideline recommendations for human epidermal growth factor receptor 2 testing in breast cancer. *J Clin Oncol*. 2007;25(1):118-145.
601. Cuadros M, Villegas R. Systematic review of HER2 breast cancer testing. *Appl Immunohistochem Mol Morphol*. 2009;17(1):1-7.
602. Vance GH, Barry TS, Bloom KJ, et al. Genetic heterogeneity in HER2 testing in breast cancer: panel summary and guidelines. *Arch Pathol Lab Med*. 2009;133(4):611-612.
603. Bartlett AI, Starcyznski J, Robson T, et al. Heterogeneous HER2 gene amplification: impact on patient outcome and a clinically relevant definition. *Am J Clin Pathol*. 2011;136(2):266-274.
604. Allison KH, Dintzis SM, Schmidt RA. Frequency of HER2 heterogeneity by fluorescence in situ hybridization according to CAP expert panel recommendations: time for a new look at how to report heterogeneity. *Am J Clin Pathol*. 2011;136(6):864-871.
605. Foulkes WD, Smith IE, Reis-Filho JS. Triple-negative breast cancer. *N Engl J Med*. 2010;363(20):1938-1948.
606. Reis-Filho JS, Tutt AN. Triple negative tumours: a critical review. *Histopathology*. 2008;52(1):108-118.
607. Prat A, Perou CM. Deconstructing the molecular portraits of breast cancer. *Mol Oncol*. 2011;5(1):5-23.
608. Cancer Genome Atlas N. Comprehensive molecular portraits of human breast tumours. *Nature*. 2012;490(7418):61-70.
609. Perou CM, Sorlie T, Eisen MB, et al. Molecular portraits of human breast tumours. *Nature*. 2000;406(6797):747-752.
610. Sorlie T, Perou CM, Tibshirani R, et al. Gene expression patterns of breast carcinomas distinguish tumor subclasses with clinical implications. *Proc Natl Acad Sci USA*. 2001;98(19):10869-10874.
611. Cheang MC, Voduc D, Bajdik C, et al. Basal-like breast cancer defined by five biomarkers has superior prognostic value than triple-negative phenotype. *Clin Cancer Res*. 2008;14(5):1368-1376.
612. Cheang MCU, Chia SK, Voduc D, et al. Ki67 index, HER2 status, and prognosis of patients with luminal B breast cancer. *J Natl Cancer Inst*. 2009;101(10):736-750.
613. Goldhirsch A, Winer EP, Coates AS, et al. Personalizing the treatment of women with early breast cancer: highlights of the St Gallen International Expert Consensus on the Primary Therapy of Early Breast Cancer 2013. *Ann Oncol*. 2013;24(9):2206-2223.
614. Coates AS, Winer EP, Goldhirsch A, et al. Tailoring therapies—improving the management of early breast cancer: St Gallen International Expert Consensus on the Primary Therapy of Early Breast Cancer 2015. *Ann Oncol*. 2015;26(8):1533-1546.
615. Weigelt B, Horlings HM, Kreike B, et al. Refinement of breast cancer classification by molecular characterization of histological special types. *J Pathol*. 2008;216(2):141-150.
616. Jones RLCA, Reis-Filho JS. Molecular classification of breast cancer. In: *Surgical Pathology Clinics Breast Pathology: Diagnosis and Insights*. 5th ed. Philadelphia: Elsevier; 2012:701-718.
617. Farmer P, Bonnefoi H, Becette V, et al. Identification of molecular apocrine breast tumours by microarray analysis. *Oncogene*. 2005;24(29):4660-4671.
618. Prat A, Parker JS, Karginova O, et al. Phenotypic and molecular characterization of the claudin-low intrinsic subtype of breast cancer. *Breast Cancer Res*. 2010;12(5):R68.
619. Lehmann BD, Jovanovic B, Chen X, et al. Refinement of triple-negative breast cancer molecular subtypes: implications for neoadjuvant chemotherapy selection. *PLoS ONE*. 2016;11(6):e0157368.
620. Weigelt B, Mackay A, A'Hern R, et al. Breast cancer molecular profiling with single sample predictors: a retrospective analysis. *Lancet Oncol*. 2010;11(4):339-349.
621. Schnitt SJ. Will molecular classification replace traditional breast pathology? *Int J Surg Pathol*. 2010;18(3 suppl):162S-166S.
622. Rouzier R, Pronzato P, Chereau E, et al. Multigene assays and molecular markers in breast cancer: systematic review of health economic analyses. *Breast Cancer Res Treat*. 2013;139(3):621-637.
623. Sparano JA, Gray RJ, Makower DF, et al. Prospective validation of a 21-gene expression assay in breast cancer. *N Engl J Med*. 2015;373(21):2005-2014.
624. Gluz O, Nitz UA, Christgen M, et al. West German Study Group Phase III PlanB Trial: first prospective outcome data for the 21-gene recurrence score assay and concordance of prognostic markers by central and local

For personal use only. No other uses without permission. Copyright ©2017. Elsevier Inc. All rights reserved.

pathology assessment. *J Clin Oncol*. 2016;34(20):2341-2349.
625. Goldstein NS. Does the level of E-cadherin expression correlate with the primary breast carcinoma infiltration pattern and type of systemic metastases? *Am J Clin Pathol*. 2002;118(3):425-434.
626. Rosen PP, Fracchia AA, Urban JA, et al. "Residual" mammary carcinoma following simulated partial mastectomy. *Cancer*. 1975;35(3):739-747.
627. Connolly JL, Schnitt SJ. Evaluation of breast biopsy specimens in patients considered for treatment by conservative surgery and radiation therapy for early breast cancer. *Pathol Annu*. 1988;23(Pt 1):1-23.
628. Leong C, Boyages J, Jayasinghe UW, et al. Effect of margins on ipsilateral breast tumor recurrence after breast conservation therapy for lymph node-negative breast carcinoma. *Cancer*. 2004;100(9):1823-1832.
629. Duarte GM, Tomazini MV, Oliveira A, et al. Accuracy of frozen section, imprint cytology, and permanent histology of sub-nipple tissue for predicting occult nipple involvement in patients with breast carcinoma. *Breast Cancer Res Treat*. 2015;153(3):557-563.
630. Brachtel EF, Rusby JE, Michaelson JS, et al. Occult nipple involvement in breast cancer: clinicopathologic findings in 316 consecutive mastectomy specimens. *J Clin Oncol*. 2009;27(30):4948-4954.
631. Johnson JE, Page DL, Winfield AC, et al. Recurrent mammary carcinoma after local excision. A segmental problem. *Cancer*. 1995;75(7):1612-1618.
632. Siegel RL, Miller KD, Jemal A. Cancer statistics, 2015. *CA Cancer J Clin*. 2015;65(1):5-29.
633. Veronesi U, Cascinelli N, Bufalino R, et al. Risk of internal mammary lymph node metastases and its relevance on prognosis of breast cancer patients. *Ann Surg*. 1983;198(6):681-684.
634. Qiu PF, Cong BB, Zhao RR, et al. Internal mammary sentinel lymph node biopsy with modified injection technique: high visualization rate and accurate staging. *Medicine (Baltimore)*. 2015;94(41):e1790.
635. Lamovec J, Zidar A. Association of leptomeningeal carcinomatosis in carcinoma of the breast with infiltrating lobular carcinoma. An autopsy study. *Arch Pathol Lab Med*. 1991;115(5):507-510.
636. Merrill CF, Kaufman DI, Dimitrov NV. Breast cancer metastatic to the eye is a common entity. *Cancer*. 1991;68(3):623-627.
637. Mattes MD, Bhatia JK, Metzger D, et al. Breast cancer subtype as a predictor of lymph node metastasis according to the SEER registry. *J Breast Cancer*. 2015;18(2):143-148.
638. Merino MJ, Livolsi VA. Signet ring carcinoma of the female breast: a clinicopathologic analysis of 24 cases. *Cancer*. 1981;48(8):1830-1837.
639. Gagnon Y, Tetu B. Ovarian metastases of breast carcinoma. A clinicopathologic study of 59 cases. *Cancer*. 1989;64(4):892-898.
640. Monteagudo C, Merino MJ, LaPorte N, Neumann RD. Value of gross cystic disease fluid protein-15 in distinguishing metastatic breast carcinomas among poorly differentiated neoplasms involving the ovary. *Hum Pathol*. 1991;22(4):368-372.
641. Chaubert P, Hurlimann J. Mammary origin of metastases. Immunohistochemical determination. *Arch Pathol Lab Med*. 1992;116(11):1181-1188.
642. Takeda Y, Tsuta K, Shibuki Y, et al. Analysis of expression patterns of breast cancer-specific markers (mammaglobin and gross cystic disease fluid protein 15) in lung and pleural tumors. *Arch Pathol Lab Med*. 2008;132(2):239-243.
643. Tornos C, Soslow R, Chen S, et al. Expression of WT1, CA 125, and GCDFP-15 as useful markers in the differential diagnosis of primary ovarian carcinomas versus metastatic breast cancer to the ovary. *Am J Surg Pathol*. 2005;29(11):1482-1489.
644. Nonaka D, Chiriboga L, Soslow RA. Expression of pax8 as a useful marker in distinguishing ovarian carcinomas from mammary carcinomas. *Am J Surg Pathol*. 2008;32(10):1566-1571.
645. Fisher ER, Fisher B. Relationship of pathologic and some clinical discriminants to the spread of breast cancer. *Int J Radiat Oncol Biol Phys*. 1977;2(7-8):747-750.
646. Whelan TJ, Olivotto IA, Parulekar WR, et al. Regional nodal irradiation in early-stage breast cancer. *N Engl J Med*. 2015;373(4):307-316.
647. Fayanju OM, Stoll CR, Fowler S, et al. Geographic and temporal trends in the management of occult primary breast cancer: a systematic review and meta-analysis. *Ann Surg Oncol*. 2013;20(10):3308-3316.
648. Varadarajan R, Edge SB, Yu J, et al. Prognosis of occult breast carcinoma presenting as isolated axillary nodal metastasis. *Oncology*. 2006;71(5-6):456-459.
649. Blanchard DK, Farley DR. Retrospective study of women presenting with axillary metastases from occult breast carcinoma. *World J Surg*. 2004;28(6):535-539.
650. Beek MA, Verheuvel NC, Luiten EJ, et al. Two decades of axillary management in breast cancer. *Br J Surg*. 2015;102(13):1658-1664.
651. Nadeem RM, Gudur LD, Saidan ZA. An independent assessment of the 7 nomograms for predicting the probability of additional axillary nodal metastases after positive sentinel lymph node biopsy in a cohort of British patients with breast cancer. *Clin Breast Cancer*. 2014;14(4):272-279.
652. Biolchini F, Vicentini M, Di Felice E, et al. Axillary nodal metastases in Italian early breast cancer patients with positive sentinel lymph node: can axillary node dissection be avoided by using predictive nomograms? *Tumori*. 2015;101(3):298-305.
653. Jonjic N, Mustac E, Dekanic A, et al. Predicting sentinel lymph node metastases in infiltrating breast carcinoma with vascular invasion. *Int J Surg Pathol*. 2006;14(4):306-311.
654. Viale G, Zurrida S, Maiorano E, et al. Predicting the status of axillary sentinel lymph nodes in 4351 patients with invasive breast carcinoma treated in a single institution. *Cancer*. 2005;103(3):492-500.
655. Maguire A, Brogi E. Sentinel lymph nodes for breast carcinoma: an update on current practice. *Histopathology*. 2016;68(1):152-167.
656. Krag DN, Anderson SJ, Julian TB, et al. Sentinel-lymph-node resection compared with conventional axillary-lymph-node dissection in clinically node-negative patients with breast cancer: overall survival findings from the NSABP B-32 randomised phase 3 trial. *Lancet Oncol*. 2010;11(10):927-933.
657. Lester SC, Bose S, Chen YY, et al. Protocol for the examination of specimens from patients with ductal carcinoma in situ of the breast. *Arch Pathol Lab Med*. 2009;133(1):15-25.
658. Verbanac KM, Min CJ, Mannie AE, et al. Long-term follow-up study of a prospective multicenter sentinel node trial: molecular detection of breast cancer sentinel node metastases. *Ann Surg Oncol*. 2010;17(suppl 3):368-377.
659. Bleiweiss IJ, Nagi CS, Jaffer S. Axillary sentinel lymph nodes can be falsely positive due to iatrogenic displacement and transport of benign epithelial cells in patients with breast carcinoma. *J Clin Oncol*. 2006;24(13):2013-2018.
660. Diaz NM, Cox CE, Ebert M, et al. Benign mechanical transport of breast epithelial cells to sentinel lymph nodes. *Am J Surg Pathol*. 2004;28(12):1641-1645.
661. Moore KH, Thaler HT, Tan LK, et al. Immunohistochemically detected tumor cells in the sentinel lymph nodes of patients with breast carcinoma: biologic metastasis or procedural artifact? *Cancer*. 2004;100(5):929-934.
662. van Deurzen CH, Bult P, de Boer M, et al. Morphometry of isolated tumor cells in breast cancer sentinel lymph nodes: metastases or displacement? *Am J Surg Pathol*. 2009;33(1):106-110.
663. van Deurzen CH, de Bruin PC, Koelemij R, et al. Isolated tumor cells in breast cancer sentinel lymph nodes: displacement or metastases? An immunohistochemical study. *Hum Pathol*. 2009;40(6):778-782.
664. Weber WP, Barry M, Stempel MM, et al. A 10-year trend analysis of sentinel lymph node frozen section and completion axillary dissection for breast cancer: are these procedures becoming obsolete? *Ann Surg Oncol*. 2012;19(1):225-232.
665. Caudle AS, Hunt KK, Tucker SL, et al. American College of Surgeons Oncology Group (ACOSOG) Z0011: impact on surgeon practice patterns. *Ann Surg Oncol*. 2012;19(10):3144-3151.
666. Amin MB, Edge S, Greene F, et al, eds. *Cancer AJCC. Staging Manual*. 8th ed. New York: Springer; 2017.
667. Goldhirsch A, Wood WC, Coates AS, et al. Strategies for subtypes—dealing with the diversity of breast cancer: highlights of the St. Gallen International Expert Consensus on the Primary Therapy of Early Breast Cancer 2011. *Ann Oncol*. 2011;22(8):1736-1747.
668. Hassani A, Griffith C, Harvey J. Size does matter: High volume breast surgeons accept smaller excision margins for wide local excision—a national survey of the surgical management of wide local excision margins in UK breast cancer patients. *Breast*. 2013;22(5):718-722.
669. Habermann EB, Abbott A, Parsons HM, et al. Are mastectomy rates really increasing in the United States? *J Clin Oncol*. 2010;28(21):3437-3441.
670. Lee MC, Rogers K, Griffith K, et al. Determinants of breast conservation rates: reasons for mastectomy at a comprehensive cancer center. *Breast J*. 2009;15(1):34-40.
671. Mansfield CM, Krishnan L, Komarnicky LT, et al. A review of the role of radiation therapy in the treatment of patients with breast cancer. *Semin Oncol*. 1991;18(6):525-535.
672. Solin LJ, Recht A, Fourquet A, et al. Ten-year results of breast-conserving surgery and definitive irradiation for intraductal carcinoma (ductal carcinoma in situ) of the breast. *Cancer*. 1991;68(11):2337-2344.
673. Houssami N, Macaskill P, Marinovich ML, Morrow M. The association of surgical margins and local recurrence in women with early-stage invasive breast cancer treated with breast-conserving therapy: a meta-analysis. *Ann Surg Oncol*. 2014;21(3):717-730.
674. Connolly JL, Boyages J, Nixon AJ, et al. Predictors of breast recurrence after conservative surgery and radiation therapy for invasive breast cancer. *Mod Pathol*. 1998;11(2):134-139.
675. Park CC, Mitsumori M, Nixon A, et al. Outcome at 8 years after breast-conserving surgery and radiation therapy for invasive breast cancer: influence of margin status and systemic therapy on local recurrence. *J Clin Oncol*. 2000;18(8):1668-1675.
676. Schnitt SJ, Abner A, Gelman R, et al. The relationship between microscopic margins of resection and the risk of local recurrence in

For personal use only. No other uses without permission. Copyright ©2017. Elsevier Inc. All rights reserved.

patients with breast cancer treated with breast-conserving surgery and radiation therapy. *Cancer*. 1994;74(6):1746-1751.
677. Goldstein NS, Kestin L, Vicini F. Factors associated with ipsilateral breast failure and distant metastases in patients with invasive breast carcinoma treated with breast-conserving therapy. A clinicopathologic study of 607 neoplasms from 583 patients. *Am J Clin Pathol*. 2003;120(4):500-527.
678. Van Zee KJ, Subhedar P, Olcese C, et al. Relationship Between Margin Width and Recurrence of Ductal Carcinoma In Situ: Analysis of 2996 Women Treated With Breast-conserving Surgery for 30 Years. *Ann Surg*. 2015;262(4):623-631.
679. Morrow M, Van Zee KJ. Margins in DCIS: does residual disease provide an answer? *Ann Surg Oncol*. 2016;23(11):3423-3425.
680. Goldhirsch A, Wood WC, Gelber RD, et al. Meeting highlights: updated international expert consensus on the primary therapy of early breast cancer. *J Clin Oncol*. 2003;21(17):3357-3365.
681. Brufsky A. Trastuzumab-based therapy for patients with HER2-positive breast cancer: from early scientific development to foundation of care. *Am J Clin Oncol*. 2010;33(2):186-195.
682. Harris JR, Lippman ME, Morrow M, Osborne CK. *Diseases of the Breast*. 4th ed. Philadelphia: Lippincott Williams & Wilkins; 2014.
683. Rodler ET, Kurland BF, Griffin M, et al. Phase I study of veliparib (ABT-888) combined with cisplatin and vinorelbine in advanced triple-negative breast cancer and/or BRCA mutation-associated breast cancer. *Clin Cancer Res*. 2016;22(12):2855-2864.
684. Schnitt SJ, Connolly JL, Harris JR, Cohen RB. Radiation-induced changes in the breast. *Hum Pathol*. 1984;15(6):545-550.
685. Moore GH, Schiller JE, Moore GK. Radiation-induced histopathologic changes of the breast: the effects of time. *Am J Surg Pathol*. 2004;28(1):47-53.
686. Kennedy S, Merino MJ, Swain SM, Lippman ME. The effects of hormonal and chemotherapy on tumoral and nonneoplastic breast tissue. *Hum Pathol*. 1990;21(2): 192-198.
687. Sahoo S, Lester SC. Pathology of breast carcinomas after neoadjuvant chemotherapy: an overview with recommendations on specimen processing and reporting. *Arch Pathol Lab Med*. 2009;133(4):633-642.
688. Rabban JT, Glidden D, Kwan ML, Chen YY. Pure and predominantly pure intralymphatic breast carcinoma after neoadjuvant chemotherapy: an unusual and adverse pattern of residual disease. *Am J Surg Pathol*. 2009;33(2):256-263.
689. Symmans WF, Peintinger F, Hatzis C, et al. Measurement of residual breast cancer burden to predict survival after neoadjuvant chemotherapy. *J Clin Oncol*. 2007;25(28):4414-4422.
690. Ogston KN, Miller ID, Payne S, et al. A new histological grading system to assess response of breast cancers to primary chemotherapy: prognostic significance and survival. *Breast*. 2003;12(5):320-327.
691. Kitchen SB, Paletta CE, Shehadi SI, Bauer WC. Epithelialization of the lining of a breast implant capsule. Possible origins of squamous cell carcinoma associated with a breast implant capsule. *Cancer*. 1994;73(5):1449-1452.
692. Adrada BE, Miranda RN, Rauch GM, et al. Breast implant-associated anaplastic large cell lymphoma: sensitivity, specificity, and findings of imaging studies in 44 patients. *Breast Cancer Res Treat*. 2014;147(1):1-14.
693. Kim B, Predmore ZS, Mattke S, et al. Breast implant-associated anaplastic large cell lymphoma: updated results from a structured expert consultation process. *Plast Reconstr Surg Glob Open*. 2015;3(1):e296.
694. Bertheau P, Steinberg SM, Cowan K, Merino MJ. Breast cancer in young women: clinicopathologic correlation. *Semin Diagn Pathol*. 1999;16(3):248-256.
695. Jayasinghe UW, Taylor R, Boyages J. Is age at diagnosis an independent prognostic factor for survival following breast cancer? *ANZ J Surg*. 2005;75(9):762-767.
696. Adami HO, Malker B, Holmberg L, et al. The relation between survival and age at diagnosis in breast cancer. *N Engl J Med*. 1986;315(9):559-563.
697. Bosma SC, van der Leij F, van Werkhoven E, et al. Very low local recurrence rates after breast-conserving therapy: analysis of 8485 patients treated over a 28-year period. *Breast Cancer Res Treat*. 2016;156(2):391-400.
698. Rennert G, Bisland-Naggan S, Barnett-Griness O, et al. Clinical outcomes of breast cancer in carriers of BRCA1 and BRCA2 mutations. *N Engl J Med*. 2007;357(2):115-123.
699. Schedin P. Pregnancy-associated breast cancer and metastasis. *Nat Rev Cancer*. 2006;6(4):281-291.
700. Collins LC, Gelber S, Marotti JD, et al. Molecular phenotype of breast cancer according to time since last pregnancy in a large cohort of young women. *Oncologist*. 2015;20(7):713-718.
701. Kroman N, Mouridsen HT. Prognostic influence of pregnancy before, around, and after diagnosis of breast cancer. *Breast*. 2003;12:516-521.
702. Puckridge PJ, Saunders CM, Ives AD, Semmens JB. Breast cancer and pregnancy: a diagnostic and management dilemma. *ANZ J Surg*. 2003;73:500-503.
703. Rosner D, Lane WW. Oral contraceptive use has no adverse effect on the prognosis of breast cancer. *Cancer*. 1986;57(3): 591-596.
704. Seidman H, Gelb SK, Silverberg E, et al. Survival experience in the Breast Cancer Detection Demonstration Project. *CA Cancer J Clin*. 1987;37(5):258-290.
705. Carter CL, Allen C, Henson DE. Relation of tumor size, lymph node status, and survival in 24,740 breast cancer cases. *Cancer*. 1989;63(1):181-187.
706. Seidman JD, Schnaper LA, Aisner SC. Relationship of the size of the invasive component of the primary breast carcinoma to axillary lymph node metastasis. *Cancer*. 1995;75(1):65-71.
707. Quiet CA, Ferguson DJ, Weichselbaum RR, Hellman S. Natural history of node-negative breast cancer: a study of 826 patients with long-term follow-up. *J Clin Oncol*. 1995;13(5):1144-1151.
708. Abner AL, Collins L, Peiro G, et al. Correlation of tumor size and axillary lymph node involvement with prognosis in patients with T1 breast carcinoma. *Cancer*. 1998;83(12):2502-2508.
709. Brautigam E, Track C, Seewald DH, et al. Medial tumor localization in breast cancer—an unappreciated risk factor? *Strahlenther Onkol*. 2009;185(10):663-668.
710. Lohrisch C, Jackson J, Jones A, et al. Relationship between tumor location and relapse in 6,781 women with early invasive breast cancer. *J Clin Oncol*. 2000;18(15):2828-2835.
711. Lynch SP, Lei X, Hsu L, et al. Breast cancer multifocality and multicentricity and locoregional recurrence. *Oncologist*. 2013;18(11):1167-1173.
712. Santiago RJ, Harris EE, Qin L, et al. Similar long-term results of breast-conservation treatment for Stage I and II invasive lobular carcinoma compared with invasive ductal carcinoma of the breast: The University of Pennsylvania experience. *Cancer*. 2005;103(12):2447-2454.
713. Dawson PJ, Ferguson DJ, Karrison T. The pathological findings of breast cancer in patients surviving 25 years after radical mastectomy. *Cancer*. 1982;50(10):2131-2138.
714. Bloom HJ, Richardson WW. Histological grading and prognosis in breast cancer; a study of 1409 cases of which 359 have been followed for 15 years. *Br J Cancer*. 1957;11(3):359-377.
715. Black MM, Barclay TH, Hankey BF. Prognosis in breast cancer utilizing histologic characteristics of the primary tumor. *Cancer*. 1975;36(6):2048-2055.
716. Elston CW, Ellis IO. Pathological prognostic factors in breast cancer. I. The value of histological grade in breast cancer: experience from a large study with long-term follow-up. *Histopathology*. 1991;19(5):403-410.
717. Fisher ER, Redmond C, Fisher B, Bass G. Pathologic findings from the National Surgical Adjuvant Breast and Bowel Projects (NSABP). Prognostic discriminants for 8-year survival for node-negative invasive breast cancer patients. *Cancer*. 1990;65(9 suppl):2121-2128.
718. Simpson JF, Page DL. Status of breast cancer prognostication based on histopathologic data. *Am J Clin Pathol*. 1994;102(4 suppl 1):S3-S8.
719. Dalton LW, Page DL, Dupont WD. Histologic grading of breast carcinoma. A reproducibility study. *Cancer*. 1994;73(11):2765-2770.
720. Robbins P, Pinder S, de Klerk N, et al. Histological grading of breast carcinomas: a study of interobserver agreement. *Hum Pathol*. 1995;26(8):873-879.
721. Bane AL, Tjan S, Parkes RK, et al. Invasive lobular carcinoma: to grade or not to grade. *Mod Pathol*. 2005;18(5):621-628.
722. Carbognin L, Pilotto S, Nortilli R, et al. Predictive and prognostic role of tumor-infiltrating lymphocytes for early breast cancer according to disease subtypes: sensitivity analysis of randomized trials in adjuvant and neoadjuvant setting. *Oncologist*. 2016;21(3):283-291.
723. Loi S, Michiels S, Salgado R, et al. Tumor infiltrating lymphocytes are prognostic in triple negative breast cancer and predictive for trastuzumab benefit in early breast cancer: results from the FinHER trial. *Ann Oncol*. 2014;25(8):1544-1550.
724. Rosen PP, Lesser ML, Arroyo CD, et al. Immunohistochemical detection of HER2/neu in patients with axillary lymph node negative breast carcinoma. A study of epidemiologic risk factors, histologic features, and prognosis. *Cancer*. 1995;75(6):1320-1326.
725. Baak JP, Chin D, van Diest PJ, et al. Comparative long-term prognostic value of quantitative HER-2/neu protein expression, DNA ploidy, and morphometric and clinical features in paraffin-embedded invasive breast cancer. *Lab Invest*. 1991;64(2):215-223.
726. Sears HF, Janus C, Levy W, et al. Breast cancer without axillary metastases. Are there high-risk biologic subpopulations? *Cancer*. 1982;50(9):1820-1827.
727. Arnaout-Alkarain A, Kahn HJ, Narod SA, et al. Significance of lymph vessel invasion identified by the endothelial lymphatic marker D2-40 in node negative breast cancer. *Mod Pathol*. 2007;20(2):183-191.
728. Acs G, Dumoff KL, Solin LJ, et al. Extensive retraction artifact correlates with lymphatic invasion and nodal metastasis and predicts poor outcome in early stage breast carcinoma. *Am J Surg Pathol*. 2007;31(1):129-140.
729. Fisher ER, Anderson S, Tan-Chiu E, et al. Fifteen-year prognostic discriminants for invasive breast carcinoma: National Surgical Adjuvant Breast and Bowel Project Protocol-06. *Cancer*. 2001;91(8 suppl):1679-1687.

For personal use only. No other uses without permission. Copyright ©2017. Elsevier Inc. All rights reserved.

730. Ortiz-Pagan S, Cunto-Amesty G, Narayan S, et al. Effect of Paget's disease on survival in breast cancer: an exploratory study. *Arch Surg*. 2011;146(11):1267-1270.
731. Fitzgibbons PL, Page DL, Weaver D, et al. Prognostic factors in breast cancer. College of American Pathologists Consensus Statement 1999. *Arch Pathol Lab Med*. 2000;124(7):966-9678.
732. Lee AK, Wiley B, Loda M, et al. DNA ploidy, proliferation, and neu-oncogene protein overexpression in breast carcinoma. *Mod Pathol*. 1992;5(1):61-67.
733. Olszewski W, Darzynkiewicz Z, Rosen PP, et al. Flow cytometry of breast carcinoma: I. Relation of DNA ploidy level to histology and estrogen receptor. *Cancer*. 1981; 48(4):980-984.
734. Fan C, Oh DS, Wessels L, et al. Concordance among gene-expression-based predictors for breast cancer. *N Engl J Med*. 2006;355(6):560-569.
735. Wirapati P, Sotiriou C, Kunkel S, et al. Meta-analysis of gene expression profiles in breast cancer: toward a unified understanding of breast cancer subtyping and prognosis signatures. *Breast Cancer Res*. 2008;10(4):R65.
736. Weaver DL, Ashikaga T, Krag DN, et al. Effect of occult metastases on survival in node-negative breast cancer. *N Engl J Med*. 2011;364(5):412-421.
737. Noguchi M, Tsugawa K, Taniya T, Miwa K. The role of internal mammary lymph node metastases in the management of breast cancer. *Breast Cancer*. 1998;5(2):117-125.
738. Paoletti C, Hayes DF. Circulating tumor cells. *Adv Exp Med Biol*. 2016;882:235-258.
739. Sopik V, Nofech-Mozes S, Sun P, Narod SA. The relationship between local recurrence and death in early-stage breast cancer. *Breast Cancer Res Treat*. 2016;155(1):175-185.
740. Fisher B, Redmond C, Poisson R, et al. Eight-year results of a randomized clinical trial comparing total mastectomy and lumpectomy with or without irradiation in the treatment of breast cancer. *N Engl J Med*. 1989;320(13):822-828.
741. Jacobson JA, Danforth DN, Cowan KH, et al. Ten-year results of a comparison of conservation with mastectomy in the treatment of stage I and II breast cancer [see comments]. *N Engl J Med*. 1995;332(14):907-911.
742. Morrow M, Strom EA, Bassett LW, et al. Standard for breast conservation therapy in the management of invasive breast carcinoma. *CA Cancer J Clin*. 2002;52(5):277-300.
743. Moran MS, Schnitt SJ, Giuliano AE, et al. Society of Surgical Oncology-American Society for Radiation Oncology consensus guideline on margins for breast-conserving surgery with whole-breast irradiation in stages I and II invasive breast cancer. *Ann Surg Oncol*. 2014;21(3):704-716.
744. DeSnyder SM, Hunt KK, Smith BD, et al. Assessment of practice patterns following publication of the SSO-ASTRO consensus guideline on margins for breast-conserving therapy in stage i and ii invasive breast cancer. *Ann Surg Oncol*. 2015;22(10):3250-3256.
745. Chagpar AB, Killelea BK, Tsangaris TN, et al. A randomized, controlled trial of cavity shave margins in breast cancer. *N Engl J Med*. 2015;373(6):503-510.
746. Ross JS, Hatzis C, Symmans WF, et al. Commercialized multigene predictors of clinical outcome for breast cancer. *Oncologist*. 2008;13(5):477-493.
747. van de Vijver MJ, He YD, van't Veer LJ, et al. A gene-expression signature as a predictor of survival in breast cancer. *N Engl J Med*. 2002;347(25):1999-2009.
748. van 't Veer LJ, Dai H, van de Vijver MJ, et al. Gene expression profiling predicts clinical outcome of breast cancer. *Nature*. 2002;415(6871):530-536.
749. Correa Geyer F, Reis-Filho JS. Microarray-based gene expression profiling as a clinical tool for breast cancer management: are we there yet? *Int J Surg Pathol*. 2009;17(4):285-302.
750. Ross JS. Multigene classifiers, prognostic factors, and predictors of breast cancer clinical outcome. *Adv Anat Pathol*. 2009;16(4):204-215.
751. Sparano JA, Paik S. Development of the 21-gene assay and its application in clinical practice and clinical trials. *J Clin Oncol*. 2008;26(5):721-728.
752. Wick MR, Ockner DM, Mills SE, et al. Homologous carcinomas of the breasts, skin, and salivary glands. A histologic and immunohistochemical comparison of ductal mammary carcinoma, ductal sweat gland carcinoma, and salivary duct carcinoma. *Am J Clin Pathol*. 1998;109(1):75-84.
753. Rakha EA, Badve S, Eusebi V, et al. Breast lesions of uncertain malignant nature and limited metastatic potential: proposals to improve their recognition and clinical management. *Histopathology*. 2016;68(1):45-56.
754. Rakha EA, Aleskandarany MA, Samaka RM, et al. Pleomorphic adenoma-like tumour of the breast. *Histopathology*. 2016;68(3):405-410.
755. Tavassoli FA. Myoepithelial lesions of the breast. Myoepitheliosis, adenomyoepithelioma, and myoepithelial carcinoma. *Am J Surg Pathol*. 1991;15(6):554-568.
756. Rosen PP. Adenomyoepithelioma of the breast. *Hum Pathol*. 1987;18(12):1232-1237.
757. Zarbo RJ, Oberman HA. Cellular adenomyoepithelioma of the breast. *Am J Surg Pathol*. 1983;7(8):863-870.
758. McLaren BK, Smith J, Schuyler PA, et al. Adenomyoepithelioma: clinical, histologic, and immunohistologic evaluation of a series of related lesions. *Am J Surg Pathol*. 2005;29(10):1294-1299.
759. Vorburger SA, Xing Y, Hunt KK, et al. Angiosarcoma of the breast. *Cancer*. 2005;104(12):2682-2688.
760. Liberman L, Dershaw DD, Kaufman RJ, Rosen PP. Angiosarcoma of the breast. *Radiology*. 1992;183(3):649-654.
761. Macias-Martinez V, Murrieta-Tiburcio L, Molina-Cardenas H, Dominguez-Malagon H. Epithelioid angiosarcoma of the breast. Clinicopathological, immunohistochemical, and ultrastructural study of a case. *Am J Surg Pathol*. 1997;21(5):599-604.
762. Brentani MM, Pacheco MM, Oshima CT, et al. Steroid receptors in breast angiosarcoma. *Cancer*. 1983;51(11):2105-2111.
763. Shin SJ, Lesser M, Rosen PP. Hemangiomas and angiosarcomas of the breast: diagnostic utility of cell cycle markers with emphasis on Ki-67. *Arch Pathol Lab Med*. 2007;131(4):538-544.
764. Steingaszner LC, Enzinger FM, Taylor HB. Hemangiosarcoma of the Breast. *Cancer*. 1965;18:352-361.
765. Donnell RM, Rosen PP, Lieberman PH, et al. Angiosarcoma and other vascular tumors of the breast. *Am J Surg Pathol*. 1981;5(7):629-642.
766. Merino MJ, Carter D, Berman M. Angiosarcoma of the breast. *Am J Surg Pathol*. 1983;7(1):53-60.
767. Rosen PP, Kimmel M, Ernsberger D. Mammary angiosarcoma. The prognostic significance of tumor differentiation. *Cancer*. 1988;62(10):2145-2151.
768. Nascimento AF, Raut CP, Fletcher CD. Primary angiosarcoma of the breast: clinicopathologic analysis of 49 cases, suggesting that grade is not prognostic. *Am J Surg Pathol*. 2008;32(12):1896-1904.
769. Benda JA, Al-Jurf AS, Benson AB 3rd. Angiosarcoma of the breast following segmental mastectomy complicated by lymphedema. *Am J Clin Pathol*. 1987;87(5):651-655.
770. Patton KT, Deyrup AT, Weiss SW. Atypical vascular lesions after surgery and radiation of the breast: a clinicopathologic study of 32 cases analyzing histologic heterogeneity and association with angiosarcoma. *Am J Surg Pathol*. 2008;32(6):943-950.
771. Fineberg S, Rosen PP. Cutaneous angiosarcoma and atypical vascular lesions of the skin and breast after radiation therapy for breast carcinoma. *Am J Clin Pathol*. 1994;102(6):757-763.
772. Brenn T, Fletcher CD. Postradiation vascular proliferations: an increasing problem. *Histopathology*. 2006;48(1):106-114.
773. Lucas DR. Angiosarcoma, radiation-associated angiosarcoma, and atypical vascular lesion. *Arch Pathol Lab Med*. 2009;133(11):1804-1809.
774. Monroe AT, Feigenberg SJ, Mendenhall NP. Angiosarcoma after breast-conserving therapy. *Cancer*. 2003;97(8):1832-1840.
775. Otis CN, Peschel R, McKhann C, et al. The rapid onset of cutaneous angiosarcoma after radiotherapy for breast carcinoma. *Cancer*. 1986;57(11):2130-2134.
776. Rosso R, Gianelli U, Carnevali L. Acquired progressive lymphangioma of the skin following radiotherapy for breast carcinoma. *J Cutan Pathol*. 1995;22(2):164-167.
777. Weaver J, Billings SD. Postradiation cutaneous vascular tumors of the breast: a review. *Semin Diagn Pathol*. 2009;26(3):141-149.
778. Di Tommaso L, Fabbri A. Cutaneous angiosarcoma arising after radiotherapy treatment of a breast carcinoma. Description of a case and review of the literature. *Pathologica*. 2003;95(4):196-202.
779. Fernandez AP, Sun Y, Tubbs RR, et al. FISH for MYC amplification and anti-MYC immunohistochemistry: useful diagnostic tools in the assessment of secondary angiosarcoma and atypical vascular proliferations. *J Cutan Pathol*. 2011;39(2):234-242.
780. Guo T, Zhang L, Chang NE, et al. Consistent MYC and FLT4 gene amplification in radiation-induced angiosarcoma but not in other radiation-associated atypical vascular lesions. *Genes Chromosomes Cancer*. 2011;50(1):25-33.
781. Manner J, Radlwimmer B, Hohenberger P, et al. MYC high level gene amplification is a distinctive feature of angiosarcomas after irradiation or chronic lymphedema. *Am J Pathol*. 2010;176(1):34-39.
782. Mentzel T, Schildhaus HU, Palmedo G, et al. Postradiation cutaneous angiosarcoma after treatment of breast carcinoma is characterized by MYC amplification in contrast to atypical vascular lesions after radiotherapy and control cases: clinicopathological, immunohistochemical and molecular analysis of 66 cases. *Mod Pathol*. 2012;25(1):75-85.
783. Parham DM, Fisher C. Angiosarcomas of the breast developing post radiotherapy. *Histopathology*. 1997;31(2):189-195.
784. Billings SD, McKenney JK, Folpe AL, et al. Cutaneous angiosarcoma following breast-conserving surgery and radiation: an analysis of 27 cases. *Am J Surg Pathol*. 2004;28(6):781-788.
785. Rosen PP. Vascular tumors of the breast. V. Nonparenchymal hemangiomas of mammary subcutaneous tissues. *Am J Surg Pathol*. 1985;9(10):723-729.
786. Yu GH, Fishman SJ, Brooks JS. Cellular angiolipoma of the breast. *Mod Pathol*. 1993;6(4):497-499.

For personal use only. No other uses without permission. Copyright ©2017. Elsevier Inc. All rights reserved.

787. Mantilla JG, Koenigsberg T, Reig B, et al. Core biopsy of vascular neoplasms of the breast: pathologic features, imaging, and clinical findings. *Am J Surg Pathol*. 2016;40(10):1424-1434.
788. Rosen PP, Ridolfi RL. The perilobular hemangioma. A benign microscopic vascular lesion of the breast. *Am J Clin Pathol*. 1977;68(1):21-23.
789. Lesueur GC, Brown RW, Bhathal PS. Incidence of perilobular hemangioma in the female breast. *Arch Pathol Lab Med*. 1983;107(6):308-310.
790. Jozefczyk MA, Rosen PP. Vascular tumors of the breast. II. Perilobular hemangiomas and hemangiomas. *Am J Surg Pathol*. 1985;9(7):491-503.
791. Rosen PP, Jozefczyk MA, Boram LH. Vascular tumors of the breast. IV. The venous hemangioma. *Am J Surg Pathol*. 1985;9(9):659-6565.
792. Rosen PP. Vascular tumors of the breast. III. Angiomatosis. *Am J Surg Pathol*. 1985;9(9):652-658.
793. Norris HJ, Taylor HB. Sarcomas and related mesenchymal tumors of the breast. *Cancer*. 1968;22(1):22-28.
794. Leibl S, Moinfar F. Mammary NOS-type sarcoma with CD10 expression: a rare entity with features of myoepithelial differentiation. *Am J Surg Pathol*. 2006;30(4):450-456.
795. Pollard SG, Marks PV, Temple LN, Thompson HH. Breast sarcoma. A clinicopathologic review of 25 cases. *Cancer*. 1990;66(5):941-944.
796. Talwalkar SS, Miranda RN, Valbuena JR, et al. Lymphomas involving the breast: a study of 106 cases comparing localized and disseminated neoplasms. *Am J Surg Pathol*. 2008;32(9):1299-1309.
797. Aguilera NS, Tavassoli FA, Chu WS, Abbondanzo SL. T-cell lymphoma presenting in the breast: a histologic, immunophenotypic and molecular genetic study of four cases. *Mod Pathol*. 2000;13(6):599-605.
798. Gualco G, Chioato L, Harrington WJ Jr, et al. Primary and secondary T-cell lymphomas of the breast: clinico-pathologic features of 11 cases. *Appl Immunohistochem Mol Morphol*. 2009;17(4):301-306.
799. Abbondanzo SL, Seidman JD, Lefkowitz M, et al. Primary diffuse large B-cell lymphoma of the breast. A clinicopathologic study of 31 cases. *Pathol Res Pract*. 1996;192(1):37-43.
800. Arber DA, Simpson JF, Weiss LM, Rappaport H. Non-Hodgkin's lymphoma involving the breast. *Am J Surg Pathol*. 1994;18(3): 288-295.
801. Yoshida S, Nakamura N, Sasaki Y, et al. Primary breast diffuse large B-cell lymphoma shows a non-germinal center B-cell phenotype. *Mod Pathol*. 2005;18(3):398-405.
802. Lin JJ, Farha GJ, Taylor RJ. Pseudolymphoma of the breast. I. In a study of 8,654 consecutive tylectomies and mastectomies. *Cancer*. 1980;45(5):973-978.
803. Salman WD, Al-Dawoud A, Howat AJ, Twaij Z. Lymphoid tissue in the breast: a histological conundrum. *Histopathology*. 2007;51(4):572-573.
804. Boudova L, Kazakov DV, Sima R, et al. Cutaneous lymphoid hyperplasia and other lymphoid infiltrates of the breast nipple: a retrospective clinicopathologic study of fifty-six patients. *Am J Dermatopathol*. 2005;27(5):375-386.
805. Bobrow LG, Richards MA, Happerfield LC, et al. Breast lymphomas: a clinicopathologic review. *Hum Pathol*. 1993;24(3):274-278.
806. Kirshenbaum G, Rhone DP. Solitary extramedullary plasmacytoma of the breast with serum monoclonal protein: a case report and review of the literature. *Am J Clin Pathol*. 1985;83(2):230-232.
807. Monteiro M, Duarte I, Cabecadas J, Orvalho ML. Intravascular large B-cell lymphoma of the breast. *Breast*. 2005;14(1):75-78.
808. Ho CW, Mantoo S, Lim CH, Wong CY. Synchronous invasive ductal carcinoma and intravascular large B-cell lymphoma of the breast: a case report and review of the literature. *World J Surg Oncol*. 2014;12:88.
809. Doren EL, Miranda RN, Selber JC, et al. United States epidemiology of breast implant-associated anaplastic large cell lymphoma. *Plast Reconstr Surg*. 2017;139(5):1042-1050.
810. Byrd JC, Edenfield WJ, Shields DJ, Dawson NA. Extramedullary myeloid cell tumors in acute nonlymphocytic leukemia: a clinical review. *J Clin Oncol*. 1995;13(7):1800-1816.
811. Valbuena JR, Admirand JH, Gualco G, Medeiros LJ. Myeloid sarcoma involving the breast. *Arch Pathol Lab Med*. 2005;129(1):32-38.
812. Brooks JJ, Krugman DT, Damjanov I. Myeloid metaplasia presenting as a breast mass. *Am J Surg Pathol*. 1980;4(3):281-285.
813. Wang J, Darvishian F. Extramedullary hematopoiesis in breast after neoadjuvant chemotherapy for breast carcinoma. *Ann Clin Lab Sci*. 2006;36(4):475-478.
814. Charpin C, Mathoulin MP, Andrac L, et al. Reappraisal of breast hamartomas. A morphological study of 41 cases. *Pathol Res Pract*. 1994;190(4):362-371.
815. Daya D, Trus T, D'Souza TJ, et al. Hamartoma of the breast, an underrecognized breast lesion. A clinicopathologic and radiographic study of 25 cases. *Am J Clin Pathol*. 1995;103(6):685-689.
816. Fisher CJ, Hanby AM, Robinson L, Millis RR. Mammary hamartoma—a review of 35 cases. *Histopathology*. 1992;20(2):99-106.
817. Oberman HA. Hamartomas and hamartoma variants of the breast. *Semin Diagn Pathol*. 1989;6(2):135-145.
818. Tse GM, Law BK, Ma TK, et al. Hamartoma of the breast: a clinicopathological review. *J Clin Pathol*. 2002;55(12):951-954.
819. Herbert M, Sandbank J, Liokumovich P, et al. Breast hamartomas: clinicopathological and immunohistochemical studies of 24 cases. *Histopathology*. 2002;41(1):30-34.
820. Daroca PJ Jr, Reed RJ, Love GL, Kraus SD. Myoid hamartomas of the breast. *Hum Pathol*. 1985;16(3):212-219.
821. Garfein CF, Aulicino MR, Leytin A, et al. Epithelioid cells in myoid hamartoma of the breast: a potential diagnostic pitfall for core biopsies [see comments]. *Arch Pathol Lab Med*. 1996;120(7):676-680.
822. Adeniran A, Al-Ahmadie H, Mahoney MC, Robinson-Smith TM. Granular cell tumor of the breast: a series of 17 cases and review of the literature. *Breast J*. 2004;10(6):528-531.
823. Damiani S, Dina R, Eusebi V. Eosinophilic and granular cell tumors of the breast. *Semin Diagn Pathol*. 1999;16(2):117-125.
824. DeMay RM, Kay S. Granular cell tumors of the breast. In: Sommers SC, Rosen PP, eds. *Pathology Annual, Part 1*. Norwalk, CT: Appleton-Century-Crofts; 1984.
825. Damiani S, Koerner FC, Dickersin GR, et al. Granular cell tumour of the breast. *Virchows Arch A Pathol Anat Histopathol*. 1992;420(3):219-226.
826. Magro G, Fletcher C, Eusebi V. Myofibroblastoma. In: Lakhani SR, Ellis IO, Schnitt SJ, et al, eds. *WHO Classifiction of Tumours of the Breast*. Lyon, France: IARC; 2012:130-131.
827. Magro G. Mammary myofibroblastoma: a tumor with a wide morphologic spectrum. *Arch Pathol Lab Med*. 2008;132(11):1813-1820.
828. Howitt BE, Fletcher CD. Mammary-type myofibroblastoma: clinicopathologic characterization in a series of 143 cases. *Am J Surg Pathol*. 2016;40(3):361-367.
829. Magro G, Bisceglia M, Michal M, Eusebi V. Spindle cell lipoma-like tumor, solitary fibrous tumor and myofibroblastoma of the breast: a clinico-pathological analysis of 13 cases in favor of a unifying histogenetic concept. *Virchows Arch*. 2002;440(3):249-260.
830. McMenamin ME, Fletcher CD. Mammary-type myofibroblastoma of soft tissue: a tumor closely related to spindle cell lipoma. *Am J Surg Pathol*. 2001;25(8):1022-1029.
831. Chen BJ, Marino-Enriquez A, Fletcher CD, Hornick JL. Loss of retinoblastoma protein expression in spindle cell/pleomorphic lipomas and cytogenetically related tumors: an immunohistochemical study with diagnostic implications. *Am J Surg Pathol*. 2012;36(8):1119-1128.
832. Pauwels P, Sciot R, Croiset F, et al. Myofibroblastoma of the breast: genetic link with spindle cell lipoma. *J Pathol*. 2000;191(3):282-285.
833. Magro G, Angelico G, Leone G, Palazzo J. Solitary fibrous tumor of the breast: report of a case with emphasis on diagnostic role of STAT6 immunostaining. *Pathol Res Pract*. 2016;212(5):463-467.
834. Nascimento AG, Karas M, Rosen PP, Caron AG. Leiomyoma of the nipple. *Am J Surg Pathol*. 1979;3(2):151-154.
835. Minami S, Matsuo S, Azuma T, et al. Parenchymal leiomyoma of the breast: a case report with special reference to magnetic resonance imaging findings and an update review of literature. *Breast Cancer*. 2011;18(3):231-236.
836. Roncaroli F, Rossi R, Severi B, et al. Epithelioid leiomyoma of the breast with granular cell change: a case report. *Hum Pathol*. 1993;24(11):1260-1263.
837. Rosso R, Scelsi M, Carnevali L. Granular cell traumatic neuroma: a lesion occurring in mastectomy scars. *Arch Pathol Lab Med*. 2000;124(5):709-711.
838. Govender D, Sabaratnam RM, Essa AS. Clear cell 'sugar' tumor of the breast: another extrapulmonary site and review of the literature. *Am J Surg Pathol*. 2002;26(5):670-675.
839. Rosen PP, Ernsberger D. Mammary fibromatosis. A benign spindle-cell tumor with significant risk for local recurrence. *Cancer*. 1989;63(7):1363-1369.
840. Abraham SC, Reynolds C, Lee JH, et al. Fibromatosis of the breast and mutations involving the APC/beta-catenin pathway. *Hum Pathol*. 2002;33(1):39-46.
841. Balzer BL, Weiss SW. Do biomaterials cause implant-associated mesenchymal tumors of the breast? Analysis of 8 new cases and review of the literature. *Hum Pathol*. 2009;40(11):1564-1570.
842. Devouassoux-Shisheboran M, Schammel MD, Man YG, Tavassoli FA. Fibromatosis of the breast: age-correlated morphofunctional features of 33 cases. *Arch Pathol Lab Med*. 2000;124(2):276-280.
843. Vuitch MF, Rosen PP, Erlandson RA. Pseudoangiomatous hyperplasia of mammary stroma. *Hum Pathol*. 1986;17(2):185-191.
844. Powell CM, Cranor ML, Rosen PP. Pseudoangiomatous stromal hyperplasia (PASH). A mammary stromal tumor with myofibroblastic differentiation. *Am J Surg Pathol*. 1995;19(3):270-277.
845. Anderson C, Ricci A Jr, Pedersen CA, Cartun RW. Immunocytochemical analysis of estrogen and progesterone receptors in benign stromal lesions of the breast. Evidence for hormonal etiology in pseudoangiomatous hyperplasia of mammary stroma. *Am J Surg Pathol*. 1991;15(2):145-149.

For personal use only. No other uses without permission. Copyright ©2017. Elsevier Inc. All rights reserved.

846. Rosen PP. Multinucleated mammary stromal giant cells: a benign lesion that simulates invasive carcinoma. *Cancer*. 1979;44(4):1305-1308.
847. Khanafshar E, Phillipson J, Schammel DP, et al. Inflammatory myofibroblastic tumor of the breast. *Ann Diagn Pathol*. 2005;9(3):123-129.
848. Zhou Y, Zhu J, Zhang Y, et al. An inflammatory myofibroblastic tumour of the breast with ALK overexpression. *BMJ Case Rep*. 2013;2013.
849. Luo JH, Rotterdam H. Primary amyloid tumor of the breast: a case report and review of the literature. *Mod Pathol*. 1997;10(7):735-738.
850. Rocken C, Kronsbein H, Sletten K, et al. Amyloidosis of the breast. *Virchows Arch*. 2002;440(5):527-535.
851. Morkowski JJ, Nguyen CV, Lin P, et al. Rosai-Dorfman disease confined to the breast. *Ann Diagn Pathol*. 2010;14(2):81-87.
852. Provenzano E, Barter SJ, Wright PA, et al. Erdheim-chester disease presenting as bilateral clinically malignant breast masses. *Am J Surg Pathol*. 2010;34(4):584-588.
853. Shin SJ, Scamman W, Gopalan A, Rosen PP. Mammary presentation of adult-type "juvenile" xanthogranuloma. *Am J Surg Pathol*. 2005;29(6):827-831.
854. Sanati S, Leonard M, Khamapirad T, Eltorky MA. Nodular mucinosis of the breast: a case report with pathologic, ultrasonographic, and clinical findings and review of the literature. *Arch Pathol Lab Med*. 2005;129(3):e58-e61.
855. Di Bonito L, Luchi M, Giarelli L, et al. Metastatic tumors to the female breast. An autopsy study of 12 cases. *Pathol Res Pract*. 1991;187(4):432-436.
856. Yamasaki H, Saw D, Zdanowitz J, Faltz LL. Ovarian carcinoma metastasis to the breast case report and review of the literature. *Am J Surg Pathol*. 1993;17(2):193-197.
857. Tempfer CB, El Fizazi N, Ergonenc H, Solass W. Metastasis of ovarian cancer to the breast: a report of two cases and a review of the literature. *Oncol Lett*. 2016;11(6):4008-4012.
858. Fishman A, Kim HS, Girtanner RE, Kaplan AL. Solitary breast metastasis as first manifestation of ovarian carcinoid tumor. *Gynecol Oncol*. 1994;54(2):222-226.
859. Harrist TJ, Kalisher L. Breast metastasis: an unusual manifestation of a malignant carcinoid tumor. *Cancer*. 1977;40(6):3102-3106.
860. Kashlan RB, Powell RW, Nolting SF. Carcinoid and other tumors metastatic to the breast. *J Surg Oncol*. 1982;20(1):25-30.
861. Lozowski MS, Faegenburg D, Mishriki Y, Lundy J. Carcinoid tumor metastatic to breast diagnosed by fine needle aspiration. Case report and literature review. *Acta Cytol*. 1989;33(2):191-194.
862. Rubio IT, Korourian S, Brown H, et al. Carcinoid tumor metastatic to the breast. *Arch Surg*. 1998;133(10):1117-1119.
863. Gupta D, Merino MI, Farhood A, Middleton LP. Metastases to breast simulating ductal carcinoma in situ: report of two cases and review of the literature. *Ann Diagn Pathol*. 2001;5(1):15-20.
864. D'Angelo P, Carli M, Ferrari A, et al. Breast metastases in children and adolescents with rhabdomyosarcoma: experience of the Italian Soft Tissue Sarcoma Committee. *Pediatr Blood Cancer*. 2010;55(7):1306-1309.
865. Howarth CB, Caces JN, Pratt CB. Breast metastases in children with rhabdomyosarcoma. *Cancer*. 1980;46(11):2520-2524.
866. Pettinato G, Manivel JC, Kelly DR, et al. Lesions of the breast in children exclusive of typical fibroadenoma and gynecomastia. A clinicopathologic study of 113 cases. *Pathol Annu*. 1989;24(Pt 2):296-328.
867. Bauer BS, Jones KM, Talbot CW. Mammary masses in the adolescent female. *Surg Gynecol Obstet*. 1987;165(1):63-65.
868. Shehata BM, Fishman I, Collings MH, et al. Pseudoangiomatous stromal hyperplasia of the breast in pediatric patients: an underrecognized entity. *Pediatr Dev Pathol*. 2009;12(6):450-454.
869. Rosen PP. Papillary duct hyperplasia of the breast in children and young adults. *Cancer*. 1985;56(7):1611-1617.
870. Wilson M, Cranor ML, Rosen PP. Papillary duct hyperplasia of the breast in children and young women. *Mod Pathol*. 1993;6(5):570-574.
871. Rosen PP, Cantrell B, Mullen DL, DePalo A. Juvenile papillomatosis (Swiss cheese disease) of the breast. *Am J Surg Pathol*. 1980;4(1): 3-12.
872. Taffurelli M, Santini D, Martinelli G, et al. Juvenile papillomatosis of the breast. A multidisciplinary study. *Pathol Annu*. 1991;26(Pt 1):25-35.
873. Rosen PP, Kimmel M. Juvenile papillomatosis of the breast. A follow-up study of 41 patients having biopsies before 1979. *Am J Clin Pathol*. 1990;93(5):599-603.
874. Bannayan GA, Hajdu SI. Gynecomastia: clinicopathologic study of 351 cases. *Am J Clin Pathol*. 1972;57(4):431-437.
875. Wilson SE, Hutchinson WB. Breast masses in males with carcinoma of the prostate. *J Surg Oncol*. 1976;8(2):105-112.
876. Carlson HE. Gynecomastia. *N Engl J Med*. 1980;303(14):795-799.
877. Damiani S, Eusebi V. Gynecomastia in type-1 neurofibromatosis with features of pseudoangiomatous stromal hyperplasia with giant cells. Report of two cases. *Virchows Arch*. 2001;438(5):513-516.
878. Hunfeld KP, Bassler R, Kronsbein H. "Diabetic mastopathy" in the male breast—a special type of gynecomastia. A comparative study of lymphocytic mastitis and gynecomastia. *Pathol Res Pract*. 1997;193(3):197-205.
879. Ng AM, Dissanayake D, Metcalf C, Wylie E. Clinical and imaging features of male breast disease, with pathological correlation: a pictorial essay. *J Med Imaging Radiat Oncol*. 2014;58(2):189-198.
880. Fisher ER, Creed DL. Nature of the periductal stroma in gynecomastia. *Lab Invest*. 1956;5(3):267-275.
881. Kalekou H, Kostopoulos I, Milias S, Papadimitriou CS. Comparative study of CD34, alpha-SMA and h-caldesmon expression in the stroma of gynaecomastia and male breast carcinoma. *Histopathology*. 2005;47(1):74-81.
882. Gottfried MR. Extensive squamous metaplasia in gynecomastia. *Arch Pathol Lab Med*. 1986;110(10):971-973.
883. Guillou L, Gebhard S. Gynecomastia with unusual intraductal "clear cell" changes mimicking pagetoid ductal spread of lobular neoplasia. *Pathol Res Pract*. 1995;191(2):156-163, discussion 64-5.
884. Andersen JA, Gram JB. Gynecomasty: histological aspects in a surgical material. *Acta Pathol Microbiol Immunol Scand [A]*. 1982;90(3):185-190.
885. Wells JM, Liu Y, Ginter PS, et al. Elucidating encounters of atypical ductal hyperplasia arising in gynaecomastia. *Histopathology*. 2015;66(3):398-408.
886. Toker C, Tang CK, Whitely JF, et al. Benign spindle cell breast tumor. *Cancer*. 1981;48(7):1615-1622.
887. Wargotz ES, Weiss SW, Norris HJ. Myofibroblastoma of the breast. Sixteen cases of a distinctive benign mesenchymal tumor. *Am J Surg Pathol*. 1987;11(7):493-502.
888. Fentiman IS, Fourquet A, Hortobagyi GN. Male breast cancer. *Lancet*. 2006;367(9510):595-604.
889. Gomez-Raposo C, Zambrana Tevar F, Sereno Moyano M, et al. Male breast cancer. *Cancer Treat Rev*. 2010;36(6):451-457.
890. Donegan WL. Cancer of the breast in men. *CA Cancer J Clin*. 1991;41(6):339-354.
891. El-Gazayerli MM, Abdel-Aziz AS. On Bilharziasis and Male Breast Cancer in Egypt: A Preliminary Report and Review of the Literature. *Br J Cancer*. 1963;17:566-571.
892. Brinton LA. Breast cancer risk among patients with Klinefelter syndrome. *Acta Paediatr*. 2011;100(6):814-818.
893. Ottini L, Rizzolo P, Zanna I, et al. BRCA1/BRCA2 mutation status and clinical-pathologic features of 108 male breast cancer cases from Tuscany: a population-based study in central Italy. *Breast Cancer Res Treat*. 2009;116(3):577-586.
894. Kozak FK, Hall JG, Baird PA. Familial breast cancer in males. A case report and review of the literature. *Cancer*. 1986;58(12):2736-2739.
895. Benson WR. Carcinoma of the prostate with metastases to breasts and testis; critical review of the literature and report of a case. *Cancer*. 1957;10(6):1235-1245.
896. Anderson WF, Jatoi I, Tse J, Rosenberg PS. Male breast cancer: a population-based comparison with female breast cancer. *J Clin Oncol*. 2010;28(2):232-239.
897. Burga AM, Fadare O, Lininger RA, Tavassoli FA. Invasive carcinomas of the male breast: a morphologic study of the distribution of histologic subtypes and metastatic patterns in 778 cases. *Virchows Arch*. 2006;449(5):507-512.
898. Moten A, Obirieze A, Wilson LL. Characterizing lobular carcinoma of the male breast using the SEER database. *J Surg Res*. 2013;185(2):e71-e76.
899. Muir D, Kanthan R, Kanthan SC. Male versus female breast cancers. A population-based comparative immunohistochemical analysis. *Arch Pathol Lab Med*. 2003;127(1):36-41.
900. Visfeldt J, Scheike O. Male breast cancer. I. Histologic typing and grading of 187 Danish cases. *Cancer*. 1973;32(4):985-990.
901. Wang-Rodriguez J, Cross K, Gallagher S, et al. Male breast carcinoma: correlation of ER, PR, Ki-67, Her2-Neu, and p53 with treatment and survival, a study of 65 cases. *Mod Pathol*. 2002;15(8):853-861.
902. Ansah-Boateng Y, Tavassoli FA. Fibroadenoma and cystosarcoma phyllodes of the male breast. *Mod Pathol*. 1992;5(2):114-116.
903. Haj M, Loberant N, Cohen I. Pseudoangiomatous hyperplasia of mammary stroma in a male breast presenting as a discrete nodule. *Breast J*. 2005;11(6):472-473.
904. Hernandez FJ. Leiomyosarcoma of male breast originating in the nipple. *Am J Surg Pathol*. 1978;2(3):299-304.
905. Lipper S, Willson CF, Copeland KC. Pseudogynecomastia due to neurofibromatosis—a light microscopic and ultrastructural study. *Hum Pathol*. 1981;12(8):755-759.
906. Gupta RK. Immunoreactivity of prostate-specific antigen in male breast carcinomas: two examples of a diagnostic pitfall in discriminating a primary breast cancer from metastatic prostate carcinoma. *Diagn Cytopathol*. 1999;21(3):167-169.
907. Gatalica Z, Norris BA, Kovatich AJ. Immunohistochemical localization of prostate-specific antigen in ductal epithelium of male breast. Potential diagnostic pitfall in patients with gynecomastia. *Appl Immunohistochem Mol Morphol*. 2000;8(2):158-161.

For personal use only. No other uses without permission. Copyright ©2017. Elsevier Inc. All rights reserved.

37 Lymph Nodes

Daniel A. Arber

CHAPTER CONTENTS

Normal anatomy, *1530*
Lymph node evaluation, *1531*
Biopsy, *1531*
Needle biopsy, *1531*
Infectious disease examination, *1533*
Immunophenotyping, *1533*
Molecular genetic and cytogenetic studies, *1533*
Primary immunodeficiencies, *1538*
Patterns of hyperplasia, *1539*
Follicular hyperplasia, *1539*
Mantle/marginal zone hyperplasia, *1541*
Paracortical hyperplasia, *1541*
Sinus hyperplasia, *1541*
Granulomatous inflammation, *1541*
Other cell types involved in nodal hyperplasia, *1541*
Inflammatory/hyperplastic diseases, *1543*
Acute nonspecific lymphadenitis, *1543*
Kikuchi necrotizing lymphadenitis, *1544*
Chronic nonspecific lymphadenitis, *1544*
Tuberculosis, *1544*
Atypical mycobacteriosis, *1544*
Sarcoidosis, *1545*
Fungal infections, *1547*
Toxoplasmosis, *1547*
Syphilis, *1548*
Leprosy, *1548*
Mesenteric lymphadenitis, *1548*
Cat-scratch disease, *1548*
Lymphogranuloma venereum, *1550*
Tularemia, *1550*
Brucellosis, *1551*
Acquired immunodeficiency syndrome–related lymphadenopathy, *1551*
Infectious mononucleosis, *1552*
Other viral (including postvaccinial) lymphadenitides, *1552*
Mucocutaneous lymph node syndrome, *1552*
Lupus erythematosus, *1553*
Rheumatoid arthritis, *1554*
Castleman disease, *1554*
Drug hypersensitivity, *1557*
Dermatopathic lymphadenitis, *1557*
Rosai–Dorfman disease, *1558*
Kimura disease, *1560*
Chronic granulomatous disease, *1560*
Lipophagic reactions, *1561*
Malignant lymphoma, *1561*
Hodgkin lymphoma, *1561*
Non-Hodgkin lymphoma, *1570*
Lymphoma in immunodeficiency states, *1589*
Peripheral (post-thymic) T-cell and NK-cell lymphomas, *1590*
Tumors of the accessory immune system, *1594*
Vascular tumors and tumorlike conditions, *1597*
Other primary tumors and tumorlike conditions, *1598*
Lymph node inclusions, *1601*
Other non-neoplastic lesions, *1604*
Metastatic tumors, *1605*

Normal Anatomy

The lymph node is one of the major anatomic components of the immune system.[1,2]

The three major regions of a lymph node are the *cortex*, *paracortex*, and *medulla* (Fig. 37.1A). The cortex is situated beneath the capsule and represents the compartment where most lymphoid follicles reside and is composed of primarily B lymphocytes and follicular dendritic cells. The medulla, close to the hilum, grows in the form of cords. It is rich in lymph sinuses, arteries, and veins but contains only a minor lymphocytic component that is a mix of B and T lymphocytes. The appearance of the follicles varies according to their state of activity. Primary follicles appear as round aggregates of small lymphocytes with little cytoplasm; secondary follicles appear following antigenic stimulation and are characterized by the presence of germinal centers surrounded by mantle zones.[3] The germinal center cells are predominantly B lymphocytes known as follicular center cells (centroblasts and centrocytes or small and large cleaved and noncleaved cells), macrophages, and follicular dendritic cells, but a population of T follicular–helper cells also reside normally in this compartment. The germinal center contains pale-staining large cells on hematoxylin and eosin (H&E) sections that are normally highly proliferative and shows polarization toward the side of antigen stimulation. The surrounding mantle zone B lymphocytes are small

For personal use only. No other uses without permission. Copyright ©2017. Elsevier Inc. All rights reserved.

Abstract

The disorders that may present in lymph nodes are diverse and include infectious diseases, neoplasms, and reactive responses to injury elsewhere. This chapter reviews the histologic patterns of various reactive conditions that involve lymph nodes, as well as the hematologic neoplasms that may primarily involve lymph nodes. The approach to the immunophenotypic evaluation as well as the role of molecular genetic studies, particularly in the hematopoietic neoplasms, are reviewed. In addition, unusual inclusions and disorders that may mimic malignancy in lymph nodes are discussed.

Keywords

Malignant lymphoma,
Hodgkin lymphoma,
Reactive follicular hyperplasia

For personal use only. No other uses without permission. Copyright ©2017. Elsevier Inc. All rights reserved.

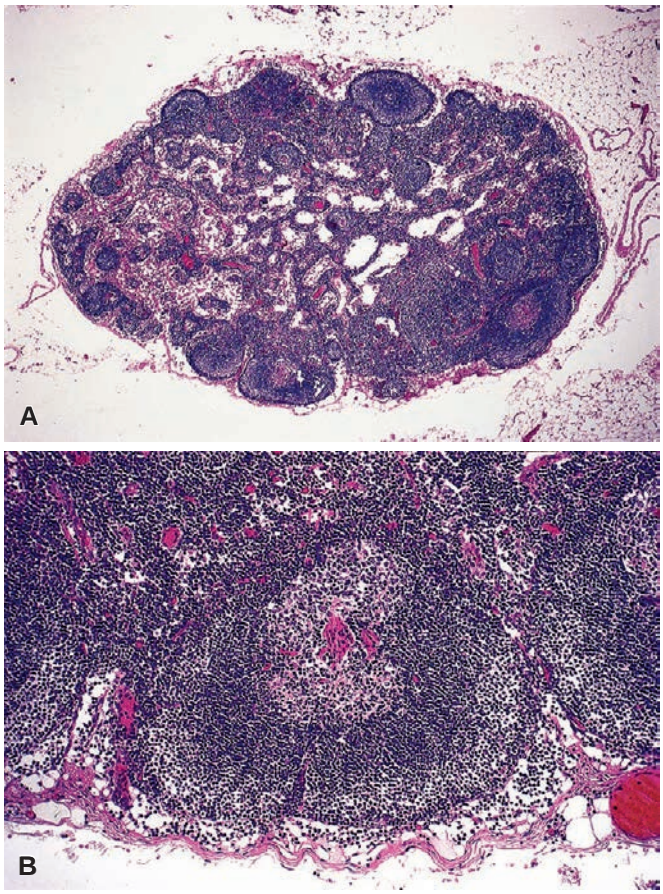

Figure 37.1 Normal Lymph Node. A, The morphologic differences among the various nodal compartments are particularly evident in mesenteric lymph nodes, of which this is an example. **B**, Secondary lymphoid follicle with obvious polarity of the germinal center.

and stain dark blue and contain little cytoplasm (see Fig. 37.1B).[1] Proliferated germinal centers are always indicative of humoral antibody production. Under conditions of intense antigenic stimulation, they also can appear within the medullary cords.[4]

The paracortex is the zone situated between the cortex and the medulla, which contains the mobile pool of T lymphocytes responsible for cell-mediated immune responses.[1] A characteristic feature is the presence of postcapillary venules, which are identifiable by their lining of high endothelial cells and the presence of lymphocytes migrating through their cytoplasm. Another cell type present in the paracortex is the interdigitating dendritic cell, a member of the accessory immune system. Expansion of the paracortex is indicative of a cell-mediated immunologic reaction. The number of lymphocytes within the lumen and wall of postcapillary venules gives a rough indication of the degree of lymphocyte recirculation.[5]

Afferent lymph vessels penetrate the nodal capsule to open into the marginal sinus; this communicates with an intricate intranodal sinus network that merges into efferent lymph vessels exiting the node at the hilum. The endothelial lining of the outer (subcapsular) side of the marginal sinus is nonphagocytic and similar to that of the afferent and efferent vessels; the lining of the intranodal sinuses has strong phagocytic properties. The main arteries and veins pass through the hilum and radiate to the medulla, paracortex, and inner part of the cortex; other blood vessels penetrate the capsule to supply the superficial cortex and a small area surrounding the trabeculae.

The morphologic and phenotypic features of the various populations of lymphoid cells and cells of the accessory immune system are discussed in the next sections and in connection with the respective proliferative pathologic changes affecting these populations.

Lymph Node Evaluation

The proper examination of a lymph node is a complicated task that may require the performance of a variety of specialized procedures depending on the nature of the case.

Biopsy

Selection of the lymph node to be biopsied is of great importance. In cases of generalized lymphadenopathy, inguinal nodes are to be avoided whenever possible because of a high frequency of nonspecific chronic inflammatory and fibrotic changes. Axillary or cervical nodes are more likely to be informative. Whenever possible, the largest lymph node in the region should be excised. Small superficial nodes may show only nonspecific hyperplasia, whereas a deeper node of the same group may show diagnostic features.

The surgeon biopsying intra-abdominal nodes or large cervical or axillary masses should have a frozen section or touch preparations performed to be certain that the tissue is representative—*not* necessarily to obtain a specific diagnosis at this point. This may save a second biopsy.

Adherence to a strict technique for the preparation of lymph nodes in the pathology laboratory is of paramount importance (see later).[6] The specimen should be received fresh in the laboratory immediately after excision, bisected as soon as it is received, and sampled for the appropriate studies. The portion to be embedded in paraffin (which should not exceed 3 mm in thickness) can be placed in 10% buffered formalin and/or a mercury-containing fixative such as B5. As a routine procedure, initial examination of a preparation stained with H&E is perfectly adequate, followed by whatever additional stains and special techniques the nature of the case may require (which may range from very many to none).

A technique that complements the study of tissue sections and that is too often neglected is the examination of touch preparations from the cut surface of the fresh lymph node stained with Giemsa or Wright solution. This is particularly useful in the evaluation of lymphoma and leukemia, and in the initial triage of the specimen (such as sending tissue for culture if granulomas are seen). For instance, granulocytic leukemia can closely simulate large cell lymphoma in a hematoxylin–eosin-stained section, but an imprint may readily distinguish the two conditions.

Needle Biopsy

Core needle biopsy is adequate for the diagnosis of metastatic carcinoma. Although not preferred for the evaluation of primary lymphoid disorders, core biopsies are increasingly used nowadays, putting pressure on the pathologist to render a diagnosis based on limited amounts of tissue. Compression artifact is very common in core biopsies, with the cells appearing smaller and the nuclei appearing darker compared with those seen in excisional biopsies. Very often, flow cytometry immunophenotyping and more extensive immunohistochemical evaluation are required to maximize the information obtainable from the biopsies.

Fine-needle aspiration of lymph nodes is particularly useful for the documentation of metastatic carcinoma (Fig. 37.2). It is used most often in cervical lymph nodes[7] but also in other locations, including intra-abdominal and retroperitoneal regions.[8] The cytologic diagnosis of malignant lymphoma can be made in 50%–75% of the cases, the accuracy being greatest in the high-grade lesions (see Fig. 37.2).[9] A primary diagnosis of malignant lymphoma based on

For personal use only. No other uses without permission. Copyright ©2017. Elsevier Inc. All rights reserved.

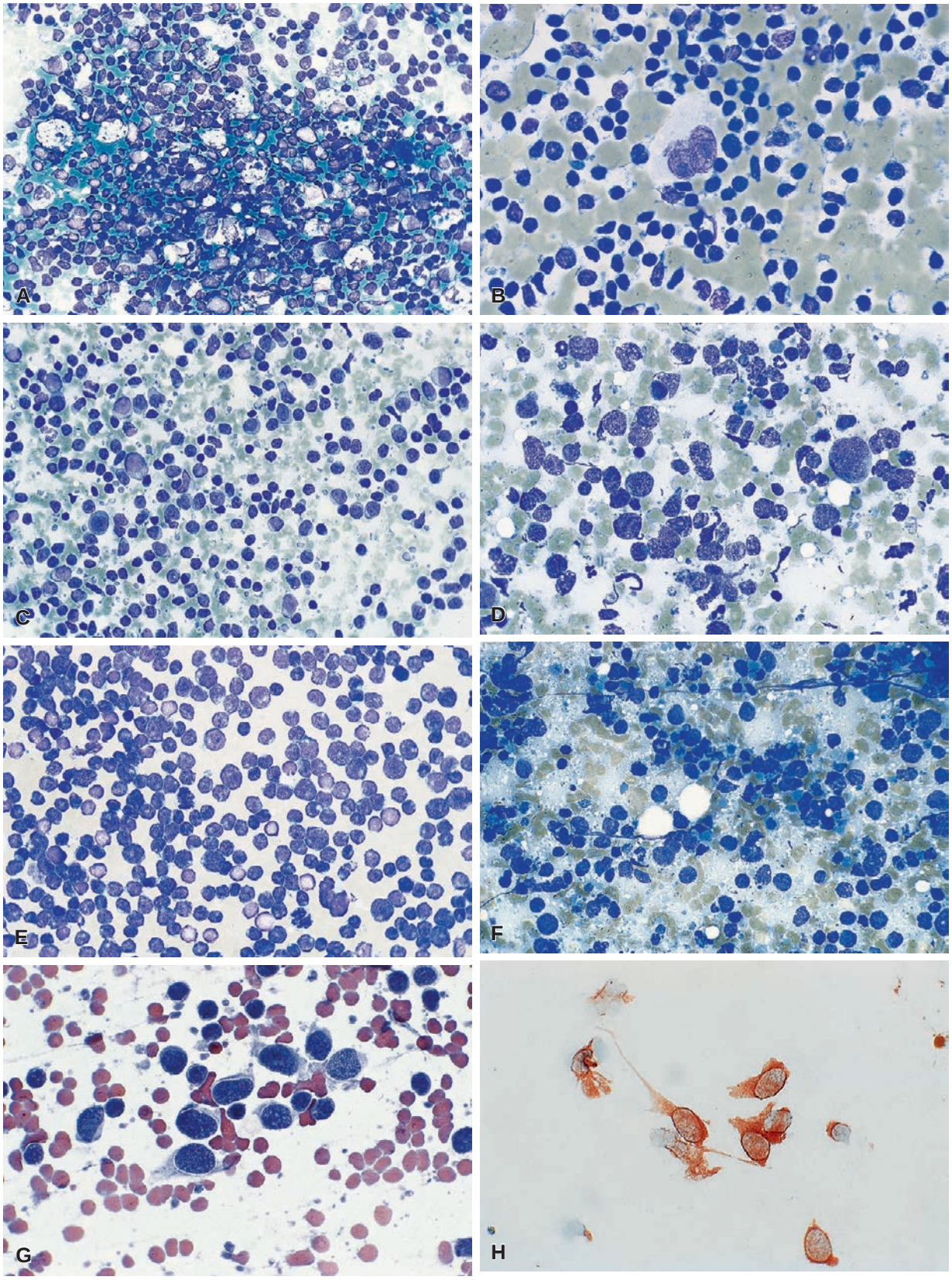

Figure 37.2 Appearance of Various Lymph Node Diseases as Seen in Fine Needle Aspiration Specimens. A, follicular hyperplasia; **B**, Hodgkin lymphoma (Reed–Sternberg cell); **C**, small lymphocytic lymphoma/chronic lymphocytic leukemia; **D**, follicular lymphoma, grade 3; **E**, lymphoblastic lymphoma; **F**, metastatic pulmonary small cell carcinoma; **G**, metastatic alveolar rhabdomyosarcoma; **H**, same case as **G** immunostained for desmin. (Courtesy of L. Alasio, Milan, Italy.)

For personal use only. No other uses without permission. Copyright ©2017. Elsevier Inc. All rights reserved.

cytology morphology, however, is not adequate, and all cases undergoing fine-needle aspiration for possible lymphoma should have an aspirate sample submitted for flow cytometry immunophenotyping, and preferably, be accompanied by a core biopsy for architectural evaluation. Even with this combination, complete lymphoma classification may not be possible in up to 35% of cases, requiring an excisional biopsy. The fine-needle aspiration technique has been found most useful for the selection of a representative node for biopsy, for the diagnosis of recurrent lymphoma, for staging the extent of the disease, for monitoring treatment and to collect material for ancillary testing. Hemorrhage, necrosis, and myofibroblastic proliferation may develop along the needle tract; the latter should not be confused with Kaposi sarcoma or other neoplasms.

Infectious Disease Examination

If there is a possibility that the node contains an infectious process, an adequate, sterilely collected sample of the biopsied lymph node must be sent directly for bacteriologic, fungal, and viral studies or at least be placed in a sterile Petri dish in the refrigerator. If permanent sections show an inflammatory process, the material can then be retrieved and studied for infectious diseases. For some reason, this technically trivial step is the one most commonly forgotten; but molecular assays to identify infectious agents may now be performed on formalin-fixed, paraffin-embedded tissues[10–13] and should be considered if the histologic changes suggest an infectious etiology, even if cultures are negative.

Immunophenotyping

Phenotyping of lymphoid disorders has evolved into a highly complex field, as a result of the enormous cellular diversity within the immune system and the huge number (over 1000) of markers that have become available for this purpose.

Rosetting tests with coated or uncoated red blood cells and polyclonal antibodies, which were so useful for the early characterization of lymphomas, have been all but replaced by the use of monoclonal antibodies. These have received a multitude of designations, which are more dependent on the manufacturer's source than the features of the antibody. Fortunately, an internationally agreed-upon nomenclature (the CD system, which stands for *cluster designation* or *cluster of differentiation*) has evolved, and this has allowed for better communication among the various laboratories. Over 300 CD antigens have been identified. Many of these monoclonal antibodies are now applicable to paraffin sections (Table 37.1). A detailed discussion of these tests and their optimal use in the differential diagnosis of hematolymphoid disorders is outside the scope of this book.

Immunophenotyping can be performed by flow cytometry (requiring fresh tissue) or on paraffin-embedded materials.[14,15] Two major advantages of the former are rapid availability of results, and excellent assessment of surface immunoglobulin and hence B-cell clonality. The disadvantages are the need for immediate handling of fresh tissue, and suboptimal architectural–morphologic correlation.

Molecular Genetic and Cytogenetic Studies

Gene Rearrangement Analysis

Individual T and B lymphocytes normally undergo rearrangements of antigen receptor genes as part of normal maturation, resulting in the development of unique immunoglobulin or T-cell receptor molecules. The vast majority of mature B cells have undergone rearrangement of the immunoglobulin heavy chain (IGH) gene and the immunoglobulin kappa light chain (IGK) gene, and approximately one-third of B cells have also undergone rearrangement of the immunoglobulin lambda (IGL) gene. Maturing T cells normally rearrange the T-cell receptor gamma and delta genes (TRG and TRD, respectively), and most cells then undergo rearrangement of the T-cell receptor alpha and beta genes (TRA and TRB, respectively). These mature T cells express the alpha and beta proteins and are termed α/β T cells. A small percentage of normal T cells fail to undergo TRA and TRB rearrangements, resulting in expression of surface gamma and delta proteins and these cells are termed δ/γ T cells. The gene rearrangement process results in editing of the original germline DNA to move one variable or V-region of the gene in contact with a single joining or J-region, sometimes with an individual diversity or D-region in between the two (Fig. 37.3). Varying numbers of small nucleotides are added between these regions. This shuffling of V-, D-, and J-regions results in variation in size of an individual reactive lymphocyte's antigen receptor gene, while clonal populations will have large numbers of cells with identically sized gene rearrangements. Molecular genetic assays attempt to capitalize on this difference between reactive and clonal populations, but some normal antigen responses may result in oligoclonal proliferations that can result in false positive results.

Mature B-cell lymphomas almost always show clonal rearrangements of the immunoglobulin genes, although rare cases may show simultaneous rearrangements of T-cell receptor genes.[16] Mature T-cell lymphomas almost always show clonal rearrangements of the T-cell receptor genes, but rare cases may show simultaneous rearrangements of the immunoglobulin genes, an occurrence which is particularly common in angioimmunoblastic T-cell lymphoma (AITL) (20%–30%), probably due to the presence of an associated B-cell proliferation.[17] However, precursor lymphoblastic lymphomas frequently show cross-lineage antigen receptor gene rearrangements.[18]

Analysis of the immunoglobulin and T-cell receptor gene status in lymphoid proliferations may help in determining clonality, which generally but not invariably indicates a neoplastic process,[19] and in determining lineage in mature lymphoid proliferations, with the caveats of possible cross-lineage gene rearrangements.[16,20] Demonstration of clonal immunoglobulin or T-cell receptor gene rearrangements is most commonly achieved by methods using the polymerase chain reaction (PCR) technique, which has superseded the much more laborious and demanding Southern blot technique.[21] Although PCR is a highly sensitive technique, being able to demonstrate even minor clonal populations, there can be significant false-negative results due to imperfect annealing of the consensus primers with the target DNA sequences which can be particularly difficult when fragmented DNA from formalin-fixed, paraffin-embedded tissue is used.[16,22,23] However, false-negative results can be significantly reduced by using multiple primer pairs against the antigen receptor gene target, such as using the BIOMED-2 primers.[18,24] False-positive results also occur with these assays, often related to oligoclonal proliferations or small numbers of lymphocytes in the specimens.[25] Newly developed next-generation sequencing assays appear to be useful in overcoming some of these obstacles.[26]

Chromosomal Translocation

In addition to clonal rearrangements of antigen receptor genes, a subset of non-Hodgkin lymphomas are associated with nonrandom chromosomal translocations, the more common of which are summarized in Table 37.2. Although most are not entirely specific for a single lymphoma type, their detection may be useful in the proper clinical setting which is discussed in more detail with the various lymphoma types.

Text continued on p. 1538

For personal use only. No other uses without permission. Copyright ©2017. Elsevier Inc. All rights reserved.

Table 37.1 Principal antibodies applicable on paraffin tissue sections for lymphoid proliferations

CD ANTIGEN AND/ OR ANTIBODY	PREDOMINANT NORMAL CELL REACTIVITY	REACTIVITY IN NEOPLASMS	COMMENT/CAUTION
Leukocytes			
CD45RB Leukocyte common antigen	B cells and most T cells, macrophages, myeloid cells	Most lymphomas and leukemias	Plasma cell neoplasms and Reed–Sternberg cells usually unreactive; some lymphoblastic and anaplastic large cell lymphomas unreactive
B Lymphocytes			
C20 (L26)	B cells, except plasma cells	Most B-cell lymphomas; L&H cells in NLPHL; some Reed–Sternberg cells in ~20% of classic Hodgkin lymphomas; rare T-cell lymphomas	Plasmablastic and plasma cell neoplasms usually unreactive; epithelium of some thymomas may stain
Immunoglobulin light chains	B cells and plasma cells	B-cell and plasma cell neoplasms	Cytoplasmic Ig often detectable in paraffin sections; surface Ig often requires flow cytometry or frozen tissue
CD79A	B cells, including most plasma cells	Most B-cell lymphomas; B-lymphoblastic leukemias	CD79A is associated with antigen receptor (Ig) on B cells in a similar manner as CD3 on T cells
PAX5	B cells, except most plasma cells	B-cell neoplasms, including B-lymphoblastic neoplasms; L&H cells in NLPHL; Reed–Sternberg cells in classic Hodgkin lymphoma show moderate to weak staining	Plasma cell neoplasms are usually unreactive
OCT2	B cells, including plasma cells	B-cell neoplasms, including plasma cell and plasmablastic neoplasms; strong nuclear expression in L&H cells of NLPHL; weak or absent staining in classical Hodgkin lymphoma	
BOB.1	B cells, including plasma cells	B-cell neoplasms, including plasma cell and plasmablastic neoplasms; weak or absent staining in classical Hodgkin lymphoma	Some T-cell lymphomas can be BOB.1 positive
B Lymphocyte Differentiation Stage			
CD10 (CALLA)	Precursor B cells, follicular center B cells; follicular center T helper cells; granulocytes	Many B-cell and some T-cell lymphoblastic lymphomas/leukemias; follicular lymphoma; Burkitt lymphoma; some large B-cell lymphomas; angioimmunoblastic T-cell lymphoma	Useful in separating follicular from other low-grade B-cell lymphomas; expressed by subset of myeloma; reactive with a variety of nonhematolymphoid neoplasms
BCL6	Follicular center B cells; follicular center T-helper cells; rare subpopulations of T cells	Follicular lymphoma; Burkitt lymphomas; some large B-cell lymphomas; angioimmunoblastic T-cell lymphoma; anaplastic large cell lymphoma	
MUM1	Plasma cells and plasmablasts; subpopulation of BCL6 follicular center B cells; small percentage of activated T cells	Plasma cell and plasmablastic neoplasms; lymphoplasmacytic lymphoma; diffuse large B-cell lymphoma (75% of cases); other B-cell lymphomas (variable); some T-cell lymphomas (variable)	MUM1 may be positive in nonhematolymphoid neoplasms, such as malignant melanoma
CD138	Plasma cells and plasmablasts; some immunoblasts	Plasma cell and plasmablastic neoplasms; some large B-cell lymphomas	CD138 is positive in normal epithelial cells and many nonhematolymphoid neoplasms

For personal use only. No other uses without permission. Copyright ©2017. Elsevier Inc. All rights reserved.

Table 37.1 Principal antibodies applicable on paraffin tissue sections for lymphoid proliferations—cont'd

CD ANTIGEN AND/ OR ANTIBODY	PREDOMINANT NORMAL CELL REACTIVITY	REACTIVITY IN NEOPLASMS	COMMENT/CAUTION
CD23	Mantle zone B cells, subset of follicular dendritic cells	CLL/small lymphocytic lymphomas usually reactive; follicular lymphoma (some cases); mediastinal large B-cell lymphoma; follicular dendritic cell tumor	Low-affinity Fc receptor for IgE; upregulated by EBV infection
T and NK Lymphocytes			
Cytoplasmic CD3 (detected by polyclonal or monoclonal antibody)	T cells and NK cells	Most T-cell and NK-cell lymphomas; exceptional cases of B-cell lymphoma can be CD3+	CD3 demonstrable in paraffin sections represents cytoplasmic CD3; this is present in T cells as well as NK cells. Surface CD3, which is typically positive in T cells but negative in NK cells (and their neoplasms), requires fresh or frozen tissue for demonstration.
CD2	T cells, NK cells	Most T-cell and NK-cell lymphomas and leukemias; few myeloid leukemias; systemic mastocytosis	CD2 is the sheep erythrocyte receptor
CD5	T cells, weak expression by small B-cell subset	Most T-cell lymphomas and leukemia; chronic lymphocytic leukemia/small lymphocytic lymphoma; mantle cell lymphoma; rare subset of diffuse large B-cell lymphoma	CD5-reactive B cells may be elevated in autoimmune disorders; expression of CD5 by diffuse small B-cell neoplasms useful in diagnosis; CD5 typically negative in NK cells and their neoplasms; CD5 can be expressed in nonhematolymphoid neoplasms, such as thymic carcinoma
CD7	Most T cells, NK cells	Most T-cell and some NK-cell lymphomas and leukemias; some myeloid leukemias	Earliest expressed antigen in T-cell ontogeny and one of the best T-cell markers for lymphoblastic neoplasms; most commonly deleted antigen in peripheral T-cell malignancy, particularly mycosis fungoides
TCRβ	Expressed by over 95% of mature T cells	Many T-cell lymphomas	NK cells and their neoplasms are unreactive
TCRγ	Expressed by a small population of mature T cells, often in extranodal sites	T-cell lymphomas of gamma/delta type, usually extranodal	NK cells and their neoplasms are unreactive
CD56	NK cells, minor subpopulation of T cells, neural tissues	NK-cell lymphomas; some peripheral T-cell lymphomas; some plasma cell neoplasms	Also reacts with neural and neuroendocrine cells and their neoplasms
CD43	T cells, macrophages, Langerhans cells, myeloid cells, minor subset of B cells	Most T-cell lymphomas; some B-cell lymphomas (CLL/small lymphocytic lymphoma, mantle cell lymphoma some marginal zone lymphomas); myeloid leukemias; histiocytic neoplasms; Langerhans cell histiocytosis; some plasma cell neoplasms	Coexpression on B cells is helpful for diagnosis, but caution should be used in interpreting partial coexpression due to heterogeneity of cell types that react with CD43

Continued

For personal use only. No other uses without permission. Copyright ©2017. Elsevier Inc. All rights reserved.

Table 37.1 Principal antibodies applicable on paraffin tissue sections for lymphoid proliferations—cont'd

CD ANTIGEN AND/ OR ANTIBODY	PREDOMINANT NORMAL CELL REACTIVITY	REACTIVITY IN NEOPLASMS	COMMENT/CAUTION
T- or NK-Cell Subset or Differentiation Stage			
CD57	Some NK cells; subset of germinal center T cells	T-cell large granular lymphocyte leukemia; rare cases of T-lymphoblastic neoplasm	CD57+ cells often rosette around L&H cells in NLPHL
PD1	Follicle helper T cells	Angioimmunoblastic T-cell lymphoma	PD1+ cells frequently rosette around L&H cells in NLPHL
CD4	Most helper/inducer T cells, many macrophages, many dendritic cells	Many peripheral T-cell lymphomas; histiocytic neoplasms; Langerhans cell histiocytosis	
CD8	Most cytotoxic/suppressor T cells, subset of NK cells, splenic sinus lining cells	Minority of peripheral T-cell lymphomas	
Precursor Cell Marker			
Terminal deoxynucleotidyl transferase (TdT)	Precursor cells in marrow B-cell precursors, cortical thymocytes	Most lymphoblastic lymphomas and leukemias of a T or B lymphoblastic lineage; some myeloid leukemias	Useful as marker of precursor cell
CD34	Various cell types, including endothelial cells and immature hematopoietic cells	Vascular tumors, gastrointestinal stromal tumors, many lymphoblasts and myeloblasts	May confirm immaturity in rare TdT negative lymphoblastic proliferations
Hodgkin Lymphoma-Associated			
CD30	Some activated B and T cells, some plasma cells	Reed–Sternberg cells in most cases of classic Hodgkin lymphoma; anaplastic large cell lymphomas; some B- and T-cell lymphomas	Embryonal carcinomas and few other nonhematolymphoid neoplasms reactive
CD15 (Leu-M1)	Granulocytes, some macrophages	Reed–Sternberg cells in most cases of classic Hodgkin lymphoma; large cells in some B- and T-cell lymphomas; histiocytic neoplasms; some myeloid leukemias	Many carcinomas reactive; CMV-infected cells reactive; antibody of IgM isotype and thus may benefit from isotype-specific detection; L&H cells usually unreactive
Accessory Cells			
CD68	Macrophages and monocytes; myeloid cells positive with KP1 but not PGM1 antibody	True histiocytic neoplasms; monocytic leukemias; myeloid leukemias positive with KP1	Reactive in granular cell tumors, some melanomas, malignant fibrous histiocytomas, and renal cell carcinomas
CD163	Macrophages except those of germinal centers and splenic white pulp	Histiocytic neoplasms; acute monocytic leukemia	Dendritic cells and their tumors are unreactive
Lysozyme	Macrophages, myeloid cells	Histiocytic neoplasms; many myeloid leukemias	Reactive with many nonhematolymphoid neoplasms
S100 protein	Langerhans cells, interdigitating (IDRC) and sometimes follicular dendritic cells	Langerhans cell histiocytosis; IDRC tumors; rare T-cell lymphomas; histiocytic neoplasms; Rosai–Dorfman disease	Reactive with many nonhematolymphoid neoplasms
CD1a	Cortical thymocytes, Langerhans cells	Some T-lymphoblastic lymphomas/ leukemias; Langerhans cell histiocytosis	
CD207 (langerin)	Langerhans cells	Langerhans cell histiocytosis	

For personal use only. No other uses without permission. Copyright ©2017. Elsevier Inc. All rights reserved.

Table 37.1 Principal antibodies applicable on paraffin tissue sections for lymphoid proliferations—cont'd

CD ANTIGEN AND/ OR ANTIBODY	PREDOMINANT NORMAL CELL REACTIVITY	REACTIVITY IN NEOPLASMS	COMMENT/CAUTION
CD21	Mantle and marginal zone B cells, follicular dendritic cells	Some B-cell lymphomas; follicular dendritic cell tumors	C3d (CR2) complement receptor; receptor for EBV; expanded CD21-positive follicular dendritic cell networks characteristic of angioimmunoblastic T-cell lymphoma
CD35	Mantle and marginal zone B cells, follicular dendritic cells, some macrophages	Some B-cell lymphomas; follicular dendritic cell tumors; some myeloid leukemias	C3b (CR1) complement receptor
Miscellaneous			
BCL2	Nongerminal center B cells, most T cells, plasma cells	Overexpressed in most follicular lymphomas and some diffuse large B-cell lymphomas; also expressed in many other lymphomas and leukemias	Most useful in differentiating follicular lymphoma from reactive follicular hyperplasia
Cyclin D1	Some histiocytes; normal lymphoid cells are negative	Mantle cell lymphoma; proliferation centers of some cases of CLL/small lymphocytic lymphoma; some plasma cell neoplasms; hairy cell leukemia	Cyclin D1 is expressed in many nonhematolymphoid neoplasms but is useful in confirming mantle cell lymphoma in a CD5 positive small B-cell proliferation
ALK	None	ALK+ anaplastic large cell lymphoma; ALK+ large B-cell lymphoma	ALK also positive in some cases of inflammatory myofibroblastic tumor
Myeloperoxidase	Myeloid cells	Myeloid leukemias	Most sensitive and specific marker for myeloid neoplasms

ALK, Anaplastic lymphoma kinase; *CLL,* chronic lymphocytic leukemia; *CMV,* cytomegalovirus; *EBV,* Epstein–Barr virus; *NLPHL,* nodular lymphocyte predominant Hodgkin lymphoma.

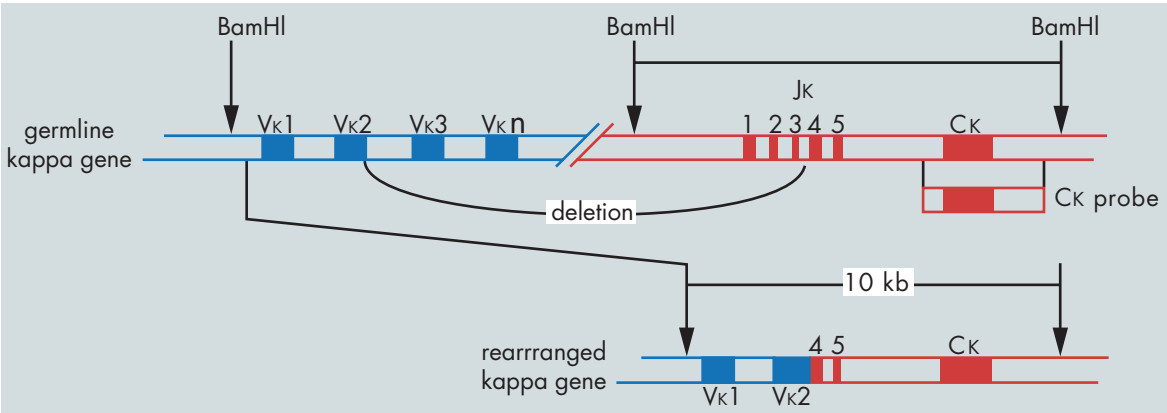

Figure 37.3 Schematic representation of an immunoglobulin gene rearrangement, in this case the kappa (IGK) gene. The germline configuration of the kappa light chain gene (upper line) consists of numerous variable gene segments (V-kappa, 1–*n*), five joining gene segments (J-kappa, 1–5), and a single constant region gene segment (C-kappa). To assemble a functional light chain gene (lower line), select V and J segments are juxtaposed with each other by deletion of the intervening DNA. The deletion reconfigures restriction enzyme cutting sites upstream of J-kappa, changing the size of the *BamH1* fragment detected with a C-kappa hybridization probe (12 kb germline vs. 10 kb rearranged in figure) when examined by Southern blot analysis. Current polymerase chain reaction method target detection of the rearranged product (lower line). (From Warnke RA, Weiss LM, Chan JKC, et al. *Tumors of the Lymph Nodes and Spleen. Atlas of Tumor Pathology*, series 3, fascicle 14. Washington, DC: Armed Forces Institute of Pathology; 1995.)

For personal use only. No other uses without permission. Copyright ©2017. Elsevier Inc. All rights reserved.

Table 37.2 Recurrent chromosomal abnormalities in lymphomas

CHROMOSOMAL ABNORMALITY	MOST FREQUENT TYPES OF LYMPHOMA	ANTIGEN RECEPTOR GENE	ONCOGENE
t(8;14)(q24;q32.33) t(2;8)(2p11.2;q24) t(8;22)(q24;q11.2)	Burkitt lymphoma, some high-grade B-cell lymphomas, and rarely diffuse large B-cell lymphoma	IGH IGK *IGL*	*MYC* *MYC* *MYC*
t(14;18)(q32.33;q21.3)	Follicular lymphoma; subset of diffuse large B-cell lymphomas and high grade B-cell lymphomas	IGH	*BCL2*
t(11;14)(q13;q32.33)	Mantle cell lymphoma	IGH	*CCND1* (cyclin D1)
t(3;v)(q27;v)[a]	Large B-cell lymphoma; some high grade B-cell lymphomas; small subset of follicular lymphomas	IGH, IGK, IGL, others	*BCL6*
t(14;v)(q11.2;v)	T-lymphoblastic lymphoma; adult T-cell leukemia/lymphoma	TRA	Several
t(7;v)(q34;v)	T-lymphoblastic lymphoma	TRB	Several
t(2;5)(p23;q35.1) and t(5;v)(q35.1;v)	Anaplastic large cell lymphoma, ALK+	NA	*NPM–ALK* fusion gene
t(11;18)(q22;q21) t(14;18)(q32.33;q21) t(3;14)(p13;q32.33) t(1;14)(p22;q32.33)	Extranodal marginal zone lymphoma of mucosa-associated lymphoid tissue	NA IGH IGH IGH	*BIRC3–MALT1* fusion gene *MALT1* *FOXP1* *BCL10*

[a]Variable.
NA, Not applicable.

Chromosomal translocations are most often detected by conventional cytogenetics, direct or reverse transcriptase PCR, and fluorescence in situ hybridization (FISH). Each of these techniques has its own advantages and limitations. However, the FISH technique, either using break-apart probe or dual-fusion probes, generally offers the highest sensitivity and can often be performed in formalin-fixed, paraffin-embedded tissue.[27,28]

Chromosome Copy Change and Chromosomal Gain or Deletion

Increase in copies of entire chromosomes is common in certain lymphoma types, such as trisomy 3 or trisomy 18 in extranodal marginal zone lymphoma, and trisomy 12 in chronic lymphocytic leukemia (CLL)/small lymphocytic lymphoma (SLL).[29,30] Lymphomas can also exhibit deletions or gains of specific regions of chromosome, such as del 6q21–25 in extranodal NK/T-cell lymphoma, del 6q23.3 in marginal zone lymphoma, and gain of 3q26 in mantle cell lymphoma.[31] These chromosomal changes can be demonstrated by conventional cytogenetics, FISH, or single nucleotide polymorphism (SNP) microarrays but are usually less helpful diagnostically when compared to gene rearrangement studies or detection of chromosomal translocations.

Gene Mutation, Amplification, and Hypermethylation

Point mutations in specific genes are characteristic of some lymphoma types, including activating mutations of proto-oncogenes, such as point mutations in genes involved in regulation of the nuclear factor kappa B (NFκB) in some cases of diffuse large B-cell lymphoma (DLBCL), and inactivating mutations of tumor suppressor genes, such as *A20* in various lymphoma types.[32–35] An inactivating mutation in a tumor suppressor gene is often accompanied by chromosomal/gene deletion in the remaining allele, resulting in complete loss of function of the gene.[33,35] Tumor suppressors genes are alternatively inactivated in some lymphomas through hypermethylation of the gene promoters, such as p16 in mantle cell lymphoma.[36] Gene amplifications are found in some lymphomas, such as *REL* in DLBCL.[37]

Gene Expression Profiling

Some highly publicized studies have demonstrated the use of molecular profiling with the microarray technology to segregate DLBCLs into subtypes[38] and to predict survival after chemotherapy.[39] Although microarray-based gene expression profiling has provided tremendous information on various lymphoma types, this technology has not been reproducibly applied in the diagnostic setting[38] Instead, immunohistochemical algorithms[40] predictive of gene expression profiling results have become routine while new methods of detecting complex molecular lymphoma subtypes are being developed.

Primary Immunodeficiencies

Primary immunodeficiency syndromes are congenital abnormalities of the immune system that most often result in an increased risk of infection but are now also known to be associated with an increased risk for developing malignant lymphoma.[41,42] Over 250 genetic abnormalities have identified in associated with primary immunodeficiency, and the range of these defects and disorders is beyond the scope of this textbook. However, the genetic defects result in a decrease in number and/or function of normal B, T, and/or NK cells or their subsets. While loss of T cells, a feature of some types of severe combined immunodeficiency, is most striking in the

For personal use only. No other uses without permission. Copyright ©2017. Elsevier Inc. All rights reserved.

thymus, lymph nodes also often demonstrate loss of the normal immunoarchitecture. This may also include complete loss of B-cell follicles or the presence of "naked" germinal centers without normal mantle zones. Some disorders, such as Omenn's syndrome,[43] have normal or elevated numbers of T cells despite genetic mutations that impact T-cell function. Rare X-linked disorders associated with mutations of *SH2D1A* and *BIRC4* are associated with an Epstein–Barr virus (EBV) positive, fatal infectious mononucleosis-like proliferation that affects young males.[44]

Autoimmune lymphoproliferative syndrome (ALPS; Canale–Smith disease) occurs in young males with lymphadenopathy and hepatosplenomegaly and an average age of onset of 3 years.[45,46] It is an inherited disorder due to defects in FAS-mediated apoptosis and characterized in most instances by lymphadenopathy, splenomegaly, hypergammaglobulinemia, and autoimmune phenomena.[45,47] Most patients present in childhood, but cases of adult onset are on record.[48] Most patients with ALPS have germline, and less commonly somatic, mutations of *FAS* (*TNFRSF6*), *FASL*, or *CASP10* genes.[49] Four subtypes of this condition have been described.[49]

Microscopically, the main change in the affected lymph nodes is a marked paracortical expansion by a mixed population of small- and intermediate-sized lymphocytes and numerous large immunoblasts.[50,51] The interfollicular areas are expanded by a proliferation of T cells that lack both CD4 and CD8 ("double negative") with increased S100 positive dendritic cells.[52] This expansion can be so extensive as to simulate a lymphoma. In addition, there is often florid follicular hyperplasia, frequently accompanied by focal progressive transformation of germinal centers. A polyclonal plasmacytosis is also common.[51]

An increased incidence of malignant lymphoma has been detected in this population.[53] Interestingly, as many as 41% of patients with type Ia ALPS have Rosai–Dorfman disease (RDD)-like changes in their lymph nodes, raising the possibility that RDD may be related to ALPS and possibly represent a forme fruste of it.[52]

While the morphologic features of most primary immunodeficiency syndromes are nonspecific, the findings of recurrent atypical hyperplasia or persistent infectious mononucleosis-like changes in a young person should warrant further clinical and genetic evaluation for an underlying immune defect.[54]

Patterns of Hyperplasia

The various components of the lymph node react to various known and unknown stimuli by undergoing reactive changes, some being the expression of an inflammatory reaction and some being indicative of an immune response. The two are often present together. A similar microscopic picture may result from a variety of causes, but some agents produce a characteristic microscopic picture. When the hyperplastic change is very intense, the differential diagnosis with malignant lymphoma may become difficult[5,55,56] and may require the application of immunophenotyping and molecular genetic methods.[57]

Although most lymph node reactions involve several compartments, it is useful to evaluate these compartments individually, not only because their presence and relative intensity correlate with various specific disorders (thus providing important etiologic clues), but also because each of them raises differential diagnostic problems with different types of malignant processes. From a topographic and functional standpoint, the major patterns of reactive lymphoid proliferations are *follicular/nodular*, *interfollicular/paracortical*, *diffuse*, *sinus*, and *mixed*. These patterns also apply to the various types of malignant lymphoma (Table 37.3).

Follicular Hyperplasia

The criteria laid down in the classic article by Hicks et al.[58] and further elaborated by Nathwani et al.[59] remain extremely useful and reliable to distinguish reactive follicular hyperplasia from follicular lymphoma (Table 37.4). In general, reactive follicles vary considerably in size and shape; their margins are sharply defined and surrounded by a mantle of small lymphocytes often arranged circumferentially with an onion-skin pattern and sometimes concentrating on one pole of the follicle (corresponding to the side of the antigenic stimulation); the follicles are composed of an admixture of small and large lymphoid cells with irregular (elongated and cleaved) nuclei; mitoses are numerous; and phagocytosis of nuclear debris by histiocytes is prominent, resulting in a starry sky pattern. The lymphoid tissue present between the follicles is distinctly different from that of the follicles themselves (although this also may be true

Table 37.3 Differential diagnosis of reactive proliferations based upon recognition of predominant pattern in lymph node at low magnification

FOLLICULAR/ NODULAR	INTERFOLLICULAR/ PARACORTICAL	DIFFUSE	SINUS	MIXED/OTHER
Non-Neoplastic				
Reactive follicular hyperplasia Explosive follicular hyperplasia (HIV) Progressive transformation of germinal centers Castleman disease Rheumatoid lymphadenopathy Luetic lymphadenitis Kimura disease	Immunoblastic proliferations Viral lymphadenitis (EBV, CMV, herpes) Post-vaccination lymphadenitis Drug sensitivity, e.g., diphenylhydantoin (Dilantin)	Immunoblastic proliferations Viral lymphadenitis (EBV, CMV, herpes) Post-vaccination lymphadenitis Drug sensitivity, e.g., diphenylhydantoin	Sinus hyperplasia Rosai–Dorfman disease Lymphangiogram effect Whipple disease Vascular transformation of sinuses Hemophagocytic syndrome	Mixed hyperplasia Dermatopathic lymphadenopathy Toxoplasmosis Cat-scratch disease Systemic lupus erythematosus Kawasaki disease Kikuchi lymphadenitis Granulomatous lymphadenitis Inflammatory pseudotumor

CMV, Cytomegalovirus; *EBV*, Epstein–Barr virus.
Modified from Warnke RA, Weiss LM, Chan JKC, et al. *Tumors of the Lymph Nodes and Spleen*. *Atlas of Tumor Pathology*, series 3, fascicle 14. Washington, DC: Armed Forces Institute of Pathology; 1995.

For personal use only. No other uses without permission. Copyright ©2017. Elsevier Inc. All rights reserved.

Table 37.4 Architectural and cytologic features of follicular lymphoma and of reactive follicular hyperplasia

FOLLICULAR LYMPHOMA	REACTIVE FOLLICULAR HYPERPLASIA
Architectural Features	
Complete effacement of normal architecture	Preservation of nodal architecture
Even distribution of follicles throughout cortex and medulla	Follicles more prominent in cortical portion of lymph node
Slight or moderate variations in size and shape of follicles	Marked variations in size and shape of follicles with presence of elongated, angulated, and dumbbell-shaped forms
Fading of follicles	Sharply demarcated reaction centers
Massive infiltration of capsule and pericapsular fat with or without formation of neoplastic follicles outside capsule	No, or only moderate, infiltration of capsule and pericapsular fat tissue with inflammatory cells that may be arranged in perivascular focal aggregates (when associated with lymphadenitis)
Condensation of reticulin fibers at periphery of follicles	Little or no alteration of reticular framework
Cytologic Features	
Follicles composed of neoplastic cells exhibiting cellular pleomorphism with nuclear irregularities	Centers of follicles (germinal centers) composed of lymphoid cells, histiocytes, and "reticulum cells," with few or no cellular and nuclear irregularities
Lack of phagocytosis	Active phagocytosis in germinal centers
Relative paucity of mitotic figures usually without significant difference in their number inside and outside the follicles; occurrence of atypical mitoses	Moderate to pronounced mitotic activity in germinal centers; rare or no mitoses outside germinal centers; no atypical mitoses
Similarity of cell type inside and outside follicles	Infiltration of tissue between germinal centers with inflammatory cells (when associated with lymphadenitis)

Slightly modified from Rappaport H, Winter WJ, Hicks EB. Follicular lymphoma. A re-evaluation of its position in the scheme of malignant lymphoma, based on a survey of 253 cases. *Cancer.* 1956;9:792–821.

for follicular lymphoma); it is composed of a mixture of small lymphocytes, large lymphoid cells, prominent postcapillary venules, and sometimes a prominent component of mature plasma cells (Fig. 37.4).

Follicular hyperplasia can accompany a large number of inflammatory and noninfectious conditions. When the reactive follicles are particularly large ("giant"), particularly if there is associated zonal or single cell necrosis and a polymorphous, plasmacytoid paracortical expansion, infection by EBV should be suspected.

It should be kept in mind that follicular hyperplasia may coexist in the same node with follicular lymphoma or other types of malignant lymphoma.

The immunophenotypic differences between follicular hyperplasia and follicular lymphoma are discussed later, but the B-cells reactive follicles should not express BCL2 and should not harbor the *IGH/BCL2* fusion. However, immunoglobulin gene rearrangement studies may detect clonal or oligoclonal populations in reactive follicular hyperplasia, especially in association with EBV infection, and this test alone should not be used to diagnose lymphoma.

Progressively and Regressively Transformed Germinal Centers

Progressively transformed germinal centers are the morphologic expression of a distinct type of follicular hyperplasia. They usually are seen in conjunction with more typical reactive germinal centers and are often located more centrally within the node (Fig. 37.5).[60] They are large and contain numerous small lymphocytes, the borders are indistinct, and the interphase between the germinal center and the cuff of small lymphocytes is blurred. However, residual starry sky macrophages are present, together with scattered large lymphoid cells (cleaved and noncleaved) and occasional collections of epithelioid cells at the periphery.[61] There is an increased network of follicular dendritic cells, a larger number of mantle zone lymphocytes, and a relatively large number of T lymphocytes.[62] While multiple transformed germinal centers may be present, they do not form a distinct mass within the lymph node and are admixed with the more typical, small reactive follicles. Remnants of residual, BCL2-negative germinal center B cells remain within the transformed follicles and the surrounding mantle zones retain IgD-positive cells. Evaluation of these features should allow the differential diagnosis between progressively transformed germinal centers and follicular lymphoma to be made with ease in most instances; however, cases exist in which this is extremely difficult on the basis of routinely stained sections,[63] and immunohistochemical studies are warranted in most cases.

Progressively transformed germinal centers can occur as an isolated self-limited reactive process, particularly in young men.[63,64] However, they also show an interesting and still poorly understood relation with nodular lymphocyte predominant Hodgkin lymphoma (NLPHL), which may manifest itself in three ways: they may precede the development of NLPHL, they may accompany NLPHL in involved nodes, or they may appear in the absence of NLPHL in recurrent post-therapy adenopathy done for the latter.[65–67] Indeed, the main differential diagnosis of progressively transformed germinal centers is with NLPHL, which should be suspected if T-cell rosettes are prominent, if large B cells extend beyond the transformed germinal center or if the expanded nodules form tumor masses that displace

For personal use only. No other uses without permission. Copyright ©2017. Elsevier Inc. All rights reserved.

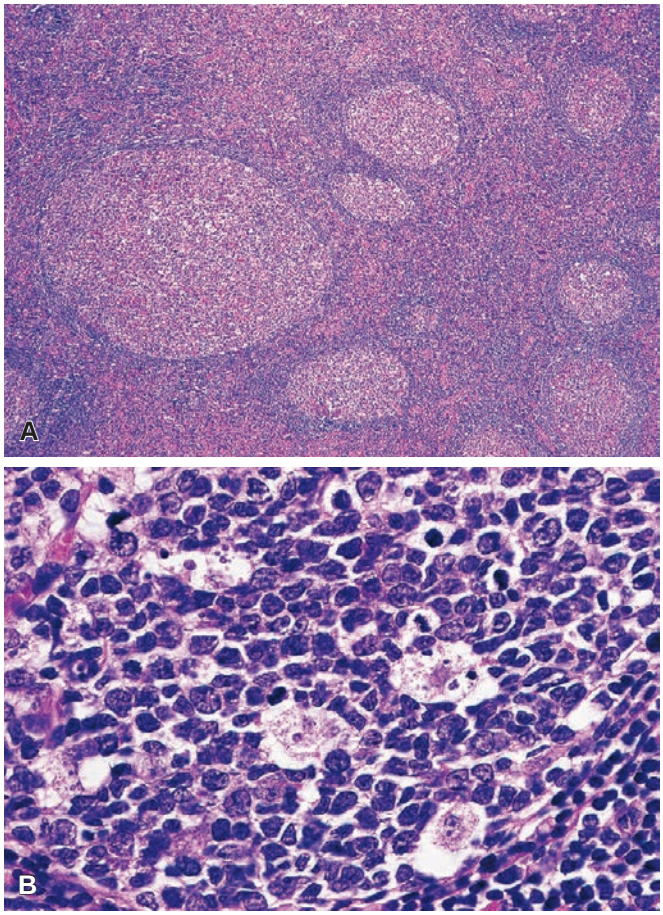

Figure 37.4 Follicular Hyperplasia. A, Low-power view showing marked differences in size of germinal centers, their well-circumscribed character, and the fact that they are surrounded by a well-defined mantle. **B**, High-power view showing numerous "tingible body" macrophages.

adjacent reactive or normal lymph node tissue. A thorough search for the atypical cells seen in NLPHL (see later) should then be undertaken.[68]

Regressively transformed germinal centers are small, practically devoid of lymphoid cells, and composed of follicular dendritic cells, vascular endothelial cells, and hyalinized periodic acid–Schiff (PAS)-positive intercellular material. These abnormal centers have an onion-skin appearance on low-power examination. Regressively transformed germinal centers are particularly prominent and numerous in Castleman disease (see later) but may also be seen with HIV infection or in association with AITL. A peculiar form of regressive germinal centers with "follicular dendritic cells only" has been described in organ transplant recipients.[69]

Mantle/Marginal Zone Hyperplasia

This pattern of hyperplasia, which blends with the lymphoid subtype of hyaline vascular Castleman disease, is characterized by a monomorphic proliferation of small lymphoid cells with round nuclei and clear cytoplasm which may be arranged in a nodular, inverse follicular, and/or marginal zone pattern. The main differential diagnosis is with the rare mantle zone pattern of mantle cell lymphoma and the monocytoid B-cell pattern of some cases of nodal marginal zone lymphoma. Features in favor of benignancy at the H&E level are the lack of pericapsular infiltration, preservation of sinuses, scattered reactive follicles, and paracortical nodular hyperplasia.[70] In addition, reactive "monocytoid B cells" are frequently BCL2 negative and contain admixed neutrophils. In contrast, the cells of marginal zone lymphoma are usually BCL2 positive and show aberrant coexpression of CD43 in approximately 40% of cases.[71,72] Mantle cell lymphoma shows aberrant coexpression of CD5 and CD43 on the B cells in the vast majority of cases as well as nuclear expression of cyclin D1, all features that are absent in reactive proliferations.

Paracortical Hyperplasia

Expansion of the paracortical (interfollicular) region can be nodular or diffuse. The nodular form is characteristic of dermatopathic lymphadenitis, while viral lymphadenitis, drug reactions, postvaccinial proliferations, and immunoblastic proliferations in general tend to be more diffuse (Fig. 37.6). The differential diagnosis of the diffuse form is often with peripheral T-cell lymphoma. These specific types of hyperplasia are discussed in more detail later.

Sinus Hyperplasia

The sinuses appear dilated and prominent in various disorders. The most common and least significant is *sinus hyperplasia* (sinus histiocytosis, sinus "catarrh") seen in nodes draining infectious or neoplastic processes and characterized by an increased number of macrophages in the lumen (Fig. 37.7). Other reactive disorders involving primarily the sinuses are RDD/sinus histiocytosis with massive lymphadenopathy (SHML), Langerhans cell histiocytosis (LCH), Whipple disease, vascular transformation of sinuses, and hemophagocytic syndromes.

Granulomatous Inflammation

There are a large number of diseases that can result in granulomatous formations in lymph nodes. They include various types of infection, foreign body reactions, aberrant immune reactions, sarcoidosis, and secondary responses in lymph nodes draining carcinoma[73,74] or in patients with Hodgkin lymphoma and other lymphomas, whether the node is involved by the malignancy or not,[75–77] and associated with metastatic seminoma. Sometimes the appearance of the granulomas is such that a specific diagnosis can be strongly suggested on the basis of the hematoxylin–eosin-stained slide.[78] Features of importance in this regard are the presence and type of necrosis; presence, number, and size of Langhans giant cells; size, shape, and distribution of the granulomas; and type of associated changes in the intervening tissue. In most cases, however, a combination of clinical, morphologic, and culture data is necessary to determine the etiology of the granulomas. It is therefore important that any node suspected of harboring a granulomatous process be sampled for culture analysis in addition to being subjected to the standard microscopic examination.

Other Cell Types Involved in Nodal Hyperplasia

Monocytoid B Cells

Monocytoid B-cell hyperplasia, a variation on marginal zone hyperplasia mentioned previously, is characterized by the filling of the sinuses by small lymphoid cells with round or angulated nuclei and clear cytoplasm, sometimes admixed with neutrophils (Fig. 37.8). It was originally described as *immature sinus histiocytosis*, but marker studies have shown that these monocytoid clear cells are of

For personal use only. No other uses without permission. Copyright ©2017. Elsevier Inc. All rights reserved.

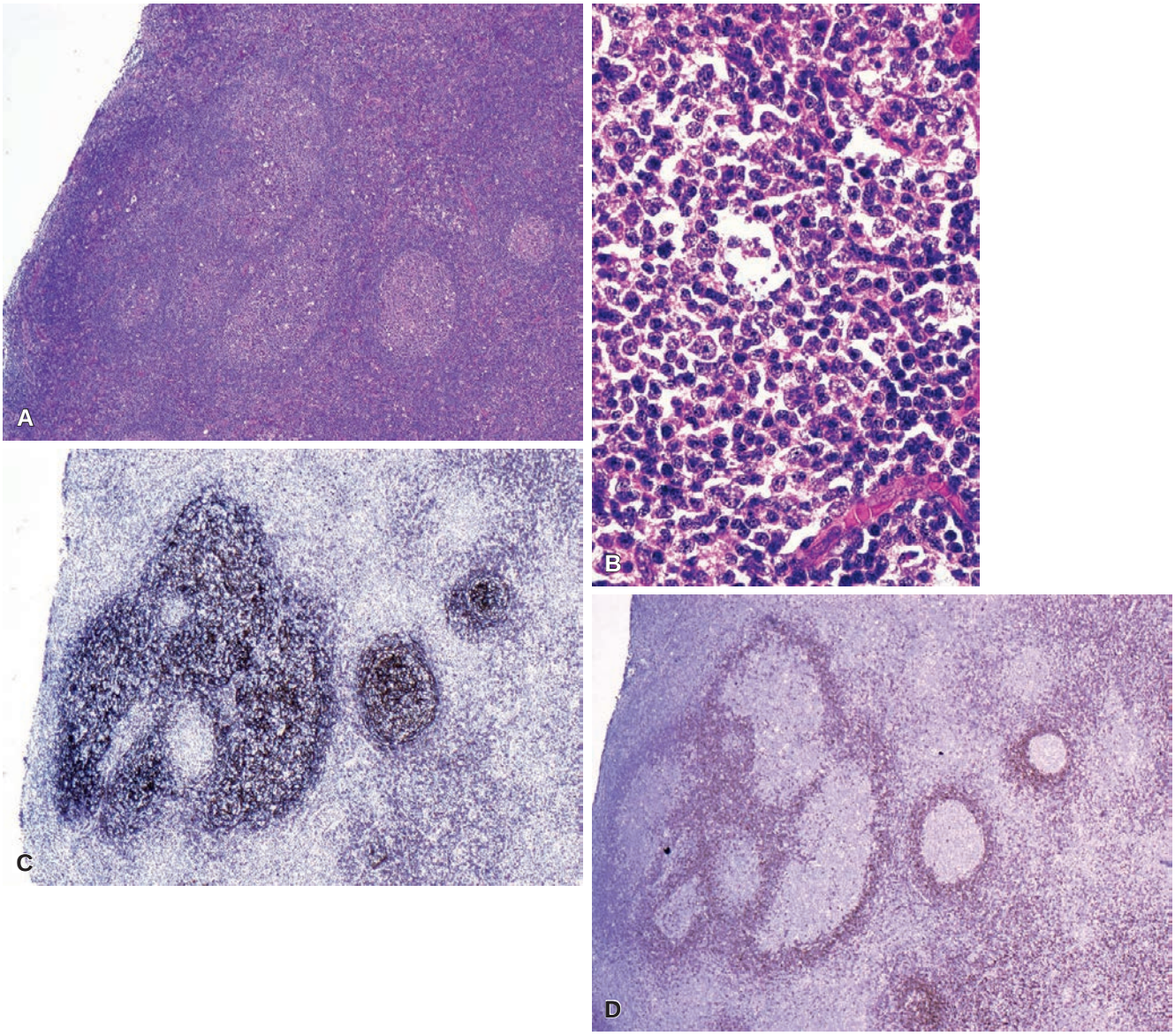

Figure 37.5 Progressively Transformed Germinal Centers. A, Low-power view showing that this formation is larger and less well defined than the adjacent hyperplastic follicles. **B**, High-power view showing cytologic composition not too dissimilar from that of ordinary hyperplastic follicles. **C**, CD21 staining highlights the expanded and disrupted follicular dendritic cell network of follicle. **D**, IgD staining shows preserved mantle zones with infiltration into the transformed germinal center.

B-cell type.[79,80] This alteration occurs most frequently in toxoplasmosis, but it has also been seen in many other reactive disorders, including cat-scratch disease,[81] infectious mononucleosis, AIDS, and autoimmune disorders[82]; it may also accompany malignant lymphomas, including Hodgkin lymphoma.[83] It should be distinguished from other nodal lesions featuring cells with clear cytoplasm (such as peripheral T-cell lymphomas, hairy cell leukemia, and mastocytosis) and also from a type of malignant lymphoma composed of cells with features of monocytoid B cells (nodal marginal zone B-cell lymphoma).[84]

Plasmacytoid Dendritic Cells

Clusters of cells with plasmacytoid cytoplasm, fine nuclear chromatin pattern, and small nucleoli are sometimes seen in a variety of reactive nodal lesions (Fig. 37.9). Pyknosis and starry sky pattern may be present.[85] These cells were originally interpreted as T-associated plasma cells and later as a subtype of T cells, but then as macrophages/monocytes (plasmacytoid monocytes), and more recently as a special form of dendritic cells.[86–88] They are particularly common in Kikuchi necrotizing lymphadenitis and Castleman disease,[89,90] but they can also be seen in other lymphadenitides[91] and in association with chronic myelomonocytic leukemia. Neoplasms of blastic plasmacytoid dendritic cells also occur.

Polykaryocytes

The term *polykaryocyte* is used for a type of multinucleated giant cell found in lymphoid tissues, of which the Warthin–Finkeldey giant cell of measles is the paradigm. These cells can be found in lymph nodes in association with a variety of reactive and neoplastic disorders.

For personal use only. No other uses without permission. Copyright ©2017. Elsevier Inc. All rights reserved.

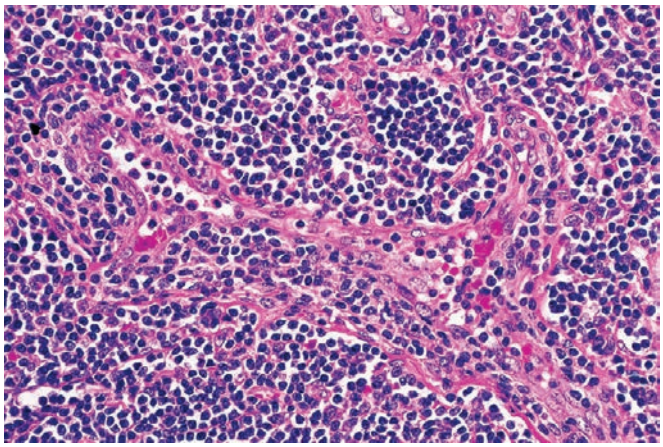

Figure 37.6 Paracortical hyperplasia, identified by the prominence of postcapillary venules.

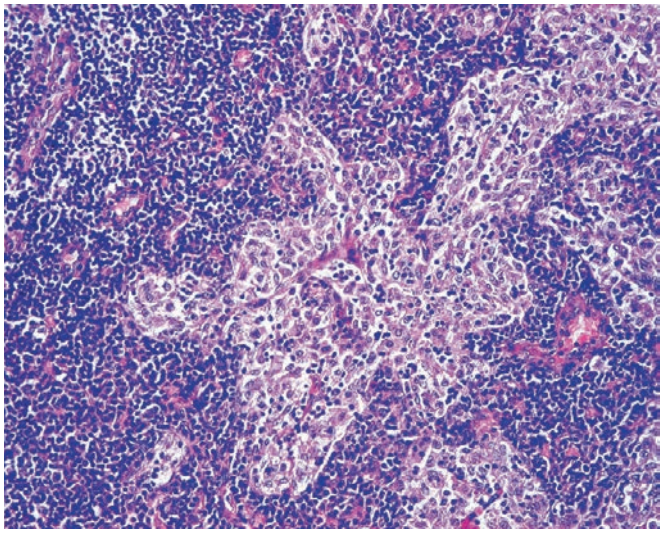

Figure 37.7 Sinus Hyperplasia. The cells present in the sinus represent an admixture of histiocytes and sinus lining cells.

They measure 25–150 μm in diameter and have as many as 60 nuclei arranged in grapevine clusters.[92] Their cytoplasm is very scanty (Fig. 37.10). Although some early studies suggested a T-cell phenotype, more recent evaluations are in keeping with the hypothesis that these cells are multinucleated forms of follicular dendritic cells, a possibility that fits much better their morphologic appearance.[93]

Inflammatory/Hyperplastic Diseases

Acute Nonspecific Lymphadenitis

The typical case of acute nonspecific lymphadenitis is rarely biopsied. Microscopically, the earliest change is sinus dilation resulting from increased flow of lymph, followed by accumulation of neutrophils, vascular dilation, and edema of the capsule. *Suppurative lymphadenitis* is a feature of staphylococcal infection, mesenteric lymphadenitis, lymphogranuloma venereum, and cat-scratch disease. *Necrotizing features* may be seen in bubonic plague, tularemia, anthrax, typhoid fever, melioidosis, and the entity known as Kikuchi necrotizing lymphadenitis (see next section).

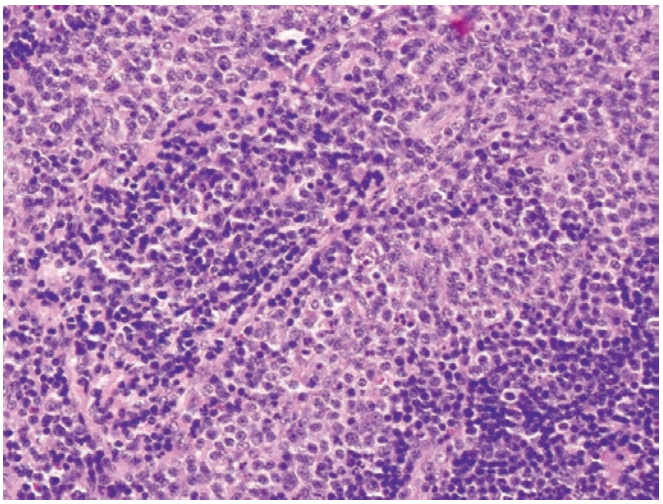

Figure 37.8 Monocytoid B-Cell Hyperplasia in a Case of Toxoplasmic Lymphadenitis. Clusters of small to medium-sized cells are present with clear cytoplasm. Note the presence of admixed neutrophils and nuclear remnants, a feature of reactive monocytoid B-cells.

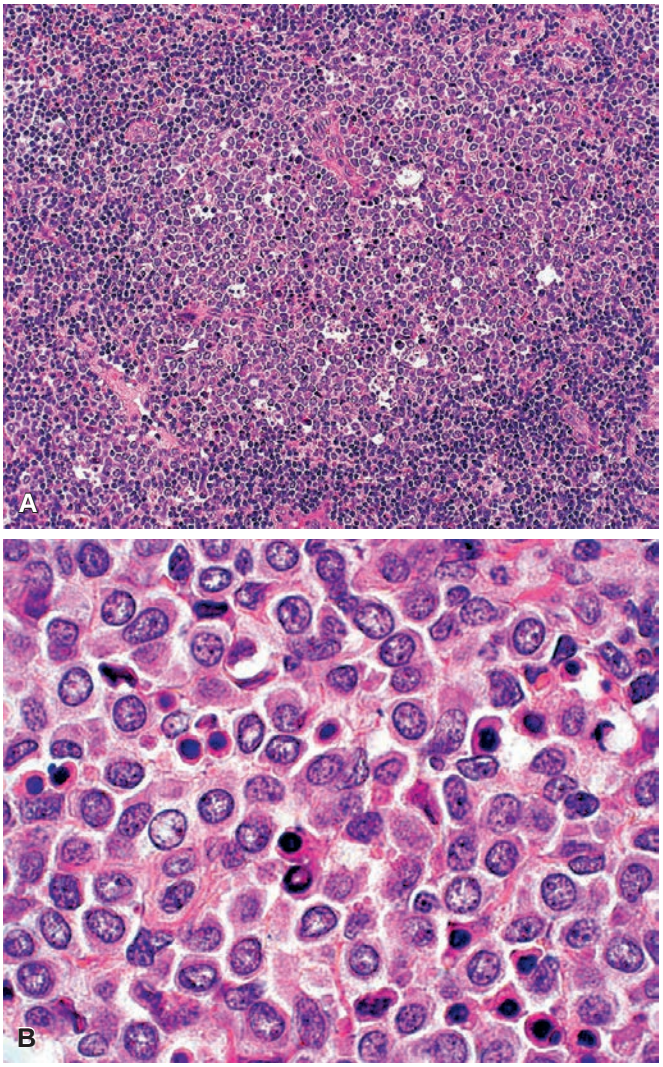

Figure 37.9 Plasmacytoid monocytes as seen on low (**A**) and high power (**B**).

For personal use only. No other uses without permission. Copyright ©2017. Elsevier Inc. All rights reserved.

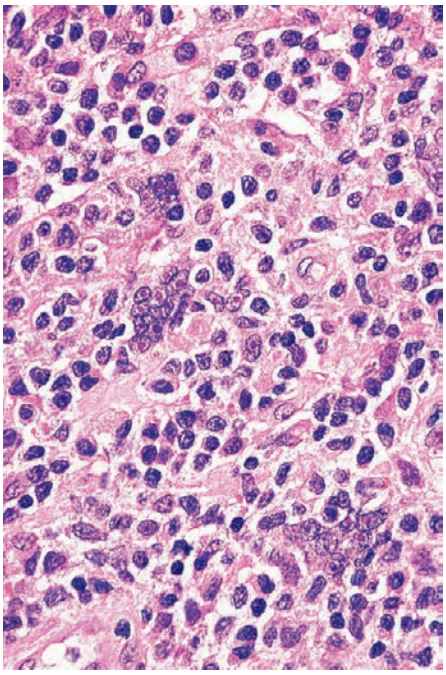

Figure 37.10 So-Called Polykaryocytes. These cells are characterized by numerous clustered nuclei.

Kikuchi Necrotizing Lymphadenitis

Kikuchi necrotizing lymphadenitis (Kikuchi lymphadenitis; Kikuchi–Fujimoto disease) is seen most commonly in Japan and other Asian countries,[94] but it also occurs elsewhere, including the United States and Western Europe. Most patients are young women with persistent, painless cervical lymphadenopathy of modest dimensions that may be accompanied by fever.[95] Microscopically, the affected nodes show focal, well-circumscribed, paracortical necrotizing lesions. There are abundant karyorrhectic debris, scattered fibrin deposits, and collections of mononuclear cells[96] with cellular debris but an absence of intact neutrophils (Fig. 37.11). Special studies have shown that the necrosis is the expression of cytotoxic lymphocyte-mediated apoptotic cell death.[97,98] Plasma cells are very scanty, and intact neutrophils are absent, a feature of diagnostic importance.[99,100] Instead, plasmacytoid dendritic cells, macrophages, and activated T cells are often numerous.[89,101] When these cells are abundant, the appearance may simulate that of malignant lymphoma.[102–104] The main lesional cells include histiocytes (CD68 and CD163+) that contain cytoplasmic myeloperoxidase and are associated with aggregates of plasmacytoid dendritic cells (TCL1 and CD123+).[87,105] On occasion, a prominent secondary xanthomatous reaction is seen and may be prominent.[106] Such cases may lack areas of necrosis, but the apoptotic debris without neutrophils remains in association with the xanthomatous change. Ultrastructurally, tubuloreticular structures and intracytoplasmic rodlets similar to those described in lupus erythematosus are often found.[107]

The diagnosis can be made or at least suspected in material from fine-needle aspiration because of the prominence of phagocytic histiocytes with peripherally placed ("crescentic") nuclei and medium-sized cells with eccentrically placed nuclei consistent with plasmacytoid dendritic cells.[108]

The evolution is generally benign and self-limited. However, cases have been described with recurrent lymphadenopathy or accompanied by skin lesions.[109,110] Isolated fatal cases are also on record.[111] The etiology is unknown. The most important differential diagnosis is with malignant lymphoma with secondary necrosis and the admixed T-cell component with large crescentic histiocytes may be overinterpreted as a peripheral T-cell lymphoma. Lupus lymphadenitis may demonstrate features identical to Kikuchi lymphadenitis, and the possibility of lupus should be investigated in all cases.[112] The hematoxylin bodies of lupus, which are not always present, should not be seen with Kikuchi disease.

Chronic Nonspecific Lymphadenitis

The morphologic features and the very concept of chronic lymphadenitis merge with those of hyperplasia. The general features of chronic lymphadenitis are follicular hyperplasia; prominence of postcapillary venules; increased number of immunoblasts, plasma cells, and histiocytes; and fibrosis. The capsule may appear inflamed and/or fibrotic, and the process may extend into the immediate perinodal tissues. In some cases, one may find an undue predominance in the number of eosinophils, foamy macrophages, and/or mast cells. Terms such as *eosinophilic* or *xanthogranulomatous lymphadenitis* have been sometimes used, depending on the type of the infiltrate.[113] The presence of numerous eosinophils in a lymph node should raise the possibility of Langerhans cell histiocytosis, parasitic infections, Hodgkin lymphoma, autoimmune disorders, and Kimura disease. Eosinophils can also be numerous in epithelioid hemangioma/angiolymphoid hyperplasia with eosinophilia (which may rarely involve lymph nodes), Churg–Strauss disease, T-cell lymphomas, and various chronic eosinophilic neoplasms.

Tuberculosis

Lymph nodes involved by tuberculosis may become adherent to each other and form a large multinodular mass that can be confused clinically with metastatic carcinoma (Fig. 37.12). The most common location of clinically apparent lymphadenopathy is the cervical region ("scrofula"), where a draining sinus that communicates with the skin ("scrofuloderma") may form.[114] Microscopically, the appearance ranges from multiple small epithelioid granulomas reminiscent of sarcoidosis to huge caseous masses surrounded by Langhans giant cells, epithelioid cells, and lymphocytes. Demonstration of the organisms by special stains, cultures, or PCR is necessary to establish the diagnosis.[115]

Atypical Mycobacteriosis

Atypical mycobacteria are a common cause of granulomatous lymphadenitis. In the United States, caseating granulomatous disease in a cervical lymph node of a child unaccompanied by pulmonary involvement is more likely to be caused by an atypical mycobacterium. The process typically involves lateral nodes in the midportion of the neck. Drainage may continue for months or years in the absence of specific therapy, and healing may result in scarring and contractures. Microscopically, the host reaction may be indistinguishable from that of tuberculosis, but often the granulomatous response is overshadowed by suppurative changes.[116–118] A nontuberculous mycobacterial etiology should also be suspected if the granulomas are ill-defined (nonpalisading), irregularly shaped, or serpiginous.[50,117] An acid-fast stain should be performed in every granulomatous and suppurative lymphadenitis of unknown etiology, especially if the patient is a child or an HIV-infected individual.[119] The final identification of the organism rests on the culture or molecular characteristics.

In immunosuppressed patients, mycobacterial infections may result in a florid spindle cell proliferation that can simulate a neoplastic process *(mycobacterial spindle cell pseudotumor)*.[120]

For personal use only. No other uses without permission. Copyright ©2017. Elsevier Inc. All rights reserved.

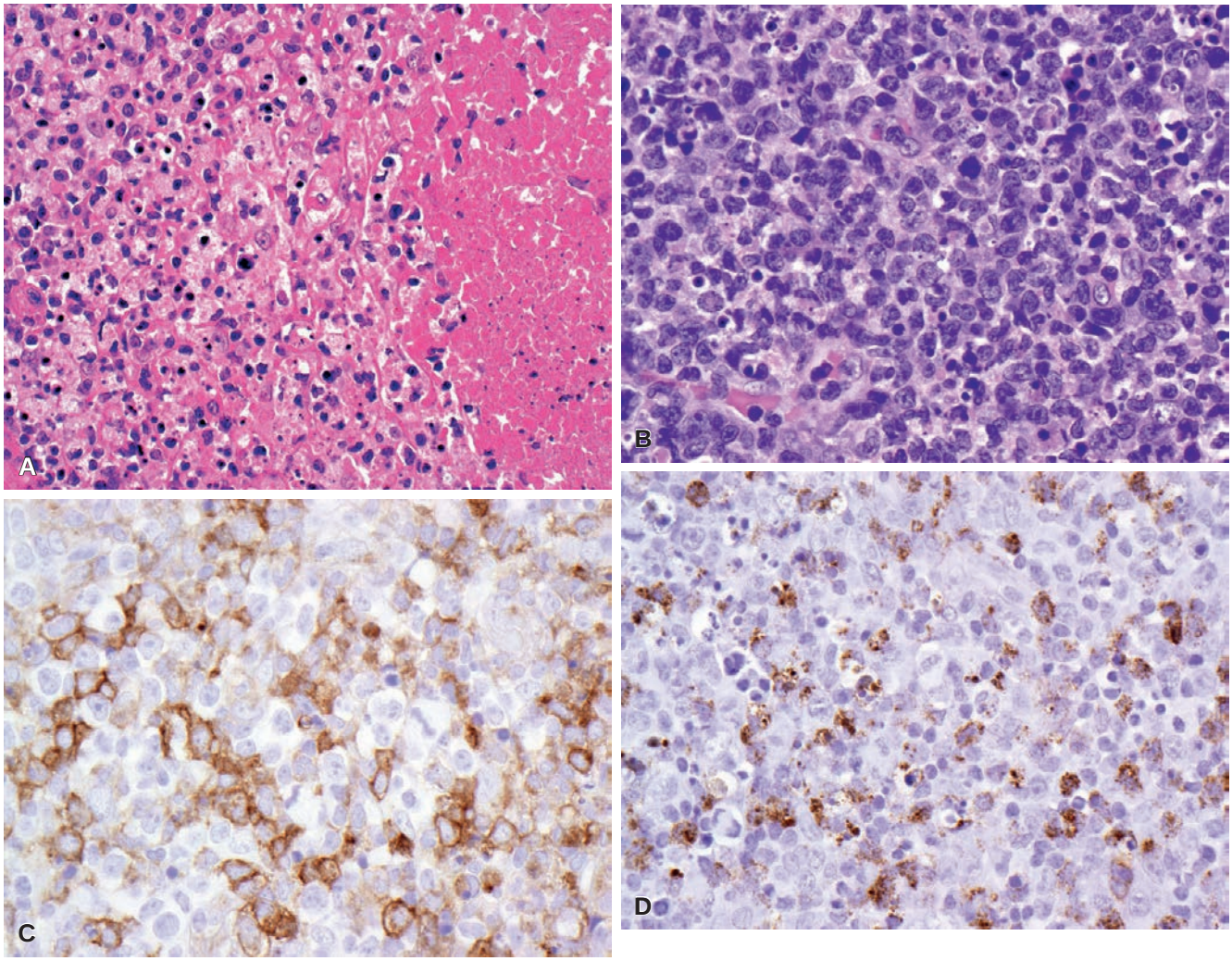

Figure 37.11 Necrotizing Lymphadenitis (Kikuchi-Fujimoto Disease). A, The most common pattern shows necrosis with karyorrhexis/pyknosis with nuclear debris but no neutrophils. **B**, Other cases show a more mononuclear infiltrate with debris without zonal necrosis. **C**, Increased numbers of CD123-positive cells, and **D,** myeloperoxidase positive histiocytes, support the diagnosis.

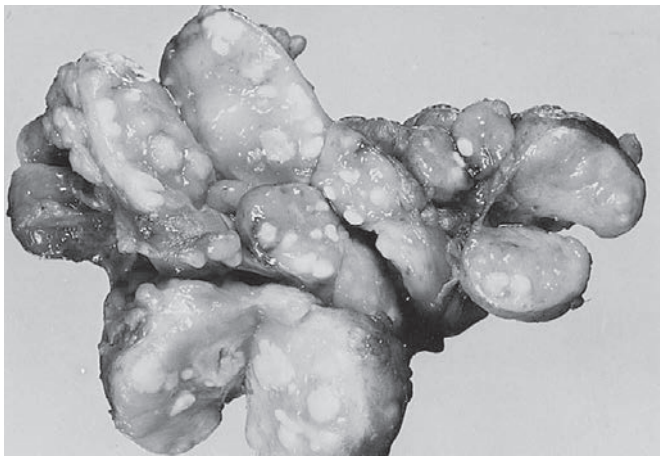

Figure 37.12 Large adherent tuberculous lymph nodes containing extensive foci of caseation necrosis.

Sarcoidosis

The enigmatic clinicopathologic entity known as sarcoidosis has a worldwide distribution.[121] Scandinavian countries are particularly affected.[122] In the United States, the disease is 10–15 times more common in blacks than in whites. Practically every organ can be involved, but the ones most commonly affected are lung, lymph nodes, eyes, skin, and liver.[123–125] Erythema nodosum often precedes or accompanies the disease. Functional hypoparathyroidism is the rule, although a few cases of sarcoidosis coexisting with primary hyperparathyroidism have also been reported.[126,127] This seems to be due to the secretion of a parathyroid hormone (PTH)-related protein by the cells in the granuloma.[128]

Microscopically, the basic lesion is a small granuloma mainly composed of epithelioid cells, with scattered Langhans giant cells and lymphocytes (Fig. 37.13).[129] As a general rule, the Langhans giant cells are smaller and have fewer nuclei than those typically seen in tuberculosis. Necrosis is either absent or limited to a small central fibrinoid focus ("hard" granulomas); a "necrotizing" variant of sarcoidosis exists, but this is usually extranodal. Schaumann bodies, asteroid bodies, and calcium oxalate crystals are sometimes found

For personal use only. No other uses without permission. Copyright ©2017. Elsevier Inc. All rights reserved.

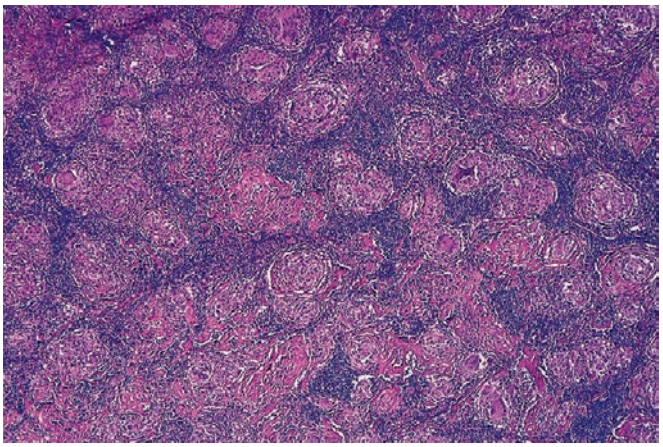

Figure 37.13 Numerous confluent non-necrotizing granulomas mainly composed of epithelioid cells in a lymph node affected by sarcoidosis.

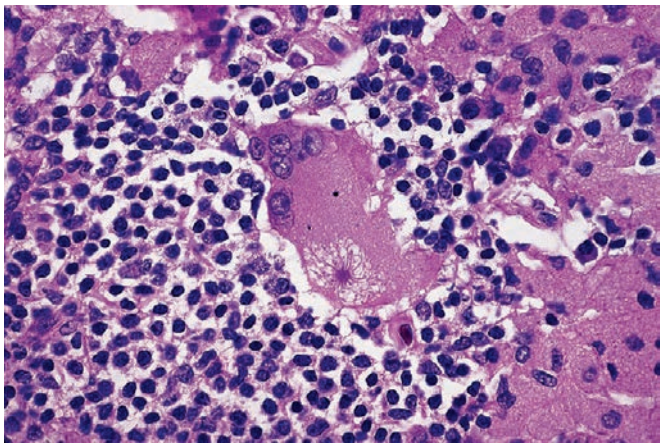

Figure 37.14 Asteroid body in the cytoplasm of a multinucleated giant cell in sarcoidosis.

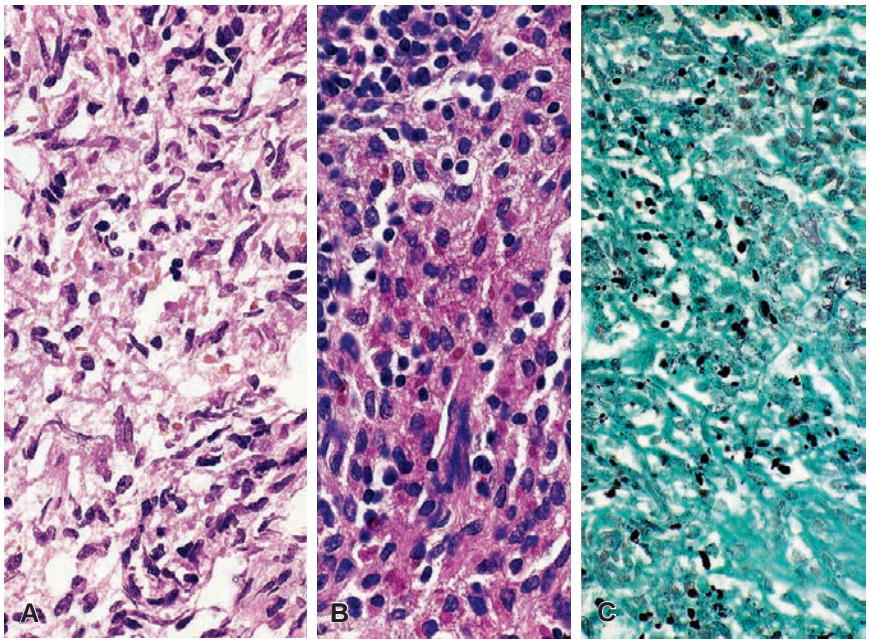

Figure 37.15 Hamazaki–Wesenberg bodies in a lymph node with sarcoidosis, as shown in (**A**) hematoxylin–eosin, (**B**) periodic acid–Schiff, and (**C**) Gomori methenamine-silver stains.

in the cytoplasm of the giant cells (Figs. 37.14 and 37.15).[130] Schaumann bodies are round, have concentric laminations, and contain iron and calcium. Ultrastructurally, asteroid bodies are composed of radiating filamentous arms enveloped by "myelonoid" membranes.[131] Elemental analysis has shown calcium, phosphorus, silicon, and aluminum in these formations.[129,131] Peculiar PAS-positive inclusions known as Hamazaki–Wesenberg, yellow, or ovoid bodies were claimed to be specific for sarcoidosis, but subsequent histochemical and ultrastructural studies[132] have shown that they have no etiologic or pathogenetic significance. They probably represent large lysosomes containing hemolipofuscin material and are found in a large variety of conditions.[130,133] None of these inclusions is specific for sarcoidosis. From a pathologic standpoint the diagnosis of sarcoidosis is always one of exclusion. A noncaseating granulomatous inflammation in the lymph nodes or skin microscopically indistinguishable from sarcoidosis can be seen in tuberculosis, atypical mycobacteriosis (including swimming pool granuloma), fungus diseases, leprosy, syphilis, leishmaniasis, brucellosis, tularemia, chalazion, zirconium granuloma, berylliosis, Crohn disease, and Hodgkin lymphoma; in nodes draining a carcinoma; and in several other conditions.[134] Only when all these possibilities have been excluded and the clinical picture is characteristic is there justification in labeling a case as consistent with sarcoidosis.

Most of the lymphocytes present in the sarcoidal granulomas are CD4-positive T cells; both these cells and the epithelioid histiocytes exhibit features of proliferation and/or activation, as shown by their immunocytochemical positivity with the Ki-67 antibody and for interleukin-1, respectively.[135,136] Pathogenetically, sarcoidosis is thought to represent a dysfunction of circulating T cells with overactivity of B cells.[137] The association of particular human leukocyte antigens (HLAs) with sarcoidosis suggests a role for HLA-linked immune response genes and disease susceptibility.[138] Specifically, it has been shown that certain types of genetic polymorphism are associated with increased risk of disease or affect disease presentation.[139]

For personal use only. No other uses without permission. Copyright ©2017. Elsevier Inc. All rights reserved.

The Kveim test for sarcoidosis is an intradermal reaction that occurs following inoculation with an extract of human spleen involved with the disease. It is positive in 60%–85% of patients with sarcoidosis, and the number of false-positive results is small. The test is regarded as positive when a biopsy of the area taken 4–6 weeks after inoculation shows microscopically sarcoid-type granuloma. A trial employing a single test suspension among 2400 subjects in 37 countries on six continents showed a similar level of reactivity and microscopic appearance from country to country, supporting the concept that sarcoidosis is the same disease the world over. The Kveim test is rarely practiced today because of lack of availability of the antigen. The etiology and pathogenesis of sarcoidosis remain elusive.[140]

Fungal Infections

Fungal infections of lymph nodes may present as chronic suppurative lesions, as granulomatous processes, or as a combination of the two. The most important fungal lymphadenitis is *histoplasmosis*, which in addition to the previously mentioned patterns can also result in widespread nodal necrosis and in marked diffuse hyperplasia of sinus histiocytes (Fig. 37.16). Other fungal diseases known to result in lymphadenitis are blastomycosis, paracoccidioidomycosis, coccidioidomycosis, and sporotrichosis.[141] To these, one should add opportunistic infections such as cryptococcosis, aspergillosis, mucormycosis, and candidiasis.

The fungal organisms can usually be demonstrated with Gomori methenamine silver (GMS) or PAS–Gridley stains, but sometimes their number is so small that they can be detected only in cultures or by molecular testing.[10]

Toxoplasmosis

Toxoplasmosis, one of the most common parasitic infections of humans and other warm-blooded animals, is caused by the protozoan parasite *Toxoplasma gondii*.[142] Toxoplasmic lymphadenitis (formerly known as Piringer–Kuchinka lymphadenitis), in its most typical form, involves the posterior cervical nodes of young women.[143] On palpation, the nodes are firm and only moderately enlarged. Microscopically, the nodal architecture is rather well preserved. The typical triad of the disease, which is not present in all cases, is constituted by: (1) marked follicular hyperplasia, associated with intense mitotic activity and phagocytosis of nuclear debris; (2) small, loose collections of epithelioid histiocytes, located within the hyperplastic follicles and at the periphery, encroaching on and blurring their margins; and (3) distention of marginal and cortical sinuses by monocytoid B cells (Fig. 37.17). An additional feature is the presence of immunoblasts and plasma cells in the medullary cords.[144] Variations on the theme include presence in

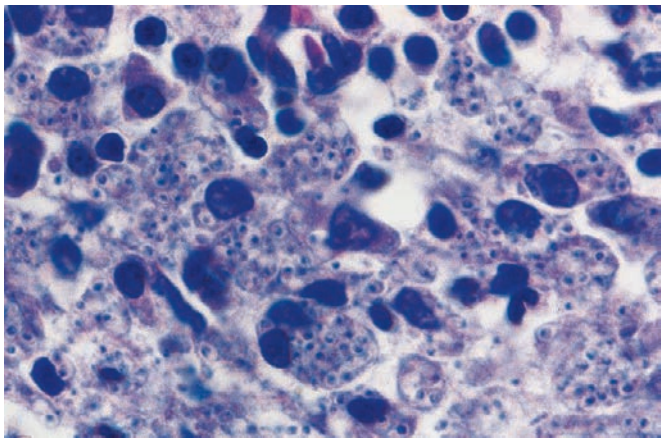

Figure 37.16 Numerous *Histoplasma* organisms in the cytoplasm of histiocytes.

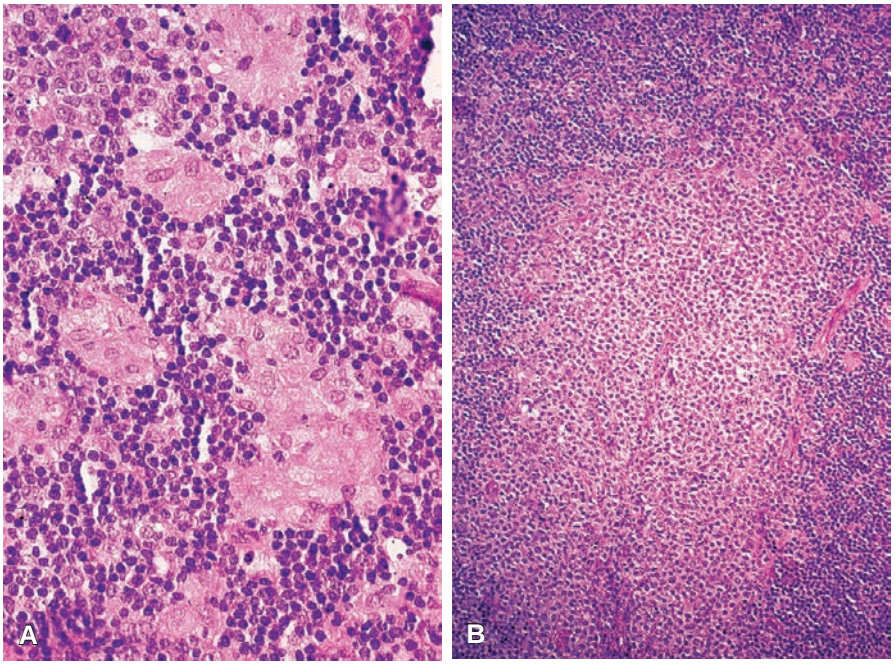

Figure 37.17 Toxoplasmosis of Lymph Node. A, Small noncaseating granulomas composed of epithelioid cells are located at the periphery of a hyperplastic follicle. This picture is almost pathognomonic of this disease. **B**, An area of massive monocytoid B-cell hyperplasia.

For personal use only. No other uses without permission. Copyright ©2017. Elsevier Inc. All rights reserved.

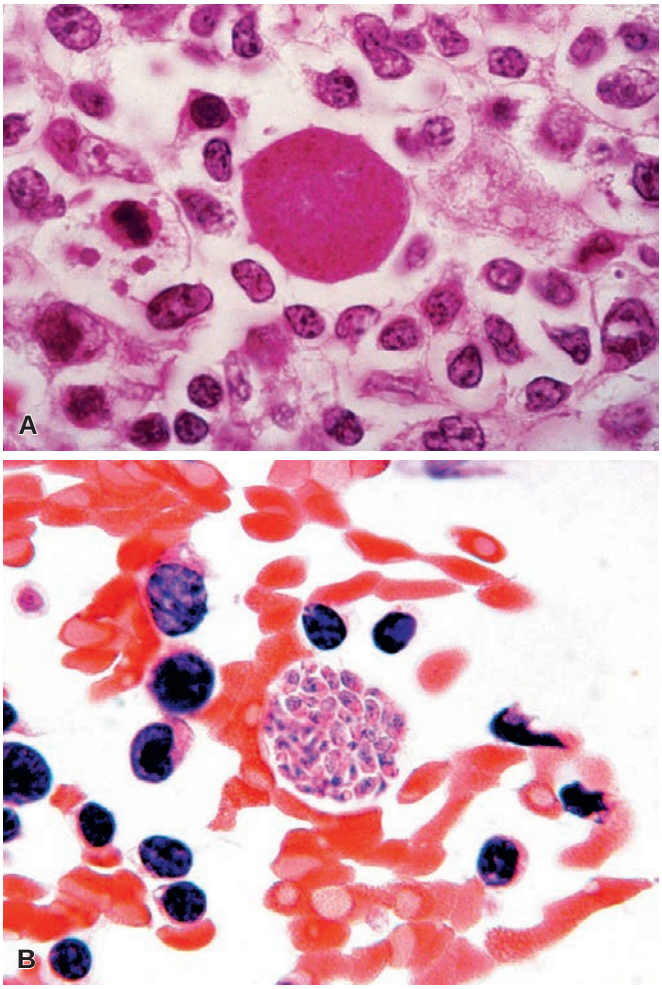

Figure 37.18 *Toxoplasma* cyst as seen in a microscopic section, (**A**) and a touch preparation (**B**). This is a very unusual finding in lymph nodes affected by the disease.

the granulomas of necrosis or more than an occasional Langhans giant cell.

It is extremely rare to find *Toxoplasma* organisms in the lymph node by morphologic examination, immunohistochemistry, or PCR (Fig. 37.18).[145,146] This finding contrasts sharply with the results obtained in toxoplasmic encephalitis and myocarditis[146] and suggest that the lymph node findings may be an immunologic response to infection at other sites. The combination of microscopic features described correlates remarkably well with serologic studies. Of 31 cases studied by Dorfman and Remington[147] the Sabin–Feldman dye test was positive in all and the IgM immunofluorescent antibody test was positive in 97% of the cases.

If the diagnosis of toxoplasmic lymphadenitis is suspected from the microscopic pattern, it should be confirmed serologically, keeping in mind that these tests may be normal in the early stages of the disease.[148]

The differential diagnosis of toxoplasmosis includes other infectious diseases and the lymphocyte predominant form of Hodgkin lymphoma. In this regard, Miettinen and Franssila[149] have made the interesting point that occurrence of collections of epithelioid cells *within* germinal centers seems to be a nearly specific feature for toxoplasmosis.

Syphilis

Generalized lymphadenopathy is a common finding in secondary syphilis, whereas localized node enlargement can be seen in the primary and tertiary stages of the disease. In secondary syphilis, the changes are those of a florid follicular hyperplasia. In primary syphilis, the combination of changes may result in a mistaken diagnosis of malignant lymphoma. Most of the cases have presented as solitary inguinal lymphadenopathy.[150] There are capsular and pericapsular inflammation and extensive fibrosis, diffuse plasma cell infiltration with extension often into or beyond the capsule, proliferation of blood vessels with endothelium swelling and inflammatory infiltration of vessel walls (phlebitis and endarteritis), and follicular hyperplasia (Fig. 37.19).[150] Rarely, noncaseating granulomas and abscesses are present. Exceptionally, the appearance is that of a nodal inflammatory pseudotumor, the message being that spirochetes should be searched for whenever making that diagnosis in a nodal biopsy, by histochemical or immunohistochemical stain.[151]

The morphologic features of syphilitic infection are not substantially different when occurring in HIV-infected patients[152] and can be identified in most cases by the Warthin–Starry or Levaditi stains, by immunofluorescence techniques applied to imprint preparations, or immunohistochemical staining on paraffin section.[153] The organisms are most frequently found in the wall of blood vessels. Detection of *Treponema pallidum* is now also feasible in lymph node biopsies and fine needle aspirations by PCR.[154]

Leprosy

Lymph nodes involved by the lepromatous type of leprosy have a very characteristic microscopic appearance. The main change is the progressive accumulation of large, pale, rounded histiocytes ("lepra" or "Virchow" cells), without granuloma formation and with minimal or no necrosis (Fig. 37.20). Wade–Fite and Fite–Faraco stains (which are modified Ziehl–Neelsen reactions) demonstrate packing of the cytoplasm by acid-fast organisms, which can also be demonstrated by a fluorescent method,[155] and by PCR.[156]

Mesenteric Lymphadenitis

Mesenteric (Masshoff) lymphadenitis is produced by *Yersinia pseudotuberculosis* or *Yersinia enterocolitica*, two gram-negative polymorphic coccoid or ovoid motile organisms.[157–160] It is a benign, self-limited disease that can clinically simulate acute appendicitis. Microscopically, there are capsular thickening and edema, increase of immunoblasts and plasma cells in the cortical and paracortical region, dilation of sinuses with accumulation of large lymphocytes within, and germinal center hyperplasia.[161,162] In the lymphadenitis produced by *Y. pseudotuberculosis*, small granulomas and abscesses are commonly present, whereas this is unusual in infection caused by *Y. enterocolitica*.[162] These nodal changes are accompanied by inflammatory changes of the terminal ileum and cecum. Ideally, the diagnosis should be confirmed with cultures. Too often, the diagnosis of mesenteric lymphadenitis is made on normal or mildly hyperplastic nodes in an attempt to explain why a patient with the clinical picture of acute appendicitis has a normal appendix.

The organism can be identified by PCR. Interestingly, *Yersinia* DNA has been detected in mesenteric lymph nodes in patients with Crohn disease.[163]

Cat-Scratch Disease

Cat-scratch disease is characterized by a primary cutaneous lesion and enlargement of regional lymph nodes, usually axillary or cervical

For personal use only. No other uses without permission. Copyright ©2017. Elsevier Inc. All rights reserved.

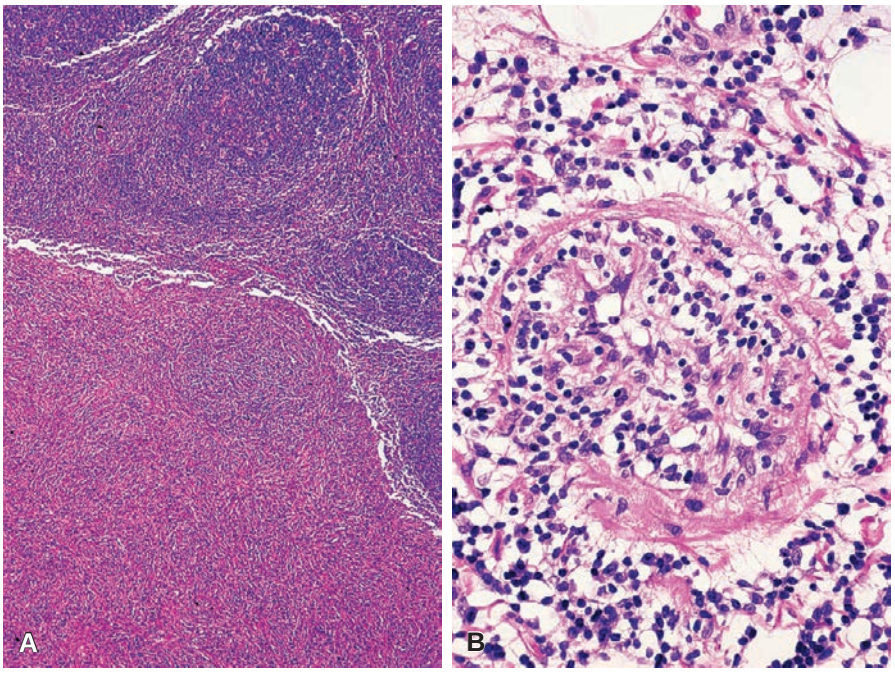

Figure 37.19 Syphilis of Lymph Node. A, Follicular hyperplasia associated with striking pericapsular inflammation and fibrosis. **B**, The prominent vasculitis seen in this field is an important clue to the diagnosis.

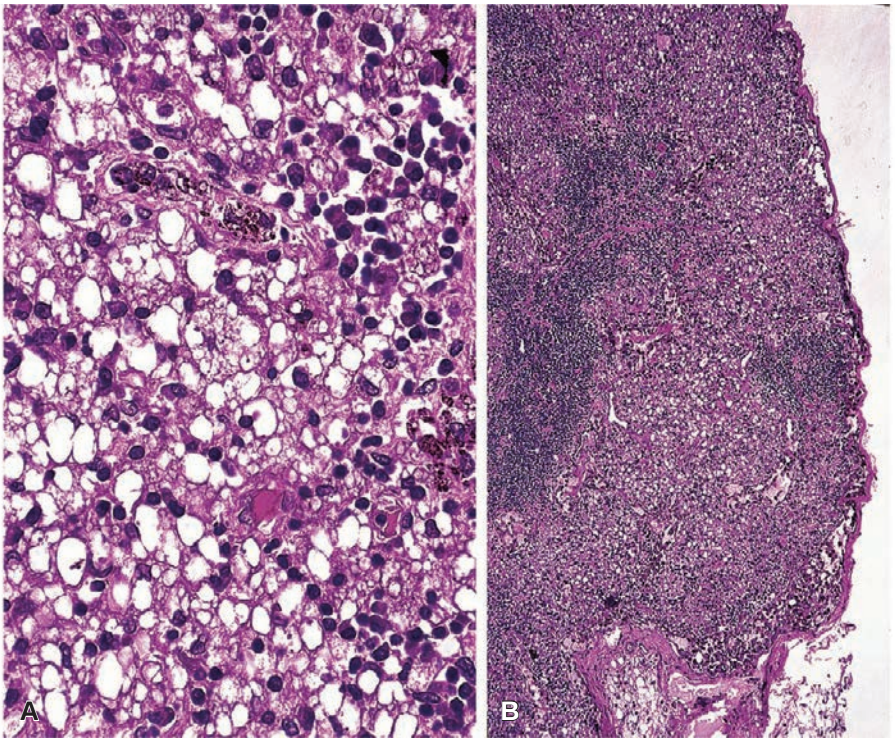

Figure 37.20 A and **B**, Lymph node involvement by lepromatous leprosy. The sinuses are massively dilated as a result of the accumulation of foamy histiocytes.

(Fig. 37.21).[164] The changes in the nodes vary with time. Early lesions have histiocytic proliferation and follicular hyperplasia, intermediate lesions have granulomatous changes, and late lesions have abscesses of various sizes (Fig. 37.22).[165] These abscesses are very suggestive of the diagnosis because of their pattern of central, sometimes stellate necrosis with abundant neutrophils, surrounded by a palisading of histiocytes.[166] However, similar abscesses can be seen in lymphogranuloma venereum. Another common feature of lymph nodes with cat-scratch disease is the packing of sinuses by monocytoid B cells, which, together with the follicular hyperplasia, may simulate

For personal use only. No other uses without permission. Copyright ©2017. Elsevier Inc. All rights reserved.

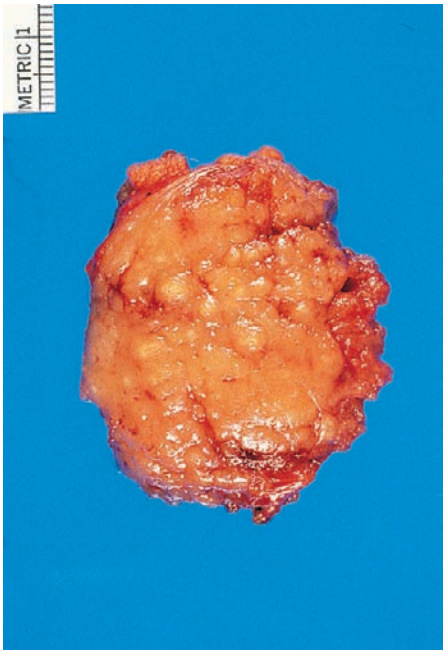

Figure 37.21 Lymph Node Involved by Cat-Scratch Disease.

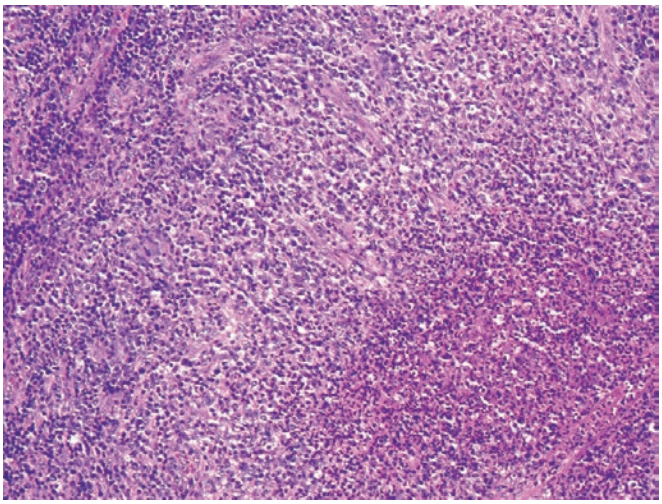

Figure 37.22 Cat-scratch disease with an area of stellate necrosis with neutrophils surrounded by histiocytes.

toxoplasmosis.[81] However, clusters of perifollicular and intrafollicular epithelioid cells are absent.[55]

The primary lesion is a red papule in the skin at the site of inoculation, usually appearing between 7 and 12 days following contact. It may become pustular or crusted. Microscopically, there are foci of necrosis in the dermis surrounded by a mantle of histiocytes. Multinucleated giant cells, lymphocytes, and eosinophils are also present.[167]

The agent of cat-scratch disease is a coccobacillary pleomorphic extracellular bacterium that can be identified with the Warthin–Starry silver stain or by immunohistochemistry, particularly in those cases exhibiting extensive necrosis.[168–170] This organism, which has also been detected ultrastructurally,[171] was originally designated *Rochalimaea henselae* and has been renamed *Bartonella henselae*. The diagnosis can be confirmed by serology, immunohistochemistry, or PCR.[172–175]

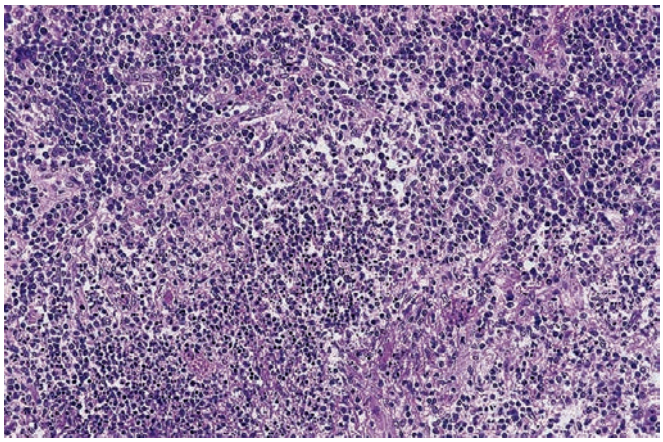

Figure 37.23 Necrotizing granuloma in a lymph node affected by lymphogranuloma venereum, showing features similar, if not identical, to cat-scratch disease.

Rare complications of the disease include granulomatous conjunctivitis ("oculoglandular syndrome of Parinaud"), thrombocytopenic purpura, and central nervous system manifestations.[176]

Lymphogranuloma Venereum

This sexually transmitted disease (not to be confused with granuloma inguinale) is caused by *Chlamydia trachomatis* organisms corresponding to serotypes L1, L2, and L3.[177] The initial lesion is a small (2–3 mm), painless genital vesicle or ulcer that often goes unnoticed and heals in a few days. This is followed by inguinal adenopathy, which can be very prominent. As mentioned, the morphologic features are similar to cat-scratch disease, although the site of disease is a helpful clue to the diagnosis. The earliest microscopic change in an affected node is represented by tiny necrotic foci infiltrated by neutrophils. These enlarge and coalesce to form the stellate abscess that represents the most characteristic feature of this disease (Fig. 37.23). In later stages, epithelioid cells, scattered Langhans giant cells, and fibroblasts are seen to line the abscess walls. Confluence of these abscesses is common, and cutaneous sinus tracts may develop. The healing stage is represented by nodules with dense fibrous walls surrounding amorphous material.[178]

The microscopic picture just described is not pathognomonic of this disease. Similar changes can occur in cat-scratch disease, atypical mycobacteriosis, and tularemia. Therefore a presumptive diagnosis of lymphogranuloma venereum should be confirmed with the Frei test (a delayed hypersensitivity skin test using purified "lygranum" chlamydial antigen), complement fixation, immunofluorescence, or molecular testing.[177,179–181]

Tularemia

Tularemia is a bacterial disease produced by *Francisella tularensis*, an extremely virulent pathogen,[182–184] which has recently gained notoriety as a potential biowarfare agent.[185,186] In the ulcero-glandular form of the disease, prominent lymphadenopathy occurs; this predominates in the axillary region when mammalian vectors are involved and in cervical or inguinal regions with arthropod vectors.[187] A history of handling rabbits suggests the diagnosis in the first instance. The diagnosis is supported by a rise in hemagglutinin titers.[183,188]

Microscopically, the picture in the acute phase is that of an intense lymphadenitis with widespread necrosis, sometimes associated with

For personal use only. No other uses without permission. Copyright ©2017. Elsevier Inc. All rights reserved.

irregularly shaped microabscesses and granulomas.[185] In the more chronic forms, there is a granulomatous reaction that in some cases may have a frankly tuberculosis-like appearance.[189] Although the histologic and cytologic features are not specific, fine-needle aspiration specimens may be useful to obtain material for molecular identification of the organism.[190]

Brucellosis

Brucellosis is caused by *Brucella abortus*, *melitensis*, or *suis*.[191] In the United States it has evolved from an occupational to a food-borne illness related to consumption of milk and cheese.[192] The most common clinical manifestations are fever, hepatomegaly, and splenomegaly.[193] Lymphadenopathy is uncommon and, when present, usually of modest dimensions. Microscopically, there may be nonspecific follicular hyperplasia and clusters of epithelioid histiocytes sometimes forming large noncaseating granulomas. This is accompanied by a polymorphic infiltrate containing eosinophils, plasma cells, and immunoblasts. When the latter are numerous, the microscopic picture may show a vague resemblance to Hodgkin lymphoma.

A definitive diagnosis can only be made by recovery of the organism with bacteriologic or PCR techniques[194] or the detection of a high agglutination titer.[195]

Acquired Immunodeficiency Syndrome–Related Lymphadenopathy

The lymph node abnormalities in AIDS patients can be of various types. They include mycobacterial and other opportunistic infections (some resulting in spindle cell pseudotumors),[120,196] Kaposi sarcoma, malignant lymphomas of either Hodgkin or non-Hodgkin type, and *florid reactive hyperplasia*.[197–199] The lymphomas, discussed later, and reactive hyperplasia are the most common (Fig. 37.24). Hyperplasia may be accompanied by collections of monocytoid B cells in the sinuses, neutrophils, and features of dermatopathic lymphadenopathy. In many of the cases, the reactive germinal centers show a feature termed *follicle lysis*, characterized by invagination of mantle lymphocytes into the germinal centers, and this feature is often associated with interfollicular hemorrhage. Follicle lysis is associated with disruption of these centers ("moth-eaten appearance") and a distinctive clustering of large follicular center cells,[200,201] resulting in an appearance that has been termed *explosive follicular hyperplasia*. Ultrastructurally, a prominence of follicular dendritic cells exhibiting alterations of their fine processes has been described;[202] it has been suggested also on the basis of immunohistochemically (fascin stain) that the AIDS virus preferentially infects these cells.[203,204] It has been suggested that the polykaryocytes (Warthin–Finkeldey cells) that are sometimes seen in HIV-infected nodes are a multinucleated form of follicular dendritic cell.[93] Immunohistochemically, positive stain for the HIV core protein P24 has been documented within the abnormal germinal centers.[205,206]

This combination of follicular changes is not pathognomonic of AIDS, but the possibility of this disease should be considered and investigated whenever they are found, such as by immunostaining for P24 or by serologic study.[205]

Some lymph nodes in untreated AIDS patients may also show advanced lymphocyte depletion, with or without abnormal (regressively transformed) germinal centers.[200,202]

The interfollicular tissue may show prominent vascular proliferation, the resulting picture acquiring a vague resemblance to Castleman disease. It is important to search in these areas and in the subcapsular region for the earliest signs of development of Kaposi sarcoma.[207] These changes should be distinguished from those of vascular transformation of the sinuses.

A rough relationship has been found among the pattern of nodal reaction, the cell suspension immunophenotypic data, and the patient's HIV status.[208,209]

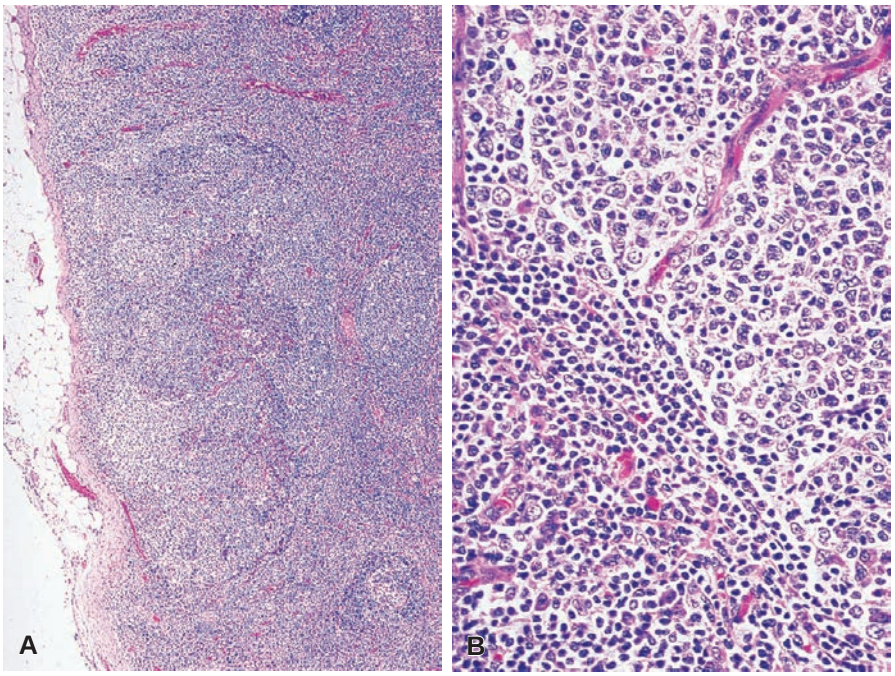

Figure 37.24 Low-power (**A**) and high-power (**B**) microscopic views of AIDS-related lymphadenopathy. The depicted germinal center shows disruption of its architecture by intrusion of small lymphocytes from the mantle zone. This is a common but not pathognomonic feature of this disease.

For personal use only. No other uses without permission. Copyright ©2017. Elsevier Inc. All rights reserved.

The term *chronic lymphadenopathy syndrome* has been defined as an unexplained enlargement of nodes of at least 3 months' duration at two or more extrainguinal sites in an individual at risk for AIDS.[210] The microscopic picture is similar to that described previously.[211] Overall, up to a fourth of the patients have developed AIDS on follow-up, cachexia and weight loss being the clinical signs of this progression.[212,213]

The HIV-associated lymphoproliferative diseases of lymph nodes are discussed later in this chapter.

Infectious Mononucleosis

The etiologic agent of classic infectious mononucleosis is EBV,[214] but other agents may be involved in atypical cases.[215] It is rare for the pathologist to see a lymph node from a patient with a typical clinical picture because in most instances the presumptive clinical diagnosis is confirmed by examination of the peripheral blood and serologic evaluation without need of a lymph node biopsy.[216] It is in the atypical case, presenting with lymphadenopathy without fever, sore throat, or splenomegaly, that the clinician will perform a lymph node biopsy to rule out the possibility of malignant lymphoma.

Microscopically, nodes and other lymphoid organs affected by infectious mononucleosis can be confused with malignant lymphoma because of the effacement of the architecture; infiltration of the trabecular, capsule, and perinodal fat; and the marked proliferation of immunoblasts, immature plasma cells, and mature plasma cells ("polymorphic B-cell hyperplasia") (Figs. 37.25 and 37.26). These features are particularly prominent when the disease develops in transplant recipients or other immunosuppressed patients.[217] Necrosis may also be present; this is usually only focal, but in immunodeficient children it may be massive.

Features of importance in the differential diagnosis with lymphoma include the predominantly sinus distribution of the large lymphoid cells, follicular hyperplasia with marked mitotic activity and phagocytosis (these follicles being usually small), increase in the number of plasma cells, often polymorphic in appearance, and vascular proliferation.[218] Another important feature is the fact that, although the nodal architecture may appear effaced, the sinus pattern remains intact or even focally accentuated. Another characteristic feature of this disease is the presence in the sinuses of clusters or "colonies" of lymphocytes in graduated sizes, from the small lymphocyte to the large lymphoid cell or immunoblast, often with plasmacytoid features.[219] The immunoblasts usually have only one large vesicular nucleus with a thin nuclear membrane and one or two prominent amphophilic or basophilic nucleoli. A paranuclear "hof" is often seen. When binucleated, this cell may closely resemble a Reed–Sternberg cell and result in a mistaken diagnosis of Hodgkin lymphoma (see Fig. 37.26).[220,221] A combination of immunophenotyping and in situ hybridization for EBV should resolve the issue in most cases (Fig. 37.27),[222–224] but it should be recognized that many enlarged, EBV-infected cells that may morphologically mimic Hodgkin cells will also express CD30[225] and the neoplastic cells of approximately 40% of cases of classical Hodgkin lymphoma will be EBV positive. The EBV infection in Hodgkin disease, however, is largely restricted to the neoplastic cells, while in infectious mononucleosis the EBV positive cells are more variable in size and include small cells. Because of the morphologic overlap between infectious mononucleosis and Hodgkin lymphoma and even DLBCL, extreme caution should be used before diagnosing either malignancy in immunocompetent adolescent or young adults in the head and neck region, especially on a tonsil biopsy.

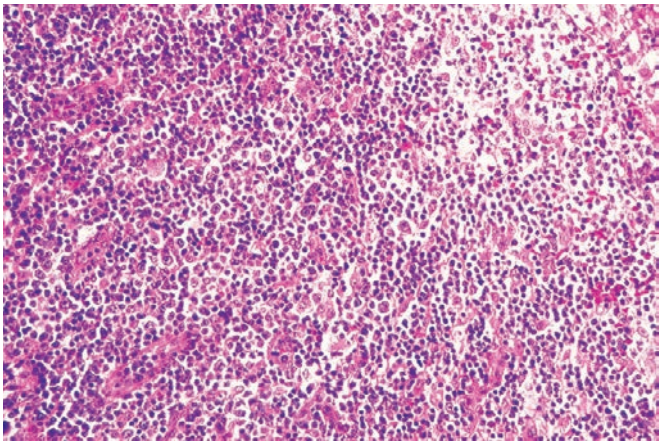

Figure 37.25 Lymph Node Involved by Infectious Mononucleosis. There is a marked effacement of the architecture by a polymorphic lymphoid infiltrate.

Other Viral (Including Postvaccinial) Lymphadenitides

Lymph nodes draining an area of the skin subjected to smallpox vaccination can enlarge and become painful. If removed and examined microscopically, they can be easily confused with lymphoma, especially if the history of vaccination is overlooked. Of 20 cases of postvaccinial lymphadenitis reported by Hartsock,[226] 13 were located in the supraclavicular region on the side of the vaccination. The largest node measured 6 cm in diameter. The interval between the vaccination and the biopsy varied between 1 week and 3 months.

Microscopically, the changes are those of a diffuse or nodular paracortical expansion, with mixed cellular proliferation, consisting of eosinophils, plasma cells, and a large number of immunoblasts. The alterations are accompanied by vascular and sinus changes and focal discrete necrosis. The most important histologic feature of postvaccinial hyperplasia is the presence of numerous immunoblasts scattered among the lymphocytes and imparting to the lymphoid tissue a mottled appearance (Fig. 37.28). Hartsock[226] noted that follicular hyperplasia was present only in those nodes removed more than 15 days after vaccination. These changes have been reproduced experimentally.[226]

Viral lymphadenitis resulting from *herpes simplex infection* may be localized[227] or generalized.[228] The morphologic features are similar to those of postvaccinial lymphadenitis, particularly in reference to the marked immunoblastic proliferation.[229,230] Intranuclear viral inclusions may be found, especially at the edge of necrotic areas.[231–233] The nodal changes seen in herpes zoster lymphadenitis and infectious mononucleosis are of similar nature; the latter are discussed under a separate heading (see preceding section). It is likely that analogous morphologic changes occurring in the absence of these clinical conditions are, in most cases, the result of some unidentified viral infection.

Prominent regional lymphadenopathy also may follow the administration of live attenuated measles virus vaccine. Microscopically, the typical multinucleated giant cell of Warthin–Finkeldey (polykaryocytes) may be found (see Fig. 37.10).[234]

Mucocutaneous Lymph Node Syndrome

Mucocutaneous lymph node syndrome, also known as Kawasaki syndrome, is a febrile disorder of unknown etiology usually affecting children, originally described in the Japanese literature but having a worldwide distribution.[235] Fever, cervical lymphadenopathy, pharyngeal and conjunctival inflammation, and erythematous skin

For personal use only. No other uses without permission. Copyright ©2017. Elsevier Inc. All rights reserved.

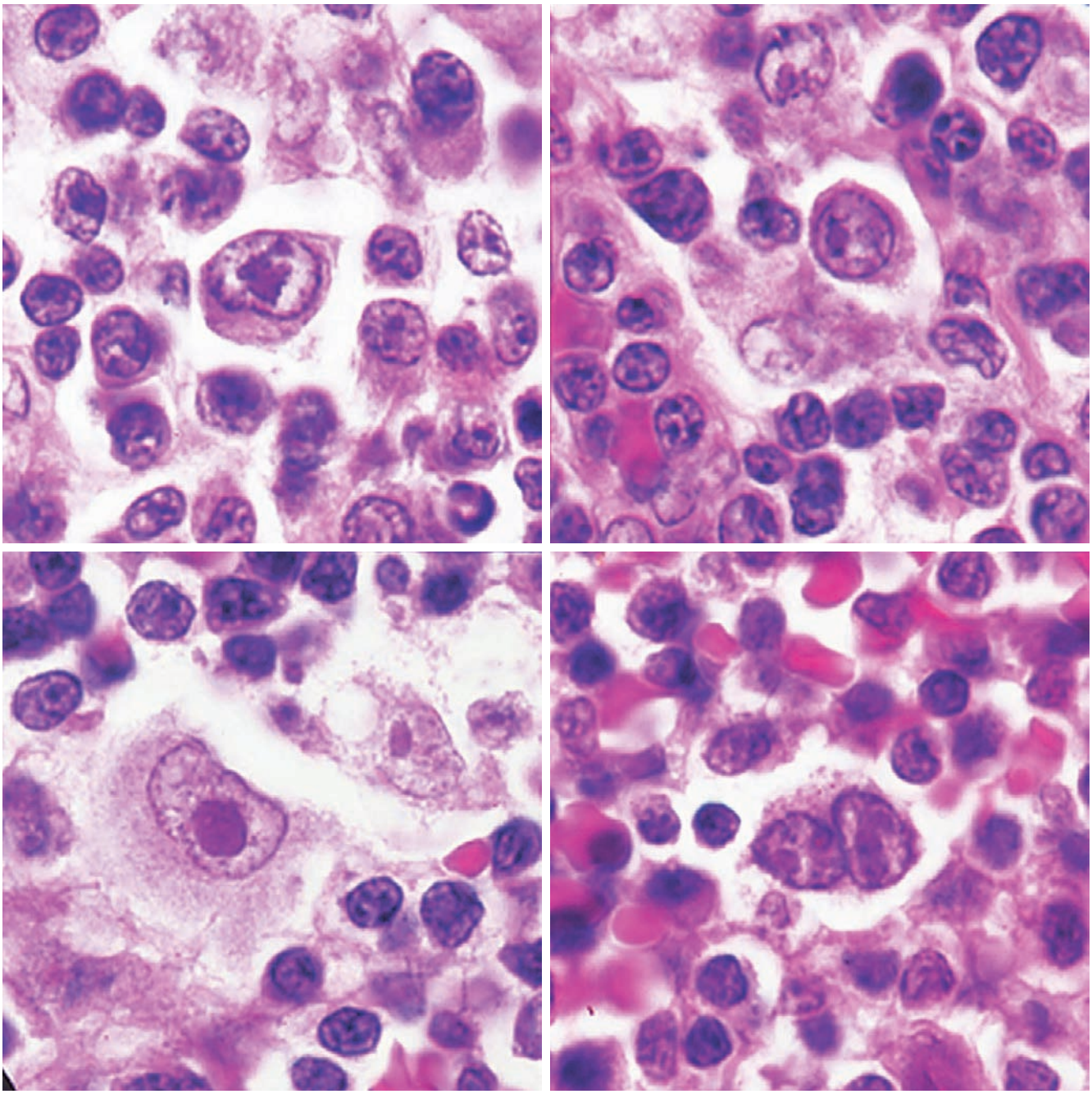

Figure 37.26 Various types of immunoblast seen in a lymph node involved by infectious mononucleosis. The binucleated form (shown in the fourth image) can simulate Reed–Sternberg cells. Note the basophilic character of the nucleus and the presence of a paranuclear hof. Also note the variability in size of background lymphocytes that also demonstrate a plasmacytoid appearance. This variability is characteristic of infectious mononucleosis.

rashes are the most common clinical symptoms. Sometimes lymphadenopathy represents the dominant manifestation of the disease.[236] Arthritis is present in approximately 40% of the cases. Coronary arteritis may lead to fatal complications. The etiology is unknown, but an infectious agent is suspected.

Microscopically, the affected lymph nodes often show fibrin thrombi in the smaller vessels accompanied by patchy infarcts/areas of nongranulomatous necrosis with or without neutrophils.[237,238] These changes have been interpreted as the expression of an acute vasculitis. The main differential diagnosis is Kikuchi necrotizing lymphadenitis, but the presence of thrombi would favor Kawasaki disease. Persistent damage to the coronary arteries occurs in approximately one-fourth of untreated children.[239]

Lupus Erythematosus

The lymph node changes in lupus erythematosus are generally of a nonspecific nature and consist of moderate follicular hyperplasia

For personal use only. No other uses without permission. Copyright ©2017. Elsevier Inc. All rights reserved.

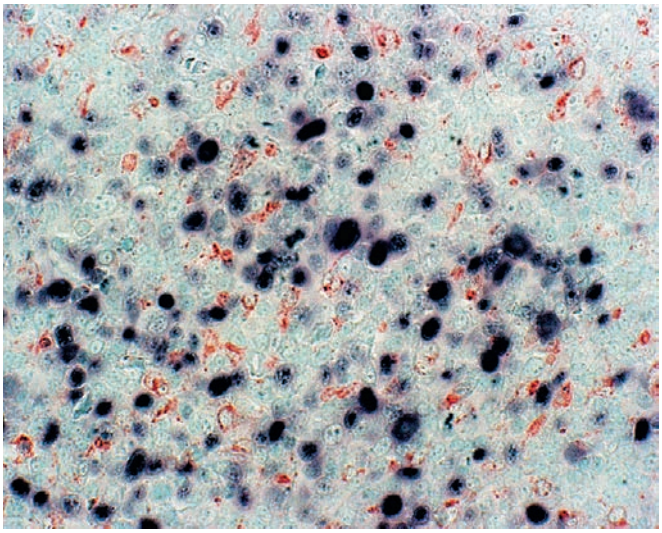

Figure 37.27 Demonstration of EBV EBER by in situ hybridization in a case of infectious mononucleosis. Note that both large and small cells are positive, in contrast to EBV+ Hodgkin lymphoma in which the EBV is primarily in large cells.

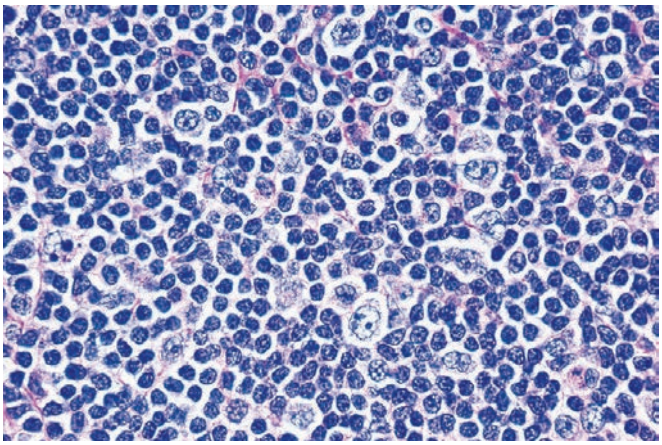

Figure 37.28 Viral lymphadenitis showing scattered immunoblasts resulting in a "salt-and-pepper" appearance.

associated with increased vascularization and scattered immunoblasts and plasma cells; some of the latter contain PAS-positive cytoplasmic bodies that represent sites of immunoglobulin production.[240] Occasionally, one encounters a peculiar form of necrosis characterized by the deposition of hematoxyphilic material in the stroma, in the sinuses, and on the wall of blood vessels (Fig. 37.29).[241] These have been found to be composed of DNA derived from karyorrhectic nuclear material, presumably from lymphocytes. As mentioned previously, the microscopic appearance of lupus lymphadenitis may be indistinguishable from that of Kikuchi disease,[242] and some patients originally diagnosed with Kikuchi disease may actually represent an early presentation of systemic lupus erythematosus.[112] The presence of hematoxylin bodies is considered relatively specific for lupus over Kikuchi disease. On occasion the changes of lupus are morphologically similar to those of either the hyaline vascular or intermediate types of Castleman disease.[243,240] In other instances, Warthin–Finkeldey-like polykaryocytes have been numerous.[244] The immunophenotype of lupus lymphadenitis is nonspecific.[241]

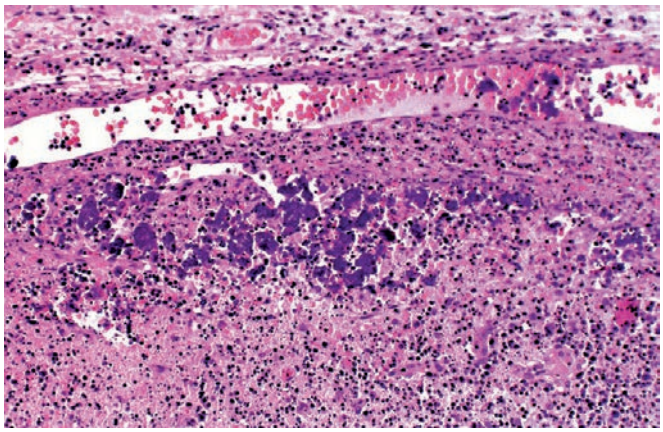

Figure 37.29 Large accumulations of DNA-containing basophilic material in the subcapsular region of a lymph node in a patient with systemic lupus erythematosus.

Rheumatoid Arthritis

Most patients with rheumatoid arthritis have generalized lymphadenopathy at some time during their illness.[245] The lymph node enlargement may precede the arthritis and raise the clinical suspicion of lymphoma.

Microscopically, the most important changes are follicular hyperplasia and plasma cell proliferation, with formation of Russell bodies.[246] Vascular proliferation is also a consistent finding. The appearance may be quite similar to that of the plasma cell type of Castleman disease. Small foci of necrosis and clumps of neutrophils are seen in some instances. The capsule is often infiltrated by lymphocytes. Immunohistochemically, the plasma cell proliferation is polytypic.[247] Adult-onset **Still disease** can also result in an intense hyperplastic change that can vaguely resemble peripheral T-cell lymphoma.[248] Other immune-mediated diseases, such as lupus erythematosus, polyarteritis nodosa, and scleroderma, are usually not associated with this type of lymph node abnormality.

Patients with rheumatoid arthritis treated with gold compounds can develop **gold-associated lymphadenopathy**.[249] They are also said to have a slightly increased incidence of malignant lymphomas.[250,251]

Castleman Disease

Castleman disease (giant lymph node hyperplasia) represents a morphologically distinct lymph node proliferation that in most cases is of unknown etiology. It occurs most commonly in adults, but it can also affect children.[252] Two major clinical and microscopic categories have been described that do not always correlate with each other[253,254] The first microscopic category, designated as *hyaline-vascular type* or angiofollicular, shows large follicles scattered in a mass of lymphoid tissue. The follicles show marked vascular proliferation and hyalinization of their abnormal germinal centers; they have been confused with Hassall corpuscles and with splenic white pulp, prompting in the first case a mistaken diagnosis of thymoma and in the second of ectopic spleen (Fig. 37.30). Their appearance corresponds to that of regressively transformed germinal centers. Many of the large cells with vesicular nuclei present in the hyaline center are follicular dendritic cells, as evidenced by their strong immunoreactivity for CD21 and CD35.[255] There is a tight concentric layering of lymphocytes at the periphery of the follicles (corresponding to the mantle zone), resulting in an onion-skin appearance. The interfollicular stroma is also prominent, with

For personal use only. No other uses without permission. Copyright ©2017. Elsevier Inc. All rights reserved.

numerous hyperplastic vessels of the postcapillary venule type and an admixture of plasma cells, eosinophils, and immunoblasts, as well as tight collections of CD123-positive plasmacytoid dendritic cells and frequently admixed TdT-positive T cells.[256–259] Sinuses are characteristically absent. In the variant of the hyaline-vascular type described as the *lymphoid subtype*, the follicles have a marked expansion of the mantle zone and small, relatively inconspicuous germinal centers. This variant of Castleman disease merges with the process known as *mantle zone hyperplasia*, and it is the one more likely to be confused with malignant lymphoma of either follicular or mantle cell type. Immunohistochemically, there is polyclonal immunoglobulin production by plasma cells, and large numbers of suppressor T cells are found in the interfollicular areas. An aberrant phenotype of Ki-B3–negative B lymphocytes has been detected in the mantle zone cells.[260]

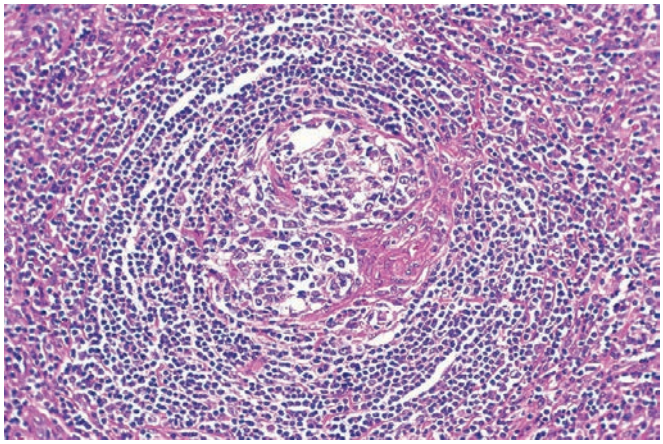

Figure 37.30 Castleman Disease of Hyaline Vascular Type. There is a prominent germinal center showing well-developed changes.

The second major morphologic category of Castleman disease is known as the *plasma cell type*.[254] It is characterized by a diffuse plasma cell proliferation in the interfollicular tissue, sometimes accompanied by numerous Russell bodies. The hyaline-vascular changes in the follicles are inconspicuous or absent; instead, one often encounters in the center of these follicles a deposition of an amorphous acidophilic material that probably contains fibrin and immune complexes. The overall appearance is reminiscent of that seen in the lymph nodes from patients with rheumatoid arthritis (Fig. 37.31). The abundant expression of interleukin-6 that has been detected in this condition is thought to be responsible for the marked plasma cell infiltration.[261]

Based on clinical presentation, Castleman disease has been divided into a solitary and a multicentric form. The *solitary form* presents as a mass located most commonly in the mediastinum but also described in the neck, lung, axilla, mesentery, broad ligament, retroperitoneum, soft tissues of the extremities (including subcutis and skeletal muscle),[262] nasopharynx, meninges, and several other sites.[263] Grossly, it is round, well circumscribed, with a solid gray cut surface and can measure 15 cm or more in diameter (Fig. 37.32). Although this form by definition presents as a single mass, microscopic changes suggesting an early stage of the same process are sometimes seen in adjacent nodes. Microscopically, over 90% of the cases are of the hyaline-vascular type (including the lymphoid subtype), and the remainder are of the plasma cell type. The former is usually asymptomatic, whereas the plasma cell type is often associated with fever, anemia, elevated erythrocyte sedimentation rate, hypergammaglobulinemia, and hypoalbuminemia. The disease reported in Asia as *idiopathic plasmacytic lymphadenopathy with polyclonal hypergammaglobulinemia* is probably different from the plasma cell type of Castleman disease but may represent IgG4-related lymphadenopathy in a significant proportion of cases.[264,265] The treatment of solitary Castleman disease is surgical excision, which has been found to result in rapid regression of the associated abnormalities whenever present.[266]

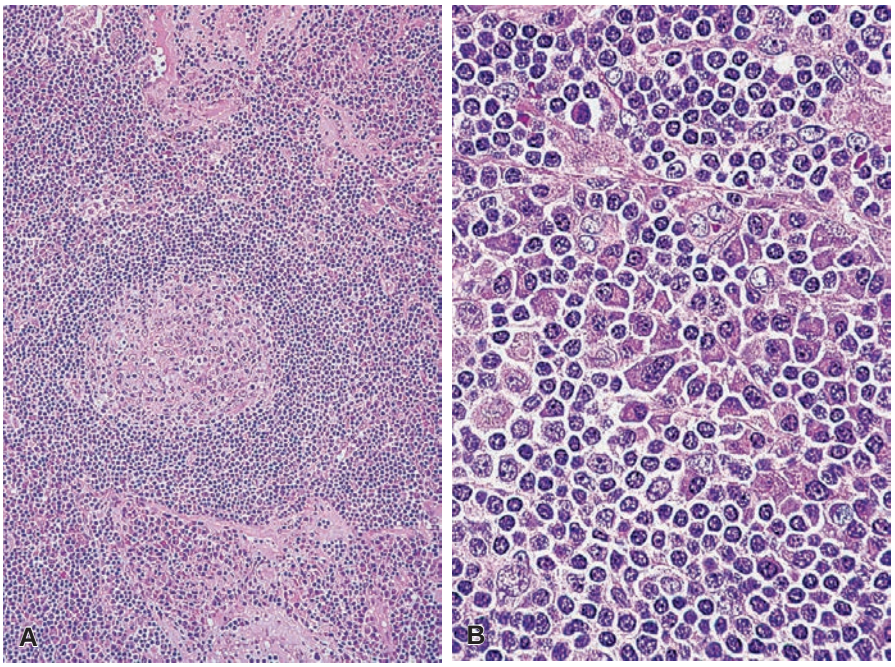

Figure 37.31 Castleman Disease of Plasma Cell Type. A, Low-power view showing follicular hyperplasia without hyaline vascular changes. **B**, High-power view of the interfollicular region showing a massive infiltration by plasma cells. Some of these plasma cells show multinucleation and mild nuclear atypia.

For personal use only. No other uses without permission. Copyright ©2017. Elsevier Inc. All rights reserved.

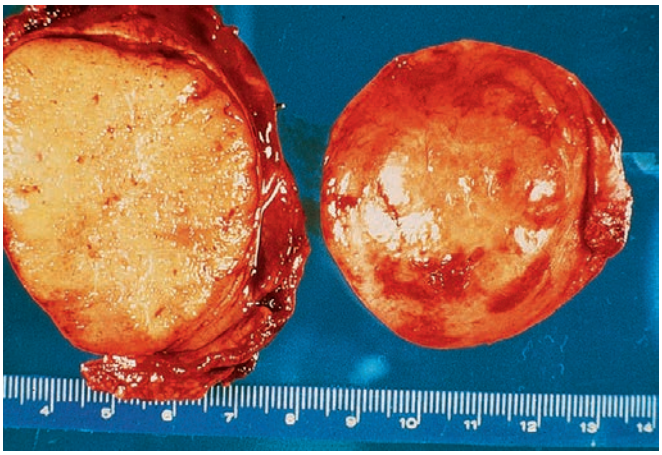

Figure 37.32 Gross appearance of Castleman disease of the hyaline vascular type.

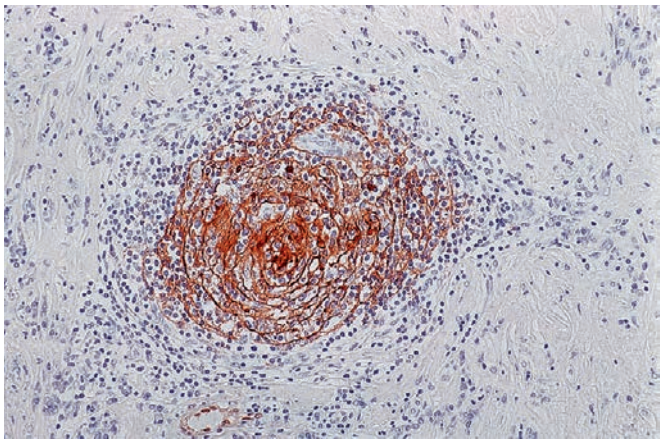

Figure 37.33 Prominent network of CD21-positive dendritic follicular cells in the abnormal germinal center of Castleman disease.

The *multicentric* or *systemic form* is nearly always of the plasma cell type,[267] although occasional examples of the hyaline-vascular type (involving even the skin) are on record.[268] It presents with generalized lymphadenopathy and may also involve the spleen.[269–271] The etiology is unknown, the two main hypotheses (not mutually exclusive) being abnormal immune response and viral infection.[272] Regarding the latter, a definite link has been documented between HHV8 and multicentric Castleman disease (this virus being also linked to Kaposi sarcoma and primary effusion sarcoma and can be identified by immunohistochemistry).[273–275] Cases of HHV8+ Castleman disease are said to be characterized morphologically by dissolution of the lymphoid follicles.[276] It has been hypothesized that HHV8 induces the changes of Castleman disease through the production of interleukin-6.[277,278]

Sometimes multicentric Castleman disease is seen in association with the POEMS syndrome, an acronymic designation for polyneuropathy, organomegaly, endocrinopathy, M-protein, and skin changes.[279,280] The latter include a distinctive vascular lesion known as glomeruloid hemangioma.[281] In other instances, Castleman disease has been reported in association with amyloid deposits.[282,283]

The long-term prognosis of systemic Castleman disease is poor; the disease tends to persist for months or years and to result sometimes in renal or pulmonary complications.[284] Furthermore, some of the patients have been found to have Kaposi sarcoma. Indeed, the coexistence of multicentric Castleman disease and Kaposi sarcoma in the same tissue sample is not an uncommon phenomenon.[285] Other cases have developed large cell lymphomas with plasmablastic features, most of which are associated with HHV8 infection. Evidence of clonal rearrangement for immunoglobulin and T-cell receptor genes has been found in cases of systemic Castleman disease together with copies of the EBV genome; no such features having been detected in the solitary form of the disease.[286–289] This suggests that multicentric Castleman disease is a disorder different from the classic localized type and one that may evolve into a clonal lymphoproliferation. Some authors actually regard it as a lymphoproliferative process rather than a reactive/inflammatory condition.

An important theme of the hyaline-vascular type of Castleman disease is the active participation of a variety of nonlymphoid cellular components. One such component is the follicular dendritic cell, which is prominently present in the hyalinized nodules that characterize the disease and which is thought by some authors to be at the core of the pathogenesis of this disorder (Fig. 37.33).[290,291] These cells can become atypical ("dysplastic") both in the abnormal germinal centers and in the intervening tissue[291] and can manifest cytogenetic and molecular evidence of clonality (Fig. 37.34).[292–294] Furthermore, they may result in the formation of full-blown follicular dendritic cell tumors.[295,296] Another type of proliferation involves the vascular and related contractile (myoid) elements that are present in the interfollicular tissue. Cases of Castleman disease in which these elements are unduly prominent have been referred to as *stroma rich* (Fig. 37.35).[256] Further proliferation of this component results in the formation of *angiomyoid proliferative lesions*,[296] and of lesions that have been referred to as *angiomatous hamartomas* (Fig. 37.36)[297] or *vascular neoplasms*, the latter sometimes having hemangiopericytoma-like features.[298] Finally, cases have been described of high-grade spindle cell sarcomas arising in Castleman disease, which have been originally interpreted as of probable vascular nature because of the presence of myoid tumor cells adjacent to vascular structures (Fig. 37.37).[299] Whether these myoid cells are truly vessel related or whether they originate from yet another member of the reticulum/dendritic cell family (so-called fibroblastic reticulum cells, myoid reticulum cells, or dychthyocytes) is not clear.

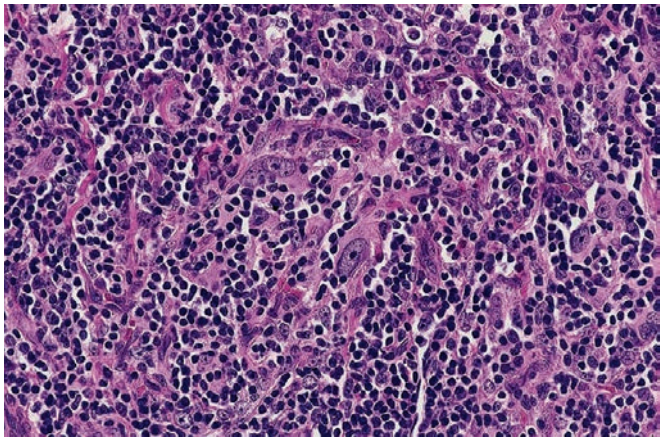

Figure 37.34 "Dysplasia" of Reticular/Dendritic Cells in Castleman Disease. These cells were immunoreactive for desmin.

In the light of the above information, one might conclude that the neoplastic potentialities of Castleman disease tend to manifest themselves mainly through the development of lymphoid tumors in the plasma cell type and of dendritic/stromal tumors in the hyaline-vascular type. However exceptions occur, in the sense that isolated cases of the latter have been accompanied or preceded by

For personal use only. No other uses without permission. Copyright ©2017. Elsevier Inc. All rights reserved.

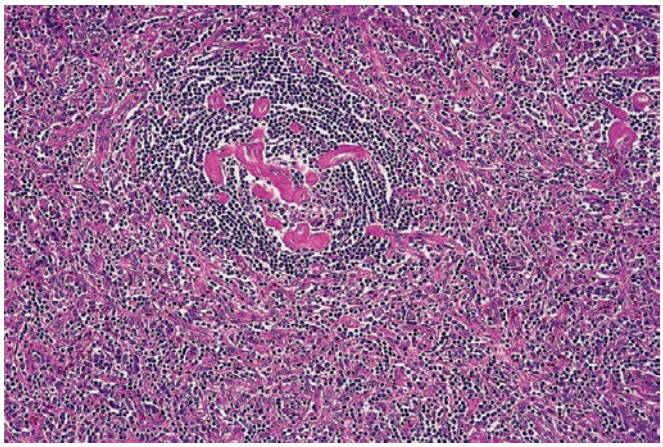

Figure 37.35 Castleman disease of hyaline vascular type with a prominent stromal component which is richly vascularized ("stroma-rich" variant).

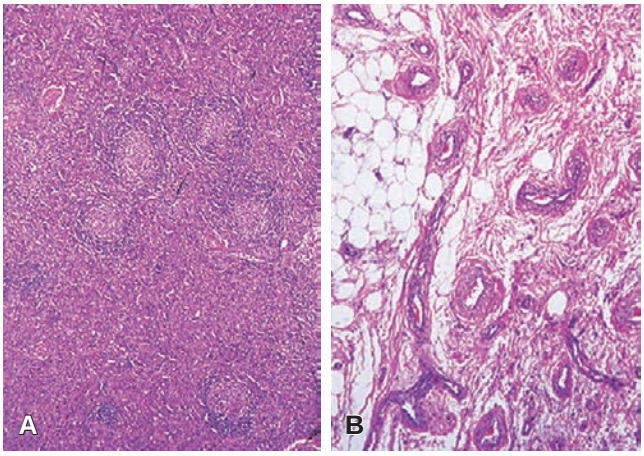

Figure 37.36 Castleman disease associated with vascular proliferation in the surrounding soft tissues. (Courtesy of Dr. Pietro Muretto, Pesaro, Italy.)

plasmacytoma,[300,301] follicular lymphoma,[302,303] and particularly Hodgkin lymphoma.[304–306]

Drug Hypersensitivity

Antiepileptic drugs derived from hydantoin, such as diphenylhydantoin (Dilantin) and mephenytoin (Mesantoin), can result in a hypersensitivity reaction manifested by skin rash, fever, generalized lymphadenopathy (mainly cervical), and peripheral eosinophilia. The reaction, which is quite uncommon, tends to occur within the first few months of therapy. The changes disappear if the drug is discontinued. The nodal enlargement can occur in the absence of some of the other manifestations of the drug reaction.

Microscopically, partial effacement of the architecture by a polymorphic cellular infiltration is seen.[307] Histiocytes, immunoblasts, eosinophils, neutrophils, and plasma cells are all present. Some of the immunoblasts have atypical nuclear features, including rare cases with Reed–Sternberg-like cells. Foci of necrosis were noted in the classic article by Salzstein and Ackerman in which this condition was first described.[308] In some of the cases, the microscopic appearance may mimic viral infections, postvaccinial lymphadenopathy and even angioimmunoblastic T-cell lymphoma and classical Hodgkin lymphoma. Detailed medication history and clinical information is needed to diagnose appropriately and the diagnosis might only be confirmed with clinical resolution after discontinuation of the drug.

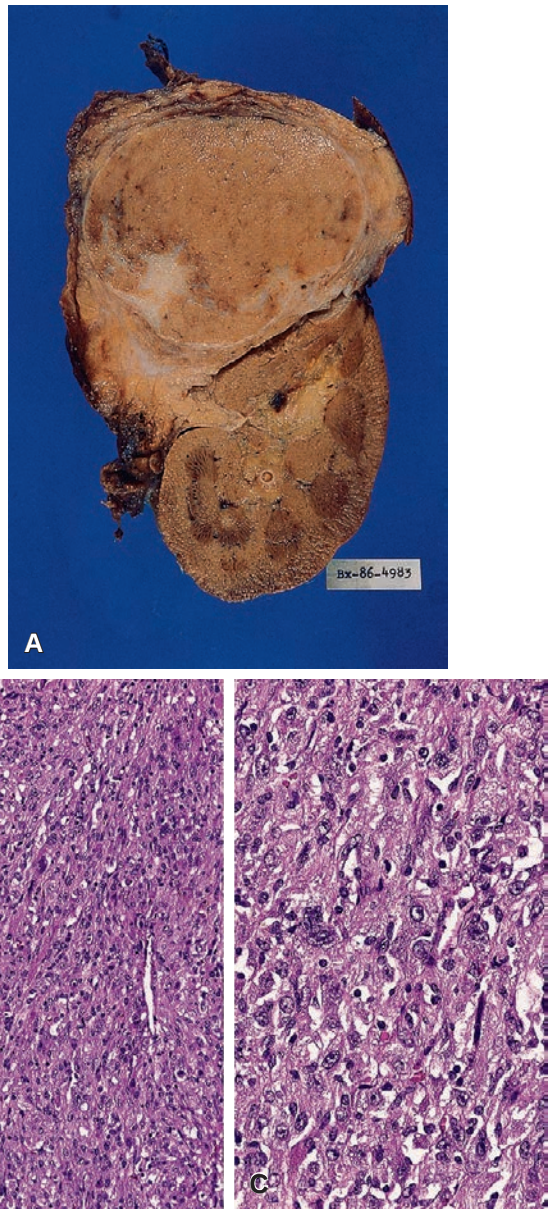

Figure 37.37 Castleman Disease Complicated by the Development of Sarcoma. A, Gross appearance of a case located in the perirenal region. **B**, Microscopic appearance of another case. The tumor has a vaguely hemangiopericytomatous quality. **C**, High-power view.

Dermatopathic Lymphadenitis

Dermatopathic lymphadenitis (lipomelanosis reticularis of Pautrier) is a form of nodal hyperplasia usually secondary to a generalized dermatitis, particularly those with exfoliative features. Pathogenetically, it represents a T-cell response to skin antigens processed and presented by interdigitating dendritic cells. It may occur in any skin disorder in which itching and scratching are prominent; this includes inflammatory dermatoses such as psoriasis and neoplastic diseases such as mycosis fungoides. Rarely, the morphologic changes of dermatopathic lymphadenitis are seen in the absence of clinical skin disease.[309]

For personal use only. No other uses without permission. Copyright ©2017. Elsevier Inc. All rights reserved.

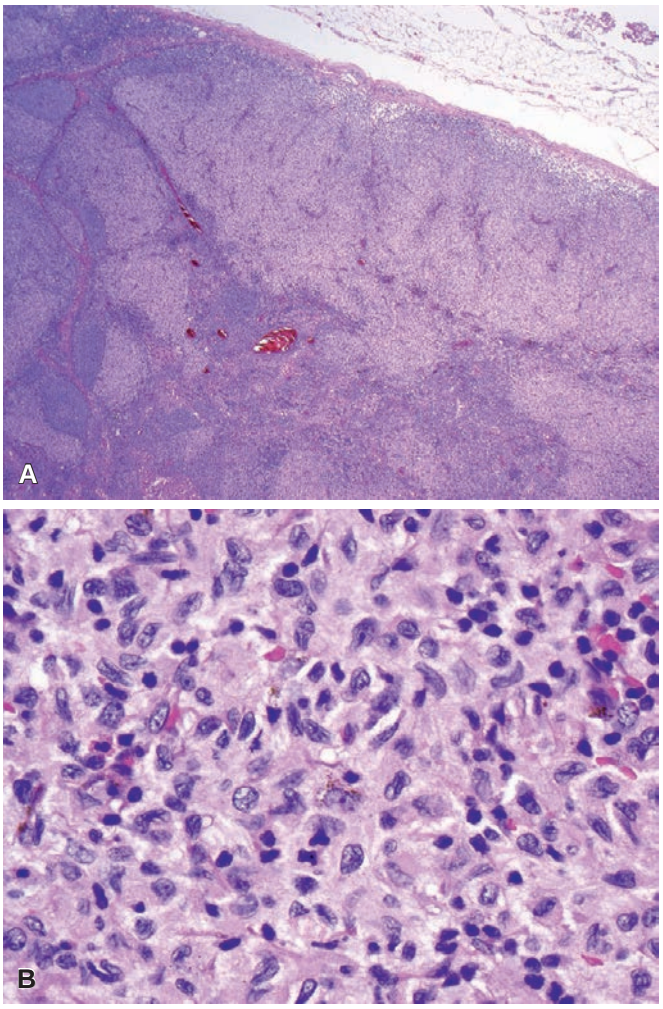

Figure 37.38 Dermatopathic Lymphadenitis. A, Massive expansion of the paracortical region, resulting in a wide, pale area between the capsule and the lymphoid follicles. **B**, High-power view of the paracortical region showing numerous cells with oval vesicular nuclei, which correspond to an admixture of interdigitating dendritic cells and Langerhans cells with nuclear grooves. Scattered cells containing pigment are also present.

Grossly, the lymph node is enlarged, the cut surface bulging, and the color pale yellow. In florid cases, black linear areas are seen in the periphery, representing clumps of melanin pigment and simulating the appearance of malignant melanoma.

Microscopically, the nodal architecture is preserved. The main change is represented by a marked pale widening of the paracortical zone, which stands out prominently on low-power examination (Fig. 37.38).[310] Most of the large nonlymphoid cells occupying this area are thought to be of three types: histiocytes, Langerhans cells, and interdigitating dendritic cells marking with a mix of CD163, CD1a, langerin, and S100 positivity.[311,312] Many of the histiocytes contain phagocytosed melanin and neutral fat in their cytoplasm. Plasma cell infiltration and follicular hyperplasia are often present. A scattering of eosinophils also may be seen.

Nodes affected by dermatopathic lymphadenitis may be confused with Hodgkin lymphoma, mycosis fungoides, monocytic leukemia, or LCH. The differential diagnosis with mycosis fungoides is of particular concern because of the fact that mycosis fungoides is one of the cutaneous disorders that can be associated with dermatopathic lymphadenitis.[313,314] Diagnostic assistance can be obtained from immunohistochemistry and molecular pathology. Dermatopathic lymph nodes *that are also involved by mycosis fungoides* may show loss of CD7 and CD62L expression, and sometimes also loss of the pan–T-cell markers CD5, CD3, and CD2.[315] At the molecular level, clonal rearrangements of T-cell receptor genes may be demonstrated in cases involved by mycosis fungoides.[316] The presence of dermatopathic lymphadenitis in a patient with known mycosis fungoides, even in the absence of involvement by mycosis fungoides, is considered an abnormal finding and results in an N1 staging status and the need for molecular studies for T-cell receptor gene rearrangements.[317,318]

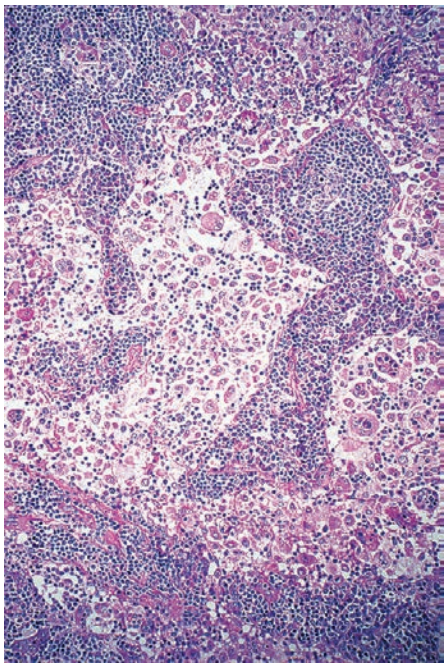

Figure 37.39 Rosai–Dorfman Disease. Low-power view showing massive distension of the sinuses by the histiocytic infiltrate.

Rosai–Dorfman Disease

Rosai-Dorfman disease (RDD), also known as sinus histiocytosis with massive lymphadenopathy (SHML), presents in its most typical form as massive, painless, bilateral lymph node enlargement in the neck, associated with fever, leukocytosis, elevated erythrocyte sedimentation rate, and polyclonal hypergammaglobulinemia.[319,320] Most cases occur during the first or second decade of life, but any age group can be affected. A few cases have affected two members of the same family.[321] There is a predisposition for the condition in blacks. Although the disease has a widespread geographic distribution and most of the reported cases have been from the United States and Western Europe, there is a disproportionally high number of cases from Africa and the Caribbean region.[319] The cervical region is by far the most common and most prominent site of involvement, but other peripheral or central lymph node groups can be affected, with or without cervical disease.

Grossly, the nodes are matted together by prominent perinodal fibrosis. Their cut surface varies from gray to golden yellow, depending on the amount of fat present.

Microscopically, there is a pronounced dilation of the lymph sinuses, resulting in partial or complete architectural effacement (Fig. 37.39). These sinuses are occupied by lymphocytes, plasma cells, and—most notably—by numerous cells of histiocytic appearance

For personal use only. No other uses without permission. Copyright ©2017. Elsevier Inc. All rights reserved.

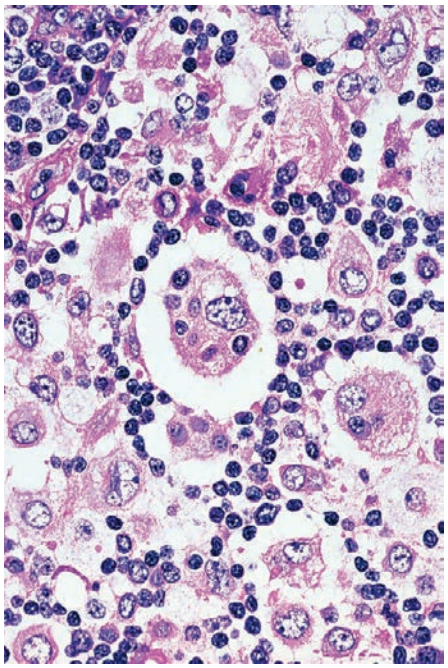

Figure 37.40 Rosai–Dorfman Disease. High-power view showing lymphocytophagocytosis by the sinus histiocytes.

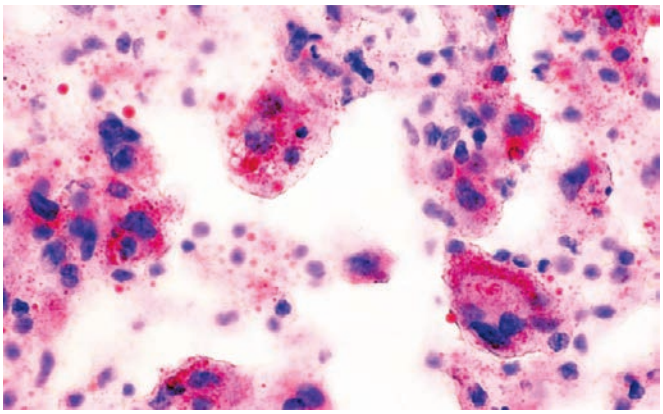

Figure 37.41 Rosai–Dorfman Disease. Oil red O stain showing abundant neutral lipid in the cytoplasm of the histiocytes.

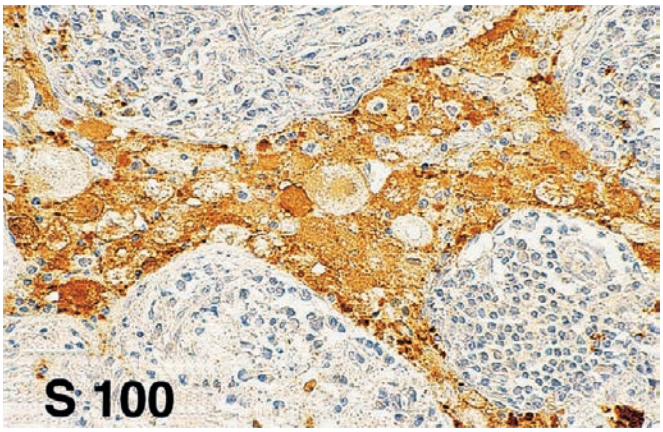

Figure 37.42 Strong immunoreactivity of the sinus histiocytes for S100 protein in Rosai–Dorfman disease.

with a large vesicular nucleus and abundant clear or lightly eosinophilic cytoplasm that may contain large amounts of neutral lipids. Many of these histiocytes have within their cytoplasm numerous intact lymphocytes, a feature that has been designated as emperipolesis or lymphocytophagocytosis. Although not specific, this is a constant feature of RDD (as least in the lymph node location) and is therefore of great diagnostic significance (Fig. 37.40). Sometimes other cell types are present within the cytoplasm of the histiocytes, such as plasma cells and red blood cells.

The intersinusal tissue exhibits a variable but sometimes impressive number of mature plasma cells, some of which may contain Russell bodies. Capsular and pericapsular inflammation and fibrosis are common, but intranodal fibrosis is minimal or absent. In a minority of cases, small microabscesses or foci of necrosis are found within the dilated sinuses. Ultrastructurally, the histiocytes located in the sinuses have extensive pseudopodia and lack Birbeck granules; viral particles or other evidence of infection is consistently lacking. The sinus histiocytes contain cytoplasmic fat (Fig. 37.41) and are strongly reactive for S100 protein[322] and CD68 (Fig. 37.42) but negative for CD1a; some of them are also positive for immunoglobulin, presumably phagocytosed from the surroundings. Their immunohistochemical profile (including the adhesion molecules pattern) suggests that they are monocytes that have been recently recruited from the circulation.[323–326] The plasma cells show a polyclonal pattern of immunoglobulin expression. Some cases show an increase in IgG4-positive plasma cells and the relationship between RDD and IgG4-related disease requires clarification.[327–329] The lymphocytes present are an admixture of B and T cells.

In over one-fourth of the cases, RDD involves extranodal sites.[319] This usually occurs in the presence of massive lymphadenopathy, and the disease is therefore easily recognized. However, in some cases these extranodal manifestations represent the predominant or even exclusive manifestation of the disease. Practically all organ systems have been recorded as being the site of the disease. The most common are eyes and ocular adnexa (especially orbit),[330] head and neck region,[331] upper respiratory tract,[332,333] skin and subcutaneous tissue (perhaps more commonly in Asia),[334–339] skeletal system,[340] and central nervous system.[341–343] However, the disease has been reported in many other sites, including gastrointestinal tract,[344–346] pancreas,[347] salivary glands,[348] genitourinary tract, thyroid,[349] mediastinum,[350] breast,[351,352] uterine cervix,[353] and bone marrow.[354] In some instances, widespread nodal and extranodal dissemination is found.[355] Organs that stand out because of their almost universal sparing by the disorder are lung, and spleen, and bone marrow (the latter exclusive of the focal bone lesions mentioned previously). The histopathologic features of RDD in extranodal sites are similar to the nodal disease except for the fact that fibrosis tends to be more pronounced and emperipolesis less conspicuous.

The etiology of RDD remains unknown, the two most likely possibilities (not mutually exclusive) being infection by a virus or some other microorganism and the manifestation of a subtle undefined immunologic defect. It has been suggested that stimulation of monocytes/macrophages via macrophage colony-stimulating factor (M-CSF) leading to immune suppressive macrophages may be the main pathogenetic mechanism.[356] Despite some suggestive early data derived from serologic tests, most studies fail to demonstrate an infectious etiology.[357,358] Molecular studies done on involved tissue have failed to show evidence of clonality, in keeping with their presumed reactive nature. This contrasts with the findings in at least some studies of LCH, a disease that it otherwise resembles in many clinical, morphologic, and phenotypic aspects,[325,359,360] and with which it can coexist.[361,362]

For personal use only. No other uses without permission. Copyright ©2017. Elsevier Inc. All rights reserved.

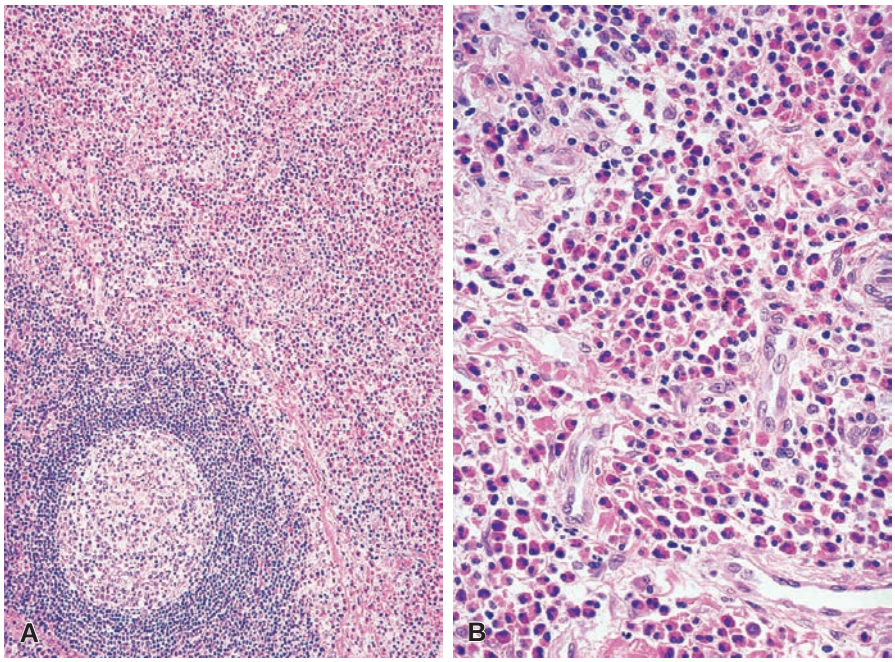

Figure 37.43 **A** and **B,** Lymph node involvement by Kimura disease. There is follicular hyperplasia and massive perinodal inflammation, which is predominantly composed of eosinophils. (Courtesy of Dr. T.-T. Kuo, Taipei, Taiwan.)

RDD is relatively unaffected by therapy, although chemotherapy has proved effective in some cases,[363–365] occasionally with allegedly complete and permanent results.[366] In many cases, RDD undergoes quick and complete spontaneous resolution. In others, it follows a protracted clinical course for years or decades. The latter is particularly true in cases with widespread extranodal involvement. In some instances the disease disappears, only to come back years later at another site. Some patients have died as a result of RDD, either because of extensive disease affecting vital organs or because of complications related to the immunologic abnormalities that may be present,[367,368] such as amyloidosis.[369]

The differential diagnosis of RDD includes nonspecific sinus hyperplasia (in which the cells lack emperipolesis and are S100 protein-negative), LCH (in which the cells are positive for S100 protein, langerin, and CD1a), leprosy, rhinoscleroma (with which it can apparently coexist[370]), and metastatic malignant melanoma. Perhaps the condition that resembles it most is the sinus histiocytosis induced by cobalt-chromium and titanium that can occur in pelvic lymph nodes after hip replacement.[344]

It should also be noted that focal RDD-like changes can sometimes be seen in lymph nodes involved by other processes, such as Hodgkin[371] or non-Hodgkin lymphoma, a phenomenon analogous to that sometimes seen in LCH.[372] Similar changes can also occur in lymph nodes involved by ALPS.[52]

Kimura Disease

Kimura disease is an inflammatory disorder of unknown etiology seen in an endemic form in Asia[373] but also in other parts of the world, including the United States and Europe.[374] It usually presents as a mass lesion in the subcutaneous tissue of the head and neck region or the major salivary glands, often associated with regional lymphadenopathy. Sometimes lymph node enlargement is the only manifestation of the disease.

Microscopically, the involved nodes show marked hyperplasia of germinal centers, a few of which may be of the progressively transformed type. These germinal centers are often well vascularized and contain polykaryocytes, interstitial fibrosis, and deposition of a proteinaceous material. There is also extensive infiltration by mature eosinophils, with occasional formation of eosinophilic abscesses (Fig. 37.43). Hyalinized vessels are often seen in the paracortical region, and there is a variable degree of sinus and paracortical sclerosis. An increase in the number of plasma cells and mast cells has been noted in the paracortex,[375] together with proliferation of postcapillary venules.[374] Some cases are associated with increases in IgG4-positive plasma cells, a feature of unclear significance.[376]

Despite early statements to the contrary, current evidence strongly suggests that Kimura disease and the disease known to dermatologists as angiolymphoid hyperplasia with eosinophilia are different entities (see Chapter 3); specifically, the former disorder lacks the epithelioid (histiocytoid) endothelial cells that are the morphologic hallmark of the latter.[377–380] The differential diagnosis of Kimura disease includes parasitic infections as well as tissue manifestations of chronic eosinophilic leukemia and the related clonal eosinophilic disorders reviewed in Chapter 39.

Chronic Granulomatous Disease

Chronic granulomatous disease is the result of a genetically determined enzymatic defect of granulocytes and monocytes.[381–383] These cells ingest microorganisms but are unable to destroy them because of their inability to generate superoxide anion (O_2^-). This is due to a defect in any one of five components of NADPH oxidases, the enzyme responsible for the generation of the antimicrobial oxidants.[382] A pattern of X-linked inheritance is seen in approximately 65% of the patients and results from mutations in the gene that encodes the g91-phox subunit of the cytochrome b558 component of the oxidase. The remaining 35% of patients inherit the disease in an autosomal recessive manner resulting from mutations in the genes that encode the other three oxidase components.[384–386]

For personal use only. No other uses without permission. Copyright ©2017. Elsevier Inc. All rights reserved.

The traditional laboratory technique for the detection of the disease is the nitro blue tetrazolium test although detection of dihydrorhodamine oxidation can be performed by flow cytometry.[383,387]

The main clinical features are recurrent lymphadenitis, hepatosplenomegaly, skin rash, pulmonary infiltrates, anemia, leukocytosis, and hypergammaglobulinemia.[388–390] Microscopically, granulomas with necrotic purulent centers are seen in lymph nodes and other organs. They closely simulate the appearance of cat-scratch disease and lymphogranuloma venereum. Collections of histiocytes containing a lipofuscin-like pigment are also commonly observed and represent an important clue to the diagnosis.[391]

Lipophagic Reactions

Accumulation of neutral lipid with formation of foamy macrophages (xanthoma cells) can be seen as an inconsequential secondary event in a variety of inflammatory and neoplastic conditions of lymph nodes, including LCH, RDD, Erdheim–Chester disease, and Hodgkin lymphoma. There are, in addition, conditions in which the **lipophagic granuloma** is the primary alteration. The lipophagic granuloma is defined as a collection of mononuclear and multinucleated giant cells, both of them exhibiting a cytoplasmic foamy appearance and lacking a significant participation of other cell types. By far the most common situation in which this occurs (so common as to be nearly universal, at least in Western countries) is represented by the incidental microscopic finding in periportal and mesenteric nodes in asymptomatic individuals, probably the result of mineral oil ingestion (Fig. 37.44).[392] Boitnott and Margolis[393] found this change in 78% of a series of 49 autopsied adults. Their chemical and histochemical studies showed that the oil droplets represent deposits of liquid-saturated hydrocarbons. Mineral oil is extensively used in the food processing industry, as a release agent and lubricant in capsules, tablets, bakery products, and dehydrated fruits and vegetables. Lipophagic granulomas of an extensive degree have been reported in association with long-term total parenteral nutrition therapy for short bowel syndrome.[394]

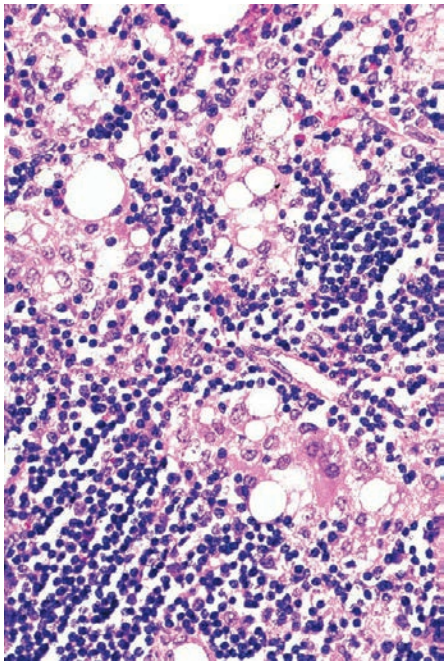

Figure 37.44 Lymph Node Containing Lipophagic Granulomas. The change is manifested by the presence of mononuclear and multinucleated histiocytes located in the sinuses and containing large cytoplasmic vacuoles.

Whipple disease can result in marked enlargement of mesenteric lymph nodes, with formation of numerous lipophagic granulomas.[395] Collections of histiocytes containing a PAS-positive glycoprotein are also present.[396] Under oil immersion and with electron microscopy, the characteristic bacillary bodies can be identified. Collections of PAS-positive histiocytes can also develop in peripheral nodes and may be the first clue to the diagnosis in a patient with gradual weight loss, weakness, and polyarthritis. Steatorrhea, the other classic symptom of the disease, may appear only in a later stage. In the presence of suggestive findings in routinely stained sections, confirmation of the diagnosis can now be obtained by the demonstration of the responsible organism *(Tropheryma whipplei)* by immunohistochemistry or PCR.[397–399]

Lymphangiography, a procedure now largely abandoned, induces a lipophagic granulomatous reaction that may persist for several months. The sinuses are markedly distended and lined by histiocytes, many of which are multinucleated. Eosinophils may be present in appreciable numbers in the medullary cords. This is preceded by a predominantly neutrophilic infiltration.[400]

Malignant Lymphoma

Malignant lymphoma is the generic term given to tumors of the lymphoid system and specifically of lymphocytes and their precursor cells, whether of T, B, or null phenotypes. Tumors now known to be composed of histiocytes, and other cells of the accessory immune system were previously included in the category of malignant lymphoma but are now regarded separately for both conceptual and practical reasons. Many tumors that were designated in the past as histiocytic lymphomas or reticulum cell sarcomas, however, are in reality of lymphocytic nature and therefore true malignant lymphomas and an interrelationship between some true histiocytic tumors and malignant lymphomas is becoming clear.[401]

Although some overlapping exists, the term *malignant lymphoma* is reserved for those neoplastic processes that initially present as localized lesions and are characterized by the formation of gross tumor nodules. Conversely, neoplastic lymphoid proliferations that are systemic and diffuse from their inception are usually termed leukemias (see Chapter 39).

The malignant lymphomas can be divided into two major categories: Hodgkin lymphoma and all the others, which, for lack of a better term, are known collectively as non-Hodgkin lymphomas.[402–406] Both groups are further subdivided into several more or less distinct subcategories, with the most currently and widely accepted classification being the 2016 WHO revision.[407] This classification has incorporated a wealth of information gathered from the fields of immunophenotyping, molecular genetics, genomics, and proteomics but also relies on clinical information and morphology. While other classification systems, including those of Rappaport, Kiel, and the so-called Working Formulation,[408–410] have historic significance, they should no longer be used.

Hodgkin Lymphoma

The disease originally described by Thomas Hodgkin in 1832 and which Samuel Wilks first proposed to be called Hodgkin's disease makes one of the richest chapters of history of oncologic pathology.[411–414] The original color illustrations have become icons,[415] and the original cases, still housed at the pathology museum of Guy's Hospital in London, have been "exhumed" and studied microscopically and immunohistochemically, and the diagnosis has been confirmed (at least in some of the cases) after well over a

For personal use only. No other uses without permission. Copyright ©2017. Elsevier Inc. All rights reserved.

century of fixation.[416] The interest in this enigmatic disease remains unabated, having been quoted as the paradigm for the emerging science of "molecular morphology."[414]

The conventional definition of Hodgkin's disease, now termed Hodgkin lymphoma, is that of a type of malignant lymphoma in which Reed–Sternberg cells are present in a "characteristic background" of reactive inflammatory cells of various types, accompanied by fibrosis of a variable degree. This definition still applies, at least in part, for cases of so-called classical Hodgkin lymphoma, but it is now recognized that cases of nodular lymphocyte predominance Hodgkin lymphoma (NLPHL) are distinct from this group. While identification of typical Reed–Sternberg cells is useful for the initial diagnosis of classical Hodgkin lymphoma, cells with similar features may be seen in other neoplasms, including some non-Hodgkin lymphomas and a diagnosis of Hodgkin lymphoma, in some cases, can be made without identification of cells with the classic binucleated Reed-Sternberg appearance. As far as the "characteristic background" or "appropriate milieu" is concerned, it is highly variable, but in classical Hodgkin lymphoma, it lacks the monomorphic appearance of most other malignant lymphomas. Mature lymphocytes, eosinophils, plasma cells, and histiocytes may all be present in greater or lesser amount, depending on the microscopic type. Many of the Reed–Sternberg cells are surrounded by T lymphocytes arranged in a rosettelike fashion.

Most cases of classical Hodgkin lymphoma and all cases of NLPHL are derived from B cells,[417–420] and approximately 40% of cases of classical Hodgkin lymphoma cases are associated with EBV infection.[421] Individuals with a history of infectious mononucleosis have an increased incidence of Hodgkin lymphoma;[422,423] patients with Hodgkin lymphoma have an altered antibody pattern to EBV prior to diagnosis;[424] marked phenotypic similarities exist between infectious mononucleosis and Hodgkin lymphoma;[425] and EBV genomes have been identified in Reed–Sternberg cells at least 40% of the cases (particularly in the mixed cellularity subtype, in young patients, and/or in developing countries) (Fig. 37.45).[426–430] There is also evidence for a genetic susceptibility factor.[431]

Gross Features

Except for the very early stages, lymph nodes involved by Hodgkin lymphoma are enlarged, sometimes massively so. The gross appearance is somewhat dependent on the microscopic subtypes (see later section). The consistency varies from soft to hard depending on the amount of fibrosis. Some degree of nodularity is often appreciated, particularly in the nodular sclerosis form (Fig. 37.46). Foci of necrosis may be present. Except for NLPHL, the cut surface of the node has a more heterogeneous appearance than most non-Hodgkin lymphomas. In advanced cases, several nodes from the same group become matted together, a feature spectacularly demonstrated in the drawing that accompanied Hodgkin's classic article.

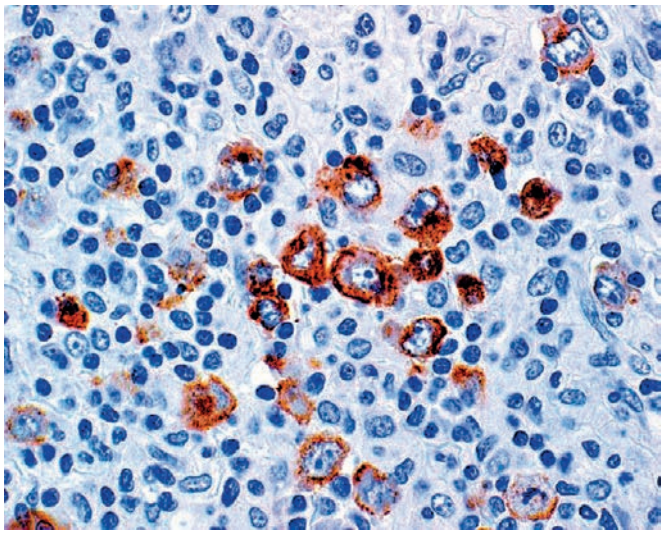

Figure 37.45 Presence of the EBV in a the neoplastic cells of Hodgkin lymphoma as demonstrated immunohistochemically by the detection of LMP1 antigen.

Classical Hodgkin Lymphoma

Reed–Sternberg Cell

The classic Reed–Sternberg cell, as seen in all subtypes of classic Hodgkin lymphoma (but not in NLPHL, see later), is a large cell (20–50 μm in diameter or more) with abundant weakly acidophilic or amphophilic cytoplasm, which may appear homogeneous or granular and which lacks a pale zone in the Golgi area (Fig. 37.47). The nucleus is bilobed or polylobed so that the cell appears binucleated or multinucleated; it is possible that in some cases bona fide

Figure 37.46 **A** and **B,** Gross appearance of lymph nodes involved by Hodgkin lymphoma. Note nodularity and sclerosis.

For personal use only. No other uses without permission. Copyright ©2017. Elsevier Inc. All rights reserved.

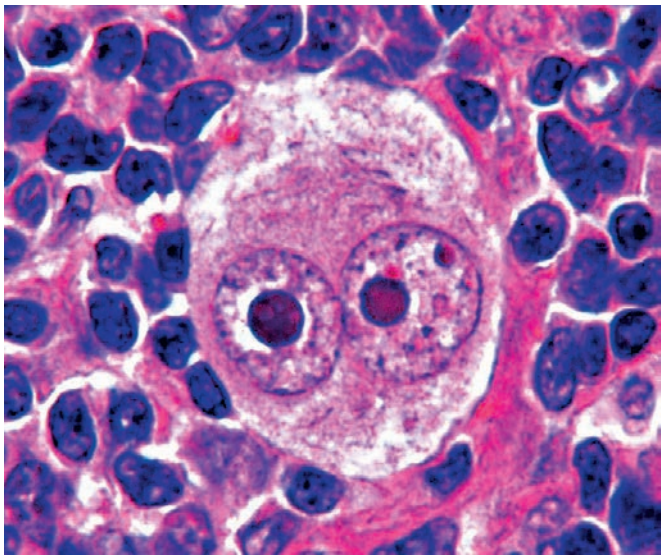

Figure 37.47 Spectacular example of a Reed–Sternberg cell. (Courtesy of Dr. Fabio Facchetti, Brescia, Italy.)

binucleation or multinucleation actually occurs (Fig. 37.48). The nuclear membrane is thick and sharply defined. The nuclear pattern is usually vesicular but with some coarse chromatin clumps scattered throughout. There is a very large, variously shaped, but usually rounded, highly acidophilic central nucleolus surrounded by a clear halo. In the most typical example of the Reed–Sternberg cell, the two nuclear lobes face each other ("mirror image"), resulting in the oft-cited "owl eye" appearance. When multilobation occurs, the appearance has been likened to that of an "egg basket." Cells with this set of features but lacking nuclear lobation have been referred to as mononuclear variants of Reed–Sternberg cells or Hodgkin cells. It has been stated that the minimal requirement for a diagnostic Reed–Sternberg cell is a bilobed nucleus in which at least one of the lobes has a prominent acidophilic nucleolus. At the other end of this spectrum is the Reed–Sternberg cell of giant size and highly pleomorphic hyperchromatic nuclei, having an appearance such as to simulate the cells of anaplastic carcinoma or one of the pleomorphic sarcomas. Another type of Reed–Sternberg cell, characterized by a darkly staining and retracted quality, is referred to as the mummified or necrobiotic variant and appears to be the morphologic expression of apoptosis (Fig. 37.49). Additional morphologic variations of Reed–Sternberg cells exist, and these will be discussed with the various types of Hodgkin lymphoma.

The Reed–Sternberg cell of Hodgkin lymphoma needs to be distinguished from other multinucleated cells that may be present in lymph nodes. Megakaryocytes can simulate it closely in hematoxylin–eosin-stained sections, but they can be identified by the presence of a strongly PAS-positive substance in their cytoplasm and their different immunophenotype, which includes positivity for Factor VIII–related antigen and CD61. Cells morphologically very similar to Reed–Sternberg cells, representing pleomorphic immunoblasts, can be seen in infectious mononucleosis and other viral diseases.[221] Neoplastic cells from a variety of epithelial and mesenchymal tumors also can resemble Reed–Sternberg cells.[432] Finally, some malignant lymphomas of non-Hodgkin type may be accompanied by cells with the appearance of Reed–Sternberg cells. In all of these disorders—and especially in the lymphomas—it is of the utmost importance to examine not only the putative Reed–Sternberg cells but also the background in which they are situated. The more cytologically atypical the lymphoid population, the less likely is the diagnosis of Hodgkin lymphoma. Despite these fairly distinctive morphologic features, a diagnosis of Hodgkin lymphoma is no longer made based on morphology alone and should be confirmed by demonstration of the characteristic immunophenotype of the neoplastic cells (see later).

The immunohistochemical profile of the Reed–Sternberg cell and mononuclear variants in classic Hodgkin lymphoma have been summarized in numerous studies.[433–447] While variability in antigen expression exists, immunohistochemical studies, usually by paraffin section immunohistochemistry, are essential for proper diagnosis and to exclude disorders that may morphologically mimic classical Hodgkin lymphoma. The vast majority of cases are CD30 positive (Fig. 37.50), and caution should be taken if there is not fairly strong expression of CD30 in most if not all atypical large cells. CD15 expression, in membrane, Golgi, or cytoplasmic patterns, is reported in up to 80% of cases but appears to be slightly less common in the author's experience. The neoplastic cells of classical Hodgkin lymphoma are CD45 negative, but interpretation of CD45 staining is often difficult unless large numbers of back-to-back neoplastic cells are present in the specimen. Although classical Hodgkin lymphoma is usually derived from a B cell, expression of B-cell antigens is inconsistent and typically variable. CD20 expression is reported in approximately 20% of cases, but even those cases show variable expression with some neoplastic cells usually negative. A finding of strong and uniform CD20 expression should raise consideration for an alternative diagnosis. The B-cell transcription factor PAX5 demonstrates weak nuclear positivity in at least 90% of cases, but expression of other transcription factors, specifically OCT2 and BOB1, is usually not present or minimal. Individual pan–T cell markers may rarely be expressed, but strong expression of multiple T-cell antigens should suggest a T-cell neoplasm.

Molecular studies are usually of limited utility in the diagnosis of classical Hodgkin lymphoma. Most cases yield a germline configuration for immunoglobulin heavy and light chain genes and the T-cell receptor genes, but this simply results from a dilution factor by the non-neoplastic cells; indeed, studies of cases with an increased number of Reed–Sternberg cells and their variants show clonal rearrangements, usually of the IGH,[448–452] while cases studied after microdissection also reveal evidence of B-cell clonality.[417,420]

General and Clinical Features

Classical Hodgkin lymphoma accounts for 20%–30% of all malignant lymphomas in the United States and Western Europe but a much lower percentage in Japan and other Asian countries.[453] There is a wide range in age incidence, which varies according to geographic location. In the United States, there is a bimodal distribution, with a peak at 15–40 years and a second, smaller peak in the seventh decade. In Japan, the peak in young adulthood is absent. In poorly developed countries, there is a high incidence in children, a relatively low incidence in the 15- to 40-year age group, and a third peak later in life.[454,455] There is a male preponderance (approximately 1.5 : 1) in all microscopic types except nodular sclerosis. The disease may present in a variety of ways, the most common (approximately 90% of the cases) being painless enlargement of superficial (usually cervical) lymph nodes. Fever, night sweats, and loss of weight (so-called B symptoms) occur in approximately 25% of the cases; their presence influences the clinical staging. Pruritus is also frequent.

Nodular sclerosis is by far the most common type of Hodgkin lymphoma in the United States. It characteristically presents in the neck and/or mediastinum of young females.[456] Lymphocyte depletion Hodgkin lymphoma may present in adults or elderly patients as a febrile illness with pancytopenia or lymphocytopenia, hepatomegaly, abnormal liver function tests, and no peripheral lymphadenopathy,[457] or it may manifest the usual clinical presentation of Hodgkin

For personal use only. No other uses without permission. Copyright ©2017. Elsevier Inc. All rights reserved.

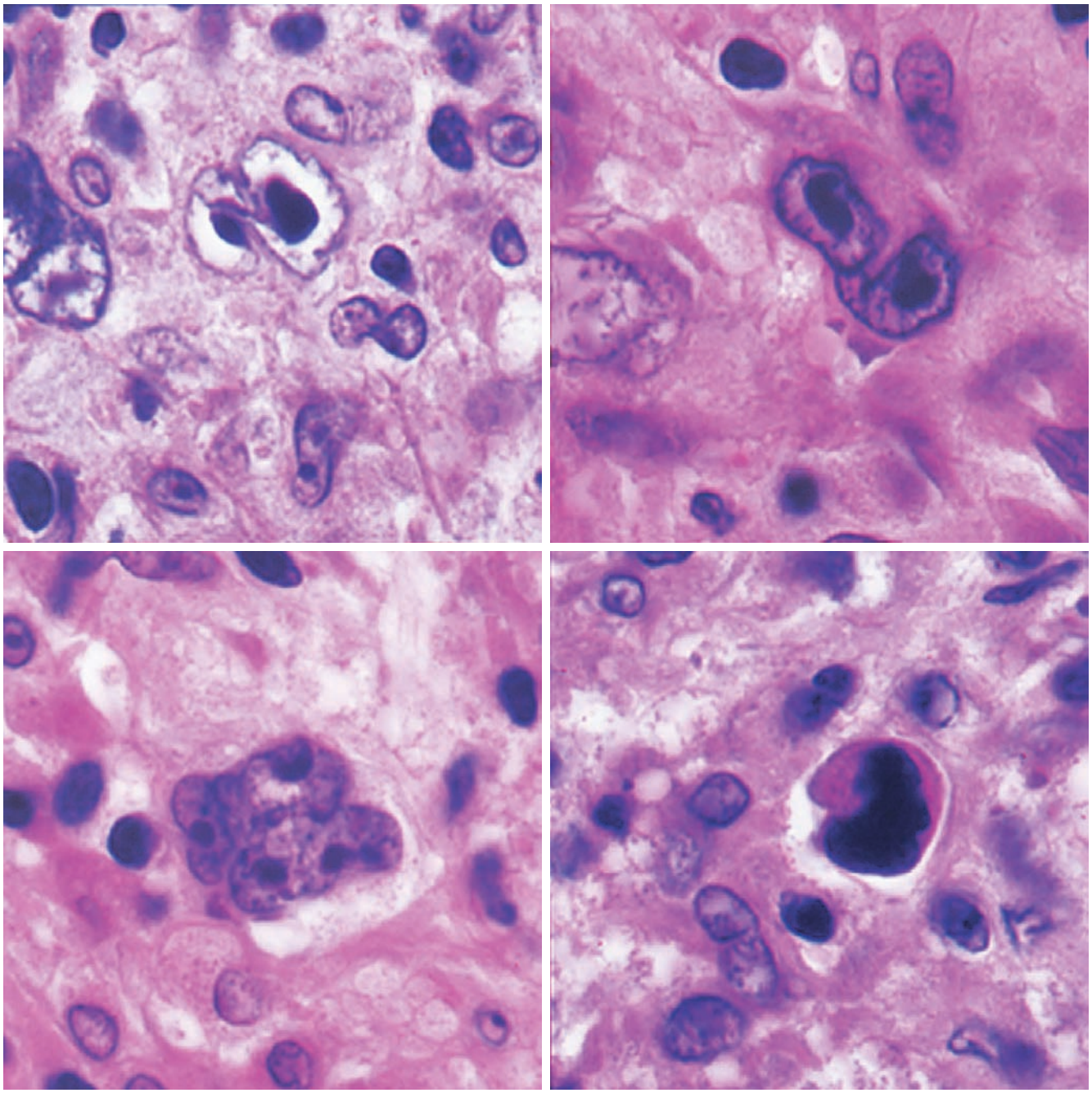

Figure 37.48 Various Appearances of Reed–Sternberg Cells. The cell located at the bottom right has a "mummified" appearance.

lymphoma.[458] This form is extremely rare in children, in whom nodular sclerosis and lymphocyte predominance predominate greatly.[459,460]

Mediastinal involvement is the rule in nodular sclerosis and is inconstant in mixed cellularity and lymphocyte depletion.[461] The risk of abdominal involvement is greater in patients with B symptoms and in lymphocyte depletion or mixed cellularity types; the lowest risk is for asymptomatic females with nodular sclerosis histology (6%).[462]

The diagnosis of Hodgkin lymphoma should be questioned for any lymphoma initially involving Waldeyer's ring, the skin, and the gastrointestinal tract or presenting below the diaphragm. Most of these cases are examples of non-Hodgkin lymphomas with Hodgkin-like cells.

Patients with Hodgkin lymphoma often have defects in cellular immunity, which leads to an increased susceptibility to some infections.[463] However, a diagnosis of Hodgkin lymphoma should be viewed with suspicion if it presents as a complication of a natural immune deficiency, immunosuppression, or other immune diseases. Although clear cases of this association exist (particularly in patients with ataxia–telangiectasia and with HIV infection),[464,465] most of these cases actually represent other neoplasms. HIV-associated Hodgkin lymphoma tends to present at a high stage and to run an aggressive clinical course.[466]

For personal use only. No other uses without permission. Copyright ©2017. Elsevier Inc. All rights reserved.

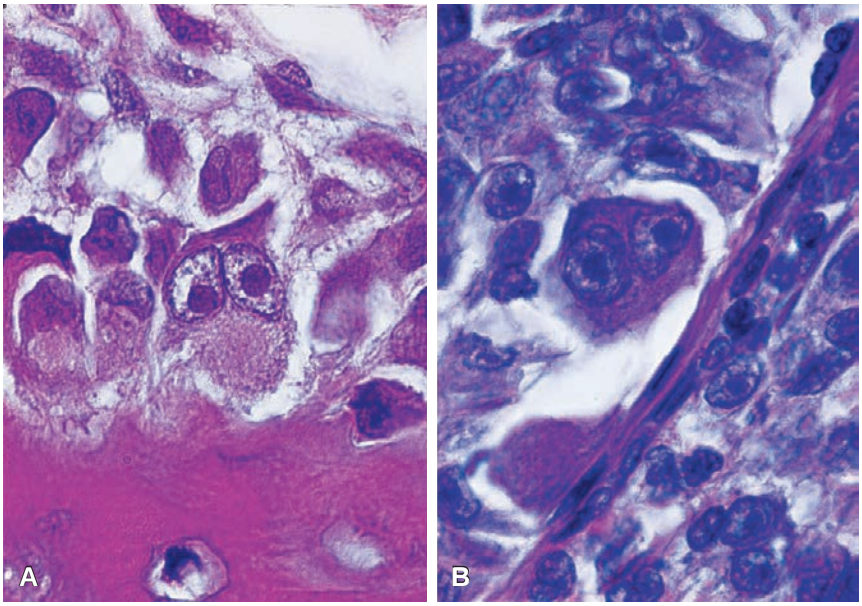

Figure 37.49 Reed–Sternberg-like cells in malignant melanoma (**A**), and osteoblastoma (**B**).

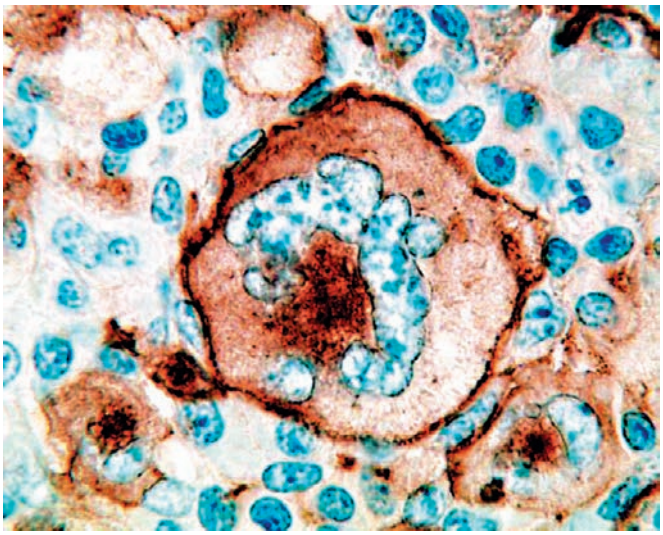

Figure 37.50 Membrane and Golgi-type immunoreactivity for CD30 in a Reed–Sternberg cell. (Courtesy of Dr. Fabio Facchetti, Brescia, Italy.)

Spread

Most cases of classical Hodgkin lymphoma begin in lymph nodes above the diaphragm and spread from there to other lymph node groups and to extranodal sites. Important information has been acquired in regard to the frequency and significance of this spread as a result of an aggressive diagnostic approach, particularly with the use of laparotomy as a routine staging procedure.[467,468]

1. *Direct extension*. The disease may spread to the perinodal tissues, sometimes extensively, and result in a fusion of the involved nodes. In advanced cases, direct invasion of skin, skeletal muscle, and other sites can occur. Mediastinal Hodgkin lymphoma can extend by continuity into the large vessels, lung, and chest wall.[469]
2. *Other lymph node groups*. Most cases of classical Hodgkin lymphoma spread by involvement of adjacent lymph node groups.[470] This contiguous manner of spread is particularly common in the nodular sclerosis type.[469] Nodal spread has been evaluated with lymphangiogram, CT scan, and staging laparotomy. When it was carried out with some frequency, lymphangiography had an overall diagnostic accuracy in excess of 90%; it was more effective in detecting involvement below the level of the second lumbar vertebra but inconsistent for nodes situated higher in the periaortic area. Approximately 30% of patients with negative lymphangiograms in whom the para-aortic nodes were left untreated later demonstrated disease below the diaphragm.[471] Of the nodes biopsied at laparotomy during the course of a staging procedure, the most likely to be involved were those located in the splenic hilum and retroperitoneum. Mesenteric nodes are almost always spared.
3. *Spleen*. A spleen weighing 400 g or more is practically always histologically positive. The converse is not true: spleens below this weight are involved in a high proportion of cases. The focal nature of the disease calls for a careful gross examination of this organ. The specimens should be sectioned throughout in thin slices, and every suspicious area should be examined microscopically. If no nodules are detected on gross inspection, the chances of finding Hodgkin lymphoma in random microscopic sections are negligible. Splenic involvement is thought to represent a critical stage in the spread of Hodgkin lymphoma and is an early manifestation of blood vessel dissemination. The approximate number of tumor nodules present in the spleen should be indicated because of their relation to prognosis; specifically, it should be stated whether there are five or more.
4. *Liver*. Hepatic disease is almost invariably associated with splenic and retroperitoneal lymph node involvement and with so-called B symptoms. Clinical assessment of liver involvement is quite unreliable. Care should be exercised in distinguishing involvement by Hodgkin lymphoma from benign lymphoid aggregates, some of which may show mild atypia.[472]
5. *Bone marrow*. This is discussed in Chapter 39.
6. *Others*. Practically any other organ can show secondary involvement by Hodgkin lymphoma, such as the lung, skin, gastrointestinal tract, and central nervous system (see respective chapters).

For personal use only. No other uses without permission. Copyright ©2017. Elsevier Inc. All rights reserved.

Microscopic Types

A variety of classification systems for Hodgkin lymphoma have been proposed and historically accepted,[473–475] with numerous histologic subtypes described. The 2016 WHO classification, however, is the currently accepted nomenclature system for this disease and should be used for all cases.[407] NLPHL is now recognized to be morphologically, biologically, and clinically distinct from more traditional types of Hodgkin lymphoma, termed classical Hodgkin lymphoma, and it is described separately later. With current therapy, the histologic subtypes of classical Hodgkin lymphoma have no clinical or prognostic significance and, especially on small needle biopsies, a simple diagnosis of "classical Hodgkin lymphoma" is appropriate for patient care.

As mentioned, the category of classical Hodgkin lymphoma subsumes all types of Hodgkin lymphoma except for NLPHL. It is regarded as a nosologic entity because of the similar immunophenotype of the tumor cells. The differences consist in sites of involvement, clinical features, growth pattern, presence of fibrosis, composition of cellular background, number and degree of atypia of the tumor cells, and prevalence of EBV infection. These subtypes are nodular sclerosis, mixed cellularity, lymphocyte rich, and lymphocyte depleted.

Nodular sclerosis Hodgkin lymphoma is characterized in its fully developed stage by broad bands of birefringent collagen separating the lymphoid tissue in well-defined nodules (Fig. 37.51). These fibrous bands, which have a birefringent quality when examined under polarized light, often center around blood vessels. In addition to the classic Reed–Sternberg cell, nodular sclerosis Hodgkin lymphoma also displays a variant known as *lacunar* cells (Fig. 37.52). This cell type is quite large (40–50 μm in diameter), with an abundant clear cytoplasm and multilobulated nuclei having complicated infoldings and nucleoli of smaller size than those of the classic Reed–Sternberg cell. The "frail" cytoplasm of these cells is retracted close to the nuclear membrane so that the cell appears to be floating in a "lacuna." This is the result of an artifact induced by formalin fixation, inasmuch as it is absent in tissues fixed in B5 or Zenker. In some cases, there is clustering of these lacunar cells, particularly around areas of necrosis. They form sheets and cohesive nests, to the point that a mistaken diagnosis of large cell non-Hodgkin lymphoma, carcinoma, germ cell tumor, or thymoma can be made. Cases of nodular sclerosis Hodgkin lymphoma showing prominence of this feature have been referred to as the *syncytial*, *sarcomatoid*, or *sarcomatous* variant.[476]

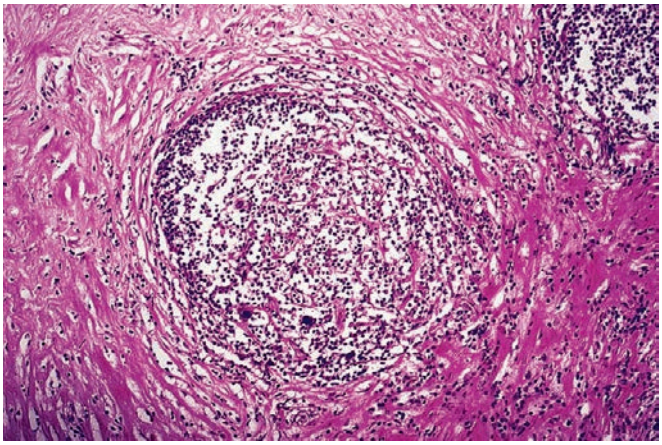

Figure 37.51 A Typical Case of Nodular Sclerosis Hodgkin Lymphoma. The lymphoid nodule is encased in dense fibrohyaline tissue.

The composition of the non-neoplastic infiltrate varies widely, to the point that some authors have proposed to subdivide nodular sclerosis Hodgkin lymphoma into lymphocyte predominant, mixed cellularity, and lymphocyte depletion categories, and this subdivision carried some prognostic implications in the past. Along similar lines, the British National Lymphoma Investigation group proposed to divide cases of nodular sclerosis Hodgkin lymphoma into two grades. In their scheme, cases were assigned to the allegedly more aggressive grade II if any of these features are present: (1) a "reticular" or "pleomorphic" pattern of lymphocytic depletion in over 25% of the cellular nodules; (2) a "fibrohistiocytic" pattern of lymphocyte depletion in over 80% of the cellular nodules; and (3) the presence of numerous bizarre and highly anaplastic Reed–Sternberg and Hodgkin cells without lymphocyte depletion in over 25% of the nodules.[477] Grade II lesions include the already mentioned "syncytial" variant of other authors. With current therapy, these subtypes of nodular sclerosis Hodgkin lymphoma have no prognostic significance and such subtyping is not necessary.[478]

By electron microscopy, nodular sclerosis Hodgkin lymphoma shows abundant collagen fibers together with myofibroblasts;[479] it has been suggested that the latter contribute to the retraction seen in this condition. In regard to the fibrosis, it should be kept in mind that practically all types of Hodgkin lymphoma can exhibit some degree of this change, particularly after therapy and recurrent cases of classical Hodgkin lymphoma should not be further subtyped.

In **mixed cellularity** Hodgkin lymphoma, a large number of eosinophils, plasma cells, and atypical mononuclear cells are admixed with classic Reed–Sternberg cells, which tend to be numerous. Focal necrosis may be present, but fibrosis should be minimal or absent (Fig. 37.53). This type tends to occur more frequently in the head and neck region and be associated with EBV infection of the Hodgkin cells.

The **lymphocyte-rich** type is characterized by the presence of Reed–Sternberg cells scattered against a nodular (most commonly) or diffuse background, largely composed of small B lymphocytes (in contrast to the striking T-cell background of other classical Hodgkin lymphoma types) and practically devoid of eosinophils and neutrophils.[480] The main differential diagnosis is with NLPHL, and is primarily based on the presence of cells with the typical morphologic and immunohistochemical features of classic Hodgkin cells.

The **lymphocyte-depletion** group, which comprises less than 5% of all cases of Hodgkin lymphoma, includes two morphologically different subtypes, designated as "diffuse fibrosis" and "reticular" in the original Lukes classification. In the diffuse fibrosis subtype, the number of lymphocytes and other cells progressively decreases as the result of heavy deposition of collagen fibers. The reticular subtype is characterized by a very large number of diagnostic Reed–Sternberg cells (many of them of bizarre configuration) among atypical mononuclear cells and other elements (Fig. 37.54). Areas of necrosis are more common than in other types. The "reticular" subtype of lymphocyte depletion Hodgkin lymphoma needs to be distinguished from non-Hodgkin lymphoma of large cell type (including anaplastic large cell lymphoma [ALCL]) and from the variant of nodular sclerosis Hodgkin lymphoma with aggregates of lacunar cells.[481]

The immunophenotypic profile of the neoplastic cells in classic Hodgkin lymphoma is described in a preceding section on "Reed–Sternberg cells." The background lymphocytes are predominantly T cells with the exception of lymphocyte-rich classical Hodgkin lymphoma.

While relapsed Hodgkin lymphoma often retains the same immunophenotypic and morphologic features as the primary disease, radiation and chemotherapy may result in morphologic

For personal use only. No other uses without permission. Copyright ©2017. Elsevier Inc. All rights reserved.

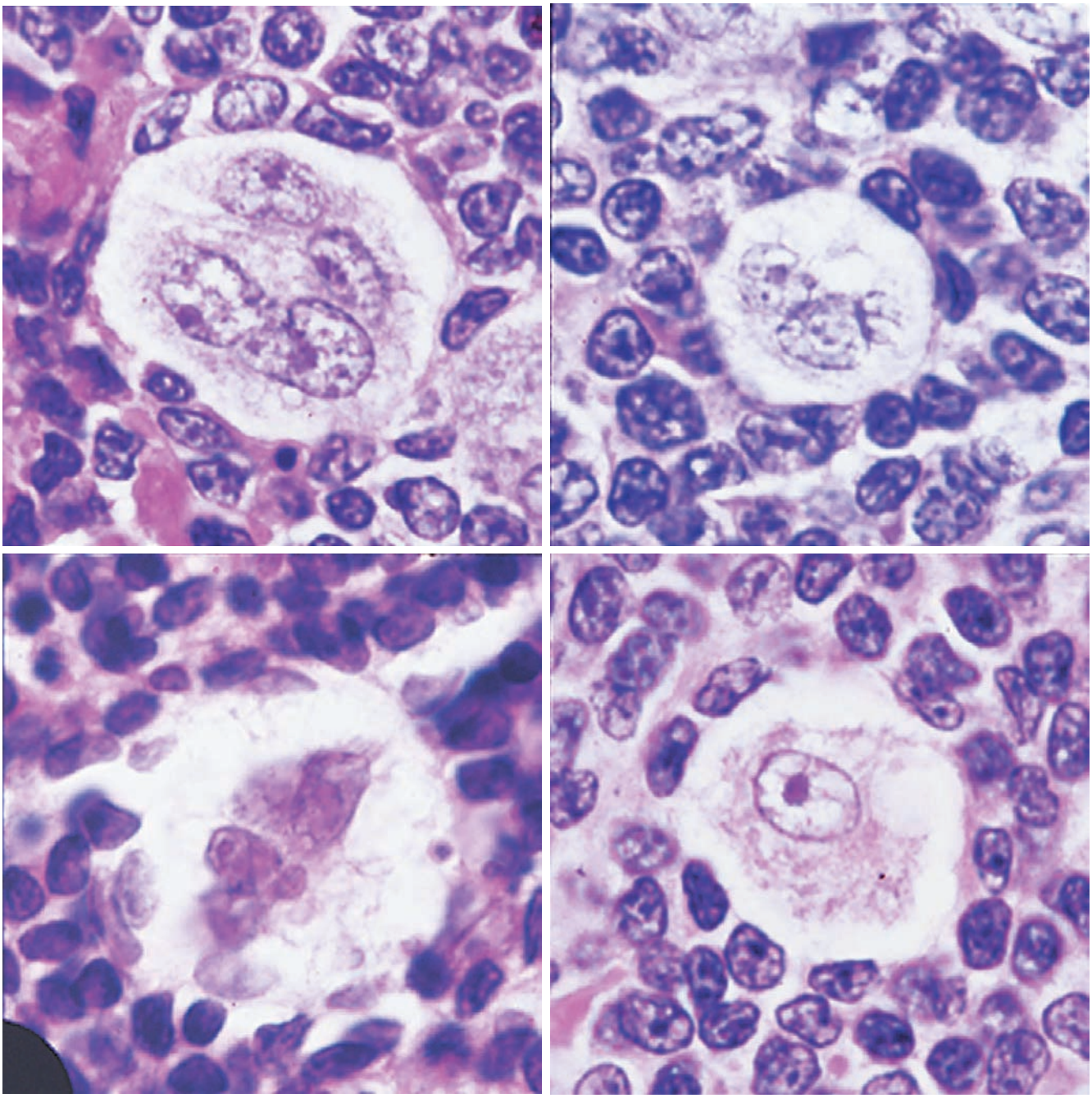

Figure 37.52 Various appearances of lacunar cells in nodular sclerosis Hodgkin lymphoma.

changes that differ from the untreated disease.[482–484] Additionally, some cases relapse with higher numbers of neoplastic cells, more typical of lymphocyte-depleted Hodgkin disease, but an attempt to reclassify relapsed disease is confusing and not advised. Such cases should be studied by immunohistochemistry to confirm that they represent recurrent disease rather than a new neoplasm but are probably best diagnosed simply as recurrent classical Hodgkin lymphoma.

Other Microscopic Features

There are some microscopic variations on the theme of classical Hodgkin lymphoma worth mentioning, mainly because lack of knowledge of their occurrence may result in mistaken diagnoses.

1. *Foamy macrophages*. Clumps of foamy macrophages resulting in a xanthogranulomatous appearance may be found, particularly in the nodular sclerosis form.[485]
2. *Eosinophils*. In some instances, the intensity of eosinophilic infiltration is massive and accompanied by so-called eosinophilic microabscesses. Such cases may be confused with LCH, hypersensitivity reaction, or "allergic granulomatosis."
3. *Other inflammatory cells*. S100 protein–positive dendritic cells,[486] mast cells,[487] and monocytoid B cells[488] may be very numerous.
4. *Focal interfollicular involvement*. In the early stages of the disease, only focal involvement of a lymph node may be encountered,[489] often restricted to the paracortical region between florid

For personal use only. No other uses without permission. Copyright ©2017. Elsevier Inc. All rights reserved.

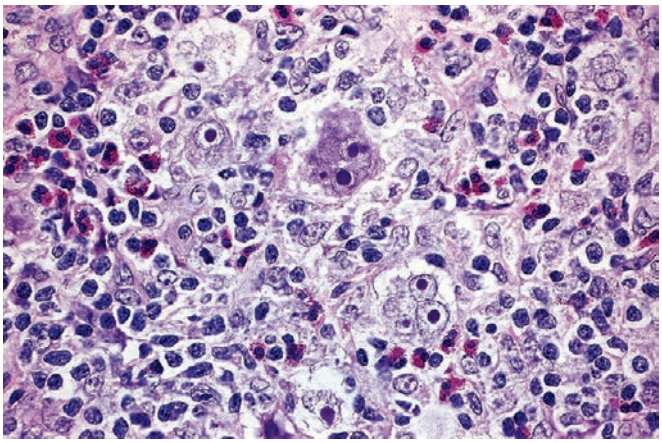

Figure 37.53 Mixed Cellularity Hodgkin Lymphoma. Several diagnostic Reed–Sternberg cells are seen admixed with a polymorphic lymphoid infiltrate rich in eosinophils.

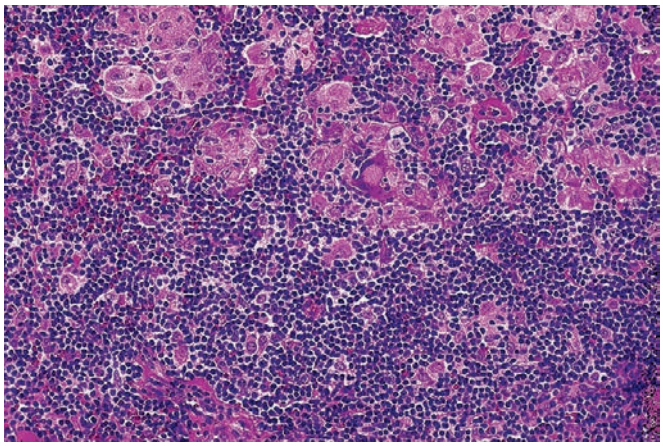

Figure 37.55 Hodgkin Lymphoma Accompanied by Numerous Sarcoid-Like Granulomas. The presence of this component can obscure the basic nature of the disease.

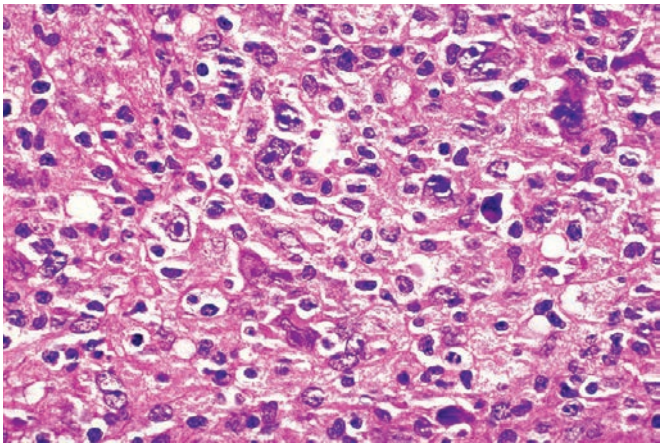

Figure 37.54 Lymphocyte Depletion Type of Hodgkin Lymphoma. Numerous atypical cells are present in a densely fibrotic stroma. Lymphocytes are scanty.

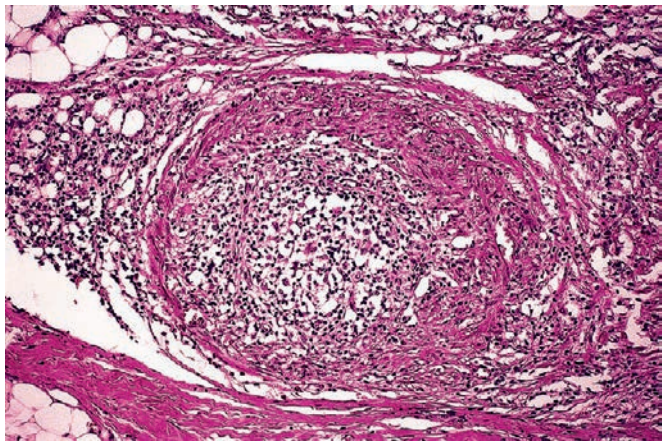

Figure 37.56 Blood Vessel Invasion in Hodgkin Lymphoma.

hyperplastic follicles; this pattern has been referred to as *interfollicular Hodgkin lymphoma*.[490]

5. *Follicular involvement*. Sometimes the nodal involvement by Hodgkin lymphoma is mainly in the germinal centers, the appearance being reminiscent of NLPHL.[491]
6. *Castleman disease–like features*. Cases of Hodgkin lymphoma may be accompanied or preceded by a plasmacytic infiltrate and abnormalities of germinal centers closely resembling those seen in plasma cell type Castleman disease, probably attributable to interleukin-6 secretion by Reed–Sternberg cells.
7. *Fibrosis*. In cases of nodular sclerosis Hodgkin lymphoma but sometimes also in other types, the amount of fibrosis can be such as to simulate the appearance of one of the inflammatory fibroscleroses (such as sclerosing mediastinitis or retroperitoneal fibrosis).
8. *Spindle cell proliferation*. In rare cases of Hodgkin lymphoma, there is a proliferation of oval to spindle cells of such a degree as to simulate fibrosarcoma, malignant fibrous histiocytoma, or a follicular dendritic cell tumor; such lesions have been referred to as **fibrosarcomatous or fibroblastic Hodgkin lymphoma**. Some of these spindle cells have a degree of nuclear atypia such as to indicate their neoplastic nature and relationship with Reed–Sternberg and Hodgkin cells; indeed, most of these lesions would be included in the grade II category of nodular sclerosis Hodgkin lymphoma proposed by the British National Lymphoma Investigation Group. Others are of a reactive nature and stromal derivation (i.e. made up of fibroblasts and myofibroblasts).[492]
9. *Noncaseating granulomas*. These formations are sometimes present in nodes and other organs involved by Hodgkin lymphoma. Occasionally they are so numerous as to obscure the diagnostic features of the disease (Fig. 37.55). In other instances, these granulomas may be seen within otherwise uninvolved organs of patients with Hodgkin lymphoma.[77] Their significance is unknown. Perhaps they represent an expression of delayed hypersensitivity. Some seen in the past were reactions to the contrast material used in lymphangiography.[493] Their presence does not indicate involvement of that organ by Hodgkin lymphoma and should therefore not influence the staging criteria. Actually, it has been suggested that, within a given stage, the presence of these granulomas is associated with a better prognosis.[494]
10. *Vascular invasion*. Blood vessel infiltration has been detected microscopically in 6%–14% of the cases of Hodgkin lymphoma by the use of elastic tissue stains (Fig. 37.56).[495] This finding is said to be associated with an increased incidence of extranodal organ involvement,[496] but the statement and the very validity of the observation have been questioned.

For personal use only. No other uses without permission. Copyright ©2017. Elsevier Inc. All rights reserved.

Molecular Genetics

In almost all cases of classical Hodgkin lymphoma, clonal immunoglobulin gene rearrangements can be demonstrated in microdissected neoplastic (Reed–Sternberg) cells or tissue samples rich in neoplastic cells; only exceptionally are clonal T-cell receptor gene rearrangements present instead.[417,497–499] The variable regions of the immunoglobulin genes frequently show hypermutation but not ongoing mutations. Remarkably, immunoglobulin mRNA transcripts are usually absent, which may result from functional defects in immunoglobulin gene regulatory elements or crippling mutations in the immunoglobulin genes.[500,498] That is, the neoplastic cells are compatible with germinal center B cells that have lost the capacity to express a functional antigen receptor, but which differ from their normal counterpart in having been rescued from apoptosis by various mechanisms, such as presence of EBV or aberrant activation of the NFκB pathway.[501–503]

Cytogenetic studies of classic Hodgkin lymphoma reveal complex karyotypes, commonly featuring hyperdiploidy or hypertetraploidy.[504,505] Recent FISH studies have shown rearrangements of the immunoglobulin genes in approximately 20% of cases, involving variable partners genes which may include *BCL2*, *BCL3*, *BCL6*, *REL*, *MYC*, *MHCT2A*, and unidentified genes,[506–508] and mutations of other genes, including NFκB.[509,510]

About 40% of cases of classic Hodgkin lymphoma are associated with EBV, which can be demonstrated by EBV-LMP1 immunohistochemistry or EBV-encoded early RNA (EBER) in situ hybridization.[511] The association with EBV is stronger at the extremes of age, that is children/young adults and elderly adults, and in the mixed cellularity subtype. Of note, the overall frequency of EBV association is much higher in individuals with immunodeficiency (approximately 100%) or from developing countries (80%–100%).[512–515]

Nodular Lymphocyte Predominant Hodgkin Lymphoma

In NLPHL, the predominant cell is an irregular, medium-sized B lymphocyte (L&H or popcorn cell), with or without an accompanying population of benign-appearing histiocytes.[516,517] Postcapillary venules with high endothelium may be prominent.[518,519] The lymph node architecture is partially or totally effaced, and the infiltrate has a variously well-developed nodular pattern of growth.[520] The nodularity may be so pronounced as to simulate on low power the appearance of follicular lymphoma; however, the nodules of NLPHL are more irregular in size and staining quality, and the admixture of lymphocytes and epithelioid cells gives them a mottled appearance (Fig. 37.57). A rim of uninvolved or hyperplastic lymphoid tissue which may include progressively transformed germinal centers may be present but reactive follicles are not admixed with the large tumor nodules. Eosinophils, plasma cells, and foci of fibrosis are scanty or absent. Classic Reed–Sternberg cells are usually absent. One sees instead a variable but usually large number of a type of Reed–Sternberg cell (the L&H cell, LP cell, or "popcorn" cell) characterized by a folded, multilobed nucleus with smaller nucleoli. These cells are most commonly found within the nodules but tend to also spill into the internodular areas. If numerous typical Reed–Sternberg cells are found in a node with a lymphocyte predominant background, the case probably belongs in the classical Hodgkin lymphoma category (lymphocyte-rich subtype). Occasionally, the L&H cells predominate at the margins of the nodules, creating a "wreath" around them. In others, they may cluster in large confluent sheets resembling diffuse large cell lymphoma.[521]

Poppema et al.[61,522,523] first proposed that cases of NLPHL arise from B-cell regions of the node and specifically from progressively transformed germinal centers. They supported their theory by showing that the L&H cell that is characteristic of this condition is of B-cell lineage, and this has been confirmed by many others.[524–526] L&H cells express the pan–B-cell markers CD19, CD20, CD22, CD79A, PAX5, and OCT2.[525,527,528] They are also positive for CD45RB (LCA) but consistently negative for T-cell markers. They commonly express epithelial membrane antigen (EMA) and generally lack CD30 and CD15 expression. The neoplastic cells characteristically occur within nodules of small B cells (CD20+) with expanded follicular dendritic cell networks and spill out into the T-cell zones. OCT2 nuclear staining is usually strong in the tumor cells and highlights their expansion beyond the B-cell nodules. These "popcorn" cells are

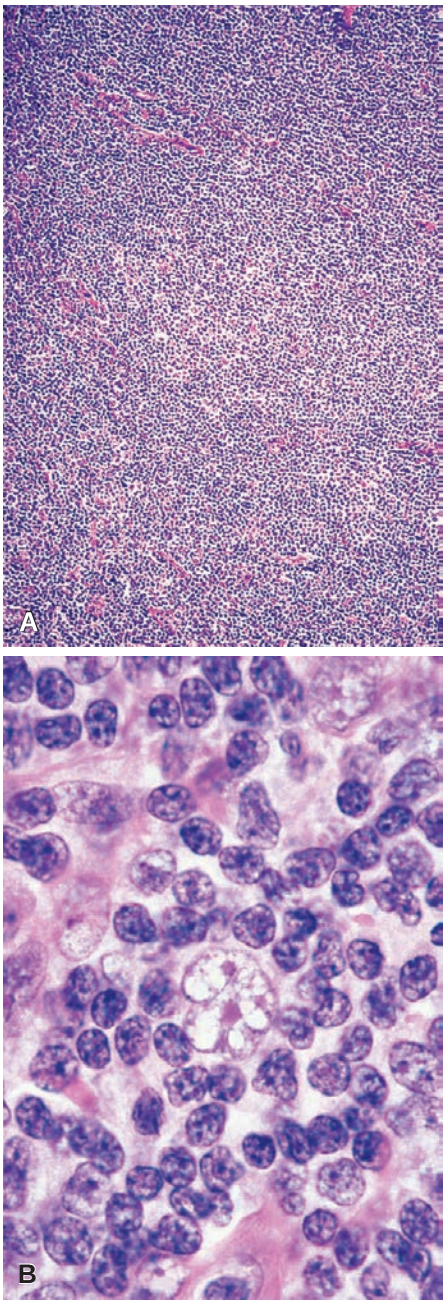

Figure 37.57 Lymphocyte Predominant Hodgkin Lymphoma. **A**, Low-power view showing a mottled appearance of the node. **B**, High-power view showing the lymphocytic and/or histiocytic (L&H) type of cell ("popcorn" cell) that is characteristic of this condition.

For personal use only. No other uses without permission. Copyright ©2017. Elsevier Inc. All rights reserved.

typically rosetted by follicular helper T (TFH) cells which express CD3, PD1, BCL6, and CD57.[529,530]

NLPHL should be sharply separated (also on epidemiologic and clinical grounds) from classical Hodgkin lymphoma, even if occasionally the two are seen to coexist.[531,532] Although usually a rather indolent tumor, some cases will transform to DLBCL and such cases have been demonstrated to be clonally related.[533]

The differential diagnosis between NLPHL and T-cell/histiocyte-rich B-cell lymphoma, which is discussed in more detail later, may not be resolvable on small biopsies. A nodular pattern with background small B cells and associated follicular dendritic cells networks support NLPHL when this differential diagnosis arises.

Molecular Genetics

Microdissected neoplastic (L&H/LP) cells exhibit clonal rearrangements of the immunoglobulin genes, which show hypermutation and ongoing mutations, compatible with transformed antigen-selected germinal center B cells.[418,502,534,535] The rearranged immunoglobulin genes are functional, and can be transcribed into immunoglobulin mRNA, and further translated to immunoglobulin.[535,536]

Cytogenetic studies reveal complex karyotypes, often in the diploid range, with the commonest abnormalities being gain or partial gain of 1q, loss of chromosome 4q28–q32, and rearrangement involving 3q27 (shown to implicate *BCL6*, which is fused with a variety of partner genes, including the *IGH* gene at 14q32).[537–539] Array comparative genomic hybridization (CGH) studies have demonstrated gains in 2p16.1, the site of *REL*, and loses at 2p11.2 and 9p11.2, features similar to T-cell/histiocyte-rich large B-cell lymphoma.[540]

Although the vast majority of cases of NLPHL are not associated with EBV, a few rare cases have been recently reported.[541,542]

Non-Hodgkin Lymphoma

The 2016 WHO classification contains numerous categories of non-Hodgkin lymphomas that are listed in Box 37.1. While most of these involve lymph nodes, some are primarily extranodal diseases and those are discussed in more detail in other chapters. As mentioned, the WHO classification is based on a combination of clinical features, morphology, immunophenotyping, and genetics to define disease entities; morphology alone is no longer sufficient to make a lymphoma diagnosis.

The non-Hodgkin lymphomas are grouped into general categories of B-cell lineage or T/NK-cell lineage diseases and these are further grouped into mature and precursor neoplasms. The precursor neoplasms represent lymphoblastic leukemias/lymphomas and are grouped together because of similarities in the disease despite variations in their clinical presentation (leukemic, tissue based, or both).

Precursor Lymphoid Neoplasms

Lymphoblastic lymphomas represent the tissue-based presentation of either T- or B-lymphoblastic leukemia/lymphoma. The leukemic presentations are discussed in more detail in Chapter 39. Most lymphoblastic leukemias are of precursor T-cell lineage.

Lymphoblastic lymphoma is seen primarily in children and adolescents, but it also occurs in adults.[543,544] T-lymphoblastic lymphoma has a distinctive clinical presentation. In approximately half of the cases there is a mediastinal mass in the thymic region (the old Sternberg sarcoma). The clinical course of the untreated disease is extremely aggressive, with rapid multisystem dissemination and development of a leukemic blood picture,[545] and death after a few months.[546] Grossly, the tumor is whitish and soft and often exhibits foci of hemorrhage and necrosis. Microscopically, there is a diffuse and relatively monomorphic pattern of proliferation, broken only by a focal starry sky appearance in some of the cases. The tumor often extends outside the node or thymus to invade the adipose tissue in a diffuse fashion. Permeation of the wall of blood vessels in a targetoid fashion is another characteristic feature. The neoplastic cells have scanty cytoplasm and a nucleus that has a round contour (instead of the angulated shape typical of follicular lymphoma) that, on close examination, shows in some cases the presence of delicate convolutions resulting from multiple small invaginations of the nuclear membrane. Oil-immersion examination of well-prepared, very thin sections is necessary to demonstrate this feature, which may be present in only a small percentage of the tumor cells or sometimes practically absent (Fig. 37.58).[546] The chromatin is finely stippled, and nucleoli are inconspicuous. Mitotic activity is extremely high. These convoluted cells are similar to the cerebroid cells of mycosis fungoides–Sézary syndrome (as one might assume from their similar names) but differ from the latter because the nuclear membrane is thinner, the chromatin more dispersed, and the invaginations more delicate. Actually, the need for distinction between these two cell types is more theoretical than real because of the fact that the two diseases are vastly different in their clinical presentation.

Remnants of thymus often are found in the mediastinal mass, and this may lead to a mistaken diagnosis of thymoma; in this regard, it should be remembered that thymoma is very infrequent in children and that, when it occurs, it is characterized by a population of small or activated lymphocytes but not convoluted ones. When lymphoblastic lymphoma spreads to lymph nodes, it preferentially involves the paracortical (thymic-dependent) zone.

The immunohistochemical hallmark of lymphoblastic lymphoma is TdT, a marker for precursor lymphoid cells. The precursor T-cell cases express pan–T antigens, such as CD1, CD2, CD7, cytoplasmic CD3, and CD43, but usually do not express surface CD3.[547] The latter feature is of importance if flow cytometry immunophenotyping is performed without study of cytoplasmic markers but is not a major concern by immunohistochemistry, with routinely detects cytoplasmic CD3. Approximately one-third of cases of T-lymphoblastic leukemia/lymphoma will express CD10, which may cause confusion with a B-cell lymphoma. CD34 expression may also be present and is useful for rare cases that demonstrate weak or negative TdT expression. Positivity is also consistently encountered for CD99.

Translocations involving the alpha and delta T-cell receptor loci at 14q11.2, the beta locus at 7q35, and the gamma locus at 7p14–15 with a variety of partner genes (such as *MYC*, *TAL1*, *RBTN1*, *RBTN2*, and *HOX11*), leading to a dysregulation of transcription of the latter, are relatively common in T-lymphoblastic leukemia/lymphoma. *NOTCH1* and/or NOTCH1 pathway mutations are identified in the majority of cases.[548] Rare cases may be associated with eosinophilia and translocations involving *FGFR1*, particularly t(8;13)(p11;q12). Such cases are considered a distinct entity in the WHO classification (myeloid/lymphoid neoplasms with *FGFR1* rearrangement) and may relapse with a significantly different immunophenotype.[549] While cases presenting as leukemia or as lymphoma are similar in most regards, one study has found upregulation of *BCL2*, *S1PR1*, and *ICAM1* in cases with a tissue-based presentation, suggesting a role in homing of tumor cells to tissue rather than marrow in these patients.[550]

In 15%–20% of the cases of lymphoblastic lymphoma, the tumor cells are precursor B cells expressing CD19 and CD79A and most are CD10 positive.[551] They also usually express TdT but not surface immunoglobulin, and many are CD20 negative. These cases usually do not present in the mediastinum. These are predominantly extranodal tumors with low propensity for leukemic involvement.[552] The genetic changes of B-lymphoblastic lymphoma are similar to

For personal use only. No other uses without permission. Copyright ©2017. Elsevier Inc. All rights reserved.

Box 37.1 2016 World Health Organization classification of mature lymphoid neoplasms

Provisional entities are in italics. Only entities that primarily involve lymph nodes are discussed in this chapter.

Mature B-cell neoplasms

Chronic lymphocytic leukemia/small lymphocytic lymphoma
Monoclonal B-cell lymphocytosis
B-cell prolymphocytic leukemia
Splenic marginal zone lymphoma
Hairy cell leukemia
Splenic B-cell lymphoma/leukemia, unclassifiable
  Splenic diffuse red pulp small B-cell lymphoma
  Hairy cell leukemia variant
Lymphoplasmacytic lymphoma
  Waldenström macroglobulinemia
Monoclonal gammopathy of undetermined significance (MGUS), IgM+
μ heavy chain disease
γ heavy chain disease
α heavy chain disease
MGUS, IgG/A+
Plasma cell neoplasms
Solitary plasmacytoma of bone
Extraosseous plasmacytoma
Monoclonal immunoglobulin deposition diseases
Extranodal marginal zone lymphoma of mucosa-associated lymphoid tissue (MALT-lymphoma)
Nodal marginal zone lymphoma
  Pediatric nodal marginal zone lymphoma
Follicular lymphoma
  In situ follicular neoplasia
  Duodenal-type follicular lymphoma
Pediatric-type follicular lymphoma
Large B-cell lymphoma with IRF4 rearrangement
Primary cutaneous follicle center lymphoma
Mantle cell lymphoma
  In situ mantle cell neoplasia
Diffuse large B-cell lymphoma (DLBCL), not otherwise specified
  Germinal center B-cell type
  Activated B-cell type
T-cell/histiocyte-rich large B-cell lymphoma
Primary DLBCL of the central nervous system
Primary cutaneous DLBCL, leg-type
Epstein–Barr virus (EBV) + DLBCL, NOS
EBV+ mucocutaneous ulcer
DLBCL associated with chronic inflammation
Lymphomatoid granulomatosis
Primary mediastinal (thymic) large B-cell lymphoma
Intravascular large B-cell lymphoma
ALK+ large B-cell lymphoma
Plasmablastic lymphoma
Primary effusion lymphoma
HHV8+ DLBCL, NOS
Burkitt lymphoma
Burkitt-like lymphoma with 11q aberration
High-grade B-cell lymphoma with *MYC* and *BCL2* and/or *BCL6* rearrangements
High-grade B-cell lymphoma, NOS
B-cell lymphoma, unclassifiable, with features intermediate between diffuse large B-cell lymphoma and classical Hodgkin lymphoma

Mature T-cell and NK cell neoplasms

T-cell prolymphocytic leukemia
T-cell large granular lymphocytic leukemia
Chronic lymphoproliferative disorder of NK cells
Aggressive NK cell leukemia
Systemic EBV+ T-cell lymphoma of childhood
Hydroa vacciniforme-like lymphoproliferative disorder
Adult T-cell leukemia/lymphoma
Extranodal NK-/T-cell lymphoma, nasal type
Enteropathy-associated T-cell lymphoma
Monomorphic epitheliotropic intestinal T-cell lymphoma
Indolent T-cell lymphoproliferative disorder of the GI tract
Hepatosplenic T-cell lymphoma
Subcutaneous panniculitis-like T-cell lymphoma
Mycosis fungoides
Sézary syndrome
Primary cutaneous CD30+ T-cell lymphoproliferative disorders
Primary cutaneous γδT-cell lymphoma
Primary cutaneous CD8+ aggressive epidermotropic cytotoxic T-cell lymphoma
Primary cutaneous acral CD8+ T-cell lymphoma
Primary cutaneous CD4+ small/medium T-cell lymphoproliferative disorder
Peripheral T-cell lymphoma, NOS
Angioimmunoblastic T-cell lymphoma
Follicular T-cell lymphoma
Nodal peripheral T-cell lymphoma with TFH phenotype
Anaplastic large cell lymphoma, ALK+
Anaplastic large cell lymphoma, ALK–
Breast-implant associated anaplastic large-cell lymphoma

Data from Swerdlow SH, Campo E, Pileri SA, Harris NL, Stein H, Siebert R, et al. The 2016 revision of the World Health Organization classification of lymphoid neoplasms. *Blood.* 2016;127(20):2375-2390.

B-lymphoblastic leukemia and are discussed in more detail in Chapter 39.

The differential diagnosis of lymphoblastic lymphoma includes the already mentioned thymoma when in a mediastinal location, as well as Ewing sarcoma/ peripheral neuroectodermal tumor (PNET), Burkitt lymphoma, and the blastoid variant of mantle cell lymphoma.[553–556] Other than thymoma, the detection of TdT should exclude the other possibilities. Non–mass-forming TdT-positive proliferations, however, may occur in lymph nodes and tonsils, often in association with other disorders, and are not by themselves evidence of lymphoblastic lymphoma.[557] Similarly, some more diffuse lymphoblastic proliferations, especially in extranodal sites, have been identified as having an indolent clinical course and correlation with clinical findings is essential for proper classification of these rare cases.[558]

Mature Lymphoid Neoplasms of B Lineage

Chronic Lymphocytic Leukemia/Small Lymphocytic Lymphoma and Related Disorders

Similar to the lymphoblastic neoplasms, CLL and SLL are considered to represent different manifestations of the same disease. CLL is discussed in more detail in Chapter 39 but now requires a presence of $\geq 5 \times 10^9$/L neoplastic cells in the blood[407] and is also usually accompanied by bone marrow involvement, with our without other tissue involvement. The term SLL is reserved for rare cases that present with only tissue involvement and such a diagnosis should trigger an evaluation of the peripheral blood for evidence of CLL. SLL preferentially occurs in middle-aged and elderly individuals.[559,560] The patients often have few or no symptoms, the evolution is

For personal use only. No other uses without permission. Copyright ©2017. Elsevier Inc. All rights reserved.

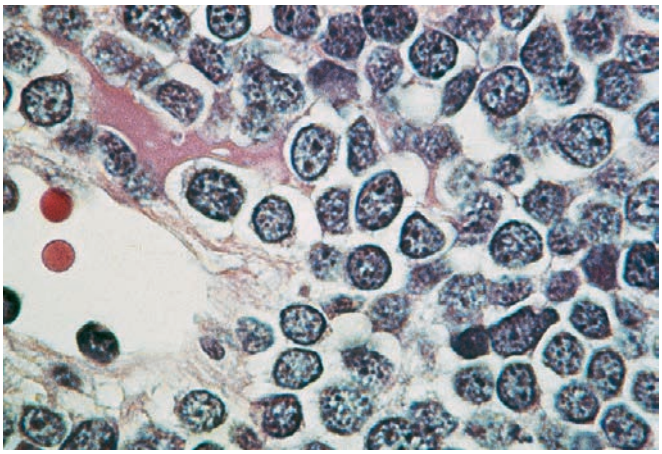

Figure 37.58 Lymphoblastic Lymphoma. The immature lymphoma cells have fine nuclear chromatin more characteristic of blasts over large mature B cells.

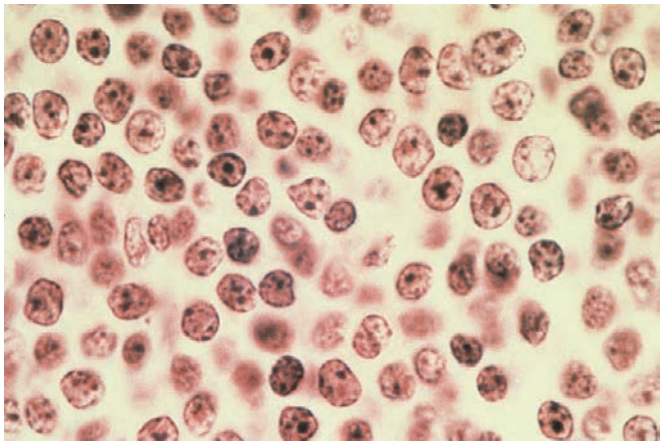

Figure 37.60 High-Power View of Small Lymphocytic Lymphoma. There is some variability in cell size. The nuclear contours are regular, the chromatin is clumped, and nucleoli are inconspicuous.

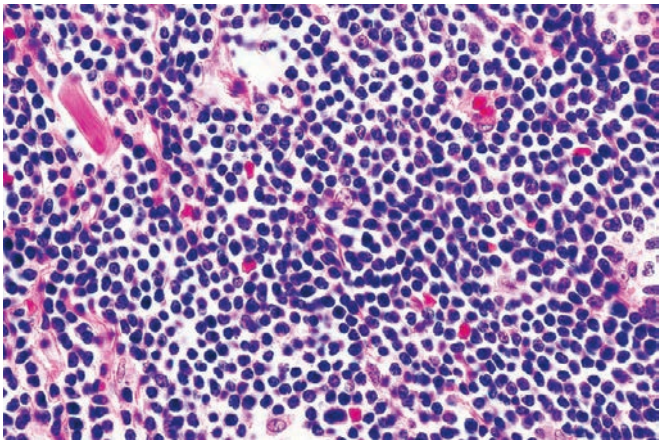

Figure 37.59 Low-Power View of Small Lymphocytic Lymphoma. A proliferation of small lymphocytes effaces the architecture of the node.

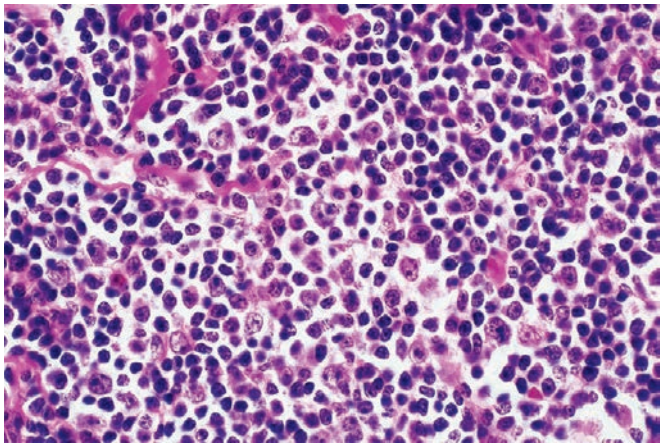

Figure 37.61 So-called proliferation center in a lymph node involved by small lymphocytic lymphoma.

prolonged, and the survival is very good. It is not unusual to find the disease incidentally in lymph node dissections done for carcinoma of one type or another.[561]

The architecture of the node in most cases of SLL is massively effaced by a population of predominantly small round lymphocytes with clumped chromatin, inconspicuous nucleoli, barely visible cytoplasm, and scanty mitotic activity (Figs. 37.59 and 37.60). There are also variable numbers of larger cells (prolymphocytes and paraimmunoblasts) with vesicular nuclei and distinct nucleoli, singly or in small aggregates, termed proliferation centers (Fig. 37.61).[562–565] The presence of proliferations centers and of a heterogeneous mixture of small lymphocytes with prolymphocytes/paraimmunoblasts is characteristic of SLL as opposed to mantle cell lymphoma.

Lymph node infiltration is usually diffuse, but on occasion a similar infiltrate is confined to the marginal zone, the perifollicular regions, or the interfollicular regions surrounding benign lymphoid follicles, the latter pattern being referred to as *interfollicular SLL*.[566–568] Such cases might be considered partial lymph node involvement by monoclonal B-cell lymphocytosis (MBL) (see later). Extranodal extension of SLL is seen in approximately one-third of the cases.[569]

By definition, SLLs are always of mature B-cell lineage.[570] Monoclonal immunoglobulins, including both IgM and IgD types, are consistently found on their surface, but both surface heavy and light chain expression is characteristically dim compared to normal B lymphocytes and most other B-cell lymphomas. They are usually weakly CD20+ with aberrant expression of CD5+ and CD43+. They also usually express CD23, as well as CD200, BCL2, and LEF1, but are negative for CD10, cyclin D1, and SOX11.[571–576] At the molecular level, Ig heavy and light chain genes are rearranged. While most tumors are slow growing and demonstrate a negative karyotype on routine analysis, cytogenetic abnormalities are detectable in approximately 80% of cases by FISH analysis and these findings have prognostic significance.[577] The presence of somatic hypermutations in IGH is also a good prognostic indicator[578,579] (often correlating with the absence of ZAP70 expression), and a variety of gene mutations and array CGH findings with potentially prognostic importance have been identified, including mutations of *NOTCH1* and *SF3B1*.[580–584] These prognostic markers are discussed in more detail with CLL in Chapter 39. On occasion one sees cases of SLL with admixed typical Reed–Sternberg cells. Such cases may relapse as classical Hodgkin lymphoma but should not be diagnosed as a composite lymphoma unless there are discrete areas of typical classical Hodgkin lymphoma.[585] A development of even greater clinical significance is the transformation of a SLL into another lymphoma, usually DLBCL (Figs. 37.62 and 37.63).[586] This occurrence has been

For personal use only. No other uses without permission. Copyright ©2017. Elsevier Inc. All rights reserved.

traditionally known as *Richter syndrome*[587,588] and is accompanied by a precipitous decline in the clinical course.

Monoclonal B-cell lymphocytosis (MBL) is generally defined by peripheral blood findings of less than 5×10^9/L monotypic B-cells[589] but may also infiltrate tissues. Most cases have an immunophenotype similar to CLL/SLL, and similar infiltrates found in lymph nodes without nodal enlargement are probably best classified as MBL rather than partial involvement by SLL unless more extensive disease is identified in the blood or elsewhere.[590]

B-prolymphocytic leukemia is a rare disorder that is defined by peripheral blood findings with 55% or more circulating B-lineage prolymphocytes[591] but can involve lymph nodes in a diffuse or vaguely nodular pattern. Prolymphocytes are small- to medium-sized cells with a central, prominent nucleolus and usually also show an increased proliferation rate. Most cases differ from CLL/SLL by demonstrating bright immunoglobulin heavy and light chains, bright CD20 expression, and lack of CD5 and CD23 expression. Some cases of mantle cell lymphoma in a leukemic phase may mimic these features but will demonstrate nuclear expression of cyclin D1,[592] which should not be seen in B-cell prolymphocytic leukemia.

Figure 37.62 Gross appearance of lymph nodes involved by chronic lymphocytic leukemia/small lymphocytic lymphoma with anaplastic transformation (so-called Richter syndrome).

Lymphoplasmacytic Lymphoma

Lymphoplasmacytic lymphoma is an indolent neoplasm of small B-lymphocytes with admixed plasmacytoid lymphocytes and plasma cells.[593,594] By definition, other lymphomas of small B cells, which may also have a plasmacytoid component, must be excluded before the diagnosis can be made. The bone marrow and spleen are frequently involved, with lymph node involvement in a smaller percentage of cases. Most patients have elevations of monotypic IgM, which may cause hyperviscosity, and meet clinical criteria for Waldenström's macroglobulinemia. Two patterns of lymph node involvement by lymphoplasmacytic lymphoma have been described, but the first is probably more specific. This generally diffuse infiltration of mostly small cells with admixed plasmacytoid cells often includes small plasma cells with intranuclear inclusions or Dutcher bodies (Fig. 37.64). Reactive mast cells are commonly admixed with the lymphoplasmacytic cells. The extent of the plasma cell proliferation can be quite variable, ranging to very little to sheets of small plasma cells. These cases may show a prominent interfollicular component with residual germinal centers. A more polymorphous type has also been described with epithelioid histiocytes and more variably sized plasmacytoid cells. This latter group appears to include cases of so-called polymorphous immunocytoma (Fig. 37.65), which has subsequently been shown to be a nonspecific pattern that includes a variety of lymphoma types of both T- and B-cell lineage.

The neoplastic cells in lymphoplasmacytic lymphoma show CD20 expression on at least the more mature lymphocyte component and

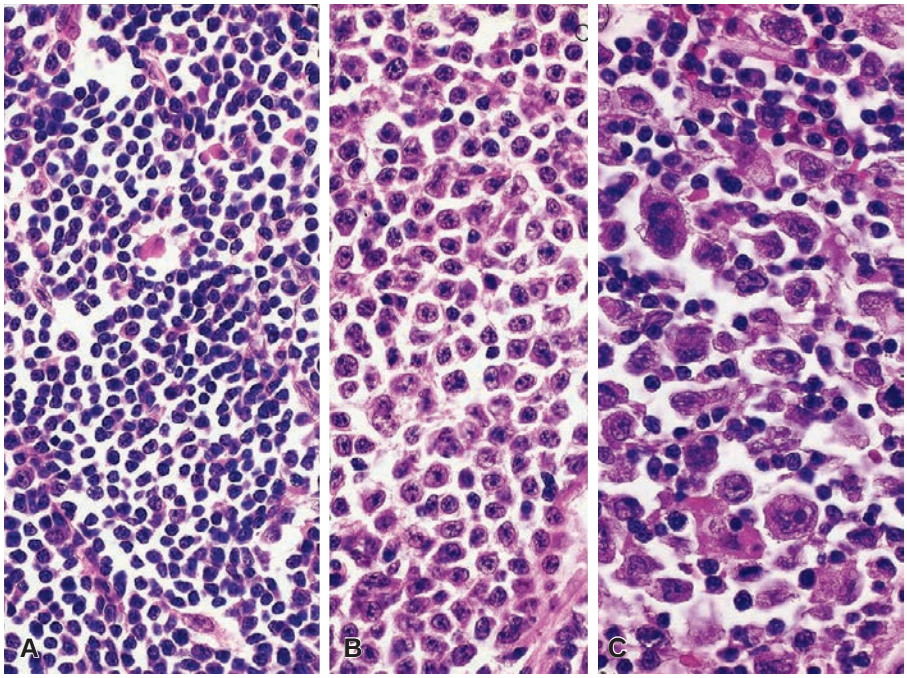

Figure 37.63 Various morphologic types of lymph node involvement by chronic lymphocytic leukemia/small lymphocytic lymphoma: **A**, monotonous infiltrate of small mature lymphocytes; **B**, increased prolymphocytes, with slightly larger nuclei and more open chromatin; **C**, large pleomorphic tumor cells (so-called Richter syndrome).

For personal use only. No other uses without permission. Copyright ©2017. Elsevier Inc. All rights reserved.

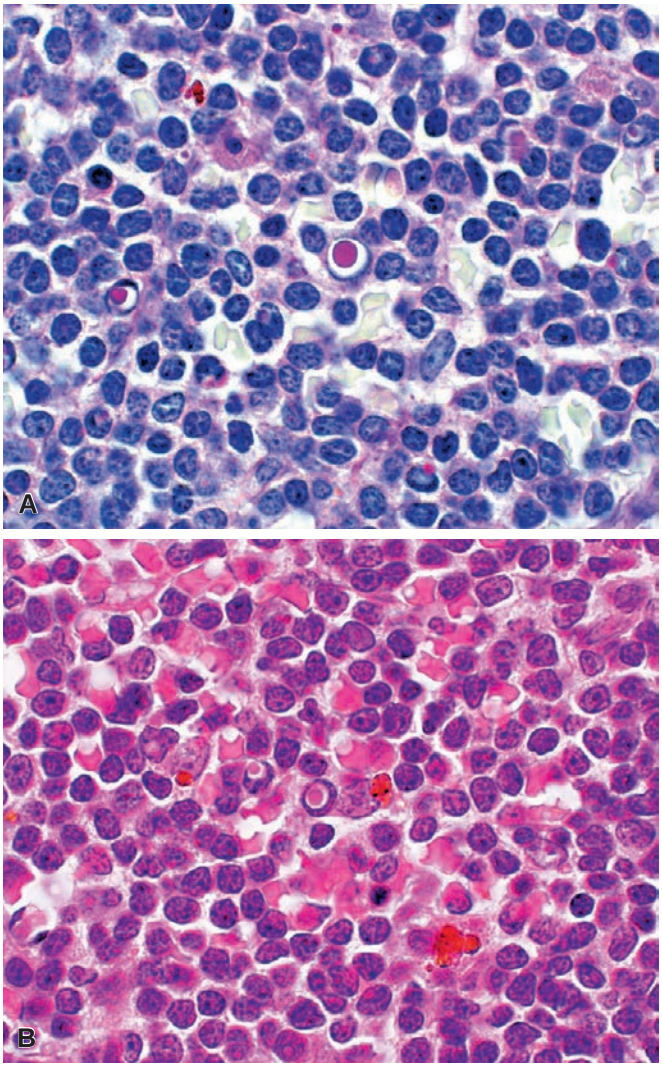

Figure 37.64 Intranuclear immunoglobulin inclusions (Dutcher bodies) in a lymph node affected by lymphoplasmacytoid lymphoma as seen after hematoxylin–eosin (**A**) and PAS stains (**B**).

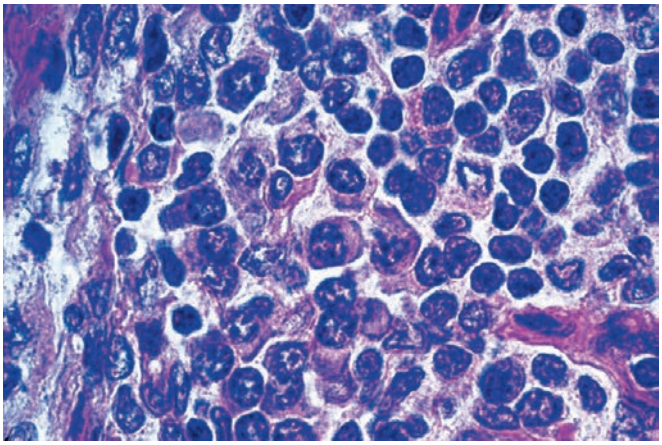

Figure 37.65 Malignant lymphoma composed of lymphocytes and immature plasmacytoid forms (so-called pleomorphic immunocytoma).

monotypic light chain expression in the plasmacytoid cell component. The B cells generally lack CD5 and CD10 expression and are cyclin D1 and CD103 negative. This immunophenotype, however, is nonspecific and can be seen in a variety of B-cell lymphomas, most notably marginal zone lymphoma.

Mutations in *MYD88* have been recently described in over 90% of cases of lymphoplasmacytic lymphoma[595,596] with features described previously for the diffuse type (but not the polymorphous type). While a small percentage of other lymphomas of small B cells will have this mutation, its detection in the proper clinical and morphologic setting is helpful in confirming a diagnosis of lymphoplasmacytic lymphoma.

The differential diagnosis of lymphoplasmacytic lymphoma ranges from marginal zone lymphoma to plasma cell myeloma. As mentioned, detection of a mutation in *MYD88* would favor lymphoplasmacytic lymphoma or marginal zone lymphoma; this finding is not entirely sensitive or specific, and it may not be possible to resolve this differential diagnosis on small biopsies. Some cases of plasma cell myeloma may have a prominent lymphoid component and even express IgM (in contrast to most myeloma cases that are IgG or IgA producing).[597] These lymphoid predominant myeloma cases may have cyclin D1 translocations and express the cyclin D1 protein, which is not a feature of lymphoplasmacytic lymphoma. Recognition of clinical features of plasma cell myeloma, including lytic bone lesions, may be the only means of differentiating these unusual types of myeloma from lymphoplasmacytic lymphoma.

Heavy Chain Diseases

The so-called heavy chain diseases are monoclonal plasma cell and B-lymphocyte proliferations that do not typically express immunoglobulin light chains and only express heavy chains.[598] While rare, they can mimic other lymphoma types and may involve lymph nodes. *Mu heavy chain disease* resembles CLL/SLL but usually lacks light chains. *Gamma heavy chain disease* may show a variety of tissue presentations, including mimicking lymphoplasmacytic lymphoma, marginal zone lymphoma, and even T-cell lymphomas and Hodgkin lymphoma.[599] It does not, however, show mutations of *MYD88*.[600] *Alpha heavy chain disease* is a subtype of extranodal marginal zone lymphoma, usually involving the gastrointestinal tract, but may involve regional lymph nodes as well.[601]

Nodal Marginal Zone B-Cell Lymphoma

Marginal zone B-cell lymphoma is the general term used to designate a group of low-grade B-cell lymphomas composed of a heterogeneous population of small B cells. The concept represents a grouping of entities that had been described separately, most of them at extranodal sites.[602] There appears to be considerable clinical, morphologic, and immunohistochemical overlap among the three entities (extranodal marginal zone lymphoma of mucosa-associated lymphoid tissue [MALT lymphoma], nodal marginal zone lymphoma, and splenic marginal zone lymphoma).[603] Consequently, the proposal has been made that they represent a related family of neoplasms showing morphologic evidence of differentiation into cells of marginal zone type.[604,605] These cells are thought to have the capacity to mature into both monocytoid B cells and plasma cells and to display tissue-specific homing patterns. A corollary of this proposal is that the various clinical syndromes may be the result of the homing pattern of the specific neoplastic clone.[602] The three main categories of marginal zone lymphoma, however, are distinct and differ, especially on the genetic level. Extranodal and splenic marginal zone lymphomas are discussed elsewhere in association with their anatomic sites, but nodal marginal zone lymphoma is covered here.

Nodal marginal zone lymphoma, previously termed monocytoid B-cell lymphoma, is a tumor of small to medium-sized postgerminal

For personal use only. No other uses without permission. Copyright ©2017. Elsevier Inc. All rights reserved.

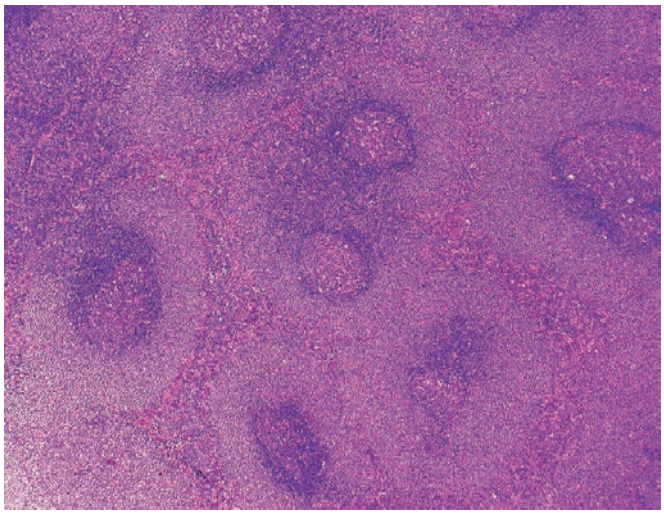

Figure 37.66 Lymph node involvement by marginal zone B-cell lymphoma with a prominent perifollicular or marginal zone pattern. There are numerous residual, non-neoplastic germinal centers.

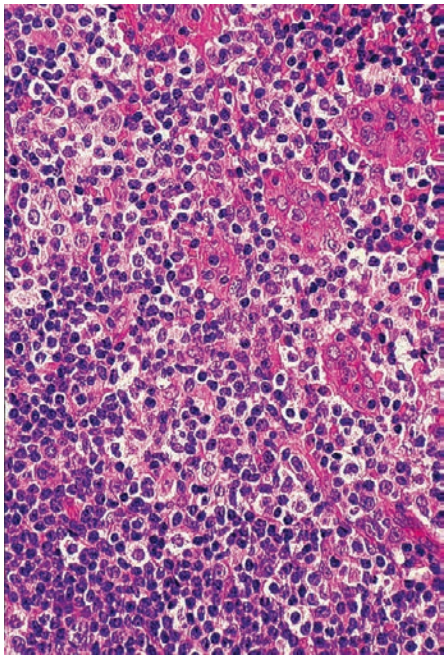

Figure 37.67 Lymph node involvement by marginal zone B-cell lymphoma with small lymphoma cells with clear cytoplasm. This tumor also affected the thymus gland. (Courtesy of Dr. John Chan, Hong Kong.)

center B lymphocytes with round or slightly indented nuclei and relatively abundant clear cytoplasm, usually located in lymph nodes, hence its designation as nodal (Figs. 37.66 and 37.67).[606] The tumor cells have been regarded as the neoplastic counterpart of the monocytoid B lymphocytes found in lymph node sinuses in toxoplasmosis and other reactive disorders.[607] Plasmacytoid features are prominent in some cases. The pattern of involvement is predominantly perifollicular or interfollicular,[608] but cases have been seen with "follicular colonization" and with "floral" features.[609] Clinically, the disease is more common in women and can be localized or generalized at presentation.[610] Some patients have suffered from autoimmune disorders such as Sjögren disease. In all cases, the possibility of nodal spread from an extranodal marginal zone lymphoma has to be excluded by clinical work-up. Histologic transformation to large cell lymphoma has been documented in some cases.

The neoplastic cells of nodal marginal zone lymphoma are monotypic, mature B-cells that express CD19, CD20, CD79A, and PAX5 and are weakly positive for BCL2.[611–613] They usually lack CD5 and are negative for CD10, CD23, and cyclin D1. Approximately 40% of cases show aberrant coexpression of CD43 on the B-cells.[72] CD21 or CD23, while negative on the neoplastic cells, may highlight expanded follicular dendritic cell networks that are infiltrated by the lymphoma cells (follicular colonization). Plasma cells are monotypic in some but not all cases.

There are no specific genetic markers for nodal marginal zone lymphomas.[614] They demonstrate clonal immunoglobulin gene rearrangements, similar to other B-cell neoplasms but do not usually demonstrate the recurring cytogenetic abnormalities associated with extranodal marginal zone lymphoma. Abnormalities of chromosome 3, including trisomy 3, are common but nonspecific in nodal marginal zone lymphoma. Mutations of *MYD88* are uncommon in this disease.

Pediatric nodal marginal zone lymphoma is a provisional entity in the 2016 WHO classification that occurs as localized disease, usually in cervical lymph nodes.[407,615] Patients have a median age of 16 years with a marked male predominance. Because of the very indolent and localized nature of such proliferations in contrast to the more systemic presentation of usual type nodal marginal zone lymphoma, this provisional designation has been proposed.

Follicular Lymphoma

Follicular (nodular) lymphoma is a B-cell neoplasm that recapitulates the architectural and cytologic features of the normal germinal center.[616] This tumor comprises up to 40% of all adult non-Hodgkin lymphomas in the United States, but in other countries the relative incidence is much lower. Most cases occur in elderly individuals. It is very unusual under 20 years of age and relatively uncommon in patients of African descent.[617]

Grossly and at low-power examination, the most distinctive feature of these tumors is the nodular pattern of growth (Figs. 37.68 and 37.69). The morphologic features that are useful in the differential diagnosis of follicular lymphoma and reactive follicular hyperplasia were described earlier in this chapter. With progression of the disease, this distinct nodularity becomes blurred, and eventually most of the proliferation acquires a diffuse pattern. The cytologic composition of the neoplastic nodules is characterized by a mixture in different proportions of small and large lymphoid cells, both of which resemble their normal follicular counterparts.[618] The small cells have scanty cytoplasm and an irregular, elongated cleaved nucleus with prominent indentations and infoldings; the size is similar to or slightly larger than that of normal lymphocytes, the chromatin is coarse, and the nucleolus is inconspicuous (Figs. 37.70–37.72). These cells have been variously referred to as centrocytes, poorly differentiated lymphocytes, and small cleaved follicular center cells. The large cells are 2 or 3 times the size of normal lymphocytes; they have a distinct rim of cytoplasm and a vesicular nucleus with one or three nucleoli often adjacent to the nuclear membrane. These cells, which have a rapid turnover rate and probably represent the proliferating component of the tumor, have been designated over the years as germinoblasts, centroblasts, histiocytes, large (cleaved or noncleaved) follicular center cells, large lymphoid cells, and lymphoblasts. Some may be binucleated and simulate Reed–Sternberg cells.[619] Another type of large cell seen in follicular lymphoma is the non-neoplastic follicular dendritic cell. It is recognized because of its finely dispersed chromatin, the lack of identifiable cell boundaries, and the inconspicuousness of the nucleolus.

Immunohistochemically, the follicles of follicular lymphoma (including all its variants) are composed of a monoclonal population

For personal use only. No other uses without permission. Copyright ©2017. Elsevier Inc. All rights reserved.

of mature B cells admixed with variable numbers of non-neoplastic small T cells, macrophages, and follicular dendritic cells, corresponding to the cellular composition of a normal germinal center (Fig. 37.73).[620,621] The tumor cells express pan–B antigens, such as CD19, CD20, CD22, PAX5, and CD79A, in addition to HLA-DR. They also express surface and/or cytoplasmic immunoglobulins (usually of the IgM type) with light chain restriction. CD10, a germinal center cell marker that is also present in lymphoblastic proliferations, Burkitt lymphoma, and some large B-cell lymphomas, is detected in approximately 60%–70% of the cases.[622] This marker can aid in distinction from reactive follicular hyperplasia when significant numbers of CD10+ cells are found in the interfollicular zone as an indication of interfollicular invasion. Other germinal center cell markers, such as BCL6, HGAL, and LMO2, are expressed in most cases. CD5 and CD43 are usually negative.

Figure 37.68 Gross Appearance of a Lymph Node Affected by Follicular Lymphoma. The neoplastic nodules bulge onto the surface. (Courtesy of Dr. R. A. Cooke, Brisbane, Australia; from Cooke RA, Stewart B. *Colour Atlas of Anatomical Pathology*. Edinburgh: Churchill Livingstone; 2004.)

The BCL2 protein can be identified immunohistochemically in approximately 85% of cases[71] and is thus one of the most useful markers for the differential diagnosis with reactive follicular hyperplasia (BCL2 negative), although it is important to realize that BCL2 negativity does not totally rule out follicular lymphoma.[621,623,624] Immunostaining for BCL2 cannot be used for distinction of follicular lymphoma from other low-grade B-cell lymphomas, because the latter are commonly BCL2 positive; to deal with such a diagnostic problem, immunostaining for follicular center cell markers such as CD10 and BCL6 is more helpful.[625,626]

Follicular lymphoma shows clonal rearrangements of the immunoglobulin genes, which also feature hypermutations and ongoing somatic mutations, as characteristic of follicle center B cells.[627]

The hallmark genetic alteration of follicular lymphoma is t(14;18)(q32;q21), found in 90% of cases.[628] The chromosomal translocation juxtaposes IGH with the *BCL2* gene, driving overexpression of BCL2 protein, an anti-apoptotic molecule located in the inner mitochondrial membrane whose expression is typically switched off in normal follicle center B cells.[629–631] As a result of aberrant BCL2 expression, the neoplastic follicle center cells do not undergo apoptosis. Thus follicular lymphoma results more from cell accumulation than cell proliferation. Although *BCL2* rearrangement is also seen in some cases of DLBCL, demonstration of this molecular alteration provides a good support for a diagnosis of follicular lymphoma in the appropriate context, such as distinction from atypical follicular hyperplasia, marginal zone lymphoma with follicular growth pattern

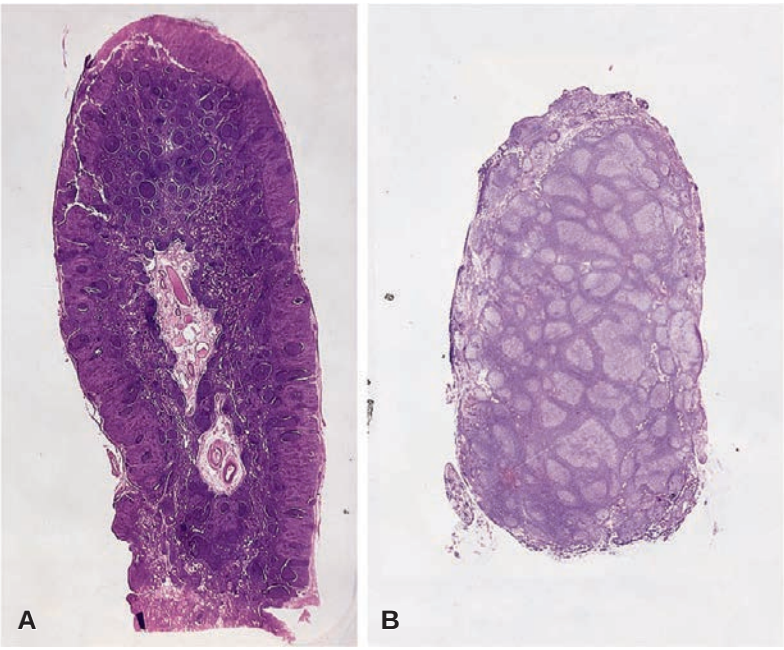

Figure 37.69 Even distribution of neoplastic follicles in follicular lymphoma (**B**), as opposed to the predominantly cortical distribution typical of follicular hyperplasia (**A**).

For personal use only. No other uses without permission. Copyright ©2017. Elsevier Inc. All rights reserved.

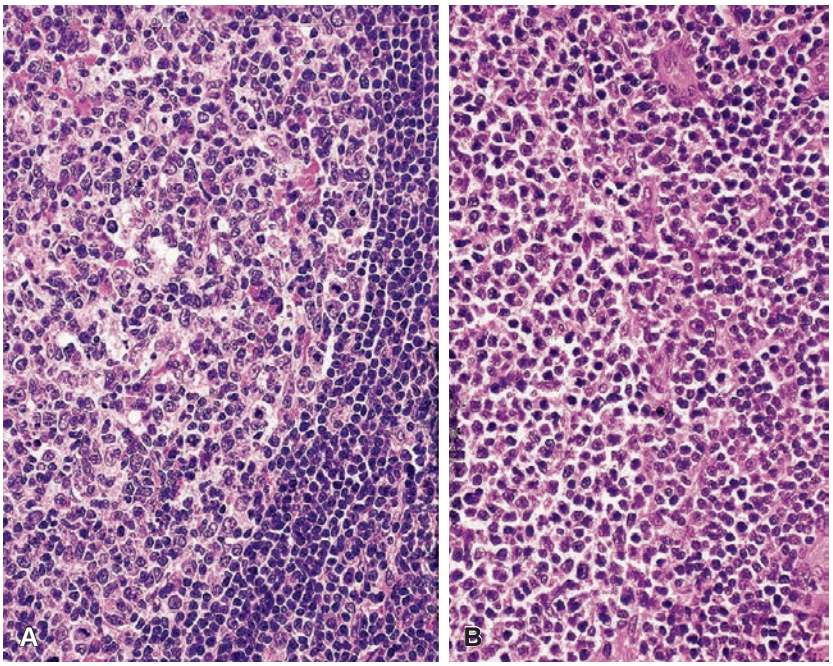

Figure 37.70 Fuzzy edge of neoplastic nodule of follicular lymphoma (**B**), as opposed to sharp edge bound by the mantle zone in follicular hyperplasia (**A**).

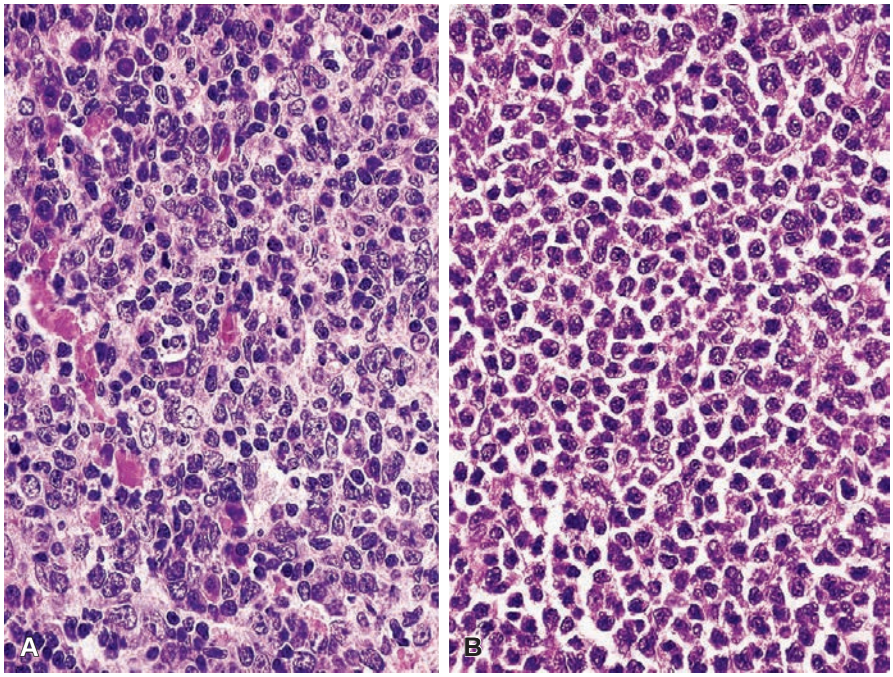

Figure 37.71 Homogeneous population of small cleaved cells in follicular lymphoma (**B**), as opposed to the polymorphic composition seen in follicular hyperplasia, including the presence of tingible-body macrophages (**A**).

and mantle cell lymphoma. For this purpose, FISH is more sensitive than PCR.[628,632] Certain types of follicular lymphoma uncommonly or do not exhibit *BCL2* rearrangement, including pediatric follicular lymphoma, primary cutaneous follicle center lymphoma, and grade 3b follicular lymphoma (see later).[633–638]

The presence of t(14;18) alone appears to be insufficient for the development of follicular lymphoma, because this is rarely the sole genetic aberration and even healthy subjects commonly harbor low numbers of B lymphocytes with t(14;18).[639–643] Common additional genetic changes include −1p36, +2p15, +6q, +7p, +7q, −9p, +12q, −17p, +18q, and +X, with some of them, such as −1p36, −6q, −9p, and +18q, being associated with a worse prognosis.[643–646]

BCL6 translocation occurs in approximately 10% of the cases, usually mutually exclusive to *BCL2* translocation.[637,647] This is correlated with grade 3b histology, high proliferative index, and infrequent expression of CD10 and BCL2.[635,648,649] Follicular

For personal use only. No other uses without permission. Copyright ©2017. Elsevier Inc. All rights reserved.

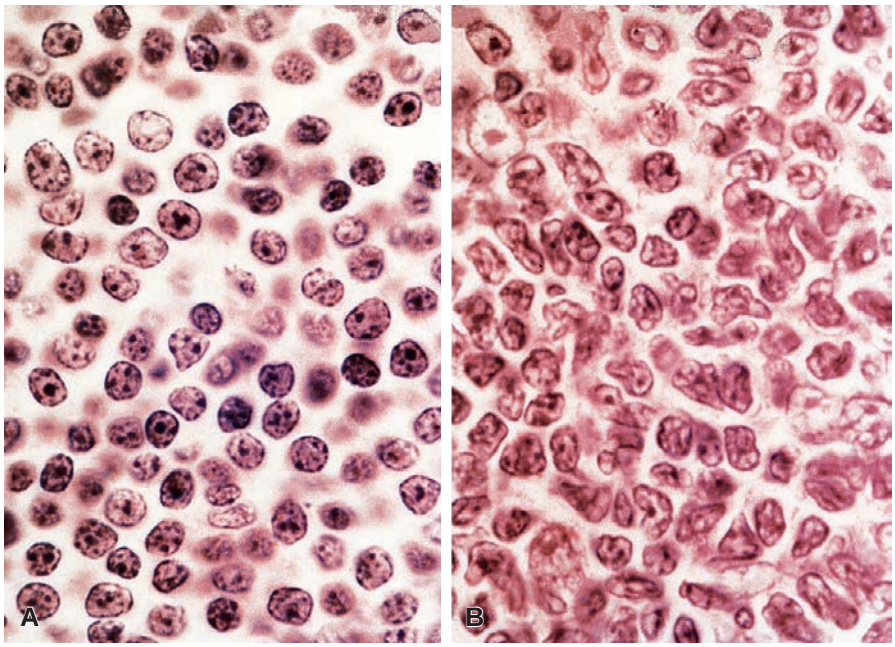

Figure 37.72 Marked contrast between the cleaved cells of follicular lymphoma (**B**) and the regular mature lymphocytes of small lymphocytic lymphoma (**A**).

lymphomas with del6q23–26 or del17p at presentation are at increased risk of transformation to high-grade B-cell lymphoma.[631] Genetic changes that mediate such a transformation may include *MYC* translocation, *TP53* mutation, *BCL2* mutation, deletions of 9p21 involving P16 and P15, and mutation of the 5′ noncoding region of *BCL6*.[650–652]

The gene expression profile of follicular lymphoma recapitulates that of normal germinal center B cells and furthermore clusters close to resting B cell samples, in keeping with its indolent nature.[38] On microarray analysis, the immune response-1 signature, reflecting presence of a complex infiltrate of T cells and other immune cells, predicts long survival, while immune response-2 signature, reflecting a significant infiltrate of monocytes and dendritic cells, predicts short survival.[653]

Depending on the relative proportion of small and large cells, typical follicular lymphomas are subdivided into two categories. Because of reproducibility issues in grading and a lack of prognostic significance, low-grade cases are now designated as grade 1/2 and are defined by the presence of 15 or fewer centroblasts (large B cells) per high-power field. Grade 3 is defined as more than 15 centroblasts per high-power field and are further subdivided into grades 3a and 3b. Cases with admixed centrocytes (small cleaved B cells) are referred to as grade 3a, which is most common, while cases with solid sheets of centroblasts are referred to as grade 3b.

Several important clinical differences exist between these groups.[654,655] Patients with grade 1/2 follicular lymphoma are often asymptomatic, usually have generalized disease (often involving extranodal sites, such as the liver and bone marrow), and have a good prognosis,[656] to the point that some authors advise against aggressive treatment for them.[657–662] Grade 3 tumors are more commonly localized at the time of presentation but run a more aggressive clinical course[617,663] and are more likely to lose their nodular pattern of growth and become diffuse.

The extranodal spread of follicular lymphoma is quite predictable. In the spleen, it tends to affect the B-derived lymphoid follicles located eccentrically in the white pulp. In the liver, the infiltrate is predominantly periportal. The bone marrow infiltrates tend to have a paratrabecular location. In the skin, there is an extensive dermal infiltrate without particular relation to vessels or adnexa.

In some cases of follicular lymphoma (particularly grade 1/2), malignant cells are found in the peripheral blood; hematologists refer to them by the inelegant term "buttock" cells because of their prominent nuclear cleft (Fig. 37.74). No prognostic significance has been assigned to this finding.

Specimens from subsequent biopsies or autopsy from patients with grade 1/2 follicular lymphomas may show a similar microscopic appearance or a progression to grade 3 or to DLBCL.[664,665] A more ominous development is represented by the occasional "blastic" or "blastoid" transformation of follicular lymphoma, in which the tumor cells resemble those of Burkitt or lymphoblastic lymphoma; this is accompanied by a highly aggressive clinical course.[666,] The resulting high-grade malignant tumor may also express CD30 but remains a mature B-cell neoplasm and not true ALCL.[667]

Several morphologic variations on the theme of follicular lymphoma have been described. They include the following:

1. Presence of fine or coarse bands of fibrosis that accentuate even more the nodular character of the lesion but, in so doing, may induce confusion with carcinoma. This feature is more commonly seen in grade 3 tumors;[668] it is particularly frequent in the retroperitoneum, but it also occurs in the cervical region, mediastinum, and other locations.
2. Presence of monocytoid B cell/marginal zone differentiation. In about 10% of follicular lymphomas, discrete foci of monocytoid B cells are seen, typically appearing on low-power examination as a pale rim around the neoplastic follicles.[669,670] Molecular studies have shown a common clonal origin of the monocytoid B cells from follicle center cells.[671,672] Clinically, this feature is said to be associated with a shorter survival time.[673]
3. Deposition of proteinaceous material in the center of the nodules, similar to that seen in some reactive conditions, particularly the plasma cell variant of Castleman disease (Fig. 37.75). The material is amorphous, acellular, brightly eosinophilic, and PAS

For personal use only. No other uses without permission. Copyright ©2017. Elsevier Inc. All rights reserved.

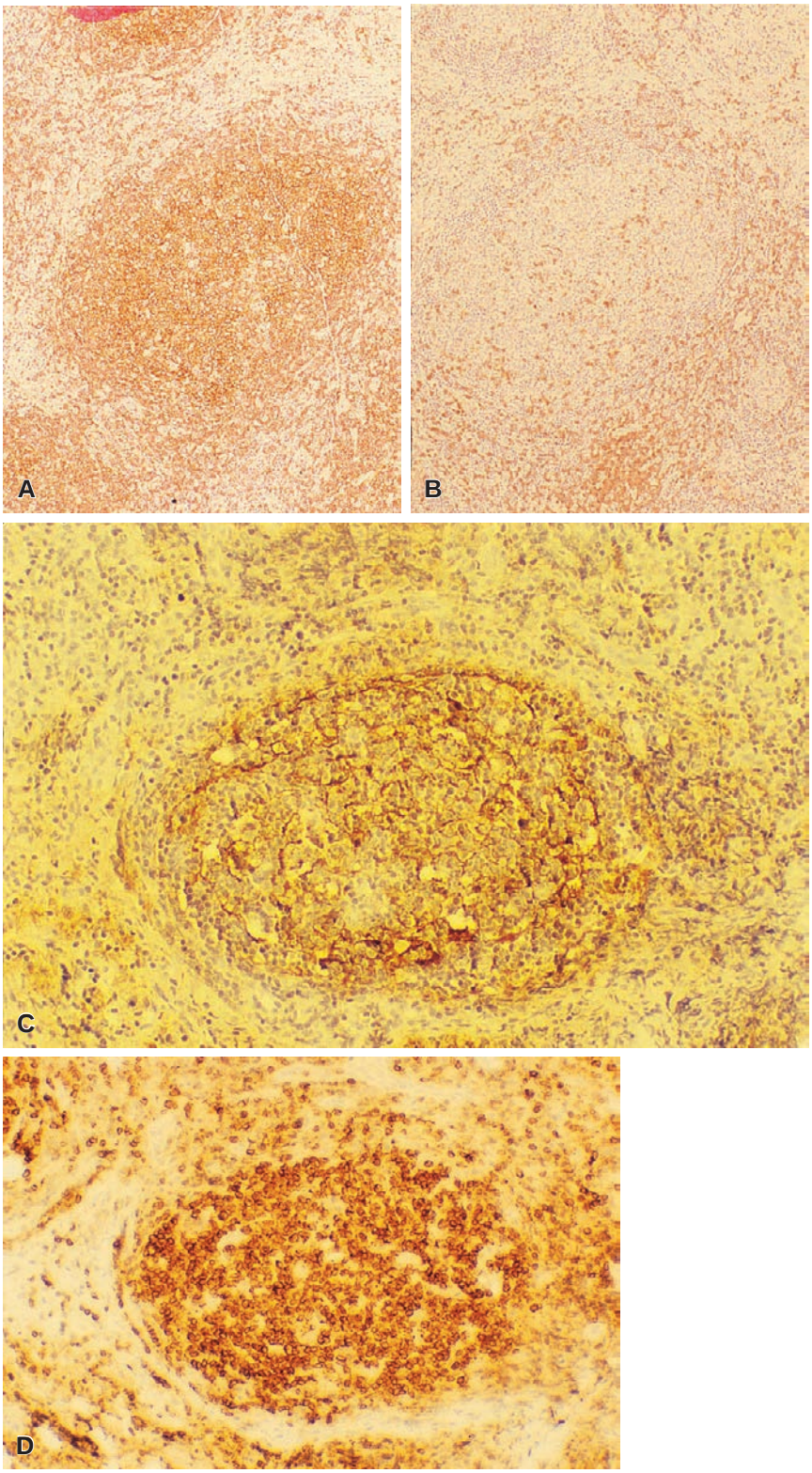

Figure 37.73 Follicular Lymphoma. A, CD20 stain decorates the neoplastic nodule and identifies the cells as of B-cell nature. **B**, CD3 stain shows a rim of non-neoplastic T cells around the follicles. **C**, CD21 stain shows a large number of dendritic follicular cells within the neoplastic follicle. **D**, BCL2 stains the B cells within the germinal centers. (Courtesy of Dr. Glauco Frizzera, New York, NY, USA.)

For personal use only. No other uses without permission. Copyright ©2017. Elsevier Inc. All rights reserved.

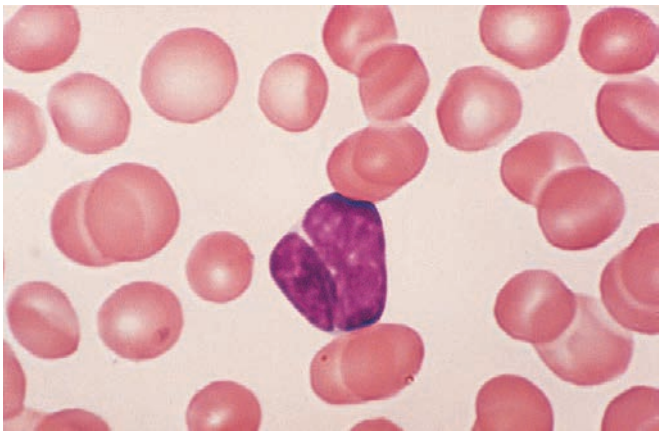

Figure 37.74 Blood smear from a patient with follicular lymphoma showing a so-called notched nucleus cell or buttock cell.

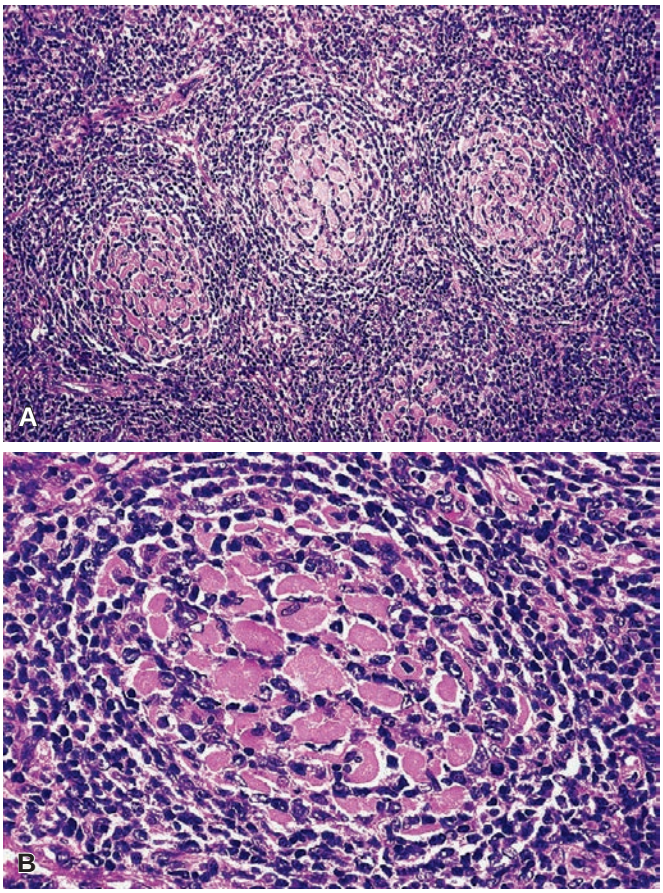

Figure 37.75 **A** and **B**, Follicular lymphoma with deposition of proteinaceous material among the tumor cells. Ultrastructurally, some of this material was found to be within the cytoplasm of dendritic follicular cells.

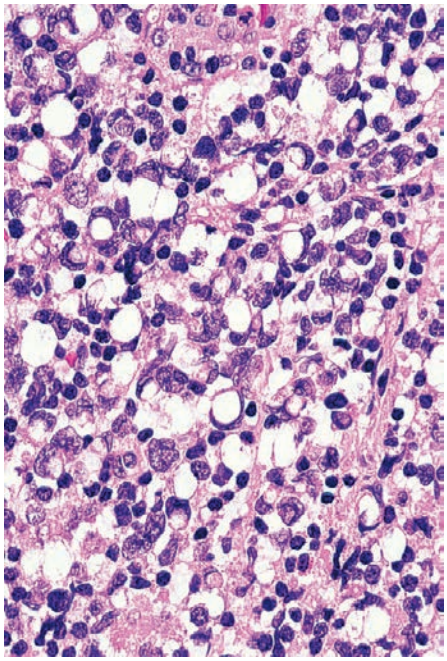

Figure 37.76 Follicular lymphoma featuring signet ring changes in some of the tumor cells.

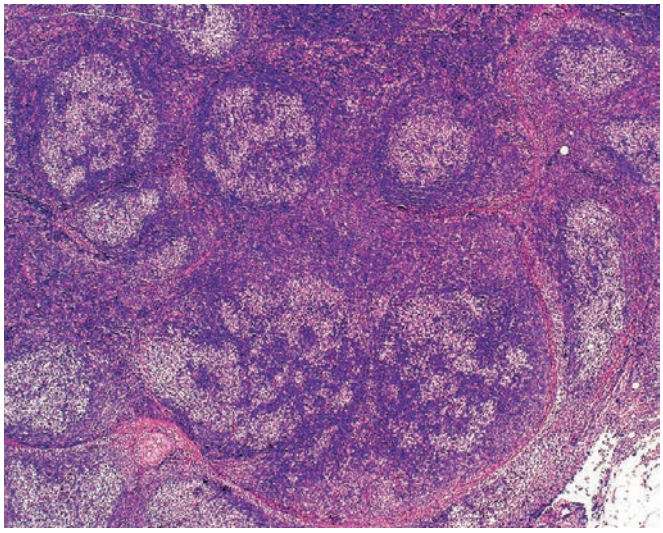

Figure 37.77 So-called floral variant of follicular lymphoma which refers to the flower-like pattern of the expanded, disrupted neoplastic follicles.

positive.[654,674] Ultrastructurally, it is composed of membranous structures, membrane-bound vesicles, and electron-dense bodies.[654] It is described in grade 1/2 follicular lymphomas.[675]

4. Presence of large cytoplasmic eosinophilic globules—presumably immunoglobulins—or a single vacuole that push the nucleus laterally and result in a signet ring effect (Fig. 37.76).[676]
5. Clear-cut plasmacytic differentiation in some or many of the neoplastic follicular center cells.[669,677]
6. Presence of cells with cerebriform nuclei (similar to those of T-cell lymphoma)[678] or multilobated nuclei.[679]
7. Permeation of the tumor follicles by small round lymphocytes of presumably mantle zone origin, the appearance simulating that of progressively transformed germinal centers ("floral" variant) (Fig. 37.77).[63,680]
8. Presence of rosettes made up of cytoplasm and cytoplasmic processes of the lymphoid tumor cells and simulating the appearance of a neuroendocrine neoplasm (Fig. 37.78).[270]
9. Presence of hyaline vascular follicles similar to those seen in the hyaline-vascular type of Castleman disease.
10. Inversion of the usual staining pattern as seen on low-power examination so that the neoplastic follicles appear darker than

For personal use only. No other uses without permission. Copyright ©2017. Elsevier Inc. All rights reserved.

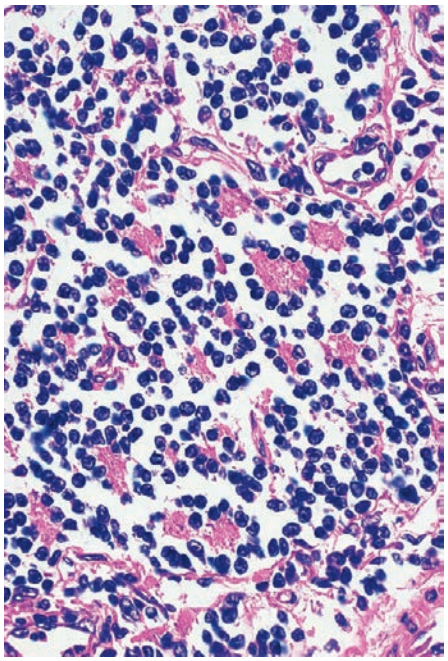

Figure 37.78 Follicular lymphoma showing rosette formation by some of the lymphoid cells.

the surrounding lymphoid tissue. This pattern, which is referred to as the "reverse" or "inverse" variant of follicular lymphoma, carries no prognostic significance.[681]

11. Prominent epithelioid granulomatous response.[682]
12. Preserved reactive germinal centers in some foci of the involved lymph node. This feature is said to be a strong indicator of limited disease stage,[683] and such reported cases may have represented in situ follicular neoplasia (see later).

In some reactive lymph nodes, BCL2-positive germinal centers can be detected in the absence of infiltration beyond the germinal center or other evidence of follicular lymphoma. Such cases may occur in patient with follicular lymphoma or another lymphoma type elsewhere but may also occur in otherwise healthy individuals. Their presence does not consistently predict development of frank lymphoma and such lesions should diagnosed *in situ follicular neoplasia* rather than follicular lymphoma.[407,684,685]

Pediatric-type follicular lymphoma is a distinct entity in the 2016 WHO classification.[407,686,687] It is a localized disease that usually occurs in children but is reported in adults. It usually shows grade 3b features with a blastoid, large cell predominance. These cases often do not express BCL2 and should not demonstrate a t(14;18). They have an indolent course and should only be diagnosed in the setting of localized disease and in the absence of diffuse areas.

Large B-cell lymphoma with *IRF4* rearrangement is a provisional entity in the 2016 WHO classification that also tends to occur in children and young adults, is negative for t(14;18), and is usually localized to cervical lymph nodes or Waldeyer's ring.[686,688] These may have a follicular or diffuse pattern, show strong expression of BCL6 and IRF4 (MUM1), and usually demonstrate a translocation involving *IRF4*. Although more aggressive than pediatric-type follicular lymphoma, these patients usually respond well to lymphoma therapy.

Finally, duodenal-type follicular lymphoma is a distinct category in the WHO classification that tends to present at a low stage with a more indolent course when compared to traditional follicular lymphoma or even follicular lymphoma involving other gastrointestinal sites.[689]

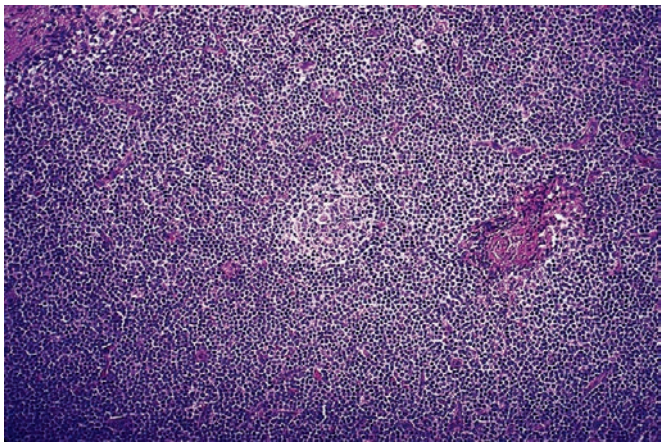

Figure 37.79 Mantle cell lymphoma surrounding a small residual germinal center.

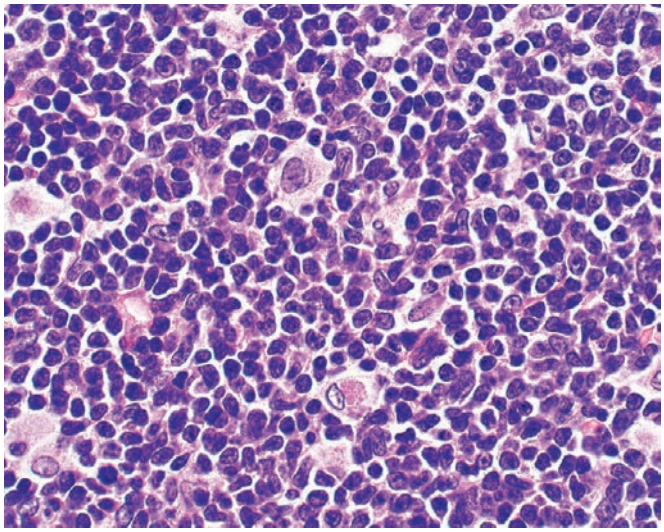

Figure 37.80 High-Power View of Mantle Cell Lymphoma. There are subtle abnormalities of the nuclear contours, the appearance being intermediate between that seen in small cleaved follicular lymphoma and that of small lymphocytic lymphoma. Note the individual epithelioid histiocytes that are characteristically associated with this disorder.

Mantle Cell Lymphoma

Mantle cell lymphoma is a relatively aggressive neoplasm of small B-lymphocytes that includes cases previously known as intermediate lymphocytic, mantle zone, centrocytic, and diffuse small cleaved cell lymphoma.[690–692] It comprises from 3% to 10% of all cases of non-Hodgkin lymphoma. Like follicular lymphoma, it usually occurs in middle-aged and elderly individuals.[693,694] The low-power appearance is largely that of a diffuse lymphoma, although nodular and mantle zone patterns also occur (Fig. 37.79).[695] The neoplastic cells are small and often show irregular and indented nuclear contours similar to those seen in small cleaved cell follicular lymphoma without an admixed large cell component (Fig. 37.80).[696] On occasion, some of the tumor cells show plasma cell differentiation.[697] In some cases, the tumor cells have larger nuclei with more dispersed chromatin and a higher proliferative fraction ("blastoid" or "pleomorphic" variant)[698] (Fig. 37.81), but the lymphoma cells retain a homogeneous pattern of cell size in contrast to CLL/SLL and follicular lymphoma. Admixed epithelioid histiocytes are common but do not form clusters

For personal use only. No other uses without permission. Copyright ©2017. Elsevier Inc. All rights reserved.

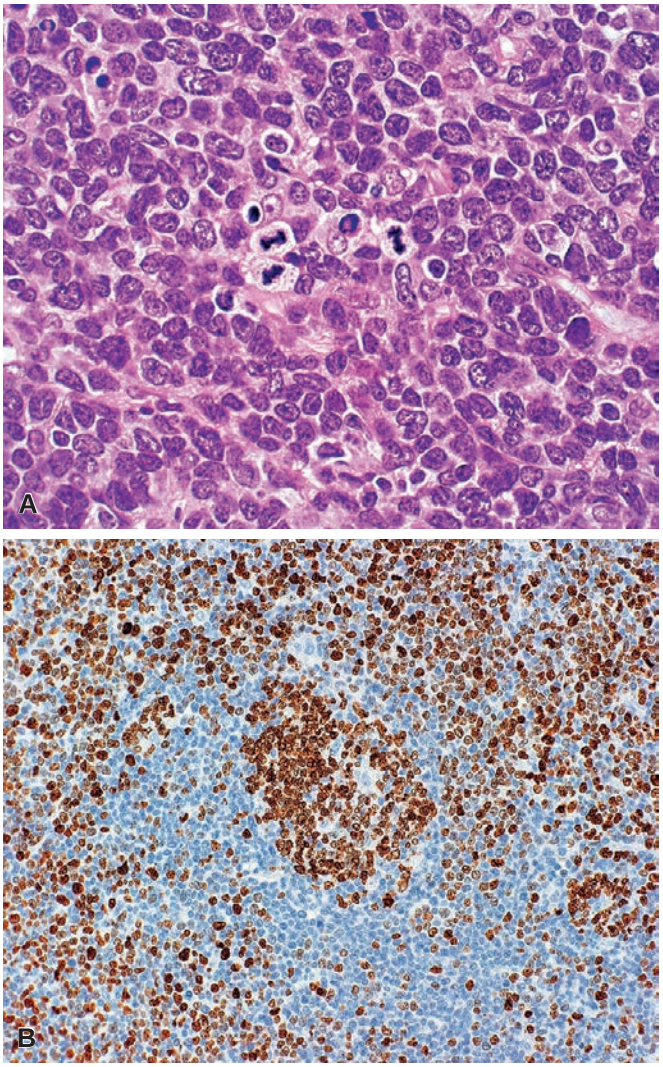

Figure 37.81 So-Called Blastoid Variant of Mantle Cell Lymphoma. **A**, Hematoxylin–eosin-stained section showing high mitotic activity. **B**, A high percentage of the tumor cells show nuclear immunoreactivity for MIB-1.

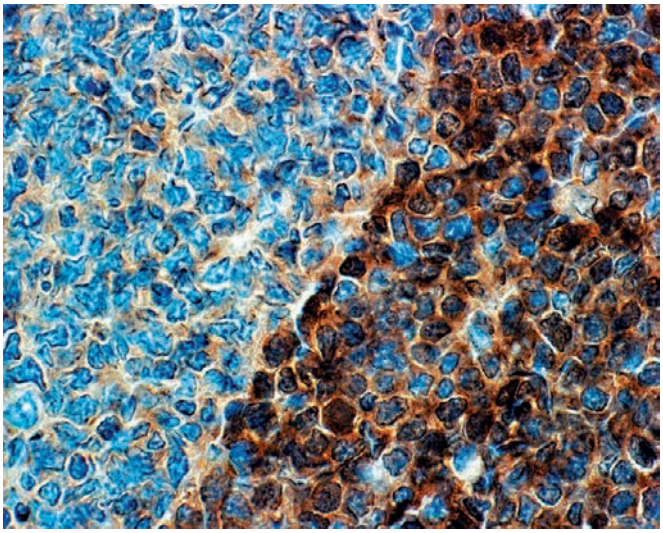

Figure 37.82 Immunoreactivity for cyclin D1 in mantle zone lymphoma.

or granulomas and do not contain cellular debris. The blastoid form of mantle cell lymphoma (and sometimes also the classic form) may be accompanied by blood, bone marrow, and spleen involvement ("mantle cell leukemia").[699–702]

The tumor cells are mature B cells, positive for immunoglobulins (IgM and often also IgD), and immunoglobulin light chain restricted; express B cell–associated antigens such as CD19, CD20, CD79A, and PAX5; and demonstrate aberrant expression of CD43 and CD5.[703,704] The general absence of CD23 is useful in distinguishing mantle cell lymphoma from SLL,[572,705] and the presence of CD5 is useful in the differential diagnosis with follicular and marginal zone lymphomas. It should be remarked, however, that CD5 expression is not always present in mantle cell lymphoma[706] and can be present in some DLBCLs apparently unrelated to mantle cell lymphoma.[707] Most cases demonstrate nuclear expression of cyclin D1, correlating with the presence of a t(11;14)(q13;q32) (Fig. 37.82).[708,709] Rare cases are cyclin D1 negative, and SOX11 is usually expressed in such cases.[575]

The immunoglobulin genes are clonally rearranged, and the variable regions are usually nonmutated, suggesting a naive B-cell stage of differentiation.[710,711] Nearly all cases show fusion of *CCND1* (cyclin D1) with the IGH gene, which results from t(11;14)(q13;q32) (in approximately 70% of cases by karyotype and almost 100% with molecular methods).[692,712] As a consequence, cyclin D1, a cell cycle protein, is overexpressed, promoting cell proliferation. *CCND1* translocation is practically specific for mantle cell lymphoma, except that it also occurs in some cases of plasma cell myeloma, and thus its demonstration may help confirm a diagnosis of mantle cell lymphoma.[713,714] FISH gives the highest sensitivity (>95%) and is superior to conventional cytogenetics, Southern blot, or PCR.[712,715] Additional genetic changes are common in mantle cell lymphoma, such as inactivating mutation of *ATM* (11q22–23), homozygous deletions of *INK4a/ARF* (p16), and *TP53* mutation.[710,716,717] The blastoid/pleomorphic variant is correlated with presence of *TP53* mutation, *MYC* abnormalities, and tetraploidy.[718–721]

Microarray studies have shown that mantle cell lymphoma exhibits a unique gene expression signature distinct from other lymphoma types, and furthermore confirm the existence of a cyclin D1-negative subset of mantle cell lymphoma (up to 7% of cases).[722,723] At least some cases of the latter subset express cyclin D2 or cyclin D3 instead of cyclin D1,[723–725] and most express SOX11.[575] Mantle cell lymphoma may be difficult to distinguish from follicular hyperplasia with a prominence of mantle zone cells ("mantle zone hyperplasia") and Castleman disease.[70] Determination of clonality of the infiltrate by immunohistochemical techniques is of importance in this regard as is demonstration of cyclin D1 in mantle cell lymphoma. The differential diagnosis also includes grade 1 follicular lymphoma. The fact that centroblasts and immunoblast-like cells are totally absent in mantle cell lymphoma is an important differential feature. Expression of cyclin D1, while very useful in the diagnosis, is not specific for mantle cell lymphoma and may also occur in hairy cell leukemia, multiple myeloma, and proliferation centers of CLL/SLL.

Finally, the blastoid form of mantle cell lymphoma needs to be distinguished from either T- or B-cell lineage lymphoblastic lymphoma.[556]

The median survival of mantle cell lymphoma is approximately 3–5 years. As a group, it is characterized by more widespread disease and a much lower response rate to chemotherapy than follicular lymphoma.[709,726] The blastic variant has a more aggressive clinical course.[690,727] A rare indolent type of mantle cell lymphoma has also

For personal use only. No other uses without permission. Copyright ©2017. Elsevier Inc. All rights reserved.

been described.[728] Proliferation rate is a strong predictor of survival for all types of mantle cell lymphoma, with rates of 30% or higher associated with a worse prognosis.[729] For this reason, Ki-67 staining should be performed on all new diagnosis specimens.

Some clonal mantle cell proliferations have a more indolent clinical course. *Leukemic nonnodal mantle cell lymphoma* is one such example.[730] In addition to lack of lymph node involvement, it tends to involve the spleen and be negative for SOX11. Cases with cyclin D1–positive cells restricted to the mantle zones without infiltration to surrounding structures or diffuse nodal involvement are now termed *in situ mantle cell neoplasia* to reflect the low rate of progression of such lesions.[731]

Diffuse Large B-Cell Lymphoma and Related Disorders

DLBCL encompasses a heterogeneous group of disorders. The term replaces the old histiocytic lymphoma, which in turn replaced the older reticulum cell sarcoma. It is characterized morphologically by large size of the cells, vesicular nuclei with prominent nucleoli, and relatively abundant cytoplasm, and immunophenotypically by expression of B-lineage markers. In general, DLBCLs can be diagnosed based on a limited panel of markers that confirm that the diffuse, large cell proliferation is of B-cell lineage, but there are now numerous subtypes of DLBCL that require additional studies and there are numerous prognostic markers that must now be performed on individual cases.

As a group, DLBCL occurs in both children and adults but mostly in the latter.[732] In comparison with most other types of lymphoma, it has a greater tendency for extranodal presentation and for being localized at the time of presentation. The progression is rapid, and the prognosis is poor if untreated. Indeed, it constitutes a high percentage of so-called aggressive lymphomas.[733,734] However, excellent responses have been obtained with multidrug chemotherapy, in particular in combination with rituximab (anti-CD20 therapy),[735–737] and new therapies are being developed for some subtypes.[738] In many cases, the tumor is limited to one side of the diaphragm (40%, as opposed to 90% for follicular lymphoma).[739] Involvement of the bone marrow or liver is less common than in follicular or SLLs.[740] Approximately 40% of the cases present in extranodal sites, such as the digestive system, skin, and skeletal system.[739] When the liver or spleen is involved, it is usually in the form of scattered large tumor masses instead of the multiple smaller nodules or miliary type seen with the group of lymphomas composed of small lymphocytes. The involved nodes are usually markedly enlarged, homogeneous, individualized, and with little or no necrosis (Fig. 37.83).

Microscopically, the pattern of nodal involvement is by definition diffuse. However, it may be complete or partial, and on occasion it may be interfollicular or show a sinus pattern (see later). There is commonly extranodal extension, sometimes with accompanying sclerosis. Mitoses are numerous, and a starry sky pattern may be present.

In the past, a separation based on cytologic features was made between tumors composed of germinal center (large cleaved and noncleaved; centroblastic) cells (Fig. 37.84) and immunoblastic cells with a large vesicular nucleus with prominent central nucleolus and thick nuclear membrane, and a deeply staining amphophilic and pyroninophilic cytoplasm with a distinct nuclear hof (Fig. 37.85). Such distinctions, however, have shown poor intraobserver and interobserver reproducibility and are no longer recommended.

The majority of cases of DLBCL fall into the "not otherwise specified", or NOS group, but even within this group there is great morphologic variability. Most of these variations do not have an impact on therapy or prognosis and for this reason are not formally subclassified, but they are important because they may result in a mistaken diagnosis. They include the following:

1. *Sclerosis*. Diffuse large cell lymphomas can undergo marked sclerosing changes, similar to those seen in follicular lymphomas (Fig. 37.86).[668,674,741,742] This material is mainly composed of types I, III, and V collagen and fibronectin.[743] Sclerosis is a

Figure 37.83 Gross appearance of lymph nodes involved by non-Hodgkin lymphoma of diffuse large B-cell type. The nodes are enlarged and show a homogeneous tan cut surface.

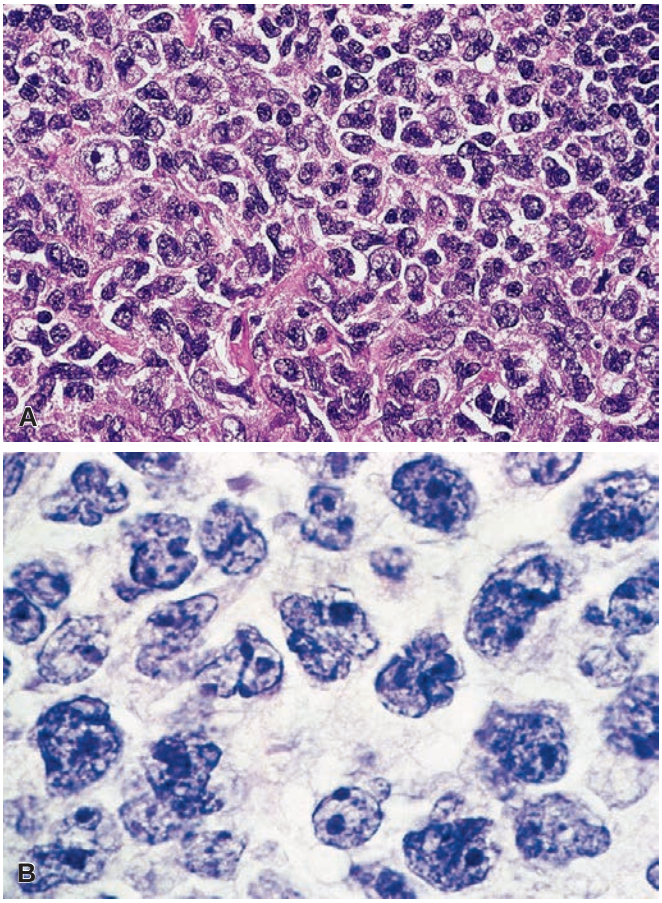

Figure 37.84 Medium- (**A**) and high-power (**B**) views of diffuse large B-cell lymphoma with large cleaved cells.

For personal use only. No other uses without permission. Copyright ©2017. Elsevier Inc. All rights reserved.

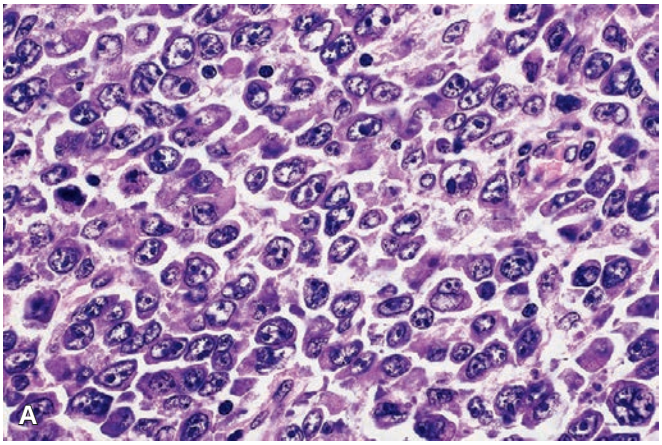

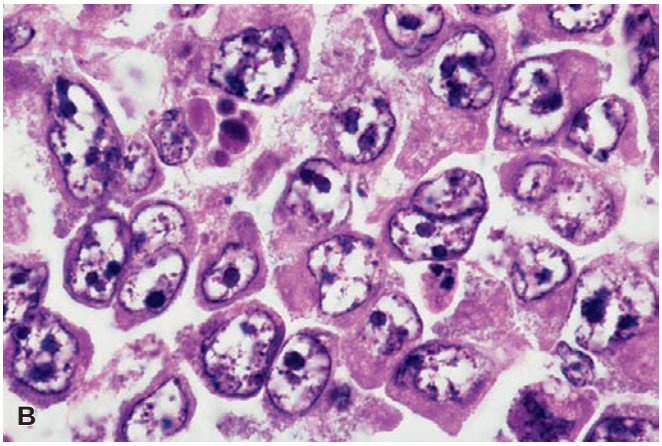

Figure 37.85 Medium- (**A**) and high-power (**B**) views of diffuse large B-cell lymphoma with immunoblastic features.

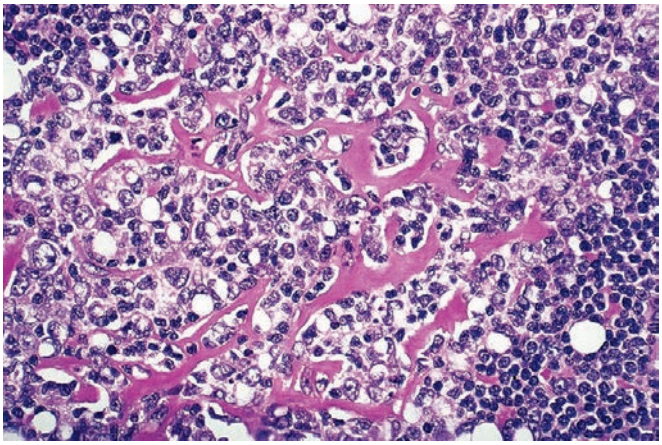

Figure 37.86 Marked sclerosis and hyalinization in diffuse large B-cell lymphoma.

particularly common feature in mediastinal (thymic) large B-cell lymphomas.

2. *Spindling of tumor cells*. This phenomenon, which is probably related to the aforementioned fibrosis, seems to be more common in large cell lymphomas of mediastinum and bone but it can be seen in any location, including lymph nodes.[744] It is thought to be related to the presence of markers characteristic of a germinal center B-cell origin.[745]

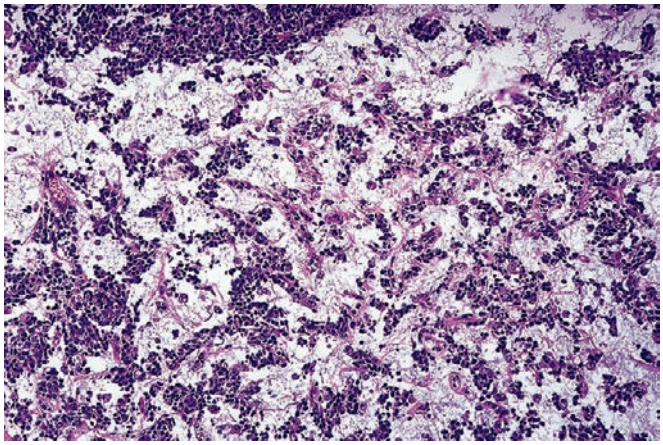

Figure 37.87 Myxoid stromal change in diffuse large B-cell lymphoma. This is an exceptional occurrence.

3. Presence of a *myxoid stroma* that can simulate the appearance of myxoid malignant fibrous histiocytoma or myxoid chondrosarcoma (Fig. 37.87).[746,747]
4. *Rosette formation*. This peculiar change, originally described in follicular lymphoma, has also been seen in large cell lymphoma. Ultrastructural studies have shown that the material in the center of the rosettes is made up of complex cell prolongations.[748]
5. *Filiform cell prolongations*. This phenomenon, which is probably related to that described in the previous paragraph, is appreciable in ultrastructural preparations and is similar to that sometimes seen in carcinomas, mesotheliomas, and other neoplasms. Large cell lymphomas exhibiting this spectacular feature have been designated anemone cell, microvillous, filiform cell, villiform cell, and porcupine lymphomas.[749,750]
6. *Signet ring features*. This alteration, which is more common in follicular lymphoma, is rarely seen in large cell lymphoma and may simulate metastatic adenocarcinoma.[751]
7. *Sinus pattern of spread*, in which the tumor cells are predominantly or entirely confined to the lymph node sinuses, resulting in an appearance closely simulating that of metastatic carcinoma, malignant melanoma, or ALCL (Fig. 37.88).[737,752] Such cases may also demonstrate anaplastic morphology and even expression of CD30, but should not be diagnosed as ALCLs, which is a distinct entity of T- or null-cell lineage.
8. *Interfollicular pattern of growth*. This is more common in T-cell tumors but has also been described in B-cell neoplasms.
9. *Nuclear multilobation*. Although originally thought to be a feature of T-cell tumors, this alteration is now known to occur in B-cell neoplasms.[753,754]

Immunophenotypically, DLBCL is by definition a monotypic B-cell neoplasm positive for B-lineage markers (most importantly CD20 but also CD19, CD79A, and PAX5) and variably immunoglobulin (surface or cytoplasmic).[755] The follicle center cell markers CD10 and BCL6 are expressed in 40% and 60% of cases, respectively. A proportion of cases express postgerminal center cell or plasma cell–associated markers such as CD38, VS38, and MUM1. About 50% of cases express BCL2 protein. A minority of DLBCLs express CD30, usually in a heterogeneous pattern. CD5 is expressed in 10% of cases and a pleomorphic variant of mantle cell lymphoma must be excluded in such cases. Ki-67 staining usually shows a variable, but usually high proliferation index, with some cases showing an index approaching 100%. An exceptionally rare occurrence is immunoreactivity for cytokeratin, which may lead the unwary to a misdiagnosis of carcinoma.[756]

For personal use only. No other uses without permission. Copyright ©2017. Elsevier Inc. All rights reserved.

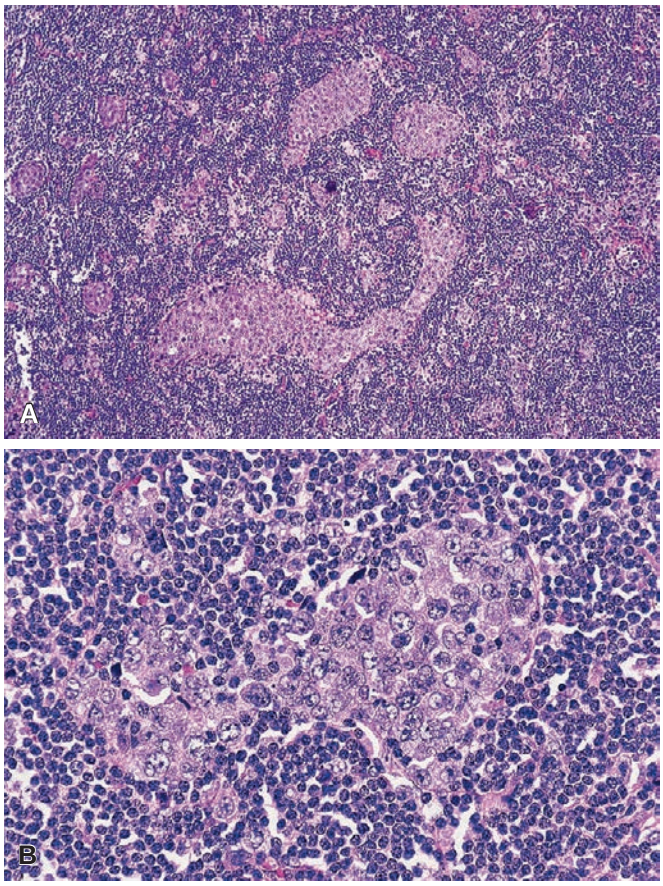

Figure 37.88 **A** and **B**, Large B-cell lymphoma with a sinus pattern of growth that simulates a metastatic tumor.

DLBCLs show rearrangements of the immunoglobulin genes as expected for a B-lineage neoplasm. The variable region of the IGH is usually hypermutated, with some cases also showing ongoing somatic mutations, indicating a germinal center or postgerminal center stage of B-cell differentiation.[757]

Approximately 20% of cases of DLBCLs show *BCL2* rearrangement due to t(14;18)(q32;q21), a hallmark of follicular lymphoma.[758–760] Such cases may have transformed from a known or occult follicular lymphoma, or may have even directly evolved to DLBCL without a precursor phase of follicular lymphoma. However, additional genetic alterations are required for the development of DLBCL, such as *TP53* mutation. The *BCL6* gene encodes a transcription factor essential for formation of secondary lymphoid follicles and T-cell-dependent antibody responses, and its aberrant expression plays an important role in the *de novo* pathway of DLBCL formation. In about 35% of cases of DLBCLs, translocation of *BCL6* (3q27) with a variety of partner genes (with IGH gene located on 14q32 being the commonest) results in constitutive overexpression of BCL6 protein, causing a sustained proliferative setting in which additional mutations can occur.[761–764] This translocation is not specific for DLBCL but is also found in a subset of follicular lymphomas.[648,765] In addition, about 75% of cases of DLBCLs show somatic mutations in the 5′ noncoding regions of the *BCL6* gene, a phenomenon also commonly observed in other germinal center and postgerminal center B-cell lymphomas.[766,767] At least some of the mutations result in deregulation of *BCL6* expression.[768] These mutations, occurring independent of *BCL6* translocation, are generated by the same somatic hypermutation mechanism that targets the variable regions of immunoglobulin genes.[769,770] *MYC* (8q24) translocation is found in up to 10% of DLBCLs.[771–774] In contrast to Burkitt lymphoma, the *MYC* gene may be fused with a non-immunoglobulin gene, and the karyotype is complex. *MYC* translocation is associated with a highly aggressive behavior.[775] *MYC* translocations in DLBCL are often associated with translocations of *BCL2* or *BCL6* and these "double-hit" lymphomas have a particularly aggressive clinical behavior.[776] A *MYC* translocation alone in a case with morphologic features of DLBCL does not alter the diagnosis of DLBCL, NOS; however, the finding of double hit would now change the diagnosis to *high-grade B-cell lymphoma with* MYC *and* BCL2 *and/or* BCL6 *rearrangements* (see later). For this reason, routine testing for translocations of these three genes by FISH is recommended for many patients with DLBCL, NOS. Expression of MYC, BCL2, and/or BCL6, detected by immunohistochemistry, does not directly correlate with translocations detected by FISH, but so-called double expressors are also associated with a worse prognosis,[777] and some centers routinely perform immunohistochemistry for MYC to identify this group.

Gene expression profiling studies can identify three major groups of DLBCLs[33,34,38,778,779]: (1) germinal center B cell–like (GCB) DLBCL that expresses genes characteristic of germinal center B cells, and is correlated with presence of t(14;18) and *C-REL* amplification; (2) activated B cell–like (ABC) DLBCL that expresses genes normally induced during in vitro activation of peripheral blood B cells, and is correlated with presence of *BCL6* translocation, *PRDM1/BLIMP1* inactivation, and constitutive activation of NFκB due to somatic mutations in genes encoding the NFκB pathway components, such as *A20/TNFAIP3* and *CARD11*; and (3) a type 3 that did not correlate with either of the first two groups.[34] The GCB group is associated with a better prognosis than the ABC group, with 5-year overall survival of 60% versus 35% with CHOP or CHOP-like therapy.[39] Although gene expression profiling for these subtypes is not available in most diagnostic laboratories, several immunohistochemical algorithms have been proposed to distinguish the GCB group from the non-GCB lymphomas. The Hans algorithm is most commonly used and is now recommended for all cases of DLBCL, NOS.[40] This approach uses three immunohistochemical markers: CD10, BCL6, and MUM1. Cases are defined as GCB if CD10 positive (without regard to BCL6 or MUM1 status) or if CD10–/BCL6+/MUM1–. All others (CD10-/BCL6+/MUM1+ or CD10–/BCL6–/MUM1+/–) are considered as non-GCB type. While this approach does not perfectly match CGH studies, it still identifies prognostically significant disease groups and some novel DLBCL therapies are recommended for the non-GCB type.[738,780] The WHO classification now includes *germinal center B-cell type* and *activated B-cell type* as subgroups of DLBCL, NOS.[407]

Although most cases of DLBCL fall into the NOS category of the 2016 WHO classification, this classification also defines a number of specific types of DLBCL.[407] Some do not primarily involve the lymph node and are discussed elsewhere in this text, including *primary mediastinal (thymic) large B-cell lymphoma*, *primary cutaneous DLBCL, leg type*, *primary DLBCL of the central nervous system*, *EBV+ mucocutaneous ulcer*, and *lymphomatoid granulomatosis*. **Intravascular large B-cell lymphoma** (angiotropic lymphoma)[781] is a systemic malignant disease that may present in lymph nodes or any organ. It was originally regarded as a multicentric malignant transformation of endothelial cells and designated as malignant angioendotheliomatosis but is now known to be a type of large B-cell lymphoma with a remarkable tropism for blood vessels.[782]

T-cell/histiocyte-rich large B-cell lymphoma is a large B cell overshadowed by a reactive population of T cells (Fig. 37.89).[783,784] The tumor cells may represent less than 10% of the entire cell population. The pattern of growth is diffuse, and there may be a fine interstitial fibrosis. The main differential diagnosis is with NLPHL,

For personal use only. No other uses without permission. Copyright ©2017. Elsevier Inc. All rights reserved.

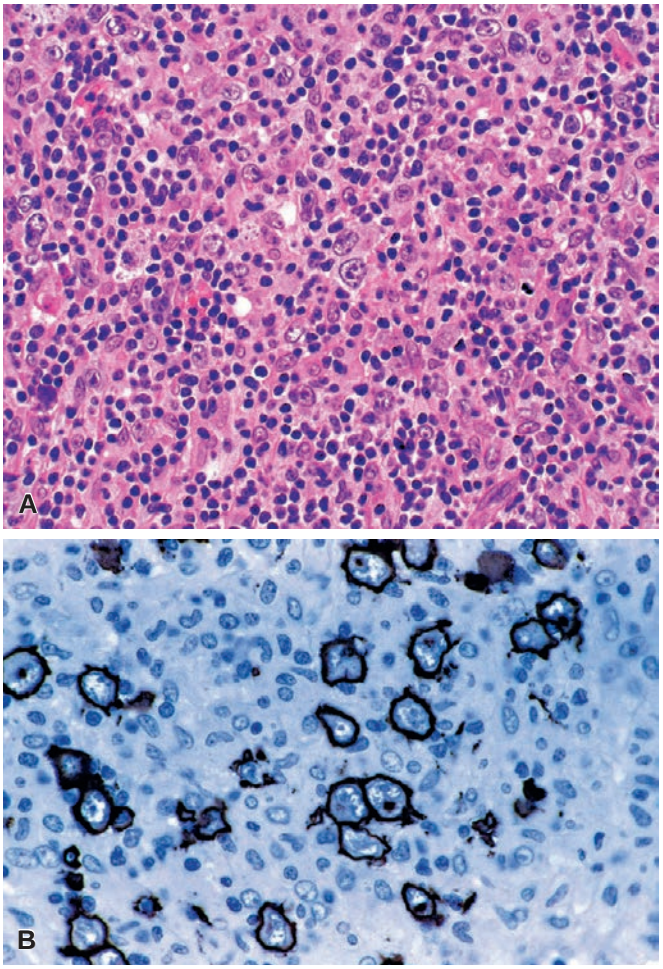

Figure 37.89 T-Cell/Histiocyte-Rich Large B-Cell Lymphoma. A, hematoxylin–eosin; **B**, membrane and Golgi-type immunoreactivity for CD20 in the large tumor cells.

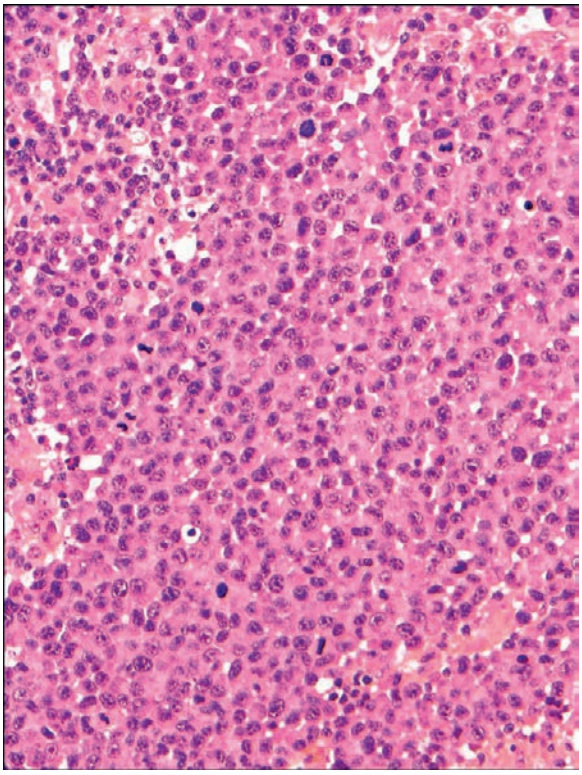

Figure 37.90 The neoplastic cells of this case of plasmablastic lymphoma have fairly fine nuclear chromatin with abundant eosinophilic cytoplasm and a high mitotic rate.

with which it shares many phenotypic features,[785] but NLPHL should demonstrate a nodular growth pattern, usually with admixed small B lymphocytes. Some authors have questioned the validity of separating the two entities.[786] It would seem, though, that there are enough clinical, morphologic, and molecular genetic differences to keep them distinct. T-cell/histiocyte-rich large B-cell lymphoma is clinically more aggressive,[787] has a different pattern of follicular dendritic cell staining,[788] and has a different genetic pattern on comparative genomic hybridization.[789]

DLBCL associated with chronic inflammation. This variant occurs in the context of long-standing chronic inflammation, and shows consistent association with EBV.[755] Most cases involve body cavities or narrow spaces, with the prototype being pyothorax-associated lymphoma, which involves the pleural cavity of patients with longstanding pyothorax.[790] Occasional cases are discovered incidentally in surgical specimens, such as splenic cyst, hydrocele sac, and atrial myxoma.[791]

EBV-positive DLBCL, NOS was previously termed EBV-positive DLBCL of the elderly or senile EBV-positive lymphoproliferative disorder.[792] This is a type of DLBCL that may occur at any age but is most common in adults aged over 50 years, without overt underlying immunodeficiency.[793–796] It is, by definition, EBV positive by in situ hybridization. It frequently shows associated necrosis but has no specific or distinctive morphologic features. This is a diagnosis of exclusion, in the sense that a case will not be classified as such if it fits other defined DLBCL entities (such as DLBCL associated with chronic inflammation, EBV+ mucocutaneous ulcer, or plasmablastic lymphoma).

Plasmablastic lymphoma was originally described as neoplastic proliferation of the oral cavity associated with HIV infection, but it may occur in any site, including lymph nodes, and in association with other causes of immunodeficiency or with aging.[797–799] Two morphologic types of plasmablastic lymphoma have been described. The monomorphic variant has features more typical of DLBCL, with large cells with vesicular nuclei, a single centrally located prominent nucleolus, or multiple peripheral nucleoli and abundant basophilic cytoplasm (Fig. 37.90), while the plasmacytic variant may mimic an anaplastic plasmacytoma with multinucleation and paranuclear hofs. The immunophenotype usually mirrors that of plasma cells, being CD45–, CD20–, CD79a+/–, PAX5–, CD38+, VS38c+, CD138+, and MUM1+. There is variable expression of cytoplasmic immunoglobulin. EBV is positive in 60%–75% of cases, and HHV8 is, by definition, negative. B lineage can be confirmed by demonstrating rearrangement of IGH, and translocations of *MYC* are present in approximately half of cases.[800,801]

The diagnosis of plasmablastic lymphoma should be considered in cases with morphologic features of DLBCL that lack the common B cell markers, such as CD20, CD79A, or PAX5, and for cases with features of anaplastic myeloma but are EBV positive. Other disorders have morphologic features similar to plasmablastic lymphoma. These include ALK+ large B-cell lymphoma, tissue infiltrates of primary effusion lymphoma, and HHV8+ DLBCL that may be associated with Castleman disease (see later). These are all distinct entities that take diagnostic precedence over plasmablastic lymphoma.

For personal use only. No other uses without permission. Copyright ©2017. Elsevier Inc. All rights reserved.

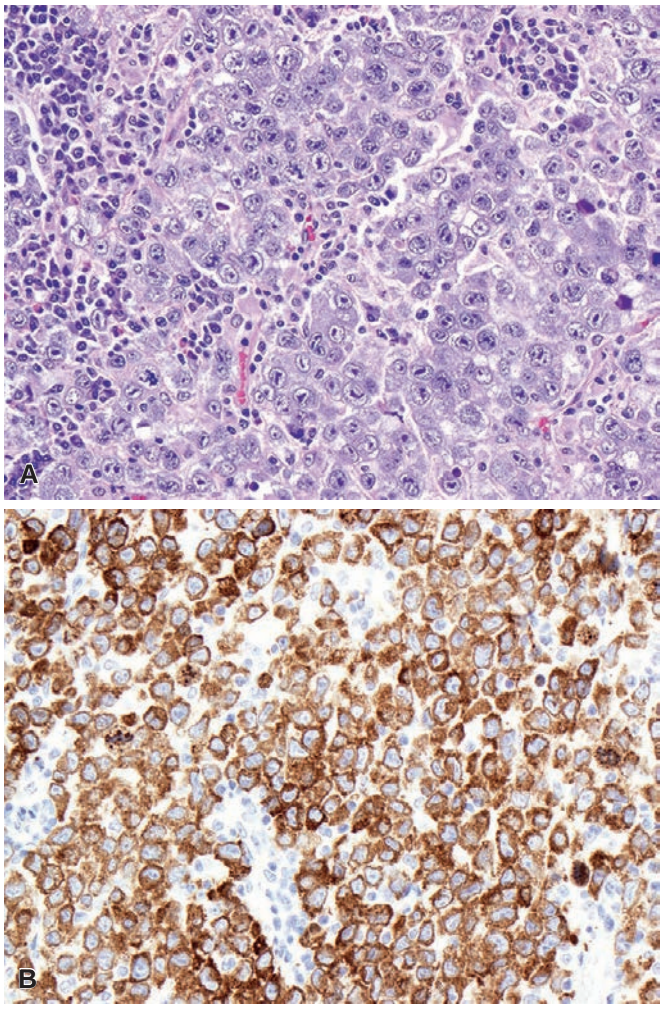

Figure 37.91 ALK-Positive Large B Cell Lymphoma. A, The large atypical cells cluster and may mimic metastatic carcinoma. **B**, the neoplastic cells demonstrate ALK expression.

ALK+ large B-cell lymphoma is an uncommon form of DLBCL with plasmablastic differentiation and a poor prognosis. The tumor cells have an immunoblastic or plasmablastic appearance, and sinusoidal infiltration is common.[802,803] Since they can appear deceptively cohesive, they may be misinterpreted as carcinoma cells (Fig. 37.91). The immunophenotype is similar to plasmablastic lymphoma, CD30 is negative and IgA is commonly positive. The commonest molecular alteration is t(2;17)(p23;q23), which fuses the *ALK* gene with the *CLTC* gene.[804,805] Since *CLTC* encodes a granule-associated protein, immunostaining for ALK is typically in the form of cytoplasmic granules. These tumors are negative for EBV and HHV8 and lack *MYC* translocations.[806]

Primary effusion lymphoma does not usually involve lymph nodes but is briefly mentioned here due to its potential overlap with plasmablastic lymphoma. This is a large B-cell lymphoma with plasmablastic differentiation, occurring predominantly as a pleural or pericardial effusion in patients with AIDS.[807] These effusions contain markedly pleomorphic cells that may suggest carcinoma or mesothelioma. Similar to plasmablastic lymphoma, the cells tend to lack B-cell antigen expression and are associated with both HIV and EBV. The also show a strong association with HHV8, which does not occur with plasmablastic lymphoma. A solid tissue counterpart also exists.[808] The tumor differs from plasmablastic lymphoma by the presence of HHV8, its clinical presentation in body fluids, and by the absence of MYC translocations.

HHV8-positive DLBCL, NOS is an aggressive lymphoma type that was previously termed *large B-cell lymphoma arising in HHV8-associated multicentric Castleman disease*.[809,810] While the association with Castleman disease remains, cases arising outside of this disorder may occur. These lymphomas have plasmablastic morphologic features (Fig. 37.92), similar to plasmablastic lymphoma, but are more likely to express CD20, are EBV-negative, and are positive for HHV8, which can be detected with LANA-1 antibodies by immunohistochemistry; all features that do not occur in plasmablastic lymphoma. The neoplastic cells only express lambda light chains, a feature of HHV8 infection even in non-neoplastic settings. In contrast to individual atypical lambda positive plasmablastic cells in multicentric Castleman disease, these lymphomas form sheets of neoplastic cells. Some cases are associated with Kaposi sarcoma in the same lymph node.

Current Testing in Diffuse Large B-Cell Lymphoma

While demonstrating sheets of large B-cells with a CD20 stain may be sufficient for an overall diagnosis of DLBCL, the above discussion highlights the need for a variety of other tests to be performed currently in the routine evaluation of these cases. As mentioned, testing for CD10, BCL6, and MUM1 are now necessary to subclassify cases of DLBCL, NOS into germinal center versus non-germinal center types. FISH testing for translocations involving *MYC*, *BCL2*, and *BCL6* are also now routinely done to identify the high-risk "double-hit" group. Most centers also perform Ki-67 staining for prognosis and CD30 staining may be performed since new anti-CD30 antibodies make this is a potential therapeutic target. In situ hybridization is necessary to identify the EBV-associated NOS group. CD5 staining, which when present would warrant further evaluation (cyclin D1 staining, etc) to exclude a pleomorphic mantle cell lymphoma, may also be useful. MYC and BCL2 immunohistochemistry to identify so-called high risk "double expressors" is not currently routine but will probably be more commonly performed in the near future.

Burkitt Lymphoma

Burkitt lymphoma is a high-grade malignant lymphoma composed of germinal center B cells, which can present in three clinical settings:

1. *Endemic*. This occurs in the equatorial strip of Africa and is the most common form of childhood malignancy in that area. The patients characteristically present with jaw and orbital lesions. Involvement of the gastrointestinal tract, ovaries, kidney, and breast are also common.
2. *Sporadic*. This is seen throughout the world. It affects mainly children and adolescents and has a greater tendency for involvement of the abdominal cavity than the endemic form.[811]
3. *Immunodeficiency associated*. This is seen primarily in association with HIV infection and often occurs as the initial manifestation of the disease.[812,813]

In all three forms peripheral lymphadenopathy is rare and, when present, usually limited to a single group.[814,815] Bone marrow involvement is common in the late stage of the disease, but leukemic manifestations are less common.[811,816]

Microscopically, the pattern of growth of Burkitt lymphoma is usually diffuse, although early cases may show preferential involvement of germinal centers.[817] The tumor cells are medium sized (10–25 μm) and round. The nuclei are round or oval and have *several* prominent basophilic nucleoli. The chromatin is coarse and the nuclear membrane is rather thick. The cytoplasm is easily identifiable; it is amphophilic in hematoxylin–eosin-stained preparations

For personal use only. No other uses without permission. Copyright ©2017. Elsevier Inc. All rights reserved.

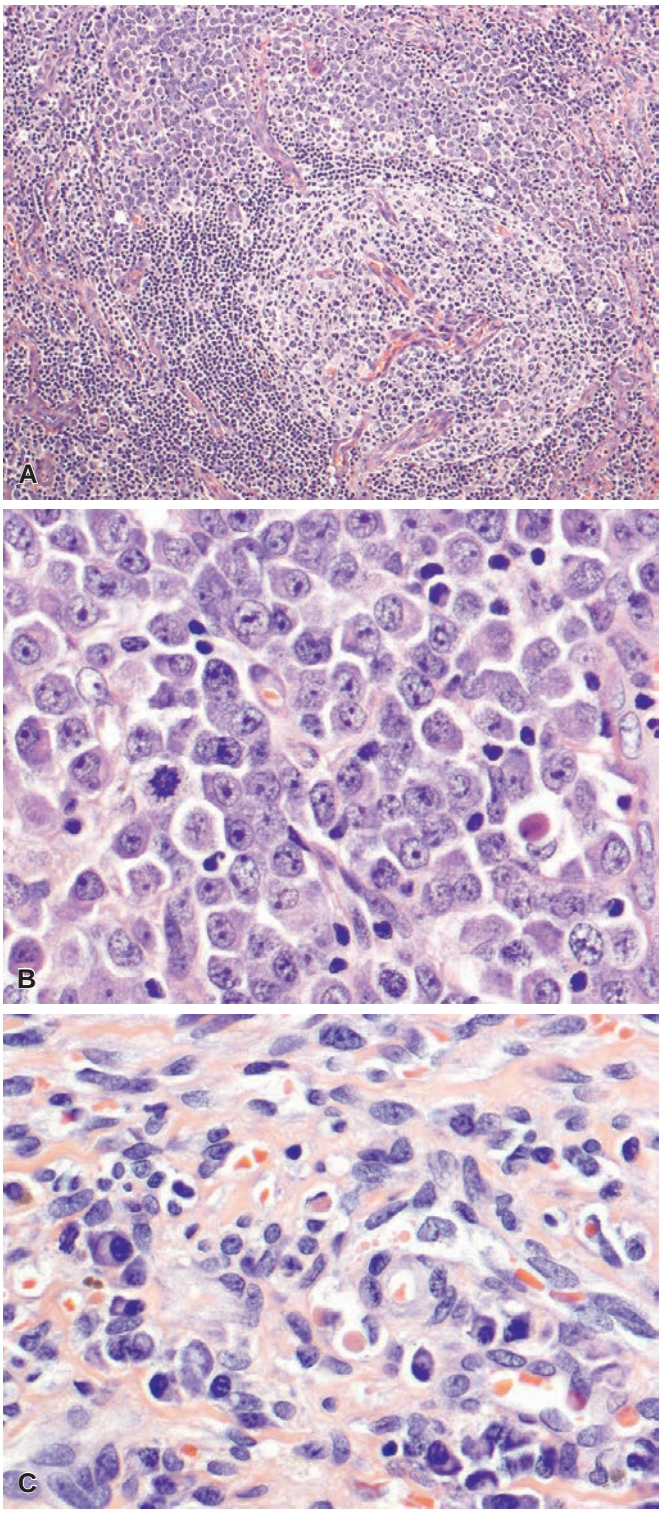

Figure 37.92 HHV+ DLBCL, NOS Arising in a Patient With Castleman Disease. A, The lymphoma cells surround the upper left portion of the typical Castleman germinal center. **B**, The cells have morphologic features similar to plasmablastic lymphoma but were HHV8 positive and EBV negative. **C**, The lymph node capsule also showed a focus of Kaposi sarcoma.

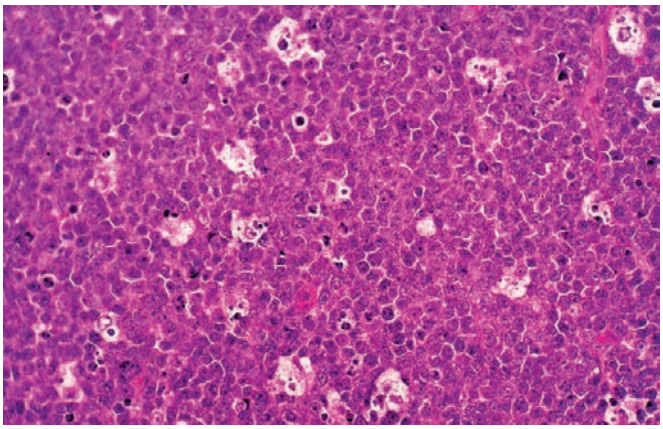

Figure 37.93 Burkitt lymphoma with characteristic starry sky appearance.

and strongly pyroninophilic. Fat-containing small vacuoles are present; these are particularly well appreciated in touch preparations. Mitoses are numerous, and a prominent starry sky pattern is the rule, although by no means pathognomonic (Fig. 37.93).[818] There are also many admixed apoptotic bodies. In well-fixed material, the cytoplasm of individual cells "squares off," forming acute angles in which the membranes of adjacent cells abut on each other. Occasionally, the tumor is accompanied by a florid granulomatous reaction.[819] Ultrastructurally, the main features are abundant ribosomes, frequent lipid inclusions, lack of glycogen particles, and presence of nuclear pockets or projections.[820]

Burkitt lymphomas are of mature B-cell lineage. They express immunoglobulins (predominantly IgM), invariably associated with heavy and light chain restriction.[821] B cell–specific antigens (such as CD19, CD20, and CD22) as well as the germinal center cell markers CD10 and BCL6 are expressed.[822] They are negative for the activation markers CD25 and CD30 and are BCL2 negative. In contrast to lymphoblastic lymphoma, they do not express TdT. The most helpful immunohistochemical profile to aid in diagnosis of Burkitt lymphoma includes CD20+, CD10+, BCL2–, and a Ki-67 index over 95%.

As expected of a B-lineage neoplasm, Burkitt lymphoma shows clonal rearrangements of the immunoglobulin genes. The hallmark genetic change is t(8;14), t(2;8), or t(8;22), which fuses the *MYC* gene with an IGH, kappa light chain, or lambda light chain gene.[823] As a result, the *MYC* gene is overexpressed, promoting cell cycle progression and inhibiting differentiation.[824] However, *MYC* translocation is not entirely specific for Burkitt lymphoma; it can also be observed in transformed follicular lymphomas, rare cases of DLBCL, and the highly lethal "double-hit" lymphomas (with presence of both *MYC* and *BCL2* translocation).[775,825–828] In Burkitt lymphoma, as currently defined, the *MYC* translocation should be the sole abnormality.[775]

FISH studies are now necessary to support a diagnosis of Burkitt lymphoma by demonstrating the presence of a *MYC* translocation together with absence of *BCL2* and *BCL6* translocations.[819]

There is an association of Burkitt lymphoma with EBV, with frequencies of approximately 100% for the endemic type, 20%–30% for the sporadic type, and 25%–40% for the immunodeficiency-associated type (Fig. 37.94).[823] The EBV shows type I latency, that is EBER and EBNA1 are expressed, while LMP1 and EBNA2 are negative.

In the past, some cases resembling Burkitt lymphoma but having atypical morphologic and/or immunophenotypic features were diagnosed as *atypical Burkitt lymphoma*, *Burkitt-like lymphoma*, *small non-cleaved*, *non-Burkitt lymphoma*, *gray-zone lymphoma*, or *B-cell*

For personal use only. No other uses without permission. Copyright ©2017. Elsevier Inc. All rights reserved.

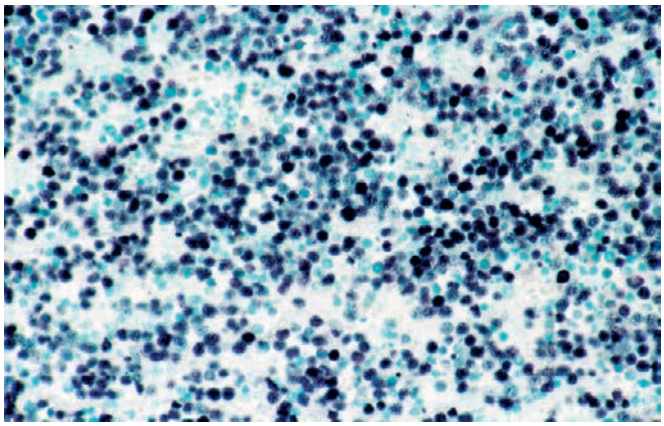

Figure 37.94 Presence of EBV genome in Burkitt lymphoma, as demonstrated with in situ hybridization for EBER.

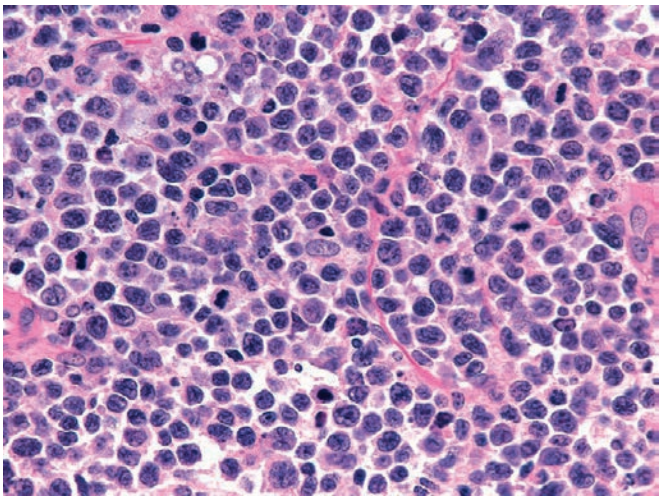

Figure 37.95 High-Grade B-Cell Lymphoma With *MYC* and *BCL2* Rearrangements. The morphologic features are intermediate between diffuse large B-cell lymphoma and Burkitt lymphoma. The presence of a so-called double hit of the two translocations confirms this diagnosis.

lymphoma, unclassifiable with features intermediate between DLBCL and Burkitt lymphoma. These terms are no longer used and have been replaced with several new categories/names in the 2016 WHO classification.[407]

Burkitt-like lymphoma with 11q aberration is a provisional entity in the 2016 WHO classification. It has morphologic and immunophenotypic features similar to Burkitt lymphoma described previously except it may have more nuclear pleomorphism than usual type Burkitt lymphoma.[829,830] In contrast to Burkitt lymphoma, which has *MYC* translocations without other complex cytogenetic abnormalities, Burkitt-like lymphoma with 11q aberration has gains or losses at 11q and may have an associated complex karyotype. Some cases of this type are reported post-transplantation or in association with immunodeficiency. Since testing for these 11q aberrations is not routinely available, most cases currently would be classified as high-grade B-cell lymphoma, NOS (described next).

High-Grade B-Cell Lymphomas

Some lymphomas, particularly those with features similar to Burkitt lymphoma, either lack *MYC* translocations or have *MYC* translocations as well as additional cytogenetic abnormalities, particularly translocations of *BCL2* or *BCL6*.[776,831] Cases with a *MYC* translocation with either a *BCL2* or *BCL6* translocation are now termed **high-grade B-cell lymphoma with *MYC* and *BCL2* and/or *BCL6* rearrangements**. These cases may have morphologic features of DLBCL or Burkitt lymphoma and often express CD10 and BCL2 and demonstrate a very high proliferation rate (Fig. 37.95). No single finding, however, is predictive of these combined cytogenetic abnormalities. Many cases also have other cytogenetic abnormalities. Some prognostic variation is reported based on the second "hit" and for "triple-hit" cases that have all three translocations,[832–834] but any combination of two or more translocations would qualify a case for this category. Cases with a morphologic appearance similar to Burkitt lymphoma or intermediate between DLBCL and Burkitt lymphoma, but lack a *MYC* translocation or an 11q aberration are now termed **high-grade B-cell lymphoma, NOS**.

Lymphoma in Immunodeficiency States

An increase in the incidence of malignant lymphoma has been documented in most types of congenital and acquired immunodeficiency.[835–837] Chronic antigenic stimulation—possibly by oncogenic viruses—and perhaps loss of antibody feedback inhibition of the lymphoid proliferation may account for the high rate of lymphoid malignancies.[838] EBV in particular has been repeatedly implicated.[839]

1. *Primary immunodeficiencies*. Patients with genetically determined immune deficiencies have an increased incidence of malignant tumors, especially lymphomas.[835,840,841] This includes ataxia–telangiectasia, Wiskott–Aldrich syndrome, X-linked lymphoproliferative syndrome, common variable immunodeficiency, and severe combined immunodeficiency syndrome.[842]
2. *Post-transplant lymphoproliferative disorders (PTLDs)*. The incidence of lymphoma is increased in recipients of all types of solid organ transplant as a direct or indirect result of the induced immunosuppression.[843–847] In renal transplant recipients, this incidence is in the order of 4%–6%.[848] Skin tumors, malignant lymphomas, Kaposi sarcoma, and cervical carcinoma are the most common neoplasms. The frequency of lymphoma has been estimated to be 350 times higher than in the age-matched general population.[848–850] The incidence has been found to be particularly high in adult cardiac transplant patients treated with OKT-3–containing regimens.[851,852] In approximately half of the reported cases, the central nervous system is involved, compared with less than 1% in lymphoma patients in general. In 30% of the cases, the allograft is also involved.

   A number of microscopic patterns of PTLD occur. More indolent cases involve lymph nodes or tonsils without a destructive architectural pattern. These include *plasmacytic hyperplasia*, *infectious mononucleosis,* and *florid follicular hyperplasia* types of PTLD. While these may progress to destructive and frankly neoplastic proliferations, many do not, and it is controversial whether these types all actually represent PTLDs or are unrelated hyperplastic lesions. This is particularly true for plasmacytic hyperplasia and florid follicular hyperplasia types that may have only rare EBV-positive cells and are similar to reactive lesions seen in patients with no transplant history. The infectious mononucleosis type of PTLDs is morphologically identical to what is seen in infectious mononucleosis in immunocompetent individuals but may at times be difficult to differentiate from polymorphic PTLDs (see later). Reactive-appearing proliferations without EBV should probably not be considered as a PTLD.

   There is better agreement that destructive lesions, often similar to other lymphoma types, represent true PTLDs. These include

For personal use only. No other uses without permission. Copyright ©2017. Elsevier Inc. All rights reserved.

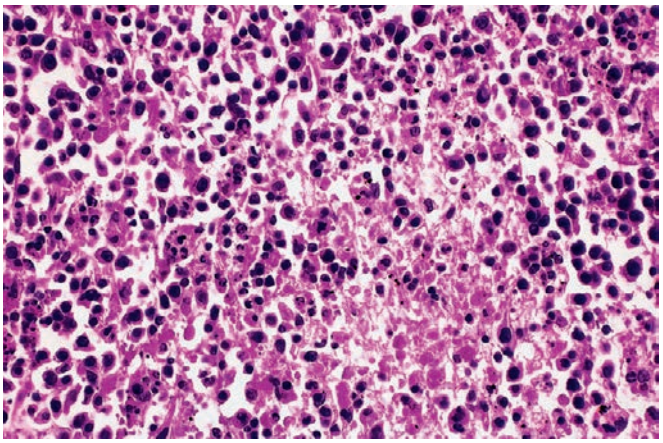

Figure 37.96 Polymorphic lymphoproliferative process associated with necrosis in lymph node of a renal transplant patient. There was evidence of active EBV infection.

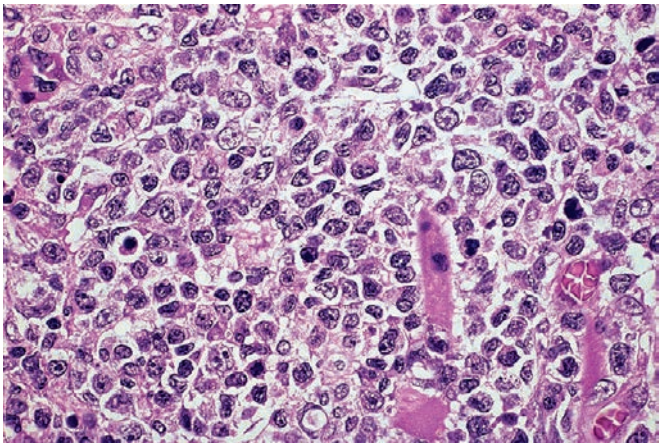

Figure 37.97 Monomorphic posttransplant lymphoproliferative disorder (diffuse large B-cell lymphoma) in a recipient of a renal transplant.

polymorphic, *monomorphic*, and *classical Hodgkin lymphoma types.* **Polymorphic PTLD** distorts the normal lymph node architecture with a heterogeneous mix of B cells and plasma cells (Fig. 37.96).[853] Large, admixed immunoblasts and cells with Hodgkin-like features are often present. The B-cell and plasma cell component may be monotypic or polytypic in these proliferations. The large atypical cells are frequently CD30 positive and EBV is present in most cells of the majority of cases. **Monomorphic PTLD** has histologic features similar to well-established non-Hodgkin lymphoma types of non-immunocompromised patients (Fig. 37.97). These most commonly are DLBCL, Burkitt lymphoma, or plasmacytoma and are usually EBV positive.[854] T- or NK-cell lineage cases of monomorphic PTLD are also described.[855] Rare cases of monomorphic PTLD of marginal zone lymphoma type are reported and are EBV positive,[856] a feature that is otherwise uncommon in marginal zone lymphoma. In general, however, most lymphomas of small B cells arising in the post-transplant setting are not considered to be PTLD. The **classical Hodgkin lymphoma PTLDs** have morphologic and immunophenotypic features of classical Hodgkin and are usually EBV positive. Cases with Hodgkin-like cells admixed with a polymorphous background, not typical of classical Hodgkin lymphoma, are considered polymorphic PTLD and not the classical Hodgkin lymphoma type.

Molecular studies have confirmed the recipient origin of the lymphoma following solid organ transplantation, with donor origin more common after hematopoietic cell transplantation.[857–859]

The clinical course of post-transplant lymphoma/lymphoproliferative disease is usually very rapid.[860,861] Treatment of PTLDs consists of a combination of immunosuppression reduction and standard lymphoma therapy (chemotherapy and radiation).[862]

3. *HIV*. Patients with HIV infection are at a high risk for developing malignant tumors, principally Kaposi sarcoma and malignant lymphoma,[863–869] sometimes in combination.[809] It has been estimated that approximately 3% of AIDS patients develop non-Hodgkin lymphoma, and that the risk of developing a lymphoma in this population is 60-fold greater than in the normal population. The majority of the cases present with multiple sites of extranodal involvement, with a high incidence of involvement of the gastrointestinal tract, central nervous system, bone marrow, liver, oral cavity, body cavities, and heart.[866,870] Practically all cases are of B-cell lineage and—as such—show clonal immunoglobulin gene rearrangements.[864,871,872] Distinct morphologic subtypes of lymphoma associated with HIV have already been described, but many patients have DLBCL or Burkitt lymphoma, with similarities to non-HIV cases.[812,813,873,874] Cases have also been reported of peripheral T-cell lymphomas with a peculiar component of Touton-like giant cells,[875] and others having the features of the polymorphic lymphoproliferative disorders seen more often in solid organ transplant recipients.[876] HIV-associated lymphomas, especially the unique types of plasmablastic lymphoma, primary effusion lymphoma, and HHV8+ DLBCL (see earlier), have an increased association with HHV8 and/or EBV infection.[877–880]
4. *Others*. Acquired diseases of the immune system in which an increased incidence of lymphoma has been recorded include rheumatoid arthritis,[881,882] Sjögren syndrome,[883] Hashimoto thyroiditis, and other autoimmune diseases.[884]

Peripheral (Post-Thymic) T-Cell and Natural Killer–Cell Lymphomas

Peripheral (post-thymic) T-cell and NK-cell lymphoma is the generic term given to a family of tumors composed of neoplastic lymphocytes with phenotypic and genotypic features of mature T cells or NK cells.[885,886] This is an extremely heterogeneous group of lesions, many of them occurring primarily at extranodal sites, and which have received a myriad of designations. Most of them were identified as entities long before their peripheral T-cell or NK-cell nature was ascertained.

Peripheral T-cell and NK-cell lymphomas in general are highly aggressive. Their morphologic features are variable depending on the type, but immunohistochemical studies are always required to confirm their T-cell or NK-cell nature. They commonly express CD3, CD45RO, CD2, CD5, and CD7, although expression of one or more of these pan–T-cell markers may be lost (so-called aberrant immunophenotype, which is sometimes utilized to support the neoplastic nature of a T-cell proliferation). NK-cell lymphomas are commonly CD2+, cytoplasmic CD3+, surface CD3–, CD5–, and CD56+ and are EBV-positive by in situ hybridization. Most cases of peripheral T-cell lymphoma express a CD4+/CD8– mature helper phenotype; approximately 20% express a CD4–/CD8+ cytotoxic/suppressor phenotype, with rare cases having CD4–/CD8– or CD4+/CD8+ phenotypes.

At the molecular level, peripheral T-cell lymphomas exhibit clonal rearrangements of the γ and β T-cell receptor genes, although about 10% of cases may show simultaneous clonal rearrangements of IGH.[887]

For personal use only. No other uses without permission. Copyright ©2017. Elsevier Inc. All rights reserved.

The T/NK neoplasms of the 2016 WHO classification are listed in Box 37.1. Many do not primarily involve lymph nodes and are discussed in other chapters. The major lymph node disease categories are AITL, ALCL, and peripheral T-cell lymphoma, NOS.

Angioimmunoblastic T-Cell Lymphoma

AITL includes cases originally described as angioimmunoblastic lymphadenopathy (AILD) and immunoblastic lymphadenopathy. AILD was originally considered a premalignant proliferation with a high risk for transformation to T-cell lymphoma but is not considered neoplastic from its origin.[888] AILD was originally described as occurring almost exclusively in adults and elderly individuals and is characterized clinically by fever, anemia (usually hemolytic), polyclonal hypergammaglobulinemia, and generalized lymphadenopathy.[889–891] Other common manifestations include hepatomegaly, splenomegaly, constitutional symptoms, and skin rash.[892–894] In 27% of the patients studied in the classic series by Lukes and Tindle[891] the disease occurred abruptly after administration of drugs, particularly penicillin. Some of these cases, however, might now be considered as mimics of AITL rather than lymphoma based on more extensive testing now performed.

Microscopically, the disease is systemic, with lesions in the lymph nodes, spleen, liver, bone marrow, and skin. The lymph node changes are characterized by obliteration of the nodal architecture (with focal preservation of sinuses) by a polymorphic cellular infiltrate and by an extensive proliferation of finely arborizing vessels of the caliber of postcapillary venules (Fig. 37.98). The cellular infiltrate is composed of small lymphocytes, plasma cells, numerous immunoblasts, frequent and sometimes abundant eosinophils, and, occasionally, multinucleated giant cells. Normal germinal centers are usually absent; what one may find instead are germinal centers composed of loose aggregates of pale histiocytes, rare immunoblasts, or large epithelioid cells; these are referred to as "burnt-out germinal centers" and can closely resemble the appearance of granulomas. Only occasionally one finds hyperplastic germinal centers.[895] There is also a component of proliferating cells of dendritic/reticulum nature[896] that extends beyond the residual germinal centers and is highlighted by CD21 or CD23 staining. An amorphous, eosinophilic PAS-positive intercellular material may be found scattered throughout the node. Extension of the infiltrate in the capsule and pericapsular tissue is common. Although subtle in many cases, some cases demonstrate clusters of large, often clear cells that represent the clonal T-cell proliferation in most cases (Fig. 37.99). These T cells are now believed to arise from the germinal center and are termed TFH cells. Immunohistochemical studies for CD21 or CD23 are useful to identify the expanded follicular dendritic cell networks characteristic of this disorder. The identification of TFH cells outside of follicles is also a helpful feature. These T cells express CD10, CXCL13, BCL6, and PD1. Lymphoid cells positive for EBV are found in over 75% of the cases, but these cells may be infrequent and do not correlate with the neoplastic T cell population.[897] Additionally, admixed atypical large B cells and/or increased plasma cells may be present, and these may be monotypic. Hodgkin-like cells may also occur in AITL. The increase in large B cells may create diagnostic difficulties,[898] with the T-cell component missed in some cases at presentation or the lymphoma correctly identified as AITL relapsing with features of DLBCL.

While AITL expectedly shows clonal rearrangements of the T-cell receptor genes in most cases, up to 40% of cases show simultaneous clonal rearrangements of the immunoglobulin genes supportive of an underlying B cell clone. This finding has been attributed to EBV infection of B cells in the past but is also seen in EBV-negative cases.[17,899,900] Chromosomal alterations in AITL are common but nondistinctive, such as +3, +5, +18, +19, +21, +X, −6q, and −7.[505,899,901,902] The gene expression profile shows a strong contribution by the admixed follicular dendritic cells, B cells, and stromal components, as well as overexpression of genes characteristic of normal TFH cells.[903–905] A variety of mutations have now been described in AITL, including mutations in myeloid-associated genes *TET2*, *DNMT3A*, and *IDH2*.[906–908] Mutations in *RHOA*, however, appear to be most common reported in approximately 60% of cases.[909] A subset of cases demonstrate t(5;9)(q33;q22) involving *ITK* and *SYK*.

Two rare lymphoma types are now considered provisional entities in the 2016 WHO classification and both are closely related to AITL.[407,910] Both are neoplasms of TFH cells with expression of CD10, BCL6, CXCL13, and/or PD1 on the neoplastic T cells. **Follicular T-cell lymphoma** shows a prominent follicular pattern with extensive follicular dendritic cell networks. **Nodal peripheral T-cell lymphoma with TFH phenotype** does not show all typical features of AITL but has a similar lymphoma cell immunophenotype.

Anaplastic Large Cell Lymphoma

ALCL in its most typical form is characterized by highly atypical and pleomorphic neoplastic cells with expression of the activation marker CD30.[911–914] ALCL is distinguished from CD30-positive transformation of other lymphomas, especially mycosis fungoides, and only includes cases of T-cell or null lineage. Primary cutaneous ALCL is also a distinct entity that is part of the spectrum of primary cutaneous CD30+ T-cell lymphoproliferative disorders and is not discussed here.

The systemic form of ALCL can involve lymph nodes or extranodal sites, such as the bone marrow, bone, respiratory tract, skin, and gastrointestinal tract.[915–917] It can occur in children or adults.[918–921] Exceptionally, it is accompanied by leukemic manifestations.[922] Systemic symptoms such as fever can be present. Currently two types are segregated based on ALK expression, owing to differences in clinical features and prognosis. ALK+ ALCL tends to occur in children and young adults, and the outcome is good if appropriate treatment is given. ALK− ALCL tends to occur over a wider age range, especially older adults, and is associated with a poor outcome similar to peripheral T-cell lymphoma, NOS.

Microscopically, the infiltrate has a polymorphic appearance, often with a variable admixture of neutrophils, lymphocytes, and histiocytes, with the highly atypical large lymphoma cells showing marked pleomorphism.[923] The nuclei of these cells are often horseshoe shaped or multilobed, and nucleoli are prominent. Cells indistinguishable from Reed–Sternberg cells may be seen. The cytoplasm is abundant and eosinophilic. Cohesive growth and preferential sinus involvement are common (Fig. 37.100). The undue prominence of the latter feature in some cases was one of the reasons for this lesion to be mistakenly placed in the category of malignant histiocytosis. ALCL can also simulate malignant melanoma, undifferentiated carcinoma, and various types of soft tissue sarcoma.[924]

Several morphologic variants of ALCL (usually ALK+) have been described.

1. *Small cell*. As the name indicates, this shows a predominant population of small- to medium-sized cells. A very important clue is the presence of the characteristic large anaplastic cells around blood vessels.[923,925] Cases of the small cell variant have been seen to transform into the classic anaplastic large cell form.[926]
2. *Lymphohistiocytic*. The distinctiveness of this variant results from the presence of a large number of admixed reactive (nonepithelioid) histiocytes (Fig. 37.101).[927–929] As for the previous variant, an important diagnostic clue is the clustering of anaplastic tumor cells around vessels.

For personal use only. No other uses without permission. Copyright ©2017. Elsevier Inc. All rights reserved.

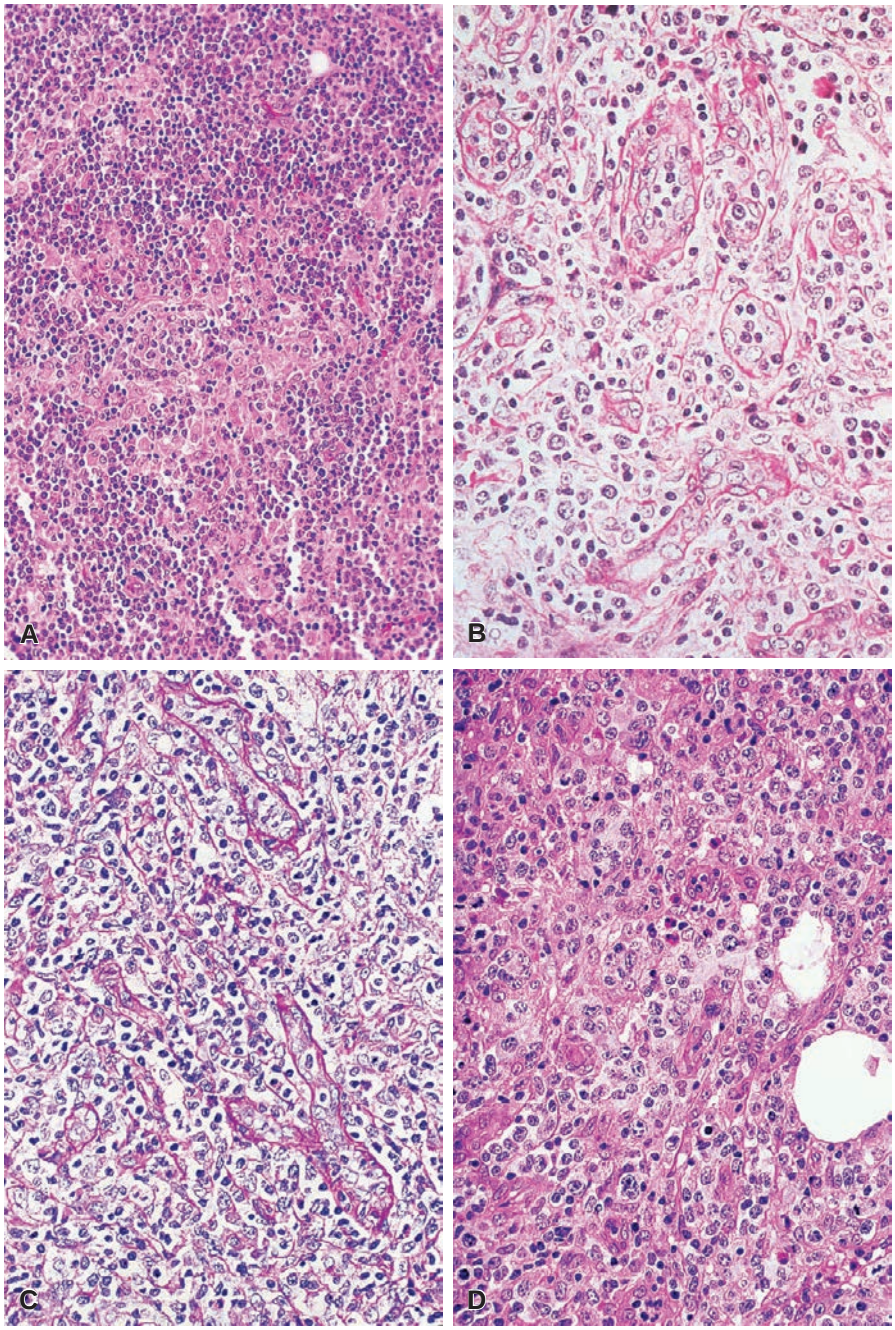

Figure 37.98 Lymph Node Involvement by Angioimmunoblastic T-Cell Lymphoma. A, Low-power view showing a moderate effacement of the architecture by a polymorphic infiltrate composed of lymphocytes, plasma cells, and histiocytes. There is also marked vascular proliferation. **B** and **C**, The PAS stain highlights the prominence of the postcapillary venules. **D**, Atypical lymphoid cells are present in this polymorphic infiltrate, often with clusters of cells with clear cytoplasm. There are also scattered eosinophils.

3. Other morphologic variations of ALCL that do not qualify as bona fide tumor variants are the neutrophil—and/or eosinophil—rich,[930,931] sarcomatoid,[924] giant cell,[932] signet ring-like,[933] and hypocellular.[934]

Immunohistochemically, the tumor cells of ALCL are by definition CD30+ (Ki-1) positive (Fig. 37.102).[935] There is also consistent positivity for EMA, interleukin-2 receptor,[936] clusterin (in a Golgi pattern),[937] cadherins,[938,937] and galectin-3 (a β-galactoside-binding animal lectin).[939,940] There is occasional reactivity for keratin.[940]

There is variable expression of T-lineage markers, and application of a wide panel may be required to have one or two markers staining. In the so-called null-cell cases, T-lineage markers cannot be demonstrated. B-cell markers are, by definition, absent. The B-cell transcription factor PAX5 is usually not expressed, and this marker is extremely helpful for distinction of ALCL from classic Hodgkin lymphoma (PAX5+). ALK, by definition, is expressed in ALK+ ALCL, but not in ALK– ALCL (Fig. 37.103). EBV is generally negative.[941]

For personal use only. No other uses without permission. Copyright ©2017. Elsevier Inc. All rights reserved.

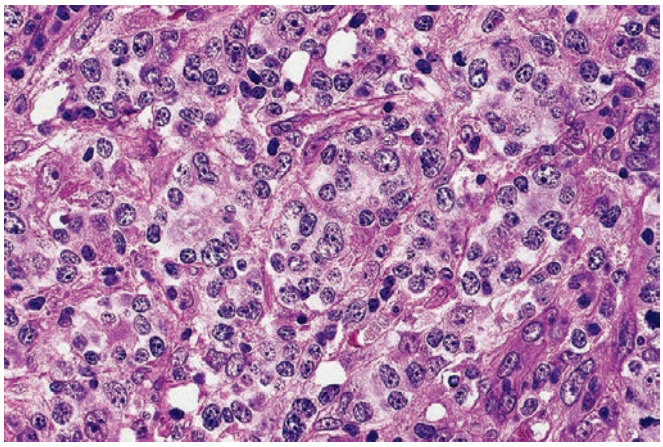

Figure 37.99 Angioimmunoblastic T-cell lymphoma with a uniform proliferation of large neoplastic lymphoid cells.

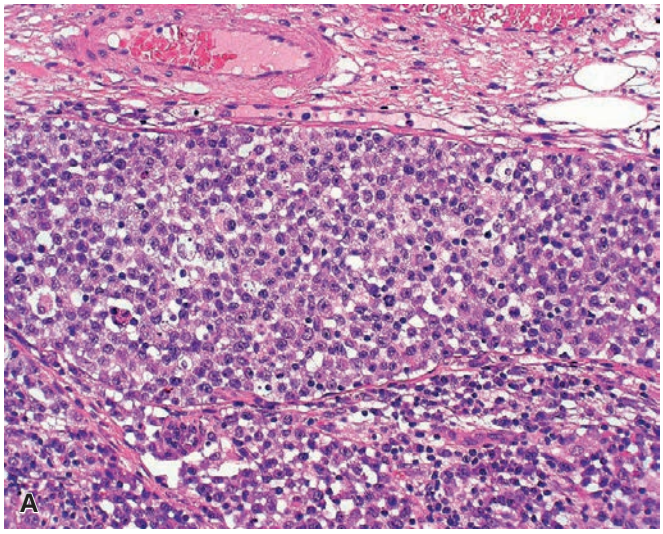

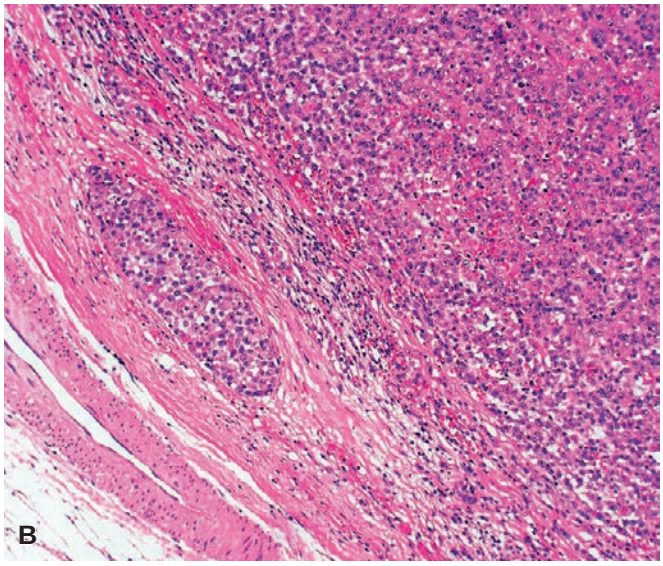

Figure 37.100 Anaplastic Large Cell Lymphoma. A, Packing of the peripheral sinus. **B**, Vascular involvement.

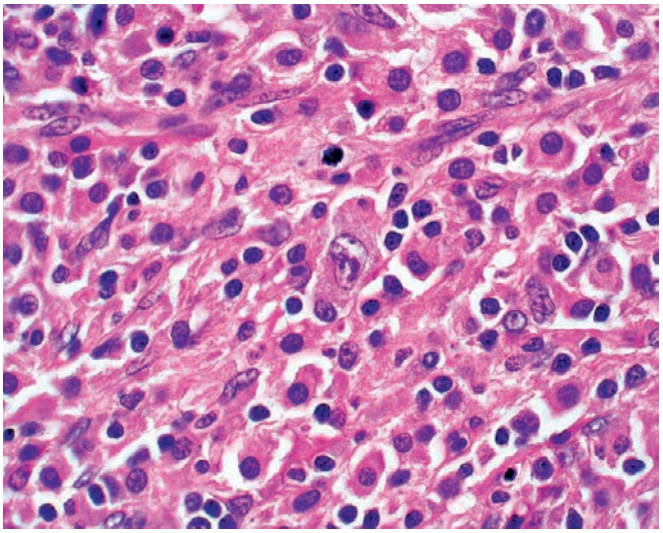

Figure 37.101 So-called lymphohistiocytic variant of anaplastic large cell lymphoma with only scattered, large neoplastic cells.

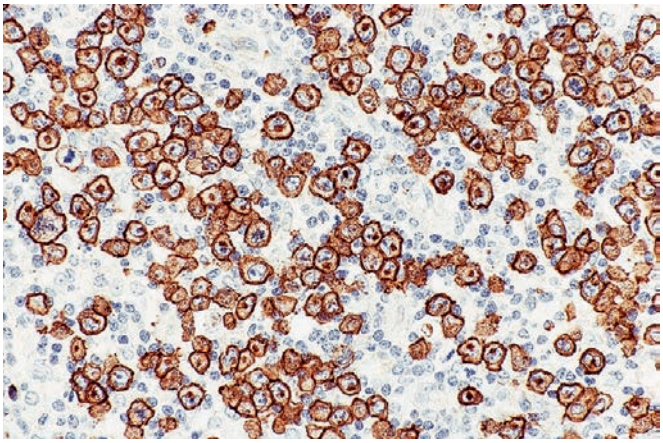

Figure 37.102 Strong membranous and Golgi-type immunoreactivity for CD30 in anaplastic large cell lymphoma.

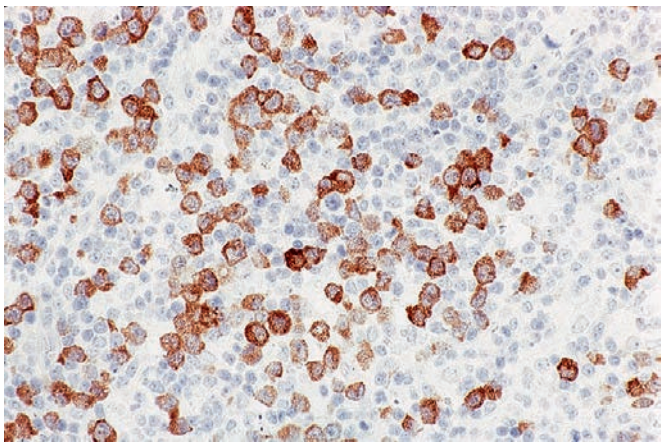

Figure 37.103 ALK immunoreactivity in anaplastic large cell lymphoma.

For personal use only. No other uses without permission. Copyright ©2017. Elsevier Inc. All rights reserved.

The T-cell receptor genes are clonally rearranged in approximately 90% of cases of ALK+ ALCL, including cases lacking expression of T-lineage markers.[936,941] The hallmark of this lymphoma type is translocation of anaplastic lymphoma kinase gene (*ALK* on 2p23), although this molecular alteration is also found in an uncommon subtype of DLBCL (ALK+ large B-cell lymphoma), ALK+ histiocytosis, inflammatory myofibroblastic tumor and an uncommon subset of pulmonary adenocarcinoma.[802,942–947] The *ALK* gene can be fused with a variety of partner genes, most of which are housekeeping genes.[948] The translocation results in production of a chimeric protein, in which the ALK domain (a tyrosine kinase receptor) is constitutively activated due to presence of an oligomerization domain at the N-terminus. The commonest partner gene is *NPM* (nucleophosmin gene on 5q35), accounting for 80% of cases. Other partner genes include *TPM3* (tropomyosin-III), *TPM4* (tropomyosin-IV), *TFG* (*TRK* fused gene), *ATIC*, *CLTL* (clathrin), *MSN* (moesin), *CARS*, and *MYH9*. Interestingly, the subcellular localization of ALK on immunostaining correlates well with the normal distribution of the protein encoded by the partner gene, for example, nuclear-cytoplasmic staining for nucleophosmin, cytoplasmic staining with subplasmalemmal accentuation for tropomyosin, cell membrane staining for moesin, and cytoplasmic granular staining for clathrin. The partner gene fused with the *ALK* gene does not influence the prognosis of ALK+ ALCL.[949]

ALCLs with *ALK* translocation have a much more favorable prognosis than ALK– ALCLs.[949–952] Gene expression profiling studies have also confirmed that these two types of ALCL represent distinct entities.[953] Recent studies, however, have identified two additional recurring genetic abnormalities in ALCL that are exclusive of *ALK* translocations.[954,955] Translocations involving *DUSP22*, usually as a t(6;7)(p25.3;q32.3), are found in approximately 30% of cases and abnormalities of *TP63*, usually as in inv(3)(q26q28), occur in approximately 8% of cases. *DUSP22* translocations appear to be associated with a more favorable prognosis, similar to ALK+ ALCL, while *TP63* abnormalities are associated with a worse prognosis, possibly worse than peripheral T-cell lymphoma, NOS. Patients with ALCL lacking *ALK*, *DUSP22*, and *TP63* abnormalities have an intermediate prognosis.

The differential diagnosis for ALCL is broad due to the large number of CD30-positive tumors now known. Classical Hodgkin lymphoma with high numbers of Hodgkin cells usually lacks T-cell antigen expression and is PAX5 positive. CD30 positive lymphoma cells are relatively common in peripheral T-cell lymphoma, NOS, but the expression is not strong and uniform in most cases. Cases of DLBCL with pleomorphic, CD30 positive lymphoma cells are excluded by the expression of B-lineage markers. Primary cutaneous ALCL is biologically distinct from systemic ALCL and should be ALK negative and localized to skin. Identification of ALK-positive cutaneous disease should result in a thorough systemic evaluation. Finally, an ALK-negative ALCL is now recognized in association with serous fluid accumulations in women with breast implants. Such cases are considered biologically distinct from systemic ALCL, do not infiltrate the breast stroma, and are often clinically indolent.[956]

Peripheral T-Cell Lymphoma, Not Otherwise Specified

Peripheral T-cell lymphoma, NOS is a fairly common "waste basket" group of peripheral T-cell neoplasms that do not meet criteria for other T- or NK-cell lymphoma types. They show a gene expression profile distinct from that of AITL and ALCL with diverse profiles, indicating that it represents a heterogeneous category.[904,905,957] Morphologic features are quite variable with infiltration by virtually any combination of cell sizes. A proportion of cases (5%–11%) show association with EBV[958,959]; they may show variable expression of CD30 and may have an associated B-cell proliferations similar to AITL. Similar to DLBCL, NOS, this category will continue to shrink over time as specific biologic entities are identified.

Current Testing in Peripheral T- and Natural Killer–Cell Lymphomas

Because of the large number of disease categories associated with these rare disorders, a fairly extensive work-up is needed to diagnose peripheral T- and NK-cell neoplasms. Multiple T-cell associated antigens, such as CD2, CD3, CD5, CD7, CD4, and CD8, should be performed on each case due to the high frequency of loss of one or more antigen as well as the lack of specificity of some markers (such as CD5 on some B-cell neoplasms). Markers such as CD10, CXCL13, BCL6, and PD1 are useful to evaluate TFH cells and CD21 and/or CD23 are useful to evaluate follicular dendritic cell networks that are characteristically disrupted in AILT. Additionally, in situ hybridization for EBV and CD56 immunohistochemistry are necessary to identify the nasal-type NK/T cell lymphoma (discussed elsewhere) and CD30 staining (with ALK staining when positive) should be performed to evaluate for ALCL. T-cell receptor gene rearrangement studies are helpful when the differential diagnosis is with reactive conditions, but care must be taken to not overinterpret such studies since oligoclonal reactive proliferations may result in false positive clonality results in some cases.

Tumors of the Accessory Immune System

The accessory immune system includes two major categories of cells: antigen-presenting cells (dendritic cells) and antigen-processing cells (macrophages).[960–965] The dendritic cells belong to the group of nonlymphoid elements traditionally designated by histologists and pathologists as reticulum cells, which have been divided into more or less well-defined subtypes on the basis of location, enzyme histochemical, ultrastructural, and immunohistochemical features. Tumors of most, if not all, of these cell types are now described, and both the WHO and the Histiocyte Society offer recently revised classifications of these neoplasms.[407,966]

Follicular dendritic cell tumor (follicular dendritic cell sarcoma; dendritic reticulum cell sarcoma) often presents as a solitary mass in a cervical lymph node (Fig. 37.104)[967] but can involve other lymph node groups and a large variety of extranodal sites,[968] including stomach,[969] small bowel,[970] large bowel,[971] omentum,[972] mesentery,[973] liver,[974] nasopharynx,[975] oral cavity,[295] tonsil,[976] soft tissues of head and neck region,[977] mediastinum,[978] spleen,[979] lung,[980] and breast.[981,982] Some cases of follicular dendritic cell tumor have occurred as a complication of the hyaline vascular type of Castleman disease,[983,984] and others in connection with inflammatory pseudotumor of the liver and spleen,[985] although the latter instance has been a constant association with EBV that is not seen in other sites.[974,986,987]

Microscopically, follicular dendritic cell tumor is characterized by a proliferation of oval to spindle cells that form fascicles and whorls (Fig. 37.105).[988] Sometimes there is a suggestion of a storiform or palisading pattern.[967,989] In other instances the stroma has a myxoid quality.[981] The appearance at low power may simulate that of meningioma. The nuclei are generally oval, with a vesicular chromatin pattern, small nucleoli, and scanty mitotic activity. Pseudonuclear inclusions and multinucleated giant cells may be present. A characteristic feature is the presence of small lymphocytes scattered throughout the tumor cells, resulting in a thymoma-like appearance.[990] The ultrastructural and immunohistochemical features correspond

For personal use only. No other uses without permission. Copyright ©2017. Elsevier Inc. All rights reserved.

to those of follicular dendritic cells (Fig. 37.106). Markers that are particularly useful for their identification are CD21, CD35, clusterin, Ki-M4P, and Ki-FDRC1p.[991,992]

The tumor cells are negative or equivocal for CD45RB and erratically positive for S100 protein. Although it was thought previously that these tumors do not exhibit clonal rearrangements of the immunoglobulin or the T-cell receptor genes, it has been shown recently that a proportion of cases indeed exhibit clonal rearrangements of immunoglobulin genes.[993]

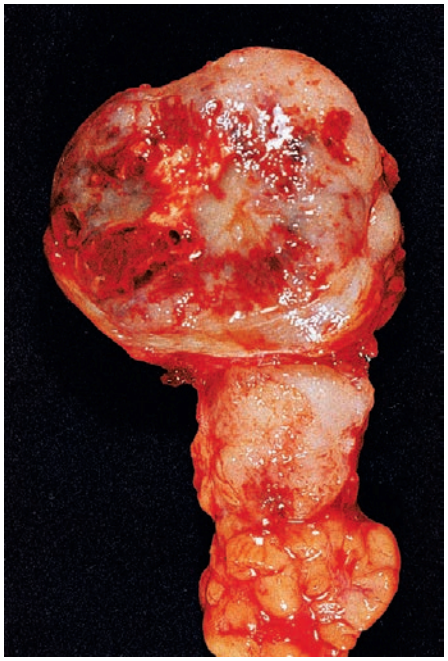

Figure 37.104 Gross appearance of follicular dendritic cell tumor.

The behavior is that of a malignant tumor, with local recurrence and distant metastases to sites such as the liver and lung.[994,992] The pattern of spread resembles that of a soft tissue sarcoma more than that of a malignant lymphoma. Intra-abdominal neoplasms tend to be particularly aggressive.[995] Recurrent and metastatic lesions may show increased atypia and pleomorphism.[992]

Interdigitating dendritic cell tumor (interdigitating reticulum cell sarcoma) is even more uncommon or perhaps not as easily recognized.[996] Most patients are adults, but it can also occur in the pediatric population.[997] Most of the reported cases have arisen in lymph nodes,[998,999] but instances of extranodal involvement in sites such as skin, bowel, spleen, and testis have been recorded.[979,1000–1002] The microscopic appearance can be indistinguishable from that of follicular dendritic cell tumor, but there is more tendency to spindling

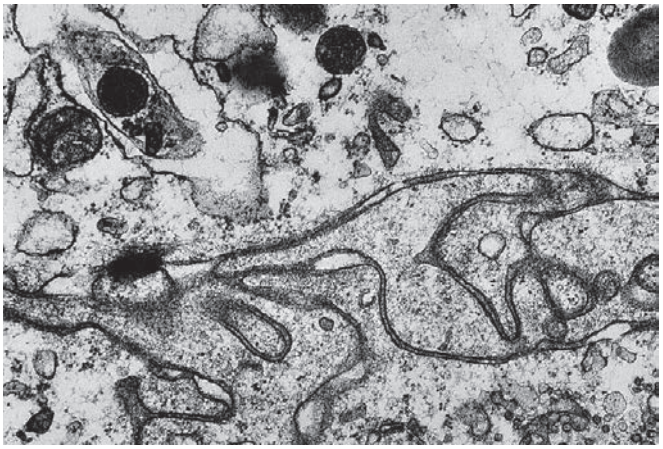

Figure 37.106 Electron Microscopic Appearance of Follicular Dendritic Cell Tumor. A characteristic feature is the presence of well-developed cytoplasmic prolongations joined by desmosomes.

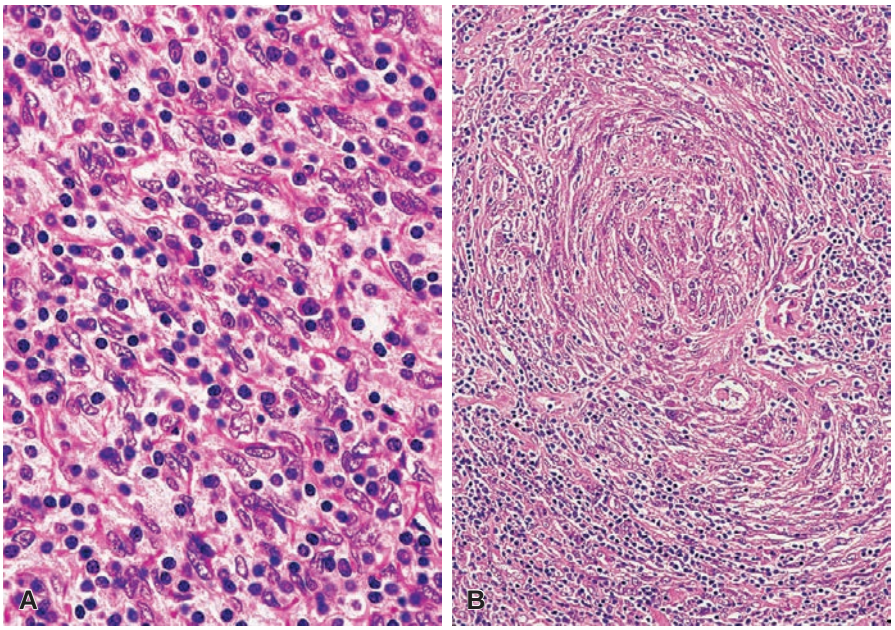

Figure 37.105 Follicular Dendritic Cell Tumor of Lymph Node. A, The admixture of neoplastic cells with predominantly oval vesicular nuclei and non-neoplastic small lymphocytes results in an appearance reminiscent of thymoma. **B**, Prominent whorling in a case of follicular dendritic cell tumor, engrafted upon Castleman disease.

For personal use only. No other uses without permission. Copyright ©2017. Elsevier Inc. All rights reserved.

and pleomorphism.[1003,1004] The diagnosis is dependent on the immunohistochemical profile, which unfortunately is not entirely specific. The tumor cells are positive for S100 protein but are negative for CD21 and CD35. The behavior seems more aggressive than for follicular dendritic cell tumor. Contrary to earlier belief, a proportion of cases are shown to exhibit clonal rearrangements of the immunoglobulin genes.[993,400]

Langerhans cell histiocytosis (LCH), also known as Langerhans cell granulomatosis, histiocytosis X, differentiated histiocytosis, and eosinophilic granuloma, is applied to a specific, although remarkably variable, clinicopathologic entity characterized and defined by the proliferation of Langerhans cells.[1005–1007] These cells are regarded as a distinct type of immune "accessory" cells that are involved in the capturing of some antigens and their presentation to the lymphoid cells. Contrary to a formerly held belief, these cells are not primarily phagocytic in nature. Their nuclei are highly characteristic: irregular, usually elongated, with prominent grooves and folds that traverse them in all directions. The cytoplasm is abundant and acidophilic, sometimes to the point that an embryonal rhabdomyosarcoma or ALCL is simulated. Most Langerhans cells are mononuclear, but occasional ones contain several nuclei while still maintaining the aforementioned nuclear and cytoplasmic features. An extensive eosinophil infiltrate usually accompanies LCH. Histochemically, they show weak acid phosphatase and nonspecific esterase activity but considerable leucyl-β-naphthylamidase activity and membrane-bound ATPase activity.[1008] They are believed to develop from a lymphoid-committed precursor,[1009] a hypothesis supported by the presence of an identical rearrangement of the IGH in cases with B-cell lymphoma and in cases without an associated lymphoma.[1010,1011]

In paraffin sections, both Langerhans cells and the cells of LCH are reactive for S100 protein, vimentin, langerin (CD207), fascin (a dendritic cell marker), CD1a, CD74, and HLA-DR in most cases (Fig. 37.107).[1012–1014] They also tend to be positive for peanut agglutinin lectin and the macrophage-associated antigens CD68, cathepsin D, and cathepsin E.[1015–1017] They generally do not express CD45RA, CD45RB, CDw75, α1-antitrypsin, EMA, or CD15. The most useful of these formalin-resistant epitopes are S100, CD1a,[1018] and langerin, the latter having a great degree of specificity and sensitivity.[1019,1020]

By electron microscopy, they contain a highly characteristic and apparently diagnostic organelle: the Birbeck or Langerhans granule, which correlates with langerin immunohistochemistry. This is an elongated, zipperlike cytoplasmic structure of unknown function, sometimes continuous with the cell membrane.[1021]

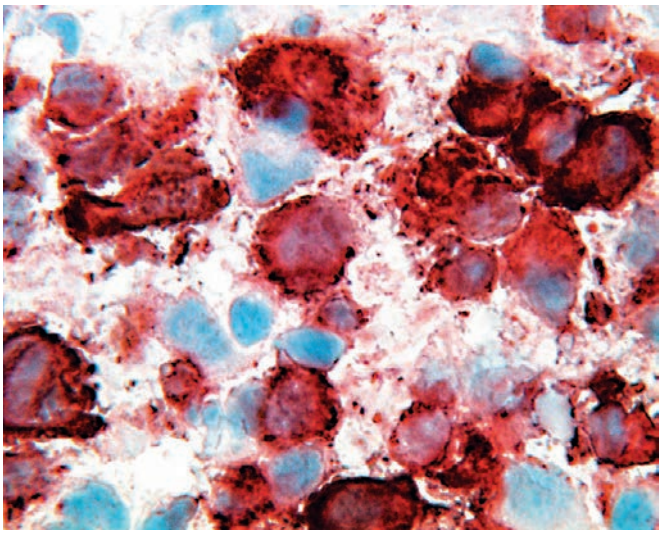

Figure 37.107 Immunoreactivity of the cells of Langerhans cell histiocytosis for langerin.

Scattered Langerhans cells are present in the skin, lymph node, thymus, and other organs in normal conditions and may be slightly increased in some disorders, such as interstitial lung diseases and dermatopathic lymphadenitis. Therefore the identification of a few cells with these features in one of these sites is not necessarily indicative that the patient has LCH.[1022] Rather, the infiltrate should have a sizable number of these cells before such a diagnosis is entertained.[1020] Conversely, the identification of Langerhans cells is necessary for the diagnosis of LCH. There is already too much confusion in the literature stemming from the fact that cases have been given this label only because a widespread proliferation of histiocytes was associated with a compatible clinical picture.

LCH can present as solitary or multiple lesions in one organ system (bone being the most common) or as a disseminated disease.[1023] Most patients are children or adolescents, but the disease can affect any age group, including the elderly.[1024] The treatment, prognosis, and terminology used largely depend on the extent (staging) of the disease rather than the microscopic features or the pattern of DNA ploidy.[1025–1028] The term **Letterer–Siwe disease** was used in the past for the systemic form occurring in infants, and **Hand–Schüller–Christian disease** for the less widespread and more indolent type seen in older children and adults.[1029] A self-healing, congenital form is known as **Hashimoto–Pritzker disease**.[1030]

Lymph node involvement can be seen as a component of the systemic form, or it may represent the initial and sometimes exclusive manifestation of the disease.[1031–1033] The microscopic appearance is characteristic. There is distention of the sinuses by an infiltrate of mononuclear and multinuclear Langerhans cells, admixed with a variable number of eosinophils (Fig. 37.108); foci of necrosis are common, often surrounded by a rim of eosinophils (so-called "eosinophilic microabscesses"), and always confined to the sinuses. The nodal architecture may be preserved or variably effaced.[1034]

Sometimes, incidental foci of LCH are seen in lymph nodes involved by non-Hodgkin lymphoma or Hodgkin lymphoma, a sharp segregation existing between the two processes.[1035,1036] In most of these cases, the Langerhans cell proliferation is limited to the node and may represent a reaction to the lymphoma,[1037] but in others it is an expression of generalized LCH.[1038] Follow-up studies have shown a broad spectrum of involvement, embracing all those syndromes that have been associated with LCH. However, the prognosis is usually excellent.

In addition to bone and lymph nodes, solitary LCH has been described in the lung, thymus, skin, central nervous system, and many other sites, including stomach, liver, anus, female genital tract, and thyroid[1039–1044] (see respective chapters). Changes morphologically consistent with LCH have been seen in coexistence with RDD, with Erdheim–Chester disease, and in lymph nodes draining malignant melanoma or papillary thyroid carcinoma.[1045,1046]

The differential diagnosis of LCH is wide and to some extent influenced by the site of involvement. It includes RDD, parasitic infections, Kimura disease, hypersensibility reactions, cat-scratch disease, Erdheim–Chester disease, and some types of malignant lymphoma, such as Hodgkin lymphoma and peripheral T-cell lymphoma.[1047]

The etiology of LCH remains unknown. A viral cause has been suggested but not substantiated.[1048,1049] Molecular studies have shown evidence of clonality in most cases, but some cases of localized pulmonary belch may be nonclonal.[359,1050,1051] Approximately 60% of cases have mutations of *BRAF* or associated pathways[1052–1054] and most *BRAF* V600E mutations can be identified by immunohistochemistry.[1051] The Langerhans cells are affected by recurrent cytogenetic

For personal use only. No other uses without permission. Copyright ©2017. Elsevier Inc. All rights reserved.

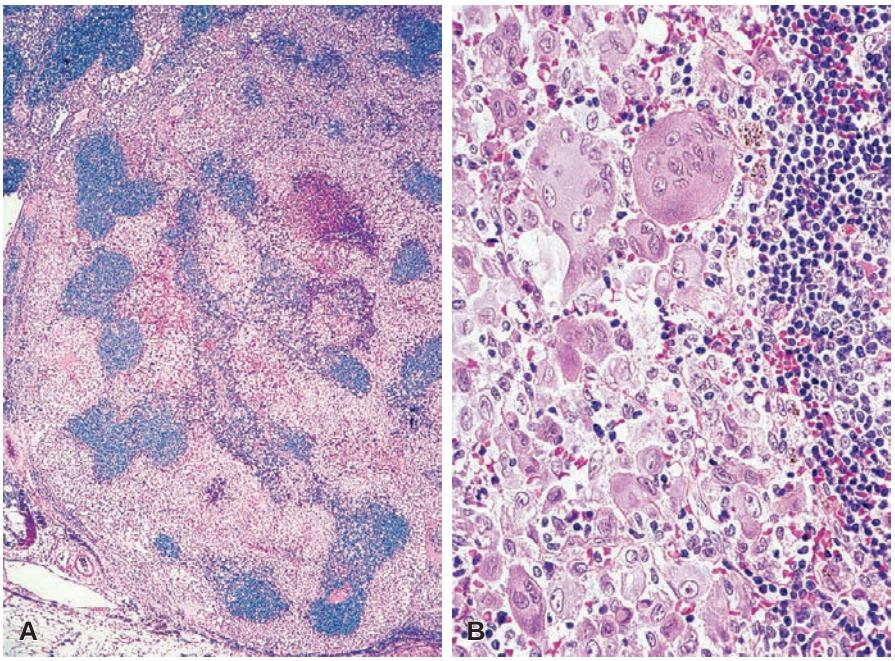

Figure 37.108 Lymph Node Involvement by Langerhans Cell Histiocytosis. A, The infiltrate has a predominantly sinus distribution. **B**, High-power view showing mononuclear and multinucleated Langerhans cells. There are also numerous eosinophils.

alterations[1055] and do not appear to be a particularly proliferative cell population.[1056]

Exceptionally, a morphologically malignant process is seen in which the tumor cells have the ultrastructural and immunohistochemical features of Langerhans cells.[1057–1059] This is to be regarded as **Langerhans cell sarcoma**.[1060]

Indeterminate dendritic cell tumor is a rare neoplasm that more commonly involves skin but has been reported in lymph nodes.[1061,1062] It has features of LCH, with expression of S100 and CD1A, but lacks Birbeck granules by electron microscopy and langerin by immunohistochemistry. Recently, a fusion of *ETV3-NCOA2* has been reported as unique to this tumor.[1063]

Erdheim–Chester disease is another "histiocytosis" of unknown etiology involving mainly the central nervous system, bones, and lung. The histiocytes in this condition are only focally S100 positive, are negative for CD1a and langerin, and lack Birbeck granules.[1064]

Histiocytic sarcomas (malignant histiocytosis) are malignant neoplasms of histiocytic lineage that do not meet criteria for other accessory cell neoplasms. Their presentation is highly variable, with a high proportion of extranodal involvement in sites such as the spleen, skin, bone, and particularly the gastrointestinal tract.[1065–1069] As in the case of the dendritic cell tumors, some "true histiocytic sarcomas" have been seen in combination with bona fide malignant lymphoma,[1070] and some subdivide these tumors into primary and secondary disease.[966] Microscopically, the tumor cells are large, with irregularly shaped nuclei and abundant, generally acidophilic cytoplasm. Immunohistochemically, the tumor cells lack by definition B cell– and T cell–related markers and show reactivity for histiocytic markers, such as CD68, CD163, lysozyme, and CD4.[1071–1073]

Although the presence of immunoglobulin or T-cell receptor gene rearrangement was previously considered to be incompatible with a diagnosis of histiocytic sarcoma, recent studies have shown that clonal immunoglobulin gene rearrangement, and rarely T-cell receptor gene rearrangement, can occur in up to 50% of cases.[401,993] This phenomenon is observed in sporadic cases as well as cases that occur subsequent to or concurrent with B- or T-lymphoblastic leukemia/lymphoma or low-grade B-cell lymphoma (especially follicular lymphoma).[401,993,1074–1076] In the latter scenario, the histiocytic sarcoma often shares the clonal markers of the previous leukemia/lymphoma, such as immunoglobulin gene rearrangement, *BCL2* rearrangement, and clonal cytogenetic aberrations.[401,1074]

Vascular Tumors and Tumorlike Conditions

Hemangioma and **lymphangioma** involving nodes usually represent extension by contiguity of primary soft tissue lesions. However, rare cases of primary nodal hemangioma and lymphangioma have been described (Fig. 37.109).[1077,1078]

Epithelioid vascular neoplasms of lymph nodes include epithelioid hemangioma, epithelioid hemangioendothelioma, spindle and epithelioid hemangioendothelioma, and polymorphous hemangioendothelioma, which are discussed in more detail elsewhere.[1079–1082]

Bacillary angiomatosis, which occurs almost exclusively in the setting of immunodeficiency (especially in patients with HIV infection), presents as multiple coalescent intranodal clusters of proliferating vessels. These vessels are lined by plump, somewhat epithelioid endothelial cells (hence the original term epithelioid angiomatosis for this condition). A feature of great diagnostic importance is the presence of abundant eosinophilic to amphophilic, amorphous, or granular material in the interstitium. Another helpful feature is the presence of neutrophils, sometimes forming microabscesses.[1083–1085] When stained with the Warthin–Starry technique, this material is shown to be composed of aggregated bacillary organisms, now known to represent *Bartonella henselae* and *Bartonella quintana*, that are indistinguishable from those of cat-scratch disease (also

For personal use only. No other uses without permission. Copyright ©2017. Elsevier Inc. All rights reserved.

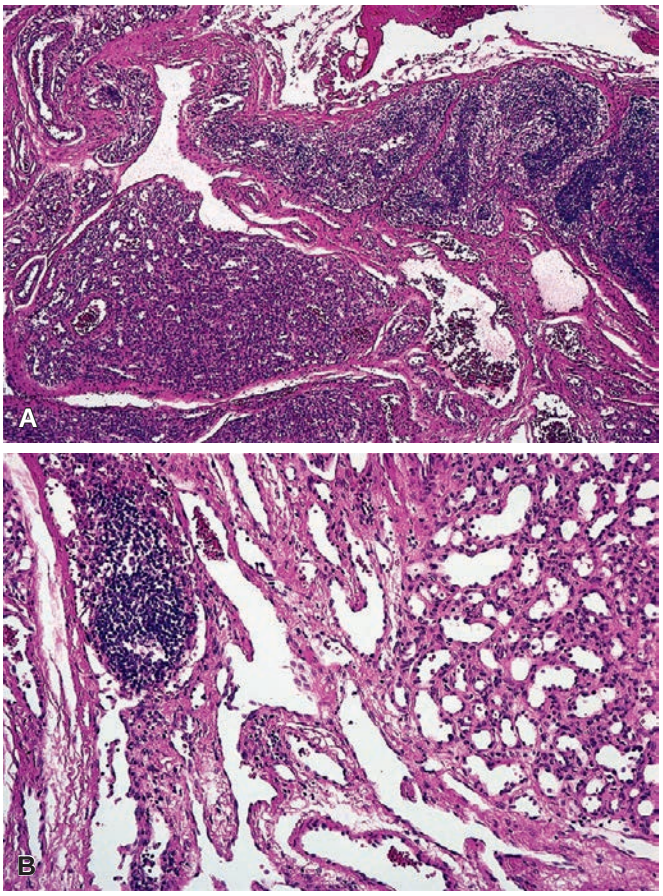

Figure 37.109 Low-power (**A**) and medium-power (**B**) views of nodal hemangioma.

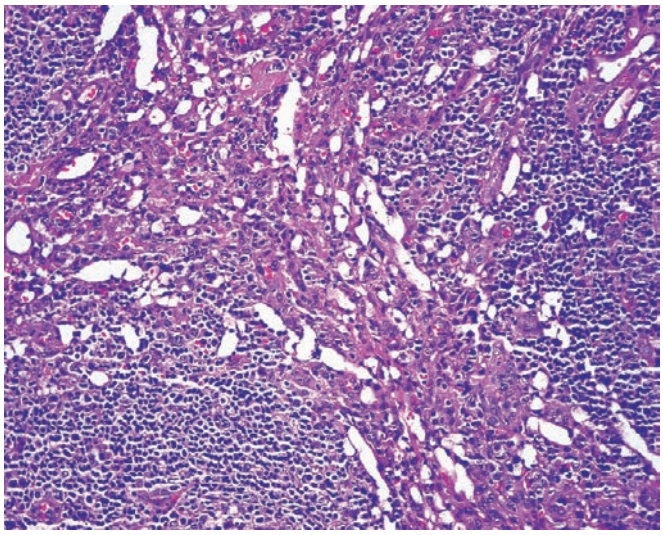

Figure 37.110 Lymph Node Involvement by Bacillary Angiomatosis. An intense vascular proliferation featuring epithelioid endothelial cells is seen in the interfollicular region, accompanied by neutrophils and other inflammatory cells.

caused by *B. henselae*). These organisms may be more precisely detected by immunohistochemistry or PCR. A recent study of the lymph nodes changes associated with *B. henselae*, however, found that infection was usually not associated with features of bacillary angiomatosis.[1086]

Vascular transformation of sinuses is characterized by a conversion of lymph node sinuses into a complex network of anastomosing endothelial-lined channels (Fig. 37.110).[1087] Fibrosis and reactive stromal changes are commonly present.[1088] *Nodal angiomatosis* probably refers to a more cellular form of the same condition (Fig. 37.111).[1089,1090] In the *nodular spindle-cell variant*, spindle-cell nodules composed of interlacing fascicles alternate with the vascular clefts.[1091] This variant is particularly likely to be misdiagnosed as Kaposi sarcoma. It is distinguished from the latter because it is HHV8-negative, is confined to the sinuses (with sparing of the capsule and parenchyma), shows no cellular atypia, contains fascicles that blend with well-formed vascular channels, commonly is associated with fibrosis, and almost invariably lacks the PAS-positive hyaline globules of Kaposi sarcoma (Fig. 37.112).[1092,1093] Other cases of vascular transformation may result from proximal obstruction of the efferent vessels; indeed, the process has been reproduced experimentally by complete occlusion of these vessels.[1094]

Angiolipoma (including its cellular variant) is usually located in the soft tissue, but exceptionally it may be centered in a lymph node.[1095]

Kaposi sarcoma of the lymph nodes may be associated with typical skin lesions or develop in their absence.[1096] The latter occurrence is seen mainly in African children, but it also occurs in adults (usually but not always HIV infected). Microscopically, the involved nodes show proliferation of spindle cells separated by slitlike spaces containing red blood cells (Fig. 37.113).[1097] The earliest changes are seen in the nodal capsule, but eventually there is involvement of the entire node and extension into the perinodal tissues. Cytoplasmic and extracellular hyaline globules that are positive for PAS and PTAH are almost always present.[1098] Recognition of early nodal involvement by Kaposi sarcoma is an extremely difficult task; although a definitive diagnosis can be made if immunostaining for HHV8 is positive in the proliferating spindle cells. In well-developed cases, the tumor may grow in a diffuse fashion or as discrete deposits. The spindle-cell lesion is often accompanied by a lymphoid proliferation with a prominent component of plasma cells and immunoblasts. Kaposi sarcoma is also associated with HHV8+ multicentric Castleman disease, usually of the plasma cell type.[269] In other instances, nodal Kaposi sarcoma coexists with malignant lymphoma or leukemia.[1099]

If a lymph node is involved by a malignant tumor with the morphologic features of **angiosarcoma**, there is a high probability that the tumor is metastatic (Fig. 37.114).

Other Primary Tumors and Tumorlike Conditions

Systemic mastocytosis often involves lymph nodes, resulting in partial (usually interfollicular) or complete effacement of the architecture by a monotonous proliferation of round, spindled or polygonal cells (Fig. 37.115).[1100,1101] Clues as to the nature of the proliferation include the regular contours of the round or oval nucleus, the clear or granular cytoplasm, the well-defined cell outlines, admixture of eosinophils, and accompanying sclerosis. Special techniques that confirm mast cell lineage, especially immunohistochemical stains for CD117 and tryptase, are required for diagnosis[1102–1108].

Acute myeloid leukemia can first be seen in a lymph node biopsy and misdiagnosed as malignant lymphoma.[1109] Traditionally, the disease has been referred to as granulocytic sarcoma, myeloid sarcoma, or chloroma when appearing as a tumor mass in a lymph node or

For personal use only. No other uses without permission. Copyright ©2017. Elsevier Inc. All rights reserved.

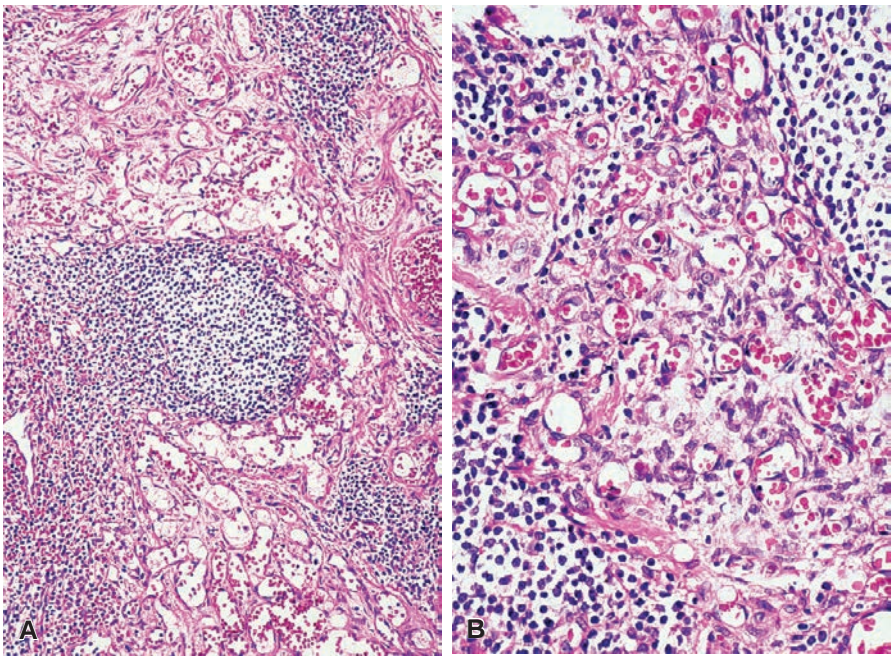

Figure 37.111 **A** and **B**, Vascular transformation of lymph nodes. The process involves the sinuses, and it has a reactive appearance.

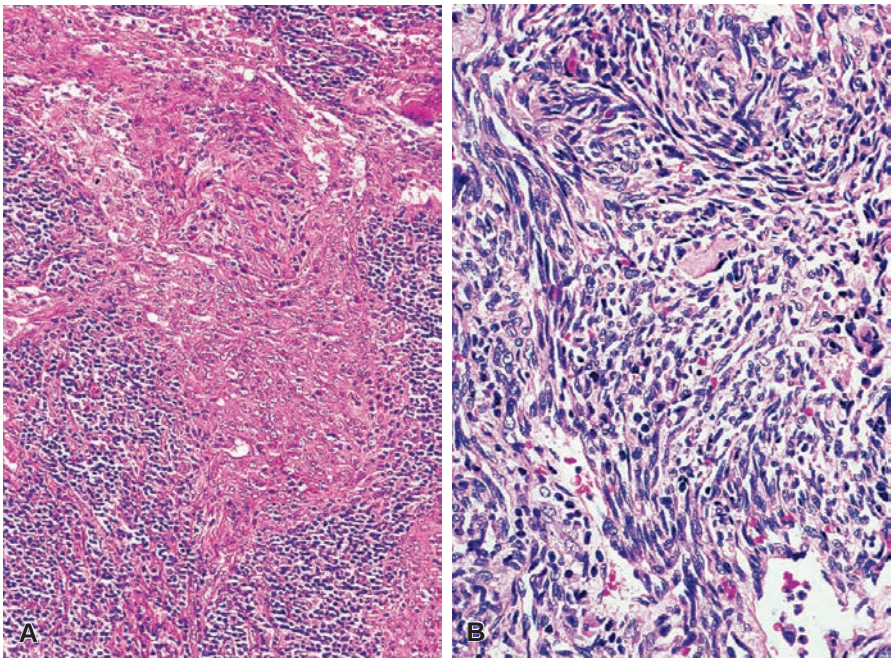

Figure 37.112 **Solid Form of Vascular Transformation of Lymph Nodes.** This process has also been designated as nodal angiomatosis. **A,** Predominantly sinus distribution of the lesions. **B,** Example in a retroperitoneal lymph node in a patient with renal cell carcinoma.

some other location outside the bone marrow (Fig. 37.116). Clues to the diagnosis include a patchy or sinus type of nodal involvement, sometimes associated with a single-file pattern of infiltration in the capsule; fine granularity of the cytoplasm; fine nuclear chromatin without the typical chromatin clearing of DLBCL, and presence of eosinophilic myelocytes. Immunohistochemically, there is reactivity for CD43, lysozyme, myeloperoxidase, CD99, and CD117.[1110,1111] Identification of a myeloid sarcoma should trigger a bone marrow evaluation. If negative, additional material from lymph nodes, even if by fine-needle aspiration, should be obtained to preform complete immunophenotyping, karyotype analysis, and molecular studies necessary to complete classify the acute myeloid leukemia (see Chapter 39) *Extramedullary hematopoiesis,* either reactive or secondary to a myeloproliferative neoplasm, accompanied by megakaryocytes can

For personal use only. No other uses without permission. Copyright ©2017. Elsevier Inc. All rights reserved.

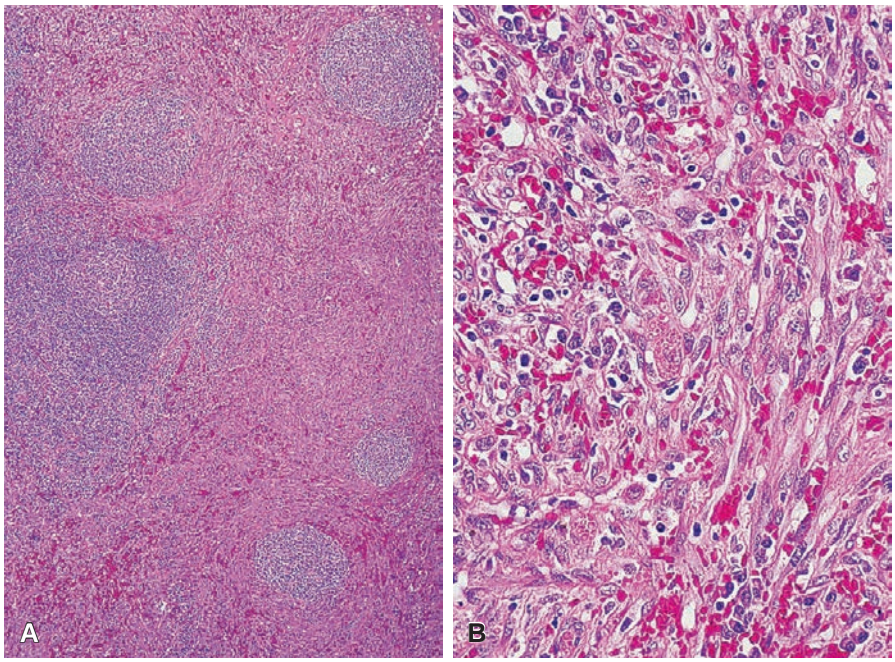

Figure 37.113 **A** and **B**, Lymph node involvement by Kaposi sarcoma. The infiltrate is predominantly in sinuses and is characterized by a proliferation of spindle cells forming slits containing red blood cells.

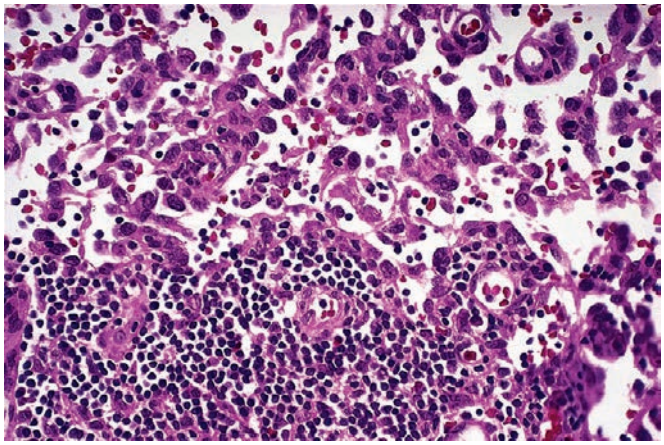

Figure 37.114 **Angiosarcoma of Skin of Scalp Metastatic to a Posterior Cervical Lymph Node.** The nodal lesion was the first manifestation of the disease.

be confused with Hodgkin lymphoma and other malignancies (Fig. 37.117). A Leder chloroacetate or myeloperoxidase stain will reveal the maturing myeloid forms.

Smooth muscle proliferations of a primary nature can be seen within lymph nodes in the following situations:

1. *Smooth muscle proliferation in the hilum*. This is often accompanied by fibrosis and prominent vascularity.[1112] It is most common in the inguinal region and is of no clinical significance.
2. *Angiomyolipoma*. The most common location is the retroperitoneal region, usually in conjunction with a renal tumor of the same type.[1113] Immunoreactivity for HMB45 and other melanocyte-related markers is a constant feature of this entity.
3. *Lymphangiomyomatosis*. This is seen exclusively in women, often in association with pulmonary involvement, but sometimes showing pelvic lymph node involvement alone as an incidental

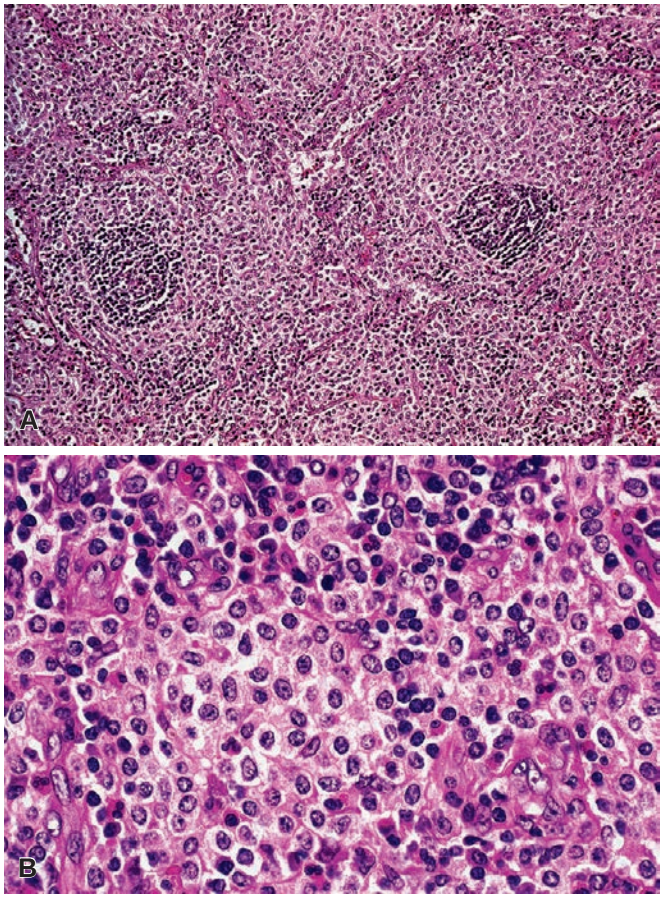

Figure 37.115 Medium-power (**A**) and high-power (**B**) views of lymph node involvement in systemic mastocytosis. Note the perfectly round shape of the centrally located nuclei, the finely granular cytoplasm, and the well-defined cell membranes.

For personal use only. No other uses without permission. Copyright ©2017. Elsevier Inc. All rights reserved.

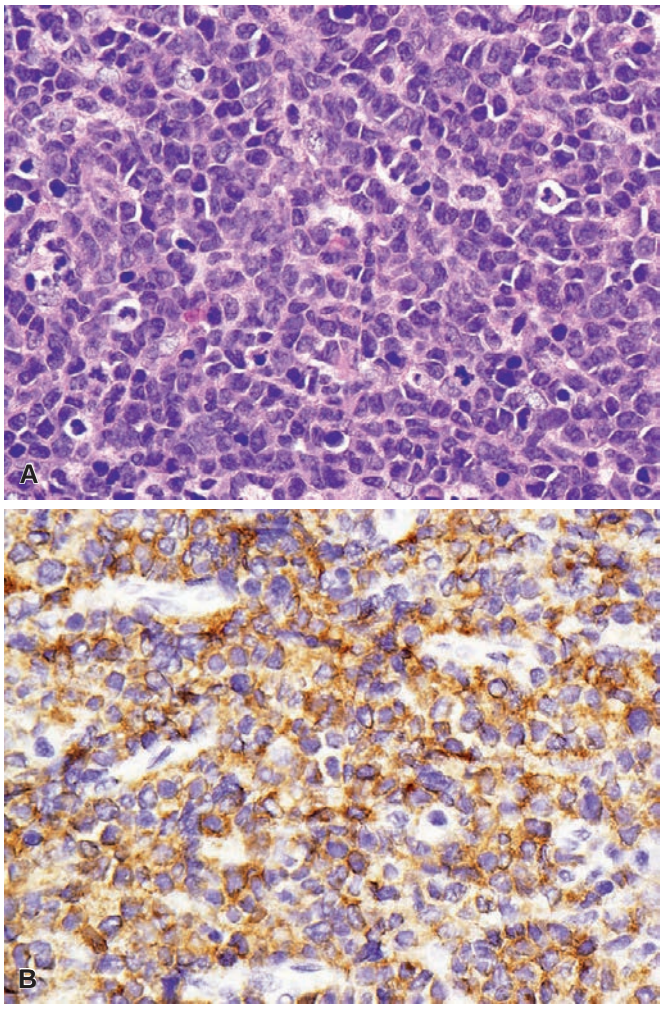

Figure 37.116 Lymph Node Involved by Acute Myeloid Leukemia (Myeloid Sarcoma). A, The infiltrate is medium in size with irregular nuclear contours but fine nuclear chromatin. **B**, The cells express the myeloid-associated antigen CD33.

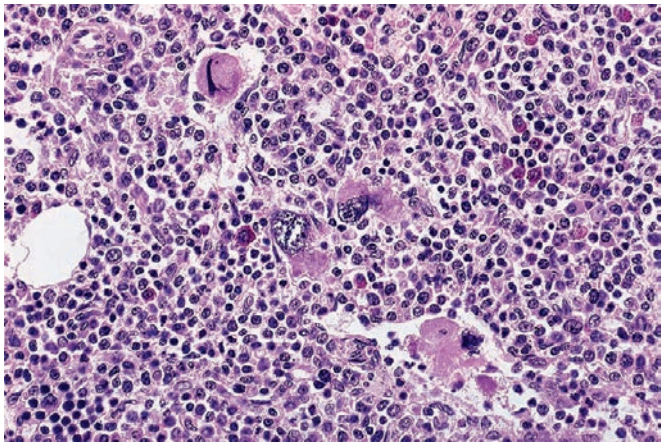

Figure 37.117 Scattered Megakaryocytes in Lymph Node Involved by Extramedullary Hematopoiesis. These elements should not be confused with Reed–Sternberg cells or carcinoma cells.

finding.[1114] Like the previous entity, to which it is histogenetically related, it exhibits immunoreactivity for HMB45.

4. *Leiomyomatosis*. This has been reported mainly in intra-abdominal nodes, sometimes in association with uterine leiomyomas or leiomyomatosis peritonealis disseminata.[1115,1116]
5. *Angiomatous hamartoma*. This is a distinctive form of smooth muscle proliferation that seems to occur only in the inguinal region. It is characterized by a proliferation of thick-walled hilar blood vessels that sometimes extends into the nodal parenchyma.[1079]
6. *Intranodal leiomyoma*. Some of the reported cases have occurred in the setting of HIV infection.[1117]

Hemorrhagic spindle-cell tumor with amianthoid fibers (also known as palisaded myofibroblastoma) is a distinctive benign neoplasm that occurs preferentially in inguinal lymph nodes but that can involve nodes of other sites, such as the neck and mediastinum.[1117–1123] The main microscopic features are the proliferation of bland-looking spindle cells, sometimes in a palisading fashion; extensive foci of recent and old hemorrhage; and giant rosettelike collections of collagen fibers (so-called "amianthoid fibers") (Fig. 37.118).[1124–1126] The differential diagnosis includes Kaposi sarcoma and intranodal schwannoma. Immunohistochemically, the spindle cells are reactive for vimentin and actin, particularly around the rosettelike formations, and are negative for LANA-1 (HHV8) and S100 protein. The staining qualities and ultrastructural features are more in favor of a smooth muscle than a myofibroblastic derivation.[1127] The behavior has been benign in all reported cases, but there has been an isolated instance of recurrence.[1128]

Inflammatory pseudotumor-like change of lymph nodes may be localized or affect several lymph node groups and may be accompanied by fever, anemia, elevated erythrocyte sedimentation rate, and hypergammaglobulinemia.[1129–1133] Microscopically, the process involves primarily the fibrous stroma of the node, with secondary spread into the lymphoid tissue and perinodal tissues. It is characterized by a storiform pattern of growth, vascular proliferation, and a polymorphic infiltrate composed of fibroblasts, plasma cells, immunoblasts, small lymphocytes, histiocytes, dendritic cells, and neutrophils (Fig. 37.119). Morphologic variations on this basic theme exist, which have been attributed to the stage of the disease at which the biopsy has been taken.[1134] In contrast to morphologically similar, but neoplastic, lesions in the spleen and liver, EBV is not usually present in lymph node cases.[1135] A diagnosis of inflammatory pseudotumor in lymph nodes is not a specific diagnosis and often represents a chronic response to infection or other damage. The cause is unknown in most patients, but some are responses to infectious organisms, including syphilitic infection[151] and *Mycobacterium avium-intracellulare* infection.[120] The latter occurs in immunocompromised individuals (mycobacterial spindle cell pseudotumor) (Fig. 37.120).

Anthracosis and **anthracosilicosis** can result in a pseudoneoplastic appearance because of the presence of a sometimes intense histiocytic proliferation with a focally storiform pattern of growth (Fig. 37.121).[1136]

Solar elastotic material can be found in the subcapsular sinus and parenchyma of lymph nodes, presumably as a result of mechanical transport from the skin.[1137]

Lymph Node Inclusions

Inclusions of various types of benign tissue can occur within lymph nodes.[1138] Lack of awareness of this phenomenon can lead to a mistaken diagnosis of metastatic carcinoma. These include the following:

1. *Salivary gland tissue*. This is an extremely common finding in high cervical nodes, to be regarded as a normal event related to

For personal use only. No other uses without permission. Copyright ©2017. Elsevier Inc. All rights reserved.

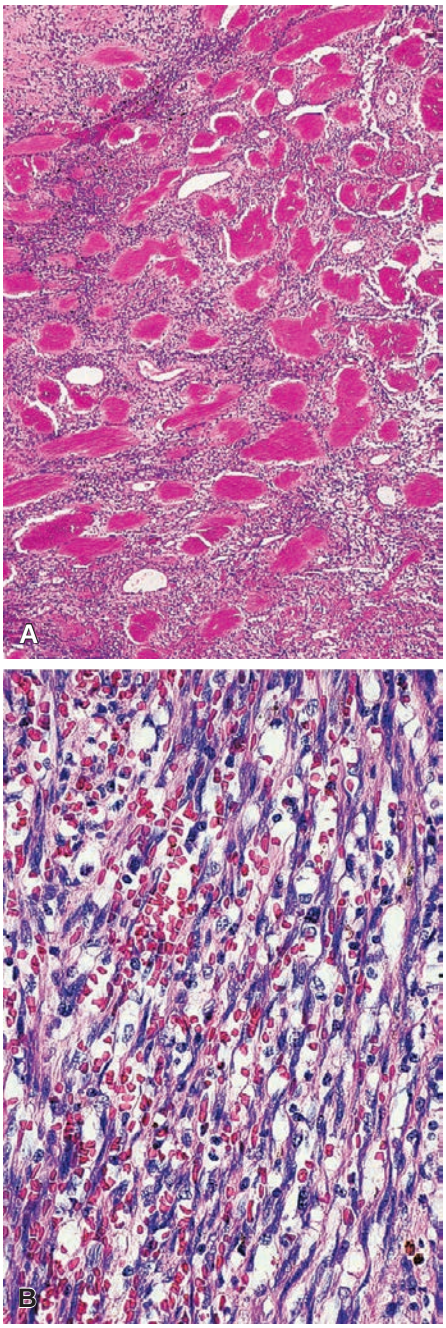

Figure 37.118 Hemorrhagic Spindle Cell Tumor With Amianthoid Fibers. A, Prominent deposition of "amianthoid" collagen throughout the tumor. **B**, The admixture of neoplastic spindle cells and extravasated red blood cells results in a Kaposi sarcoma-like appearance.

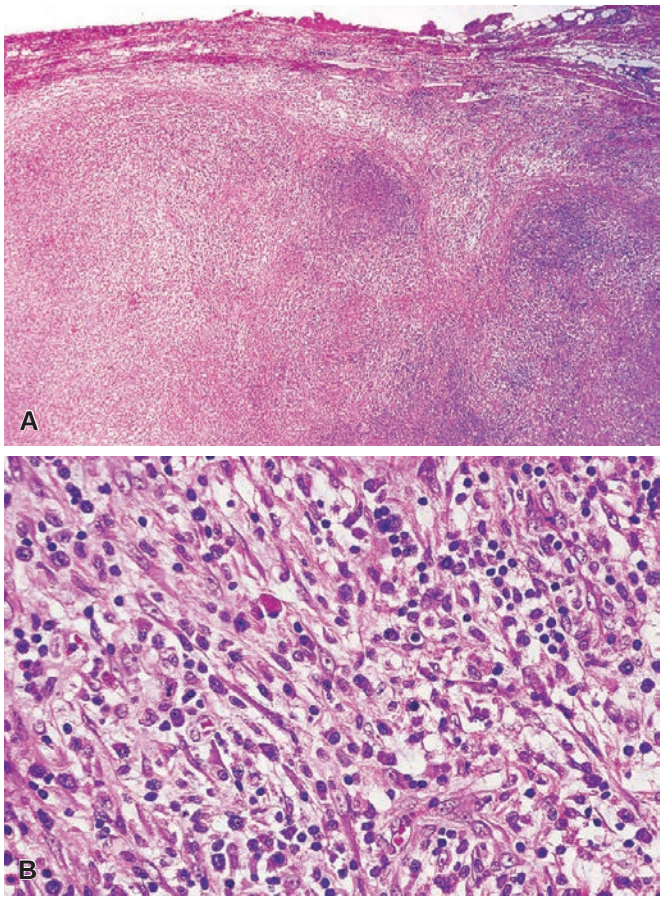

Figure 37.119 Inflammatory Pseudotumor of Lymph Node. A, Low-power appearance showing partial effacement of architecture and expansion of the sinusal and perinodal regions by a reactive proliferation. **B**, High-power view showing a polymorphic infiltrate composed of lymphocytes, plasma cells, and myofibroblasts.

the embryology of the region (Fig. 37.122).[1139] Both ducts and acini are usually present. These inclusions may undergo neoplastic changes. Warthin tumor is the most common type, but many other types have been reported, including benign mixed tumor, monomorphic adenoma, mucoepidermoid carcinoma, and acinic cell carcinoma.

2. *Squamous epithelium*. Microscopic cystic structures lined by well-differentiated squamous epithelium are sometimes seen in the upper cervical lesion. They are thought to represent an anomaly related to the aforementioned one, in the sense of being composed of branchial pouch derivatives. The term "benign lymphoepithelial cyst" is sometimes applied to them. We have hypothesized that these formations result from cystic dilation of preexisting epithelial inclusions as the result of their stimulation by the lymphoid component that surrounds them, a pathogenesis that also applies to multilocular thymic cysts, other cystic structures of the head and neck region, and possibly to Warthin tumor itself (see Chapter 6). Similar formations have been described in peripancreatic lymph nodes.[1140] The obvious differential diagnosis is metastatic well-differentiated squamous cell carcinoma, which in the cervical region is notorious for its tendency to undergo marked cystic changes.[1141]
3. *Thyroid follicles*. These can be found in the capsular or subcapsular region of midcervical nodes in the absence of pathologic changes of the thyroid gland. The differential diagnosis with metastatic thyroid carcinoma can be very difficult.
4. *Decidual reaction*. During pregnancy, decidual reaction may occur within pelvic nodes and mimic metastatic carcinoma.[1142] The decidual reaction can occur in the stromal cells of endometriosis or in hormonally receptive cells of the region, in a fashion similar to that seen in peritoneal decidual reaction.
5. *Müllerian-type epithelium*. Glandular inclusions lined by cuboidal cells with a müllerian or coelomic appearance are commonly found in the capsule of the pelvic lymph nodes of females and sometimes within the node itself.[1143,1144] Their appearance and pathogenesis are similar to those of the peritoneal lesions generally known as endosalpingiosis (Fig. 37.123). Like the latter, these

For personal use only. No other uses without permission. Copyright ©2017. Elsevier Inc. All rights reserved.

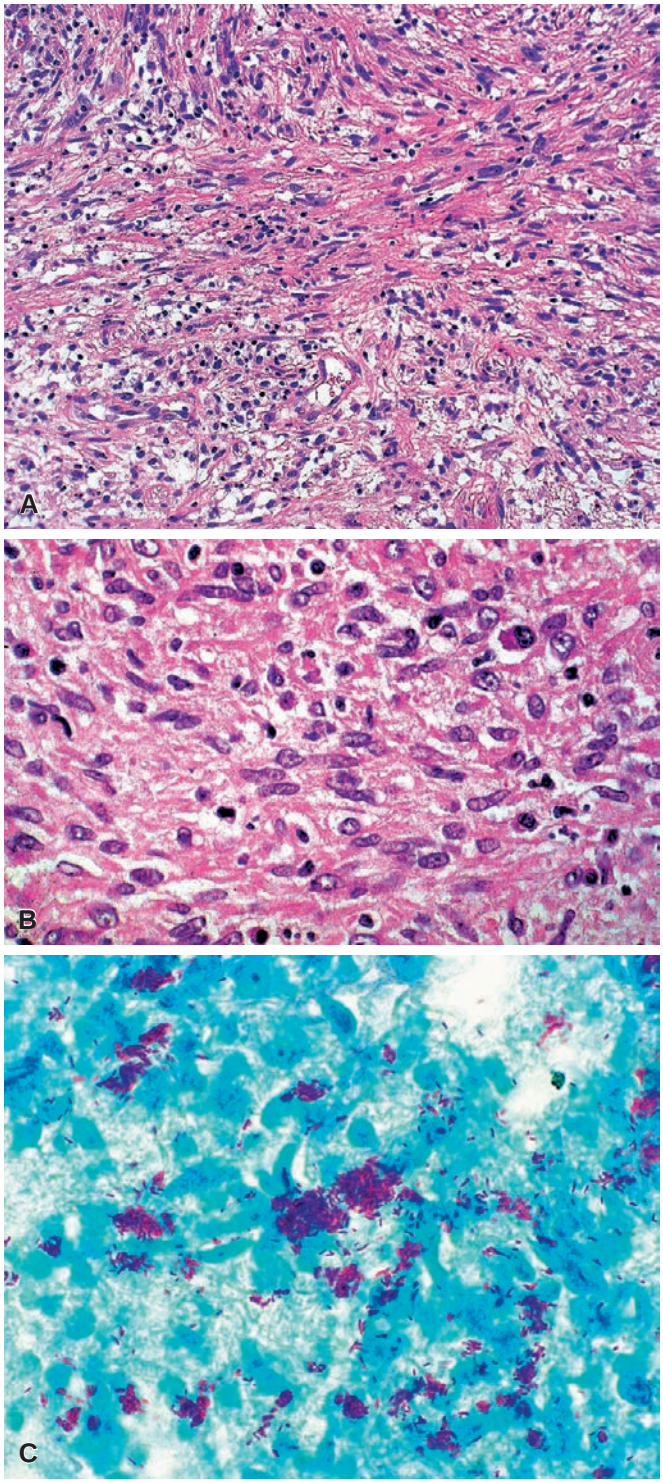

Figure 37.120 Inflammatory Pseudotumor of Lymph Node Due to *Mycobacterium avium-Intracellulare* Infection in an HIV-Infected Patient. A, Low-power view, showing spindle cell admixed with lymphocytes. **B**, High-power view. **C**, Acid-fast stain.

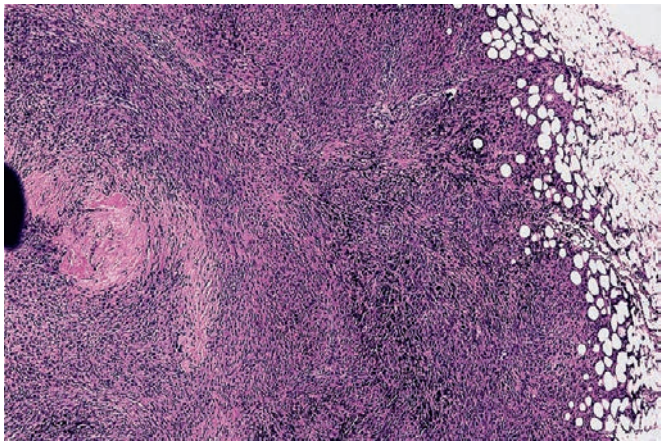

Figure 37.121 Anthracosilicotic Nodules in Mediastinal Lymph Node. When florid, these changes may acquire pseudoneoplastic features.

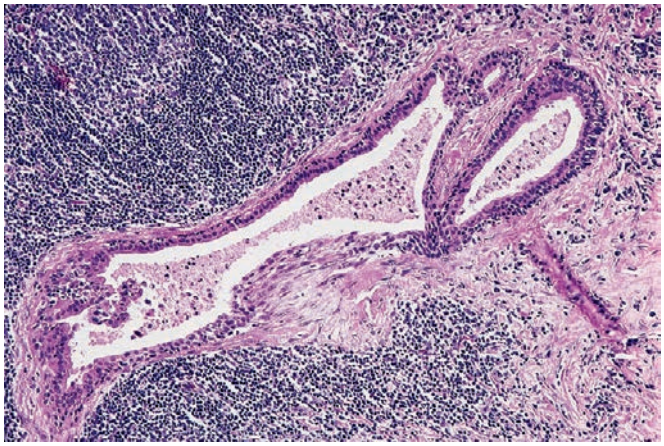

Figure 37.122 Salivary Gland Inclusion Composed of Ductal Structures in a High Cervical Lymph Node. This is a very common occurrence.

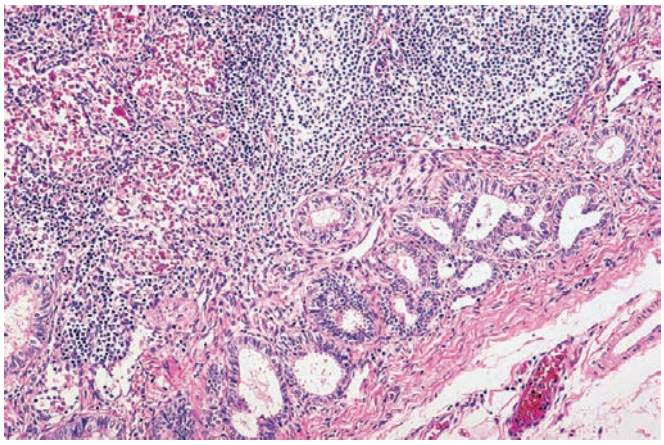

Figure 37.123 Pelvic Lymph Node Involved by Endosalpingiosis. Glands lined by cuboidal cells with a müllerian appearance and lacking atypical figures are present in the capsule of the node.

For personal use only. No other uses without permission. Copyright ©2017. Elsevier Inc. All rights reserved.

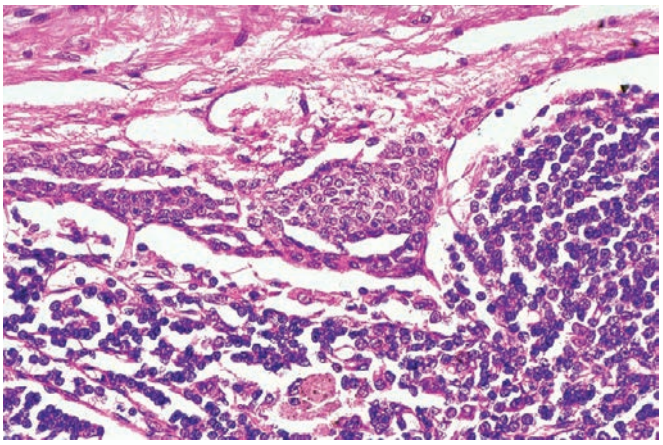

Figure 37.124 Nevus Cells in the Capsule of an Axillary Lymph Node. These inconsequential formations should not be mistaken for metastatic melanoma or metastatic carcinoma.

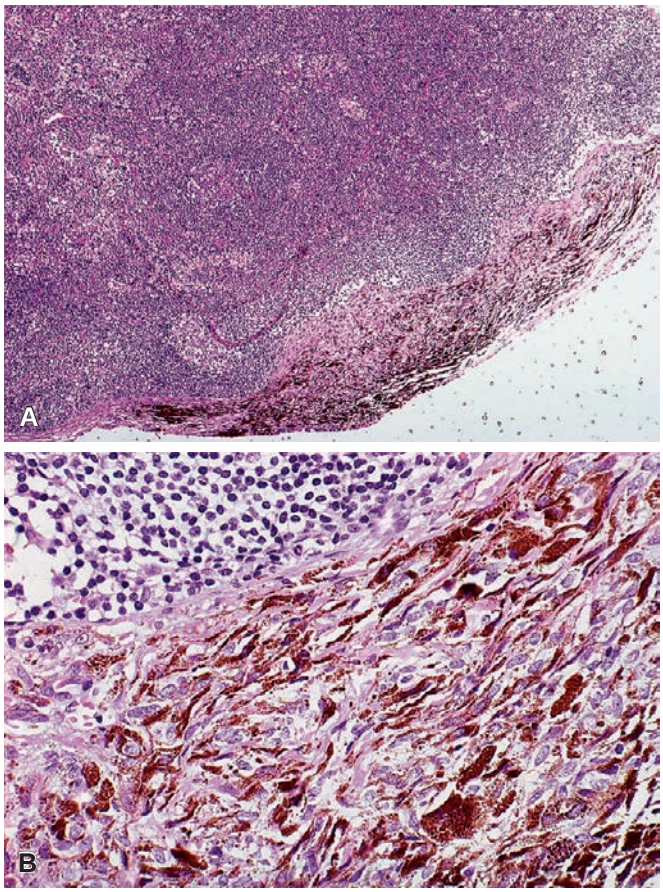

Figure 37.125 A and **B**, Blue nevus involving lymph node capsule.

lymph node inclusions may be difficult to distinguish from metastases originating in low-grade ovarian neoplasms, since they may grow into the peripheral sinuses, form papillae, be accompanied by psammoma bodies, and even proliferate as small sheets of cells.[1145] Some authors have suggested that some of these "inclusions" are actually metastases from ovarian serous borderline tumors.[1146] Morphologically similar inclusions have been seen in the mediastinal nodes of males[1138] and axillary nodes of females. Nodal glandular inclusions of similar appearance but surrounded by endometrial-type stroma occur less frequently and represent *nodal endometriosis*.

6. *Nevus cells*. Clusters of normal-appearing nevus cells are occasionally found in the capsule of lymph nodes, without involvement of the nodal parenchyma (Fig. 37.124). Most of the reported cases have occurred in axillary lymph nodes.[1147] A related lesion is the *blue nevus* that has been reported in the lymph node capsule (Fig. 37.125).[1148] The morphologic features of these formations and their differential diagnosis with metastatic malignant melanoma are discussed in Chapter 3.
7. *Mesothelial cells*. Occasionally, mesothelial cells are found within lymph nodes in the apparent absence of a malignant mesothelioma.[1149–1151] The obvious differential diagnosis is with metastatic malignant mesothelioma from an occult primary in the peritoneal cavity or pleura.[1152]
8. *Breast tissue*. One of the most unusual forms of ectopia is represented by normal mammary lobules within axillary lymph nodes.[1153–1155] A slightly more common occurrence is the presence in axillary nodes of tubules lined by a single layer of cuboidal cells (sometimes with a hobnail appearance), located in the nodal capsule or immediately beneath. These formations are similar to the müllerian-type epithelial inclusions in pelvic lymph nodes previously described. Since some of these cases occur in patients with breast carcinoma, the distinct possibility exists of mistaking them for metastatic tumor.[1156,1157] Epithelial inclusions in axillary lymph nodes of females can be classified into three major groups: those composed exclusively of glandular structures, those made up only of squamous cysts, and those containing both glandular and squamous epithelium.[1158]

Other Non-Neoplastic Lesions

Adipose metaplasia of lymph nodes is very common. When extensive, it may lead to the formation of large masses, up to 10 cm or more in diameter. These nodes are sometimes referred to as *lipolymph nodes*; the external iliac and obturator groups are the sites most commonly involved.[1159]

Ectopic thymus sometimes seen in supraclavicular lymph node biopsies should be mentioned here for the sake of differential diagnosis even if it is not a lymph node lesion. The pathologist unaware of this occurrence might easily misinterpret the Hassall corpuscles as islands of metastatic squamous cell carcinoma.

Vasculitis involving lymph nodes may be seen in a large number of disorders: polyarteritis nodosa (having necrotizing qualities and only rarely biopsied), Henoch–Schönlein purpura (leukocytoclastic, also rarely biopsied), Wegener granulomatosis (sometimes accompanied by extensive infarct), systemic lupus erythematosus, drug hypersensitivity, and mucocutaneous lymph node syndrome. One should also mention the obliterative vasculitis often seen in syphilitic lymphadenitis.

Infarction of the lymph nodes presents with painful swelling, usually located in a superficial lymph node chain. Microscopically, there is extensive necrosis of medullary and cortical lymphoid cells, with marked reactive perinodal inflammation and a layer of granulation tissue. A thin rim of viable subcapsular lymphoid tissue may be present.[1160] Thrombosis of veins within the substance and the hilum of the nodes has been suggested as the pathogenesis.[1160] Similar changes can be seen in mesenteric lymph nodes in patients with intestinal volvulus.[1161] Other cases are the result of embolism, arterial occlusion in cases of polyarteritis nodosa and related disorders, or fine-needle aspiration;[1162,1163] in these instances, the nodal infarct tends to have a segmental quality. The differential diagnosis of lymph node infarction includes necrotizing lymphadenitis, mucocutaneous

For personal use only. No other uses without permission. Copyright ©2017. Elsevier Inc. All rights reserved.

lymph node syndrome, infectious mononucleosis,[1164] necrotizing granulomatous inflammation, and necrotic malignant tumors. Two types of malignancy that have been occasionally found to undergo extensive and sometimes massive infarct-type necrosis when involving lymph nodes are malignant lymphoma[1165,1166] and metastatic malignant melanoma. Therefore thorough examination of the infarcted node, the extranodal region, and other nodes submitted is mandatory in order to exclude a concomitant or underlying malignancy (Fig. 37.126A and B).[1166] A thorough immunohistochemical study is also in order. Tumor cells reactivity for CD20 in the face of extensive necrotic changes is retained (see Fig. 37.126C).[1167,1168] As a general rule, the possibility of an underlying malignancy should be suspected if the infarcted node is markedly enlarged.

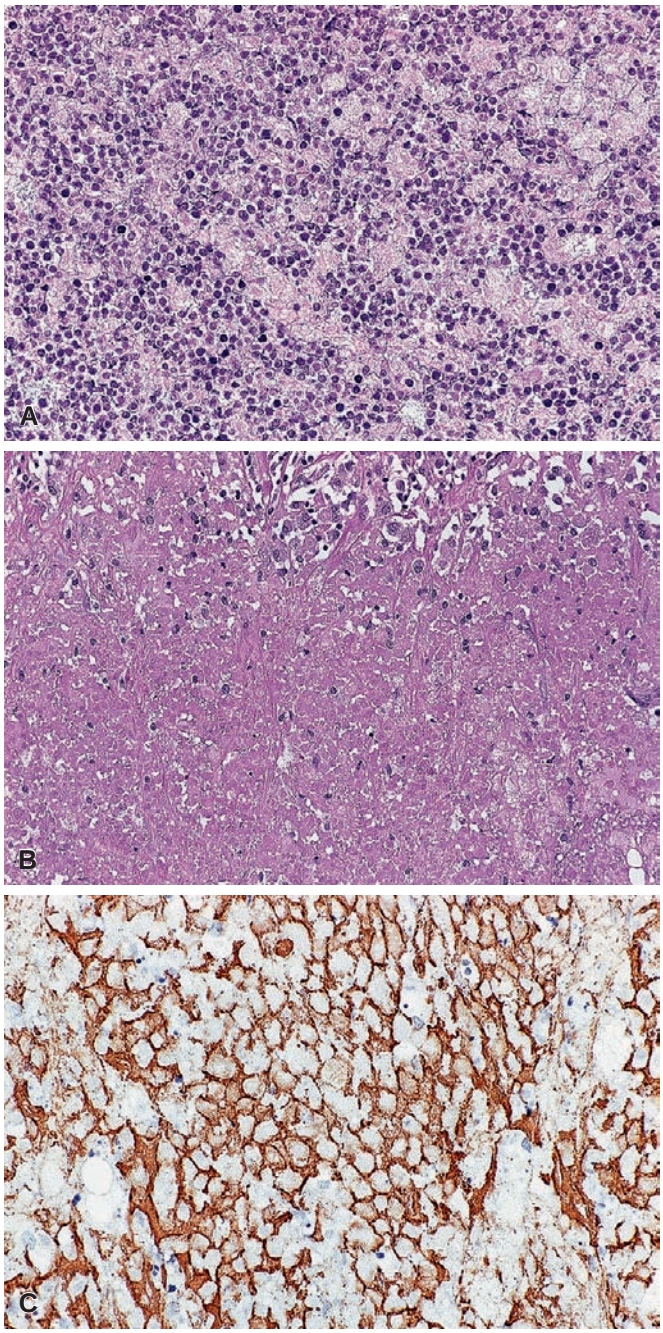

Figure 37.126 **A–C**, Large B-cell lymphoma that has undergone massive infarct-type necrosis. **A**, The outlines of the tumor cells can still be discerned. **B**, A totally necrotic area, indistinguishable from that of a "benign" infarct. **C**, There is a remarkable degree of retained immunoreactivity for CD20 in the necrotic area.

Hyaline material sometimes accumulates in the stroma of lymph nodes. This finding is very frequent in those situated in the aorto-iliac region (Fig. 37.127). The material can undergo secondary calcification. Because of its homogeneous eosinophilic appearance, it can be confused with amyloid and has been referred to in the past as *pseudo-amyloid*. It should also be distinguished from the hyaline material deposited in nodes in cases of hemorrhagic spindle cell tumor with amianthoid fibers. The presence of this hyaline material, which is probably an abnormal type of collagen, has no clinical significance.

Proteinaceous lymphadenopathy is the name given to a lymph node abnormality in which an eosinophilic extracellular material of proteinaceous nature is deposited in lymph nodes. This material simulates the appearance of amyloid but is histochemically and ultrastructurally distinct from it. The few patients who have been described with this obscure abnormality had hypergammaglobulinemia, and the hyaline material itself has been shown to contain precipitated immunoglobulin.[1169]

Foreign material of various types can accumulate in lymph nodes. One example is the *silicone lymphadenopathy* developing as a side effect of mammary augmentation produced by injection of liquid silicone or by placement of a bag-gel prosthesis. Microscopically, a nonbirefringent refractive material is present in the sinuses, together with variously sized vacuoles and multinucleated giant cells (Fig. 37.128).[1170]

Another example is the already mentioned sinus histiocytosis of pelvic lymph nodes, which is induced by the cobalt-chromium and titanium contained in hip prostheses (Fig. 37.129).[1171]

Metastatic Tumors

Lymph nodes are the most common site of metastatic malignancy and sometimes constitute the first clinical manifestation of the disease.[1172–1174] The task of the pathologist is to identify the presence of a malignant process in the node, to establish whether it is metastatic or not, and—if metastatic—to provide an estimate of its amount, microscopic type, and possible source. If malignant cells are identified within the efferent lymph vessels and/or extranodal adipose tissue, this should also be noted in the report because of the possible prognostic significance of these findings.

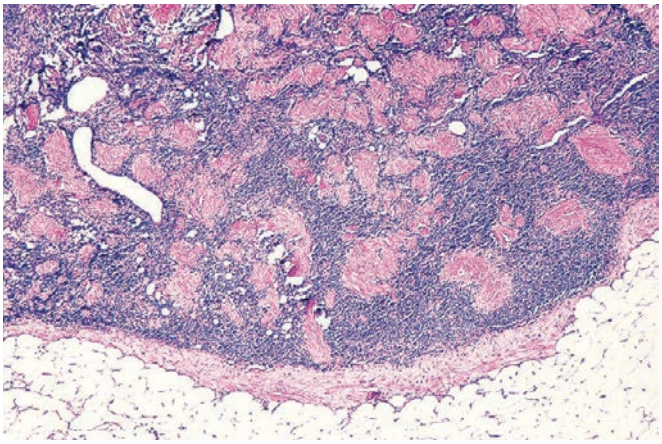

Figure 37.127 **Hyaline Deposits in Pelvic Lymph Node.** This change is of no clinical significance.

For personal use only. No other uses without permission. Copyright ©2017. Elsevier Inc. All rights reserved.

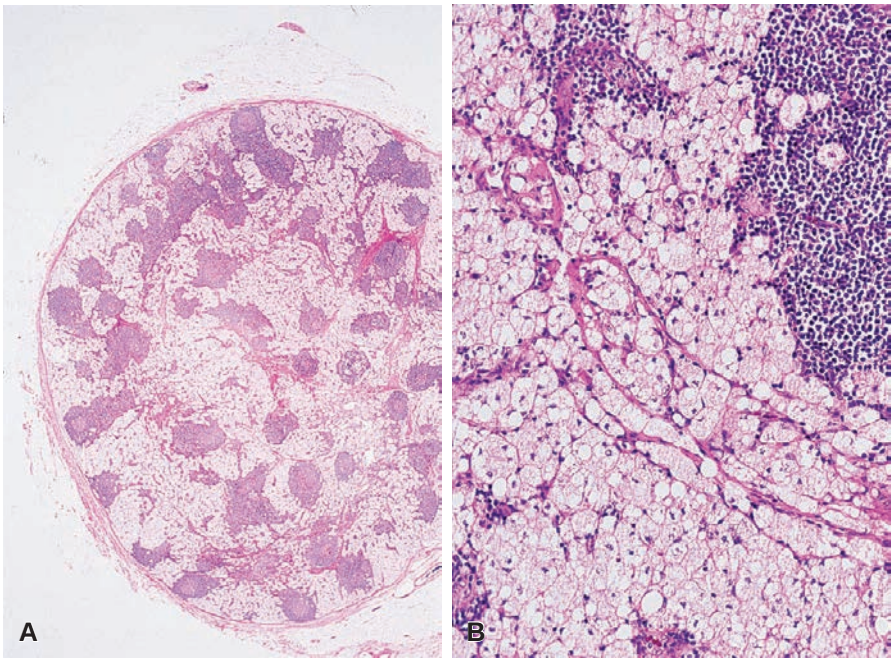

Figure 37.128 Low-power (**A**) and medium-power (**B**) appearances of silicone lymphadenitis. The sinuses are massively expanded by a histiocytic infiltrate, which simulates the appearance of Rosai–Dorfman disease.

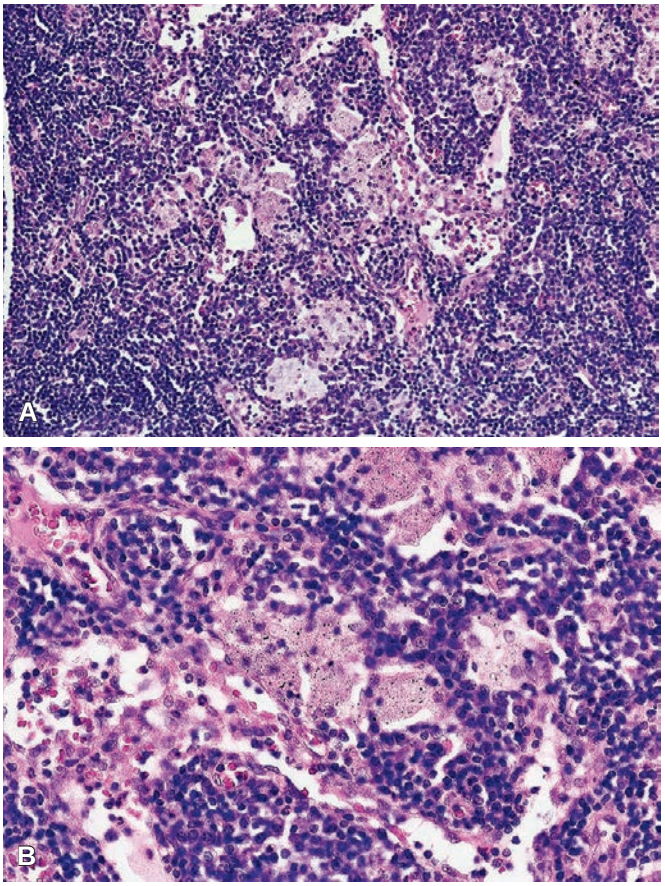

Figure 37.129 **A** and **B**, Lymph node changes in a patient who had a prosthesis implanted in the joint drained by this node. A fine particulate black material can be appreciated in the high-power view. It is easy to dismiss this material as "dirt."

Any malignant tumor can give rise to lymph node metastases, but the incidence varies greatly depending on the tumor type. It is common with carcinomas, malignant melanomas, and germ cell tumors, and rare with sarcomas and central nervous system tumors. It should also be noted that large cell lymphomas primary in an organ (such as stomach or thyroid) sometimes involve the regional nodes in a pattern consistent with metastatic spread and the pattern of lymph node infiltration of ALCL may mimic a metastasis.

An additional diagnosis to consider in a lymph node involvement by metastatic tumor is that of malignant mesothelioma (Fig. 37.130). Examples of this tumor type presenting initially with lymphadenopathy in the cervical or inguinal region are reported; most of the primary tumors were located in the peritoneum rather than the pleura, regardless of the location of the nodes.[1152] The differential diagnosis includes reactive benign mesothelial cells in lymph nodes (see later) (Fig. 37.131).

It is very rare for soft tissue sarcomas to present initially as a lymph node metastasis. The outstanding exception is alveolar rhabdomyosarcoma (particularly the solid variant), which can be confused with malignant lymphoma not only on morphologic grounds but also because it may involve several lymph node groups (so-called "lymphadenopathic form") (Fig. 37.132). Other sarcomas that have a greater than average tendency to metastasize to regional nodes are embryonal rhabdomyosarcoma, angiosarcoma, epithelioid sarcoma, and synovial sarcoma.

The differential diagnosis between metastatic undifferentiated carcinoma and diffuse large cell lymphoma in routine sections may be difficult or even impossible without ancillary studies in some cases. Features favoring lymphoma are presence of focal nodularity within the tumor not induced by fibrosis, and diffuse permeation of walls of veins (as opposed to tumor thrombi) and adipose tissue if an extranodal component is present. Features favoring metastatic tumor are focal nodal involvement, definite nesting, extensive necrosis, predominantly sinus distribution, and solid tumor plugs in lymphatic vessels. The types of malignant lymphoma most likely to be misdiagnosed as metastatic carcinoma are ALCL, large B-cell lymphoma

For personal use only. No other uses without permission. Copyright ©2017. Elsevier Inc. All rights reserved.

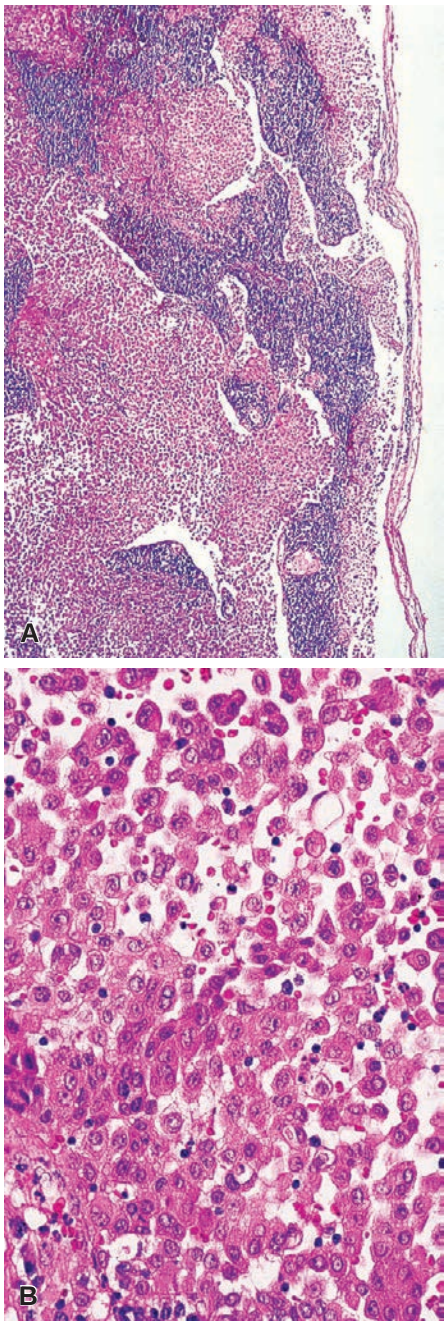

Figure 37.130 **A** and **B**, Lymph node involved by metastatic mesothelioma. The tumor massively expands the sinuses and is composed of cuboidal cells with a central nucleus and acidophilic cytoplasm. The primary tumor was located in the peritoneal cavity.

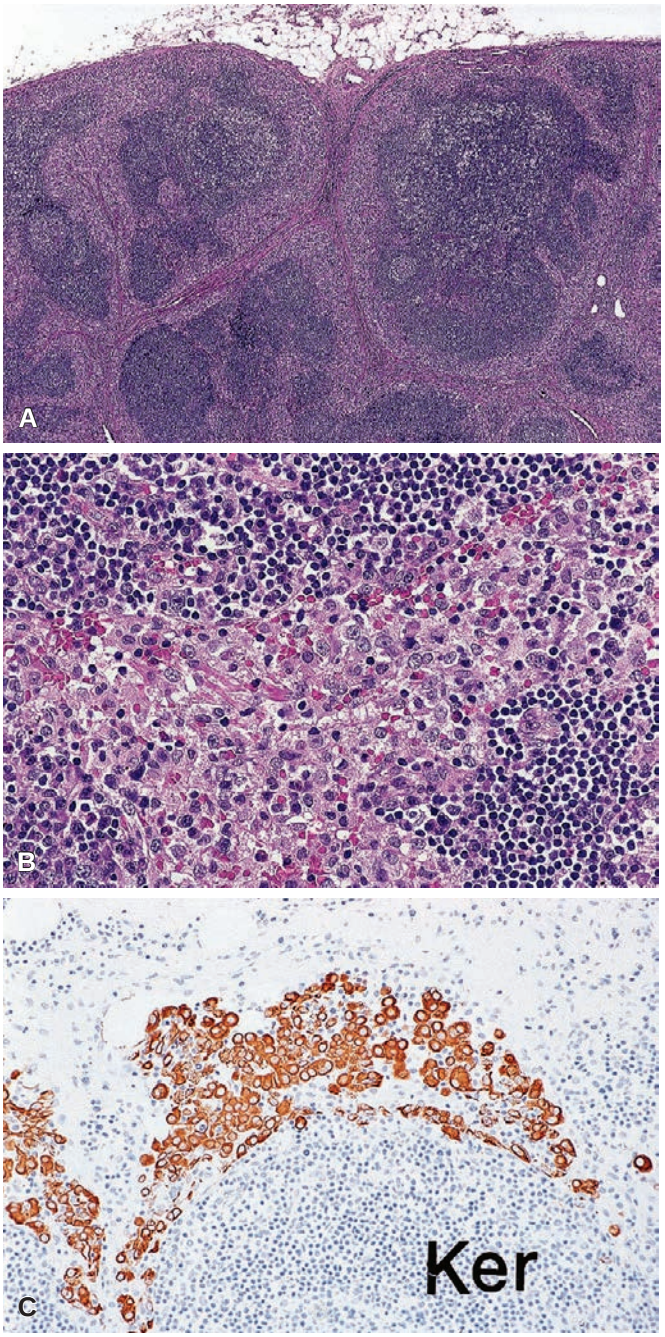

Figure 37.131 **Hyperplastic Mesothelial Cells in Lymph Node.** **A**, Sinusal distribution. **B**, Bland cytologic appearance. **C**, Strong immunoreactivity for keratin. *Ker,* Keratin.

with sclerosis resulting in prominent nesting, large B-cell lymphoma with a predominantly sinus pattern of growth, nodular sclerosis Hodgkin lymphoma with concentration of large mononuclear variants of Reed–Sternberg cells around areas of necrosis, and signet ring cell lymphoma. Yet another type is the composite lymphoma made up of follicular small cleaved and diffuse large cell components, the double error consisting in diagnosing the latter component as metastatic carcinoma and the former as follicular hyperplasia.

The metastatic carcinomas that most closely simulate a malignant lymphoid process are nasopharyngeal lymphoepithelial carcinoma and lobular carcinoma of the breast (Figs. 37.133 and 37.134). The first may masquerade clinically and pathologically as Hodgkin lymphoma because of its common presentation in a young adult with painless unilateral cervical lymphadenopathy, EBV positivity, and the presence of a polymorphic population (including eosinophils) on microscopic examination.[1175] The second may be confused with malignant lymphomas of one type or another, including signet ring lymphoma (Fig. 37.135), or the carcinoma cells may be mistaken for histiocytes. Metastatic small cell neuroendocrine carcinoma from the lung or other sites can be difficult to distinguish from lymphoma;

For personal use only. No other uses without permission. Copyright ©2017. Elsevier Inc. All rights reserved.

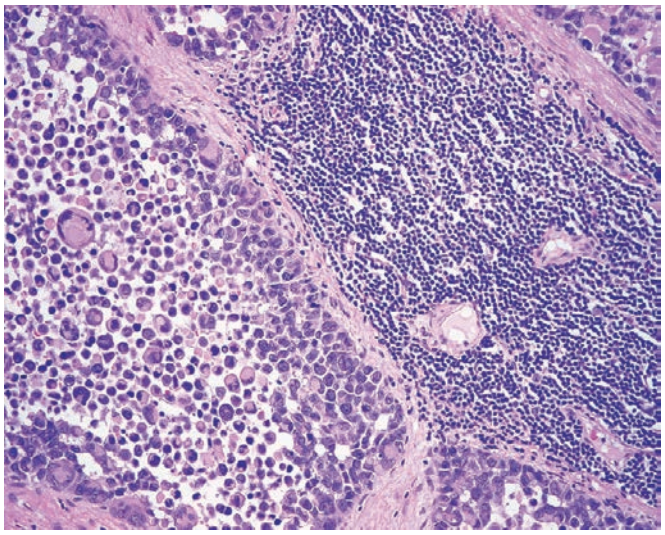

Figure 37.132 Alveolar Rhabdomyosarcoma Metastatic to a Lymph Node. This is a relatively common occurrence in this tumor type, and it may be the first clinical manifestation of the disease.

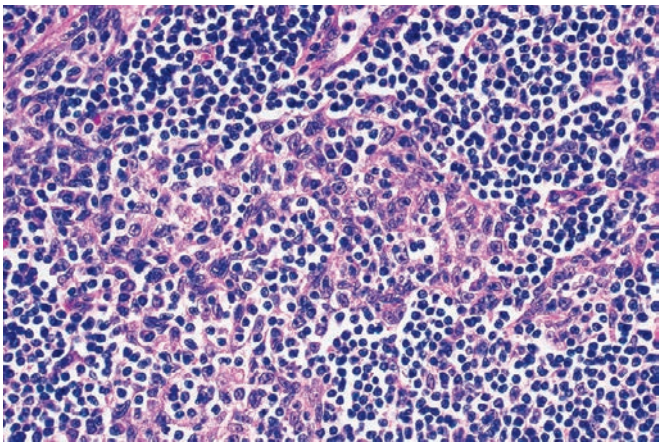

Figure 37.133 Lymph Node Involved by Metastatic Lymphoepithelioma From the Nasopharynx. The relatively diffuse pattern of the proliferation may result in a mistaken diagnosis of malignant lymphoma.

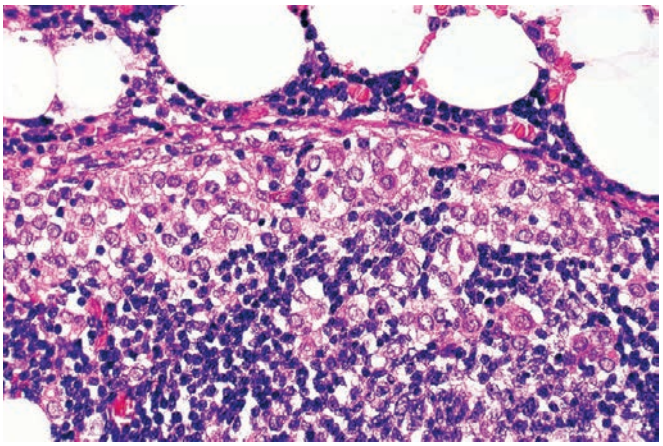

Figure 37.134 Breast Carcinoma of Lobular Type Metastatic to the Sinuses of a Lymph Node. The cytologic appearance may be confused with that of a malignant lymphoma or a benign histiocytic proliferation.

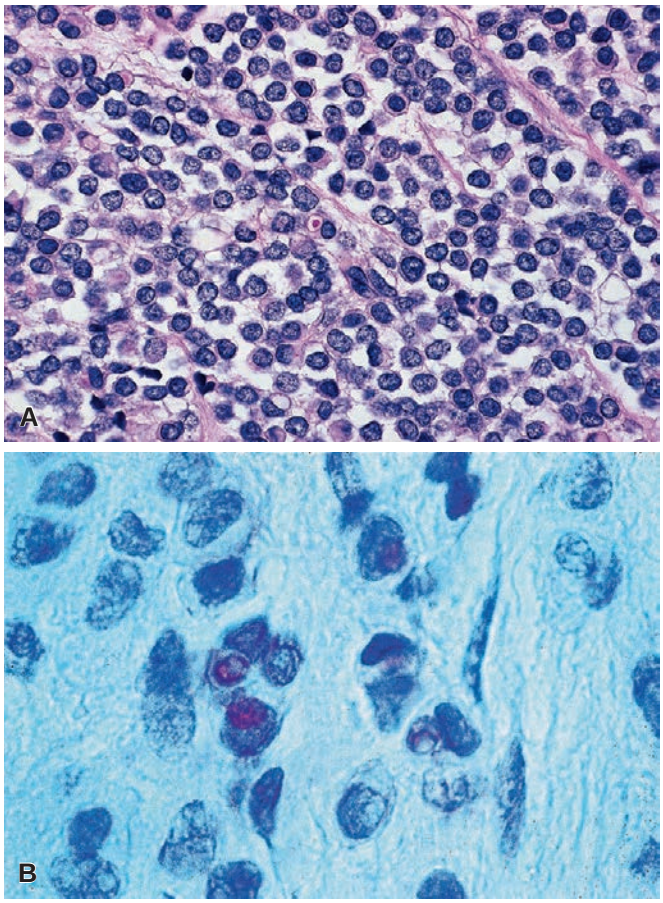

Figure 37.135 Poorly Differentiated Adenocarcinoma With Signet Ring Features Initially Misinterpreted as a Malignant Lymphoma. The mistake may have been partially induced by the fact that the tumor developed in a renal transplant recipient. **A**, Hematoxylin–eosin. **B**, Mucicarmine stain, showing a few droplets of intracytoplasmic mucin.

dense nuclear chromatin pattern, nuclear molding, focal areas of necrosis, and hematoxyphilic staining of vessel walls favor a diagnosis of small cell carcinoma. Somewhat similar considerations pertain to the diagnosis of metastatic Merkel cell carcinoma. Metastatic melanoma can closely simulate on cytologic grounds the appearance of large cell lymphoma and plasmacytoma. The balloon cell variety can closely mimic RDD (Fig. 37.136). One should also not forget that metastases can develop in a node already involved by lymphoma or leukemia.

Nodal metastases of squamous cell carcinoma have a particular tendency to undergo cystic changes. When these are prominent in a node located in the neck, a mistaken diagnosis of branchial cleft cyst may ensue (Figs. 37.137 and 37.138).

The location of a node involved by metastatic carcinoma gives important clues about the possible site of the primary. The large majority of tumors metastatic to *upper cervical* lymph nodes originate from the upper aerodigestive tract. Sites well known for harboring small, clinically undetectable primaries in the presence of cervical adenopathy are the nasopharynx and retrotonsillar pillar.[1176–1178] *Midcervical* nodes containing papillary carcinoma are usually examples of metastatic thyroid carcinoma, a possibility that becomes a virtual certainty in the presence of psammoma bodies. However, these papillary tumors may also originate from salivary gland, female genital tract, or thymus (see respective chapters). Squamous cell

For personal use only. No other uses without permission. Copyright ©2017. Elsevier Inc. All rights reserved.

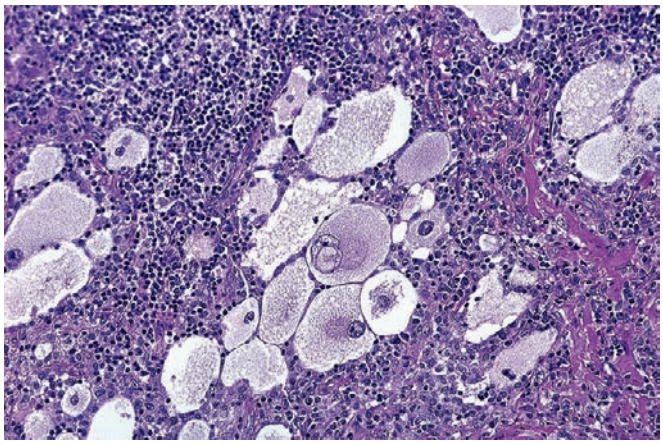

Figure 37.136 Balloon cell melanoma metastatic to a lymph node and simulating a histiocytic disorder.

Figure 37.137 Squamous Cell Carcinoma Metastatic to Lymph Node. The tumor has undergone partial cystic transformation.

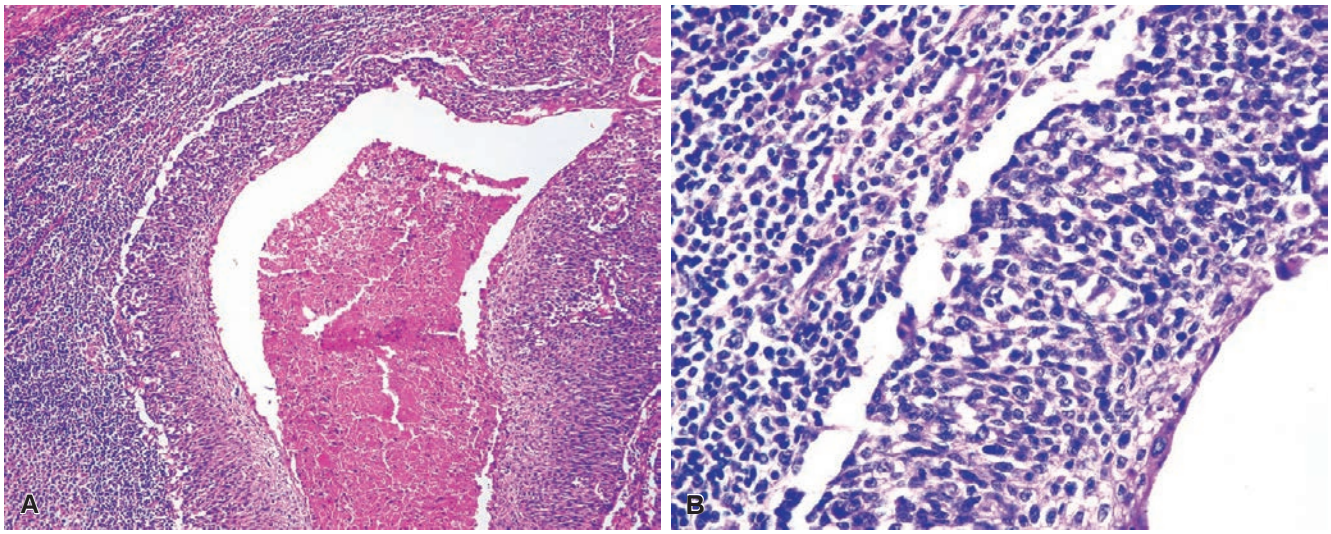

Figure 37.138 Squamous Cell Carcinoma Metastatic to Cervical Lymph Node. A, Medium-power view, showing marked cystic change that may result in a mistaken diagnosis of branchial cleft cyst. **B**, High-power view showing malignant cytologic features involving the entire thickness of the epithelial strip.

carcinomas in lymph nodes of this region usually arise in the upper aerodigestive tract, particularly pharynx and larynx.[1179] Most carcinomas metastatic to *supraclavicular* lymph nodes originate in the lung or breast. Other sources of metastases to this nodal group, particularly if located on the left side, are carcinoma of stomach, pancreas, prostate, and testis.[1177,1180] These reach the node through the terminal collecting lymphatic trunks. Supraclavicular nodes involved by intra-abdominal carcinomas are sometimes referred to as Virchow or Troisier nodes.[1181] The large majority of metastatic tumors in *axillary* nodes of adult females are breast carcinoma and malignant melanoma.[1182,1183] Lung carcinoma should also be considered, especially in older patients with a smoking history.[1184] *Inguinal* nodes are often the recipients of carcinomas from the external genital organs (usually evident on clinical examination) or malignant melanomas of the lower extremities, but only rarely from the internal abdominal organs (ovary, uterine cervix, anal canal) and even less commonly from the testis, unless direct extension to the scrotal skin has occurred.[1185]

The immunohistochemical approach to an obviously malignant tumor involving a lymph node is CD45, keratin, and S100 protein, as markers for lymphoid, epithelial, and melanocytic cells, respectively. A second line of reagents could include EMA, CEA, CD20, CD3, CD30, and—depending on the circumstances—GCDFP-15 and lactalbumin (for breast), chromogranin (for endocrine tumors), PSA/PAP (for prostate), and keratin subsets. The specific immunoprofiles of various tumor types are discussed in more detail in other chapters. When properly applied and interpreted, the performance of these studies should solve all but a very small minority of cases.

It is just as important to mention some of the benign conditions of lymph nodes that can mistakenly be interpreted as metastatic carcinoma. They include hyperplastic mesothelial cells,[1149] megakaryocytes,[1186] signet ring sinus histiocytosis,[1187] the related nodal muciphages and mucicarminophilic histiocytosis,[1188,1189] florid anthracosis/anthracosilicosis,[1136] and the various lymph node epithelial inclusions listed above, without forgetting the banal germinal centers of hyperplastic follicles cut tangentially.

For personal use only. No other uses without permission. Copyright ©2017. Elsevier Inc. All rights reserved.

References

1. Stein H, Bonk A, Tolksdorf G, et al. Immunohistologic analysis of the organization of normal lymphoid tissue and non-Hodgkin's lymphomas. *J Histochem Cytochem*. 1980;28(8):746-760.
2. Campo E, Jaffe ES, Harris NL. Normal lymphoid organs and tissues. In: Jaffe ES, Arber DA, Campo E, et al, eds. *Hematopathology*. 2nd ed. Philadelphia, PA: Elsevier; 2017:131-152.
3. Liu YJ, Zhang J, Lane PJ, et al. Sites of specific B cell activation in primary and secondary responses to T cell-dependent and T cell-independent antigens. *Eur J Immunol*. 1991;21(12):2951-2962.
4. Szakal AK, Kosco MH, Tew JG. Microanatomy of lymphoid tissue during humoral immune responses: structure function relationships. *Annu Rev Immunol*. 1989;7:91-109.
5. Ioachim HL, Medeiros LJ. *Ioachim's Lymph Node Pathology*. 4th ed. Philadelphia, PA: Lippincott Williams & Wilkins; 2008.
6. Prakash S, Banks PM. Technical factors in the preparation and evaluation of lymph node biopsies. In: Orazi A, Weiss LM, Foucar K, Knowles DM, eds. *Neoplastic Hematopathology*. 3rd ed. Philadelphia, PA: Lippincott Williams & Wilkins; 2014:286-292.
7. Kardos TF, Maygarden SJ, Blumberg AK, et al. Fine needle aspiration biopsy in the management of children and young adults with peripheral lymphadenopathy. *Cancer*. 1989;63(4):703-707.
8. Cafferty LL, Katz RL, Ordonez NG, et al. Fine needle aspiration diagnosis of intraabdominal and retroperitoneal lymphomas by a morphologic and immunocytochemical approach. *Cancer*. 1990;65(1):72-77.
9. Frable WJ, Kardos TF. Fine needle aspiration biopsy. Applications in the diagnosis of lymphoproliferative diseases. *Am J Surg Pathol*. 1988;12(suppl 1):62-72.
10. Moncada PA, Budvytiene I, Ho DY, et al. Utility of DNA sequencing for direct identification of invasive fungi from fresh and formalin-fixed specimens. *Am J Clin Pathol*. 2013;140(2):203-208.
11. Mills AM, Guo FP, Copland AP, et al. A comparison of CMV detection in gastrointestinal mucosal biopsies using immunohistochemistry and PCR performed on formalin-fixed, paraffin-embedded tissue. *Am J Surg Pathol*. 2013;37(7):995-1000.
12. Fukumoto H, Sato Y, Hasegawa H, et al. Development of a new real-time PCR system for simultaneous detection of bacteria and fungi in pathological samples. *Int J Clin Exp Pathol*. 2015;8(11):15479-15488.
13. Safont M, Angelakis E, Richet H, et al. Bacterial lymphadenitis at a major referral hospital in France from 2008 to 2012. *J Clin Microbiol*. 2014;52(4):1161-1167.
14. Chu PG, Chang KL, Arber DA, Weiss LM. Immunophenotyping of hematopoietic neoplasms. *Semin Diagn Pathol*. 2000;17(3):236-256.
15. Heel K, Tabone T, Rohrig KJ, et al. Developments in the immunophenotypic analysis of haematological malignancies. *Blood Rev*. 2013;27(4):193-207.
16. Chan JK, Kwong YL. Common misdiagnoses in lymphomas and avoidance strategies. *Lancet Oncol*. 2010;11(6):579-588.
17. Tan BT, Warnke RA, Arber DA. The frequency of B- and T-cell gene rearrangements and epstein-barr virus in T-cell lymphomas: a comparison between angioimmunoblastic T-cell lymphoma and peripheral T-cell lymphoma, unspecified with and without associated B-cell proliferations. *J Mol Diagn*. 2006;8(4):466-475, quiz 527.
18. van Dongen JJ, Langerak AW, Bruggemann M, et al. Design and standardization of PCR primers and protocols for detection of clonal immunoglobulin and T-cell receptor gene recombinations in suspect lymphoproliferations: report of the BIOMED-2 Concerted Action BMH4-CT98-3936. *Leukemia*. 2003;17(12):2257-2317.
19. Collins RD. Is clonality equivalent to malignancy: specifically, is immunoglobulin gene rearrangement diagnostic of malignant lymphoma? *Hum Pathol*. 1997;28(7):757-759.
20. Jevremovic D, Viswanatha DS. Molecular diagnosis of hematopoietic and lymphoid neoplasms. *Hematol Oncol Clin North Am*. 2009;23(4):903-933.
21. Sandberg Y, van Gastel-Mol EJ, Verhaaf B, et al. BIOMED-2 multiplex immunoglobulin/T-cell receptor polymerase chain reaction protocols can reliably replace Southern blot analysis in routine clonality diagnostics. *J Mol Diagn*. 2005;7(4):495-503.
22. Arber DA, Braziel RM, Bagg A, Bijwaard KE. Evaluation of T cell receptor testing in lymphoid neoplasms: results of a multicenter study of 29 extracted DNA and paraffin-embedded samples. *J Mol Diagn*. 2001;3(4):133-140.
23. Bagg A, Braziel RM, Arber DA, et al. Immunoglobulin heavy chain gene analysis in lymphomas: a multi-center study demonstrating the heterogeneity of performance of polymerase chain reaction assays. *J Mol Diagn*. 2002;4(2):81-89.
24. van Krieken JH, Langerak AW, Macintyre EA, et al. Improved reliability of lymphoma diagnostics via PCR-based clonality testing: report of the BIOMED-2 Concerted Action BHM4-CT98-3936. *Leukemia*. 2007;21(2):201-206.
25. Elenitoba-Johnson KS, Bohling SD, Mitchell RS, et al. PCR analysis of the immunoglobulin heavy chain gene in polyclonal processes can yield pseudoclonal bands as an artifact of low B cell number. *J Mol Diagn*. 2000;2(2):92-96.
26. Sufficool KE, Lockwood CM, Abel HJ, et al. T-cell clonality assessment by next-generation sequencing improves detection sensitivity in mycosis fungoides. *J Am Acad Dermatol*. 2015;73(2):228-236 e2.
27. Belaud-Rotureau MA, Parrens M, Carrere N, et al. Interphase fluorescence in situ hybridization is more sensitive than BIOMED-2 polymerase chain reaction protocol in detecting IGH-BCL2 rearrangement in both fixed and frozen lymph node with follicular lymphoma. *Hum Pathol*. 2007;38(2):365-372.
28. Merker JD, Arber DA. Molecular diagnostics of non-Hodgkin lymphoma. *Expert Opin Med Diagn*. 2007;1(1):47-63.
29. Streubel B, Simonitsch-Klupp I, Mullauer L, et al. Variable frequencies of MALT lymphoma-associated genetic aberrations in MALT lymphomas of different sites. *Leukemia*. 2004;18(10):1722-1726.
30. Wotherspoon AC, Finn TM, Isaacson PG. Trisomy 3 in low-grade B-cell lymphomas of mucosa-associated lymphoid tissue. *Blood*. 1995;85(8):2000-2004.
31. Wong KF, Chan JK, Kwong YL. Identification of del(6)(q21q25) as a recurring chromosomal abnormality in putative NK cell lymphoma/leukaemia. *Br J Haematol*. 1997;98(4):922-926.
32. Compagno M, Lim WK, Grunn A, et al. Mutations of multiple genes cause deregulation of NF-kappaB in diffuse large B-cell lymphoma. *Nature*. 2009;459(7247):717-721.
33. Kato M, Sanada M, Kato I, et al. Frequent inactivation of A20 in B-cell lymphomas. *Nature*. 2009;459(7247):712-716.
34. Lenz G, Davis RE, Ngo VN, et al. Oncogenic CARD11 mutations in human diffuse large B cell lymphoma. *Science*. 2008;319(5870):1676-1679.
35. Novak U, Rinaldi A, Kwee I, et al. The NF-κB negative regulator TNFAIP3 (A20) is inactivated by somatic mutations and genomic deletions in marginal zone lymphomas. *Blood*. 2009;113(20):4918-4921.
36. Hutter G, Scheubner M, Zimmermann Y, et al. Differential effect of epigenetic alterations and genomic deletions of CDK inhibitors [p16(INK4a), p15(INK4b), p14(ARF)] in mantle cell lymphoma. *Genes Chromosomes Cancer*. 2006;45(2):203-210.
37. Houldsworth J, Mathew S, Rao PH, et al. REL proto-oncogene is frequently amplified in extranodal diffuse large cell lymphoma. *Blood*. 1996;87(1):25-29.
38. Alizadeh AA, Eisen MB, Davis RE, et al. Distinct types of diffuse large B-cell lymphoma identified by gene expression profiling. *Nature*. 2000;403(6769):503-511.
39. Rosenwald A, Wright G, Chan WC, et al. The use of molecular profiling to predict survival after chemotherapy for diffuse large-B-cell lymphoma. *N Engl J Med*. 2002;346(25):1937-1947.
40. Hans CP, Weisenburger DD, Greiner TC, et al. Confirmation of the molecular classification of diffuse large B-cell lymphoma by immunohistochemistry using a tissue microarray. *Blood*. 2004;103(1):275-282.
41. Chinen J, Notarangelo LD, Shearer WT. Advances in basic and clinical immunology in 2013. *J Allergy Clin Immunol*. 2014;133(4):967-976.
42. Al-Herz W, Bousfiha A, Casanova JL, et al. Primary immunodeficiency diseases: an update on the classification from the international union of immunological societies expert committee for primary immunodeficiency. *Front Immunol*. 2014;5:162.
43. Villa A, Notarangelo LD, Roifman CM. Omenn syndrome: inflammation in leaky severe combined immunodeficiency. *J Allergy Clin Immunol*. 2008;122(6):1082-1086.
44. Tangye SG. XLP: clinical features and molecular etiology due to mutations in SH2D1A encoding SAP. *J Clin Immunol*. 2014;34(7):772-779.
45. Oliveira JB, Bleesing JJ, Dianzani U, et al. Revised diagnostic criteria and classification for the autoimmune lymphoproliferative syndrome (ALPS): report from the 2009 NIH International Workshop. *Blood*. 2010;116(14):e35-e40.
46. Holzelova E, Vonarbourg C, Stolzenberg MC, et al. Autoimmune lymphoproliferative syndrome with somatic Fas mutations. *N Engl J Med*. 2004;351(14):1409-1418.
47. Teachey DT, Seif AE, Grupp SA. Advances in the management and understanding of autoimmune lymphoproliferative syndrome (ALPS). *Br J Haematol*. 2010;148(2):205-216.
48. Deutsch M, Tsopanou E, Dourakis SP. The autoimmune lymphoproliferative syndrome (Canale-Smith) in adulthood. *Clin Rheumatol*. 2004;23(1):43-44.
49. Jackson CE, Puck JM. Autoimmune lymphoproliferative syndrome, a disorder of apoptosis. *Curr Opin Pediatr*. 1999;11(6):521-527.

For personal use only. No other uses without permission. Copyright ©2017. Elsevier Inc. All rights reserved.

50. Kraus MD, Shenoy S, Chatila T, Hess JL. Light microscopic, immunophenotypic, and molecular genetic study of autoimmune lymphoproliferative syndrome caused by FAS mutation. *Pediatr Dev Pathol*. 2000;3(1):101-109.
51. Lim MS, Straus SE, Dale JK, et al. Pathological findings in human autoimmune lymphoproliferative syndrome. *Am J Pathol*. 1998;153(5):1541-1550.
52. Maric I, Pittaluga S, Dale JK, et al. Histologic features of sinus histiocytosis with massive lymphadenopathy in patients with autoimmune lymphoproliferative syndrome. *Am J Surg Pathol*. 2005;29(7):903-911.
53. Straus SE, Jaffe ES, Puck JM, et al. The development of lymphomas in families with autoimmune lymphoproliferative syndrome with germline Fas mutations and defective lymphocyte apoptosis. *Blood*. 2001;98(1):194-200.
54. Casanova JL, Conley ME, Seligman SJ, et al. Guidelines for genetic studies in single patients: lessons from primary immunodeficiencies. *J Exp Med*. 2014;211(11):2137-2149.
55. Dorfman RF, Warnke R. Lymphadenopathy simulating the malignant lymphomas. *Hum Pathol*. 1974;5(5):519-550.
56. van der Valk P, Meijer CJ. Lymph nodes. In: Mills SE, ed. *Histology for Pathologists*. 3rd ed. Philadelphia, PA: Lippincott Williams & Wilkins; 2007:763-782.
57. Swerdlow SH. Genetic and molecular genetic studies in the diagnosis of atypical lymphoid hyperplasias versus lymphoma. *Hum Pathol*. 2003;34(4):346-351.
58. Hicks EB, Rappaport H, Winter WJ. Follicular lymphoma: a re-evaluation of its position in the scheme of malignant lymphoma, based on a survey of 253 cases. *Cancer*. 1956;9(4):792-821.
59. Nathwani BN, Winberg CD, Diamond LW, et al. Morphologic criteria for the differentiation of follicular lymphoma from florid reactive follicular hyperplasia: a study of 80 cases. *Cancer*. 1981;48(8):1794-1806.
60. Kojima M, Nakamura S, Motoori T, et al. Progressive transformation of germinal centers: a clinicopathological study of 42 Japanese patients. *Int J Surg Pathol*. 2003;11(2):101-107.
61. Poppema S, Kaiserling E, Lennert K. Hodgkin's disease with lymphocytic predominance, nodular type (nodular paragranuloma) and progressively transformed germinal centres—a cytohistological study. *Histopathology*. 1979;3(4):295-308.
62. Stein H, Gerdes J, Mason DY. The normal and malignant germinal centre. *Clin Haematol*. 1982;11(3):531-559.
63. Osborne BM, Butler JJ. Follicular lymphoma mimicking progressive transformation of germinal centers. *Am J Clin Pathol*. 1987;88(3):264-269.
64. Ferry JA, Zukerberg LR, Harris NL. Florid progressive transformation of germinal centers. A syndrome affecting young men, without early progression to nodular lymphocyte predominance Hodgkin's disease. *Am J Surg Pathol*. 1992;16(3):252-258.
65. Burns BF, Colby TV, Dorfman RF. Differential diagnostic features of nodular L & H Hodgkin's disease, including progressive transformation of germinal centers. *Am J Surg Pathol*. 1984;8(4):253-261.
66. Hansmann ML, Fellbaum C, Hui PK, Moubayed P. Progressive transformation of germinal centers with and without association to Hodgkin's disease. *Am J Clin Pathol*. 1990;93(2):219-226.
67. Poppema S, Kaiserling E, Lennert K. Nodular paragranuloma and progressively transformed germinal centers. Ultrastructural and immunohistologic findings. *Virchows Arch, B, Cell Pathol*. 1979;31(3):211-225.
68. Nguyen PL, Ferry JA, Harris NL. Progressive transformation of germinal centers and nodular lymphocyte predominance Hodgkin's disease: a comparative immunohistochemical study. *Am J Surg Pathol*. 1999;23(1):27-33.
69. Yamakawa M, Ikeda I, Masuda A, et al. An unusual regressive germinal center, the 'FDC-only lymphoid follicle,' in lymph nodes of organ transplant recipients. *Am J Surg Pathol*. 1999;23(5):536-545.
70. Hunt JP, Chan JA, Samoszuk M, et al. Hyperplasia of mantle/marginal zone B cells with clear cytoplasm in peripheral lymph nodes. A clinicopathologic study of 35 cases. *Am J Clin Pathol*. 2001;116(4): 550-559.
71. Lai R, Arber DA, Chang KL, et al. Frequency of bcl-2 expression in non-Hodgkin's lymphoma: a study of 778 cases with comparison of marginal zone lymphoma and monocytoid B-cell hyperplasia. *Mod Pathol*. 1998;11(9):864-869.
72. Lai R, Weiss LM, Chang KL, Arber DA. Frequency of CD43 expression in non-Hodgkin lymphoma. A survey of 742 cases and further characterization of rare CD43+ follicular lymphomas. *Am J Clin Pathol*. 1999;111(4):488-494.
73. Gorton G, Linell F. Malignant tumours and sarcoid reactions in regional lymph nodes. *Acta Radiol*. 1957;47(5):381-392.
74. Nadel EM, Ackerman LV. Lesions resembling Boeck's sarcoid in lymph nodes draining an area containing a malignant neoplasm. *Am J Clin Pathol*. 1950;20(10):952-957.
75. Hall PA, Kingston J, Stansfeld AG. Extensive necrosis in malignant lymphoma with granulomatous reaction mimicking tuberculosis. *Histopathology*. 1988;13(3):339-346.
76. Hollingsworth HC, Longo DL, Jaffe ES. Small noncleaved cell lymphoma associated with florid epithelioid granulomatous response. A clinicopathologic study of seven patients. *Am J Surg Pathol*. 1993;17(1):51-59.
77. Kadin ME, Donaldson SS, Dorfman RF. Isolated granulomas in Hodgkin's disease. *N Engl J Med*. 1970;283(16):859-861.
78. Ioachim HL, ed. *Pathology of Granulomas*. New York, NY: Raven Press; 1983.
79. Sheibani K, Fritz RM, Winberg CD, et al. "Monocytoid" cells in reactive follicular hyperplasia with and without multifocal histiocytic reactions: an immunohistochemical study of 21 cases including suspected cases of toxoplasmic lymphadenitis. *Am J Clin Pathol*. 1984;81(4):453-458.
80. van den Oord JJ, de Wolf-Peeters C, De Vos R, Desmet VJ. Immature sinus histiocytosis. Light- and electron-microscopic features, immunologic phenotype, and relationship with marginal zone lymphocytes. *Am J Pathol*. 1985;118(2):266-277.
81. Kojima M, Hosomura Y, Itoh H, et al. Monocytoid B lymphocytes and epithelioid cell clusters in abscess-forming granulomatous lymphadenitis. With special reference to cat scratch disease. *Acta Pathol Jpn*. 1991;41(5):363-368.
82. Aozasa K, Ohsawa M, Horiuchi K, et al. The occurrence of monocytoid B-lymphocytes in autoimmune disorders. *Mod Pathol*. 1993;6(2):121-124.
83. Ohsawa M, Kanno H, Naka N, Aozasa K. Occurrence of monocytoid B-lymphocytes in Hodgkin's disease. *Mod Pathol*. 1994;7(5):540-543.
84. Shin SS, Sheibani K. Monocytoid B-cell lymphoma. *Am J Clin Pathol*. 1993;99(4):421-425.
85. Vollenweider R, Lennert K. Plasmacytoid T-cell clusters in non-specific lymphadenitis. *Virchows Arch, B, Cell Pathol*. 1983;44(1):1-14.
86. Facchetti F, de Wolf-Peeters C, Mason DY, et al. Plasmacytoid T cells. Immunohistochemical evidence for their monocyte/macrophage origin. *Am J Pathol*. 1988;133(1):15-21.
87. Jegalian AG, Facchetti F, Jaffe ES. Plasmacytoid dendritic cells: physiologic roles and pathologic states. *Adv Anat Pathol*. 2009;16(6):392-404.
88. Koo CH, Mason DY, Miller R, et al. Additional evidence that "plasmacytoid T-cell lymphoma" associated with chronic myeloproliferative disorders is of macrophage/monocyte origin. *Am J Clin Pathol*. 1990;93(6):822-827.
89. Facchetti F, de Wolf-Peeters C, van den Oord JJ, et al. Plasmacytoid monocytes (so-called plasmacytoid T-cells) in Kikuchi's lymphadenitis. An immunohistologic study. *Am J Clin Pathol*. 1989;92(1):42-50.
90. Hansmann ML, Kikuchi M, Wacker HH, et al. Immunohistochemical monitoring of plasmacytoid cells in lymph node sections of Kikuchi-Fujimoto disease by a new pan-macrophage antibody Ki-M1P. *Hum Pathol*. 1992;23(6):676-680.
91. Facchetti F, De Wolf-Peeters C, De Vos R, et al. Plasmacytoid monocytes (so-called plasmacytoid T cells) in granulomatous lymphadenitis. *Hum Pathol*. 1989;20(6):588-593.
92. Kjeldsberg CR, Kim H. Polykaryocytes resembling Warthin-Finkeldey giant cells in reactive and neoplastic lymphoid disorders. *Hum Pathol*. 1981;12(3):267-272.
93. Orenstein JM. The Warthin-Finkeldey-type giant cell in HIV infection, what is it? *Ultrastruct Pathol*. 1998;22(4):293-303.
94. Chan JK, Saw D. Histiocytic necrotizing lymphadenitis (Kikuchi's disease) a clinicopathologic study of 9 cases. *Pathology*. 1986;18(1):22-28.
95. Bosch X, Guilabert A, Miquel R, Campo E. Enigmatic Kikuchi-Fujimoto disease: a comprehensive review. *Am J Clin Pathol*. 2004;122(1):141-152.
96. Dorfman RF, Berry GJ. Kikuchi's histiocytic necrotizing lymphadenitis: an analysis of 108 cases with emphasis on differential diagnosis. *Semin Diagn Pathol*. 1988;5(4):329-345.
97. Felgar RE, Furth EE, Wasik MA, et al. Histiocytic necrotizing lymphadenitis (Kikuchi's disease): in situ end-labeling, immunohistochemical, and serologic evidence supporting cytotoxic lymphocyte-mediated apoptotic cell death. *Mod Pathol*. 1997;10(3):231-241.
98. Takakuwa T, Ohnuma S, Koike J, et al. Involvement of cell-mediated killing in apoptosis in histiocytic necrotizing lymphadenitis (Kikuchi-Fujimoto disease). *Histopathology*. 1996;28(1):41-48.
99. Pileri S, Kikuchi M, Lennert K. Histiocytic necrotizing lymphadenitis without granulocytic infiltration. *Virchows Arch A Pathol Anat Histol*. 1982;395:257-271.
100. Turner RR, Martin J, Dorfman RF. Necrotizing lymphadenitis. A study of 30 cases. *Am J Surg Pathol*. 1983;7(2):115-123.
101. Sumiyoshi Y, Kikuchi M, Ohshima K, et al. Human herpesvirus-6 genomes in histiocytic necrotizing lymphadenitis (Kikuchi's disease) and other forms of lymphadenitis. *Am J Clin Pathol*. 1993;99(5):609-614.
102. Chamulak GA, Brynes RK, Nathwani BN. Kikuchi-Fujimoto disease mimicking

For personal use only. No other uses without permission. Copyright ©2017. Elsevier Inc. All rights reserved.

malignant lymphoma. *Am J Surg Pathol*. 1990;14(6):514-523.
103. Menasce LP, Banerjee SS, Edmondson D, Harris M. Histiocytic necrotizing lymphadenitis (Kikuchi-Fujimoto disease): continuing diagnostic difficulties. *Histopathology*. 1998;33(3):248-254.
104. Tsang WY, Chan JK, Ng CS. Kikuchi's lymphadenitis. A morphologic analysis of 75 cases with special reference to unusual features. *Am J Surg Pathol*. 1994;18(3):219-231.
105. Pilichowska ME, Pinkus JL, Pinkus GS. Histiocytic necrotizing lymphadenitis (Kikuchi-Fujimoto disease): lesional cells exhibit an immature dendritic cell phenotype. *Am J Clin Pathol*. 2009;131(2):174-182.
106. Kuo TT. Kikuchi's disease (histiocytic necrotizing lymphadenitis). A clinicopathologic study of 79 cases with an analysis of histologic subtypes, immunohistology, and DNA ploidy. *Am J Surg Pathol*. 1995;19(7):798-809.
107. Eimoto T, Kikuchi M, Mitsui T. Histiocytic necrotizing lymphadenitis. An ultrastructural study in comparison with other types of lymphadenitis. *Acta Pathol Jpn*. 1983;33(5):863-879.
108. Tsang WY, Chan JK. Fine-needle aspiration cytologic diagnosis of Kikuchi's lymphadenitis. A report of 27 cases. *Am J Clin Pathol*. 1994;102(4):454-458.
109. Kuo TT. Cutaneous manifestation of Kikuchi's histiocytic necrotizing lymphadenitis. *Am J Surg Pathol*. 1990;14(9):872-876.
110. Spies J, Foucar K, Thompson CT, LeBoit PE. The histopathology of cutaneous lesions of Kikuchi's disease (necrotizing lymphadenitis): a report of five cases. *Am J Surg Pathol*. 1999;23(9):1040-1047.
111. Chan JK, Wong KC, Ng CS. A fatal case of multicentric Kikuchi's histiocytic necrotizing lymphadenitis. *Cancer*. 1989;63(9):1856-1862.
112. Dumas G, Prendki V, Haroche J, et al. Kikuchi-Fujimoto disease: retrospective study of 91 cases and review of the literature. *Medicine (Baltimore)*. 2014;93(24):372-382.
113. Cozzutto C, Soave F. Xanthogranulomatous lymphadenitis. *Virchows Arch A Pathol Anat Histol*. 1979;385(1):103-108.
114. Moore SW, Schneider JW, Schaaf HS. Diagnostic aspects of cervical lymphadenopathy in children in the developing world: a study of 1,877 surgical specimens. *Pediatr Surg Int*. 2003;19(4):240-244.
115. Ikonomopoulos JA, Gorgoulis VG, Zacharatos PV, et al. Multiplex polymerase chain reaction for the detection of mycobacterial DNA in cases of tuberculosis and sarcoidosis. *Mod Pathol*. 1999;12(9):854-862.
116. Mackellar A, Hilton HB, Masters PL. Mycobacterial lymphadenitis in childhood. *Arch Dis Child*. 1967;42(221):70-74.
117. Pinder SE, Colville A. Mycobacterial cervical lymphadenitis in children. Can histological assessment help differentiate infections caused by nontuberculous mycobacteria from *Mycobacterium tuberculosis*? *Histopathology*. 1993;22:59-64.
118. Reid JD, Wolinsky E. Histopathology of lymphadenitis caused by atypical mycobacteria. *Am Rev Respir Dis*. 1969;99(1):8-12.
119. Smith MB, Molina CP, Schnadig VJ, et al. Pathologic features of Mycobacterium kansasii infection in patients with acquired immunodeficiency syndrome. *Arch Pathol Lab Med*. 2003;127(5):554-560.
120. Logani S, Lucas DR, Cheng JD, et al. Spindle cell tumors associated with mycobacteria in lymph nodes of HIV-positive patients: 'Kaposi sarcoma with mycobacteria' and 'mycobacterial pseudotumor'. *Am J Surg Pathol*. 1999;23(6):656-661.
121. Newman LS, Rose CS, Maier LA. Sarcoidosis. *N Engl J Med*. 1997;336(17):1224-1234.
122. Siltzbach LE. Geographic aspects of sarcoidosis. *Trans N Y Acad Sci*. 1967;29(4):364-374.
123. Collison JM, Miller NR, Green WR. Involvement of orbital tissues by sarcoid. *Am J Ophthalmol*. 1986;102(3):302-307.
124. Devaney K, Goodman ZD, Epstein MS, et al. Hepatic sarcoidosis. Clinicopathologic features in 100 patients. *Am J Surg Pathol*. 1993;17(12):1272-1280.
125. Fink SD, Kremer JM. Cutaneous and musculoskeletal features, diagnostic modalities, and immunopathology in sarcoidosis. *Curr Opin Rheumatol*. 1994;6(1):78-81.
126. Cushard WG Jr, Simon AB, Canterbury JM, Reiss E. Parathyroid function in sarcoidosis. *N Engl J Med*. 1972;286(8):395-398.
127. Winnacker JL, Becker KL, Friedlander M, et al. Sarcoidosis and hyperparathyroidism. *Am J Med*. 1969;46(2):305-312.
128. Zeimer HJ, Greenaway TM, Slavin J, et al. Parathyroid-hormone-related protein in sarcoidosis. *Am J Pathol*. 1998;152(1):17-21.
129. Rosen Y, Vuletin JC, Pertschuk LP, Silverstein E. Sarcoidosis: from the pathologist's vantage point. *Pathol Annu*. 1979;14(Pt 1):405-439.
130. Reid JD, Andersen ME. Calcium oxalate in sarcoid granulomas. With particular reference to the small ovoid body and a note on the finding of dolomite. *Am J Clin Pathol*. 1988;90(5):545-558.
131. Kirkpatrick CJ, Curry A, Bisset DL. Light- and electron-microscopic studies on multinucleated giant cells in sarcoid granuloma: new aspects of asteroid and Schaumann bodies. *Ultrastruct Pathol*. 1988;12(6):581-597.
132. Sieracki JC, Fisher ER. The ceroid nature of the so-called "Hamazaki-Wesenberg bodies". *Am J Clin Pathol*. 1973;59(2):248-253.
133. Tudway AJ. Yellow bodies in superficial and deep lymph nodes. *J Clin Pathol*. 1979;32(1):52-55.
134. Cunningham JA. Sarcoidosis. *Pathol Annu*. 1967;2:31-46.
135. Chilosi M, Menestrina F, Capelli P, et al. Immunohistochemical analysis of sarcoid granulomas. Evaluation of Ki67+ and interleukin-1+ cells. *Am J Pathol*. 1988;131(2):191-198.
136. Devergne O, Emilie D, Peuchmaur M, et al. Production of cytokines in sarcoid lymph nodes: preferential expression of interleukin-1 beta and interferon-gamma genes. *Hum Pathol*. 1992;23(3):317-323.
137. James DG, Williams WJ. Immunology of sarcoidosis. *Am J Med*. 1982;72(1):5-8.
138. Gardner J, Kennedy HG, Hamblin A, Jones E. HLA associations in sarcoidosis: a study of two ethnic groups. *Thorax*. 1984;39(1):19-22.
139. Baughman RP, Lower EE, du Bois RM. Sarcoidosis. *Lancet*. 2003;361(9363):1111-1118.
140. Roman J, Galis ZS. Sarcoidosis: a mysterious tale of inflammation, tissue remodeling, and matrix metalloproteinases. *Hum Pathol*. 2002;33(12):1155-1157.
141. Brook I, Frazier EH. Microbiology of cervical lymphadenitis in adults. *Acta Otolaryngol*. 1998;118(3):443-446.
142. Hill D, Dubey JP. *Toxoplasma gondii*: transmission, diagnosis and prevention. *Clin Microbiol Infect*. 2002;8(10):634-640.
143. McCabe RE, Brooks RG, Dorfman RF, Remington JS. Clinical spectrum in 107 cases of toxoplasmic lymphadenopathy. *Rev Infect Dis*. 1987;9(4):754-774.
144. Saxen L, Saxen E, Tenhunen A. The significance of histological diagnosis in glandular toxoplasmosis. *Acta Pathol Microbiol Scand*. 1962;56:284-294.
145. Bastien P. Molecular diagnosis of toxoplasmosis. *Trans R Soc Trop Med Hyg*. 2002;96(suppl 1):S205-S215.
146. Weiss LM, Chen YY, Berry GJ, et al. Infrequent detection of *Toxoplasma gondii* genome in toxoplasmic lymphadenitis: a polymerase chain reaction study. *Hum Pathol*. 1992;23(2):154-158.
147. Dorfman RF, Remington JS. Value of lymph-node biopsy in the diagnosis of acute acquired toxoplasmosis. *N Engl J Med*. 1973;289(17):878-881.
148. Frenkel JK. Toxoplasmosis. Mechanisms of infection, laboratory diagnosis and management. *Curr Top Pathol*. 1971;54:28-75.
149. Miettinen M, Franssila K. Malignant lymphoma simulating lymph node toxoplasmosis. *Histopathology*. 1982;6(2):129-140.
150. Hartsock RJ, Halling LW, King FM. Luetic lymphadenitis: a clinical and histologic study of 20 cases. *Am J Clin Pathol*. 1970;53(3):304-314.
151. Facchetti F, Incardona P, Lonardi S, et al. Nodal inflammatory pseudotumor caused by luetic infection. *Am J Surg Pathol*. 2009;33(3):447-453.
152. Farhi DC, Wells SJ, Siegel RJ. Syphilitic lymphadenopathy. Histology and human immunodeficiency virus status. *Am J Clin Pathol*. 1999;112(3):330-334.
153. Choi YJ, Reiner L. Syphilitic lymphadenitis: immunofluorescent identification of spirochetes from imprints. *Am J Surg Pathol*. 1979;3(6):553-555.
154. Kouznetsov AV, Prinz JC. Molecular diagnosis of syphilis: the Schaudinn-Hoffmann lymph-node biopsy. *Lancet*. 2002;360(9330):388-389.
155. Nayak SV, Shivarudrappa AS, Mukkamil AS. Role of fluorescent microscopy in detecting *Mycobacterium leprae* in tissue sections. *Ann Diagn Pathol*. 2003;7(2):78-81.
156. Rastogi N, Goh KS, Berchel M. Species-specific identification of *Mycobacterium leprae* by PCR-restriction fragment length polymorphism analysis of the hsp65 gene. *J Clin Microbiol*. 1999;37(6):2016-2019.
157. Cover TL, Aber RC. *Yersinia enterocolitica*. *N Engl J Med*. 1989;321(1):16-24.
158. Jansson E, Wallgren GR, Ahvonen P. *Yersinia enterocolitica* as a cause of acute mesenteric lymphadenitis. *Acta Paediatr Scand*. 1968;57(5):448-450.
159. Knapp W. Mesenteric adenitis due to *Pasteurella* pseudotuberculosis in young people. *N Engl J Med*. 1958;259(16):776-778.
160. Nilehn B. Studies on *Yersinia enterocolitica* with special reference to bacterial diagnosis and occurrence in human acute enteric disease. *Acta Pathol Microbiol Scand Suppl*. 1969;206(suppl 206):5+.
161. Ahlqvist J, Ahvonen P, Räsänen JA, Wallgren GR. Enteric infection with *Yersinia enterocolitica*. Large pyroninophilic cell reaction in mesenteric lymph nodes associated with early production of specific antibodies. *Acta Pathol Microbiol Scand A*. 1971;79(2):109-122.
162. Schapers RF, Reif R, Lennert K, Knapp W. Mesenteric lymphadenitis due to *Yersinia enterocolitica*. *Virchows Arch A Pathol Anat Histol*. 1981;390(2):127-138.
163. Lamps LW, Madhusudhan KT, Havens JM, et al. Pathogenic Yersinia DNA is detected in bowel and mesenteric lymph nodes from

For personal use only. No other uses without permission. Copyright ©2017. Elsevier Inc. All rights reserved.

patients with Crohn's disease. *Am J Surg Pathol*. 2003;27(2):220-227.
164. Carithers HA. Cat-scratch disease. An overview based on a study of 1,200 patients. *Am J Dis Child*. 1985;139(11): 1124-1133.
165. Winship T. Pathologic changes in so-called cat-scratch fever; review of findings in lymph node of 29 patients and cutaneous lesions of 2 patients. *Am J Clin Pathol*. 1953;23(10):1012-1018.
166. Kojima M, Nakamura S, Hosomura Y, et al. Abscess-forming granulomatous lymphadenitis: histological typing of suppurative granulomas and clinicopathological findings with special reference to cat scratch disease. *Acta Pathol Jpn*. 1993;43(1-2):11-17.
167. Johnson WT, Helwig EB. Cat-scratch disease. Histopathologic changes in the skin. *Arch Dermatol*. 1969;100(2):148-154.
168. English CK, Wear DJ, Margileth AM, et al. Cat-scratch disease. Isolation and culture of the bacterial agent. *JAMA*. 1988;259(9):1347-1352.
169. Miller-Catchpole R, Variakojis D, Vardiman JW, et al. Cat scratch disease. Identification of bacteria in seven cases of lymphadenitis. *Am J Surg Pathol*. 1986;10(4):276-281.
170. Wear DJ, Margileth AM, Hadfield TL, et al. Cat scratch disease: a bacterial infection. *Science*. 1983;221(4618):1403-1405.
171. Osborne BM, Butler JJ, Mackay B. Ultrastructural observations in cat scratch disease. *Am J Clin Pathol*. 1987;87(6):739-744.
172. Adal KA, Cockerell CJ, Petri WA Jr. Cat scratch disease, bacillary angiomatosis, and other infections due to Rochalimaea. *N Engl J Med*. 1994;330(21):1509-1515.
173. Cheuk W, Chan AK, Wong MC, Chan JK. Confirmation of diagnosis of cat scratch disease by immunohistochemistry. *Am J Surg Pathol*. 2006;30(2):274-275.
174. Scott MA, McCurley TL, Vnencak-Jones CL, et al. Cat scratch disease: detection of *Bartonella henselae* DNA in archival biopsies from patients with clinically, serologically, and histologically defined disease. *Am J Pathol*. 1996;149(6):2161-2167.
175. Windsor JJ. Cat-scratch disease: epidemiology, aetiology and treatment. *Br J Biomed Sci*. 2001;58(2):101-110.
176. Carithers HA, Carithers CM, Edwards RO Jr. Cat-scratch disease: its natural history. *JAMA*. 1969;207(2):312-316.
177. Mabey D, Peeling RW. Lymphogranuloma venereum. *Sex Transm Infect*. 2002;78(2):90-92.
178. Smith EB, Custer RP. The histopathology of lymphogranuloma venereum. *J Urol*. 1950;63:546-563.
179. Joseph AK, Rosen T. Laboratory techniques used in the diagnosis of chancroid, granuloma inguinale, and lymphogranuloma venereum. *Dermatol Clin*. 1994;12(1):1-8.
180. Mittal A, Sachdeva KG. Monoclonal antibody for the diagnosis of lymphogranuloma venereum: a preliminary report. *Br J Biomed Sci*. 1993;50(1):3-7.
181. Van Dyck E, Piot P. Laboratory techniques in the investigation of chancroid, lymphogranuloma venereum and donovanosis. *Genitourin Med*. 1992;68(2):130-133.
182. Ellis J, Oyston PC, Green M, Titball RW. Tularemia. *Clin Microbiol Rev*. 2002;15(4):631-646.
183. Evans ME, Gregory DW, Schaffner W, McGee ZA. Tularemia: a 30-year experience with 88 cases. *Medicine (Baltimore)*. 1985;64(4):251-269.
184. Tarnvik A, Berglund L. Tularaemia. *Eur Respir J*. 2003;21(2):361-373.
185. Lamps LW, Havens JM, Sjostedt A, et al. Histologic and molecular diagnosis of tularemia: a potential bioterrorism agent endemic to North America. *Mod Pathol*. 2004;17(5):489-495.
186. Tjaden JA, Lazarus AA, Martin GJ. Bacteria as agents of biowarfare. How to proceed when the worst is suspected. *Postgrad Med*. 2002;112(2):57-60, 3-4, 7-70.
187. Ohara Y, Sato T, Fujita H, et al. Clinical manifestations of tularemia in Japan—analysis of 1,355 cases observed between 1924 and 1987. *Infection*. 1991;19(1):14-17.
188. Sato T, Fujita H, Ohara Y, Homma M. Microagglutination test for early and specific serodiagnosis of tularemia. *J Clin Microbiol*. 1990;28(10):2372-2374.
189. Sutinen S, Syrjala H. Histopathology of human lymph node tularemia caused by *Francisella tularensis* var palaearctica. *Arch Pathol Lab Med*. 1986;110(1):42-46.
190. Tuncer E, Onal B, Simsek G, et al. Tularemia: potential role of cytopathology in differential diagnosis of cervical lymphadenitis: multicenter experience in 53 cases and literature review. *APMIS*. 2014;122(3):236-242.
191. Trujillo IZ, Zavala AN, Caceres JG, Miranda CQ. Brucellosis. *Infect Dis Clin North Am*. 1994;8(1):225-241.
192. Chomel BB, DeBess EE, Mangiamele DM, et al. Changing trends in the epidemiology of human brucellosis in California from 1973 to 1992: a shift toward foodborne transmission. *J Infect Dis*. 1994;170(5):1216-1223.
193. Namiduru M, Gungor K, Dikensoy O, et al. Epidemiological, clinical and laboratory features of brucellosis: a prospective evaluation of 120 adult patients. *Int J Clin Pract*. 2003;57(1):20-24.
194. Nimri LF. Diagnosis of recent and relapsed cases of human brucellosis by PCR assay. *BMC Infect Dis*. 2003;3:5.
195. Weed LA, Dahlin DC. Bacteriologic examination of tissue removed for biopsy. *Am J Clin Pathol*. 1950;20(2):116-132.
196. Umlas J, Federman M, Crawford C, et al. Spindle cell pseudotumor due to *Mycobacterium avium*-intracellulare in patients with acquired immunodeficiency syndrome (AIDS). Positive staining of mycobacteria for cytoskeleton filaments. *Am J Surg Pathol*. 1991;15(12):1181-1187.
197. Baroni CD, Uccini S. The lymphadenopathy of HIV infection. *Am J Clin Pathol*. 1993;99(4):397-401.
198. Said JW. AIDS-related lymphadenopathies. *Semin Diagn Pathol*. 1988;5(4):365-375.
199. Bogoch II, Andrews JR, Nagami EH, et al. Clinical predictors for the aetiology of peripheral lymphadenopathy in HIV-infected adults. *HIV Med*. 2013;14(3):182-186.
200. Burns BF, Wood GS, Dorfman RF. The varied histopathology of lymphadenopathy in the homosexual male. *Am J Surg Pathol*. 1985;9(4):287-297.
201. Wood GS, Garcia CF, Dorfman RF, Warnke RA. The immunohistology of follicle lysis in lymph node biopsies from homosexual men. *Blood*. 1985;66(5):1092-1097.
202. Schuurman HJ, Kluin PM, Gmelig Meijling FH, et al. Lymphocyte status of lymph node and blood in acquired immunodeficiency syndrome (AIDS) and AIDS-related complex disease. *J Pathol*. 1985;147(4): 269-280.
203. Said JW, Pinkus JL, Yamashita J, et al. The role of follicular and interdigitating dendritic cells in HIV-related lymphoid hyperplasia: localization of fascin. *Mod Pathol*. 1997;10(5):421-427.
204. Tacchetti C, Favre A, Moresco L, et al. HIV is trapped and masked in the cytoplasm of lymph node follicular dendritic cells. *Am J Pathol*. 1997;150(2):533-542.
205. de Paiva GR, Laurent C, Godel A, et al. Discovery of human immunodeficiency virus infection by immunohistochemistry on lymph node biopsies from patients with unexplained follicular hyperplasia. *Am J Surg Pathol*. 2007;31(10):1534-1538.
206. O'Hara CJ, Groopman JE, Federman M. The ultrastructural and immunohistochemical demonstration of viral particles in lymph nodes from human immunodeficiency virus-related and non-human immunodeficiency virus-related lymphadenopathy syndromes. *Hum Pathol*. 1988;19(5):545-549.
207. Harris NL. Hypervascular follicular hyperplasia and Kaposi's sarcoma in patients at risk for AIDS. *N Engl J Med*. 1984;310(7):462-463.
208. Chadburn A, Metroka C, Mouradian J. Progressive lymph node histology and its prognostic value in patients with acquired immunodeficiency syndrome and AIDS-related complex. *Hum Pathol*. 1989;20(6):579-587.
209. Westermann CD, Hurtubise PE, Linnemann CC, Swerdlow SH. Comparison of histologic nodal reactive patterns, cell suspension immunophenotypic data, and HIV status. *Mod Pathol*. 1990;3(1):54-60.
210. Abrams DI. Lymphadenopathy syndrome in male homosexuals. *Adv Host Def Mech*. 1985;5:75-97.
211. Ioachim HL, Cronin W, Roy M, Maya M. Persistent lymphadenopathies in people at high risk for HIV infection. Clinicopathologic correlations and long-term follow-up in 79 cases. *Am J Clin Pathol*. 1990;93(2):208-218.
212. Fishbein DB, Kaplan JE, Spira TJ, et al. Unexplained lymphadenopathy in homosexual men. A longitudinal study. *JAMA*. 1985;254(7):930-935.
213. Groopman JE. Clinical symptomatology of the acquired immunodeficiency syndrome (AIDS) and related disorders. *Prog Allergy*. 1986;37:182-193.
214. Rickinson A. Epstein-Barr virus. *Virus Res*. 2002;82(1-2):109-113.
215. Godshall SE, Kirchner JT. Infectious mononucleosis. Complexities of a common syndrome. *Postgrad Med*. 2000;107(7):175-179, 83-84, 86.
216. Luzuriaga K, Sullivan JL. Infectious mononucleosis. *N Engl J Med*. 2010;362(21):1993-2000.
217. Frizzera G, Hanto DW, Gajl-Peczalska KJ, et al. Polymorphic diffuse B-cell hyperplasias and lymphomas in renal transplant recipients. *Cancer Res*. 1981;41(11 Pt 1):4262-4279.
218. Salvador AH, Harrison EG Jr, Kyle RA. Lymphadenopathy due to infectious mononucleosis: its confusion with malignant lymphoma. *Cancer*. 1971;27(5):1029-1040.
219. Sieracki JC, Fisher ER. Diagnostic problems involving nodal lymphomas. *Pathol Annu*. 1970;5:91-124.
220. McMahon NJ, Gordon HW, Rosen RB. Reed-Sternberg cells in infectious mononucleosis. *Am J Dis Child*. 1970;120(2):148-150.
221. Tindle BH, Parker JW, Lukes RJ. "Reed-Sternberg cells" in infectious mononucleosis? *Am J Clin Pathol*. 1972;58(6):607-617.
222. Gulley ML. Molecular diagnosis of Epstein-Barr virus-related diseases. *J Mol Diagn*. 2001;3(1):1-10.
223. Shin SS, Berry GJ, Weiss LM. Infectious mononucleosis. Diagnosis by in situ hybridization in two cases with atypical

For personal use only. No other uses without permission. Copyright ©2017. Elsevier Inc. All rights reserved.

features. *Am J Surg Pathol*. 1991;15(7):625-631.
224. Strickler JG, Fedeli F, Horwitz CA, et al. Infectious mononucleosis in lymphoid tissue. Histopathology, in situ hybridization, and differential diagnosis. *Arch Pathol Lab Med*. 1993;117(3):269-278.
225. Louissaint A Jr, Ferry JA, Soupir CP, et al. Infectious mononucleosis mimicking lymphoma: distinguishing morphological and immunophenotypic features. *Mod Pathol*. 2012;25(8):1149-1159.
226. Hartsock RJ. Postvaccinial lymphadenitis. Hyperplasia of lymphoid tissue that simulates malignant lymphomas. *Cancer*. 1968;21(4):632-649.
227. Miliauskas JR, Leong AS. Localized herpes simplex lymphadenitis: report of three cases and review of the literature. *Histopathology*. 1991;19(4):355-360.
228. Howat AJ, Campbell AR, Stewart DJ. Generalized lymphadenopathy due to herpes simplex virus type I. *Histopathology*. 1991;19(6):563-564.
229. Lapsley M, Kettle P, Sloan JM. Herpes simplex lymphadenitis: a case report and review of the published work. *J Clin Pathol*. 1984;37(10):1119-1122.
230. Tamaru J, Mikata A, Horie H, et al. Herpes simplex lymphadenitis. Report of two cases with review of the literature. *Am J Surg Pathol*. 1990;14(6):571-577.
231. Audouin J, Le Tourneau A, Aubert JP, Diebold J. Herpes simplex virus lymphadenitis mimicking tumoral relapse in a patient with Hodgkin's disease in remission. *Virchows Arch A Pathol Anat Histopathol*. 1985;408(2-3):313-321.
232. Gaffey MJ, Ben-Ezra JM, Weiss LM. Herpes simplex lymphadenitis. *Am J Clin Pathol*. 1991;95(5):709-714.
233. Witt MD, Torno MS, Sun N, Stein T. Herpes simplex virus lymphadenitis: case report and review of the literature. *Clin Infect Dis*. 2002;34(1):1-6.
234. Dorfman RF, Herweg JC. Live, attenuated measles virus vaccine. Inguinal lymphadenopathy complicating administration. *JAMA*. 1966;198(3):320-321.
235. Beitz LO, Barron KS. Kawasaki syndrome. *Curr Opin Dermatol*. 1995;1:114-122.
236. Stamos JK, Corydon K, Donaldson J, Shulman ST. Lymphadenitis as the dominant manifestation of Kawasaki disease. *Pediatrics*. 1994;93(3):525-528.
237. Giesker DW, Pastuszak WT, Forouhar FA, et al. Lymph node biopsy for early diagnosis in Kawasaki disease. *Am J Surg Pathol*. 1982;6(6):493-501.
238. Marsh WL Jr, Bishop JW, Koenig HM. Bone marrow and lymph node findings in a fatal case of Kawasaki's disease. *Arch Pathol Lab Med*. 1980;104(11):563-567.
239. Burns JC. Kawasaki disease: the mystery continues. *Min Pediatr*. 2002;54(4):287-294.
240. Kojima M, Nakamura S, Morishita Y, et al. Reactive follicular hyperplasia in the lymph node lesions from systemic lupus erythematosus patients: a clinicopathological and immunohistological study of 21 cases. *Pathol Int*. 2000;50(4):304-312.
241. Medeiros LJ, Kaynor B, Harris NL. Lupus lymphadenitis: report of a case with immunohistologic studies on frozen sections. *Hum Pathol*. 1989;20(3):295-299.
242. Hu S, Kuo TT, Hong HS. Lupus lymphadenitis simulating Kikuchi's lymphadenitis in patients with systemic lupus erythematosus: a clinicopathological analysis of six cases and review of the literature. *Pathol Int*. 2003;53(4):221-226.
243. Kojima M, Nakamura S, Itoh H, et al. Systemic lupus erythematosus (SLE) lymphadenopathy presenting with histopathologic features of Castleman' disease: a clinicopathologic study of five cases. *Pathol Res Pract*. 1997;193(8):565-571.
244. Kubota K, Tamura J, Kurabayashi H, et al. Warthin-Finkeldey-like giant cells in a patient with systemic lupus erythematosus. *Hum Pathol*. 1988;19(11):1358-1359.
245. Robertson MD, Hart FD, White WF, et al. Rheumatoid lymphadenopathy. *Ann Rheum Dis*. 1968;27(3):253-260.
246. Nosanchuk JS, Schnitzer B. Follicular hyperplasia in lymph nodes from patients with rheumatoid arthritis. A clinicopathologic study. *Cancer*. 1969;24(2):243-254.
247. Kojima M, Hosomura Y, Itoh H, et al. Reactive proliferative lesions in lymph nodes from rheumatoid arthritis patients. A clinicopathological and immunohistological study. *Acta Pathol Jpn*. 1990;40(4):249-254.
248. Kojima M, Nakamura S, Miyawaki S, et al. Lymph node lesion in adult-onset Still's disease resembling peripheral T-cell lymphoma: a report of three cases. *Int J Surg Pathol*. 2002;10(3):197-202.
249. Rollins SD, Craig JP. Gold-associated lymphadenopathy in a patient with rheumatoid arthritis. Histologic and scanning electron microscopic features. *Arch Pathol Lab Med*. 1991;115(2):175-177.
250. Kamel OW, van de Rijn M, LeBrun DP, et al. Lymphoid neoplasms in patients with rheumatoid arthritis and dermatomyositis: frequency of Epstein-Barr virus and other features associated with immunosuppression. *Hum Pathol*. 1994;25(7):638-643.
251. Kojima M, Itoh H, Shimizu K, et al. Malignant lymphoma in patients with systemic rheumatic disease (rheumatoid arthritis, systemic lupus erythematosus, systemic sclerosis, and dermatomyositis): a clinicopathologic study of 24 Japanese cases. *Int J Surg Pathol*. 2006;14(1):43-48.
252. Smir BN, Greiner TC, Weisenburger DD. Multicentric angiofollicular lymph node hyperplasia in children: a clinicopathologic study of eight patients. *Mod Pathol*. 1996;9(12):1135-1142.
253. Frizzera G. Castleman's disease and related disorders. *Semin Diagn Pathol*. 1988;5(4):346-364.
254. Keller AR, Hochholzer L, Castleman B. Hyaline-vascular and plasma-cell types of giant lymph node hyperplasia of the mediastinum and other locations. *Cancer*. 1972;29(3):670-683.
255. Nguyen PL, Harris NL, Ritz J, Robertson MJ. Expression of CD95 antigen and Bcl-2 protein in non-Hodgkin's lymphomas and Hodgkin's disease. *Am J Pathol*. 1996;148(3):847-853.
256. Danon AD, Krishnan J, Frizzera G. Morpho-immunophenotypic diversity of Castleman's disease, hyaline-vascular type: with emphasis on a stroma-rich variant and a new pathogenetic hypothesis. *Virchows Arch A Pathol Anat Histopathol*. 1993;423(5):369-382.
257. Nagai K, Sato I, Shimoyama N. Pathohistological and immunohistochemical studies on Castleman's disease of the lymph node. *Virchows Arch A Pathol Anat Histopathol*. 1986;409(2):287-297.
258. Rollins-Raval MA, Marafioti T, Swerdlow SH, Roth CG. The number and growth pattern of plasmacytoid dendritic cells vary in different types of reactive lymph nodes: an immunohistochemical study. *Hum Pathol*. 2013;44(6):1003-1010.
259. Ohgami RS, Zhao S, Ohgami JK, et al. TdT+ T-lymphoblastic populations are increased in Castleman disease, in Castleman disease in association with follicular dendritic cell tumors, and in angioimmunoblastic T-cell lymphoma. *Am J Surg Pathol*. 2012;36(11):1619-1628.
260. Menke DM, Tiemann M, Camoriano JK, et al. Diagnosis of Castleman's disease by identification of an immunophenotypically aberrant population of mantle zone B lymphocytes in paraffin-embedded lymph node biopsies. *Am J Clin Pathol*. 1996;105(3):268-276.
261. Hsu SM, Waldron JA, Xie SS, Barlogie B. Expression of interleukin-6 in Castleman's disease. *Hum Pathol*. 1993;24(8):833-839.
262. Kazakov DV, Fanburg-Smith JC, Suster S, et al. Castleman disease of the subcutis and underlying skeletal muscle: report of 6 cases. *Am J Surg Pathol*. 2004;28(5):569-577.
263. Gulati P, Sun NC, Herman BK, et al. Isolated leptomeningeal Castleman's disease with viral particles in the follicular dendritic cells. *Arch Pathol Lab Med*. 1998;122(11):1026-1029.
264. Cheuk W, Yuen HK, Chu SY, et al. Lymphadenopathy of IgG4-related sclerosing disease. *Am J Surg Pathol*. 2008;32(5):671-681.
265. Kojima M, Nakamura S, Shimizu K, et al. Clinical implication of idiopathic plasmacytic lymphadenopathy with polyclonal hypergammaglobulinemia: a report of 16 cases. *Int J Surg Pathol*. 2004;12(1):25-30.
266. Bowne WB, Lewis JJ, Filippa DA, et al. The management of unicentric and multicentric Castleman's disease: a report of 16 cases and a review of the literature. *Cancer*. 1999;85(3):706-717.
267. Menke DM, Camoriano JK, Banks PM. Angiofollicular lymph node hyperplasia: a comparison of unicentric, multicentric, hyaline vascular, and plasma cell types of disease by morphometric and clinical analysis. *Mod Pathol*. 1992;5(5):525-530.
268. Skelton HG, Smith KJ. Extranodal multicentric Castleman's disease with cutaneous involvement. *Mod Pathol*. 1998;11(1):93-98.
269. Frizzera G, Banks PM, Massarelli G, Rosai J. A systemic lymphoproliferative disorder with morphologic features of Castleman's disease. Pathological findings in 15 patients. *Am J Surg Pathol*. 1983;7(3):211-231.
270. Frizzera G, Gajl-Peczalska K, Sibley RK, et al. Rosette formation in malignant lymphoma. *Am J Pathol*. 1985;119(3):351-356.
271. Weisenburger DD, Nathwani BN, Winberg CD, Rappaport H. Multicentric angiofollicular lymph node hyperplasia: a clinicopathologic study of 16 cases. *Hum Pathol*. 1985;16(2):162-172.
272. Isaacson PG. Commentary: Castleman's disease. *Histopathology*. 1989;14: 429-432.
273. Ascoli V, Sirianni MC, Mezzaroma I, et al. Human herpesvirus-8 in lymphomatous and nonlymphomatous body cavity effusions developing in Kaposi's sarcoma and multicentric Castleman's disease. *Ann Diagn Pathol*. 1999;3(6):357-363.
274. Cronin DM, Warnke RA. Castleman disease: an update on classification and the spectrum of associated lesions. *Adv Anat Pathol*. 2009;16(4):236-246.
275. Parravicini C, Chandran B, Corbellino M, et al. Differential viral protein expression in Kaposi's sarcoma-associated herpesvirus-infected diseases: Kaposi's sarcoma, primary effusion lymphoma, and multicentric Castleman's disease. *Am J Pathol*. 2000;156(3):743-749.
276. Amin HM, Medeiros LJ, Manning JT, Jones D. Dissolution of the lymphoid follicle is a feature of the HHV8+ variant of plasma cell Castleman's disease. *Am J Surg Pathol*. 2003;27(1):91-100.

For personal use only. No other uses without permission. Copyright ©2017. Elsevier Inc. All rights reserved.

277. Hengge UR, Ruzicka T, Tyring SK, et al. Update on Kaposi's sarcoma and other HHV8 associated diseases. Part 2: pathogenesis, Castleman's disease, and pleural effusion lymphoma. *Lancet Infect Dis*. 2002;2(6):344-352.
278. Menke DM, Chadbum A, Cesarman E, et al. Analysis of the human herpesvirus 8 (HHV-8) genome and HHV-8 vIL-6 expression in archival cases of castleman disease at low risk for HIV infection. *Am J Clin Pathol*. 2002;117(2):268-275.
279. Mandler RN, Kerrigan DP, Smart J, et al. Castleman's disease in POEMS syndrome with elevated interleukin-6. *Cancer*. 1992;69(11):2697-2703.
280. Munoz G, Geijo P, Moldenhauer F, et al. Plasmacellular Castleman's disease and POEMS syndrome. *Histopathology*. 1990;17(2):172-174.
281. Chan JK, Fletcher CD, Hicklin GA, Rosai J. Glomeruloid hemangioma. A distinctive cutaneous lesion of multicentric Castleman's disease associated with POEMS syndrome. *Am J Surg Pathol*. 1990;14(11):1036-1046.
282. Altiparmak MR, Pamuk GE, Pamuk ON, Dogusoy G. Secondary amyloidosis in Castleman's disease: review of the literature and report of a case. *Ann Hematol*. 2002;81(6):336-339.
283. Ordi J, Grau JM, Junque A, et al. Secondary (AA) amyloidosis associated with Castleman's disease. Report of two cases and review of the literature. *Am J Clin Pathol*. 1993;100(4):394-397.
284. Peterson BA, Frizzera G. Multicentric Castleman's disease. *Semin Oncol*. 1993;20(6):636-647.
285. Naresh KN, Rice AJ, Bower M. Lymph nodes involved by multicentric Castleman disease among HIV-positive individuals are often involved by Kaposi sarcoma. *Am J Surg Pathol*. 2008;32(7):1006-1012.
286. Hall PA, Donaghy M, Cotter FE, et al. An immunohistological and genotypic study of the plasma cell form of Castleman's disease. *Histopathology*. 1989;14(4):333-346, discussion 429-432.
287. Hanson CA, Frizzera G, Patton DF, et al. Clonal rearrangement for immunoglobulin and T-cell receptor genes in systemic Castleman's disease. Association with Epstein-Barr virus. *Am J Pathol*. 1988;131(1):84-91.
288. Ohyashiki JH, Ohyashiki K, Kawakubo K, et al. Molecular genetic, cytogenetic, and immunophenotypic analyses in Castleman's disease of the plasma cell type. *Am J Clin Pathol*. 1994;101(3):290-295.
289. Radaszkiewicz T, Hansmann ML, Lennert K. Monoclonality and polyclonality of plasma cells in Castleman's disease of the plasma cell variant. *Histopathology*. 1989;14(1):11-24.
290. Nguyen DT, Diamond LW, Hansmann ML, et al. Castleman's disease. Differences in follicular dendritic network in the hyaline vascular and plasma cell variants. *Histopathology*. 1994;24(5):437-443.
291. Ruco LP, Gearing AJ, Pigott R, et al. Expression of ICAM-1, VCAM-1 and ELAM-1 in angiofollicular lymph node hyperplasia (Castleman's disease): evidence for dysplasia of follicular dendritic reticulum cells. *Histopathology*. 1991;19(6):523-528.
292. Cokelaere K, Debiec-Rychter M, De Wolf-Peeters C, et al. Hyaline vascular Castleman's disease with HMGIC rearrangement in follicular dendritic cells: molecular evidence of mesenchymal tumorigenesis. *Am J Surg Pathol*. 2002;26(5):662-669.
293. Pauwels P, Dal Cin P, Vlasveld LT, et al. A chromosomal abnormality in hyaline vascular Castleman's disease: evidence for clonal proliferation of dysplastic stromal cells. *Am J Surg Pathol*. 2000;24(6):882-888.
294. Chang KC, Wang YC, Hung LY, et al. Monoclonality and cytogenetic abnormalities in hyaline vascular Castleman disease. *Mod Pathol*. 2014;27(6):823-831.
295. Chan JK, Tsang WY, Ng CS, et al. Follicular dendritic cell tumors of the oral cavity. *Am J Surg Pathol*. 1994;18(2):148-157.
296. Lin O, Frizzera G. Angiomyoid and follicular dendritic cell proliferative lesions in Castleman's disease of hyaline-vascular type: a study of 10 cases. *Am J Surg Pathol*. 1997;21(11):1295-1306.
297. Madero S, Onate JM, Garzon A. Giant lymph node hyperplasia in an angiolipomatous mediastinal mass. *Arch Pathol Lab Med*. 1986;110(9):853-855.
298. Chan JK, Tsang WY, Ng CS. Follicular dendritic cell tumor and vascular neoplasm complicating hyaline-vascular Castleman's disease. *Am J Surg Pathol*. 1994;18(5):517-525.
299. Gerald W, Kostianovsky M, Rosai J. Development of vascular neoplasia in Castleman's disease. Report of seven cases. *Am J Surg Pathol*. 1990;14(7):603-614.
300. Gould SJ, Diss T, Isaacson PG. Multicentric Castleman's disease in association with a solitary plasmacytoma: a case report. *Histopathology*. 1990;17(2):135-140.
301. Rolon PG, Audouin J, Diebold J, et al. Multicentric angiofollicular lymph node hyperplasia associated with a solitary osteolytic costal IgG lambda myeloma. POEMS syndrome in a South American (Paraguayan) patient. *Pathol Res Pract*. 1989;185(4):468-475, discussion 76-79.
302. Larroche C, Cacoub P, Soulier J, et al. Castleman's disease and lymphoma: report of eight cases in HIV-negative patients and literature review. *Am J Hematol*. 2002;69(2):119-126.
303. Vasef M, Katzin WE, Mendelsohn G, Reydman M. Report of a case of localized Castleman's disease with progression to malignant lymphoma. *Am J Clin Pathol*. 1992;98(6):633-636.
304. Abdel-Reheim FA, Koss W, Rappaport ES, Arber DA. Coexistence of Hodgkin's disease and giant lymph node hyperplasia of the plasma-cell type (Castleman's disease). *Arch Pathol Lab Med*. 1996;120(1):91-96.
305. Maheswaran PR, Ramsay AD, Norton AJ, Roche WR. Hodgkin's disease presenting with the histological features of Castleman's disease. *Histopathology*. 1991;18(3):249-253.
306. Zarate-Osorno A, Medeiros LJ, Danon AD, Neiman RS. Hodgkin's disease with coexistent Castleman-like histologic features. A report of three cases. *Arch Pathol Lab Med*. 1994;118(3):270-274.
307. Abbondazo SL, Irey NS, Frizzera G. Dilantin-associated lymphadenopathy. Spectrum of histopathologic patterns. *Am J Surg Pathol*. 1995;19(6):675-686.
308. Saltzstein SL, Ackerman LV. Lymphadenopathy induced by anticonvulsant drugs and mimicking clinically pathologically malignant lymphomas. *Cancer*. 1959;12(1):164-182.
309. Gould E, Porto R, Albores-Saavedra J, Ibe MJ. Dermatopathic lymphadenitis. The spectrum and significance of its morphologic features. *Arch Pathol Lab Med*. 1988;112(11):1145-1150.
310. Ree H, Fanger H. Paracortical alteration in lymphadenopathic and tumor-draining lymph nodes: histologic study. *Hum Pathol*. 1975;6(3):363-372.
311. Asano S, Muramatsu T, Kanno H, Wakasa H. Dermatopathic lymphadenopathy. Electronmicroscopic, enzyme-histochemical and immunohistochemical study. *Acta Pathol Jpn*. 1987;37(6):887-900.
312. Rausch E, Kaiserling E, Goos M. Langerhans cells and interdigitating reticulum cells in the thymus-dependent region in human dermatopathic lymphadenitis. *Virchows Arch B Cell Pathol*. 1977;25(4):327-343.
313. Burke JS, Colby TV. Dermatopathic lymphadenopathy. Comparison of cases associated and unassociated with mycosis fungoides. *Am J Surg Pathol*. 1981;5(4):343-352.
314. Scheffer E, Meijer CJ, Van Vloten WA. Dermatopathic lymphadenopathy and lymph node involvement in mycosis fungoides. *Cancer*. 1980;45(1):137-148.
315. Weiss LM, Wood GS, Warnke RA. Immunophenotypic differences between dermatopathic lymphadenopathy and lymph node involvement in mycosis fungoides. *Am J Pathol*. 1985;120(2):179-185.
316. Weiss LM, Hu E, Wood GS, et al. Clonal rearrangements of T-cell receptor genes in mycosis fungoides and dermatopathic lymphadenopathy. *N Engl J Med*. 1985;313(9):539-544.
317. Olsen E, Vonderheid E, Pimpinelli N, et al. Revisions to the staging and classification of mycosis fungoides and Sezary syndrome: a proposal of the International Society for Cutaneous Lymphomas (ISCL) and the cutaneous lymphoma task force of the European Organization of Research and Treatment of Cancer (EORTC). *Blood*. 2007;110(6):1713-1722.
318. Olsen EA, Whittaker S, Kim YH, et al. Clinical end points and response criteria in mycosis fungoides and Sezary syndrome: a consensus statement of the International Society for Cutaneous Lymphomas, the United States Cutaneous Lymphoma Consortium, and the Cutaneous Lymphoma Task Force of the European Organisation for Research and Treatment of Cancer. *J Clin Oncol*. 2011;29(18):2598-2607.
319. Foucar E, Rosai J, Dorfman R. Sinus histiocytosis with massive lymphadenopathy (Rosai-Dorfman disease): review of the entity. *Semin Diagn Pathol*. 1990;7(1):19-73.
320. Rosai J, Dorfman RF. Sinus histiocytosis with massive lymphadenopathy: a pseudolymphomatous benign disorder. Analysis of 34 cases. *Cancer*. 1972;30(5):1174-1188.
321. Marsh WL Jr, McCarrick JP, Harlan DM. Sinus histiocytosis with massive lymphadenopathy. Occurrence in identical twins with retroperitoneal disease. *Arch Pathol Lab Med*. 1988;112(3):298-301.
322. Miettinen M, Paljakka P, Haveri P, Saxen E. Sinus histiocytosis with massive lymphadenopathy. A nodal and extranodal proliferation of S-100 protein positive histiocytes? *Am J Clin Pathol*. 1987;88(3):270-277.
323. Bonetti F, Chilosi M, Menestrina F, et al. Immunohistological analysis of Rosai-Dorfman histiocytosis. A disease of S-100 + CD1-histiocytes. *Virchows Arch A Pathol Anat Histopathol*. 1987;411(2):129-135.
324. Eisen RN, Buckley PJ, Rosai J. Immunophenotypic characterization of sinus histiocytosis with massive lymphadenopathy (Rosai-Dorfman disease). *Semin Diagn Pathol*. 1990;7(1):74-82.
325. Paulli M, Rosso R, Kindl S, et al. Immunophenotypic characterization of the cell infiltrate in five cases of sinus histiocytosis with massive lymphadenopathy (Rosai-Dorfman disease). *Hum Pathol*. 1992;23(6):647-654.
326. Quaglino P, Tomasini C, Novelli M, et al. Immunohistologic findings and adhesion molecule pattern in primary pure cutaneous

For personal use only. No other uses without permission. Copyright ©2017. Elsevier Inc. All rights reserved.

Rosai-Dorfman disease with xanthomatous features. *Am J Dermatopathol*. 1998;20(4):393-398.
327. Zhang X, Hyjek E, Vardiman J. A subset of Rosai-Dorfman disease exhibits features of IgG4-related disease. *Am J Clin Pathol*. 2013;139(5):622-632.
328. Park BH, Son DH, Kim MH, et al. Rosai-Dorfman Disease: report of a Case Associated with IgG4-Related Sclerotic Lesions. *Korean J Pathol*. 2012;46(6):583-586.
329. Liu L, Perry AM, Cao W, et al. Relationship between Rosai-Dorfman disease and IgG4-related disease: study of 32 cases. *Am J Clin Pathol*. 2013;140(3):395-402.
330. Foucar E, Rosai J, Dorfman RF. The ophthalmologic manifestations of sinus histiocytosis with massive lymphadenopathy. *Am J Ophthalmol*. 1979;87(3):354-367.
331. Wenig BM, Abbondanzo SL, Childers EL, et al. Extranodal sinus histiocytosis with massive lymphadenopathy (Rosai-Dorfman disease) of the head and neck. *Hum Pathol*. 1993;24(5):483-492.
332. Foucar E, Rosai J, Dorfman RF. Sinus histiocytosis with massive lymphadenopathy. *Arch Otolaryngol*. 1978;104(12):687-693.
333. Leighton SE, Gallimore AP. Extranodal sinus histiocytosis with massive lymphadenopathy affecting the subglottis and trachea. *Histopathology*. 1994;24(4):393-394.
334. Al-Daraji W, Anandan A, Klassen-Fischer M, et al. Soft tissue Rosai-Dorfman disease: 29 new lesions in 18 patients, with detection of polyomavirus antigen in 3 abdominal cases. *Ann Diagn Pathol*. 2010;14(5):309-316.
335. Brenn T, Calonje E, Granter SR, et al. Cutaneous rosai-dorfman disease is a distinct clinical entity. *Am J Dermatopathol*. 2002;24(5):385-391.
336. Kong YY, Kong JC, Shi DR, et al. Cutaneous rosai-dorfman disease: a clinical and histopathologic study of 25 cases in China. *Am J Surg Pathol*. 2007;31(3):341-350.
337. Lu CI, Kuo TT, Wong WR, Hong HS. Clinical and histopathologic spectrum of cutaneous Rosai-Dorfman disease in Taiwan. *J Am Acad Dermatol*. 2004;51(6):931-939.
338. Montgomery EA, Meis JM, Frizzera G. Rosai-Dorfman disease of soft tissue. *Am J Surg Pathol*. 1992;16(2):122-129.
339. Thawerani H, Sanchez RL, Rosai J, Dorfman RF. The cutaneous manifestations of sinus histiocytosis with massive lymphadenopathy. *Arch Dermatol*. 1978;114(2):191-197.
340. Walker PD, Rosai J, Dorfman RF. The osseous manifestations of sinus histiocytosis with massive lymphadenopathy. *Am J Clin Pathol*. 1981;75(2):131-139.
341. Andriko JA, Morrison A, Colegial CH, et al. Rosai-Dorfman disease isolated to the central nervous system: a report of 11 cases. *Mod Pathol*. 2001;14(3):172-178.
342. Foucar E, Rosai J, Dorfman RF, Brynes RK. The neurologic manifestations of sinus histiocytosis with massive lymphadenopathy. *Neurology*. 1982;32(4):365-372.
343. Song SK, Schwartz IS, Strauchen JA, et al. Meningeal nodules with features of extranodal sinus histiocytosis with massive lymphadenopathy. *Am J Surg Pathol*. 1989;13(5):406-412.
344. Alatassi H, Ray MB, Galandiuk S, Sahoo S. Rosai-Dorfman disease of the gastrointestinal tract: report of a case and review of the literature. *Int J Surg Pathol*. 2006;14(1):95-99.
345. Lauwers GY, Perez-Atayde A, Dorfman RF, Rosai J. The digestive system manifestations of Rosai-Dorfman disease (sinus histiocytosis with massive lymphadenopathy): review of 11 cases. *Hum Pathol*. 2000;31(3):380-385.
346. Osborne BM, Hagemeister FB, Butler JJ. Extranodal gastrointestinal sinus histiocytosis with massive lymphadenopathy. Clinically presenting as a malignant tumor. *Am J Surg Pathol*. 1981;5(6):603-611.
347. Podberezin M, Angeles R, Guzman G, et al. Primary pancreatic sinus histiocytosis with massive lymphadenopathy (Rosai-Dorfman disease): an unusual extranodal manifestation clinically simulating malignancy. *Arch Pathol Lab Med*. 2010;134(2):276-278.
348. Juskevicius R, Finley JL. Rosai-Dorfman disease of the parotid gland: cytologic and histopathologic findings with immunohistochemical correlation. *Arch Pathol Lab Med*. 2001;125(10):1348-1350.
349. Cocker RS, Kang J, Kahn LB. Rosai-Dorfman disease. Report of a case presenting as a midline thyroid mass. *Arch Pathol Lab Med*. 2003;127(4):e197-e200.
350. Hida AI, Yagi S, Obase Y, et al. Rosai-Dorfman disease presenting as a solitary mediastinal mass. *Pathol Int*. 2009;59(4):265-268.
351. Green I, Dorfman RF, Rosai J. Breast involvement by extranodal Rosai-Dorfman disease: report of seven cases. *Am J Surg Pathol*. 1997;21(6):664-668.
352. Morkowski JJ, Nguyen CV, Lin P, et al. Rosai-Dorfman disease confined to the breast. *Ann Diagn Pathol*. 2010;14(2):81-87.
353. Murray J, Fox H. Rosai-Dorfman disease of the uterine cervix. *Int J Gynecol Pathol*. 1991;10(2):209-213.
354. Huang Q, Chang KL, Weiss LM. Extranodal Rosai-Dorfman disease involving the bone marrow: a case report. *Am J Surg Pathol*. 2006;30(9):1189-1192.
355. Wright DH, Richards DB. Sinus histiocytosis with massive lymphadenopathy (Rosai-Dorfman disease): report of a case with widespread nodal and extra nodal dissemination. *Histopathology*. 1981;5(6):697-709.
356. Middel P, Hemmerlein B, Fayyazi A, et al. Sinus histiocytosis with massive lymphadenopathy: evidence for its relationship to macrophages and for a cytokine-related disorder. *Histopathology*. 1999;35(6):525-533.
357. Tsang WY, Yip TT, Chan JK. The Rosai-Dorfman disease histiocytes are not infected by Epstein-Barr virus. *Histopathology*. 1994;25(1):88-90.
358. Levine PH, Jahan N, Murari P, et al. Detection of human herpesvirus 6 in tissues involved by sinus histiocytosis with massive lymphadenopathy (Rosai-Dorfman disease). *J Infect Dis*. 1992;166(2):291-295.
359. Willman CL, Busque L, Griffith BB, et al. Langerhans'-cell histiocytosis (histiocytosis X)—a clonal proliferative disease. *N Engl J Med*. 1994;331(3):154-160.
360. Woda BA, Sullivan JL. Reactive histiocytic disorders. *Am J Clin Pathol*. 1993;99(4):459-463.
361. Wang KH, Cheng CJ, Hu CH, Lee WR. Coexistence of localized Langerhans cell histiocytosis and cutaneous Rosai-Dorfman disease. *Br J Dermatol*. 2002;147(4):770-774.
362. O'Malley DP, Duong A, Barry TS, et al. Co-occurrence of Langerhans cell histiocytosis and Rosai-Dorfman disease: possible relationship of two histiocytic disorders in rare cases. *Mod Pathol*. 2010;23(12):1616-1623.
363. Komp DM. The treatment of sinus histiocytosis with massive lymphadenopathy (Rosai-Dorfman disease). *Semin Diagn Pathol*. 1990;7(1):83-86.
364. Pulsoni A, Anghel G, Falcucci P, et al. Treatment of sinus histiocytosis with massive lymphadenopathy (Rosai-Dorfman disease): report of a case and literature review. *Am J Hematol*. 2002;69(1):67-71.
365. Suarez CR, Zeller WP, Silberman S, et al. Sinus histiocytosis with massive lymphadenopathy: remission with chemotherapy. *Am J Pediatr Hematol Oncol*. 1983;5(3):235-241.
366. Jabali Y, Smrcka V, Pradna J. Rosai-Dorfman disease: successful long-term results by combination chemotherapy with prednisone, 6-mercaptopurine, methotrexate, and vinblastine: a case report. *Int J Surg Pathol*. 2005;13(3):285-289.
367. Foucar E, Rosai J, Dorfman RF. Sinus histiocytosis with massive lymphadenopathy. An analysis of 14 deaths occurring in a patient registry. *Cancer*. 1984;54(9):1834-1840.
368. Foucar E, Rosai J, Dorfman RF, Eyman JM. Immunologic abnormalities and their significance in sinus histiocytosis with massive lymphadenopathy. *Am J Clin Pathol*. 1984;82(5):515-525.
369. Rocken C, Wieker K, Grote HJ, et al. Rosai-Dorfman disease and generalized AA amyloidosis: a case report. *Hum Pathol*. 2000;31(5):621-624.
370. Kasper HU, Hegenbarth V, Buhtz P. Rhinoscleroma associated with Rosai-Dorfman reaction of regional lymph nodes. *Pathol Int*. 2004;54(2):101-104.
371. Falk S, Stutte HJ, Frizzera G. Hodgkin's disease and sinus histiocytosis with massive lymphadenopathy-like changes. *Histopathology*. 1991;19(3):221-224.
372. Lu D, Estalilla OC, Manning JT Jr, Medeiros LJ. Sinus histiocytosis with massive lymphadenopathy and malignant lymphoma involving the same lymph node: a report of four cases and review of the literature. *Mod Pathol*. 2000;13(4):414-419.
373. Kung IT, Gibson JB, Bannatyne PM. Kimura's disease: a clinico-pathological study of 21 cases and its distinction from angiolymphoid hyperplasia with eosinophilia. *Pathology*. 1984;16(1):39-44.
374. Chen H, Thompson LD, Aguilera NS, Abbondanzo SL. Kimura disease: a clinicopathologic study of 21 cases. *Am J Surg Pathol*. 2004;28(4):505-513.
375. Hui PK, Chan JK, Ng CS, et al. Lymphadenopathy of Kimura's disease. *Am J Surg Pathol*. 1989;13(3):177-186.
376. McKelvie PA, Lyons B, Barnett G, Allen PW. Kimura's disease in two Caucasians, one with multiple recurrences associated with prominent IgG4 production. *Pathology*. 2012;44(3):275-278.
377. Chan JK, Hui PK, Ng CS, et al. Epithelioid haemangioma (angiolymphoid hyperplasia with eosinophilia) and Kimura's disease in Chinese. *Histopathology*. 1989;15(6):557-574.
378. Googe PB, Harris NL, Mihm MC Jr. Kimura's disease and angiolymphoid hyperplasia with eosinophilia: two distinct histopathological entities. *J Cutan Pathol*. 1987;14(5):263-271.
379. Kuo TT, Shih LY, Chan HL. Kimura's disease. Involvement of regional lymph nodes and distinction from angiolymphoid hyperplasia with eosinophilia. *Am J Surg Pathol*. 1988;12(11):843-854.
380. Urabe A, Tsuneyoshi M, Enjoji M. Epithelioid hemangioma versus Kimura's disease. A comparative clinicopathologic study. *Am J Surg Pathol*. 1987;11(10):758-766.
381. Lakshman R, Finn A. Neutrophil disorders and their management. *J Clin Pathol*. 2001;54(1):7-19.
382. Segal BH, Leto TL, Gallin JI, et al. Genetic, biochemical, and clinical features of chronic granulomatous disease. *Medicine (Baltimore)*. 2000;79(3):170-200.
383. Holland SM. Chronic granulomatous disease. *Hematol Oncol Clin North Am*. 2013;27(1):89-99, viii.

For personal use only. No other uses without permission. Copyright ©2017. Elsevier Inc. All rights reserved.

384. Curnutte JT. Chronic granulomatous disease: the solving of a clinical riddle at the molecular level. *Clin Immunol Immunopathol*. 1993;67(3 Pt 2):S2-S15.
385. Roos D. The genetic basis of chronic granulomatous disease. *Immunol Rev*. 1994;138:121-157.
386. Umeki S. Mechanisms for the activation/electron transfer of neutrophil NADPH-oxidase complex and molecular pathology of chronic granulomatous disease. *Ann Hematol*. 1994;68(6):267-277.
387. Baehner RL, Nathan DG. Quantitative nitroblue tetrazolium test in chronic granulomatous disease. *N Engl J Med*. 1968;278(18):971-976.
388. Johnston RB Jr. Clinical aspects of chronic granulomatous disease. *Curr Opin Hematol*. 2001;8(1):17-22.
389. Lekstrom-Himes JA, Gallin JI. Immunodeficiency diseases caused by defects in phagocytes. *N Engl J Med*. 2000;343(23):1703-1714.
390. Segal BH, Holland SM. Primary phagocytic disorders of childhood. *Pediatr Clin North Am*. 2000;47(6):1311-1338.
391. Levine S, Smith VV, Malone M, Sebire NJ. Histopathological features of chronic granulomatous disease (CGD) in childhood. *Histopathology*. 2005;47(5):508-516.
392. Kelsall GR, Blackwell JB. The occurrence and significance of lipophage clusters in lymph nodes and spleen. *Pathology*. 1969;1(3):211-220.
393. Boitnott JK, Margolis S. Mineral oil in human tissues. II. Oil droplets in lymph nodes of the porta hepatis. *Bull Johns Hopkins Hosp*. 1966;118:414-422.
394. Perez-Jaffe LA, Furth EE, Minda JM, et al. Massive macrophage lipid accumulation presenting as hepatosplenomegaly and lymphadenopathy associated with long-term total parenteral nutrition therapy for short bowel syndrome. *Hum Pathol*. 1998;29(6):651-655.
395. Walters S, Valliani T, Przemioslo R, Rooney N. Whipple's disease: an unexpected finding in a peripheral lymph node biopsy. *Lancet*. 2014;383(9936):2268.
396. Fisher ER. Whipple's disease: pathogenetic considerations. Electron microscopic and histochemical observations. *JAMA*. 1962;181:396-403.
397. Alkan S, Beals TF, Schnitzer B. Primary diagnosis of whipple disease manifesting as lymphadenopathy: use of polymerase chain reaction for detection of *Tropheryma whippelii*. *Am J Clin Pathol*. 2001;116(6):898-904.
398. Baisden BL, Lepidi H, Raoult D, et al. Diagnosis of Wihipple disease by immunohistochemical analysis: a sensitive and specific method for the detection of *Tropheryma whipplei* (the Whipple bacillus) in paraffin-embedded tissue. *Am J Clin Pathol*. 2002;118(5):742-748.
399. Gunther U, Moos V, Offenmuller G, et al. Gastrointestinal diagnosis of classical Whipple disease: clinical, endoscopic, and histopathologic features in 191 patients. *Medicine (Baltimore)*. 2015;94(15):e714.
400. Ravel R. Histopathology of lymph nodes after lymphangiography. *Am J Clin Pathol*. 1966;46(3):335-340.
401. Feldman AL, Arber DA, Pittaluga S, et al. Clonally related follicular lymphomas and histiocytic/dendritic cell sarcomas: evidence for transdifferentiation of the follicular lymphoma clone. *Blood*. 2008;111(12):5433-5439.
402. Jaffe ES. *Surgical Pathology of the Lymph Nodes and Related Organs*. 2nd ed. Philadelphia, PA: WB Saunders; 1995.
403. Knowles DM. Molecular pathology of acquired immunodeficiency syndrome-related non-Hodgkin's lymphoma. *Semin Diagn Pathol*. 1997;14(1):67-82.
404. Lennert K, Feller AC. *Histopathology of Non-Hodgkin's Lymphomas*. 2nd ed. New York, NY: Springer-Verlag; 1992.
405. Swerdlow SH, Campo E, Harris NL, et al. *WHO Classification of Tumours of Haematopoietic and Lymphoid Tissues*. 4th ed. Lyon: IARC Press; 2008.
406. Warnke RA, Weiss LM, Chan JKC, et al. *Tumors of the Lymph Nodes and Spleen. Atlas of Tumor Pathology*. Washington, DC: Armed Forces Institute of Pathology; 1995.
407. Swerdlow SH, Campo E, Pileri SA, et al. The 2016 revision of the World Health Organization classification of lymphoid neoplasms. *Blood*. 2016;127(20):2375-2390.
408. Rappaport H. *Tumors of the Hematopoietic System. Atlas of Tumor Pathology*. series 3, fascicle 8. Washington, DC: Armed Forces Institute of Pathology; 1966:91-206.
409. Lennert K. Classification of non-Hodgkin's lymphomas. In: Lennert K, Mohri N, Stein H, et al, eds. *Malignant Lymphomas Other Than Hodgkin's Disease. Histology, Cytology, Ultrastructure, Immunology*. pt 3. Berlin: Springer-Verlag; 1978:83-110.
410. National Cancer Institute sponsored study of classifications of non-Hodgkin's lymphomas: summary and description of a working formulation for clinical usage. The Non-Hodgkin's Lymphoma Pathologic Classification Project. *Cancer*. 1982;49(10):2112-2135.
411. Bonadonna G. Historical review of Hodgkin's disease. *Br J Haematol*. 2000;110(3):504-511.
412. Kaplan HS. *Hodgkin's Disease*. 2nd ed. London: Harvard University Press; 1980:689.
413. Kass AM, Kass EH. *Perfecting the World: The Life and Times of Dr Thomas Hodgkin 1798–1866*. Boston, MA: Harcourt Brace Jovanovich; 1988.
414. Taylor CR, Riley CR. Molecular morphology of Hodgkin lymphoma. *Appl Immunohistochem Mol Morphol*. 2001;9(3):187-202.
415. Dawson PJ. The original illustrations of Hodgkin's disease. *Ann Diagn Pathol*. 1999;3(6):386-393.
416. Poston RN. Positive Leu-M1 immunohistochemistry and diagnosis of the lymphoma cases described by Hodgkin in 1832. *Appl Immunohistochem Mol Morphol*. 1999;7:6-8.
417. Kuppers R, Rajewsky K, Zhao M, et al. Hodgkin disease: Hodgkin and Reed-Sternberg cells picked from histological sections show clonal immunoglobulin gene rearrangements and appear to be derived from B cells at various stages of development. *Proc Natl Acad Sci USA*. 1994;91(23):10962-10966.
418. Braeuninger A, Kuppers R, Strickler JG, et al. Hodgkin and Reed-Sternberg cells in lymphocyte predominant Hodgkin disease represent clonal populations of germinal center-derived tumor B cells. *Proc Natl Acad Sci USA*. 1997;94(17):9337-9342.
419. Delabie J, Tierens A, Wu G, et al. Lymphocyte predominance Hodgkin's disease: lineage and clonality determination using a single-cell assay. *Blood*. 1994;84(10):3291-3298.
420. Delabie J, Tierens A, Gavriil T, et al. Phenotype, genotype and clonality of Reed-Sternberg cells in nodular sclerosis Hodgkin's disease: results of a single-cell study. *Br J Haematol*. 1996;94(1): 198-205.
421. Chang KL, Chen YY, Shibata D, Weiss LM. Description of an in situ hybridization methodology for detection of Epstein-Barr virus RNA in paraffin-embedded tissues, with a survey of normal and neoplastic tissues. *Diagn Mol Pathol*. 1992;1(4):246-255.
422. Gutensohn N, Cole P. Childhood social environment and Hodgkin's disease. *N Engl J Med*. 1981;304(3):135-140.
423. Hjalgrim H, Askling J, Rostgaard K, et al. Characteristics of Hodgkin's lymphoma after infectious mononucleosis. *N Engl J Med*. 2003;349(14):1324-1332.
424. Mueller N, Evans A, Harris NL, et al. Hodgkin's disease and Epstein-Barr virus. Altered antibody pattern before diagnosis. *N Engl J Med*. 1989;320(11):689-695.
425. Reynolds DJ, Banks PM, Gulley ML. New characterization of infectious mononucleosis and a phenotypic comparison with Hodgkin's disease. *Am J Pathol*. 1995;146(2):379-388.
426. Chang KL, Albujar PF, Chen YY, et al. High prevalence of Epstein-Barr virus in the Reed-Sternberg cells of Hodgkin's disease occurring in Peru. *Blood*. 1993;81(2):496-501.
427. Jarrett RF, Gallagher A, Jones DB, et al. Detection of Epstein-Barr virus genomes in Hodgkin's disease: relation to age. *J Clin Pathol*. 1991;44(10):844-848.
428. Pallesen G, Hamilton-Dutoit SJ, Rowe M, Young LS. Expression of Epstein-Barr virus latent gene products in tumour cells of Hodgkin's disease. *Lancet*. 1991;337(8737):320-322.
429. Weiss LM, Chang KL. Molecular biologic studies of Hodgkin's disease. *Semin Diagn Pathol*. 1992;9(4):272-278.
430. Weiss LM, Chen YY, Liu XF, Shibata D. Epstein-Barr virus and Hodgkin's disease. A correlative in situ hybridization and polymerase chain reaction study. *Am J Pathol*. 1991;139(6):1259-1265.
431. Mack TM, Cozen W, Shibata DK, et al. Concordance for Hodgkin's disease in identical twins suggesting genetic susceptibility to the young-adult form of the disease. *N Engl J Med*. 1995;332(7):413-418.
432. Strum SB, Park JK, Rappaport H. Observation of cells resembling Sternberg-Reed cells in conditions other than Hodgkin's disease. *Cancer*. 1970;26(1):176-190.
433. Agnarsson BA, Kadin ME. The immunophenotype of Reed-Sternberg cells. A study of 50 cases of Hodgkin's disease using fixed frozen tissues. *Cancer*. 1989;63(11):2083-2087.
434. Carbone A, Gloghini A, Gruss HJ, Pinto A. CD40 antigen expression on Reed-Sternberg cells. A reliable diagnostic tool for Hodgkin's disease. *Am J Pathol*. 1995;146(3):780-781.
435. Casey TT, Olson SJ, Cousar JB, Collins RD. Immunophenotypes of Reed-Sternberg cells: a study of 19 cases of Hodgkin's disease in plastic-embedded sections. *Blood*. 1989;74(8):2624-2628.
436. Chang KL, Curtis CM, Momose H, et al. Sensitivity and specificity of *Bauhinia purpurea* as a paraffin section marker for the Reed–Sternberg cells of Hodgkin's disease. *Appl Immunohistochem Mol Morphol*. 1993;1:208-212.
437. Chittal SM, Caveriviere P, Schwarting R, et al. Monoclonal antibodies in the diagnosis of Hodgkin's disease. The search for a rational panel. *Am J Surg Pathol*. 1988;12(1):9-21.
438. Delabie J, Shipman R, Bruggen J, et al. Expression of the novel intermediate filament-associated protein restin in Hodgkin's disease and anaplastic large-cell lymphoma. *Blood*. 1992;80(11):2891-2896.
439. Foss HD, Hummel M, Gottstein S, et al. Frequent expression of IL-7 gene transcripts in tumor cells of classical Hodgkin's disease. *Am J Pathol*. 1995;146(1):33-39.
440. Hsu SM, Yang K, Jaffe ES. Phenotypic expression of Hodgkin's and Reed-Sternberg

For personal use only. No other uses without permission. Copyright ©2017. Elsevier Inc. All rights reserved.

cells in Hodgkin's disease. *Am J Pathol*. 1985;118(2):209-217.
441. Hyder DM, Schnitzer B. Utility of Leu M1 monoclonal antibody in the differential diagnosis of Hodgkin's disease. *Arch Pathol Lab Med*. 1986;110(5):416-419.
442. Kadin ME, Muramoto L, Said J. Expression of T-cell antigens on Reed-Sternberg cells in a subset of patients with nodular sclerosing and mixed cellularity Hodgkin's disease. *Am J Pathol*. 1988;130(2):345-353.
443. O'Grady JT, Stewart S, Lowrey J, et al. CD40 expression in Hodgkin's disease. *Am J Pathol*. 1994;144(1):21-26.
444. Sarker AB, Akagi T, Jeon HJ, et al. *Bauhinia purpurea*—a new paraffin section marker for Reed-Sternberg cells of Hodgkin's disease. A comparison with Leu-M1 (CD15), LN2 (CD74), peanut agglutinin, and Ber-H2 (CD30). *Am J Pathol*. 1992;141(1):19-23.
445. Schmid C, Pan L, Diss T, Isaacson PG. Expression of B-cell antigens by Hodgkin's and Reed-Sternberg cells. *Am J Pathol*. 1991;139(4):701-707.
446. Zukerberg LR, Collins AB, Ferry JA, Harris NL. Coexpression of CD15 and CD20 by Reed-Sternberg cells in Hodgkin's disease. *Am J Pathol*. 1991;139(3):475-483.
447. Venkataraman G, Song JY, Tzankov A, et al. Aberrant T-cell antigen expression in classical Hodgkin lymphoma is associated with decreased event-free survival and overall survival. *Blood*. 2013;121(10):1795-1804.
448. Dallenbach FE, Stein H. Expression of T-cell-receptor beta chain in Reed-Sternberg cells. *Lancet*. 1989;2(8667):828-830.
449. Griesser H, Feller AC, Mak TW, Lennert K. Clonal rearrangements of T-cell receptor and immunoglobulin genes and immunophenotypic antigen expression in different subclasses of Hodgkin's disease. *Int J Cancer*. 1987;40(2):157-160.
450. Knowles DM 2nd, Neri A, Pelicci PG, et al. Immunoglobulin and T-cell receptor beta-chain gene rearrangement analysis of Hodgkin's disease: implications for lineage determination and differential diagnosis. *Proc Natl Acad Sci USA*. 1986;83(20):7942-7946.
451. Manzanal AI, Santon A, Acevedo A, et al. Molecular analysis of the IgH gene in 212 cases of Hodgkin's disease: correlation of IgH clonality with the histologic and the immunocytochemical features. *Mod Pathol*. 1997;10(7):679-685.
452. Weiss LM, Strickler JG, Hu E, et al. Immunoglobulin gene rearrangements in Hodgkin's disease. *Hum Pathol*. 1986;17(10):1009-1014.
453. Akazaki K, Wakasa H. Frequency of lymphoreticular tumors and leukemias in Japan. *J Natl Cancer Inst*. 1974;52(2):339-343.
454. Correa P, O'Conor GT. Epidemiologic patterns of Hodgkin's disease. *Int J Cancer*. 1971;8(2):192-201.
455. Grufferman S, Delzell E. Epidemiology of Hodgkin's disease. *Epidemiol Rev*. 1984;6:76-106.
456. Cross RM. A clinicopathological study of nodular sclerosing Hodgkin's disease. *J Clin Pathol*. 1968;21(3):303-310.
457. Neiman RS, Rosen PJ, Lukes RJ. Lymphocyte-depletion Hodgkin's disease. A clinicopathological entity. *N Engl J Med*. 1973;288(15):751-755.
458. Greer JP, Kinney MC, Cousar JB, et al. Lymphocyte-depleted Hodgkin's disease. Clinicopathologic review of 25 patients. *Am J Med*. 1986;81(2):208-214.
459. Poppema S, Lennert K. Hodgkin's disease in childhood: histopathologic classification in relation to age and sex. *Cancer*. 1980;45(6):1443-1447.
460. White L, McCourt BA, Isaacs H, et al. Patterns of Hodgkin's disease at diagnosis in young children. *Am J Pediatr Hematol Oncol*. 1983;5(3):251-257.
461. Bodis S, Kraus MD, Pinkus G, et al. Clinical presentation and outcome in lymphocyte-predominant Hodgkin's disease. *J Clin Oncol*. 1997;15(9):3060-3066.
462. Trotter MC, Cloud GA, Davis M, et al. Predicting the risk of abdominal disease in Hodgkin's lymphoma. A multifactorial analysis of staging laparotomy results in 255 patients. *Ann Surg*. 1985;201(4):465-469.
463. Levy R, Kaplan HS. Impaired lymphocyte function in untreated Hodgkin's disease. *N Engl J Med*. 1974;290(4):181-186.
464. Bellas C, Santon A, Manzanal A, et al. Pathological, immunological, and molecular features of Hodgkin's disease associated with HIV infection. Comparison with ordinary hodgkin's disease. *Am J Surg Pathol*. 1996;20(12):1520-1524.
465. Unger PD, Strauchen JA. Hodgkin's disease in AIDS complex patients. Report of four cases and tissue immunologic marker studies. *Cancer*. 1986;58(4):821-825.
466. Thompson LD, Fisher SI, Chu WS, et al. HIV-associated Hodgkin lymphoma: a clinicopathologic and immunophenotypic study of 45 cases. *Am J Clin Pathol*. 2004;121(5):727-738.
467. Glatstein E, Trueblood HW, Enright LP, et al. Surgical staging of abdominal involvement in unselected patients with Hodgkin's disease. *Radiology*. 1970;97(2):425-432.
468. Kadin ME, Glatstein E, Dorfman RF. Clinicopathologic studies of 117 untreated patients subjected to laparotomy for the staging of Hodgkin's disease. *Cancer*. 1971;27(6):1277-1294.
469. Keller AR, Kaplan HS, Lukes RJ, Rappaport H. Correlation of histopathology with other prognostic indicators in Hodgkin's disease. *Cancer*. 1968;22(3):487-499.
470. Kaplan HS. Contiguity and progression in Hodgkin's disease. *Cancer Res*. 1971;31(11):1811-1813.
471. Aisenberg AC. Malignant lymphoma. 1. *N Engl J Med*. 1973;288(17):883-890, 935–941.
472. Leslie KO, Colby TV. Hepatic parenchymal lymphoid aggregates in Hodgkin's disease. *Hum Pathol*. 1984;15(9):808-809.
473. Jackson H, Parker F. Hodgkin's disease. 1. General considerations. *N Engl J Med*. 1944;230:1-8.
474. Lukes RJ, Butler JJ, Hicks EB. Natural history of Hodgkin's disease as related to its pathologic picture. *Cancer*. 1966;19:317-344.
475. Lukes RJ, Craver LF, Hall TC, et al. Report of Nomenclature Committee. *Cancer Res*. 1966;16:1311.
476. Strickler JG, Michie SA, Warnke RA, Dorfman RF. The "syncytial variant" of nodular sclerosing Hodgkin's disease. *Am J Surg Pathol*. 1986;10(7):470-477.
477. MacLennan KA, Bennett MH, Tu A, et al. Relationship of histopathologic features to survival and relapse in nodular sclerosing Hodgkin's disease. A study of 1659 patients. *Cancer*. 1989;64(8):1686-1693.
478. van Spronsen DJ, Vrints LW, Hofstra G, et al. Disappearance of prognostic significance of histopathological grading of nodular sclerosing Hodgkin's disease for unselected patients, 1972–1992. *Br J Haematol*. 1997;96(2):322-327.
479. Seemayer TA, Lagace R, Schurch W. On the pathogenesis of sclerosis and nodularity in nodular sclerosing Hodgkin's disease. *Virchows Arch A Pathol Anat Histol*. 1980;385(3):283-291.
480. Nam-Cha SH, Montes-Moreno S, Salcedo MT, et al. Lymphocyte-rich classical Hodgkin's lymphoma: distinctive tumor and microenvironment markers. *Mod Pathol*. 2009;22(8):1006-1015.
481. Benharroch D, Levy A, Gopas J, Sacks M. Lymphocyte-depleted classic Hodgkin lymphoma-a neglected entity? *Virchows Arch*. 2008;453(6):611-616.
482. Strum SB, Rappaport H. Interrelations of the histologic types of Hodgkin's disease. *Arch Pathol*. 1971;91(2):127-134.
483. Colby TV, Warnke RA. The histology of the initial relapse of Hodgkin's disease. *Cancer*. 1980;45(2):289-292.
484. Vasef MA, Alsabeh R, Medeiros LJ, Weiss LM. Immunophenotype of Reed-Sternberg and Hodgkin's cells in sequential biopsy specimens of Hodgkin's disease: a paraffin-section immunohistochemical study using the heat-induced epitope retrieval method. *Am J Clin Pathol*. 1997;108(1):54-59.
485. Variakojis D, Strum SB, Rappaport H. The foamy macrophages in Hodgkin's disease. *Arch Pathol*. 1972;93(5):453-456.
486. Alavaikko MJ, Hansmann ML, Nebendahl C, et al. Follicular dendritic cells in Hodgkin's disease. *Am J Clin Pathol*. 1991;95(2):194-200.
487. Crocker J, Smith PJ. A quantitative study of mast cells in Hodgkin's disease. *J Clin Pathol*. 1984;37(5):519-522.
488. Mohrmann RL, Nathwani BN, Brynes RK, Sheibani K. Hodgkin's disease occurring in monocytoid B-cell clusters. *Am J Clin Pathol*. 1991;95(6):802-808.
489. Strum SB, Rappaport H. Significance of focal involvement of lymph nodes for the diagnosis and staging of Hodgkin's disease. *Cancer*. 1970;25(6):1314-1319.
490. Doggett RS, Colby TV, Dorfman RF. Interfollicular Hodgkin's disease. *Am J Surg Pathol*. 1983;7(2):145-149.
491. Kansal R, Singleton TP, Ross CW, et al. Follicular hodgkin lymphoma: a histopathologic study. *Am J Clin Pathol*. 2002;117(1):29-35.
492. Colby TV, Hoppe RT, Warnke RA. Hodgkin's disease: a clinicopathologic study of 659 cases. *Cancer*. 1982;49(9):1848-1858.
493. Pak HY, Friedman NB. Pseudosarcoid granulomas in Hodgkin's disease. *Hum Pathol*. 1981;12(9):832-837.
494. Sacks EL, Donaldson SS, Gordon J, Dorfman RF. Epithelioid granulomas associated with Hodgkin's disease: clinical correlations in 55 previously untreated patients. *Cancer*. 1978;41(2):562-567.
495. Strum SB, Hutchison GB, Park JK, Rappaport H. Further observations on the biologic significance of vascular invasion in Hodgkin's disease. *Cancer*. 1971;27(1):1-6.
496. Rappaport H, Strum SB, Hutchison G, Allen LW. Clinical and biological significance of vascular invasion in Hodgkin's disease. *Cancer Res*. 1971;31(11):1794-1798.
497. Chute DJ, Cousar JB, Mahadevan MS, et al. Detection of immunoglobulin heavy chain gene rearrangements in classic hodgkin lymphoma using commercially available BIOMED-2 primers. *Diagn Mol Pathol*. 2008;17(2):65-72.
498. Marafioti T, Hummel M, Foss HD, et al. Hodgkin and reed-sternberg cells represent an expansion of a single clone originating from a germinal center B-cell with functional immunoglobulin gene rearrangements but defective immunoglobulin transcription. *Blood*. 2000;95(4):1443-1450.
499. Seitz V, Hummel M, Marafioti T, et al. Detection of clonal T-cell receptor gamma-chain gene rearrangements in Reed-Sternberg cells of classic Hodgkin disease. *Blood*. 2000;95(10):3020-3024.
500. Kanzler H, Kuppers R, Hansmann ML, Rajewsky K. Hodgkin and Reed-Sternberg

For personal use only. No other uses without permission. Copyright ©2017. Elsevier Inc. All rights reserved.

cells in Hodgkin's disease represent the outgrowth of a dominant tumor clone derived from (crippled) germinal center B cells. *J Exp Med*. 1996;184(4):1495-1505.
501. Bechtel D, Kurth J, Unreel C, Kipper's R. Transformation of BCR-deficient germinal-center B cells by EBV supports a major role of the virus in the pathogenesis of Hodgkin and posttransplantation lymphomas. *Blood*. 2005;106(13):4345-4350.
502. Kuppers R, Hansmann ML, Rajewsky K. Clonality and germinal centre B-cell derivation of Hodgkin/Reed-Sternberg cells in Hodgkin's disease. *Ann Oncol*. 1998;9(suppl 5):S17-S20.
503. Kuppers R, Hansmann ML. The Hodgkin and Reed/Sternberg cell. *Int J Biochem Cell Biol*. 2005;37(3):511-517.
504. Ladanyi M, Parsa NZ, Offit K, et al. Clonal cytogenetic abnormalities in Hodgkin's disease. *Genes Chromosomes Cancer*. 1991;3(4):294-299.
505. Schlegelberger B, Weber-Matthiesen K, Himmler A, et al. Cytogenetic findings and results of combined immunophenotyping and karyotyping in Hodgkin's disease. *Leukemia*. 1994;8(1):72-80.
506. Martin-Subero JI, Klapper W, Sotnikova A, et al. Chromosomal breakpoints affecting immunoglobulin loci are recurrent in Hodgkin and Reed-Sternberg cells of classical Hodgkin lymphoma. *Cancer Res*. 2006;66(21):10332-10338.
507. Szymanowska N, Klapper W, Gesk S, et al. BCL2 and BCL3 are recurrent translocation partners of the IGH locus. *Cancer Genet Cytogenet*. 2008;186(2):110-114.
508. Steidl C, Shah SP, Woolcock BW, et al. MHC class II transactivator CIITA is a recurrent gene fusion partner in lymphoid cancers. *Nature*. 2011;471(7338):377-381.
509. Schmitz R, Hansmann ML, Bohle V, et al. TNFAIP3 (A20) is a tumor suppressor gene in Hodgkin lymphoma and primary mediastinal B cell lymphoma. *J Exp Med*. 2009;206(5):981-989.
510. Emmerich F, Theurich S, Hummel M, et al. Inactivating I kappa B epsilon mutations in Hodgkin/Reed-Sternberg cells. *J Pathol*. 2003;201(3):413-420.
511. Glaser SL, Lin RJ, Stewart SL, et al. Epstein-Barr virus-associated Hodgkin's disease: epidemiologic characteristics in international data. *Int J Cancer*. 1997;70(4):375-382.
512. Carbone A, Gloghini A, Serraino D, Spina M. HIV-associated Hodgkin lymphoma. *Curr Opin HIV AIDS*. 2009;4(1):3-10.
513. Glaser SL, Clarke CA, Gulley ML, et al. Population-based patterns of human immunodeficiency virus-related Hodgkin lymphoma in the Greater San Francisco Bay Area, 1988–1998. *Cancer*. 2003;98(2):300-309.
514. Leoncini L, Spina D, Nyong'o A, et al. Neoplastic cells of Hodgkin's disease show differences in EBV expression between Kenya and Italy. *Int J Cancer*. 1996;65(6):781-784.
515. Weinreb M, Day PJ, Niggli F, et al. The role of Epstein-Barr virus in Hodgkin's disease from different geographical areas. *Arch Dis Child*. 1996;74(1):27-31.
516. Regula DP Jr, Weiss LM, Warnke RA, Dorfman RF. Lymphocyte predominance Hodgkin's disease: a reappraisal based upon histological and immunophenotypical findings in relapsing cases. *Histopathology*. 1987;11(11):1107-1120.
517. Trudel MA, Krikorian JG, Neiman RS. Lymphocyte predominance Hodgkin's disease. A clinicopathologic reassessment. *Cancer*. 1987;59(1):99-106.
518. Moller P, Lennert K. On the angiostructure of lymph nodes in Hodgkin's disease. An immunohistochemical study using the lectin I of Ulex europaeus as endothelial marker. *Virchows Arch A Pathol Anat Histopathol*. 1984;403(3):257-270.
519. Soderstrom N, Norberg B. Observations regarding the specific post-capillary venules of lymph nodes in malignant lymphomas. *Acta Pathol Microbiol Scand A*. 1974;82(1):71-79.
520. Regula DP Jr, Hoppe RT, Weiss LM. Nodular and diffuse types of lymphocyte predominance Hodgkin's disease. *N Engl J Med*. 1988;318(4):214-219.
521. Fan Z, Natkunam Y, Bair E, et al. Characterization of variant patterns of nodular lymphocyte predominant hodgkin lymphoma with immunohistologic and clinical correlation. *Am J Surg Pathol*. 2003;27(10):1346-1356.
522. Poppema S, Kaiserling E, Lennert K. Epidemiology of nodular paragranuloma (Hodgkin's disease with lymphocytic predominance, nodular). *J Cancer Res Clin Oncol*. 1979;95(1):57-63.
523. Poppema S. Lymphocyte-predominance Hodgkin's disease. *Semin Diagn Pathol*. 1992;9(4):257-264.
524. Chittal SM, Alard C, Rossi JF, et al. Further phenotypic evidence that nodular, lymphocyte-predominant Hodgkin's disease is a large B-cell lymphoma in evolution. *Am J Surg Pathol*. 1990;14(11):1024-1035.
525. Coles FB, Cartun RW, Pastuszak WT. Hodgkin's disease, lymphocyte-predominant type: immunoreactivity with B-cell antibodies. *Mod Pathol*. 1988;1(4):274-278.
526. von Wasielewski R, Werner M, Fischer R, et al. Lymphocyte-predominant Hodgkin's disease. An immunohistochemical analysis of 208 reviewed Hodgkin's disease cases from the German Hodgkin Study Group. *Am J Pathol*. 1997;150(3):793-803.
527. Pinkus GS, Said JW. Hodgkin's disease, lymphocyte predominance type, nodular—a distinct entity? Unique staining profile for L&H variants of Reed-Sternberg cells defined by monoclonal antibodies to leukocyte common antigen, granulocyte-specific antigen, and B-cell-specific antigen. *Am J Pathol*. 1985;118(1):1-6.
528. McCune RC, Syrbu SI, Vasef MA. Expression profiling of transcription factors Pax-5, Oct-1, Oct-2, BOB.1, and PU.1 in Hodgkin's and non-Hodgkin's lymphomas: a comparative study using high throughput tissue microarrays. *Mod Pathol*. 2006;19(7):1010-1018.
529. Poppema S. The nature of the lymphocytes surrounding Reed-Sternberg cells in nodular lymphocyte predominance and in other types of Hodgkin's disease. *Am J Pathol*. 1989;135(2):351-357.
530. Nam-Cha SH, Roncador G, Sanchez-Verde L, et al. PD-1, a follicular T-cell marker useful for recognizing nodular lymphocyte-predominant Hodgkin lymphoma. *Am J Surg Pathol*. 2008;32(8):1252-1257.
531. Gelb AB, Dorfman RF, Warnke RA. Coexistence of nodular lymphocyte predominance Hodgkin's disease and Hodgkin's disease of the usual type. *Am J Surg Pathol*. 1993;17(4):364-374.
532. Mason DY, Banks PM, Chan J, et al. Nodular lymphocyte predominance Hodgkin's disease. A distinct clinicopathological entity. *Am J Surg Pathol*. 1994;18(5):526-530.
533. Ohno T, Huang JZ, Wu G, et al. The tumor cells in nodular lymphocyte-predominant Hodgkin disease are clonally related to the large cell lymphoma occurring in the same individual. Direct demonstration by single cell analysis. *Am J Clin Pathol*. 2001;116(4):506-511.
534. Brune V, Tiacci E, Pfeil I, et al. Origin and pathogenesis of nodular lymphocyte-predominant Hodgkin lymphoma as revealed by global gene expression analysis. *J Exp Med*. 2008;205(10):2251-2268.
535. Marafioti T, Hummel M, Anagnostopoulos I, et al. Origin of nodular lymphocyte-predominant Hodgkin's disease from a clonal expansion of highly mutated germinal-center B cells. *N Engl J Med*. 1997;337(7):453-458.
536. Schmid C, Sargent C, Isaacson PG. L and H cells of nodular lymphocyte predominant Hodgkin's disease show immunoglobulin light-chain restriction. *Am J Pathol*. 1991;139(6):1281-1289.
537. Renne C, Martin-Subero JI, Hansmann ML, Siebert R. Molecular cytogenetic analyses of immunoglobulin loci in nodular lymphocyte predominant Hodgkin's lymphoma reveal a recurrent IGH-BCL6 juxtaposition. *J Mol Diagn*. 2005;7(3):352-356.
538. Stamatoullas A, Picquenot JM, Dumesnil C, et al. Conventional cytogenetics of nodular lymphocyte-predominant Hodgkin's lymphoma. *Leukemia*. 2007;21(9):2064-2067.
539. Wlodarska I, Nooyen P, Maes B, et al. Frequent occurrence of BCL6 rearrangements in nodular lymphocyte predominance Hodgkin lymphoma but not in classical Hodgkin lymphoma. *Blood*. 2003;101(2):706-710.
540. Hartmann S, Doring C, Vucic E, et al. Array comparative genomic hybridization reveals similarities between nodular lymphocyte predominant Hodgkin lymphoma and T cell/histiocyte rich large B cell lymphoma. *Br J Haematol*. 2015;169(3):415-422.
541. Wang S, Medeiros LJ, Xu-Monette ZY, et al. Epstein-Barr virus-positive nodular lymphocyte predominant Hodgkin lymphoma. *Ann Diagn Pathol*. 2014;18(4):203-209.
542. Huppmann AR, Nicolae A, Slack GW, et al. EBV may be expressed in the LP cells of nodular lymphocyte-predominant Hodgkin lymphoma (NLPHL) in both children and adults. *Am J Surg Pathol*. 2014;38(3):316-324.
543. Picozzi VJ Jr, Coleman CN. Lymphoblastic lymphoma. *Semin Oncol*. 1990;17(1):96-103.
544. Rosen PJ, Feinstein DI, Pattengale PK, et al. Convoluted lymphocytic lymphoma in adults: a clinicopathologic entity. *Ann Intern Med*. 1978;89(3):319-324.
545. Pui CH, Relling MV, Downing JR. Acute lymphoblastic leukemia. *N Engl J Med*. 2004;350(15):1535-1548.
546. Nathwani BN, Kim H, Rappaport H. Malignant lymphoma, lymphoblastic. *Cancer*. 1976;38(2):964-983.
547. Patel JL, Smith LM, Anderson J, et al. The immunophenotype of T-lymphoblastic lymphoma in children and adolescents: a Children's Oncology Group report. *Br J Haematol*. 2012;159(4):454-461.
548. Asnafi V, Buzyn A, Le Noir S, et al. NOTCH1/FBXW7 mutation identifies a large subgroup with favorable outcome in adult T-cell acute lymphoblastic leukemia (T-ALL): a Group for Research on Adult Acute Lymphoblastic Leukemia (GRAALL) study. *Blood*. 2009;113(17):3918-3924.
549. Reiter A, Sohal J, Kulkarni S, et al. Consistent fusion of ZNF198 to the fibroblast growth factor receptor-1 in the t(8;13)(p11;q12) myeloproliferative syndrome. *Blood*. 1998;92(5):1735-1742.
550. Feng H, Stachura DL, White RM, et al. T-lymphoblastic lymphoma cells express high levels of BCL2, S1P1, and ICAM1, leading to a blockade of tumor cell intravasation. *Cancer Cell*. 2010;18(4):353-366.

For personal use only. No other uses without permission. Copyright ©2017. Elsevier Inc. All rights reserved.

551. Sheibani K, Nathwani BN, Winberg CD, et al. Antigenically defined subgroups of lymphoblastic lymphoma. Relationship to clinical presentation and biologic behavior. *Cancer*. 1987;60(2):183-190.
552. Lin P, Jones D, Dorfman DM, Medeiros LJ. Precursor B-cell lymphoblastic lymphoma: a predominantly extranodal tumor with low propensity for leukemic involvement. *Am J Surg Pathol*. 2000;24(11):1480-1490.
553. Brownell MD, Sheibani K, Battifora H, et al. Distinction between undifferentiated (small noncleaved) and lymphoblastic lymphoma. An immunohistologic study on paraffin-embedded, fixed tissue sections. *Am J Surg Pathol*. 1987;11(10):779-787.
554. Ozdemirli M, Fanburg-Smith JC, Hartmann DP, et al. Differentiating lymphoblastic lymphoma and Ewing's sarcoma: lymphocyte markers and gene rearrangement. *Mod Pathol*. 2001;14(11):1175-1182.
555. Soslow RA, Bhargava V, Warnke RA. MIC2, TdT, bcl-2, and CD34 expression in paraffin-embedded high-grade lymphoma/acute lymphoblastic leukemia distinguishes between distinct clinicopathologic entities. *Hum Pathol*. 1997;28(10):1158-1165.
556. Soslow RA, Zukerberg LR, Harris NL, Warnke RA. BCL-1 (PRAD-1/cyclin D-1) overexpression distinguishes the blastoid variant of mantle cell lymphoma from B-lineage lymphoblastic lymphoma. *Mod Pathol*. 1997;10(8):810-817.
557. Ohgami RS, Arber DA, Zehnder JL, et al. Indolent T-lymphoblastic proliferation (iT-LBP): a review of clinical and pathologic features and distinction from malignant T-lymphoblastic lymphoma. *Adv Anat Pathol*. 2013;20(3):137-140.
558. Velankar MM, Nathwani BN, Schlutz MJ, et al. Indolent T-lymphoblastic proliferation: report of a case with a 16-year course without cytotoxic therapy. *Am J Surg Pathol*. 1999;23(8):977-981.
559. Ben-Ezra J, Burke JS, Swartz WG, et al. Small lymphocytic lymphoma: a clinicopathologic analysis of 268 cases. *Blood*. 1989;73(2):579-587.
560. Morrison WH, Hoppe RT, Weiss LM, et al. Small lymphocytic lymphoma. *J Clin Oncol*. 1989;7(5):598-606.
561. Weir EG, Epstein JI. Incidental small lymphocytic lymphoma/chronic lymphocytic leukemia in pelvic lymph nodes excised at radical prostatectomy. *Arch Pathol Lab Med*. 2003;127(5):567-572.
562. Dick FR, Maca RD. The lymph node in chronic lymphocytic leukemia. *Cancer*. 1978;41(1):283-292.
563. Inamdar KV, Bueso-Ramos CE. Pathology of chronic lymphocytic leukemia: an update. *Ann Diagn Pathol*. 2007;11(5):363-389.
564. Pangalis GA, Nathwani BN, Rappaport H. Malignant lymphoma, well differentiated lymphocytic: its relationship with chronic lymphocytic leukemia and macroglobulinemia of Waldenstrom. *Cancer*. 1977;39(3):999-1010.
565. Schmid C, Isaacson PG. Proliferation centres in B-cell malignant lymphoma, lymphocytic (B-CLL): an immunophenotypic study. *Histopathology*. 1994;24(5):445-451.
566. Carbone A, Pinto A, Gloghini A, et al. B-zone small lymphocytic lymphoma: a morphologic, immunophenotypic, and clinical study with comparison to "well-differentiated" lymphocytic disorders. *Hum Pathol*. 1992;23(4):438-448.
567. Ellison DJ, Nathwani BN, Cho SY, Martin SE. Interfollicular small lymphocytic lymphoma: the diagnostic significance of pseudofollicles. *Hum Pathol*. 1989;20(11):1108-1118.
568. Gupta D, Lim MS, Medeiros LJ, Elenitoba-Johnson KS. Small lymphocytic lymphoma with perifollicular, marginal zone, or interfollicular distribution. *Mod Pathol*. 2000;13(11):1161-1166.
569. Swerdlow SH. Small B-cell lymphomas of the lymph nodes and spleen: practical insights to diagnosis and pathogenesis. *Mod Pathol*. 1999;12(2):125-140.
570. Spier CM, Grogan TM, Fielder K, et al. Immunophenotypes in "well-differentiated" lymphoproliferative disorders, with emphasis on small lymphocytic lymphoma. *Hum Pathol*. 1986;17(11):1126-1136.
571. Dorfman DM, Pinkus GS. Distinction between small lymphocytic and mantle cell lymphoma by immunoreactivity for CD23. *Mod Pathol*. 1994;7(3):326-331.
572. Kumar S, Green GA, Teruya-Feldstein J, et al. Use of CD23 (BU38) on paraffin sections in the diagnosis of small lymphocytic lymphoma and mantle cell lymphoma. *Mod Pathol*. 1996;9(9):925-929.
573. Sundeen JT, Longo DL, Jaffe ES. CD5 expression in B-cell small lymphocytic malignancies. Correlations with clinical presentation and sites of disease. *Am J Surg Pathol*. 1992;16(2):130-137.
574. Sandes AF, de Lourdes Chauffaille M, Oliveira CR, et al. CD200 has an important role in the differential diagnosis of mature B-cell neoplasms by multiparameter flow cytometry. *Cytometry B Clin Cytom*. 2014;86(2):98-105.
575. Chen YH, Gao J, Fan G, Peterson LC. Nuclear expression of sox11 is highly associated with mantle cell lymphoma but is independent of t(11;14)(q13;q32) in non-mantle cell B-cell neoplasms. *Mod Pathol*. 2010;23(1):105-112.
576. Tandon B, Peterson L, Gao J, et al. Nuclear overexpression of lymphoid-enhancer-binding factor 1 identifies chronic lymphocytic leukemia/small lymphocytic lymphoma in small B-cell lymphomas. *Mod Pathol*. 2011;24(11):1433-1443.
577. Dohner H, Stilgenbauer S, Benner A, et al. Genomic aberrations and survival in chronic lymphocytic leukemia. *N Engl J Med*. 2000;343(26):1910-1916.
578. Hamblin TJ, Davis Z, Gardiner A, et al. Unmutated Ig V(H) genes are associated with a more aggressive form of chronic lymphocytic leukemia. *Blood*. 1999;94(6):1848-1854.
579. Damle RN, Wasil T, Fais F, et al. Ig V gene mutation status and CD38 expression as novel prognostic indicators in chronic lymphocytic leukemia. *Blood*. 1999;94(6):1840-1847.
580. Jeromin S, Weissmann S, Haferlach C, et al. SF3B1 mutations correlated to cytogenetics and mutations in NOTCH1, FBXW7, MYD88, XPO1 and TP53 in 1160 untreated CLL patients. *Leukemia*. 2014;28(1):108-117.
581. Villamor N, Conde L, Martinez-Trillos A, et al. NOTCH1 mutations identify a genetic subgroup of chronic lymphocytic leukemia patients with high risk of transformation and poor outcome. *Leukemia*. 2013;27(5):1100-1106.
582. Houldsworth J, Guttapalli A, Thodima V, et al. Genomic imbalance defines three prognostic groups for risk stratification of patients with chronic lymphocytic leukemia. *Leuk Lymphoma*. 2014;55(4):920-928.
583. Landau DA, Tausch E, Taylor-Weiner AN, et al. Mutations driving CLL and their evolution in progression and relapse. *Nature*. 2015;526(7574):525-530.
584. Puente XS, Bea S, Valdes-Mas R, et al. Non-coding recurrent mutations in chronic lymphocytic leukaemia. *Nature*. 2015;526(7574):519-524.
585. Momose H, Jaffe ES, Shin SS, et al. Chronic lymphocytic leukemia/small lymphocytic lymphoma with Reed-Sternberg-like cells and possible transformation to Hodgkin's disease. Mediation by Epstein-Barr virus. *Am J Surg Pathol*. 1992;16(9):859-867.
586. Armitage JO, Dick FR, Corder MP. Diffuse histiocytic lymphoma complicating chronic lymphocytic leukemia. *Cancer*. 1978;41(2):422-427.
587. Long JC, Aisenberg AC. Richter's syndrome. A terminal complication of chronic lymphocytic leukemia with distinct clinicopathologic features. *Am J Clin Pathol*. 1975;63(6):786-795.
588. Nakamura N, Abe M. Richter syndrome in B-cell chronic lymphocytic leukemia. *Pathol Int*. 2003;53(4):195-203.
589. Marti GE, Rawstron AC, Ghia P, et al. Diagnostic criteria for monoclonal B-cell lymphocytosis. *Br J Haematol*. 2005;130(3):325-332.
590. Gibson SE, Swerdlow SH, Ferry JA, et al. Reassessment of small lymphocytic lymphoma in the era of monoclonal B-cell lymphocytosis. *Haematologica*. 2011;96(8):1144-1152.
591. Galton DA, Goldman JM, Wiltshaw E, et al. Prolymphocytic leukaemia. *Br J Haematol*. 1974;27(1):7-23.
592. Schlette E, Bueso-Ramos C, Giles F, et al. Mature B-cell leukemias with more than 55% prolymphocytes. A heterogeneous group that includes an unusual variant of mantle cell lymphoma. *Am J Clin Pathol*. 2001;115(4):571-581.
593. Swerdlow SH, Kuzu I, Dogan A, et al. The many faces of small B cell lymphomas with plasmacytic differentiation and the contribution of MYD88 testing. *Virchows Arch*. 2016;468(3):259-275.
594. Lin P, Bueso-Ramos C, Wilson CS, et al. Waldenstrom macroglobulinemia involving extramedullary sites: morphologic and immunophenotypic findings in 44 patients. *Am J Surg Pathol*. 2003;27(8):1104-1113.
595. Hamadeh F, MacNamara SP, Aguilera NS, et al. MYD88 L265P mutation analysis helps define nodal lymphoplasmacytic lymphoma. *Mod Pathol*. 2015;28(4):564-574.
596. Treon SP, Xu L, Yang G, et al. MYD88 L265P somatic mutation in Waldenstrom's macroglobulinemia. *N Engl J Med*. 2012;367(9):826-833.
597. King RL, Howard MT, Hodnefield JM, Morice WG. IgM multiple myeloma: pathologic evaluation of a rare entity. *Am J Clin Pathol*. 2013;140(4):519-524.
598. Bianchi G, Anderson KC, Harris NL, Sohani AR. The heavy chain diseases: clinical and pathologic features. *Oncology*. 2014;28(1):45-53.
599. Bieliauskas S, Tubbs RR, Bacon CM, et al. Gamma heavy-chain disease: defining the spectrum of associated lymphoproliferative disorders through analysis of 13 cases. *Am J Surg Pathol*. 2012;36(4):534-543.
600. Hamadeh F, MacNamara S, Bacon CM, et al. Gamma heavy chain disease lacks the MYD88 L265p mutation associated with lymphoplasmacytic lymphoma. *Haematologica*. 2014;99(9):e154-e155.
601. Seligmann M. Immunochemical, clinical, and pathological features of alpha-chain disease. *Arch Intern Med*. 1975;135(1):78-82.
602. Maes B, De Wolf-Peeters C. Marginal zone cell lymphoma—an update on recent advances. *Histopathology*. 2002;40(2):117-126.
603. Isaacson PG, Spencer J. Monocytoid B-cell lymphomas. *Am J Surg Pathol*. 1990;14(9):888-891.
604. Piris MA, Rivas C, Morente M, et al. Monocytoid B-cell lymphoma, a tumour related to the marginal zone. *Histopathology*. 1988;12(4):383-392.

For personal use only. No other uses without permission. Copyright ©2017. Elsevier Inc. All rights reserved.

605. van Krieken JH, von Schilling C, Kluin PM, Lennert K. Splenic marginal zone lymphocytes and related cells in the lymph node: a morphologic and immunohistochemical study. *Hum Pathol*. 1989;20(4):320-325.
606. Ngan BY, Warnke RA, Wilson M, et al. Monocytoid B-cell lymphoma: a study of 36 cases. *Hum Pathol*. 1991;22(5):409-421.
607. Sheibani K, Burke JS, Swartz WG, et al. Monocytoid B-cell lymphoma. Clinicopathologic study of 21 cases of a unique type of low-grade lymphoma. *Cancer*. 1988;62(8):1531-1538.
608. Cousar JB, McGinn DL, Glick AD, et al. Report of an unusual lymphoma arising from parafollicular B-lymphocytes (PBLs) or so-called "monocytoid" lymphocytes. *Am J Clin Pathol*. 1987;87(1):121-128.
609. Karube K, Ohshima K, Tsuchiya T, et al. A "floral" variant of nodal marginal zone lymphoma. *Hum Pathol*. 2005;36(2):202-206.
610. Cogliatti SB, Lennert K, Hansmann ML, Zwingers TL. Monocytoid B cell lymphoma: clinical and prognostic features of 21 patients. *J Clin Pathol*. 1990;43(8):619-625.
611. Bob R, Falini B, Marafioti T, et al. Nodal reactive and neoplastic proliferation of monocytoid and marginal zone B cells: an immunoarchitectural and molecular study highlighting the relevance of IRTA1 and T-bet as positive markers. *Histopathology*. 2013;63(4):482-498.
612. Dyhdalo KS, Lanigan C, Tubbs RR, Cook JR. Immunoarchitectural patterns of germinal center antigens including LMO2 assist in the differential diagnosis of marginal zone lymphoma vs follicular lymphoma. *Am J Clin Pathol*. 2013;140(2):149-154.
613. van den Brand M, van Krieken JH. Recognizing nodal marginal zone lymphoma: recent advances and pitfalls. A systematic review. *Haematologica*. 2013;98(7):1003-1013.
614. Arcaini L, Lucioni M, Boveri E, Paulli M. Nodal marginal zone lymphoma: current knowledge and future directions of an heterogeneous disease. *Eur J Haematol*. 2009;83(3):165-174.
615. Taddesse-Heath L, Pittaluga S, Sorbara L, et al. Marginal zone B-cell lymphoma in children and young adults. *Am J Surg Pathol*. 2003;27(4):522-531.
616. Isaacson PG. Malignant lymphomas with a follicular growth pattern. *Histopathology*. 1996;28(6):487-495.
617. Jones SE, Fuks Z, Bull M, et al. Non-Hodgkin's lymphomas. IV. Clinicopathologic correlation in 405 cases. *Cancer*. 1973;31(4):806-823.
618. Levine GD, Dorfman RF. Nodular lymphoma: an ultrastructural study of its relationship to germinal centers and a correlation of light and electron microscopic findings. *Cancer*. 1975;35(1):148-164.
619. McKenna RW, Brunning RD. Reed-Sternberg-like cells in nodular lymphoma involving the bone marrow. *Am J Clin Pathol*. 1975;63(6):779-785.
620. Scoazec JY, Berger F, Magaud JP, et al. The dendritic reticulum cell pattern in B cell lymphomas of the small cleaved, mixed, and large cell types: an immunohistochemical study of 48 cases. *Hum Pathol*. 1989;20(2):124-131.
621. Utz GL, Swerdlow SH. Distinction of follicular hyperplasia from follicular lymphoma in B5-fixed tissues: comparison of MT2 and bcl-2 antibodies. *Hum Pathol*. 1993;24(11):1155-1158.
622. Wood BL, Bacchi MM, Bacchi CE, et al. Immunocytochemical differentiation of reactive hyperplasia from follicular lymphoma using monoclonal antibodies to cell surface and proliferation-related markers. *Diagn Immunohistochem*. 1994;2:48-53.
623. Gaulard P, d'Agay MF, Peuchmaur M, et al. Expression of the bcl-2 gene product in follicular lymphoma. *Am J Pathol*. 1992;140(5):1089-1095.
624. Veloso JD, Rezuke WN, Cartun RW, et al. Immunohistochemical distinction of follicular lymphoma from follicular hyperplasia in formalin-fixed tissues using monoclonal antibodies MT2 and bcl-2. *Appl Immunohistochem Mol Morphol*. 1995;3:153-159.
625. Almasri NM, Iturraspe JA, Braylan RC. CD10 expression in follicular lymphoma and large cell lymphoma is different from that of reactive lymph node follicles. *Arch Pathol Lab Med*. 1998;122(6):539-544.
626. Barcus ME, Karageorge LS, Veloso YL, Kornstein MJ. CD10 expression in follicular lymphoma versus reactive follicular hyperplasia: evaluation in paraffin-embedded tissue. *Appl Immunohistochem Mol Morphol*. 2000;8(4):263-266.
627. Ottensmeier CH, Thompsett AR, Zhu D, et al. Analysis of VH genes in follicular and diffuse lymphoma shows ongoing somatic mutation and multiple isotype transcripts in early disease with changes during disease progression. *Blood*. 1998;91(11):4292-4299.
628. Weinberg OK, Ai WZ, Mariappan MR, et al. "Minor" BCL2 breakpoints in follicular lymphoma: frequency and correlation with grade and disease presentation in 236 cases. *J Mol Diagn*. 2007;9(4):530-537.
629. Aster JC, Longtine JA. Detection of BCL2 rearrangements in follicular lymphoma. *Am J Pathol*. 2002;160(3):759-763.
630. Horsman DE, Gascoyne RD, Coupland RW, et al. Comparison of cytogenetic analysis, southern analysis, and polymerase chain reaction for the detection of t(14; 18) in follicular lymphoma. *Am J Clin Pathol*. 1995;103(4):472-478.
631. Tilly H, Rossi A, Stamatoullas A, et al. Prognostic value of chromosomal abnormalities in follicular lymphoma. *Blood*. 1994;84(4):1043-1049.
632. Gu K, Chan WC, Hawley RC. Practical detection of t(14;18)(IgH/BCL2) in follicular lymphoma. *Arch Pathol Lab Med*. 2008;132(8):1355-1361.
633. Bosga-Bouwer AG, van den Berg A, Haralambieva E, et al. Molecular, cytogenetic, and immunophenotypic characterization of follicular lymphoma grade 3B: a separate entity or part of the spectrum of diffuse large B-cell lymphoma or follicular lymphoma? *Hum Pathol*. 2006;37(5):528-533.
634. Cerroni L, Volkenandt M, Rieger E, et al. bcl-2 protein expression and correlation with the interchromosomal 14;18 translocation in cutaneous lymphomas and pseudolymphomas. *J Invest Dermatol*. 1994;102(2):231-235.
635. Goodlad JR, Batstone PJ, Hamilton DA, et al. BCL2 gene abnormalities define distinct clinical subsets of follicular lymphoma. *Histopathology*. 2006;49(3):229-241.
636. Lorsbach RB, Shay-Seymore D, Moore J, et al. Clinicopathologic analysis of follicular lymphoma occurring in children. *Blood*. 2002;99(6):1959-1964.
637. Ott G, Katzenberger T, Lohr A, et al. Cytomorphologic, immunohistochemical, and cytogenetic profiles of follicular lymphoma: 2 types of follicular lymphoma grade 3. *Blood*. 2002;99(10):3806-3812.
638. Willemze R, Jaffe ES, Burg G, et al. WHO-EORTC classification for cutaneous lymphomas. *Blood*. 2005;105(10):3768-3785.
639. Aster JC, Kobayashi Y, Shiota M, et al. Detection of the t(14;18) at similar frequencies in hyperplastic lymphoid tissues from American and Japanese patients. *Am J Pathol*. 1992;141(2):291-299.
640. Bentz M, Werner CA, Dohner H, et al. High incidence of chromosomal imbalances and gene amplifications in the classical follicular variant of follicle center lymphoma. *Blood*. 1996;88(4):1437-1444.
641. Hirt C, Dolken G, Janz S, Rabkin CS. Distribution of t(14;18)-positive, putative lymphoma precursor cells among B-cell subsets in healthy individuals. *Br J Haematol*. 2007;138(3):349-353.
642. Roulland S, Navarro JM, Grenot P, et al. Follicular lymphoma-like B cells in healthy individuals: a novel intermediate step in early lymphomagenesis. *J Exp Med*. 2006;203(11):2425-2431.
643. Schwaenen C, Viardot A, Berger H, et al. Microarray-based genomic profiling reveals novel genomic aberrations in follicular lymphoma which associate with patient survival and gene expression status. *Genes Chromosomes Cancer*. 2009;48(1):39-54.
644. Horsman DE, Connors JM, Pantzar T, Gascoyne RD. Analysis of secondary chromosomal alterations in 165 cases of follicular lymphoma with t(14;18). *Genes Chromosomes Cancer*. 2001;30(4):375-382.
645. Lestou VS, Gascoyne RD, Sehn L, et al. Multicolour fluorescence in situ hybridization analysis of t(14;18)-positive follicular lymphoma and correlation with gene expression data and clinical outcome. *Br J Haematol*. 2003;122(5):745-759.
646. Viardot A, Moller P, Hogel J, et al. Clinicopathologic correlations of genomic gains and losses in follicular lymphoma. *J Clin Oncol*. 2002;20(23):4523-4530.
647. Horsman DE, Okamoto I, Ludkovski O, et al. Follicular lymphoma lacking the t(14;18)(q32;q21): identification of two disease subtypes. *Br J Haematol*. 2003;120(3):424-433.
648. Gu K, Fu K, Jain S, et al. t(14;18)-negative follicular lymphomas are associated with a high frequency of BCL6 rearrangement at the alternative breakpoint region. *Mod Pathol*. 2009;22(9):1251-1257.
649. Leich E, Salaverria I, Bea S, et al. Follicular lymphomas with and without translocation t(14;18) differ in gene expression profiles and genetic alterations. *Blood*. 2009;114(4):826-834.
650. Lo Coco F, Gaidano G, Louie DC, et al. p53 mutations are associated with histologic transformation of follicular lymphoma. *Blood*. 1993;82(8):2289-2295.
651. Matolcsy A, Casali P, Warnke RA, Knowles DM. Morphologic transformation of follicular lymphoma is associated with somatic mutation of the translocated Bcl-2 gene. *Blood*. 1996;88(10):3937-3944.
652. Szereday Z, Csernus B, Nagy M, et al. Somatic mutation of the 5′ noncoding region of the BCL-6 gene is associated with intraclonal diversity and clonal selection in histological transformation of follicular lymphoma. *Am J Pathol*. 2000;156(3):1017-1024.
653. Dave SS, Wright G, Tan B, et al. Prediction of survival in follicular lymphoma based on molecular features of tumor-infiltrating immune cells. *N Engl J Med*. 2004;351(21):2159-2169.
654. Chittal SM, Caveriviere P, Voigt JJ, et al. Follicular lymphoma with abundant PAS-positive extracellular material. Immunohistochemical and ultrastructural observations. *Am J Surg Pathol*. 1987;11(8):618-624.
655. van den Berg HM, Molenaar WM, Poppema S, Halie MR. The heterogeneity of follicular follicle center cell tumors. II. Clinical

For personal use only. No other uses without permission. Copyright ©2017. Elsevier Inc. All rights reserved.

follow-up of 30 patients. *Cancer*. 1983;52(12):2264-2268.
656. Goodlad JR, MacPherson S, Jackson R, et al. Extranodal follicular lymphoma: a clinicopathological and genetic analysis of 15 cases arising at non-cutaneous extranodal sites. *Histopathology*. 2004;44(3):268-276.
657. Bastion Y, Berger F, Bryon PA, et al. Follicular lymphomas: assessment of prognostic factors in 127 patients followed for 10 years. *Ann Oncol*. 1991;2(suppl 2):123-129.
658. Coiffier B, Bastion Y, Berger F, et al. Prognostic factors in follicular lymphomas. *Semin Oncol*. 1993; 20(5 suppl 5):89-95.
659. Kim H, Dorfman RF. Morphological studies of 84 untreated patients subjected to laparotomy for the staging of non-Hodgkin's lymphomas. *Cancer*. 1974;33(3):657-674.
660. Lister TA. The management of follicular lymphoma. *Ann Oncol*. 1991;2(suppl 2):131-135.
661. Rohatiner AZ, Lister TA. New approaches to the treatment of follicular lymphoma. *Br J Haematol*. 1991;79(3):349-354.
662. Young RC, Longo DL, Glatstein E, et al. The treatment of indolent lymphomas: watchful waiting v aggressive combined modality treatment. *Semin Hematol*. 1988;25(2 suppl 2):11-16.
663. Horning SJ, Weiss LM, Nevitt JB, Warnke RA. Clinical and pathologic features of follicular large cell (nodular histiocytic) lymphoma. *Cancer*. 1987;59(8):1470-1474.
664. Garvin AJ, Simon RM, Osborne CK, et al. An autopsy study of histologic progression in non-Hodgkin's lymphomas. 192 cases from the National Cancer Institute. *Cancer*. 1983;52(3):393-398.
665. Oviatt DL, Cousar JB, Collins RD, et al. Malignant lymphomas of follicular center cell origin in humans. V. Incidence, clinical features, and prognostic implications of transformation of small cleaved cell nodular lymphoma. *Cancer*. 1984;53(5):1109-1114.
666. Come SE, Jaffe ES, Andersen JC, et al. Non-Hodgkin's lymphomas in leukemic phase: clinicopathologic correlations. *Am J Med*. 1980;69(5):667-674.
667. Alsabeh R, Medeiros LJ, Glackin C, Weiss LM. Transformation of follicular lymphoma into CD30-large cell lymphoma with anaplastic cytologic features. *Am J Surg Pathol*. 1997;21(5):528-536.
668. Bennett MH. Sclerosis in non-Hodgkin's lymphomata. *Br J Cancer Suppl*. 1975;2:44-52.
669. Keith TA, Cousar JB, Glick AD, et al. Plasmacytic differentiation in follicular center cell (FCC) lymphomas. *Am J Clin Pathol*. 1985;84(3):283-290.
670. Schmid U, Cogliatti SB, Diss TC, Isaacson PG. Monocytoid/marginal zone B-cell differentiation in follicle centre cell lymphoma. *Histopathology*. 1996;29(3):201-208.
671. Abou-Elella A, Shafer MT, Wan XY, et al. Lymphomas with follicular and monocytoid B-cell components. Evidence for a common clonal origin from follicle center cells. *Am J Clin Pathol*. 2000;114(4):516-522.
672. Yegappan S, Schnitzer B, Hsi ED. Follicular lymphoma with marginal zone differentiation: microdissection demonstrates the t(14;18) in both the follicular and marginal zone components. *Mod Pathol*. 2001;14(3):191-196.
673. Nathwani BN, Anderson JR, Armitage JO, et al. Clinical significance of follicular lymphoma with monocytoid B cells. Non-Hodgkin's Lymphoma Classification Project. *Hum Pathol*. 1999;30(3): 263-268.
674. Rosas-Uribe A, Rappaport H. Malignant lymphoma, histiocytic type with sclerosis (sclerosing reticulum cell sarcoma). *Cancer*. 1972;29(4):946-953.
675. Rosas-Uribe A, Variakojis D, Rappaport H. Proteinaceous precipitate in nodular (follicular) lymphomas. *Cancer*. 1973;31(3):532-542.
676. Kim H, Dorfman RF, Rappaport H. Signet ring cell lymphoma. A rare morphologic and functional expression of nodular (follicular) lymphoma. *Am J Surg Pathol*. 1978;2(2):119-132.
677. Frizzera G, Anaya JS, Banks PM. Neoplastic plasma cells in follicular lymphomas. Clinical and pathologic findings in six cases. *Virchows Arch A Pathol Anat Histopathol*. 1986;409(2):149-162.
678. Nathwani BN, Sheibani K, Winberg CD, et al. Neoplastic B cells with cerebriform nuclei in follicular lymphomas. *Hum Pathol*. 1985;16(2):173-180.
679. Chan JK, Ng CS, Tung S. Multilobated B-cell lymphoma, a variant of centroblastic lymphoma. Report of four cases. *Histopathology*. 1986;10(6):601-612.
680. Goates JJ, Kamel OW, LeBrun DP, et al. Floral variant of follicular lymphoma. Immunological and molecular studies support a neoplastic process. *Am J Surg Pathol*. 1994;18(1):37-47.
681. Chan JK, Ng CS, Hui PK. An unusual morphological variant of follicular lymphoma. Report of two cases. *Histopathology*. 1988;12(6):649-658.
682. Kojima M, Nakamura S, Ichimura K, et al. Centroblastic and centroblastic/centrocytic lymphoma associated with a prominent epithelioid granulomatous response: a clinicopathologic study of 50 cases. *Mod Pathol*. 2002;15(7):750-758.
683. Adam P, Katzenberger T, Eifert M, et al. Presence of preserved reactive germinal centers in follicular lymphoma is a strong histopathologic indicator of limited disease stage. *Am J Surg Pathol*. 2005;29(12):1661-1664.
684. Pillai RK, Surti U, Swerdlow SH. Follicular lymphoma-like B cells of uncertain significance (in situ follicular lymphoma) may infrequently progress, but precedes follicular lymphoma, is associated with other overt lymphomas and mimics follicular lymphoma in flow cytometric studies. *Haematologica*. 2013;98(10):1571-1580.
685. Jegalian AG, Eberle FC, Pack SD, et al. Follicular lymphoma in situ: clinical implications and comparisons with partial involvement by follicular lymphoma. *Blood*. 2011;118(11):2976-2984.
686. Liu Q, Salaverria I, Pittaluga S, et al. Follicular lymphomas in children and young adults: a comparison of the pediatric variant with usual follicular lymphoma. *Am J Surg Pathol*. 2013;37(3):333-343.
687. Louissaint A Jr, Ackerman AM, Dias-Santagata D, et al. Pediatric-type nodal follicular lymphoma: an indolent clonal proliferation in children and adults with high proliferation index and no BCL2 rearrangement. *Blood*. 2012;120(12):2395-2404.
688. Salaverria I, Philipp C, Oschlies I, et al. Translocations activating IRF4 identify a subtype of germinal center-derived B-cell lymphoma affecting predominantly children and young adults. *Blood*. 2011;118(1):139-147.
689. Schmatz AI, Streubel B, Kretschmer-Chott E, et al. Primary follicular lymphoma of the duodenum is a distinct mucosal/submucosal variant of follicular lymphoma: a retrospective study of 63 cases. *J Clin Oncol*. 2011;29(11):1445-1451.
690. Campo E, Raffeld M, Jaffe ES. Mantle-cell lymphoma. *Semin Hematol*. 1999;36(2):115-127.
691. Kurtin PJ. Mantle cell lymphoma. *Adv Anat Pathol*. 1998;5(6):376-398.
692. Swerdlow SH, Williams ME. From centrocytic to mantle cell lymphoma: a clinicopathologic and molecular review of 3 decades. *Hum Pathol*. 2002;33(1):7-20.
693. Duggan MJ, Weisenburger DD, Ye YL, et al. Mantle zone lymphoma. A clinicopathologic study of 22 cases. *Cancer*. 1990;66(3):522-529.
694. Pittaluga S, Wlodarska I, Stul MS, et al. Mantle cell lymphoma: a clinicopathological study of 55 cases. *Histopathology*. 1995;26(1):17-24.
695. Yatabe Y, Suzuki R, Matsuno Y, et al. Morphological spectrum of cyclin D1-positive mantle cell lymphoma: study of 168 cases. *Pathol Int*. 2001;51(10):747-761.
696. Weisenburger DD, Nathwani BN, Diamond LW, et al. Malignant lymphoma, intermediate lymphocytic type: a clinicopathologic study of 42 cases. *Cancer*. 1981;48(6):1415-1425.
697. Young KH, Chan WC, Fu K, et al. Mantle cell lymphoma with plasma cell differentiation. *Am J Surg Pathol*. 2006;30(8):954-961.
698. Ellison DJ, Turner RR, Van Antwerp R, et al. High-grade mantle zone lymphoma. *Cancer*. 1987;60(11):2717-2720.
699. Molina TJ, Delmer A, Cymbalista F, et al. Mantle cell lymphoma, in leukaemic phase with prominent splenomegaly. A report of eight cases with similar clinical presentation and aggressive outcome. *Virchows Arch*. 2000;437(6):591-598.
700. Schlette E, Lai R, Onciu M, et al. Leukemic mantle cell lymphoma: clinical and pathologic spectrum of twenty-three cases. *Mod Pathol*. 2001;14(11):1133-1140.
701. Singleton TP, Anderson MM, Ross CW, Schnitzer B. Leukemic phase of mantle cell lymphoma, blastoid variant. *Am J Clin Pathol*. 1999;111(4):495-500.
702. Viswanatha DS, Foucar K, Berry BR, et al. Blastic mantle cell leukemia: an unusual presentation of blastic mantle cell lymphoma. *Mod Pathol*. 2000;13(7):825-833.
703. Banks PM, Chan J, Cleary ML, et al. Mantle cell lymphoma. A proposal for unification of morphologic, immunologic, and molecular data. *Am J Surg Pathol*. 1992;16(7):637-640.
704. Bookman MA, Lardelli P, Jaffe ES, et al. Lymphocytic lymphoma of intermediate differentiation: morphologic, immunophenotypic, and prognostic factors. *J Natl Cancer Inst*. 1990;82(9):742-748.
705. Dunphy CH, Wheaton SE, Perkins SL. CD23 expression in transformed small lymphocytic lymphomas/chronic lymphocytic leukemias and blastic transformations of mantle cell lymphoma. *Mod Pathol*. 1997;10(8):818-822.
706. Liu Z, Dong HY, Gorczyca W, et al. CD5- mantle cell lymphoma. *Am J Clin Pathol*. 2002;118(2):216-224.
707. Kroft SH, Howard MS, Picker LJ, et al. De novo CD5+ diffuse large B-cell lymphomas. A heterogeneous group containing an unusual form of splenic lymphoma. *Am J Clin Pathol*. 2000;114(4):523-533.
708. Aguilera NS, Bijwaard KE, Duncan B, et al. Differential expression of cyclin D1 in mantle cell lymphoma and other non-Hodgkin's lymphomas. *Am J Pathol*. 1998;153(6):1969-1976.
709. Miranda RN, Briggs RC, Kinney MC, et al. Immunohistochemical detection of cyclin D1 using optimized conditions is highly specific for mantle cell lymphoma and hairy cell leukemia. *Mod Pathol*. 2000;13(12):1308-1314.
710. Camacho FI, Algara P, Rodriguez A, et al. Molecular heterogeneity in MCL defined by

For personal use only. No other uses without permission. Copyright ©2017. Elsevier Inc. All rights reserved.

the use of specific VH genes and the frequency of somatic mutations. *Blood*. 2003;101(10):4042-4046.
711. Kienle D, Krober A, Katzenberger T, et al. VH mutation status and VDJ rearrangement structure in mantle cell lymphoma: correlation with genomic aberrations, clinical characteristics, and outcome. *Blood*. 2003;102(8):3003-3009.
712. Li JY, Gaillard F, Moreau A, et al. Detection of translocation t(11;14)(q13;q32) in mantle cell lymphoma by fluorescence in situ hybridization. *Am J Pathol*. 1999;154(5):1449-1452.
713. Bergsagel PL, Kuehl WM. Molecular pathogenesis and a consequent classification of multiple myeloma. *J Clin Oncol*. 2005;23(26):6333-6338.
714. Fonseca R, Bergsagel PL, Drach J, et al. International Myeloma Working Group molecular classification of multiple myeloma: spotlight review. *Leukemia*. 2009;23(12):2210-2221.
715. Belaud-Rotureau MA, Parrens M, Dubus P, et al. A comparative analysis of FISH, RT-PCR, PCR, and immunohistochemistry for the diagnosis of mantle cell lymphomas. *Mod Pathol*. 2002;15(5):517-525.
716. Louie DC, Offit K, Jaslow R, et al. p53 overexpression as a marker of poor prognosis in mantle cell lymphomas with t(11;14)(q13;q32). *Blood*. 1995;86(8):2892-2899.
717. Pinyol M, Hernandez L, Cazorla M, et al. Deletions and loss of expression of p16INK4a and p21Waf1 genes are associated with aggressive variants of mantle cell lymphomas. *Blood*. 1997;89(1):272-280.
718. Bea S, Ribas M, Hernandez JM, et al. Increased number of chromosomal imbalances and high-level DNA amplifications in mantle cell lymphoma are associated with blastoid variants. *Blood*. 1999;93(12):4365-4374.
719. Hao S, Sanger W, Onciu M, et al. Mantle cell lymphoma with 8q24 chromosomal abnormalities: a report of 5 cases with blastoid features. *Mod Pathol*. 2002;15(12):1266-1272.
720. Ott G, Kalla J, Ott MM, et al. Blastoid variants of mantle cell lymphoma: frequent bcl-1 rearrangements at the major translocation cluster region and tetraploid chromosome clones. *Blood*. 1997;89(4):1421-1429.
721. Parrens M, Belaud-Rotureau MA, Fitoussi O, et al. Blastoid and common variants of mantle cell lymphoma exhibit distinct immunophenotypic and interphase FISH features. *Histopathology*. 2006;48(4):353-362.
722. Martinez N, Camacho FI, Algara P, et al. The molecular signature of mantle cell lymphoma reveals multiple signals favoring cell survival. *Cancer Res*. 2003;63(23):8226-8232.
723. Rosenwald A, Wright G, Wiestner A, et al. The proliferation gene expression signature is a quantitative integrator of oncogenic events that predicts survival in mantle cell lymphoma. *Cancer Cell*. 2003;3(2):185-197.
724. Fu K, Weisenburger DD, Greiner TC, et al. Cyclin D1-negative mantle cell lymphoma: a clinicopathologic study based on gene expression profiling. *Blood*. 2005;106(13):4315-4321.
725. Wlodarska I, Dierickx D, Vanhentenrijk V, et al. Translocations targeting CCND2, CCND3, and MYCN do occur in t(11;14)-negative mantle cell lymphomas. *Blood*. 2008;111(12):5683-5690.
726. Hiddemann W, Unterhalt M, Herrmann R, et al. Mantle-cell lymphomas have more widespread disease and a slower response to chemotherapy compared with follicle-centre lymphomas: results of a prospective comparative analysis of the German Low-grade Lymphoma Study Group. *J Clin Oncol*. 1998;16:1922-1930.
727. Bosch F, Lopez-Guillermo A, Campo E, et al. Mantle cell lymphoma: presenting features, response to therapy, and prognostic factors. *Cancer*. 1998;82(3):567-575.
728. Nodit L, Bahler DW, Jacobs SA, et al. Indolent mantle cell lymphoma with nodal involvement and mutated immunoglobulin heavy chain genes. *Hum Pathol*. 2003;34(10):1030-1034.
729. Hoster E, Rosenwald A, Berger F, et al. Prognostic value of Ki-67 index, cytology, and growth pattern in mantle-cell lymphoma: Results from randomized trials of the European mantle cell lymphoma network. *J Clin Oncol*. 2016;34(12):1386-1394.
730. Angelopoulou MK, Siakantariz MP, Vassilakopoulos TP, et al. The splenic form of mantle cell lymphoma. *Eur J Haematol*. 2002;68(1):12-21.
731. Carvajal-Cuenca A, Sua LF, Silva NM, et al. In situ mantle cell lymphoma: clinical implications of an incidental finding with indolent clinical behavior. *Haematologica*. 2012;97(2):270-278.
732. Straus DJ, Filippa DA, Lieberman PH, et al. The non-Hodgkin's lymphomas. I. A retrospective clinical and pathologic analysis of 499 cases diagnosed between 1958 and 1969. *Cancer*. 1983;51(1):101-109.
733. Lenz G, Staudt LM. Aggressive lymphomas. *N Engl J Med*. 2010;362(15):1417-1429.
734. Leoncini L, Delsol G, Gascoyne RD, et al. Aggressive B-cell lymphomas: a review based on the workshop of the XI Meeting of the European Association for Haematopathology. *Histopathology*. 2005;46(3):241-255.
735. Armitage JO. Treatment of non-Hodgkin's lymphoma. *N Engl J Med*. 1993;328(14):1023-1030.
736. Coiffier B. State-of-the-art therapeutics: diffuse large B-cell lymphoma. *J Clin Oncol*. 2005;23(26):6387-6393.
737. Lai R, Medeiros LJ, Dabbagh L, et al. Sinusoidal CD30-positive large B-cell lymphoma: a morphologic mimic of anaplastic large cell lymphoma. *Mod Pathol*. 2000;13(3):223-228.
738. Caimi PF, Hill BT, Hsi ED, Smith MR. Clinical approach to diffuse large B cell lymphoma. *Blood Rev*. 2016;30(6):477-491.
739. Chabner BA, Johnson RE, Young RC, et al. Sequential nonsurgical and surgical staging of non-Hodgkin's lymphoma. *Ann Intern Med*. 1976;85(2):149-154.
740. Veronesi U, Musumeci R, Pizzetti F, et al. Proceedings: the value of staging laparotomy in non-Hodgkin's lymphomas (with emphasis on the histiocytic type). *Cancer*. 1974;33(2):446-459.
741. Ree HJ, Leone LA, Crowley JP. Sclerosis in diffuse histiocytic lymphoma: a clinicopathologic study of 25 cases. *Cancer*. 1982;49(8):1636-1648.
742. Waldron JA Jr, Newcomer LN, Katz ME, Cadman E. Sclerosing variants of follicular center cell lymphomas presenting in the retroperitoneum. *Cancer*. 1983;52(4):712-720.
743. McCurley TL, Gay RE, Gay S, et al. The extracellular matrix in "sclerosing" follicular center cell lymphomas: an immunohistochemical and ultrastructural study. *Hum Pathol*. 1986;17(9):930-938.
744. Wang J, Sun NC, Nozawa Y, et al. Histological and immunohistochemical characterization of extranodal diffuse large-cell lymphomas with prominent spindle cell features. *Histopathology*. 2001;39(5):476-481.
745. Carbone A, Gloghini A, Libra M, et al. A spindle cell variant of diffuse large B-cell lymphoma possesses genotypic and phenotypic markers characteristic of a germinal center B-cell origin. *Mod Pathol*. 2006;19(2):299-306.
746. Fung DT, Chan JK, Tse CC, Sze WM. Myxoid change in malignant lymphoma. Pathogenetic considerations. *Arch Pathol Lab Med*. 1992;116(1):103-105.
747. Tse CC, Chan JK, Tang SK, et al. Malignant lymphoma with myxoid stroma: a new pattern in need of recognition. *Histopathology*. 1991;18(1):31-35.
748. Tsang WY, Chan JK, Tang SK, et al. Large cell lymphoma with fibrillary matrix. *Histopathology*. 1992;20(1):80-82.
749. Bernier V, Azar HA. Filiform large-cell lymphomas. An ultrastructural and immunohistochemical study. *Am J Surg Pathol*. 1987;11(5):387-396.
750. Osborne BM, Mackay B, Butler JJ, Ordonez NG. Large cell lymphoma with microvillus-like projections: an ultrastructural study. *Am J Clin Pathol*. 1983;79(4):443-450.
751. Weiss LM, Wood GS, Dorfman RF. T-cell signet-ring cell lymphoma. A histologic, ultrastructural, and immunohistochemical study of two cases. *Am J Surg Pathol*. 1985;9(4):273-280.
752. Osborne BM, Butler JJ, Mackay B. Sinusoidal large cell ("histiocytic") lymphoma. *Cancer*. 1980;46(11):2484-2491.
753. O'Hara CJ, Said JW, Pinkus GS. Non-Hodgkin's lymphoma, multilobated B-cell type: report of nine cases with immunohistochemical and immunoultrastructural evidence for a follicular center cell derivation. *Hum Pathol*. 1986;17(6):593-599.
754. Weiss RL, Kjeldsberg CR, Colby TV, Marty J. Multilobated B cell lymphomas. A study of 7 cases. *Hematol Oncol*. 1985;3(2):79-86.
755. Chan ACL, Chan JKC. Diffuse large B-cell lymphoma. In: Jaffe ES, Harris NL, Vardiman J, et al, eds. *Hematopathology*. Philadelphia, PA: Saunders; 2010.
756. Lasota J, Hyjek E, Koo CH, et al. Cytokeratin-positive large-cell lymphomas of B-cell lineage. A study of five phenotypically unusual cases verified by polymerase chain reaction. *Am J Surg Pathol*. 1996;20(3):346-354.
757. Lossos IS, Alizadeh AA, Eisen MB, et al. Ongoing immunoglobulin somatic mutation in germinal center B cell-like but not in activated B cell-like diffuse large cell lymphomas. *Proc Natl Acad Sci USA*. 2000;97(18):10209-10213.
758. Gascoyne RD, Adomat SA, Krajewski S, et al. Prognostic significance of Bcl-2 protein expression and Bcl-2 gene rearrangement in diffuse aggressive non-Hodgkin's lymphoma. *Blood*. 1997;90(1):244-251.
759. Hill ME, MacLennan KA, Cunningham DC, et al. Prognostic significance of BCL-2 expression and bcl-2 major breakpoint region rearrangement in diffuse large cell non-Hodgkin's lymphoma: a British National Lymphoma Investigation Study. *Blood*. 1996;88(3):1046-1051.
760. Xu Y, McKenna RW, Doolittle JE, et al. The t(14;18) in diffuse large B-cell lymphoma: correlation with germinal center-associated markers and clinical features. *Appl Immunohistochem Mol Morphol*. 2005;13(2):116-123.
761. Lo Coco F, Ye BH, Lista F, et al. Rearrangements of the BCL6 gene in diffuse large cell non-Hodgkin's lymphoma. *Blood*. 1994;83(7):1757-1759.
762. Ohno H. Pathogenetic role of BCL6 translocation in B-cell non-Hodgkin's

For personal use only. No other uses without permission. Copyright ©2017. Elsevier Inc. All rights reserved.

lymphoma. *Histol Histopathol*. 2004;19(2):637-650.
763. Otsuki T, Yano T, Clark HM, et al. Analysis of LAZ3 (BCL-6) status in B-cell non-Hodgkin's lymphomas: results of rearrangement and gene expression studies and a mutational analysis of coding region sequences. *Blood*. 1995;85(10):2877-2884.
764. Saito M, Gao J, Basso K, et al. A signaling pathway mediating downregulation of BCL6 in germinal center B cells is blocked by BCL6 gene alterations in B cell lymphoma. *Cancer Cell*. 2007;12(3):280-292.
765. Bosga-Bouwer AG, Haralambieva E, Booman M, et al. BCL6 alternative translocation breakpoint cluster region associated with follicular lymphoma grade 3B. *Genes Chromosomes Cancer*. 2005;44(3):301-304.
766. Capello D, Vitolo U, Pasqualucci L, et al. Distribution and pattern of BCL-6 mutations throughout the spectrum of B-cell neoplasia. *Blood*. 2000;95(2):651-659.
767. Migliazza A, Martinotti S, Chen W, et al. Frequent somatic hypermutation of the 5′ noncoding region of the BCL6 gene in B-cell lymphoma. *Proc Natl Acad Sci USA*. 1995;92(26):12520-12524.
768. Wang X, Li Z, Naganuma A, Ye BH. Negative autoregulation of BCL-6 is bypassed by genetic alterations in diffuse large B cell lymphomas. *Proc Natl Acad Sci USA*. 2002;99(23):15018-15023.
769. Pasqualucci L, Migliazza A, Fracchiolla N, et al. BCL-6 mutations in normal germinal center B cells: evidence of somatic hypermutation acting outside Ig loci. *Proc Natl Acad Sci USA*. 1998;95(20):11816-11821.
770. Peng HZ, Du MQ, Koulis A, et al. Nonimmunoglobulin gene hypermutation in germinal center B cells. *Blood*. 1999;93(7):2167-2172.
771. Kawasaki C, Ohshim K, Suzumiya J, et al. Rearrangements of bcl-1, bcl-2, bcl-6, and c-myc in diffuse large B-cell lymphomas. *Leuk Lymphoma*. 2001;42(5):1099-1106.
772. Kramer MH, Hermans J, Wijburg E, et al. Clinical relevance of BCL2, BCL6, and MYC rearrangements in diffuse large B-cell lymphoma. *Blood*. 1998;92(9):3152-3162.
773. Ladanyi M, Offit K, Jhanwar SC, et al. MYC rearrangement and translocations involving band 8q24 in diffuse large cell lymphomas. *Blood*. 1991;77(5):1057-1063.
774. McClure RF, Remstein ED, Macon WR, et al. Adult B-cell lymphomas with burkitt-like morphology are phenotypically and genotypically heterogeneous with aggressive clinical behavior. *Am J Surg Pathol*. 2005;29(12):1652-1660.
775. Hummel M, Bentink S, Berger H, et al. A biologic definition of Burkitt's lymphoma from transcriptional and genomic profiling. *N Engl J Med*. 2006;354(23):2419-2430.
776. Aukema SM, Siebert R, Schuuring E, et al. Double-hit B-cell lymphomas. *Blood*. 2011;117(8):2319-2331.
777. Miura K, Takahashi H, Nakagawa M, et al. Clinical significance of co-expression of MYC and BCL2 protein in aggressive B-cell lymphomas treated with a second line immunochemotherapy. *Leuk Lymphoma*. 2016;57(6):1335-1341.
778. Iqbal J, Greiner TC, Patel K, et al. Distinctive patterns of BCL6 molecular alterations and their functional consequences in different subgroups of diffuse large B-cell lymphoma. *Leukemia*. 2007;21(11):2332-2343.
779. Tam W, Gomez M, Chadburn A, et al. Mutational analysis of PRDM1 indicates a tumor-suppressor role in diffuse large B-cell lymphomas. *Blood*. 2006; 107(10):4090-4100.
780. Zelenetz AD, Gordon LI, Wierda WG, et al. Non-Hodgkin's lymphomas, version 4.2014. *J Natl Compr Canc Netw*. 2014;12(9):1282-1303.
781. Yegappan S, Coupland R, Arber DA, et al. Angiotropic lymphoma: an immunophenotypically and clinically heterogeneous lymphoma. *Mod Pathol*. 2001;14(11):1147-1156.
782. Nakamura S, Suchi T, Koshikawa T, et al. Clinicopathologic study of CD56 (NCAM)-positive angiocentric lymphoma occurring in sites other than the upper and lower respiratory tract. *Am J Surg Pathol*. 1995;19(3):284-296.
783. Lim MS, Beaty M, Sorbara L, et al. T-cell/histiocyte-rich large B-cell lymphoma: a heterogeneous entity with derivation from germinal center B cells. *Am J Surg Pathol*. 2002;26(11):1458-1466.
784. Wang J, Sun NC, Chen YY, Weiss LM. T-cell/histiocyte-rich large B-cell lymphoma displays a heterogeneity similar to diffuse large B-cell lymphoma: a clinicopathologic, immunohistochemical, and molecular study of 30 cases. *Appl Immunohistochem Mol Morphol*. 2005;13(2):109-115.
785. Rudiger T, Ott G, Ott MM, et al. Differential diagnosis between classic Hodgkin's lymphoma, T-cell-rich B-cell lymphoma, and paragranuloma by paraffin immunohistochemistry. *Am J Surg Pathol*. 1998;22(10):1184-1191.
786. De Jong D, Van Gorp J, Sie-Go D, Van Heerde P. T-cell rich b-cell non-hodgkin's lymphoma: a progressed form of follicle centre cell lymphoma and lymphocyte predominance hodgkin's disease. *Histopathology*. 1996;28(1):15-24.
787. Fraga M, Sanchez-Verde L, Forteza J, et al. T-cell/histiocyte-rich large B-cell lymphoma is a disseminated aggressive neoplasm: differential diagnosis from Hodgkin's lymphoma. *Histopathology*. 2002;41(3):216-229.
788. Fleming MD, Shahsafaei A, Dorfman DM. Absence of dendritic reticulum cell staining is helpful for distinguishing T-cell-rich B-cell lymphoma from lymphocyte predominance Hodgkin's disease. *Appl Immunohistochem Mol Morphol*. 1998;6:16-22.
789. Franke S, Wlodarska I, Maes B, et al. Comparative genomic hybridization pattern distinguishes T-cell/histiocyte-rich B-cell lymphoma from nodular lymphocyte predominance Hodgkin's lymphoma. *Am J Pathol*. 2002;161(5):1861-1867.
790. Aozasa K, Takakuwa T, Nakatsuka S. Pyothorax-associated lymphoma: a lymphoma developing in chronic inflammation. *Adv Anat Pathol*. 2005;12(6):324-331.
791. Loong F, Chan AC, Ho BC, et al. Diffuse large B-cell lymphoma associated with chronic inflammation as an incidental finding and new clinical scenarios. *Mod Pathol*. 2010;23(4):493-501.
792. Oyama T, Ichimura K, Suzuki R, et al. Senile EBV+ B-cell lymphoproliferative disorders: a clinicopathologic study of 22 patients. *Am J Surg Pathol*. 2003;27(1):16-26.
793. Cohen M, Narbaitz M, Metrebian F, et al. Epstein-Barr virus-positive diffuse large B-cell lymphoma association is not only restricted to elderly patients. *Int J Cancer*. 2014;135(12):2816-2824.
794. Montes-Moreno S, Odqvist L, Diaz-Perez JA, et al. EBV-positive diffuse large B-cell lymphoma of the elderly is an aggressive post-germinal center B-cell neoplasm characterized by prominent nuclear factor-κB activation. *Mod Pathol*. 2012;25(7):968-982.
795. Dojcinov SD, Venkataraman G, Pittaluga S, et al. Age-related EBV-associated lymphoproliferative disorders in the Western population: a spectrum of reactive lymphoid hyperplasia and lymphoma. *Blood*. 2011;117(18):4726-4735.
796. Oyama T, Yamamoto K, Asano N, et al. Age-related EBV-associated B-cell lymphoproliferative disorders constitute a distinct clinicopathologic group: a study of 96 patients. *Clin Cancer Res*. 2007;13(17):5124-5132.
797. Castillo JJ, Bibas M, Miranda RN. The biology and treatment of plasmablastic lymphoma. *Blood*. 2015;125(15):2323-2330.
798. Colomo L, Loong F, Rives S, et al. Diffuse large B-cell lymphomas with plasmablastic differentiation represent a heterogeneous group of disease entities. *Am J Surg Pathol*. 2004;28(6):736-747.
799. Delecluse HJ, Anagnostopoulos I, Dallenbach F, et al. Plasmablastic lymphomas of the oral cavity: a new entity associated with the human immunodeficiency virus infection. *Blood*. 1997;89(4):1413-1420.
800. Taddesse-Heath L, Meloni-Ehrig A, Scheerle J, et al. Plasmablastic lymphoma with MYC translocation: evidence for a common pathway in the generation of plasmablastic features. *Mod Pathol*. 2010;23(7):991-999.
801. Valera A, Balague O, Colomo L, et al. IG/MYC rearrangements are the main cytogenetic alteration in plasmablastic lymphomas. *Am J Surg Pathol*. 2010;34(11):1686-1694.
802. Laurent C, Do C, Gascoyne RD, et al. Anaplastic lymphoma kinase-positive diffuse large B-cell lymphoma: a rare clinicopathologic entity with poor prognosis. *J Clin Oncol*. 2009;27(25):4211-4216.
803. Delsol G, Lamant L, Mariame B, et al. A new subtype of large B-cell lymphoma expressing the ALK kinase and lacking the 2; 5 translocation. *Blood*. 1997;89(5):1483-1490.
804. De Paepe P, Baens M, van Krieken H, et al. ALK activation by the CLTC-ALK fusion is a recurrent event in large B-cell lymphoma. *Blood*. 2003;102(7):2638-2641.
805. Gascoyne RD, Lamant L, Martin-Subero JI, et al. ALK-positive diffuse large B-cell lymphoma is associated with Clathrin-ALK rearrangements: report of 6 cases. *Blood*. 2003;102(7):2568-2573.
806. Valera A, Colomo L, Martinez A, et al. ALK-positive large B-cell lymphomas express a terminal B-cell differentiation program and activated STAT3 but lack MYC rearrangements. *Mod Pathol*. 2013;26(10):1329-1337.
807. Nador RG, Cesarman E, Chadburn A, et al. Primary effusion lymphoma: a distinct clinicopathologic entity associated with the Kaposi's sarcoma-associated herpes virus. *Blood*. 1996;88(2):645-656.
808. Carbone A, Gloghini A, Vaccher E, et al. Kaposi's sarcoma-associated herpesvirus/human herpesvirus type 8-positive solid lymphomas: a tissue-based variant of primary effusion lymphoma. *J Mol Diagn*. 2005;7(1):17-27.
809. Engels EA, Pittaluga S, Whitby D, et al. Immunoblastic lymphoma in persons with AIDS-associated Kaposi's sarcoma: a role for Kaposi's sarcoma-associated herpesvirus. *Mod Pathol*. 2003;16(5):424-429.
810. Courville EL, Sohani AR, Hasserjian RP, et al. Diverse clinicopathologic features in human herpesvirus 8-associated lymphomas lead to diagnostic problems. *Am J Clin Pathol*. 2014;142(6):816-829.
811. Nkrumah FK, Perkins IV. Burkitt's lymphoma: a clinical study of 110 patients. *Cancer*. 1976;37(2):671-676.
812. Davi F, Delecluse HJ, Guiet P, et al. Burkitt-like lymphomas in AIDS patients: characterization within a series of 103 human immunodeficiency virus-associated

For personal use only. No other uses without permission. Copyright ©2017. Elsevier Inc. All rights reserved.

non-Hodgkin's lymphomas. Burkitt's Lymphoma Study Group. *J Clin Oncol*. 1998;16(12):3788-3795.
813. Spina M, Tirelli U, Zagonel V, et al. Burkitt's lymphoma in adults with and without human immunodeficiency virus infection: a single-institution clinicopathologic study of 75 patients. *Cancer*. 1998;82(4):766-774.
814. Arseneau JC, Canellos GP, Banks PM, et al. American Burkitt's lymphoma: a clinicopathologic study of 30 cases. I. Clinical factors relating to prolonged survival. *Am J Med*. 1975;58(3):314-321.
815. Banks PM, Arseneau JC, Gralnick HR, et al. American Burkitt's lymphoma: a clinicopathologic study of 30 cases. II. Pathologic correlations. *Am J Med*. 1975;58(3):322-329.
816. Minerbrook M, Schulman P, Budman DR, et al. Burkitt's leukemia: a re-evaluation. *Cancer*. 1982;49(7):1444-1448.
817. Mann RB, Jaffe ES, Braylan RC, et al. Non-endemic Burkitts's lymphoma. A B-cell tumor related to germinal centers. *N Engl J Med*. 1976;295(13):685-691.
818. Berard CB, O'Connor GT, Thomas LB, Torloni H. Histopathologic definition of Burkitt's tumor. *Bull WHO*. 1969;40:601-608.
819. Haralambieva E, Rosati S, van Noesel C, et al. Florid granulomatous reaction in Epstein-Barr virus-positive nonendemic Burkitt lymphomas: report of four cases. *Am J Surg Pathol*. 2004;28(3):379-383.
820. Bernhard W. Fine structure of Burkitt's lymphoma. In: Burkitt DP, Wright DH, eds. *Burkitt's Lymphoma*. Edinburgh: E and S Livingstone; 1970:103-117.
821. Garcia CF, Weiss LM, Warnke RA. Small noncleaved cell lymphoma: an immunophenotypic study of 18 cases and comparison with large cell lymphoma. *Hum Pathol*. 1986;17(5):454-461.
822. Haralambieva E, Boerma EJ, van Imhoff GW, et al. Clinical, immunophenotypic, and genetic analysis of adult lymphomas with morphologic features of Burkitt lymphoma. *Am J Surg Pathol*. 2005;29(8):1086-1094.
823. Leoncini L, Raphael M, Stein H, et al. Burkitt lymphoma. In: Swerdlow SH, Campo E, Harris NL, et al, eds. *WHO Classification of Tumours of Haematopoietic and Lymphoid Tissues*. 4th ed. Lyon: IARC Press; 2008:262-264.
824. Dang CV. c-Myc target genes involved in cell growth, apoptosis, and metabolism. *Mol Cell Biol*. 1999;19(1):1-11.
825. Johnson NA, Savage KJ, Ludkovski O, et al. Lymphomas with concurrent BCL2 and MYC translocations: the critical factors associated with survival. *Blood*. 2009;114(11):2273-2279.
826. Klapper W, Stoecklein H, Zeynalova S, et al. Structural aberrations affecting the MYC locus indicate a poor prognosis independent of clinical risk factors in diffuse large B-cell lymphomas treated within randomized trials of the German High-Grade Non-Hodgkin's Lymphoma Study Group (DSHNHL). *Leukemia*. 2008;22(12):2226-2229.
827. Niitsu N, Okamoto M, Miura I, Hirano M. Clinical features and prognosis of de novo diffuse large B-cell lymphoma with t(14;18) and 8q24/c-MYC translocations. *Leukemia*. 2009;23(4):777-783.
828. Savage KJ, Johnson NA, Ben-Neriah S, et al. MYC gene rearrangements are associated with a poor prognosis in diffuse large B-cell lymphoma patients treated with R-CHOP chemotherapy. *Blood*. 2009;114(17):3533-3537.
829. Ferreiro JF, Morscio J, Dierickx D, et al. Post-transplant molecularly defined Burkitt lymphomas are frequently MYC-negative and characterized by the 11q-gain/loss pattern. *Haematologica*. 2015;100(7):e275-e279.
830. Salaverria I, Martin-Guerrero I, Wagener R, et al. A recurrent 11q aberration pattern characterizes a subset of MYC-negative high-grade B-cell lymphomas resembling Burkitt lymphoma. *Blood*. 2014;123(8):1187-1198.
831. Dunleavy K. Aggressive B cell Lymphoma: Optimal Therapy for MYC-positive, Double-hit, and Triple-hit DLBCL. *Curr Treat Options Oncol*. 2015;16(12):58.
832. Li S, Desai P, Lin P, et al. MYC/BCL6 double-hit lymphoma (DHL): a tumour associated with an aggressive clinical course and poor prognosis. *Histopathology*. 2016;68(7):1090-1098.
833. Li S, Lin P, Fayad LE, et al. B-cell lymphomas with MYC/8q24 rearrangements and IGH@ BCL2/t(14;18)(q32;q21): an aggressive disease with heterogeneous histology, germinal center B-cell immunophenotype and poor outcome. *Mod Pathol*. 2012;25(1):145-156.
834. Kallen ME, Alexanian S, Said J, Quintero-Rivera F. Triple hit lymphoma: rare cases with less dire than usual prognosis. *Int J Surg Pathol*. 2016;24(8):709-714.
835. Elenitoba-Johnson KS, Jaffe ES. Lymphoproliferative disorders associated with congenital immunodeficiencies. *Semin Diagn Pathol*. 1997;14(1):35-47.
836. Ioachim HL. Neoplasms associated with immune deficiencies. *Pathol Annu*. 1987;22(Pt 2):177-222.
837. Knowles DM. Immunodeficiency-associated lymphoproliferative disorders. *Mod Pathol*. 1999;12(2):200-217.
838. Said J. Genetic and molecular genetic studies in the diagnosis of immune-related lymphoproliferative disorders. *Hum Pathol*. 2003;34(4):341-345.
839. Louie S, Schwartz RS. Immunodeficiency and the pathogenesis of lymphoma and leukemia. *Semin Hematol*. 1978;15(2):117-138.
840. Kersey JH, Spector BD, Good RA. Primary immunodeficiency diseases and cancer: the immunodeficiency-cancer registry. *Int J Cancer*. 1973;12(2):333-347.
841. Spector BD, Perry GS 3rd, Kersey JH. Genetically determined immunodeficiency diseases (GDID) and malignancy: report from the immunodeficiency—cancer registry. *Clin Immunol Immunopathol*. 1978;11(1):12-29.
842. Sander CA, Medeiros LJ, Weiss LM, et al. Lymphoproliferative lesions in patients with common variable immunodeficiency syndrome. *Am J Surg Pathol*. 1992;16(12):1170-1182.
843. Ramalingam P, Rybicki L, Smith MD, et al. Posttransplant lymphoproliferative disorders in lung transplant patients: the Cleveland Clinic experience. *Mod Pathol*. 2002;15(6):647-656.
844. Al-Mansour Z, Nelson BP, Evens AM. Post-transplant lymphoproliferative disease (PTLD): risk factors, diagnosis, and current treatment strategies. *Curr Hematol Malig Rep*. 2013;8(3):173-183.
845. Wu TT, Swerdlow SH, Locker J, et al. Recurrent Epstein-Barr virus-associated lesions in organ transplant recipients. *Hum Pathol*. 1996;27(2):157-164.
846. Swerdlow SH. Classification of the posttransplant lymphoproliferative disorders: from the past to the present. *Semin Diagn Pathol*. 1997;14(1):2-7.
847. Knowles DM, Cesarman E, Chadburn A, et al. Correlative morphologic and molecular genetic analysis demonstrates three distinct categories of posttransplantation lymphoproliferative disorders. *Blood*. 1995;85(2):552-565.
848. Ferry JA, Jacobson JO, Conti D, et al. Lymphoproliferative disorders and hematologic malignancies following organ transplantation. *Mod Pathol*. 1989;2(6):583-592.
849. Leblond V, Sutton L, Dorent R, et al. Lymphoproliferative disorders after organ transplantation: a report of 24 cases observed in a single center. *J Clin Oncol*. 1995;13(4):961-968.
850. Penn I. Tumor incidence in human allograft recipients. *Transplant Proc*. 1979;11(1):1047-1051.
851. Cleary ML, Warnke R, Sklar J. Monoclonality of lymphoproliferative lesions in cardiac-transplant recipients. Clonal analysis based on immunoglobulin-gene rearrangements. *N Engl J Med*. 1984;310(8):477-482.
852. Swinnen LJ, Costanzo-Nordin MR, Fisher SG, et al. Increased incidence of lymphoproliferative disorder after immunosuppression with the monoclonal antibody OKT3 in cardiac-transplant recipients. *N Engl J Med*. 1990;323(25):1723-1728.
853. Harris NL, Ferry JA, Swerdlow SH. Posttransplant lymphoproliferative disorders: summary of Society for Hematopathology Workshop. *Semin Diagn Pathol*. 1997;14(1):8-14.
854. Randhawa PS, Jaffe R, Demetris AJ, et al. The systemic distribution of Epstein-Barr virus genomes in fatal post-transplantation lymphoproliferative disorders. An in situ hybridization study. *Am J Pathol*. 1991;138(4):1027-1033.
855. Tiede C, Maecker-Kolhoff B, Klein C, et al. Risk factors and prognosis in T-cell posttransplantation lymphoproliferative diseases: reevaluation of 163 cases. *Transplantation*. 2013;95(3):479-488.
856. Hsi ED, Singleton TP, Swinnen L, et al. Mucosa-associated lymphoid tissue-type lymphomas occurring in post-transplantation patients. *Am J Surg Pathol*. 2000;24(1):100-106.
857. Wood BL, Sabath D, Broudy VC, Raghu G. The recipient origin of posttransplant lymphoproliferative disorders in pulmonary transplant patients. A report of three cases. *Cancer*. 1996;78(10):2223-2228.
858. Shapiro RS, McClain K, Frizzera G, et al. Epstein-Barr virus associated B cell lymphoproliferative disorders following bone marrow transplantation. *Blood*. 1988;71(5):1234-1243.
859. Larson RS, Scott MA, McCurley TL, Vnencak-Jones CL. Microsatellite analysis of posttransplant lymphoproliferative disorders: determination of donor/recipient origin and identification of putative lymphomagenic mechanism. *Cancer Res*. 1996;56(19):4378-4381.
860. Orazi A, Hromas RA, Neiman RS, et al. Posttransplantation lymphoproliferative disorders in bone marrow transplant recipients are aggressive diseases with a high incidence of adverse histologic and immunobiologic features. *Am J Clin Pathol*. 1997;107(4):419-429.
861. Randhawa PS, Yousem SA, Paradis IL, et al. The clinical spectrum, pathology, and clonal analysis of Epstein-Barr virus-associated lymphoproliferative disorders in heart-lung transplant recipients. *Am J Clin Pathol*. 1989;92(2):177-185.
862. Armitage JM, Kormos RL, Stuart RS, et al. Posttransplant lymphoproliferative disease in thoracic organ transplant patients. Ten years of cyclosporine-based immunosuppression. *J Heart Lung Transplant*. 1991;10:877-887.

For personal use only. No other uses without permission. Copyright ©2017. Elsevier Inc. All rights reserved.

863. Beral V, Peterman T, Berkelman R, Jaffe H. AIDS-associated non-Hodgkin lymphoma. *Lancet*. 1991;337(8745):805-809.
864. Di Carlo EF, Amberson JB, Metroka CE, et al. Malignant lymphomas and the acquired immunodeficiency syndrome. Evaluation of 30 cases using a working formulation. *Arch Pathol Lab Med*. 1986;110(11):1012-1016.
865. Gail MH, Pluda JM, Rabkin CS, et al. Projections of the incidence of non-Hodgkin's lymphoma related to acquired immunodeficiency syndrome. *J Natl Cancer Inst*. 1991;83(10):695-701.
866. Ioachim HL, Cooper MC, Hellman GC. Lymphomas in men at high risk for acquired immune deficiency syndrome (AIDS). A study of 21 cases. *Cancer*. 1985;56(12):2831-2842.
867. Knowles DM. Acquired immunodeficiency syndrome-related lymphoma. *Blood*. 1992;80(1):8-20.
868. Said JW. Human immunodeficiency virus-related lymphoid proliferations. *Semin Diagn Pathol*. 1997;14(1):48-53.
869. Wang CY, Snow JL, Su WP. Lymphoma associated with human immunodeficiency virus infection. *Mayo Clin Proc*. 1995;70(7):665-672.
870. Carbone A. AIDS-related non-Hodgkin's lymphomas: from pathology and molecular pathogenesis to treatment. *Hum Pathol*. 2002;33(4):392-404.
871. Chetty R, Hlatswayo N, Muc R, et al. Plasmablastic lymphoma in HIV+ patients: an expanding spectrum. *Histopathology*. 2003;42(6):605-609.
872. Lowenthal DA, Straus DJ, Campbell SW, et al. AIDS-related lymphoid neoplasia. The Memorial Hospital experience. *Cancer*. 1988;61(11):2325-2337.
873. Carbone A, Gloghini A, Gaidano G, et al. AIDS-related Burkitt's lymphoma. Morphologic and immunophenotypic study of biopsy specimens. *Am J Clin Pathol*. 1995;103(5):561-567.
874. Raphael M, Gentilhomme O, Tulliez M, et al. Histopathologic features of high-grade non-Hodgkin's lymphomas in acquired immunodeficiency syndrome. The French Study Group of Pathology for Human Immunodeficiency Virus-Associated Tumors. *Arch Pathol Lab Med*. 1991;115(1):15-20.
875. Arber DA, Chang KL, Weiss LM. Peripheral T-cell lymphoma with Toutonlike tumor giant cells associated with HIV infection: report of two cases. *Am J Surg Pathol*. 1999;23(5):519-522.
876. Nador RG, Chadburn A, Gundappa G, et al. Human immunodeficiency virus (HIV)-associated polymorphic lymphoproliferative disorders. *Am J Surg Pathol*. 2003;27(3):293-302.
877. Katano H, Suda T, Morishita Y, et al. Human herpesvirus 8-associated solid lymphomas that occur in AIDS patients take anaplastic large cell morphology. *Mod Pathol*. 2000;13(1):77-85.
878. Hamilton-Dutoit SJ, Raphael M, Audouin J, et al. situ demonstration of Epstein-Barr virus small RNAs (EBER 1) in acquired immunodeficiency syndrome-related lymphomas. Correlation with tumor morphology and primary site. *Blood*. 1993;92:610-624.
879. Liebowitz D. Epstein-Barr virus and a cellular signaling pathway in lymphomas from immunosuppressed patients. *N Engl J Med*. 1998;338(20):1413-1421.
880. Pedersen C, Gerstoft J, Lundgren JD, et al. HIV-associated lymphoma: histopathology and association with Epstein-Barr virus genome related to clinical, immunological and prognostic features. *Eur J Cancer*. 1991;27(11):1416-1423.
881. Ellman MH, Hurwitz H, Thomas C, Kozloff M. Lymphoma developing in a patient with rheumatoid arthritis taking low dose weekly methotrexate. *J Rheumatol*. 1991;18(11):1741-1743.
882. Kamel OW, van de Rijn M, Weiss LM, et al. Brief report: reversible lymphomas associated with Epstein-Barr virus occurring during methotrexate therapy for rheumatoid arthritis and dermatomyositis. *N Engl J Med*. 1993;328(18):1317-1321.
883. Schmid U, Helbron D, Lennert K. Development of malignant lymphoma in myoepithelial sialadenitis (Sjogren's syndrome). *Virchows Arch A Pathol Anat Histol*. 1982;395(1):11-43.
884. Banks PM, Witrak GA, Conn DL. Lymphoid neoplasia following connective tissue disease. *Mayo Clin Proc*. 1979;54(2):104-108.
885. Cabecadas JM, Isaacson PG. Phenotyping of T-cell lymphomas in paraffin sections—which antibodies? *Histopathology*. 1991;19(5):419-424.
886. van Krieken JH, Elwood L, Andrade RE, et al. Rearrangement of the T-cell receptor delta chain gene in T-cell lymphomas with a mature phenotype. *Am J Pathol*. 1991;139(1):161-168.
887. Sheibani K, Wu A, Ben-Ezra J, et al. Rearrangement of kappa-chain and T-cell receptor beta-chain genes in malignant lymphomas of "T-cell" phenotype. *Am J Pathol*. 1987;129(2):201-207.
888. Attygalle AD, Kyriakou C, Dupuis J, et al. Histologic evolution of angioimmunoblastic T-cell lymphoma in consecutive biopsies: clinical correlation and insights into natural history and disease progression. *Am J Surg Pathol*. 2007;31(7):1077-1088.
889. Freter CE, Cossman J. Angioimmunoblastic lymphadenopathy with dysproteinemia. *Semin Oncol*. 1993;20(6):627-635.
890. Frizzera G, Moran EM, Rappaport H. Angio-immunoblastic lymphadenopathy with dysproteinaemia. *Lancet*. 1974;1(7866):1070-1073.
891. Lukes RJ, Tindle BH. Immunoblastic lymphadenopathy. A hyperimmune entity resembling Hodgkin's disease. *N Engl J Med*. 1975;292(1):1-8.
892. Bernengo MG, Levi L, Zina G. Skin lesions in angioimmunoblastic lymphadenopathy: histological and immunological studies. *Br J Dermatol*. 1981;104(2):131-139.
893. Frizzera G, Moran EM, Rappaport H. Angio-immunoblastic lymphadenopathy. Diagnosis and clinical course. *Am J Med*. 1975;59(6):803-818.
894. Seehafer JR, Goldberg NC, Dicken CH, Su WP. Cutaneous manifestations of angioimmunoblastic lymphadenopathy. *Arch Dermatol*. 1980;116(1):41-45.
895. Ree HJ, Kadin ME, Kikuchi M, et al. Angioimmunoblastic lymphoma (AILD-type T-cell lymphoma) with hyperplastic germinal centers. *Am J Surg Pathol*. 1998;22(6):643-655.
896. Jones D, Jorgensen JL, Shahsafaei A, Dorfman DM. Characteristic proliferations of reticular and dendritic cells in angioimmunoblastic lymphoma. *Am J Surg Pathol*. 1998;22(8):956-964.
897. Ohshima K, Takeo H, Kikuchi M, et al. Heterogeneity of Epstein-Barr virus infection in angioimmunoblastic lymphadenopathy type T-cell lymphoma. *Histopathology*. 1994;25(6):569-579.
898. Nathwani BN, Kim H, Rappaport H, et al. Non-Hodgkin's lymphomas: a clinicopathologic study comparing two classifications. *Cancer*. 1978;41(1):303-325.
899. Lachenal F, Berger F, Ghesquieres H, et al. Angioimmunoblastic T-cell lymphoma: clinical and laboratory features at diagnosis in 77 patients. *Medicine (Baltimore)*. 2007;86(5):282-292.
900. Smith JL, Hodges E, Quin CT, et al. Frequent T and B cell oligoclones in histologically and immunophenotypically characterized angioimmunoblastic lymphadenopathy. *Am J Pathol*. 2000;156(2):661-669.
901. Nelson M, Horsman DE, Weisenburger DD, et al. Cytogenetic abnormalities and clinical correlations in peripheral T-cell lymphoma. *Br J Haematol*. 2008;141(4):461-469.
902. Thorns C, Bastian B, Pinkel D, et al. Chromosomal aberrations in angioimmunoblastic T-cell lymphoma and peripheral T-cell lymphoma unspecified: a matrix-based CGH approach. *Genes Chromosomes Cancer*. 2007;46(1):37-44.
903. de Leval L, Rickman DS, Thielen C, et al. The gene expression profile of nodal peripheral T-cell lymphoma demonstrates a molecular link between angioimmunoblastic T-cell lymphoma (AITL) and follicular helper T (TFH) cells. *Blood*. 2007;109(11):4952-4963.
904. Iqbal J, Weisenburger DD, Greiner TC, et al. Molecular signatures to improve diagnosis in peripheral T-cell lymphoma and prognostication in angioimmunoblastic T-cell lymphoma. *Blood*. 2010;115(5):1026-1036.
905. Piccaluga PP, Agostinelli C, Califano A, et al. Gene expression analysis of angioimmunoblastic lymphoma indicates derivation from T follicular helper cells and vascular endothelial growth factor deregulation. *Cancer Res*. 2007;67(22):10703-10710.
906. Cairns RA, Iqbal J, Lemonnier F, et al. IDH2 mutations are frequent in angioimmunoblastic T-cell lymphoma. *Blood*. 2012;119(8):1901-1903.
907. Odejide O, Weigert O, Lane AA, et al. A targeted mutational landscape of angioimmunoblastic T-cell lymphoma. *Blood*. 2014;123(9):1293-1296.
908. Lemonnier F, Couronne L, Parrens M, et al. Recurrent TET2 mutations in peripheral T-cell lymphomas correlate with TFH-like features and adverse clinical parameters. *Blood*. 2012;120(7):1466-1469.
909. Vallois D, Dobay MP, Morin RD, et al. Activating mutations in genes related to TCR signaling in angioimmunoblastic and other follicular helper T-cell-derived lymphomas. *Blood*. 2016;128(11):1490-1502.
910. Huang Y, Moreau A, Dupuis J, et al. Peripheral T-cell lymphomas with a follicular growth pattern are derived from follicular helper T cells (TFH) and may show overlapping features with angioimmunoblastic T-cell lymphomas. *Am J Surg Pathol*. 2009;33(5):682-690.
911. Agnarsson BA, Kadin ME. Ki-1 positive large cell lymphoma. A morphologic and immunologic study of 19 cases. *Am J Surg Pathol*. 1988;12(4):264-274.
912. Chott A, Kaserer K, Augustin I, et al. Ki-1-positive large cell lymphoma. A clinicopathologic study of 41 cases. *Am J Surg Pathol*. 1990;14(5):439-448.
913. Kaudewitz P, Greer JP, Glick AD, et al. Anaplastic large-cell Ki-1 malignant lymphomas. Recognition, biological and clinical implications. *Pathol Annu*. 1991;26(Pt 1):1-24.
914. Kaudewitz P, Stein H, Dallenbach F, et al. Primary and secondary cutaneous Ki-1+ (CD30+) anaplastic large cell lymphomas. Morphologic, immunohistologic, and clinical-characteristics. *Am J Pathol*. 1989;135(2):359-367.
915. Bakshi NA, Ross CW, Finn WG, et al. ALK-positive anaplastic large cell lymphoma with primary bone involvement in children. *Am J Clin Pathol*. 2006;125(1):57-63.

For personal use only. No other uses without permission. Copyright ©2017. Elsevier Inc. All rights reserved.

916. Chan JK, Ng CS, Hui PK, et al. Anaplastic large cell Ki-1 lymphoma of bone. *Cancer*. 1991;68(10):2186-2191.
917. Wong KF, Chan JK, Ng CS, et al. Anaplastic large cell Ki-1 lymphoma involving bone marrow: marrow findings and association with reactive hemophagocytosis. *Am J Hematol*. 1991;37(2):112-119.
918. d'Amore ES, Menin A, Bonoldi E, et al. Anaplastic large cell lymphomas: a study of 75 pediatric patients. *Pediatr Dev Pathol*. 2007;10(3):181-191.
919. Kadin ME. Ki-1/CD30+ (anaplastic) large-cell lymphoma: maturation of a clinicopathologic entity with prospects of effective therapy. *J Clin Oncol*. 1994;12(5):884-887.
920. Shulman LN, Frisard B, Antin JH, et al. Primary Ki-1 anaplastic large-cell lymphoma in adults: clinical characteristics and therapeutic outcome. *J Clin Oncol*. 1993;11(5):937-942.
921. Zinzani PL, Bendandi M, Martelli M, et al. Anaplastic large-cell lymphoma: clinical and prognostic evaluation of 90 adult patients. *J Clin Oncol*. 1996;14(3): 955-962.
922. Anderson MM, Ross CW, Singleton TP, et al. Ki-1 anaplastic large cell lymphoma with a prominent leukemic phase. *Hum Pathol*. 1996;27(10):1093-1095.
923. Kinney MC, Kadin ME. The pathologic and clinical spectrum of anaplastic large cell lymphoma and correlation with ALK gene dysregulation. *Am J Clin Pathol*. 1999;111(1 suppl 1):S56-S67.
924. Chan JK, Buchanan R, Fletcher CD. Sarcomatoid variant of anaplastic large-cell Ki-1 lymphoma. *Am J Surg Pathol*. 1990;14(10):983-988.
925. Chan JK. The perivascular cuff of large lymphoid cells: a clue to diagnosis of anaplastic large cell lymphoma. *Int J Surg Pathol*. 2000;8(2):153-156.
926. Hodges KB, Collins RD, Greer JP, et al. Transformation of the small cell variant Ki-1+ lymphoma to anaplastic large cell lymphoma: pathologic and clinical features. *Am J Surg Pathol*. 1999;23(1):49-58.
927. Klapper W, Bohm M, Siebert R, Lennert K. Morphological variability of lymphohistiocytic variant of anaplastic large cell lymphoma (former lymphohistiocytic lymphoma according to the Kiel classification). *Virchows Arch*. 2008;452(6):599-605.
928. Pileri S, Falini B, Delsol G, et al. Lymphohistiocytic T-cell lymphoma (anaplastic large cell lymphoma CD30+/Ki-1 + with a high content of reactive histiocytes). *Histopathology*. 1990;16(4):383-391.
929. Pileri SA, Pulford K, Mori S, et al. Frequent expression of the NPM-ALK chimeric fusion protein in anaplastic large-cell lymphoma, lympho-histiocytic type. *Am J Pathol*. 1997;150(4):1207-1211.
930. McCluggage WG, Walsh MY, Bharucha H. Anaplastic large cell malignant lymphoma with extensive eosinophilic or neutrophilic infiltration. *Histopathology*. 1998;32(2):110-115.
931. Mann KP, Hall B, Kamino H, et al. Neutrophil-rich, Ki-1-positive anaplastic large-cell malignant lymphoma. *Am J Surg Pathol*. 1995;19(4):407-416.
932. Falini B, Liso A, Pasqualucci L, et al. CD30+ anaplastic large-cell lymphoma, null type, with signet-ring appearance. *Histopathology*. 1997;30(1):90-92.
933. Falini B, Bigerna B, Fizzotti M, et al. ALK expression defines a distinct group of T/null lymphomas ("ALK lymphomas") with a wide morphological spectrum. *Am J Pathol*. 1998;153(3):875-886.
934. Cheuk W, Hill RW, Bacchi C, et al. Hypocellular anaplastic large cell lymphoma mimicking inflammatory lesions of lymph nodes. *Am J Surg Pathol*. 2000;24(11):1537-1543.
935. Hansmann ML, Fellbaum C, Bohm A. Large cell anaplastic lymphoma: evaluation of immunophenotype on paraffin and frozen sections in comparison with ultrastructural features. *Virchows Arch A Pathol Anat Histopathol*. 1991;418(5):427-433.
936. Delsol G, Al Saati T, Gatter KC, et al. Coexpression of epithelial membrane antigen (EMA), Ki-1, and interleukin-2 receptor by anaplastic large cell lymphomas. Diagnostic value in so-called malignant histiocytosis. *Am J Pathol*. 1988;130(1):59-70.
937. Nascimento AF, Pinkus JL, Pinkus GS. Clusterin, a marker for anaplastic large cell lymphoma immunohistochemical profile in hematopoietic and nonhematopoietic malignant neoplasms. *Am J Clin Pathol*. 2004;121(5):709-717.
938. Ashton-Key M, Cowley GP, Smith ME. Cadherins in reactive lymph nodes and lymphomas: high expression in anaplastic large cell lymphomas. *Histopathology*. 1996;28(1):55-59.
939. Konstantinov KN, Robbins BA, Liu FT. Galectin-3, a beta-galactoside-binding animal lectin, is a marker of anaplastic large-cell lymphoma. *Am J Pathol*. 1996;148(1):25-30.
940. Gustmann C, Altmannsberger M, Osborn M, et al. Cytokeratin expression and vimentin content in large cell anaplastic lymphomas and other non-Hodgkin's lymphomas. *Am J Pathol*. 1991;138(6):1413-1422.
941. Tan BT, Seo K, Warnke RA, Arber DA. The frequency of immunoglobulin heavy chain gene and T-cell receptor gamma-chain gene rearrangements and Epstein-Barr virus in ALK+ and ALK- anaplastic large cell lymphoma and other peripheral T-cell lymphomas. *J Mol Diagn*. 2008;10(6):502-512.
942. Chan JK, Lamant L, Algar E, et al. ALK+ histiocytosis: a novel type of systemic histiocytic proliferative disorder of early infancy. *Blood*. 2008;112(7):2965-2968.
943. Coffin CM, Patel A, Perkins S, et al. ALK1 and p80 expression and chromosomal rearrangements involving 2p23 in inflammatory myofibroblastic tumor. *Mod Pathol*. 2001;14(6):569-576.
944. Delsol G, Campo E, Gascoyne RD. ALK-positive large B-cell lymphoma. In: Swerdlow SH, Campo E, Harris NL, et al, eds. *WHO Classification of Tumours of Haematopoietic and Lymphoid Tissues*. 4th ed. Lyon: IARC Press; 2008:254-255.
945. Delsol G, Falini B, Müller-Hermelink HK, et al. Anaplastic large cell lymphoma (ALCL), ALK-positive. In: Swerdlow SH, Campo E, Harris NL, et al, eds. *WHO Classification of Tumours of Haematopoietic and Lymphoid Tissues*. 4th ed. Lyon: IARC Press; 2008:312-316.
946. Rodig SJ, Mino-Kenudson M, Dacic S, et al. Unique clinicopathologic features characterize ALK-rearranged lung adenocarcinoma in the western population. *Clin Cancer Res*. 2009;15(16):5216-5223.
947. Soda M, Choi YL, Enomoto M, et al. Identification of the transforming EML4-ALK fusion gene in non-small-cell lung cancer. *Nature*. 2007;448(7153):561-566.
948. Stein H, Foss HD, Durkop H, et al. CD30(+) anaplastic large cell lymphoma: a review of its histopathologic, genetic, and clinical features. *Blood*. 2000;96(12):3681-3695.
949. Falini B, Pulford K, Pucciarini A, et al. Lymphomas expressing ALK fusion protein(s) other than NPM-ALK. *Blood*. 1999;94(10):3509-3515.
950. Savage KJ, Harris NL, Vose JM, et al. ALK- anaplastic large-cell lymphoma is clinically and immunophenotypically different from both ALK+ ALCL and peripheral T-cell lymphoma, not otherwise specified: report from the International Peripheral T-Cell Lymphoma Project. *Blood*. 2008;111(12):5496-5504.
951. Parrilla Castellar ER, Jaffe ES, Said JW, et al. ALK-negative anaplastic large cell lymphoma is a genetically heterogeneous disease with widely disparate clinical outcomes. *Blood*. 2014;124(9):1473-1480.
952. ten Berge RL, Oudejans JJ, Ossenkoppele GJ, Meijer CJ. ALK-negative systemic anaplastic large cell lymphoma: differential diagnostic and prognostic aspects—a review. *J Pathol*. 2003;200(1):4-15.
953. Lamant L, de Reynies A, Duplantier MM, et al. Gene-expression profiling of systemic anaplastic large-cell lymphoma reveals differences based on ALK status and two distinct morphologic ALK+ subtypes. *Blood*. 2007;109(5):2156-2164.
954. Vasmatzis G, Johnson SH, Knudson RA, et al. Genome-wide analysis reveals recurrent structural abnormalities of TP63 and other p53-related genes in peripheral T-cell lymphomas. *Blood*. 2012;120(11):2280-2289.
955. Feldman AL, Dogan A, Smith DI, et al. Discovery of recurrent t(6;7)(p25.3;q32.3) translocations in ALK-negative anaplastic large cell lymphomas by massively parallel genomic sequencing. *Blood*. 2011;117(3):915-919.
956. Miranda RN, Aladily TN, Prince HM, et al. Breast implant-associated anaplastic large-cell lymphoma: long-term follow-up of 60 patients. *J Clin Oncol*. 2014;32(2):114-120.
957. Ballester B, Ramuz O, Gisselbrecht C, et al. Gene expression profiling identifies molecular subgroups among nodal peripheral T-cell lymphomas. *Oncogene*. 2006;25(10):1560-1570.
958. Dupuis J, Emile JF, Mounier N, et al. Prognostic significance of Epstein-Barr virus in nodal peripheral T-cell lymphoma, unspecified: a Groupe d'Etude des Lymphomes de l'Adulte (GELA) study. *Blood*. 2006;108(13):4163-4169.
959. Went P, Agostinelli C, Gallamini A, et al. Marker expression in peripheral T-cell lymphoma: a proposed clinical-pathologic prognostic score. *J Clin Oncol*. 2006;24(16):2472-2479.
960. Banchereau J, Steinman RM. Dendritic cells and the control of immunity. *Nature*. 1998;392(6673):245-252.
961. Dorfman DM, Shahsafaei A, Chan JKC, Fletcher CD. Dendritic reticulum cell (DRC) sarcomas are immunoreactive for low-affinity nerve growth factor receptor (LNGFR). Further evidence for DRC differentiation. *Appl Immunohistochem Mol Morphol*. 1996;4:249-258.
962. Imal Y, Yamakawa M. Morphology, function and pathology of follicular dendritic cells. *Pathol Int*. 1996;46(11):807-833.
963. Takahashi K, Naito M, Takeya M. Development and heterogeneity of macrophages and their related cells through their differentiation pathways. *Pathol Int*. 1996;46(7):473-485.
964. Wacker HH, Frahm SO, Heidebrecht HJ, Parwaresch R. Sinus-lining cells of the lymph nodes recognized as a dendritic cell type by the new monoclonal antibody Ki-M9. *Am J Pathol*. 1997;151(2):423-434.
965. Wright-Browne V, McClain KL, Talpaz M, et al. Physiology and pathophysiology of dendritic cells. *Hum Pathol*. 1997;28(5):563-579.
966. Emile JF, Abla O, Fraitag S, et al. Revised classification of histiocytoses and neoplasms

For personal use only. No other uses without permission. Copyright ©2017. Elsevier Inc. All rights reserved.

of the macrophage-dendritic cell lineages. *Blood*. 2016;127(22):2672-2681.
967. Monda L, Warnke R, Rosai J. A primary lymph node malignancy with features suggestive of dendritic reticulum cell differentiation. A report of 4 cases. *Am J Pathol*. 1986;122(3):562-572.
968. Shia J, Chen W, Tang LH, et al. Extranodal follicular dendritic cell sarcoma: clinical, pathologic, and histogenetic characteristics of an underrecognized disease entity. *Virchows Arch*. 2006;449(2):148-158.
969. Han JH, Kim SH, Noh SH, et al. Follicular dendritic cell sarcoma presenting as a submucosal tumor of the stomach. *Arch Pathol Lab Med*. 2000;124(11):1693-1696.
970. Hollowood K, Stamp G, Zouvani I, Fletcher CD. Extranodal follicular dendritic cell sarcoma of the gastrointestinal tract. Morphologic, immunohistochemical and ultrastructural analysis of two cases. *Am J Clin Pathol*. 1995;103(1):90-97.
971. Chang KC, Jin YT, Chen FF, Su IJ. Follicular dendritic cell sarcoma of the colon mimicking stromal tumour. *Histopathology*. 2001;38(1):25-29.
972. Yamakawa M, Andoh A, Masuda A, et al. Follicular dendritic cell sarcoma of the omentum. *Virchows Arch*. 2002;440(6):660-663.
973. Moriki T, Takahashi T, Wada M, et al. Follicular dendritic cell tumor of the mesentery. *Pathol Res Pract*. 1997;193(9):629-639, discussion 40-42.
974. Chen TC, Kuo TT, Ng KF. Follicular dendritic cell tumor of the liver: a clinicopathologic and Epstein-Barr virus study of two cases. *Mod Pathol*. 2001;14(4):354-360.
975. Beham-Schmid C, Beham A, Jakse R, et al. Extranodal follicular dendritic cell tumour of the nasopharynx. *Virchows Arch*. 1998;432(3):293-298.
976. Nayler SJ, Verhaart MJ, Cooper K. Follicular dendritic cell tumour of the tonsil. *Histopathology*. 1996;28(1):89-92.
977. Biddle DA, Ro JY, Yoon GS, et al. Extranodal follicular dendritic cell sarcoma of the head and neck region: three new cases, with a review of the literature. *Mod Pathol*. 2002;15(1):50-58.
978. Fassina A, Marino F, Poletti A, et al. Follicular dendritic cell tumor of the mediastinum. *Ann Diagn Pathol*. 2001;5(6):361-367.
979. Kawachi K, Nakatani Y, Inayama Y, et al. Interdigitating dendritic cell sarcoma of the spleen: report of a case with a review of the literature. *Am J Surg Pathol*. 2002;26(4):530-537.
980. Shah RN, Ozden O, Yeldandi A, et al. Follicular dendritic cell tumor presenting in the lung: a case report. *Hum Pathol*. 2001;32(7):745-749.
981. Fisher C, Magnusson B, Hardarson S, Smith ME. Myxoid variant of follicular dendritic cell sarcoma arising in the breast. *Ann Diagn Pathol*. 1999;3(2):92-98.
982. Pruneri G, Masullo M, Renne G, et al. Follicular dendritic cell sarcoma of the breast. *Virchows Arch*. 2002;441(2): 194-199.
983. Chan AC, Chan KW, Chan JK, et al. Development of follicular dendritic cell sarcoma in hyaline-vascular Castleman's disease of the nasopharynx: tracing its evolution by sequential biopsies. *Histopathology*. 2001;38(6):510-518.
984. Saiz AD, Chan O, Strauchen JA. Follicular dendritic cell tumor in Castleman's disease: a report of two cases. *Int J Surg Pathol*. 1997;5:25-30.
985. Selves J, Meggetto F, Brousset P, et al. Inflammatory pseudotumor of the liver. Evidence for follicular dendritic reticulum cell proliferation associated with clonal Epstein-Barr virus. *Am J Surg Pathol*. 1996;20(6):747-753.
986. Cheuk W, Chan JK, Shek TW, et al. Inflammatory pseudotumor-like follicular dendritic cell tumor: a distinctive low-grade malignant intra-abdominal neoplasm with consistent Epstein-Barr virus association. *Am J Surg Pathol*. 2001;25(6):721-731.
987. Shek TW, Ho FC, Ng IO, et al. Follicular dendritic cell tumor of the liver. Evidence for an Epstein-Barr virus-related clonal proliferation of follicular dendritic cells. *Am J Surg Pathol*. 1996;20(3):313-324.
988. Weiss LM, Berry GJ, Dorfman RF, et al. Spindle cell neoplasms of lymph nodes of probable reticulum cell lineage. True reticulum cell sarcoma? *Am J Surg Pathol*. 1990;14(5):405-414.
989. Hollowood K, Pease C, Mackay AM, Fletcher CD. Sarcomatoid tumours of lymph nodes showing follicular dendritic cell differentiation. *J Pathol*. 1991;163(3):205-216.
990. Chan JK. Proliferative lesions of follicular dendritic cells: an overview, including a detailed account of follicular dendritic cell sarcoma, a neoplasm with many faces and uncommon etiologic association. *Adv Anat Pathol*. 1997;4:387-411.
991. Grogg KL, Lae ME, Kurtin PJ, Macon WR. Clusterin expression distinguishes follicular dendritic cell tumors from other dendritic cell neoplasms: report of a novel follicular dendritic cell marker and clinicopathologic data on 12 additional follicular dendritic cell tumors and 6 additional interdigitating dendritic cell tumors. *Am J Surg Pathol*. 2004;28(8):988-998.
992. Perez-Ordonez B, Erlandson RA, Rosai J. Follicular dendritic cell tumor: report of 13 additional cases of a distinctive entity. *Am J Surg Pathol*. 1996;20(8):944-955.
993. Chen W, Lau SK, Fong D, et al. High frequency of clonal immunoglobulin receptor gene rearrangements in sporadic histiocytic/dendritic cell sarcomas. *Am J Surg Pathol*. 2009;33(6):863-873.
994. Perez-Ordonez B, Rosai J. Follicular dendritic cell tumor: review of the entity. *Semin Diagn Pathol*. 1998;15(2):144-154.
995. Chan JK, Fletcher CD, Nayler SJ, Cooper K. Follicular dendritic cell sarcoma. Clinicopathologic analysis of 17 cases suggesting a malignant potential higher than currently recognized. *Cancer*. 1997;79(2):294-313.
996. Gaertner EM, Tsokos M, Derringer GA, et al. Interdigitating dendritic cell sarcoma. A report of four cases and review of the literature. *Am J Clin Pathol*. 2001;115(4):589-597.
997. Pillay K, Solomon R, Daubenton JD, Sinclair-Smith CC. Interdigitating dendritic cell sarcoma: a report of four paediatric cases and review of the literature. *Histopathology*. 2004;44(3):283-291.
998. Feltkamp CA, van Heerde P, Feltkamp-Vroom TM, Koudstaal J. A malignant tumor arising from interdigitating cells; light microscopical, ultrastructural, immuno- and enzyme-histochemical characteristics. *Virchows Arch A Pathol Anat Histol*. 1981;393:183-192.
999. Gould VE, Bloom KJ, Franke WW, et al. Increased numbers of cytokeratin-positive interstitial reticulum cells (CIRC) in reactive, inflammatory and neoplastic lymphadenopathies: hyperplasia or induced expression? *Virchows Arch*. 1995;425(6):617-629.
1000. Hui PK, Feller AC, Kaiserling E, et al. Skin tumor of T accessory cells (interdigitating reticulum cells) with high content of T lymphocytes. *Am J Dermatopathol*. 1987;9(2):129-137.
1001. Luk IS, Shek TW, Tang VW, Ng WF. Interdigitating dendritic cell tumor of the testis: a novel testicular spindle cell neoplasm. *Am J Surg Pathol*. 1999;23(9):1141-1148.
1002. Miettinen M, Fletcher CD, Lasota J. True histiocytic lymphoma of small intestine. Analysis of two S-100 protein-positive cases with features of interdigitating reticulum cell sarcoma. *Am J Clin Pathol*. 1993;100(3):285-292.
1003. van den Oord JJ, de Wolf-Peeters C, de Vos R, et al. Sarcoma arising from interdigitating reticulum cells: report of a case, studied with light and electron microscopy, and enzyme- and immunohistochemistry. *Histopathology*. 1986;10(5):509-523.
1004. Yamakawa M, Matsuda M, Imai Y, et al. Lymph node interdigitating cell sarcoma. A case report. *Am J Clin Pathol*. 1992;97(1):139-146.
1005. Favara BE. Langerhans' cell histiocytosis pathobiology and pathogenesis. *Semin Oncol*. 1991;18(1):3-7.
1006. Lieberman PH, Jones CR, Steinman RM, et al. Langerhans cell (eosinophilic) granulomatosis. A clinicopathologic study encompassing 50 years. *Am J Surg Pathol*. 1996;20(5):519-552.
1007. Nezelof C, Basset F. From histiocytosis X to Langerhans cell histiocytosis: a personal account. *Int J Surg Pathol*. 2001;9(2):137-146.
1008. Beckstead JH, Wood GS, Turner RR. Histiocytosis X cells and Langerhans cells: enzyme histochemical and immunologic similarities. *Hum Pathol*. 1984;15(9):826-833.
1009. Anjuere F, del Hoyo GM, Martin P, Ardavin C. Langerhans cells develop from a lymphoid-committed precursor. *Blood*. 2000;96(5):1633-1637.
1010. Magni M, Di Nicola M, Carlo-Stella C, et al. Identical rearrangement of immunoglobulin heavy chain gene in neoplastic Langerhans cells and B-lymphocytes: evidence for a common precursor. *Leuk Res*. 2002;26(12):1131-1133.
1011. Chen W, Wang J, Wang E, et al. Detection of clonal lymphoid receptor gene rearrangements in langerhans cell histiocytosis. *Am J Surg Pathol*. 2010;34(7):1049-1057.
1012. Herzog KM, Tubbs RR. Langerhans cell histiocytosis. *Adv Anat Pathol*. 1998;5(6):347-358.
1013. Pinkus GS, Lones MA, Matsumura F, et al. Langerhans cell histiocytosis immunohistochemical expression of fascin, a dendritic cell marker. *Am J Clin Pathol*. 2002;118(3):335-343.
1014. Santamaria M, Llamas L, Ree HJ, et al. Expression of sialylated Leu-M1 antigen in histiocytosis X. *Am J Clin Pathol*. 1988;89(2):211-216.
1015. Hage C, Willman CL, Favara BE, Isaacson PG. Langerhans' cell histiocytosis (histiocytosis X): immunophenotype and growth fraction. *Hum Pathol*. 1993;24(8):840-845.
1016. Paulli M, Feller AC, Boveri E, et al. Cathepsin D and E co-expression in sinus histiocytosis with massive lymphadenopathy (Rosai-Dorfman disease) and Langerhans' cell histiocytosis: further evidences of a phenotypic overlap between these histiocytic disorders. *Virchows Arch*. 1994;424(6):601-606.
1017. Ree HJ, Kadin ME. Peanut agglutinin. A useful marker for histiocytosis X and interdigitating reticulum cells. *Cancer*. 1986;57(2):282-287.
1018. Emile JF, Wechsler J, Brousse N, et al. Langerhans' cell histiocytosis. Definitive

For personal use only. No other uses without permission. Copyright ©2017. Elsevier Inc. All rights reserved.

diagnosis with the use of monoclonal antibody O10 on routinely paraffin-embedded samples. *Am J Surg Pathol*. 1995;19(6):636-641.
1019. Lau SK, Chu PG, Weiss LM. Immunohistochemical expression of Langerin in Langerhans cell histiocytosis and non-Langerhans cell histiocytic disorders. *Am J Surg Pathol*. 2008;32(4):615-619.
1020. Sholl LM, Hornick JL, Pinkus JL, et al. Immunohistochemical analysis of langerin in langerhans cell histiocytosis and pulmonary inflammatory and infectious diseases. *Am J Surg Pathol*. 2007;31(6):947-952.
1021. Mierau GW, Favara BE, Brenman JM. Electron microscopy in histiocytosis X. *Ultrastruct Pathol*. 1982;3(2):137-142.
1022. Vernon ML, Fountain L, Krebs HM, et al. Birbeck granules (Langerhans' cell granules) in human lymph nodes. *Am J Clin Pathol*. 1973;60(6):771-779.
1023. Ornvold K, Nielsen MH, Clausen N. Disseminated histiocytosis X. A clinical and immunohistochemical retrospective study. *Acta Pathol Microbiol Immunol Scand A*. 1985;93(6):311-316.
1024. Giona F, Caruso R, Testi AM, et al. Langerhans' cell histiocytosis in adults: a clinical and therapeutic analysis of 11 patients from a single institution. *Cancer*. 1997;80(9):1786-1791.
1025. Howarth DM, Gilchrist GS, Mullan BP, et al. Langerhans cell histiocytosis: diagnosis, natural history, management, and outcome. *Cancer*. 1999;85(10):2278-2290.
1026. Komp DM. Concepts in staging and clinical studies for treatment of Langerhans' cell histiocytosis. *Semin Oncol*. 1991;18(1): 18-23.
1027. Lahey ME. Prognostic factors in histiocytosis X. *Am J Pediatr Hematol Oncol*. 1981;3(1):57-60.
1028. Risdall RJ, Dehner LP, Duray P, et al. Histiocytosis X (Langerhans' cell histiocytosis). Prognostic role of histopathology. *Arch Pathol Lab Med*. 1983;107(2):59-63.
1029. Bingham EA, Bridges JM, Kelly AM, et al. Letterer-Siwe disease: a study of thirteen cases over a 21—year period. *Br J Dermatol*. 1982;106(2):205-209.
1030. Hashimoto K, Griffin D, Kohsbaki M. Self-healing reticulohistiocytosis: a clinical, histologic, and ultrastructural study of the fourth case in the literature. *Cancer*. 1982;49(2):331-337.
1031. Motoi M, Helbron D, Kaiserling E, Lennert K. Eosinophilic granuloma of lymph nodes—a variant of histiocytosis X. *Histopathology*. 1980;4(6):585-606.
1032. Reid H, Fox H, Whittaker JS. Eosinophilic granuloma of lymph nodes. *Histopathology*. 1977;1(1):31-37.
1033. Williams JW, Dorfman RF. Lymphadenopathy as the initial manifestation of histiocytosis X. *Am J Surg Pathol*. 1979;3(5):405-421.
1034. Edelweiss M, Medeiros LJ, Suster S, Moran CA. Lymph node involvement by Langerhans cell histiocytosis: a clinicopathologic and immunohistochemical study of 20 cases. *Hum Pathol*. 2007;38(10):1463-1469.
1035. Burns BF, Colby TV, Dorfman RF. Langerhans' cell granulomatosis (histiocytosis X) associated with malignant lymphomas. *Am J Surg Pathol*. 1983;7(6):529-533.
1036. Kjeldsberg CR, Kim H. Eosinophilic granuloma as an incidental finding in malignant lymphoma. *Arch Pathol Lab Med*. 1980;104(3):137-140.
1037. Christie LJ, Evans AT, Bray SE, et al. Lesions resembling Langerhans cell histiocytosis in association with other lymphoproliferative disorders: a reactive or neoplastic phenomenon? *Hum Pathol*. 2006;37(1):32-39.
1038. Neumann MP, Frizzera G. The coexistence of Langerhans' cell granulomatosis and malignant lymphoma may take different forms: report of seven cases with a review of the literature. *Hum Pathol*. 1986;17(10):1060-1065.
1039. Axiotis CA, Merino MJ, Duray PH. Langerhans cell histiocytosis of the female genital tract. *Cancer*. 1991;67(6):1650-1660.
1040. Gilcrease MZ, Rajan B, Ostrowski ML, et al. Localized thymic Langerhans' cell histiocytosis and its relationship with myasthenia gravis. Immunohistochemical, ultrastructural, and cytometric studies. *Arch Pathol Lab Med*. 1997;121(2):134-138.
1041. Kaplan KJ, Goodman ZD, Ishak KG. Liver involvement in Langerhans' cell histiocytosis: a study of nine cases. *Mod Pathol*. 1999;12(4):370-378.
1042. Meehan SA, Smoller BR. Cutaneous Langerhans cell histiocytosis of the genitalia in the elderly: a report of three cases. *J Cutan Pathol*. 1998;25(7):370-374.
1043. Otis CN, Fischer RA, Johnson N, et al. Histiocytosis X of the vulva: a case report and review of the Scliterature. *Obstet Gynecol*. 1990;75(3 Pt 2):555-558.
1044. Thompson LD, Wenig BM, Adair CF, et al. Langerhans cell histiocytosis of the thyroid: a series of seven cases and a review of the literature. *Mod Pathol*. 1996;9(2):145-149.
1045. Richmond I, Eyden BP, Banerjee SS. Intranodal Langerhans' cell histiocytosis associated with malignant melanoma. *Histopathology*. 1995;26(4):380-382.
1046. Safali M, McCutcheon JM, Wright DH. Langerhans cell histiocytosis of lymph nodes: draining a papillary carcinoma of the thyroid. *Histopathology*. 1997;30(6):599-603.
1047. Berg LC, Norelle A, Morgan WA, Washa DM. Cat-scratch disease simulating Histiocytosis X. *Hum Pathol*. 1998;29(6):649-651.
1048. Leahy MA, Krejci SM, Friednash M, et al. Human herpesvirus 6 is present in lesions of Langerhans cell histiocytosis. *J Invest Dermatol*. 1993;101(5):642-645.
1049. McClain K, Jin H, Gresik V, Favara B. Langerhans cell histiocytosis: lack of a viral etiology. *Am J Hematol*. 1994;47(1):16-20.
1050. Yousem SA, Colby TV, Chen YY, et al. Pulmonary Langerhans' cell histiocytosis: molecular analysis of clonality. *Am J Surg Pathol*. 2001;25(5):630-636.
1051. Roden AC, Hu X, Kip S, et al. BRAF V600E expression in Langerhans cell histiocytosis: clinical and immunohistochemical study on 25 pulmonary and 54 extrapulmonary cases. *Am J Surg Pathol*. 2014;38(4):548-551.
1052. Rollins BJ. Genomic alterations in Langerhans cell histiocytosis. *Hematol Oncol Clin North Am*. 2015;29(5):839-851.
1053. Nelson DS, van Halteren A, Quispel WT, et al. MAP2K1 and MAP3K1 mutations in Langerhans cell histiocytosis. *Genes Chromosomes Cancer*. 2015;54(6):361-368.
1054. Badalian-Very G, Vergilio JA, Degar BA, et al. Recurrent BRAF mutations in Langerhans cell histiocytosis. *Blood*. 2010;116(11):1919-1923.
1055. Murakami I, Gogusev J, Fournet JC, et al. Detection of molecular cytogenetic aberrations in langerhans cell histiocytosis of bone. *Hum Pathol*. 2002;33(5):555-560.
1056. Brabencova E, Tazi A, Lorenzato M, et al. Langerhans cells in Langerhans cell granulomatosis are not actively proliferating cells. *Am J Pathol*. 1998;152(5):1143-1149.
1057. Ben-Ezra J, Bailey A, Azumi N, et al. Malignant histiocytosis X. A distinct clinicopathologic entity. *Cancer*. 1991;68(5):1050-1060.
1058. Terracciano L, Kocher T, Cathomas G, et al. Langerhans cell histiocytosis of the stomach with atypical morphological features. *Pathol Int*. 1999;49(6):553-556.
1059. Wood C, Wood GS, Deneau DG, et al. Malignant histiocytosis X. Report of a rapidly fatal case in an elderly man. *Cancer*. 1984;54(2):347-352.
1060. Ferringer T, Banks PM, Metcalf JS. Langerhans cell sarcoma. *Am J Dermatopathol*. 2006;28(1):36-39.
1061. Berti E, Gianotti R, Alessi E. Unusual cutaneous histiocytosis expressing an intermediate immunophenotype between Langerhans' cells and dermal macrophages. *Arch Dermatol*. 1988;124(8):1250-1253.
1062. Rezk SA, Spagnolo DV, Brynes RK, Weiss LM. Indeterminate cell tumor: a rare dendritic neoplasm. *Am J Surg Pathol*. 2008;32(12):1868-1876.
1063. Brown RA, Kwong BY, McCalmont TH, et al. ETV3-NCOA2 in indeterminate cell histiocytosis: clonal translocation supports sui generis. *Blood*. 2015;126(20):2344-2345.
1064. Kenn W, Eck M, Allolio B, et al. Erdheim-Chester disease: evidence for a disease entity different from Langerhans cell histiocytosis? Three cases with detailed radiological and immunohistochemical analysis. *Hum Pathol*. 2000;31(6):734-739.
1065. Copie-Bergman C, Wotherspoon AC, Norton AJ, et al. True histiocytic lymphoma: a morphologic, immunohistochemical, and molecular genetic study of 13 cases. *Am J Surg Pathol*. 1998;22(11):1386-1392.
1066. Franchino C, Reich C, Distenfeld A, et al. A clinicopathologically distinctive primary splenic histiocytic neoplasm. Demonstration of its histiocyte derivation by immunophenotypic and molecular genetic analysis. *Am J Surg Pathol*. 1988;12(5):398-404.
1067. Hornick JL, Jaffe ES, Fletcher CD. Extranodal histiocytic sarcoma: clinicopathologic analysis of 14 cases of a rare epithelioid malignancy. *Am J Surg Pathol*. 2004;28(9):1133-1144.
1068. Milchgrub S, Kamel OW, Wiley E, et al. Malignant histiocytic neoplasms of the small intestine. *Am J Surg Pathol*. 1992;16(1):11-20.
1069. Soria C, Orradre JL, Garcia-Almagro D, et al. True histiocytic lymphoma (monocytic sarcoma). *Am J Dermatopathol*. 1992;14(6):511-517.
1070. Martin Rodilla C, Fernandez Acenero J, Pena Mayor L, Alvarez Carmona A. True histiocytic lymphoma as a second neoplasm in a follicular centroblastic-centrocytic lymphoma. *Pathol Res Pract*. 1997;193(4):319-322.
1071. Hanson CA, Jaszcz W, Kersey JH, et al. True histiocytic lymphoma: histopathologic, immunophenotypic and genotypic analysis. *Br J Haematol*. 1989;73(2):187-198.
1072. Hsu SM, Ho YS, Hsu PL. Lymphomas of true histiocytic origin. Expression of different phenotypes in so-called true histiocytic lymphoma and malignant histiocytosis. *Am J Pathol*. 1991;138(6):1389-1404.
1073. Ralfkiaer E, Delsol G, O'Connor NT, et al. Malignant lymphomas of true histiocytic origin. A clinical, histological, immunophenotypic and genotypic study. *J Pathol*. 1990;160(1):9-17.
1074. Castro EC, Blazquez C, Boyd J, et al. Clinicopathologic features of histiocytic lesions following ALL, with a review of the literature. *Pediatr Dev Pathol*. 2010;13(3):225-237.
1075. Feldman AL, Berthold F, Arceci RJ, et al. Clonal relationship between precursor T-lymphoblastic leukaemia/lymphoma and Langerhans-cell histiocytosis. *Lancet Oncol*. 2005;6(6):435-437.
1076. Feldman AL, Minniti C, Santi M, et al. Histiocytic sarcoma after acute lymphoblastic

For personal use only. No other uses without permission. Copyright ©2017. Elsevier Inc. All rights reserved.

leukaemia: a common clonal origin. *Lancet Oncol*. 2004;5(4):248-250.
1077. Almagro UA, Choi H, Rouse TM. Hemangioma in a lymph node. *Arch Pathol Lab Med*. 1985;109(6):576-578.
1078. Goldstein J, Bartal N. Hemangioendothelioma of the lymph node: a case report. *J Surg Oncol*. 1985;28(4):314-317.
1079. Chan JK, Frizzera G, Fletcher CD, Rosai J. Primary vascular tumors of lymph nodes other than Kaposi's sarcoma. Analysis of 39 cases and delineation of two new entities. *Am J Surg Pathol*. 1992;16(4):335-350.
1080. Cho NH, Yang WI, Lee WJ. Spindle and epithelioid haemangioendothelioma of the inguinal lymph nodes. *Histopathology*. 1997;30(6):595-598.
1081. Silva EG, Phillips MJ, Langer B, Ordonez NG. Spindle and histiocytoid (epithelioid) hemangioendothelioma. Primary in lymph node. *Am J Clin Pathol*. 1986;85(6):731-735.
1082. Tsang WY, Chan JK, Dorfman RF, Rosai J. Vasoproliferative lesions of the lymph node. *Pathol Annu*. 1994;29(Pt 1):63-133.
1083. Chan JK, Lewin KJ, Lombard CM, et al. Histopathology of bacillary angiomatosis of lymph node. *Am J Surg Pathol*. 1991;15(5):430-437.
1084. Cockerell CJ, Whitlow MA, Webster GF, Friedman-Kien AE. Epithelioid angiomatosis: a distinct vascular disorder in patients with the acquired immunodeficiency syndrome or AIDS-related complex. *Lancet*. 1987;2(8560):654-656.
1085. Perez-Piteira J, Ariza A, Mate JL, et al. Bacillary angiomatosis: a gross mimicker of malignancy. *Histopathology*. 1995;26(5):476-478.
1086. Jabcuga CE, Jin L, Macon WR, et al. Broadening the morphologic spectrum of *Bartonella henselae* lymphadenitis: analysis of 100 molecularly characterized cases. *Am J Surg Pathol*. 2016;40(3):342-347.
1087. Haferkamp O, Rosenau W, Lennert K. Vascular transformation of lymph node sinuses due to venous obstruction. *Arch Pathol*. 1971;92(2):81-83.
1088. Ostrowski ML, Siddiqui T, Barnes RE, Howton MJ. Vascular transformation of lymph node sinuses. A process displaying a spectrum of histologic features. *Arch Pathol Lab Med*. 1990;114(7):656-660.
1089. Fayemi AO, Toker C. Nodal angiomatosis. *Arch Pathol*. 1975;99(3):170-172.
1090. Lott MF, Davies JD. Lymph node hypervascularity: haemangiomatoid lesions and pan-nodal vasodilatation. *J Pathol*. 1983;140(3):209-219.
1091. Chan JK, Warnke RA, Dorfman R. Vascular transformation of sinuses in lymph nodes. A study of its morphological spectrum and distinction from Kaposi's sarcoma. *Am J Surg Pathol*. 1991;15(8):732-743.
1092. Cook PD, Czerniak B, Chan JK, et al. Nodular spindle-cell vascular transformation of lymph nodes. A benign process occurring predominantly in retroperitoneal lymph nodes draining carcinomas that can simulate Kaposi's sarcoma or metastatic tumor. *Am J Surg Pathol*. 1995;19(9):1010-1020.
1093. Le Jan S, Amy C, Cazes A, et al. Angiopoietin-like 4 is a proangiogenic factor produced during ischemia and in conventional renal cell carcinoma. *Am J Pathol*. 2003;162(5):1521-1528.
1094. Steinmann G, Foldi E, Foldi M, et al. Morphologic findings in lymph nodes after occlusion of their efferent lymphatic vessels and veins. *Lab Invest*. 1982;47(1):43-50.
1095. Kazakov DV, Hes O, Hora M, et al. Primary intranodal cellular angiolipoma. *Int J Surg Pathol*. 2005;13(1):99-101.
1096. O'Connell KM. Kaposi's sarcoma in lymph nodes: histological study of lesions from 16 cases in Malawi. *J Clin Pathol*. 1977;30(8):696-703.
1097. Bonzanini M, Togni R, Barabareschi M, et al. Primary Kaposi's sarcoma of intraparotid lymph node. *Histopathology*. 1992;21(5):489-491.
1098. Fukunaga M, Silverberg SG. Hyaline globules in Kaposi's sarcoma: a light microscopic and immunohistochemical study. *Mod Pathol*. 1991;4(2):187-190.
1099. Weshler Z, Leviatan A, Krasnokuki D, Kopolovitch J. Primary Kaposi's sarcoma in lymph nodes concurrent with chronic lymphatic leukemia. *Am J Clin Pathol*. 1979;71(2):234-237.
1100. Brunning RD, McKenna RW, Rosai J, et al. Systemic mastocytosis. Extracutaneous manifestations. *Am J Surg Pathol*. 1983;7(5):425-438.
1101. Lennert K, Parwaresch MR. Mast cells and mast cell neoplasia: a review. *Histopathology*. 1979;3(5):349-365.
1102. Arber DA, Tamayo R, Weiss LM. Paraffin section detection of the c-kit gene product (CD117) in human tissues: value in the diagnosis of mast cell disorders. *Hum Pathol*. 1998;29(5):498-504.
1103. Craig SS, DeBlois G, Schwartz LB. Mast cells in human keloid, small intestine, and lung by an immunoperoxidase technique using a murine monoclonal antibody against tryptase. *Am J Pathol*. 1986;124(3):427-435.
1104. Horny HP, Menke DM, Kaiserling E. Neoplastic human tissue mast cells express the adhesion molecule CD44/HCAM. *Virchows Arch*. 1996;429(2-3):91-94.
1105. Horny HP, Sillaber C, Menke D, et al. Diagnostic value of immunostaining for tryptase in patients with mastocytosis. *Am J Surg Pathol*. 1998;22(9):1132-1140.
1106. Hudock J, Chatten J, Miettinen M. Immunohistochemical evaluation of myeloid leukemia infiltrates (granulocytic sarcomas) in formaldehyde-fixed, paraffin-embedded tissue. *Am J Clin Pathol*. 1994;102(1):55-60.
1107. Li WV, Kapadia SB, Sonmez-Alpan E, Swerdlow SH. Immunohistochemical characterization of mast cell disease in paraffin sections using tryptase, CD68, myeloperoxidase, lysozyme, and CD20 antibodies. *Mod Pathol*. 1996;9(10):982-988.
1108. Yang F, Tran TA, Carlson JA, et al. Paraffin section immunophenotype of cutaneous and extracutaneous mast cell disease: comparison to other hematopoietic neoplasms. *Am J Surg Pathol*. 2000;24(5):703-709.
1109. Menasce LP, Banerjee SS, Beckett E, Harris M. Extra-medullary myeloid tumour (granulocytic sarcoma) is often misdiagnosed: a study of 26 cases. *Histopathology*. 1999;34(5):391-398.
1110. Audouin J, Comperat E, Le Tourneau A, et al. Myeloid sarcoma: clinical and morphologic criteria useful for diagnosis. *Int J Surg Pathol*. 2003;11(4):271-282.
1111. Roth MJ, Medeiros LJ, Elenitoba-Johnson K, et al. Extramedullary myeloid cell tumors. An immunohistochemical study of 29 cases using routinely fixed and processed paraffin-embedded tissue sections. *Arch Pathol Lab Med*. 1995;119(9):790-798.
1112. Channer JL, Davies JD. Smooth muscle proliferation in the hilum of superficial lymph nodes. *Virchows Arch A Pathol Anat Histopathol*. 1985;406(3):261-270.
1113. Brecher ME, Gill WB, Straus FH 2nd. Angiomyolipoma with regional lymph node involvement and long-term follow-up study. *Hum Pathol*. 1986;17(9):962-963.
1114. Corrin B, Liebow AA, Friedman PJ. Pulmonary lymphangiomyomatosis. A review. *Am J Pathol*. 1975;79(2):348-382.
1115. Horie A, Ishii N, Matsumoto M, et al. Leiomyomatosis in the pelvic lymph node and peritoneum. *Acta Pathol Jpn*. 1984;34(4):813-819.
1116. Mazzoleni G, Salerno A, Santini D, et al. Leiomyomatosis in pelvic lymph nodes. *Histopathology*. 1992;21(6):588-589.
1117. Starasoler L, Vuitch F, Albores-Saavedra J. Intranodal leiomyoma. Another distinctive primary spindle cell neoplasm of lymph node. *Am J Clin Pathol*. 1991;95(6):858-862.
1118. Barbareschi M, Mariscotti C, Ferrero S, Pignatiello U. Intranodal haemorrhagic spindle cell tumour: a benign Kaposi-like nodal tumour. *Histopathology*. 1990;17(1):93-96.
1119. Fletcher CD, Stirling RW. Intranodal myofibroblastoma presenting in the submandibular region: evidence of a broader clinical and histological spectrum. *Histopathology*. 1990;16(3):287-293.
1120. Hisaoka M, Hashiomoto H, Daimaru Y. Intranodal palisaded myofibroblastoma with so-called amianthoid fibers: a report of two cases with a review of the literature. *Pathol Int*. 1998;48(4):307-312.
1121. Lee JY, Abell E, Shevechik GJ. Solitary spindle cell tumor with myoid differentiation of the lymph node. *Arch Pathol Lab Med*. 1989;113(5):547-550.
1122. Suster S, Rosai J. Intranodal hemorrhagic spindle-cell tumor with "amianthoid" fibers. Report of six cases of a distinctive mesenchymal neoplasm of the inguinal region that simulates Kaposi's sarcoma. *Am J Surg Pathol*. 1989;13(5):347-357.
1123. Weiss SW, Gnepp DR, Bratthauer GL. Palisaded myofibroblastoma. A benign mesenchymal tumor of lymph node. *Am J Surg Pathol*. 1989;13(5):341-346.
1124. Michal M, Chlumska A, Povysilova V. Intranodal "amianthoid" myofibroblastoma. Report of six cases immunohistochemical and electron microscopical study. *Pathol Res Pract*. 1992;188(1-2):199-204.
1125. Skalova A, Michal M, Chlumska A, Leivo I. Collagen composition and ultrastructure of the so-called amianthoid fibres in palisaded myofibroblastoma. Ultrastructural and immunohistochemical study. *J Pathol*. 1992;167(3):335-340.
1126. Tanda F, Massarelli G, Cossu A, et al. Primary spindle cell tumor of lymph node with "amianthoid" fibers: a histological, immunohistochemical and ultrastructural study. *Ultrastruct Pathol*. 1993;17(2):195-205.
1127. White JE, Chan YF, Miller MV. Intranodal leiomyoma or myofibroblastoma: an identical lesion? *Histopathology*. 1995;26(2):188-190.
1128. Creager AJ, Garwacki CP. Recurrent intranodal palisaded myofibroblastoma with metaplastic bone formation. *Arch Pathol Lab Med*. 1999;123(5):433-436.
1129. Davis RE, Warnke RA, Dorfman RF. Inflammatory pseudotumor of lymph nodes. Additional observations and evidence for an inflammatory etiology. *Am J Surg Pathol*. 1991;15(8):744-756.
1130. Facchetti F, De Wolf Peeters C, De Wever I, Frizzera G. Inflammatory pseudotumor of lymph nodes. Immunohistochemical evidence for its fibrohistiocytic nature. *Am J Pathol*. 1990;137(2):281-289.
1131. Kemper CA, Davis RE, Deresinski SC, Dorfmann RF. Inflammatory pseudotumor of intra-abdominal lymph nodes manifesting as recurrent fever of unknown origin: a case report. *Am J Med*. 1991;90(4):519-523.
1132. Kojima M, Nakamura S, Shimizu K, et al. Inflammatory pseudotumor of lymph nodes: clinicopathologic and immunohistological study of 11 Japanese cases. *Int J Surg Pathol*. 2001;9(3):207-214.

For personal use only. No other uses without permission. Copyright ©2017. Elsevier Inc. All rights reserved.

1133. Perrone T, De Wolf-Peeters C, Frizzera G. Inflammatory pseudotumor of lymph nodes. A distinctive pattern of nodal reaction. *Am J Surg Pathol*. 1988;12(5):351-361.
1134. Moran CA, Suster S, Abbondanzo SL. Inflammatory pseudotumor of lymph nodes: a study of 25 cases with emphasis on morphological heterogeneity. *Hum Pathol*. 1997;28(3):332-338.
1135. Arber DA, Kamel OW, van de Rijn M, et al. Frequent presence of the Epstein-Barr virus in inflammatory pseudotumor. *Hum Pathol*. 1995;26(10):1093-1098.
1136. Argani P, Ghossein R, Rosai J. Anthracotic and anthracosilicotic spindle cell pseudotumors of mediastinal lymph nodes: report of five cases of a reactive lesion that stimulates malignancy. *Hum Pathol*. 1998;29(8):851-855.
1137. Pulitzer MP, Gerami P, Busam K. Solar elastotic material in dermal lymphatics and lymph nodes. *Am J Surg Pathol*. 2010;34(10):1492-1497.
1138. Longo S. Benign lymph node inclusions. *Hum Pathol*. 1976;7(3):349-354.
1139. Brown RB, Gaillard RA, Turner JA. The significance of aberrant or heterotopic parotid gland tissue in lymph nodes. *Ann Surg*. 1953;138(6):850-856.
1140. Arai T, Kino I, Nakamura S, Ogawa H. Epidermal inclusions in abdominal lymph nodes. Report of two cases studied immunohistochemically. *Acta Pathol Jpn*. 1992;42(2):126-129.
1141. Micheau C, Cachin Y, Caillou B. Cystic metastases in the neck revealing occult carcinoma of the tonsil. A report of six cases. *Cancer*. 1974;33(1):228-233.
1142. Covell LM, Disciullo AJ, Knapp RC. Decidual change in pelvic lymph nodes in the presence of cervical squamous cell carcinoma during pregnancy. *Am J Obstet Gynecol*. 1977;127(6):674-676.
1143. Koss LG. Miniature adenoacanthoma arising in an endometriotic cyst in an obturator lymph node: report of first case. *Cancer*. 1963;16:1369-1372.
1144. Maassen V, Hiller K. Glandular inclusions in lymph nodes: pattern of distribution and metaplastic transformation. *Arch Gynecol Obstet*. 1994;255(1):1-8.
1145. Ehrmann RL, Federschneider JM, Knapp RC. Distinguishing lymph node metastases from benign glandular inclusions in low-grade ovarian carcinoma. *Am J Obstet Gynecol*. 1980;136(6):737-746.
1146. Moore WF, Bentley RC, Berchuck A, Robboy SJ. Some mullerian inclusion cysts in lymph nodes may sometimes be metastases from serous borderline tumors of the ovary. *Am J Surg Pathol*. 2000;24(5):710-718.
1147. Johnson WT, Helwig EB. Benign nevus cells in the capsule of lymph nodes. *Cancer*. 1969;23(3):747-753.
1148. Azzopardi JG, Ross CM, Frizzera G. Blue naevi of lymph node capsule. *Histopathology*. 1977;1(6):451-461.
1149. Argani P, Rosai J. Hyperplastic mesothelial cells in lymph nodes: report of six cases of a benign process that can stimulate metastatic involvement by mesothelioma or carcinoma. *Hum Pathol*. 1998;29(4):339-346.
1150. Brooks JS, LiVolsi VA, Pietra GG. Mesothelial cell inclusions in mediastinal lymph nodes mimicking metastatic carcinoma. *Am J Clin Pathol*. 1990;93(6):741-748.
1151. Parkash V, Vidwans M, Carter D. Benign mesothelial cells in mediastinal lymph nodes. *Am J Surg Pathol*. 1999;23(10):1264-1269.
1152. Sussman J, Rosai J. Lymph node metastasis as the initial manifestation of malignant mesothelioma. Report of six cases. *Am J Surg Pathol*. 1990;14(9):819-828.
1153. Edlow DW, Carter D. Heterotopic epithelium in axillary lymph nodes: report of a case and review of the literature. *Am J Clin Pathol*. 1973;59(5):666-673.
1154. Maiorano E, Mazzarol GM, Pruneri G, et al. Ectopic breast tissue as a possible cause of false-positive axillary sentinel lymph node biopsies. *Am J Surg Pathol*. 2003;27(4):513-518.
1155. Turner DR, Millis RR. Breast tissue inclusions in axillary lymph nodes. *Histopathology*. 1980;4(6):631-636.
1156. Fisher CJ, Hill S, Millis RR. Benign lymph node inclusions mimicking metastatic carcinoma. *J Clin Pathol*. 1994;47(3):245-247.
1157. Holdsworth PJ, Hopkinson JM, Leveson SH. Benign axillary epithelial lymph node inclusions—a histological pitfall. *Histopathology*. 1988;13(2):226-228.
1158. Fellegara G, Carcangiu ML, Rosai J. Benign epithelial inclusions in axillary lymph nodes: report of 18 cases and review of the literature. *Am J Surg Pathol*. 2011;35(8):1123-1133.
1159. Magrina JF, Symmonds RE, Dahlin DC. Pelvic "lipolymph nodes": a consideration in the differential diagnosis of pelvic masses. *Am J Obstet Gynecol*. 1980;136(6):727-731.
1160. Davies JD, Stansfeld AG. Spontaneous infarction of superficial lymph nodes. *J Clin Pathol*. 1972;25(8):689-696.
1161. Mahy NJ, Davies JD. Ischaemic changes in human mesenteric lymph nodes. *J Pathol*. 1984;144(4):257-267.
1162. Davies JD, Webb AJ. Segmental lymph-node infarction after fine-needle aspiration. *J Clin Pathol*. 1982;35(8):855-857.
1163. Shah KH, Kisilevsky R. Infarction of the lymph nodes: a cause of a palisading macrophage reaction mimicking necrotizing granulomas. *Hum Pathol*. 1978;9(5):597-599.
1164. Kojima M, Nakamura S, Sugihara S, et al. Lymph node infarction associated with infectious mononucleosis: report of a case resembling lymph node infarction associated with malignant lymphoma. *Int J Surg Pathol*. 2002;10(3):223-226.
1165. Cleary KR, Osborne BM, Butler JJ. Lymph node infarction foreshadowing malignant lymphoma. *Am J Surg Pathol*. 1982;6(5):435-442.
1166. Maurer R, Schmid U, Davies JD, et al. Lymph-node infarction and malignant lymphoma: a multicentre survey of European, English and American cases. *Histopathology*. 1986;10(6):571-588.
1167. Strauchen JA, Miller LK. Lymph node infarction. An immunohistochemical study of 11 cases. *Arch Pathol Lab Med*. 2003;127(1):60-63.
1168. Vega F, Lozano MD, Alcalde J, Pardo-Mindan FJ. Utility of immunophenotypic and immunogenotypic analysis in the study of necrotic lymph nodes. *Virchows Arch*. 1999;434(3):245-248.
1169. Banerjee D, Mills DM, Hearn SA, et al. Proteinaceous lymphadenopathy due to monoclonal nonamyloid immunoglobulin deposit disease. *Arch Pathol Lab Med*. 1990;114(1):34-39.
1170. Truong LD, Cartwright J Jr, Goodman MD, Woznicki D. Silicone lymphadenopathy associated with augmentation mammaplasty. Morphologic features of nine cases. *Am J Surg Pathol*. 1988;12(6):484-491.
1171. Albores-Saavedra J, Vuitch F, Delgado R, et al. Sinus histiocytosis of pelvic lymph nodes after hip replacement. A histiocytic proliferation induced by cobalt-chromium and titanium. *Am J Surg Pathol*. 1994;18(1):83-90.
1172. Didolkar MS, Fanous N, Elias EG, Moore RH. Metastatic carcinomas from occult primary tumors. A study of 254 patients. *Ann Surg*. 1977;186(5):625-630.
1173. Haagensen CD, Feind CR, Herter FP, et al. *The Lymphatics in Cancer*. Philadelphia, PA: WB Saunders; 1972.
1174. Willis RA. *The Spread of Tumours in the Human Body*. Stoneham, MA: Butterworth; 1973.
1175. Giffler RF, Gillespie JJ, Ayala AG, Newland JR. Lymphoepithelioma in cervical lymph nodes of children and young adults. *Am J Surg Pathol*. 1977;1:293-302.
1176. Batsakis JG. The pathology of head and neck tumors: the occult primary and metastases to the head and neck, part 10. *Head Neck Surg*. 1981;3(5):409-423.
1177. Lindberg R. Distribution of cervical lymph node metastases from squamous cell carcinoma of the upper respiratory and digestive tracts. *Cancer*. 1972;29(6):1446-1449.
1178. Mancuso AA, Hanafee WN. Elusive head and neck carcinomas beneath intact mucosa. *Laryngoscope*. 1983;93(2):133-139.
1179. Silverman C, Marks JE. Metastatic cancer of unknown origin: epidermoid and undifferentiated carcinomas. *Semin Oncol*. 1982;9(4):435-441.
1180. Markman M. Metastatic adenocarcinoma of unknown primary site: analysis of 245 patients seen at The Johns Hopkins Hospital from 1965 to 1979. *Med Pediatr Oncol*. 1982;10(6):569-574.
1181. Cervin JR, Silverman JF, Loggie BW, Geisinger KR. Virchow's node revisited. Analysis with clinicopathologic correlation of 152 fine-needle aspiration biopsies of supraclavicular lymph nodes. *Arch Pathol Lab Med*. 1995;119(8):727-730.
1182. Copeland EM, McBride CM. Axillary metastases from unknown primary sites. *Ann Surg*. 1973;178(1):25-27.
1183. Feigenberg Z, Zer M, Dintsman M. Axillary metastases from an unknown primary source. *Isr J Med Sci*. 1976;12(10): 1153-1158.
1184. Clary CF, Michel RP, Wang NS, Hanson RE. Metastatic carcinoma. The lung as the site for the clinically undiagnosed primary. *Cancer*. 1983;51(2):362-366.
1185. Zaren HA, Copeland EM 3rd. Inguinal node metastases. *Cancer*. 1978;41(3): 919-923.
1186. Hoda SA, Resetkova E, Yusuf Y, et al. Megakaryocytes mimicking metastatic breast carcinoma. *Arch Pathol Lab Med*. 2002;126(5):618-620.
1187. Guerrero-Medrano J, Delgado R, Albores-Saavedra J. Signet-ring sinus histiocytosis: a reactive disorder that mimics metastatic adenocarcinoma. *Cancer*. 1997;80(2):277-285.
1188. De Petris G, Lev R, Siew S. Peritumoral and nodal muciphages. *Am J Surg Pathol*. 1998;22(5):545-549.
1189. Groisman GM, Amar M, Weiner P, Zamir D. Mucicarminophilic histiocytosis (benign signet-ring cells) and hyperplastic mesothelial cells: two mimics of metastatic carcinoma within a single lymph node. *Arch Pathol Lab Med*. 1998;122(3):282-284.

For personal use only. No other uses without permission. Copyright ©2017. Elsevier Inc. All rights reserved.

38 Spleen

Daniel A. Arber

CHAPTER CONTENTS

Normal anatomy, *1632*
Biopsy and fine-needle aspiration, *1632*
Rupture and splenectomy, *1633*
Congenital anomalies, *1633*
Cysts, *1634*
Inflammation, *1635*
Hypersplenism, *1636*
Thrombocytopenic purpuras, *1636*
Hemolytic anemia, *1637*
Congestive splenomegaly, *1638*
Other non-neoplastic disorders, *1638*
Hematolymphoid tumors and tumorlike conditions, *1639*
Non-Hodgkin lymphoma, *1639*
Hodgkin lymphoma, *1643*
Leukemias, *1644*
Myeloproliferative neoplasms, *1644*
Mastocytosis, *1645*
Other hematolymphoid conditions, *1645*
Vascular tumors, *1645*
Other primary tumors and tumorlike conditions, *1649*
Metastatic tumors, *1651*

Normal Anatomy

The normal spleen serves as a lymphoid organ as well as a filtering organ.[1–3] While fetal hematopoiesis occurs in the spleen, the spleen is not normally a hematopoietic organ after birth but may contain evidence of extramedullary hematopoiesis in a variety of settings. The splenic architecture largely reflects its functions. The splenic white pulp (or malpighian corpuscles) and the periarterial lymphoid sheaths constitute the primary lymphoid component, and the splenic red pulp with its associated cords and sinuses provides the filtering component, but the white pulp is closely associated with the splenic arterial circulation. The white pulp in infants and children, as well as antigenically stimulated adults, normally contains germinal centers composed predominantly of B cells, surrounded by a dark staining mantle zone and a more pale-staining outer marginal zone. In healthy adults, the germinal centers disappear, but normal B cell–rich mantle zones remain, similar to inactive lymph node follicles. In contrast to most other lymphoid organs, however, the white pulp B-cell compartment is also surrounded by an outer marginal zone of medium-sized lymphocytes with moderately abundant cytoplasm that is an admixture of B and T lymphocytes. This marginal zone tends to expand in reactive conditions that induce germinal center formation in the spleen, but B lymphocytes tend to remain localized to the white pulp areas and do not normally form aggregates in the red pulp. The periarterial lymphoid sheath contains primarily T lymphocytes in a less organized architecture and scattered T lymphocytes also circulate normally in the red pulp component. The splenic red pulp is composed of the splenic vascular sinuses with lining cells often termed littoral cells, and the cords of Billroth. These are made up of a matrix of splenic macrophages, capillaries, venules, and stromal cells and provide the filtering function of the spleen.

Biopsy and Fine-Needle Aspiration

Historically, biopsy of the spleen was rarely attempted because of the possibility of hemorrhage and the preconceived notion that the biopsy will not be of diagnostic help. Obviously, the procedure should not be performed on patients with a bleeding tendency. More recently, such procedures have become more routine, either with the Vim–Silverman-type needle to obtain a core of tissue or with a fine needle to obtain an aspirate.[4] These procedures are often performed with ultrasound or computed tomography guidance.[5] This approach has demonstrated limited complications, and the technique frequently results in a definitive diagnosis that is not easily obtainable by other means. A multicenter study in Italy on ultrasound-guided fine-needle aspiration (FNA) of the spleen documented the high yield and low risk of the procedure.[6] The overall accuracy was 91%, and the incidence of major complications was less than 1%. Aspiration cytology and core needle biopsy gave similar diagnostic yields, except for malignant lymphoma, in which core needle biopsy proved superior.

The material obtained by FNA is suitable for flow cytometry immunophenotyping,[7] as well as molecular genetic studies.

For personal use only. No other uses without permission. Copyright ©2017. Elsevier Inc. All rights reserved.

Keywords

Spleen
vascular tumors,
stromal tumors,
lymphoma,
cysts

For personal use only. No other uses without permission. Copyright ©2017. Elsevier Inc. All rights reserved.

Rupture and Splenectomy

Blunt trauma to the abdomen and surgical intervention within the abdominal cavity are the two most common factors responsible for rupture of the normal spleen.[8] In most instances, hemoperitoneum is an immediate consequence, leading to an emergency splenectomy. In about 15% of the cases, the rupture is "delayed" anywhere from 48 hours to several months.[9] Examination of the excised spleen will reveal the ruptured area, which, in many cases, is limited to a deceptively small capsular tear, often in the superior pole and/or hilum. A neutrophilic infiltrate may be seen subcapsularly and along the edges of the tear. Foci of intraparenchymal hemorrhage are often present. Germinal centers with an expanded marginal zone and other signs of lymphoid hyperplasia were found more commonly by Farhi and Ashfaq[10] in ruptured spleens than in control cases, leading them to conclude that immunologically stimulated organs may be more prone to traumatic rupture. If the marginal zone expansion is prominent, the possibility of a splenic marginal zone lymphoma (SMZL) needs to be considered; however, it has been shown that the large majority of ruptured spleens with expanded marginal zones do not contain a clonal B-cell population.[11]

Following traumatic rupture, splenic tissue may implant in the form of encapsulated nodules on the peritoneal surface, abdominal wall (including surgical scars), and even within the pleural cavity, lung parenchyma, and brain, a process known as **splenosis**.[12–17] Although some are poorly developed architecturally,[18] others show a full complement of red and white pulp, resulting in an appearance similar to that of accessory spleen.[19] In most cases, the pathogenesis is probably through mechanical implant on the surface, but in the single instance of cerebral splenosis, a hematogenous spread of splenic tissue has to be assumed.[16]

The diseases most commonly associated with spontaneous rupture of the spleen are infectious mononucleosis,[20] malaria, typhoid fever, subacute bacterial endocarditis, peliosis lienis (see later),[21,22] malignant lymphomas (including those occurring in HIV-infected patients),[23] leukemias, and primary nonlymphoid splenic neoplasms.[24] In every case of ruptured spleen without a history of trauma or in which the trauma seems insignificant, a careful microscopic study should be performed in order to rule out these possibilities. Rupture of the spleen with resulting hemoperitoneum is the most frequent cause of death in infectious mononucleosis. This complication usually occurs from 10 to 21 days after the onset of the disease.[25] In rare cases, "spontaneous" rupture may occur in an apparently normal spleen, particularly during pregnancy.[26]

Splenectomy performed in adults for traumatic rupture of the spleen, including intraoperative trauma, often does not result in any sequelae of significance.[27] Asplenic patients, however, are at risk for sepsis due to encapsulated bacteria.[28] While the sepsis risk is highest in children and immunocompromised patients, sepsis may occur years after splenectomy and pneumococcal, meningococcal, and *Haemophilus influenzae* vaccines are recommended in all patients.[29] Other complications of splenectomy include bleeding and pelvic vein thrombosis, and a recent large study suggests that asplenic patients have a slightly higher long-term risk of malignancy.[28,30]

Splenectomy performed in the presence of diffuse splenomegaly or a discrete splenic mass for the purpose of obtaining a diagnosis almost always achieves that purpose. About 75% of the cases proved to be malignant tumors in one study,[31] but improved detection methods appear to currently identify a higher percentage of incidental, nonmalignant proliferations than reflected in that report. Whenever splenectomy is performed for hematologic disorders, a thorough search should be made for accessory spleens in order to excise them if present. A similar precept applies if the operation is done laparoscopically, a procedure that is now commonly performed and has proved safe and effective for a variety of splenic diseases.[32]

Congenital Anomalies

Accessory (supernumerary) spleen is found in about 10% of individuals. It may be solitary or multiple, usually measures no more than 4 cm in diameter, and has a gross and microscopic appearance similar to that of the parent organ. Its most common location is the hilum of the spleen, and it is sometimes seen in contiguity with the tail of the pancreas. It should be distinguished from lymph nodes (especially when the latter are involved by Castleman disease) and splenosis (see previous section). Accessory spleens may contain epithelial cysts within them (see later).

Congenital absence of the spleen (asplenia) is associated in more than 80% of the cases with malformations of the heart, nearly always involving the atrioventricular endocardial cushion and the ventricular outflow tracts.[33] Anomalies of the blood vessels, lung, and abdominal viscera also are frequent.[34] In polysplenia, the cardiac anomalies are less severe and the prognosis is therefore more favorable.[35] A hereditary form of splenic hypoplasia has been reported.[36] Similarly, rare cases of isolated congenital asplenia, without other organ abnormalities, occur.[37] Most appear to be familial with a probable autosomal dominant inheritance pattern. Recently, mutations of the *RPSA* gene have been found in the majority of cases of isolated congenital asplenia.[38] Not surprisingly, these patients have increase pneumococcal infections in childhood and a high mortality rate due to fulminant infections.

Splenic–gonadal fusion occurs in two forms. One is continuous, in which the main spleen is connected by a cord of splenic and fibrous tissue to the gonadal (usually testicular) mesonephric structures; the other is discontinuous, in which discrete masses of splenic tissue are found fused to these same structures (Fig. 38.1).[39–41] Of the 52 cases reviewed by Watson,[42] only four were in females. Eleven were associated with other congenital defects, such as peromelus and micrognathia. Various degrees of testicular ectopia and inguinal hernias are common. All of the reported cases have been on the left side.[43]

Cases of splenohepatic and splenorenal fusion have also been recorded, as a well as an isolated case of ectopic prostatic tissue in the spleen.[44–46]

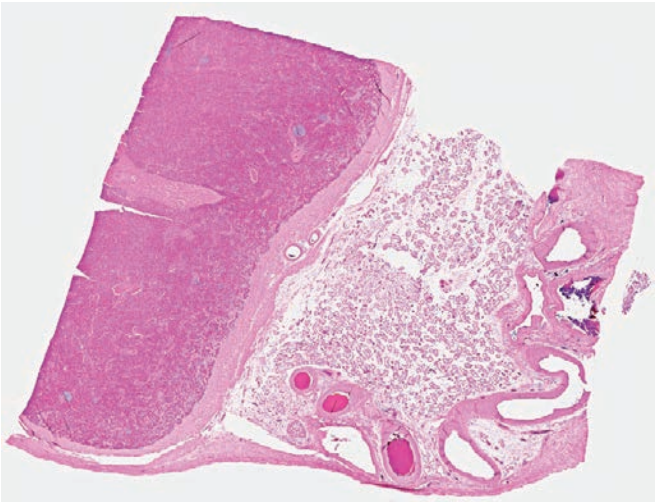

Figure 38.1 Splenogonadal Fusion. Splenic tissue *(left)* is attached to testicular tissue.

For personal use only. No other uses without permission. Copyright ©2017. Elsevier Inc. All rights reserved.

Figure 38.2 **A,** Primary (epithelial) cyst. Grossly, it is very difficult, if not impossible, to distinguish this lesion from a pseudocyst. **B,** Squamous lining of the inner surface.

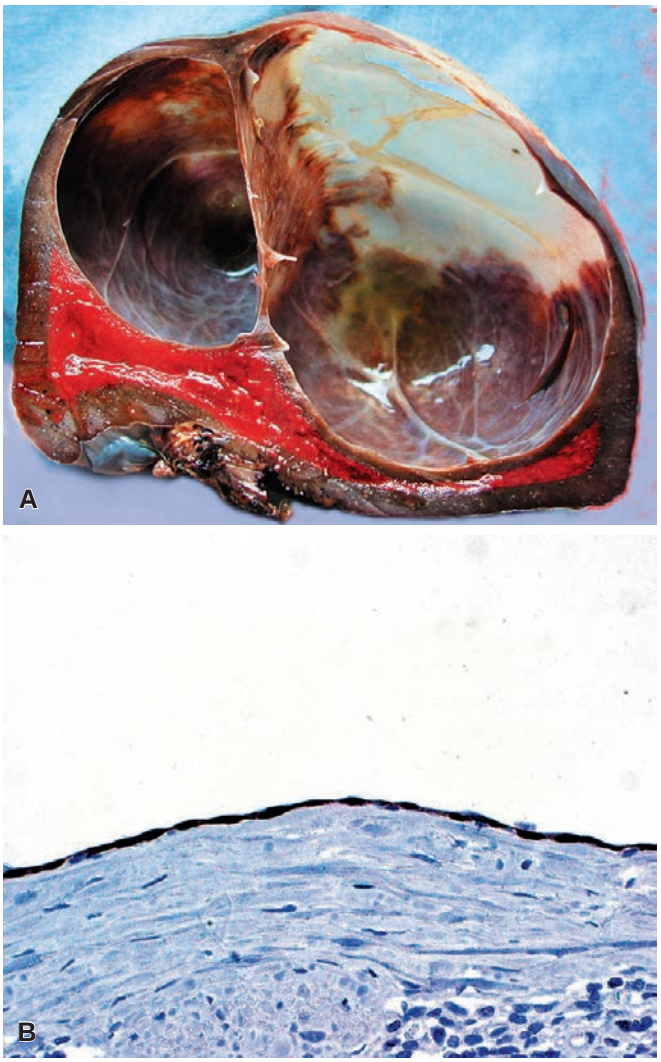

Figure 38.3 **Primary Splenic Cyst Lined by Mesothelial Cells.** **A,** Gross appearance. **B,** Immunoreactivity of the lining cells for calretinin.

Cysts

Cysts of the spleen are now categorized as primary (or true) and secondary (or false) cysts based on the detection of an epithelial lining, even focally, as definitional of a primary cysts. **Primary (epithelial) cysts** are mainly seen in children or young adults[47–49] but may be an incidental finding at any age. They are usually solitary but can be multiple. Cases have also been described in accessory spleens.[50,51] Grossly, a glistening inner surface with marked trabeculation is often seen (Fig. 38.2A). Microscopically, the wall is lined by columnar, cuboidal (mesothelial-like), or squamous epithelium (see Fig. 38.2B). When the latter is the case, the term *epidermoid cyst* has been employed in the past,[52] but because mixed epithelium is often frequent such designations are not necessary. Curiously, the stratified epithelium lining these cysts is immunoreactive for carcinoembryonic antigen (CEA) and CA 19-9, and these markers can be elevated in the serum.[53] Skin adnexa are absent. The histogenesis is unknown; embryonic inclusions of epithelial cells from adjacent structures, invagination of capsular surface mesothelium, and a monodermal teratomatous nature have been proposed,[54,55] and a subset of cysts may be small and subcapsular in location mimicking lymphangiomas.[47] The immunohistochemical profile of some is in keeping with a teratomatous derivation or origin from fetal squamous epithelium,[56] though most have the profile of mesothelial cells (mesothelial cyst) (Fig. 38.3).[47] A case occurring in an intrapancreatic accessory spleen that has the appearance of a lymphoepithelial cyst has been reported by Tateyama.[51] While some are incidental findings, large splenic cysts may require splenectomy. If enough parenchyma is preserved, the performance of a partial splenectomy should be attempted, particularly in children. Parasitic cysts of the spleen, usually secondary to *Echinococcus* infestation, are a subtype of primary cyst (Fig. 38.4).

Mucinous epithelial cysts of the spleen are usually associated with pseudomyxoma peritonei; rarely, splenomegaly due to this change is the presenting manifestation of the disease or an indicator of recurrence.[57]

Secondary (false or pseudocysts) cysts constitute approximately 75% of the nonparasitic cysts of the spleen (Fig. 38.5).[58] Their wall is composed of dense fibrous tissue, often calcified, with no epithelial lining. The content is a mixture of blood and necrotic debris. If the cyst ruptures, massive hemoperitoneum may result. The majority of these cysts are solitary and asymptomatic. Trauma and resolving abscess are the most likely etiologic factors, although it is possible that some are epithelial cysts of the type described below in which the lining has been destroyed.

For personal use only. No other uses without permission. Copyright ©2017. Elsevier Inc. All rights reserved.

Inflammation

Reactive follicular hyperplasia of the spleen can be seen as an acute phenomenon in response to a systemic infection or immune stimulation. Morphologically, infectious causes are often associated with variable degrees of congestion, diffuse immunoblastic and plasmacytic proliferation, and outpouring of neutrophils in the red pulp (so-called **septic spleen** or **acute septic splenitis**); measles and typhoid fever are the two better known etiologies. It also occurs in a chronic form in a large number of infectious diseases—including AIDS[59,60]—and in immune-mediated diseases, such as idiopathic thrombocytopenic purpura, acquired hemolytic anemia, rheumatoid arthritis (including Felty syndrome),[61] and the systemic form of Castleman disease,[62,63] as well as in hemodialyzed patients.[64]

Figure 38.4 Primary cysts due to hydatidosis of spleen.

Diffuse lymphoid hyperplasia with production of immunoblasts and plasma cells can be the result of infection (particularly viral) and graft rejection. In infectious mononucleosis, the splenic involvement is mainly in the red pulp with a spectrum of plasmacytoid lymphocytes present, often with capsular infiltration, but reactive white pulp hyperplasia may also be present.

Bagshawe[65] compared the clinical and laboratory features of hypersplenism (see next section) among 46 patients with congestive splenomegaly and 29 with reactive splenomegaly and found no significant differences between them. Massive splenomegaly of a reactive nature is commonly seen in inhabitants of several tropical countries, such as Madagascar, the Democratic Republic of Congo, Nigeria, and New Guinea.[66] Spleens removed for this tropical splenomegaly syndrome are often extremely heavy (mean, 3270 g) and exhibit a uniform dark red, cut surface. Microscopically, there is marked dilation of the sinuses and foci of extramedullary hematopoiesis but no significant fibrosis or hemosiderin deposition.[67] Signs of hypersplenism are the rule. Epidemiologic and therapeutic studies suggest a causal relationship with malaria,[67,68] and such cases often meet criteria for the so-called hyperactive malarial splenomegaly syndrome (HMSS).[69] In this regard, it is interesting that the cases of idiopathic splenomegaly reported by Banti in 1883[70] were from an area of central Italy that at the time was endemic for malaria. The criteria for HMSS require persistent gross splenomegaly, elevated anti-malarial antibodies (an IgM titer more than 2 standard deviations above the local mean) and a response to long-term malaria prophylaxis. Molecular assessment for chronic malaria infection may

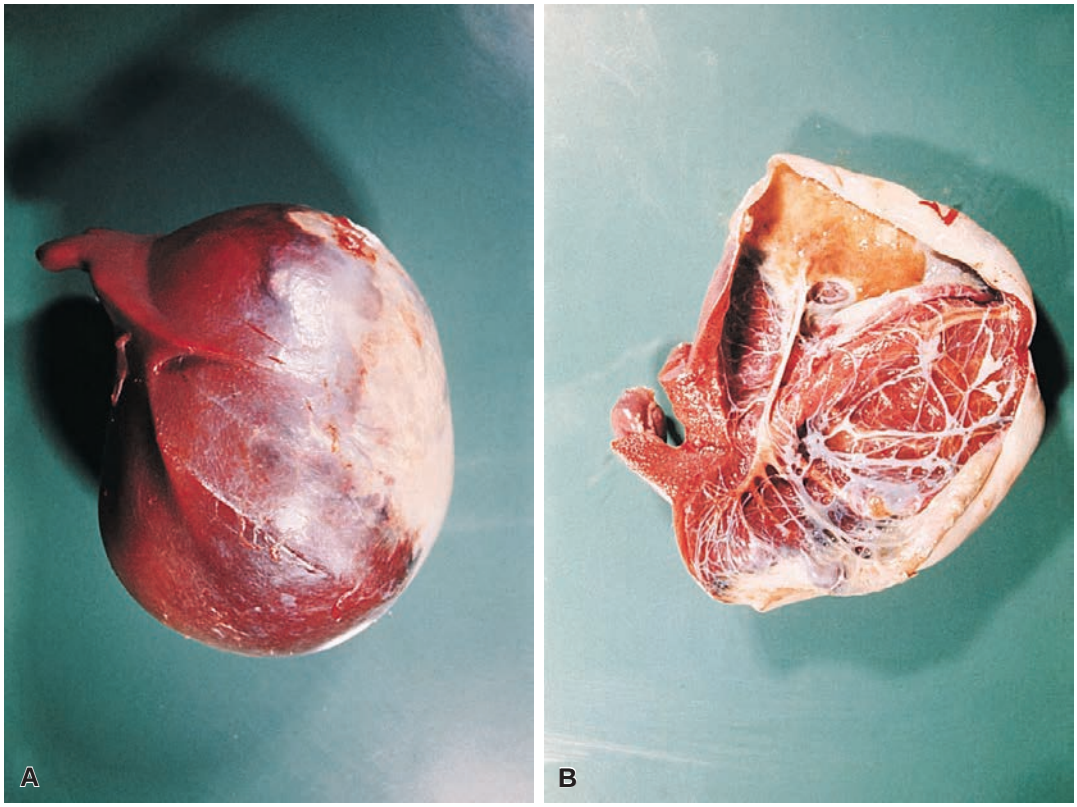

Figure 38.5 **Splenic Secondary Cyst (False or Pseudocyst). A,** Outer aspect. **B,** Inner surface. Notice the white trabeculation.

For personal use only. No other uses without permission. Copyright ©2017. Elsevier Inc. All rights reserved.

Figure 38.6 Gross appearance of a thick-walled splenic abscess. The content is partially purulent and partially hemorrhagic.

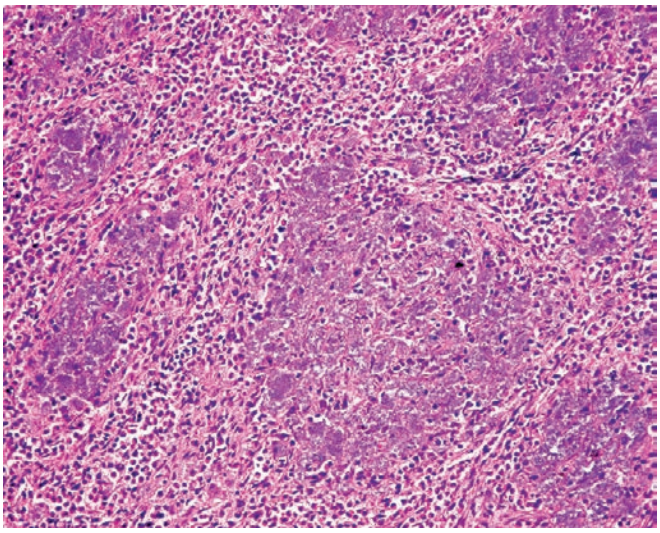

Figure 38.7 Granulomas of spleen due to *Mycobacterium avium* in an immunosuppressed patient.

be useful in patients suspected of having HMSS, because a lack of such molecular evidence correlates with lack of a response to therapy,[71] which could be a sign of splenic lymphoma rather than infection.

Abscess of the spleen, a rare condition, can be the result of trauma, functional asplenia secondary to sickle cell disease, or systemic infection (Fig. 38.6).[72,73] Septic abscesses of the spleen secondary to subacute bacterial endocarditis may necessitate surgical intervention.[74] As mentioned, after resolution of the abscess the remaining capsule may form a lesion identical to a secondary splenic cyst.

Granulomatous inflammation is a relatively common finding in splenectomy specimens. The granulomas can be roughly divided into three major types: (1) large active granulomas containing epithelioid and Langhans-type giant cells, with or without central necrosis; (2) small, widespread, sarcoid-like epithelioid granulomas with scanty giant cells and no necrosis (not to be equated with "epithelioid" germinal centers)[75]; and (3) old inactive granulomas, with fibrosis and calcification. A variant of the first type, characterized by extensive necrotizing changes, has been seen as a complication of leukemia in childhood.[76]

The third type of granuloma, which can be solitary or found scattered throughout the spleen, is particularly common in areas of endemic histoplasmosis.[77] Kuo and Rosai evaluated 20 cases of splenectomy done for splenomegaly and/or hypersplenism in which the only major pathologic finding was the presence of active granulomas of either the first or second type.[78] All of the patients were adults. Fever, weight loss, hepatosplenomegaly, and the various manifestations of hypersplenism were the most common symptoms, and these were markedly ameliorated with splenectomy. The splenic granulomas were nearly always the expression of a generalized disease, which also often involved lymph nodes, liver, and bone marrow. Despite the performance of special stains and cultures, the etiology remained unknown in all but three cases. In these, the organisms identified were *Histoplasma capsulatum*, an atypical *Mycobacterium*, and *Sporotrichum schenckii*, respectively (Fig. 38.7). None of the patients developed malignant lymphoma on follow-up.

Sarcoid-like granulomas can be seen in the spleen of patients with Hodgkin lymphoma[79] and, less commonly, non-Hodgkin lymphoma and hairy cell leukemia,[80] with or without involvement of the spleen by tumor. In some cases of non-Hodgkin lymphoma, the numerous granulomas may obscure the underlying lymphoma.[81] It should be emphasized that the presence of splenic granulomas in patients with lymphoma is not an indication per se that the spleen is involved by tumor. Actually, some authors have suggested that in patients with Hodgkin lymphoma, this finding is associated with an improved prognosis.[82] Neiman[83] found sarcoid-like granulomas in 24 of 412 splenectomy specimens; in addition to the conditions previously listed, he found them in chronic uremia and in a single case of IgA deficiency. He pointed out that in all cases the granulomas appeared to arise in the periarteriolar lymphoid sheath, suggesting that they are the result of abnormal or defective processing of antigen presented to the spleen. Granulomas have also been described in spleens affected by infectious mononucleosis.[84] Lipogranulomas are reported in approximately half of autopsy spleens in North America and may be related to dietary intake.[85,86]

Perisplenitis presents as thick white fibrous plaques coating the surface. It is a common incidental finding at autopsy (Fig. 38.8).

Hypersplenism

Hypersplenism (dysplenism) is the generic term used for the group of disorders in which the removal of hematopoietic elements by the spleen increases to a pathologic degree.[87,88] Any of the cellular elements of the blood may be affected, singly or in combination. Thus neutropenia, thrombocytopenia, hemolytic anemia, or pancytopenia may all be present. In some conditions, such as spherocytic hemolytic anemia or idiopathic thrombocytopenic purpura, the basic abnormality resides in the blood elements themselves. In others, the hypersplenism results from widening of the splenic cords with an increase in macrophages and/or connective tissue fibers and premature destruction of the normal elements of the blood. Hypersplenism resulting from this mechanism can be seen with congestive splenomegaly, Gaucher disease (Fig. 38.9), malignant lymphoma, leukemia, Langerhans cell histiocytosis, hemangioma, hamartoma, angiosarcoma, and practically any condition involving more or less diffusely the splenic parenchyma and particularly in the red pulp.[2]

A syndrome of hypersplenism developing in uremic hemodialyzed patients has also been recognized.[64] Splenectomy results in a marked improvement; a striking degree of lymphoid hyperplasia is found in the excised spleens.

Thrombocytopenic Purpuras

Immune thrombocytopenic purpura (traditionally known as idiopathic thrombocytopenic purpura) is caused by an antiplatelet

For personal use only. No other uses without permission. Copyright ©2017. Elsevier Inc. All rights reserved.

Figure 38.8 Typical gross appearance of perisplenitis ("sugar-coated" or "snow-covered" spleen). (Courtesy of Dr. RA Cooke, Brisbane, Australia. From Cooke RA, Stewart B. *Colour Atlas of Anatomical Pathology*. Edinburgh: Churchill Livingstone; 2004)

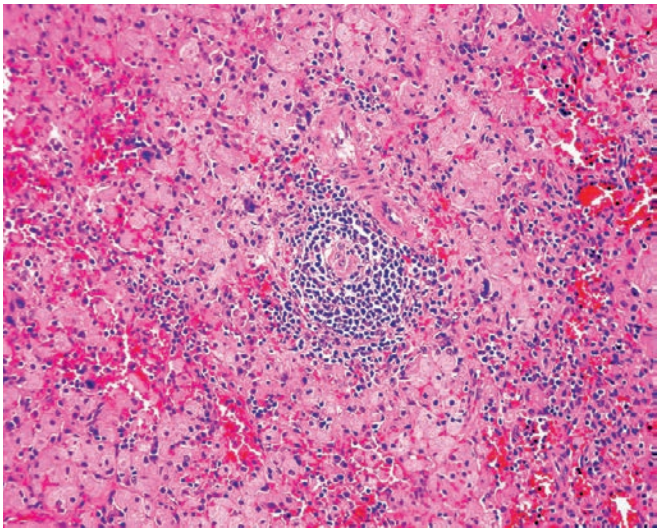

Figure 38.9 **Gaucher Disease of Spleen.** Macrophages with abundant pale acidophilic cytoplasm pack the red pulp.

IgG, which is produced largely in the spleen.[89,90] Occasionally, thrombocytopenic purpura is seen as a manifestation of lupus erythematosus, viral infection, drug hypersensitivity,[91] chronic lymphocytic leukemia,[92] or Hodgkin lymphoma.[93] The antibody-coated platelets have a short life span because they are rapidly removed by the cells of the reticuloendothelial system, particularly in the spleen and liver. There is some evidence that the number of antibody molecules bound to the platelets may determine the main site of removal. Heavily coated platelets are removed by the liver phagocytes, whereas lightly coated platelets pass through the liver but are sequestered in the spleen.

While immune-mediated disorders were a common indication for splenectomy in the past, the effective use of immune-modulatory mediations, including monoclonal antibodies such as rituximab and thrombopoietin receptor agonists, have significantly reduced the need for splenectomy in these patients.[94] When removed, however, the spleen in immune thrombocytopenic purpura is of normal size or only mildly enlarged[95]; white pulp may be grossly prominent, imparting a miliary pattern to the cut splenic surface. Microscopically, there is expansion of the white pulp due to formation of secondary follicles with well-developed germinal centers,[96] prominence of histiocytes in the red pulp, dilation of sinuses, variable numbers of perivascular plasma cells in the marginal zone, and infiltration with neutrophils of the red pulp.[97] Mild extramedullary hematopoiesis in the red pulp, usually in the form of megakaryocytes, is present in most cases.[98,97,95] The germinal centers, which usually show phagocytosis of nuclear debris and periarterial fibrosis,[99] are no longer prominent in cases previously treated with steroids.[100]

Collections of foamy macrophages containing phospholipid deposits are present in the red pulp in some of the cases.[101,102] They are the result of phagocytosis of platelets and of incompletely degraded membrane-derived phospholipids,[103,104] as supported by the fact that the platelet antigen CD41 has been detected immunohistochemically in them.[96] The phagocytosis of platelets by splenic histiocytes can be better appreciated in touch preparations. It should be noted that the presence of foamy macrophages in the spleen is not pathognomonic of this disorder.

Splenectomy in idiopathic thrombocytopenic purpura is reserved for patients unresponsive to steroid or immunosuppressive therapy.[105] It achieves sustained remission in 50%–80% of the cases.[106] It is difficult to predict its effectiveness in an individual case. However, Chang et al.[97] have shown that patients with prominent secondary follicles have a higher rate of antiplatelet antibody production and exhibit a better initial response, with a great increase in platelets postoperatively.

Thrombotic thrombocytopenic purpura may be accompanied by splenic enlargement.[107] The most important pathologic change is the presence of thrombi in arteries and arterioles without associated inflammation. PAS-positive hyaline subendothelial deposits are present. Other changes include expanded white pulp with germinal center formation, periarteriolar concentric fibrosis, hemosiderin-laden macrophages, hemophagocytosis, and extramedullary hematopoiesis.[108]

Hemolytic Anemia

Hereditary spherocytosis (congenital hemolytic anemia) is a genetically determined disease in which the red blood cells become rigid spheres (spherocytes) without the usual central pallor.[109] The abnormality lies in the cell membrane of the red blood cell. Consistent molecular alterations of spectrin and ankyrin have been detected, resulting in defects in the horizontal interactions that hold the membrane skeleton together, particularly the critical spectrin self-association reaction.[110–113] As a result, the erythrocytes lack the plasticity

For personal use only. No other uses without permission. Copyright ©2017. Elsevier Inc. All rights reserved.

of normal red blood cells and become trapped in the interstices of the spleen.[114] The splenic function itself is normal.

Acquired hemolytic anemia can be caused by toxins (bacterial hemolysins), plasma lipid abnormalities, parasites that invade red blood cells, and—most important—immune reactions that result in deposition of immune complexes on red blood cell membranes.[115] About half of the cases of immune hemolytic anemias are unassociated with other significant pathologic abnormalities. The remaining cases are seen as a manifestation of a large variety of disease, such as various forms of acute and chronic leukemia, Hodgkin lymphoma, sarcoidosis, lupus erythematosus, tuberculosis, and brucellosis. The Coombs test is the classic method to distinguish between the acquired (positive) and congenital (negative) types of hemolytic anemia. A positive Coombs test consists of agglutination of the patient's washed red blood cells following mixture with antihuman globulin rabbit serum.

Grossly, the spleen of both congenital and acquired hemolytic anemia is fairly firm and deep red, has a thin capsule and no grossly discernible white pulp, and ranges in weight from 100 to 1000 g. In congenital hemolytic anemia, the splenic cords are congested, whereas the sinusoids appear relatively empty because of the presence of ghost red blood cells.[116] The lining cells of the sinuses are prominent, sometimes resulting in a gland-like appearance. Hemosiderin deposition and erythrophagocytosis are present in both conditions but are usually more pronounced in the acquired variety. Ultrastructural studies have shown that the splenic cords are not empty but rather contain red blood cells that have lost their electron density, thus corresponding to the red cell ghosts of light microscopy.[117]

In acquired hemolytic anemia, the congestion may predominate in the cords or sinuses or be equally prominent in both. A high correlation exists between spherocytosis and increased osmotic fragility on one hand and the degree of cord congestion on the other. Foci of extramedullary hematopoiesis may be present. Splenic infarcts are found in one-fourth of the cases.[2]

Hereditary spherocytosis is the hematologic disease that most benefits from splenectomy.[118] The clinical cure rate is almost 100%, although the intrinsic red cell abnormality persists.[119] In acquired hemolytic anemia, splenectomy is usually reserved for cases that cannot be controlled by steroid or immunosuppressive therapy. A sustained remission rate is obtained in about 50% of the cases, and an objective improvement is obtained in an additional 25% of the cases. Studies of splenic sequestration using Cr^{35}-tagged red cells give a rough estimation of the benefit to be expected from splenectomy.[120]

Congestive Splenomegaly

Congestive splenomegaly is a direct consequence of portal hypertension. It may be caused by cirrhosis (by far the most common pathogenesis); thrombosis of hepatic veins (Budd–Chiari syndrome); thrombosis of the splenic veins; or occlusive thrombosis, cavernous transformation (recanalized thrombosis), sclerosis, or stenosis of the portal vein. Portal vein thrombosis may be the result of inflammation, trauma, or extrinsic pressure by inflammatory or neoplastic tissue.[87] Stenotic or sclerotic changes may be the result of extension into the main portal vein of the physiologic obliterative process that takes place at birth in the umbilical vein and the ductus venosum as they empty into the left portal vein. Cases of portal hypertension accompanied by congestive splenomegaly in which no apparent cause is discernible either in the liver or in the hepatic or portal veins are referred to as **idiopathic portal hypertension** (also known as *Banti syndrome*). It has been regarded by many with skepticism, but cases with similar features are still being seen today, particularly in Japan and India.[121,122]

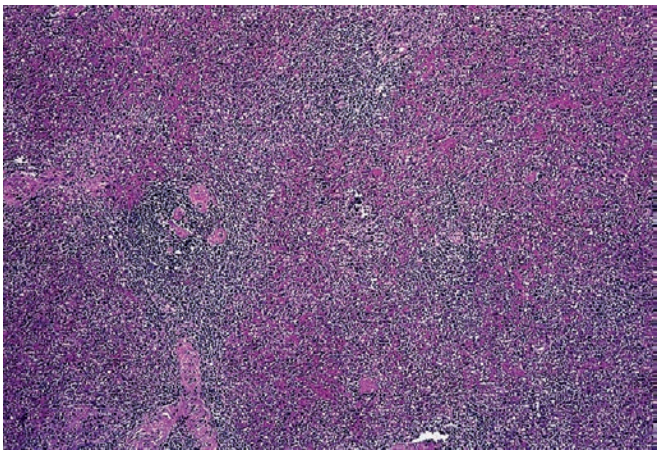

Figure 38.10 Passive Congestion of Spleen. The red pulp is massively expanded due to increased content of red blood cells.

Congestive splenomegaly may be accompanied by signs of hypersplenism, such as anemia, leukopenia, and/or thrombocytopenia. Grossly, the spleen is large, firm, and dark. Fibrous thickening of the capsule is frequent.[123] Microscopically, there is marked dilation of the veins and sinuses, fibrosis of the red pulp, and accumulation of hemosiderin-containing macrophages (Fig. 38.10). Lymphoid follicles are inconspicuous. Iron incrustation of the connective tissue and sclerosiderotic nodules, often with an associated foreign body reaction, ("Gamna–Gandy bodies") develop as a result of focal hemorrhages. Because fibrosis is commonly present in advanced cases, the condition is also known as fibrocongestive splenomegaly.

Splenectomy without shunt is successful when the coronary vein joins the portal system central to the point of obstruction. Otherwise, shunt is indicated. Various types have been done, including anastomosis of the splenic vein to the renal vein and anastomosis of the portal vein to the vena cava. These operations have been successful as a means of controlling repetitive hemorrhage from esophageal varices but do not seem to prolong life.[124]

Other Non-Neoplastic Disorders

Foamy macrophages can be found in the spleens of patients with idiopathic thrombocytopenic purpura, as already indicated. They also occur, as an incidental finding without clinical significance, in the malpighian follicles of normal individuals (so-called follicular or mineral oil lipidosis mentioned previously) in association with similar changes in the liver and intra-abdominal lymph nodes.[125] They are much more common in North American than in Latin American or African populations.[85,86] Biochemical studies have demonstrated the presence of saturated hydrocarbons, which imply the ingestion of exogenous mineral oil. The most common source seems to be material related to the packaging and display of foodstuff.[85,126]

Foamy histiocytes have also been described in Gaucher disease, Niemann–Pick disease,[127] Tay–Sachs disease, chronic granulomatous disease, thalassemia,[128] and hyperlipemic stages.[129] Histochemical techniques usually may be useful for a distinction among these various conditions,[130] but biochemical genetic studies are now recommended to fully assess individuals for the specific storage diseases. It is now accepted that the process originally designated as sea-blue histiocyte syndrome[131] is not a specific entity and that histiocytes with a sea-blue appearance can be present in any of the disorders previously mentioned[132] and also in chronic myeloid leukemia and other hematologic disorders with high cell turnover.

For personal use only. No other uses without permission. Copyright ©2017. Elsevier Inc. All rights reserved.

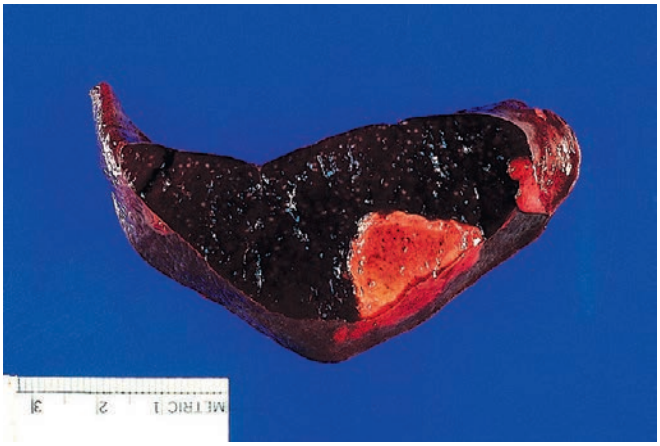

Figure 38.11 Typical wedge-shaped appearance and "anemic" quality of splenic infarct. A second smaller infarct is also present.

Infarction of the spleen may result from thrombosis of the splenic vein, a phenomenon not always associated with a detectable etiology. Infarct of the spleen is one of the complications of Wegener granulomatosis and may result in rupture of the organ.[133–135] Splenic infarcts are also common in cases of massive splenomegaly, regardless of its cause (Fig. 38.11).

Peliosis of the spleen (peliosis lienis) is characterized by widespread, blood-filled cystic spaces. Most reported cases have been associated with peliosis hepatis,[136] but it may occur independently from it.[137] The most common location for the lesions is the parafollicular region.[137] Cases have been reported in which this condition led to splenic rupture[138] and death.[137] Most cases have occurred in patients with wasting diseases, such as tuberculosis and carcinomatosis, or in patients who have received anabolic–androgenic steroids.[139] They have also been seen in association with chronic leukemia[138] and following liver transplantation.[140]

Radiation injury to the spleen, usually produced in the course of therapy for lymphoma, results in an organ with a wrinkled, thick capsule and parenchymal collapse, with diffuse fibrosis of the red pulp and lymphocyte depletion.[141]

Amyloidosis of the spleen is nearly always an expression of the "secondary" form of the disease and has been associated with spontaneous splenic rupture in several reports.[142–145] "Sago spleen" and "lardaceous spleen" are the classic descriptions, depending respectively on the follicular versus diffuse locations of the deposits. Exceptional cases of localized splenic amyloid nodules ("amyloid tumor") have also been described.[146] Amyloidosis of the spleen should be distinguished from the common hyaline adventitial thickening of splenic vessels, a change sometimes referred to as para-amyloid and said to be accentuated in AIDS patients.[147]

Hematolymphoid Tumors and Tumorlike Conditions

Non-Hodgkin Lymphoma

Malignant lymphoma is by far the most common malignant tumor involving the spleen. Although usually affected as part of a generalized process, in some cases the spleen represents the first or only detectable site of disease. In either case, splenic involvement by malignant lymphoma may present as an asymptomatic splenomegaly or result in a picture of hypersplenism. Ahmann et al.[148] described four gross patterns of involvement: homogeneous, miliary, multiple masses, and solitary masses, which show some correspondence to the various microscopic types (Fig. 38.12).

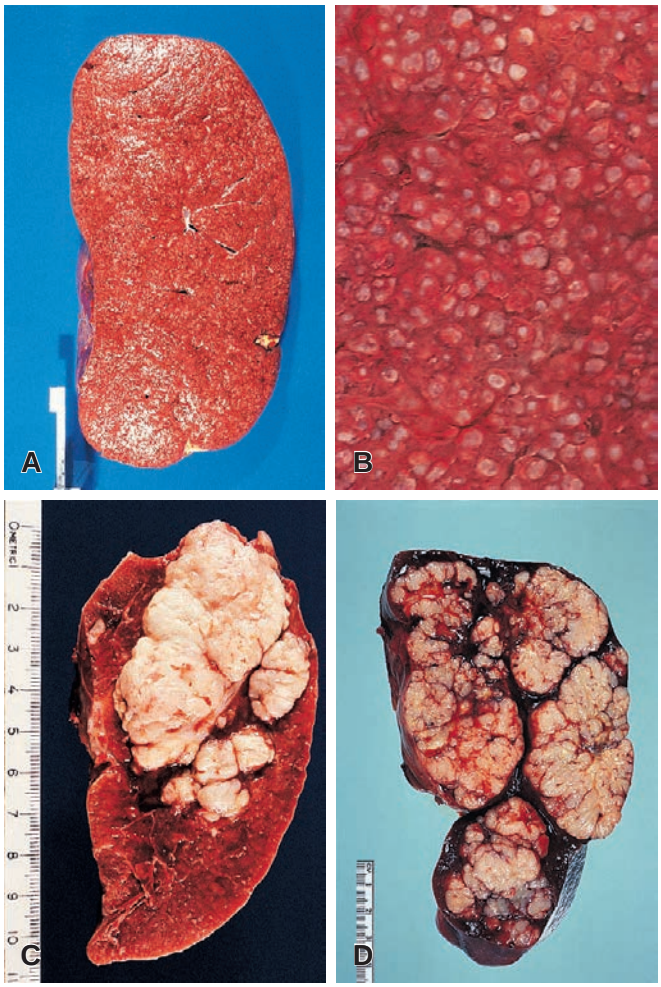

Figure 38.12 Gross Appearances of Various Types of Malignant Lymphoma Involving the Spleen. A, Miliary pattern in small lymphocytic lymphoma/chronic lymphocytic leukemia. **B,** Miliary pattern with follicular lymphoma. **C** and **D,** Nodular pattern due to involvement by large B-cell lymphoma.

Primary splenic lymphoma (defined as restricted to the spleen and hilar lymph nodes) is rare, accounting for less than 1% of all lymphomas. Although a few types of primary splenic lymphoma, discussed later, are unique to the spleen, most other lymphoma types, described in more detail in Chapter 37, may rarely present as a primary splenic disorder.[149] **Diffuse large B-cell lymphoma**, the most common disseminated lymphoma, most often involves the spleen in a macronodular pattern, as either primary or secondary disease. Two other primary patterns of splenic large B-cell lymphoma have also been described: a micronodular pattern in which the tumor nodules, although smaller, show a diffuse proliferation of mixed cells that include small T cells, large B cell and histiocytes similar to *T-cell/histiocyte-rich large B-cell lymphoma* of other sites, and a diffuse infiltration of the red pulp that mimics splenic involvement by acute leukemia.[150–152] The diffuse red pulp pattern is the least common of the three.

Patients with splenic large B-cell lymphoma often present with left upper quadrant pain, fever, weight loss, and an elevated erythrocyte sedimentation rate.[153] Some of the cases have been seen in association with HIV infection,[154] and others (particularly in Japan) have occurred

For personal use only. No other uses without permission. Copyright ©2017. Elsevier Inc. All rights reserved.

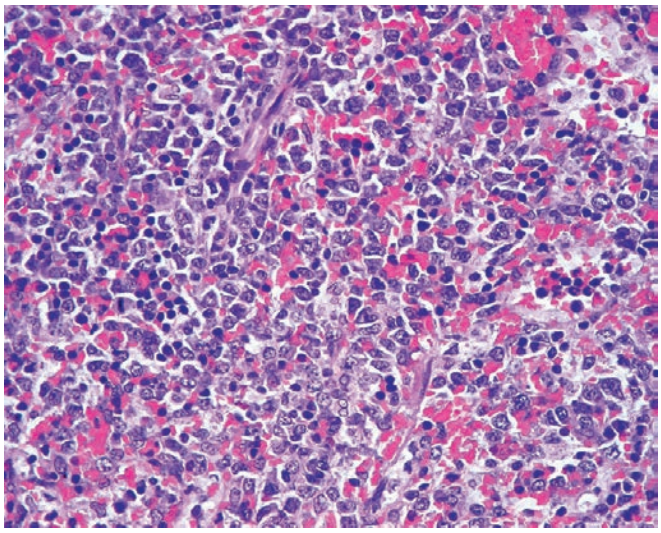

Figure 38.13 Large B-cell lymphoma of spleen causing diffuse infiltration of the tumor nodule.

in patients with hepatitis C virus infection.[155] Grossly, transgression of the splenic capsule is common, sometimes accompanied by invasion of adjacent structures. Hilar and retroperitoneal lymph nodes are often involved. Immunophenotypically, these neoplasms express B cell–associated antigens such as CD20, CD79A, and PAX5; most are BCL6 positive.[156,150] Morphologically, they most often form multiple discrete nodules in the white pulp or large coalescing nodules (Fig. 38.13). Some peripheral T-cell lymphomas may also show a predominance of large cells in nodules, mimicking diffuse large B-cell lymphoma, but these cases are easily excluded by routine immunohistochemical studies. Morphologic features that are common in T-cell lymphoma include an epithelioid histiocytic reaction, tumor confinement to the periarteriolar lymphoid sheath and marginal zone, and clear cell or polymorphous cytologic features (Fig. 38.14),[157–159] but none of these are sufficient to assign lineage without immunophenotyping studies. Along these lines, it should be mentioned that the cases originally interpreted as a chronic form of malignant histiocytosis with predominant splenic involvement on the basis of phagocytic activity, lysozyme positivity, and clinical evolution probably represent instead variants of large T-cell lymphoma.[160]

Secondary splenic involvement by tumor is particularly common in low-grade lymphomas, most of which are of B-cell type.[161] This includes small lymphocytic lymphoma/chronic lymphocytic leukemia (Fig. 38.15), lymphoplasmacytic lymphoma, mantle cell lymphoma, and follicular lymphoma. While the characteristics of these various systemic lymphoma types are discussed in more detail in Chapter 37, some characteristic features in the spleen are discussed here.

Small lymphocytic lymphoma/chronic lymphocytic leukemia in the spleen usually presents grossly as nodules measuring a few millimeters in diameter (miliary pattern) scattered throughout the organ (Fig. 38.16). The low-power appearance is also distinctly nodular because of the preferential involvement of the white pulp.[162] In this regard, it is important to point out that this miliary pattern of growth is common to several types of lymphoproliferative disease of the spleen (including small lymphocytic lymphoma/chronic lymphocytic leukemia, mantle cell lymphoma, and SMZL). In these disorders, the "nodular" pattern is due to expansion of the normal splenic white pulp by the lymphoma and not an expansion of true follicles and that its presence should not be equated with a diagnosis of follicular lymphoma.[160]

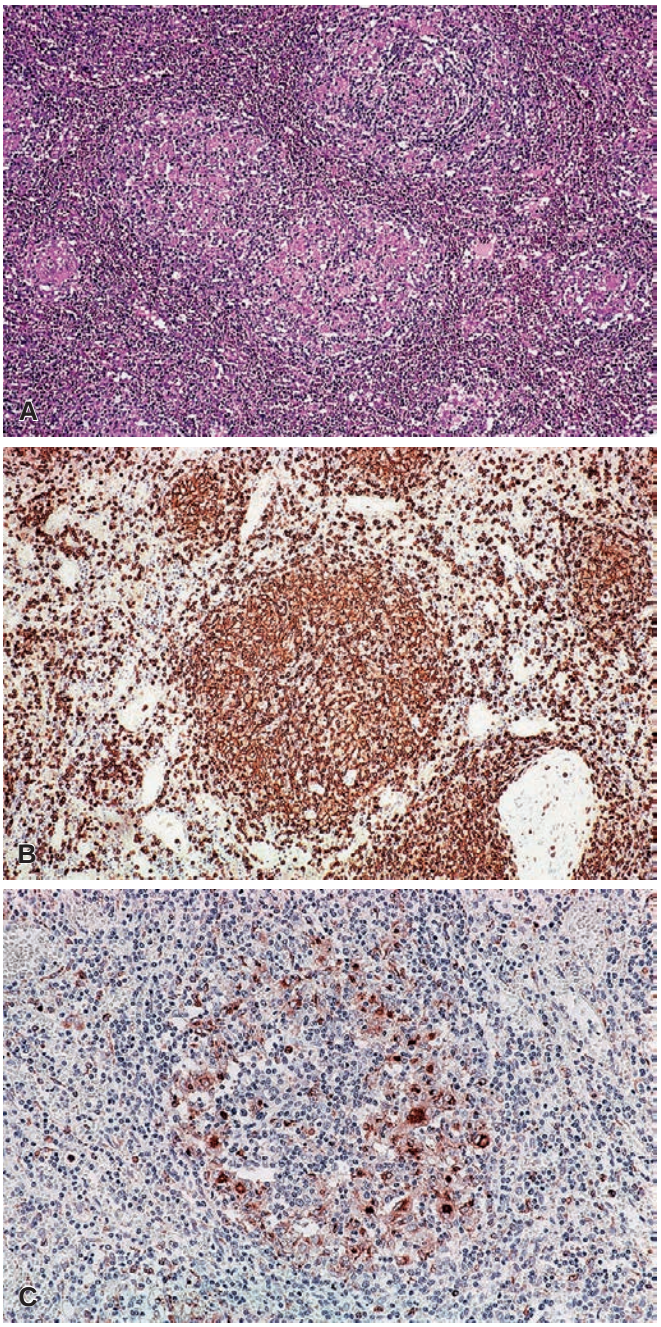

Figure 38.14 Peripheral T-Cell Lymphoma of Spleen Rich in Reactive Histiocytes. A, Low-power appearance. **B,** CD43 immunoreactivity of neoplastic T cells. **C,** Lysozyme positivity of reactive histiocytes.

In the early stages, the diagnosis of small lymphocytic lymphoma/chronic lymphocytic leukemia can be easily missed. Clues to the diagnosis in these cases include prominent enlargement and coalescence of follicles; marked expansion of the mantle zone; germinal centers that are absent, inconspicuous, or overrun by small cells; presence of B cells in the red pulp; and presence of clusters of small lymphoid cells protruding beneath the endothelium of trabecular veins.[163] Infiltration of endothelium and trabecular veins by small lymphocytes may also be seen in infectious mononucleosis, but the infiltrate in infectious mononucleosis is predominantly T cells compared to the monotypic B cells in small lymphocytic lymphoma/

For personal use only. No other uses without permission. Copyright ©2017. Elsevier Inc. All rights reserved.

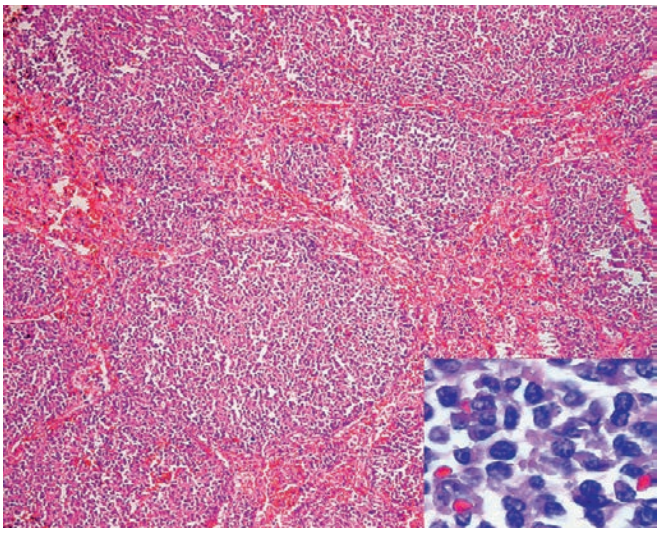

Figure 38.15 Small lymphocytic lymphoma/chronic lymphocytic leukemia of spleen, replacing normal white pulp with fusion of white pulp nodules and extension of small lymphocytes into the red pulp.

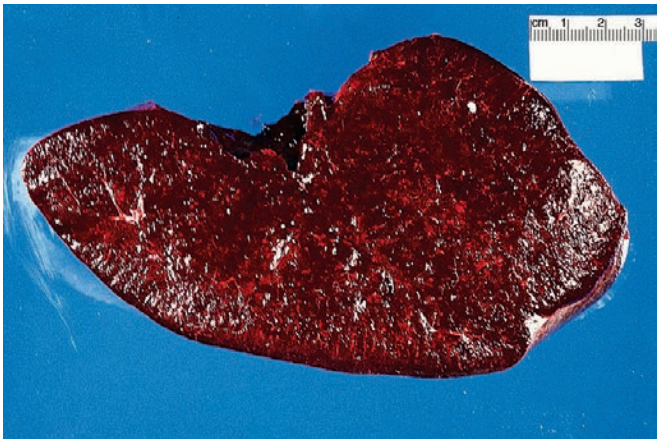

Figure 38.16 The splenic involvement by small lymphocytic lymphoma/chronic lymphocytic leukemia results in marked diffuse enlargement of the organ.

chronic lymphocytic leukemia. Infiltration of the subendothelial space by red cell precursors in infants with erythroblastosis fetalis and (together with granulocyte precursors) in adults with myelofibrosis may also mimic this process. A helpful hint for the diagnosis of lymphoma is to carefully dissect and examine the lymph nodes in the splenic hilum, since they may show obvious lymphoma when the changes in the spleen are only equivocal. Additionally, immunohistochemical studies to assess the immunoarchitecture of the splenic lymphocytes are extremely helpful in identifying abnormal B-cell populations infiltrating the red pulp in B-cell lymphoma.

An "entity" that exemplifies the difficulties sometimes encountered in the recognition of splenic small lymphocytic lymphoma is so-called *idiopathic nontropical splenomegaly* (see earlier). Although originally regarded as a benign and probably reactive form of splenomegaly,[164] a follow-up study by the same group showed that half of these cases actually represented malignant lymphoma.[165]

Such cases now can be diagnosed on biopsies or primary splenic lymphoma can at least be strongly suggested by pattern and immunophenotype of disease in the bone marrow, and many

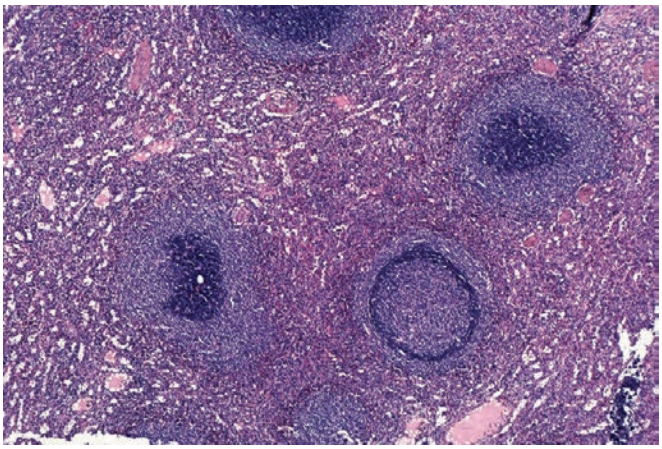

Figure 38.17 Follicular Lymphoma Involving the Spleen. The lower right nodule contains follicular lymphoma, mimicking a germinal center, surrounded by a thin mantle zone. Note the expanded outer marginal zones that may cause confusion with splenic marginal zone lymphoma.

patients are now treated with chemotherapy and without undergoing splenectomy.

Splenic involvement by follicular lymphoma can cause prominent architectural abnormalities, creating gross tumor nodules, or result in preservation of the splenic architecture with expansion of what appear to be germinal centers in the white pulp (Fig. 38.17). Most cases demonstrate a consistent CD10+/BCL2+ phenotype,[166] which aids in excluding reactive follicles, but similar to follicular lymphoma in other sites, some cases will be negative for these markers.[167] Most, if not all, patients with follicular lymphoma involving the spleen, however, have disseminated disease with involvement of hilar lymph nodes and disseminated adenopathy.

Two types of primary malignant lymphoma of the spleen that need to be singled out because their distinctive features are splenic marginal zone B-cell lymphoma and hepatosplenic T-cell lymphoma.

SMZL tends to occur in older adults, with no sex predilection, and usually presents with splenomegaly, anemia, and weight loss.[168–170] The bone marrow is involved with an intrasinusoidal component in nearly all cases, and liver involvement is also common,[171] but nonsplenic hilar lymph node involvement is rare. Grossly, the spleen usually weighs 1000 g or more, and splenic involvement manifests itself through miliary expansion of the white pulp.

Histologically, the white pulp is expanded by a proliferation of small- to medium-sized lymphocytes with clusters of similar lymphocytes in the red pulp.[172] Classically, the lymphoid component has been described as biphasic with an inner zone of dark staining small lymphocytes with scant cytoplasm surrounded by a ring of medium-sized lymphocytes with more abundant, clear cytoplasm mimicking the normal splenic marginal zone (Fig. 38.18). Both white pulp lymphocyte components in such cases represent lymphoma cells. Some cases with this pattern will have central areas of reactive germinal centers, especially if the patient has associated immune disorders with the neoplastic white pulp elements mimicking both the mantle and marginal zones of the reactive spleen. Red pulp lymphocytes, however, are also increased and occur in clusters and often have moderately abundant cytoplasm, similar to the outer white pulp zone of the neoplastic infiltrate. In contrast to this classic pattern of splenic infiltration, many cases of SMZL will expand the white pulp with a more monotonous cell population without a distinct outer and inner zone. Immunohistochemically, the neoplastic

For personal use only. No other uses without permission. Copyright ©2017. Elsevier Inc. All rights reserved.

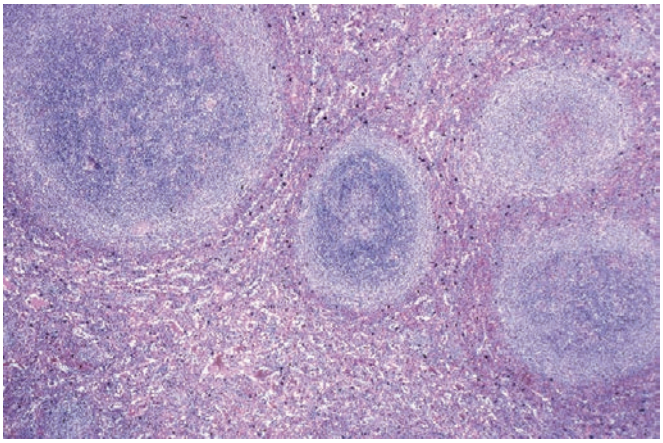

Figure 38.18 Splenic marginal zone lymphoma showing the classic biphasic pattern of nodules with central small, dark blue-staining lymphocytes with scant cytoplasm surrounded by an outer zone of cells with more abundant and clear cytoplasm. Small B-lymphocytes also infiltrate the red pulp in aggregates.

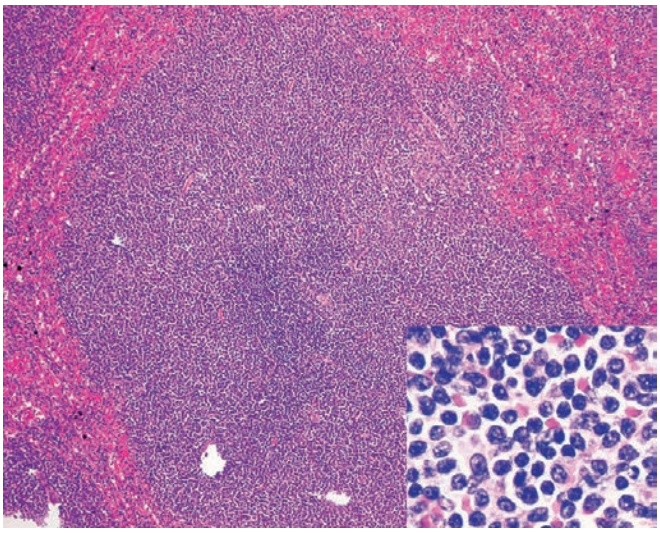

Figure 38.19 Mantle Cell Lymphoma. Note the tiny residual germinal center. The inset shows the monotonous proliferation of centrocyte-like tumor cells.

cells express CD20 and other B cell–associated antigens such as CD79A and PAX5, surface immunoglobulin (usually IgM ± IgD), and BCL2 but not CD10, BCL6, CD23, CD11c, or CD43.[173] There is no cyclin D1 protein,[174] Annexin A1 or LEF1 expression, features typical of mantle cell lymphoma, hairy cell leukemia, and chronic lymphocytic leukemia, respectively, although a subset of cases express CD103, which is common in hairy cell leukemia. A subset of cases also shows aberrant expression of CD5, which is associated with higher white blood cell counts and more frequent bone marrow involvement.[175] Such cases are otherwise similar to SMZL and do not have other immunophenotypic, molecular genetic, or clinical features to suggest chronic lymphocytic leukemia. SMZL lacks the common translocations seen in the other small B-cell lymphomas, including those of extranodal marginal zone lymphoma. Various chromosomal abnormalities have been reported, with complete or partial trisomy 3q being the commonest but not specific.[176–178] On the other hand, deletion or translocation involving 7q32, found in 40% of cases, is a characteristic chromosomal aberration in SMZL.[176,179,178] Although SMZL is reported to have a unique gene expression profile, such testing is not routinely necessary for diagnosis.[180] Various gene mutations, including mutations of *TP53*, *NOTCH1*, and *KLF2*, are reported to be frequent in SMZL, but none do date are unique to this lymphoma type.[181]

The differential diagnosis of SMZL includes mantle cell lymphoma (Fig. 38.19),[182,183] follicular lymphoma with marginal zone differentiation,[184] hairy cell leukemia, chronic lymphocytic leukemia/small lymphocytic lymphoma, and the diffuse red pulp small B-cell lymphomas, including hairy cell leukemia variant. As mentioned, the immunophenotype of the neoplastic cells is very helpful in this differential diagnosis, and in the case of splenic diffuse red pulp small B-cell lymphoma, the pattern of splenic infiltration is essential. Several lymphoma types, but especially follicular lymphoma,[149,184] involving the spleen may be associated with an expanded outer marginal zone that may mimic SMZL and histologic identification of small cleaved cells, as well as detection of CD10 expression are useful to exclude SMZL in these cases (see Fig. 38.17).

Ten to 15% of cases of SMZL will transform to diffuse large B-cell lymphoma, usually with late lymph node involvement at a distant site.[185]

Hepatosplenic T-cell lymphoma, previously known as hepatosplenic γ/δT-cell and erythrophagocytic Tγ lymphoma, is a distinct

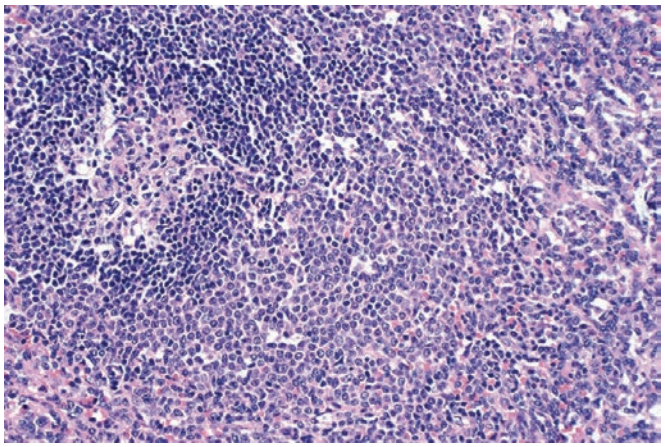

Figure 38.20 Hepatosplenic T-Cell Lymphoma. Medium-sized atypical lymphocytes infiltrate the red pulp, surround a white pulp nodule on the left.

clinical entity within the spectrum of peripheral T-cell lymphomas.[186,187–189] It typically presents with massive hepatosplenomegaly, fever, and weight loss in young males and carries a poor prognosis. Cases have been described in immunocompromised patients, in association with Epstein–Barr virus (EBV) and in patients with inflammatory bowel disease.[190–193] In the latter group, the increased risk of hepatosplenic T-cell lymphoma is controversial but appears to be increase in patients that are treated with a combination of tumor necrosis factor alpha (TNF-α) and thiopurines.[193] Grossly, the spleen is usually 1000 g or larger, with a uniform, beefy red cut surface without malpighian follicles. Microscopically, the neoplastic infiltration involves the cords and sinuses and is composed of variably sized lymphoid cells with oval or folded nuclei, moderately condensed chromatin, and pale cytoplasm (Fig. 38.20). Tumor involvement of the liver and bone marrow is characterized by an intrasinusoidal distribution and marrow involvement may be subtle on H&E sections alone.[194]

The neoplastic cells are mature T cells that usually express CD2, CD3, CD56, perforin, TIA-1, and TCRG but usually lack CD5, CD4,

For personal use only. No other uses without permission. Copyright ©2017. Elsevier Inc. All rights reserved.

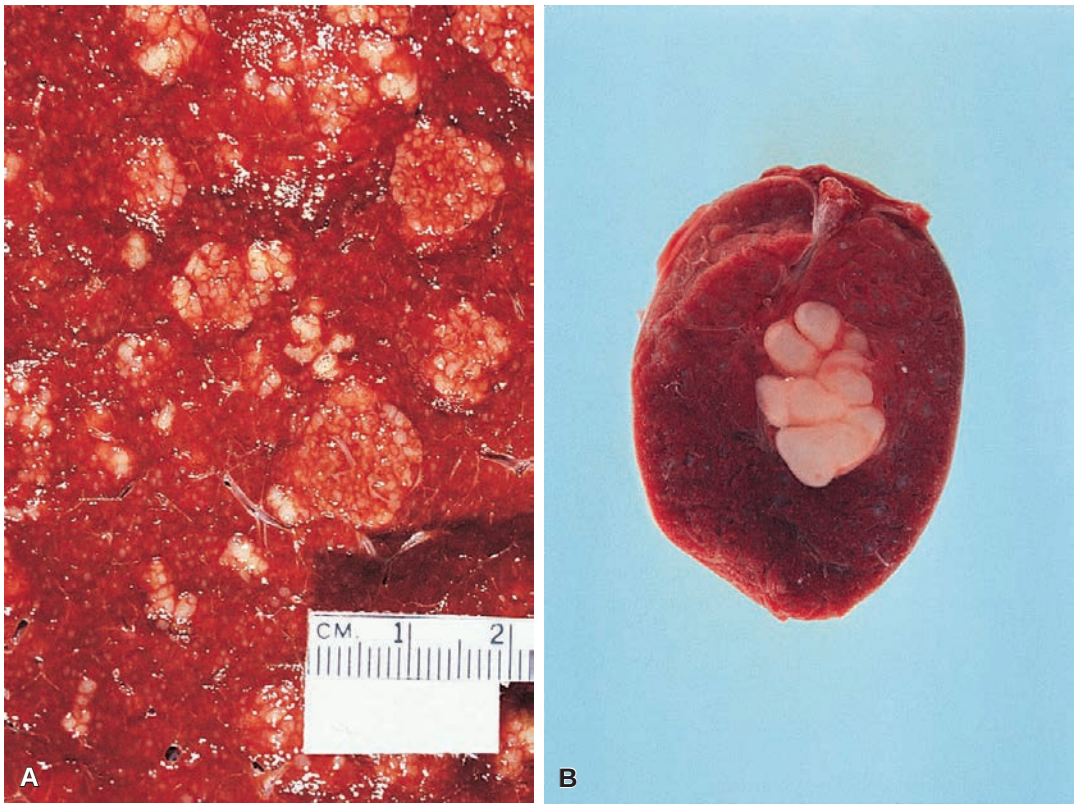

Figure 38.21 **A** and **B,** Gross appearance of Hodgkin lymphoma involving the spleen.

CD8, granzyme B, and TCRB.[195] Cases, however, may be of the α/β type and express TCRB without TCRG.[196] Based on histologic sections, the primary differential diagnosis is with hairy cell leukemia, from which it is distinguished by the absence of blood lakes and its different immunophenotype.

At the molecular level, there is usually clonal rearrangement of the gamma of the T-cell receptor gene, but this assay cannot be used to distinguish the α/β from the γ/δ type. Both immunophenotypic types are associated with isochromosome 7q and trisomy 8. Mutations of *STAT5B* are also common.[195]

The treatment of primary malignant lymphoma of the spleen has historically involved splenectomy, followed by chemotherapy,[197] but patients are now treated commonly without splenectomy. Some of these patients have presumptive splenic lymphoma, based on the presence of splenomegaly with evidence of blood involvement or sinusoidal disease in the bone marrow if no evidence of adenopathy. The prognosis is directly related to the microscopic type and the clinical stage, in the sense that it is distinctly better for low-grade tumors and for stage I and II disease.[148,198] Patients with localized splenic non-Hodgkin lymphoma seem to have the same rate of survival as other stage I non-Hodgkin lymphoma patients.[199]

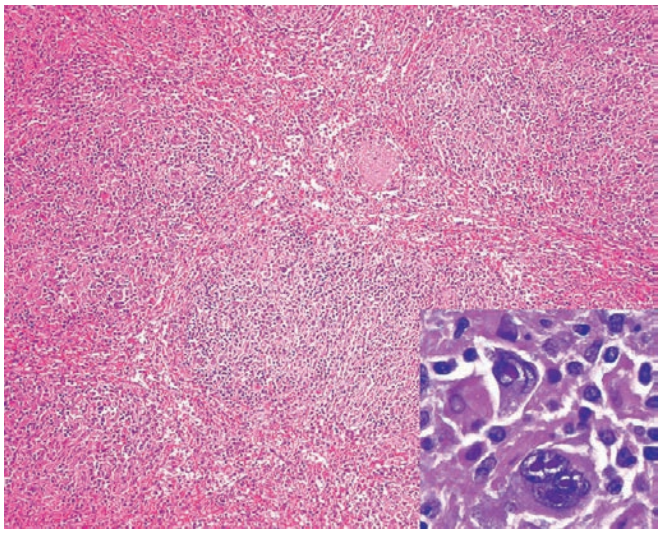

Figure 38.22 Classic Hodgkin lymphoma of spleen. The inset shows typical Reed–Sternberg cells.

Hodgkin Lymphoma

The spleen is the most common site of extranodal organ involvement by Hodgkin lymphoma, but primary Hodgkin lymphoma of the spleen is extremely rare. The morphologic features of Hodgkin lymphoma are discussed in Chapter 37. Grossly the involvement is in the form of one or multiple nodules, grossly indistinguishable from those of large cell lymphoma (Fig. 38.21). Foci of involvement can be only a few millimeters in size, a fact which calls for a very meticulous gross inspection of the organ. The earliest lesions are located in the periarterial lymphoid sheath or marginal zones of the follicles. By far the most common type is the nodular sclerosis subtype of classic Hodgkin lymphoma, but others may be seen as well, including lymphocyte predominance (Fig. 38.22).[200,201] Some cases have initially presented with spontaneous splenic rupture.[202] As already mentioned, sarcoid-type granulomas can be seen in spleens of patients with Hodgkin lymphoma and should not be construed by themselves as evidence of splenic involvement by the lymphoma.

For personal use only. No other uses without permission. Copyright ©2017. Elsevier Inc. All rights reserved.

Leukemias

Any type of leukemia can involve the spleen, the location being predominantly the red pulp except in chronic lymphocytic leukemia (see earlier for small lymphocytic lymphoma/chronic lymphocytic leukemia),[160,203] but the spleen is rarely removed or sampled for such a diagnosis. The earliest involvement is in the cords, with secondary spillage into the sinuses.

Hairy cell leukemia is a specific indolent B-cell malignancy that must be distinguished from other lymphomas of small B cells[204,205]; it is further discussed in Chapter 39. Grossly the spleen shows diffuse and usually marked enlargement without formation of nodules (Fig. 38.23).[206] Microscopically, hairy cell leukemia is a disease of the red pulp, which shows diffuse infiltration by a monotonous population of small mononuclear cells with very scanty mitotic activity and practically no phagocytosis (Fig. 38.24).[207,208] The initial involvement occurs around the fibrous trabeculae. The nuclei of the hairy cells are small, round, or oval, with irregular contours, occasional deep indentations ("coffee beans"), and inconspicuous nucleoli. Rarely, the nuclei have a multilobular appearance.[209] The cytoplasm is usually moderate to abundant and lightly stained. Ultrastructurally, prominent cytoplasmic villous projections are evident.[210] The distinctive enzyme histochemical feature of the disease is the presence of tartrate-resistant acid phosphatase (isoenzyme 5),[211] but this assay is no longer performed in most laboratories and immunophenotyping is required for diagnosis. The hairy cell leukemia cells are monotypic B cells that express CD20 and other B-lineage antigens, as well as CD103, annexin A1, and CD123. They are negative for CD5 and CD43, but a subset of cases express CD10. The cells are also positive for TRAP and DBA.44, but these markers are less specific for hairy cell leukemia.[212–216] The splenic vasculature is abnormal in the sense of showing an absolute increase in the volume, surface, and length of pulp arterial vessels, as well as enlargement of pulp cords and sinuses.[217] Pools of blood in the red pulp, lined by hairy cells and simulating dilated sinuses or even hemangiomas, are commonly seen and constitute an important diagnostic feature termed "red blood cell lakes."[218] It has been suggested that this results from the hairy cells adhering to the sinus surface, producing endothelial cell injury and impeding the venous blood flow.[219] In what is perhaps the preceding stage of this process, some of the tumor cells are seen to aggregate in the subendothelial spaces of trabecular veins; sometimes this is the only recognizable site of involvement.[220] The lymph nodes in the splenic hilum are often involved, the pattern of permeation being interfollicular.

Figure 38.23 Gross Appearance of Hairy Cell Leukemia. Note the diffuse involvement, lack of nodularity, and dark red color.

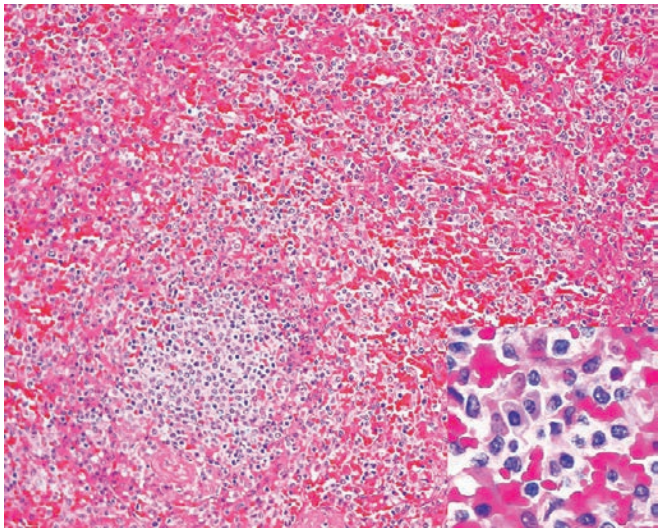

Figure 38.24 Splenic Involvement by Hairy Cell Leukemia. The inset shows the bland monotonous appearance of the red pulp infiltrate.

Myeloproliferative Neoplasms

Chronic myeloid leukemia, *BCR-ABL1* positive results grossly in a large, dark red, diffusely involved organ in which malpighian follicles are inconspicuous or absent. The red pulp is infiltrated by granulocytic precursors as well as scattered abnormal megakaryocytes. Infarcts are common. In rare cases, blastic transformation is first seen in a splenectomy specimen, and immunohistochemistry for CD34 expression on blast cells is useful when such transformation is suspected.

Primary myelofibrosis is discussed in detail in Chapter 39 but is characteristically associated with splenomegaly and splenectomy is often performed due to an associated wasting syndrome. The average spleen weight is 2 kg.[221] Grossly, the spleen is diffusely dark red and moderately firm, with frequent areas of hemorrhage (Fig. 38.25) and frequently associated with infarcts. Microscopically, the diagnostic feature is the presence in the red pulp of abnormal hematopoietic cell lines: megakaryocytes, erythroid precursors, and granulocyte precursors. The latter are made evident with Leder chloroacetate esterase stain or myeloperoxidase (Fig. 38.26). The

Figure 38.25 Diffuse involvement of the spleen by primary myelofibrosis.

For personal use only. No other uses without permission. Copyright ©2017. Elsevier Inc. All rights reserved.

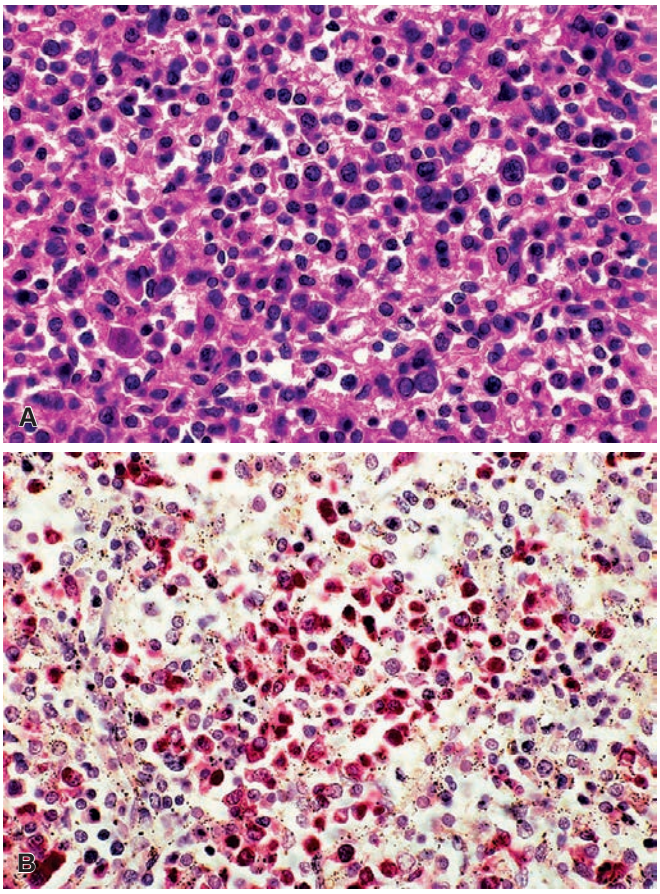

Figure 38.26 Abnormal hematopoiesis in splenic red pulp due to involvement by primary myelofibrosis, as seen in H&E section **(A)** and with Leder chloroacetate esterase stain **(B)**.

megakaryocytes often have atypical nuclear features and can be confused with Reed–Sternberg cells, but Hodgkin lymphoma of the spleen forms tumor nodules in contrast to the diffuse red pulp infiltration of primary myelofibrosis.[222] It is believed that the hematopoietic cells present in the spleen result from filtration of circulating cells from the peripheral blood rather than arising de novo from splenic stem cells.[223,224] Other splenic changes in myelofibrosis include congestion, hemosiderosis, and paucity of lymphoid follicles.[225,226]

Splenic changes similar to primary myelofibrosis are seen in the so-called spent phase of polycythemia vera. Splenomegaly in early polycythemia vera and essential thrombocythemia is less common and is often due to congestion of the red pulp and increases in red pulp macrophages containing platelets. Splenic enlargement in chronic myelomonocytic leukemia may also occur, due to increases in red pulp monocytes, and may demonstrate red blood cell lakes similar to those seen in hairy cell leukemia.[138,227]

Mastocytosis

The general features of systemic mastocytosis are discussed in Chapter 39. The spleen is frequently involved, and the morphologic changes in it can be very deceptive.[228] Grossly, the spleen is typically enlarged, with ill-defined nodules having a fibrotic appearance scattered throughout the organ. Microscopically, these highly fibrotic foci are often centered on a vessel or surround the white pulp, an important diagnostic clue.[228,229] The diagnosis depends on the identification of mast cells, which usually appear as pale-staining small clusters embedded in fibrous tissue, accompanied by a variable number of eosinophils, lymphocytes, or histiocytes (Fig. 38.27). The nucleus is centrally located and of regular outline; the cytoplasm is light staining, with a variable degree of granularity; the cell borders tend to be sharply outlined. Confirmation of the diagnosis is obtained by the immunohistochemical demonstration of mast cell tryptase and CD117 (KIT).[149,228,230,231] The mast cells also express CD68 and CD43 and often show aberrant expression of CD2, CD25, and CD30.[232]

Most patients with systemic mastocytosis exhibit the D816V point mutation in the *KIT* gene, involving the tyrosine kinase domain of the transmembrane receptor.[233]

The lymph nodes in the splenic hilum are often involved; the diagnosis may be easier on them than on the spleen. The foci of involvement in the lymph nodes are usually perifollicular and may also show a perivascular distribution. The gastrointestinal tract is also commonly affected.[234] Approximately one-third of patients with systemic mastocytosis have another hematologic disorder that may be life-threatening, such as chronic myelomonocytic leukemia and acute myeloid leukemia, and the red pulp cords and sinuses may be filled by this second neoplasm. Identification of the associated hematologic neoplasm is critical for management of the patient.

Other Hematolymphoid Conditions

Focal lymphoid hyperplasia can present in the spleen as a solitary nodule that may be confused grossly with lymphoma, especially if the patient is known to suffer from that condition. Microscopically, the nodule is formed either by aggregates of reactive germinal centers or by a localized proliferation of lymphocytes, immunoblasts, and plasma cells.[235,236] Focal lymphoid hyperplasia, however, is rare and care must be taken to exclude lymphoma, especially in patients with a history of Hodgkin lymphoma.

Castleman disease can involve the spleen, although it rarely results in prominent splenomegaly. Most of the reported types have been of the multicentric and plasma cell type,[63] but a few instances of the hyaline vascular type are also on record (Fig. 38.28).[62] As an aside, it could be mentioned here that the hyaline vascular form of Castleman disease shows a close resemblance to spleen on low-power examination, to the point that it is sometimes misdiagnosed as ectopic or supernumerary spleen when located in places such as mediastinum or retroperitoneum.

Wiskott–Aldrich syndrome, an X-linked hematologic disorder characterized by thrombocytopenia, eczema, and immunodeficiency, is accompanied by a general depletion of the splenic white pulp, with significant reduction of the marginal zone thickness.[237]

Vascular Tumors

Hemangioma is the most common primary tumor of the spleen.[238,58,239] They may be of the cavernous or capillary variety with morphologic features similar to hemangiomas at other sites. Most are less than 2 cm in diameter and present as incidental findings. Rarely, they are large and/or multiple, and they may involve the entire spleen (Fig. 38.29). They may be associated with hemangiomas of other sites *(angiomatosis)*. The most common complication is rupture and bleeding.[240] Cases associated with anemia, thrombocytopenia, and consumption coagulopathy (Kasabach–Merritt syndrome) have been reported.[241,242]

Littoral cell angioma is a vascular tumor unique to the spleen, originally thought to arise from normal splenic lining (littoral) cells.[243] It varies in size from minute foci to large nodules almost completely replacing the splenic tissue (Fig. 38.30). Microscopically, it is composed of anastomosing vascular channels resembling

For personal use only. No other uses without permission. Copyright ©2017. Elsevier Inc. All rights reserved.

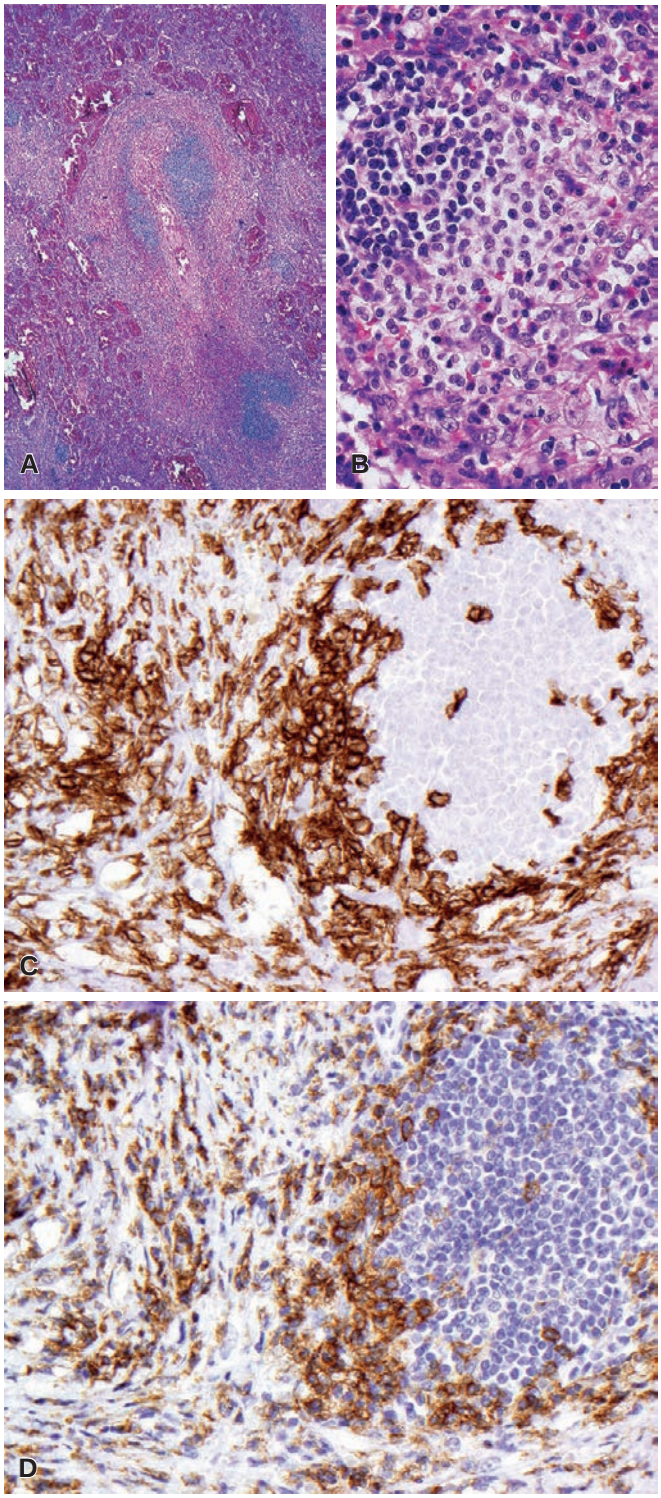

Figure 38.27 Involvement of the Spleen by Systemic Mastocytosis. A, Low-power view showing the perimalpighian and perivascular arrangement of the infiltrate. **B,** High-power view showing clusters of mast cells. **C,** The mast cells are strongly positive for CD117 and, **D,** show aberrant expression of CD25.

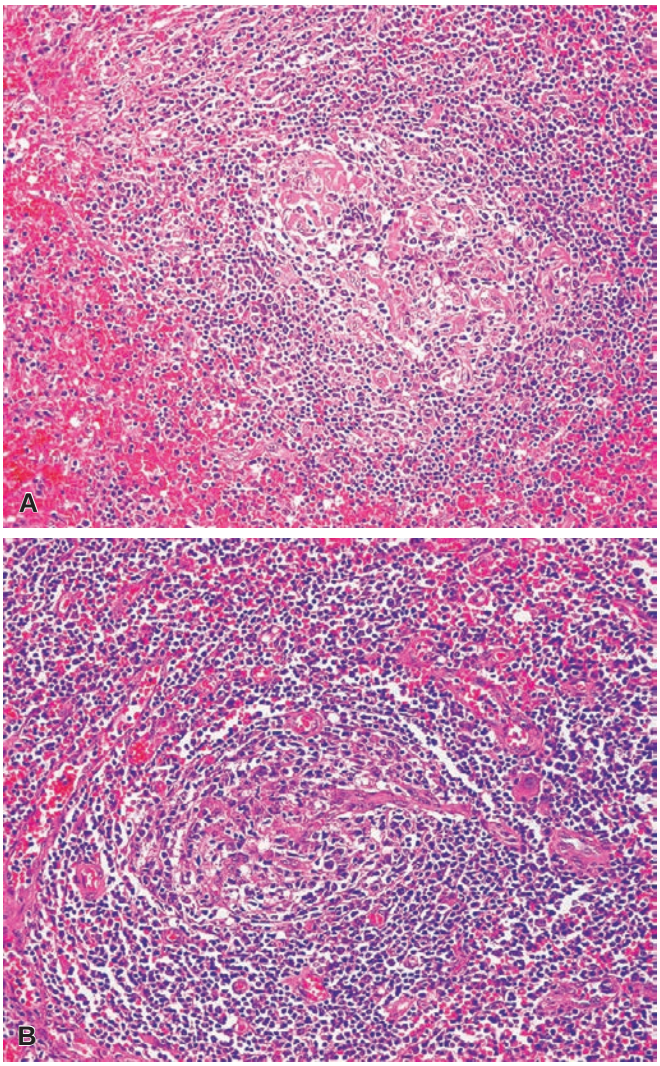

Figure 38.28 Castleman Disease of Hyaline-Vascular Type. A, Splenic involvement. **B,** Lymph node involvement in the same case.

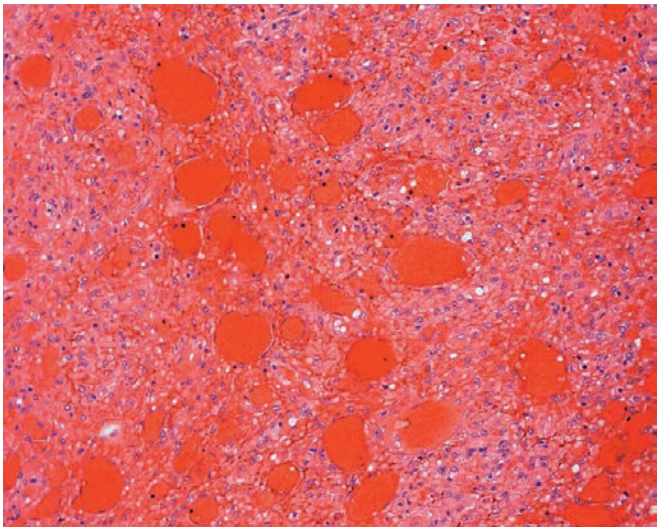

Figure 38.29 Diffuse involvement of spleen by benign vascular tumor ("angiomatosis").

For personal use only. No other uses without permission. Copyright ©2017. Elsevier Inc. All rights reserved.

splenic sinuses (Fig. 38.31). These channels have irregular lumina often featuring papillary projections and cyst-like spaces, often containing individual lining cells or histiocytes. They are lined by tall endothelial-like cells, some of which show hemophagocytosis. The lining cells show nuclear enlargement, but a low mitotic rate and no evidence of necrosis. Immunohistochemically, the neoplastic cells express some endothelial (factor VIII–related antigen) and histiocytic (KP1/CD68, lysozyme) markers, which suggested a littoral cell origin (Table 38.1). The lining cells also express CD31, but not CD34, and do not express CD8, typical of normal splenic sinus lining cells. Interestingly, most cases demonstrate at least focal expression of CD21 on the lining cells (Fig. 38.32).[238] Typical cases of littoral cell angioma are indolent and adequately treated with splenectomy. However, two cases, both with foci of clear cells in sheets, have developed late abdominal metastases of only the clear cell component and were diagnosed in retrospect as littoral cell hemangioendotheliomas.[244,245] Reported cases of so-called littoral cell angiosarcoma are usually based solely on expression CD8, which is a nonspecific finding in angiosarcoma and is not normally expressed in littoral cell angioma. No such cases have documented evidence of typical littoral cell angioma prior to development of angiosarcoma.

Lymphangioma of the spleen is historically described as being located in the subcapsular region but may involve the entire organ *(diffuse lymphangiomatosis)* (Fig. 38.33).[246] Most of the subcapsular lesions diagnosed as splenic lymphangioma actually represent mesothelial cysts.[47] Most larger or diffuse cases have been reported in children, sometimes in association with lymphangiomas in other organs.[247] **Hemangioendothelioma** is the term that has been applied in the spleen (as in many other sites) in a somewhat loose fashion to vascular endothelial neoplasms that are either more cellular and/or are thought to be potentially more aggressive than conventional hemangiomas but are not full-fledged angiosarcomas. Some of these tumors have been described as *epithelioid* (sometimes associated with functional hyposplenism),[248] some as *epithelioid and spindle cell,*[249] and some as combining endothelial and myoid features *(myoid angioendothelioma)*.[250] Other than the very rare littoral cell hemangioendothelioma described previously, some tumors called hemangioendotheliomas in the past may represent other proliferations,

Figure 38.30 Gross Appearance of Littoral Cell Angioma. Numerous hemorrhagic lesions with a lobular configuration are seen.

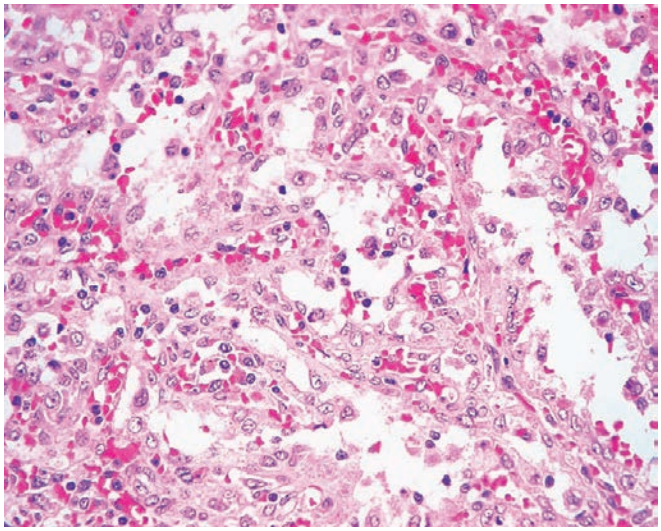

Figure 38.31 Littoral Cell Angioma of Spleen. The vascular spaces are lined by plump cells with the appearance of sinus lining ("littoral") cells.

Table 38.1 Useful markers in the differential diagnosis of non-hematopoietic primary splenic proliferations

MARKER/ DIAGNOSIS	HEMANGIOMA	LITTORAL CELL ANGIOMA	HAMARTOMA	SCLEROSING ANGIOMATOID NODULAR TRANSFORMATION	INFLAMMATORY PSEUDOTUMOR-LIKE FOLLICULAR/ FIBROBLASTIC DENDRITIC CELL SARCOMA[a]
CD31	+	+	+	+	–
CD34	+	–	+/–	–/+	–
CD8	–	–	+	–	–
CD68	–/+	+	–	–	–
CD21	–	+ (focal)	–	–	+/–
Smooth muscle actin	–	–	–	–	–/+
Epstein–Barr virus	–	–	–	–	+

[a]Refers to spindle cell component; all other results are for the vascular or endothelial-like cellular component.

For personal use only. No other uses without permission. Copyright ©2017. Elsevier Inc. All rights reserved.

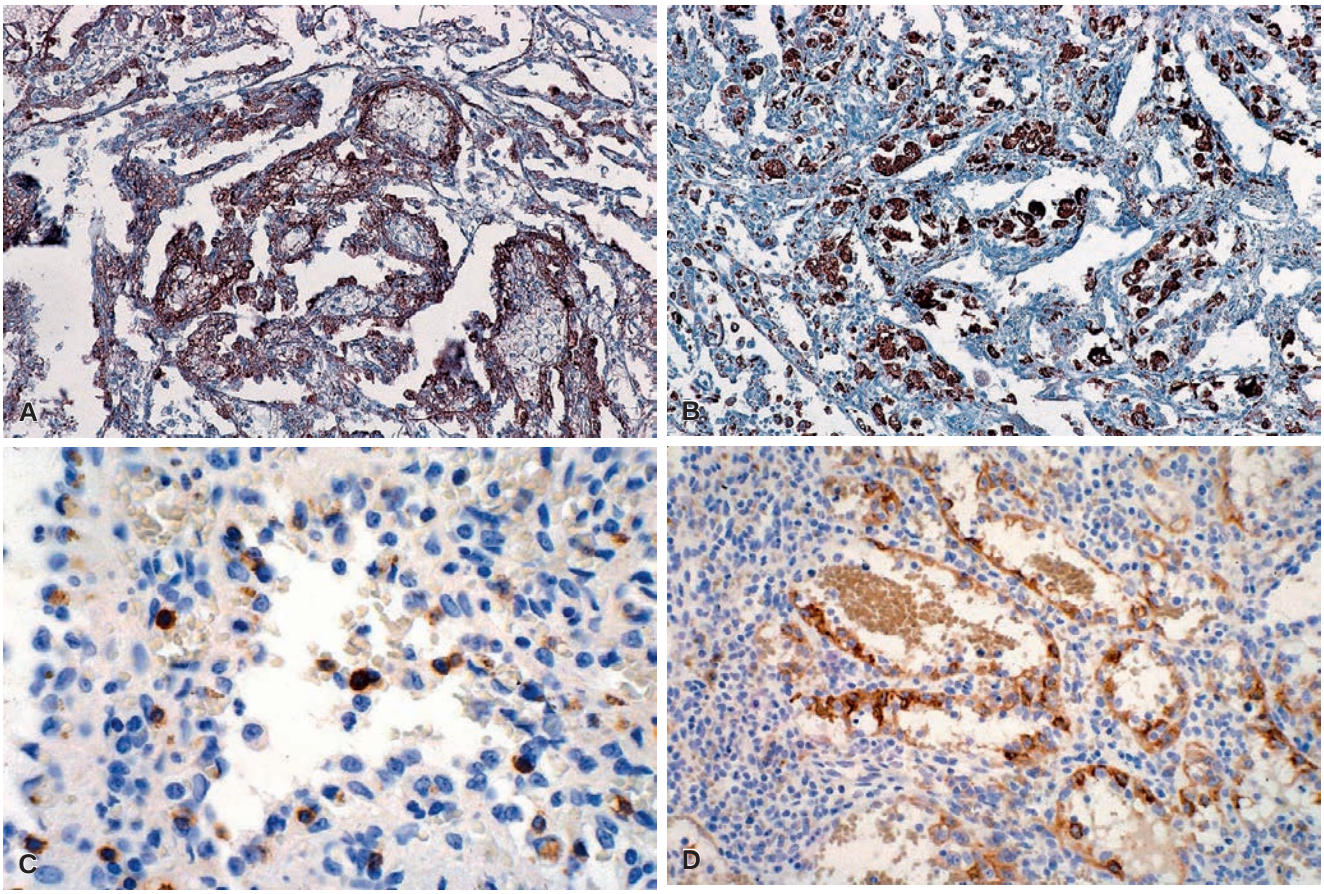

Figure 38.32 Littoral cell angioma of spleen showing combined expression of endothelial (**A,** factor VIII–related antigen) and histiocytic markers (**B,** lysozyme). The cells lack CD8 **(C)** a marker expressed by normal splenic sinus lining cells, but show expression of CD21 **(D)**.

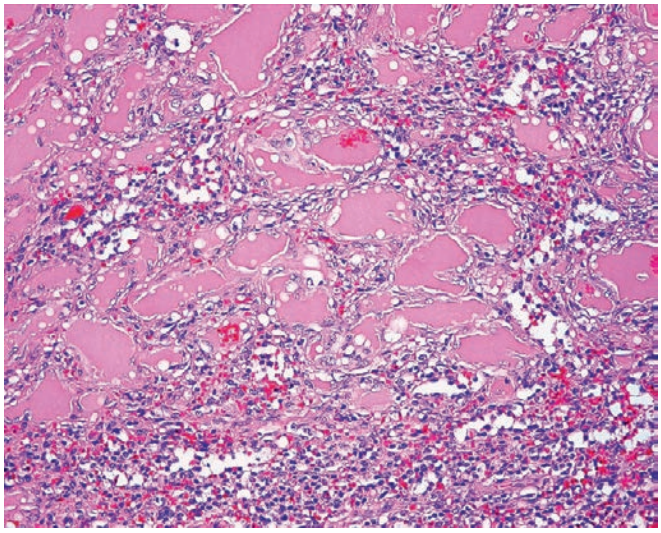

Figure 38.33 Lymphangioma of Spleen.

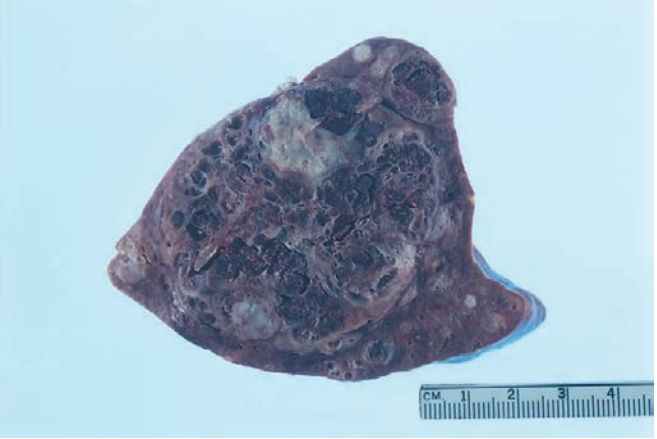

Figure 38.34 **Angiosarcoma of Spleen.** The tumor is markedly hemorrhagic and necrotic.

such as sclerosing angiomatoid nodular transformation (SANT; see later).

Angiosarcoma (malignant hemangioendothelioma) is considered the most common malignant primary nonlymphoid tumor of the spleen,[251] but the tumor is often disseminated at diagnosis and proving splenic origin is often difficult or impossible in those cases. In the spleen, it may present as a well-defined hemorrhagic nodule or involve the spleen diffusely and may lead to spontaneous rupture of the organ (Fig. 38.34).[252,253] It may also be accompanied by microangiopathic anemia, thrombocytopenia, and consumption coagulopathy.[254] As in other sites, there are cases of angiosarcoma of spleen that have developed many years following the insertion of a foreign body (gauze sponge).[255] Microscopically, the pattern of

For personal use only. No other uses without permission. Copyright ©2017. Elsevier Inc. All rights reserved.

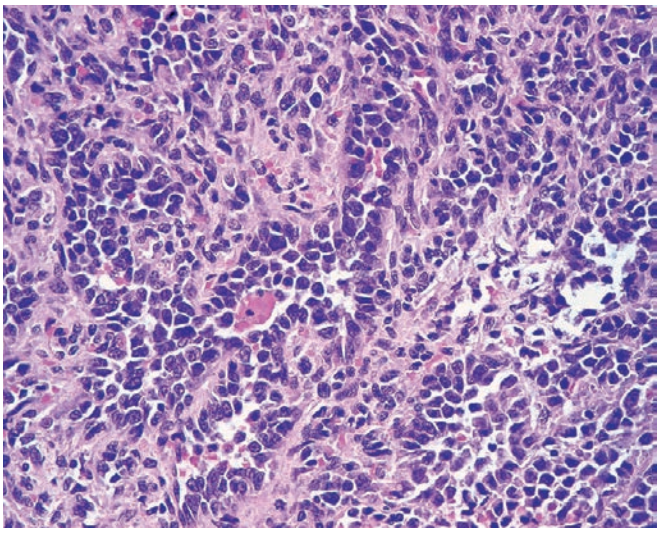

Figure 38.35 Angiosarcoma of Spleen. The tumor cells have markedly hyperchromatic nuclei that protrude into the vascular lumina.

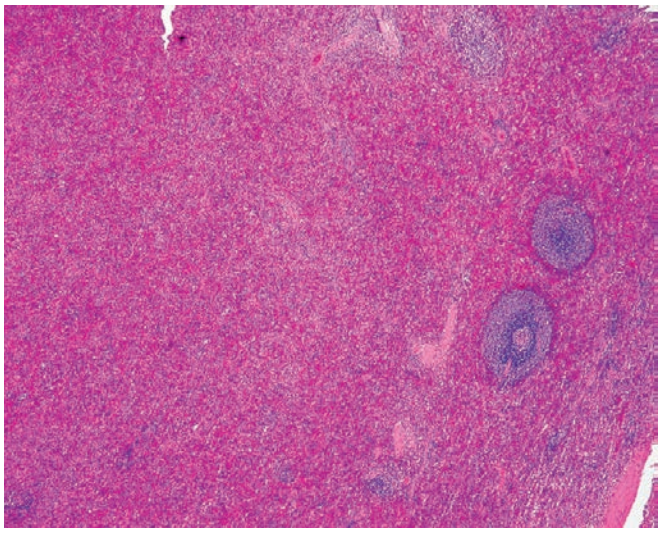

Figure 38.36 Low-Power Appearance of Splenic Hamartoma. The lesion is formed by disorganized red pulp without white pulp. Residual normal spleen is seen on the right.

growth of angiosarcoma may be solid, papillary, or characterized by the classic freely anastomosing vascular channels (Fig. 38.35).[256] Intracytoplasmic hyaline globules are common. Sometimes the tumor cells have an epithelioid appearance *(epithelioid angiosarcoma)*.[257] Immunohistochemically, the tumor cells exhibit endothelial markers, though some may show focal antigen loss, and often express CD68 and other less lineage-specific markers.[238,256] The clinical course of splenic angiosarcoma is rapid and almost invariably fatal, with widespread metastases occurring frequently.[256]

Hemangiopericytoma is mentioned last in this listing of vascular splenic tumor because of its exceptional rarity[257] and the controversies that exist about its real nature.

Other Primary Tumors and Tumorlike Conditions

Hamartoma (splenadenoma or splenoma) is the term used for a nodular lesion of the spleen composed exclusively of red pulp elements, without intervening white pulp (Fig. 38.36).[2,258–260] It does not contain follicles or follicular dendritic cells, fibrous trabeculae are scanty, and foci of extramedullary hematopoiesis may be present.[261] Occasionally, it may contain a population of bizarre stromal cells of probable dendritic/reticulum or myoid cell nature, which should not be overdiagnosed as malignant.[262,263] Immunohistochemically, a reverse pattern of factor VIII and CD31 staining when compared with the adjacent normal spleen has been described in splenic hamartoma.[264] Otherwise, predominant cell type is CD8 positive, similar to normal splenic sinus lining cells.[238] This lesion may attain a large size and be accompanied by thrombocytopenia and other signs of hypersplenism.[265]

Sclerosing angiomatoid nodular transformation (SANT) of the spleen is a distinctive splenic process that forms a distinct gross tumor nodule (Fig. 38.37) and has a striking multinodular quality that can simulate the appearance of granulomas on low-power histologic examination (Fig. 38.38A).[266–268] The individual nodules, which have a vaguely lobular architecture, are surrounded by a hyaline shell (see Fig. 38.38B). The vessels within the nodules are markedly cellular, to the point that they were initially interpreted as neoplastic and were named in a previous edition of his book as multinodular hemangioma. Immunostaining reveals three distinct types of vessel: CD34+/CD8–/CD31+ capillaries, CD34–/CD8+/

Figure 38.37 Gross Appearance of Sclerosing Angiomatoid Nodular Transformation. The bisected spleen shows a firm, stellate, tan-white lesion with foci of hemorrhage,

For personal use only. No other uses without permission. Copyright ©2017. Elsevier Inc. All rights reserved.

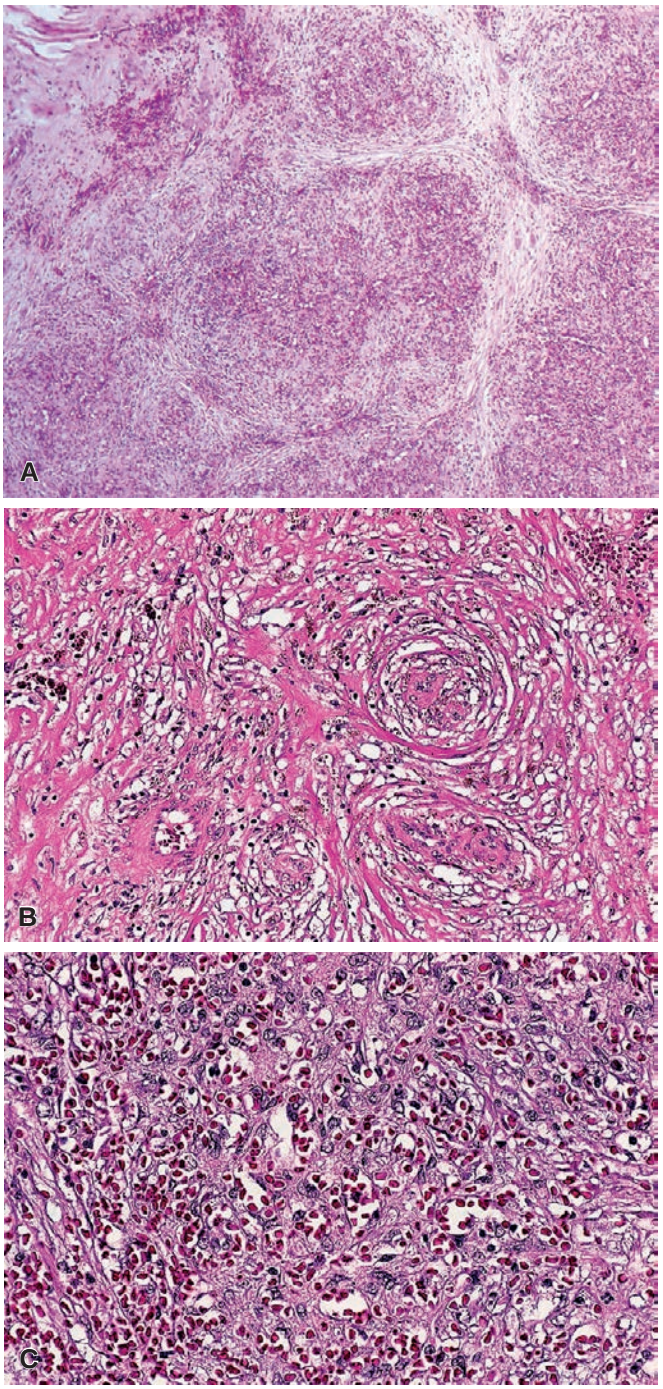

Figure 38.38 Sclerosing Angiomatoid Nodular Transformation of Spleen (SANT). A, Low-power appearance showing a distinctly nodular architecture. **B,** Highly hyalinized area simulating an ancient granuloma. **C,** Cellular area of clearly angiomatous nature.

CD31+ sinusoids, and CD34–/CD8–/CD31+ small veins (see Fig. 38.38C). The internodular stroma consists of variably myxoid to dense fibrous tissue with scattered plump myofibroblasts, plasma cells, lymphocytes, and siderophages. The lesion is almost always solitary and the evolution is benign. Its pathogenesis remains controversial. It shares a number of features with inflammatory pseudotumor,[269] a nonspecific diagnosis in the spleen; it may contain numerous IgG4-positive plasma cells,[270] and it was reported in one instance to be positive for EBV.[271]

Figure 38.39 Gross appearance of inflammatory pseudotumor-like fibroblastic/follicular dendritic cell sarcoma of the spleen. The cut surface has a variegated color resulting from a combination of necrosis, hemorrhage, and cellular infiltration.

The term **inflammatory pseudotumor** has been used in the past to describe a supposedly reactive tumorlike condition that may be encountered as an incidental finding at laparotomy or that may present as an asymptomatic splenic mass.[258,272] This term, however, is nonspecific and represents a variety of proliferations that range from inflammatory responses to malignant neoplasms. Infectious causes include the *splenic spindle cell pseudoneoplastic lesions* that can result from mycobacterial infection in immunocompromised patients.[273] Also, as mentioned, sclerosing angiomatoid nodular transformation of the spleen can have features of so-called inflammatory pseudotumor. Most cases with this presentation, however, represent what is now termed **inflammatory pseudotumor-like follicular/fibroblastic dendritic cell sarcoma**. These proliferations are unique to the liver and spleen and were originally described as EBV-positive inflammatory pseudotumors and subsequently as inflammatory pseudotumor-like follicular dendritic cell tumors.[274,275] They differ from traditional follicular dendritic cell tumors, and although it is remains as a subtype of follicular dendritic cell tumor, the name has been modified again in 2016 World Health Organization classification of hematopoietic neoplasms.[276] These tumors usually present with fever and abdominal pain. Grossly, the spleen demonstrates a discrete, firm tan lesion, sometimes with focal hemorrhage, without capsular extension (Fig. 38.39). Histologically,

For personal use only. No other uses without permission. Copyright ©2017. Elsevier Inc. All rights reserved.

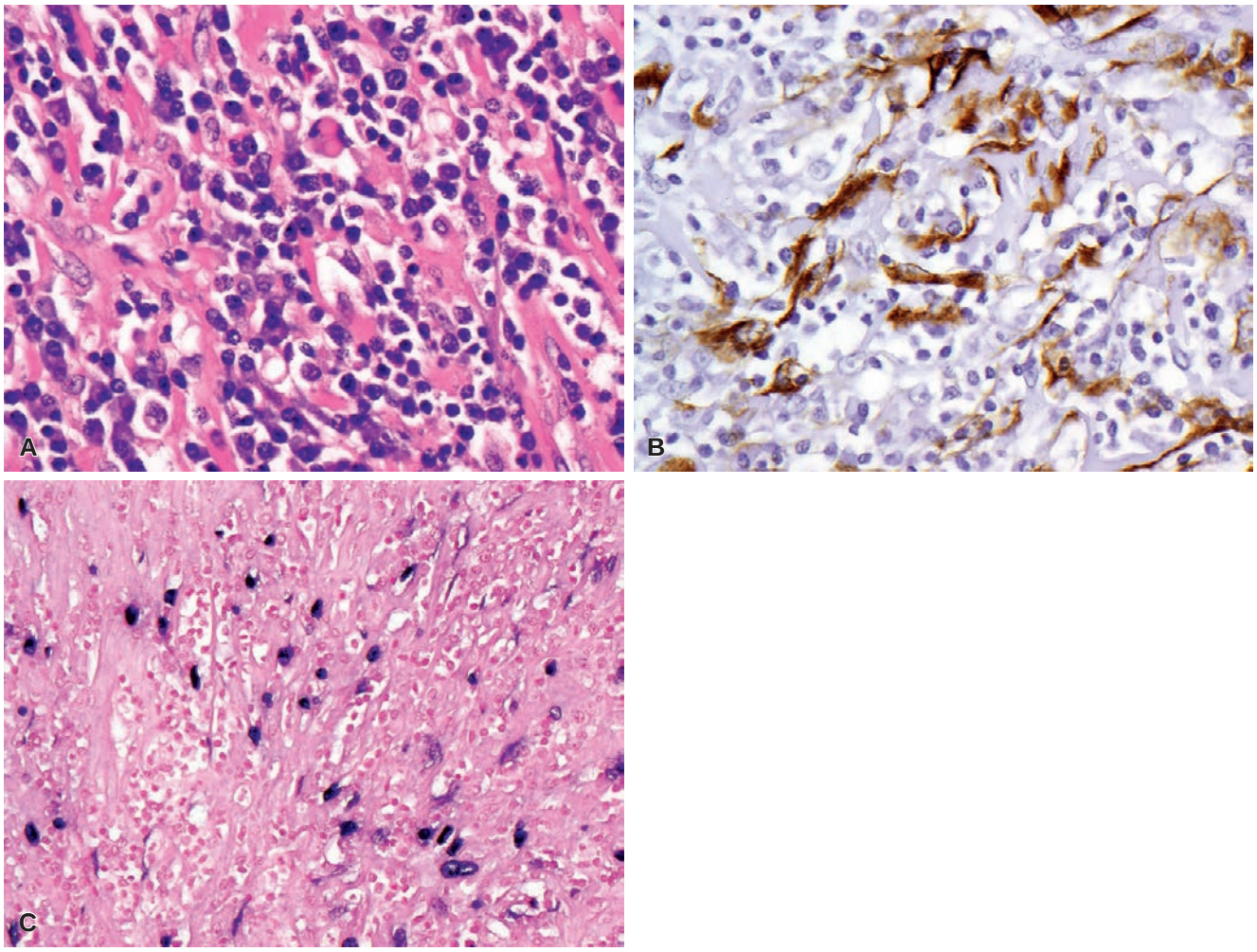

Figure 38.40 Inflammatory Pseudotumor-Like Fibroblastic/Follicular Dendritic Cell Sarcoma of Spleen. Spindle cells of myofibroblastic appearance are admixed with various types of inflammatory cell **(A)**. The spindle cells are focally positive for smooth muscle actin **(B)** and are EBV positive **(C)**.

the tumor is composed of a mixture of inflammatory cells as well as a spindle cell proliferation with interspersed variable amounts of collagenous stroma (Fig. 38.40). The inflammatory component is usually extensive, including lymphocytes, plasma cells, histiocytes, and eosinophils, and foci of necrosis are common. Unlike inflammatory pseudotumors in other organs, the spindled cells in the spleen are positive for EBV and may express smooth muscle actin (SMA), and vimentin. Spindle cells in many, but not all, tumors express CD21, CD23, or CD35. All cases of inflammatory pseudotumor-like follicular/fibroblastic dendritic cell sarcoma are negative for ALK1 in contrast to inflammatory myofibroblastic tumor of soft tissue which is generally positive for ALK1. Because of the presence of EBV in essentially all cases, and the lack of follicular dendritic cell markers in some, this tumor is biologically (as well as clinically) distinct from traditional follicular dendritic cell sarcoma. Splenectomy is curative for symptomatic cases, but cases that are partially resected may recur or metastasize.

Other primary neoplasms of the spleen are rare. Rare reported mesenchymal tumors of the spleen include the *EBV-related smooth muscle neoplasms* seen in the context of AIDS (often occurring in children) and following renal transplantation,[277,278] as well as other rare primary sarcomas.[58,279–281] Rare primary lipomas, carcinosarcomas, low-grade mucinous cystadenocarcinoma, and transitional cell carcinoma have all also been reported in the spleen.[282–285]

Metastatic Tumors

Metastatic malignancy of the spleen is a very uncommon clinical problem[286] but is not an unusual finding at autopsy if a thorough examination of the organ is carried out.[287] Malignant melanoma and carcinoma of lung, breast, stomach, large bowel, pancreas, and liver are the most common types.[288] Many others have been encountered, including ileal carcinoid.[289,290] There appears to be an unusual tendency for gynecologic cancers to develop delayed solitary metastasis in the spleen (Fig. 38.41).[291–295] Grossly, splenic metastases can appear as solitary or diffuse nodules, involve the organ diffusely, or be limited to the splenic capsule.[290] Breast carcinoma diffusely metastatic to the spleen may present as idiopathic thrombocytopenic purpura.[296] Occasionally, metastases in the spleen may be accompanied by nodular transformation of the red pulp, simulating follicular lymphoma on low-power examination.[297] The metastases can be superimposed on preexistent diseases of the spleen, such as hairy cell leukemia.[298]

For personal use only. No other uses without permission. Copyright ©2017. Elsevier Inc. All rights reserved.

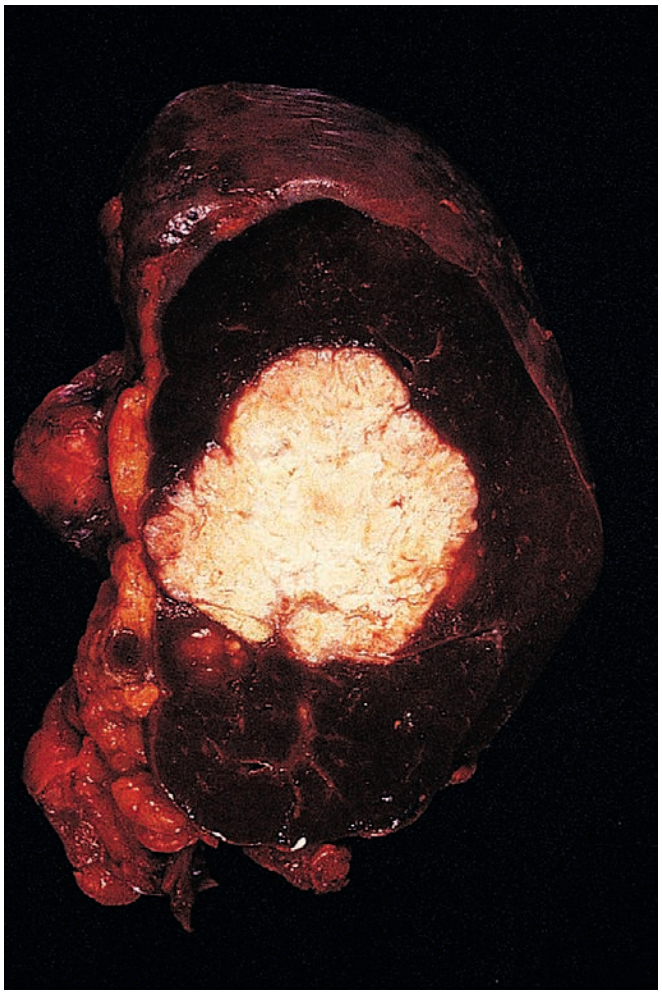

Figure 38.41 Metastatic endometrial carcinoma to the spleen presenting as a single well-circumscribed nodule.

References

1. van Krieken JHJM, Orazi A. Spleen. In: Mills SE, ed. *Histology for Pathologists*. 3rd ed. Philadelphia: Lippincott Williams & Wilkins; 2012:835-848.
2. Rappaport H. The pathologic anatomy of the splenic red pulp. In: Lennert K, Harms D, eds. *Die Milz/The Spleen*. Berlin: Springer-Verlag; 1970:24-41.
3. Weiss L. The structure of the normal spleen. *Semin Hematol*. 1965;2:205-228.
4. Soderström N. Cytologie der Milz in Punktaten. In: Lennert K, Harms D, eds. *Die Milz*. Berlin: Springer-Verlag; 1970.
5. Olson MC, Atwell TD, Harmsen WS, et al. Safety and accuracy of percutaneous image-guided core biopsy of the spleen. *Am J Roentgenol*. 2016;206(3):655-659.
6. Civardi G, Vallisa D, Berte R, et al. Ultrasound-guided fine needle biopsy of the spleen: high clinical efficacy and low risk in a multicenter Italian study. *Am J Hematol*. 2001;67(2):93-99.
7. Zeppa P, Picardi M, Marino G, et al. Fine-needle aspiration biopsy and flow cytometry immunophenotyping of lymphoid and myeloproliferative disorders of the spleen. *Cancer*. 2003;99(2):118-127.
8. Pratt DB, Andersen RC, Hitchcock CR. Splenic rupture. A review of 114 cases. *Minn Med*. 1971;54(3):177-184.
9. Foster RP. Delayed haemorrhage from the ruptured spleen. *Br J Surg*. 1970;57(3):189-192.
10. Farhi DC, Ashfaq R. Splenic pathology after traumatic injury. *Am J Clin Pathol*. 1996;105(4):474-478.
11. Kroft SH, Singleton TP, Dahiya M, et al. Ruptured spleens with expanded marginal zones do not reveal occult B-cell clones. *Mod Pathol*. 1997;10(12):1214-1220.
12. Baack BR, Varsa EW, Burgdorf WH, Blaugrund AC. Splenosis. A report of subcutaneous involvement. *Am J Dermatopathol*. 1990;12(6):585-588.
13. Boudova L, Kazakov DV, Hes O, et al. Subcutaneous splenosis of the abdominal wall. *Am J Dermatopathol*. 2006;28(3):208-210.
14. Carr NJ, Turk EP. The histological features of splenosis. *Histopathology*. 1992;21(6):549-553.
15. O'Connor JV, Brown CC, Thomas JK, et al. Thoracic splenosis. *Ann Thorac Surg*. 1998;66(2):552-553.
16. Rickert CH, Maasjosthusmann U, Probst-Cousin S, et al. A unique case of cerebral spleen. *Am J Surg Pathol*. 1998;22(7):894-896.
17. Sarda R, Sproat I, Kurtycz DF, Hafez R. Pulmonary parenchymal splenosis. *Diagn Cytopathol*. 2001;24(5):352-355.
18. Fleming CR, Dickson ER, Harrison EG Jr. Splenosis: autotransplantation of splenic tissue. *Am J Med*. 1976;61(3):414-419.
19. Dalton ML Jr, Strange WH, Downs EA. Intrathoracic splenosis. Case report and review of the literature. *Am Rev Respir Dis*. 1971;103(6):827-830.
20. Aldrete JS. Spontaneous rupture of the spleen in patients with infectious mononucleosis. *Mayo Clin Proc*. 1992;67(9):910-912.
21. Gabor S, Back F, Csiffary D. Peliosis lienis: uncommon cause of rupture of the spleen. *Pathol Res Pract*. 1992;188(3):380-382. discussion 2-3.
22. Kubosawa H, Konno A, Komatsu T, et al. Peliosis hepatis. An unusual case involving the spleen and lymph nodes. *Acta Pathol Jpn*. 1989;39(3):212-215.
23. Fausel R, Sun NC, Klein S. Splenic rupture in a human immunodeficiency virus-infected patient with primary splenic lymphoma. *Cancer*. 1990;66(11):2414-2416.
24. Stites TB, Ltmann JE. Spontaneous rupture of the spleen in chronic lymphocytic leukemia. *Cancer*. 1966;19(11):1587-1590.
25. Rawsthorne GB, Cole TP, Kyle J. Spontaneous rupture of the spleen in infectious mononucleosis. *Br J Surg*. 1970;57(5):396-398.

For personal use only. No other uses without permission. Copyright ©2017. Elsevier Inc. All rights reserved.

26. Debnath D, Valerio D. Atraumatic rupture of the spleen in adults. *J R Coll Surg Edinb*. 2002;47(1):437-445.
27. Pedersen B, Videbaek A. On the late effects of removal of the normal spleen. A follow-up study of 40 persons. *Acta Chir Scand*. 1966;131(1):89-98.
28. Buzele R, Barbier L, Sauvanet A, Fantin B. Medical complications following splenectomy. *J Visc Surg*. 2016;153(4):277-286.
29. Mourtzoukou EG, Pappas G, Peppas G, Falagas ME. Vaccination of asplenic or hyposplenic adults. *Br J Surg*. 2008;95(3):273-280.
30. Kristinsson SY, Gridley G, Hoover RN, et al. Long-term risks after splenectomy among 8,149 cancer-free American veterans: a cohort study with up to 27 years follow-up. *Haematologica*. 2014;99(2):392-398.
31. Kraus MD, Fleming MD, Vonderheide RH. The spleen as a diagnostic specimen: a review of 10 years' experience at two tertiary care institutions. *Cancer*. 2001;91(11):2001-2009.
32. Katkhouda N, Hurwitz MB, Rivera RT, et al. Laparoscopic splenectomy: outcome and efficacy in 103 consecutive patients. *Ann Surg*. 1998;228(4):568-578.
33. Putschar WG, Manion WC. Congenital absence of the spleen and associated anomalies. *Am J Clin Pathol*. 1956;26(5):429-470.
34. Esterly JR, Oppenheimer EH. Lymphangiectasis and other pulmonary lesions in the asplenia syndrome. *Arch Pathol*. 1970;90(6):553-560.
35. Rose V, Izukawa T, Moes CA. Syndromes of asplenia and polysplenia. A review of cardiac and non-cardiac malformations in 60 cases withspecial reference to diagnosis and prognosis. *Br Heart J*. 1975;37(8):840-852.
36. Kevy SV, Tefft M, Vawier GF, Rosen FS. Hereditary splenic hypoplasia. *Pediatrics*. 1968;42(5):752-757.
37. Mahlaoui N, Minard-Colin V, Picard C, et al. Isolated congenital asplenia: a French nationwide retrospective survey of 20 cases. *J Pediatr*. 2011;158(1):142-148, 148 e1.
38. Bolze A, Mahlaoui N, Byun M, et al. Ribosomal protein SA haploinsufficiency in humans with isolated congenital asplenia. *Science*. 2013;340(6135):976-978.
39. Meneses MF, Ostrowski ML. Female splenic-gonadal fusion of the discontinuous type. *Hum Pathol*. 1989;20(5):486-488.
40. Oliva E, Young RH. Paratesticular tumor-like lesions. *Semin Diagn Pathol*. 2000;17(4):340-358.
41. Putschar WGJ, Manion WC. Splenic-gonadal fusion. *Cancer*. 1956;32:15-34.
42. Watson RJ. Splenogonadal fusion. *Surgery*. 1968;63(5):853-858.
43. Sherman R. Management of trauma to the spleen. *Adv Surg*. 1984;17:37-71.
44. Cotelingam JD, Saito R. Hepatolienal fusion: case report of an unusual lesion. *Hum Pathol*. 1978;9(2):234-236.
45. Gonzalez-Crussi F, Raibley S, Ballantine TV, Grosfeld JL. Splenorenal fusion: heterotopia simulating a primary renal neoplasm. *Am J Dis Child*. 1977;131(9):994-996.
46. Vogel U, Negri G, Bultmann B. Ectopic prostatic tissue in the spleen. *Virchows Arch*. 1996;427(5):543-545.
47. Arber DA, Strickler JG, Weiss LM. Splenic mesothelial cysts mimicking lymphagiomas. *Am J Surg Pathol*. 1997;21(3):334-338.
48. Talerman A, Hart S. Epithelial cysts of the spleen. *Br J Surg*. 1970;57(3):201-204.
49. Tsakraklides V, Hadley TW. Epidermoid cysts of the spleen. A report of five cases. *Arch Pathol*. 1973;96(4):251-254.
50. Morohoshi T, Hamamoto T, Kunimura T, et al. Epidermoid cyst derived from an accessory spleen in the pancreas. A case report with literature survey. *Acta Pathol Jpn*. 1991;41(12):916-921.
51. Tateyama H, Tada T, Murase T, et al. Lymphoepithelial cyst and epidermoid cyst of the accessory spleen in the pancreas. *Mod Pathol*. 1998;11(12):1171-1177.
52. Blank E, Campbell JR. Epidermoid cysts of the spleen. *Pediatrics*. 1973;51(1):75-84.
53. Higaki K, Jimi A, Watanabe J, et al. Epidermoid cyst of the spleen with CA19-9 or carcinoembryonic antigen productions: report of three cases. *Am J Surg Pathol*. 1998;22(6):704-708.
54. Burrig KF. Epithelial (true) splenic cysts. Pathogenesis of the mesothelial and so-called epidermoid cyst of the spleen. *Am J Surg Pathol*. 1988;12(4):275-281.
55. Ough YD, Nash HR, Wood DA. Mesothelial cysts of the spleen with squamous metaplasia. *Am J Clin Pathol*. 1981;76(5):666-669.
56. Lifschitz-Mercer B, Open M, Kushnir I, Czernobilsky B. Epidermoid cyst of the spleen: a cytokeratin profile with comparison to other squamous epithelia. *Virchows Arch*. 1994;424(2):213-216.
57. Du Plessis DG, Louw JA, Wranz PA. Mucinous epithelial cysts of the spleen associated with pseudomyxoma peritonei. *Histopathology*. 1999;35(6):551-557.
58. Garvin DF, King FM. Cysts and nonlymphomatous tumors of the spleen. *Pathol Annu*. 1981;16(Pt 1):61-80.
59. Falk S, Muller H, Stutte HJ. The spleen in acquired immunodeficiency syndrome (AIDS). *Pathol Res Pract*. 1988;183(4):425-433.
60. Klatt EC, Meyer PR. Pathology of the spleen in the acquired immunodeficiency syndrome. *Arch Pathol Lab Med*. 1987;111(11):1050-1053.
61. Fishman D, Isenberg DA. Splenic involvement in rheumatic diseases. *Semin Arthritis Rheum*. 1997;27(3):141-155.
62. Gaba AR, Stein RS, Sweet DL, Variakojis D. Multicentric giant lymph node hyperplasia. *Am J Clin Pathol*. 1978;69(1):86-90.
63. Weisenburger DD. Multicentric angiofollicular lymph node hyperplasia. Pathology of the spleen. *Am J Surg Pathol*. 1988;12(3):176-181.
64. Neiman RS, Bischel MD, Lukes RJ. Hypersplenism in the uremic hemodialyzed patient: pathology and proposed pathophysiologic mechanisms. *Am J Clin Pathol*. 1973;60(4):502-511.
65. Bagshawe A. A comparative study of hypersplenism in reactive and congestive splenomegaly. *Br J Haematol*. 1970;19(6):729-737.
66. Editorial. Tropical splenomegaly syndrome. *Lancet*. 1976;307(7968):1058-1059.
67. Pitney WR. The tropical splenomegaly syndrome. *Trans R Soc Trop Med Hyg*. 1968;62(5):717-728.
68. Sagoe AS. Tropical splenomegaly syndrome: long-term proguanil therapy correlated with spleen size, serum IgM, and lymphocyte transformation. *Br Med J*. 1970;3(5719):378-382.
69. Leoni S, Buonfrate D, Angheben A, et al. The hyper-reactive malarial splenomegaly: a systematic review of the literature. *Malar J*. 2015;14:185.
70. Klemperer P. The pathologic anatomy of splenomegaly. *Am J Clin Pathol*. 1936;6:99-159.
71. McGregor A, Doherty T, Lowe P, et al. Hyperreactive malarial splenomegaly syndrome–can the diagnostic criteria be improved? *Am J Trop Med Hyg*. 2015;93(3):573-576.
72. Briggs RD, Davidson AI, Fletcher BR. Solitary abscesses of the spleen. *J R Coll Surg Edinb*. 1977;22(5):345-347.
73. Chun CH, Raff MJ, Contreras L, et al. Splenic abscess. *Medicine (Baltimore)*. 1980;59(1):50-65.
74. Hermann RE, De Haven KE, Hawk WA. Splenectomy for the diagnosis of splenomegaly. *Ann Surg*. 1968;168(5):896-900.
75. Millikin PD. Epitheloid germinal centers in the human spleen. *Arch Pathol*. 1970;89(4):314-320.
76. Walker DA, Howat AJ, Shannon RS, et al. Necrotizing granulomatous splenitis complicating leukemia in childhood. *Cancer*. 1985;56(2):371-373.
77. Bills RJ, Ulrich E, Young JM. Discrete splenic calcification in necropsy material. *Am J Pathol*. 1957;33(1):189-197.
78. Kuo T, Rosai J. Granulomatous inflammation in splenectomy specimens. Clinicopathologic study of 20 cases. *Arch Pathol*. 1974;98(4):261-268.
79. Kadin ME, Donaldson SS, Dorfman RF. Isolated granulomas in Hodgkin's disease. *N Engl J Med*. 1970;283(16):859-861.
80. Bendix-Hansen K, Bayer Kristensen I. Granulomas of spleen and liver in hairy cell leukaemia. *Acta Pathol Microbiol Immunol Scand [A]*. 1984;92(3):157-160.
81. Braylan RC, Long JC, Jaffe ES, et al. Malignant lymphoma obscured by concomitant extensive epithelioid granulomas: report of three cases with similar clinicopathologic features. *Cancer*. 1977;39(3):1146-1155.
82. Sacks EL, Donaldson SS, Gordon J, Dorfman RF. Epithelioid granulomas associated with Hodgkin's disease: clinical correlations in 55 previously untreated patients. *Cancer*. 1978;41(2):562-567.
83. Neiman RS. Incidence and importance of splenic sarcoid-like granulomas. *Arch Pathol Lab Med*. 1977;101(10):518-521.
84. Thomas DM, Akosa AB, Lampert IA. Granulomatous inflammation of the spleen in infectious mononucleosis. *Histopathology*. 1990;17(3):265-267.
85. Cruickshank B. Follicular (mineral oil) lipidosis: I. Epidemiologic studies of involvement of the spleen. *Hum Pathol*. 1984;15(8):724-730.
86. Cruickshank B, Thomas MJ. Mineral oil (follicular) lipidosis: II. Histologic studies of spleen, liver, lymph nodes, and bone marrow. *Hum Pathol*. 1984;15(8):731-737.
87. Bowdler AJ. Splenomegaly and hypersplenism. *Clin Haematol*. 1983;12(2):467-488.
88. Peck-Radosavljevic M. Hypersplenism. *Eur J Gastroenterol Hepatol*. 2001;13(4):317-323.
89. Cines DB, Blanchette VS. Immune thrombocytopenic purpura. *N Engl J Med*. 2002;346(13):995-1008.
90. McMillan R. Chronic idiopathic thrombocytopenic purpura. *N Engl J Med*. 1981;304(19):1135-1147.
91. Baldini M. Idiopathic thrombocytopenic purpura. *N Engl J Med*. 1966;274: 1245-1251.
92. Ebbe S, Wittels B, Dameshek W. Autoimmune thrombocytopenic purpura ("ITP" type) with chronic lymphocytic leukemia. *Blood*. 1962;19:23-37.
93. Rudders RA, Aisenberg AC, Schiller AL. Hodgkin's disease presenting as "idiopathic" thrombocytopenic purpura. *Cancer*. 1972;30(1):220-230.
94. Browning MG, Bullen N, Nokes T, et al. The evolving indications for splenectomy. *Br J Haematol*. 2016;doi:10.1111/bjh.14060.
95. Hayes MM, Jacobs P, Wood L, Dent DM. Splenic pathology in immune thrombocytopenia. *J Clin Pathol*. 1985;38(9):985-988.
96. Jiang DY, Li CY. Immunohistochemical study of the spleen in chronic immune thrombocytopenic purpura. With special reference to hyperplastic follicles and foamy macrophages. *Arch Pathol Lab Med*. 1995;119(6):533-537.

For personal use only. No other uses without permission. Copyright ©2017. Elsevier Inc. All rights reserved.

97. Chang CS, Li CY, Cha SS. Chronic idiopathic thrombocytopenic purpura. Splenic pathologic features and their clinical correlation. *Arch Pathol Lab Med*. 1993;117(10):981-985.
98. Bowman HE, Pettit VD, Caldwell FT, Smith EB. Morphology of the spleen in idiopathic thrombocytopenic purpura. *Lab Invest*. 1955;4(3):206-216.
99. Berendt HL, Mant MJ, Jewell LD. Periarterial fibrosis in the spleen in idiopathic thrombocytopenic purpura. *Arch Pathol Lab Med*. 1986;110(12):1152-1154.
100. Hassan NM, Neiman RS. The pathology of the spleen in steroid-treated immune thrombocytopenic purpura. *Am J Clin Pathol*. 1985;84(4):433-438.
101. Cohn J, Tygstrup I. Foamy histiocytosis of the spleen in patients with chronic thrombocytopenia. *Scand J Haematol*. 1976;16(1):33-37.
102. Saltzstein SL. Phospholipid accumulation in histiocytes of splenic pulp associated with thrombocytopenic purpura. *Blood*. 1961;18:73-88.
103. Luk SC, Musclow E, Simon GT. Platelet phagocytosis in the spleen of patients with idiopathic thrombocytopenic purpura (ITP). *Histopathology*. 1980;4(2):127-136.
104. Tavassoli M, McMillan R. Structure of the spleen in idiopathic thrombocytopenic purpura. *Am J Clin Pathol*. 1975;64(2):180-191.
105. Bowdler AJ. The role of the spleen and splenectomy in autoimmune hemolytic disease. *Semin Hematol*. 1976;13(4):335-348.
106. Sandler SG. The spleen and splenectomy in immune (idiopathic) thrombocytopenic purpura. *Semin Hematol*. 2000;37(1 suppl 1):10-12.
107. Moake JL. Thrombotic thrombocytopenic purpura: the systemic clumping "plague. *Annu Rev Med*. 2002;53:75-88.
108. Saracco SM, Farhi DC. Splenic pathology in thrombotic thrombocytopenic purpura. *Am J Surg Pathol*. 1990;14(3):223-229.
109. Jacob HS. The defective red blood cell in hereditary spherocytosis. *Annu Rev Med*. 1969;20:41-46.
110. Miraglia del Giudice E, Iolascon A, Pinto L, et al. Erythrocyte membrane protein alterations underlying clinical heterogeneity in hereditary spherocytosis. *Br J Haematol*. 1994;88(1):52-55.
111. Peters LL, Lux SE. Ankyrins: structure and function in normal cells and hereditary spherocytes. *Semin Hematol*. 1993;30(2):85-118.
112. Saad ST, Costa FF, Vicentim DL, et al. Red cell membrane protein abnormalities in hereditary spherocytosis in Brazil. *Br J Haematol*. 1994;88(2):295-299.
113. Tse WT, Lux SE. Red blood cell membrane disorders. *Br J Haematol*. 1999;104(1):2-13.
114. Weed RI. The importance of erythrocyte deformability. *Am J Med*. 1970;49(2): 147-150.
115. Patten E. Immunohematologic diseases. *JAMA*. 1987;258(20):2945-2951.
116. Wiland OK, Smith EB. The morphology of the spleen in congenital hemolytic anemia (hereditary spherocytosis). *Am J Clin Pathol*. 1956;26(6):619-629.
117. Molnar Z, Rappaport H. Fine structure of the red pulp of the spleen in hereditary spherocytosis. *Blood*. 1972;39(1):81-98.
118. Sandusky WR, Leavell BS, Benjamin BI. Splenectomy: indications and results in hematologic disorders. *Ann Surg*. 1964;159:695-710.
119. Crosby WH. Splenectomy in hematologic disorders. *N Engl J Med*. 1972;286(23):1252-1254.
120. Amorosi EL. Hypersplenism. *Semin Hematol*. 1965;2:249-285.
121. Ludwig J, Hashimoto E, Obata H, Baldus WP. Idiopathic portal hypertension; a histopathological study of 26 Japanese cases. *Histopathology*. 1993;22(3):227-234.
122. Okudaira M, Ohbu M, Okuda K. Idiopathic portal hypertension and its pathology. *Semin Liver Dis*. 2002;22(1):59-72.
123. Wanless IR, Bernier V. Fibrous thickening of the splenic capsule. A response to chronic splenic congestion. *Arch Pathol Lab Med*. 1983;107(11):595-599.
124. Satterfield JV, Mulligan LV, Butcher HR Jr. Bleeding esophageal varices: comparison of operative and nonoperative treatment. *Arch Surg*. 1965;90:667-672.
125. Wanless IR, Geddie WR. Mineral oil lipogranulomata in liver and spleen. A study of 465 autopsies. *Arch Pathol Lab Med*. 1985;109(3):283-286.
126. Liber AF, Rose HG. Saturated hydrocarbons in follicular lipodosis of the spleen. *Arch Pathol*. 1967;83(2):116-122.
127. Dawson PJ, Dawson G. Adult Niemann-Pick disease with sea-blue histiocytes in the spleen. *Hum Pathol*. 1982;13(12):1115-1120.
128. Sen Gupta PC, Chatterjea JB, Mukherjee AM, Chatterji A. Observations on the foam cell in thalassemia. *Blood*. 1960;16:1039-1044.
129. Rywlin AM, Lopez-Gomez A, Tachmes P, Pardo V. Ceroid histiocytosis of the spleen in hyperlipemia: relationship to the syndrome of the sea-blue histiocyte. *Am J Clin Pathol*. 1971;56(5):572-579.
130. Reidbord HR, Horvat BL, Fisher ER. Splenic lipidoses. Histochemical and ultrastructural differentiation with special reference to the syndrome of the sea-blue histiocyte. *Arch Pathol*. 1972;93(6):518-524.
131. Silverstein MN, Ellefson RD, Ahern EJ. The syndrome of the sea-blue histiocyte. *N Engl J Med*. 1970;282(1):1-4.
132. Parker AC, Bain AD, Brydon WG, et al. Sea-blue histiocytosis associated with hyperlipidaemia. *J Clin Pathol*. 1976;29(7):634-638.
133. Gal AA, Masor JJ. Splenic involvement in Wegener's granulomatosis. *Arch Pathol Lab Med*. 1996;120(10):974-977.
134. McCain M, Quinet R, Davis W, et al. Splenic rupture as the presenting manifestation of vasculitis. *Semin Arthritis Rheum*. 2002;31(5):311-316.
135. Rentsch J, McColl G. Splenic infarction in Wegener's granulomatosis. *J Rheumatol*. 2000;27:1553-1555.
136. Lacson A, Berman LD, Neiman RS. Peliosis of the spleen. *Am J Clin Pathol*. 1979;71(5):586-590.
137. Tada T, Wakabayashi T, Kishimoto H. Peliosis of the spleen. *Am J Clin Pathol*. 1983;79(6):708-713.
138. Diebold J, Audouin J. Peliosis of the spleen. Report of a case associated with chronic myelomonocytic leukemia, presenting with spontaneous splenic rupture. *Am J Surg Pathol*. 1983;7(2):197-204.
139. Warfel KA, Ellis GH. Peliosis of the spleen. Report of a case and review of the literature. *Arch Pathol Lab Med*. 1982;106(2):99-100.
140. Raghavan R, Alley S, Tawfik O, et al. Splenic peliosis: a rare complication following liver transplantation. *Dig Dis Sci*. 1999;44(6):1128-1131.
141. Dailey MO, Coleman CN, Fajardo LF. Splenic injury caused by therapeutic irradiation. *Am J Surg Pathol*. 1981;5(4):325-331.
142. Gupta R, Singh G, Bose SM, et al. Spontaneous rupture of the amyloid spleen: a report of two cases. *J Clin Gastroenterol*. 1998;26(2):161.
143. Russell TJ, Ferrera PC. Spontaneous rupture of an amyloid spleen in a patient on continuous ambulatory peritoneal dialysis. *Am J Emerg Med*. 1998;16(3):279-280.
144. Tanno S, Ohsaki Y, Osanai S, et al. Spontaneous rupture of the amyloid spleen in a case of usual interstitial pneumonia. *Intern Med*. 2001;40(5):428-431.
145. Chau EM, Chan AC, Chan WK. Spontaneous atraumatic rupture of a normal-sized spleen due to AL amyloid angiopathy. *Amyloid*. 2008;15(3):213-215.
146. Chen KT, Flam MS, Workman RD. Amyloid tumor of the spleen. *Am J Surg Pathol*. 1987;11(9):723-725.
147. Markowitz GS, Factor SM, Borczuk AC. Splenic para-amyloid material: a possible vasculopathy of the acquired immunodeficiency syndrome. *Hum Pathol*. 1998;29(4):371-376.
148. Ahmann DL, Kiely JM, Harrison EG Jr, Payne WS. Malignant lymphoma of the spleen. A review of 49 cases in which the diagnosis was made at splenectomy. *Cancer*. 1966;19(4):461-469.
149. Arber DA, Rappaport H, Weiss LM. Non-Hodgkin's lymphoproliferative disorders involving the spleen. *Mod Pathol*. 1997;10(1):18-32.
150. Mollejo M, Algara P, Mateo MS, et al. Large B-cell lymphoma presenting in the spleen: identification of different clinicopathologic conditions. *Am J Surg Pathol*. 2003;27(7):895-902.
151. Dogan A, Burke JS, Goteri G, et al. Micronodular T-cell/histiocyte-rich large B-cell lymphoma of the spleen: histology, immunophenotype, and differential diagnosis. *Am J Surg Pathol*. 2003;27(7):903-911.
152. Li S, Mann KP, Holden JT. T-cell-rich B-cell lymphoma presenting in the spleen: a clinicopathologic analysis of 3 cases. *Int J Surg Pathol*. 2004;12(1):31-37.
153. Harris NL, Aisenberg AC, Meyer JE, et al. Diffuse large cell (histiocytic) lymphoma of the spleen. Clinical and pathologic characteristics of ten cases. *Cancer*. 1984;54(11):2460-2467.
154. Bellamy CO, Krajewski AS. Primary splenic large cell anaplastic lymphoma associated with HIV infection. *Histopathology*. 1994;24(5):481-483.
155. Takeshita M, Sakai H, Okamura S, et al. Splenic large B-cell lymphoma in patients with hepatitis C virus infection. *Hum Pathol*. 2005;36(8):878-885.
156. Falk S, Stutte HJ. Primary malignant lymphomas of the spleen. A morphologic and immunohistochemical analysis of 17 cases. *Cancer*. 1990;66(12):2612-2619.
157. Chan JK. Splenic involvement by peripheral T-cell and NK-cell neoplasms. *Sem Diagn Pathol*. 2003;20(2):105-120.
158. Stroup RM, Burke JS, Sheibani K, et al. Splenic involvement by aggressive malignant lymphomas of B-cell and T-cell types. A morphologic and immunophenotypic study. *Cancer*. 1992;69(2):413-420.
159. van Krieken JH, Feller AC, te Velde J. The distribution of non-Hodgkin's lymphoma in the lymphoid compartments of the human spleen. *Am J Surg Pathol*. 1989;13(9): 757-765.
160. Burke JS. Surgical pathology of the spleen: an approach to the differential diagnosis of splenic lymphomas and leukemias. Part I. Diseases of the white pulp. *Am J Surg Pathol*. 1981;5(6):551-563.
161. Swerdlow SH. Small B-cell lymphomas of the lymph nodes and spleen: practical insights to diagnosis and pathogenesis. *Mod Pathol*. 1999;12(2):125-140.
162. Kansal R, Ross CW, Singleton TP, et al. Histopathologic features of splenic small B-cell lymphomas. A study of 42 cases with a definitive diagnosis by the World Health Organization classification. *Am J Clin Pathol*. 2003;120(3):335-347.

For personal use only. No other uses without permission. Copyright ©2017. Elsevier Inc. All rights reserved.

163. Goldberg GM, Emanuel B. a study of malignant lymphomas and leukemias. VII. Lymphogenous leukemia and lymphosarcoma involvement of the lymphatic and hemic bed, with reference to differentiating criteria. *Cancer*. 1964;17:277-287.
164. Dacie JV, Brain MC, Harrison CV, et al. 'Non-tropical idiopathic splenomegaly' ("primary hypersplenism"): a review of ten cases and their relationship to malignant lymphomas. *Br J Haematol*. 1969;17(4):317-333.
165. Dacie JV, Galton DA, Gordon-Smith EC, Harrison CV. Non-tropical "idiopathic splenomegaly": a follow-up study of ten patients described in 1969. *Br J Haematol*. 1978;38(2):185-193.
166. Howard MT, Dufresne S, Swerdlow SH, Cook JR. Follicular lymphoma of the spleen: multiparameter analysis of 16 cases. *Am J Clin Pathol*. 2009;131(5):656-662.
167. Mollejo M, Rodriguez-Pinilla MS, Montes-Moreno S, et al. Splenic follicular lymphoma: clinicopathologic characteristics of a series of 32 cases. *The Am J Surg Pathol*. 2009;33(5):730-738.
168. Hammer RD, Glick AD, Greer JP, et al. Splenic marginal zone lymphoma. A distinct B-cell neoplasm. *Am J Surg Pathol*. 1996;20(5):613-626.
169. Isaacson PG, Piris MA. Splenic marginal zone lymphoma. *Adv Anat Pathol*. 1997;4:191-201.
170. Spier CM, Kjeldsberg CR, Eyre HJ, Behm FG. Malignant lymphoma with primary presentation in the spleen. A study of 20 patients. *Arch Pathol Lab Med*. 1985;109(12):1076-1080.
171. Iannitto E, Ambrosetti A, Ammatuna E, et al. Splenic marginal zone lymphoma with or without villous lymphocytes. Hematologic findings and outcomes in a series of 57 patients. *Cancer*. 2004;101(9):2050-2057.
172. Dogan A, Isaacson PG. Splenic marginal zone lymphoma. *Sem Diagn Pathol*. 2003;20(2):121-127.
173. Mollejo M, Lloret E, Menarguez J, et al. Lymph node involvement by splenic marginal zone lymphoma: morphological and immunohistochemical features. *Am J Surg Pathol*. 1997;21(7):772-780.
174. Savilo E, Campo E, Mollejo M, et al. Absence of cyclin D1 protein expression in splenic marginal zone lymphoma. *Mod Pathol*. 1998;11(7):601-606.
175. Baseggio L, Traverse-Glehen A, Petinataud F, et al. CD5 expression identifies a subset of splenic marginal zone lymphomas with higher lymphocytosis: a clinico-pathological, cytogenetic and molecular study of 24 cases. *Haematologica*. 2010;95(4):604-612.
176. Andersen CL, Gruszka-Westwood A, Atkinson S, et al. Recurrent genomic imbalances in B-cell splenic marginal-zone lymphoma revealed by comparative genomic hybridization. *Cancer Genet Cytogenet*. 2005;156(2):122-128.
177. Hernandez JM, Garcia JL, Gutierrez NC, et al. Novel genomic imbalances in B-cell splenic marginal zone lymphomas revealed by comparative genomic hybridization and cytogenetics. *Am J Pathol*. 2001;158(5):1843-1850.
178. Sole F, Salido M, Espinet B, et al. Splenic marginal zone B-cell lymphomas: two cytogenetic subtypes, one with gain of 3q and the other with loss of 7q. *Haematologica*. 2001;86(1):71-77.
179. Mateo M, Mollejo M, Villuendas R, et al. 7q31–32 allelic loss is a frequent finding in splenic marginal zone lymphoma. *Am J Pathol*. 1999;154(5):1583-1589.
180. Ruiz-Ballesteros E, Mollejo M, Rodriguez A, et al. Splenic marginal zone lymphoma: proposal of new diagnostic and prognostic markers identified after tissue and cDNA microarray analysis. *Blood*. 2005;106(5):1831-1838.
181. Parry M, Rose-Zerilli MJ, Ljungstrom V, et al. Genetics and prognostication in splenic marginal zone lymphoma: revelations from deep sequencing. *Clin Cancer Res*. 2015;21(18):4174-4183.
182. Molina TJ, Delmer A, Cymbalista F, et al. Mantle cell lymphoma, in leukaemic phase with prominent splenomegaly. A report of eight cases with similar clinical presentation and aggressive outcome. *Virchows Arch*. 2000;437(6):591-598.
183. Pittaluga S, Verhoef G, Criel A, et al. "Small" B-cell non-Hodgkin's lymphomas with splenomegaly at presentation are either mantle cell lymphoma or marginal zone cell lymphoma. A study based on histology, cytology, immunohistochemistry, and cytogenetic analysis. *Am J Surg Pathol*. 1996;20:211-223.
184. Alkan S, Ross CW, Hanson CA, Schnitzer B. Follicular lymphoma with involvement of the splenic marginal zone: a pitfall in the differential diagnosis of splenic marginal zone cell lymphoma. *Hum Pathol*. 1996;27(5):503-506.
185. Camacho FI, Mollejo M, Mateo MS, et al. Progression to large B-cell lymphoma in splenic marginal zone lymphoma: a description of a series of 12 cases. *Am J Surg Pathol*. 2001;25(10):1268-1276.
186. Kadin ME, Kamoun M, Lamberg J. Erythrophagocytic T gamma lymphoma: a clinicopathologic entity resembling malignant histiocytosis. *N Engl J Med*. 1981;304(11):648-653.
187. Wong KF, Chan JK, Matutes E, et al. Hepatosplenic gamma delta T-cell lymphoma. A distinctive aggressive lymphoma type. *Am J Surg Pathol*. 1995;19(6):718-726.
188. Belhadj K, Reyes F, Farcet JP, et al. Hepatosplenic gammadelta T-cell lymphoma is a rare clinicopathologic entity with poor outcome: report on a series of 21 patients. *Blood*. 2003;102(13):4261-4269.
189. Cooke CB, Krenacs L, Stetler-Stevenson M, et al. Hepatosplenic T-cell lymphoma: a distinct clinicopathologic entity of cytotoxic gamma delta T-cell origin. *Blood*. 1996;88(11):4265-4274.
190. Francois A, Lesesve JF, Stamatoullas A, et al. Hepatosplenic gamma/delta T-cell lymphoma: a report of two cases in immunocompromised patients, associated with isochromosome 7q. *Am J Surg Pathol*. 1997;21(7):781-790.
191. Ohshima K, Haraoka S, Harada N, et al. Hepatosplenic gammadelta T-cell lymphoma: relation to Epstein-Barr virus and activated cytotoxic molecules. *Histopathology*. 2000;36(2):127-135.
192. Wu H, Wasik MA, Przybylski G, et al. Hepatosplenic gamma-delta T-cell lymphoma as a late-onset posttransplant lymphoproliferative disorder in renal transplant recipients. *Am J Clin Pathol*. 2000;113(4):487-496.
193. Deepak P, Sifuentes H, Sherid M, et al. T-cell non-Hodgkin's lymphomas reported to the FDA AERS with tumor necrosis factor-alpha (TNF-alpha) inhibitors: results of the REFURBISH study. *Am J Gastroenterol*. 2013;108(1):99-105.
194. Franco V, Florena AM, Campesi G. Intrasinusoidal bone marrow infiltration: a possible hallmark of splenic lymphoma. *Histopathology*. 1996;29(6):571-575.
195. Nicolae A, Xi L, Pittaluga S, et al. Frequent STAT5B mutations in gammadelta hepatosplenic T-cell lymphomas. *Leukemia*. 2014;28(11):2244-2248.
196. Macon WR, Levy NB, Kurtin PJ, et al. Hepatosplenic alphabeta T-cell lymphomas: a report of 14 cases and comparison with hepatosplenic gammadelta T-cell lymphomas. *Am J Surg Pathol*. 2001;25(3):285-296.
197. Morel P, Dupriez B, Gosselin B, et al. Role of early splenectomy in malignant lymphomas with prominent splenic involvement (primary lymphomas of the spleen). A study of 59 cases. *Cancer*. 1993;71(1):207-215.
198. Hollema H, Visser L, Poppema S. Small lymphocytic lymphomas with predominant splenomegaly: a comparison of immunophenotypes with cases of predominant lymphadenopathy. *Mod Pathol*. 1991;4(6):712-717.
199. Kehoe J, Straus DJ. Primary lymphoma of the spleen. Clinical features and outcome after splenectomy. *Cancer*. 1988;62(7):1433-1438.
200. Siebert JD, Stuckey JH, Kurtin PJ, Banks PM. Extranodal lymphocyte predominance Hodgkin's disease. Clinical and pathologic features. *Am J Clin Pathol*. 1995;103(4):485-491.
201. Chang KL, Kamel OW, Arber DA, et al. Pathologic features of nodular lymphocyte predominance Hodgkin's disease in extranodal sites. *Am J Surg Pathol*. 1995;19(11):1313-1324.
202. Brissette M, Dhru RD. Hodgkin's disease presenting as spontaneous splenic rupture. *Arch Pathol Lab Med*. 1992;116(10):1077-1079.
203. Butler JJ. Pathology of the spleen in benign and malignant conditions. *Histopathology*. 1983;7(4):453-474.
204. Chang KL, Stroup R, Weiss LM. Hairy cell leukemia. Current status. *Am J Clin Pathol*. 1992;97(5):719-738.
205. Van Norman AS, Nagorney DM, Martin JK, et al. Splenectomy for hairy cell leukemia. A clinical review of 63 patients. *Cancer*. 1986;57(3):644-648.
206. Hogan SF, Osborne BM, Butler JJ. Unexpected splenic nodules in leukemic patients. *Hum Pathol*. 1989;20(1):62-68.
207. Burke JS, Byrne GE Jr, Rappaport H. Hairy cell leukemia (leukemic reticuloendotheliosis). I. A clinical pathologic study of 21 patients. *Cancer*. 1974;33(5):1399-1410.
208. Pilon VA, Davey FR, Gordon GB. Splenic alterations in hairy cell leukemia. *Arch Pathol Lab Med*. 1981;105(11):577-581.
209. Hanson CA, Ward PC, Schnitzer B. A multilobular variant of hairy cell leukemia with morphologic similarities to T-cell lymphoma. *Am J Surg Pathol*. 1989;13(8):671-679.
210. Burke JS, Mackay B, Rappaport H. Hairy cell leukemia (leukemic reticuloendotheliosis) II. Ultrastructure of the spleen. *Cancer*. 1976;37(5):2267-2274.
211. Hoyer JD, Li CY, Yam LT, et al. Immunohistochemical demonstration of acid phosphatase isoenzyme 5 (tartrate-resistant) in paraffin sections of hairy cell leukemia and other hematologic disorders. *Am J Clin Pathol*. 1997;108(3):308-315.
212. Dong HY, Weisberger J, Liu Z, Tugulea S. Immunophenotypic analysis of CD103+ B-lymphoproliferative disorders: hairy cell leukemia and its mimics. *Am J Clin Pathol*. 2009;131(4):586-595.
213. Falini B, Tiacci E, Liso A, et al. Simple diagnostic assay for hairy cell leukaemia by immunocytochemical detection of annexin A1 (ANXA1). *Lancet*. 2004;363(9424):1869-1870.
214. Johrens K, Stein H, Anagnostopoulos I. T-bet transcription factor detection facilitates the diagnosis of minimal hairy cell leukemia infiltrates in bone marrow trephines. *Am J Surg Pathol*. 2007;31(8):1181-1185.
215. Strickler JG, Schmidt CM, Wick MR. Methods in pathology. Immunophenotype of hairy cell leukemia in paraffin sections. *Mod Pathol*. 1990;3(4):518-523.

For personal use only. No other uses without permission. Copyright ©2017. Elsevier Inc. All rights reserved.

216. Stroup R, Sheibani K. Antigenic phenotypes of hairy cell leukemia and monocytoid B-cell lymphoma: an immunohistochemical evaluation of 66 cases. *Hum Pathol*. 1992;23(2):172-177.
217. Re G, Pileri S, Cau R, et al. Histometry of splenic microvascular architecture in hairy cell leukaemia. *Histopathology*. 1988;13(4):425-434.
218. Nanba K, Soban EJ, Bowling MC, Berard CW. Splenic pseudosinuses and hepatic angiomatous lesions. Distinctive features of hairy cell leukemia. *Am J Clin Pathol*. 1977;67(5):415-426.
219. Pilon VA, Davey FR, Gordon GB, Jones DB. Splenic alterations in hairy-cell leukemia: II. an electron microscopic study. *Cancer*. 1982;49(8):1617-1623.
220. Burke JS, Sheibani K, Winberg CD, Rappaport H. Recognition of hairy cell leukemia in a spleen of normal weight. The contribution of immunohistologic studies. *Am J Clin Pathol*. 1987;87(2):276-281.
221. Pitcock JA, Reinhard EH, Justus BW, Mendelsohn RS. A clinical and pathological study of seventy cases of myelofibrosis. *Ann Intern Med*. 1962;57:73-84.
222. Fisher ER, Hazard JB. Differentiation of megakaryocyte and Reed-Sternberg cell, with reference to the periodic-acid–Schiff reaction. *Lab Invest*. 1954;3(4):261-269.
223. O'Keane JC, Wolf BC, Neiman RS. The pathogenesis of splenic extramedullary hematopoiesis in metastatic carcinoma. *Cancer*. 1989;63(8):1539-1543.
224. Wilkins BS, Green A, Wild AE, Jones DB. Extramedullary haemopoiesis in fetal and adult human spleen: a quantitative immunohistological study. *Histopathology*. 1994;24(3):241-247.
225. Söderström N, Bandmann U, Lundh B. Patho-anatomical features of the spleen and liver. *Clin Haematol*. 1975;4(2):309-329.
226. Varki A, Lottenberg R, Griffith R, Reinhard E. The syndrome of idiopathic myelofibrosis. A clinicopathologic review with emphasis on the prognostic variables predicting survival. *Medicine (Baltimore)*. 1983;62(6):353-371.
227. Kraus MD, Bartlett NL, Fleming MD, Dorfman DM. Splenic pathology in myelodysplasia: a report of 13 cases with clinical correlation. *Am J Surg Pathol*. 1998;22(10):1255-1266.
228. Brunning RD, McKenna RW, Rosai J, et al. Systemic mastocytosis. Extracutaneous manifestations. *Am J Surg Pathol*. 1983;7(5):425-438.
229. Travis WD, Li CY. Pathology of the lymph node and spleen in systemic mast cell disease. *Mod Pathol*. 1988;1(1):4-14.
230. Horny HP, Sillaber C, Menke D, et al. Diagnostic value of immunostaining for tryptase in patients with mastocytosis. *Am J Surg Pathol*. 1998;22(9):1132-1140.
231. Weidner N, Horan RF, Austen KF. Mast-cell phenotype in indolent forms of mastocytosis. Ultrastructural features, fluorescence detection of avidin binding, and immunofluorescent determination of chymase, tryptase, and carboxypeptidase. *Am J Pathol*. 1992;140(4):847-857.
232. Horny HP, Sotlar K, Valent P. Mastocytosis: immunophenotypical features of the transformed mast cells are unique among hematopoietic cells. *Immunol Allergy Clin North Am*. 2014;34(2):315-321.
233. Akin C. Molecular diagnosis of mast cell disorders: a paper from the 2005 William Beaumont Hospital Symposium on Molecular Pathology. *J Mol Diagn*. 2006;8(4):412-419.
234. Kirsch R, Geboes K, Shepherd NA, et al. Systemic mastocytosis involving the gastrointestinal tract: clinicopathologic and molecular study of five cases. *Mod Pathol*. 2008;21(12):1508-1516.
235. Burke JS. Splenic lymphoid hyperplasias versus lymphomas/leukemias. A diagnostic guide. *Am J Clin Pathol*. 1993;99(4):486-493.
236. Burke JS, Osborne BM. Localized reactive lymphoid hyperplasia of the spleen simulating malignant lymphoma. A report of seven cases. *Am J Surg Pathol*. 1983;7(4):373-380.
237. Vermi W, Blanzuoli L, Kraus MD, et al. The spleen in the Wiskott-Aldrich syndrome: histopathologic abnormalities of the white pulp correlate with the clinical phenotype of the disease. *Am J Surg Pathol*. 1999;23(2):182-191.
238. Arber DA, Strickler JG, Chen YY, Weiss LM. Splenic vascular tumors: a histologic, immunophenotypic, and virologic study. *Am J Surg Pathol*. 1997;21(7):827-835.
239. Kutok JL, Fletcher CD. Splenic vascular tumors. *Semin Diagn Pathol*. 2003;20(2):128-139.
240. Husni EA. The clinical course of splenic hemangioma with emphasis on spontaneous rupture. *Arch Surg*. 1961;83:681-688.
241. Dufau JP, le Tourneau A, Audouin J, et al. Isolated diffuse hemangiomatosis of the spleen with Kasabach-Merritt-like syndrome. *Histopathology*. 1999;35(4):337-344.
242. Shanberge JN, Tanaka K, Gruhl MC. Chronic consumption coagulopathy due to hemangiomatous transformation of the spleen. *Am J Clin Pathol*. 1971;56(6): 723-729.
243. Falk S, Stutte HJ, Frizzera G. Littoral cell angioma. A novel splenic vascular lesion demonstrating histiocytic differentiation. *Am J Surg Pathol*. 1991;15(11):1023-1033.
244. Ben-Izhak O, Bejar J, Ben-Eliezer S, Vlodavsky E. Splenic littoral cell haemangioendothelioma: a new low-grade variant of malignant littoral cell tumour. *Histopathology*. 2001;39(5):469-475.
245. Fernandez S, Cook GW, Arber DA. Metastasizing splenic littoral cell hemangioendothelioma. *Am J Surg Pathol*. 2006;30(8):1036-1040.
246. Schmid C, Beham A, Uranus S, et al. Non-systemic diffuse lymphangiomatosis of spleen and liver. *Histopathology*. 1991;18(5):478-480.
247. Hamoudi AB, Vassy LE, Morse TS. Multiple lymphangioendothelioma of the spleen in a 13-year-old girl. *Arch Pathol*. 1975;99(11):605-606.
248. Budke HL, Breitfeld PP, Neiman RS. Functional hyposplenism due to a primary epithelioid hemangioendothelioma of the spleen. *Arch Pathol Lab Med*. 1995;119(8):755-757.
249. Suster S. Epithelioid and spindle-cell hemangioendothelioma of the spleen. Report of a distinctive splenic vascular neoplasm of childhood. *Am J Surg Pathol*. 1992;16(8):785-792.
250. Karim RZ, Ma-Wyatt J, Cox M, Scolyer RA. Myoid angioendothelioma of the spleen. *Int J Surg Pathol*. 2004;12(1):51-56.
251. Smith VC, Eisenberg BL, McDonald EC. Primary splenic angiosarcoma. Case report and literature review. *Cancer*. 1985;55(7):1625-1627.
252. Autry JR, Weitzner S. Hemangiosarcoma of spleen with spontaneous rupture. *Cancer*. 1975;35(2):534-539.
253. Chen KT, Bolles JC, Gilbert EF. Angiosarcoma of the spleen: a report of two cases and review of the literature. *Arch Pathol Lab Med*. 1979;103(3):122-124.
254. Hermann GG, Fogh J, Graem N, et al. Primary hemangiosarcoma of the spleen with angioscintigraphic demonstration of metastases. *Cancer*. 1984;53(8):1682-1685.
255. Cokelaere K, Vanvuchelen J, Michielsen P, Sciot R. Epithelioid angiosarcoma of the splenic capsule. Report of a case reiterating the concept of inert foreign body tumorigenesis. *Virchows Arch*. 2001;438(4):398-403.
256. Neuhauser TS, Derringer GA, Thompson LD, et al. Splenic angiosarcoma: a clinicopathologic and immunophenotypic study of 28 cases. *Mod Pathol*. 2000;13(9):978-987.
257. Neill JS, Park HK. Hemangiopericytoma of the spleen. *Am J Clin Pathol*. 1991;95(5):680-683.
258. Krishnan J, Frizzera G. Two splenic lesions in need of clarification: hamartoma and inflammatory pseudotumor. *Semin Diagn Pathol*. 2003;20(2):94-104.
259. Silverman ML, LiVolsi VA. Splenic hamartoma. *Am J Clin Pathol*. 1978;70(2):224-229.
260. Zukerberg LR, Kaynor BL, Silverman ML, Harris NL. Splenic hamartoma and capillary hemangioma are distinct entities: immunohistochemical analysis of CD8 expression by endothelial cells. *Hum Pathol*. 1991;22(12):1258-1261.
261. Falk S, Stutte HJ. Hamartomas of the spleen: a study of 20 biopsy cases. *Histopathology*. 1989;14(6):603-612.
262. Cheuk W, Lee AK, Arora N, et al. Splenic hamartoma with bizarre stromal cells. *Am J Surg Pathol*. 2005;29(1):109-114.
263. Laskin WB, Alasadi R, Variakojis D. Splenic hamartoma. *Am J Surg Pathol*. 2005;29(8):1114-1115.
264. Ali TZ, Beyer G, Taylor M, et al. Splenic hamartoma: immunohistochemical and ultrastructural profile of two cases. *Int J Surg Pathol*. 2005;13(1):103-111.
265. Ross CF, Schiller KF. Hamartoma of spleen associated with thrombocytopenia. *J Pathol*. 1971;105(1):62-64.
266. Awamleh AA, Perez-Ordonez B. Sclerosing angiomatoid nodular transformation of the spleen. *Arch Pathol Lab Med*. 2007;131(6):974-978.
267. Koreishi AF, Saenz AJ, Fleming SE, Teruya-Feldstein J. Sclerosing angiomatoid nodular transformation (SANT) of the spleen: a report of 3 cases. *Int J Surg Pathol*. 2009;17(5):384-389.
268. Martel M, Cheuk W, Lombardi L, et al. Sclerosing angiomatoid nodular transformation (SANT): report of 25 cases of a distinctive benign splenic lesion. *Am J Surg Pathol*. 2004;28(10):1268-1279.
269. Diebold J, Le Tourneau A, Marmey B, et al. Is sclerosing angiomatoid nodular transformation (SANT) of the splenic red pulp identical to inflammatory pseudotumour? Report of 16 cases. *Histopathology*. 2008;53(3):299-310.
270. Kuo TT, Chen TC, Lee LY. Sclerosing angiomatoid nodular transformation of the spleen (SANT): clinicopathological study of 10 cases with or without abdominal disseminated calcifying fibrous tumors, and the presence of a significant number of IgG4+ plasma cells. *Pathol Int*. 2009;59(12):844-850.
271. Weinreb I, Bailey D, Battaglia D, et al. CD30 and Epstein-Barr virus RNA expression in sclerosing angiomatoid nodular transformation of spleen. *Virchows Archiv*. 2007;451(1):73-79.
272. Monforte-Munoz H, Ro JY, Manning JT Jr, et al. Inflammatory pseudotumor of the spleen. Report of two cases with a review of the literature. *Am J Clin Pathol*. 1991;96(4):491-495.
273. Suster S, Moran CA, Blanco M. Mycobacterial spindle-cell pseudotumor of the spleen. *Am J Clin Pathol*. 1994;101(4):539-542.
274. Arber DA, Kamel OW, van de Rijn M, et al. Frequent presence of the Epstein-Barr virus in inflammatory pseudotumor. *Hum Pathol*. 1995;26(10):1093-1098.
275. Cheuk W, Chan JK, Shek TW, et al. Inflammatory pseudotumor-like follicular dendritic cell tumor: a distinctive low-grade

For personal use only. No other uses without permission. Copyright ©2017. Elsevier Inc. All rights reserved.

malignant intra-abdominal neoplasm with consistent Epstein-Barr virus association. *Am J Surg Pathol*. 2001;25(6):721-731.
276. Swerdlow SH, Campo E, Pileri SA, et al. The 2016 revision of the World Health Organization classification of lymphoid neoplasms. *Blood*. 2016;127(20):2375-2390.
277. Barbashina V, Heller DS, Hameed M, et al. Splenic smooth-muscle tumors in children with acquired immunodeficiency syndrome: report of two cases of this unusual location with evidence of an association with Epstein-Barr virus. *Virchows Arch*. 2000;436(2):138-139.
278. Le Bail B, Morel D, Merel P, et al. Cystic smooth-muscle tumor of the liver and spleen associated with Epstein-Barr virus after renal transplantation. *Am J Surg Pathol*. 1996;20(11):1418-1425.
279. Feakins RM, Norton AJ. Rhabdomyosarcoma of the spleen. *Histopathology*. 1996;29(6):577-579.
280. Wick MR, Scheithauer BW, Smith SL, Beart RW Jr. Primary nonlymphoreticular malignant neoplasms of the spleen. *Am J Surg Pathol*. 1982;6(3):229-242.
281. Martel M, Sarli D, Colecchia M, et al. Fibroblastic reticular cell tumor of the spleen: report of a case and review of the entity. *Hum Pathol*. 2003;34(9):954-957.
282. Easler RE, Dowlin WM. Primary lipoma of the spleen. Report of a case. *Arch Pathol*. 1969;88(5):557-559.
283. Westra WH, Anderson BO, Klimstra DS. Carcinosarcoma of the spleen. An extragenital malignant mixed mullerian tumor? *Am J Surg Pathol*. 1994;18(3):309-315.
284. Morinaga S, Ohyama R, Koizumi J. Low-grade mucinous cystadenocarcinoma in the spleen. *Am J Surg Pathol*. 1992;16(9):903-908.
285. Naik S, Kapoor S, Sharma S, et al. Primary transitional cell carcinoma of spleen. *Indian J Gastroenterol*. 2006;25(4):215.
286. Klein B, Stein M, Kuten A, et al. Splenomegaly and solitary spleen metastasis in solid tumors. *Cancer*. 1987;60(1):100-102.
287. Berge T. Splenic metastases. Frequencies and patterns. *Acta Pathol Microbiol Scand [A]*. 1974;82(4):499-506.
288. Comperat E, Bardier-Dupas A, Camparo P, et al. Splenic metastases: clinicopathologic presentation, differential diagnosis, and pathogenesis. *Arch Pathol Lab Med*. 2007;131(6):965-969.
289. Falk S, Stutte HJ. Splenic metastasis in an ileal carcinoid tumor. *Pathol Res Pract*. 1989;185(2):238-242. discussion 42-44.
290. Lam KY, Tang V. Metastatic tumors to the spleen: a 25-year clinicopathologic study. *Arch Pathol Lab Med*. 2000;124(4):526-530.
291. Gilks CB, Acker BD, Clement PB. Recurrent endometrial adenocarcinoma: presentation as a splenic mass mimicking malignant lymphoma. *Gynecol Oncol*. 1989;33(2):209-211.
292. Giuliani A, Caporale A, Di Bari M, et al. Isolated splenic metastasis from endometrial carcinoma. *J Exp Clin Cancer Res*. 1999;18(1):93-96.
293. Goktolga U, Dede M, Deveci G, et al. Solitary splenic metastasis of squamous cell carcinoma of the uterine cervix: a case report and review of the literature. *Eur J Gynaecol Oncol*. 2004;25(6):742-744.
294. Hadjileontis C, Amplianitis I, Valsamides C, et al. Solitary splenic metastasis of endometrial carcinoma ten years after hysterectomy. Case report and review of the literature. *Eur J Gynaecol Oncol*. 2004;25(2):233-235.
295. Jorgensen LN, Chrintz H. Solitary metastatic endometrial carcinoma of the spleen. *Acta Obstet Gynecol Scand*. 1988;67(1):91-92.
296. Cummings OW, Mazur MT. Breast carcinoma diffusely metastatic to the spleen. A report of two cases presenting as idiopathic thrombocytopenic purpura. *Am J Clin Pathol*. 1992;97(4):484-489.
297. Fakan F, Michal M. Nodular transformation of splenic red pulp due to carcinomatous infiltration. A diagnostic pitfall. *Histopathology*. 1994;25(2):175-178.
298. Sharpe RW, Rector JT, Rushin JM, et al. Splenic metastasis in hairy cell leukemia. *Cancer*. 1993;71(7):2222-2226.

For personal use only. No other uses without permission. Copyright ©2017. Elsevier Inc. All rights reserved.

39 Bone Marrow

Daniel A. Arber

CHAPTER CONTENTS

Biopsy procedure and processing of specimen, *1658*
Immunohistochemistry, *1660*
Normocellular bone marrow, *1662*
Alterations in cellularity, *1663*
Aplastic anemia, *1663*
Marrow hyperplasia, *1664*
Gelatinous transformation (serous atrophy/degeneration), *1664*
Osteopetrosis, *1665*
Bone marrow necrosis, *1665*
Inflammatory disorders, *1666*
Granulomatous inflammation, *1666*
Nonspecific inflammatory reactions, *1669*
Human immunodeficiency virus syndrome (HIV, AIDS), *1669*
Leukemias and related disorders, *1670*
Acute leukemia, *1670*
Myeloid sarcoma, *1674*
Myelodysplastic syndromes, *1675*
Myeloproliferative neoplasms, *1678*
Systemic mastocytosis, *1684*
Mature B-cell neoplasms, *1687*
Chronic lymphocytic leukemia, *1687*
Monoclonal B-cell lymphocytosis, *1687*
Richter syndrome, *1689*
Prolymphocytic leukemia, *1689*
Hairy cell leukemia, *1690*
Hairy cell leukemia variant, *1691*
Splenic marginal zone lymphoma, *1692*
Burkitt lymphoma/leukemia, *1693*
Non-Hodgkin lymphoma, *1693*
B-cell lymphoma, *1693*
T- and NK-cell lymphomas/leukemias, *1697*
Benign lymphocytic aggregates, *1703*
Hodgkin lymphoma, *1704*
Histiocytic disorders, *1706*
Malignant histiocytosis, *1706*
Hemophagocytic syndromes, *1707*
Langerhans cell histiocytosis, *1709*
Plasma cell dyscrasias, *1709*
Plasma cell myeloma, *1709*
Osteosclerotic myeloma and POEMS (polyneuropathy, organomegaly, endocrinopathy, monoclonal gammopathy, and skin changes) syndrome, *1712*
Plasmacytoma, *1712*
Monoclonal gammopathy of undetermined significance, *1714*
Lymphoplasmacytic lymphoma, *1715*
Heavy chain disease, *1715*
Amyloidosis, *1716*
Systemic polyclonal B-immunoblastic proliferation, *1716*
Metastatic tumors, *1717*
Lipid storage diseases, *1719*
Gaucher disease, *1719*
Niemann–Pick disease, *1720*
Fabry disease, *1721*
Sea-blue histiocyte syndrome, *1721*
Hematopoietic cell transplantation, *1721*

Biopsy Procedure and Processing of Specimen

Trephine biopsy of the bone marrow has wide application in clinical medicine; its greatest utility is in the evaluation of patients with malignant lymphoma, acute leukemias, myeloproliferative neoplasms (MPNs), myelodysplastic syndromes (MDSs), metastatic tumor, granulomatous disorders, myelofibrosis, aplastic anemia, and plasma cell dyscrasias.[1–8] It also serves as the most reliable method for assessing marrow cellularity following the administration of antineoplastic drugs and in assessing the status of engraftment following hematopoietic cell transplantation. Marrow biopsy is also utilized in the investigation of patients with infectious disease and metabolic disorders.

The trephine biopsy should be viewed as one component of the bone marrow specimen that should also include smears and particle crush preparations from aspirated marrow and touch imprint preparations of the core biopsy specimen. In some instances, because of marrow fibrosis, the trephine biopsy specimen will be the only marrow tissue available for examination. Marrow biopsy can usually

For personal use only. No other uses without permission. Copyright ©2017. Elsevier Inc. All rights reserved.

Abstract

Bone marrow examination is performed for both staging and primary diagnosis. This chapter reviews the features of reactive conditions as well as primary bone marrow neoplasms, including leukemias, myelodysplastic syndromes, and myeloproliferative neoplasms. It also reviews the features of marrow involvement by various types of malignant lymphoma and metastatic tumors.

Keywords

Bone marrow,
leukemia,
lymphoma,
reactive lesions

For personal use only. No other uses without permission. Copyright ©2017. Elsevier Inc. All rights reserved.

be done with relatively little discomfort to the patient and is accompanied by very low morbidity when performed by experienced individuals with the biopsy needles presently available.[9] The posterior superior iliac spines are the preferred sites. Bilateral trephine biopsies may be useful in the staging of patients with some types of lymphoma, granulomatous disorders, and metastatic tumor, although improved imaging studies have replaced bilateral staging marrow biopsies in some institutions. This approach should be decided on an individual basis, considering both the reason for the procedure and the impact of positive findings for therapy.[3,10,11] In general, severe thrombocytopenia is not a contraindication to marrow biopsy. Whenever a marrow biopsy is performed, careful attention should be directed to preventing hematoma formation by applying an adequate pressure bandage to the biopsy site following the procedure. Prior to performing a biopsy on a patient with a bleeding disorder or on anticoagulants, consultation should be obtained from a physician expert in coagulation disorders.

Considerable discussion has occurred about the relative merits of trephine biopsy of the bone marrow as opposed to sections of particles obtained by aspiration biopsy.[5,6,12,13] Particle sections are of limited value in marrow disorders that are accompanied by fibrosis; these frequently result in inadequately aspirated specimens.[1,2] In addition, assessment of cellularity, determination of the extent of marrow involvement by neoplastic processes, and the relationship of lesions to marrow structures such as bone trabeculae and vasculature can be accurately assessed only in trephine biopsies. Nevertheless, any particles obtained in a marrow aspirate should be processed for histologic examination, as this material provides additional sampling that may be important when disease involvement is focal.

Paraffin embedding is the preferred method for the routine processing of bone marrow biopsies, and the observations described in this chapter are based primarily on examination of specimens prepared in this manner.[10,14] Plastic embedding offers some advantages over the paraffin method, such as excellent cytology and the ability to perform numerous histochemical reactions.[15] However, plastic embedding techniques are more time consuming than the processing of paraffin-embedded tissue, and with careful attention to technical detail, excellent results can be obtained with specimens processed in paraffin. Additionally, immunohistochemistry with a wide range of antibodies can now be performed with excellent results on most paraffin-embedded specimens.[16] For these reasons, plastic embedding is not routinely performed in most laboratories at this time.

Myelofibrosis is one of the more vexing problems in bone marrow histopathology because of the wide range of disorders that may cause marrow fibrosis and the usual difficulty in obtaining satisfactory aspirates for cytologic studies.[17] Although marrow fibrosis occurs as a primary disorder, it is usually a secondary phenomenon; the most common causes are metastatic tumor and malignant lymphoma. Fibrosis also occurs relatively frequently in the evolution of chronic MPNs, such as chronic myeloid leukemia (CML) and polycythemia vera (PV). In general, fibrosis that occurs as a component of hematopoietic proliferations is characterized initially by the deposition of increased reticulin fibers; metastatic tumors such as breast and prostate are usually characterized by a severe desmoplastic reaction with collagenous fibrosis and possibly osteosclerosis.

In those instances in which the etiology for the marrow fibrosis is not apparent, several techniques may be used in an attempt to determine the cause. Immunohistochemistry, using paraffin-embedded specimens and the several antibodies described in the section on immunohistochemistry, may be particularly helpful in identifying lymphoma or metastatic tumor; antibodies to myeloperoxidase, lysozyme, CD14, CD68, and CD117 are particularly useful for identifying cells of granulocytic or monocytic origin.[18] An additional procedure that may be useful in hematopoietic disorders associated with marrow fibrosis is the preparation of particle crush preparations from trephine biopsy specimens. This approach may necessitate a second biopsy unless the problem of fibrosis is anticipated before the initial procedure. As soon as possible after the trephine specimen is obtained and before it is placed in a fixative, small portions of the biopsy are cut away with a sharp scalpel blade and used for particle crush preparations in the same manner as particles from aspirated specimens. These crush preparations can be used for routine stains, cytochemistry, and immunocytochemistry. Portions of the biopsy specimen obtained in this manner may also be used for cytogenetics, molecular genetics, flow cytometry studies, routine electron microscopy, and ultrastructural cytochemistry. However, electron microscopy is generally no longer performed because of the availability of immunohistochemistry.

The use of special stains in bone marrow pathology should be determined following review of the routinely stained aspirate smears and biopsy and the patient's clinical history.

Several instruments are available for the bone marrow trephine biopsy procedure. The most satisfactory from the standpoint of safety, ease of performance, and overall quality of specimen obtained is the Jamshidi-type biopsy needle; several such instruments, both reusable and disposable, are commercially available.[9] These instruments are produced in several sizes for both adult and pediatric patients. The 11-gauge needle is the most commonly used for routine procedures in adults and older children. The 8-gauge instruments are preferred by some for lymphoma staging procedures; this size may result in more postbiopsy discomfort. If difficulty is encountered with the 11-gauge needle in obtaining adequate specimens from patients with severe osteoporosis, an 8- or 9-gauge instrument should be used. Numerous modifications of the original instruments are available.

The importance of proper technique in performing the biopsy procedure cannot be overemphasized. Instructions for the use of the biopsy needles are included with the instruments, and some manufacturers provide audiovisual aids that illustrate proper technique. Accurate identification of body landmarks is crucial in obtaining satisfactory specimens; an improperly positioned needle may cause considerable discomfort to the patient and frequently yields an inadequate biopsy specimen. Individuals not acquainted with the biopsy technique are advised to familiarize themselves with the procedure on cadavers.

Optimally, the biopsy specimen should be at least 1.5 cm in length and should be free of distortion caused by crushing or other damage. Crush artifact and the deposition of fibrin in torn biopsies may render accurate interpretation difficult or impossible. In such instances the biopsy should be repeated. Aspiration through the biopsy needle prior to obtaining the trephine biopsy specimen should be discouraged because of the possibility of introducing hemorrhage or other artifact in the biopsy specimen.

Occasionally, in patients undergoing frequent repeat biopsies, a specimen may be obtained from a recently biopsied site. In these instances, the changes will reflect the stage of healing. The presence of granulation tissue in the biopsy may result in misinterpretation of cellularity. The appearance of the marrow biopsy may be inconsistent with the marrow smears, which show recovering or normal hematopoiesis (Fig. 39.1).

Imprint preparations should be routinely made from the biopsy specimen immediately after it is removed from the biopsy needle and prior to being placed in a fixative. These can be used for Romanowsky stains and special cytochemical and immunocytochemical procedures. Following the preparation of imprints, the specimen is placed in an appropriate fixative; the most satisfactory are B5, 10% buffered neutral formalin, and acetic acid–zinc-formalin (AZF).[18,19] Zenker acetic acid gives excellent cytology but ablates several antigens that may be useful in evaluating neoplastic processes;

For personal use only. No other uses without permission. Copyright ©2017. Elsevier Inc. All rights reserved.

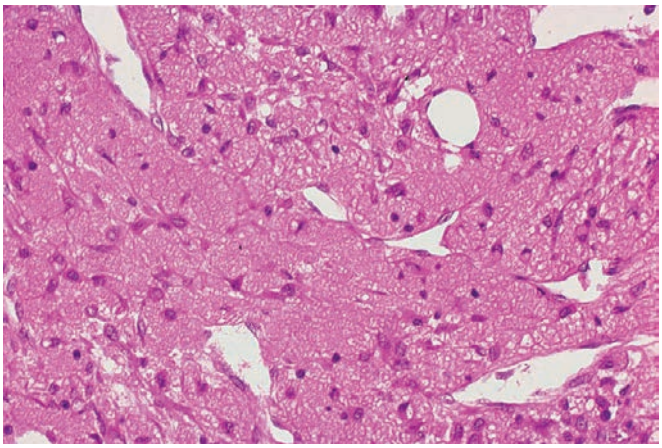

Figure 39.1 Marrow biopsy obtained at site of a biopsy performed 14 days previously. The marrow space is replaced by granulation tissue.

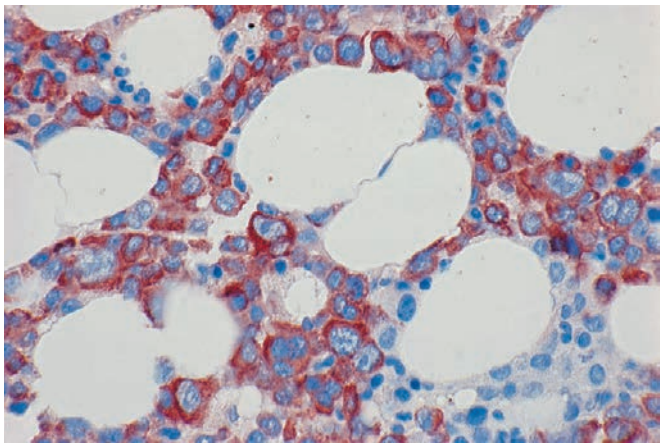

Figure 39.2 Marrow biopsy from patient with multiple myeloma reacted with polyclonal antibody to lambda light chain; the blastic appearing plasma cells show intense cytoplasmic reaction. (Immunoperoxidase.)

importantly it and B5 contain mercury, which is environmentally hazardous. In laboratories where bone marrow specimens are processed with other tissues, buffered neutral formalin may be the preferred fixative. Because of the environmental concerns and disposal problems, some institutions prohibit the use of mercury-based fixatives. As noted in the section on immunohistochemistry, reactivity with some antibodies may be ablated by some fixatives, and the choice of fixative may be determined by the reason for the biopsy. Following fixation for an appropriate period of time, the biopsy is decalcified. Several decalcification solutions are commercially available. Most biopsy specimens will be adequately decalcified following 45–60 minutes in a rapid decalcifying solution. Most rapid decalcification methods, however, destroy nucleic acids making the samples unsuitable for molecular genetic studies. Formalin-fixed clot sections that do not undergo decalcification are commonly collected to overcome this limitation. Alternatively, slower decalcification with ethylenediaminetetraacetic acid (EDTA) allows for preservation of nucleic acids.[20] A discussion of the relative merits and disadvantages of several fixatives and decalcifying agents used for bone marrow biopsies has been published.[18]

The biopsies should be sectioned at 3–4 μm with a sharp knife that is checked frequently for the presence of defects. In those patients being evaluated for the extent of lymphomatous involvement, metastatic tumor, or granulomatous disease, the specimens should be completely sectioned and stepwise serial sections mounted for hematoxylin and eosin staining.[3,11] The remaining ribbons should be numbered and retained in a manner that will facilitate the ready and accurate mounting of additional sections for special stains, immunohistochemical studies, and molecular studies.[8,18] Most of the stains used for other fixed tissues are also applicable to bone marrow sections. However, tissue processed with acid fixatives, such as B5 and Zenker, or with acid decalcifiers will yield unsatisfactory results with the chloroacetate esterase stain.

Optimally, when interpreting the trephine biopsy, the pathologist should examine the trephine imprints, bone marrow aspirate, blood smears, and other pathology specimens. Knowledge of the patient's clinical history, hematology profile, immunoelectrophoretic studies, and radiographic findings may be of considerable importance and may greatly facilitate the interpretation of the biopsy specimen.

Immunohistochemistry

As in other areas of pathology, immunohistochemistry is an important resource in the evaluation of proliferative processes involving the marrow.[21] The availability of antibodies reactive in paraffin-embedded tissue and the use of antigen retrieval have been of considerable importance in the application of immunohistochemistry in bone marrow pathology. Although cryostat sections of marrow may be used for immunohistochemistry, the procedure is difficult and is not routinely performed.[22] In addition, cytologic preservation in cryostat sections is frequently of marginal quality.

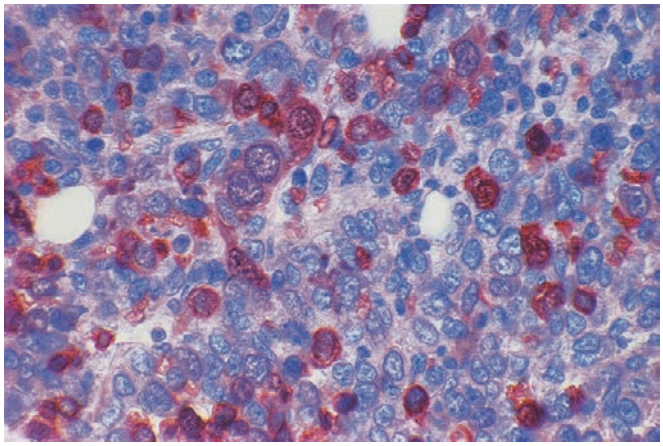

Figure 39.3 Marrow from patient with pure erythroleukemia reacted with antibody to hemoglobin A; many of the erythroblasts show a positive cytoplasmic reaction. Intensity of reaction varies from very slight to marked. (Immunoperoxidase.)

Although decalcification with rapid acid decalcifiers may result in ablation of some antigens, an increasing number of antibodies to membrane antigens and cytoplasmic constituents are reactive in paraffin-embedded decalcified marrow biopsies and can be of considerable aid in identifying the lineage of immature cell populations in the marrow; these include antibodies to kappa and lambda light chains, leukocyte common antigen (CD45), myeloperoxidase, CD33, CD117, glycophorin, hemoglobin A, E-cadherin, von Willebrand factor (factor VIII–related antigen), CD61, CD14, CD68, CD163, CD20 (L26), CD79a, PAX5, CD3, CD5, CD30, CD15, CD34, terminal deoxynucleotidyl transferase (TdT), and tumor-related antigens, and proliferation antigens (Figs. 39.2–39.10).[22–32] Antibodies to kappa and lambda immunoglobulin light chains are particularly useful

For personal use only. No other uses without permission. Copyright ©2017. Elsevier Inc. All rights reserved.

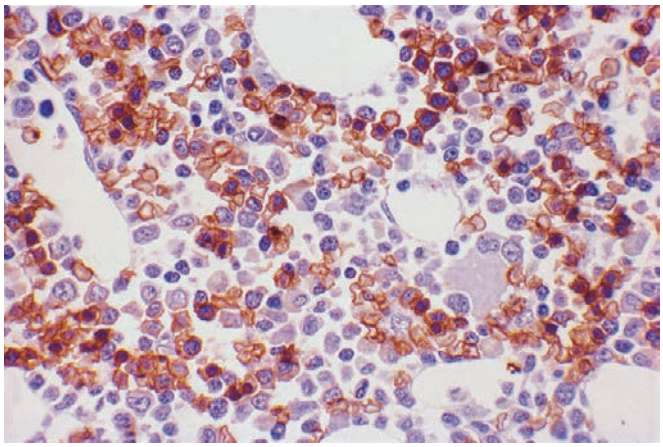

Figure 39.4 Marrow biopsy from a 2-year-old child with congenital neutropenia reacted with antibody to glycophorin A. There are numerous positive erythroid precursors at all stages of maturation. (Immunoperoxidase.)

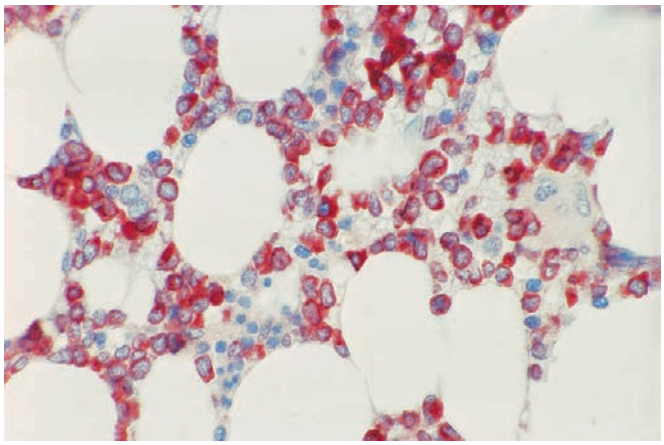

Figure 39.5 Bone marrow biopsy from a patient with hypocellular acute myeloid leukemia reacted with polyclonal antibody to myeloperoxidase. The predominant myeloblasts and promyelocytes show intense cytoplasmic reactivity. (Immunoperoxidase.)

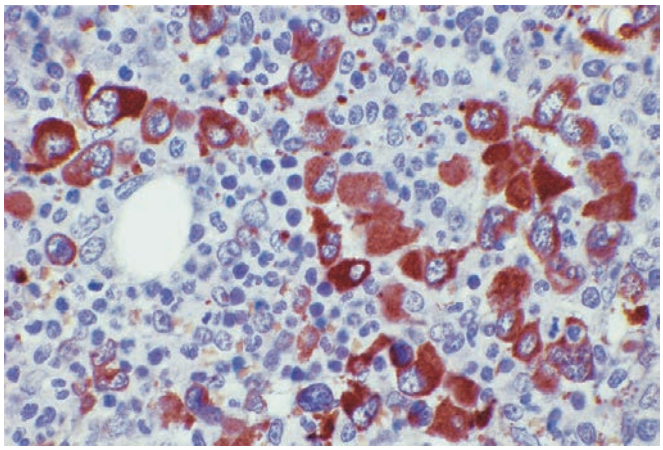

Figure 39.6 Bone marrow biopsy from a patient with chronic myeloid leukemia in accelerated phase reacted with polyclonal antibody to factor VIII–related antigen (von Willebrand factor). There are numerous dysplastic megakaryocytes with hypolobulated nuclei which show intense cytoplasmic reactivity. (Immunoperoxidase.)

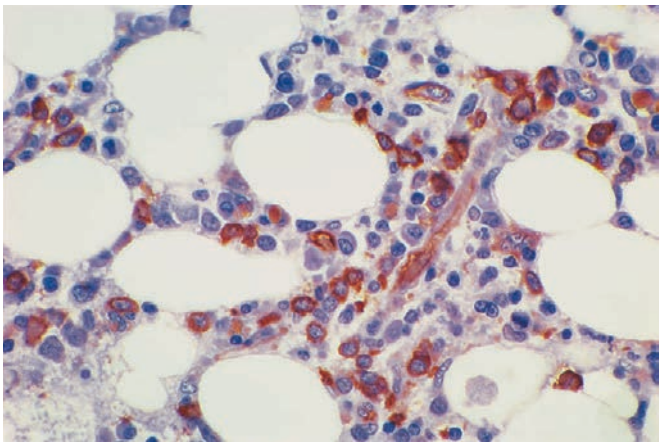

Figure 39.7 Bone marrow biopsy from an adult man with therapy-related myelodysplastic syndrome and hypocellular marrow reacted with antibody to CD34. The number of positive cells approximates the 18.5% blasts in the marrow smear. (Immunoperoxidase.)

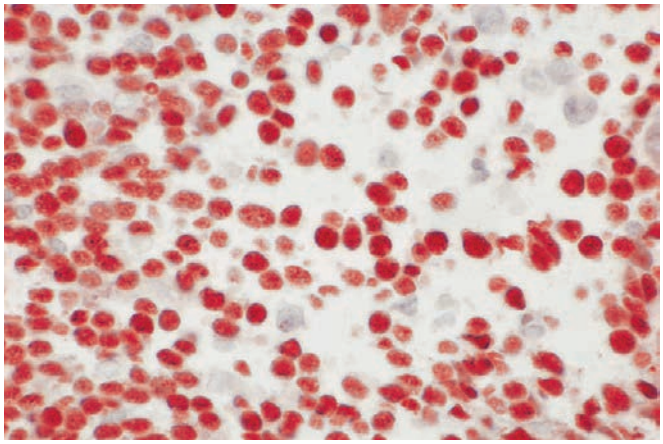

Figure 39.8 Marrow biopsy from a child with precursor B acute lymphoblastic leukemia reacted with polyclonal antibody to TdT; the lymphoblasts show intense nuclear reactivity. (Immunoperoxidase.)

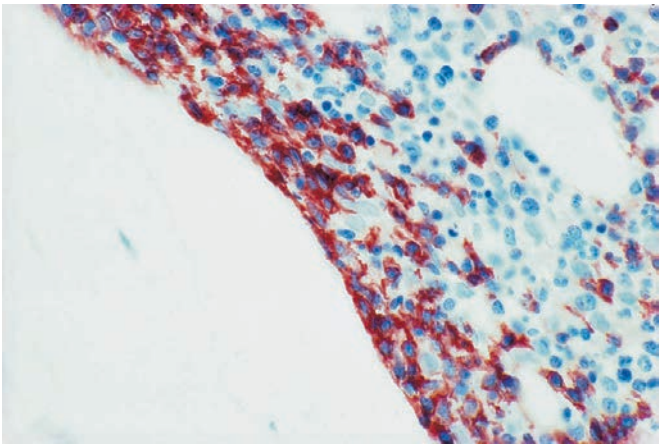

Figure 39.9 Marrow biopsy from an adult man with recurrent follicular lymphoma positive for CD20. Numerous positive lymphocytes are present in a paratrabecular location. (Immunoperoxidase.)

For personal use only. No other uses without permission. Copyright ©2017. Elsevier Inc. All rights reserved.

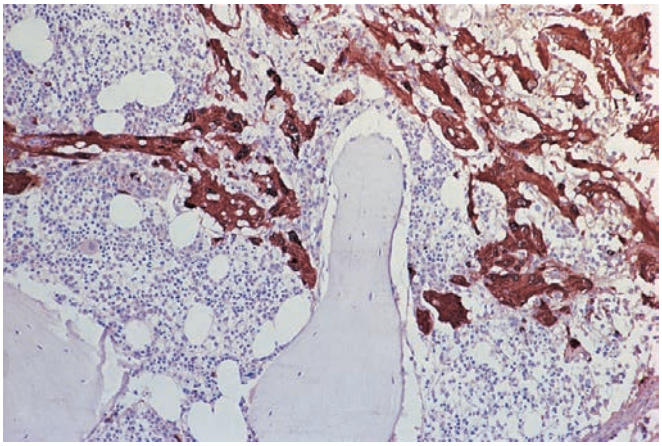

Figure 39.10 Marrow biopsy from a child with neuroblastoma with ganglion differentiation reacted with antibody to neuron-specific enolase. The tumor cells are intensely reactive. (Immunoperoxidase.)

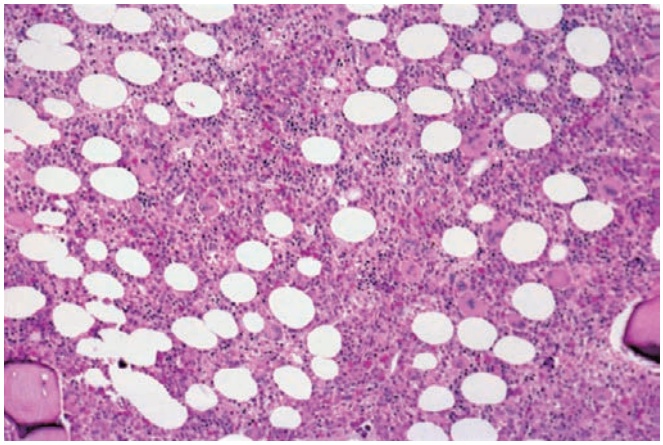

Figure 39.11 Normocellular bone marrow from 42-year-old man obtained as part of evaluation as potential donor for bone marrow transplantation. Hematopoietic cells and adipose tissue are present in approximately equal quantities.

for determining the relative proportions of kappa- and lambda-containing cells in immunoproliferative disorders such as multiple myeloma.[33] Reactivity with these antibodies is generally restricted to processes in which the cells contain cytoplasmic immunoglobulin. The technique is not sufficiently sensitive to detect surface immunoglobulin on the lymphocytes in most B lymphoproliferative diseases. Occasionally the lymphocytes in a B-cell lymphocytic lymphoma contain cytoplasmic immunoglobulin that may be detected by this method. With some fixatives, in situ hybridization methods for immunoglobulin light chains work well in marrow specimens, often with less background staining than immunohistochemical methods.[34] The antibodies to lymphocyte antigens are useful in determining the B- or T-cell origin of the lymphoproliferative processes and the extent of marrow involvement (see Fig. 39.9). These antibodies are not determinants of clonality. Polyclonal antibody to myeloperoxidase is a specific and sensitive antibody for cells of neutrophil origin that reacts with the myeloblasts in most cases of acute myeloid leukemia (AML; see Fig. 39.5).[24,35,36] Some studies, however, have shown that in paraffin-embedded tissue, monoclonal antibodies to myeloperoxidase are more specific. Several panels for the immunohistochemical characterization of acute leukemia have been described.[18,24,25,35,37,38] These generally include antibodies to CD68 (both PGM1 and KP1), myeloperoxidase, CD34, lysozyme, lymphocyte antibodies, and TdT, with addition of other antibodies as needed.

It is important that the reactivity pattern of all antibodies be determined by each laboratory. The range of reactivity attributed to an antibody by the manufacturer should be confirmed with lesions of known antigenicity. The pattern of reactivity of the antibodies to lymphoid cells is generally based on studies of lymph nodes fixed in B5 or buffered neutral formalin. The same reactivity results may not be applicable to marrow biopsies decalcified with a rapid acid decalcifier; L26, an excellent antibody to CD20, a pan B-cell antigen, works well in bone marrow biopsies decalcified with a rapid acid decalcifier but may not react in Zenker-fixed tissue decalcified in the same manner. The effects of decalcification on antibody reactivity should be determined by subjecting lymph node tissue to the same decalcification procedure employed for bone marrow biopsies as part of the antibody validation procedure.

Most large histopathology laboratories use automated instruments for immunohistochemistry; with careful attention to detail, generally very good results are obtained.

In addition to routine histopathologic studies, the bone marrow specimen is being increasingly utilized for molecular and cytogenetic studies.[8,39] These special techniques should, if possible, be anticipated prior to obtaining the biopsy in order for the specimen to be processed in an appropriate manner. However, not infrequently, the need for these studies is not determined until a biopsy specimen is examined with routine stains. In these instances, it would be appropriate to repeat the biopsy for the necessary specimens. Fixed specimens embedded in paraffin may have been used for some of these studies. This may suffice if the reliability of the technique is ensured from quality control studies. Decalcified specimens may yield distinctly different, often inferior, results from nondecalcified fixed specimens.

This section is not intended to serve as a complete description of all of the antibodies available for bone marrow immunohistochemistry; the individual antibodies that may be useful will be noted in the discussion of the various disease conditions.

Normocellular Bone Marrow

Assessment of marrow cellularity must take into account the age of the patient because the amount of hematopoietic tissue in bone marrow from normal individuals varies with age, as demonstrated in both histologic and radiologic imaging studies.[40–42] The simplistic formula "100 minus the patient age" to estimate normal cellularity for age is relatively inaccurate and may overestimate or underestimate the normal cellularity of many patients because the decrease in cellularity is not constant throughout human life. In the first decade, the mean marrow cellularity is 79%; the mean cellularity in the eighth decade is 29%. In the first three decades of life more than half of the marrow is composed of hematopoietic cells. During this period, there is a gradual decrease in the amount of hematopoietic tissue with an increase in fat cells. From the fourth to the seventh decade, there is relative stabilization of the number of hematopoietic cells (Figs. 39.11 and 39.12); beginning in the eighth decade, there is a renewed decrease. The increase in adipose tissue results from a decrease in both hematopoietic and bone tissue.[42]

The immediate subcortical area of the bone marrow may normally be more hypocellular than the deeper medullary areas. As a result, specimens that contain a substantial amount of subcortical marrow may be inadequate for estimating cellularity. In addition, the immediate paratrabecular areas may be preferentially hypocellular.

For personal use only. No other uses without permission. Copyright ©2017. Elsevier Inc. All rights reserved.

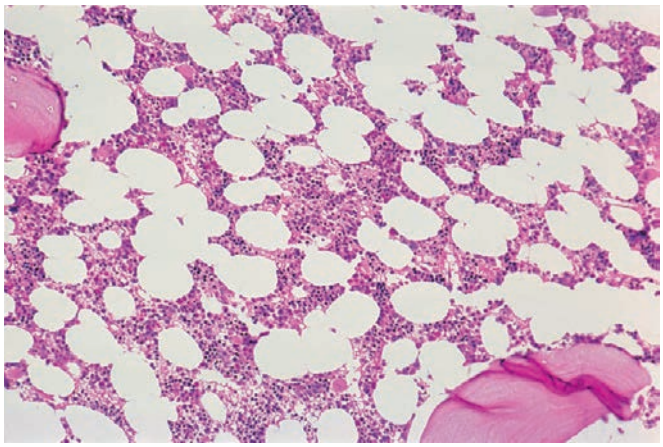

Figure 39.12 Marrow biopsy from a 70-year-old man being evaluated for metastatic tumor. The marrow is approximately 30%–35% cellular, normal for age. There was no evidence of tumor.

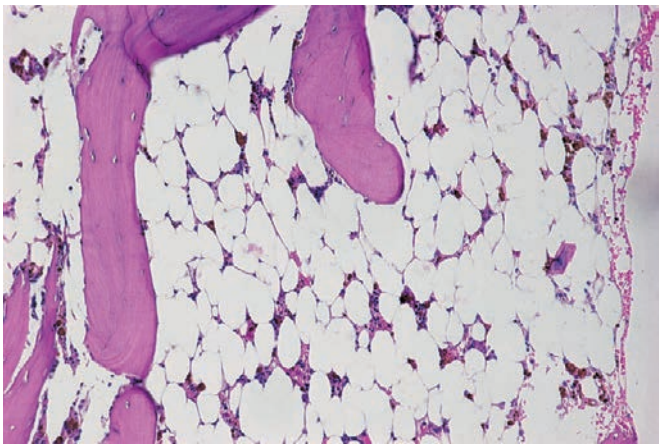

Figure 39.13 Bone Marrow Section From a 7-Year-Old Girl With Idiopathic Acquired Aplastic Anemia. Hematopoietic cells are almost totally absent. Sinuses and capillaries are prominent. Iron-laden macrophages reflecting increased iron stores from repeated red blood cell transfusions are present.

Alterations in Cellularity

Aplastic Anemia

Acquired aplastic anemia has historically been classified as idiopathic or secondary, the latter cases allegedly resulting from exposure to drugs, chemicals, viral infections, or ionizing radiation.[43–48] Contemporary theories have focused on immunologic mechanisms as the causative factor in the majority of cases.[49,50] These mechanisms involve activation of T-cell subsets that attack marrow stem cells and progenitor cells. In some instances, apparently acquired aplastic anemia is related to inherited genetic mutations and telomere shortening.[51] Severe aplastic anemia is defined by a markedly hypocellular bone marrow (<25% of normal for age or 25%–50% of normal with <30% hematopoietic cells) accompanied by two of the following: granulocytes less than 0.5×10^9/L; platelets less than 20×10^9/L; or a corrected reticulocyte count less than 1%.[52]

The biologic mechanisms underlying the occasional evolution of aplastic anemia to paroxysmal nocturnal hemoglobinuria (PNH) is not presently known,[53] but the presence of small PNH clones in aplastic anemia may be associated with in improved response to immunosuppressive therapy.[54]

The term "constitutional aplastic anemia" has been used collectively for all congenital aplastic anemias, familial and nonfamilial, with and without associated abnormalities of body structures. There are several inherited bone marrow failure syndromes that may manifest marrow aplasia or hypoplasia, including Fanconi anemia, Shwachman–Diamond syndrome, dyskeratosis congenita, and Diamond–Blackfan anemia.[55–63]

Fanconi anemia is a syndrome of familial hypoplastic anemia occurring primarily in the first decade of life that is associated with multiple organ malformations, including hypoplasia of the kidneys and absent or hypoplastic thumbs or radii.[56,58–60] It is associated with numerous gene mutations and is the most common cause of aplasia in the first decade of life.[64,65] An association of hypoplastic bone marrow and pancreatic dysfunction (Shwachman–Diamond syndrome) is a rare disorder occurring in children.[61] Diamond–Blackfan anemia is characterized by erythroid aplasia or hypoplasia related to mutations of genes encoding ribosomal structural proteins, manifesting usually in the first year of life.[66]

Selective aplasia or hypoplasia of the megakaryocytes associated with missing radii (TAR syndrome) is a rare disorder. An inherited autosomal dominant hematologic disorder associated with proximal fusion of the radius and ulna has been reported; the hematologic manifestations are somewhat variable and include adult onset of generalized bone marrow failure and amegakaryocytic thrombocytopenia presenting in childhood. The latter presentation has been associated with a mutation in homeobox genes *HOXA11*. The homeobox genes encode regulatory proteins that have a role in skeletal morphogenesis and hematopoiesis.[57,67,63]

In the most severe form of aplastic anemia, the intertrabecular marrow space is occupied predominantly by adipose tissue with scattered lymphocytes, plasma cells, tissue mast cells, and hemosiderin-laden macrophages (Fig. 39.13). In less severe processes, there is an increased amount of fat tissue and scattered small collections of erythroblasts, granulocytes, and megakaryocytes; in some instances, the decrease in megakaryocytes is disproportionate to other cell types. The blood findings in aplastic anemia are characterized by varying degrees of pancytopenia.

Uncommonly, the marrow biopsy in a patient with aplastic anemia contains aggregates of well-differentiated lymphocytes similar to the lesions that occur in a variety of immune disorders; these are described in this chapter as polymorphous lymphoid aggregates. Unusually large aggregates of benign T lymphocytes have been observed in aplastic marrows in patients with invasive malignant thymoma with an associated nonclonal T lymphocytosis in the blood (Fig. 39.14).[68]

Hypoplastic marrows may be encountered in some newly diagnosed cases of acute leukemia and MDS. These can generally be distinguished from true aplastic anemia by the population of blasts and immature granulocytes, in contrast to the mature lymphocytes, plasma cells, and tissue mast cells in aplastic/hypoplastic marrows. The use of CD34 is an additional aid in identifying blast cells.[69] However, it is important to note that not all blasts express CD34 and a negative reaction does not exclude a blast population. Concurrent staining for myeloperoxidase should be performed. Cytogenetic studies show distinct clinical outcomes for cytogenetic abnormalities arising in aplastic anemia.[70]

The use of hematopoietic cell transplantation as a therapeutic approach to aplastic anemia in patients who do not respond to immunosuppressive therapy has gained wide acceptance. Evidence of marrow reconstitution usually is present in biopsies obtained 2–3 weeks following transplantation and consists of foci or islands

For personal use only. No other uses without permission. Copyright ©2017. Elsevier Inc. All rights reserved.

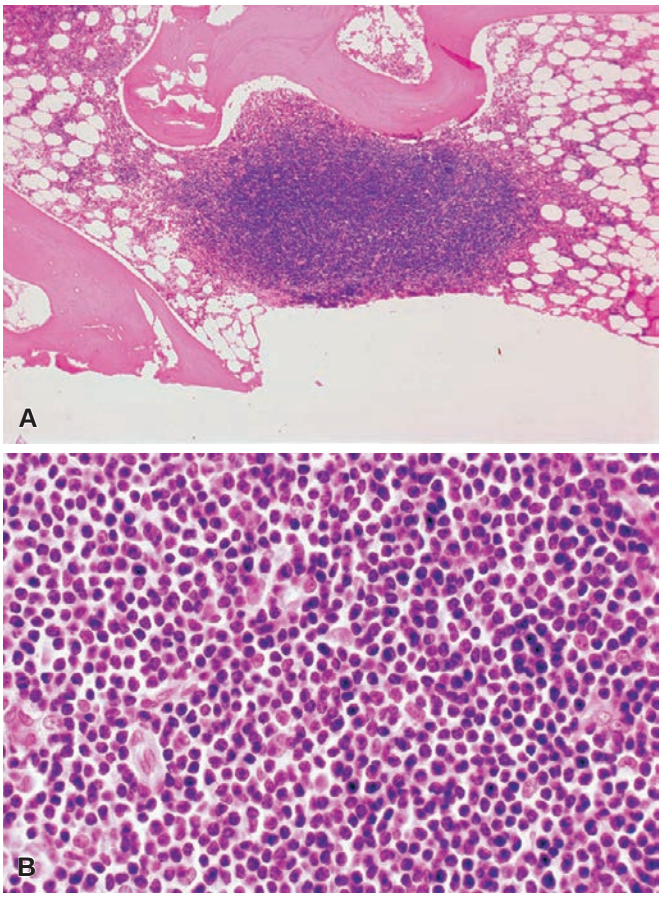

Figure 39.14 **A,** Marrow biopsy from a 75-year-old man with invasive thymoma and nonclonal T-cell CD3+, CD4+, CD5+, CD8+ lymphocytosis. The markedly hypocellular marrow contains several large aggregates of small lymphocytes as illustrated; the predominant lymphocytes in the marrow specimen had the same phenotype as the blood and were nonclonal by molecular studies. The repeat marrow biopsy following thymectomy showed regression of the lymphocytic aggregates but persistence of hypoplasia. **B**, High magnification of specimen in **A**.

of hematopoietic cells. Sequential marrow biopsies in the subsequent 5- to 10-week period show increasing numbers of erythroid precursors, granulocytes, and megakaryocytes in patients with engraftment. Impending rejection of engraftment may be heralded by a decrease in one marrow cell line. An association between high mast cell counts in post marrow transplant specimens from patients with aplastic anemia and marrow rejection has been reported, but this has not been a uniform observation.[71,72]

Growth factor therapy and immunosuppressive and antibiotic therapy may alter the morphology of the proliferating engrafted cells, and evidence of dyserythropoiesis and dysgranulopoiesis may be present. At times, agranulocytosis with a "maturation arrest" of the proliferating neutrophil precursors at the promyelocyte stage may occur as a result of antibiotic or other drug therapy. The use of recombinant granulocyte growth factor may result in a marked shift to immaturity in the developing neutrophils. Selective hypoplasia of myeloid cell lines may occur and is frequently related to specific drug- or virus-related immune mechanisms. Selective erythroid hypoplasia may occur in patients with parvovirus B19 infection and in association with some drugs such as the immunosuppressive drug mycophenolate mofetil, used after solid organ transplantation.[73–75]

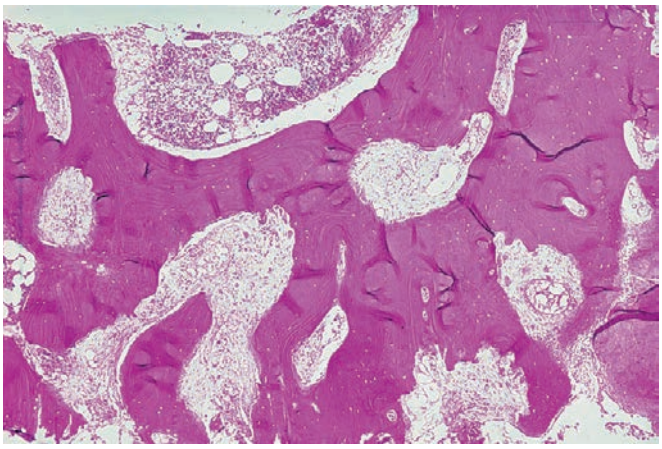

Figure 39.15 **Osteitis Fibrosa Cystica.** Marrow biopsy from posterior iliac spine from a patient with chronic renal disease and secondary hyperparathyroidism. A portion of normal-appearing marrow is at the top. The remainder of this area shows new bone formation, loose marrow fibrosis, and increased osteoblasts and osteoclasts.

Marrow Hyperplasia

Hyperplasia of one or more myeloid cell lines (erythroid, granulocytic–monocytic, megakaryocytic) may be found in several hematopoietic disorders. Several benign hematologic disorders are characterized by hypercellularity; these include cell maturation defects such as the megaloblastic and sideroblastic anemias or disorders with increased rates of destruction or utilization of various cell types in which the hypercellularity is due to compensatory hyperplasia. Hemolytic anemias are generally characterized by a marked erythroid hyperplasia. In immune thrombocytopenia in which there is an increased rate of platelet destruction, the megakaryocytes are normal to increased in number. One of the major problems in evaluation of marrow from patients with benign disorders, such as megaloblastic anemia in which the marrow may be very hypercellular and precursor cells may show striking nuclear changes, is that the proliferating erythroblasts or other myeloid cells may be misinterpreted as a leukemic proliferation; examination of the blood and marrow smears in combination with review of the clinical history and laboratory data should prevent the possibility of this type of error.

Infrequently, a posterior iliac spine biopsy may contain findings unrelated to the reason for which the biopsy is performed. One such finding is osteitis fibrosa cystica related to secondary hyperparathyroidism in patients with chronic renal disease (Fig. 39.15). It is imperative for pathologists and hematologists to recognize the potential for diseases other than hematologic disorders that manifest in marrow biopsies.

Gelatinous Transformation (Serous Atrophy/Degeneration)

Gelatinous (serous) transformation is a degenerative change of the marrow characterized by atrophy of the fat and hematopoietic cells and accumulation of serous fluid in the interstitium.[76–79] It is an epiphenomenon associated with several disorders that are usually accompanied by extreme malnourishment and weight loss; it is potentially reversible with resolution of the underlying problem and restoration of normal nutritional status. The etiologic bases are somewhat age related: anorexia nervosa, human immunodeficiency virus (HIV) syndrome, and acute febrile illnesses are the most common factors in young individuals; alcoholism and lymphomas in middle

For personal use only. No other uses without permission. Copyright ©2017. Elsevier Inc. All rights reserved.

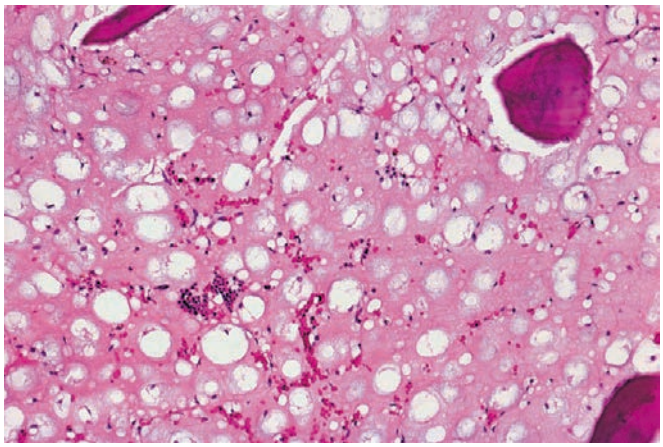

Figure 39.16 Bone marrow section from a 19-year-old man with anorexia nervosa and severe weight loss showing marked serous degeneration (gelatinous transformation). There is marked reduction in hematopoietic and fat cells with accumulation of an amorphous, eosinophilic substance.

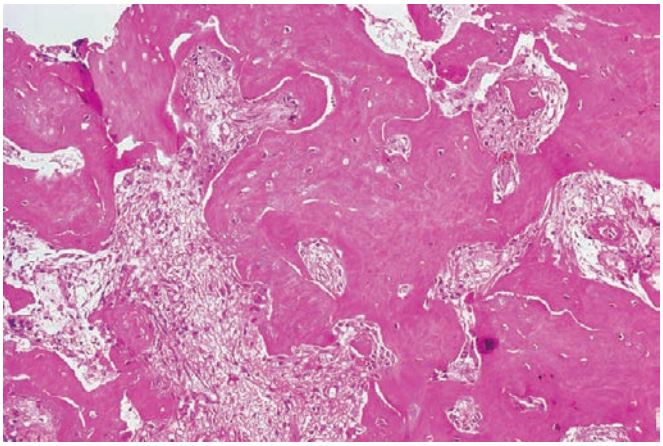

Figure 39.17 Decalcified Posterior Iliac Spine Bone Marrow Trephine Biopsy From an 8-Month-Old Girl With Osteopetrosis. Marrow space is markedly reduced as consequence of widely expanded bone structure. Lighter areas in bone structure represent cartilaginous plates. Numerous osteoclasts are present in some areas along the endosteal surface.

age; and carcinomas, lymphomas, and congestive heart failure in older individuals. It may also be observed in the pediatric population.[80,81] The majority of patients are anemic.

The areas of gelatinous transformation in the marrow biopsy may be focal with intervening areas of normal hematopoietic and fat cells, or the entire biopsy may manifest the transformation, which appears as a homogeneous lightly eosinophilic appearance in sections stained with hematoxylin and eosin; it is pale pink with periodic acid–Schiff (PAS) and slightly bluish with Giemsa (Fig. 39.16). Bone marrow aspirate smears contain a dense metachromatic, mucoid-appearing material with Giemsa stain.

Osteopetrosis

Osteopetrosis is a rare genetic disorder of osteoclast function and/or development, characterized by impaired bone resorption and increased bone sclerosis.[82–84] There are several possible genetic mutations that may result in osteoclast dysfunction or lack of development.[82,83,85] Several classifications have been proposed. Generally two major groups are recognized: autosomal recessive osteopetrosis and autosomal dominant osteopetrosis. A rare sex-linked form has also been reported. There is wide variation in the clinical severity of the disease, both in the autosomal dominant group (also known as Albers–Schönberg disease, which includes asymptomatic individuals and adults) and the autosomal recessive group. The most severe forms of the disease, which occur in young infants, are lethal unless treated with hematopoietic cell transplantation and are usually autosomal recessive (infantile malignant osteopetrosis).[82,86] A less severe form of autosomal recessive osteopetrosis is caused by a mutation in the gene encoding carbonic anhydrase II, resulting in carbonic anhydrase II deficiency; in addition to the osteopetrosis, these patients have renal tubular acidosis and cerebral calcifications. The few X-linked cases have been associated with ectodermal dysplasia, lymphedema, and immune deficiency.[82–84,87] The incidence of infantile malignant osteopetrosis is 1 in 300,000 births, except in Costa Rica where it is 3–4 in 100,000 births.

Most cases of osteopetrosis are associated with a failure of osteoclast function resulting in disturbances of intracellular and extracellular pH of the osteoclast resorption compartment which leads to impaired resorption of organic and inorganic bone matrix.[83] In some cases there is a failure of osteoclast development; this autosomal recessive form is associated with mutations of a variety of genes in 70% of cases that disrupt osteoclast development, differentiation, and function.[82,84,86–88] In the severe forms of the disease there is sclerosis of all of the bones. In the less severe forms there is sclerosis of the bones of the skull, pelvis, vertebrae, and phalanges.

The radiographs in osteopetrosis show increased bone density. The increased bone sclerosis results in reduced marrow space and impaired myeloid hematopoiesis, essentially a form of bone marrow failure; this is accompanied by extramedullary hematopoiesis with hepatosplenomegaly and a leukoerythroblastic blood picture. Reduction in the size of the foramina in the skull leads to optic and auditory nerve compression with visual and auditory defects. Although the bones are dense there is increased fragility and propensity for fractures. Dentition problems are also a part of the clinical picture. The only known cure for the infantile malignant form of the disease is hematopoietic cell transplantation. Many cases of the autosomal dominant form of osteopetrosis are asymptomatic; the most common clinical manifestation is increased fragility of bone leading to fractures.

Posterior iliac crest biopsy may be performed prior to and following hematopoietic cell transplantation. The diagnostic features of the disorder include marked thickening of the bone trabeculae and marked reduction in the medullary cavity (Fig. 39.17). There is usually increased connective tissue in the medullary space, although this may be difficult to judge because of the overall reduction in the space. The bone structures contain cartilaginous plates, which in nondecalcified specimens show calcium deposition. Osteoclasts are frequently numerous along the endosteal surface. The osteoclasts lack a normal ruffled border.[89] In the small number of cases of failure of osteoclast production associated with a mutation of the *RANKL* gene, there is an absence of osteoclasts.

Following successful allogeneic transplantation there is gradual resorption of the abnormal bone structure, regression of the cartilaginous plates, and expansion of the medullary space with abundant hematopoietic tissue. This is accompanied by regression of splenomegaly and reversal of the leukoerythroblastic blood picture.[90,91]

Bone Marrow Necrosis

Bone marrow necrosis unrelated to chemotherapy or radiation therapy occurs occasionally in patients with acute leukemia, malignant

For personal use only. No other uses without permission. Copyright ©2017. Elsevier Inc. All rights reserved.

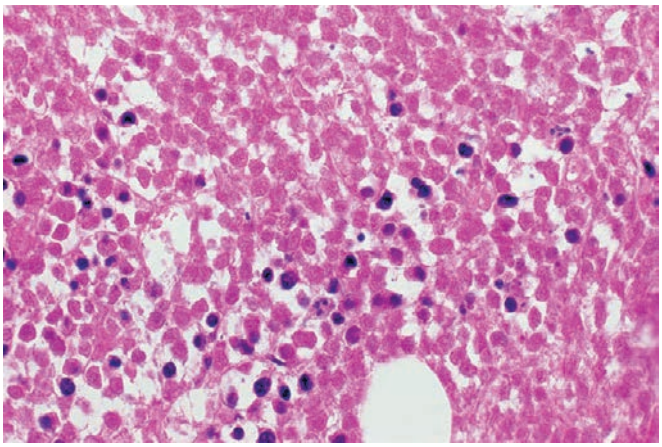

Figure 39.18 Marrow Biopsy From a Patient With Marrow Involvement by Burkitt Lymphoma. Most of the lymphoma cells show evidence of karyolysis; a few scattered pyknotic cells are present.

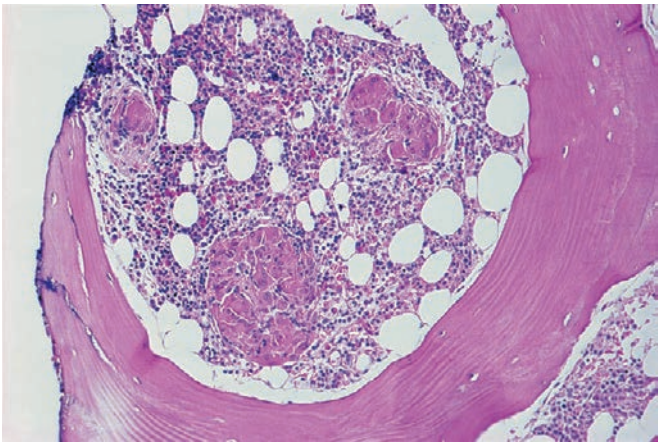

Figure 39.19 Multiple noncaseating granulomas in marrow biopsy of a 33-year-old man admitted with marked hypercalcemia. A clinical diagnosis of sarcoidosis was established.

lymphoma, and metastatic tumor[92–97]; it has also been observed in patients with sickle cell anemia, infectious processes, systemic lupus erythematosus, caisson disease, voluntary starvation, and megaloblastic anemia complicated by infection.[93,94,97] The process may be accompanied by severe and generalized bone pain.

The aspirated marrow specimens from these patients frequently have a gelatinous consistency. The microscopic picture in the trephine section reflects the stage of necrosis; different stages are frequently found in the same biopsy specimen. In the early stages, the nuclei show pyknosis and karyorrhexis, and the cells have a granular appearance; this is followed by karyolysis. In advanced stages, all cell outlines disappear, and the marrow space is replaced by amorphous, granular, eosinophilic debris. The trabeculae may be involved and show loss of osteocytes. The necrosis may be patchy or involve virtually all of the cells in the biopsy specimen (Fig. 39.18).

Inflammatory Disorders

Granulomatous Inflammation

The inflammatory diseases that are most readily identified in marrow biopsies are those associated with a granulomatous reaction; the etiologic bases include fungi, *Mycobacterium tuberculosis*, *Mycobacterium avium-intracellulare*, sarcoidosis, *Mycoplasma pneumoniae*, and viral infections such as Epstein–Barr.[98–110] Marrow granulomas have been observed in patients with cytopenias who are on the antidysrhythmic agent amiodarone.[111,112] Granulomas may also be found in patients with Hodgkin disease and non-Hodgkin lymphomas, with or without marrow involvement by the lymphoma, and in occasional cases of a drug reaction.[107,113,114] Perivascular granulomas may be related to hypersensitivity states. With a combination of studies, including histochemical stains, microbiologic culture, serology, enzyme immunoassay of body fluids, and molecular analysis, the etiologic basis for the granulomas should be established in a very high percentage of cases, approximately 80%–90%. In approximately 80% of the cases, the etiologic basis is identified by culture, stain, or molecular studies.[102,103,115]

Granulomas in the marrow are similar to those in other sites; the most commonly encountered are composed only of a collection of epithelioid histiocytes that may be surrounded by a rim of well-differentiated lymphocytes. Others may contain large numbers of multinucleated giant cells. The number may range from a single lesion to numerous and confluent granulomas (Figs. 39.19–39.21).

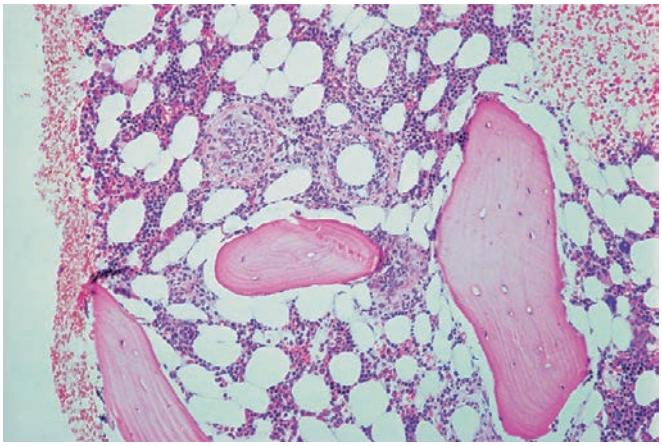

Figure 39.20 Marrow biopsy with scattered granuloma-like lesions; many of the lesions had a central lumen and were interpreted as "doughnut" granulomas. No etiologic basis was identified.

An unusual granulomatous lesion referred to as a "doughnut" or ring granuloma, because of a central clear area or lumen, has been described in the bone marrow of some patients with Q fever.[99,106] The appearance of these lesions, which is similar to those in other organs, such as the liver, varies from what appear to be vascular structures or fat globules encircled by a rim of fibrinoid material, polymorphonuclear leukocytes, and monocytes to a collection of epithelioid histiocytes surrounding a clear space (see Fig. 39.20). The vascular-associated granulomas observed in hypersensitivity states are similar in appearance. In addition to Q fever, these lesions may be observed in marrows from patients with a variety of diseases, both neoplastic and non-neoplastic.[105] In one series the most frequent association was with Epstein–Barr virus (EBV) infection.

Cells with prominent intranuclear inclusions may be found in granulomas in the marrow of patients with cytomegalovirus or other viral infection.

Acute parvovirus B19 infection in immunocompetent individuals may be associated with marked erythroblast hypoplasia and very immature giant erythroblasts; scattered erythroblasts may contain intranuclear inclusions (Fig. 39.22).[49] Recovery from the erythroid hypoplasia may be marked by a wave of regeneration with a large number of erythroblasts at an early stage of maturation, analogous

For personal use only. No other uses without permission. Copyright ©2017. Elsevier Inc. All rights reserved.

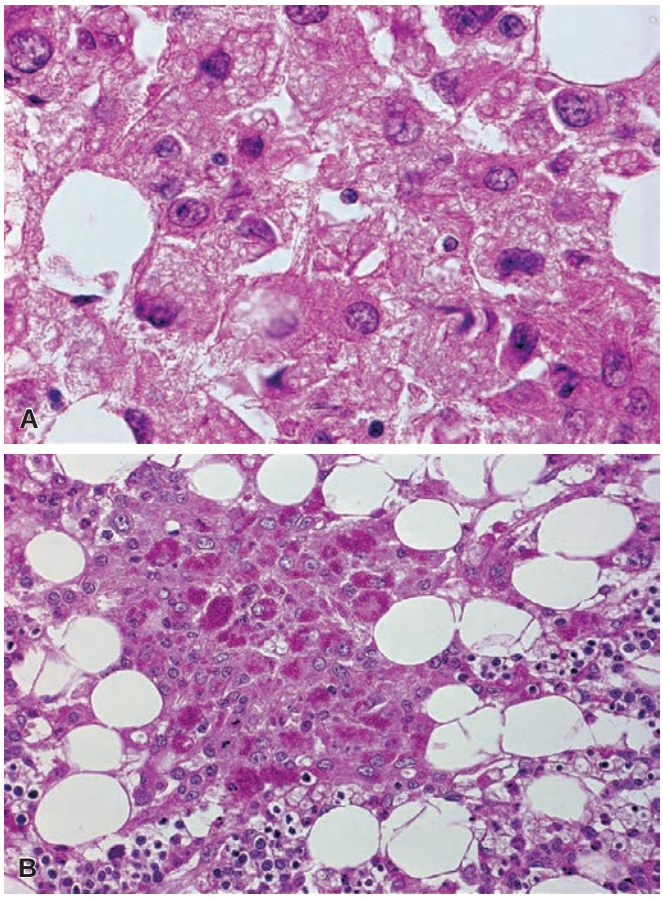

Figure 39.21 Marrow Biopsy From a Patient With Treated Hodgkin Disease. Numerous granulomas contain macrophages with numerous organisms **(A)** which were intensely PAS positive **(B)**. Culture studies were positive for histoplasmosis.

to the proliferation of promyelocytes and myelocytes that occurs in agranulocytosis. Immunodeficient patients may develop a chronic parvovirus B19 infection; in these cases there may be an erythroid hyperplasia with numerous intranuclear inclusions in the erythroid precursors; the inclusions are most prominent in the basophilic and polychromatic stages of maturation (see Fig. 39.22C).[49] The parvovirus B19 relationship to the inclusions may be demonstrated with immunohistochemical or in situ hybridization studies.

As with other tissues, stains for acid-fast bacilli (AFB) and fungi should be performed in all cases of marrow granulomas. Failure to detect AFB does not exclude infection with *M. tuberculosis*; organisms are found in approximately 25%–35% of marrow specimens from patients with documented disease by culture studies.[107,116–118] Occasional patients with negative culture studies have AFB stain–positive biopsies. The need for culture of a portion of the bone marrow aspirate for AFB and fungi should be anticipated in all patients suspected of having a granulomatous disorder, particularly those with acquired immune deficiency syndrome (AIDS) or patients being investigated for a fever of undetermined etiology.[103,109,115]

Bone marrow biopsies performed on immunosuppressed patients should always be thoroughly examined for opportunistic infections (Figs. 39.23–39.25; see also Fig. 39.21). Typical granuloma formation may not be present in the marrows of some patients with disseminated fungal or mycobacterial disease. Marrow biopsies from patients with HIV may contain scattered macrophages with AFB in the absence of granuloma formation (see Fig. 39.25). Uncommonly, *Pneumocystis*

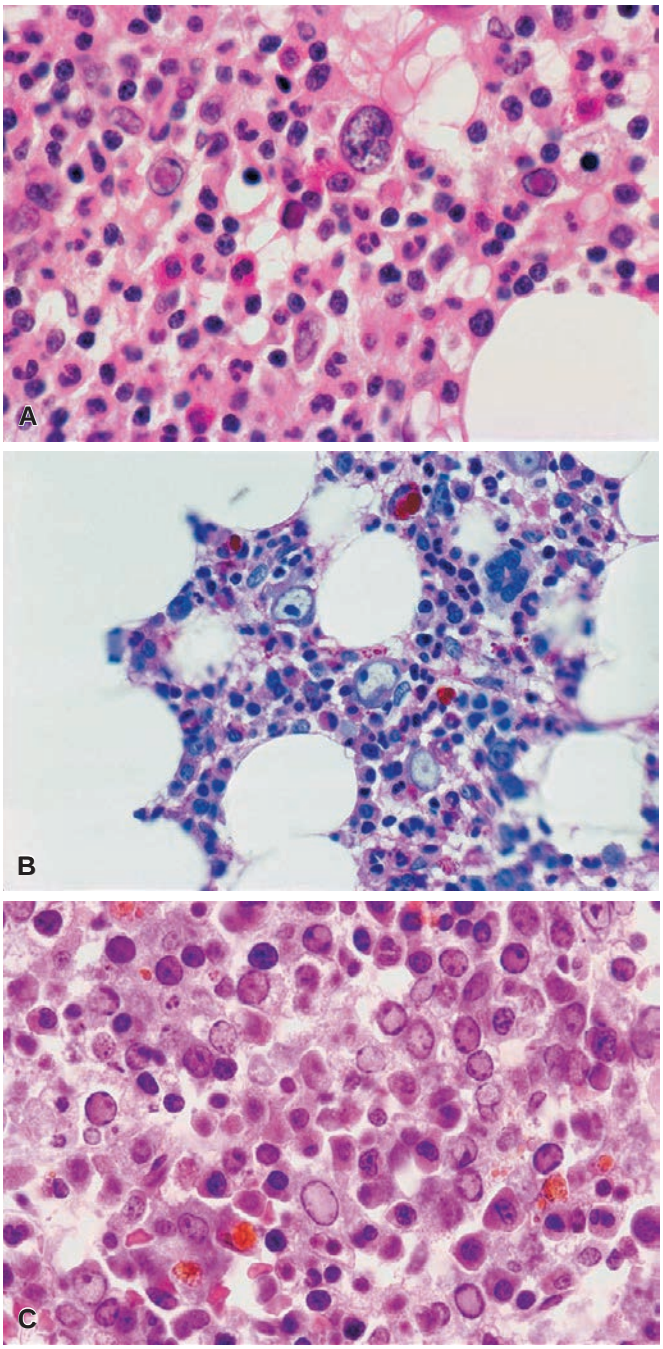

Figure 39.22 **A**, Pre-transplant marrow biopsy from a 4-year-old child with Hunter syndrome (acid mucopolysaccharides, type II) and erythroid aplasia. Several cells that reacted with antihemoglobin A contained intranuclear inclusions. Giant erythroblasts were present in the marrow smear and biopsy as illustrated and the findings were interpreted as consistent with infection with parvovirus B19. **B**, Marrow biopsy from a 17-year-old being treated for metastatic medulloblastoma; occasional, very large erythroblasts with abundant cytoplasm and very prominent nucleoli were present. These cells and the overall marked erythroid hypoplasia are characteristic findings in parvovirus B19 infection. (Wright–Giemsa) **C**, Marrow biopsy from an adult male with AIDS and concurrent parvovirus B19 infection. There are numerous erythroid precursors at all stages of maturation. Many of the more immature erythroblasts contain prominent intranuclear inclusions. (**C,** Contributed by Dr. Robert W. McKenna, Dallas, USA.)

For personal use only. No other uses without permission. Copyright ©2017. Elsevier Inc. All rights reserved.

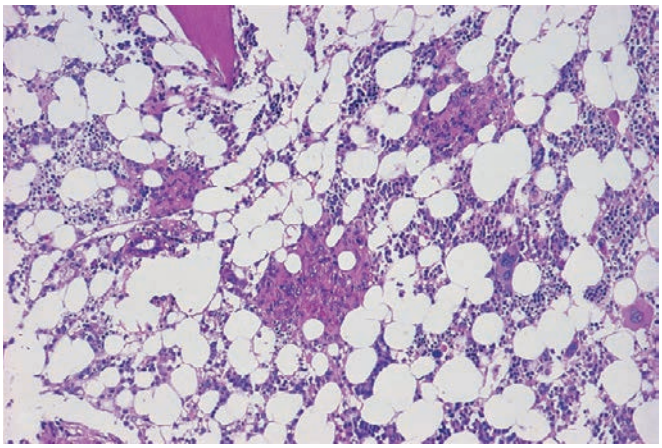

Figure 39.23 Post-Chemotherapy Marrow Biopsy From Patient With Marrow Involvement by Mantle Cell Lymphoma. Several granulomas containing microorganisms interpreted as cryptococcus are shown. The organisms were positive with Gomori methenamine silver; culture studies were confirmatory of cryptococcus.

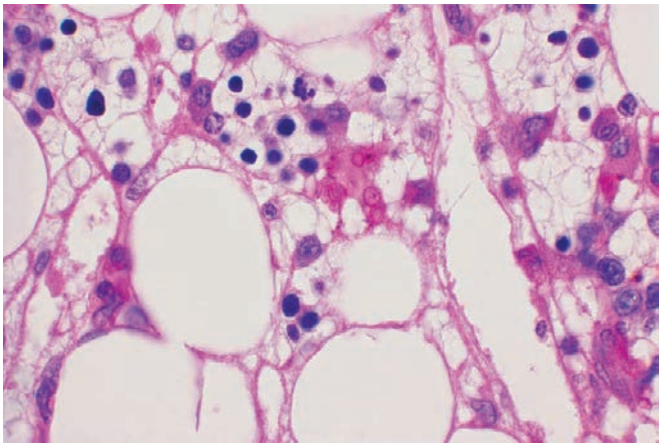

Figure 39.24 Marrow from a patient with AIDS with scattered *Pneumocystis jirovecii* microorganisms occurring both singly and in small clusters. Microorganisms are not associated with any recognizable tissue response. (Periodic acid–Schiff.)

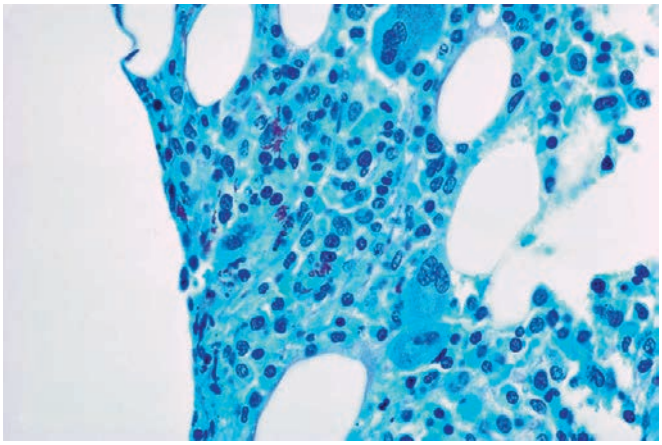

Figure 39.25 Marrow Biopsy From an AIDS Patient. No granulomas were identified but numerous macrophages containing acid-fast bacilli were scattered throughout the marrow interstitium, some in perivascular locations as illustrated.

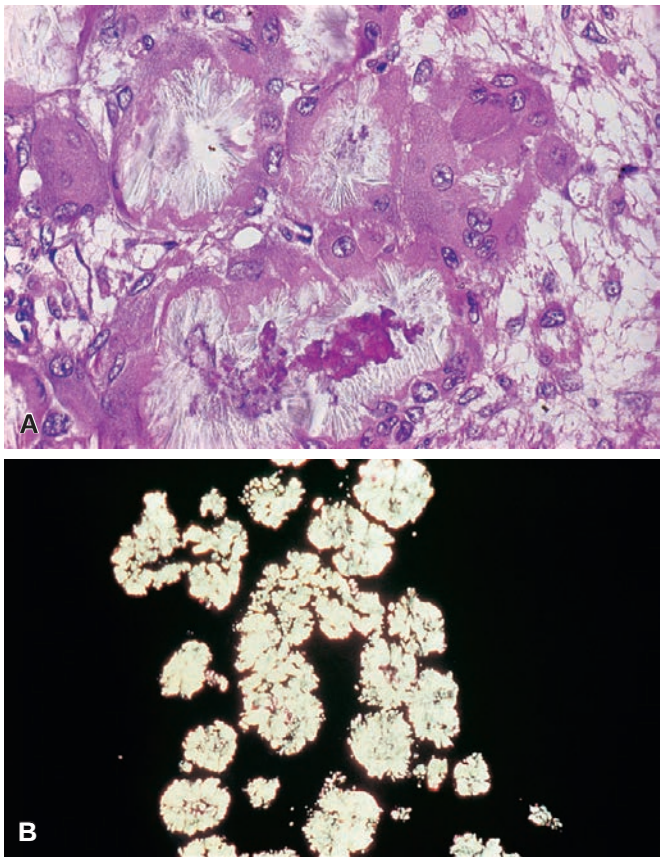

Figure 39.26 A, Section of bone marrow trephine biopsy from a child with primary oxaluria. Calcium oxalate crystals in giant cells form a radial pattern. **B**, Calcium oxalate crystals are doubly refractile in polarized light.

jirovecii (formerly *P. carinii*) may be observed in scattered macrophages in sections stained with PAS or methenamine silver (see Fig. 39.24). An increased number of macrophages with or without evident phagocytosis is sufficient reason to perform special stains for microorganisms.

The presence of infection-related granulomas in the bone marrow sections may occasionally be accompanied by macrophages containing microorganisms in the Romanowsky-stained bone marrow smears or trephine imprints. The morphology of the organisms in these preparations is usually sufficient to establish a diagnosis.

Lipid granulomas, which have been reported to be the most frequent type of granuloma in bone marrow, are similar to those found in the liver, spleen, and lymph node.[119,120] These granulomas range from 0.2 to 0.8 μm in size and usually are associated with lymphocytic aggregates or sinusoids. The loosely spaced macrophages contain fat vacuoles of varying size. The lesions also contain admixed lymphocytes, plasma cells, and eosinophils; giant cells are found in approximately 5% of cases. Some of these granulomas resemble those found in sarcoidosis.

An unusual form of granulomatous reaction can be found in the bone marrow of patients with the genetic disorder of glyoxylate metabolism, primary hyperoxaluria.[121,122] This finding is secondary to the deposition of calcium oxalate crystals. The crystals, which have a slightly yellowish tinge, form a radial pattern, are encircled or engulfed by epithelioid and giant cells, and are doubly refractile with polarized light (Fig. 39.26). Substantial portions of the marrow biopsy may be replaced by these lesions, which are similar to those found in the kidneys and other tissues.

For personal use only. No other uses without permission. Copyright ©2017. Elsevier Inc. All rights reserved.

Nonspecific Inflammatory Reactions

Nonspecific inflammatory alterations may be noted in the marrow from patients with a variety of systemic disorders, including acute infection, malignancy, connective tissue disease, and immune disorders, most notably AIDS. These alterations generally are characterized by changes in both the vascular structures and parenchyma. The terms tumor myelopathy and myelitis have been applied to the nonspecific marrow changes that are observed in a high percentage of patients with malignant lymphoma.[123] These changes include edema of the vessel walls, plasma cell and mast cell proliferations in the adventitia, protein deposits adjacent to the vessels, patchy edema, depressed erythropoiesis, and increased granulopoiesis and megakaryocytopoiesis. Acute necrosis of bone marrow tissue is reported in patients with tuberculosis and typhoid fever.[124]

Human Immunodeficiency Virus Syndrome (HIV, AIDS)

Marrow biopsies from untreated patients with HIV have been generally reported to be hypercellular, although normocellular and hypocellular specimens may be observed; nonspecific findings include marrow damage, increased plasma cells, myelodysplasia, serous degeneration, lymphocytic infiltration, increased reticulin and "naked" megakaryocytic nuclei.[125–131] The marrow specimen may serve as a vehicle for the rapid diagnosis of febrile illnesses in HIV-infected patients.[126,132,127] Opportunistic organisms including AFB and *P. jirovecii* and fungal organisms may be present, occasionally without granuloma formation (Fig. 39.27; see also Figs. 39.24 and 39.25).[102,133–135] Immune thrombocytopenia may be observed,[135–137] but the frequency of severe thrombocytopenia in HIV-infected patients has decreased with the use of anti-retroviral therapy.[138]

HIV-infected individuals may develop a persistent parvovirus B19 infection because of ineffective production of IgG parvovirus-neutralizing antibodies.[73,139] This may result in chronic anemia and erythroid hyperplasia with all stages of maturation in contrast to the erythroid aplasia that may occur in acute parvovirus B19 infection. The erythroid precursors in these patients may show intranuclear inclusions primarily in the basophilic and polychromatic erythroblasts (see Fig. 39.22C).

Negative stains for microorganisms and absence of granulomas do not exclude the possibility of infection by microorganism; a minority of patients with infection by *M. avium* complex have demonstrable granulomas or AFB in their marrow biopsies. In addition, although infrequent, marrow with only mild nonspecific changes may contain scattered macrophages with mycobacteria. These macrophages may resemble pseudo-Gaucher cells in hematoxylin and eosin–stained sections. Scattered macrophages containing *P. jirovecii* may also be present in a background of essentially normal-appearing or only slightly altered marrow. As a result, it is considered prudent by some observers to routinely stain marrows from HIV patients for AFB and fungi, regardless of the appearance of the marrow with routine stains.

The marrow damage that may be present in HIV patients is characterized principally by a loosely structured, hypocellular interstitium. Areas of fibrinoid necrosis may be present. The changes resemble those found in marrows from patients recovering from chemotherapy with myelotoxic agents and are distinct from serous degeneration, which usually occurs in severely malnourished individuals and which may also be present in marrow biopsies from patients with HIV. Both of these alterations may be accompanied by an increase in plasma cells.

Lymphocytic aggregates of varying size occur in the marrow of a relatively high percentage of patients with HIV.[140,141] These are randomly distributed without any preferential paratrabecular distribution; in some cases the lesions appear to be preferentially perisinusoidal. They are composed primarily of small lymphocytes, some of which may have irregularly shaped nuclei. There are usually associated plasma cells, histiocytes, and increased vascular structures; eosinophils may be increased (Fig. 39.28). Occasional immunoblasts may be noted. This type of lymphocyte proliferation, polymorphous reactive lymphoid hyperplasia, is not unique to patients with HIV and may be observed in marrow biopsies in a wide range of immunologic disorders. Because of the large size and cellular composition, these aggregates may be difficult to distinguish from the lesions of peripheral T-cell lymphoma; the latter lesions are frequently accompanied by numerous epithelioid histiocytes and scattered large transformed cells. In some instances, the distinction between the two processes based on morphologic criteria may not be possible.[141] Peripheral T-cell lymphoma in HIV patients, however, is quite rare, and such a diagnosis should be established with considerable caution and only after review of all pathology specimens.[142] Biopsy of other organ sites as well as molecular studies for T-cell receptor rearrangement may be necessary.

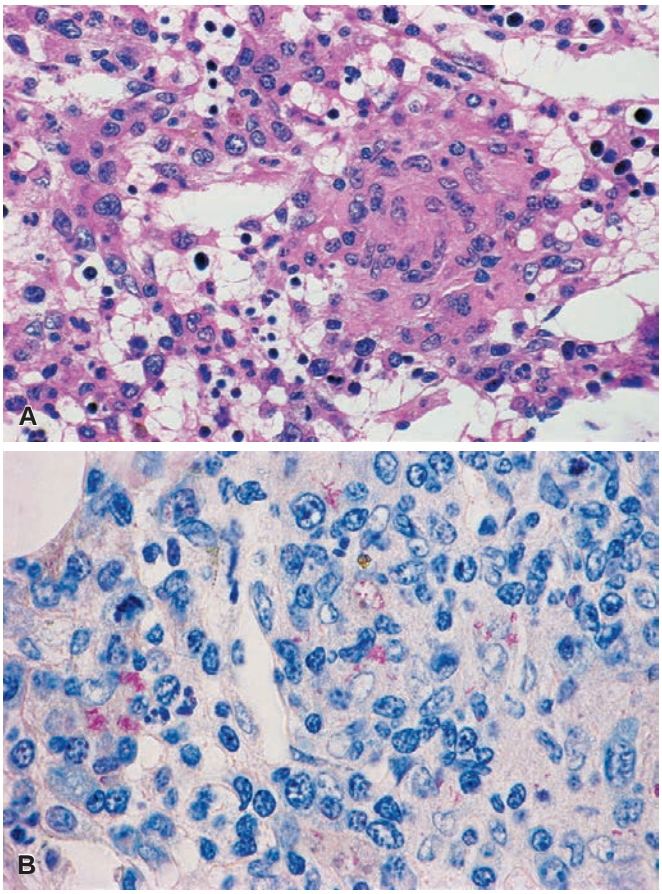

Figure 39.27 **A**, Marrow biopsy from a patient with AIDS showing granuloma without evident necrosis. **B**, One of the granulomas in **A** showing numerous intracellular acid-fast bacilli. (**B** Fite.)

Occasionally, marrow specimens from patients with HIV contain benign lymphoid follicles with germinal centers.

In addition to reactive lymphocytic lesions, the marrow biopsies from AIDS patients may rarely exhibit a florid plasmacytoid immunoblastic proliferation that may resemble a neoplastic process because of the degree of replacement of marrow. The use of immunohistochemical studies with anti-kappa and anti-lambda antibodies can be very useful in demonstrating the polyclonal nature of these lesions.

For personal use only. No other uses without permission. Copyright ©2017. Elsevier Inc. All rights reserved.

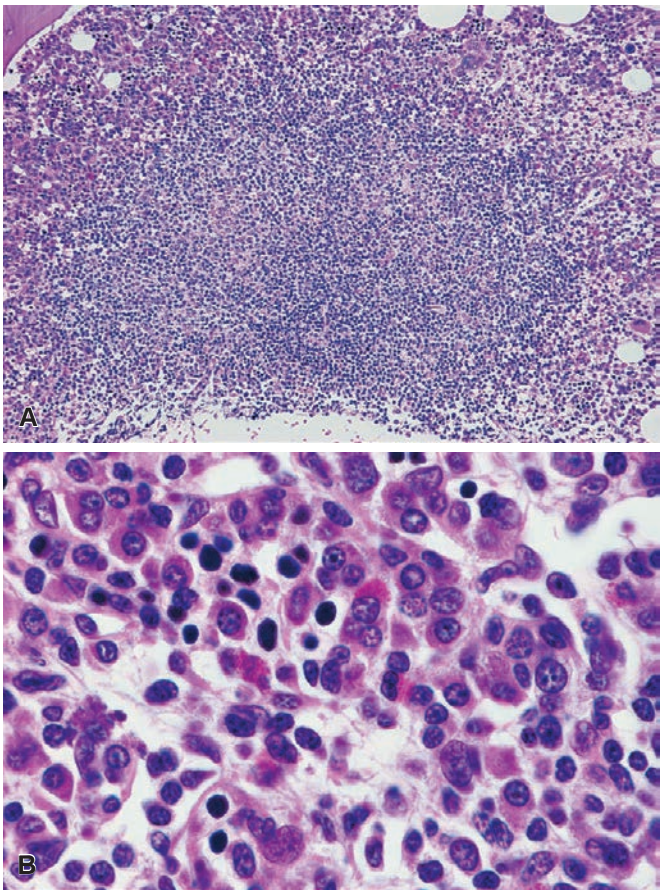

Figure 39.28 **A**, One of several lymphocytic–histiocytic aggregates in marrow biopsy from a patient with advanced AIDS. Acid-fast bacilli were also identified in this specimen. **B**, High magnification of specimen in **A** illustrating polycellular characteristics of the lesion.

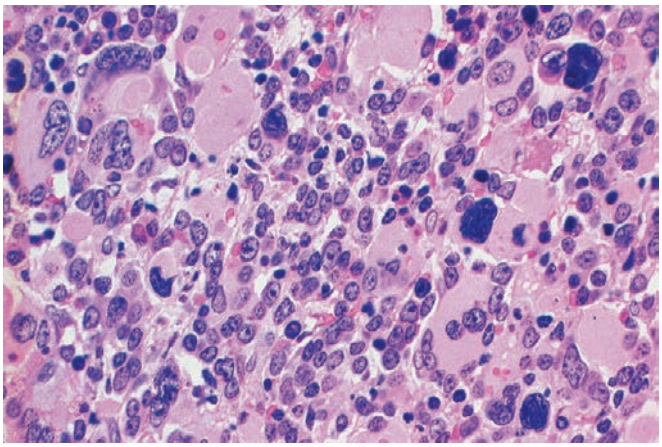

Figure 39.29 **Marrow From a Patient With Acute Megakaryoblastic Leukemia.** The predominant cell population consists of blasts and numerous megakaryocytes at varying stages of maturation. Mature megakaryocytes have abundant cytoplasm that is uniformly eosinophilic.

Although it is important to recognize that marrow biopsies from patients with HIV may show a variety of reactive lymphocytic proliferations, it is equally important to appreciate that these patients have an increased incidence of malignant lymphoma, of either non-Hodgkin or Hodgkin type, and the marrow biopsy may be the initial diagnostic specimen.[142,143] The most common HIV-associated lymphomas that may involve the marrow are B-cell lymphomas, including Burkitt lymphoma, diffuse large B-cell lymphoma, and plasmablastic lymphoma. A single biopsy may contain both reactive lymphocytic lesions and malignant lymphoma. In suspected cases of Hodgkin disease, adherence to established criteria for marrow involvement by Hodgkin disease should be observed.

Patients with HIV who are receiving zidovudine (AZT) may develop evidence of marrow suppression such as anemia and neutropenia. Marrow hypoplasia may be present.[144] Abnormal megakaryocytes with sparse cytoplasm, "naked" megakaryocyte nuclei, may be numerous; this finding is not specific for AIDS and may be present in other disorders, including the MPNs. The incidence of immune thrombocytopenia is increased in individuals with HIV.[145]

Leukemias and Related Disorders

Acute Leukemia

The diagnosis and classification of the acute leukemias are optimally established from examination of Romanowsky-stained blood and bone marrow smears in conjunction with appropriate immunophenotypic, cytogenetic, and/or molecular genetic and cytochemical techniques; this approach forms the basis for the World Health Organization (WHO) classification.[146–148] Terminology from the French–American–British (FAB) Cooperative Group classification remains in common usage, but this classification system should no longer be used.[149] Chromosome analysis has an important role in the evaluation of cases of acute leukemia, primarily in regard to prognostic significance, and is incorporated into the diagnosis of many categories of acute leukemia in the 2016 WHO classification.[148,150,151] The ideal approach to the diagnosis and classification of acute leukemia requires correlation of clinical and peripheral blood findings, bone marrow aspirate smear morphology, and the bone marrow trephine biopsy.[152] Immunophenotyping and cytogenetic or molecular genetic studies, which are now performed on all cases, are best performed on marrow aspirate material. Although smears and imprint preparations are generally superior to sections in classifying the majority of cases of acute leukemia, there are some types of acute leukemia that are accompanied by fibrosis or with unusual morphologic patterns, such as acute megakaryocytic leukemia with an associated t(1;22)(p13.3;q13.1) cytogenetic abnormality that occurs in infants in which the bone marrow sections are often more informative than the bone marrow smears (Figs. 39.29–39.31). In addition, as noted in the section on immunohistochemistry, the development of antibodies reactive in paraffin-embedded tissue, most notably myeloperoxidase, lysozyme, TdT, and CD34 antibodies, has greatly enhanced the recognition of myeloid leukemia in trephine biopsy sections.[24,25,38]

The 2016 WHO classification of acute leukemia includes general categories of AML, precursor lymphoid neoplasms, which include the related acute lymphoblastic leukemias (ALLs) and their corresponding lymphoblastic lymphomas, and acute leukemias of ambiguous lineage. AML (Box 39.1) is further subdivided into AML with recurrent genetic abnormalities, AML with myelodysplasia-related changes, therapy-related myeloid neoplasms, myeloid proliferations of Down syndrome, and AML, not otherwise specified.[153–158] AML with myelodysplasia-related changes may be diagnosed by the presence of: (1) a history of prior myelodysplasia; (2) presence of a myelodysplasia-related cytogenetic abnormality (Box 39.2); or (3) multilineage dysplasia defined as dysplasia in 50% or more of two nonblast cell lines; and the absence of prior cytotoxic chemotherapy

For personal use only. No other uses without permission. Copyright ©2017. Elsevier Inc. All rights reserved.

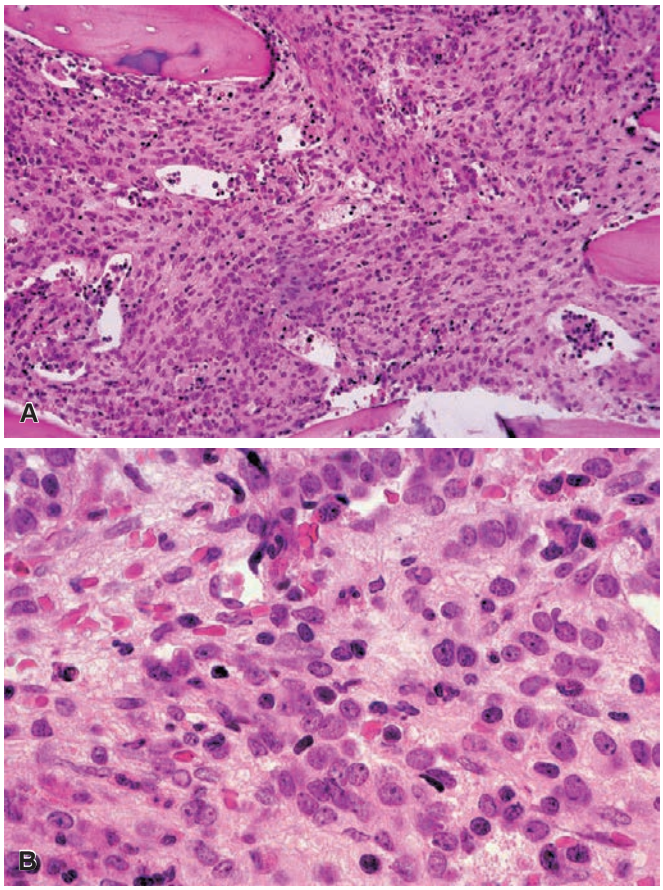

Figure 39.30 **A**, Marrow biopsy from a 14-month-old child with acute megakaryoblastic leukemia with an associated t(1;22)(p13.3;q13.1) cytogenetic abnormality. The blasts frequently have a spindle shape and sometimes form intertwining bundles resembling metastatic tumor. **B**, High magnification of the specimen in **A** showing undifferentiated blasts.

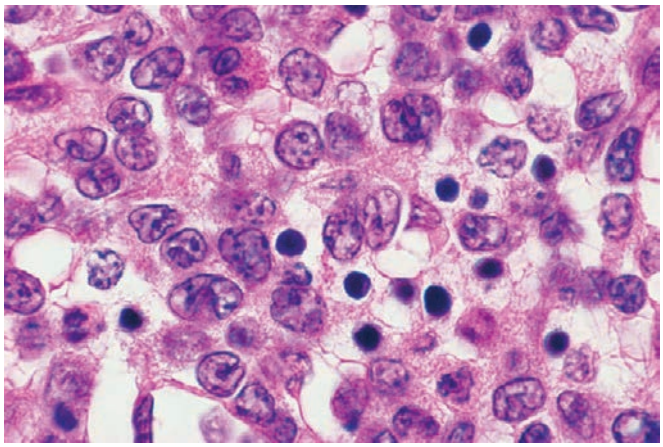

Figure 39.31 Bone marrow biopsy from an adult woman with a mediastinal mass and partial marrow involvement by precursor T-lymphoblastic lymphoma. In this area the lymphoblasts are the predominant cells; some of the lymphoblasts have convoluted nuclei. Scattered erythroid precursors are present.

Box 39.1 2016 World Health Organization classification of acute myeloid leukemia

AML with recurrent genetic abnormalities
- AML with t(8;21)(q22;q22.1); *RUNX1-RUNX1T1*
- AML with inv(16)(p13.1q22) or t(16;16)(p13;q22); *CBFB-MYH11*
- Acute promyelocytic leukemia with *PML-RARA*
- AML with t(9;11)(p21.3;q23.3); *KMT2A-MLLT3*
- AML with t(6;9)(p23;q34.1); *DEK-NUP214*
- AML with inv(3)(q21.3q26.2) or t(3;3)(q21.3;q26.2); *GATA2, MECOM*
- AML (megakaryoblastic) with t(1;22)(p13.3;q13.3); *RBM15-MKL1*
- Provisional entity: AML with *BCR-ABL1*
- AML with mutated *NPM1*
- AML with biallelic mutations of *CEBPA*
- Provisional entity: AML with mutated *RUNX1*

AML with myelodysplasia-related changes

Therapy-related myeloid neoplasms

AML, not otherwise specified
- AML minimally differentiated
- AML without maturation
- AML with maturation
- Acute myelomonocytic leukemia
- Acute monoblastic/monocytic leukemia
- Pure erythroid leukemia
- Acute megakaryocytic leukemia
- Acute basophilic leukemia
- Acute panmyelosis with myelofibrosis

Myeloid sarcoma

Myeloid proliferations related to Down syndrome

Data from Arber DA, Orazi A, Hasserjian R, et al. The 2016 revision to the World Health Organization classification of myeloid neoplasms and acute leukemia. *Blood*. 2016;127(20):2391–2405.

Box 39.2 Cytogenetic abnormalities sufficient for a diagnosis of acute myeloid leukemia with myelodysplasia-related changes, in the absence of prior cytotoxic therapy, when bone marrow or blood blasts are 20% or more

- Complex karyotype (three or more abnormalities)
- Unbalanced abnormalities
  - –7/del(7q)
  - del(5q)/t(5q)
  - i(17q)/t(17p)
  - –13/del(13q)
  - del(11q)
  - del(12p)/t(12p)
  - idic(X)(q13)
- Balanced abnormalities
  - t(11;16)(q23.3;p13.3)
  - t(3;21)(q26.2;q22.1)
  - t(1;3)(p36.3;q21.2)
  - t(2;11)(p21;q23.3)
  - t(5;12)(q32;p13.2)
  - t(5;7)(q32;q11.2)
  - t(5;17)(q32;p13.2)
  - t(5;10)(q32;q21.2)
  - t(3;5)(q25.3;q35.1)

For personal use only. No other uses without permission. Copyright ©2017. Elsevier Inc. All rights reserved.

Box 39.3 2016 World Health Organization classification of acute lymphoblastic leukemia

B-lymphoblastic leukemia/lymphoma, not otherwise specified
B-lymphoblastic leukemia/lymphoma with recurrent genetic abnormalities
- B-lymphoblastic leukemia/lymphoma with t(9;22)(q34.1;q11.2); *BCR/ABL1*
- B-lymphoblastic leukemia/lymphoma with t(v;11q23.3); *KMT2A* rearranged
- B-lymphoblastic leukemia/lymphoma with t(12;21)(p13.2;q22.1); *ETV6-RUNX1*
- B-lymphoblastic leukemia/lymphoma with hyperdiploidy
- B-lymphoblastic leukemia/lymphoma with hypodiploidy
- B-lymphoblastic leukemia/lymphoma with t(5;14)(q31.1;q32.3); *IL3*-IGH
- B-lymphoblastic leukemia/lymphoma with t(1;19)(q23;p13.3); *TCF3-PBX1*
- Provisional entity: B-lymphoblastic leukemia/lymphoma, *BCR-ABL1*-like
- Provisional entity: B-lymphoblastic leukemia/lymphoma with iAMP21

T-lymphoblastic leukemia/lymphoma
- Provisional entity: Early T-cell precursor leukemia/lymphoma
- Provisional entity: Natural killer cell lymphoblastic leukemia/lymphoma

Data from Arber DA, Orazi A, Hasserjian R, et al. The 2016 revision to the World Health Organization classification of myeloid neoplasms and acute leukemia. *Blood*. 2016;127(20):2391–2405.

Box 39.4 2016 World Health Organization classification of acute leukemias of ambiguous lineage

- Acute undifferentiated leukemia
- Mixed phenotype acute leukemia with t(9;22)(q34.1;q11.2); *BCR/ABL1*
- Mixed phenotype acute leukemia with t(v;11q23.3); *KMT2A* rearranged
- Mixed phenotype acute leukemia, B/myeloid, not otherwise specified
- Mixed phenotype acute leukemia, T/myeloid, not otherwise specified

Data from Arber DA, Orazi A, Hasserjian R, et al. The 2016 revision to the World Health Organization classification of myeloid neoplasms and acute leukemia. *Blood*. 2016;127(20):2391–2405.

for an unrelated disease and absence of any of the genetic abnormalities of AML with recurrent genetic abnormalities. All cases of AML are defined by the presence of 20% or more blast cells in the peripheral blood, except for cases of AML with t(8;21)(q22;q22.1), AML with inv(16)(p13.1q22) or t(16;16)(p13.1;q22), and acute promyelocytic leukemia with *PML-RARA* in which a diagnosis of AML can be made with less than 20% peripheral blood and bone marrow blast cells. A large number of gene mutations occur in AML and detection of some *(NPM1, CEBPA, RUNX1)* are critical for a complete diagnosis, whereas others assist in defining prognostic disease groups.[148,158,159] Testing for multiple gene mutations using next-generation sequencing methods is quickly becoming routine in evaluation of AML.

ALL (Box 39.3) is subdivided into precursor B- and T-cell types, with precursor B-ALL further subgrouped into cases with recurrent genetic abnormalities and B-ALL, not otherwise specified.[148,160–162] ALL is biologically and morphologically identical to lymphoblastic lymphoma, although the clinical presentation varies between the two. For this reason, the two are combined in the WHO classification. While most cases of ALL are of precursor B lineage, lymphoblastic lymphoma is of precursor T-cell origin in approximately 80% of cases and B-cell precursor type in 20%. Precursor T-cell ALL/lymphoma has a high incidence of mediastinal mass, occurs in young adults, more frequently in males, and has a predilection for early blood and marrow involvement (see Fig. 39.31).[160–164] Lymphoblasts of both precursor B and T lineage are TdT positive. The blood and marrow may be involved at the time of initial diagnosis and the designation of a case as lymphoblastic lymphoma or ALL is arbitrary. The presence of extramedullary tumor masses and evidence of sparing of marrow function as indicated by a normal platelet count, hemoglobin levels greater than 10 g/dL, and a normal number of neutrophils in the blood are more compatible with a diagnosis of lymphoma with marrow involvement as opposed to ALL. The Children's Cancer Study Group proposed distinguishing leukemia from lymphoblastic lymphoma on the basis of the percentage of lymphoblasts in the marrow.[165] If there are less than 25% lymphoblasts, the case is classified as lymphoma; if there are 25% or more lymphoblasts, the case is classified as leukemia. In the cases of lymphoma, there may be substantial residual normal marrow with the lymphoma cells diffusely scattered in the interstitium. The therapeutic approach in these two fundamentally similar processes is the same. B lymphoblastic lymphoma appears to have lower propensity for blood and marrow involvement than T lymphoblastic lymphoma.[164]

The acute leukemias of ambiguous lineage (Box 39.4) are divided into acute undifferentiated leukemia and mixed phenotype acute leukemias.[166] The latter group also includes specific genetic subtypes.

In the majority of cases of acute leukemia, both myeloid and lymphoblastic, in children and adults, the marrow is markedly hypercellular because of the proliferation of leukemic cells, with replacement of normal hematopoietic cells. In a small minority of patients, particularly older individuals, AML and, rarely, ALL may present with a hypocellular marrow (i.e., hypoplastic or hypocellular acute leukemia).[167–169] The marrow biopsies in these patients may, on low magnification, suggest the diagnosis of aplastic anemia (Fig. 39.32). In contrast to aplastic anemia, in which the residual cells are well-differentiated lymphocytes and plasma cells, the cell population in the interstitium is principally blasts; some normal cells may be present but are markedly reduced. The diagnosis is confirmed by examination of blood and bone marrow smears and the use of appropriate immunohistochemical studies, particularly myeloperoxidase, lysozyme, CD79A, TdT CD117 *(KIT)*, and CD34. In rare instances, ALL in children is preceded by an aplastic or hypocellular phase.

Myelofibrosis with a slight-to-moderate increase in reticulin fibers may be present in the initial or late stages of acute leukemia in a minority of cases; it may occur in both acute lymphoblastic and AML.[170] The presence of myelofibrosis in acute leukemia may result in difficult and inadequate marrow aspiration and an erroneous diagnosis of aplastic anemia if trephine biopsy sections are not available. This emphasizes the importance of obtaining adequate marrow biopsies. The long-held view that difficult aspirations in acute leukemia are caused by "packed" marrows has little basis in fact. The vast majority of hypercellular marrows in acute leukemia are readily aspirated. If aspiration is difficult, it is probably a result of poor biopsy technique or an increase in reticulin fibers.

The trephine biopsy provides the only accurate assessment of marrow cellularity and is of considerable importance in monitoring changes following treatment for leukemia. The rapidity of development and degree of necrosis and aplasia following the institution

For personal use only. No other uses without permission. Copyright ©2017. Elsevier Inc. All rights reserved.

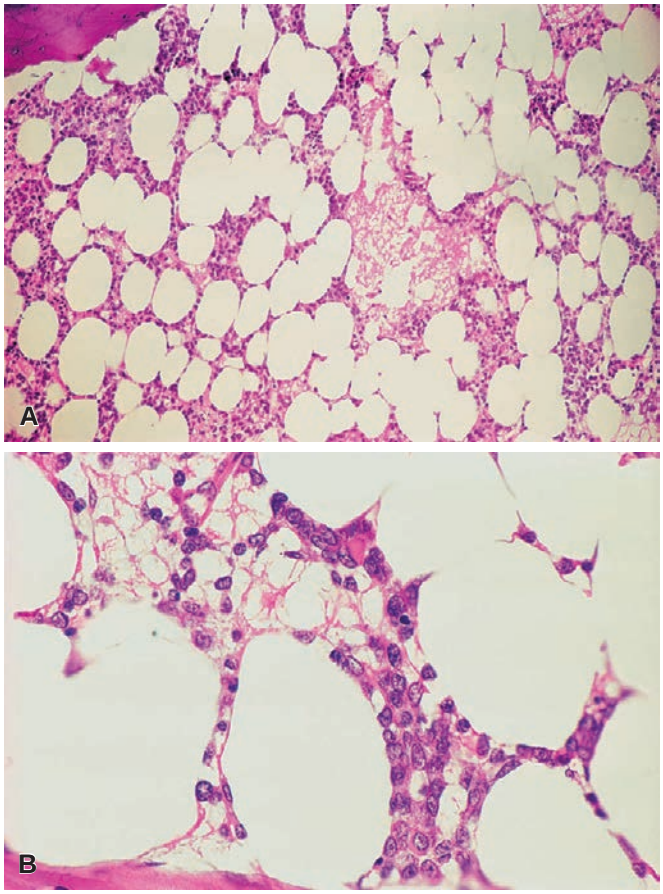

Figure 39.32 **A**, Marrow section from a 67-year-old man with acute myeloid leukemia with markedly hypocellular marrow. **B**, Higher magnification of the same specimen showing numerous blast cells in the interstitium.

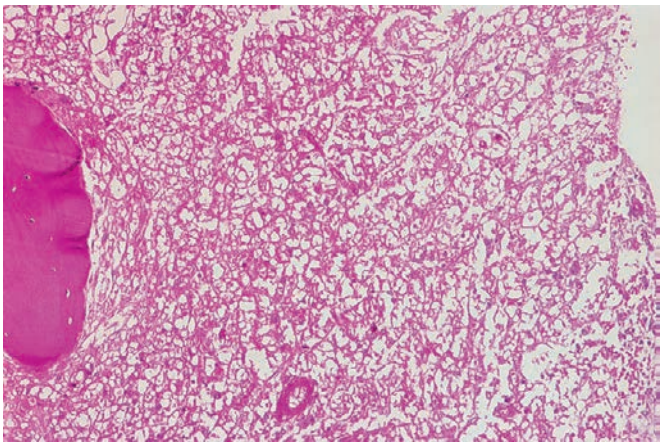

Figure 39.33 Marrow biopsy 14 days after institution of therapy with daunorubicin and cytosine arabinoside for acute myeloid leukemia. Marrow is markedly hypocellular with dilated sinuses. Interstitial areas contain lightly eosinophilic, proteinaceous debris that represents residue of leukemic cell necrosis.

of therapy will vary with the different chemotherapeutic agents or combination of agents used. In general, the sequence of histopathologic events is marked initially by nuclear karyorrhexis followed by karyolysis; the cells then disintegrate into relatively uniform granular, eosinophilic debris.[171] Subsequently the marrow shows a somewhat irregular, loosely structured appearance with scattered fat cells, vessels, stromal elements, and distended sinusoids (Fig. 39.33). Regeneration of fat cells is followed by regeneration of normal hematopoietic cells in the successfully treated patient. The erythroid cells are usually the first to recover and frequently manifest dyserythropoietic changes as the result of chemotherapeutic drugs.[172] The regeneration of the erythroid cells is followed in sequence by that of the granulocytes and megakaryocytes. This sequence may be altered with different drug regimens and the use of recombinant growth factors. The marrow from patients receiving recombinant granulocyte growth factor may show an early marked increase in neutrophil promyelocytes and myelocytes. In some patients, particularly in the pediatric age group, the post-chemotherapy marrow may contain numerous hematogones, which may resemble lymphoblasts. These can usually be distinguished from lymphoblasts by careful morphologic assessment and immunophenotypic characteristics.[173] The bone marrow biopsy can be particularly useful in this differential diagnosis, as leukemic blasts tend to cluster on biopsy sections, while hematogones represent a spectrum of B lymphocyte maturation dispersed throughout the biopsy. The infiltration pattern can be further assessed by immunohistochemical markers for CD34 or TdT to identify the clusters of leukemia cells versus the more scattered B cell progenitors (hematogones).

As noted, the course of events described in the preceding discussion is characteristic of effective therapy. In those patients in whom there has been partial or no response to treatment, the marrow will show varying numbers of leukemic cells. In the totally nonresponsive patient, the findings are essentially those of the pretreatment specimen; scattered isolated areas of necrosis may be present. In a partial response, the areas of residual leukemia will be intermixed with necrotic or regenerating normal marrow cells. In some patients, the areas of residual leukemia may be very small and difficult to distinguish from foci of regenerating normal cells, particularly early erythroblasts and promyelocytes. Careful comparison of suspicious foci with the cytologic pattern in the initial diagnostic biopsy should always be performed. Distinguishing foci of normal regenerative promyelocytes from the foci of leukemic promyelocytes in patients being treated for acute promyelocytic leukemia may be particularly troublesome. Normal promyelocyte regeneration is usually accentuated along the endosteal surface of the bone trabeculae and in perivascular locations. Acute promyelocytic leukemia in marrows with partial response may manifest as large or small focal lesions unrelated to bone trabeculae or vascular structures (Fig. 39.34). The cytoplasm of the leukemic promyelocyte may be more abundant than in normal promyelocytes.

In addition to assessment of the effects of chemotherapy, post-chemotherapy biopsy specimens should always be carefully evaluated for the presence of granulomas or other evidence of infection. In some instances, a focus of microorganisms may be present only as an area of nonspecific necrosis with a few histiocytes. These foci may be very difficult to recognize in a marrow biopsy showing cell necrosis as a result of chemotherapy. Any suspicious lesion should be studied with special stains. Proliferation of histiocytes, with and without hemophagocytosis, may be prominent in infected patients. The histiocytes are widely dispersed throughout the interstitium and in the sinusoids; in some patients this may be a very prominent feature.

Patients being monitored for the effects of chemotherapy will usually have sequential marrow biopsies at relatively short time intervals. If a specimen is from the area of a recent biopsy procedure, there may be evidence of granulation tissue and new bone formation (see Fig. 39.1). The biopsy repair site will usually be relatively well

For personal use only. No other uses without permission. Copyright ©2017. Elsevier Inc. All rights reserved.

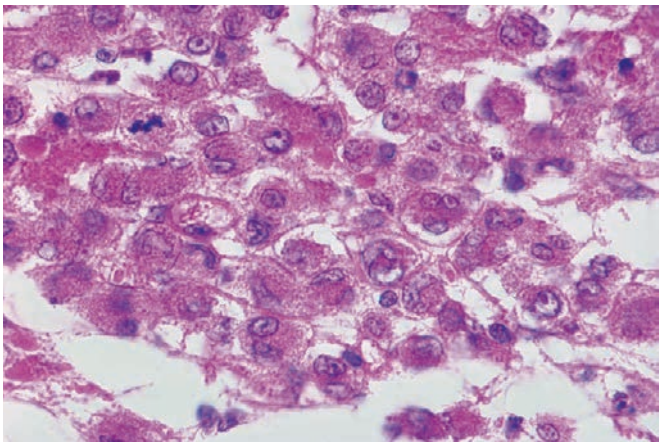

Figure 39.34 Marrow biopsy from an adult woman with acute promyelocytic leukemia following two courses of chemotherapy which did not include all-*trans*-retinoic acid. Large areas of marrow are replaced by leukemic promyelocytes.

demarcated from the remainder of the biopsy specimen but at times may lead to difficulties in interpretation.

Myeloid Sarcoma

Myeloid sarcoma (granulocytic sarcoma; extramedullary myeloid tumor) is an unusual variant of myeloid malignancy in which there is an extramedullary tumor mass composed of myeloblasts, with or without mature neutrophils.[174–183] The tumor may occur as an isolated finding or may be associated with AML, CML, primary myelofibrosis (PMF), hypereosinophilic syndrome, and PV.[178,184–186] An association of myeloid sarcoma and AML with the t(8;21) chromosome abnormality has been reported[181] and appears to be more common in children. These tumors have also been associated with AML with abnormalities of chromosome 16. In earlier literature, the term chloroma was used for these lesions because of the green appearance of the freshly cut surface of the tumor. The green color, which is due to the presence of peroxidase in the leukemic cells, is not present in all tumors of this type, and the less specific designation of myeloid sarcoma is preferred. Although tumors of monocytes have not previously been classified with the myeloid sarcomas, they represent a similar process with a similar predilection to leukemic evolution, primarily acute monoblastic leukemia,[187,188] and are now considered in the spectrum of myeloid sarcoma if they create a tumor mass.[180]

The myeloid sarcomas are more frequent in children than in adults and are most commonly associated with the subperiosteal bone structures; the most common sites are the skull, paranasal sinuses, sternum, ribs, vertebrae, and pelvis; lymph nodes and skin are also relatively frequently involved. Orbital masses leading to proptosis and spinal canal lesions resulting in neurologic manifestations are two of the clinical presentations associated with these tumors (Fig. 39.35). A high incidence of myeloid sarcomas involving the orbit has been reported in Turkish children with acute myelomonocytic leukemia.[189] Myeloid sarcomas may present as a mediastinal mass and clinically resemble a mediastinal lymphoma.[185]

A myeloid sarcoma may occur simultaneously with a typical blood and bone marrow pattern of AML or other type of MPN or may antedate leukemia by many months or rarely years.[176] It may be the first evidence of relapse in a patient with AML on maintenance chemotherapy and may be the only evidence of recurrence. These tumors may also represent the initial manifestation of a blast crisis

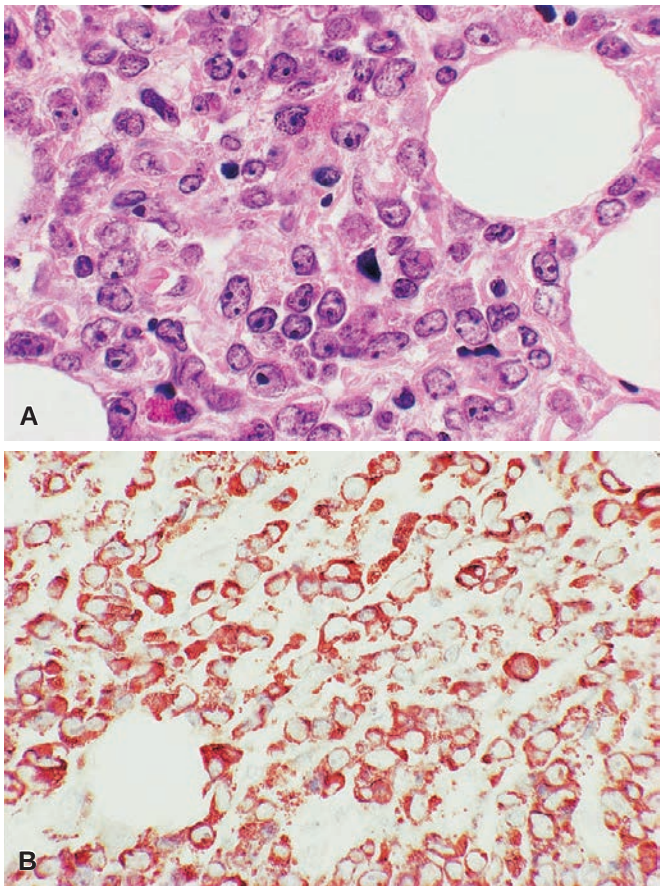

Figure 39.35 **A**, Biopsy of orbital myeloid sarcoma from a 6-year-old child who presented with bilateral proptosis. Numerous blasts are present. Cytogenetic studies of this lesion showed t(8;21)(q22;q22.1) chromosome abnormality. Blood and marrow smears showed acute myeloid leukemia with maturation. **B**, The same specimen reacted with antibody to myeloperoxidase. Virtually all blasts are positive. (**B**, Immunoperoxidase.)

of CML, and an isolated tumor mass or enlarged lymph node in a patient with CML should be evaluated for this possibility, including cytogenetic studies for the t(9;22)(234.1;q11.2) or molecular studies for evidence of the *BCR/ABL1* fusion gene.[178,186]

Histologically, the tumor is composed of a relatively uniform population of immature cells and may be misdiagnosed as an aggressive malignant lymphoma; this is particularly a problem with those lesions comprised predominantly of blasts. Occasionally, the presence of immature eosinophils and maturing neutrophils may indicate the true nature of the lesion. Attempts at histopathologic classification have generally resulted in three levels of differentiation: blastic, immature, and differentiated.[176,178,182] The blastic type is composed primarily of myeloblasts with little evidence of maturation to the promyelocyte stage (Fig. 39.36). The myeloblasts have a slight-to-moderate rim of basophilic cytoplasm, fine nuclear chromatin, and two to four nucleoli. Eosinophil myelocytes are not usually found with this degree of maturation. The immature type with an intermediate degree of differentiation contains principally myeloblasts and promyelocytes; eosinophil myelocytes are usually present. The differentiated type primarily consists of promyelocytes and later stages of maturation. Eosinophil myelocytes are most abundant in this type. Immunohistochemistry using antibodies to myeloperoxidase, lysozyme, CD68 (PGM1), CD34, and CD117 *(KIT)* are very useful in identification (see Fig. 39.35B).[36] The naphthol

For personal use only. No other uses without permission. Copyright ©2017. Elsevier Inc. All rights reserved.

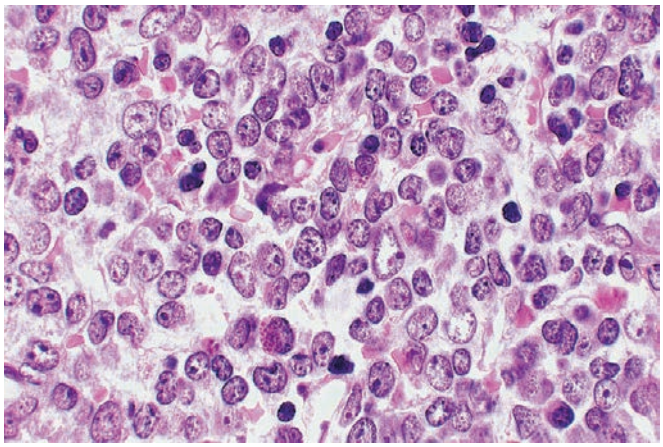

Figure 39.36 Biopsy of a Myeloid Sarcoma From Subcutaneous Tissue of the Chest Wall of a 49-Year-Old Man. The tumor is composed of poorly differentiated blast cells interpreted as myeloid sarcoma. There is essentially no evidence of differentiation. Blood and marrow showed no evidence of leukemia.

ASD chloroacetate esterase reaction, which is positive only in neutrophils and mast cells, is also useful for the diagnosis of some of the lesions; however, the reaction is partially ablated by mercury-based fixation and has largely been replaced by immunohistochemical reactions.[190] In the unusual myeloid lesions composed of immature erythroid cells or megakaryocytes, antibodies to hemoglobin A, glycophorin A and E-cadherin for red blood cells, and von Willebrand factor (factor VIII-related antigen), CD41, CD61, and CD31 for megakaryocytes may be used. Monocytic lesions react with antibodies to lysozyme, CD14, CD68 (KP1 and PGM1), and CD163.

Imprint preparations of tumor masses may be particularly useful in identifying the myeloid nature of the cells. Auer rods may be found, and the myeloblasts may show intense staining with the myeloperoxidase cytochemical reaction.

Localized tumor masses occurring in the absence of blood or marrow involvement may respond to local radiation therapy. Eventually the process in the majority of patients will evolve into a form of AML or may be associated with additional tumor masses at other sites. The leukemic evolution may be characterized by a gradual increase in myeloblasts in the blood and marrow; frequently, blasts containing Auer rods are identified. Rarely the leukemic cells may be identified in body fluids due to the occurrence of myeloid sarcoma in one of these areas.

In 7 of 16 patients with isolated granulocytic sarcomas reported by Meis et al.,[176] the process did not show a leukemic evolution, although three of the seven patients developed granulocytic sarcomas at additional sites and died 2–8 months following initial presentation. The other four patients showed no evidence of recurrent disease from 3.5 to 16 years following presentation.

Unlike the myeloid sarcomas that occur in patients with established hematologic disorders, which are usually correctly diagnosed, the predominantly blastic myeloid sarcomas occurring as isolated lesions in the absence of some type of leukemia may be initially misdiagnosed as a malignant lymphoma or poorly differentiated tumor because of the lack of diagnostic features.[176] In lymph nodes involved by myeloid sarcoma, the germinal centers are frequently preserved; the infiltrate is usually present in the sinuses and occasionally in the paracortical and medullary areas. In other tissues, the cells usually display an infiltrative pattern with the overall architecture remaining intact. The presence of immature eosinophils or cells with lobulated nuclei should evoke suspicion of a myeloid sarcoma.

Myelodysplastic Syndromes

The MDS are a heterogeneous group of myeloid disorders with varying potential for bone marrow failure and evolution to AML.[191–194] The MDS are basically disorders of ineffective myelopoiesis with hyperplastic marrows and cytopenias, dysplastic changes, and frequently pancytopenia with or without an increase in blasts. In a minority of cases, the marrow is hypocellular.[69,195] The 2016 WHO Classification of hematopoietic neoplasms has changed the terminology in MDS, but most categories are similar to the prior classification. The major categories are: (1) MDS with single lineage dysplasia (previously termed refractory anemia); (2) MDS with ring sideroblasts (refractory anemia with ring sideroblasts); (3) MDS with ring sideroblasts and multilineage dysplasia; (4) MDS with multilineage dysplasia (refractory cytopenia with multilineage dysplasia); (5) MDS with excess blasts-1 (refractory anemia with excess blasts-1); (6) MDS with excess blasts-2 (refractory anemia with excess blasts-2); (7) MDS, unclassified; and (8) MDS with isolated del(5q).[148,192] The classification is based primarily on examination of blood and bone marrow smears. However, marrow section specimens may add important diagnostic information, such as foci of blasts, increased fibrosis, and megakaryocyte dysplasia.[194,196–200] Marrow sections in MDS with isolated del(5q) may be particularly informative in demonstrating megakaryocytes with hypolobulated nuclei characteristic of the disorder.[201,202]

The WHO proposal also includes a category of myeloid disorders, referred to as MDS/MPN, for those myeloid processes that share features of both an MDS and a myeloproliferative process.[152] This category includes chronic myelomonocytic leukemia, juvenile myelomonocytic leukemia, atypical CML, MDS/MPN with ring sideroblasts and thrombocytosis, and MDS/MPN, unclassified.[148,203]

The trephine biopsy has a very important role in the evaluation of MDS and may provide important prognostic information.[69,192,194–196,200,204] The cell population in biopsy specimens varies according to the subtype.[192] In MDS with ring sideroblasts (sideroblastic anemia), there is generally a marked increase in erythroid precursors, with greatly increased iron accumulation in macrophages. In MDS with excess blasts 1 and 2, the marrow is hypercellular in the majority of patients, with an increase in neutrophil precursors. Chronic myelomonocytic leukemia, which is classified by the WHO as a myelodysplastic/MPN, is characterized by a hypercellular marrow with an increase in both monocytes and neutrophils.[203] In any of these types of MDS, the marrow may be hypocellular in a minority of patients (Fig. 39.37).[69,195] This has been associated with an adverse prognosis in some studies.

Increased reticulin fibers may be observed in chronic myelomonocytic leukemia and MDS with excess blasts but is not usually a prominent feature.[197,204] In approximately 10% of patients there is a marked increase in reticulin fibers (Fig. 39.38). These cases usually satisfy the criteria for MDS with excess blasts. These cases have been associated with an adverse prognosis in some studies.

A finding referred to as abnormal localization of immature precursors (ALIPs), characterized by aggregates (3–5 cells) and clusters (>5 cells) of myeloblasts and promyelocytes in central areas of the marrow tissue away from the endosteal surface of the bone trabeculae and vascular structures, has been described in the MDS (Fig. 39.39)[200]; the finding of three or more ALIPs in a bone marrow section has been reported to have predictive value for evolution to leukemia. Apoptosis may be a prominent feature in some cases (Fig. 39.40).

Although the precise classification of the MDS is based principally on the evaluation of blood and marrow smears, there are some types of MDS in which the bone marrow biopsy findings are highly suggestive of a specific classification. The de novo MDS with isolated

For personal use only. No other uses without permission. Copyright ©2017. Elsevier Inc. All rights reserved.

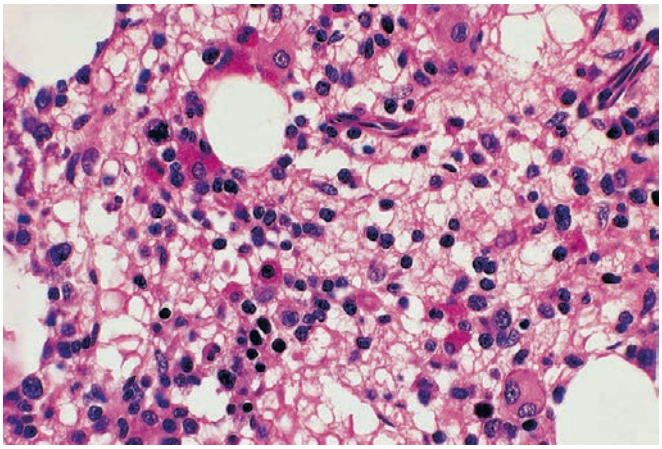

Figure 39.37 Marrow biopsy from a 2-year-old child with myelodysplastic syndrome associated with isolated monosomy 7 cytogenetic abnormality. Marrow is moderately to markedly hypocellular for age with increased fat and prominent interstitial cell depletion. Small megakaryocytes with hypolobulated nuclei are present.

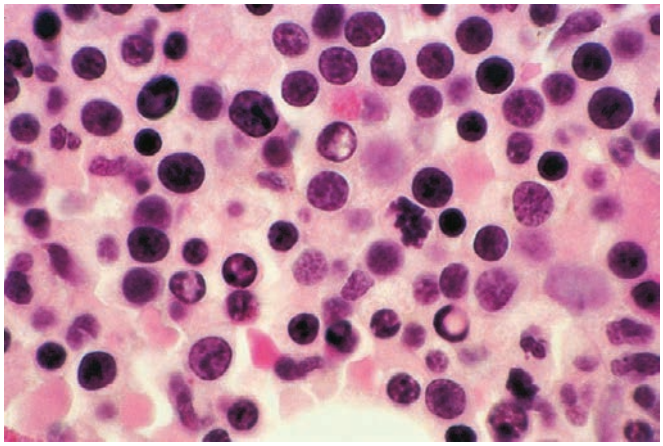

Figure 39.40 Marrow from a patient with MDS with single lineage dysplasia (refractory anemia) with marked erythroid hyperplasia and dyserythropoiesis. Several erythroid precursors with apoptotic nuclei are present.

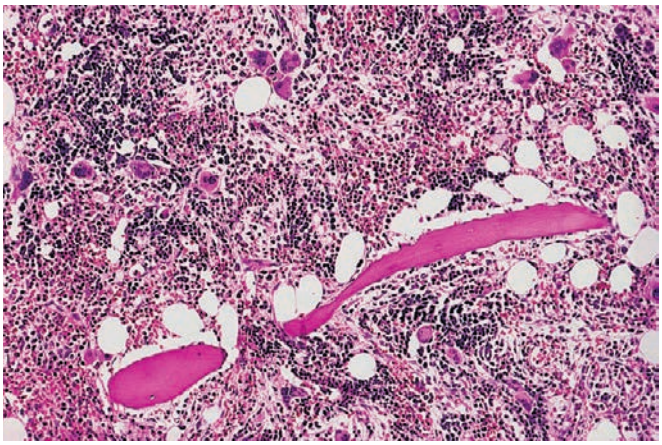

Figure 39.38 Bone marrow biopsy from an adult man with MDS with excess blasts-2 based on presence of 18% marrow blasts and myeloblasts with Auer rods. There is marked fibrosis with numerous megakaryocytes.

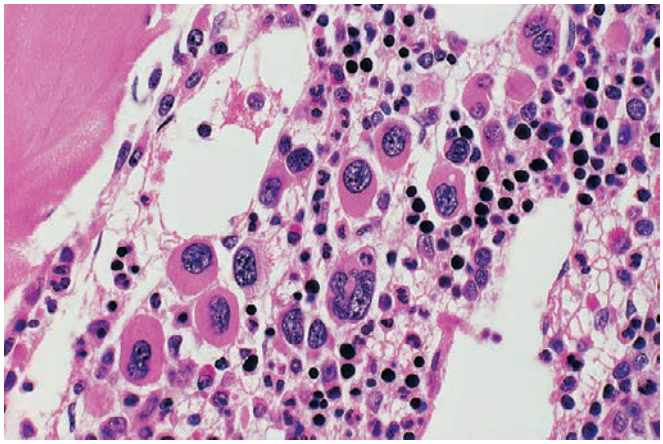

Figure 39.41 Marrow biopsy from an adult woman with de novo myelodysplastic syndrome associated with an isolated del(5q) (q21;q32) cytogenetic abnormality. There is an increase in megakaryocytes, many of which have hypolobulated nuclei. The majority of megakaryocytes are normal in size; small megakaryocytes are present.

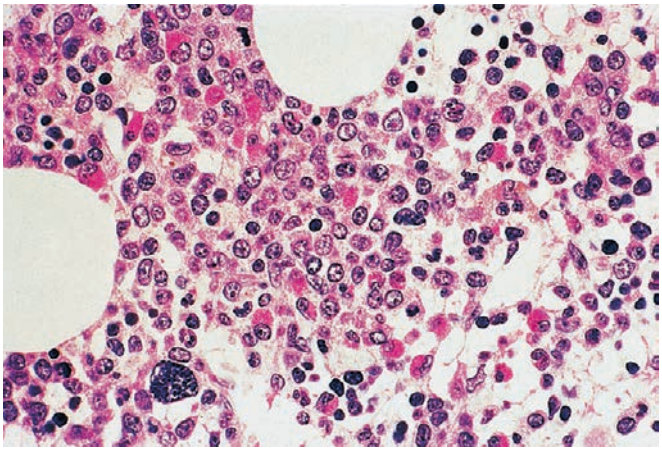

Figure 39.39 Marrow Biopsy From an Adult With MDS With Excess Blasts-2. Marrow is hypercellular. There are occasional foci of immature myeloid cells in the central marrow in nonparatrabecular and nonperivascular locations (ALIP).

del(5q) occurs primarily in older women who present with a macrocytic anemia that is often severe, normal-to-increased platelet count, and usually prolonged survival; the blast percentage in the marrow is less than 5% and less than 1% in the blood.[201,202] The marrow biopsy usually shows increased normal sized to slightly small megakaryocytes, many with hypolobulated nuclei (Fig. 39.41). There is usually no significant dysplasia in the erythroid and neutrophil series. The presence of an isolated del(5q) cytogenetic abnormality with the described findings characterizes the del(5q) syndrome. Despite the name, patients with a second clonal cytogenetic abnormality (other than −7) have a similarly favorable prognosis to those with isolated del(5q) and may now also be diagnosed with this disorder.[148,205,206] Three clonal abnormalities that included del(5q), however, are not allowed and are associated with a worse prognosis. Patients with this syndrome may respond favorably to treatment with the thalidomide analogue, lenalidomide. Patients with del(5q) and more than one additional cytogenetic abnormalities or blasts in excess of 5% in the marrow may also benefit from lenalidomide but have a generally worse prognosis and should not be diagnosed as MDS with isolated del(5q).

For personal use only. No other uses without permission. Copyright ©2017. Elsevier Inc. All rights reserved.

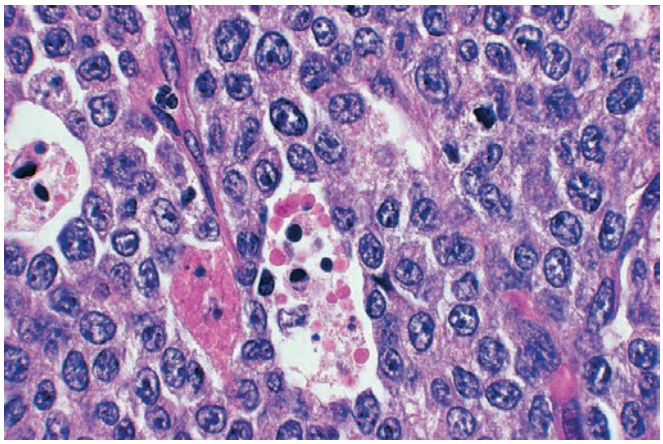

Figure 39.42 Portion of a myeloid sarcoma presenting as a subcutaneous chest wall mass in an elderly woman with a 1-year history of chronic myelomonocytic leukemia with less than 5% blasts in marrow and blood. The mass consists of a relatively uniform population of blasts; scattered mitotic figures are present. Numerous tingible body macrophages impart a "starry sky" appearance to the lesion. Many of the blasts reacted with antibody to myeloperoxidase and CD68 (KP1). Blood and marrow examination at the time of appearance of the chest wall mass was essentially unchanged from the previous year, with less than 5% blasts.

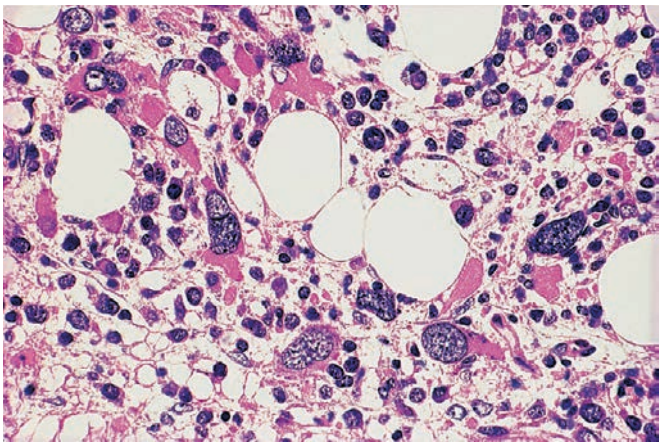

Figure 39.43 Bone Marrow Biopsy From a Patient With Therapy-Related Myelodysplasia With Myelofibrosis. There is predominance of neutrophils and megakaryocytes. Megakaryocytes show marked dysplasia.

Increased megakaryocytes may also be observed in association with inv((3)q21.2q26.2) or t(3;3)(q21.3;q26.2), which may present as MDS or AML. The megakaryocytes in cases with this association are abnormally small, many with hypolobulated nuclei, as well as more pronounced dyspoiesis in other cell types. The very small megakaryocyte size and associated multilineage dyspoiesis are not features usually seen in MDS with isolated del(5q).

Similar to the AMLs and MPNs, extramedullary myeloid sarcomas may occur in the course of a MDS (Fig. 39.42).

The therapy-related myeloid neoplasms (AML and MDS) occur in patients who have been treated with chemotherapy, radiation therapy, or both for a variety of malignant and nonmalignant conditions. Two major forms have been recognized: alkylating agent/radiation-related type and topoisomerase II inhibitor–related type, but many patients have received both types of therapeutic agents.[157] The alkylating agent–related type is generally a panmyelopathy, which may evolve to acute leukemia; in either instance, AML or MDS, it is a poor prognosis lesion with relatively short survival. The topoisomerase II–related type usually presents as acute leukemia with specific cytogenetic abnormalities, notably abnormalities involving chromosome 11q23.3. The bone marrow cellularity in the therapy-related MDS related to alkylating agents is more variable than with de novo MDS: in approximately 50% of patients the marrow is hypercellular; in 25% normocellular; and in 25% hypocellular.[192] In addition to changes characteristic of an MDS, the marrow specimen may show evidence of the initial lesion for which treatment was indicated. Megakaryocyte abnormalities may be particularly prominent in marrow biopsies (Fig. 39.43). Reticulin fibrosis may be marked, and some of these cases have been described as acute myelodysplasia with myelofibrosis when there is a pronounced shift to immature cells.

Immunohistochemistry may be very useful in evaluating the MDS. CD34 may be particularly useful in identifying blast in cases of hypoplastic MDS that may resemble aplastic anemia.[204] However, the absence of CD34 reactivity does not exclude blasts since not all myeloblasts are CD34 positive. Myeloperoxidase, CD15, CD117, and lysozyme antibodies are useful for recognizing myeloblasts and monoblasts. Antibodies to von Willebrand factor (factor VIII–related antigen), CD41, CD61, and CD31 may facilitate the recognition of small and abnormal megakaryocytes.

Cytogenetic studies performed on an aspirate specimen have a critical role in the evaluation of the MDS, both for determining clonality and for prognostic factors (see Box 39.2).[192,200,201,207]

The WHO classification recognizes refractory cytopenia of childhood (RCC) as a provisional entity.[152,208,209] Although this entity is reported to be the most common subtype of MDS in children, accounting for approximately 50% of MDS, it is very uncommon since MDS accounts for approximately 4% of hematologic malignancies in children. Patients present with persistent cytopenias; there are less than 5% blasts in the bone marrow and less than 2% blasts in the blood. Dysplastic features are present in all cell lineages in the smears. Evaluation of a marrow biopsy is critical for the diagnosis. About 75% of the patients have a markedly hypocellular marrow biopsy, which may have the appearance of aplastic anemia. The distinction may not always be possible on initial examination and repeat biopsies may be necessary.

The disorder occurs in all childhood age groups, and both sexes are affected with equal frequency. The evaluation of marrow biopsies is critical to the diagnosis.

The majority of children with RCC have marrows with a cellularity of 5%–10%. There are one to several foci of 10 or more immature erythroid precursors with increased mitoses. Megakaryocytes are usually markedly decreased to absent. Rare micromegakaryocytes may be found and are helpful in establishing a diagnosis; anti–von Willebrand factor (factor VIII–related antigen) and CD61 may facilitate their detection. Granulopoiesis is sparsely distributed and left shifted. In the minority of patients with RCC who present with normal or hypercellular marrows there is a slight-to-moderate increase in erythropoiesis, with a predominance of proerythroblasts with increased mitoses. Granulopoiesis is slightly to moderately decreased with a shift to immaturity. Blasts are less than 5% of the cells. Most cases show a normal karyotype; the most common cytogenetic abnormality when one is present is monosomy 7. The demonstration of a clonal abnormality is extremely helpful in establishing the diagnosis.

As noted, it may be very difficult to distinguish RCC from aplastic anemia and also, as noted, more than one observation may be necessary. In aplastic anemia there is generally no evidence of dysplasia in the smears. The erythropoiesis in the marrow sections is markedly

For personal use only. No other uses without permission. Copyright ©2017. Elsevier Inc. All rights reserved.

decreased to absent; the several foci characteristic of RCC are usually not found, and if one is present it contains fewer than 10 cells that show evidence of maturation. Dysplastic megakaryocytes are not present. Granulocytes are markedly diminished and show normal maturation.

Myeloproliferative Neoplasms

Considerable progress has been made in the classification of the MPNs in the past decade. This progress is the result of several discoveries of molecular alterations which may accompany these disorders. These discoveries have had impact on both the classification of these neoplasms as well as the recognition of entities, which previously were grouped under a nonspecific morphologic classification.[152]

The discovery of the *JAK2*V617F mutation has been the most significant contribution to the classification of the MPNs since the discovery of the Philadelphia chromosome in 1959 and subsequently of its molecular counterpart, the *BCR/ABL1* fusion gene in CML. Since then, additional mutations in *MPL* and *CALR* have been reported, mostly in the *JAK2* negative cases. The relationship of the these mutations to the specific MPNs will be noted in the diagnostic criteria for these individual disorders.

Although affecting a much smaller number of patients, the discovery of the genetic abnormalities in the *PDGFRA*, *PDGFRB*, and *FGFR1* genes has important implications, at least in some of them, for possible therapy with tyrosine kinase inhibitors for a group of diseases previously refractory to most forms of therapy. The recognition of this group of diseases is based on cytogenetic studies, fluorescence in situ hybridization (FISH), and molecular genetic analysis. Most, but not all, of these patients present with marked eosinophilia.

Chronic Myeloid Leukemia

CML is a stem cell disorder arising from fusion of the *ABL1* gene on chromosome 9 with the *BCR* gene on chromosome 22. The altered chromosome 22 is referred to as the Philadelphia chromosome.[210,211] CML, *BCR/ABL1* positive, is distinct from other myeloproliferative disorders, which are *BCR/ABL1* negative.[152,212] CML usually has three clinical pathologic stages, not always clearly distinguished: chronic, accelerated, and blast. The vast majority of patients present in the chronic phase; uncommonly patients present in an accelerated or blast phase.

The initial presentation in the chronic phase is characterized by marked leukocytosis, thrombocytosis, and basophilia and usually splenomegaly.[211] Atypical presentations such as marked thrombocytosis or basophilia without leukocytosis may occur. The number of myeloblasts in the blood and marrow smears in the chronic phase does not usually exceed 5%. The trephine sections are markedly hypercellular, primarily because of an increase in granulocytes and megakaryocytes.[211,213] Macrophages resembling Gaucher cells, usually occurring singly, may be present in the bone marrow smears and sections; they are more prominent in perivascular locations. Increased reticulin fibers are present in approximately 30% of cases and megakaryocytes are increased in approximately 40% of cases. Many of the megakaryocytes are small with hypolobulated nuclei. The increase in reticulin fibers correlates with an increase in microvascularity.[213,214]

The chronic phase, usually of 3–4 years' duration, is followed by the accelerated phase of shorter duration, characterized by increasing blasts in the blood and marrow, progressive basophilia, increasing myelofibrosis, and additional cytogenetic changes. The blast phase usually occurs abruptly and may occur without an intermediate accelerated phase; the blasts exceed 20% in the blood or marrow

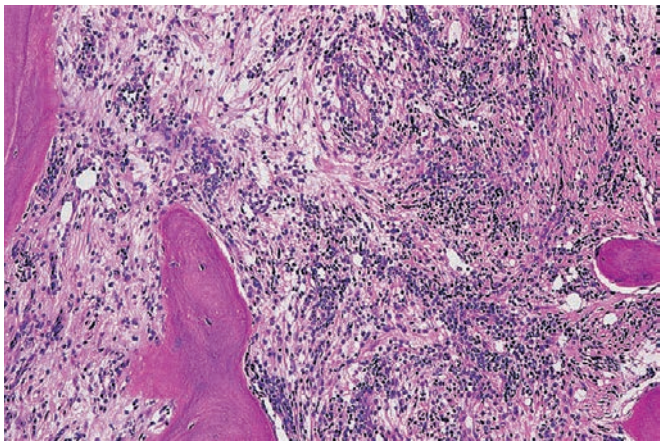

Figure 39.44 Marrow Biopsy From a Patient in Accelerated Phase of Chronic Myeloid Leukemia. There is marked reticulin fibrosis and small clusters of blasts.

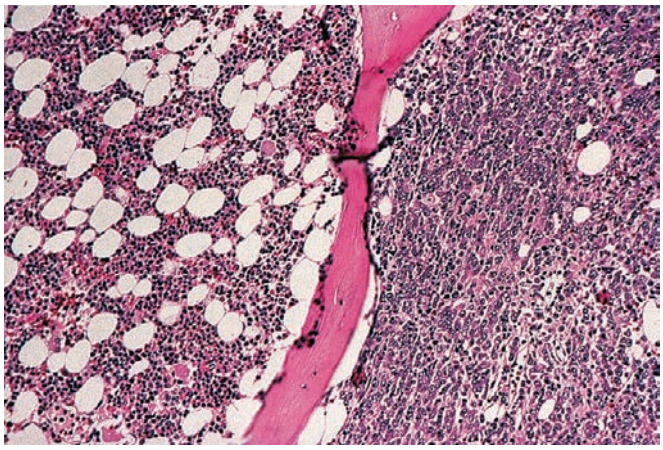

Figure 39.45 Erythroblastic Crisis of Chronic Myeloid Leukemia. The marrow to the left of the bone trabecula shows the findings of treated chronic phase. The proliferation of primitive erythroblasts to the right of the bone represents a focus of blast transformation.

(Figs. 39.44–39.46).[210,211,215] Approximately 70% of blast crises are morphologically and immunophenotypically myeloid, and 30% are lymphoblastic. The myeloid type may be characterized by proliferation of any of the myeloid cell lineages, including myeloblasts, erythroblasts, and megakaryoblasts. Immunohistochemical studies may be very useful in identifying the distribution and lineage of blast populations. In some patients, blast transformation may be initially manifest in bone marrow sections as large, irregular, focal collections of blasts. Extramedullary manifestation of blast crisis also occurs, and the diagnosis should be suspected in any patient with CML who develops a tumor mass or lymphadenopathy.

The development of extensive myelofibrosis in patients with CML usually occurs late in the disease and has been associated with a more aggressive clinical course.[211,216,217] Exceptions to this generalization have been reported and myelofibrosis may occur in the early stages of CML with the same prognostic implications as when it occurs late in the disease.[216,218] The myelofibrosis in CML is usually characterized by an increase in reticulin fibers; collagenous fibrosis is not common but may occasionally occur (see Fig. 39.44). As noted, the increase in reticulin fibers correlates with an increase in angiogenesis. Reversal of myelofibrosis may occur following hematopoietic cell

For personal use only. No other uses without permission. Copyright ©2017. Elsevier Inc. All rights reserved.

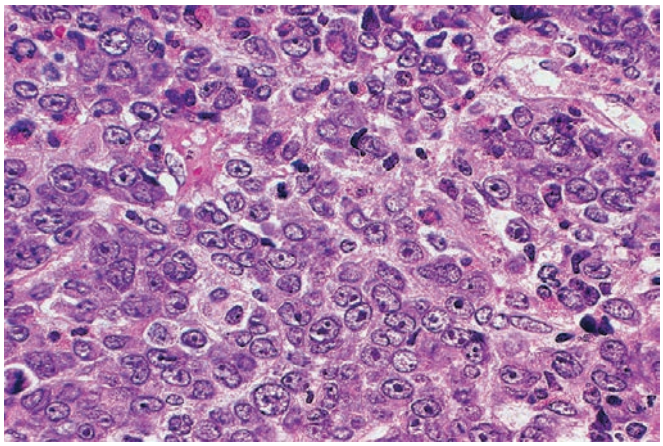

Figure 39.46 High magnification of marrow biopsy from a patient with erythroblastic transformation of chronic myeloid leukemia. Cells are large with prominent nucleoli and basophilic cytoplasm.

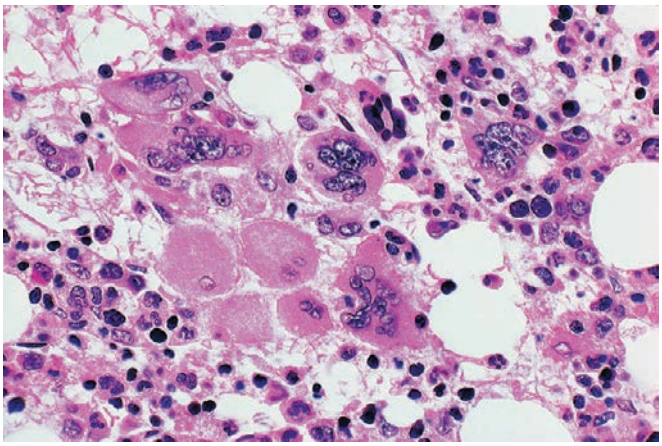

Figure 39.47 Hyperplastic Bone Marrow From a Patient With Polycythemia Vera. All cellular elements are increased. Megakaryocytes are prominent and show considerable variation in size; many are unusually large with hyperlobulated nuclei.

transplantation and imatinib therapy.[219,220] A positive correlation between the degree of reticulin fibrosis and the number of CD61-positive megakaryocytes has been reported both pre- and post-allogeneic marrow transplant.[221]

The introduction of therapy with the tyrosine kinase inhibitor imatinib mesylate (Gleevec), and now next-generation tyrosine kinase inhibitors, for CML has been one of the major success stories in the field of leukemia therapy; the agent induces hematologic remission in a high percentage of patients with CML in the chronic phase and accelerated phases of the disease.[218,222–225] The hematologic remission is accompanied by morphologic normalization or near normalization of the bone marrow in most cases. The normalization of the marrow may occur even with persistence of the Philadelphia chromosome, or evidence of the *BCR/ABL1* fusion gene. The normalization of the marrow usually may lag behind remission of blood findings and may not be complete for several months.[222] Other therapies for CML are now less common. Treatment with interferon usually results in a decrease in overall marrow cellularity and an increase in erythroid precursors. There may be a concurrent increase in megakaryocytes and reticulin fibers. Hydroxyurea therapy generally results in a decrease in cellularity and no increase in megakaryocytes or reticulin fibers.[226]

Box 39.5 2016 World Health Organization diagnostic criteria for polycythemia vera

Major criteria

1. Hemoglobin >16.5 g/dL in men; >16.0 g/dL women, or Hematocrit >49% in men; >48% in women, or
2. Other evidence of increased red blood cell mass (>25% above mean normal predicted value). Bone marrow biopsy showing hypercellularity for age with trilineage growth (panmyelosis) including prominent erythroid, granulocytic, and megakaryocytic proliferation with pleomorphic mature megakaryocytes (differences in size)
3. *JAK2*V617F or *JAK2* exon 12 mutation

Minor criterion

- Subnormal serum erythropoietin level.

Diagnosis requires either all three major criteria or the first two major and the minor criterion

Data from Arber DA, Orazi A, Hasserjian R, et al. The 2016 revision to the World Health Organization classification of myeloid neoplasms and acute leukemia. *Blood*. 2016;127(20):2391–2405.

Polycythemia Vera

PV is an MPN in which the major diagnostic feature is an increased red blood cell mass. There is usually splenomegaly and some degree of leukocytosis and thrombocytosis.[227] Precise criteria for the diagnosis of PV have been established by the Polycythemia Vera Study Group (PVSG); these were modified in the WHO proposal for the classification of hematopoietic neoplasms. An important addition to the diagnostic criteria for PV in the 2008 WHO classification is the recognition of the Janus 2 kinase gene mutation *JAK2*V617F or similar mutations, such as *JAK2* exon 12 mutation, present in over 95% of cases (Box 39.5).[227–232] The discovery of this mutation has also led to the identification of a marker for familial cases of PV.[233]

Three clinical phases of PV are recognized: (1) prodromal pre-polycythemia phase with borderline to slight erythrocytosis; (2) overt PV with a significant increase in red blood cell mass; and (3) spent phase or post polycythemia with myelofibrosis.[227,234–240]

The blood smear in the overt phase shows increased erythrocytes, reflecting the increased red blood cell mass, leukocytosis, and thrombocytosis. The bone marrow is usually markedly hypercellular.[227,241–244] However, this is not an invariant finding; 13% of the patients enrolled in the National Cancer Institute Polycythemia Vera Study had marrow biopsies with cellularity of less than 60%.[242] The cellularity of the marrows from patients in the study ranged from 37% to 100%, with a mean of 82%. The hypercellularity is due to a panhyperplasia of myeloid cells, principally erythroid precursors and megakaryocytes; the megakaryocytes range in size from small to unusually large, frequently with hyperlobulated nuclei and in clusters (Fig. 39.47).[227,241–244] The clusters may be accentuated in perisinusoidal and paratrabecular locations. Stains for iron usually show decreased or no hemosiderin deposits.[241] A slight increase in reticulin fibers is present at the outset of the disease in 25% of cases; 11% of pretreatment biopsies show a marked increase in reticulin fibers.[241] The increase in reticulin corresponds, in general, to an increase in marrow cellularity and the number of megakaryocytes. An increase in reticulin fibers in pretreatment marrow biopsies is not necessarily indicative of the spent phase of the disease. Similar to other MPNs, there is an increase in vascular structures in PV.[214,245]

Approximately 20% of patients with PV have cytogenetic abnormalities; the most frequently detected are +8, +9, del(20q), del(13q), and del(9p). The incidence increases with disease progression.[227]

For personal use only. No other uses without permission. Copyright ©2017. Elsevier Inc. All rights reserved.

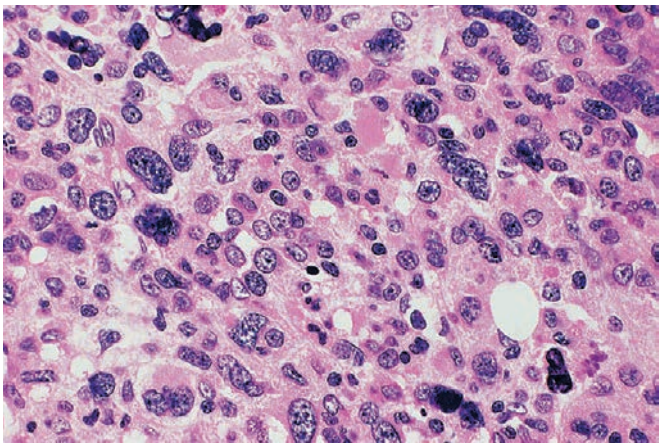

Figure 39.48 Marrow Biopsy From a Patient in Spent Phase of Polycythemia Vera. Marrow is markedly hypercellular as a result of granulocytic and megakaryocytic hyperplasia. Megakaryocytes show dysplastic features.

PV may be difficult to distinguish from the other non-CML MPNs based solely on marrow examination. As a result, it is critical to adhere to established diagnostic guidelines when making a diagnosis.[227,244] Although the *JAK2*V617F mutation readily distinguishes PV from other causes of erythrocytosis, the mutation is shared by essential thrombocythemia and PMF, albeit less frequently. Morphology continues to have a central role in the diagnosis along with the clinical data.[227,243,244,246,247]

The evolution of PV to the spent or post-polycythemic phase may be marked by a decrease in red blood cell mass with anemia and the development of myelofibrosis with a marked increase in reticulin fibers, increased angiogenesis, collagenous fibrosis, and clusters of abnormal megakaryocytes; the incidence of this complication varies from 9% to 20% (Fig. 39.48).[227,235–239,247] This is accompanied by a leukoerythroblastic blood picture and increased red blood cell poikilocytosis with numerous dacryocytes and increasing splenomegaly due to extramedullary hematopoiesis. An additional complication in some patients is the development of acute leukemia and myelodysplasia; the incidence is higher in patients treated with chemotherapy or radiation as opposed to those treated only with phlebotomy.[248–251]

Essential Thrombocythemia

Essential thrombocythemia (ET) is a myeloproliferative disorder that is closely related to PV but lacks the essential diagnostic criteria of PV, most notably an increase of red blood cell mass.[229,252–254] The principal morphologic findings relate to the increased megakaryocytes and thrombocytosis. The marrow is usually normocellular for age but may be hypercellular or hypocellular. The bone marrow findings are principally related to increased and large megakaryocytes with hyperlobulated nuclei (Fig. 39.49).[235] The megakaryocytes occur singly and in clusters. The erythroid and granulocytic cell lines are usually normal. Reticulin is usually normal but may be slightly increased, and there may be an associated increase in angiogenesis.[255] There is no specific molecular marker for ET, such as the *BCR/ABL1* fusion gene in CML, but half of patients with ET have the *JAK2*V617F mutation, which may also be present in PV and PMF.[230,254] Another approximately 25% of cases show mutations of *CALR*, and 3%–5% have *MPL* mutations, both usually in the absence of a *JAK2* mutation.[256,257] The WHO criteria for diagnosis of ET are listed in Box 39.6.

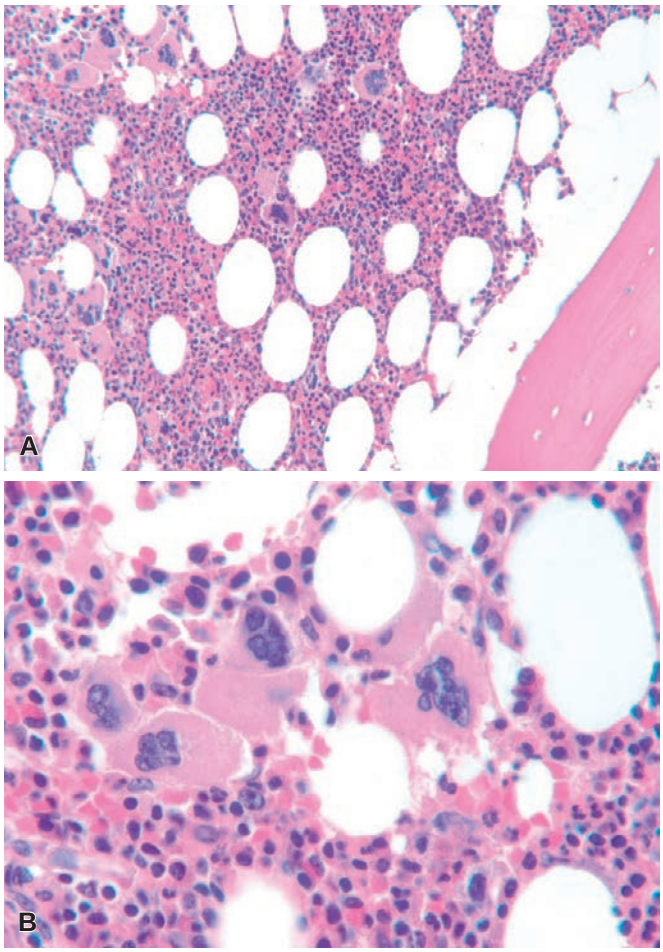

Figure 39.49 **A**, Marrow biopsy from a patient with essential thrombocythemia. Marrow is normocellular with numerous scattered large megakaryocytes. **B**, High magnification of specimen in **A** showing the very large megakaryocytes, some with hyperlobulated nuclei.

Box 39.6 2016 World Health Organization diagnostic criteria for essential thrombocythemia

Major criteria

1. Platelet count of ≥450 × 10^9/L
2. Bone marrow biopsy showing proliferation mainly of the megakaryocyte lineage with increased numbers of enlarged, mature megakaryocytes with hyperlobulated nuclei. No significant increase or left shift in neutrophil granulopoiesis or erythropoiesis and very rarely minor (grade 1) increase in reticulin fibers
3. Not meeting WHO criteria for *BCR-ABL1*+ chronic myeloid leukemia, polycythemia vera, primary myelofibrosis, myelodysplastic syndrome or other myeloid neoplasms
4. Presence of *JAK3*, *CALR* or *MPL* mutation

Minor criterion

Presence of a clonal marker or absence of evidence for reactive thrombocytosis

Diagnosis requires meeting all four major criteria, or the first three and the minor criterion

Data from Arber DA, Orazi A, Hasserjian R, et al. The 2016 revision to the World Health Organization classification of myeloid neoplasms and acute leukemia. *Blood*. 2016;127(20):2391–2405.

For personal use only. No other uses without permission. Copyright ©2017. Elsevier Inc. All rights reserved.

The distinction between essential thrombocytosis and secondary forms of thrombocytosis may be difficult from routine morphologic studies.[255] The clinical history is important in excluding possible causes for a secondary thrombocytosis. Demonstration of the *JAK2*V617F or other ET-associated mutations would be definitive in excluding a secondary thrombocytosis.[228–230,258] However, other mutations may be detectable in reactive cases, associated with so-called clonal hematopoiesis of indeterminate prognosis (CHIP), and the detection of a mutation alone does not equate with neoplasia.[259–261]

ET is an indolent disease in most patients, with survival of 10–15 years. Transformation to AML occurs in less than 5% of patients and may be related to chemotherapy.[254]

Primary Myelofibrosis

PMF (chronic idiopathic myelofibrosis, agnogenic myeloid metaplasia) is a clonal myeloproliferative disease of undetermined etiology characterized by myeloid cell proliferation and reactive fibrosis.[229,237,262–272] It occurs primarily in adults; the average age at diagnosis is approximately 60 years.[262,269,273] Rare cases have been reported in the pediatric population.[274] There is some degree of detectable hepatosplenomegaly caused by extramedullary hematopoiesis.

PMF may, at times, be confused with CML or other types of MPNs because of occasional similarities in the blood findings; the important differentiating clinical and laboratory findings have been described in detail.[265,268,269] The principal clinical and morphologic features have been described in the WHO Classification (Boxes 39.7 and 39.8).[148,269] The most important distinguishing biologic feature is the presence of the Philadelphia chromosome or molecular evidence of the *BCR/ABL1* fusion gene in the hematopoietic cells in CML and its absence in the cells from patients with PMF and the possible presence of a *JAK2*V617F (50%–60%), *CALR* (30%) or *MPL* (5%–10%) mutation in PMF.[228–230,268,275] Marrow fibrosis in CML is generally a late occurrence, and its onset usually heralds a more aggressive evolution, unlike PMF in which marrow fibrosis is present to some extent from inception and is generally associated with a more prolonged clinical course.[276,277] Approximately 30% of patients have a cytogenetic abnormality at presentation; the incidence increases with leukemic progression. The most common abnormalities are del(13q), del(20q), +8, +9, and abnormalities of chromosomes 1, and 7.[268,278]

PMF is usually characterized by progression from an early or prefibrotic stage to a fibrotic stage, although biopsies from different sites have been reported to show substantial variation in the degree of fibrosis. Approximately 20%–30% of patients with PMF present in the early or prefibrotic stage.[268,269] The marrow in this stage is hypercellular for age; there is an increase in abnormal megakaryocytes and granulocytes (Fig. 39.50). Erythroid precursors may be reduced. The megakaryocytes may form clusters adjacent to sinuses and bone trabeculae. The megakaryocytes vary in size and are frequently very large with abnormal clumping of the chromatin. There is minimal increase in reticulin fibers in the early or prefibrotic stage. Aggregates of well-differentiated lymphocytes may be present. The fibrotic stage is marked by variable degrees of reticulin and/or collagen fibrosis; the marrow varies from hypocellular to hypercellular. Expansion of the bone trabeculae may be present. The density of reticulin fibers may vary substantially in different areas of the biopsy. Sinusoids are usually increased in number and distended and contain hematopoietic cells. Megakaryocytes may be particularly prominent in the sinusoids (Fig. 39.51). In some cases, the marrow may be almost uniformly densely fibrotic with scattered foci of hematopoietic cells (Fig. 39.52). Scattered abnormal megakaryocytes may be the only recognizable hematopoietic cells. In approximately 40% of the patients with PMF, osteosclerotic changes can be demonstrated by radiographic

Box 39.7 2016 World Health Organization diagnostic criteria for early/pre-primary myelofibrosis

Major criteria:

1. Megakaryocytic proliferation and atypia, without reticulin fibrosis > grade 1, accompanied by increased age-adjusted bone marrow cellularity, granulocytic proliferation and often decreased erythropoiesis
2. Not meeting the WHO criteria for *BCR-ABL1*+ chronic myeloid leukemia, polycythemia vera, essential thrombocythemia, myelodysplastic syndromes, or other myeloid neoplasms
3. Presence of *JAK2*, *CALR* or *MPL* mutation or in the absence of these mutations, presence of another clonal marker or absence of minor reactive bone marrow reticulin fibrosis[a]

Minor criteria:

Presence of at least one of the following, confirmed in two consecutive determinations:

a. Anemia not attributed to a comorbid condition
b. Leukocytosis ≥11 × 10^9/L
c. Palpable splenomegaly
d. LDH increased to above upper normal limit of institutional reference range

Diagnosis of early/prePMF requires meeting all three major criteria, and at least one minor criterion

[a]minor (grade 1) reticulin fibrosis secondary to infection, autoimmune disorder or other chronic inflammatory conditions, hairy cell leukemia or other lymphoid neoplasm, metastatic malignancy, or toxic (chronic) myelopathies

Data from Arber DA, Orazi A, Hasserjian R, et al. The 2016 revision to the World Health Organization classification of myeloid neoplasms and acute leukemia. *Blood*. 2016;127(20):2391–2405.

Box 39.8 2016 World Health Organization diagnostic criteria for overt primary myelofibrosis

Major criteria

1. Presence of megakaryocytic proliferation and atypia, accompanied by either reticulin and/or collagen fibrosis grades 2 or 3
2. Not meeting WHO criteria for *BCR-ABL1*+ chronic myeloid leukemia, polycythemia vera, essential thrombocythemia, myelodysplastic syndromes, or other myeloid neoplasms
3. Presence of *JAK2*, *CALR*, or *MPL* mutation or in the absence of these mutations, presence of another clonal marker or absence of reactive myelofibrosis[a]

Minor criteria

Presence of at least one of the following, confirmed in two consecutive determinations:

1. Anemia not attributed to a comorbid condition
2. Leukocytosis ≥11 × 10^9/L
3. Palpable splenomegaly
4. LDH increased to above upper normal limit of institutional reference range
5. Leukoerythroblastosis

Diagnosis of overt PMF requires meeting all three major criteria, and at least one minor criterion

[a]BM fibrosis secondary to infection, autoimmune disorder or other chronic inflammatory conditions, hairy cell leukemia or other lymphoid neoplasm, metastatic malignancy, or toxic (chronic) myelopathies

Data from Arber DA, Orazi A, Hasserjian R, et al. The 2016 revision to the World Health Organization classification of myeloid neoplasms and acute leukemia. *Blood*. 2016;127(20):2391–2405.

For personal use only. No other uses without permission. Copyright ©2017. Elsevier Inc. All rights reserved.

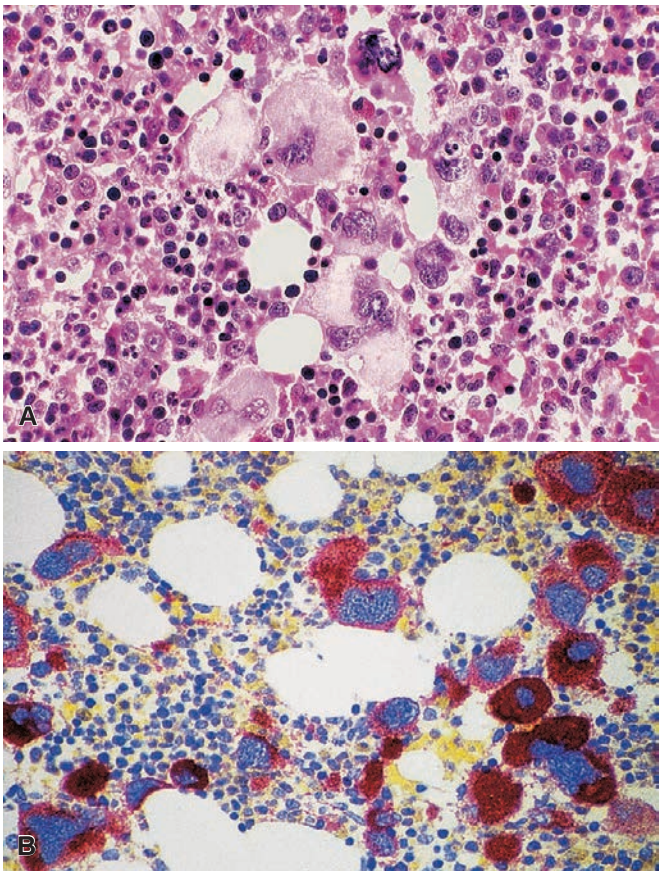

Figure 39.50 **A**, Marrow biopsy from the prefibrotic stage of primary myelofibrosis. There is a cluster of megakaryocytes which vary in size. Several are large with marked variation in nucleocytoplasmic ratio. **B**, Bone marrow section from prefibrotic stage of primary myelofibrosis stained with antibody to CD61. This highlights the megakaryocytes, which vary in size from small to large. The nuclei show markedly abnormal chromatin clumping. (**B,** Contributed by Dr. J. Thiele, Cologne, Germany, and reproduced from Jaffe ES, Harris NL, Stein H, Vardiman JW, eds. World Health Organization Classification of Tumours: Pathology and Genetics of Tumours of Haematopoietic and Lymphoid Tissues. Lyon: IARC Press; 2001.)

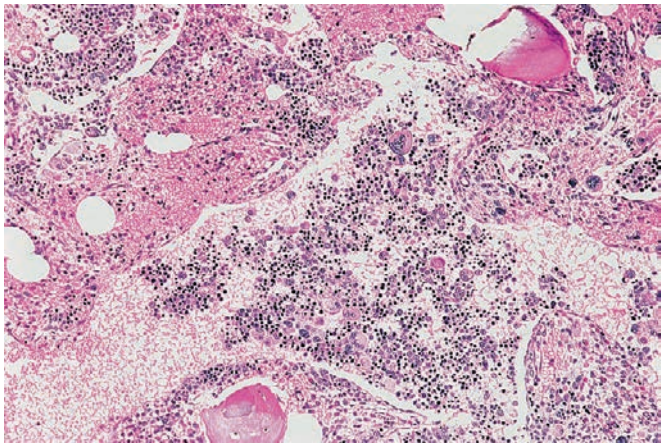

Figure 39.51 Bone marrow biopsy from a patient with primary myelofibrosis showing prominent intrasinusoidal hematopoiesis. Predominant cells in the sinusoid are erythroid precursors and megakaryocytes.

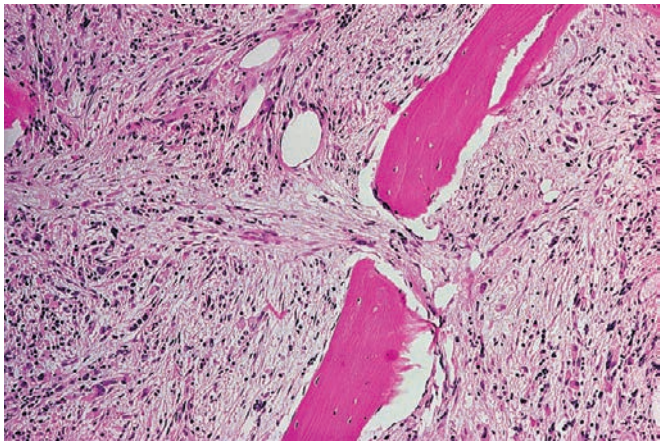

Figure 39.52 Trephine biopsy from an adult with a 7-year history of primary myelofibrosis (agnogenic myeloid metaplasia). There is extensive marrow fibrosis with marked reduction in hematopoietic tissue.

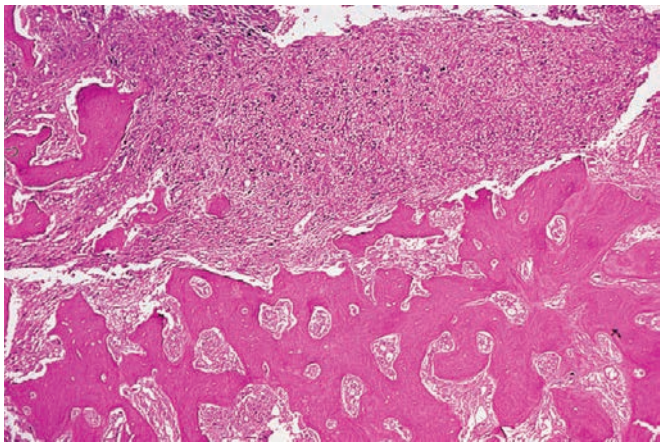

Figure 39.53 Marrow biopsy from a patient with primary myelofibrosis shows extensive osteosclerosis and a cellular area composed predominantly of blasts.

examination, most notably in the bones of the axial skeleton and the proximal portions of the long bones.[270] The relative proportion of hematopoietic cells and fibrous tissue has been generally assumed to vary with the stage of disease, the amount of fibrous connective tissue progressively increasing, with the end stage characterized by marked marrow fibrosis and marked splenomegaly. Studies have been reported that show no correlation between extent of marrow fibrosis and duration of disease and spleen size.[272]

Similar to CML, PMF may progress to an accelerated phase with increased blasts (Fig. 39.53). These may be present diffusely or uncommonly in focal aggregates. Myeloid sarcomas have been reported in patients with longstanding PMF.[184] The lesions occur most frequently in the retroperitoneum, pelvis, mesentery, and pleura; lymph node and skin may also be involved. The tumors are usually composed primarily of hematopoietic cells with varying degrees of stromal reaction. The megakaryocytes may be particularly prominent because of their number and frequently bizarre appearance. Rarely, marked fibrosis may be present.[184] A hyperplasia of hematogones has been reported in the bone marrow of patients with PMF following therapy.[279]

The majority of patients with PM have a relatively long clinical course, with an estimated median survival of 3–5 years from the onset of disease.[268] A minor population of patients with this disorder

For personal use only. No other uses without permission. Copyright ©2017. Elsevier Inc. All rights reserved.

has a more aggressive clinical course with a median survival of approximately 2 years.[280,281] Amyloidosis has been reported as a concurrent condition.[282]

Marrow fibrosis may be an accompaniment of several disorders, both hematologic and nonhematologic, including autoimmune disorders, and a diagnosis of PMF should be based on firm diagnostic criteria.[283,284]

Myeloid/Lymphoid Neoplasms With Eosinophilia and Rearrangement of *PDGFRA*, *PDGFRB*, or *FGFR1* or With *PCM1-JAK2*

PDGFRA Abnormalities

The most common MPN associated with an abnormality of *PDGFRA* results from an *FIP1L1/PDGFRA* fusion gene. This results from a cryptic deletion on chromosome 4 at band q12.[285–287] The deletion also results in the loss of the *CHIC2* gene; this finding serves as a reliable surrogate marker for the *FIP1L1/PDGFRA* fusion.[288,289] There is a marked male predominance in the disorder and the median age is in the late 40s. There is usually marked eosinophilia, and cardiac and pulmonary symptoms are frequent, but rare cases occur without eosinophilia.[290] Splenomegaly is common. The serum vitamin B12 level is elevated. The presentation is similar to chronic eosinophilic leukemia (CEL). The bone marrow is hypercellular with markedly increased eosinophils and frequently increased mast cells, which are dispersed or in loose nonparatrabecular, nonperivascular clusters; occasionally the mast cells appear in dense bundles virtually indistinguishable morphologically from systemic mastocytosis (Fig. 39.54). The mast cells are highlighted by reaction with mast cell tryptase and are usually CD2–, CD25+. Importantly, this neoplasm is responsive to the tyrosine kinase inhibitor imatinib and for this reason, differentiation from mastocytosis is of importance.[285–287,291,292]

Because of the finding of increased mast cells in the marrow of patients with *FIP1L1/PDGFRA* fusion, there may be cases in which the distinction between this disorder and systemic mastocytosis is difficult based solely on the morphologic findings.[293] The definitive distinguishing finding is molecular evidence of the fusion gene. However, there are several clinical and laboratory findings which, viewed in aggregate, may aid in distinguishing the two processes. There is a marked male predominance in myeloid/lymphoid neoplasms with *PDGFRA* rearrangement; in systemic mastocytosis the sex distribution is more evenly distributed. Patients with systemic mastocytosis commonly have a history of urticaria pigmentosa and gastrointestinal symptoms; patients with myeloid/lymphoid neoplasms with *PDGFRA* rearrangement uncommonly have these manifestations. The laboratory findings for the two disorders are more distinctive; patients with systemic mastocytosis have much higher serum tryptase levels, a median level of 207 ng/mL compared to a median level of 24 ng/mL in other eosinophilias. The median peak absolute eosinophil count is 2187/mm^3 in mastocytosis and 12,474/mm^3 in myeloid/lymphoid neoplasms with *PDGFRA* rearrangement.[289,294] In systemic mastocytosis there are dense aggregates of mast cells in the marrow biopsy, whereas in myeloid/lymphoid neoplasms with *PDGFRA* rearrangement the mast cells are usually dispersed. However, this finding is not always a reliable distinguishing feature (see Fig. 39.54). The molecular studies are definitive, with the mastocytosis usually showing mutations of *KIT* and not showing *PDGFRA* rearrangements.

PDGFRB Abnormalities

The most frequent MPN associated with rearrangement of the *PDGFRB* gene on chromosome 5q31–33 usually has the morphologic features similar to chronic myelomonocytic leukemia (usually with eosinophilia) or atypical CML with eosiniphilia.[285] The disease is more

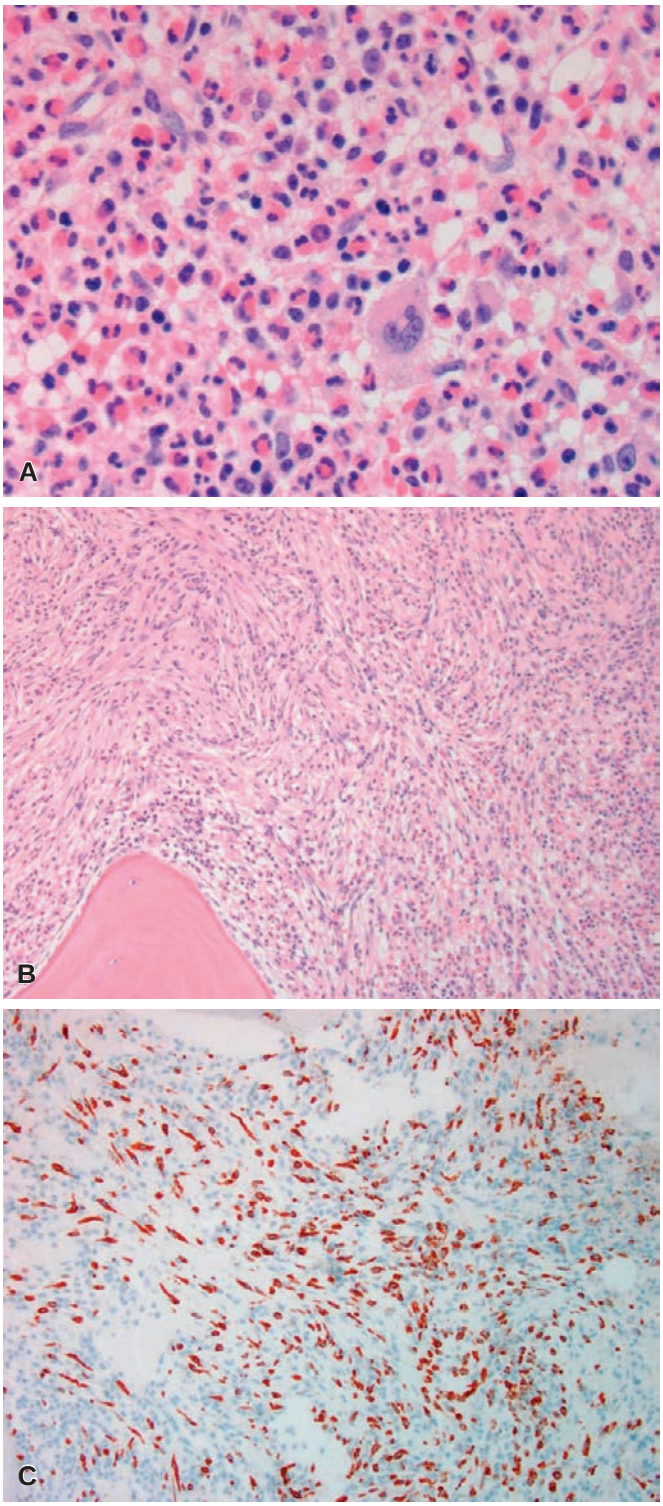

Figure 39.54 **A**, Bone marrow biopsy from an adult man with a WBC count of 18.6 × 10^9/L with 86% eosinophils. The marrow is markedly hypercellular with a marked increase in mature eosinophils. **B**, Another area of the same biopsy showing an aggregate of intertwining mast cells, most of which are fusiform in shape. The mast cell infiltrate is partly juxtaposed to a bone trabecula. **C**, Mast cell tryptase of the lesion in **B** highlighting the mast cells. Genetic studies showed a deletion of *CHIC2*, a surrogate marker for *PDGFRA/FIP1L1* fusion gene. The patient is in remission 3 years following initiation of therapy with imatinib. (Contributed by Dr. Curt Hanson, Rochester, MD.)

For personal use only. No other uses without permission. Copyright ©2017. Elsevier Inc. All rights reserved.

common in men, with a median age at presentation in the upper 40s and an age range of 8–72 years. Most patients have splenomegaly. Cytogenetic studies show a t(5;12)(q31–33;p12) abnormality and molecular analysis shows an *ETV6/PDGFRB* fusion gene.[295] The bone marrow is hypercellular with increased eosinophils, and there may be an increase in mast cells, which may be spindled or fusiform in shape. Other types of myeloid presentation with other fusion genes have been reported. The disorder is responsive to the tyrosine kinase inhibitor imatinib.

FGFR1 Abnormalities

The hematopoietic neoplasms associated with *FGFR1* rearrangement are somewhat heterogeneous and include MPNs, AML, T- and B-lymphoblastic lymphomas/leukemias, and mixed phenotype acute leukemia.[285] There is a wide age range; the median age is 32 years. The associated cytogenetic abnormality is often t(8;13)(p11;q12), but numerous 8p11 variant translocations are described. Patients presenting with a myeloproliferative disorder usually have eosinophilia. The cases presenting with lymphoma usually show eosinophilic infiltration of the lymphoma.

In contrast to the lesions associated with abnormalities of *PDGFRA* and *PDGFRB*, the neoplasms associated with abnormalities of *FGFR1* are not responsive to imatinib and the prognosis is poor.

PCM1-JAK2 Fusions

The 2016 WHO classification now includes myeloid/lymphoid neoplasms with *PCM1-JAK2* as a provisional entity that is commonly associated with eosinophilia.[296] These are usually myeloid neoplasms that show a t(8;9)(p22;q24.1). In addition to eosinophilia, the marrow shows left-shifted erythroid hyperplasia and lymphoid aggregates and may demonstrate myelofibrosis that may mimic PMF. These rare tumors may also present as lymphoblastic leukemia/lymphomas and may respond to *JAK2* inhibitors.[297]

Systemic Mastocytosis

Systemic mastocytosis is a relatively rare disorder characterized by mast cell proliferation in several organs. It usually occurs in combination with urticaria pigmentosa but may present in patients without cutaneous involvement.[298–300] The median age for patients presenting with systemic mastocytosis with urticaria pigmentosa is 45 years; the median age for patients presenting with systemic mastocytosis without urticaria pigmentosa is around 75 years.[298,301–303] The clinical symptoms are varied and include diarrhea, weakness, fractures, weight loss, arthralgia, flushing episodes, and bronchospasm.[298,304–306] An occasional patient may experience anaphylactoid shock. Slight splenomegaly may be present. Osteoblastic, osteolytic, or concurrent osteoblastic–osteolytic lesions may be found on radiologic examination; generalized osteoporosis may also occur (Fig. 39.55).

The WHO classification of mastocytosis is shown in Box 39.9.[148,301,307] The WHO proposes one major and four minor criteria for the diagnosis of systemic mastocytosis, which is the type with bone marrow involvement (Box 39.10).[301] The blood findings in systemic mastocytosis may include eosinophilia, anemia, leukocytosis or leukopenia, thrombocytopenia, and pancytopenia.[308,309]

The bone marrow is the most frequent site of noncutaneous involvement in systemic mastocytosis; lesions may be found as a result of a specific search or may be detected in a biopsy performed for some purpose unrelated to suspected mastocytosis. In the latter instance, when there is no clinical suspicion of the disease, the lesions may be overlooked or misinterpreted because of the difficulty in identifying mast cells in routine sections and because of the changes inherent in the mast cells in this disease; the cells are frequently large, spindled, or have lobulated nuclei and decreased granules that may be much smaller than normal mast cell granules.[301,306,307,310] Smears obtained by bone marrow aspirate may suggest the diagnosis of mastocytosis if large numbers of atypical mast cells are present; however, up to 7% of mast cells have been reported in aspirate preparations in patients without mast cell disease. An increase in mast cells may also be observed in lymphocytic and lymphoplasmacytic lymphomas and hairy cell leukemia.[311] A marked increase in mast cells in the marrow has been observed following the administration of stem cell growth factor. Because systemic mastocytosis may be associated with marked fibrosis, mast cells may not be readily aspirated.

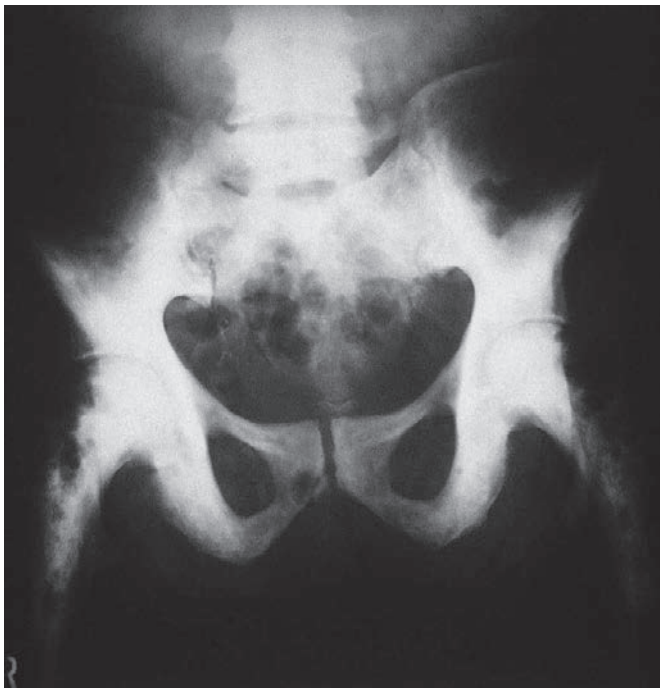

Figure 39.55 Radiograph of pelvis and upper femurs from a patient with systemic mastocytosis; both osteosclerotic and osteolytic changes are prominent.

Box 39.9 2016 World Health Organization classification of mastocytosis

1. Cutaneous mastocytosis
2. Systemic mastocytosis
   a. Indolent systemic mastocytosis[a]
   b. Smoldering systemic mastocytosis[a]
   c. Systemic mastocytosis with an associated hematological neoplasm[b]
   d. Aggressive systemic mastocytosis[a]
   e. Mast cell leukemia
3. Mast cell sarcoma

[a]These subtypes require information regarding B and C findings for complete diagnosis,[308] all of which may not be available at the time of initial tissue diagnosis.

[b]This category is equivalent to the previously described "systemic mastocytosis with an associated clonal hematological non-mast cell lineage disease (SM-AHNMD)."

Data from Arber DA, Orazi A, Hasserjian R, et al. The 2016 revision to the World Health Organization classification of myeloid neoplasms and acute leukemia. *Blood*. 2016;127(20):2391–2405.

For personal use only. No other uses without permission. Copyright ©2017. Elsevier Inc. All rights reserved.

Box 39.10 World Health Organization diagnostic criteria for systemic mastocytosis

Major criterion

Multifocal dense infiltrates of mast cells (≥15 mast cells in aggregates) detected in sections of bone marrow and/or other extracutaneous organ(s).

Minor criteria

1. In biopsy sections of bone marrow or other extracutaneous organs, >25% of mast cells in the infiltrate are spindle shaped, have atypical morphology or, of all mast cells in bone marrow aspirate films, >25% are immature or atypical.
2. Detection of an activating point mutation at codon 816 of *KIT* in bone marrow, blood or another extracutaneous organ.
3. Mast cells in bone marrow blood or other extracutaneous organs express CD25 with or without CD2 in addition to normal mast cell markers.[a]
4. Serum total tryptase persistently exceeds 20 ng/mL (unless there is an associated clonal myeloid disorder, in which case this parameter is not valid).

[a]CD25 is the more sensitive marker, both by flow cytometry and by immunohistochemistry.

The diagnosis requires the major criterion and at least one minor criterion, or at least three minor criteria

Data from Arber DA, Orazi A, Hasserjian R, et al. The 2016 revision to the World Health Organization classification of myeloid neoplasms and acute leukemia. *Blood*. 2016;127(20):2391–2405.

The marrow lesions may be focal or diffuse. Focal lesions are more common and may be paratrabecular, perivascular, or randomly distributed.[298,299,301,303–307,310,312] The paratrabecular lesions frequently are marked by a margination of the infiltrate along the bone trabeculae or juxtaposition of a lesion to a bone spicule. The perivascular lesions may be associated with prominent medial and adventitial hypertrophy and collagen fibrosis. The focal lesions are variable in appearance but generally can be classified into two primary types based on cell composition: polycellular and monocellular. Both types may be observed in the same specimen. The polycellular lesions are characterized by mast cells, lymphocytes, histiocytes, eosinophils, neutrophils, fibroblasts, and endothelial cells in varying proportions; the eosinophils are frequently more numerous at the margins of the lesion. In some cases the different cell types appear to be randomly distributed; in others, the mast cells occur in a central aggregate and are surrounded by well-differentiated lymphocytes, or the mast cells encircle a focus of lymphocytes (Fig. 39.56). The mast cells in these lesions are frequently atypical and characterized by spindle shape and abundant eosinophilic cytoplasm with very fine granules. In the monomorphic lesions, the cellular composition is predominantly mast cells with only scattered lymphocytes and eosinophils (Fig. 39.57). The mast cells in these lesions may appear as intertwining bundles and vary in shape from round in cross section to spindle shaped in longitudinal cut. The cytoplasm is pale to lightly eosinophilic. The nuclei are round or oval; occasionally the nuclei have a monocytoid configuration. Nucleoli are inconspicuous, and mitotic figures are rare. Some of these lesions may resemble aggregates of histiocytes or granulomas. The marrow exclusive of the mast cell lesions is usually hypercellular or normocellular with a granulocytic hyperplasia.[298,301,303–307] The diffuse lesions are characterized by the same cell types as the focal lesions. Changes in the bone trabeculae may be present; both widening and erosion of the trabeculae may be observed. Rarely, evidence of new bone formation may be present (Fig. 39.58). Reticulin stains show varying degrees of reticulin fibrosis.

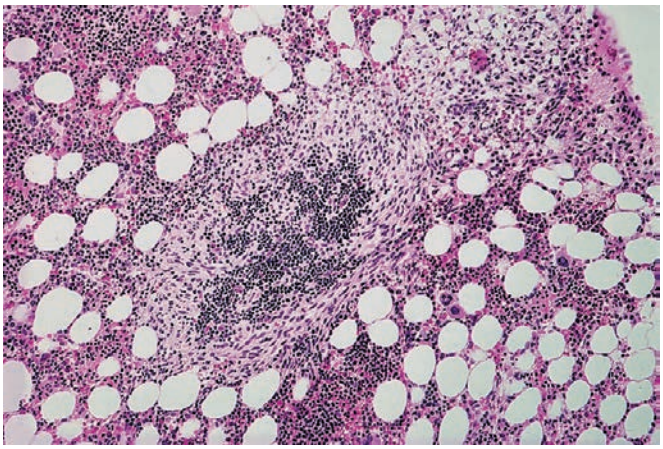

Figure 39.56 Lesion in Bone Marrow From a Patient With Systemic Mastocytosis and No Evidence of Urticaria Pigmentosa. A central focus of well-differentiated lymphocytes is surrounded by lighter-staining mast cells.

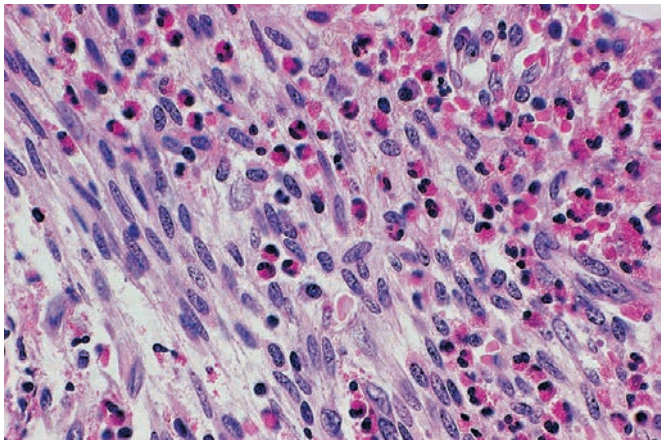

Figure 39.57 High Magnification of a Marrow Lesion in Systemic Mastocytosis. The mast cells have a spindle appearance. There are numerous interspersed eosinophils.

Mast cell leukemia is a very rare variant of mast cell disease and is defined by the presence of 20% or more atypical mast cells in aspirate smears away from spicules. The marrow shows diffuse replacement with immature-appearing mast cells, which may be hypogranular and resemble histiocytes. The disease is usually nonresponsive to traditional therapy and has a very aggressive clinical course. New tyrosine kinase inhibitors, presumably targeting the *KIT* gene mutation product, however, have shown promise in mast cell leukemia and aggressive systemic mastocytosis.[313]

There is an increased incidence of myeloid disorders in patients with systemic mastocytosis: this is recognized in the WHO classification. The spectrum of disorders includes acute leukemia, MDS, and chronic MPNs (Fig. 39.59).[301,308,309] Philadelphia chromosome–positive CML, however, is rarely encountered. Lymphoproliferative disorders have also been reported in association with mastocytosis but are considerably less frequent than myeloid neoplasms and, in contrast to myeloid disorders, the lymphoid neoplasms are probably incidental and clonally unrelated to the mast cell proliferation. The chronic myeloproliferative disorder occurring with systemic mastocytosis has more the features of chronic myelomonocytic leukemia or an unclassified chronic MPN. Caution should be exercised in the diagnosis of a concurrent myeloproliferative process in patients with mastocytosis

For personal use only. No other uses without permission. Copyright ©2017. Elsevier Inc. All rights reserved.

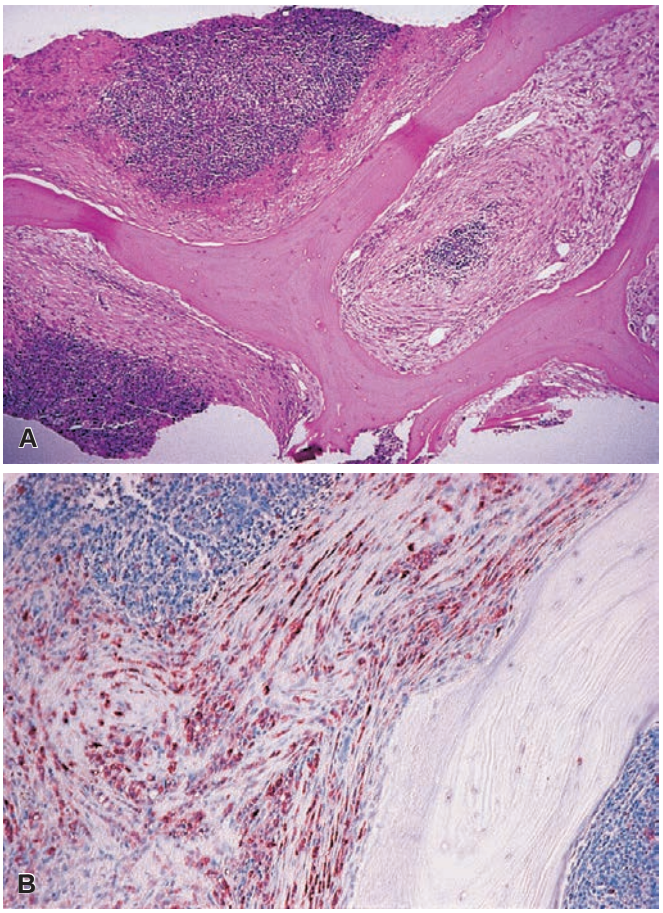

Figure 39.58 **A**, Marrow biopsy from an adult man with systemic mastocytosis associated with a myeloproliferative disorder and no evidence of urticaria pigmentosa. There is extensive paratrabecular fibrosis and widening of bone trabeculae. The intervening marrow is markedly hypercellular, principally due to myeloid hyperplasia. Radiographic studies showed diffuse osteoblastic changes. **B**, Mast cell tryptase stain of the lesion in **A** showing numerous reactive cells.

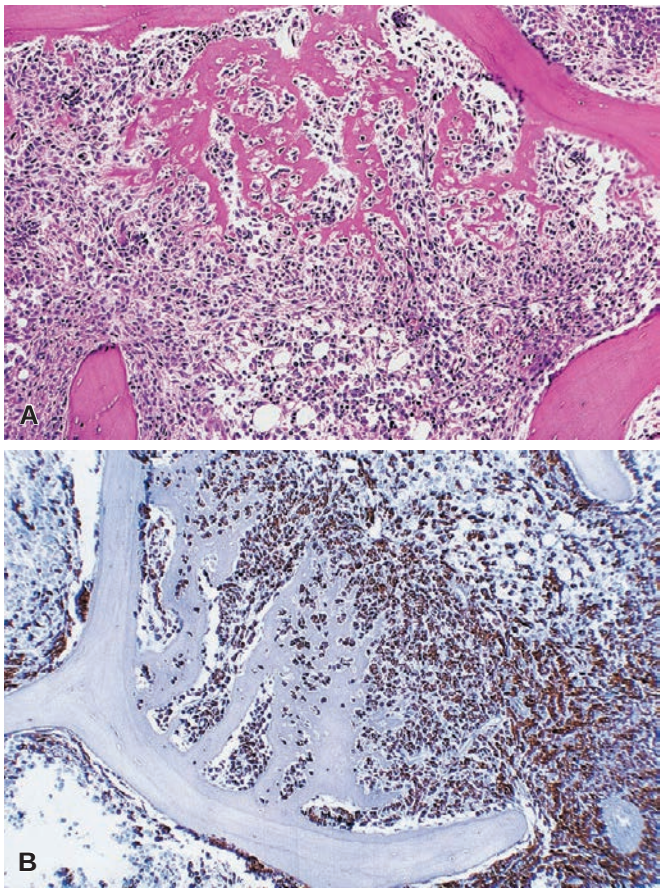

Figure 39.59 **A**, Bone marrow biopsy from a patient with concurrent acute myeloid leukemia and systemic mastocytosis. Mast cell infiltration in this area of biopsy was associated with new bone formation. No other areas in bilateral biopsies show this finding. This was the patient's first marrow biopsy. **B**, Specimen in **A** reacted with antibody to mast cell tryptase. (**B**, Immunoperoxidase.)

as it is possible that marked myeloid hyperplasia may occur as the result of cytokines produced by the mast cell proliferation.

A highly specific antibody to human mast cell tryptase that may be used on decalcified and routinely fixed and processed paraffin-embedded specimens is invaluable for identification of mast cell lesions (see Figs. 39.58 and 39.59B).[314] Although less specific, strong CD117 expression is seen in virtually all cases of mastocytosis, and this antibody is very useful for initial screening for the disorder.[303,306,315]

Normal mast cells express CD9, CD43, CD45, CD68, and CD117. Mast cells are negative for CD14 and CD15. Neoplastic mast cells also express CD2, CD25, and/or CD30. Expression of CD2 and/or CD25 is one of the minor criteria for the diagnosis of mastocytosis in the WHO criteria, although CD2 expression is often difficult to identify by paraffin section immunohistochemistry.[301,308]

The differential diagnosis of mast cell lesions in the marrow includes angioimmunoblastic T-cell lymphoma, Hodgkin disease, PMF, and granulomatous inflammation. The eosinophilic fibrohistiocytic lesion described by Rywlin and colleagues has many of the histopathologic characteristics of mastocytosis lesions and in most instances is a form of mast cell disease.[316] The primary distinction of mastocytosis from the other disorders is based on the immunohistochemical demonstration of mast cells with antibodies to CD117 and mast cell tryptase. Mast cells may be increased in lymphocytic and lymphoplasmacytic lymphomas and hairy cell leukemia in marrow biopsies but are diffusely scattered among the lymphoma cells and do not form mass lesions.[311] Aberrant mast cells, usually without clustering, are also common in the previously mentioned eosinophilic disorders with recurring genetic rearrangements, but those genetic abnormalities trump the diagnosis of systemic mastocytosis.

The treatment of systemic mast cell disease has generally been unsatisfactory with most antineoplastic agents. Fortunately for most patients with indolent systemic mastocytosis, treatment is unnecessary as the disease follows an indolent clinical course. For patients with aggressive systemic mastocytosis or mast cell leukemia, several agents including interferon alpha2b, corticosteroids, and cladribine (2-chlorodeoxyadenosine) have been used with very limited degrees of success.[306,317] Imatinib (Gleevec) has been successful in occasional patients with the wild-type *KIT* or when variant (non-D816V) *KIT* mutations are present, while newer tyrosine kinase inhibitors have shown promise in aggressive cases with the *KIT* D816V mutation, which are typically imatinib resistant.[313]

Because of the lack of satisfactory therapy for most patients with mastocytosis, it is important to exclude the possibility of an abnormality of *PDGFRA* or *PDGFRB* in which there may be an increase in marrow mast cells; these disorders may respond to the imatinib with a distinctly more favorable prognosis than mastocytosis without this association. These entities are described in more detail in the section on MPNs.

For personal use only. No other uses without permission. Copyright ©2017. Elsevier Inc. All rights reserved.

Mature B-Cell Neoplasms

Mature B-cell neoplasms may involve the bone marrow as primary leukemias or may represent lymphomas secondarily involving the marrow. Lymphomas that frequently involve marrow and blood may present terminology problems because of their close relationship to leukemic processes: these include small B-lymphocytic lymphoma, Burkitt lymphoma, lymphoblastic lymphoma, and adult T-cell leukemia/lymphoma. The designation of these processes as leukemia or lymphoma may be arbitrary.

Chronic Lymphocytic Leukemia

Chronic lymphocytic leukemia (CLL), as currently defined, is a monoclonal B-cell disorder that is characterized by weak surface immunoglobulin heavy and light chain and CD20 expression, as well as expression of CD5 and CD23.[318–323] Cases previously diagnosed as T-cell CLL[324] are now considered to be other specific T-cell neoplasms involving the blood, including T-cell prolymphocytic leukemia (PL) and T-cell large granular lymphocytic leukemia (T-LGL). The diagnosis of B-cell CLL is usually established when there is a persistent absolute lymphocytosis in excess of 10×10^9/L, although the diagnosis can be made when a persistent, monoclonal absolute lymphocyte count exceeding 5×10^9/L is present with a characteristic CLL immunophenotype.[319,325] CLL is usually accompanied by some degree of lymphadenopathy and hepatosplenomegaly. The morphology of the proliferating lymphocytes in CLL and small lymphocytic lymphoma is the same, and the two disorders are considered by the WHO as different manifestations of the same process.[322,323] The distinction between these two closely related entities is based on arbitrary criteria; if the marrow shows a pattern of infiltration by small lymphocytes, and the absolute lymphocyte count in the blood is less than 5×10^9/L, the diagnosis of small lymphocytic lymphoma is more appropriate. Small lymphocytic lymphoma may progress to blood involvement, but the magnitude of the leukocytosis does not usually reach the levels observed in CLL.

Clinical staging systems based on both laboratory and clinical features have been introduced: the higher the stage, the greater the tumor burden.[319,326,327] The system proposed by Rai et al. includes five stages: 0, lymphocytosis in blood and marrow; I, lymphocytosis and lymphadenopathy; II, lymphocytosis and hepatomegaly and/or splenomegaly; III, lymphocytosis and anemia; and IV, lymphocytosis and thrombocytopenia.[327] The system introduced by Binet has three stages: (A) no anemia, no thrombocytopenia, fewer than three lymphoid areas enlarged (cervical, axillary, and inguinal lymphadenopathy, spleen, liver); (B) no anemia, no thrombocytopenia, more than three lymphoid areas involved; and (C) anemia (hemoglobin <10 g/dL) and/or platelet count less than 100×10^9/L.[326] The higher clinical stages are generally associated with a shorter survival compared to the lower clinical stages. Additionally, high CD38 or ZAP70 expression on the lymphocytes has been reported to be associated with a significantly shorter survival than cases lacking CD38 or ZAP70 expression regardless of clinical stage.[328–330] Two factors have been shown to have major prognostic impact on prognosis in CLL: the mutation status of the surface immunoglobulin variable region gene and the presence and type of genomic aberrations.[329,331] Patients in whom the leukemic cells have apparently traversed the germinal center and undergone somatic mutations of the immunoglobulin variable region gene have a significantly better prognosis than patients in whom the mutation has not occurred (pre-germinal center lymphocytes). There appears to be an inverse relationship in the majority of cases between expression of CD38 and/or ZAP70 on the lymphocytes and the mutation status. CD38 and ZAP70 expression, however, do not always correlate with mutational status[328,330] and is often difficult to measure in a reliable manner by flow cytometry; therefore, determination of the mutation status is considered the most reliable means of assessing this prognostic factor.

The detection of genomic aberrations in the lymphocyte in CLL by FISH has shown significant differences in survival patterns, and such changes are detectable in over 80% of cases. Patients with 17p13, 11q22–23, and 6q21 deletions appear to have a worse outcome than patients with trisomy 12, normal karyotype, and 13q14.3 deletion. Patients with 17p– have the shortest survival, and patients with 13q– have the longest survival.[331] *TP53* abnormalities (located at 17p13) in B-CLL have been associated with an excess of prolymphocytes and poor prognosis,[332] while patients with trisomy 12 often have an atypical or mixed morphology. In addition to *TP53*, mutations in *ATM*, *NOTCH1*, *SF3B1*, and *BIRC3* are common in CLL and are associated with a worse prognosis.[333,334]

Histopathologic staging of B-CLL is based on the pattern of involvement in bone marrow sections.[323,335] Five possible patterns are generally recognized: focal, diffuse, interstitial, focal and interstitial, and focal and diffuse (Fig. 39.60). In small lymphocytic lymphoma, the focal pattern is the most common, whereas in CLL the pattern is usually interstitial, mixed interstitial and focal, or diffuse. Patients with focal, interstitial, or a combination of focal and interstitial involvement are predominantly in low clinical stages. The diffuse or focal and diffuse patterns generally occur in patients with advanced clinical stages. The diffuse pattern of marrow involvement has been found to have adverse prognostic significance in several studies.[323,336,337]

Marrow biopsies from approximately 25% of patients with B-CLL demonstrate a slight increase in reticulin fibers.

In some patients with B-CLL, there is a dedifferentiation or transformation of the proliferating cell type; this usually occurs late in the course of the disease in less than 5% of the patients and has been referred to as "prolymphocytoid" transformation.[338] This dedifferentiation is distinct from B PL, which is a de novo process with different morphologic features. In these patients, the marrow infiltration may contain foci of prolymphocytoid lymphocytes and paraimmunoblasts (Fig. 39.61). The prolymphocytoid lymphocytes have a moderate amount of basophilic to amphophilic cytoplasm, coarsely reticular nuclear chromatin, and relatively prominent single nucleoli. The paraimmunoblasts are larger, with more abundant cytoplasm, more dispersed nuclear chromatin, and frequently a single prominent eosinophilic nucleolus. These foci may be circumscribed by more well-differentiated lymphocytes and are similar to the immature foci or proliferation centers noted in the lymph nodes of some patients with this process (Fig. 39.62).[335] Difficulties may occur in distinguishing foci of transformation in CLL from follicular lymphoma. An important feature in CLL is the residual population of well-differentiated lymphocytes. In most instances, examination of the blood and marrow smears aids considerably in distinguishing these processes, as well as immunophenotyping studies demonstrating aberrant CD5 expression in CLL as opposed to the common expression of CD10 on the B cells of follicular lymphoma. Concurrence of CLL and other B-cell neoplasms, including multiple myeloma and hairy cell leukemia, has been reported.[339]

Monoclonal B-Cell Lymphocytosis

Monoclonal B-cell lymphocytosis is defined as a peripheral blood monoclonal B-cell proliferation of less than 5×10^9/L in patients without adenopathy, organomegaly, other tissue involvement or evidence of another lymphoproliferative disorder.[340] The cells usually have the immunophenotype of CLL but may have an atypical or non-CLL immunophenotype. Some cases will have small nodules of monotypic B cells in the bone marrow, similar to CLL, but should

For personal use only. No other uses without permission. Copyright ©2017. Elsevier Inc. All rights reserved.

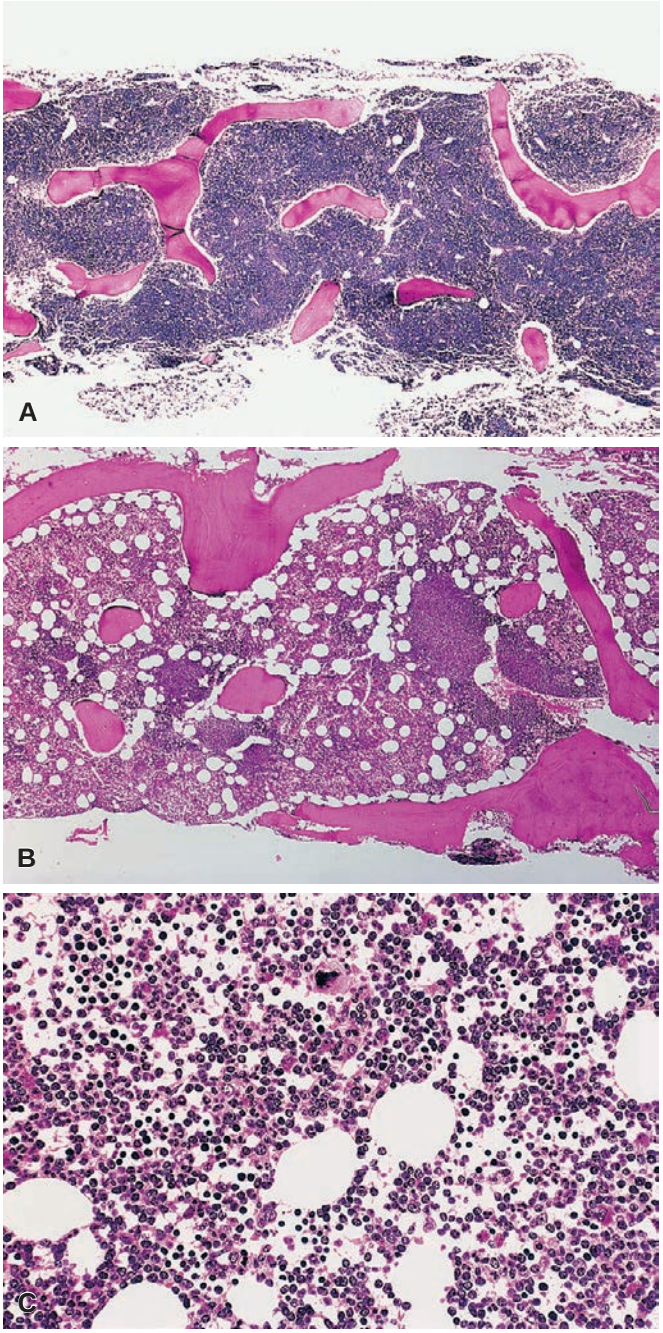

Figure 39.60 **A**, Marrow biopsy from a patient with chronic lymphocytic leukemia (CLL) showing diffuse pattern of involvement. The small lymphocytes completely replace normal marrow cells. **B**, Marrow biopsy from a patient with CLL with focal involvement. Leukemic cells occur in relatively well-demarcated foci, which are randomly distributed and surrounded by normal-appearing marrow. **C**, Marrow section from a patient with CLL illustrating an interstitial pattern of involvement; overall marrow architecture is preserved.

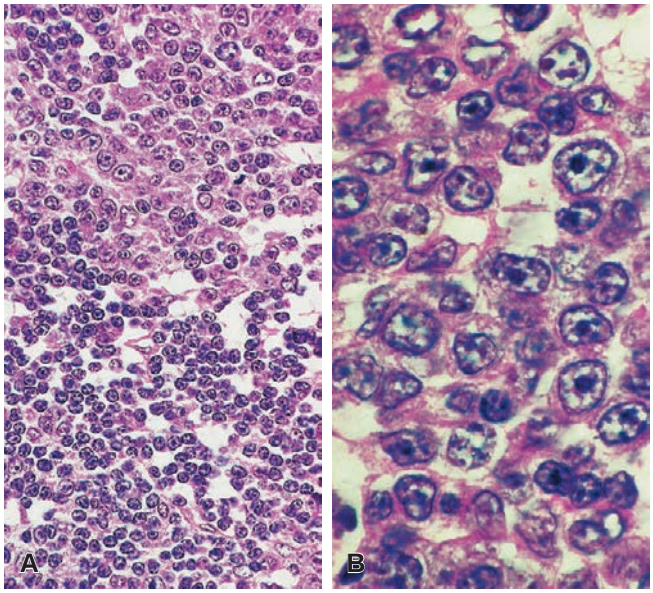

Figure 39.61 **A**, Marrow biopsy from an adult woman with a 4-year history of untreated B-cell chronic lymphocytic leukemia. There are two morphologic populations of lymphocytes; the lower portion of the figure is predominantly small lymphocytes; the upper portion is predominantly prolymphocytoid lymphocytes and paraimmunoblasts. **B**, High magnification of the upper area of the specimen illustrating the prominent prolymphocytoid lymphocytes and paraimmunoblasts with very prominent, usually single, nucleoli.

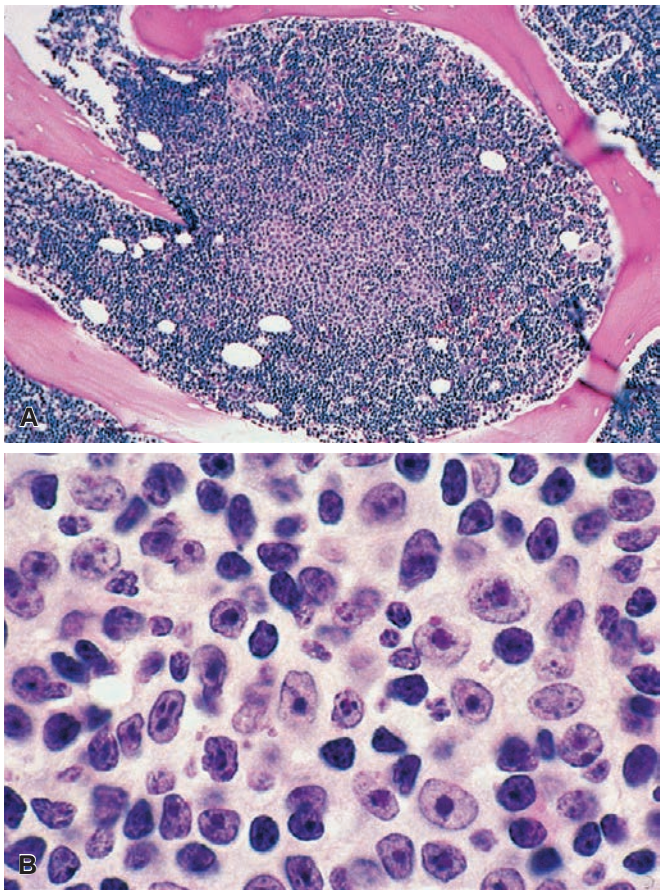

Figure 39.62 **A**, Marrow biopsy illustrating a proliferation center in a patient with B-CLL. **B**, High magnification of the central portion of the proliferation center with prominent prolymphocytoid lymphocytes and paraimmunoblasts.

For personal use only. No other uses without permission. Copyright ©2017. Elsevier Inc. All rights reserved.

be diagnosed as MBL if there is no other tissue disease and the peripheral blood involvement is low. Cases with very low numbers of circulating monoclonal cells ($<0.5 \times 10^9$/L) are now termed "low-count MBL" and are unlikely to progress to CLL.[341,342] Those with higher counts, however, require close follow-up and have features similar to Rai stage 0 CLL.

Richter Syndrome

Richter syndrome is the occurrence of an aggressive lymphoma, usually diffuse large B-cell lymphoma, in a patient with a prior history of B-CLL[343–349] or another low-grade B-cell lymphoproliferative disorder. The reported incidence in B-CLL ranges from less than 1% to 10%.[349] The syndrome is usually characterized by an abrupt change in clinical course with the onset of fever, weight loss, localized adenopathy, dysglobulinemia, and histopathologic evidence of an aggressive lymphoma frequently containing multinucleated giant cells. A Hodgkin-type variant has been described[350] but is less common than diffuse large B cell lymphoma and should show the typical background of classical Hodgkin lymphoma so as not to be confused with cases of CLL with admixed Reed–Sternberg cells.[351] The locus of the lymphomatous process is not restricted to hematopoietic organs.[343] A high incidence of lytic bone lesions has been reported.[349] The bone marrow may be involved by the aggressive lymphoma; evidence of CLL and the supervening lymphoma may be present in the same biopsy specimen (Fig. 39.63). The blood smear usually shows no involvement by the non-CLL cells, and there may be lymphocytopenia. This transformation is marked by an aggressive clinical course and rapid deterioration. The term Richter transformation has been used to describe a somewhat broader spectrum of pathologic findings in patients with B-CLL who present with a similar clinical evolution.[352]

The biologic events resulting in Richter transformation are not completely understood, but a dedifferentiation or transformation of the well-differentiated lymphocyte has been suggested.[353,354] This theory is supported by evidence in some cases in which an identical clone has been detected in the patient's CLL as in the transformed lymphoma (Fig. 39.64).[348,355] This clonal relation appears to occur more commonly in the unmutated type of CLL, and instances in which the lymphocytes of the CLL and the cells of the second lymphoma are different clones are more commonly associated with mutated type of CLL.[356] Approximately half of cases of CLL transformation demonstrate abnormalities of cell cycle regulation involving *TP53* or *CDKN2A*.[357]

Prolymphocytic Leukemia

Prolymphocytic leukemia (PL), initially described by Galton et al.,[358] is a very rare disease that occurs primarily in older individuals and is characterized by a predominant proliferation of lymphocytes referred to as prolymphocytes. The disorder is distinct from CLL and prolymphocytoid transformation of CLL. Approximately 80% of the initially reported cases of this type of leukemia were of B-cell origin, the remainder of T-cell type.[359] The exact ratio of B- to T-cell PL is difficult to determine because of the low frequency of both disorders and the reclassification of many of the B-cell disorders into other B-cell lymphoma categories. The lymphocyte count in PL of either B or T type is usually moderately to markedly increased; the number of prolymphocytes in the blood usually exceeds 55% of lymphocytes and may be more than 90%.

B-PL is a clonal B-cell disorder that may lack expression of CD5 and/or CD23 and does not include cases of transformed CLL, CLL with increased prolymphocytes, or cases with cyclin D1 expression or evidence of t(11;14)(q13;q32).[360] The patients with B-PL usually have massive splenomegaly without prominent peripheral lymphadenopathy.[361,362] The prolymphocytes in B-PL are more uniform in appearance than the prolymphocytoid cells in prolymphocytoid transformation of B-CLL. In B-PL the prolymphocytes are medium to large in size, with a moderate amount of basophilic cytoplasm. There is usually a single prominent nucleolus. The marrow infiltration is usually diffusely interstitial. Mitotic activity is reported as low, although cases with increased mitotic activity have been observed.[363,364] B-PL is usually marked by an aggressive clinical course; occasionally patients have a prolonged survival. The leukemic phase of the blastic variant of mantle cell lymphoma may be characterized by large lymphocytes with prominent nucleoli[365,366]; it can be distinguished from PL by cytogenetic and molecular studies for t(11;14)(q13;q32).[367]

A very uncommon variant of B-CLL intermediate between typical B-CLL and B-PL and referred to as CLL/PL, atypical CLL or mixed-type

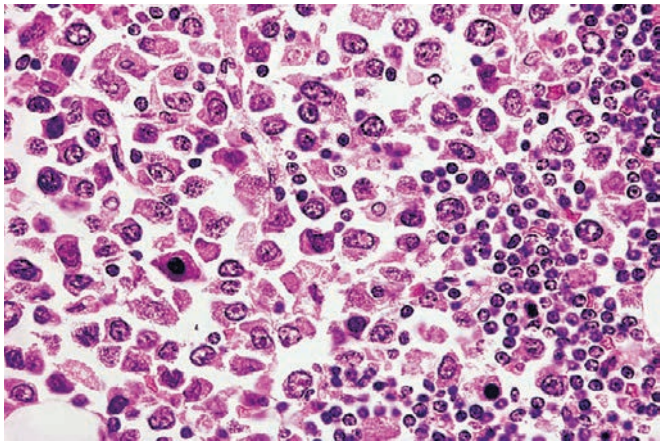

Figure 39.63 Bone marrow trephine biopsy from a patient with a history of chronic lymphocytic leukemia who developed a pleomorphic lymphoma (B-immunoblastic lymphoma) and a clinical picture typical of Richter syndrome. Biopsy contains two distinct cell populations, small lymphocytes, and large pleomorphic cells, some of which are multinucleated.

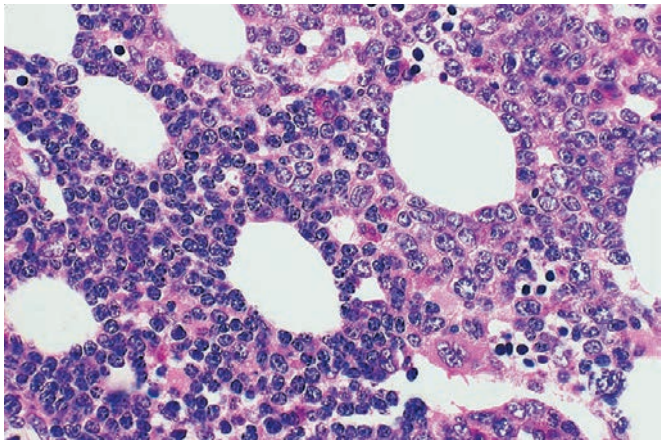

Figure 39.64 Marrow Biopsy From an Adult Man With a 9-Year History of B-CLL. The patient had recent onset of fever, night sweats, myalgia, and axillary, cervical, and inguinal adenopathy prior to this biopsy. A population of small lymphocytes is at lower left. Burkitt lymphoma cells predominate at upper right. Blood and marrow smears contained two lymphocyte populations: small well-differentiated lymphocytes and Burkitt lymphoma cells. Cytogenetic studies of the marrow specimen showed t(8;22)(q24;q11) cytogenetic abnormality.

For personal use only. No other uses without permission. Copyright ©2017. Elsevier Inc. All rights reserved.

CLL has been described; it is distinguished by the presence of 11%–55% prolymphocytoid lymphocytes in the blood.[361,362] Typical B-CLL has less than 11% prolymphocytes in the blood; B-PL is distinguished by more than 55% prolymphocytes. The degree of splenomegaly in patients with CLL/PL is disproportionate to the degree of lymphadenopathy. Two major clinical patterns are described in this variant: one is characterized by a course similar to typical CLL and the other by a more rapidly progressive clinical evolution. The distinction of B-CLL/PL from prolymphocytoid transformation of B-CLL may be very difficult unless prior material more typical of CLL is available (which would suggest transformation). Leukemic mantle cell lymphoma may resemble CLL/PL and because of its more aggressive clinical course it is important to exclude the possibility of leukemic mantle cell lymphoma when findings suggest CLL/PL.

T-PL has a somewhat variable presentation. Patients often have hepatosplenomegaly and lymphadenopathy, and 20% have skin lesions. While the absolute lymphocyte count is usually over 100×10^9/L, some cases may show only a modest elevation.[359,368] Unlike B-PL, the lymphocytes of T-PL may not have an unusually prominent nucleolus. Such cases are often termed small cell variant of T-PL, and this type of T-PL was considered as T-CLL in the past. Marrow infiltration may be modest with very substantial sparing of normal myeloid cells. T-PL is a clonal T-cell disorder that may show weak CD3 expression and is usually CD4 positive. Increased expression of CD52 and T-cell leukemia 1 (TCL-1) is characteristic of the disorder. The majority of cases of T-PL have inv(14)(q11;q32) or t(14;14)(q11;q32). Most cases also have abnormalities of chromosome 8. Recently, mutations in the JAK-STAT signaling pathway (*JAK3*, *JAK1*, or *STAT5B*) have been reported in T-PL.[369,370]

Hairy Cell Leukemia

Hairy cell leukemia is a clonal chronic lymphoproliferative disorder of B-cell origin that is manifest primarily in blood, marrow, and spleen. There is a male predominance.[318,371–374] The age range is 20–80 years, with a median of approximately 50 years. The patients generally have cytopenias or pancytopenia and splenomegaly without prominent peripheral lymphadenopathy; there is usually an associated monocytopenia. The majority of patients present with leukopenia and only occasional leukemic cells in the blood. Some 5%–10% of patients have white blood cell counts exceeding 10×10^9/L; the hairy cells usually comprise the majority of the blood leukocytes in these patients.

The typical hairy cell measures 10–14 μm. The clear to lightly basophilic cytoplasm is variable in amount. The surface of the cell is marked by numerous delicate and broad projections; this finding is particularly striking in specimens examined by phase and electron microscopy.[375] Vacuoles and occasionally delicate azurophilic granules may be identified in the cytoplasm. The nucleus is oval, folded, or indented; the chromatin is coarsely reticular, and nucleoli are inconspicuous.

Aspiration biopsy of the marrow in patients with hairy cell leukemia is unsuccessful in 30%–50% of cases because of increased reticulin fibrosis.[372,373] The interstitial pattern of marrow infiltration in trephine sections is virtually diagnostic in most patients.[376–379] The marrow in the majority of patients is hypercellular; in 10%–15% of patients the involved marrow is hypocellular.[380] The involvement may be diffuse or partial; the diffuse type is more common (Fig. 39.65). Leukemic infiltrates in partial involvement are irregular in outline and poorly demarcated from the normal marrow cells. In the very early stages of the disease, partial involvement may take the form of relatively small, indistinctly outlined foci of leukemic cells. In formalin-fixed tissue, there is frequently a halo-like effect or clear area around the nucleus because of the abundant cytoplasm.

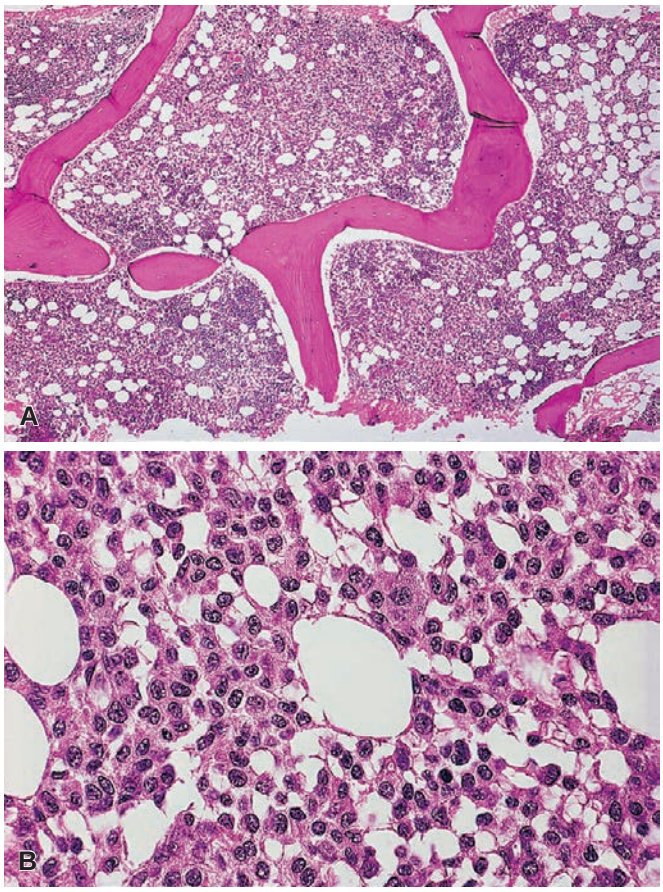

Figure 39.65 **A**, Bone marrow section from a patient with extensive replacement by hairy cell leukemia; scattered foci of normal hematopoiesis are present. **B**, High magnification of specimen in **A**. Hairy cells are loosely spaced, in contrast to aggregates of lymphocytes in chronic lymphocytic leukemia and small lymphocyte lymphoma. Hairy cells have a relatively abundant, lightly eosinophilic cytoplasm. Many of their nuclei are folded or irregular in outline. Nucleoli are inconspicuous and mitotic figures rare. The halo effect around nuclei, characteristic of formalin-fixed tissue, is not prominent in this specimen fixed with Zenker acetic acid.

The cell borders have an interlocking appearance. With some fixatives, such as Zenker, the cytoplasm of the hairy cells is retracted with a resultant loosely structured appearance. The loosely structured appearance and widely spaced nuclei in hairy cell leukemia contrast with the marrow infiltrates in the lymphocytic lymphomas and CLL in which the nuclei of the cells are in close apposition. The nuclear chromatin of the hairy cells is relatively fine. Nucleoli are distinct but not usually prominent, and mitotic figures are infrequent. In an occasional case, the hairy cells have a spindled or fusiform appearance and may resemble the marrow lesions in systemic mastocytosis (Fig. 39.66). A morphologic variant with hyperlobulated nuclei resembling T-cell lymphoma has been described.[381] Marrow uninvolved by the leukemic process may be hypocellular or hypercellular. Morphologic subtypes of hairy cell leukemia based on histopathology have been reported to have prognostic significance.[382] Normal-appearing mast cells may be increased.

Reticulin stain shows increased deposition of thickened reticulin fibers in the areas of the infiltrates; the reticulin fibers often appear to encircle individual cells. The reticulin fibers frequently extend into the adjacent normal-appearing marrow.

Hairy cells express light chain–restricted cytoplasmic and surface immunoglobulin and pan-B-cell antigens, including CD19, CD20,

For personal use only. No other uses without permission. Copyright ©2017. Elsevier Inc. All rights reserved.

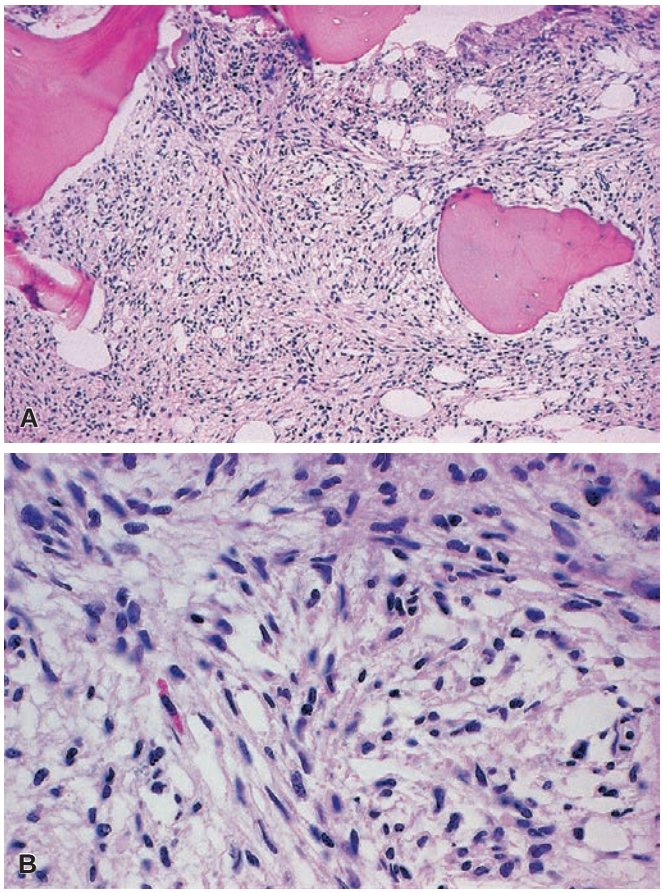

Figure 39.66 **A**, Marrow biopsy from a patient with the stromal variant of hairy cell leukemia. **B**, High magnification of the biopsy in **A**. Many leukemia cells are elongated or spindle shaped.

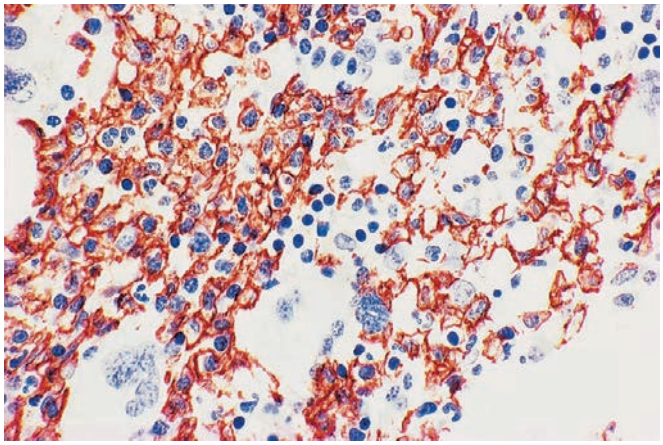

Figure 39.67 **Bone Marrow Biopsy From a Patient With Hairy Cell Leukemia Reacted With Antibody to CD20.** Reactivity accentuates the leukemic infiltrate. Scattered normal myeloid cells, principally erythroid precursors, are present. (Immunoperoxidase.)

CD22, DBA44, CD79a, and PAX5 but not CD79b[371,383]; CD20 and DBA44 are of considerable aid in evaluating the extent of the leukemic infiltrate and in assessing the effects of chemotherapy in paraffin-embedded biopsy sections (Fig. 39.67).[384] In addition, they express CD11c, which is also expressed on myeloid cells, CD25, interleukin-2 receptor, CD123, CD103, cyclin D1, and annexin A1,[385,386] and mark with mutation specific BRAF (V600E) antibodies.[387] They are negative for CD5, a T-cell antigen, and CD23, which are expressed on the lymphocytes in the majority of cases of B-CLL, but a subset of cases express CD10.[388] Hairy cells also contain tartrate-resistant acid phosphatase (TRAP),[389] although this finding alone by immunohistochemistry is not entirely specific, and paraffin section detection of annexin A1 and V600E-mutated BRAF protein on B cells is considered more specific for hairy cell leukemia.[385,387] While no recurring karyotypic abnormalities occur in hairy cell leukemia, essentially all cases demonstrate V600E mutations of *BRAF*,[390] which, as mentioned above, can be detected by immunohistochemistry.

Rarely, hairy cell leukemia may focally involve the skeleton as a painful localized destructive lesion. This usually occurs in a patient with an established diagnosis; more rarely, hairy cell leukemia may present as a localized skeletal lesion as the initial and only manifestation of the disease.[391–394] These lesions occur principally in the upper portion of the femurs. Although the majority of these localized lesions are osteolytic, osteoblastic lesions may also occur. The localized lesions appear to respond to the purine analogues 2-deoxycoformycin and 2-deoxyadenosine and to radiation.

Treatment of hairy cell leukemia with the purine analogues, often coupled with rituximab or other monoclonal antibodies, results in durable complete or partial remissions in the majority of cases.[374,395–397] The bone marrow biopsies from these patients generally show a return to normal marrow hematopoiesis. As noted, the recognition of residual leukemia is facilitated by the use of pan-B-cell monoclonal antibodies reactive in paraffin-embedded biopsies; anti-CD20, BRAF V600E, and T-bet are particularly good antibodies for this purpose.[384,398,399] Treatment with the interferons frequently results in characteristic marrow changes with some evidence of residual leukemia.[400] Despite the success with purine analogues and rituximab, targeting mutated BRAF has shown great success in patients who have relapsed with this approach,[401] and more targeted therapy may become first line therapy in the near future. Approximately 0.25% of cases of hairy cell leukemia develop abdominal lymphadenopathy, as demonstrated by CT studies. The incidence is higher in patients who relapse after previously successful therapy or have long-standing disease. The development of abdominal adenopathy may be associated with resistant disease and with the appearance of large hairy cells in both the bone marrow and the enlarged lymph node. This constellation of clinical and morphologic findings has been interpreted as a type of transformation.[402]

Hairy Cell Leukemia Variant

Hairy cell leukemia variant is a lymphoproliferative disorder usually presenting with a marked leukocytosis and was originally restricted to cases with lymphocytes with morphologic characteristics intermediate between hairy cells and prolymphocytes (Fig. 39.68).[318,403,404] In those cases, the cells are large with basophilic cytoplasm with stellate projections and relatively prominent nucleoli. Other morphologic variants, including cases with blastic or convoluted nuclear features, as well as cases showing immunophenotypic variations, are not included in this category, which is felt to be biologically distinct from typical hairy cell leukemia.[405] The disease is very rare and occurs primarily in older individuals. In contrast to typical hairy cell leukemia, there is no associated neutropenia and monocytopenia and cases do not demonstrate mutations of *BRAF*.[390] The cells may be TRAP positive. The cells usually express CD11c but are negative for CD25; they express CD103 and annexin A1 less commonly than typical cases of hairy cell leukemia.[404] The marrow shows a diffuse interstitial pattern of infiltration similar to typical hairy cell leukemia. The pattern of splenic infiltration is similar to hairy cell leukemia, with a predominantly red pulp involvement. Hairy cell leukemia

For personal use only. No other uses without permission. Copyright ©2017. Elsevier Inc. All rights reserved.

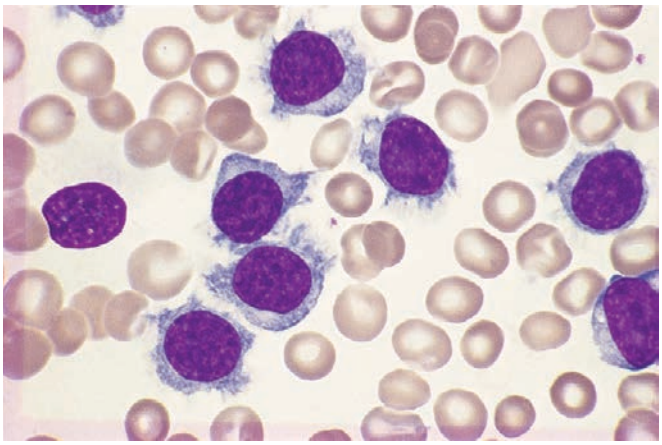

Figure 39.68 Hairy Cell Leukemia Variant. Several lymphoid cells in the blood smear of an adult man with markedly elevated leukocyte count. The hairy cell variant lymphocytes are large with a moderate amount of basophilic cytoplasm with stellate projections. The nuclei of several cells contain variably prominent nucleoli. (Wright–Giemsa.)

variant, unlike typical hairy cell leukemia, does not respond to interferon alpha or purine analogues but still has a relatively indolent clinical course.

Splenic Marginal Zone Lymphoma

Splenic marginal zone lymphoma (SMZL) is a clonal proliferation of small B lymphocytes with clinical and hematologic features that may resemble hairy cell leukemia.[406–409] When it involves the blood, it often shows morphologic features that have also been described as splenic lymphoma with villous lymphocytes (SLVL). The disease shows no sex predilection and usually occurs in adults over 50 years of age. With blood involvement, there is a slight-to-moderate lymphocytosis; the leukocyte count is less than 25×10^9/L in the majority of patients. Anemia and thrombocytopenia are present in approximately 50% of cases with blood involvement. Most patients have marked splenomegaly.[408]

The lymphocytes in the blood often have short villous projections that may have a polar distribution. Villi may not be present on all of the lymphoma cells, and there may be considerable variation in the appearance of the cells. Some have a distinct but not prominent nucleolus (Fig. 39.69A). Plasmacytoid lymphocytes may be present.

The lymphocytes express moderate-to-intense surface immunoglobulin and pan-B-lymphocyte markers, including CD19, CD22, and CD24,[407,410] while they are usually negative for CD5, CD10, CD43, BCL6, cyclin D1, BRAF V600E, and annexin A1. Many cases have a low IgM monoclonal gammopathy.[409] In general, SMZL lacks balanced cytogenetic translocations, including those common to extranodal marginal zone lymphoma, the t(14;18) of follicular lymphoma, and the t(11;14) of mantle cell lymphoma. Chromosome 7q deletion is found in approximately 30% of cases; trisomy 3 or gain of 3q is present in 17% of cases.[407] No gene mutations specific for SMZL have been identified, and *MYD88* mutations, common in lymphoplasmacytic lymphoma, are uncommon in SMZL.

Virtually all patients with SMZL have some degree of marrow involvement. The degree and pattern of marrow involvement vary substantially; the pattern may be focal nonparatrabecular, focal paratrabecular, interstitial, diffuse, or intrasinusoidal; there may be a predominance of one pattern in an individual case, but mixed patterns are common (see Fig. 39.69B,C).[407,411–415] The lymphoma cells may be predominantly small lymphocytes or an admixture of small lymphocytes and scattered large lymphocytes with relatively abundant cytoplasm, slightly dispersed chromatin, and variably prominent nucleoli. Mitotic figures are usually sparse. Some degree of plasma cell proliferation may be present. Occasionally, foci of lymphoma with remnants of germinal centers may be found (Fig. 39.70).

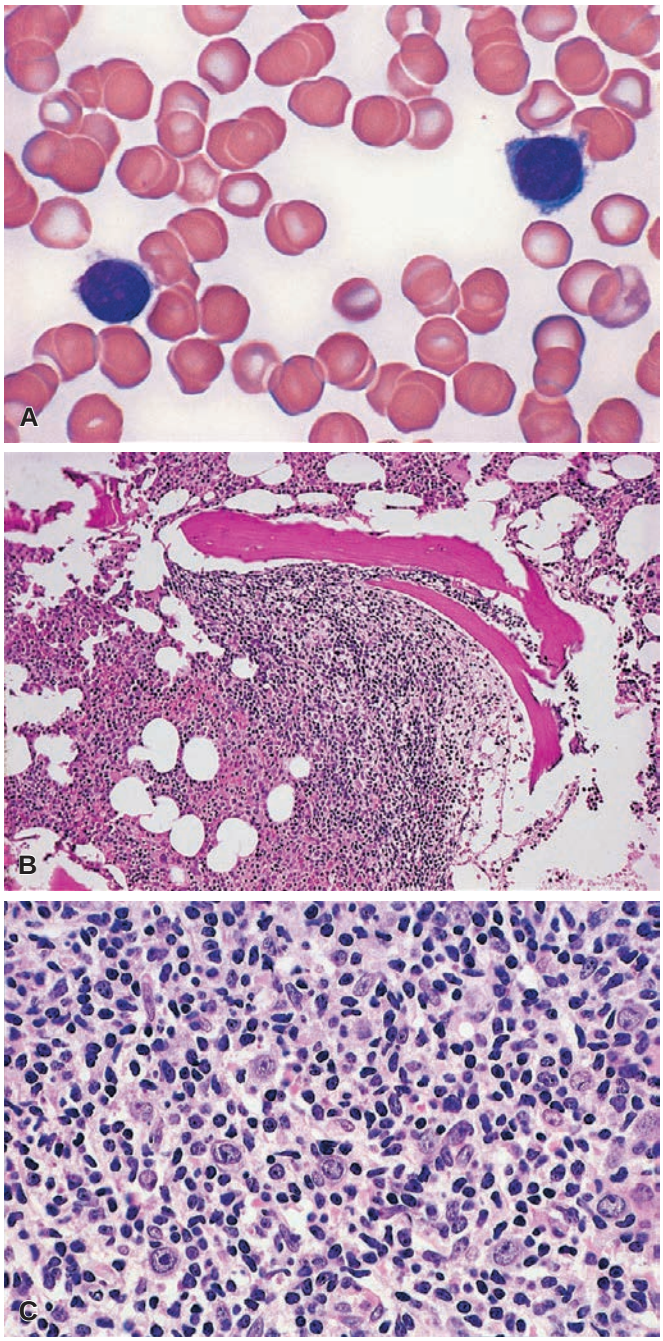

Figure 39.69 **A**, Lymphocytes in blood smear from an adult male with splenic marginal zone lymphoma (SMZL) with villous lymphocytes. The cytoplasm of two of the lymphocytes has small villous projections. Nuclear chromatin is coarse. There are distinct but not prominent nucleoli. **B**, Bone marrow biopsy from a patient with SMZL showing a paratrabecular, poorly demarcated aggregate of lymphocytes. **C**, High magnification of a lesion from a patient with SMZL showing a predominant population of small lymphocytes with scattered large cells with abundant cytoplasm and prominent nucleoli. (**A**, Wright–Giemsa.)

Patients with SMZL generally have a prolonged clinical course. Splenectomy is frequently beneficial in patients with severe anemia,

For personal use only. No other uses without permission. Copyright ©2017. Elsevier Inc. All rights reserved.

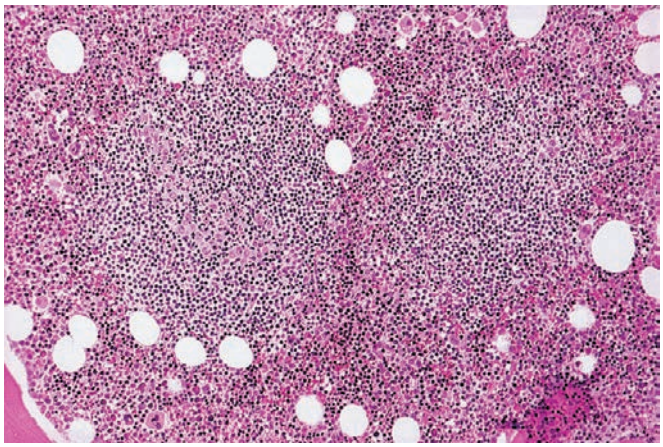

Figure 39.70 Bone Marrow Biopsy From a Patient With Splenic Marginal Zone Lymphoma Illustrating Two Well-Circumscribed Foci of Lymphocytes. The lesion on the left contains a central area suggesting remnants of a germinal center with several centroblast-like cells.

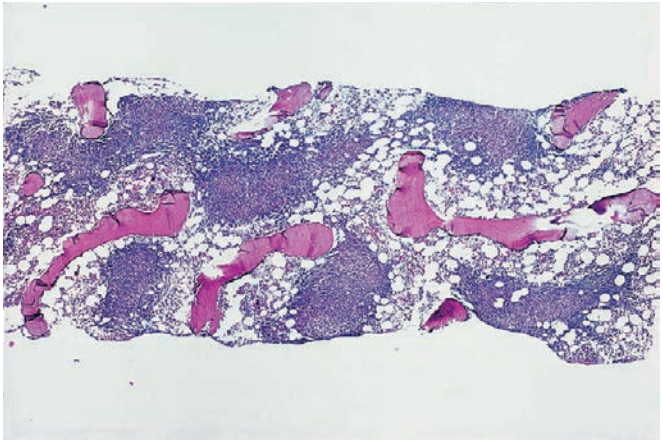

Figure 39.71 Several Focal Aggregates of Lymphocytes in Marrow in a Patient With Small Lymphocytic Lymphoma. Foci of lymphocytes vary in size and have irregular, poorly circumscribed outlines.

neutropenia, and thrombocytopenia. Rare cases have recurred as diffuse large B-cell lymphoma at other sites.[416]

A small number of patients with SMZL and concurrent hepatitis C infection have undergone remission of the lymphoma with antiviral therapy.[417]

Burkitt Lymphoma/Leukemia

Burkitt lymphoma presents with marrow involvement in 15%–30% of patients.[418–422] In the WHO classification of hematopoietic tumors, the FAB designation of ALL L3 has been replaced by combining the leukemic presentation with Burkitt lymphoma, reflecting the fundamental identities of these two different manifestations of the same process.[411,423] A leukemic presentation is frequently associated with Burkitt lymphoma involving the ileocecal region of the small bowel with a t(8;14)(q24;q32) or variant chromosome translocation, (t(2;8)(q12;q24), t(8;22)(q24;q11)) and is TdT negative.[418,420,423] The diagnostic terminology used in these cases should reflect the status of the marrow and blood. If tumor cells are present in the blood and the marrow is diffusely replaced, Burkitt leukemia is an appropriate designation. If few or no tumor cells are present in the blood, and the marrow is partially involved with substantial sparing of normal hematopoiesis, a diagnosis of lymphoma is more appropriate. The therapeutic approach in these two situations is the same. Marrow involvement in Burkitt lymphoma is usually characterized by diffuse infiltration of the interstitium with some preservation of adipose tissue, although small focal lesions may occur. The "starry sky" appearance characteristic of lymph nodes in Burkitt lymphoma is infrequently present in bone marrow biopsies. In contrast to the majority of cases of B-cell precursor ALL in which mitotic figures are sparse, there is prominent mitotic activity in Burkitt lymphoma/leukemia. Burkitt lymphoma is a mature B-cell neoplasm, expressing CD20 and clonal surface immunoglobulin light chains as well as CD10. In contrast to B-ALL, it does not express CD34 or TdT.

Non-Hodgkin Lymphoma

B-Cell Lymphoma

The incidence of marrow involvement in non-Hodgkin lymphoma at the time of initial diagnosis, other than those previously described with a leukemic presentation, varies with the different histopathologic subtypes; the incidence in aggregate for all types ranges from 40% to 55% in most of the larger studies of adults.[424] The incidence is higher in the low-grade lymphomas than in many of the high-grade lymphomas. Approximately 60%–70% of the cases of follicular center cell lymphoma have marrow involvement at the time of initial diagnosis, compared to 25%–33% for large cell lymphomas. Splenic marginal zone B-cell lymphoma is reported to have a very high incidence of involvement, approximately 80%–90%; a similarly high incidence of involvement has been observed in mantle cell lymphoma.[378,425–427] Marrow involvement in mucosa-associated lymphoid tissue (MALT) lymphoma was reported in approximately 20% of cases in one study.[428] The incidence of marrow involvement in peripheral T-cell or node-based T-cell lymphoma varies from 30% to 70% in different series.[429–431] Blood involvement may occur with all types of lymphoma.[320,425,432–435]

The extent of lymphomatous infiltration varies considerably; it is less than 30% in more than half of cases with involvement.[411,433,436] In general, the small lymphocytic and follicular center cell lymphomas are characterized by substantial sparing of normal bone marrow.

The pattern of marrow involvement may be diffuse, focal paratrabecular, focal nonparatrabecular, interstitial, intrasinusoidal, and rarely intravascular (Figs. 39.71–39.78); uncommonly, marrow lesions of follicular lymphoma are characterized by recapitulation of the neoplastic follicle as found in the lymph node (see Figs. 39.74 and 39.75).[411,433,437–443] The diffuse and focal nonparatrabecular patterns may occur with all types of lymphoma of both B- and T-cell type. The focal paratrabecular pattern occurs principally but not exclusively in the follicular center cell lymphomas; follicular lymphomas may also involve the marrow in a focal nonparatrabecular pattern. The marrow biopsies from patients with mantle cell lymphoma and splenic marginal zone B-cell lymphoma may also show both focal paratrabecular and nonparatrabecular lesions.[411,444] The infiltrate in an occasional case of mantle cell lymphoma and splenic marginal zone B-cell lymphoma may contain remnants of benign germinal centers (see Fig. 39.76B).[445] Splenic marginal zone B-cell lymphoma and hepatosplenic T-cell lymphoma may occur principally in an intrasinusoidal pattern (see Fig. 39.78).[415]

The interstitial pattern of involvement, in which the lymphoma cells infiltrate the interstitium of the marrow with preservation of the overall marrow architecture with some sparing of normal hematopoiesis, may occur with all types of non-Hodgkin lymphoma.

For personal use only. No other uses without permission. Copyright ©2017. Elsevier Inc. All rights reserved.

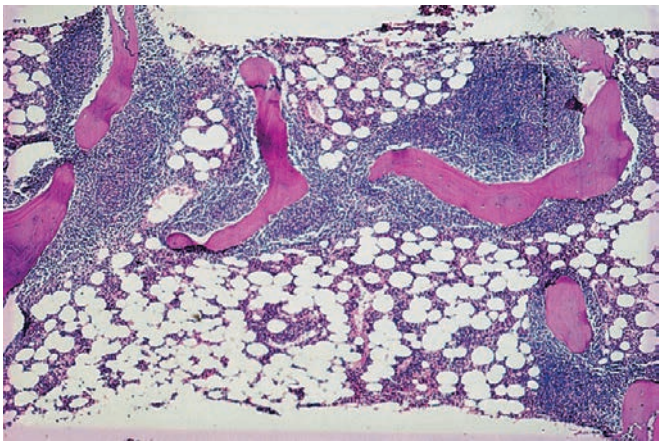

Figure 39.72 Bone marrow section from a patient with follicular lymphoma illustrating the prominent paratrabecular distribution of the infiltrate.

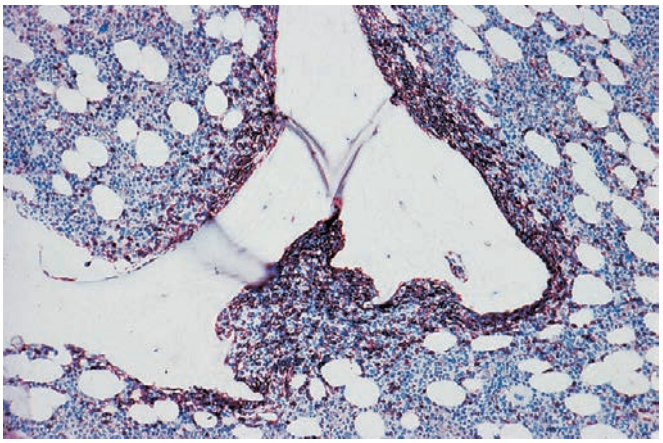

Figure 39.73 Marrow from a patient with marrow involvement by follicular lymphoma with prominent paratrabecular involvement reacted with antibody to CD20. The infiltrate is accentuated by CD20 antibody. (Immunoperoxidase.)

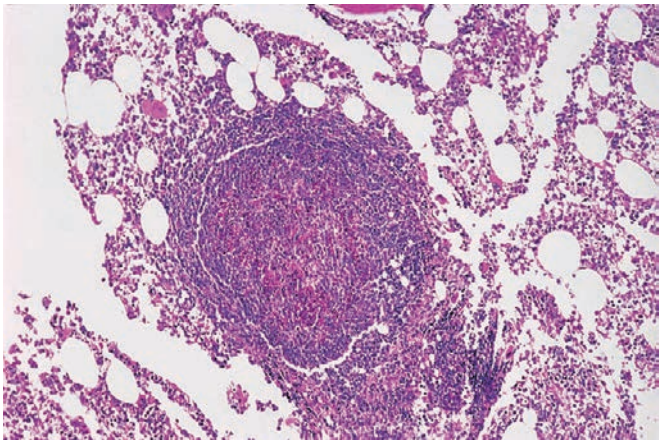

Figure 39.74 Marrow Biopsy From a Patient With Follicular Lymphoma With Focal Paratrabecular and Nonparatrabecular Involvement. A few of the nonparatrabecular foci, as illustrated, recapitulate neoplastic follicles. Amorphous eosinophilic proteinaceous debris is deposited in the central portion of the lesion.

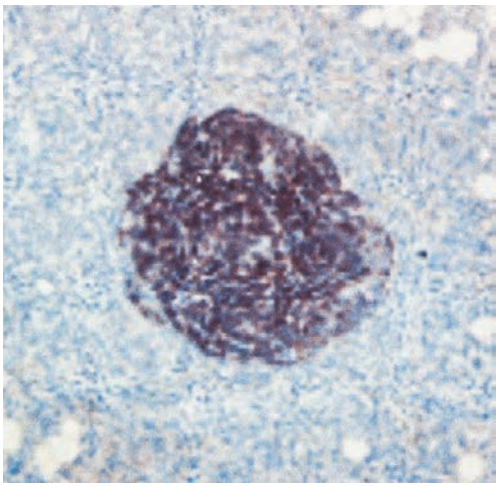

Figure 39.75 Neoplastic Follicle in Marrow Reacted With Antibodies to CD21 and BCL2. The dendritic cells express CD21 and the lymphocytes express CD20. (Immunoperoxidase.) (Reproduced from *Am J Clin Pathol*. 2002 American Society for Clinical Pathology. Reprinted with permission.)

The bone marrow in this type of involvement may be deceptively normal in appearance at low magnification and emphasizes the importance of examination of marrow biopsies at high magnification when evaluating for lymphoma involvement (see Fig. 39.77). This pattern of infiltration may be present at the time of initial diagnosis or in patients who have received chemotherapy. Interstitial involvement in the more aggressive lymphomas may be accompanied by considerable depletion of normal hematopoietic cells.

The intrasinusoidal pattern of involvement may be particularly difficult to identify in routinely stained sections, even in well-prepared specimens. The use of immunohistochemistry has been particularly important in recognizing this type of lesion, which appears to occur most frequently with splenic lymphomas, including splenic marginal zone B-cell lymphoma and hepatosplenic T-cell lymphoma, in which it may be the predominant pattern of involvement (see Fig. 39.78). It may be observed in other types of lymphoma, usually combined with other patterns.[415]

The follicular pattern of follicular lymphoma as observed in lymph nodes is uncommonly recapitulated in the marrow lesions (see Fig. 39.74).[411,443] Occasionally foci of transformation in B-CLL may mimic follicle formation (see Fig. 39.62). As noted, benign germinal centers may be found in occasional cases of mantle cell lymphoma and splenic marginal zone B-cell lymphoma (see Fig. 39.76).[445] In some marrow lesions of follicular lymphoma, the margins of the lymphomatous focus may be composed of transforming cells, imparting a somewhat reverse germinal center character to the lesion. In addition, the paratrabecular lesions may show a zoning phenomenon with a less differentiated population of cells immediately adjacent to the endosteal surface.

The cytopathology of the lesions in the marrow sections usually parallels the cytologic characteristics in the lymph node; this is particularly true for the T-cell lymphomas and Burkitt lymphoma.[446,447] In 20%–25% of lymphomas, predominantly follicular, there may be discordance between the predominant cell type in the lymph node and the predominant cell type in the marrow.[411,426,440,448,449] In these cases, the marrow lesions usually consist of small cleaved cells, and the lymph node findings are a mixed or large cell type; the converse occurs but is less frequent. Those patients with diffuse large cells in the lymph node and small cleaved cells in the bone

For personal use only. No other uses without permission. Copyright ©2017. Elsevier Inc. All rights reserved.

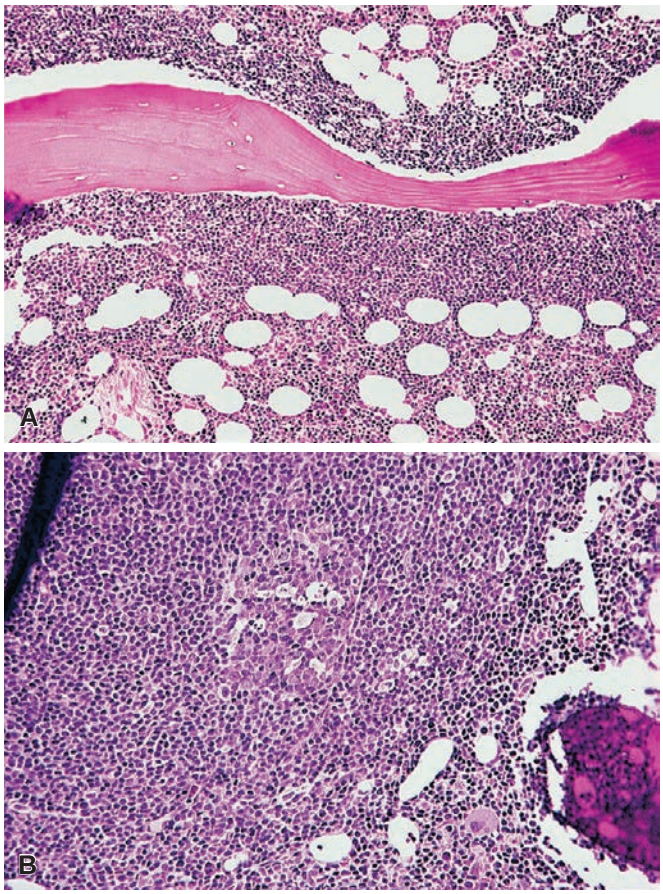

Figure 39.76 **A**, Bone marrow biopsy from an adult man with extensive blood and marrow involvement by mantle cell lymphoma. Lymphoma cells expressed pan-B-cell markers, CD5, and intense surface immunoglobulin. In some areas, lymphoma marginates along the bone trabecula. **B**, Focus of marrow involvement from the same biopsy showing structure with remnants of germinal center including dendritic histiocytes.

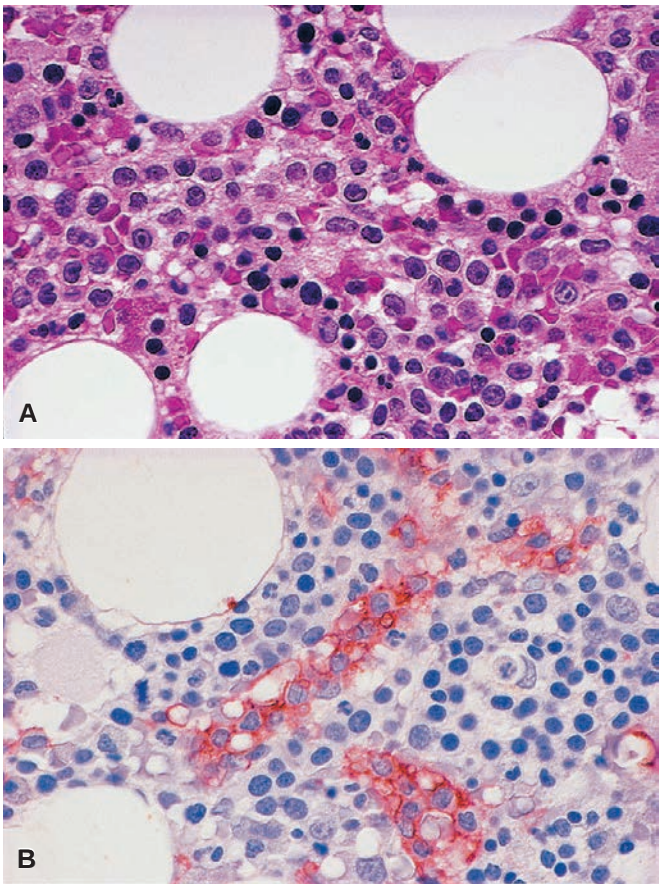

Figure 39.78 **A**, Bone marrow biopsy from a patient with splenic marginal zone B-cell lymphoma showing a preferential intrasinusoidal localization of the lymphoma cells. **B**, The same specimen as **A** reacted with antibody to CD20 illustrating the preferential intrasinusoidal location of lymphoma cells. (**B**, Immunoperoxidase.)

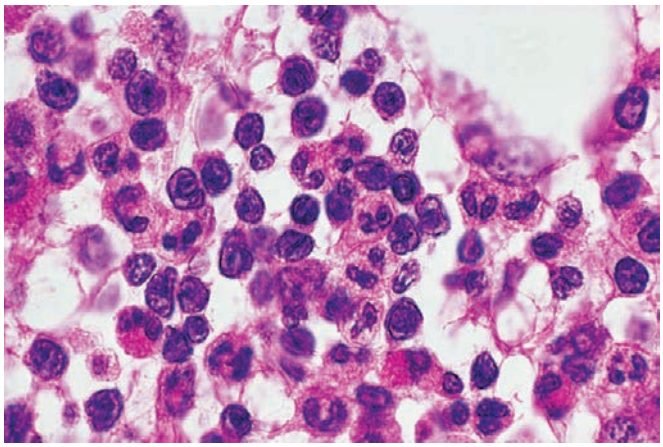

Figure 39.77 **High Magnification of a Marrow Biopsy From a Patient Being Treated for Follicular Lymphoma.** There is an infiltration of the interstitium by a population of small lymphocytes, several of which have irregular and cleaved nuclei.

marrow usually have a high rate of complete remission and a high rate of 5-year survival compared to patients with large cells in the lymph node and bone marrow that have a low rate of complete remission with low 5-year survival.[449] In either instance, the cytologic characteristics in both sites are usually those of follicular center cell lymphoma. Molecular studies of microdissected lesions in 21 cases of discordant lymphoma have shown the same clone in the lymph node and marrow lesions in 44% of the specimens.[450] In two cases different clones were identified and in four cases the marrow lesions were polyclonal. These studies emphasize the importance of critical evaluation of lesions in post-therapy marrow; it cannot be assumed that all lymphocytic infiltrates are residual lymphomas, nor can it be assumed that a small lymphocyte proliferation in the marrow of a patient with large cell lymphoma elsewhere is benign. These caveats are particularly important in those instances where there is discordant morphology following antibody therapy.

Immunohistochemistry with an appropriate panel of antibodies has an important role in the evaluation of marrow biopsies in patients with lymphoma. It has utility in defining the cell type, extent of involvement, and detection of residual disease following therapy.[29,451]

Similar to the findings in lymph nodes, lymphomas of predominantly small lymphocytes in the marrow, B-cell CLL or B small

For personal use only. No other uses without permission. Copyright ©2017. Elsevier Inc. All rights reserved.

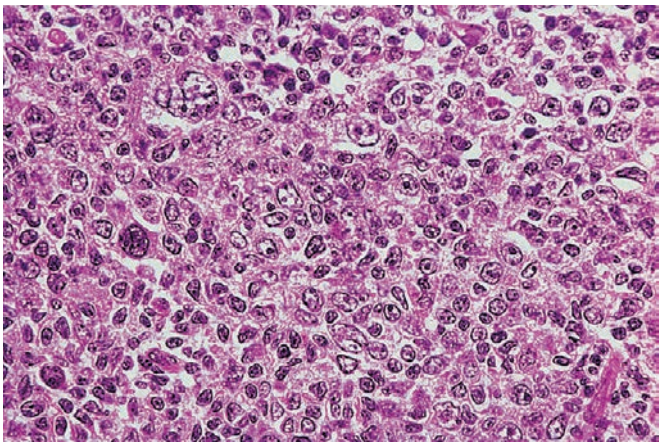

Figure 39.79 Bone Marrow Section From a Patient With a 6-Year History of Follicular Lymphoma. Cells resembling Reed–Sternberg cells and mononuclear variants are present.

lymphocytic lymphoma, may show foci of transformation. In occasional cases of follicular cell lymphoma or CLL, transformed cells resembling Reed–Sternberg cells or Reed–Sternberg mononuclear variants may be present (Fig. 39.79).[351,452]

There is no relationship between a diffuse or follicular pattern in the lymph node and the presence of focal or diffuse lesions in the marrow. Cases in which the lymph node has a diffuse pattern of involvement, such as small lymphocytic lymphoma or CLL, may manifest as focal lesions in the marrow. Cases with a follicular pattern in the lymph node may manifest as diffuse marrow involvement. Only rarely is the follicular pattern recapitulated in the marrow.[411,443]

Unusual variants of non-Hodgkin lymphoma involving marrow may lead to diagnostic problems because of the unusual morphology of the lymphoma cells or because of an accompanying proliferation of reactive cells. In anaplastic large cell lymphoma, the lymphoma cells may by virtue of size and nuclear irregularity mimic megakaryocytes. The problem is accentuated when the foci of lymphoma are small and indistinctly demarcated from the surrounding normal marrow tissue or when the lymphoma cells are intermingled with normal marrow cells. In cases of the small cell variant of anaplastic large cell lymphoma, the marrow infiltration may be scattered in the interstitium and difficult to recognize among the normal myeloid cells.[431] Despite this, marrow involvement by anaplastic large cell lymphoma can be detected on hematoxylin and eosin–stained sections alone in most cases. Antibody studies, including CD30, may be useful in clarifying the origin of the abnormal cells in equivocal cases.[431,453,454] The lymphoma cells in histiocyte-rich B-cell lymphoma and T cell–rich B-cell lymphoma may be partially obscured by the nonmalignant cell proliferation.[455] In T-cell/histiocyte-rich B-cell lymphoma, reactions with antibodies to B lymphocytes such as CD20 and histiocytes (CD68) are useful in delineating the two cell populations (Fig. 39.80). The blastic variant of mantle cell lymphoma may resemble ALL. Reactions for TdT (positive in lymphoblastic lymphoma/leukemia) and cyclin D1 (positive in mantle cell lymphoma) will help to distinguish those two processes.[456]

Post-transplant lymphoma of B-cell type does not commonly involve the marrow; when it does, the degree of infiltrate varies considerably.[457,458] Immunohistochemical reactions for B-cell origin and EBV in situ hybridization (EBER) studies may be very helpful in establishing the diagnosis (Fig. 39.81).

Granulomas may be found in all types of lymphoma in the marrow, with and without marrow involvement.[113]

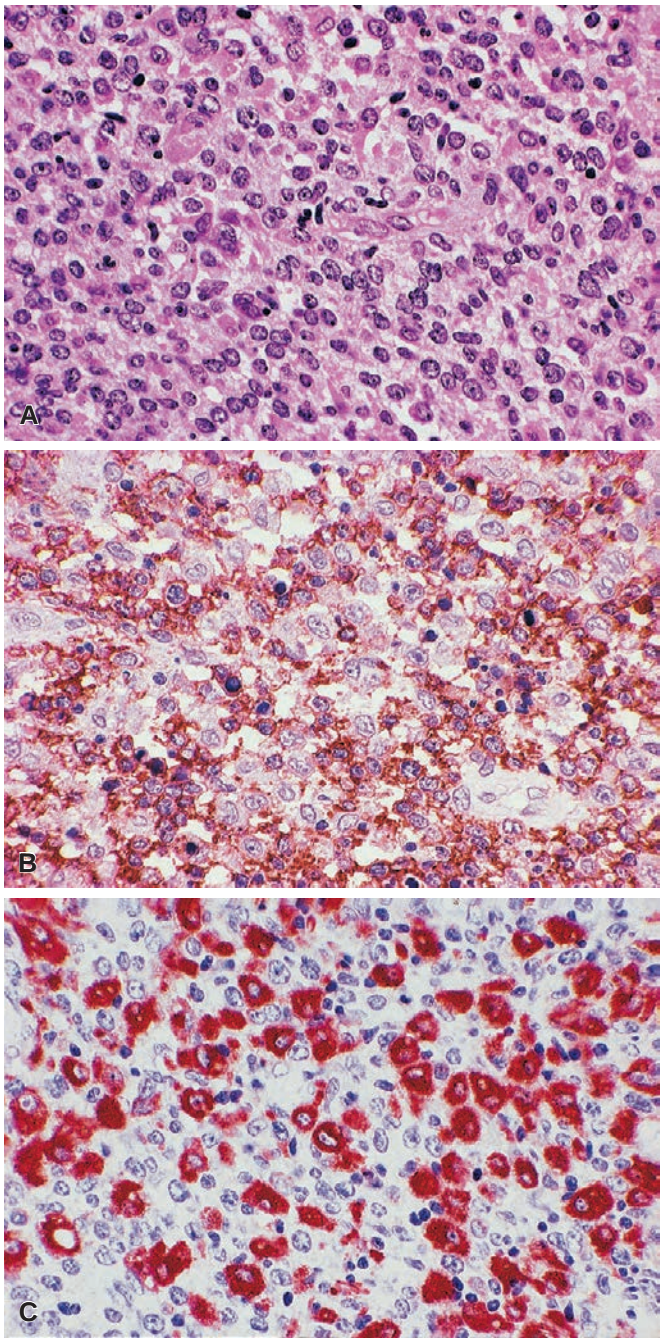

Figure 39.80 **A**, Marrow from a patient with T-cell/histiocyte-rich B-cell lymphoma. Histiocytes predominate in this area. **B**, The specimen in **A** reacted with antibody to CD20. The numerous lymphocytes are reactive, contrasting with the negative histiocytes. **C**, The marrow biopsy in **A** reacted with antibody to CD68 (KP1). The numerous positively reacting histiocytes in this area contrast with the negatively reacting lymphoma cells. (**B** and **C**, Immunoperoxidase.)

Other types of lymphoma with marrow involvement may present with blood involvement. Twenty to 40% of the cases of follicular center cell lymphoma with lymphoma in the marrow have lymphoma cells in the blood.[411,434] In some instances, the count may be very high and resemble CLL. The distinction is based on the presence of lymphocytes with cleaved nuclei and the characteristic pattern of focal paratrabecular involvement in small cleaved cell lymphoma.

For personal use only. No other uses without permission. Copyright ©2017. Elsevier Inc. All rights reserved.

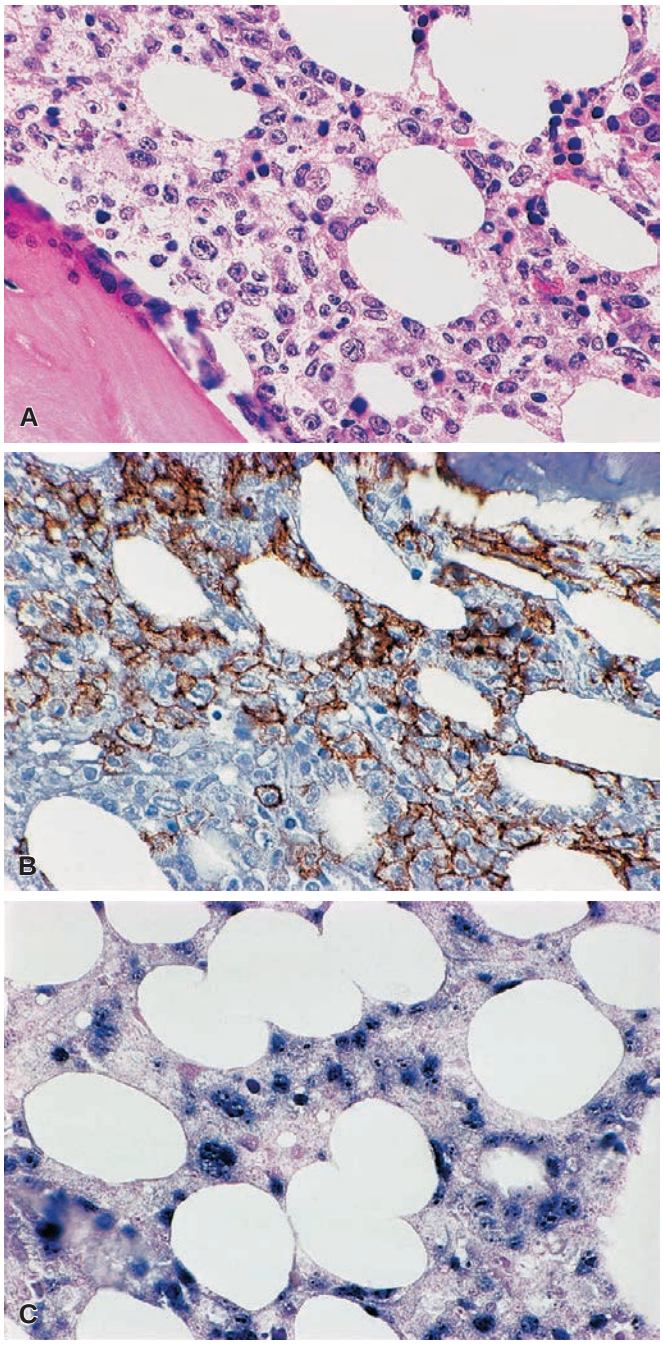

Figure 39.81 Post-transplant B-Cell Lymphoma. A, The lymphoma cells extensively infiltrate the marrow interstitium in this area; some residual myelopoiesis is present. **B**, The same specimen as **A** reacted with antibody to CD20; large lymphoma cells are positive. **C**, Numerous lymphoma cells are positive for EBV. (**B**, Immunoperoxidase; **C**, EBER.)

Expression of CD5 and weak surface immunoglobulin on the lymphocytes supports a diagnosis of CLL; lack of CD5 and expression of CD10 and intense surface immunoglobulin are more compatible with follicular lymphoma.[320,459] The lymph node findings are definitive.

Mantle cell lymphoma may present with marked involvement of the marrow and blood, and blood involvement is present in approximately half of cases with marrow disease.[411] Leukocyte counts of 270×10^9/L have been reported.[435,460,461] The blood findings may

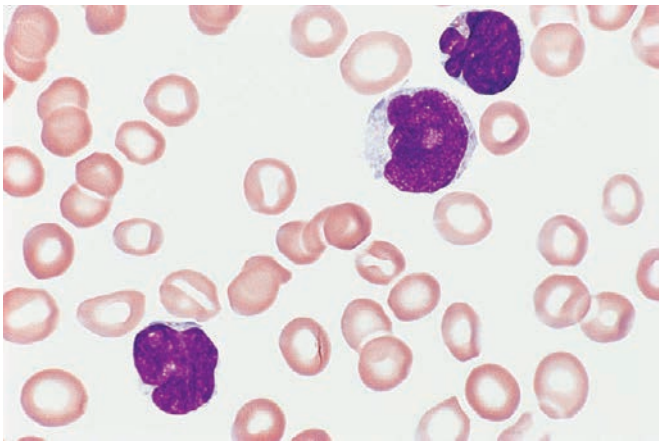

Figure 39.82 Blood Smear From an Adult Man With Leukemic Mantle Cell Lymphoma. The lymphoma cells vary considerably in size, nuclear lobulation, and degree of chromatin clumping. The large cell with a prominent nucleolus resembles a prolymphocyte. The smear is from the same patient as the specimen illustrated in Fig. 39.76.

resemble CLL, CLL/PL, PLL, and small cleaved cell lymphoma. The lymphoma cells may be quite pleomorphic with variation in size, nucleocytoplasmic ratio, degree of nuclear irregularity, and prominence of nucleoli (Fig. 39.82).[365] The lymphocytes express pan-B-cell antigens, CD5, and strong surface immunoglobulin. The lymphocytes usually do not express CD23 or CD10. The bone marrow involvement may be diffuse or focal; the focal involvement may be paratrabecular or nonparatrabecular. Rarely, naked germinal centers may be observed in the marrow lesions. The lymphoma cells express cyclin D1 by immunohistochemistry and the t(11;14)(q13;q32) chromosome abnormality by fluorescence in situ hybridization. The latter assay is particularly useful on peripheral blood samples.

T- and NK-Cell Lymphomas/Leukemias

Peripheral T-Cell Lymphoma, Not Otherwise Specified

Peripheral T-cell lymphoma, not otherwise specified (PTCL, NOS) consists of all mature T-cell lymphomas that do not correspond to any of the more specific disease entities in the WHO classification.[462,463] It has such unusual features in bone marrow biopsies as to warrant separate consideration.[429,430,464,465] This type of lymphoma is characterized by a high incidence of marrow involvement at the time of initial diagnosis, ranging from 30% to 70% in some studies. The marrow lesions are diffuse in approximately 60% of involved cases and focal in 40%.[430] The focal lesions are usually randomly distributed in contrast to the preferential paratrabecular involvement in follicular center cell lymphomas; occasional cases present with a focal nonparatrabecular and paratrabecular pattern. The infiltrates vary substantially in size and are usually irregular in configuration with poorly demarcated margins; in many instances the lesions appear to extend almost imperceptibly into adjacent normal marrow (Fig. 39.83). The diffuse lesions are characterized by complete intertrabecular replacement of marrow; in some instances the entire biopsy specimen is replaced (Fig. 39.84). Increased reticulin fibers are present in the area of lymphomatous involvement and frequently extend into the adjacent normal-appearing marrow.

The predominant cytologic pattern in the marrow lesions usually corresponds to the pattern in lymph node or other tissue biopsies

For personal use only. No other uses without permission. Copyright ©2017. Elsevier Inc. All rights reserved.

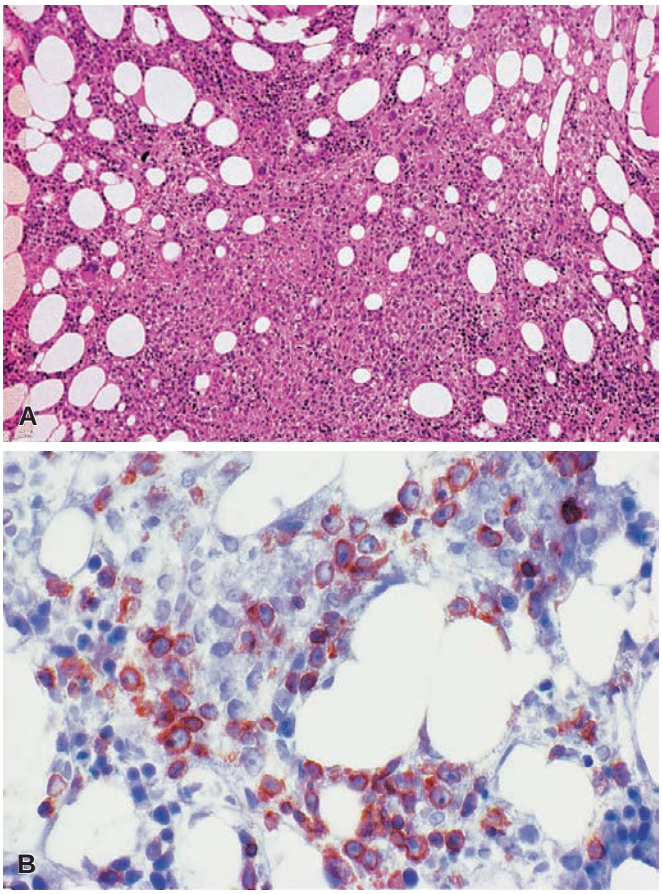

Figure 39.83 **A**, Marrow section from a patient with partial involvement by peripheral T-cell lymphoma. The lymphoma population is poorly demarcated and infiltrates the interstitium with some preservation of normal architecture. **B**, Margin of the lesion in **A** reacted with antibody to CD3. Numerous large lymphocytes, some with prominent nucleoli, are positive. (**B**, Immunoperoxidase.)

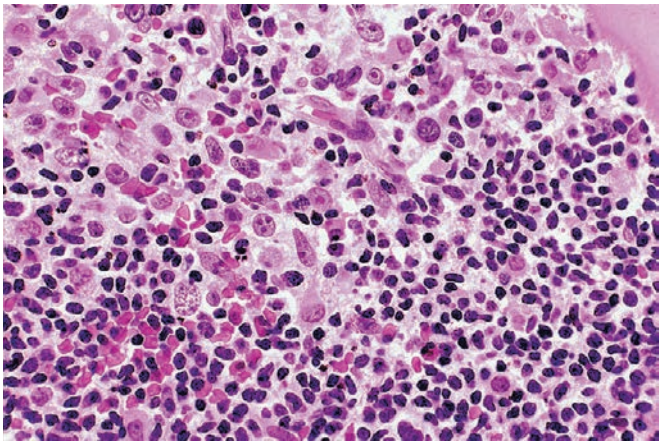

Figure 39.84 Marrow biopsy from a patient with peripheral T-cell lymphoma, showing extensive diffuse marrow involvement. The predominant cell population consists of small lymphocytes with a focus of large lymphocytes that have prominent nucleoli.

and can be heterogeneous, ranging from small cells with irregular nuclei to cases with predominantly large, pleomorphic cells. Mixed and large cell infiltrates are most frequently encountered. In some instances there is a relatively distinct demarcation between large and small cells. Large lymphoid cells with abundant amphophilic cytoplasm and prominent eosinophilic nucleoli, resembling Reed–Sternberg cells and mononuclear Reed–Sternberg variants, may be present. The small- and medium-sized lymphocytes have nuclei with condensed chromatin, which vary from regular to irregular in outline. The mixed cell and large cell/immunoblastic types usually have an associated polycellular infiltrate consisting of histiocytes, plasma cells, eosinophils, and neutrophils. Epithelioid histiocytes are frequently noted, either in focal clusters or scattered throughout the lesions. The focal collections frequently have a granulomatous appearance. Increased vascularity may be a prominent feature; the vascular component is primarily an endothelial cell proliferation with straight-lined channels. Immunohistochemical reactions are useful in identifying the atypical cells as T cells.

The differential diagnosis of PTCL, NOS in marrow includes Hodgkin disease, systemic mastocytosis, and polymorphous reactive lymphoid hyperplasia.[429,430] The most difficult problem relates to the last lesion, which may be present in marrow specimens from patients with a wide variety of immunologic disorders, including AIDS. Polymorphous reactive lymphoid hyperplasia has many histopathologic features similar to PTCL, NOS, including a heterogeneous population of lymphocytes with intermixed plasma cells, immunoblasts, eosinophils, endothelial cells, and epithelioid histiocytes. Distinction between the focal lesions of PTCL, NOS and the polymorphous reactive lymphoid lesions may not be possible solely on morphologic features. Markedly atypical cells with prominent nucleoli are more compatible with lymphoma. The size of the lesions is not always a reliable distinguishing feature; reactive lesions may show extensive marrow replacement, particularly in patients with AIDS. The lesions of PTCL, NOS may be relatively small. Correlation with non-marrow tissue biopsies and molecular genetic studies to detect a clonal T-cell population, supportive of T-cell lymphoma, may be useful in this differential diagnosis.

Hodgkin disease in the marrow may appear similar to the lesions of PTCL, NOS. The presence of classical Reed–Sternberg cells and the lack of atypia in the background lymphocyte population are suggestive of Hodgkin disease. Multinucleated immunoblasts resembling Reed–Sternberg cells may be present in PTCL, NOS; in these instances, review of lymph nodes and other tissue biopsies and immunohistochemical studies are critical in distinguishing PTCL, NOS from Hodgkin disease.

The lesions of systemic mastocytosis may be distinguished from PTCL by the reactivity of mast cells with CD117 and mast cell tryptase. The cells of systemic mastocytosis, however, may aberrantly express the T lineage-associated marker CD2 but should not express other T-cell markers, such as CD3, CD5, or CD7.

Genotypic studies to determine T-cell clonality are an important advance in distinguishing PTCL in marrow biopsies or other tissues from the disorders considered in the differential diagnosis.[466] Clonal rearrangement of one of the T-cell receptors is substantial evidence of a malignant process. The determination of clonality may be made on fresh aspirate or trephine biopsy specimens and fixed, paraffin-embedded tissue,[467] but decalcification and/or heavy metal fixation often destroys nucleic acids needed for these assays.

Adult T-Cell Leukemia/Lymphoma

Adult T-cell leukemia/lymphoma is an unusual form of mature (post-thymic) T-cell lymphoma occurring primarily in Japan; it is associated with the human retrovirus HTLV-1.[468–470] The highest

For personal use only. No other uses without permission. Copyright ©2017. Elsevier Inc. All rights reserved.

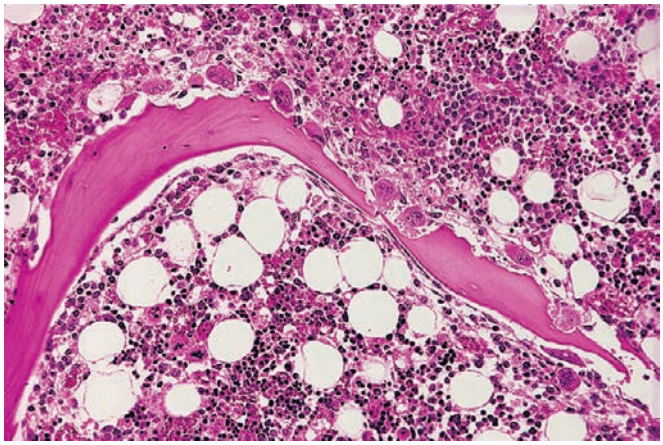

Figure 39.85 Marrow Biopsy From a Patient With Adult T-Cell Leukemia and Hypercalcemia. Marked osteoclastic activity with bone resorption is present.

incidence of this disease is in the Kyushu region of Japan; other endemic areas include the Caribbean basin and parts of western Africa. Sporadic cases are observed in other areas of the world, including the United States. The disease occurs in three principal clinical forms: smoldering, chronic, and acute. There are several histopathologic types including small, medium, and large pleomorphic cell types, large cell anaplastic, and Hodgkin-like. Blood and marrow involvement occurs principally in the acute form. Marrow involvement is characterized by a patchy infiltration of abnormal lymphocytes with lobulated or round nuclei. The distribution may be patchy even in cases with marked leukocytosis. Hypercalcemia is present in 28% of patients at diagnosis and in 50% of patients at some time during the course of the disease. The vast majority of patients with hypercalcemia have bone marrow involvement. However, increased osteoclastic activity may be present in cases with or without marrow involvement by the lymphoma and the findings may be those of osteitis fibrosa generalisata (Fig. 39.85).[468,471]

Sézary Syndrome

Sézary syndrome is a lymphoproliferative disorder, usually of CD4-positive T-helper lymphocytes, defined by the presence of erythroderma, generalized lymphadenopathy, and neoplastic T cells in the blood, skin, and lymph nodes.[472–476] The leukocyte count may be normal or markedly elevated with a high percentage of Sézary cells. The Sézary cells, as observed in Romanowsky-stained blood smears, have distinctive features. The nucleus frequently has an unusual configuration that has been characterized as cerebriform (Fig. 39.86A). Cytoplasmic vacuoles, which stain positively with the PAS reaction, may be present in a perinuclear location. Large and small cell variants have been described.[472] Ultrastructurally, the cells show marked nuclear convolutions (see Fig. 39.86B).[476,477] Despite the generalized nature of the disorder, the bone marrow sections in the majority of patients are normal. Involved cases usually show a sparse, interstitial infiltrate.[478] Marked marrow infiltration with replacement of normal hematopoietic cells is very uncommon. Rarely, small aggregates of Sézary cells may be observed.[472]

T-Cell Large Granular Lymphocytic Leukemia

T-LGL is characterized by a persistent, defined as 6 months or more, increase in peripheral blood large granular lymphocytes with no apparent cause and is usually associated with neutropenia.[479–483] The

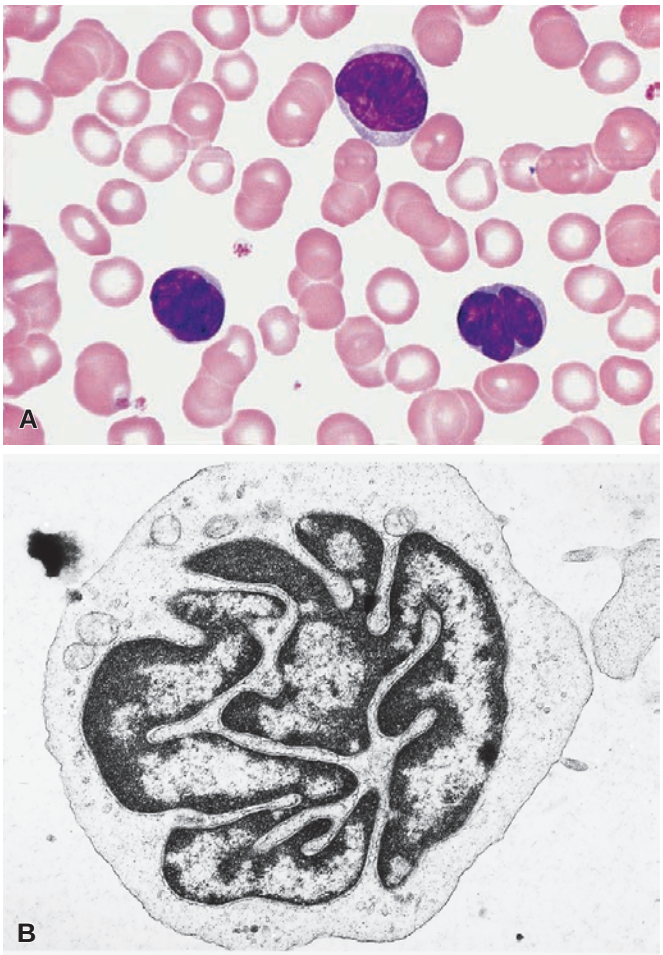

Figure 39.86 A, Three Sézary cells in blood smear. The nucleus in the larger cell in the upper field has delicate folds imparting a "cerebriform" appearance. The two smaller cells in the lower field have a more condensed chromatin and markedly lobulated nuclei. **B**, Ultrastructure of a Sézary cell; extreme convolution of the nucleus is a characteristic feature. (**B**, Uranyl acetate–lead citrate; ×22 000.)

characteristic lymphocytes in the blood are medium to large, with abundant slightly basophilic to pale cytoplasm containing a variable number of coarse azurophilic granules, and are frequently abundant in reactive processes, most notably viral infections and immune reactions. They may also be increased after myocardial infarction. Immunophenotypic and clonal studies are essential to the diagnosis.

There frequently are cytopenias, especially severe neutropenia, in T-LGL. Approximately 50% of patients have splenomegaly, but lymphadenopathy is uncommon. Rheumatoid factor and hypergammaglobulinemia are present in a subset of patients. The lymphocytes in T-LGL characteristically express CD3 and CD8, and are CD4 negative; CD11b, CD56, and CD57 are variably present.[484–486] Occasional cases express CD4 or CD4/CD8, and some cases may express primarily NK-cell markers. The definitive diagnostic evidence is based on a combination of T-cell receptor gene rearrangement studies, which usually show TRB and TRG rearrangements, and clinical features.[479,487–492]

The marrow involvement in T-LGL, which is usually interstitial, may be very difficult to recognize in routine sections; reactivity with antibody to CD8 is particularly useful in identifying the infiltrates (Fig. 39.87).[479,480,487,491] Approximately 50% of cases also have an

For personal use only. No other uses without permission. Copyright ©2017. Elsevier Inc. All rights reserved.

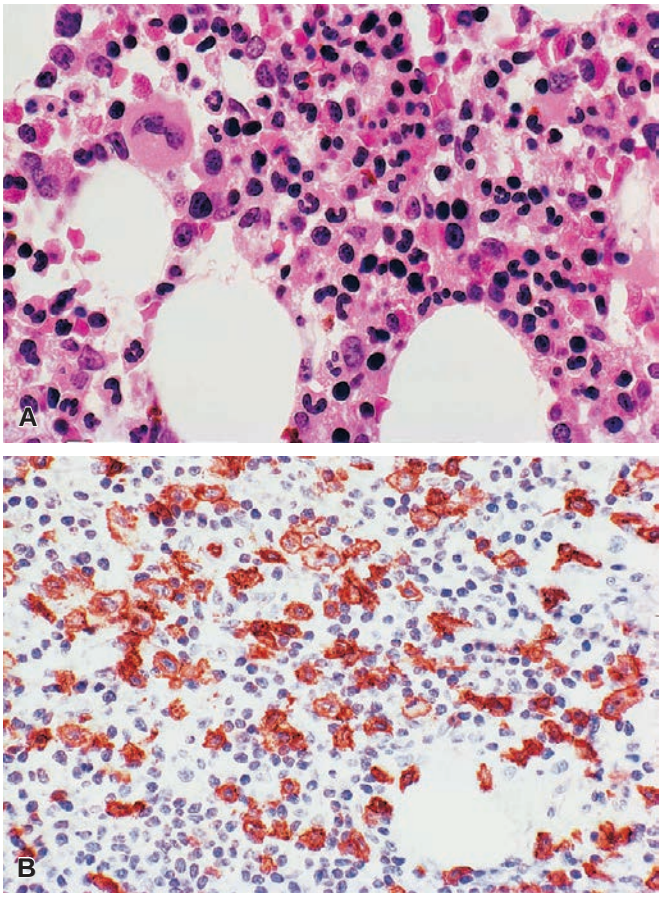

Figure 39.87 **A**, Bone marrow biopsy from an adult woman with large granulated T-cell lymphocytic leukemia. The leukemic lymphocytes are interspersed in the interstitium. **B**, Specimen in **A** reacted with antibody to CD8. There are numerous CD8-positive cells in the interstitium. (**B**, Immunoperoxidase.)

intrasinusoidal distribution of the leukemic lymphocytes. Occasional aggregates of lymphocytes may be present, and they usually contain an admixture of T and B cells. The T cells in these aggregates are usually CD4 positive and are not part of the leukemic process. The splenic infiltration is principally in the red pulp.

T-LGL does not show recurring cytogenetic abnormalities but usually demonstrates T-cell antigen receptor clonality and approximately one-third of cases have mutations of *STAT3*.[493]

Angioimmunoblastic T-Cell Lymphoma

The reported incidence of marrow involvement in this lesion, originally described as angioimmunoblastic lymphadenopathy, is 50%–70%.[494–496] The blood may show several abnormalities, including reactive lymphocytes, immunoblasts, and eosinophilia.[497,498]

The bone marrow lesions may be diffuse or focal; focal involvement is more common.[499,500] The margins of the focal lesions are usually somewhat indistinct, with poor demarcation from the surrounding hematopoietic tissue. In some cases, confluent multifocal lesions replace extensive areas of normal marrow. The lesions of angioimmunoblastic T-cell lymphoma are somewhat loosely structured and contain varying proportions of lymphocytes, immunoblasts, plasma cells, and histiocytes; neutrophils and eosinophils are also present (Fig. 39.88). Vascular proliferation, endothelial cells, and fibroblasts are frequently identified. Stains for reticulin show a marked

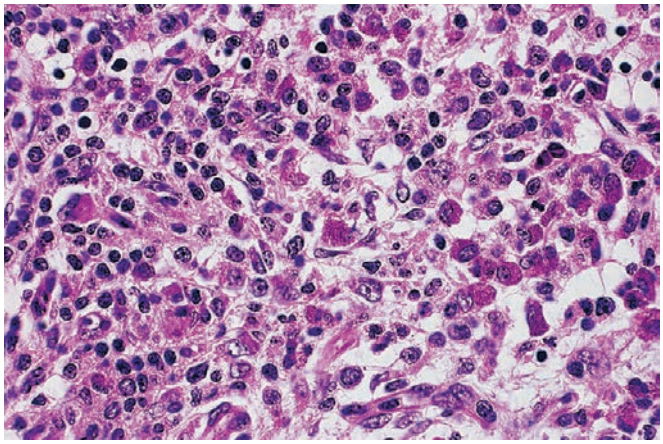

Figure 39.88 Bone marrow biopsy from a patient with lymph node diagnosis of angioimmunoblastic T-cell lymphoma. Marrow is diffusely involved by the process with a heterogeneous cell population.

increase in reticulin fibers in the involved areas. Collections of epithelioid histiocytes, imparting a granulomatoid appearance to some of the lesions, are reported. The amorphous PAS-positive material found in lymph node biopsies is less frequently encountered in bone marrow lesions. Immunohistochemical studies for kappa and lambda light chains show a polyclonal proliferation of immunoblasts and plasma cells in most cases, but coexisting B cell and clonal plasma cell proliferations may occur with some cases.[501] The neoplastic T cells are of germinal center origin in this lymphoma and often express CD10, CXCL13, and PD1 and scattered EBV-positive B cells are present in some cases by in situ hybridization.[500] The uninvolved marrow is frequently hypercellular. The hypercellularity may be a result of panhyperplasia or principally erythroid hyperplasia. The bone marrow and blood smears may contain varying numbers of lymphocytes at varying stages of development, including immunoblasts and mature plasma cells. Reactive lymphocytes and eosinophilia may be observed. Because of the high number of admixed reactive cells in the marrow with this disease, gene rearrangement studies for T-cell clonality are often useful if a prior lymph node or other tissue diagnosis of lymphoma has not been made.[466] Most cases show nonspecific clonal cytogenetic abnormalities and mutations in *TET2*, *IDH2*, *DNMT3A*, and *RHOA* are also common in this disorder.[502–504]

The significance of marrow involvement in regard to clinical outcome is unclear. Some, but not all, studies have indicated that patients with marrow involvement have a shorter survival than patients without marrow involvement.[494,498]

Anaplastic Large Cell Lymphoma

The diagnosis of anaplastic large cell lymphoma is now restricted to cases of T- or null-cell type and are subdivided into anaplastic lymphoma kinase (ALK)-positive and ALK-negative types.[505,506] Peripheral blood involvement is rare and is associated with extensive extranodal disease, including marrow involvement.[507] The marrow usually shows massive involvement, but in rare cases the cells may be almost imperceptibly scattered among the normal hematopoietic cells. The interstitium in the cases with marrow involvement may be very loosely structured with cell depletion (Fig. 39.89). The cases with lymphoma cells scattered among the normal hematopoietic cells may be overlooked in routinely stained sections, and immunohistochemical study for CD30 expression will detect these subtle cases (Fig. 39.89B).[453,454]

For personal use only. No other uses without permission. Copyright ©2017. Elsevier Inc. All rights reserved.

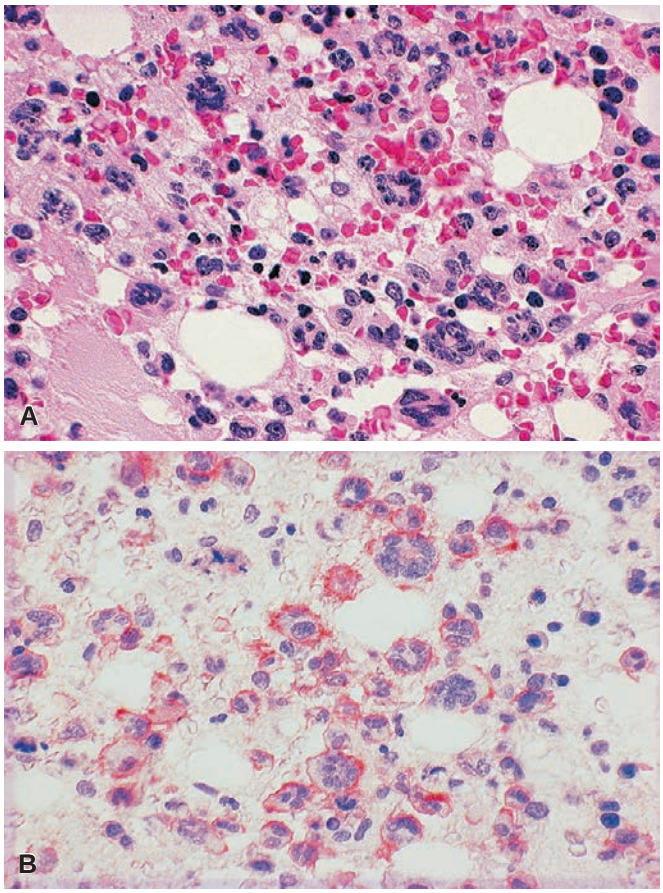

Figure 39.89 **A**, Area of marrow biopsy from a patient with anaplastic large cell lymphoma. The lymphoma cells are intermixed with normal marrow cells. **B**, Specimen in **A** reacted with antibody to CD30. The lymphoma cells are positive. (**B**, Immunoperoxidase.)

The small cell variant of anaplastic large cell lymphoma has a high incidence of marrow involvement when evaluated by routine morphology and immunohistochemistry (Fig. 39.90)[431] and appears to be more commonly associated with peripheral blood involvement. The degree of marrow involvement may be difficult to appreciate in routinely stained sections, and immunohistochemistry may be useful in such cases (see Fig. 39.90B). Because many cases of anaplastic large cell lymphoma show aberrant expression of the myeloid-associated marker CD13,[508,509] detection of CD30 and T-cell antigens, as well as evidence of a clonal T-cell gene rearrangement, are helpful in the differential diagnosis with AML.

Hepatosplenic T-Cell Lymphoma, Post-Transplant T-Cell Lymphoma, and Aggressive NK-Cell Lymphoma

Several uncommon types of T-cell lymphomas and NK-cell lymphomas have been reported in which the marrow is commonly involved. They include hepatosplenic T-cell lymphoma, post-transplant T-cell lymphoma, and aggressive NK-cell lymphoma. These are of relatively rare occurrence, and it is difficult to generalize about patterns of involvement.

Hepatosplenic T-cell lymphoma may be marked by an intrasinusoidal pattern but may also show subtle interstitial involvement without the characteristic intrasinusoidal pattern (Fig. 39.91).[465,510–512] The lymphoma cells may have blastic features or be very atypical.

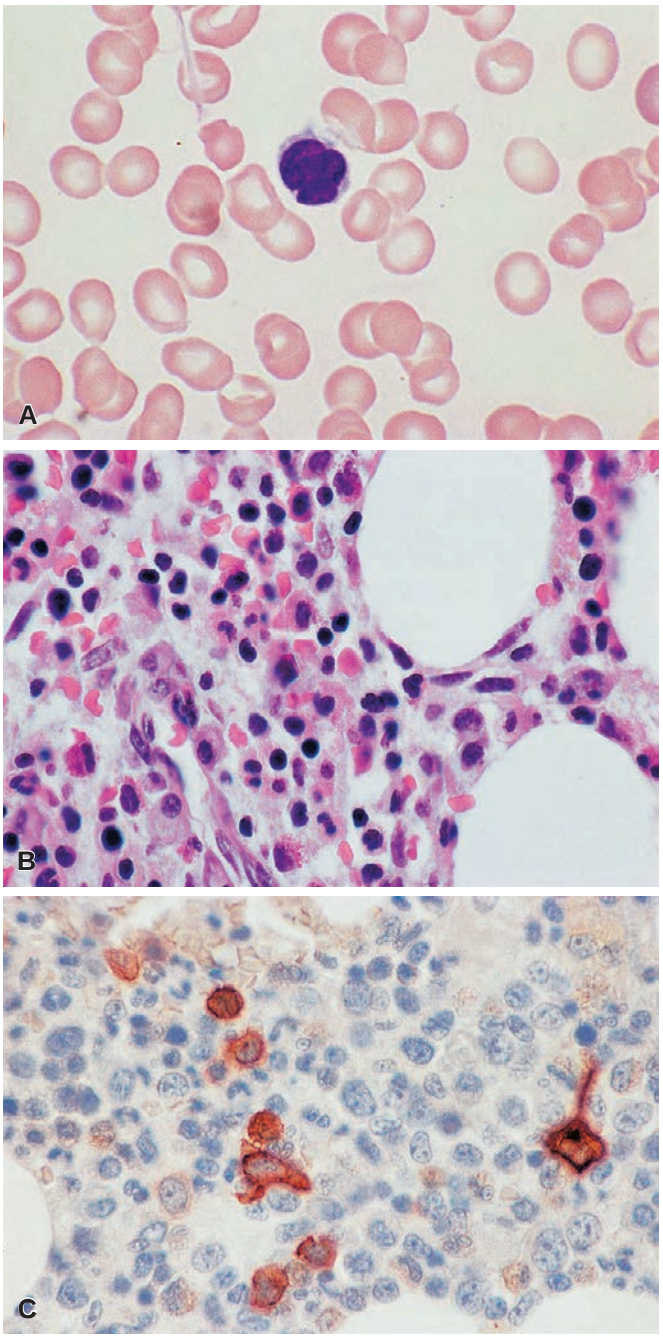

Figure 39.90 **A**, Lymphoma cell in blood smear from a 17-year-old male with small cell variant of anaplastic large cell lymphoma with associated t(2;5)(p23;p35). The cell has a convoluted nucleus. **B**, Bone marrow section from the same patient. The few lymphoma cells are scattered in the interstitium and difficult to recognize in this H&E stain. **C**, The same specimen as **B** reacted with antibody to CD30, which highlights the small and large lymphoma cells. (**C**, Immunoperoxidase.)

Cases with interstitial blast-like cells may be misinterpreted as MDS with excess blasts. The lymphoma cells are CD3+, TCRγδ+, TCRαβ–, CD56+/–, CD4–, CD8–/+, and CD5+ in most cases, but TCRαβ-positive cases occur and are otherwise similar to the TCRγδ cases. Immunohistochemistry, particularly anti-CD3, is very important in identifying the extent of disease and the intrasinusoidal pattern of involvement. Cytogenetic studies usually show

For personal use only. No other uses without permission. Copyright ©2017. Elsevier Inc. All rights reserved.

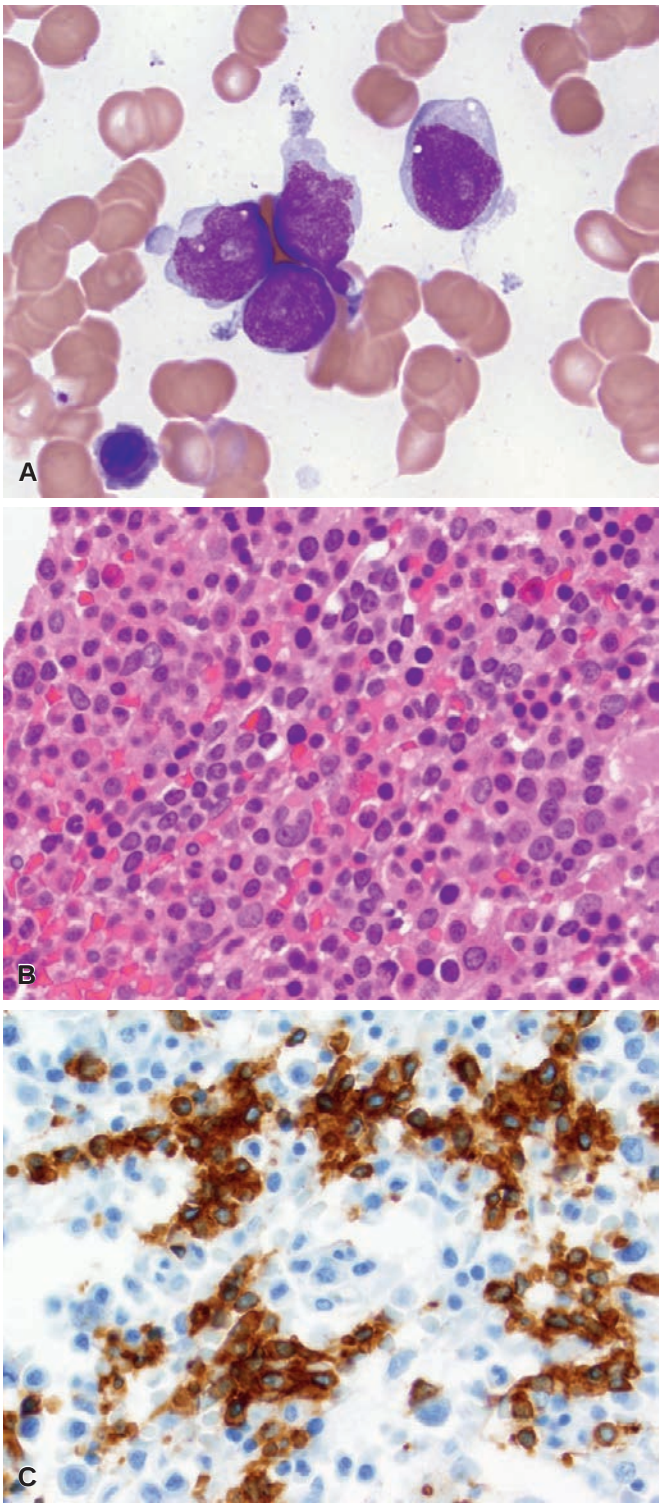

Figure 39.91 **A**, Bone marrow smear from a 17-year-old male with hepatosplenic gamma/delta T-cell lymphoma. The lymphoma cells vary in appearance and some have blast-like features. **B**, The marrow biopsy is markedly hypercellular, with extensive involvement and both an interstitial and intrasinusoidal pattern. **C,** Specimen in **B** reacted with anti-CD3 which highlights the intrasinusoidal pattern. (**C,** Immunoperoxidase.)

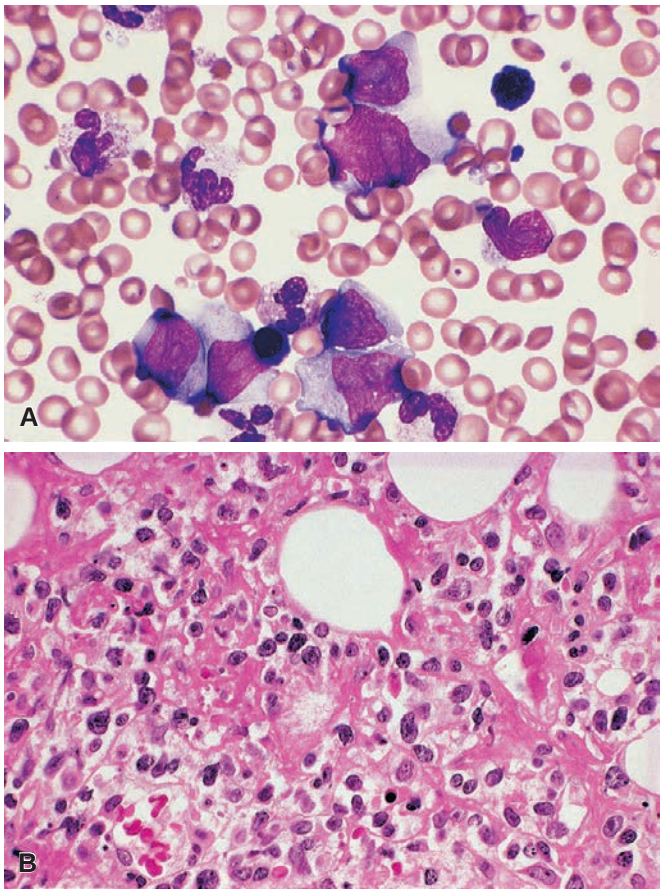

Figure 39.92 **Post-Transplant T-Cell Lymphoma.** **A**, Bone marrow smear from a 40-year-old woman, 28 and 8 years following renal transplantation. The lymphoma cells, which expressed CD2 and CD3, are large with abundant cytoplasm and very prominent nucleoli. **B**, High magnification of marrow section showing extensive interstitial involvement by noncohesive lymphoma cells. There is substantial depletion of normal hematopoiesis with cellular debris.

isochromosome 7, which is frequently associated with trisomy 8 and other abnormalities.[513–515]

Post-transplant T-cell lymphoma may be characterized by focal or extensive interstitial marrow involvement (Fig. 39.92). The use of immunohistochemistry may be important in identifying the presence, extent, and nature of these lesions since they may be overlooked in suboptimally prepared specimens. Examination of cytologic preparations, immunophenotyping, cytogenetics, and molecular studies may be important in classifying these lymphomas.

Aggressive NK-cell leukemia is a rare type of leukemia/lymphoma; it occurs most frequently in Asian teenagers and young adults.[516,517] This disorder may represent the leukemic counterpart of extranodal NK/T-cell lymphoma, nasal type.[518] The blood, marrow, liver, and spleen are commonly involved. The leukemia/lymphoma cells are large with ample and pale to slightly basophilic cytoplasm, which may contain fine or coarse azurophilic granules (Fig. 39.93A). The bone marrow infiltrates in biopsy sections may be diffuse, focal, or minimally interstitial. The leukemic cells appear monotonous with regularly shaped nuclei, coarse chromatin, and small nucleoli (see Fig. 39.93B). The cells usually mark as true NK cells, lacking surface CD3, but expressing cytoplasmic CD3 and CD56 and positive for EBV. The disease generally follows an aggressive clinical course as the name implies.

For personal use only. No other uses without permission. Copyright ©2017. Elsevier Inc. All rights reserved.

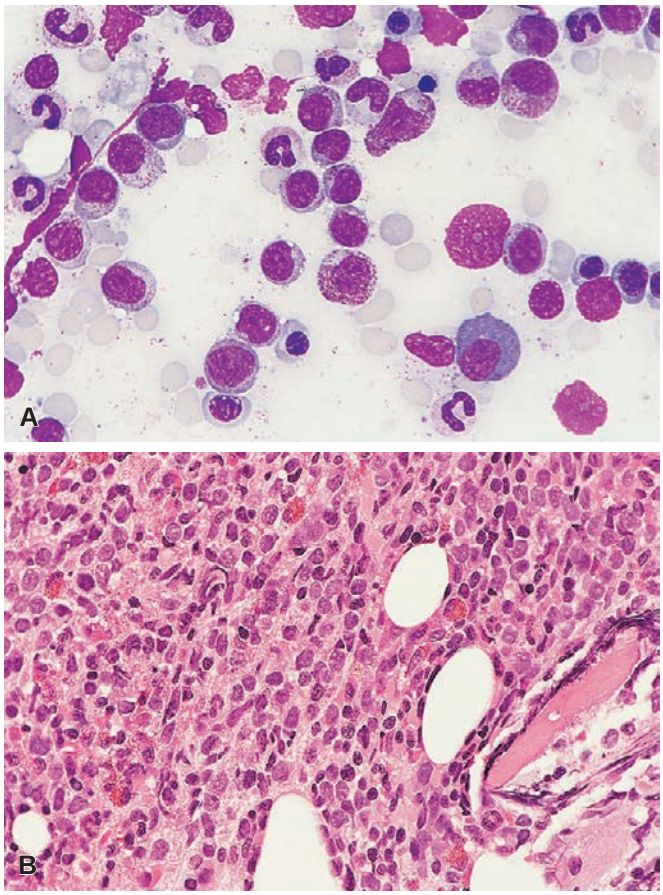

Figure 39.93 Aggressive NK-Cell Leukemia. A, Bone marrow smear from a patient with aggressive NK-cell leukemia. The lymphoma cells have relatively abundant cytoplasm containing numerous coarse azurophilic granules; the lymphoma cells are distinguished from neutrophil myelocytes by the lack of specific granules. **B**, Marrow biopsy from the patient in **A** showing extensive replacement. The lymphoma cells are relatively uniform in appearance with round nuclei and abundant cytoplasm. (Slides contributed by Dr. John K.C. Chan, Hong Kong.)

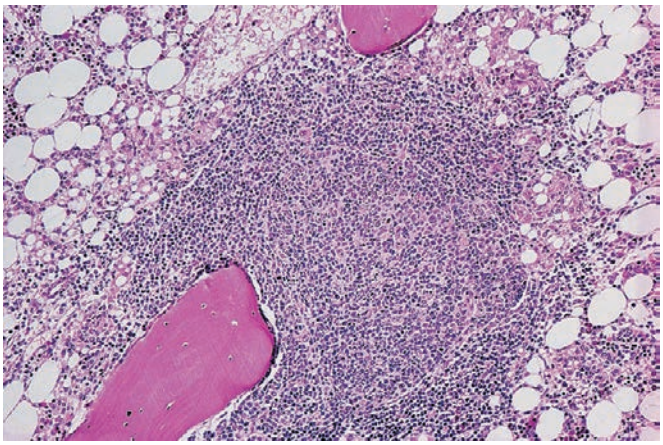

Figure 39.94 Paratrabecular germinal center formation in marrow of a patient receiving interleukin-2 therapy for metastatic melanoma. Several vacuolated macrophages are present at the margin of the lesion.

Benign Lymphocytic Aggregates

Benign lymphocytic aggregates occur relatively frequently in bone marrow trephine and particle sections. The incidence in biopsy specimens varies from 3% to 47%.[519–521] The reported incidence in autopsy specimens is 26%–62%. The incidence appears to increase with age and is higher in females than males. The aggregates occur in patients with a wide range of disorders, and the number and size in individual specimens vary considerably. Although lesions up to 1000 μm have been reported, the majority of aggregates are relatively small and well circumscribed.[522] Unusually large aggregates may occur in the marrows of patients with diseases related to the immune system, such as AIDS and rheumatoid arthritis. Large and numerous lymphoid aggregates, sometimes with germinal center formation, may be observed in the marrow of patients receiving immunotherapy. These lesions may occasionally be paratrabecular (Fig. 39.94), but paratrabecular aggregates should be viewed with a high suspicion for malignancy, particularly follicular lymphoma. The biologic significance of marrow lymphocytic aggregates in the majority of patients is unknown.[523]

The morphologic distinction between benign lymphocytic aggregates and malignant lymphoma, of small lymphocytes, in marrow biopsies from adults may be very difficult on morphology alone, and usually require immunophenotyping studies. Such studies show a T-cell predominance in most reactive lymphoid aggregates and a clonal B-cell predominance with aberrant CD5 expression in small lymphocytic lymphoma. Although general guidelines for making this distinction have been proposed, it is important to recognize that exceptions to these generalizations occur with distressing frequency.[524,525]

Benign aggregates are usually few in number, well circumscribed, loosely structured, and contain histiocytes and plasma cells and frequently mast cells in addition to lymphocytes. The lymphocytes are usually small with generally round nuclei that have condensed chromatin and inconspicuous or no evident nucleoli. Occasional nuclei may have irregular outlines. Vascular structures are frequently present. Germinal centers are uncommon in lymphocytic lesions in the marrow but when present are usually but not always evidence of a benign process. As previously noted, germinal centers may be observed in marrow lesions of mantle cell lymphoma and splenic marginal zone B-cell lymphoma. A preferential paratrabecular margination of a lymphoid infiltrate, usually associated with reticulin fibrosis, is evidence for a diagnosis of lymphoma. A random distribution of lymphoid aggregates with an occasional aggregate juxtaposed to a trabecula has no diagnostic specificity, since this pattern may occur with benign or malignant lesions. In occasional cases of follicular lymphoma, the follicular pattern in the lymph node is recapitulated in marrow lesions.

A particularly difficult diagnostic problem is the lymphocytic lesion referred to as polymorphous reactive lymphoid hyperplasia (see Fig. 39.28). These lymphoid aggregates are usually focal, poorly circumscribed, and randomly distributed. The lymphocytes are generally well differentiated; the nuclei of some and sometimes of many of the lymphocytes may be irregular. The infiltrate may be predominantly T-lymphocytes or have associated populations of plasma cells, immunoblasts, eosinophils, endothelial cells, phagocytic histiocytes, and epithelioid histiocytes. This lesion may occur in the marrow in any age group and is frequently associated with immune disorders such as immune cytopenias, collagen vascular disease, and, most notably, AIDS. The aggregates may be very large and in certain instances be virtually indistinguishable from the lesions of PTCL. Lesions of this type in marrow specimens from patients with AIDS are almost invariably reactive. In other instances in which the clinical or other tissue findings are equivocal, immunophenotypic or genotypic studies for clonality may be necessary.

For personal use only. No other uses without permission. Copyright ©2017. Elsevier Inc. All rights reserved.

It is important to recognize that benign lymphocytic aggregates may be present in marrow of patients with a prior diagnosis of marrow involvement by lymphoma; lymphoid aggregates in marrow specimens following chemotherapy should be evaluated as critically as those in the initial staging marrow biopsy. Marrow involvement by lymphoma in a patient with no other manifestation of the disease is very uncommon, and the diagnosis in such a situation should be approached with considerable caution and only if supporting immunophenotypic or genotypic evidence of a clonal process is present.

Marrow biopsies containing lymphocytic aggregates from patients treated with rituximab therapy for lymphoma should be carefully evaluated with immunohistochemistry to ascertain if the lymphocytes express the same antigens as the lymphoma cells which were present in the pretreatment specimen. Some loosely structured lesions, both randomly distributed and in paratrabecular locations, may be composed of reactive T cells rather than the B-cell lymphoma; this phenomenon is probably related to the therapeutic effects of the antibody (Fig. 39.95). Because rituximab is directed against CD20, other B-cell markers, such as CD79a and PAX5, are needed to exclude the presence of admixed neoplastic B cells in this setting.[451,526]

The application of antibodies that react with lymphocytes in paraffin-embedded, decalcified specimens often aids in distinguishing benign from malignant lymphocytic aggregates; as noted, this may be particularly critical after chemotherapy or therapy with monoclonal antibodies.[23,28] However, antibodies to B lymphocytes and T lymphocytes do not provide information about clonality. Antibodies to kappa and lambda light chains which may impart evidence of clonality are not sufficiently sensitive in most instances to identify surface immunoglobulins in lymphomas in paraffin-embedded biopsies. Despite this, most reactive marrow lymphocytes are T cells, and detection of an increased B-cell population in the marrow in the absence of germinal centers is usually supportive of B-cell lymphoma. One exception is in the setting of autoimmune disease in which B cells may predominate in reactive lymphoid aggregates. The presence of a mixed reactivity pattern (i.e., lymphocyte populations expressing both T and B surface antigens) in marrow lesions has been found to be more consistent with reactive lesions with the exception of follicular lymphoma which characteristically shows a mix of B and T cells when involving the marrow. A panel of antibodies, including CD10, CD5, CD3, and CD20, has been suggested as useful in distinguishing benign or atypical lymphocytic aggregates in the marrow from lymphoma; most benign aggregates do not express CD10 and CD23. As mentioned, in the setting of anti-CD20 therapy, the addition of other B-cell markers such as CD79a and PAX5 may also be useful. There are exceptions to all generalizations, and caution should be exercised in the interpretation of immunohistochemical studies. Careful analysis of both lymph node and bone marrow specimens with the same panel of antibodies is necessary in evaluating marrow biopsies for lymphoma. Genotypic studies should be performed in those instances in which the marrow findings are indeterminate, and a therapeutic decision is contingent on the presence or absence of marrow involvement. Even with this approach, difficulties in distinguishing benign from malignant lesions persist, especially in the setting of autoimmune disease,[527] and continued observation is the most prudent course in some patients. In cases in which the morphologic and immunophenotypic studies are inconclusive, some authors have suggested the terminology "indeterminate for lymphoma" for staging marrows.[524,528]

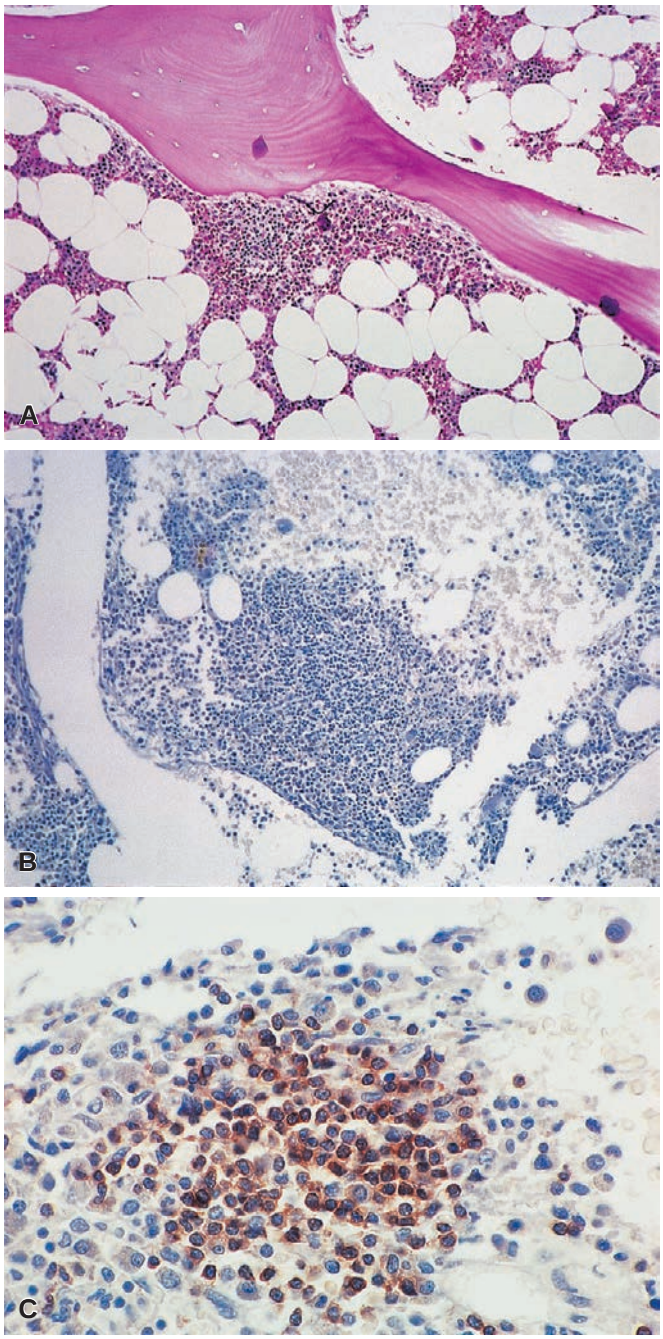

Figure 39.95 Post Rituximab Therapy. A, One of several paratrabecular and nonparatrabecular lymphocytic aggregates in bone marrow biopsy following rituximab therapy. **B**, Same specimen as **A** evaluated with antibody to CD20; the lymphocytes are nonreactive. Similar results were found with antibody to CD79a. **C**, Same specimen as **A** and **B** reacted with antibody to CD3. Most of the lymphocytes are intensely reactive. Similar results were found in other lymphocytic aggregates. (**B** and **C**, Immunoperoxidase.)

Hodgkin Lymphoma

The incidence of marrow involvement in Hodgkin lymphoma varies with the histopathologic type: it is approximately 10% in classical Hodgkin mixed cellularity type and approximately 1% in lymphocyte-predominant Hodgkin and lymphocyte-rich classical Hodgkin disease.[529–531] Nodular sclerosis has an incidence of approximately 3%.[531–533] The overall incidence of bone marrow involvement in patients with stage IV disease is reported to be 32% and varies with the histologic subtype: 3% lymphocyte predominant, 37% nodular sclerosis, 49% mixed cellularity, and 10% unclassified type.[533] The

For personal use only. No other uses without permission. Copyright ©2017. Elsevier Inc. All rights reserved.

prognosis for patients with stage IV disease does not appear to be adversely affected by bone marrow involvement.

The lymphocyte depletion type of Hodgkin lymphoma, which has a high incidence of marrow involvement, approximately 50%, is an uncommon form of Hodgkin lymphoma.[534,535] Because the clinical presentation in some patients with lymphocyte depletion–type disease is characterized by little or no peripheral lymphadenopathy, the initial diagnostic specimen may be the bone marrow biopsy. In the vast majority of patients, however, other sites of disease, especially above the diaphragm, are present at the time of marrow involvement by classical Hodgkin lymphoma.

The detection of marrow involvement appears in part to be related to the amount of tissue available for examination. Marrow involvement in most instances results from widely disseminated disease, is significantly associated with B symptoms, bulky disease, involvement of lymph nodes both above and below the diaphragm, and is negatively correlated with a large mediastinal mass.[533] Forty percent to 50% of patients with AIDS who develop Hodgkin lymphoma have marrow involvement; the marrow may be the initial diagnostic specimen and the only site of involvement in this situation.[143]

The histopathologic classification of Hodgkin lymphoma should not be based on examination of involved bone marrow because of different manifestations of the disease in lymph node and bone marrow tissue. Fibrosis is a common finding in Hodgkin lesions in the marrow and is not limited to nodular sclerosis and lymphocyte depletion types.

Definitive histopathologic criteria for the diagnosis of marrow involvement in Hodgkin lymphoma include typical Reed–Sternberg cells in a cellular background characteristic of Hodgkin lymphoma or mononuclear Reed–Sternberg variants in a cellular background typical of Hodgkin lymphoma if typical Reed–Sternberg cells are identified in other specimens (Fig. 39.96).[536–538] The presence of atypical cells lacking the features of Reed–Sternberg cells or mononuclear variants in a characteristic Hodgkin environment in a patient with histopathologically proven disease has historically been considered highly suspicious for involvement; however, if the atypical cells express CD30 and CD15, typical immunophenotypic features of classical Hodgkin lymphoma, the marrow can be considered involved by disease. Foci of fibrosis in the absence of Reed–Sternberg cells or mononuclear variants in a patient with an established diagnosis of Hodgkin lymphoma is not in itself sufficient evidence for a definitive diagnosis of marrow involvement but should be viewed as suspicious. In the latter instance, multiple levels of the biopsy should be examined, and when immunophenotyping studies of atypical cells are not conclusive, repeat biopsies should be performed.

Hodgkin lesions in marrow may be diffuse or focal; the extent of involvement ranges from a single, small lesion to complete replacement of multiple biopsy specimens. Diffuse involvement is found in 70%–80% of positive marrow biopsies; the Hodgkin tissue in these cases replaces the entire area between trabeculae.[539] Focal lesions are variable in size and may be surrounded by normal hematopoietic tissue or scattered in a hypocellular background (Fig. 39.97); the latter pattern is more frequent following chemotherapy. The focal lesions tend to be polycellular, with a predominant population of small lymphocytes with admixed neutrophils, eosinophils, plasma cells, histiocytes, Reed–Sternberg cells, and mononuclear variants. The diffuse lesions may manifest in several patterns. In the majority of cases, the Hodgkin tissue is hypercellular with a population of cells characteristic of mixed cellularity Hodgkin lymphoma in the lymph node (see Fig. 39.96). In some patients the marrow shows extensive hypocellularity characterized by a generally loose, sparsely cellular connective tissue with scattered, variably sized hypercellular areas containing lymphocytes, histiocytes, Reed–Sternberg cells, and mononuclear variants. Areas of necrosis may be present and are more common in post-therapy specimens than at initial diagnosis (Fig. 39.98). Varying degrees of fibrosis may be present. In some cases, entire biopsy specimens show replacement by dense fibrous connective tissue with few identifiable lymphocytes or histiocytes (Fig. 39.99). In others, scattered islands of cells are interspersed among the collagen fibers: some of these cells show features suggestive of Hodgkin cells; others are too distorted for accurate identification. In some instances the Hodgkin lesions are very hypercellular with a predominant population of Reed–Sternberg cells or mononuclear variants. Various combinations of these patterns may be present in the same biopsy specimen or in different specimens from the same patient. Necrosis and hypocellularity are more common in marrow from treated patients than untreated patients. In marrow involvement with lymphocyte depletion Hodgkin lymphoma, a typical consolidated lesion characterized by an inflammatory cellular infiltrate accompanied by a distinct amorphous deposition of eosinophilic background substance and Reed–Sternberg cells has been described.[534]

The presence of Reed–Sternberg cells or mononuclear variants is of critical importance to the recognition of Hodgkin lymphoma in marrow, and a definitive primary diagnosis should not be established without their identification in the appropriate cellular milieu.

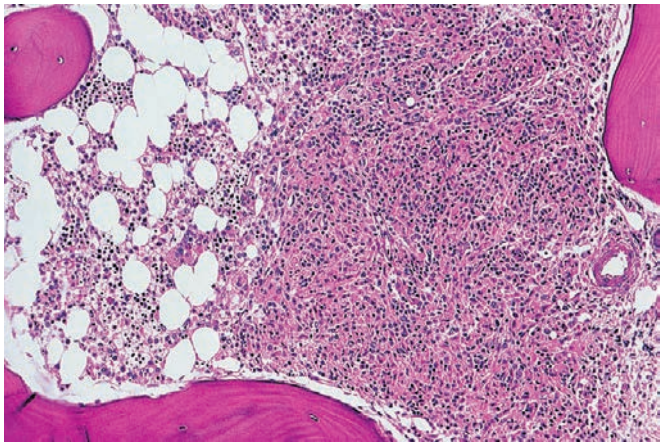

Figure 39.96 Bone marrow biopsy from a patient with mixed cellularity Hodgkin lymphoma. There is extensive involvement in this area of the biopsy.

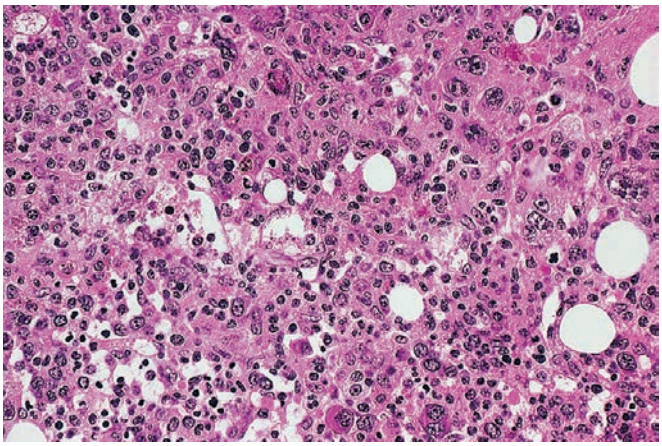

Figure 39.97 Marrow With Several Scattered Foci of Hodgkin Lymphoma. The lesions, which contain several Reed–Sternberg cells, are indistinctly demarcated from normal marrow.

For personal use only. No other uses without permission. Copyright ©2017. Elsevier Inc. All rights reserved.

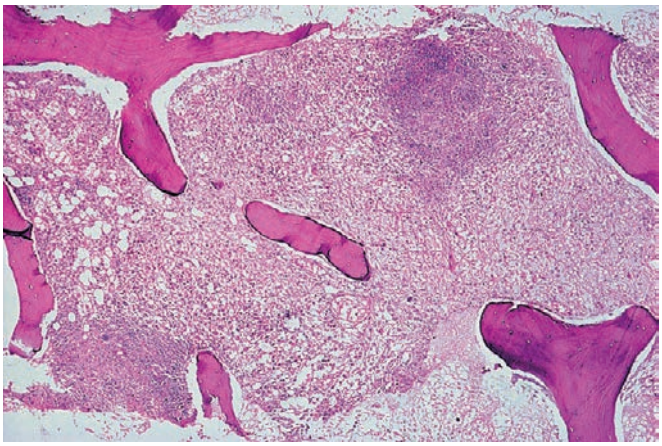

Figure 39.98 Two foci of Hodgkin lymphoma in a large area of necrotic debris in a post-treatment marrow specimen.

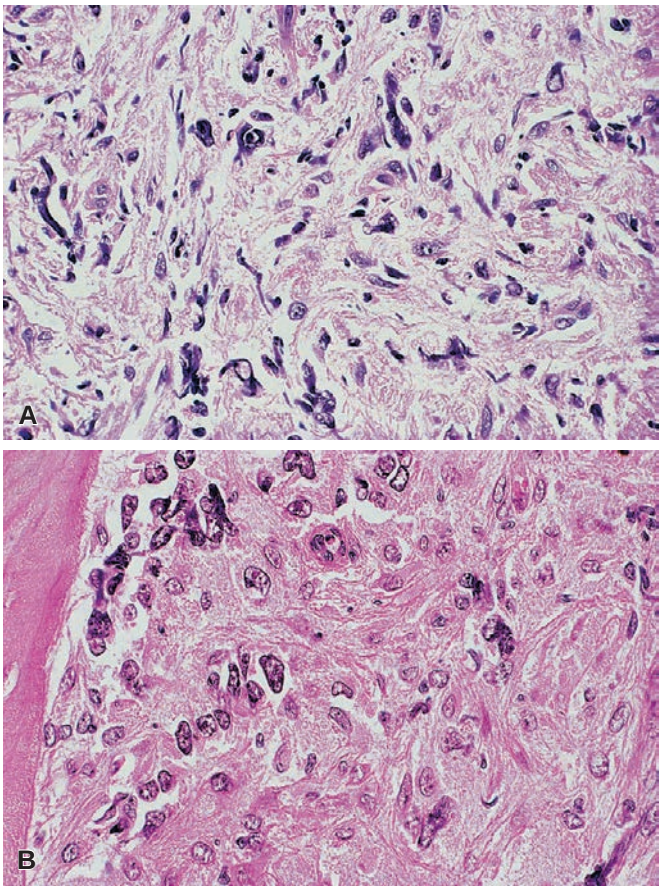

Figure 39.99 **A**, Marrow biopsy from a patient with Hodgkin lymphoma. The marrow space is completely replaced by dense fibrous connective tissue. Numerous vascular structures and small foci of distorted cells resembling Reed–Sternberg cells and mononuclear variants are present. **B**, Same specimen as **A** showing several focal collections of cells that resemble distorted Reed–Sternberg cells and mononuclear variants.

Several serial sections of the marrow biopsies may have to be examined before satisfactory Reed–Sternberg cells or mononuclear variants are detected. It is important not to misinterpret megakaryocytes as forms of Reed–Sternberg cells; this problem can be avoided by strict adherence to the principle of identifying Reed–Sternberg cells or variants only in the appropriate cellular background and by the use of immunohistochemical studies. Reed–Sternberg-like cells may be observed in marrow specimens with involvement by follicular lymphoma, PTCL, and anaplastic large cell lymphoma (see Fig. 39.79); the clinical history, membrane surface marker studies, and characteristic tissue changes of Hodgkin lymphoma should aid in distinguishing these disorders.[452] In classical Hodgkin lymphoma, the Reed–Sternberg cells and mononuclear variants express CD30 and usually express CD15. The cells also show weak nuclear expression of PAX5, may show weak and variable expression of CD20, and are CD45 and CD3 negative. Approximately 40% of cases are EBV positive by in situ hybridization. In some instances, in which a T-cell lymphoma such as anaplastic large cell lymphoma is in the differential diagnosis, genotypic studies for T-cell clonality may be necessary.

Although marrow involvement by lymphocyte-predominant Hodgkin lymphoma is rare, when present it shows features more similar to histiocyte and T cell–rich large B-cell lymphoma than classical Hodgkin lymphoma, with large atypical cells admixed with T cells and histiocytes, and usually lacking a prominent eosinophil component.[530,540] In contrast to classical Hodgkin lymphoma, the neoplastic cells of lymphocyte-predominant Hodgkin lymphoma are strongly and uniformly CD20 positive and usually CD30 negative.[529,531]

Uninvolved areas of marrow in specimens with involvement by Hodgkin lymphoma may be hypercellular, normocellular, or hypocellular.[541] Nonspecific alterations, including stromal damage, inflammatory cell infiltration, and disturbed hematopoiesis, may be present.[542] These alterations may occur singly or in combination.

Similar to spleen, liver, and lymph nodes, benign granulomatous lesions may be present in bone marrow sections in patients with Hodgkin lymphoma.[539] The marrow is the least likely organ in this group to contain the granulomas, but their presence may lead to diagnostic difficulty. The lack of typical Reed–Sternberg cells or mononuclear variants is an important feature in distinguishing these lesions from Hodgkin lymphoma. The presence of granulomas does not constitute evidence of involvement. Granulomas in post-therapy patients should always be evaluated for the possibility of an infectious agent.[539,543] Benign lymphocytic aggregates may also be present.

Rarely, a patient whose disease is being staged for marrow involvement by Hodgkin lymphoma has a concurrent parvovirus B19 infection. The presence of very large erythroid precursors in the smears or sections may result in confusion with Reed–Sternberg cells and consideration of marrow Hodgkin lymphoma (see Fig. 39.22B). The lack of a characteristic cellular environment and the usually marked erythroid hypoplasia are strong evidence of parvovirus B19 infection. Serologic or molecular studies for parvovirus B19 should be performed in suspected cases.

Histiocytic Disorders

Malignant Histiocytosis

Malignant histiocytosis is a rare disease that uncommonly involves marrow. As a result, any comments about the characteristics of these lesions in the marrow are based on limited observations. The histiocytic and dendritic cell neoplasms arise from phagocytic and accessory cells which have major roles in the processing and presentation of antigens to lymphocytes.[544–546] The changing concept of "malignant histiocytosis," and the recognition that many of the lesions previously classified under this term represent other disorders, mean that prior descriptions of marrow involvement in malignant histiocytosis may no longer be valid.[313,547,548,549–553] Generalizations about patterns of marrow involvement must be qualified because of the rare occurrence of the disorder and the even more rare

For personal use only. No other uses without permission. Copyright ©2017. Elsevier Inc. All rights reserved.

occurrence of marrow involvement. If the morphologic characteristics of a marrow lesion suggest a histiocytic disorder, appropriate immunohistochemical, cytogenetic, and molecular studies should be performed. The diagnosis is essentially one of exclusion. Other poorly differentiated neoplasms of the hematopoietic system may have morphologic features that have been associated with malignant histiocytosis.[553] Cell marker studies for B- and T-cell lineage should be performed to exclude poorly differentiated lymphomas, but true histiocytic neoplasms arising from, and clonally related to, B-cell lymphomas are now well described.[554] Poorly differentiated carcinomas and plasmablastic tumors must also be excluded. Since the macrophage is derived from the monocyte system it may be difficult in some instances to distinguish between what is termed malignant histiocytosis and what is monoblastic/monocytic leukemia. The use of one or other of these terms may be arbitrary based on the constellation of clinical and morphologic findings.

In marrow biopsies, the infiltration by malignant histiocytes may be focal or diffuse (see Fig. 39.102). Bone marrow involvement may be extremely difficult to recognize in sections that contain only scattered malignant cells. In smear preparations, the cells occur singly or in small groups scattered among the normal hematopoietic cells or, because of their large size, at the edges of the smears. The malignant histiocytes vary in size; cells up to 40–50 µm or larger may be found. The cytoplasm is usually abundant, with evidence of pseudopod formation and fragmentation; it is variably basophilic, occasionally with numerous small, sharply defined vacuoles in some cells. Very small azurophilic granules may be present in the cytoplasm of some of the larger cells. Occasional malignant histiocytes show evidence of phagocytosis; prominent hemophagocytosis is a relatively uncommon finding in unequivocally malignant-appearing cells. The nucleus may be round or contorted; the larger cells generally have more contorted nuclei. The chromatin is coarsely reticular. Nucleoli may be very prominent or inconspicuous. Stains for nonspecific esterase and acid phosphatase are positive. The demonstration of nonspecific esterase reactivity in poorly differentiated cells, however, is not sufficient to establish a diagnosis of malignant histiocytosis since this enzyme may be present in other poorly differentiated malignant cells. The malignant histiocyte should be reactive with antibodies to lysozyme and CD68 (KP1 and PGM1) and nonreactive to antibodies to T and B lymphocytes (Fig. 39.100B). There may be some degree of reactivity with antibody to S100 protein. The proliferation of the malignant histiocytes may be accompanied by a proliferation of benign-appearing histiocytes with abundant cytoplasm and prominent hemophagocytosis; this probably results from cytokine stimulation related to the malignant cell proliferation.

Cytogenetic studies may be helpful in identifying a clonal abnormality in the malignant cells, for example, the presence of an abnormality involving chromosome 11 at band q23.3 characteristic of monoblastic leukemia.

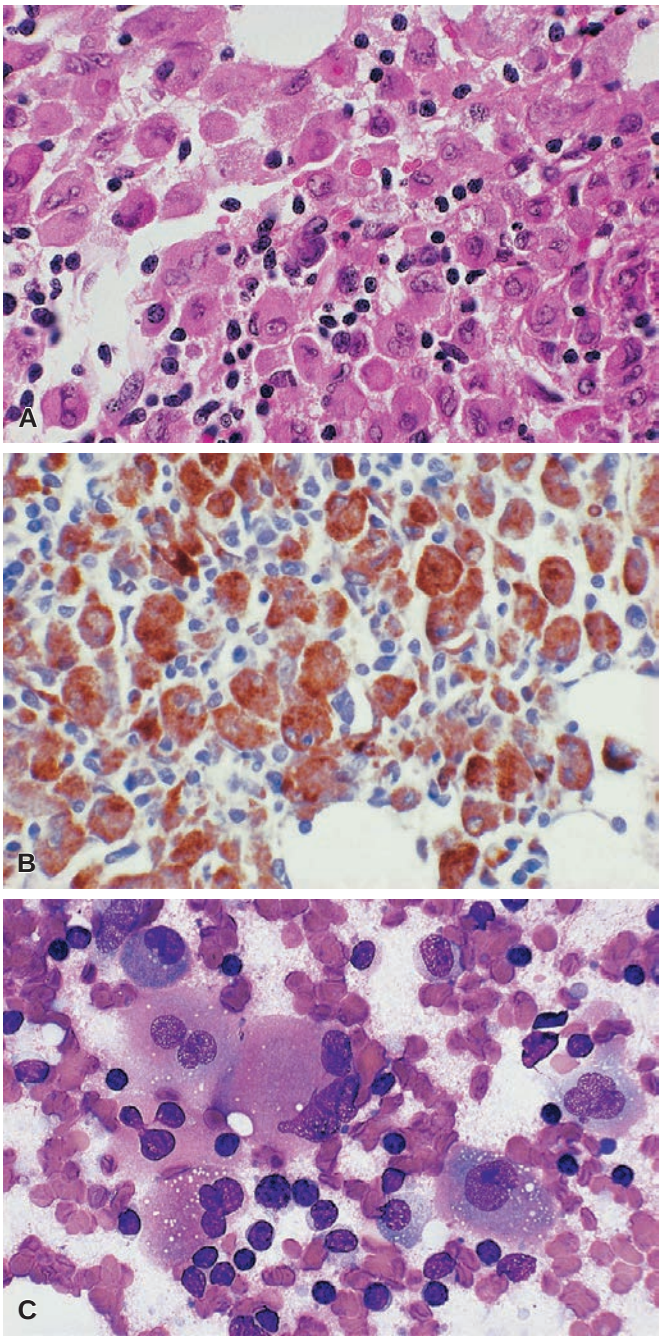

Figure 39.100 **A**, Marrow biopsy from an adult woman with marrow involvement by a histiocytic proliferation with an associated clonal t(9;11)(p21.3;q23.3) cytogenetic abnormality. The histiocytes have a somewhat bland appearance with abundant cytoplasm. **B**, The biopsy in **A** reacted with antibody to CD68 (KP1). **C**, Smear from the specimen in **A** and **B** showing several histiocytes, most of which have lobulated nuclei and abundant cytoplasm. (**B**, Immunoperoxidase.)

Hemophagocytic Syndromes

The hemophagocytic syndromes are a group of disorders with the unifying morphologic features of a proliferation of phagocytic histiocytes that may be present in all hematopoietic organs. These processes usually have systemic manifestations and may be accompanied by a fulminant clinical course and high mortality.

The hemophagocytic syndromes occur both as genetic and acquired disorders.[555–558] The genetic disorders include primary (familial) hemophagocytic lymphohistiocytosis (PHLH), which is an autosomal recessive disorder and in which the hemophagocytosis is the only manifestation of the disease, and the immune deficiency syndromes Chédiak–Higashi syndrome, Griscelli syndrome, and X-linked lymphoproliferative syndrome which have additional clinical features. Several genetic abnormalities associated with lymphocyte cytotoxic defects are involved in PHLH: 13%–50% of the patients have mutations in the perforin 1 *(PFR1)* gene, which results in impaired perforin production.[559,560] Mutations of the *UNC13D* gene, which is on chromosome 17q25, occur in 17%–30% of cases and result in impaired granule exocytosis.[555,557,560,561] Recent studies have found numerous other genetic abnormalities associated with PHLH.[546]

For personal use only. No other uses without permission. Copyright ©2017. Elsevier Inc. All rights reserved.

The acquired hemophagocytic syndromes occur at all ages. Several agents, including viruses and other infectious organisms, and malignant lymphomas have been implicated as causative factors. The viruses most frequently implicated include EBV, cytomegalovirus, adenovirus, and parvovirus B19.[555,562–575] The syndrome has also been associated with protozoan infections including *Babesia microti* and *Leishmania*.

The macrophage activation syndrome (MAC) is a subtype of the secondary hemophagocytic syndromes which is a complication of systemic inflammatory diseases in children, particularly juvenile rheumatoid arthritis.[576,577] Similar to other types of these syndromes, it appears to be related to hyperactivation and proliferation of T lymphocytes and macrophages.

The hemophagocytic syndromes are an epiphenomenon in which the underlying mechanism appears to be activation of the immune system including NK cells, cytotoxic T lymphocytes, and the monocyte–macrophage system, which then interact. Defective cytotoxic activity on the part of this system leads to sustained high cytotoxic levels, which result in the constellation of the findings in the syndrome.[556,557,564,566,568,570–583]

The hemophagocytic syndromes frequently have an abrupt onset. Evidence of multisystem disease is usually present, particularly in patients with viral infections.[556,569,575] A high percentage of patients have coagulation abnormalities with disseminated intravascular coagulation. Laboratory studies show elevated triglycerides, ferritin, transaminases, and lactate dehydrogenase. The fibrinogen level is decreased. There are usually cytopenias, frequently pancytopenia.

The marrow smears contain numerous histiocytes, many showing evidence of phagocytosis of erythrocytes and precursors, platelets, and granulocytes. There is frequently an accompanying depression of erythroid precursors, granulocyte precursors, or both; megakaryocytes may be normal or increased in number. In biopsy sections, the increased histiocytes are dispersed throughout the interstitium and sinuses; occasional clusters may be present (Fig. 39.101). The evidence of phagocytic activity may be less prominent in sections compared with smear preparations (Fig. 39.102). In addition to the histiocytic proliferation, granulomas may be noted, and areas of cellular necrosis are frequently present. The bone marrow findings may change substantially over a period of days, with fluctuations in the number of granulocyte and erythroid precursors and megakaryocytes. Lymph nodes may show a marked increase in histiocytes in the sinusoidal spaces; evidence of hemophagocytosis may be much less marked than in the bone marrow or there may be marked erythrophagocytosis. The spleen may be markedly enlarged with prominent histiocytic infiltration in the red pulp. Areas of nonsuppurative necrosis have been observed in lymph nodes and spleen.[579]

The mechanism of macrophage activation in the hemophagocytic syndromes is not completely understood but appears to be related to the release of chemokines and cytokines, including macrophage inflammatory protein-1 alpha and interferon gamma.[570] The phenomenon appears to be preceded in some patients by proliferation of activated or neoplastic EBV-infected T lymphocytes that produce tumor necrosis factor alpha (TNF-α).

The EBV or T cell–related hemophagocytic syndromes may be difficult to distinguish morphologically from primary hemophagocytic lymphocytic histiocytosis. The latter disorder appears to be related to mutation of the perforin gene and diminished perforin in cytotoxic T cells and T/NK cells.[559,560] This contrasts with the normal levels of perforin in cytotoxic cells in patients with secondary hemophagocytic syndromes.

The clinicopathologic features of virus-associated hemophagocytic syndrome (VAHS) have been reported in 80% of a group of patients with fatal infectious mononucleosis.[571] The VAHS phase was preceded by features of a viral-like illness. Sequential changes were present in the marrows of these patients; initially there was infiltration by atypical lymphoid cells with areas of necrosis, followed by depletion of normal hematopoietic cells and histiocytic activation with prominent hemophagocytosis; the end stage was marked by marrow aplasia. A similar sequence of histopathologic changes was found in the lymph nodes, spleen, and thymus gland.

Hemophagocytic histiocytosis has been reported as a terminal event in patients with T-cell lymphomas and T/NK-cell lymphomas; uncommonly it is associated with B-cell lymphoma.[564,566,581] The pathologic findings are similar to those in VAHS. The production of macrophage-activating cytokines by the malignant cells has been suggested as a causative mechanism of the histiocyte proliferation. The hemophagocytic syndrome may be associated with other types of lymphoma, including ALK-positive anaplastic large cell lymphoma.[562]

The distinction between the hemophagocytic syndrome and "malignant histiocytosis" may be difficult because of similarities in clinical presentation.[584,585,568,569] The cells in the hemophagocytic syndrome are morphologically distinct; they have a low nucleocytoplasmic ratio and abundant lightly staining cytoplasm containing large vacuoles of varying sizes and phagocytosed cells or cellular

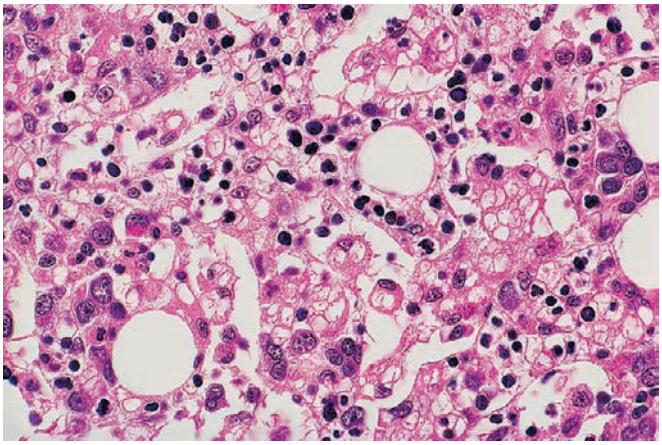

Figure 39.101 Marrow biopsy from an adult man who developed hemophagocytic syndrome associated with bacterial infection. Numerous histiocytes, some showing hemophagocytosis, are present in sinusoids and interstitium.

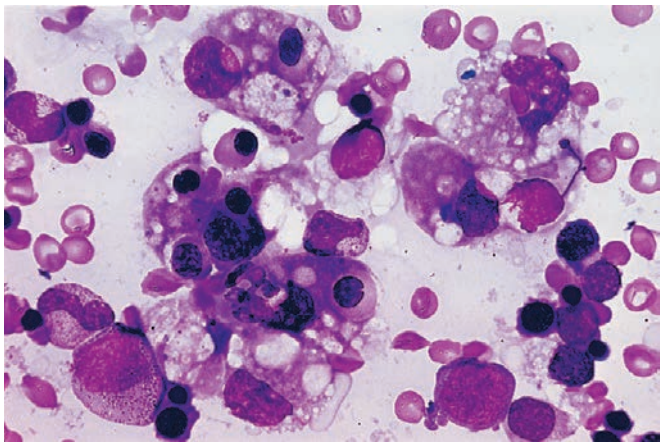

Figure 39.102 Bone marrow smear from a lupus erythematosus patient with virus-associated hemophagocytic syndrome. Numerous macrophages with ingested red blood cells and erythroblasts are present. (Wright–Giemsa.)

For personal use only. No other uses without permission. Copyright ©2017. Elsevier Inc. All rights reserved.

products. Nucleoli, when present, are not prominent, and mitotic figures are rare. Although the hemophagocytic histiocyte proliferation may coexist with "malignant histiocytosis" or a malignant lymphoma, there is no evidence of a transition from the obviously malignant cells to the benign histiocytes.

Serologic studies for viral infection in patients with the picture of a hemophagocytic syndrome may not be reliable because impaired immune function may preclude a detectable antibody response. In these cases, in situ hybridization studies may be useful in documenting an EBV or parvovirus B19 infection.[565,568,569] In addition to studies for a viral infection, it is important that patients with a hemophagocytic process be carefully evaluated for immune suppression and non-Hodgkin lymphoma. Patients with a hemophagocytic syndrome with both an EBV infection and a malignant lymphoproliferative lesion may be observed.

Treatment for both primary and secondary hemophagocytic syndromes is to control hyperinflammation, which may include etoposide therapy.[586] Hematopoietic cell transplantation, however, is considered the only possible cure for PHLH.[587]

Langerhans Cell Histiocytosis

Marrow involvement in Langerhans cell histiocytosis (histiocytosis X) is uncommon and usually associated with the multisystem multifocal form of the disease (Letterer–Siwe disease).[588] The marrow lesions may be focal and small and barely perceptible or confluent and extensive replacing large areas of a biopsy (Fig. 39.103).[589] The small lesions may have a granulomatous appearance. Similar to the lesions in other organs, the Langerhans cells have a low nucleocytoplasmic ratio; the nuclei are grooved, folded, or lobulated with dispersed chromatin and inconspicuous nucleoli. Hemosiderin and lipofuscin-like granules may be present in the cytoplasm. Mitotic activity is variable. The lesions may be relatively monocellular or polycellular with admixed phagocytic histiocytes, multinucleate giant cells, lymphocytes, plasma cells, eosinophils, and neutrophils. Stains for reticulin show an increased number of reticulin fibers. Immunohistochemical reactions for S100 protein, langerin, and CD1a highlight the Langerhans cell infiltrate. However, with some fixatives and decalcifying agents, the reaction with antibody to CD1a may be suboptimal in bone marrow biopsies. The cells are variably reactive for CD68 (KP1), HLA-DR, CD45, lysozyme, and nonspecific esterase.[588] In smear preparations and touch imprints, the Langerhans cell has abundant cytoplasm, which frequently contains particulate green–blue debris (see Fig. 39.103C). Characteristic Birbeck granules are observed on ultrastructural examination.

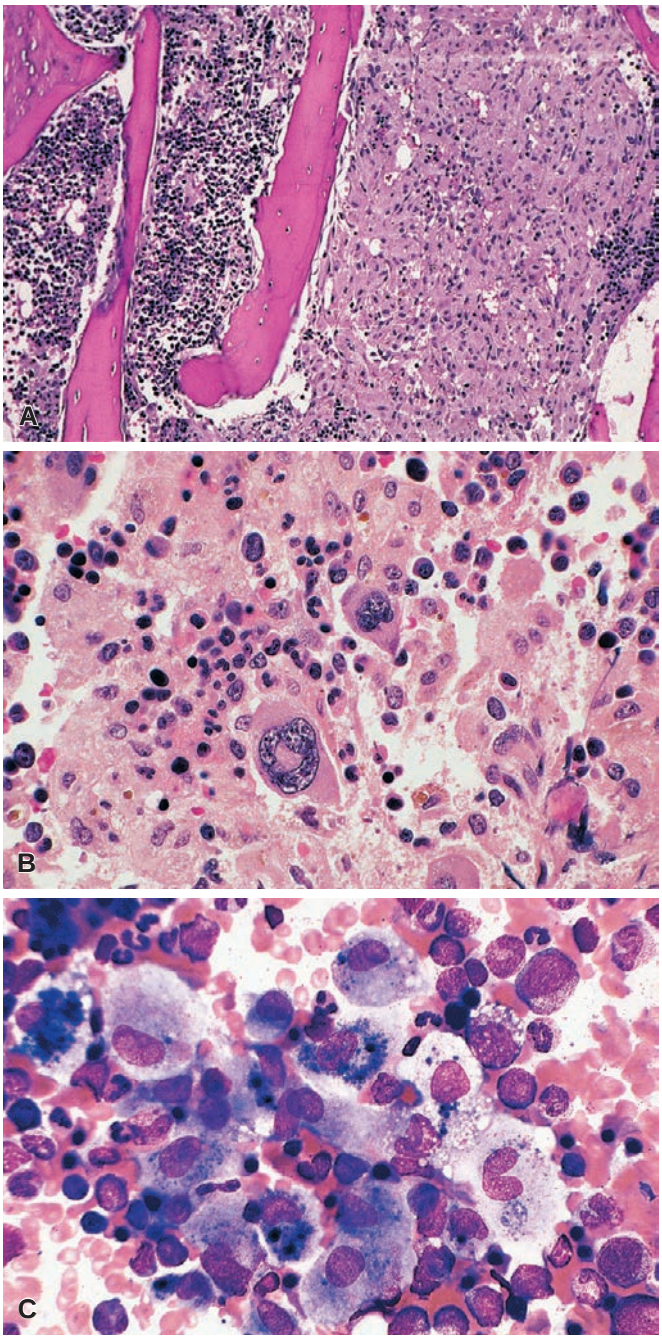

Figure 39.103 **A**, Marrow biopsy from a child with Langerhans cell histiocytosis showing extensive replacement. **B**, High magnification of the lesion in **A** showing giant cells and several histiocytes. Some residual myeloid cells are present. **C**, Bone marrow smear from the case illustrated in **A** and **B**. The Langerhans cells are very large with abundant cytoplasm; several histiocytes contain nonspecific debris and occasionally red blood cells.

Plasma Cell Dyscrasias

The plasma cell dyscrasias are proliferations of immunosecretory cells generally associated with perturbation of serum immunoglobulins. This group of diseases includes the plasma cell proliferations and lymphoplasmacytic lymphoma, although the latter is included as a mature B-cell lymphoma in the WHO classification.

The prototype disorder for this group of diseases is plasma cell myeloma (PCM), of which the clinical syndrome is multiple myeloma. Monoclonal gammopathy of undetermined significance (MGUS) is viewed as a precursor lesion.

The criteria for the diagnosis of symptomatic and asymptomatic PCM are listed in Box 39.11.[590]

Plasma Cell Myeloma

PCM is a neoplastic proliferation of plasma cells accompanied by the production of a monoclonal immunoglobulin detectable in the serum, urine, or both.[590–592] There are several clinical variants, including asymptomatic or smoldering myeloma, nonsecretory myeloma, and plasma cell leukemia. The peak incidence is in the seventh decade; the disease is slightly more frequent in males than females. Osteolytic lesions in the skull, ribs, sternum, vertebrae, and pelvis are present in approximately 70% of cases; in rare cases, x-ray films reveal osteosclerotic lesions.

For personal use only. No other uses without permission. Copyright ©2017. Elsevier Inc. All rights reserved.

Box 39.11 2016 World Health Organization diagnostic criteria for plasma cell myeloma

Symptomatic plasma cell myeloma

Clonal bone marrow plasma cells >10%, or biopsy-proven plasmacytoma,

AND

any one or more of the following:

- End-organ damage attributable to the plasma cell proliferation
- Hypercalcemia (serum calcium >0.25 mmol/L [>1 mg/dL] higher than the upper limit of normal or >2.75 mmol/L [>11 mg/dL])
- Renal insufficiency (creatine clearance <40 mL per minute or serum creatinine >177 μmol/L [>2 mg/dL])
- Anemia (hemoglobin value of >20 g/L below the lower limit of normal or a hemoglobin value <100 g/L)
- Bone lesions (one or more osteolytic lesions on skeletal radiology, CT or PET-CT)

AND

any one or more of the following:

- Clonal marrow plasma cell percentage >60%
- Involved:uninvolved serum free light chain ratio >100
- >1 focal lesions on MRI studies

Asymptomatic (smoldering) myeloma (both required)

- Serum M-protein (IgG or IgA) >30 g/L, or urine M-protein >500 mg per 24 hours, and/or clonal marrow plasma cells of 10%–60%, and
- Absence of myeloma-defining events or amyloidosis

Data from Arber DA, Orazi A, Hasserjian R, et al. The 2016 revision to the World Health Organization classification of myeloid neoplasms and acute leukemia. *Blood*. 2016;127(20):2391–2405.

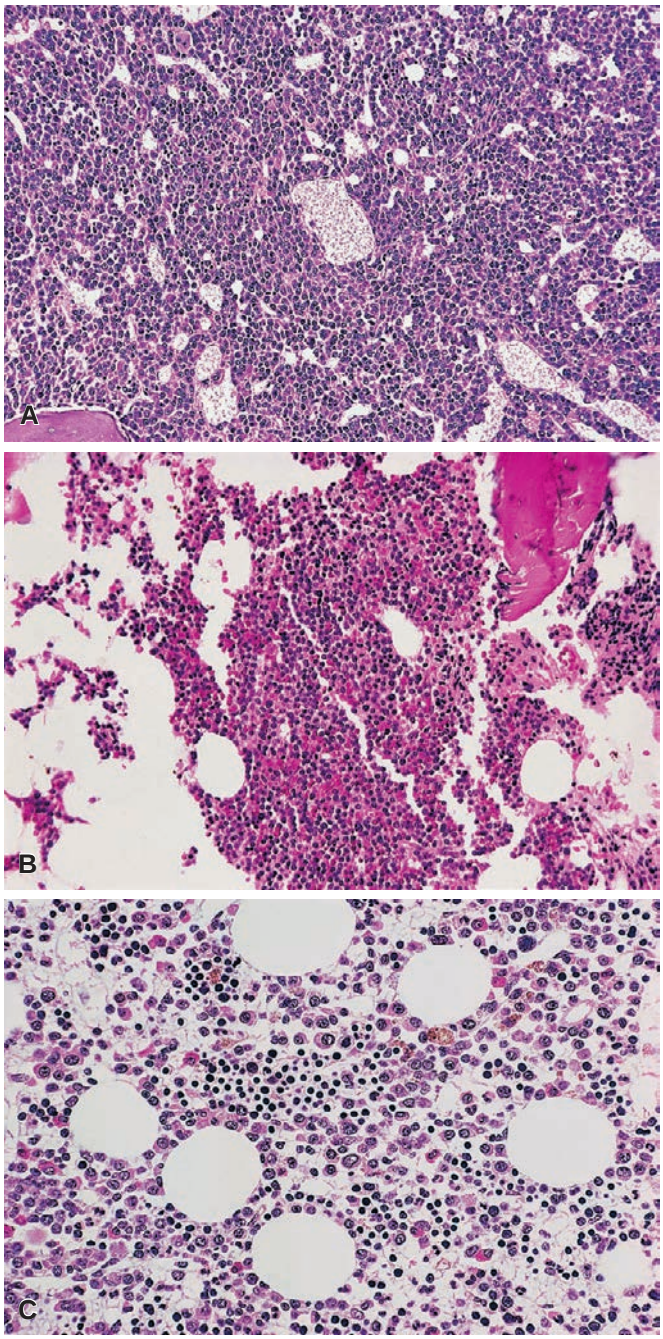

Figure 39.104 **A**, Marrow biopsy from a patient with plasma cell myeloma with extensive diffuse replacement by myeloma cells. **B**, Marrow biopsy with a large focus of myeloma cells. **C**, Marrow biopsy showing essentially normal marrow architecture and interstitial infiltration by myeloma cells.

Marrow involvement in myeloma may be patchy, and the percentage of plasma cells may vary in aspirates and biopsies from different sites. In trephine sections, the distribution of plasma cells may be focal, interstitial, diffuse, or a combination of these patterns (Fig. 39.104).[593–596] There is variability in the appearance of the plasma cells in different cases from very immature plasma cells with a blast-like appearance to pleomorphic cells to mature-appearing plasma cells (Fig. 39.105).[597–599] Nucleoli may be very prominent in some of the more immature types, and binucleate cells resembling Reed–Sternberg cells may be found. Nuclear and cytoplasmic inclusions of varying types may be noted; these are usually related to immunoglobulin production (Fig. 39.106). The marrow in approximately 10%–20% of cases shows associated fibrosis (Fig. 39.107).[600,601]

Several approaches to the staging of myeloma have been introduced: these have included the correlation of myeloma cell mass with presenting laboratory findings, including hemoglobin, monoclonal immunoglobulin, and calcium levels and the presence of osteolytic bone lesions.[602–606] The serum β_2-microglobulin level and the plasma cell labeling index have been found to be significant prognostic factors.[599,607–609] β_2-Microglobulin levels above 3.5 ng/μL and plasma cell labeling index greater than 0.4% are associated with a shorter survival than β_2-microglobulin levels less than 1 ng/μL and labeling index of 0.[608–611]

The occurrence of genetic abnormalities detected by interphase FISH has been reported in up to 90% of patients with PCM. The most frequent abnormalities are del(13q14), hyperdiploidy, t(11;14), t(4;14), *MYC* translocations, and del(17p13). del(13q14) is frequently associated with t(4;14) or del(17p13).[612–616] The most frequent translocations involve 14q32 and occur in 55%–70% of cases. The five major translocations involving 14q32 are t(4;11), t(4;14), t(14;16), t(14;14), and t(14;20); combined these translocations occur in approximately 40% of cases.[590,612,617] t(4;14), t(14;16), and t(14;20) have been associated with poor response to conventional induction therapy and short overall median survival.[617] del(17p13) has also been associated with a poor prognosis. The prognosis of cases with monosomy 13 or del(13q14) with concurrent t(4;14) or del(17p13) appears to be dictated by the non-13 abnormality. In a large multi-institutional study, the most important predictive genetic factors for survival were t(4;14) and del(17p13) combined with the serum β_2-microglobulin level. The combination of one of these genetic abnormalities and an elevated β_2-microglobulin level was an adverse predictive factor.[618]

For personal use only. No other uses without permission. Copyright ©2017. Elsevier Inc. All rights reserved.

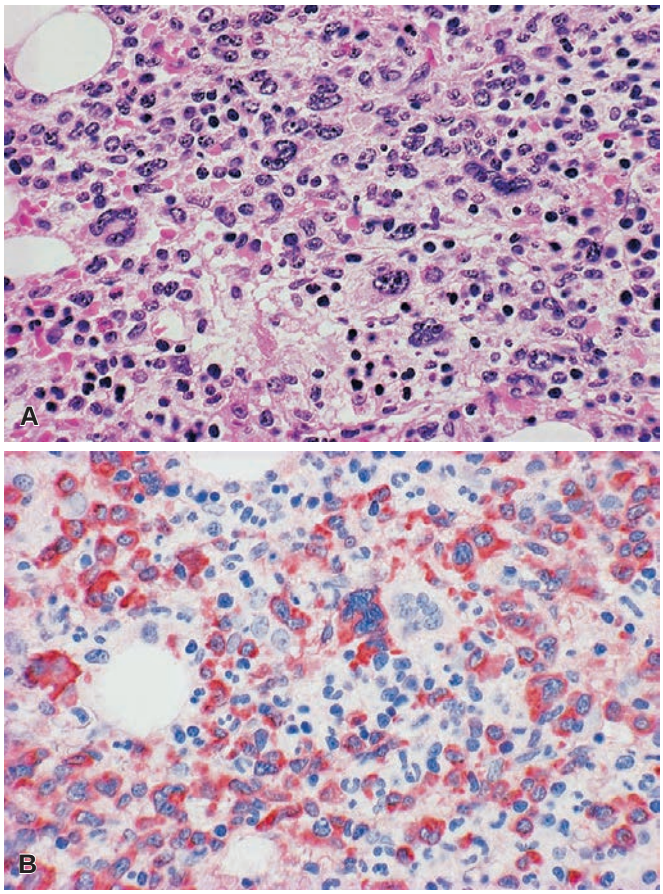

Figure 39.105 **A**, Marrow from a patient with anaplastic myeloma; many of the plasma cells are large with lobulated nuclei. **B**, Specimen in **A** reacted with antibody to lambda light chains. The plasma cells show intense cytoplasmic reactivity. Numerous nonreactive residual myeloid cells are present. (**B**, Immunoperoxidase.)

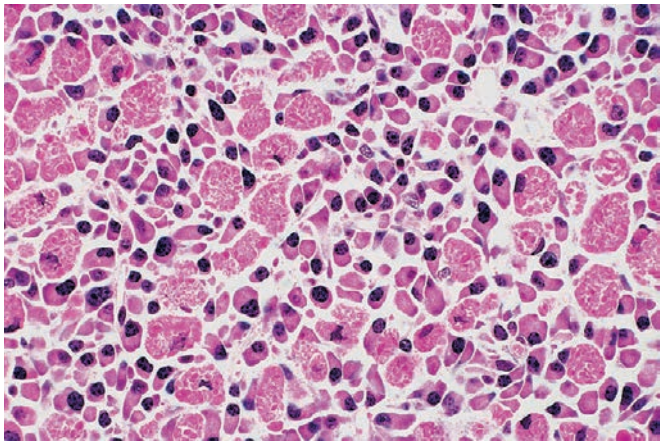

Figure 39.106 Marrow biopsy from a 63-year-old patient with plasma cell myeloma with hypogammaglobulinemia and kappa light chain Bence Jones proteinuria. The cytoplasm of myeloma cells is distended by numerous, frequently confluent eosinophilic inclusions.

Similar to mantle cell lymphoma with t(11;14)(q13;q32), the nuclei of the myeloma cells in patients with this translocation are cyclin D1 positive.[619,620]

Histopathologic staging of myeloma in bone marrow biopsies based on cytologic features of the myeloma cells and the degree of

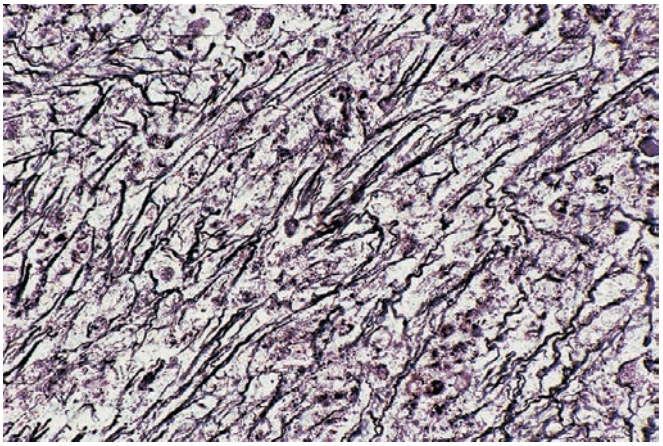

Figure 39.107 Marrow biopsy from a patient with plasma cell myeloma and marked reticulin fibrosis.

plasma cell infiltration has been shown to have prognostic significance.[590] The more mature type of PCM, plasmacytic, and less than 20% marrow replacement are favorable prognostic factors. The more immature or poorly differentiated the myeloma cells, that is, plasmablastic, and the more extensive the marrow involvement (>50% replacement), the more unfavorable the prognosis. An anaplastic evolution of myeloma may occur, and some of these cases have the histopathologic features of immunoblastic lymphoma.[621] Studies comparing anaplastic myeloma with B-immunoblastic lymphoma have demonstrated clinical and immunologic differences.[622,623] The plasma cells in anaplastic myeloma are usually of the IgG or IgA heavy chain class in contrast to B-immunoblastic lymphoma, in which the cells are IgM. The cells in immunoblastic lymphoma usually express pan-B-cell antigens; the plasma cells in approximately 80% of cases of myeloma do not express pan-B-cell antigens. Exceptions to these generalizations occur. All clinical and laboratory findings should be considered. Histopathologic staging of myeloma in the marrow, using an approach similar to that used for CLL, has shown good correlation between pattern of marrow involvement and clinical stage; a diffuse pattern of involvement is usually associated with a more advanced clinical stage.[596] In some patients, the pattern of marrow involvement may be somewhat inconsistent from biopsy to biopsy, and focal involvement may be associated with an advanced clinical stage. Immunohistologic studies on paraffin-embedded biopsy specimens, utilizing antibodies to CD38 and CD138, are very useful in identifying myeloma cells and detecting extent of marrow involvement.[33,624–626] Anti-kappa and anti-lambda antibodies are used for detection and determining monoclonality. Immunohistochemistry is particularly helpful following chemotherapy and hematopoietic cell transplant for detecting residual disease.

As noted, the myeloma cells in patients with an associated t(11;14)(q13;q32) are usually cyclin D1 positive; a substantial number of these cases are reported as having lymphoplasmacytoid morphology and extensive marrow infiltration.[619,620]

Nonsecretory Myeloma

Approximately 3% of patients with PCM present with the clinical, radiographic, and histopathologic features of multiple myeloma but lack evidence of monoclonal immunoglobulin production in the serum or urine. These cases have been referred to as "nonsecretory" myeloma.[627,628] Considerable caution should be exercised in the use of this term, since striking reactive plasmacytosis may be observed with nonmalignant conditions, including liver disease, connective

For personal use only. No other uses without permission. Copyright ©2017. Elsevier Inc. All rights reserved.

tissue disorders, chronic granulomatous disorders, hypersensitivity states, and drug-related agranulocytosis.[629] When a nonsecretory myeloma is suspected, the monoclonal nature of the proliferating plasma cells should be confirmed by immunoperoxidase or immunofluorescent techniques that will demonstrate kappa or lambda light chain restriction.[33,605,626] An increase in reactive plasma cells will be characterized by a relatively balanced population of kappa- and lambda-containing cells.

Asymptomatic (Smoldering) Plasma Cell Myeloma

Asymptomatic and smoldering myeloma are the terms used for cases of PCM in which the criteria for myeloma are present but there is no related organ or tissue impairment, that is, no hypercalcemia, renal insufficiency, anemia, or bone lesions (so-called CRAB features).[590,592,630] Approximately 8% of patients presenting with myeloma are of this type. The majority of these cases have between 10% and 20% plasma cells in the marrow, but some have up to 60%, and there is no morphologic cutoff to distinguish smoldering from symptomatic myeloma when plasma cells are below 60% of marrow cells. The cumulative probability of progression to symptomatic myeloma is 10% per year for the first 5 years following diagnosis and approximately 1% per year for the next 10 years.

Plasma Cell Leukemia

The term plasma cell leukemia is applied to those processes in which a patient presents with a plasma cell proliferation in the blood; the plasma cells exceed 20% of the blood leukocytes, or the absolute plasma cell count exceeds 20×10^9/L (Fig. 39.108).[590,631–633] The term should be reserved for cases with this finding at initial presentation. In contrast to cases of PCM presenting with detectable monoclonal immunoglobulin production, usually of IgG or IgA type, cases of plasma cell leukemia frequently present with a higher incidence of light chain disease, IgD or IgE paraprotein than the other forms of myeloma.[590,634] The marrow in plasma cell leukemia usually shows diffuse and extensive replacement of normal hematopoietic cells by the plasma cells. In some cases, the myeloma cells have a lymphoid appearance. Patients with plasma cell leukemia have a higher incidence of organomegaly than those with other forms of myeloma, and the disease is usually associated with an unfavorable prognosis with a higher incidence of unfavorable cytogenetic profiles than other patients with PCM.[635,636] Osteolytic lesions and bone pain are less frequent than other forms of myeloma.

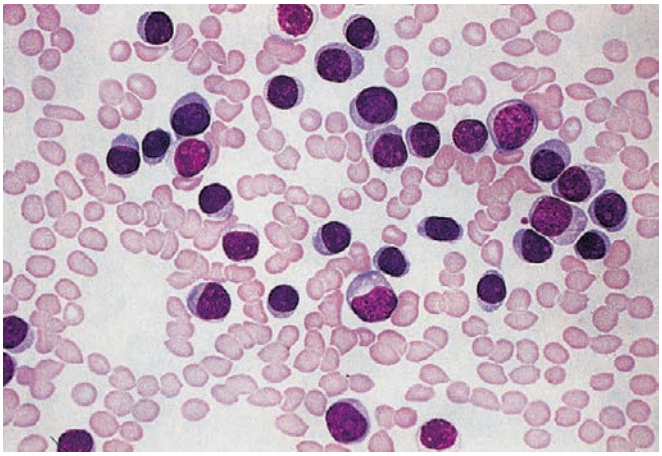

Figure 39.108 Blood smear from a 47-year-old woman with leukocytosis of 24.0×10^9/L and 90% plasma cells. Many of the plasma cells have "lymphoid" features. There was a serum IgG kappa monoclonal protein. (Wright–Giemsa.) (Reproduced from Brunning RD, McKenna RW. Tumors of the Hematopoietic System. Atlas of Tumor Pathology, series 3, fascicle 9. Washington, DC: Armed Forces Institute of Pathology; 1994.)

Multiple myeloma or amyloidosis may occur in patients with the adult Fanconi syndrome; the renal abnormalities may precede the overt manifestations of the plasma cell dyscrasia by several years. Bence Jones proteinuria of kappa light chain type is a common finding. A high percentage of the patients with this variant of myeloma manifest crystalline inclusions in the cytoplasm of the proliferating plasma cells and renal tubular cells.[637]

Osteosclerotic Myeloma and POEMS (Polyneuropathy, Organomegaly, Endocrinopathy, Monoclonal Gammopathy, and Skin Changes) Syndrome

Osteosclerotic myeloma is a form of plasma cell dyscrasia characterized by sclerotic bone lesions and progressive demyelinating polyneuropathy.[590,638–642] The bone marrow aspirate usually contains less than 10% plasma cells. The plasma cell proliferation is usually evident as a plasmacytoma in the sclerotic lesions or in lymph nodes (Fig. 39.109A,B). The marrow from areas uninvolved by the sclerotic process may show typical myeloma cell infiltration, or commonly show lymphoid aggregates surrounded by lambda monotypic plasma cells.[643] The megakaryocytes in the noninvolved areas may be increased and large with hyperlobulated nuclei, which may incorrectly suggest a MPN (see Fig. 39.109C). The involved lymph nodes may show angiofollicular hyperplasia with a parafollicular infiltration of monoclonal plasma cells, the plasma cell variant of Castleman disease.[638] A high percentage of patients with osteosclerotic myeloma have multiorgan involvement, including polyneuropathy, organomegaly, endocrinopathy, and skin changes, the so-called POEMS syndrome.[590,638–642,644–646] Approximately 75% of patients have a thrombocytosis. Polycythemia and leukocytosis are present in about one-third of cases. There is usually a low level of monoclonal protein of IgG or IgA class, with a predominance of lambda light chain type.

The median age of onset is 51 years compared with 64 years for typical myeloma; median survival is 14.7 years, in contrast to 3–4 years for typical myeloma. The disease appears to be more common in Japan than in the United States or Europe.

An association of giant lymph node hyperplasia with osteoblastic bone lesions and the POEMS syndrome has been reported.[638,644]

The recently described telangiectasias, elevated erythropoietin level and erythrocytosis, monoclonal gammopathy, perinephric fluid collections, and intrapulmonary shunting (TEMPI) syndrome is related to POEMS syndrome and characteristically shows an erythroid hyperplasia in the marrow accompanied by monotypic plasma cells.[647]

Plasmacytoma

A solitary plasmacytoma, in contrast to the disseminated proliferation of plasma cells in multiple myeloma, is a single focus of plasma cells occurring in either bone or soft tissue.[33,590,623,648–660] Solitary plasmacytomas are more frequent in males than females and have a peak incidence in the sixth decade, slightly earlier than multiple myeloma. Plasmacytomas are generally divided into two broad groups based on location: plasmacytoma of bone and extramedullary or soft tissue plasmacytoma. The recommended diagnostic criteria for solitary plasmacytoma of bone are shown in Box 39.12.[651]

Evidence for different biologic behavior of these two types has been reported: plasmacytoma of bone has been reported to have a greater predilection to progress to multiple myeloma than soft tissue

For personal use only. No other uses without permission. Copyright ©2017. Elsevier Inc. All rights reserved.

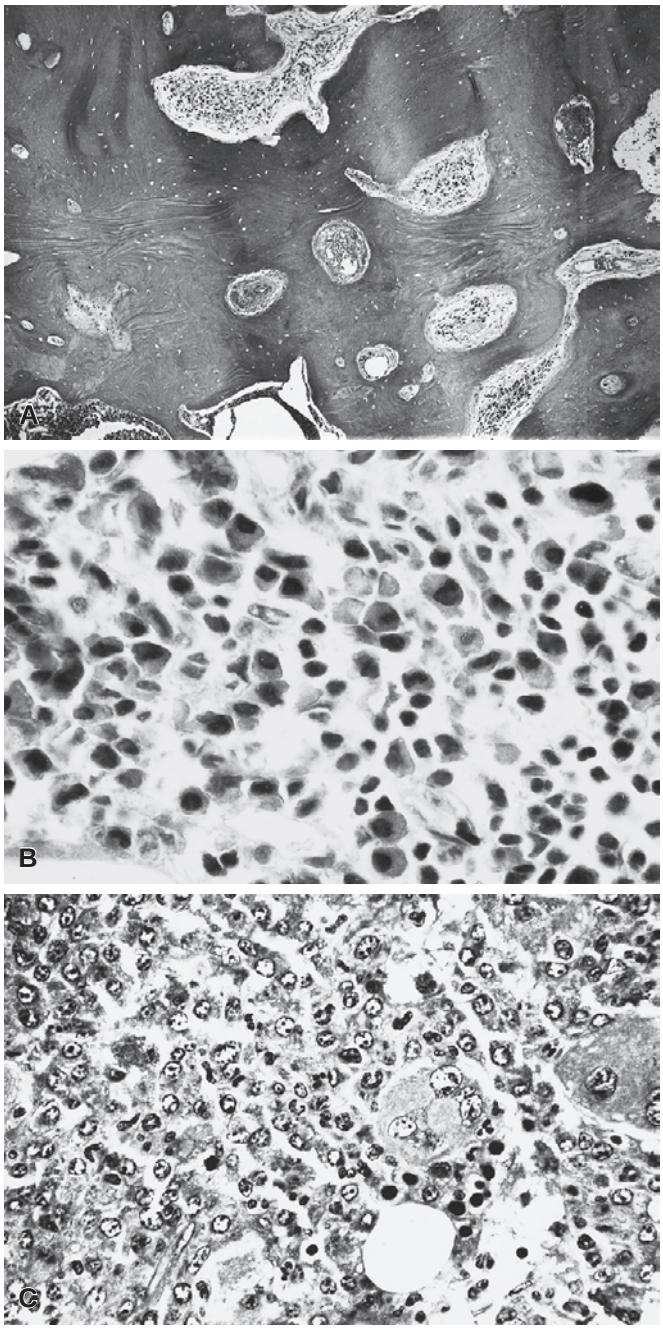

Figure 39.109 **A**, An osteosclerotic bone lesion from a patient with osteosclerotic myeloma. **B**, High magnification of the marrow in the specimen in **A**. This area shows a large number of plasma cells that were lambda light chain restricted on immunohistochemical study. **C**, Marrow biopsy from a nonsclerotic area from a patient with osteosclerotic myeloma with POEMS syndrome. There was a thrombocytosis. The marrow in this area shows an infiltration by immature plasma cells. There was also an increase in large megakaryocytes, two of which are at right.

plasmacytoma. Other studies have shown no significant difference between these two locations and the incidence of evolution to myeloma.[655] The solitary plasmacytoma of bone may occur in both flat and long bones; the most common site is the axial skeleton, particularly a vertebra.[590,649,650,652,654,655] The thoracic vertebrae are more frequently involved than the cervical or lumbar vertebrae. Soft tissue extension from bone lesions may occur. The majority of

Box 39.12 Criteria for diagnosis of solitary plasmacytoma

- Biopsy-proven solitary lesion of bone or soft tissue consisting of clonal plasma cells
- Normal random bone marrow biopsy with no evidence of clonal plasma cells[a]
- Normal skeletal survey and MRI or CT except for the solitary lesion
- Absence of end-organ damage attributable to a plasma cell proliferative disorder

[a]A diagnosis of solitary plasmacytoma can be made with minimal bone marrow involvement as long as all other criteria are met and the clonal plasma cells represent <10% of marrow cells on a random biopsy. These small clonal populations are usually identified by flow cytometry.

Data from Arber DA, Orazi A, Hasserjian R, et al. The 2016 revision to the World Health Organization classification of myeloid neoplasms and acute leukemia. *Blood*. 2016;127(20):2391–2405.

plasmacytomas of bone show osteolytic change on radiologic examination, although osteolytic/osteoblastic lesions may occur.[660] The most frequent sites of extramedullary or soft tissue plasmacytomas are the nasal fossa, maxillary sinus, and nasopharynx.[654,655] Extension into adjacent bone tissue may occur, and multiple lesions may be present.

On microscopic examination the plasmacytoma is frequently very vascular with a minimal stromal component and consists of sheets of plasma cells of varying degrees of differentiation (Fig. 39.110).[649] The plasmacytic nature of the proliferating cells is readily recognized in the better-differentiated lesions. In plasmacytomas with a predominant population of more immature cells with a dispersed nuclear chromatin and single prominent nucleolus, there usually is a minor population of more differentiated plasma cells. Amyloid may be present and was noted in 25% of the lesions in one series.[655]

Immunohistochemical study with antibodies to kappa and lambda light chains is an important approach to the evaluation of a suspected plasmacytoma.[33] A kappa or lambda light chain-restricted population confirms a diagnosis of plasmacytoma (see Fig. 39.110B). There is a predominance of IgG heavy chain type in solitary plasmacytoma of bone and IgA heavy chain type in plasmacytomas from the upper respiratory tract.

Patients with an apparent solitary plasmacytoma should be carefully evaluated for the presence of disseminated disease; studies should include bilateral iliac crest bone marrow biopsies, radiologic skeletal survey, MRI of the spine, pelvis, humeri, and femurs, immunoelectrophoretic examination of the serum and urine, and β_2-microglobulin assay. The patient with a solitary plasmacytoma usually has a normal hemoglobin level and no hypercalcemia. The diagnosis of a solitary plasmacytoma should be made only if all studies for disseminated disease are negative.

Approximately 50% of patients with a plasmacytoma have a monoclonal protein in the serum and/or urine; the level almost invariably is less than 20 g/L, and the nonmonoclonal immunoglobulins are normal in contrast to multiple myeloma, in which they are generally decreased. A marked reduction or disappearance of the monoclonal immunoglobulin will usually occur following tumoricidal radiation; the maximum reduction may not occur for several years.[655] Persistence of the monoclonal protein for more than 1 year after radiotherapy of the plasmacytoma has been identified as an adverse prognostic factor.[658]

Approximately 35% of patients with a solitary plasmacytoma who receive treatment, including radiation, chemotherapy, and surgical excision, will eventually develop multiple myeloma; this evolution may occur up to 12 years following initial diagnosis.[655,657] The presence of nuclear immaturity with prominent nucleoli appears

For personal use only. No other uses without permission. Copyright ©2017. Elsevier Inc. All rights reserved.

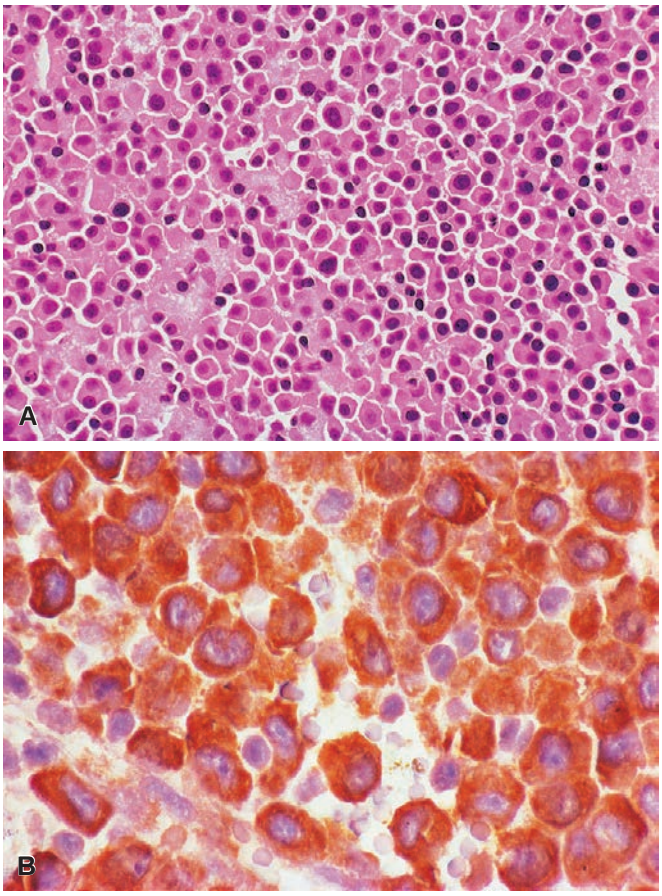

Figure 39.110 **A**, Extramedullary plasmacytoma from the region of the nasopharynx. **B**, Plasmacytoma reacted with antibody to kappa light chains. The plasma cells show intense cytoplasmic reactivity. (**B**, Immunoperoxidase.)

to have some positive predictive value for the development of multiple myeloma. However, the presence of a monoclonal protein in serum, urine, or both does not predict the development of disseminated disease. Plasmacytomas of non-IgG class have been reported to have a higher predilection for systemic spread than IgG-producing tumors. Local recurrence of the lesion is uncommon.

The differential diagnosis of a plasmacytoma includes plasma cell granuloma, plasmacytoid lymphoma, large cell lymphoma of immunoblastic type, and plasmablastic lymphoma. The plasma cell granuloma shows a balanced proliferation of kappa- and lambda-reacting cells on immunohistochemical evaluation. The plasmacytoid lymphoma comprises a mixture of lymphocytes and plasma cells. Some of the large cell lymphomas, particularly the B-immunoblastic lymphoma, may be difficult to distinguish from a plasmacytoma. Immunoblastic lymphoma will usually involve lymph nodes in contrast to plasmacytoma. Immunophenotypic studies of plasmacytoma and immunoblastic lymphoma using a panel of monoclonal antibodies have shown significant immunophenotypic differences between these two processes.[623] The immunoblastic lymphomas have cytoplasmic IgM heavy chain and express pan-B-cell surface antigens such as CD19 and CD20. The plasmacytomas contain IgA or IgG heavy chain and are generally negative for pan-B-surface antigens; approximately 20% of plasmacytomas and myelomas are positive with pan-B-cell antibodies. Plasmablastic lymphomas are usually EBV positive by in situ hybridization, a finding that should not be present in plasmacytoma.

Monoclonal Gammopathy of Undetermined Significance

Approximately 3%–5% of individuals over the age of 50 and 2%–3% of patients over age 65 have a serum monoclonal gammopathy without other evidence of a plasma cell dyscrasia; this constellation of findings is referred to as MGUS.[661–663] The monoclonal protein in these individuals is usually less than 30 g/L, and there is usually no or minimal Bence Jones protein in the urine. There is no associated hypercalcemia, anemia, renal impairment, or radiologic evidence of bone lesions.[664] The bone marrow in these patients may be entirely normal or may manifest a slight increase in mature-appearing plasma cells; the increase is less than 10%. Some of these cases represent incipient myeloma or another type of plasma cell dyscrasia or lymphoproliferative disorder; others continue for several years without undergoing an obvious neoplastic evolution. In a study from the Mayo Clinic, MGUS constituted approximately 50% of the cases of monoclonal gammopathy.[662]

The incidence of MGUS varies in different studies. In one very large contemporary study of the population of Olmsted County in Minnesota in the United States using sensitive laboratory techniques, MGUS was identified in 3.2% of individuals 50 years of age or older and 5.3% of patients 70 years of age or older.[663] The concentration of monoclonal immunoglobulin was less than 10 g/L in 63.5% of individuals and greater than 20 g/L in 4.5%. The incidence of MGUS is higher in black individuals than in whites.

Two important issues must be addressed when contemplating a diagnosis of MGUS: distinction from overt myeloma and probability of progression to an overt plasma cell dyscrasia if a diagnosis of MGUS is made. If the morphologic or clinical findings are suspicious for but not diagnostic of overt myeloma, the patient should be followed with marrow examination and repeat protein electrophoresis at 6-month intervals. An increase in the number of abnormal plasma cells or light chain-restricted plasma cells and an increase in the amount of monoclonal immunoglobulin suggest evolution to a neoplastic process.[664–667] A stable immunoglobulin level and plasma cell percentage are more reflective of MGUS. The plasma cell labeling index as described by Greipp and Kyle has been useful in distinguishing MGUS and smoldering myeloma from overt multiple myeloma.[664] The diagnostic accuracy of a plasma cell labeling index of greater than 0.4 was 83% in distinguishing myeloma from MGUS and smoldering myeloma. The accuracy is increased when combined with the percentage of marrow plasma cells. Approximately 8% of patients with MGUS eventually develop a neoplastic plasma cell dyscrasia or related process; the interval to occurrence ranges up to 29 years, and the rate of progression is approximately 1% per year.[666–668] Factors predicting transformation have varied in different studies: percentage of marrow plasma cells greater than or equal to 5% and paraprotein isotype at initial presentation have been found to have some value. Bone marrow angiogenesis is reported to increase progressively in those patients who manifest progression of MGUS to overt myeloma; median microvessel density correlated with the bone marrow plasma cell labeling index and the percentage of marrow plasma cells.[33] In a large series of patients with MGUS, the only independent risk factors for progression to an overt myeloma or related plasma cell dyscrasia was concentration of the serum monoclonal protein at diagnosis and the type of monoclonal protein. The risk for progression to myeloma or a related disorder at 10 years was 6% for an initial monoclonal protein of 5 g/L or less compared to 34% for an initial monoclonal protein of 30 g/L. Monoclonal proteins of IgM or IgA type had a higher risk of progression than an IgG paraprotein.[667] Patients with an abnormal serum light chain ratio have a significantly higher rate of progression to an overt plasma cell malignancy. Several cytogenetic abnormalities, including

For personal use only. No other uses without permission. Copyright ©2017. Elsevier Inc. All rights reserved.

monosomy 13, t(4;14)(p16.3;q32), and t(14;16)(q32;q23), have been found in MGUS; no obvious clinical or biologic correlations have been established. Similar cytogenetic findings are present in overt myeloma.[669]

Immunohistochemistry on paraffin-embedded specimens using antibodies to kappa and lambda light chains can be a very important approach to the study of myeloma and related disorders.[33] The primary use of the technique in this group of diseases is to determine the relative proportion of kappa- or lambda-reacting cells; a predominant population of plasma cells reacting with a single light chain antibody is evidence for a monoclonal proliferation (see Fig. 39.2). A balanced proliferation of kappa- and lambda-reacting plasma cells usually indicates a benign process. A light chain ratio determined by dividing the number of positively reacting plasma cells for the predominant light chain by the number of positively reacting cells for the other light chain has been proposed as an aid in the distinction of myeloma from MGUS or a reactive increase in plasma cells.[33] Patients with overt myeloma generally have values above 16; patients with MGUS or a reactive process have values less than 16. These results should not be viewed in isolation but should be combined with the plasma cell labeling index.

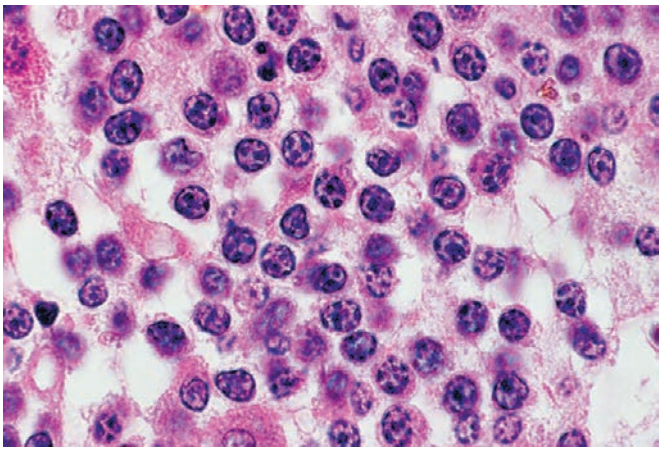

Figure 39.111 Marrow From a Patient With Lymphoplasmacytic Lymphoma and Associated IgM Gammopathy. The predominant lymphocytes have nuclei with very clumped chromatin and a slight to moderate amount of cytoplasm. Some lymphocytes contain small cytoplasmic and intranuclear inclusions. There is an increase of tissue mast cells.

Lymphoplasmacytic Lymphoma

In 1944, Waldenström described a clinical syndrome characterized by hyperglobulinemia, increased serum viscosity, and a proliferation of lymphocytes in hematopoietic tissue as well as other organs.[670] The clinical syndrome is referred to as Waldenström macroglobulinemia in recognition of the original description and identification of the globulin as a macroglobulin in the majority of patients. The median age of onset is 60 years, and there is a slight male predominance. Hepatosplenomegaly, lymphadenopathy, and neurologic abnormalities are frequent findings; anemia and hyperviscosity are commonly noted laboratory abnormalities.[670–672] The lymphoproliferative process associated with this syndrome usually involves the small B lymphocyte or the small B lymphocyte and plasmacytoid lymphocyte, that is, lymphoplasmacytic lymphoma in the WHO classification.[340,672,673] Although commonly used to describe the histopathologic lesion occurring in patients with this syndrome, the term Waldenström macroglobulinemia should be reserved for those patients with IgM paraproteinemia and bone marrow involvement by lymphoplasmacytic lymphoma.[672] Cases of lymphoplasmacytic lymphoma may also be associated with paraprotein of IgG and IgA type,[674] but clinical features of PCM should be excluded before making such a diagnosis. Some cases of lymphoplasmacytic lymphoma have no associated serum gammopathy.[672] IgM gammopathy may occur with other hematopoietic tumors and has been reported in cases of multiple myeloma and marginal zone lymphoma.[675–677] The recent discovery of *MYD88* L265P mutations in approximately 90% of cases of lymphoplasmacytic lymphoma has helped to clarify and define this disease entity.[678]

The peripheral blood shows a leukemic picture in approximately 30% of cases; the predominant cells are small lymphocytes or a mixture of small lymphocytes and plasmacytoid lymphocytes. A similar population of cells predominates in the bone marrow (Fig. 39.111).[673,679,680] Mature plasma cells, tissue mast cells, and histiocytes may also be increased. In some cases, plasma cells may predominate. In marrow sections, the infiltrate may be focal or diffuse; the focal lesions may be preferentially paratrabecular, interstitial or nonparatrabecular.[411] Marrow involvement may be very extensive with a marked decrease in normal hematopoietic cells. Intranuclear inclusions, frequently referred to as Dutcher bodies, may be observed in some of the lymphocytes and plasma cells[679]; these inclusions, which are variably PAS positive, may be observed in other lymphomas, multiple myeloma, and reactive proliferations, and are not diagnostic of lymphoplasmacytic lymphoma.[681] In some cases of plasmacytoid lymphoma, the plasma cells and plasmacytoid lymphocytes contain abundant cytoplasmic inclusions. These inclusions may be numerous, and some of these cells resemble histiocytes; the inclusions are usually intensely PAS positive (Fig. 39.112). Plasma cells with similar inclusions may occasionally predominate in multiple myeloma. Like other small lymphocytic lymphomas, the lymphoplasmacytic lymphoma associated with Waldenström macroglobulinemia may terminate with a clinicopathologic picture of Richter syndrome.[344]

The differential diagnosis of lymphoplasmacytic lymphoma in the marrow includes multiple myeloma and marginal zone lymphoma. The presence of an IgM paraprotein, as well as lack of clinical features of multiple myeloma, would favor lymphoplasmacytic lymphoma. Correlation with clinical features and lymph node morphology and *MYD88* mutation studies is often necessary to exclude marginal zone lymphoma, and this differential diagnosis cannot always be resolved on marrow biopsy tissue alone.[411,675]

Heavy Chain Disease

The heavy chain diseases are clinical syndromes that are associated with the production of heavy chain fragments of the immunoglobulin molecule.[354,682–686] Gamma-chain disease has more of the features of a malignant lymphoma, lymphoplasmacytic type, than of multiple myeloma. The median age for this disease is 61 years, but it has been reported in individuals younger than 20.[686] Weakness, fatigue, fever, and lymphadenopathy are common symptoms; hepatomegaly, splenomegaly, and peripheral lymphadenopathy are each present in slightly more than half of the cases. There are frequently anemia, leukopenia, and thrombocytopenia. Atypical lymphocytes and plasma cells may be found in the peripheral blood. The bone marrow is usually abnormal and shows an increase in lymphocytes, plasma cells, or both. Occasionally the marrow is normal. There may be an accompanying eosinophilia. *MYD88* mutations have not been reported in this disease. Most of the reported cases of mu-chain disease have features similar to CLL, but the patients usually have hepatosplenomegaly rather than the typical lymphadenopathy of CLL.[683–685] The marrow in several of the reported cases contained vacuolated plasma

For personal use only. No other uses without permission. Copyright ©2017. Elsevier Inc. All rights reserved.

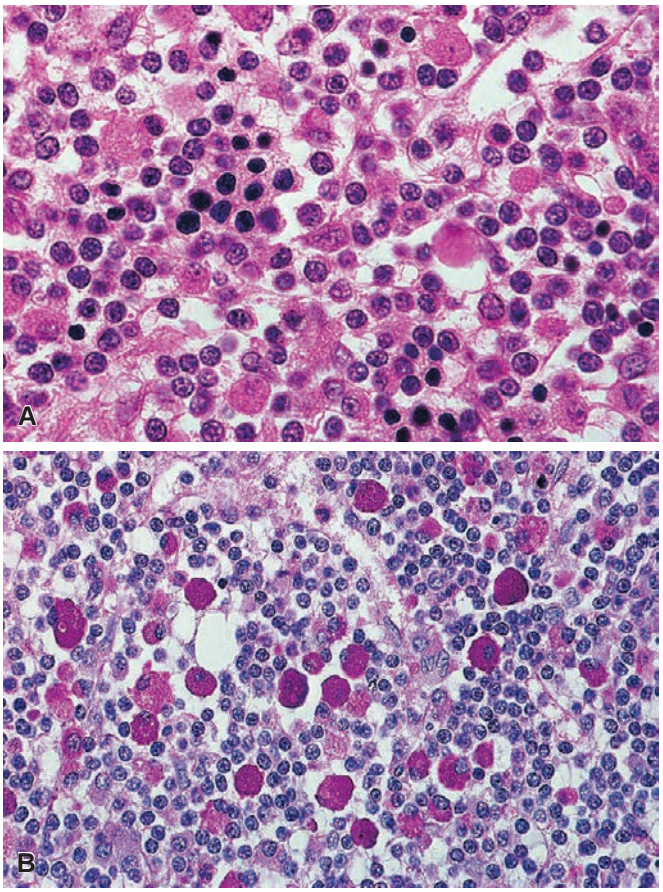

Figure 39.112 **A**, Marrow section from a patient with lymphoplasmacytic lymphoma associated with serum IgM monoclonal gammopathy. Marrow is replaced by an infiltrate of lymphocytes and plasma cells; many of the plasma cells contain numerous cytoplasmic inclusions. Some lymphocytes contain prominent intranuclear inclusions (Dutcher bodies). **B**, Specimen illustrated in **A** reacted with PAS stain. Inclusions in plasma cells are strongly positive.

cells. Alpha-chain disease, also known as immunoproliferative small intestinal disease or Mediterranean lymphoma, is considered a variant of extranodal marginal zone B-cell lymphoma (MALToma); the marrow is not usually involved. The occurrence of tumors composed of undifferentiated lymphoid cells in patients with heavy chain disease has been reported.[685,687]

Amyloidosis

Amyloidosis is the primary monoclonal immunoglobulin deposition disease to involve the bone marrow.[592,688] Bone marrow biopsies in patients with systemic amyloidosis are performed to detect evidence of the disease and to ascertain the number of plasma cells and whether there is a light chain predominant population of plasma cells. In a large single institution study of 474 patients with primary systemic amyloidosis, 56% of marrow biopsies were positive; abdominal fat aspirate was positive in 80%.[689] One or both sites were positive in 89% of patients. In rare cases, amyloid may be detected in marrow biopsies from patients without any clinical evidence of disease.

Primary systemic amyloidosis is associated with another form of plasma cell dyscrasia in approximately 35% of patients; the two most common disorders are multiple myeloma and MGUS,[689–693]

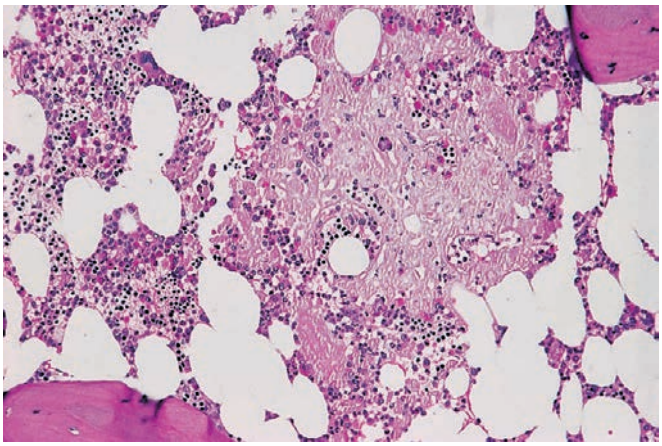

Figure 39.113 Marrow with amyloid accumulation from a 50-year-old woman with primary amyloidosis.

although amyloidosis may also occur with lymphoplasmacytic lymphoma. The distinction between primary amyloidosis with or without associated myeloma can be difficult and is usually based on a constellation of clinical and morphologic findings. The majority of patients with concurrent myeloma and primary systemic amyloidosis have more than 10% marrow plasma cells, which show either lambda or kappa light chain predominance demonstrated by flow cytometric or immunohistochemical studies.

Marrow involvement may manifest either as small focal lesions or as extensive marrow replacement.[694] Early involvement is characterized by focal deposits of amyloid in the medullary vessels; these range from small deposits in the media to large accumulations that greatly expand the vessel walls, resulting in narrowing of the lumen. With more extensive involvement, the accumulation of amyloid is present in the perivascular tissue and marrow substance (Fig. 39.113). Congo red staining should be performed to confirm the diagnosis.

Very rarely a proteinaceous deposition resembling amyloid but lacking the histochemical and electron microscopic characteristics of amyloid, similar to the findings in proteinaceous lymphadenopathy, may occur in the marrow in association with immune disorders (Fig. 39.114). The origin of the proteinaceous substance appears to be immunoglobulin or portions of the immunoglobulin molecule produced by cells of the immune system, and the findings have been referred to as monoclonal light and heavy chain deposition diseases.[590,695–698]

Systemic Polyclonal B-Immunoblastic Proliferation

A florid polyclonal proliferation of B immunoblasts accompanied by a polyclonal hypergammaglobulinemia may occur in patients with a variety of immune disorders and involve blood, bone marrow, and lymph nodes.[699–702] The leukocyte count may be elevated with a high percentage of B immunoblasts, cells with intensely basophilic cytoplasm, relatively coarse nuclear chromatin, and distinct nucleoli. There frequently is some evidence of maturation of these cells to plasma cells. The bone marrow may show extensive infiltration and may resemble lymphoma or plasmablastic myeloma with immunoblasts, plasma cells, and intermediate forms (Fig. 39.115). Lymph nodes may show a similar infiltrate, with complete effacement of the normal architecture. Immunologic studies are critical in the evaluation of these lesions. The polyclonal nature of the infiltrate is demonstrated with immunohistochemical reactions that show

For personal use only. No other uses without permission. Copyright ©2017. Elsevier Inc. All rights reserved.

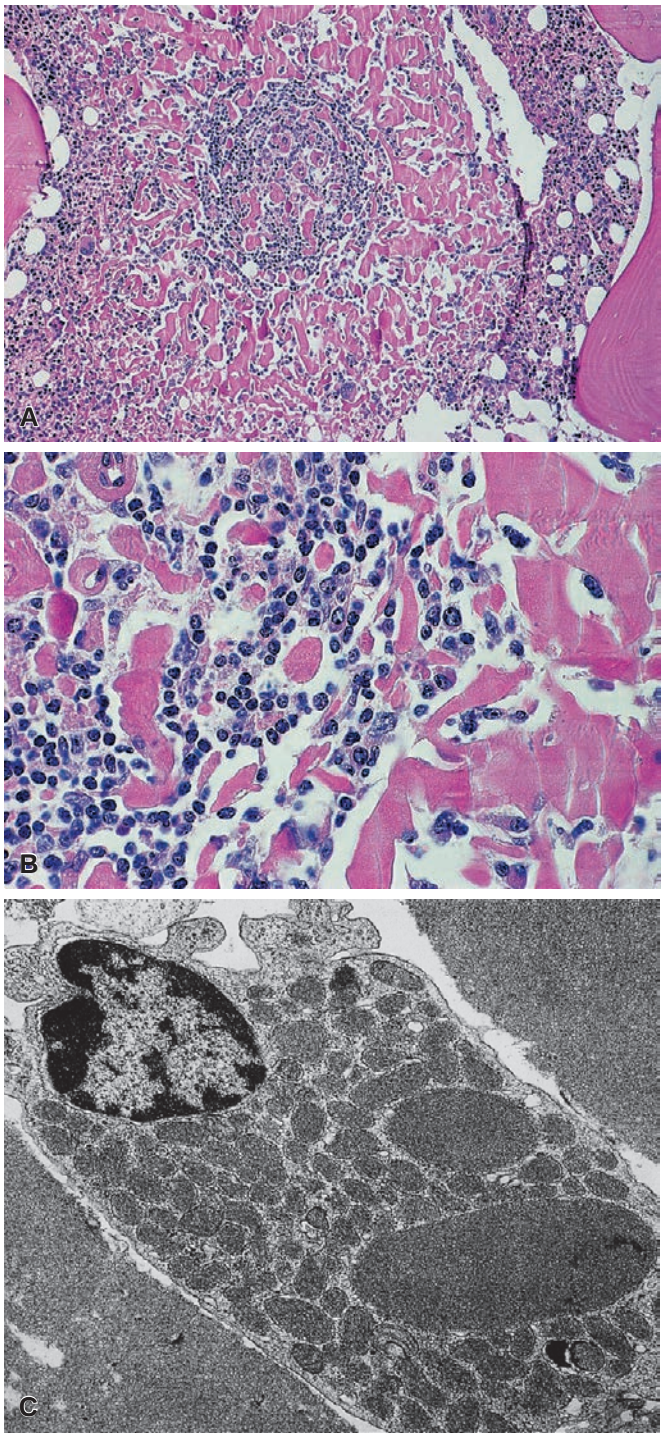

Figure 39.114 Proteinaceous Myelopathy. A, Marrow biopsy from a 25-year-old woman with a 10-year history of lupus erythematosus. There is extensive intercellular accumulation of an amorphous eosinophilic substance resembling amyloid but lacking the histochemical and ultrastructural findings of amyloid. There is an associated proliferation of plasma cells and small lymphocytes. The plasma cells consisted of both kappa and lambda light chain positive populations. **B**, High magnification of the specimen in **A**. **C**, Ultrastructure of the intracellular and extracellular material. There was complete regression of the finding following high dose steroid and vinblastine therapy.

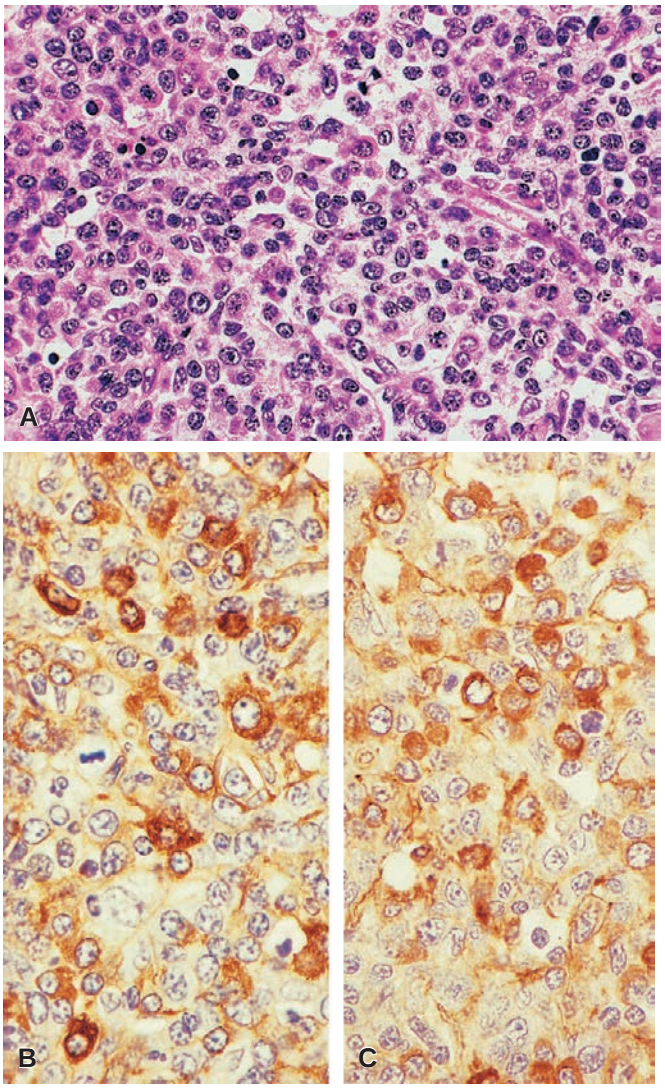

Figure 39.115 A, Marrow biopsy from a 28-year-old woman with an autoimmune disorder characterized by extensive infiltration of marrow by plasma cells, lymphocytes, and immunoblasts. **B** and **C**, Specimen in **A** demonstrated balanced reactivity for kappa (**B**)- and lambda (**C**)-reacting cells. (**B** and **C**, Immunoperoxidase.)

essentially a balanced population of kappa- and lambda-reacting cells (see Fig. 39.115B and C).[33]

The biology of this process is not completely clear; in some patients it appears to represent an acute immune reaction, and it has been observed in patients with laboratory findings of acute lupus erythematosus. It may in some instances be analogous to the polymorphous lymphoid lesions observed in transplant patients. There may be dramatic regression following steroid therapy.[701,702]

Metastatic Tumors

Bone marrow biopsies are used frequently for the staging of patients with histologically documented malignancies; they also may be performed on patients with suspected malignancy in an attempt to obtain material for a histologic diagnosis.[11,703–709] Due to the focal nature of marrow involvement by metastatic disease, the yield of marrow biopsies is increased by the amount of biopsy tissue obtained.

For personal use only. No other uses without permission. Copyright ©2017. Elsevier Inc. All rights reserved.

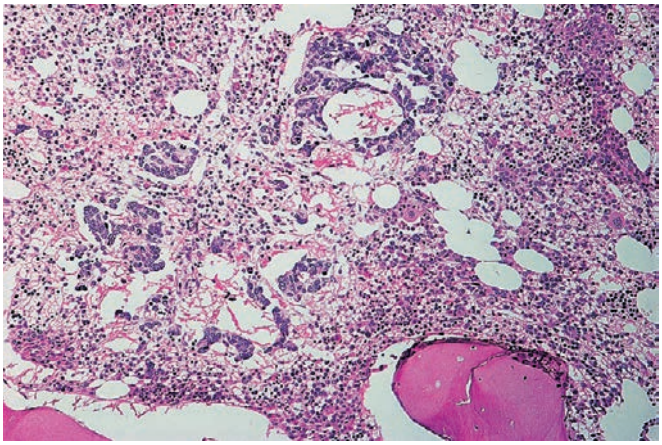

Figure 39.116 Marrow biopsy from a child with metastatic neuroblastoma. Several foci of tumor are present.

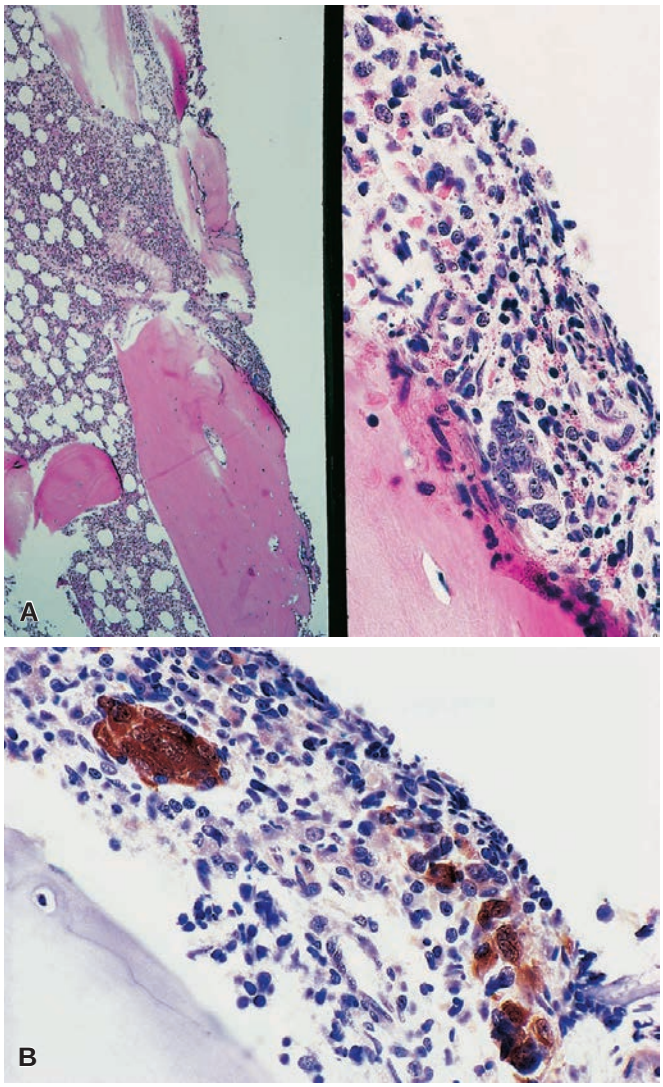

Figure 39.117 **A**, Low *(left)* and high *(right)* magnification of a marrow biopsy from a child with metastatic neuroblastoma with small focal lesions. **B**, Specimen reacted with antibody to neuron-specific enolase. Small clusters of reactive cells are present. This was the only involved area in the biopsy. (**B**, Immunoperoxidase.)

For this reason, either bilateral iliac crest biopsies or two biopsies from a single site are recommended for adequate staging.[3,11] The tumors most frequently detected in bone marrow biopsies in adults are carcinoma of the breast, lung, prostate, stomach, colon, kidney, and thyroid gland. The bone marrow biopsy is widely used for staging small cell carcinoma of the lung.[706,710–721] Sarcomas have a relatively low incidence of marrow metastasis in adults.[722] In the pediatric age group, neuroblastoma is the most common metastatic lesion, followed by rhabdomyosarcoma, Ewing sarcoma, and retinoblastoma.[705,723–725] Wilms tumor metastatic to marrow is extremely uncommon.

In smears, tumor cells frequently, but not invariably, occur in clusters. This may be an important diagnostic feature because tumors of hematopoietic origin generally do not occur in cohesive aggregates. In marrows with extensive involvement, both clusters and individual cells may be present. In some small cell tumors the individual cells may resemble malignant lymphoid cells. In trephine sections, metastatic tumor may occur as small focal lesions surrounded by normal hematopoietic cells, or it may replace virtually the entire specimen. In focal lesions or those occupying only a portion of the biopsy, the tumor foci may be sharply demarcated from the adjacent hematopoietic tissue or may be associated with an irregularly shaped area of fibrosis (Figs. 39.116 and 39.117). Many tumors, most notably breast and prostate, may be associated with a marked desmoplastic reaction, and attempts at aspiration may be unsuccessful. These tumors also may be accompanied by marked osteosclerosis (Figs. 39.118 and 39.119). In the unusual occurrence of a metastatic sarcoma in the marrow, the lesion may resemble PMF.

In the majority of cases of metastatic tumor in marrow smears and aspirates, the tumor cells have characteristics that clearly distinguish them from normal hematopoietic cells. This distinction is aided by the frequent desmoplastic reaction that accompanies some of the tumors that most commonly metastasize to the marrow. In some instances the metastatic tumor cells may have features suggesting a hematopoietic origin, particularly megakaryocytes. This may be a particular problem with some cases of rhabdomyosarcoma in which the tumor cells may react with antibodies to platelet glycoproteins (Fig. 39.120). Antibody studies for actin, desmin, and myogenin and cytogenetic studies may be useful in recognizing this tumor (see Fig. 39.120B). Less commonly, individual tumor cells may involve the marrow and such cases may require immunohistochemical studies even in the absence of obvious marrow involvement on hematoxylin and eosin–stained slides. Metastatic lobular carcinoma and neuroblastoma are the two most common tumors to infiltrate the marrow as individual tumor cells, and routine immunohistochemical studies may be warranted if either of these diagnoses is suspected.[721,726]

The approach to determining the site of origin of a metastatic tumor in a patient without a known primary lesion should be the same as for determining metastatic lesions in other sites. Immunohistochemical techniques may be particularly useful both for determining the possible site of origin and for detecting small lesions.[705,707,721] Antibodies to the common leukocyte antigen are useful in distinguishing a malignant lymphoma from metastatic carcinoma or sarcoma. As with other tissue, it is important to use a panel of antibodies that has the capacity to recognize all reasonable possibilities. For metastatic carcinoma of unknown primary, a panel that includes cytokeratins 7 and 20 as well as synaptophysin, TTF1, and estrogen receptor and BRST1 in women and prostate-specific antigen in men will suggest a primary tumor in most cases.[705] In instances in which small foci are identified with the

For personal use only. No other uses without permission. Copyright ©2017. Elsevier Inc. All rights reserved.

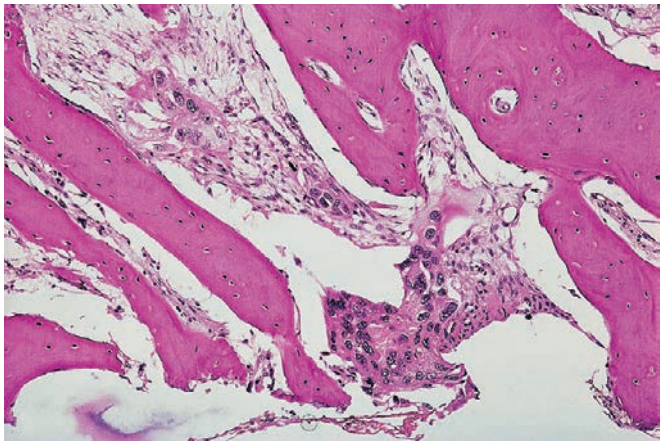

Figure 39.118 Marrow from a patient with metastatic carcinoma of breast with osteosclerotic reaction and foci of tumor cells.

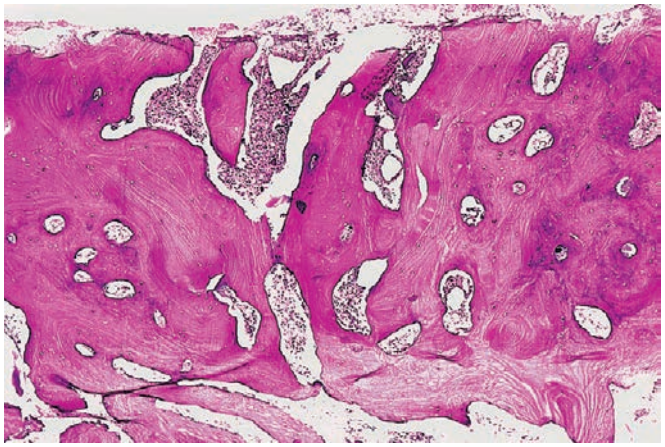

Figure 39.119 Marrow biopsy from a patient with metastatic carcinoma of prostate with a marked osteoblastic lesion.

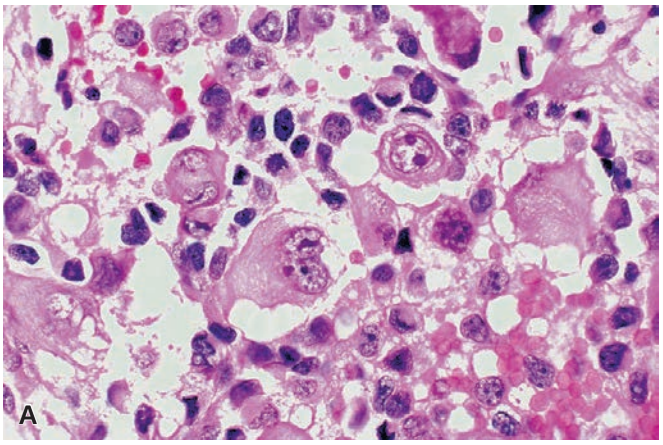

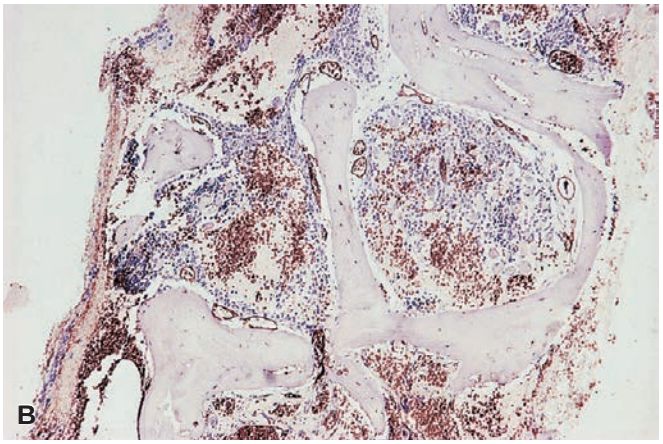

Figure 39.120 **A**, Bone marrow biopsy from a 17-year-old male with partial replacement of marrow by a pleomorphic population of cells, some of which are large with very abundant cytoplasm. Larger cells have one or two nuclei with distinct and frequently prominent nucleoli. The majority of the cells reacted with antibodies to actin (**B**) and desmin; chromosome studies of the cells showed a t(2;13)(q35;q14) abnormality, a characteristic cytogenetic finding in alveolar rhabdomyosarcoma.

immunohistochemical reaction, the tumor should be found in adjacent sections stained with hematoxylin and eosin.

Detection of micrometastasis from lung and breast carcinoma in bone marrow is increased with the use of immunologic markers applied to smears prepared from Ficoll Hypaque–separated specimens of bone marrow aspirate.[727–729] Molecular techniques for the identification of markers increase the detection level of micrometastasis.[730]

Special note is made here of neuroblastoma because the bone marrow biopsy may serve as the primary diagnostic specimen in patients with neuroblastoma if the aspirate or trephine biopsy specimen contains unequivocal tumor cells and there is significantly increased serum or urinary catecholamines or metabolites.[731–733] Because the detection rate increases with multiple biopsies, two aspirates and one trephine biopsy specimen from each posterior iliac crest are recommended for assessment of marrow involvement. Patients with stage 4S disease have less than 10% involvement; if there is more than 10%, the disease is stage 4.[732]

Tumor cells may be detected in bone marrow smears, particle sections, trephine imprints, or trephine biopsies. The relative merits of these various techniques for detecting tumor have been the subject of considerable discussion. The yield of positive results has increased with the performance of multiple trephine biopsies. Metastatic neuroblastoma in marrow sections may show varying degrees of differentiation. Following therapy, the lesions may show marked differentiation to ganglion cells (Fig. 39.121).

Immunologic markers may be used for the identification of neuroblastoma cells; antibodies to neuron-specific enolase, synaptophysin, and chromogranin have been recommended by the Second International Neuroblastoma Staging System Conference.[732] Newer and more specific markers of neuroblastoma, including GD2 synthetase, also appear to be useful in the primary diagnosis of neuroblastoma.[726,734,735] Immunohistochemical quantification of neuroblastoma cells in bone marrow and blood at diagnosis and in marrow during induction therapy can identify patients with very high-risk disease.[736]

Lipid Storage Diseases

Gaucher Disease

Gaucher disease is an autosomal recessive sphingolipid storage disorder resulting from the accumulation of glucosylceramide (glucocerebroside) in organs and tissues as a result of a deficiency in lysosomal β-glycosidase (glucocerebrosidase) which is encoded by the *GBA* gene on chromosome 1q22.[737–741] It occurs in three forms: type I, chronic non-neuronopathic (adult) type which is the

For personal use only. No other uses without permission. Copyright ©2017. Elsevier Inc. All rights reserved.

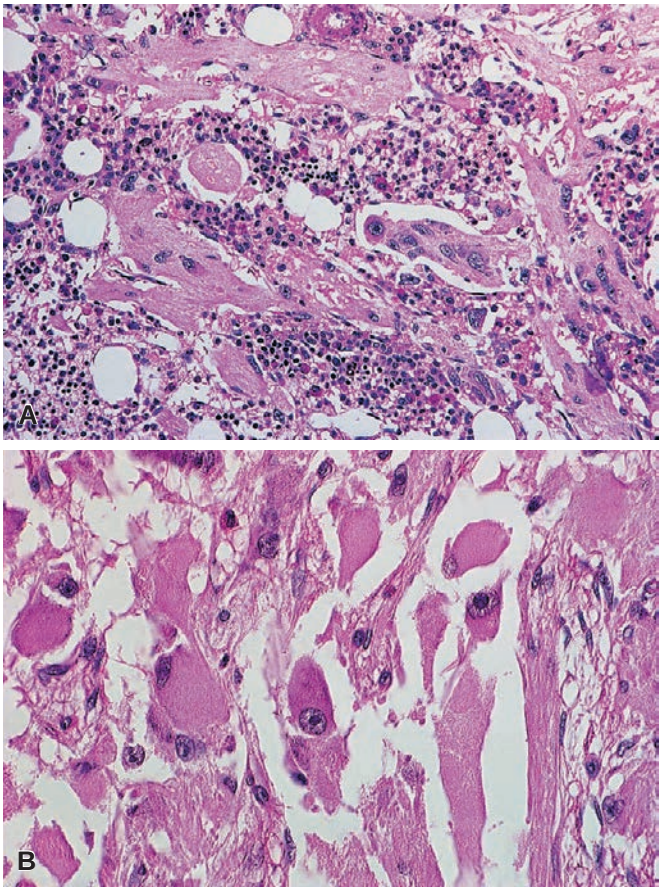

Figure 39.121 **A**, Marrow biopsy from a child with metastatic neuroblastoma with ganglion differentiation. **B**, High magnification of the specimen in **A** showing marked variability in size of the tumor cells. In contrast to megakaryocytes, some tumor cells contain single, very prominent, nuclei. (See Fig. 39.10, which is the same specimen reacted with antibody to neuron-specific enolase.)

most common Ashkenazi Jewish disorder; type II, acute neuronopathic type which is the most severe form; and type III, subacute neuronopathic (juvenile) type.

The characteristic diagnostic morphologic feature of the disorder is the presence of Gaucher cells in the bone marrow, spleen, liver, and lymph nodes and other organs.

In the bone marrow sections, Gaucher cells may be found in small focal accumulations or may replace large portions of a biopsy. There is an associated increase in reticulin fibers. In imprint and smear preparations, the Gaucher cell is large, 30–100 µm in diameter, and has one or more centrally or eccentrically located nuclei.[742,743] The cytoplasm has a characteristic fibrillary or striated pattern and is pale blue–gray in color. In sections stained with hematoxylin and eosin, the cytoplasm is slightly eosinophilic; a fibrillary pattern may be very prominent (Fig. 39.122). The Gaucher cells are variably and often intensely positive with the PAS reaction. The cells also stain positively for iron in older children and adults. Cells similar to Gaucher cells, pseudo-Gaucher cells, may be found in the marrow of some patients with CML,[744–748] type II congenital dyserythropoietic anemia, and thalassemia.[749]

A monoclonal gammopathy may be present in patients with chronic Gaucher disease and may be associated with a marrow plasmacytosis.[750] The coincidence of multiple myeloma, plasmacytoid lymphoma, and Gaucher disease has been reported.[751]

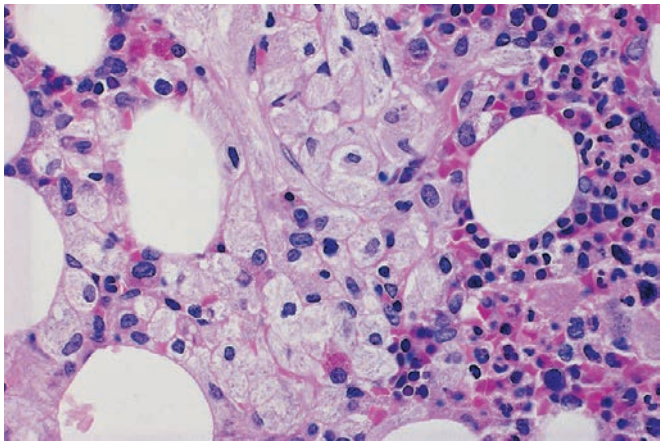

Figure 39.122 Bone marrow section from an adult with type I chronic non-neuronopathic Gaucher disease. The cytoplasm of many Gaucher cells has a fibrillary or granular appearance. Nuclei are small and usually eccentric in location.

Treatment of patients with type I (adult type) Gaucher disease with recombinant β-glucocerebrosidase (imiglucerase) results in a decrease in the relative volume of bone replaced by Gaucher cells and an increase in hematopoietic and fat cells and a decreased cortical bone structure. The decrease in amount of marrow replaced by Gaucher cells is the result of a decrease in both the number and size of Gaucher cells.[744,745,748] An additional form of therapy is directed at substrate reduction which may be used in addition to enzyme replacement.

Niemann–Pick Disease

Niemann–Pick (NP) disease is a group of autosomal recessive sphingomyelin–cholesterol lipidoses characterized by organomegaly and the accumulation of sphingomyelin and other lipids throughout the tissues of the body as a result of a deficiency of lysosomal acid sphingomyelinase.[743,747,752,753,754] The gene encoding acid sphingomyelinase in types NPA and NPB *(SMPD1)* is located at 11p15.4. Three major clinical types are recognized: an acute neuronopathic form (A); a chronic form without nervous system involvement (B); and chronic neuronopathic forms (C1 and C2).[743,747,752,753] The foam cell, as seen in the bone marrow in NP disease, does not have diagnostic specificity and may be found in other disorders of lipid metabolism such as hypercholesterolemia and Tangier disease; in NP disease type C1 the enzymatic defect results in cholesterol accumulation in the macrophages in the marrow and elsewhere.[742,745] In Romanowsky-stained smears, the cell measures 20–50 µm; the cytoplasm is filled with clear vacuoles of varying size.[742,745] In sections, the cells are randomly scattered singly and in aggregates; the cytoplasm of the NP cell is marked by confluent clear vacuoles of varying size. The cells may be difficult to appreciate because of the very light-staining cytoplasm. The nucleus is randomly located (Fig. 39.123). The vacuoles are PAS negative and positive with lipid stains.

NP disease types C1 and C2 are panethnic autosomal recessive lipidoses associated with mutations of *NPC1* (at 18q11.2) and *NPC2* (at 14q24.3).[743,747,753,754] The basic defect involves a unique error in cellular trafficking of exogenous cholesterol that is associated with a lysosomal accumulation of unesterified cholesterol; the disease is distinct from the sphingomyelin lipidoses, NP disease types A and B. Foam cells or sea-blue histiocytes may be present in the marrow; these, however, are not distinctive and may be observed in several different lipidoses.

For personal use only. No other uses without permission. Copyright ©2017. Elsevier Inc. All rights reserved.

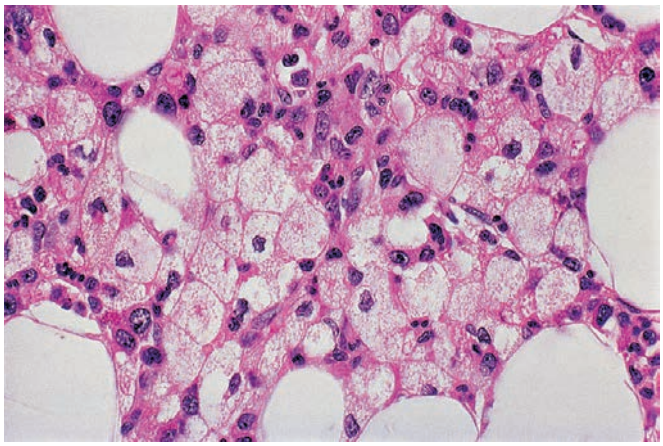

Figure 39.123 Biopsy From a 14-Month-Old Child With Niemann–Pick Disease. Focal accumulations of foam cells are present. The cytoplasm of the foam cells is clear, with the suggestion of numerous confluent vacuoles.

Fabry Disease

Fabry disease is an X-linked recessive inborn error of glycosphingolipid metabolism caused by variants of the *GLA* gene that results in deficient activity of α-galactosidase.[755] It is characterized by multiorgan involvement with accumulation of globotriaosylceramide in cells throughout the body, including macrophages in the marrow. The characteristic storage cells in bone marrow specimens in this disease are filled with small globular inclusions that stain blue in Romanowsky-stained smears and are lightly eosinophilic in sections stained with hematoxylin and eosin.[742] The cytoplasmic substance reacts intensely with the PAS and Sudan black B stains.

Similar to Gaucher disease, therapy for Fabry disease consists of enzyme replacement, substrate reduction, and enzyme enhancement.[745]

Sea-Blue Histiocyte Syndrome

The macrophages of the sea-blue histiocyte syndrome[743,756] contain a substance that stains blue in Romanowsky-stained smears and yellow to tan in sections stained with hematoxylin and eosin. Positive reactions occur with the PAS and Sudan black B stains. In some instances, the substance appears to be ceroid; in others the material has not been well characterized. Macrophages containing blue pigment may be observed in several unrelated disorders and lack diagnostic specificity. This cell type has also been reported in some cases of NP disease. The sea-blue histiocytes may resemble the macrophages in Whipple disease, which may rarely be detected in marrow specimens.[757]

Hematopoietic Cell Transplantation

Hematopoietic cell transplantation, using either bone marrow or peripheral blood cells, is now commonly used as a therapeutic approach in patients with primary bone marrow disease.[758] Bone marrow examination is performed for a variety of reasons following hematopoietic cell transplantation. While evaluation for residual or recurrent disease in these specimens remains important, the marrow also provides clues to the success of engraftment and to possible infectious complications of the procedure.

The objective of hematopoietic cell transplantation is reconstitution of normal hematopoiesis in marrows that are aplastic; the aplasia may be the result of aplastic anemia or the marrow is rendered aplastic with chemotherapy and radiation in the preparative regimen employed prior to marrow transplantation for various neoplastic processes or, less commonly, inherited disorders.

The source of the graft may be the patient's own marrow or peripheral blood cells that have been harvested prior to the preparatory regimen (autologous) or from another individual (allogeneic). Autologous stem cells in some cases are "purged" with chemotherapeutic agents and/or monoclonal antibodies to eradicate malignant cells. Umbilical cord blood stem cells are also being used.[759]

Hematopoietic cell transplantation involves preparing the patient for transplant with a regimen utilizing chemotherapy with or without total body irradiation therapy. The preparative regimen has two purposes: to immunosuppress the patient and to eradicate malignant cells that may be present in the recipient. For patients with severe aplastic anemia, cyclophosphamide alone or cyclophosphamide plus antithymocyte globulin or cyclophosphamide plus total lymphoid irradiation has been utilized most commonly and now provides long-term success rates of over 80% in matched sibling donor patients. For patients with leukemia, regimens including chemotherapy and total body irradiation have most commonly been used; the combination of busulfan and cyclophosphamide has been successful in the preparation of patients with AML.

The major complications associated with hematopoietic cell transplantation involve infection in the severely immunosuppressed host, graft rejection, and graft-versus-host disease.[760] Recurrent disease is also a cause of failure in patients with malignant diseases. Infection continues to be a major cause of peritransplant morbidity and, in some cases, mortality. The use of better antibiotics and growth factors to accelerate white blood cell production has decreased but not eliminated infectious complications. Graft rejection is an infrequent complication of matched sibling donor transplant; however, it is a significant complication in patients undergoing unrelated donor transplant, especially for diseases such as aplastic anemia. Certain methods of graft-versus-host disease prophylaxis, specifically T-cell depletion, may be associated with an increased risk of graft rejection.

The rate of engraftment following hematopoietic cell transplantation is influenced by several factors, and although some generalizations can be made about reconstitution of hematopoiesis, there are frequent exceptions.[71,760–763] The amount of marrow damage incurred prior to the transplant from chemotherapy and radiation used for treatment of the disease for which the transplant is necessary may influence the success rate. Autologous marrow specimens that have been purged with antibodies or chemotherapeutic agents may reconstitute less quickly than allogeneic marrow grafts. The disease for which the transplant was performed may recur early in the transplant period.

Marrow biopsies are not usually performed in the first 7 days following transplantation. However, the marrow biopsies performed during this period show marked hypocellularity with hemorrhage and proteinaceous debris. Scattered fat cells and macrophages are present. The findings are similar to those in patients treated with myelotoxic agents for acute leukemia.[71,761–763] At 7–14 days, adipose tissue is reconstituted. The appearance of the marrow in the second to third week is variable; there may be evidence of hematopoiesis, or the marrow may be markedly hypocellular (Figs. 39.124 and 39.125). The initial stages of engraftment are usually characterized by foci of hematopoietic cells scattered throughout the adipose tissue in what appears to be a random distribution. These foci initially are usually unilineage and composed of tight clusters of erythroid precursors followed by aggregates of promyelocytes and myelocytes (see Fig. 39.124B). Blasts are not increased. There is no preferential paratrabecular distribution of the promyelocyte and myelocyte islands in this period. Megakaryocytes are usually sparse. Following this stage there is progressive spreading of the hematopoietic cells

For personal use only. No other uses without permission. Copyright ©2017. Elsevier Inc. All rights reserved.

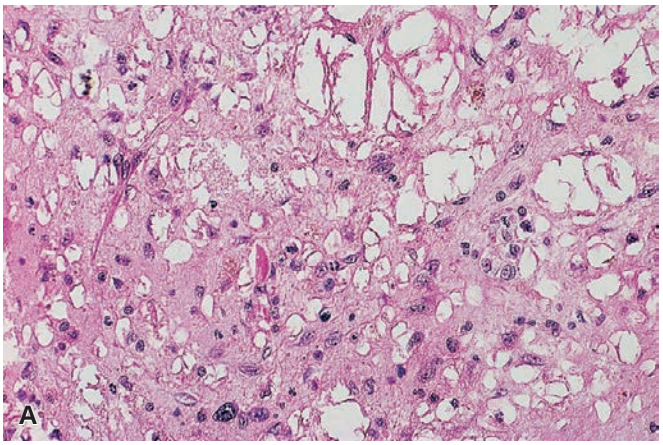

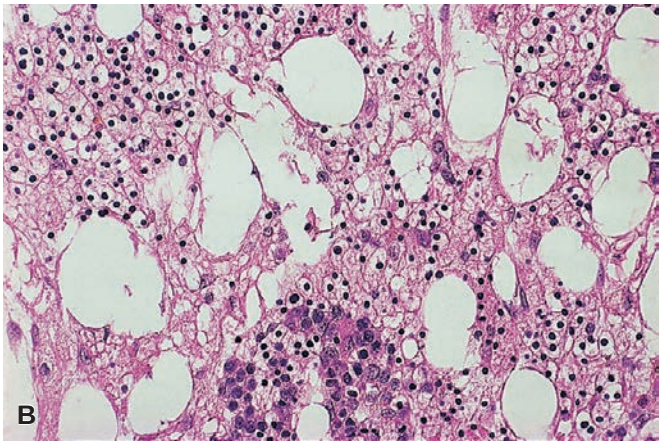

Figure 39.124 **A**, Marrow biopsy 4 days post allogeneic marrow transplantation for blast crisis of chronic myeloid leukemia. The marrow is markedly hypocellular with scattered cells and abundant interstitial proteinaceous debris. **B**, Marrow biopsy from the patient illustrated in **A** 28 days post transplant. Evidence of engraftment is characterized principally by erythroid precursors at a late stage of maturation and foci of more immature forms. There was no evidence of a t(9;22) cytogenetic abnormality in either biopsy.

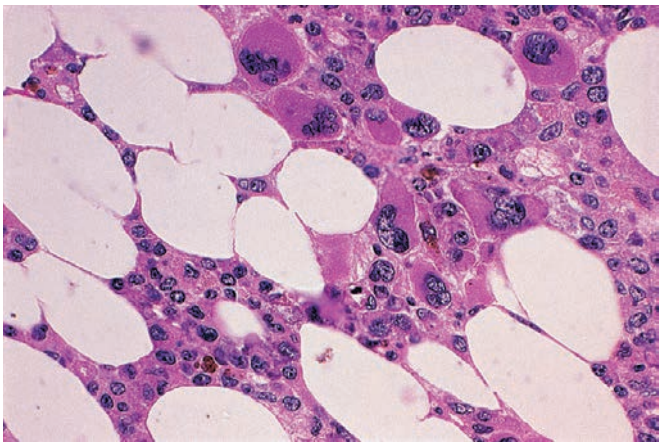

Figure 39.126 Marrow from an adult man 18 days post unrelated marrow transplantation for acute myeloid leukemia. The marrow is markedly hypocellular with scattered clusters of normal-appearing megakaryocytes; there is no evidence of leukemia.

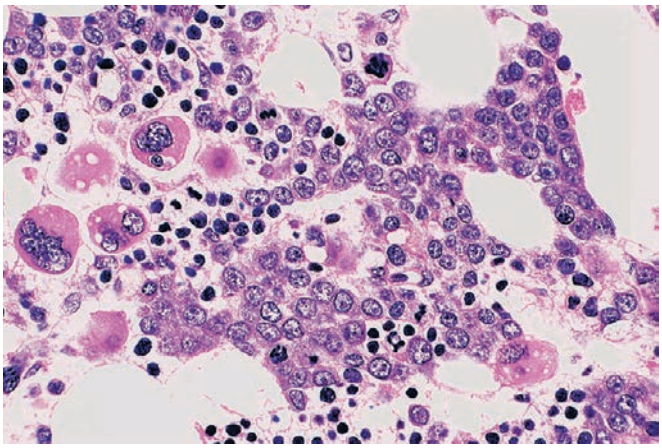

Figure 39.127 Marrow from an adult woman 21 days post autologous marrow transplantation for chronic myeloid leukemia illustrating a focus of erythroid precursors at an early stage of maturation in an overall hypocellular marrow. Erythroid precursors at a late stage of maturation are located in the surrounding interstitium; there are several normal-appearing megakaryocytes.

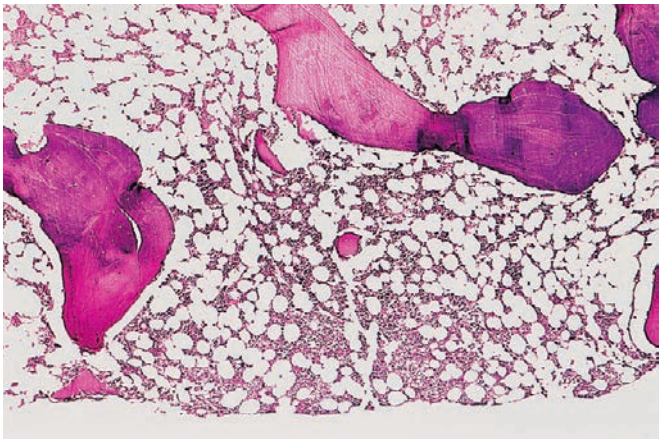

Figure 39.125 Marrow biopsy from a 7-year-old child 14 days post allogeneic bone marrow transplantation for aplastic anemia. The marrow is moderately to markedly hypocellular. Subsequent biopsies showed failure of engraftment.

throughout the interstitium and gradual regression of adipose tissue; the foci of hematopoiesis at this stage of recovery are usually multilineage, although predominantly monolineage proliferation may persist (Figs. 39.126 and 39.127). Megakaryocyte reconstitution may lag behind the granulocytic and erythroid cells for prolonged periods. In some patients, megakaryocytes appear early in the engraftment period and may form small aggregates. There may be considerable variability in the amount of hematopoietic tissue in different areas of a large biopsy specimen; clot sections, small specimens, or fragmented specimens may be misleading.

There may be a marked shift to promyelocytes and myelocytes early in the post-transplant period; this is accentuated by the administration of recombinant granulocyte growth factor (Fig. 39.128). This shift to immaturity is not usually accompanied by an increase in blasts. During this period, patients frequently receive a large number of drugs, some of which may be associated with agranulocytosis. This factor should be considered in patients who manifest prolonged neutropenia with a morphologic appearance of "maturation arrest" of neutrophils in the marrow specimen.

For personal use only. No other uses without permission. Copyright ©2017. Elsevier Inc. All rights reserved.

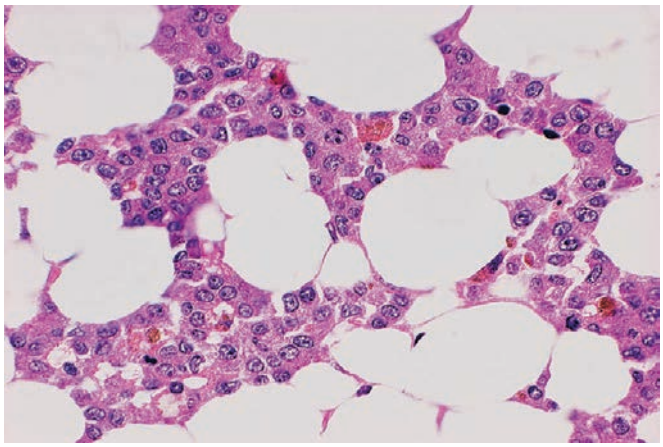

Figure 39.128 Marrow biopsy 20 days post allogeneic sibling transplantation for chronic myeloid leukemia; 3 days prior to the biopsy the patient received granulocyte colony-stimulating factor for marked neutropenia. The cells in the interstitium are neutrophil precursors at the promyelocyte–myelocyte stage of maturation, a characteristic early effect of growth factor stimulation.

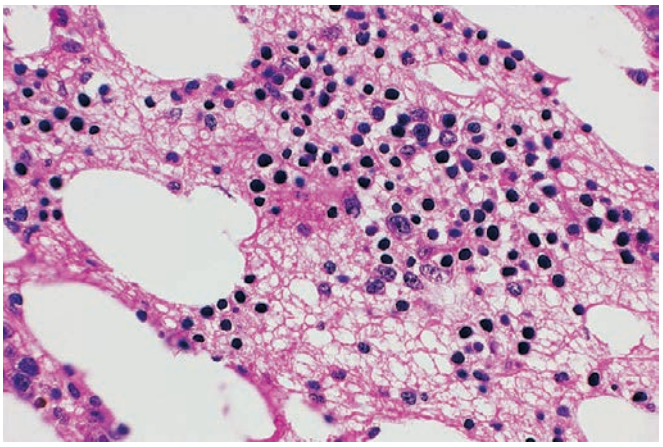

Figure 39.130 Marrow biopsy from an adult 8 months following autologous marrow transplantation for chronic myeloid leukemia. The marrow is markedly hypocellular with markedly decreased granulocytes and megakaryocytes. The interstitium is markedly depleted with principally late-stage erythroid precursors.

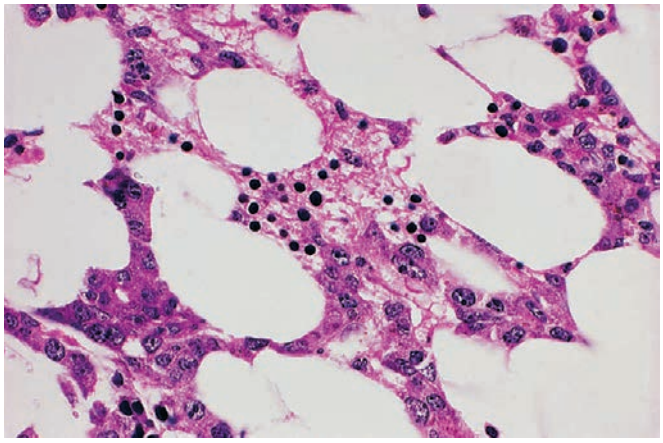

Figure 39.129 Marrow biopsy from an 11-year-old child 100 days following unrelated donor marrow transplantation for chronic myeloid leukemia. The marrow is moderately to markedly hypocellular with erythroid and granulocyte precursors and only rare megakaryocytes.

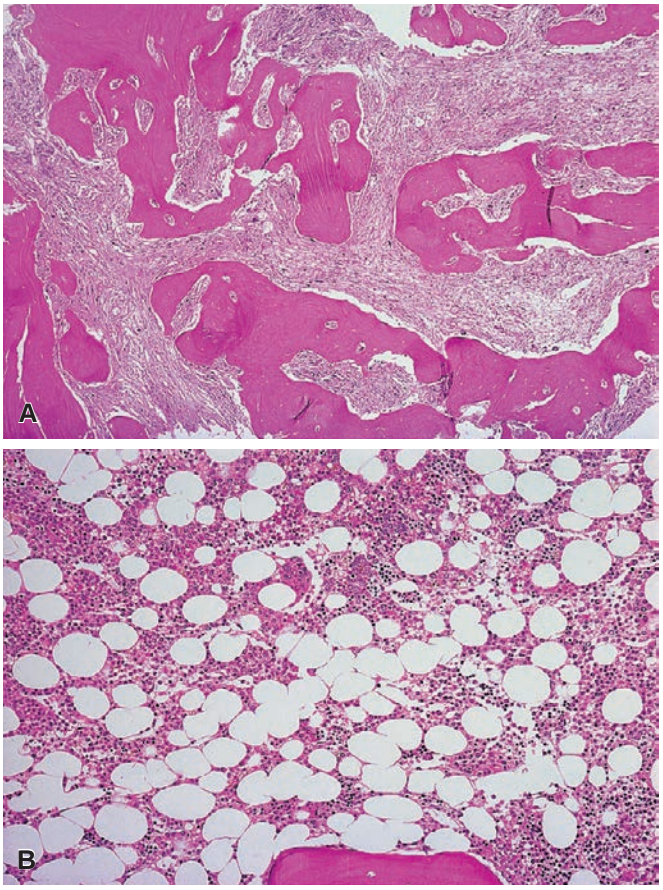

Figure 39.131 **A**, Marrow biopsy with marked osteosclerosis from a 32-year-old patient with Philadelphia chromosome–positive chronic myeloid leukemia immediately prior to marrow transplantation. **B**, Marrow biopsy from the patient illustrated in **A** 5 months post allogeneic marrow transplantation. There is complete resolution of the osteosclerosis. The cytogenetics from this specimen were normal.

Granulomas occur with greater frequency in post-transplant marrows than in marrows from other groups of patients; these granulomas usually consist of only a small collection of epithelioid histiocytes. In some cases, giant cells are present. Phagocytic histiocytes may be increased and diffusely scattered throughout the marrow. The histiocytes may manifest marked phagocytic activity; this finding warrants evaluation for an infectious process.

The rate of growth of the graft varies substantially in the first 3–4 weeks. In some cases the marrow may remain hypocellular for many months or years; in other cases one of the major myeloid cell lines remains depressed (Figs. 39.129 and 39.130). Remission of myelofibrosis and osteosclerosis may occur (Fig. 39.131).

Loss of graft is reflected by decreasing marrow cellularity and progressive cytopenias. This may occur gradually or abruptly. In some instances, there is a discrepancy between the blood counts and marrow cellularity, with very hypocellular marrows and normal blood counts or normocellular marrows and blood cytopenias. Marrow sampling may be the basis of the discrepancy when normal

For personal use only. No other uses without permission. Copyright ©2017. Elsevier Inc. All rights reserved.

blood counts occur with hypocellular marrow. There are no specific marrow findings reflecting graft-versus-host disease.

Marrow transplants in patients with leukemia present the additional problem of recognition of recurrent disease. Cytogenetics, membrane surface markers, and molecular studies are very important adjuncts to morphology in the evaluation of these patients. In addition, molecular genetic studies for engraftment now focus primarily on the ratio of donor to recipient histocompatibility markers.[764]

Acknowledgment

The author thanks Dr. Richard Brunning, an author and co-author of prior editions of this chapter.

References

1. Bain BJ. Bone marrow aspiration. *J Clin Pathol*. 2001;54(9):657-663.
2. Bain BJ. Bone marrow trephine biopsy. *J Clin Pathol*. 2001;54(10):737-742.
3. Brunning RD, Bloomfield CD, McKenna RW, Peterson LA. Bilateral trephine bone marrow biopsies in lymphoma and other neoplastic diseases. *Ann Intern Med*. 1975;82(3):365-366.
4. Burkhardt R, Frisch B, Bartl R. Bone biopsy in haematological disorders. *J Clin Pathol*. 1982;35(3):257-284.
5. Contreras E, Ellis LD, Lee RE. Value of the bone marrow biopsy in the diagnosis of metastatic carcinoma. *Cancer*. 1972;29(3):778-783.
6. Dee JW, Valdivieso M, Drewinko B. Comparison of the efficacies of closed trephine needle biopsy, aspirated paraffin-embedded clot section, and smear preparation in the diagnosis of bone-marrow involvement by lymphoma. *Am J Clin Pathol*. 1976;65(2):183-194.
7. Ellman L. Bone marrow biopsy in the evaluation of lymphoma, carcinoma and granulomatous disorders. *Am J Med*. 1976;60(1):1-7.
8. Fend F, Bock O, Kremer M, et al. Ancillary techniques in bone marrow pathology: molecular diagnostics on bone marrow trephine biopsies. *Virchows Arch*. 2005;447(6):909-919.
9. Jamshidi K, Swaim WR. Bone marrow biopsy with unaltered architecture: a new biopsy device. *J Lab Clin Med*. 1971;77(2):335-342.
10. Nguyen PL. Collection, processing and examination of bone marrow specimens. In: Jaffe ES, Arber DA, Campo E, et al, eds. *Hematopathology*. 2nd ed. Philadelphia, PA: Elsevier; 2017:29-40.
11. Wang J, Weiss LM, Chang KL, et al. Diagnostic utility of bilateral bone marrow examination: significance of morphologic and ancillary technique study in malignancy. *Cancer*. 2002;94(5):1522-1531.
12. Gruppo RA, Lampkin BC, Granger S. Bone marrow cellularity determination: comparison of the biopsy, aspirate, and buffy coat. *Blood*. 1977;49(1):29-31.
13. Liao KT. The superiority of histologic sections of aspirated bone marrow in malignant lymphomas. A review of 1,124 examinations. *Cancer*. 1971;27(3):618-628.
14. Garrett TJ, Gee TS, Lieberman PH, et al. The role of bone marrow aspiration and biopsy in detecting marrow involvement by nonhematologic malignancies. *Cancer*. 1976;38(6):2401-2403.
15. Brinn NT, Pickett JP. Glycol methacrylate for routine, special stains, histochemistry, enzyme histochemistry and immunohistochemistry. A simplified method for surgical biopsy tissue. *J Histotechnol*. 1979;2:125-130.
16. Gatter KC, Heryet A, Brown DC, Mason DY. Is it necessary to embed bone marrow biopsies in plastic for haematological diagnosis? *Histopathology*. 1987;11(1):1-7.
17. McCarthy DM. Annotation. Fibrosis of the bone marrow: content and causes. *Br J Haematol*. 1985;59(1):1-7.
18. Torlakovic EE, Naresh KN, Brunning RD. *Bone Marrow Immunohistochemistry*. Chicago: America Society for Clinical Pathology Press; 2008.
19. Peterson LC, Brunning RD. Bone marrow specimen processing. In: Knowles DM, ed. *Neoplastic Hematopathology*. 2nd ed. Philadelphia: Lippincott Williams & Wilkins; 2001:1391-1406.
20. Schrijver WA, van der Groep P, Hoefnagel LD, et al. Influence of decalcification procedures on immunohistochemistry and molecular pathology in breast cancer. *Mod Pathol*. 2016;29(12):1460-1470.
21. Brown DC, Gatter KC. The bone marrow trephine biopsy: a review of normal histology. *Histopathology*. 1993;22(5):411-422.
22. Kronland R, Grogan T, Spier C, et al. Immunotopographic assessment of lymphoid and plasma cell malignancies in the bone marrow. *Hum Pathol*. 1985;16(12):1247-1254.
23. Bluth RF, Casey TT, McCurley TL. Differentiation of reactive from neoplastic small-cell lymphoid aggregates in paraffin-embedded marrow particle preparations using L-26 (CD20) and UCHL-1 (CD45RO) monoclonal antibodies. *Am J Clin Pathol*. 1993;99(2):150-156.
24. Arber DA, Jenkins KA. Paraffin section immunophenotyping of acute leukemias in bone marrow specimens. *Am J Clin Pathol*. 1996;106(4):462-468.
25. Chuang SS, Li CY. Useful panel of antibodies for the classification of acute leukemia by immunohistochemical methods in bone marrow trephine biopsy specimens. *Am J Clin Pathol*. 1997;107(4):410-418.
26. Erber WN, Gibbs TA, Ivey JG. Antigen retrieval by microwave oven heating for immunohistochemical analysis of bone marrow trephine biopsies. *Pathology*. 1996;28(1):45-50.
27. Erber WN, Willis JI, Hoffman GJ. An enhanced immunocytochemical method for staining bone marrow trephine sections. *J Clin Pathol*. 1997;50(5):389-393.
28. Horny HP, Wehrmann M, Griesser H, et al. Investigation of bone marrow lymphocyte subsets in normal, reactive, and neoplastic states using paraffin-embedded biopsy specimens. *Am J Clin Pathol*. 1993;99(2):142-149.
29. Kremer M, Dirnhofer S, Nickl A, et al. p27(Kip1) immunostaining for the differential diagnosis of small b-cell neoplasms in trephine bone marrow biopsies. *Mod Pathol*. 2001;14(10):1022-1029.
30. Kremer M, Quintanilla-Martinez L, Nahrig J, et al. Immunohistochemistry in bone marrow pathology: a useful adjunct for morphologic diagnosis. *Virchows Arch*. 2005;447(6):920-937.
31. Kubic VL, Brunning RD. Immunohistochemical evaluation of neoplasms in bone marrow biopsies using monoclonal antibodies reactive in paraffin-embedded tissue. *Mod Pathol*. 1989;2(6):618-629.
32. Manion EM, Rosenthal NS. Bone marrow biopsies in patients 85 years or older. *Am J Clin Pathol*. 2008;130(5):832-835.
33. Peterson LC, Brown BA, Crosson JT, Mladenovic J. Application of the immunoperoxidase technic to bone marrow trephine biopsies in the classification of patients with monoclonal gammopathies. *Am J Clin Pathol*. 1986;85(6):688-693.
34. Segal GH, Shick HE, Tubbs RR, et al. In situ hybridization analysis of lymphoproliferative disorders. Assessment of clonality by immunoglobulin light-chain messenger RNA expression. *Diagn Mol Pathol*. 1994;3(3):170-177.
35. Arber DA, Snyder DS, Fine M, et al. Myeloperoxidase immunoreactivity in adult acute lymphoblastic leukemia. *Am J Clin Pathol*. 2001;116(1):25-33.
36. Pinkus GS, Pinkus JL. Myeloperoxidase: a specific marker for myeloid cells in paraffin sections. *Mod Pathol*. 1991;4(6):733-741.
37. Dunphy CH, Polski JM, Evans HL, Gardner LJ. Evaluation of bone marrow specimens with acute myelogenous leukemia for CD34, CD15, CD117, and myeloperoxidase. *Arch Pathol Lab Med*. 2001;125(8):1063-1069.
38. Pileri SA, Ascani S, Milani M, et al. Acute leukaemia immunophenotyping in bone-marrow routine sections. *Br J Haematol*. 1999;105(2):394-401.
39. Fend F, Tzankov A, Bink K, et al. Modern techniques for the diagnostic evaluation of the trephine bone marrow biopsy: methodological aspects and applications. *Prog Histochem Cytochem*. 2008;42(4):203-252.
40. Hartsock RJ, Smith EB, Petty CS. Normal variations with aging of the amount of hematopoietic tissue in bone marrow from the anterior iliac crest. A study made from 177 cases of sudden death examined by necropsy. *Am J Clin Pathol*. 1965;43:326-331.
41. Ricci C, Cova M, Kang YS, et al. Normal age-related patterns of cellular and fatty bone marrow distribution in the axial skeleton: MR imaging study. *Radiology*. 1990;177(1):83-88.
42. Wickramasinghe SN. Bone marrow. In: Sternberg SS, ed. *Histopathology for Pathologists*. 2nd ed. Philadelphia: Lippincott-Raven; 1997:707-744.
43. Ajlouni K, Doeblin TD. The syndrome of hepatitis and aplastic anaemia. *Br J Haematol*. 1974;27(2):345-355.
44. Goswitz FA, Andrews GA, Kniseley RM. Effects of local irradiation (Co60 teletherapy) on the peripheral blood and bone marrow. *Blood*. 1963;21:605-619.
45. Haak HL, Hartgrink-Groeneveld CA, Eernisse JG, et al. Acquired aplastic anaemia in adults. I. A retrospective analysis of 40 cases: single factors influencing the prognosis. *Acta Haematol*. 1977;58(5):257-277.
46. Kurtzman G, Young N. Viruses and bone marrow failure. *Baillieres Clin Haematol*. 1989;2(1):51-67.
47. Nissen C. The pathophysiology of aplastic anemia. *Semin Hematol*. 1991;28(4):313-318.

For personal use only. No other uses without permission. Copyright ©2017. Elsevier Inc. All rights reserved.

48. Dolberg OJ, Levy Y. Idiopathic aplastic anemia: diagnosis and classification. *Autoimmun Rev*. 2014;13(4-5): 569-573.
49. Young N. Hematologic and hematopoietic consequences of B19 parvovirus infection. *Semin Hematol*. 1988;25(2):159-172.
50. Young NS, Calado RT, Scheinberg P. Current concepts in the pathophysiology and treatment of aplastic anemia. *Blood*. 2006;108(8):2509-2519.
51. Calado RT, Young NS. Telomere maintenance and human bone marrow failure. *Blood*. 2008;111(9):4446-4455.
52. Marsh JC, Ball SE, Cavenagh J, et al. Guidelines for the diagnosis and management of aplastic anaemia. *Br J Haematol*. 2009;147(1):43-70.
53. Rosse WF. Paroxysmal nocturnal haemoglobinuria in aplastic anaemia. *Clin Haematol*. 1978;7(3):541-553.
54. Pu JJ, Mukhina G, Wang H, et al. Natural history of paroxysmal nocturnal hemoglobinuria clones in patients presenting as aplastic anemia. *Eur J Haematol*. 2011;87(1):37-45.
55. Alter BP, Potter NU, Li FP. Classification and aetiology of the aplastic anaemias. *Clin Haematol*. 1978;7(3):431-465.
56. Dawson JP. Congenital pancytopenia associated with multiple congenital anomalies (Fanconi type); review of the literature and report of a twenty-year-old female with a ten-year follow-up and apparently good response to splenectomy. *Pediatrics*. 1955;15(3):325-333.
57. Dokal I, Ganly P, Riebero I, et al. Late onset bone marrow failure associated with proximal fusion of radius and ulna: a new syndrome. *Br J Haematol*. 1989;71(2):277-280.
58. Estren S, Dameshek W. Familial hypoplastic anemia of childhood; report of eight cases in two families with beneficial effect of splenectomy in one case. *Am J Dis Child*. 1947;73(6):671-687.
59. Evans DI. Congenital defects of the marrow stem cell. *Baillieres Clin Haematol*. 1989;2(1):162-190.
60. Gordon-Smith EC, Rutherford TR. Fanconi anaemia—constitutional, familial aplastic anaemia. *Baillieres Clin Haematol*. 1989;2(1):139-152.
61. Shwachman H, Diamond LK, Oski FA, Khaw KT. The syndrome of pancreatic insufficiency and bone marrow dysfunction. *J Pediatr*. 1964;65:645-663.
62. Shimamura A. Inherited bone marrow failure syndromes: molecular features. *Hematology Am Soc Hematol Educ Program*. 2006;63-71.
63. Thompson AA, Nguyen LT. Amegakaryocytic thrombocytopenia and radio-ulnar synostosis are associated with HOXA11 mutation. *Nat Genet*. 2000;26(4):397-398.
64. Parikh S, Bessler M. Recent insights into inherited bone marrow failure syndromes. *Curr Opin Pediatr*. 2012;24(1):23-32.
65. Chirnomas SD, Kupfer GM. The inherited bone marrow failure syndromes. *Pediatr Clin North Am*. 2013;60(6):1291-1310.
66. Horos R, von Lindern M. Molecular mechanisms of pathology and treatment in Diamond Blackfan Anaemia. *Br J Haematol*. 2012;159(5):514-527.
67. Mark M, Rijli FM, Chambon P. Homeobox genes in embryogenesis and pathogenesis. *Pediatr Res*. 1997;42(4):421-449.
68. Smith GP, Perkins SL, Segal GH, Kjeldsberg CR. T-cell lymphocytosis associated with invasive thymomas. *Am J Clin Pathol*. 1994;102(4):447-453.
69. Orazi A, Albitar M, Heerema NA, et al. Hypoplastic myelodysplastic syndromes can be distinguished from acquired aplastic anemia by CD34 and PCNA immunostaining of bone marrow biopsy specimens. *Am J Clin Pathol*. 1997;107(3):268-274.
70. Maciejewski JP, Risitano A, Sloand EM, et al. Distinct clinical outcomes for cytogenetic abnormalities evolving from aplastic anemia. *Blood*. 2002;99(9):3129-3135.
71. Naeim F, Smith GS, Gale RP. Morphologic aspects of bone marrow transplantation in patients with aplastic anemia. *Hum Pathol*. 1978;9(3):295-308.
72. Sale GE, Marmont BS. Marrow mast cell counts do not predict bone marrow graft rejection. *Hum Pathol*. 1980;12:605-608.
73. Crook TW, Rogers BB, McFarland RD, et al. Unusual bone marrow manifestations of parvovirus B19 infection in immunocompromised patients. *Hum Pathol*. 2000;31(2):161-168.
74. Dessypris EN. The biology of pure red cell aplasia. *Semin Hematol*. 1991;28(4):275-284.
75. Saarinen UM, Chorba TL, Tattersall P, et al. Human parvovirus B19-induced epidemic acute red cell aplasia in patients with hereditary hemolytic anemia. *Blood*. 1986;67(5):1411-1417.
76. Abella E, Feliu E, Granada I, et al. Bone marrow changes in anorexia nervosa are correlated with the amount of weight loss and not with other clinical findings. *Am J Clin Pathol*. 2002;118(4):582-588.
77. Bohm J. Gelatinous transformation of the bone marrow: the spectrum of underlying diseases. *Am J Surg Pathol*. 2000;24(1): 56-65.
78. Mehta K, Gascon P, Robboy S. The gelatinous bone marrow (serous atrophy) in patients with acquired immunodeficiency syndrome. Evidence of excess sulfated glycosaminoglycan. *Arch Pathol Lab Med*. 1992;116(5):504-508.
79. Seaman JP, Kjeldsberg CR, Linker A. Gelatinous transformation of the bone marrow. *Hum Pathol*. 1978;9(6):685-692.
80. Jain R, Singh ZN, Khurana N, Singh T. Gelatinous transformation of bone marrow: a study of 43 cases. *Indian J Pathol Microbiol*. 2005;48(1):1-3.
81. Sen R, Singh S, Singh H, et al. Clinical profile in gelatinous bone marrow transformation. *J Assoc Physicians India*. 2003;51:585-588.
82. Del Fattore A, Cappariello A, Teti A. Genetics, pathogenesis and complications of osteopetrosis. *Bone*. 2008;42(1):19-29.
83. Kilpatrick L. Osteopetrosis. In: Damjanov I, Linder J, eds. *Anderson's Pathology*. 10th ed. St Louis: Mosby; 1996:2585.
84. Tolar J, Teitelbaum SL, Orchard PJ. Osteopetrosis. *N Engl J Med*. 2004;351(27):2839-2849.
85. Gerritsen EJ, Vossen JM, van Loo IH, et al. Autosomal recessive osteopetrosis: variability of findings at diagnosis and during the natural course. *Pediatrics*. 1994;93(2):247-253.
86. Natsheh J, Drozdinsky G, Simanovsky N, et al. Improved outcomes of hematopoietic stem cell transplantation in patients with infantile malignant osteopetrosis using fludarabine-based conditioning. *Pediatr Blood Cancer*. 2016;63(3):535-540.
87. Askmyr MK, Fasth A, Richter J. Towards a better understanding and new therapeutics of osteopetrosis. *Br J Haematol*. 2008;140(6):597-609.
88. Pangrazio A, Cassani B, Guerrini MM, et al. RANK-dependent autosomal recessive osteopetrosis: characterization of five new cases with novel mutations. *J Bone Miner Res*. 2012;27(2):342-351.
89. Helfrich MH, Aronson DC, Everts V, et al. Morphologic features of bone in human osteopetrosis. *Bone*. 1991;12(6):411-419.
90. Coccia PF, Krivit W, Cervenka J, et al. Successful bone-marrow transplantation for infantile malignant osteopetrosis. *N Engl J Med*. 1980;302(13):701-708.
91. Gerritsen EJ, Vossen JM, Fasth A, et al. Bone marrow transplantation for autosomal recessive osteopetrosis. A report from the Working Party on Inborn Errors of the European Bone Marrow Transplantation Group. *J Pediatr*. 1994;125(6 Pt 1):896-902.
92. Brown CH 3rd. Bone marrow necrosis. A study of seventy cases. *Johns Hopkins Med J*. 1972;131(3):189-203.
93. Goodall HB. Atypical changes in the bone marrow in acute infections. In: Clark WJ, Howard EB, Hachett PL, eds. *Myeloproliferative Disorder of Animal and Man*. Oak Ridge, TN: United States Energy Commission; 1970:314-339.
94. Kundel DW, Brecher G, Bodey GP, Brittin GM. Reticulin fibrosis and bone infarction in acute leukemia. Implications for prognosis. *Blood*. 1964;23:526-544.
95. Niebrugge DJ, Benjamin DR. Bone marrow necrosis preceding acute lymphoblastic leukemia in childhood. *Cancer*. 1983;52(11):2162-2164.
96. Pui CH, Stass S, Green A. Bone marrow necrosis in children with malignant disease. *Cancer*. 1985;56(7):1522-1525.
97. Smith RR, Spivak JL. Marrow cell necrosis in anorexia nervosa and involuntary starvation. *Br J Haematol*. 1985;60(3):525-530.
98. Browne PM, Sharma OP, Salkin D. Bone marrow sarcoidosis. *JAMA*. 1978;240(24):2654-2655.
99. Delsol G, Pellegrin M, Familiades J, Auvergnat JC. Bone marrow lesions in Q fever. *Blood*. 1978;52(3):637-638.
100. Diebold J, Molina T, Camilleri-Broet S, et al. Bone marrow manifestations of infections and systemic diseases observed in bone marrow trephine biopsy review. *Histopathology*. 2000;37(3):199-211.
101. Farhi DC, Mason UG 3rd, Horsburgh CR Jr. The bone marrow in disseminated Mycobacterium avium-intracellulare infection. *Am J Clin Pathol*. 1985;83(4):463-468.
102. Hussong J, Peterson LR, Warren JR, Peterson LC. Detecting disseminated Mycobacterium avium complex infections in HIV-positive patients. The usefulness of bone marrow trephine biopsy specimens, aspirate cultures, and blood cultures. *Am J Clin Pathol*. 1998;110(6):806-809.
103. Kilby JM, Marques MB, Jaye DL, et al. The yield of bone marrow biopsy and culture compared with blood culture in the evaluation of HIV-infected patients for mycobacterial and fungal infections. *Am J Med*. 1998;104(2):123-128.
104. Kvasnicka HM, Thiele J. [Differentiation of granulomatous lesions in the bone marrow]. *Pathologe*. 2002;23(6):465-471.
105. Rywlin AM. A pathologist's view of the bone marrow. *J Fla Med Assoc*. 1980;67(2):121-124.
106. Srigley JR, Vellend H, Palmer N, et al. Q-fever. The liver and bone marrow pathology. *Am J Surg Pathol*. 1985;9(10):752-758.
107. Swerdlow SH, Collins RD. Marrow granulomas. In: Ioachim HE, ed. *Pathology of Granulomas*. New York: Raven Press; 1983:125-150.
108. Vilalta-Castel E, Valdes-Sanchez MD, Guerra-Vales JM, et al. Significance of granulomas in bone marrow: a study of 40 cases. *Eur J Haematol*. 1988;41(1):12-16.
109. Volk EE, Miller ML, Kirkley BA, Washington JA. The diagnostic usefulness of bone marrow cultures in patients with fever of unknown origin. *Am J Clin Pathol*. 1998;110(2): 150-153.
110. White RM, Johnston CL Jr. Granulomatous bone marrow disease in Virginia: study of 50 cases. *Va Med*. 1985;112(5):316-319.
111. Mohamed T, Sanjay R, Sycheva T, et al. Amiodarone-associated bone marrow granulomas: a report of 2 cases and review of

For personal use only. No other uses without permission. Copyright ©2017. Elsevier Inc. All rights reserved.

the literature. *Int J Hematol*. 2007;85(2):101-104.
112. Mukhopadhyay S, Mukhopadhyay S, Abraham NZ Jr, et al. Unexplained bone marrow granulomas: is amiodarone the culprit? A report of 2 cases. *Am J Hematol*. 2004;75(2):110-112.
113. Choe JK, Hyun BH, Salazar GH, et al. Epithelioid granulomas of the bone marrow in non-Hodgkin's lymphoproliferative malignancies. *Am J Clin Pathol*. 1984;81(1):19-24.
114. Kadin ME, Donaldson SS, Dorfman RF. Isolated granulomas in Hodgkin's disease. *N Engl J Med*. 1970;283(16):859-861.
115. Ker CC, Hung CC, Huang SY, et al. Comparison of bone marrow studies with blood culture for etiological diagnosis of disseminated mycobacterial and fungal infection in patients with acquired immunodeficiency syndrome. *J Microbiol Immunol Infect*. 2002;35(2):89-93.
116. Hakawi AM, Alrajhi AA. Tuberculosis of the bone marrow: clinico-pathological study of 22 cases from Saudi Arabia. *Int J Tuberc Lung Dis*. 2006;10(9):1041-1044.
117. Park DY, Kim JY, Choi KU, et al. Comparison of polymerase chain reaction with histopathologic features for diagnosis of tuberculosis in formalin-fixed, paraffin-embedded histologic specimens. *Arch Pathol Lab Med*. 2003;127(3):326-330.
118. Riley UB, Crawford S, Barrett SP, Abdalla SH. Detection of mycobacteria in bone marrow biopsy specimens taken to investigate pyrexia of unknown origin. *J Clin Pathol*. 1995;48(8):706-709.
119. Cruickshank B, Thomas MJ. Mineral oil (follicular) lipidosis: II. Histologic studies of spleen, liver, lymph nodes, and bone marrow. *Hum Pathol*. 1984;15(8):731-737.
120. Rywlin AM, Ortega R. Lipid granulomas of the bone marrow. *Am J Clin Pathol*. 1972;57(4):457-462.
121. McKenna RW, Dehner LP. Oxalosis. An unusual cause of myelophthisis in childhood. *Am J Clin Pathol*. 1976;66(6):991-997.
122. Williams HE, Smith LHJ. Primary hyperoxaluria. In: Stanbury JB, Wyngaarden JB, Fredrickson DS, et al, eds. *The Metabolic Basis of Inherited Disease*. New York: McGraw-Hill Book Co; 1983:204-228.
123. Georgii A, Vykoupil KF. Unspecific mesenchymal reaction in bone marrow in patients with Hodgkin's disease. *Recent Results Cancer Res*. 1974;46:39-44.
124. Custer RP. *An Atlas of the Blood and Bone Marrow*. Philadelphia: W.B.Saunders; 1974.
125. Geller SA, Muller R, Greenberg ML, Siegal FP. Acquired immunodeficiency syndrome. Distinctive features of bone marrow biopsies. *Arch Pathol Lab Med*. 1985;109(2):138-141.
126. Karcher DS, Frost AR. The bone marrow in human immunodeficiency virus (HIV)-related disease. Morphology and clinical correlation. *Am J Clin Pathol*. 1991;95(1):63-71.
127. Namiki TS, Boone DC, Meyer PR. A comparison of bone marrow findings in patients with acquired immunodeficiency syndrome (AIDS) and AIDS related conditions. *Hematol Oncol*. 1987;5(2):99-106.
128. Schneider DR, Picker LJ. Myelodysplasia in the acquired immune deficiency syndrome. *Am J Clin Pathol*. 1985;84(2):144-152.
129. Spivak JL, Bender BS, Quinn TC. Hematologic abnormalities in the acquired immune deficiency syndrome. *Am J Med*. 1984;77(2):224-228.
130. Treacy M, Lai L, Costello C, Clark A. Peripheral blood and bone marrow abnormalities in patients with HIV related disease. *Br J Haematol*. 1987;65(3):289-294.
131. Zon LI, Arkin C, Groopman JE. Haematologic manifestations of the human immune deficiency virus (HIV). *Br J Haematol*. 1987;66(2):251-256.
132. Luther JM, Lakey DL, Larson RS, et al. Utility of bone marrow biopsy for rapid diagnosis of febrile illnesses in patients with human immunodeficiency virus infection. *South Med J*. 2000;93(7):692-697.
133. Castella A, Croxson TS, Mildvan D, et al. The bone marrow in AIDS. A histologic, hematologic, and microbiologic study. *Am J Clin Pathol*. 1985;84(4):425-432.
134. Ioachim HL, Dorsett B, Cronin W, et al. Acquired immunodeficiency syndrome-associated lymphomas: clinical, pathologic, immunologic, and viral characteristics of 111 cases. *Hum Pathol*. 1991;22(7):659-673.
135. Nichols L, Florentine B, Lewis W, et al. Bone marrow examination for the diagnosis of mycobacterial and fungal infections in the acquired immunodeficiency syndrome. *Arch Pathol Lab Med*. 1991;115(11):1125-1132.
136. Abrams DI, Kiprov DD, Goedert JJ, et al. Antibodies to human T-lymphotropic virus type III and development of the acquired immunodeficiency syndrome in homosexual men presenting with immune thrombocytopenia. *Ann Intern Med*. 1986;104(1):47-50.
137. Morris L, Distenfeld A, Amorosi E, Karpatkin S. Autoimmune thrombocytopenic purpura in homosexual men. *Ann Intern Med*. 1982;96(6 Pt 1):714-717.
138. Franzetti M, Adorni F, Oreni L, et al. Changes in the incidence of severe thrombocytopenia and its predisposing conditions in HIV-infected patients since the introduction of highly active antiretroviral therapy. *J Acquir Immune Defic Syndr*. 2014;67(5):493-498.
139. Frickhofen N, Abkowitz JL, Safford M, et al. Persistent B19 parvovirus infection in patients infected with human immunodeficiency virus type 1 (HIV-1): a treatable cause of anemia in AIDS. *Ann Intern Med*. 1990;113(12):926-933.
140. Brynes RK, Ewing EP Jr, Joshi VV, Chan WC. The histopathology of HIV infection: an overview. *Prog AIDS Pathol*. 1989;1:1-28.
141. Osborne BM, Guarda LA, Butler JJ. Bone marrow biopsies in patients with the acquired immunodeficiency syndrome. *Hum Pathol*. 1984;15(11):1048-1053.
142. Nasr SA, Brynes RK, Garrison CP, Chan WC. Peripheral T-cell lymphoma in a patient with acquired immune deficiency syndrome. *Cancer*. 1988;61(5):947-951.
143. Ponzoni M, Fumagalli L, Rossi G, et al. Isolated bone marrow manifestation of HIV-associated Hodgkin lymphoma. *Mod Pathol*. 2002;15(12):1273-1278.
144. Richman DD, Fischl MA, Grieco MH, et al. The toxicity of azidothymidine (AZT) in the treatment of patients with AIDS and AIDS-related complex. A double-blind, placebo-controlled trial. *N Engl J Med*. 1987;317(4):192-197.
145. Savona S, Nardi MA, Lennette ET, Karpatkin S. Thrombocytopenic purpura in narcotics addicts. *Ann Intern Med*. 1985;102(6): 737-741.
146. Arber DA, Cousar JB. Hematopoietic tumors: principles of pathologic diagnosis. In: Greer JP, Foerster J, Rodgers GM, et al, eds. *Wintrobe's Clinical Hematology*. 12th ed. Philadelphia: Lippincott Williams & Wilkins; 2009:1663-1668.
147. Vardiman JW, Thiele J, Arber DA, et al. The 2008 revision of the World Health Organization (WHO) classification of myeloid neoplasms and acute leukemia: rationale and important changes. *Blood*. 2009;114(5):937-951.
148. Arber DA, Orazi A, Hasserjian R, et al. The 2016 revision to the World Health Organization classification of myeloid neoplasms and acute leukemia. *Blood*. 2016;127(20):2391-2405.
149. Bennett JM, Catovsky D, Daniel MT, et al. Proposals for the classification of the acute leukaemias. French-American-British (FAB) co-operative group. *Br J Haematol*. 1976;33(4):451-458.
150. Arber DA, Stein AS, Carter NH, et al. Prognostic impact of acute myeloid leukemia classification. Importance of detection of recurring cytogenetic abnormalities and multilineage dysplasia on survival. *Am J Clin Pathol*. 2003;119(5):672-680.
151. Yunis JJ, Brunning RD. Prognostic significance of chromosomal abnormalities in acute leukaemias and myelodysplastic syndromes. *Clin Haematol*. 1986;15(3):597-620.
152. Vardiman JW, Brunning RD, Arber DA, et al. Introduction and overview of the classification of the myeloid neoplasms. In: Swerdlow SH, Campo E, Harris N, et al, eds. *WHO Classification of Tumours of the Haematopoietic and Lymphoid Tissues*. Lyon: IARC Press; 2008:18-30.
153. Arber DA, Brunning RD, LeBeau MM, et al. Acute myeloid leukaemia with recurrent genetic abnormalities. In: Swerdlow SH, Campo E, Harris NL, et al, eds. *WHO Classification of Tumours of Haematopoietic and Lymphoid Tissues*. Lyon: IARC Press; 2008:110-123.
154. Arber DA, Brunning RD, Orazi A, et al. Acute myeloid leukaemia with myelodysplasia-related changes. In: Swerdlow SH, Campo E, Harris NL, et al, eds. *WHO Classification of Tumours of Haematopoietic and Lymphoid Tissues*. Lyon: IARC Press; 2008:124-126.
155. Arber DA, Brunning RD, Orazi A, et al. Acute myeloid leukaemia, not otherwise specified. In: Swerdlow SH, Campo E, Harris NL, et al, eds. *WHO Classification of Tumours of Haematopoietic and Lymphoid Tissues*. Lyon: IARC Press; 2008:130-139.
156. Baumann I, Niemeyer CM, Brunning RD, et al. Myeloid proliferations related to Down syndrome. In: Swerdlow SH, Campo E, Harris NL, et al, eds. *WHO Classification of Tumours of Haematopoietic and Lymphoid Tissues*. Lyon: IARC Press; 2008:142-144.
157. Vardiman JW, Arber DA, Brunning RD, et al. Therapy-related myeloid neoplasms. In: Swerdlow SH, Campo E, Harris NL, et al, eds. *WHO Classification of Tumours of Haematopoietic and Lymphoid Tissues*. Lyon: IARC Press; 2008:127-129.
158. Arber DA. Acute myeloid leukemia. In: Jaffe ES, Arber DA, Campo E, eds. *Hematopathology*. 2nd ed. Philadelphia, PA: Elsevier; 2017:817-845.
159. Cancer Genome Atlas Research N. Genomic and epigenomic landscapes of adult de novo acute myeloid leukemia. *N Engl J Med*. 2013;368(22):2059-2074.
160. Borowitz MJ, Chan JKC. B lymphoblastic leukaemia/lymphoma, not otherwise specified. In: Swerdlow SH, Campo E, Harris NL, et al, eds. *WHO Classification of Tumours of Haematopoietic and Lymphoid Tissues*. Lyon: IARC Press; 2008:168-170.
161. Borowitz MJ, Chan JKC. B lymphoblastic leukaemia/lymphoma with recurrent genetic abnormalities. In: Swerdlow SH, Campo E, Harris NL, et al, eds. *WHO Classification of Tumours of Haematopoietic and Lymphoid Tissues*. Lyon: IARC Press; 2008:171-175.
162. Borowitz MJ, Chan JKC. T lymphoblastic leukaemia/lymphoma. In: Swerdlow SH, Campo E, Harris NL, et al, eds. *WHO Classification of Tumours of Haematopoietic and Lymphoid Tissues*. Lyon: IARC Press; 2008:176-178.
163. Barcos MP, Lukes RJ. Malignant lymphomas of convoluted lymphocytes. A new entity of

For personal use only. No other uses without permission. Copyright ©2017. Elsevier Inc. All rights reserved.

possible T-cell type. In: Sinks LR, Godden JO, eds. *Conflicts in Childhood Cancer an Evaluation of Current Management*. 4th ed. New York: Alan R. Liss; 1975:147-178.
164. Lin P, Jones D, Dorfman DM, Medeiros LJ. Precursor B-cell lymphoblastic lymphoma: a predominantly extranodal tumor with low propensity for leukemic involvement. *Am J Surg Pathol*. 2000;24(11):1480-1490.
165. Murphy SB, Hustu HO. A randomized trial of combined modality therapy of childhood non-Hodgkin's lymphoma. *Cancer*. 1980;45(4):630-637.
166. Borowitz MJ, Béné M-C, Harris NL, et al. Acute leukaemias of ambiguous lineage. In: Swerdlow SH, Campo E, Harris NL, et al, eds. *WHO Classification of Tumours of Haematopoietic and Lymphoid Tissues*. Lyon: IARC Press; 2008:150-155.
167. Berdeaux DH, Glasser L, Serokmann R, et al. Hypoplastic acute leukemia: review of 70 cases with multivariate regression analysis. *Hematol Oncol*. 1986;4(4):291-305.
168. Breatnach F, Chessells JM, Greaves MF. The aplastic presentation of childhood leukaemia: a feature of common-ALL. *Br J Haematol*. 1981;49(3):387-393.
169. Howe RB, Bloomfield CD, McKenna RW. Hypocellular acute leukemia. *Am J Med*. 1982;72(3):391-395.
170. Manoharan A, Horsley R, Pitney WR. The reticulin content of bone marrow in acute leukaemia in adults. *Br J Haematol*. 1979;43(2):185-190.
171. Ohgami RS, Arber DA. Evaluation of the bone marrow after therapy. In: Jaffe ES, Arber DA, Campo E, eds. *Hematopathology*. 2nd ed. Philadelphia, PA: Elsevier; 2017:1065-1087.
172. Brunning RD. The effects of leukemia and lymphoma chemotherapy on hematopoietic cells. *Am J Med Technol*. 1973;39(5):165-174.
173. Rimsza LM, Larson RS, Winter SS, et al. Benign hematogone-rich lymphoid proliferations can be distinguished from B-lineage acute lymphoblastic leukemia by integration of morphology, immunophenotype, adhesion molecule expression, and architectural features. *Am J Clin Pathol*. 2000;114(1):66-75.
174. Gralnick HR, Dittmar K. Development of myeloblastoma with massive breast and ovarian involvement during remission in acute leukemia. *Cancer*. 1969;24(4):746-749.
175. Mason TE, Demaree RS Jr, Margolis CI. Granulocytic sarcoma (chloroma), two years preceding myelogenous leukemia. *Cancer*. 1973;31(2):423-432.
176. Meis JM, Butler JJ, Osborne BM, Manning JT. Granulocytic sarcoma in nonleukemic patients. *Cancer*. 1986;58(12):2697-2709.
177. Muller S, Sangster G, Crocker J, et al. An immunohistochemical and clinicopathological study of granulocytic sarcoma ('chloroma'). *Hematol Oncol*. 1986;4(2):101-112.
178. Neiman RS, Barcos M, Berard C, et al. Granulocytic sarcoma: a clinicopathologic study of 61 biopsied cases. *Cancer*. 1981;48(6):1426-1437.
179. Pileri SA, Ascani S, Cox MC, et al. Myeloid sarcoma: clinico-pathologic, phenotypic and cytogenetic analysis of 92 adult patients. *Leukemia*. 2007;21(2):340-350.
180. Pileri SA, Orazi A, Falini B. Myeloid sarcoma. In: Swerdlow SH, Campo E, Harris NL, et al, eds. *WHO Classification of Tumours of Haematopoietic and Lymphoid Tissues*. Lyon: IARC Press; 2008:140-141.
181. Tallman MS, Hakimian D, Shaw JM, et al. Granulocytic sarcoma is associated with the 8;21 translocation in acute myeloid leukemia. *J Clin Oncol*. 1993;11(4):690-697.
182. Traweek ST, Arber DA, Rappaport H, Brynes RK. Extramedullary myeloid cell tumors. An immunohistochemical and morphologic study of 28 cases. *Am J Surg Pathol*. 1993;17(10):1011-1019.
183. Wiernik PH, Serpick AA. Granulocytic sarcoma (chloroma). *Blood*. 1970;35(3):361-369.
184. Beckman EN, Oehrle JS. Fibrous hematopoietic tumors arising in agnogenic myeloid metaplasia. *Hum Pathol*. 1982;13(9):804-810.
185. Brunning R, McKenna RW. *Tumors of the Hematopoietic System*. Washington DC: Armed Forces Institute of Pathology; 1994:93-100.
186. Garfinkel LS, Bennett DE. Extramedullary myeloblastic transformation in chronic myelocytic leukemia simulating a coexistent malignant lymphoma. *Am J Clin Pathol*. 1969;51(5):638-645.
187. McKenna RW, Bloomfield CD, Dick F, et al. Acute monoblastic leukemia: diagnosis and treatment of ten cases. *Blood*. 1975;46(4):481-494.
188. Peterson L, Dehner LP, Brunning RD. Extramedullary masses as presenting features of acute monoblastic leukemia. *Am J Clin Pathol*. 1981;75(2):140-148.
189. Cavdar AO, Arcasoy A, Babacan E, et al. Ocular granulocytic sarcoma (chloroma) with acute myelomonocytic leukemia in Turkish children. *Cancer*. 1978;41(4):1606-1609.
190. Leder LD. [On the selective enzyme-cytochemical demonstration of neutrophilic myeloid cells and tissue mast cells in paraffin sections]. *Klin Wochenschr*. 1964;42:553.
191. Bennett JM, Catovsky D, Daniel MT, et al. Proposals for the classification of the myelodysplastic syndromes. *Br J Haematol*. 1982;51(2):189-199.
192. Brunning RD, Orazi A, Germing U, et al. Myelodysplastic syndromes/neoplasms. In: Swerdlow SH, Campo E, Harris NL, et al, eds. *WHO Classification of Tumours of Haematopoietic and Lymphoid Tissues*. Lyon: IARC Press; 2008:89-93.
193. List AF, Garewal HS, Sandberg AA. The myelodysplastic syndromes: biology and implications for management. *J Clin Oncol*. 1990;8(8):1424-1441.
194. Verburgh E, Achten R, Maes B, et al. Additional prognostic value of bone marrow histology in patients subclassified according to the International Prognostic Scoring System for myelodysplastic syndromes. *J Clin Oncol*. 2003;21(2):273-282.
195. Lim ZY, Killick S, Germing U, et al. Low IPSS score and bone marrow hypocellularity in MDS patients predict hematological responses to antithymocyte globulin. *Leukemia*. 2007;21(7):1436-1441.
196. Delacretaz F, Schmidt PM, Piguet D, et al. Histopathology of myelodysplastic syndromes. The FAB classification (proposals) applied to bone marrow biopsy. *Am J Clin Pathol*. 1987;87(2):180-186.
197. Maschek H, Georgii A, Kaloutsi V, et al. Myelofibrosis in primary myelodysplastic syndromes: a retrospective study of 352 patients. *Eur J Haematol*. 1992;48(4):208-214.
198. Orazi A. Histopathology in the diagnosis and classification of acute myeloid leukemia, myelodysplastic syndromes, and myelodysplastic/myeloproliferative diseases. *Pathobiology*. 2007;74(2):97-114.
199. Orazi A, Brunning RD, Hasserjian RO, et al. Refractory anaemia with excess blasts. In: Swerdlow SH, Campo E, Harris NL, et al, eds. *WHO Classification of Tumours of Haematopoietic and Lymphoid Tissues*. Lyon: IARC Press; 2008:100-101.
200. Tricot G, Vlietinck R, Boogaerts MA, et al. Prognostic factors in the myelodysplastic syndromes: importance of initial data on peripheral blood counts, bone marrow cytology, trephine biopsy and chromosomal analysis. *Br J Haematol*. 1985;60(1):19-32.
201. Hasserjian RP, LeBeau MM, List AF, et al. Myelodysplastic syndrome with isolated del(5q−). In: Swerdlow SH, Campo E, Harris NL, et al, eds. *WHO Classification of Tumours of Haematopoietic and Lymphoid Tissues*. Lyon: IARC Press; 2008:102-103.
202. Mathew P, Tefferi A, Dewald GW, et al. The 5q- syndrome: a single-institution study of 43 consecutive patients. *Blood*. 1993;81(4):1040-1045.
203. Orazi A, Bennett JM, Germing U, et al. Chronic myelomonocytic leukaemia. In: Swerdlow SH, Campo E, Harris NL, et al, eds. *WHO Classification of Tumours of Haematopoietic and Lymphoid Tissues*. Lyon: IARC Press; 2008:76-79.
204. Horny HP, Sotlar K, Valent P. Diagnostic value of histology and immunohistochemistry in myelodysplastic syndromes. *Leuk Res*. 2007;31(12):1609-1616.
205. Mallo M, Cervera J, Schanz J, et al. Impact of adjunct cytogenetic abnormalities for prognostic stratification in patients with myelodysplastic syndrome and deletion 5q. *Leukemia*. 2011;25(1):110-120.
206. Germing U, Lauseker M, Hildebrandt B, et al. Survival, prognostic factors and rates of leukemic transformation in 381 untreated patients with MDS and del(5q): a multicenter study. *Leukemia*. 2012;26(6):1286-1292.
207. Liu YC, Ito Y, Hsiao HH, et al. Risk factor analysis in myelodysplastic syndrome patients with del(20q): prognosis revisited. *Cancer Genet Cytogenet*. 2006;171(1):9-16.
208. Baumann I, Niemeyer CM, Bennett JM, Shannon K. Childhood myelodysplastic syndrome. In: Swerdlow SH, Campo E, Harris NL, et al, eds. *WHO classification of tumours of haematopoietic and lymphoid tissues*. Lyon: IARC Press; 2008:104-107.
209. Baumann I, Fuhrer M, Behrendt S, et al. Morphological differentiation of severe aplastic anaemia from hypocellular refractory cytopenia of childhood: reproducibility of histopathological diagnostic criteria. *Histopathology*. 2012;61(1):10-17.
210. Kantarjian HM, Deisseroth A, Kurzrock R, et al. Chronic myelogenous leukemia: a concise update. *Blood*. 1993;82(3):691-703.
211. Vardiman JW, Melo JV, Baccarinii M, Thiele J. Chronic myelogenous leukaemia, BCR/ABL1 positive. In: Swerdlow SH, Campo E, Harris N, et al, eds. *WHO Classification of Tumours of Haematopoietic and Lymphoid Tissues*. Lyon: IARC Press; 2008:32-37.
212. Vardiman JW, Bennett JM, Bain BJ, et al. Atypical chronic myeloid leukaemia, BCR/ABL1 negative. In: Swerdlow SH, Campo E, Harris NL, et al, eds. *WHO Classification of Tumours of Haematopoietic and Lymphoid Tissues*. Lyon: IARC Press; 2008:80-81.
213. Thiele J, Kvasnicka HM, Orazi A. Bone marrow histopathology in myeloproliferative disorders—current diagnostic approach. *Semin Hematol*. 2005;42(4):184-195.
214. Kvasnicka HM, Thiele J. Bone marrow angiogenesis: methods of quantification and changes evolving in chronic myeloproliferative disorders. *Histol Histopathol*. 2004;19(4):1245-1260.
215. Muehleck SD, McKenna RW, Arthur DC, et al. Transformation of chronic myelogenous leukemia: clinical, morphologic, and cytogenetic features. *Am J Clin Pathol*. 1984;82(1):1-14.
216. Clough V, Geary CG, Hashmi K, et al. Myelofibrosis in chronic granulocytic leukaemia. *Br J Haematol*. 1979;42(4):515-526.
217. Thiele J, Kvasnicka HM. Myelofibrosis—what's in a name? Consensus on definition and EUMNET grading. *Pathobiology*. 2007;74(2):89-96.
218. Dekmezian R, Kantarjian HM, Keating MJ, et al. The relevance of reticulin stain-measured

For personal use only. No other uses without permission. Copyright ©2017. Elsevier Inc. All rights reserved.

fibrosis at diagnosis in chronic myelogenous leukemia. *Cancer*. 1987;59(10):1739-1743.
219. Kvasnicka HM, Thiele J, Staib P, et al. [Therapy-related changes of angiogenesis in Philadelphia chromosome positive chronic myelogenous leukemia]. *Pathologe*. 2004;25(2):127-134.
220. McGlave PB, Brunning RD, Hurd DD, Kim TH. Reversal of severe bone marrow fibrosis and osteosclerosis following allogeneic bone marrow transplantation for chronic granulocytic leukaemia. *Br J Haematol*. 1982;52(2):189-194.
221. Thiele J, Kvasnicka HM, Beelen DW, et al. Megakaryopoiesis and myelofibrosis in chronic myeloid leukemia after allogeneic bone marrow transplantation: an immunohistochemical study of 127 patients. *Mod Pathol*. 2001;14(2):129-138.
222. Braziel RM, Launder TM, Druker BJ, et al. Hematopathologic and cytogenetic findings in imatinib mesylate-treated chronic myelogenous leukemia patients: 14 months' experience. *Blood*. 2002;100(2):435-441.
223. Kantarjian H, Sawyers C, Hochhaus A, et al. Hematologic and cytogenetic responses to imatinib mesylate in chronic myelogenous leukemia. *N Engl J Med*. 2002;346(9): 645-652.
224. Lugli A, Ebnother M, Tichelli A, et al. Bone marrow morphology in CML patients during treatment with STI571 (Glivec): evidence of complete morphological remission and correlation to hematologic and cytogenetic response. *J Clin Pathol*. 2002;55(A6).
225. Palandri F, Castagnetti F, Alimena G, et al. The long-term durability of cytogenetic responses in patients with accelerated phase chronic myeloid leukemia treated with imatinib 600 mg: the GIMEMA CML Working Party experience after a 7-year follow-up. *Haematologica*. 2009;94(2):205-212.
226. Thiele J, Kvasnicka HM, Schmitt-Graeff A, et al. Effects of chemotherapy (busulfan-hydroxyurea) and interferon-alfa on bone marrow morphologic features in chronic myelogenous leukemia. Histochemical and morphometric study on sequential trephine biopsy specimens with special emphasis on dynamic features. *Am J Clin Pathol*. 2000;114(1):57-65.
227. Thiele J, Kvasnicka HM, Orazi A, et al. Polycythemia vera. In: Swerdlow SH, Campo E, Harris NL, et al, eds. *WHO Classification of Tumours of Haematopoietic and Lymphoid Tissues*. Lyon: IARC Press; 2008:40-43.
228. Kralovics R, Passamonti F, Buser AS, et al. A gain-of-function mutation of JAK2 in myeloproliferative disorders. *N Engl J Med*. 2005;352(17):1779-1790.
229. Levine RL, Gilliland DG. Myeloproliferative disorders. *Blood*. 2008;112(6):2190-2198.
230. Levine RL, Wadleigh M, Cools J, et al. Activating mutation in the tyrosine kinase JAK2 in polycythemia vera, essential thrombocythemia, and myeloid metaplasia with myelofibrosis. *Cancer Cell*. 2005;7(4):387-397.
231. Tefferi A, Thiele J, Orazi A, et al. Proposals and rationale for revision of the World Health Organization diagnostic criteria for polycythemia vera, essential thrombocythemia, and primary myelofibrosis: recommendations from an ad hoc international expert panel. *Blood*. 2007;110(4):1092-1097.
232. Tefferi A, Lasho TL, Gilliland G. JAK2 mutations in myeloproliferative disorders. *N Engl J Med*. 2005;353(13):1416-1417, author reply -7.
233. Spivak JL. MPDs: it's all in the family. *Blood*. 2008;112(6):2173-2174.
234. Klein H. Morphology of the hematopoietic tissues. In: Klein H, ed. *Polycythemia, Theory and Management*. Springfield, IL: Charles Thomas; 1973:201-208.
235. Kvasnicka HM, Thiele J. The impact of clinicopathological studies on staging and survival in essential thrombocythemia, chronic idiopathic myelofibrosis, and polycythemia rubra vera. *Semin Thromb Hemost*. 2006;32(4 Pt 2):362-371.
236. Laszlo J. Myeloproliferative disorders (MPD): myelofibrosis, myelosclerosis, extramedullary hematopoiesis, undifferentiated MPD, and hemorrhagic thrombocythemia. *Semin Hematol*. 1975;12(4):409-432.
237. Mesa RA, Verstovsek S, Cervantes F, et al. Primary myelofibrosis (PMF), post polycythemia vera myelofibrosis (post-PV MF), post essential thrombocythemia myelofibrosis (post-ET MF), blast phase PMF (PMF-BP): Consensus on terminology by the international working group for myelofibrosis research and treatment (IWG-MRT). *Leuk Res*. 2007;31(6):737-740.
238. Roberts BE, Miles DW, Woods CG. Polycythaemia vera and myelosclerosis: a bone marrow study. *Br J Haematol*. 1969;16(1):75-85.
239. Silverstein MN. The evolution into and the treatment of late stage polycythemia vera. *Semin Hematol*. 1976;13(1):79-84.
240. Spivak JL. Polycythemia vera: myths, mechanisms, and management. *Blood*. 2002;100(13):4272-4290.
241. Ellis JT, Peterson P, Geller SA, Rappaport H. Studies of the bone marrow in polycythemia vera and the evolution of myelofibrosis and second hematologic malignancies. *Semin Hematol*. 1986;23(2):144-155.
242. Ellis JT, Silver RT, Coleman M, Geller SA. The bone marrow in polycythemia vera. *Semin Hematol*. 1975;12(4):433-444.
243. Thiele J, Kvasnicka HM. Diagnostic impact of bone marrow histopathology in polycythemia vera (PV). *Histol Histopathol*. 2005;20(1):317-328.
244. Thiele J, Kvasnicka HM, Diehl V. Initial (latent) polycythemia vera with thrombocytosis mimicking essential thrombocythemia. *Acta Haematol*. 2005;113(4):213-219.
245. Lundberg LG, Lerner R, Sundelin P, et al. Bone marrow in polycythemia vera, chronic myelocytic leukemia, and myelofibrosis has an increased vascularity. *Am J Pathol*. 2000;157(1):15-19.
246. Gianelli U, Iurlo A, Vener C, et al. The significance of bone marrow biopsy and JAK2V617F mutation in the differential diagnosis between the "early" prepolycythemic phase of polycythemia vera and essential thrombocythemia. *Am J Clin Pathol*. 2008;130(3):336-342.
247. Rossi D, Cortini F, Deambrogi C, et al. Usefulness of JAK2V617F mutation in distinguishing idiopathic erythrocytosis from polycythemia vera. *Leuk Res*. 2007;31(1):97-101.
248. Landaw SA. Acute leukemia in polycythemia vera. *Semin Hematol*. 1986;23(2):156-165.
249. Lawrence JH, Winchell HS, Donald WG. Leukemia in polycythemia vera. Relationship to splenic myeloid metaplasia and therapeutic radiation dose. *Ann Intern Med*. 1969;70(4):763-771.
250. Modan B, Lilienfeld AM. Polycythemia vera and leukemia—the role of radiation treatment. A study of 1222 patients. *Medicine (Baltimore)*. 1965;44:305-344.
251. Vykoupil KF, Thiele J, Stangel W, et al. Polycythemia vera. II. Transgression towards leukemia with special emphasis on histological differential diagnosis, cytogenetics and survival. *Virchows Arch A Pathol Anat Histol*. 1980;389(3):325-341.
252. Buss DH, O'Connor ML, Woodruff RD, et al. Bone marrow and peripheral blood findings in patients with extreme thrombocytosis. A report of 63 cases. *Arch Pathol Lab Med*. 1991;115(5):475-480.
253. Murphy S, Iland H, Rosenthal D, Laszlo J. Essential thrombocythemia: an interim report from the Polycythemia Vera Study Group. *Semin Hematol*. 1986;23(3):177-182.
254. Thiele J, Kvasnicka HM, Orazi A, Tefferi A. Gissliknger H. Essential thrombocythaemia. In: Swerdlow SH, Campo E, Harris NL, et al, eds. *WHO Classification of Tumours of Haematopoietic and Lymphoid Tissues*. Lyon: IARC Press; 2008:48-50.
255. Mesa RA, Hanson CA, Li CY, et al. Diagnostic and prognostic value of bone marrow angiogenesis and megakaryocyte c-Mpl expression in essential thrombocythemia. *Blood*. 2002;99(11):4131-4137.
256. Tefferi A, Barbui T. Polycythemia vera and essential thrombocythemia: 2015 update on diagnosis, risk-stratification and management. *Am J Hematol*. 2015;90(2):162-173.
257. Milosevic JD, Kralovics R. Genetic and epigenetic alterations of myeloproliferative disorders. *Int J Hematol*. 2013;97(2):183-197.
258. Gisslinger H. Update on diagnosis and management of essential thrombocythemia. *Semin Thromb Hemost*. 2006;32(4 Pt 2):430-436.
259. Fernandez-Pol S, Ma L, Ohgami RS, Arber DA. Significance of myelodysplastic syndrome-associated somatic variants in the evaluation of patients with pancytopenia and idiopathic cytopenias of undetermined significance. *Mod Pathol*. 2016;29(9):996-1003.
260. Genovese G, Kahler AK, Handsaker RE, et al. Clonal hematopoiesis and blood-cancer risk inferred from blood DNA sequence. *N Engl J Med*. 2014;371(26):2477-2487.
261. Jaiswal S, Fontanillas P, Flannick J, et al. Age-related clonal hematopoiesis associated with adverse outcomes. *N Engl J Med*. 2014;371(26):2488-2498.
262. Block M, Burkhardt R, Chelloul N, et al. Myelofibrosis–osteosclerosis syndrome. *Pathol Morphol Adv Biosci*. 1975;16:219-240.
263. Tefferi A. Myelofibrosis with myeloid metaplasia. *N Engl J Med*. 2000;342(17):1255-1265.
264. Thiele J, Kvasnicka HM. Diagnostic differentiation of essential thrombocythaemia from thrombocythaemias associated with chronic idiopathic myelofibrosis by discriminate analysis of bone marrow features—a clinicopathological study on 272 patients. *Histol Histopathol*. 2003;18(1):93-102.
265. Thiele J, Kvasnicka HM. Prefibrotic chronic idiopathic myelofibrosis—a diagnostic enigma? *Acta Haematol*. 2004;111(3):155-159.
266. Thiele J, Kvasnicka HM. Hematopathologic findings in chronic idiopathic myelofibrosis. *Semin Oncol*. 2005;32(4):380-394.
267. Thiele J, Kvasnicka HM, Facchetti F, et al. European consensus on grading bone marrow fibrosis and assessment of cellularity. *Haematologica*. 2005;90(8):1128-1132.
268. Thiele J, Kvasnicka HM, Tefferi A, et al. Primary myelofibrosis. In: Swerdlow SH, Campo E, Harris NL, et al, eds. *WHO Classification of Tumours of Haematopoietic and Lymphoid Tissues*. Lyon: IARC Press; 2008:44-47.
269. Thiele J, Zankovich R, Steinberg T, et al. Agnogenic myeloid metaplasia (AMM)—correlation of bone marrow lesions with laboratory data: a longitudinal clinicopathological study on 114 patients. *Hematol Oncol*. 1989;7(5):327-343.
270. Ward HP, Block MH. The natural history of agnogenic myeloid metaplasia (AMM) and a critical evaluation of its relationship with the

For personal use only. No other uses without permission. Copyright ©2017. Elsevier Inc. All rights reserved.

myeloproliferative syndrome. *Medicine (Baltimore)*. 1971;50(5):357-420.
271. Weinstein IM. Idiopathic myelofibrosis: historical review, diagnosis and management. *Blood Rev*. 1991;5(2):98-104.
272. Wolf BC, Neiman RS. Myelofibrosis with myeloid metaplasia: pathophysiologic implications of the correlation between bone marrow changes and progression of splenomegaly. *Blood*. 1985;65(4):803-809.
273. Varki A, Lottenberg R, Griffith R, Reinhard E. The syndrome of idiopathic myelofibrosis. A clinicopathologic review with emphasis on the prognostic variables predicting survival. *Medicine (Baltimore)*. 1983;62(6):353-371.
274. Tobin MS, Tan C, Argano SA. Myelofibrosis in pediatric age group. *N Y State J Med*. 1969;69(8):1080-1083.
275. Tefferi A, Lasho TL, Tischer A, et al. The prognostic advantage of calreticulin mutations in myelofibrosis might be confined to type 1 or type 1-like CALR variants. *Blood*. 2014;124(15):2465-2466.
276. Burston J, Pinniger JL. The reticulin content of bone marrow in haematological disorders. *Br J Haematol*. 1963;9:172-184.
277. Georgii A, Buesche G, Kreft A. The histopathology of chronic myeloproliferative diseases. *Baillieres Clin Haematol*. 1998;11(4):721-749.
278. Reilly JT. Cytogenetic and molecular genetic abnormalities in agnogenic myeloid metaplasia. *Semin Oncol*. 2005;32(4):359-364.
279. Lebwaze BM, Le Tourneau A, Rio B, et al. [Histopathologic pattern of hyperplasia of bone marrow hematogones (medullar b lymphoid cell precursors) occurring after treatment of idiopathic myelofibrosis]. *Ann Pathol*. 2008;28(1):27-31.
280. Bearman RM, Pangalis GA, Rappaport H. Acute ("malignant") myelosclerosis. *Cancer*. 1979;43(1):279-293.
281. Lubin J, Rozen S, Rywlin M. Malignant myelosclerosis. *Arch Intern Med*. 1976;136(2):141-145.
282. Akikusa B, Komatsu T, Kondo Y, et al. Amyloidosis complicating idiopathic myelofibrosis. *Arch Pathol Lab Med*. 1987;111(6):525-529.
283. Bass RD, Pullarkat V, Feinstein DI, et al. Pathology of autoimmune myelofibrosis. A report of three cases and a review of the literature. *Am J Clin Pathol*. 2001;116(2):211-216.
284. Rondeau E, Solal-Celigny P, Dhermy D, et al. Immune disorders in agnogenic myeloid metaplasia: relations to myelofibrosis. *Br J Haematol*. 1983;53(3):467-475.
285. Bain BJ, Gilliland DG, Horny HP, Vardiman JW. Myeloid and lymphoid neoplasms with eosinophilia and abnormalities of PDGFRA, PDGFRB or FGFR1. In: Swerdlow SH, Campo E, Harris NL, et al, eds. *WHO Classification of Tumours of Haematopoietic and Lymphoid Tissues*. Lyon: IARC Press; 2008:68-73.
286. Cools J, DeAngelo DJ, Gotlib J, et al. A tyrosine kinase created by fusion of the PDGFRA and FIP1L1 genes as a therapeutic target of imatinib in idiopathic hypereosinophilic syndrome. *N Engl J Med*. 2003;348(13):1201-1214.
287. Gotlib J, Cools J. Five years since the discovery of FIP1L1-PDGFRA: what we have learned about the fusion and other molecularly defined eosinophilias. *Leukemia*. 2008;22(11):1999-2010.
288. Fink SR, Belongie KJ, Paternoster SF, et al. Validation of a new three-color fluorescence in situ hybridization (FISH) method to detect CHIC2 deletion, FIP1L1/PDGFRA fusion and PDGFRA translocations. *Leuk Res*. 2009;33(6):843-846.
289. Pardanani A, Ketterling RP, Brockman SR, et al. CHIC2 deletion, a surrogate for FIP1L1-PDGFRA fusion, occurs in systemic mastocytosis associated with eosinophilia and predicts response to imatinib mesylate therapy. *Blood*. 2003;102(9):3093-3096.
290. Rudzki Z, Giles L, Cross NC, Lumley M. Myeloid neoplasm with rearrangement of PDGFRA, but with no significant eosinophilia: should we broaden the World Health Organization definition of the entity? *Br J Haematol*. 2012;156(5):558.
291. Klion AD, Noel P, Akin C, et al. Elevated serum tryptase levels identify a subset of patients with a myeloproliferative variant of idiopathic hypereosinophilic syndrome associated with tissue fibrosis, poor prognosis, and imatinib responsiveness. *Blood*. 2003;101(12):4660-4666.
292. Kilon AD, Akin C, Nutman TB. Hypereosinophilic syndrome with elevated serum tryptase is a syndrome that differs from systemic mast cell disease with eosinophilia. *Blood*. 2003;102:3074.
293. Tefferi A, Pardanani A, Li CY. Hypereosinophilic syndrome with elevated serum tryptase versus systemic mast cell disease associated with eosinophilia: 2 distinct entities? *Blood*. 2003;102(8):3073-3074, author reply 4.
294. Maric I, Robyn J, Metcalfe DD, et al. KIT D816V-associated systemic mastocytosis with eosinophilia and FIP1L1/PDGFRA-associated chronic eosinophilic leukemia are distinct entities. *J Allergy Clin Immunol*. 2007;120(3):680-687.
295. Curtis CE, Grand FH, Waghorn K, et al. A novel ETV6-PDGFRB fusion transcript missed by standard screening in a patient with an imatinib responsive chronic myeloproliferative disease. *Leukemia*. 2007;21(8):1839-1841.
296. Patterer V, Schnittger S, Kern W, et al. Hematologic malignancies with PCM1-JAK2 gene fusion share characteristics with myeloid and lymphoid neoplasms with eosinophilia and abnormalities of PDGFRA, PDGFRB, and FGFR1. *Ann Hematol*. 2013;92(6):759-769.
297. Rumi E, Milosevic JD, Selleslag D, et al. Efficacy of ruxolitinib in myeloid neoplasms with PCM1-JAK2 fusion gene. *Ann Hematol*. 2015;94(11):1927-1928.
298. Brunning RD, McKenna RW, Rosai J, et al. Systemic mastocytosis. Extracutaneous manifestations. *Am J Surg Pathol*. 1983;7(5):425-438.
299. Czarnetzki BM, Kolde G, Schoemann A, et al. Bone marrow findings in adult patients with urticaria pigmentosa. *J Am Acad Dermatol*. 1988;18(1 Pt 1):45-51.
300. Valent P. Diagnosis and management of mastocytosis: an emerging challenge in applied hematology. *Hematology Am Soc Hematol Educ Program*. 2015;2015:98-105.
301. Horny H-P, Metcalf DD, Bennett JM, et al. Systemic mastocytosis. In: Swerdlow SH, Campo E, Harris NL, et al, eds. *WHO Classification of Tumours of the Haematopoietic and Lymphoid Tissues*. Lyon: IARC Press; 2008:54-63.
302. Scully RE, Mark EJ, McNeely BU. Case records of the Massachusetts General Hospital. *N Engl J Med*. 1986;315:816.
303. Webb TA, Li CY, Yam LT. Systemic mast cell disease: a clinical and hematopathologic study of 26 cases. *Cancer*. 1982;49(5): 927-938.
304. Stevens EC, Rosenthal NS. Bone marrow mast cell morphologic features and hematopoietic dyspoiesis in systemic mast cell disease. *Am J Clin Pathol*. 2001;116(2):177-182.
305. Travis WD, Li CY, Bergstralh EJ, et al. Systemic mast cell disease. Analysis of 58 cases and literature review. *Medicine (Baltimore)*. 1988;67(6):345-368.
306. Valent P, Akin C, Sperr WR, et al. Diagnosis and treatment of systemic mastocytosis: state of the art. *Br J Haematol*. 2003;122(5):695-717.
307. Valent P, Horny HP, Escribano L, et al. Diagnostic criteria and classification of mastocytosis: a consensus proposal. *Leuk Res*. 2001;25(7):603-625.
308. Horny HP, Ruck M, Wehrmann M, Kaiserling E. Blood findings in generalized mastocytosis: evidence of frequent simultaneous occurrence of myeloproliferative disorders. *Br J Haematol*. 1990;76(2):186-193.
309. Lawrence JB, Friedman BS, Travis WD, et al. Hematologic manifestations of systemic mast cell disease: a prospective study of laboratory and morphologic features and their relation to prognosis. *Am J Med*. 1991;91(6):612-624.
310. Horny HP, Parwaresch MR, Lennert K. Bone marrow findings in systemic mastocytosis. *Hum Pathol*. 1985;16(8):808-814.
311. Wilkins BS, Buchan SL, Webster J, Jones DB. Tryptase-positive mast cells accompany lymphocytic as well as lymphoplasmacytic lymphoma infiltrates in bone marrow trephine biopsies. *Histopathology*. 2001;39(2):150-155.
312. Rappaport H. *Tumors of the Hematopoietic System. Atlas of tumor pathology. Fascicle 8*. Washington DC: Armed Forces Institute of Pathology; 2001:336-344.
313. Gotlib J, Kluin-Nelemans HC, George TI, et al. Efficacy and safety of midostaurin in advanced systemic mastocytosis. *N Engl J Med*. 2016;374(26):2530-2541.
314. Walls AF, Jones DB, Williams JH, et al. Immunohistochemical identification of mast cells in formaldehyde-fixed tissue using monoclonal antibodies specific for tryptase. *J Pathol*. 1990;162(2):119-126.
315. Yang F, Tran TA, Carlson JA, et al. Paraffin section immunophenotype of cutaneous and extracutaneous mast cell disease: comparison to other hematopoietic neoplasms. *Am J Surg Pathol*. 2000;24(5):703-709.
316. Natkunam Y, Rouse RV. Utility of paraffin section immunohistochemistry for C-KIT (CD117) in the differential diagnosis of systemic mast cell disease involving the bone marrow. *Am J Surg Pathol*. 2000;24(1):81-91.
317. Tefferi A, Li CY, Butterfield JH, Hoagland HC. Treatment of systemic mast-cell disease with cladribine. *N Engl J Med*. 2001;344(4):307-309.
318. Bennett JM, Catovsky D, Daniel MT, et al. Proposals for the classification of chronic (mature) B and T lymphoid leukaemias. French-American-British (FAB) Cooperative Group. *J Clin Pathol*. 1989;42(6):567-584.
319. Hallek M, Cheson BD, Catovsky D, et al. Guidelines for the diagnosis and treatment of chronic lymphocytic leukemia: a report from the International Workshop on Chronic Lymphocytic Leukemia updating the National Cancer Institute-Working Group 1996 guidelines. *Blood*. 2008;111(12):5446-5456.
320. Litz CE, Brunning RD. Chronic lymphoproliferative disorders: classification and diagnosis. *Baillieres Clin Haematol*. 1993;6(4):767-783.
321. Montserrat E, Rozman C. Chronic lymphocytic leukaemia: prognostic factors and natural history. *Baillieres Clin Haematol*. 1993;6(4):849-866.
322. Müller-Hermelink HK, Montserrat E, Catovsky D, Harris NL. Chronic lymphocytic leukaemia/small lymphocytic lymphoma. In: Swerdlow SH, Campo E, Harris NL, et al, eds. *WHO Classification of Tumours of Haematopoietic and Lymphoid Tissues*. Lyon: IARC Press; 2008:180-182.
323. Pangalis GA, Roussou PA, Kittas C, et al. B-chronic lymphocytic leukemia. Prognostic implication of bone marrow histology in 120 patients experience from a single hematology unit. *Cancer*. 1987;59(4):767-771.

For personal use only. No other uses without permission. Copyright ©2017. Elsevier Inc. All rights reserved.

324. Brouet JC, Sasportes M, Flandrin G, et al. Chronic lymphocytic leukaemia of T-cell origin. Immunological and clinical evaluation in eleven patients. *Lancet*. 1975;2(7941):890-893.
325. Eichhorst B, Robak T, Montserrat E, et al. Chronic lymphocytic leukaemia: ESMO Clinical Practice Guidelines for diagnosis, treatment and follow-up. *Ann Oncol*. 2015;26(suppl 5):v78-v84.
326. Binet L, Catovsky D, Chandra P, et al. Chronic lymphocytic leukaemia. Proposals for a revised prognostic staging system. *Br J Haematol*. 1981;48:365-367.
327. Rai KR, Sawitsky A, Cronkite EP, et al. Clinical staging of chronic lymphocytic leukemia. *Blood*. 1975;46(2):219-234.
328. Crespo M, Bosch F, Villamor N, et al. ZAP-70 expression as a surrogate for immunoglobulin-variable-region mutations in chronic lymphocytic leukemia. *N Engl J Med*. 2003;348(18):1764-1775.
329. Damle RN, Wasil T, Fais F, et al. Ig V gene mutation status and CD38 expression as novel prognostic indicators in chronic lymphocytic leukemia. *Blood*. 1999;94(6):1840-1847.
330. Rassenti LZ, Huynh L, Toy TL, et al. ZAP-70 compared with immunoglobulin heavy-chain gene mutation status as a predictor of disease progression in chronic lymphocytic leukemia. *N Engl J Med*. 2004;351(9):893-901.
331. Dohner H, Stilgenbauer S, Benner A, et al. Genomic aberrations and survival in chronic lymphocytic leukemia. *N Engl J Med*. 2000;343(26):1910-1916.
332. Lens D, Dyer MJ, Garcia-Marco JM, et al. p53 abnormalities in CLL are associated with excess of prolymphocytes and poor prognosis. *Br J Haematol*. 1997;99(4):848-857.
333. Landau DA, Tausch E, Taylor-Weiner AN, et al. Mutations driving CLL and their evolution in progression and relapse. *Nature*. 2015;526(7574):525-530.
334. Puente XS, Bea S, Valdes-Mas R, et al. Non-coding recurrent mutations in chronic lymphocytic leukaemia. *Nature*. 2015;526(7574):519-524.
335. Rausing A. Lymphatic leukemia and malignant lymphoma in the adult. A clinicopathologic study of their interrelationship. *Acta Med Scand Suppl*. 1976;595:1-270.
336. Montserrat E, Marques-Pereira JP, Gallart MT, Rozman C. Bone marrow histopathologic patterns and immunologic findings in B-chronic lymphocytic leukemia. *Cancer*. 1984;54(3):447-551.
337. Rozman C, Hernandez-Nieto L, Montserrat E, Brugues R. Prognostic significance of bone-marrow patterns in chronic lymphocytic leukaemia. *Br J Haematol*. 1981;47(4):529-537.
338. Enno A, Catovsky D, O'Brien M, et al. Prolymphocytoid' transformation of chronic lymphocytic leukaemia. *Br J Haematol*. 1979;41(1):9-18.
339. Brouet JC, Fermand JP, Laurent G, et al. The association of chronic lymphocytic leukaemia and multiple myeloma: a study of eleven patients. *Br J Haematol*. 1985;59(1):55-66.
340. Swerdlow SH, Campo E, Pileri SA, et al. The 2016 revision of the World Health Organization classification of lymphoid neoplasms. *Blood*. 2016;127(20): 2375-2390.
341. Vardi A, Dagklis A, Scarfo L, et al. Immunogenetics shows that not all MBL are equal: the larger the clone, the more similar to CLL. *Blood*. 2013;121(22):4521-4528.
342. Rawstron AC, Shanafelt T, Lanasa MC, et al. Different biology and clinical outcome according to the absolute numbers of clonal B-cells in monoclonal B-cell lymphocytosis (MBL). *Cytometry B Clin Cytom*. 2010;78(suppl 1):S19-S23.
343. Brousse N, Solal-Celigny P, Herrera A, et al. Gastrointestinal Richter's syndrome. *Hum Pathol*. 1985;16(8):854-857.
344. Case records of the Massachusetts General Hospital. Weekly clinicopathological exercises. Case 6-1978. *N Engl J Med*. 1978;298(7):387-396.
345. Goldstein J, Baden J. Richter's syndrome. *South Med J*. 1977;70(11):1381-1382.
346. Long JC, Aisenberg AC. Richter's syndrome. A terminal complication of chronic lymphocytic leukemia with distinct clinicopathologic features. *Am J Clin Pathol*. 1975;63(6):786-795.
347. Richter MN. Generalized reticular cell sarcoma of lymph nodes associated with lymphatic leukemia. *Am J Pathol*. 1928;4(4):285-292.7.
348. Traweek ST, Liu J, Johnson RM, et al. High-grade transformation of chronic lymphocytic leukemia and low-grade non-Hodgkin's lymphoma. Genotypic confirmation of clonal identity. *Am J Clin Pathol*. 1993;100(5):519-526.
349. Trump DL, Mann RB, Phelps R, et al. Richter's syndrome: diffuse histiocytic lymphoma in patients with chronic lymphocytic leukemia. A report of five cases and review of the literature. *Am J Med*. 1980;68(4):539-548.
350. Brecher M, Banks PM. Hodgkin's disease variant of Richter's syndrome. Report of eight cases. *Am J Clin Pathol*. 1990;93(3):333-339.
351. Momose H, Jaffe ES, Shin SS, et al. Chronic lymphocytic leukemia/small lymphocytic lymphoma with Reed-Sternberg-like cells and possible transformation to Hodgkin's disease. Mediation by Epstein-Barr virus. *Am J Surg Pathol*. 1992;16(9):859-867.
352. Foucar K, Rydell RE. Richter's syndrome in chronic lymphocytic leukemia. *Cancer*. 1980;46(1):118-134.
353. Kroft SH. Lymphoma transformation: genetic relatedness, stealth lymphomas, and the final frontier. *Am J Clin Pathol*. 2001;116(6):811-814.
354. Seligmann M, Preud'Homme JL, Brouet JC. Membrane markers in human lymphoid malignancies. Clinicopathologic correlations and insights into the differentiation of normal and neoplastic cells. In: Clarkson B, Marks P, Till JR, eds. *Differentiation of Normal and Neoplastic Cells*. Cold Spring Harbor, NY: Cold Spring Harbor Laboratory; 1978:859-876.
355. Litz CE, Arthur DC, Gajl-Peczalska KJ, et al. Transformation of chronic lymphocytic leukemia to small non-cleaved cell lymphoma: a cytogenetic, immunological, and molecular study. *Leukemia*. 1991;5(11):972-978.
356. Mao Z, Quintanilla-Martinez L, Raffeld M, et al. IgVH mutational status and clonality analysis of Richter's transformation: diffuse large B-cell lymphoma and Hodgkin lymphoma in association with B-cell chronic lymphocytic leukemia (B-CLL) represent 2 different pathways of disease evolution. *Am J Surg Pathol*. 2007;31(10):1605-1614.
357. Chigrinova E, Rinaldi A, Kwee I, et al. Two main genetic pathways lead to the transformation of chronic lymphocytic leukemia to Richter syndrome. *Blood*. 2013;122(15):2673-2682.
358. Galton DA, Goldman JM, Wiltshaw E, et al. Prolymphocytic leukaemia. *Br J Haematol*. 1974;27(1):7-23.
359. Matutes E, Brito-Babapulle V, Swansbury J, et al. Clinical and laboratory features of 78 cases of T-prolymphocytic leukemia. *Blood*. 1991;78(12):3269-3274.
360. Campo E, Catovsky D, Montserrat E, et al. B-cell prolymphocytic leukaemia. In: Swerdlow SH, Campo E, Harris NL, et al, eds. *WHO Classification of Tumours of Haematopoietic and Lymphoid Tissues*. Lyon: IARC Press; 2008:183-184.
361. Melo JV, Catovsky D, Galton DA. The relationship between chronic lymphocytic leukaemia and prolymphocytic leukaemia. I. Clinical and laboratory features of 300 patients and characterization of an intermediate group. *Br J Haematol*. 1986;63(2):377-387.
362. Melo JV, Catovsky D, Galton DA. The relationship between chronic lymphocytic leukaemia and prolymphocytic leukaemia. II. Patterns of evolution of 'prolymphocytoid' transformation. *Br J Haematol*. 1986;64(1):77-86.
363. Bearman RM, Pangalis GA, Rappaport H. Prolymphocytic leukemia: clinical, histopathological, and cytochemical observations. *Cancer*. 1978;42(5):2360-2372.
364. Owens MR, Strauchen JA, Rowe JM, Bennett JM. Prolymphocytic leukemia: histologic findings in atypical cases. *Hematol Oncol*. 1984;2(3):249-257.
365. Onciu M, Schlette E, Bueso-Ramos C, Medeiros LJ. Leukemic mantle cell lymphoma with cells resembling prolymphocytes. *Am J Clin Pathol*. 2002;118(2):305-306, author reply 6.
366. Wong KF, Chan JK, So JC, Yu PH. Mantle cell lymphoma in leukemic phase: characterization of its broad cytologic spectrum with emphasis on the importance of distinction from other chronic lymphoproliferative disorders. *Cancer*. 1999;86(5):850-857.
367. Brito-Babapulle V, Catovsky D. Inversions and tandem translocations involving chromosome 14q11 and 14q32 in T-prolymphocytic leukemia and T-cell leukemias in patients with ataxia telangiectasia. *Cancer Genet Cytogenet*. 1991;55(1):1-9.
368. Catovsky D, Müller-Hermelink HK, Ralfkiaer E. T-cell prolymphocytic leukaemia. In: Swerdlow SH, Campo E, Harris NL, et al, eds. *WHO Classification of Tumours of Haematopoietic and Lymphoid Tissues*. Lyon: IARC Press; 2008:270-271.
369. Stengel A, Kern W, Zenger M, et al. Genetic characterization of T-PLL reveals two major biologic subgroups and JAK3 mutations as prognostic marker. *Genes Chromosomes Cancer*. 2016;55(1):82-94.
370. Bellanger D, Jacquemin V, Chopin M, et al. Recurrent JAK1 and JAK3 somatic mutations in T-cell prolymphocytic leukemia. *Leukemia*. 2014;28(2):417-419.
371. Foucar K, Falini B, Catovsky D, Stein H. Hairy cell leukaemia. In: Swerdlow SH, Campo E, Harris NL, et al, eds. *WHO Classification of Tumours of Haematopoietic and Lymphoid Tissues*. Lyon: IARC Press; 2008:188-190.
372. Golomb HM, Catovsky D, Golde DW. Hairy cell leukemia: a clinical review based on 71 cases. *Ann Intern Med*. 1978;89(5 Pt 1):677-683.
373. Paoletti M, Bitter MA, Vardiman JW. Hairy-cell leukemia. Morphologic, cytochemical, and immunologic features. *Clin Lab Med*. 1988;8(1):179-195.
374. Platanias LC, Golomb HM. Hairy cell leukaemia. *Baillieres Clin Haematol*. 1993;6(4):887-898.
375. Katayama I, Schneider GB. Further ultrastructural characterization of hairy cells of leukemic reticuloendotheliosis. *Am J Pathol*. 1977;86(1):163-182.
376. Burke JS. The value of the bone-marrow biopsy in the diagnosis of hairy cell leukemia. *Am J Clin Pathol*. 1978;70(6):876-884.
377. Burke JS, Byrne GE Jr, Rappaport H. Hairy cell leukemia (leukemic reticuloendotheliosis). I. A clinical pathologic study of 21 patients. *Cancer*. 1974;33(5):1399-1410.
378. Pittaluga S, Tierens A, Dodoo YL, et al. How reliable is histologic examination of bone marrow trephine biopsy specimens for the staging of non-Hodgkin lymphoma? A study

For personal use only. No other uses without permission. Copyright ©2017. Elsevier Inc. All rights reserved.

of hairy cell leukemia and mantle cell lymphoma involvement of the bone marrow trephine specimen by histologic, immunohistochemical, and polymerase chain reaction techniques. *Am J Clin Pathol*. 1999;111(2):179-184.
379. Vykoupil KF, Thiele J, Georgii A. Hairy cell leukemia. Bone marrow findings in 24 patients. *Virchows Arch A Pathol Anat Histol*. 1976;370(4):273-289.
380. Lee WM, Beckstead JH. Hairy cell leukemia with bone marrow hypoplasia. *Cancer*. 1982;50(10):2207-2210.
381. Hanson CA, Ward PC, Schnitzer B. A multilobular variant of hairy cell leukemia with morphologic similarities to T-cell lymphoma. *Am J Surg Pathol*. 1989;13(8):671-679.
382. Bartl R, Frisch B, Hill W, et al. Bone marrow histology in hairy cell leukemia. Identification of subtypes and their prognostic significance. *Am J Clin Pathol*. 1983;79(5):531-545.
383. Robbins BA, Ellison DJ, Spinosa JC, et al. Diagnostic application of two-color flow cytometry in 161 cases of hairy cell leukemia. *Blood*. 1993;82(4):1277-1287.
384. Hakimian D, Tallman MS, Kiley C, Peterson L. Detection of minimal residual disease by immunostaining of bone marrow biopsies after 2-chlorodeoxyadenosine for hairy cell leukemia. *Blood*. 1993;82(6):1798-1802.
385. Falini B, Tiacci E, Liso A, et al. Simple diagnostic assay for hairy cell leukaemia by immunocytochemical detection of annexin A1 (ANXA1). *Lancet*. 2004;363(9424):1869-1870.
386. Morgan EA, Yu H, Pinkus JL, Pinkus GS. Immunohistochemical detection of hairy cell leukemia in paraffin sections using a highly effective CD103 rabbit monoclonal antibody. *Am J Clin Pathol*. 2013;139(2):220-230.
387. Turakhia S, Lanigan C, Hamadeh F, et al. Immunohistochemistry for BRAF V600E in the differential diagnosis of hairy cell leukemia vs other splenic B-cell lymphomas. *Am J Clin Pathol*. 2015;144(1):87-93.
388. Chen YH, Tallman MS, Goolsby C, Peterson L. Immunophenotypic variations in hairy cell leukemia. *Am J Clin Pathol*. 2006;125(2):251-259.
389. Hoyer JD, Li CY, Yam LT, et al. Immunohistochemical demonstration of acid phosphatase isoenzyme 5 (tartrate-resistant) in paraffin sections of hairy cell leukemia and other hematologic disorders. *Am J Clin Pathol*. 1997;108(3):308-315.
390. Tiacci E, Trifonov V, Schiavoni G, et al. BRAF mutations in hairy-cell leukemia. *N Engl J Med*. 2011;364(24):2305-2315.
391. Demanes DJ, Lane N, Beckstead JH. Bone involvement in hairy-cell leukemia. *Cancer*. 1982;49(8):1697-1701.
392. Herold CJ, Wittich GR, Schwarzinger I, et al. Skeletal involvement in hairy cell leukemia. *Skeletal Radiol*. 1988;17(3):171-175.
393. Lal A, Tallman MS, Soble MB, et al. Hairy cell leukemia presenting as localized skeletal involvement. *Leuk Lymphoma*. 2002;43(11):2207-2211.
394. Lembersky BC, Ratain MJ, Golomb HM. Skeletal complications in hairy cell leukemia: diagnosis and therapy. *J Clin Oncol*. 1988;6(8):1280-1284.
395. Piro LD, Carrera CJ, Carson DA, Beutler E. Lasting remissions in hairy-cell leukemia induced by a single infusion of 2-chlorodeoxyadenosine. *N Engl J Med*. 1990;322(16):1117-1121.
396. Robak T. Current treatment options in hairy cell leukemia and hairy cell leukemia variant. *Cancer Treat Rev*. 2006;32(5):365-376.
397. Spiers AS, Moore D, Cassileth PA, et al. Remissions in hairy-cell leukemia with pentostatin (2′-deoxycoformycin). *N Engl J Med*. 1987;316(14):825-830.
398. Johrens K, Stein H, Anagnostopoulos I. T-bet transcription factor detection facilitates the diagnosis of minimal hairy cell leukemia infiltrates in bone marrow trephines. *Am J Surg Pathol*. 2007;31(8):1181-1185.
399. Sigal DS, Sharpe R, Burian C, Saven A. Very long-term eradication of minimal residual disease in patients with hairy cell leukemia after a single course of cladribine. *Blood*. 2010;115(10):1893-1896.
400. Naeim F, Jacobs AD. Bone marrow changes in patients with hairy cell leukemia treated by recombinant alpha 2-interferon. *Hum Pathol*. 1985;16(12):1200-1205.
401. Tiacci E, Park JH, De Carolis L, et al. Targeting mutant BRAF in relapsed or refractory hairy-cell leukemia. *N Engl J Med*. 2015;373(18):1733-1747.
402. Mercieca J, Matutes E, Moskovic E, et al. Massive abdominal lymphadenopathy in hairy cell leukaemia: a report of 12 cases. *Br J Haematol*. 1992;82(3):547-554.
403. Catovsky D, O'Brien M, Melo JV, et al. Hairy cell leukemia (HCL) variant: an intermediate disease between HCL and B prolymphocytic leukemia. *Semin Oncol*. 1984;11(4):362-369.
404. Matutes E, Wotherspoon A, Brito-Babapulle V, Catovsky D. The natural history and clinico-pathological features of the variant form of hairy cell leukemia. *Leukemia*. 2001;15(1):184-186.
405. Piris M, Foucar K, Mollejo M, et al. cell lymphoma/leukaemia, unclassifiable. In: Swerdlow SH, Campo E, Harris NL, et al, eds. *WHO Classification of Tumours of Haematopoietic and Lymphoid Tissues*. Lyon: IARC Press; 2008:191-193.
406. Catovsky D, Matutes E. Splenic lymphoma with circulating villous lymphocytes/splenic marginal-zone lymphoma. *Semin Hematol*. 1999;36(2):148-154.
407. Isaacson PG, Piris MA, Berger F, et al. Splenic B-cell marginal zone lymphoma. In: Swerdlow SH, Campo E, Harris NL, et al, eds. *WHO Classification of Tumours of Haematopoietic and Lymphoid Tissues*. Lyon: IARC Press; 2008:185-187.
408. Melo JV, Hegde U, Parreira A, et al. Splenic B cell lymphoma with circulating villous lymphocytes: differential diagnosis of B cell leukaemias with large spleens. *J Clin Pathol*. 1987;40(6):642-651.
409. Oscier DG, Matutes E, Gardiner A, et al. Cytogenetic studies in splenic lymphoma with villous lymphocytes. *Br J Haematol*. 1993;85(3):487-491.
410. Matutes E, Morilla R, Owusu-Ankomah K, et al. The immunophenotype of splenic lymphoma with villous lymphocytes and its relevance to the differential diagnosis with other B-cell disorders. *Blood*. 1994;83(6):1558-1562.
411. Arber DA, George TI. Bone marrow biopsy involvement by non-Hodgkin's lymphoma: frequency of lymphoma types, patterns, blood involvement, and discordance with other sites in 450 specimens. *Am J Surg Pathol*. 2005;29(12):1549-1557.
412. Audouin J, Le Tourneau A, Molina T, et al. Patterns of bone marrow involvement in 58 patients presenting primary splenic marginal zone lymphoma with or without circulating villous lymphocytes. *Br J Haematol*. 2003;122(3):404-412.
413. Franco V, Florena AM, Campesi G. Intrasinusoidal bone marrow infiltration: a possible hallmark of splenic lymphoma. *Histopathology*. 1996;29(6):571-575.
414. Franco V, Florena AM, Stella M, et al. Splenectomy influences bone marrow infiltration in patients with splenic marginal zone cell lymphoma with or without villous lymphocytes. *Cancer*. 2001;91(2):294-301.
415. Kent SA, Variakojis D, Peterson LC. Comparative study of marginal zone lymphoma involving bone marrow. *Am J Clin Pathol*. 2002;117(5):698-708.
416. Camacho FI, Mollejo M, Mateo MS, et al. Progression to large B-cell lymphoma in splenic marginal zone lymphoma: a description of a series of 12 cases. *Am J Surg Pathol*. 2001;25(10):1268-1276.
417. Hermine O, Lefrere F, Bronowicki JP, et al. Regression of splenic lymphoma with villous lymphocytes after treatment of hepatitis C virus infection. *N Engl J Med*. 2002;347(2):89-94.
418. Banks PM, Arseneau JC, Gralnick HR, et al. American Burkitt's lymphoma: a clinicopathologic study of 30 cases. II. Pathologic correlations. *Am J Med*. 1975;58(3):322-329.
419. Brunning RD, McKenna RW, Bloomfield CD, et al. Bone marrow involvement in Burkitt's lymphoma. *Cancer*. 1977;40(4):1771-1779.
420. Dayton VD, Arthur DC, Gajl-Peczalska KJ, Brunning R. L3 acute lymphoblastic leukemia. Comparison with small noncleaved cell lymphoma involving the bone marrow. *Am J Clin Pathol*. 1994;101(2):130-139.
421. Dorfman RF. Childhood lymphosarcoma in st. Louis, Missouri, clinically and histologically resembling Burkitt's tumor. *Cancer*. 1965;18:418-430.
422. O'Conor GT, Rappaport H, Smith EB. Childhood lymphoma resembling "burkitt tumor" in the United States. *Cancer*. 1965;18:411-417.
423. Leoncini L, Raphaël M, Stein H, et al. Burkitt lymphoma. In: Swerdlow SH, Campo E, Harris NL, et al, eds. *WHO Classification of Tumours of Haematopoietic and Lymphoid Tissues*. Lyon: IARC Press; 2008:185-187.
424. Dick F, Bloomfield CD, Brunning RD. Incidence cytology, and histopathology of non-Hodgkin's lymphomas in the bone marrow. *Cancer*. 1974;33(5):1382-1398.
425. Cohen PL, Kurtin PJ, Donovan KA, Hanson CA. Bone marrow and peripheral blood involvement in mantle cell lymphoma. *Br J Haematol*. 1998;101(2):302-310.
426. Conlan MG, Bast M, Armitage JO, Weisenburger DD. Bone marrow involvement by non-Hodgkin's lymphoma: the clinical significance of morphologic discordance between the lymph node and bone marrow. Nebraska Lymphoma Study Group. *J Clin Oncol*. 1990;8(7):1163-1172.
427. Wasman J, Rosenthal NS, Farhi DC. Mantle cell lymphoma. Morphologic findings in bone marrow involvement. *Am J Clin Pathol*. 1996;106(2):196-200.
428. Thieblemont C, Berger F, Dumontet C, et al. Mucosa-associated lymphoid tissue lymphoma is a disseminated disease in one third of 158 patients analyzed. *Blood*. 2000;95(3):802-806.
429. Gaulard P, Kanavaros P, Farcet JP, et al. Bone marrow histologic and immunohistochemical findings in peripheral. T-cell lymphoma: a study of 38 cases. *Hum Pathol*. 1991;22(4):331-338.
430. Hanson CA, Brunning RD, Gajl-Peczalska KJ, et al. Bone marrow manifestations of peripheral T-cell lymphoma. A study of 30 cases. *Am J Clin Pathol*. 1986;86(4):449-460.
431. Kinney MC, Collins RD, Greer JP, et al. A small-cell-predominant variant of primary Ki-1 (CD30)+ T-cell lymphoma. *Am J Surg Pathol*. 1993;17(9):859-868.
432. Bain B, Matutes E, Robinson D, et al. Leukaemia as a manifestation of large cell lymphoma. *Br J Haematol*. 1991;77(3):301-310.
433. Foucar K, McKenna RW, Frizzera G, Brunning RD. Incidence and patterns of bone marrow and blood involvement by lymphoma in relationship to the Lukes-Collins classification. *Blood*. 1979;54(6):1417-1422.

For personal use only. No other uses without permission. Copyright ©2017. Elsevier Inc. All rights reserved.

434. McKenna RW, Bloomfield CD, Brunning RD. Nodular lymphoma: bone marrow and blood manifestations. *Cancer*. 1975;36(2):428-440.
435. Schlette E, Lai R, Onciu M, et al. Leukemic mantle cell lymphoma: clinical and pathologic spectrum of twenty-three cases. *Mod Pathol*. 2001;14(11):1133-1140.
436. Foon KA, Todd RF 3rd. Immunologic classification of leukemia and lymphoma. *Blood*. 1986;68(1):1-31.
437. Bartl R, Frisch B, Burkhardt R, et al. Assessment of bone marrow histology in the malignant lymphomas (non-Hodgkin's): correlation with clinical factors for diagnosis, prognosis, classification and staging. *Br J Haematol*. 1982;51(4):511-530.
438. Crotty PL, Smith BR, Tallini G. Morphologic, immunophenotypic, and molecular evaluation of bone marrow involvement in non-Hodgkin's lymphoma. *Diagn Mol Pathol*. 1998;7(2):90-95.
439. Estalilla OC, Koo CH, Brynes RK, Medeiros LJ. Intravascular large B-cell lymphoma. A report of five cases initially diagnosed by bone marrow biopsy. *Am J Clin Pathol*. 1999;112(2):248-255.
440. Foucar K, McKenna RW, Frizzera G, Brunning RD. Bone marrow and blood involvement by lymphoma in relationship to the Lukes—Collins classification. *Cancer*. 1982;49(5):888-897.
441. McKenna RW, Hernandez JA. Bone marrow in malignant lymphoma. *Hematol Oncol Clin North Am*. 1988;2(4):617-635.
442. Perry DA, Bast MA, Armitage JO, Weisenburger DD. Diffuse intermediate lymphocytic lymphoma. A clinicopathologic study and comparison with small lymphocytic lymphoma and diffuse small cleaved cell lymphoma. *Cancer*. 1990;66(9):1995-2000.
443. Torlakovic E, Torlakovic G, Brunning RD. Follicular pattern of bone marrow involvement by follicular lymphoma. *Am J Clin Pathol*. 2002;118(5):780-786.
444. Van Huyen JP, Molina T, Delmer A, et al. Splenic marginal zone lymphoma with or without plasmacytic differentiation. *Am J Surg Pathol*. 2000;24:1581-1592.
445. Weir EG, Borowitz MJ, Racke FR. Germinal centers in bone marrow specimens are associated with marginal zone lymphoma. *Mod Pathol*. 2001;14:182.
446. Bartl R, Hansmann ML, Frisch B, Burkhardt R. Comparative histology of malignant lymphomas in lymph node and bone marrow. *Br J Haematol*. 1988;69(2):229-237.
447. Diebold J, Jaffe ES, Raphael M, Warnke RA. Burkitt lymphoma. In: Jaffe ES, Harris NL, Stein H, Vardiman JW, eds. *World Health Organization Classification of Tumors Pathology and Genetics of Tumours of Haematopoietic and Lymphoid Tissues*. Lyon: IARC Press; 2001:181-184.
448. Fisher DE, Jacobson JO, Ault KA, Harris NL. Diffuse large cell lymphoma with discordant bone marrow histology. Clinical features and biological implications. *Cancer*. 1989;64(9):1879-1887.
449. Robertson LE, Redman JR, Butler JJ, et al. Discordant bone marrow involvement in diffuse large-cell lymphoma: a distinct clinical-pathologic entity associated with a continuous risk of relapse. *J Clin Oncol*. 1991;9(2):236-242.
450. Kremer M, Spitzer M, Mandl-Weber S, et al. Discordant bone marrow involvement in diffuse large B-cell lymphoma; molecular analysis of microdissected bone marrow infiltrates reveals a heterogeneous group of disorders. *J Clin Pathol*. 2002;55(suppl 1):A5.
451. Douglas VK, Gordon LI, Goolsby CL, et al. Lymphoid aggregates in bone marrow mimic residual lymphoma after rituximab therapy for non-Hodgkin lymphoma. *Am J Clin Pathol*. 1999;112(6):844-853.
452. McKenna RW, Brunning RD. Reed-Sternberg-like cells in nodular lymphoma involving the bone marrow. *Am J Clin Pathol*. 1975;63(6):779-785.
453. Fraga M, Brousset P, Schlaifer D, et al. Bone marrow involvement in anaplastic large cell lymphoma. Immunohistochemical detection of minimal disease and its prognostic significance. *Am J Clin Pathol*. 1995;103(1):82-89.
454. Weinberg OK, Seo K, Arber DA. Prevalence of bone marrow involvement in systemic anaplastic large cell lymphoma: are immunohistochemical studies necessary? *Hum Pathol*. 2008;39(9):1331-1340.
455. Delabie J, Vandenberghe E, Kennes C, et al. Histiocyte-rich B-cell lymphoma. A distinct clinicopathologic entity possibly related to lymphocyte predominant Hodgkin's disease, paragranuloma subtype. *Am J Surg Pathol*. 1992;16(1):37-48.
456. Vasef MA, Medeiros LJ, Koo C, et al. Cyclin D1 immunohistochemical staining is useful in distinguishing mantle cell lymphoma from other low-grade B-cell neoplasms in bone marrow. *Am J Clin Pathol*. 1997;108(3):302-307.
457. Swerdlow SH, Webber SA, Chadburn A, Ferry JA. Post-transplant lymphoproliferative disorders. In: Swerdlow SH, Campo E, Harris NL, et al, eds. *WHO Classification of Tumours of Haematopoietic and Lymphoid Tissues*. Lyon: IARC Press; 2008:343-349.
458. Koeppen H, Newell K, Baunoch DA, Vardiman JW. Morphologic bone marrow changes in patients with posttransplantation lymphoproliferative disorders. *Am J Surg Pathol*. 1998;22(2):208-214.
459. Zukerberg LR, Medeiros LJ, Ferry JA, Harris NL. Diffuse low-grade B-cell lymphomas. Four clinically distinct subtypes defined by a combination of morphologic and immunophenotypic features. *Am J Clin Pathol*. 1993;100(4):373-385.
460. De Oliveira MS, Jaffe ES, Catovsky D. Leukaemic phase of mantle zone (intermediate) lymphoma: its characterisation in 11 cases. *J Clin Pathol*. 1989;42(9):962-972.
461. Pittaluga S, Verhoef G, Criel A, et al. Prognostic significance of bone marrow trephine and peripheral blood smears in 55 patients with mantle cell lymphoma. *Leuk Lymphoma*. 1996;21(1-2):115-125.
462. Pileri SA, Weisenburger DD, Sng I, et al. Peripheral T-cell lymphoma, not otherwise specified. In: Swerdlow SH, Campo E, Harris NL, et al, eds. *WHO Classification of Tumours of Haematopoietic and Lymphoid Tissues*. Lyon: IARC Press; 2008:306-308.
463. Rizvi MA, Evens AM, Tallman MS, et al. T-cell non-Hodgkin lymphoma. *Blood*. 2006;107(4):1255-1264.
464. Dogan A, Morice WG. Bone marrow histopathology in peripheral T-cell lymphomas. *Br J Haematol*. 2004;127(2):140-154.
465. Jaffe ES. Pathologic and clinical spectrum of post-thymic T-cell malignancies. *Cancer Invest*. 1984;2(5):413-426.
466. Tan BT, Seo K, Warnke RA, Arber DA. The frequency of immunoglobulin heavy chain gene and T-cell receptor gamma-chain gene rearrangements and Epstein-Barr virus in ALK+ and ALK- anaplastic large cell lymphoma and other peripheral T-cell lymphomas. *J Mol Diagn*. 2008;10(6):502-512.
467. Gebhard S, Benhattar J, Bricod C, et al. Polymerase chain reaction in the diagnosis of T-cell lymphoma in paraffin-embedded bone marrow biopsies: a comparative study. *Histopathology*. 2001;38(1):37-44.
468. Ohshima K. Pathological features of diseases associated with human T-cell leukemia virus type I. *Cancer Sci*. 2007;98(6):772-778.
469. Ohshima K, Jaffe ES, Kikuchi M, Adult T. cell leukaemia/lymphoma. In: Swerdlow SH, Campo E, Harris NL, et al, eds. *WHO Classification of Tumours of Haematopoietic and Lymphoid Tissues*. Lyon: IARC Press; 2008:281-284.
470. Yamaguchi K, Takatsuki K. Adult T cell leukaemia-lymphoma. *Baillieres Clin Haematol*. 1993;6(4):899-915.
471. Kiyokawa T, Yamaguchi K, Takeya M, et al. Hypercalcemia and osteoclast proliferation in adult T-cell leukemia. *Cancer*. 1987;59(6):1187-1191.
472. Flandrin G, Brouet JC. The Sezary cell: cytologic, cytochemical, and immunologic studies. *Mayo Clin Proc*. 1974;49(8):575-583.
473. Ralfkiaer E, Willemze R, Whittaker SJ. Sézary syndrome. In: Swerdlow SH, Campo E, Harris NL, et al, eds. *WHO Classification of Tumours of Haematopoietic and Lymphoid Tissues*. Lyon: IARC Press; 2008:306-308.
474. Taswell HF, Winkelmann RK. Sezary syndrome—a malignant reticulemic erythroderma. *JAMA*. 1961;177:465-472.
475. Variakojis D, Rosas-Uribe A, Rappaport H. Mycosis fungoides: pathologic findings in staging laparotomies. *Cancer*. 1974;33(6):1589-1600.
476. Zucker-Franklin D, Melton JW 3rd, Quagliata F. Ultrastructural, immunologic, and functional studies on Sezary cells: a neoplastic variant of thymus-derived (T) lymphocytes. *Proc Natl Acad Sci USA*. 1974;71(5):1877-1881.
477. Lutzner MA, Jordan HW. The ultrastructure of an abnormal cell in Sezary's syndrome. *Blood*. 1968;31(6):719-726.
478. Sibaud V, Beylot-Barry M, Thiebaut R, et al. Bone marrow histopathologic and molecular staging in epidermotropic T-cell lymphomas. *Am J Clin Pathol*. 2003;119(3):414-423.
479. Alekshun TJ, Sokol L. Diseases of large granular lymphocytes. *Cancer Control*. 2007;14(2):141-150.
480. Costes V, Duchayne E, Taib J, et al. Intrasinusoidal bone marrow infiltration: a common growth pattern for different lymphoma subtypes. *Br J Haematol*. 2002;119(4):916-922.
481. O'Malley DP. T-cell large granular leukemia and related proliferations. *Am J Clin Pathol*. 2007;127(6):850-859.
482. Osuji N, Matutes E, Catovsky D, et al. Histopathology of the spleen in T-cell large granular lymphocyte leukemia and T-cell prolymphocytic leukemia: a comparative review. *Am J Surg Pathol*. 2005;29(7):935-941.
483. Tefferi A, Li CY, Witzig TE, et al. Chronic natural killer cell lymphocytosis: a descriptive clinical study. *Blood*. 1994;84(8):2721-2725.
484. Cady FM, Morice WG. Flow cytometric assessment of T-cell chronic lymphoproliferative disorders. *Clin Lab Med*. 2007;27(3):513-532, vi.
485. Chan WC, Foucar K, Morice WG, Catovsky D. T-cell large granular lymphocytic leukaemia. In: Swerdlow SH, Campo E, Harris NL, et al, eds. *WHO Classification of Tumours of Haematopoietic and Lymphoid Tissues*. Lyon: IARC Press; 2008:272-273.
486. Ohgami RS, Ohgami JK, Pereira IT, et al. Refining the diagnosis of T-cell large granular lymphocytic leukemia by combining distinct patterns of antigen expression with T-cell clonality studies. *Leukemia*. 2011;25(9):1439-1443.
487. Evans HL, Burks E, Viswanatha D, Larson RS. Utility of immunohistochemistry in bone marrow evaluation of T-lineage large granular lymphocyte leukemia. *Hum Pathol*. 2000;31(10):1266-1273.

For personal use only. No other uses without permission. Copyright ©2017. Elsevier Inc. All rights reserved.

488. Lundell R, Hartung L, Hill S, et al. T-cell large granular lymphocyte leukemias have multiple phenotypic abnormalities involving pan-T-cell antigens and receptors for MHC molecules. *Am J Clin Pathol*. 2005;124(6):937-946.
489. Morice WG. The immunophenotypic attributes of NK cells and NK-cell lineage lymphoproliferative disorders. *Am J Clin Pathol*. 2007;127(6):881-886.
490. Morice WG, Jevremovic D, Hanson CA. The expression of the novel cytotoxic protein granzyme M by large granular lymphocytic leukaemias of both T-cell and NK-cell lineage: an unexpected finding with implications regarding the pathobiology of these disorders. *Br J Haematol*. 2007;137(3):237-239.
491. Morice WG, Kurtin PJ, Tefferi A, Hanson CA. Distinct bone marrow findings in T-cell granular lymphocytic leukemia revealed by paraffin section immunoperoxidase stains for CD8, TIA-1, and granzyme B. *Blood*. 2002;99(1):268-274.
492. Wlodarski MW, Schade AE, Maciejewski JP. T-large granular lymphocyte leukemia: current molecular concepts. *Hematology*. 2006;11(4):245-256.
493. Koskela HL, Eldfors S, Ellonen P, et al. Somatic STAT3 mutations in large granular lymphocytic leukemia. *N Engl J Med*. 2012;366(20):1905-1913.
494. Frizzera G, Moran EM, Rappaport H. Angio-immunoblastic lymphadenopathy with dysproteinaemia. *Lancet*. 1974;1(7866):1070-1073.
495. Frizzera G, Moran EM, Rappaport H. Angio-immunoblastic lymphadenopathy. Diagnosis and clinical course. *Am J Med*. 1975;59(6):803-818.
496. Lukes RJ, Tindle BH. Immunoblastic lymphadenopathy. A hyperimmune entity resembling Hodgkin's disease. *N Engl J Med*. 1975;292(1):1-8.
497. Pangalis GA, Moran EM, Rappaport H. Blood and bone marrow findings in angioimmunoblastic lymphadenopathy. *Blood*. 1978;51(1):71-83.
498. Schnaidt U, Vykoupil KF, Thiele J, Georgii A. Angioimmunoblastic lymphadenopathy. Histopathology of bone marrow involvement. *Virchows Arch A Pathol Anat Histol*. 1980;389(3):369-380.
499. Ghani AM, Krause JR. Bone marrow biopsy findings in angioimmunoblastic lymphadenopathy. *Br J Haematol*. 1985;61(2):203-213.
500. Grogg KL, Morice WG, Macon WR. Spectrum of bone marrow findings in patients with angioimmunoblastic T-cell lymphoma. *Br J Haematol*. 2007;137(5):416-422.
501. Higgins JP, van de Rijn M, Jones CD, et al. Peripheral T-cell lymphoma complicated by a proliferation of large B cells. *Am J Clin Pathol*. 2000;114(2):236-247.
502. Sakata-Yanagimoto M, Enami T, Yoshida K, et al. Somatic RHOA mutation in angioimmunoblastic T cell lymphoma. *Nat Genet*. 2014;46(2):171-175.
503. Odejide O, Weigert O, Lane AA, et al. A targeted mutational landscape of angioimmunoblastic T-cell lymphoma. *Blood*. 2014;123(9):1293-1296.
504. Schlegelberger B, Zhang Y, Weber-Matthiesen K, Grote W. Detection of aberrant clones in nearly all cases of angioimmunoblastic lymphadenopathy with dysproteinemia-type T-cell lymphoma by combined interphase and metaphase cytogenetics. *Blood*. 1994;84(8):2640-2648.
505. Delsol G, Falini B, Müller-Hermelink HK, et al. Anaplastic large cell lymphoma (ALCL), ALK-positive. In: Swerdlow SH, Campo E, Harris NL, et al, eds. *WHO Classification of Tumours of Haematopoietic and Lymphoid Tissues*. Lyon: IARC Press; 2008:312-316.
506. Mason DY, Harris NL, Delsol G, Stein H. Anaplastic large cell lymphoma, ALK-negative. In: Swerdlow SH, Campo E, Harris NL, et al, eds. *WHO Classification of Tumours of Haematopoietic and Lymphoid Tissues*. Lyon: IARC Press; 2008:317-319.
507. Grewal JS, Smith LB, Winegarden JD 3rd, et al. Highly aggressive ALK-positive anaplastic large cell lymphoma with a leukemic phase and multi-organ involvement: a report of three cases and a review of the literature. *Ann Hematol*. 2007;86(7):499-508.
508. Bovio IM, Allan RW. The expression of myeloid antigens CD13 and/or CD33 is a marker of ALK+ anaplastic large cell lymphomas. *Am J Clin Pathol*. 2008;130(4):628-634.
509. Juco J, Holden JT, Mann KP, et al. Immunophenotypic analysis of anaplastic large cell lymphoma by flow cytometry. *Am J Clin Pathol*. 2003;119(2):205-212.
510. de Wolf-Peeters C, Achten R. gammadelta T-cell lymphomas: a homogeneous entity? *Histopathology*. 2000;36(4):294-305.
511. Macon WR, Levy NB, Kurtin PJ, et al. Hepatosplenic alphabeta T-cell lymphomas: a report of 14 cases and comparison with hepatosplenic gammadelta T-cell lymphomas. *Am J Surg Pathol*. 2001;25(3):285-296.
512. Vega F, Medeiros LJ, Bueso-Ramos C, et al. Hepatosplenic gamma/delta T-cell lymphoma in bone marrow. A sinusoidal neoplasm with blastic cytologic features. *Am J Clin Pathol*. 2001;116(3):410-419.
513. Alonsozana EL, Stamberg J, Kumar D, et al. Isochromosome 7q: the primary cytogenetic abnormality in hepatosplenic gammadelta T cell lymphoma. *Leukemia*. 1997;11(8):1367-1372.
514. Gaulard P, Jaffe ES, Krenacs L. Macin WR. Hepatosplenic T-cell lymphoma. In: Swerdlow SH, Campo E, Harris NL, et al, eds. *WHO Classification of Tumours of Haematopoietic and Lymphoid Tissues*. Lyon: IARC Press; 2008:292-293.
515. Jonveaux P, Daniel MT, Martel V, et al. Isochromosome 7q and trisomy 8 are consistent primary, non-random chromosomal abnormalities associated with hepatosplenic T gamma/delta lymphoma. *Leukemia*. 1996;10(9):1453-1455.
516. Chan JK, Sin VC, Wong KF, et al. Nonnasal lymphoma expressing the natural killer cell marker CD56: a clinicopathologic study of 49 cases of an uncommon aggressive neoplasm. *Blood*. 1997;89(12):4501-4513.
517. Shaw PH, Cohn SL, Morgan ER, et al. Natural killer cell lymphoma: report of two pediatric cases, therapeutic options, and review of the literature. *Cancer*. 2001;91(4):642-646.
518. Wong KF, Chan JK, Cheung MM, So JC. Bone marrow involvement by nasal NK cell lymphoma at diagnosis is uncommon. *Am J Clin Pathol*. 2001;115(2):266-270.
519. Hashimoto M, Hashimoto N. The occurrence of lymph nodules in human bone marrow, with particular reference to their number. *Kyushu J Med Sci*. 1963;14:343-354.
520. Hashimoto M, Higuchi M, Saito T. Lymph nodules in human bone marrow. *Acta Pathol Jpn*. 1957;7:33-52.
521. Maeda K, Hyun BH, Rebuck JW. Lymphoid follicles in bone marrow aspirates. *Am J Clin Pathol*. 1977;67(1):41-48.
522. Rywlin AM, Ortega RS, Dominguez CJ. Lymphoid nodules of bone marrow: normal and abnormal. *Blood*. 1974;43(3):389-400.
523. Faulkner-Jones BE, Howie AJ, Boughton BJ, Franklin IM. Lymphoid aggregates in bone marrow: study of eventual outcome. *J Clin Pathol*. 1988;41(7):768-775.
524. Cheson BD, Pfistner B, Juweid ME, et al. Revised response criteria for malignant lymphoma. *J Clin Oncol*. 2007;25(5):579-586.
525. Thiele J, Zirbes TK, Kvasnicka HM, Fischer R. Focal lymphoid aggregates (nodules) in bone marrow biopsies: differentiation between benign hyperplasia and malignant lymphoma—a practical guideline. *J Clin Pathol*. 1999;52(4):294-300.
526. Chu PG, Chen YY, Molina A, et al. Recurrent B-cell neoplasms after Rituximab therapy: an immunophenotypic and genotypic study. *Leuk Lymphoma*. 2002;43(12):2335-2341.
527. Engels K, Oeschger S, Hansmann ML, et al. Bone marrow trephines containing lymphoid aggregates from patients with rheumatoid and other autoimmune disorders frequently show clonal B-cell infiltrates. *Hum Pathol*. 2007;38(9):1402-1411.
528. Cheson BD, Horning SJ, Coiffier B, et al. Report of an international workshop to standardize response criteria for non-Hodgkin's lymphomas. NCI Sponsored International Working Group. *J Clin Oncol*. 1999;17(4):1244.
529. Poppema S, Delsol G, Pileri SA, et al. Nodular lymphocyte predominant Hodgkin lymphoma. In: Swerdlow SH, Campo E, Harris NL, et al, eds. *WHO Classification of Tumours of Haematopoietic and Lymphoid Tissues*. Lyon: IARC Press; 2008:323-325.
530. Siebert JD, Stuckey JH, Kurtin PJ, Banks PM. Extranodal lymphocyte predominance Hodgkin's disease. Clinical and pathologic features. *Am J Clin Pathol*. 1995;103(4):485-491.
531. Stein H, Delsol G, Pileri SA, et al. Classical Hodgkin lymphoma, introduction. In: Swerdlow SH, Campo E, Harris NL, et al, eds. *WHO Classification of Tumours of Haematopoietic and Lymphoid Tissues*. Lyon: IARC Press; 2008:326-329.
532. Diehl V, Sextro M, Franklin J, et al. Clinical presentation, course, and prognostic factors in lymphocyte-predominant Hodgkin's disease and lymphocyte-rich classical Hodgkin's disease: report from the European Task Force on Lymphoma Project on Lymphocyte-Predominant Hodgkin's Disease. *J Clin Oncol*. 1999;17(3):776-783.
533. Munker R, Hasenclever D, Brosteanu O, et al. Bone marrow involvement in Hodgkin's disease: an analysis of 135 consecutive cases. German Hodgkin's Lymphoma Study Group. *J Clin Oncol*. 1995;13(2):403-409.
534. Kinney MC, Greer JP, Stein RS, et al. Lymphocyte-depletion Hodgkin's disease. Histopathologic diagnosis of marrow involvement. *Am J Surg Pathol*. 1986;10(3):219-226.
535. Neiman RS, Rosen PJ, Lukes RJ. Lymphocyte-depletion Hodgkin's disease. A clinicopathological entity. *N Engl J Med*. 1973;288(15):751-755.
536. Dorfman RF. Formal discussion of Robert J. Lukes' paper, "Criteria for involvement of lymph node, bone marrow, spleen, and liver in Hodgkin's disease.". *Cancer Res*. 1971;31(11):1768-1769.
537. Lukes RJ. Criteria for involvement of lymph node, bone marrow, spleen, and liver in Hodgkin's disease. *Cancer Res*. 1971;31(11):1755-1767.
538. Rappaport H, Berard CW, Butler JJ, et al. Report of the committee on histopathological criteria contributing to staging of Hodgkin's disease. *Cancer Res*. 1971;31(11):1864-1865.
539. O'Carroll DI, McKenna RW, Brunning RD. Bone marrow manifestations of Hodgkin's disease. *Cancer*. 1976;38(4):1717-1728.
540. Chang KL, Kamel OW, Arber DA, et al. Pathologic features of nodular lymphocyte predominance Hodgkin's disease in extranodal sites. *Am J Surg Pathol*. 1995;19(11):1313-1324.
541. Te Velde J, Den Ottolander GJ, Spaander PJ, et al. The bone marrow in Hodgkin's disease:

For personal use only. No other uses without permission. Copyright ©2017. Elsevier Inc. All rights reserved.

the non-involved marrow. *Histopathology*. 1978;2(1):31-46.
542. Bartl R, Frisch B, Burkhardt R, et al. Assessment of bone marrow histology in Hodgkin's disease: correlation with clinical factors. *Br J Haematol*. 1982;51(3):345-360.
543. Koene-Bogman J. Granulomas and the diagnosis of Hodgkin's disease. *N Engl J Med*. 1978;299:533.
544. Grogan TM, Pileri SA, Chan JKC, et al. Histiocytic sarcoma. In: Swerdlow SH, Campo E, Harris NL, et al, eds. *WHO Classification of Tumours of Haematopoietic and Lymphoid Tissues*. Lyon: IARC Press; 2008:356-357.
545. Jaffe R, Pileri SA, Fachetti F, et al. Histiocytic and dendritic cell neoplasms. Introduction. In: Swerdlow SH, Campo E, Harris NL, et al, eds. *WHO Classification of Tumours of Haematopoietic and Lymphoid Tissues*. Lyon: IARC Press; 2008:354-355.
546. Emile JF, Abla O, Fraitag S, et al. Revised classification of histiocytoses and neoplasms of the macrophage-dendritic cell lineages. *Blood*. 2016;127(22):2672-2681.
547. Copie-Bergman C, Wotherspoon AC, Norton AJ, et al. True histiocytic lymphoma: a morphologic, immunohistochemical, and molecular genetic study of 13 cases. *Am J Surg Pathol*. 1998;22(11):1386-1392.
548. Lampert IA, Catovsky D, Bergier N. Malignant histiocytosis: a clinico-pathological study of 12 cases. *Br J Haematol*. 1978;40(1):65-77.
549. Rousseau-Merck MF, Jaubert F, Nezelof C. Malignant histiocytosis in childhood. *Hum Pathol*. 1985;16(3):321.
550. van Heerde P, Feltkamp CA, Hart AA, et al. Malignant histiocytosis and related tumors. A clinicopathologic study of 42 cases using cytological, histochemical and ultrastructural parameters. *Hematol Oncol*. 1984;2(1):13-32.
551. Warnke RA, Kim H, Dorfman RF. Malignant histiocytosis (histiocytic medullary reticulosis). I. Clinicopatholigic study of 29 cases. *Cancer*. 1975;35(1):215-230.
552. Weiss LM, Azzi R, Dorfman RF, Warnke RA. Sinusoidal hematolymphoid malignancy ("malignant histiocytosis") presenting as atypical sinusoidal proliferation. A study of nine cases. *Cancer*. 1986;58(8):1681-1688.
553. Wilson MS, Weiss LM, Gatter KC, et al. Malignant histiocytosis. A reassessment of cases previously reported in 1975 based on paraffin section immunophenotyping studies. *Cancer*. 1990;66(3):530-536.
554. Feldman AL, Arber DA, Pittaluga S, et al. Clonally related follicular lymphomas and histiocytic/dendritic cell sarcomas: evidence for transdifferentiation of the follicular lymphoma clone. *Blood*. 2008;111(12):5433-5439.
555. Filipovich AH. Hemophagocytic lymphohistiocytosis and other hemophagocytic disorders. *Immunol Allergy Clin North Am*. 2008;28(2):293-313, viii.
556. Risdall RJ, McKenna RW, Nesbit ME, et al. Virus associated hemophagocytic syndrome. *Hum Pathol*. 1981;12:395-398.
557. Verbsky JW, Grossman WJ. Hemophagocytic lymphohistiocytosis: diagnosis, pathophysiology, treatment, and future perspectives. *Ann Med*. 2006;38(1):20-31.
558. Henter JI, Horne A, Arico M, et al. HLH-2004: Diagnostic and therapeutic guidelines for hemophagocytic lymphohistiocytosis. *Pediatr Blood Cancer*. 2007;48(2):124-131.
559. Kogawa K, Lee SM, Villanueva J, et al. Perforin expression in cytotoxic lymphocytes from patients with hemophagocytic lymphohistiocytosis and their family members. *Blood*. 2002;99(1):61-66.
560. Stepp SE, Dufourcq-Lagelouse R, Le Deist F, et al. Perforin gene defects in familial hemophagocytic lymphohistiocytosis. *Science*. 1999;286(5446):1957-1959.
561. Henter JI, Arico M, Elinder G, et al. Familial hemophagocytic lymphohistiocytosis. Primary hemophagocytic lymphohistiocytosis. *Hematol Oncol Clin North Am*. 1998;12(2):417-433.
562. Chott A, Kaserer K, Augustin I, et al. Ki-1-positive large cell lymphoma. A clinicopathologic study of 41 cases. *Am J Surg Pathol*. 1990;14(5):439-448.
563. Daum GS, Sullivan JL, Ansell J, et al. Virus-associated hemophagocytic syndrome: identification of an immunoproliferative precursor lesion. *Hum Pathol*. 1987;18(10):1071-1074.
564. Falini B, Pileri S, De Solas I, et al. Peripheral T-cell lymphoma associated with hemophagocytic syndrome. *Blood*. 1990;75(2):434-444.
565. Gaffey MJ, Frierson HF Jr, Medeiros LJ, Weiss LM. The relationship of Epstein-Barr virus to infection-related (sporadic) and familial hemophagocytic syndrome and secondary (lymphoma-related) hemophagocytosis: an in situ hybridization study. *Hum Pathol*. 1993;24(6):657-667.
566. Jaffe ES, Costa J, Fauci AS, et al. Malignant lymphoma and erythrophagocytosis simulating malignant histiocytosis. *Am J Med*. 1983;75(5):741-749.
567. Janka G, Imashuku S, Elinder G, et al. Infection- and malignancy-associated hemophagocytic syndromes. Secondary hemophagocytic lymphohistiocytosis. *Hematol Oncol Clin North Am*. 1998;12(2):435-444.
568. Kikuta H, Sakiyama Y, Matsumoto S, et al. Fatal Epstein-Barr virus-associated hemophagocytic syndrome. *Blood*. 1993;82(11):3259-3264.
569. Kimura H, Hoshino Y, Kanegane H, et al. Clinical and virologic characteristics of chronic active Epstein-Barr virus infection. *Blood*. 2001;98(2):280-286.
570. Lay JD, Tsao CJ, Chen JY, et al. Upregulation of tumor necrosis factor-alpha gene by Epstein-Barr virus and activation of macrophages in Epstein-Barr virus-infected T cells in the pathogenesis of hemophagocytic syndrome. *J Clin Invest*. 1997;100(8):1969-1979.
571. Mroczek EC, Weisenburger DD, Grierson HL, et al. Fatal infectious mononucleosis and virus-associated hemophagocytic syndrome. *Arch Pathol Lab Med*. 1987;111(6):530-535.
572. Reiner AP, Spivak JL. Hematophagocytic histiocytosis. A report of 23 new patients and a review of the literature. *Medicine (Baltimore)*. 1988;67:349-368.
573. Shirono K, Tsuda H. Parvovirus B19-associated haemophagocytic syndrome in healthy adults. *Br J Haematol*. 1995;89(4):923-926.
574. Su IJ, Wang CH, Cheng AL, Chen RL. Hemophagocytic syndrome in Epstein-Barr virus-associated T-lymphoproliferative disorders: disease spectrum, pathogenesis, and management. *Leuk Lymphoma*. 1995;19(5-6):401-406.
575. Sullivan JL, Woda BA, Herrod HG, et al. Epstein-Barr virus-associated hemophagocytic syndrome: virological and immunopathological studies. *Blood*. 1985;65(5):1097-1104.
576. Ravelli A. Macrophage activation syndrome. *Curr Opin Rheumatol*. 2002;14(5):548-552.
577. Ravelli A, Magni-Manzoni S, Pistorio A, et al. Preliminary diagnostic guidelines for macrophage activation syndrome complicating systemic juvenile idiopathic arthritis. *J Pediatr*. 2005;146(5):598-604.
578. Allory Y, Challine D, Haioun C, et al. Bone marrow involvement in lymphomas with hemophagocytic syndrome at presentation: a clinicopathologic study of 11 patients in a Western institution. *Am J Surg Pathol*. 2001;25(7):865-874.
579. Reisman RP, Greco MA. Virus-associated hemophagocytic syndrome due to Epstein-Barr virus. *Hum Pathol*. 1984;15(3):290-293.
580. Risdall RJ, Brunning RD, Hernandez JI, Gordon DH. Bacteria-associated hemophagocytic syndrome. *Cancer*. 1984;54(12):2968-2972.
581. Shimazaki C, Inaba T, Shimura K, et al. B-cell lymphoma associated with haemophagocytic syndrome: a clinical, immunological and cytogenetic study. *Br J Haematol*. 1999;104(4):672-679.
582. Teruya-Feldstein J, Setsuda J, Yao X, et al. MIP-1alpha expression in tissues from patients with hemophagocytic syndrome. *Lab Invest*. 1999;79(12):1583-1590.
583. Woda BA, Sullivan JL. Reactive histiocytic disorders. *Am J Clin Pathol*. 1993;99(4):459-463.
584. Ashby MA, Williams CJ, Buchanan RB, et al. Mediastinal germ cell tumour associated with malignant histiocytosis and high rubella titres. *Hematol Oncol*. 1986;4(3):183-194.
585. Chen RL, Su IJ, Lin KH, et al. Fulminant childhood hemophagocytic syndrome mimicking histiocytic medullary reticulosis. An atypical form of Epstein-Barr virus infection. *Am J Clin Pathol*. 1991;96(2):171-176.
586. Imashuku S, Kuriyama K, Teramura T, et al. Requirement for etoposide in the treatment of Epstein-Barr virus-associated hemophagocytic lymphohistiocytosis. *J Clin Oncol*. 2001;19(10):2665-2673.
587. Trottestam H, Horne A, Arico M, et al. Chemoimmunotherapy for hemophagocytic lymphohistiocytosis: long-term results of the HLH-94 treatment protocol. *Blood*. 2011;118(17):4577-4584.
588. Jaffee R, Weiss LM, Fachetti F. Tumours derived from Langerhans cells. In: Swerdlow SH, Campo E, Harris NL, et al, eds. *WHO Classification of Tumours of Haematopoietic and Lymphoid Tissues*. Lyon: IARC Press; 2008:358-360.
589. McClain K, Ramsay NK, Robison L, et al. Bone marrow involvement in histiocytosis X. *Med Pediatr Oncol*. 1983;11(3):167-171.
590. McKenna RW, Kyle RA, Kuehl WM, et al. Plasma cell neoplasms. In: Swerdlow SH, Campo E, Harris NL, et al, eds. *WHO Classification of Tumours of Haematopoietic and Lymphoid Tissues*. Lyon: IARC Press; 2008:200-213.
591. Kyle RA, Gertz MA, Witzig TE, et al. Review of 1027 patients with newly diagnosed multiple myeloma. *Mayo Clin Proc*. 2003;78(1):21-33.
592. Rajkumar SV, Dimopoulos MA, Palumbo A, et al. International Myeloma Working Group updated criteria for the diagnosis of multiple myeloma. *Lancet Oncol*. 2014;15(12):e538-e548.
593. Bartl R, Frisch B, Fateh-Moghadam A, et al. Histologic classification and staging of multiple myeloma. A retrospective and prospective study of 674 cases. *Am J Clin Pathol*. 1987;87(3):342-355.
594. Carbone A, Volpe R, Manconi R, et al. Bone marrow pattern and clinical staging in multiple myeloma. *Br J Haematol*. 1987;65(4):502-503.
595. Cavo M, Baccarani M, Gobbi M, et al. Prognostic value of bone marrow plasma cell infiltration in stage I multiple myeloma. *Br J Haematol*. 1983;55(4):683-690.
596. Sukpanichnant S, Cousar JB, Leelasiri A, et al. Diagnostic criteria and histologic grading in multiple myeloma: histologic and immunohistologic analysis of 176 cases with clinical correlation. *Hum Pathol*. 1994;25(3):308-318.
597. Carter A, Hocherman I, Linn S, et al. Prognostic significance of plasma cell

For personal use only. No other uses without permission. Copyright ©2017. Elsevier Inc. All rights reserved.

morphology in multiple myeloma. *Cancer*. 1987;60(5):1060-1065.
598. Fritz E, Ludwig H, Kundi M. Prognostic relevance of cellular morphology in multiple myeloma. *Blood*. 1984;63(5):1072-1079.
599. Greipp PR, Raymond NM, Kyle RA, O'Fallon WM. Multiple myeloma: significance of plasmablastic subtype in morphological classification. *Blood*. 1985;65(2):305-310.
600. Case records of the Massachusetts General Hospital. Weekly clinicopathological exercises. Case 4-1992. Pancytopenia, splenomegaly, and retinal hemorrhage in a 52-year-old diabetic man. *N Engl J Med*. 1992;326(4):255-263.
601. Krzyzaniak RL, Buss DH, Cooper MR, Wells HB. Marrow fibrosis and multiple myeloma. *Am J Clin Pathol*. 1988;89(1):63-68.
602. Durie BG. Staging and kinetics of multiple myeloma. *Semin Oncol*. 1986;13(3):300-309.
603. Durie BG, Salmon SE, Moon TE. Pretreatment tumor mass, cell kinetics, and prognosis in multiple myeloma. *Blood*. 1980;55(3):364-372.
604. Gassmann W, Pralle H, Haferlach T, et al. Staging systems for multiple myeloma: a comparison. *Br J Haematol*. 1985;59(4):703-711.
605. Greipp PR. Advances in the diagnosis and management of myeloma. *Semin Hematol*. 1992;29(3 suppl 2):24-45.
606. Stewart AK, Bergsagel PL, Greipp PR, et al. A practical guide to defining high-risk myeloma for clinical trials, patient counseling and choice of therapy. *Leukemia*. 2007;21(3):529-534.
607. Bataille R, Durie BG, Grenier J. Serum beta2 microglobulin and survival duration in multiple myeloma: a simple reliable marker for staging. *Br J Haematol*. 1983;55(3):439-447.
608. Facon T, Avet-Loiseau H, Guillerm G, et al. Chromosome 13 abnormalities identified by FISH analysis and serum beta2-microglobulin produce a powerful myeloma staging system for patients receiving high-dose therapy. *Blood*. 2001;97(6):1566-1571.
609. Greipp PR, Katzmann JA, O'Fallon WM, Kyle RA. Impact of pretreatment β2 microglobulin levels on survival in patients with multiple myeloma. *Blood Rev*. 1985;66:188a.
610. Gertz MA, Kyle RA, Greipp PR. The plasma cell labeling index: a valuable tool in primary systemic amyloidosis. *Blood*. 1989;74(3):1108-1111.
611. Greipp PR, Witzig TE, Gonchoroff NJ, et al. Immunofluorescence labeling indices in myeloma and related monoclonal gammopathies. *Mayo Clin Proc*. 1987;62(11):969-977.
612. Konigsberg R, Zojer N, Ackermann J, et al. Predictive role of interphase cytogenetics for survival of patients with multiple myeloma. *J Clin Oncol*. 2000;18(4):804-812.
613. Smadja NV, Bastard C, Brigaudeau C, et al. Hypodiploidy is a major prognostic factor in multiple myeloma. *Blood*. 2001;98(7):2229-2238.
614. Fonseca R, Bergsagel PL, Drach J, et al. International Myeloma Working Group molecular classification of multiple myeloma: spotlight review. *Leukemia*. 2009;23(12):2210-2221.
615. Kuehl WM, Bergsagel PL. Molecular pathogenesis of multiple myeloma and its premalignant precursor. *J Clin Invest*. 2012;122(10):3456-3463.
616. Lohr JG, Stojanov P, Carter SL, et al. Widespread genetic heterogeneity in multiple myeloma: implications for targeted therapy. *Cancer Cell*. 2014;25(1):91-101.
617. Moreau P, Facon T, Leleu X, et al. Recurrent 14q32 translocations determine the prognosis of multiple myeloma, especially in patients receiving intensive chemotherapy. *Blood*. 2002;100(5):1579-1583.
618. Avet-Loiseau H, Attal M, Moreau P, et al. Genetic abnormalities and survival in multiple myeloma: the experience of the Intergroupe Francophone du Myelome. *Blood*. 2007;109(8):3489-3495.
619. Fonseca R, Blood EA, Oken MM, et al. Myeloma and the t(11;14)(q13;q32); evidence for a biologically defined unique subset of patients. *Blood*. 2002;99(10):3735-3741.
620. Hoyer JD, Hanson CA, Fonseca R, et al. The (11;14)(q13;q32) translocation in multiple myeloma. A morphologic and immunohistochemical study. *Am J Clin Pathol*. 2000;113(6):831-837.
621. Falini B, De Solas I, Levine AM, et al. Emergence of B-immunoblastic sarcoma in patients with multiple myeloma: a clinicopathologic study of 10 cases. *Blood*. 1982;59(5):923-933.
622. Strand WR, Banks PM, Kyle RA. Anaplastic plasma cell myeloma and immunoblastic lymphoma. Clinical, pathologic, and immunologic comparison. *Am J Med*. 1984;76(5):861-867.
623. Strickler JG, Audeh MW, Copenhaver CM, Warnke RA. Immunophenotypic differences between plasmacytoma/multiple myeloma and immunoblastic lymphoma. *Cancer*. 1988;61(9):1782-1786.
624. Petruch UR, Horny HP, Kaiserling E. Frequent expression of haemopoietic and non-haemopoietic antigens by neoplastic plasma cells: an immunohistochemical study using formalin-fixed, paraffin-embedded tissue. *Histopathology*. 1992;20(1):35-40.
625. Pileri S, Poggi S, Baglioni P, et al. Histology and immunohistology of bone marrow biopsy in multiple myeloma. *Eur J Haematol Suppl*. 1989;51:52-59.
626. Thiry A, Delvenne P, Fontaine MA, Boniver J. Comparison of bone marrow sections, smears and immunohistological staining for immunoglobulin light chains in the diagnosis of benign and malignant plasma cell proliferations. *Histopathology*. 1993;22(5):423-428.
627. Preud'Homme JL, Hurez D, Danon F, et al. Intracytoplasmic and surface-bound immunoglobulins in "nonsecretory" and Bence-Jones myeloma. *Clin Exp Immunol*. 1976;25(3):428-436.
628. Smith DB, Harris M, Gowland E, et al. Non-secretory multiple myeloma: a report of 13 cases with a review of the literature. *Hematol Oncol*. 1986;4(4):307-313.
629. Hyun BH, Kwa D, Gabaldon H, Ashton JK. Reactive plasmacytic lesions of the bone marrow. *Am J Clin Pathol*. 1976;65(6): 921-928.
630. Kyle RA, Remstein ED, Therneau TM, et al. Clinical course and prognosis of smoldering (asymptomatic) multiple myeloma. *N Engl J Med*. 2007;356(25):2582-2590.
631. Kosmo MA, Gale RP. Plasma cell leukemia. *Semin Hematol*. 1987;24(3):202-208.
632. Kyle RA, Maldonado JE, Bayrd ED. Plasma cell leukemia. Report on 17 cases. *Arch Intern Med*. 1974;133(5):813-818.
633. Fernandez de Larrea C, Kyle RA, Durie BG, et al. Plasma cell leukemia: consensus statement on diagnostic requirements, response criteria and treatment recommendations by the International Myeloma Working Group. *Leukemia*. 2013;27(4):780-791.
634. Garcia-Sanz R, Orfao A, Gonzalez M, et al. Primary plasma cell leukemia: clinical, immunophenotypic, DNA ploidy, and cytogenetic characteristics. *Blood*. 1999;93(3):1032-1037.
635. Tiedemann RE, Gonzalez-Paz N, Kyle RA, et al. Genetic aberrations and survival in plasma cell leukemia. *Leukemia*. 2008;22(5):1044-1052.
636. Gonsalves WI, Rajkumar SV, Go RS, et al. Trends in survival of patients with primary plasma cell leukemia: a population-based analysis. *Blood*. 2014;124(6):907-912.
637. Maldonado JE, Velosa JA, Kyle RA, et al. Fanconi syndrome in adults. A manifestation of a latent form of myeloma. *Am J Med*. 1975;58(3):354-364.
638. Case records of the Massachusetts General Hospital. Weekly clinicopathological exercises. Case 39-1992. A 49-year-old woman with peripheral neuropathy, hepatosplenomegaly, and intermittent abdominal pain. *N Engl J Med*. 1992;327(14):1014-1021.
639. Diego Miralles G, O'Fallon JR, Talley NJ. Plasma-cell dyscrasia with polyneuropathy. The spectrum of POEMS syndrome. *N Engl J Med*. 1992;327:1919-1923.
640. Dispenzieri A, Kyle RA, Lacy MQ, et al. POEMS syndrome: definitions and long-term outcome. *Blood*. 2003;101(7):2496-2506.
641. Imawari M, Akatsuka N, Ishibashi M, et al. Syndrome of plasma cell dyscrasia, polyneuropathy, and endocrine disturbances. Report of a case. *Ann Intern Med*. 1974;81(4):490-493.
642. Miralles GD, O'Fallon JR, Talley NJ. Plasma-cell dyscrasia with polyneuropathy. The spectrum of POEMS syndrome. *N Engl J Med*. 1992;327(27):1919-1923.
643. Dao LN, Hanson CA, Dispenzieri A, et al. Bone marrow histopathology in POEMS syndrome: a distinctive combination of plasma cell, lymphoid, and myeloid findings in 87 patients. *Blood*. 2011;117(24):6438-6444.
644. Bitter MA, Komaiko W, Franklin WA. Giant lymph node hyperplasia with osteoblastic bone lesions and the POEMS (Takatsuki's) syndrome. *Cancer*. 1985;56(1):188-194.
645. Soubrier MJ, Dubost JJ, Sauvezie BJ. POEMS syndrome: a study of 25 cases and a review of the literature. French Study Group on POEMS Syndrome. *Am J Med*. 1994;97(6):543-553.
646. Takatsuki K, Sanada I. Plasma cell dyscrasia with polyneuropathy and endocrine disorder: clinical and laboratory features of 109 reported cases. *Jpn J Clin Oncol*. 1983;13(3):543-555.
647. Rosado FG, Oliveira JL, Sohani AR, et al. Bone marrow findings of the newly described TEMPI syndrome: when erythrocytosis and plasma cell dyscrasia coexist. *Mod Pathol*. 2015;28(3):367-372.
648. Alexanian R. Localized and indolent myeloma. *Blood*. 1980;56(3):521-525.
649. Alexiou C, Kau RJ, Dietzfelbinger H, et al. Extramedullary plasmacytoma: tumor occurrence and therapeutic concepts. *Cancer*. 1999;85(11):2305-2314.
650. Corwin J, Lindberg RD. Solitary plasmacytoma of bone vs. extramedullary plasmacytoma and their relationship to multiple myeloma. *Cancer*. 1979;43(3):1007-1013.
651. Dimopoulos MA, Moulopoulos LA, Maniatis A, Alexanian R. Solitary plasmacytoma of bone and asymptomatic multiple myeloma. *Blood*. 2000;96(6):2037-2044.
652. Galieni P, Cavo M, Avvisati G, et al. Solitary plasmacytoma of bone and extramedullary plasmacytoma: two different entities? *Ann Oncol*. 1995;6(7):687-691.
653. Holland J, Trenkner DA, Wasserman TH, Fineberg B. Plasmacytoma. Treatment results and conversion to myeloma. *Cancer*. 1992;69(6):1513-1517.
654. Kotner LM, Wang CC. Plasmacytoma of the upper air and food passages. *Cancer*. 1972;30(2):414-418.
655. Meis JM, Butler JJ, Osborne BM, Ordonez NG. Solitary plasmacytomas of bone and extramedullary plasmacytomas. A

For personal use only. No other uses without permission. Copyright ©2017. Elsevier Inc. All rights reserved.

clinicopathologic and immunohistochemical study. *Cancer*. 1987;59(8):1475-1485.
656. Meyer JE, Schulz MD. Solitary" myeloma of bone: a review of 12 cases. *Cancer*. 1974;34(2):438-440.
657. Mill WB, Griffith R. The role of radiation therapy in the management of plasma cell tumors. *Cancer*. 1980;45(4):647-652.
658. Wilder RB, Ha CS, Cox JD, et al. Persistence of myeloma protein for more than one year after radiotherapy is an adverse prognostic factor in solitary plasmacytoma of bone. *Cancer*. 2002;94(5):1532-1537.
659. Wiltshaw E. The natural history of extramedullary plasmacytoma and its relation to solitary myeloma of bone and myelomatosis. *Medicine (Baltimore)*. 1976;55(3):217-238.
660. Woodruff RK, Whittle JM, Malpas JS. Solitary plasmacytoma. I: extramedullary soft tissue plasmacytoma. *Cancer*. 1979;43(6):2340-2343.
661. Kyle RA. "Benign" monoclonal gammopathy—after 20 to 35 years of follow-up. *Mayo Clin Proc*. 1993;68(1):26-36.
662. Kyle RA, Rajkumar SV. Monoclonal gammopathy of undetermined significance. *Br J Haematol*. 2006;134(6):573-589.
663. Kyle RA, Therneau TM, Rajkumar SV, et al. Prevalence of monoclonal gammopathy of undetermined significance. *N Engl J Med*. 2006;354(13):1362-1369.
664. Greipp PR, Kyle RA. Clinical, morphological, and cell kinetic differences among multiple myeloma, monoclonal gammopathy of undetermined significance, and smoldering multiple myeloma. *Blood*. 1983;62(1):166-171.
665. Cesana C, Klersy C, Barbarano L, et al. Prognostic factors for malignant transformation in monoclonal gammopathy of undetermined significance and smoldering multiple myeloma. *J Clin Oncol*. 2002;20(6):1625-1634.
666. Kyle RA, Therneau TM, Rajkumar SV, et al. Long-term follow-up of IgM monoclonal gammopathy of undetermined significance. *Blood*. 2003;102(10):3759-3764.
667. Kyle RA, Therneau TM, Rajkumar SV, et al. A long-term study of prognosis in monoclonal gammopathy of undetermined significance. *N Engl J Med*. 2002;346(8):564-569.
668. Kyle RA, Rajkumar SV, Therneau TM, et al. Prognostic factors and predictors of outcome of immunoglobulin M monoclonal gammopathy of undetermined significance. *Clin Lymphoma*. 2005;5(4):257-260.
669. Fonseca R, Bailey RJ, Ahmann GJ, et al. Genomic abnormalities in monoclonal gammopathy of undetermined significance. *Blood*. 2002;100(4):1417-1424.
670. Waldenström J. Incipient myelomatosis or 'essential' hypergammaglobulinemia with fibrinogenopenia. A new syndrome. *Acta Med Scand Suppl*. 1944;117:216-247.
671. Owen RG, Treon SP, Al-Katib A, et al. Clinicopathological definition of Waldenstrom's macroglobulinemia: consensus panel recommendations from the Second International Workshop on Waldenstrom's Macroglobulinemia. *Semin Oncol*. 2003;30(2):110-115.
672. Swerdlow SH, Berger F, Pileri SA, et al. Lymphoplasmacytic lymphoma. In: Swerdlow SH, Campo E, Harris NL, et al, eds. *WHO Classification of Tumours of Haematopoietic and Lymphoid Tissues*. Lyon: IARC Press; 2008:194-195.
673. Pangalis GA, Nathwani BN, Rappaport H. Malignant lymphoma, well differentiated lymphocytic: its relationship with chronic lymphocytic leukemia and macroglobulinemia of Waldenstrom. *Cancer*. 1977;39(3):999-1010.
674. Tursz T, Brouet JC, Flandrin G, et al. Clinical and pathologic features of Waldenstrom's macroglobulinemia in seven patients with serum monoclonal IgG or IgA. *Am J Med*. 1977;63(4):499-502.
675. Berger F, Traverse-Glehen A, Felman P, et al. Clinicopathologic features of Waldenstrom's macroglobulinemia and marginal zone lymphoma: are they distinct or the same entity? *Clin Lymphoma*. 2005;5(4):220-224.
676. Lin P, Bueso-Ramos C, Wilson CS, et al. Waldenstrom macroglobulinemia involving extramedullary sites: morphologic and immunophenotypic findings in 44 patients. *Am J Surg Pathol*. 2003;27(8):1104-1113.
677. Tubbs RR, Hoffman GC, Deodhar SD, Hewlett JS. IgM monoclonal gammopathy. Histopathologic and clinical spectrum. *Cleve Clin Q*. 1976;43(4):217-235.
678. Treon SP, Xu L, Yang G, et al. MYD88 L265P somatic mutation in Waldenstrom's macroglobulinemia. *N Engl J Med*. 2012;367(9):826-833.
679. Dutcher TF, Fahey JL. The histopathology of the macroglobulinemia of Waldenstrom. *J Natl Cancer Inst*. 1959;22(5):887-917.
680. Rywlin AM, Civantos F, Ortega RS, Dominguez CJ. Bone marrow histology in monoclonal macroglobulinemia. *Am J Clin Pathol*. 1975;63(6):769-778.
681. Brittin GM, Tanaka Y, Brecher G. Intranuclear inclusions in multiple myeloma and macroglobulinemia. *Blood*. 1963;21:335-351.
682. Frangione B, Franklin EC. Heavy chain diseases: clinical features and molecular significance of the disordered immunoglobulin structure. *Semin Hematol*. 1973;10(1):53-64.
683. Franklin EC. Mu-chain disease. *Arch Intern Med*. 1975;135(1):71-72.
684. Harris NL, Isaacson PG, Grogan TM, Jaffee ES. Heavy chain diseases. In: Swerdlow SH, Campo E, Harris NL, et al, eds. *WHO Classification of Tumours of Haematopoietic and Lymphoid Tissues*. Lyon: IARC Press; 2008:196-199.
685. Jonsson V, Videbek A, Axelsen NH, Harboe M. mu-chain disease in a case of chronic lymphocytic leukaemia and malignant histiocytoma. I. Clinical aspects. *Scand J Haematol*. 1976;16(3):209-217.
686. Kyle RA, Greipp PR, Banks PM. The diverse picture of gamma heavy-chain disease. Report of seven cases and review of literature. *Mayo Clin Proc*. 1981;56(7):439-451.
687. Seligmann M. Immunochemical, clical, and pathological features of alpha-chain disease. *Arch Intern Med*. 1975;135(1):78-82.
688. Jacobs P, Ruff P, Wood L, et al. Amyloidosis: a changing clinical perspective. *Hematology*. 2007;12(2):163-167.
689. Kyle RA, Gertz MA. Primary systemic amyloidosis: clinical and laboratory features in 474 cases. *Semin Hematol*. 1995;32(1):45-59.
690. Falk RH, Comenzo RL, Skinner M. The systemic amyloidoses. *N Engl J Med*. 1997;337(13):898-909.
691. Gertz MA, Greipp PR, Kyle RA. Classification of amyloidosis by the detection of clonal excess of plasma cells in the bone marrow. *J Lab Clin Med*. 1991;118(1):33-39.
692. Gertz MA, Kyle RA. Primary systemic amyloidosis—a diagnostic primer. *Mayo Clin Proc*. 1989;64(12):1505-1519.
693. Kyle RA, Greipp PR. Amyloidosis (AL). Clinical and laboratory features in 229 cases. *Mayo Clin Proc*. 1983;58(10):665-683.
694. Wolf BC, Kumar A, Vera JC, Neiman RS. Bone marrow morphology and immunology in systemic amyloidosis. *Am J Clin Pathol*. 1986;86(1):84-88.
695. Banerjee D, Mills DM, Hearn SA, et al. Proteinaceous lymphadenopathy due to monoclonal nonamyloid immunoglobulin deposit disease. *Arch Pathol Lab Med*. 1990;114(1):34-39.
696. Buxbaum JN, Chuba JV, Hellman GC, et al. Monoclonal immunoglobulin deposition disease: light chain and light and heavy chain deposition diseases and their relation to light chain amyloidosis. Clinical features, immunopathology, and molecular analysis. *Ann Intern Med*. 1990;112(6):455-464.
697. Feiner HD. Pathology of dysproteinemia: light chain amyloidosis, non-amyloid immunoglobulin deposition disease, cryoglobulinemia syndromes, and macroglobulinemia of Waldenstrom. *Hum Pathol*. 1988;19(11):1255-1272.
698. Osborne BM, Butler JJ, Mackay B. Proteinaceous lymphadenopathy with hypergammaglobulinemia. *Am J Surg Pathol*. 1979;3(2):137-145.
699. Hanto DW, Frizzera G, Purtilo DT, et al. Clinical spectrum of lymphoproliferative disorders in renal transplant recipients and evidence for the role of Epstein-Barr virus. *Cancer Res*. 1981;41(11 Pt 1):4253-4261.
700. Koo CH, Nathwani BN, Winberg CD, et al. Atypical lymphoplasmacytic and immunoblastic proliferation in lymph nodes of patients with autoimmune disease (autoimmune-disease-associated lymphadenopathy). *Medicine (Baltimore)*. 1984;63(5):274-290.
701. Peterson LC, Kueck B, Arthur DC, et al. Systemic polyclonal immunoblastic proliferations. *Cancer*. 1988;61(7):1350-1358.
702. Poje EJ, Soori GS, Weisenburger DD. Systemic polyclonal B-immunoblastic proliferation with marked peripheral blood and bone marrow plasmacytosis. *Am J Clin Pathol*. 1992;98(2):222-226.
703. Ceci G, Franciosi V, Passalacqua R, et al. The value of bone marrow biopsy in breast cancer at the time of first relapse. A prospective study. *Cancer*. 1988;61(5):1041-1045.
704. Cote RJ, Rosen PP, Lesser ML, et al. Prediction of early relapse in patients with operable breast cancer by detection of occult bone marrow micrometastases. *J Clin Oncol*. 1991;9(10):1749-1756.
705. Krishnan C, George TI, Arber DA. Bone marrow metastases: a survey of nonhematologic metastases with immunohistochemical study of metastatic carcinomas. *Appl Immunohistochem Mol Morphol*. 2007;15(1):1-7.
706. Mead GM, Williams CJ, Thompson J, et al. Bone marrow examination in small cell carcinoma of the bronchus: an unnecessary procedure? *Hematol Oncol*. 1985;3(3):159-163.
707. Meinshausen J, Choritz H, Georgii A. Frequency of skeletal metastases as revealed by routinely taken bone marrow biopsies. *Virchows Arch A Pathol Anat Histol*. 1980;389(3):409-417.
708. Ridell B, Landys K. Incidence and histopathology of metastases of mammary carcinoma in biopsies from the posterior iliac crest. *Cancer*. 1979;44(5):1782-1788.
709. Singh G, Krause JR, Breitfeld V. Bone marrow examination: for metastatic tumor: aspirate and biopsy. *Cancer*. 1977;40(5):2317-2321.
710. Anner RM, Drewinko B. Frequency and significance of bone marrow involvement by metastatic solid tumors. *Cancer*. 1977;39(3):1337-1344.
711. Bezwoda WR, Lewis D, Livini N. Bone marrow involvement in anaplastic small cell lung cancer. Diagnosis, hematologic features, and prognostic implications. *Cancer*. 1986;58(8):1762-1765.
712. Clamon GH, Edwards WR, Hamous JE, Scupham RK. Patterns of bone marrow involvement with small cell lung cancer. *Cancer*. 1984;54(1):100-102.
713. Hansen HH, Muggia FM, Selawry OS. Bone-marrow examination in 100 consecutive

For personal use only. No other uses without permission. Copyright ©2017. Elsevier Inc. All rights reserved.

patients with bronchogenic carcinoma. *Lancet*. 1971;2(7722):443-445.
714. Hirsch F, Hansen HH, Dombernowsky P, Hainau B. Bone-marrow examination in the staging of small-cell anaplastic carcinoma of the lung with special reference to subtyping. An evaluation of 203 consecutive patients. *Cancer*. 1977;39(6):2563-2567.
715. Ingle JN, Tormey DC, Tan HK. The bone marrow examination in breast cancer: diagnostic considerations and clinical usefulness. *Cancer*. 1978;41(2): 670-674.
716. Kelly BW, Morris JF, Harwood BP, Bruya TE. Methods and prognostic value of bone marrow examination in small cell carcinoma of the lung. *Cancer*. 1984;53(1):99-102.
717. Kristjansen PE, Osterlind K, Hansen M. Detection of bone marrow relapse in patients with small cell carcinoma of the lung. *Cancer*. 1986;58(11):2538-2541.
718. Landys K. Prognostic value of bone marrow biopsy in breast cancer. *Cancer*. 1982;49(3):513-518.
719. Lawrence JB, Eleff M, Behm FG, Johnston CL Jr. Bone marrow examination in small cell carcinoma of the lung. Comparison of trephine biopsy with aspiration. *Cancer*. 1984;53(10):2188-2190.
720. Levitan N, Byrne RE, Bromer RH, et al. The value of the bone scan and bone marrow biopsy staging small cell lung cancer. *Cancer*. 1985;56(3):652-654.
721. Lyda MH, Tetef M, Carter NH, et al. Keratin immunohistochemistry detects clinically significant metastases in bone marrow biopsy specimens in women with lobular breast carcinoma. *Am J Surg Pathol*. 2000;24(12):1593-1599.
722. Bramwell VH, Littley MB, Chang J, Crowther D. Bone marrow involvement in adult soft tissue sarcomas. *Eur J Cancer Clin Oncol*. 1982;18(11):1099-1106.
723. Finklestein JZ, Ekert H, Isaacs H Jr, Higgins G. Bone marrow metastases in children with solid tumors. *Am J Dis Child*. 1970;119(1):49-52.
724. Penchansky L. Bone marrow biopsy in the metastatic work-up of solid tumors in children. *Cancer*. 1984;54(7):1447-1448.
725. Ruymann FB, Newton WA Jr, Ragab AH, et al. Bone marrow metastases at diagnosis in children and adolescents with rhabdomyosarcoma. A report from the intergroup rhabdomyosarcoma study. *Cancer*. 1984;53(2):368-373.
726. Krishnan C, Twist CJ, Fu T, Arber DA. Detection of isolated tumor cells in neuroblastoma by immunohistochemical analysis in bone marrow biopsy specimens: improved detection with use of beta-catenin. *Am J Clin Pathol*. 2009;131(1):49-57.
727. Cote RJ, Rosen PP, Hakes TB, et al. Monoclonal antibodies detect occult breast carcinoma metastases in the bone marrow of patients with early stage disease. *Am J Surg Pathol*. 1988;12(5):333-340.
728. Diel IJ, Kaufmann M, Goerner R, et al. Detection of tumor cells in bone marrow of patients with primary breast cancer: a prognostic factor for distant metastasis. *J Clin Oncol*. 1992;10(10):1534-1539.
729. Pantel K, Izbicki JR, Angstwurm M, et al. Immunocytological detection of bone marrow micrometastasis in operable non-small cell lung cancer. *Cancer Res*. 1993;53(5): 1027-1031.
730. Ballestrero A, Coviello DA, Garuti A, et al. Reverse-transcriptase polymerase chain reaction of the maspin gene in the detection of bone marrow breast carcinoma cell contamination. *Cancer*. 2001;92(8): 2030-2035.
731. Bostrom B, Nesbit ME Jr, Brunning RD. The value of bone marrow trephine biopsy in the diagnosis of metastatic neuroblastoma. *Am J Pediatr Hematol Oncol*. 1985;7(3):303-305.
732. Brodeur GM, Pritchard J, Berthold F, et al. Revisions of the international criteria for neuroblastoma diagnosis, staging, and response to treatment. *J Clin Oncol*. 1993;11(8):1466-1477.
733. Reid MM, Hamilton PJ. Histology of neuroblastoma involving bone marrow: the problem of detecting residual tumour after initiation of chemotherapy. *Br J Haematol*. 1988;69(4):487-490.
734. Cheung NK, Heller G, Kushner BH, et al. Detection of metastatic neuroblastoma in bone marrow: when is routine marrow histology insensitive? *J Clin Oncol*. 1997;15(8):2807-2817.
735. Lo Piccolo MS, Cheung NK, Cheung IY. GD2 synthase: a new molecular marker for detecting neuroblastoma. *Cancer*. 2001;92(4):924-931.
736. Seeger RC, Reynolds CP, Gallego R, et al. Quantitative tumor cell content of bone marrow and blood as a predictor of outcome in stage IV neuroblastoma: a Children's Cancer Group Study. *J Clin Oncol*. 2000;18(24):4067-4076.
737. Barranger JA, Ginns BI. Glucosylceramide lipidoses: Gaucher disease. In: Scriver CR, Beaudet AL, Sly WS, Valle E, eds. *The Metabolic Basis of Inherited Disease*. 6th ed. New York: McGraw-Hill Book Co; 1989:1655-1676.
738. Brady RO, Barranger JA. Glucosyl ceramide lipidosis. Gaucher's disease. In: Stanbury JB, Wyngaarden JB, Fredrickson DS, et al, eds. *The Metabolic Basis of Inherited Disease*. New York: McGraw–Hill Book Co; 1983:842-856.
739. Chen M, Wang J. Gaucher disease: review of the literature. *Arch Pathol Lab Med*. 2008;132(5):851-853.
740. Imcerti C. Gaucher disease: an overview. *Semin Hematol*. 1995;32(suppl):3-9.
741. Horowitz M, Elstein D, Zimran A, Goker-Alpan O. New directions in Gaucher disease. *Hum Mutat*. 2016;37(11):1121-1136.
742. Brunning RD. Morphologic alterations in nucleated blood and marrow cells in genetic disorders. *Hum Pathol*. 1970;99-124.
743. Hansen HGGE. *Hematologic Cytology of Storage Diseases*. Berlin; New York: Springer-Verlag; 1985.
744. Beck M. New therapeutic options for lysosomal storage disorders: enzyme replacement, small molecules and gene therapy. *Hum Genet*. 2007;121(1):1-22.
745. Burrow TA, Hopkin RJ, Leslie ND, et al. Enzyme reconstitution/replacement therapy for lysosomal storage diseases. *Curr Opin Pediatr*. 2007;19(6):628-635.
746. Dosik H, Rosner F, Sawitsky A. Acquired lipidosis: Gaucher-like cells and "blue cells" in chronic granulocytic leukemia. *Semin Hematol*. 1972;9(3):309-316.
747. Grabowski A, Leslie N. Lysosomal storage diseases: perspectives and principles. In: Hoffman R, Benz EJ, Shattil SJ, et al, eds. *Hematology: Basic Principles and Practice*. 4th ed. Edinburgh: Churchill Livingstone; 2005:873-890.
748. Jmoudiak M, Futerman AH. Gaucher disease: pathological mechanisms and modern management. *Br J Haematol*. 2005;129:178-188.
749. Zaino EC, Rossi MB, Pham TD, Azar HA. Gaucher's cells in thalassemia. *Blood*. 1971;38(4):457-462.
750. Pratt PW, Kochwa S, Estren S. Immunoglobulin abnormalities in Gaucher's disease. Report of 16 cases. *Blood*. 1968;31(5):633-640.
751. Ruestow PC, Levinson DJ, Catchatourian R, et al. Coexistence of IgA myeloma and Gaucher's disease. *Arch Intern Med*. 1980;140(8):1115-1116.
752. Patterson MC, Vanier MT, Suzuki K, et al. Niemann–Pick disease type C. A lipid trafficking disorder. In: Scriver CR, Beaudet AL, Sly WS, Valle D, eds. *The Metabolic and Molecular Basis of Inherited Disease. II*. 8th ed. New York: Mulencer Hill; 2001:3611-3634.
753. Schuchman EH, Desnick RJ. Niemann–Pick disease types A and B. Acid sphingomyelinase deficiencies. In: Scriver CR, Beaudet AL, Sly WS, Valle D, eds. *The Metabolic and Molecular Basis of Inherited Disease. II*. 8th ed. New York: Mulencer Hill; 2001:3589-3610.
754. Schuchman EH, Wasserstein MP. Types A and B Niemann-Pick disease. *Best Pract Res Clin Endocrinol Metab*. 2015;29(2):237-247.
755. Schiffmann R, Ries M. Fabry disease: a disorder of childhood onset. *Pediatr Neurol*. 2016;64:10-20.
756. Silverstein MN, Ellefson RD, Ahern EJ. The syndrome of the sea-blue histiocyte. *N Engl J Med*. 1970;282(1):1-4.
757. Rausing A. Bone marrow biopsy in diagnosis of Whipple's disease. *Acta Med Scand*. 1973;193(1-2):5-8.
758. Blume KG, Forman SJ, Appelbaum FR, eds. *Thoma's Hematopoietic Cell Transplantation*. 3rd ed. London: Blackwell Publishing Ltd; 2004.
759. Eapen M, Rubinstein P, Zhang MJ, et al. Outcomes of transplantation of unrelated donor umbilical cord blood and bone marrow in children with acute leukaemia: a comparison study. *Lancet*. 2007;369(9577):1947-1954.
760. Sloane JP, Norton J. The pathology of bone marrow transplantation. *Histopathology*. 1993;22:201-209.
761. Hurwitz N. Bone marrow changes following chemotherapy and/or bone marrow transplantation. *Curr Diagn Pathol*. 1997;1997:196-200.
762. Sale GE, Buckner CD. Pathology of bone marrow in transplant recipients. *Hematol Oncol Clin North Am*. 1988;2(4):735-756.
763. van den berg H, Kluin PM, Zwaan FE, Vossen JM. Histopathology of bone marrow reconstitution after allogeneic bone marrow transplantation. *Histopathology*. 1989;15(4):363-373.
764. Baron F, Sandmaier BM. Chimerism and outcomes after allogeneic hematopoietic cell transplantation following nonmyeloablative conditioning. *Leukemia*. 2006;20(10):1690-1700.

For personal use only. No other uses without permission. Copyright ©2017. Elsevier Inc. All rights reserved.

40 Bone and Joints

John D. Reith

CHAPTER CONTENTS

Bone, *1740*
Normal anatomy, *1740*
Metabolic bone diseases, *1741*
Fractures, *1741*
Osteomyelitis, *1742*
Bone necrosis, *1744*
Paget disease, *1745*
Osteopetrosis, *1747*
Tumors, *1747*
Tumorlike lesions, *1783*
Joints and related structures, *1789*
Normal anatomy, *1789*
Non-neoplastic diseases, *1789*
Tumors and tumorlike conditions, *1795*

Bone

Normal Anatomy

Adult bones are classified according to their shape into long (such as femur), flat (such as pelvis), and short (such as bones of hand and feet). Long bones (and some short bones, such as metacarpal bones) are divided topographically into three regions: epiphysis, metaphysis, and diaphysis. The epiphysis, or secondary ossification center, occupies the region of the bone extending from the articular cartilage to the physis. The diaphysis, or shaft of the bone, is separated from the epiphysis by the metaphysis, or primary ossification center. An apophysis is a secondary ossification center on which a tendon or ligament is attached (such as the greater trochanter of the femur). Bone growth occurs at the physis by endochondral ossification, a process by which longitudinal, regularly spaced columns of vascularized cartilage are replaced by bone.[1] At skeletal maturity, endochondral ossification ceases and the physis "closes" by becoming totally ossified. The time of closure of the physis differs in various bones and between sexes. Not only is the physeal region a common site of occurrence for primary bone tumors, but its state of being open or closed influences the extension of pathologic processes in the sense that cartilage is often at least a partial barrier to spreading osteosarcoma. If the physis is closed and cartilage is no longer present, this area is more easily invaded.[2]

Bones are also classified according to their embryologic development. With intramembranous ossification, the bone forms de novo from primitive connective tissue (mainly flat bones). In contrast, with endochondral ossification, the bone formation is preceded by a cartilaginous anlage; this occurs primarily in tubular bones.[1,3]

Topographically, mature bones have an outer *compact layer* (cortex, cortical bone, compact bone) and a central *spongy region* (spongiosa, medulla, cancellous bone). Cortical bone contains vascular channels, which are divided into two types on the basis of their orientation and their relation to the lamellar structure of the surrounding bone: longitudinal (haversian canals) and transverse/oblique (Volkmann canals). Except for the region of the articular cartilage, the cortex is surrounded by the *periosteum*, which consists of an outer fibrous layer and an inner cellular (cambium) layer of osteoprogenitor cells. The periosteum also contains nerve filaments that carry proprioceptive and sensory impulses; small nerve filaments also may pass with the nutrient vessels into the medullary canal. Coarse bundles of collagenous fibers penetrating the outer compact layer from the outer layer of the periosteum are called Sharpey fibers or perforating fibers.[1]

The periosteum may become detached and elevated from the bone in pathologic processes such as trauma, infection, and neoplasms. When this happens, new bone formation between the elevated periosteum and the bone will occur. This appears by radiographic examination as fine spicules placed perpendicular to the long axis of the bone. This finding is often considered a manifestation of a primary malignant neoplasm, particularly osteosarcoma and Ewing sarcoma. However, periosteal bone proliferation also can occur in a wide variety of neoplastic and non-neoplastic conditions.

An understanding of the blood supply of bone helps to explain the spread and limitation of infection, the healing of fractures, and the involvement of bone by primary or secondary neoplasms. The metaphysis is mainly supplied by end arteries that enter from the diaphysis and terminate at the level of the growth plate. The epiphyses receive their blood supply from a network of widely anastomosing vessels. The diaphyseal cortex is supplied by vessels that enter through Volkmann canals and communicate with the haversian system. A nutrient artery enters the medullary canal near the center of the diaphysis, divides, and extends both distally and proximally. Lymphatic vessels exist in the connective tissue overlying the periosteum, but apparently not in the cortex or medulla.[4]

For personal use only. No other uses without permission. Copyright ©2017. Elsevier Inc. All rights reserved.

Abstract

This chapter describes the radiographic, gross, and microscopic features of diseases of the bones and joints. A wide spectrum of diseases is covered in this chapter, including both non-neoplastic and neoplastic processes. Where applicable, radiographic information is included, and differential diagnoses are discussed.

Keywords

Bone
tumors
arthritis
metabolic bone disease
joint disease

For personal use only. No other uses without permission. Copyright ©2017. Elsevier Inc. All rights reserved.

The constituent cells involved in bone production include *osteoblasts* and *osteocytes*. *Osteoblasts* are bone-producing cells derived from marrow-residing osteoprogenitor cells under direction of the master gene *Runx2*. They have a plump appearance and often exhibit a perinuclear halo resulting from a prominent Golgi zone that gives them a plasmacytoid appearance. They have a high cytoplasmic content of alkaline phosphatase and produce RANKL.[5] Ultrastructurally, they resemble fibroblasts by virtue of a well-developed rough endoplasmic reticulum and Golgi apparatus. Indeed, osteoblasts are regarded as a specialized form of fibroblast. Once these are incorporated into the bone matrix and housed in lacunae, they are referred to as *osteocytes*. SATB2 (special AT-rich sequence-binding protein 2) has been shown to be an excellent marker of osteoblast differentiation, and while not entirely specific for bone-forming neoplasms, it can be useful in distinguishing osteosarcoma from histologic mimics.[6]

Osteoclasts are multinucleated giant cells involved in bone resorption.[7] As such, they typically are found in shallow concavities in the surface of bone called *Howship lacunae*. Osteoclasts arise from mononuclear monocyte–macrophage precursors.[8] Osteoclasts contain abundant tartrate-resistant acid phosphatase, respond to osteotropic hormones, and contract under the influence of several inhibitors, including calcitonin. Osteoclasts develop from bone marrow stromal cells under the influence of receptor activator of nuclear factor kappa-beta (RANK ligand), which is produced by osteoblasts. Ultrastructurally, the cytoplasm of osteoclasts has a very large number of mitochondria and lysosomes; a ruffled edge is present in the area of the cell membrane that is in the process of bone resorption.

Osteoid is the unmineralized organic precursor matrix of bone. It is composed of a mixture of collagen (mainly type I), acid mucopolysaccharides, and noncollagen proteins.[9] These include osteopontin, osteocalcin, and bone morphogenetic protein. Although only one component of a very complex process, the latter is thought to play a critical role in initiating the process that begins with cartilage resorption and ends with bone formation.[10] Osteoid is not a homogeneous mass but rather shows a constant, patterned sequence of maturation and organization. It has acidophilic properties in hematoxylin–eosin-stained sections, and it may be difficult to distinguish from hyalinized collagen.

Bone is formed through mineralization of the organic matrix of the osteoid. Extracellular matrix vesicles are present at or near the mineralization front and constitute the initial site of hydroxyapatite mineral deposition.[11] In immature *woven bone*, there is a haphazard arrangement of collagen fibers within the matrix, which is best appreciated with reticulum stains or under polarized light. *Lamellar bone* is characterized by concentric or parallel lamellae, best appreciated with polarized light. Four types of lamellar bone exist in the skeleton: circumferential, concentric, and interstitial lamellar bone comprise the cortex, while cancellous lamellar bone is found in the medullary cavity.

Bone production can be recognized by the presence of well-stained small spicules of bone with cells in their lacunae and a prominent row of osteoblasts lining their surfaces. New bone formation can be found in a variety of physiologic and pathologic processes, including healing fracture, Paget disease, metaplastic ossification, myositis ossificans, and hyperparathyroidism, among others. However, woven bone in a skeletally mature patient is not normal and indicates an abnormality. *Bone resorption (destruction)* can be recognized by the presence of numerous osteoclasts in the bone margins and in Howship lacunae. It can involve necrotic bone or viable bone. Molecules thought to regulate the growth plate thickness and bone length through their action on chondrocytes during endochondral ossification are fibroblast growth factor receptor-3, parathyroid hormone (PTH)-related protein, and tartrate-resistant acid phosphatase. The interactions between the various bone cells and bone matrix, as well as bone homeostasis, is a complex system regulated by a variety of factors, including integrins, PTH, calcitonin, 1,25-dihydroxyvitamin D3, and estrogen. Bone remodeling is also a complex process, and bone formation and resorption is regulated by such factors as RANKL, transforming growth factor (TGF)-β, fibroblast growth factor, and bone morphogenetic proteins.[12]

Skeletal substitute material of an increasingly varying nature is being used by orthopedic surgeons to replace or "extend" bone grafts, and these can be found by the pathologist in biopsy and resection specimens in which a previous operation had taken place. Bauer has provided a useful list of these substitutes and the criteria for their recognition.[13]

Metabolic Bone Diseases

A thorough discussion of metabolic bone diseases is outside the scope of this chapter. Some metabolic bone diseases will be mentioned briefly, but for a detailed discussion the reader is referred to the books, monographs, and excellent articles that have been written on the subject.[14,15] **Osteoporosis** refers to a decreased mass of normally mineralized bone, resulting in microarchitectural deterioration and an increased risk for fractures. It develops when an individual is unable to repair and maintain the mass of bone tissue that has been acquired throughout growth and maturation.[16] Quantitative microradiographic studies have shown that the main difference between the bone in most forms of osteoporosis and normal bone is an increase in the amount of resorption, bone formation levels being generally normal.[17] Osteoporosis occurs frequently after menopause, largely due to deficiencies of estrogen. However, there are many causes of osteoporosis.

Histologic parameters are seldom used to assess for osteoporosis currently, and dual energy/photon x-ray absorptiometry, or DEXA scan, is the gold standard.[18,19] This radiographic technique compares bone mineral density to a reference population, and a measurement greater than 2.5 standard deviations below the mean is considered osteoporotic. The most common scenario in which pathologists see osteoporotic bone is in fracture specimens, particularly in the proximal femur.

The treatment of osteoporosis is based on medications that slow down bone resorption by inhibiting the formation or activity of osteoclasts, and on those that promote bone formation, such as growth factors and hormones.[20]

Osteomalacia (or rickets in a skeletally immature patient) refers to the accumulation of unmineralized bone matrix resulting from a diminished rate of mineralization. It may be secondary to a wide spectrum of congenital and acquired metabolic abnormalities that result in sufficient decrease in serum calcium, phosphorus, or both to impair mineralization of the skeleton and physeal growth.[21] Some cases have been seen as a complication of bone and soft tissue neoplasms, a phenomenon termed "tumor-induced osteomalacia" (see Chapter 41).[22] Osteomalacia changes can be demonstrated in adequate biopsies from long bones and iliac crests with preparation of nondecalcified specimens and examination with bright-field and phase-contrast microscopes and with the use of fluorescent tetracycline markers.[23]

Sophisticated methods of investigating these metabolic bone processes have been devised, but many of them are difficult to implement in the routine pathology laboratory.[24]

Fractures

Fractures are breaks in the continuity of bone, usually with interruption of periosteum, blood vessels, and sometimes muscles.

For personal use only. No other uses without permission. Copyright ©2017. Elsevier Inc. All rights reserved.

The speed of return of bone to a normal state following fracture depends on factors such as the age and nutrition of the patient, severity of the fracture, vascularity of the area, and type of treatment. Fractures may fail to heal because of improper immobilization, complete devascularization of the fractured bone segments, persistent infection, and interposition of soft tissue between the ends of the bone.

Following a fracture, a hematoma forms between the two severed ends of bone. Organization of this hematoma begins with the ingrowth of capillaries. Shortly thereafter, bone in the area of the fracture becomes necrotic. Seven to 10 days following the fracture, the hemorrhage becomes more organized, and fibroblastic, chondroid, and osteoid matrix (fracture callus) begin to appear, resulting in a histologic appearance potentially confused for osteosarcoma or chondrosarcoma. Assuming fixation is adequate and the fracture is properly immobilized, the callus is eventually remodeled to normal bone once the fracture has completely healed. The formation and persistence of cartilage largely depend on mechanical factors.[25]

With early proper reduction of the fracture, adequate blood supply, no infection, and normal metabolism, the fracture heals rapidly with little visible callus. Exuberant callus usually means slow fracture healing. In children, even with prominent angulation or deformity, the bone remodels itself to an astonishing degree. For this reason, open reduction and internal fixation of fractures in children are seldom justified. Shortening of a long bone resulting from overriding of fragments will nearly always correct itself in children by overgrowth of bone.

The formation of exuberant cartilage and disorderly woven bone in rapidly forming primary callus results in a bewildering microscopic pattern that may be confused with osteosarcoma or chondrosarcoma. This phenomenon is particularly troubling in osteogenesis imperfecta.[26] The organization and gradual transition between the various components of fracture callus help distinguish it from neoplastic processes.

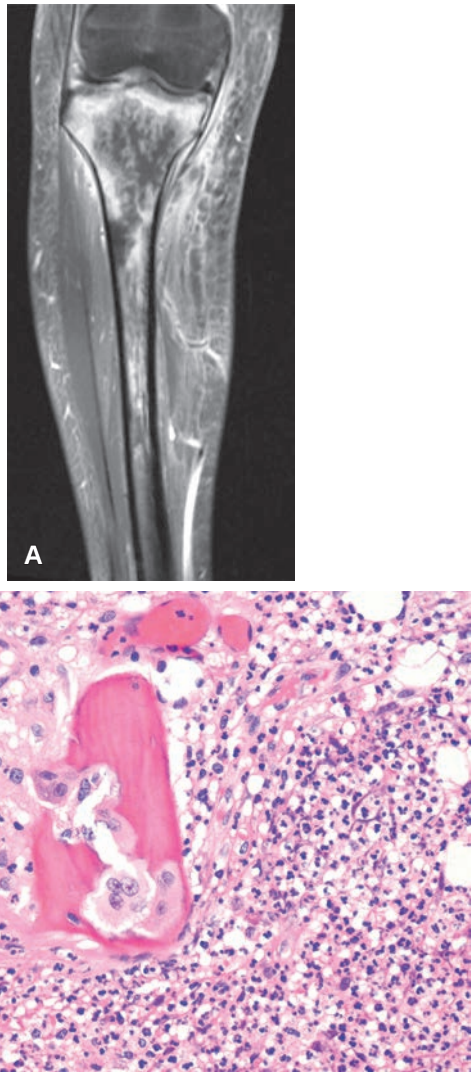

Figure 40.1 **A,** Coronal-plane MRI shows a diffuse infiltrate of variable signal intensity in the proximal tibia with adjacent soft tissue edema. **B,** In acute osteomyelitis, the inflammatory infiltrate consists primarily of neutrophils, and necrotic bone is resorbed by osteoclasts.

Osteomyelitis

Bacterial osteomyelitis may be caused by a large variety of microorganisms. About 70%–90% of the cases are due to *Staphylococcus aureus* (Fig. 40.1).[27] Other common offending organisms include *Klebsiella*, *Pseudomonas*, *Escherichia coli*, *Streptococcus*, and *Salmonella*. The latter organism is often involved in the osteomyelitis that affects individuals with abnormal hemoglobin, particularly sickle cell disease.[28] These various organisms gain access to bone via hematogenous spread or through direct extension or inoculation (compound fracture, spread from an adjacent cutaneous ulcer).[29] In skeletally immature patients, the metaphyses of long bones are prone to hematogenously spread osteomyelitis due to intricacies of the vascular supply near the growth plate. The vertebral column is a more common site for osteomyelitis in adult patients.

Early after the onset of osteomyelitis, plain radiographs may show vague radiolucency or no changes at all, and at this stage magnetic resonance imaging (MRI) may be necessary to identify the abnormality.[30] However, as the infection evolves, aggressive radiolucent lesions with prominent periosteal reaction can develop which simulate malignant lesions, particularly Ewing sarcoma and lymphoma, prompting biopsy.[31]

Histologically, osteomyelitis can be described as acute, subacute, or chronic. Acute osteomyelitis is characterized by acute inflammation, edema, and bone necrosis. In subacute osteomyelitis, the inflammatory infiltrate contains more lymphocytes and plasma cells, and in chronic osteomyelitis fibrosis and creeping substitution are prominent (Fig. 40.2). When the plasma cell population is particularly prominent, the disease has been designated *plasma cell osteomyelitis*,[32] and when foamy macrophages are abundant, it has been called *xanthogranulomatous osteomyelitis*.[33]

In the acute phase, the suppurative component may extend through the cortex into the subperiosteal space. A segment of necrotic cortex trapped in pus is termed a ***sequestrum***. The subperiosteal inflammation stimulates a periosteal reaction surrounding the sequestrum termed an ***involucrum***. A fenestration in the involucrum is referred to as a ***cloaca***. Osteomyelitic sinus tracts in the adult may become lined by squamous epithelium that extends deeply into the bone and becomes discontinuous with the cutaneous surface. Despite apparent healing of the overlying skin, large epidermal inclusion cysts can slowly develop in the underlying bone. These are filled with keratin-containing debris similar to that present in epidermal inclusion cysts of the skin. Rarely, after a long period, squamous cell carcinoma develops within these sinuses. This complication is heralded by the appearance of pain and increasingly malodorous discharge.[34] Chronic osteomyelitis may be accompanied by prominent periosteal bone proliferation.

For personal use only. No other uses without permission. Copyright ©2017. Elsevier Inc. All rights reserved.

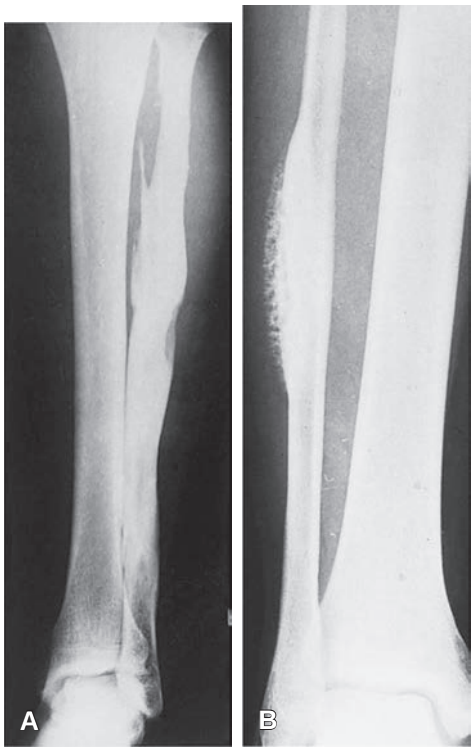

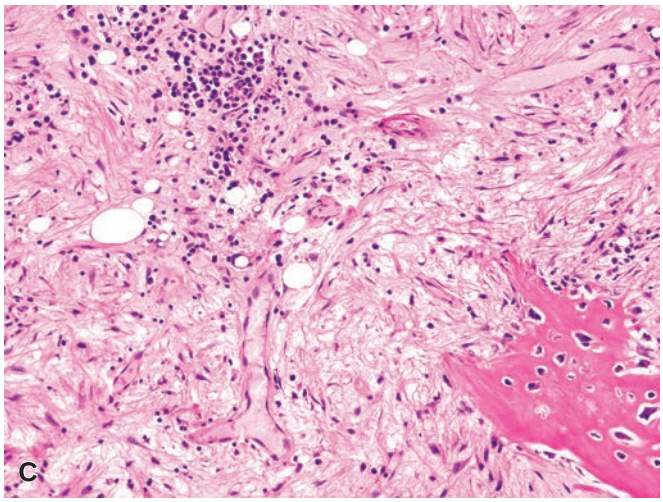

Figure 40.2 Two Examples of Chronic Osteomyelitis Involving the Fibula. A, Dense, irregular bone is evident. **B,** Prominent periosteal bone formation may cause confusion with a primary bone tumor. **C,** In chronic osteomyelitis, there is extensive fibrosis of the marrow space and a chronic inflammatory infiltrate.

A Brodie abscess is a localized form of osteomyelitis commonly occurring in the long bones. Imaging studies typically show a circumscribed, radiolucent lesion with surrounding reactive bone that may be mistaken for an osteoid osteoma.[35] Despite a predominance of neutrophils in this lesion, cultures are often negative.

A form of osteomyelitis characterized by recurrent multifocal involvement in children, sometimes associated with palmoplantar pustulosis, has been described (see also SAPHO syndrome); bacterial cultures are negative and the etiology is unknown.[36] Another variant of osteomyelitis characterized by very extensive regenerative bone changes is referred to as Garré sclerosing osteomyelitis. This form is particularly common in the jawbone.[37] It is unclear whether these variants of osteomyelitis are due to an organism or represent rheumatologic conditions.

Figure 40.3 Gummatous involvement of tibia in a 45-year-old woman.

Tuberculous osteomyelitis has increased in incidence with the AIDS epidemic and in underdeveloped countries and can be seen in children and adults.[38] The bones most often infected are the vertebrae (tuberculous spondylodiscitis, Pott disease), pelvis, knee, ankle, elbow, and wrist. The areas usually involved are the metaphysis, epiphysis, and synovium.[39]

There has been considerable controversy as to which of these areas is the one first involved. Metaphyseal infection is more common in children, and epiphyseal infection is more common in adults; however, with progression of the disease, all zones become affected. Tuberculous granulomatous synovitis destroys the joint and articular cartilage, allowing the inflammation to extend into the epiphysis and finally into the metaphyseal area. If the process begins in the epiphysis, granulomatous tissue quickly extends into the adjacent joint. When the process begins in the metaphyseal area, extension into the joint may be heralded by the development of fluid in it.

Histologically, tuberculous synovitis and osteomyelitis contain the same caseating granulomas seen in pulmonary tuberculosis. The acid-fast organisms may be identified by histochemical stains, but culture and polymerase chain reaction may be necessary for definitive diagnosis. Other causes of granulomatous inflammation in synovium and bone should be considered in the differential diagnosis, such as sarcoid and fungal infections.

Fungal infections of bone include blastomycosis, actinomycosis, histoplasmosis, and coccidioidomycosis.[40] Actinomycosis is particularly common following osteoradionecrosis.[41]

Bone involvement by **syphilis** most often occurs in congenital and tertiary syphilis but may also be encountered in secondary syphilis.[42] Tertiary syphilis may also lead to neuropathic arthropathy through tabes dorsalis.[43] Both bone destruction and periostitis can occur, resulting in the classic "saber shin" deformity when the tibia is involved (Fig. 40.3). The necrotic, well-defined defects are mainly cortical and periosteal and are surrounded by reactive bone. They may occur in the vertebrae, small bones of the hands and feet, and

For personal use only. No other uses without permission. Copyright ©2017. Elsevier Inc. All rights reserved.

diaphysis of long tubular bones. Treponemal spirochetes cause microangiitis and obliterative endarteritis, ultimately leading to granuloma-like lesions, or gummas. The spirochetes can be demonstrated by silver stain or by specific immunohistochemical stains.

Malakoplakia of bone has been described. As in the bladder and other sites, it probably represents an unusual host reaction to bacterial infection.[45]

Bone Necrosis

Necrotic bone can be recognized by the loss of osteocytes and changes in the marrow, including fat necrosis, fibrosis, and calcification. The histologic changes in the bone are identical regardless of the cause of the necrosis (Fig. 40.4).

Bone Infarct

Bone infarct can be the result of a large number of etiologic factors. Radiographically, the changes depend on the age of the lesion and the degree of repair. During the first 1 or 2 weeks, no abnormalities are detected on a plain radiograph. Resorption of the dead bone results in areas of decreased density, whereas new bone formation growing in apposition to necrotic trabeculae ("creeping substitution") leads to an increase in bone density. The increased bone density is due to both creeping substitution and calcification of the fibrotic marrow space, resulting in a lesion that vaguely resembles an enchondroma radiographically (Fig. 40.5).

An increased incidence of primary malignant bone tumors has been seen in association with large infarcts of long bones. Most of the reported cases have occurred in the medulla of the femur or tibia of male adults and have been diagnosed as undifferentiated pleomorphic sarcoma, osteosarcoma, "fibrosarcoma," or angiosarcoma.[46–49]

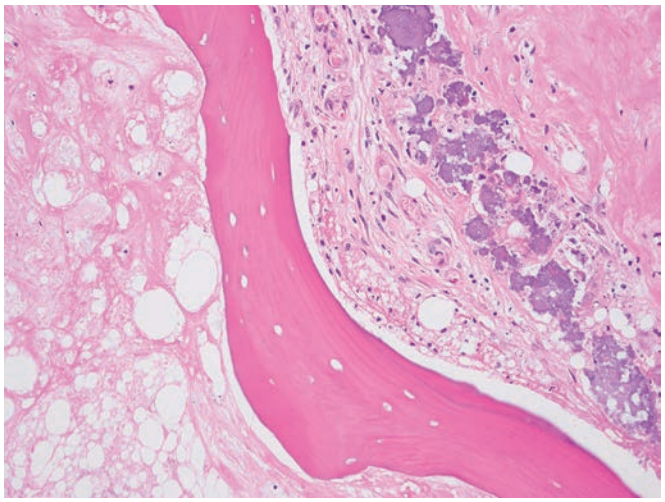

Figure 40.4 Bone necrosis is characterized by loss of osteocytes and necrosis or fibrosis of the fatty marrow.

Figure 40.5 AP **(A)** and lateral **(B)** radiographs show a large metadiaphyseal bone infarct of femur. The irregular area of increased radiodensity is indicative of new bone production superimposed on necrosis. (Courtesy of Dr H Danziger, Welland, Ontario, Canada)

For personal use only. No other uses without permission. Copyright ©2017. Elsevier Inc. All rights reserved.

Osteonecrosis (Avascular/Aseptic Bone Necrosis)

Osteonecrosis (avascular/aseptic necrosis) is a common abnormality that has been reported at the ends of virtually all long bones, most commonly the proximal femur and proximal humerus (Fig. 40.6).[50] Many of these sites have been described separately and given eponymic designations such as Legg-Calvé Perthes disease (osteonecrosis of the femoral head in childhood), Kienbock disease (osteonecrosis of the lunate), or Freiburg disease (osteonecrosis of the metatarsal).

When the blood supply to the involved bone is interrupted, whether intrinsically (thrombosis induced by sickle cell disease) or extrinsically (by fracture or dislocation), an infarct occurs in the subchondral bone.[51,52] In the femoral head, the area of osteonecrosis appears radiodense, and a "crescent sign" may be present representing separation of the subchondral plate and overlying articular cartilage from the remainder of the bone.[53] Osteonecrosis of the femoral head is mistaken for severe osteoarthritis with some frequency, and the underlying cause may not be recognized until the femoral head is examined pathologically.[54]

Grossly, the necrotic bone of avascular necrosis has a yellow, friable appearance. Often the articular cartilage and subchondral plate are separated from the underlying bone. With collapse, and the onset of secondary arthritis, the infarct may be difficult to identify. Histologically, the well-defined area of osteonecrosis is surrounded by fibrovascular tissue and reactive bone. The interface between the infarct and viable bone is rich in osteoclastic activity, and necrotic bone is eventually replaced by a process referred to as "creeping substitution" in which woven bone is directly deposited onto necrotic bone trabeculae.

Osteochondritis Dissecans

Osteochondritis dissecans results from a small area of necrosis involving the articular cartilage and subchondral bone that totally or partially separates from the adjacent structures. The etiology is uncertain but is probably related to trauma in most of the cases.[55,56] It occurs most frequently on the lateral aspect of the medial femoral condyle, near the intercondylar notch (Fig. 40.7). Microscopically, a portion of articular cartilage is always present, often exhibiting secondary calcification; in addition, a fragment of subchondral bone is found in approximately half of the cases.[57] If this osteocartilaginous fragment remains attached to the joint surface or synovium, both components remain viable. If, instead, it becomes completely detached, its osseous portion dies, but the cartilage remains alive, apparently through nutrients obtained from the synovial fluid, resulting in an osteocartilaginous loose body. Patients with bilateral symmetric involvement and cases with familial incidence have been described.

Osteochemonecrosis

Bisphosphonates and other osteoclast inhibitors, vascular endothelial growth factor (VEGF) inhibitors, and tyrosine kinase inhibitors have all been associated with osteonecrosis of the jaw.[58,59] The devitalized bone is often accompanied by inflammation and actinomyces, and there may be evidence of bone resorption without accompanying osteoclasts.[60]

Radiation Necrosis

Damage to the underlying bone can be a major complication of radiation therapy, whether alone or combined with chemotherapy.[61] Radiation changes resulting in serious complications have been reported in the jaw, ribs, pelvis, spine, humerus, and several other bones. The changes usually occur within 3 years of the therapy. Microscopically, these changes consist of necrotic bone, fibrosis of the bone marrow, and neovascularization. Irregular, heavily staining cement lines may develop and lead to confusion with Paget disease. Radiation necrosis of the jaw can be complicated by actinomycosis, an often underdiagnosed occurrence.[41]

Paget Disease

Paget disease is a preneoplastic condition characterized by increased bone turnover, followed by compensatory bone formation. The highest incidence occurs in England, Australia, and western Europe.[62] In an often-quoted autopsy series from England, about one in 30 patients over 40 years of age had Paget disease.[63] The majority of patients with Paget disease are over 55 years of age at diagnosis, and the disease is rare before the age of 40 years. Cases of juvenile Paget disease are described in which patients have osteoprotegerin deficiency.[64] Paget disease affects men slightly more often than women (4 : 3). It can be monostotic or polyostotic, and the most common sites include the pelvis, lumbosacral spine, and craniofacial bones, but long bones are commonly involved as well. Patients with Paget disease are commonly asymptomatic but may present with bone pain, deformities, pathologic fracture, or arthritis.[62]

Radiographically, early Paget lesions are radiolucent, resulting in "osteoporosis circumscripta" in the skull and mimicking a neoplasm in long bones. However, over time the affected bone becomes enlarged, and cortical thickening and coarsening of the trabecular architecture becomes more prominent. During the inactive, terminal phase of Paget disease, the blastic features become even more prominent, resulting in cotton wool-like densities in the skull and bowing deformities of long bones (Figs. 40.8 and 40.9).[65]

Microscopically, early Paget lesions are characterized by osteoclastic resorption, peritrabecular fibrosis, and prominent vascularity, very similar to what is seen in hyperparathyroidism (Fig. 40.10). During the middle phase of Paget disease, bone formation becomes more prominent. Bone trabeculae tend to be enlarged and irregular, with prominent osteoblastic activity and irregular cement lines. In the final phase of Paget disease, osteoblastic and osteoclastic activity diminishes, leaving markedly thickened, irregular bone trabeculae with prominent "mosaic pattern" cement lines. It is not uncommon to identify all phases of Paget disease simultaneously in a tissue sample. "Mosaic pattern" cement lines are not specific for Paget disease and can be identified in any high turnover condition involving the bone.

One very important, albeit uncommon, complication of Paget disease is the development of a sarcoma. Osteosarcoma is by far the most common type (about 80% of all cases), but chondrosarcoma, fibrosarcoma, and giant cell tumors have also been observed.[66,67] Instances of familial or geographic clustering of this complication have been reported. The most common locations of sarcomas arising in Paget disease are the femur, humerus, pelvis, tibia, and skull. Osteosarcoma should be distinguished from the periosteal (juxtacortical) bone masses that can be seen as an exaggerated expression of the basic pathologic process of Paget disease.[68] The prognosis of Paget sarcoma remains very poor.

Proposed etiologies for Paget disease have historically included infectious, environmental, and genetic factors.[69] The suggestion that it might be of viral origin has been raised by the finding of nuclear inclusions resembling paramyxovirus nucleocapsids in the lesional osteoclasts but is unlikely. Mutations in the coding region of the sequestosome 1 *(SQSTM1)* gene, which produces the p62 protein, are associated with both sporadic and familial Paget disease.[69,70]

For personal use only. No other uses without permission. Copyright ©2017. Elsevier Inc. All rights reserved.

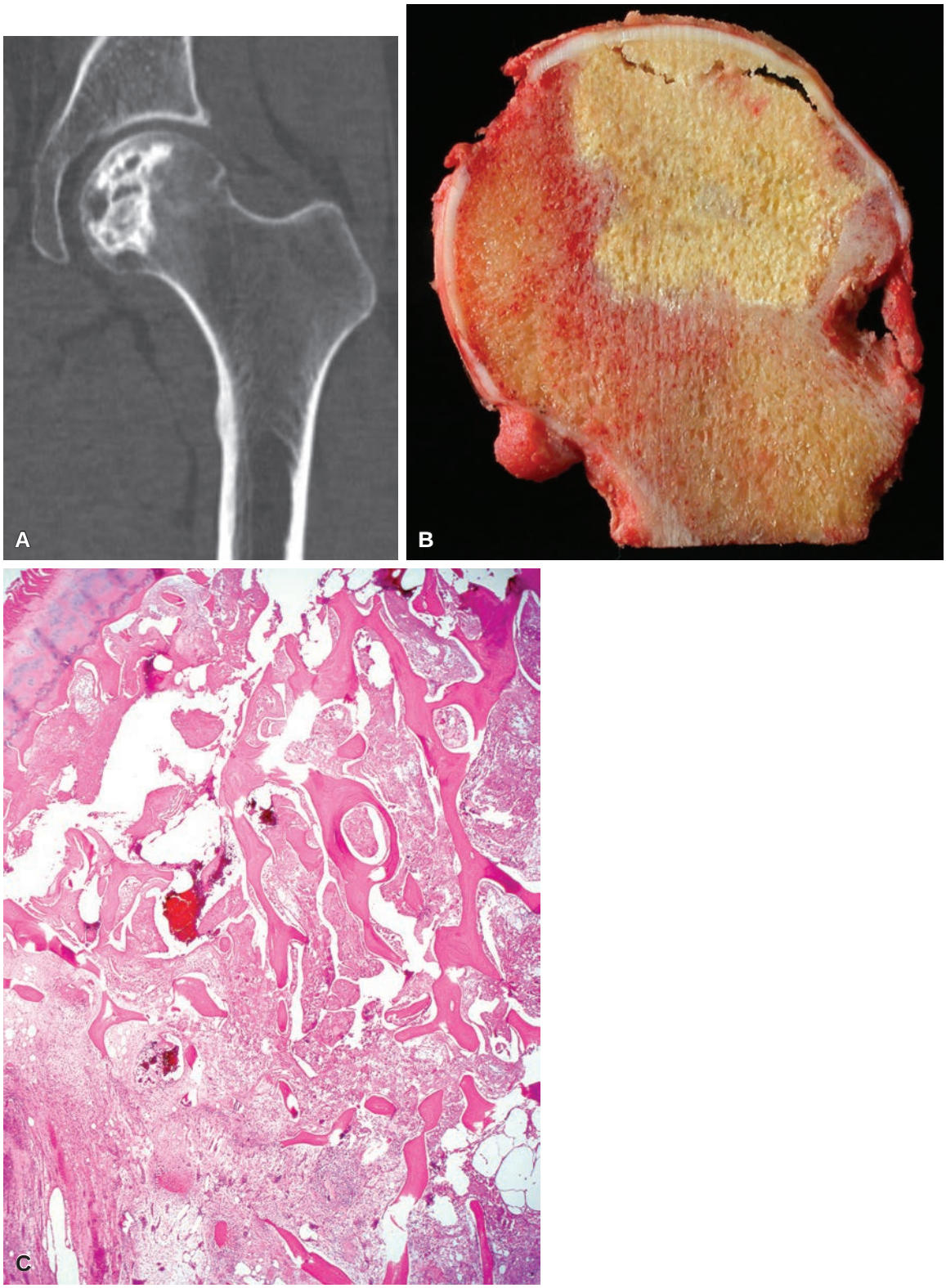

Figure 40.6 **A,** Coronal CT shows a discrete area of subchondral density with cystic change, indicative of avascular necrosis. **B,** A discrete area of avascular necrosis, which appears yellowish on cut section. Separation of the articular cartilage and subchondral bone is characteristic. **C,** The infarct is contained by a hypervascular reactive zone. The separation of the articular cartilage and subchondral bone is evident histologically.

For personal use only. No other uses without permission. Copyright ©2017. Elsevier Inc. All rights reserved.

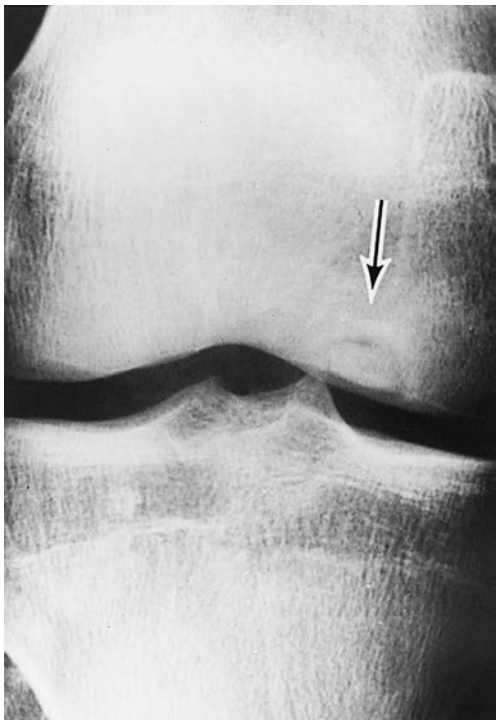

Figure 40.7 Sharply delimited area of osteochondritis dissecans of medial condyle *(arrow)*. This was easily enucleated.

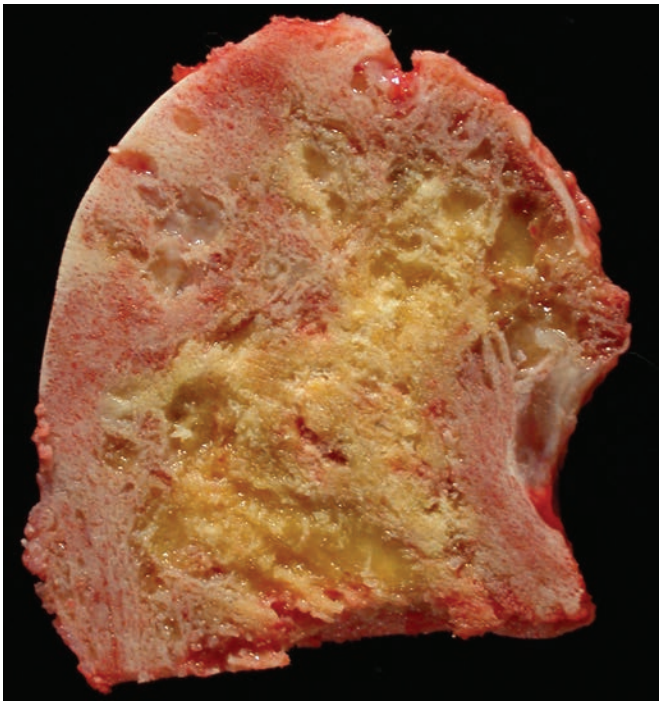

Figure 40.9 Paget disease involving the femoral head. There is marked deformity of the femoral head with coarsening of the bone, as well as secondary osteoarthritis.

Figure 40.8 Radiograph of Paget disease involving the tibia. Both cortical thickening and coarsening of the cancellous bone is accompanied by an anterior bowing deformity.

Genome-wide association studies have identified other genes also associated with Paget disease.

Osteopetrosis

Osteopetrosis (Albers–Schönberg disease, marble-bone disease) is a group of genetically determined disorders resulting from defects in osteoclast function or development.[71,72] At least 10 genes have been identified as causative, such as those encoding molecules involved in acidification machinery (e.g., *TCIRG1*, *CLCN7*, *OSTM1*, and *CLCN7*) and those affecting osteoclast differentiation, which result in the osteoclast-poor form of the disease (e.g., *LRP5*, *RANKL*).[73,74]

Microscopically, the disorder is characterized by persistence in the marrow cavity of unresorbed primary spongiosa, with or without alterations in osteoclast number and morphology, depending on the subtype of the disease.[75] Infantile forms of osteopetrosis, generally inherited autosomal recessively, have a poor prognosis, whereas adult forms, generally inherited autosomal dominantly, have a good prognosis but are often complicated by severe arthritis. The disease has been reversed by bone marrow transplantation, and complications such as arthritis and fracture typically require surgical intervention.

Tumors

Classification and Distribution

The terminology and classification of bone tumors and tumorlike lesions are largely those recommended by the World Health Organization (WHO).[76]

In the WHO classification, neoplasms are classified as either benign, intermediate (locally aggressive or rarely metastasizing), or malignant. In the most recent WHO publication, several entities have been shifted from one of these categories to another. For example, grade 1 chondrosarcoma/atypical cartilaginous neoplasm, while traditionally thought of as "malignant," is now found in the "intermediate (locally aggressive)" category. Most malignant bone tumors arise de novo, but there are a small number of benign bone lesions that predispose the patient to the development of skeletal

For personal use only. No other uses without permission. Copyright ©2017. Elsevier Inc. All rights reserved.

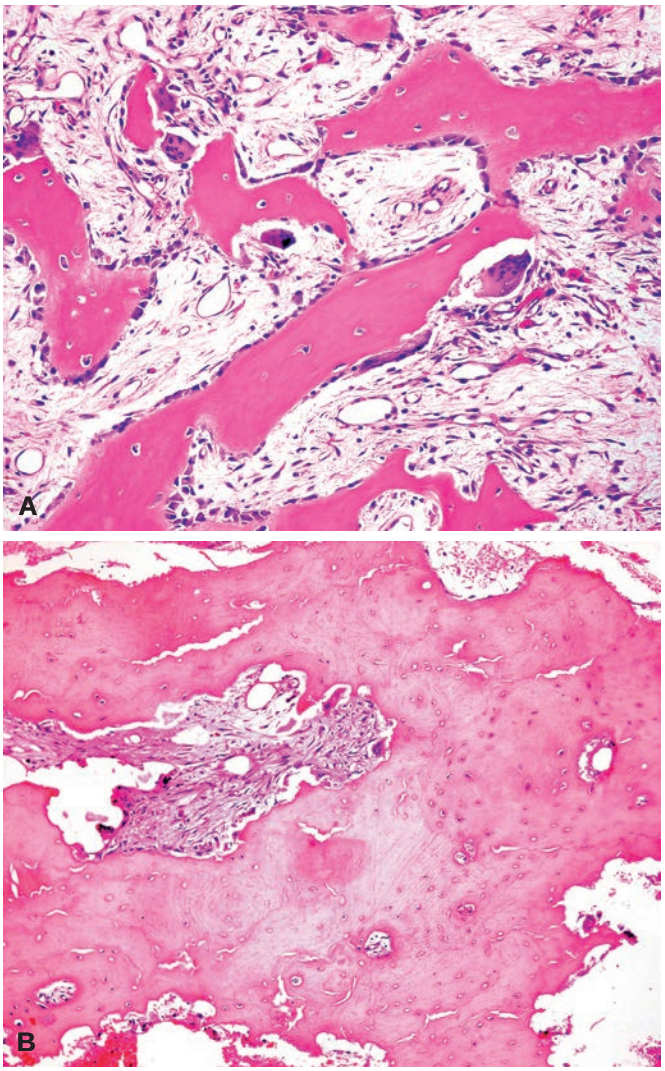

Figure 40.10 Paget Disease. A, Early changes. There is prominent osteoclastic activity, osteoblastic activity, and fibrosis. **B,** A well-established case, with thick, irregularly shaped bone trabeculae and cracking artifact along reversal lines.

malignancies; these include Paget disease, enchondromatosis, osteochondromatosis, and fibrous dysplasia.[77]

Tumors of the skeletal system are relatively constant in their pattern of presentation when one takes into consideration the patient's age and status of the growth plate, the bone involved, the specific area within the bone that is involved (epiphysis, metaphysis, diaphysis, medullary cavity, cortex, bone surface), the radiographic appearance, and the histologic appearance. Table 40.1 should assist in providing a quick orientation for the pathologist confronted with a bone neoplasm.

Bone-Forming Tumors

Osteoma

Osteoma is seen primarily in the flat bones of the craniofacial skeleton, typically arising from the surface of the involved bone. It may protrude into the orbit or a paranasal sinus (particularly the frontal and ethmoid) and block the normal drainage from these sinuses. Similar lesions, albeit smaller in size, located within the medullary cavity are referred to as enostoses or "bone islands." Microscopically, osteoma is composed of dense, mature lamellar bone. Occasional cases of sino-orbital osteoma contain foci that closely resemble osteoblastoma (Fig. 40.11).[78]

Osteoma is benign and probably not a true neoplasm. Some cases may represent end stages of fibrous dysplasia, related fibro-osseous lesions, or even subperiosteal hematomas. Patients with familial adenomatous polyposis (intestinal polyposis and soft tissue tumors) may have multiple osteomas and other abnormalities,[79] whereas cases of solitary osteoma are usually nonsyndromic.[80] Osteopoikilosis is an autosomal dominant form of sclerosing bone dysplasia characterized by multiple, symmetrically distributed bone islands.[81]

Occasionally, osteomas involve non-craniofacial bones. Most of these have a parosteal location and need to be distinguished from parosteal osteosarcoma.[82]

Osteoid Osteoma and Osteoblastoma

Osteoid osteoma is a benign bone neoplasm that is found most frequently in patients between 10 and 30 years of age and that exhibits a 2 : 1 male-to-female ratio. Intense pain relieved by nonsteroidal anti-inflammatory drugs is the most prominent symptom; the pain is often sharply localized, more severe at night, and unaccompanied by clinical or laboratory evidence of infection. Vertebral lesions may be associated with scoliosis.[83]

Osteoid osteoma has been reported in practically every bone but occurs most frequently in the femur, tibia, humerus, bones of the hands and feet, vertebrae, and fibula.[84,85] Lesions of long bones are usually metaphyseal, but they may be epiphyseal and even juxta-/intra-articular (arising within the portion of the bone contained within the joint capsule).[86] Most are centered in the cortex (85%), but they may also occur in the medullary cavity (13%) or subperiosteal region (2%).[87] Vertebral lesions typically affect the posterior elements.

Radiographically, osteoid osteomas contain a radiolucent central nidus smaller than 1.5 cm that may or may not contain a radiodense center (Fig. 40.12). This nidus is surrounded by a peripheral sclerotic reaction that may extend for several centimeters along both sides of the cortex; however, osteoid osteomas arising within the medullary cavity may lack this reaction. The radiographic differential diagnosis includes Brodie abscess, sclerosing osteomyelitis, and stress fracture. Juxta-articular lesions may be mistaken for an inflammatory arthropathy due to the induction of a marked chronic synovitis, and lesions in this location may be better visualized with MRI scans.[86]

Microscopically, the sharply delineated central nidus is composed of more or less calcified osteoid and woven bone lined by plump osteoblasts and growing within highly vascularized connective tissue, without evidence of inflammation (Fig. 40.13). The appearance is so characteristic that the lesion can still be diagnosed when removed piecemeal. Surrounding the nidus, there is a variably thick layer of dense bone.

The pain associated with osteoid osteoma is characteristically more intense at night, relieved by nonsteroidal anti-inflammatory drugs such as aspirin, and eliminated by removal of the nidus. It has been attributed by some authors to the effect on nerves and vessels of osteoblast-produced prostaglandin E2, which is typically present in large amounts in these lesions.[88,89] Others believe that the pain is simply related to the presence of entrapped and proliferating nerves within and around the nidus.[90,91]

CT-guided radiofrequency ablation has largely replaced surgical excision for osteoid osteoma, and proven to be an extremely effective treatment modality for both spinal and extra-spinal tumors. This technique provides excellent pain relief, reduces operative morbidity, and is associated with a low recurrence rate.[92–94]

For personal use only. No other uses without permission. Copyright ©2017. Elsevier Inc. All rights reserved.

Table 40.1 Usual age, gender, location, and behavior of the most common primary bone tumors and tumorlike lesions[a]

TUMOR OR TUMORLIKE LESION	AGE (YR)	GENDER (M:F)	BONES MOST COMMONLY AFFECTED (IN ORDER OF FREQUENCY)	USUAL LOCATION WITHIN LONG BONE	BEHAVIOR
Osteoma	40–50	2:1	Skull and facial bones	—	Benign
Osteoid osteoma	10–30	2:1	Femur, tibia, humerus, hands and feet, vertebrae, fibula	Cortex of metaphysis	Benign
Osteoblastoma	10–30	2:1	Vertebrae, tibia, femur, humerus, pelvis, ribs	Medulla of metaphysis	Benign
Osteosarcoma	10–25	3:2	Femur, tibia, humerus, pelvis, jaw, fibula	Medulla of metaphysis	Malignant; 20% 5-year survival rate
Juxtacortical (parosteal) osteosarcoma	30–60	1:1	Femur, tibia, humerus	Juxtacortical area of metaphysis	Malignant; 80% 5-year survival rate
Chondroma	10–40	1:1	Hands and feet, ribs, femur, humerus	Medulla of diaphysis	Benign
Osteochondroma	10–30	1:1	Femur, tibia, humerus, pelvis	Cortex of metaphysis	Benign
Chondroblastoma	10–25	2:1	Femur, humerus, tibia, feet, pelvis, scapula	Epiphysis, adjacent to cartilage plate	Practically always benign
Chondromyxoid fibroma	10–25	1:1	Tibia, femur, feet, pelvis	Metaphysis	Benign
Chondrosarcoma	30–60	3:1	Pelvis, ribs, femur, humerus, vertebrae	Central: medulla of diaphysis; peripheral: cortex or periosteum of metaphysis	Malignant. 5-year survival rate: low grade, 78%; moderate grade, 53%; high grade, 22%
Mesenchymal chondrosarcoma	20–60	1:1	Ribs, skull and jaw, vertebrae, pelvis	Medulla or cortex of diaphysis	Malignant; extremely poor prognosis
Giant cell tumor	20–40	4:5	Femur, tibia, radius	Epiphysis and metaphysis	Potentially malignant; 50% recur; 10% metastasize
Ewing sarcoma/PNET	5–20	1:2	Femur, pelvis, tibia, humerus, ribs, fibula	Medulla of diaphysis or metaphysis	Highly malignant; 20%–30% 5-year survival rate in recent series
Malignant lymphoma, large cell, and mixed cell types	30–60	1:1	Femur, pelvis, vertebrae, tibia, humerus, jaw, skull, ribs	Medulla of diaphysis or metaphysis	Malignant; 22%–50% 5-year survival rate
Plasma cell myeloma	40–60	2:1	Vertebrae, pelvis, ribs, sternum, skull	Medulla of diaphysis, metaphysis, or epiphysis	Malignant; diffuse form uniformly fatal, localized form often controlled with radiation therapy
Hemangioma	20–50	1:1	Skull, vertebrae, jaw	Medulla	Benign
Desmoplastic fibroma	20–30	1:1	Humerus, tibia, pelvis, jaw, femur, scapula	Metaphysis	Benign
Fibrosarcoma	20–60	1:1	Femur, tibia, jaw, humerus	Medulla of metaphysis	Malignant; 28% 5-year survival rate
Chordoma	40–60	2:1	Sacrococcygeal, spheno-occipital, cervical vertebrae	—	Malignant; slow course; locally invasive; 48% distant metastases
Solitary bone cyst	10–20	3:1	Humerus, femur	Medulla of metaphysis	Benign

For personal use only. No other uses without permission. Copyright ©2017. Elsevier Inc. All rights reserved.

Table 40.1 Usual age, gender, location, and behavior of the most common primary bone tumors and tumorlike lesions—cont'd

TUMOR OR TUMORLIKE LESION	AGE (YR)	GENDER (M:F)	BONES MOST COMMONLY AFFECTED (IN ORDER OF FREQUENCY)	USUAL LOCATION WITHIN LONG BONE	BEHAVIOR
Aneurysmal bone cyst	10–20	1:1	Vertebrae, flat bones, femur, tibia	Metaphysis	Benign, sometimes secondary to another bone lesion
Metaphyseal fibrous defect	10–20	1:1	Tibia, femur, fibula	Metaphysis	Benign
Fibrous dysplasia	10–30	3:2	Ribs, femur, tibia, jaw, skull	Medulla of diaphysis or metaphysis	Locally aggressive; rarely complicated by sarcoma
Langerhans cell histiocytosis	5–15	3:2	Skull, jaw, humerus, rib, femur	Metaphysis or diaphysis	Benign

[a]It should be emphasized that these data correspond to the typical case and should not be taken in an absolute sense. Isolated exceptions to practically every one of these statements have occurred.
PNET, Primitive neuroectodermal tumor.

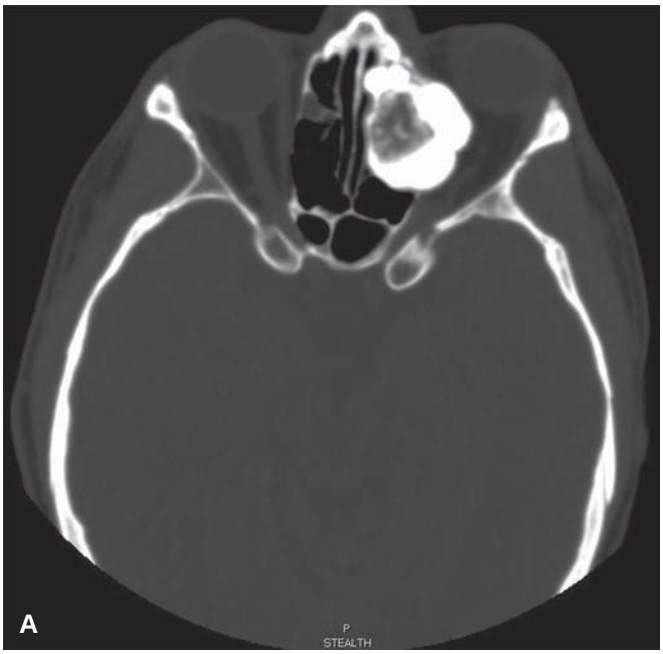

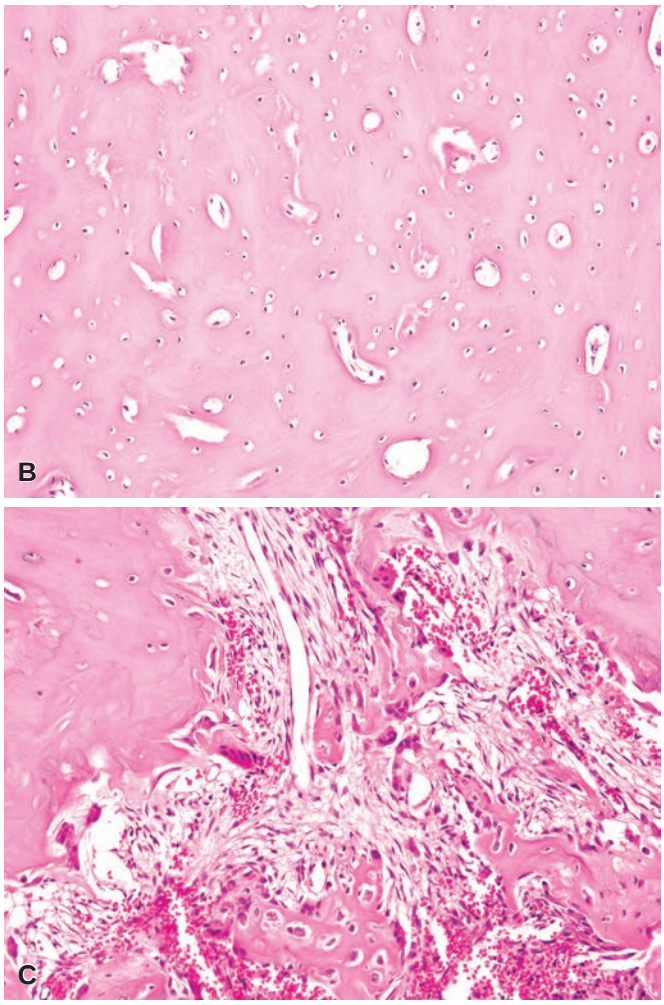

Figure 40.11 Sino-Nasal Osteoma With Osteoblastoma-Like Foci. **A,** CT scan shows a lobulated, radiodense mass. The less dense, central area has osteoblastoma-like features. **B,** Portion of the mass resembling cortical bone. **C,** Osteoblastoma-like focus, consisting of woven bone with prominent osteoblasts and osteoclasts.

For personal use only. No other uses without permission. Copyright ©2017. Elsevier Inc. All rights reserved.

Osteoblastoma is a tumor closely related to osteoid osteoma both microscopically and immunohistochemically (Fig. 40.14).[95] It is distinguished from osteoid osteoma by its larger size, the absence or inconspicuousness of a surrounding area of reactive bone formation, and less intense pain.[96] Most cases arise in the medullary cavity of the bone, but cortical and subperiosteal forms also occur. The majority of the cases are located in the spine or major bones of the lower extremity.[97]

Figure 40.12 AP radiograph of an osteoid osteoma of the tibia. The radiolucent central nidus is surrounded by dense, reactive bone.

Radiographically, osteoblastomas appear as well-defined radiolucent lesions with haphazardly distributed foci of mineralization. Their size (>2 cm) is larger than osteoid osteoma, and the perilesional reactive bone is typically less pronounced. When osteoblastomas arise in flat bones, they may have radiographic findings that mimic a malignant bone tumor.[98]

Microscopically, the features of osteoblastoma are very similar to the nidus of osteoid osteoma. It is sharply circumscribed from adjacent bone, and those that extend beyond the cortex are encompassed by a thin rim of reactive bone. Anastomosing trabeculae of woven bone prominently lined by osteoblasts are separated by a loose fibrovascular stroma, and multinucleated giant cells may be prominent. A cartilaginous matrix may be encountered in rare cases.[99] The differential diagnosis between osteoblastoma and osteosarcoma can be extremely difficult because the latter may be very well differentiated and the former is sometimes accompanied by the presence of scattered bizarre tumor cells probably of a degenerative nature[100,101] or may be composed of large epithelioid cells accompanied by telangiectatic features.[102] Permeation of host bone trabeculae should raise suspicion for osteosarcoma, as should foci of necrosis and the presence of mitotic activity. As is the case in many other bone tumors, the radiographic pattern is of great assistance in this differential diagnosis. However, in some cases of osteoblastoma the radiographic picture suggests a malignant neoplasm.

Epithelioid (aggressive) osteoblastoma and related lesions. Some lesions with the radiographic and architectural features of osteoblastoma show atypical cytologic features that some authors believe correlate with a tendency for local recurrence. These tumors have been designated epithelioid (aggressive) osteoblastomas. According to Dorfman and Weiss, these tumors are distinguished microscopically from the ordinary osteoblastomas mainly by the presence of large, epithelioid-appearing osteoblasts, which are at least twice the size of ordinary tumor osteoblasts.[103] They are distinguished from conventional osteosarcomas because of a low mitotic rate and the absence of the following features: lace-like osteoid, permeation of surrounding intertrabecular spaces, and atypical

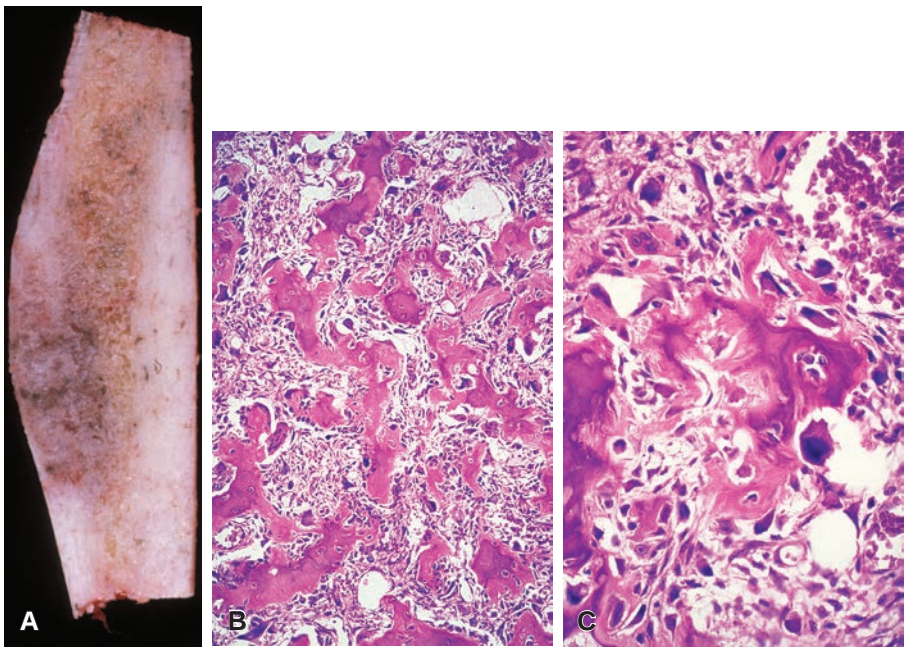

Figure 40.13 **Osteoid Osteoma. A,** Grossly, the gritty 8-mm nidus of the osteoid osteoma is evident within dense bone. **B,** Medium-power and **C**, high-power microscopic views of osteoid osteoma. There is woven bone surrounded by plump osteoblasts. The stroma is cellular and well vascularized.

For personal use only. No other uses without permission. Copyright ©2017. Elsevier Inc. All rights reserved.

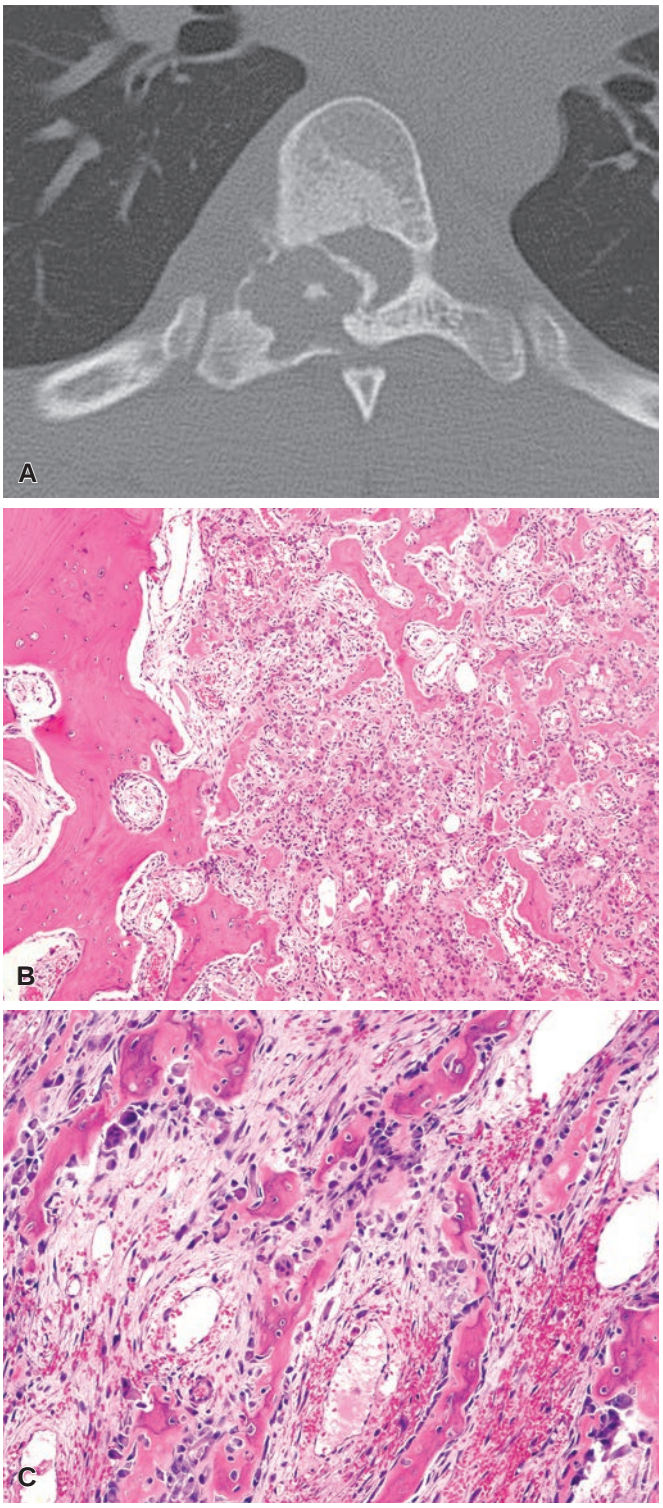

Figure 40.14 Osteoblastoma of the Spine. A, CT scan shows a well-circumscribed radiolucent lesion with central density arising in the posterior elements of the vertebra. Reactive bone formation is evident in the vertebral body adjacent to the lesion. **B,** Low-power view shows a sharply circumscribed border. **C,** Woven bone with prominent osteoblasts, fibrovascular stroma, and ectatic blood vessels characterize osteoblastoma.

mitoses. The entity "epithelioid multinodular osteoblastoma" is characterized by multiple nodules of epithelioid osteoblasts either lacking bone formation or containing irregular blue-staining osteoid.[104] The entities of epithelioid osteoblastoma, malignant osteoblastoma,[105] pseudoanaplastic osteoblastoma,[106] osteosarcoma resembling osteoblastoma,[100] and osteoblastoma-like osteosarcoma[107] are histologically similar lesions, some of which have been reported to metastasize.

Osteosarcoma

The WHO defines osteosarcoma as a malignant neoplasm in which the neoplastic cells produce bone.[76,108] It is the most common primary malignant bone tumor, exclusive of hematopoietic malignancies. It usually occurs as a painful mass in patients between 10 and 25 years of age and is exceptionally rare in very young children. A second peak age incidence occurs after 40, usually in association with other preexisting disorders (see the following discussion). There is a slight male predominance (1.5 : 1).

Predisposing factors. Most osteosarcomas arise de novo, but others arise within the context of a preexisting condition:

1. *Paget disease*. A high number of osteosarcomas developing in patients over the age of 40 are located in bones affected by Paget disease.[109]
2. *Radiation exposure*. One of the classic cases of human carcinogenesis occurred in a group of factory workers in Illinois who developed osteosarcomas from moistening brushes in their mouths when applying radium paint to create luminous numerals on watches.[110,111] Some cases of osteosarcoma have also been reported years after Thorotrast administration.[112] However, in more recent times, osteosarcoma is known to be a complication of external beam radiation therapy.[113] The average latency period ranges from 10 to 15 years in the various reported series.[114] While many radiotherapy-associated sarcomas of bone are osteosarcomas, many are not classifiable at the microscopic and immunohistochemical level.
3. *Chemotherapy*. Children treated with alkylating agents for retinoblastoma and other malignancies have an increased risk of osteosarcoma.[115] Genetic factors probably play an important contributory role.
4. *Preexisting benign bone lesions*. These include fibrous dysplasia, bone infarct, and osteogenesis imperfecta[116] (see respective sections).
5. *Foreign bodies*. Rare well-documented cases of osteosarcoma have been reported arising at the site of a total hip replacement or at sites of other orthopedic implants.[117,118]
6. *Genetic predisposition*. Patients with Li–Fraumeni syndrome (usually caused by germline mutation of the *TP53* gene), hereditary retinoblastoma (caused by germline mutation of the *RB1* gene), Rothmund–Thomson syndrome, Werner syndrome, and familial Paget disease have an increased risk of developing osteosarcoma.[119,120]

Location. Most osteosarcomas arising de novo arise in the metaphyseal area of long bones, particularly the distal femur, the proximal tibia, and the proximal humerus. A few cases arise in the diaphyses and an even smaller number in the epiphyses. Less commonly, osteosarcomas are found in flat bones (such as craniofacial bones, pelvis, and scapula),[121] spine,[122] and short tubular bones.[123] Occasionally, osteosarcomas are multicentric, in either a synchronous or a metachronous fashion: most of these multicentric cases occur in children and tend to be densely sclerotic radiographically and extremely aggressive.[124,125]

Radiographic features. Conventional osteosarcoma causes destruction of both the medullary cavity and cortical bone, often resulting in an aggressive pattern of periosteal reaction, such as a

For personal use only. No other uses without permission. Copyright ©2017. Elsevier Inc. All rights reserved.

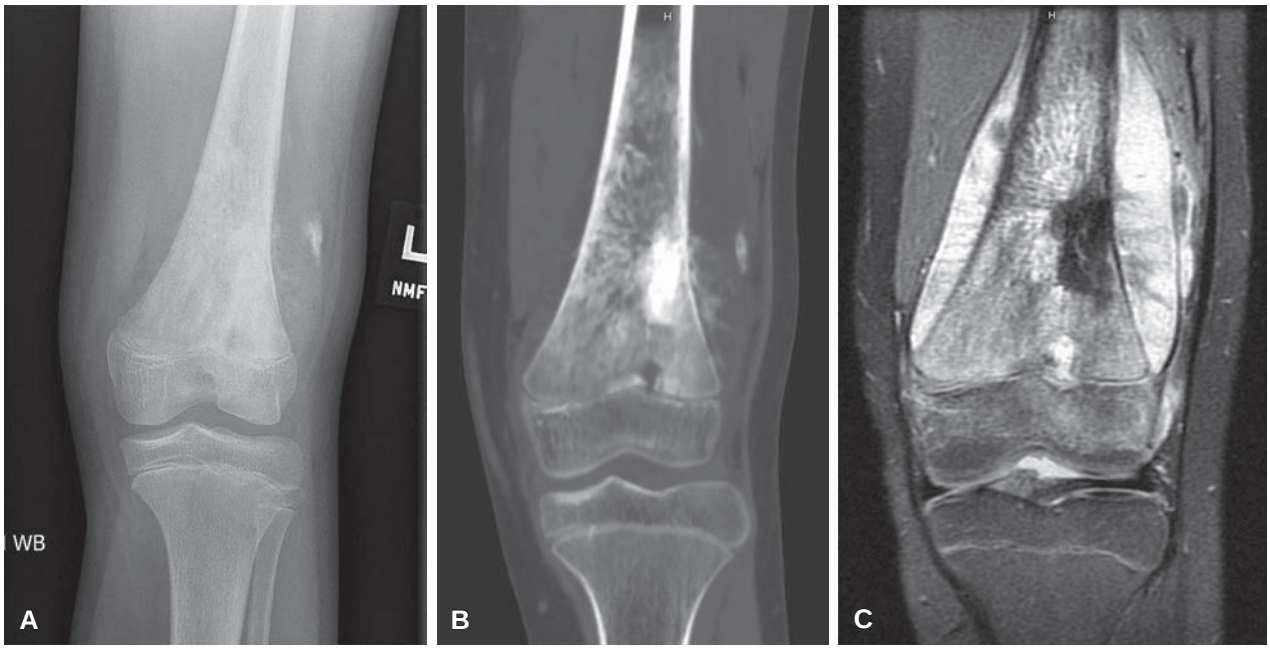

Figure 40.15 Radiographic Features of Conventional Osteosarcoma of the Distal Femur. A, Radiograph, **B,** coronal CT, and **C,** coronal MRI show a highly destructive bone-forming mass arising in the metaphysis and involving adjacent soft tissue.

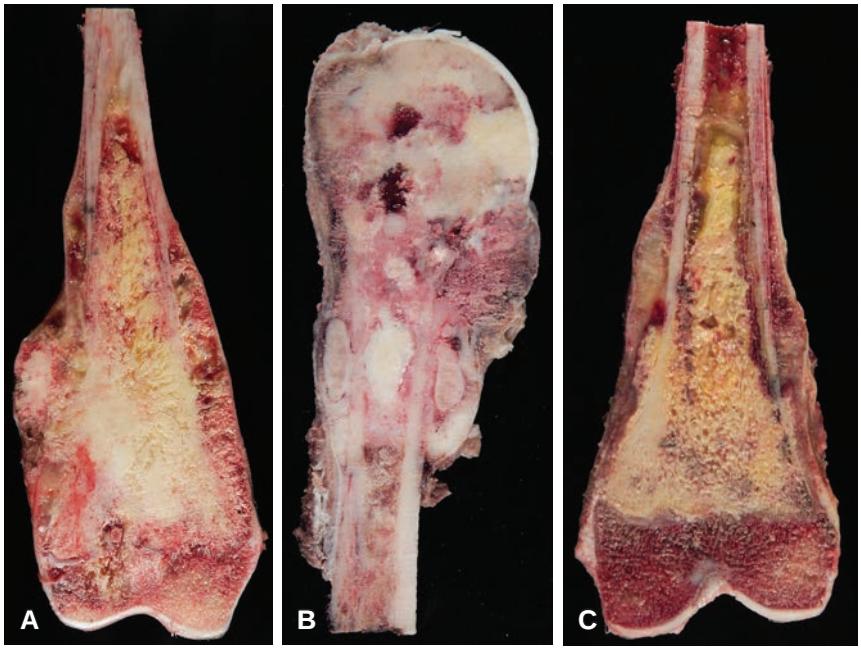

Figure 40.16 Gross appearance of osteosarcoma of the **A,** distal femur, **B,** proximal humerus, and **C,** distal femur. All three lesions extend into soft tissue and cause elevation of the periosteum.

Codman triangle or a sunburst appearance (Fig. 40.15). The degree and appearance of the mineralization within the tumor depends on the histologic subtype of osteosarcoma and the amount of matrix produced; however, most tumors contain a mixture of radiolucent and matrix-forming foci.[126] MRI is an excellent modality for determining the extent of the tumor in the medullary cavity and soft tissue, and is the study of choice for surgical planning.[127]

Gross appearance and spread. The gross appearance of the cut surface of an osteosarcoma is highly variable, depending on the histologic subtype and response to neoadjuvant chemotherapy (Fig. 40.16). The range extends from bony hard to cystic, friable, and hemorrhagic.

Osteosarcomas typically arise in the metaphysis and spread longitudinally in the medullary cavity. While the growth plate often acts as a barrier to tumor spread, occasionally osteosarcomas breach the physis and extend into the epiphysis.[128] They invade through the cortex by either directly destroying cortical bone or by invading through the vascular channels in the cortex. When the overlying

For personal use only. No other uses without permission. Copyright ©2017. Elsevier Inc. All rights reserved.

periosteum becomes irritated, it responds by forming reactive bone, or a periosteal reaction. This typically results in the formation of a Codman triangle, a "hair-on-end" or "sunburst" appearance, or less commonly a lamellated appearance, all of which are visible grossly. The bone underneath a Codman triangle is reactive and does not contain tumor. Osteosarcomas may also extend through the periosteum and into adjacent soft tissues, a feature sometimes seen in the setting of a suboptimal response to chemotherapy. Finally, on rare occasions osteosarcomas may involve the joint or extend across the joint via ligamentous connections such as the anterior cruciate ligament.[129]

Discontinuous foci of tumor within the same bone are defined as a "satellite lesion" when the separate focus occurs within reactive changes around the main mass, and a "skip metastasis" when it occurs outside reactive changes in normal bone and hematopoietic marrow.[130,131] The prognosis for patients with skip metastases is poor.

Osteosarcomas metastasize through the bloodstream to distant sites, particularly the lung, but they may also metastasize to other bones, the pleura, or other visceral sites. Metastases to regional lymph nodes are extremely uncommon.

Microscopic features. Microscopically, osteosarcoma is defined by the direct production of immature bone or osteoid by neoplastic cells. The most common histologic subtypes of conventional osteosarcoma are osteoblastic, chondroblastic, and fibroblastic, and less common subtypes include giant cell-rich, osteoblastoma-like, epithelioid, clear cell, and chondroblastoma-like.[76] In each of the various subtypes of osteosarcoma, osteoid may be abundant, as in the case of an osteoblastic osteosarcoma, or focal, which is often the case in fibroblastic osteosarcoma. The pattern of osteoid deposition is highly variable, ranging from fine to extremely dense, or "sclerosing."[132] Osteoid is recognized by its glassy, eosinophilic appearance following decalcification and may be difficult to distinguish from hyalinized collagen. A homogeneous rather than fibrillary appearance, punctate calcification, and a plump appearance of the cells around it are more in keeping with osteoid. The SATB2 immunostain can also be useful in this setting.[6] Occasionally the tumor osteoid appears as thin, tubular, anastomosing "microtrabeculae," which are very basophilic and vaguely reminiscent of the appearance of fungal hyphae (Fig. 40.17).

Conventional osteosarcomas are often composed of a mixture of osteoblastic, fibroblastic, and chondroblastic foci, the relative proportions among these three components varying a great deal from case to case. While the predominant component determines which histologic subtype is diagnosed, there is no prognostic significance to this division. The important fact to remember is that a malignant bone tumor should be designated as osteosarcoma whenever osteoid is formed directly by the tumor cells regardless of the predominate stromal cell type.

Morphologic variations in conventional osteosarcoma are plentiful.[133,134] The osteoid may be sparse or massive, surrounded by pleomorphic, bizarre cells, or relatively acellular and surrounded by tumor cells in a rosettelike configuration (the latter allegedly being a more aggressive variant).[135] The tumor cells may grow in diffuse, nested, or pseudopapillary arrangements. The vessels may be scanty or numerous, sometimes with a dilated or hemangiopericytomatous appearance. The tumor cells may be spindled, oval, or round, and their size may range from small to giant; exceptionally, they have a distinctly epithelial-like appearance.[136,137] Osteoclast-like multinucleated giant cells are present in many cases and may be so numerous as to simulate a giant cell tumor (so-called giant cell-rich osteosarcoma); the cartilage may be immature, mineralized, or highly myxoid. In the latter instance, the tumor may simulate a chondromyxoid fibroma.[138]

Depending on which one of the previously mentioned microscopic patterns happens to be present, the differential diagnosis of osteosarcoma may include a remarkably high number of benign and malignant lesions, such as fracture callus, fibrous dysplasia, osteoblastoma, "fibrosarcoma," chondrosarcoma, giant cell tumor, or even metastatic carcinoma. Exuberant fracture callus is particularly likely to be misdiagnosed as osteosarcoma by the unwary, with disastrous consequences for the patient. This callus may be secondary to a pathologic fracture in a benign lesion (such as a metaphyseal fibrous defect or aneurysmal bone cyst), in a metastatic carcinoma, or in osteogenesis imperfecta (where it may be particularly exuberant).[139,140] Other entities that need to be considered in the differential diagnosis are discussed in connection with the osteosarcoma variants described in the following section.

Histochemical and immunohistochemical features. Osteosarcoma cells usually exhibit strong alkaline phosphatase activity, regardless of their appearance (osteoblastic or other), but the use of histochemistry to detect alkaline phosphatase as a diagnostic tool is highly nonspecific. Likewise, immunohistochemistry has proven to be of limited value in the diagnosis of osteosarcoma due to lack of specificity; however, SATB2 may be useful in establishing osteoblastic lineage in osteosarcoma.[6] An important pitfall in the diagnosis of osteosarcoma is cytokeratin expression.[141]

Molecular genetic features. Osteosarcoma typically shows complex karyotypes, with structural alterations (including translocations) and numerical alterations (gain and loss) involving multiple chromosomes.[142,143] At the molecular level, alterations of both the *TP53* gene and retinoblastoma gene pathways are found in many cases, not unexpectedly since germline mutations in these genes are known to predispose to development of osteosarcoma.[144] The *TP53* pathway is altered through loss-of-function mutation in *TP53* (50%) and *MDM2* amplification (14%–27%).[145] Alterations in other cell cycle genes, such as *CDK4* and *CDKN2A*, are also detected in some osteosarcomas.[146] Deletions and amplifications of chromosomes 3, 6, and 8 result in gene alterations that may have prognostic significance, including *LSAMP*, *RUNX2*, and *MYC*.[76]

Microscopic variants and special types. In addition to conventional osteosarcoma, the WHO also recognizes other specific variants with characteristics that justify their own category.[76] Many of these osteosarcoma variants simulate other bone processes radiographically and microscopically, and some of them carry distinctive prognostic connotations.

Telangiectatic osteosarcoma. This variant has low-magnification architectural features resulting in an appearance similar to that of aneurysmal bone cyst radiographically and pathologically. Pathologic fractures are very frequent.[147] Telangiectatic osteosarcoma is characterized histologically by numerous blood-filled spaces separated by septa containing highly pleomorphic mononuclear and multinucleated giant cells accompanied by abundant mitotic activity (Fig. 40.18).[148] Telangiectatic osteosarcoma is treated with the same neoadjuvant chemotherapy and surgery as other high-grade osteosarcomas and appears to have a similar prognosis as other conventional osteosarcomas.[149]

Small cell osteosarcoma. This rare variant of osteosarcoma is composed of small, uniform, round or spindled cells closely simulating the appearance of Ewing sarcoma and malignant lymphoma.[150,151] The identification of osteoid and the exclusion of other round cell neoplasms with immunohistochemistry or molecular diagnostic testing is necessary for diagnosis. Small cell osteosarcomas are immunoreactive for SATB2 but negative for CD99. Furthermore, small cell osteosarcomas lack any of the Ewing or Ewing-like sarcoma gene fusions.[152] Nevertheless, care must be taken to distinguish this lesion from Ewing sarcoma or related lesions, lymphoma, and mesenchymal chondrosarcoma.

For personal use only. No other uses without permission. Copyright ©2017. Elsevier Inc. All rights reserved.

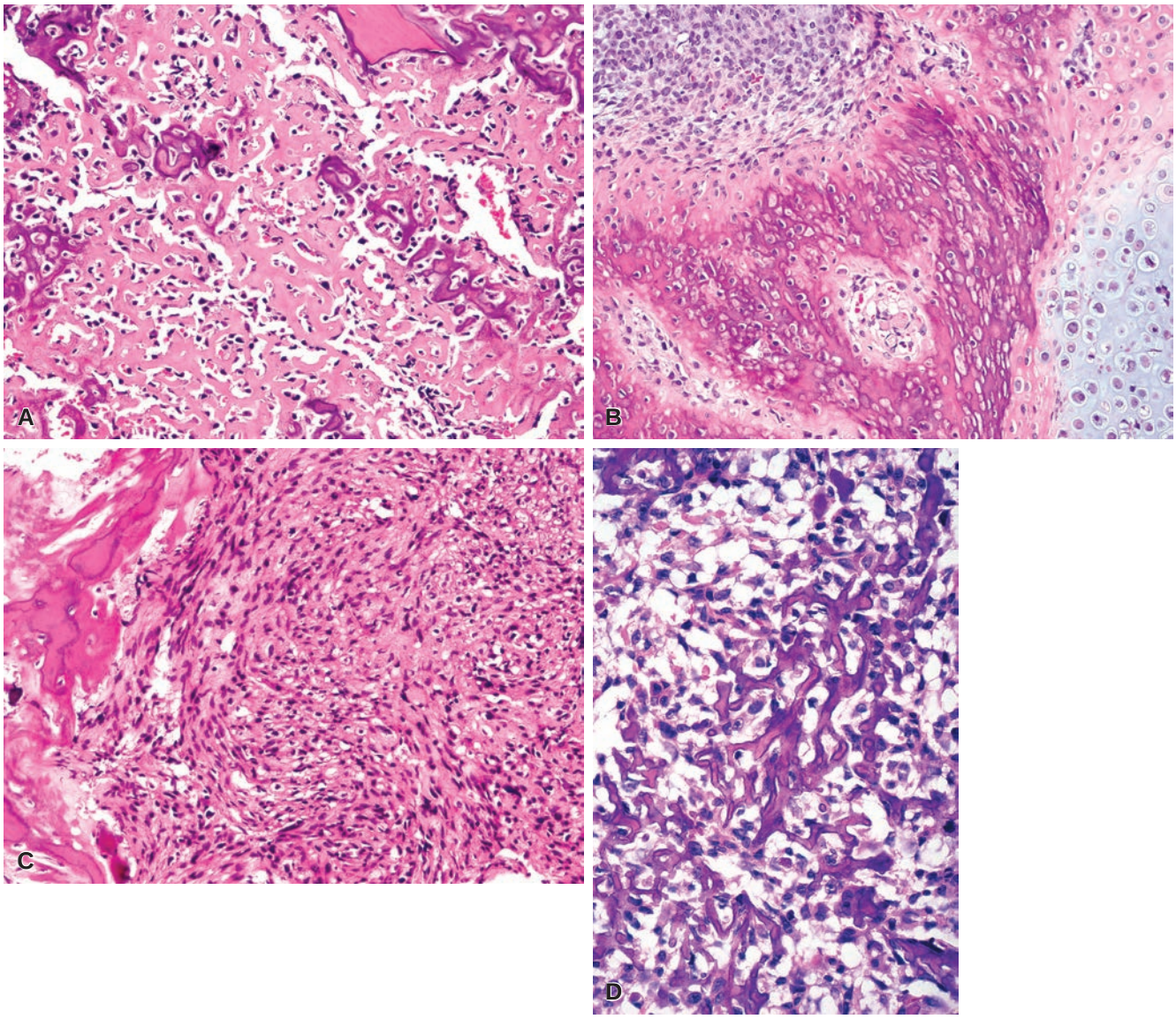

Figure 40.17 Main Histologic Variants of Conventional Osteosarcoma. A, Osteoblastic osteosarcoma. **B**, Chondroblastic osteosarcoma. **C,** High-grade fibroblastic osteosarcoma. In each instance, osteoid deposition is identified. **D,** Microscopic appearance of osteosarcoma showing characteristic basophilic osteoid with an appearance that is reminiscent of fungal hyphae.

Low-grade central osteosarcoma (Fig. 40.19). This osteosarcoma variant is historically difficult to recognize because of its deceptively bland microscopic appearance and is often underdiagnosed as a benign lesion such as fibrous dysplasia or desmoplastic fibroma. It closely resembles parosteal osteosarcoma.[153] Most patients are adults, and the femur and tibia are the most commonly involved sites; however, other sites, such as the gnathic bones, may be involved. Histologically, low-grade central osteosarcoma is a fibroblastic osteosarcoma with minimal cytologic atypia and minimal mitotic activity. The bone within the lesion may resemble fibrous dysplasia or have a Pagetic appearance. Recurrences are common with inadequate treatment, but metastases are very rare unless the tumor "dedifferentiates."[154,155] In contrast to fibrous dysplasia, this tumor shows radiographic evidence of cortical destruction.[154] This feature and the infiltrative growth pattern are helpful in distinguishing this tumor from fibrous dysplasia.

The *GNAS1* gene mutation consistently found in fibrous dysplasia is generally absent in low-grade central osteosarcoma, pointing to a different pathogenesis for each of the two processes and providing a tool for their differential diagnosis.[156,157] Low-grade central osteosarcomas frequently show gain or amplification of *MDM2* and12q13-15.[158] Gene amplification can be detected by molecular diagnostic techniques, or MDM2 or CDK4 protein can be detected by immunohistochemistry if only decalcified tissue is available.[159,160]

Other variants of osteosarcoma are defined on the basis of topographic, clinical, or radiographic features or a combination of them:

Parosteal osteosarcoma. This is the most common surface variant of osteosarcoma. It occurs in a slightly older age group than the

For personal use only. No other uses without permission. Copyright ©2017. Elsevier Inc. All rights reserved.

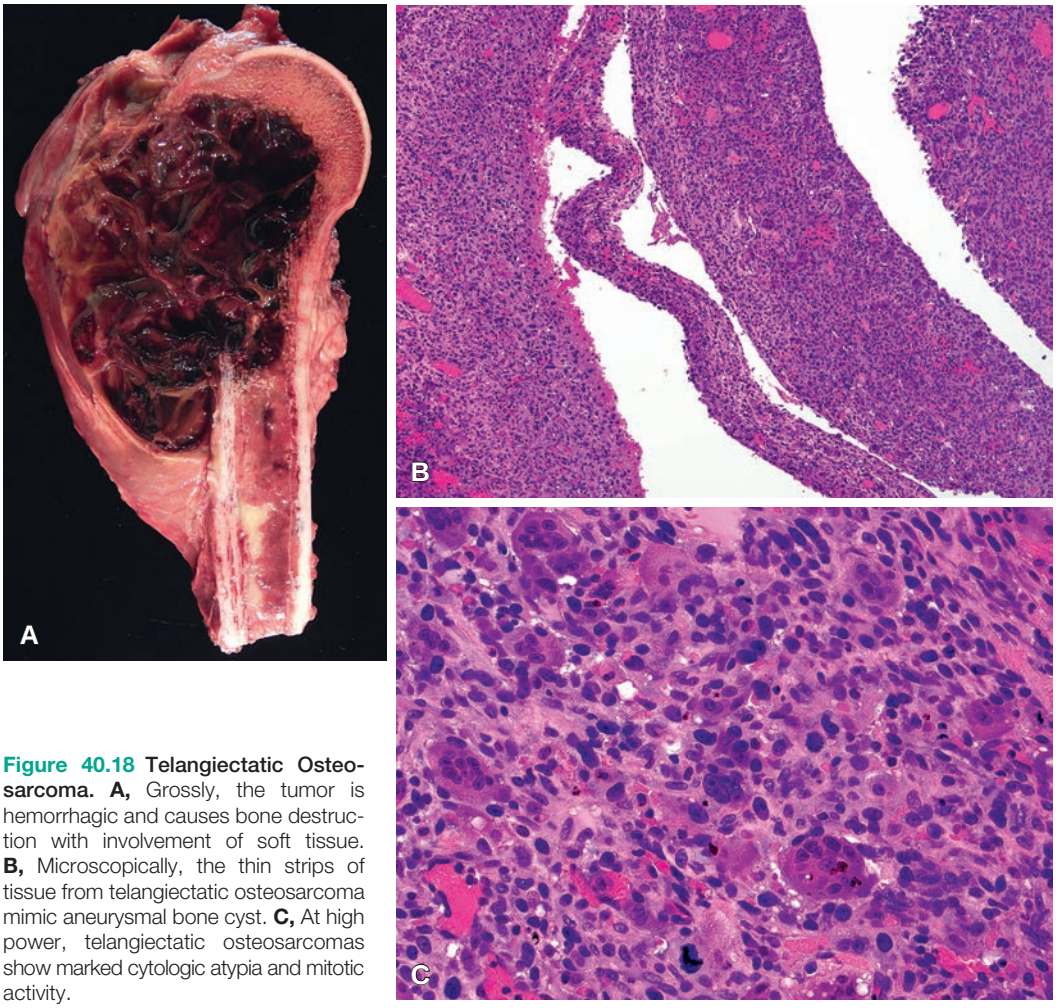

Figure 40.18 Telangiectatic Osteosarcoma. A, Grossly, the tumor is hemorrhagic and causes bone destruction with involvement of soft tissue. **B,** Microscopically, the thin strips of tissue from telangiectatic osteosarcoma mimic aneurysmal bone cyst. **C,** At high power, telangiectatic osteosarcomas show marked cytologic atypia and mitotic activity.

Figure 40.19 Gross appearance of low-grade central osteosarcoma of the tibia. (Courtesy of Dr Juan José Segura, San José, Costa Rica).

conventional variety.[161] It usually arises from the metaphyseal surface of long bones (usually the posterior aspect of the distal femur) and grows very slowly. Eventually, it forms a large lobulated mass with a tendency to encircle the bone (Fig. 40.20) and may penetrate into the medullary cavity, a feature sometimes associated with dedifferentitation.[162] Satellite nodules may be present. Rare cases have been described at other sites, such as the craniofacial bones. The radiographic appearance is highly characteristic.[163]

Microscopically, parosteal osteosarcoma closely resembles low-grade central osteosarcoma and is composed of bland fibrous stroma containing disorganized, immature bone (Fig. 40.21). Cartilage may be present on the periphery of the tumor or embedded deep within it. The cytologic signs of malignancy in the fibrous stroma are often subtle, thus accounting for the great frequency of misdiagnoses made in this tumor. Parosteal osteosarcomas are characterized genetically by supernumerary ring chromosomes which contain amplified material from 12q13-15, corresponding to the *CDK4* and *MDM2* genes, among others. The evaluation of these gene amplifications or detection of their protein products by immunohistochemistry may be useful in distinguishing parosteal osteosarcoma from benign mimics.[159,164]

The prognosis for parosteal osteosarcoma is very good, even with segmental excision. It should be emphasized that not all osteosarcomas originating from the bone surface belong to this variety. Those having morphologic features equivalent to those of the conventional intramedullary osteosarcoma are referred to as *high-grade surface*

For personal use only. No other uses without permission. Copyright ©2017. Elsevier Inc. All rights reserved.

Figure 40.20 Parosteal Osteosarcoma. A, On lateral plain radiograph and **B,** lateral CT scan, a lobulated, dense mass arises from the surface of the posterior femoral metaphysis and encompasses the bone. **C,** The gross appearance of the lesion closely reflects its radiographic features.

osteosarcomas and behave as aggressively as the former.[165,166] Sometimes, features of high-grade osteosarcoma are seen focally in what is otherwise a typical parosteal osteosarcoma, either initially or—more commonly—following repeated tumor recurrences; this phenomenon, which is referred to as "dedifferentiation," is associated with a markedly decreased survival rate.[161,167,168]

Periosteal osteosarcoma. This variant of osteosarcoma, which is very different from parosteal osteosarcoma despite the similarities in the nomenclature, also arises from the surface of long bones.[169] Most of the reported cases have been located in the tibial or femoral diaphysis and have presented as small lenticular lesions on the bone surface accompanied by reactive bone arranged perpendicular to the surface. The lesions are limited to the cortex and only rarely invade the medullary cavity (Fig. 40.22).[170,171] Microscopically, periosteal osteosarcomas are largely chondroblastic in appearance. The prognosis is better than for conventional osteosarcoma.[169]

Osteosarcoma of the jaw. Although not technically recognized as an entity in the WHO classification of osteosarcomas, gnathic osteosarcoma is distinctive enough to be discussed individually.[172] Patients affected are slightly older (average age, 34 years), and most lesions show a prominent chondroblastic component (Fig. 40.23). The most common sites of involvement are the body of the mandible

For personal use only. No other uses without permission. Copyright ©2017. Elsevier Inc. All rights reserved.

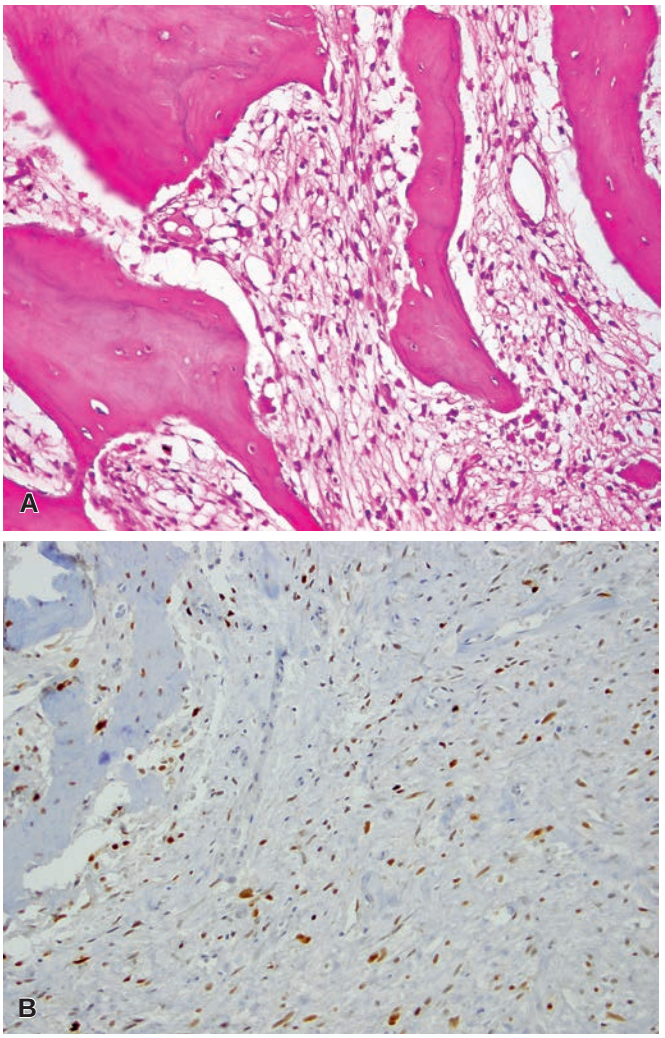

Figure 40.21 Parosteal Osteosarcoma. A, Mildly atypical spindle cells grow between irregularly shaped woven bone trabeculae. **B,** An immunostain for MDM2 is positive in the majority of the spindled cells in parosteal osteosarcoma.

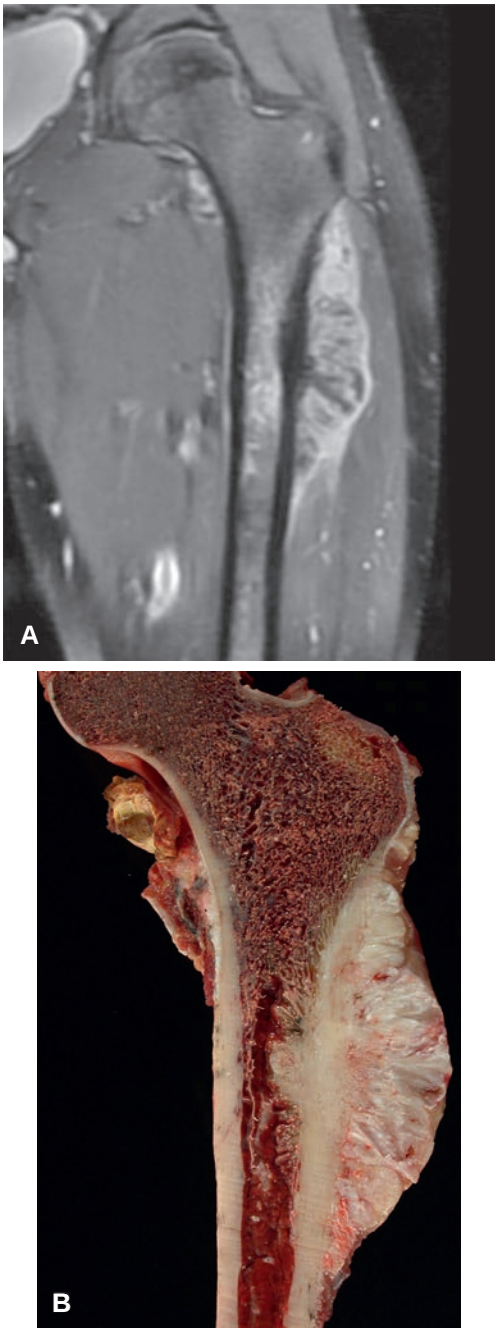

Figure 40.22 A, MRI and **B,** gross features of periosteal osteosarcoma. The lesion arises from the surface of the proximal femoral metadiaphysis, and the cut surface is cartilaginous and contains reactive bone oriented perpendicular to the femoral surface.

and the alveolar ridge of the maxilla. The prognosis is relatively good.

Osteosarcoma in Paget disease. Most cases of Paget osteosarcoma arise in the setting of polyostotic Paget disease. The most common locations are the pelvis, humerus, femur, tibia, and skull.[173–175] Their prognosis is extremely poor.

Therapy. Formerly, the therapy for osteosarcoma of the extremities typically consisted of amputation or disarticulation, depending on the location of the tumor, and overall survival was less than 20%. Current treatment protocols include neoadjuvant chemotherapy, followed by limb salvage surgery when feasible, and further chemotherapy following resection.

Microscopic studies of the tumor successfully treated with chemotherapy show extensive areas of necrosis and hemorrhage[176]; sites where viable tumor is more likely to persist are the soft tissue, adjacent to the cortex, and adjacent to the growth plate (Fig. 40.24).[177] The presence of extensive tumor necrosis following chemotherapy constitutes a good prognostic sign[178,179] (see next section).

Prognosis. The overall prognosis for osteosarcoma has significantly improved. For many years, the 5-year survival rate fluctuated very little from the figure of 20% in most series. Recently, many reports listing 5-year disease-free rates of 60% or better have appeared.[180] The routine use of multiagent neoadjuvant chemotherapy has had a dramatic positive effect on prognosis; patients with greater than 90% necrosis following chemotherapy generally have a better prognosis than those with less than 90% necrosis.[181]

A variety of other factors, including age, tumor size, stage, location, and surgical margins, have been examined with respect to prognosis.[178,182,183] However, the plateau in prognosis has led investigators to look beyond clinical parameters in the hope of discovering

For personal use only. No other uses without permission. Copyright ©2017. Elsevier Inc. All rights reserved.

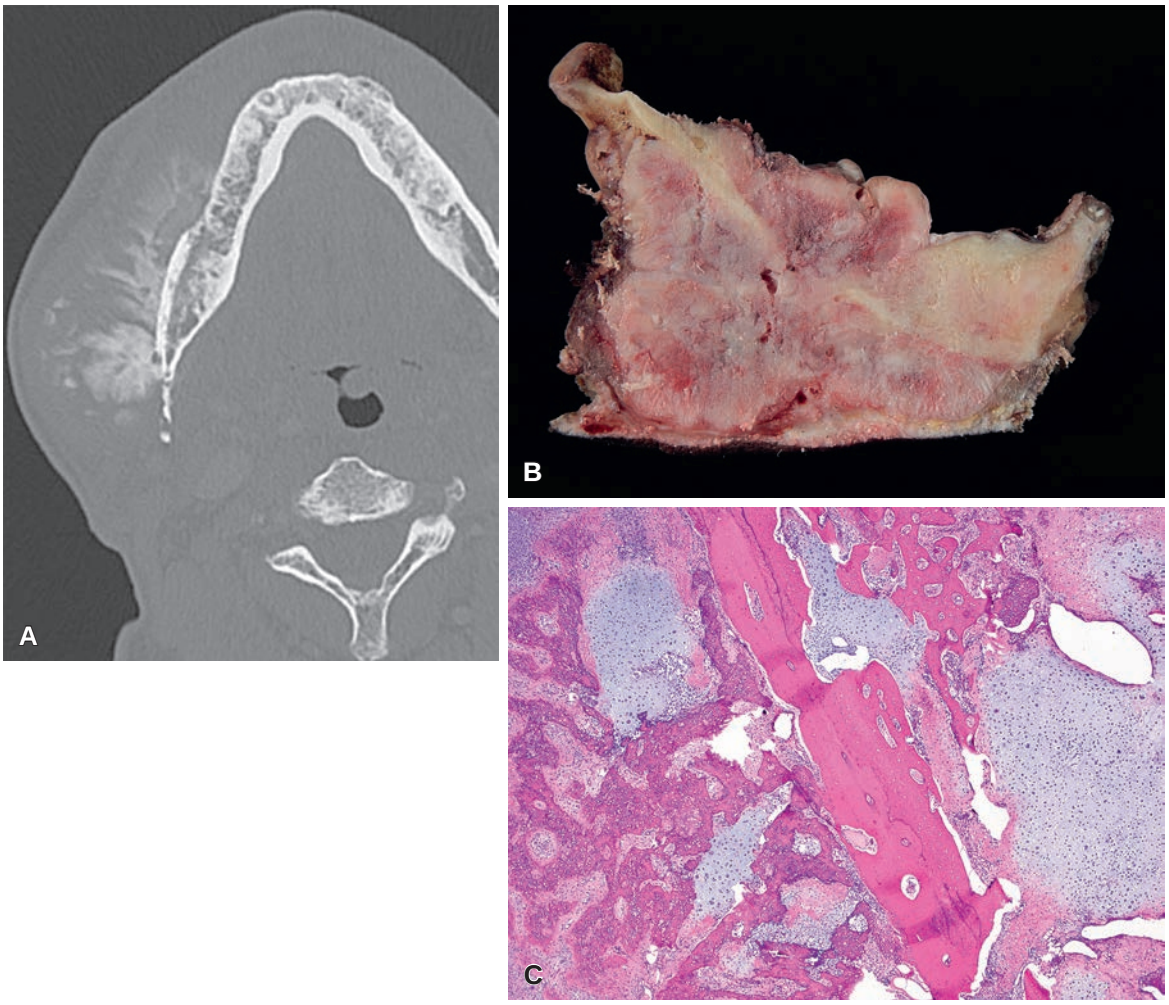

Figure 40.23 **A,** CT and **B,** gross features of osteosarcoma of the jaw. **C,** Most gnathic osteosarcomas are of the chondroblastic variety.

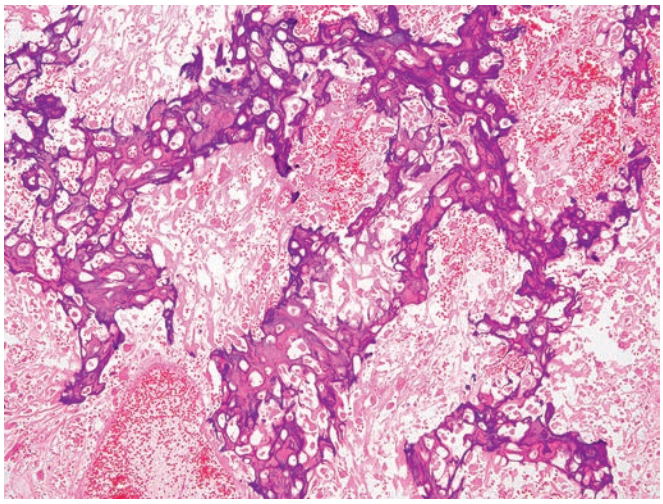

Figure 40.24 When treated with neoadjuvant chemotherapy, susceptible osteosarcomas show dropout of viable tumor cells ("necrosis"), but the osteoid matrix persists.

improved treatment regimens. Historically, the significance of P-glycoprotein and HER2/neu expression was heavily studied but highly controversial.[184–186] More recently, expression of p16, the product of the *CDKN2A* gene, has been shown to correlate with response to chemotherapy and outcome in high-grade localized osteosarcoma.[187–189]

Cartilage-Forming Tumors

Enchondroma

Enchondromas are relatively common neoplasms that occur over a wide age range. The most common site of origin is the small bones of the hands and feet, and enchondromas are extremely uncommon in flat bones. Enchondromas are non-growing lesions that are asymptomatic and often discovered incidentally during the work-up of other conditions such as arthritis, internal derangement of the knee, rotator cuff tears, or in the evaluation of a patient for metastatic disease.[190]

Enchondromas are composed of lobules of hyaline cartilage, often separated by normal cancellous bone or marrow. The lobules are often bounded by bone (so-called encasement pattern), and endochondral ossification may be present at the periphery of individual lobules (Fig. 40.25). Enchondromas lack invasive properties, differentiating them from low-grade chondrosarcomas.

For personal use only. No other uses without permission. Copyright ©2017. Elsevier Inc. All rights reserved.

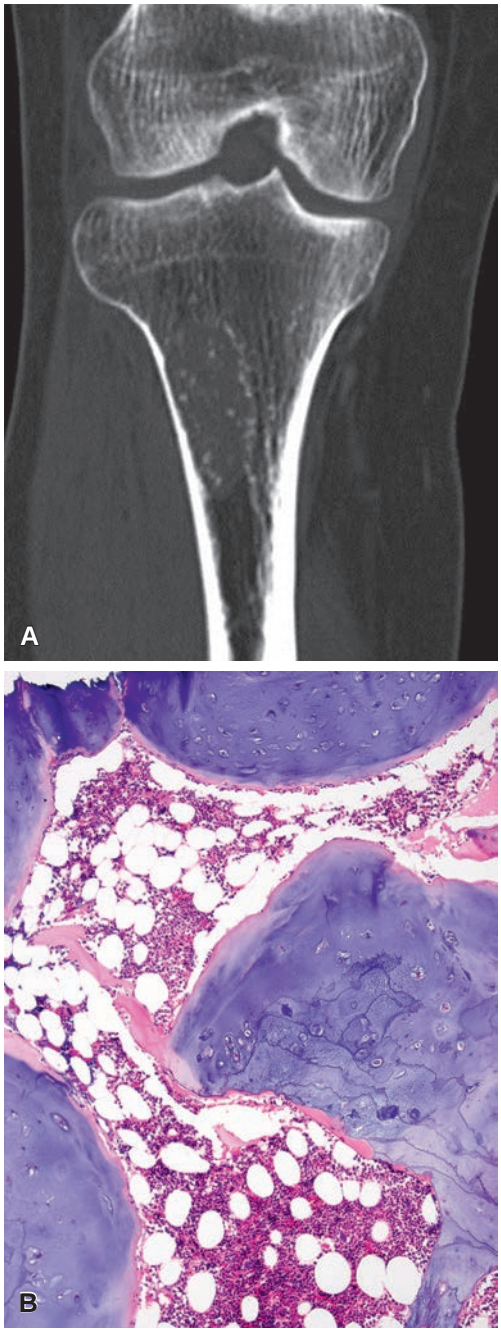

Figure 40.25 **A,** Coronal-plane CT shows a circumscribed metaphyseal enchondroma with stippled calcifications. **B,** Histologically, enchondromas are composed of lobules of mature hyaline cartilage which are partially or complete encompassed by bone.

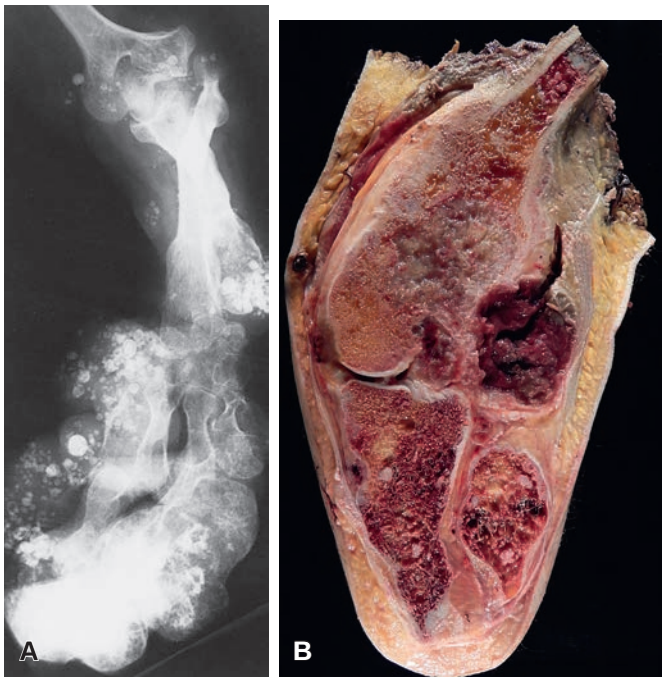

Figure 40.26 **A,** Arm of a patient affected by Maffucci syndrome. Innumerable chondromas are seen concentrated in the distal aspect of the extremity, and calcified phleboliths indicate hemangiomas in the soft tissue. **B,** Above-knee amputation specimen from a patient with Maffucci syndrome who developed a chondrosarcoma of the distal femur. Nodules of enchondroma can also be seen in the tibial and fibular stumps.

Cytologically, there is significant overlap between enchondromas and low-grade chondrosarcomas, and high-magnification evaluation cannot reliably separate these two entities. Nonetheless, most enchondromas are paucicellular and contain small, pyknotic chondrocyte nuclei. Lesions arising in the small bones of the hands and feet, those occurring in the setting of enchondromatosis, and those in children may appear somewhat more cellular.[191]

The differentiation of enchondroma from low-grade chondrosarcoma cannot be reliably achieved without radiographic (and clinical) correlation. Enchondromas are typically radiolucent with areas of mineralization that vary from punctate to ring-like. Endosteal scalloping may be seen with both enchondromas and low-grade chondrosarcomas (see later); however, endosteal scalloping associated with cortical thickening is an ominous feature. The most important radiographic features of enchondromas are those that are not present, including extensive bone destruction, cortical destruction, periosteal reaction, and the formation of a soft tissue mass.[191–194] It is important to understand that the radiographic features that help distinguish enchondromas from low-grade chondrosarcomas in the long bones are not applicable to lesions in the small bones of the hands and feet, in the setting of enchondromatosis, or in skeletally immature patients.

Enchondromas of long bones may be managed by observation alone, whereas those in the hands or feet may require curettage. Biopsy of well-differentiated cartilage tumors is of limited utility, and sampling issues often preclude reliably distinguishing enchondromas and low-grade chondrosarcomas. It should be emphasized that radiographic and clinical features are extremely valuable in separating enchondroma from low-grade chondrosarcoma.

Multiple enchondromas having a predominantly unilateral distribution are referred to as *Ollier disease*. The association of multiple enchondromas with soft tissue hemangiomas (including spindle cell hemangiomas) is known as *Maffucci syndrome* (Fig. 40.26).[195,196] In both of these nonheritable conditions, there is a significant risk of malignant transformation, usually in the form of chondrosarcoma.[197–200]

Periosteal (juxtacortical) chondromas are much less common than enchondromas. They arise from the periosteal region of a long bone, often the humerus, or a small bone of the hand or foot.[201,202] They characteristically erode and induce reactive changes in the underlying cortex. Radiographically, periosteal chondromas are small,

For personal use only. No other uses without permission. Copyright ©2017. Elsevier Inc. All rights reserved.

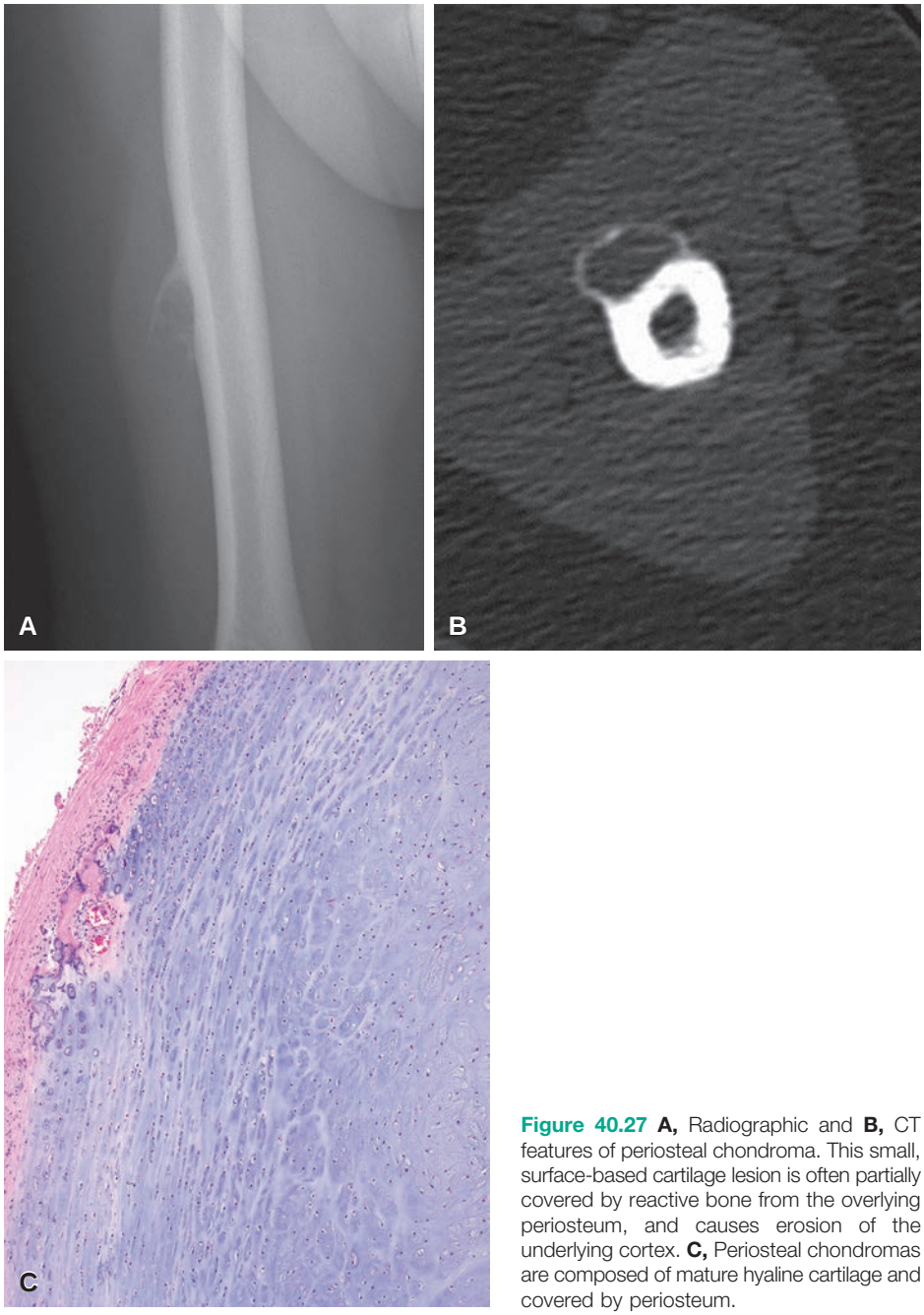

Figure 40.27 **A,** Radiographic and **B,** CT features of periosteal chondroma. This small, surface-based cartilage lesion is often partially covered by reactive bone from the overlying periosteum, and causes erosion of the underlying cortex. **C,** Periosteal chondromas are composed of mature hyaline cartilage and covered by periosteum.

circumscribed surface lesions that scallop the underlying cortex and are often accompanied by a buttress of reactive bone at the advancing edges of the lesion.[203]

Microscopically, periosteal chondroma tends to be more cellular than its medullary counterpart and may contain mild atypia (Fig. 40.27).[201]

Solitary enchondromas, periosteal chondromas, and the enchondromas of Ollier and Maffucci syndrome have heterozygous mutations in the *IDH1*/*IDH2* genes.[204]

Although not strictly a chondroma, the peculiar chest wall lesion of infancy known as **vascular and cartilaginous hamartoma (chest wall hamartoma, mesenchymal hamartoma)** is discussed here because of its benign nature and predominant cartilaginous composition.[205,206] These chondroid areas, which often exhibit endochondral ossification, are mixed with spindled cells forming vascular channels, hemangioma-like foci, and aneurysmal bone cyst-like foci. Most of the cases are already present at birth, and the behavior is benign.

Osteochondroma and Related Lesions

Osteochondroma is one of the most frequently encountered benign bone tumors in surgical pathology. The average age of the patient at onset is approximately 10 years; in the large majority of the cases, the tumor appears before the patient is 20 years old. It is usually asymptomatic, but it may become symptomatic if the stalk fractures, an overlying bursa develops, or if the mass impinges on adjacent neurovascular structures.[207] The most common locations are the metaphyses of the distal femur, proximal tibia, proximal humerus, and pelvis.

Radiographically, osteochondromas have a very characteristic appearance. These exophytic osteocartilaginous lesions can be

For personal use only. No other uses without permission. Copyright ©2017. Elsevier Inc. All rights reserved.

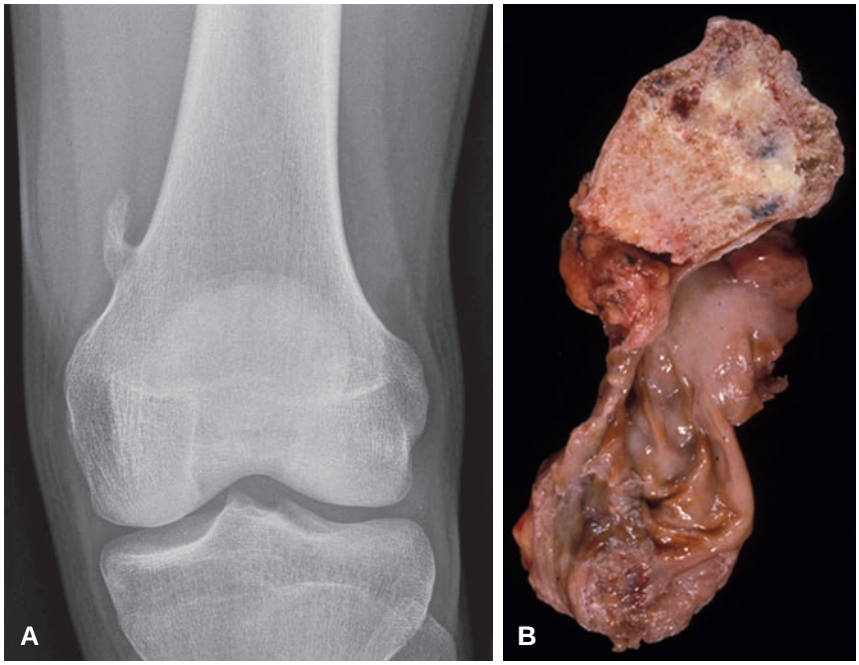

Figure 40.28 **A,** Radiograph showing a pedunculated osteochondroma arising from the distal femoral metaphysis and pointing away from the knee joint. **B,** Grossly, this osteochondroma was covered by only a thin cartilage cap and was complicated by the formation of a bursa.

pedunculated (with a thin stalk) or sessile (with a broad base). The cortical and medullary portions of the osteochondroma stalk merge with the same structures in the underlying bone (Fig. 40.28). These features are easily demonstrated on computed tomography (CT). The cartilage cap of the osteochondroma, best assessed with MRI, seldom exceeds 1 cm, is typically thinner than that, and diminishes as the patient's skeleton matures.[208]

Grossly, the surface of an osteochondroma is covered by a thin layer of fibrous tissue that represents a continuation of the periosteum. The measurable hyaline cartilage cap ranges from a few millimeters to a centimeter in thickness and is often thicker in skeletally immature patients. The surface may appear bosselated in larger sessile osteochondromas. The junction of the cartilage cap and underlying stalk contains calcified cartilage, and the stalk itself is composed of cortical and cancellous bone.

Microscopically, the cartilage cap is composed of hyaline cartilage, and endochondral ossification is evident at the junction of the cap and underlying stalk. The stalk is composed of cortical and cancellous bone (Fig. 40.29). The cap of the osteochondroma actively proliferates until the patient reaches skeletal maturity. In older patients, an osteochondroma may lack a cartilage cap altogether. A bursa may develop around the head of a longstanding osteochondroma; in turn, this bursa may develop complications such as osteocartilaginous loose bodies or synovial (bursal) chondromatosis.

Multiple hereditary exostoses (MHE) is an autosomal dominant condition characterized by multiple osteochondromas that are identical to sporadic osteochondromas. Because there is variable penetrance and expression in this disorder, the number of osteochondromas may vary considerably. In addition to multiple osteochondromas, patients often have modeling defects at the ends of bones and other bone deformities.

MHE is caused by germline mutation in the *EXT1* (at 8q24) or *EXT2* (at 11p11–12) genes.[209] These genes have been implicated in the formation of both sporadic and hereditary osteochondromas; defects in *EXT1* are roughly twice as common as defects in *EXT2*.[210–212]

Secondary chondrosarcomas arise in a very small proportion of solitary osteochondromas, but the incidence reaches 10% in the patients with MHE. The cells in secondary chondrosarcoma are frequently wild type for *EXT* genes, suggesting that separate genetic alterations are responsible for the malignant conversion.[213–216]

Osteochondroma should be distinguished from the **bizarre parosteal osteochondromatous proliferation (Nora lesion)**, which usually involves the small bones of the hands and feet[217,218] and occasionally in other long and flat bones.[219,220] These lesions are radiographically distinctive but can simulate chondrosarcoma microscopically because of the presence of enlarged, bizarre, and binucleated chondrocytes.[218,221] Recurrent chromosomal alterations have been found, suggesting that this condition is of neoplastic nature.[222]

Subungual exostosis (Dupuytren exostosis) is an osteochondroma-like lesion involving the distal phalanx, most commonly located on the great toe. This lesion is histologically similar to bizarre parosteal osteochondromatous proliferation and contains a proliferating cartilaginous cap that merges into relatively mature cancellous bone at its base. These exostoses may recur but are invariably benign.[223,224] Similar to bizarre parosteal osteochondromatous proliferation, cytogenetic studies have demonstrated a recurrent t(X;6), suggesting this is likely a neoplastic process.[225–227]

Dysplasia epiphysealis hemimelica (Trevor disease), a rare developmental disorder of childhood characterized by asymmetric enlargement of the epiphyseal cartilage of long bones, is yet another condition that can mimic osteochondroma.[228]

Osteochondromyxoma is a rare recently described congenital neoplasm associated with lentigines and other extraskeletal disorders; the syndrome seems to represent a variation of the Carney complex.[229]

Chondroblastoma

Chondroblastoma occurs predominantly in skeletally immature patients under 20 years of age and can be quite painful.[230] It usually arises in the epiphysis or apophysis of long bones prior to skeletal

For personal use only. No other uses without permission. Copyright ©2017. Elsevier Inc. All rights reserved.

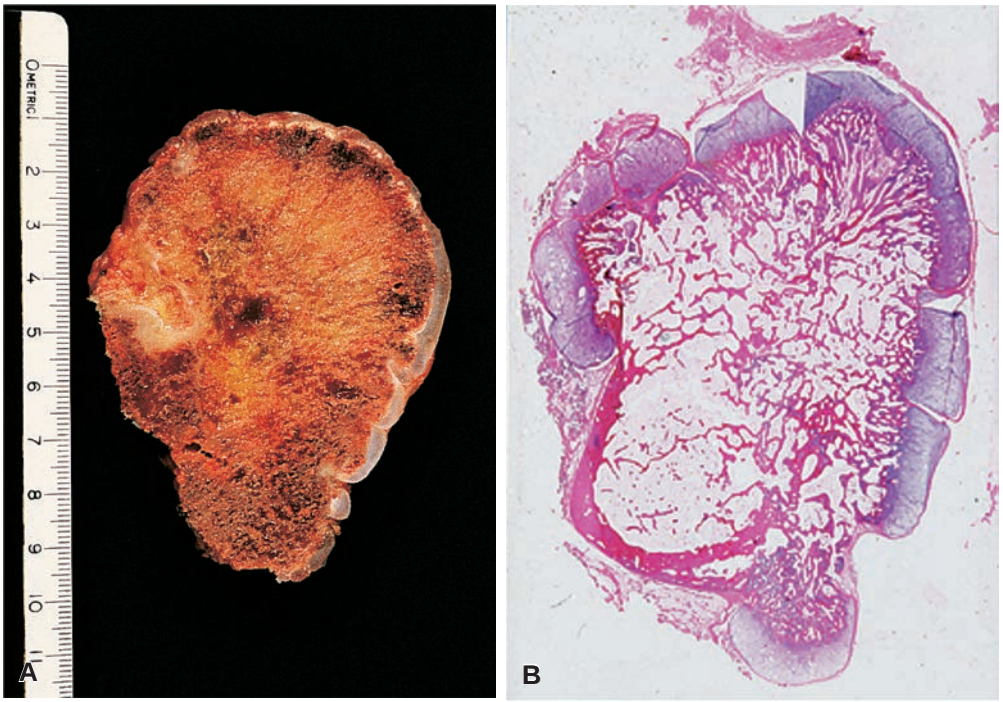

Figure 40.29 **A** and **B,** Gross and whole-mount appearance of osteochondroma. Mature bone is covered by a well-differentiated cartilaginous cap.

maturity, particularly in the distal femur, proximal humerus, and proximal tibia.

Radiographically, chondroblastoma usually appears as a sharply circumscribed radiolucent lesion and may contain small foci of mineralization. MRI typically shows extensive perilesional edema.[231] From the epiphysis, it may extend into the metaphyseal area or the joint space. Rarely, it is found entirely in a metaphyseal location or in a small bone.[232,233]

Microscopically, this lesion may be confusing because of its extreme cellularity and variability.[234] The occasional scattered collections of giant cells may lead to an erroneous diagnosis of giant cell tumor (Fig. 40.30). The basic tumor cell is the chondroblast with only a limited capacity for the production of a cartilaginous matrix. The shape of this cell is usually epithelioid, although spindle elements can also be present. Chondroblasts have sharply circumscribed cytoplasmic borders, and the nuclei vary in shape from round to indented and lobulated; some resemble those of Langerhans cells with a prominent longitudinal nuclear groove. Mitoses are not prominent. Recurrent lesions may show some degree of atypia, a feature that should not be interpreted as a sign of malignant transformation. A distinctive microscopic change is the presence of small zones of calcification. The calcifications range from a network of thin lines ("chicken wire") to obvious deposits surrounded by giant cells. The cartilaginous matrix in chondroblastoma often has an immature, eosinophilic appearance, and hyaline cartilage is uncommon. Secondary aneurysmal bone cyst is present in a significant number of chondroblastomas.

Immunohistochemically, the cells of chondroblastoma coexpress vimentin and S-100 protein. They may also be immunoreactive for SOX9, low-molecular-weight cytokeratins, p63, neuron-specific enolase, and muscle-specific actin.[235,236]

Recently, it has been shown that chondroblastomas have distinctive driver mutations in the genes that encode histone H3.3. Chondroblastomas harbor mutations in the *H3F3B* gene far more commonly than the *H3F3A* gene.[237] An antibody directed against the H3F3 K36M mutation has been found to be specific for chondroblastoma.[238]

The diagnosis is possible on the basis of fine-needle aspiration material, which in a typical case will consist of neoplastic chondroblasts, multinucleated osteoclast-like giant cells, and chondroid matrix fragments.[239] Curetting with bone grafting, which is the preferred treatment, provides local control in over 80% of the cases. Local recurrences can be treated similarly.[240]

Several cases of chondroblastoma, microscopically indistinguishable from the rest, have behaved locally in an aggressive fashion, invading the soft tissues and developing tumor thrombi in angiolymphatic channels. Most of these aggressive tumors have been located in the pelvis.[241] A few others have given rise to distant metastases, usually to the lungs.[242–245] In nearly all of the reported cases of this phenomenon, the metastases have occurred after surgical manipulation of the primary tumor.[246]

Chondromyxoid Fibroma

Chondromyxoid fibroma of bone is a rare benign tumor of cartilaginous nature.[247] It usually occurs in the long bones of young adults, but it has also been reported in the small bones of the hands and feet, pelvis, ribs, vertebrae, and skull base. In the skull base or flat bones, chondromyxoid fibroma may be misdiagnosed as myxoid chondrosarcoma or chordoma.[248]

Radiographically, it is sharply defined and often has a pronounced shell of surrounding reactive bone (Fig. 40.31). It is usually located in the medullary portion of the bone, but a juxtacortical variant arising on the bone surface has been described.[249] Grossly, it is solid and yellowish white or tan, replaces bone, and thins the cortex.

Microscopically, chondromyxoid fibroma is distinctly lobular, with individual lobules composed of paucicellular myxochondroid matrix separated by intersecting bands of highly cellular tissue composed of fibroblast-like spindle cells and osteoclasts (Fig. 40.32).[250]

For personal use only. No other uses without permission. Copyright ©2017. Elsevier Inc. All rights reserved.

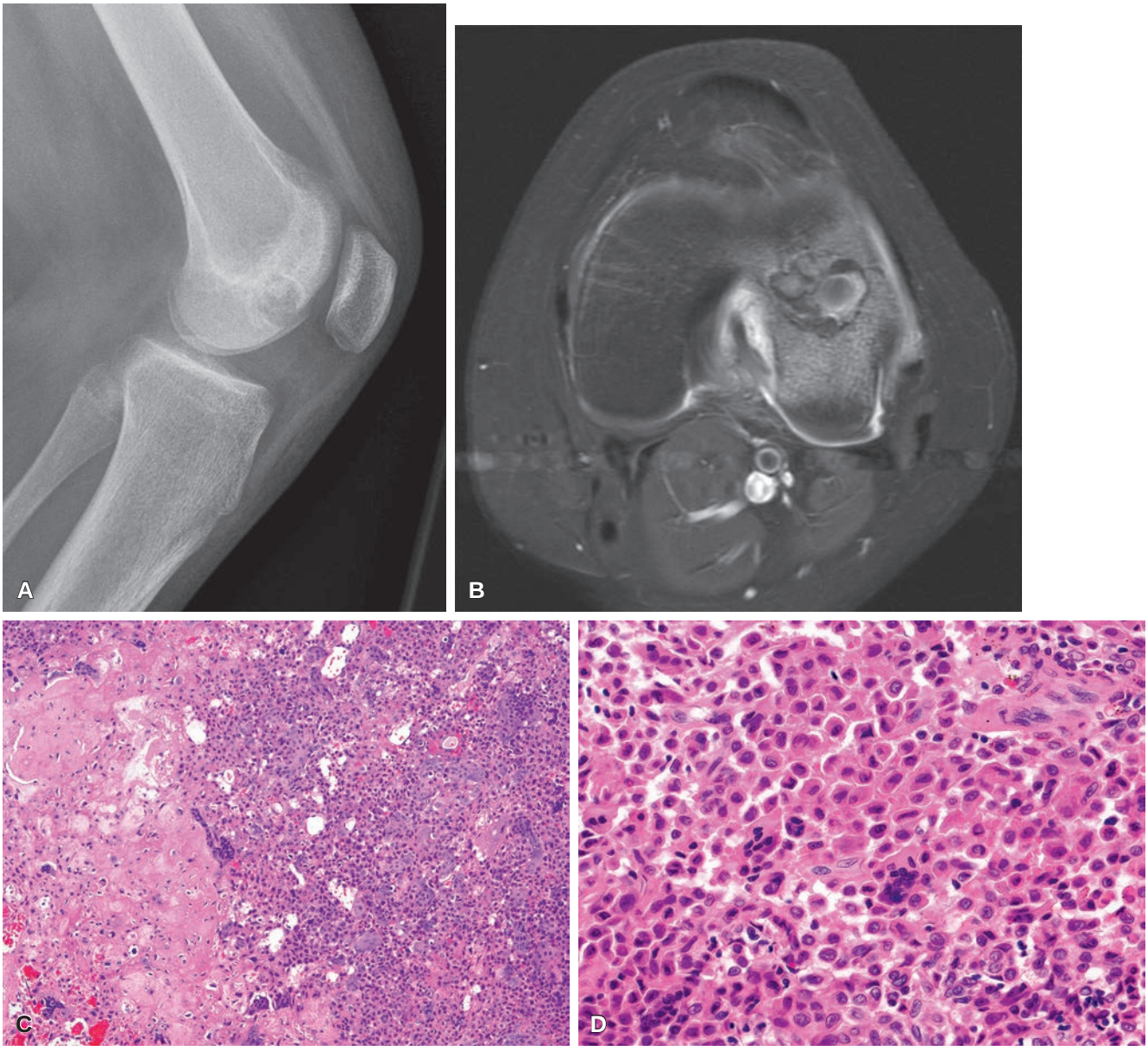

Figure 40.30 Chondroblastoma. A, Lateral radiograph of the knee shows a well-circumscribed radiolucent lesion arising in the epiphysis. **B,** MRI shows the circumscribed chondroblastoma with intense surrounding edema, a characteristic imaging feature. **C,** On low magnification, chondroblastomas are composed of islands of immature cartilage, mononuclear chondroblasts, and multinucleated giant cells. **D,** Chondroblasts have characteristic features, including well-defined cytoplasmic borders and longitudinal nuclear grooves.

Calcification may occur, particularly in the juxtacortical variant.[249] The occasional presence of large pleomorphic cells may result in an erroneous diagnosis of chondrosarcoma, particularly in recurrent lesions.[251,252] However, mitotic figures are exceptional. Some tumors show a combination of the features of chondroblastoma and chondromyxoid fibroma, and in such cases radiographic information must be incorporated for accurate diagnosis.

Immunohistochemical reactivity for S-100 protein is the rule, in keeping with its presumed cartilaginous nature,[253] but there are also cells with myofibroblastic and myochondroblastic features.[254] The basic cartilaginous nature of this tumor has been demonstrated through its immunoreactivity for SOX9 (an essential regulator of chondrogenesis) and further supported by the presence of type II collagen. In contrast to chondroblastoma, it is consistently negative for keratin.

Cytogenetically, chondromyxoid fibroma is characterized by rearrangements of chromosome 6 at band q13 or q25.[255,256] Aberrations in 6q13 map to the *COL12A1* locus.[257]

Local recurrence follows curettage of chondromyxoid fibroma in about 25% of cases, sometimes after an interval as long as 30 years.[258] Soft tissue extension or implantation may occur,[259] but distant metastases have not been reported.

Chondrosarcoma

Chondrosarcoma, a malignant tumor with chondroid differentiation, is divided into two broad categories on the basis of microscopic

For personal use only. No other uses without permission. Copyright ©2017. Elsevier Inc. All rights reserved.

Figure 40.31 Radiograph of chondromyxoid fibroma, which appears as a well-defined metaphyseal radiolucency with surrounding reactive bone. The overlying cortex may be absent in larger lesions.

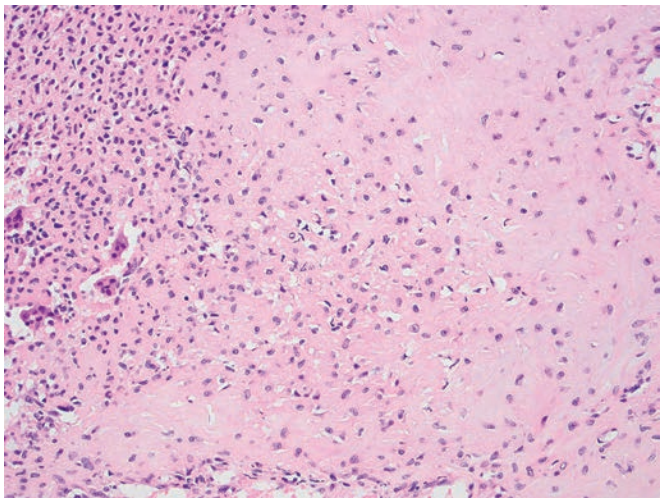

Figure 40.32 Microscopic appearance of chondromyxoid fibroma. Peripheral hypercellularity is common, and giant cells are encountered at the periphery of lobules.

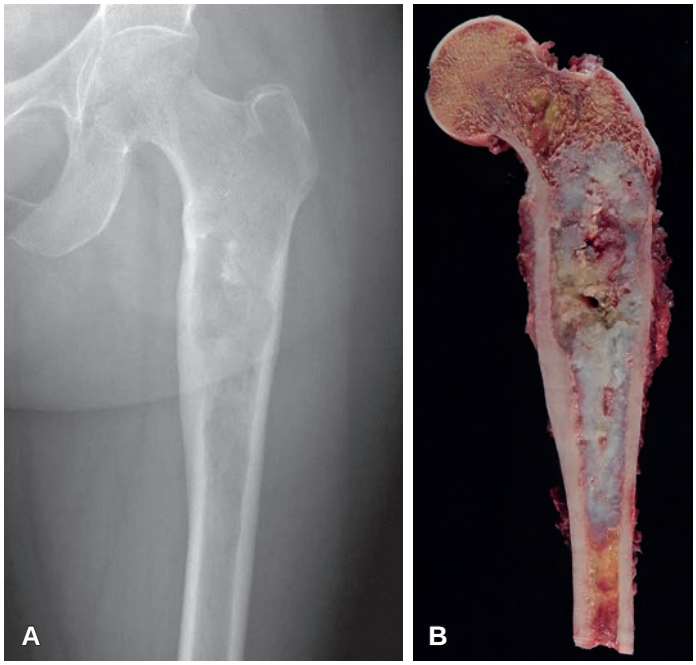

Figure 40.33 **A,** Radiographic and **B,** gross appearance of central chondrosarcoma. The lesion consists of gray hyaline cartilage which causes deep endosteal scalloping accompanied by cortical thickening.

criteria: conventional chondrosarcoma and chondrosarcoma variants. Each of these categories comprises several distinct types, some defined on microscopic grounds and others on the basis of location within the affected bone.

Conventional chondrosarcoma. The majority of patients with conventional chondrosarcoma are adults, usually aged 50 or more. Chondrosarcoma in childhood is distinctly uncommon,[260–262] and most malignant bone tumors in this age group exhibiting cartilage formation are actually osteosarcomas with a predominant cartilaginous component.

Chondrosarcomas are divided according to location into central (in the medullary cavity) or peripheral (on the surface of the bone), and can be primary (without an associated benign lesion) or secondary (associated with a benign precursor lesion) in either site.[76] **Central chondrosarcomas** are located in the medullary cavity, usually of a flat or long bone.[263] Although the radiographic features can vary depending on the grade, most central chondrosarcomas are radiolucent with areas of calcification (Fig. 40.33). Ill-defined margins, fusiform, expansile remodeling of bone with endosteal scalloping, and cortical destruction with a soft tissue mass are three important diagnostic signs.[191] The pelvic bones, ribs (usually at the costochondral junction), shoulder girdle, and femur are the most common locations. Chondrosarcomas of the small bones of the hands and feet are exceptional but have been described by several authors.[264–266] Chondrosarcoma can also involve the bones of the skull, especially the temporal bone and base of the skull, where the differential diagnosis also includes primarily chordoma.[267,268]

Peripheral chondrosarcomas may arise from the cartilaginous cap of a preexisting osteochondroma or far less commonly de novo (Fig. 40.34). Patients with MHE are particularly prone to this complication, as already indicated. The risk of malignant transformation in a solitary osteochondroma is between 1% and 2%. The signs of malignant progression in an osteochondroma include increased growth after skeletal maturity, or irregularity and thickening of the cartilage cap or destruction of the stalk radiographically.[269]

Juxtacortical (periosteal) chondrosarcoma is a rare tumor that commonly involves the diaphysis of a long bone (most often the femur) and is characterized by a cartilaginous lobular pattern with areas of spotty calcification and endochondral ossification.[270] These tumors are usually low grade and should be separated from the periosteal variant of osteosarcoma.[271]

Microscopically, conventional chondrosarcomas—whether central or peripheral—show a remarkably wide range of differentiation, the common denominator being the production of a cartilaginous matrix and the lack of direct bone formation by the tumor cells (see discussion later). The differential diagnosis between well-differentiated

For personal use only. No other uses without permission. Copyright ©2017. Elsevier Inc. All rights reserved.

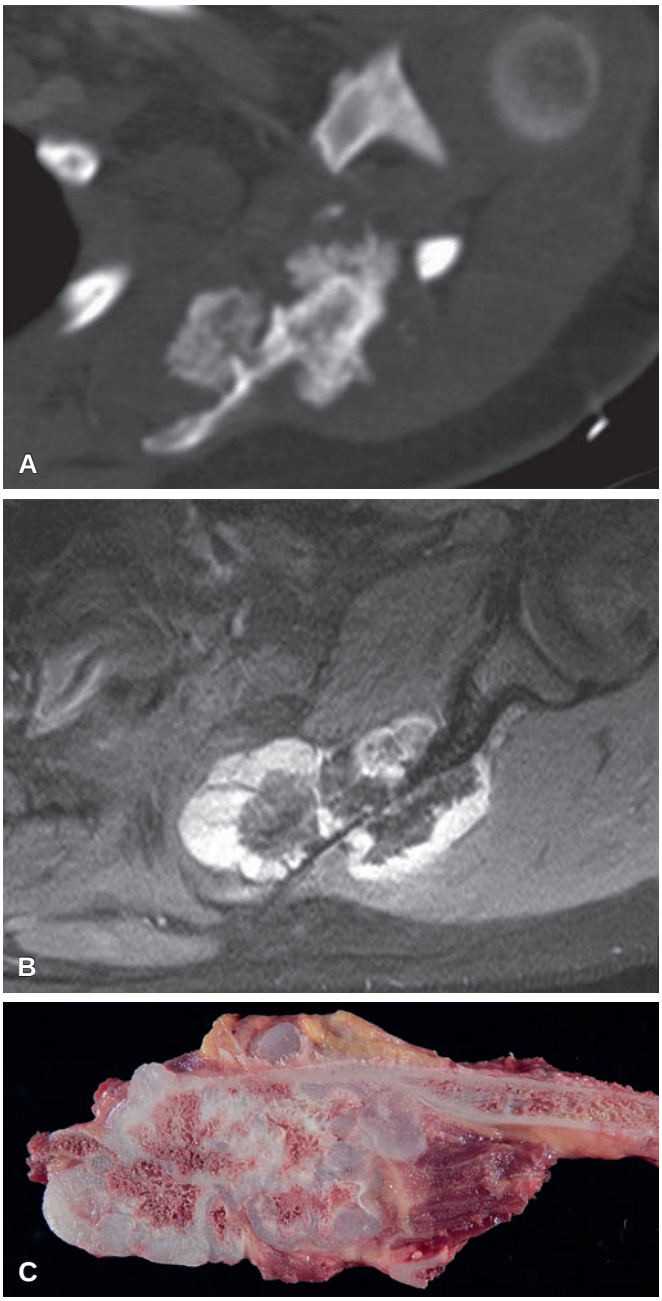

Figure 40.34 **A,** CT, **B,** MRI, and **C,** gross appearance of a secondary peripheral chondrosarcoma arising from an osteochondroma of the scapula. The cartilage cap is thick and highly irregular, and the lesion surrounds the scapula.

chondrosarcoma and enchondroma rests on a combination of clinical, radiographic, and architectural findings.[191] This differentiation can be very difficult and is subject to a distressingly high degree of interobserver variability.[272] Chondrosarcomas of all grades are characterized histologically by permeation and invasion. Mirra et al.[273] emphasized permeation of the bone marrow and cancellous bone with entrapment of host lamellar bone on all sides in well-differentiated chondrosarcoma as an important sign in the differential diagnosis with enchondroma. It cannot be overstated that correlation of the microscopic features with the clinical and especially the radiographic findings is essential in distinguishing benign and malignant hyaline cartilage tumors.

Peripheral chondrosarcomas are usually of low histologic grade. These tumors are characterized by thickening of the cartilage cap (often >3 cm) and the development of satellite nodules resulting in an irregular cartilage cap. Higher-grade chondrosarcoma is distinguished from osteosarcoma by the lack of direct osteoid or bone formation by the tumor cells. Bone can be present in a bona fide chondrosarcoma, but this is non-neoplastic and often represents either entrapped lamellar bone from the medullary cavity or results from endochondral ossification.

Cytogenetically, there is considerable heterogeneity among chondrosarcomas depending on grade, but also evidence that some of the karyotypic anomalies are not random.[274–276] *IDH1* and *IDH2* mutations are common in central chondrosarcoma,[204] and higher-grade chondrosarcomas can be distinguished from chondroblastic osteosarcomas on the basis of *IDH* mutation analysis.[277]

The management of chondrosarcoma is entirely surgical, and adjuvant therapies are of limited benefit. Higher-grade chondrosarcomas are treated with en bloc resection; conservative management of low-grade chondrosarcoma is used by some, while others also use resection techniques for these tumors.[278,279] Soft tissue implantation following biopsy is a well-known complication of chondrosarcoma. Therefore, biopsy tracts should be excised with the tumor.

The microscopic grade of chondrosarcomas is an important prognostic factor. Chondrosarcomas are divided into three grades based on cytologic features, cellularity, and mitotic activity.[280] Grade 1 tumors have similar cytologic features as enchondromas but show infiltrative properties. Grade 2 tumors often have abundant myxoid stroma and are more cellular and mitotically active than grade 1 tumors. Grade 3 tumors show high cellularity, marked cytologic atypia, and abundant mitotic activity and may be difficult to distinguish from chondroblastic osteosarcoma (Fig. 40.35). Survival is excellent for grade 1 tumors but steadily decreases with increasing grade.[280–282] Recurrences may be higher in microscopic grade than the original tumor.[283] Equally important prognostically is the adequacy of initial therapy.[284,285] An association between 6q13–21 chromosome aberrations and locally aggressive behavior has been described.[286] High-grade chondrosarcomas metastasize early, particularly to the lungs, but lymph node metastases are practically nonexistent.

Chondrosarcoma Variants

Clear Cell Chondrosarcoma. Clear cell chondrosarcoma is a rare variant of chondrosarcoma characterized by tumor cells with an abundant clear or ground glass cytoplasm and sharply defined borders, often interspersed with small trabeculae of woven bone, numerous multinucleated giant cells, and foci of cartilage.[287,288] It has overlapping clinical and radiographic features with chondroblastoma, and some have proposed that it may represent its malignant counterpart (Fig. 40.36).[289] Most patients are older than those affected by chondroblastoma.[290] Radiographically, the lesion is usually entirely radiolucent, often sharply circumscribed, and may be complicated by pathologic fracture. Most cases involve the proximal femoral or humeral epiphysis, and the behavior is generally that of a low-grade malignancy, with some outstanding exceptions.[291] In addition—and like conventional chondrosarcoma—it can undergo dedifferentiation.[292]

Cytogenetic analysis of clear cell chondrosarcoma has shown recurrent chromosome 9 and 20 abnormalities[293]; *IDH* mutations are absent.

Myxoid Chondrosarcoma (Chordoid Sarcoma). This variant of chondrosarcoma can occur in bone but is much more common in the soft tissues (see Chapter 41).[294,295] It is morphologically reminiscent of chordoma because of the rows of round to spindled cells separated by a myxoid background. Demmico et al. reported

For personal use only. No other uses without permission. Copyright ©2017. Elsevier Inc. All rights reserved.

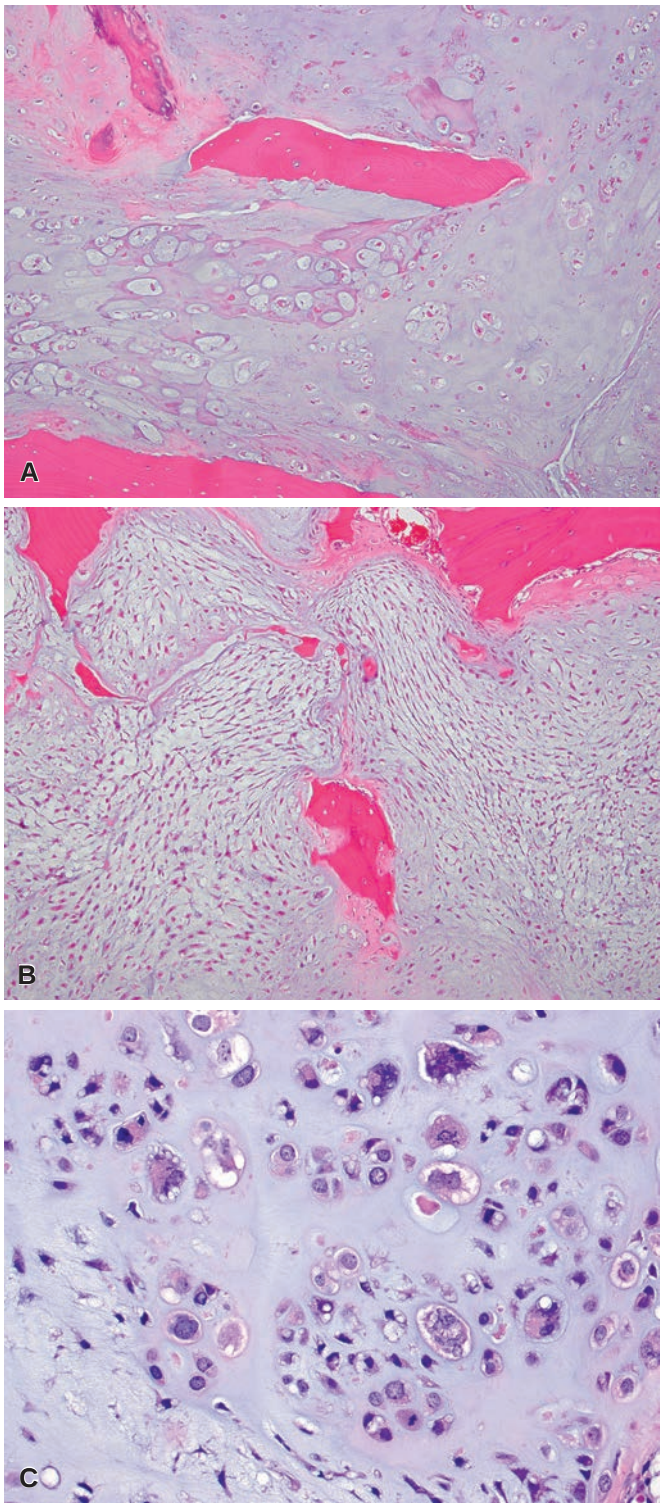

Figure 40.35 Microscopic features of **A,** grade 1, **B,** grade 2, and **C,** grade 3 chondrosarcoma.

five cases of osseous myxoid chondrosarcoma and demonstrated *EWSR1* and *NR4A3* gene rearrangements in all cases.[296]

Dedifferentiated Chondrosarcoma. The term dedifferentiated chondrosarcoma refers to the combination of low-grade chondrosarcoma with an intermixed high-grade sarcomatous component.[297–299] This phenomenon occurs most commonly in central chondrosarcoma but can occasionally be encountered in peripheral chondrosarcoma as well.[300,301] The dedifferentiation can be encountered in the initial lesion or in a locally recurrent tumor. The microscopic appearance of the high-grade component may resemble osteosarcoma, undifferentiated pleomorphic sarcoma, rhabdomyosarcoma, or other sarcomatous phenotypes, and there is typically a sharp transition between the low-grade and high-grade components (Fig. 40.37).[302,303] Simultaneous cytogenetic and immunophenotyping studies, as well as the finding that both components harbor *IDH1/2* mutations, suggest that both the differentiated and the "dedifferentiated" components originate from a common primitive mesenchymal cell progenitor, and that the term "dedifferentiated" may be an inaccurate designation.[304,305] At the molecular level, the process of anaplastic transformation is accompanied by overexpression of *TP53* and *HRAS* mutation.[306]

Regardless of terminology, the development of this component in chondrosarcoma is accompanied by a marked acceleration of the clinical course and a decidedly worsened prognosis.[307,308] The overall 5-year survival rate is around 10%.

Mesenchymal Chondrosarcoma. Mesenchymal chondrosarcoma is a relatively rare variant of chondrosarcoma that arises in females more commonly than males, most in the second or third decade of life. A high percentage of these neoplasms involve extraosseous sites and arise in the orbit, paraspinal region, meninges, or somatic soft tissue of the extremities. The bones most commonly affected are those of the axial skeleton and craniofacial bones, including the jaw, pelvis, ribs, and spine; however, bones of the extremities can also give rise to mesenchymal chondrosarcoma. The radiographic appearance resembles that of conventional chondrosarcomas in that most lesions contain foci of mineralization.[309,310] The prognosis is generally poor, although there is great variability in the clinical course.

Mesenchymal chondrosarcoma is characterized microscopically by a biphasic pattern in which areas of cellular cartilage are dispersed among a population of small, undifferentiated, round to spindled cells, often with staghorn-shaped blood vessels (Fig. 40.38).[309,310] The undifferentiated component can resemble malignant lymphoma or Ewing sarcoma. Small foci of osteoid matrix may be identified.

Immunohistochemically, the small cell component is positive for CD99 but not for S-100 protein; the latter is found instead in the chondroid areas. There is also nuclear immunoreactivity for Sox9 (a master regulator of chondrogenesis) and for osteocalcin.[311–315] Surprisingly, immunoreactivity for desmin and myogenin has been found in exceptional instances.[316]

Mesenchymal chondrosarcomas have a recurrent *HEY1-NCOA2* fusion, the detection of which may be useful in excluding other round cell neoplasms; *IDH* gene mutations are absent.[317]

Giant Cell Tumor

Giant cell tumor is usually seen in skeletally mature patients over 20 years of age.[318] It is more common in women than in men and seems to occur more frequently in China than in Western countries.[319] Giant cell tumors involve the epiphysis of a long bone, from which they may spread into the metaphyseal area, extend through the cortex, or even cross a joint space via structures such as the anterior cruciate ligament or ligamentum teres. The sites most commonly affected (in order of frequency) are the distal femur, the proximal tibia, and the distal radius.[318] It also occurs in the humerus, fibula, and skull, particularly the sphenoid bone. Occasionally, a giant cell tumor will be seen in a child[320] and/or in a metaphyseal or diaphyseal location.[321] Involvement of the bones of the hands and feet, jaw,

For personal use only. No other uses without permission. Copyright ©2017. Elsevier Inc. All rights reserved.

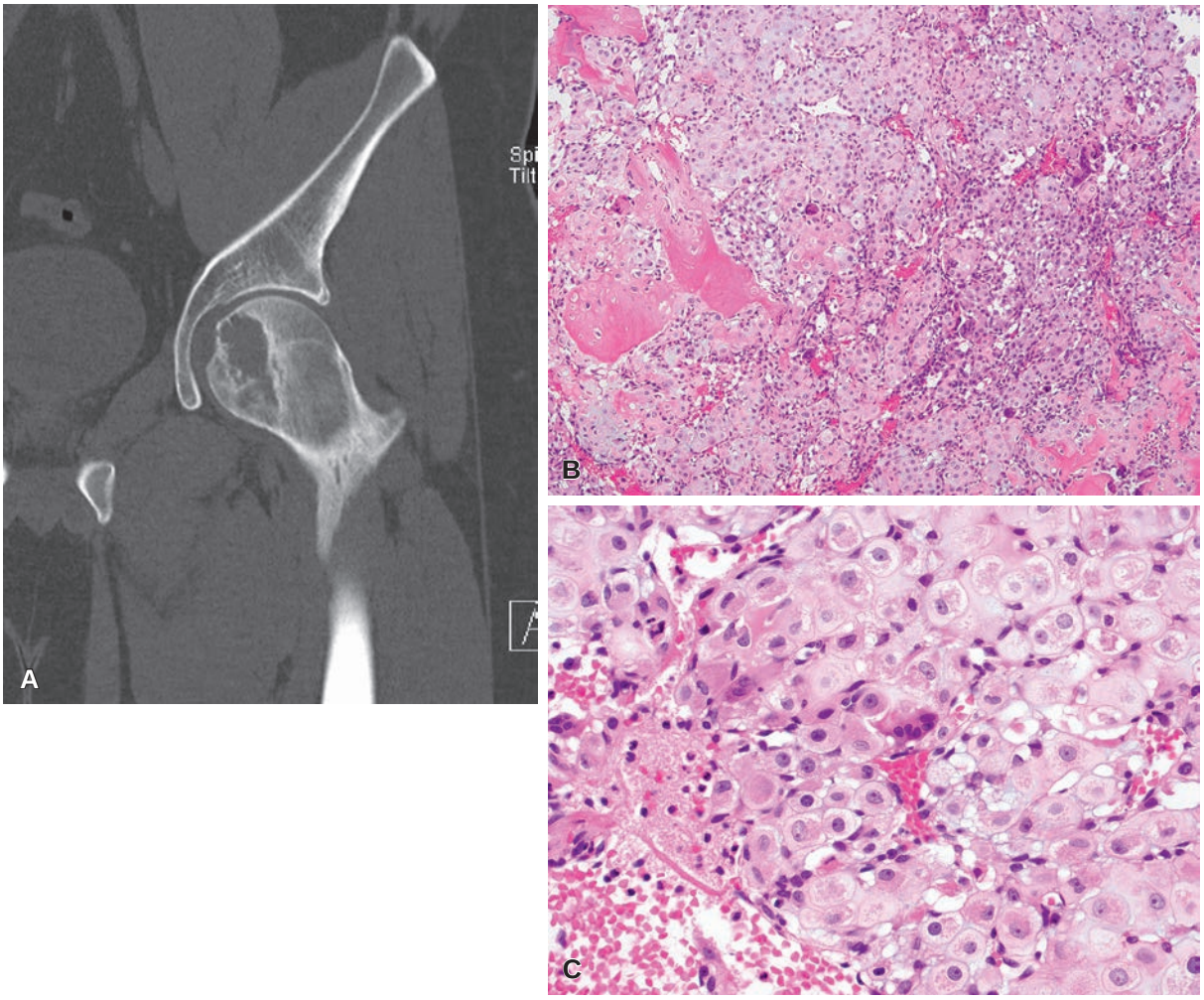

Figure 40.36 Clear Cell Chondrosarcoma. A, CT shows a deceptively circumscribed epiphyseal lesion, suggesting the possibility of a benign lesion. **B,** On low magnification, clear cell chondrosarcomas often contain large areas of woven bone and numerous multinucleated giant cells. **C,** The defining cells are large and contain either eosinophilic or clear cytoplasm, large nuclei, and a prominent central nucleolus.

and vertebrae (other than sacrum) is unusual. Although giant cell tumor has been documented at all of these sites, the occurrence of a giant cell–containing lesion in any of these locations should suggest an alternative diagnosis. Multicentricity has been reported, particularly in young patients and in the small bones of hands and feet.[322]

Radiographically, the typical appearance of a giant cell tumor is that of a radiolucent lesion involving the epiphysis and metaphysis. The lesion is usually well circumscribed, but lacks surrounding reactive bone. Giant cell tumor may be confined to the bone or extend into adjacent soft tissue.[323] Secondary aneurysmal bone cyst formation is better appreciated with CT or MRI (Fig. 40.39).

Grossly, the cut surface is solid or friable and has a variegated red–brown and yellow appearance. Hemorrhage and necrosis may be prominent. (Fig. 40.40). When the cortex is thinned or destroyed, a thin rim of reactive bone may surround the tumor.

Microscopically, the two main components of giant cell tumor are the so-called stromal cells and giant cells (Fig. 40.41). The giant cells are usually large and have over 20 or 30 nuclei. The giant cells are evenly dispersed among a population of mononuclear stromal cells, which are round to oval, and the nuclei of the two components frequently resemble one another. Mitoses can be prominent in the mononuclear stromal cells. Secondary changes, including hemorrhage, necrosis, fibrohistiocytic changes, or aneurysmal bone cyst may obscure the classic histologic features of giant cell tumor. In such cases, correlation of the histologic features with the radiographic findings is necessary for diagnosis. Symplastic or pseudoanaplastic changes are present in some giant cell tumors.[324]

Although the prominence of the giant cells gives this tumor its name, the principle tumor cells are a subset of the mononuclear cell component, while the remainder of the mononuclear cells are likely osteoclast precursors. The neoplastic stromal cells are osteoblast-like and express RANKL, which stimulates the formation of osteoclasts via the RANK-RANKL mechanism.[325] The giant cells resemble osteoclasts morphologically, ultrastructurally, histochemically, and immunohistochemically.[326–328]

Several important mutations have been identified in the neoplastic stromal cells of giant cell tumor. Kato Kaneko et al. recently identified *IDH2-R172S* mutations in 80% of the giant cell tumors they evaluated.[329] More recently, Behjati et al. identified driver mutations exclusive to the *H3F3A* gene in giant cell tumor.[237] A follow-up study by Presneau confirmed this finding but was not able to reproduce any *IDH2* mutations in their group of giant cell tumors.[330]

For personal use only. No other uses without permission. Copyright ©2017. Elsevier Inc. All rights reserved.

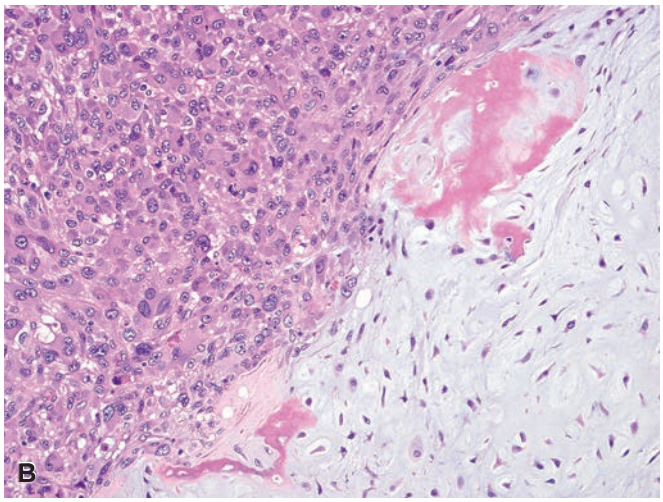

Figure 40.37 **A,** Gross and **B,** microscopic features of dedifferentiated chondrosarcoma. The low-grade chondroid component can be seen in the medullary cavity, and the high-grade component is present in the soft tissue.

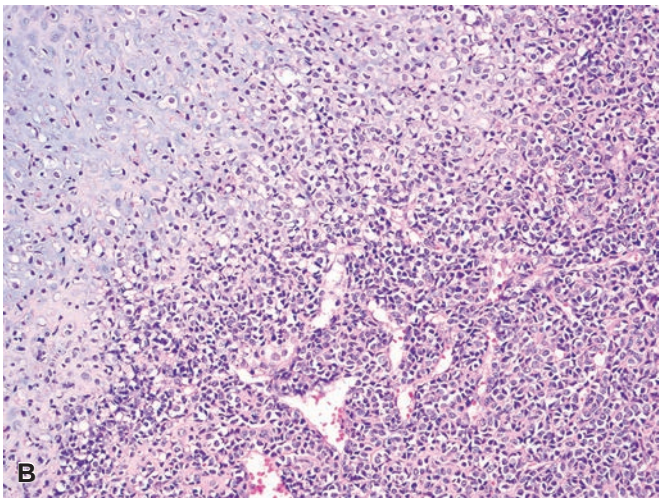

Figure 40.38 **A,** Gross photograph of a mesenchymal chondrosarcoma involving the bones of the midfoot. **B,** Mesenchymal chondrosarcomas contain areas of immature cartilage that alternate with primitive, round cell foci with prominent branching blood vessels.

Many benign lesions with giant cells have been confused with giant cell tumor in the past. A plethora of bone lesions—including fibrous cortical defect/nonossifying fibroma, chondromyxoid fibroma, chondroblastoma, Langerhans cell histiocytosis, brown tumor of hyperparathyroidism, giant cell reparative granuloma, and aneurysmal bone cyst—contain numerous giant cells. So-called giant cell tumors of tendon sheath are also unrelated to giant cell tumors of bone. One of the main microscopic differences between true giant cell tumor and these mimics resides in the spatial relationship between the giant and stromal cells. Giant cells tend to be distributed regularly and uniformly in giant cell tumor (except in areas showing secondary changes such as hemorrhage, fibrosis or fibrohistiocytic reaction), whereas in the lesions that simulate it, foci containing numerous, clumped giant cells alternate with large areas completely lacking this component. Additionally, most of these lesions are distinguishable with careful radiographic correlation as well. Although exceptions to all of the following statements have been recorded, a diagnosis of a lesion *other than* giant cell tumor should be favored if: (1) the patient is a child; (2) the lesion is located in the metaphysis or diaphysis of a long bone rather than the epiphysis; (3) the lesion is multiple (except if a patient has Goltz syndrome)[331]; and (4) the lesion is located in the vertebrae (other than sacrum), jaw (except for patients with Paget disease), or bones of the hands or feet. The distinction is of clinical importance because of the better prognosis associated with most of the giant cell–containing lesions that simulate giant cell tumor.

The treatment of giant cell tumor is usually surgical for tumors in most sites and consists of extended curettage with adjuvants and cementation with or without bone grafting.[332] En bloc excision is utilized less frequently. The use of radiation therapy should be reserved

For personal use only. No other uses without permission. Copyright ©2017. Elsevier Inc. All rights reserved.

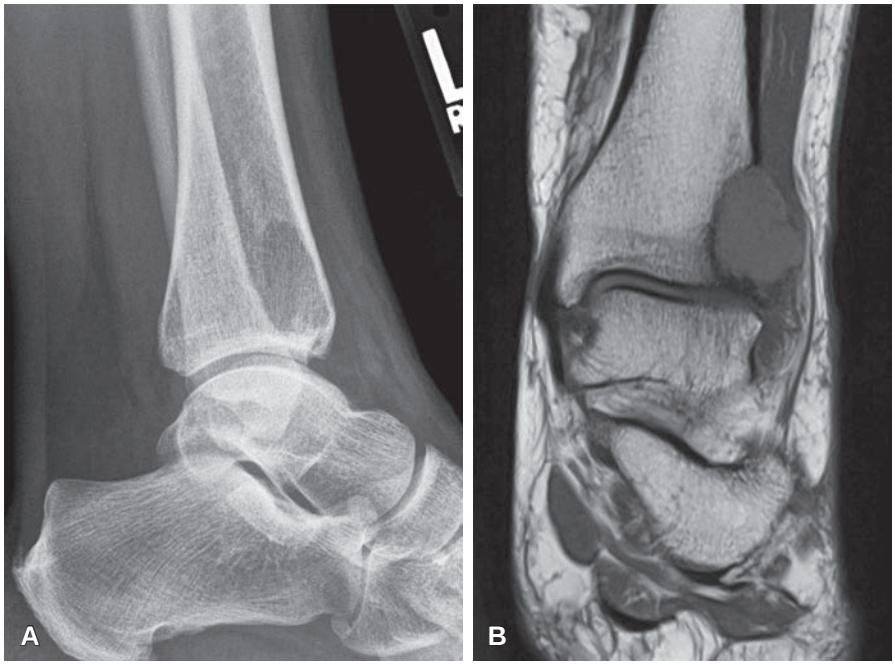

Figure 40.39 Radiographic Features of Giant Cell Tumor. A, Radiograph, **B,** MRI. Giant cell tumors involve the epiphysis and metaphysis of skeletally mature patients.

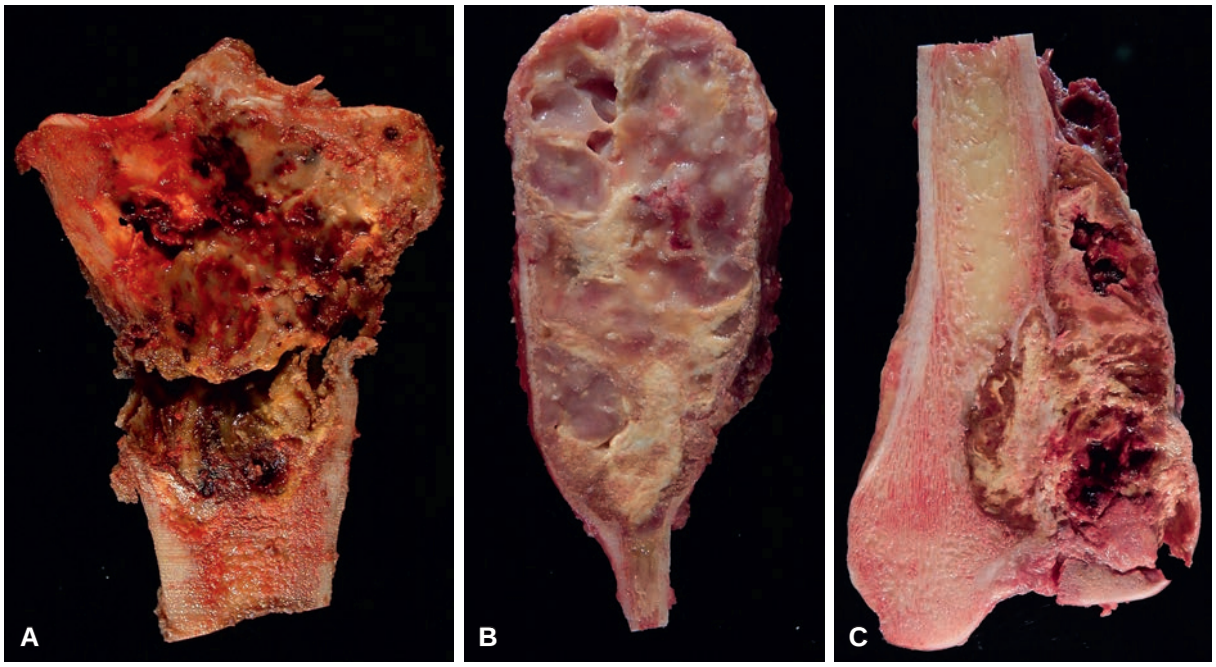

Figure 40.40 Gross Appearance of Giant Cell Tumor of Bone. This tumor can vary from red-brown and hemorrhagic, as in this example in the proximal tibia complicated by a pathologic fracture **(A)**, to yellow, as seen in this lesion in the fibula **(B)**. **C,** Giant cell tumor can aggressively destroy bone and involve soft tissue.

only for cases in which surgical removal is impossible, in view of the relatively high number of reported cases of malignant transformation following this therapeutic modality.[333] As a matter of fact, review of series of postradiation sarcomas of bone shows that in a disproportionate number of cases the initial lesion was a giant cell tumor. Giant cell tumors of the spine have been traditionally treated with radiation therapy, but they are also amenable to surgical excision.

There is growing experience with the treatment of giant cell tumors with denosumab, a monoclonal antibody antagonist of RANKL.[334] This drug offers an alternative to radiotherapy for lesions arising in locations not amenable to surgery or for local recurrences and is a highly effective adjuvant for local control. Histologically, denosumab-treated giant cell tumors show a marked diminution in the number of giant cells and an abundance of bone formation or calcification,

For personal use only. No other uses without permission. Copyright ©2017. Elsevier Inc. All rights reserved.

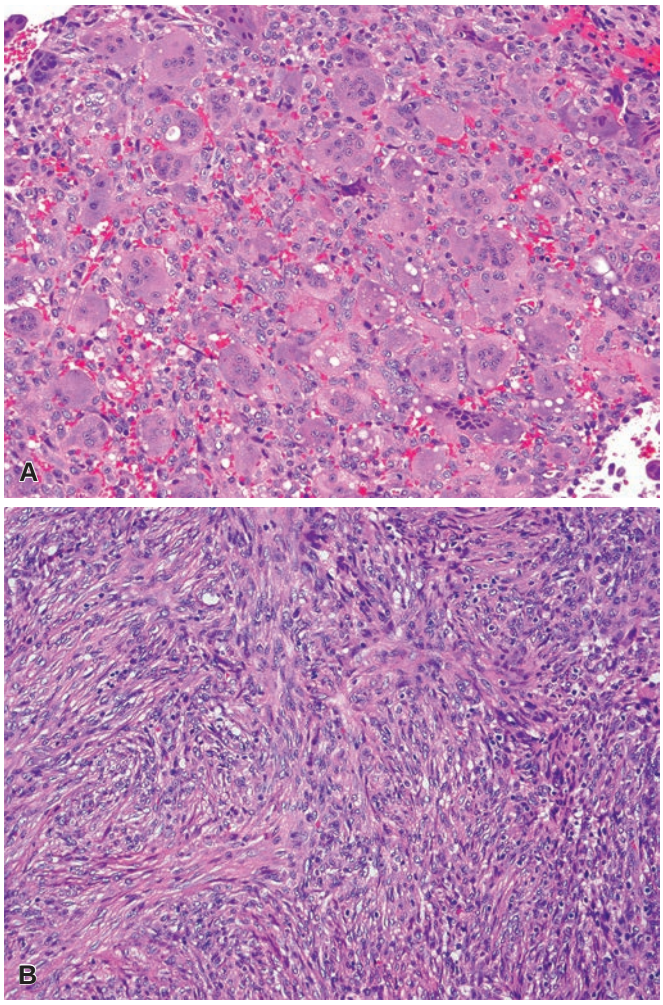

Figure 40.41 Giant Cell Tumor. A, The "typical" giant cell tumor contains numerous giant cells arranged diffusely and evenly, with mononuclear stromal cells in between. **B,** Some lesions may contain prominent fibrous or fibrohistiocytic areas devoid of giant cells.

resulting in an appearance resembling osteosarcoma. Lack of cytologic atypia, mitotic activity, and infiltrative borders are features that help to separate denosumab-treated giant cell tumor from true osteosarcoma.[335,336]

The natural history of giant cell tumor is that of a low-grade malignancy. A small number of giant cell tumors (1%–2%) metastasize, almost always following surgical manipulation. No relationship has been found between metastases and the presence of giant cell tumor invasion of blood vessels. Metastases are more likely in younger patients, from tumors located in the axial skeleton, following local recurrences, and in lesions that present with extraosseous extension.[337] Giant cell tumor metastases have a benign histologic appearance and do not ultimately cause death. Nevertheless, all patients with giant cell tumor are staged with imaging of the chest. Local recurrences follow curettage more often than resection.[338] Most cases of giant cell tumor exhibit chromosomal abnormalities, usually in the form of telomeric association that can involve a variety of chromosomes, such as 11p, 13p, 14p, 15p, 19q, 20q, and 21p.[339,340] Telomeric association is a rare form of cytogenetic abnormality characterized by end-to-end fusion of intact chromosomes. Clonal structural abnormalities may be present in addition.[341] There is no clear association between chromosomal aberrations and clinical outcome.

Malignant Giant Cell Tumor

As already mentioned, all giant cell tumors of bone should be regarded as potentially low-grade malignancies because of their tendency to recur and their occasional capacity to metastasize regardless of histologic appearance. The terminology related to malignant giant cell tumor is both confusing and controversial. "Primary" malignant giant cell tumor refers to a tumor that contains foci of typical giant cell tumor and pleomorphic sarcoma at first diagnosis (also sometimes referred to as "dedifferentiated giant cell tumor").[342,343] However, most malignant giant cell tumors are secondary malignant giant cell tumors in which the initial tumor has the appearance of classic giant cell tumor and sarcomatous transformation occurs after local recurrence or following radiotherapy.[344–346] A contentious issue is the existence of a cytologically malignant giant cell tumor (i.e., a lesion that retains the clinical, topographic, and general microscopic features of giant cell tumor that exhibits clear-cut evidence of malignancy in the mononuclear stromal component). As such, it is equivalent to a grade 3 giant cell tumor. It represents a most unusual process, part of the reason being the conceptual and practical difficulties in separating it from other malignant tumors, particularly so-called giant cell–rich osteosarcoma (when osteoid production is present) and other pleomorphic sarcomas (when osteoid production is absent).

Marrow Tumors

Ewing Sarcoma Family of Tumors

Ewing sarcoma was first described by James Ewing in the 1920s and represents the prototypic small, round cell sarcoma of bone.[347] Although Ewing sarcoma has been linked with primitive neuroectodermal tumor (PNET) and Askin tumor, it is now clear that all of these tumors are linked by common genetic features and should collectively be referred to as the "Ewing sarcoma family of tumors."[348] Tumors such as neuroblastoma and related sympathetic nervous system tumors, as well as esthesioneuroblastoma, are distinct from the Ewing sarcoma family of tumors.[349]

Ewing sarcoma of bone is the second most common bone sarcoma in children and is usually seen in patients between the ages of 5 and 20 years,[350] with only a minority of the cases presenting in infancy or adulthood.[351,352] Clinically, Ewing sarcoma may simulate osteomyelitis because of pain, fever, and leukocytosis. It can arise in virtually any bone in the body but occurs most often in long bones (femur, tibia, humerus, and fibula) and in bones of the pelvis, ribs, vertebrae, and clavicle.[76] It generally arises in the medullary canal of the metaphysis or diaphysis, from which it permeates the cortex and invades the soft tissues. Rarely, it is predominantly periosteal in location.[353] Ewing sarcoma may also arise in a wide variety of sites, including skin and viscera[354,355]; these are discussed in the respective chapters.

Radiographically, Ewing sarcoma causes permeative destruction of bone, usually accompanied by an aggressive periosteal reaction ("onion skinning"). There is intense uptake on scintigraphy, and CT and MRI typically show extensive soft tissue involvement that is often underappreciated on plain radiographs. The differential diagnosis for these changes includes lymphoma, osteomyelitis, Langerhans cell histiocytosis, and even osteosarcoma (Fig. 40.42).

Microscopically, the typical Ewing sarcoma consists of solid sheets of cells divided into irregular nests by fibrovascular septa (Fig. 40.43). Individual cells are primitive, small, and uniform. The cell outlines are indistinct, resulting in a "syncytial" appearance. The nuclei are round, with frequent indentations, small nucleoli, and variable mitotic activity. There is a well-developed vascular network. Some of the tumor cells may arrange themselves around the vessels in a pseudorosette fashion. Exceptionally, a few true rosettes

For personal use only. No other uses without permission. Copyright ©2017. Elsevier Inc. All rights reserved.

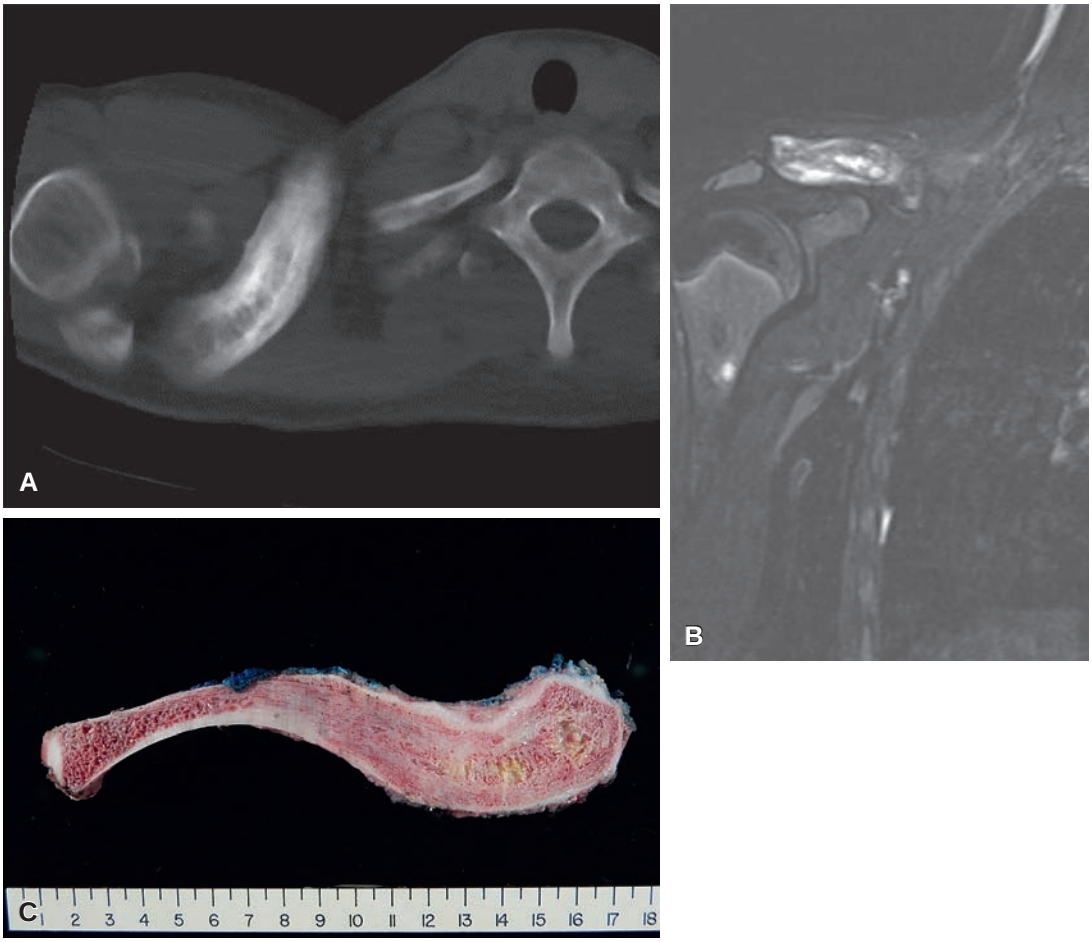

Figure 40.42 Ewing Sarcoma of the Clavicle. A and **B,** CT and MRI show an aggressive lesion with associated periosteal reaction. **C,** The resection specimen shows enlargement of the clavicle, but the tumor is extensively necrotic following neoadjuvant chemotherapy.

(without a central lumen) are formed, these having provided some of the earlier evidence for neuroepithelial differentiation in these neoplasms.[356] Necrosis is common and may dominate the microscopic picture. A fair degree of histologic heterogeneity exists.[357,358] Some tumors are composed of larger and more pleomorphic cells exhibiting conspicuous nucleoli (so-called large cell or atypical Ewing sarcoma).[359] The differential diagnosis of Ewing sarcoma includes practically all other "small round cell tumors," particularly lymphoblastic lymphoma, small cell osteosarcoma, and mesenchymal chondrosarcoma.[360,361] Immunohistochemical and molecular genetic features (described later) are necessary to definitively diagnose Ewing sarcoma.[357]

A most peculiar morphologic variation in the theme is the lesion combining features of Ewing sarcoma/PNET and adamantinoma, and variously called adamantinoma-like Ewing sarcoma and Ewing sarcoma-like adamantinoma.[362,363] The fact that these cases display the t(11;22) would seem to indicate that they represent a subtype of Ewing sarcoma family of tumors resembling adamantinoma rather than the reverse.[364] Cases of adamantinoma-like Ewing sarcoma of the head and neck may be challenging to differentiate from carcinomas.[365] Cases of Ewing family of tumors exhibiting complex epithelial differentiation (including expression of high-molecular-weight keratin) are probably an expression of the same theme.[366]

Histochemical and immunohistochemical features. Historically, histochemical stains and electron microscopy were used to help distinguish between the various small, round cell tumors. Currently, a combination of immunohistochemistry and molecular diagnostic techniques are necessary for diagnosis.

Immunohistochemically, detection of the *MIC2* gene product CD99 is important in establishing a diagnosis of Ewing sarcoma.[367] CD99 is a cell-surface glycoprotein encoded by the *MIC2* gene located on the short arms of the X and Y chromosomes that is consistently expressed by the cells of ES/PNET.[367,368] It is not specific for the Ewing family of tumors, inasmuch as expression of this antigen has been documented in many other tumors, including lymphoblastic lymphoma.[369–373] Antibodies to FLI1 and ERG may also be immunoreactive in Ewing sarcoma, given the *EWSR1–FLI1* (and less common) *EWSR1-ERG* fusions.[374–376] Further immunohistochemical work-up is useful to exclude entities such as lymphoblastic lymphoma, and CD3, CD20, CD34, and TDT are negative in Ewing sarcoma.

Molecular genetic features. About 95% of cases of Ewing family of tumors show on cytogenetic examination the reciprocal translocation t(11;22)(q24;q12) or t(21;22)(q22;q12), which results in the fusion of the *EWSR1* gene at 22q12 with the *FLI1* or *ERG* genes, respectively.[377,378] The most common fusion is the one that results in "in frame linking" of *EWSR1* exon 7 with *FLI1* exon 6. In the remaining cases, *EWSR1* or *FUS* fuses with other ETS and non-ETS family genes, such as *ETV1*, *ETV4*, *ERG*, *NFATC2*, *SMARCA*, *or SP3*.[379,380] These translocations are useful diagnostically and can be

For personal use only. No other uses without permission. Copyright ©2017. Elsevier Inc. All rights reserved.

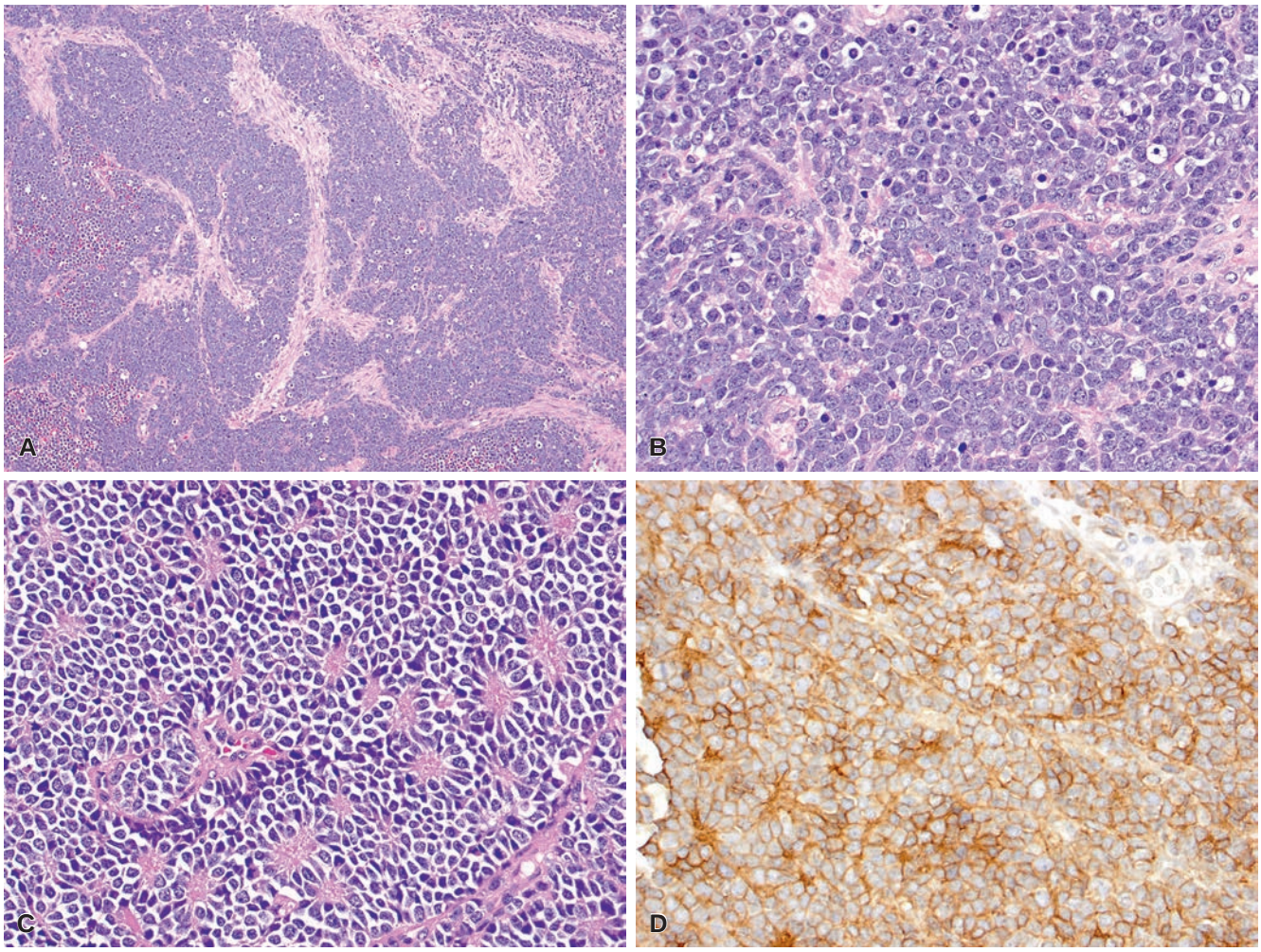

Figure 40.43 Microscopic Features of Ewing Sarcoma. A and **B,** Sheets of primitive, small, round cells are separated by fibrous septa. **C,** Some lesions contain rosettes. **D,** Ewing sarcoma shows strong immunoreactivity for CD99 in a membranous pattern.

detected by RT-PCR[381–387] The *EWSR1* and *FUS* rearrangements can also be detected by molecular cytogenetic analysis (FISH).[388–390] It has been demonstrated that those tumors harboring *ERG* abnormalities are frequently negative for *EWSR1* and *FUS* abnormalities when studied with FISH and suggest the need for additional molecular evaluation in this specific setting.[391] Two other "Ewing-like" sarcomas have been identified. *CIC-DUX4* tumors closely resemble Ewing sarcoma histologically and immunohistochemically but are frequently positive for WT1 and harbor the t(4;19)(q35;q13.1).[392] These tumors appear to be even more clinically aggressive than Ewing sarcoma.[393] The other recently discovered Ewing-like tumor is characterized by the *BCOR-CCNB3* gene fusion. These tumors contain both round cell and spindled cell elements and often lack the diffuse membranous CD99 immunoreactivity seen in Ewing sarcoma.[394]

Spread and metastases. The metastatic spread of ES/PNET is to the lungs and pleura, other bones (particularly the skull), central nervous system, and (rarely) regional lymph nodes. About 25% of patients have multiple bone and/or visceral lesions at the time of presentation.[395,396]

Treatment. The mainstay of treatment for Ewing family of tumors is chemotherapy, which has improved survival dramatically. In addition to chemotherapy, either radiotherapy or surgery—depending on the location of the tumor—is used for local control. Local control is achieved in over 85% of cases, and the actuarial 5-year disease-free survival is 75%. Assessment of the effect of chemotherapy is an important aspect of the patient's prognosis. A system similar to that used for osteosarcoma may be used, but it does not take into account the volume changes that occur in treated Ewing sarcoma. The alternative system is the so-called "Picci system," in which poor response (grade 1) is dictated by finding macroscopic evidence of viable residual tumor (or one nodule of tumor or multiple foci of viable tumor measuring greater than one 10× field) following chemotherapy; a grade 2 response, characterized by isolated foci of viable tumor measuring less than one 10× field in aggregate; or grade 3 response (no viable tumor).[397,398] Other poor prognostic factors include high stage, large tumor size, and pelvic location.

Malignant Lymphoma and Related Lesions

Malignant lymphomas can involve the skeletal system primarily or as a manifestation of systemic disease.[399,400]

Large B-cell lymphoma is the most common type of primary bone lymphoma in adults, 60% of the cases occurring in patients over the age of 30 years.[401] However, they can also affect children.[402] There is no gender predilection. Most cases are solitary, but there are also polyostotic examples limited to the skeletal system, without visceral or lymph node involvement.[403]

For personal use only. No other uses without permission. Copyright ©2017. Elsevier Inc. All rights reserved.

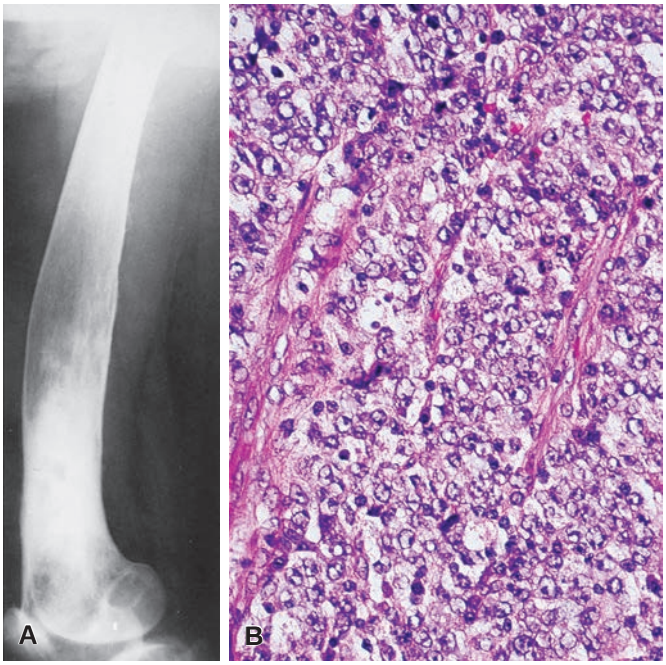

Figure 40.44 **A,** Malignant lymphoma involving the distal femur associated with bone destruction and bone production. These lesions may be erroneously diagnosed as chronic osteomyelitis. **B,** The tumor is of large cell type and is associated with some fibrosis.

Radiographically, large cell lymphomas have an aggressive pattern of bone destruction and often elicit a pronounced periosteal reaction. Less commonly, large cell lymphomas are associated with a sclerotic reaction. CT and MRI are useful in visualizing highly aggressive lesions and assessing the extent of bony involvement.[404,405] The differential diagnosis for these findings includes osteomyelitis and Ewing sarcoma.

Microscopically, the appearance is similar to that of large cell lymphomas in nodal and other extranodal sites.[406] Some cases are accompanied by prominent fibrosis or coagulative necrosis, compromising the morphology or resulting in an appearance that simulates a sarcoma. The cells of large cell lymphoma infiltrate the marrow space, leaving the cancellous bone intact. The tumor cells are large, and their nuclei are somewhat pleomorphic, with many indented, multilobulated, or horseshoe-shaped forms. They usually have prominent nucleoli, unlike the fine nucleoli of Ewing sarcoma (Fig. 40.44). Immunohistochemically, large cell lymphomas have the same pattern of immunoreactivity as their nodal counterparts. They are positive for CD45, the B-cell markers CD20, CD79a, and PAX5, and germinal center or non-germinal center markers CD10, BCL6, and MUM 1.[348]

The 5-year survival rate for localized large B-cell lymphomas of bone has now reached nearly 95%[407] with combination of radiotherapy and chemotherapy.[408]

Hodgkin lymphoma produces radiographically detectable bone lesions in approximately 15% of patients. The involvement is multifocal in about 60% of cases, the most frequent sites being vertebrae, pelvis, ribs, sternum, and femur.[409] The osseous lesions of Hodgkin lymphoma are often asymptomatic and in half of the cases are not demonstrable radiographically. When they become apparent radiographically, the foci may be osteolytic, mixed, or purely osteoblastic. The latter appearance is particularly common in vertebrae. Exceptionally, Hodgkin lymphoma will present initially as a bone mass,[410] with or without associated involvement of the adjacent soft tissues.[411–413]

Anaplastic large cell lymphoma of bone is extremely rare. The tumor cells are immunoreactive for CD30, EMA, CD3, CD4, and anaplastic lymphoma kinase (ALK1).[414–416]

Burkitt lymphoma, as originally reported from Africa, typically presents with massive jawbone involvement. It can also result in tumor masses in the long bones and pelvis.[417]

Lymphoblastic lymphoma of precursor B-cell type can present as a solitary bone tumor and very closely simulates Ewing sarcoma histologically and immunohistochemically.[418] The tumor cells are positive for CD99 but also positive for terminal deoxynucleotidyl transferase (TdT), PAX5, CD43, CD34, CD79a, and variably positive for CD20.

Acute leukemia of childhood is frequently associated with radiographic abnormalities in the skeletal system.[419] In the large majority of instances, the changes are widespread and therefore unlikely to be confused with a primary bone neoplasm. In contrast, destructive bone lesions are extremely rare in the chronic leukemias.

Plasma cell myeloma and **plasmacytoma** are discussed in Chapter 39. *Amyloidoma* of bone is regarded as a manifestation of plasma cell neoplasm and is also addressed in that same chapter.[420]

Vascular Tumors

Hemangiomas of bone are commonly seen in the vertebrae as incidental findings on radiographs. These lesions should probably be regarded as vascular malformations rather than true neoplasms. Radiographically, hemangiomas in the spine result in thick linear striations causing a "honeycomb" or "corduroy" pattern.

The most common location of clinically significant osseous hemangiomas is the craniofacial skeleton.[421] Hemangiomas in the long bones are uncommon. When a lesion involves the flat bones (particularly the skull), sunburst trabeculation occurs because of elevation of the periosteum. Grossly, the cut section of these tumors often has a currant jelly appearance. Microscopically, osseous hemangiomas are composed of thin-walled vessels and are usually cavernous in appearance (Fig. 40.45).

Multiple hemangiomas are mainly seen in children and are associated in about half of the cases with cutaneous, soft tissue, or visceral hemangiomas ("angiomatosis").[422]

Lymphangiomas of bone are exceptional.[426] Most cases are multiple and associated with soft tissue tumors of similar appearance; variations on the theme have been termed *cystic angiomatosis*.[427]

Glomus tumor of the subungual soft tissues may erode the underlying bone. Much rarer is the occurrence of a purely intraosseous glomus tumor involving the terminal phalanx.[428]

Cases previously diagnosed as "**hemangiopericytoma**" of bone are likely a combination of solitary fibrous tumors and synovial sarcomas.[429]

Epithelioid hemangioma is a distinctive hemangioma variant composed of well-formed vessels lined by epithelioid endothelial cells; alternatively, the endothelial cells may also grow in solid sheets. The stroma of these lesions contains loose fibrovascular tissue, and an inflammatory infiltrate rich in eosinophils may be prominent (Fig. 40.46). The myxohyaline stroma that characterizes epithelioid hemangioendothelioma is absent in epithelioid hemangioma.[430]

Epithelioid hemangiomas are usually solitary, but a small percentage can be multifocal. Most are circumscribed radiographically, but lesions arising in small bones can extend into adjacent soft tissue. Local recurrences following curettage are uncommon. Rarely, patients can have involvement of regional lymph nodes or present with epithelioid hemangiomas involving the skin.[430]

FOS gene rearrangements have been described in epithelioid hemangiomas in most locations but appear to be most common in skeletal lesions.[431,432]

For personal use only. No other uses without permission. Copyright ©2017. Elsevier Inc. All rights reserved.

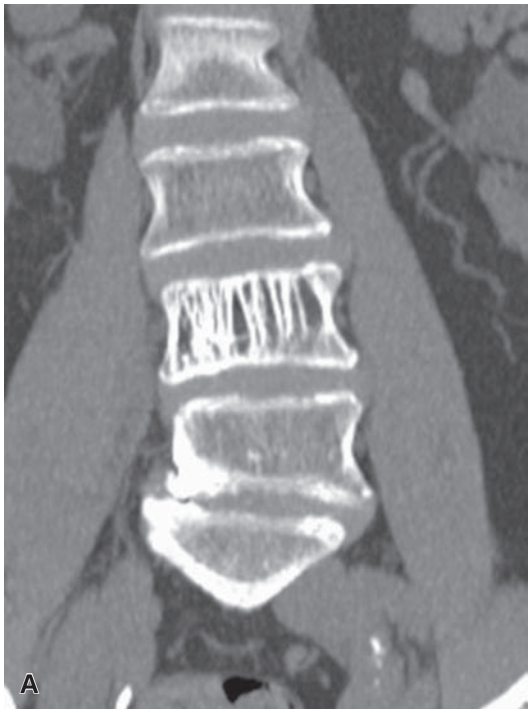

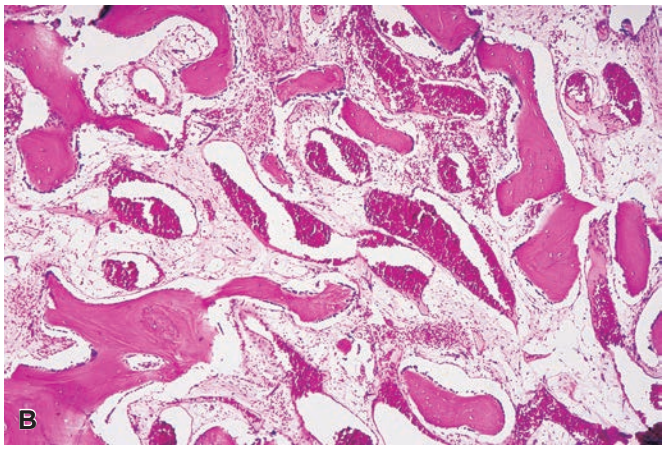

Figure 40.45 Vertebral Hemangioma. A, CT scan showing the typical corduroy pattern associated with hemangiomas in this site. **B,** Histologic features of a cavernous hemangioma of bone.

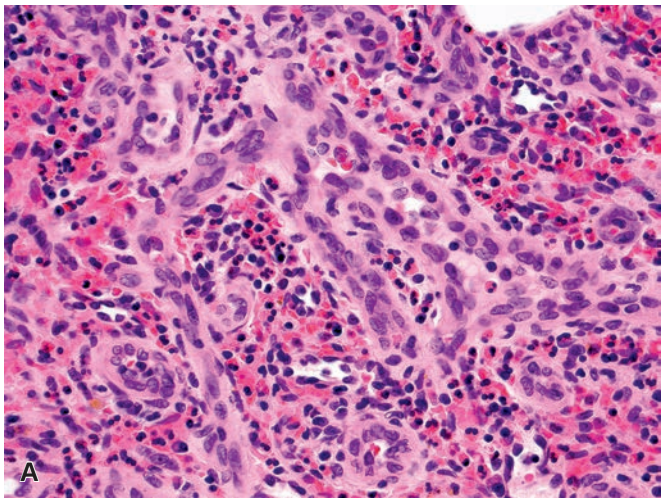

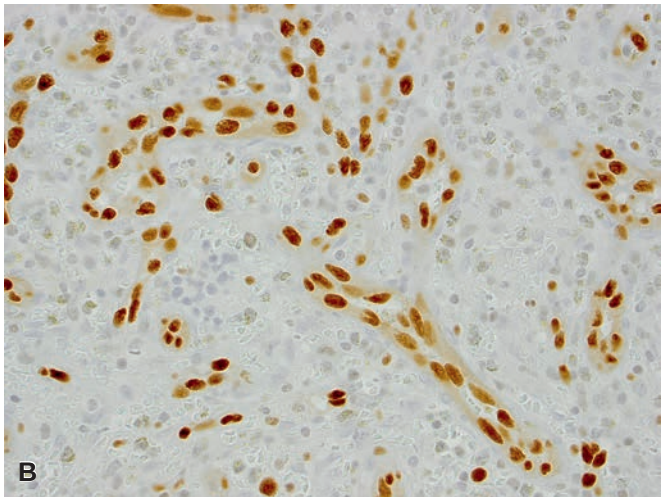

Figure 40.46 Epithelioid Hemangioma of Bone. A, Epithelioid hemangioma is composed of well-formed vessels lined by prominent epithelioid endothelial cells. The vessels are separated by an inflammatory infiltrate rich in eosinophils. **B,** An immunostain for ERG highlights the endothelial cells.

Gorham disease (Gorham–Stout syndrome, massive osteolysis, disappearing bone disease) is a florid vascular proliferation that causes resorption of large segments of bone. It is unclear whether this represents a neoplastic process or not. Involved bones, which may include the humerus or femur, pelvis, thorax, or jaw, are progressively resorbed as a result of the proliferation.[423–425]

Epithelioid hemangioendothelioma of bone is the most common and distinctive member of the family of epithelioid vascular neoplasms.[433,434] The WHO considers epithelioid hemangioendothelioma to be a malignant neoplasm of low to intermediate grade.[76]

Epithelioid hemangioendothelioma of bone is often multifocal[435] and may be associated with similar lesions in the skin, soft tissue, liver, or lung (Fig. 40.47). The clinical course is highly variable, but multifocal bone involvement, regardless of the presence or absence of visceral involvement, is associated with a worse prognosis.[436] Resection or radiotherapy are both effective in the treatment of this tumor.[437]

Microscopically, epithelioid hemangioendothelioma is characterized by the presence of epithelioid endothelial cells with abundant eosinophilic and often vacuolated cytoplasm, large vesicular nuclei (sometimes with prominent grooves), and inconspicuous or absent anastomosing channels (Fig. 40.48). A myxoid or hyalinized stroma is characteristic of this tumor.[438] **Pseudomyogenic hemangioendothelioma** has also been described in bone.[439]

Immunohistochemically, the cells of epithelioid vascular neoplasms display endothelial cell markers, including ERG, CD31, CD34, FLI1, and factor VIII. Keratin immunoreactivity is also quite common, and the aforementioned markers are useful in the distinction of epithelioid hemangioendothelioma and metastatic carcinoma in bone.[440,441]

YAP1-TFE3 (10%) and *WWTR1-CAMTA1* (90%) gene fusions have been described in epithelioid hemangioendothelioma,[442,443] and an antibody directed against the protein product of CAMTA1 appears to be useful in distinguishing epithelioid hemangioendothelioma from other epithelioid vascular and nonvascular mesenchymal neoplasms.[444]

Angiosarcoma exhibits obvious atypia of the tumor cells, formation of solid areas alternating with others with anastomosing vascular channels, and foci of necrosis and hemorrhage (Fig. 40.49).[445] A

For personal use only. No other uses without permission. Copyright ©2017. Elsevier Inc. All rights reserved.

Figure 40.47 Gross appearance of multicentric epithelioid hemangioendothelioma involving femur and tibia.

wide range of differentiation exists from tumor to tumor and sometimes within the same case. In some cases the cells have an epithelioid appearance (epithelioid angiosarcoma).[446] Similar to the other vascular neoplasms, angiosarcomas express ERG, CD31, FLI1, and CD34. Multicentric examples occur but are rare.[447] Distant metastases are common, particularly to the lungs. Before a diagnosis of angiosarcoma in a bone lesion is made, other more common lesions such as metastatic carcinoma should be excluded.[433]

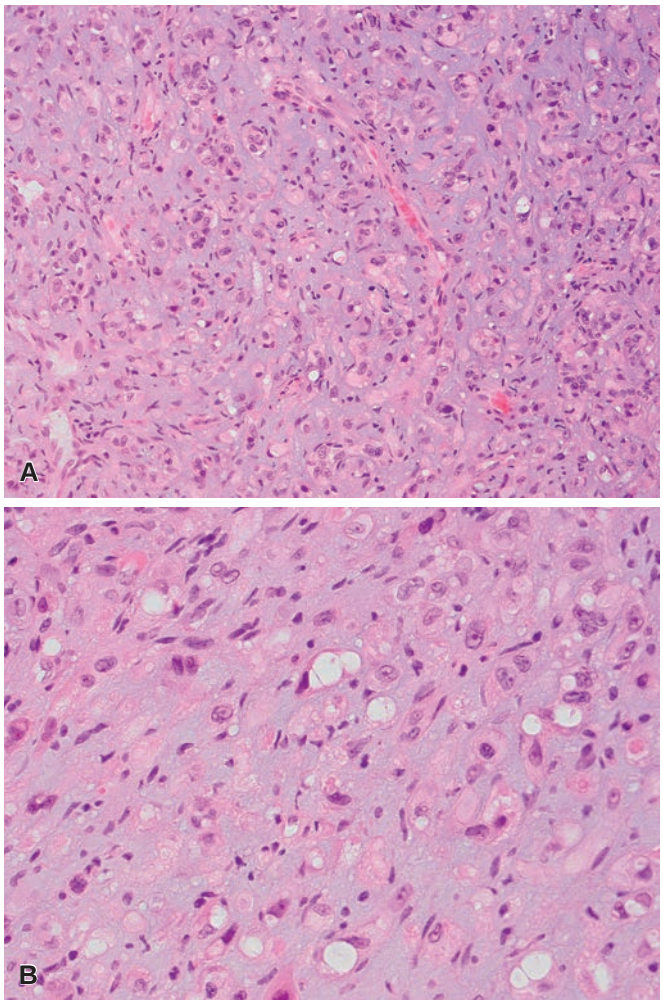

Figure 40.48 **A** and **B,** Microscopic appearance of epithelioid hemangioendothelioma of bone. Cords and nests of epithelioid endothelial cells are deposited in a prominent matrix. Occasional tumor cells contain intracytoplasmic vacuoles or blisters.

Other Mesenchymal Tumors

Fibrous and Related Tumors

Desmoplastic fibroma is a rare neoplasm formed by long fascicles of mature fibroblasts separated by abundant collagen.[448,449] Pleomorphism, necrosis, and mitotic activity are lacking (Fig. 40.50), and the lesion closely resembles soft tissue fibromatosis histologically. However, immunohistochemical and molecular genetic studies have not shown the type of β-catenin pathway alterations that are typical of the latter.[450] Desmoplastic fibroma should also be distinguished from low-grade central osteosarcoma and fibrocartilaginous mesenchymoma.

Desmoplastic fibroma occurs most often in the long bones and jaw. There is a male predominance, and three-fourths of the patients are below the age of 30 years.[451] Radiographically, it has a destructive, purely lytic, honeycombed appearance. It is destructive locally and often recurs following incomplete excision, but metastases do not occur.[452]

Infantile myofibromatosis can present as a solitary lesion in bone. Most of the cases occur in patients 2 years or younger, and they almost always involve the craniofacial bones.[453,454] The microscopic appearance is the same as for its more common soft tissue counterpart.

Solitary fibrous tumor has been described as a pedunculated periosteal mass,[455] as well as an intraosseous lesion.[429]

Most examples of **fibrosarcoma** of bone likely represent other histologic entities, including dedifferentiated chondrosarcoma and fibroblastic osteosarcoma. In one study of fibrosarcomas arising in soft tissue, the majority were reclassifiable as other entities based on modern diagnostic methods.[456] Primary sclerosing epithelioid fibrosarcoma of bone has been well documented.[457,458]

Undifferentiated high-grade pleomorphic sarcoma has a histologic appearance identical to its soft tissue counterpart (Fig. 40.51).[459–461] The most common sites of involvement include the long bones, especially the knee region, and the pelvis.[462] Close to 30% of these tumors arise in bone infarcts[48,463,464] around foreign bodies,[465,466] following irradiation,[467] in Paget disease,[66] or as expression of "dedifferentiation" in tumors such as chondrosarcoma. Most patients present at age 40 or older.[459]

Thorough sampling, careful correlation of radiographs, and extensive immunohistochemical work-up is necessary to exclude the possibilities of metastatic sarcomatoid carcinoma, osteosarcoma, and dedifferentiated chondrosarcoma.

Muscle Tumors

Leiomyomas of bone are practically nonexistent. **Leiomyosarcomas** are very rare, most of the reported cases being located in the jaw and in long bones, particularly the femur.[468–472] The morphologic and immunohistochemical features are analogous to those of its soft tissue counterpart.[470] Specifically, the tumor cells are immunoreactive for common and smooth muscle actin, desmin, and h-caldesmon,

For personal use only. No other uses without permission. Copyright ©2017. Elsevier Inc. All rights reserved.

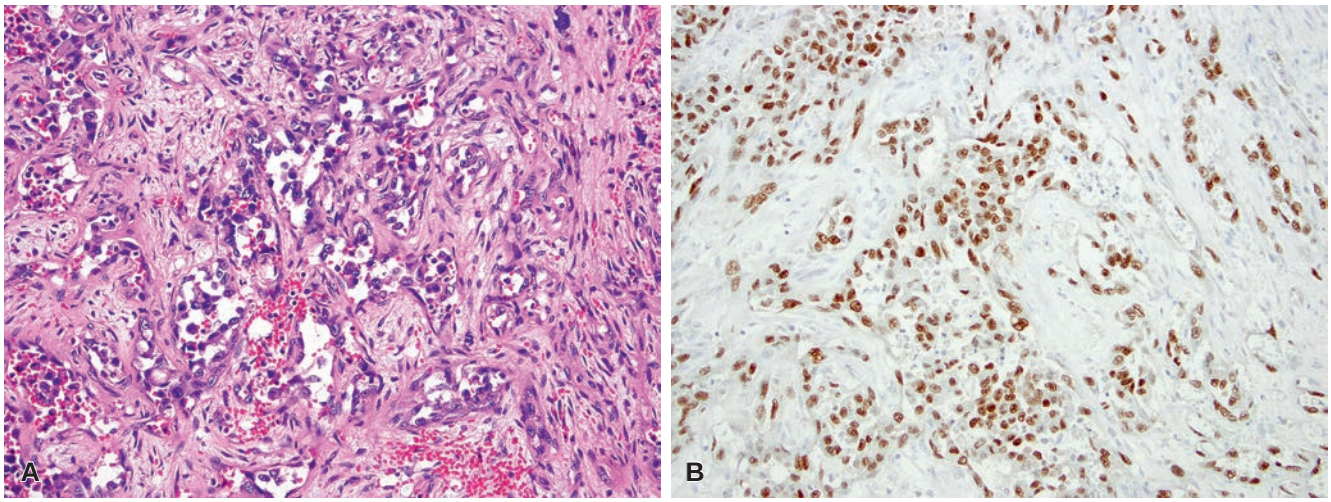

Figure 40.49 Angiosarcoma of Bone. A, Highly atypical endothelial cells line irregular vascular spaces. **B,** Tumor cells are strongly positive for ERG.

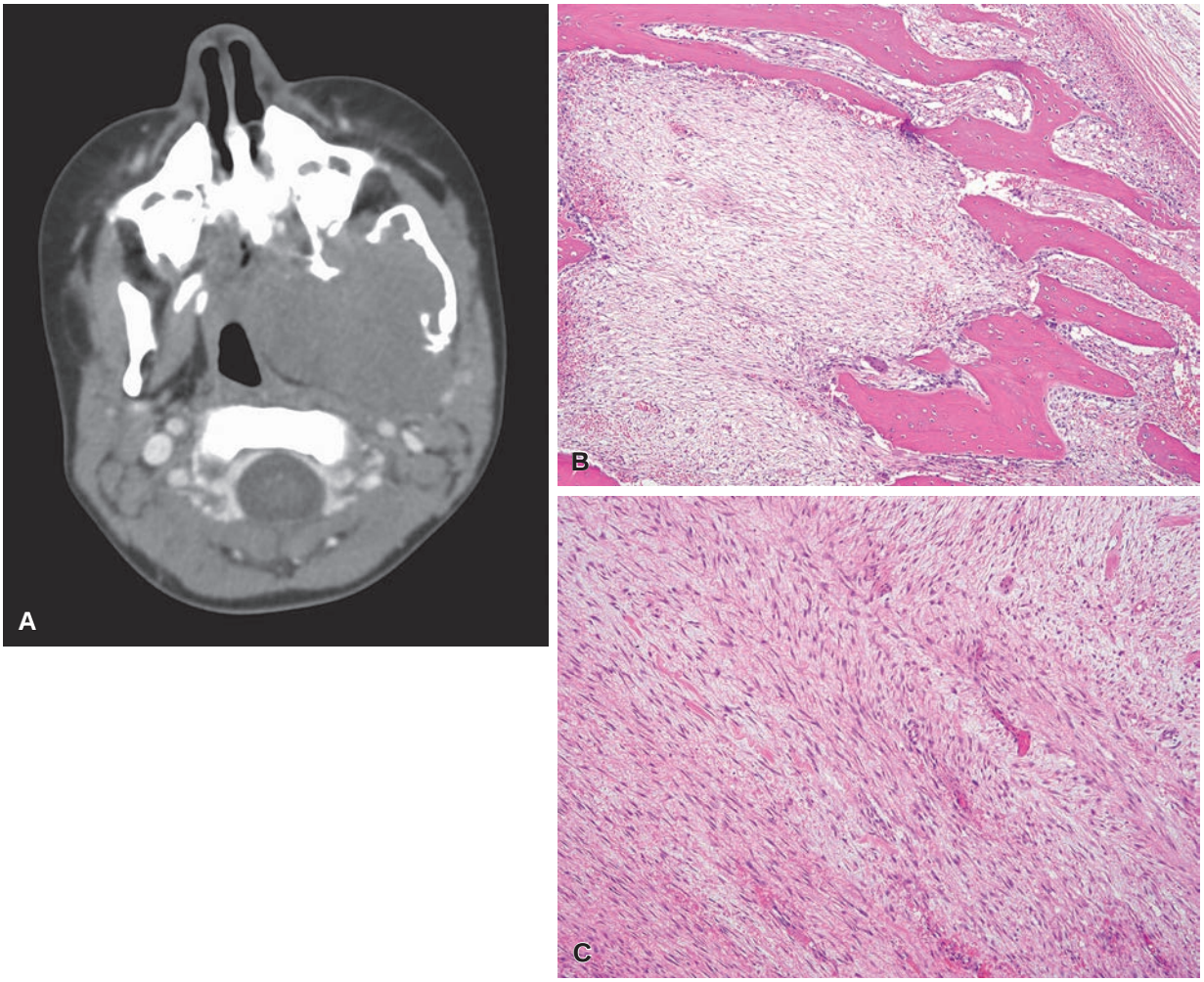

Figure 40.50 Desmoplastic Fibroma. A, CT highlights a large, destructive mass arising in the jaw. **B** and **C,** Desmoplastic fibroma is poorly circumscribed and composed of fascicles of bland fibroblasts, similar to soft tissue fibromatosis.

For personal use only. No other uses without permission. Copyright ©2017. Elsevier Inc. All rights reserved.

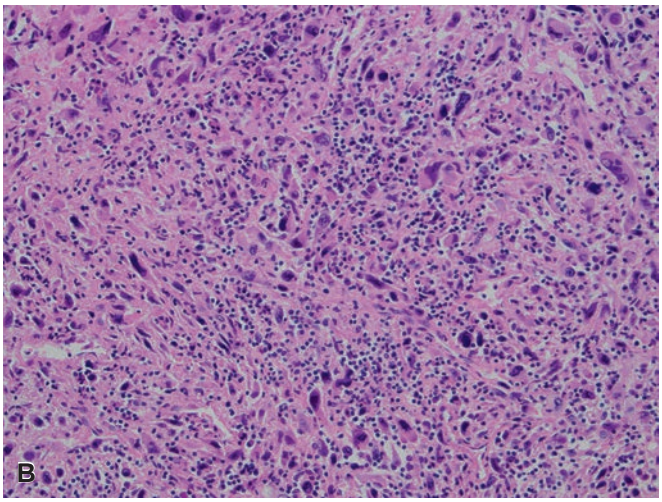

Figure 40.51 A, An infarct-associated undifferentiated pleomorphic sarcoma of the proximal humerus. The serpiginous infarct appears yellowish and calcified, while the sarcoma is gray and fleshy. **B,** Undifferentiated pleomorphic sarcoma of bone is histologically identical to its soft tissue counterpart.

and they are enveloped by type IV collagen.[470,473] They may also be positive for keratin and S-100 protein.[474,475] Exceptional cases have been seen of the epithelioid variety.[476] About half of the patients present with metastatic disease or develop metastases within 1 year of diagnosis.[477]

Isolated examples of primary **rhabdomyosarcomas** of bone are on record.[478,479] Some have been of the pleomorphic type and others had embryonal features.[480,481]

Adipose Tissue Tumors

Lipoma of bone is a very rare tumor. The few reported cases have occurred in the long bones of adults and have presented radiographically as sharply outlined lytic lesions with sclerotic margins.[482,483] Some may arise from the surface of the bone ("parosteal lipoma"). Microscopically, they are composed of mature adipose tissue devoid of hematopoietic elements; dystrophic calcification, fat necrosis, and hemorrhage may be present.[484,485]

Liposarcoma of bone is even more exceptional,[486] and metastatic liposarcoma to bone is more common than primary liposarcoma of bone.

Chordoma and Other Notochordal Lesions

The notochord is a phylogenetic structure representing a primitive spine, which in higher organisms is replaced by the vertebrae and sacrum. **Notochordal remnants** are found in humans within the vertebral bodies and intervertebral disks.[487] *Ecchordosis physaliphora* is the name given to a grossly visible notochordal remnant found incidentally at autopsy as a discrete gelatinous nodule attached to the clivus or overlying the anterior surface of the pons.[488] Other sites where ectopic notochordal tissues can be found are the odontoid process of the axis, the nasopharynx, and the coccyx and adjacent presacral soft tissues.[489]

According to the WHO, the term **benign notochordal cell tumor** encompasses giant notochordal rest and notochordal hamartoma.[76] When located in the vertebrae, these lesions can be easily overdiagnosed as chordoma, from which it is distinguished by a combination of clinical, radiographic, and microscopic features.[490] Radiographically, benign notochordal cell tumors are confined to the vertebra and may show varying degrees of sclerosis. They are easily identified on MRI, but there is no uptake on scintigraphy.[491] Histologically, these tumors are composed of sheets of vacuolated, lipoblast-like cells or physaliferous cells with bland cytologic features. The intervening cancellous bone is intact, and there is no myxoid matrix or necrosis.[492] Although benign, they are regarded by some authors as precursors of chordomas.[493,494]

Chordoma is most frequent in the fifth and sixth decades but occurs in all ages and in both sexes. Chordomas grow slowly, the duration of the symptoms before diagnosis usually being over 5 years. About 50% arise in the sacrococcygeal area, 35% in the spheno-occipital area, and the remainder along the cervico-thoraco-lumbar ("mobile") spine.[495] The sacrococcygeal tumors are more common in the fifth and sixth decades of life, whereas many of the spheno-occipital neoplasms occur in children and adolescents.[496,497] If the tumor encroaches on the spine, symptoms of spinal cord compression arise. The retroperitoneal space is often involved by direct extension, and the tumor may grow large enough to compress the rectum or bladder. Spheno-occipital chordomas may present with a nasal, paranasal, or nasopharyngeal mass, multiple cranial nerve involvement and/or destruction of bone.[498]

Radiographically, chordomas are destructive, midline lesions that may be extremely difficult to identify on plain radiographs. However, they are readily evident on CT or MRI. In the sacrum and coccyx, chordomas form lobular masses that extend anteriorly toward the rectum and bladder.[499] Lesions arising in the skull base arise in the midline, destroy surrounding bone, and may encroach on the brainstem or optic nerves.

Grossly, chordoma is lobulated, gelatinous, and soft and contains areas of hemorrhage. Microscopically, chordoma contains cohesive cords and nests of epithelioid cells deposited in an abundant myxoid stroma organized into distinct lobules by fibrous septa. Individual tumor cells have eosinophilic cytoplasm, and those with prominent vacuoles are referred to as "physaliphorous" cells (Fig. 40.52). Tumor cells are variable in size and may have prominent nucleoli, but cytologic atypia may be pronounced. Mitotic figures are generally scanty or absent. The microscopic differential diagnosis includes mainly metastatic carcinoma and chondrosarcoma, but myxopapillary ependymoma and chordoid meningioma may also enter the differential diagnosis.[500]

For personal use only. No other uses without permission. Copyright ©2017. Elsevier Inc. All rights reserved.

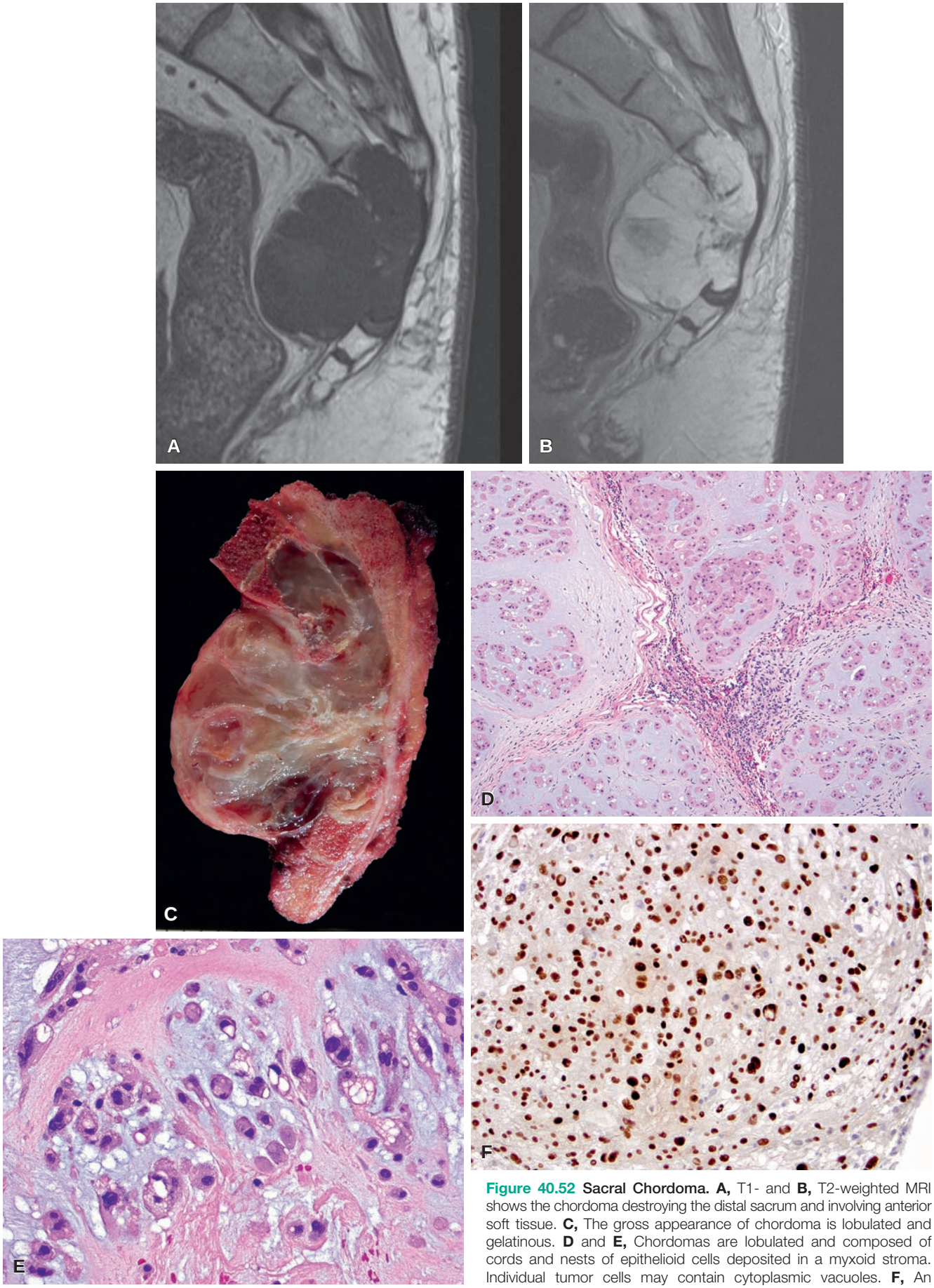

Figure 40.52 Sacral Chordoma. A, T1- and **B,** T2-weighted MRI shows the chordoma destroying the distal sacrum and involving anterior soft tissue. **C,** The gross appearance of chordoma is lobulated and gelatinous. **D** and **E,** Chordomas are lobulated and composed of cords and nests of epithelioid cells deposited in a myxoid stroma. Individual tumor cells may contain cytoplasmic vacuoles. **F,** An immunostain for brachyury confirms the diagnosis of chordoma.

For personal use only. No other uses without permission. Copyright ©2017. Elsevier Inc. All rights reserved.

Immunohistochemically, chordoma shows reactivity for S-100 protein, keratin, epithelial membrane antigen (EMA), and SOX9.[501–504] Among the keratins, those regularly expressed are cytokeratin 8, cytokeratin 19, and (less consistently) cytokeratin 5; they are usually negative for cytokeratin 7 and cytokeratin 20.[505] Glial fibrillary acidic protein (GFAP) reactivity is commonly encountered with the use of polyclonal antibodies, less so with their monoclonal counterparts.[506] The introduction of the brachyury antibody has simplified the work-up of chordoma.[504,507] This transcription factor—the product of the T gene—is necessary for notochord formation and is a highly sensitive and specific marker for chordoma. It is immunoreactive in only a limited selection of other neoplasms, most of which do not resemble chordoma histologically.[508–510]

The characteristic features of chordoma can be identified in material from fine-needle aspiration, which is also amenable to histochemical and immunohistochemical evaluation.[511]

Chordomas commonly show hypodiploid karyotype, frequently with loss of chromosomes 3 (especially 3p), 4, 10, and 13.[512–514] Comparative genomic hybridization shows that the most frequent changes are: −1p, −3p, +5q, +7q, +12q, and +20.[515] The candidate region for sporadic and inherited chordoma development has been mapped to 1p36.13.[516]

The natural history of chordoma is characterized by repeated episodes of local recurrence and an often fatal outcome. Recurrences may develop 10 years or longer after the initial therapy.[517] Distant metastases may also develop late in the evolution of the disease, and approximately 30% of patients develop metastatic disease.[518] The most common sites are the skin and subcutis (where they can simulate a sweat gland tumor) and bone, but they can occur in many other places, including rare sites such as the ovary.[519]

Treatment is in the form of surgical excision, radiation therapy, or a combination of both modalities.[520,521] Proton therapy, in particular, has proven to be an effective means for local control.[522] The recurrence rate is very high following surgery, particularly when the tumor is entered during the procedure. Adverse prognostic factors are represented by large tumor size, positive surgical margins, tumor necrosis, and high proliferative activity.[523–527]

"Dedifferentiated chordoma" is characterized by foci of high-grade spindle cell and/or pleomorphic sarcoma in conjunction with areas of typical chordoma, either in the primary tumor or in the recurrences.[528,529] This phenomenon is analogous to that of "dedifferentiated" chondrosarcoma and carries an equally ominous prognostic significance. Like in the latter, these foci may exhibit "divergent differentiation" in the form of rhabdomyoblasts or other cell types.[530] The high-grade foci exhibit a high proliferative index and are not immunoreactive for brachyury, in stark contrast to that of the conventional chordomatous component.[531] Indeed, dedifferentiation is a very poor prognostic factor in chordomas.[532]

Chondroid chordoma is a histologic variant that contains hyaline cartilage matrix, whether focal or extensive.[533] This entity has been controversial throughout the years, particularly with regard to the clinical significance of the chondroid foci in the tumor. However, at present, there is no definitive evidence that these tumors behave differently than conventional chordomas.

Adamantinoma of Long Bones

Classic adamantinoma is an extremely rare primary bone tumor of long bones that characteristically arises in the tibia but has been reported in other long bones, such as the femur, ulna, and fibula.[534,535] Occasionally, adamantinoma may involve the tibia and fibula simultaneously.[536]

Radiographically, classic adamantinomas typically arise in the anterior metaphyseal or diaphyseal cortex and may extend into the medullary cavity or adjacent soft tissue. Multiple foci of radiolucency are present, the margins of which may be sharply or poorly defined. An anterior bowing defect may be present.[537]

Grossly, classic adamantinoma can appear fleshy or contain gritty areas with the consistency of a fibro-osseous lesion. It is poorly defined and may extend into the overlying soft tissues. Microscopically, classic adamantinomas are dominated by an epithelial component that can appear basaloid, tubular, squamous, or spindled. The basaloid pattern is the most common and consists of solid nests of basaloid cells with palisading at the periphery and sometimes a stellate configuration in the center. The tubular pattern simulates closely the appearance of a vascular neoplasm (Fig. 40.53).[538] The keratins expressed by adamantinoma are mainly 14 and 19, with lesser representation of keratins 5, 17, 7, and 13. In contrast to other bone and soft tissue tumors with epithelial phenotypes—such as synovial sarcoma, chordoma, and epithelioid sarcoma—it lacks immunoreactivity for keratins 8 and 18.[539] Adamantinomas commonly show recurrent numerical chromosomal abnormalities, mainly gain of chromosomes 7, 8, 12, 19, and 21.[540]

Adamantinoma of bone is a low-grade malignant tumor characterized by a tendency for local recurrence and the occasional development of lymph node and distant metastases, particularly to lung. En bloc excision and amputation are the therapeutic choices, depending on the circumstances of the case.[534] A unique case has been described with complete sarcomatoid dedifferentiation.[541]

Differentiated (osteofibrous dysplasia-like) adamantinoma is a variant of adamantinoma that occurs in a younger age group than classic adamantinoma, frequently involves both the tibia and fibula, remains confined to the cortex, and is composed predominately of an osteofibrous dysplasia-like fibro-osseous component.[537,542] The epithelial nests in this variant can be sparse and difficult to identify and may only be recognized by cytokeratin immunostains. The behavior of differentiated adamantinoma is closer to that of osteofibrous dysplasia (see later) than classic adamantinoma, and Dorfman and Czerniak have proposed that the histologic features of this variant may reflect healing or regression of a classic adamantinoma.[543] The location, histologic features, and cytokeratin expression in classic and differentiated adamantinoma and osteofibrous dysplasia certainly suggest that these lesions are related.[544,545]

Peripheral Nerve Tumors

Schwannoma rarely presents as an intraosseous mass.[546] Although a strong predilection for the mandible has been noted, schwannomas also occur in the appendicular skeleton. Schwannomas of the sacrum can reach huge dimensions and present as retrorectal masses; they may simulate a malignant tumor on radiographic grounds (particularly chordoma) and present great technical difficulties for their surgical removal.[547] While most osseous schwannomas have conventional histologic features, a few of the reported cases of intraosseous schwannoma have been of the *melanotic* or *cellular* variety.[548]

Neurofibromatosis may be complicated by several types of skeletal abnormalities, including scoliosis, bowing, pseudoarthrosis, and other disorders of growth and may be accompanied by malignant bone tumors[549,550]; however, intraosseous neurofibromas are extremely rare.

Malignant peripheral nerve sheath tumor has been rarely seen in bone in patients with or without neurofibromatosis; several of the cases have involved jawbones.[551,552]

Xanthoma of bone presents in patients over the age of 20 years and has a male-to-female ratio of 2 : 1. It is almost always solitary, and the flat bones (pelvis, ribs, skull) are the most frequent sites. Radiographically, it presents as a well-defined, sometimes expansile lytic lesion, often with a sclerotic margin. Microscopically, an admixture of foamy cells, multinucleated giant cells, cholesterol clefts, and fibrosis is seen. The differential diagnosis includes Rosai–Dorfman disease

For personal use only. No other uses without permission. Copyright ©2017. Elsevier Inc. All rights reserved.

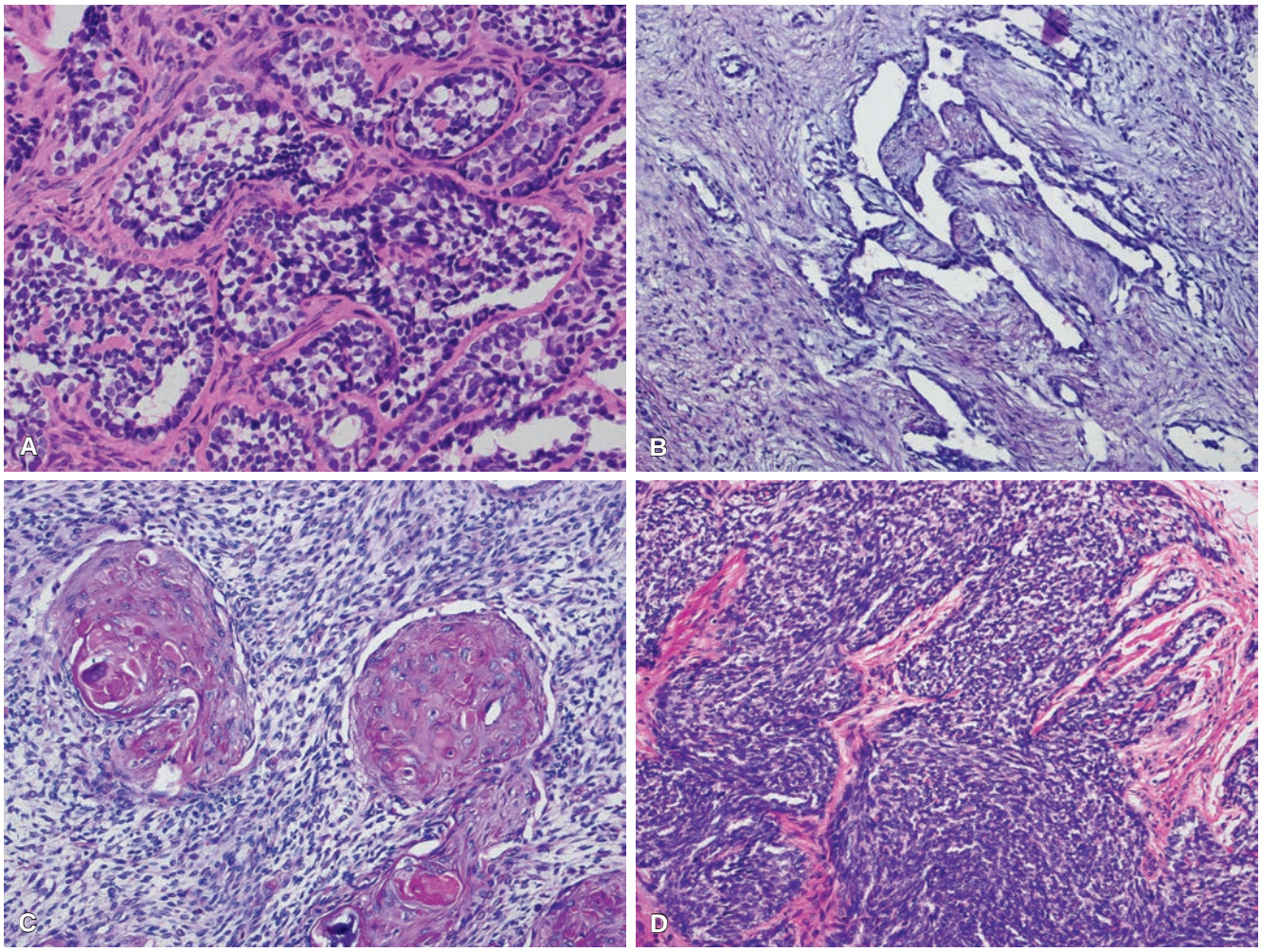

Figure 40.53 Microscopic Patterns of Adamantinoma. A, Basaloid, **B,** Tubular, **C,** Squamoid, and **D,** Spindled.

and secondary xanthomatous changes in other bone lesions, such as Langerhans cell histiocytosis or fibrous dysplasia.[553]

Fibrocartilaginous mesenchymoma is a term that has been applied to a rare benign neoplasm affecting the metaphysis of long bones, characterized microscopically by an admixture of spindle cells, bone trabeculae, and islands of cartilage. Some of the cartilage is in the form of structures resembling growth plates.[554,555] Fibrocartilaginous mesenchymoma may mimic desmoplastic fibroma and low-grade central osteosarcoma. Recurrences may supervene, but metastases have not been reported.[556]

Phosphaturic mesenchymal tumor is an unusual neoplasm often responsible for tumor-induced osteomalacia, a rare paraneoplastic syndrome due to phosphate wasting. This tumor may occur as a primary bone tumor but is far more common in soft tissue.[22] This entity is discussed in more detail in the following chapter.

Other types of mesenchymal neoplasms that have exceptionally presented as primary bone lesions include clear cell sarcoma,[557] alveolar soft part sarcoma,[558] desmoplastic small round cell tumor,[559] and perivascular epithelioid cell tumor (PEComa).[560]

Metastatic Tumors

Metastases are the most commonly diagnosed malignant neoplasms in bone. Multiple lesions are one of the hallmarks of metastases, and in most cases the presence of a tumor elsewhere is known, so the diagnosis is obvious. However, solitary metastases from occult primaries can be confused with primary bone tumors. More than 80% of all bone metastases originate in the breast, lung, prostate, thyroid, or kidney. Soft tissue sarcomas rarely metastasize to the skeletal system,[561] the outstanding exception being embryonal rhabdomyosarcoma of the soft tissues in children.[562]

About 70% of bone metastases affect the axial skeleton (cranium, ribs, spine, sacrum), and the remaining involve the appendicular skeleton (long bones) or both compartments. In all bones, metastases are preferentially situated in the red bone marrow.[563] When located in long bones, the area usually involved is the metaphysis.

Metastatic bone lesions are usually osteolytic but may be osteoblastic or mixed. Tumors with a tendency to produce pure osteoblastic metastases are prostatic carcinoma, carcinoid tumor and other neuroendocrine neoplasms, and breast carcinoma (Fig. 40.54).[564,565] The mechanism for blastic metastases is thought to involve both systemic and local factors that induce osteoblast proliferation, including TGF-β, fibroblast growth factor, and bone morphogenetic proteins.[566] Likewise, the mechanism of bone resorption is thought to be related to the stimulation of osteoclast formation via PTH, vitamin D_3, interleukins, and other factors activating the RANK-RANKL pathway.

For personal use only. No other uses without permission. Copyright ©2017. Elsevier Inc. All rights reserved.

Figure 40.54 Ill-defined lytic lesion in midshaft of fibula produced by metastasis of lung carcinoma.

Figure 40.55 Radiograph of a metastatic pulmonary carcinoma involving the metacarpal.

The bone(s) involved and the character of the changes seen radiographically are helpful in predicting the site of the primary neoplasm. Thyroid carcinoma often metastasizes to the bones of the shoulder girdle, skull, ribs, and sternum, whereas carcinoma of the kidney tends to involve the skull, sternum, flat bones of the pelvis, humerus, and scapula.[567] Bone metastases peripheral to the knees or elbows are rare, but they certainly occur, as distally as the terminal phalanges, which may occur with pulmonary carcinomas (Fig. 40.55).[568]

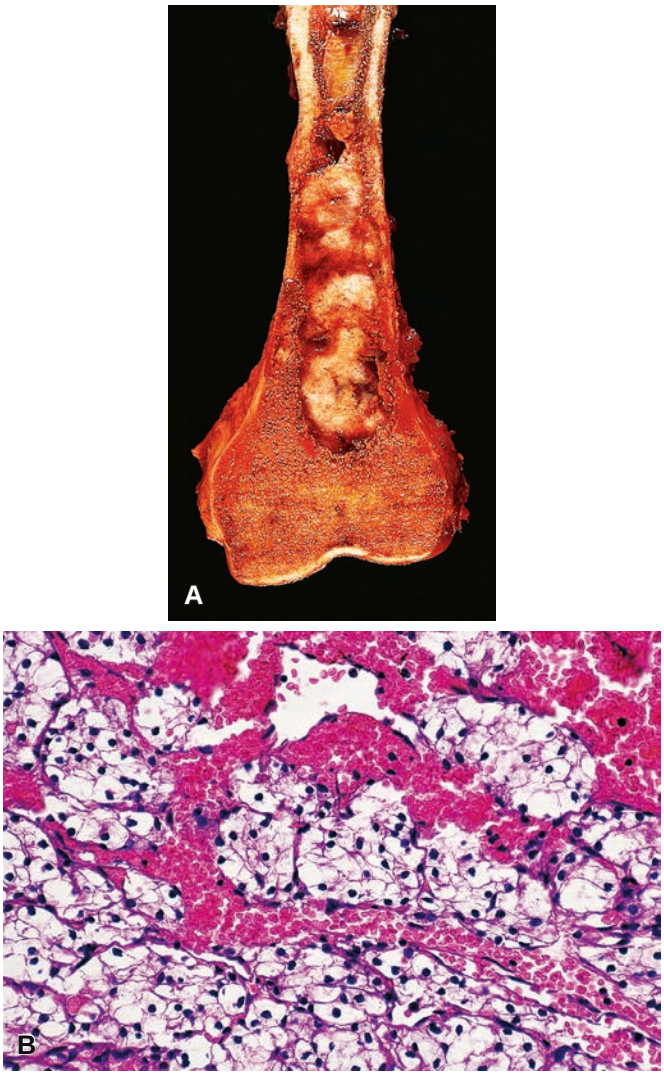

Figure 40.56 **A,** Gross appearance of femur with medullary involvement by metastatic renal cell carcinoma. **B,** Microscopic appearance. The optically clear appearance of the cytoplasm and the extensive hemorrhage are characteristic features.

Periosteal bone proliferation may rarely accompany a metastatic lesion. This is more likely to occur in certain blastic metastases such as those caused by prostate carcinoma. Exuberant new bone formation can also occur because of a pathologic fracture associated with metastatic carcinoma and lead to diagnostic confusion with osteosarcoma.[140] Metastatic malignant tumors—including carcinoma and melanoma—can be accompanied by a prominent population of osteoclasts and simulate a giant cell tumor.[569] Any tumor metastatic to bone, if extensive enough, may lead to hypercalcemia and elevation of serum acid phosphatase.

The work-up of metastatic tumors in bone, particularly when the primary site is unknown, includes the use of antibodies to the cytokeratin subsets—particularly cytokeratins 7 and 20—and antibodies more specific to specific organs, such as TTF-1, PSA, PAX8, GATA3, CDX2, and others (Fig. 40.56).

The treatment of metastatic carcinomas in bone involves providing analgesia and fracture fixation through a combination of surgery, radiotherapy, and the use of medications which reduce osteoclastic resorption, such as bisphosphonates.

For personal use only. No other uses without permission. Copyright ©2017. Elsevier Inc. All rights reserved.

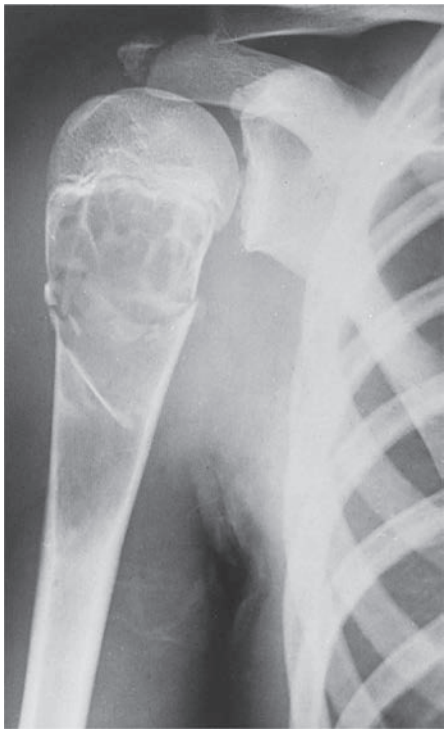

Figure 40.57 Typical solitary bone cyst of upper end of humerus abutting against epiphyseal plate in a 13-year-old boy.

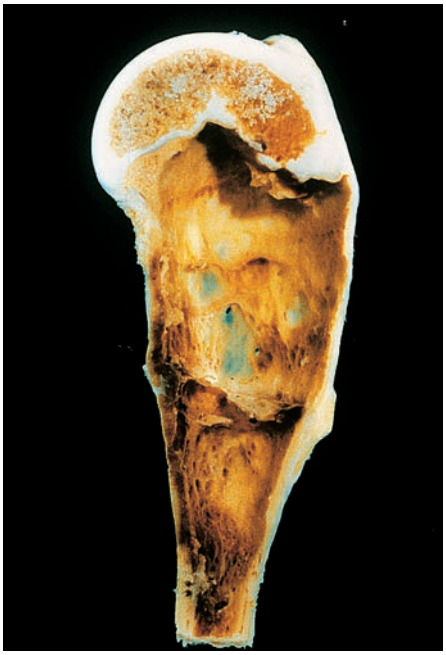

Figure 40.58 Gross appearance of solitary bone cyst. A large lesion located in the upper metaphysis of the humerus.

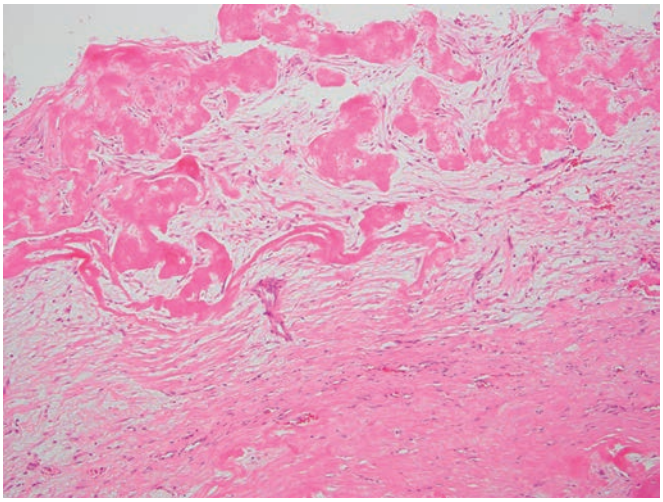

Figure 40.59 Microscopically, unicameral bone cyst contains a fibrous wall with adherent fibrin-like material that may incorporate into the wall.

Tumorlike Lesions

Unicameral Bone Cyst

Unicameral (solitary, simple) bone cysts usually occur in long bones, most often in the proximal humerus and femur (Fig. 40.57). They also may be seen in short bones, particularly the calcaneus.[570] Most cases are seen in males, and almost all occur in patients under 20 years of age.

Unicameral bone cysts arise in the metaphysis adjacent to the growth plate, but the growth plate grows away from the lesion resulting in the appearance that the cyst has "migrated." The cortex is thinned, but periosteal bone proliferation does not take place except in areas of fracture. Bones affected by these lesions often fracture, usually in the proximal portion of the cystic area, and a portion of cortical bone often drops to the bottom of the cyst, a feature referred to as a "fallen fragment sign."[571]

The unicameral bone cyst contains a clear or yellow fluid and is lined by a smooth fibrous membrane that may be brown (Fig. 40.58). The fluid may be hemorrhagic if a previous fracture has occurred. Microscopically, the cyst is lined by a thin fibrous membrane and well-vascularized connective tissue containing hemosiderin (often within macrophages), and cholesterol clefts are frequent. Fibrin deposits may become incorporated within the wall and calcify, at which point they resemble cementum-like material (Fig. 40.59).[572–574] Lesions with pathologic fracture often have areas resembling aneurysmal bone cyst.

Unicameral bone cysts can be treated with a variety injectables, decompression techniques, or curettage.[575]

Aneurysmal Bone Cyst

Aneurysmal bone cyst is seen usually in patients between 10 and 20 years of age[576] and is slightly more common in females. It occurs mainly in the vertebrae and flat bones but can also arise in long bones.[577] Vertebral lesions often involve the posterior elements of multiple spinal levels. Exceptionally, a lesion with the features of an osseous aneurysmal bone cyst is seen in a soft tissue location.[578,579]

Radiographically, aneurysmal bone cysts arise in the metaphysis (of long bones) and appear as a radiolucent lesion that thins the cortex, covered only by a thin shell of reactive periosteal bone. CT and MRI highlight the multiloculated nature of aneurysmal bone cysts; the characteristic fluid-fluid levels are best appreciated on MRI (Fig. 40.60).[580] Occasional lesions arise in subperiosteal locations.

Grossly, it forms a spongy, hemorrhagic mass covered by a thin shell of reactive bone, which may extend into the soft tissue; frequently

For personal use only. No other uses without permission. Copyright ©2017. Elsevier Inc. All rights reserved.

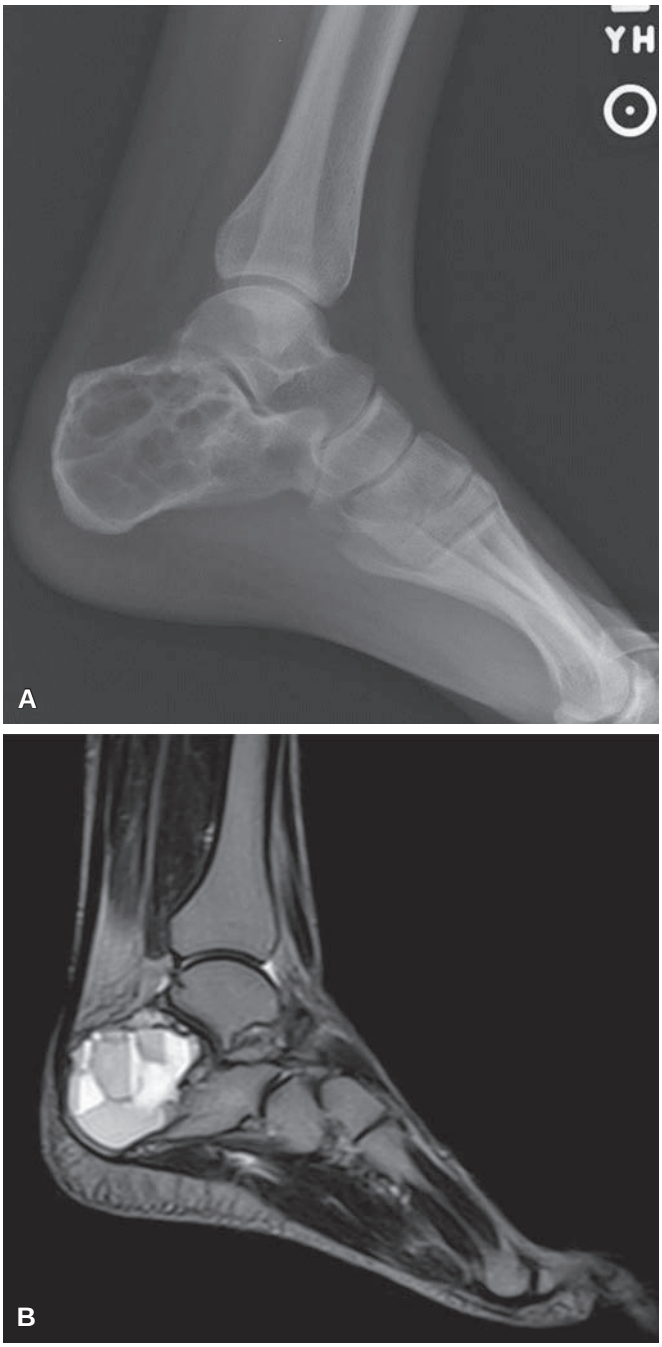

Figure 40.60 Radiographic Features of Aneurysmal Bone Cyst. A, Radiograph, **B,** MRI. Prominent fluid-fluid levels are seen on MRI.

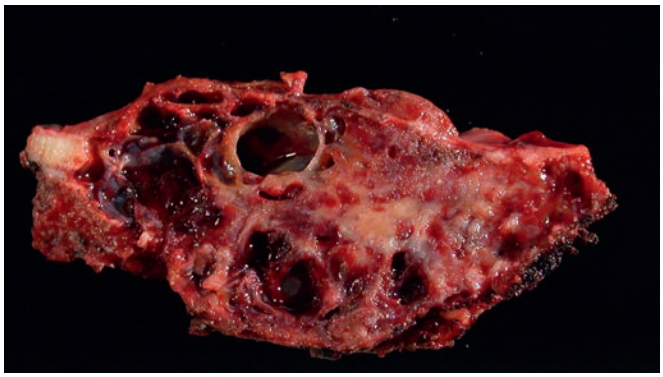

Figure 40.61 Gross appearance of an aneurysmal bone cyst, which contains multiple blood-filled cystic structures.

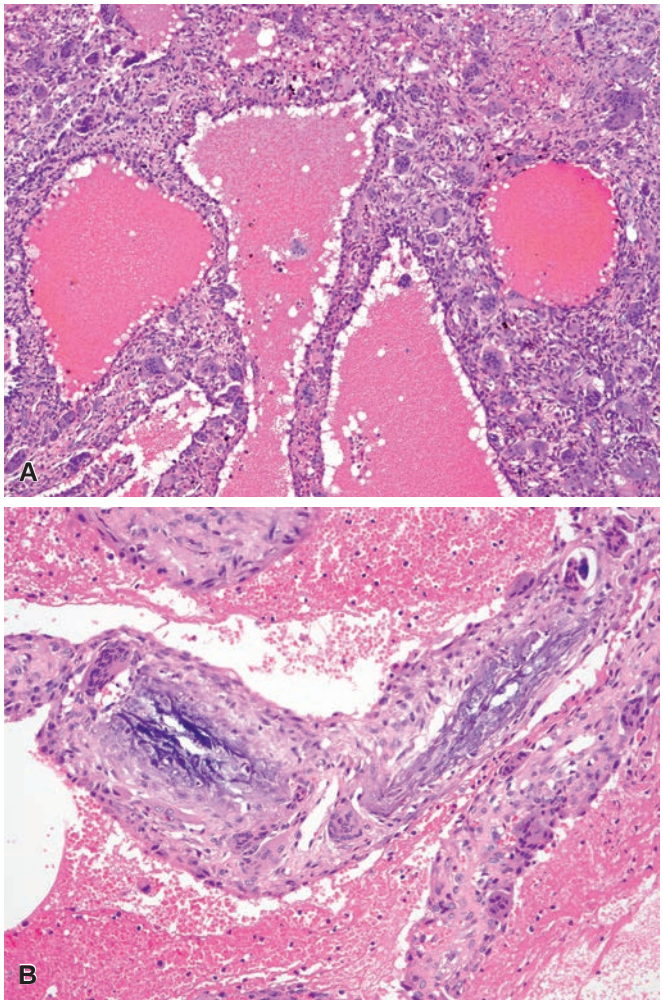

Figure 40.62 Microscopic Features of Aneurysmal Bone Cyst. A, Multiple blood lakes are surrounded by a giant cell–rich fibroblastic proliferation. **B,** Amorphous, calcified material is commonly identified in the walls of aneurysmal bone cyst and is a diagnostically useful finding.

aneurysmal bone cysts contain primarily blood with only small bits of tissue (Fig. 40.61). Microscopically, large spaces filled with blood are seen, separated by cellular septa containing fibrovascular tissue, inflammatory cells, and giant cells (Fig. 40.62). These septa do not have a true endothelial lining but are rather delimited by cells with the morphologic, ultrastructural, and immunohistochemical features of fibroblasts, myofibroblasts, and histiocytes.[581] Osteoclast-like giant cells may be prominent and often align along the bloody spaces. The septa also contain foci of osteoid and bone, and an additional feature of great diagnostic significance is the deposition of a peculiar degenerated calcifying fibromyxoid tissue.[582]

The differential diagnosis includes solitary bone cyst, giant cell tumor, hemangioma, telangiectatic osteosarcoma, and—especially for the lesions located in the jaw—central giant cell granuloma.

Once regarded as reactive lesions, current evidence suggests that primary aneurysmal bone cysts are likely neoplastic.[583] Approximately

For personal use only. No other uses without permission. Copyright ©2017. Elsevier Inc. All rights reserved.

70% of primary aneurysmal bone cysts have rearrangements of the *USP6* gene, located on chromosome 17. The most common translocation is t(16;17)(q22;p13), fusing *USP6* with *CDH11*.[584] Other partner genes include *TRAP-150* (chromosome 1), *OMD* (chromosome 9), *ANF9* (chromosome 3), and *COL1A1* (chromosome 17).[585] Secondary aneurysmal bone cysts may be associated with a variety of benign and malignant primary lesions, including chondroblastoma, giant cell tumor, osteoblastoma, and osteosarcoma; however, these secondary aneurysmal bone cysts lack *USP6* rearrangements. It has been suggested that insulin-like growth factor-1, which has been consistently found in this lesion, may play a role in its pathogenesis.[586]

Aneurysmal bone cysts recur approximately one-fourth of the time when treated by curettage alone because of incompleteness of surgical excision.[576,586]

A few cases of reasonably convincing malignant transformation of aneurysmal bone cyst into osteosarcoma have been described; this exceptionally rare phenomenon should be distinguished from telangiectatic osteosarcoma and osteosarcoma with aneurysmal cyst-like areas.[587,588]

Sometimes lesions with the features of aneurysmal bone cysts are seen in association with solid areas composed of an admixture of fibrous tissue, woven bone formation, and osteoclasts. In other instances, solid areas with this mixed appearance are seen in the absence of typical aneurysmal bone cyst features. Depending on the location of the lesion, variation in microscopic appearance, and the pathologist's bias, these lesions have been variously referred to as *giant cell reaction*, *(extragnathic) giant cell reparative granuloma*, *giant cell lesion of small bones*, and *solid variant of aneurysmal bone cyst*.[589–595] Locations include the small bones of the hand and feet, vertebrae, sacrum, and—less commonly—long bones. In the latter locations, they tend to have a metaphyseal location.

Other Cysts

Ganglion cysts morphologically indistinguishable from those commonly seen in the periarticular soft tissue are occasionally found in an intraosseous location, always close to a joint space (Fig. 40.63).[596,597] The cyst is surrounded by a zone of condensed bone, is often multiloculated, and has a gelatinous content and a wall of attenuated fibrous tissue. The bones of the ankle, particularly the tibia, are those most commonly affected.[598] Intraosseous ganglia are similar to the geodes those seen in association with degenerative joint disease.

Subpubic cartilaginous cyst is the name given to a fibrocartilaginous mass with extensive degenerative cystic changes that has been observed in the proximity of the symphysis pubis.[599]

Non-ossifying Fibroma (Fibrous Cortical Defect)

Non-ossifying fibromas are extremely common and distinctive lesions of bone that occur in adolescents, most often in long tubular bones, particularly the proximal and distal tibia or the distal femur.[600] Radiographically, they appear as eccentric, sharply delimited radiolucent lesions that arise in the metaphyseal cortex (Fig. 40.64). Smaller, completely intracortical lesions are typically referred to as fibrous cortical defects, whereas larger lesions that encroach on the medullary cavity are designated as non-ossifying fibromas. It is unclear whether these are neoplastic lesions or developmental aberrations.

Grossly, the lesion is granular and brown or dark red and may contain yellowish areas as well. Microscopically, it consists of cellular masses of fibrous tissue, often arranged in a storiform pattern (Fig. 40.65). Scattered osteoclasts and collections of foamy and hemosiderin-laden macrophages are frequent. The microscopic appearance is very reminiscent of a benign fibrous histiocytoma and is designated as such by some authors, especially when it occurs in adult patients in places other than metaphyses of long bones.[601]

Clinically, there are few or no symptoms except pain. The lesion is usually found incidentally on x-ray examination. Fractures can occur through the thinned cortex,[602] at which point surgical intervention is necessary. Most non-ossifying fibromas will spontaneously heal and do not require surgery.

Figure 40.63 MRI shows a well-circumscribed intraosseous ganglion cyst of the medial malleolus of the ankle.

Figure 40.64 Radiograph of a non-ossifying fibroma. This radiolucent lesion arises in the metaphysis of the distal tibial cortex and is surrounded by prominent reactive bone.

For personal use only. No other uses without permission. Copyright ©2017. Elsevier Inc. All rights reserved.

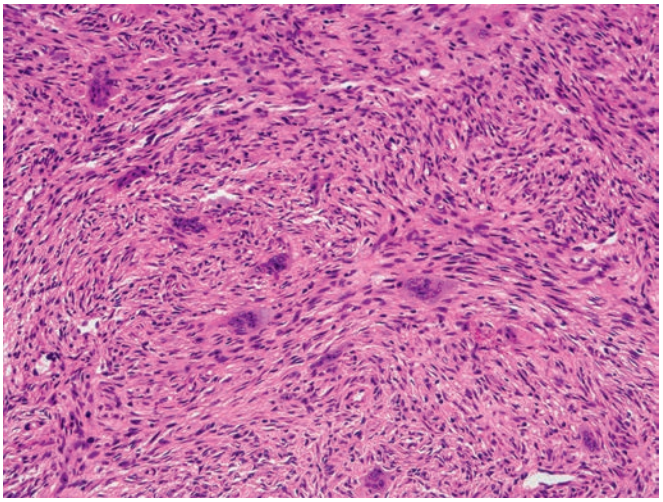

Figure 40.65 Non-ossifying fibromas are composed of bland spindled cells, often arranged in a vague storiform pattern, and contain scattered giant cells.

Figure 40.66 Fibrous Dysplasia. This lesion, located in the femoral neck, is well defined, radiolucent, and surrounded by reactive bone. A pathologic fracture extends through the lesion.

Fibrous Dysplasia and Osteofibrous Dysplasia

Fibrous dysplasia can present in two forms: monostotic and polyostotic. The monostotic variety is usually seen in older children and young adults and most commonly affects the rib, femur, tibia, and craniofacial bones. The less common polyostotic type may be unilateral or have widespread skeletal involvement. Patients with widespread skeletal involvement may also have associated endocrine dysfunction, precocious puberty in female individuals, and areas of cutaneous hyperpigmentation (McCune–Albright syndrome). Monostotic fibrous dysplasia, polyostotic fibrous dysplasia, and McCune–Albright syndrome all occur sporadically and are caused by activating mutations in the *GNAS1* gene (located in 20q13, encoding the α-stimulatory subunit of heterotrimeric G proteins) that occur postzygotically in a somatic cell.[603–605] The differences in clinical manifestations relate to the time in which the mutation takes place, with mutation occurring during embryonic life being more likely to result in McCune–Albright syndrome, and mutation occurring in postnatal life more likely to cause monostotic disease. The bone lesions of fibrous dysplasia have been found to be clonal, in keeping with a neoplastic process.[606]

Radiographically, fibrous dysplasia arises within the medullary cavity and may cause expansile remodeling of the bone. The lesions are usually well circumscribed and may have surrounding reactive bone. The appearance of the lesion on plain radiography and CT depends on the relative proportion of bone and fibrous tissue within the lesion but is often described as having "ground-glass opacity" (Fig. 40.66). Punctate areas of calcification may be seen in fibrocartilaginous dysplasia (see later). Lesions in craniofacial bones may appear radiodense. Occasionally the lesion protrudes far beyond the normal bone contour ("fibrous dysplasia protuberans").[607]

Grossly, the tissue cuts with a gritty consistency and is grayish white (Fig. 40.67). The cortical bone often is thinned and expanded. Microscopically, fibrous dysplasia is composed of irregularly shaped trabeculae of woven bone deposited in a fibrous stroma of variable cellularity. The bone trabeculae may have a "C" or "S" shape or can appear round (Fig. 40.68). These bone trabeculae are woven when viewed with polarized light and lack the accompanying osteoblastic rimming that would be expected given the immaturity of the bone. Older lesions may become cystic or develop a histiocytic infiltrate. Stromal hemorrhage may elicit a giant cell reaction.

Figure 40.67 Gross appearance of fibrous dysplasia of the rib. The lesion forms a fusiform, expanded mass that is grayish white.

Occasionally, lesions of fibrous dysplasia show calcified spherules similar to those seen in cementifying fibromas.[608,609] Other cases show highly cellular areas that may be diagnosed incorrectly as sarcoma. Focal areas of hyaline cartilage and cystic areas may also be present.[610] The former are more common in the polyostotic variety and can dominate the microscopic picture to such a degree that a mistaken diagnosis of a cartilaginous tumor can be made.

It has been suggested that some rib lesions resembling fibrous dysplasia but showing progressive maturation of the bone toward the periphery are secondary to trauma ("post-traumatic dysplasia or lesion").[611,612] Some of these lesions are bilateral and strikingly symmetrical.[613] A conceptually related issue is the so-called *liposclerosing myxofibrous tumor*, which some authors have hypothesized represents a form of fibrous dysplasia with secondary trauma-induced changes.[614,615] However, several authors have carefully

For personal use only. No other uses without permission. Copyright ©2017. Elsevier Inc. All rights reserved.

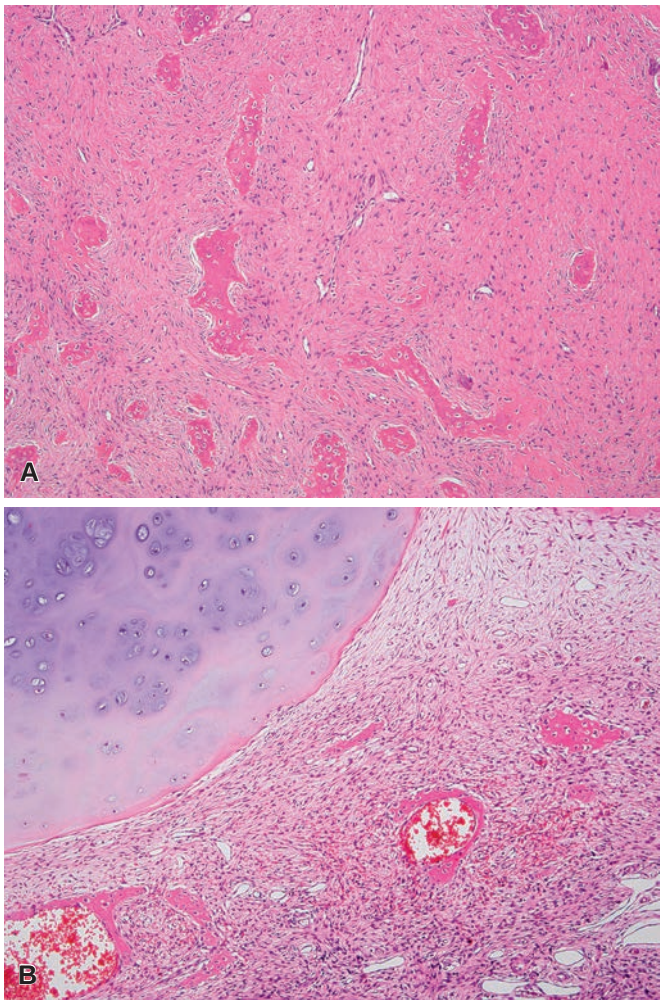

Figure 40.68 Histologic Features of Fibrous Dysplasia. A, Irregularly shaped woven bone spicules are surrounded by fibrous stroma. The surfaces of the trabeculae are devoid of osteoblasts. **B,** Chondroid nodules may be prominent.

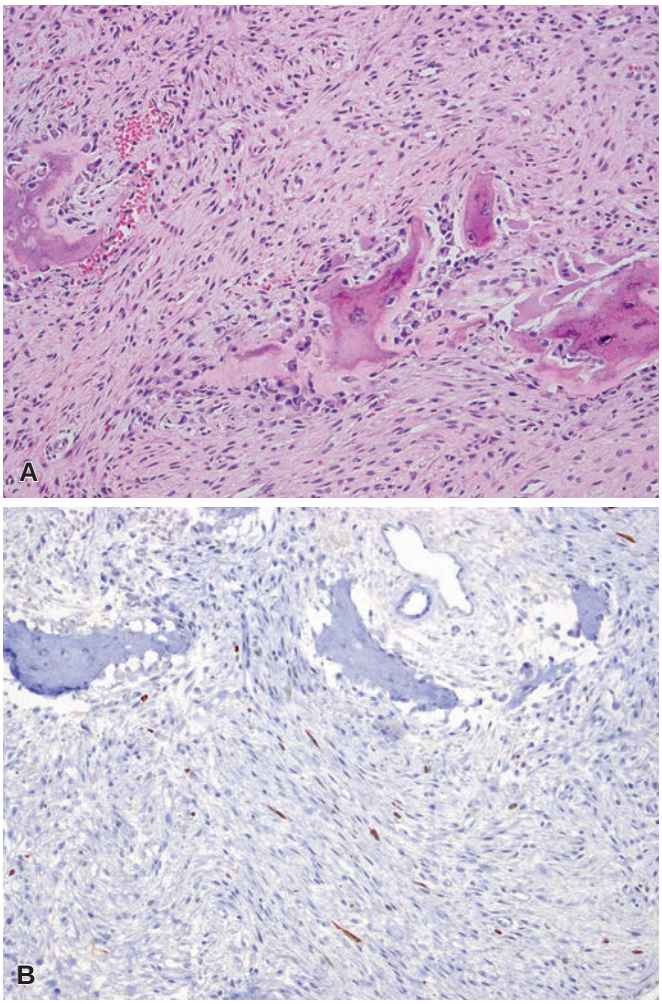

Figure 40.69 Osteofibrous Dysplasia. A, Osteoblastic rimming is a prominent feature of osteofibrous dysplasia. **B,** Individual keratin-positive spindled stromal cells are seen, but nests of epithelial cells are absent.

reviewed the histologic features in cohorts of patients with this condition and concluded that most cases are examples of fibrous dysplasia; others have shown that the lesions harbor an activating Gs alpha mutation, again suggesting these are examples of fibrous dysplasia.[616,617]

Fibrous dysplasia may be accompanied by intramuscular myxoma of the same extremity (Mazabraud syndrome).[618] In addition, fibrous dysplasia of either monostotic or polyostotic type can be complicated not only by the development of a primary bone sarcoma, particularly osteosarcoma,[619] but also chondrosarcoma and undifferentiated pleomorphic sarcoma.[620,621]

Resection cures fibrous dysplasia in bones such as the rib. Curettage is adequate in long bones such as the tibia. In the maxilla, where some deformity may exist, partial removal of the lesion is all that is necessary.

Osteofibrous dysplasia (ossifying fibroma, Campanacci lesion) is a benign fibro-osseous lesion more closely related to adamantinoma than fibrous dysplasia. It is distinguished microscopically from fibrous dysplasia by the cortical location of the process, prominent osteoblastic rimming of the bone trabeculae, and the presence of keratin-immunoreactive stromal cells (Fig. 40.69).[622,623] The tibia and fibula are affected almost exclusively, the lesions typically located in the anterior cortex.[622,624]

Clonal chromosomal abnormalities have been identified in this lesion, suggesting a neoplastic nature.[625,626] Immunohistochemically, reactivity for keratin, neurofibromin, S-100 protein, and Leu7 are commonly found in osteofibrous dysplasia.[627–629] In contrast to fibrous dysplasia, there are no activating mutations of *GNAS1*, suggesting that the two disorders are not pathogenetically related, despite their morphologic and some phenotypic similarities.[630]

Langerhans Cell Histiocytosis

This disorder is a histiocytic/dendritic cell proliferation characterized by the accumulation of dendritic cells and other inflammatory cells, including eosinophils, giant cells, neutrophils, foamy histiocytes, and often accompanied by areas of fibrosis (Fig. 40.70). Langerhans cells have a characteristic morphologic appearance. Their nuclei often are lobulated or indented, sometimes with a longitudinal groove; their cytoplasm is, for the most part, distinctly eosinophilic. A specific intracytoplasmic organelle, known as Langerhans or Birbeck granule, can be identified on electron microscopic examination. Diagnostic immunohistochemical markers include S-100 protein, CD1a, and langerin (CD207).[631]

Langerhans cell histiocytosis of bone can be divided into three major categories on the basis of type and extent of the organ

For personal use only. No other uses without permission. Copyright ©2017. Elsevier Inc. All rights reserved.

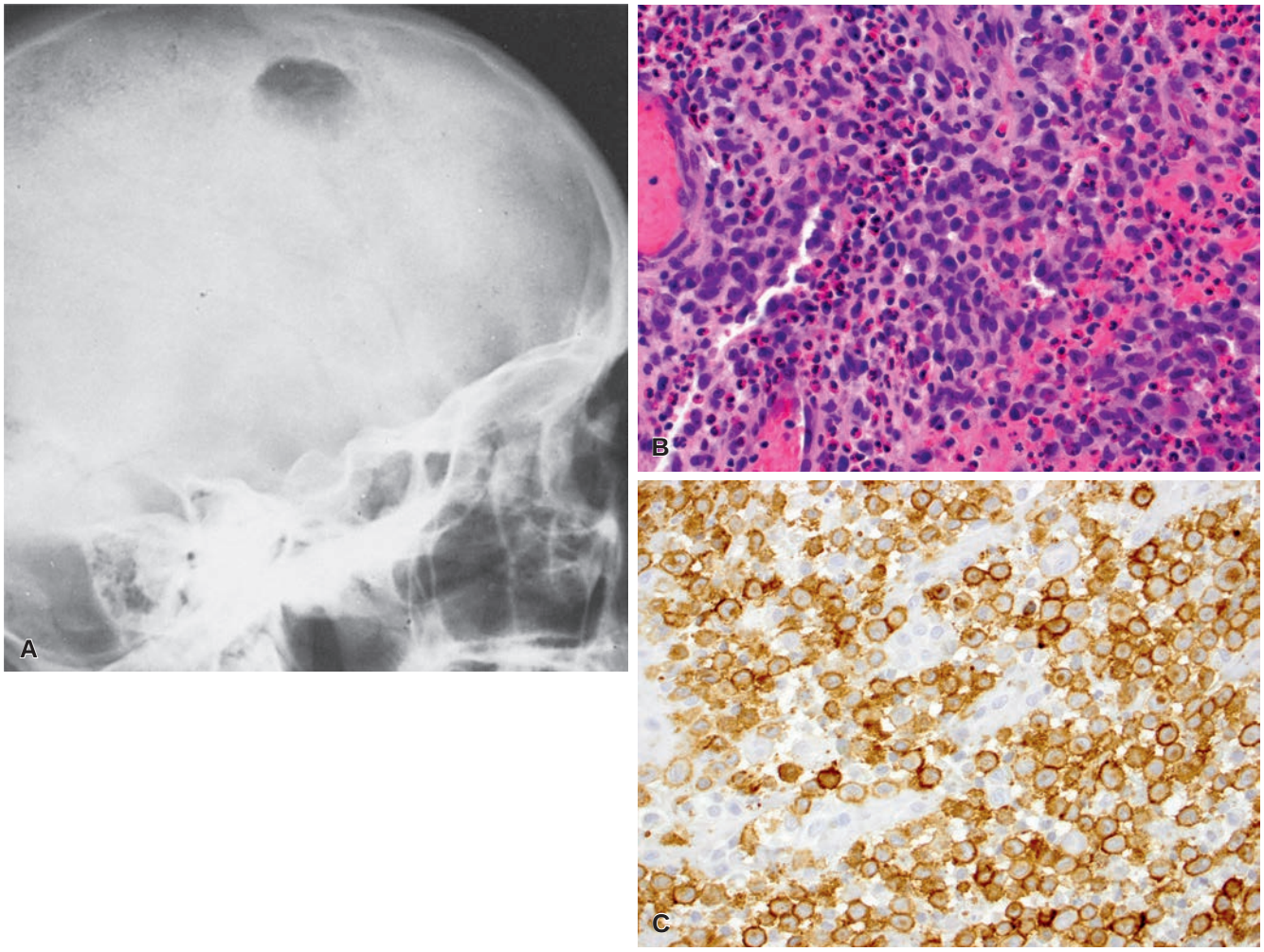

Figure 40.70 Langerhans Cell Histiocytosis. A, Punched out lesion of the skull. **B,** Histologic features of Langerhans cell histiocytosis include large, ovoid Langerhans cells with surrounding inflammation rich in eosinophils. **C,** An immunostain for CD1a highlights Langerhans cells.

involvement. Solitary bone involvement, multiple bone involvement (with or without skin involvement), or multiple organ involvement (bone, liver, spleen, and others).

The cases with solitary bone involvement, which represent the most common variety, have been traditionally referred to as eosinophilic granuloma. Young adults are most commonly affected. Any bone can be involved, with the possible exception of the hands and feet. The most common sites are the cranial vault, jaw, humerus, rib, and femur.[632,633] Radiographically, Langerhans cell histiocytosis is "the great imitator." Most lesions appear as well-circumscribed, punched out radiolucent lesions. In flat bones, Langerhans cell histiocytosis can have an aggressive pattern of bone destruction reminiscent of Ewing sarcoma or lymphoma. In the spine, this lesion causes vertebra plana.

The treatment may include observation, surgery, radiotherapy, or chemotherapy, depending on the extent of the disease. Many solitary lesions regress following biopsy. The long-term prognosis, particularly for solitary lesions, is excellent.[634] It is exceptional for these patients to develop other bone lesions or involvement of other organs.

Multiple bone lesions can be accompanied by proptosis, diabetes insipidus, chronic otitis media, or a combination of these conditions, historically referred to as Hand–Schüller–Christian disease. This form is characterized by a prolonged clinical course, often marked by alternating episodes of regressions and recrudescences, although the eventual outcome is favorable in most cases. By contrast, Letterer–Siwe disease—the development of Langerhans cell histiocytosis in multiple organ systems—follows a more aggressive clinical course.[632]

Langerhans cell histiocytosis should be regarded as a neoplastic disease. Recently, it has been shown that a relatively high percentage of cases of Langerhans cell histiocytosis harbor *BRAF* V600E mutations, resulting in activation of the MAPK pathway. A smaller percentage of lesions have mutations in the *MAP2K1* gene; these mutations are mutually exclusive.[635]

The differential diagnosis of Langerhans cell histiocytosis of bone at the microscopic level includes osteomyelitis and the osseous manifestations of Rosai–Dorfman disease.[636]

Other Histiocytic Lesions

Rosai–Dorfman disease (sinus histiocytosis with massive lymphadenopathy) can involve the skeletal system either as a manifestation of multisystem disease or, less commonly, as a mass limited to this site.[637] The morphologic features are similar to those seen at other extranodal sites, in the sense that secondary xanthomatous changes

For personal use only. No other uses without permission. Copyright ©2017. Elsevier Inc. All rights reserved.

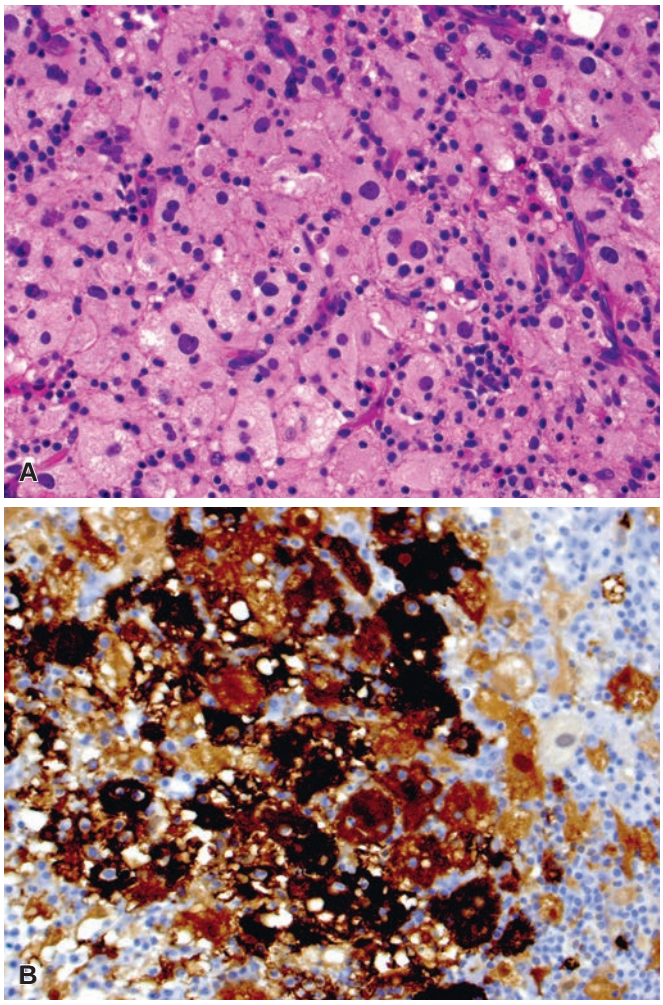

Figure 40.71 **Rosai–Dorfman Disease. A,** Large histiocytes admixed with acute and chronic inflammatory cells. The histiocytes engulf other inflammatory cells ("emperipolesis"). **B,** The histiocytes in Rosai–Dorfman disease are strongly immunoreactive for S-100 protein.

and fibrosis are common. These features, plus the paucity of emperipolesis, can render its recognition difficult (Fig. 40.71).[636]

Erdheim–Chester disease is a lipid-storing histiocytosis of non-Langerhans cell type which may be restricted to the bones or involve multiple organ systems, including lung and central nervous system. The foamy histiocytes that accumulate in this disease are CD68 positive and CD1a negative. The radiographic findings are virtually diagnostic and include mixed radiolucent and osteoblastic foci in the metaphyses and diaphysis of long bones. In the lung the involvement is primarily septal, a fact of diagnostic significance both radiographically and morphologically. As in the case of Langerhans cell histiocytosis, there is controversy as to whether the disease is reactive or neoplastic.[638–640]

Joints and Related Structures

Normal Anatomy

Joints that permit free movement of the bone, referred to as *diarthroses*, are covered by hyaline cartilage and enclosed in a capsule. This capsule is composed of an outer fibrous layer of dense connective tissues, which is continuous with the periosteum of the bones, and

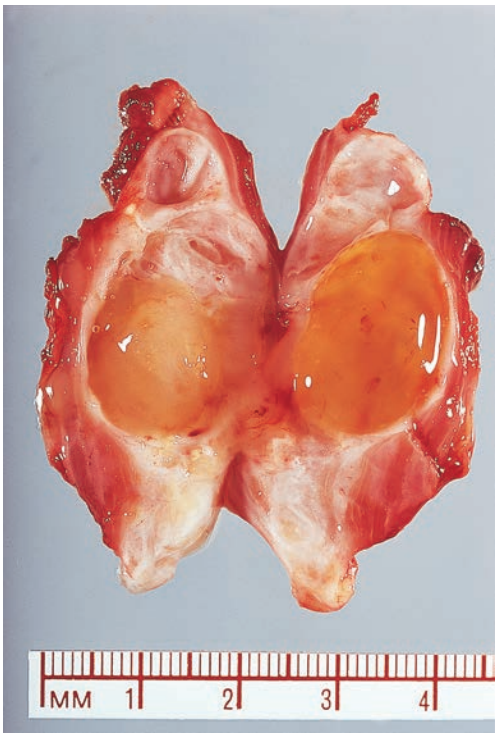

Figure 40.72 Gross appearance of ganglion cyst. (Courtesy of Dr RA Cooke, Brisbane, Australia; from Cooke RA, Stewart B. *Colour Atlas of Anatomical Pathology*. Edinburgh: Churchill Livingstone; 2004).

an inner synovial layer.[1] The latter, also referred to as *synovial membrane*, contains fibroblast-like cells (synoviocytes, type B cells) and macrophage-like cells (type A cells).[641] Synoviocytes secrete proteoglycan, and the synovial membrane is organized such that cells and proteins move easily between joint fluid and synovium. A layer of loose connective tissue or adipose tissue is present in some regions of the joint between the synovial and the fibrous layers, resulting in the formation of folds or "villi," which protrude into the joint cavity.

Tendons are composed of closely packed parallel type I collagen fibers. They are surrounded by a layer of connective tissue known as the *tendon sheath*. In long tendons, this sheath is composed of an inner layer adjacent to the collagen and an outer layer that is loosely bound to the tissues surrounding the tendon. The space between these two layers is somewhat reminiscent of a joint cavity.

Non-neoplastic Diseases

Ganglion and Meniscal Cysts

Ganglion cysts occur around joints and—less commonly—around tendon sheaths. They are annoying deformities that may cause pain, weakness, partial disability of the joint, and bone changes. Individuals overusing the wrist and fingers (pianists, computer operators) are prone to this condition. A history of injury preceding ganglion formation may exist.

Ganglia develop by myxoid degeneration and cystic softening of the connective tissue of the joint capsule or tendon sheath. The most common location of ganglia is on the dorsal carpal area of the hand, where the cystic lesion pushes its way toward the surface between the tendons of the extensor indicis proprius and the extensor carpi radialis (Fig. 40.72). The second most frequent location is

For personal use only. No other uses without permission. Copyright ©2017. Elsevier Inc. All rights reserved.

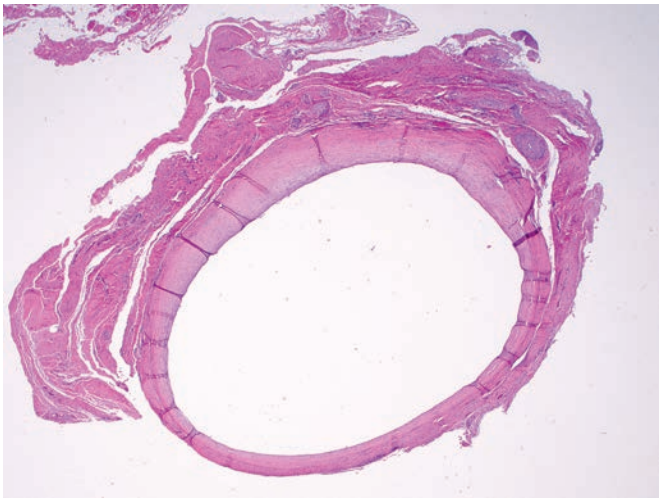

Figure 40.73 Microscopic appearance of ganglion cyst. The wall is composed of dense fibrous tissue, and there is no synovial lining.

the volar surface of the wrist, superficial and medial to the radial artery. Ganglia also arise on the volar surfaces of the fingers just distal to the metacarpophalangeal joints, in the dorsum of the foot, around the ankle and knee, and in the various articular and ligamentous areas of the spine. Ganglia are not lined by synovium and do not communicate with the joint cavity, two features distinguishing them from synovial (Baker) cysts (see next section; Fig. 40.73).

A lesion microscopically similar to soft tissue ganglion may occur in the menisci of the knee and is referred to simply as *meniscal cyst*. The most common site is the peripheral portion of the middle third of the lateral meniscus.[642,643] It may remain confined to the meniscus or extend extracapsularly. A traumatic etiology is favored.

Bursae and Baker Cyst

Bursae are found where muscles, tendons, and skin glide over bony prominences. They are composed of a fibrohyaline wall with no inner lining. Bursae are subject to all the diseases that occur in large joint spaces. Inflammation may be associated with the formation of cysts, fluid accumulation, and rice bodies (Fig. 40.74).

Baker cyst occurs in the popliteal space from herniation of the synovial membrane through the posterior part of the capsule or from escape of joint fluid through normal anatomic connections of the knee joint with the semimembranous bursa (Fig. 40.75). The cyst is lined by true synovium and may have cartilage in its wall. Any joint disease leading to increased intra-articular pressure, such as degenerative joint disease, neuropathic arthropathy, and rheumatoid arthritis, may result in the formation of Baker cysts.[644]

An unusual form of tenosynovitis characterized by the formation of psammoma bodies has been described that seems to result from repetitive motion or injury at the affected site.[645]

Carpal Tunnel Syndrome

The carpal tunnel is the space between the flexor retinaculum or transverse carpal ligament and the carpal bones. The median nerve courses through this tunnel, and its compression in this location by a variety of causes produces the symptoms of carpal tunnel syndrome.[646] These include bony deformity following trauma, masses within the canal (i.e., hemangiomas, lipomas, ganglia), rheumatoid arthritis, and amyloidosis.[647] Often, no specific etiology can be demonstrated.[648]

Figure 40.74 Gross appearance of prepatellar bursa with chronic inflammation.

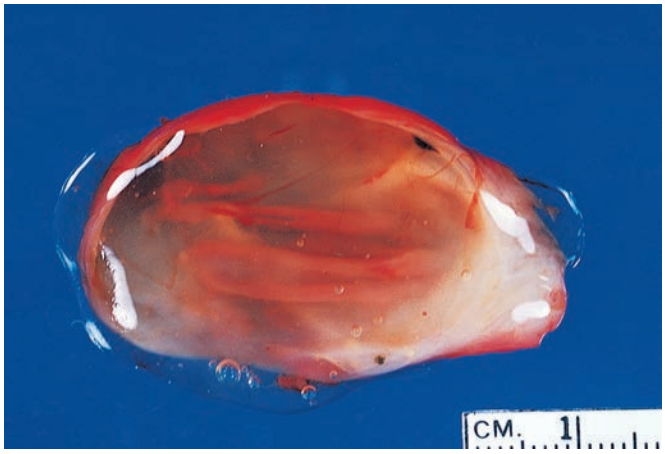

Figure 40.75 Gross appearance of Baker cyst.

Arthritis

Biopsies of the synovium or other articular structures may aid in the assessment of synovial inflammatory conditions, particularly when accompanied by synovial fluid evaluation.[649] Specimens can be obtained by blind needle biopsy, by minimally invasive arthroscopy, or under ultrasound guidance.[650] It is indicated for inflammatory joint diseases when the etiology remains in doubt, particularly when only one joint is affected. While it may not be possible to provide a definitive diagnosis in the case of chronic synovitis, other findings, such as acute synovitis, crystal deposits, or granulomas may point to a specific etiology.[649–651] Unfortunately, the histologic findings in

For personal use only. No other uses without permission. Copyright ©2017. Elsevier Inc. All rights reserved.

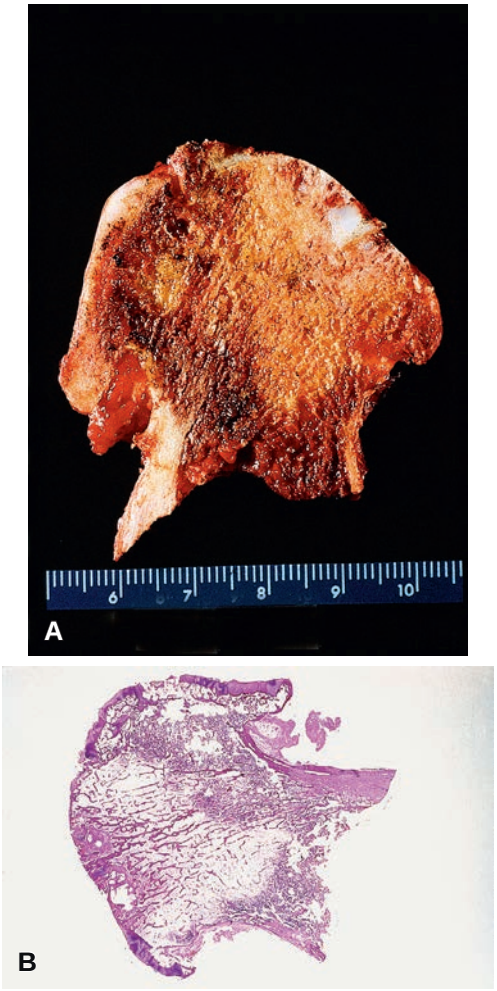

Figure 40.76 Advanced osteoarthritis of femoral head: **A,** gross appearance, showing near-total disappearance of articular cartilage; **B,** whole mount of the same case.

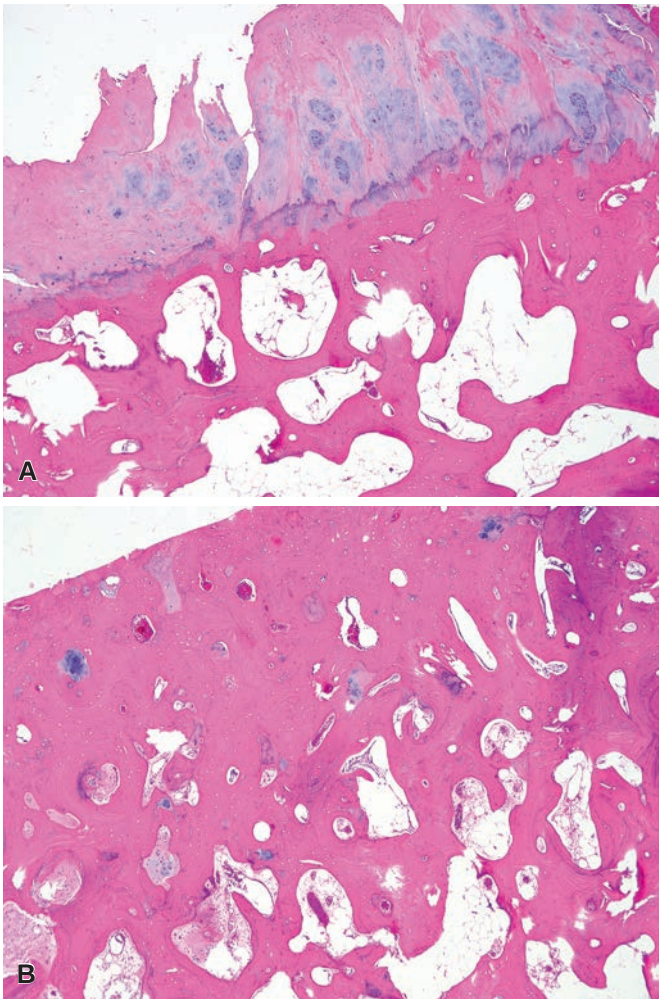

Figure 40.77 Early changes in osteoarthritis include cracking of the articular cartilage and cloning of chondrocytes **(A)**. **B,** Later, the cartilage is completely eroded, resulting in thickened subchondral bone.

the most common rheumatic diseases are often nonspecific[651]; however, the combination of prominent lymphoid follicles and marked hyperplasia of synovial cells is highly suggestive of rheumatoid arthritis or another inflammatory arthropathy.

Osteoarthritis (Degenerative Joint Disease)

Osteoarthritis is somewhat of a misnomer because this type of joint disease is degenerative and not inflammatory in nature. It may occur as a primary process as the result of repeated injury to the cartilage, or secondary to a variety of other conditions such as hip dysplasia, post-traumatically, or as the result of underlying conditions such as Paget disease or avascular necrosis. The earliest changes occur in the superficial hyaline articular cartilage, where the first detectable degenerative changes include fibrillation of the cartilaginous matrix at a right angle to the surface, and eventually resulting in a "papillary" appearance and sometimes in the freeing of fragments of cartilage. Initially, the chondrocytes clone in an attempt to repair the degenerative damage. Ultimately, the cartilage is completely worn, resulting in the articulation of two opposing subchondral bone surfaces (Fig. 40.76). The thickened, polished-appearing bone is referred to as "eburnated" (Fig. 40.77). Osteophytes, which are reactive osteocartilaginous projections, form at the peripheral margin of the joint. Subchondral cysts ("geodes") may form in the subchondral bone. The synovium may remain normal or undergo thickening, with formation of villous structures and chronic inflammation.[652]

In some cases of severe osteoarthritis, there are foci of subchondral acute inflammation resembling osteomyelitis, but these are probably of a noninfectious nature.[653]

It should be emphasized that the changes of degenerative joint disease are centered in the cartilage, a type of tissue notorious for its poor capacity for repair.[654] These changes are more prominent on the joint surface exposed to friction, weight bearing, or movement, but they also occur in areas of the joint not subject to these mechanical forces. The biology of osteoarthritis is highly complex but involves degradation of extracellular matrix, proteinases, cytokines, and inherent properties of the chondrocytes.[655]

Neuropathic arthropathy (Charcot joint) is a particularly destructive variant of degenerative joint disease that occurs as the result of neuropathy secondary to a variety of underlying causes, including diabetes, neurologic disorders, syringomyelia, or tertiary syphilis (Fig. 40.78). The underlying cause correlates with which joint is involved.[656] The process is usually progressive, and on occasion it may have an extremely rapid evolution. Particles of dead bone and cartilage often are seen in large amounts embedded in the synovial membrane ("detritic synovitis"). However, this is not specific for this condition.

For personal use only. No other uses without permission. Copyright ©2017. Elsevier Inc. All rights reserved.

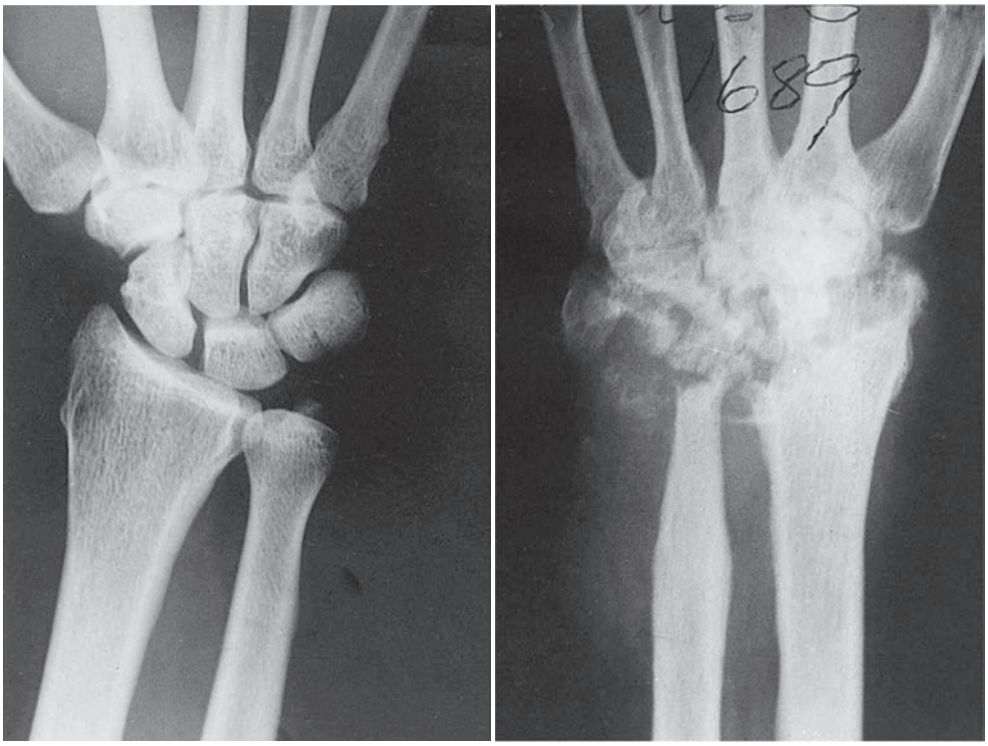

Figure 40.78 Neuropathic changes in wrist secondary to syringomyelia.

Chondromalacia patellae is the name given to a condition of obscure etiology characterized by softening, fibrillation, fissuring, and erosion of the articular cartilage of the patella.[657] Microscopically, the changes are indistinguishable from those of degenerative joint disease.

Rheumatoid arthritis is the most common inflammatory arthropathy and is an immune-complex disease that manifests as a chronic, polyarticular arthritis. It is mostly seen in women during the second and third decades of life. The joints of the feet and hands are nearly always involved. Other joints frequently affected are the elbows, knees, wrists, ankles, hips, spine, and temporomandibular articulations.[658]

The pathogenesis of rheumatoid arthritis starts with genetic susceptibility, and HLA-DRB1 plays a prominent role.[659] Autoantibodies against citrullinated peptides combine with IgG autoantibodies (rheumatoid factor) to form complexes that activate the complement system.[660,661] A T lymphocyte–mediated tissue response causes the marked joint inflammation seen in rheumatoid arthritis, and synovial fibroblasts and several key cytokines play a key role in tissue injury.[662] It has been suggested that a viral trigger may play a role in rheumatoid arthritis.[663]

The earliest morphologic changes occur in the synovial membrane. Hyperemia of the synovium is followed by proliferation of the synovial lining cells and infiltration by plasma cells and lymphocytes (Fig. 40.79).[664] Lymphoid follicles are often present. The small synovial blood vessels are lined by plump endothelial cells, and fibrin deposits often are seen close to the synovial lining or within the stroma. Two additional microscopic features, which are also nonspecific, include the presence of synovial giant cells and bone and cartilage fragments within the actual synovial membrane. The detritic cartilage and bone fragments tend to occur in joints with advanced disease and are likely the result of the erosive, destructive process of the articular surface.

As the process progresses, a granulation tissue pannus grows over the articular surface and erodes into the subchondral bone at the margin of the joint, resulting in osteopenic areas in the bone. The ensuing destruction of the articular cartilage (Fig. 40.80) may be followed by fibrous ankylosis and eventually bony ankylosis, or joint fusion. The pronounced tissue destruction not only involves the articular cartilage but the subchondral bone (leading to cysts) and the joint structures (leading to Baker cysts and synovial cysts) as well.[665] End-stage rheumatoid arthritis resembles osteoarthritis.

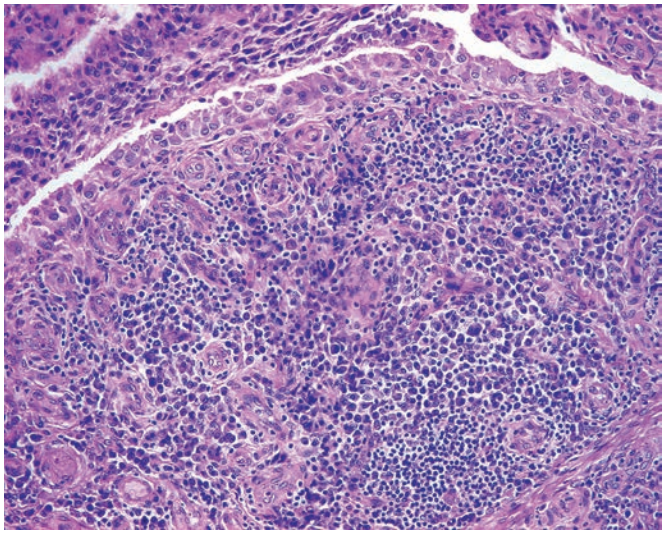

Figure 40.79 Synovial hyperplasia and heavy lymphoplasmacytic infiltrate in rheumatoid arthritis.

Tenosynovitis and "rheumatoid nodules" are the two most common extra-articular manifestations of rheumatoid arthritis. The changes seen in the former are indistinguishable from those seen in the joint membrane.[666] Rheumatoid nodules, which are seen in

For personal use only. No other uses without permission. Copyright ©2017. Elsevier Inc. All rights reserved.

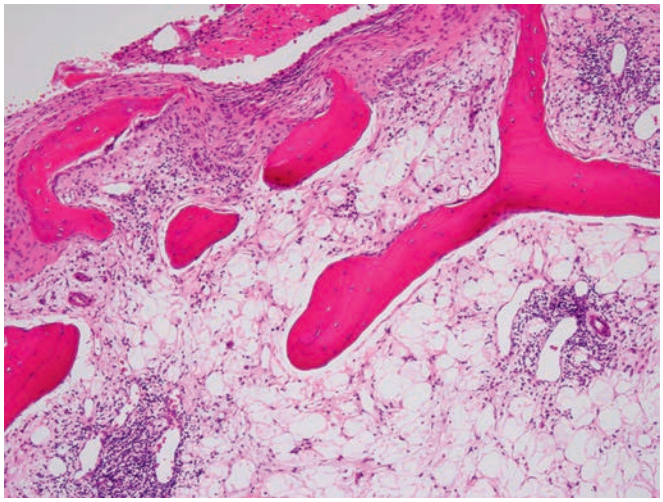

Figure 40.80 Examination of the bone in rheumatoid arthritis shows destruction of the articular surface by pannus, as well as lymphoid aggregates in the subchondral bone.

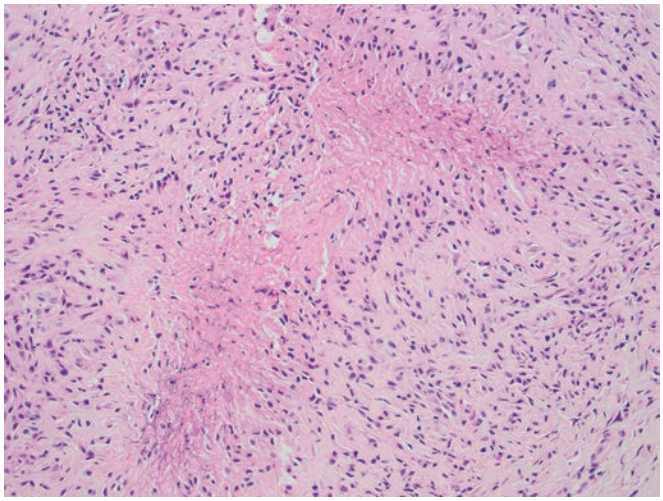

Figure 40.81 Rheumatoid nodule with early cystic change of the "necrobiotic" center. Note the peripheral palisading of histiocytes.

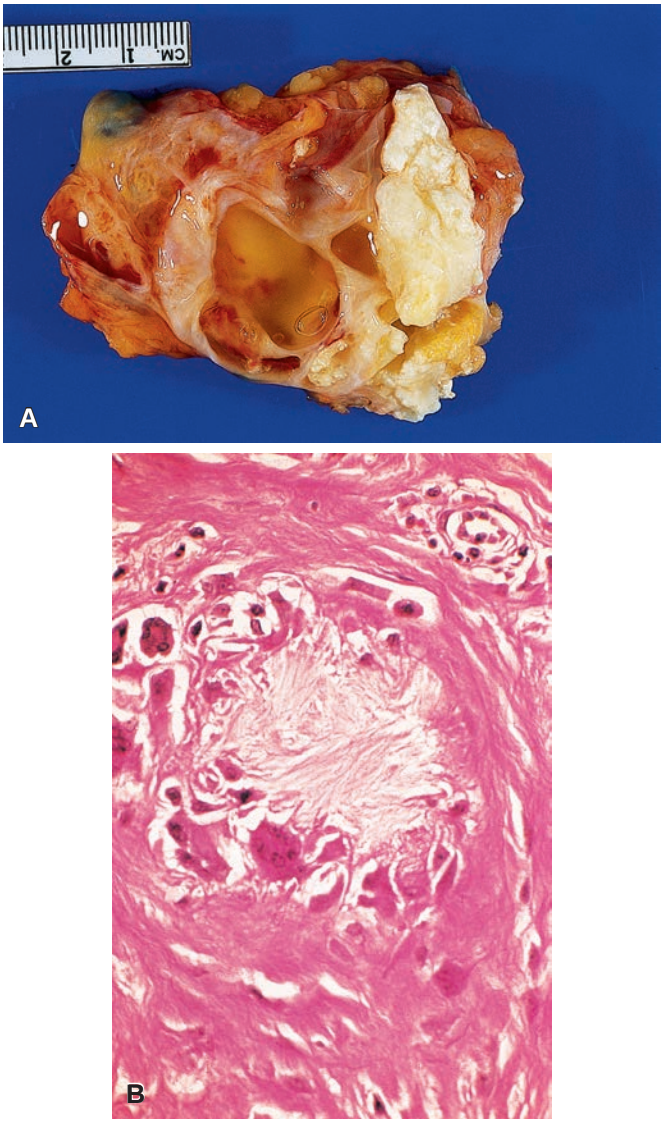

Figure 40.82 **Gout. A,** Gross appearance of large gouty deposit in the posterior knee. **B,** A lesion of periarticular gout showing a foreign body–type giant cell reaction to the deposited crystals. The crystalline nature of this material is not obvious in this formalin-fixed specimen.

approximately 20% of the patients, occur most often in tendons and tendon sheaths and periarticular subcutaneous tissue but also have been seen in the heart and large vessels, lung and pleura, kidney, meninges, and synovial membrane itself.[667] Microscopically, they are composed of a necrotic center containing fibrin, surrounded by a predominantly histiocytic inflammatory reaction, often arranged in a palisading fashion (Fig. 40.81). Rheumatoid nodules need to be distinguished from other palisading granulomatous processes, infectious granulomas, and on occasion epithelioid sarcoma.

Infectious Arthritis

Bacterial, fungal, and parasitic infections can reach the joints either by hematogenous spread or by contiguous extension from a neighboring osteomyelitis. A form of infectious arthritis that has risen dramatically in recognition and frequency in recent years is *Lyme disease*, an arthropod-transmitted infection caused by *Borrelia* species that can also involve skin, heart, and nervous system.[668–670] Erythema migrans occurs at the site of the initiating tick bite. The microscopic changes in the synovium are those of a nonspecific chronic synovitis, and serologic testing is typically used to establish the diagnosis.[671]

Gout and Pseudogout

Calcium pyrophosphate and monosodium urate crystal deposits are among the most common articular/periarticular deposits. About 2%–5% of chronic joint disease is caused by gout (caused by monosodium urate crystal deposits). The metatarsophalangeal joints are often the first to be involved, but other joints of the hands and feet are also frequently involved. The disease may also involve the joints of the long bones (Fig. 40.82). Uric acid deposits elicit a severe inflammatory reaction and progressively destroy the cartilage and may cause osteolytic, irregular destruction of subchondral bone. These deposits may extend out from a joint into the soft tissue and cause destruction of the ligaments. This destruction eventually leads to subcutaneous deposits that may erode through the skin. The

For personal use only. No other uses without permission. Copyright ©2017. Elsevier Inc. All rights reserved.

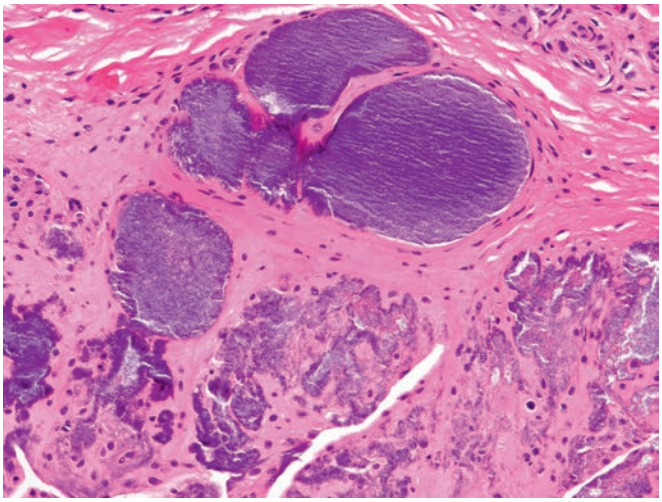

Figure 40.83 Aggregates of calcium pyrophosphate crystals appear bluish and lack a significant inflammatory response. Examination with polarized light will highlight the typical diamond or rhomboid shape of the crystals.

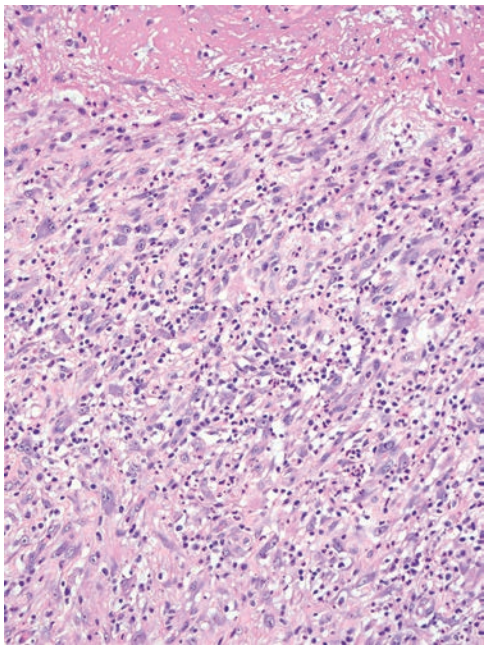

Figure 40.84 Periprosthetic joint infection. Tissue beneath the fibrin surface showing marked acute inflammation (greater than five neutrophils in five high-power fields, suggesting infection).

microscopic pattern of gout is unmistakable. The crystals appear as needle-like structures by polarized light examination. The crystals dissolve readily in water-based solutions; however, fixation in alcohol will help preserve the crystals, and alternatively thickly sectioned, unstained and coverslipped sections may allow the crystal to be visualized. Furthermore, the negative birefringence of these crystals can still be demonstrated after staining with nonaqueous alcoholic eosin.[672] Histiocytes and foreign body giant cells predominate in the inflammatory infiltrate.

Monosodium urate crystals should be distinguished from calcium pyrophosphate crystals *(pseudogout, "chondrocalcinosis")*. Calcium pyrophosphate crystals are commonly identified in articular cartilage, meniscal cartilage, and synovium. Calcium pyrophosphate crystals are recognizable as polarizable crystals that have a rhomboid or diamond shape, and the crystals do not elicit the same inflammatory response as urate crystals (Fig. 40.83). Tophaceous pseudogout, or the accumulation of calcium pyrophosphate crystal in a manner similar to tophaceous gout, is a much rarer condition.[673] Chondroid metaplasia can be prominent in this condition, resulting in a mistaken diagnosis of chondrosarcoma. Many of these cases involve the temporomandibular joint, but tophaceous pseudogout has been identified in many different sites.

Intervertebral disc prolapse is a complication of mechanical overload-induced degeneration of the disc. This process seems to be mediated through the mitochondrial apoptotic pathway.[674] Material curetted from an intervertebral disc because of prolapse is a very common surgical specimen. Features such as fibrillation, clustering of chondrocytes, and degenerative changes are generally regarded as indicators of degeneration related to prolapse.[675] Weidner and Rice[676] found instead that the feature that better correlated with prolapse was neovascularization occurring at the edges of the fibrocartilaginous fragments.

Other Articular and Periarticular Diseases

Hemophilia is characterized by the accumulation of hemosiderin in the synovium (hemosiderotic synovitis). In contrast to pigmented villonodular synovitis (PVNS), the iron pigment is deposited in superficial layers of the synovium and is accompanied by a chronic synovitis rather than a giant cell–rich histiocytic infiltrate with foamy histiocytes. The morphologic features of hemophilic arthropathy are those of a degenerative rather than an inflammatory process.[677]

Scleroderma (progressive systemic sclerosis) is often accompanied by arthralgia or arthritis, and sometimes these dominate the clinical picture. The main microscopic changes in the synovial membrane are superficial deposition of fibrin, mild mononuclear infiltrate, minimal hyperplasia of synovial lining cells, proliferation of collagen fibers, and focal obliteration of small vessels.[678]

Lupus erythematosus may be accompanied by microscopic changes in the synovium that are indistinguishable from those of rheumatoid arthritis. As a rule, however, there is a more intense surface fibrin deposition and less degree of proliferation of synovial cells.[651]

Amyloid can deposit in the synovium, articular cartilage, menisci, periarticular tissue, and intervertebral disk in old age, apparently unrelated to osteoarthritis and in the absence of systemic amyloidosis.[679–683] Heavier amounts can be seen as an expression of primary amyloidosis or multiple myeloma.[420] Amyloidosis is one of the causes of the carpal tunnel syndrome.[684]

SAPHO is a peculiar syndrome in which synovitis is seen in combination with acne, pustulosis, hyperostosis, and osteitis.[685]

The Pathology of Prostheses

A comprehensive review of joint implant pathology is beyond the scope of this text. However, surgical pathologists are often asked to review biopsies from tissue surrounding a prosthesis to assess for the possibility of infection. In the appropriate context, five or more neutrophils per high-power field in at least five fields suggests infection (Fig. 40.84). Care must be taken not to evaluate surface fibrin for neutrophils. The presence of foamy histiocytes, foreign body granulomas, and opaque particles or polyethylene suggests the possibility of aseptic loosening.[686] The histologic findings, particularly at the time of intraoperative consultation, are more reliably interpreted with knowledge of C-reactive protein levels, erythrocyte sedimentation rate, or alpha defensin results.

For personal use only. No other uses without permission. Copyright ©2017. Elsevier Inc. All rights reserved.

Tumors and Tumorlike Conditions

Tenosynovial Giant Cell Tumor and Pigmented Villonodular Synovitis

Localized tenosynovial giant cell tumor (giant cell tumor of tendon sheath, nodular tenosynovitis) and diffuse tenosynovial giant cell tumor (PVNS) are essentially the same lesion, differing mainly in their clinical features. Localized tenosynovial giant cell tumor is a common lesion that occurs more frequently in women than men, usually appearing in young and middle-aged patients. Most cases are located in the hands and fingers, followed by the feet. Other sites can be affected, including the vertebral column.

Grossly, these tumors are small (1–3 cm in diameter), circumscribed, and vary in color from brown to yellowish (Fig. 40.85). Microscopically, localized tenosynovial giant cell tumors are composed of mononuclear cells, foamy histiocytes, and multinucleated giant cells containing hemosiderin (Fig. 40.86). Mitoses may be prominent, and zones of hyalinization may constitute a variable proportion of the mass. Immunohistochemically, the mononuclear stromal cells express clusterin,[687] and some cells express desmin as well.[688] The multinucleated giant cells have the phenotypic features of osteoclasts.[689] Despite the similarities in the anatomic sites of origin, the lesion referred to as fibroma of tendon sheath appears to be a distinct entity. We suspect that the cases reported as *tendon sheath fibromas* are histogenetically related to tenosynovial giant cell tumor.[690] Their location, clinical presentation, and recurrence rate are certainly comparable.

The great cellularity of this tumor, its variable pattern, and the presence of mitotic figures may lead to an erroneous diagnosis of sarcoma. However, these tumors are nearly always benign. They may erode contiguous bone by pressure. If incompletely removed, they may recur locally.

Both localized and diffuse tenosynovial giant cell tumor share similar genetic features suggesting they are neoplastic.[691] Both lesions harbor a chromosomal translocation involving the *CSF1* gene (located at 1p13 and encoding ligand of the tyrosine kinase receptor).[692,693] Interestingly, the translocation is present in only a small percentage of the lesional cells.[693] There is high expression of *CSF1* mRNA and protein, even in tumors lacking demonstrable *CSF1* translocation.

A very rare malignant counterpart of this lesion has been described in both the localized and diffuse forms.[694,695] Features that should suggest malignancy are a high number of mitotic figures, marked nuclear hyperchromasia, and lack or paucity of multinucleated giant cells. The main differential diagnosis of tenosynovial giant cell tumor is epithelioid sarcoma. The presence of granuloma-like formations, necrosis, invasiveness, epithelioid features, and keratin immunoreactivity favors the latter.

Figure 40.85 **A,** Gross appearance of tenosynovial giant cell tumor. The lesion is small, well circumscribed, solid, and with a brownish cast. **B,** Whole-mount appearance of the cross section of a lesion located in the finger. Note the lobulated quality.

Pigmented Villonodular Synovitis and Bursitis

PVNS, or diffuse intra-articular tenosynovial giant cell tumor, is closely related to its localized counterpart. The diffuse variant occurs in young adults.[696,697] Although the knee joint is the usual site, the process may also involve the ankle, hip, shoulder, or even the elbow joint.[698] Usually only one joint is affected, instances of bilateral disease being exceptional. Occasionally, the lesion may cause cystic lesions in the bone adjacent to the involved joint.

The process diffusely involves the synovium of the affected joint. The lesion imparts a villous pattern in the synovium, which has a brown or yellowish appearance; the synovial fluid may be hemorrhagic. Microscopically and immunohistochemically, the cellular component is similar to that of localized tenosynovial giant cell tumor, but rather than having a circumscribed appearance, it is diffuse

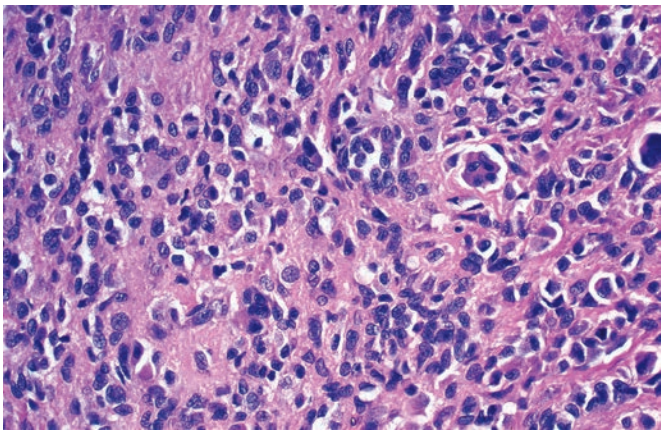

Figure 40.86 Microscopic appearance of tenosynovial giant cell tumor. A polymorphic infiltrate of small histiocytes and multinucleated giant cells is embedded in dense fibrous tissue.

For personal use only. No other uses without permission. Copyright ©2017. Elsevier Inc. All rights reserved.

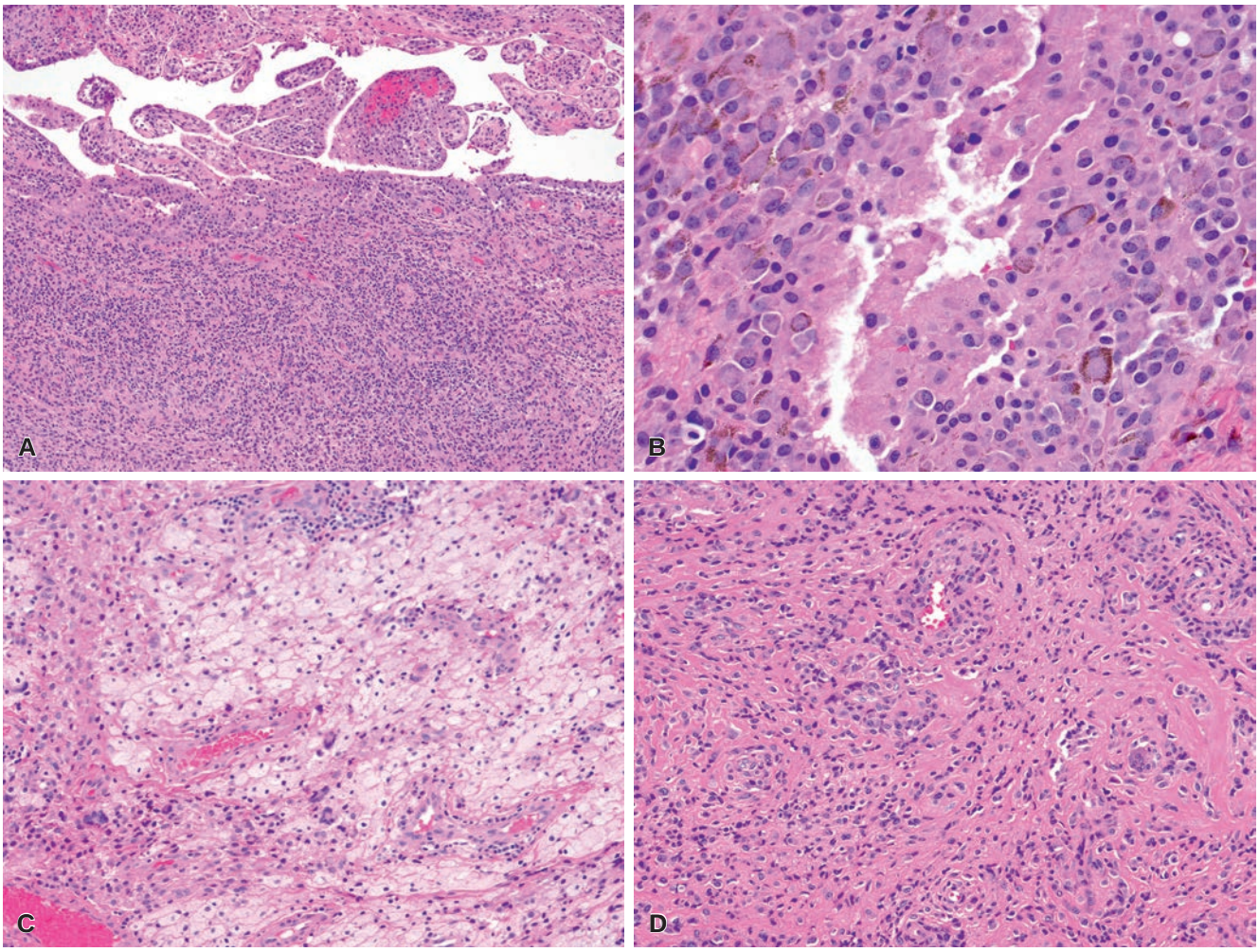

Figure 40.87 Pigmented Villonodular Synovitis. A, The villous architecture is evident on the surface of the lesion. **B,** Giant cells and histiocyte-like cells contain rings of iron in their cytoplasm. **C,** Foamy histiocytes may be prominent. **D,** Hyalinization may be striking.

and contains papillary projections (Fig. 40.87). Large clefts and pseudoglandular or alveolar spaces lined by synovial cells are also present. Occasionally, foci of chondroid metaplasia resembling osseous chondroblastoma are found.[699]

Clonal chromosomal aberrations similar to those of localized tenosynovial giant cell tumor have been found in PVNS, supporting a pathogenetic link between the two conditions and the neoplastic nature of both.[693]

This disease is treated by synovectomy, and local recurrences are common. Radiotherapy may be effective for local control for incompletely excised or recurrent tumors.[700] As for localized tenosynovial giant cell tumors, isolated examples of malignant PVNS have been described.[701]

Synovial Chondromatosis and Chondrosarcoma

Synovial chondromatosis is characterized by the formation of cartilaginous nodules in the synovial membrane.[702] This condition most often is monoarticular, affecting the knee or hip and communicating bursae, but it can also occur in extra-articular, tenosynovial sites.[703] The etiology is unknown, but the presence of clonal chromosomal aberrations suggests that it represents a neoplastic condition.[704] *IDH* mutations are not present in synovial chondromatosis.

Grossly, the osteocartilaginous bodies may remain confined to the synovium or be extruded into the joint cavity. They usually are partially calcified (Fig. 40.88). Innumerable small bodies can be seen grossly in the resected lesion.

Histologically, the nodules of synovial chondromatosis are composed of hyaline cartilage in which the chondrocytes are arranged in a characteristic clustered manner. Some nuclear atypia may be present. It is important to distinguish primary synovial chondromatosis from secondary forms, in which osteocartilaginous loose bodies are seen. The distinction is important because primary synovial chondromatosis is treated with synovectomy, whereas the secondary form is treated by simple removal of loose bodies and correction of the underlying cause.[705] Rare cases of malignant transformation to chondrosarcoma have been reported,[706] as have primary synovial chondrosarcomas.[707]

Other Tumors and Tumorlike Conditions

Most tumors involving the joint space represent direct extension from neoplasms initially located in the adjacent bones.

The only primary tumor of the joints that is seen with any frequency in addition to those already mentioned is **synovial hemangioma**. Most patients are young adults, and there is a predominance

For personal use only. No other uses without permission. Copyright ©2017. Elsevier Inc. All rights reserved.

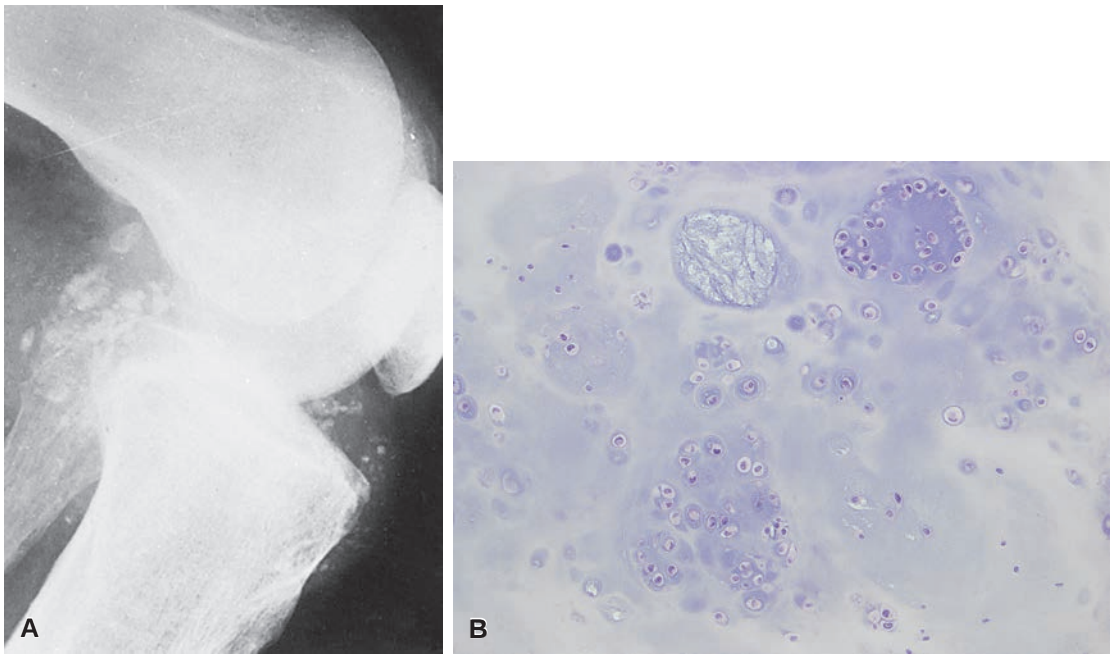

Figure 40.88 **A,** Synovial chondromatosis. Nodules can be seen clearly in the joint space on radiographic examination. **B,** Microscopically, the chondrocytes in synovial chondromatosis maintain a characteristic nested appearance.

for the male sex. The knee is the most common site, followed by the elbow and finger. In most cases the tumor is confined to the intra-articular synovium, but sometimes it is located in a bursa adjacent to a joint. The most common microscopic pattern is cavernous hemangioma, followed by lobular capillary hemangioma, arteriovenous hemangioma, and venous hemangioma.[708]

Isolated cases of *intra-articular synovial sarcoma* and other unusual neoplasms have been reported.

Nodular fasciitis can be seen in an intra-articular location. It is microscopically similar to its more common soft tissue counterpart, except for a greater tendency for stromal hyalinization and adjacent hemosiderin deposition.[709]

References

1. Rosenberg AE, Sanford IR. Bone. In: Mills SE, ed. *Histology for Pathologists*. 4th ed. Philadelphia: Lippincott Williams & Wilkins; 2012.
2. Enneking WF, Kagan A 2nd. Transepiphyseal extension of osteosarcoma: incidence, mechanism, and implications. *Cancer*. 1978;41:1526-1537.
3. Boyce BF, Hughes DE, Wright KR, et al. Recent advances in bone biology provide insight into the pathogenesis of bone diseases. *Lab Invest*. 1999;79:83-94.
4. Edwards JR, Williams K, Kindblom LG, et al. Lymphatics and bone. *Hum Pathol*. 2008;39(1):49-55.
5. Martin TJ, Sims NA. RANKL/OPG; critical role in bone physiology. *Rev Endocr Metab Disord*. 2015;16:131-139.
6. Connor JR, Hornick JL. SATB2 is a novel marker of osteoblastic differentiation in bone and soft tissue tumours. *Histopathology*. 2013;63:36-49.
7. Teitelbaum SL. Bone resorption by osteoclasts. *Science*. 2000;289(5484):1504-1508.
8. Udagawa N, Takahashi N, Akatsu T, et al. Origin of osteoclasts: mature monocytes and macrophages are capable of differentiating into osteoclasts under a suitable microenvironment prepared by bone marrow-derived stromal cells. *Proc Natl Acad Sci USA*. 1990;87(18):7260-7264.
9. Heinegard D, Oldberg A. Structure and biology of cartilage and bone matrix noncollagenous macromolecules. *FASEB J*. 1989;3:2042-2051.
10. Miyazono K, Shimanuki T. Bone morphogenetic protein receptors and actions. In: Bilezekian JP, Raisz LG, Martin TJ, eds. *Principles of Bone Biology*. 3rd ed. Elsevier; 2008.
11. Anderson HC. Mechanism of mineral formation in bone. *Lab Invest*. 1989;60:320-330.
12. Florencino R, Sasso GR, Sasso-Cerri E, et al. Biology of bone tissue: structure, function, and factors that influence bone cells. *Biomed Res Int*. 2015;2015:421746.
13. Bauer TW. An overview of the histology of skeletal substitute materials. *Arch Pathol Lab Med*. 2007;131(2):217-224.
14. Klein MJ, Bonar SF, Freemont T, et al. *Non-Neoplastic Diseases of Bones and Joints: Atlas of Nontumor Pathology*. Annapolis Junction, MD: American Registry of Pathology; 2012.
15. Bullough P. *Orthopaedic Pathology*. 5th ed. St Louis: Mosby; 2010.
16. Riggs BL, Melton LJ 3rd. Involutional osteoporosis. *N Engl J Med*. 1986;314(26):1676-1686.
17. Jowsey J, Phil D, Kelly PJ, et al. Quantitative microradiographic studies of normal and osteoporotic bone. *J Bone Joint Surg Am*. 1965;47:785-806.
18. Hoiberg MP, Rubing KH, Hermann AP, et al. Diagnostic devices for osteoporosis in the general population: a systematic review. *Bone*. 2016;92:58-69.
19. Schousboe JT, Shepherd JA, Bilezikian JP, Baim S. Executive summary of the 2013 International Society for Clinical Densitometry Position Development Conference on bone densitometry. *J Clin Densitom*. 2013;16:455-466.
20. Rodan GA, Martin TJ. Therapeutic approaches to bone diseases. *Science*. 2000;289(5484):1508-1514.
21. Mankin HJ. Rickets, osteomalacia, and renal osteodystrophy. Part II. *J Bone Joint Surg Am*. 1974;56(2):352-386.
22. Folpe AL, Fanburg-Smith JC, Billings SD, et al. Most osteomalacia-associated mesenchymal tumors are a single histopathologic entity: an analysis of 32 cases and a comprehensive review of the literature. *Am J Surg Pathol*. 2004;28:1-30.
23. Fallon MD, Teitelbaum SL. The interpretation of fluorescent tetracycline markers in the diagnosis of metabolic bone diseases. *Hum Pathol*. 1982;13(5):416-417.
24. Vigorita VJ. The bone biopsy protocol for evaluating osteoporosis and osteomalacia. *Am J Surg Pathol*. 1984;8(12):925-930.
25. Mindell ER, Rodbard S, Kwasman BG. Chondrogenesis in bone repair. A study of the healing fracture callus in the rat. *Clin Orthop Relat Res*. 1971;79:187-196.
26. Cheung MS, Glorieux FH, Rauch F. Natural history of hyperplastic callus formation in

For personal use only. No other uses without permission. Copyright ©2017. Elsevier Inc. All rights reserved.

osteogenesis imperfecta type V. *J Bone Miner Res*. 2007;22:1181-1186.
27. Beck-Broichsitter BE, Smeets R, Heiland M. Current concepts in pathogenesis of acute and chronic osteomyelitis. *Curr Opin Infect Dis*. 2015;28:240-245.
28. Chambers JB, Forsythe DA, Bertrand SL, et al. Retrospective review of osteoarticular infections in a pediatric sickle cell age group. *J Pediatr Orthop*. 2000;20(5):682-685.
29. Bohm E, Josten C. What's new in exogenous osteomyelitis? *Pathol Res Prac*. 1992;188(1-2):254-258.
30. Juramillo D. Infection: musculoskeletal. *Pediatr Radiol*. 2011;41(suppl 1):S127-S134.
31. Stacy GS, Kapur A. Mimics of bone and soft tissue neoplasms. *Radiol Clin N Am*. 2011;49:1261-1286.
32. Yasuma T, Nakajima Y. Clinicopathological study on plasma cell osteomyelitis. *Acta Pathol Jpn*. 1981;31:835-844.
33. Cozzutto C. Xanthogranulomatous osteomyelitis. *Arch Pathol Lab Med*. 1984;108:973-976.
34. Li Q, Cui H, Dong J, et al. Squamous cell carcinoma resulting from chronic osteomyelitis: a retrospective study of 8 cases. *Int J Clin Exp Pathol*. 2015;8:10178-10184.
35. Stephens MM, MacAuley P. Brodie's abscess: a long-term review. *Clin Orthop Rel Res*. 1989;234:211-216.
36. Girschick HJ, Huppertz HI, Harmsen D, et al. Chronic recurrent multifocal osteomyelitis in children: diagnostic value of histopathology and microbial testing. *Hum Pathol*. 1999;30:59-65.
37. Felsberg GJ, Gore RL, Schweitzer ME, Jui V. Sclerosing osteomyelitis of Garre (periostitis ossificans). *Oral Surg Oral Med Oral Pathol*. 1990;70:117-120.
38. Pigrau-Serralach C, Rodriguez-Pardo D. Bone and joint tuberculosis. *Eur Spin J*. 2013;22(suppl 4):556-566.
39. Berney S, Goldstein M, Bishko F. Clinical and diagnostic features of tuberculous arthritis. *Am J Med*. 1972;53(1):36-42.
40. Schwarz J. What's new in mycotic bone and joint diseases? *Pathol Res Prac*. 1984;178(6):617-634.
41. Hansen T, Kunkel M, Kirkpatrick CJ, Weber A. Actinomyces in infected osteoradionecrosis–underestimated? *Hum Pathol*. 2006;37(1):61-67.
42. Reginato AJ. Syphilitic arthritis and osteitis. *Rheum Dis Clin North Am*. 1993;19:379-398.
43. Park KH, Lee MS, Hong IK, et al. Bone involvement in secondary syphilis: a case report and systematic review of the literature. *Sex Trans Dis*. 2014;41:532-537.
44. Reference deleted in proofs.
45. Weisenburger DD, Vinh TN, Levinson B. Malakoplakia of bone. An unusual cause of pathologic fracture in an immunosuppressed patient. *Clin Orthop Relat Res*. 1985;201:106-110.
46. Cerilli LA, Fechner RE. Angiosarcoma arising in a bone infarct. *Ann Diagn Pathol*. 1999;3(6):370-373.
47. Desai P, Perino G, Present D, Steiner GC. Sarcoma in association with bone infarcts. Report of five cases. *Arch Pathol Lab Med*. 1996;120(5):482-489.
48. Domson GF, Shahlaee A, Reith JD, et al. Infarct-associated bone sarcomas. *Clin Orthop Rel Res*. 2009;407:1820-1825.
49. Torres FX, Kyriakos M. Bone infarct-associated osteosarcoma. *Cancer*. 1992;70(10):2418-2430.
50. Mankin HJ. Nontraumatic necrosis of bone (osteonecrosis). *N Engl J Med*. 1992;326(22):1473-1479.
51. Yamamoto T, Yamaguchi T, Lee KB, Bullough PG. A clinicopathologic study of osteonecrosis in the osteoarthritic hip. *Osteoarthritis Cartilage*. 2000;8(4):303-308.
52. Yamamoto T, DiCarlo EF, Bullough PG. The prevalence and clinicopathological appearance of extension of osteonecrosis in the femoral head. *J Bone Joint Surg Br*. 1999;81(2):328-332.
53. Manenti G, Altobelli S, Pugliese L, Tarantino V. The role of imaging in diagnosis and management of femoral head osteonecrosis. *Clin Cases Miner Bone Metab*. 2015;12(suppl 1):31-38.
54. DiCarlo EF, Klein MJ. Comparison of clinical and histologic diagnoses in 16,587 total joint arthroplasties. *Am J Clin Pathol*. 2014;141:111-118.
55. De Franceschi L, Grigolo B, Roseti L, et al. Osteochondritis dissecans. *Histopathology*. 2007;51(1):133-135.
56. Milgram JW. Radiological and pathological manifestations of osteochondritis dissecans of the distal femur. A study of 50 cases. *Radiology*. 1978;126(2):305-311.
57. Kusumi T, Ishibashi Y, Tsuda E, et al. Osteochondritis dissecans of the elbow: histopathological assessment of the articular cartilage and subchondral bone with emphasis on their damage and repair. *Pathol Int*. 2006;56(10):604-612.
58. Marx RE. Pamidrenate (Aredia) and zoledronate (Zometa) induced avascular necrosis of the jaws: a growing development. *J Oral Maxillofac Sur*. 2003;61:1111-1117.
59. Hamadeh IS, Ngwa BA, Gong Y. Drug induced osteonecrosis of the jaw. *Cancer Treat Rev*. 2015;41:455-464.
60. Hellstein J. Osteochemonecrosis: an overview. *Head Neck Pathol*. 2014;8:482-490.
61. Dzik-Jurasz AS, Brooker S, Husband JE, Tait D. What is the prevalence of symptomatic or asymptomatic femoral head osteonecrosis in patients previously treated with chemoradiation? A magnetic resonance study of anal cancer patients. *Clin Oncol (R Coll Radiol)*. 2001;13(2):130-134.
62. Bolland MJ, Cundy T. Paget's disease of bone: clinical review and update. *J Clin Pathol*. 2013;66:924-927.
63. Collins DH. Paget's disease of bone; incidence and subclinical forms. *Lancet*. 1956;271(6933):51-57.
64. Naot D, Choi A, Masson DS, et al. Novel homozygous mutations in the osteoprotegerin gene TNFRSF11B in two unrelated patients with juvenile Paget's disease. *Bone*. 2014;68:6-10.
65. Theodrou DJ, Theodrou SJ, Kakitsubata Y. Imaging of Paget disease of bone and its musculoskeletal complications: review. *AJR*. 2011;196:564-575.
66. Deyrup AT, Montag AG, Inwards CY, et al. Sarcomas arising in Paget disease of bone: a clinicopathologic analysis of 70 cases. *Arch Pathol Lab Med*. 2007;131(6):942-946.
67. Hadjipavlou A, Lander P, Srolovitz H, Enker IP. Malignant transformation in Paget disease of bone. *Cancer*. 1992;70(12):2802-2808.
68. Lamovec J, Rener M, Spiler M. Pseudosarcoma in Paget's disease of bone. *Ann Diagn Pathol*. 1999;3(2):99-103.
69. Albaghu OME, Visconti MR, Alonso N, et al. Common susceptibility alleles and SQSTM1 mutations predict disease exent and severity in a multinational study of patients with Paget's disease. *J Bone Mineral Res*. 2013;28:2338-2346.
70. Singer FR. Paget's disease of bone - genetic and environmental factors. *Nat Rev Endocrinol*. 2015;11:662-671.
71. Del Fattore A, Cappariello A, Teti A. Genetics, pathogenesis and complications of osteopetrosis. *Bone*. 2008;42(1):19-29.
72. Stark Z, Savarirayan R. Osteopetrosis. *Orphanet J Rare Dis*. 2009;4:5.
73. Bollerslev J, Henriksen K, Nielsen MF, et al. Autosomal dominant osteopetrosis revisited: lessons from recent studies. *Eur J Endocrinol*. 2013;169:R39-R57.
74. Sobacchi C, Schulz A, Coxon FP, et al. Osteopetrosis: genetics, treatment and new insights into osteoclast function. *Nat Rev Endocrinol*. 2013;9:522-536.
75. Milgram JW, Jasty M. Osteopetrosis. A morphological study of twenty-one cases. *J Bone Joint Surg Am*. 1982;64(6):912-929.
76. Fletcher CDM, Bridge JA, Hogendoorn PCW, Mertens F, eds. *WHO Classification of Tumours of Soft Tissue and Bone*. Lyon: IARC Press; 2013.
77. Horvai A, Unni KK. Premalignant conditions of bone. *J Orthop Sci*. 2006;11:412-423.
78. McHugh JB, Mukherji SK, Lucas DR. Sino-orbital osteoma: a clinicopathologic study of 45 surgically treated cases with emphasis on tumors with osteoblsatoma-like features. *Arch Pathol Lab Med*. 2009;133:1587-1593.
79. Groen EJ, Roos A, Muntinghe FL, et al. Extra-intestinal manifestations of familial adenomatous polyposis. *Ann Surg Oncol*. 2008;15:2439-2450.
80. Kaplan I, Nicolaou Z, Hatuel D, Calderon S. Solitary central osteoma of the jaws: a diagnostic dilemma. *Oral Surg Oral Med Oral Pathol Oral Radiol Endod*. 2008;106(3):e22-e29.
81. Ihde LL, Forrester DM, Gottsegen CJ. Sclerosing bone dysplasias: review and differentiation from other causes of osteosclerosis. *Radiographics*. 2011;31:1865-1882.
82. Bertoni F, Unni KK, Beabout JW, Sim FH. Parosteal osteoma of bones other than of the skull and face. *Cancer*. 1995;75(10):2466-2473.
83. Pettine KA, Klassen RA. Osteoid-osteoma and osteoblastoma of the spine. *J Bone Joint Surg Am*. 1986;68(3):354-361.
84. Green JT, Mills AM. Osteogenic tumors of bone. *Semin Diagn Pathol*. 2014;31:21-29.
85. Loizaga JM, Calvo M, Lopez Barea F, et al. Osteoblastoma and osteoid osteoma. Clinical and morphological features of 162 cases. *Pathol Res Prac*. 1993;189(1):33-41.
86. Bauer TW, Zehr RJ, Belhobek GH, Marks KE. Juxta-articular osteoid osteoma. *Am J Surg Pathol*. 1991;15(4):381-387.
87. Garcia RA, Inwards CY, Unni KK. Benign bone tumors - recent deveopments. *Semin Diagn Pathol*. 2011;28:73-85.
88. Healey JH, Ghelman B. Osteoid osteoma and osteoblastoma. Current concepts and recent advances. *Clin Orthop Relat Res*. 1986;204:76-85.
89. Wold LE, Pritchard DJ, Bergert J, Wilson DM. Prostaglandin synthesis by osteoid osteoma and osteoblastoma. *Mod Pathol*. 1988;1(2):129-131.
90. Hasegawa T, Hirose T, Sakamoto R, et al. Mechanism of pain in osteoid osteomas: an immunohistochemical study. *Histopathology*. 1993;22(5):487-491.
91. O'Connell JX, Nanthakumar SS, Nielsen GP, Rosenberg AE. Osteoid osteoma: the uniquely innervated bone tumor. *Mod Pathol*. 1998;11(2):175-180.
92. Barei DP, Moreau G, Scarborough MT, Neel MD. Percutaneous radiofrequency ablation of osteoid osteoma. *Clin Orthop Relat Res*. 2000;373:115-124.
93. Rimondi E, Mavrogenis AF, Rossi G, et al. Radiofrequency ablation for non-spinal osteoid osteomas in 557 patients. *Eur Radiol*. 2012;22:181-188.
94. Weber MA, Springel SD, Omlor GW, et al. Clinical long-term outcome, technical success, and cost analysis of radiofrequency ablation for the treatment of osteoblastomas and spinal osteoid osteomas in comparison to open surgical resection. *Skeletal Radiol*. 2015;44:981-993.

For personal use only. No other uses without permission. Copyright ©2017. Elsevier Inc. All rights reserved.

95. Barlow E, Davies AM, Cool WP, et al. Osteoid osteoma and osteoblastoma: novel histological and immunohistochemical observations as evidence for a single entity. *J Clin Pathol*. 2013;66:768-774.
96. Yalcinkaya U, Doganavsargil B, Sezak M, et al. Clinical and morphologic characteristics of osteoid osteoma and osteoblastoma: a retrospective single-center analysis of 204 patients. *Ann Diagn Pathol*. 2014;18:319-325.
97. Lucas DR. Osteoblastoma. *Arch Pathol Lab Med*. 2010;134:1460-1466.
98. Lucas DR, Unni KK, McLeod RA, et al. Osteoblastoma: clinicopathologic study of 306 cases. *Hum Pathol*. 1994;25:117-134.
99. Bertoni F, Unni KK, Lucas DR, McLeod RA. Osteoblastoma with cartilaginous matrix. An unusual morphologic presentation in 18 cases. *Am J Surg Pathol*. 1993;17(1):69-74.
100. Bertoni F, Unni KK, McLeod RA, Dahlin DC. Osteosarcoma resembling osteoblastoma. *Cancer*. 1985;55(2):416-426.
101. Cheung FM, Wu WC, Lam CK, Fu YK. Diagnostic criteria for pseudomalignant osteoblastoma. *Histopathology*. 1997;31(2):196-200.
102. Angervall L, Persson S, Stenman G, Kindblom LG. Large cell, epithelioid, telangiectatic osteoblastoma: a unique pseudosarcomatous variant of osteoblastoma. *Hum Pathol*. 1999;30(10):1254-1259.
103. Dorfman HD, Weiss SW. Borderline osteoblastic tumors: problems in the differential diagnosis of aggressive osteoblastoma and low-grade osteosarcoma. *Sem Diagn Pathol*. 1984;1(3)):215-234.
104. Zon Filippi R, Swee RG, Krishnan Unni K. Epithelioid multinodular osteoblastoma: a clinicopathologic analysis of 26 cases. *Am J Surg Pathol*. 2007;31(8):1265-1268.
105. Schajowicz F, Lemos C. Malignant osteoblastoma. *J Bone Joint Surg Br*. 1976;58(2):202-211.
106. Mirra JM, Kendrick RA, Kendrick RE. Pseudomalignant osteoblastoma versus arrested osteosarcoma. *Cancer*. 1976;37:2005-2014.
107. Bertoni F, Bacchini P, Donati D, et al. Osteoblastoma-like osteosarcoma. The Rizzoli Institute experience. *Mod Pathol*. 1993;6(6):707-716.
108. Osasan S, Zhang M, Shen F, et al. Osteogenic sarcoma: a 21st century review. *Anticancer Res*. 2016;36:4391-4398.
109. Al-Rashid M, Ramkumar DB, Raskin K, et al. Paget disease of bone. *Orthop Clin North Am*. 2015;46:577-585.
110. Martland HS, Humphries RE. Osteogenic sarcoma in dial painters using luminous paint. *Arch Pathol*. 1929;7:406-417.
111. Polednak AP. Bone cancer among female radium dial workers. Latency periods and incidence rates by time after exposure: brief communication. *J Natl Cancer Inst*. 1978;60(1):77-82.
112. Sindelar WF, Costa J, Ketcham AS. Osteosarcoma associated with Thorotrast administration: report of two cases and literature review. *Cancer*. 1978;42(6):2604-2609.
113. Kalra S, Grimer RJ, Spooner D, et al. Radiation-induced sarcomas of bone. Factors that affect outcome. *J Bone Joint Surg Br*. 2007;89-B:808-813.
114. Huvos AG, Woodard HQ, Cahan WG, et al. Postradiation osteogenic sarcoma of bone and soft tissues. A clinicopathologic study of 66 patients. *Cancer*. 1985;55(6):1244-1255.
115. Turaka K, Shields CL, Meadows AT, Leahey A. Second malignant neoplasms following chemoreduction with carboplatin, etoposide, and vincristine in 245 patients with intraocular retinoblastoma. *Pediatr Blood Cancer*. 2012;59:121-125.
116. Takahashi S, Okada K, Nagasawa H, et al. Osteosarcoma occurring in osteogenesis imperfecta. *Virch Arch*. 2004;444(5):454-458.
117. Keel SB, Jaffe KA, Petur Nielsen G, Rosenberg AE. Orthopaedic implant-related sarcoma: a study of twelve cases. *Mod Pathol*. 2001;14(10):969-977.
118. Penman HG, Ring PA. Osteosarcoma in association with total hip replacement. *J Bone Joint Surg Br*. 1984;66(5):632-634.
119. Palmero EI, Achatz MI, Ashton-Prolla P, et al. Tumor protein 53 mutations and inherited cancer: beyond Li-Fraumeni syndrome. *Curr Opin Oncol*. 2010;22(1):64-69.
120. Zils K, Klingebiel T, Behnisch W, et al. Osteosarcoma in patients with Rothmund-Thomson syndrome. *Pediatr Hematol Oncol*. 2015;32:32-40.
121. Nielsen GP, Rosenberg AE. Update on bone forming tumors of the head and neck. *Head Neck Pathol*. 2007;1:87-93.
122. Ozaki T, Flege S, Liljenqvist U, et al. Osteosarcoma of the spine: experience of the Cooperative Osteosarcoma Study Group. *Cancer*. 2002;94(4):1069-1077.
123. Okada K, Wold LE, Beabout JW, Shives TC. Osteosarcoma of the hand. A clinicopathologic study of 12 cases. *Cancer*. 1993;72(3):719-725.
124. Parham DM, Pratt CB, Parvey LS, et al. Childhood multifocal osteosarcoma. Clinicopathologic and radiologic correlates. *Cancer*. 1985;55(11):2653-2658.
125. Bacci G, Picci P, Ferrari S, et al. Synchronous multifocal osteosarcoma: results in twelve patients treated with neoadjuvant chemotherapy and simultaneous resection of all involved bones. *Ann Oncol*. 1996;7:864-866.
126. Murphey MD, Robbin MR, McRae GA, et al. The many faces of osteosarcoma. *Radiographics*. 1997;17:1205-1231.
127. Inikul E, Fletcher BD, Parham D, Chen G. Accuracy of MR imaging for estimating intraosseous extent of osteosarcoma. *Am J Roentgenol*. 1996;167:1211-1215.
128. Simon MA, Bos GD. Epiphyseal extension of metaphyseal osteosarcoma in skeletally immature individuals. *J Bone Joint Surg Am*. 1980;62(2):195-204.
129. Simon MA, Hecht JD. Invasion of joints by primary bone sarcomas in adults. *Cancer*. 1982;50(8):1649-1655.
130. Leavey PJ, Day MD, Booth T, Maale G. Skip metastases in osteosarcoma. *J Pediatr Hematol Oncol*. 2003;25:806-808.
131. Wuisman P, Enneking WF. Prognosis for patients who have osteosarcoma with skip metastases. *J Bone Joint Surg Am*. 1990;72-A:60-68.
132. Gonzalez AL, Cates JM. Osteosarcoma: differential diagnostic considerations. *Surg Pathol*. 2012;5:117-146.
133. Dahlin DC, Unni KK. Osteosarcoma of bone and its important recognizable varieties. *Am J Surg Pathol*. 1977;1(1):61-72.
134. Klein MJ, Siegal GP. Osteosarcoma: anatomic and histologic variants. *Am J Clin Pathol*. 2006;125:555-581.
135. Okada K, Hasegawa T, Yokoyama R. Rosette-forming epithelioid osteosarcoma: a histologic subtype with highly aggressive clinical behavior. *Hum Pathol*. 2001;32(7):726-733.
136. Hasegawa T, Shibata T, Hirose T, et al. Osteosarcoma with epithelioid features. An immunohistochemical study. *Arch Pathol Lab Med*. 1993;117(3):295-298.
137. Kramer K, Hicks DG, Palis J, et al. Epithelioid osteosarcoma of bone. Immunocytochemical evidence suggesting divergent epithelial and mesenchymal differentiation in a primary osseous neoplasm. *Cancer*. 1993;71(10):2977-2982.
138. Chow LT, Lin J, Yip KM, et al. Chondromyxoid fibroma-like osteosarcoma: a distinct variant of low-grade osteosarcoma. *Histopathology*. 1996;29(5):429-436.
139. Banta JV, Schreiber RR, Kulik WJ. Hyperplastic callus formation in osteogenesis imperfecta simulating osteosarcoma. *J Bone Joint Surg Am*. 1971;53(1):115-122.
140. Kahn LB, Wood FW, Ackerman LV. Fracture callus associated with benign and malignant bone lesions and mimicking osteosarcoma. *Am J Clin Pathol*. 1969;52(1):14-24.
141. Okada K, Hasegawaa T, Yokoyama R, et al. Osteosarcoma with cytokeratin expression: a clinicopathologic study of six cases with emphasis on differential diagnosis from metastatic cancer. *J Clin Pathol*. 2003;56:742-746.
142. Bridge JA, Nelson M, McComb E, et al. Cytogenetic findings in 73 osteosarcoma specimens and a review of the literature. *Cancer Genet Cytogenet*. 1997;95(1):74-87.
143. Sandberg AA. Cytogenetics and molecular genetics of bone and soft-tissue tumors. *Am J Med Genet*. 2002;115(3):189-193.
144. Wang LL. Biology of osteogenic sarcoma. *Cancer J*. 2005;11(4):294-305.
145. Mejia-Gurerero S, Quejada M, Gokgoz N, et al. Characterization of the 12q15 MDM2 and 12q13-14 CDK4 amplicons and clinical correlations in osteosarcoma. *Genes Chromosomes Cancer*. 2010;49:518-525.
146. Rickel K, Fang F, Tao J. Moleular genetics of osteosarcoma. *Bone*. 2016;http://dx.doi.org/10.1016/j.bone.2016.10.017.
147. Huvos AG, Rosen G, Bretsky SS, Butler A. Telangiectatic osteogenic sarcoma: a clinicopathologic study of 124 patients. *Cancer*. 1982;49(8):1679-1689.
148. Bertoni F, Pignatti G, Bachini P, et al. Telangiectatic or hemorrhagic osteosarcoma of bone. A clinicopathologic study of 41 patients at the Rizzoli Institute. *Progr Surg Pathol*. 1989;10:63-82.
149. Angelini A, Mavrogenis AF, Trovarelli G, et al. Telangiectatic osteosarcoma: a review of 87 cases. *J Cancer Res Clin Oncol*. 2016;142:2197-2207.
150. Nakajima H, Sim FH, Bond JR, Unni KK. Small cell osteosarcoma of bone. Review of 72 cases. *Cancer*. 1997;79(11):2095-2106.
151. Bertoni F, Present D, Bacchini P, et al. The Istituto Rizzoli experience with small cell osteosarcoma. *Cancer*. 1989;64(12):2591-2599.
152. Righi A, Gambarotti M, Longo S, et al. Small cell osteosarcoma. Clinicopathologic, immunohistochemical, and molecular analyses of 36 cases. *Am J Surg Pathol*. 2015;39:691-699.
153. Bertoni F, Bacchini P, Fabbri N, et al. Osteosarcoma. Low-grade intraosseous-type osteosarcoma, histologically resembling parosteal osteosarcoma, fibrous dysplasia, and desmoplastic fibroma. *Cancer*. 1993;71(2):338-345.
154. Kurt AM, Unni KK, McLeod RA, Pritchard DJ. Low-grade intraosseous osteosarcoma. *Cancer*. 1990;65(6):1418-1428.
155. Ogose A, Hotta T, Emura I, et al. Repeated dedifferentiation of low-grade intraosseous osteosarcoma. *Hum Pathol*. 2000;31(5):615-618.
156. Carter JM, Inwards CY, Jin L, et al. Activating GNAS mutations in parosteal osteosarcoma. *Am J Surg Pathol*. 2014;38:402-409.
157. Salinas-Souza C, De Andrea C, Bihl M, et al. GNAS mutations are not detected in parosteal and low-grade central osteosarcoma. *Mod Pathol*. 2015;28:1336-1342.
158. Park HR, Jung WW, Bertoni F, et al. Molecular analysis of p53, MDM2, and H-Ras genes in low-grade central osteosarcoma. *Pathol Res Pract*. 2004;200:439-445.

For personal use only. No other uses without permission. Copyright ©2017. Elsevier Inc. All rights reserved.

159. Dujardin F, Binh MB, Bourier C, et al. MDM2 and CDK4 immunohistochemistry is a valuable tool in the differential diagnosis of low-grade osteosarcomas and other primary fibro-osseous lesion of the bone. *Mod Pathol*. 2011;24:624-637.
160. Yoshida A, Ushiku T, Motoi T, et al. Immunohistochemical analysis of MDM2 and CDK4 distinguishes low-grade osteosarcoma from benign mimics. *Mod Pathol*. 2010;23:1279-1288.
161. Unni KK, Dahlin DC, Beabout JW, Ivins JC. Parosteal osteogenic sarcoma. *Cancer*. 1976;37(5):2466-2475.
162. Campanacci M, Picci P, Gherlinzoni F, et al. Parosteal osteosarcoma. *J Bone Joint Surg Br*. 1984;66(3):313-321.
163. Bertoni F, Present D, Hudson T, et al. The meaning of radiolucencies in parosteal osteosarcoma. *J Bone Joint Surg Am*. 1985;67-A:901-910.
164. Duhamel LA, Ye H, Halai D, et al. Frequency of Mouse Double Minute 2 (MDM2) and Mouse Double Minute 4 (MDM4) amplification in parosteal and conventional osteosarcoma subtypes. *Histopathology*. 2012;60:357-359.
165. Okada K, Unni KK, Swee RG, Sim FH. High grade surface osteosarcoma: a clinicopathologic study of 46 cases. *Cancer*. 1999;85(5):1044-1054.
166. Wold LE, Unni KK, Beabout JW, Pritchard DJ. High-grade surface osteosarcomas. *Am J Surg Pathol*. 1984;8(3):181-186.
167. Sheth DS, Yasko AW, Raymond AK, et al. Conventional and dedifferentiated parosteal osteosarcoma. Diagnosis, treatment, and outcome. *Cancer*. 1996;78(10):2136-2145.
168. Wold LE, Unni KK, Beabout JW, et al. Dedifferentiated parosteal osteosarcoma. *J Bone Joint Surg Am*. 1984;66(1):53-59.
169. Unni KK, Dahlin DC, Beabout JW. Periosteal osteogenic sarcoma. *Cancer*. 1976;37(5):2476-2485.
170. deSantos LA, Murray JA, Finklestein JB, et al. The radiographic spectrum of periosteal osteosarcoma. *Radiology*. 1978;127(1):123-129.
171. Hall RB, Robinson LH, Malawar MM, Dunham WK. Periosteal osteosarcoma. *Cancer*. 1985;55(1):165-171.
172. Clark JL, Unni KK, Dahlin DC, Devine KD. Osteosarcoma of the jaw. *Cancer*. 1983;51(12):2311-2316.
173. Huvos AG, Butler A, Bretsky SS. Osteogenic sarcoma associated with Paget's disease of bone. A clinicopathologic study of 65 patients. *Cancer*. 1983;52(8):1489-1495.
174. Huvos AG, Sundaresan N, Bretsky SS, Butler A. Osteogenic sarcoma of the skull. A clinicopathologic study of 19 patients. *Cancer*. 1985;56(5):1214-1221.
175. Wick MR, Siegal GP, Unni KK, et al. Sarcomas of bone complicating osteitis deformans (Paget's disease): fifty years' experience. *Am J Surg Pathol*. 1981;5(1):47-59.
176. Ayala AG, Raymond AK, Jaffe N. The pathologist's role in the diagnosis and treatment of osteosarcoma in children. *Hum Pathol*. 1984;15(3):258-266.
177. Picci P, Bacci G, Campanacci M, et al. Histologic evaluation of necrosis in osteosarcoma induced by chemotherapy. Regional mapping of viable and nonviable tumor. *Cancer*. 1985;56(7):1515-1521.
178. Chui MH, Kandel RA, Wong M, et al. Histopathologic features of prognostic significance in high-grade osteosarcoma. *Arch Pathol Lab Med*. 2016;140:1231-1242.
179. Raymond AK, Chawla SP, Carrasco CH, et al. Osteosarcoma chemotherapy effect: a prognostic factor. *Sem Diagn Pathol*. 1987;4(3):212-236.
180. Allison DC, Carney SC, Ahlmann ER, et al. A meta-analysis of osteosarcoma outcomes in the modern medical era. *Sarcoma*. 2012;doi:10.1155/2012/704872.
181. Provisor AJ, Ettinger LJ, Nachman JB, et al. Treatment of nonmetastatic osteosarcoma of the extremity with preoperative and postoperative chemotherapy: a report from the Children's Cancer Group. *J Clin Oncol*. 1997;15:76-84.
182. Belak SS, Kempf-Bielack B, Delling G, et al. Prognosti factors in high-grade osteosarcoma of the extremities or trunk: an analysis of 1702 patients treated on neoadjuvant cooperative osteosarcoma study group protocols. *J Clin Oncol*. 2002;20: 776-790.
183. Xing D, Qasem SA, Owusu K, et al. Changing prognostic factors in osteosarcoma: analysis of 381 cases from two institutions. *Hum Pathol*. 2014;45:1688-1696.
184. Onda M, Matsuda S, Higaki S, et al. ErbB-2 expression is correlated with poor prognosis for patients with osteosarcoma. *Cancer*. 1996;77(1):71-78.
185. Kilpatrick SE, Geisinger KR, King TS, et al. Clinicopathologic analysis of HER-2/neu immunoexpression among various histologic subtypes and grades of osteosarcoma. *Mod Pathol*. 2001;14(12):1277-1283.
186. Baldini N, Scotlandi K, Serra M, et al. P-glycoprotein expression in osteosarcoma: a basis for risk-adapted adjuvant chemotherapy. *J Orthop Res*. 1999;17(5):629-632.
187. Borys D, Canter RJ, Hoch B, et al. P16 expression predicts necrotic response among patients with osteosarcoma receiving neoadjuvant chemotherapy. *Hum Pathol*. 2012;43:1948-1954.
188. Kosemehmetoglu K, Ardic F, Karslioglu Y, et al. P16 expression predicts neoadjuvant tumor necrosis in osteosarcomas: reappraisal with a larger series using whole sections. *Hum Pathol*. 2016;50:170-175.
189. Righi A, Gambarotti M, Sbaraglia M, et al. P16 expression as a prognostic and predictive marker in high-grade localized osteosarcoma of the extremities: an analysis of 357 cases. *Hum Pathol*. 2016;58:15-23.
190. Scarborough MT, Moreau G. Benign cartilage tumors. *Orthop Clin North Am*. 1996;27:583-589.
191. Duckworth LV, Reith JD. Well-differentiated central cartilage tumors of bone: an overview. *Surg Pathol*. 2012;5:147-161.
192. Greenspan A. Tumor of cartilage origin. *Orthop Clin North Am*. 1989;20:347-366.
193. Bui KL, Ilaslan H, Bauer TW, et al. Cortical scalloping and cortical penetration by small eccentric chondroid lesions in long tubular bones: not a sign of malignancy? *Skeletal Radiol*. 2009;38:791-796.
194. Flemming DJ, Murphey MD. Enchondroma and chondrosarcoma. *Semin Musculoskelet Radiol*. 2000;4:59-71.
195. Pansuriya TC, Kroon HM, Bovee JV, Rosenberg AE. Enchondromatosis: insights on the different subtypes. *Int J Clin Exp Pathol*. 2010;3:557-569.
196. Fanburg JC, Meis-Kindblom JM, Rosenberg AE. Multiple enchondromas associated with spindle cell hemangioendotheliomas. An overlooked variant of Maffucci's syndrome. *Am J Surg Pathol*. 1995;19: 1029-1038.
197. Bovee JV, van Roggen JF, Cleton-Jansen AM, et al. Malignant progression in multiple enchondromatosis (Ollier's disease): an autopsy-based molecular genetic study. *Hum Pathol*. 2000;31(10):1299-1303.
198. Liu J, Hudkins PG, Swee RG, Unni KK. Bone sarcomas associated with Ollier's disease. *Cancer*. 1987;59(7):1376-1385.
199. Sun TC, Swee RG, Shives TC, Unni KK. Chondrosarcoma in Maffucci's syndrome. *J Bone Joint Surg Am*. 1985;67(8):1214-1219.
200. Verdegaal SH, Bovee JV, Pansuriya TC, et al. Incidence, predictive factors, and prognosis of chondrosarcoma in patients with Ollier disease and Maffucci syndrome: an international multicenter study of 161 patients. *Oncologist*. 2011;16:1771-1779.
201. Boriani S, Bacchini P, Bertoni F, Campanacci M. Periosteal chondroma. A review of twenty cases. *J Bone Joint Surg Am*. 1983;65(2):205-212.
202. Bauer TW, Dorfman HD, Latham JT. Periosteal chondroma: a clinicopathologic study of 23 cases. *Am J Surg Pathol*. 1982;6:631-637.
203. De Santos LA, Spjut HG. Periosteal chondroma: a radiologic spectrum. *Skeletal Radiol*. 1981;6:15-20.
204. Amary MF, Bacsi K, Maggiani F, et al. IDH1 and IDH2 mutations are frequent events in central chondrosarcoma and central and periosteal chondromas but not in other mesenchymal tumours. *J Pathol*. 2011;224:334-343.
205. McCarthy EF, Dorfman HD. Vascular and cartilaginous hamartoma of the ribs in infancy with secondary aneurysmal bone cyst formation. *Am J Surg Pathol*. 1980;4(3):247-253.
206. Ayala AG, Ro JY, Bolio-Solis A, et al. Mesenchymal hamartoma of the chest wall in infants and children: a clinicopathological study of five patients. *Skeletal Radiol*. 1993;22:569-576.
207. Griffiths HJ, Thompson RC, Galloway HR, et al. Bursitis in association with solitary osteochondromas presenting as mass lesions. *Skeletal Radiol*. 1991;20:513-516.
208. Brien EW, Mirra JM, Luck JV. Benign and malignant cartilage tumors of bone and joint: their anatomic and theoretical basis with an emphasis on radiology, pathology and clinical biology. II. Juxtacortical cartilage tumors. *Skeletal Radiol*. 1999;28:1-20.
209. Bovee JV. Multiple osteochondromas. *Orphanet J Rare Dis*. 2008;3:3.
210. Bovee JV, Cleton-Jansen AM, Wuyts W, et al. EXT-mutation analysis and loss of heterozygosity in sporadic and hereditary osteochondromas and secondary chondrosarcomas. *Am J Hum Genet*. 1999;65(3):689-698.
211. Bridge JA, Nelson M, Orndal C, et al. Clonal karyotypic abnormalities of the hereditary multiple exostoses chromosomal loci 8q24.1 (EXT1) and 11p11-12 (EXT2) in patients with sporadic and hereditary osteochondromas. *Cancer*. 1998;82(9):1657-1663.
212. Feely MG, Boehm AK, Bridge RS, et al. Cytogenetic and molecular cytogenetic evidence of recurrent 8q24.1 loss in osteochondroma. *Cancer Genet Cytogenet*. 2002;137(2):102-107.
213. de Andrea CE, Reijnders CM, Kroon HM, et al. Sceondary peripheral chondrosarcoma evolving from osteochondroma as a result of outgrowth of cells with functional EXT. *Oncogene*. 2012;9:1095-1104.
214. Bovee JV, van den Broek LJ, Cleton-Jansen AM, Hogendoorn PC. Up-regulation of PTHrP and Bcl-2 expression characterizes the progression of osteochondroma towards peripheral chondrosarcoma and is a late event in central chondrosarcoma. *Lab Invest*. 2000;80(12):1925-1934.
215. Bovee JV, Cleton-Jansen AM, Kuipers-Dijkshoorn NJ, et al. Loss of heterozygosity and DNA ploidy point to a diverging genetic mechanism in the origin of peripheral and central chondrosarcoma. *Genes Chromosomes Cancer*. 1999;26(3):237-246.
216. Hallor KH, Staaf J, Bovee JV, et al. Genomic profiling of chondrosarcoma: chromosomal

For personal use only. No other uses without permission. Copyright ©2017. Elsevier Inc. All rights reserved.

patterns in central and peripheral tumors. *Clin Cancer Res*. 2009;15(8):2685-2694.
217. Horiguchi H, Sakane M, Matsui M, Wadano Y. Bizarre parosteal osteochondromatous proliferation (Nora's lesion) of the foot. *Pathol Int*. 2001;51(10):816-823.
218. Nora FE, Dahlin DC, Beabout JW. Bizarre parosteal osteochondromatous proliferations of the hands and feet. *Am J Surg Pathol*. 1983;7(3):245-250.
219. Bush JB, Reith JD, Meyer MS. Bizarre parosteal osteochondromatous proliferation of the proximal humerus: a case report. *Skeletal Radiol*. 2007;36:535-540.
220. Dashti HM, Reith JD, Schlott BJ, et al. Bizarre parosteal osteochondromatous proliferation (Nora's lesion) of the mandible: a rare bony lesion. *Head Neck Pathol*. 2012;6:264-269.
221. Meneses MF, Unni KK, Swee RG. Bizarre parosteal osteochondromatous proliferation of bone (Nora's lesion). *Am J Surg Pathol*. 1993;17(7):691-697.
222. Nilsson M, Domanski HA, Mertens F, Mandahl N. Molecular cytogenetic characterization of recurrent translocation breakpoints in bizarre parosteal osteochondromatous proliferation (Nora's lesion). *Hum Pathol*. 2004;35(9):1063-1069.
223. Landon GC, Johnson KA, Dahlin DC. Subungual exostoses. *J Bone Joint Surg Am*. 1979;61(2):256-259.
224. Miller-Breslow A, Dorfman HD. Dupuytren's (subungual) exostosis. *Am J Surg Pathol*. 1988;12(5):368-378.
225. Zambrano E, Nose V, Perez-Atayde AR, et al. Distinct chromosomal rearrangements in subungual (Dupuytren) exostosis and bizarre parosteal osteochondromatous proliferation (Nora lesion). *Am J Surg Pathol*. 2004;28(8):1033-1039.
226. Storlazzi CT, Wozniak A, Panagopoulos I, et al. Rearrangement of the COL12A1 and COL4A5 genes in subungual exostosis: a molecular cytogenetic delineation of the tumor-specific translocation t(X;6)(q13-14;q22). *Int J Cancer*. 2006;118:1972-1976.
227. Mertens F, Moller E, Mandahl N, et al. The t(X;6) in subungual exostosis results in transcriptional deregulation of the gene for insulin receptor substrate 4. *Int J Cancer*. 2011;128:487-491.
228. Glick R, Khaldi L, Ptaszynski K, Steiner GC. Dysplasia epiphysealis hemimelica (Trevor disease): a rare developmental disorder of bone mimicking osteochondroma of long bones. *Hum Pathol*. 2007;38(8):1265-1272.
229. Carney JA, Boccon-Gibod L, Jarka DE, et al. Osteochondromyxoma of bone: a congenital tumor associated with lentigines and other unusual disorders. *Am J Surg Pathol*. 2001;25:164-176.
230. Springfield DS, Capanna R, Gherlinzoni F, et al. Chondroblastoma. A review of seventy cases. *J Bone Joint Surg Br*. 1985;67(5):748-755.
231. James SL, Panicek DM, Davies AM. Bone marrow oedema associated with benign and malignant bone tumours. *Eur J Radiol*. 2008;67:11-21.
232. Aronsohn RS, Hart WR, Martel W. Metaphyseal chondroblastoma of bone. *AJR Am J Roentgenol*. 1976;127(4):686-688.
233. Bousdras K, O'Donnell P, Vujovic S, et al. Chondroblastomas but not chondromyxoid fibromas express cytokeratins: an unusual presentation of a chondroblastoma in the metaphyseal cortex of the tibia. *Histopathology*. 2007;51(3):414-416.
234. de Silva MV, Reid R. Chondroblastoma: varied histologic appearance, potential diagnostic pitfalls, and clinicopathologic features associated with local recurrence. *Ann Diagn Pathol*. 2003;7(4):205-213.
235. Konishi E, Nakashima Y, Iwasa Y, et al. Immunohistochemical analysis for Sox9 reveals the cartilaginous character of chondroblastoma and chondromyxoid fibroma of the bone. *Hum Pathol*. 2010;41(2):208-213.
236. Povysil C, Tomanova R. Matejovsky Z. Muscle-specific actin expression in chondroblastomas. *Hum Pathol*. 1997;28(3):316-320.
237. Behjati S, Tarpey PS, Presneau N, et al. Distinct H3F3A and H3F3B driver mutations define chondroblastoma and giant cell tumor of bone. *Nat Genet*. 2013;45:1479-1482.
238. Amary MF, Berish F, Mozela R, et al. The H3F3 K36M mutant antibody is a sensitive and specific marker for the diagnosis of chondroblastoma. *Histopathology*. 2016;69:121-127.
239. Fanning CV, Sneige NS, Carrasco CH, et al. Fine needle aspiration cytology of chondroblastoma of bone. *Cancer*. 1990;65(8):1847-1863.
240. Turcotte RE, Kurt AM, Sim FH, et al. Chondroblastoma. *Hum Pathol*. 1993;24(9):944-949.
241. Reyes CV, Kathuria S. Recurrent and aggressive chondroblastoma of the pelvis with late malignant neoplastic changes. *Am J Surg Pathol*. 1979;3(5):449-455.
242. Birch PJ, Buchanan R, Golding P, Pringle JA. Chondroblastoma of the rib with widespread bone metastases. *Histopathology*. 1994;25(6):583-585.
243. Kahn LB, Wood FM, Ackerman LV. Malignant chondroblastoma. Report of two cases and reviw of the literature. *Arch Pathol*. 1969;88(4):371-376.
244. Kyriakos M, Land VJ, Penning HL, Parker SG. Metastatic chondroblastoma. Report of a fatal case with a review of the literature on atypical, aggressive, and malignant chondroblastoma. *Cancer*. 1985;55(8):1770-1789.
245. Posl M, Werner M, Amling M, et al. Malignant transformation of chondroblastoma. *Histopathology*. 1996;29(5):477-480.
246. Kunze E, Graewe T, Peitsch E. Histology and biology of metastatic chondroblastoma. Report of a case with a review of the literature. *Pathol Res Prac*. 1987;182(1):113-123.
247. Wu CT, Inwards CY, O'Laughlin S, et al. Chondromyxoid fibroma of bone: a clinicopathologic review of 278 cases. *Hum Pathol*. 1998;29(5):438-446.
248. Keel SB, Bhan AK, Liebsch NJ, Rosenberg AE. Chondromyxoid fibroma of the skull base: a tumor which may be confused with chordoma and chondrosarcoma. A report of three cases and review of the literature. *Am J Surg Pathol*. 1997;21(5):577-582.
249. Baker AC, Rezeanu L, O'Laughlin S, et al. Juxtacortical chondromyxoid fibroma of bone: a unique variant: a case study of 20 patients. *Am J Surg Pathol*. 2007;31(11):1662-1668.
250. Gherlinzoni F, Rock M, Picci P. Chondromyxoid fibroma. The experience at the Istituto Ortopedico Rizzoli. *J Bone Joint Surg Am*. 1983;65(2):198-204.
251. Bahk WJ, Mirra JM, Sohn KR, Shin DS. Pseudoanaplastic chondromyxoid fibroma. *Ann Diagn Pathol*. 1998;2(4):241-246.
252. Zillmer DA, Dorfman HD. Chondromyxoid fibroma of bone: thirty-six cases with clinicopathologic correlation. *Hum Pathol*. 1989;20(10):952-964.
253. Bleiweiss IJ, Klein MJ. Chondromyxoid fibroma: report of six cases with immunohistochemical studies. *Mod Pathol*. 1990;3(6):664-666.
254. Nielsen GP, Keel SB, Dickersin GR, et al. Chondromyxoid fibroma: a tumor showing myofibroblastic, myochondroblastic, and chondrocytic differentiation. *Mod Pathol*. 1999;12(5):514-517.
255. Granter SR, Renshaw AA, Kozakewich HP, Fletcher JA. The pericentromeric inversion, inv (6)(p25q13), is a novel diagnostic marker in chondromyxoid fibroma. *Mod Pathol*. 1998;11(11):1071-1074.
256. Safar A, Nelson M, Neff JR, et al. Recurrent anomalies of 6q25 in chondromyxoid fibroma. *Hum Pathol*. 2000;31(3):306-311.
257. Yasuda T, Nishio J, Sumegi J, et al. Aberrations of 6q13 mapped to the COL12A1 locus in chondromyxoid fibroma. *Mod Pathol*. 2009;11:1499-1506.
258. Kikuchi F, Dorfman HD, Kane PB. Recurrent chondromyxoid fibroma of the thoracic spine 30 years after primary excision: case report and review of the literature. *Int J Surg Pathol*. 2001;9(4):323-329.
259. Kyriakos M. Soft tissue implantation of chondromyxoid fibroma. *Am J Surg Pathol*. 1979;3(4):363-372.
260. Gadwal SR, Fanburg-Smith JC, Gannon FH, Thompson LD. Primary chondrosarcoma of the head and neck in pediatric patients: a clinicopathologic study of 14 cases with a review of the literature. *Cancer*. 2000;88(9):2181-2188.
261. Young CL, Sim FH, Unni KK, McLeod RA. Chondrosarcoma of bone in children. *Cancer*. 1990;66(7):1641-1648.
262. Huvos AG, Marcove RC. Chondrosarcoma in the young. A clinicopathologic analysis of 79 patients younger than 21 years of age. *Am J Surg Pathol*. 1987;11(12):930-942.
263. Bjornsson J, McLeod RA, Unni KK, et al. Primary chondrosarcoma of long bones and limb girdles. *Cancer*. 1998;83(10):2105-2119.
264. Bovee JV, van der Heul RO, Taminiau AH, Hogendoorn PC. Chondrosarcoma of the phalanx: a locally aggressive lesion with minimal metastatic potential: a report of 35 cases and a review of the literature. *Cancer*. 1999;86(9):1724-1732.
265. Ogose A, Unni KK, Swee RG, et al. Chondrosarcoma of small bones of the hands and feet. *Cancer*. 1997;80(1):50-59.
266. Ostrowski ML, Spjut HJ. Lesions of the bones of the hands and feet. *Am J Surg Pathol*. 1997;21(6):676-690.
267. Coltrera MD, Googe PB, Harrist TJ, et al. Chondrosarcoma of the temporal bone. Diagnosis and treatment of 13 cases and review of the literature. *Cancer*. 1986;58(12):2689-2696.
268. Rosenberg AE, Nielsen GP, Keel SB, et al. Chondrosarcoma of the base of the skull: a clinicopathologic study of 200 cases with emphasis on its distinction from chordoma. *Am J Surg Pathol*. 1999;23(11):1370-1378.
269. Murphey MD, Choi JJ, Kransforf MJ, et al. Imaging of osteochondroma: variants and complications with radiologic-pathologic correlation. *Radiographics*. 2000;20:1407-1434.
270. Schajowicz F. Juxtacortical chondrosarcoma. *J Bone Joint Surg Br*. 1977;59-b(4):473-480.
271. Bertoni F, Boriani S, Laus M, Campanacci M. Periosteal chondrosarcoma and periosteal osteosarcoma. Two distinct entities. *J Bone Joint Surg Br*. 1982;64(3):370-376.
272. Eefting D, Schrage YM, Geirnaerdt MJ, et al. Assessment of interobserver variability and histologic parameters to improve reliability in classification and grading of central cartilaginous tumors. *Am J Surg Pathol*. 2009;33(1):50-57.
273. Mirra JM, Gold R, Downs J, Eckardt JJ. A new histologic approach to the differentiation of enchondroma and chondrosarcoma of the bones. A clinicopathologic analysis of 51 cases. *Clin Orthop Relat Res*. 1985;201:214-237.
274. Larramendy ML, Mandahl N, Mertens F, et al. Clinical significance of genetic imbalances revealed by comparative genomic hybridization in chondrosarcomas. *Hum Pathol*. 1999;30(10):1247-1253.

For personal use only. No other uses without permission. Copyright ©2017. Elsevier Inc. All rights reserved.

275. Mandahl N, Heim S, Arheden K, et al. Chromosomal rearrangements in chondromatous tumors. *Cancer*. 1990;65(2):242-248.
276. Sandberg AA, Bridge JA. Updates on the cytogenetics and molecular genetics of bone and soft tissue tumors: chondrosarcoma and other cartilaginous neoplasms. *Cancer Genet Cytogenet*. 2003;143(1):1-31.
277. Kerr DA, Lopez HU, Deshpande V, et al. Molecular distinction of chondrosarcoma from chondroblastic osteosarcoma through IDH1/2 mutations. *Am J Surg Pathol*. 2013;37:787-795.
278. Donati D, Colangeli S, Colangeli M, et al. Surgical treatment of grade I central chondrosarcoma. *Clin Orthop Rel Res*. 2010;468:581-589.
279. Hickey M, Rarrokhyar F, Deheshi B, et al. A systematic review and meta-analysis of intralesional versus wide resection for intramedullary grade 1 chondrosarcoma of the extremities. *Ann Surg Oncol*. 2011;18:1705-1709.
280. Evans HL, Ayala AG, Romsdahl MM. Prognostic factors in chondrosarcoma of bone: a clinicopathologic analysis with emphasis on histologic grading. *Cancer*. 1977;40(2):818-831.
281. Lee FY, Mankin HJ, Fondren G, et al. Chondrosarcoma of bone: an assessment of outcome. *J Bone Joint Surg Am*. 1999;81-A:326-338.
282. Reith JD, Horodyski MB, Scarborough MT. Grade 2 chondrosarcoma: stage I or stage II tumor? *Clin Orthop Rel Res*. 2003;415:45-51.
283. Kristensen IB, Sunde LM, Jensen OM. Chondrosarcoma. Increasing grade of malignancy in local recurrence. *Acta Pathol Microbiol Immunol Scand [A]*. 1986;94(2):73-77.
284. Bergh P, Gunterberg B, Meis-Kindblom JM, Kindblom LG. Prognostic factors and outcome of pelvic, sacral, and spinal chondrosarcomas: a center-based study of 69 cases. *Cancer*. 2001;91(7):1201-1212.
285. Sheth DS, Yasko AW, Johnson ME, et al. Chondrosarcoma of the pelvis. Prognostic factors for 67 patients treated with definitive surgery. *Cancer*. 1996;78(4):745-750.
286. Sawyer JR, Swanson CM, Lukacs JL, et al. Evidence of an association between 6q13-21 chromosome aberrations and locally aggressive behavior in patients with cartilage tumors. *Cancer*. 1998;82(3):474-483.
287. Masui F, Ushigome S, Fujii K. Clear cell chondrosarcoma: a pathological and immunohistochemical study. *Histopathology*. 1999;34(5):447-452.
288. Swanson PE. Clear cell tumors of bone. *Sem Diagn Pathol*. 1998;14:281-291.
289. Unni KK, Dahlin DC, Beabout JW, Sim FH. Chondrosarcoma: clear-cell variant. A report of sixteen cases. *J Bone Joint Surg Am*. 1976;58(5):676-683.
290. Bjornsson J, Unni KK, Dahlin DC, et al. Clear cell chondrosarcoma of bone. Observations in 47 cases. *Am J Surg Pathol*. 1984;8(3):223-230.
291. Corradi D, Bacchini P, Campanini N, Bertoni F. Aggressive clear cell chondrosarcomas: do distinctive characteristics exist?: a report of 4 cases. *Arch Pathol Lab Med*. 2006;130(11):1673-1679.
292. Kalil RK, Inwards CY, Unni KK, et al. Dedifferentiated clear cell chondrosarcoma. *Am J Surg Pathol*. 2000;24(8):1079-1086.
293. Nishio J, Reith JD, Ogose A, et al. Cytogenetic findings in clear cell chondrosracoma. *Cancer Genet Cytogenet*. 2005;162:74-77.
294. Antonescu CR, Argani P, Erlandson RA, et al. Skeletal and extraskeletal myxoid chondrosarcoma: a comparative clinicopathologic, ultrastructural, and molecular study. *Cancer*. 1998;83(8):1504-1521.
295. Kilpatrick SE, Inwards CY, Fletcher CD, et al. Myxoid chondrosarcoma (chordoid sarcoma) of bone: a report of two cases and review of the literature. *Cancer*. 1997;79(10):1903-1910.
296. Demmico EG, Wang WL, Madewell JE, et al. Osseous myxochondroid sarcoma: a detailed study of 5 cases of extraskeletal myxoid chondrosarcoma of the bone. *Am J Surg Pathol*. 2013;37:752-762.
297. Dahlin DC, Beabout JW. Dedifferentiation of low-grade chondrosarcomas. *Cancer*. 1971;28(2):461-466.
298. McFarland GB Jr, McKinley LM, Reed RJ. Dedifferentiation of low grade chondrosarcomas. *Clin Orthop Relat Res*. 1977;122:157-164.
299. Staals EL, Bacchini P, Bertoni F. Dedifferentiated central chondrosarcoma. *Cancer*. 2006;106(12):2682-2691.
300. Bertoni F, Present D, Bacchini P, et al. Dedifferentiated peripheral chondrosarcomas. A report of seven cases. *Cancer*. 1989;63(10):2054-2059.
301. Mitchell A, Rudan JR, Fenton PV. Juxtacortical dedifferentiated chondrosarcoma from a primary periosteal chondrosarcoma. *Mod Pathol*. 1996;9(3):279-283.
302. Johnson S, Tetu B, Ayala AG, Chawla SP. Chondrosarcoma with additional mesenchymal component (dedifferentiated chondrosarcoma). I. A clinicopathologic study of 26 cases. *Cancer*. 1986;58(2):278-286.
303. Reith JD, Bauer TW, Fischler DF, et al. Dedifferentiated chondrosarcoma with rhabdomyosarcomatous differentiation. *Am J Surg Pathol*. 1996;20(3):293-298.
304. Aigner T, Dertinger S, Neureiter D, Kirchner T. De-differentiated chondrosarcoma is not a 'de-differentiated' chondrosarcoma. *Histopathology*. 1998;33(1):11-19.
305. Bridge JA, DeBoer J, Travis J, et al. Simultaneous interphase cytogenetic analysis and fluorescence immunophenotyping of dedifferentiated chondrosarcoma. Implications for histopathogenesis. *Am J Pathol*. 1994;144(2):215-220.
306. Sakamoto A, Oda Y, Adachi T, et al. H-ras oncogene mutation in dedifferentiated chondrosarcoma: polymerase chain reaction-restriction fragment length polymorphism analysis. *Mod Pathol*. 2001;14(4):343-349.
307. McCarthy EF, Dorfman HD. Chondrosarcoma of bone with dedifferentiation: a study of eighteen cases. *Hum Pathol*. 1982;13(1):36-40.
308. Meis JM. Dedifferentiation" in bone and soft-tissue tumors. A histological indicator of tumor progression. *Pathol Annu*. 1991;26(Pt 1):37-62.
309. Bertoni F, Picci P, Bacchini P, et al. Mesenchymal chondrosarcoma of bone and soft tissues. *Cancer*. 1983;52(3):533-541.
310. Nakashima Y, Unni KK, Shives TC, et al. Mesenchymal chondrosarcoma of bone and soft tissue. A review of 111 cases. *Cancer*. 1986;57(12):2444-2453.
311. Fanburg-Smith JC, Auerbach A, Marwaha JS, et al. Reappraisal of mesenchymal chondrosarcoma: novel morphologic observations of the hyaline cartilage and endochondral ossification and beta-catenin, SOX9 and osteocalcin immunostaining of 22 cases. *Hum Pathol*. 2010;41:653-662.
312. Stewart BD, Reith JD, Knapik JA, Chi AC. Bone- and cartilage-forming tumors and Ewing sarcoma: an update with gnathic emphasis. *Head Neck Pathol*. 2014;8: 454-462.
313. Granter SR, Renshaw AA, Fletcher CD, et al. CD99 reactivity in mesenchymal chondrosarcoma. *Hum Pathol*. 1996;27(12):1273-1276.
314. Swanson PE, Lillemoe TJ, Manivel JC, Wick MR. Mesenchymal chondrosarcoma. An immunohistochemical study. *Arch Pathol Lab Med*. 1990;114(9):943-948.
315. Wehrli BM, Huang W, De Crombrugghe B, et al. Sox9, a master regulator of chondrogenesis, distinguishes mesenchymal chondrosarcoma from other small blue round cell tumors. *Hum Pathol*. 2003;34(3):263-269.
316. Gengler C, Letovanec I, Taminelli L, et al. Desmin and myogenin reactivity in mesenchymal chondrosarcoma: a potential diagnostic pitfall. *Histopathology*. 2006;48(2):201-203.
317. Wang L, Motoi T, Khanin R, et al. Identification of a novel, recurrent HEY1-NCOA2 fusion in mesenchymal chondrosarcoma based on a genome-wide screen of exon-level expression data. *Genes Chromosomes Cancer*. 2012;51:127-134.
318. Campanacci M, Giunti A, Olmi R. Giant-cell tumours of bone. A study of 209 cases with long-term follow-up in 130. *Ital J Orthop Traumatol*. 1975;1:249-277.
319. Sung HW, Kuo DP, Shu WP, et al. Giant-cell tumor of bone: analysis of two hundred and eight cases in Chinese patients. *J Bone Joint Surg Am*. 1982;64(5):755-761.
320. Picci P, Manfrini M, Zucchi V, et al. Giant-cell tumor of bone in skeletally immature patients. *J Bone Joint Surg Am*. 1983;65(4):486-490.
321. Fain JS, Unni KK, Beabout JW, Rock MG. Nonepiphyseal giant cell tumor of the long bones. Clinical, radiologic, and pathologic study. *Cancer*. 1993;71(11):3514-3519.
322. Hoch BL, Inwards C, Sundaram M, Rosenberg AE. Multicentric giant cell tumor of bone: a clinicopathologic analysis of thirty cases. *J Bone Joint Surg Am*. 2006;88-A:1998-2008.
323. Hudson TM, Scheibler M, Springfield DS, et al. Radiology of giant cell tumors of bone: computed tomography, arthro-tomography, and scintigraphy. *Skeletal Radiol*. 1984;11:85-95.
324. Sarungbam J, Agaram N, Hwang S, et al. Symplastic/pseudoanaplastic giant cell tumor of the bone. *Skeletal Radiol*. 2016;45:929-935.
325. Lucas DR. Giant cell tumor of bone. *Surg Pathol*. 2012;5:183-200.
326. Athanasou NA, Bliss E, Gatter KC, et al. An immunohistological study of giant-cell tumour of bone: evidence for an osteoclast origin of the giant cells. *J Pathol*. 1985;147(3):153-158.
327. Medeiros J, Beckstead J, Rosenberg A, et al. Giant cells and mononuclear cells of giant cell tumor of bone resemble histiocytes. *Appl Immunohistochem*. 1993;1:115-122.
328. Seethala RR, Goldblum JR, Hicks DG, et al. Immunohistochemical evaluation of microphthalmia-associated transcription factor expression in giant cell lesions. *Mod Pathol*. 2004;17(12):1491-1496.
329. Kato Kaneko M, Liu X, Oki H, et al. Isocitrate dehydrogenase mutation is frequently observed in giant cell tumor of bone. *Cancer Sci*. 2014;105:744-748.
330. Presneau N, Baumhoer D, Behjati S, et al. Diagnostic value of H3H3A mutations in giant cell tumour of bone compared to osteoclast-rich mimics. *J Pathol Clin Res*. 2015;1:113-123.
331. Sybrandy S, De la Fuente AA. Multiple giant-cell tumour of bone. Report of a case. *J Bone Joint Surg Br*. 1973;55(2):350-358.
332. Mendenhall WM, Zlotecki RA, Scarborough MT, et al. Giant cell tumor of bone. *Am J Clin Oncol*. 2006;29:96-99.
333. Shi W, Indelicato DJ, Reith JD, et al. Radiotherapy in the management of giant cell tumor of bone. *Am J Clin Oncol*. 2013;36:505-508.

For personal use only. No other uses without permission. Copyright ©2017. Elsevier Inc. All rights reserved.

334. Thomas D, Henshaw R, Skubitz K, et al. Denosumab in patients with giant cell tumor of bone: an open-label, phase 2 study. *Lancet Oncol*. 2010;11:275-280.
335. Branstetter DG, Nelson SD, Manivel JC, et al. Denosumab induces tumor reduction and bone formation in patients with giant cell tumor of bone. *Clin Cancer Res*. 2012;18:4415-4424.
336. Wojcik J, Rosenberg AE, Brandella MA, et al. Denosumab-treated giant cell tumor of bone exibits morphologic overlap with malignant giant cell tumor of bone. *Am J Surg Pathol*. 2016;40:72-80.
337. Chan CM, Adler Z, Reith JD, Gibbs CP. Risk factors for pulmonary metastases from giant cell tumor of bone. *J Bone Joint Surg Am*. 2015;97:420-428.
338. Klenke FM, Wenger DE, Inwards CY, et al. Giant cell tumor of bone: risk factors for recurrence. *Clin Orthop Rel Res*. 2011;469:591-599.
339. Bridge JA, Neff JR, Mouron BJ. Giant cell tumor of bone. Chromosomal analysis of 48 specimens and review of the literature. *Cancer Genet Cytogenet*. 1992;58(1):2-13.
340. Sciot R, Dorfman H, Brys P, et al. Cytogenetic-morphologic correlations in aneurysmal bone cyst, giant cell tumor of bone and combined lesions. A report from the CHAMP study group. *Mod Pathol*. 2000;13(11):1206-1210.
341. McComb EN, Johansson SL, Neff JR, et al. Chromosomal anomalies exclusive of telomeric associations in giant cell tumor of bone. *Cancer Genet Cytogenet*. 1996;88(2):163-166.
342. Czerniak B. *Dorfman and Czerniak's Bone Tumors*. 2nd ed. Philadelphia: Elsevier; 2016.
343. Meis JM, Dorfman HD, Nathanson SD, et al. Primary malignant giant cell tumor of bone: "dedifferentiated" giant cell tumor. *Mod Pathol*. 1989;2(5):541-546.
344. Oda Y, Sakamoto A, Saito T, et al. Secondary malignant giant-cell tumour of bone: molecular abnormalities of p53 and H-ras gene correlated with malignant transformation. *Histopathology*. 2001;39(6):629-637.
345. Bertoni F, Bacchini P, Staals EL. Malignancy in giant cell tumor of bone. *Cancer*. 2003;97(10):2520-2529.
346. Gong L, Liu W, Sun X, et al. Histological and clinical characteristics of malignant giant cell tumor of bone. *Virchows Arch*. 2012;460:327-344.
347. Ewing J. Diffuse endothelioma of bone. *Proc NY Path Soc*. 1921;12:17-24.
348. Seningen JL, Inwards CY. Small round cell tumors of bone. *Surg Pathol*. 2012;5:231-236.
349. Askin FB, Perlman EJ. Neuroblastoma and peripheral neuroectodermal tumors. *Am J Clin Pathol*. 1998;109(4 suppl 1):S23-S30.
350. Wilkins RM, Pritchard DJ, Burgert EO Jr, Unni KK. Ewing's sarcoma of bone. Experience with 140 patients. *Cancer*. 1986;58(11):2551-2555.
351. Fizazi K, Dohollou N, Blay JY, et al. Ewing's family of tumors in adults: multivariate analysis of survival and long-term results of multimodality therapy in 182 patients. *J Clin Oncol*. 1998;16(12):3736-3743.
352. Verrill MW, Judson IR, Harmer CL, et al. Ewing's sarcoma and primitive neuroectodermal tumor in adults: are they different from Ewing's sarcoma and primitive neuroectodermal tumor in children? *J Clin Oncol*. 1997;15(7):2611-2621.
353. Bator SM, Bauer TW, Marks KE, Norris DG. Periosteal Ewing's sarcoma. *Cancer*. 1986;58(8):1781-1784.
354. Hasegawa SL, Davison JM, Rutten A, et al. Primary cutaneous Ewing's sarcoma: immunophenotypic and molecular cytogenetic evaluation of five cases. *Am J Surg Pathol*. 1998;22(3):310-318.
355. O'Sullivan MJ, Perlman EJ, Furman J, et al. Visceral primitive peripheral neuroectodermal tumors: a clinicopathologic and molecular study. *Hum Pathol*. 2001;32(10):1109-1115.
356. Jaffe R, Santamaria M, Yunis EJ, et al. The neuroectodermal tumor of bone. *Am J Surg Pathol*. 1984;8(12):885-898.
357. Folpe AL, Goldblum JR, Rubin BP, et al. Morphologic and immunophenotypic diverity in Ewing family tumors: a study of 66 genetically confirmed cases. *Am J Surg Pathol*. 2005;29:1025-1033.
358. Llombart-Bosch A, Machado I, Navarro S, et al. Histological heterogeneity of Ewing's sarcoma/PNET: an immunohistochemical analysis of 415 genetically confirmed cases with clinical support. *Virchows Arch*. 2009;455(5):397-411.
359. Machado I, Noguera R, Mateos IA, et al. The many faces of atypical Ewing's sarcoma. A true entity mimicking sarcomas, carcinomas, and lymphomas. *Virchows Arch*. 2011;458:281-290.
360. Hameed M. Small round cell tumors of bone. *Arch Pathol Lab Med*. 2007;131(2):192-204.
361. Meis-Kindblom JM, Stenman G, Kindblom LG. Differential diagnosis of small round cell tumors. *Sem Diagn Pathol*. 1996;13(3):213-241.
362. Bridge JA, Fidler ME, Neff JR, et al. Adamantinoma-like Ewing's sarcoma: genomic confirmation, phenotypic drift. *Am J Surg Pathol*. 1999;23(2):159-165.
363. Fukunaga M, Ushigome S. Periosteal Ewing-like adamantinoma. *Virch Arch*. 1998;433(4):385-389.
364. Fujii H, Honoki K, Enomoto Y, et al. Adamantinoma-like Ewing's sarcoma with EWS-FLI1 fusion gene: a case report. *Virch Arch*. 2006;449(5):579-584.
365. Bishop JA, Alaggio R, Zhang L, et al. Adamantinoma-like Ewing family tumors of the head and neck: a ptifall in the differential diagnosis of basaloid and myoepithelial carcinomas. *Am J Surg Pathol*. 2015;39:1267-1274.
366. Weinreb I, Goldstein D, Perez-Ordonez B. Primary extraskeletal Ewing family tumor with complex epithelial differentiation: a unique case arising in the lateral neck presenting with Horner syndrome. *Am J Surg Pathol*. 2008;32(11):1742-1748.
367. Ambros IM, Ambros PF, Strehl S, et al. MIC2 is a specific marker for Ewing's sarcoma and peripheral primitive neuroectodermal tumors. Evidence for a common histogenesis of Ewing's sarcoma and peripheral primitive neuroectodermal tumors from MIC2 expression and specific chromosome aberration. *Cancer*. 1991;67(7):1886-1893.
368. Scotlandi K, Serra M, Manara MC, et al. Immunostaining of the p30/32MIC2 antigen and molecular detection of EWS rearrangements for the diagnosis of Ewing's sarcoma and peripheral neuroectodermal tumor. *Hum Pathol*. 1996;27(4):408-416.
369. Fellinger EJ, Garin-Chesa P, Glasser DB, et al. Comparison of cell surface antigen HBA71 (p30/32MIC2), neuron-specific enolase, and vimentin in the immunohistochemical analysis of Ewing's sarcoma of bone. *Am J Surg Pathol*. 1992;16(8):746-755.
370. Hess E, Cohen C, DeRose PB, et al. Nonspecificity of p30/32MIC2 immunolocalization with the 013 monoclonal antibody in the diagnosis of Ewing's sarcoma: application of an algorithmic immunohistochemical analysis. *Appl Immunohistochem*. 1997;5:94-103.
371. Perlman EJ, Dickman PS, Askin FB, et al. Ewing's sarcoma–routine diagnostic utilization of MIC2 analysis: a Pediatric Oncology Group/Children's Cancer Group Intergroup Study. *Hum Pathol*. 1994;25(3):304-307.
372. Stevenson AJ, Chatten J, Bertoni P, Miettinen M. CD99 (p30/32MIC) neuroectodermal/Ewing's sarcoma antigen as an immunohistochemical marker. Review of more than 600 tumors and the literature experience. *Appl Immunohistochem*. 1994;2:231-240.
373. Weidner N, Tjoe J. Immunohistochemical profile of monoclonal antibody O13: antibody that recognizes glycoprotein p30/32MIC2 and is useful in diagnosing Ewing's sarcoma and peripheral neuroepithelioma. *Am J Surg Pathol*. 1994;18(5):486-494.
374. Folpe AL, Hill CE, Parham DM, et al. Immunohistochemical detection of FLI-1 protein expression: a study of 132 round cell tumors with emphasis on CD99-positive mimics of Ewing's sarcoma/primitive neuroectodermal tumor. *Am J Surg Pathol*. 2000;24(12):1657-1662.
375. Llombart-Bosch A, Navarro S. Immunohistochemical detection of EWS and FLI-1 proteinss in Ewing sarcoma and primitive neuroectodermal tumors: comparative analysis with CD99 (MIC-2) expression. *Appl Immunohistochem Mol Morphol*. 2001;9(3):255-260.
376. Wang WL, Patel NR, Caragea M, et al. Expression of ERG, an Ets family transcription factor, identifies ERG-rearranged Ewing sarcoma. *Mod Pathol*. 2012;25:1378-1383.
377. Dockhorn-Dworniczak B, Schafer KL, Dantcheva R, et al. Diagnostic value of the molecular genetic detection of the t(11;22) translocation in Ewing's tumours. *Virch Arch*. 1994;425(2):107-112.
378. Ladanyi M, Lewis R, Garin-Chesa P, et al. EWS rearrangement in Ewing's sarcoma and peripheral neuroectodermal tumor. Molecular detection and correlation with cytogenetic analysis and MIC2 expression. *Diagn Mol Pathol*. 1993;2(3):141-146.
379. Barr FG, Womer RB. Molecular diagnosis of ewing family tumors: too many fusions? *J Mol Diagn*. 2007;9(4):437-440.
380. Wang L, Bhargava R, Zheng T, et al. Undifferentiated small round cell sarcomas with rare EWS gene fusions: identification of a novel EWS-SP3 fusion and of additional cases with the EWS-ETV1 and EWS-FEV fusions. *J Mol Diagn*. 2007;9(4):498-509.
381. Adams V, Hany MA, Schmid M, et al. Detection of t(11;22)(q24;q12) translocation breakpoint in paraffin-embedded tissue of the Ewing's sarcoma family by nested reverse transcription-polymerase chain reaction. *Diagn Mol Pathol*. 1996;5(2):107-113.
382. Downing JR, Head DR, Parham DM, et al. Detection of the (11;22)(q24;q12) translocation of Ewing's sarcoma and peripheral neuroectodermal tumor by reverse transcription polymerase chain reaction. *Am J Pathol*. 1993;143(5):1294-1300.
383. Fidelia-Lambert MN, Zhuang Z, Tsokos M. Sensitive detection of rare Ewing's sarcoma cells in peripheral blood by reverse transcriptase polymerase chain reaction. *Hum Pathol*. 1999;30(1):78-80.
384. Mangham DC, Williams A, McMullan DJ, et al. Ewing's sarcoma of bone: the detection of specific transcripts in a large, consecutive series of formalin-fixed, decalcified, paraffin-embedded tissue samples using the reverse transcriptase-polymerase chain reaction. *Histopathology*. 2006;48(4):363-376.
385. Selleri L, Hermanson GG, Eubanks JH, et al. Molecular localization of the t(11;22)(q24;q12) translocation of Ewing sarcoma by chromosomal in situ suppression hybridization. *Proc Natl Acad Sci USA*. 1991;88(3):887-891.

For personal use only. No other uses without permission. Copyright ©2017. Elsevier Inc. All rights reserved.

386. Sorensen PH, Liu XF, Delattre O, et al. Reverse transcriptase PCR amplification of EWS/FLI-1 fusion transcripts as a diagnostic test for peripheral primitive neuroectodermal tumors of childhood. *Diagn Mol Pathol*. 1993;2(3):147-157.
387. Stephenson CF, Bridge JA, Sandberg AA. Cytogenetic and pathologic aspects of Ewing's sarcoma and neuroectodermal tumors. *Hum Pathol*. 1992;23(11):1270-1277.
388. Bridge RS, Rajaram V, Dehner LP, et al. Molecular diagnosis of Ewing sarcoma/primitive neuroectodermal tumor in routinely processed tissue: a comparison of two FISH strategies and RT-PCR in malignant round cell tumors. *Mod Pathol*. 2006;19(1):1-8.
389. Kumar S, Pack S, Kumar D, et al. Detection of EWS-FLI-1 fusion in Ewing's sarcoma/peripheral primitive neuroectodermal tumor by fluorescence in situ hybridization using formalin-fixed paraffin-embedded tissue. *Hum Pathol*. 1999;30(3):324-330.
390. Monforte-Munoz H, Lopez-Terrada D, Affendie H, et al. Documentation of EWS gene rearrangements by fluorescence in-situ hybridization (FISH) in frozen sections of Ewing's sarcoma-peripheral primitive neuroectodermal tumor. *Am J Surg Pathol*. 1999;23(3):309-315.
391. Chen S, Deniz K, Sung Y, et al. Ewing sarcoma with ERG gene rearrangements: a molecular study focusing on the prevalance of FUS-ERG and common pitfalls in detecting EWSR1-ERG by FISH. *Am J Surg Pathol*. 2016;55:340-349.
392. Choi EY, Thomas DG, McHugh JB, et al. Undifferentiated small round cell sarcoma with t(4;19)(q35;q13.1) CIC-DUX4 gene fusion: a novel highly aggressive soft tissue tumor with distinctive histopathology. *Am J Surg Pathol*. 2013;37:1379-1386.
393. Wei S, Siegal GP. Round cell tumors of bone: an update on recent molecular genetic advances. *Adv Anat Pathol*. 2014;21:359-372.
394. Puls F, Niblett A, Marland G, et al. BCOR-CCNB3 (Ewing-like) sarcoma: a clinicopathologic analysis of 10 cases in comparison with conventinal Ewing sarcoma. *Am J Surg Pathol*. 2014;38:1307-1318.
395. Cangir A, Vietti TJ, Gehan EA, et al. Ewing's sarcoma metastatic at diagnosis. Results and comparisons of two intergroup Ewing's sarcoma studies. *Cancer*. 1990;66(5):887-893.
396. Gasparini M, Barni S, Lattuada A, et al. Ten years experience with Ewing's sarcoma. *Tumori*. 1977;63(1):77-90.
397. Picci P, Bohling T, Bacci G, et al. Chemotherapy-induced tumor necrosis as a prognostic factor in localized Ewing's sarcoma of the extremities. *J Clin Oncol*. 1997;15:1553-1559.
398. Rubin BP, Antonescu CR, Gannon FH, et al. Protocol for the examination of specimens from patients with tumors of bone. *Arch Pathol Lab Med*. 2010;134:e1-e7.
399. Baar J, Burkes RL, Gospodarowicz M. Primary non-Hodgkin's lymphoma of bone. *Sem Oncol*. 1999;26(3):270-275.
400. Gianelli U, Patriarca C, Moro A, et al. Lymphomas of the bone: a pathological and clinical study of 54 cases. *Int J Surg Pathol*. 2002;10(4):257-266.
401. Bhagavathi S, Micale MA, Les K, et al. Primary bone diffuse large B-cell lymphoma: clinicopathologic study of 21 cases and review of literature. *Am J Surg Pathol*. 2009;33(10):1463-1469.
402. Zhao XF, Young KH, Frank D, et al. Pediatric primary bone lymphoma-diffuse large B-cell lymphoma: morphologic and immunohistochemical characteristics of 10 cases. *Am J Clin Pathol*. 2007;127(1):47-54.
403. Adams H, Tzankov A, d'Hondt S, et al. Primary diffuse large B-cell lymphomas of the bone: prognostic relevance of protein expression and clinical factors. *Hum Pathol*. 2008;39(9):1323-1330.
404. Clayton F, Butler JJ, Ayala AG, et al. Non-Hodgkin's lymphoma in bone. Pathologic and radiologic features with clinical correlates. *Cancer*. 1987;60(10):2494-2501.
405. Krishnan A, Shirkhoda A, Tehranzadeh J, et al. Primary bone lymphoma: radiographic-MRI imaging correlation. *Radiographics*. 2003;23:1371-1383.
406. Howat AJ, Thomas H, Waters KD, Campbell PE. Malignant lymphoma of bone in children. *Cancer*. 1987;59(2):335-339.
407. Beal K, Allen L, Yahalom J. Primary bone lymphoma: treatment results and prognostic factors with long-term follow-up of 82 patients. *Cancer*. 2006;106(12):2652-2656.
408. Gill P, Wenger DE, Inwards DJ. Primary lymphomas of bone. *Clin Lymphoma Myeloma*. 2005;6:140-142.
409. Horan FT. Bone involvement in Hodgkin's disease. A survey of 201 cases. *Br J Surg*. 1969;56(4):277-281.
410. Chan KW, Rosen G, Miller DR, Tan CT. Hodgkin's diseases in adolescents presenting as a primary bone lesion. A report of four cases and review of literature. *Am J Pediatr Hematol Oncol*. 1982;4(1):11-17.
411. Abbondanzo SL, Devaney K. Hodgkin's disease involving bone and adjacent soft tissue in adults: a clinicopathologic and immunophenotypic study of seven cases. *Int J Surg Pathol*. 1996;3:147-154.
412. Ostrowski ML, Inwards CY, Strickler JG, et al. Osseous Hodgkin disease. *Cancer*. 1999;85(5):1166-1178.
413. Ozdemirli M, Mankin HJ, Aisenberg AC, Harris NL. Hodgkin's disease presenting as a solitary bone tumor. A report of four cases and review of the literature. *Cancer*. 1996;77(1):79-88.
414. Bhagavathi S, Fu K. Primary bone lymphoma. *Arch Pathol Lab Med*. 2009;133:1868-1871.
415. Nagasaka T, Nakamura S, Medeiros LJ, et al. Anaplastic large cell lymphomas presented as bone lesions: a clinicopathologic study of six cases and review of the literature. *Mod Pathol*. 2000;13(10):1143-1149.
416. Gustafson S, Medeiros LJ, Kalhor N, et al. Anaplastic large cell lymphoma: another entity in the differential diagnosis of small round blue cell tumors. *Ann Diagn Pathol*. 2009;13:413-427.
417. Fowles JV, Olweny CL, Katongole-Mbidde E, et al. Burkitt's lymphoma in the appendicular skeleton. *J Bone Joint Surg Br*. 1983;65(4):464-471.
418. Iravani S, Singleton TP, Ross CW, Schnitzer B. Precursor B lymphoblastic lymphoma presenting as lytic bone lesions. *Am J Clin Pathol*. 1999;112(6):836-843.
419. Marsh WL Jr, Bylund DJ, Heath VC, Anderson MJ. Osteoarticular and pulmonary manifestations of acute leukemia. Case report and review of the literature. *Cancer*. 1986;57(2):385-390.
420. Pambuccian SE, Horyd ID, Cawte T, Huvos AG. Amyloidoma of bone, a plasma cell/plasmacytoid neoplasm. Report of three cases and review of the literature. *Am J Surg Pathol*. 1997;21(2):179-186.
421. Wold LE, Swee RG, Sim FH. Vascular lesions of bone. *Pathol Annu*. 1985;20(Pt 2):101-137.
422. Bruder E, Perez-Atayde AR, Jundt G, et al. Vascular lesions of bone in children, adolescents, and young adults. A clinicopathologic reappraisal and application of the ISSVA classification. *Virch Arch*. 2009;454(2):161-179.
423. Gorham LW, Wright AW, Shultz HH, Maxon FC. Disappearing bones: a rare form of massive osteolysis. *Am J Med*. 1954;17:674-682.
424. Gorham LW, Stout AP. Massive osteolysis (acute spontaneous absorption of bone, phantom bone, disappearing bone). Its relation to hemangiomatosis. *J Bone Joint Surg*. 1955;37-A:985-1004.
425. Choma ND, Biscotti CV, Bauer TW, et al. Gorham's syndrome: a case report and review of the literature. *Am J Med*. 1987;83:1151-1156.
426. Jumbelic M, Feuerstein IM, Dorfman HD. Solitary intraosseous lymphangioma. A case report. *J Bone Joint Surg Am*. 1984;66(9):1479-1481.
427. Schajowicz F, Aiello CL, Francone MV, Giannini RE. Cystic angiomatosis (hamartous haemolymphagiomatosis) of bone. A clinicopathological study of three cases. *J Bone Joint Surg Br*. 1978;60(1):100-106.
428. Bjorkengren AG, Resnick D, Haghighi P, et al. Intraosseous glomus tumor: report of a case and review of the literature. *Am J Roentgenol*. 1986;147:739-741.
429. Verbeke SL, Fletcher CD, Alberghini M, et al. A reappraisal of hemangiopericytoma of bone; analysis of cases reclassified as synovial sarcoma and solitary fibrous tumor of bone. *Am J Surg Pathol*. 2010;34(6):777-783.
430. Nielsen GP, Srivastava A, Kattapuram S, et al. Epithelioid hemangioma of bone revisited. A study of 50 cases. *Am J Surg Pathol*. 2009;33:270-277.
431. Huang SC, Zhang L, Sung YS, et al. Frequent FOS gene rearrangements in epithelioid hemangioma: a molecular study of 58 cases with morphologic reappraisal. *Am J Surg Pathol*. 2015;39:1313-1321.
432. van Ijzendoorn DGP, de Jong D, Romagosa C, et al. Fusion events lead to truncation of FOS in epithelioid hemangioma of bone. *Genes Chromosomes Cancer*. 2015;54:565-574.
433. Deyrup AT, Montag AG. Epithelioid and epithelial neoplasms of bone. *Arch Pathol Lab Med*. 2007;131(2):205-216.
434. Kleer CG, Unni KK, McLeod RA. Epithelioid hemangioendothelioma of bone. *Am J Surg Pathol*. 1996;20(11):1301-1311.
435. Bollinger BK, Laskin WB, Knight CB. Epithelioid hemangioendothelioma with multiple site involvement. Literature review and observations. *Cancer*. 1994;73(3):610-615.
436. Lau K, Massad M, Pollak C, et al. Clincal patterns of outcome in epithelioid hemangioendothelioma wth or without pulmonary involvement: insights from an internet registry in the study of a rare cancer. *Chest*. 2011;140:1312-1318.
437. Scott MT, Indelicato DJ, Morris CG, et al. Radiation therapy for hemangioendothelioma: the University of Florida experience. *Am J Clin Oncol*. 2014;37:360-363.
438. O'Connell JX, Nielsen GP, Rosenberg AE. Epithelioid vascular tumors of bone: a review and proposal of a classification scheme. *Adv Anat Pathol*. 2001;8:74-82.
439. Inyang A, Mertens F, Puls F, et al. Primary pseudomyogenic hemangioendothelioma of bone. *Am J Surg Pathol*. 2016;40:587-598.
440. Tsuneyoshi M, Dorfman HD, Bauer TW. Epithelioid hemangioendothelioma of bone. A clinicopathologic, ultrastructural, and immunohistochemical study. *Am J Surg Pathol*. 1986;10(11):754-764.
441. Gill R, O'Donnell RJ, Horvai A. Utility of immunohistochemistry for endothelial markers in distinguishing epithelioid hemangioendothelioma from carcinoma metastatic to bone. *Arch Pathol Lab Med*. 2009;133:967-972.
442. Antonescu CR, Le Loarer F, Mosquera JM, et al. Novel YAP1-TFE3 fusion defines a distinct subset of epithelioid hemangioendothelioma. *Genes Chromosomes Cancer*. 2013;52:775-784.

For personal use only. No other uses without permission. Copyright ©2017. Elsevier Inc. All rights reserved.

443. Errani C, Zhang L, Sung YS, et al. A novel WWTR1-CAMTA1 gene fusion is a consistent abnormality in epithelioid hemangioendothelioma of different anatomica sites. *Genes Chromosomes Cancer*. 2011;50:644-653.
444. Doyle LA, Fletcher CD, Hornick JL. Nuclear expression of CAMTA1 distinguishes epithelioid hemangioendothelioma from histologic mimics. *Am J Surg Pathol*. 2016;40:94-102.
445. Deshpande V, Rosenberg AE, O'Connell JX, Nielsen GP. Epithelioid angiosarcoma of the bone: a series of 10 cases. *Am J Surg Pathol*. 2003;27(6):709-716.
446. Hasegawa T, Fujii Y, Seki K, et al. Epithelioid angiosarcoma of bone. *Hum Pathol*. 1997;28(8):985-989.
447. Mitsuhashi T, Shimizu Y, Ban S, et al. Multicentric contiguous variant of epithelioid angiosarcoma of the bone. A rare variant showing angiotropic spread. *Ann Diagn Pathol*. 2005;9(1):33-37.
448. Bertoni F, Calderoni P, Bacchini P, Campanacci M. Desmoplastic fibroma of bone. A report of six cases. *J Bone Joint Surg Br*. 1984;66(2):265-268.
449. Bohm P, Krober S, Greschniok A, et al. Desmoplastic fibroma of the bone. A report of two patients, review of the literature, and therapeutic implications. *Cancer*. 1996;78(5):1011-1023.
450. Hauben EI, Jundt G, Cleton-Jansen AM, et al. Desmoplastic fibroma of bone: an immunohistochemical study including beta-catenin expression and mutational analysis for beta-catenin. *Hum Pathol*. 2005;36(9):1025-1030.
451. Inwards CY, Unni KK, Beabout JW, Sim FH. Desmoplastic fibroma of bone. *Cancer*. 1991;68(9):1978-1983.
452. Gebhardt MC, Campbell CJ, Schiller AL, Mankin HJ. Desmoplastic fibroma of bone. A report of eight cases and review of the literature. *J Bone Joint Surg Am*. 1985;67(5):732-747.
453. Hasegawa T, Hirose T, Seki K, et al. Solitary infantile myofibromatosis of bone. An immunohistochemical and ultrastructural study. *Am J Surg Pathol*. 1993;17(3):308-313.
454. Inwards CY, Unni KK, Beabout JW, Shives TC. Solitary congenital fibromatosis (infantile myofibromatosis) of bone. *Am J Surg Pathol*. 1991;15(10):935-941.
455. O'Connell JX, Logan PM, Beauchamp CP. Solitary fibrous tumor of the periosteum. *Hum Pathol*. 1995;26(4):460-462.
456. Bahrami A, Folpe AL. Adult-type fibrosarcoma: a reevaluation of 163 putative cases diagnosed at a single institution over a 48-year period. *Am J Surg Pathol*. 2010;34:1504-1513.
457. Wojcik JB, Bellizzi AM, Dal Cin P, et al. Primary sclerosing epithelioid fibrosarcoma of bone: analysis of a series. *Am J Surg Pathol*. 2014;38:1538-1544.
458. Abdulkader I, Cameselle-Teijeiro J, Fraga M, et al. Sclerosing epithelioid fibrosarcoma primary of the bone. *Int J Surg Pathol*. 2002;10(3):227-230.
459. Huvos AG, Heilweil M, Bretsky SS. The pathology of malignant fibrous histiocytoma of bone. A study of 130 patients. *Am J Surg Pathol*. 1985;9(12):853-871.
460. McCarthy EF, Matsuno T, Dorfman HD. Malignant fibrous histiocytoma of bone: a study of 35 cases. *Hum Pathol*. 1979;10(1):57-70.
461. Nishida J, Sim FH, Wenger DE, Unni KK. Malignant fibrous histiocytoma of bone. A clinicopathologic study of 81 patients. *Cancer*. 1997;79(3):482-493.
462. Bielack SS, Schroeders A, Fuchs N, et al. Malignant fibrous histiocytoma of bone: a retrospective EMSOS study of 125 cases. *Acta Orthop Scand*. 1999;70:353-360.
463. Duong S, Sallis JG, Zee SY. Malignant fibrous histiocytoma arising within a bone infarct in a patient with sickle cell trait. *Int J Surg Pathol*. 2004;12(1):67-73.
464. Frierson HF Jr, Fechner RE, Stallings RG, Wang GJ. Malignant fibrous histiocytoma in bone infarct. Association with sickle cell trait and alcohol abuse. *Cancer*. 1987;59(3):496-500.
465. Bago-Granell J, Aguirre-Canyadell M, Nardi J, Tallada N. Malignant fibrous histiocytoma of bone at the site of a total hip arthroplasty. A case report. *J Bone Joint Surg Br*. 1984;66(1):38-40.
466. Lee YS, Pho RW, Nather A. Malignant fibrous histiocytoma at site of metal implant. *Cancer*. 1984;54(10):2286-2289.
467. Huvos AG, Woodard HQ, Heilweil M. Postradiation malignant fibrous histiocytoma of bone. A clinicopathologic study of 20 patients. *Am J Surg Pathol*. 1986;10(1):9-18.
468. Amstalden EM, Barbosa CS, Gamba R. Primary leiomyosarcoma of bone: report of two cases in extragnathic bones. *Ann Diagn Pathol*. 1998;2(2):103-110.
469. Angervall L, Berlin O, Kindblom LG, Stener B. Primary leiomyosarcoma of bone: a study of five cases. *Cancer*. 1980;46(5):1270-1279.
470. Antonescu CR, Erlandson RA, Huvos AG. Primary leiomyosarcoma of bone: a clinicopathologic, immunohistochemical, and ultrastructural study of 33 patients and a literature review. *Am J Surg Pathol*. 1997;21(11):1281-1294.
471. Khoddami M, Bedard YC, Bell RS, Kandel RA. Primary leiomyosarcoma of bone: report of seven cases and review of the literature. *Arch Pathol Lab Med*. 1996;120(7):671-675.
472. von Hochstetter AR, Eberle H, Ruttner JR. Primary leiomyosarcoma of extragnathic bones. Case report and review of literature. *Cancer*. 1984;53(10):2194-2200.
473. Watanabe K, Tajino T, Sekiguchi M, Suzuki T. h-Caldesmon as a specific marker for smooth muscle tumors. Comparison with other smooth muscle markers in bone tumors. *Am J Clin Pathol*. 2000;113(5):663-668.
474. Jundt G, Moll C, Nidecker A, et al. Primary leiomyosarcoma of bone: report of eight cases. *Hum Pathol*. 1994;25(11):1205-1212.
475. Young MP, Freemont AJ. Primary leiomyosarcoma of bone. *Histopathology*. 1991;19(3):257-262.
476. Lopez-Barea F, Rodriguez-Peralto JL, Sanchez-Herrera S, et al. Primary epithelioid leiomyosarcoma of bone. Case report and literature review. *Virch Arch*. 1999;434(4):367-371.
477. Adelani MA, Schultenover SJ, Holt GE, Cates JM. Primary leiomyosarcoma of extragnathic bone: clinicopathologic features and reevaluation of prognosis. *Arch Pathol Lab Med*. 2009;133(9):1448-1456.
478. Lamovec J, Zidar A, Bracko M, Golouh R. Primary bone sarcoma with rhabdomyosarcomatous component. *Pathol Res Prac*. 1994;190(1):51-60.
479. Oda Y, Tsuneyoshi M, Hashimoto H, et al. Primary rhabdomyosarcoma of the iliac bone in an adult: a case mimicking fibrosarcoma. *Virch Arch*. 1993;423(1):65-69.
480. Lucas DR, Ryan JR, Zalupski MM, et al. Primary embryonal rhabdomyosarcoma of long bone. Case report and review of the literature. *Am J Surg Pathol*. 1996;20(2):239-244.
481. Rashid A, Dickersin GR, Rosenthal DI, et al. Rhabdomyosarcoma of the long bone in an adult. A case report and literature review. *Int J Surg Pathol*. 1994;1:253-260.
482. Eyzaguirre E, Liqiang W, Karla GM, et al. Intraosseous lipoma. A clinical, radiologic, and pathologic study of 5 cases. *Ann Diagn Pathol*. 2007;11(5):320-325.
483. Yamamoto T, Marui T, Akisue T, et al. Intracortical lipoma of the femur. *Am J Surg Pathol*. 2002;26(6):804-808.
484. Barcelo M, Pathria MN, Abdul-Karim FW. Intraosseous lipoma. A clinicopathologic study of four cases. *Arch Pathol Lab Med*. 1992;116(9):947-950.
485. Chow LT, Lee KC. Intraosseous lipoma. A clinicopathologic study of nine cases. *Am J Surg Pathol*. 1992;16(4):401-410.
486. Pardo-Mindan FJ, Ayala H, Joly M, et al. Primary liposarcoma of bone: light and electron microscopic study. *Cancer*. 1981;48(2):274-280.
487. Wang WL, Abramson JH, Ganguly A, Rosenberg AE. The surgical pathology of notochordal remnants in adult intervertebral disks: a report of 3 cases. *Am J Surg Pathol*. 2008;32(8):1123-1129.
488. Sarasa JL, Fortes J. Ecchordosis physaliphora: an immunohistochemical study of two cases. *Histopathology*. 1991;18(3):273-275.
489. Houghton J, Korda M, Quick C, McClure M. Diagnostic dilemma of ectopic notochord tissue in the nasopharynx. *Histopathology*. 2008;52(4):518-519.
490. Yamaguchi T, Iwata J, Sugihara S, et al. Distinguishing benign notochordal cell tumors from vertebral chordoma. *Skeletal Radiol*. 2008;37:291-299.
491. Lalam R, Cassar-Pullicino VN, McClure J, Singh J. Entrapped intralesional marrow: a hitherto undescribed imaging features of benign notochordal cell tumor. *Skeletal Radiol*. 2012;41:725-731.
492. Yamaguchi T, Suzuki S, Ishiiwa H, et al. Benign notochordal cell tumors: A comparative histological study of benign notochordal cell tumors, classic chordomas, and notochordal vestiges of fetal intervertebral discs. *Am J Surg Pathol*. 2004;28(6):756-761.
493. Deshpande V, Nielsen GP, Rosenthal DI, Rosenberg AE. Intraosseous benign notochord cell tumors (BNCT): further evidence supporting a relationship to chordoma. *Am J Surg Pathol*. 2007;31(10):1573-1577.
494. Yamaguchi T, Suzuki S, Ishiiwa H, Ueda Y. Intraosseous benign notochordal cell tumours: overlooked precursors of classic chordomas? *Histopathology*. 2004;44(6):597-602.
495. Bjornsson J, Wold LE, Ebersold MJ, Laws ER. Chordoma of the mobile spine. A clinicopathologic analysis of 40 patients. *Cancer*. 1993;71(3):735-740.
496. Coffin CM, Swanson PE, Wick MR, Dehner LP. Chordoma in childhood and adolescence. A clinicopathologic analysis of 12 cases. *Arch Pathol Lab Med*. 1993;117(9):927-933.
497. Hoch BL, Nielsen GP, Liebsch NJ, Rosenberg AE. Base of skull chordomas in children and adolescents: a clinicopathologic study of 73 cases. *Am J Surg Pathol*. 2006;30(7):811-818.
498. Campbell WM, McDonald TJ, Unni KK, Laws ER Jr. Nasal and paranasal presentations of chordomas. *Laryngoscope*. 1980;90(4):612-618.
499. Rosenthal DI, Scott JA, Mankin HJ, et al. Sacrococcygeal chordoma: magnetic resonance imaging and computed tomography. *Am J Roentgenol*. 1985;148:143-147.
500. Cho HY, Lee M, Takei H, et al. Immunohistochemical comparison of chordoma with chondrosarcoma, myxopapillary ependymoma, and chordoid meningioma. *Appl Immunohistochem Mol Morphol*. 2009;17(2):131-138.
501. Abenoza P, Sibley RK. Chordoma: an immunohistologic study. *Hum Pathol*. 1986;17(7):744-747.
502. Coffin CM, Swanson PE, Wick MR, Dehner LP. An immunohistochemical comparison of chordoma with renal cell carcinoma, colorectal adenocarcinoma, and myxopapillary

For personal use only. No other uses without permission. Copyright ©2017. Elsevier Inc. All rights reserved.

ependymoma: a potential diagnostic dilemma in the diminutive biopsy. *Mod Pathol*. 1993;6(5):531-538.
503. Meis JM, Giraldo AA. Chordoma. An immunohistochemical study of 20 cases. *Arch Pathol Lab Med*. 1988;112(5):553-556.
504. Oakley GJ, Fuhrer K, Seethala RR. Brachyury, SOX-9, and podoplanin, new markers in the skull base chordoma vs chondrosarcoma differential: a tissue microarray-based comparative analysis. *Mod Pathol*. 2008;21(12):1461-1469.
505. Naka T, Iwamoto Y, Shinohara N, et al. Cytokeratin subtyping in chordomas and the fetal notochord: an immunohistochemical analysis of aberrant expression. *Mod Pathol*. 1997;10(6):545-551.
506. Wittchow R, Landas SK. Glial fibrillary acidic protein expression in pleomorphic adenoma, chordoma, and astrocytoma. A comparison of three antibodies. *Arch Pathol Lab Med*. 1991;115(10):1030-1033.
507. Vujovic S, Henderson S, Presneau N, et al. Brachyury, a crucial regulator of notochordal development, is a novel biomarker for chordoma. *J Pathol*. 2006;209:157-165.
508. Sangoi AR, Karamchandani J, Lane B, et al. Specificity of brachyury in the distinction of chordoma from clear cell renal cell carcinoma and germ cell tumors: a study of 305 cases. *Mod Pathol*. 2011;24:425-429.
509. Miettinen M, Wang Z, Lasota J, et al. Nuclear brachyury expression is consistent in chordoma, common in germ cell tumors and small cell carcinomas, and rarae in other carcinomas and sarcomas. *Am J Surg Pathol*. 2015;39:1305-1312.
510. Tirabosco R, Mangham DC, Rosenberg AE, et al. Brachyury expression in extra-axial skeletal and soft tissue chordomas: a marker that distinguishes chordoma from mixed tumor/myoepithelioma/parachordoma in soft tissue. *Am J Surg Pathol*. 2008;32(4):572-580.
511. Walaas L, Kindblom LG. Fine-needle aspiration biopsy in the preoperative diagnosis of chordoma: a study of 17 cases with application of electron microscopic, histochemical, and immunocytochemical examination. *Hum Pathol*. 1991;22(1):22-28.
512. Kuzniacka A, Mertens F, Strombeck B, et al. Combined binary ratio labeling fluorescence in situ hybridization analysis of chordoma. *Cancer Genet Cytogenet*. 2004;151(2):178-181.
513. Mertens F, Kreicbergs A, Rydholm A, et al. Clonal chromosome aberrations in three sacral chordomas. *Cancer Genet Cytogenet*. 1994;73(2):147-151.
514. Tallini G, Dorfman H, Brys P, et al. Correlation between clinicopathological features and karyotype in 100 cartilaginous and chordoid tumours. A report from the Chromosomes and Morphology (CHAMP) Collaborative Study Group. *J Pathol*. 2002;196(2):194-203.
515. Scheil S, Bruderlein S, Liehr T, et al. Genome-wide analysis of sixteen chordomas by comparative genomic hybridization and cytogenetics of the first human chordoma cell line, U-CH1. *Genes Chromosomes Cancer*. 2001;32(3):203-211.
516. Riva P, Crosti F, Orzan F, et al. Mapping of candidate region for chordoma development to 1p36.13 by LOH analysis. *Int J Cancer*. 2003;107(3):493-497.
517. Angelini A, Pala E, Calabro E, et al. Prognostic factors in surgical resection of sacral chordoma. *J Surg Oncol*. 2015;112:344-351.
518. Ruosi C, Colella G, Di Donato SL, et al. Surgical treatment of sacral chordoma: survival and prognostic factors. *Eur Spine J*. 2015;24(suppl 7):912-917.
519. Zukerberg LR, Young RH. Chordoma metastatic to the ovary. *Arch Pathol Lab Med*. 1990;114(2):208-210.
520. O'Connell JX, Renard LG, Liebsch NJ, et al. Base of skull chordoma. A correlative study of histologic and clinical features of 62 cases. *Cancer*. 1994;74(8):2261-2267.
521. Yonemoto T, Tatezaki S, Takenouchi T, et al. The surgical management of sacrococcygeal chordoma. *Cancer*. 1999;85(4):878-883.
522. Indelicato DJ, Rotondo RL, Begosh-Mayne D, et al. A prospective outcomes study of proton therapy for chordomas and chondrosarcomas of the spine. *Int J Radiat Oncol Biol Phys*. 2016;95:297-303.
523. Bergh P, Kindblom LG, Gunterberg B, et al. Prognostic factors in chordoma of the sacrum and mobile spine: a study of 39 patients. *Cancer*. 2000;88(9):2122-2134.
524. Kilgore S, Prayson RA. Apoptotic and proliferative markers in chordomas: a study of 26 tumors. *Ann Diagn Pathol*. 2002;6(4):222-228.
525. Matsuno A, Sasaki T, Nagashima T, et al. Immunohistochemical examination of proliferative potentials and the expression of cell cycle-related proteins of intracranial chordomas. *Hum Pathol*. 1997;28(6):714-719.
526. Naka T, Fukuda T, Chuman H, et al. Proliferative activities in conventional chordoma: a clinicopathologic, DNA flow cytometric, and immunohistochemical analysis of 17 specimens with special reference to anaplastic chordoma showing a diffuse proliferation and nuclear atypia. *Hum Pathol*. 1996;27(4):381-388.
527. Tauziede-Esperiat D, Bresson D, Polivka M, et al. Prognostic and therapeutic markers in chordomas: a study of 287 tumors. *J Neuropathol Exp Neurol*. 2016;75:111-120.
528. Hruban RH, May M, Marcove RC, Huvos AG. Lumbo-sacral chordoma with high-grade malignant cartilaginous and spindle cell components. *Am J Surg Pathol*. 1990;14(4):384-389.
529. Meis JM, Raymond AK, Evans HL, et al. Dedifferentiated" chordoma. A clinicopathologic and immunohistochemical study of three cases. *Am J Surg Pathol*. 1987;11(7):516-525.
530. Bisceglia M, D'Angelo VA, Guglielmi G, et al. Dedifferentiated chordoma of the thoracic spine with rhabdomyosarcomatous differentiation. Report of a case and review of the literature. *Ann Diagn Pathol*. 2007;11(4):262-273.
531. Jambhekar NA, Rekhi B, Thorat K, et al. Revisiting chordoma with brachyury, a "new age" marker: analysis of a validation study on 51 cases. *Arch Pathol Lab Med*. 2010;134:1181-1187.
532. Meng T, Yin H, Li B, et al. Clinical features and prognostic factors of patients with chordoma in the spine: a retrospective analysis of 153 patients in a single center. *Neuro Oncol*. 2015;17:725-732.
533. Rosenberg AE, Brown GA, Bhan AK, Lee JM. Chondroid chordoma–a variant of chordoma. A morphologic and immunohistochemical study. *Am J Clin Pathol*. 1994;101(1):36-41.
534. Keeney GL, Unni KK, Beabout JW, Pritchard DJ. Adamantinoma of long bones. A clinicopathologic study of 85 cases. *Cancer*. 1989;64(3):730-737.
535. Moon NF, Mori H. Adamantinoma of the appendicular skeleton–updated. *Clin Orthop Relat Res*. 1986;204:215-237.
536. Campanacci M, Giunti A, Bertoni F, et al. Adamantinoma of the long bones. The experience at the Istituto Ortopedico Rizzoli. *Am J Surg Pathol*. 1981;5(6):533-542.
537. Kahn LB. Adamantinoma, osteofibrous dysplasia, and differentiated adamantinoma. *Skeletal Radiol*. 2003;32:245-258.
538. Jundt G, Remberger K, Roessner A, et al. Adamantinoma of long bones. A histopathological and immunohistochemical study of 23 cases. *Pathol Res Prac*. 1995;191(2):112-120.
539. Hazelbag HM, Fleuren GJ, vd Broek LJ, et al. Adamantinoma of the long bones: keratin subclass immunoreactivity pattern with reference to its histogenesis. *Am J Surg Pathol*. 1993;17(12):1225-1233.
540. Kanamori M, Antonescu CR, Scott M, et al. Extra copies of chromosomes 7, 8, 12, 19, and 21 are recurrent in adamantinoma. *J Mol Diagn*. 2001;3(1):16-21.
541. Izquierdo FM, Ramos LR, Sanchez-Herraez S, et al. Dedifferentiated classic adamantinoma of the tibia: a report of a case with eventual complete revertant mesenchymal phenotype. *Am J Surg Pathol*. 2010;34(9):1388-1392.
542. Knapik JA. Fibro-osseous lesions. *Surg Pathol*. 2012;5:201-229.
543. Czerniak B, Rojas-Corona RR, Dorfman HD. Morphologic diversity of long bone adamantinoma. The concept of differentiated (regressing) adamantinoma and its relationship to osteofibrous dysplasia. *Cancer*. 1989;64(11):2319-2334.
544. Benassi MS, Campanacci L, Gamberi G, et al. Cytokeratin expression and distribution in adamantinoma of the long bones and osteofibrous dysplasia of tibia and fibula. An immunohistochemical study correlated to histogenesis. *Histopathology*. 1994;25(1):71-76.
545. Kuruvilla G, Steiner GC. Osteofibrous dysplasia-like adamantinoma of bone: a report of five cases with immunohistochemical and ultrastructural studies. *Hum Pathol*. 1998;29(8):809-814.
546. Ida CM, Scheithauer BW, Yapicier O, et al. Primary schwannoma of the bone: a clinicopathologic and radiologic study of 17 cases. *Am J Surg Pathol*. 2011;35:989-997.
547. Turk PS, Peters N, Libbey NP, Wanebo HJ. Diagnosis and management of giant intrasacral schwannoma. *Cancer*. *1992*;70(11):2650-2657.
548. Myers JL, Bernreuter W, Dunham W. Melanotic schwannoma. Clinicopathologic, immunohistochemical, and ultrastructural features of a rare primary bone tumor. *Am J Clin Pathol*. 1990;93(3):424-429.
549. Hunt JC, Pugh DG. Skeletal lesions in neurofibromatosis. *Radiology*. 1961;76:1-20.
550. Ducatman BS, Scheithauer BW, Dahlin DC. Malignant bone tumors associated with neurofibromatosis. *Mayo Clin Proc*. 1983;58(9):578-582.
551. Bullock MJ, Bedard YC, Bell RS, Kandel R. Intraosseous malignant peripheral nerve sheath tumor. Report of a case and review of the literature. *Arch Pathol Lab Med*. 1995;119(4):367-370.
552. Zakhary I, El Salanty M, Ishag I, et al. Malignant peripheral nerve sheath tumor of mandible. *J Craniofac Surg*. 2011;22:762-766.
553. Bertoni F, Unni KK, McLeod RA, Sim FH. Xanthoma of bone. *Am J Clin Pathol*. 1988;90(4):377-384.
554. Kim CJ, Choi IH, Cho TJ, et al. The histological spectrum of subperiosteal fibrocartilaginous pseudotumor of long bone (focal fibrocartilaginous dysplasia). *Pathol Int*. 1999;49(11):1000-1006.
555. Lin J, Shulman SC, Steelman CK, et al. Fibrocartilaginous mesenchymoma, a unique osseous lesion: case report with review of the literature. *Skeletal Radiol*. 2011;40:1495-1499.
556. Bulychova IV, Unni KK, Bertoni F, Beabout JW. Fibrocartilagenous mesenchymoma of bone. *Am J Surg Pathol*. 1993;17(8):830-836.
557. Zhang W, Shen Y, Wan R, Zhu Y. Primary clear cell sarcoma of the sacrum: a case report. *Skeletal Radiol*. 2011;40:633-639.
558. Park YK, Unni KK, Kim YW, et al. Primary alveolar soft part sarcoma of bone. *Histopathology*. 1999;35(5):411-417.

For personal use only. No other uses without permission. Copyright ©2017. Elsevier Inc. All rights reserved.

559. Adsay V, Cheng J, Athanasian E, et al. Primary desmoplastic small cell tumor of soft tissues and bone of the hand. *Am J Surg Pathol*. 1999;23(11):1408-1413.
560. Yamashita K, Fletcher CD. PEComa presenting in bone: clinicopathologic analysis of 6 cases and literature review. *Am J Surg Pathol*. 2010;34:1622-1629.
561. Lucas DR, Kolodziej P, Gross ML, et al. Metastatic uterine leiomyosarcoma to bone: a clinicopathologic study. *Int J Surg Pathol*. 1997;4:159-168.
562. Caffey J, Andersen DH. Metastatic embryonal rhabdomyosarcoma in the growing skelton; clinical, radiographic, and microscopic features. *AMA Am J Dis Child*. 1958;95(6):581-600.
563. Berrettoni BA, Carter JR. Mechanisms of cancer metastasis to bone. *J Bone Joint Surg Am*. 1986;68(2):308-312.
564. Carlin BI, Andriole GL. The natural history, skeletal complications, and management of bone metastases in patients with prostate carcinoma. *Cancer*. 2000;88(12 suppl):2989-2994.
565. Thomas BM. Three unusual carcinoid tumours, with particular reference to osteoblastic bone metastases. *Clin Radiol*. 1968;19(2):221-225.
566. Roodman GD. Mechanisms of bone metastasis. *N Engl J Med*. 2004;350:1655-1664.
567. Gurney H, Larcos G, McKay M, et al. Bone metastases in hypernephroma. Frequency of scapular involvement. *Cancer*. 1989;64(7):1429-1431.
568. Healey JH, Turnbull AD, Miedema B, Lane JM. Acrometastases. A study of twenty-nine patients with osseous involvement of the hands and feet. *J Bone Joint Surg Am*. 1986;68(5):743-746.
569. Daroca PJ Jr, Reed RJ, Martin PC. Metastatic amelanotic melanoma simulating giant-cell tumor of bone. *Hum Pathol*. 1990;21(9):978-980.
570. Mascard E, Gomez-Brouchet A, Lambot K. Bone cysts: unicameral and aneurysmal bone cyst. *Orthop Traumatol Surg Res*. 2015;101(1 sup pl):s119-s127.
571. Struhl S, Edelson C, Pritzker H, et al. Solitary (unicameral) bone cyst: the fallen fragment sign revisited. *Skeletal Radiol*. 1989;18:261-265.
572. Amling M, Werner M, Posl M, et al. Calcifying solitary bone cyst: morphological aspects and differential diagnosis of sclerotic bone tumours. *Virch Arch*. 1995;426(3):235-242.
573. Campanacci M, Capanna R, Picci P. Unicameral and aneurysmal bone cysts. *Clin Orthop Relat Res*. 1986;204:25-36.
574. Mirra JM, Bernard GW, Bullough PG, et al. Cementum-like bone production in solitary bone cysts. (so-called "cementoma" of long bones). Report of three cases. Electron microscopic observations supporting a synovial origin to the simple bone cyst. *Clin Orthop Relat Res*. 1978;135:295-307.
575. Pretell-Massini J, Murphey RFF, Kushare I, Dormans JP. Unicameral bone cysts: general characteristics and management controversies. *J Am Acad Orthop Surg*. 2014;22:295-303.
576. Vergel De Dios AM, Bond JR, Shives TC, et al. Aneurysmal bone cyst. A clinicopathologic study of 238 cases. *Cancer*. 1992;69(12):2921-2931.
577. Capanna R, Albisinni U, Picci P, et al. Aneurysmal bone cyst of the spine. *J Bone Joint Surg Am*. 1985;67(4):527-531.
578. Rodriguez-Peralto JL, Lopez-Barea F, Sanchez-Herrera S, Atienza M. Primary aneurysmal cyst of soft tissues (extraosseous aneurysmal cyst). *Am J Surg Pathol*. 1994;18(6):632-636.
579. Shannon P, Bedard Y, Bell R, Kandel R. Aneurysmal cyst of soft tissue: report of a case with serial magnetic resonance imaging and biopsy. *Hum Pathol*. 1997;28(2):255-257.
580. Kransdorf MJ, Sweet DE. Aneurysmal bone cyst: concept, controversy, clinical presentation, and imaging. *AJR Am J Roentgenol*. 1995;164:573-580.
581. Alles JU, Schulz A. Immunocytochemical markers (endothelial and histiocytic) and ultrastructure of primary aneurysmal bone cysts. *Hum Pathol*. 1986;17(1):39-45.
582. Bahk WJ, Mirra JM. Differential diagnostic value of "blue reticulated chondroid-like material" in aneuysmal bone cysts: a classic histopathologic analysis of 215 cases. *Am J Clin Pathol*. 2015;143:823-829.
583. Althof PA, Ohmori K, Zhou M, et al. Cytogenetic and molecular cytogenetic findings in 43 aneurysmal bone cysts: aberrations of 17p mapped to 17p13.2 by fluorescence in situ hybridization. *Mod Pathol*. 2004;17(5):518-525.
584. Oliveira AM, Perez-Atayde AR, Inwards CY, et al. USP6 and CDH11 oncogenes identify the neoplastic cell in primary aneurysmal bone cysts and are absent in so-called secondary aneurysmal bone cysts. *Am J Pathol*. 2004;165(5):1773-1780.
585. Oliveira AM, Perez-Atayde AR, Dal Cin P, et al. Aneurysmal bone cyst variant translocations upregulate USP6 transcription by promoter swapping with the ZNF9, COL1A1, TRAP150, and OMD genes. *Oncogene*. 2005;24(21):3419-3426.
586. Leithner A, Lang S, Windhager R, et al. Expression of insulin-like growth factor-I (IGF-I) in aneurysmal bone cyst. *Mod Pathol*. 2001;14(11):1100-1104.
587. Kyriakos M, Hardy D. Malignant transformation of aneurysmal bone cyst, with an analysis of the literature. *Cancer*. 1991;68(8):1770-1780.
588. Kansagra AP, Wan JJ, Devulapalli KK, et al. Malignant transformation of an aneurysmal bone cyst to fibroblastic osteosarcoma. *Am J Orthop*. 2016;45:E367-E372.
589. Dehner LP, Risdall RJ, L'Heureux P. Giant-cell containing "fibrous" lesion of the sacrum. A roentgenographic, pathologic, and ultrastructural study of three cases. *Am J Surg Pathol*. 1978;2(1):55-70.
590. Oda Y, Tsuneyoshi M, Shinohara N. "Solid" variant of aneurysmal bone cyst (extragnathic giant cell reparative granuloma) in the axial skeleton and long bones. A study of its morphologic spectrum and distinction from allied giant cell lesions. *Cancer*. 1992;70(11):2642-2649.
591. Panico L, Passeretti U, De Rosa N, et al. Giant cell reparative granuloma of the distal skeletal bones. A report of five cases with immunohistochemical findings. *Virch Arch*. 1994;425(3):315-320.
592. Sanerkin NG, Mott MG, Roylance J. An unusual intraosseous lesion with fibroblastic, osteoclastic, osteoblastic, aneurysmal and fibromyxoid elements. "Solid" variant of aneurysmal bone cyst. *Cancer*. 1983;51(12):2278-2286.
593. Wold LE, Dobyns JH, Swee RG, Dahlin DC. Giant cell reaction (giant cell reparative granuloma) of the small bones of the hands and feet. *Am J Surg Pathol*. 1986;10(7):491-496.
594. Yamaguchi T, Dorfman HD. Giant cell reparative granuloma: a comparative clinicopathologic study of lesions in gnathic and extragnathic sites. *Int J Surg Pathol*. 2001;9(3):189-200.
595. Bertoni F, Bacchini P, Capanna R, et al. Solid variant of aneurysmal bone cyst. *Cancer*. 1993;71(3):729-734.
596. Bauer TW, Dorfman HD. Intraosseous ganglion: a clinicopathologic study of 11 cases. *Am J Surg Pathol*. 1982;6(3):207-213.
597. Schajowicz F, Clavel Sainz M, Slullitel JA. Juxta-articular bone cysts (intra-osseous ganglia): a clinicopathological study of eighty-eight cases. *J Bone Joint Surg Br*. 1979;61(1):107-116.
598. Sim FH, Dahlin DC. Ganglion cysts of bone. *Mayo Clin Proc*. 1971;46(7):484-488.
599. Alguacil-Garcia A, Littman CD. Subpubic cartilaginous cyst: report of two cases. *Am J Surg Pathol*. 1996;20(8):975-979.
600. Betsy M, Kupersmith LM, Springfield DS. Metaphyseal fibrous defects. *J Am Acad Orthop Surg*. 2004;12:89095.
601. Clarke BE, Xipell JM, Thomas DP. Benign fibrous histiocytoma of bone. *Am J Surg Pathol*. 1985;9(11):806-815.
602. Arata MA, Peterson HA, Dahlin DC. Pathological fractures through non-ossifying fibromas. Review of the Mayo Clinic experience. *J Bone Joint Surg Am*. 1981;63(6):980-988.
603. Cohen MM Jr. The new bone biology: pathologic, molecular, and clinical correlates. *Am J Med Genet A*. 2006;140(23):2646-2706.
604. de Sanctis L, Delmastro L, Russo MC, et al. Genetics of McCune-Albright syndrome. *J Pediatr Endocrinol Metab*. 2006;19(suppl 2):577-582.
605. Marie PJ, de Pollak C, Chanson P, Lomri A. Increased proliferation of osteoblastic cells expressing the activating Gs alpha mutation in monostotic and polyostotic fibrous dysplasia. *Am J Pathol*. 1997;150(3):1059-1069.
606. Mikami M, Koizumi H, Ishii M, Nakajima H. The identification of monoclonality in fibrous dysplasia by methylation-specific polymerase chain reaction for the human androgen receptor gene. *Virch Arch*. 2004;444(1):56-60.
607. Dorfman HD, Ishida T, Tsuneyoshi M. Exophytic variant of fibrous dysplasia (fibrous dysplasia protuberans). *Hum Pathol*. 1994;25(11):1234-1237.
608. Sissons HA, Steiner GC, Dorfman HD. Calcified spherules in fibro-osseous lesions of bone. *Arch Pathol Lab Med*. 1993;117(3):284-290.
609. Voytek TM, Ro JY, Edeiken J, Ayala AG. Fibrous dysplasia and cemento-ossifying fibroma. A histologic spectrum. *Am J Surg Pathol*. 1995;19(7):775-781.
610. Ishida T, Dorfman HD. Massive chondroid differentiation in fibrous dysplasia of bone (fibrocartilaginous dysplasia). *Am J Surg Pathol*. 1993;17:924-930.
611. Kandel RA, Pritzker KP, Bedard YC. Symmetrical fibro-osseous dysplasia of rib–post-traumatic dysplasia? *Histopathology*. 1981;5(6):651-658.
612. McDermott MB, Kyriakos M, Flanagan FL. Posttraumatic fibro-osseous lesion of rib. *Hum Pathol*. 1999;30(7):770-780.
613. Gouldesbrough DR. Symmetrical fibro-osseous dysplasia of rib–evidence for a traumatic aetiology. *Histopathology*. 1990;17(3):267-270.
614. Heim-Hall JM, Williams RP. Liposclerosing myxofibrous tumour: a traumatized variant of fibrous dysplasia? Report of four cases and review of the literature. *Histopathology*. 2004;45(4):369-376.
615. Deel C, Hassell L. Liposclerosing myxofibrous tumor: a review. *Arch Pathol Lab Med*. 2016;140:473-476.
616. Matsuba A, Ogose A, Tokunaga K, et al. Activating Gs alpha mutation at the Arg 201 codon in, liposclerosing myxofibrous tumor. *Hum Pathol*. 2003;34:1204-1209.
617. Dattilo J, McCarthy EF. Liposclerosing myxofibrous tumor (LSMFT), a study of 33 patients: should if be a distinct entity? *Iowa Orthop J*. 2012;32:35-39.
618. Aoki T, Kouho H, Hisaoka M, et al. Intramuscular myxoma with fibrous dysplasia: a report of two cases with a review of the literature. *Pathol Int*. 1995;45(2):165-171.

For personal use only. No other uses without permission. Copyright ©2017. Elsevier Inc. All rights reserved.

619. Huvos AG, Higinbotham NL, Miller TR. Bone sarcomas arising in fibrous dysplasia. *J Bone Joint Surg Am*. 1972;54(5):1047-1056.
620. Ishida T, Machinami R, Kojima T, Kikuchi F. Malignant fibrous histiocytoma and osteosarcoma in association with fibrous dysplasia of bone. Report of three cases. *Pathol Res Prac*. 1992;188(6):757-763.
621. Ruggieri P, Sim FH, Bond JR, Unni KK. Malignancies in fibrous dysplasia. *Cancer*. 1994;73(5):1411-1424.
622. Campanacci M, Laus M. Osteofibrous dysplasia of the tibia and fibula. *J Bone Joint Surg Am*. 1981;63(3):367-375.
623. Campbell CJ, Hawk T. A variant of fibrous dysplasia (osteofibrous dysplasia). *J Bone Joint Surg Am*. 1982;64(2):231-236.
624. Nakashima Y, Yamamuro T, Fujiwara Y, et al. Osteofibrous dysplasia (ossifying fibroma of long bones). A study of 12 cases. *Cancer*. 1983;52(5):909-914.
625. Bridge JA, Dembinski A, DeBoer J, et al. Clonal chromosomal abnormalities in osteofibrous dysplasia. Implications for histopathogenesis and its relationship with adamantinoma. *Cancer*. 1994;73(6):1746-1752.
626. Gleason BC, Liegl-Atzwanger B, Kozakewich HP, et al. Osteofibrous dysplasia and adamantinoma in children and adolescents: a clinicopathologic reappraisal. *Am J Surg Pathol*. 2008;32(3):363-376.
627. Park YK, Unni KK, McLeod RA, Pritchard DJ. Osteofibrous dysplasia: clinicopathologic study of 80 cases. *Hum Pathol*. 1993;24(12):1339-1347.
628. Sakamoto A, Oda Y, Oshiro Y, et al. Immunoexpression of neurofibromin, S-100 protein, and leu-7 and mutation analysis of the NF1 gene at codon 1423 in osteofibrous dysplasia. *Hum Pathol*. 2001;32(11): 1245-1251.
629. Sweet DE, Vinh TN, Devaney K. Cortical osteofibrous dysplasia of long bone and its relationship to adamantinoma. A clinicopathologic study of 30 cases. *Am J Surg Pathol*. 1992;16(3):282-290.
630. Sakamoto A, Oda Y, Iwamoto Y, Tsuneyoshi M. A comparative study of fibrous dysplasia and osteofibrous dysplasia with regard to expressions of c-fos and c-jun products and bone matrix proteins: a clinicopathologic review and immunohistochemical study of c-fos, c-jun, type I collagen, osteonectin, osteopontin, and osteocalcin. *Hum Pathol*. 1999;30(12):1418-1426.
631. Lau SK, Chu PG, Weiss LM. Immunohistochemical expression of Langerin in Langerhans cell histiocytosis and non-Langerhans cell histiocytic disorders. *Am J Surg Pathol*. 2008;32(4):615-619.
632. El Demellawy D, Young JL, de Nanassy J, et al. Langerhans cell histiocytosis: a comprehensive review. *Pathology*. 2015;47:294-301.
633. Gibson SE, Prayson RA. Primary skull lesions in the pediatric population: a 25-year experience. *Arch Pathol Lab Med*. 2007;131(5):761-766.
634. Howarth DM, Gilchrist GS, Mullan BP, et al. Langerhans cell histiocytosis: diagnosis, natural history, management, and outcome. *Cancer*. 1999;85(10):2278-2290.
635. Harmon CM, Brown N. Langerhans cell histiocytosis. A clinicopathologic review and molecular pathogenetic update. *Arch Pathol Lab Med*. 2015;139:1211-1214.
636. Walker PD, Rosai J, Dorfman RF. The osseous manifestations of sinus histiocytosis with massive lymphadenopathy. *Am J Clin Pathol*. 1981;75(2):131-139.
637. Demicco EG, Rosenberg AE, Bjornsson J, et al. Primary Rosai-Dorfman disease of bone: a clinicopathologic study of 15 cases. *Am J Surg Pathol*. 2010;34(9):1324-1333.
638. Al-Quran S, Reith J, Bradley J, Rimsza L. Erdheim-Chester disease: case report, PCR-based analysis of clonality, and review of literature. *Mod Pathol*. 2002;15(6):666-672.
639. Chetritt J, Paradis V, Dargere D, et al. Chester-Erdheim disease: a neoplastic disorder. *Hum Pathol*. 1999;30(9):1093-1096.
640. Kenn W, Eck M, Allolio B, et al. Erdheim-Chester disease: evidence for a disease entity different from Langerhans cell histiocytosis? Three cases with detailed radiological and immunohistochemical analysis. *Hum Pathol*. 2000;31(6):734-739.
641. Wilkinson LS, Pitsillides AA, Worrall JG, Edwards JC. Light microscopic characterization of the fibroblast-like synovial intimal cell (synoviocyte). *Arthritis and Rheum*. 1992;35(10):1179-1184.
642. Glasgow MM, Allen PW, Blakeway C. Arthroscopic treatment of cysts of the lateral meniscus. *J Bone Joint Surg Br*. 1993;75(2):299-302.
643. Romanini L, Calvisi V, Collodel M, Masciocchi C. Cystic degeneration of the lateral meniscus. Pathogenesis and diagnostic approach. *Ital J Orthop Traumatol*. 1988;14(4):493-500.
644. Herman AM, Marzo JM. Popliteal cysts: a current review. *Orthopedics*. 2014;37:e678-e684.
645. Shon W, Folpe AL. Tenosynovitis with psammomatous calcification: a poorly recognized pseudotumor related to repetitive tendinous injury. *Am J Surg Pathol*. 2010;34(6):892-895.
646. Spinner RJ, Bachman JW, Amadio PC. The many faces of carpal tunnel syndrome. *Mayo Clin Proc*. 1989;64(7):829-836.
647. Bastian FO. Amyloidosis and the carpal tunnel syndrome. *Am J Clin Pathol*. 1974;61(5):711-717.
648. Uchiyama S, Itsubo T, Nakamura K, et al. Current concepts of carpal tunnel syndrome: pathophysiology, treatment, and evaluation. *J Orthop Sci*. 2010;15(1):1-13.
649. O'Connell JX. Pathology of the synovium. *Am J Clin Pathol*. 2000;114(5):773-784.
650. Vordenbaumen S, Joosten LA, Friemann J, et al. Utility of synovial biopsy. *Arthritis Res Ther*. 2009;11(6):256.
651. Goldenberg DL, Cohen AS. Synovial membrane histopathology in the differential diagnosis of rheumatoid arthritis, gout, pseudogout, systemic lupus erythematosus, infectious arthritis and degenerative joint disease. *Medicine (Baltimore)*. 1978;57(3):239-252.
652. DiCarlo EF, Klein MJ. Arthritis pathology. *Surg Pathol*. 2012;5:15-65.
653. O'Connell JX, Nielsen GP, Rosenberg AE. Subchondral acute inflammation in severe arthritis: a sterile osteomyelitis? *Am J Surg Pathol*. 1999;23(2):192-197.
654. Hamerman D. The biology of osteoarthritis. *N Engl J Med*. 1989;320(20):1322-1330.
655. Malfait AM. Osteoarthritis year in review 2015: biology. *Osteoarthritis Cartilage*. 2016;24:21-26.
656. Madan SS, Pai DR. Charcot neuroarthropathy of the foot and ankle. *Orthop Surg*. 2013;5:86-93.
657. Insall J, Falro KA, Wise DW. Chondromalacia patellae: a prospective study. *J Bone Joint Surg Am*. 1976;58:1-8.
658. Smolen JS, Aletaha D, McInnes IB. Rheumatoid arthritis. *Lancet*. 2016;388:2032-2038.
659. Okada Y, Wu D, Tryaka G, et al. Genetics of rheumatoid arthritis contributes to biology and drug discovery. *Nature*. 2014;506: 376-381.
660. Zhao X, Okeke NL, Sharpe O, et al. Circulatory immune complexes contain citrullinated fibrinogen in rheumatoid arthritis. *Arthritis Res Ther*. 2008;10:R94.
661. Sabharwal UK, Vaughan JH, Fong S, et al. Activation of the classical pathway of complement by rheumatoid factors. Assessment by radioimmunoassay for C4. *Arthritis Rheum*. 1982;25:161-167.
662. McInnes IB, Schett G. The pathogenesis of rheumatoid arthriits. *N Engl J Med*. 2011;365:2205-2219.
663. Ziegler B, Gay RE, Huang GQ, et al. Immunohistochemical localization of HTLV-I p19- and p24-related antigens in synovial joints of patients with rheumatoid arthritis. *Am J Pathol*. 1989;135(1):1-5.
664. Koizumi F, Matsuno H, Wakaki K, et al. Synovitis in rheumatoid arthritis: scoring of characteristic histopathological features. *Pathol Int*. 1999;49(4):298-304.
665. Jayson MI, Dixon AS, Kates A, et al. Popliteal and calf cysts in rheumatoid arthritis. Treatment by anterior synovectomy. *Ann Rheum Dis*. 1972;31(1):9-15.
666. Kaibara N, Yamada H, Shuto T, et al. Comparative histopathological analysis between tenosynovitis and joint synovitis in rheumatoid arthritis. *Histopathology*. 2008;52(7):856-864.
667. Tilstra JS, Lienesch DW. Rheumatoid nodules. *Dermatol Clin*. 2015;33:361-371.
668. Baumgarten JM, Montiel NJ, Sinha AA. Lyme disease—part I: epidemiology and etiology. *Cutis*. 2002;69(5):349-352.
669. Montiel NJ, Baumgarten JM, Sinha AA. Lyme disease—part II: clinical features and treatment. *Cutis*. 2002;69(6):443-448.
670. Steere AC. Lyme disease. *N Engl J Med*. 1989;321(9):586-596.
671. Sanchez E, Vannier E, Wormser GP, Hu LT. Diagnosis, treatment, and prevention of Lyme disease, human granulocytic anaplasmosis, and babesiosis. A review. *JAMA*. 2016;315:1767-1777.
672. Shidham V, Chivukula M, Basir Z, Shidham G. Evaluation of crystals in formalin-fixed, paraffin-embedded tissue sections for the differential diagnosis of pseudogout, gout, and tumoral calcinosis. *Mod Pathol*. 2001;14(8):806-810.
673. Ishida T, Dorfman HD, Bullough PG. Tophaceous pseudogout (tumoral calcium pyrophosphate dihydrate crystal deposition disease). *Hum Pathol*. 1995;26(6):587-593.
674. Rannou F, Lee TS, Zhou RH, et al. Intervertebral disc degeneration: the role of the mitochondrial pathway in annulus fibrosus cell apoptosis induced by overload. *Am J Pathol*. 2004;164(3):915-924.
675. Ford JL, Downes S. Cellularity of human annulus tissue: an investigation into the cellularity of tissue of different pathologies. *Histopathology*. 2002;41(6):531-537.
676. Weidner N, Rice DT. Intervertebral disk material: criteria for determining probable prolapse. *Hum Pathol*. 1988;19(4):406-410.
677. Roosendaal G, van Rinsum AC, Vianen ME, et al. Haemophilic arthropathy resembles degenerative rather than inflammatory joint disease. *Histopathology*. 1999;34(2):144-153.
678. Rodnan GP, Medsger TA. The rheumatic manifestaions of progressive systemic sclerosis (scleroderma). *Clin Orthop Relat Res*. 1968;57:81-93.
679. Athanasou NA, Sallie B. Localized deposition of amyloid in articular cartilage. *Histopathology*. 1992;20(1):41-46.
680. Cary NR. Clinicopathological importance of deposits of amyloid in the femoral head. *J Clin Pathol*. 1985;38(8):868-872.
681. Ladefoged C, Merrild U, Jorgensen B. Amyloid deposits in surgically removed articular and periarticular tissue. *Histopathology*. 1989;15(3):289-296.
682. Mihara S, Kawai S, Gondo T, Ishihara T. Intervertebral disc amyloidosis: histochemical, immunohistochemical and ultrastructural

For personal use only. No other uses without permission. Copyright ©2017. Elsevier Inc. All rights reserved.

observations. *Histopathology*. 1994;25(5):415-420.
683. Rumpelt HJ, Braun A, Spier R, et al. Localized amyloid in the menisci of the knee joint. *Pathol Res Prac*. 1996;192(6):547-551.
684. Kyle RA, Gertz MA, Linke RP. Amyloid localized to tenosynovium at carpal tunnel release. Immunohistochemical identification of amyloid type. *Am J Clin Pathol*. 1992;97(2):250-253.
685. Reith JD, Bauer TW, Schils JP. Osseous manifestations of SAPHO (synovitis, acne, pustulosis, hyperostosis, osteitis) syndrome. *Am J Surg Pathol*. 1996;20(11):1368-1377.
686. Bauer TW, Hayashi R. The role of the pathologist in diagnosing periprosthetic infection. *Surg Pathol*. 2012;5:67-77.
687. O'Connell JX, Fanburg JC, Rosenberg AE. Giant cell tumor of tendon sheath and pigmented villonodular synovitis: immunophenotype suggests a synovial cell origin. *Hum Pathol*. 1995;26(7):771-775.
688. Folpe AL, Weiss SW, Fletcher D, Gown AM. Tenosynovial giant cell tumors: evidence for a desmin-positive dendritic cell subpopulation. *Mod Pathol*. 1998;11:939-944.
689. Darling JM, Goldring SR, Harada Y, et al. Multinucleated cells in pigmented villonodular synovitis and giant cell tumor of tendon sheath express features of osteoclasts. *Am J Pathol*. 1997;150(4):1383-1393.
690. Maluf HM, DeYoung BR, Swanson PE, Wick MR. Fibroma and giant cell tumor of tendon sheath: a comparative histological and immunohistological study. *Mod Pathol*. 1995;8(2):155-159.
691. Sciot R, Rosai J, Dal Cin P, et al. Analysis of 35 cases of localized and diffuse tenosynovial giant cell tumor: a report from the Chromosomes and Morphology (CHAMP) study group. *Mod Pathol*. 1999;12(6):576-579.
692. Cupp JS, Miller MA, Montgomery KD, et al. Translocation and expression of CSF1 in pigmented villonodular synovitis, tenosynovial giant cell tumor, rheumatoid arthritis and other reactive synovitides. *Am J Surg Pathol*. 2007;31(6):970-976.
693. West RB, Rubin BP, Miller MA, et al. A landscape effect in tenosynovial giant-cell tumor from activation of CSF1 expression by a translocation in a minority of tumor cells. *Proc Natl Acad Sci USA*. 2006;103(3):690-695.
694. Li CF, Wang JW, Huang WW, et al. Malignant diffuse-type tenosynovial giant cell tumors: a series of 7 cases comparing with 24 benign lesions with review of the literature. *Am J Surg Pathol*. 2008;32(4):587-599.
695. Bertoni F, Unni KK, Beabout JW, Sim FH. Malignant giant cell tumor of the tendon sheaths and joints (malignant pigmented villonodular synovitis). *Am J Surg Pathol*. 1997;21(2):153-163.
696. Myers BW, Masi AT. Pigmented villonodular synovitis and tenosynovitis: a clinical epidemiologic study of 166 cases and literature review. *Medicine (Baltimore)*. 1980;59(3):223-238.
697. Ottaviani S, Ayral X, Dougados M, et al. Pigmented villonodular synovitis: a retrospective single center study of 122 cases and review of the literature. *Semin Arthritis Rheum*. 2011;40:539-546.
698. Rao AS, Vigorita VJ. Pigmented villonodular synovitis (giant-cell tumor of the tendon sheath and synovial membrane). A review of eighty-one cases. *J Bone Joint Surg Am*. 1984;66(1):76-94.
699. Oda Y, Izumi T, Harimaya K, et al. Pigmented villonodular synovitis with chondroid metaplasia, resembling chondroblastoma of the bone: a report of three cases. *Mod Pathol*. 2007;20(5):545-551.
700. Mendenhall WM, Mendenhall CM, Reith JD, et al. Pigmented villonodular synovitis. *Am J Clin Oncol*. 2006;29:548-550.
701. Layfield LJ, Meloni-Ehrig A, Liu K, et al. Malignant giant cell tumor of synovium (malignant pigmented villonodular synovitis). *Arch Pathol Lab Med*. 2000;124(11):1636-1641.
702. Baunsgaard P, Nielsen BB. Primary synovial chondrometaplasia. Histologic variations in the structure of metaplastic nodules. *Acta Pathol Microbiol Immunol Scand [A]*. 1984;92(6):455-460.
703. Fetsch JF, Vinh TN, Remotti F, et al. Tenosynovial (extraarticular) chondromatosis: an analysis of 37 cases of an underrecognized clinicopathologic entity with a strong predilection for the hands and feet and a high local recurrence rate. *Am J Surg Pathol*. 2003;27(9):1260-1268.
704. Sciot R, Dal Cin P, Bellemans J, et al. Synovial chondromatosis: clonal chromosome changes provide further evidence for a neoplastic disorder. *Virch Arch*. 1998;433(2):189-191.
705. Villacin AB, Brigham LN, Bullough PG. Primary and secondary synovial chondrometaplasia: histopathologic and clinicoradiologic differences. *Hum Pathol*. 1979;10(4):439-451.
706. Sah AP, Geller DS, Mankin HJ, et al. Malignant transformation of synovial chondromatosis of the shoulder to chondrosarcoma. A case report. *J Bone Joint Surg*. 2007;89:1321-1328.
707. Bertoni F, Unni KK, Beabout JW, Sim FH. Chondrosarcomas of the synovium. *Cancer*. 1991;67(1):155-162.
708. Devaney K, Vinh TN, Sweet DE. Synovial hemangioma: a report of 20 cases with differential diagnostic considerations. *Hum Pathol*. 1993;24(7):737-745.
709. Hornick JL, Fletcher CD. Intraarticular nodular fasciitis–a rare lesion: clinicopathologic analysis of a series. *Am J Surg Pathol*. 2006;30(2):237-241.

For personal use only. No other uses without permission. Copyright ©2017. Elsevier Inc. All rights reserved.

41 Soft Tissues

John R. Goldblum

CHAPTER CONTENTS

Normal anatomy, *1810*
Infections and hematomas, *1811*
Tumors, *1811*
Classification, *1811*
Clinical features, *1811*
Diagnosis and special techniques, *1811*
Grading and staging, *1812*
Prognosis, *1812*
Therapy, *1813*
Pathogenesis, *1814*
Tumors and tumorlike conditions of fibroblasts and myofibroblasts, *1814*
Fibrohistiocytic tumors, *1829*
Tumors of synovial tissues, *1836*
Tumors and tumorlike conditions of peripheral nerves, *1838*
Tumors of adipose tissue, *1849*
Tumors and tumorlike conditions of blood and lymph vessels, *1858*
Tumors of smooth muscle and modified smooth muscles, *1865*
Tumors of striated muscle, *1868*
Osseous or cartilaginous tumors, *1873*
Tumors of extragonadal germ cells, *1874*
Tumors of neural tissue (other than peripheral nerves), *1875*
Tumors of hematopoietic tissue, *1876*
Miscellaneous tumors and tumors of uncertain cell type*1876*
Metastatic tumors, *1889*
Other tumorlike conditions, *1889*

Normal Anatomy

Soft tissue is loosely defined as the complex of nonepithelial extraskeletal structures of the body exclusive of the supportive tissue of the various organs and the hematopoietic/lymphoid tissue. It is composed of fibrous (connective) tissue, adipose tissue, skeletal muscle, blood and lymph vessels, and peripheral nervous system.

Fibrous tissue consists primarily of fibroblasts and an extracellular matrix that contains fibrillary structures (collagen and elastin) and nonfibrillary extracellular matrix ("ground substance"). Fibrous tissue is classified according to its texture into loose (most locations) and dense (tendons, aponeuroses, and ligaments). *Fibroblasts* are responsible for the production of the various extracellular materials, including the many types of collagen. Their shape varies from spindle (especially when stretched along bundles of collagen fibers) to stellate (in myxoid areas). Immunohistochemically, they stain for actin, including smooth muscle actin (SMA), but are negative for h-caldesmon and often desmin as well. *Fibrocytes* represent the quiescent stage of fibroblasts. *Myofibroblasts* are modified fibroblasts that show features intermediate between fibroblasts and smooth muscle cells.[1,2]

Adipose tissue is divided into two major types: *white fat*, mainly located in the subcutaneous tissue, mediastinum, abdomen, and retroperitoneum; and *brown fat*, which is concentrated in the interscapular region, neck, mediastinum, axillae, and retroperitoneum (especially perirenal region).[3] Brown fat, whose main function is heat production, is much more conspicuous in infants and children. White fat consists of round or oval cells having most of the cytoplasm occupied by a single large lipid droplet that pushes the crescent-shaped nucleus to the periphery. *Brown fat cells* are smaller, with an acidophilic multivacuolated cytoplasm and a centrally located nucleus showing fine indentations; mitochondria are numerous at the ultrastructural level.

Skeletal muscle is mainly derived from within myotomes through the formation of myoblasts and eventually of myotubes (muscle fibers). The most distinguishing feature of these fibers is the presence of myofibrils, which are composed of two types of microfilament: thin (made of actin) and thick (made of myosin). The periodic arrangement and interdigitation of thin and thick filaments results in the cross-banding seen at the light microscopic level. The I (isotropic) band is made only of thin filaments, the adjacent A (anisotropic) band is a zone of overlapping thin and thick filaments, and the H band is made up only of thick myofilaments. The I band is divided in its center by the Z line or disc, which is thought to serve as an attachment site for the *sarcomere*, the repeating individual unit of the muscle fiber.

Vessels are divided into blood vessels and lymph vessels. *Blood vessels* are further subdivided into arterial and venous compartments joined by a network of capillaries. Blood vessels have two major

For personal use only. No other uses without permission. Copyright ©2017. Elsevier Inc. All rights reserved.

Abstract

Soft tissue tumors (and tumor-like lesions) are some of the most difficult diagnostic issues faced by practicing pathologists. The wide array of reactive and neoplastic soft tissue lesions can be overwhelming, and this chapter provides a comprehensive discussion of these entities, including some of the more recently described soft tissue tumors and their molecular genetic alterations. A thorough discussion of useful ancillary diagnostic techniques is also provided.

Keywords

fat,
fibroma,
fibroblast,
solitary fibrous tumor,
fibrosarcoma,
neuroma,
schwannoma,
perineurioma,
peripheral nerve sheath,
lipoma,
hibernoma,
liposarcoma,
hemangioma,
glomus,
hemangioendothelioma,
smooth muscle tumors,
striated muscle tumors

For personal use only. No other uses without permission. Copyright ©2017. Elsevier Inc. All rights reserved.

cell types: endothelial cells (located toward the lumen) and a closely related group of cells including pericytes, smooth muscle cells, and glomus cells (located toward the outside). Ultrastructurally, endothelial cells exhibit numerous pinocytotic vesicles, cytoplasmic microfilaments, specialized cell junctions, microvilli, continuous basal lamina, and—most important—the Weibel–Palade body, a membrane-bound organelle thought to be specific to this cell type and shown to contain the von Willebrand factor (factor VIII-related antigen).[4]

Immunohistochemically, endothelial cells express a number of antigens including factor VIII-related antigen (FVIII-RA), CD34, CD31, FLI-1, and ERG.[5–7] CD31 is both highly sensitive and specific, although histiocytes and plasma cells are also positive. FVIII-RA is also very specific (the only other positive cell type being the megakaryocyte), but the labile nature of this antigen and its tendency to diffuse out in the tissues limit its utility. FLI-1 (a nuclear transcription factor involved in the pathogenesis of Ewing sarcoma/primitive neuroectodermal tumor [PNET]) is also a sensitive vascular marker. Perhaps most useful is ERG, given its strong nuclear positivity in virtually all benign, intermediate, and malignant vascular tumors, although it too is not completely specific.

The cells of the pericyte–smooth muscle–glomus family are characterized ultrastructurally by cytoplasmic microfilaments exhibiting focal condensations, numerous pinocytotic vesicles, and a thick continuous basal lamina. Immunohistochemically, they show reactivity for actin and myosin; positivity for desmin is largely restricted to smooth muscle cells.

Lymph vessels are lined by endothelial cells exhibiting a much weaker staining for FVIII-RA than endothelial cells from blood vessels. They also stain for Lyve-1 and podoplanin (D2-40).[8]

Peripheral nerves are formed by axons, Schwann cells, perineurial cells, and fibroblasts. Most of the fibroblasts are located in the *epineurium*, which is the outer sheath of fully developed nerves. Each nerve fascicle is surrounded by the *perineurium*, a structure continuous with the pia arachnoid of the central nervous system (CNS); unlike Schwann cells, *perineurial cells* are immunoreactive for epithelial membrane antigen (EMA) and GLUT-1 and negative for S-100 protein.[9] *Schwann cells* look somewhat similar to fibroblasts at the light microscopic level but are easily distinguished from them immunohistochemically because of their strong immunoreactivity for S-100 protein and ultrastructurally by an intimate relationship to axons (with the formation of mesoaxons) and the presence of a continuous basal lamina that coats the surface of the cell facing the endoneurium.

Infections and Hematomas

Soft tissue involvement by infectious processes usually is the result of direct extension from cutaneous, visceral, or osseous foci or the complication of trauma or surgery. Rarely, the process has a hematogenous source.

The severity of the inflammatory reaction and the type of tissue response observed pathologically depend on the type, dose, and virulence of the infecting organism, the resistance of the host tissues, the presence or absence of necrotic tissue, hematoma, or foreign body, and the anatomic features of the infected area.

Clinical types of infectious processes such as hemolytic streptococcal gangrene and necrotizing fasciitis must be diagnosed by clinical appearance and bacteriologic study. N**ecrotizing fasciitis** is accompanied by severe systemic toxicity and is usually caused by group A streptococci.[10] All of the pyogenic and necrotizing infections result in acute inflammatory tissue reactions that are indistinguishable microscopically. **Granulomatous inflammation** of soft tissue can be caused by *tuberculosis*, *atypical mycobacteriosis*, *actinomycosis*, *blastomycosis*, *coccidioidomycosis*, *sporotrichosis*, *cryptococcosis*, and *dirofilariasis*. A proper search for microorganisms should be made with appropriate special stains and cultures.

Hematoma, if deep and encysted, can simulate a sarcoma both clinically and radiographically. They occur most commonly in and around the tensor fasciae latae and have been variously referred to as ancient hematoma, calcifying myonecrosis, chronic expanding hematoma, and post-traumatic cyst of soft tissues.[11,12]

Tumors

Classification

Soft tissue tumors constitute a large and heterogeneous group of neoplasms. This chapter deals primarily with tumors located in the somatic soft tissues; it excludes those arising from the soft tissues of the mediastinum, retroperitoneum, and visceral organs and those primarily involving the dermis, such as Kaposi sarcoma and dermatofibrosarcoma protuberans (DFSP).

Traditionally, soft tissue sarcomas have been classified according to a histogenetic concept (e.g., fibrosarcoma as a tumor arising from fibroblasts, osteosarcoma as a tumor arising from osteoblasts). However, it seems clear that most if not all sarcomas arise from primitive multipotential mesenchymal cells, which in the course of neoplastic transformation undergo differentiation along one or more lines.[13] The acceptance of this alternative scheme does not require a change in terminology: a liposarcoma remains as such but is now viewed not as a tumor arising from a lipoblast but as a tumor exhibiting lipoblastic differentiation.

Clinical Features

A definite relationship exists between soft tissue tumor type and the age of presentation.[14] For instance, embryonal rhabdomyosarcoma is typically a tumor of infants and children, synovial sarcoma mainly affects adolescents and young adults, and liposarcomas and undifferentiated pleomorphic sarcomas (UPSs) are usually seen in middle-aged and elderly patients. Most soft tissue sarcomas are solitary; synchronous or metachronous multiple sarcomas are exceedingly rare.[15]

Diagnosis and Special Techniques

For any large soft tissue tumor in which the possibility of malignancy exists, the proper initial diagnostic procedure is to obtain material through excisional or incisional biopsy, core needle biopsy, or percutaneous fine-needle aspiration. The latter technique is being used with increasing frequency in the United States, with rates of accuracy equivalent to those obtainable with frozen section.[16] Excisional or incisional biopsy has the advantage of providing more tissue for diagnosis but, given the risk of bleeding and infection, should be performed only when a definitive diagnosis cannot be made by less invasive techniques. Importantly, site of biopsy or aspiration should be excised in continuity with the tumor at the time of definitive surgery.

Performance of frozen sections is useful in determining the type of neoplasm, the degree of malignancy, and the adequacy of surgical margins, but margins are often best assessed grossly at the time the specimen comes to surgical pathology, often done most effectively when the surgeon and pathologist examine the specimen simultaneously.

Light microscopic evaluation of hematoxylin–eosin-stained sections remains the standard technique for the initial diagnostic approach to these tumors and is sufficient in the majority of the cases. However, a significant percentage of cases require ancillary

For personal use only. No other uses without permission. Copyright ©2017. Elsevier Inc. All rights reserved.

diagnostic techniques including immunohistochemistry, molecular genetic methods, and rarely electron microscopy. Occasionally, histochemical stains may be used (e.g., PAS for assessing for intracytoplasmic crystals in alveolar soft part sarcoma), but many of these stains have been supplanted by other techniques.

The systematic use of cytogenetics has shown the existence of nonrandom chromosomal alterations (mainly translocations) in association with many types of soft tissue tumor.[17] The findings have validated the morphologic approach to classification of soft tissue tumors, helped to refine the boundaries of some entities (such as broadening morphology and location of desmoplastic small cell tumor, merging of spindle cell lipoma with pleomorphic lipoma, and merging of round cell liposarcoma with myxoid liposarcoma), and offered insight into the genesis of the tumors. Furthermore, the molecular alterations (gene fusions) that result from the chromosomal translocations can now be readily demonstrated in routine paraffin-embedded tissues by reverse transcription-polymerase chain reaction (RT-PCR) or fluorescence in situ hybridization (FISH). Such studies can be extremely helpful in the diagnosis of these tumors, especially in small biopsies, tumors with unusual morphology, or tumors in unusual sites.[18] A break-apart FISH probe for *EWSR1* is particularly helpful since this gene is implicated in many different soft tissue tumor types, including Ewing sarcoma/PNET, angiomatoid fibrous histiocytoma, extraskeletal myxoid chondrosarcoma, myxoid liposarcoma, clear cell sarcoma, and desmoplastic small cell tumor. Similarly, a break-apart FISH probe for *FUS* can aid in the diagnosis of low-grade fibromyxoid sarcoma (LGFMS), myxoid liposarcoma, and angiomatoid fibrous histiocytoma. FISH may be a particularly useful technique when evaluating cytologic preparations. As in other fields of oncology, gene expression profiling has significantly contributed to our understanding of the molecular underpinnings of many types of soft tissue tumors.[19–21] The specific applications of these various methods are described under the respective tumor types.

Grading and Staging

Some degree of microscopic grading of soft tissue tumors is already built into the conventional microscopic classification of these tumors. For example, DFSP is by definition a low-grade neoplasm, whereas all alveolar rhabdomyosarcomas are high-grade tumors. In addition, several attempts have been made to establish general guidelines for the grading of soft tissue sarcomas independent of their histologic type.[22–24] The number of grades has varied including two (low grade and high grade), three (I, II, and III, or low grade, intermediate grade, and high grade), and four (I, II, III, and IV) grade systems.

The criteria used to grade sarcomas have included degree of cellularity, pleomorphism, mitotic activity, and necrosis, and these features have been found to be of definite prognostic value for both adult and pediatric soft tissue tumors. However, there are some limitations to grading, including the inherently subjective nature of the evaluation, limited sampling in biopsy material, and the confounding effect of preoperative therapy.[25] Despite these limitations, grading (within the various histotypes and whenever applicable) remains one of the most powerful and inexpensive ways of assessing prognosis in a soft tissue sarcoma. The system devised by the French Federation of Cancer Centers Sarcoma Groups (also known as the FNCLCC grading system) is a three-grade system that is most widely used to grade sarcomas and is based on the evaluation of three separate parameters: tumor differentiation, mitotic rate, and extent of tumor necrosis.[22,24]

The most widely used staging system is that proposed by the American Joint Committee on Cancer (AJCC), which is largely based on the TNM system, in that it uses the size of the primary tumor (T), the status of lymph nodes (N), the presence of distant metastasis (M), and the tumor's histologic grade (G) (Tables 41.1–41.4).[26]

Table 41.1 Differentiation score in sarcomas as component of FNCLCC

HISTOLOGIC TYPE	DIFFERENTIATION SCORE
Atypical lipomatous tumor	1
Well-differentiated leiomyosarcoma	1
Myxoid liposarcoma	2
Conventional leiomyosarcoma	2
Conventional MPNST	2
Myxofibrosarcoma	2
Myxoid chondrosarcoma	2
Conventional angiosarcoma	2
Round cell liposarcoma	3
Pleomorphic liposarcoma	3
Dedifferentiated liposarcoma	3
Rhabdomyosarcoma	3
Pleomorphic leiomyosarcoma	3
Poorly differentiated/epithelioid angiosarcoma	3
Poorly differentiated MPNST	3
Synovial sarcoma	3
Extraskeletal osteosarcoma	3
Ewing family of tumors	3
Mesenchymal chondrosarcoma	3
Clear cell sarcoma	3
Epithelioid sarcoma	3
Alveolar soft part sarcoma	3
Undifferentiated pleomorphic sarcoma	3

MPNST, malignant peripheral nerve sheath tumor.
Data from Amin M, Edge S, Greene F, et al., eds. *AJCC Cancer Staging Manual*. Vol. 8. New York: Springer; 2017.

Prognosis

The prognosis of soft tissue tumors depends on a variety of parameters, many of which are interrelated.

1. **Tumor size.** There is a definite relationship between tumor size and outcome. This is true for practically all tumor types in which this parameter has been analyzed.[27,28]
2. **Depth.** Superficially located tumors (dermis and subcutaneous tissue) have a much better prognosis than deep-seated ones (intermuscular or intramuscular, retroperitoneal) of similar microscopic type.[29,30] The difference is largely due to the fact that superficial lesions tend to be considerably smaller at the time of excision and are generally more amenable to complete excision.
3. **Location.** Tumors of the retroperitoneum do much worse than microscopically similar lesions located in the extremities.[28,31] Among the latter, local recurrence has been found to be more frequent with those of the upper extremity than those of the lower extremity.[30]

For personal use only. No other uses without permission. Copyright ©2017. Elsevier Inc. All rights reserved.

Table 41.2 Details of FNCLCC grading system

PARAMETER		DEFINITION
Tumor differentiation	Score 1:	Closely resembles normal adult mesenchymal tissue; potentially difficult to distinguish from counterpart benign tumor
	Score 2:	Sarcomas for which histologic type is certain (e.g., myxoid liposarcoma)
	Score 3:	Embryonal and undifferentiated sarcoma, synovial sarcoma, sarcomas of uncertain type
Mitotic count	Score 1:	0–9/10 HPF
	Score 2:	10–19/10 HPF
	Score 3:	>19/10 HPF
Tumor necrosis	Score 0:	No necrosis
	Score 1:	<50% tumor necrosis
	Score 2:	≥50% tumor necrosis
Histologic grade	Grade 1:	Total score 2, 3
	Grade 2:	Total score 4, 5
	Grade 3:	Total score 6, 7, 8

Data from Amin M, Edge S, Greene F, et al., eds. *AJCC Cancer Staging Manual*. Vol. 8. New York: Springer; 2017.

Table 41.3 Definitions of American Joint Committee on Cancer TNM*

Definition of Primary Tumor (T)	
T Category	**T Criteria**
TX	Primary tumor cannot be assessed
T0	No evidence of primary tumor
T1	Tumor 5 cm or less in greatest dimension
T2	Tumor more than 5 cm and less than or equal to 10 cm in greatest dimension
T3	Tumor more than 10 cm and less than or equal to 15 cm in greatest dimension
T4	Tumor more than 15 cm in greatest dimension
Definition of Regional Lymph Node (N)	
N Category	**N Criteria**
N0	No regional lymph node metastasis or unknown lymph node status
N1	Regional lymph node metastasis
Definition of Distant Metastasis (M)	
M Category	**M Criteria**
M0	No distant metastasis
M1	Distant metastasis
Definition of Grade (G) FNCLCC Histologic Grade—see Histologic Grade (G)	
G	**G Definition**
GX	Grade cannot be assessed
G1	Total differentiation, mitotic count and necrosis score of 2 or 3
G2	Total differentiation, mitotic count and necrosis score of 4 or 5
G3	Total differentiation, mitotic count and necrosis score of 6, 7, or 8

*For tumors arising in the trunk, extremities, or retroperitoneum.
Data from Amin M, Edge S, Greene F, et al., eds. *AJCC Cancer Staging Manual*. Vol. 8. New York: Springer; 2017.

4. **Microscopic type.** Some soft tissue neoplasms (such as atypical lipomatous tumors [ALTs]) are low-grade lesions with no capacity to metastasize, whereas other neoplasms of similar cell type (such as pleomorphic liposarcoma) are highly aggressive and prone to spread distantly.
5. **Vascular invasion.** This has been shown to be the strongest predictor of distant metastases in several series.[32]
6. **Surgical margins.** Not surprisingly, adequacy of surgical margins is statistically associated with local relapse.[33–35] The relationship between local recurrence and subsequent risk of metastasis is less clear.
7. **Histologic grade.** As already indicated, a relationship has been found between various microscopic grading systems and outcome (see discussion on grading).
8. **Clinical stage.** As for most other tumors, this determination—which incorporates several of the previously mentioned parameters, as well as the presence or absence of metastases—is the most powerful prognostic determinator.
9. **Other factors.** A number of other prognostic factors have been implicated including DNA ploidy,[36] cell proliferation (MIB-1),[37] and specific genetic alterations such as mutations of *TP53*.[38] Along similar lines, claims have been made of a relationship between the type of gene fusion in the sarcomas associated with chromosomal translocations and prognosis (as in alveolar rhabdomyosarcoma and synovial sarcoma; these are discussed in the respective sections).

Therapy

Soft tissue tumors that are relatively small and/or clearly benign on clinical grounds (such as superficially located lipomas, schwannomas, hemangiomas, and tenosynovial giant cell tumors) can be removed without prior manipulation, but in most others the excision should be preceded by a biopsy or fine-needle aspiration. A few tumors (such as schwannomas) can be safely enucleated, but for most others—even if benign—a rim of uninvolved normal tissue should be excised in continuity with the neoplasm to prevent recurrence. Many soft tissue sarcomas, such as fibrosarcoma, myxoid liposarcoma, and leiomyosarcoma, may appear grossly encapsulated, but microscopic examination will often show tumor cells beyond the apparent capsule; therefore enucleation will usually fail. A wide local excision is particularly important for infiltrative lesions such as desmoid-type fibromatosis and DFSP.

Full-fledged soft tissue sarcomas in children are currently treated, for the most part, by a combination of surgery, radiation therapy, and multidrug chemotherapy, with results that are vastly superior to those obtained in the prechemotherapy era.[39]

For personal use only. No other uses without permission. Copyright ©2017. Elsevier Inc. All rights reserved.

Table 41.4 American Joint Committee on Cancer prognostic stage groups*

WHEN T IS...	AND N IS...	AND M IS...	AND GRADE IS...	THEN THE STAGE GROUP IS...
T1	N0	M0	G1, GX	IA
T2, T3, T4	N0	M0	G1, GX	IB
T1	N0	M0	G2, G3	II
T2	N0	M0	G2,G3	IIIA
T3, T4	N0	M0	G2, G3	IIIB
Any T	N1	M0	Any G	IV
Any T	Any N	M1	Any G	IV

*Applies only to tumor of the trunk and extremities.
Data from Amin M, Edge S, Greene F, et al., eds. *AJCC Cancer Staging Manual*. Vol. 8. New York: Springer; 2017.

The treatment of high-grade soft tissue sarcomas in adults has undergone radical changes. It has been thought for many years that amputation or disarticulation offered the best chances of cure for sarcomas involving an extremity. However, many studies have shown wide local excision with adjuvant therapy to have survival rates similar to those for amputation. Details of therapeutic options go beyond this discussion, but superb reviews on this topic can be found in the recent literature.[40,41] Similar to other types of neoplasms, increased emphasis has been placed on identifying targeted therapies for patients with recurrent or metastatic soft tissue sarcoma.[42,43]

Pathogenesis

The pathogenesis of most soft tissue tumors remains unknown. Environmental, oncogenic, immunologic, and genetic factors have all been implicated and, in fact, several of these factors may be involved in the development of a given tumor.

Trauma is frequently implicated in the development of sarcomas, but trauma often seems to merely call attention to the presence of a tumor which antedated the trauma.[44] Other environmental factors implicated in the pathogenesis of sarcomas include phenoxyacetic acid herbicides,[45] vinyl chloride (which is clearly associated with hepatic angiosarcoma)[46] and radiation exposure.[47] Although dioxin, a contaminant of the defoliant Agent Orange, which was used in Vietnam, has been implicated in sarcomagenesis, case control studies have found no increased risk of sarcomas.[48]

Oncogenic viruses play a role in the development of a small group of sarcomas. The human herpesvirus 8 (HHV8) is clearly the causative agent of Kaposi sarcoma.[49] Epstein-Barr virus (EBV) also seems to play a central role in the development of smooth muscle tumors in patients with immunodeficiencies or immunosuppression.[50]

A number of genetic diseases are associated with soft tissue tumors, including neurofibromatosis type 1 (malignant peripheral nerve sheath tumors [MPNSTs]), familial adenomatous polyposis/Gardner syndrome (Gardner-associated fibroma and fibromatosis), Li-Fraumeni syndrome (germline mutations of *TP53* associated with a number of sarcoma types), Carney complex (psammomatous melanotic schwannoma, cutaneous myxoma), and tuberous sclerosis (perivascular epithelioid cell tumor/PEComa).

It should be noted that most soft tissue sarcomas arise de novo rather than from malignant transformation of a preexisting benign tumor, an exception being transformation of neurofibroma into an MPNST. In most cases in which a benign tumor has been thought to become malignant, review of the original material shows the tumor to be malignant from its inception.

Figure 41.1 Gross appearance of calcifying aponeurotic fibroma. The mass is unencapsulated and ill defined.

Tumors and Tumorlike Conditions of Fibroblasts and Myofibroblasts

Calcifying Aponeurotic Fibroma

Calcifying aponeurotic fibroma is a distinctive lesion originally described as juvenile aponeurotic fibroma, typically presenting as a soft tissue mass in the hand or wrist of a child or adolescent (peak 8–14 years of age) but sometimes also occurring in the proximal extremities or trunk.[51] At surgery, it may appear as a nodule or as an ill-defined infiltrating mass in the subcutaneous tissue or attached to a tendon (Fig. 41.1). Sometimes, foci of calcification may be detected on gross inspection.

Microscopically, the lesion is characterized by an infiltrative proliferation of cells associated with spotty calcification (Figs. 41.2 and 41.3). Infiltration of fat and skeletal muscle is often seen at the periphery. Mitoses are scarce, and atypical cytologic features are absent. Scattered osteoclast-like giant cells are frequently seen. Cellularity varies from region to region; the cells are plump with ovoid nuclei and indistinct cytoplasm separated by dense fibrous stroma. There may be a cartwheel, linear, or whorled growth pattern. Calcifications vary from fine granules to larger areas with cells radiating out from them in linear columns. Immunohistochemically, the proliferating cells stain variably for actins, CD68, S-100 protein, and even CD99.[51]

Calcifying aponeurotic fibroma can be confused with rheumatoid nodule, schwannoma, soft tissue chondroma, and fibromatosis,

For personal use only. No other uses without permission. Copyright ©2017. Elsevier Inc. All rights reserved.

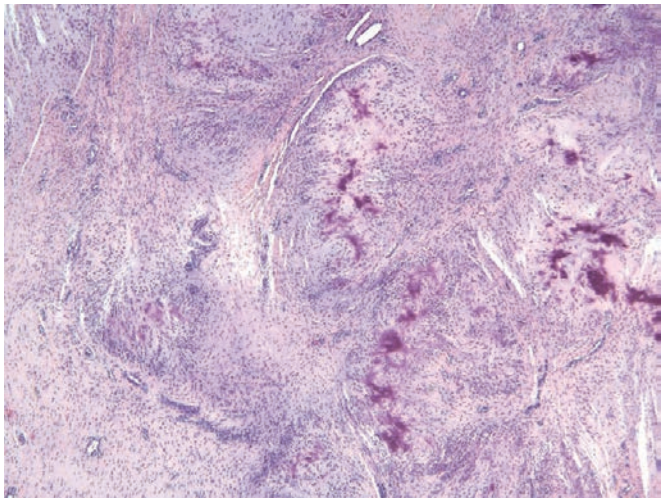

Figure 41.2 Low-power appearance of calcifying aponeurotic fibroma.

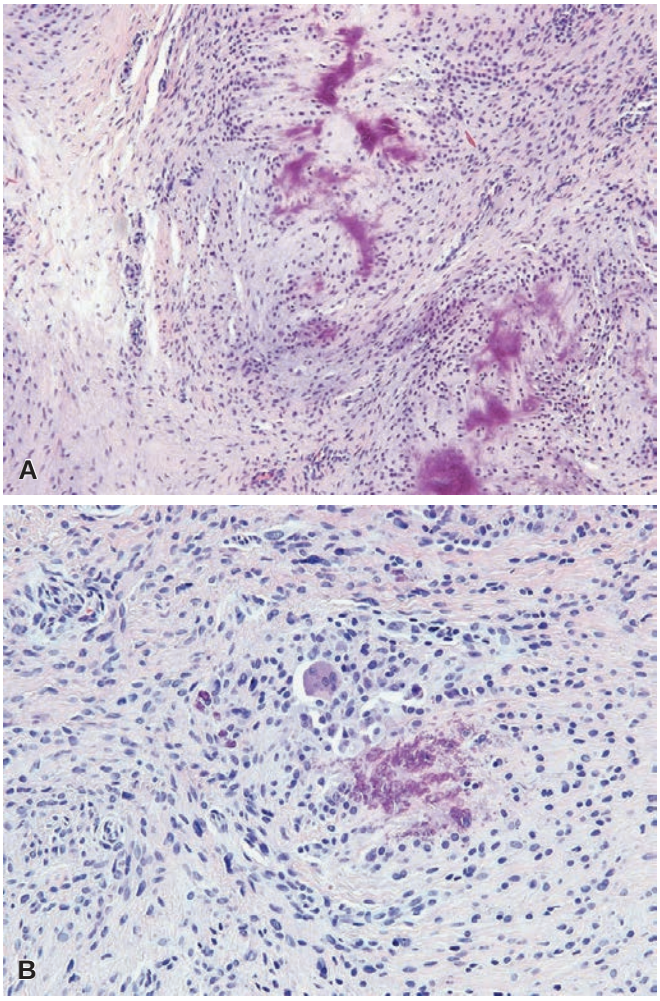

Figure 41.3 Calcifying Aponeurotic Fibroma. A, Tumor cells emanate from calcifications. **B,** High-power view of calcifying aponeurotic fibroma with bland spindle to round cells associated with calcifications and a single giant cell.

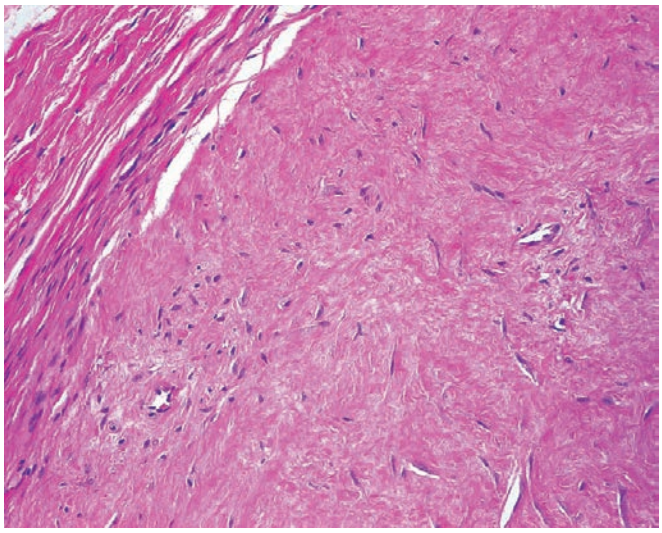

Figure 41.4 Fibroma of Tendon Sheath. The lesion is hypocellular and contains abundant collagen.

including infantile fibromatosis. Local recurrence is common, especially in young children (less than 5 years of age). However, distant metastases do not occur.[51,52]

Fibroma of Tendon Sheath

Fibroma of tendon sheath is a well-circumscribed, often lobulated tumor found attached to tendon or tendon sheath.[53] Microscopically, it is composed of dense fibrous tissue containing spindle and sometimes stellate mesenchymal cells deposited in a collagenous stroma (Fig. 41.4), although myxoid foci may be seen. Frequently, there are dilated or slit-like channels, particularly at the periphery of lobules.[54–56] Occasionally, a component of bizarre tumor cells unaccompanied by mitoses is seen (so-called pleomorphic fibroma of tendon sheath).[57] Ultrastructurally, most of the cells have features of myofibroblasts and, by immunohistochemistry, the cells express actins but not desmin.[58] The translocation t(2;11)(q31–32;q12) has been identified in rare cases.[59] More recently, some cases of fibroma of tendon sheath, particularly those that are highly cellular, have been shown to harbor rearrangements of *USP6*, suggesting a relationship to nodular fasciitis in these cases. Interestingly, however, these alterations were not identified in any classic cases of fibroma of tendon sheath.[59a] This suggests that lesions previously identified as cellular fibromas of tendon sheath are probably underrecognized examples of tenosynovial fasciitis.[60,61] The lesion is benign and only very rarely recurs.

Collagenous Fibroma

Collagenous fibroma (desmoplastic fibroblastoma) is a benign lesion usually centered in the subcutaneous tissue and with a wide anatomic distribution, usually arising in adults. A subset of these lesions may occur in deeper locations including intramuscular examples. The most distinctive microscopic feature is the presence of stellate fibroblasts (together with ordinary spindle-shaped fibroblasts) separated by a collagenous matrix with or without myxoid features (Fig. 41.5).[62–64] By immunohistochemistry, most cases show staining for SMA but are negative for desmin, consistent with myofibroblastic differentiation.[65] Some have suggested this lesion could represent the end stage of a reactive process. However, aberrations of 11q12 suggest a neoplastic process, as well as a possible link to fibroma of tendon sheath.[66–69] Interestingly, a recent study found consistent expression of FOSL1 in

For personal use only. No other uses without permission. Copyright ©2017. Elsevier Inc. All rights reserved.

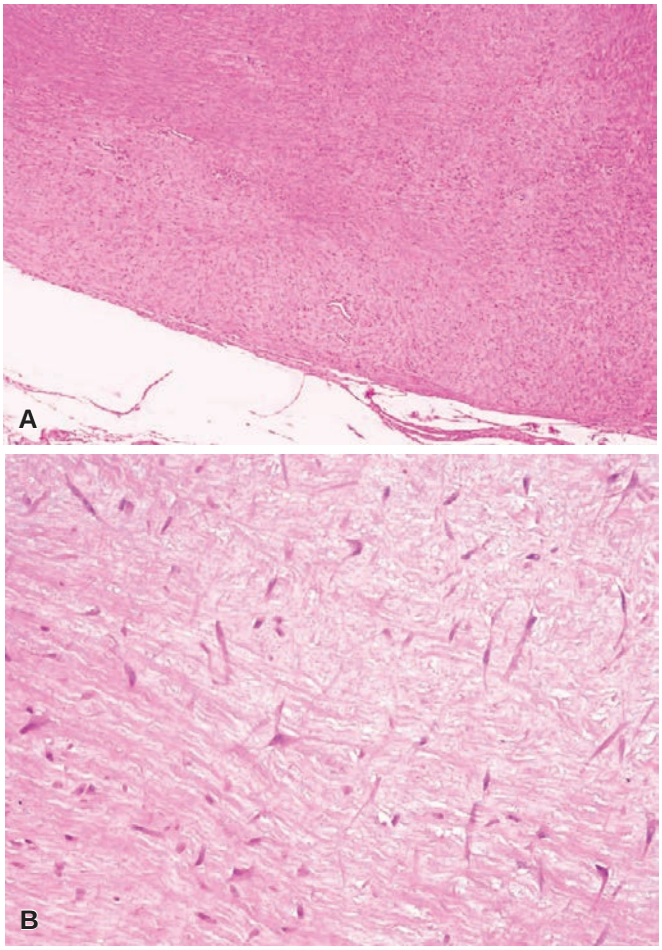

Figure 41.5 Collagenous Fibroma. A, The lesion is well circumscribed and hypocellular. **B,** The cells are spindle to stellate shaped.

collagenous fibroma, while none of the cases of fibroma of tendon sheath showed expression of this antigen, suggesting these are distinct lesions.[69a]

Nuchal-Type Fibroma

Nuchal-type fibroma is a benign lesion typically found in the posterior aspect of the neck and characterized microscopically by hypocellular bundles of thick collagen fibers, with entrapped adipose tissue and traumatic neuroma-like structures.[70] A high percentage of the patients are diabetic.[71] However, up to 30% occur in other soft tissue sites (buttocks, extremities, among others), and hence the reason the term nuchal-type fibroma is preferred over nuchal fibroma.

Gardner-associated fibroma has overlapping features with nuchal-type fibroma but seems distinct given its close association with Gardner syndrome/familial adenomatous polyposis.[72–74] These patients tend to be younger than those with nuchal-type fibroma, with most patients presenting in the first decade of life. Most arise in the back and paraspinal region, and histologically there is close resemblance to nuchal-type fibroma, although entrapped nerves are not conspicuous. The majority of cells express CD34, CD99, and nuclear β-catenin staining.[72,75] This lesion is benign, but it may recur if incompletely excised, and rare cases transform into a full-blown fibromatosis.[76] This process is probably distinct from **nuchal fibrocartilaginous pseudotumor**, which is characteristically located in the deep soft tissue overlying the posterior aspect of the lower cervical vertebrae and thought to be due to fibrocartilaginous metaplasia of the nuchal ligament, probably trauma induced.[77]

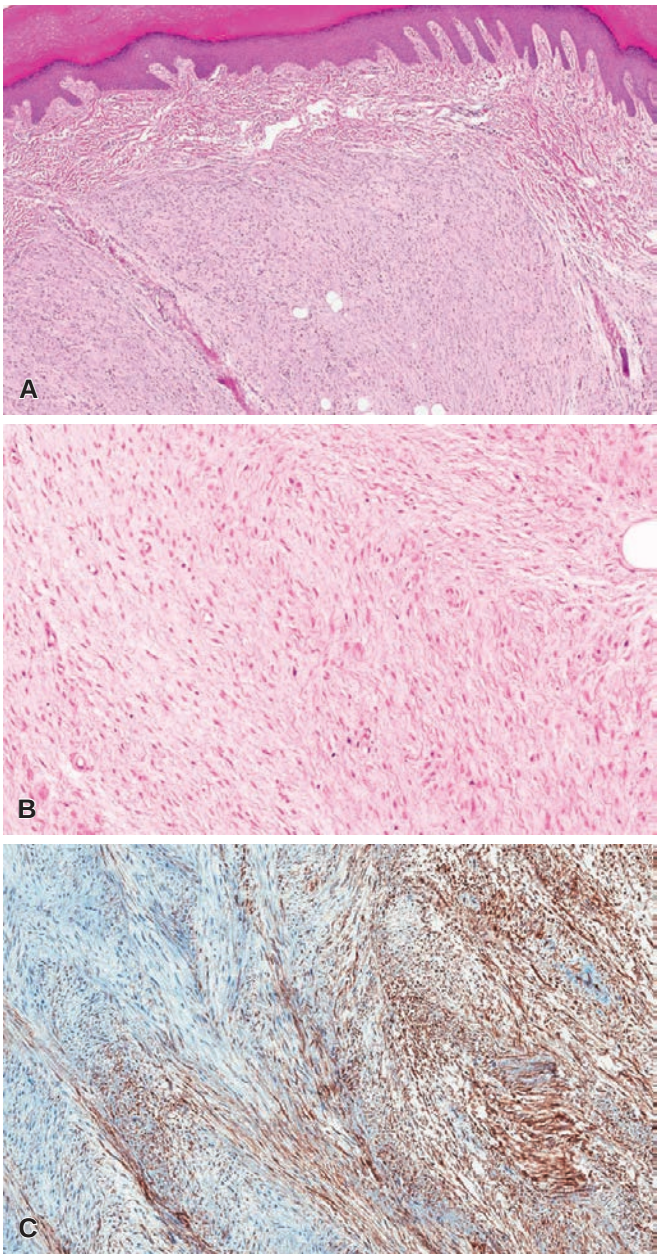

Figure 41.6 Superficial Acral Fibromyxoma. A, The dermis is expanded by a nodular proliferation of bland spindle cells deposited in a fibromyxoid matrix. **B,** Bland spindle cells are arranged in a vaguely whorled growth pattern. **C,** Strong CD34 staining in the neoplastic cells.

Superficial Acral Fibromyxoma

Superficial acral fibromyxoma (also referred to as *digital fibromyxoma*) is a soft tissue tumor with a predilection for the fingers and toes and composed of spindle- to stellate-shaped usually CD34-positive tumor cells arranged in a nondescript, storiform, or fascicular pattern of growth, embedded in a myxoid, fibromyxoid, or collagenous stroma (Fig. 41.6).[78,79] A cellular variant has also been described.[80] Some believe this lesion may be related to *cellular digital fibroma*,[81] but a recent study detected frequent RB-1 loss or deletions, suggesting a relationship to

For personal use only. No other uses without permission. Copyright ©2017. Elsevier Inc. All rights reserved.

other members of the RB-1 deleted tumor family (spindle cell lipoma, mammary-type myofibroblastoma, and cellular angiofibroma).[81a] The tumor arises in patients of all ages, with a 2:1 male to female ratio.[82,83] Although most are cured by local excision, up to 25% recur.[82]

Angiofibroma of Soft Tissue

Angiofibroma of soft tissue is a recently described fibrovascular tumor which most commonly arises in the soft tissues of the extremities. The tumor shows a proliferation of bland spindled cells in a myxocollagenous matrix with a distinct network of thin, finely branched blood vessels.[84–86] The cells variably express EMA, desmin, SMA, and CD34, but they characteristically show aberrations of the *NCOA2* gene on 8q13, which can be detected by FISH.[85,87,88] The lesion is benign and only rarely recurs following local excision.

Fibrous Hamartoma of Infancy

Fibrous hamartoma of infancy is a tumorlike condition seen almost exclusively during the first 2 years of life and sometimes present at birth.[89] It predominates in boys, and the most common locations are the region of the axilla, shoulder, and upper arm.[89a] It is almost always solitary. Grossly, it is poorly circumscribed and composed of white fibrous tissue intermixed with islands of fat.

Microscopically, the distinctive feature of this lesion is an organoid pattern with three distinct types of tissue being present: (1) well-differentiated spindle cells of fibroblastic/myofibroblastic appearance accompanied by deposition of collagen; (2) mature adipose tissue; and (3) immature cellular areas arranged in a whorling pattern and resembling primitive mesenchyme (Fig. 41.7). Very rare cases with overt sarcomatous-appearing foci have been reported, characterized

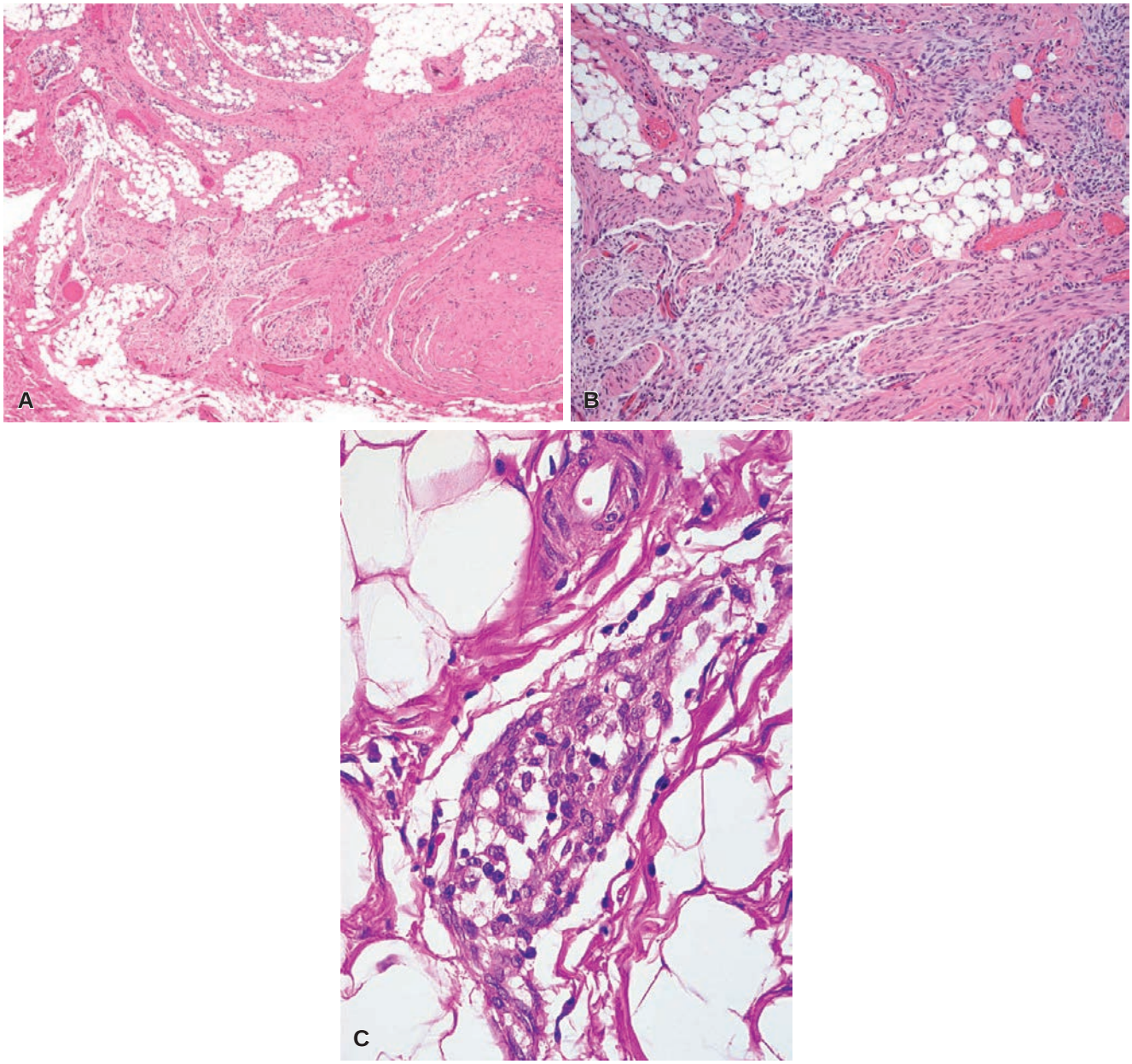

Figure 41.7 Fibrous Hamartoma of Infancy. A, An admixture of cellular fibrous foci and mature adipose tissue. **B,** A cellular spindle cell focus is seen surrounding mature adipose tissue. **C,** High-power view showing an oval cluster of plump mesenchymal cells.

For personal use only. No other uses without permission. Copyright ©2017. Elsevier Inc. All rights reserved.

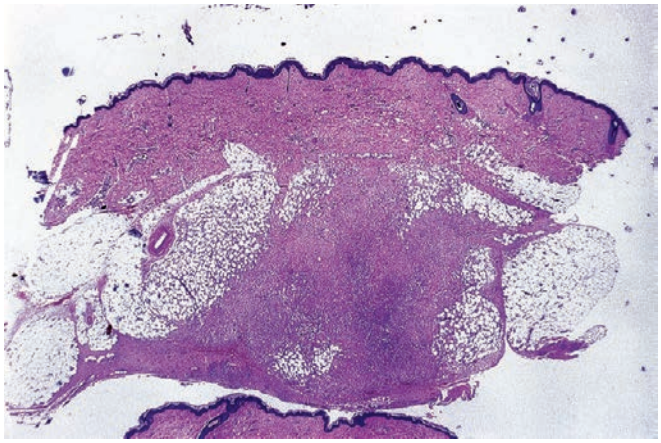

Figure 41.8 Panoramic View of Nodular Fasciitis. The lesion is small, ill defined, and centered in the subcutaneous tissue.

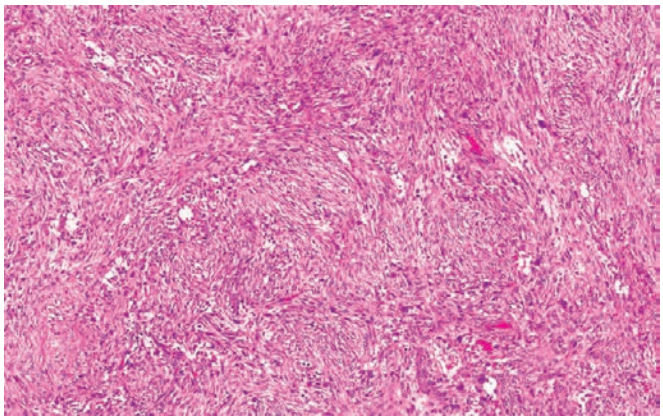

Figure 41.9 Strikingly cellular zone in nodular fasciitis.

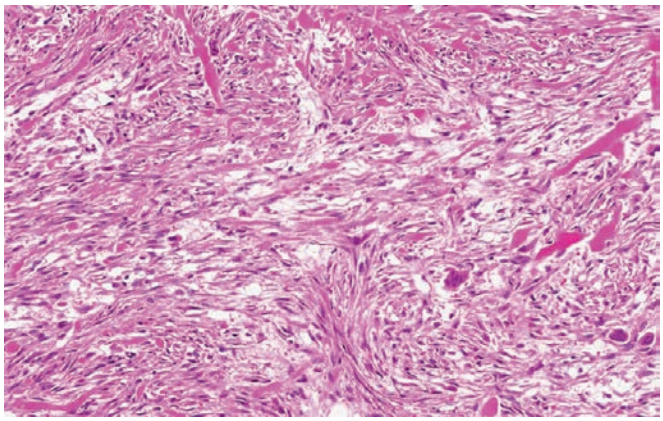

Figure 41.10 Nodular fasciitis with prominent collagen deposition and scattered giant cells.

by high cellularity, high nuclear grade, and brisk mitotic activity.[89a] Immunoreactivity for actin (and sometimes desmin) is found mainly in the spindle cell areas, suggesting myofibroblastic differentiation.[90–92] Recently a case of fibrous hamartoma of infancy with an EGFR exon 20 insertion/duplication mutation was reported.[92a] Although there may be local recurrence, the clinical course is benign.

Nodular Fasciitis and Related Lesions

Nodular fasciitis is a distinctive pseudosarcomatous myofibroblastic proliferation that is important because of its ability to simulate a malignant process.[93–95] It can affect patients of all ages but is most prevalent in young adults, with a peak between 20 and 40 years of age.

The most common locations are the upper extremities (particularly the flexor aspect of the forearms), trunk, and neck, but this lesion has been described in virtually every anatomic location. It presents as a rapidly growing mass of short duration, sometimes following known trauma. It usually extends above the fascia into the subcutis, but it may grow beneath it into skeletal muscle, remain within the fascia as a fusiform expansion, or even be centered in the dermis.[96,97]

Microscopically, the lesion is characterized by a cellular spindle cell growth set in a loosely textured myxoid matrix. Microcystic change, red blood cell extravasation, and lymphocytic infiltration are also often present (Figs. 41.8 to 41.11). A feature of diagnostic significance is the presence of undulating wide bands of collagen lined on the sides by spindle cells. Some areas have a storiform growth pattern. Focal metaplastic bone formation may be present, establishing a link between nodular fasciitis and myositis ossificans. The high cellularity of the lesion and the presence of numerous mitotic figures are responsible for the frequent confusion of this lesion with a sarcoma. However, the constituent cells lack nuclear hyperchromasia, a critical feature in distinguishing a reactive process from a sarcoma.

Ultrastructurally and immunohistochemically, many of the proliferating spindle cells have features of myofibroblasts with strong expression of SMA.[98,99] This lesion is completely benign and often resolves spontaneously. If a lesion originally diagnosed as nodular fasciitis recurs, it is wise to re-review the original pathology since recurrence is so uncommon. Interestingly, there are a number of reports of clonal chromosomal rearrangements involving *USP6* on 17p13 and *MYH9* on 22q13, which has led some authors to favor the interpretation that it is a neoplastic process.[100–102]

Cranial fasciitis is a distinct variant of nodular fasciitis generally seen in infants and characterized by involvement of the skull with erosion of the outer table of the cranium.[103] It shows histologic and immunohistochemical features identical to nodular fasciitis, including strong expression of SMA. Birth trauma has been implicated as causative in at least some cases.[103,104]

Intravascular fasciitis is another morphologic variant of fasciitis in which involvement of the wall and lumen of medium-sized veins and arteries occurs.[97,105] This is an exaggerated expression of a phenomenon seen frequently in ordinary nodular fasciitis and which constitutes a useful diagnostic sign, that is, the fact that, at the periphery of the lesion, the walls of small to medium-sized vessels are involved by the reactive mesenchymal process.

In ***proliferative fasciitis*** the location of the lesion, rapidity of growth, and self-limited nature are the same as those of nodular fasciitis, but the presence of large basophilic cells resembling ganglion cells indicates a link with proliferative myositis (see subsequent discussion) (Fig. 41.12). It usually affects adults, although it can also be seen in children.[106,107] As in the other conditions described in this section, myofibroblasts are the cells that predominate in this proliferation. It should be mentioned here that the presence of ganglion-like cells in a soft tissue lesion does not guarantee that the condition is of a reactive nature. Indeed, we have seen several cases of soft tissue sarcoma containing similar-appearing cells.

Nodular fasciitis and the variants described previously are characteristically located in the somatic soft tissues, but reactive fasciitis-like lesions with a somewhat different morphologic

For personal use only. No other uses without permission. Copyright ©2017. Elsevier Inc. All rights reserved.

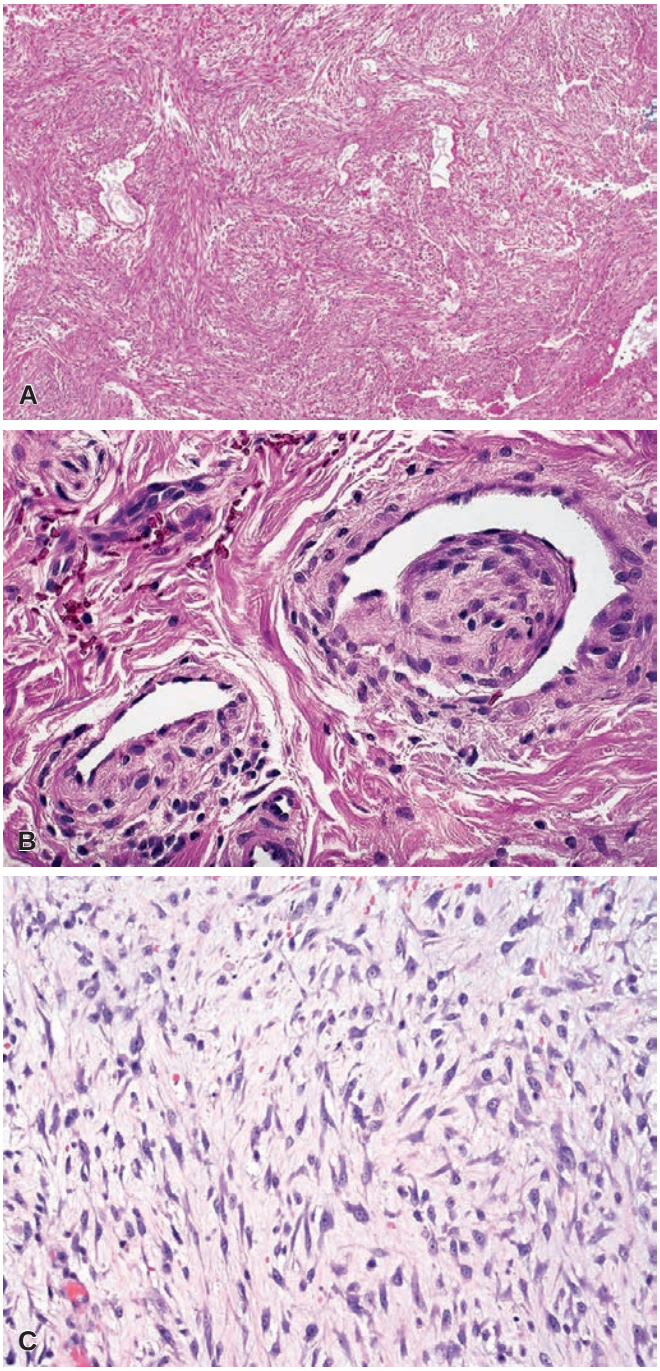

Figure 41.11 Nodular Fasciitis. A, Area of myxoid degeneration in nodular fasciitis. **B,** The proliferation involves the wall and lumen of blood vessels. **C,** High-power view of reactive myofibroblasts in nodular fasciitis.

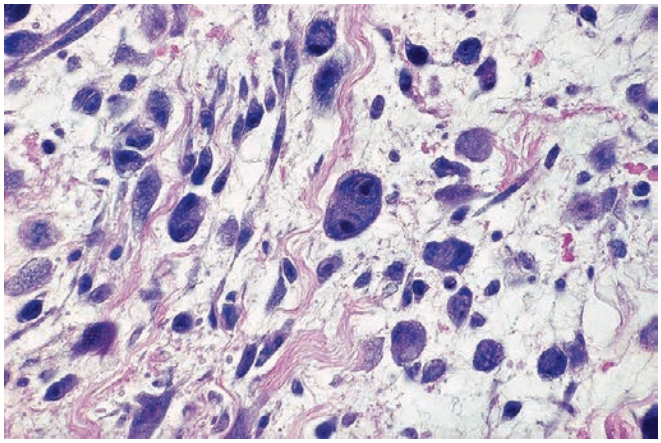

Figure 41.12 Ganglion-like cells in proliferative fasciitis.

Figure 41.13 Gross Appearance of Proliferative Myositis. There is ill-defined whitish material in between the skeletal muscle fibers.

appearance (even more sarcomatoid) can develop from the stromal tissue of a variety of organs, such as the bladder, prostate, vulva, vagina, and cervix (see respective chapters).

Proliferative myositis can be confused with sarcoma not only clinically but also microscopically.[108] The skeletal muscles of the shoulder, thorax, and thigh are most commonly affected. Most patients are over the age of 45 years, but it can also present in children.[106] Grossly, there is typically induration of muscle with an ill-defined scar-like lesion (Fig. 41.13). Microscopically, a cellular proliferation rich in fibroblasts and myofibroblasts is seen surrounding individual muscle fibers, creating a checkerboard pattern (Fig. 41.14). The hallmark of the lesion is the presence of large basophilic cells with vesicular nuclei and prominent nucleoli, resembling ganglion cells or rhabdomyoblasts (Fig. 41.15). Conservative surgery is curative.[109]

Other pseudoneoplastic myofibroblastic proliferations pathogenetically related to nodular fasciitis and representing an exaggerated reaction to injury include *proliferative funiculitis* (involving the spermatic cord and probably secondary to ischemia or torsion)[110] and ***atypical decubital fibroplasia***, otherwise known as ***ischemic fasciitis***.[111–113] This is a myofibroblastic proliferation that predominantly involves soft tissue overlying bony prominences, often occurring in debilitated or immobilized patients. Most of those affected are elderly (peak incidence in eighth or ninth decade), but this lesion rarely affects young patients as well.[111] The soft tissues of the shoulder, chest wall, and hip or sacrococcygeal region are most commonly affected. Microscopically, a zonal pattern best appreciated at low magnification is seen with a

For personal use only. No other uses without permission. Copyright ©2017. Elsevier Inc. All rights reserved.

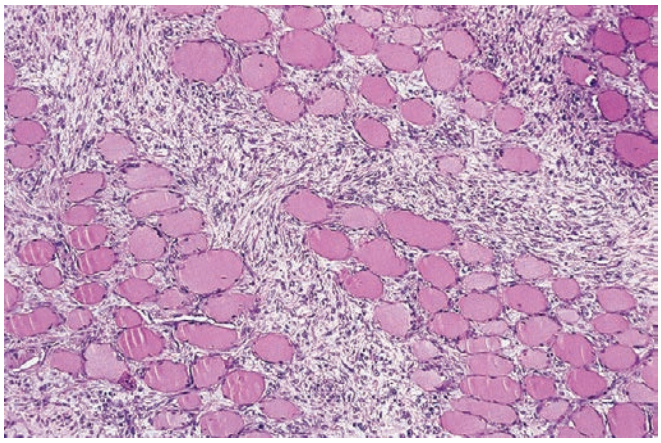

Figure 41.14 Low-power checkerboard appearance of proliferative myositis.

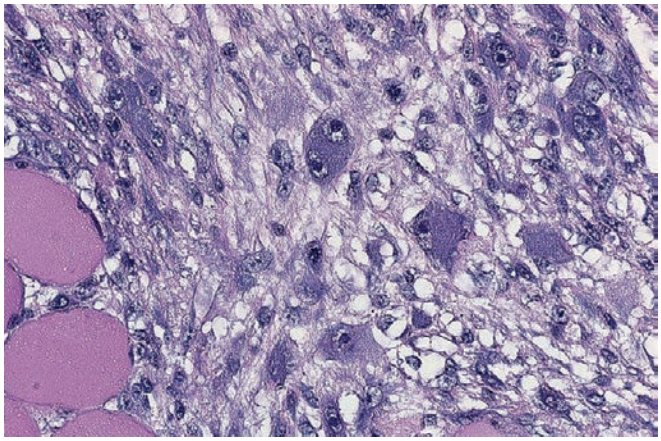

Figure 41.15 On high-power, the ganglion-like cells of proliferative myositis look similar to those of proliferative fasciitis (see Fig. 41.12).

central liquefactive zone surrounded by proliferating vessels and myofibroblasts, some of which have smudgy chromatin or resemble the ganglion-like cells in proliferative fasciitis/myositis (Fig. 41.16). The lesion is benign but can recur if the patient remains debilitated.

Myositis Ossificans

Myositis ossificans and related conditions such as *fibro-osseous pseudotumor of the digits* are located in the soft tissue and are pathogenetically and histologically linked to the previous entities (Fig. 41.17). They are more fully discussed in Chapter 40.

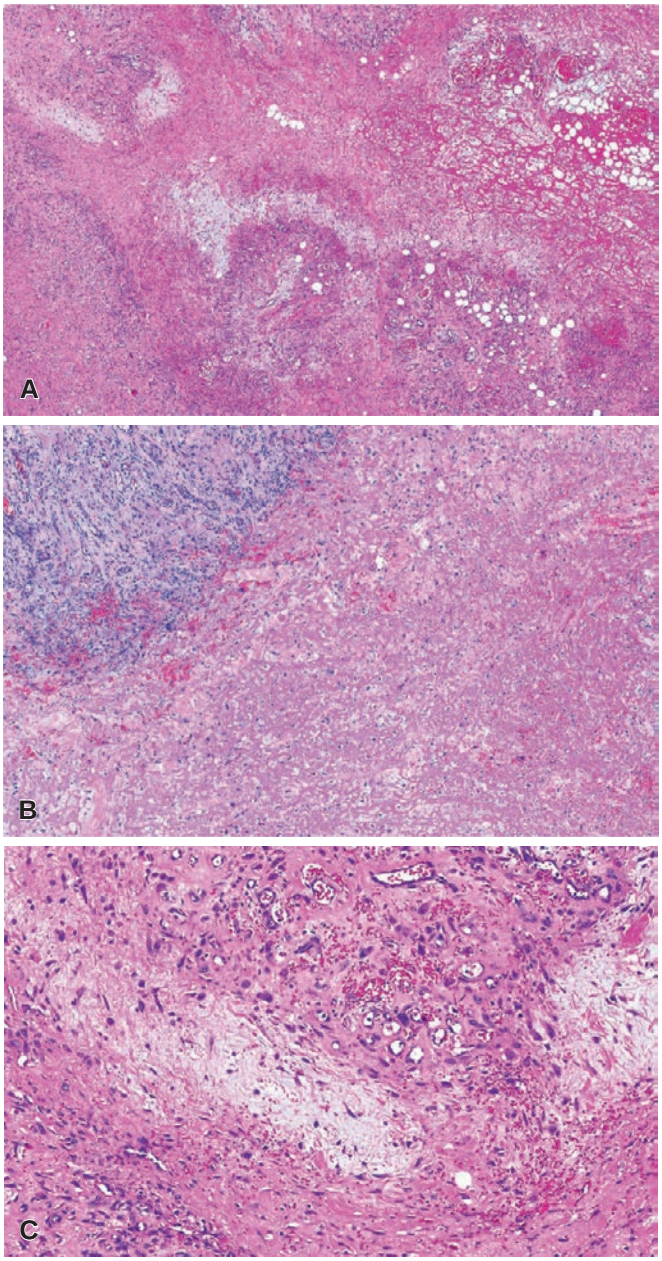

Figure 41.16 **Ischemic Fasciitis. A,** Central area of fibrinous necrosis surrounded by a proliferation of blood vessels and myofibroblasts. **B,** Junction of area of fibrinous necrosis and proliferating blood vessels resembling granulation tissue. **C,** High-power view of atypical stromal cells in an area of vascular proliferation.

Intranodal Palisaded Myofibroblastoma

This is a distinctive benign neoplasm that arises in lymph nodes, most commonly in the groin, usually in middle-aged adults.[114–117] Microscopically, the tumor is well circumscribed with residual nodal tissue at the periphery and is composed of bland spindle cells arranged in short fascicles with vague nuclear palisading. The most distinctive feature is the presence of thick densely eosinophilic collagen (so-called amianthoid fibers) that is variably found throughout the tumor (Fig. 41.18). The cells have myofibroblastic features, as they express actins but not desmin.[118–120] Recently, mutations of *CTNNB1* (β-catenin gene) have been described.[121] The tumor does not recur or metastasize.

Mammary-Type Myofibroblastoma

Mammary-type myofibroblastoma arises in both males and females with a slight male predominance. Although initially described to occur in the breast, the inguinal region is actually the most common location (45% of cases), followed by the lower extremities, trunk, breast, and intraabdominal/retroperitoneum,[121a] although many extra-mammary sites have been described.[122–126] Patients present with a slowly growing, well-circumscribed mass. The tumor is composed of a haphazard arrangement of slender spindle cells separated by collagen bundles (Fig. 41.19). The cells may be arranged in short fascicles or packets, and they have bland chromatin, inconspicuous nucleoli, and occasional intracytoplasmic inclusions.[124] Some cases

For personal use only. No other uses without permission. Copyright ©2017. Elsevier Inc. All rights reserved.

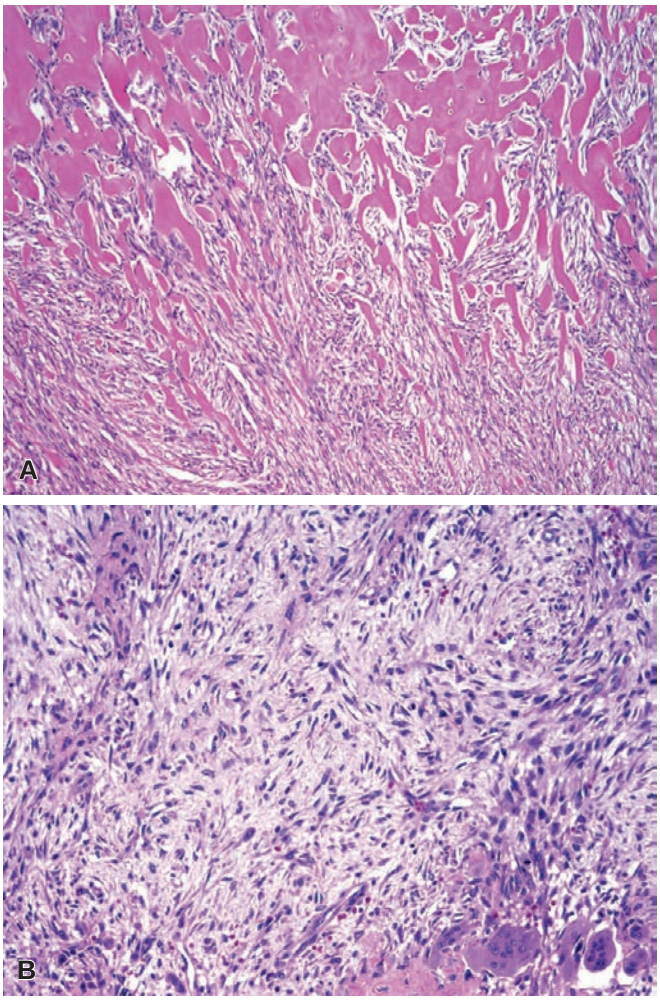

Figure 41.17 Myositis Ossificans. A, Interface between reactive bone and reactive myofibroblasts in myositis ossificans. **B,** High-power view of reactive myofibroblasts.

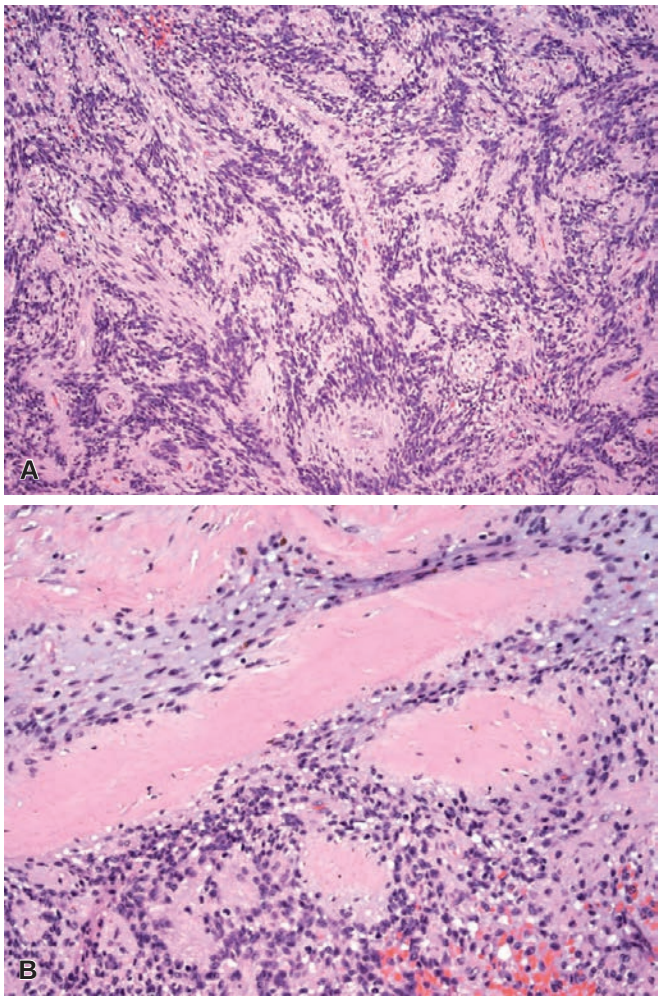

Figure 41.18 Intranodal Palisaded Myofibroblastoma. A, Bland spindle cells and brightly eosinophilic collagen. **B,** High-power view with characteristic amianthoid-like collagen.

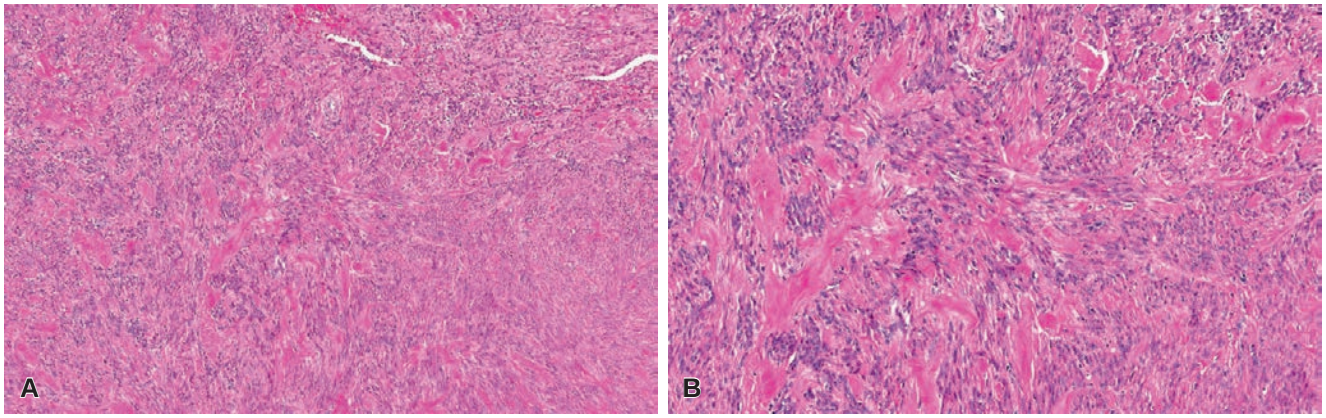

Figure 41.19 Mammary-Type Myofibroblastoma. A, Low-power view. **B,** The lesion is composed of bland spindle cells and dense collagen.

have extensive amounts of mature adipose tissue, and others have focal thick-walled blood vessels. Extensive hyalinization and myxoid stroma may also be seen. Tumors composed predominantly of epithelioid cells have also been described.[127] By immunohistochemistry, the cells typically coexpress CD34 and desmin, with variable expression of SMA. The tumor consistently shows rearrangements or deletions of 13q14, resulting in loss of Rb-1 expression by immunohistochemistry.[121a,128–130] Given overlapping morphology with spindle cell lipoma and cellular angiofibroma, and the fact that these all show loss of Rb-1, it is now believed these lesions are a family of closely related tumors. Mammary-type myofibroblastoma is benign and is generally cured by local excision, with very rare local recurrences.

For personal use only. No other uses without permission. Copyright ©2017. Elsevier Inc. All rights reserved.

Figure 41.20 Gross appearance of elastofibroma.

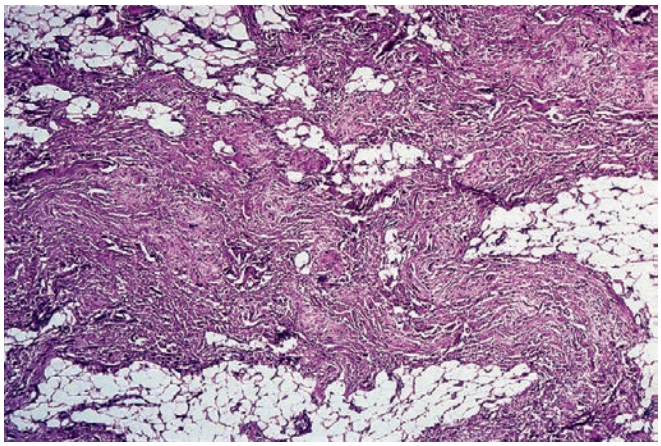

Figure 41.21 Low-power view of elastofibroma with an irregularly shaped fibrohyaline mass within adipose tissue.

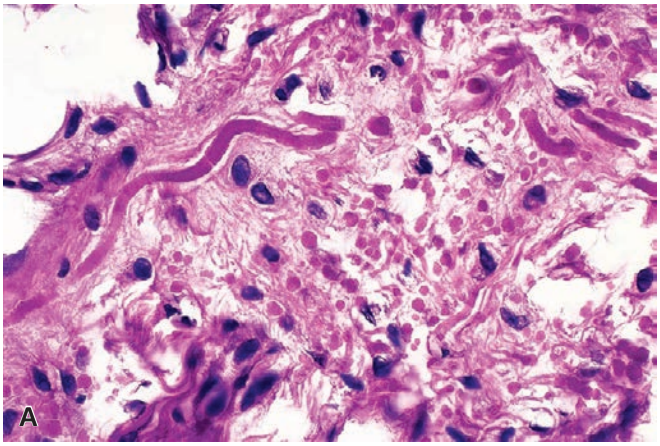

Figure 41.22 High-power view of elastofibroma showing **(A)** diagnostic rods of elastic tissue (**B,** elastic tissue stain).

Elastofibroma

Elastofibroma is a benign, poorly circumscribed process involving almost exclusively the subscapular region of elderly individuals, although isolated cases have been seen in a number of other locations including the gastrointestinal tract.[131] Multicentric and familial cases have also been described.[132] There is often a history of strenuous, repetitive manual labor. At surgery, the lesion is usually found at the apex of the scapula, beneath the rhomboid and latissimus dorsi muscles.

Microscopically, collagen bundles alternate with numerous acidophilic, refractive cylinders often containing a central dense core, both of which stain strongly with elastic stains (Figs. 41.20 and 41.22). Occasionally, adipose tissue is found intermingled with the collagen and elastic fibers, a variation in the theme that has been dignified with the name *elastofibrolipoma*.[133]

The biochemical composition of the fibers is that of elastin but with an amino acid composition slightly different from that of normal elastic tissue.[134] The collagen deposited in the lesion is a mixture of types I, II, and III; the presence of type II collagen is perplexing because this is normally present only in articular cartilage and some ocular structures.[135] Traditionally, this lesion has not been regarded as a true neoplasm but rather a reactive hyperplasia involving abnormal elastogenesis[136]; however, several recent reports have found cytogenetic alterations of various types.[137,138]

Solitary Fibrous Tumor

This neoplasm is ubiquitous in soft tissues and has been described in virtually every anatomic site, although it is most common in the

For personal use only. No other uses without permission. Copyright ©2017. Elsevier Inc. All rights reserved.

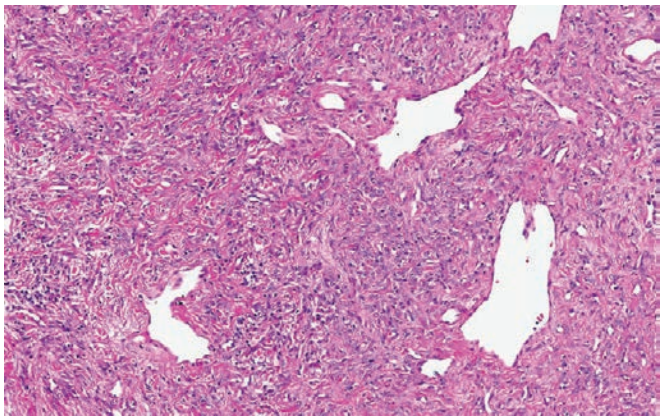

Figure 41.23 Solitary fibrous tumor showing a prominent hemangiopericytoma-like vascular pattern and variable cellularity.

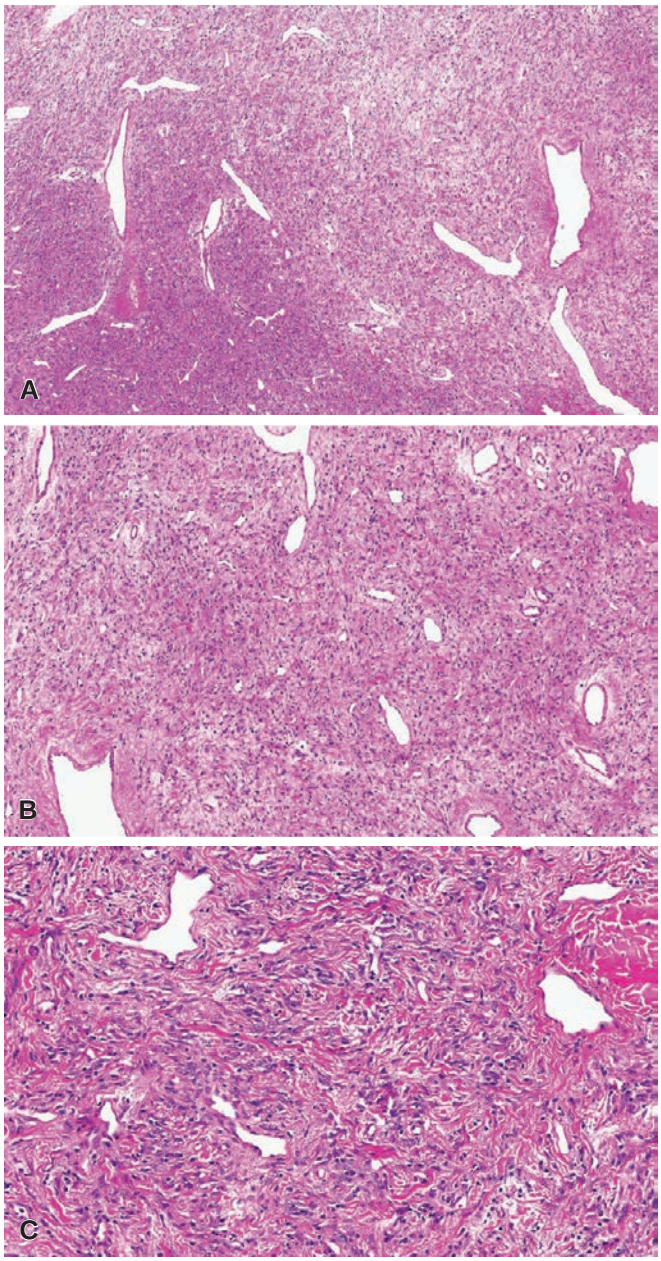

Figure 41.24 **Solitary Fibrous Tumor. A,** Prominent hemangiopericytoma-like vascular pattern. **B,** Hypocellular zone. **C,** Wire-like collagen in solitary fibrous tumor.

pleura. The tumor is composed of fibroblastic spindle cells arranged in a patternless pattern and associated with wire-like collagen and often a staghorn or hemangiopericytoma-like vascular pattern (Figs. 41.23 and 41.24).[139] Other features may include myxoid change, mature adipose tissue, floret-like giant cells (formerly referred to as giant cell angiofibroma),[140,141] and even dedifferentiation.[142–144] Although CD34 is virtually always expressed, this marker lacks specificity. More recently, STAT6 has been found to be a more sensitive and specific marker,[145–147] which is not unexpected given the identification of *NAB2-STAT6* gene fusions in a significant subset of these tumors.[148–152] Although most cases are clinically benign, some are both histologically and clinically malignant, particularly those with areas of high cellularity, necrosis, and greater than four mitotic figures per 10 high power field (HPF).[153–157]

Desmoid-Type Fibromatosis

The generic term **desmoid-type fibromatosis** was originally proposed by Stout[158] for a group of related conditions having in common the following features:

1. Proliferation of well-differentiated fibroblasts and myofibroblasts
2. Infiltrative pattern of growth
3. Presence of a variable (but usually abundant) amount of collagen between the proliferating cells
4. Lack of cytologic features of malignancy
5. Low or absent mitotic activity
6. Aggressive clinical behavior characterized by repeated local recurrences but lack of capacity to metastasize distantly

Grossly, these lesions are often large, firm, and white, with ill-defined outlines and an irregularly whorled cut surface (Fig. 41.25).[159] Microscopically, most of the proliferating cells have features of fibroblasts or myofibroblasts (Figs. 41.26 and 41.27).[1,160] Other light microscopic features commonly encountered in fibromatosis are a perivascular lymphocytic infiltrate located at the advancing edge of the lesion, and thick-walled often ectatic vessels sharply outlined from the surrounding tissue.

Clonal chromosomal aberrations are present in approximately half of the deep-seated fibromatoses but only in 10% of those located superficially. Trisomies 8 and 20 and loss of 5q material represent the recurring cytogenetic changes.[161,162] At the molecular level, there are activating mutations of *CTNNB1* (encoding β-catenin), leading to frequent nuclear expression of β-catenin.[163,164] For cases associated with Gardner syndrome, there is germline mutation of the *APC* gene (5q22), together with loss of heterozygosity at the locus.[165] The end result is similar, since both APC and β-catenin are components of the Wnt signaling pathway. The cells of fibromatosis are also immunoreactive for SMA and desmin, with variable staining for calponin, and estrogen receptor-beta (but not estrogen receptor-alpha or CD34).[166]

Some pathologists add the adjective *aggressive* to some forms of fibromatosis to emphasize its potential behavior. We do not use the term, since we regard it as redundant, being that all deep-seated fibromatoses are potentially aggressive. Other authors have gone even further and have used *well-differentiated fibrosarcoma* as a synonym for the histologically more cellular or clinically more aggressive types of fibromatosis. We are opposed to this terminology because the designation of sarcoma endows this lesion in the mind of many surgeons with a metastasizing potential that it simply does not possess.

For personal use only. No other uses without permission. Copyright ©2017. Elsevier Inc. All rights reserved.

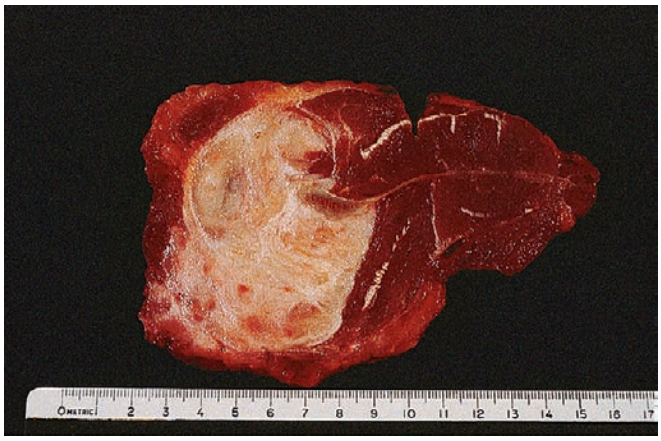

Figure 41.25 Deep-seated fibromatosis embedded within major skeletal muscle.

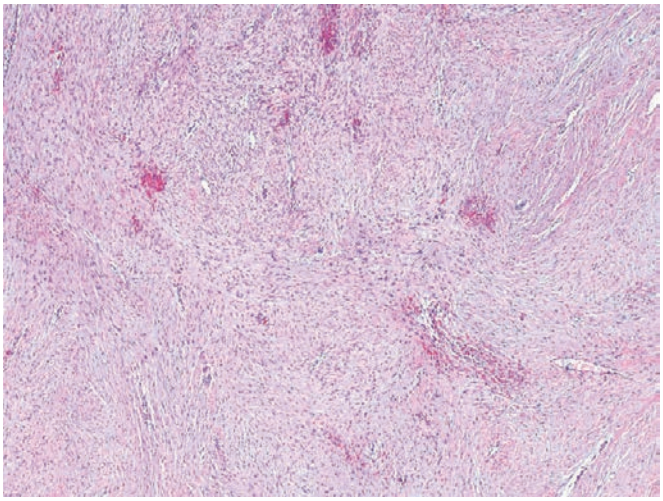

Figure 41.26 Low-power view of abdominal wall fibromatosis with a cellular proliferation arranged in fascicles associated with prominent blood vessels.

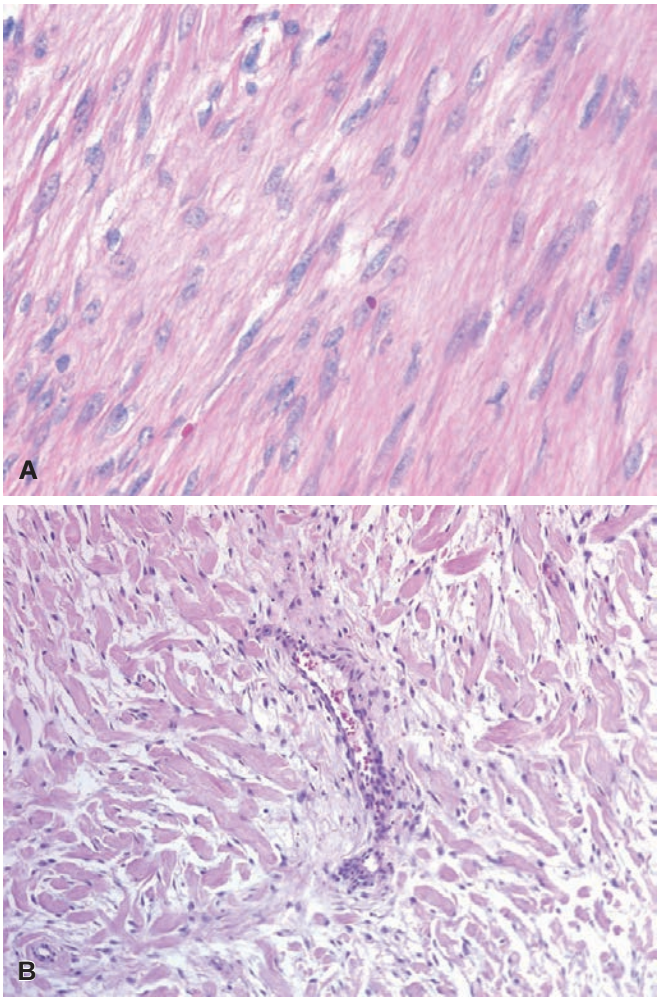

Figure 41.27 **Abdominal Wall Fibromatosis. A,** High-power view of cells in fibromatosis. **B,** Keloid-like collagen is often seen.

Although some cases are challenging, we always attempt to distinguish between fibromatosis and well-differentiated fibrosarcoma, reserving the latter term for tumors showing atypical cytologic features.

Most soft tissue fibromatoses are in intimate contact with skeletal muscles and their aponeuroses—hence their designation as *musculoaponeurotic fibromatosis*,[167] although the WHO refers to these lesions as desmoid-type fibromatosis. Although such lesions often arise in the abdominal wall in women during or following pregnancy, in our experience, this lesion is almost as common in men and in other locations, such as the shoulder girdle, head and neck area, and thigh.[168,169] It can also occur in the mediastinum, pleural cavity (with lung invasion), retroperitoneum, abdominal cavity (see subsequent discussion), and breast, among many other sites.

The treatment of deep fibromatoses should be individualized, and, in fact, a number of modalities can be utilized, including surgery alone or in conjunction with radiation and cytotoxic and noncytotoxic drugs (tamoxifen, Gleevec, and nonsteroidal anti-inflammatory drugs including sulindac). The tumor does have a strong propensity for local recurrence, but some authors have advised against the re-excision of a recurrent lesion that does not appear to be growing.[169] In the study by Gronchi et al., 76% of tumors locally recurred by 10 years.[170] Tumor size was associated with recurrence risk, but surprisingly, microscopic deposits of surgical margins were not predictive of recurrence. Recently, Colombo and colleagues found that sporadic tumors with mutations in codon 45 in the β-catenin gene *(CTNNB1)* have a greater tendency to locally recur.[163]

Juvenile fibromatosis is an antiquated term that has been applied to fibromatoses occurring in children and adolescents.[171] There is very little either on clinical or microscopic grounds that differentiates fibromatosis in children from that occurring in other age groups. There are, however, three variants of fibromatosis that predominantly occur in childhood that present a distinctive clinicopathologic picture: fibromatosis colli (congenital torticollis), inclusion body fibromatosis (infantile digital fibromatosis), and infantile myofibroma/myofibromatosis.

Fibromatosis colli (congenital torticollis) is a type of fibromatosis affecting the lower third of the sternocleidomastoid muscle and appearing at birth or shortly thereafter, sometimes bilaterally.[172] It is frequently associated with various congenital anomalies including rib cage anomalies and congenital hip dysplasia.[173,174] An association between complicated deliveries (particularly breech deliveries) and fibromatosis colli has been established.[175] Although some instances of spontaneous regression have been recorded, this condition usually necessitates resection of the muscle. Microscopically, there is partial replacement of the sternocleidomastoid muscle by a fibroblastic

For personal use only. No other uses without permission. Copyright ©2017. Elsevier Inc. All rights reserved.

proliferation of varying cellularity admixed with atrophic skeletal muscle fibers.

Inclusion body fibromatosis (infantile digital fibromatosis) is a form of fibromatosis usually restricted to childhood.[176] The typical location is on the exterior surface of the end phalanges of the fingers and toes, but it may also occur outside the digits and at sites such as the oral cavity and breast.[177,178] The lesions can be solitary or multiple and either present at birth or appear during the first 2 years of life. However, morphologically identical lesions in adults are on record.[179] A distinctive microscopic feature, generally not observed in other forms of fibromatosis, is the presence of peculiar eosinophilic cytoplasmic inclusions, often situated close to the nucleus and separated by a narrow clear zone (Fig. 41.28). A trichrome stain can highlight these inclusions. Ultrastructural findings suggest they represent bundles of microfilaments.[180,181] The spindle cells stain for SMA, desmin, calponin, and CD99.[182] Inclusion body fibromatosis has a high tendency for local recurrence.[182]

Very rare cases of inclusion body fibromatosis lacking inclusion bodies may be a component (and sometimes the first clinical manifestation) of the syndrome known as *terminal osseous dysplasia with pigmentary defects*.[183]

Infantile myofibroma/myofibromatosis presents as solitary (myofibroma)[184] or multiple (myofibromatosis)[185] nodules in the skin, soft tissues, or bone, either limited to these sites or associated with internal organ involvement.[186] A large majority of the cases occur before the age of 2 years, and approximately 60% are congenital.[184] However, this lesion can also occur in adults.[187] Solitary forms are more common in males, and multicentric forms are more common in females.[186] A familial incidence has been suggested, and evidence for both an autosomal dominant and recessive pattern of transmission has been proposed.[185,188] Microscopically, peripheral areas that resemble smooth muscle alternate with hemangiopericytoma-like areas and foci having a more typical fibroblastic appearance (Fig. 41.29). Central necrosis and intravascular growth may be present.[184] Both immunohistochemical and ultrastructural studies suggest the lesion is largely composed of myofibroblasts. However, a whole range of differentiation exists between fibroblasts and fully developed, desmin-positive smooth muscle cells.[187] Indeed, myofibromatosis seems to be a member of a family of tumors showing vessel-related myoid differentiation, which also includes glomangiopericytoma and myopericytoma[189,190] given that tumors with overlapping features exist. Solitary and multicentric lesions confined to the bone and soft tissues carry an excellent prognosis, with frequent spontaneous regression.[184,186] The prognosis is far less favorable in patients with multiple visceral lesions.

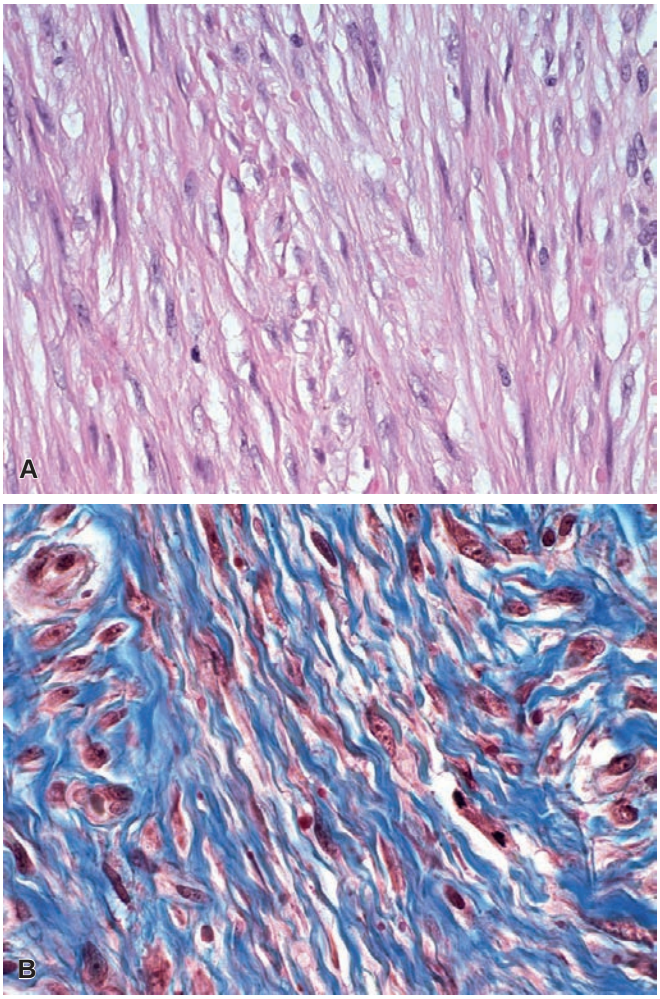

Figure 41.28 Inclusion Body Fibromatosis. A, Spindle cells with eosinophilic inclusions are seen. **B,** Trichrome stain revealing rare eosinophilic inclusions.

Interestingly, recurrent somatic *PDGFRB* mutations have been identified in sporadic infantile and solitary adult myofibromas, but these mutations were not identified in cases of angioleiomyoma and myopericytoma.[190a] However, recurrent *PDGFRB* alterations were identified in myopericytomatosis, suggesting a relationship between myopericytomatosis and infantile myofibroma/myofibromatosis. Alterations in *PDGFRB* also suggest the possible utility of tyrosine kinase inhibitors as a potential therapy for these lesions.[190b] A recurrent *SRF-RELA* fusion was recently found in highly cellular variants of myofibroma and myopericytoma, but cases of typical myofibroma and myopericytoma lack this fusion.[190c]

Lipofibromatosis is a minor variation on the theme of infantile fibromatosis, in which a spindle cell component of fibroblastic appearance (mainly located in septa and skeletal muscle) is admixed with mature adipose tissue.[191] This lesion affects children from birth to up to 10 years of age, usually arising in the muscles of the extremities, trunk, or head and neck. Like other forms of fibromatosis, this lesion frequently recurs but does not metastasize.

Recently, a series of locally aggressive lipofibromatosis-like neural tumors with recurrent *NTRK1* gene fusions were identified.[191a] These lesions occurred in children and young adults with an infiltrative growth pattern similar to that seen in lipofibromatosis, but with variable cytologic atypia and immunoreactivity for S-100 protein and CD34 suggesting neural differentiation.

Juvenile hyaline fibromatosis/infantile systemic hyalinosis is a distinctive group of lesions affecting children and characterized microscopically by cords of spindle cells embedded in an eosinophilic hyalinized matrix within the connective tissue of the skin, oral cavity, articular capsule, and bone.[192,193] Several studies have found mutations of the capillary morphogenesis genes 2 *(CMG2)* on 4q21 in both diseases, confirming these are part of a disease spectrum.[194,195] Inheritance is in an autosomal recessive manner, and there is a distinct predilection for patients of Middle Eastern descent.[196,197]

The superficial fibromatoses derive their names from their particular location. **Penile fibromatosis** (Peyronie disease) will be discussed in greater detail elsewhere. **Palmar fibromatosis** (Fig. 41.30) is also known as Dupuytren contracture and **plantar fibromatosis** as Ledderhose disease.[198] These conditions occur predominantly in adults but can also be seen in children and adolescents. Contracture of the fingers or toes is the leading clinical manifestation. The lesions can be multiple and bilateral and may coexist in the upper and lower extremities. The plantar form tends to be more localized than its palmar counterpart.

For personal use only. No other uses without permission. Copyright ©2017. Elsevier Inc. All rights reserved.

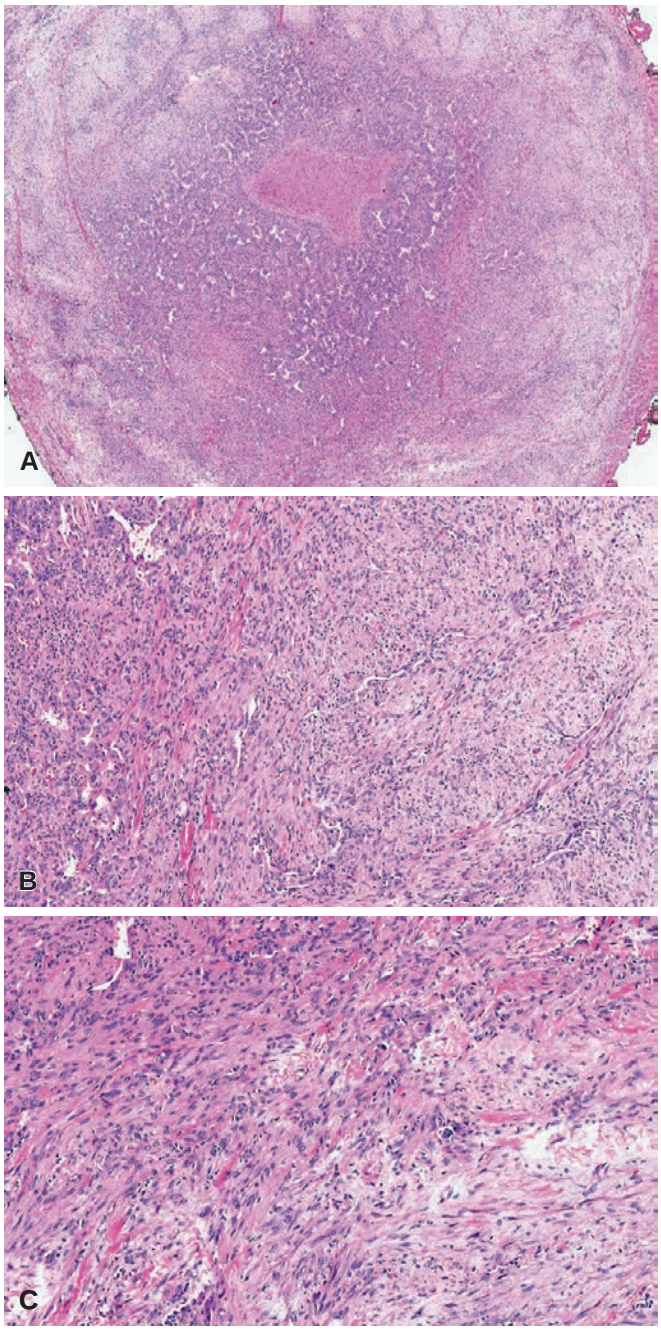

Figure 41.29 Infantile Myofibroma. A, Low-power view with central cellular zone with a hemangiopericytoma-like pattern and a peripheral myoid zone. **B,** Junction of hemangiopericytoma-like zone and myoid zone. **C,** High-power view of myoid zone in infantile myofibroma.

Microscopically, both often show a cellular proliferative phase (especially for the plantar lesions), which may lead to a mistaken diagnosis of fibrosarcoma. It is well to remember that fibrosarcoma of the palmar and plantar areas is exceptional and that the differential diagnosis of a cellular spindle cell tumor of the sole is usually between fibromatosis, synovial sarcoma, malignant melanoma, and Kaposi sarcoma. The cells are spindled with open chromatin and small nucleoli and are separated by variable amounts of collagen. Older lesions are often less cellular and more collagenous.

The association of soft tissue tumors, usually Gardner-type fibroma and desmoid-type fibromatosis, with colonic polyposis

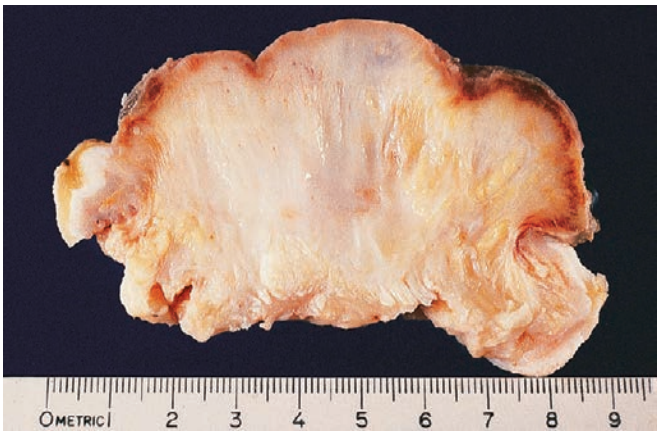

Figure 41.30 Plantar Fibromatosis. The tissue is whitish and unencapsulated with an elastic consistency.

and occasionally multiple osteomas is known as **Gardner syndrome**.[199] In this condition, the fibromatosis has a particular tendency to involve intra-abdominal structures, especially the mesentery, and to manifest itself following a surgical procedure in the area.[200,201] It is important not to misdiagnose intra-abdominal fibromatosis involving the intestinal wall (a not uncommon occurrence) as a gastrointestinal stromal tumor (GIST).[202] Along these lines, it should be mentioned that—despite early statements to the contrary—fibromatosis is a CD117-negative tumor, as opposed to the vast majority of GISTs.[203] As previously discussed, patients with Gardner syndrome can also develop *Gardner-associated fibroma*, a soft tissue tumor most often located in the back or paraspinal region and characterized microscopically by a bland hypocellular proliferation of spindle cells embedded in a background of haphazardly oriented coarse collagen fibers, similar to nuchal-type fibroma.[72]

Fibrosarcoma and Variants

Adult-type fibrosarcoma can arise from superficial and deep connective tissues such as fascia, tendon, and periosteum; they often grow slowly and appear well circumscribed.[204] They usually are soft and may contain area of necrosis and hemorrhage (Fig. 41.31).

Microscopically, the well-differentiated tumors (low grade) are easily recognized as fibroblastic; the cells are arranged in long fascicles that intersect at acute angles, resulting in a "herringbone" appearance (Fig. 41.32). Mitotic activity varies. High-grade tumors have closely packed, less well-oriented, smaller, rounder tumor cells with a less distinct fascicular arrangement, greater mitotic activity, and often extensive necrosis. It should be remembered that many other soft tissue tumors, particularly synovial sarcoma, MPNST, and UPS may harbor areas closely resembling fibrosarcoma. Careful examination of different blocks of the tumor coupled with select adjunctive studies will provide the correct diagnosis in almost all instances. Although a pleomorphic type of fibrosarcoma probably exists, one should question the diagnosis of fibrosarcoma in the presence of a soft tissue sarcoma with numerous tumor giant cells. As a matter of fact, the diagnosis of fibrosarcoma (especially the low-grade type) should be viewed as a diagnosis of exclusion.[205,206] Both immunohistochemical and ultrastructural studies have shown most of the cells show fibroblastic features, although it is common to also find cells with myofibroblastic differentiation, including the expression of SMA.[205] The distinction of fibrosarcoma from fibromatosis is critical, given that the former has a significant risk of metastasis and the latter only has a risk of local recurrence.

For personal use only. No other uses without permission. Copyright ©2017. Elsevier Inc. All rights reserved.

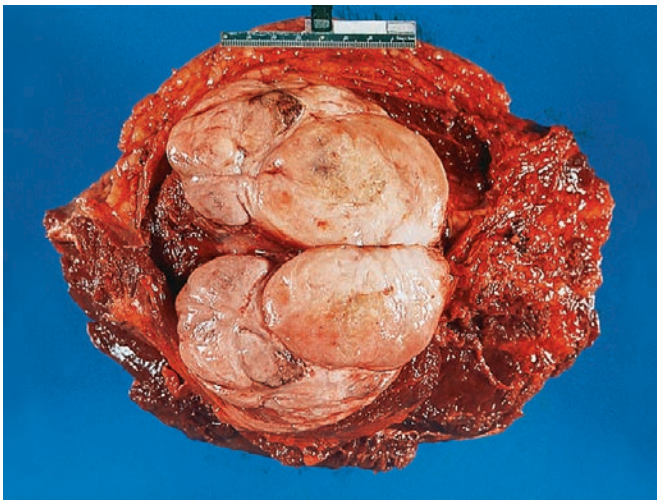

Figure 41.31 Well-circumscribed fibrosarcoma growing within skeletal muscle.

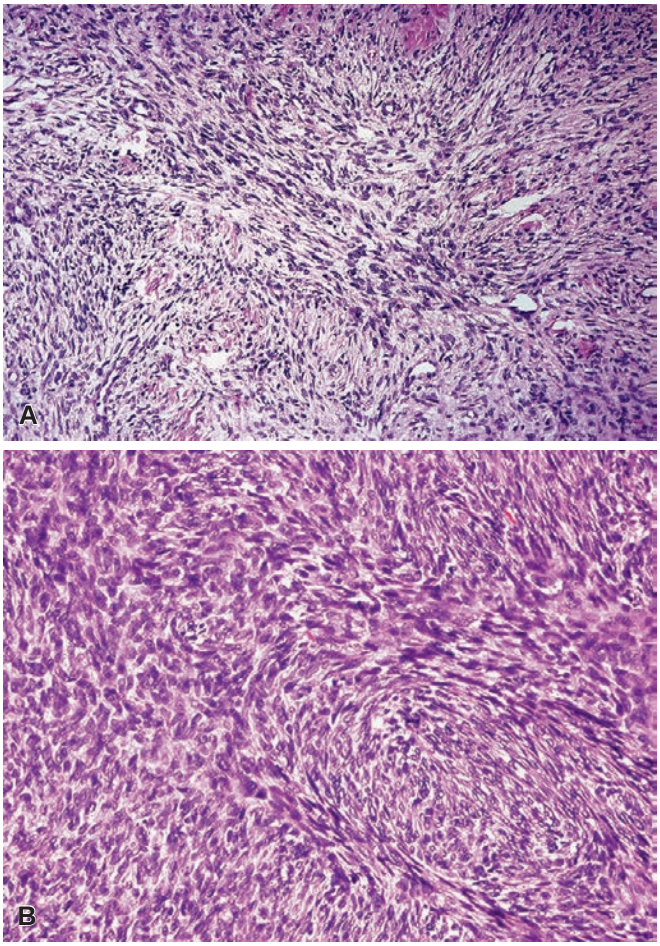

Figure 41.32 **Adult-Type Fibrosarcoma. A,** Low-power view. **B,** High-power view.

Generally, the more superficial and lower grade the tumor, the better the prognosis. In the study by Scott et al., the overall rate of recurrence was 42% at 5 years.[204] The status of the surgical margins was strongly predictive of local recurrence, but neither tumor grade nor stage were predictive factors. The treatment of choice is radical excision, and postoperative radiation therapy should be considered if microscopic residual or positive margins are encountered. Since subclinical microscopic metastases are presumed to exist in many patients at the time of surgery, adjuvant chemotherapy has been recommended following surgical excision of high-grade tumors.

Congenital fibrosarcoma (infantile fibrosarcoma) is an extremely cellular tumor characterized by very rapid growth and the capability for extensive local invasion, but its metastatic rate is negligible.[207] Microscopically, this tumor is composed of a cellular proliferation of spindle cells that are fairly uniform and arranged in fascicles or bundles, often admixed with lymphocytes and a hemangiopericytoma-like vascular pattern. At the molecular level, it is characterized by the *ETV6–NTRK3* gene fusion, which results from the chromosomal translocation t(12;15)(p13;q25).[208,209] This gene fusion is not present in adult-type fibrosarcoma or other pediatric fibroblastic tumors in the differential diagnosis. In addition, trisomies of chromosomes 8, 11, 17, and 20 are common.[210] Of interest, cellular congenital mesoblastic nephroma of the kidney shows identical genetic alterations, suggesting that these two entities are closely related.[211]

Low-grade fibromyxoid sarcoma (LGFMS), also known as Evans tumor, is a low-grade sarcoma with deceptively bland histologic features. Most patients are young to middle-aged adults and present with a slowly enlarging mass in the deep soft tissue of the extremities, although this tumor has been reported in virtually every anatomic site.[212–215] The tumor is of low to moderate cellularity with bland spindle-shaped cells deposited in a variably myxoid and collagenous matrix. There is often an elaborate network of capillaries in the myxoid zones, which are usually longer and less organized in comparison to the delicate vasculature of myxoid liposarcoma (Figs. 41.33 to 41.35). Some tumors show collagen rosettes (formerly known as hyalinizing spindle cell tumor with giant rosettes) (Fig. 41.36),[216] and others show cords of epithelioid cells with features overlapping that seen in sclerosing epithelioid fibrosarcoma (see later).[217,218] Rare cases show higher-grade areas with increased cellularity, mitotic activity, and nuclear pleomorphism. By immunohistochemistry, many express EMA and virtually all show strong staining for MUC4.[219,220] The vast majority harbor translocations involving either *CREB3L2* or *CREB3L1* with the *FUS* gene, resulting from either a t(7;16) or t(11;16), respectively.[221–223] Rare cases show involvement of *EWSR1* rather than *FUS*.[224,225]

Despite its bland histologic appearance, LGFMS can locally recur and metastasize. In the study by Folpe et al. in 2000, of 54 patients with follow-up, only 5 (9%) developed local recurrence, and 3 (6%) had metastatic disease; only 1 patient died of their tumor.[215] In a more recent study by Evans in 2011 with long-term follow-up, the rates of local recurrence, metastasis, and death were 64%, 45%, and 42%, respectively.[212,213]

Sclerosing epithelioid fibrosarcoma is a variant of fibrosarcoma that simulates the appearance of infiltrating carcinoma.[226,227] It is composed of small, round to ovoid tumor cells embedded in a dense hyalinized stroma. The scanty cytoplasm often has a clear appearance, and there may be a single file pattern of growth (Fig. 41.37). Necrosis and bone invasion may be found.[228] Up to 50% express EMA, and, like LGFMS, most express MUC4, particularly those with FUS translocations.[229] Some cases exhibit the same distinctive chromosomal translocation [t(7;16)] of LGFMS, suggesting a close relationship between these two tumor types.[220,225] Other examples of sclerosing epithelioid fibrosarcoma (like LGFMS) show involvement of *EWSR1* rather than *FUS*.[225,230] The tumor is associated with a high incidence of local recurrence and distant metastasis.

For personal use only. No other uses without permission. Copyright ©2017. Elsevier Inc. All rights reserved.

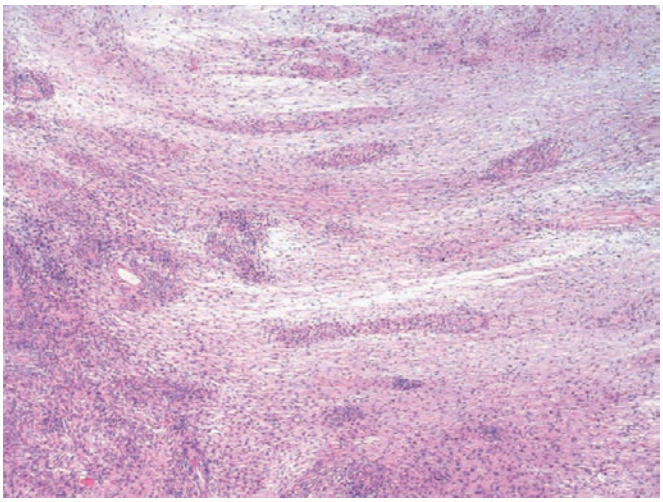

Figure 41.33 Characteristic low-power appearance of low-grade fibromyxoid sarcoma with alternating fibrous and myxoid zones.

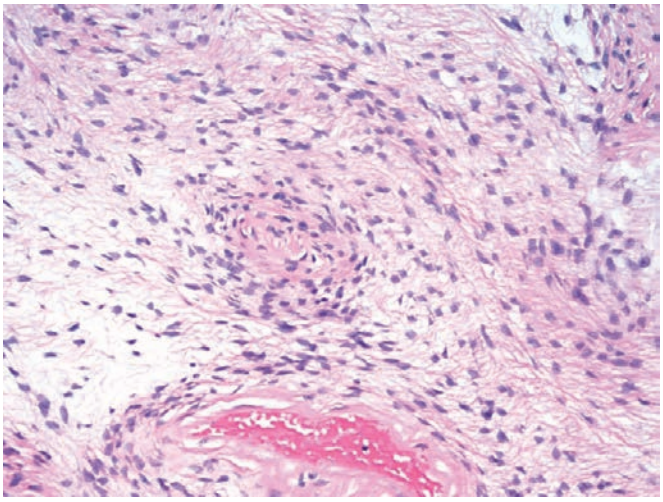

Figure 41.34 Low-grade fibromyxoid sarcoma with prominent blood vessels and perivascular hypercellularity.

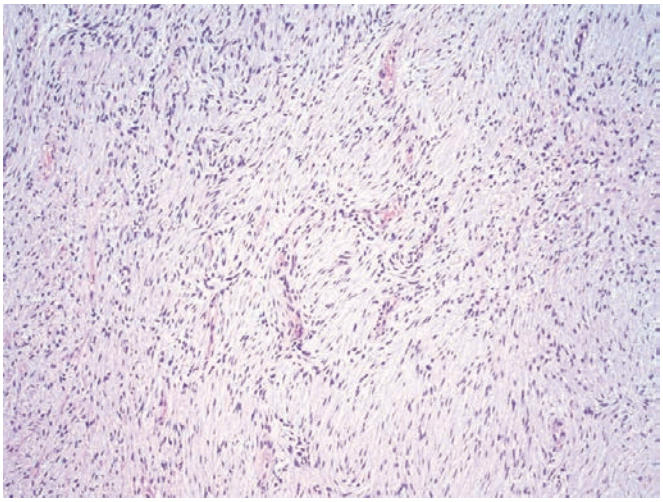

Figure 41.35 Bland spindle cells within myxoid stroma in low-grade fibromyxoid sarcoma.

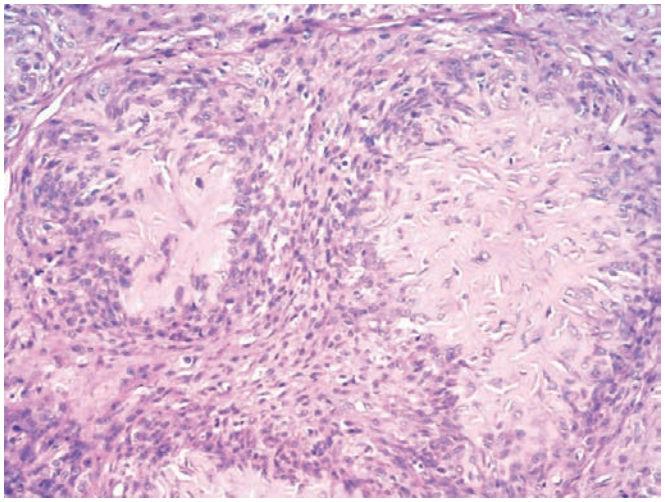

Figure 41.36 Collagen rosettes in a low-grade fibromyxoid sarcoma.

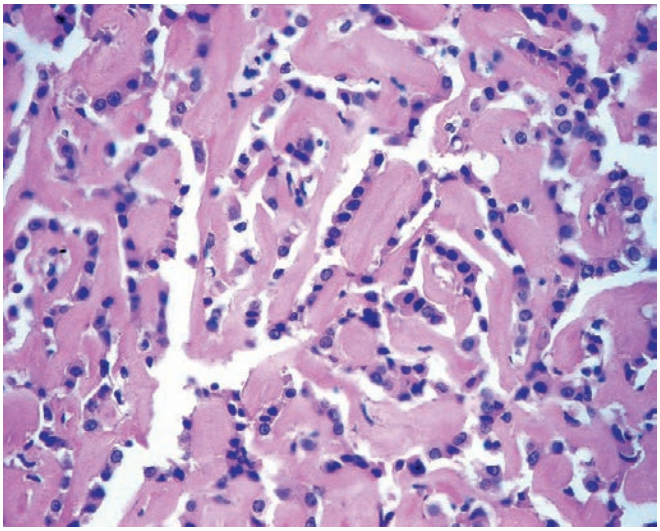

Figure 41.37 Sclerosing epithelioid fibrosarcoma. The single file disposition of cells simulates carcinoma.

Myxoinflammatory fibroblastic sarcoma (MIFS), also known as inflammatory myxohyaline tumor, is a low-grade sarcoma most commonly found in the distal extremities of adults.[231–233] This lesion can simulate an inflammatory condition, Hodgkin lymphoma, and various other types of soft tissue sarcomas, including myxofibrosarcoma. Microscopically, it has an infiltrative multinodular quality and a polymorphic cellular composition in a hyaline or myxoid background (Fig. 41.38). There is a dense mononuclear inflammatory infiltrate containing scattered stromal cells of either epithelioid or spindle shape, including some with large bizarre nuclei and prominent nucleoli resulting in a resemblance to Reed–Sternberg cells or virus-infected cells.[233] The immunohistochemical profile is nonspecific, but at least a subset of tumors have a recurrent t(1;10)(p22;q24) involving *TGFBR3* on chromosome 1 and *MGEA5* on chromosome 10.[234,235] Interestingly, this alteration has been identified in hemosiderotic fibrolipomatous tumor (also known as hemosiderotic fibrohistiocytic lipomatous tumor), and some cases of pleomorphic hyalinizing angiectatic tumor (PHAT) suggesting a relationship among these tumors.[234,236] Local recurrence is common, but distant metastases are exceptionally uncommon.[232,237]

For personal use only. No other uses without permission. Copyright ©2017. Elsevier Inc. All rights reserved.

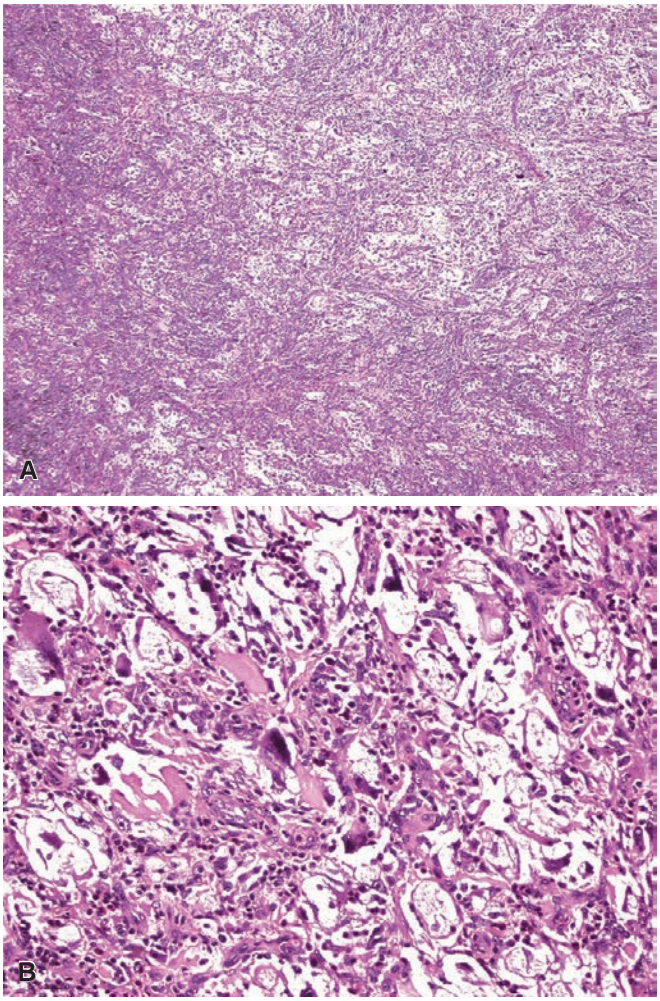

Figure 41.38 Myxoinflammatory Fibroblastic Sarcoma. A, Low-power view showing a heterogeneous appearance with alternating cellular and myxoid zones. **B,** Pseudolipoblasts and enlarged atypical smudgy cells can be seen.

Myofibroblastic Tumors

A particularly difficult issue in the classification of soft tissue tumors is the role played by myofibroblasts. Some authors have taken a very restrictive view of the definition of a myofibroblast (including the requirement of ultrastructural confirmation), whereas others do not believe ultrastructural confirmation should be required. Part of the problem is that there are no specific immunohistochemical markers for myofibroblasts, although the most common immunophenotype is strong staining for SMA with an absence of staining for desmin and h-caldesmon.[238]

The other problem concerns the fact that cells with myofibroblastic features can be found in a large number of benign and malignant soft tissue lesions, including lesions in which they constitute only a small percentage of the neoplastic cells. Therefore, if there is to be a category of myofibroblastic tumors, it would be wise to reserve it for lesions that are composed almost entirely of cells having myofibroblastic features.

Inflammatory myofibroblastic tumor is a distinctive entity that has gone by a number of different names, including inflammatory pseudotumor and inflammatory fibrosarcoma, among many others. Although they have been described in virtually every anatomic site, many of the cases arise in the mesentery or retroperitoneum of children or adults, often accompanied by anemia and fever.[239,240]

Histologically, a variety of patterns may be seen including a fasciitis-like pattern, cellular spindle cell areas, and hypocellular hyalinized zones. Lymphocytes and plasma cells are often intermixed within any of these patterns (Fig. 41.39). The constituent cells show the immunohistochemical features of myofibroblasts, as previously discussed, and up to 50% also stain for ALK.[240–243] There is imperfect correlation between ALK staining and *ALK* rearrangements approximately 50% of these tumors harbor clonal rearrangements of the *ALK* gene at 2p23.[244] Recently, gene fusions involving other kinases have been identified, including *ROS1* and *PDGFRB*.[244a] A number of other fusion partners have been identified including *TPM3*, *TPM4*, *CARS*, *ATIC*, *SEC31L1*, *RANBP2*, and *CLTC*.[245–249] Tumors in the abdomen and retroperitoneum have a higher propensity for aggressive clinical behavior than those arising elsewhere, including frequent local recurrences and definite risk of metastasis.[240,250] Although surgery is the mainstay of therapy, *ALK* inhibitors such as crizotinib have been found to be efficacious in treating aggressive lesions.[251,252]

Myofibrosarcoma

Sarcomas composed predominantly or exclusively of myofibroblasts do exist but are uncommon and are referred to as myofibrosarcoma or myofibroblastic sarcoma. At the high-grade end of the spectrum, such lesions often are grouped as UPS. Low-grade lesions have a peak incidence in the fourth decade of life[238,253] and most commonly arise in the head and neck region.[254] The tumor is composed of spindled- to stellate-shaped cells arranged into sheets, whorls, or intersecting fascicles with variable amounts of myxoid and collagenous stroma (Fig. 41.40). At least focal nuclear hyperchromasia is seen, a key feature in distinguishing this low-grade sarcoma from a reactive/benign process. There is often infiltration into the surrounding soft tissues, although mitotic activity is low and necrosis is absent. The cells show the characteristic immunophenotypic features of myofibroblasts. Most show indolent behavior, but some recur and still others progress to a higher-grade sarcoma and can metastasize.[238]

Fibrohistiocytic Tumors

This large, complex, and controversial family of tumors was originally defined by the presence of a dual cellular composition: cells with a fibroblastic appearance intimately mixed with others having some of the morphologic and functional attributes of histiocytes.[255] Stout and his colleagues at Columbia Presbyterian Hospital in New York City first proposed that these tumors originate from tissue histiocytes, some of which were said to acquire fibroblastic features.[256] Another proposed interpretation of these lesions is that they arise from primitive mesenchymal cells with the capacity for dual differentiation into histiocytes and fibroblasts.[257,258] Both theories assume the existence in these lesions of a true neoplastic histiocytic component. To be sure, some of the cells in these tumors do show phagocytic properties, accumulate fat and hemosiderin, exhibit lysosomes ultrastructurally, and manifest immunohistochemical reactivity for hydrolytic enzymes[259,260]; however, the specific cell markers of "true histiocytes" derived from bone marrow have been found to be absent in the tumor cells and present only in the osteoclast-like giant cells occasionally seen in these lesions.[261–263] In most studies, the majority of tumor cells have a phenotypic appearance resembling that of fibroblasts or myofibroblasts.[264] It seems increasingly evident that the tumors in the fibrohistiocytic group are pathogenetically diverse but share common morphologic features.

For personal use only. No other uses without permission. Copyright ©2017. Elsevier Inc. All rights reserved.

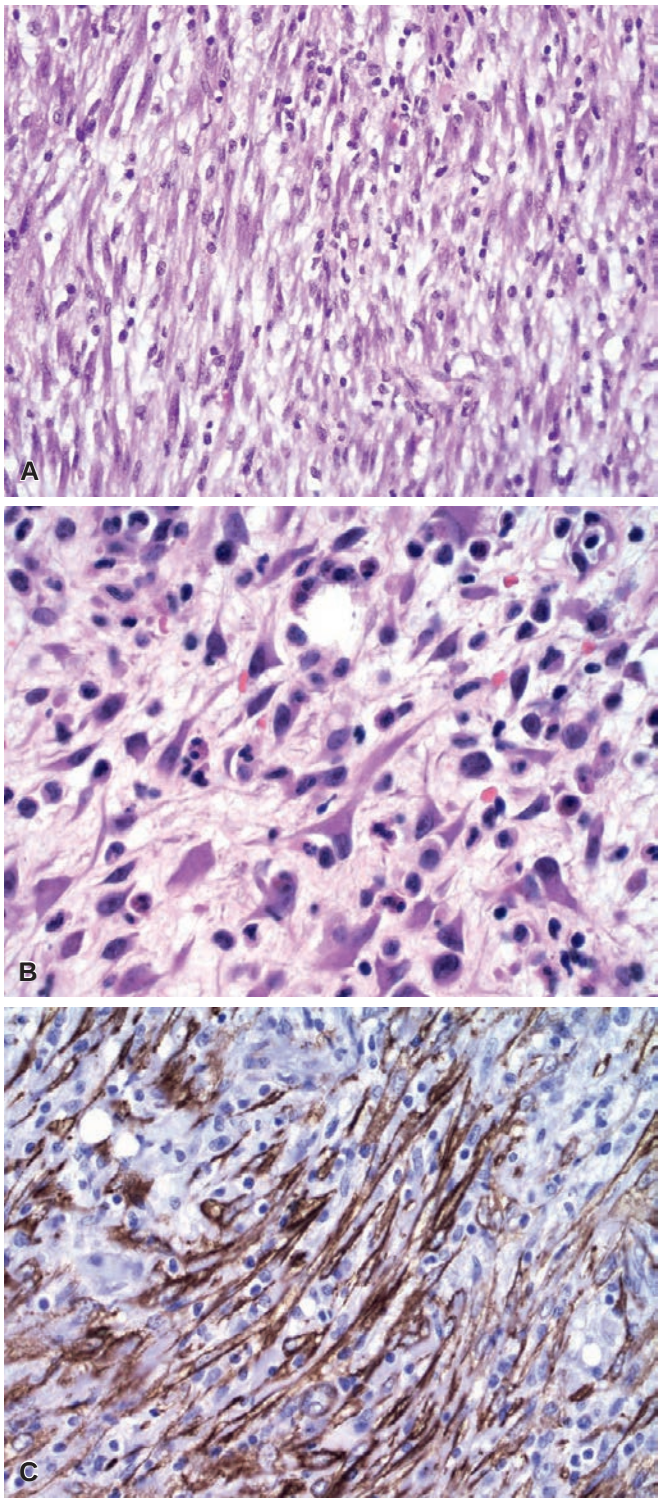

Figure 41.39 Inflammatory Myofibroblastic Tumor. A, Cellular zone with spindle cells and scattered inflammatory cells. **B,** High-power view of myofibroblasts. **C,** "Tram track" pattern of smooth muscle actin staining of myofibroblasts.

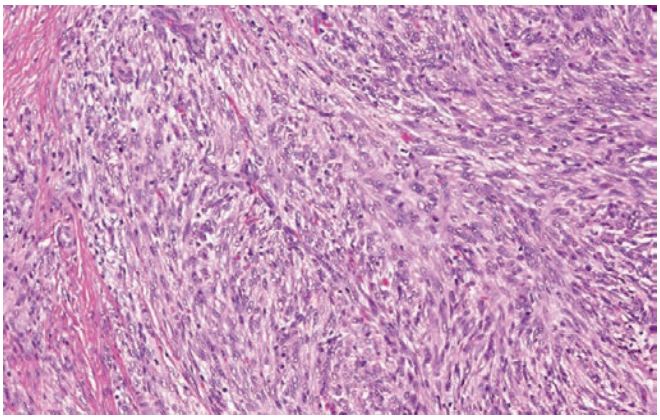

Figure 41.40 Cellular zone of a myofibrosarcoma with plump spindle cells arranged in fascicles.

Benign fibrous histiocytoma. Benign fibrous histiocytoma of skin (also known as dermatofibroma) and soft tissue typically arises in the extremities of young to middle-aged adults.[265] Microscopically, the usual case is composed of closely packed polygonal cells with little or no intervening stroma. The cytoplasm is eosinophilic and may contain lipid droplets. Inflammatory cells are frequently present, as are multinucleated cells (Figs. 41.41 to 41.43). Collagen trapping at the periphery of the lesion is a characteristic feature. Some lesions can be extremely cellular (**cellular fibrous histiocytoma**) (Fig. 41.44),[266,267] and some may have large atypical nuclei (**atypical fibrous histiocytoma**) (Fig. 41.45).[268,269] Still others are composed predominantly of cells with an epithelioid morphology (**epithelioid fibrous histiocytoma**). This variant has recently been associated with rearrangements of the *ALK* gene, with immunohistochemical staining in almost 90% of cases.[270] Some examples also show blood-filled tumor-lined spaces associated with extensive hemosiderin deposition (**aneurysmal fibrous histiocytoma**) (Fig. 41.46).[271]

The classic benign fibrous histiocytoma is superficially located in the skin, but deeply seated examples occur.[272] These have a better-developed storiform pattern, are more circumscribed, and may exhibit prominent hemangiopericytoma-like vessels. They have a 20% incidence of local recurrence. In extremely rare cases, these lesions can metastasize to distant sites.[273,274]

Other benign fibrohistiocytic lesions include xanthoma, solitary (juvenile) xanthogranuloma, and solitary/multicentric reticulohistiocytoma, all of which are described in further detail in Chapter 3.

Hemosiderotic fibrohistiocytic tumor (also known as *hemosiderotic fibrolipomatous lipomatous tumor*, or HFLT) characteristically occurs almost exclusively in the ankle region of elderly patients (usually females).[275] While some have referred to these lesions as "early PHAT" given that some cases of pleomorphic hyalinizing angiectatic tumor (PHAT) are surrounded by areas resembling this lesion,[276] others have found cytogenetic aberrations identical to those found in MIFS—namely a t(1;10) involving *TGFBR3* and *MGEA5*.[235,277] Histologically, it is composed of a poorly circumscribed proliferation of bland spindle cells admixed with fat and hemosiderin.

Cellular neurothekeoma is a tumor that some believe to be histogenetically related to benign fibrous histiocytoma, but this relationship remains unclear. It is clear, however, that this lesion is quite distinct from the lesion which used to be known as classical myxoid neurothekeoma, now better referred to as dermal nerve sheath myxoma. The latter entity is a benign schwannian neoplasm and is discussed later in this chapter.

Cellular neurothekeoma usually occurs in young patients, with a peak incidence in the second decade of life.[278,279] They occur more commonly in women and usually involve the head and neck region, shoulder, or upper extremities. Most are centered in the dermis, but they may extend to involve the underlying subcutaneous tissue in almost half of the cases.

For personal use only. No other uses without permission. Copyright ©2017. Elsevier Inc. All rights reserved.

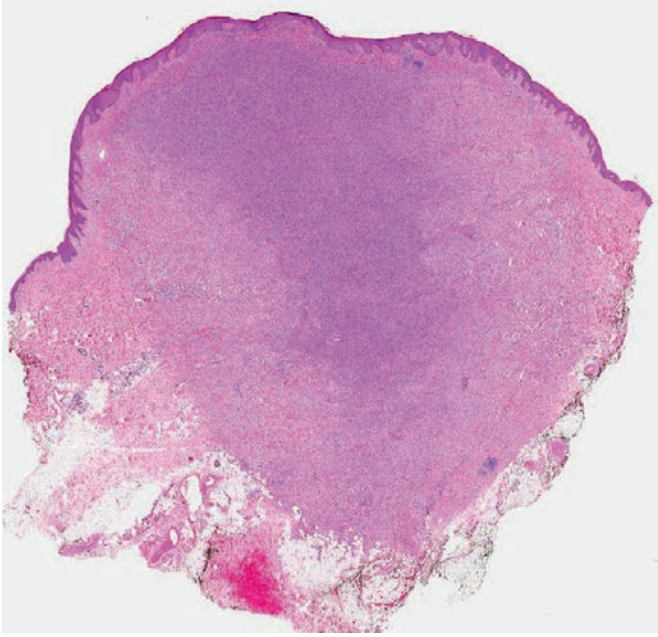

Figure 41.41 Low-power view of classical benign fibrous histiocytoma. The lesion is well circumscribed at its base, and epidermal hyperplasia is apparent.

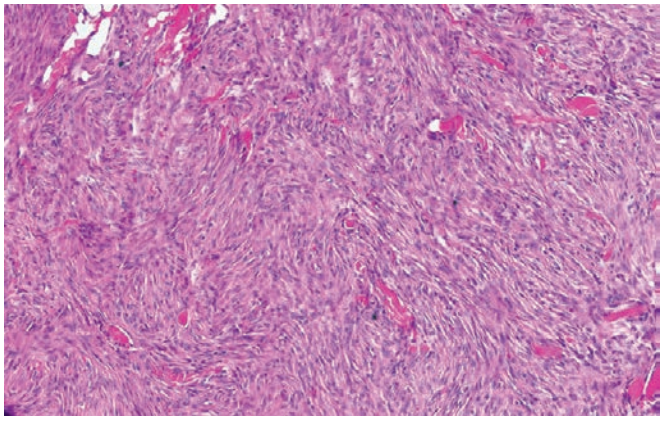

Figure 41.42 Storiform zone in classical benign fibrous histiocytoma.

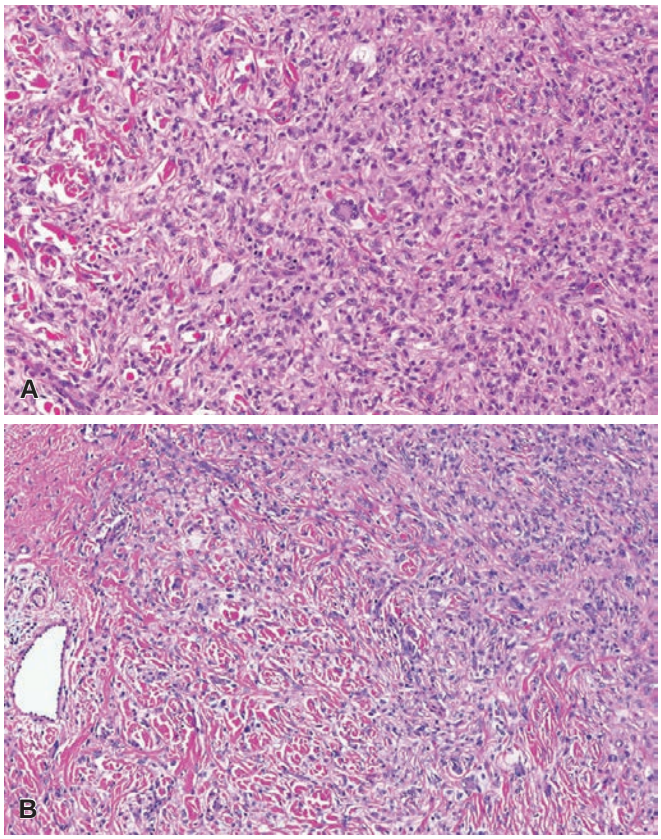

Figure 41.43 **Classical Benign Fibrous Histiocytoma. A,** Scattered multinucleated giant cells and foam cells are seen. **B,** Collagen trapping is often seen at the lateral edge.

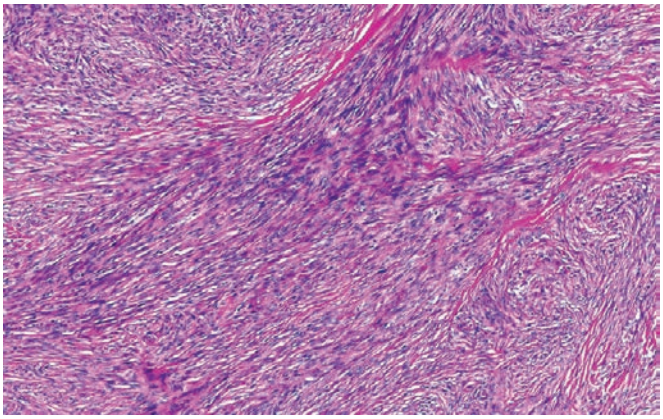

Figure 41.44 Cellular benign fibrous histiocytoma composed of a highly cellular proliferation arranged into fascicles. This is easily mistaken for a sarcoma.

Microscopically, a multinodular, lobular, or plexiform growth pattern is often apparent at low magnification. The tumor cells are typically arranged into nests of varying sizes and are often separated by bands of dense collagen (Fig. 41.47). A whorling growth pattern is frequently prominent, but some cases grow in solid sheets, and still others show prominent myxoid change, thereby making the diagnosis even more difficult. The tumor cells are epithelioid to spindle-shaped, with lightly eosinophilic cytoplasm and bland nuclei. Rare cases display moderate to marked nuclear atypia, which can raise its own challenges for this diagnosis.[279] Mitotic activity can be conspicuous, and rare cases can even show atypical mitotic figures.[278,279] By immunohistochemistry, the tumor cells coexpress CD10 and NKI/C3, but they are negative for S-100 protein.[280] Other frequently positive markers include smooth muscle actin and MiTF.[281]

Cellular neurothekeoma is a benign tumor that can locally recur, particularly for those tumors that arise on the face and those that are incompletely excised.[279] Interestingly, worrisome histologic features, including marked cytologic atypia, prominent mitotic activity, and atypical mitotic figures, have not been associated with a more aggressive clinical course.[279] Recent data (gene expression profiling data) suggest this tumor likely falls within the spectrum of fibrohistiocytic tumors.[282]

Fibrohistiocytic tumors of intermediate (borderline) malignancy. This group of tumors is characterized by local aggressiveness (manifested by a high tendency for local recurrence) but an extremely low rate of distant metastases. This category includes DFSP and its pigmented (Bednar tumor) and "juvenile" variants (giant cell

For personal use only. No other uses without permission. Copyright ©2017. Elsevier Inc. All rights reserved.

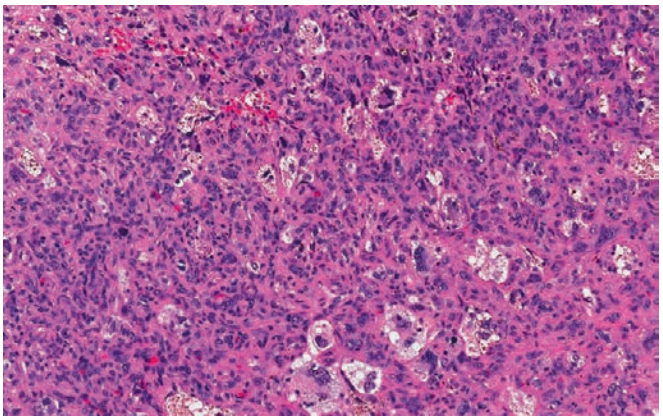

Figure 41.45 Scattered bizarre cells in atypical benign fibrous histiocytoma.

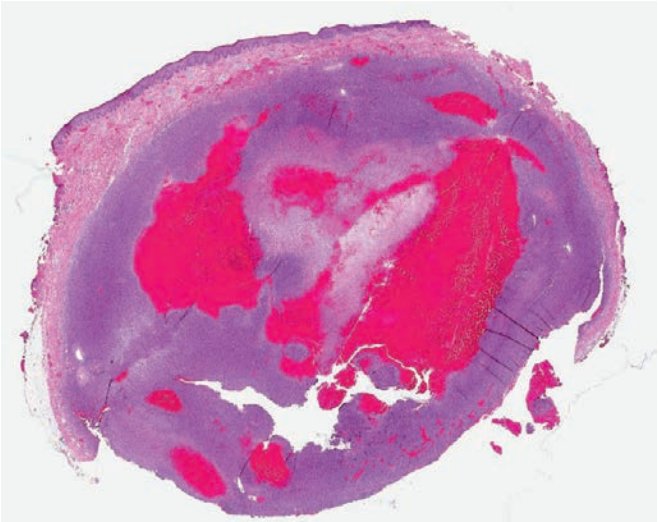

Figure 41.46 Low-power view of aneurysmal benign fibrous histiocytoma with tumor-lined blood-filled lakes.

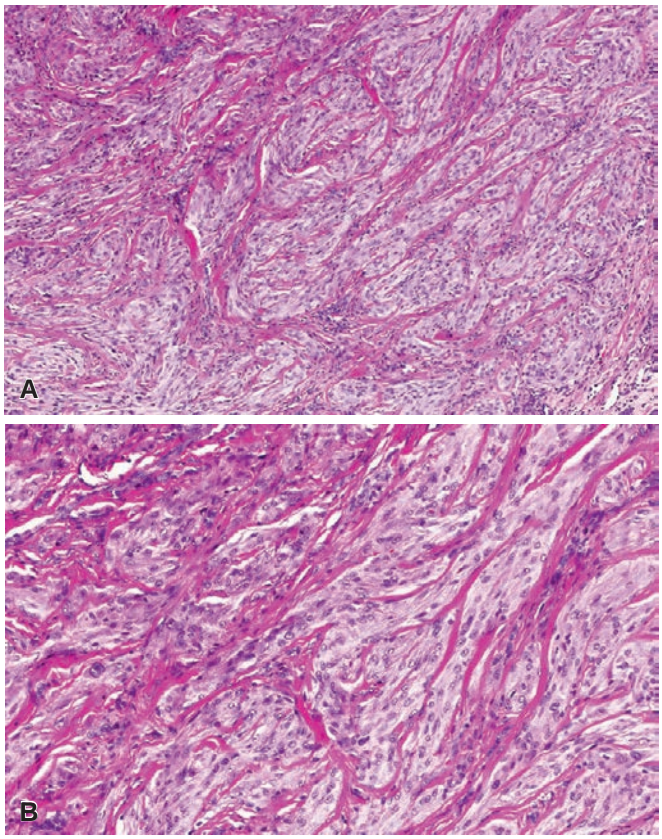

Figure 41.47 **Cellular Neurothekeoma. A,** Nests of plump spindle cells separated by collagen bands. **B,** High-power view of cellular neurothekeoma.

fibroblastoma [GCF]), angiomatoid fibrous histiocytoma, plexiform fibrohistiocytic tumor, and soft tissue giant cell tumor of low malignant potential.

DFSP is typically centered in the dermis, but it can occur in deeper soft tissues.[283] This lesion is characterized microscopically by a lack of circumscription and a proliferation of uniform bland spindle cells arranged in a monotonous storiform pattern (Fig. 41.48). This storiform pattern can also be seen in benign fibrous histiocytomas, as well as in tumors of totally unrelated types (e.g., thymoma), and as such is not specific for DFSP. The collagen appears as nonpolarizable thin strands, in contrast to that present in most benign fibrous histiocytomas, which show prominent thickened entrapped collagen at the periphery.[284,285] Sometimes the tumor has prominent myxoid features.[286,287] The neoplastic cells infiltrate around adnexal structures and into the underlying subcutis in a "lace-like" pattern, thus making it difficult to surgically excise, accounting for the high rate of local recurrence. Virtually all examples stain strongly for CD34, but this marker lacks specificity. Given that at least focal CD34 positivity can be seen in many cutaneous mesenchymal neoplasms, there tends to be overinterpretation of this stain, resulting in a misdiagnosis of DFSP.

Virtually all cases of DFSP have a translocation that involves chromosomes 17 and 22, resulting in fusion of the collagen type I α I *(COL1A1)* and platelet-derived growth factor β *(PDGFβ)* genes, which can be detected by RT-PCR or FISH.[288] This can be used as an adjunctive test in difficult cases, given the specificity of this translocation. A recent study by Karanian et al. found FISH analysis to be helpful in 25% of cases and necessary in 5% of cases.[289]

As previously noted, a close link exists between DFSP and GCF, which shares the same translocation.[290] Indeed, the latter is often regarded as the "juvenile" variant of DFSP.[291–293] It should be noted, however, that classic forms of DFSP can also be seen in the pediatric age group.[294] GCF is characterized by a proliferation of spindle- to stellate-shaped cells deposited in a fibromyxoid stroma with tumor-lined cleft-like spaces with characteristic floret-like giant cells (Fig. 41.49). Like DFSP, this tumor stains strongly for CD34 and has a similar propensity for local recurrence.

Pigmented DFSP (Bednar tumor) looks like the usual DFSP except for the presence of a population of dendritic cells heavily loaded with melanin (Fig. 41.50); the occurrence of this variant is of interest because it raises the possibility of a peripheral nerve sheath origin.[295,296] An alternative possibility, that is, that the melanin-containing dendritic cells are not neoplastic but rather represent secondary melanocyte colonization, has been suggested.[297,298] This pigmented pattern has also been described in cases of GCF, reaffirming the close relationship among these entities.[299]

Some cases of DFSP (as well as GCF and Bednar tumor) progress to a higher-grade sarcoma, most commonly resembling a deep soft tissue fibrosarcoma (**fibrosarcomatous DFSP**). Rarely, the tumor can progress to a UPS ("MFH-like"). In the typical case, there is an abrupt transition from a less-cellular, bland, mitotically inactive spindle cell proliferation arranged in a storiform pattern to a far

For personal use only. No other uses without permission. Copyright ©2017. Elsevier Inc. All rights reserved.

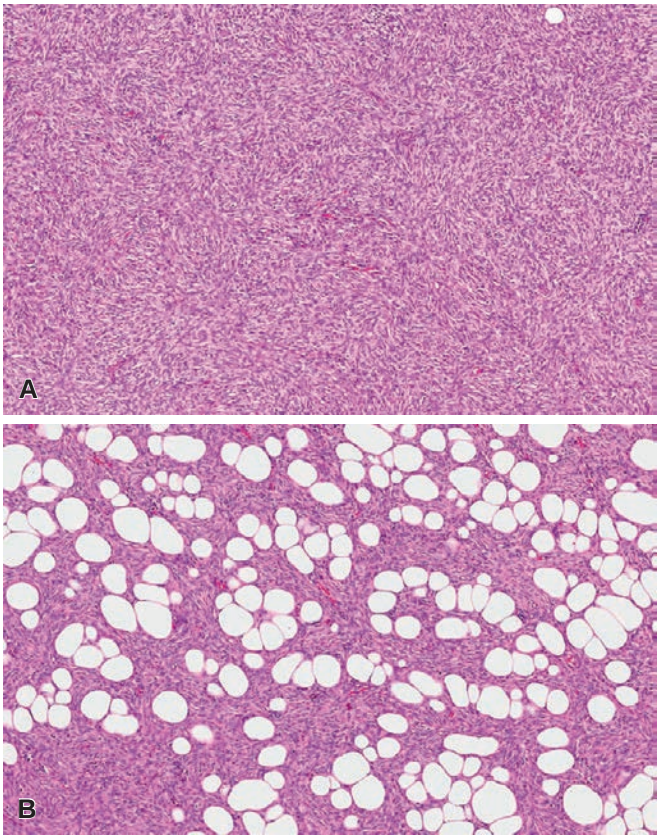

Figure 41.48 Dermatofibrosarcoma Protuberans. A, Characteristic storiform pattern. **B,** Lace-like infiltration into fat at the base of a dermatofibrosarcoma protuberans.

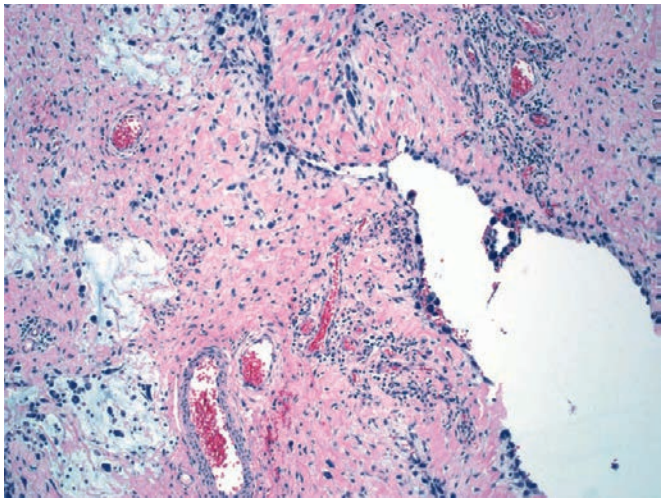

Figure 41.49 Giant cell fibroblastoma with myxoid and pseudovascular spaces lined by atypical giant cells.

more cellular proliferation of hyperchromatic, mitotically active spindle cells arranged in long fascicles (herringbone pattern) (Fig. 41.51). On occasion, this transition is more gradual, going from classical DFSP to a hypercellular DFSP to fibrosarcoma. Often but not always, there is decreased or absent CD34 staining in the fibrosarcomatous component. This transformation clearly increases the clinical aggressiveness of this tumor, with a higher rate of metastasis and occasionally even resulting in the death of the

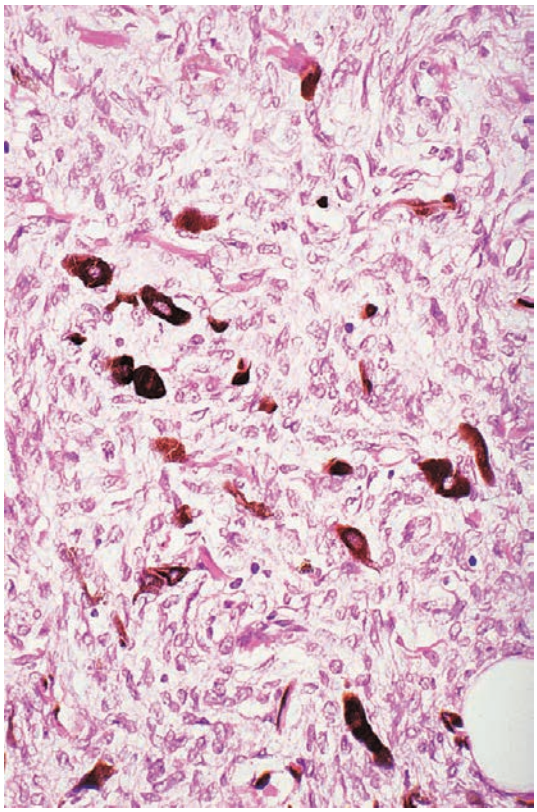

Figure 41.50 Pigmented dermatofibrosarcoma protuberans (Bednar tumor). Scattered pigmented cells are seen among the spindle cells.

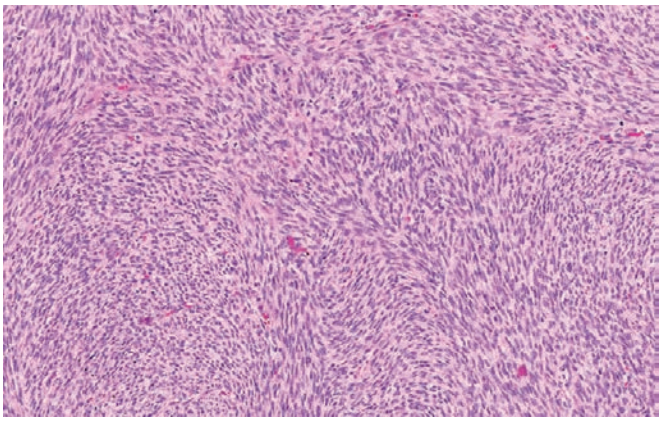

Figure 41.51 Fibrosarcomatous transformation of a dermatofibrosarcoma protuberans with a herringbone spindle cell pattern.

patient.[300] However, complete excision with tumor-free margins seems to improve the long-term outcome of these patients.[301]

Angiomatoid fibrous histiocytoma was originally considered a variant of so-called malignant fibrous histiocytoma (MFH) but subsequently was found to be unrelated to that group of tumors. It usually arises in the extremities of children and young adults as a circumscribed, multinodular, or multicystic hemorrhagic tumor.[302–304] Microscopically, it is composed of epithelioid or sometimes spindle cells arranged in sheets and often punctuated by blood-filled tumor-lined spaces (Figs. 41.52 to 41.54). The cells have "histiocytoid" features and eosinophilic cytoplasm with mild nuclear pleomorphism, although occasionally marked nuclear pleomorphism can be seen.[305,306] Some cases lack the ectatic blood-filled spaces and are solidly cellular,

For personal use only. No other uses without permission. Copyright ©2017. Elsevier Inc. All rights reserved.

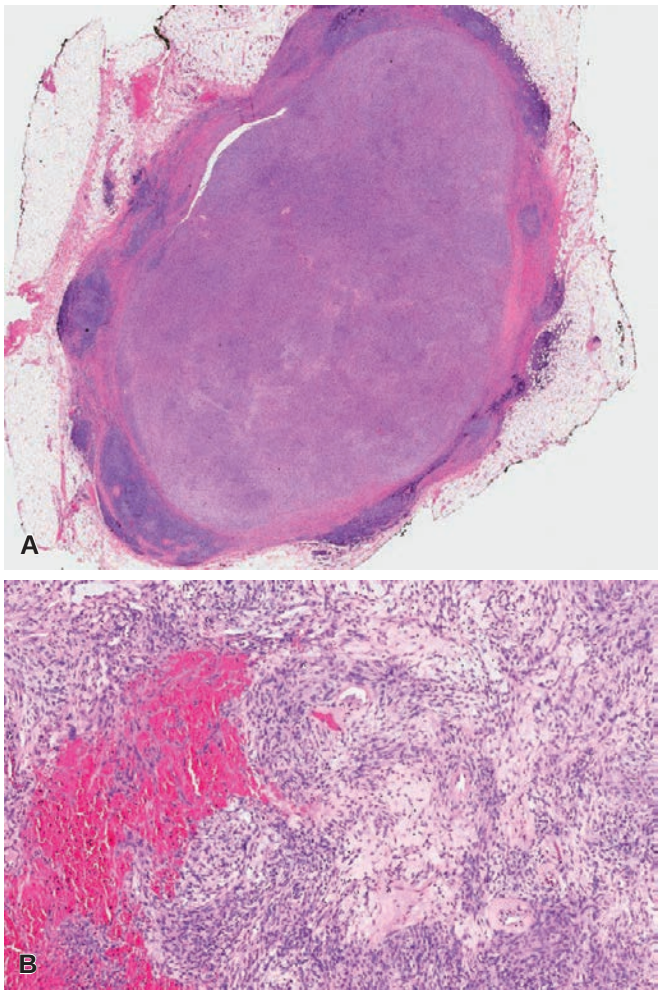

Figure 41.52 Angiomatoid Fibrous Histiocytoma. A, Low-power view closely mimicking a tumor metastasis to a lymph node. **B,** Blood lake in angiomatoid fibrous histiocytoma.

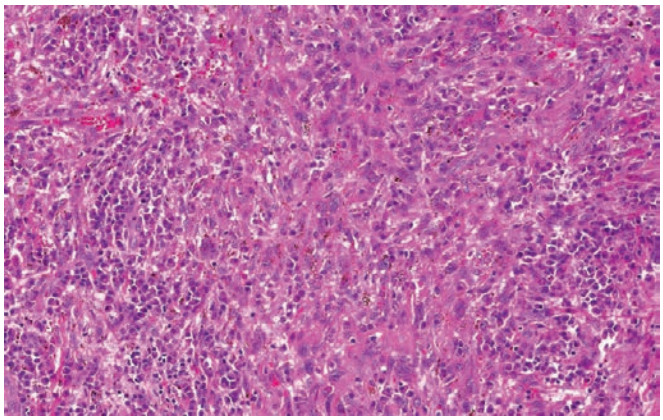

Figure 41.53 Hemosiderin deposition in histiocyte-like tumor cells in angiomatoid fibrous histiocytoma.

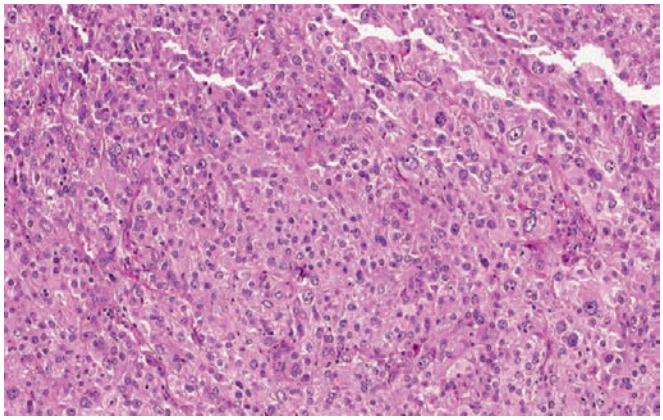

Figure 41.54 Eosinophilic histiocyte-like cells in a solid zone of angiomatoid fibrous histiocytoma.

and others show a prominent myxoid stroma.[307,308] The tumor is characteristically surrounded by nodular lymphoid aggregates, which may even simulate a lymph node, resulting in the mistaken impression of a tumor metastatic to a lymph node. By immunohistochemistry, the tumor stains for desmin in up to 50% of cases,[304] and staining for EMA and CD99 is also commonly seen. Recurrent chromosomal aberrations have been found, most commonly t(2;22)(q33;q12) with *EWSR1-CREB1* fusion, and less commonly t(12;16)(q13;p11) with *FUS-ATF1* fusion or t(12;22)(q13;q12) with *EWSR1-ATF1* fusion.[309–312] Angiomatoid fibrous histiocytoma is a low-grade tumor that has a tendency for local recurrence, but can also rarely metastasize to distant sites.[304]

Plexiform fibrohistiocytic tumor occurs almost exclusively in children or young adults.[313] It usually presents as a superficial, slowly growing lesion in the upper or lower extremities. Most are small ill-defined masses centered in the deep dermis or subcutis and are composed of an intimate admixture of spindled cells and nodules of round histiocyte-like cells with multinucleated osteoclast-like giant cells (Fig. 41.55). The spindle cells have fibroblastic features and are arranged in short fascicles and have bland nuclear features. The overall low-power appearance imparts a plexiform pattern of growth. The two areas vary in proportion from case to case. The histiocyte-like cells often stain for CD68, and the spindle cells express SMA (without desmin or h-caldesmon) consistent with myofibroblastic differentiation. The tumor recurs in up to 40% of cases and rarely metastasizes to lymph nodes or the lungs.[314–317]

Giant cell tumor of soft tissue (also known as soft tissue giant cell tumor of low malignant potential) is similar in many ways to giant cell tumor of bone.[318,319] It occurs in patients of all ages, most commonly in the superficial or deep soft tissues of the hand or arm. At low power, there are multiple tumor nodules that infiltrate the surrounding soft tissue. The predominant cell types are bland mononuclear cells, osteoclasts, and short spindle cells (Fig. 41.56). Although both mitotic activity and vascular invasion may be present, these lesions rarely recur or metastasize.[320–322] These lesions are histologically nearly identical to giant cell tumor of bone, but recent molecular studies suggest they are distinct entities.[322a]

Malignant Fibrohistiocytic Tumors

In prior editions of this textbook, MFH had a prominent place in this chapter. However, it has become apparent that this term encompasses a number of related and unrelated entities, and the term UPS has supplanted MFH as the preferred term for a high-grade pleomorphic sarcoma that usually arises in the deep soft tissue of elderly patients.[323] In Fletcher's classic paper re-reviewing cases previously classified as MFH, over 60% of cases were reclassified as some type of pleomorphic sarcoma showing a specific line of differentiation (e.g., pleomorphic liposarcoma, pleomorphic

For personal use only. No other uses without permission. Copyright ©2017. Elsevier Inc. All rights reserved.

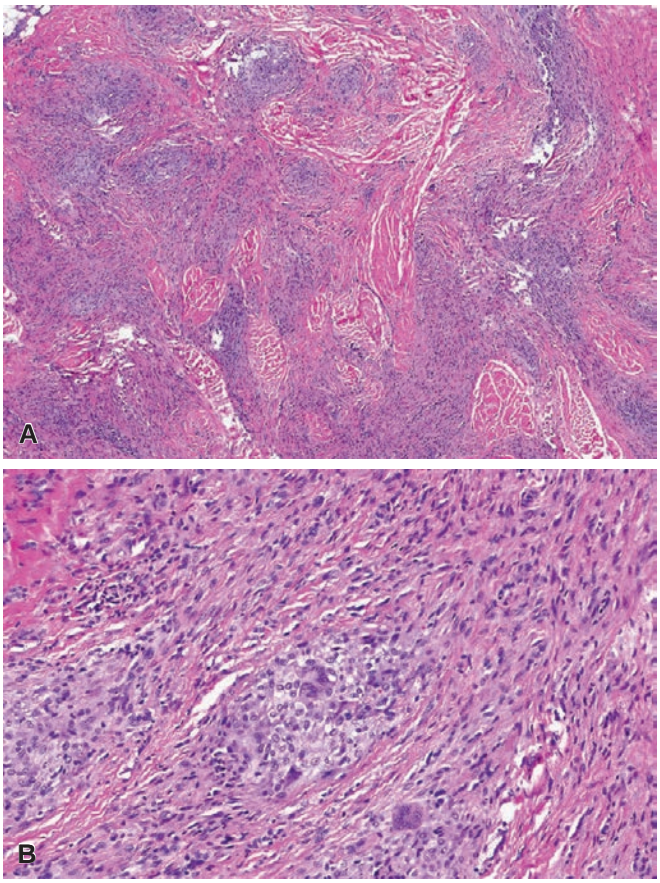

Figure 41.55 Plexiform Fibrohistiocytic Tumor. A, Nodules of spindle cells in a myxoid stroma are arranged in a plexiform pattern. **B,** Nodules of histiocytoid cells with rare giant cells are often seen.

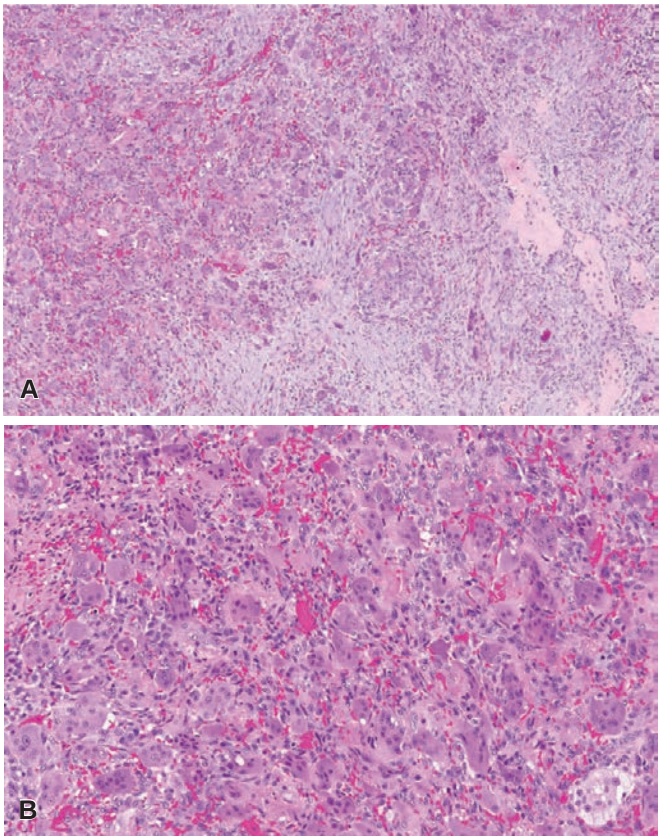

Figure 41.56 Giant Cell Tumor of Soft Tissue. A, Nodules of giant cells are seen. **B,** High-power view of giant cells within a nodule.

leiomyosarcoma, pleomorphic rhabdomyosarcoma). About 12.5% of cases proved to be some other type of pleomorphic malignant neoplasm resembling a sarcoma, most commonly a sarcomatoid carcinoma. This still left about 25% of cases which were unclassifiable and by exclusion were felt to represent an UPS. This observation has been substantiated by others and hence the preference for the term UPS.[324,325]

As previously mentioned, most cases of UPS arise in the deep soft tissues of the extremities of middle-aged to elderly patients (Fig. 41.57), although they have been described in virtually every anatomic site. Of particular note are those cases arising in the retroperitoneum, as extensive sampling and molecular analysis for *MDM2* amplification usually reveal such lesions to represent the dedifferentiated component of a dedifferentiated liposarcoma.[326] The classic form of UPS shows both storiform and pleomorphic features, with plump spindle cells with marked cytologic atypia arranged in tight whorls (Fig. 41.58). Mitotic figures including atypical forms are typically seen, as are secondary elements including chronic inflammatory cells, xanthoma cells, multinucleated giant cells, and extensive areas of necrosis. Some examples have numerous giant cells, a lesion formerly referred to as *giant cell MFH* (Fig. 41.59).[318] Those with a prominent neutrophilic and xanthomatous infiltrate have also been referred to as *inflammatory MFH* (Fig. 41.60),[327] but inasmuch as most of these arise in the retroperitoneum, it is now believed that almost all tumors of this type also represent dedifferentiated liposarcomas.[328] Some examples show prominent myxoid change, with an elaborate curvilinear vascular pattern. In the past, *myxoid MFH* was used for such tumors that were greater than 50% myxoid. However, that term has

Figure 41.57 Large undifferentiated pleomorphic sarcoma with areas of necrosis.

For personal use only. No other uses without permission. Copyright ©2017. Elsevier Inc. All rights reserved.

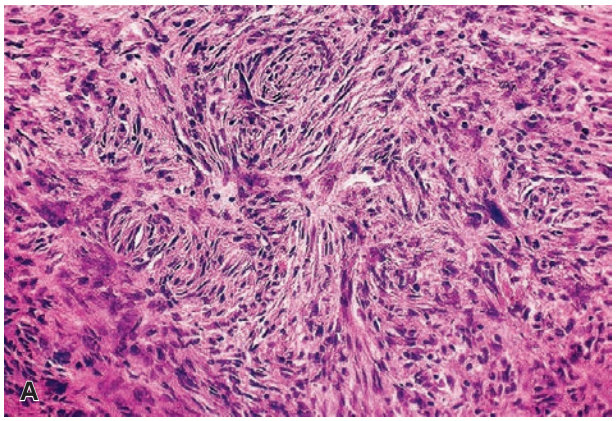

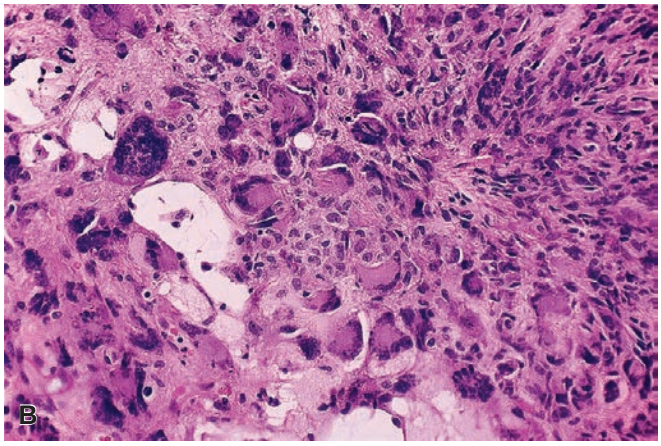

Figure 41.58 Undifferentiated Pleomorphic Sarcoma. A, Prominent storiform growth pattern. **B,** Marked nuclear pleomorphism and scattered giant cells are seen.

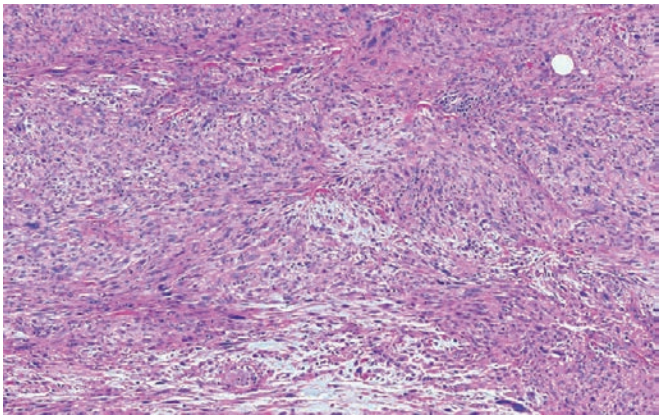

Figure 41.59 Undifferentiated pleomorphic sarcoma with very focal myxoid change comprising less than 5% of the tumor.

been replaced by *myxofibrosarcoma* (described in greater detail later in this chapter). Admittedly, an arbitrary distinction must sometimes be made between UPS with focal myxoid change and a high-grade myxofibrosarcoma.[327,329]

By immunohistochemistry, UPS has no distinctive staining pattern, although many show evidence of myofibroblastic differentiation with patchy staining for smooth muscle actin and the absence of staining for desmin or h-caldesmon.[330] "Aberrant" cytokeratin staining may occur focally and is not necessarily evidence of a sarcomatoid carcinoma.[331,332] By cytogenetics, UPS, like all types of

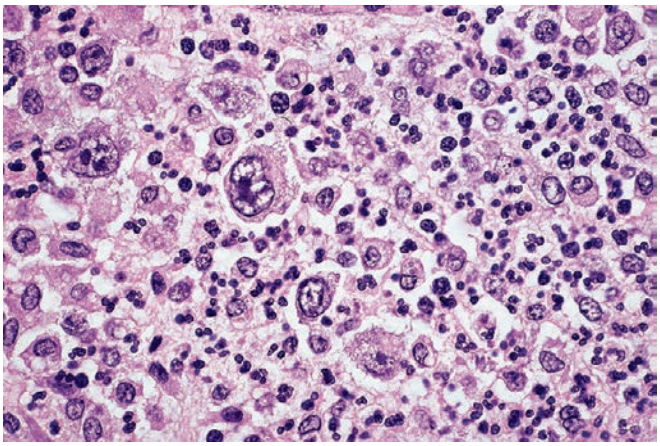

Figure 41.60 Undifferentiated pleomorphic sarcoma with prominent acute inflammation, a lesion formerly known as "inflammatory MFH."

pleomorphic sarcomas, has a complex but nonspecific karyotype, and, as such, this technique is not helpful in subtyping pleomorphic sarcomas.[333]

The tumor is prone to local recurrence and has the capacity to metastasize to distant sites, especially the lungs. Prognostic factors include tumor depth, tumor size, grade, extent of necrosis, and local recurrence.[334]

Myxofibrosarcoma is the term currently preferred for the tumor formerly known as myxoid MFH. Most of these tumors arise in the extremities of adults, often centered in the subcutis with attachments to the fascia.[314,329] Grossly, they often have a mucoid cut surface. Microscopically, the low-grade forms exhibit an abundant myxoid matrix, spindle cells with at least a minor degree of cytologic atypia, and an arborizing vascular pattern (Figs. 41.61 and 41.62).[335] At the higher end of the spectrum, tumors have greater cellularity, a greater degree of nuclear atypia, and an elaborate vascular pattern with interconnecting curvilinear vessels. These high-grade areas merge with foci resembling UPS. Lipoblast-like cells (pseudolipoblasts) may be identified, but these are not true lipoblasts but rather are cells that have imbibed the acid mucopolysaccharide-rich stroma resulting in cytoplasmic vacuoles. Rare cases show focal or even a predominant epithelioid morphology, making the diagnosis even more difficult.[336] There is a relationship between tumor grade (which can range from 1 to 3) and prognosis, but even low-grade tumors have the potential for local recurrence and tumor progression.[326,337–339]

Tumors of Synovial Tissues

Giant Cell Tumor of Tendon Sheath (Tenosynovial Giant Cell Tumor, Localized Type)

The localized form of **giant cell tumor of tendon sheath** is a common lesion seen on the distal extremities (hands more than toes) and is twice as common in women as men with a peak in the fourth through sixth decades of life.[340,341] The tumor grows slowly over time and presents as a discrete nodule, which is attached to deep structures. Erosion of adjacent cortical bone may occur, but true bony invasion is extremely rare.[342]

Microscopically, it is a well-circumscribed, lobulated mass partially invested by a dense collagenous capsule, although nodules may be seen outside of this capsule. There is a variable proportion of small and large mononuclear cells, multinucleated giant cells, xanthoma cells, inflammatory cells, and hemosiderin. Most tumors are

For personal use only. No other uses without permission. Copyright ©2017. Elsevier Inc. All rights reserved.

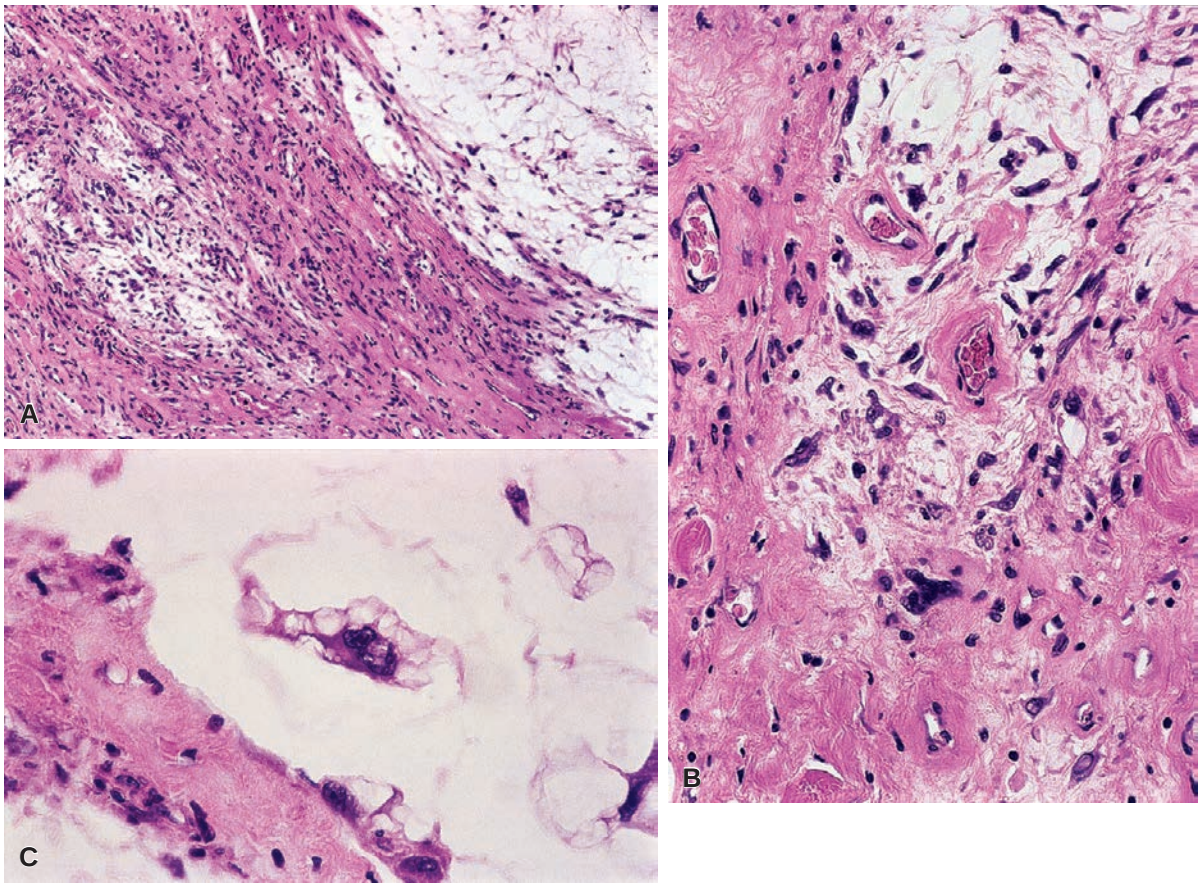

Figure 41.61 Myxofibrosarcoma, Formerly Known as "Myxoid MFH." A, Alternation of cellular and myxoid zones. **B,** There is moderate nuclear pleomorphism of the tumor cells. **C,** Rare lipoblast-like cells (pseudolipoblasts) are often seen.

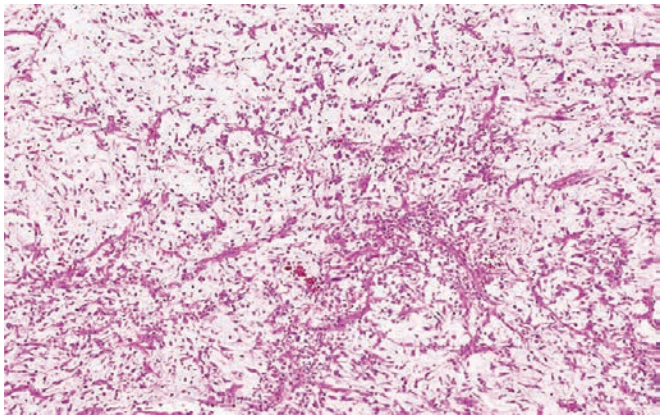

Figure 41.62 Myxofibrosarcoma with arborizing blood vessels and perivascular hypercellularity.

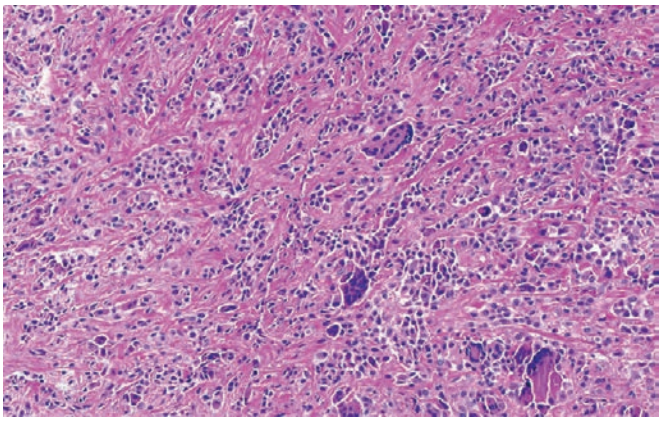

Figure 41.63 Giant cell tumor of tendon sheath with linear arrays of mononuclear cells deposited in a collagen background admixed with multinucleated giant cells.

moderately cellular, with cells blending with hyalinized collagen (Figs. 41.63 and 41.64). Others are less cellular and more extensively hyalinized. Multinucleated cells form by fusion of the smaller mononuclear cells, and in some cases, they are quite sparse, making recognition of this tumor more challenging. Cleft-like spaces are often a prominent feature at the tumor periphery. Some cases show high cellularity, vigorous mitotic activity and even involvement of vascular structures, but none of these features seems to portend a more aggressive clinical course.

By immunohistochemistry, the mononuclear cells stain for CD45, CD68, and CD163, consistent with histiocytic differentiation.[343–345] The larger mononuclear cells express clusterin, but the small mononuclear cells and multinucleated giant cells are negative for this antigen.[346] These same larger mononuclear cells also often express desmin,[346] an immunophenotype similar to normal synoviocytes. While some have argued for a non-neoplastic origin, the presence of clonal cytogenetic abnormalities[347] and, more specifically, rearrangements of the *CSF1* gene at 1p11-13[348,349] support a neoplastic origin.

For personal use only. No other uses without permission. Copyright ©2017. Elsevier Inc. All rights reserved.

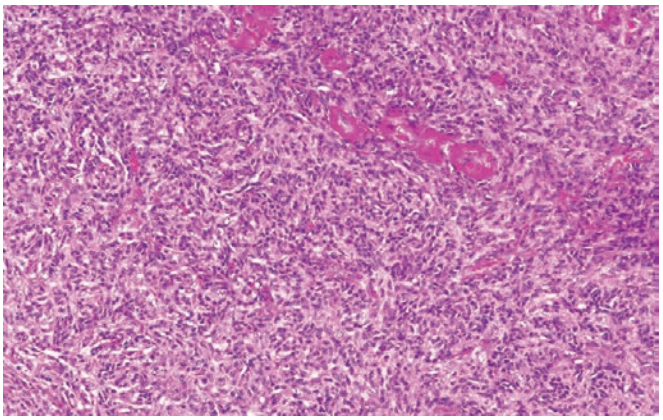

Figure 41.64 A monotonous population of mononuclear cells in a giant cell tumor of tendon sheath. No giant cells are seen in this case.

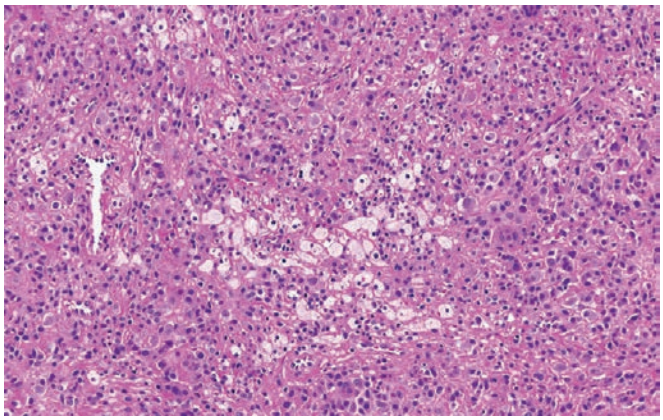

Figure 41.65 Sheets of mononuclear cells and xanthoma cells in a diffuse-type giant cell tumor.

The lesion is benign but locally recurs in 10%–20% of cases.[341,350,351] These recurrences are nondestructive and can be reexcised without much difficulty.

Very rarely, malignancy seems to arise in the setting of a giant cell tumor (**malignant giant cell tumor of tendon sheath**). This designation should be reserved for tumors with unequivocal malignant areas that arise either next to or subsequent to classical giant cell tumor.[352,353] The malignant areas are usually composed of sheets or discrete nodules of large ovoid cells with prominent nucleoli, although some resemble fibrosarcoma or UPS.[353] Up to 50% of these tumors metastasize, usually to regional lymph nodes. Wide local excision or even amputation is the recommended mode of therapy.

Giant Cell Tumor of Tendon Sheath, Diffuse-Type/ Pigmented Villonodular Synovitis

The **diffuse giant cell tumor of tendon sheath** can be regarded as the extra-articular counterpart of **pigmented villonodular synovitis**, which is an intra-articular process. In the majority of cases, soft tissue involvement is secondary to extensive growth from an intra-articular process, but some cases are exclusively in the soft tissues.[345,354,355] These lesions are far less common than the localized type, and they tend to occur in younger patients, with a peak incidence in the fifth decade of life.[345] They most commonly occur near the knee, followed by the ankle and foot. Unlike the localized form, they arise as a less circumscribed process with infiltration of surrounding tissues, accounting for the much higher rate of local recurrence. The cellular constituents and immunophenotype are identical to those seen in the localized form, although giant cells tend to be less conspicuous (Fig. 41.65). *CSF1* aberrations are also seen in these tumors, indicating a clear histogenetic connection to the localized form. Given the high rate of local recurrence, therapy should be directed at an attempt to remove the tumor as completely as possible while minimizing morbidity.

Tumors and Tumorlike Conditions of Peripheral Nerves

Proliferative lesions of peripheral nerves are divided into non-neoplastic (such as traumatic neuroma), benign tumors (such as schwannomas, neurofibromas, and perineuriomas), and malignant tumors, collectively designated as MPNSTs. Despite the fact that these lesions may overlap and coexist with each other, it is important to make a distinction among them in view of their markedly different natural history.

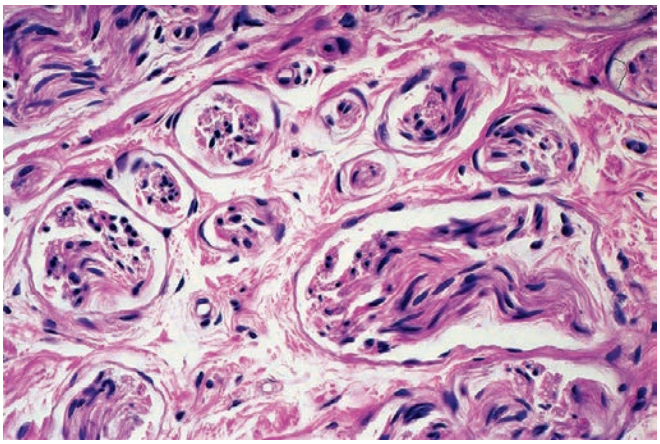

Figure 41.66 Traumatic neuroma with a haphazard distribution of nerve trunks surrounded by fibrous tissue.

Neuroma

The large majority of neuromas follow trauma—hence their designation as **traumatic neuromas**. When a peripheral nerve is severed or crushed, the distal end undergoes wallerian degeneration, whereas the proximal end regenerates. If it fails to meet the distal end, a tangled mass of nerve fibers results. Microscopically, all the elements of a nerve can be recognized: axons, Schwann cells, perineurial cells, and fibroblasts (Fig. 41.66). In addition, scar tissue is often present. Not surprisingly, this lesion may be exquisitely painful. Immunohistochemically, the Schwann cells of traumatic neuroma show aberrant expression of the macrophage-associated antigens CD68 and Ki-M1P, in keeping with the macrophagic properties that they are known to acquire under these circumstances.[356] **Amputation neuroma**, a term made popular during the First World War, is a type of traumatic neuroma in which the original trauma involves the loss of part or all of an extremity.

Morton neuroma (Morton metatarsalgia) can be regarded as a subtype of traumatic neuroma caused by repeated mild trauma to the region.[357] Its typical location is the interdigital plantar nerve between the third and fourth toes. The lesion is more common in female adults. Microscopically, the affected nerve is markedly distorted with extensive perineurial fibrosis, often arranged in a concentric fashion.

Palisaded encapsulated neuroma (solitary circumscribed neuroma) presents as a small, solitary, asymptomatic papule in the

For personal use only. No other uses without permission. Copyright ©2017. Elsevier Inc. All rights reserved.

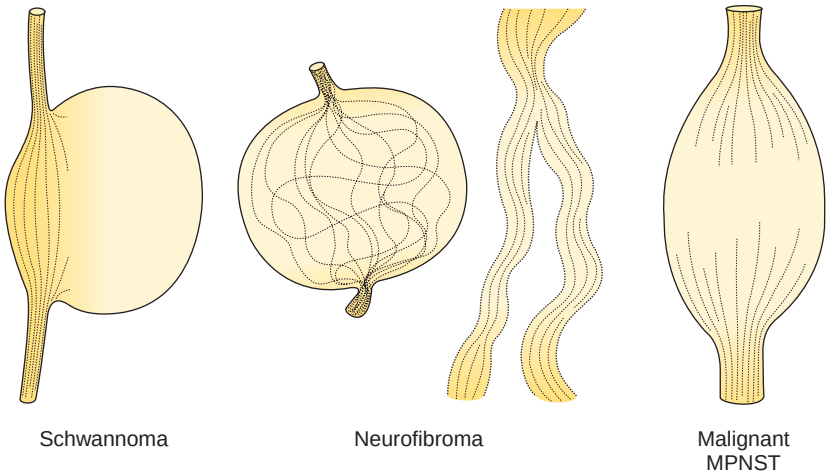

Figure 41.67 Schematic drawing emphasizing the main differences between the three major types of peripheral nerve tumors. Note diameter of nerve involved and behavior of neurites *(thin black lines)* in relation to the neoplasm. *MPNST*, malignant peripheral nerve sheath tumor.

skin,[358,359] usually arising on the face of middle-aged individuals. Microscopically, the lesion is centered in the dermis (in contrast to schwannoma, which is rarely seen in this location) and is characterized by a proliferation of Schwann cells and numerous axons located within a capsule derived from perineurium.[360] Immunohistochemically, the Schwann cells are reactive for S-100 protein, the axons for neurofilaments, and the capsule for EMA, the latter indicating the presence of perineurial cells.[360,361]

Schwannoma (Neurilemoma)

Schwannoma (neurilemoma) is one of the few truly encapsulated neoplasms. Its most common locations are the flexor surfaces of the extremities, neck, mediastinum, retroperitoneum, posterior spinal roots, and cerebellopontine angle. The nerve of origin often can be demonstrated in the periphery, flattened along the capsule but not penetrating the substance of the tumor (Fig. 41.67). Since this is a benign neoplasm that only rarely recurs locally, every attempt should be made to preserve the nerve, if this is of any clinical significance (e.g., facial nerve or vagus nerve). The great majority of cases occur sporadically, while a small percentage of cases are associated with type 2 neurofibromatosis (caused by a germline mutation in the *NF2* gene located on 22q12, which encodes merlin, also known as schwannomin).[362]

Grossly, the larger schwannomas often contain cystic areas (Fig. 41.68). The microscopic appearance is distinctive with Antoni A and B zones (Figs. 41.69 to 41.72). The Antoni A zones, which in small tumors comprise almost their entirety, are quite cellular, composed of spindle cells often arranged in a palisading fashion or in an organoid arrangement (Verocay bodies). In Antoni B zones, the tumor cells are separated by abundant edematous fluid that may form cystic spaces. Occasionally, isolated cells with bizarre hyperchromatic nuclei are observed (so-called ancient schwannoma) and are of no particular significance.[363] Mitoses are usually absent or rare. Thick-walled hyalinized blood vessels are a characteristic finding, sometimes with thrombosis. Some cases show prominent nuclear palisading, but this is not unique to schwannoma, as this feature may also be seen in smooth muscle tumors, among others. The traditional wisdom is that (in contrast to neurofibromas, see later) axons are not present in schwannoma, except in the portion of the

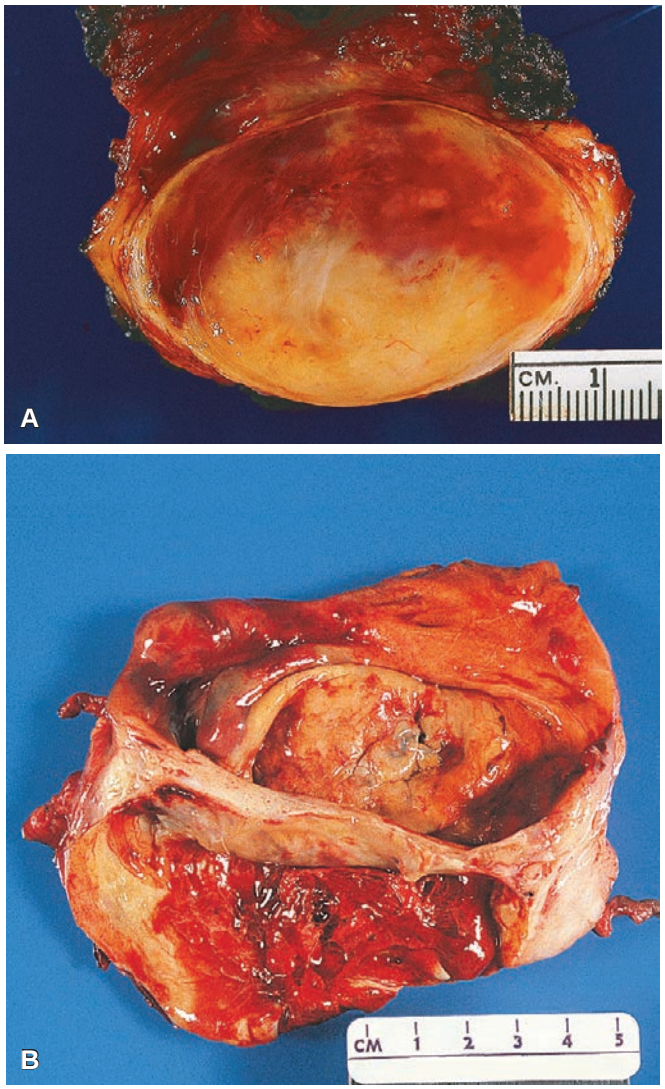

Figure 41.68 Gross Appearances of Schwannoma. The tumor shown in **B** has undergone marked secondary cystic changes.

For personal use only. No other uses without permission. Copyright ©2017. Elsevier Inc. All rights reserved.

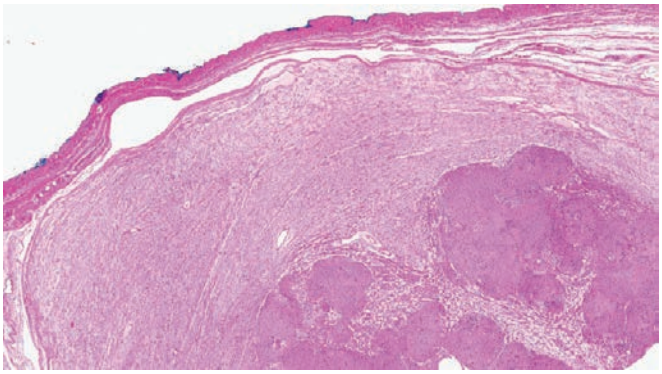

Figure 41.69 Low-power view of schwannoma with capsule and Antoni A and B areas.

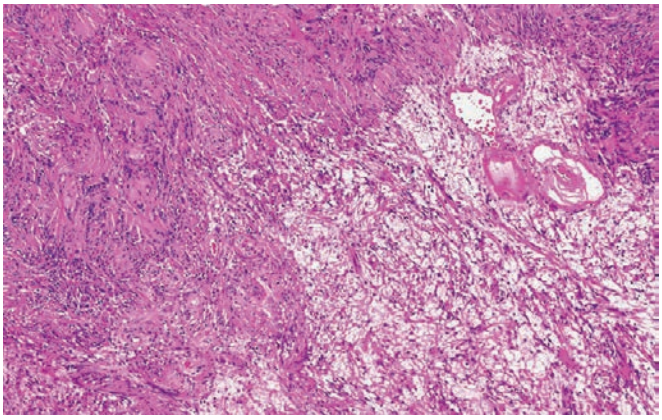

Figure 41.70 Junction of Antoni A and B zones in a schwannoma.

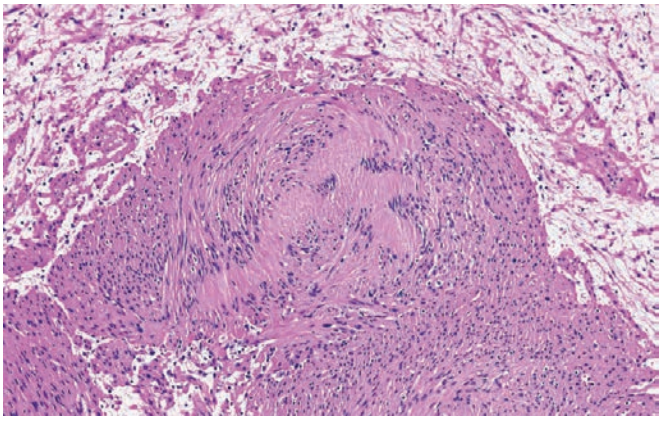

Figure 41.71 Verocay bodies in a schwannoma.

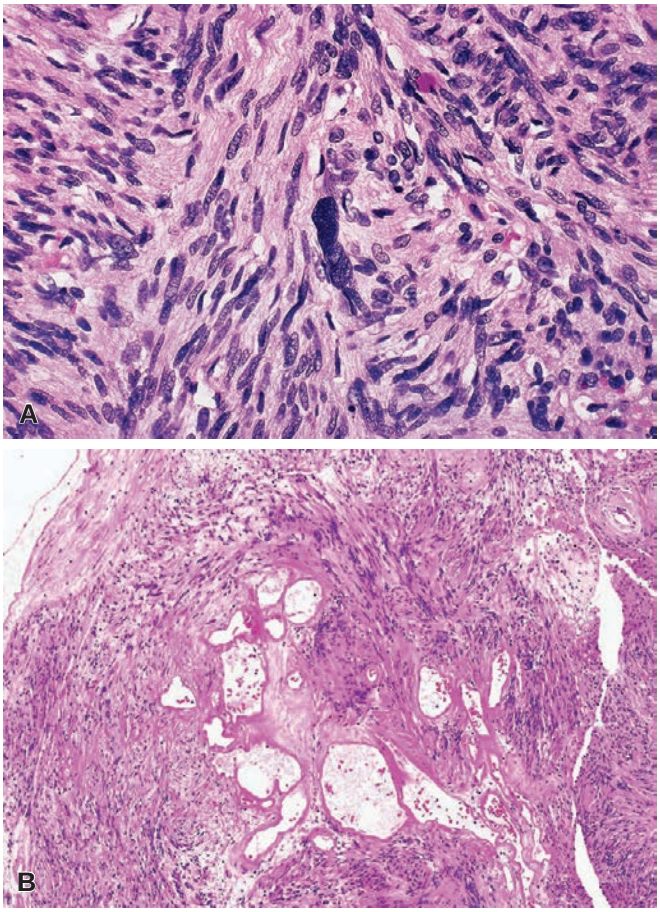

Figure 41.72 **Schwannoma. A,** Large hyperchromatic nuclei are seen. This does not necessarily indicate malignant change. **B,** Thick-walled hyalinized blood vessels are a prominent feature.

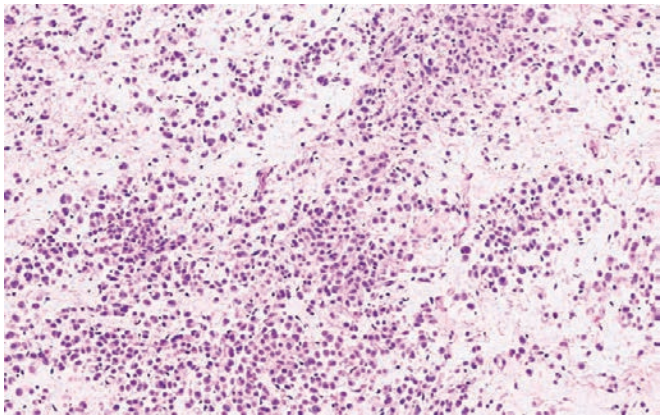

Figure 41.73 Epithelioid schwannoma with epithelioid Schwann cells deposited in a myxoid matrix.

capsule where the nerve is attached; however, recent studies employing an antibody against neurofilament have challenged that assumption.[336] Collections of foamy macrophages are sometimes seen, especially in larger neoplasms. More unusual is the presence of clusters of granular cells similar to those seen in granular cell tumors.[364] The rare occurrence of plexiform areas in schwannoma may cause them to be mistaken for neurofibroma. Most of these *plexiform schwannomas* are found superficially in the dermis or subcutaneous tissue, but they can also be deep-seated.[365,366]

Epithelioid areas can also be present, although much less commonly than in neurofibroma and MPNST.[367] When these areas predominate, the tumor has been referred to as *benign epithelioid schwannoma* (Fig. 41.73). Recently, it has been found that almost 50% of these lesions showed loss of INI1 expression.[367a] Some of these lesions can show striking cytologic atypia and in rare cases can transform into epithelioid MPNST. A few cases of schwannoma containing a glandular component have been described *(benign glandular schwannomas)*.[368,369] These should be distinguished from the pseudoglandular formations lined by low columnar or cuboidal

For personal use only. No other uses without permission. Copyright ©2017. Elsevier Inc. All rights reserved.

Schwann cells having an epithelial-like appearance,[370,371] as well as from entrapped sweat glands.

Rare schwannomas are found to contain melanin pigment. When this feature is prominent and accompanied by psammoma body formation, the possibility of the tumor representing a psammomatous melanotic schwannoma should be considered[372] (see subsequent sections). Rarely, schwannomas (and neurofibromas) can exhibit a lipoblastic component, accompanied by cells with signet ring–like features.[373] Other schwannomas have a predominant *microcystic/reticular* appearance; these manifest a predilection for visceral locations, particularly the gastrointestinal tract.[374]

Exceptionally, otherwise typical schwannomas or those with epithelioid features have been found to contain foci of small, round hyperchromatic Schwann cells with scanty cytoplasm, sometimes forming rosettes and simulating neuroblastoma.[375,376]

By electron microscopy, the tumor cells show features of schwannian differentiation with a continuous and often reduplicated basal lamina; numerous, extremely thin cytoplasmic processes; aggregates of intracytoplasmic microfibrils; peculiar intracytoplasmic lamellar bodies; and extracellular long-spacing collagen.[377] Immunohistochemically, the tumor cells show immunoreactivity for S-100 protein (Fig. 41.74), calretinin (in contrast to neurofibromas) and basal lamina components (such as laminin and type IV collagen).[335] Curiously, keratin is often expressed in retroperitoneal schwannomas but virtually never in peripheral schwannomas.[378] Genetically, schwannoma, whether sporadic or associated with type 2 neurofibromatosis, is characterized by somatic mutation (sporadic form) or germline mutation (type 2 neurofibromatosis) of the *NF2* gene in one allele, and loss of *NF2* in the remaining allele through deletion or monosomy 22.[379,380]

Malignant transformation of schwannoma is—in contrast to neurofibroma—an exceptionally rare event, but undoubtedly occurs.[381,382] Interestingly, in most of these cases the malignant component has exhibited an epithelioid morphology.[383]

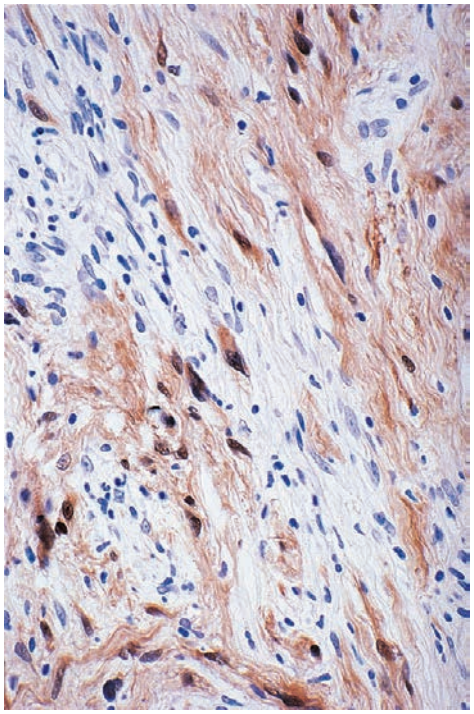

Figure 41.74 S-100 protein immunoreactivity in a schwannoma.

Cellular schwannoma is the term used for highly cellular schwannomas that are exclusively composed of Antoni A areas but lack Verocay bodies (Fig. 41.75).[384–386] These changes can be accompanied by nuclear atypia, mitotic activity, and focal necrosis. Most reported cases have been in the retroperitoneum, pelvis, and mediastinum. The differential diagnosis with a low-grade MPNST is a difficult distinction, but strong and diffuse S-100 protein staining is in keeping with a cellular schwannoma.

Psammomatous melanotic schwannoma is a distinctive type of peripheral nerve sheath tumor that occurs as a component of the Carney complex.[372] Most arise from the spinal nerve roots. As the name indicates, the tumor is characterized microscopically by the presence of melanin pigmentation and the deposition of psammoma bodies (Fig. 41.76). In contrast to all other types of schwannoma described in this section, the psammomatous melanotic variety is regarded as a low-grade malignancy because of its tendency for local recurrence and ability to metastasize. In fact, Torres-Mora et al. argue that the term "malignant melanotic schwannian tumor" is more appropriate given that 44% of patients in their series developed metastatic disease.[387]

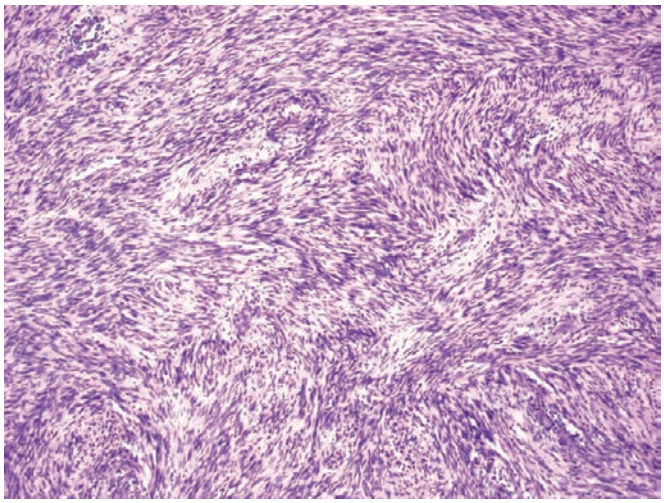

Figure 41.75 Cellular schwannoma with a compact proliferation of spindle cells arranged in short fascicles. Verocay bodies are not seen.

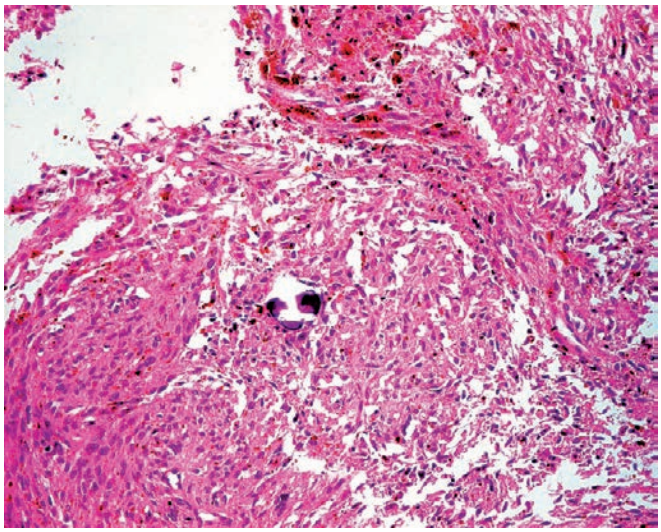

Figure 41.76 Psammomatous melanotic schwannoma in a patient with Carney syndrome.

For personal use only. No other uses without permission. Copyright ©2017. Elsevier Inc. All rights reserved.

Granular Cell Tumor

The classic location of granular cell tumor is the tongue, but it has been reported in innumerable other locations, such as skin, vulva, breast, larynx, bronchus, throughout the gastrointestinal tract, and soft tissue, among others.[388,389] Some patients have multiple lesions, particularly in the GI tract.[390] There are reports of congenital lesions, most of which arise in the gingiva, but such lesions are S-100-negative and probably represent a distinct entity (congenital epulis).[391,392]

These tumors are usually small, although we have seen cases measuring up to 5 cm in diameter. They have a hard consistency and ill-defined margins. This, together with the ulceration sometimes complicating the larger cutaneous tumors, explains why they are sometimes confused clinically and on gross inspection with a malignant neoplasm. The individual cells are large and their cytoplasm is filled with small, regular granules (Figs. 41.77 to 41.80). They alternate with larger round droplets having a homogeneous eosinophilic appearance and strong PAS positivity. The pattern of growth is ill-defined and pseudoinvasive; some can be found in the wall or lumen of blood vessels, not to be taken as a sign of malignancy.[393] If the tumor grows near an epithelial surface (e.g., skin, vulva, or larynx), pseudoepitheliomatous hyperplasia occurs that may be incorrectly diagnosed as squamous cell carcinoma.[394] Elastosis is often present in the stroma.[395]

Histochemically, the cytoplasmic granules contain large amounts of hydrolytic enzymes (such as acid phosphatase), and they are consistently positive for Luxol fast blue.[396] Ultrastructurally, they have the appearance of lysosomes. Other interesting electron microscopic findings are the presence of a second cell population with "angulated bodies" resulting in a Gaucher cell-like appearance[389,397] and of replicated basal lamina material around the granular cells, the latter suggesting repeated cycles of cellular injury and repair. Immunohistochemically, virtually all cases stain strongly for S-100 protein, as one would expect for a schwannian neoplasm; most also express Sox10.[398] Other stains often expressed include CD68, calretinin, and inhibin.[399,400]

The large majority of granular cell tumors pursue a benign clinical course. Most cases reported in the old literature as malignant granular cell myoblastomas are in reality examples of alveolar soft part sarcoma. However, there have been several well-documented cases of tumors with a light and electron microscopic appearance entirely consistent with that of granular cell tumor that have resulted in distant metastases.[401] Features favoring malignancy include necrosis, high mitotic activity, spindling of tumor cells, vesicular nuclei with large nucleoli, and high MIB-1 values.[401]

Although it is clear that most lesions diagnosed as true granular cell tumors show evidence of schwannian differentiation, a subset of tumors with granular cells likely are unrelated, particularly those

Figure 41.77 Granular Cell Tumor of Skin. There is an ill-defined permeation of the dermis by whitish tissue.

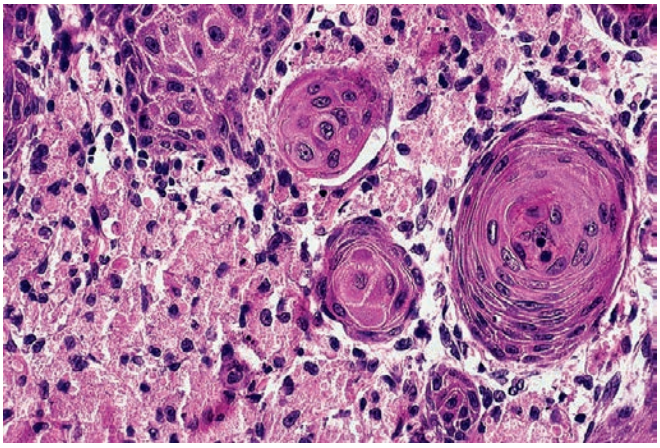

Figure 41.79 Pseudoepitheliomatous hyperplasia in squamous epithelium overlying a granular cell tumor.

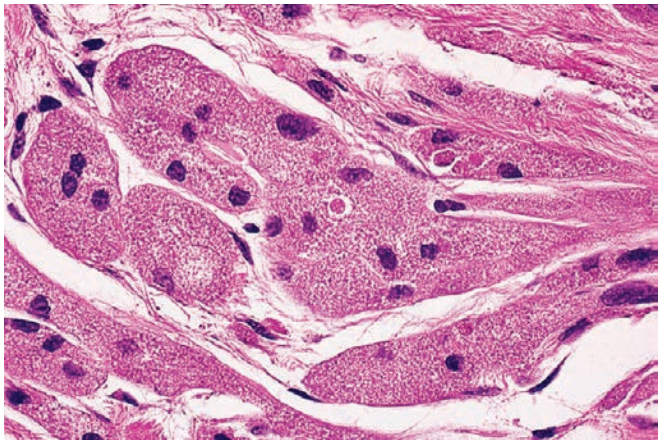

Figure 41.78 Granular Cell Tumor. The cells contain innumerable fine cytoplasmic granules as well as scattered larger eosinophilic globules.

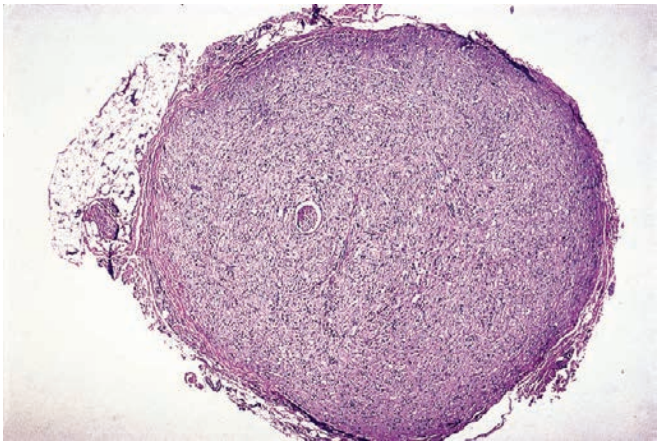

Figure 41.80 Granular cell tumor growing concentrically within and around a nerve cut transversely.

For personal use only. No other uses without permission. Copyright ©2017. Elsevier Inc. All rights reserved.

Figure 41.81 Well-circumscribed neurofibroma of soft tissue. The tumor has a gelatinous appearance.

Figure 41.82 Typical gross appearance of a plexiform neurofibroma. This tumor is indicative of neurofibromatosis type 1.

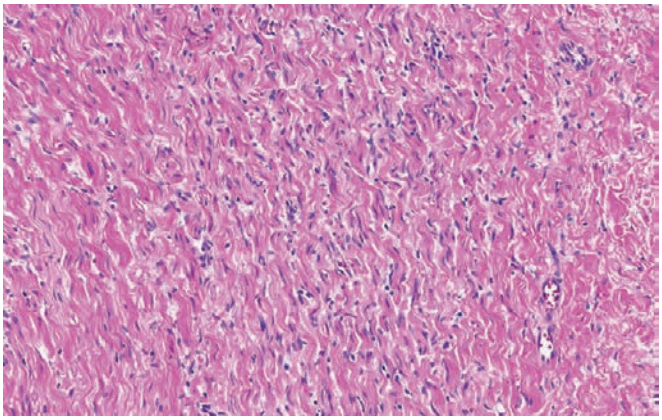

Figure 41.83 Neurofibroma with spindle cells deposited in a collagen matrix with a "shredded carrot" appearance.

that are S-100 protein negative[402–405]; many of these are cutaneous, polypoid lesions which stain for CD68 and NKI/C3.[403] The precise line of differentiation of these rare tumors remains obscure. Granular cell change may also be found in a number of other unrelated tumors including vascular and smooth muscle tumors.[406,407] We favor making the diagnosis of granular cell tumor only when the entire lesion is granular and S-100 protein positive and to designate the other cases according to their basic component, noting that focal granular changes are present.

Neurofibroma

The gross, microscopic, and ultrastructural features of neurofibroma, as well as its natural history, are distinct from those of schwannoma. The fact that in some instances the differential diagnosis may be difficult or that in isolated cases features of both lesions may coexist does not justify lumping them together.

The gross appearance of neurofibroma varies a great deal from lesion to lesion. As a rule, the tumors are not encapsulated and have a softer consistency than schwannoma (Fig. 41.81). The more superficial tumors appear as small, soft, pedunculated nodules protruding from the skin ("molluscum pendulum"). Deeper tumors grow larger. Tumors resulting in diffuse tortuous enlargement of peripheral nerves are designated as *plexiform neurofibromas* (Fig. 41.82) and are usually seen in the context of type 1 neurofibromatosis (von Recklinghausen disease, caused by a germline mutation in the *NF1* gene located on 17q11.2, which encodes neurofibromin).[408,409] The diffuse involvement of the nerves may make a complete resection impossible. This particular form of neurofibroma is more commonly seen in the orbit, neck, back, and inguinal region.

Microscopically, neurofibromas are formed by a combined proliferation of all the elements of a peripheral nerve: axons, Schwann cells, fibroblasts, and (in the plexiform type) perineurial cells. Schwann cells usually represent the predominant cellular element. Most have markedly elongated nuclei, with a wavy, serpentine configuration and pointed ends (Fig. 41.83). Ultrastructurally, they are seen to enclose axons in plasmalemmal invaginations (mesaxons).[410] They are immunoreactive for S-100 protein and surrounded by basement membrane components.[411] A population of factor XIIIa-positive and CD34-positive cells is also present; the nature of these cells and their histogenetic relationship with normal nerve constituents is not clear.[412,413] EMA-positive perineurial cells are common in plexiform but not in ordinary neurofibromas.[414] The stroma contains a rich network of collagen fibers, among which almost all major types are represented (I, III, IV, V, and VI).[411] Mucinous changes in the stroma may be prominent and result in a mistaken diagnosis of myxoma or even myxoid liposarcoma.[415] As with schwannomas, neurofibromas may exhibit scattered large hyperchromatic nuclei; these *neurofibromas with atypia* may also have increased cellularity but mitotic activity is absent (Fig. 41.84).[416] The stroma of neurofibromas

For personal use only. No other uses without permission. Copyright ©2017. Elsevier Inc. All rights reserved.

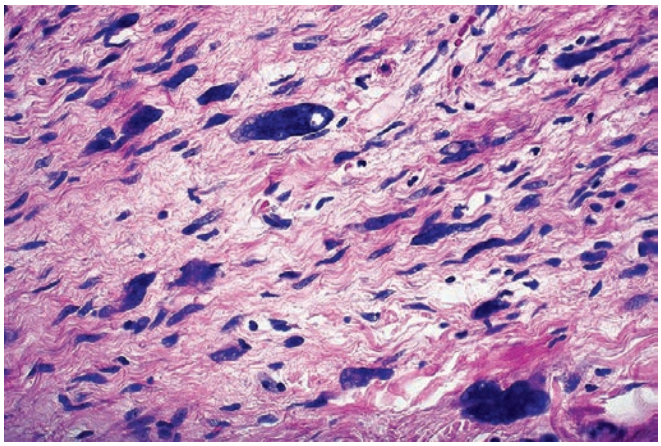

Figure 41.84 Neurofibroma with large bizarre hyperchromatic nuclei.

Figure 41.85 Marked deformation of distal upper extremity by diffuse neurofibromatosis. This patient developed a malignant peripheral nerve sheath tumor.

often contains numerous mast cells. Distorted organoid structures resembling Wagner–Meissner bodies or Pacinian corpuscles are sometimes seen.

In contrast to schwannomas, Verocay bodies, palisading of nuclei, and hyaline thickening of vessel walls are almost always absent in neurofibromas. Sometimes, otherwise typical neurofibromas contain melanin, a feature not unexpected in view of the embryologic relationship between Schwann cells and melanocytes.[415] These *pigmented neurofibromas* should be differentiated from blue nevi and malignant melanomas. Occasionally, an otherwise typical neurofibroma will show foci of skeletal muscle differentiation *(neuromuscular hamartoma; benign triton tumor)*.[417] Some neurofibromas (as well as other types of benign and malignant peripheral nerve tumors) may be partially composed of granular cells, similar in all respects to those of granular cell tumor.[418] Rare examples have prominent epithelioid features, similar to those seen in schwannoma and MPNST.[367]

Neurofibromas that occur in the setting of type 1 neurofibromatosis typically show a germline mutation of *NF1* in one allele and loss or mutation of *NF1* on the other allele, conforming to the "two-hit hypothesis" in tumorigenesis.[419] The genetic alterations are less clear in sporadic neurofibromas, but *NF1* alterations are present in at least some cases.[420]

Malignant transformation of neurofibroma should be suspected in the presence of mitotic activity in conjunction with increased cellularity, cytologic atypia, and the formation of fascicles.

Neurofibromatosis. Multiple neurofibromas represent the most important component of the genetically determined disorder known as type 1 neurofibromatosis or von Recklinghausen disease. This is one of the most common autosomal dominant diseases in humans, affecting one in about 3500 individuals.[421] The responsible gene *(NF1)* is located on chromosome 17q11.2 and encodes a ubiquitous protein known as neurofibromin, which is necessary for the correct negative regulation of RAS proteins.[422] In this setting, neurofibromas may occur in every conceivable site: axilla, thigh, buttock, deep soft tissue, orbit, mediastinum, retroperitoneum, tongue, gastrointestinal tract, and many others. Plexiform neurofibromas may result in massive enlargement of a limb or some other part of the body ("elephantiasis neuromatosa") (Fig. 41.85). In addition to neurofibromas, patients often have *café au lait spots*. This consists microscopically of an increase in the amount of melanin in the epidermal basal layer and is sometimes seen overlying a neurofibroma. It can be distinguished from the pigmented spots associated with McCune-Albright syndrome by virtue of its distribution and smooth, delicate margins.[423] Solitary café au lait spots are common in normal individuals, but when five or more are detected, type 1 neurofibromatosis should be suspected. Patients with this disease may also have GISTs, which are often present as multiple nodules in the small bowel,[424] and lack mutations in *KIT* and *PDGFRA*.[425,426]

Type 2 neurofibromatosis is genetically distinct from type 1, resulting from an alteration of the *NF2* gene located on chromosome 22q12 encoding merlin.[427] It is characterized by the presence of a variety of neoplasms in the CNS, the most distinctive of which are bilateral acoustic schwannomas. Meningiomas, astrocytomas, and tumors of other types also occur.[428]

A small proportion (between 5% and 20%) of patients with type 1 neurofibromatosis develop MPNST,[429] usually in large nerve trunks of the neck or extremities. For practical purposes, peripheral superficial neurofibromas never become malignant, and the only reasons for surgical removal are size and unsightliness.

Perineurioma

Benign tumors of the peripheral nerve composed predominantly or exclusively of perineurial cells are increasingly recognized. Microscopically, they are composed of extremely elongated cells arranged in parallel bundles, the appearance being not too dissimilar from that of neurofibroma or pacinian neurofibroma.[430] Some cases have a storiform pattern of growth and may correspond to the former *storiform perineurial fibromas*.[431] The diagnosis of perineurioma should be suspected in myxoid lesions of soft tissue in which a storiform or fascicular pattern of growth is evident (Fig. 41.86). There is an *intraneural* variant of perineurioma, associated with nonrandom chromosomal abnormalities and therefore presumably neoplastic.[432] It seems likely that at least some of the cases reported in the past as *localized hypertrophic neuropathy* belong in the same category.[433] Other recently recognized variants of this tumor include *sclerosing perineurioma*, which has a predilection for the fingers and palms of young adults[434]; *reticular (retiform) perineurioma*, with a predominant lace-like or reticular growth pattern composed of anastomosing cords of spindle cells; *plexiform perineurioma*; and the exceptionally rare *granular cell perineurioma*.[435] *Hybrid forms* of schwannoma and perineurioma have also been described,[436] as well as **malignant** forms of perineurioma, the latter representing a subtype of MPNST (see later).

Ultrastructurally, perineurioma is characterized by nonbranching, thin cytoplasmic processes coated by an external lamina and joined at their ends by a tight junction, few organelles, actin and vimentin filaments, and numerous pinocytotic vesicles (Fig. 41.87).[437]

For personal use only. No other uses without permission. Copyright ©2017. Elsevier Inc. All rights reserved.

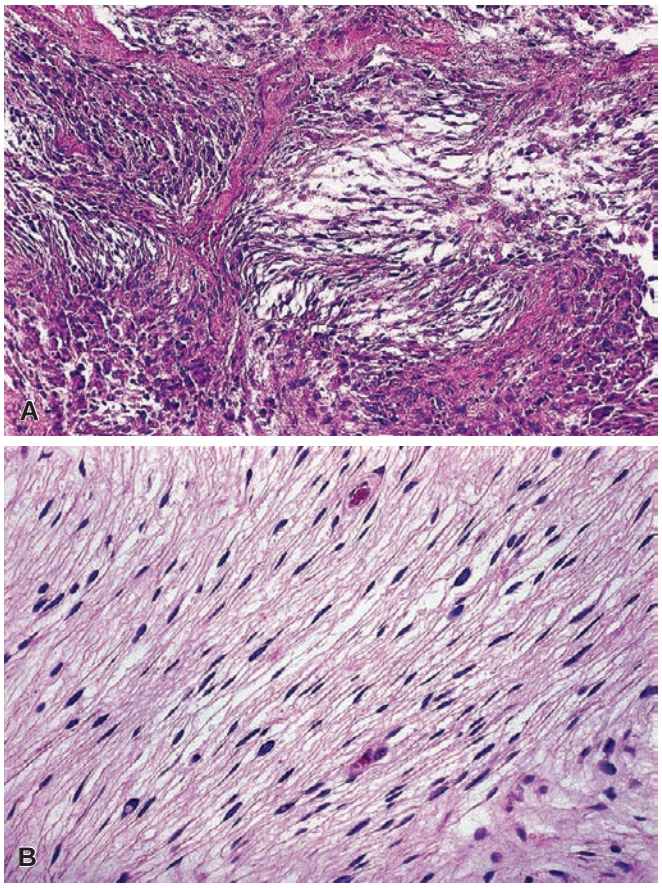

Figure 41.86 **A** and **B,** Two morphologic appearances of perineurioma. The tumor shown in **A** simulates a myxofibrosarcoma.

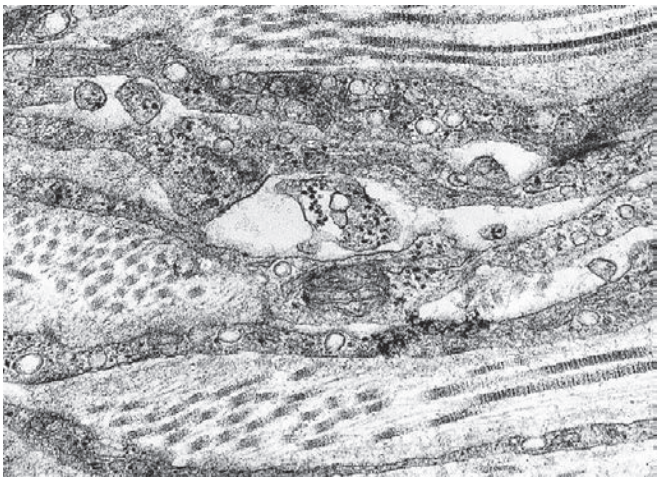

Figure 41.87 **Electron Microscopic Appearance of Perineurioma.** Thin perineurial cell cytoplasmic processes with prominent pinocytotic vesicles. The processes are coated by a continuous basal lamina. (×42000; Courtesy of Dr. Robert A. Erlandson, Memorial Sloan-Kettering Cancer Center.)

Immunohistochemically, the tumor cells are positive for EMA (Fig. 41.88), GLUT-1, CD34, and claudin-1, but they are negative for S-100 protein.[438] At the cytogenetic level, many cases show deletion of part or all of chromosome 22.[439] In addition, mutations of the *NF2* gene and loss of chromosome 13 have also been documented.[440]

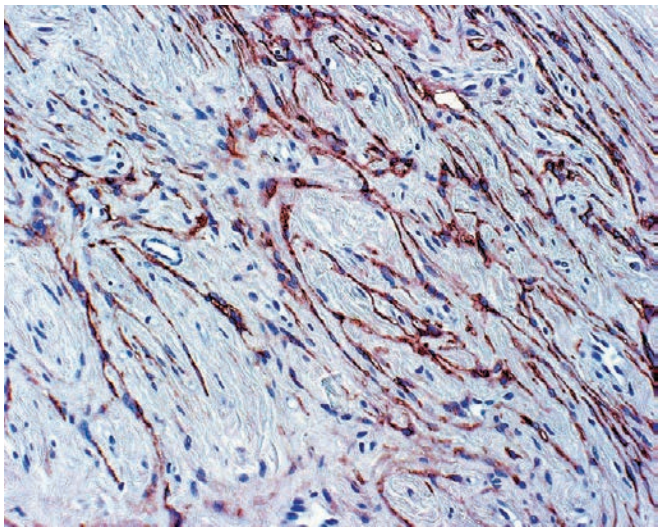

Figure 41.88 Epithelial membrane antigen immunoreactivity in perineurioma.

Dermal Nerve Sheath Myxoma

This is a benign, superficial myxoid neoplasm that most commonly arises on the distal extremities, particularly the fingers. Although originally categorized as a neurothekeoma, this lesion seems unrelated to cellular neurothekeoma, and there is compelling evidence to suggest true nerve sheath differentiation.[441,442] It has a gross and microscopic appearance reminiscent of myxoma, except for the prominent multinodularity with a fibrous border and the presence of plumper, epithelial-like cells and a distinct fascicular or plexiform arrangement (Fig. 41.89). Immunohistochemically, the cells stain for S-100 protein, unlike cellular neurothekeoma. Up to 50% locally recur.

Malignant Peripheral Nerve Sheath Tumor

MPNST is the currently preferred term for the neoplasm also known over the years as *malignant schwannoma*, *neurogenic sarcoma*, and *neurofibrosarcoma*. Approximately half of these tumors arise de novo, and the other half from neurofibromas as part of type 1 neurofibromatosis. Some arise in areas of previous irradiation typically after a latent period of at least 10 years,[443] and a few have originated from the Schwann cell-like (satellite cell) component of a ganglioneuroma.[444]

The large majority of MPNSTs arise in adults, but they have also been recorded in children.[445] The most common locations are the neck, forearm, lower leg, and buttock. They can also arise from cranial nerves or their branches. Grossly, the finding of a large mass producing fusiform enlargement of a major nerve, such as the sciatic nerve, is characteristic. Most MPNSTs are deep-seated, but they can occur in the subcutis or even in the skin.[446]

Because of its difficult microscopic recognition, errors are often made, more often than not by diagnosing MPNST as some other type of soft tissue sarcoma. There are two circumstances in which the diagnosis of MPNST should be the primary consideration in the presence of a malignant tumor of soft tissues composed of spindle cells: (1) when the tumor develops in a patient with type 1 neurofibromatosis; or (2) when the tumor is obviously arising within the anatomic compartment of a major nerve or in continuity with a neurofibroma. In the absence of these circumstances, the light microscopic diagnosis of MPNST is often only presumptive and dependent on a combination of features, none of which is

For personal use only. No other uses without permission. Copyright ©2017. Elsevier Inc. All rights reserved.

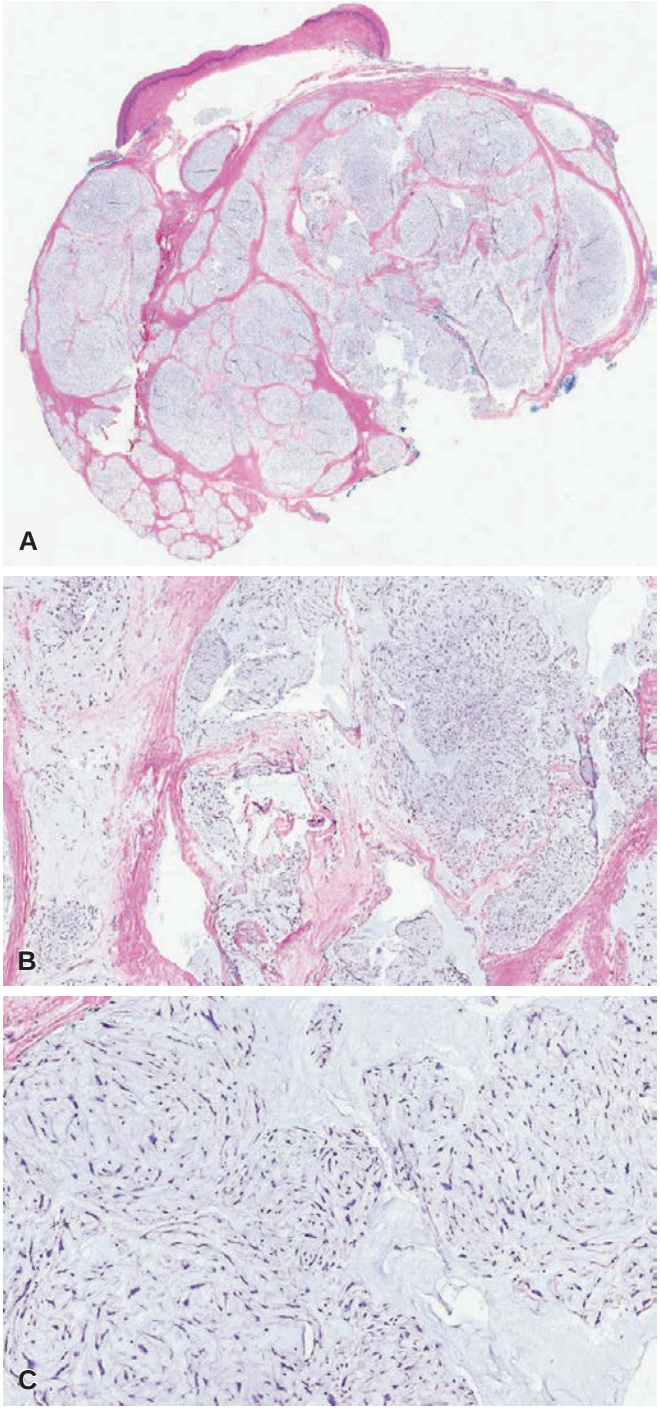

Figure 41.89 Dermal Nerve Sheath Myxoma. A, Low power. **B,** Medium power. **C,** High power. The lesion has a distinct lobulated appearance.

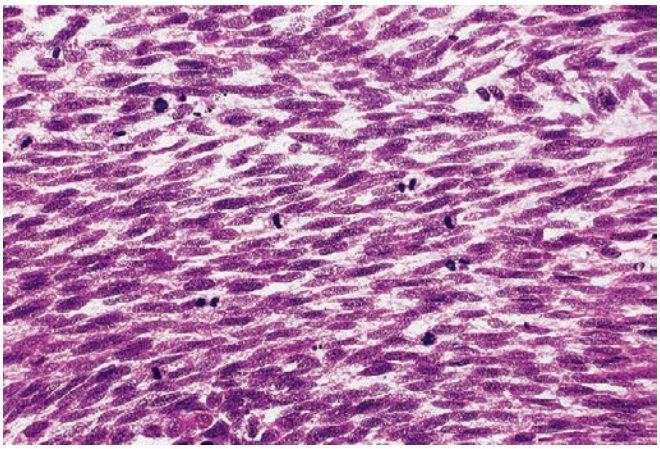

Figure 41.90 Malignant Peripheral Nerve Sheath Tumor. The marked hypercellularity and high mitotic activity in the absence of significant pleomorphism are commonly seen in this tumor type.

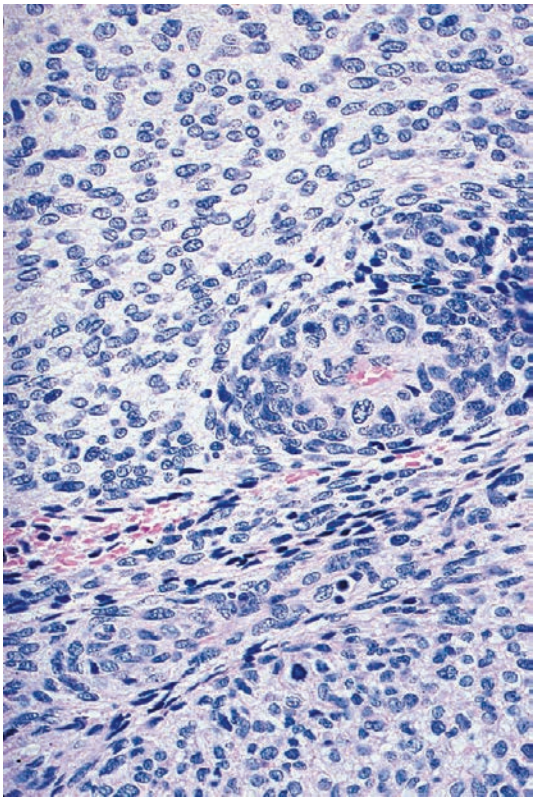

Figure 41.91 Malignant peripheral nerve sheath tumor with plump, almost epithelioid cells surrounding a blood vessel, a common feature of this tumor.

diagnostic by itself. They include: serpentine shape of the tumor cells; arrangement in palisades or whorls; marked contrast between the deeply hyperchromatic nuclei and the pale cytoplasm ("punched-out nuclei"); perivascular concentration of tumor cells, with a plumper shape; epithelioid appearance of the endothelial cells of these vessels; presence of large gaping vascular spaces resulting in a hemangiopericytoma-like appearance; and geographic areas of necrosis, with tumor palisading at the edges (Figs. 41.90 to 41.92). In most areas the appearance is that of an extremely cellular spindle cell neoplasm with easily identified mitotic figures. Although most tumors are quite monomorphic (a feature they share with monophasic synovial sarcoma), some can be extremely bizarre. At the light microscopic level, the latter can simulate the appearance of an UPS. Metaplastic tissues (heterologous elements) are present in approximately 15% of the cases, including chondrosarcomatous, osteosarcomatous, rhabdomyosarcomatous, or angiosarcomatous differentiation (Figs. 41.93 and 41.94).[447,448] The most well-known variant is characterized by the presence of rhabdomyosarcomatous

For personal use only. No other uses without permission. Copyright ©2017. Elsevier Inc. All rights reserved.

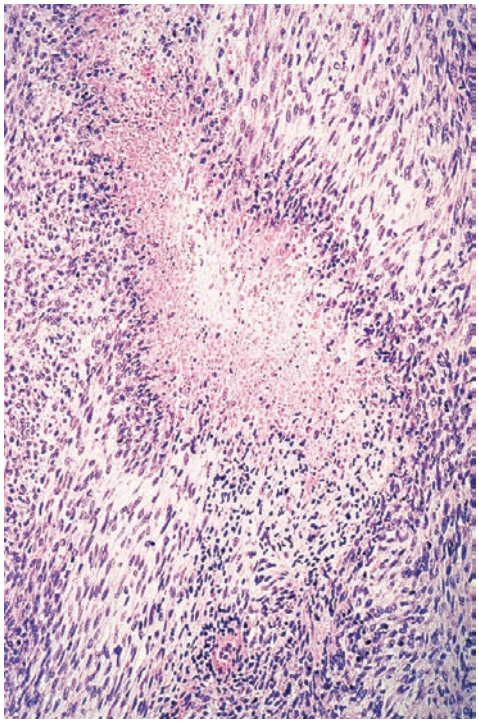

Figure 41.92 Malignant peripheral nerve sheath tumor with an area of necrosis.

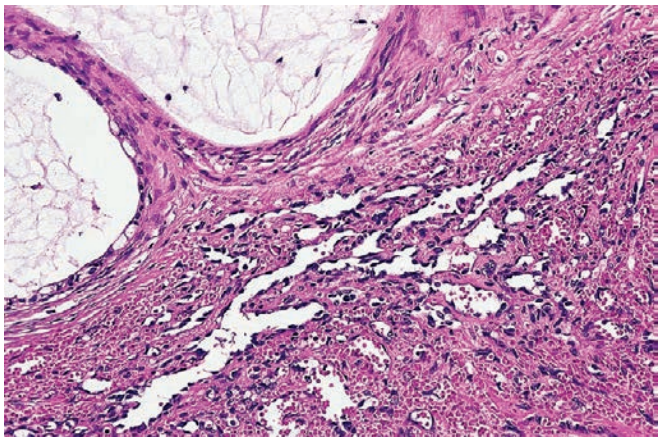

Figure 41.93 Malignant peripheral nerve sheath tumor with divergent angiosarcomatous differentiation as well as rare mucin-producing glands.

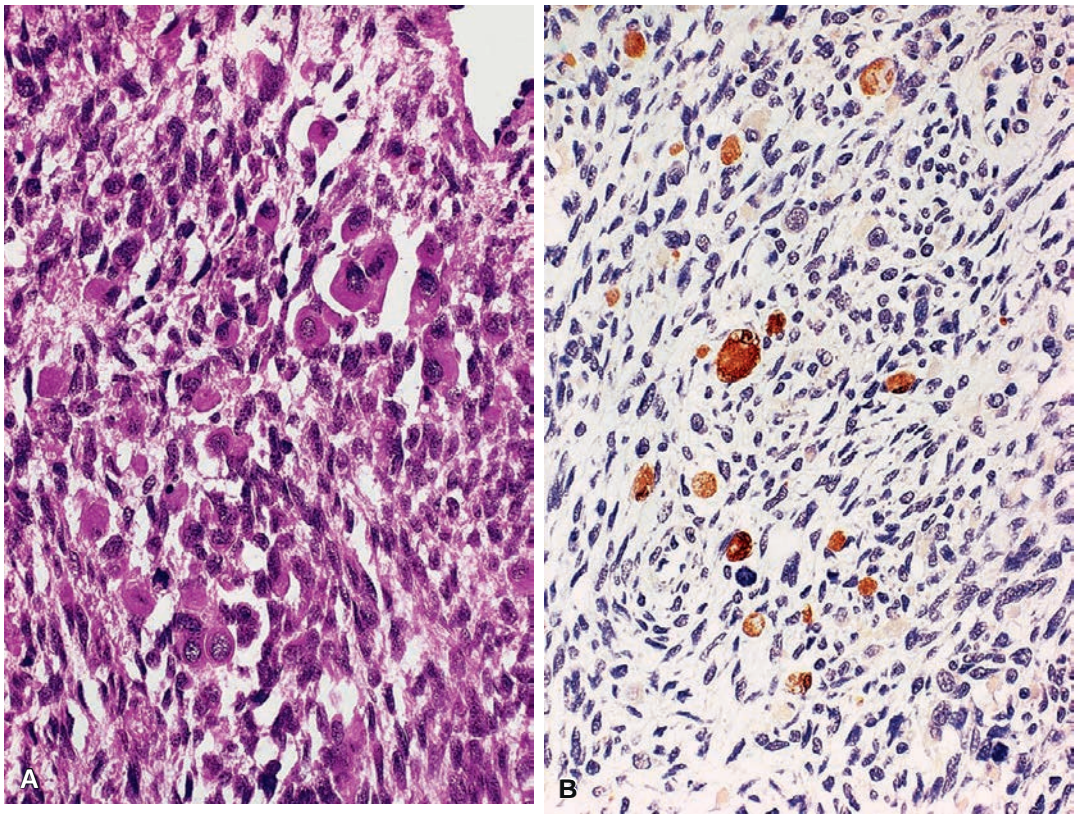

Figure 41.94 Malignant peripheral nerve sheath tumor with rhabdomyosarcomatous differentiation (so-called Triton tumor, **A**) with positive immunoreactivity for myoglobin **(B)**.

For personal use only. No other uses without permission. Copyright ©2017. Elsevier Inc. All rights reserved.

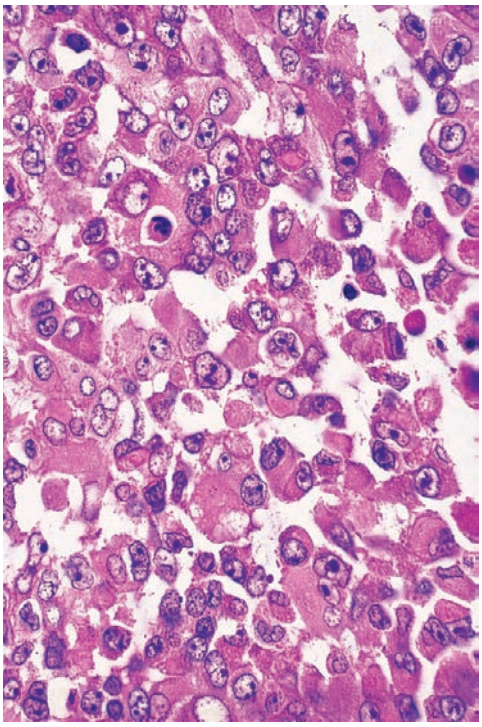

Figure 41.95 Epithelioid malignant peripheral nerve sheath tumor.

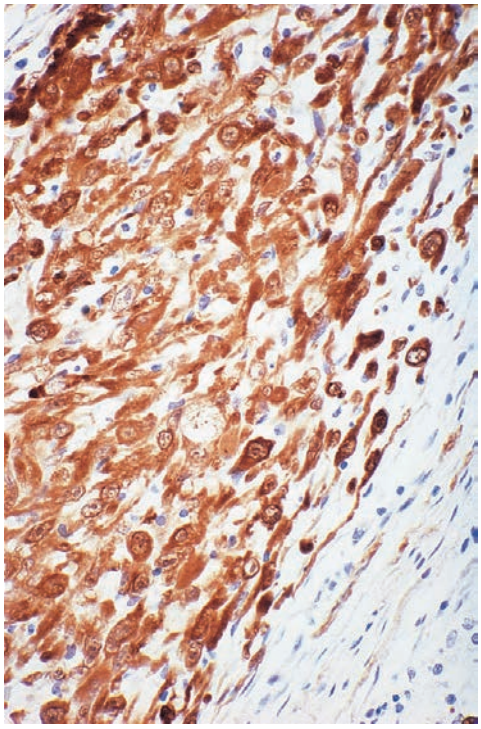

Figure 41.96 Strong S-100 protein immunoreactivity in epithelioid malignant peripheral nerve sheath tumor.

differentiation, often referred to as *malignant triton tumor*.[449] Areas of recognizable MPNST should be present to make such a diagnosis in these metaplastic tumors; otherwise a diagnosis corresponding to the morphologic appearance of the tumor is appropriate, even if the patient has type 1 neurofibromatosis. Although rare MPNSTs show foci of *glandular differentiation* (Fig. 41.93), this feature is found only in patients with type 1 neurofibromatosis.[450]

In some MPNSTs, part or most of the tumor is composed of plump cells with polygonal acidophilic cytoplasm and an epithelioid-like appearance; these are designated as *epithelioid MPNST* (Fig. 41.95).[451,452] These account for approximately 5% of all MPNSTs. Interestingly, most of the MPNSTs that have arisen from malignant transformation of benign schwannomas have been of the epithelioid type. Histologically, most cases show a vaguely nodular appearance with epithelioid cells arranged in sheets or cords. The cells have melanoma-like nuclei with prominent nucleoli. Some examples show rhabdoid morphology with paranuclear inclusions. Most stain strongly for S-100 protein, a pattern that contrasts with spindled MPNST (Figs. 41.96 and 41.97).[452] They lack melanoma-associated antigens (HMB-45 and Melan-A) and typically do not stain for cytokeratins. Almost 50% show loss of staining for SMARCB1 (also known as INI1) which is typically retained in melanoma.[453]

Conventional MPNST does not have a characteristic immunophenotype. Between 50% and 90% of these tumors stain for S-100 protein, typically in a patchy fashion.[454] Although often taken as evidence of nerve sheath differentiation, this marker lacks specificity given that other lesions in the differential diagnosis (e.g., synovial sarcoma) also stain for this antigen. More recently, Sox10, a neural crest transcription factor, has been found to be expressed in the majority of MPNSTs, including those which are S-100 protein negative.[398,455,456] CD34 and EMA may also be expressed in MPNSTs, likely reflecting focal perineurial differentiation. More recently, loss of histone H3K27 trimethylation by immunohistochemistry has been noted in approximately 50% of MPNSTs, with complete loss

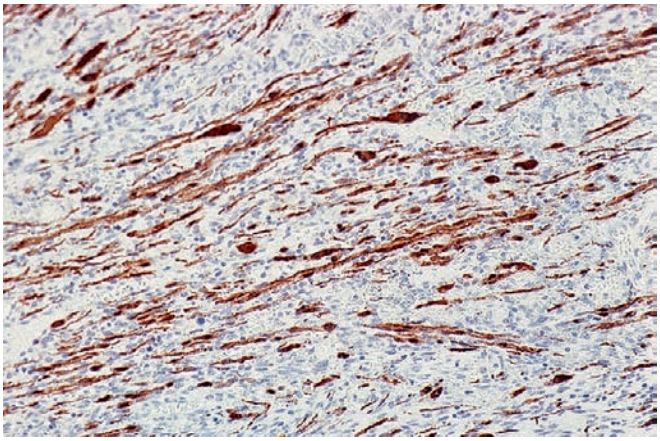

Figure 41.97 Patchy S-100 protein immunoreactivity in a spindle cell type of malignant peripheral nerve sheath tumor.

of staining in a higher percentage of cases as tumor grade increases.[456a] Although this marker is not particularly sensitive, it does seem to be highly specific for MPNST. Other markers reported in MPNST include nestin,[457] HMGA2,[458] and CD57.[459]

The clinical evolution is generally that of a highly malignant neoplasm, with frequent local recurrences and distant metastases.[460–462] Prognostic factors vary among studies; however, tumor size and metastatic disease at initial presentation are consistently identified as important variables. Most metastases occur in the lungs.

MPNSTs usually show a complex karyotype with numerical and structural abnormalities.[380,463] Whether occurring sporadically or in the setting of type 1 neurofibromatosis, both alleles of the *NF1* gene are often inactivated.[464] In addition, there are commonly mutations in the *TP53* gene, deletion of *CDKN2A* (9p21), and gain or amplification of 17q25, probably involving *BIRC5/SURVIVIN*.[465–468] More

For personal use only. No other uses without permission. Copyright ©2017. Elsevier Inc. All rights reserved.

Figure 41.98 Gross Appearance of Lipoma. Except for the circumscription, the appearance is indistinguishable from that of normal fat.

recently, loss of function mutations of the Polycomb repressive complex 2 (PRC2) components (*EED* or *SUZ12*) was identified in the vast majority of MPNSTs, including both NF1-associated and radiotherapy-associated MPNSTs.[468a]

Tumors of Adipose Tissue

Lipoma

Benign fatty tumors can arise in any location in which fat is normally present. The majority occur in the upper half of the body, particularly the trunk and neck, but they can develop in any other site, including hands and feet. Most lipomas are subcutaneous, an important point in the differential diagnosis with liposarcomas, which are almost always deep-seated. However, lipomas can also occur in the deep soft tissues; these are subclassified into *intramuscular* (most common in the trunk) and *intermuscular* (most common in the anterior abdominal wall).[469] Most patients are in the fifth or sixth decade of life. Only rarely are children affected. Lipomas may be single or multiple. Multiple lipomas are more common in women; many are seen in a familial setting, and some occur in patients with neurofibromatosis or multiple endocrine neoplasia. In **diffuse lipomatosis**, massive enlargement of a limb may be seen as a result of diffuse proliferation of mature adipose tissue. In the familial variant of this process, lipomatosis has a symmetric distribution.[470]

Lipomas can grow to a large size; they are usually encapsulated when located in the superficial soft tissues but tend to be poorly circumscribed when arising in deeper structures. Grossly, lipomas consist of bright yellow fat separated by fine fibrous trabeculae (Fig. 41.98). Microscopically, they are composed of mature adipose tissue with no cellular atypia. They are cytologically and immunohistochemically indistinguishable from normal fat, including positivity for S-100 protein and calretinin.[471]

Areas of fat necrosis, infarct, and calcification may be present. It is important not to confuse the histiocytes associated with fat necrosis with lipoblasts. The fact that they are often seen arranged in a circumferential fashion around a large lipid droplet (as is also the case in fat necrosis at other sites) is a helpful diagnostic sign. Rarely, lipomas harbor foci of mature metaplastic cartilage or bone.[472]

Ultrastructurally, only univacuolar mature adipocytes are present in typical lipomas.[473] Although the light microscopic and electron microscopic appearance of a lipoma does not differ significantly from that of normal adult fat, its lipid content as determined by biochemical extraction and the activity of lipoprotein lipase is different.[474]

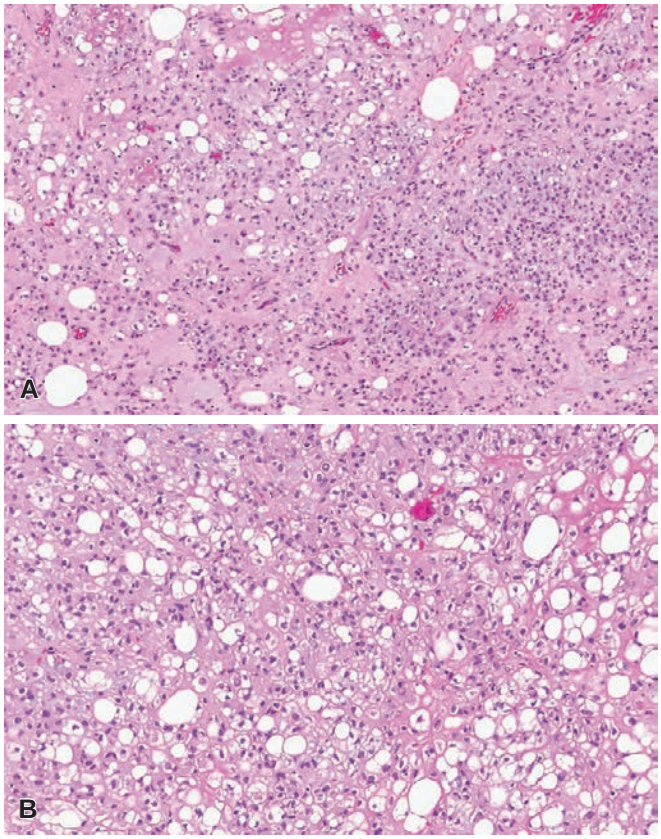

Figure 41.99 Chondroid Lipoma. A, Low-power and **B,** High-power views.

Morphologic variations that lipomas may exhibit include the following:

1. **Fibrolipoma**. This is characterized by the presence of prominent bundles of *mature* collagenous or myxocollagenous stroma intermixed with mature adipocytes, usually involving the distal extremities.[475,476]
2. **Myxolipoma.** This tumor shows extensive stromal myxoid change and should not be overdiagnosed as myxoid liposarcoma.[477]
3. **Chondroid lipoma.** This variant is usually deep-seated and is characterized by a component of eosinophilic and vacuolated cells containing glycogen and lipid that resembles brown fat cells, lipoblasts, and chondroblasts (Fig. 41.99).[478,479] This tumor can be mistaken for either chondrosarcoma or myxoid liposarcoma.
4. **Myolipoma.** This tumor is characterized by an admixture in variable proportions of mature adipose tissue and bundles of well-differentiated smooth muscle.[480]
5. **Spindle cell lipoma.** This is a benign fatty tumor characteristically located in the regions of the shoulder, upper back, and posterior neck of middle-aged adults but also found in many other locations, including the limbs, face, oral cavity, and trunk. It is composed of an admixture of mature lipocytes and uniform spindle cells set in a mucinous and fibrous background (Fig. 41.100).[481] Features that assist in distinguishing it from myxoid liposarcoma include the absence of lipoblasts and of a prominent plexiform vascular pattern, the presence of thick ("ropey") collagen bundles, and the great uniformity of the proliferating small spindle cells. In some instances the presence of irregular branching spaces with

For personal use only. No other uses without permission. Copyright ©2017. Elsevier Inc. All rights reserved.

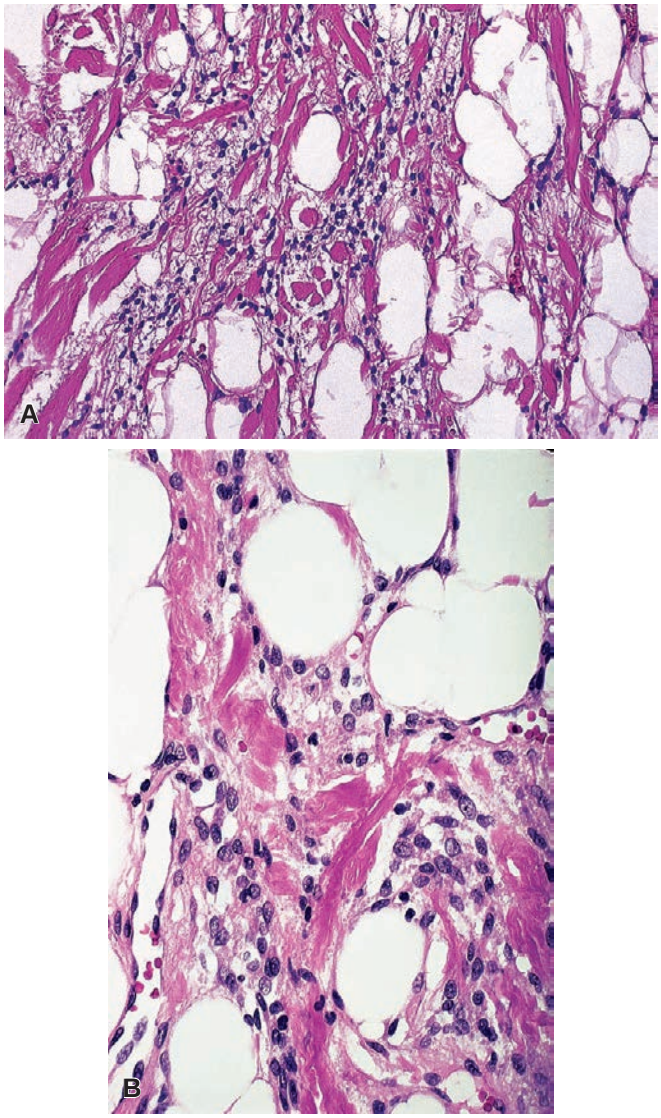

Figure 41.100 Spindle Cell Lipoma. Ropey collagen is a prominent feature.

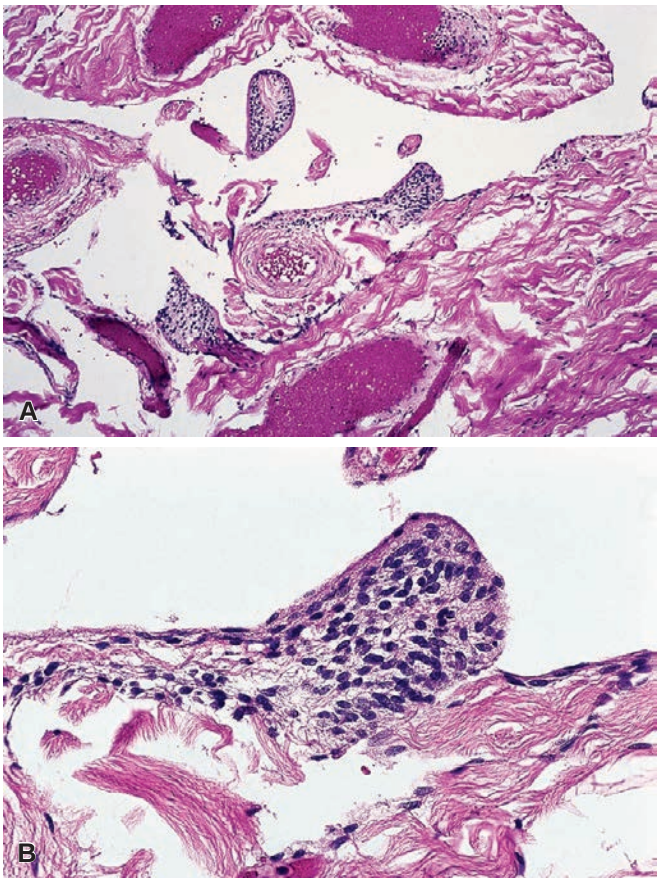

Figure 41.101 **A** and **B,** Spindle cell lipoma with a pseudoangiomatous appearance resulting from accumulation of tumor cells beneath artifactual tissue spaces.

villiform projections results in an angiomatoid appearance.[482] Although the spaces were originally thought to be nonvascular ("pseudoangiomatous"), they have been found to be lined by cells with the immunohistochemical features of endothelial cells (Fig. 41.101).[483] Cases of spindle cell lipoma in which mature fat is scanty or absent can be misdiagnosed as neurofibromas or even low-grade sarcomas (so-called fat-free spindle cell lipoma).[484] Immunohistochemically, these lesions uniformly express CD34, but this marker is commonly found in many other spindle lesions in the differential diagnosis.[485] This is also one of the lesions that typically shows loss of Rb-1 by immunohistochemistry given deletions in that tumor suppressor gene.[485a]

6. **Pleomorphic lipoma.** This is a lipoma containing hyperchromatic multinucleated ("floret-like") tumor cells. Given that this lesion is now felt to be histogenetically related to spindle cell lipoma, it is not surprising that it also most commonly is found in the posterior neck, upper back, and shoulder region of middle-aged men.[486] The tumor also has ropey collagen and prominent mast cells and often has areas identical to spindle cell lipoma (Fig. 41.102). It too stains strongly for CD34 (Fig. 41.103)[485] and similarly shows loss of Rb-1 staining.[485a] The most difficult differential diagnosis is with the sclerosing form of well-differentiated liposarcoma. The location of the lesion is an important clue, as is the presence of ropey collagen. Pleomorphic lipoma with little or no fat may be a diagnostic challenge.[487] Pleomorphic lipoma can be simulated microscopically by *subconjunctival herniated orbital fat*, a non-neoplastic process due to prolapse of the subconjunctival intraconal orbital fat.[488]
7. **Angiolipoma.** These well-circumscribed small tumors occur shortly after puberty. They are often painful and characteristically multiple. They are located in the subcutis, most commonly on the trunk or extremities. Vascularity often is limited to a band of tissue at the periphery of the neoplasm. Hyaline thrombi are common and constitute an important diagnostic sign (Fig. 41.104).[489] Angiolipomas in which the vascular component predominates *(cellular angiolipomas)* can be confused with Kaposi sarcoma or angiosarcoma.[490] The pain correlates well with the degree of vascularity.[491] The fact that angiolipomas lack chromosomal aberrations (like hemangiomas and unlike lipomas) suggests that they are hemangiomas with fat rather than true mixed tumors.[492] So-called *infiltrating angiolipomas* are unrelated to the lesion just described. They are probably not true mixed tumors but rather intramuscular large-vessel hemangiomas in which portions of the affected muscle tissue have been replaced by fat.[493]
8. **Myelolipoma.** This lesion combines mature adipose tissue and bone marrow elements and is most common in the adrenal gland,[494] although it also occurs in extra-adrenal sites (retroperitoneum, presacral region and mediastinum, among others).[495,496] Most occur

For personal use only. No other uses without permission. Copyright ©2017. Elsevier Inc. All rights reserved.

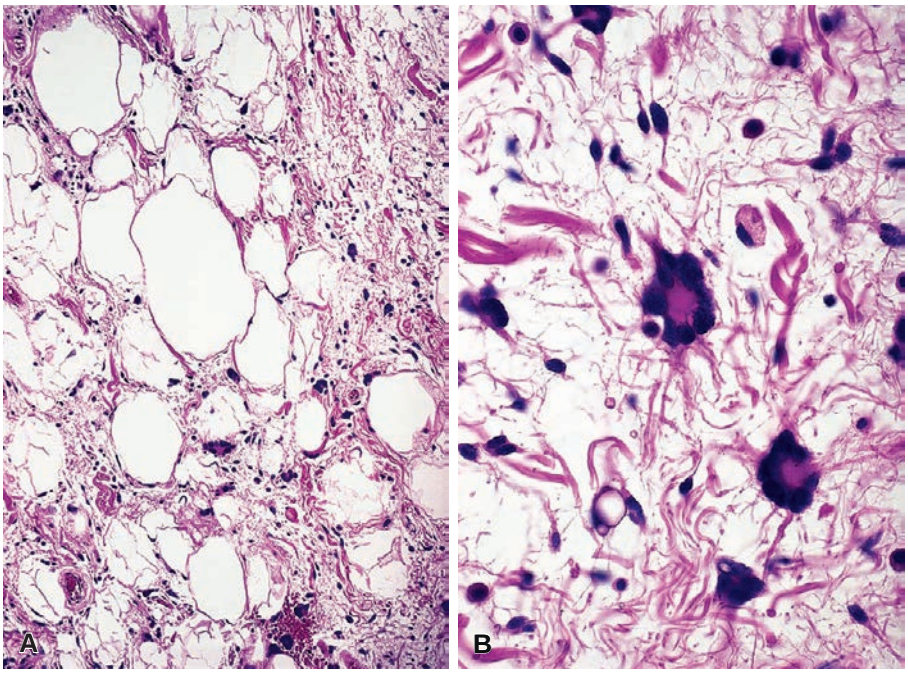

Figure 41.102 **A** and **B,** Pleomorphic lipoma with characteristic floret-type giant cells.

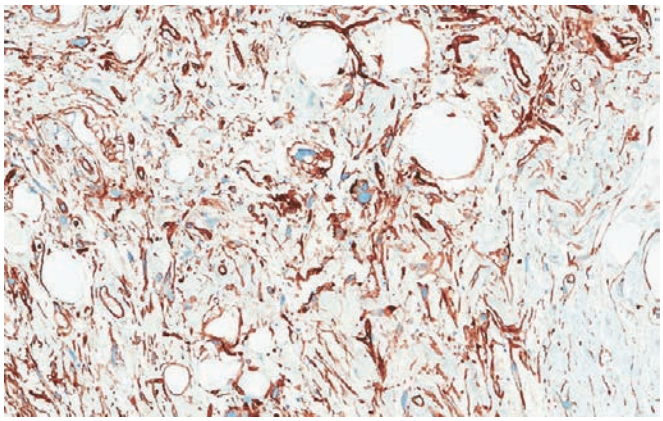

Figure 41.103 Strong CD34 staining in a pleomorphic lipoma.

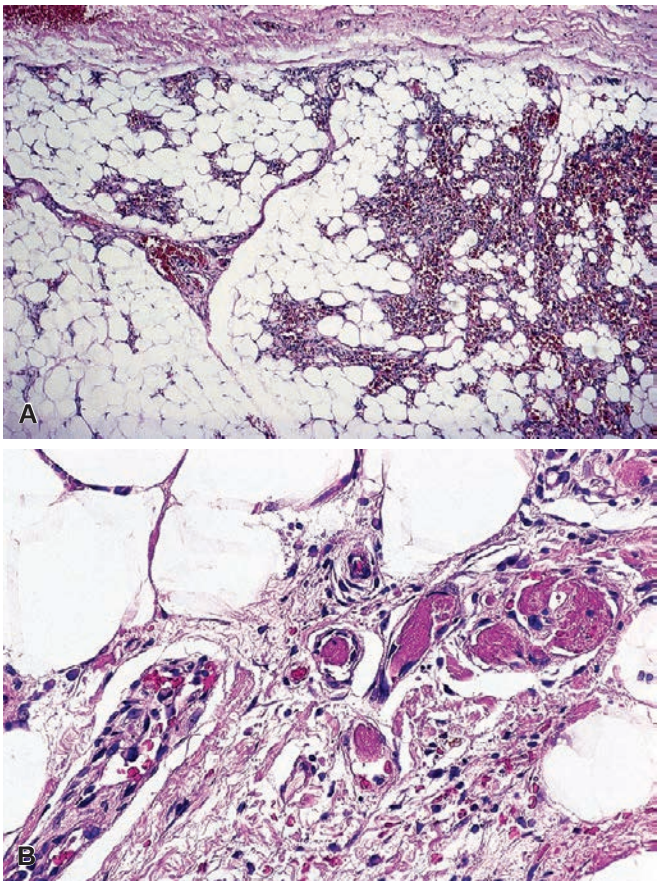

Figure 41.104 **Angiolipoma. A,** Intimate admixture of blood vessels and mature adipose tissue. **B,** Numerous fibrin thrombi can be seen.

in patients older than 40 years of age. Although many are small and found incidentally, others become enormous, and the latter cause symptoms that depend upon the site of origin.[497] Some are associated with hormonally active adrenal tumors, such as adrenal cortical adenomas,[498] adrenal cortical carcinomas,[499] and pheochromocytomas.[500] Given the identification of nonrandom, X-chromosome inactivation, a neoplastic origin has been proposed.[501]

9. **Intra/intermuscular lipoma.** These lesions are worrisome given their deep location, and they can grow to large sizes. Most arise in adults, more commonly in men, usually in the large muscles of the extremities, especially the thigh, upper arm, and shoulder.[502] Histologically, there is an intimate comingling of mature adipocytes and skeletal muscle fibers (Fig. 41.105). The latter may become atrophic and mimic the enlarged, hyperchromatic cells that are diagnostic of an ALT/well-differentiated liposarcoma. These lesions must be extensively sampled to exclude an ALT/well-differentiated liposarcoma. In addition, performing an analysis for *MDM2* amplification (preferably by FISH) can be exceedingly useful in excluding an ALT with the expectation that the

For personal use only. No other uses without permission. Copyright ©2017. Elsevier Inc. All rights reserved.

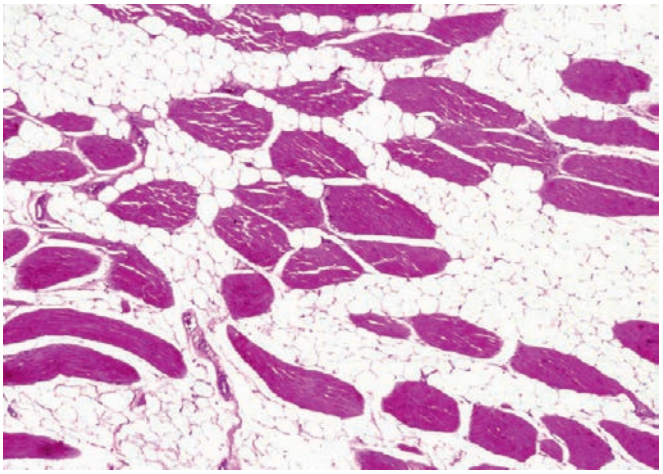

Figure 41.105 Intramuscular lipoma with interdigitation of mature adipose tissue and skeletal muscle.

intramuscular lipoma will be negative for *MDM2* amplification.[503] Due to the tumor depth, these lesions can be difficult to completely excise surgically, and, as such, they frequently recur,[502,504] but they have no capacity to undergo dedifferentiation or metastasis.

Cytogenetically, 80% of solitary lipomas exhibit chromosomal aberrations, such as rearrangements of 12q14–15, rearrangements of 6p21–22, or deletions of 13q12–14 and 13q22.[505–507] The gene involved in 12q14–15 is *HMGA2* (also known as *HMGIC*, which encodes a high mobility group protein), and the gene involved in 6p21–22 is *HMGA1*. In contrast with ALTs, marker ring or giant chromosomes are extremely rare.

Nearly all spindle cell and pleomorphic lipomas show deletions or unbalanced rearrangements of chromosome 13q and/or 16q, supporting the close link between these two tumor types and the fact that they are distinct from ALTs.[508–510]

Lipoblastoma/Lipoblastomatosis

Lipoblastoma/lipoblastomatosis affects almost exclusively infants and young children (below the age of 5 years),[511,512] but occasional cases in adolescents and young adults are on record.[513] It commonly involves the proximal portion of the lower and upper extremities. Grossly, the lesion is soft and lobulated. It is subdivided into lipoblastoma when well circumscribed and lipoblastomatosis when deep-seated and ill defined. Microscopically, it closely resembles fetal fat and may be confused with myxoid liposarcoma because of the presence of lipoblasts, a plexiform vascular pattern, and an abundant myxoid stroma (Fig. 41.106). It is distinguished from the latter by virtue of the young age of the patient, distinct lobulation, and absence of the characteristic translocation seen in myxoid liposarcoma involving the *DDIT3* gene. Cytogenetically, lipoblastoma/lipoblastomatosis is often associated with rearrangements of 8q11–13, with the implicated gene being *PLAG1* (pleomorphic adenoma gene).[514,515] A number of partner genes have been identified, such as *HAS2* on 8q24 and *COL1A2* on 7q22. Some cases show gain of chromosome 8, with or without simultaneous 8q11–13 rearrangement. The clinical course is benign, with a low risk of local recurrence. Lipoblastomas that are not removed in infancy mature into lipomas.

Hibernoma

Hibernoma is a rare benign neoplasm usually occurring in the interscapular region, axilla, and thigh, but it may arise in the mediastinum and retroperitoneum.[516] Its cut surface has a typical brown color, and its microscopic pattern is characteristic—an organoid arrangement of large cells with a centrally located nucleus and cytoplasm filled with many small vacuoles that stain for neutral fat (Fig. 41.107). Cytogenetically, it is often associated with rearrangements involving 11q13.[517,518]

This tumor has received its name because it resembles the brown fat of the hibernating glands of animals, a similarity that is maintained at the electron microscopic level.[519] Sometimes the features of hibernoma are seen mixed with those of ordinary lipoma or of spindle cell lipoma (hybrid tumors). Other hibernomas are accompanied by a myxoid matrix.[520] Malignant soft tissue tumors in which many of the tumor cells have features of brown fat occur and are regarded as a morphologic variant of liposarcoma.

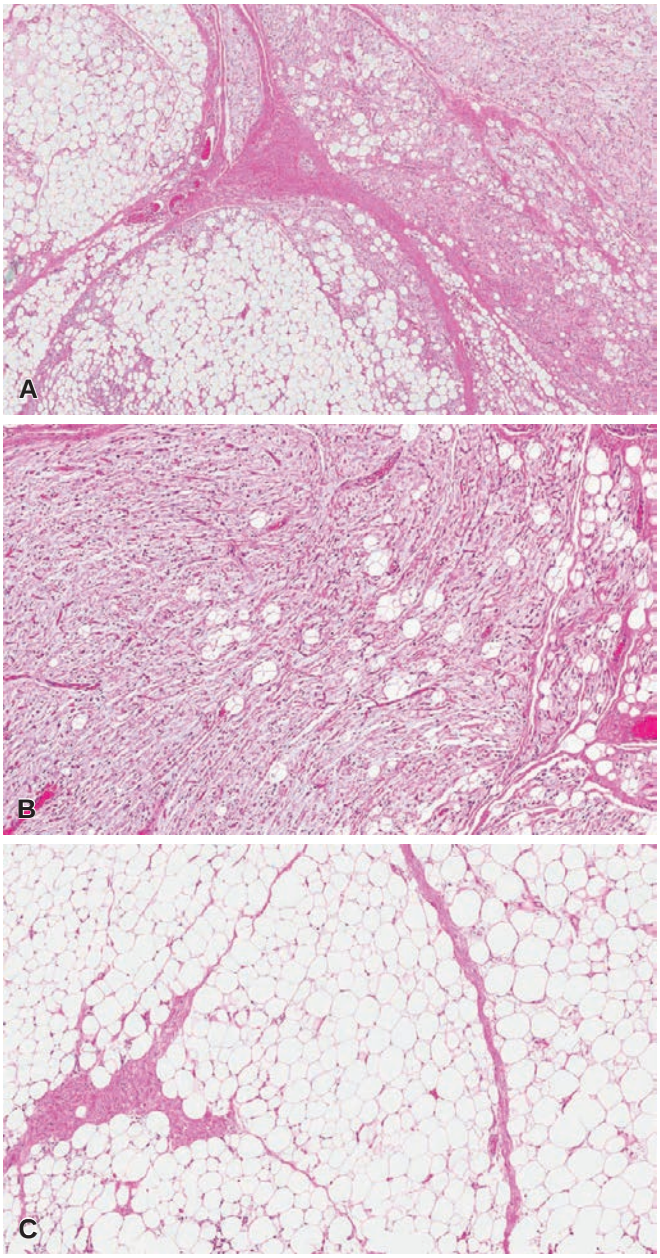

Figure 41.106 **Lipoblastoma. A,** Lobulated appearance and nodules of both mature adipose tissue and others with myxoid change. **B,** A myxoid nodule in a lipoblastoma showing some resemblance to myxoid liposarcoma. **C,** Area of mature adipose tissue in lipoblastoma.

For personal use only. No other uses without permission. Copyright ©2017. Elsevier Inc. All rights reserved.

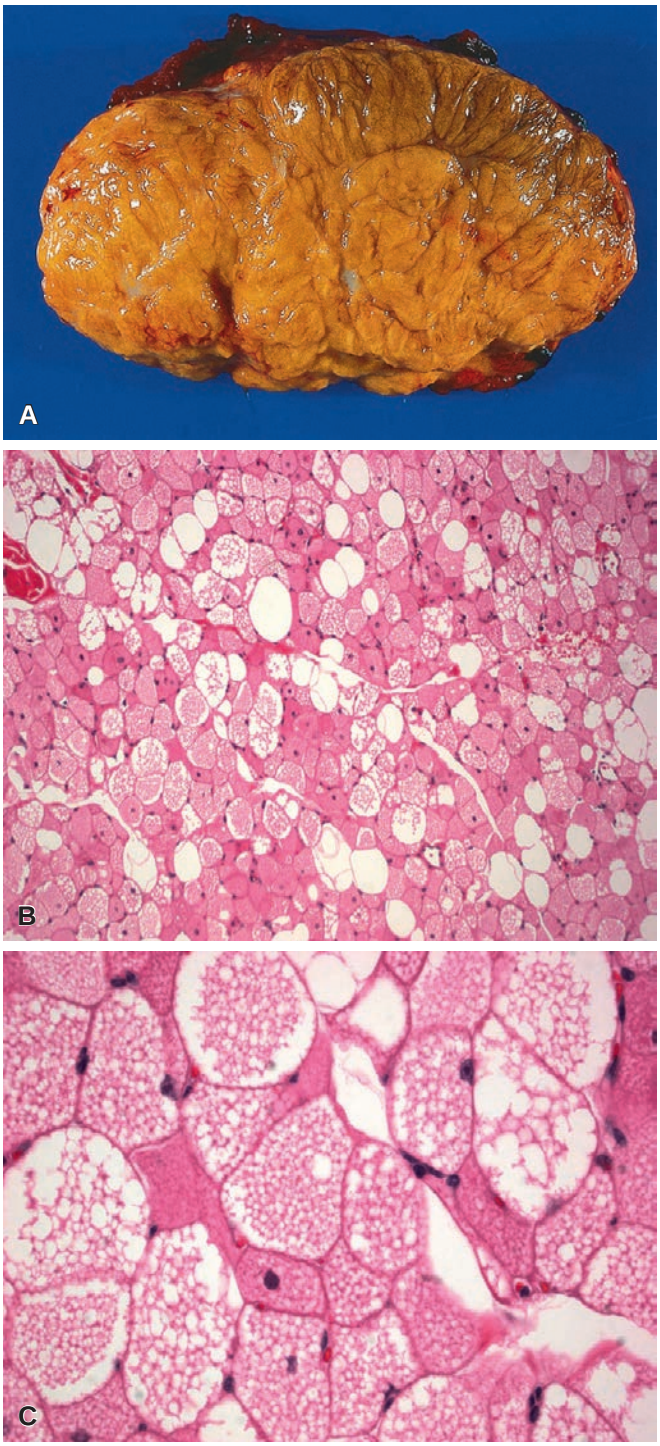

Figure 41.107 **A,** Gross appearance of benign adipose tissue that had features of both hibernoma and lipoma. Low-power **(B)** and high-power **(C)** views of a hibernoma.

Neural Fibrolipoma

Neural fibrolipoma (also sometimes referred to as *lipofibromatous hamartoma of nerves*) is a tumorlike lipomatous process that involves the volar aspect of the hands, wrists, and forearms of young persons.[521] Up to one-third are associated with macrodactyly.[521] Most are present at birth or within the first few years of life, and there is a female predominance when macrodactyly is present. Most commonly it affects the median nerve and its digital branches, but other nerves may be involved. Fibrofatty tissue is seen growing along the epineurium and perineurium and infiltrates the involved nerve, which itself is often atrophic (Fig. 41.108). Complete excision is not possible given the intimate involvement with the nerve.

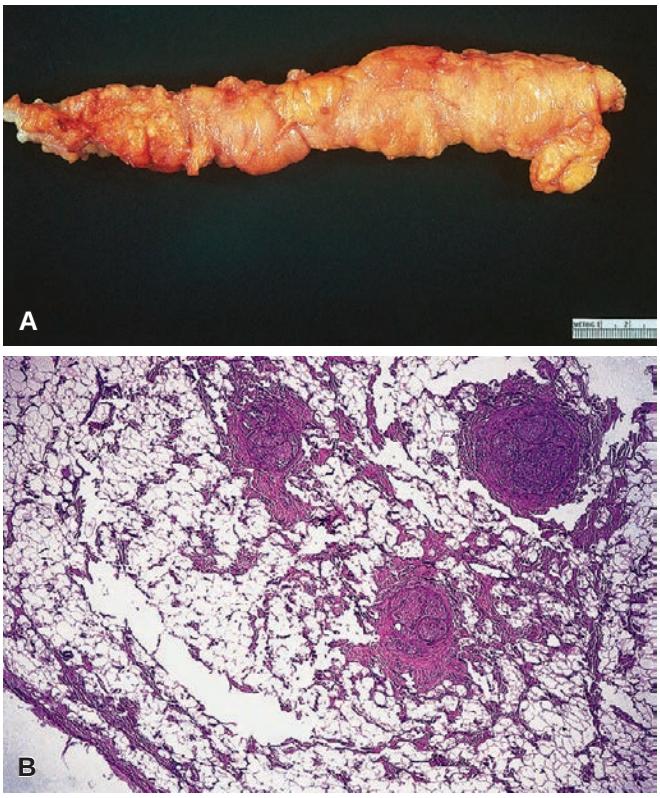

Figure 41.108 **A,** Gross and **B,** Microscopic appearance of fibrolipomatous hamartoma of nerve.

Liposarcoma

Liposarcoma is the most frequent soft tissue sarcoma in adults; this tumor is quite rare in adolescents and children, but unequivocal cases have been reported.[522,523] However, most cases so diagnosed in this age group (particularly in the past) were in reality examples of lipoblastomatosis or GCF.[524]

Liposarcomas are usually large and occur most frequently in the lower extremities (popliteal fossa and medial thigh), retroperitoneal, perirenal, mesenteric region, and shoulder area. Their relative frequency at these various sites is greatly dependent on the tumor subtype (see later). Although liposarcomas of the posterior neck, upper back, and shoulder certainly occur, it should be remembered that this is the classic site for benign adipose tissue tumors that can simulate liposarcoma, including spindle cell lipoma/pleomorphic lipoma, lipoblastoma/lipoblastomatosis, and hibernoma. Grossly, liposarcomas are well circumscribed but not encapsulated. Depending on the subtype, they may have a mucoid cut surface suggestive of myxoma, a bright yellow appearance mimicking lipoma, or a surface resembling cerebral convolutions.

Although not necessarily conspicuous or even required for the diagnosis of some subtypes (see later), the common morphologic denominator of liposarcoma is the *lipoblast*. This appears as a mononuclear or multinucleated cell with one or more cytoplasmic vacuoles that contain lipid. The nucleus is often pushed aside by a single large vacuole, resulting in a signet ring configuration, or it

For personal use only. No other uses without permission. Copyright ©2017. Elsevier Inc. All rights reserved.

Figure 41.109 Atypical Lipomatous Tumor. The neoplasm is well circumscribed and not much different from an ordinary lipoma.

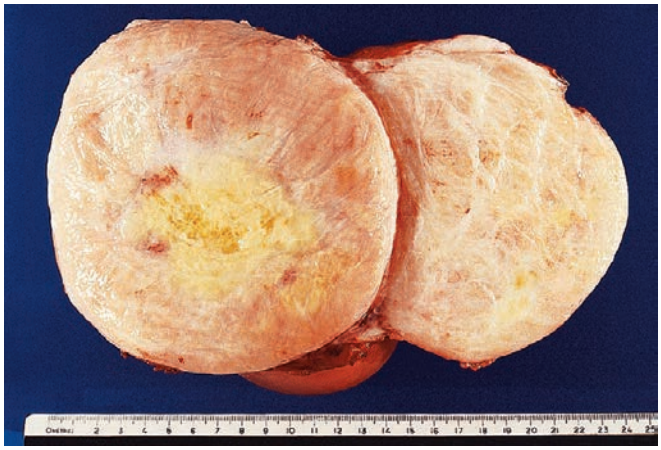

Figure 41.110 Gross appearance of a retroperitoneal atypical lipomatous tumor (well-differentiated liposarcoma) that microscopically combined features of the sclerosing and lipoma-like subtypes.

may remain centrally located but exhibit small sharp indentations by multiple small lipid vacuoles.

In their classic article on liposarcoma, Enzinger and Winslow divided liposarcomas into four types: myxoid, round cell, well differentiated, and pleomorphic, acknowledging the existence of mixed forms.[525] Several modifications have been incorporated into this classification in subsequent years, but the basic scheme remains essentially intact.

Atypical lipomatous tumor (ALT) is a synonym for **well-differentiated liposarcoma (WDL)** and is the most common subtype of liposarcoma. Grossly, it often resembles a usual lipoma (Figs. 41.109 and 41.110). Histologically, it also often resembles a lipoma on low-power examination, but closer inspection shows scattered tumor cells with large hyperchromatic nuclei. These atypical cells may be found preferentially in fibrous bands that traverse the adipose tissue lobules *(sclerosing subtype)* or be scattered among the mature adipocytes or within the walls of thick-walled blood vessels *(lipoma-like subtype)* (Figs. 41.111 to 41.114). Some of the atypical cells have features of lipoblasts by virtue of the cytoplasmic vacuoles producing nuclear indentations, but most do not. Some of the nuclei have sharply outlined vacuoles ("Lockhern"), which at the ultrastructural level are seen to correspond to invaginations of the nuclear membrane, that is, pseudoinclusions. It should be pointed out that occasional

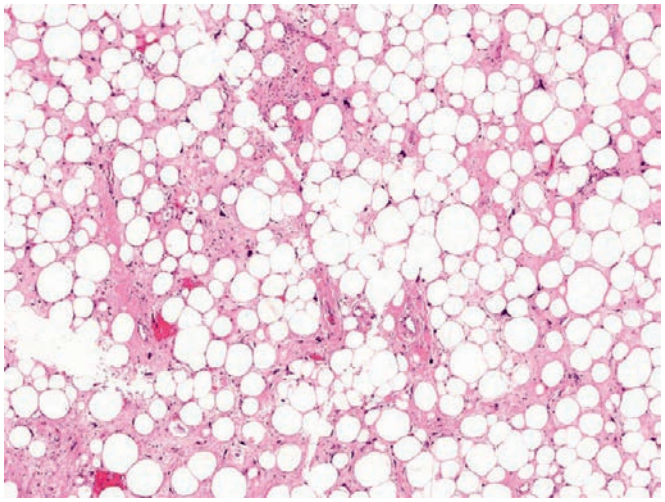

Figure 41.111 Low-power view of atypical lipomatous tumor with fibrous bands and enlarged hyperchromatic nuclei identified within the fibrous bands.

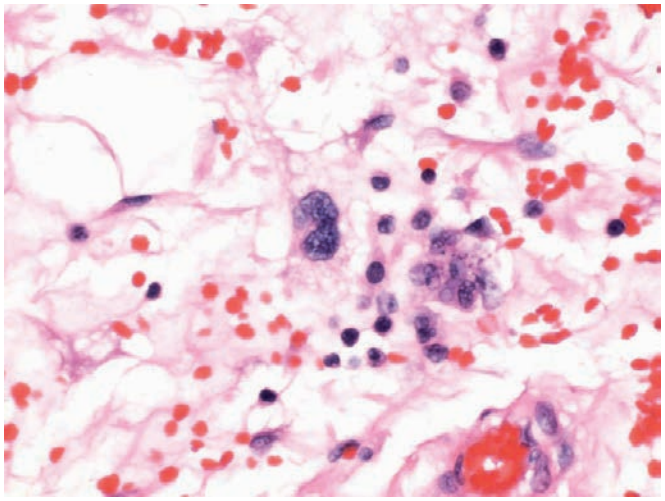

Figure 41.112 High-power view of atypical nucleus in atypical lipomatous tumor.

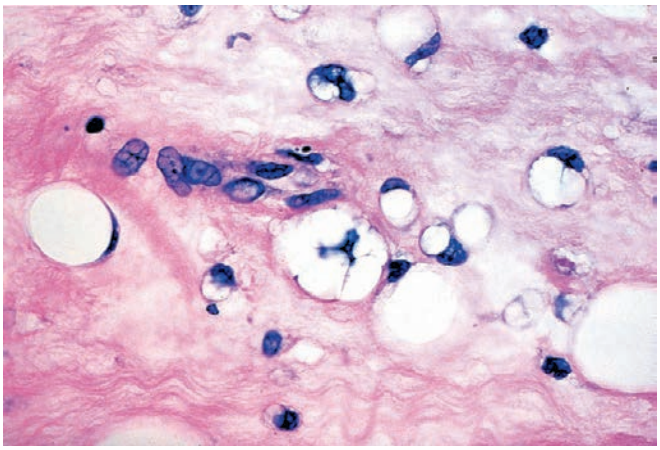

Figure 41.113 Typical lipoblasts from a case of metastatic liposarcoma showing nuclear indentation by lipid-containing cytoplasmic vacuoles.

For personal use only. No other uses without permission. Copyright ©2017. Elsevier Inc. All rights reserved.

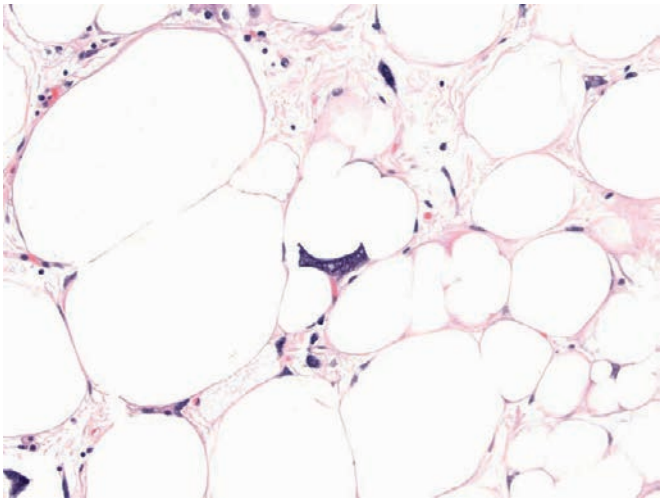

Figure 41.114 Hyperchromatic atypical nucleus in lipoma-like atypical lipomatous tumor.

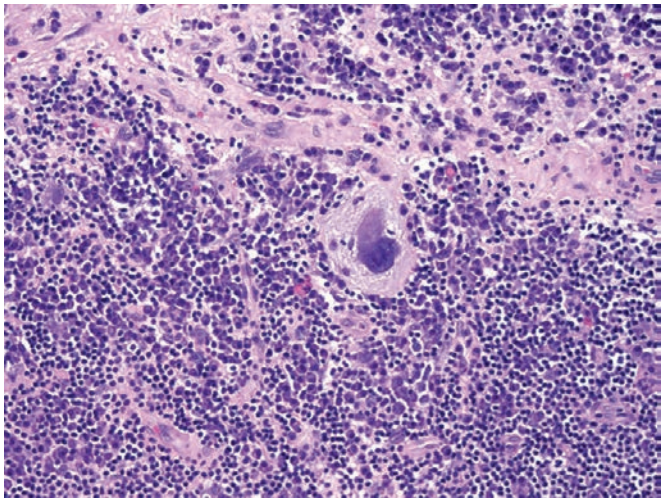

Figure 41.116 Inflammatory-type atypical lipomatous tumor with atypical nucleus amongst a dense lymphoplasmacytic infiltrate.

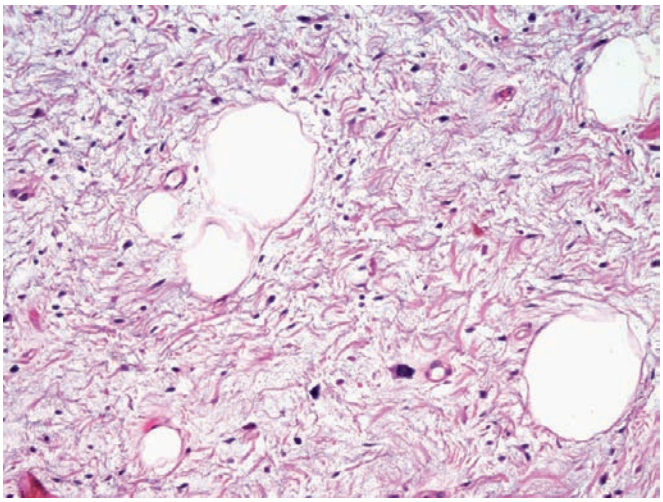

Figure 41.115 Myxoid area of atypical lipomatous tumor with rare atypical cells.

adipocytes with hyperchromatic and slightly enlarged nuclei containing pseudoinclusions can be seen in the non-neoplastic fat of somatic soft tissues and other sites, such as breast. True lipoblasts are often identified in ALT but are not required for the diagnosis.

It is not unusual for ALTs to exhibit secondary myxoid changes (Fig. 41.115); when prominent, these tumors may be confused with myxoid liposarcoma, a phenomenon which is most common in retroperitoneal tumors. However, these tumors have been shown to lack the characteristic cytogenetic aberration of myxoid liposarcoma (see later).[526] True mixed myxoid/well-differentiated liposarcomas, if they exist at all, are vanishingly rare.[527]

Occasionally, smooth muscle bundles are seen in these neoplasms, and these tumors have been referred to as *lipoleiomyosarcomas*, which should not be overinterpreted as dedifferentiated liposarcomas.[528] In other instances, a heavy inflammatory infiltrate of either neutrophilic or lymphoplasmacytic nature is present, with some of the inflammatory cells being located within the cytoplasm of the giant tumor cells. Tumors with this appearance have been called *inflammatory liposarcoma* and *lymphocyte-rich liposarcoma* (Fig. 41.116).[529,530] This inflammatory pattern can be seen in association with or independently from dedifferentiation.

The entity known as *spindle cell liposarcoma* is highly controversial. This lesion was originally described as a spindle cell variant of ALT, characterized by a population of relatively bland spindle cells arranged in fascicles and whorls and set in a variably myxoid stroma.[531] A reappraisal of cases initially diagnosed as spindle cell liposarcoma revealed some to be variants of ALT, others to be spindle cell lipomas, but most were found to cytogenetically distinct from either of these tumors.[532] In this study by Deyrup et al., patient age ranged from 15 to 82 years (mean, 50 years), and the tumors arose in the deep or superficial soft tissues of the groin, buttock, and thigh, among other sites. Clinical follow-up revealed no recurrences or metastases. The authors proposed the term "fibrosarcoma-like lipomatous neoplasm" to emphasize that it is a unique lipomatous tumor distinct from ALT, myxoid, and dedifferentiated liposarcoma.

More recently, Mariño-Enriquez et al. reported 232 cases of "atypical spindle cell lipomatous tumor."[532a] These lesions arose in patients ranging in age from 6 to 87 years (mean, 54 years) with a wide anatomic distribution including the limbs and limb girdles (63% of cases) and hands (17%) and feet (11%), with an equal distribution between subcutaneous and deeper locations. Histologically, the tumors were made up of mildly atypical spindle cells deposited in a variably myxoid or fibrous stroma with a prominent admixed lipomatous component with scattered atypical nuclei and univacuolated or multivacuolated lipoblasts. Immunohistochemically, the tumor cells stained for CD34 (64%), S-100 protein (40%), and desmin (23%). Interestingly, loss of Rb-1 expression was found in 57% of cases. Importantly, however, FISH for *MDM2* amplification was consistently negative, emphasizing the distinctness of this tumor from ALT/WDL. The vast majority of patients (87%) were alive with no evidence of recurrence or metastatic disease, but local recurrence was reported in 12% of patients; none of the patients developed metastasis or died of disease.

Cytogenetically, close to 80% of ALTs (including the dedifferentiated examples) show supernumerary ring or giant marker chromosomes, in stark contrast to lipomas of either ordinary or spindle/pleomorphic type.[506,533,534] At the molecular level, these chromosomal changes result in amplification of the 12q13–15 region, which includes *MDM2*, *SAS*, *HMGA2*, and *CDK4* genes. Demonstration of *MDM2* or *CDK4* amplification in tissue sections with the FISH technique is both highly sensitive and specific for distinguishing ALT from all variants of lipoma (Fig. 41.117).[535] Overexpression of these proteins by immunohistochemistry is also useful but is not as sensitive or specific as FISH.[536] Recently, it has been shown that

For personal use only. No other uses without permission. Copyright ©2017. Elsevier Inc. All rights reserved.

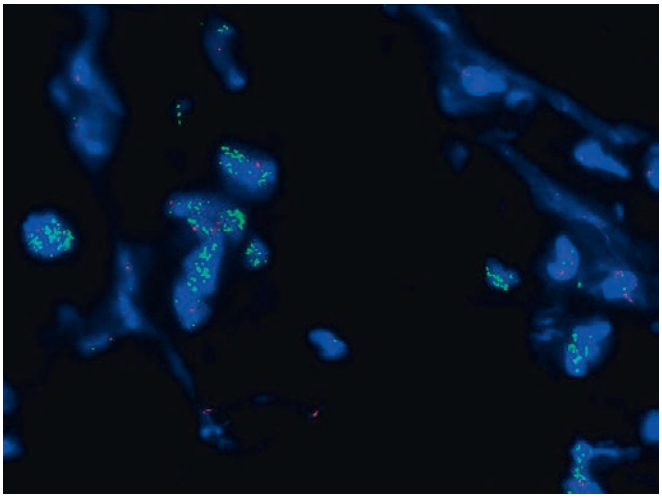

Figure 41.117 Fluorescence in situ hybridization showing amplification of *MDM2* (green signal) in atypical lipomatous tumor.

p16 (an important cell cycle regulator) is expressed in the majority of ALTs but apparently not in lipomas.[537,538]

Myxoid liposarcoma, which is the second most common type of liposarcoma, shows a marked predilection for the lower extremities, particularly the thigh and popliteal fossa. It practically never occurs in the retroperitoneum, and most cases so diagnosed are examples of ALT with prominent myxoid change.[539] Microscopically, myxoid liposarcoma has few or no mitotic figures and is characterized by proliferating lipoblasts in different stages of differentiation, a prominent anastomosing ("chicken wire") capillary network, and a mucoid matrix rich in hyaluronidase-sensitive acid mucopolysaccharides. The presence of a delicate network of thin-walled vessels is an important feature in the differential diagnosis with myxoma and other myxoid tumors (Fig. 41.118). The mucoid extracellular material may accumulate in large pools (so-called "pulmonary edema" pattern), thus simulating a tumor of lymph vessel origin. Metaplastic cartilage is found in rare instances.[540] The spindle cells show only mild atypia; a myxoid neoplasm with more striking atypia is likely a myxofibrosarcoma.

Cytogenetically, myxoid liposarcoma is characterized most commonly by the reciprocal translocation t(12;16)(q13;p11), which results in the *FUS-DDIT3* (formerly known as *TLS-CHOP*) fusion, and less commonly, t(12;22)(q13;q12) with *EWSR1-DDIT3* fusion.[526,541] *DDIT3* is a gene involved in adipocyte differentiation. The chimeric protein encoded by *FUS-DDIT3* can be detected immunohistochemically.[542]

Round cell liposarcoma is the high-grade variant of myxoid liposarcoma and is characterized by a cellular proliferation of round cells with high-grade nuclei (Fig. 41.119). The myxoid stroma and plexiform vasculature become inconspicuous. As little as 5% of the tumor being composed of such areas constitutes round cell liposarcoma and has a significant negative impact on prognosis.[543,544] As expected, this variant harbors the same translocations found in myxoid liposarcoma and on occasion, especially in cases in which lipoblasts are inconspicuous or the myxoid areas are not found, molecular analysis can be diagnostically helpful.[545]

Pleomorphic liposarcoma is a highly cellular, poorly differentiated neoplasm containing numerous tumor giant cells, some of them having the features of pleomorphic lipoblasts.[546–548] Mitoses and foci of necrosis are frequent. An *epithelioid variant* of pleomorphic liposarcoma has been described that simulates adrenal, hepatic, or renal cell carcinoma at the morphologic level (Fig. 41.120), including focal immunoreactivity for cytokeratins.[549,550] The differential diagnosis includes UPS and pleomorphic rhabdomyosarcoma; the recognition of pleomorphic lipoblasts is the only diagnostic criterion.

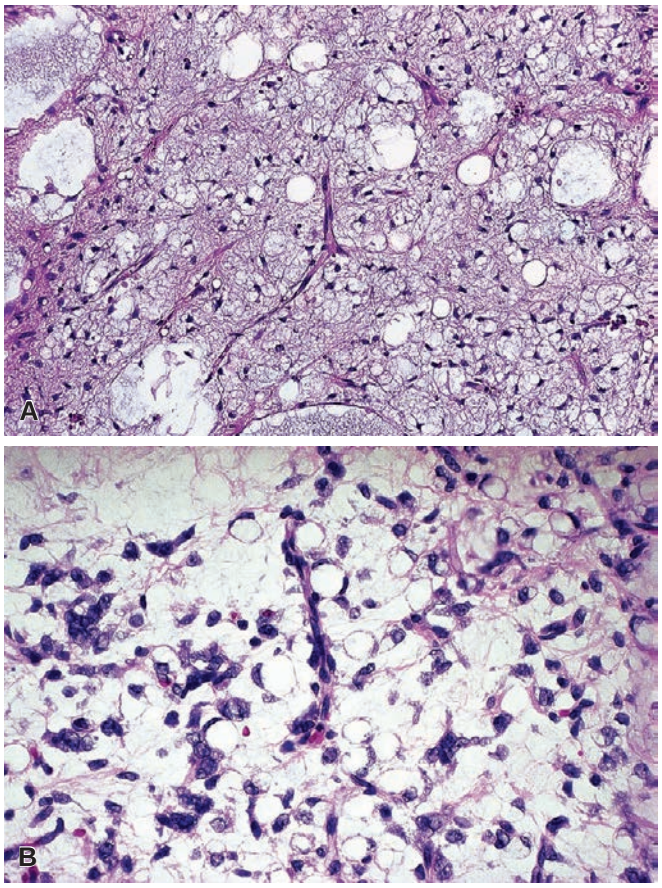

Figure 41.118 **A** and **B,** Myxoid liposarcoma.

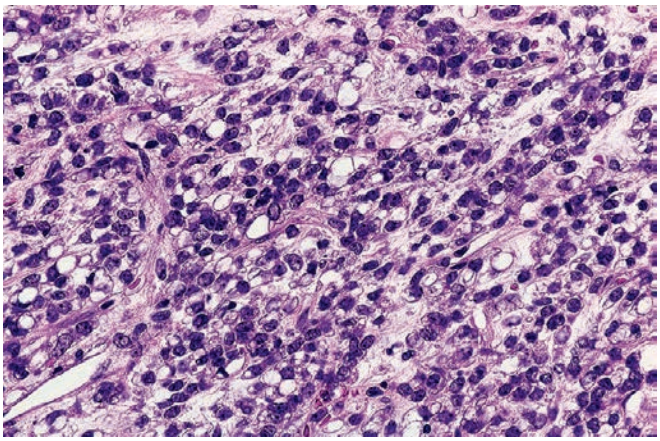

Figure 41.119 **Round Cell Liposarcoma.** This tumor is a poorly differentiated form of myxoid liposarcoma.

Dedifferentiated liposarcoma is the term used for the emergence of a generally nonlipogenic component within an ALT. The dedifferentiated component may already be present at the time of the original excision, but it may also emerge in recurrent or metastatic foci. It is much more common in retroperitoneal neoplasms, but it has also been documented in tumors of the extremities (Fig. 41.121).[551,552] Microscopically, the dedifferentiated component is

For personal use only. No other uses without permission. Copyright ©2017. Elsevier Inc. All rights reserved.

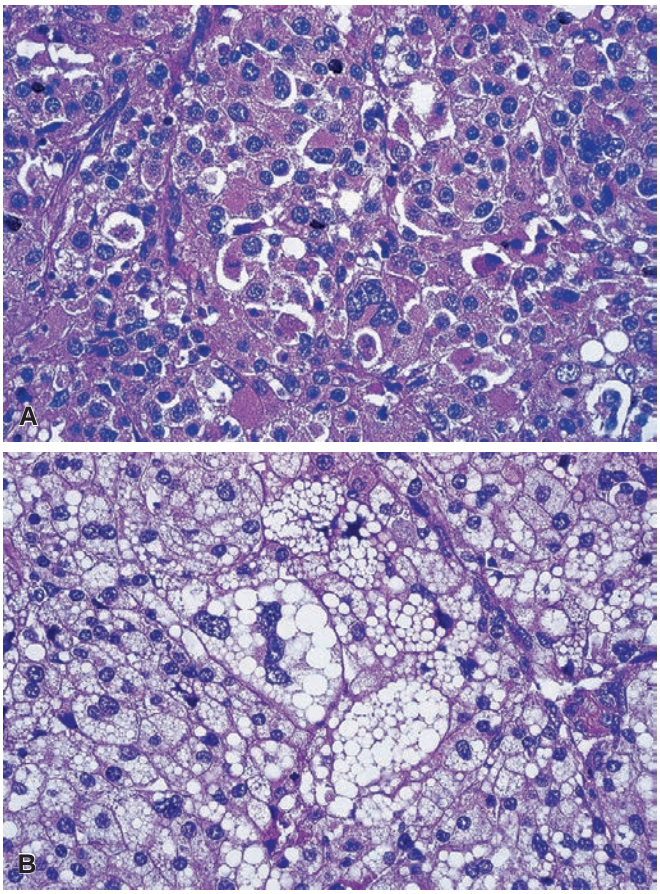

Figure 41.120 Epithelioid variant of pleomorphic liposarcoma **(A)**. The liposarcomatous nature of the tumor is better shown in **B**.

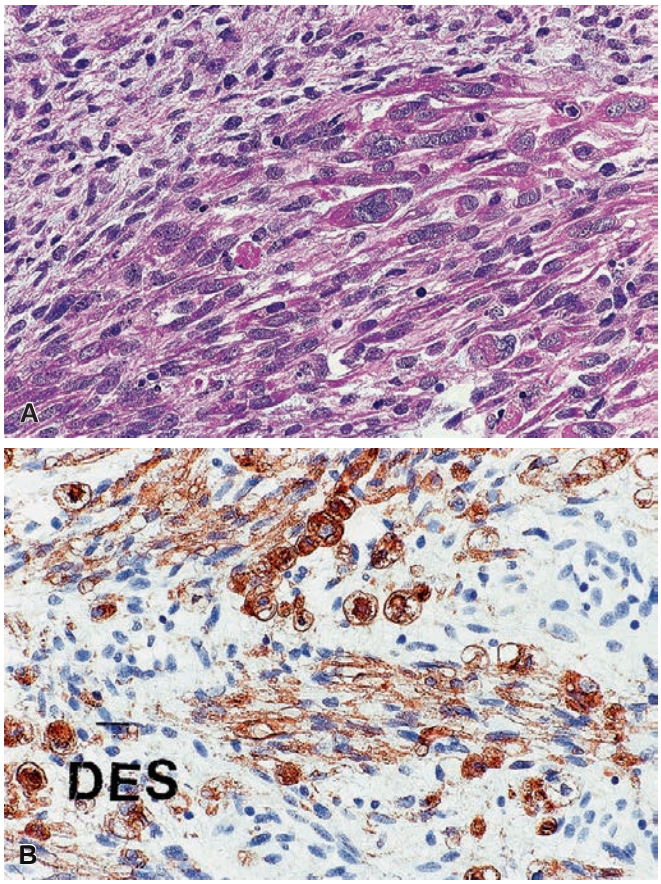

Figure 41.122 Dedifferentiated retroperitoneal liposarcoma. **A,** Divergent rhabdomyosarcomatous differentiation with **(B)** desmin immunoreactivity.

Figure 41.121 Dedifferentiated liposarcoma of retroperitoneum abutting the kidney, a common occurrence.

usually (but not always) high grade, with an appearance reminiscent of fibrosarcoma or UPS, with or without myxoid features.[553–555] Heterologous elements showing rhabdomyosarcomatous (Fig. 41.122), chondrosarcomatous, or angiosarcomatous differentiation may be present[556–558]; these foci, which are viewed as evidence of divergent differentiation, are accompanied by their respective immunohistochemical markers. Recently, the existence of a "homologous" form of dedifferentiation (with the appearance of a pleomorphic liposarcoma) has been proposed.[559,560] Occasionally, the dedifferentiated component appears in the form of a discontinuous micronodular pattern throughout the tumor.[552] In other cases, it exhibits a whorling pattern with a neural-like or meningothelial-like appearance associated with metaplastic bone formation.[561,562] A high percentage of dedifferentiated liposarcomas stain for PPAR-gamma, whereas this is true for only one-fourth of other sarcoma types.[563] Dedifferentiated liposarcoma shows the same genetic changes as the preexisting ALT but often shows additional genetic changes, such as amplifications (e.g., gain of 1q21–24, 6q22–24, 20q13, or 12q24), deletions (e.g., loss of 13q14–21 or 11q22–23), and *TP53* mutation.[564,565]

It should be noted that the dedifferentiated component does not have to be high grade, as some show resemblance to fibromatosis (Fig. 41.123), well-differentiated fibrosarcoma,[551] or osteosarcoma (so-called low-grade dedifferentiation).[566] Along these lines, Evans has proposed the existence of a *cellular atypical lipomatous tumor*, defined as an ALT with increased cellularity but fewer than five mitoses per 10 high-power fields in the nonlipogenic component.[553] Regardless of terminology, these cellular tumors are not to be equated with conventional high-grade dedifferentiated tumors in view of their significantly different behavior.[553]

Differential diagnosis. The benign lesions most commonly confused with ALT are lipoblastoma/lipoblastomatosis, spindle cell/pleomorphic lipoma, myxoid, inflamed or necrotic lipoma, lipogranuloma (such as that resulting from injection of liquid silicone), *localized lipoatrophy* (such as that seen at sites of insulin or steroid injections), *subconjunctival herniated orbital fat* (prolapse of subconjunctival intraconal orbital fat), and *massive localized lymphedema* (a

For personal use only. No other uses without permission. Copyright ©2017. Elsevier Inc. All rights reserved.

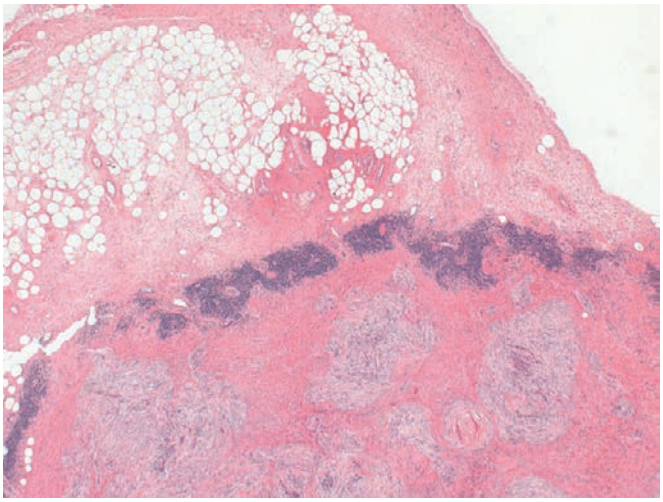

Figure 41.123 Area of so-called low-grade dedifferentiation which is devoid of adipocytic differentiation. This area shows extensive myxoid change and is more cellular than the usual atypical lipomatous tumor.

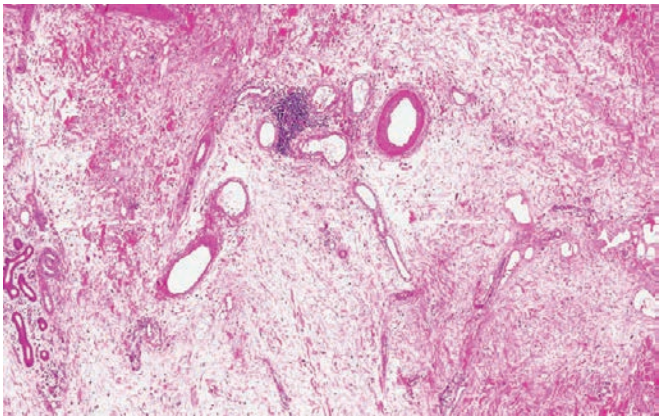

Figure 41.124 Massive lymphedema in a morbidly obese patient resembling an atypical lipomatous tumor.

non-neoplastic disease most often occurring in the lower extremities of morbidly obese patients) (Fig. 41.124).[567] We have also been impressed by the similarity to myxoid liposarcoma that lipomas present in individuals who have subjected themselves to a drastic diet program can have. As a general rule, the diagnosis of liposarcoma should be questioned for any tumor seen in the pediatric age group or any tumor that is small, superficial, embedded within a major muscle, or located in the neck region. Although bona fide liposarcomas have been documented in all of these situations, the features of malignancy need to be assessed in a particularly critical fashion because of the high frequency with which benign lesions simulate liposarcoma in these settings.

Treatment and prognosis. The primary treatment of all types of liposarcoma is surgical, inasmuch as radiation therapy and chemotherapy are generally of only dubious value.

Tumor location, size, and histologic subtype are the most important prognostic indicators. Both the pure myxoid liposarcomas and the ALT (particularly the latter) tend to recur locally. Although pure myxoid liposarcoma can metastasize, ALT does not unless it undergoes dedifferentiation. By contrast, round cell and pleomorphic liposarcoma often give rise to metastases, most often to the lungs.

Tumors and Tumorlike Conditions of Blood and Lymph Vessels

Hemangioma

Hemangiomas are frequently designated and regarded as tumors because of their usually localized nature and mass effect. However, the fact that they consistently lack chromosomal alterations speaks against a true neoplastic process. The presence or absence of nerve bundles intimately admixed with the vascular proliferation has been used to place them into a malformative or a neoplastic category, respectively.[568,569] Although clearly benign, they can become very large and unsightly and can even be fatal if they affect vital structures. They almost never become malignant, although a few well-documented examples of this complication are on record. Many arise in children, and a significant number are present at birth.[570] Over half arise in the head and neck area, but they can also occur in the trunk or extremities. Most hemangiomas are solitary; when multiple (with or without associated lesions in internal organs) or affecting a large segment of the body, the condition is known as *angiomatosis*.[571]

Hemangiomas have been classified according to their clinical appearance and the caliber of vessel involved. A close correlation exists between these two parameters.

Capillary hemangiomas are made up of small vessels of capillary caliber and can occur in any organ but is most common in the skin, where it appears as an elevated nodule with an intense crimson color. Such a hemangioma is traditionally known to dermatologists as a *strawberry hemangioma* because of its clinical appearance. It is usually present at birth or appears during the first month of life and enlarges rapidly during the first few months, only to stop growing when the child is approximately 6 months old. Subsequently, it becomes flaccid, pale blue, and covered with tiny wrinkles, and it eventually disappears completely.[572]

Microscopically, the lesion exhibits a lobular configuration on low-power examination (Fig. 41.125). Masses of closely packed spindle cells are seen with neoformed spaces that contain little blood. Mitotic figures are usually present and can be numerous. At the periphery, the tumor may be seen to invade subcutaneous tissue or skeletal muscle. Perineurial involvement has also been observed.[573]

By immunohistochemistry, most of the cells have the features of endothelial cells, including positivity for FVIII-RA, CD31, CD34, ERG, FLI-1, estrogen receptor-beta, annexin II (ANX2, a cell surface receptor for angiostatin), and LMO2 (a transcription factor involved in vascular and hematopoietic development).[166,574,575] The issue as to whether they also express lymph vessel–type markers, such as LYVE-1, remains controversial.[576,577] Hemangiomas also have a component of pericytes/smooth muscle cells and fibroblasts.[578]

Infantile hemangioma (also known as *cellular hemangioma of infancy*) is a form of capillary hemangioma.[579] Most cases are sporadic, but some appear to be familial and have been linked to mutations at 5q31-33.[580] Rare cases are associated with a number of other abnormalities, including *p*osterior fossa brain malformations, *h*emangiomas, *a*rterial cerebrovascular abnormalities, *c*ardiovascular abnormalities, and *e*ye anomalies (also known as PHACE syndrome).[581]

Most lesions appear shortly after birth and rapidly enlarge over several months, typically reaching their maximum size between the ages of 6 and 12 months. Many regress over the ensuing years, often resulting in a small pigmented scar.

Microscopically, these lesions have a multinodular pattern fed by a single arteriole.[582] The nodules are composed of plump endothelial cells and pericytes. The cellularity may be so striking such

For personal use only. No other uses without permission. Copyright ©2017. Elsevier Inc. All rights reserved.

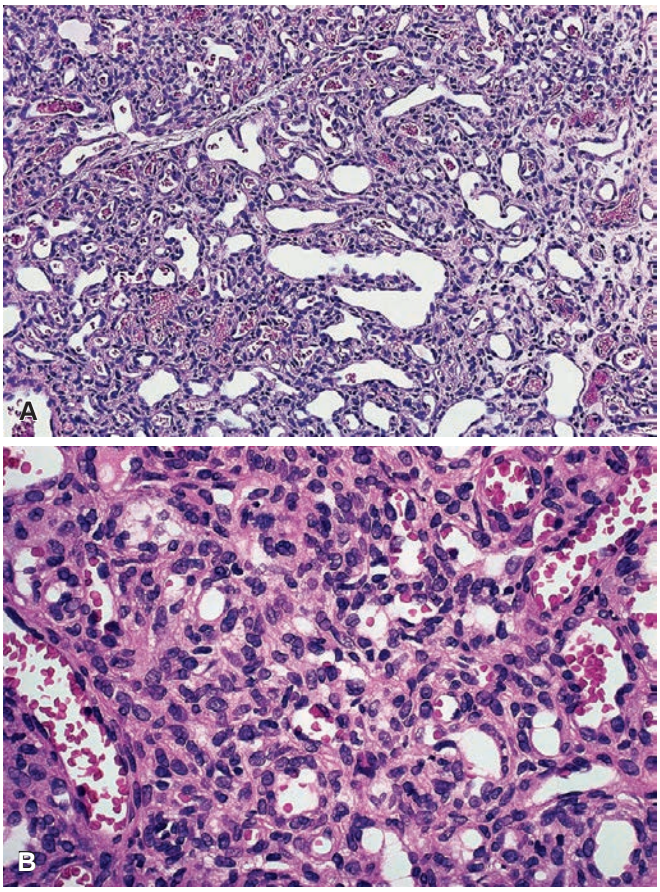

Figure 41.125 Infantile hemangioma. **A,** Vaguely lobulated architecture. **B,** The high cellularity and mitotic activity should not lead to an overdiagnosis of malignancy.

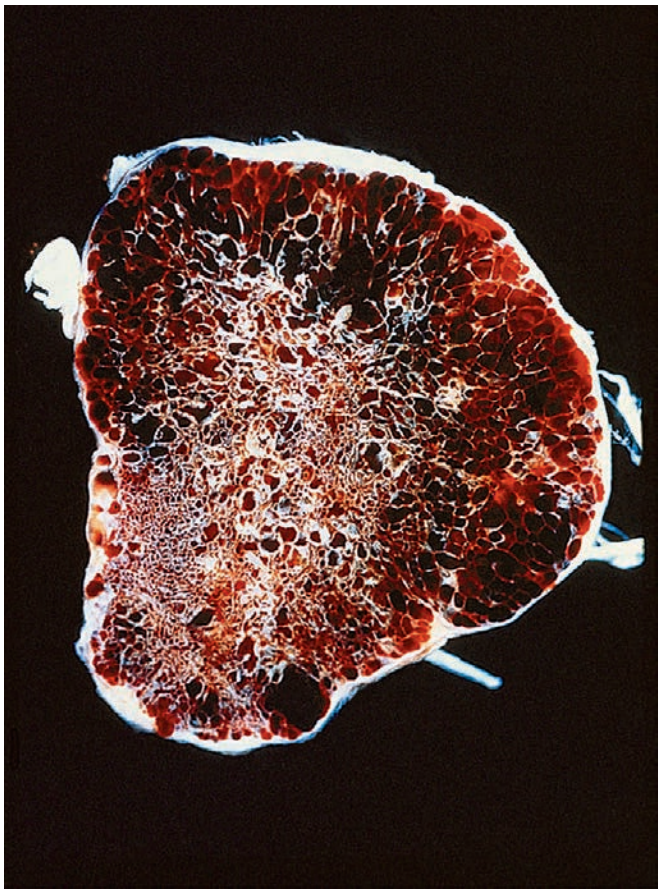

Figure 41.126 Cavernous hemangioma of soft tissues of the orbit.

that the underlying vascular nature of the lesion may not be obvious. Mitotic figures are prominent, but the lobular growth pattern is consistent with a benign lesion. Immunohistochemically, these lesions characteristically express GLUT-1, a glucose transport receptor and a marker which is not found in other types of hemangioma.[583]

As previously mentioned, most of these tumors regress spontaneously, but some require surgery, corticosteroids, or laser therapy.[583]

Cavernous hemangiomas are composed of larger vessels with cystically dilated lumina and thin walls (Figs. 41.126 and 41.127). Those occurring in the skin are traditionally known as *port-wine nevus* or *nevus flammeus*. This lesion, which is present at birth, grows very slowly and in proportion to the growth of the patient; in time, it becomes nodular and soft. In contrast to the strawberry nevus, it does not regress spontaneously.[572] Large, deep cavernous hemangiomas may undergo thrombosis, ulceration, and infection. The thrombi may be seen in various stages of organization and recanalization, the latter including papillary endothelial hyperplasia (Masson lesion). They can also be associated with thrombocytopenia and with intravascular coagulation, which are corrected by removal of the tumor.[584] Cavernous hemangiomas containing dilated, interconnecting thin-walled channels with occasional pseudopapillary projections have been designated as *sinusoidal hemangiomas*.[585]

Large-vessel hemangiomas may be composed of vessels with the structure of veins *(venous hemangiomas)* or a combination of veins and arteries (*racemose*, *cirsoid*, or *arteriovenous hemangiomas*).[586] The structure of the vessel wall is often abnormal and not easily identifiable as arterial or venous. They occur in the back, gluteal region, thigh, and other sites; sometimes an entire extremity is involved. The association of varicose veins, cutaneous hemangiomas, and soft tissue and bone hypertrophy is known as *Klippel–Trénaunay syndrome*.[587] Thrombosis and calcification are common in large-vessel hemangiomas; the latter can be large enough to be detectable radiographically.

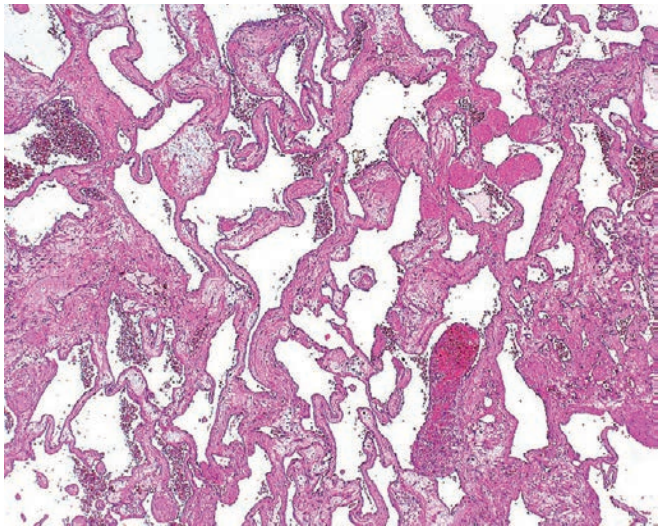

Figure 41.127 Cavernous hemangioma with widely dilated vascular spaces.

For personal use only. No other uses without permission. Copyright ©2017. Elsevier Inc. All rights reserved.

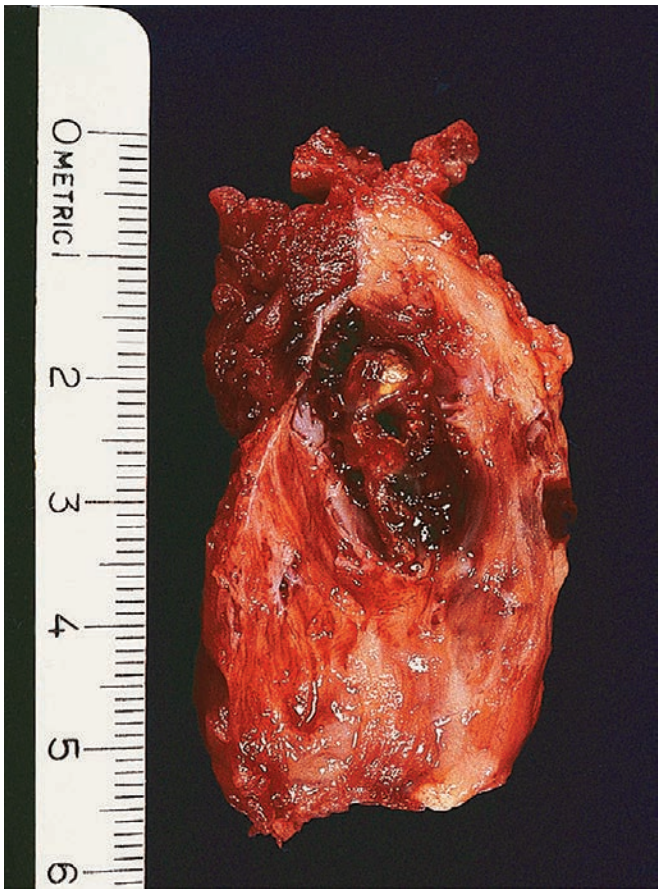

Figure 41.128 Gross appearance of an intramuscular hemangioma.

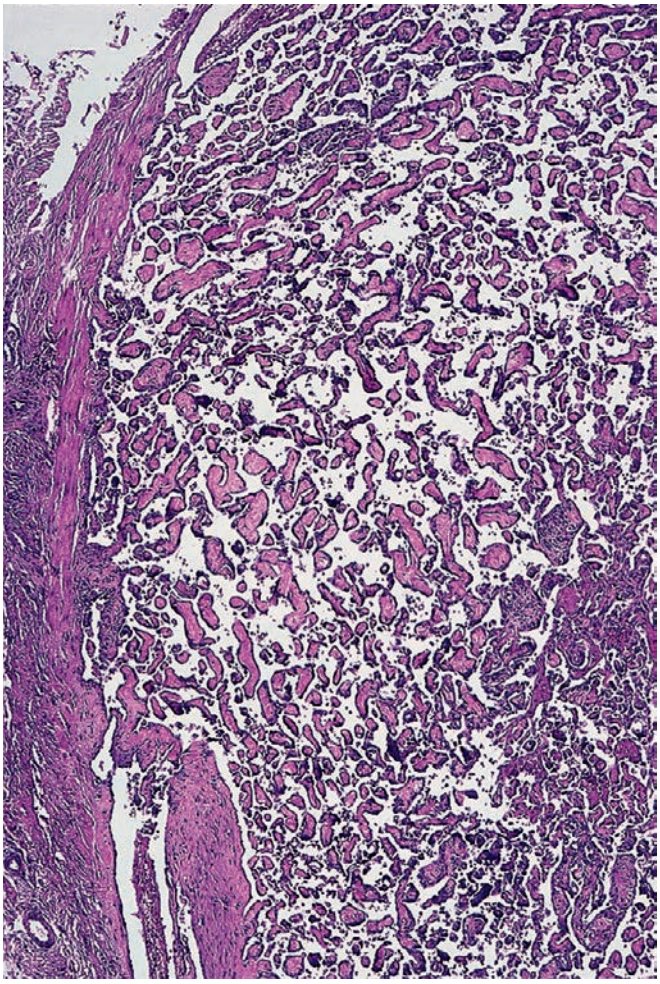

Figure 41.129 Intravascular Papillary Endothelial Hyperplasia. The confinement of the lesion to the vascular lumen with hyaline cores within the papillae is a characteristic feature.

Intramuscular hemangiomas usually have a venous or cavernous microscopic appearance (Fig. 41.128).[588] In other cases, they are very cellular, with plump nuclei, mitotic figures, intraluminal papillary projections, and even infiltration of perineurial spaces. It should be remembered that bona fide angiosarcomas of skeletal muscle are quite uncommon.

Intravascular papillary endothelial hyperplasia (Masson hemangioma or Masson lesion) is probably not a true neoplasm but is discussed here because of its capacity to simulate microscopically benign and malignant vascular tumors.[589] First described by Masson in hemorrhoidal vessels as "vegetant intravascular hemangioendothelioma," it is currently thought to represent an exuberant organization and recanalization of a thrombus, an interpretation supported by immunohistochemical studies.[590] It can occur in previously normal vessels or in varices, hemorrhoids, hematomas, hemangiomas, and angiosarcomas.[591] The de novo ("pure") form is usually found in the extremities (particularly the fingers) and the head and neck region. It simulates angiosarcoma because of the presence of papillary formations, anastomosing vascular channels, and plump endothelial cells (Fig. 41.129). It is identified because of the exclusively intravascular nature of the process; the lack of necrosis, bizarre cells, and atypical mitoses; the characteristically fibrinous and/or hyaline (deeply eosinophilic) appearance of the papillary stalks; and the frequent finding of residual organizing thrombi.

Spindle cell hemangioma, a vascular tumor originally described as spindle cell hemangioendothelioma,[592] may present at any age, has a male predominance, occurs preferentially in the dermis and subcutaneous tissue of the distal extremities, and combines histologically the features of cavernous hemangioma and Kaposi sarcoma.[593] The latter areas often have a component of epithelioid endothelial cells (Figs. 41.130 and 41.131). The immunohistochemical features are those of endothelial cells.[593] Development of recurrences or new lesions is common, but metastases have been documented in only one case following repeated recurrences and radiation therapy.[592] Some cases have occurred in patients with Maffucci or Klippel–Trénaunay syndrome.[594]

Epithelioid hemangioma (also known as *angiolymphoid hyperplasia with eosinophilia*) is an epithelioid vascular tumor which appears to be distinct from Kimura disease, although these two lesions have been frequently linked in the literature.[595,596] It typically occurs in young adults, more often in women, and is most often found in the head and neck region, particularly around the ear. Almost 50% of patients develop multiple lesions, usually in the same anatomic area. Some patients have associated lymphadenopathy and peripheral blood eosinophilia.

The lesion is typically circumscribed and centered either in the dermis or subcutaneous tissue, but rare examples involve the deep soft tissue or even parenchymal organs.[597] A lobular configuration is apparent at low magnification, often with a centrally located larger blood vessel. The characteristic cell is the epithelioid endothelial cell which lines the apparent vascular structures, often with abundant eosinophilic cytoplasm. Some show intracytoplasmic vacuoles indicative of vascular lumen formation. There is often a prominent

For personal use only. No other uses without permission. Copyright ©2017. Elsevier Inc. All rights reserved.

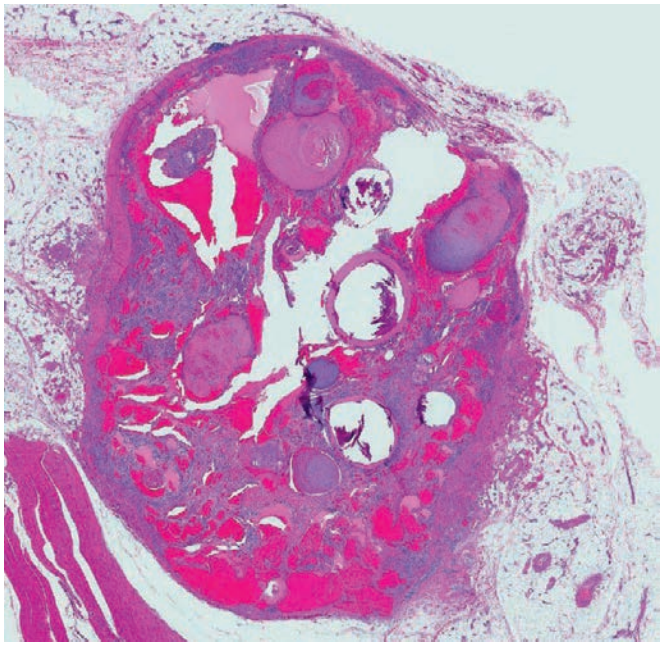

Figure 41.130 Low-power view of spindle cell hemangioma with rare phleboliths.

inflammatory component, particularly eosinophils, but plasma cells, lymphocytes, and mast cells may also be present. Those tumors that show a more solid pattern of growth can be easily confused with a more ominous epithelioid neoplasm, such as epithelioid angiosarcoma or even epithelioid sarcoma.

Recently, a recurrent translocation involving the *FOS* gene has been identified in a significant proportion of epithelioid hemangiomas.[597a] Antonescu et al. described a subset of epithelioid hemangiomas with atypical features (solid growth, increased cellularity, mild to moderate nuclear pleomorphism, or necrosis) with a distinct *ZFP36-FOSB* fusion.[597b]

Although these lesions are clearly benign, up to one-third locally recur.[597] Some appear to be associated with antecedent trauma.[598]

Hobnail hemangioma (also known as targetoid hemosiderotic hemangioma) typically develops on the skin of the extremities of young adults and presents as a pigmented elevated lesion.[599] Histologically, the superficial aspect of the tumor consists of dilated vascular channels lined by hobnail endothelial cells, some of which have intraluminal papillary tufts. The deeper portion consists of slit-like capillaries which infiltrate the dermis but lack cytologic atypia (unlike angiosarcoma). The cells stain for CD31 and D2-40 but not CD34, suggesting true lymphatic differentiation.[599]

Anastomosing hemangioma is a recently described variant that most commonly arises in the genitourinary tract (especially the kidney), although it has also been reported in the paraspinal region and retroperitoneum.[600–602] Histologically, it is composed of tightly packed capillaries arranged in an anastomosing pattern resembling splenic red pulp. Hyaline globules may be seen, as well as extramedullary hematopoiesis.

Acquired tufted angioma (also known as angioblastoma of Nakagawa) seems to be identical to kaposiform hemangioendothelioma (described later in this chapter), and both arise in children and are associated with Kasabach–Merritt phenomenon (KMP).[603,604] However, it seems as if those lesions arising in adults unassociated with KMP have been labeled as acquired tufted angioma. In addition, the latter has been associated with a familial predisposition, suggesting an autosomal dominant pattern of inheritance.[604]

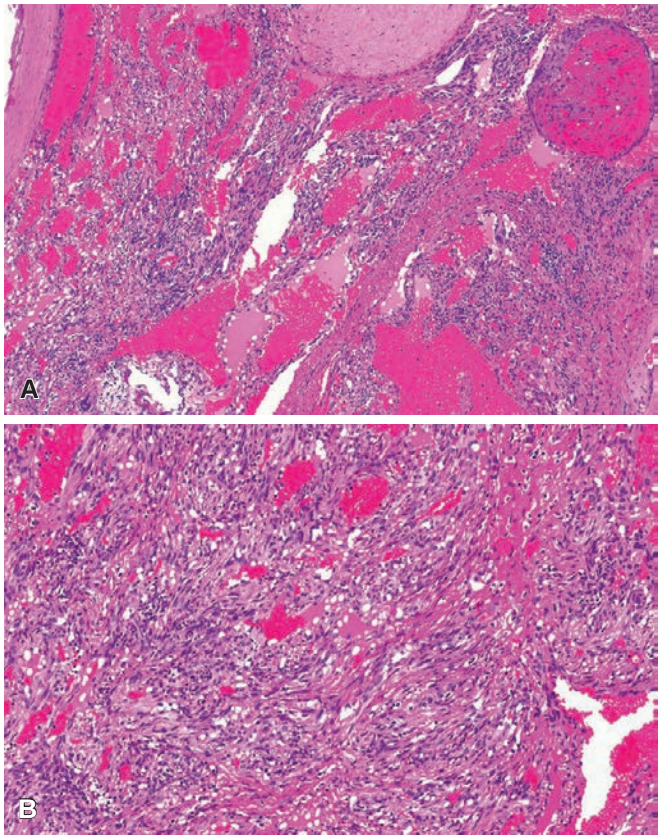

Figure 41.131 **Spindle Cell Hemangioma. A,** Cavernous spaces admixed with Kaposi-like spindle cells. **B,** Kaposi-like areas are prominent in this case.

Angiomatosis is defined as extensive involvement of one tissue plane or across tissue planes by a vascular proliferation.[571,605] Most patients are less than 20 years of age and present with diffuse swelling, which may be associated with discoloration of the overlying skin. These lesions are composed of a variety of vessel types, including capillary-sized vessels admixed with large venous and cavernous vessels, often associated with abundant fat. In fact, it is easy to confuse this lesion with a lipomatous tumor rather than recognizing it as a primary vascular proliferation (hence the older term infiltrating angiolipoma). Almost all patients develop recurrences, which is probably related to incomplete excision due to the ill-circumscribed nature of this lesion.[571] These lesions do not appear to progress to angiosarcoma, and thus conservative excision is probably the best course of action in order to minimize morbidity.

Hemangioendothelioma

The term *hemangioendothelioma* has been used over the years for both benign and malignant vascular tumors composed of endothelial cells and therefore lacks specificity. Currently, its preferred use is for vascular tumors of an endothelial nature that occupy an *intermediate* (borderline malignancy) position between the benign hemangioma and the full-blown angiosarcoma.

Epithelioid hemangioendothelioma is composed of epithelioid endothelial cells with abundant and eosinophilic, often vacuolated cytoplasm. The nucleus is round, vesicular, and occasionally indented.[606] Vascular lumina are present, most of them small; some are located intracellularly and are responsible for the cytoplasmic vacuolation (Fig. 41.132). Mitoses, pleomorphism, and necrosis are

For personal use only. No other uses without permission. Copyright ©2017. Elsevier Inc. All rights reserved.

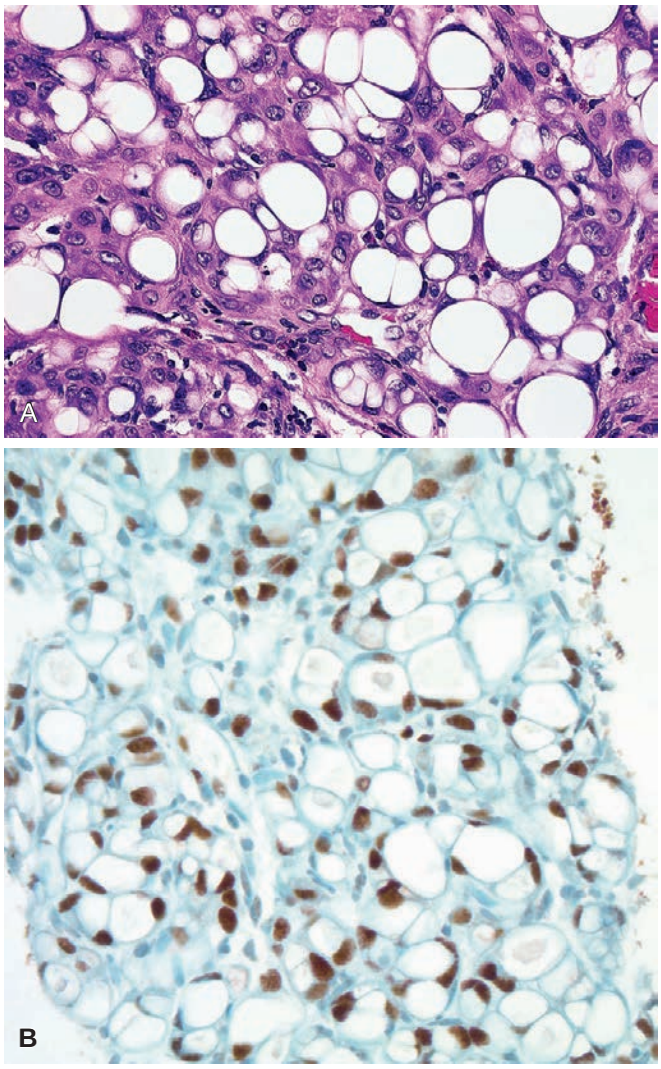

Figure 41.132 Epithelioid Hemangioendothelioma. A, Prominent cytoplasmic vacuolization resembling lipoblasts. **B,** Strong nuclear immunoreactivity for ERG is seen.

variable but area typically scanty or absent. An inflammatory infiltrate is often present at the periphery; this may contain well-formed germinal centers and/or a large number of eosinophils. The stroma may be scanty or have a prominent myxoid appearance. Osteoclast-like multinucleated giant cells may be present.[607] The endothelial nature of the tumor cells has been confirmed ultrastructurally and immunohistochemically (see later).

Tumors with this set of morphologic features have been described in a large number of sites, including skin, bone, lung, pleura, liver, peritoneum, and lymph nodes.[608] Those located in the soft tissue are seen in adults and often arise from the wall of a vein in an extremity.[606] They also occur in the head and neck area.[609] Local recurrences and distant metastases can develop, but the prognosis remains better than for angiosarcoma of either the conventional or epithelioid type (see later).[610] Mitotic activity and tumor size are associated with increased clinical aggressiveness.[611] A recurrent chromosomal aberration t(1;3)(p36.3;q25) has been reported in epithelioid hemangioendothelioma and involves *WWTR1* on chromosome 3 and *CAMTA1* on chromosome 1.[612,613] Doyle et al. found consistent nuclear expression of CAMTA1 in epithelioid hemangioendothelioma (86% of cases), indicating this marker might be extremely useful in recognizing difficult to diagnose examples of this tumor.[614]

A morphologically distinct subtype of epithelioid hemangioendothelioma is characterized by a marked histologic resemblance to epithelioid sarcoma, to the point of having been named *epithelioid sarcoma–like hemangioendothelioma*.[615] Despite some controversy, the preferred name is **pseudomyogenic hemangioendothelioma**.[616] One of the clues to the diagnosis is the presence of cytoplasmic vacuoles consistent with intracytoplasmic vascular lumen formation. Immunohistochemically, the tumor cells are immunoreactive for cytokeratins, CD31, and FLI-1 but not CD34.[615] Recently, a *SERPINE1-FOSB* fusion has been identified as a consistent genetic alteration in pseudomyogenic hemangioendothelioma and diffuse nuclear immunoreactivity for FOSB can be found in virtually all examples of this tumor.[616a]

Kaposiform hemangioendothelioma is a rare vascular tumor that arises most commonly in the retroperitoneum or deep soft tissue of the extremities in children, with almost 50% arising during the first year of life.[617,618] It shares features with capillary hemangioma and Kaposi sarcoma. An interesting phenomenon seen in patients with this tumor is a consumption coagulopathy and thrombocytopenia, known as KMP. Some cases are associated with lymphangiomatosis,[617] and one case has been described to arise in the setting of chronic lymphedema.[619]

Microscopically, there is a striking low-magnification appearance with tumor nodules surrounded by a desmoplastic stroma. The nodules show areas that resemble capillary hemangioma, whereas other areas resemble Kaposi sarcoma. Glomeruloid structures are a characteristic and striking feature. Thin-walled lymphatic vessels are often seen (albeit subtly) at the periphery of the tumor nodules. Markers indicating lymph vessel differentiation are often found, including PROX1, LYVE1, and D2-40, especially in the Kaposi-like areas, whereas the glomeruloid areas do not mark with these antigens, but rather stain for CD31 and CD34.[620] In contrast to infantile hemangioma, this tumor is negative for GLUT-1. The tumor is also negative for HHV8, which allows easy distinction from Kaposi sarcoma.

Clinical behavior depends upon the site, tumor extent, and presence or absence of KMP. Most patients are cured by complete surgical excision, but those with KMP may require cytotoxic agents and/or corticosteroids, as well as other drugs.[621–623] Up to 10% of patients die from KMP or the local effects of the tumor. Rare cases metastasize to regional lymph nodes, but distant metastases have not been reported.

Hobnail (Dabska-retiform) hemangioendothelioma is the preferred name that links the Dabska-type hemangioendothelioma and retiform hemangioendothelioma, given their many overlapping features, particularly the hobnail-shaped endothelial cell. The Dabska-type hemangioendothelioma was first described in 1969[624] as a tumor arising in the skin or subcutis of infants and young children. This seems to be the same tumor described under the terms *endovascular papillary angioendothelioma* and *papillary endolymphatic angioendothelioma*.[625–627] The retiform hemangioendothelioma has similar features but arises in adults and is characterized by long "retiform" vessels lined by hobnail endothelial cells.[628]

Hobnail hemangioendotheliomas are seen in both children and adults, with tumors showing the classic features of Dabska-type lesions arising in children and those with a retiform appearance arising in adults. Both appear as ill-defined, plaque-like lesions in the skin and subcutaneous tissue, most commonly in the distal extremities. Dabska-type lesions have well-formed vessels lined by hobnail endothelial cells with characteristic intraluminal papillations with fibrous cores lined by hobnail cells (Fig. 41.133). These vessels are surrounded by a dense fibrous stroma with prominent lymphocytes.[629]

For personal use only. No other uses without permission. Copyright ©2017. Elsevier Inc. All rights reserved.

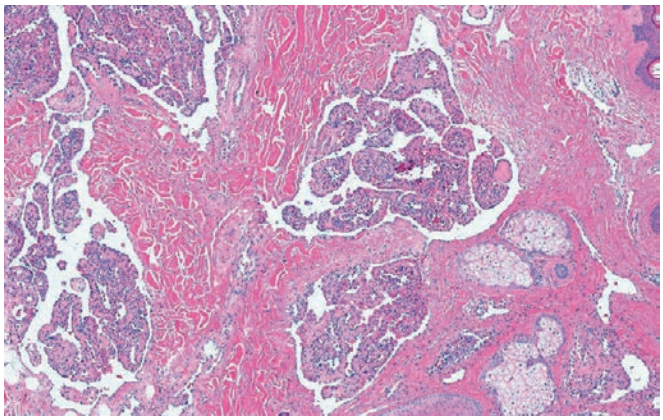

Figure 41.133 Intraluminal papillations with fibrous cores lined by hobnail endothelial cells in hobnail hemangioendothelioma, Dabska-type.

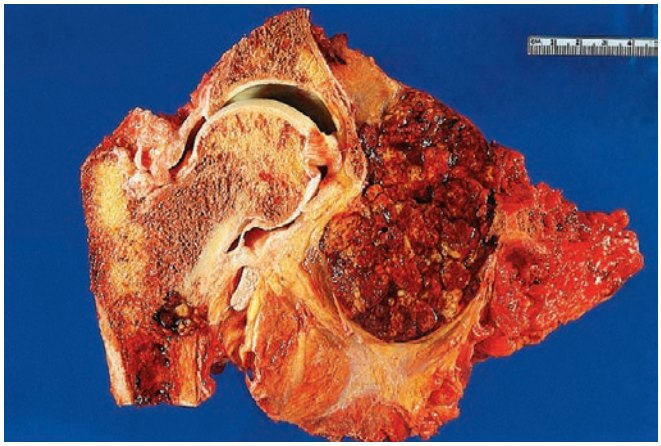

Figure 41.134 Gross hemorrhagic appearance of angiosarcoma in the region of the hip.

On the other end of the histologic spectrum, retiform-type lesions are characterized by elongated vessels which have been descriptively compared to the rete testis filling the dermis and extending into the subcutis lined by hobnail cells with a "matchstick" appearance.[630] Similar to Dabska-type lesions, the vessels are surrounded by hyaline stroma with prominent lymphocytes. Rarely one encounters Dabska-type intraluminal papillations. On occasion, tumors share features overlapping these two ends of the spectrum, lending further support to their grouping as hobnail hemangioendothelioma as a unifying concept. By immunohistochemistry, the cells express CD31 and CD34, as well as lymphatic markers including VEGFR-3.[626,631,632] These lesions have a propensity to recur locally and some metastasize to regional lymph nodes, but distant metastases do not seem to occur.

Composite hemangioendothelioma is the name that has been proposed for a vascular neoplasm showing various combinations of benign, low-grade malignant, and malignant components.[633,634] The two most common patterns are those of epithelioid and retiform hemangioendothelioma. This probably does not represent a specific entity but rather the manifestation of the fact that there is a great deal of overlap between the seemingly endless number of types and subtypes of vascular tumors that have been described.

Angiosarcoma

Angiosarcoma usually is seen in adults and the elderly, but it can also rarely occur in children.[635,636] The most common locations are the skin, soft tissue, breast, bone, liver, and spleen. Some soft tissue angiosarcomas arise from major vessels, such as the inferior vena cava, pulmonary artery, or aorta.[637,638] These tend to have a very undifferentiated appearance and a solid pattern of growth, to such an extent that they may not be identifiable as being of endothelial nature.[637] Accordingly, topographic terms such as intimal sarcoma, luminal sarcoma, and arterial/venous trunk sarcoma have been used for them.[639]

Angiosarcomas have been reported in previously irradiated fields,[640] around long-standing foreign bodies,[641] in arteriovenous fistulas[642] (including surgically constructed ones),[643] as a secondary somatic-type which develops in mediastinal or retroperitoneal germ cell tumors,[644] or arising within preexisting benign tumors (e.g., schwannoma, neurofibroma).[645]

Grossly, angiosarcomas tend to be highly hemorrhagic and deeply invasive (Fig. 41.134). Their microscopic appearance ranges from a pattern that is so well differentiated as to simulate a benign hemangioma to one so undifferentiated and solid as to simulate carcinoma, malignant melanoma, or other types of sarcoma.[646] The diagnostic areas of angiosarcoma are represented by the freely anastomosing vascular channels lined by atypical endothelial cells (Fig. 41.135). Clusters of reactive lymphocytes and clumps of hemosiderin are common.

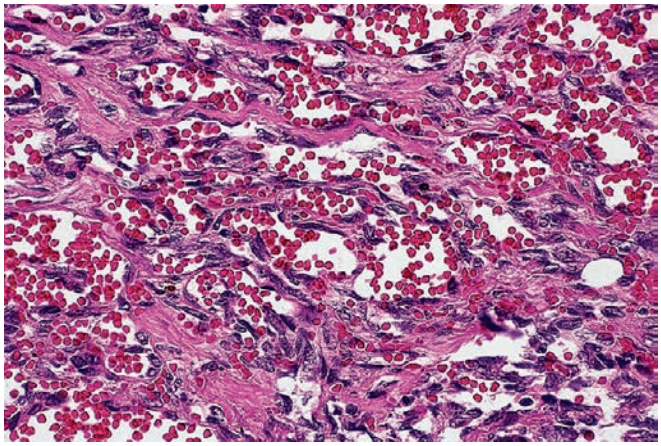

Figure 41.135 Angiosarcoma of the mediastinum showing anastomosing vascular channels.

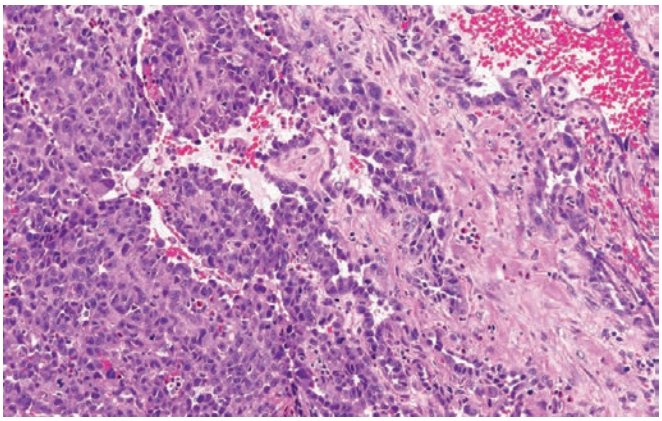

Figure 41.136 Epithelioid angiosarcoma with large epithelioid cells arranged in sheets and vasoformative spaces.

Variations in the appearance of the neoplastic endothelial cells are great. Their shape ranges from very elongated to plump and epithelioid (Fig. 41.136), and their size from small to giant, with occasional development of multinucleated forms.[647]

For personal use only. No other uses without permission. Copyright ©2017. Elsevier Inc. All rights reserved.

The differential diagnosis of angiosarcoma includes hemangioma for the better differentiated lesions, Kaposi sarcoma for those with a predominantly spindle component, and carcinoma or amelanotic melanoma for the poorly differentiated types. Metastatic renal cell carcinoma, because of its high degree of vascularity, is particularly notorious for its ability to simulate angiosarcoma; in this regard, it should be kept in mind that clear tumor cells are not a feature of angiosarcoma.

Immunohistochemically, various endothelial markers can be demonstrated depending on the degree of differentiation. Of these, CD31 and ERG are the most reliable.[6,648] In some cases (particularly the epithelioid variant) there is coexpression of cytokeratin, which can even be strong and diffuse.[649] In other cases there is expression of D2-40, suggesting differentiation toward lymph vessel endothelial cells.[650]

A well-defined clinicopathologic form of angiosarcoma involves the head and neck region (particularly the scalp) of elderly individuals. It begins in the skin but often extends into the subcutis. The clinical course includes repeated local occurrences over a long period of time, followed in some cases by lymph node and pulmonary metastases.[651,652]

Lymphangioma and Lymphangiomyoma

Most **lymphangiomas** represent malformations rather than true neoplasms and are thought to result from failure of the lymphatic system to communicate with the venous system.[653] Three forms exist: *capillary*, *cavernous*, and *cystic* (Fig. 41.137). The capillary form occurs in the skin, whereas the cavernous variety prefers deep soft tissues. Cystic lymphangioma has been traditionally known as *hygroma*. Its most common presentation is in the form of a poorly defined soft tissue mass in the neck of children, usually situated posterior to the sternocleidomastoid muscle and sometimes extending into the mediastinum. Those developing in utero often progress to hydrops and cause fetal death. Many of the fetuses have karyotypes consistent with Turner syndrome or other chromosomal abnormalities.[654,655] Some lymphangiomas are diffuse and/or multicentric, the condition being designated as *lymphangiomatosis*. These cases may be limited to the soft tissues or be accompanied by osseous and/or visceral manifestations.[656] A preferred location is the thoracic cavity, with resulting chylous pleural effusion and/or chylopericardium.[657,658] Other cases diffusely affect the extremities.[659]

Microscopically, lymphangioma consists of large lymphatic channels growing in loose connective tissue (Fig. 41.138). A few disorganized bundles of smooth muscle can be present in the wall of the larger channels. Focal areas of papillary endothelial proliferation similar to those described by Masson in blood vessels are sometimes found. Large collections of lymphocytes may be present in the stroma and cause mistakes in interpretation. Lymphangioma practically never becomes malignant and is curable by excision, although it can locally recur.

Lymphangiomyoma is the preferred term for a benign neoplasm seen exclusively in females and originally described as lymphangiopericytoma.[660,661] The localized form is restricted to the mediastinum and retroperitoneum, often seen in close association with the thoracic duct and its tributaries, and often results in chylothorax. Chylous ascites and chyluria (secondary to ureteral wall involvement) may also be present. The diffuse form of the disease, known as *lymphangio(leio)myomatosis*, typically involves the lung.[662]

Microscopically, there is a proliferation of intimately mingled lymph vessels and smooth muscle elements. Immunohistochemically, the lining cells show lymph vessel markers such as D2-40,[663] whereas the tumor cells (which are plumper and paler than those of ordinary leiomyomas) are reactive for actin, desmin, HMB-45, and other melanocytic markers, such as MiTF, tyrosinase, and melan-A.[664] This profile (particularly the HMB-45 immunoreactivity), plus their occurrence in patients with the tuberous sclerosis complex,[665] links these tumors with renal and extrarenal angiomyolipomas (including their epithelioid and monotypic variants), pulmonary clear cell ("sugar") tumor, clear cell myomelanocytic tumor, and other neoplasms into the continuously enlarging **PEComa** family.[666] Indeed,

Figure 41.137 Cavernous Lymphangioma. (Courtesy of Dr. R.A. Cooke, Brisbane, Australia; from Cooke RA, Stewart B. *Colour Atlas of Anatomical Pathology*. Edinburgh: Churchill Livingstone; 2004.)

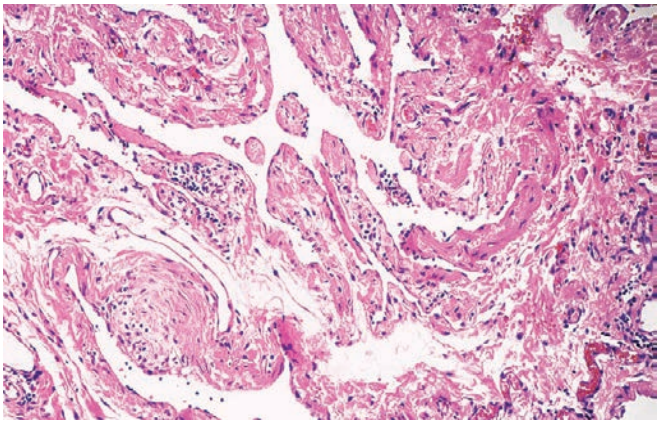

Figure 41.138 Lymphangioma of soft tissue showing dilated spaces lined by flattened endothelium. A scattering of lymphocytes is present in the stroma.

For personal use only. No other uses without permission. Copyright ©2017. Elsevier Inc. All rights reserved.

Figure 41.139 Amputated upper extremity in a case of post-mastectomy angiosarcoma.

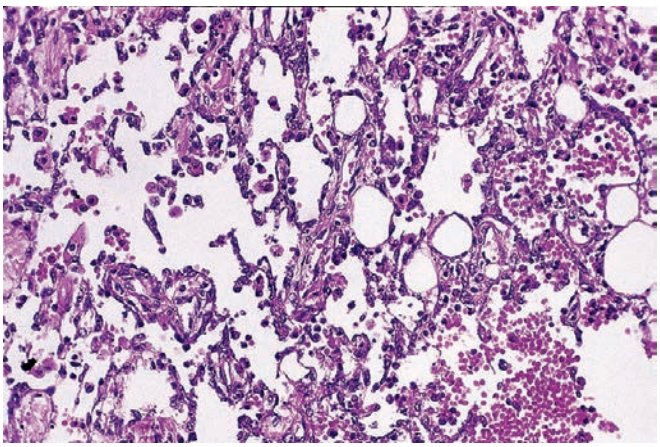

Figure 41.140 Post-mastectomy angiosarcoma showing an intricate network of neoplastic vessels.

cases are increasingly being reported of **PEComas** of soft tissue of both benign and malignant nature.[667–669] A subset of PEComas of soft tissue shows expression of TFE3 (a DNA-binding factor closely linked to MiTF) particularly those with a nested or alveolar soft part sarcoma-like growth pattern, and a perplexing link has been postulated between a subset of PEComas with melanotic Xp11 translocation renal cancers and melanotic Xp11 neoplasms.[670–672b]

Although immunohistochemical evaluation of hormone receptors in lymphangiomyoma/lymphangiomyomatosis has resulted in conflicting findings, good therapeutic results have been reported with progesterone therapy or oophorectomy.[673,674] More recently, mTOR inhibitors (sirolimus and everolimus) have shown promising results.[675]

Angiosarcoma associated with lymphedema (so-called **lymphangiosarcoma**) was first described by Stewart and Treves in 1949 in six patients who developed vascular sarcomas following radical mastectomy and axillary node dissection for breast cancer.[676] Chronic lymphedema was felt to be the predisposing factor in these patients, and subsequently, many cases of lymphedema-associated angiosarcoma have been described (Fig. 41.139). Histologically, there is a wide variation of patterns, ranging from solid undifferentiated areas to well-differentiated, capillary sized vessels with minimal cytologic atypia (Fig. 41.140). These are typically clinically aggressive lesions.[677,678]

With the decrease in the number of radical mastectomies performed during the past few decades, and the corresponding increase in the number of conservative breast operations followed by radiation, the pattern of breast carcinoma–associated vascular proliferative processes has changed. The malignant tumors developing under these circumstances have similar morphologic features, but the interval from the time of therapy is generally shorter, the tumor is in the skin overlying the breast rather than in the arm, and there is no accompanying lymphedema.[679] The matter is complicated by the fact that radiation therapy may also induce lymph vessel proliferations with the appearance of lymphangioma circumscriptum[680] or progressive acquired lymphangioma.[681] Furthermore, an increasingly large number of cases of *atypical vascular lesions* (AVLs) in the skin of radiated breast have been reported.[682] These lesions are characterized by dermal vascular proliferation and associated inflammation but not enough architectural or cytologic atypia to justify a diagnosis of malignancy.

Clinically, these lesions are small papules, often multifocal, that develop within 3 years of radiation. Most consist of ectatic vessels confined to the superficial dermis lined by flattened or hobnail cells that stain for CD31 and D2-40. Rare cases show infiltration and interconnecting vessels. It has recently been shown that postradiation angiosarcomas show amplification of *MYC*, whereas AVLs do not.[683,684] This can also be demonstrated using MYC antibodies.[685] The vast majority of patients with AVLs pursue a favorable clinical course[686,687]; however, rare cases seem to progress to angiosarcoma, particularly those deemed "vascular type" AVLs.[687]

Hemangioblastoma

So-called hemangioblastoma, a tumor characteristically located in the CNS and linked with the von Hippel–Lindau syndrome, can occasionally involve other sites, including soft tissues.[688–690] Some of the reported cases have been anatomically associated with a peripheral nerve.[691] As in the case for its more common CNS counterpart, the nature of the "stromal cells" located in between the numerous vessels remains controversial. The tumor cells express inhibin in almost all cases, but some stain for S-100 protein, GLUT1, SMA, and EMA.[688] This tumor seems to act in a clinically benign fashion. Some of these patients have von Hippel–Lindau syndrome.

Tumors of Smooth Muscle and Modified Smooth Muscles

Leiomyoma

Several types of leiomyoma exist. **Cutaneous leiomyomas** located in the dermis arise from arrectores pilorum muscles; they are characteristically superficial, small, multiple, and grouped.

Genital leiomyomas are solitary tumors that arise from smooth muscle bundles located in the superficial subcutaneous tissue of genital areas and structures that are topographically and functionally related to them, such as the nipple, areola, axilla, scrotum, penis, vulvar labia, and anal skin.

Vascular leiomyomas (angioleiomyomas) arise from the smooth muscle of blood vessels (Fig. 41.141). They occur more frequently in females and are usually located in the soft tissues of the lower limbs.[692,693] They constitute, together with traumatic neuroma, glomus tumor, eccrine spiradenoma, and angiolipoma, the classic five spontaneously painful nodules of skin and soft tissues.

Grossly, vascular leiomyomas are yellow or yellowish pink, sharply circumscribed, and fairly firm. Microscopically, they are made up of intersecting fascicles of smooth muscle cells encircling vascular lumina lined by normal endothelial cells. The vascular organoid appearance resulting from this feature is marked, but the vascular elastic lamina is absent. Mitotic activity is absent, and there is no

For personal use only. No other uses without permission. Copyright ©2017. Elsevier Inc. All rights reserved.

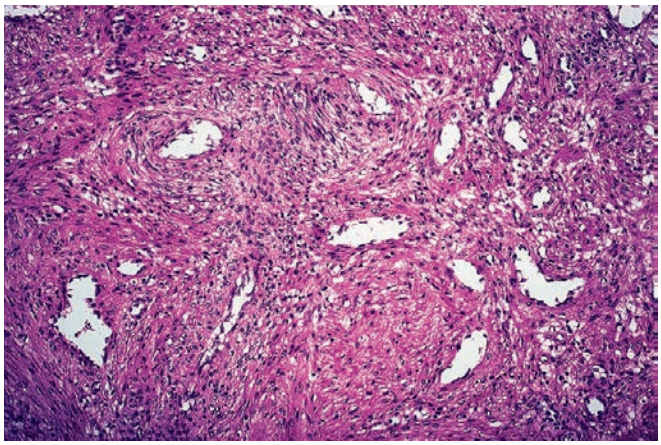

Figure 41.141 Vascular leiomyoma (angioleiomyoma) with neoplastic smooth muscle cells closely related to blood vessels.

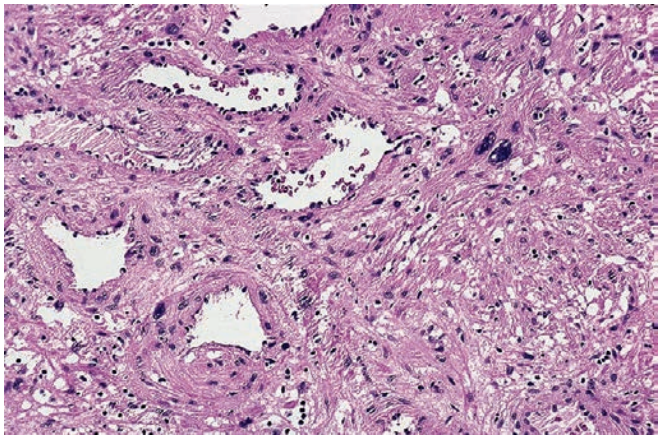

Figure 41.142 Vascular leiomyoma (angioleiomyoma) with scattered bizarre tumor cells, a feature of no prognostic significance.

necrosis or hemorrhage. Islands of mature fat or cartilage may be present in between the smooth muscle fibers. Occasionally, bizarre nuclear forms similar to those seen in uterine symplastic leiomyoma are encountered (Fig. 41.142).[694] Transitional forms with glomus tumor and myopericytoma are occasionally seen.[695]

The pain often associated with vascular leiomyomas is thought to be mediated by the nerves present within the tumor and in the capsule, whether by mechanical stretching or through mast cell mediation.[696,697] The behavior of these tumors is completely benign.

Deep-seated leiomyomas of nonvascular type occur most commonly in the extremities[698]; they can also be seen in the pelvic region of females where they stain for hormone receptors similar to uterine leiomyomas.[699]

Leiomyosarcoma

Leiomyosarcoma of soft tissue is typically a tumor of adults and the elderly, although cases in children are on record.[140,700–702] Smooth muscle tumors have also been seen with increasing frequency in immunosuppressed patients (HIV-infected individuals and organ transplant recipients), and such cases have been closely associated with Epstein-Barr virus infection (EBV-associated smooth muscle tumors).[50,703,704]

Most soft tissue leiomyosarcomas are located in the extremities, but they can occur anywhere, including the head and neck region.[705]

Figure 41.143 Leiomyosarcoma of Soft Tissues of the Arm. The fusiform shape of the tumor is due to the tumor following the course of the large blood vessels from which it arose.

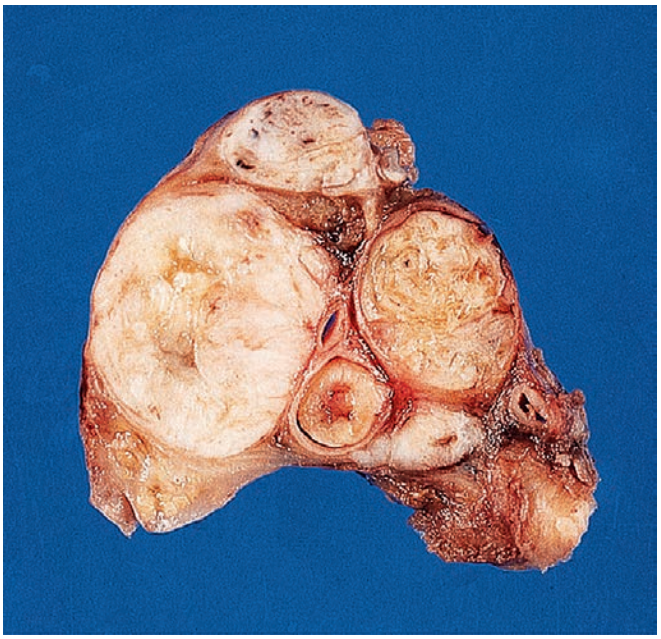

Figure 41.144 Leiomyosarcoma filling the lumen of the popliteal vein and its branches, as seen on cross section. The popliteal artery is uninvolved.

Many arise from the walls of arteries and veins of widely differing caliber, ranging from large ones (inferior vena cava, saphenous vein, femoral vein, pulmonary artery, femoral artery, and aorta, in that order of frequency) to venules and arterioles.[701,706] Those located in the inferior vena cava can result in Budd–Chiari syndrome.[707]

Grossly, leiomyosarcomas can be as well circumscribed as leiomyomas but are larger and softer and have a tendency to show tumor necrosis, hemorrhage, and cystic degeneration (Fig. 41.143). Those arising from major vessels can protrude in a polypoid fashion within the lumen or be predominantly intramural (Fig. 41.144).

Microscopically, the pattern of growth is predominantly fascicular, with the tumor bundles intersecting each other at wide angles (Fig. 41.145). Merging of tumor cells with blood vessel walls is an important diagnostic clue. In some cases the vascular pattern is particularly prominent, resulting in a hemangiopericytoma-like appearance. The individual cells have elongated, blunt-ended nuclei

For personal use only. No other uses without permission. Copyright ©2017. Elsevier Inc. All rights reserved.

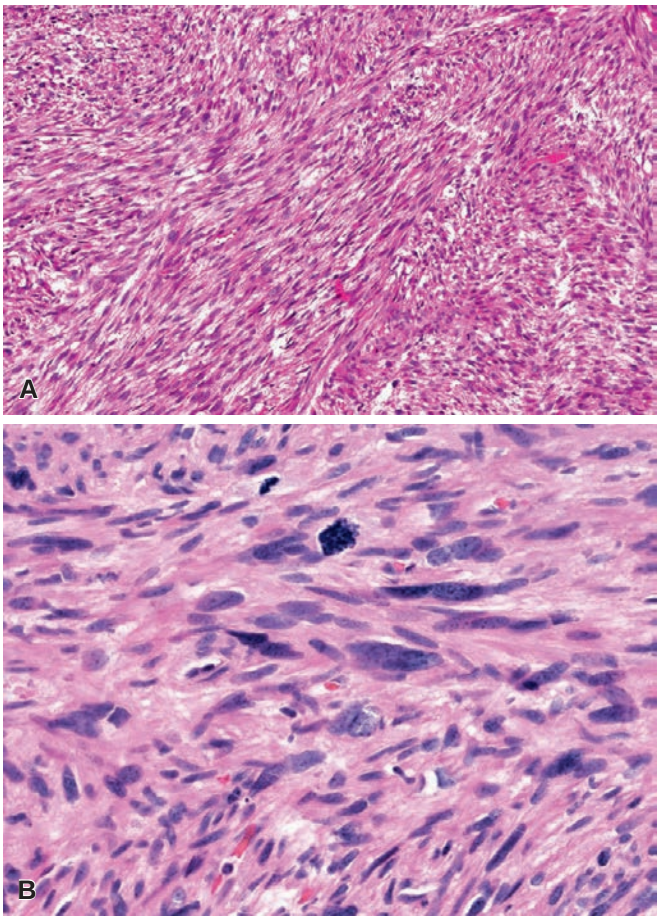

Figure 41.145 **A,** Low-power and **B,** High-power views of a leiomyosarcoma with arrangement into fascicles.

and acidophilic fibrillary cytoplasm, features that are also apparent in cytologic preparations. Palisading of nuclei may occur, a feature that may cause confusion with peripheral nerve sheath tumors. The degree of nuclear atypia is highly variable; in extreme cases, it may result in an "MFH-like" picture.[708] In fact, the most common line of differentiation seen in tumors formerly diagnosed as MFH is smooth muscle differentiation.[323] Cytoplasmic vacuoles are often located at one nuclear pole, sometimes indenting the nucleus, representing another diagnostic clue. Other features occasionally seen include granular cell change,[407] myxoid stroma,[709] inflammatory changes,[710] and osteoclast-like multinucleated giant cells.[711] Rhabdoid features can be present; as for other tumor types, this feature is an indicator of aggressive behavior.[712] The EBV-related tumors lack significant pleomorphism and often have a component of primitive round cells and numerous intratumoral T cells.[50]

Immunohistochemically, both leiomyomas and well-differentiated leiomyosarcomas show reactivity for SMA, smooth muscle myosin, desmin, h-caldesmon, and basal lamina components, including laminin and type IV collagen.[713,714] Surprisingly, normal and neoplastic smooth muscle cells may also stain for cytokeratins (Fig. 41.146) and EMA; this feature seems to be particularly prominent in tumors of the female genital tract and large vessels.[715,716] Estrogen receptor protein has also been detected in some of these tumors, raising the possibility of hormonal responsiveness.[717]

Cytogenetic analysis has shown a variety of chromosomal aberrations but no specific karyotype. Curiously, a relatively high number of these tumors show no detectable karyotypic abnormalities.[718–720]

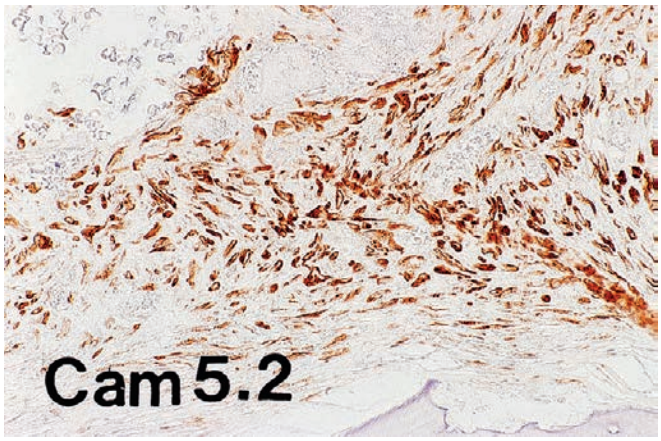

Figure 41.146 Immunoreactivity for low-molecular-weight cytokeratin *(CAM5.2)* in leiomyosarcoma.

Common genetic alterations include *RB1*, *CDKN2A*, *CCND1*, and *CCND3*.[140] The gene expression profiles of leiomyosarcomas greatly overlap with those of UPSs.[721,722]

The differential diagnosis between leiomyoma and leiomyosarcoma of the soft tissues depends on a combination of features. Nuclear atypia, even if focal, should prompt an evaluation of mitotic activity. Any degree of mitotic activity in conjunction with cytologic atypia should lead to strong consideration of a diagnosis of leiomyosarcoma. Prognosis in leiomyosarcoma correlates primarily with tumor size and depth, two parameters that are closely related. In one large series, 40% of cutaneous leiomyosarcomas recurred, but none metastasized; among the subcutaneous tumors, one-half recurred, and one-third resulted in metastases or tumor-related deaths.[723] Gustafson et al. found vascular invasion and age over 60 years to be independent risk factors for tumor-related death,[724] whereas Farshid et al. found tumor grade and surgical tumor disruption to be independent predictors of metastasis.[701] Simple enucleation of the tumor virtually guarantees local recurrence. The majority of these tumors eventually give rise to distant metastases, sometimes 15 years or more after the original excision.

It should be noted that all those previous comments are intended for the smooth muscle tumors located in soft tissues and do not necessarily apply to those in the uterus or gastrointestinal tract.

Epithelioid Smooth Muscle Tumors

Smooth muscle tumors of soft tissues may have an epithelioid configuration, in whole or in part, similar to that seen more often in mesenchymal tumors of the stomach and other intra-abdominal sites (Fig. 41.147).[725] We classify them as benign or malignant by using similar criteria to those applied for smooth muscle tumors in general. Immunohistochemical markers of smooth muscle differentiation tend to be expressed only focally and imperfectly in these tumors.[725]

Glomus Tumor

Glomus tumor originates in the neuromyoarterial glomus, a normal arteriovenous shunt abundantly supplied with nerve fibers and fulfilling a temperature-regulating function.[726] The classic location of the glomus tumor is the subungual region, but it can occur elsewhere in the skin, soft tissues (particularly in the flexor surface of the arms and about the knee), nerves, stomach, nasal cavity, and trachea.[727–729] It has also been reported in the sacrococcygeal region, arising from the coccygeal body (glomus coccygeum) and

For personal use only. No other uses without permission. Copyright ©2017. Elsevier Inc. All rights reserved.

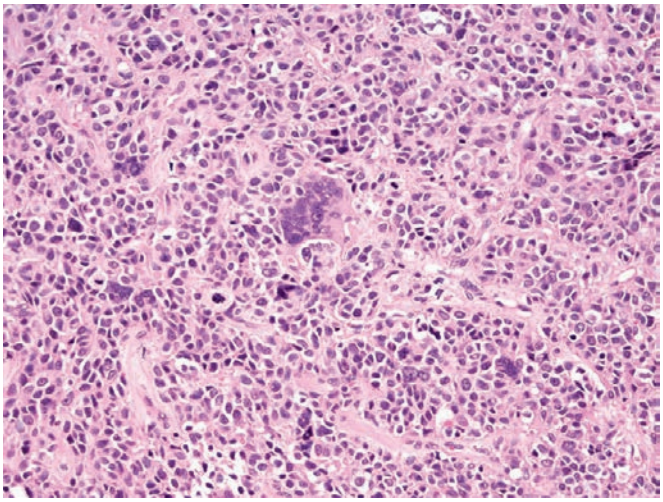

Figure 41.147 Epithelioid leiomyosarcoma composed of malignant epithelioid cells and rare giant cells.

associated with coccydynia,[730] but there is some question as to whether this is a true neoplasm or simply a normal structure of this region.[731]

Subungual lesions are always supplied by numerous nerve fibers and are exquisitely painful, two features often absent in glomus tumors arising elsewhere. The tumor may erode the terminal phalanx or even present as an intraosseous lesion in this location. Superficial lesions are well circumscribed. Glomus tumors in children tend to be multiple and of an infiltrative nature.[732] They may present clinically as varicosities of the lower extremities.

Microscopically, glomus tumors consist of blood vessels lined by normal endothelial cells and surrounded by a solid proliferation of round or cuboidal cells with perfectly round nuclei and acidophilic cytoplasm (Fig. 41.148). As seen under an electron microscope, the tumor cells have features of smooth muscle rather than of pericytes.[733] Immunohistochemically, they manifest reactivity for actin and basal lamina components but usually not for desmin.[734]

Three microscopic types of glomus tumor have been recognized: *solid*, *angiomatous* (*glomangioma*), and *myxoid* (Fig. 41.149). The solid type can be confused with sweat gland tumor, melanocytic nevus, or metastatic carcinoma.[735] This is particularly the case when the tumor cells are very epithelioid and/or grow in a single file fashion.[736] The angiomatous type can have a diffuse quality, in the sense of looking like an angiomatosis with an increased number of glomus cells in the vessel wall.[737] An *oncocytic variant* of glomus tumor, in which the cytoplasm of the glomus cells is packed with mitochondria, has also been described.[738] Often the telltale relationship between tumor cells and blood vessels can be clearly seen only at the very periphery of the neoplasm. There also is a spectrum that overlaps with lesions including glomangiomyoma, glomangiopericytoma, and myopericytoma, all of which show evidence of perivascular myoid differentiation (Fig. 41.150).[189]

On rare occasions, glomus tumors behave in an aggressive fashion, with local recurrences, invasion of adjacent structures, and exceptionally even distant metastases.[737,739] In other instances, lesions with the typical cytoarchitectural features of glomus tumor merge with a cytologically malignant tumor; these have been designated *glomangiosarcomas*.[740]

There are also examples of cytologically atypical glomus tumors. A proposal has been made to subclassify these as symplastic, of uncertain malignant potential, and malignant.[737] Those called malignant (the only ones to metastasize) were defined as glomus tumors with a deep location and a size of more than 2 cm, or atypical mitotic figures, or moderate to high nuclear grade and five or more mitoses per 50 high-power fields.

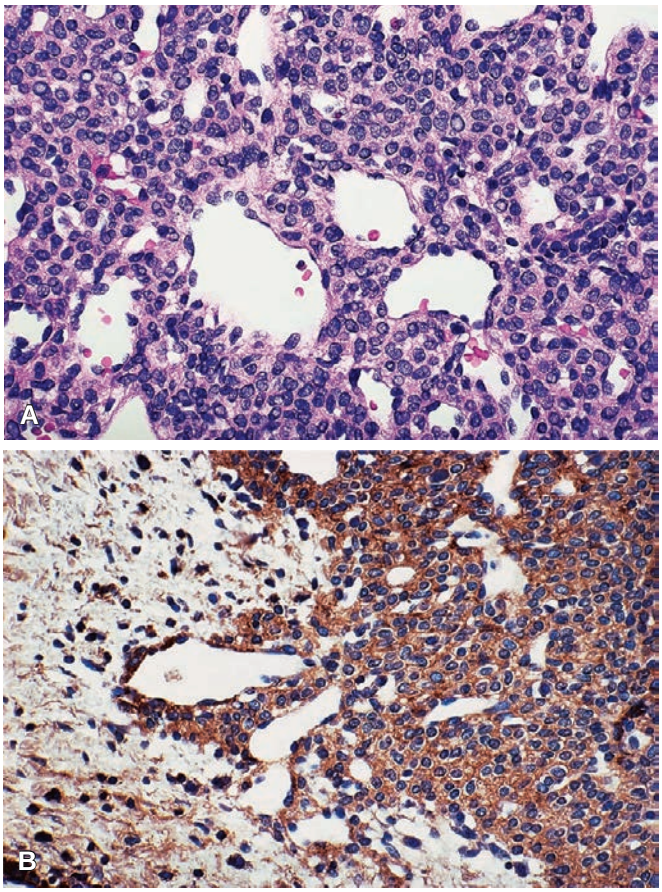

Figure 41.148 **A,** Glomus tumor with round glomus cells surrounding open vascular spaces. **B,** Strong SMA immunoreactivity is characteristic.

Tumors of Striated Muscle

Rhabdomyoma

Rhabdomyomas can be divided into distinct subtypes, although some overlap exists. Those known as the *adult* type are found almost exclusively in the oral cavity and its vicinity in adult patients.[741,742] Up to 20% may be multifocal.[743] Microscopically, the cells are well differentiated, large, rounded or polygonal, with abundant acidophilic cytoplasm containing variable amounts of lipid and glycogen. Some cells have features of "spider cells." Cross striations and intracytoplasmic rod-like ("jack straw") inclusions are frequent, and intranuclear inclusions may be seen. There is no mitotic activity or nuclear atypia. The differential diagnosis includes granular cell tumor, hibernoma, and the peculiar condition known as crystal-storing histiocytosis.[744]

The *fetal* form of rhabdomyoma is seen almost exclusively in two locations: the head and neck area (particularly the retroauricular area) in children under 3 years of age and the vulvovaginal region of middle-aged women.[745–747] The latter, also referred to as *genital rhabdomyoma*, is separated by some authors from the other fetal types. Microscopically, both forms are quite cellular, formed by immature skeletal muscle fibers (some containing cross striations)

For personal use only. No other uses without permission. Copyright ©2017. Elsevier Inc. All rights reserved.

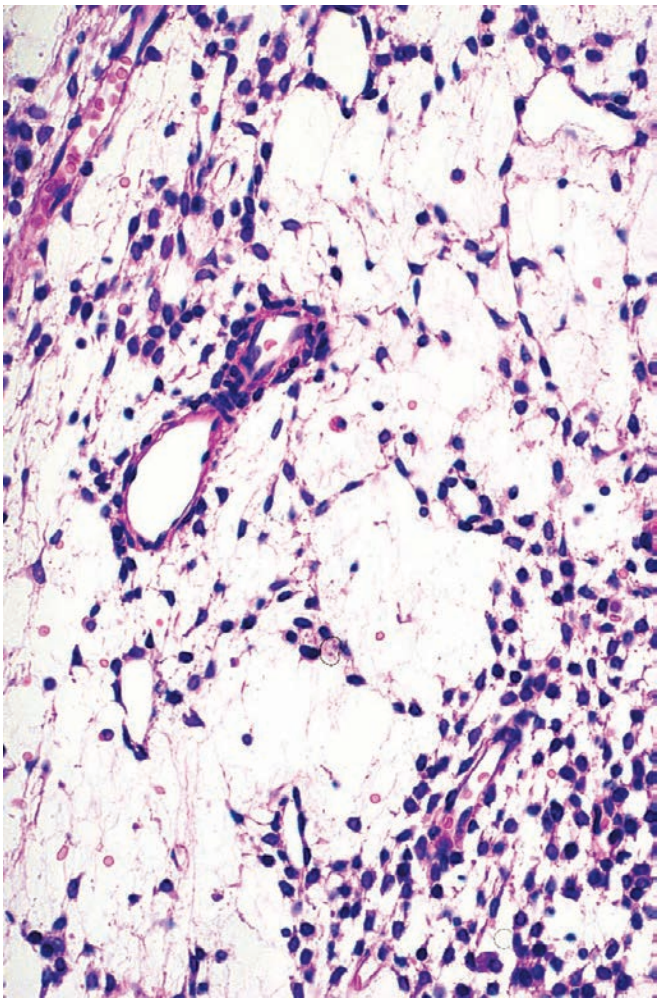

Figure 41.149 Myxoid zone in a glomus tumor.

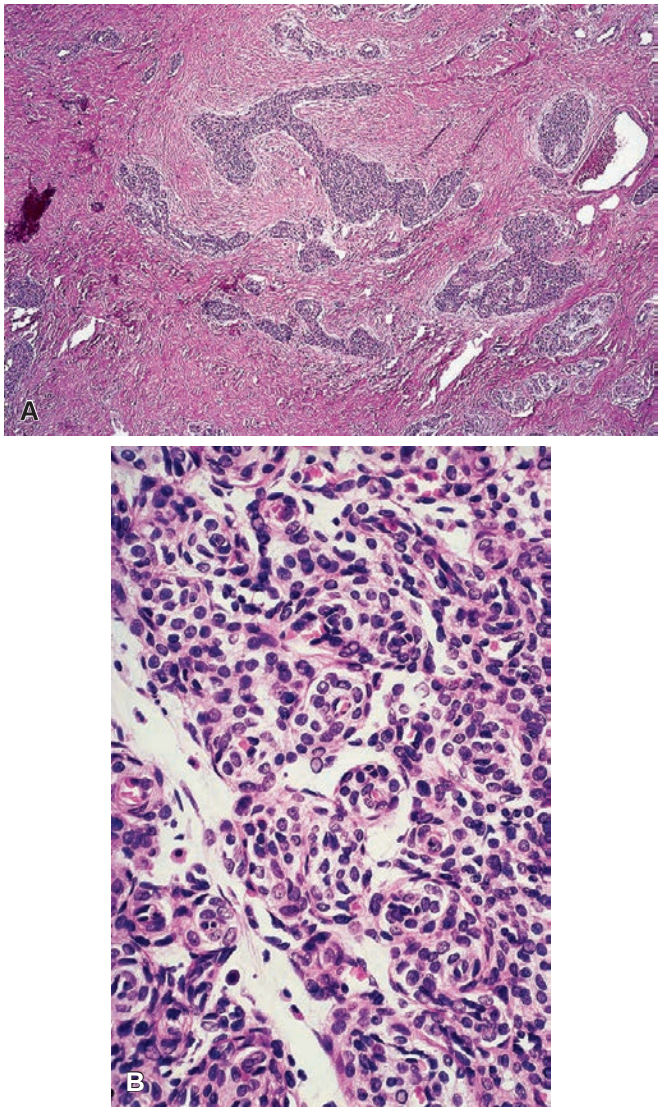

Figure 41.150 **Glomangiopericytoma. A,** Low-power and **B,** High-power views.

and primitive mesenchymal cells (Fig. 41.151). Their development is equivalent to that of fetal skeletal muscle of 7–12 weeks gestation. Nuclear atypia is absent, and mitoses are generally rare. The vulvovaginal cases tend to have a myxoid quality. Kapadia et al. have divided their cases of fetal rhabdomyoma into "classic" (having the previously described features) and "intermediate" types; the latter were characterized by the presence of large, ganglion cell-like rhabdomyoblasts with vesicular nuclei and prominent nucleoli, interlacing ribbon- or strap-like rhabdomyoblasts with deeply acidophilic cytoplasm, fascicles simulating smooth muscle, plexiform patterns with infiltration of fat, and intimate relationship with peripheral nerves.[747]

The main differential diagnosis of fetal rhabdomyoma is with embryonal or spindle cell rhabdomyosarcoma. The distinction can be extremely difficult because of the overlap of many histologic features. However, fetal rhabdomyomas tend to be well circumscribed and superficial and lack significant cytologic atypia, mitotic activity, and necrosis.

The immunohistochemical features of rhabdomyoma (especially the adult type) recapitulate those of normal skeletal muscle cells (desmin, muscle-specific actin). Ultrastructurally, hypertrophied Z band material, thick and thin filaments, numerous mitochondria (some with abnormal configuration or with inclusions), intranuclear bodies, and cytoplasmic bodies have been observed. Cardiac rhabdomyoma is distinct from the aforementioned lesions.

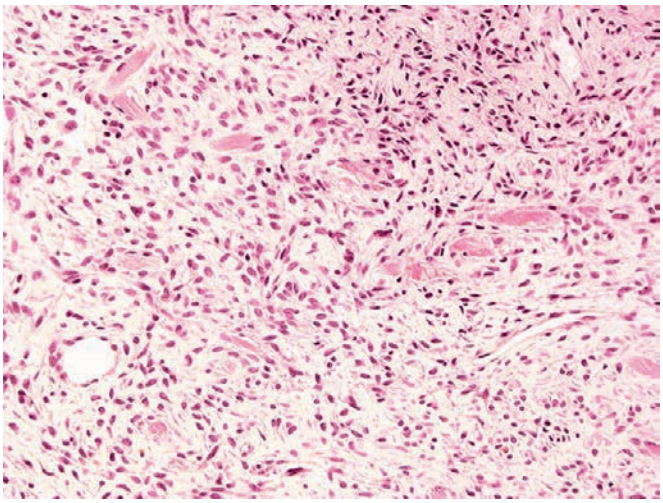

Figure 41.151 Fetal rhabdomyoma with eosinophilic spindle cells and rare cells with obvious cross striations.

For personal use only. No other uses without permission. Copyright ©2017. Elsevier Inc. All rights reserved.

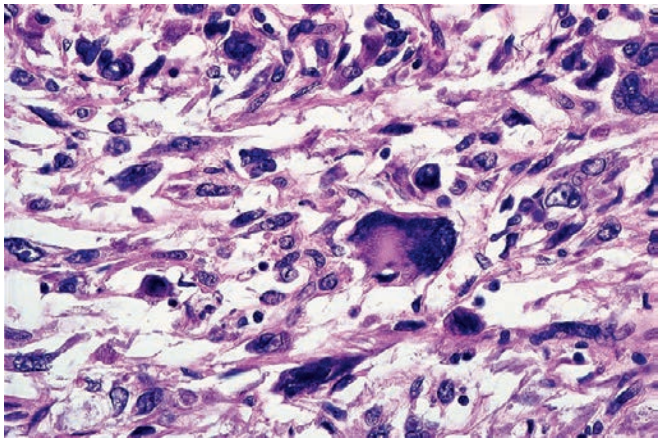

Figure 41.152 Pleomorphic rhabdomyosarcoma showing some resemblance to an undifferentiated pleomorphic sarcoma but with rare eosinophilic giant cells. This tumor stained for both desmin and myogenin.

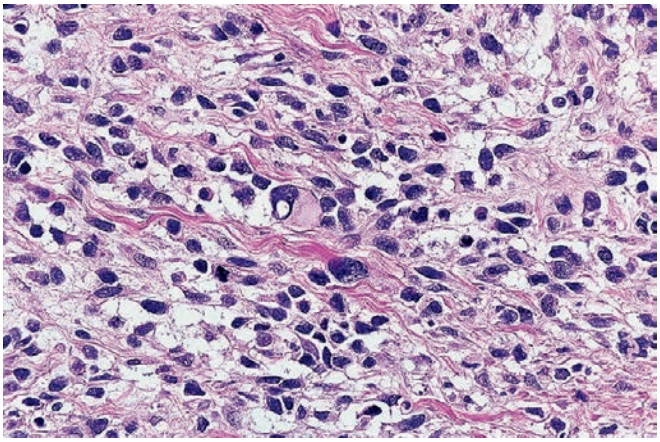

Figure 41.153 **Embryonal Rhabdomyosarcoma.** Most of the nuclei are oval; the cytoplasm is scanty and acidophilic.

Rhabdomyosarcoma

There are three major categories of rhabdomyosarcoma: pleomorphic, embryonal, and alveolar, as well as several less common subtypes.[748]

Pleomorphic rhabdomyosarcoma. This tumor, which constituted practically all the cases of rhabdomyosarcoma in the older literature, is actually the least common of the three major categories. It most often arises in the deep soft tissues of the extremities of adult patients,[749–752] although rare cases do arise in children.[749] It typically resembles an UPS except for the presence of scattered pleomorphic rhabdomyoblasts with cross striations (Fig. 41.152) and myogenin immunoreactivity.[753] One should be very careful to avoid the following pitfalls: (1) entrapped non-neoplastic skeletal muscle fibers; (2) release of myoglobin from necrotic muscle with subsequent nonspecific absorption by tumor cells, which thus become immunoreactive; and (3) presence of skeletal muscle differentiation in other malignant tumors. In regard to the latter event, it is somewhat ironic that the best evidence of skeletal muscle differentiation in malignant tumors is often found not in rhabdomyosarcoma per se but rather in tumors such as MPNST, malignant thymoma, mixed müllerian tumor of the female genital tract, malignant germ cell tumors (particularly extragonadal ones), medulloblastoma, and Wilms tumor. When defined by the restrictive criteria listed previously, pleomorphic rhabdomyosarcoma actually is a very rare neoplasm. The behavior of pleomorphic rhabdomyosarcoma seems not to be substantially different from that of other pleomorphic sarcomas of soft tissue.

The other two major types of rhabdomyosarcomas occur primarily in children and adolescents and constitute the most common form of soft tissue sarcoma in this age group.

Embryonal rhabdomyosarcoma. This tumor type most commonly arises in the head and neck region (particularly the orbit, nasopharynx, middle ear, and oral cavity), retroperitoneum, bile ducts, and genitourinary tract.[754] The large majority occur in children between the ages of 3 and 12 years, but they can also be seen in younger patients and adults.[755]

Microscopically, the tumor cells are small and spindle shaped (Fig. 41.153). Some have a deeply acidophilic cytoplasm. A feature of diagnostic value is the presence of highly cellular areas usually surrounding blood vessels, alternating with paucicellular regions that have abundant myxoid intercellular material. Cross striations may or may not be present; in contrast to pleomorphic rhabdomyosarcoma in adults, their presence is not indispensable for the light microscopic diagnosis, as long as all the other features are present.

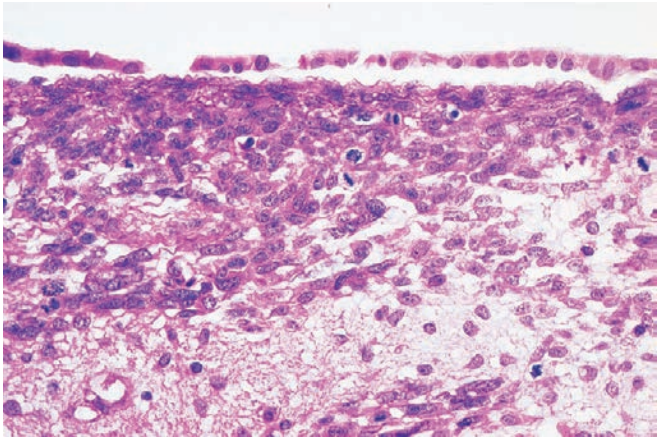

Figure 41.154 Botryoid rhabdomyosarcoma of common bile duct showing a concentration of tumor cells immediately beneath the epithelium ("cambium layer").

Confirmation of the diagnosis by select immunohistochemical markers is necessary.

The most common sites of metastatic involvement are the soft tissues, serosal surfaces, lung, bone marrow, and lymph nodes.[756] Cases associated with diffuse bone marrow involvement may simulate acute leukemia.[757] Rhabdomyosarcomas arising from genitourinary sites or extremities are particularly prone to metastasize to lymph nodes,[758] whereas tumors originating in head and neck structures adjacent to meningeal surfaces have a high incidence of direct meningeal extension.

The prognosis of embryonal rhabdomyosarcoma has markedly improved following multimodality treatment with excision, radiation therapy, and multidrug chemotherapy.[759] Over 80% of children now survive when the disease is localized to the region of origin.[760]

Embryonal rhabdomyosarcoma: variants and related tumors. When growing beneath a mucosal membrane, such as the vagina, urinary bladder, or nasal cavity, the tumor frequently forms large polypoid masses resembling a bunch of grapes—hence the name *sarcoma botryoides* (Fig. 41.154). This is regarded as a variation in the pattern of growth of embryonal rhabdomyosarcoma and is referred to as the *botryoid subtype*. A highly characteristic feature of these polypoid ("botryoid") tumors is the presence of a dense zone of undifferentiated tumor cells immediately beneath the epithelium known as a *cambium layer*.

For personal use only. No other uses without permission. Copyright ©2017. Elsevier Inc. All rights reserved.

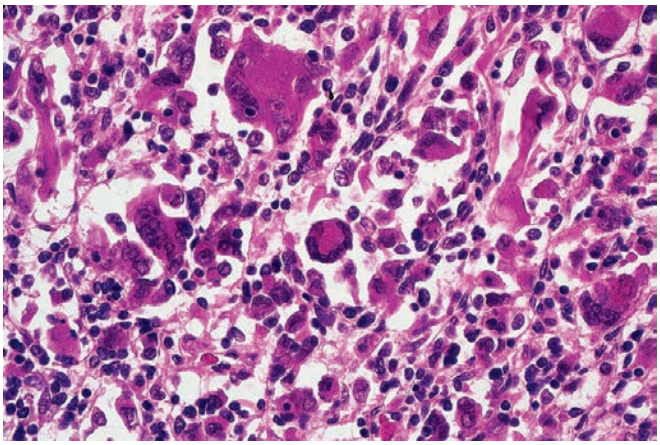

Figure 41.155 Embryonal rhabdomyosarcoma with anaplastic features in a child.

Occasional tumors within the embryonal category have focally anaplastic features, with bizarre nuclear forms; these should not be classified as pleomorphic rhabdomyosarcomas but rather as *embryonal rhabdomyosarcoma with anaplastic features* (Fig. 41.155). It has been suggested that they are associated with a more aggressive clinical course, especially when the anaplastic features are extensive[761]; conversely, well-differentiated tumors (with over 50% rhabdomyoblasts) are associated with an excellent response to chemotherapy.[762]

Tumors examined following multidrug chemotherapy tend to show a greater degree of differentiation than the pretherapy specimen, suggesting that the drugs have either induced maturation or resulted in a selection of the better differentiated components.[763,764]

Very rarely, accumulation of cytoplasmic glycogen or lipids in embryonal rhabdomyosarcoma results in a *clear cell appearance* that can simulate clear cell carcinoma.[765] Another morphologic variation is represented by tumor cells containing cytoplasmic globular inclusions composed of intermediate filaments and resulting in a *rhabdoid appearance*.[766]

Occasionally, in infants and children, tumors with a location and appearance otherwise characteristic of embryonal rhabdomyosarcoma are seen to contain collections of cells exhibiting neuronal, melanocytic, and/or schwannian differentiation; these have been interpreted by some as originating from the migratory neural crest (ectomesenchyme) and designated as *ectomesenchymomas*.[767,768] Most of these tumors have been located in the head and neck region.

Although originally described as variants of embryonal rhabdomyosarcoma, **spindle cell/sclerosing rhabdomyosarcoma** seems to represent related tumors that are distinct from classic embryonal rhabdomyosarcoma.[769] Most of the initially published cases of spindle cell rhabdomyosarcoma occurred in male children. The most common locations were the paratesticular area and the head and neck region, and their prognosis was reported to be favorable.[770] Subsequently, spindle cell rhabdomyosarcomas were reported in adults with preferential location in the head and neck region and a more aggressive clinical course than their pediatric counterparts.[771,772] Spindle cell rhabdomyosarcoma bears some resemblance to the tumors described by Lundgren et al. as *infantile rhabdomyosarcomas*, but it is not clear whether the two are identical.[773] The latter tumors microscopically simulated fibrosarcoma and were characterized by an aggressive clinical course.

Subsequently, the entity of *sclerosing rhabdomyosarcoma* was described and characterized by a prominent deposition of matrix material that simulated the appearance of an osteosarcoma or chondrosarcoma.[774,775] The initial reported cases arose in adults, but some have also been identified in children.[776,777] More recently, *MyoD1* mutations have been found in both spindle cell and sclerosing rhabdomyosarcomas, suggesting a strong relationship between these two entities.[778,778a] In fact, some data suggest that tumors with *MyoD1* mutations pursue a relatively aggressive clinical course.[778a] A subset of congenital cases of spindle cell/sclerosing rhabdomyosarcoma display *NCOA2* gene rearrangements, whereas tumors occurring in older children or adults tend to harbor *MyoD1* gene mutations, with or without mutations in *PIK3CA*.[778b] Immunohistochemically, spindle cell/sclerosing rhabdomyosarcomas tend to show even more nuclear immunoreactivity for *MyoD1* than for myogenin.[778]

Epithelioid rhabdomyosarcoma is a recently described variant that mostly arises in middle-aged to elderly patients, especially males, usually in the extremities, head and neck, or trunk.[779] It is composed of sheets of large epithelioid cells with abundant eosinophilic cytoplasm, vesicular nuclei, and prominent nucleoli reminiscent of melanoma or carcinoma.[780] It is highly aggressive, as one would expect based upon the high-grade histologic features.

Alveolar rhabdomyosarcoma predominates in an older age group (10–25 years) when compared to embryonal rhabdomyosarcoma and occurs more frequently in the extremities, the most common locations being forearms, arms, and perirectal and perineal regions. It also occurs in the head and neck, including the parameningeal region.[781,782]

Microscopically, small, round, or oval tumor cells are seen separated into nests by connective tissue septa (Figs. 41.156 to 41.158). The tumor cells in contact with these fibrous strands remain firmly attached to them, but the others tend to detach because of a lack of cohesiveness, which results in a typical alveolar or pseudoglandular appearance. The deep acidophilia of the cytoplasm and the presence of occasional multinucleated giant cells are important diagnostic features.[783] Cases in which the alveolar pattern is poorly developed are referred to as the "solid" variant of alveolar rhabdomyosarcoma and are particularly difficult to diagnose.[784]

The poor prognosis of alveolar rhabdomyosarcoma is distinctly worse than for the embryonal variety, even with the current multimodality therapies.[759] The lung and regional lymph nodes are the most common metastatic sites. Peripheral lymph node involvement may be the first manifestation of the disease. A common site for occult primary alveolar rhabdomyosarcoma is the perirectal-perineal region. As described in the following section, alveolar rhabdomyosarcoma is characterized by *PAX-FOXO1A* fusion; although this fusion is more common in patients who pursue an aggressive clinical course, this has not been found to be an independent marker of prognosis.[784a,784b]

Special Techniques in Rhabdomyosarcoma

Electron microscopic features. Ultrastructural examination may confirm a diagnosis of rhabdomyosarcoma through the identification of sarcomere-related structures, such as Z bands, thick and thin filaments in a hexagonal array, an A band containing thick filaments, and H and M bands, or leptomeric structures.[785] Drawbacks of this technique are those related to sampling and the absence of these features in the poorly differentiated cells. These facts, plus the availability of a large panel of relatively specific immunohistochemical (and, in the case of alveolar rhabdomyosarcoma, molecular) markers, has greatly diminished the diagnostic utility of electron microscopy in this field.

Histochemical and immunohistochemical features. Hardly any other tumor type has been described for which the array of markers is as varied as for rhabdomyosarcoma, and the list continues to grow.[786] There is a range of specificity and sensitivity among these markers, and this translates into their relative practical utility.

Myogenin is clearly the most sensitive and specific marker of rhabdomyosarcoma (Fig. 41.159). The myogenin gene codes for a phosphoprotein that induces skeletal muscle differentiation in

For personal use only. No other uses without permission. Copyright ©2017. Elsevier Inc. All rights reserved.

Figure 41.156 Gross Appearance of Alveolar Rhabdomyosarcoma. The tumor is embedded within skeletal muscle.

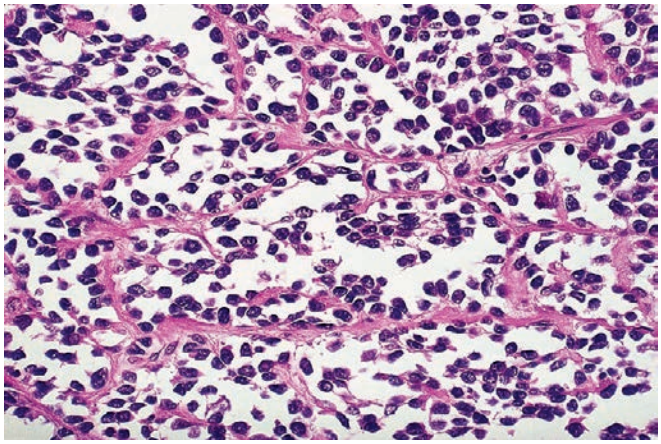

Figure 41.157 Typical low-power appearance of alveolar rhabdomyosarcoma with alignment of tumor cells along fibrovascular septa.

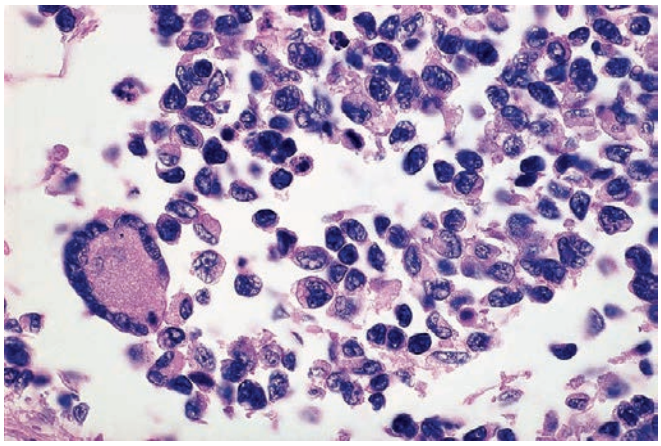

Figure 41.158 Alveolar rhabdomyosarcoma showing a multinucleated tumor giant cell among the smaller mononuclear cells, an important diagnostic clue.

mesenchymal cells. The protein can be demonstrated in the nuclei of the tumor cells in all types and virtually all cases of rhabdomyosarcoma, but it is expressed in a particularly strong and diffuse fashion in the alveolar type.[787–789] Diffuse expression of this marker has been found to be an independent marker of poor survival in

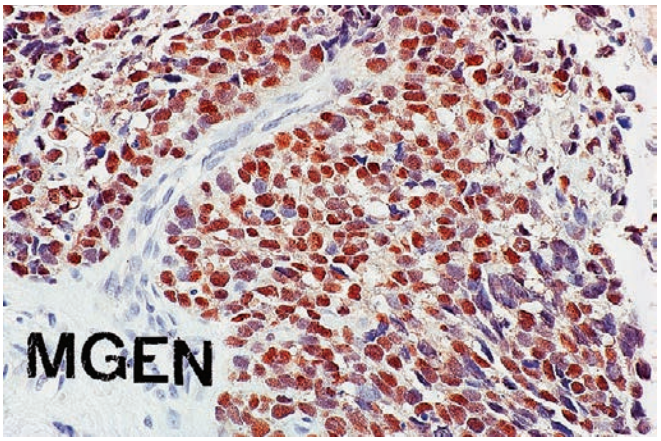

Figure 41.159 Strong nuclear immunoreactivity for myogenin (MGEN) in alveolar rhabdomyosarcoma.

pediatric rhabdomyosarcoma.[790] MyoD1 is a related nuclear protein with a similar degree of specificity, but—in contrast to myogenin—not well demonstrated in formalin-fixed, paraffin-embedded material, and therefore of lesser diagnostic utility.[789,791] Desmin is an intermediate filament that is a specific indicator for muscle differentiation, but it is present in both smooth and striated muscle. In general, only tumors with round rhabdomyoblasts or strap cells show positivity for this marker.[792] Rhabdomyosarcomas consistently express sarcomeric actin, which represents one of the best markers for this tumor.[793] Rhabdomyosarcoma cells also express muscle-specific actin, but little or no SMA. Other markers including myosin, myoglobin, titin, and Z-protein have also been reported but are less useful and less frequently used in clinical practice.

This is a wide and somewhat confusing choice of options. In our institution, we most often utilize myogenin and desmin for the routine investigation of these neoplasms. It also should be mentioned that some cases, particularly the alveolar subtype, express cytokeratins and neuroendocrine markers.[794] As previously mentioned, the spindle cell/sclerosing rhabdomyosarcoma family tends to stain more intensely for MyoD1.

Molecular genetic features. Approximately 75%–80% of alveolar rhabdomyosarcomas are associated with the translocation t(2;13) or t(1;13), which results in the gene fusions *PAX3-FOXO1A* and *PAX7-FOXO1A*, respectively (*FOXO1A* being previously known as *FKHR*).[795–797] The translocations can be detected in paraffin-embedded tissue with the FISH technique.[798] There is limited correlation between the morphologic appearance and the presence or absence of *PAX/FOXO1A* fusion or type of fusion.[799] In a study by Sorensen et al., alveolar rhabdomyosarcomas with *PAX3-FOXO1A* were associated with a more aggressive clinical course than those having *PAX7-FOXO1A*.[797] Up to 20% of cases diagnosed morphologically as alveolar rhabdomyosarcoma are fusion *(FOXO1A)* negative. Interestingly, array analysis of such tumors has shown significant overlap with embryonal rhabdomyosarcoma, raising consideration that these tumors are in fact poorly differentiated embryonal rhabdomyosarcomas with morphologic features suggestive of the alveolar subtype.[800] *MYCN* amplification has been detected in close to half of alveolar rhabdomyosarcomas but not in the embryonal types.[801]

Embryonal rhabdomyosarcomas do not exhibit the distinctive genetic alterations of alveolar rhabdomyosarcomas. They often show complex karyotypes, commonly with gains of chromosomes 2, 8, and 13.[802] Most cases show allelic loss of 11p15, the same genetic region altered in Beckwith–Wiedemann syndrome (an imprinting disorder resulting from mutations or epigenetic events affecting imprinted genes at 11p15.5).[803]

For personal use only. No other uses without permission. Copyright ©2017. Elsevier Inc. All rights reserved.

Osseous or Cartilaginous Tumors

Soft tissue (extraskeletal) chondromas are seen most frequently in the soft tissues of the hands and feet of adults.[804,805] Grossly, they are lobulated, have a typical hyaline appearance, and are often calcified (Fig. 41.160). Some show features reminiscent of chondroblastoma with hypercellularity, numerous multinucleated giant cells, and delicate calcification (Fig. 41.161).[806] Chondrosarcomas of the hands and feet exist, but they are exceptionally rare.[807] The occasional presence of a cellular fibroblastic growth around the lobules may prompt confusion with calcifying aponeurotic fibroma. Also confusing is the fact that sometimes the cartilaginous cells have an acidophilic cytoplasm simulating that of a histiocyte and sometimes a vacuolated appearance reminiscent of a lipoblast. Local recurrence is not infrequent.

Soft tissue (extraskeletal) chondrosarcoma, when used without a qualifier, refers to a soft tissue neoplasm composed of lobules of well-differentiated cartilage. In general, these tumors exhibit a less aggressive behavior than their skeletal counterparts.[808]

Extraskeletal myxoid chondrosarcoma is a specific type of soft tissue tumor, which may have been incorrectly named, given that there is accumulating evidence to the effect that it is unrelated to cartilage (Fig. 41.162).[809,810] This tumor type rarely if ever occurs within bone.[811] Most of the cases arise in the extremities of adult patients,[812–814] but they have also been reported in the trunk and/or in children.[815] Microscopically, the tumor is characterized by a multinodular growth pattern, often associated with prominent hemorrhage and hemosiderin deposition. There are strands and cords of relatively small cells with acidophilic cytoplasm that are occasionally vacuolated, embedded in an abundant myxoid matrix. Well-differentiated chondrocytes are absent (Fig. 41.163). Glycogen is present in many of the tumor cells and acid mucopolysaccharides are abundant in the myxoid stroma, which are resistant to hyaluronidase treatment because they are largely composed of chondroitin-4-sulfate, chondroitin-6-sulfate, and keratan sulfate. Rhabdoid features may be present; as usual, they portend an aggressive behavior.[816] A high-grade form of myxoid chondrosarcoma has been described, characterized by the presence of numerous large epithelioid cells and a very aggressive behavior.[817]

Ultrastructurally, the most conspicuous features of the cells of myxoid chondrosarcoma are a well-developed granular endoplasmic reticulum (sometimes containing peculiar parallel microtubules, a very distinctive feature of this entity), abundant cytoplasmic filaments, and cytoplasmic glycogen.[818,819] In addition, some tumor cells have been shown to contain microtubules and neuroendocrine-type granules.[820] Immunohistochemically, myxoid chondrosarcomas are only focally positive for S-100 protein, much less so than one would expect in a true cartilaginous neoplasm. We and others have found that a high proportion of the cases show focal immunoreactivity for neural/neuroendocrine markers, such as NSE, CD56, synaptophysin, and Tau proteins (microtubule-associated proteins required for

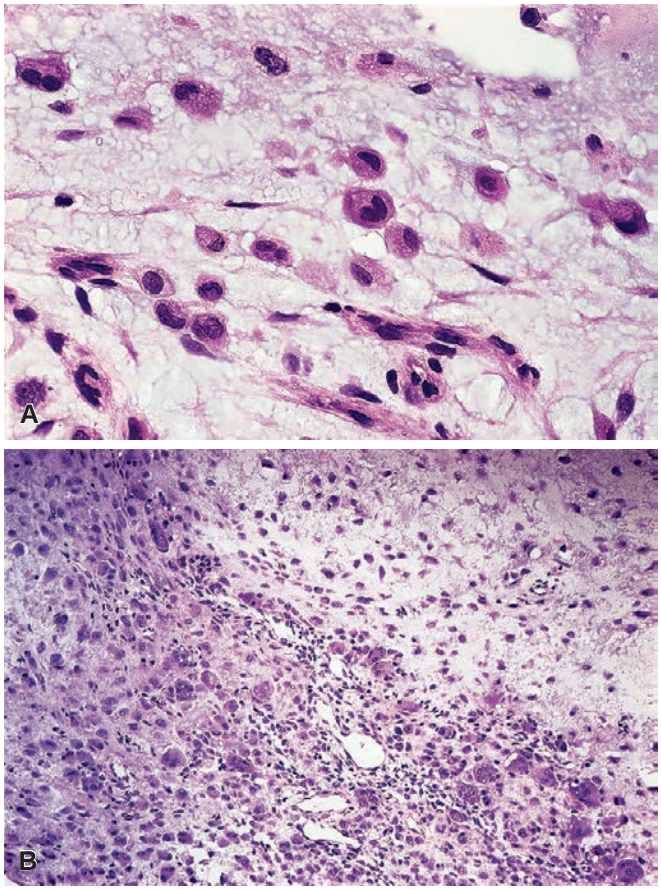

Figure 41.161 **A,** The tumor cells of this soft tissue chondroma have a histiocyte-like quality, similar to that seen in chondroblastoma of bone. **B,** Soft tissue chondroma with a hypercellular component having osteoclast-like giant cells with some resemblance to chondromyxoid fibroma of bone.

Figure 41.160 Gross appearance of chondroma of soft tissues of hand. The tumor was partially calcified.

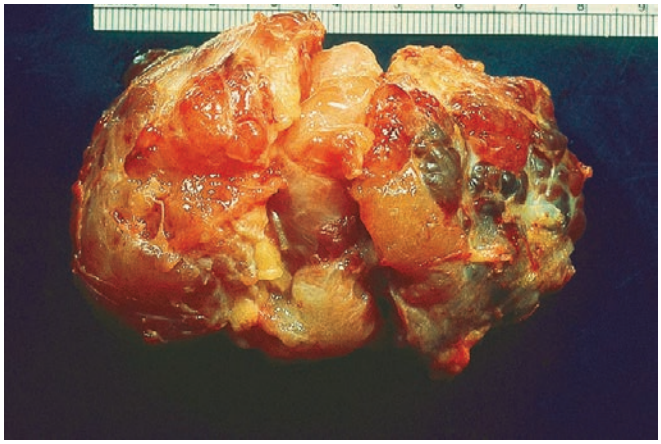

Figure 41.162 Lobulated outer appearance of myxoid chondrosarcoma.

For personal use only. No other uses without permission. Copyright ©2017. Elsevier Inc. All rights reserved.

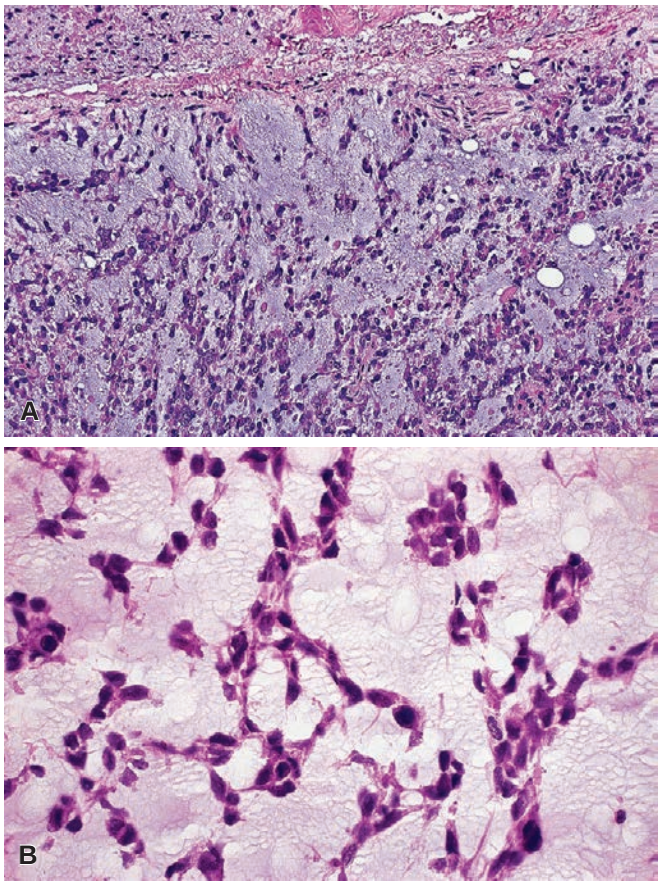

Figure 41.163 Low-power **(A)** and high-power **(B)** views of myxoid chondrosarcoma. There are thin anastomosing strands of tumor cells surrounded by an abundant myxoid matrix. In contrast to myxoid liposarcoma, vascularity is scanty.

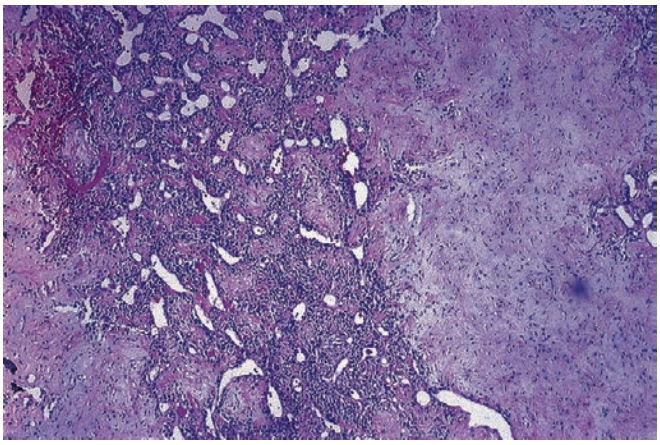

Figure 41.164 **Mesenchymal Chondrosarcoma.** Hypercellular areas with hemangiopericytoma-like features are admixed with islands of well-differentiated cartilage.

polymerization of tubulin) but not for keratin.[821–823] These findings, which are supported by microarray analyses,[824] suggest that this peculiar lesion may represent a primary myxoid neuroendocrine tumor of soft tissue.

Cytogenetically, myxoid chondrosarcoma is characterized most commonly by a specific chromosomal translocation t(9;22)(q22-31;q11-12),[825] or t(9;17)(q22;q11) that results in the gene fusions *EWSR1-NR4A3* (formerly *EWS-CHN*) or *RBP56-NR4A3* (formerly *RBP56-CHN*), respectively.[826] These alterations are detectable in paraffin-embedded material with the FISH technique.[827]

Extraskeletal myxoid chondrosarcoma is an aggressive neoplasm that recurs locally and metastasizes distantly, particularly to the lungs[813,828,829]; in some instances, the lung metastasis is the first manifestation of the tumor.[830]

It seems likely that cases reported as *chordoid sarcoma* or *chordoid tumor*[831,832] belong to the same category as extraskeletal myxoid chondrosarcoma, whereas the cases published as *parachordomas*[833] are clearly related to myoepitheliomas of soft tissue.

Mesenchymal chondrosarcoma has been described in the orbit, dura, trunk, retroperitoneum, extremities, and kidney, among other locations.[834–836] Like its counterpart in bone, it is characterized microscopically by an alternating pattern of highly cellular undifferentiated small cells (often growing in a hemangiopericytoma-like fashion) and islands of well-differentiated cartilage (Fig. 41.164). Immunohistochemically, it may show a polyphenotypic profile, including expression of CD99 (in the small cell component), S-100 protein (in the cartilaginous component), and focal positivity for actin, desmin, myogenin, and NSE.[837] Despite the morphologic resemblance of the small cell component of mesenchymal chondrosarcoma to Ewing sarcoma/PNET, the chromosomal translocation associated with the latter is uniformly absent. Recently, these tumors have been found to harbor a *HEY1-NCOA2* gene fusion and more rarely a *IRF2BP2-CDX1* fusion.[838] The prognosis is poor.[836]

Soft tissue (extraskeletal) osteosarcoma is distinguished from chondrosarcoma by applying the same criteria used for skeletal tumors (i.e., the occurrence of osteoid and bone formation directly produced by the tumor cells, without interposition of cartilage).[839] It usually occurs in the extremities of adults.[840] A small proportion of these tumors arise following exposure to x-rays.[841] As for their counterpart in the skeletal system, the predominant histologic pattern may be osteoblastic, chondroblastic, fibroblastic, MFH-like, telangiectatic, or well differentiated (the latter being analogous to parosteal osteosarcoma) (Fig. 41.165).[842,843] The immunohistochemical profile is also analogous to that of skeletal osteosarcoma, including expression of osteocalcin, osteonectin, and SATB2.[844,844a] In general, the prognosis is much worse than for chondrosarcoma, the overall mortality rate being over 60%.[845] However, well-differentiated variants associated with an indolent clinical course do occur.[846] The most important differential diagnosis of extraskeletal osteosarcoma is with myositis ossificans. The presence of marked nuclear atypia and lack of differentiation ("zone phenomenon") are the critical distinguishing features. It should also be distinguished from other soft tissue tumors in which metaplastic bone is formed (e.g., synovial sarcoma, UPS).

Tumors of Extragonadal Germ Cells

Soft tissue teratomas are more frequent in females and present either at birth or in early childhood.[847,848] In some cases, there is an association with twinning or malformations. The most common locations, in descending order of frequency, are the sacrococcygeal area, head and neck, retroperitoneum, mediastinum, and CNS.[849,850] Taken as a whole, approximately three-fourths are benign. However, there are important variations in the incidence of malignancy according to location, completeness of resection, age, and sex.[848] Nearly all teratomas presenting in the neck during infancy are benign, usually asymmetric, and massive; the rare teratomas of the neck presenting in adults have a high incidence of malignancy.[851]

The terminology and diagnostic criteria used in the evaluation of these lesions are the same as for those of gonadal origin. The

For personal use only. No other uses without permission. Copyright ©2017. Elsevier Inc. All rights reserved.

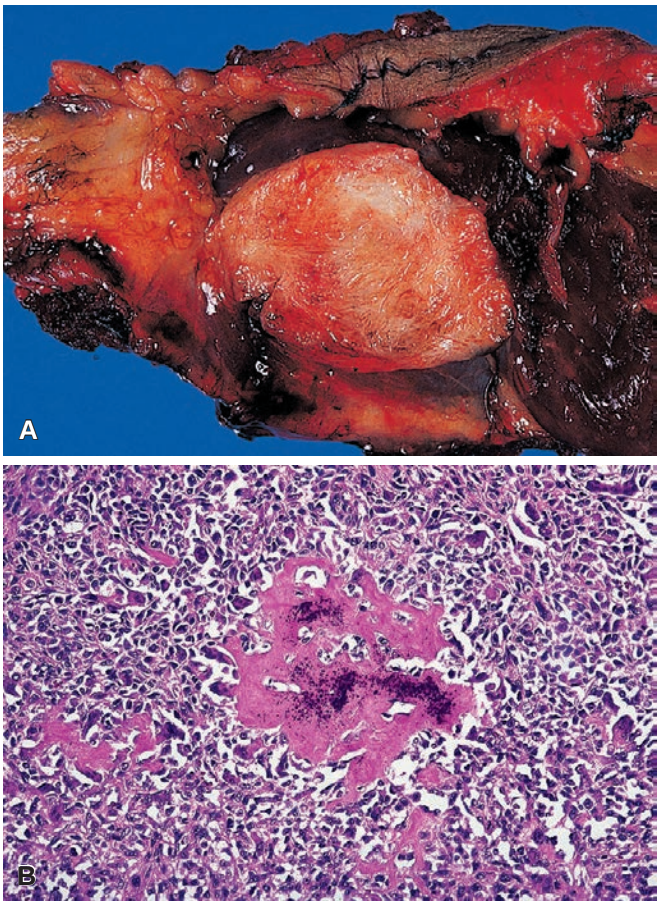

Figure 41.165 Extraskeletal Osteosarcoma. A, The neoplasm is embedded within skeletal muscle and is relatively well circumscribed. **B,** Extraskeletal osteosarcoma with a central nidus of neoplastic bone.

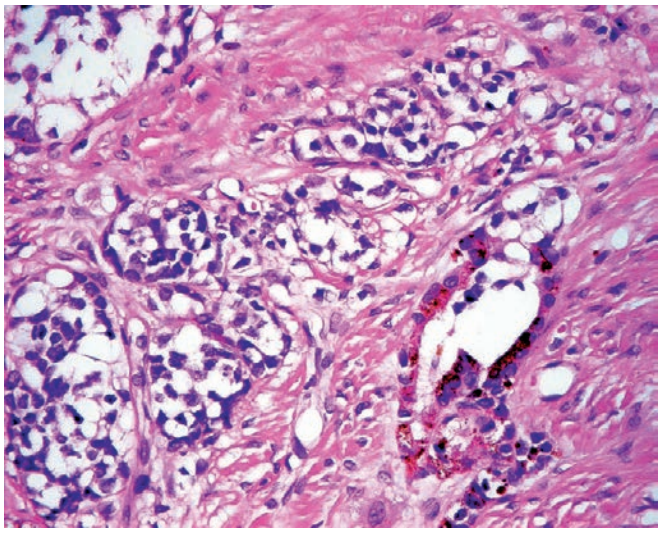

Figure 41.166 Melanotic Neuroectodermal Tumor of Infancy. Nests of neuroblast-like cells are adjacent to gland-like spaces lined by larger cells containing neural-type melanin.

Figure 41.167 Myxopapillary ependymoma of the sacrococcygeal region resulting in a huge protruding mass that is focally ulcerated. (Courtesy of Dr. Juan Jose Segura, San Jose, Costa Rica.)

benign form is often multicystic and contains a variety of well-differentiated tissues. The malignant types may have the appearance of teratocarcinoma, embryonal carcinoma, or yolk sac tumor. Immature neuroectodermal components are common in otherwise mature teratomas; although they occasionally exhibit metastasizing capacity, their natural tendency is toward spontaneous maturation.[852]

Tumors of Neural Tissue (Other Than Peripheral Nerves)

Melanotic neuroectodermal tumor of infancy has been referred to by a variety of names including pigmented neuroectodermal tumor of infancy, melanotic progonoma, and retinal anlage tumor. It is a neurally derived neoplasm and is generally located at the root of the nose in infants (also referred to a nasal glial heterotopia), but it can occur in other sites.[853] The classic location is the maxilla, but it also has been reported in a number of other sites including the mandible, skull, and other bones, mediastinum, soft tissues (thigh, forearm, cheek), and epididymis.[854] Microscopically, most tumor cells are small and round, with the appearance of neuroblasts (Fig. 41.166). As a result, this tumor may be misdiagnosed as neuroblastoma. The diagnostic feature is the presence of pseudoglandular or alveolar formations lined by a wall of larger cells containing abundant CNS-type (spiculated) melanin in their cytoplasm. Rarely, a skeletal muscle component is present.[855] Immunohistochemically, the large cells are strongly reactive for cytokeratin and HMB-45 and less so for NSE, whereas the small cells show only positivity for NSE. Both cell components are negative for S-100 protein.[856,857] Ultrastructurally, there are melanosomes at various stages of maturation in the large cells and neurosecretory granules and cytoplasmic processes in the small cells.[855]

The clinical course is usually benign. Most supposedly malignant varieties probably represent malignant teratomas with a pigmented neuroectodermal component. However, unquestionable recurrent and metastatic cases of pigmented neuroectodermal tumor of infancy have been reported.[855,858]

Meningiomas can present as a soft tissue mass at the base of the nose or scalp.[859,860]

Myxopapillary ependymomas can appear as soft tissue masses over the sacrococcygeal area, unconnected with the spine or spinal cord structures.[861] The clinical diagnosis is usually that of pilonidal cyst. Grossly, they are well circumscribed and can be shelled out easily (Fig. 41.167). Their microscopic appearance is homologous to that of their more common counterpart in the filum terminale and cauda equina (Fig. 41.168). Metastases arise in approximately one-fifth of cases.[862]

Myxopapillary ependymomas should be distinguished from sacrococcygeal ependymal rests, which probably represent their

For personal use only. No other uses without permission. Copyright ©2017. Elsevier Inc. All rights reserved.

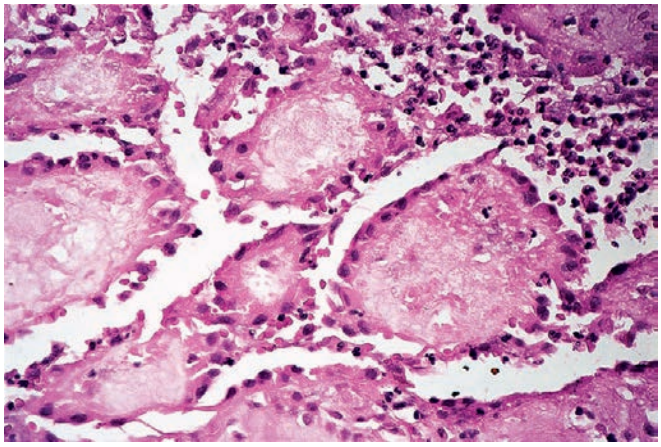

Figure 41.168 Myxopapillary ependymoma involving soft tissues of buttock. The tumor papillae have an abundant hyalinized core.

precursors. These are small (less than 0.5 cm) nodules that are usually found incidentally in tissue from pilonidal sinuses and consist of clusters of ependymal cells near the junction of the dermis and subcutis.[863,864]

Gliomas of soft tissue are generally located at the root of the nose in infants, but they can occur in other sites such as orbit, scalp, chest wall, and gluteal region[865]; they are probably not neoplasms but examples of heterotopic glial tissue (Fig. 41.169).[866]

Tumors of Hematopoietic Tissue

Malignant lymphomas may exceptionally manifest themselves initially as soft tissue masses, usually located in an extremity.[867] This occurrence is more common with non-Hodgkin lymphomas than with Hodgkin lymphoma, but both of these major types occur. Most cases are of B-cell derivation, but examples of peripheral T-cell lymphoma (including NK and NK-like T-cell lymphomas) with primary involvement of soft tissues are on record.[868,869] Exceptionally, these lymphomas develop in areas of post-mastectomy lymphedema and are confused clinically with angiosarcoma.[870]

True **histiocytic sarcomas** have been described in soft tissues.[871] Microscopically, they are composed of sheets of large epithelioid cells with abundant eosinophilic cytoplasm, round to oval (sometimes indented) nuclei, and large nucleoli. Some of the tumor cells are bi- or multinucleated. Immunohistochemically, they are reactive to CD45, CD45RO, CD68, and CD163. They also often express CD4, lysozyme, and CD31.[871]

Plasmacytomas of soft tissue represent, for the most part, direct extension from underlying osseous foci.[872] However, isolated soft tissue plasmacytomas can rarely occur in the absence of bone involvement; they have a tendency to become disseminated.

Extramedullary hematopoiesis may present in the form of nodules in the mediastinum, retroperitoneum, or other soft tissue areas; they have been described in agnogenic myeloid metaplasia and congenital spherocytosis and in other types of anemia,[873,874] and should be distinguished from myelolipoma.

Miscellaneous Tumors and Tumors of Uncertain Cell Type

Synovial Sarcoma

Synovial sarcoma typically arises near the knee and ankle joints of children and young adults,[875] but it can also occur in older patients.[876]

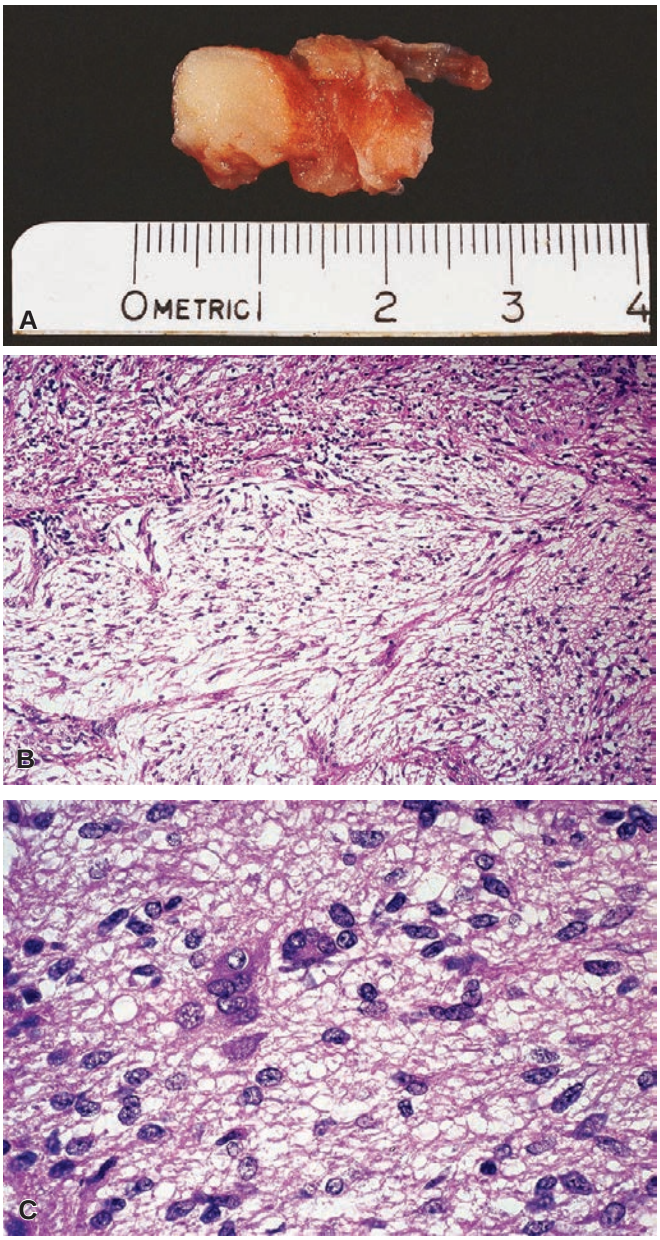

Figure 41.169 Soft Tissue Glioma Involving the Orbit. A, Gross appearance; **B,** Low-power view; **C,** High-power view showing the glial fibrillary background and scattered multinucleated cells. This lesion is probably a malformation rather than a true neoplasm.

It also occurs around other joints, such as the shoulder and hip. It often grows close to the joints, tendon sheaths, and bursae, but it is extremely rare for it to actually invade the joint space and synovial membrane, with which it is probably unrelated. This tumor has been described in virtually every anatomic site so it should always be considered in the differential diagnosis of any cellular spindle cell tumor.

Grossly, it tends to be well circumscribed, firm, and grayish pink (Fig. 41.170). Focal calcification is frequent and may be detected radiographically.[877] When located in the hands or feet, it may be extremely small.[878]

Microscopically, one form of synovial sarcoma is that of a *biphasic* tumor composed of sharply segregated epithelial and sarcomatous components (the terms being used descriptively and not

For personal use only. No other uses without permission. Copyright ©2017. Elsevier Inc. All rights reserved.

Figure 41.170 Gross appearance of deep-seated synovial sarcoma involving periosteum of the femur in an adolescent boy.

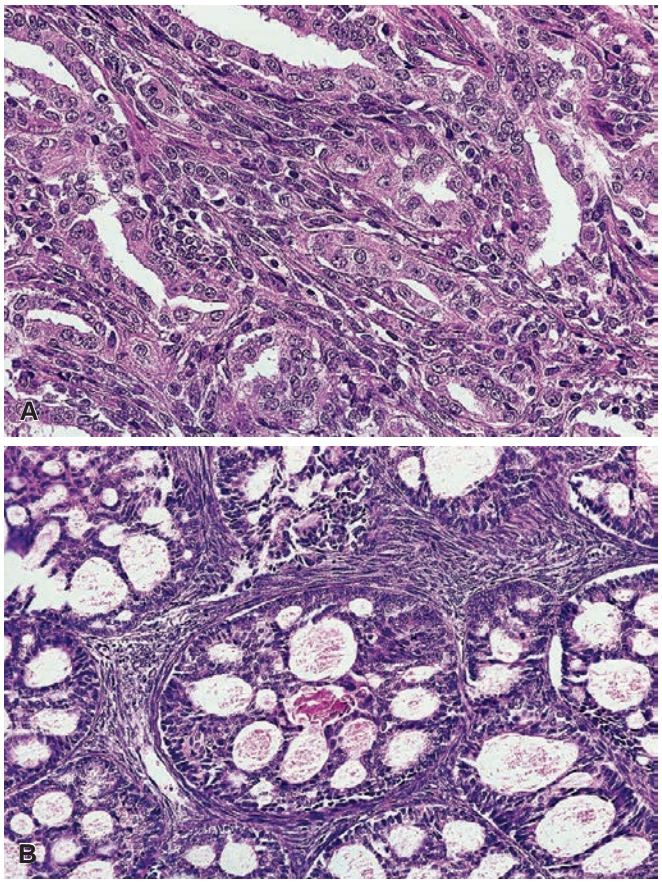

Figure 41.171 A, Typical biphasic appearance of synovial sarcoma. **B,** Synovial sarcoma with an adenocarcinoma-like appearance of the epithelial component.

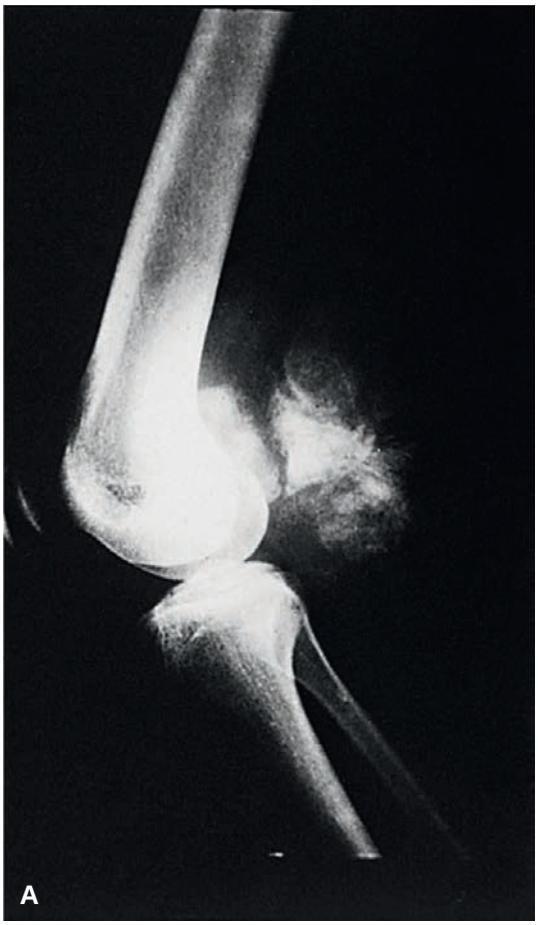

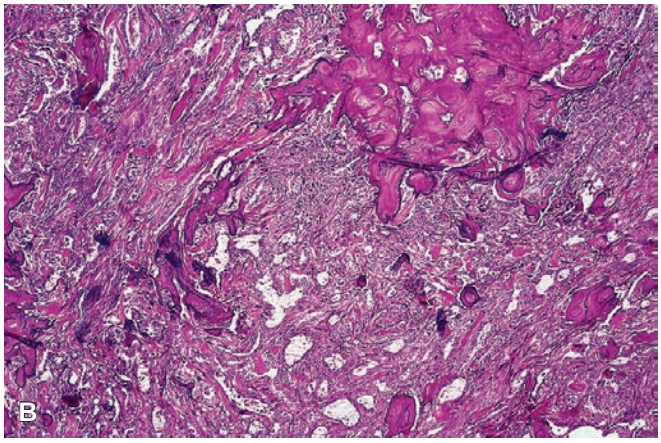

Figure 41.172 A, Radiographic appearance of a calcifying synovial sarcoma located in the popliteal space. **B,** Microscopic appearance. (**A,** from Varela-Duran J, Enzinger FM. Calcifying synovial sarcoma. A clinicopathologic study of 32 cases. *Cancer*. 1982;50:345–352.)

histogenetically) (Fig. 41.171). The epithelial areas usually appear in the form of gland-like spaces lined by cuboidal or columnar cells but can also present as solid nests of large pale cells.

The sarcomatous component is composed of spindle cells with a fibroblast-like appearance. It tends to be hypercellular but with a relatively monotonous appearance, plump nuclei, a focally whorled pattern, distinct lobulation or fasciculation, a focal hemangiopericytoma-like vascular pattern and a prominent number of mast cells. Hyalinization, calcification, and osseous metaplasia can be present. When the calcification is particularly heavy, the term *calcifying synovial sarcoma* has been used,[879] which rarely can be extensive enough to obscure the true nature of the tumor (Fig. 41.172).[880] In other instances, the stroma may have a prominent myxoid quality.[881]

Monophasic synovial sarcoma is composed of only one of the two components. In the large majority of cases, this applies to the spindle

For personal use only. No other uses without permission. Copyright ©2017. Elsevier Inc. All rights reserved.

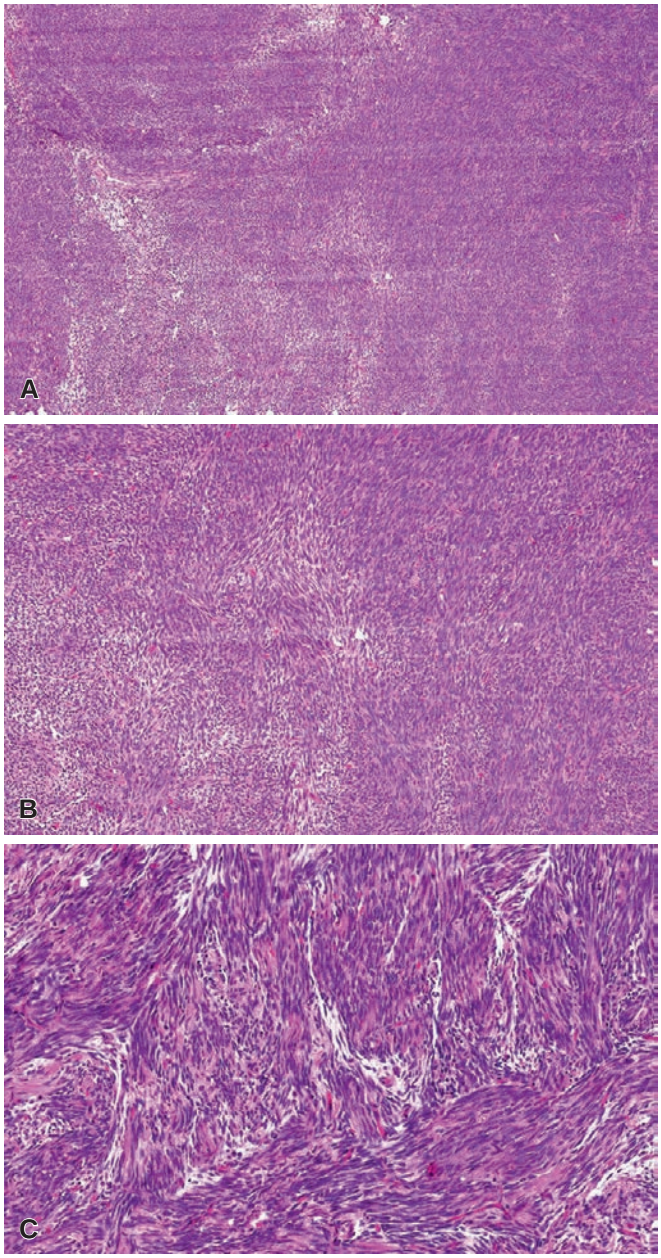

Figure 41.173 **A,** Low-power view of monophasic synovial sarcoma with spindle cells arranged in fascicles imparting a "marbled" appearance. **B,** Fascicles of spindle cells in monophasic synovial sarcoma. **C,** High-power view of uniform, slightly plump spindle cells in monophasic synovial sarcoma.

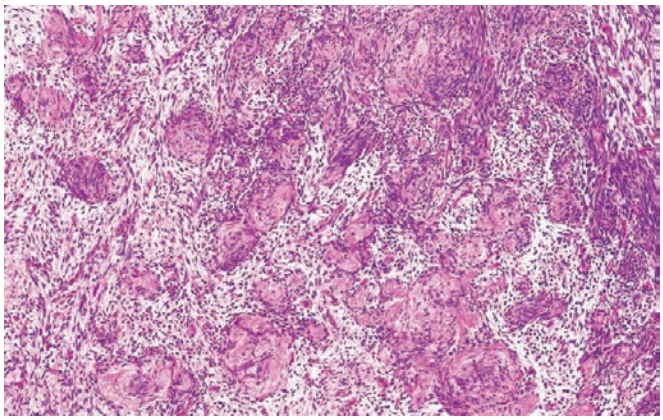

Figure 41.174 Myxoid areas with prominent collagen deposition in monophasic synovial sarcoma.

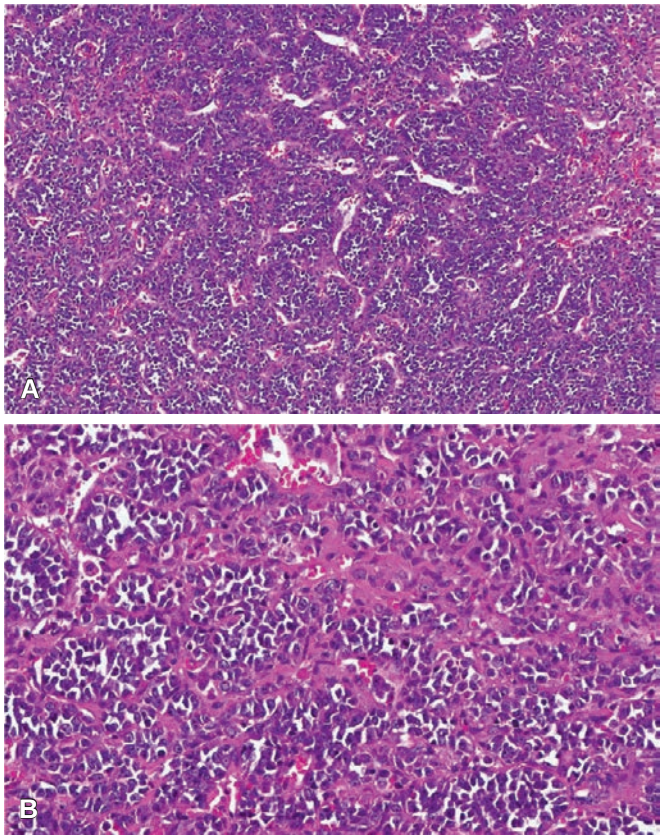

Figure 41.175 Low-power **(A)** and high-power **(B)** views of a poorly differentiated synovial sarcoma composed of high-grade round cells surrounding a hemangiopericytoma-like vascular pattern.

cell sarcomatous component, which is easily misdiagnosed as fibrosarcoma, MPNST, or some other spindle cell neoplasm (Figs. 41.173 and 41.174). A search for epithelial-looking foci should be carried out in these situations, as well as a thorough immunohistochemical (and possibly molecular) evaluation (see later).

Theoretically, a monophasic form of synovial sarcoma composed only of the epithelial elements of the tumor should also exist. The fact that in some neoplasms the glandular elements are so prominent as to simulate a metastatic adenocarcinoma cannot be denied.[882] However, the existence of a pure form of monophasic epithelial synovial sarcoma has yet to be convincingly demonstrated at the cytogenetic/molecular level.

A *poorly differentiated* form of synovial sarcoma also exists and is characterized by a greater degree of cellularity, atypia, and mitotic activity.[883–885] The tumor cells may be round, spindled, or large and clear (Fig. 41.175).[886]

Ultrastructurally, the epithelial areas have features of true glandular epithelium; subtle features of epithelial differentiation are sometimes also found in the spindle cell component, such as intercellular spaces within processes and specialized cell junctions.[887]

Immunohistochemically, there is strong reactivity for cytokeratin in the epithelial areas and often in the spindle cells as well, although

For personal use only. No other uses without permission. Copyright ©2017. Elsevier Inc. All rights reserved.

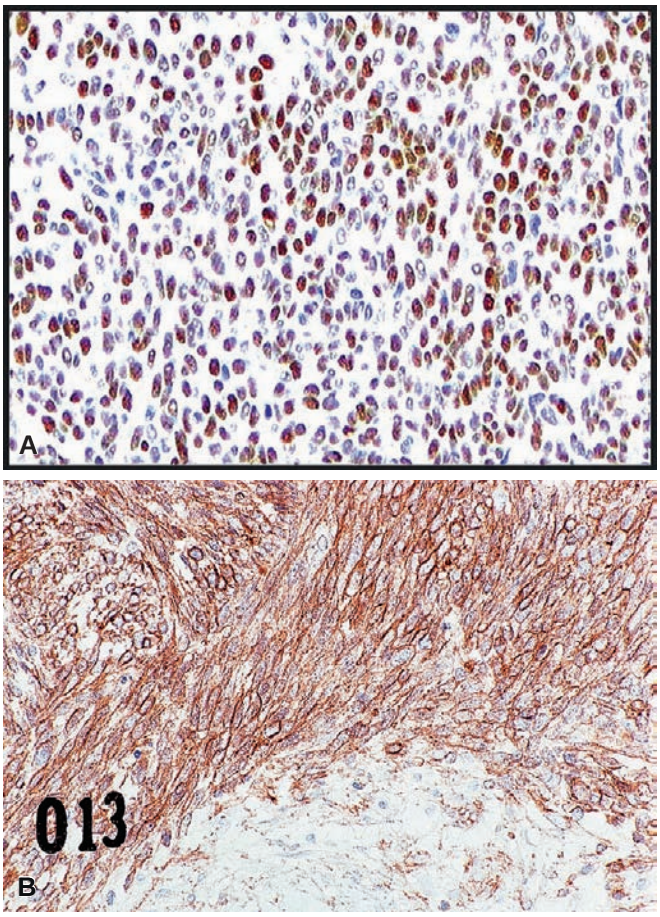

Figure 41.176 **A,** Strong nuclear TLE3 immunoreactivity in monophasic synovial sarcoma. **B,** Strong CD99 immunoreactivity in monophasic synovial sarcoma.

the latter areas usually stain in a patchy manner.[888] Synovial sarcoma shows positivity for cytokeratins 7, 14, and 19, as well as for the specialized cell junction-associated protein desmoplakin ZO-1, claudin-1, and occludin.[889–891] Some cases of monophasic synovial sarcoma stain for EMA and may not express cytokeratin. Patchy staining for S-100 protein is seen in up to 30% of cases and may cause confusion with MPNST,[892] although the former very rarely stain for SOX10, in contrast to the latter.[398] It has also been found that a significant number of cases of synovial sarcoma are immunoreactive for CD99, the marker characteristically associated with Ewing sarcoma.[893] Other frequently positive markers include BCL2,[894] calponin,[895] calretinin (which may cause confusion with mesothelioma),[896] and TLE1 (a transcriptional corepressor that inhibits Wnt signaling) (Fig. 41.176).[897] The latter marker typically shows strong and diffuse nuclear staining and, at least in our hands, rarely stains MPNST (usually in a small percentage of cells).

Synovial sarcoma exhibits in over 90% of the cases the chromosomal translocation t(X;18)(p11.2;q11.2), which results in the fusion of the *SS18* (formerly known as *SYT*) gene on chromosome 18 with either *SSX1* (in two-thirds of the cases) or *SSX2* (the other third) on chromosome X.[898] This highly specific genetic alteration can be detected with RT-PCR in fresh or paraffin-embedded material,[899] conventional cytogenetics or FISH,[900,901] and the hybrid protein SS18/SSX can be visualized immunohistochemically.[902] Notably, a high degree of correlation exists between the type of gene fusion and the tumor subtype, in that nearly all biphasic tumors carry the *SS18–SSX1* fusion, whereas most of those with *SS18–SSX2* are monophasic.[903]

Synovial sarcoma can recur locally and metastasize distantly, particularly to the lung and lymph nodes. The incidence of nodal metastases is in the range of 10%–15% (i.e., much higher than that of most soft tissue sarcomas of adults). Synovial sarcoma has been traditionally regarded as a tumor of ominous prognosis; in several series, however, the 5-year survival rate has approached 50%. The prognosis is even better for synovial sarcomas associated with heavy calcification (calcifying synovial sarcoma), where the survival rate reaches the figure of 80%.[879] The prognosis is also related to age (better in young patients),[904] site (better for distal lesions),[905] tumor size (better for tumors less than 5 cm in diameter),[906] status of the surgical margins,[907] mitotic activity (better for tumors having fewer than 15 mitoses per 10 high-power fields),[908] necrosis (worse for tumors having tumor necrosis of more than 50%),[909] rhabdoid cells (worse when present),[910] microscopic grade (which takes into account some of the parameters just listed),[911] dysadherin expression (worse when present, indicating E-cadherin dysfunction),[912] and DNA ploidy pattern (worse for aneuploid tumors).[913] Early reports that the type of gene fusion showed a significant association with prognosis[914] have not been confirmed in other series.[901,915,916]

Myxoma and Related Tumors

Myxomas almost always occur in adults and are more common in females (Fig. 41.177).[917] The diagnosis of myxoma in a child should be seriously questioned. A high proportion of myxomas arise within skeletal muscle (intramuscular myxoma), especially in the thigh region. The prognosis is excellent. In most of the reported series, there was not a single case of local recurrence.[917,918] Multiple intramuscular myxomas are nearly always seen in association with fibrous dysplasia of the bones of the same extremity.[919,920] The presence of multiple myxomas in the skin, breast, or other locations should raise the possibility of Carney complex, which also includes spotty cutaneous pigmentation, nodular pigmented adrenal disease, and other endocrine abnormalities.[921] Another important location of myxoma is the juxta-articular region *(juxta-articular myxoma)*, particularly near the knee.[922]

Microscopically, a typical myxoma has a bland and hypocellular appearance throughout, mitotic activity is practically absent, and blood vessels are extremely scanty (Fig. 41.178). Focal aggregates of foamy histiocytes may be present; these contain neutral fat with the oil red O stain and should not be confused with the lipoblasts of myxoid liposarcoma.[918]

Ultrastructurally, the principal cell of intramuscular myxoma resembles a fibroblast, with prominent granular endoplasmic reticulum, well-developed Golgi apparatus, and cytoplasmic filaments.[923] Immunohistochemically, the cells may stain for smooth muscle actin suggesting focal myofibroblastic differentiation, but the cells are negative for S-100 protein.

Genetically, intramuscular myxoma commonly exhibits activating mutations in the *GNAS1* gene, the same gene involved in the genesis of fibrous dysplasia of bone,[924] resulting in the downstream activation of the cellular oncogene protein c-Fos.[925] Mutations of *GNAS1*, on the other hand, are not seen in juxta-articular myxomas.[926]

The differential diagnosis of myxoma comprises two types of disease. The first is a group of neoplasms in which myxoid change can be a prominent secondary feature, such as liposarcoma, myxofibrosarcoma, chondrosarcoma, leiomyosarcoma, embryonal rhabdomyosarcoma, neurofibroma, nerve sheath myxoma, and aggressive angiomyxoma. If a myxoid tumor is hypercellular and hypervascular, the alternative possibility of low-grade myxofibrosarcoma should be considered. However, a *cellular variant* of myxoma has been described which is more cellular and more vascular than the ordinary type[927,928]; this tumor lacks the pleomorphism, nuclear atypia, and curvilinear vascular pattern of low-grade myxofibrosarcoma.

For personal use only. No other uses without permission. Copyright ©2017. Elsevier Inc. All rights reserved.

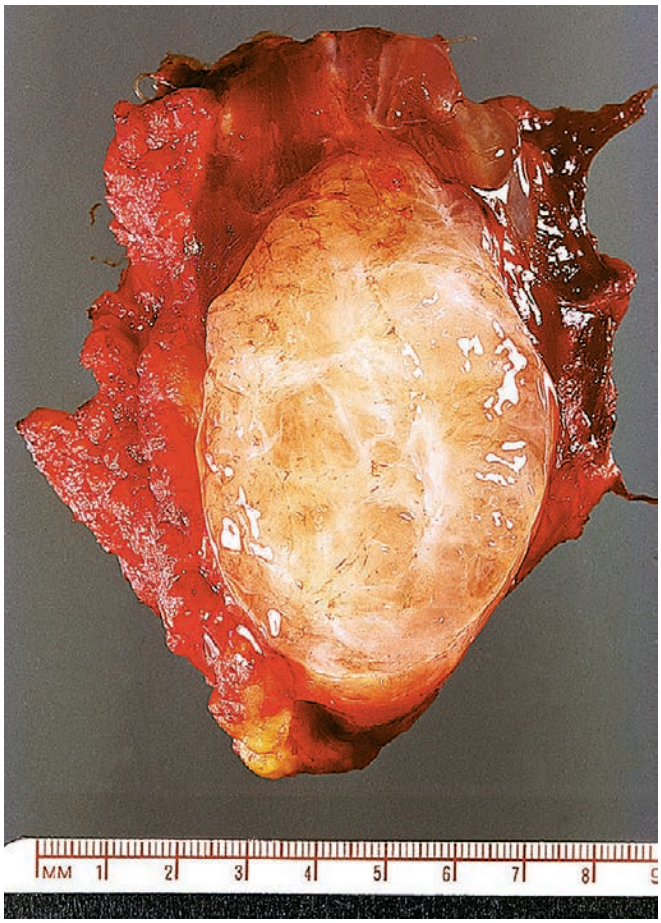

Figure 41.177 Typical gross appearance of intramuscular myxoma. (Courtesy of Dr. R.A. Cooke, Brisbane, Australia: from Cooke RA, Stewart B. *Colour Atlas of Anatomical Pathology*. Edinburgh: Churchill Livingstone; 2004.)

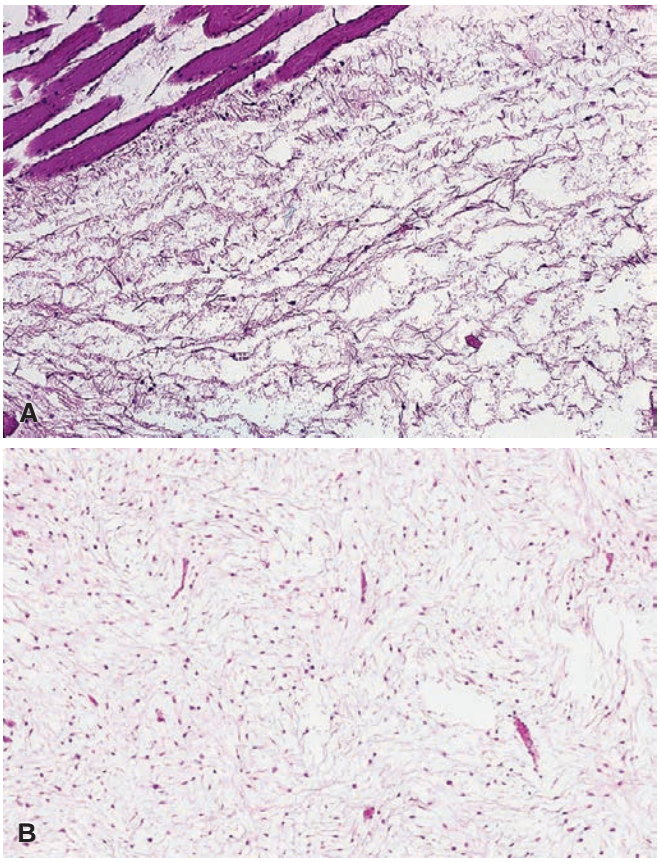

Figure 41.178 Low-power **(A)** and high-power **(B)** views of intramuscular myxoma with a paucity of blood vessels.

The second group of diseases from which myxoma should be distinguished is a variety of non-neoplastic disorders resulting in focal mucinous degeneration of the skin or soft tissues, such as nodular fasciitis, localized myxedema, mucous (myxoid) cyst, ganglion, follicular mucinosis (alopecia mucinosa), papular mucinosis, and cutaneous focal mucinosis.

Alveolar Soft Part Sarcoma

Alveolar soft part sarcoma most often arises in the deep soft tissues of the thigh and leg,[929] but it is not uncommon in the oral cavity and pharynx (including tongue).[930] Other sites of involvement include the mediastinum (sometimes arising from the pulmonary vein), stomach, retroperitoneum, orbit, bladder, uterus, and vagina.[931] Grossly, the tumors are well circumscribed, usually large, moderately firm, and gray or yellowish (Fig. 41.179). Areas of necrosis or hemorrhage are common in the larger neoplasms.[932]

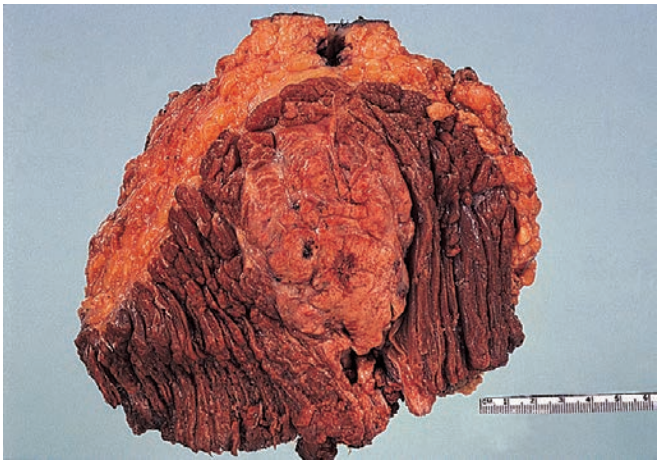

Figure 41.179 **Alveolar Soft Part Sarcoma.** The tumor is multinodular, relatively well circumscribed, and embedded within skeletal muscle.

Microscopically, the tumor cells are separated by fibrous septa into well-defined nests. Detachment of the central cells results in the typical alveolar pattern. The individual cells are large and have vesicular nuclei, prominent nucleoli, and a granular cytoplasm (Fig. 41.180). Mitoses are exceptional. PAS stain sometimes demonstrates the presence of diastase-resistant intracytoplasmic needle-like structures (Fig. 41.181A). These are seen by electron microscopy as membrane-bound crystals with a periodicity of 58–100 nm, sometimes arranged in a cross-grid pattern (see Fig. 41.181B).[933] Other ultrastructural features include numerous vesicles with an electron-dense content in the Golgi region (possibly representing the precursors of the crystals) and smooth tubular aggregates associated with plasmalemmal invaginations.[934]

Alveolar soft part sarcomas occurring in children are often associated with a more solid pattern of growth and therefore tend to be misdiagnosed. Conversely, the alveolar appearance of this entity can be closely simulated by other malignant neoplasms, notably malignant melanoma (Fig. 41.182), PEComa, and renal cell carcinoma.

For personal use only. No other uses without permission. Copyright ©2017. Elsevier Inc. All rights reserved.

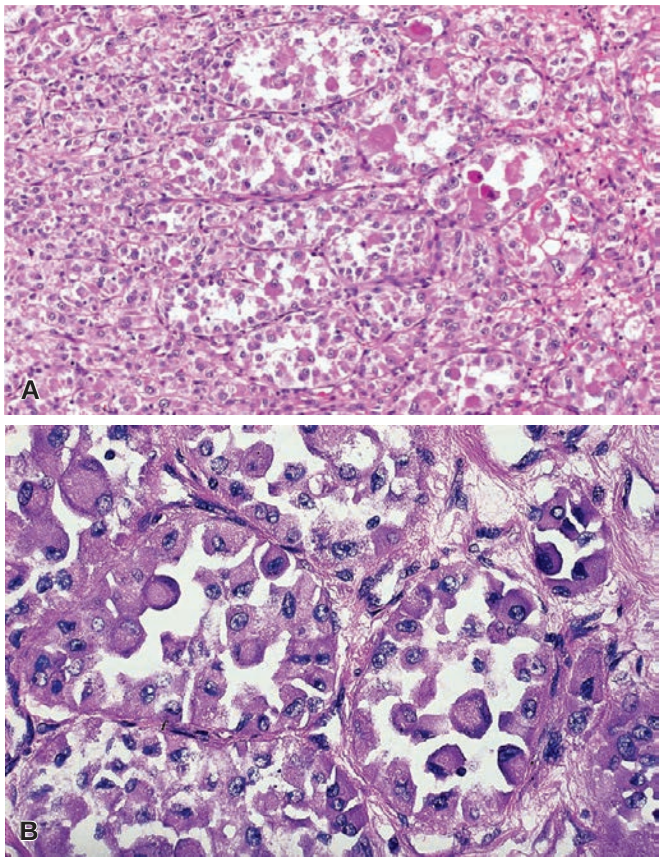

Figure 41.180 Low-power **(A)** and high-power **(B)** views of alveolar soft part sarcoma with a prominent nested growth pattern.

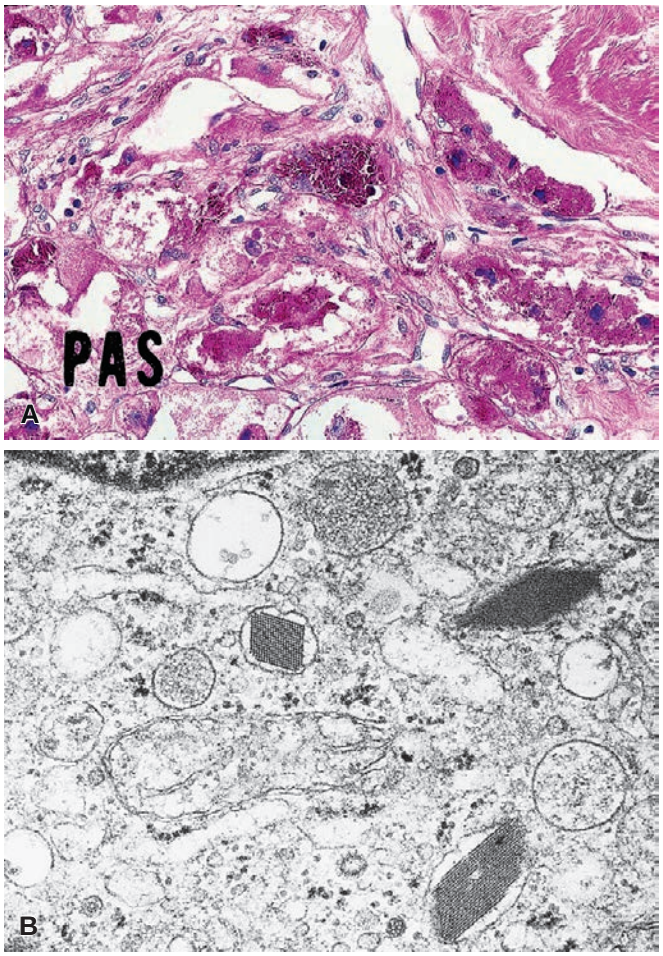

Figure 41.181 **A,** PAS-positive cytoplasmic granules in alveolar soft part sarcoma, some having a crystalline appearance. **B,** Electron microscopic appearance of alveolar soft part sarcoma. Detailed view of characteristic crystalloid inclusions that demonstrate orderly 70- angstrom periodicity. Both linear and cross-hatched crystalloid pattern may be noted. (×70,000; Courtesy of Dr. J. Sciubba, New Hyde Park, New York.)

Alveolar soft part sarcoma is highly malignant, despite its deceptively slow and indolent clinical course. Vein invasion is common. Blood-borne metastases appear in the lungs and other organs as long as 30 years or more following excision of the primary tumor.[929,935] Not infrequently, a metastasis in the lung or another organ is the first manifestation of the disease. There is a good correlation between tumor size and survival.[936]

The histogenesis of this unusual neoplasm has not yet been definitely established. We believe there is no convincing evidence to support the theory that this tumor represents a malignant counterpart of granular cell tumor, that it arises from nonchromaffin paraganglia, or that it is related to renin-producing cells of blood vessel walls. There are some data in recent years supporting the interpretation that alveolar soft part sarcoma is of myogenous derivation including the (admittedly inconsistent) immunohistochemical demonstration of smooth muscle and sarcomeric actin, desmin, Z-protein, fast myosin, β-enolase, and the MM isozyme of creatine kinase.[937–939] Some have demonstrated MyoD1 protein, a nuclear phosphoprotein that is the product of a regulatory gene that controls the commitment of a cell to a myogenic lineage, in the cells of this tumor.[940] In the end, this remains a tumor of uncertain histogenesis.

At the cytogenetic level, alveolar soft part sarcoma has been found to be associated with the chromosomal unbalanced translocation der(17)t(X;17)(p11.2;q25), which results in the fusion of the *TFE3* transcription factor gene to the *ASPSCR1* (formerly known as *ASPL*) gene.[941] Interestingly, a similar but balanced translocation has been detected in a type of renal neoplasm that is probably epithelial but which bears some morphologic resemblance to alveolar soft part sarcoma (see also Chapter 24). The presence of aberrant nuclear

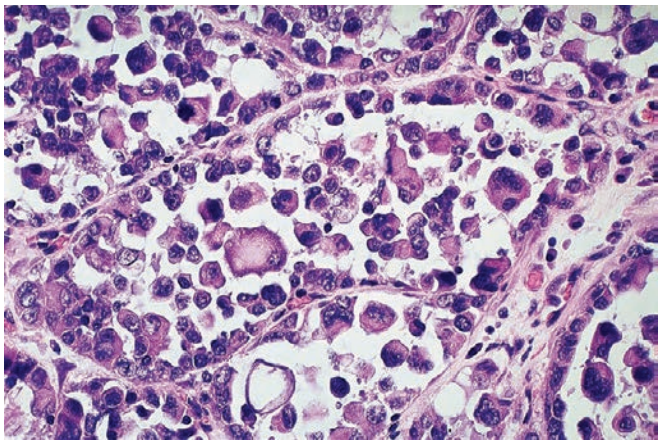

Figure 41.182 Metastatic malignant melanoma closely simulating the appearance of alveolar soft part sarcoma.

For personal use only. No other uses without permission. Copyright ©2017. Elsevier Inc. All rights reserved.

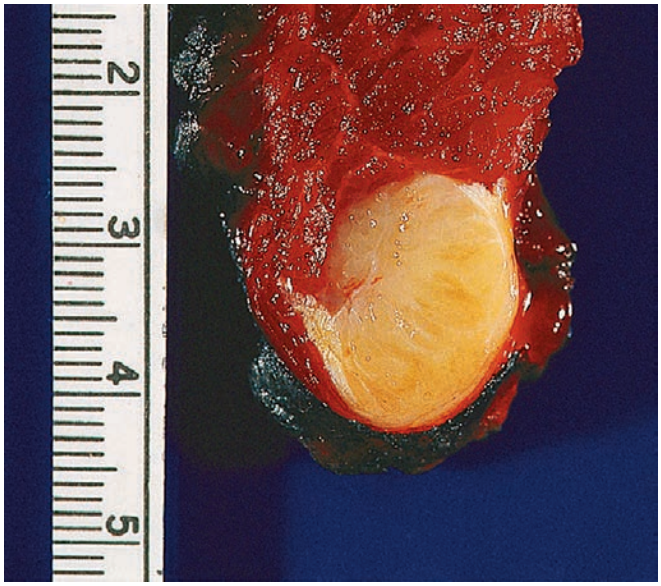

Figure 41.183 Gross appearance of clear cell sarcoma located in the posterior thigh.

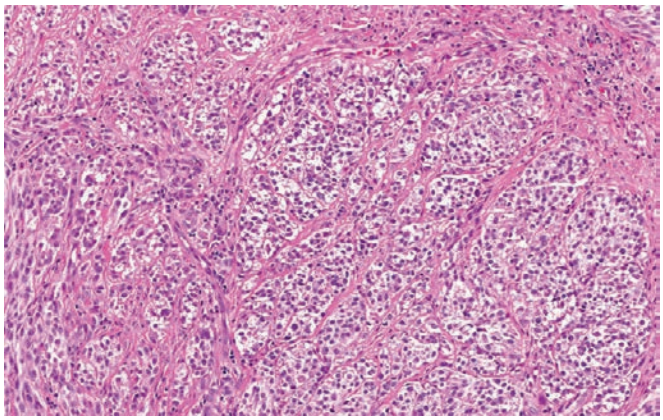

Figure 41.184 Clear cell sarcoma with nests of cells with clear cytoplasm.

expression of TFE3 can be demonstrated in these tumors by immunohistochemistry.[942]

Clear Cell Sarcoma

This malignant tumor arises chiefly in association with large tendons and aponeuroses of the extremities.[943,944] The feet are the most common site, but it has been described in many other sites. Most of the patients are young adults, and there is a male predominance.[945]

Grossly, the tumors are firm, well circumscribed, and gray or white, and cut with a gritty sensation (Fig. 41.183). Microscopically, solid nests and fascicles of pale fusiform or cuboidal cells are present. The nucleoli are large and deeply basophilic (Fig. 41.184). Multinucleated giant cells are often seen. Abundant extracellular and intracellular iron is present. In many of the cases the tumor cells also contain cytoplasmic melanin.[946] In keeping with this observation is the consistent immunoreactivity for S-100 protein, HMB-45, and melan-A,[947,948] as well as the ultrastructural observation of melanosomes.[949] Like conventional melanoma, clear cell sarcoma may rarely exhibit immunoreactivity for cytokeratin.[950]

Clear cell sarcoma is associated with the chromosomal translocation t(12;22)(q13;q12),[951,952] which results in the *EWSR1-ATF1* gene fusion and the expression of the melanocyte-specific splice form of the MiTF transcript.[953] Some cases have a t(2;22) resulting in the *EWSR1-CREB1* fusion, especially those arising in the GI tract.[954–956] However, at least some of the cases arising in the GI tract show no evidence of melanocytic differentiation and are more likely examples of **gastrointestinal neuroectodermal tumor** (GNET, also known as clear cell–like tumor of the GI tract).[957] The latter tumor is composed of nests or sheets of uniform epithelioid or oval to spindled cells with small nucleoli, rare mitoses, and scattered osteoclast-type multinucleated giant cells. Like true clear cell sarcoma, GNET stains strongly for S-100 protein, but there is no immunohistochemical or ultrastructural evidence of melanocytic differentiation.[958]

The clinical course of clear cell sarcoma is characterized by slow but relentless progression with frequent local recurrences and eventual nodal and distant metastases.[959,960] Large tumor size and necrosis are significant predictors of poor prognosis.[960,961]

Epithelioid Sarcoma

Epithelioid sarcoma usually affects adolescents and young adults.[962,963] The extremities are the most common location, particularly the hands and fingers. The tumors tend to be superficially located and are sometimes centered in the reticular dermis. Others are found in the subcutis or deeper soft tissues, particularly fascial planes, aponeuroses, and tendon sheaths. The necrosis often seen in the center of the nodules and the epithelioid appearance of the tumor cells may result in a mistaken diagnosis of infectious granuloma or, more frequently, necrobiotic granulomatous inflammation (Fig. 41.185).

One of the most characteristic features of this lesion is the striking acidophilia of the tumor, which is due to the combined effect of the staining characteristics of the cytoplasm and the extensive desmoplasia (Fig. 41.186). Metaplastic elements such as bone and cartilage are rarely present.[964] Sometimes, most of the tumor cells have a spindle shape and simulate other spindle cell neoplasms.[965] Some epithelioid sarcomas exhibit rhabdoid features; this is particularly common in the so-called proximal type (see later).[966,967]

Ultrastructurally, the tumor cells exhibit abundant intermediate filaments, desmosome-like cell junctions, and small intercellular spaces surrounded by filopodia or microvilli.[968] Immunohistochemically, the cells stain strongly for cytokeratins (Fig. 41.187), EMA, and often CD34.[969–972] Similar to malignant rhabdoid tumor, SMARCB1/INI1 expression is commonly lost in the neoplastic cells[973,974] and are a manifestation of deletions of the *INI1* gene on chromosome 22q11.2 (Fig. 41.188).[974] Regarding cytokeratin subtypes, Miettinen et al. found positivity for CK8 in 94% of the cases, CK19 in 72%, 34βEH12 in 48%, and CK7 in 22%.[968] CK5/6 is usually negative or expressed only focally, in contrast to squamous cell carcinoma.[975] Some tumors also express ERG, which can be a pitfall with epithelioid angiosarcoma.[976]

The histogenesis of this tumor remains obscure. It clearly exhibits features of epithelial differentiation, but whether the epithelial features present in these tumors derive from metaplasia of mesenchymal elements remains to be determined.

The tumor spreads to noncontiguous areas of skin, soft tissue, fascia, and bone, as well as by direct extension along fascial planes. Local recurrence is the rule, although it may take years for this to develop. Lymph node metastases are relatively common and constitute an ominous prognostic sign.[977] Sometimes lymph node metastasis is the first clinical manifestation of the disease. Metastases also occur in the lungs, other organs, and skin; for some peculiar reason, the scalp is a preferred site.[978] A more aggressive clinical course is associated

For personal use only. No other uses without permission. Copyright ©2017. Elsevier Inc. All rights reserved.

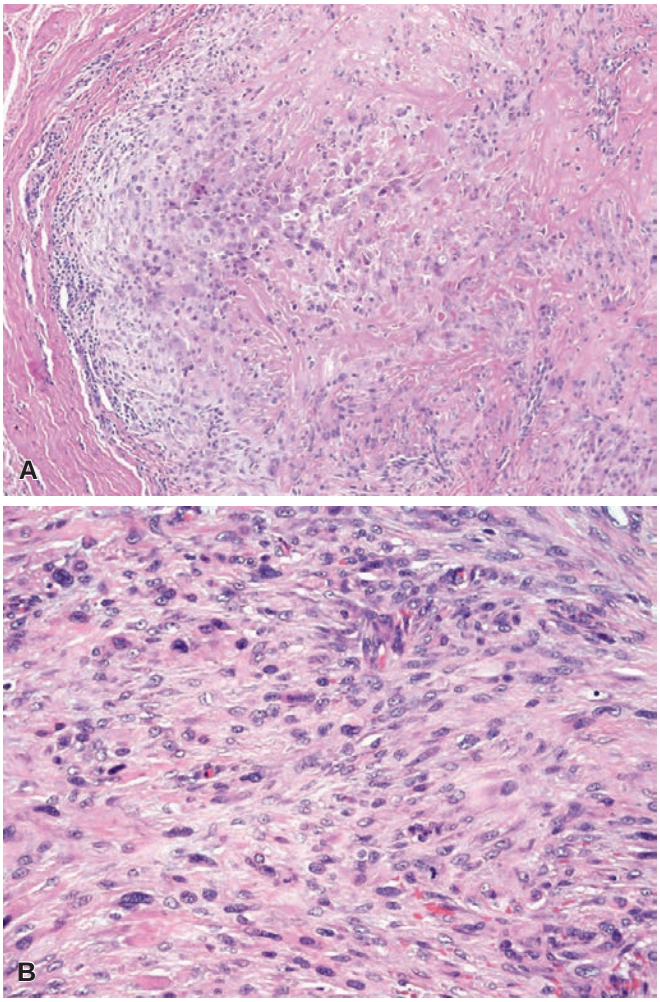

Figure 41.185 Low-power **(A)** and high-power **(B)** views of epithelioid sarcoma. Central necrobiotic areas simulate granuloma annulare or rheumatoid nodule.

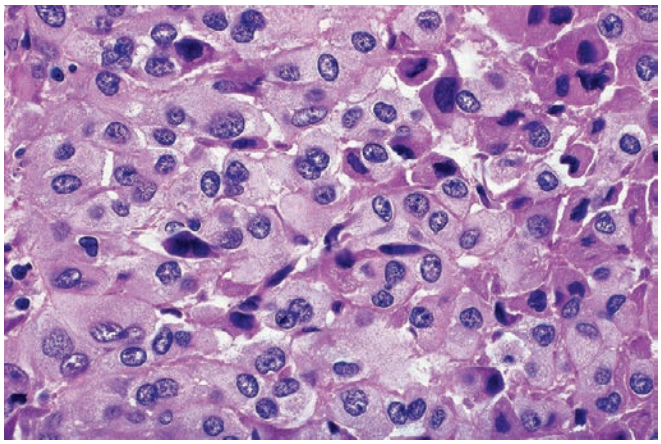

Figure 41.186 Remarkable epithelioid quality of tumor cells in epithelioid sarcoma with densely eosinophilic cytoplasm.

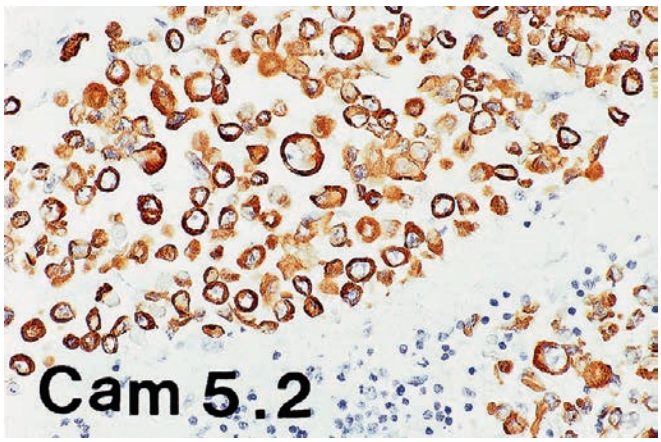

Figure 41.187 Strong cytokeratin immunoreactivity *(CAM5.2)* in epithelioid sarcoma.

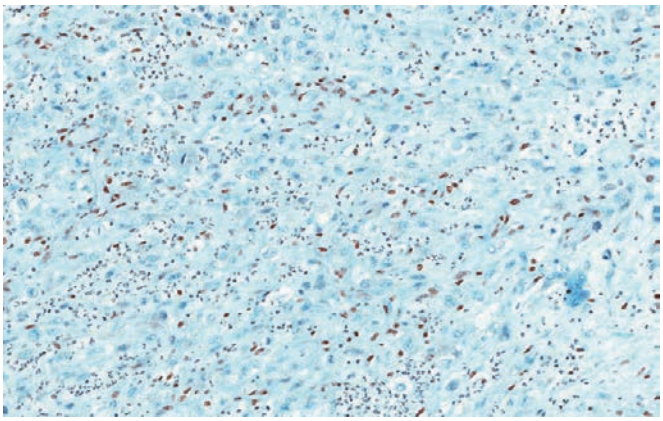

Figure 41.188 Loss of INI1 staining in epithelioid sarcoma. Internal control staining is present in endothelial cells and inflammatory cells.

with a proximal or axial tumor location, increased size and depth, hemorrhage, mitotic figures, necrosis, rhabdoid features, and vascular invasion.[979,980] Special mention should be made of the *proximal type* of epithelioid sarcoma, characterized by a proximal location (pelvis, perineal and pubic region, vulva, buttock), deep invasion, necrosis, and sometimes prominent rhabdoid features (Fig. 41.189).[981–983] Dysadherin (a cell membrane glycoprotein which downregulates E-cadherin) is expressed more commonly in proximal-type epithelioid sarcoma than in the conventional distal type.[984] Loss of SMARCB1/INI1 is found in almost all cases.[973,985]

Ossifying Fibromyxoid Tumor

Ossifying fibromyxoid tumor is a soft tissue neoplasm that usually presents in adult patients as a small, painless, well-circumscribed mass in the subcutaneous tissue or muscle of the extremities.[986,987] Microscopically, the tumor cells are typically arranged in a cord- or nest-like pattern within a myxoid matrix that blends with foci of fibrosis and osteoid formation. The low-power appearance is distinctive by virtue of lobulation and (in the majority of cases) an incomplete shell of mature bone in the region corresponding to the tumor capsule.[986] The tumor cells are small and round, with minimal atypia and few mitoses (Fig. 41.190).

Immunohistochemically, there is immunoreactivity for S-100 protein (which may be diffuse or patchy), associated with focal reactivity for Leu7 and glial fibrillary acidic protein and negativity for type II collagen.[987] Ultrastructurally, there are complex cell processes and basement membrane deposition suggesting schwannian differentiation.[988] However, the detection of desmin, SMA, and

For personal use only. No other uses without permission. Copyright ©2017. Elsevier Inc. All rights reserved.

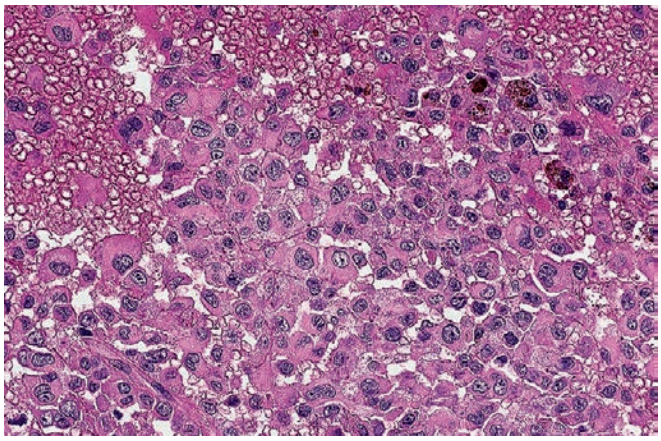

Figure 41.189 Proximal variant of epithelioid sarcoma. Some of the tumor cells have rhabdoid features.

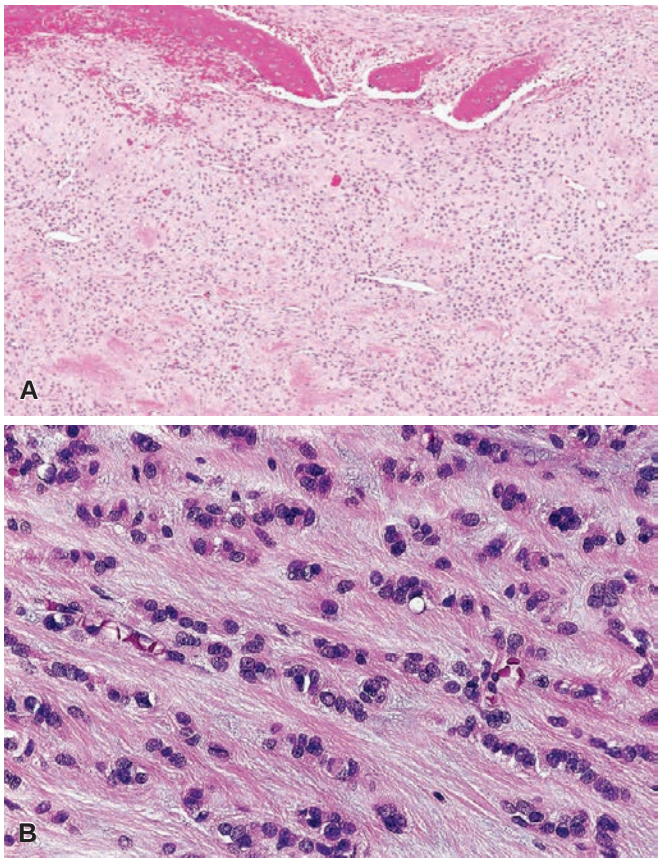

Figure 41.190 **A,** Low-power view of ossifying fibromyxoid tumor with a rim of lamellar bone at the periphery of a tumor nodule. **B,** High-power view with medium-sized cells arranged in cords embedded in a hyaline matrix.

cytokeratin, plus some ultrastructural features, raise consideration of partial smooth muscle or myoepithelial differentiation.[989,990] Recently, recurrent rearrangement of the *PHF1* gene has been reported in ossifying fibromyxoid tumor (found in almost 50% of the cases, including typical, atypical, and malignant cases).[990a] Rare examples of ossifying fibromyxoid tumor have also been reported with *CREBBT-BCORL1* and *KDM2A-WWTR1* fusions.[990b]

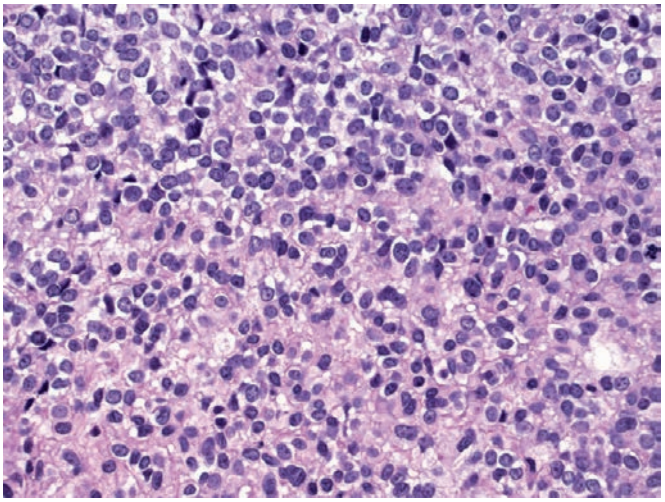

Figure 41.191 Uniform appearance of round cells in classical Ewing sarcoma.

The behavior of this tumor is indolent, but local recurrences develop in up to 25% of patients.[986,987] However, distant metastases are quite rare. Folpe and Weiss found that tumors with high nuclear grade or high cellularity with mitotic activity ≥2 mitotic figures/50 HPF should be considered sarcomas with potential for metastasis.[991]

Extraskeletal Ewing Sarcoma/Primitive Neuroectodermal Tumor (Ewing Family of Tumors)

Tumors morphologically indistinguishable from **Ewing sarcoma** of the skeletal system can present as soft tissue masses. In some cases, they simply represent soft tissue extensions of tumor originating in the underlying bone. In others, bone involvement is absent, and these are regarded as primary extraskeletal Ewing sarcomas.[992] Most of the patients are adolescents or young adults, and the usual sites of involvement are the deep soft tissues of the lower extremity and paravertebral region,[993] but they have been described in virtually every anatomic site. Occasionally, the tumors are superficial, with primary involvement of subcutis or skin.[994] Microscopically, like their skeletal counterpart, they are composed of uniform small, round, or oval cells containing cytoplasmic glycogen (Fig. 41.191). Ultrastructurally, the cells are rather primitive, with abundant cytoplasmic glycogen, poorly developed cell junctions and no overt evidence of neural differentiation.[995] The course is aggressive and distant metastases are common, particularly to lung and skeleton.

On a histologic spectrum with Ewing sarcoma is **peripheral PNET**,[996] which subsumes the clinicopathologic entity originally described as malignant small cell tumor of the thoracopulmonary region (Fig. 41.192).[997] Taken together, this group of neoplasms is often referred to as the Ewing family of tumors (EFT). The nosologic unity of Ewing sarcoma/PNET is strongly supported by the existence of numerous intermediate forms,[992] the strong immunoreactivity for CD99,[998] and—most important—the presence of a consistent chromosomal translocation, most commonly t(11;22)(q24;q12),[999] which leads to the fusion of the Ewing sarcoma gene *(EWSR1)* on chromosome 22 to the *FLI-1* gene (or other partners) on chromosome 11.[1000] This genetic alteration can be detected with RT-PCR or FISH in fresh or paraffin-embedded material.[1001,1002]

CD99 recognizes a cell membrane protein of yet unknown function, which is the product of *MIC2*, a pseudoautosomal gene located

For personal use only. No other uses without permission. Copyright ©2017. Elsevier Inc. All rights reserved.

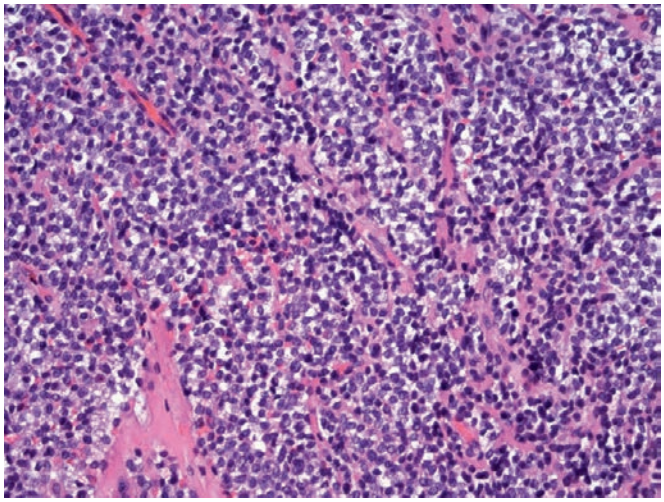

Figure 41.192 Low-power appearance of nests of cells in a peripheral primitive neuroectodermal tumor.

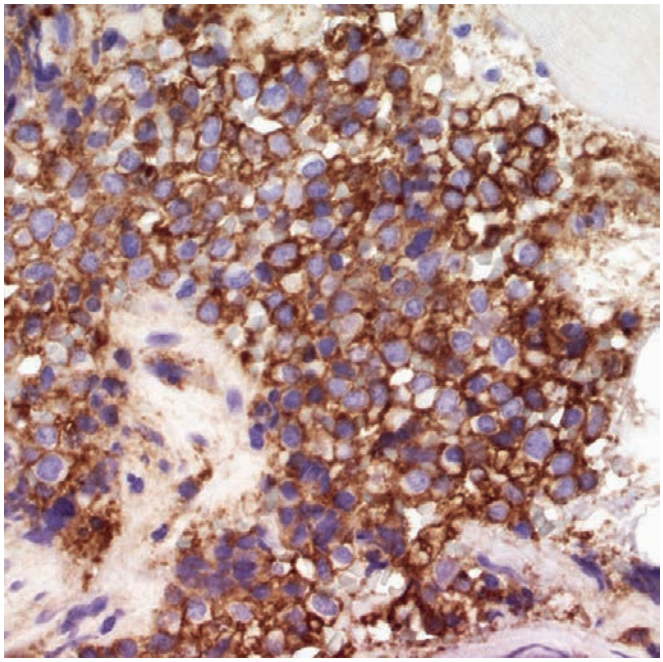

Figure 41.193 Strong CD99 membranous immunoreactivity in a classical Ewing sarcoma.

on the short arm of the X and Y chromosomes (Fig. 41.193).[1003] Although it is a highly sensitive marker of the EFT being found in approximately 95% of cases, it lacks specificity, since it can be detected (albeit with lower frequency) in many other round cell tumors. Importantly, cytokeratin reactivity has been detected in up to 20% of cases, and it may be quite extensive.[1004] Cell junction–related proteins, such as claudin-1 and occludin, are also sometimes expressed.[1005,1006] Many cases also stain with an antibody to FLI-1.[1007] More recently, NKX2-2 has been found to be a highly sensitive but not completely specific marker of this family of tumors, but might be a useful additional marker in the workup of round cell tumors.[1007a]

The claim that tumors having easily detectable neuroectodermal markers run a more aggressive clinical course than those without these markers[996] has not been substantiated.[998] Furthermore, most attempts to subdivide them on phenotypic grounds have been unsuccessful.[1008] When treated in a similar manner, degree of neuroectodermal differentiation has not been found to significantly impact prognosis, and hence the reason to be a "lumper" (EFT), as opposed to a "splitter."

The differential diagnosis of EFT of soft tissues includes alveolar rhabdomyosarcoma (especially the solid variant), malignant lymphoma, desmoplastic small cell tumor, and many other tumors with round cell morphology. A combined morphologic, immunohistochemical, and molecular approach will place most tumors into one or another of these categories.

Also recognized is a group of round cell neoplasms with Ewing-like features but lacking molecular evidence supporting their inclusion in the EFT. Such tumors have been referred to as "*Ewing-like*," but recent molecular discoveries have started to emerge amongst this group of neoplasms. By far, the largest group of Ewing-like round cell sarcomas is comprised of those with *CIC* rearrangements involving the *CIC* and *DUX4* genes located on chromosomes 4 and 19, respectively.[1009–1011] Rare examples show a *CIC-FOXO4* fusion.[1012] These tumors tend to be lobulated with high-grade round cells with focal cytoplasmic clearing and extensive areas of necrosis, often with myxoid change.[1009] A recent large study of 115 cases of *CIC*-rearranged sarcomas had a mean age of 32 years with a slight male predominance, with the vast majority of tumors (86%) arising in the deep soft tissues predominantly of the trunk and extremities.[1012a] Although most cases do show CD99 immunoreactivity (84%), the pattern is more often patchy when compared to the EFT. Most show nuclear WT1 immunoreactivity. In this study, the 5-year survival was only 43%, which was found to be significantly lower than the 77% 5-year survival in the control group of Ewing sarcoma patients.[1012a] Less commonly, a group of Ewing-like round cell sarcomas show evidence of a *BCOR-CCNB3* fusion, although there are less common partners for the *BCOR* gene.[1013–1015a]

Desmoplastic Small Cell Tumor

Desmoplastic small cell tumor is typically located within the abdominal cavity of young patients, especially males, but has also been seen in the pleural cavity, CNS, orbit, and other soft tissue sites.[1016,1017] It is characterized by nests and sheets of small round cells typically surrounded by desmoplastic stroma (Fig. 41.194). Foci of cells with rhabdoid morphology are often seen.[1018] Features which can also be seen include papillary architecture, Homer Wright–like rosettes and spindled zones. Immunohistochemically, this polyphenotypic tumor coexpresses vimentin, cytokeratin, and desmin, the latter typically in a distinct perinuclear globular pattern (Fig. 41.195).[1018] The vast majority also show nuclear positivity for the Wilms tumor gene product (WT1) using antibodies to the carboxy terminus.[1019] Up to 20% stain for CD99, a potential pitfall resulting in a misdiagnosis of EFT. Neural markers including NSE and CD57 are often expressed, but markers including S-100 protein and myogenin are negative.

The tumor is characterized by a unique t(11;22)(p13;q12) involving the *WT1* gene on 11p13 and *EWSR1* gene on 22q12.[1020,1021] This fusion can be detected by FISH or RT-PCR using fresh or paraffin-embedded tissue.[1022,1023] The tumor is highly aggressive, resulting in widespread metastases and often death within 5 years.[1017,1024]

Malignant Extrarenal Rhabdoid Tumor

Tumors with histologic features very similar to rhabdoid tumor of the kidney have been described in virtually every extrarenal site, particularly the soft tissues.[1025,1026] Most patients are infants or children, but it can also occur in adults. Microscopically, solid sheets of cells are present with deeply and homogeneously acidophilic cytoplasm (the

For personal use only. No other uses without permission. Copyright ©2017. Elsevier Inc. All rights reserved.

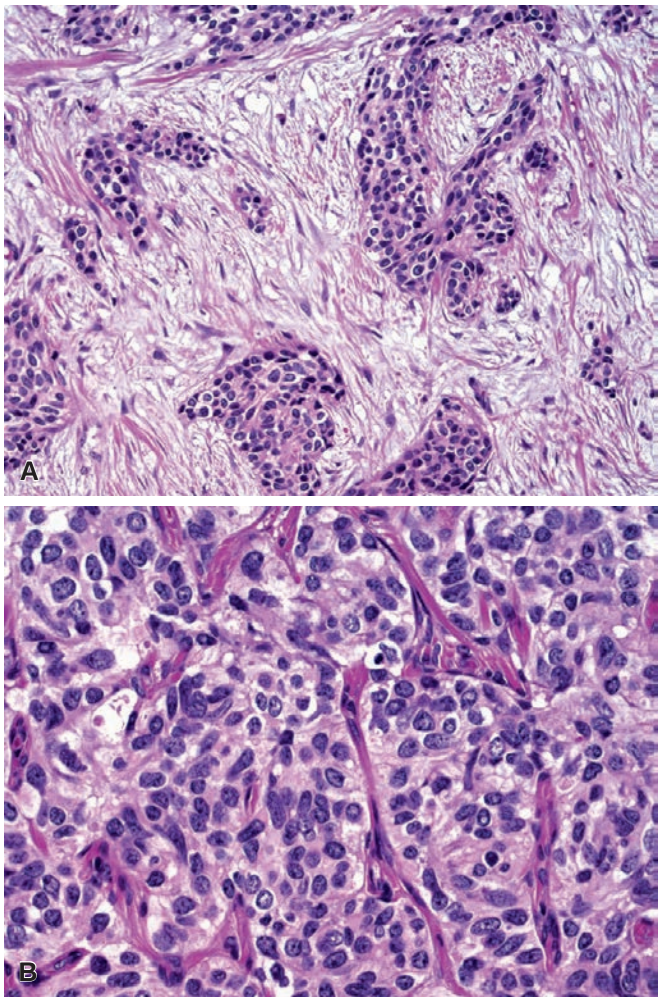

Figure 41.194 **A,** Nests of cells deposited on a desmoplastic stroma in desmoplastic small cell tumor. **B,** High-power view of round cells arranged in nests in desmoplastic small cell tumor.

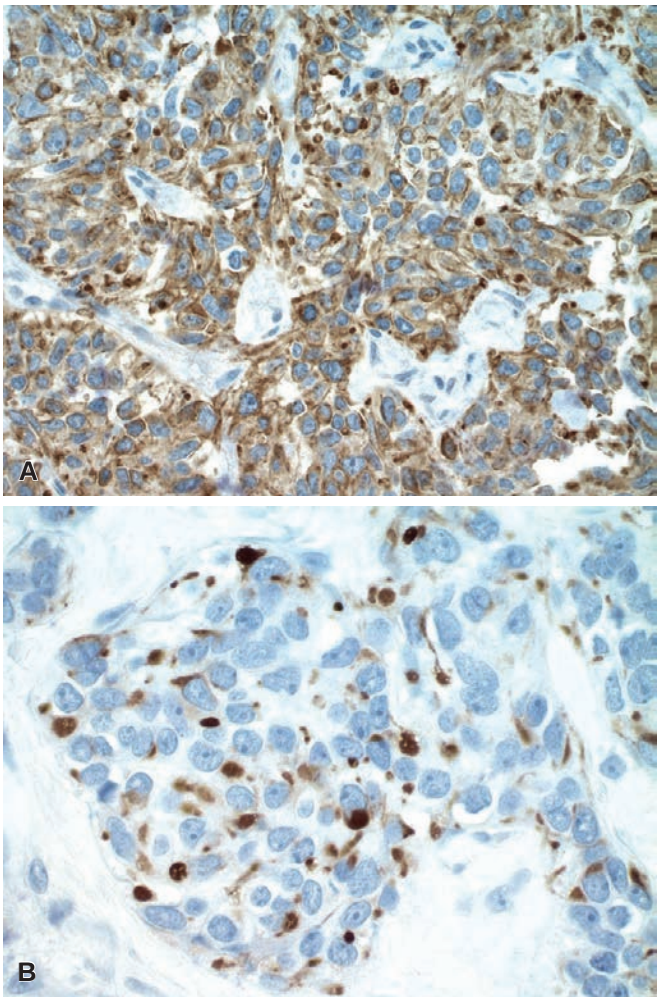

Figure 41.195 **A,** Strong cytokeratin immunoreactivity in desmoplastic small cell tumor. **B,** Characteristic perinuclear dot-like pattern of desmin staining.

result of packing by intermediate filaments), with lateral displacement of the nucleus (Fig. 41.196). Myxoid, pseudoalveolar, and hyalinized areas may be present.[1027] Immunohistochemically, there is positivity for vimentin and often for cytokeratin and EMA but generally not for skeletal muscle markers or S-100 protein (Figs. 41.197 and 41.198).[1025,1028] However, a great deal of phenotypic diversity has been recorded in these lesions, including the common expression of neural/neuroendocrine markers.[1025,1029,1030] "De novo" rhabdoid tumors (those that do not represent other specific tumor types showing rhabdoid morphology), like their renal and CNS counterparts, show alterations of chromosome 22, in the form of deletions or translocations involving 22q11.2 (harboring the *hSNF5/INI1/SMARCB1* gene), which can be demonstrated by FISH or loss of heterozygosity studies.[1031,1032] As such, loss of expression of SMARCB1 (INI1) can be revealed by immunohistochemistry in almost all tumors.[1033,1034]

Metastases occur early (to the lungs, liver, and lymph nodes), response to therapy is poor, and the clinical course is extremely aggressive.[1035] Evidence suggests that many rhabdoid tumors of soft tissues are actually an expression of a particular phenotype that can develop in a wide variety of tumor types, including epithelioid sarcoma, synovial sarcoma, desmoplastic small cell tumor, rhabdomyosarcoma, malignant melanoma, and various types of carcinoma.[1027,1029,1036] Of practical importance is the fact that the emergence of the rhabdoid phenotype is invariably associated with an aggressive and often lethal clinical course, regardless of the phenotype of the "parent" tumor.[1025,1037]

Phosphaturic Mesenchymal Tumor

An interesting association has been reported between some tumors of soft tissue or bone and osteomalacia or rickets.[1038,1039] The syndrome results from tumor production of a renal phosphaturic substance that depletes total body phosphates by inhibiting tubular reabsorption of phosphate.[1040] It is characterized biochemically by hypophosphatemia, renal phosphate wasting, and decreased serum 1,25-dihydroxyvitamin D3 levels.[1038] The soft tissue tumors associated with this complication have shown an array of microscopic features.[1041] In our experience, the most characteristic feature has been the association of hemangiopericytoma-like areas and osteoclast-like giant cells, with or without foci of osseous and cartilaginous metaplasia. A "grungy" or flocculent calcified matrix is particularly distinctive (Fig. 41.199). Recently, a unique *FN1-FGFR1* fusion has been detected in this tumor.[1042] Presumably as a result of this fusion, the tumor secretes high levels of fibroblastic growth factor-23 (FGF23) which can be detected by chromogenic in situ hybridization,[277] as commercially available antibodies to FGF23 have dubious specificity.[1041] The behavior is generally benign,[1039] but malignant examples are on record.[1041]

For personal use only. No other uses without permission. Copyright ©2017. Elsevier Inc. All rights reserved.

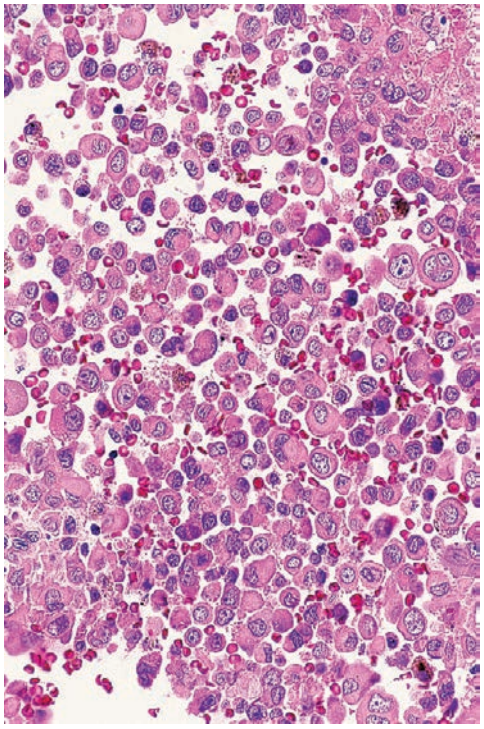

Figure 41.196 Soft tissue tumor of the vulvar region with rhabdoid features.

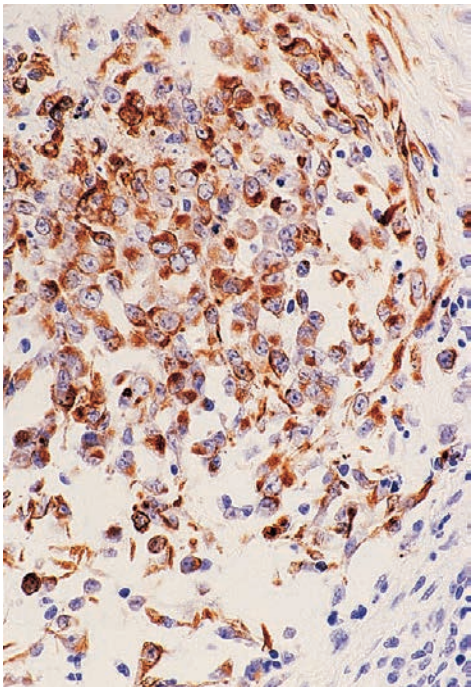

Figure 41.197 Rhabdoid tumor stained for cytokeratin. Perinuclear globular immunoreactivity can be seen in some of the cells.

Pleomorphic Hyalinizing Angiectatic Tumor

Most examples of pleomorphic hyalinizing angiectatic tumor (PHAT) arise in the soft tissues of adults, most commonly in the subcutaneous tissue of the lower extremities.[276,1043] PHAT can simulate schwannoma by virtue of the angiectatic vasculature, the presence of hemosiderin-laden macrophages, and the occurrence of a spindle cell component with scattered bizarre nuclear forms but little mitotic activity.[276,1043] Two diagnostic clues are represented by the nuclear pseudoinclusions and the fact that many of the bizarre cells are embedded within a fibrinous material surrounding the angiectatic vessels (Fig. 41.200). CD34 is focally positive and S-100 protein is negative, thereby excluding schwannoma. In some cases, a monomorphic, partially myxoid spindle cell component resembling HFLT may be identified at the periphery, possibly representing an early stage or precursor lesion (early PHAT).[276]

At the cytogenetic level, some cases of PHAT have been reported to harbor t(1;10) involving a *TGFBR3-MGEA5* fusion[236] similar to what has been described in HFLT and MIFS. This observation raises consideration that these three entities are histogenetically related along a histologic spectrum, but the relationship among these tumors remains a bit unclear.

Local recurrences have been described but not distant metastases.[1043] Some of the recurrences exhibit a sarcomatous appearance, such as high-grade myxofibrosarcoma.[1044]

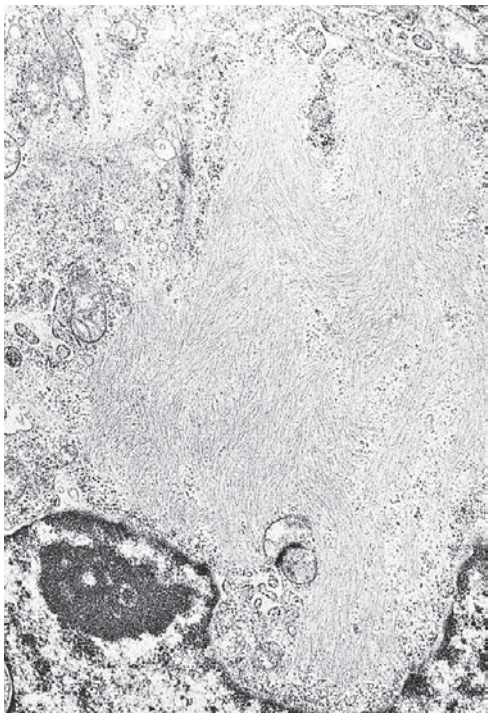

Figure 41.198 Electron microscopic appearance of rhabdoid tumor of soft tissue. The cytoplasmic organelles are displaced by a large aggregate of intermediate filaments. (×15,000; Courtesy of Dr. Robert A. Erlandson, Memorial Sloan-Kettering Cancer Center.)

Myoepithelioma of Soft Tissue

The proposal has been made that there exists in the soft tissue a group of tumors showing differentiation toward myoepithelial cells which can occur either in a pure form (myoepitheliomas) or in association with glandular structures (mixed tumors).[1045,1046] Microscopically, the myoepithelial component is present in the form of nests, cords and ductules of epithelioid cells, and/or nests of spindle cells within a hyalinized or chondromyxoid stroma (Fig. 41.201). Osteoid production and chondroid differentiation may be present. Immunohistochemically, there is often coexpression of cytokeratins and/or EMA, and S-100 protein (Fig. 41.202). Other myoepithelial markers may also be expressed including Sox10, SMA, calponin, GFAP, and p63.[1047]

For personal use only. No other uses without permission. Copyright ©2017. Elsevier Inc. All rights reserved.

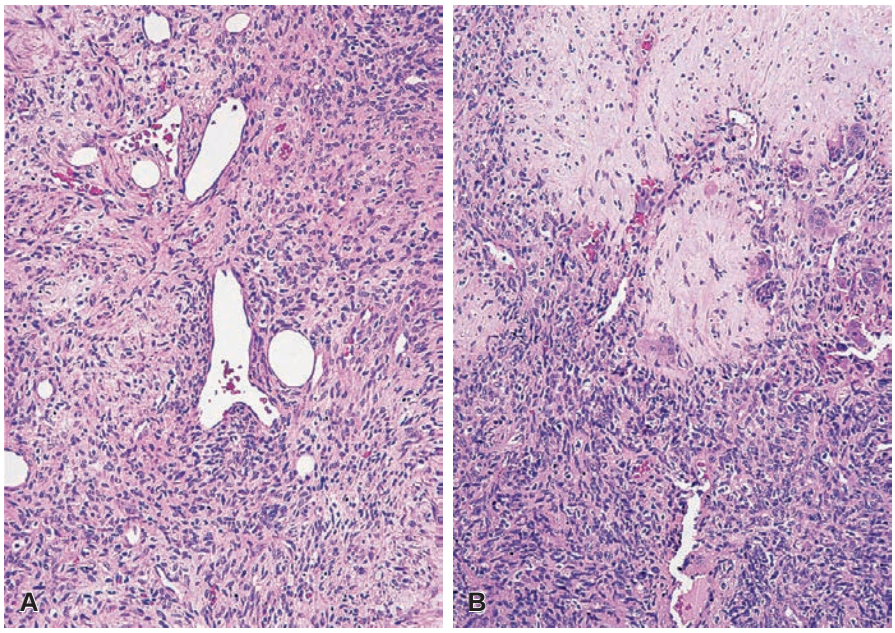

Figure 41.199 Phosphaturic Mesenchymal Tumor. A, This area has a prominent hemangiopericytoma-like quality. **B,** This area from the same tumor shows chondroid differentiation and scattered osteoclast-like giant cells.

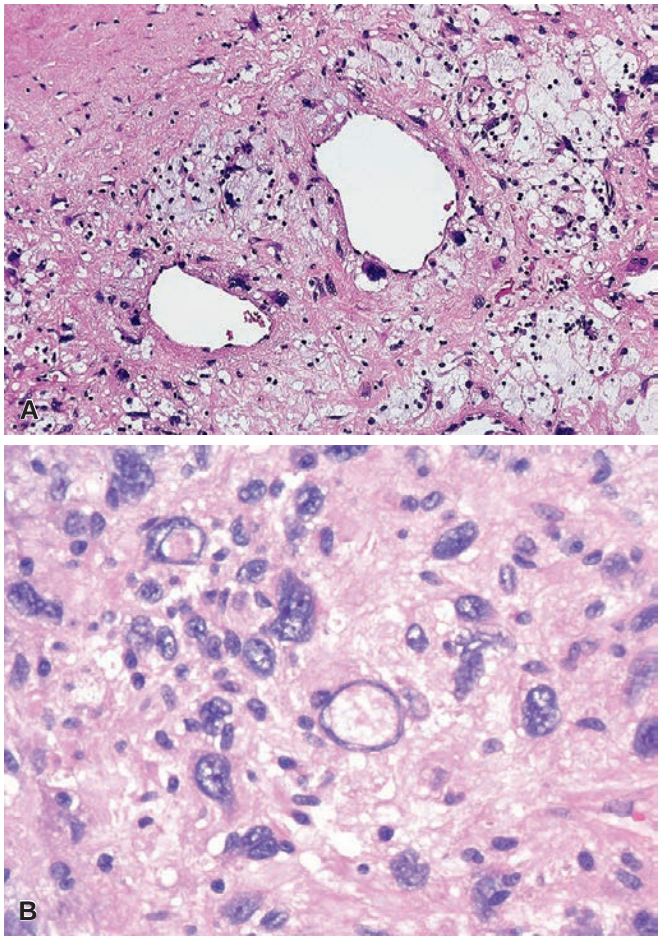

Figure 41.200 A, Pleomorphic hyalinizing angiectatic tumor with pleomorphic tumor cells surrounding dilated blood vessels. **B,** Intranuclear inclusions are identified in some of the neoplastic cells.

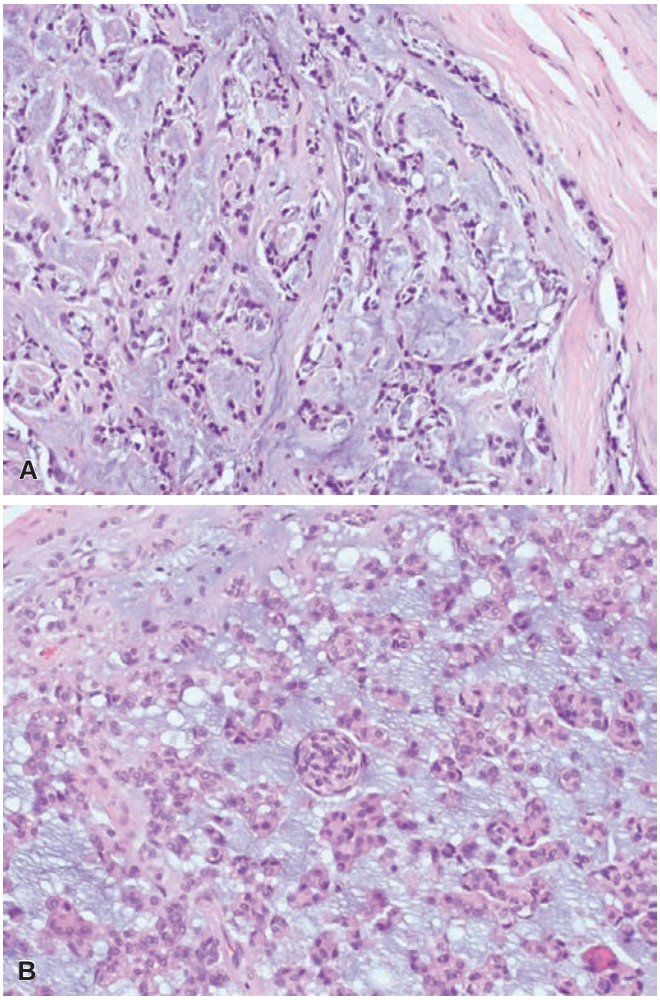

Figure 41.201 A, Myoepithelioma of soft tissue closely resembling extraskeletal myxoid chondrosarcoma with cords of cells deposited in a myxoid stroma. **B,** Parachordoma-like myoepithelioma of soft tissue.

For personal use only. No other uses without permission. Copyright ©2017. Elsevier Inc. All rights reserved.

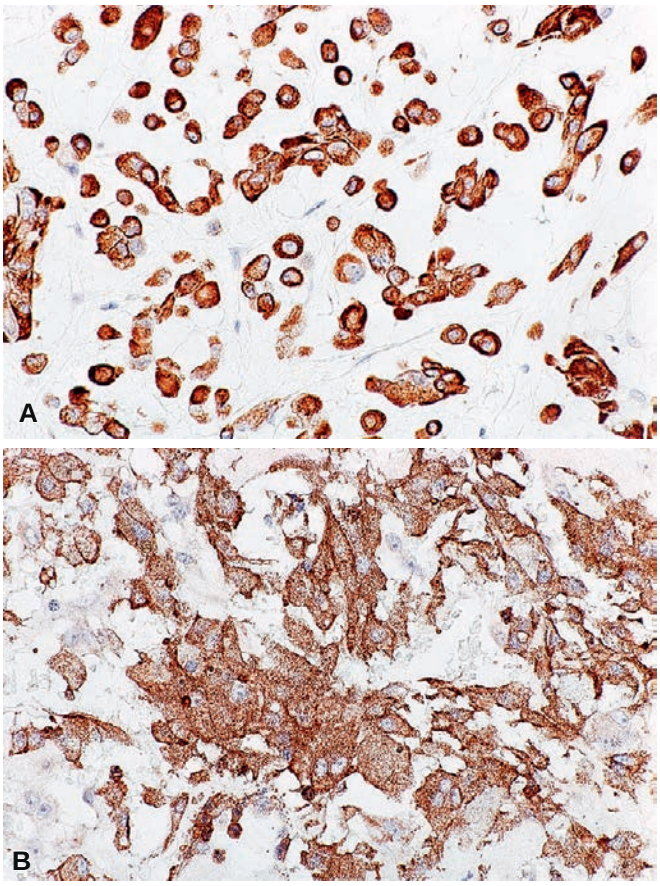

Figure 41.202 **A,** Strong cytokeratin immunoreactivity (CAM5.2) and **(B)** strong smooth muscle actin staining in myoepithelioma of soft tissue.

Recently, it has become clear that soft tissue myoepitheliomas are associated with aberrations of the *EWSR1* gene in up to 50% of cases.[1048] Although a variety of fusion partners have been found, the most frequent appears to be *POU5F1*, but others include *PBX3*, *ZNF444*, *FUS*, and *KLF17*.[1048–1050] Interestingly, some have also been found to harbor deletions of *SMARCB1*, resulting in loss of IN11 protein expression.[1051]

Clinically, these tumors have the capability for local recurrence and distant metastases. The malignant form of this tumor has been referred to as *myoepithelial carcinoma*, a relatively high percentage of them occurring in children.[1052] It has further been suggested that the mysterious neoplasm originally reported by Dabska as *parachordoma*[833] is almost certainly a myoepithelial neoplasm.[1047] Recently, a series of myoepithelioma-like *SMARCB1*-deficient tumors has been described in the vulvar region, which share many but not all features with classic myoepitheliomas.[1052a]

Other Tumors

Oncocytoma has been reported as a primary tumor of soft tissues, and we have seen a similar example.[1053,1054] The appearance does not differ from that of oncocytomas at other sites. It seems likely that this is also related to soft tissue myoepithelioma.

Metastatic Tumors

Skeletal muscle or other deep soft tissue metastases of carcinoma or melanoma occur, but only rarely do they represent the first clinical manifestation of the disease. Reported cases include metastases from carcinoma of the kidney, lung, breast, stomach, and large bowel (Fig. 41.203).[1055]

Figure 41.203 Carcinoma of the large bowel metastatic to soft tissues and skin.

Other Tumorlike Conditions

Bronchogenic cysts of skin and soft tissue are usually discovered at or seen after birth in male infants. The most common location is the suprasternal notch and manubrium sterni[1056]; despite their name, they are probably of branchial arch derivation (i.e., *branchiogenic*).

Tumoral calcinosis is characterized by the formation of large, painless, calcified masses in the periarticular soft tissues, especially along extensor surfaces.[1057] The elbows and hips are the most common sites (Fig. 41.204). Curiously, the knee is always spared. Acral lesions are similar histologically but are smaller and may be the first manifestation of scleroderma in patients who are normophosphatemic (Fig. 41.205).[1057]

The disease can be inherited as an autosomal dominant trait with variable clinical expressivity. Germline mutations in the *FGF23* (encoding a potent phosphaturic protein), *GALNT3* (encoding a glycosyltransferase for initiating O-glycosylation), or *SAMD9* (encoding tumor necrosis factor-α responsive protein) gene have been described.[1058–1060] The largest series have been reported from African countries. The serum calcium is usually normal, but there is hyperphosphatemia and elevated serum dihydroxyvitamin D levels.[1061] The disease may recur after excision.[1062]

Calcifying fibrous pseudotumor is a benign and probably nonneoplastic fibrous lesion characterized by the presence of abundant hyalinized collagen with psammomatous or dystrophic calcifications and a lymphoplasmacytic infiltrate (Fig. 41.206). Most patients are adolescents and young adults, and the behavior is benign.[1063] There is immunoreactivity for CD34 in most cases but not for ALK-1. The latter finding does not lend support to the suggestion that calcifying fibrous pseudotumor represents a late stage of inflammatory myofibroblastic tumor.[1064]

Amyloid tumor (amyloidoma) can present as a localized mass in the soft tissue, most commonly in the mediastinum and retroperitoneum.[1065] The amyloid may be of AL (more frequently) or AA type.[1066]

Aneurysmal (bone) cyst morphologically similar to that more commonly seen in the skeletal system can develop in the soft tissues.[1067,1068] Like nodular fasciitis, these lesions have been associated with *USP6* rearrangements.[1068]

For personal use only. No other uses without permission. Copyright ©2017. Elsevier Inc. All rights reserved.

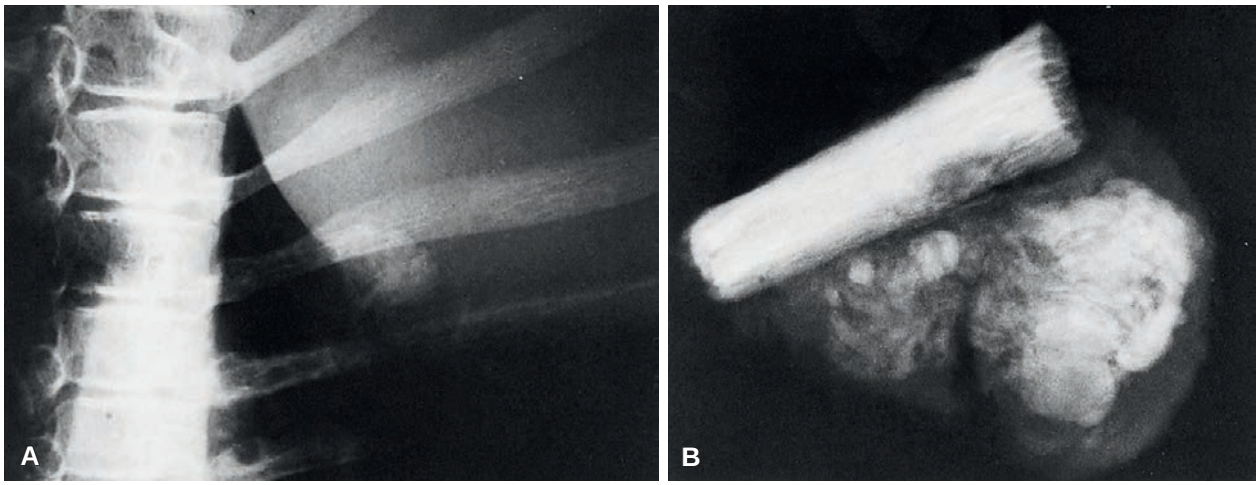

Figure 41.204 **A,** Radiograph showing an area of tumoral calcinosis adjacent to a posterior rib in a 9-year-old child. **B,** Radiograph of the excised specimen. Calcification is lobulated, splotchy, and independent of the eighth rib.

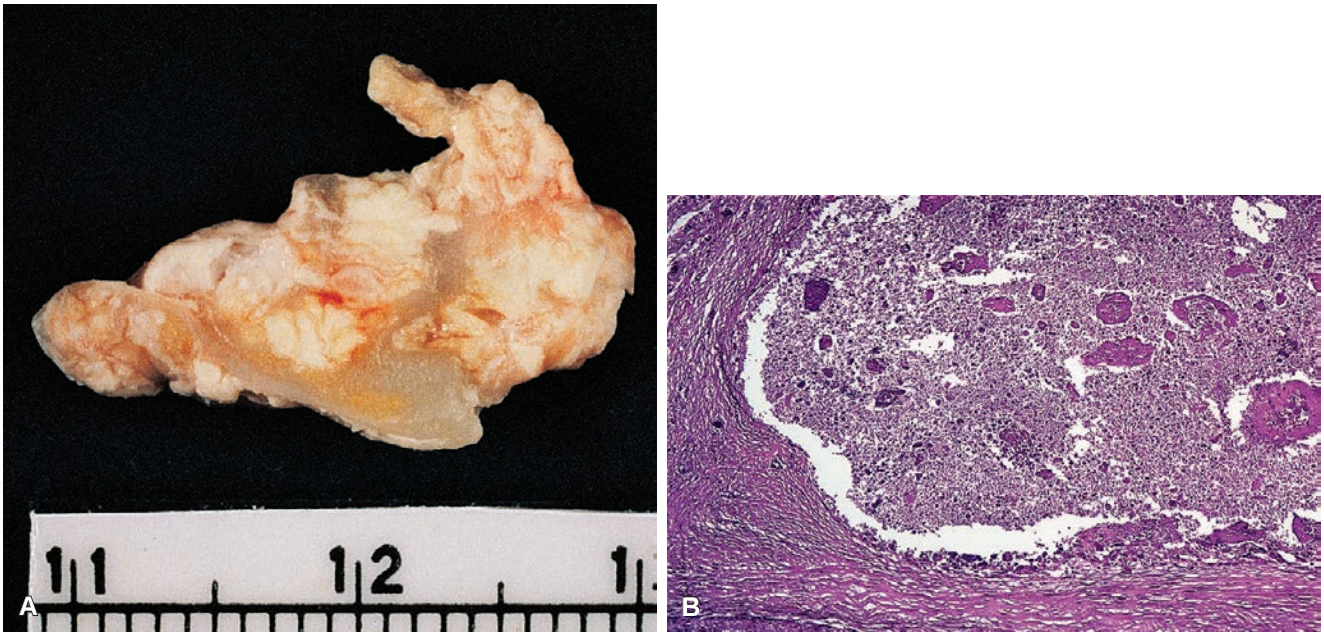

Figure 41.205 **Tumoral Calcinosis. A,** Gross appearance. The lesion is characteristically multinodular, and the material has a chalky quality. **B,** Microscopic appearance. Note the absence of cartilaginous features.

For personal use only. No other uses without permission. Copyright ©2017. Elsevier Inc. All rights reserved.

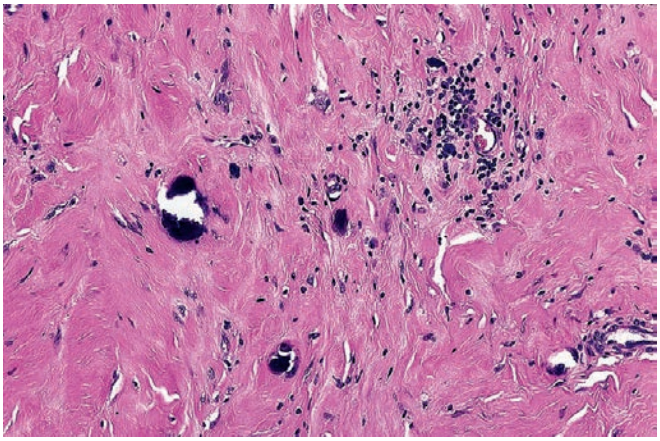

Figure 41.206 Calcifying fibrous pseudotumor with round calcific concretions seen against a fibrohyaline background containing scattered lymphocytes.

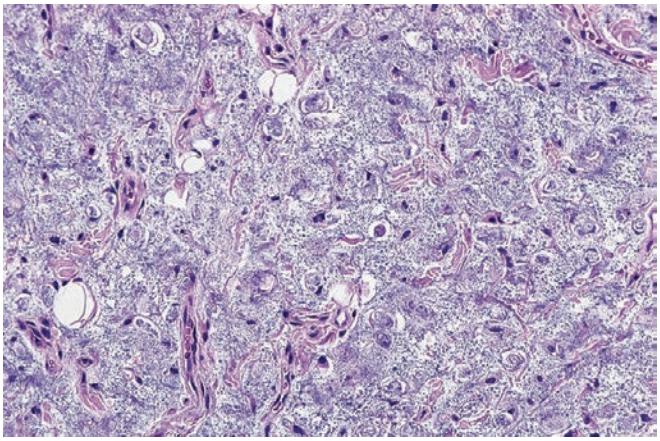

Figure 41.207 So-called mucicarminophilic histiocytosis. The highly myxoid quality of this lesion may induce confusion with a myxoid neoplasm.

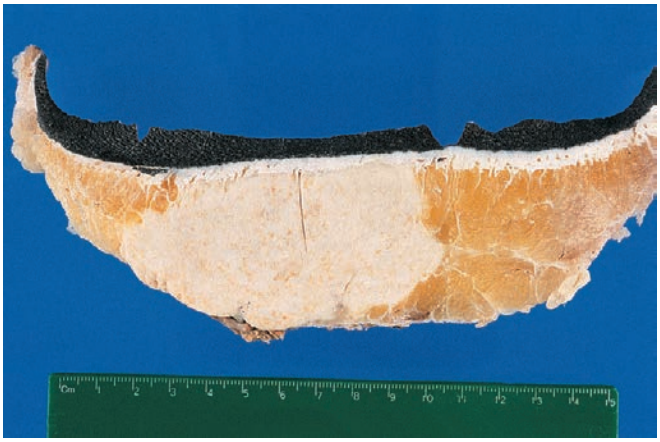

Figure 41.208 Gross appearance of Rosai–Dorfman disease (sinus histiocytosis with massive lymphadenopathy) involving skin and soft tissue in the buttock region.

Polyvinylpyrrolidone (PVP) granuloma is a tumorlike condition of skin or soft tissue that follows systemic injections of drugs containing PVP.[1069,1070] The prominent myxoid features and focal cellularity may simulate a neoplastic process, particularly myxoid liposarcoma and signet ring carcinoma (Fig. 41.207). PVP is localized in the cytoplasm of foamy histiocytes and multinucleated giant cells, many of which appear vacuolated. These cells are positive for mucicarmine, colloidal iron, Grocott methenamine silver, Congo red, Sudan black B, and argentaffin stains, and the PVP can be detected by infrared spectrophotometry.[1071] **Aluminum granuloma** is another iatrogenic process that occurs at sites of injection done for the purposes of vaccination or allergen desensitization.[1072,1073] The microscopic appearance is variable, the clue to the diagnosis being the presence of histiocytes with abundant violaceous granular cytoplasm.[1073]

Rosai–Dorfman disease (sinus histiocytosis with massive lymphadenopathy) may present as a mass in the soft tissue (Fig. 41.208), with or without associated lymph node involvement.[1074] It is most commonly located in the extremities, but it can also occur in the trunk and head and neck region. As is also the case in other extranodal sites, emperipolesis is usually conspicuous, and secondary collagen deposition is prominent.[1075] The cells stain strongly for S-100 protein but are negative for CD1a (Fig. 41.209).

Castleman disease of the hyaline-vascular type can rarely present as a subcutaneous or intramuscular mass.[1076,1077]

For personal use only. No other uses without permission. Copyright ©2017. Elsevier Inc. All rights reserved.

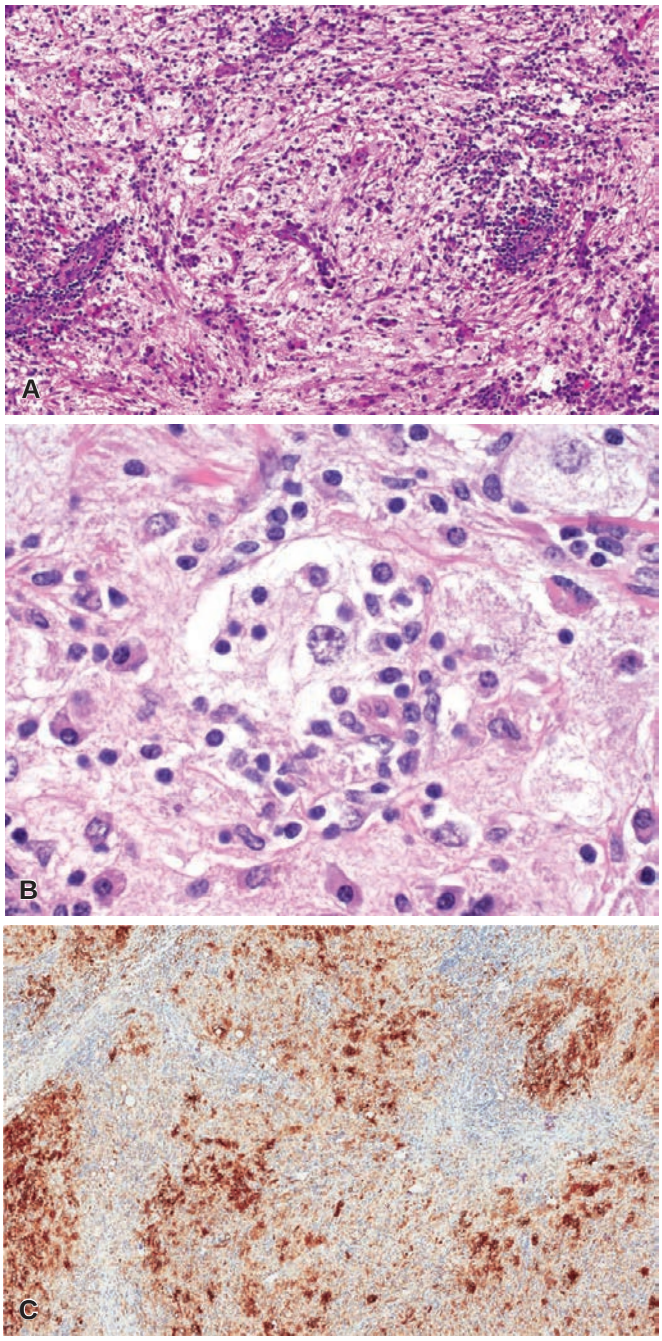

Figure 41.209 **A,** Characteristic heterogeneous low-power view of Rosai–Dorfman disease of soft tissue. **B,** Emperipolesis is present in this case. **C,** Strong S-100 protein immunoreactivity is characteristic.

References

1. Eyden B. The myofibroblast: a study of normal, reactive and neoplastic tissues, with an emphasis on ultrastructure. Part 1—normal and reactive cells. *J Submicrosc Cytol Pathol.* 2005;37(2):109-204.
2. Eyden B. The myofibroblast: a study of normal, reactive and neoplastic tissues, with an emphasis on ultrastructure. Part 2—tumours and tumour-like lesions. *J Submicrosc Cytol Pathol.* 2005;37(3-4):231-296.
3. Nnodim JO. Development of adipose tissues. *Anat Rec.* 1987;219(4):331-337.
4. Nightingale T, Cutler D. The secretion of von Willebrand factor from endothelial cells; an increasingly complicated story. *J Thromb Haemost.* 2013;11(suppl 1):192-201.
5. Chan JKC. Newly available antibodies with practical applications in surgical pathology. *Int J Surg Pathol.* 2013;21(6):553-572.
6. Miettinen M, Wang Z-F, Paetau A, et al. ERG transcription factor as an immunohistochemical marker for vascular endothelial tumors and prostatic carcinoma. *Am J Surg Pathol.* 2011;35(3):432-441.
7. Rossi S, Orvieto E, Furlanetto A, et al. Utility of the immunohistochemical detection of FLI-1 expression in round cell and vascular neoplasm using a monoclonal antibody. *Mod Pathol.* 2004;17(5):547-552.
8. Kalof AN, Cooper K. D2-40 immunohistochemistry—so far! *Adv Anat Pathol.* 2009;16(1):62-64.
9. Hirose T, Tani T, Shimada T, et al. Immunohistochemical demonstration of

For personal use only. No other uses without permission. Copyright ©2017. Elsevier Inc. All rights reserved.

EMA/Glut1-positive perineurial cells and CD34-positive fibroblastic cells in peripheral nerve sheath tumors. *Mod Pathol*. 2003;16(4):293-298.
10. Chauhan A, Wigton MD, Palmer BA. Necrotizing fasciitis. *J Hand Surg*. 2014;39(8):1598-1601.
11. Colman MW, Lozano-Calderon S, Raskin KA, et al. Non-neoplastic soft tissue masses that mimic sarcoma. *Orthop Clin North Am*. 2014;45(2):245-255.
12. Mentzel T, Goodlad JR, Smith MA, Fletcher CD. Ancient hematoma: a unifying concept for a post-traumatic lesion mimicking an aggressive soft tissue neoplasm. *Mod Pathol*. 1997;10(4):334-340.
13. Rodriguez R, Rubio R, Menendez P. Modeling sarcomagenesis using multipotent mesenchymal stem cells. *Cell Res*. 2012;22(1):62-77.
14. Ferrari A, Sultan I, Huang TT, et al. Soft tissue sarcoma across the age spectrum: a population-based study from the Surveillance Epidemiology and End Results database. *Pediatr Blood Cancer*. 2011;57(6):943-949.
15. Grobmyer SR, Luther N, Antonescu CR, et al. Multiple primary soft tissue sarcomas. *Cancer*. 2004;101(11):2633-2635.
16. Lima PM, Oliveira MP, da Silva HJ, de Mello RJV. The role of cytology in the diagnosis of musculoskeletal neoplasms: systematic review. *Acta Ortop Bras*. 2012;20(1):48-52.
17. Sandberg AA, Bridge JA. Updates on the cytogenetics and molecular genetics of bone and soft tissue tumors: osteosarcoma and related tumors. *Cancer Genet Cytogenet*. 2003;145(1):1-30.
18. Antonescu CR, Dal Cin P. Promiscuous genes involved in recurrent chromosomal translocations in soft tissue tumours. *Pathology (Phila)*. 2014;46(2):105-112.
19. Nielsen TO. Microarray analysis of sarcomas. *Adv Anat Pathol*. 2006;13(4):166-173.
20. Tschoep K, Kohlmann A, Schlemmer M, et al. Gene expression profiling in sarcomas. *Crit Rev Oncol Hematol*. 2007;63(2):111-124.
21. Villacis RAR, Silveira SM, Barros-Filho MC, et al. Gene expression profiling in leiomyosarcomas and undifferentiated pleomorphic sarcomas: SRC as a new diagnostic marker. *PLoS ONE*. 2014;9(7):e102281.
22. Coindre JM, Terrier P, Guillou L, et al. Predictive value of grade for metastasis development in the main histologic types of adult soft tissue sarcomas: a study of 1240 patients from the French Federation of Cancer Centers Sarcoma Group. *Cancer*. 2001;91(10):1914-1926.
23. Coindre JM, Nguyen BB, Bonichon F, et al. Histopathologic grading in spindle cell soft tissue sarcomas. *Cancer*. 1988;61(11):2305-2309.
24. Trojani M, Contesso G, Coindre JM, et al. Soft-tissue sarcomas of adults; study of pathological prognostic variables and definition of a histopathological grading system. *Int J Cancer*. 1984;33(1):37-42.
25. Brown FM, Fletcher CD. Problems in grading soft tissue sarcomas. *Am J Clin Pathol*. 2000;114(suppl):S82-S89.
26. Amin M, Edge S, Greene F, et al, eds. *AJCC Cancer Staging Manual*. Vol. 8. New York: Springer; 2017.
27. Italiano A, Le Cesne A, Mendiboure J, et al. Prognostic factors and impact of adjuvant treatments on local and metastatic relapse of soft-tissue sarcoma patients in the competing risks setting. *Cancer*. 2014;120(21):3361-3369.
28. Toulmonde M, Le Cesne A, Mendiboure J, et al. Long-term recurrence of soft tissue sarcomas: prognostic factors and implications for prolonged follow-up. *Cancer*. 2014;120(19):3003-3006.
29. Coindre JM, Terrier P, Bui NB, et al. Prognostic factors in adult patients with locally controlled soft tissue sarcoma. A study of 546 patients from the French Federation of Cancer Centers Sarcoma Group. *J Clin Oncol*. 1996;14(3):869-877.
30. Gerrand CH, Bell RS, Wunder JS, et al. The influence of anatomic location on outcome in patients with soft tissue sarcoma of the extremity. *Cancer*. 2003;97(2):485-492.
31. Toulmonde M, Bonvalot S, Méeus P, et al. Retroperitoneal sarcomas: patterns of care at diagnosis, prognostic factors and focus on main histological subtypes: a multicenter analysis of the French Sarcoma Group. *Ann Oncol*. 2014;25(3):735-742.
32. Engellau J, Bendahl P-O, Persson A, et al. Improved prognostication in soft tissue sarcoma: independent information from vascular invasion, necrosis, growth pattern, and immunostaining using whole-tumor sections and tissue microarrays. *Hum Pathol*. 2005;36(9):994-1002.
33. Daigeler A, Zmarsly I, Hirsch T, et al. Long-term outcome after local recurrence of soft tissue sarcoma: a retrospective analysis of factors predictive of survival in 135 patients with locally recurrent soft tissue sarcoma. *Br J Cancer*. 2014;110(6):1456-1464.
34. O'Donnell PW, Griffin AM, Eward WC, et al. The effect of the setting of a positive surgical margin in soft tissue sarcoma. *Cancer*. 2014;120(18):2866-2875.
35. Zagars GK, Ballo MT, Pisters PWT, et al. Prognostic factors for patients with localized soft-tissue sarcoma treated with conservation surgery and radiation therapy: an analysis of 1225 patients. *Cancer*. 2003;97(10):2530-2543.
36. Dreinhöfer KE, Baldetorp B, Akerman M, et al. DNA ploidy in soft tissue sarcoma: comparison of flow and image cytometry with clinical follow-up in 93 patients. *Cytometry*. 2002;50(1):19-24.
37. Sorbye SW, Kilvaer TK, Valkov A, et al. Prognostic impact of Jab1, p16, p21, p62, Ki67 and Skp2 in soft tissue sarcomas. *PLoS ONE*. 2012;7(10):e47068.
38. Kawai A, Noguchi M, Beppu Y, et al. Nuclear immunoreaction of p53 protein in soft tissue sarcomas. A possible prognostic factor. *Cancer*. 1994;73(10):2499-2505.
39. Weiss A, Gill J, Goldberg J, et al. Advances in therapy for pediatric sarcomas. *Curr Oncol Rep*. 2014;16(8):395.
40. Linch M, Miah AB, Thway K, et al. Systemic treatment of soft-tissue sarcoma-gold standard and novel therapies. *Nat Rev Clin Oncol*. 2014;11(4):187-202.
41. Mathoulin-Pélissier S, Chevreau C, Bellera C, et al. Adherence to consensus-based diagnosis and treatment guidelines in adult soft-tissue sarcoma patients: a French prospective population-based study. *Ann Oncol*. 2014;25(1):225-231.
42. Aranha O, Agulnik M. Molecularly targeted therapies in adult soft tissue sarcomas: present approach and future directions. *Expert Opin Ther Targets*. 2008;12(2):197-207.
43. Patel SR. Fifty years of advances in sarcoma treatment: moving the needle from conventional chemotherapy to targeted therapy. *Am Soc Clin Oncol Educ Book*. 2014;259-262.
44. Monkman GR, Orwoll G, Ivins JC. Trauma and oncogenesis. *Mayo Clin Proc*. 1974;49(3):157-163.
45. Collins JJ, Bodner K, Aylward LL, et al. Mortality rates among workers exposed to dioxins in the manufacture of pentachlorophenol. *J Occup Environ Med*. 2009;51(10):1212-1219.
46. Sherman M. Vinyl chloride and the liver. *J Hepatol*. 2009;51(6):1074-1081.
47. Inoue YZ, Frassica FJ, Sim FH, et al. Clinicopathologic features and treatment of postirradiation sarcoma of bone and soft tissue. *J Surg Oncol*. 2000;75(1):42-50.
48. Zahm SH, Fraumeni JF. The epidemiology of soft tissue sarcoma. *Semin Oncol*. 1997;24(5):504-514.
49. Chang Y, Cesarman E, Pessin MS, et al. Identification of herpesvirus-like DNA sequences in AIDS-associated Kaposi's sarcoma. *Science*. 1994;266(5192):1865-1869.
50. Deyrup AT, Lee VK, Hill CE, et al. Epstein-Barr virus-associated smooth muscle tumors are distinctive mesenchymal tumors reflecting multiple infection events: a clinicopathologic and molecular analysis of 29 tumors from 19 patients. *Am J Surg Pathol*. 2006;30(1):75-82.
51. Fetsch JF, Miettinen M. Calcifying aponeurotic fibroma: a clinicopathologic study of 22 cases arising in uncommon sites. *Hum Pathol*. 1998;29(12):1504-1510.
52. Allen PW, Enzinger FM. Juvenile aponeurotic fibroma. *Cancer*. 1970;26(4):857-867.
53. Humphreys S, McKee PH, Fletcher CD. Fibroma of tendon sheath: a clinicopathologic study. *J Cutan Pathol*. 1986;13(5):331-338.
54. Al-Qattan MM. Fibroma of tendon sheath of the hand: a series of 20 patients with 23 tumours. *J Hand Surg Eur Vol*. 2014;39(3):300-305.
55. Chung EB, Enzinger FM. Fibroma of tendon sheath. *Cancer*. 1979;44(5):1945-1954.
56. Hashimoto H, Tsuneyoshi M, Daimaru Y, et al. Fibroma of tendon sheath: a tumor of myofibroblasts. A clinicopathologic study of 18 cases. *Acta Pathol Jpn*. 1985;35(5):1099-1107.
57. Lamovec J, Bracko M, Voncina D. Pleomorphic fibroma of tendon sheath. *Am J Surg Pathol*. 1991;15(12):1202-1205.
58. Maluf HM, DeYoung BR, Swanson PE, Wick MR. Fibroma and giant cell tumor of tendon sheath: a comparative histological and immunohistological study. *Mod Pathol*. 1995;8(2):155-159.
59. Dal Cin P, Sciot R, De Smet L, Van den Berghe H. Translocation 2;11 in a fibroma of tendon sheath. *Histopathology*. 1998;32(5):433-435.
59a. Cater JM, Wang X, Dong J, et al. USP6 genetic rearrangements in cellular fibroma of tendon sheath. *Mod Pathol*. 2016;29(8):865-869.
60. Pulitzer DR, Martin PC, Reed RJ. Fibroma of tendon sheath. A clinicopathologic study of 32 cases. *Am J Surg Pathol*. 1989;13(6):472-479.
61. Satti MB. Tendon sheath tumours: a pathological study of the relationship between giant cell tumour and fibroma of tendon sheath. *Histopathology*. 1992;20(3):213-220.
62. Evans HL. Desmoplastic fibroblastoma. A report of seven cases. *Am J Surg Pathol*. 1995;19(9):1077-1081.
63. Miettinen M, Fetsch JF. Collagenous fibroma (desmoplastic fibroblastoma): a clinicopathologic analysis of 63 cases of a distinctive soft tissue lesion with stellate-shaped fibroblasts. *Hum Pathol*. 1998;29(7):676-682.
64. Nielsen GP, O'Connell JX, Dickersin GR, Rosenberg AE. Collagenous fibroma (desmoplastic fibroblastoma): a report of seven cases. *Mod Pathol*. 1996;9(7):781-785.

For personal use only. No other uses without permission. Copyright ©2017. Elsevier Inc. All rights reserved.

65. Takahara M, Ichikawa R, Oda Y, et al. Desmoplastic fibroblastoma: a case presenting as a protruding nodule in the dermis. *J Cutan Pathol*. 2008;35(suppl 1):70-73.
66. Bernal K, Nelson M, Neff JR, et al. Translocation (2;11)(q31;q12) is recurrent in collagenous fibroma (desmoplastic fibroblastoma). *Cancer Genet Cytogenet*. 2004;149(2):161-163.
67. Maghari A, Ma N, Aisner S, et al. Collagenous fibroma (desmoplastic fibroblastoma) with a new translocation involving 11q12: a case report. *Cancer Genet Cytogenet*. 2009;192(2):73-75.
68. Sakamoto A, Yamamoto H, Yoshida T, et al. Desmoplastic fibroblastoma (collagenous fibroma) with a specific breakpoint of 11q12. *Histopathology*. 2007;51(6):859-860.
69. Sciot R, Samson I, van den Berghe H, et al. Collagenous fibroma (desmoplastic fibroblastoma): genetic link with fibroma of tendon sheath? *Mod Pathol*. 1999;12(6):565-568.
69a. Kato I, Yoshida A, Ikegami M, et al. FOSL1 immunohistochemistry clarifies the distinction between desmoplastic fibroblastoma and fibroma of tendon sheath. *Histopathology*. 2016;69(6):1012-1020.
70. Balachandran K, Allen PW, MacCormac LB. Nuchal fibroma. A clinicopathological study of nine cases. *Am J Surg Pathol*. 1995;19(3):313-317.
71. Michal M, Fetsch JF, Hes O, Miettinen M. Nuchal-type fibroma: a clinicopathologic study of 52 cases. *Cancer*. 1999;85(1):156-163.
72. Coffin CM, Hornick JL, Zhou H, Fletcher CDM. Gardner fibroma: a clinicopathologic and immunohistochemical analysis of 45 patients with 57 fibromas. *Am J Surg Pathol*. 2007;31(3):410-416.
73. Michal M, Boudova L, Mukensnabl P. Gardner's syndrome associated fibromas. *Pathol Int*. 2004;54(7):523-526.
74. Wehrli BM, Weiss SW, Yandow S, Coffin CM. Gardner-associated fibromas (GAF) in young patients: a distinct fibrous lesion that identifies unsuspected Gardner syndrome and risk for fibromatosis. *Am J Surg Pathol*. 2001;25(5):645-651.
75. Diwan AH, Graves ED, King JA, Horenstein MG. Nuchal-type fibroma in two related patients with Gardner's syndrome. *Am J Surg Pathol*. 2000;24(11):1563-1567.
76. Allen PW. Nuchal-type fibroma appearance in a desmoid fibromatosis. *Am J Surg Pathol*. 2001;25(6):828-829.
77. Laskin WB, Fetsch JF, Miettinen M. Nuchal fibrocartilaginous pseudotumor: a clinicopathologic study of five cases and review of the literature. *Mod Pathol*. 1999;12(7):663-668.
78. Al-Daraji WI, Miettinen M. Superficial acral fibromyxoma: a clinicopathological analysis of 32 tumors including 4 in the heel. *J Cutan Pathol*. 2008;35(11):1020-1026.
79. Fetsch JF, Laskin WB, Miettinen M. Superficial acral fibromyxoma: a clinicopathologic and immunohistochemical analysis of 37 cases of a distinctive soft tissue tumor with a predilection for the fingers and toes. *Hum Pathol*. 2001;32(7):704-714.
80. Luzar B, Calonje E. Superficial acral fibromyxoma: clinicopathological study of 14 cases with emphasis on a cellular variant. *Histopathology*. 2009;54(3):375-377.
81. Guitart J, Ramirez J, Laskin WB. Cellular digital fibromas: what about superficial acral fibromyxoma? *J Cutan Pathol*. 2006;33(11):762-763, author reply 764.
81a. Agaimy A, Michal M, Giedel J, et al. Superficial acral fibromyxoma: clinicopathological, immunohistochemical, and molecular study of 11 cases highlighting frequent Rb-1 loss/deletions. *Hum Pathol*. 2017;60:192-198.
82. Hollmann TJ, Bovée JVMG, Fletcher CDM. Digital fibromyxoma (superficial acral fibromyxoma): a detailed characterization of 124 cases. *Am J Surg Pathol*. 2012;36:789-798.
83. Prescott RJ, Husain EA, Abdellaoui A, et al. Superficial acral fibromyxoma: a clinicopathological study of new 41 cases from the U.K.: should myxoma (NOS) and fibroma (NOS) continue as part of 21st-century reporting? *Br J Dermatol*. 2008;159(6):1315-1321.
84. Edgar MA, Lauer SR, Bridge JA, Rizzo M. Soft tissue angiofibroma: report of 2 cases of a recently described tumor. *Hum Pathol*. 2013;44(3):438-441.
85. Mariño-Enríquez A, Fletcher CDM. Angiofibroma of soft tissue: clinicopathologic characterization of a distinctive benign fibrovascular neoplasm in a series of 37 cases. *Am J Surg Pathol*. 2012;36(4):500-508.
86. Zhao M, Sun K, Li C, et al. Angiofibroma of soft tissue: clinicopathologic study of 2 cases of a recently characterized benign soft tissue tumor. *Int J Clin Exp Pathol*. 2013;6(10):2208-2215.
87. Jin Y, Möller E, Nord KH, et al. Fusion of the AHRR and NCOA2 genes through a recurrent translocation t(5;8)(p15;q13) in soft tissue angiofibroma results in upregulation of aryl hydrocarbon receptor target genes. *Genes Chromosomes Cancer*. 2012;51(5):510-520.
88. Sugita S, Aoyama T, Kondo K, et al. Diagnostic utility of NCOA2 fluorescence in situ hybridization and Stat6 immunohistochemistry staining for soft tissue angiofibroma and morphologically similar fibrovascular tumors. *Hum Pathol*. 2014;45(8):1588-1596.
89. Enzinger FM. Fibrous hamartoma of infancy. *Cancer*. 1965;18:241-248.
89a. Al-Ibraheemi A, Martinez A, Weiss SW, et al. Fibrous hamartoma of infancy: a clinicopathologic study of 145 cases, including 2 with sarcomatous features. *Mod Pathol*. 2017;30(4):474-485.
90. Fletcher CD, Powell G, van Noorden S, McKee PH. Fibrous hamartoma of infancy: a histochemical and immunohistochemical study. *Histopathology*. 1988;12(1):65-74.
91. Groisman G, Lichtig C. Fibrous hamartoma of infancy: an immunohistochemical and ultrastructural study. *Hum Pathol*. 1991;22(9):914-918.
92. Michal M, Mukensnábl P, Chlumská A, Kodet R. Fibrous hamartoma of infancy. A study of eight cases with immunohistochemical and electron microscopical findings. *Pathol Res Pract*. 1992;188(8):1049-1053.
92a. Ellington N, Park JY, King K, et al. EGFR exon 20 insertion/duplication mutation in fibrous hamartoma of infancy with predominantly pseudoangiomatous pattern mimicking giant cell fibroblastoma. *Int J Surg Pathol*. 2017;25(5):421-424.
93. Allen PW. Nodular fasciitis. *Pathology (Phila)*. 1972;4(1):9-26.
94. Bernstein KE, Lattes R. Nodular (pseudosarcomatous) fasciitis, a nonrecurrent lesion: clinicopathologic study of 134 cases. *Cancer*. 1982;49(8):1668-1678.
95. Shimizu S, Hashimoto H, Enjoji M. Nodular fasciitis: an analysis of 250 patients. *Pathology (Phila)*. 1984;16(2):161-166.
96. de Feraudy S, Fletcher CDM. Intradermal nodular fasciitis: a rare lesion analyzed in a series of 24 cases. *Am J Surg Pathol*. 2010;34(9):1377-1381.
97. Price SK, Kahn LB, Saxe N. Dermal and intravascular fasciitis. Unusual variants of nodular fasciitis. *Am J Dermatopathol*. 1993;15(6):539-543.
98. Ceballos KM, Nielsen GP, Selig MK, O'Connell JX. Is anti-h-caldesmon useful for distinguishing smooth muscle and myofibroblastic tumors? An immunohistochemical study. *Am J Clin Pathol*. 2000;114(5):746-753.
99. Montgomery EA, Meis JM. Nodular fasciitis. Its morphologic spectrum and immunohistochemical profile. *Am J Surg Pathol*. 1991;15(10):942-948.
100. Amary MF, Ye H, Berisha F, et al. Detection of USP6 gene rearrangement in nodular fasciitis: an important diagnostic tool. *Virchows Arch*. 2013;463(1):97-98.
101. Erickson-Johnson MR, Chou MM, Evers BR, et al. Nodular fasciitis: a novel model of transient neoplasia induced by MYH9-USP6 gene fusion. *Lab Invest*. 2011;91(10):1427-1433.
102. Oliveira AM, Chou MM. USP6-induced neoplasms: the biologic spectrum of aneurysmal bone cyst and nodular fasciitis. *Hum Pathol*. 2014;45(1):1-11.
103. Lauer DH, Enzinger FM. Cranial fasciitis of childhood. *Cancer*. 1980;45(2):401-406.
104. Oh C-K, Whang S-M, Kim B-G, et al. Congenital cranial fasciitis—"watch and wait" or early intervention. *Pediatr Dermatol*. 2007;24(3):263-266.
105. Patchefsky AS, Enzinger FM. Intravascular fasciitis: a report of 17 cases. *Am J Surg Pathol*. 1981;5(1):29-36.
106. Meis JM, Enzinger FM. Proliferative fasciitis and myositis of childhood. *Am J Surg Pathol*. 1992;16(4):364-372.
107. Rosa G, Billings SD. A report of three cases of pediatric proliferative fasciitis. *J Cutan Pathol*. 2014;41(9):720-723.
108. Kern WH. Proliferative myositis; a pseudosarcomatous reaction to injury: a report of seven cases. *Arch Pathol*. 1960;69:209-216.
109. Enzinger FM, Dulcey F. Proliferative myositis. Report of thirty-three cases. *Cancer*. 1967;20(12):2213-2223.
110. Hollowood K, Fletcher CD. Pseudosarcomatous myofibroblastic proliferations of the spermatic cord ("proliferative funiculitis"). Histologic and immunohistochemical analysis of a distinctive entity. *Am J Surg Pathol*. 1992;16(5):448-454.
111. Liegl B, Fletcher CDM. Ischemic fasciitis: analysis of 44 cases indicating an inconsistent association with immobility or debilitation. *Am J Surg Pathol*. 2008;32(10):1546-1552.
112. Montgomery EA, Meis JM, Mitchell MS, Enzinger FM. Atypical decubital fibroplasia. A distinctive fibroblastic pseudotumor occurring in debilitated patients. *Am J Surg Pathol*. 1992;16(7):708-715.
113. Perosio PM, Weiss SW. Ischemic fasciitis: a juxta-skeletal fibroblastic proliferation with a predilection for elderly patients. *Mod Pathol*. 1993;6(1):69-72.
114. Michal M, Chlumská A, Skálová A, Fakan F. Palisaded intranodal myofibroblastoma. Electron microscopic study. *Zentralbl Pathol*. 1993;139(1):81-88.
115. Nguyen T, Eltorky MA. Intranodal palisaded myofibroblastoma. *Arch Pathol Lab Med*. 2007;131(2):306-310.
116. Suster S, Rosai J. Intranodal hemorrhagic spindle-cell tumor with "amianthoid" fibers. Report of six cases of a distinctive mesenchymal neoplasm of the inguinal region that simulates Kaposi's sarcoma. *Am J Surg Pathol*. 1989;13(5):347-357.

For personal use only. No other uses without permission. Copyright ©2017. Elsevier Inc. All rights reserved.

117. Weiss SW, Gnepp DR, Bratthauer GL. Palisaded myofibroblastoma. A benign mesenchymal tumor of lymph node. *Am J Surg Pathol*. 1989;13(5):341-346.
118. Bhullar JS, Herschman BR, Dubay L. Intranodal palisaded myofibroblastoma: a new entity of axillary tumors. *Am Surg*. 2013;79(1):E19-E21.
119. Kandemir NO, Barut F, Ekinci T, et al. Intranodal palisaded myofibroblastoma (intranodal hemorrhagic spindle cell tumor with amianthoid fibers): a case report and literature review. *Diagn Pathol*. 2010;5:12.
120. Koseoglu RD, Ozkan N, Filiz NO, et al. Intranodal palisaded myofibroblastoma; a case report and review of the literature. *Pathol Oncol Res*. 2009;15(2):297-300.
121. Laskin WB, Lasota JP, Fetsch JF, et al. Intranodal palisaded myofibroblastoma: another mesenchymal neoplasm with CTNNB1 (β-catenin gene) mutations: clinicopathologic, immunohistochemical, and molecular genetic study of 18 cases. *Am J Surg Pathol*. 2015;39(2):197-205.
121a. Howitt BE, Fletcher CD. Mammary-type myofibroblastoma: clinicopathologic characterization in a series of 143 cases. *Am J Surg Pathol*. 2016;40(3):361-367.
122. Chan KW, Ghadially FN, Alagaratnam TT. Benign spindle cell tumour of breast—a variant of spindled cell lipoma or fibroma of breast? *Pathology (Phila)*. 1984;16(3):331-336.
123. Magro G. Mammary myofibroblastoma: a tumor with a wide morphologic spectrum. *Arch Pathol Lab Med*. 2008;132(11):1813-1820.
124. McMenamin ME, Fletcher CD. Mammary-type myofibroblastoma of soft tissue: a tumor closely related to spindle cell lipoma. *Am J Surg Pathol*. 2001;25(8):1022-1029.
125. Toker C, Tang CK, Whitely JF, et al. Benign spindle cell breast tumor. *Cancer*. 1981;48(7):1615-1622.
126. Wargotz ES, Weiss SW, Norris HJ. Myofibroblastoma of the breast. Sixteen cases of a distinctive benign mesenchymal tumor. *Am J Surg Pathol*. 1987;11(7):493-502.
127. Magro G. Epithelioid-cell myofibroblastoma of the breast: expanding the morphologic spectrum. *Am J Surg Pathol*. 2009;33(7):1085-1092.
128. Flucke U, van Krieken JHJM, Mentzel T. Cellular angiofibroma: analysis of 25 cases emphasizing its relationship to spindle cell lipoma and mammary-type myofibroblastoma. *Mod Pathol*. 2011;24(1):82-89.
129. Fritchie KJ, Carver P, Sun Y, et al. Solitary fibrous tumor: is there a molecular relationship with cellular angiofibroma, spindle cell lipoma, and mammary-type myofibroblastoma? *Am J Clin Pathol*. 2012;137(6):963-970.
130. Pauwels P, Sciot R, Croiset F, et al. Myofibroblastoma of the breast: genetic link with spindle cell lipoma. *J Pathol*. 2000;191(3):282-285.
131. Ishida M, Iwai M, Kagotani A, et al. Elastofibromatous change of the intestine: report of four lesions from three patients with review of the literature. *Int J Clin Exp Pathol*. 2014;7(5):2291-2297.
132. Akçam Tİ, Cağırıcı U, Cakan A, Akın H. Bilateral familial elastofibroma dorsi: is genetic abnormality essential? *Ann Thorac Surg*. 2014;98(2):e31-e32.
133. De Nictolis M, Goteri G, Campanati G, Prat J. Elastofibrolipoma of the mediastinum. A previously undescribed benign tumor containing abnormal elastic fibers. *Am J Surg Pathol*. 1995;19(3):364-367.
134. Kahn HJ, Hanna WM. "Aberrant elastic" in elastofibroma: an immunohistochemical and ultrastructural study. *Ultrastruct Pathol*. 1995;19(1):45-50.
135. Madri JA, Dise CA, LiVolsi VA, et al. Elastofibroma dorsi: an immunochemical study of collagen content. *Hum Pathol*. 1981;12(2):186-190.
136. Fukuda Y, Miyake H, Masuda Y, Masugi Y. Histogenesis of unique elastinophilic fibers of elastofibroma: ultrastructural and immunohistochemical studies. *Hum Pathol*. 1987;18(5):424-429.
137. Hernández JLG, Rodríguez-Parets JO, Valero JM, et al. High-resolution genome-wide analysis of chromosomal alterations in elastofibroma. *Virchows Arch*. 2010;456(6):681-687.
138. Schepel JA, Wille J, Seldenrijk CA, van Ramshorst B. Elastofibroma: a familial occurrence. *Eur J Surg*. 1998;164(7):557-558.
139. Lee JY, Abell E, Shevechik GJ. Solitary spindle cell tumor with myoid differentiation of the lymph node. *Arch Pathol Lab Med*. 1989;113(5):547-550.
140. Dei Tos AP, Maestro R, Doglioni C, et al. Tumor suppressor genes and related molecules in leiomyosarcoma. *Am J Pathol*. 1996;148(4):1037-1045.
141. Guillou L, Gebhard S, Coindre JM. Orbital and extraorbital giant cell angiofibroma: a giant cell-rich variant of solitary fibrous tumor? Clinicopathologic and immunohistochemical analysis of a series in favor of a unifying concept. *Am J Surg Pathol*. 2000;24(7):971-979.
142. Collini P, Negri T, Barisella M, et al. High-grade sarcomatous overgrowth in solitary fibrous tumors: a clinicopathologic study of 10 cases. *Am J Surg Pathol*. 2012;36(8):1202-1215.
143. Mosquera J-M, Fletcher CDM. Expanding the spectrum of malignant progression in solitary fibrous tumors: a study of 8 cases with a discrete anaplastic component—is this dedifferentiated SFT? *Am J Surg Pathol*. 2009;33(9):1314-1321.
144. Thway K, Hayes A, Ieremia E, Fisher C. Heterologous osteosarcomatous and rhabdomyosarcomatous elements in dedifferentiated solitary fibrous tumor: further support for the concept of dedifferentiation in solitary fibrous tumor. *Ann Diagn Pathol*. 2013;17(5):457-463.
145. Cheah AL, Billings SD, Goldblum JR, et al. STAT6 rabbit monoclonal antibody is a robust diagnostic tool for the distinction of solitary fibrous tumour from its mimics. *Pathology (Phila)*. 2014;46(5):389-395.
146. Doyle LA, Tao D, Mariño-Enríquez A. STAT6 is amplified in a subset of dedifferentiated liposarcoma. *Mod Pathol*. 2014;27(9):1231-1237.
147. Yoshida A, Tsuta K, Ohno M, et al. STAT6 immunohistochemistry is helpful in the diagnosis of solitary fibrous tumors. *Am J Surg Pathol*. 2014;38(4):552-559.
148. Barthelmeß S, Geddert H, Boltze C, et al. Solitary fibrous tumors/hemangiopericytomas with different variants of the NAB2-STAT6 gene fusion are characterized by specific histomorphology and distinct clinicopathological features. *Am J Pathol*. 2014;184(4):1209-1218.
149. Chmielecki J, Crago AM, Rosenberg M, et al. Whole-exome sequencing identifies a recurrent NAB2-STAT6 fusion in solitary fibrous tumors. *Nat Genet*. 2013;45(2):131-132.
150. Koelsche C, Schweizer L, Renner M, et al. Nuclear relocation of STAT6 reliably predicts NAB2-STAT6 fusion for the diagnosis of solitary fibrous tumour. *Histopathology*. 2014;65(5):613-622.
151. Mohajeri A, Tayebwa J, Collin A, et al. Comprehensive genetic analysis identifies a pathognomonic NAB2/STAT6 fusion gene, nonrandom secondary genomic imbalances, and a characteristic gene expression profile in solitary fibrous tumor. *Genes Chromosomes Cancer*. 2013;52(10):873-886.
152. Robinson DR, Wu Y-M, Kalyana-Sundaram S, et al. Identification of recurrent NAB2-STAT6 gene fusions in solitary fibrous tumor by integrative sequencing. *Nat Genet*. 2013;45(2):180-185.
153. Cardillo G, Carbone L, Carleo F, et al. Solitary fibrous tumors of the pleura: an analysis of 110 patients treated in a single institution. *Ann Thorac Surg*. 2009;88(5):1632-1637.
154. England DM, Hochholzer L, McCarthy MJ. Localized benign and malignant fibrous tumors of the pleura. A clinicopathologic review of 223 cases. *Am J Surg Pathol*. 1989;13(8):640-658.
155. Gold JS, Antonescu CR, Hajdu C, et al. Clinicopathologic correlates of solitary fibrous tumors. *Cancer*. 2002;94(4):1057-1068.
156. Nielsen GP, O'Connell JX, Dickersin GR, Rosenberg AE. Solitary fibrous tumor of soft tissue: a report of 15 cases, including 5 malignant examples with light microscopic, immunohistochemical, and ultrastructural data. *Mod Pathol*. 1997;10(10):1028-1037.
157. Vallat-Decouvelaere AV, Dry SM, Fletcher CD. Atypical and malignant solitary fibrous tumors in extrathoracic locations: evidence of their comparability to intra-thoracic tumors. *Am J Surg Pathol*. 1998;22(12):1501-1511.
158. Stout AP. The fibromatoses and fibrosarcoma. *Bull Hosp Joint Dis*. 1951;12(2):126-130.
159. Allen PW. The fibromatoses: a clinicopathologic classification based on 140 cases. *Am J Surg Pathol*. 1977;1(3):255-270.
160. Gabbiani G, Majno G. Dupuytren's contracture: fibroblast contraction? An ultrastructural study. *Am J Pathol*. 1972;66(1):131-146.
161. De Wever I, Dal Cin P, Fletcher CD, et al. Cytogenetic, clinical, and morphologic correlations in 78 cases of fibromatosis: a report from the CHAMP Study Group. CHromosomes And Morphology. *Mod Pathol*. 2000;13(10):1080-1085.
162. Qi H, Dal Cin P, Hernández JM, et al. Trisomies 8 and 20 in desmoid tumors. *Cancer Genet Cytogenet*. 1996;92(2):147-149.
163. Colombo C, Miceli R, Lazar AJ, et al. CTNNB1 45F mutation is a molecular prognosticator of increased postoperative primary desmoid tumor recurrence: an independent, multicenter validation study. *Cancer*. 2013;119(20):3696-3702.
164. Lazar AJF, Tuvin D, Hajibashi S, et al. Specific mutations in the beta-catenin gene (CTNNB1) correlate with local recurrence in sporadic desmoid tumors. *Am J Pathol*. 2008;173(5):1518-1527.
165. Alman BA, Li C, Pajerski ME, et al. Increased beta-catenin protein and somatic APC mutations in sporadic aggressive fibromatoses (desmoid tumors). *Am J Pathol*. 1997;151(2):329-334.
166. Deyrup AT, Tretiakova M, Khramtsov A, Montag AG. Estrogen receptor beta expression in vascular neoplasia: an analysis of 53 benign and malignant cases. *Mod Pathol*. 2004;17(11):1372-1377.
167. Enzinger FM, Shiraki M. Musculo-aponeurotic fibromatosis of the shoulder girdle (extra-abdominal desmoid). Analysis of thirty cases followed up for ten or more years. *Cancer*. 1967;20(7):1131-1140.

For personal use only. No other uses without permission. Copyright ©2017. Elsevier Inc. All rights reserved.

168. Reitamo JJ, Häyry P, Nykyri E, Saxén E. The desmoid tumor. I. Incidence, sex-, age- and anatomical distribution in the Finnish population. *Am J Clin Pathol*. 1982;77(6):665-673.
169. Rock MG, Pritchard DJ, Reiman HM, et al. Extra-abdominal desmoid tumors. *J Bone Joint Surg Am*. 1984;66(9):1369-1374.
170. Gronchi A, Casali PG, Mariani L, et al. Quality of surgery and outcome in extra-abdominal aggressive fibromatosis: a series of patients surgically treated at a single institution. *J Clin Oncol*. 2003;21(7):1390-1397.
171. Ayala AG, Ro JY, Goepfert H, et al. Desmoid fibromatosis: a clinicopathologic study of 25 children. *Semin Diagn Pathol*. 1986;3(2):138-150.
172. Skelton E, Howlett D. Fibromatosis colli: the sternocleidomastoid pseudotumour of infancy. *J Paediatr Child Health*. 2014;50(10):833-835.
173. Canale ST, Griffin DW, Hubbard CN. Congenital muscular torticollis. A long-term follow-up. *J Bone Joint Surg Am*. 1982;64(6):810-816.
174. Minihane KP, Grayhack JJ, Simmons TD, et al. Developmental dysplasia of the hip in infants with congenital muscular torticollis. *Am J Orthop Belle Mead NJ*. 2008;37(9):E155-E158, discussion E158.
175. Kumar V, Prabhu BV, Chattopadhayay A, Nagendhar MY. Bilateral sternocleidomastoid tumor of infancy. *Int J Pediatr Otorhinolaryngol*. 2003;67(6):673-675.
176. Enzinger FM. *Dermal Fibromatosis*. Chicago: Year Book; 1965:375.
177. Pettinato G, Manivel JC, Gould EW, Albores-Saavedra J. Inclusion body fibromatosis of the breast. Two cases with immunohistochemical and ultrastructural findings. *Am J Clin Pathol*. 1994;101(6):714-718.
178. Purdy LJ, Colby TV. Infantile digital fibromatosis occurring outside the digit. *Am J Surg Pathol*. 1984;8(10):787-790.
179. Viale G, Doglioni C, Iuzzolino P, et al. Infantile digital fibromatosis-like tumour (inclusion body fibromatosis) of adulthood: report of two cases with ultrastructural and immunocytochemical findings. *Histopathology*. 1988;12(4):415-424.
180. Mukai M, Torikata C, Iri H, et al. Immunohistochemical identification of aggregated actin filaments in formalin-fixed, paraffin-embedded sections. I. A study of infantile digital fibromatosis by a new pretreatment. *Am J Surg Pathol*. 1992;16(2):110-115.
181. Mukai M, Torikata C, Iri H, et al. Infantile digital fibromatosis. An electron microscopic and immunohistochemical study. *Acta Pathol Jpn*. 1986;36(11):1605-1615.
182. Laskin WB, Miettinen M, Fetsch JF. Infantile digital fibroma/fibromatosis: a clinicopathologic and immunohistochemical study of 69 tumors from 57 patients with long-term follow-up. *Am J Surg Pathol*. 2009;33(1):1-13.
183. Drut R, Pedemonte L, Rositto A. Noninclusion-body infantile digital fibromatosis: a lesion heralding terminal osseous dysplasia and pigmentary defects syndrome. *Int J Surg Pathol*. 2005;13(2):181-184.
184. Chung EB, Enzinger FM. Infantile myofibromatosis. *Cancer*. 1981;48(8):1807-1818.
185. Narchi H. Four half-siblings with infantile myofibromatosis: a case for autosomal-recessive inheritance. *Clin Genet*. 2001;59(2):134-135.
186. Wiswell TE, Davis J, Cunningham BE, et al. Infantile myofibromatosis: the most common fibrous tumor of infancy. *J Pediatr Surg*. 1988;23(4):315-318.
187. Beham A, Badve S, Suster S, Fletcher CD. Solitary myofibroma in adults: clinicopathological analysis of a series. *Histopathology*. 1993;22(4): 335-341.
188. Smith A, Orchard D. Infantile myofibromatosis: two families supporting autosomal dominant inheritance. *Australas J Dermatol*. 2011;52(3):214-217.
189. Granter SR, Badizadegan K, Fletcher CD. Myofibromatosis in adults, glomangiopericytoma, and myopericytoma: a spectrum of tumors showing perivascular myoid differentiation. *Am J Surg Pathol*. 1998;22(5):513-525.
190. Mentzel T, Calonje E, Nascimento AG, Fletcher CD. Infantile hemangiopericytoma versus infantile myofibromatosis. Study of a series suggesting a continuous spectrum of infantile myofibroblastic lesions. *Am J Surg Pathol*. 1994;18(9):922-930.
190a. Agaimy A, Bieg M, Michal M, et al. Recurrent somatic PDGFRB mutations in sporadic infantile/solitary adult myofibromas but not in angioleiomyomas and myopericytomas. *Am J Surg Pathol*. 2017;41(2):195-203.
190b. Hung YP, Fletcher CDM. Myopericytomatosis: clinicopathologic analysis of 11 cases with molecular identification of recurrent PDGFRB alterations in myopericytomatosis and myopericytoma. *Am J Surg Pathol*. 2017;41(8):1034-1044.
190c. Antonescu CR, Sung YS, Zhang L, et al. Recurrent SRF-RELA fusions define a novel subset of cellular myofibroma/myopericytoma: a potential diagnostic pitfall with sarcomas with myogenic differentiation. *Am J Surg Pathol*. 2017;41(5):677-684.
191. Fetsch JF, Miettinen M, Laskin WB, et al. A clinicopathologic study of 45 pediatric soft tissue tumors with an admixture of adipose tissue and fibroblastic elements, and a proposal for classification as lipofibromatosis. *Am J Surg Pathol*. 2000;24(11):1491-1500.
191a. Agaram NT, Zhang L, Sung YS, et al. Recurrent NTRK1 gene fusions define a novel subset of locally aggressive lipofibromatosis-like neural tumors. *Am J Surg Pathol*. 2016;40(10):1407-1416.
192. Finlay AY, Ferguson SD, Holt PJ. Juvenile hyaline fibromatosis. *Br J Dermatol*. 1983;108(5):609-616.
193. Woyke S, Domagala W, Markiewicz C. A 19-year follow-up of multiple juvenile hyaline fibromatosis. *J Pediatr Surg*. 1984;19(3):302-304.
194. Dowling O, Difeo A, Ramirez MC, et al. Mutations in capillary morphogenesis gene-2 result in the allelic disorders juvenile hyaline fibromatosis and infantile systemic hyalinosis. *Am J Hum Genet*. 2003;73(4):957-966.
195. Hanks S, Adams S, Douglas J, et al. Mutations in the gene encoding capillary morphogenesis protein 2 cause juvenile hyaline fibromatosis and infantile systemic hyalinosis. *Am J Hum Genet*. 2003;73(4):791-800.
196. Al-Mayouf SM, AlMehaidib A, Bahabri S, et al. Infantile systemic hyalinosis: a fatal disorder commonly diagnosed among Arabs. *Clin Exp Rheumatol*. 2005;23(5):717-720.
197. Stucki U, Spycher MA, Eich G, et al. Infantile systemic hyalinosis in siblings: clinical report, biochemical and ultrastructural findings, and review of the literature. *Am J Med Genet*. 2001;100(2):122-129.
198. Iwasaki H, Müller H, Stutte HJ, Brennscheidt U. Palmar fibromatosis (Dupuytren's contracture). Ultrastructural and enzyme histochemical studies of 43 cases. *Virchows Arch A Pathol Anat Histopathol*. 1984;405(1):41-53.
199. Rodriguez-Bigas MA, Mahoney MC, Karakousis CP, Petrelli NJ. Desmoid tumors in patients with familial adenomatous polyposis. *Cancer*. 1994;74(4):1270-1274.
200. Burke AP, Sobin LH, Shekitka KM. Mesenteric fibromatosis. A follow-up study. *Arch Pathol Lab Med*. 1990;114(8):832-835.
201. Burke AP, Sobin LH, Shekitka KM, et al. Intra-abdominal fibromatosis. A pathologic analysis of 130 tumors with comparison of clinical subgroups. *Am J Surg Pathol*. 1990;14(4):335-341.
202. Rodriguez JA, Guarda LA, Rosai J. Mesenteric fibromatosis with involvement of the gastrointestinal tract. A GIST simulator: a study of 25 cases. *Am J Clin Pathol*. 2004;121(1):93-98.
203. Yantiss RK, Spiro IJ, Compton CC, Rosenberg AE. Gastrointestinal stromal tumor versus intra-abdominal fibromatosis of the bowel wall: a clinically important differential diagnosis. *Am J Surg Pathol*. 2000;24(7):947-957.
204. Scott SM, Reiman HM, Pritchard DJ, Ilstrup DM. Soft tissue fibrosarcoma. A clinicopathologic study of 132 cases. *Cancer*. 1989;64(4):925-931.
205. Bahrami A, Folpe AL. Adult-type fibrosarcoma: a reevaluation of 163 putative cases diagnosed at a single institution over a 48-year period. *Am J Surg Pathol*. 2010;34(10):1504-1513.
206. Hansen T, Katenkamp K, Brodhun M, Katenkamp D. Low-grade fibrosarcoma—report on 39 not otherwise specified cases and comparison with defined low-grade fibrosarcoma types. *Histopathology*. 2006;49(2):152-160.
207. Chung EB, Enzinger FM. Infantile fibrosarcoma. *Cancer*. 1976;38(2):729-739.
208. Knezevich SR, Garnett MJ, Pysher TJ, et al. ETV6-NTRK3 gene fusions and trisomy 11 establish a histogenetic link between mesoblastic nephroma and congenital fibrosarcoma. *Cancer Res*. 1998;58(22):5046-5048.
209. Rubin BP, Chen CJ, Morgan TW, et al. Congenital mesoblastic nephroma t(12;15) is associated with ETV6-NTRK3 gene fusion: cytogenetic and molecular relationship to congenital (infantile) fibrosarcoma. *Am J Pathol*. 1998;153(5):1451-1458.
210. Schofield DE, Fletcher JA, Grier HE, Yunis EJ. Fibrosarcoma in infants and children. Application of new techniques. *Am J Surg Pathol*. 1994;18(1):14-24.
211. Argani P, Fritsch M, Kadkol SS, et al. Detection of the ETV6-NTRK3 chimeric RNA of infantile fibrosarcoma/cellular congenital mesoblastic nephroma in paraffin-embedded tissue: application to challenging pediatric renal stromal tumors. *Mod Pathol*. 2000;13(1):29-36.
212. Evans HL. Low-grade fibromyxoid sarcoma: a clinicopathologic study of 33 cases with long-term follow-up. *Am J Surg Pathol*. 2011;35(10):1450-1462.
213. Evans HL. Low-grade fibromyxoid sarcoma. A report of 12 cases. *Am J Surg Pathol*. 1993;17(6):595-600.
214. Evans HL. Low-grade fibromyxoid sarcoma. A report of two metastasizing neoplasms having a deceptively benign appearance. *Am J Clin Pathol*. 1987;88(5):615-619.
215. Folpe AL, Lane KL, Paull G, Weiss SW. Low-grade fibromyxoid sarcoma and hyalinizing spindle cell tumor with giant rosettes: a clinicopathologic study of 73 cases supporting their identity and assessing the

For personal use only. No other uses without permission. Copyright ©2017. Elsevier Inc. All rights reserved.

impact of high-grade areas. *Am J Surg Pathol*. 2000;24(10):1353-1360.
216. Lane KL, Shannon RJ, Weiss SW. Hyalinizing spindle cell tumor with giant rosettes: a distinctive tumor closely resembling low-grade fibromyxoid sarcoma. *Am J Surg Pathol*. 1997;21(12):1481-1488.
217. Rekhi B, Deshmukh M, Jambhekar NA. Low-grade fibromyxoid sarcoma: a clinicopathologic study of 18 cases, including histopathologic relationship with sclerosing epithelioid fibrosarcoma in a subset of cases. *Ann Diagn Pathol*. 2011;15(5):303-311.
218. Mohamed M, Fisher C, Thway K. Low-grade fibromyxoid sarcoma: clinical, morphologic and genetic features. *Ann Diagn Pathol*. 2017;28:60-67.
219. Doyle LA, Möller E, Dal Cin P, et al. MUC4 is a highly sensitive and specific marker for low-grade fibromyxoid sarcoma. *Am J Surg Pathol*. 2011;35(5):733-741.
220. Guillou L, Benhattar J, Gengler C, et al. Translocation-positive low-grade fibromyxoid sarcoma: clinicopathologic and molecular analysis of a series expanding the morphologic spectrum and suggesting potential relationship to sclerosing epithelioid fibrosarcoma: a study from the French Sarcoma Group. *Am J Surg Pathol*. 2007;31(9):1387-1402.
221. Mertens F, Fletcher CDM, Antonescu CR, et al. Clinicopathologic and molecular genetic characterization of low-grade fibromyxoid sarcoma, and cloning of a novel FUS/CREB3L1 fusion gene. *Lab Invest*. 2005;85(3):408-415.
222. Reid R, de Silva MVC, Paterson L, et al. Low-grade fibromyxoid sarcoma and hyalinizing spindle cell tumor with giant rosettes share a common t(7;16)(q34;p11) translocation. *Am J Surg Pathol*. 2003;27(9):1229-1236.
223. Rose B, Tamvakopoulos GS, Dulay K, et al. The clinical significance of the FUS-CREB3L2 translocation in low-grade fibromyxoid sarcoma. *J Orthop Surg*. 2011;6(1):15.
224. Argani P, Lewin JR, Edmonds P, et al. Primary renal sclerosing epithelioid fibrosarcoma: report of 2 cases with EWSR1-CREB3L1 gene fusion. *Am J Surg Pathol*. 2015;39(3):365-373.
225. Prieto-Granada C, Zhang L, Chen H-W, et al. A genetic dichotomy between pure sclerosing epithelioid fibrosarcoma (SEF) and hybrid SEF/low-grade fibromyxoid sarcoma: a pathologic and molecular study of 18 cases. *Genes Chromosomes Cancer*. 2015;54(1):28-38.
226. Meis-Kindblom JM, Kindblom LG, Enzinger FM. Sclerosing epithelioid fibrosarcoma. A variant of fibrosarcoma simulating carcinoma. *Am J Surg Pathol*. 1995;19(9):979-993.
227. Reid R, Barrett A, Hamblen DL. Sclerosing epithelioid fibrosarcoma. *Histopathology*. 1996;28(5):451-455.
228. Antonescu CR, Rosenblum MK, Pereira P, et al. Sclerosing epithelioid fibrosarcoma: a study of 16 cases and confirmation of a clinicopathologically distinct tumor. *Am J Surg Pathol*. 2001;25(6):699-709.
229. Doyle LA, Wang W-L, Dal Cin P, et al. MUC4 is a sensitive and extremely useful marker for sclerosing epithelioid fibrosarcoma: association with FUS gene rearrangement. *Am J Surg Pathol*. 2012;36(10):1444-1451.
230. Stockman DL, Ali SM, He J, et al. Sclerosing epithelioid fibrosarcoma presenting as intraabdominal sarcomatosis with a novel EWSR1-CREB3L1 gene fusion. *Hum Pathol*. 2014;45(10):2173-2178.
231. Laskin WB, Fetsch JF, Miettinen M. Myxoinflammatory fibroblastic sarcoma: a clinicopathologic analysis of 104 cases, with emphasis on predictors of outcome. *Am J Surg Pathol*. 2014;38(1):1-12.
232. Meis-Kindblom JM, Kindblom LG. Acral myxoinflammatory fibroblastic sarcoma: a low-grade tumor of the hands and feet. *Am J Surg Pathol*. 1998;22(8):911-924.
233. Montgomery EA, Devaney KO, Giordano TJ, Weiss SW. Inflammatory myxohyaline tumor of distal extremities with virocyte or Reed-Sternberg-like cells: a distinctive lesion with features simulating inflammatory conditions, Hodgkin's disease, and various sarcomas. *Mod Pathol*. 1998;11(4):384-391.
234. Antonescu CR, Zhang L, Nielsen GP, et al. Consistent t(1;10) with rearrangements of TGFBR3 and MGEA5 in both myxoinflammatory fibroblastic sarcoma and hemosiderotic fibrolipomatous tumor. *Genes Chromosomes Cancer*. 2011;50(10):757-764.
235. Ieremia E, Thway K. Myxoinflammatory fibroblastic sarcoma: morphologic and genetic updates. *Arch Pathol Lab Med*. 2014;138(10):1406-1411.
236. Carter JM, Sukov WR, Montgomery E, et al. TGFBR3 and MGEA5 rearrangements in pleomorphic hyalinizing angiectatic tumors and the spectrum of related neoplasms. *Am J Surg Pathol*. 2014;38(9):1182-1992.
237. Lombardi R, Jovine E, Zanini N, et al. A case of lung metastasis in myxoinflammatory fibroblastic sarcoma: analytical review of one hundred and thirty eight cases. *Int Orthop*. 2013;37(12):2429-2436.
238. Mentzel T, Dry S, Katenkamp D, Fletcher CD. Low-grade myofibroblastic sarcoma: analysis of 18 cases in the spectrum of myofibroblastic tumors. *Am J Surg Pathol*. 1998;22(10):1228-1238.
239. Coffin CM, Hornick JL, Fletcher CDM. Inflammatory myofibroblastic tumor: comparison of clinicopathologic, histologic, and immunohistochemical features including ALK expression in atypical and aggressive cases. *Am J Surg Pathol*. 2007;31(4):509-520.
240. Coffin CM, Dehner LP, Meis-Kindblom JM. Inflammatory myofibroblastic tumor, inflammatory fibrosarcoma, and related lesions: an historical review with differential diagnostic considerations. *Semin Diagn Pathol*. 1998;15(2):102-110.
241. Cessna MH, Zhou H, Sanger WG, et al. Expression of ALK1 and p80 in inflammatory myofibroblastic tumor and its mesenchymal mimics: a study of 135 cases. *Mod Pathol*. 2002;15(9):931-938.
242. Chan JK, Cheuk W, Shimizu M. Anaplastic lymphoma kinase expression in inflammatory pseudotumors. *Am J Surg Pathol*. 2001;25(6):761-768.
243. Meis JM, Enzinger FM. Inflammatory fibrosarcoma of the mesentery and retroperitoneum. A tumor closely simulating inflammatory pseudotumor. *Am J Surg Pathol*. 1991;15(12):1146-1156.
244. Griffin CA, Hawkins AL, Dvorak C, et al. Recurrent involvement of 2p23 in inflammatory myofibroblastic tumors. *Cancer Res*. 1999;59(12):2776-2780.
244a. Antonescu CR, Suurmeijer AJ, Zhang L, et al. Molecular characterization of inflammatory myofibroblastic tumors with frequent ALK and ROS1 gene fusions and rare novel RET rearrangement. *Am J Surg Pathol*. 2015;39(7):957-967.
245. Bridge JA, Kanamori M, Ma Z, et al. Fusion of the ALK gene to the clathrin heavy chain gene, CLTC, in inflammatory myofibroblastic tumor. *Am J Pathol*. 2001;159(2):411-415.
246. Cook JR, Dehner LP, Collins MH, et al. Anaplastic lymphoma kinase (ALK) expression in the inflammatory myofibroblastic tumor: a comparative immunohistochemical study. *Am J Surg Pathol*. 2001;25(11):1364-1371.
247. Debelenko LV, Arthur DC, Pack SD, et al. Identification of CARS-ALK fusion in primary and metastatic lesions of an inflammatory myofibroblastic tumor. *Lab Invest*. 2003;83(9):1255-1265.
248. Lawrence B, Perez-Atayde A, Hibbard MK, et al. TPM3-ALK and TPM4-ALK oncogenes in inflammatory myofibroblastic tumors. *Am J Pathol*. 2000;157(2):377-384.
249. Panagopoulos I, Nilsson T, Domanski HA, et al. Fusion of the SEC31L1 and ALK genes in an inflammatory myofibroblastic tumor. *Int J Cancer*. 2006;118(5):1181-1186.
250. Coffin CM, Watterson J, Priest JR, Dehner LP. Extrapulmonary inflammatory myofibroblastic tumor (inflammatory pseudotumor). A clinicopathologic and immunohistochemical study of 84 cases. *Am J Surg Pathol*. 1995;19(8):859-872.
251. Butrynski JE, D'Adamo DR, Hornick JL, et al. Crizotinib in ALK-rearranged inflammatory myofibroblastic tumor. *N Engl J Med*. 2010;363(18):1727-1733.
252. Tothova Z, Wagner AJ. Anaplastic lymphoma kinase-directed therapy in inflammatory myofibroblastic tumors. *Curr Opin Oncol*. 2012;24(4):409-413.
253. Montgomery E, Fisher C. Myofibroblastic differentiation in malignant fibrous histiocytoma (pleomorphic myofibrosarcoma): a clinicopathological study. *Histopathology*. 2001;38(6):499-509.
254. Keller C, Gibbs CN, Kelly SM, et al. Low-grade myofibrosarcoma of the head and neck: importance of surgical therapy. *J Pediatr Hematol Oncol*. 2004;26(2):119-120.
255. Ozzello L, Stout AP, Murray MR. Cultural characteristics of malignant histiocytomas and fibrous xanthomas. *Cancer*. 1963;16:331-344.
256. O'brien JE, Stout AP. Malignant fibrous xanthomas. *Cancer*. 1964;17:1445-1455.
257. Alguacil-Garcia A, Unni KK, Goellner JR. Malignant fibrous histiocytoma: an ultrastructural study of six cases. *Am J Clin Pathol*. 1978;69(2):121-129.
258. Fu YS, Gabbiani G, Kaye GI, Lattes R. Malignant soft tissue tumors of probable histiocytic origin (malignant fibrous histiocytomas): general considerations and electron microscopic and tissue culture studies. *Cancer*. 1975;35(1):176-198.
259. Iwasaki H, Kikuchi M, Takii M, Enjoji M. Benign and malignant fibrous histiocytomas of the soft tissues: functional characterization of the cultured cells. *Cancer*. 1982;50(3):520-530.
260. Reed R. Histiocytes, fibrocytes, and facultative transformations. *Am J Dermatopathol*. 1982;4(3):253-262.
261. Brecher ME, Franklin WA, Simon MA. Immunohistochemical study of mononuclear phagocyte antigens in giant cell tumor of bone. *Am J Pathol*. 1986;125(2):252-257.
262. Brecher ME, Franklin WA. Absence of mononuclear phagocyte antigens in malignant fibrous histiocytoma. *Am J Clin Pathol*. 1986;86(3):344-348.
263. Enzinger FM. Malignant fibrous histiocytoma 20 years after Stout. *Am J Surg Pathol*. 1986;10(suppl 1):43-53.
264. Iwasaki H, Isayama T, Ohjimi Y, et al. Malignant fibrous histiocytoma. A tumor of facultative histiocytes showing mesenchymal differentiation in cultured cell lines. *Cancer*. 1992;69(2):437-447.
265. Gonzalez S, Duarte I. Benign fibrous histiocytoma of the skin. A morphologic study of 290 cases. *Pathol Res Pract*. 1982;174(4):379-391.
266. Calonje E, Mentzel T, Fletcher CD. Cellular benign fibrous histiocytoma.

For personal use only. No other uses without permission. Copyright ©2017. Elsevier Inc. All rights reserved.

Clinicopathologic analysis of 74 cases of a distinctive variant of cutaneous fibrous histiocytoma with frequent recurrence. *Am J Surg Pathol*. 1994;18(7):668-676.
267. Vanni R, Marras S, Faa G, et al. Cellular fibrous histiocytoma of the skin: evidence of a clonal process with different karyotype from dermatofibrosarcoma. *Genes Chromosomes Cancer*. 1997;18(4):314-317.
268. Beham A, Fletcher CD. Atypical "pseudosarcomatous" variant of cutaneous benign fibrous histiocytoma: report of eight cases. *Histopathology*. 1990;17(2):167-169.
269. Kaddu S, McMenamin ME, Fletcher CDM. Atypical fibrous histiocytoma of the skin: clinicopathologic analysis of 59 cases with evidence of infrequent metastasis. *Am J Surg Pathol*. 2002;26(1):35-46.
270. Doyle LA, Mariño-Enriquez A, Fletcher CD, Hornick JL. ALK rearrangement and overexpression in epithelioid fibrous histiocytoma. *Mod Pathol*. 2015;28(7):904-912.
271. Calonje E, Fletcher CD. Aneurysmal benign fibrous histiocytoma: clinicopathological analysis of 40 cases of a tumour frequently misdiagnosed as a vascular neoplasm. *Histopathology*. 1995;26(4):323-331.
272. Fletcher CD. Benign fibrous histiocytoma of subcutaneous and deep soft tissue: a clinicopathologic analysis of 21 cases. *Am J Surg Pathol*. 1990;14(9):801-809.
273. Charli-Joseph Y, Saggini A, Doyle LA, et al. DNA copy number changes in tumors within the spectrum of cellular, atypical, and metastasizing fibrous histiocytoma. *J Am Acad Dermatol*. 2014;71(2):256-263.
274. Gleason BC, Fletcher CDM. Deep "benign" fibrous histiocytoma: clinicopathologic analysis of 69 cases of a rare tumor indicating occasional metastatic potential. *Am J Surg Pathol*. 2008;32(3):354-362.
275. Marshall-Taylor C, Fanburg-Smith JC. Hemosiderotic fibrohistiocytic lipomatous lesion: ten cases of a previously undescribed fatty lesion of the foot/ankle. *Mod Pathol*. 2000;13(11):1192-1199.
276. Folpe AL, Weiss SW. Pleomorphic hyalinizing angiectatic tumor: analysis of 41 cases supporting evolution from a distinctive precursor lesion. *Am J Surg Pathol*. 2004;28(11):1417-1425.
277. Carter JM, Caron BL, Dogan A, Folpe AL. A novel chromogenic in situ hybridization assay for FGF23 mRNA in phosphaturic mesenchymal tumors. *Am J Surg Pathol*. 2015;39(1):75-83.
278. Fetsch JF, Laskin WB, Hallman JR, et al. Neurothekeoma: an analysis of 178 tumors with detailed immunohistochemical data and long-term patient follow-up information. *Am J Surg Pathol*. 2007;31(7):1103-1114.
279. Hornick JL, Fletcher CDM. Cellular neurothekeoma: detailed characterization in a series of 133 cases. *Am J Surg Pathol*. 2007;31(3):329-340.
280. Sachdev R, Sundram UN. Frequent positive staining with NKI/C3 in normal and neoplastic tissues limits its usefulness in the diagnosis of cellular neurothekeoma. *Am J Clin Pathol*. 2006;126(4):554-563.
281. Fox MD, Billings SD, Gleason BC, et al. Expression of MiTF may be helpful in differentiating cellular neurothekeoma from plexiform fibrohistiocytic tumor (histiocytoid predominant) in a partial biopsy specimen. *Am J Dermatopathol*. 2012;34(2):157-160.
282. Sheth S, Li X, Binder S, Dry SM. Differential gene expression profiles of neurothekeomas and nerve sheath myxomas by microarray analysis. *Mod Pathol*. 2011;24(3):343-354.
283. Bague S, Folpe AL. Dermatofibrosarcoma protuberans presenting as a subcutaneous mass: a clinicopathological study of 15 cases with exclusive or near-exclusive subcutaneous involvement. *Am J Dermatopathol*. 2008;30(4):327-332.
284. Barr RJ, Young EM, King DF. Non-polarizable collagen in dermatofibrosarcoma protuberans: a useful diagnostic aid. *J Cutan Pathol*. 1986;13(5):339-346.
285. Kamino H, Jacobson M. Dermatofibroma extending into the subcutaneous tissue. Differential diagnosis from dermatofibrosarcoma protuberans. *Am J Surg Pathol*. 1990;14(12):1156-1164.
286. Mentzel T, Schärer L, Kazakov DV, Michal M. Myxoid dermatofibrosarcoma protuberans: clinicopathologic, immunohistochemical, and molecular analysis of eight cases. *Am J Dermatopathol*. 2007;29(5):443-448.
287. Reimann JDR, Fletcher CDM. Myxoid dermatofibrosarcoma protuberans: a rare variant analyzed in a series of 23 cases. *Am J Surg Pathol*. 2007;31(9):1371-1377.
288. Patel KU, Szabo SS, Hernandez VS, et al. Dermatofibrosarcoma protuberans COL1A1-PDGFB fusion is identified in virtually all dermatofibrosarcoma protuberans cases when investigated by newly developed multiplex reverse transcription polymerase chain reaction and fluorescence in situ hybridization assays. *Hum Pathol*. 2008;39(2):184-193.
289. Karanian M, Pérot G, Coindre J-M, et al. Fluorescence in situ hybridization analysis is a helpful test for the diagnosis of dermatofibrosarcoma protuberans. *Mod Pathol*. 2015;28(2):230-237.
290. Terrier-Lacombe M-J, Guillou L, Maire G, et al. Dermatofibrosarcoma protuberans, giant cell fibroblastoma, and hybrid lesions in children: clinicopathologic comparative analysis of 28 cases with molecular data—a study from the French Federation of Cancer Centers Sarcoma Group. *Am J Surg Pathol*. 2003;27(1):27-39.
291. Beham A, Fletcher CD. Dermatofibrosarcoma protuberans with areas resembling giant cell fibroblastoma: report of two cases. *Histopathology*. 1990;17(2):165-167.
292. Jha P, Moosavi C, Fanburg-Smith JC. Giant cell fibroblastoma: an update and addition of 86 new cases from the Armed Forces Institute of Pathology, in honor of Dr. Franz M. Enzinger. *Ann Diagn Pathol*. 2007;11(2):81-88.
293. Shmookler BM, Enzinger FM, Weiss SW. Giant cell fibroblastoma. A juvenile form of dermatofibrosarcoma protuberans. *Cancer*. 1989;64(10):2154-2161.
294. McKee PH, Fletcher CD. Dermatofibrosarcoma protuberans presenting in infancy and childhood. *J Cutan Pathol*. 1991;18(4):241-246.
295. Dupree WB, Langloss JM, Weiss SW. Pigmented dermatofibrosarcoma protuberans (Bednar tumor). A pathologic, ultrastructural, and immunohistochemical study. *Am J Surg Pathol*. 1985;9(9):630-639.
296. Mendenhall WM, Zlotecki RA, Scarborough MT. Dermatofibrosarcoma protuberans. *Cancer*. 2004;101(11):2503-2508.
297. Ding JA, Hashimoto H, Sugimoto T, et al. Bednar tumor (pigmented dermatofibrosarcoma protuberans). An analysis of six cases. *Acta Pathol Jpn*. 1990;40(10):744-754.
298. Fletcher CD, Theaker JM, Flanagan A, Krausz T. Pigmented dermatofibrosarcoma protuberans (Bednar tumour): melanocytic colonization or neuroectodermal differentiation? A clinicopathological and immunohistochemical study. *Histopathology*. 1988;13(6):631-643.
299. De Chadarévian JP, Coppola D, Billmire DF. Bednar tumor pattern in recurring giant cell fibroblastoma. *Am J Clin Pathol*. 1993;100(2):164-166.
300. Mentzel T, Beham A, Katenkamp D, et al. Fibrosarcomatous ("high-grade") dermatofibrosarcoma protuberans: clinicopathologic and immunohistochemical study of a series of 41 cases with emphasis on prognostic significance. *Am J Surg Pathol*. 1998;22(5):576-587.
301. Goldblum JR, Reith JD, Weiss SW. Sarcomas arising in dermatofibrosarcoma protuberans: a reappraisal of biologic behavior in eighteen cases treated by wide local excision with extended clinical follow up. *Am J Surg Pathol*. 2000;24(8):1125-1130.
302. Costa MJ, Weiss SW. Angiomatoid malignant fibrous histiocytoma. A follow-up study of 108 cases with evaluation of possible histologic predictors of outcome. *Am J Surg Pathol*. 1990;14(12):1126-1132.
303. Enzinger FM. Angiomatoid malignant fibrous histiocytoma: a distinct fibrohistiocytic tumor of children and young adults simulating a vascular neoplasm. *Cancer*. 1979;44(6):2147-2157.
304. Fanburg-Smith JC, Miettinen M. Angiomatoid "malignant" fibrous histiocytoma: a clinicopathologic study of 158 cases and further exploration of the myoid phenotype. *Hum Pathol*. 1999;30(11):1336-1343.
305. Matsumura T, Yamaguchi T, Tochigi N, et al. Angiomatoid fibrous histiocytoma including cases with pleomorphic features analysed by fluorescence in situ hybridisation. *J Clin Pathol*. 2010;63(2):124-128.
306. Tornóczky T, Bogner B, Krausz T, et al. Angiomatoid fibrous histiocytoma: pleomorphic variant associated with multiplication of EWSR1-CREB1 fusion gene. *Pathol Oncol Res*. 2012;18(2):545-548.
307. Justin Wong SB, Wee A, Puhaindran ME, et al. Angiomatoid fibrous histiocytoma with prominent myxoid stroma: a case report and review of the literature. *Am J Dermatopathol*. 2015;37(8):623-631.
308. Schaefer I-M, Fletcher CDM. Myxoid variant of so-called angiomatoid "malignant fibrous histiocytoma": clinicopathologic characterization in a series of 21 cases. *Am J Surg Pathol*. 2014;38(6):816-823.
309. Antonescu CR, Dal Cin P, Nafa K, et al. EWSR1-CREB1 is the predominant gene fusion in angiomatoid fibrous histiocytoma. *Genes Chromosomes Cancer*. 2007;46(12):1051-1060.
310. Fisher C. The diversity of soft tissue tumours with EWSR1 gene rearrangements: a review. *Histopathology*. 2014;64(1): 134-150.
311. Rossi S, Szuhai K, Ijszenga M, et al. EWSR1-CREB1 and EWSR1-ATF1 fusion genes in angiomatoid fibrous histiocytoma. *Clin Cancer Res*. 2007;13(24):7322-7328.
312. Tanas MR, Rubin BP, Montgomery EA, et al. Utility of FISH in the diagnosis of angiomatoid fibrous histiocytoma: a series of 18 cases. *Mod Pathol*. 2010;23(1):93-97.
313. Remstein ED, Arndt CA, Nascimento AG. Plexiform fibrohistiocytic tumor: clinicopathologic analysis of 22 cases. *Am J Surg Pathol*. 1999;23(6):662-670.
314. Angervall L, Kindblom LG, Lindholm K, Eriksson S. Plexiform fibrohistiocytic tumor. Report of a case involving preoperative aspiration cytology and immunohistochemical and ultrastructural analysis of surgical specimens. *Pathol Res Pract*. 1992;188(3):350-356, discussion 356–359.
315. Enzinger FM, Zhang RY. Plexiform fibrohistiocytic tumor presenting in children

For personal use only. No other uses without permission. Copyright ©2017. Elsevier Inc. All rights reserved.

and young adults. An analysis of 65 cases. *Am J Surg Pathol*. 1988;12(11):818-826.
316. Hollowood K, Holley MP, Fletcher CD. Plexiform fibrohistiocytic tumour: clinicopathological, immunohistochemical and ultrastructural analysis in favour of a myofibroblastic lesion. *Histopathology*. 1991;19(6):503-513.
317. Moosavi C, Jha P, Fanburg-Smith JC. An update on plexiform fibrohistiocytic tumor and addition of 66 new cases from the Armed Forces Institute of Pathology, in honor of Franz M. Enzinger, MD. *Ann Diagn Pathol*. 2007;11(5):313-319.
318. Guccion JG, Enzinger FM. Malignant giant cell tumor of soft parts. An analysis of 32 cases. *Cancer*. 1972;29(6):1518-1529.
319. Salm R, Sissons HA. Giant-cell tumours of soft tissues. *J Pathol*. 1972;107(1):27-39.
320. Folpe AL, Morris RJ, Weiss SW. Soft tissue giant cell tumor of low malignant potential: a proposal for the reclassification of malignant giant cell tumor of soft parts. *Mod Pathol*. 1999;12(9):894-902.
321. O'Connell JX, Wehrli BM, Nielsen GP, Rosenberg AE. Giant cell tumors of soft tissue: a clinicopathologic study of 18 benign and malignant tumors. *Am J Surg Pathol*. 2000;24(3):386-395.
322. Oliveira AM, Dei Tos AP, Fletcher CD, Nascimento AG. Primary giant cell tumor of soft tissues: a study of 22 cases. *Am J Surg Pathol*. 2000;24(2):248-256.
322a. Mancini I, Righi A, Gambarotti M, et al. Phenotypic and molecular differences between giant-cell tumour of soft tissue and its bone counterpart. *Histopathology*. 2017;(epub ahead of print).
323. Fletcher CD. Pleomorphic malignant fibrous histiocytoma: fact or fiction? A critical reappraisal based on 159 tumors diagnosed as pleomorphic sarcoma. *Am J Surg Pathol*. 1992;16(3):213-228.
324. Al-Agha OM, Igbokwe AA. Malignant fibrous histiocytoma: between the past and the present. *Arch Pathol Lab Med*. 2008;132(6):1030-1035.
325. Dei Tos AP. Classification of pleomorphic sarcomas: where are we now? *Histopathology*. 2006;48(1):51-62.
326. Coindre J-M, Mariani O, Chibon F, et al. Most malignant fibrous histiocytomas developed in the retroperitoneum are dedifferentiated liposarcomas: a review of 25 cases initially diagnosed as malignant fibrous histiocytoma. *Mod Pathol*. 2003;16(3):256-262.
327. Weiss SW, Enzinger FM. Malignant fibrous histiocytoma: an analysis of 200 cases. *Cancer*. 1978;41(6):2250-2266.
328. Coindre J-M, Hostein I, Maire G, et al. Inflammatory malignant fibrous histiocytomas and dedifferentiated liposarcomas: histological review, genomic profile, and MDM2 and CDK4 status favour a single entity. *J Pathol*. 2004;203(3): 822-830.
329. Mentzel T, Calonje E, Wadden C, et al. Myxofibrosarcoma. Clinicopathologic analysis of 75 cases with emphasis on the low-grade variant. *Am J Surg Pathol*. 1996;20(4):391-405.
330. Agaimy A, Gaumann A, Schroeder J, et al. Primary and metastatic high-grade pleomorphic sarcoma/malignant fibrous histiocytoma of the gastrointestinal tract: an approach to the differential diagnosis in a series of five cases with emphasis on myofibroblastic differentiation. *Virchows Arch*. 2007;451(5):949-957.
331. Litzky LA, Brooks JJ. Cytokeratin immunoreactivity in malignant fibrous histiocytoma and spindle cell tumors: comparison between frozen and paraffin-embedded tissues. *Mod Pathol*. 1992;5(1):30-34.
332. Weiss SW, Bratthauer GL, Morris PA. Postirradiation malignant fibrous histiocytoma expressing cytokeratin. Implications for the immunodiagnosis of sarcomas. *Am J Surg Pathol*. 1988;12(7):554-558.
333. Mertens F, Fletcher CD, Dal Cin P, et al. Cytogenetic analysis of 46 pleomorphic soft tissue sarcomas and correlation with morphologic and clinical features: a report of the CHAMP Study Group. Chromosomes and MorPhology. *Genes Chromosomes Cancer*. 1998;22(1):16-25.
334. Engellau J, Anderson H, Rydholm A, et al. Time dependence of prognostic factors for patients with soft tissue sarcoma: a Scandinavian Sarcoma Group Study of 338 malignant fibrous histiocytomas. *Cancer*. 2004;100(10):2233-2239.
335. Huang H-Y, Park N, Erlandson RA, Antonescu CR. Immunohistochemical and ultrastructural comparative study of external lamina structure in 31 cases of cellular, classical, and melanotic schwannomas. *Appl Immunohistochem Mol Morphol*. 2004;12(1):50-58.
336. Nascimento AF, Fletcher CDM. The controversial nosology of benign nerve sheath tumors: neurofilament protein staining demonstrates intratumoral axons in many sporadic schwannomas. *Am J Surg Pathol*. 2007;31(9):1363-1370.
337. Merck C, Angervall L, Kindblom LG, Odén A. Myxofibrosarcoma. A malignant soft tissue tumor of fibroblastic-histiocytic origin. A clinicopathologic and prognostic study of 110 cases using multivariate analysis. *Acta Pathol Microbiol Immunol Scand Suppl*. 1983;282:1-40.
338. Sanfilippo R, Miceli R, Grosso F, et al. Myxofibrosarcoma: prognostic factors and survival in a series of patients treated at a single institution. *Ann Surg Oncol*. 2011;18(3):720-725.
339. Willems SM, Debiec-Rychter M, Szuhai K, et al. Local recurrence of myxofibrosarcoma is associated with increase in tumour grade and cytogenetic aberrations, suggesting a multistep tumour progression model. *Mod Pathol*. 2006;19(3):407-416.
340. Monaghan H, Salter DM, Al-Nafussi A. Giant cell tumour of tendon sheath (localised nodular tenosynovitis): clinicopathological features of 71 cases. *J Clin Pathol*. 2001;54(5):404-407.
341. Ushijima M, Hashimoto H, Tsuneyoshi M, Enjoji M. Giant cell tumor of the tendon sheath (nodular tenosynovitis). A study of 207 cases to compare the large joint group with the common digit group. *Cancer*. 1986;57(4):875-884.
342. Kitagawa Y, Ito H, Amano Y, et al. MR imaging for preoperative diagnosis and assessment of local tumor extent on localized giant cell tumor of tendon sheath. *Skeletal Radiol*. 2003;32(11): 633-638.
343. Folpe AL, Weiss SW, Fletcher CD, Gown AM. Tenosynovial giant cell tumors: evidence for a desmin-positive dendritic cell subpopulation. *Mod Pathol*. 1998;11(10):939-944.
344. O'Connell JX, Fanburg JC, Rosenberg AE. Giant cell tumor of tendon sheath and pigmented villonodular synovitis: immunophenotype suggests a synovial cell origin. *Hum Pathol*. 1995;26(7):771-775.
345. Somerhausen NS, Fletcher CD. Diffuse-type giant cell tumor: clinicopathologic and immunohistochemical analysis of 50 cases with extraarticular disease. *Am J Surg Pathol*. 2000;24(4):479-492.
346. Boland JM, Folpe AL, Hornick JL, Grogg KL. Clusterin is expressed in normal synoviocytes and in tenosynovial giant cell tumors of localized and diffuse types: diagnostic and histogenetic implications. *Am J Surg Pathol*. 2009;33(8):1225-1229.
347. Sciot R, Rosai J, Dal Cin P, et al. Analysis of 35 cases of localized and diffuse tenosynovial giant cell tumor: a report from the Chromosomes and Morphology (CHAMP) study group. *Mod Pathol*. 1999;12(6):576-579.
348. West RB, Rubin BP, Miller MA, et al. A landscape effect in tenosynovial giant-cell tumor from activation of CSF1 expression by a translocation in a minority of tumor cells. *Proc Natl Acad Sci USA*. 2006;103(3):690-695.
349. Cupp JS, Miller MA, Montgomery KD, et al. Translocation and expression of CSF1 in pigmented villonodular synovitis, tenosynovial giant cell tumor, rheumatoid arthritis and other reactive synovitides. *Am J Surg Pathol*. 2007;31(6):970-976.
350. Williams J, Hodari A, Janevski P, Siddiqui A. Recurrence of giant cell tumors in the hand: a prospective study. *J Hand Surg*. 2010;35(3):451-456.
351. Ehrenstein V, Andersen SL, Qazi I, et al. Tenosynovial giant cell tumor: incidence, prevalence, patient characteristics, and recurrence. A registry-based cohort study in Denmark. *J Rheumatol*. 2017 (Epub ahead of print.).
352. Bertoni F, Unni KK, Beabout JW, Sim FH. Malignant giant cell tumor of the tendon sheaths and joints (malignant pigmented villonodular synovitis). *Am J Surg Pathol*. 1997;21(2):153-163.
353. Li C-F, Wang J-W, Huang W-W, et al. Malignant diffuse-type tenosynovial giant cell tumors: a series of 7 cases comparing with 24 benign lesions with review of the literature. *Am J Surg Pathol*. 2008;32(4):587-599.
354. Jaffe HL. Giant cell tumor of bone: problems of differential diagnosis: 1944. *Bull Hosp Jt Dis*. 1995;54(2):109-112.
355. Rowlands CG, Roland B, Hwang WS, Sevick RJ. Diffuse-variant tenosynovial giant cell tumor: a rare and aggressive lesion. *Hum Pathol*. 1994;25(4):423-425.
356. Kaiserling E, Xiao JC, Ruck P, Horny HP. Aberrant expression of macrophage-associated antigens (CD68 and Ki-M1P) by Schwann cells in reactive and neoplastic neural tissue. Light- and electron-microscopic findings. *Mod Pathol*. 1993;6(4):463-468.
357. Adams WR. Morton's neuroma. *Clin Podiatr Med Surg*. 2010;27(4):535-545.
358. Hall LD, Ferringer T. Palisaded encapsulated neuroma. *Cutis*. 2013;92(4):167, 177–178.
359. Misago N, Toda S, Narisawa Y. The relationship between palisaded encapsulated neuroma and the mucocutaneous neuroma seen in multiple endocrine neoplasia 2b syndrome: a histopathologic and immunohistochemical study. *Am J Dermatopathol*. 2014;36(7):562-569.
360. Jokinen CH, Ragsdale BD, Argenyi ZB. Expanding the clinicopathologic spectrum of palisaded encapsulated neuroma. *J Cutan Pathol*. 2010;37(1):43-48.
361. Megahed M. Palisaded encapsulated neuroma (solitary circumscribed neuroma). A clinicopathologic and immunohistochemical study. *Am J Dermatopathol*. 1994;16(2):120-125.
362. Schroeder RD, Angelo LS, Kurzrock R. NF2/merlin in hereditary neurofibromatosis 2 versus cancer: biologic mechanisms and clinical associations. *Oncotarget*. 2014;5(1):67-77.

For personal use only. No other uses without permission. Copyright ©2017. Elsevier Inc. All rights reserved.

363. Dahl I, Hagmar B, Idvall I. Benign solitary neurilemoma (Schwannoma). A correlative cytological and histological study of 28 cases. *Acta Pathol Microbiol Immunol Scand [A]*. 1984;92(2):91-101.
364. Carpenter PM, Grafe MR, Varki NM. Granular cells in a cellular neurilemmoma. *Arch Pathol Lab Med*. 1992;116(10):1083-1085.
365. Agaram NP, Prakash S, Antonescu CR. Deep-seated plexiform schwannoma: a pathologic study of 16 cases and comparative analysis with the superficial variety. *Am J Surg Pathol*. 2005;29(8):1042-1048.
366. Berg JC, Scheithauer BW, Spinner RJ, et al. Plexiform schwannoma: a clinicopathologic overview with emphasis on the head and neck region. *Hum Pathol*. 2008;39(5):633-640.
367. Laskin WB, Fetsch JF, Lasota J, Miettinen M. Benign epithelioid peripheral nerve sheath tumors of the soft tissues: clinicopathologic spectrum of 33 cases. *Am J Surg Pathol*. 2005;29(1):39-51.
367a. Jo VY, Fletcher CDM. SMARCB1/INI1 loss in epithelioid schwannoma: a clinicopathologic and immunohistochemical study of 65 cases. *Am J Surg Pathol*. 2017;41(8):1013-1022.
368. Chuang S-T, Wang HL. An unusual case of glandular schwannoma. *Hum Pathol*. 2007;38(4):673-677.
369. Kim YC, Park HJ, Cinn YW, Vandersteen DP. Benign glandular schwannoma. *Br J Dermatol*. 2001;145(5):834-837.
370. Lisle A, Jokinen C, Argenyi Z. Cutaneous pseudoglandular schwannoma: a case report of an unusual histopathologic variant. *Am J Dermatopathol*. 2011;33(5):e63-e65.
371. Robinson CA, Curry B, Rewcastle NB. Pseudoglandular elements in schwannomas. *Arch Pathol Lab Med*. 2005;129(9):1106-1112.
372. Carney JA. Psammomatous melanotic schwannoma. A distinctive, heritable tumor with special associations, including cardiac myxoma and the Cushing syndrome. *Am J Surg Pathol*. 1990;14(3):206-222.
373. Plaza JA, Wakely PE, Suster S. Lipoblastic nerve sheath tumors: report of a distinctive variant of neural soft tissue neoplasm with adipocytic differentiation. *Am J Surg Pathol*. 2006;30(3):337-344.
374. Liegl B, Bennett MW, Fletcher CDM. Microcystic/reticular schwannoma: a distinct variant with predilection for visceral locations. *Am J Surg Pathol*. 2008;32(7):1080-1087.
375. Fisher C, Chappell ME, Weiss SW. Neuroblastoma-like epithelioid schwannoma. *Histopathology*. 1995;26(2):193-194.
376. Goldblum JR, Beals TF, Weiss SW. Neuroblastoma-like neurilemoma. *Am J Surg Pathol*. 1994;18(3):266-273.
377. Dickersin GR. The electron microscopic spectrum of nerve sheath tumors. *Ultrastruct Pathol*. 1987;11(2-3):103-146.
378. Fanburg-Smith JC, Majidi M, Miettinen M. Keratin expression in schwannoma; a study of 115 retroperitoneal and 22 peripheral schwannomas. *Mod Pathol*. 2006;19(1):115-121.
379. Jacoby LB, MacCollin M, Barone R, et al. Frequency and distribution of NF2 mutations in schwannomas. *Genes Chromosomes Cancer*. 1996;17(1):45-55.
380. Mertens F, Dal Cin P, De Wever I, et al. Cytogenetic characterization of peripheral nerve sheath tumours: a report of the CHAMP study group. *J Pathol*. 2000;190(1):31-38.
381. Seferis C, Torrens M, Paraskevopoulou C, Psichidis G. Malignant transformation in vestibular schwannoma: report of a single case, literature search, and debate. *J Neurosurg*. 2014;121(suppl 2):160-166.
382. Yousem SA, Colby TV, Urich H. Malignant epithelioid schwannoma arising in a benign schwannoma. A case report. *Cancer*. 1985;55(12):2799-2803.
383. McMenamin ME, Fletcher CD. Expanding the spectrum of malignant change in schwannomas: epithelioid malignant change, epithelioid malignant peripheral nerve sheath tumor, and epithelioid angiosarcoma: a study of 17 cases. *Am J Surg Pathol*. 2001;25(1):13-25.
384. Fletcher CD, Davies SE, McKee PH. Cellular schwannoma: a distinct pseudosarcomatous entity. *Histopathology*. 1987;11(1):21-35.
385. White W, Shiu MH, Rosenblum MK, et al. Cellular schwannoma. A clinicopathologic study of 57 patients and 58 tumors. *Cancer*. 1990;66(6):1266-1275.
386. Woodruff JM, Godwin TA, Erlandson RA, et al. Cellular schwannoma: a variety of schwannoma sometimes mistaken for a malignant tumor. *Am J Surg Pathol*. 1981;5(8):733-744.
387. Torres-Mora J, Dry S, Li X, et al. Malignant melanotic schwannian tumor: a clinicopathologic, immunohistochemical, and gene expression profiling study of 40 cases, with a proposal for the reclassification of "melanotic schwannoma.". *Am J Surg Pathol*. 2014;38(1):94-105.
388. Lack EE, Worsham GF, Callihan MD, et al. Granular cell tumor: a clinicopathologic study of 110 patients. *J Surg Oncol*. 1980;13(4):301-316.
389. Ordóñez NG, Mackay B. Granular cell tumor: a review of the pathology and histogenesis. *Ultrastruct Pathol*. 1999;23(4):207-222.
390. Goldblum JR, Rice TW, Zuccaro G, Richter JE. Granular cell tumors of the esophagus: a clinical and pathologic study of 13 cases. *Ann Thorac Surg*. 1996;62(3):860-865.
391. Guven S, Kaymakci A, Bugday MS, Yilmaz M. Congenital granular cell tumor. *J Craniofac Surg*. 2009;20(3):976-977.
392. Alemayehu H, Polites SF, Kats A, et al. Granular cell tumors and congenital granular cell epulis in children: similar entities. *J Pediatr Surg*. 2015;50(5):775-778.
393. Cserni G, Bori R, Sejben I. Vascular invasion demonstrated by elastic stain-a common phenomenon in benign granular cell tumors. *Virchows Arch*. 2009;454(2):211-215.
394. Zarovnaya E, Black C. Distinguishing pseudoepitheliomatous hyperplasia from squamous cell carcinoma in mucosal biopsy specimens from the head and neck. *Arch Pathol Lab Med*. 2005;129(8):1032-1036.
395. McMahon JN, Rigby HS, Davies JD. Elastosis in granular cell tumours: prevalence and distribution. *Histopathology*. 1990;16(1):37-41.
396. Mittal KR, True LD. Origin of granules in granular cell tumor. Intracellular myelin formation with autodigestion. *Arch Pathol Lab Med*. 1988;112(3):302-303.
397. Bhawan J, Malhotra R, Naik DR. Gaucher-like cells in a granular cell tumor. *Hum Pathol*. 1983;14(8):730-733.
398. Karamchandani JR, Nielsen TO, van de Rijn M, West RB. Sox10 and S100 in the diagnosis of soft-tissue neoplasms. *Appl Immunohistochem Mol Morphol*. 2012;20(5):445-450.
399. Fine SW, Li M. Expression of calretinin and the alpha-subunit of inhibin in granular cell tumors. *Am J Clin Pathol*. 2003;119(2):259-264.
400. Le BH, Boyer PJ, Lewis JE, Kapadia SB. Granular cell tumor: immunohistochemical assessment of inhibin-alpha, protein gene product 9.5, S100 protein, CD68, and Ki-67 proliferative index with clinical correlation. *Arch Pathol Lab Med*. 2004;128(7):771-775.
401. Fanburg-Smith JC, Meis-Kindblom JM, Fante R, Kindblom LG. Malignant granular cell tumor of soft tissue: diagnostic criteria and clinicopathologic correlation. *Am J Surg Pathol*. 1998;22(7):779-794.
402. Agustí J, Martínez-Ciarpaglini C, Monteagudo C. Desmoplastic primitive nonneural granular cell tumor of the skin. *Am J Dermatopathol*. 2014;36(4):e84-e86.
403. Lazar AJF, Fletcher CDM. Primitive nonneural granular cell tumors of skin: clinicopathologic analysis of 13 cases. *Am J Surg Pathol*. 2005;29(7):927-934.
404. LeBoit PE, Barr RJ, Burall S, et al. Primitive polypoid granular-cell tumor and other cutaneous granular-cell neoplasms of apparent nonneural origin. *Am J Surg Pathol*. 1991;15(1):48-58.
405. Lerman M, Freedman PD. Nonneural granular cell tumor of the oral cavity: a case report and review of the literature. *Oral Surg Oral Med Oral Pathol Oral Radiol Endod*. 2007;103(3):382-384.
406. Jarell A, McCalmont TH. Granular cell angiosarcoma. *J Cutan Pathol*. 2012;39(5):476-478, 475.
407. Sironi M, Assi A, Pasquinelli G, Cenacchi G. Not all granular cell tumors show schwann cell differentiation: a granular cell leiomyosarcoma of the thumb, a case report. *Am J Dermatopathol*. 1999;21(3):307-309.
408. Karajannis MA, Ferner RE. Neurofibromatosis-related tumors: emerging biology and therapies. *Curr Opin Pediatr*. 2015;27(1):26-33.
409. Plotkin SR, Albers AC, Babovic-Vuksanovic D, et al. Update from the 2013 International Neurofibromatosis Conference. *Am J Med Genet A*. 2014;164A(12):2969-2978.
410. Waggener JD. Ultrastructure of benign peripheral nerve sheath tumors. *Cancer*. 1966;19(5):699-709.
411. Chanoki M, Ishii M, Fukai K, et al. Immunohistochemical localization of type I, III, IV, V, and VI collagens and laminin in neurofibroma and neurofibrosarcoma. *Am J Dermatopathol*. 1991;13(4):365-373.
412. Takata M, Imai T, Hirone T. Factor-XIIIa-positive cells in normal peripheral nerves and cutaneous neurofibromas of type-1 neurofibromatosis. *Am J Dermatopathol*. 1994;16(1):37-43.
413. Weiss SW, Nickoloff BJ. CD-34 is expressed by a distinctive cell population in peripheral nerve, nerve sheath tumors, and related lesions. *Am J Surg Pathol*. 1993;17(10):1039-1045.
414. Theaker JM, Fletcher CD. Epithelial membrane antigen expression by the perineurial cell: further studies of peripheral nerve lesions. *Histopathology*. 1989;14(6):581-592.
415. Megahed M. Histopathological variants of neurofibroma. A study of 114 lesions. *Am J Dermatopathol*. 1994;16(5):486-495.
416. Lin BT, Weiss LM, Medeiros LJ. Neurofibroma and cellular neurofibroma with atypia: a report of 14 tumors. *Am J Surg Pathol*. 1997;21(12):1443-1449.
417. Markel SF, Enzinger FM. Neuromuscular hamartoma—a benign "triton tumor" composed of mature neural and striated muscle elements. *Cancer*. 1982;49(1):140-144.
418. Finkel G, Lane B. Granular cell variant of neurofibromatosis: ultrastructure of benign and malignant tumors. *Hum Pathol*. 1982;13(10):959-963.
419. Serra E, Puig S, Otero D, et al. Confirmation of a double-hit model for the NF1 gene in benign neurofibromas. *Am J Hum Genet*. 1997;61(3):512-519.

For personal use only. No other uses without permission. Copyright ©2017. Elsevier Inc. All rights reserved.

420. Storlazzi CT, Von Steyern FV, Domanski HA, et al. Biallelic somatic inactivation of the NF1 gene through chromosomal translocations in a sporadic neurofibroma. *Int J Cancer*. 2005;117(6):1055-1057.
421. McClatchey AI. Neurofibromatosis. *Annu Rev Pathol*. 2007;2:191-216.
422. Weiss B, Bollag G, Shannon K. Hyperactive Ras as a therapeutic target in neurofibromatosis type 1. *Am J Med Genet*. 1999;89(1):14-22.
423. Benedict PH, Szabó G, Fitzpatrick TB, Sinesi SJ. Melanotic macules in Albright's syndrome and in neurofibromatosis. *JAMA*. 1968;205(9):618-626.
424. Miettinen M, Fetsch JF, Sobin LH, Lasota J. Gastrointestinal stromal tumors in patients with neurofibromatosis 1: a clinicopathologic and molecular genetic study of 45 cases. *Am J Surg Pathol*. 2006;30(1):90-96.
425. Lasota J, Miettinen M. KIT and PDGFRA mutations in gastrointestinal stromal tumors (GISTs). *Semin Diagn Pathol*. 2006;23(2):91-102.
426. Miettinen M, Lasota J. Gastrointestinal stromal tumors. *Gastroenterol Clin North Am*. 2013;42(2):399-415.
427. Rouleau GA, Merel P, Lutchman M, et al. Alteration in a new gene encoding a putative membrane-organizing protein causes neuro-fibromatosis type 2. *Nature*. 1993;363(6429):515-521.
428. Evans DGR. Neurofibromatosis type 2 (NF2): a clinical and molecular review. *Orphanet J Rare Dis*. 2009;4:16.
429. Sørensen SA, Mulvihill JJ, Nielsen A. Long-term follow-up of von Recklinghausen neurofibromatosis. Survival and malignant neoplasms. *N Engl J Med*. 1986;314(16):1010-1015.
430. Hornick JL, Fletcher CDM. Soft tissue perineurioma: clinicopathologic analysis of 81 cases including those with atypical histologic features. *Am J Surg Pathol*. 2005;29(7):845-858.
431. Mentzel T, Dei Tos AP, Fletcher CD. Perineurioma (storiform perineurial fibroma): clinico-pathological analysis of four cases. *Histopathology*. 1994;25(3):261-267.
432. Boyanton BL, Jones JK, Shenaq SM, et al. Intraneural perineurioma: a systematic review with illustrative cases. *Arch Pathol Lab Med*. 2007;131(9):1382-1392.
433. Bilbao JM, Khoury NJ, Hudson AR, Briggs SJ. Perineurioma (localized hypertrophic neuropathy). *Arch Pathol Lab Med*. 1984;108(7):557-560.
434. Fetsch JF, Miettinen M. Sclerosing perineurioma: a clinicopathologic study of 19 cases of a distinctive soft tissue lesion with a predilection for the fingers and palms of young adults. *Am J Surg Pathol*. 1997;21(12):1433-1442.
435. Mentzel T, Kutzner H. Reticular and plexiform perineurioma: clinicopathological and immunohistochemical analysis of two cases and review of perineurial neoplasms of skin and soft tissues. *Virchows Arch*. 2005;447(4):677-682.
436. Hornick JL, Bundock EA, Fletcher CDM. Hybrid schwannoma/perineurioma: clinicopathologic analysis of 42 distinctive benign nerve sheath tumors. *Am J Surg Pathol*. 2009;33(10):1554-1561.
437. Ohno T, Park P, Akai M, et al. Ultrastructural study of a perineurioma. *Ultrastruct Pathol*. 1988;12(5):495-504.
438. Agaimy A, Buslei R, Coras R, et al. Comparative study of soft tissue perineurioma and meningioma using a five-marker immunohistochemical panel. *Histopathology*. 2014;65(1):60-70.
439. Giannini C, Scheithauer BW, Jenkins RB, et al. Soft-tissue perineurioma. Evidence for an abnormality of chromosome 22, criteria for diagnosis, and review of the literature. *Am J Surg Pathol*. 1997;21(2):164-173.
440. Lasota J, Fetsch JF, Wozniak A, et al. The neurofibromatosis type 2 gene is mutated in perineurial cell tumors: a molecular genetic study of eight cases. *Am J Pathol*. 2001;158(4):1223-1229.
441. Fetsch JF, Laskin WB, Miettinen M. Nerve sheath myxoma: a clinicopathologic and immunohistochemical analysis of 57 morphologically distinctive, S-100 protein- and GFAP-positive, myxoid peripheral nerve sheath tumors with a predilection for the extremities and a high local recurrence rate. *Am J Surg Pathol*. 2005;29(12):1615-1624.
442. Laskin WB, Fetsch JF, Miettinen M. The "neurothekeoma": immunohistochemical analysis distinguishes the true nerve sheath myxoma from its mimics. *Hum Pathol*. 2000;31(10):1230-1241.
443. Ducatman BS, Scheithauer BW, Piepgras DG, et al. Malignant peripheral nerve sheath tumors. A clinicopathologic study of 120 cases. *Cancer*. 1986;57(10):2006-2021.
444. Meng ZH, Yang YS, Cheng KL, et al. A huge malignant peripheral nerve sheath tumor with hepatic metastasis arising from retroperitoneal ganglioneuroma. *Oncol Lett*. 2013;5(1):123-126.
445. Meis JM, Enzinger FM, Martz KL, Neal JA. Malignant peripheral nerve sheath tumors (malignant schwannomas) in children. *Am J Surg Pathol*. 1992;16(7):694-707.
446. Allison KH, Patel RM, Goldblum JR, Rubin BP. Superficial malignant peripheral nerve sheath tumor: a rare and challenging diagnosis. *Am J Clin Pathol*. 2005;124(5):685-692.
447. Daimaru Y, Hashimoto H, Enjoji M. Malignant "triton" tumors: a clinicopathologic and immunohistochemical study of nine cases. *Hum Pathol*. 1984;15(8):768-778.
448. deCou JM, Rao BN, Parham DM, et al. Malignant peripheral nerve sheath tumors: the St. Jude Children's Research Hospital experience. *Ann Surg Oncol*. 1995;2(6):524-529.
449. McConnell YJ, Giacomantonio CA. Malignant triton tumors—complete surgical resection and adjuvant radiotherapy associated with improved survival. *J Surg Oncol*. 2012;106(1):51-56.
450. Galatian AA, Crowson AN, Fischer RJ, et al. Malignant peripheral nerve sheath tumor with glandular differentiation in a patient with neurofibromatosis type 1. *Am J Dermatopathol*. 2013;35(8):859-863.
451. DiCarlo EF, Woodruff JM, Bansal M, Erlandson RA. The purely epithelioid malignant peripheral nerve sheath tumor. *Am J Surg Pathol*. 1986;10(7):478-490.
452. Laskin WB, Weiss SW, Bratthauer GL. Epithelioid variant of malignant peripheral nerve sheath tumor (malignant epithelioid schwannoma). *Am J Surg Pathol*. 1991;15(12):1136-1145.
453. Hollmann TJ, Hornick JL. INI1-deficient tumors: diagnostic features and molecular genetics. *Am J Surg Pathol*. 2011;35(10):e47-e63.
454. Weiss SW, Langloss JM, Enzinger FM. Value of S-100 protein in the diagnosis of soft tissue tumors with particular reference to benign and malignant Schwann cell tumors. *Lab Invest*. 1983;49(3):299-308.
455. Blochin E, Nonaka D. Diagnostic value of Sox10 immunohistochemical staining for the detection of metastatic melanoma in sentinel lymph nodes. *Histopathology*. 2009;55(5):626-628.
456. Nonaka D, Chiriboga L, Rubin BP. Sox10: a pan-schwannian and melanocytic marker. *Am J Surg Pathol*. 2008;32(9):1291-1298.
456a. Schaefer IM, Fletcher CD, Hornick JL. Loss of H3K27 trimethylation distinguishes malignant peripheral nerve sheath tumors from histologic mimics. *Mod Pathol*. 2016;29(1):4-13.
457. Shimada S, Tsuzuki T, Kuroda M, et al. Nestin expression as a new marker in malignant peripheral nerve sheath tumors. *Pathol Int*. 2007;57(2):60-67.
458. Hui P, Li N, Johnson C, et al. HMGA proteins in malignant peripheral nerve sheath tumor and synovial sarcoma: preferential expression of HMGA2 in malignant peripheral nerve sheath tumor. *Mod Pathol*. 2005;18(11):1519-1526.
459. Wick MR, Swanson PE, Scheithauer BW, Manivel JC. Malignant peripheral nerve sheath tumor. An immunohistochemical study of 62 cases. *Am J Clin Pathol*. 1987;87(4):425-433.
460. Anghileri M, Miceli R, Fiore M, et al. Malignant peripheral nerve sheath tumors: prognostic factors and survival in a series of patients treated at a single institution. *Cancer*. 2006;107(5):1065-1074.
461. Okada K, Hasegawa T, Tajino T, et al. Clinical relevance of pathological grades of malignant peripheral nerve sheath tumor: a multi-institution TMTS study of 56 cases in Northern Japan. *Ann Surg Oncol*. 2007;14(2):597-604.
462. Zou C, Smith KD, Liu J, et al. Clinical, pathological, and molecular variables predictive of malignant peripheral nerve sheath tumor outcome. *Ann Surg*. 2009;249(6):1014-1022.
463. Rey JA, Pestaña A, Bello MJ. Cytogenetics and molecular genetics of nervous system tumors. *Oncol Res*. 1992;4(8-9):321-331.
464. Skuse GR, Kosciolek BA, Rowley PT. Molecular genetic analysis of tumors in von Recklinghausen neurofibromatosis: loss of heterozygosity for chromosome 17. *Genes Chromosomes Cancer*. 1989;1(1):36-41.
465. Berner JM, Sørlie T, Mertens F, et al. Chromosome band 9p21 is frequently altered in malignant peripheral nerve sheath tumors: studies of CDKN2A and other genes of the pRB pathway. *Genes Chromosomes Cancer*. 1999;26(2):151-160.
466. Birindelli S, Perrone F, Oggionni M, et al. Rb and TP53 pathway alterations in sporadic and NF1-related malignant peripheral nerve sheath tumors. *Lab Invest*. 2001;81(6):833-844.
467. Perrone F, Tabano S, Colombo F, et al. p15INK4b, p14ARF, and p16INK4a inactivation in sporadic and neurofibromatosis type 1-related malignant peripheral nerve sheath tumors. *Clin Cancer Res*. 2003;9(11):4132-4138.
468. Storlazzi CT, Brekke HR, Mandahl N, et al. Identification of a novel amplicon at distal 17q containing the BIRC5/SURVIVIN gene in malignant peripheral nerve sheath tumours. *J Pathol*. 2006;209(4):492-500.
468a. Lee W, Teckie S, Wiesner T, et al. PRC2 is recurrently inactivated through EED or SUZ12 loss in malignant peripheral nerve sheath tumors. *Nat Genet*. 2014;46(11):1227-1232.
469. Fletcher CD, Martin-Bates E. Intramuscular and intermuscular lipoma: neglected diagnoses. *Histopathology*. 1988;12(3):275-287.
470. Enzi G. Multiple symmetric lipomatosis: an updated clinical report. *Medicine (Baltimore)*. 1984;63(1):56-64.

For personal use only. No other uses without permission. Copyright ©2017. Elsevier Inc. All rights reserved.

471. Cates JMM, Coffing BN, Harris BT, Black CC. Calretinin expression in tumors of adipose tissue. *Hum Pathol*. 2006;37(3):312-321.
472. Katzer B. Histopathology of rare chondroosteoblastic metaplasia in benign lipomas. *Pathol Res Pract*. 1989;184(4):437-445.
473. Kim YH, Reiner L. Ultrastructure of lipoma. *Cancer*. 1982;50(1):102-106.
474. Solvonuk PF, Taylor GP, Hancock R, et al. Correlation of morphologic and biochemical observations in human lipomas. *Lab Invest*. 1984;51(4):469-474.
475. Allen PW. Selected case from the Arkadi M. Rywlin International Pathology Slide Seminar: sclerotic (fibroma-like) lipoma, dorsum of right hand. *Adv Anat Pathol*. 2013;20(1):68-72.
476. Laskin WB, Fetsch JF, Michal M, Miettinen M. Sclerotic (fibroma-like) lipoma: a distinctive lipoma variant with a predilection for the distal extremities. *Am J Dermatopathol*. 2006;28(4):308-316.
477. Song M, Seo S-H, Jung D-S, et al. Angiomyxolipoma (vascular myxolipoma) of subcutaneous tissue. *Ann Dermatol*. 2009;21(2):189-192.
478. Meis JM, Enzinger FM. Chondroid lipoma. A unique tumor simulating liposarcoma and myxoid chondrosarcoma. *Am J Surg Pathol*. 1993;17(11):1103-1112.
479. Thway K, Flora RS, Fisher C. Chondroid lipoma: an update and review. *Ann Diagn Pathol*. 2012;16(3):230-234.
480. Meis JM, Enzinger FM. Myolipoma of soft tissue. *Am J Surg Pathol*. 1991;15(2):121-125.
481. Enzinger FM, Harvey DA. Spindle cell lipoma. *Cancer*. 1975;36(5):1852-1859.
482. Hawley IC, Krausz T, Evans DJ, Fletcher CD. Spindle cell lipoma—a pseudoangiomatous variant. *Histopathology*. 1994;24(6):565-569.
483. Zamecnik M, Michal M. Angiomatous spindle cell lipoma: report of three cases with immunohistochemical and ultrastructural study and reappraisal of former "pseudoangiomatous" variant. *Pathol Int*. 2007;57(1):26-31.
484. Billings SD, Folpe AL. Diagnostically challenging spindle cell lipomas: a report of 34 "low-fat" and "fat-free" variants. *Am J Dermatopathol*. 2007;29(5):437-442.
485. Suster S, Fisher C. Immunoreactivity for the human hematopoietic progenitor cell antigen (CD34) in lipomatous tumors. *Am J Surg Pathol*. 1997;21(2):195-200.
485a. Chen BJ, Marino-Enriquez A, Fletcher CD, et al. Loss of retinoblastoma protein expression in spindle cell/pleomorphic lipomas and cytogenetically related tumors: an immunohistochemical study with diagnostic implications. *Am J Surg Pathol*. 2012;36(8):1119-1128.
486. Shmookler BM, Enzinger FM. Pleomorphic lipoma: a benign tumor simulating liposarcoma. A clinicopathologic analysis of 48 cases. *Cancer*. 1981;47(1):126-133.
487. Sachdeva MP, Goldblum JR, Rubin BP, Billings SD. Low-fat and fat-free pleomorphic lipomas: a diagnostic challenge. *Am J Dermatopathol*. 2009;31(5):423-426.
488. Schmack I, Patel RM, Folpe AL, et al. Subconjunctival herniated orbital fat: a benign adipocytic lesion that may mimic pleomorphic lipoma and atypical lipomatous tumor. *Am J Surg Pathol*. 2007;31(2):193-198.
489. Dixon AY, McGregor DH, Lee SH. Angiolipomas: an ultrastructural and clinicopathological study. *Hum Pathol*. 1981;12(8):739-747.
490. Hunt SJ, Santa Cruz DJ, Barr RJ. Cellular angiolipoma. *Am J Surg Pathol*. 1990;14(1):75-81.
491. Howard WR, Helwig EB. Angiolipoma. *Arch Dermatol*. 1960;82:924-931.
492. Sciot R, Akerman M, Dal Cin P, et al. Cytogenetic analysis of subcutaneous angiolipoma: further evidence supporting its difference from ordinary pure lipomas: a report of the CHAMP Study Group. *Am J Surg Pathol*. 1997;21(4):441-444.
493. Rushin JM, Flick MW. Pathologic quiz case 1. Intramuscular hemangioma, small vessel type, masseter muscle (also known as infiltrating angiolipoma). *Arch Otolaryngol Head Neck Surg*. 1989;115(7):878-881.
494. Hakim A, Rozeik C. Adrenal and extra-adrenal myelolipomas—a comparative case report. *J Radiol Case Rep*. 2014;8(1):1-12.
495. Gagliardo C, Falanga G, Sutera R, et al. Presacral myelolipoma. A case report and literature review. *Neuroradiol J*. 2014;27(6):764-769.
496. Xiong Y, Wang Y, Lin Y. Primary myelolipoma in posterior mediastinum. *J Thorac Dis*. 2014;6(9):E181-E187.
497. Kumar S, Jayant K, Prasad S, et al. Rare adrenal gland emergencies: a case series of giant myelolipoma presenting with massive hemorrhage and abscess. *Nephrourol Mon*. 2015;7(1):e22671.
498. Reginelli A, Di Grezia G, Izzo A, et al. Imaging of adrenal incidentaloma: our experience. *Int J Surg*. 2014;12(suppl 1):S126-S131.
499. Wang J, Fisher C, Thway K. "Dominant" myelolipoma encasing adrenal cortical carcinoma: an unusual variation of myelolipoma occurring as a synchronous and predominant neoplasm. *Int J Surg Pathol*. 2014;22(8):731-735.
500. Kerkhofs TM, Roumen RM, Demeyere TB, et al. Adrenal tumors with unexpected outcome: a review of the literature. *Int J Endocrinol*. 2015;2015:710514.
501. Bishop E, Eble JN, Cheng L, et al. Adrenal myelolipomas show nonrandom X-chromosome inactivation in hematopoietic elements and fat: support for a clonal origin of myelolipomas. *Am J Surg Pathol*. 2006;30(7):838-843.
502. Kindblom LG, Angervall L, Stener B, Wickbom I. Intermuscular and intramuscular lipomas and hibernomas. A clinical, roentgenologic, histologic, and prognostic study of 46 cases. *Cancer*. 1974;33(3):754-762.
503. Weaver J, Rao P, Goldblum JR, et al. Can MDM2 analytical tests performed on core needle biopsy be relied upon to diagnose well-differentiated liposarcoma? *Mod Pathol*. 2010;23(10):1301-1306.
504. Dionne GP, Seemayer TA. Infiltrating lipomas and angiolipomas revisited. *Cancer*. 1974;33(3):732-738.
505. Bartuma H, Hallor KH, Panagopoulos I, et al. Assessment of the clinical and molecular impact of different cytogenetic subgroups in a series of 272 lipomas with abnormal karyotype. *Genes Chromosomes Cancer*. 2007;46(6):594-606.
506. Fletcher CD, Akerman M, Dal Cin P, et al. Correlation between clinicopathological features and karyotype in lipomatous tumors. A report of 178 cases from the Chromosomes and Morphology (CHAMP) Collaborative Study Group. *Am J Pathol*. 1996;148(2):623-630.
507. Sandberg AA. Updates on the cytogenetics and molecular genetics of bone and soft tissue tumors: lipoma. *Cancer Genet Cytogenet*. 2004;150(2):93-115.
508. Dal Cin P, Sciot R, Polito P, et al. Lesions of 13q may occur independently of deletion of 16q in spindle cell/pleomorphic lipomas. *Histopathology*. 1997;31(3):222-225.
509. Heim S, Mandahl N, Rydholm A, et al. Different karyotypic features characterize different clinico-pathologic subgroups of benign lipogenic tumors. *Int J Cancer*. 1988;42(6):863-867.
510. Mandahl N, Heim S, Arheden K, et al. Three major cytogenetic subgroups can be identified among chromosomally abnormal solitary lipomas. *Hum Genet*. 1988;79(3):203-208.
511. Coffin CM, Lowichik A, Putnam A. Lipoblastoma (LPB): a clinicopathologic and immunohistochemical analysis of 59 cases. *Am J Surg Pathol*. 2009;33(11):1705-1712.
512. Mentzel T, Calonje E, Fletcher CD. Lipoblastoma and lipoblastomatosis: a clinicopathological study of 14 cases. *Histopathology*. 1993;23(6):527-533.
513. de Saint Aubain Somerhausen N, Coindre JM, Debiec-Rychter M, et al. Lipoblastoma in adolescents and young adults: report of six cases with FISH analysis. *Histopathology*. 2008;52(3):294-298.
514. Gisselsson D, Hibbard MK, Dal Cin P, et al. PLAG1 alterations in lipoblastoma: involvement in varied mesenchymal cell types and evidence for alternative oncogenic mechanisms. *Am J Pathol*. 2001;159(3):955-962.
515. Hibbard MK, Kozakewich HP, Dal Cin P, et al. PLAG1 fusion oncogenes in lipoblastoma. *Cancer Res*. 2000;60(17):4869-4872.
516. Furlong MA, Fanburg-Smith JC, Miettinen M. The morphologic spectrum of hibernoma: a clinicopathologic study of 170 cases. *Am J Surg Pathol*. 2001;25(6):809-814.
517. Gisselsson D, Höglund M, Mertens F, et al. Hibernomas are characterized by homozygous deletions in the multiple endocrine neoplasia type I region. Metaphase fluorescence in situ hybridization reveals complex rearrangements not detected by conventional cytogenetics. *Am J Pathol*. 1999;155(1):61-66.
518. Mertens F, Rydholm A, Brosjö O, et al. Hibernomas are characterized by rearrangements of chromosome bands 11q13-21. *Int J Cancer*. 1994;58(4):503-505.
519. Gaffney EF, Hargreaves HK, Semple E, Vellios F. Hibernoma: distinctive light and electron microscopic features and relationship to brown adipose tissue. *Hum Pathol*. 1983;14(8):677-687.
520. Chirieac LR, Dekmezian RH, Ayala AG. Characterization of the myxoid variant of hibernoma. *Ann Diagn Pathol*. 2006;10(2):104-106.
521. Silverman TA, Enzinger FM. Fibrolipomatous hamartoma of nerve. A clinicopathologic analysis of 26 cases. *Am J Surg Pathol*. 1985;9(1):7-14.
522. Alaggio R, Coffin CM, Weiss SW, et al. Liposarcomas in young patients: a study of 82 cases occurring in patients younger than 22 years of age. *Am J Surg Pathol*. 2009;33(5):645-658.
523. Coffin CM, Alaggio R. Adipose and myxoid tumors of childhood and adolescence. *Pediatr Dev Pathol*. 2012;15(1 suppl):239-254.
524. Chung EB. Pitfalls in diagnosing benign soft tissue tumors in infancy and childhood. *Pathol Annu*. 1985;20(Pt 2):323-386.
525. Enzinger FM, Winslow DJ. Liposarcoma. A study of 103 cases. *Virchows Arch Pathol Anat Physiol Klin Med*. 1962;335:367-388.
526. Antonescu CR, Elahi A, Humphrey M, et al. Specificity of TLS-CHOP rearrangement for classic myxoid/round cell liposarcoma: absence in predominantly myxoid well-differentiated liposarcomas. *J Mol Diagn*. 2000;2(3):132-138.
527. Mentzel T, Palmedo G, Hantschke M, et al. Mixed-type liposarcoma: clinicopathological, immunohistochemical, and molecular analysis of a case arising in deep soft tissues

For personal use only. No other uses without permission. Copyright ©2017. Elsevier Inc. All rights reserved.

of the lower extremity. *Virchows Arch*. 2008;453(2):197-201.
528. Folpe AL, Weiss SW. Lipoleiomyosarcoma (well-differentiated liposarcoma with leiomyosarcomatous differentiation): a clinicopathologic study of nine cases including one with dedifferentiation. *Am J Surg Pathol*. 2002;26(6):742-749.
529. Argani P, Facchetti F, Inghirami G, Rosai J. Lymphocyte-rich well-differentiated liposarcoma: report of nine cases. *Am J Surg Pathol*. 1997;21(8):884-895.
530. Kraus MD, Guillou L, Fletcher CD. Well-differentiated inflammatory liposarcoma: an uncommon and easily overlooked variant of a common sarcoma. *Am J Surg Pathol*. 1997;21(5):518-527.
531. Dei Tos AP, Mentzel T, Newman PL, Fletcher CD. Spindle cell liposarcoma, a hitherto unrecognized variant of liposarcoma. Analysis of six cases. *Am J Surg Pathol*. 1994;18(9):913-921.
532. Deyrup AT, Chibon F, Guillou L, et al. Fibrosarcoma-like lipomatous neoplasm: a reappraisal of so-called spindle cell liposarcoma defining a unique lipomatous tumor unrelated to other liposarcomas. *Am J Surg Pathol*. 2013;37(9):1373-1378.
532a. Marino-Enriguez A, Nascimento AF, Ligon AH, et al. Atypical spindle cell lipomatous tumor: clinicopathologic characterization of 232 cases demonstrating a morphologic spectrum. *Am J Surg Pathol*. 2017;41(2):234-244.
533. Mandahl N, Akerman M, Aman P, et al. Duplication of chromosome segment 12q15-24 is associated with atypical lipomatous tumors: a report of the CHAMP collaborative study group. CHromosomes And MorPhology. *Int J Cancer*. 1996;67(5):632-635.
534. Rosai J, Akerman M, Dal Cin P, et al. Combined morphologic and karyotypic study of 59 atypical lipomatous tumors. Evaluation of their relationship and differential diagnosis with other adipose tissue tumors (a report of the CHAMP Study Group). *Am J Surg Pathol*. 1996;20(10):1182-1189.
535. Sirvent N, Coindre J-M, Maire G, et al. Detection of MDM2-CDK4 amplification by fluorescence in situ hybridization in 200 paraffin-embedded tumor samples: utility in diagnosing adipocytic lesions and comparison with immunohistochemistry and real-time PCR. *Am J Surg Pathol*. 2007;31(10):1476-1489.
536. Binh MBN, Sastre-Garau X, Guillou L, et al. MDM2 and CDK4 immunostainings are useful adjuncts in diagnosing well-differentiated and dedifferentiated liposarcoma subtypes: a comparative analysis of 559 soft tissue neoplasms with genetic data. *Am J Surg Pathol*. 2005;29(10):1340-1347.
537. He M, Aisner S, Benevenia J, et al. p16 immunohistochemistry as an alternative marker to distinguish atypical lipomatous tumor from deep-seated lipoma. *Appl Immunohistochem Mol Morphol*. 2009;17(1):51-56.
538. Thway K, Flora R, Shah C, et al. Diagnostic utility of p16, CDK4, and MDM2 as an immunohistochemical panel in distinguishing well-differentiated and dedifferentiated liposarcomas from other adipocytic tumors. *Am J Surg Pathol*. 2012;36(3):462-469.
539. de Vreeze R, de Jong D, Nederlof P, et al. Multifocal myxoid liposarcoma—metastasis or second primary tumor?: a molecular biological analysis. *J Mol Diagn*. 2010;12(2):238-243.
540. Wei Y-C, Li C-F, Eng H-L, et al. Myxoid liposarcoma with cartilaginous differentiation: identification of the same type II TLS-CHOP fusion gene transcript in both lipogenic and chondroid components. *Appl Immunohistochem Mol Morphol*. 2007;15(4):477-480.
541. Panagopoulos I, Höglund M, Mertens F, et al. Fusion of the EWS and CHOP genes in myxoid liposarcoma. *Oncogene*. 1996;12(3):489-494.
542. Oikawa K, Ishida T, Imamura T, et al. Generation of the novel monoclonal antibody against TLS/EWS-CHOP chimeric oncoproteins that is applicable to one of the most sensitive assays for myxoid and round cell liposarcomas. *Am J Surg Pathol*. 2006;30(3):351-356.
543. Antonescu CR, Tschernyavsky SJ, Decuseara R, et al. Prognostic impact of P53 status, TLS-CHOP fusion transcript structure, and histological grade in myxoid liposarcoma: a molecular and clinicopathologic study of 82 cases. *Clin Cancer Res*. 2001;7(12):3977-3987.
544. Smith TA, Easley KA, Goldblum JR. Myxoid/round cell liposarcoma of the extremities. A clinicopathologic study of 29 cases with particular attention to extent of round cell liposarcoma. *Am J Surg Pathol*. 1996;20(2):171-180.
545. Tallini G, Akerman M, Dal Cin P, et al. Combined morphologic and karyotypic study of 28 myxoid liposarcomas. Implications for a revised morphologic typing, (a report from the CHAMP Group). *Am J Surg Pathol*. 1996;20(9):1047-1055.
546. Downes KA, Goldblum JR, Montgomery EA, Fisher C. Pleomorphic liposarcoma: a clinicopathologic analysis of 19 cases. *Mod Pathol*. 2001;14(3):179-184.
547. Ghadimi MP, Liu P, Peng T, et al. Pleomorphic liposarcoma: clinical observations and molecular variables. *Cancer*. 2011;117(23):5359-5369.
548. Hornick JL, Bosenberg MW, Mentzel T, et al. Pleomorphic liposarcoma: clinicopathologic analysis of 57 cases. *Am J Surg Pathol*. 2004;28(10):1257-1267.
549. Huang H-Y, Antonescu CR. Epithelioid variant of pleomorphic liposarcoma: a comparative immunohistochemical and ultrastructural analysis of six cases with emphasis on overlapping features with epithelial malignancies. *Ultrastruct Pathol*. 2002;26(5):299-308.
550. Miettinen M, Enzinger FM. Epithelioid variant of pleomorphic liposarcoma: a study of 12 cases of a distinctive variant of high-grade liposarcoma. *Mod Pathol*. 1999;12(7):722-728.
551. Henricks WH, Chu YC, Goldblum JR, Weiss SW. Dedifferentiated liposarcoma: a clinicopathological analysis of 155 cases with a proposal for an expanded definition of dedifferentiation. *Am J Surg Pathol*. 1997;21(3):271-281.
552. McCormick D, Mentzel T, Beham A, Fletcher CD. Dedifferentiated liposarcoma. Clinicopathologic analysis of 32 cases suggesting a better prognostic subgroup among pleomorphic sarcomas. *Am J Surg Pathol*. 1994;18(12):1213-1223.
553. Evans HL. Atypical lipomatous tumor, its variants, and its combined forms: a study of 61 cases, with a minimum follow-up of 10 years. *Am J Surg Pathol*. 2007;31(1):1-14.
554. Evans HL, Soule EH, Winkelmann RK. Atypical lipoma, atypical intramuscular lipoma, and well differentiated retroperitoneal liposarcoma: a reappraisal of 30 cases formerly classified as well differentiated liposarcoma. *Cancer*. 1979;43(2):574-584.
555. Weiss SW, Rao VK. Well-differentiated liposarcoma (atypical lipoma) of deep soft tissue of the extremities, retroperitoneum, and miscellaneous sites. A follow-up study of 92 cases with analysis of the incidence of "dedifferentiation.". *Am J Surg Pathol*. 1992;16(11):1051-1058.
556. Binh MBN, Guillou L, Hostein I, et al. Dedifferentiated liposarcomas with divergent myosarcomatous differentiation developed in the internal trunk: a study of 27 cases and comparison to conventional dedifferentiated liposarcomas and leiomyosarcomas. *Am J Surg Pathol*. 2007;31(10):1557-1566.
557. Guillou L, Aurias A. Soft tissue sarcomas with complex genomic profiles. *Virchows Arch*. 2010;456(2):201-217.
558. Tallini G, Erlandson RA, Brennan MF, Woodruff JM. Divergent myosarcomatous differentiation in retroperitoneal liposarcoma. *Am J Surg Pathol*. 1993;17(6):546-556.
559. Boland JM, Weiss SW, Oliveira AM, et al. Liposarcomas with mixed well-differentiated and pleomorphic features: a clinicopathologic study of 12 cases. *Am J Surg Pathol*. 2010;34(6):837-843.
560. Mariño-Enríquez A, Fletcher CDM, Dal Cin P, Hornick JL. Dedifferentiated liposarcoma with "homologous" lipoblastic (pleomorphic liposarcoma-like) differentiation: clinicopathologic and molecular analysis of a series suggesting revised diagnostic criteria. *Am J Surg Pathol*. 2010;34(8):1122-1131.
561. Fanburg-Smith JC, Miettinen M. Liposarcoma with meningothelial-like whorls: a study of 17 cases of a distinctive histological pattern associated with dedifferentiated liposarcoma. *Histopathology*. 1998;33(5):414-424.
562. Nascimento AG, Kurtin PJ, Guillou L, Fletcher CD. Dedifferentiated liposarcoma: a report of nine cases with a peculiar neurallike whorling pattern associated with metaplastic bone formation. *Am J Surg Pathol*. 1998;22(8):945-955.
563. Horvai AE, Schaefer JT, Nakakura EK, O'Donnell RJ. Immunostaining for peroxisome proliferator gamma distinguishes dedifferentiated liposarcoma from other retroperitoneal sarcomas. *Mod Pathol*. 2008;21(5):517-524.
564. Horvai AE, DeVries S, Roy R, et al. Similarity in genetic alterations between paired well-differentiated and dedifferentiated components of dedifferentiated liposarcoma. *Mod Pathol*. 2009;22(11):1477-1488.
565. Rieker RJ, Weitz J, Lehner B, et al. Genomic profiling reveals subsets of dedifferentiated liposarcoma to follow separate molecular pathways. *Virchows Arch*. 2010;456(3):277-285.
566. Yoshida A, Ushiku T, Motoi T, et al. Well-differentiated liposarcoma with low-grade osteosarcomatous component: an underrecognized variant. *Am J Surg Pathol*. 2010;34(9):1361-1366.
567. Farshid G, Weiss SW. Massive localized lymphedema in the morbidly obese: a histologically distinct reactive lesion simulating liposarcoma. *Am J Surg Pathol*. 1998;22(10):1277-1283.
568. Adegboyega PA, Qiu S. Hemangioma versus vascular malformation: presence of nerve bundle is a diagnostic clue for vascular malformation. *Arch Pathol Lab Med*. 2005;129(6):772-775.
569. Meijer-Jorna LB, Breugem CC, de Boer OJ, et al. Presence of a distinct neural component in congenital vascular malformations relates to the histological type and location of the lesion. *Hum Pathol*. 2009;40(10):1467-1473.
570. Coffin CM, Dehner LP. Vascular tumors in children and adolescents: a clinicopathologic

For personal use only. No other uses without permission. Copyright ©2017. Elsevier Inc. All rights reserved.

study of 228 tumors in 222 patients. *Pathol Annu*. 1993;28(Pt 1):97-120.
571. Rao VK, Weiss SW. Angiomatosis of soft tissue. An analysis of the histologic features and clinical outcome in 51 cases. *Am J Surg Pathol*. 1992;16(8):764-771.
572. Finn MC, Glowacki J, Mulliken JB. Congenital vascular lesions: clinical application of a new classification. *J Pediatr Surg*. 1983;18(6):894-900.
573. Calonje E, Mentzel T, Fletcher CD. Pseudomalignant perineurial invasion in cellular ("infantile") capillary haemangiomas. *Histopathology*. 1995;26(2):159-164.
574. Gratzinger D, Zhao S, West R, et al. The transcription factor LMO2 is a robust marker of vascular endothelium and vascular neoplasms and selected other entities. *Am J Clin Pathol*. 2009;131(2):264-278.
575. Syed SP, Martin A-M, Haupt HM, et al. Angiostatin receptor annexin II in vascular tumors including angiosarcoma. *Hum Pathol*. 2007;38(3):508-513.
576. Debelenko LV, Perez-Atayde AR, Mulliken JB, et al. D2-40 immunohistochemical analysis of pediatric vascular tumors reveals positivity in kaposiform hemangioendothelioma. *Mod Pathol*. 2005;18(11):1454-1460.
577. Nguyen VA, Kutzner H, Fürhapter C, et al. Infantile hemangioma is a proliferation of LYVE-1-negative blood endothelial cells without lymphatic competence. *Mod Pathol*. 2006;19(2):291-298.
578. Smoller BR, Apfelberg DB. Infantile (juvenile) capillary hemangioma: a tumor of heterogeneous cellular elements. *J Cutan Pathol*. 1993;20(4):330-336.
579. Walter JW, Blei F, Anderson JL, et al. Genetic mapping of a novel familial form of infantile hemangioma. *Am J Med Genet*. 1999;82(1):77-83.
580. Blei F, Walter J, Orlow SJ, Marchuk DA. Familial segregation of hemangiomas and vascular malformations as an autosomal dominant trait. *Arch Dermatol*. 1998;134(6):718-722.
581. Metry DW, Haggstrom AN, Drolet BA, et al. A prospective study of PHACE syndrome in infantile hemangiomas: demographic features, clinical findings, and complications. *Am J Med Genet A*. 2006;140(9):975-986.
582. Tompkins VN, Walsh TS. Some observations on the strawberry nevus of infancy. *Cancer*. 1956;9(5):869-904.
583. Drut R, Altamirano E. Endothelial cells of intramuscular (infantile) hemangioma express glut1. *Int J Surg Pathol*. 2007;15(2):166-168.
584. Weinblatt ME, Kahn E, Kochen JA. Hemangioendothelioma with intravascular coagulation and ischemic colitis. *Cancer*. 1984;54(10):2300-2304.
585. Calonje E, Fletcher CD. Sinusoidal hemangioma. A distinctive benign vascular neoplasm within the group of cavernous hemangiomas. *Am J Surg Pathol*. 1991;15(12):1130-1135.
586. Koutlas IG, Jessurun J. Arteriovenous hemangioma: a clinicopathological and immunohistochemical study. *J Cutan Pathol*. 1994;21(4):343-349.
587. Lee BB, Baumgartner I, Berlien P, et al. Diagnosis and treatment of venous malformations. Consensus document of the International Union of Phlebology (IUP): updated 2013. *Int Angiol*. 2015;34(2):97-149.
588. Beham A, Fletcher CD. Intramuscular angioma: a clinicopathological analysis of 74 cases. *Histopathology*. 1991;18(1):53-59.
589. Pegado PF, Ordi QC, Roche S, et al. Intravascular papillary endothelial hyperplasia (Masson tumor) mimicking a sarcoma and developing from an arteriovenous hemodialysis fistula. *Skeletal Radiol*. 2015;44(6):859-862.
590. Albrecht S, Kahn HJ. Immunohistochemistry of intravascular papillary endothelial hyperplasia. *J Cutan Pathol*. 1990;17(1):16-21.
591. Pins MR, Rosenthal DI, Springfield DS, Rosenberg AE. Florid extravascular papillary endothelial hyperplasia (Masson's pseudoangiosarcoma) presenting as a soft-tissue sarcoma. *Arch Pathol Lab Med*. 1993;117(3):259-263.
592. Weiss SW, Enzinger FM. Spindle cell hemangioendothelioma. A low-grade angiosarcoma resembling a cavernous hemangioma and Kaposi's sarcoma. *Am J Surg Pathol*. 1986;10(8):521-530.
593. Perkins P, Weiss SW. Spindle cell hemangioendothelioma. An analysis of 78 cases with reassessment of its pathogenesis and biologic behavior. *Am J Surg Pathol*. 1996;20(10):1196-1204.
594. Fletcher CD, Beham A, Schmid C. Spindle cell haemangioendothelioma: a clinicopathological and immunohistochemical study indicative of a non-neoplastic lesion. *Histopathology*. 1991;18(4):291-301.
595. Chan JK, Hui PK, Ng CS, et al. Epithelioid haemangioma (angiolymphoid hyperplasia with eosinophilia) and Kimura's disease in Chinese. *Histopathology*. 1989;15(6):557-574.
596. Urabe A, Tsuneyoshi M, Enjoji M. Epithelioid hemangioma versus Kimura's disease. A comparative clinicopathologic study. *Am J Surg Pathol*. 1987;11(10):758-766.
597. Fetsch JF, Sesterhenn IA, Miettinen M, Davis CJ. Epithelioid hemangioma of the penis: a clinicopathologic and immunohistochemical analysis of 19 cases, with special reference to exuberant examples often confused with epithelioid hemangioendothelioma and epithelioid angiosarcoma. *Am J Surg Pathol*. 2004;28(4):523-533.
597a. van Jzendoorn DG, de Jong D, Romagosa C, et al. Fusion events lead to the truncation of FOS in epithelioid hemangioma of bone. *Genes Chromosomes Cancer*. 2015;54(9):565-574.
597b. Antonescu CR, Chen HW, Zhang L, et al. ZFP36-FOSB fusion defines a subset of epithelioid hemangioma with atypical features. *Genes Chromosomes Cancer*. 2014;53(11):951-959.
598. Moesner J, Pallesen R, Sørensen B. Angiolymphoid hyperplasia with eosinophilia (Kimura's disease). A case with dermal lesions in the knee region and a popliteal arteriovenous fistula. *Arch Dermatol*. 1981;117(10):650-653.
599. Guillou L, Calonje E, Speight P, et al. Hobnail hemangioma: a pseudomalignant vascular lesion with a reappraisal of targetoid hemosiderotic hemangioma. *Am J Surg Pathol*. 1999;23(1):97-105.
600. Brown JG, Folpe AL, Rao P, et al. Primary vascular tumors and tumor-like lesions of the kidney: a clinicopathologic analysis of 25 cases. *Am J Surg Pathol*. 2010;34(7):942-949.
601. Kryvenko ON, Gupta NS, Meier FA, et al. Anastomosing hemangioma of the genitourinary system: eight cases in the kidney and ovary with immunohistochemical and ultrastructural analysis. *Am J Clin Pathol*. 2011;136(3):450-457.
602. Montgomery E, Epstein JI. Anastomosing hemangioma of the genitourinary tract: a lesion mimicking angiosarcoma. *Am J Surg Pathol*. 2009;33(9):1364-1369.
603. Padilla RS, Orkin M, Rosai J. Acquired "tufted" angioma (progressive capillary hemangioma). A distinctive clinicopathologic entity related to lobular capillary hemangioma. *Am J Dermatopathol*. 1987;9(4):292-300.
604. Tille JC, Morris MA, Bründler MA, Pepper MS. Familial predisposition to tufted angioma: identification of blood and lymphatic vascular components. *Clin Genet*. 2003;63(5):393-399.
605. Devaney K, Vinh TN, Sweet DE. Skeletal-extraskeletal angiomatosis. A clinicopathological study of fourteen patients and nosologic considerations. *J Bone Joint Surg Am*. 1994;76(6):878-891.
606. Weiss SW, Enzinger FM. Epithelioid hemangioendothelioma: a vascular tumor often mistaken for a carcinoma. *Cancer*. 1982;50(5):970-981.
607. Williams SB, Butler BC, Gilkey FW, et al. Epithelioid hemangioendothelioma with osteoclastlike giant cells. *Arch Pathol Lab Med*. 1993;117(3):315-318.
608. Weiss SW, Ishak KG, Dail DH, et al. Epithelioid hemangioendothelioma and related lesions. *Semin Diagn Pathol*. 1986;3(4):259-287.
609. Ellis GL, Kratochvil FJ. Epithelioid hemangioendothelioma of the head and neck: a clinicopathologic report of twelve cases. *Oral Surg Oral Med Oral Pathol*. 1986;61(1):61-68.
610. Mentzel T, Beham A, Calonje E, et al. Epithelioid hemangioendothelioma of skin and soft tissues: clinicopathologic and immunohistochemical study of 30 cases. *Am J Surg Pathol*. 1997;21(4):363-374.
611. Deyrup AT, Tighiouart M, Montag AG, Weiss SW. Epithelioid hemangioendothelioma of soft tissue: a proposal for risk stratification based on 49 cases. *Am J Surg Pathol*. 2008;32(6):924-927.
612. Errani C, Zhang L, Sung YS, et al. A novel WWTR1-CAMTA1 gene fusion is a consistent abnormality in epithelioid hemangioendothelioma of different anatomic sites. *Genes Chromosomes Cancer*. 2011;50(8):644-653.
613. Tanas MR, Sboner A, Oliveira AM, et al. Identification of a disease-defining gene fusion in epithelioid hemangioendothelioma. *Sci Transl Med*. 2011;3(98):98ra82.
614. Doyle LA, Fletcher CD, Hornick JL. Nuclear expression of CAMTA1 distinguishes epithelioid hemangioendothelioma from histologic mimics. *Am J Surg Pathol*. 2016;40(1):94-102.
615. Billings SD, Folpe AL, Weiss SW. Epithelioid sarcoma-like hemangioendothelioma. *Am J Surg Pathol*. 2003;27(1):48-57.
616. Hornick JL, Fletcher CDM. Pseudomyogenic hemangioendothelioma: a distinctive, often multicentric tumor with indolent behavior. *Am J Surg Pathol*. 2011;35(2):190-201.
616a. Hung YP, Fletcher CD, Hornick JL. FOSB is a useful diagnostic marker for pseudomyogenic hemangioendothelioma. *Am J Surg Pathol*. 2017;41(5):596-606.
617. Lyons LL, North PE, Mac-Moune Lai F, et al. Kaposiform hemangioendothelioma: a study of 33 cases emphasizing its pathologic, immunophenotypic, and biologic uniqueness from juvenile hemangioma. *Am J Surg Pathol*. 2004;28(5):559-568.
618. Zukerberg LR, Nickoloff BJ, Weiss SW. Kaposiform hemangioendothelioma of infancy and childhood. An aggressive neoplasm associated with Kasabach-Merritt syndrome and lymphangiomatosis. *Am J Surg Pathol*. 1993;17(4):321-328.
619. Méndez R, Capdevila A, Tellado MG, et al. Kaposiform hemangioendothelioma associated with Milroy's disease (primary hereditary lymphedema). *J Pediatr Surg*. 2003;38(7):E9-E12.

For personal use only. No other uses without permission. Copyright ©2017. Elsevier Inc. All rights reserved.

620. Le Huu AR, Jokinen CH, Rubin BP, et al. Expression of prox1, lymphatic endothelial nuclear transcription factor, in Kaposiform hemangioendothelioma and tufted angioma. *Am J Surg Pathol*. 2010;34(11):1563-1573.
621. Blatt J, Stavas J, Moats-Staats B, et al. Treatment of childhood kaposiform hemangioendothelioma with sirolimus. *Pediatr Blood Cancer*. 2010;55(7):1396-1398.
622. Haisley-Royster C, Enjolras O, Frieden IJ, et al. Kasabach-merritt phenomenon: a retrospective study of treatment with vincristine. *J Pediatr Hematol Oncol*. 2002;24(6):459-462.
623. Hermans DJJ, van Beynum IM, van der Vijver RJ, et al. Kaposiform hemangioendothelioma with Kasabach-Merritt syndrome: a new indication for propranolol treatment. *J Pediatr Hematol Oncol*. 2011;33(4):e171-e173.
624. Dabska M. Malignant endovascular papillary angioendothelioma of the skin in childhood. Clinicopathologic study of 6 cases. *Cancer*. 1969;24(3):503-510.
625. Colmenero I, Hoeger PH. Vascular tumours in infants. Part II: vascular tumours of intermediate malignancy [corrected] and malignant tumours. *Br J Dermatol*. 2014;171(3):474-484.
626. Fanburg-Smith JC, Michal M, Partanen TA, et al. Papillary intralymphatic angioendothelioma (PILA): a report of twelve cases of a distinctive vascular tumor with phenotypic features of lymphatic vessels. *Am J Surg Pathol*. 1999;23(9):1004-1010.
627. Neves RI, Stevenson J, Hancey MJ, et al. Endovascular papillary angioendothelioma (Dabska tumor): underrecognized malignant tumor in childhood. *J Pediatr Surg*. 2011;46(1):e25-e28.
628. Calonje E, Fletcher CD, Wilson-Jones E, Rosai J. Retiform hemangioendothelioma. A distinctive form of low-grade angiosarcoma delineated in a series of 15 cases. *Am J Surg Pathol*. 1994;18(2):115-125.
629. Quecedo E, Martínez-Escribano JA, Febrer I, et al. Dabska tumor developing within a preexisting vascular malformation. *Am J Dermatopathol*. 1996;18(3):302-307.
630. Sanz-Trelles A, Rodrigo-Fernandez I, Ayala-Carbonero A, Contreras-Rubio F. Retiform hemangioendothelioma. A new case in a child with diffuse endovascular papillary endothelial proliferation. *J Cutan Pathol*. 1997;24(7):440-444.
631. Folpe AL, Veikkola T, Valtola R, Weiss SW. Vascular endothelial growth factor receptor-3 (VEGFR-3): a marker of vascular tumors with presumed lymphatic differentiation, including Kaposi's sarcoma, kaposiform and Dabska-type hemangioendotheliomas, and a subset of angiosarcomas. *Mod Pathol*. 2000;13(2):180-185.
632. Miettinen M, Wang Z-F. Prox1 transcription factor as a marker for vascular tumors-evaluation of 314 vascular endothelial and 1086 nonvascular tumors. *Am J Surg Pathol*. 2012;36(3):351-359.
633. Fukunaga M, Suzuki K, Saegusa N, Folpe AL. Composite hemangioendothelioma: report of 5 cases including one with associated Maffucci syndrome. *Am J Surg Pathol*. 2007;31(10):1567-1572.
634. Nayler SJ, Rubin BP, Calonje E, et al. Composite hemangioendothelioma: a complex, low-grade vascular lesion mimicking angiosarcoma. *Am J Surg Pathol*. 2000;24(3):352-361.
635. Deyrup AT, Miettinen M, North PE, et al. Pediatric cutaneous angiosarcomas: a clinicopathologic study of 10 cases. *Am J Surg Pathol*. 2011;35(1):70-75.
636. Deyrup AT, Miettinen M, North PE, et al. Angiosarcomas arising in the viscera and soft tissue of children and young adults: a clinicopathologic study of 15 cases. *Am J Surg Pathol*. 2009;33(2):264-269.
637. Burke AP, Virmani R. Sarcomas of the great vessels. A clinicopathologic study. *Cancer*. 1993;71(5):1761-1773.
638. Mayer F, Aebert H, Rudert M, et al. Primary malignant sarcomas of the heart and great vessels in adult patients—a single-center experience. *Oncologist*. 2007;12(9):1134-1142.
639. Sebenik M, Ricci A, DiPasquale B, et al. Undifferentiated intimal sarcoma of large systemic blood vessels: report of 14 cases with immunohistochemical profile and review of the literature. *Am J Surg Pathol*. 2005;29(9):1184-1193.
640. Nanus DM, Kelsen D, Clark DG. Radiation-induced angiosarcoma. *Cancer*. 1987;60(4):777-779.
641. Joo Y-T, Jeong C-Y, Jung E-J, et al. Intra-abdominal angiosarcoma developing in a capsule of a foreign body: report of a case with associated hemorrhagic diathesis. *World J Surg Oncol*. 2005;3:60.
642. Byers RJ, McMahon RF, Freemont AJ, et al. Epithelioid angiosarcoma arising in an arteriovenous fistula. *Histopathology*. 1992;21(1):87-89.
643. Wehrli BM, Janzen DL, Shokeir O, et al. Epithelioid angiosarcoma arising in a surgically constructed arteriovenous fistula: a rare complication of chronic immunosuppression in the setting of renal transplantation. *Am J Surg Pathol*. 1998;22(9):1154-1159.
644. Idrees MT, Kuhar M, Ulbright TM, et al. Clonal evidence for the progression of a testicular germ cell tumor to angiosarcoma. *Hum Pathol*. 2010;41(1):139-144.
645. Andreu V, Elizalde I, Mallafré C, et al. Plexiform neurofibromatosis and angiosarcoma of the liver in von Recklinghausen disease. *Am J Gastroenterol*. 1997;92(7):1229-1230.
646. Meis-Kindblom JM, Kindblom LG. Angiosarcoma of soft tissue: a study of 80 cases. *Am J Surg Pathol*. 1998;22(6):683-697.
647. Fletcher CD, Beham A, Bekir S, et al. Epithelioid angiosarcoma of deep soft tissue: a distinctive tumor readily mistaken for an epithelial neoplasm. *Am J Surg Pathol*. 1991;15(10):915-924.
648. DeYoung BR, Swanson PE, Argenyi ZB, et al. CD31 immunoreactivity in mesenchymal neoplasms of the skin and subcutis: report of 145 cases and review of putative immunohistologic markers of endothelial differentiation. *J Cutan Pathol*. 1995;22(3):215-222.
649. Al-Abbadi MA, Almasri NM, Al-Quran S, Wilkinson EJ. Cytokeratin and epithelial membrane antigen expression in angiosarcomas: an immunohistochemical study of 33 cases. *Arch Pathol Lab Med*. 2007;131(2):288-292.
650. Rao P, Lahat G, Arnold C, et al. Angiosarcoma: a tissue microarray study with diagnostic implications. *Am J Dermatopathol*. 2013;35(4):432-437.
651. Dettenborn T, Wermker K, Schulze H-J, et al. Prognostic features in angiosarcoma of the head and neck: a retrospective monocenter study. *J Craniomaxillofac Surg*. 2014;42(8):1623-1628.
652. Deyrup AT, McKenney JK, Tighiouart M, et al. Sporadic cutaneous angiosarcomas: a proposal for risk stratification based on 69 cases. *Am J Surg Pathol*. 2008;32(1):72-77.
653. Wiegand S, Eivazi B, Barth PJ, et al. Pathogenesis of lymphangiomas. *Virchows Arch*. 2008;453(1):1-8.
654. Alpman A, Cogulu O, Akgul M, et al. Prenatally diagnosed Turner syndrome and cystic hygroma: incidence and reasons for referrals. *Fetal Diagn Ther*. 2009;25(1):58-61.
655. Grapsa D, Mavrigiannaki P, Kleanthis C, et al. Autopsy findings in fetuses with cystic hygroma: a literature review and our center's experience. *Clin Exp Obstet Gynecol*. 2012;39(3):369-373.
656. Ramani P, Shah A. Lymphangiomatosis. Histologic and immunohistochemical analysis of four cases. *Am J Surg Pathol*. 1993;17(4):329-335.
657. Shah AR, Dinwiddie R, Woolf D, et al. Generalized lymphangiomatosis and chylothorax in the pediatric age group. *Pediatr Pulmonol*. 1992;14(2):126-130.
658. Trenor CC, Chaudry G. Complex lymphatic anomalies. *Semin Pediatr Surg*. 2014;23(4):186-190.
659. Gomez CS, Calonje E, Ferrar DW, et al. Lymphangiomatosis of the limbs. Clinicopathologic analysis of a series with a good prognosis. *Am J Surg Pathol*. 1995;19(2):125-133.
660. Enterline HT, Roberts B. Lymphangiopericytoma; case report of a previously undescribed tumor type. *Cancer*. 1955;8(3):582-587.
661. Gupta R, Kitaichi M, Inoue Y, et al. Lymphatic manifestations of lymphangioleiomyomatosis. *Lymphology*. 2014;47(3):106-117.
662. Meraj R, Wikenheiser-Brokamp KA, Young LR, McCormack FX. Lymphangioleiomyomatosis: new concepts in pathogenesis, diagnosis, and treatment. *Semin Respir Crit Care Med*. 2012;33(5):486-497.
663. Hansen T, Katenkamp K, Bittinger F, et al. D2-40 labeling in lymphangiomyoma/lymphangiomyomatosis of the soft tissue: further evidence of lymphangiogenic tumor histogenesis. *Virchows Arch*. 2007;450(4):449-453.
664. Chan JK, Tsang WY, Pau MY, et al. Lymphangiomyomatosis and angiomyolipoma: closely related entities characterized by hamartomatous proliferation of HMB-45-positive smooth muscle. *Histopathology*. 1993;22(5):445-455.
665. Xu K-F, Lo BH. Lymphangioleiomyomatosis: differential diagnosis and optimal management. *Ther Clin Risk Manag*. 2014;10:691-700.
666. Hornick JL, Fletcher CDM. PEComa: what do we know so far? *Histopathology*. 2006;48(1):75-82.
667. Folpe AL, Mentzel T, Lehr H-A, et al. Perivascular epithelioid cell neoplasms of soft tissue and gynecologic origin: a clinicopathologic study of 26 cases and review of the literature. *Am J Surg Pathol*. 2005;29(12):1558-1575.
668. Folpe AL, Kwiatkowski DJ. Perivascular epithelioid cell neoplasms: pathology and pathogenesis. *Hum Pathol*. 2010;41(1):1-15.
669. Harris GC, McCulloch TA, Perks G, Fisher C. Malignant perivascular epithelioid cell tumour ("PEComa") of soft tissue: a unique case. *Am J Surg Pathol*. 2004;28(12):1655-1658.
670. Hodge JC, Pearce KE, Wang X, et al. Molecular cytogenetic analysis for TFE3 rearrangement in Xp11.2 renal cell carcinoma and alveolar soft part sarcoma: validation and clinical experience with 75 cases. *Mod Pathol*. 2014;27(1):113-127.
671. Schoolmeester JK, Dao LN, Sukov WR, et al. TFE3 Translocation-associated perivascular epithelioid cell neoplasm (PEComa) of the gynecologic tract: morphology, immunophenotype, differential diagnosis. *Am J Surg Pathol*. 2015;39(3):394-404.
672. Shen Q, Rao Q, Xia Q-Y, et al. Perivascular epithelioid cell tumor (PEComa) with TFE3

For personal use only. No other uses without permission. Copyright ©2017. Elsevier Inc. All rights reserved.

gene rearrangement: clinicopathological, immunohistochemical, and molecular features. *Virchows Arch*. 2014;465(5):607-613.
672a. Argani P, Aulmann S, Illei PB, et al. A distinctive subset of PEComas harbors TFE3 gene fusions. *Am J Surg Pathol*. 2010;334(10):1395-1406.
672b. Rao Q, Shen Q, Xia QY, et al. PSF/SFPQ is a very common gene fusion partner in TFE3 rearrangement-associated perivascular epithelioid cell tumors (PEComas) and melanotic Xp11 translocation renal cancers: clinicopathologic, immunohistochemical, and molecular characteristics suggesting classification as a distinct entity. *Am J Surg Pathol*. 2015;39(9):1181-1196.
673. Seyama K, Kira S, Takahashi H, et al. Longitudinal follow-up study of 11 patients with pulmonary lymphangioleiomyomatosis: diverse clinical courses of LAM allow some patients to be treated without anti-hormone therapy. *Respirology*. 2001;6(4):331-340.
674. Sun Y, Zhang E, Lao T, et al. Progesterone and estradiol synergistically promote the lung metastasis of tuberin-deficient cells in a preclinical model of lymphangioleiomyomatosis. *Horm Cancer*. 2014;5(5):284-298.
675. Taveira-DaSilva AM, Moss J. Management of lymphangioleiomyomatosis. *F1000Prime Rep*. 2014;6:116.
676. Stewart FW, Treves N. Lymphangiosarcoma in postmastectomy lymphedema; a report of six cases in elephantiasis chirurgica. *Cancer*. 1948;1(1):64-81.
677. Grobmyer SR, Daly JM, Glotzbach RE, Grobmyer AJ. Role of surgery in the management of postmastectomy extremity angiosarcoma (Stewart-Treves syndrome). *J Surg Oncol*. 2000;73(3):182-188.
678. Miettinen M, Lehto VP, Virtanen I. Postmastectomy angiosarcoma (Stewart-Treves syndrome). Light-microscopic, immunohistological, and ultrastructural characteristics of two cases. *Am J Surg Pathol*. 1983;7(4):329-339.
679. Sener SF, Milos S, Feldman JL, et al. The spectrum of vascular lesions in the mammary skin, including angiosarcoma, after breast conservation treatment for breast cancer. *J Am Coll Surg*. 2001;193(1):22-28.
680. Drachman D, Rosen L, Sharaf D, Weissmann A. Postmastectomy low-grade angiosarcoma. An unusual case clinically resembling a lymphangioma circumscriptum. *Am J Dermatopathol*. 1988;10(3):247-251.
681. Rosso R, Gianelli U, Carnevali L. Acquired progressive lymphangioma of the skin following radiotherapy for breast carcinoma. *J Cutan Pathol*. 1995;22(2):164-167.
682. Fineberg S, Rosen PP. Cutaneous angiosarcoma and atypical vascular lesions of the skin and breast after radiation therapy for breast carcinoma. *Am J Clin Pathol*. 1994;102(6):757-763.
683. Ginter PS, Mosquera JM, MacDonald TY, et al. Diagnostic utility of MYC amplification and anti-MYC immunohistochemistry in atypical vascular lesions, primary or radiation-induced mammary angiosarcomas, and primary angiosarcomas of other sites. *Hum Pathol*. 2014;45(4):709-716.
684. Mentzel T, Schildhaus HU, Palmedo G, et al. Postradiation cutaneous angiosarcoma after treatment of breast carcinoma is characterized by MYC amplification in contrast to atypical vascular lesions after radiotherapy and control cases: clinicopathological, immunohistochemical and molecular analysis of 66 cases. *Mod Pathol*. 2012;25(1):75-85.
685. Fernandez AP, Sun Y, Tubbs RR, et al. FISH for MYC amplification and anti-MYC immunohistochemistry: useful diagnostic tools in the assessment of secondary angiosarcoma and atypical vascular proliferations. *J Cutan Pathol*. 2012;39(2):234-242.
686. Gengler C, Coindre J-M, Leroux A, et al. Vascular proliferations of the skin after radiation therapy for breast cancer: clinicopathologic analysis of a series in favor of a benign process: a study from the French Sarcoma Group. *Cancer*. 2007;109(8):1584-1598.
687. Patton KT, Deyrup AT, Weiss SW. Atypical vascular lesions after surgery and radiation of the breast: a clinicopathologic study of 32 cases analyzing histologic heterogeneity and association with angiosarcoma. *Am J Surg Pathol*. 2008;32(6):943-950.
688. Doyle LA, Fletcher CDM. Peripheral hemangioblastoma: clinicopathologic characterization in a series of 22 cases. *Am J Surg Pathol*. 2014;38(1):119-127.
689. Michal M, Vanecek T, Sima R, et al. Primary capillary hemangioblastoma of peripheral soft tissues. *Am J Surg Pathol*. 2004;28(7):962-966.
690. Nonaka D, Rodriguez J, Rosai J. Extraneural hemangioblastoma: a report of 5 cases. *Am J Surg Pathol*. 2007;31(10):1545-1551.
691. Patton KT, Satcher RL, Laskin WB. Capillary hemangioblastoma of soft tissue: report of a case and review of the literature. *Hum Pathol*. 2005;36(10):1135-1139.
692. Hachisuga T, Hashimoto H, Enjoji M. Angioleiomyoma. A clinicopathologic reappraisal of 562 cases. *Cancer*. 1984;54(1):126-130.
693. Yokoyama R, Hashimoto H, Daimaru Y, Enjoji M. Superficial leiomyomas. A clinicopathologic study of 34 cases. *Acta Pathol Jpn*. 1987;37(9):1415-1422.
694. Carlà TG, Filotico R, Filotico M. Bizarre angiomyomas of superficial soft tissues. *Pathologica*. 1991;83(1084):237-242.
695. Matsuyama A, Hisaoka M, Hashimoto H. Angioleiomyoma: a clinicopathologic and immunohistochemical reappraisal with special reference to the correlation with myopericytoma. *Hum Pathol*. 2007;38(4):645-651.
696. Geddy PM, Gray S, Reid WA. Mast cell density and PGP 9.5-immunostained nerves in angioleiomyoma: their relationship to painful symptoms. *Histopathology*. 1993;22(4):387-390.
697. Hasegawa T, Seki K, Yang P, et al. Mechanism of pain and cytoskeletal properties in angioleiomyomas: an immunohistochemical study. *Pathol Int*. 1994;44(1):66-72.
698. Kilpatrick SE, Mentzel T, Fletcher CD. Leiomyoma of deep soft tissue. Clinicopathologic analysis of a series. *Am J Surg Pathol*. 1994;18(6):576-582.
699. Billings SD, Folpe AL, Weiss SW. Do leiomyomas of deep soft tissue exist? An analysis of highly differentiated smooth muscle tumors of deep soft tissue supporting two distinct subtypes. *Am J Surg Pathol*. 2001;25(9):1134-1142.
700. Bisogno G, Sotti G, Nowicki Y, et al. Soft tissue sarcoma as a second malignant neoplasm in the pediatric age group. *Cancer*. 2004;100(8):1758-1765.
701. Farshid G, Pradhan M, Goldblum J, Weiss SW. Leiomyosarcoma of somatic soft tissues: a tumor of vascular origin with multivariate analysis of outcome in 42 cases. *Am J Surg Pathol*. 2002;26(1):14-24.
702. Swanson PE, Wick MR, Dehner LP. Leiomyosarcoma of somatic soft tissues in childhood: an immunohistochemical analysis of six cases with ultrastructural correlation. *Hum Pathol*. 1991;22(6):569-577.
703. Lee ES, Locker J, Nalesnik M, et al. The association of Epstein-Barr virus with smooth-muscle tumors occurring after organ transplantation. *N Engl J Med*. 1995;332(1):19-25.
704. Weiss SW. Smooth muscle tumors of soft tissue. *Adv Anat Pathol*. 2002;9(6):351-359.
705. Tejani MA, Galloway TJ, Lango M, et al. Head and neck sarcomas: a comprehensive cancer center experience. *Cancers (Basel)*. 2013;5(3):890-900.
706. Hilliard NJ, Heslin MJ, Castro CY. Leiomyosarcoma of the inferior vena cava: three case reports and review of the literature. *Ann Diagn Pathol*. 2005;9(5):259-266.
707. Imakita M, Yutani C, Ishibashi-Ueda H, et al. Primary leiomyosarcoma of the inferior vena cava with Budd-Chiari syndrome. *Acta Pathol Jpn*. 1989;39(1):73-77.
708. Nicolas MM, Tamboli P, Gomez JA, Czerniak BA. Pleomorphic and dedifferentiated leiomyosarcoma: clinicopathologic and immunohistochemical study of 41 cases. *Hum Pathol*. 2010;41(5):663-671.
709. Rubin BP, Fletcher CD. Myxoid leiomyosarcoma of soft tissue, an underrecognized variant. *Am J Surg Pathol*. 2000;24(7):927-936.
710. Chang A, Schuetze SM, Conrad EU, et al. So-called "inflammatory leiomyosarcoma": a series of 3 cases providing additional insights into a rare entity. *Int J Surg Pathol*. 2005;13(2):185-195.
711. Mentzel T, Calonje E, Fletcher CD. Leiomyosarcoma with prominent osteoclast-like giant cells. Analysis of eight cases closely mimicking the so-called giant cell variant of malignant fibrous histiocytoma. *Am J Surg Pathol*. 1994;18(3):258-265.
712. Clarke BA, Rahimi K, Chetty R. Leiomyosarcoma of the broad ligament with osteoclast-like giant cells and rhabdoid cells. *Int J Gynecol Pathol*. 2010;29(5):432-437.
713. Hisaoka M, Wei-Qi S, Jian W, et al. Specific but variable expression of h-caldesmon in leiomyosarcomas: an immunohistochemical reassessment of a novel myogenic marker. *Appl Immunohistochem Mol Morphol*. 2001;9(4):302-308.
714. Perez-Montiel MD, Plaza JA, Dominguez-Malagon H, Suster S. Differential expression of smooth muscle myosin, smooth muscle actin, h-caldesmon, and calponin in the diagnosis of myofibroblastic and smooth muscle lesions of skin and soft tissue. *Am J Dermatopathol*. 2006;28(2):105-111.
715. Brown DC, Theaker JM, Banks PM, et al. Cytokeratin expression in smooth muscle and smooth muscle tumours. *Histopathology*. 1987;11(5):477-486.
716. Iwata J, Fletcher CD. Immunohistochemical detection of cytokeratin and epithelial membrane antigen in leiomyosarcoma: a systematic study of 100 cases. *Pathol Int*. 2000;50(1):7-14.
717. Kelley TW, Borden EC, Goldblum JR. Estrogen and progesterone receptor expression in uterine and extrauterine leiomyosarcomas: an immunohistochemical study. *Appl Immunohistochem Mol Morphol*. 2004;12(4):338-341.
718. Mandahl N, Fletcher CD, Dal Cin P, et al. Comparative cytogenetic study of spindle cell and pleomorphic leiomyosarcomas of soft tissues: a report from the CHAMP Study Group. *Cancer Genet Cytogenet*. 2000;116(1):66-73.
719. Miyajima K, Oda Y, Tamiya S, et al. Cytogenetic and clinicopathological analysis

For personal use only. No other uses without permission. Copyright ©2017. Elsevier Inc. All rights reserved.

of soft-tissue leiomyosarcomas. *Pathol Int*. 2003;53(3):163-168.
720. Nilbert M, Mandahl N, Heim S, et al. Chromosome abnormalities in leiomyosarcomas. *Cancer Genet Cytogenet*. 1988;34(2):209-218.
721. Beck AH, Lee C-H, Witten DM, et al. Discovery of molecular subtypes in leiomyosarcoma through integrative molecular profiling. *Oncogene*. 2010;29(6):845-854.
722. Carneiro A, Francis P, Bendahl P-O, et al. Indistinguishable genomic profiles and shared prognostic markers in undifferentiated pleomorphic sarcoma and leiomyosarcoma: different sides of a single coin? *Lab Invest*. 2009;89(6):668-675.
723. Fields JP, Helwig EB. Leiomyosarcoma of the skin and subcutaneous tissue. *Cancer*. 1981;47(1):156-169.
724. Gustafson P, Willén H, Baldetorp B, et al. Soft tissue leiomyosarcoma. A population-based epidemiologic and prognostic study of 48 patients, including cellular DNA content. *Cancer*. 1992;70(1):114-119.
725. Suster S. Epithelioid leiomyosarcoma of the skin and subcutaneous tissue. Clinicopathologic, immunohistochemical, and ultrastructural study of five cases. *Am J Surg Pathol*. 1994;18(3):232-240.
726. Murray MR, Stout AP. The glomus tumor: investigation of its distribution and behavior, and the identity of its "epithelioid" cell. *Am J Pathol*. 1942;18(2):183-203.
727. Aryan Z, Zaki KS, Machuzak M, Mehta AC. Glomus tumor of the trachea. *Clin Respir J*. 2016;10(4):537-539.
728. Calonje E, Fletcher CD. Cutaneous intraneural glomus tumor. *Am J Dermatopathol*. 1995;17(4):395-398.
729. Miettinen M, Paal E, Lasota J, Sobin LH. Gastrointestinal glomus tumors: a clinicopathologic, immunohistochemical, and molecular genetic study of 32 cases. *Am J Surg Pathol*. 2002;26(3): 301-311.
730. Kim H-S, Yang SH, Park HJ, et al. Glomus tumor as a cause of coccydynia. *Skeletal Radiol*. 2013;42(10):1471-1473.
731. Albrecht S, Zbieranowski I. Incidental glomus coccygeum. When a normal structure looks like a tumor. *Am J Surg Pathol*. 1990;14(10):922-924.
732. Kohout E, Stout AP. The glomus tumor in children. *Cancer*. 1961;14:555-566.
733. Venkatachalam MA, Greally JG. Fine structure of glomus tumor: similarity of glomus cells to smooth muscle. *Cancer*. 1969;23(5):1176-1184.
734. Miettinen M, Lehto VP, Virtanen I. Glomus tumor cells: evaluation of smooth muscle and endothelial cell properties. *Virchows Arch B Cell Pathol Incl Mol Pathol*. 1983;43(2):139-149.
735. Kaye VM, Dehner LP. Cutaneous glomus tumor. A comparative immunohistochemical study with pseudoangiomatous intradermal melanocytic nevi. *Am J Dermatopathol*. 1991;13(1):2-6.
736. Pulitzer DR, Martin PC, Reed RJ. Epithelioid glomus tumor. *Hum Pathol*. 1995;26(9):1022-1027.
737. Folpe AL, Fanburg-Smith JC, Miettinen M, Weiss SW. Atypical and malignant glomus tumors: analysis of 52 cases, with a proposal for the reclassification of glomus tumors. *Am J Surg Pathol*. 2001;25(1):1-12.
738. Cohen M, Sercarz JA, Huang CK, et al. Pathology quiz case 2. Oncocytic glomus tumor of the trachea. *Arch Otolaryngol Head Neck Surg*. 2009;135(8):833.
739. Khoury T, Balos L, McGrath B, et al. Malignant glomus tumor: a case report and review of literature, focusing on its clinicopathologic features and immunohistochemical profile. *Am J Dermatopathol*. 2005;27(5):428-431.
740. Mravic M, LaChaud G, Nguyen A, et al. Clinical and histopathological diagnosis of glomus tumor: an institutional experience of 138 cases. *Int J Surg Pathol*. 2015;23(3):181-188.
741. Hansen T, Katenkamp D. Rhabdomyoma of the head and neck: morphology and differential diagnosis. *Virchows Arch*. 2005;447(5):849-854.
742. Kapadia SB, Meis JM, Frisman DM, et al. Adult rhabdomyoma of the head and neck: a clinicopathologic and immunophenotypic study. *Hum Pathol*. 1993;24(6):608-617.
743. de Trey LA, Schmid S, Huber GF. Multifocal adult rhabdomyoma of the head and neck manifestation in 7 locations and review of the literature. *Case Rep Otolaryngol*. 2013;2013:758416.
744. Kapadia SB, Enzinger FM, Heffner DK, et al. Crystal-storing histiocytosis associated with lymphoplasmacytic neoplasms. Report of three cases mimicking adult rhabdomyoma. *Am J Surg Pathol*. 1993;17(5):461-467.
745. Dehner LP, Enzinger FM, Font RL. Fetal rhabdomyoma. An analysis of nine cases. *Cancer*. 1972;30(1):160-166.
746. Di Sant'Agnese PA, Knowles DM 2nd. Extracardiac rhabdomyoma: a clinicopathologic study and review of the literature. *Cancer*. 1980;46(4):780-789.
747. Kapadia SB, Meis JM, Frisman DM, et al. Fetal rhabdomyoma of the head and neck: a clinicopathologic and immunophenotypic study of 24 cases. *Hum Pathol*. 1993;24(7):754-765.
748. Parham DM. Pathologic classification of rhabdomyosarcomas and correlations with molecular studies. *Mod Pathol*. 2001;14(5):506-514.
749. Furlong MA, Fanburg-Smith JC. Pleomorphic rhabdomyosarcoma in children: four cases in the pediatric age group. *Ann Diagn Pathol*. 2001;5(4):199-206.
750. Gaffney EF, Dervan PA, Fletcher CD. Pleomorphic rhabdomyosarcoma in adulthood. Analysis of 11 cases with definition of diagnostic criteria. *Am J Surg Pathol*. 1993;17(6):601-609.
751. Hollowood K, Fletcher CD. Rhabdomyosarcoma in adults. *Semin Diagn Pathol*. 1994;11(1):47-57.
752. Mentzel T, Katenkamp D. Sclerosing, pseudovascular rhabdomyosarcoma in adults. Clinicopathological and immunohistochemical analysis of three cases. *Virchows Arch*. 2000;436(4):305-311.
753. Furlong MA, Mentzel T, Fanburg-Smith JC. Pleomorphic rhabdomyosarcoma in adults: a clinicopathologic study of 38 cases with emphasis on morphologic variants and recent skeletal muscle-specific markers. *Mod Pathol*. 2001;14(6):595-603.
754. Newton WA Jr, Soule EH, Hamoudi AB, et al. Histopathology of childhood sarcomas, Intergroup Rhabdomyosarcoma Studies I and II: clinicopathologic correlation. *J Clin Oncol*. 1988;6(1):67-75.
755. Ferrari A, Miceli R, Meazza C, et al. Soft tissue sarcomas of childhood and adolescence: the prognostic role of tumor size in relation to patient body size. *J Clin Oncol*. 2009;27(3):371-376.
756. Raney RB, Tefft M, Maurer HM, et al. Disease patterns and survival rate in children with metastatic soft-tissue sarcoma. A report from the Intergroup Rhabdomyosarcoma Study (IRS)-I. *Cancer*. 1988;62(7):1257-1266.
757. Hayashi Y, Kikuchi F, Oka T, et al. Rhabdomyosarcoma with bone marrow metastasis simulating acute leukemia. Report of two cases. *Acta Pathol Jpn*. 1988;38(6):789-798.
758. Lawrence W, Hays DM, Heyn R, et al. Lymphatic metastases with childhood rhabdomyosarcoma. A report from the Intergroup Rhabdomyosarcoma Study. *Cancer*. 1987;60(4):910-915.
759. Newton WA Jr, Gehan EA, Webber BL, et al. Classification of rhabdomyosarcomas and related sarcomas. Pathologic aspects and proposal for a new classification—an Intergroup Rhabdomyosarcoma Study. *Cancer*. 1995;76(6):1073-1085.
760. Maurer HM, Gehan EA, Beltangady M, et al. The Intergroup Rhabdomyosarcoma Study-II. *Cancer*. 1993;71(5):1904-1922.
761. Kodet R, Newton WA Jr, Hamoudi AB, et al. Childhood rhabdomyosarcoma with anaplastic (pleomorphic) features. A report of the Intergroup Rhabdomyosarcoma Study. *Am J Surg Pathol*. 1993;17(5):443-453.
762. Schmidt D, Reimann O, Treuner J, Harms D. Cellular differentiation and prognosis in embryonal rhabdomyosarcoma. A report from the Cooperative Soft Tissue Sarcoma Study 1981 (CWS 81). *Virchows Arch A Pathol Anat Histopathol*. 1986;409(2):183-194.
763. Coffin CM, Lowichik A, Zhou H. Treatment effects in pediatric soft tissue and bone tumors: practical considerations for the pathologist. *Am J Clin Pathol*. 2005;123(1):75-90.
764. Coffin CM, Rulon J, Smith L, et al. Pathologic features of rhabdomyosarcoma before and after treatment: a clinicopathologic and immunohistochemical analysis. *Mod Pathol*. 1997;10(12):1175-1187.
765. Chan JK, Ng HK, Wan KY, et al. Clear cell rhabdomyosarcoma of the nasal cavity and paranasal sinuses. *Histopathology*. 1989;14(4):391-399.
766. Kodet R, Newton WA, Hamoudi AB, Asmar L. Rhabdomyosarcomas with intermediate-filament inclusions and features of rhabdoid tumors. Light microscopic and immunohistochemical study. *Am J Surg Pathol*. 1991;15(3):257-267.
767. Dantonello TM, Leuschner I, Vokuhl C, et al. Malignant ectomesenchymoma in children and adolescents: report from the Cooperative Weichteilsarkom Studiengruppe (CWS). *Pediatr Blood Cancer*. 2013;60(2):224-229.
768. VandenHeuvel KA, Carpentieri DF, Chen J, et al. Ectomesenchymoma with embryonal rhabdomyosarcoma and ganglioneuroma, arising in association with benign triton tumor of the tongue. *Pediatr Dev Pathol*. 2014;17(3):226-230.
769. Cavazzana AO, Schmidt D, Ninfo V, et al. Spindle cell rhabdomyosarcoma. A prognostically favorable variant of rhabdomyosarcoma. *Am J Surg Pathol*. 1992;16(3):229-235.
770. Leuschner I, Newton WA Jr, Schmidt D, et al. Spindle cell variants of embryonal rhabdomyosarcoma in the paratesticular region. A report of the Intergroup Rhabdomyosarcoma Study. *Am J Surg Pathol*. 1993;17(3):221-230.
771. Mentzel T, Kuhnen C. Spindle cell rhabdomyosarcoma in adults: clinicopathological and immunohistochemical analysis of seven new cases. *Virchows Arch*. 2006;449(5):554-560.
772. Nascimento AF, Fletcher CDM. Spindle cell rhabdomyosarcoma in adults. *Am J Surg Pathol*. 2005;29(8):1106-1113.
773. Lundgren L, Angervall L, Stenman G, Kindblom LG. Infantile rhabdomyofibrosarcoma: a high-grade sarcoma distinguishable from infantile fibrosarcoma and rhabdomyosarcoma. *Hum Pathol*. 1993;24(7):785-795.

For personal use only. No other uses without permission. Copyright ©2017. Elsevier Inc. All rights reserved.

774. Folpe AL, McKenney JK, Bridge JA, Weiss SW. Sclerosing rhabdomyosarcoma in adults: report of four cases of a hyalinizing, matrix-rich variant of rhabdomyosarcoma that may be confused with osteosarcoma, chondrosarcoma, or angiosarcoma. *Am J Surg Pathol*. 2002;26(9):1175-1183.
775. Kuhnen C, Herter P, Leuschner I, et al. Sclerosing pseudovascular rhabdomyosarcom a-immunohistochemical, ultrastructural, and genetic findings indicating a distinct subtype of rhabdomyosarcoma. *Virchows Arch*. 2006;449(5):572-578.
776. Wang J, Tu X, Sheng W. Sclerosing rhabdomyosarcoma: a clinicopathologic and immunohistochemical study of five cases. *Am J Clin Pathol*. 2008;129(3):410-415.
777. Zambrano E, Pérez-Atayde AR, Ahrens W, Reyes-Múgica M. Pediatric sclerosing rhabdomyosarcoma. *Int J Surg Pathol*. 2006;14(3):193-199.
778. Folpe AL. MyoD1 and myogenin expression in human neoplasia: a review and update. *Adv Anat Pathol*. 2002;9(3):198-203.
778a. Rekhi B, Upadhyay P, Ramteke MP, et al. MYOD1 (L122R) mutations are associated with spindle cell and sclerosing rhabdomyosarcomas with aggressive clinical outcomes. *Mod Pathol*. 2016;29(12):1532-1540.
778b. Alaggio R, Zhang L, Sung YS, et al. A molecular study of pediatric spindle and sclerosing rhabdomyosarcoma: identification of novel and recurrent VGLL2-related fusions in infantile cases. *Am J Surg Pathol*. 2016;40(2):224-235.
779. Jo VY, Mariño-Enríquez A, Fletcher CDM. Epithelioid rhabdomyosarcoma: clinicopathologic analysis of 16 cases of a morphologically distinct variant of rhabdomyosarcoma. *Am J Surg Pathol*. 2011;35(10):1523-1530.
780. Feasel PC, Marburger TB, Billings SD. Primary cutaneous epithelioid rhabdomyosarcoma: a rare, recently described entity with review of the literature. *J Cutan Pathol*. 2014;41(7):588-591.
781. Montone KT, Barr FG, Zhang PJ, et al. Embryonal and alveolar rhabdomyosarcoma of parameningeal sites in adults: a report of 13 cases. *Int J Surg Pathol*. 2009;17(1):22-30.
782. Yasuda T, Perry KD, Nelson M, et al. Alveolar rhabdomyosarcoma of the head and neck region in older adults: genetic characterization and a review of the literature. *Hum Pathol*. 2009;40(3):341-348.
783. Seidal T, Mark J, Hagmar B, Angervall L. Alveolar rhabdomyosarcoma: a cytogenetic and correlated cytological and histological study. *Acta Pathol Microbiol Immunol Scand [A]*. 1982;90(5):345-354.
784. Heffner DK. The truth about alveolar rhabdomyosarcoma. *Ann Diagn Pathol*. 2003;7(4):259-263.
784a. Rudzinski ER, Anderson JR, Chi YY, et al. Histology, fusion status, and outcome in metastatic rhabdomyosarcoma: a report from the Children's Oncology Group. *Pediatr Blood Cancer*. 2017 (Epub ahead of print.).
784b. Skapek SX, Anderson J, Barr FG, et al. PAX-FOXO1 fusion status drives unfavorable outcome for children with rhabdomyosarcoma: a Children's Oncology Group report. *Pediatr Blood Cancer*. 2013;60(9):1411-1417.
785. Erlandson RA. The ultrastructural distinction between rhabdomyosarcoma and other undifferentiated "sarcomas.". *Ultrastruct Pathol*. 1987;11(2-3):83-101.
786. Tsokos M. The diagnosis and classification of childhood rhabdomyosarcoma. *Semin Diagn Pathol*. 1994;11(1):26-38.
787. Cessna MH, Zhou H, Perkins SL, et al. Are myogenin and myoD1 expression specific for rhabdomyosarcoma? A study of 150 cases, with emphasis on spindle cell mimics. *Am J Surg Pathol*. 2001;25(9):1150-1157.
788. Dias P, Parham DM, Shapiro DN, et al. Myogenic regulatory protein (MyoD1) expression in childhood solid tumors: diagnostic utility in rhabdomyosarcoma. *Am J Pathol*. 1990;137(6):1283-1291.
789. Wang NP, Marx J, McNutt MA, et al. Expression of myogenic regulatory proteins (myogenin and MyoD1) in small blue round cell tumors of childhood. *Am J Pathol*. 1995;147(6):1799-1810.
790. Heerema-McKenney A, Wijnaendts LCD, Pulliam JF, et al. Diffuse myogenin expression by immunohistochemistry is an independent marker of poor survival in pediatric rhabdomyosarcoma: a tissue microarray study of 71 primary tumors including correlation with molecular phenotype. *Am J Surg Pathol*. 2008;32(10):1513-1522.
791. Wesche WA, Fletcher CD, Dias P, et al. Immunohistochemistry of MyoD1 in adult pleomorphic soft tissue sarcomas. *Am J Surg Pathol*. 1995;19(3):261-269.
792. Molenaar WM, Oosterhuis JW, Oosterhuis AM, Ramaekers FC. Mesenchymal and muscle-specific intermediate filaments (vimentin and desmin) in relation to differentiation in childhood rhabdomyosarcomas. *Hum Pathol*. 1985;16(8):838-843.
793. Wijnaendts LC, van der Linden JC, van Unnik AJ, et al. The expression pattern of contractile and intermediate filament proteins in developing skeletal muscle and rhabdomyosarcoma of childhood: diagnostic and prognostic utility. *J Pathol*. 1994;174(4):283-292.
794. Bahrami A, Gown AM, Baird GS, et al. Aberrant expression of epithelial and neuroendocrine markers in alveolar rhabdomyosarcoma: a potentially serious diagnostic pitfall. *Mod Pathol*. 2008;21(7):795-806.
795. Downing JR, Khandekar A, Shurtleff SA, et al. Multiplex RT-PCR assay for the differential diagnosis of alveolar rhabdomyosarcoma and Ewing's sarcoma. *Am J Pathol*. 1995;146(3):626-634.
796. Mercado GE, Barr FG. Fusions involving PAX and FOX genes in the molecular pathogenesis of alveolar rhabdomyosarcoma: recent advances. *Curr Mol Med*. 2007;7(1):47-61.
797. Sorensen PHB, Lynch JC, Qualman SJ, et al. PAX3-FKHR and PAX7-FKHR gene fusions are prognostic indicators in alveolar rhabdomyosarcoma: a report from the children's oncology group. *J Clin Oncol*. 2002;20(11):2672-2679.
798. Nishio J, Althof PA, Bailey JM, et al. Use of a novel FISH assay on paraffin-embedded tissues as an adjunct to diagnosis of alveolar rhabdomyosarcoma. *Lab Invest*. 2006;86(6):547-556.
799. Parham DM, Qualman SJ, Teot L, et al. Correlation between histology and PAX/FKHR fusion status in alveolar rhabdomyosarcoma: a report from the Children's Oncology Group. *Am J Surg Pathol*. 2007;31(6):895-901.
800. Williamson D, Missiaglia E, de Reyniès A, et al. Fusion gene-negative alveolar rhabdomyosarcoma is clinically and molecularly indistinguishable from embryonal rhabdomyosarcoma. *J Clin Oncol*. 2010;28(13):2151-2158.
801. Mercado GE, Xia SJ, Zhang C, et al. Identification of PAX3-FKHR-regulated genes differentially expressed between alveolar and embryonal rhabdomyosarcoma: focus on MYCN as a biologically relevant target. *Genes Chromosomes Cancer*. 2008;47(6):510-520.
802. Gordon T, McManus A, Anderson J, et al. Cytogenetic abnormalities in 42 rhabdomyosarcoma: a United Kingdom Cancer Cytogenetics Group Study. *Med Pediatr Oncol*. 2001;36(2):259-267.
803. Loh WE, Scrable HJ, Livanos E, et al. Human chromosome 11 contains two different growth suppressor genes for embryonal rhabdomyosarcoma. *Proc Natl Acad Sci USA*. 1992;89(5):1755-1759.
804. Chung EB, Enzinger FM. Chondroma of soft parts. *Cancer*. 1978;41(4):1414-1424.
805. Humphreys S, Pambakian H, McKee PH, Fletcher CD. Soft tissue chondroma—a study of 15 tumours. *Histopathology*. 1986;10(2):147-159.
806. Cates JM, Rosenberg AE, O'Connell JX, Nielsen GP. Chondroblastoma-like chondroma of soft tissue: an underrecognized variant and its differential diagnosis. *Am J Surg Pathol*. 2001;25(5):661-666.
807. Dahlin DC, Salvador AH. Chondrosarcomas of bones of the hands and feet—a study of 30 cases. *Cancer*. 1974;34(3):755-760.
808. Wu KK, Collon DJ, Guise ER. Extra-osseous chondrosarcoma. Report of five cases and review of the literature. *J Bone Joint Surg Am*. 1980;62(2):189-194.
809. Aigner T, Oliveira AM, Nascimento AG. Extraskeletal myxoid chondrosarcomas do not show a chondrocytic phenotype. *Mod Pathol*. 2004;17(2):214-221.
810. Hisaoka M, Hashimoto H. Extraskeletal myxoid chondrosarcoma: updated clinicopathological and molecular genetic characteristics. *Pathol Int*. 2005;55(8):453-463.
811. Antonescu CR, Argani P, Erlandson RA, et al. Skeletal and extraskeletal myxoid chondrosarcoma: a comparative clinicopathologic, ultrastructural, and molecular study. *Cancer*. 1998;83(8):1504-1521.
812. Enzinger FM, Shiraki M. Extraskeletal myxoid chondrosarcoma. An analysis of 34 cases. *Hum Pathol*. 1972;3(3):421-435.
813. Meis-Kindblom JM, Bergh P, Gunterberg B, Kindblom LG. Extraskeletal myxoid chondrosarcoma: a reappraisal of its morphologic spectrum and prognostic factors based on 117 cases. *Am J Surg Pathol*. 1999;23(6):636-650.
814. Oliveira AM, Sebo TJ, McGrory JE, et al. Extraskeletal myxoid chondrosarcoma: a clinicopathologic, immunohistochemical, and ploidy analysis of 23 cases. *Mod Pathol*. 2000;13(8):900-908.
815. Hachitanda Y, Tsuneyoshi M, Daimaru Y, et al. Extraskeletal myxoid chondrosarcoma in young children. *Cancer*. 1988;61(12):2521-2526.
816. Oshiro Y, Shiratsuchi H, Tamiya S, et al. Extraskeletal myxoid chondrosarcoma with rhabdoid features, with special reference to its aggressive behavior. *Int J Surg Pathol*. 2000;8(2):145-152.
817. Lucas DR, Fletcher CD, Adsay NV, Zalupski MM. High-grade extraskeletal myxoid chondrosarcoma: a high-grade epithelioid malignancy. *Histopathology*. 1999;35(3):201-208.
818. Payne C, Dardick I, Mackay B. Extraskeletal myxoid chondrosarcoma with intracisternal microtubules. *Ultrastruct Pathol*. 1994;18(1-2):257-261.
819. Tsuneyoshi M, Enjoji M, Iwasaki H, Shinohara N. Extraskeletal myxoid chondrosarcoma—a clinicopathologic and electron microscopic study. *Acta Pathol Jpn*. 1981;31(3):439-447.

For personal use only. No other uses without permission. Copyright ©2017. Elsevier Inc. All rights reserved.

820. Goh YW, Spagnolo DV, Platten M, et al. Extraskeletal myxoid chondrosarcoma: a light microscopic, immunohistochemical, ultrastructural and immuno-ultrastructural study indicating neuroendocrine differentiation. *Histopathology*. 2001;39(5):514-524.
821. Domanski HA, Carlén B, Mertens F, Akerman M. Extraskeletal myxoid chondrosarcoma with neuroendocrine differentiation: a case report with fine-needle aspiration biopsy, histopathology, electron microscopy, and cytogenetics. *Ultrastruct Pathol*. 2003;27(5):363-368.
822. Fletcher CD, Powell G, McKee PH. Extraskeletal myxoid chondrosarcoma: a histochemical and immunohistochemical study. *Histopathology*. 1986;10(5):489-499.
823. Hu B, McPhaul L, Cornford M, et al. Expression of tau proteins and tubulin in extraskeletal myxoid chondrosarcoma, chordoma, and other chondroid tumors. *Am J Clin Pathol*. 1999;112(2):189-193.
824. Sjögren H, Meis-Kindblom JM, Orndal C, et al. Studies on the molecular pathogenesis of extraskeletal myxoid chondrosarcoma-cytogenetic, molecular genetic, and cDNA microarray analyses. *Am J Pathol*. 2003;162(3):781-792.
825. Sciot R, Dal Cin P, Fletcher C, et al. t(9;22)(q22-31;q11-12) is a consistent marker of extraskeletal myxoid chondrosarcoma: evaluation of three cases. *Mod Pathol*. 1995;8(7):765-768.
826. Panagopoulos I, Mertens F, Isaksson M, et al. Molecular genetic characterization of the EWS/CHN and RBP56/CHN fusion genes in extraskeletal myxoid chondrosarcoma. *Genes Chromosomes Cancer*. 2002;35(4):340-352.
827. Wang W-L, Mayordomo E, Czerniak BA, et al. Fluorescence in situ hybridization is a useful ancillary diagnostic tool for extraskeletal myxoid chondrosarcoma. *Mod Pathol*. 2008;21(11):1303-1310.
828. Kawaguchi S, Wada T, Nagoya S, et al. Extraskeletal myxoid chondrosarcoma: a Multi-Institutional Study of 42 Cases in Japan. *Cancer*. 2003;97(5):1285-1292.
829. Saleh G, Evans HL, Ro JY, Ayala AG. Extraskeletal myxoid chondrosarcoma. A clinicopathologic study of ten patients with long-term follow-up. *Cancer*. 1992;70(12):2827-2830.
830. D'Ambrosio FG, Shiu MH, Brennan MF. Intrapulmonary presentation of extraskeletal myxoid chondrosarcoma of the extremity. Report of two cases. *Cancer*. 1986;58(5):1144-1148.
831. Carstens PH. Chordoid tumor: a light, electron microscopic, and immunohistochemical study. *Ultrastruct Pathol*. 1995;19(4):291-295.
832. Martin RF, Melnick PJ, Warner NE, et al. Chordoid sarcoma. *Am J Clin Pathol*. 1973;59(5):623-635.
833. Dabska M. Parachordoma: a new clinicopathologic entity. *Cancer*. 1977;40(4):1586-1592.
834. Bertoni F, Picci P, Bacchini P, et al. Mesenchymal chondrosarcoma of bone and soft tissues. *Cancer*. 1983;52(3):533-541.
835. Guccion JG, Font RL, Enzinger FM, Zimmerman LE. Extraskeletal mesenchymal chondrosarcoma. *Arch Pathol*. 1973;95(5):336-340.
836. Nakashima Y, Unni KK, Shives TC, et al. Mesenchymal chondrosarcoma of bone and soft tissue. A review of 111 cases. *Cancer*. 1986;57(12):2444-2453.
837. Hoang MP, Suarez PA, Donner LR, et al. Mesenchymal chondrosarcoma: a small cell neoplasm with polyphenotypic differentiation. *Int J Surg Pathol*. 2000;8(4):291-301.
838. Nyquist KB, Panagopoulos I, Thorsen J, et al. Whole-transcriptome sequencing identifies novel IRF2BP2-CDX1 fusion gene brought about by translocation t(1;5)(q42;q32) in mesenchymal chondrosarcoma. *PLoS ONE*. 2012;7(11):e49705.
839. Lidang Jensen M, Schumacher B, Myhre Jensen O, et al. Extraskeletal osteosarcomas: a clinicopathologic study of 25 cases. *Am J Surg Pathol*. 1998;22(5):588-594.
840. Huvos AG. Osteogenic sarcoma of bones and soft tissues in older persons. A clinicopathologic analysis of 117 patients older than 60 years. *Cancer*. 1986;57(7):1442-1449.
841. Huvos AG, Woodard HQ, Cahan WG, et al. Postradiation osteogenic sarcoma of bone and soft tissues. A clinicopathologic study of 66 patients. *Cancer*. 1985;55(6):1244-1255.
842. Bane BL, Evans HL, Ro JY, et al. Extraskeletal osteosarcoma. A clinicopathologic review of 26 cases. *Cancer*. 1990;65(12):2762-2770.
843. Mirra JM, Fain JS, Ward WG, et al. Extraskeletal telangiectatic osteosarcoma. *Cancer*. 1993;71(10):3014-3019.
844. Fanburg-Smith JC, Bratthauer GL, Miettinen M. Osteocalcin and osteonectin immunoreactivity in extraskeletal osteosarcoma: a study of 28 cases. *Hum Pathol*. 1999;30(1):32-38.
844a. Davis JL, Horvai AE. Special AT-rich sequence-binding protein 2 (SATB2) expression is sensitive but may not be specific for osteosarcoma as compared with other high-grade primary bone sarcomas. *Histopathology*. 2016;69(1):84-90.
845. Chung EB, Enzinger FM. Extraskeletal osteosarcoma. *Cancer*. 1987;60(5):1132-1142.
846. Abramovici LC, Hytiroglou P, Klein RM, et al. Well-differentiated extraskeletal osteosarcoma: report of 2 cases, 1 with dedifferentiation. *Hum Pathol*. 2005;36(4):439-443.
847. Berry CL, Keeling J, Hilton C. Teratomata in infancy and childhood: a review of 91 cases. *J Pathol*. 1969;98(4):241-252.
848. Heerema-McKenney A, Harrison MR, Bratton B, et al. Congenital teratoma: a clinicopathologic study of 22 fetal and neonatal tumors. *Am J Surg Pathol*. 2005;29(1):29-38.
849. Billmire DF, Grosfeld JL. Teratomas in childhood: analysis of 142 cases. *J Pediatr Surg*. 1986;21(6):548-551.
850. Tapper D, Lack EE. Teratomas in infancy and childhood. A 54-year experience at the Children's Hospital Medical Center. *Ann Surg*. 1983;198(3):398-410.
851. Peterson CM, Buckley C, Holley S, Menias CO. Teratomas: a multimodality review. *Curr Probl Diagn Radiol*. 2012;41(6):210-219.
852. Gonzalez-Crussi F, Winkler RF, Mirkin DL. Sacrococcygeal teratomas in infants and children: relationship of histology and prognosis in 40 cases. *Arch Pathol Lab Med*. 1978;102(8):420-425.
853. Gupta R, Gupta R, Kumar S, Saxena S. Melanotic neuroectodermal tumor of infancy: review of literature, report of a case and follow up at 7 years. *J Plast Reconstr Aesthetic Surg*. 2015;68(3):e53-e54.
854. Cui Y, Mao Z, Liao C. Melanotic neuroectodermal tumor of infancy: a case report and review of the surgical treatment. *Oncol Lett*. 2015;9(1):29-34.
855. Pettinato G, Manivel JC, d'Amore ES, et al. Melanotic neuroectodermal tumor of infancy. A reexamination of a histogenetic problem based on immunohistochemical, flow cytometric, and ultrastructural study of 10 cases. *Am J Surg Pathol*. 1991;15(3):233-245.
856. Argenyi ZB, Schelper RL, Balogh K. Pigmented neuroectodermal tumor of infancy. A light microscopic and immunohistochemical study. *J Cutan Pathol*. 1991;18(1):40-45.
857. Stirling RW, Powell G, Fletcher CD. Pigmented neuroectodermal tumour of infancy: an immunohistochemical study. *Histopathology*. 1988;12(4):425-435.
858. Yoo IH, Yum SK, Oh S-J, et al. Melanotic neuroectodermal tumor of infancy disseminated by a ventriculoperitoneal shunt and diagnosed from the inguinal sac. *J Pediatr Hematol Oncol*. 2014;36(1):e61-e64.
859. Lopez DA, Silvers DN, Helwig EB. Cutaneous meningiomas—a clinicopathologic study. *Cancer*. 1974;34(3):728-744.
860. Yang X-H, Liu L, Zhang P, Hu Y-J. An ectopic meningioma in nasal floor. *J Craniofac Surg*. 2015;26(2):e88-e90.
861. King P, Cooper PN, Malcolm AJ. Soft tissue ependymoma: a report of three cases. *Histopathology*. 1993;22(4):394-396.
862. Helwig EB, Stern JB. Subcutaneous sacrococcygeal myxopapillary ependymoma. A clinicopathologic study of 32 cases. *Am J Clin Pathol*. 1984;81(2):156-161.
863. Burdick LM, Bergfeld W, Somani N, Piliang M. Subcutaneous myxopapillary ependymal rest: a potential sign of spinal dysraphism. *J Am Acad Dermatol*. 2011;65(4):851-854.
864. Pulitzer DR, Martin PC, Collins PC, Ralph DR. Subcutaneous sacrococcygeal ("myxopapillary") ependymal rests. *Am J Surg Pathol*. 1988;12(9):672-677.
865. McDermott MB, Glasner SD, Nielsen PL, Dehner LP. Soft tissue gliomatosis. Morphologic unity and histogenetic diversity. *Am J Surg Pathol*. 1996;20(2):148-155.
866. Shepherd NA, Coates PJ, Brown AA. Soft tissue gliomatosis—heterotopic glial tissue in the subcutis: a case report. *Histopathology*. 1987;11(6):655-660.
867. Travis WD, Banks PM, Reiman HM. Primary extranodal soft tissue lymphoma of the extremities. *Am J Surg Pathol*. 1987;11(5):359-366.
868. Ko YH, Cho E-Y, Kim J-E, et al. NK and NK-like T-cell lymphoma in extranasal sites: a comparative clinicopathological study according to site and EBV status. *Histopathology*. 2004;44(5):480-489.
869. Lanham GR, Weiss SW, Enzinger FM. Malignant lymphoma. A study of 75 cases presenting in soft tissue. *Am J Surg Pathol*. 1989;13(1):1-10.
870. d'Amore ES, Wick MR, Geisinger KR, Frizzera G. Primary malignant lymphoma arising in postmastectomy lymphedema. Another facet of the Stewart-Treves syndrome. *Am J Surg Pathol*. 1990;14(5):456-463.
871. Hornick JL, Jaffe ES, Fletcher CDM. Extranodal histiocytic sarcoma: clinicopathologic analysis of 14 cases of a rare epithelioid malignancy. *Am J Surg Pathol*. 2004;28(9):1133-1144.
872. Akosa AB, Ali MH. Extramedullary plasmacytoma of skeletal muscle. A case report with immunocytochemistry and ultrastructural study. *Cancer*. 1989;64(7):1504-1507.
873. Condon WB, Safarik LR, Elzi EP. Extramedullary hematopoiesis simulating intrathoracic tumor. *Arch Surg*. 1965;90:643-648.
874. Rajiah P, Hayashi R, Bauer TW, Sundaram M. Extramedullary hematopoiesis in unusual locations in hematologically compromised and noncompromised patients. *Skeletal Radiol*. 2011;40(7):947-953.
875. Herzog CE. Overview of sarcomas in the adolescent and young adult population. *J Pediatr Hematol Oncol*. 2005;27(4):215-218.

For personal use only. No other uses without permission. Copyright ©2017. Elsevier Inc. All rights reserved.

876. Chan JA, McMenamin ME, Fletcher CDM. Synovial sarcoma in older patients: clinicopathological analysis of 32 cases with emphasis on unusual histological features. *Histopathology*. 2003;43(1):72-83.
877. Liang C, Mao H, Tan J, et al. Synovial sarcoma: magnetic resonance and computed tomography imaging features and differential diagnostic considerations. *Oncol Lett*. 2015;9(2):661-666.
878. Michal M, Fanburg-Smith JC, Lasota J, et al. Minute synovial sarcomas of the hands and feet: a clinicopathologic study of 21 tumors less than 1 cm. *Am J Surg Pathol*. 2006;30(6):721-726.
879. Varela-Duran J, Enzinger FM. Calcifying synovial sarcoma. *Cancer*. 1982;50(2):345-352.
880. Milchgrub S, Ghandur-Mnaymneh L, Dorfman HD, Albores-Saavedra J. Synovial sarcoma with extensive osteoid and bone formation. *Am J Surg Pathol*. 1993;17(4):357-363.
881. Krane JF, Bertoni F, Fletcher CD. Myxoid synovial sarcoma: an underappreciated morphologic subset. *Mod Pathol*. 1999;12(5):456-462.
882. Thway K, Fisher C. Synovial sarcoma: defining features and diagnostic evolution. *Ann Diagn Pathol*. 2014;18(6):369-380.
883. de Silva MVC, McMahon AD, Paterson L, Reid R. Identification of poorly differentiated synovial sarcoma: a comparison of clinicopathological and cytogenetic features with those of typical synovial sarcoma. *Histopathology*. 2003;43(3):220-230.
884. Folpe AL, Schmidt RA, Chapman D, Gown AM. Poorly differentiated synovial sarcoma: immunohistochemical distinction from primitive neuroectodermal tumors and high-grade malignant peripheral nerve sheath tumors. *Am J Surg Pathol*. 1998;22(6):673-682.
885. Pelmus M, Guillou L, Hostein I, et al. Monophasic fibrous and poorly differentiated synovial sarcoma: immunohistochemical reassessment of 60 t(X;18)(SYT-SSX)-positive cases. *Am J Surg Pathol*. 2002;26(11):1434-1440.
886. van de Rijn M, Barr FG, Xiong QB, et al. Poorly differentiated synovial sarcoma: an analysis of clinical, pathologic, and molecular genetic features. *Am J Surg Pathol*. 1999;23(1):106-112.
887. Suster S, Moran CA. Primary synovial sarcomas of the mediastinum: a clinicopathologic, immunohistochemical, and ultrastructural study of 15 cases. *Am J Surg Pathol*. 2005;29(5):569-578.
888. Lopes JM, Bjerkehagen B, Holm R, et al. Immunohistochemical profile of synovial sarcoma with emphasis on the epithelial-type differentiation. A study of 49 primary tumours, recurrences and metastases. *Pathol Res Pract*. 1994;190(2):168-177.
889. Billings SD, Walsh SV, Fisher C, et al. Aberrant expression of tight junction-related proteins ZO-1, claudin-1 and occludin in synovial sarcoma: an immunohistochemical study with ultrastructural correlation. *Mod Pathol*. 2004;17(2):141-149.
890. Miettinen M, Limon J, Niezabitowski A, Lasota J. Patterns of keratin polypeptides in 110 biphasic, monophasic, and poorly differentiated synovial sarcomas. *Virchows Arch*. 2000;437(3):275-283.
891. Smith TA, Machen SK, Fisher C, Goldblum JR. Usefulness of cytokeratin subsets for distinguishing monophasic synovial sarcoma from malignant peripheral nerve sheath tumor. *Am J Clin Pathol*. 1999;112(5):641-648.
892. Miettinen M. Immunohistochemistry of soft tissue tumours—review with emphasis on 10 markers. *Histopathology*. 2014;64(1):101-118.
893. Machen SK, Fisher C, Gautam RS, et al. Utility of cytokeratin subsets for distinguishing poorly differentiated synovial sarcoma from peripheral primitive neuroectodermal tumour. *Histopathology*. 1998;33(6):501-507.
894. Suster S, Fisher C, Moran CA. Expression of BCL-2 oncoprotein in benign and malignant spindle cell tumors of soft tissue, skin, serosal surfaces, and gastrointestinal tract. *Am J Surg Pathol*. 1998;22(7):863-872.
895. Ono H, Yoshikawa H, Ueda T, et al. Expression of smooth muscle calponin in synovial sarcoma. *Sarcoma*. 1999;3(2):107-113.
896. Miettinen M, Limon J, Niezabitowski A, Lasota J. Calretinin and other mesothelioma markers in synovial sarcoma: analysis of antigenic similarities and differences with malignant mesothelioma. *Am J Surg Pathol*. 2001;25(5):610-617.
897. Terry J, Saito T, Subramanian S, et al. TLE1 as a diagnostic immunohistochemical marker for synovial sarcoma emerging from gene expression profiling studies. *Am J Surg Pathol*. 2007;31(2):240-246.
898. Sandberg AA, Bridge JA. Updates on the cytogenetics and molecular genetics of bone and soft tissue tumors. Synovial sarcoma. *Cancer Genet Cytogenet*. 2002;133(1):1-23.
899. Argani P, Zakowski MF, Klimstra DS, et al. Detection of the SYT-SSX chimeric RNA of synovial sarcoma in paraffin-embedded tissue and its application in problematic cases. *Mod Pathol*. 1998;11(1):65-71.
900. Tanas MR, Rubin BP, Tubbs RR, et al. Utilization of fluorescence in situ hybridization in the diagnosis of 230 mesenchymal neoplasms: an institutional experience. *Arch Pathol Lab Med*. 2010;134(12):1797-1803.
901. Ten Heuvel SE, Hoekstra HJ, Suurmeijer AJH. Diagnostic accuracy of FISH and RT-PCR in 50 routinely processed synovial sarcomas. *Appl Immunohistochem Mol Morphol*. 2008;16(3):246-250.
902. Amary MFC, Berisha F, Bernardi FDC, et al. Detection of SS18-SSX fusion transcripts in formalin-fixed paraffin-embedded neoplasms: analysis of conventional RT-PCR, qRT-PCR and dual color FISH as diagnostic tools for synovial sarcoma. *Mod Pathol*. 2007;20(4):482-496.
903. Antonescu CR, Kawai A, Leung DH, et al. Strong association of SYT-SSX fusion type and morphologic epithelial differentiation in synovial sarcoma. *Diagn Mol Pathol*. 2000;9(1):1-8.
904. Palmerini E, Staals EL, Alberghini M, et al. Synovial sarcoma: retrospective analysis of 250 patients treated at a single institution. *Cancer*. 2009;115(13):2988-2998.
905. Trassard M, Le Doussal V, Hacène K, et al. Prognostic factors in localized primary synovial sarcoma: a multicenter study of 128 adult patients. *J Clin Oncol*. 2001;19(2):525-534.
906. Canter RJ, Qin L-X, Maki RG, et al. A synovial sarcoma-specific preoperative nomogram supports a survival benefit to ifosfamide-based chemotherapy and improves risk stratification for patients. *Clin Cancer Res*. 2008;14(24):8191-8197.
907. Singer S, Baldini EH, Demetri GD, et al. Synovial sarcoma: prognostic significance of tumor size, margin of resection, and mitotic activity for survival. *J Clin Oncol*. 1996;14(4):1201-1208.
908. Cagle LA, Mirra JM, Storm FK, et al. Histologic features relating to prognosis in synovial sarcoma. *Cancer*. 1987;59(10):1810-1814.
909. Golouh R, Vuzevski V, Bracko M, et al. Synovial sarcoma: a clinicopathological study of 36 cases. *J Surg Oncol*. 1990;45(1):20-28.
910. Oda Y, Hashimoto H, Tsuneyoshi M, Takeshita S. Survival in synovial sarcoma. A multivariate study of prognostic factors with special emphasis on the comparison between early death and long-term survival. *Am J Surg Pathol*. 1993;17(1):35-44.
911. Machen SK, Easley KA, Goldblum JR. Synovial sarcoma of the extremities: a clinicopathologic study of 34 cases, including semi-quantitative analysis of spindled, epithelial, and poorly differentiated areas. *Am J Surg Pathol*. 1999;23(3):268-275.
912. Izumi T, Oda Y, Hasegawa T, et al. Dysadherin expression as a significant prognostic factor and as a determinant of histologic features in synovial sarcoma: special reference to its inverse relationship with E-cadherin expression. *Am J Surg Pathol*. 2007;31(1):85-94.
913. el-Naggar AK, Ayala AG, Abdul-Karim FW, et al. Synovial sarcoma. A DNA flow cytometric study. *Cancer*. 1990;65(10):2295-2300.
914. Kawai A, Woodruff J, Healey JH, et al. SYT-SSX gene fusion as a determinant of morphology and prognosis in synovial sarcoma. *N Engl J Med*. 1998;338(3):153-160.
915. Guillou L, Coindre J, Gallagher G, et al. Detection of the synovial sarcoma translocation t(X;18) (SYT;SSX) in paraffin-embedded tissues using reverse transcriptase-polymerase chain reaction: a reliable and powerful diagnostic tool for pathologists. A molecular analysis of 221 mesenchymal tumors fixed in different fixatives. *Hum Pathol*. 2001;32(1):105-112.
916. Heuvel SE, ten Hoekstra HJ, Bastiaannet E, Suurmeijer AJH. The classic prognostic factors tumor stage, tumor size, and tumor grade are the strongest predictors of outcome in synovial sarcoma: no role for SSX fusion type or ezrin expression. *Appl Immunohistochem Mol Morphol*. 2009;17(3):189-195.
917. Enzinger FM. Intramuscular myxoma: a review and follow-up study of 34 cases. *Am J Clin Pathol*. 1965;43:104-113.
918. Hashimoto H, Tsuneyoshi M, Daimaru Y, et al. Intramuscular myxoma. A clinicopathologic, immunohistochemical, and electron microscopic study. *Cancer*. 1986;58(3):740-747.
919. Allen PW. Myxoma is not a single entity: a review of the concept of myxoma. *Ann Diagn Pathol*. 2000;4(2):99-123.
920. Ireland DC, Soule EH, Ivins JC. Myxoma of somatic soft tissues. A report of 58 patients, 3 with multiple tumors and fibrous dysplasia of bone. *Mayo Clin Proc*. 1973;48(6):401-410.
921. Carney JA, Headington JT, Su WP. Cutaneous myxomas. A major component of the complex of myxomas, spotty pigmentation, and endocrine overactivity. *Arch Dermatol*. 1986;122(7):790-798.
922. Meis JM, Enzinger FM. Juxta-articular myxoma: a clinical and pathologic study of 65 cases. *Hum Pathol*. 1992;23(6):639-646.
923. Feldman PS. A comparative study including ultrastructure of intramuscular myxoma and myxoid liposarcoma. *Cancer*. 1979;43(2):512-525.
924. Okamoto S, Hisaoka M, Ushijima M, et al. Activating Gs(alpha) mutation in intramuscular myxomas with and without fibrous dysplasia of bone. *Virchows Arch*. 2000;437(2):133-137.
925. Willems SM, Mohseny AB, Balog C, et al. Cellular/intramuscular myxoma and grade I

For personal use only. No other uses without permission. Copyright ©2017. Elsevier Inc. All rights reserved.

myxofibrosarcoma are characterized by distinct genetic alterations and specific composition of their extracellular matrix. *J Cell Mol Med*. 2009;13(7):1291-1301.
926. Okamoto S, Hisaoka M, Meis-Kindblom JM, et al. Juxta-articular myxoma and intramuscular myxoma are two distinct entities. Activating Gs alpha mutation at Arg 201 codon does not occur in juxta-articular myxoma. *Virchows Arch*. 2002;440(1):12-15.
927. Nielsen GP, O'Connell JX, Rosenberg AE. Intramuscular myxoma: a clinicopathologic study of 51 cases with emphasis on hypercellular and hypervascular variants. *Am J Surg Pathol*. 1998;22(10):1222-1227.
928. van Roggen JF, McMenamin ME, Fletcher CD. Cellular myxoma of soft tissue: a clinicopathological study of 38 cases confirming indolent clinical behaviour. *Histopathology*. 2001;39(3):287-297.
929. Lieberman PH, Brennan MF, Kimmel M, et al. Alveolar soft-part sarcoma. A clinico-pathologic study of half a century. *Cancer*. 1989;63(1):1-13.
930. Argyris PP, Reed RC, Manivel JC, et al. Oral alveolar soft part sarcoma in childhood and adolescence: report of two cases and review of literature. *Head Neck Pathol*. 2013;7(1):40-49.
931. Ogura K, Beppu Y, Chuman H, et al. Alveolar soft part sarcoma: a single-center 26-patient case series and review of the literature. *Sarcoma*. 2012;2012:907179.
932. Zarrin-Khameh N, Kaye KS. Alveolar soft part sarcoma. *Arch Pathol Lab Med*. 2007;131(3):488-491.
933. Folpe AL, Deyrup AT. Alveolar soft-part sarcoma: a review and update. *J Clin Pathol*. 2006;59(11):1127-1132.
934. Ohno T, Park P, Higaki S, et al. Smooth tubular aggregates associated with plasmalemmal invagination in alveolar soft part sarcoma. *Ultrastruct Pathol*. 1994;18(3):383-388.
935. Lillehei KO, Kleinschmidt-DeMasters B, Mitchell DH, et al. Alveolar soft part sarcoma: an unusually long interval between presentation and brain metastasis. *Hum Pathol*. 1993;24(9):1030-1034.
936. Evans HL. Alveolar soft-part sarcoma. A study of 13 typical examples and one with a histologically atypical component. *Cancer*. 1985;55(4):912-917.
937. Foschini MP, Ceccarelli C, Eusebi V, et al. Alveolar soft part sarcoma: immunological evidence of rhabdomyoblastic differentiation. *Histopathology*. 1988;13(1):101-108.
938. Matsuno Y, Mukai K, Itabashi M, et al. Alveolar soft part sarcoma. A clinicopathologic and immunohistochemical study of 12 cases. *Acta Pathol Jpn*. 1990;40(3):199-205.
939. Mukai M, Iri H, Nakajima T, et al. Alveolar soft-part sarcoma. A review on its histogenesis and further studies based on electron microscopy, immunohistochemistry, and biochemistry. *Am J Surg Pathol*. 1983;7(7):679-689.
940. Rosai J, Dias P, Parham DM, et al. MyoD1 protein expression in alveolar soft part sarcoma as confirmatory evidence of its skeletal muscle nature. *Am J Surg Pathol*. 1991;15(10):974-981.
941. Ladanyi M, Lui MY, Antonescu CR, et al. The der(17)t(X;17)(p11;q25) of human alveolar soft part sarcoma fuses the TFE3 transcription factor gene to ASPL, a novel gene at 17q25. *Oncogene*. 2001;20(1): 48-57.
942. Argani P, Antonescu CR, Illei PB, et al. Primary renal neoplasms with the ASPL-TFE3 gene fusion of alveolar soft part sarcoma: a distinctive tumor entity previously included among renal cell carcinomas of children and adolescents. *Am J Pathol*. 2001;159(1):179-192.
943. Dim DC, Cooley LD, Miranda RN. Clear cell sarcoma of tendons and aponeuroses: a review. *Arch Pathol Lab Med*. 2007;131(1):152-156.
944. Eckardt JJ, Pritchard DJ, Soule EH. Clear cell sarcoma. A clinicopathologic study of 27 cases. *Cancer*. 1983;52(8):1482-1488.
945. Hisaoka M, Ishida T, Kuo T-T, et al. Clear cell sarcoma of soft tissue: a clinicopathologic, immunohistochemical, and molecular analysis of 33 cases. *Am J Surg Pathol*. 2008;32(3):452-460.
946. Chung EB, Enzinger FM. Malignant melanoma of soft parts. A reassessment of clear cell sarcoma. *Am J Surg Pathol*. 1983;7(5):405-413.
947. Bianchi G, Charoenlap C, Cocchi S, et al. Clear cell sarcoma of soft tissue: a retrospective review and analysis of 31 cases treated at Istituto Ortopedico Rizzoli. *Eur J Surg Oncol*. 2014;40(5):505-510.
948. Kindblom LG, Lodding P, Angervall L. Clear-cell sarcoma of tendons and aponeuroses. An immunohistochemical and electron microscopic analysis indicating neural crest origin. *Virchows Arch A Pathol Anat Histopathol*. 1983;401(1):109-128.
949. Benson JD, Kraemer BB, Mackay B. Malignant melanoma of soft parts: an ultrastructural study of four cases. *Ultrastruct Pathol*. 1985;8(1):57-70.
950. Mooi WJ, Deenik W, Peterse JL, Hogendoorn PC. Keratin immunoreactivity in melanoma of soft parts (clear cell sarcoma). *Histopathology*. 1995;27(1):61-65.
951. Bridge JA, Borek DA, Neff JR, Huntrakoon M. Chromosomal abnormalities in clear cell sarcoma. Implications for histogenesis. *Am J Clin Pathol*. 1990;93(1):26-31.
952. Sandberg AA, Bridge JA. Updates on the cytogenetics and molecular genetics of bone and soft tissue tumors: clear cell sarcoma (malignant melanoma of soft parts). *Cancer Genet Cytogenet*. 2001;130(1):1-7.
953. Antonescu CR, Tschernyavsky SJ, Woodruff JM, et al. Molecular diagnosis of clear cell sarcoma: detection of EWS-ATF1 and MITF-M transcripts and histopathological and ultrastructural analysis of 12 cases. *J Mol Diagn*. 2002;4(1):44-52.
954. Antonescu CR, Nafa K, Segal NH, et al. EWS-CREB1: a recurrent variant fusion in clear cell sarcoma—association with gastrointestinal location and absence of melanocytic differentiation. *Clin Cancer Res*. 2006;12(18):5356-5362.
955. Thway K, Fisher C. Tumors with EWSR1-CREB1 and EWSR1-ATF1 fusions: the current status. *Am J Surg Pathol*. 2012;36(7):e1-e11.
956. Wang W-L, Mayordomo E, Zhang W, et al. Detection and characterization of EWSR1/ATF1 and EWSR1/CREB1 chimeric transcripts in clear cell sarcoma (melanoma of soft parts). *Mod Pathol*. 2009;22(9):1201-1209.
957. Stockman DL, Miettinen M, Suster S, et al. Malignant gastrointestinal neuroectodermal tumor: clinicopathologic, immunohistochemical, ultrastructural, and molecular analysis of 16 cases with a reappraisal of clear cell sarcoma-like tumors of the gastrointestinal tract. *Am J Surg Pathol*. 2012;36(6):857-868.
958. Zambrano E, Reyes-Mugica M, Franchi A, Rosai J. An osteoclast-rich tumor of the gastrointestinal tract with features resembling clear cell sarcoma of soft parts: reports of 6 cases of a GIST simulator. *Int J Surg Pathol*. 2003;11(2):75-81.
959. Deenik W, Mooi WJ, Rutgers EJ, et al. Clear cell sarcoma (malignant melanoma) of soft parts: a clinicopathologic study of 30 cases. *Cancer*. 1999;86(6):969-975.
960. Lucas DR, Nascimento AG, Sim FH. Clear cell sarcoma of soft tissues. Mayo Clinic experience with 35 cases. *Am J Surg Pathol*. 1992;16(12):1197-1204.
961. Sara AS, Evans HL, Benjamin RS. Malignant melanoma of soft parts (clear cell sarcoma). A study of 17 cases, with emphasis on prognostic factors. *Cancer*. 1990;65(2):367-374.
962. Enzinger FM. Epitheloid sarcoma. A sarcoma simulating a granuloma or a carcinoma. *Cancer*. 1970;26(5):1029-1041.
963. Halling AC, Wollan PC, Pritchard DJ, et al. Epithelioid sarcoma: a clinicopathologic review of 55 cases. *Mayo Clin Proc*. 1996;71(7):636-642.
964. Chetty R, Slavin JL. Epithelioid sarcoma with extensive chondroid differentiation. *Histopathology*. 1994;24(4):400-401.
965. Mirra JM, Kessler S, Bhuta S, Eckardt J. The fibroma-like variant of epithelioid sarcoma. A fibrohistiocytic/myoid cell lesion often confused with benign and malignant spindle cell tumors. *Cancer*. 1992;69(6):1382-1395.
966. Molenaar WM, DeJong B, Dam-Meiring A, et al. Epithelioid sarcoma or malignant rhabdoid tumor of soft tissue? Epithelioid immunophenotype and rhabdoid karyotype. *Hum Pathol*. 1989;20(4):347-351.
967. Perrone T, Swanson PE, Twiggs L, et al. Malignant rhabdoid tumor of the vulva: is distinction from epithelioid sarcoma possible? A pathologic and immunohistochemical study. *Am J Surg Pathol*. 1989;13(10):848-858.
968. Miettinen M, Lehto VP, Vartio T, Virtanen I. Epithelioid sarcoma. Ultrastructural and immunohistologic features suggesting a synovial origin. *Arch Pathol Lab Med*. 1982;106(12):620-623.
969. Chase DR, Enzinger FM, Weiss SW, Langloss JM. Keratin in epithelioid sarcoma. An immunohistochemical study. *Am J Surg Pathol*. 1984;8(6):435-441.
970. Chbani L, Guillou L, Terrier P, et al. Epithelioid sarcoma: a clinicopathologic and immunohistochemical analysis of 106 cases from the French sarcoma group. *Am J Clin Pathol*. 2009;131(2):222-227.
971. Miettinen M, Fanburg-Smith JC, Virolainen M, et al. Epithelioid sarcoma: an immunohistochemical analysis of 112 classical and variant cases and a discussion of the differential diagnosis. *Hum Pathol*. 1999;30(8):934-942.
972. Arber DA, Kandalaft PL, Mehta P, Battifora H. Vimentin-negative epithelioid sarcoma. The value of an immunohistochemical panel that includes CD34. *Am J Surg Pathol*. 1993;17(3):302-307.
973. Hornick JL, Dal Cin P, Fletcher CDM. Loss of INI1 expression is characteristic of both conventional and proximal-type epithelioid sarcoma. *Am J Surg Pathol*. 2009;33(4):542-550.
974. Kohashi K, Izumi T, Oda Y, et al. Infrequent SMARCB1/INI1 gene alteration in epithelioid sarcoma: a useful tool in distinguishing epithelioid sarcoma from malignant rhabdoid tumor. *Hum Pathol*. 2009;40(3):349-355.
975. Laskin WB, Miettinen M. Epithelioid sarcoma: new insights based on an extended immunohistochemical analysis. *Arch Pathol Lab Med*. 2003;127(9):1161-1168.
976. Kohashi K, Yamada Y, Hotokebuchi Y, et al. ERG and SALL4 expressions in SMARCB1/INI1-deficient tumors: a useful tool for distinguishing epithelioid sarcoma from malignant rhabdoid tumor. *Hum Pathol*. 2015;46(2):225-230.

For personal use only. No other uses without permission. Copyright ©2017. Elsevier Inc. All rights reserved.

977. Prat J, Woodruff JM, Marcove RC. Epithelioid sarcoma: an analysis of 22 cases indicating the prognostic significance of vascular invasion and regional lymph node metastasis. *Cancer*. 1978;41(4):1472-1487.
978. Weissmann D, Amenta PS, Kantor GR. Vulvar epithelioid sarcoma metastatic to the scalp. A case report and review of the literature. *Am J Dermatopathol*. 1990;12(5):462-468.
979. Chase DR, Enzinger FM. Epithelioid sarcoma. Diagnosis, prognostic indicators, and treatment. *Am J Surg Pathol*. 1985;9(4):241-263.
980. Evans HL, Baer SC. Epithelioid sarcoma: a clinicopathologic and prognostic study of 26 cases. *Semin Diagn Pathol*. 1993;10(4):286-291.
981. Folpe AL, Schoolmeester JK, McCluggage WG, et al. SMARCB1-deficient vulvar neoplasms: a clinicopathologic, immunohistochemical, and molecular genetic study of 14 cases. *Am J Surg Pathol*. 2015;39(6):836-849.
982. Guillou L, Wadden C, Coindre JM, et al. "Proximal-type" epithelioid sarcoma, a distinctive aggressive neoplasm showing rhabdoid features. Clinicopathologic, immunohistochemical, and ultrastructural study of a series. *Am J Surg Pathol*. 1997;21(2):130-146.
983. Hasegawa T, Matsuno Y, Shimoda T, et al. Proximal-type epithelioid sarcoma: a clinicopathologic study of 20 cases. *Mod Pathol*. 2001;14(7):655-663.
984. Izumi T, Oda Y, Hasegawa T, et al. Prognostic significance of dysadherin expression in epithelioid sarcoma and its diagnostic utility in distinguishing epithelioid sarcoma from malignant rhabdoid tumor. *Mod Pathol*. 2006;19(6):820-831.
985. Li L, Fan X-S, Xia Q-Y, et al. Concurrent loss of INI1, PBRM1, and BRM expression in epithelioid sarcoma: implications for the cocontributions of multiple SWI/SNF complex members to pathogenesis. *Hum Pathol*. 2014;45(11):2247-2254.
986. Enzinger FM, Weiss SW, Liang CY. Ossifying fibromyxoid tumor of soft parts. A clinicopathological analysis of 59 cases. *Am J Surg Pathol*. 1989;13(10):817-827.
987. Miettinen M, Finnell V, Fetsch JF. Ossifying fibromyxoid tumor of soft parts—a clinicopathologic and immunohistochemical study of 104 cases with long-term follow-up and a critical review of the literature. *Am J Surg Pathol*. 2008;32(7):996-1005.
988. Donner LR. Ossifying fibromyxoid tumor of soft parts: evidence supporting Schwann cell origin. *Hum Pathol*. 1992;23(2):200-202.
989. Hirose T, Shimada S, Tani T, Hasegawa T. Ossifying fibromyxoid tumor: invariable ultrastructural features and diverse immunophenotypic expression. *Ultrastruct Pathol*. 2007;31(3):233-239.
990. Min K-W, Seo IS, Pitha J. Ossifying fibromyxoid tumor: modified myoepithelial cell tumor? Report of three cases with immunohistochemical and electron microscopic studies. *Ultrastruct Pathol*. 2005;29(6):535-548.
990a. Graham RP, Weiss SW, Sukov WR, et al. PHF1 rearrangements in ossifying fibromyxoid tumors of soft parts: a fluorescence in situ hybridization study of 41 cases with emphasis on the malignant variant. *Am J Surg Pathol*. 2013;37(11):1751-1755.
990b. Kao YC, Sung YS, Zhang L, et al. Expanding the molecular signature of ossifying fibromyxoid tumors with two novel gene fusions: CREBBP-BCORL1 and KDM2A-WWTR1. *Genes Chromosomes Cancer*. 2017;56(1):42-50.
991. Folpe AL, Weiss SW. Ossifying fibromyxoid tumor of soft parts: a clinicopathologic study of 70 cases with emphasis on atypical and malignant variants. *Am J Surg Pathol*. 2003;27(4):421-431.
992. Shimada H, Newton WA, Soule EH, et al. Pathologic features of extraosseous Ewing's sarcoma: a report from the Intergroup Rhabdomyosarcoma Study. *Hum Pathol*. 1988;19(4):442-453.
993. Angervall L, Enzinger FM. Extraskeletal neoplasm resembling Ewing's sarcoma. *Cancer*. 1975;36(1):240-251.
994. Ehrig T, Billings SD, Fanburg-Smith JC. Superficial primitive neuroectodermal tumor/Ewing sarcoma (PN/ES): same tumor as deep PN/ES or new entity? *Ann Diagn Pathol*. 2007;11(3):153-159.
995. Suh C-H, Ordóñez NG, Hicks J, Mackay B. Ultrastructure of the Ewing's sarcoma family of tumors. *Ultrastruct Pathol*. 2002;26(2):67-76.
996. Jürgens H, Bier V, Harms D, et al. Malignant peripheral neuroectodermal tumors. A retrospective analysis of 42 patients. *Cancer*. 1988;61(2):349-357.
997. Askin FB, Rosai J, Sibley RK, et al. Malignant small cell tumor of the thoracopulmonary region in childhood: a distinctive clinicopathologic entity of uncertain histogenesis. *Cancer*. 1979;43(6):2438-2451.
998. Parham DM, Hijazi Y, Steinberg SM, et al. Neuroectodermal differentiation in Ewing's sarcoma family of tumors does not predict tumor behavior. *Hum Pathol*. 1999;30(8):911-918.
999. Turc-Carel C, Philip I, Berger MP, et al. Chromosome study of Ewing's sarcoma (ES) cell lines. Consistency of a reciprocal translocation t(11;22)(q24;q12). *Cancer Genet Cytogenet*. 1984;12(1):1-19.
1000. Delattre O, Zucman J, Melot T, et al. The Ewing family of tumors—a subgroup of small-round-cell tumors defined by specific chimeric transcripts. *N Engl J Med*. 1994;331(5):294-299.
1001. Downing JR, Head DR, Parham DM, et al. Detection of the (11;22)(q24;q12) translocation of Ewing's sarcoma and peripheral neuroectodermal tumor by reverse transcription polymerase chain reaction. *Am J Pathol*. 1993;143(5):1294-1300.
1002. Kumar S, Pack S, Kumar D, et al. Detection of EWS-FLI-1 fusion in Ewing's sarcoma/peripheral primitive neuroectodermal tumor by fluorescence in situ hybridization using formalin-fixed paraffin-embedded tissue. *Hum Pathol*. 1999;30(3):324-330.
1003. Ambros IM, Ambros PF, Strehl S, et al. MIC2 is a specific marker for Ewing's sarcoma and peripheral primitive neuroectodermal tumors. Evidence for a common histogenesis of Ewing's sarcoma and peripheral primitive neuroectodermal tumors from MIC2 expression and specific chromosome aberration. *Cancer*. 1991;67(7):1886-1893.
1004. Vakar-López F, Ayala AG, Raymond AK, Czerniak B. Epithelial Phenotype in Ewing's Sarcoma/Primitive Neuroectodermal Tumor. *Int J Surg Pathol*. 2000;8(1):59-65.
1005. Folpe AL, Goldblum JR, Rubin BP, et al. Morphologic and immunophenotypic diversity in Ewing family tumors: a study of 66 genetically confirmed cases. *Am J Surg Pathol*. 2005;29(8):1025-1033.
1006. Schuetz AN, Rubin BP, Goldblum JR, et al. Intercellular junctions in Ewing sarcoma/primitive neuroectodermal tumor: additional evidence of epithelial differentiation. *Mod Pathol*. 2005;18(11):1403-1410.
1007. Folpe AL, Hill CE, Parham DM, et al. Immunohistochemical detection of FLI-1 protein expression: a study of 132 round cell tumors with emphasis on CD99-positive mimics of Ewing's sarcoma/primitive neuroectodermal tumor. *Am J Surg Pathol*. 2000;24(12):1657-1662.
1007a. Hung YP, Fleltcher CD, Hornick JL. Evaluation of NKX2-2 expression in round cell sarcomas and other tumors with EWSR1 rearrangement: imperfect specificity for Ewing sarcoma. *Mod Pathol*. 2016;29(4):370-380.
1008. Navarro S, Cavazzana AO, Llombart-Bosch A, Triche TJ. Comparison of Ewing's sarcoma of bone and peripheral neuroepithelioma. An immunocytochemical and ultrastructural analysis of two primitive neuroectodermal neoplasms. *Arch Pathol Lab Med*. 1994;118(6):608-615.
1009. Choi E-YK, Thomas DG, McHugh JB, et al. Undifferentiated small round cell sarcoma with t(4;19)(q35;q13.1) CIC-DUX4 fusion: a novel highly aggressive soft tissue tumor with distinctive histopathology. *Am J Surg Pathol*. 2013;37(9):1379-1386.
1010. Machado I, Llombart B, Calabuig-Fariñas S, Llombart-Bosch A. Superficial Ewing's sarcoma family of tumors: a clinicopathological study with differential diagnoses. *J Cutan Pathol*. 2011;38(8):636-643.
1011. Smith SC, Buehler D, Choi E-YK, et al. CIC-DUX sarcomas demonstrate frequent MYC amplification and ETS-family transcription factor expression. *Mod Pathol*. 2015;28(1):57-68.
1012. Sugita S, Arai Y, Tonooka A, et al. A novel CIC-FOXO4 gene fusion in undifferentiated small round cell sarcoma: a genetically distinct variant of Ewing-like sarcoma. *Am J Surg Pathol*. 2014;38(11):1571-1576.
1012a. Antonescu CR, Owosho AA, Zhang L, et al. Sarcomas with CIC-rearrangements are a distinct pathologic entity with aggressive outcome: a clinicopathologic and molecular study of 115 cases. *Am J Surg Pathol*. 2017;41(7):941-949.
1013. Cohen-Gogo S, Cellier C, Coindre J-M, et al. Ewing-like sarcomas with BCOR-CCNB3 fusion transcript: a clinical, radiological and pathological retrospective study from the Société Française des Cancers de L'Enfant. *Pediatr Blood Cancer*. 2014;61(12):2191-2198.
1014. Peters TL, Kumar V, Polikepahad S, et al. BCOR-CCNB3 fusions are frequent in undifferentiated sarcomas of male children. *Mod Pathol*. 2015;28(4):575-586.
1015. Puls F, Niblett A, Marland G, et al. BCOR-CCNB3 (Ewing-like) sarcoma: a clinicopathologic analysis of 10 cases, in comparison with conventional Ewing sarcoma. *Am J Surg Pathol*. 2014;38(10):1307-1318.
1015a. Specht K, Zhang L, Sung YS, et al. Novel BCOR-MAML3 and ZC3H7B-BCOR gene fusions in undifferentiated small blue round cell sarcomas. *Am J Surg Pathol*. 2016;40(4):433-442.
1016. Adsay V, Cheng J, Athanasian E, et al. Primary desmoplastic small cell tumor of soft tissues and bone of the hand. *Am J Surg Pathol*. 1999;23(11):1408-1413.
1017. Gerald WL, Ladanyi M, de Alava E, et al. Clinical, pathologic, and molecular spectrum of tumors associated with t(11;22)(p13;q12): desmoplastic small round-cell tumor and its variants. *J Clin Oncol*. 1998;16(9):3028-3036.
1018. Ordóñez NG. Desmoplastic small round cell tumor: II: an ultrastructural and immunohistochemical study with emphasis on new immunohistochemical markers. *Am J Surg Pathol*. 1998;22(11):1314-1327.
1019. Hill DA, Pfeifer JD, Marley EF, et al. WT1 staining reliably differentiates desmoplastic small round cell tumor from Ewing sarcoma/primitive neuroectodermal tumor. An

For personal use only. No other uses without permission. Copyright ©2017. Elsevier Inc. All rights reserved.

immunohistochemical and molecular diagnostic study. *Am J Clin Pathol*. 2000;114(3):345-353.
1020. Biegel JA, Conard K, Brooks JJ. Translocation (11;22)(p13;q12): primary change in intra-abdominal desmoplastic small round cell tumor. *Genes Chromosomes Cancer*. 1993;7(2):119-121.
1021. Sawyer JR, Tryka AF, Lewis JM. A novel reciprocal chromosome translocation t(11;22)(p13;q12) in an intraabdominal desmoplastic small round-cell tumor. *Am J Surg Pathol*. 1992;16(4):411-416.
1022. de Alava E, Ladanyi M, Rosai J, Gerald WL. Detection of chimeric transcripts in desmoplastic small round cell tumor and related developmental tumors by reverse transcriptase polymerase chain reaction. A specific diagnostic assay. *Am J Pathol*. 1995;147(6):1584-1591.
1023. Hill DA, O'Sullivan MJ, Zhu X, et al. Practical application of molecular genetic testing as an aid to the surgical pathologic diagnosis of sarcomas: a prospective study. *Am J Surg Pathol*. 2002;26(8):965-977.
1024. Ordóñez NG. Desmoplastic small round cell tumor: I: a histopathologic study of 39 cases with emphasis on unusual histological patterns. *Am J Surg Pathol*. 1998;22(11):1303-1313.
1025. Fanburg-Smith JC, Hengge M, Hengge UR, et al. Extrarenal rhabdoid tumors of soft tissue: a clinicopathologic and immunohistochemical study of 18 cases. *Ann Diagn Pathol*. 1998;2(6):351-362.
1026. Oda Y, Tsuneyoshi M. Extrarenal rhabdoid tumors of soft tissue: clinicopathological and molecular genetic review and distinction from other soft-tissue sarcomas with rhabdoid features. *Pathol Int*. 2006;56(6):287-295.
1027. Wick MR, Ritter JH, Dehner LP. Malignant rhabdoid tumors: a clinicopathologic review and conceptual discussion. *Semin Diagn Pathol*. 1995;12(3):233-248.
1028. Kodet R, Newton WA, Sachs N, et al. Rhabdoid tumors of soft tissues: a clinicopathologic study of 26 cases enrolled on the Intergroup Rhabdomyosarcoma Study. *Hum Pathol*. 1991;22(7):674-684.
1029. Parham DM, Weeks DA, Beckwith JB. The clinicopathologic spectrum of putative extrarenal rhabdoid tumors. An analysis of 42 cases studied with immunohistochemistry or electron microscopy. *Am J Surg Pathol*. 1994;18(10):1010-1029.
1030. Tsokos M, Kouraklis G, Chandra RS, et al. Malignant rhabdoid tumor of the kidney and soft tissues. Evidence for a diverse morphological and immunocytochemical phenotype. *Arch Pathol Lab Med*. 1989;113(2):115-120.
1031. Biegel JA, Allen CS, Kawasaki K, et al. Narrowing the critical region for a rhabdoid tumor locus in 22q11. *Genes Chromosomes Cancer*. 1996;16(2):94-105.
1032. Roberts CWM, Biegel JA. The role of SMARCB1/INI1 in development of rhabdoid tumor. *Cancer Biol Ther*. 2009;8(5):412-416.
1033. Hoot AC, Russo P, Judkins AR, et al. Immunohistochemical analysis of hSNF5/INI1 distinguishes renal and extra-renal malignant rhabdoid tumors from other pediatric soft tissue tumors. *Am J Surg Pathol*. 2004;28(11):1485-1491.
1034. Judkins AR. Immunohistochemistry of INI1 expression: a new tool for old challenges in CNS and soft tissue pathology. *Adv Anat Pathol*. 2007;14(5):335-339.
1035. Sultan I, Qaddoumi I, Rodríguez-Galindo C, et al. Age, stage, and radiotherapy, but not primary tumor site, affects the outcome of patients with malignant rhabdoid tumors. *Pediatr Blood Cancer*. 2010;54(1):35-40.
1036. Weeks DA, Beckwith JB, Mierau GW, Luckey DW. Rhabdoid tumor of kidney. A report of 111 cases from the National Wilms' Tumor Study Pathology Center. *Am J Surg Pathol*. 1989;13(6):439-458.
1037. Gururangan S, Bowman LC, Parham DM, et al. Primary extracranial rhabdoid tumors. Clinicopathologic features and response to ifosfamide. *Cancer*. 1993;71(8):2653-2659.
1038. Weidner N. Review and update: oncogenic osteomalacia-rickets. *Ultrastruct Pathol*. 1991;15(4-5):317-333.
1039. Weidner N, Santa Cruz D. Phosphaturic mesenchymal tumors. A polymorphous group causing osteomalacia or rickets. *Cancer*. 1987;59(8):1442-1454.
1040. Cai Q, Hodgson SF, Kao PC, et al. Brief report: inhibition of renal phosphate transport by a tumor product in a patient with oncogenic osteomalacia. *N Engl J Med*. 1994;330(23):1645-1649.
1041. Folpe AL, Fanburg-Smith JC, Billings SD, et al. Most osteomalacia-associated mesenchymal tumors are a single histopathologic entity: an analysis of 32 cases and a comprehensive review of the literature. *Am J Surg Pathol*. 2004;28(1):1-30.
1042. Lee J-C, Jeng Y-M, Su S-Y, et al. Identification of a novel FN1-FGFR1 genetic fusion as a frequent event in phosphaturic mesenchymal tumour. *J Pathol*. 2015;235(4):539-545.
1043. Smith ME, Fisher C, Weiss SW. Pleomorphic hyalinizing angiectatic tumor of soft parts. A low-grade neoplasm resembling neurilemoma. *Am J Surg Pathol*. 1996;20(1):21-29.
1044. Kazakov DV, Pavlovsky M, Mukensnabl P, Michal M. Pleomorphic hyalinizing angiectatic tumor with a sarcomatous component recurring as high-grade myxofibrosarcoma. *Pathol Int*. 2007;57(5):281-284.
1045. Hornick JL, Fletcher CDM. Myoepithelial tumors of soft tissue: a clinicopathologic and immunohistochemical study of 101 cases with evaluation of prognostic parameters. *Am J Surg Pathol*. 2003;27(9):1183-1196.
1046. Michal M, Miettinen M. Myoepitheliomas of the skin and soft tissues. Report of 12 cases. *Virchows Arch*. 1999;434(5):393-400.
1047. Folpe AL, Agoff SN, Willis J, Weiss SW. Parachordoma is immunohistochemically and cytogenetically distinct from axial chordoma and extraskeletal myxoid chondrosarcoma. *Am J Surg Pathol*. 1999;23(9):1059-1067.
1048. Antonescu CR, Zhang L, Chang N-E, et al. EWSR1-POU5F1 fusion in soft tissue myoepithelial tumors. A molecular analysis of sixty-six cases, including soft tissue, bone, and visceral lesions, showing common involvement of the EWSR1 gene. *Genes Chromosomes Cancer*. 2010;49(12):1114-1124.
1049. Agaram NP, Chen H-W, Zhang L, et al. EWSR1-PBX3: a novel gene fusion in myoepithelial tumors. *Genes Chromosomes Cancer*. 2015;54(2):63-71.
1050. Huang S-C, Chen H-W, Zhang L, et al. Novel FUS-KLF17 and EWSR1-KLF17 fusions in myoepithelial tumors. *Genes Chromosomes Cancer*. 2015;54(5):267-275.
1051. Le Loarer F, Zhang L, Fletcher CD, et al. Consistent SMARCB1 homozygous deletions in epithelioid sarcoma and in a subset of myoepithelial carcinomas can be reliably detected by FISH in archival material. *Genes Chromosomes Cancer*. 2014;53(6):475-486.
1052. Gleason BC, Fletcher CDM. Myoepithelial carcinoma of soft tissue in children: an aggressive neoplasm analyzed in a series of 29 cases. *Am J Surg Pathol*. 2007;31(12):1813-1824.
1052a. Yoshida A, Yoshida H, Yoshida M, et al. Myoepithelioma-like tumors of the vulvar region: a distinctive of SMARCB1-deficient neoplasms. *Am J Surg Pathol*. 2015;39(8):1102-1113.
1053. Bisceglia M, Cardone M, Fantasia L, et al. Mixed tumors, myoepitheliomas, and oncocytomas of the soft tissues are likely members of the same family: a clinicopathologic and ultrastructural study. *Ultrastruct Pathol*. 2001;25(5):399-418.
1054. Polk P, Parker KM, Biggs PJ. Soft tissue oncocytoma. *Hum Pathol*. 1996;27(2):206-208.
1055. Rastrelli M, Tropea S, Basso U, et al. Soft tissue limb and trunk sarcomas: diagnosis, treatment and follow-up. *Anticancer Res*. 2014;34(10):5251-5262.
1056. Jiang J-H, Yen S-L, Lee S-Y, Chuang J-H. Differences in the distribution and presentation of bronchogenic cysts between adults and children. *J Pediatr Surg*. 2015;50(3):399-401.
1057. Laskin WB, Miettinen M, Fetsch JF. Calcareous lesions of the distal extremities resembling tumoral calcinosis (tumoral calcinosislike lesions): clinicopathologic study of 43 cases emphasizing a pathogenesis-based approach to classification. *Am J Surg Pathol*. 2007;31(1):15-25.
1058. Garringer HJ, Malekpour M, Esteghamat F, et al. Molecular genetic and biochemical analyses of FGF23 mutations in familial tumoral calcinosis. *Am J Physiol Endocrinol Metab*. 2008;295(4):E929-E937.
1059. Ichikawa S, Baujat G, Seyahi A, et al. Clinical variability of familial tumoral calcinosis caused by novel GALNT3 mutations. *Am J Med Genet A*. 2010;152A(4):896-903.
1060. Topaz O, Indelman M, Chefetz I, et al. A deleterious mutation in SAMD9 causes normophosphatemic familial tumoral calcinosis. *Am J Hum Genet*. 2006;79(4):759-764.
1061. Inclan A. Tumoral calcinosis. *JAMA*. 1943;121:490.
1062. Finer G, Price HE, Shore RM, et al. Hyperphosphatemic familial tumoral calcinosis: response to acetazolamide and postulated mechanisms. *Am J Med Genet A*. 2014;164A(6):1545-1549.
1063. Fetsch JF, Montgomery EA, Meis JM. Calcifying fibrous pseudotumor. *Am J Surg Pathol*. 1993;17(5):502-508.
1064. Nascimento AF, Ruiz R, Hornick JL, Fletcher CDM. Calcifying fibrous "pseudotumor": clinicopathologic study of 15 cases and analysis of its relationship to inflammatory myofibroblastic tumor. *Int J Surg Pathol*. 2002;10(3):189-196.
1065. Khoo JJ. Soft tissue amyloidoma. *Pathology (Phila)*. 2002;34(3):291-293.
1066. Fischer B, Palkovic S, Rickert C, et al. Cerebral AL lambda-amyloidoma: clinical and pathomorphological characteristics. Review of the literature and of a patient. *Amyloid*. 2007;14(1):11-19.
1067. Pietschmann MF, Oliveira AM, Chou MM, et al. Aneurysmal bone cysts of soft tissue represent true neoplasms: a report of two cases. *J Bone Joint Surg Am*. 2011;93(9):e45.
1068. Sukov WR, Franco MF, Erickson-Johnson M, et al. Frequency of USP6 rearrangements in myositis ossificans, brown tumor, and cherubism: molecular cytogenetic evidence that a subset of "myositis ossificans-like lesions" are the early phases in the formation of soft-tissue aneurysmal bone cyst. *Skeletal Radiol*. 2008;37(4):321-327.
1069. Chi C-C, Wang S-H, Kuo T. Localized cutaneous polyvinylpyrrolidone storage

For personal use only. No other uses without permission. Copyright ©2017. Elsevier Inc. All rights reserved.

disease mimicking cheilitis granulomatosa. *J Cutan Pathol*. 2006;33(6):454-457.
1070. Kuo TT, Hu S, Huang CL, et al. Cutaneous involvement in polyvinylpyrrolidone storage disease: a clinicopathologic study of five patients, including two patients with severe anemia. *Am J Surg Pathol*. 1997;21(11):1361-1367.
1071. Hizawa K, Inaba H, Nakanishi S, et al. Subcutaneous pseudosarcomatous polyvinylpyrrolidone granuloma. *Am J Surg Pathol*. 1984;8(5):393-398.
1072. Avcin S, Jazbec J, Jancar J. Subcutaneous nodule after vaccination with an aluminum-containing vaccine. *Acta Dermatovenerol Alp Pannonica Adriat*. 2008;17(4):182-184.
1073. Marsee DK, Williams JM, Velazquez EF. Aluminum granuloma after administration of the quadrivalent human papillomavirus vaccine. Report of a case. *Am J Dermatopathol*. 2008;30(6):622-624.
1074. Komaragiri M, Sparber LS, Santos-Zabala ML, et al. Extranodal Rosai-Dorfman disease: a rare soft tissue neoplasm masquerading as a sarcoma. *World J Surg Oncol*. 2013;11:63.
1075. Al-Daraji W, Anandan A, Klassen-Fischer M, et al. Soft tissue Rosai-Dorfman disease: 29 new lesions in 18 patients, with detection of polyomavirus antigen in 3 abdominal cases. *Ann Diagn Pathol*. 2010;14(5):309-316.
1076. Eward WC, DeWitt SB, Brigman BE, et al. Extranodal Castleman disease of the extremities: a case report and review of the literature. *Skeletal Radiol*. 2014;43(11):1627-1631.
1077. Hakozaki M, Tajino T, Yamada H, et al. Intramuscular Castleman's disease of the deltoid: a case report and review of the literature. *Skeletal Radiol*. 2010;39(7):715-719.

For personal use only. No other uses without permission. Copyright ©2017. Elsevier Inc. All rights reserved.

42 Cardiovascular System

Dylan V. Miller

CHAPTER CONTENTS

Heart, *1916*
Normal anatomy, *1916*
Myocardial biopsy, *1917*
Cardiac valves, *1921*
Left atrial appendage, *1924*
Coronary artery bypass, *1924*
Coronary artery stents, *1924*
Cardiac tumors, *1924*
Pericardium, *1929*
Arteries, *1929*
Normal anatomy, *1929*
Arteriosclerosis and atherosclerosis, *1930*
Stents and bypass grafts, *1931*
Aneurysms, *1932*
Arterial dissection, *1933*
Coarctation of aorta, *1935*
Synthetic arterial substitution, *1935*
Arterial occlusive disease, *1935*
Cystic adventitial disease, *1936*
Fibromuscular dysplasia, *1936*
Mesenteric vascular occlusion, *1936*
Acquired arteriovenous fistula, *1937*
Arteriovenous malformation (congenital), *1937*
Thromboangiitis obliterans, *1937*
Arteritis, *1937*
Tumors, *1940*
Veins, *1941*
Normal anatomy, *1941*
Thrombophlebitis and thromboembolism, *1941*
Stasis ulcers, *1942*
Varicose veins, *1942*
Tumors, *1942*
Lymph vessels, *1942*
Normal anatomy, *1942*
Lymphedema, *1942*
Tumors, *1943*

Heart

Surgical pathology specimens received from cardiovascular procedures have evolved in parallel to advances and general trends in cardiovascular surgery over recent decades. Methods have been devised to relieve aortic, mitral, and pulmonary valvular stenosis (often by replacement with a prosthesis) and restore competency to regurgitant mitral, aortic, and tricuspid valves. Coronary artery bypass graft surgery has largely given way to less invasive endovascular coronary artery interventions for the symptomatic treatment of ischemic heart disease. Cardiac transplantation remains a mainstay of treating end-stage heart failure, and the pathologist plays a very important role in rejection monitoring. Increasingly though, mechanical circulatory support by various implanted ventricular assist device pumps is becoming a viable alternative when transplantation is not possible. Most operations for congenital cardiovascular malformations are directed toward increasing or redirecting the flow of blood by such procedures as ligating a patent ductus, closing atrial, ventricular (and atrioventricular) septal defects, creating new pulmonary flow conduits, or reconstructing stenotic arteries and valves orifices. The reader is referred to specialized texts dealing with these various abnormalities and their methods of treatment.[1–4]

Normal Anatomy

The major histologic components of the heart are pericardium, myocardium, endocardium, and the valves.[5] The *pericardium* is divided into fibrous (parietal) and serous (visceral, also known as epicardium) portions. It is lined by a single layer of mesothelial cells resting on a basement membrane and forms a cavity or potential space filled with a small amount (~60 cc) of fluid. The *myocardium* consists of bundles of cardiac muscle fibers (myocytes) separated by fibrous bands. The muscle fibers form a syncytium with end-to-end junctions, called intercalated discs, and sometimes side-to-side junctions. The nuclei of myocytes are centrally located, in contrast to those of skeletal muscle fibers (whose nuclei are peripheral). The *endocardium* consists of a single layer of endothelial cells that are continuous with those of the major blood vessels as well as a basement membrane and delicate supporting connective tissue. The *semilunar (pulmonary and aortic) valves* are composed of three layers: fibrosa (made of dense collagen), spongiosa (containing large amounts of

For personal use only. No other uses without permission. Copyright ©2017. Elsevier Inc. All rights reserved.

Abstract

Surgical pathology specimens from cardiovascular procedures are not the most frequently received in most laboratories, but they represent an important opportunity to guide clinical and surgical management of patients with cardiovascular disease. This chapter briefly reviews the normal features of cardiac tissues, arteries, veins, and lymphatics and discusses relevant aspects of pathologic conditions encountered in biopsy, resection, and explantation specimens.

Keywords

Endomyocardial biopsy,
Myocarditis,
Valve pathology,
Coronary histology,
Stent histology,
Cardiac tumors,
Aortic aneurysm,
Vasculitis pathology

For personal use only. No other uses without permission. Copyright ©2017. Elsevier Inc. All rights reserved.

proteoglycans, loosely arranged collagen fibers, and scattered fibroblasts), and ventricularis (identified by its profusion of elastic fibers). The *atrioventricular (mitral and tricuspid) valves* are composed of the annulus (a ring of circumferentially oriented collagen and elastic fibers), leaflets, chordae tendineae, and papillary muscles. The leaflets, like those of the semilunar valves, are composed of three layers: the spongiosa (on the atrial side, rich in proteoglycans), the central fibrosa, and the ventricularis (on the ventricular side, rich in elastic fibers).

Myocardial Biopsy

The procurement of myocardial or endomyocardial biopsies during cardiac catheterization has become a common procedure. These biopsies are obtained endovascularly through a catheter inserted in a systemic vein and directed to the right ventricle, or through a transthoracic route at the time of surgery for congenital or acquired heart disease. Examination of multiple levels increases the sensitivity of the procedure, particularly in cases of myocarditis.[6] Ultrastructural examination can be of importance, especially for the evaluation of drug toxicity.[7] In the particular case of Adriamycin chemotherapy toxicity, all biopsy pieces should be submitted for plastic resin embedding and "thick" toluidine blue-stained sections since this is the method upon which grading is based (Fig. 42.1).[8] Routine paraffin histologic sections are not as informative in this condition.

For inflammatory processes and other diseases with "patchy involvement" of the myocardium, the possibility of false-negative endomyocardial biopsy results should always be kept in mind because of the high likelihood of sampling error with small biopsy fragments (i.e. positive biopsies are informative, negative biopsies do not necessarily exclude the disease in question).

The current complication rate with the intravascular procedure at specialized centers is less than 1%. The most common complication is hemopericardium (which rarely requires pericardiocentesis or thoracotomy). Indications for myocardial biopsy include evaluation of myocarditis and sarcoidosis, detection and subtyping of amyloidosis, confirming storage disease and other infiltrative processes, monitoring of heart transplant rejection, and grading of Adriamycin toxicity.[9,10] They may also be performed to diagnose primary and metastatic tumors.

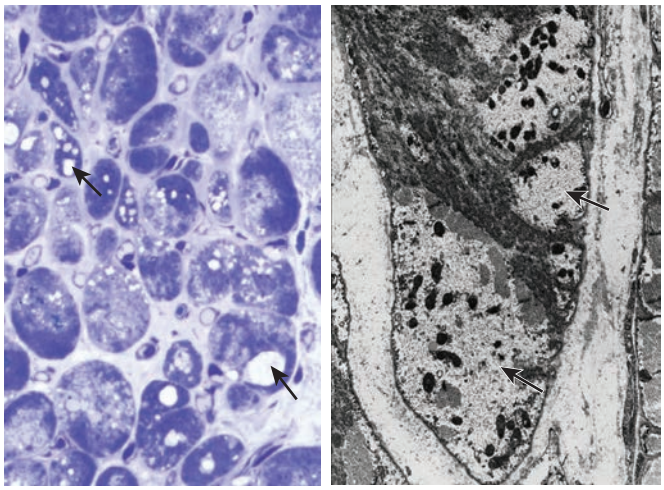

Figure 42.1 Adriamycin cardiotoxicity, manifesting as vacuolar areas of sarcoplasmic myofiber loss *(arrows)*. This change is apparent in both plastic embedded thick sections stained with toluidine blue O *(left)* and by transmission electron microscopy *(right)*.

Cardiomyopathy and Myocarditis

Hypertrophic Cardiomyopathy

This is an inherited disease of the myocardium characterized by left ventricular hypertrophy, usually in an asymmetric fashion, in the absence of a systemic or secondary cardiac cause for hypertrophy (such as hypertension or aortic stenosis) and with normal or reduced chamber size but preserved or hyperdynamic ejection fraction. It is genetically heterogeneous, with most cases caused by germline mutation in a sarcomeric protein gene (most commonly MYH7 and MYBPC3).[11] The main microscopic features of this condition (best seen in whole hearts, septal myomectomy specimens, or generous biopsies obtained via thoracotomy) are hypertrophy and interstitial fibrosis with myofiber "disarray." A nonspecific change that is commonly found in idiopathic hypertrophic myocardiopathy is *basophilic degeneration* of myocardium. This appears as pale blue (on H&E), finely granular material in the cytoplasm of isolated myocardial fibers and consists of polyglucosan deposits.

Idiopathic Dilated Cardiomyopathy

This common, but poorly understood myocardial disease has both genetic and acquired components. It is characterized by marked left ventricular chamber dilation with reduced ejection fraction. Abnormalities in the myocardial biopsy are consistently present but are nonspecific. They consist mainly of hypertrophy, fibrosis, and degenerative changes of myocardial fibers (including lipofuscin accumulation, basophilic change, and vacuolation due to myofiber loss).

Reasonable correlation has been found between the severity of the condition clinically and the extent and degree of microscopic abnormalities, although sometimes the focal nature of these changes and sampling error introduced by biopsy techniques may combine to give a misleading interpretation. Leukocytic infiltrates may be present in biopsies in this condition, an observation linking myocarditis with idiopathic dilated cardiomyopathy. About 30% of cases have an inherited basis, usually autosomal dominant, due to germline mutation in a gene encoding sarcomeric and other cardiomyocyte proteins.[12]

Restrictive (Restrictive/Obliterative) Cardiomyopathy

In the eosinophilic form of this disease in its active stage, a myocarditis with a heavy component of eosinophils is present (Fig. 42.2), along with eosinophil-rich mural thrombus at least in the active stage. In the non-eosinophilic form, or idiopathic restrictive cardiomyopathy, the left ventricle is normal size but the left atrium is markedly enlarged, reflecting physiologic ventricular stiffening and increased filling pressures during diastole. As with hypertrophic and idiopathic cardiomyopathies, the biopsy findings in this form are nonspecific.

Infiltrative Cardiomyopathies

This is the group of cardiac diseases in which endomyocardial biopsy can be particularly rewarding. However, the diagnosis of many of these conditions may be obtained more readily by biopsy of another, more easily accessible organ. These conditions include amyloidosis, hemochromatosis, and storage diseases.[13] As the name implies, these conditions results from insidious deposition of exogenous injurious material(s) in the interstitium, cardiomyocytes, or resident histiocytes in the heart. The presence of these deposits interferes with cardiac contractility and function, leading to a cardiomyopathy phenotype.

Other Cardiomyopathies

Ischemic cardiomyopathy is not a primary myocardial disease but a result of coronary artery occlusion with myocardial infarction and

For personal use only. No other uses without permission. Copyright ©2017. Elsevier Inc. All rights reserved.

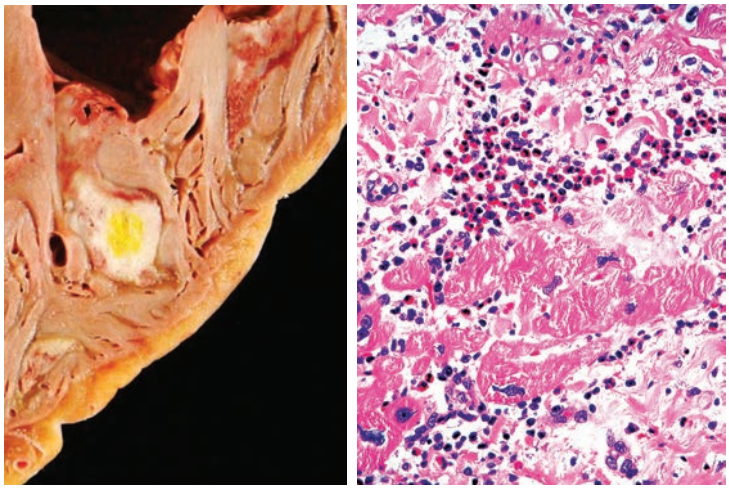

Figure 42.2 Restrictive eosinophilic endomyocardial disease, with organizing mural thrombus in the right ventricle apex *(left)*. The thrombus is eosinophil-rich and there is an associated eosinophilic myocardial infiltrate *(right)*.

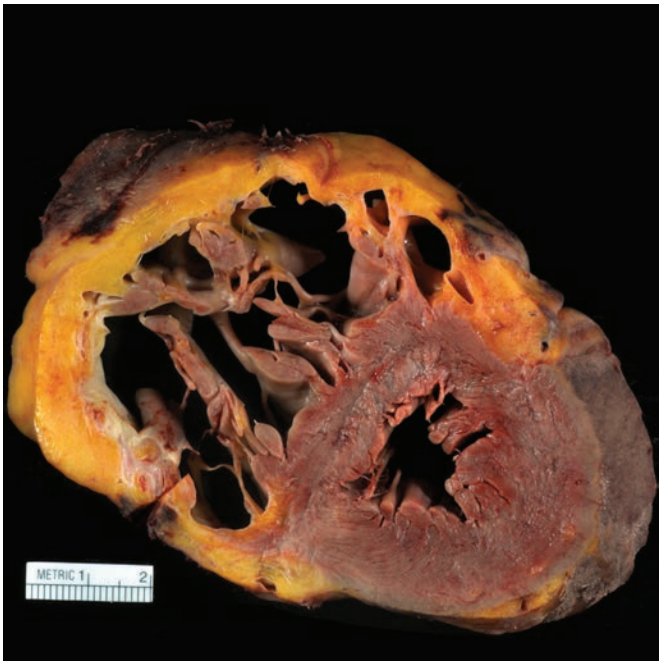

Figure 42.3 Arrhythmogenic cardiomyopathy, with primarily right ventricular involvement (by fibrofatty replacement of ventricular myocardium).

associated ventricular "remodeling" changes. This is characterized by congestive heart failure, ventricular arrhythmias, and left ventricular dilation and can be distinguished from idiopathic dilated cardiomyopathy by the presence of significant coronary artery disease and infarcts in the accompanying myocardial territories. **Arrhythmogenic cardiomyopathy (formerly "right ventricular dysplasia")** is another inherited cardiomyopathy associated with mutations in desmoglein, desmoplakin, plakoglobin, plakophilin-2, and related cell junction proteins. Its manifestations mainly affect the right ventricle.[14] The anatomic substrate is variable infiltration/replacement of the right ventricular myocardium by adipose and fibrous tissue (Fig. 42.3).

Left ventricular noncompaction (hypertrabeculation) cardiomyopathy is another unusual form of myocardial disease resulting from an embryonic failure of ventricular muscle bands to condense and coalesce during development, resulting in abnormal trabeculations in the left ventricle (comprising more than half of the ventricular wall thickness) and functionally impaired ejection fraction (Fig. 42.4). This heritable disorder has been associated with sarcomere and other sarcoplasmic proteins.[12]

Myocarditis

It is agreed that the diagnosis of myocarditis requires the presence of an inflammatory infiltrate *and* myocyte necrosis or degeneration (the two components of the so-called Dallas criteria).[15] The infiltrate is usually lymphocytic in nature, easily identifiable, and often admixed with histiocytes and occasional granulocytes (neutrophils and eosinophils) in routine sections. The H&E sections may be supplemented with CD3, CD4, CD20, CD45, and/or CD68 immunostains to increase sensitivity or clarify the nature of any ambiguous mononuclear cell,[16] but this is not necessary. In *hypersensitivity myocarditis*, the infiltrate is rich in eosinophils, is predominantly perivascular, and is accompanied by a lesser degree of myocyte injury. The myocyte alterations in myocarditis of any etiology can take the form of frank necrosis, vacuolization, or disruption and are better appreciated in longitudinally oriented cells. The presence of edema alone should not be used as a criterion for myocarditis. Fibrosis, if present, should be quantified (mild, moderate, or severe) and qualified (interstitial, endocardial, or replacement type), since this represents a more chronic change not likely to respond to acute immunosuppressive therapy.

Diagnostic terms to be used in subsequent biopsies (if obtained), using the first specimen as a reference point, are *ongoing* or *persistent* myocarditis when both the myocyte damage and the inflammation persist, *resolving* or *healing* myocarditis when these changes are substantially reduced, and *resolved* or *healed* myocarditis when these changes are no longer present (bearing in mind the high likelihood of sampling error and possible false-negative results).

The etiology of myocarditis can be viral, bacterial (including Whipple disease, *Coxiella*, and *Bartonella*), mycobacterial, fungal, or parasitic (particularly Chagas disease and toxoplasmosis, the latter often seen in AIDS patients). Myocarditis may also be caused by autoimmune disease (especially rheumatic fever "pancarditis"), drug-induced reaction, radiation, or as an expression of transplant rejection. In many cases of myocarditis, the condition remains idiopathic, although the recently introduced molecular diagnostic

For personal use only. No other uses without permission. Copyright ©2017. Elsevier Inc. All rights reserved.

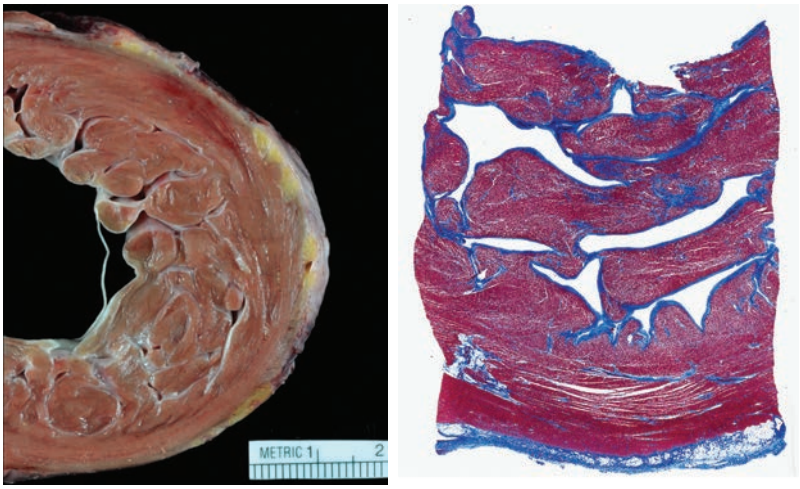

Figure 42.4 Left ventricular noncompaction cardiomyopathy with left ventricular hypertrabeculation comprising more than half of the ventricular thickness (highlighted by trichrome staining).

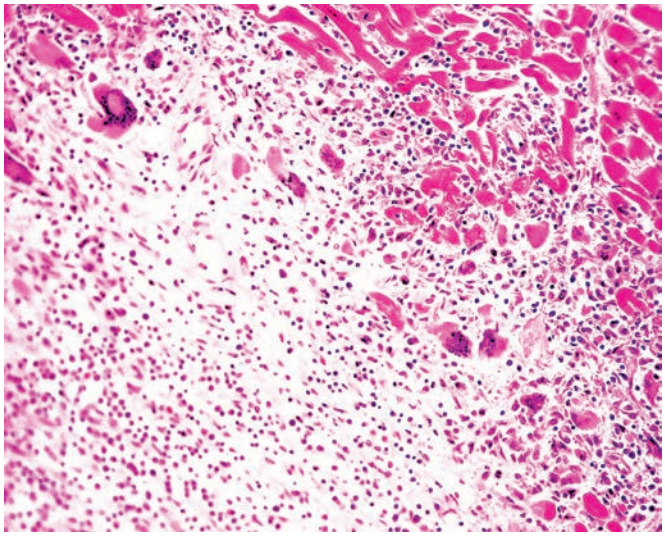

Figure 42.5 Giant Cell Myocarditis. Scattered multinucleated giant cells accompanied by lymphocytes are seen in association with loss of myocardial fibers. There are no granulomas and myocyte damage is widespread, and eosinophils are present in the background.

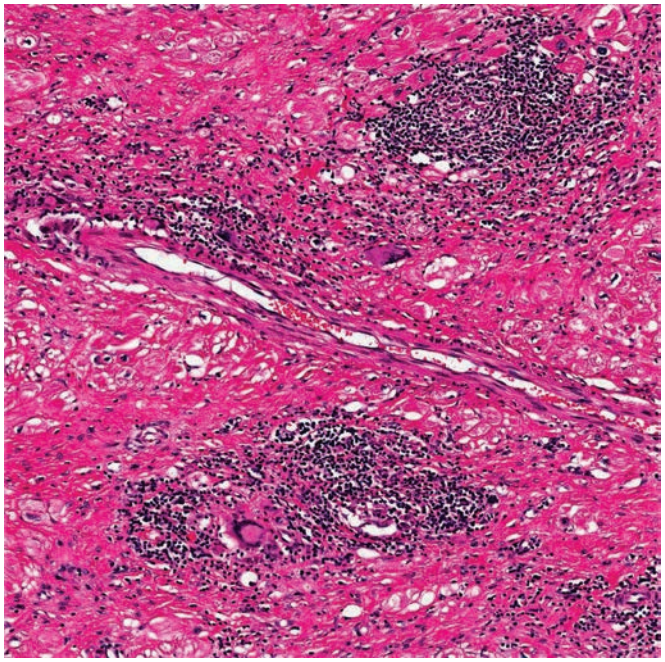

Figure 42.6 Cardiac sarcoidosis with multinucleated giant cells within well-formed granulomas. The surrounding myocytes are relatively intact.

approach may allow for the identification of viruses suspected of inciting the process (enteroviruses and adenoviruses).[16] *Giant cell myocarditis*, a particularly aggressive form, is characterized by more widespread multicentric destruction of the cardiac myocytes. The inflammatory infiltrate includes cytotoxic T cells, eosinophils, and the multinucleated cells that define the entity (Fig. 42.5). Well-formed granulomas are not seen in giant cell myocarditis.

Cardiac Sarcoidosis. The findings of typical sarcoid granulomas (as seen in lung or mediastinal lymph node biopsies) may be found in the heart as manifestation of cardiac involvement by systemically sarcoidosis, but cases in which the heart is the only involved organ have also been described.[17] Like other organs, the distribution of sarcoid granulomas tends for follow lymphatics, which are especially abundant around the cardiac conduction system tracts. Conduction block and cardiac arrhythmia are frequent signs of cardiac sarcoidosis clinically. Sarcoid appears as well-circumscribed, scar-like lesions distributed in patches throughout the full thickness of the myocardium. They appear fairly well demarcated histologically and without significant associated myocyte necrosis in the surrounding myocardium (Fig. 42.6).

Heart Transplant

Myocardial biopsy is the most sensitive and specific indicator of rejection. While historically a number of reporting approaches and grading schemes have been used to describe rejection findings,[18] an international "working formulation" was developed by the International Society for Heart and Lung Transplantation.[19,20] The approach outlined in this scheme includes assessment of both cell-mediated and antibody-mediated attacks on the graft. The main microscopic sign of cellular rejection is a perivascular and interstitial inflammatory infiltrate, predominantly lymphocytic, accompanied by focal necrosis of myocytes (similar to myocarditis) and edema (Fig. 42.7A and B).

For personal use only. No other uses without permission. Copyright ©2017. Elsevier Inc. All rights reserved.

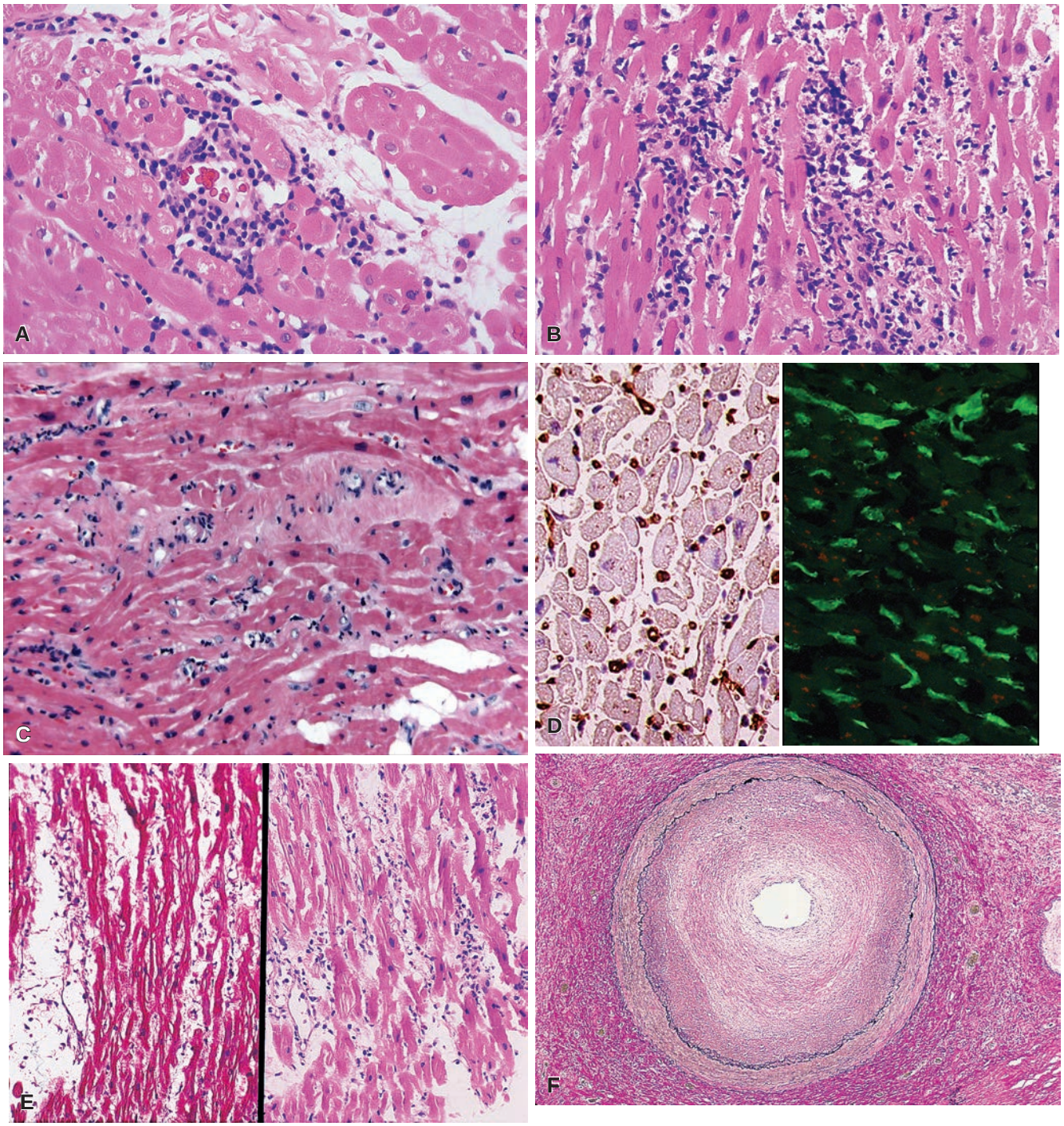

Figure 42.7 Pertinent Pathologic Changes in Cardiac Allografts. A, Endomyocardial biopsy with mild acute cellular rejection. There is patchy perivascular lymphocytic infiltrate with no myocyte injury. **B,** Moderate acute rejection showing inflammation and myocyte damage. **C,** Antibody-mediated rejection features including "activated intravascular mononuclear cells." **D,** Positive staining for complement component C4d by immunohistochemistry and immunofluorescence methods in antibody-mediated rejection. **E,** Acute/subacute ischemic changes including edema, inflammation and "wavy" myocytes showing focal contraction bands. **F,** Cardiac allograft vasculopathy with concentric narrowing of epicardial coronary artery by fibromuscular intimal proliferation. Note the preservation of internal elastic lamina (Elastic-van Gieson stain).

For personal use only. No other uses without permission. Copyright ©2017. Elsevier Inc. All rights reserved.

Table 42.1 ISHLT working formulation for cardiac transplant rejection

CELLULAR REJECTION		ANTIBODY-MEDIATED REJECTION	
0	Normal histologically	pAMR0	Normal histologically and negative immunopathology studies
1R	Interstitial or perivascular infiltrate with up to 1 focus of myocyte damage	pAMR1(H+)	Histologic features of AMR, but normal immunopathology studies
2R	Two or more foci of infiltrate with myocyte damage	pAMR1(I+)	Immunopathology features of AMR, but negative histology
3R	Diffuse infiltrate with multifocal myocyte damage, edema, hemorrhage, vasculitis	pAMR2	Histologic and immunopathologic features of AMR
		pAMR3	pAMR2 plus hemorrhage, edema, neutrophils, endothelial pyknosis -karyorrhexis

Data from Stewart S, Winters GL, Fishbein MC, et al. Revision of the 1990 working formulation for the standardization of nomenclature in the diagnosis of heart rejection. *J Heart Lung Transplant*. 2005;24(11):1710–1720; Berry GJ, Burke MM, Andersen C, et al. The 2013 International Society for Heart and Lung Transplantation Working Formulation for the standardization of nomenclature in the pathologic diagnosis of antibody-mediated rejection in heart transplantation. *J Heart Lung Transplant*. 2013;32(12):1147–1162.

Antibody-mediated rejection is assessed by evaluating the myocardial interstitial capillaries for "swollen"-appearing endothelial cells and accumulation of intravascular macrophages (collectively referred to as "intravascular activated mononuclear cells" in the working formulation). In addition, immunopathology methods are needed (frozen section immunofluorescence or paraffin immunohistochemistry) to test for deposition of complement split products and other potential indicators of antibody mediated immune mechanisms (Table 42.1) (see Fig. 42.7C and D).

Care should be taken to not misinterpret a previous biopsy site as indicative of rejection. Recent biopsy sites appear as a sharply outlined area of necrotic myocytes, sometimes associated with a thrombus and granulation tissue. Older biopsy sites show replacement fibrosis-type scarring, often with associated mononuclear inflammation. Rejection should also be distinguished from ischemic changes (see Fig. 42.7E), especially in the days and weeks following the transplant operation and in the setting of severe cardiac allograft vasculopathy. Another potential mimic of rejection is the so-called Quilty or nodular endocardial inflammatory lesion. These can be distinguished from cellular rejection on the basis of their rounded (rather than infiltrative) contours and subendocardial location.

A form of accelerated "arteriosclerosis" referred to as cardiac allograft vasculopathy (see Fig. 42.7F) is the major long-term complication of heart transplantation, occurring in the majority of grafts 10 years after transplant. Factors recognized to contribute to this disease include previous rejection episodes (especially antibody mediated rejection), circulating anti-donor antibodies detected by flow cytometry methods, and infections (especially with *Cytomegalovirus*).[21]

Other clinically impactful findings may be seen on transplant biopsies, such as EBV-associated post-transplant lymphoproliferative disorder and opportunistic infections such as *Toxoplasma* and *Cytomegalovirus*.[22] Immunohistochemical or in situ hybridization techniques may be helpful in confirming the presence of these.

Cardiac Valves

Surgeries to correct major valve defects (congenital and acquired) by resection and prosthetic replacement are the most frequently performed cardiac surgical procedures. It should be emphasized that often the most precise diagnosis will be made from the gross appearance of the valve and that usually the microscopic examination is of little value.[23] Photographic and radiographic examination of the specimen may also be helpful. The cause of valvular disease can nearly always be ascertained through careful examination of the gross specimen and knowledge of the clinical history. Microscopically, with the exception of rheumatic and myxomatous mitral valve disease, the features are fairly nonspecific, regardless of etiology, and include fibrosis, calcification, and occasional inflammatory cells. A hallmark of rheumatic valve disease is the presence of arterioles and other well-developed vessels within the valve tissue layers (which are avascular in normal and degenerative conditions). The major etiologies of valvular disease (excluding the pulmonary valve since it is rarely intervened upon) and their characteristic gross, microscopic, and clinical features are shown in Tables 42.2–42.4.

Mitral Valve

Nearly all cases of mitral valve stenosis (with or without mitral insufficiency) are acquired and postinflammatory (rheumatic) in nature. Among cases of mitral insufficiency, common causes include myxomatous (floppy) mitral valve disease (mitral valve prolapse), postinflammatory, and ischemic complication.[24] Grossly, rheumatic valves show a characteristic appearance that has been compared to repeated dipping in candle wax. The commissures are partially fused (from the annulus inward), giving a resemblance to a "fish mouth." The cords are also thickened and fused, appearing similar to the whiskers/tendrils of a catfish. As previously mentioned, the presence of vessels with the valve layers is a finding specific to rheumatic valve disease (Fig. 42.8).

Myxomatous valves shows leaflet thickening and redundancy, leading to the formation of dome-like deformities reaching above the level of the annulus. The annulus itself is also dilated. The chordae are often thin and attenuated, though with fibrosis (see Fig. 42.8). Chordal rupture is seen in over one-half of the cases, though the clinical intraoperative impression is often the only way of knowing this.

Microscopically, stromal accumulation of glycosaminoglycans is the distinguishing feature of myxomatous disease, leading to the appearance of "myxoid or myxomatous degeneration." There is no association with cardiac myxoma. Whether this alteration is the result of a genetically determined disease or a degenerative process of nonspecific nature remains controversial.[25,26]

For personal use only. No other uses without permission. Copyright ©2017. Elsevier Inc. All rights reserved.

Table 42.2 Features of mitral valve disease

	STENOSIS	REGURGITATION		
	RHEUMATIC[a]	MYXOMATOUS	POSTINFLAMMATORY	ISCHEMIC
Gross:	• Leaflet thickening (± calcification) • Commissural fusion • Cord thickening and fusion	• Leaflet thickening (gelatinous cut surface) • Mildly thickened cords without fusion	• Leaflet thickening (± calcification) • Cord thickening and fusion	• Normal leaflets • Scarred and retracted papillary muscles
Microscopic:	• Fibrosis, variable inflammation, vessels within valve layers	• Loose myxoid expansion of the spongiosa layer	• Fibrosis, variable inflammation, vessels within valve layers	• Normal leaflets • Ischemic (chronic) papillary muscle
Clinical:	Remote history of rheumatic fever	• Mitral valve prolapse • Often repaired rather than replaced	• Remote rheumatic fever • Irradiation • Healed endocarditis	History of left ventricle infarction (lateral and/or inferior)

[a]Often mixed stenosis and regurgitation

Table 42.3 Features of aortic valve disease

	STENOSIS			REGURGITATION	
	DEGENERATIVE	BICUSPID	POST-INFLAMMATORY	ANNULAR DILATATION	BICUSPID
Gross:	• Nodular calcific deposits ± ulceration • Calcification in sinus "pockets"	• Two cusps, usually different size, one with a "raphe" • Calcification around raphe and closing edge of leaflets	• Thickened, calcified leaflets • Commissural fusion	• Leaflets thin, soft, pliable • Leaflet enlargement, stretching • Leaflets ± rolling/retraction	• Two cusps, usually different size, one with a "raphe" • Leaflet enlargement, stretching
Microscopic:	• Fibrosis, calcification, variable inflammation, ± ulceration	• Fibrosis, calcification, variable inflammation, ± ulceration	• Fibrosis, calcification, inflammation, vessels within valve layers	Normal leaflets	Normal leaflets
Clinical:	• Elderly, atherosclerosis risk factors	• Congenital, 1% of population • Replacement ~10 years sooner than degenerative	• Remote rheumatic fever • Irradiation • Healed endocarditis	• Aortic root dilatation • Ascending aortic aneurysm	• "Aortopathy" • Aortic root and ascending aortic dilatation

Ischemic mitral insufficiency is actually a papillary muscle abnormality, with the leaflets generally preserved. Scarring of the infarcted papillary muscle(s) leads to retraction and foreshortening of the tendinous cords, impairing coaptation during systole.

Aortic Valve

Aortic valve specimens that are removed because of stenosis may show degenerative calcification of congenitally bicuspid valves, calcification of a normally three-leaflet valve without commissural fusion (so-called senile type degeneration), rheumatic changes similar to those described for mitral leaflets, or calcification of congenitally unicommissural valves (Fig. 42.9). It should be mentioned that in some cases, it can be difficult to differentiate congenital bicuspid aortic from a three-leaflet valve that has calcified in a manner such that two of the leaflets fuse together. In these cases, the leaflet sizes can be a helpful clue (the nonconjoined cusp in bicuspid valves is often disproportionately large). The presence of a, usually midline, raphe on the conjoined cusp can also help with this. Pure aortic insufficiency is not related to calcification but to causes such as aortic root dilation, bicuspid valve, and others.

Pulmonary Valve

Specimens of pulmonary valve may be received in the surgical pathology laboratory because of congenital pulmonary stenosis (the majority as a component of tetralogy of Fallot). Bicuspid pulmonary valve is the most common structural anomaly. Pulmonary valve

For personal use only. No other uses without permission. Copyright ©2017. Elsevier Inc. All rights reserved.

Table 42.4 Features of tricuspid valve disease

	REGURGITATION			
	POSTINFLAMMATORY	EBSTEIN ANOMALY	ENDOCARDITIS	CARCINOID VALVE DISEASE
Gross:	• Thickened, calcified leaflets • Commissural fusion	• Abnormal, redundant leaflet tissue • Fenestrations • Muscular attachments	• Perforations • Cusp aneurysms • Vegetations	• Thickening • "Pasted-on" fibrous plaques
Microscopic:	• Fibrosis, inflammation, vessels within valve layers	• Disorganized leaflet layers	• Purulent inflammation • Fibrin • Microorganisms • Postinflammatory changes (chronic)	• Normal valve architecture • Layered fibrosis enrobing the valve
Clinical:	• Remote rheumatic fever • Irradiation • Healed endocarditis	• Rare congenital defect • Leaflet stuck to ventricle walls	• IV drug use • Septic pulmonary emboli	• History of metastatic carcinoid with high liver tumor burden • History of gonadal carcinoid

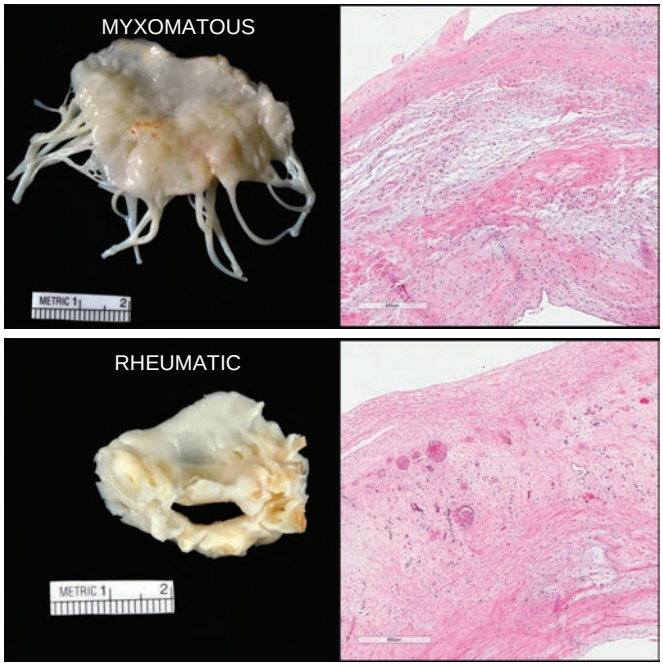

Figure 42.8 Gross and microscopic features of common mitral valve diseases (note the myxoid expansion of myxomatous disease and well-formed vessels in the valve layers in rheumatic disease).

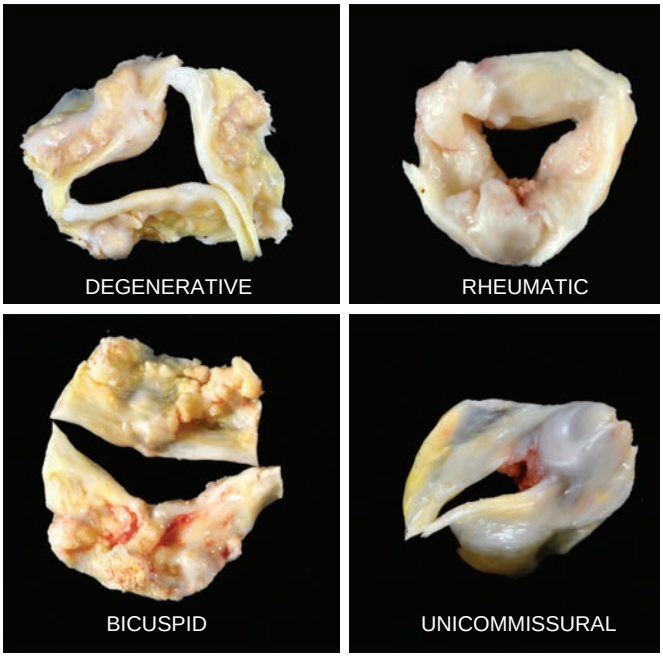

Figure 42.9 Gross features of aortic stenosis (note the number and proportionality of cusps and presence of commissural fusion help distinguish various disease processes).

endocarditis is another uncommon cause of surgery at this location.

Tricuspid Valve

Specimens of tricuspid valve can be the result of operations for pure insufficiency (by far the most common), combined stenosis and insufficiency, and pure stenosis (very rare). The most common causes of insufficiency are postinflammatory diseases, congenital disorders (such as Ebstein anomaly), pulmonary venous hypertension, and infective endocarditis.

Endocarditis

Complications of endocarditis include stenosis due to obstruction by bulky vegetations (often with associated embolic phenomena), and regurgitation due to leaflet destruction in the form of tears, perforations, and aneurysms. Preexisting valve abnormalities seem to predispose to endocarditis, such as bicuspid aortic valve and rheumatic disease. Vegetations are the hallmark of active and subacute endocarditis and grossly appear as fleshy, friable growths arising from the leaflet surfaces (Fig. 42.10). Histologically they are composed of fibrin clot that is rich in neutrophils. Bacterial colonies or other

For personal use only. No other uses without permission. Copyright ©2017. Elsevier Inc. All rights reserved.

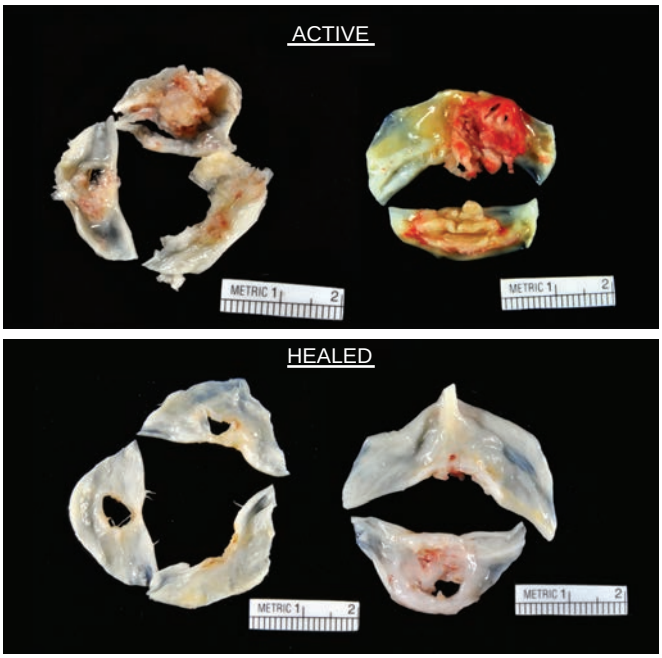

Figure 42.10 Gross features of aortic valve endocarditis (active and healed) involving three-leaflet and bicuspid valves.

microbes may be seen, especially with the help of special stains. Since surgery is often deferred as long as possible to allow for microbial killing by antibiotics (especially before implanting a foreign prosthesis in the infected bed), viable microorganisms may no longer be present. Healed endocarditis will no longer show vegetations grossly or histologically but instead may have perforations and/or leaflet aneurysms. Microscopically, healed endocarditis resembles rheumatic valve disease and may show disruption of the valve layer architecture and replacement fibrosis.

Prosthetic Valves

Given how common valve replacements have become and the finite lifespan of the prosthesis implanted, prosthetic valves are increasingly seen as surgical pathology specimens. The examination of mechanical and bioprosthetic valve prostheses is fairly straightforward and includes evaluating for the presence of thrombus, vegetation, calcification, and degenerative changes (such as leaflet tears for bioprosthetic valves). Microscopic study of these prosthetic valves has shown that, following insertion, a neo-endocardium develops at the junction with the heart wall, and from there it grows centripetally over the sewing cloth toward the valve lumen.[27] This fibrous ingrowth is referred to as "pannus," and can reach the point of causing flow obstruction.

Bioprosthetic valves may be constructed from porcine valve tissue, bovine pericardium, or preserved cadaveric homograft tissue. The pathologic changes that may be found in removed bioprosthetic heart valves include thrombosis, infection, cusp tears and perforations, fibrous sheathing, calcification, and several others. Mechanical valves may show thrombosis, infection, and various alterations associated with the valve design and the composition of the various elements. Regurgitation may be due to leaflet abnormalities or partial dehiscence of the sewing ring with a paravalvular leak.

Left Atrial Appendage

At the time of the correction of a mitral stenosis or other cardiac disease, the surgeon may "amputate" the left (and right) atrial appendage to either remove or prevent later mural thrombus formation and embolization. This is frequently accompanied by atrial ablation to disrupt atrial fibrillation pathways (the "maze" procedure). These appendages are usually abnormal, showing hypertrophy of the muscle and various other alterations. Incidental findings such as Aschoff nodules and amyloid deposits may be seen and often do not correlate with rheumatic disease or cardiac amyloid in the ventricles or systemically.[28,29]

Coronary Artery Bypass

Coronary artery bypass operations are a common treatment of coronary artery atherosclerosis, although the frequency has fallen with the wide availability and success of percutaneous intervention and stenting. Bypass grafting is still the preferred procedure for some coronary lesions and often accompanies open heart surgery when done for other reasons (e.g. aortic stenosis and coronary atherosclerosis). Conduits used to construct bypass grafts include veins (usually saphenous) and the internal mammary arteries (given their proximity to the heart). The 10-year patency rate of vein grafts is 50%–60% as compared to 80%–90% for internal mammary grafts.[30] Coronary bypass grafts on cardiac explant specimens should be evaluated by sampling: (1) the graft body at the point of greatest narrowing, (2) the anastomotic site, and (3) the native artery proximal and distal to the anastomotic site.

Coronary Artery Stents

Percutaneous endovascular approaches to treating coronary atherosclerosis have become the mainstay for this common disease in developed countries. After performing coronary angiography, it is possible to insert and expand a balloon in narrowed areas and leave a metallic stent in place to maintain an adequate luminal diameter. Endovascular extraction techniques can also be used to remove thrombus, and other obstructive material and intravascular ultrasound, optical coherence tomography, and other imaging modalities can be employed to characterize plaque morphology and composition. Stents placed may be "bare" metal alloy or may be coated with anti-inflammatory drug-eluting polymers to calm the foreign body reaction and prevent early stent thrombosis. Placement of these metallic stents renders routine histology methods completely useless in the evaluation of tissue specimens containing them. Special techniques have been devised to remove the metallic stent struts, and these are discussed in greater detail later (Arteries—Stents and Bypass Grafts).

Cardiac Tumors

Myxoma

Myxomas, together with papillary fibroelastomas, are the most common primary tumors of the heart.[31,32] Myxomas occur in two settings: sporadic and familial. Sporadic tumors occur more often in women and most often in middle adulthood. They arise most often in the left atrium and attach to the atrial septum. Familial myxomas tend to manifest at a younger age and are slightly more common in men. Sites outside the left atrium are also more common with familial tumors, as are multicentric tumors.[33] Besides cardiac myxomas, patients with the heritable Carney complex also may have cutaneous and labial lentiginosis, eyelid and cutaneous myxomas, myxoid mammary fibroadenomas (often multiple and bilateral), adrenocortical nodular dysplasia associated with Cushing syndrome, and large cell calcifying Sertoli cell tumor of the testis.[33] Carney complex patients harbor inactivating mutation of the protein

For personal use only. No other uses without permission. Copyright ©2017. Elsevier Inc. All rights reserved.

kinase A regulatory subunit gene *PRKAR1A*, which encodes a protein that plays an important role in cardiac development and myxomagenesis.[34]

Whether familial or sporadic, left-sided cardiac myxomas typically present with signs of mitral stenosis or insufficiency, and right-sided tumors with dyspnea, syncope, distension of neck veins, and other symptoms.[32] They may also lead to multiple emboli in the systemic or pulmonary circulation, depending on their location, but this is fundamentally different than metastasis. Myocardial, pulmonary, or cerebral infarcts may thus supervene. The production of emboli has been attributed to the overexpression of matrix metalloproteinases by the tumor,[35] but having a more frond-like than globose architecture may also predispose to embolization. Two-dimensional echocardiography, CT, MRI, gated radionuclide blood-pool scan, or cardiac catheterization can all visualize myxomas, but cannot differentiate between other pedunculated tumors or thrombi. Occasionally, the diagnosis is made only after histologic examination of an embolus removed from a distant site.

Grossly, myxomas are soft, polypoid, pale, lobulated masses, often attached by a stalk to the septum near the foramen ovale. Areas of hemorrhage may be present (Fig. 42.11). Calcification may occur, and this seems to be more common in those located in the right atrium. Extremely calcified myxomas have been referred to "petrified" myxoma.

Microscopically, round, polygonal, or stellate cells are seen surrounded by abundant loose stroma rich in acid mucopolysaccharides. Some of these cells form solid syncytial cords, but the hallmark finding is the presence of myxoma cells in a ring that encircles small- and medium-size tumor vessels (Fig. 42.12). Mitoses, pleomorphism, and necrosis are absent or minimal. Other microscopic variations include surface thrombosis, Gamna–Gandy bodies, ossification ("petrified" myxoma), chondroid tissue, extramedullary hematopoiesis, and presence of thymic and foregut remnants. The latter may be somehow related to the most peculiar change that cardiac myxoma can exhibit, namely the presence of well-developed mucin-producing glands that may even be apparent grossly (Fig. 42.13A and B). This phenomenon, which has been referred to as *glandular myxoma*, can be confused with metastatic adenocarcinoma, particularly when showing atypical cytoarchitectural features. Another exceptional occurrence in cardiac myxoma is the development of a thymoma, presumably arising from the previously mentioned thymic remnants.[36] Neuroendocrine components have also been observed.

This diversity of tissue types arising within myxoma lends some credence to the theory that the line of origin for myxomas may be

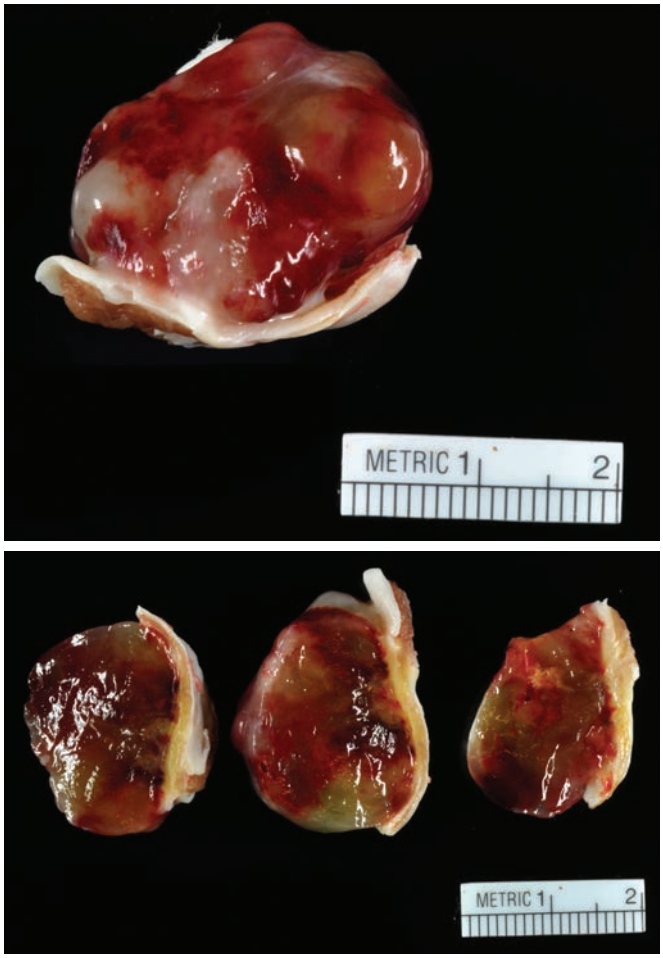

Figure 42.11 Gross Appearance of Cardiac Myxoma. The lesion has a polypoid shape and a hemorrhagic appearance. A portion of atrial septal wall is attached at the "stalk" base.

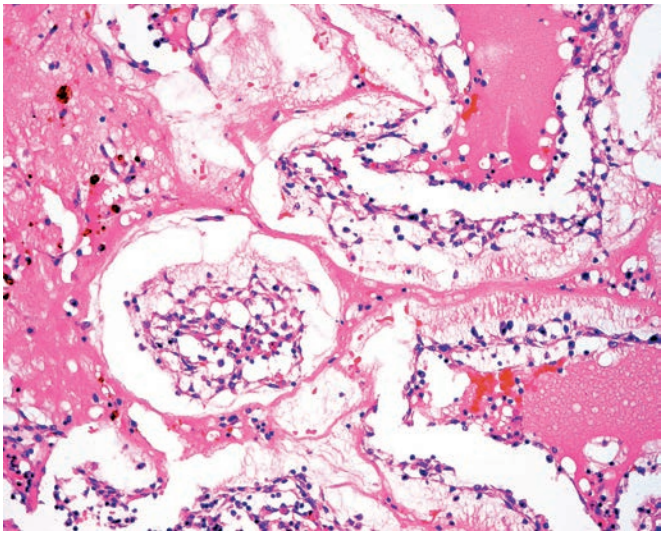

Figure 42.12 Cardiac myxoma showing a concentric arrangement of tumor cells around vascular spaces; highly characteristic of myxoma.

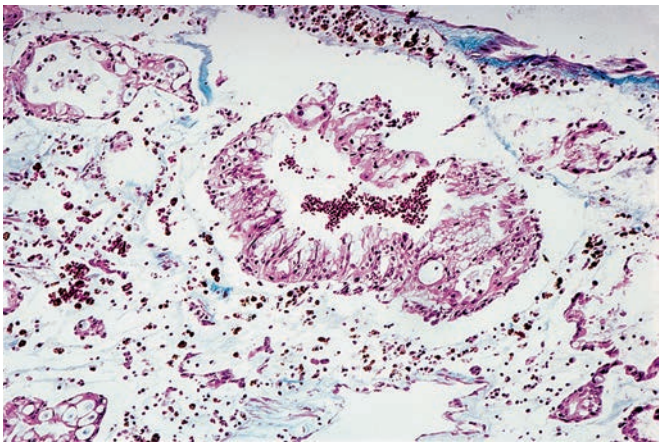

Figure 42.13 "Glandular" Myxoma. The glandular epithelium is tall columnar and contains intracytoplasmic mucin. This rare type of myxoma should not be confused with metastatic adenocarcinoma.

For personal use only. No other uses without permission. Copyright ©2017. Elsevier Inc. All rights reserved.

resident pluripotent cells. Ultrastructural studies have also suggested that myxomas arise from multipotential mesenchymal cells.[37] By immunohistochemistry, myxoma cells express endothelial markers (CD31, CD34, factor VIII), as well as calretinin, vimentin, actin, desmin, and smooth muscle myosin.[31,32] Cardiac myxoma expresses several cardiomyocyte-specific transcription factors, suggesting at least primitive cardiomyogenic differentiation as well.[38] The mucinous extracellular material stains for membrane-associated MUC1 and less so for secreted mucins MUC2 and MUC5AC. Areas of glandular differentiation may be positive for carcinoembryonic antigen (CEA), epithelial membrane antigen (EMA), and keratins.

Surgical excision of the ordinary myxoma is often curative. Several instances of local recurrence have been reported in the past; with the routine performance of partial atrial septectomy, together with the excision of the tumor, they have become very rare. Malignant transformation of myxoma is a controversial topic, and, in this author's opinion, convincing cases have not been concretely demonstrated.

Papillary fibroelastoma (fibroelastic hamartoma, fibroma, papilloma, papillary fibroblastoma) is nearly as common as myxoma, and they appear as small papillary ("sea anemone–like") growths that usually occur on the surface of the valves but may also be seen in other endocardial locations (Fig. 42.14).[31,32] It is often an incidental finding at surgery or autopsy but with the increasing resolution of cardial imaging modalities may also be found using these techniques. The myriad fronds of this tumor may be difficult to appreciate when the tumor is dry (and may actually resemble myxoma), but they readily become apparent when suspended in clear liquid (saline or formalin). Microscopically, the papillary architecture is obvious, with individual fronds consisting of a core of hyalinized hypocellular stroma that is rich in elastic fibers and a lining of hyperplastic endocardial cells (Fig. 42.15). Whether they represent a true neoplasm versus an exuberant reactive growth (organized mural thrombus, for example) remains unclear. A form of "secondary" papillary fibroelastoma is recognized in association with rheumatic valve disease, surgical scars inside the heart, and other sites of remote injury.[39]

Other Benign Tumors and Tumorlike Conditions

Rhabdomyoma and rhabdomyomatosis are mostly seen during the first decade of life, and clinically documented examples of tumor regression by adolescence have been reported. However, they can also present in adult patients. Most of the patients have tuberous sclerosis.[31,32] Grossly, rhabdomyomas present as one or more firm, white-yellow, well-circumscribed nodules. Microscopically, the most distinctive feature is the presence of "spider cells," so named because of their radial sarcoplasmic extensions. Immunohistochemically, they show reactivity for myoglobin, actin, desmin, vimentin, and sometimes HMB-45.[31] The latter is of interest because of the link of rhabdomyoma with tuberous sclerosis and the morphologic similarities with angiomyolipoma, another HMB-45-positive lesion.

Fibroma is seen mostly in the pediatric population. Although some are not detected until adulthood, it is believed fibromas are present from birth. Unlike rhabdomyoma, they are rarely multiple and rarely associated with a syndrome (namely basal cell nevus [or Gorlin], Beckwith–Wiedemann, or Sotos syndromes). They are most common in the left ventricle and ventricular septum and are usually large and intramural. Despite gross circumscription, the tumor borders are microscopically infiltrative, similar to what is seen in fibromatosis lesions. The ratio of hyalinized collagen to fibroma cells has been reported to increase with increasing patient age.[31,32]



Figure 42.14 Gross features of papillary fibroelastoma (note how the delicate fronds become apparent when floating in clear liquid).

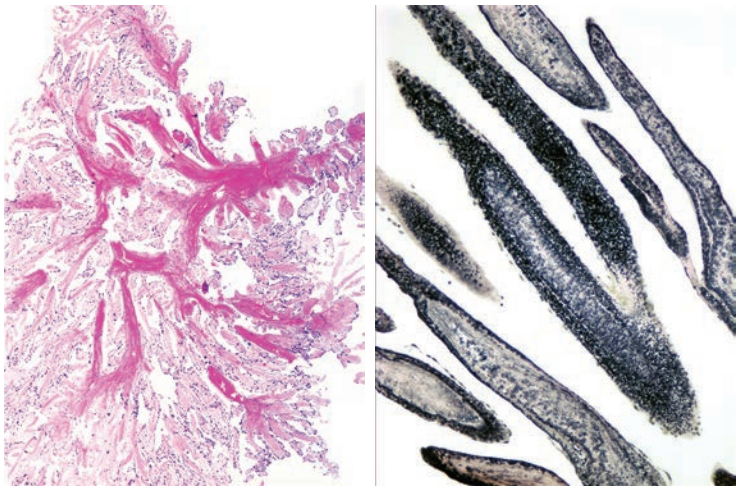

Figure 42.15 Microscopic features of papillary fibroelastoma with highly branched papillary architecture and dense elastin rich cores lined by flattened endothelium.

For personal use only. No other uses without permission. Copyright ©2017. Elsevier Inc. All rights reserved.

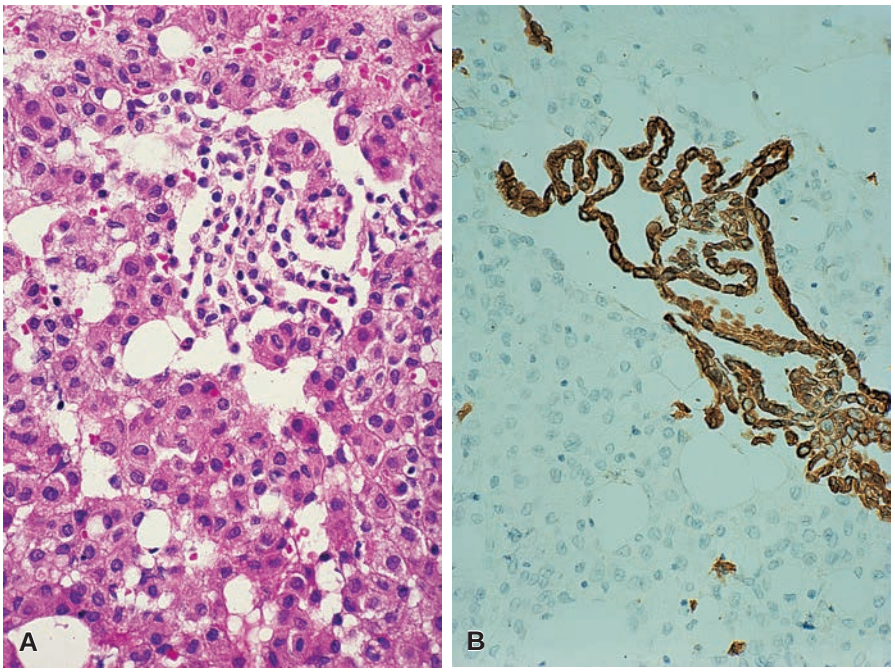

Figure 42.16 So-Called Cardiac MICE. A, This process is composed of an admixture of plump histiocytes and ribbons of small cuboidal mesothelial cells. **B,** The immunostain for keratin highlights the mesothelial cell component, which is surrounded by the negative histiocytes and other mononuclear cells.

Hamartoma of mature cardiac myocytes resembles hypertrophic cardiomyopathy microscopically but is confined as a localized process affecting only a discrete area of myocardium (often in a mass-like fashion). It is characterized by myofiber disarray, focal scarring, and arterial thickening but no inflammation or calcification. The usual but not exclusive location of this lesion is the left ventricle. Clinical correlation is important in this diagnosis, since histologically it is difficult to appreciate a distinct mass or even a border separating it from normal myocardium.[40]

Calcified amorphous tumor of the heart (cardiac CAT) is the name proposed for an endocardially based intracavitary cardiac mass characterized microscopically by nodular deposition of calcium in a background of degenerating blood cell elements and chronic inflammation. The clinical course is benign. The pathogenesis is obscure, but an origin from mural thrombi has been suggested.[41]

Mesothelial/monocytic incidental cardiac excrescences ("cardiac MICE") are incidental microscopic findings at the time of cardiac surgery (usually for valvular disease) or in an endomyocardial biopsy. They may be found attached to the endocardium, free-floating in the pericardial cavity, or even inside an aortic dissecting aneurysm. Ultrastructural and immunohistochemical studies have shown that the lesion is composed of an admixture of keratin-positive mesothelial cells and CD68-positive histiocytes (Fig. 42.16). Microscopically, the mesothelial cells form strips, tubules, and micropapillary formations surrounded by the smaller histiocytes. Huge round vacuoles are often present. Except for the latter, the appearance is very similar to that of nodular mesothelial hyperplasia seen in some hernia sacs.

MICE are thought to be an artifact produced by traumatic or iatrogenic violation of the pericardial cavity with resultant agglutination of mesothelial cells and the other constituents in a fashion similar to the "cell block" techniques used in cytopathology. Their main practical importance resides in the fact that a pathologist unaware of their existence may mistake them for a metastatic carcinoma or some other neoplasm.[42]

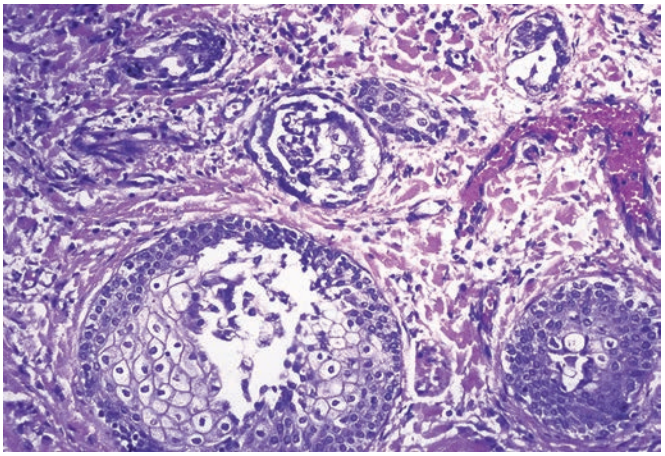

Figure 42.17 So-called cystic tumor of the atrioventricular nodal region. In this case the lining of the cysts had a definite squamoid quality.

Cystic tumor of the atrioventricular nodal region was regarded as a mesothelioma for many years, but there is now conclusive evidence that it represents a developmental abnormality of epithelial nature and endodermal origin. Specifically, it has been postulated that this condition represents a heterotopia of the ultimobranchial body analogous to solid cell rests of the thyroid gland. Because of its crucial location, it may result in complete heart block or be found at autopsy in cases of sudden death. Microscopically, the lesion consists of ductular structures, cysts, and solid nests of epithelial-like cells (Fig. 42.17). Electron microscopy studies have shown desmosomes and microvilli in the epithelial cells. Immunohistochemically, the cells are reactive for keratin, CEA, and B72.3 but not for factor VIII, calretinin, WT1, or thrombomodulin.[32] Hemangiomas and neural tumors may also occur in this location.

For personal use only. No other uses without permission. Copyright ©2017. Elsevier Inc. All rights reserved.

Adenomatoid tumor analogous to its more common counterpart in the male and female genital system has been reported in the heart. Here too the lesion is of mesothelial nature (as opposed to the tumor described in the preceding paragraph).[32]

Inflammatory myofibroblastic tumor has been reported in the heart, usually as an endocardial-based process. Its microscopic appearance is the same as that shown by this process in other locations. Positive staining for ALK and ALK gene rearrangements are a fairly constant finding. No metastases have been reported, but the lesion can result in myocardial infarct, syncope, and sudden death.[43]

Paraganglioma can present as a primary intracardiac neoplasm. The left atrium is the most common location; hypertension and elevated urine catecholamine levels are often present, in which case the term extra-adrenal pheochromocytoma has been used.[31] The microscopic, ultrastructural, and immunohistochemical features are similar to those of paraganglioma elsewhere, including an occasional pigmented example (see Chapter).

Other primary tumors of the heart include granular cell tumor (not to be mistaken for rhabdomyoma or histiocytoid cardiomyopathy), hemangioma (including the epithelioid and histiocytoid varieties), lymphangioma, lipoma (to be distinguished from lipomatous hypertrophy of the atrial septum), angiolipoma, schwannoma, ganglioneuroma, and benign teratoma.

Other non-neoplastic conditions reported in the heart are ectopic thyroid, extramedullary hematopoiesis, and Rosai–Dorfman disease.[32]

Primary Malignant Tumors

Sarcomas of the heart are exceptionally rare but are the most frequent type of primary cardiac malignancy. Despite significant advances in molecular sarcoma classification over the past decade, some highly pleomorphic cardiac tumors defy classification (i.e. pleomorphic undifferentiated sarcoma). Of those that can be placed into a lineage-specific category, angiosarcoma is the most common. They are typically located in the right atrium, where they present as a large mass (Fig. 42.18). Its microscopic appearance may be similar to that of angiosarcoma elsewhere (see Chapter), but others are more poorly differentiated. Ultrastructural and immunohistochemical features of endothelial differentiation can be demonstrated in some of the cases. It should be noted that the term "intimal sarcoma" has been applied to malignant tumors expressing an endothelial phenotype that arise in great vessels (particularly the pulmonary artery but also the aorta and its branches). The malignant cells in these tumor often grow along the surface of mural fibrin thrombus rather than invading through the vessel wall (hence the designation as "intimal"). More recently, the term has also been misapplied to any cardiac sarcoma showing molecular evidence of endothelial differentiation.[44,45] In terms of anatomic distribution and histomorphology, intimal sarcomas do appear to be distinct from other angiosarcomas. Kaposi sarcoma in its systemic form is another vascular malignancy that can involve the heart in immunocompromised (especially AIDS) patients.[46]

The second most common category of sarcoma is that of *myosarcoma*, either *leiomyosarcoma* or *rhabdomyosarcoma*. Leiomyosarcomas can have spindle cell, epithelioid, or myxoid features. Some of them contain scattered osteoclast-like multinucleated giant cells, like those more commonly seen in leiomyosarcomas of the uterine corpus. Other types described include *myxofibrosarcoma*, *pleomorphic undifferentiated sarcomas*, *osteosarcoma*, *fibrosarcoma*, *liposarcoma*, *synovial sarcoma* (Fig. 42.19), *Ewing sarcoma/primitive neuroectodermal tumor (PNET)*, and *malignant peripheral nerve sheath tumor*. All of these tumor types are more common in adults than children, and the prognosis is uniformly dismal.

Most patients with primary heart sarcomas present with intractable congestive heart failure, arrhythmias, or signs of superior vena cava obstruction.[32] The initial diagnosis is usually made incidentally while undergoing imaging studies, especially echocardiography. Attempts at tissue characterization by MRI may be made, along with assessing contrast enhancement. Metastatic lesions, especially in the lungs, may be the first manifestation of cardiac sarcomas. Though there are many exceptions, it is generally true that malignant tumors (especially angiosarcoma) are more frequently found in the right side of the heart and that benign neoplasms are more common on the left side.

Lymphoma presenting as a primary heart tumor is very rare.[47] Most of the reported cases have been of diffuse large B-cell type, some of which are EBV positive. Cases have been reported in

Figure 42.18 Gross appearance of a large angiosarcoma of the heart (right atrium).

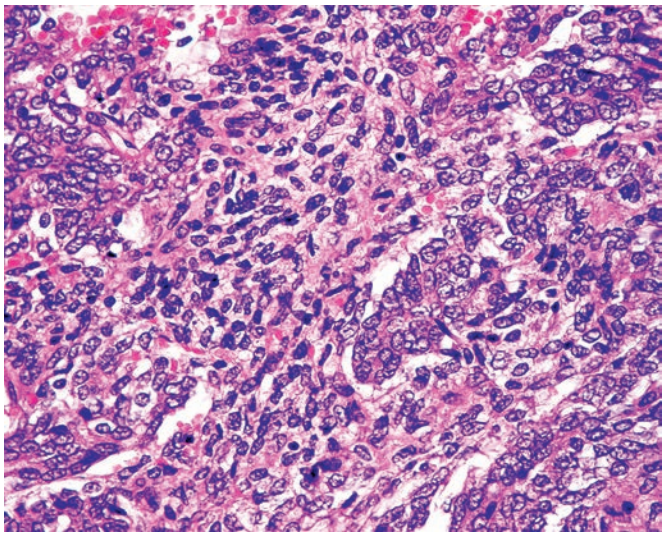

Figure 42.19 Primary synovial sarcoma of heart showing typical biphasic appearance.

For personal use only. No other uses without permission. Copyright ©2017. Elsevier Inc. All rights reserved.

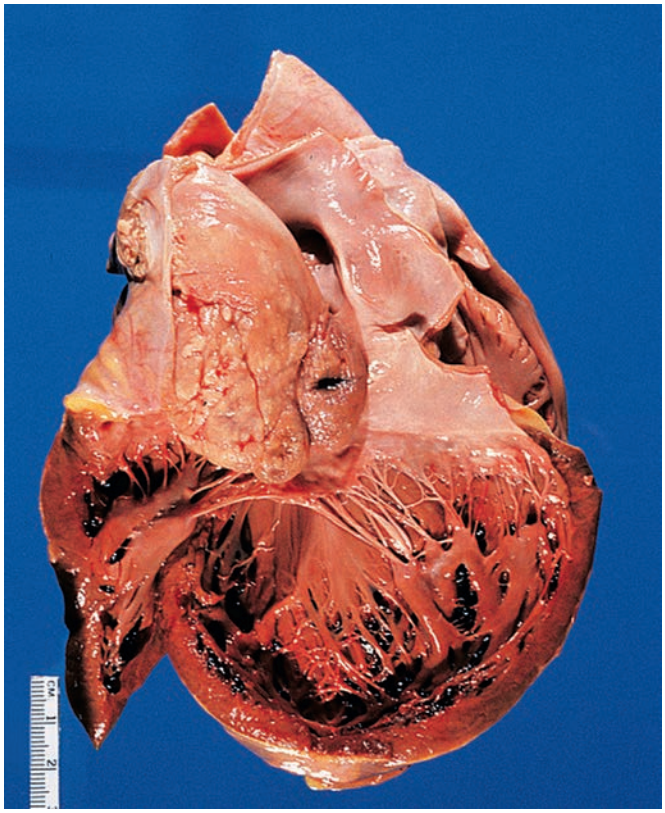

Figure 42.20 Large metastatic carcinoma in left atrium that was continuous with tumor in left pulmonary vein. This mass simulated an atrial myxoma by echocardiography. The primary tumor was a mucoepidermoid carcinoma of left submaxillary gland.

association with cardiac prostheses and mural fibrin thrombus.[48,49] Secondary cardiac involvement by advanced malignant lymphoma or leukemia is a relatively common event, although it is more often found at autopsy than clinically.

Metastatic Tumors

Involvement of the heart by metastatic carcinoma or by generalized malignant lymphoma is a more common event than primary malignancy of this organ, by a factor of 30 to 1. There metastases are rarely sampled by biopsy or surgical means unless the disease affects nonvital and accessible sites such as pericardium. Any portion of the heart can be involved by metastatic disease, including the conducting system, the latter resulting in heart block.[50]

In the majority of carcinomas metastatic to the heart, the primary tumor is in the thoracic cavity or contiguous areas, and the tumor reaches the heart by metastasizing to the mediastinal lymph nodes and from there extending in a retrograde fashion to the cardiac lymph vessels. Malignant tumors with a propensity for hematogenous spread to the heart are malignant melanoma, renal cell carcinoma, choriocarcinomas, and rhabdomyosarcoma. Rarely, the metastatic heart lesion presents as an isolated nodule (Fig. 42.20).

Pericardium

Pericardial cysts are discussed together with all other mediastinal cysts in Chapter 12. Other congenital abnormalities are extremely rare; they include the presence of ectopic tissue such as thyroid and liver.[51]

Pericarditis is of importance to the surgical pathologist for several reasons. A diagnosis of tuberculous pericarditis or sarcoidosis can be made from open pericardial biopsy (or "window" procedure) significantly impacting clinical treatment and prognosis. Acute nonspecific fibrinous, hemorrhagic, or purulent pericarditis is rarely biopsied but may be troublesome because of the reactive mesothelial hyperplasia and atypia that may mimic mesothelioma or other malignancy.

Chronic pericarditis is often accompanied by fibrosis and calcification and may lead to physiologic constriction (so-called constrictive pericarditis). This may result from tuberculosis and other infections, collagen–vascular diseases, malignant tumors, trauma, surgery, radiation therapy, or chemotherapy. Pathologic examination usually shows only dense fibrosis and a scanty inflammatory infiltrate, regardless of etiology. Residual granulomas may be found in the cases of tuberculous etiology, and bizarre atypical fibroblasts may be seen in the postirradiation setting. Calcification, either in a delicate "egg shell"–like fashion or as hard plate-like deposits, may also occur.[52] Importantly, some patients with bona fide constrictive pericarditis (confirmed intraoperatively) may not have pericardial thickening, and histologically the pericardium may appear entirely normal.[53]

Multilocular mesothelial inclusion cyst of the pericardium is morphologically and probably pathogenetically equivalent to the condition that bears the same name in the peritoneal cavity. Although originally designated as benign multicystic mesothelioma, it probably represents a reactive change secondary to chronic irritation.[54]

Mesotheliomas of the pericardium occur, but their frequency is much less than that for similar tumors in the pleura or peritoneum. They have been reported in the setting of tuberous sclerosis and may present as a single well-circumscribed mass, as multiple tumors, or as a diffuse growth encasing the heart. They are essentially identical to mesothelioma of the pleura (discussed in Chapter 11) and are staged accordingly.

Other primary tumors of the pericardium are exceptionally rare. One such group is represented by germ cell tumors: both mature teratoma and yolk sac tumor have been reported in this location. Angiosarcoma of pericardium may coat the pericardium in a diffuse fashion, thus simulating the pattern of growth of mesothelioma; some of these have been radiation induced. There have been isolated case reports of pericardial myolipoma, ectopic thymoma (associated with myasthenia gravis), and fibroma.

Metastatic carcinoma to the pericardium usually originates in the lung in the form of direct extension or lymphatic permeation. It may result in constrictive "pericarditis" as a result of the associated intense desmoplastic reaction or be associated with recurrent pleural effusion. Other tumors that commonly give rise to pericardial metastases are breast carcinoma, malignant melanoma, and malignant lymphoma (including HHV8-positive primary effusion lymphoma).[55] Cytology is the most important technique for the evaluation of malignant pericardial effusions. Pericardial biopsy may be necessary in some cases to confirm the diagnosis.

Arteries

Normal Anatomy

The reader is referred to standard textbooks and chapters on arteries, veins, capillaries, and lymph vessels for a description of the normal anatomy of these structures.[5,56] For the purposes of general surgical pathology, it will suffice to say arteries may be divided into three types: (1) elastic arteries (characterized by stacked layers of elastic tissue throughout the media layer), (2) muscular arteries (defined by the presence of two distinct elastic layers, an internal layer

For personal use only. No other uses without permission. Copyright ©2017. Elsevier Inc. All rights reserved.

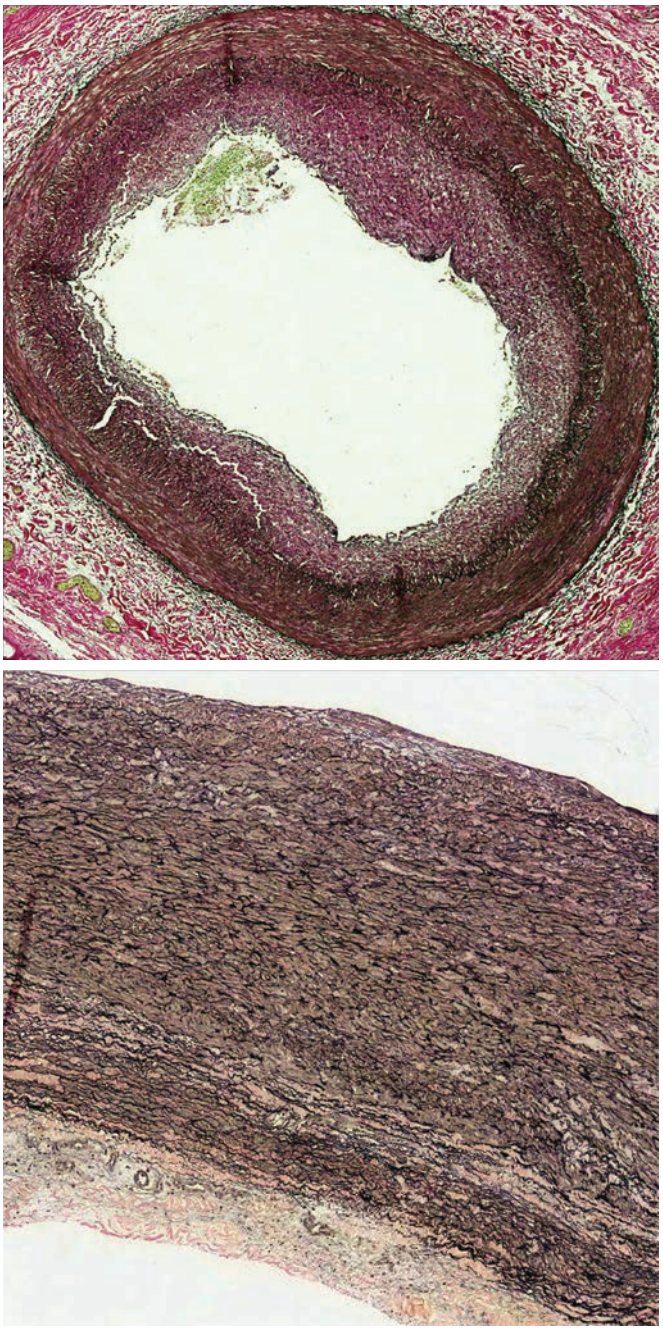

Figure 42.21 Comparative histology of muscular *(top)* and elastic *(bottom)* arteries.

separating intima from media, and an external separating media from adventitia) (Fig. 42.21), and arterioles (composed of only smooth muscle with no discernible elastic layer).

Arteriosclerosis and Atherosclerosis

Arteriosclerosis is a generalized progressive arterial disease associated with wall stiffening, localized luminal narrowing (of muscular arteries), and aneurysms. **Atherosclerosis** refers to a form of arteriosclerosis characterized by lipid-rich "atheroma" in the arterial wall. As the principal cause of heart attack and stroke, atherosclerosis remains the leading cause of death in developed countries.[57] Atherosclerosis is an intimal inflammatory process mediated by activated

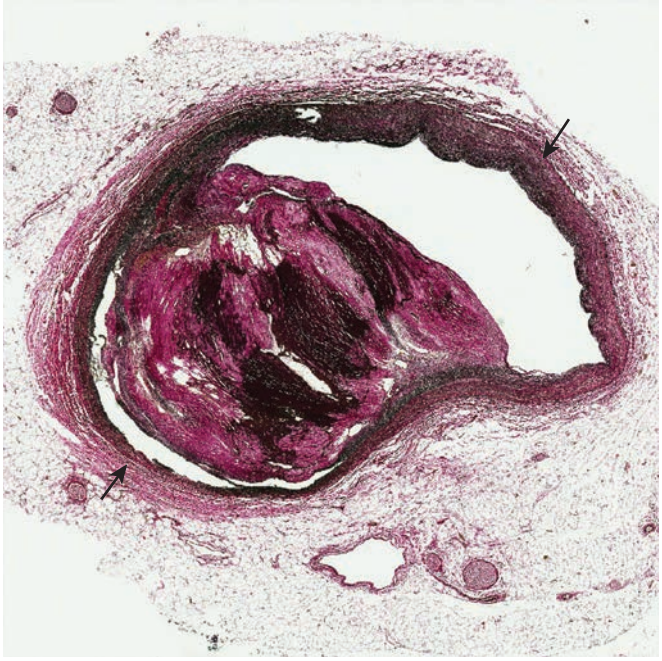

Figure 42.22 Arterial Wall Remodeling in Atherosclerosis. The wall segment underlying the atherosclerotic plaque shows marked thinning *(bottom arrow)* compared to the normal wall segment opposite the plaque *(top arrow)*.

endothelium and smooth muscle cells of the arterial wall.[58] Macrophages are also key participants, elaborating growth factor and cytokines that affect cell signaling pathways and lipid processing.[59,60] Other factors shown to be important in its pathogenesis include changes in lipid metabolism (especially oxidation of lipoproteins), increased endothelial permeability to serum lipoprotein complexes, endothelial activation/injury due to flow turbulence at major bifurcations, and activation of the clotting cascade resulting in thrombosis.

An important feature of atherosclerosis in particular is outward arterial "remodeling," ostensibly in order to maintain lumen diameter in the face of encroaching intimal atheromatous plaque.[61] In the extreme, this may lead to formation of a true atherosclerotic aneurysm. Histologic evidence of this outward remodeling manifests as thinning (atrophy) of the media underlying the plaque in comparison to the relatively thicker (hypertrophied) spared wall opposite a plaque (Fig. 42.22).

Plaque composition and morphology has gained considerable attention in recent years, as most lethal and morbid events relating to atherosclerosis are felt to be due to abrupt thrombosis rather than progressive luminal occlusion by plaque. This thrombosis results from exposing pro-thrombogenic plaque material to luminal blood through disruptions in the intima overlying the plaque. Plaques showing this type of atherothrombosis are said to be "ruptured" or "complicated" plaques, and plaques showing conditions optimal for this type of event, but without actual disruption as-of-yet, are referred to as "unstable" or "vulnerable" (Fig. 42.23).[62,63] Description of these features in surgical pathology reports are meaningful to and appreciated by clinical colleagues. Such descriptions should include the relative composition of the plaque: lipid rich ("soft"), fibrotic ("hard"), calcified, hemorrhagic, etc. The nature of the intima overlying the plaque (the "fibrous cap") in terms of its overall thickness and the presence of inflammation or erosion/ulceration should also be mentioned. Plaque instability is defined as abundant lipid-rich atheromatous material, hemorrhage, and a thin, inflamed

For personal use only. No other uses without permission. Copyright ©2017. Elsevier Inc. All rights reserved.

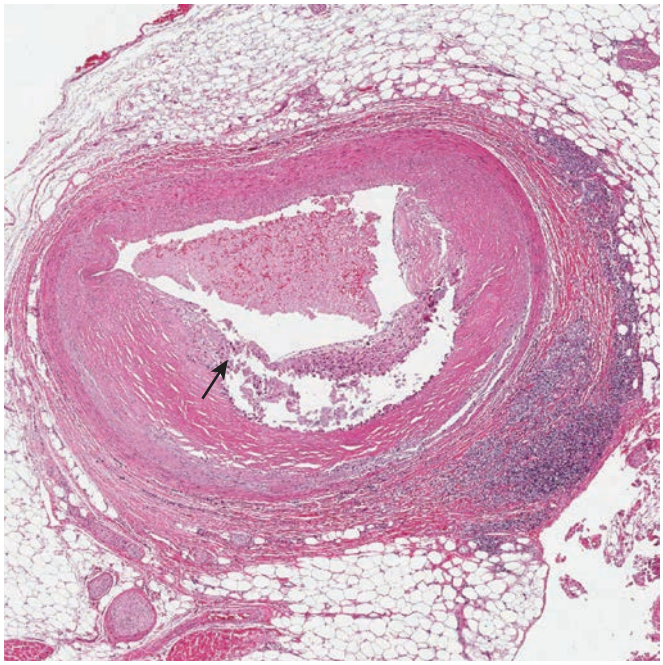

Figure 42.23 Ruptured Atherosclerotic Plaque and Luminal Thrombosis (Atherothrombosis). An arrow points to the site of probably plaque rupture (note the inflammatory infiltrate in the plaque and adventitia).

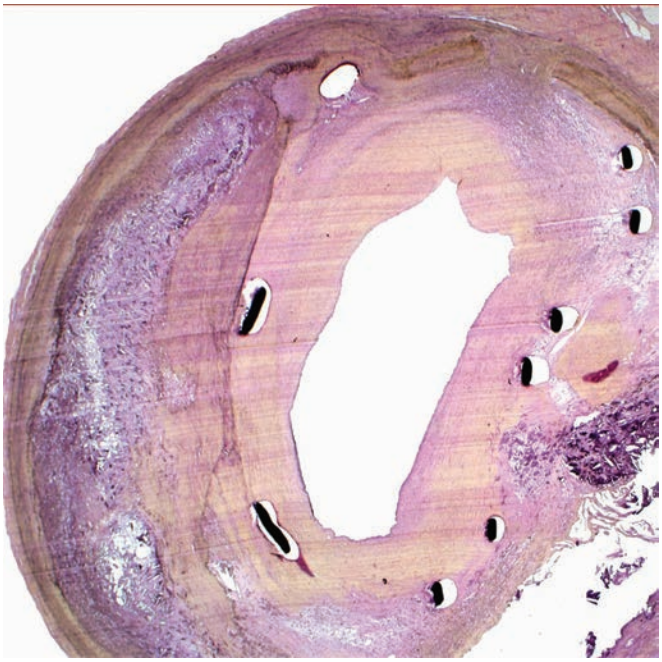

Figure 42.24 Cross section of stented artery, using plastic resin embedding techniques, metallic stent sections appear opaque *(black)*. The native plaque as well as neo-intimal plaque formation are apparent.

overlying fibrous cap. Obviously the presence of thrombus, recent or otherwise, also pertains. A numeric grading system (I–VI) for describing plaques has been developed but is largely restricted to research purposes.[64,65]

Arteriosclerosis and atherosclerosis are encountered in surgical pathology as part of the evaluation of specimens obtained from endarterectomy (carotid or coronary), heart transplantation, and amputation of ischemic limbs. They may also be encountered incidentally in a variety of other specimens. It should be noted that ascending aortic aneurysms, though common surgical specimens, rarely show atherosclerosis. During the placement of synthetic tube grafts (whether during an open vascular procedure or endovascular stenting) in the descending thoracic or abdominal aorta, it is common for the diseased arterial tissue to be left *in situ* rather than removed for examination.

With careful handling (both on the part of surgeons and pathology labs) it is possible to preserve cross sections through endarterectomy plaques in a manner that makes plaque composition and the degree of narrowing evident, even though only the intima is present. In some patients, thrombus may be aspirated endovascularly during percutaneous intervention. Histologic characterization of these clots (recent, degenerating, organized, etc.) is also clinically relevant, although precise dating based on these features is not currently feasible.[66,67]

Stents and Bypass Grafts

Arterial Stents

As mentioned earlier, angioplasty with stenting has become a mainstay and first line option for treating coronary artery disease and its complications. The role of open heart surgery for coronary bypass grafting has largely been relegated to use in patients with coronary disease who are already undergoing thoracotomy for another reason (such as valve replacement). However, these same techniques may be applied to other arteries as well. This discussion will include coronary stents but also applies to those placed in the carotid, renal, and other peripheral arteries, as well as the aorta.

Stents engineering developments have been considerable but are mostly beyond the scope of this textbook. Various metal alloys (e.g. cobalt chromium, nickel titanium, stainless steel) are used in their construction. The metallic frame may remain as "bare metal" or be coated with drug-eluting polymers to deliver anti-proliferative agents (e.g. everolimus, paclitaxel) over a sustained duration in an attempt to retard in-stent smooth muscle and fibroblast proliferation.[68,69]

The major complication following stent placement is the formation of thrombus within and/or adjacent to the stent. Patients receive aggressive anti-platelet and anticoagulation therapy for months after stent placement to prevent this. When stented specimens are removed and submitted for surgical pathology examination (whether as part of explanted hearts and other organs during transplant surgery or as arterial specimens), the primary clinical question to be addressed is stent thrombosis and neointimal narrowing.[70] Unfortunately, the metallic stent struts become embedded and incorporated into the vessel wall tissue, posing a major challenge for tissue processing and microtomy in the histology laboratory.

Several techniques exist for processing stented arterial specimens, but all involve extra effort, time, and expense so have not seen wide adoption in most labs. Still, the information gained from histology in these stented specimen certainly warrants consideration and attempts by these processing methods. Identifying the location of the stent, especially months or years after placement, may be a challenge and specimen radiography is invaluable in this endeavor. Methods for obtaining cross sections through the stented portion include resin embedding followed by sectioning using tungsten carbide blade microtomy or sanding/grinding to a specified thickness (~40 μm) before routine staining.[71] Using these methods the stent struts remain in the specimen and appear as black geometric profiles embedded in the tissue (Fig. 42.24). More recently, methods using strong acids[72] or reverse electroplating[73] to dissolve the metallic stent

For personal use only. No other uses without permission. Copyright ©2017. Elsevier Inc. All rights reserved.

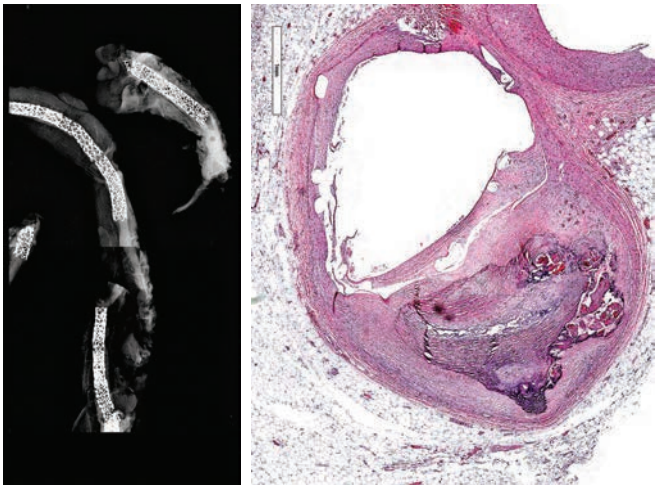

Figure 42.25 Cross Section of Stented Artery, Using Stent Dissolution Techniques. Holes can be seen where the stent struts were situated prior to dissolving *(right)*. Specimen radiography can be helpful in identifying the location of stents, prior to dissolving *(left)*.

struts have been described. After these methods are applied, the metal-free tissue can be sectioned and submitted for paraffin embedding like any other specimen. Histologic sections in such cases show the outline of tissue-strut interface, but the opaque metallic strut profiles are absent (Fig. 42.25). Practical experience with this method suggests not all stents are amendable to dissolution using this technique and strut fractures leave portions undissolved, making this a tedious and iterative endeavor. Stented specimens will be submitted for surgical pathology examination for the foreseeable future, and while better, more practical means of histologic examination are needed, laboratories should seek access to special techniques for processing at least a subset of these.

Arterial Bypass Grafts

Though coronary bypass grafts are by far the most common type to be encountered in surgical pathology, bypass graft conduits from other anatomic sites may be received as well. Where possible, cross sections from the anastomotic site, graft body, and distal vessel should be reviewed (Fig. 42.26). Since the graft conduits experience flow at arterial pressures, atherosclerosis may develop in the graft body, even in grafts of venous origin. Pseudoaneurysm formation at the anastomotic site is a frequent complication.

Aneurysms

Arterial aneurysms develop as a dynamic consequence of arterial wall weakening in the face of intraluminal arterial pressure. The wall changes leading to aneurysms may be atherosclerotic (as with abdominal aortic aneurysm), developmental (cerebral Berry aneurysm), degenerative (ascending aortic aneurysm), traumatic/vasculitic (pseudoaneurysms), or infectious (mycotic aneurysm) in nature.[74] Degenerative aneurysms tend to be "fusiform" with gradual, symmetric tapering contours, whereas nearly all other aneurysm types are asymmetric, abrupt, and "saccular." True aneurysms contain all three arterial layers (intima, media, and adventitia), although the usual dual elastic layers may not be distinguishable due to wall remodeling changes. False or "pseudo" aneurysms are merely contained ruptures resulting from some kind of penetrating wall injury and tend to occur at sites of traumatic injury, vasculitis, or prior surgical vascular anastomoses (Fig. 42.27).

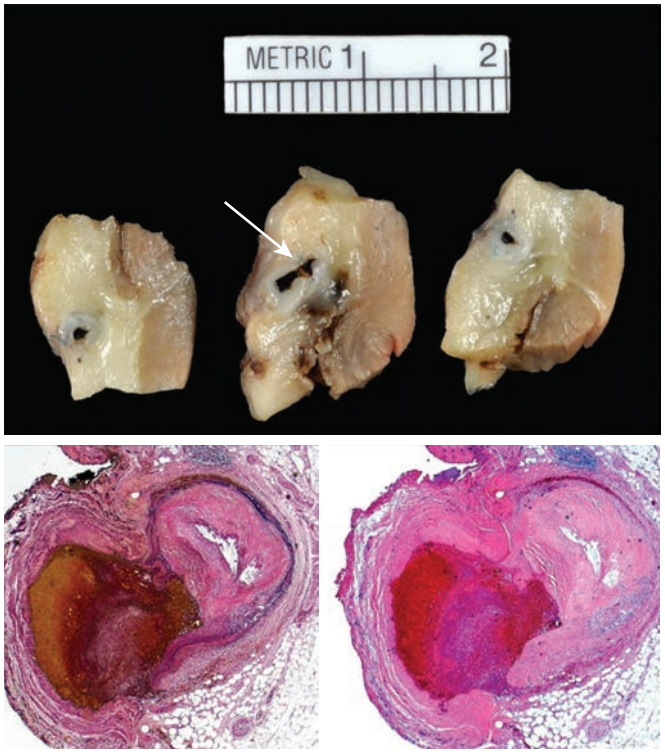

Figure 42.26 Routine Histologic Sampling of Bypass Grafts. The anastomotic site should be serially sectioned to locate the joining point of native vessel and graft *(arrow)*. Step sections through the block may be helpful in visualizing this histologically.

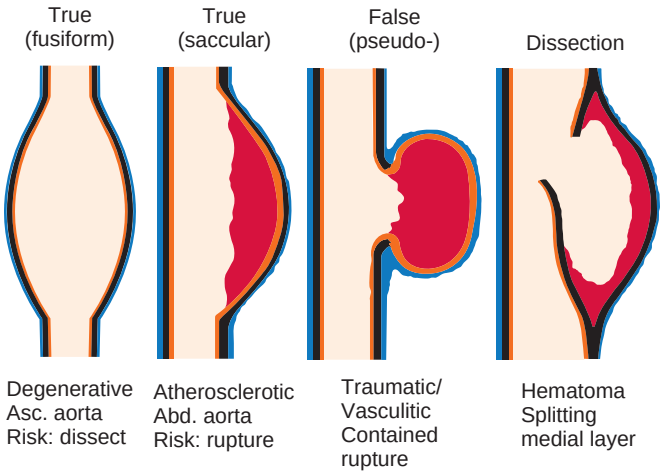

Figure 42.27 Arterial aneurysm types and their morphologic and clinical associations.

Aortic Aneurysms

As the largest artery, the aorta is the most common site of arterial aneurysm. There are important differences between aneurysms in the ascending versus descending thoracic and abdominal aorta. Size (diameter) and rate of change in size are reliable predictors of aortic aneurysm rupture risk, and site-specific guidelines exist for different anatomic locations.[75,76] Arterial dissection (discussed in more detail later) may give the same aneurysmal appearance externally but is fundamentally different. Like aneurysmal dilatation, dissection may also lead to vessel rupture. It should be made clear, however, that

For personal use only. No other uses without permission. Copyright ©2017. Elsevier Inc. All rights reserved.

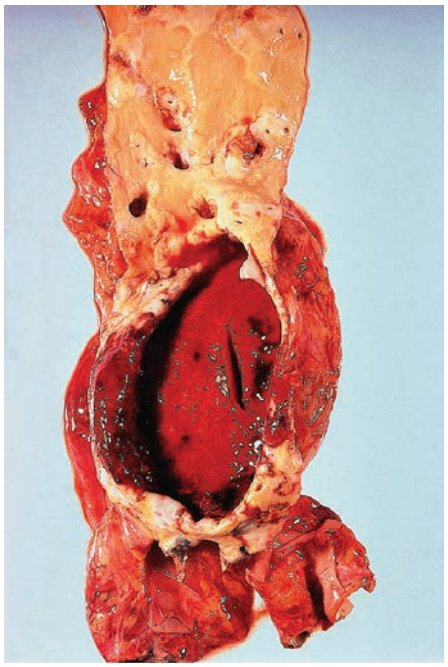

Figure 42.28 Abdominal aortic aneurysm with mural thrombus (note the presence of atherosclerotic changes and the asymmetric (saccular) configuration of the aneurysm.

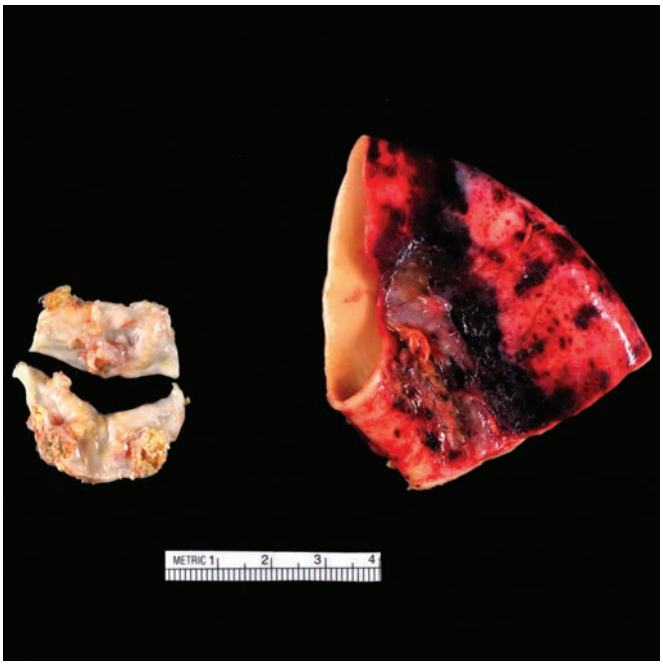

Figure 42.29 Ascending aortic aneurysm and bicuspid aortic valve. Note the uniform symmetric (fusiform) dilatation of the aneurysm.

dissection of the aorta is for all intents and purposes limited to the thoracic aorta and distinctly uncommon in atherosclerotic abdominal aneurysms.

Laminated mural thrombus is frequently present in saccular abdominal aneurysms and presents a potential source of emboli downstream (Fig. 42.28). Endovascular stent placement has largely replaced open surgical procedures for abdominal aortic aneurysms in most centers, so surgical specimens from the abdominal aorta have become scarce.[77]

The histologic features of atherosclerosis are described in detail previously. While luminal stenosis and occlusive atherothrombosis are rare in the aorta, the histology of the atheromatous plaques is similar for atherosclerotic aneurysms in comparison to those of smaller muscular arteries (with the addition of ulceration, inflammation, and laminated thrombus). Degenerative aneurysms located in the ascending aorta (Fig. 42.29) often show disruptions of the normal elastic laminar architecture (Fig. 42.30). Historic terminology for these has been imprecise and potentially misleading, including terms such as "necrosis" (which is seldom seen) and "cystic" (even though epithelial-lined structures are absent). An updated nomenclature scheme has been proposed, including the terms "mucoid extracellular matrix accumulation," "loss of smooth muscle nuclei," and "elastic fiber fragmentation," to more accurately characterize these changes.[78] This scheme is largely intended for use in comparative research studies. For the purpose of routine surgical pathology reporting, it is probably sufficient to state when degenerative changes are present in the media, realizing that correlation between histology and aneurysm etiology or size is poor (e.g. grossly impressive aneurysms may show normal media histologically).[79] Because of this, thorough sampling is encouraged (at least six pieces submitted). Histology is also not highly specific as to genetic etiology (Marfan, Loeys–Dietz syndrome, etc.), many of which are diagnosed based on clinical and genetic criteria.[80] Immunostaining for various proteins in the TGF-β signaling pathway, implicated in these diseases, may be useful in routine diagnosis but awaits further development.

Vasculitis in general is addressed in more detail later, but aortitis will be briefly addressed in this section since its primary manifestation is aortic aneurysm.[81] Giant cell and lymphoplasmacytic aortitis share overlapping features, with the obvious distinguishing feature being the presence of giant cells in the former, typically arrayed in collars and cuffs surrounding islands of collapsed elastic laminae devoid of smooth muscle nuclei (Fig. 42.31).[82] The presence of penetrating vasa vasorum in the mid to inner portion of the elastic media and increased medial collagen are also seen in these forms of aortitis. Clinically, giant cell and lymphoplasmacytic aortitis may be a large vessel manifestation of systemic vasculitis (namely giant cell or temporal arteritis, especially in the elderly) but organ-limited or isolated forms of aortitis are also recognized for which surgical resection may be curative.[83] Thorough rheumatologic assessment of the patient and possibly wider vascular imaging studies are often needed to guide management in these cases.

Aortitis of the abdominal aorta is distinctly different and represents either infection (often by *Salmonella* and other enteric organisms)[84] or so-called inflammatory abdominal aortic aneurysms. Infections may be primary in nature or secondary to seeding of thrombus within an existing atherosclerotic aneurysm. Inflammatory aneurysms are recognized as part of the continuum with IgG4-related disease and sclerosing mesenteritis. Such cases show mixed inflammatory infiltrate containing eosinophils, lymph follicles, storiform fibrosis, perineurial inflammation, obliterative phlebitis, and numerous IgG4-positive plasma cells.[85] Fistulas may develop as a complication of abdominal aortic aneurysms in particular, usually with catastrophic results.

Arterial Dissection

Dissection refers to a splitting apart of medial smooth muscle caused by an infiltration of luminal blood under arterial pressure. This often results in narrowing or occlusion of the "true" lumen and blockages in small arterial branches arising from the dissected artery.

For personal use only. No other uses without permission. Copyright ©2017. Elsevier Inc. All rights reserved.

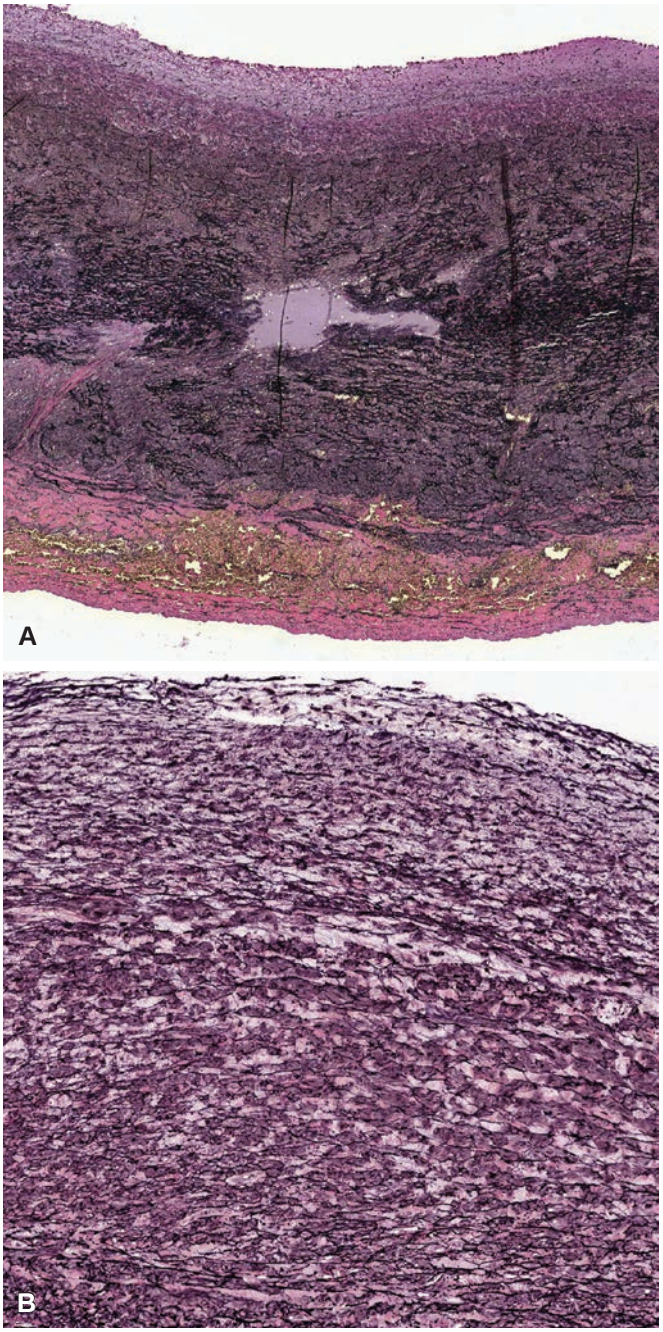

Figure 42.30 Medial Degenerative Changes in Ascending Aortic Aneurysm. A, "Cystic" change (translamellar mucoid extracellular matrix accumulation). **B,** More subtle elastic fiber fragmentation and intralamellar mucoid extracellular matrix accumulation.

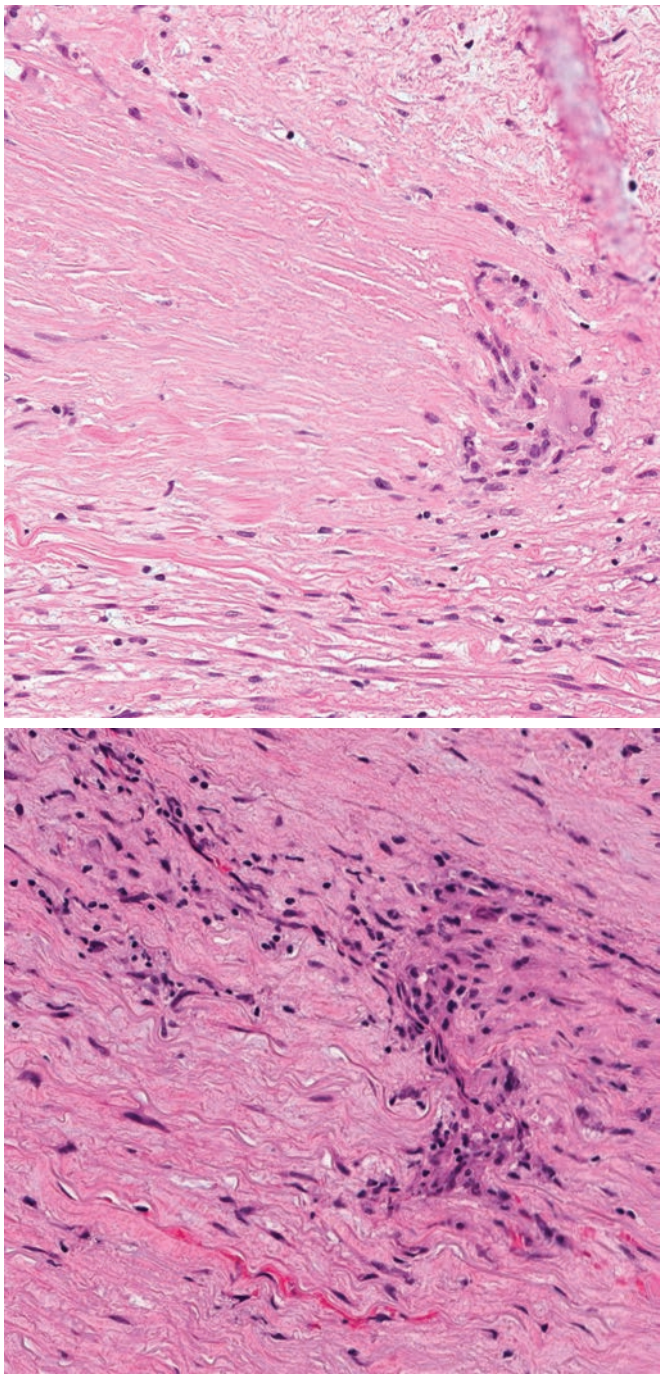

Figure 42.31 Aortitis with *(top)* and without giant cells *(bottom)*. The inflammatory component is intimately associated with areas of smooth muscle cell nuclear loss and elastic laminal collapse.

Underlying degeneration of medial elements is suspected as a precursor to dissection mechanistically but is not always convincingly demonstrated histologically. The dissection plane may extend to (and through) the adventitial connective tissue, resulting in vascular rupture and arterial hemorrhage.

Clinical factors associated with dissection include hypertension, Marfan syndrome and other related genetic disorders caused by TGF-β pathway mutations (the "TGF-β-opathies"), as well as pregnancy, bicuspid aortic valve, and traumatic (iatrogenic), atherosclerotic, or inflammatory injuries of the aortic media.[86,87]

The process of dissection is thought to begin as a transverse intimal tear that may be associated with intimal plaque located either in the ascending aorta or in the upper descending thoracic aorta near the origin of the left subclavian artery (Fig. 42.32).[88] Once this tear develops, the intramural layers of the aorta are rapidly separated by the force of the blood entering the wall (Fig. 42.33). The dissection usually involves the entire circumference of the aorta as it progresses distally. Lower extremity symptoms and signs of acute occlusion of the abdominal aorta may be prominent clinically because of distal aortic or iliac luminal occlusion by the leading

For personal use only. No other uses without permission. Copyright ©2017. Elsevier Inc. All rights reserved.

Figure 42.32 Intimal tear in the descending thoracic aorta with acute dissection. Histologically, the tear is associated with fibrin coating of the rupture tract.

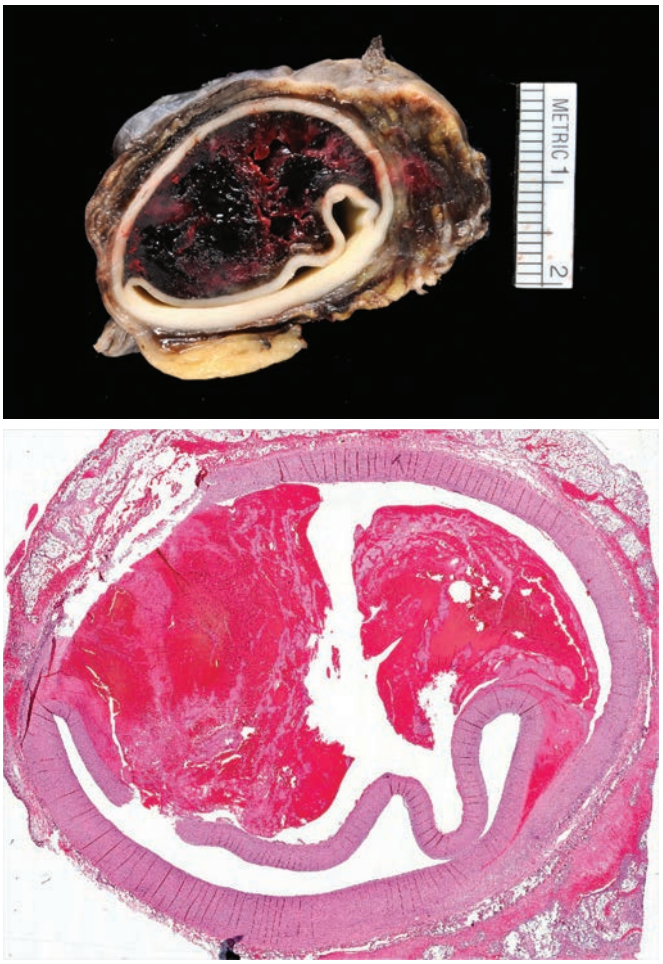

Figure 42.33 Aortic Dissection, Cross Section. Thrombus fills the intra-medial "false" lumen, compressing the true lumen beneath.

point of the dissection. Diagnostic imaging is essential in the evaluation of suspected aortic dissection.

Aortic dissections have been classified by two different systems. The most widely used (Stanford) system focuses on involvement of the ascending aorta (type A), regardless of what other segments may be involved, since these require urgent surgical intervention. Those not involving the ascending portion (type B) are often managed medically and more expectantly. In the other (DeBakey) system, type I dissection begins in the ascending aorta and extends beyond; type II is confined to the ascending aorta; type IIIA begins in the descending aorta and stops above the diaphragm; and type IIIB also begins in the descending aorta but extends below the diaphragm. Arterial dissection can also occur in muscular and elastic arteries other than the aorta, such as the renal, coronary, pulmonary, vertebral, and carotid vessels.

Acute dissection can be recognized grossly and histologically by the presence of blood and fresh fibrin within the dissection cavity, directly adjacent to exposed medial smooth muscle. Over time, the dissection cavity becomes reendothelialized. Chronic dissections are characterized by a fibrotic neo-intimal lining coating the dissection "false" lumen.

Coarctation of Aorta

Coarctation of aorta refers to discrete segmental congenital narrowing of the proximal aorta. It is classified according to its relation to the ductus arteriosus. Pre-ductal coarctation (proximal to the ductus arteriosus) is usually found early in life and creates systemic dependence on pulmonary artery flow (via the ductus—duct dependent). Post-ductal coarctation (by far the most common), manifests as a short, narrowed segment beginning just distal to the insertion of the ductus. As such, flow is only potentially restricted in the abdomen and lower extremities. Repair of coarctation is performed to restore flow but also prevent complications such as aortic rupture, endocarditis, hypertension, or congestive failure.[89]

Grossly, resected coarctation segments should be oriented to the point of insertion of the ductus/ligamentum and opened in a fashion that transects this longitudinally. Sections should be embedded so that the insertion point will be apparent histologically. Localized subintimal thickening is usually seen opposite this insertion point, beneath which the media lamina are distorted and thickened (Fig. 42.34).

Synthetic Arterial Substitution

GoreTex and Dacron synthetic tube grafts, as well as synthetic fabric lined stents, are often used in vascular surgery and occasionally require revision and replacement, resulting in surgical pathology specimens. Over time these grafts reendothelialize and develop a neo-intimal coating. Pathologic examination of these specimens should include evaluation of calcification, inflammation, thrombus, and the presence of anastomotic pseudoaneurysms.

Arterial Occlusive Disease

Thrombotic occlusions of the major arteries are often associated with arteriosclerotic changes described previously. The occlusive process is often clinically insidious, although final thrombotic

For personal use only. No other uses without permission. Copyright ©2017. Elsevier Inc. All rights reserved.

Figure 42.34 Aortic Coarctation. A discrete segment of marked narrowing in the pediatric aorta excised during coarctation repair *(top)*. Sections should be oriented in longitudinal section to the ductus arteriosus *(black arrow)*. Focal intimal thickening can often be seen opposite this *(white arrow)*.

obliteration of the lumen is occasionally quite rapid and may be clinically indistinguishable from embolization. In the distal aorta, thrombotic occlusion probably begins in the iliac arteries near the aortic bifurcation and propagates cephalad, occasionally to the level of the renal arteries. Thrombi and emboli can become secondarily infected by fungi, particularly *Aspergillus* and *Mucor*.

The syndrome of distal aortic occlusive thrombosis (Leriche syndrome) manifests with gradual progression of symptoms of pain and easy fatigability in the legs, hips, and back; intermittent claudication; and sexual impotence.[90] In this condition, arterial insufficiency in the lower extremities usually is manifested clinically by the absence of pulses below the umbilicus. If the process is partial, weak pulsations may be felt or a characteristic systolic murmur heard over the abdominal aorta and the femoral arteries.

Therapeutic approaches to occlusive arterial disease include surgical bypass using synthetic conduit, open thromboembolectomy with or without endarterectomy, and endovascular interventional thrombolysis. Microscopically, specimens from thromboendarterectomy may be fibrinous, organized, or some combination of the two, depending on the stage of the process and relative success of intrinsic thrombolytic activity.

Cystic Adventitial Disease

Cystic adventitial disease, a rare condition almost always affecting the popliteal artery, may cause luminal obstruction.[91] A collection of jelly-like material distends the wall (from the outside) and bulges into the lumen. Most cases occur in young men without a history of trauma and without general arterial change. The microscopic appearance of the involved arterial segments is that of mucin accumulation is dilated cystic spaces (Fig. 42.35). The etiology of this condition is not understood.

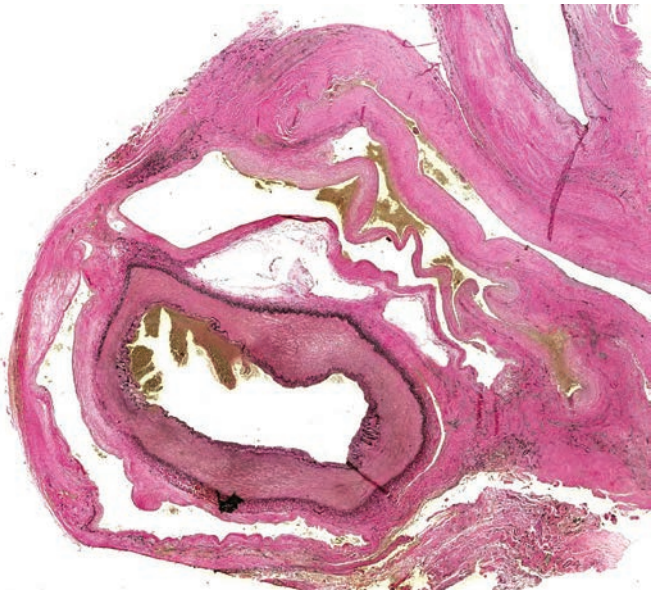

Figure 42.35 Cystic Adventitial Disease. Multiple irregular cystic spaces are seen surrounding the adventitia of this popliteal artery. Some appear to contain mucoid material.

Fibromuscular Dysplasia

Fibromuscular dysplasia is a nonarteriosclerotic, noninflammatory vascular disease of unknown pathogenesis. Developmental, mechanical, and genetic factors may play a role. It usually becomes manifest during the third or fourth decades of life, although it also can be seen in children. It involves large- and medium-sized muscular arteries, such as the renal, carotid, axillary, and mesenteric arteries, sometimes in a multicentric fashion. Imaging techniques useful for the evaluation of this disease include CT scans, MRI, and angiography.[92]

Morphologically, it is characterized by a disorderly arrangement and proliferation of the cellular and extracellular elements of the wall, particularly the media although intimal (and ostensibly adventitial) forms have also been described, with the resulting distortion of the vessel lumen (Fig. 42.36). The absence of necrosis, calcification, inflammation, and fibrinoid necrosis are important negative diagnostic features. Morphologic varieties with predominant intimal or adventitial involvement have been described.[93] Treatment for this condition may include balloon dilation with stenting or resection and replacement with conduit such as saphenous vein or synthetic tube graft.

Mesenteric Vascular Occlusion

Mesenteric vascular occlusion (enterocolic lymphocytic phlebitis) may originate in veins or arteries. Rarely, occlusion of both occurs simultaneously. After the initiation of arterial or venous thrombosis, hemorrhagic infarction of the intestine and its mesentery develops if the process is rapid in onset and extensive. Arterial occlusions are

For personal use only. No other uses without permission. Copyright ©2017. Elsevier Inc. All rights reserved.

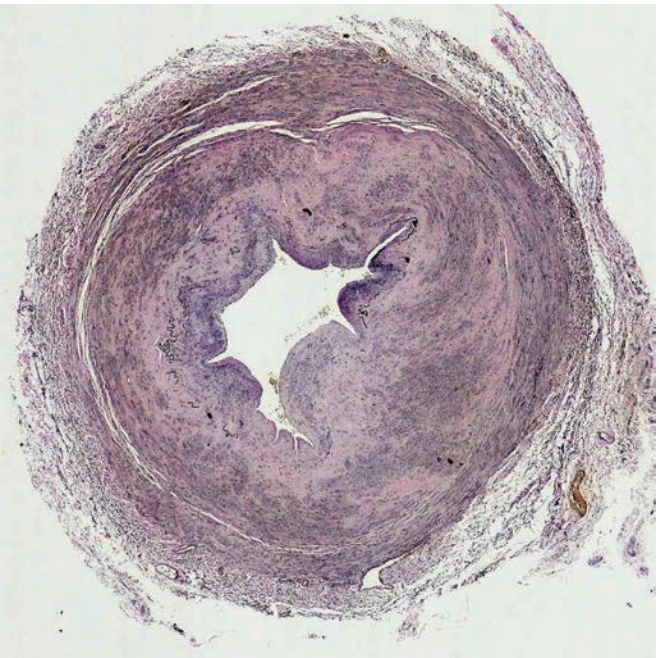

Figure 42.36 Fibromuscular Dysplasia (Medial Type). Irregular (festooned) luminal contours are created by disorganized medial smooth muscle arrangements.

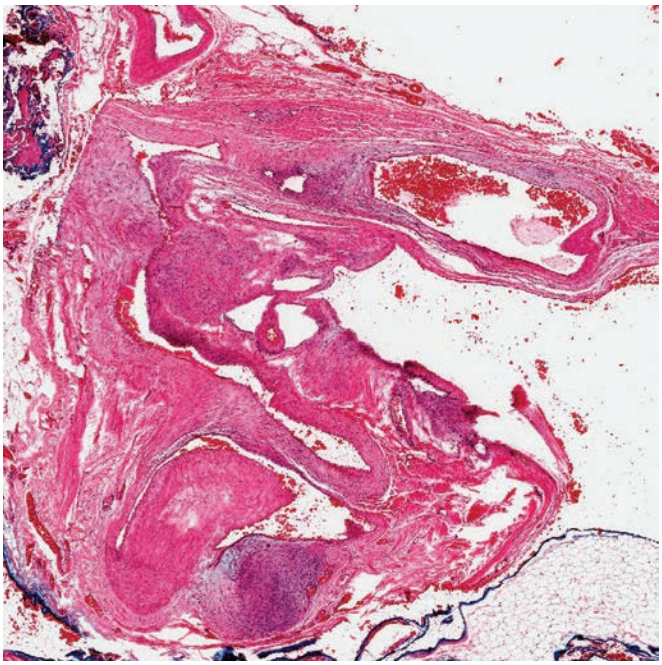

Figure 42.37 Arteriovenous Malformation. Irregular vascular spaces with varying wall thicknesses are seen in this soft tissue arteriovenous malformation.

often embolic in origin, whereas mesenteric venous thrombosis usually occurs in the setting of infection and cancer.[94]

Infarction of the bowel depends on the location, extent of occlusion, rapidity of its onset, and state of the collateral circulation, as well as the general physical condition of the patient. Acute occlusion of mesenteric arteries may produce bowel necrosis without the septic presentation seen in most cases of extensive venous thrombosis. Bloody diarrhea is less common and abdominal pain more common in arterial than in venous occlusions.[95]

Acquired Arteriovenous Fistula

Following trauma, especially involving perforating injury to both an artery and adjacent vein, a fistulous communication may form (either immediately or during the organization phase of healing). Thrombus frequently complicates these fistulas. Most patients present with a continuous pulsating (bruit) mass in the region of injury. There is usually venous dilation peripheral to the fistula. The dilation of the major artery entering an arteriovenous fistula may be marked, and the degenerative arterial wall changes may be extensive, although actual flow to downstream beds is compromised. Arteriovenous fistulas are associated with increase in cardiac output, pulse rate, and blood volume, which may lead to congestive heart failure (Fig. 42.37).

Arteriovenous Malformation (Congenital)

These lesions, occurring in soft tissue, lung, gastrointestinal organs, kidney, and the central nervous system are discussed in their organ-specific contexts in other chapters of this edition (see Chapters).

Thromboangiitis Obliterans

Thromboangiitis obliterans (Buerger disease) is a rare thrombotic and inflammatory disease of the arteries and veins of unknown etiology that occurs in young adults and is highly associated with tobacco use. Involvement of both medium-sized arteries and veins (and occasionally adjacent nerves as well), sets it apart from other forms of vasculitis. It is more common in men, with an age range between 20 and 35 years.[96] Microscopic examination of early arterial lesions shows panarteritis, often associated with thrombosis. The inflammatory process involves the entire thickness of the vessel wall and perivascular tissues, although the internal elastic lamina is usually preserved. Recanalization of thrombi may be seen but is often incomplete with numerous small vascular channels passing through the remaining fibrous tissue (Fig. 42.38). Treatment is largely symptomatic and includes the control of pain and the avoidance of tobacco. Late in the course, amputations may be necessary.

Arteritis

Inflammatory diseases of the arteries have been classified on the basis of the etiologic agent involved, the caliber and location of the vessel affected, and the type of microscopic change observed.[97,98] Imperfect as it is, a division based on the vessel caliber is quite useful. Within each group, the arteritides can be further subdivided into more or less specific types on the basis of associated features and/or pathologic appearance.

Large Vessel Arteritis

A group of related nonsyphilitic diseases primarily affect the aorta and its main branches and are characterized by chronic inflammation and patchy destruction of the elements of the media. They preferentially involve the ascending aorta and may result in aneurysm formation, as well as aortic root dilatation and valvular insufficiency, aortic arch syndrome, and aortic dissection.

Takayasu arteritis is characterized by chronic inflammation and fibrosis of the arterial wall, showing a predilection for the ascending aorta and primary aortic branches (arch vessels and renal arteries

For personal use only. No other uses without permission. Copyright ©2017. Elsevier Inc. All rights reserved.

in particular). Involvement of these branches accounts for the absence of pulses in the upper extremities that is often seen in these patients. Most patients with Takayasu disease are young, Asian, and female. The pattern of involvement includes granulomas and multinucleated giant cells, but there may be areas of more active inflammation including basophilic "dirty necrosis" as well (Fig. 42.39).[83] The coronary arteries may also be involved, particularly near the coronary ostia (Fig. 42.40).

Giant cell (or temporal) arteritis was originally thought to be a disease of temporal, cerebral, and retinal arteries. However, aortic and large arterial involvement was recognized in these patients, indicating that it is a systemic disease and best classified as a large vessel vasculitis syndrome. This condition, which is most common after age 70 is classically characterized by pain in the distribution of the temporal artery and localized tenderness. Other extracranial carotid artery branches may be affected as well, leading to jaw claudication, facial pain, and blindness (the most feared complication). The syndrome of *polymyalgia rheumatica*, characterized by muscle pain and tenderness involving mainly the muscles of the neck, shoulder, and pelvic girdle, and accompanied by an elevated erythrocyte sedimentation rate, occurs in at least half of these patients. Fortunately, this disease is almost universally responsive to corticosteroid therapy. Complications related to ascending aortic aneurysm are also a major concern.[81]

Microscopically, partial destruction of the wall by a lymphohistiocytic inflammatory infiltrate, often (but not always) containing

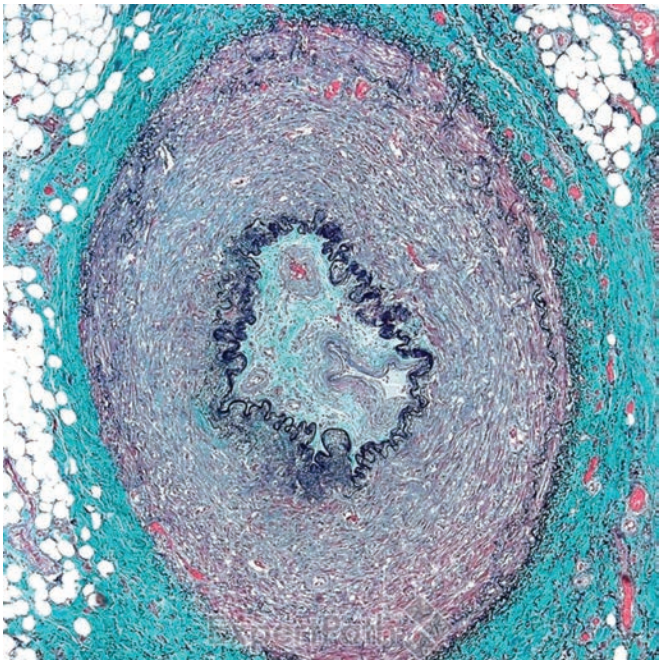

Figure 42.38 Thromboangiitis Obliterans (Buerger Disease). Hallmark features include transmural inflammation (of veins and arteries), recanalized luminal thrombus, and preservation of the internal elastic lamina.

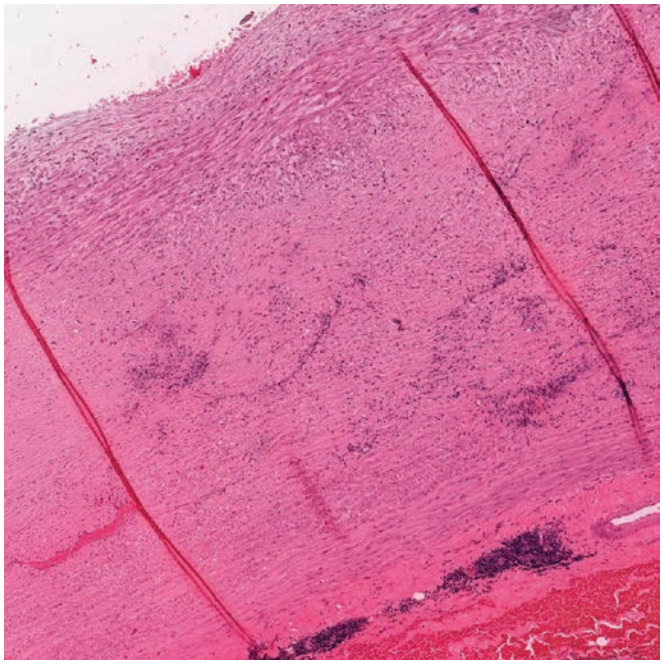

Figure 42.39 Takayasu Aortitis. Marked adventitial fibrosis and patchy lymphoplasmacytic inflammation, characteristic (although not entirely specific for) Takayasu disease.

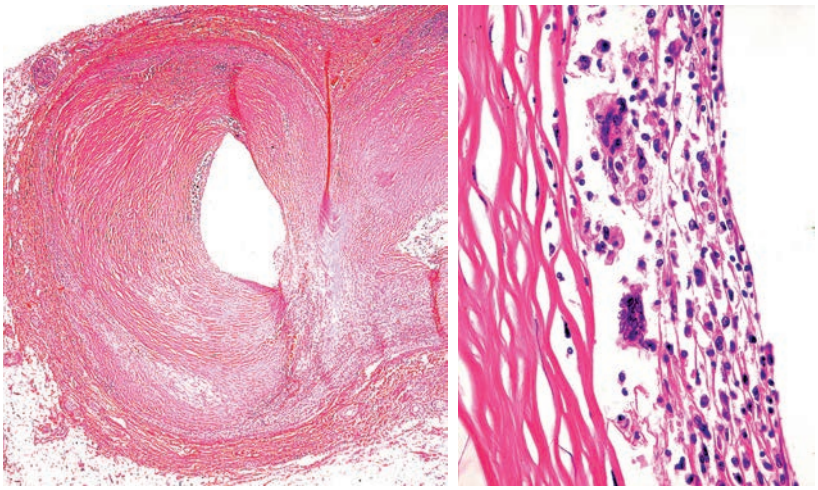

Figure 42.40 Coronary artery involvement by Takayasu arteritis, manifesting as fibrotic wall thickening with lymphoplasmacytic inflammation and intimal multinucleated giant cells (again the clinical context of aortitis with primary branch involvement in a young woman is needed to confirm Takayasu disease).

For personal use only. No other uses without permission. Copyright ©2017. Elsevier Inc. All rights reserved.

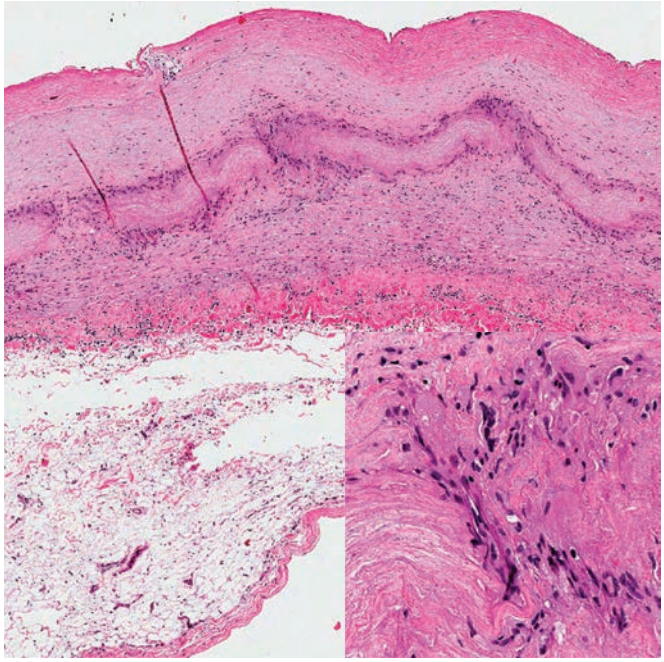

Figure 42.41 Giant cell aortitis with ribbon-like areas of elastic laminar collapse, cuffed by lymphohistiocytic inflammation including multinucleated giant cells *(inset).*

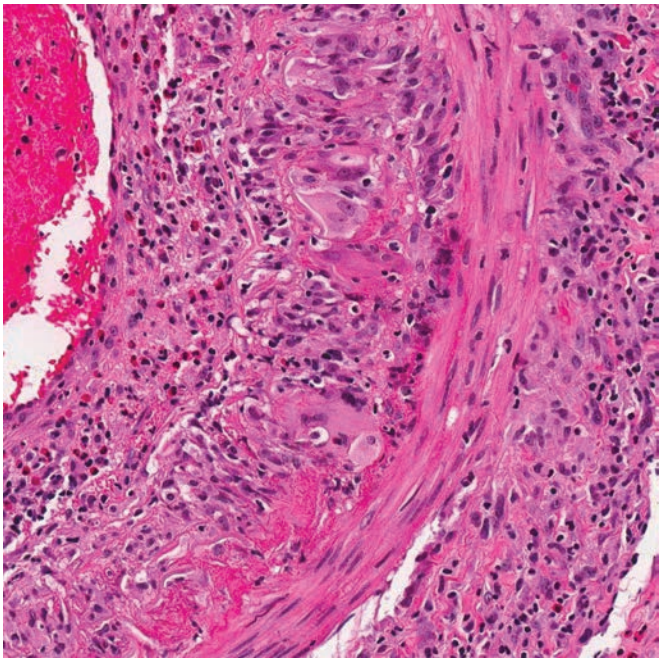

Figure 42.42 Giant cell—temporal arteritis showing transmural lymphohistiocytic inflammation with multinucleated giant cells near the internal elastic lamina.

multinucleated giant cells. In elastic arteries (especially the ascending aorta), this inflammation is found surrounding "islands" of acellular collapsed elastic lamellae (Fig. 42.41). In small muscular arteries, the giant cells are usually intimately associated with the internal elastic lamina, and some may even contain fragments of phagocytosed elastica in their cytoplasm. Transmural inflammation is the diagnostic hallmark of vasculitis in temporal artery biopsies (Fig. 42.42). The presence of perivascular inflammation in the absence of inflammatory changes in the vessel wall is not diagnostic of vasculitis. It is important to emphasize that the changes are often segmental and that a negative biopsy does not rule out the diagnosis. In one key series, only 60% of patients with clinical evidence of temporal arteritis had positive biopsies but the other 40% (showing arteriosclerosis or atherosclerosis) also responded to steroid therapy.[99] For this reason, exhaustive serial sections should be performed routinely on these specimens. The pathogenesis of this disease remains unknown, but autoimmune factors are thought to play an important role.

Aortitis can be seen associated with a host of other conditions, including rheumatoid arthritis, ankylosing spondylitis, scleroderma, granulomatosis with polyangiitis, Cogan syndrome, Behçet disease, and many others.[100]

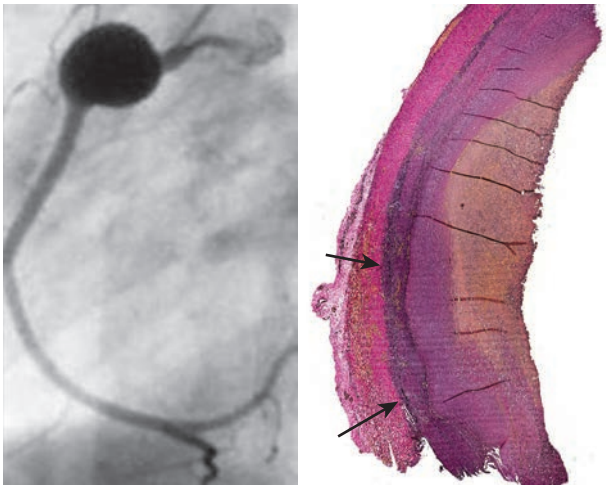

Figure 42.43 Coronary (Pseudo)aneurysm in Kawasaki Disease. Coronary angiogram showing a proximal (pseudo)aneurysm *(left)*. The aneurysm wall shows wisps of internal elastic lamina at one edge (confirming contained rupture—pseudoaneurysm).

Medium-Sized Vessel Arteritis

This group of diseases primarily affect muscular arteries, and all are characterized by active necrotizing inflammation leading to (often segmental) fibrinoid necrosis of the arterial wall. As this process resolves and evolves, pseudoaneurysms develop. Necrotizing arteritis and pseudoaneurysm formation are the hallmarks of the medium vessel vasculitis syndromes. **Kawasaki disease** is a pediatric condition that first presents as a mucocutaneous syndrome with lymphadenopathy in infants and children and later manifests as medium vessel arteritis with a particular predilection for the coronary arteries.[101] Recognition of the acute phase of this illness and treatment with aspirin and intravenous immunoglobulin are critical in preventing and forestalling the coronary artery complications. The disease may go unrecognized in childhood and only manifest later in adulthood as acute coronary syndrome due to complications of coronary pseudoaneurysm (Fig. 42.43).

Microscopically, the coronary and other affected arteries show transmural involvement of at least a segment of artery viewed in cross section. The inflammation is rich in neutrophils, and fibrin is abundant in the active phase. Healed lesions will show disruption of the internal and/or external elastic lamina(e) with replacement-type fibrosis. Confirmation of pseudoaneurysm also relies on demonstrating complete disruption of the elastic media and near-rupture

For personal use only. No other uses without permission. Copyright ©2017. Elsevier Inc. All rights reserved.

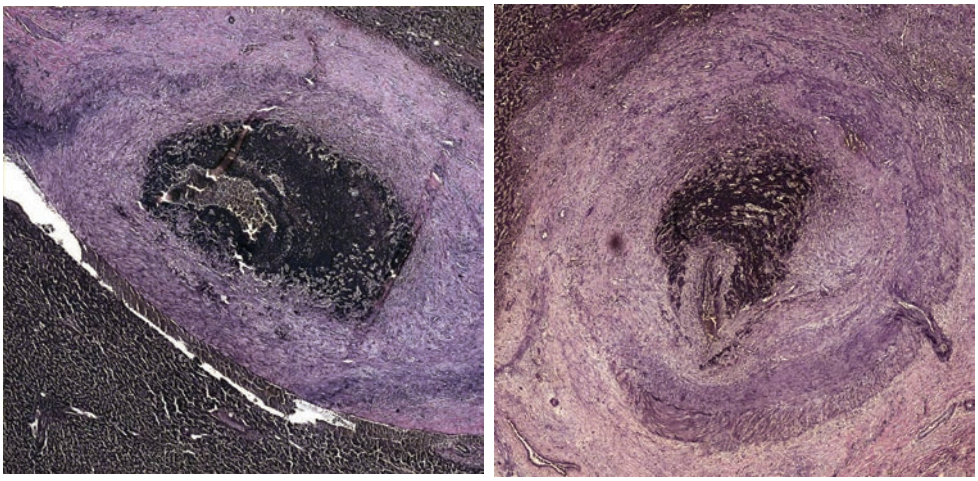

Figure 42.44 Polyarteritis Nodosa. Vascular lesions in the liver (elastic stains) showing features of active/subacute fibrinoid necrotizing arteritis *(left)* and segmental wall destruction with contained rupture (pseudoaneurysm) *(right)*. Temporal variability (active and healed lesions in the same organ) is a hallmark feature of polyarteritis nodosa.

contained only by adventitial connective tissue. Elastic staining is helpful in delineating this.

Polyarteritis nodosa, classically described at autopsy as visible nodular lesions at the points of arterial branchings, especially within the liver, spleen, and kidneys. This condition is recognized to have a strong association with chronic hepatitis B infection.[102] The skin and peripheral nerves may also be involved.[103,104]

Microscopically, the namesake nodular lesions are confirmed to be pseudoaneurysms or contained hemorrhages and the vessel walls involved by vasculitis with an active (fibrinoid) necrotizing arteritis process (Fig. 42.44). Another histologic hallmark of this disease is vascular lesions of varying ages or "temporal heterogeneity" with active and healed lesions seen in the same biopsy or surgical specimen.

Small Vessel Vasculitis

According to the revised Chapel Hill classification scheme, the small vessel vasculitis syndromes encompass those entities that preferentially affect arterioles, capillaries, and the venous side of circulation.[105] They may be broadly classified into three groups: (1) ANCA-mediated vasculitis, (2) immune complex–mediated vasculitis, and (3) vasculitis caused by direct antibody-mediated injury. The ANCA-mediated diseases include, primarily, microscopic polyangiitis, polyangiitis with granulomatosis, and eosinophilic granulomatosis with polyangiitis. Immune complex vasculitides include systemic lupus erythematosus, Henoch–Schönlein purpura, and other related disorders. Goodpasture syndrome is the prototypic vasculitis syndrome associated with direct antibody-induced injury. The pattern of inflammation in this group of diseases also tends to be acute and necrotizing, similar to the medium vessel vasculitis syndromes. Most of these conditions are discussed elsewhere in this text (particularly the pulmonary and renal chapters).

Single Organ Vasculitis

In recent years, several forms of vasculitis have been described that appear to be confined to a particular organ (and apparently cured by removal, where possible). These may involve the arterial or venous vessels in the particular organ. Examples include testicular vasculitis, uterine vasculitis, cutaneous vasculitis, gallbladder vasculitis, CNS vasculitis, and isolated aortitis.[105] Obviously a thorough and systemic rheumatologic evaluation is necessary to confirm the isolated nature of disease in these patients.

Tumors

The general subject of vascular tumors is dealt with in Chapter 41. Only those neoplasms involving major vessels are discussed here.

Great Vessels

Primary tumors of the "great vessels" (aorta or pulmonary artery) are almost invariably malignant and represent various types of sarcoma (fibrosarcoma, leiomyosarcoma, rhabdomyosarcoma, fibromyxosarcoma, and pleomorphic high-grade sarcoma). These intravascular tumors almost invariably lead to embolic metastases, and the overall prognosis is dismal.[32]

It is important to distinguish "intimal sarcoma" from other vascular sarcomas in these vessels. As mentioned previously, these tumors have a growth pattern that consists of highly pleomorphic cells with either epithelioid or spindled morphology spreading in a plaquelike fashion along the surface of acellular fibrin necrotic/thrombotic material lining the involved vessel (Fig. 42.45). There may not be any involvement of the underlying vessel wall.

Lymphomas and high-grade sarcomas have also occurred at the site of synthetic vascular prostheses and stents, as well as at the site of a surgically constructed arteriovenous fistula. Chronic immune stimulation by the foreign material at these sites is felt to play a key role in their pathogenesis.

Additional primary tumors and tumorlike conditions that may exhibit a predominant or exclusive intravascular location are epithelioid hemangioendothelioma, pyogenic granuloma, intravascular papillary endothelial hyperplasia, intravascular nodular fasciitis, synovial sarcoma, and intravascular leiomyomatosis. These entities are discussed elsewhere in this textbook.

Metastatic Tumors

These can lodge in large vessels and produce occlusion. Cases of major arterial occlusion from carcinoma of lung and other sites have been well documented.

For personal use only. No other uses without permission. Copyright ©2017. Elsevier Inc. All rights reserved.

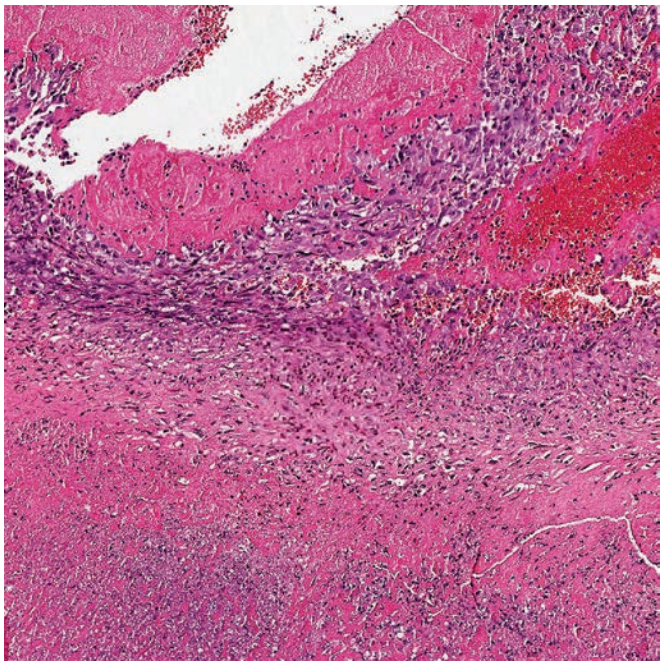

Figure 42.45 Intimal Sarcoma of the Descending Thoracic Aorta. Pleomorphic and spindled sarcoma cells are seen associated with fibrin thrombus overlying a bed of necrotic organizing fibrin debris.

Veins

Normal Anatomy

Veins have a three-layer histoarchitecture similar to arteries, but they lack an internal elastic layer separating the intima and media. The medial thickness is much thinner compared to arteries as well; in fact the adventitial layer is typically the thickest and most prominent layer in most veins. The adventitial smooth muscle is also arranged in bundles oriented in varying directions around the vessel circumference. The outer elastic layer is also less distinct than in arteries and may show fragmentation and splitting. Another important feature distinguishing veins from arteries is the presence of fibrous intimal valves in larger veins.

Thrombophlebitis and Thromboembolism

Thrombophlebitis is a thrombotic disease of veins accompanied by varying degrees of inflammation. Microscopically, the venous wall is edematous and the intimal endothelium focally eroded with resultant thrombus formation. This may be accompanied by transmural infiltration with chronic inflammatory cells. During the acute phase, attachment of the thrombus to the intima may be tenuous. As the acute inflammatory phase of the disease subsides, fibrosis develops, especially in the adventitia and media. The thrombus in this later phase may show organization or degenerative changes and becomes more fixed to the wall (or even incorporated into the fibrotic process).

The process of thrombophlebitis is associated with edema of the extremity, which may be marked. Paradoxically, the absence (or minor degree) or edema is probably more frequently associated with pulmonary emboli than is thrombophlebitis with marked edema. The degree of edema typically correlates directly with the degree of microscopic inflammation.[106] However, there are certainly exceptions to this general rule.

Thrombophlebitis may involve superficial veins, deep veins, or both. Clinical examination is notoriously inaccurate in the diagnosis of deep vein thrombosis, but when signs are present, the vein may be acutely inflamed and tender, and with superficial veins the overlying skin is red. When the thrombosis is limited to the superficial veins, there is usually little edema. However, thrombophlebitic edema may develop with marked rapidity and may be of great volume if the process extends into the deep venous system. In the most severe instances, "third spacing" of extracellular fluid in the leg may be sufficiently massive to cause shock and be accompanied by cutaneous blebs and necrosis *(phlegmasia cerulea dolens)*.

There is a statistically significant association between deep vein thrombosis and the presence of cancer in an internal organ, known as the *Trousseau syndrome.* Many of the tumors associated with this paraneoplastic complication are mucin-producing adenocarcinomas, often of the pancreas.

Pulmonary embolism is often thought to be primarily a complication of some surgical procedure or trauma such as fracture, particularly of the lower extremity, but the incidence of this complication is as high on medical as on surgical services. Some of the factors thought to favor intravenous thrombosis and subsequent pulmonary embolism are neoplasms, cardiac disease, venous stasis from any cause, infection in the immediate area of veins, trauma, spasm of vessels, intimal injury, increased coagulability, and immobilization of the limbs.

Pulmonary embolism may occur in all forms of thrombophlebitis, but it should be noted that sudden massive pulmonary emboli frequently occur in patients without antecedent symptoms or signs of peripheral thrombophlebitis.

In a classic autopsy-based study, McLachlin and Paterson reported several important observations.[106] They found that 75% of the venous thrombi arose in the veins of the thigh and pelvis and 25% in the smaller veins of the calf and feet, with 92% arising in the lower extremities. In over one-half of these there were pulmonary emboli. In their observations, they also stressed the finding of intravascular thromboses arising in relationship to the valve pockets.

For many decades, the development of deep venous thrombus and thrombophlebitis was attributed to the "Virchow's triad" hypothesis and the interaction of (1) hypercoagulability, (2) stasis, and (3) intimal injury. Blood pooling in the venous valve pockets was felt to serve as the nidus for thrombus formation in this scenario. However, in many patients thrombotic events occurred in the clear absence of one or more of these factors. More recently, a newer hypothesis has begun to supplant (or at least challenge) this paradigm. In this new model, localized (microenvironment) hypoxia develops in the venous valve pockets, as oxygen is consumed by the endothelium and venous wall, exhausting the local pool of static venous blood. This results in local hypoxia with injury to leukocytes and endothelial cells with possible platelet activation. When new blood enters this environment (through leg muscle contraction or postural change), the "fresh" intact leukocytes and platelets participate in the formation and propagation of a thrombus.[107]

The treatment of acute thrombophlebitis attempts to limit the extension of the process and to prevent pulmonary embolization through the use of heparin (convention and low-molecular-weight agents), warfarin, and newer anticoagulants. Elevation, rest with the maintenance of good hydration, elastic support, and anticoagulant therapy are also initial measures. Placement of upstream intravenous filters in the inferior vena cava has become an effective means of preventing pulmonary embolization but carries a risk of strut fracture, dislodging and migration, and other complications. Because of

For personal use only. No other uses without permission. Copyright ©2017. Elsevier Inc. All rights reserved.

long-term complications, placement of these devices is often temporary (several months) and current devices are designed to be retrievable endovascularly.[108]

Stasis Ulcers

"Downstream" complications of thrombophlebitis (i.e. pulmonary embolism) receive the primary focus for clinical significance, but there are also important "upstream" consequences occurring long term, such as venous stasis ulceration of the skin.

After managing embolization risk in patients with thrombophlebitis, measures should also be taken to avoid later stasis disease in the lower extremity. The use of elastic supports to help control any dependent edema in the extremity is generally effective and may be required for many months or years. With the passage of time, collateral venous channels may develop and communicate with the superficial venous systems, resulting in secondary superficial varicosities. Recanalization of the major deep veins is usually associated with this process. Significant varicosities in the postphlebitic extremity may be removed surgically.

Chronic venous insufficiency leads to manifestations of cutaneous pigmentation, brawny edema, dermal and subcutaneous fibrosis, extensive secondary varicosities, and ulceration of the skin develop in the lower extremity. The diagnosis of stasis disease is not usually difficult. Other rare causes of ulceration such as specific infections and neoplasms can be excluded by biopsy and culture.

Histologic features of venous stasis ulcers are not necessarily distinct from ulcers due to arterial insufficiency, but in one large series certain features were seen more often in the setting of venous stasis. These included diffuse edema, granulation tissue, hemosiderophages, and collagen-bundle degeneration, with fibrosis.[109]

Varicose Veins

Varicose veins occur more frequently in women than in men. They often develop in the second and third decades of life and may be present for many years without causing symptoms or complications. Their incidence is much higher in obese women, particularly those who have had several pregnancies (presumably through prolonged compression of pelvic veins by the gravid uterus). Varicosities may also be secondary to deep venous thrombosis.

Grossly, superficial veins of the leg become dilated and tortuous and lose valvular function. Microscopically, there is fibrosis beneath the endothelium and in the wall, with secondary elastosis and loss of muscle. Calcification may occur. Recent studies have demonstrated abnormalities in matrix metalloproteins that may explain the extracellular matrix (collagen) changes in varicose veins.[110] These may also help explain a hereditary or intrinsic susceptibility to varicose vein formation that has long been observed.

When severely symptomatic, or to prevent propagation to deeper veins and possibly increase thrombotic risk, surgical removal of varicosities may be performed. This is often done by minimally invasive endoscopic techniques. Surgical specimens received will show the changes described previously.

Tumors

Inferior Vena Cava

Most tumors arising in the inferior vena cava and other large veins are malignant and are largely represented by *leiomyosarcoma* (Fig. 42.46).

Tumors of smaller vessels are discussed in Chapter 41.

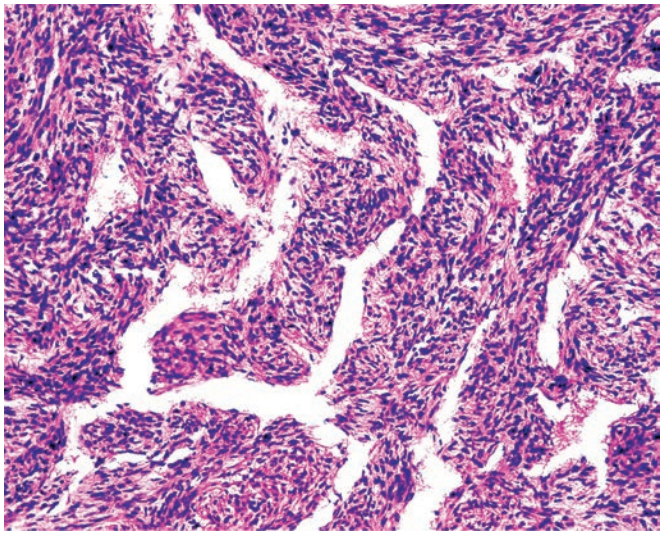

Figure 42.46 Leiomyosarcoma of inferior vena cava characterized by randomly oriented fascicles of malignant smooth muscle cells with a "staghorn" vascular pattern.

Lymph Vessels

Normal Anatomy

The smallest lymphatics resemble capillaries but often with a "gaping" lumen and elongated or irregular contours. The walls of large caliber lymphatic vessels also resemble capillaries, lacking elastic tissue and with only thin wisps of muscular media. Intimal valves may be seen in larger caliber lymphatics (similar to veins). Podoplanin (recognized by antibody clone D2-40) and LYVE-1 are antigens expressed specifically in lymphatic (but not venous or arterial) endothelium.

Lymphedema

With the exception of tumors of lymph vessels, such as lymphangioma and lymphangiosarcoma (see Chapter 41), the only primary lymphatic disease encountered clinically with some frequency is lymphedema. Chylothorax and chylous ascites also occur, but in nearly all instances these processes are secondary to trauma, neoplastic disease, or some infectious process.

Lymphedema stems from inadequate lymphatic drainage. It may be classified into postinfectious, post-traumatic, obstructive, and idiopathic etiologies. In some parts of the world, lymphedema resulting from *Schistosoma (Filaria)* is very common.[111] In the developed world, obstructive lymphedema is most often seen following obstruction of regional lymph nodes by malignant tumor or following node removal. The development of lymphedema of the arm after axillary node dissection is most common when postoperative infection complicates the surgical wound healing process or there is persistent cancer in the axilla. The advent of sentinel node sampling has significantly reduced the frequency of lymphedema.[112,113]

Lymphedema can also be seen in patients who give a history of as little trauma as a severely sprained ankle or following such infections as a furuncle. Many patients give no history of trauma or infection associated with the onset of their lymphedema. In such instances, the lymphedema is usually termed idiopathic. Congenital idiopathic lymphedema, also known as *Milroy disease*, is inherited in an autosomal dominant fashion.

For personal use only. No other uses without permission. Copyright ©2017. Elsevier Inc. All rights reserved.

Postmastectomy lymphedema and, to a lesser degree, Milroy disease can be complicated by the development of lymphangiosarcoma (see Chapter 41). Curiously, this complication is extremely rare in the cases of lymphedema resulting from schistosomiasis, although it may occur.

The swelling of lymphedema is usually slowly progressive. There is dilation of the dermal lymphatics, as well as the deeper fascial lymphatics. When the degree of swelling is advanced, there is a depression of hair follicles and gross dermal edema. In such cases, the cutaneous lymphatics may be sufficiently dilated to be associated with lymphorrhea following minor cutaneous abrasions or needle punctures. Tissue sections of such skin usually show markedly dilated dermal lymph vessels.

Whatever the mechanism, the slowly progressive nature of lymphedema in many patients is associated with dermal thickening and collagenous deposition in the subcutaneous tissues and fascia. Bouts of superficial cellulitis and lymphangitis often become superimposed on the lymphedema in an extremity. The presence of recurrent infection in such an extremity appears to hasten the deposition of collagen and may result in such a large amount of fibrotic replacement of subcutaneous fat and normal dermal structures as to make demonstration of dermal lymphatics impossible.

In a few patients with idiopathic lymphedema having no clinical evidence or history of lymphangitis or cellulitis in the extremity, enlarged regional lymph nodes have been removed. Microscopically, these nodes exhibit a mild chronic inflammatory infiltrate, sinusoidal fibrosis, and markedly dilated lymphatic channels.

Dermal and subcutaneous fibrosis similar to that seen in advanced forms of lymphedema also occurs about longstanding chronic stasis ulcers. Morbidly obese patients can develop *massive localized lymphedema* in the upper or lower limbs that can simulate histologically an atypical lipomatous tumor (well-differentiated liposarcoma) (see Chapter 41).

Expression of podoplanin (as detected by immunohistochemical methods using the D2-40 reagent clone) in lymphatic endothelium can be used to differentiate lymphatics from veins, venules, and other small caliber dilated vascular structures.[114] This staining technique has also been used to highlight lymphatic invasion in the vicinity of malignant tumors (Fig. 42.47). While arterial and venous endothelium lacks expression of podoplanin, it is present in other cell types, such as mesothelium, and may be expressed in several epithelial and vascular malignancies as well.

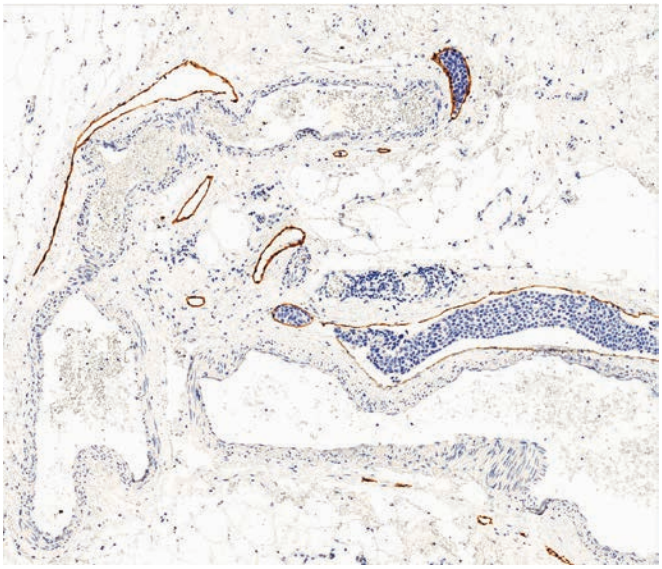

Figure 42.47 Podoplanin (D2-40) staining of breast tissue to evaluate for lymphatic invasion of an adjacent tumor. The lymphatic channel endothelium stains intensely for D2-40, whereas the arterial and venous endothelium does not.

Treatment of lymphedema consists primarily of elevation of the extremity, compression, and massage, which often must be continued (indefinitely) for many years. Secondary infections are treated with antibiotics. Conservative measures control lymphedema in most patients sufficiently to avoid operation.

Operative therapy is indicated only in a small minority of cases. Surgical approaches include excision of the thickened fibrotic skin, edematous subcutaneous tissue, and fascia overlying the muscles, followed by the split-thickness skin grafting. More recently, microsurgical techniques using fluorescence lymphography to guide creation of lymphaticovenous anastomoses have been developed as well.[115]

Tumors

Benign and malignant tumors of lymph vessels are discussed in Chapter 41 (Soft Tissues).

References

1. Cohn LH, ed. *Cardiac Surgery in the Adult*. 4th ed. New York, NY: McGraw-Hill; 2011.
2. Burke AP, Tavora F. *Practical Cardiovascular Pathology*. Philadelphia, PA: Wolters Kluwer Health/Lippincott Williams & Wilkins; 2011.
3. Kouchoukos NT, Blackstone E, Hanley F, Kirklin JK. *Kirklin/Barratt-Boyes Cardiac Surgery*. 4th ed. Philadelphia, PA: Elsevier-Saunders; 2013.
4. Buja LM, Butany J. *Cardiovascular Pathology*. 4th ed. Philadelphia, PA: Elsevier; 2016.
5. Miller DV. Normal heart. In: Lamps L, ed. *Diagnostic Pathology: Normal Histology*. 3rd ed. Salt Lake City, UT: Amirsys; 2013.
6. Burke AP, Farb A, Robinowitz M, Virmani R. Serial sectioning and multiple level examination of endomyocardial biopsies for the diagnosis of myocarditis. *Mod Pathol*. 1991;4:690-693.
7. Hammond EH. Utility of ultrastructural studies of cardiac biopsy specimens. *Ultrastruct Pathol*. 1994;18:201-202.
8. Mason JW, Bristow MR, Billingham ME, Daniels JR. Invasive and noninvasive methods of assessing adriamycin cardiotoxic effects in man: superiority of histopathologic assessment using endomyocardial biopsy. *Cancer Treat Rep*. 1978;62(6):857-864.
9. Cooper LT, Baughman KL, Feldman AM, et al. The role of endomyocardial biopsy in the management of cardiovascular disease: a scientific statement from the American Heart Association, the American College of Cardiology, and the European Society of Cardiology. *Circulation*. 2007;116(19):2216-2233.
10. Leone O, Veinot JP, Angelini A, et al. 2011 consensus statement on endomyocardial biopsy from the Association for European Cardiovascular Pathology and the Society for Cardiovascular Pathology. *Cardiovasc Pathol*. 2012;21(4):245-274.
11. Konno T, Chang S, Seidman JG, Seidman CE. Genetics of hypertrophic cardiomyopathy. *Curr Opin Cardiol*. 2010;25(3):205-209.
12. Towbin JA. Inherited cardiomyopathies. *Circ J*. 2014;78(10):2347-2356.
13. Elliott P, Andersson B, Arbustini E, et al. Classification of the cardiomyopathies: a position statement from the European Society of Cardiology Working Group on Myocardial and Pericardial Diseases. *Eur Heart J*. 2008;29:270-276.
14. Marcus FI, McKenna WJ, Sherrill D, et al. Diagnosis of arrhythmogenic right ventricular cardiomyopathy/dysplasia: proposed modification of the Task Force Criteria. *Eur Heart J*. 2010;31(7):806-814.
15. Aretz HT, Billingham ME, Edwards WD, et al. Myocarditis: a histopathologic definition and classification. *Am J Cardiovasc Pathol*. 1987;1:3-14.
16. Basso C, Calabrese F, Angelini A, et al. Classification and histological, immunohistochemical, and molecular diagnosis of inflammatory myocardial disease. *Heart Fail Rev*. 2013;18(6):673-681.
17. Lagana SM, Parwani AV, Nichols LC. Cardiac sarcoidosis: a pathology-focused review. *Arch Pathol Lab Med*. 2010;134(7):1039-1046.

For personal use only. No other uses without permission. Copyright ©2017. Elsevier Inc. All rights reserved.

18. Maleszewski JJ, Kucirka LM, Segev DL, Halushka MK. Survey of current practice related to grading of rejection in cardiac transplant recipients in North America. *Cardiovasc Pathol*. 2011;20(5):261-265.
19. Berry GJ, Burke MM, Andersen C, et al. The 2013 International Society for Heart and Lung Transplantation Working Formulation for the standardization of nomenclature in the pathologic diagnosis of antibody-mediated rejection in heart transplantation. *J Heart Lung Transplant*. 2013;32(12):1147-1162.
20. Stewart S, Winters GL, Fishbein MC, et al. Revision of the 1990 working formulation for the standardization of nomenclature in the diagnosis of heart rejection. *J Heart Lung Transplant*. 2005;24(11):1710-1720.
21. Seki A, Fishbein MC. Predicting the development of cardiac allograft vasculopathy. *Cardiovasc Pathol*. 2014;23(5):253-260.
22. Tan CD, Baldwin WM 3rd, Rodriguez ER. Update on cardiac transplantation pathology. *Arch Pathol Lab Med*. 2007;131(8):1169-1191. Review.
23. Stone JR, Basso C, Baandrup UT, et al. Recommendations for processing cardiovascular surgical pathology specimens: a consensus statement from the Standards and Definitions Committee of the Society for Cardiovascular Pathology and the Association for European Cardiovascular Pathology. *Cardiovasc Pathol*. 2012;21(1):2-16.
24. Veinot JP. Native cardiac valve pathology. *Surg Pathol Clin*. 2012;5(2):327-352.
25. Hulin A, Deroanne C, Lambert C, et al. Emerging pathogenic mechanisms in human myxomatous mitral valve: lessons from past and novel data. *Cardiovasc Pathol*. 2013;22(4):245-250.
26. Levine RA, Hagége AA, Judge DP, et al. Mitral valve disease—morphology and mechanisms. *Nat Rev Cardiol*. 2015;12(12):689-710.
27. Van der Laan PA, Padera RF, Schoen FJ. Practical approach to the evaluation prosthetic and tissue replacement heart valves. *Surg Pathol Clin*. 2012;5(2):353-369.
28. Shenthar J, Kalpana SR, Prabhu MA, et al. Histopathological study of left and right atria in isolated rheumatic mitral stenosis with and without atrial fibrillation. *J Cardiovasc Electrophysiol*. 2016;27(9):1047-1054.
29. Castonguay MC, Wang Y, Gerhart JL, et al. Surgical pathology of atrial appendages removed during the cox-maze procedure: a review of 86 cases (2004 to 2005) with implications for prognosis. *Am J Surg Pathol*. 2013;37(6):890-897.
30. Goldman S, Zadina K, Moritz T, et al. Long-term patency of saphenous vein and left internal mammary artery grafts after coronary artery bypass surgery: results from a Department of Veterans Affairs Cooperative Study. *J Am Coll Cardiol*. 2004;44(11):2149-2156.
31. Travis WD, Brambilla E, Burke AP, et al, eds. *WHO Classification of Tumors of the Lung, Pleura, Thymus, and Heart*. 4th ed. Lyon: IARC Press; 2015.
32. Burke A, Tavora AR, Maleszewski JJ, Frazier AA. *Tumors of the Heart and Great Vessels, Fasc. 22 (Atlas of Tumor Pathology)*. 4th series. Washington, DC: American Registry of Pathology; 2016.
33. Carney JA. Differences between nonfamilial and familial cardiac myxoma. *Am J Surg Pathol*. 1985;9(1):53-55.
34. Yin Z, Kirschner LS. The Carney complex gene PRKAR1A plays an essential role in cardiac development and myxomagenesis. *Trends Cardiovasc Med*. 2009;19:44-49.
35. Orlandi A, Ciucci A, Ferlosio A, et al. Increased expression and activity of matrix metalloproteinases characterize embolic cardiac myxomas. *Am J Pathol*. 2005;166(6):1619-1628.
36. Miller DV, Tazelaar HD, Handy JR, et al. Thymoma arising within cardiac myxoma. *Am J Surg Pathol*. 2005;29(9):1208-1213.
37. Lloreta J, Juanpere N, Riverola A, et al. Cardiac myxoma with glandular differentiation: an immunohistochemical and ultrastructural study. *Ultrastruct Pathol*. 2013;37(1):77-82.
38. Kodama H, Hirotani T, Suzuki Y, et al. Cardiomyogenic differentiation in cardiac myxoma expressing lineage-specific transcription factors. *Am J Pathol*. 2002;161(2):381-389.
39. Kurup AN, Tazelaar HD, Edwards WD, et al. Iatrogenic cardiac papillary fibroelastoma: a study of 12 cases (1990 to 2000). *Hum Pathol*. 2002;33(12):1165-1169.
40. Fealey ME, Edwards WD, Miller DV, et al. Hamartomas of mature cardiac myocytes: report of 7 new cases and review of literature. *Hum Pathol*. 2008;39(7):1064-1071.
41. Reynolds C, Tazelaar HD, Edwards WD. Calcified amorphous tumor of the heart (cardiac CAT). *Hum Pathol*. 1997;28(5):601-606.
42. Veinot J, Tazelaar H, Edwards W, Colby TV. Mesothelial/monocytic incidental cardiac excrescences: cardiac MICE. *Mod Pathol*. 1994;7(1):9-16.
43. Burke A, Li L, Kling E, et al. Cardiac inflammatory myofibroblastic tumor: a "benign" neoplasm that may result in syncope, myocardial infarction, and sudden death. *Am J Surg Pathol*. 2007;31(7):1115-1122.
44. Maleszewski JJ, Tavora F, Burke AP. Do "intimal" sarcomas of the heart exist? *Am J Surg Pathol*. 2014;38(8):1158-1159.
45. Neuville A, Collin F, Bruneval P, et al. Intimal sarcoma is the most frequent primary cardiac sarcoma: clinicopathologic and molecular retrospective analysis of 100 primary cardiac sarcomas. *Am J Surg Pathol*. 2014;38(4):461-469.
46. Makharoblidze E, Goishvili N, Mchedlishvili M, Jangavadze M. Primary Kaposi's sarcoma of the heart in non-immunodeficient patient: case report and literature review. *Diagn Pathol*. 2015;10:111.
47. Gordon MJ, Danilova O, Spurgeon S, Danilov AV. Cardiac non-Hodgkin's lymphoma: clinical characteristics and trends in survival. *Eur J Haematol*. 2016;97(5):445-452.
48. Miller DV, Firchau DJ, McClure RF, et al. Epstein-Barr virus-associated diffuse large B-cell lymphoma arising on cardiac prostheses. *Am J Surg Pathol*. 2010;34(3):377-384.
49. Gruver AM, Huba MA, Dogan A, Hsi ED. Fibrin-associated large B-cell lymphoma: part of the spectrum of cardiac lymphomas. *Am J Surg Pathol*. 2012;36(10):1527-1537.
50. Shehata BM, Thomas JE, Doudenko-Rufforny I. Metastatic carcinoid to the conducting system-is it a rare or merely unrecognized manifestation of carcinoid cardiopathy? *Arch Pathol Lab Med*. 2002;126(12): 1538-1540.
51. Kinnunen P, Kulmala P, Kaarteenaho-Wiik R, Vuopala K. Ectopic liver in the human pericardium. *Histopathology*. 1997;30(3):277-279.
52. Oh KY, Shimizu M, Edwards WD, et al. Surgical pathology of the parietal pericardium: a study of 344 cases (1993–1999). *Cardiovasc Pathol*. 2001;10(4):157-168.
53. Talreja DR, Edwards WD, Danielson GK, et al. Constrictive pericarditis in 26 patients with histologically normal pericardial thickness. *Circulation*. 2003;108(15):1852-1857.
54. Drut R, Quijano G. Multilocular mesothelial inclusion cysts (so-called benign multicystic mesothelioma) of pericardium. *Histopathology*. 1999;34(5):472-474.
55. Chen YB, Rahemtullah A, Hochberg E. Primary effusion lymphoma. *Oncologist*. 2007;2(5):569-576.
56. Mills SE, ed. *Histology for Pathologists*. 4th ed. Philadelphia, PA: Wolters Kluwer Health/Lippincott Williams & Wilkins; 2012.
57. Writing Group Members, Mozaffarian D, Benjamin EJ, et al. Heart disease and stroke statistics—2016 update: a report from the American Heart Association. *Circulation*. 2016;134(25):e36-e380.
58. Gimbrone MA Jr, García-Cardeña G. Vascular endothelium, hemodynamics, and the pathobiology of atherosclerosis. *Cardiovasc Pathol*. 2013;22(1):9-15.
59. Moore KJ, Tabas I. Macrophages in the pathogenesis of atherosclerosis. *Cell*. 2011;145(3):341-355.
60. Kortelainen ML, Porvari K. Adventitial macrophage and lymphocyte accumulation accompanying early stages of human coronary atherogenesis. *Cardiovasc Pathol*. 2014;23(4):193-197.
61. Glagov S, Zarins C, Giddens DP, Ku DN. Hemodynamics and atherosclerosis. Insights and perspectives gained from studies of human arteries. *Arch Pathol Lab Med*. 1988;112(10):1018-1031.
62. Sakakura K, Nakano M, Otsuka F, et al. Pathophysiology of atherosclerosis plaque progression. *Heart Lung Circ*. 2013;22(6):399-411.
63. Bentzon JF, Otsuka F, Virmani R, Falk E. Mechanisms of plaque formation and rupture. *Circ Res*. 2014;114(12):1853-1866.
64. Stary HC, Chandler AB, Glagov S, et al. A definition of initial, fatty streak, and intermediate lesions of atherosclerosis: a report from the Committee on Vascular Lesions of the Council on Arteriosclerosis, American Heart Association. Special report. *Arterioscler Thromb*. 1994;14:840-856.
65. Stary HC, Chandler AB, Dinsmore RE, et al. A definition of advanced types of atherosclerotic lesions and a histological classification of atherosclerosis: a report from the Committee on Vascular Lesions of the Council on Arteriosclerosis, American Heart Association. *Circulation*. 1995;92:1355-1374.
66. Steiner I, Spaček J, Matějková A, et al. Histopathology of aspirated thrombi during primary percutaneous coronary intervention in patients with acute myocardial infarction. *Cardiovasc Pathol*. 2014;23(5):267-271.
67. Riegger J, Byrne RA, Joner M, et al. Histopathological evaluation of thrombus in patients presenting with stent thrombosis. A multicenter European study: a report of the prevention of late stent thrombosis by an interdisciplinary global European effort consortium. *Eur Heart J*. 2016;37(19):1538-1549.
68. Mennuni MG, Pagnotta PA, Stefanini GG. Coronary stents: the impact of technological advances on clinical outcomes. *Ann Biomed Eng*. 2016;44(2):488-496.
69. Sheth SD, Giugliano RP. Coronary artery stents: advances in technology. *Hosp Pract (1995)*. 2014;42(4):83-91.
70. Yahagi K, Kolodgie FD, Otsuka F, et al. Pathophysiology of native coronary, vein graft, and in-stent atherosclerosis. *Nat Rev Cardiol*. 2016;13(2):79-98.
71. Rippstein P, Black MK, Boivin M, et al. Comparison of processing and sectioning methodologies for arteries containing metallic stents. *J Histochem Cytochem*. 2006;54(6):673-681.
72. Fishbein I, Welch T, Guerrero DT, et al. Paraffin processing of stented arteries using a postfixation dissolution of metallic and polymeric stents. *Cardiovasc Pathol*. 2016;25(6):483-488.

For personal use only. No other uses without permission. Copyright ©2017. Elsevier Inc. All rights reserved.

73. Bradshaw SH, Kennedy L, Dexter DF, Veinot JP. A practical method to rapidly dissolve metallic stents. *Cardiovasc Pathol*. 2005;18(3):127-133.
74. Belkin M, Donaldson MC, Whittemore AD. Abdominal aortic aneurysms. *Curr Opin Cardiol*. 1994;9:581-590.
75. Huang Y, Gloviczki P, Duncan AA, et al. Maximal aortic diameter affects outcome after endovascular repair of abdominal aortic aneurysms. *J Vasc Surg*. 2016;[Epub ahead of print].
76. Coady MA, Rizzo JA, Hammond GL, et al. What is the appropriate size criterion for resection of thoracic aortic aneurysms? *J Thorac Cardiovasc Surg*. 1997;113:476-491.
77. Schermerhorn ML, Buck DB, O'Malley AJ, et al. Long-term outcomes of abdominal aortic aneurysm in the medicare population. *N Engl J Med*. 2015;373(4):328-338.
78. Halushka MK, Angelini A, Bartoloni G, et al. Consensus statement on surgical pathology of the aorta from the Society for Cardiovascular Pathology and the Association For European Cardiovascular Pathology: II. Noninflammatory degenerative diseases—nomenclature and diagnostic criteria. *Cardiovasc Pathol*. 2016;25(3):247-257.
79. Homme JL, Aubry MC, Edwards WD, et al. Surgical pathology of the ascending aorta: a clinicopathologic study of 513 cases. *Am J Surg Pathol*. 2006;30(9):1159-1168.
80. Halushka M. Pathology of the aorta. *Surg Pathol Clin*. 2012;5(2):417-433.
81. Miller DV, Maleszewski JJ. The pathology of large-vessel vasculitides. *Clin Exp Rheumatol*. 2011;29(1 suppl 64):S92-S98.
82. Liang KP, Chowdhary VR, Michet CJ, et al. Noninfectious ascending aortitis: a case series of 64 patients. *J Rheumatol*. 2009;36(10):2290-2297.
83. Miller DV, Isotalo PA, Weyand CM, et al. Surgical pathology of noninfectious ascending aortitis: a study of 45 cases with emphasis on an isolated variant. *Am J Surg Pathol*. 2006;30(9):1150-1158.
84. Miller DV, Oderich GS, Aubry MC, et al. Surgical pathology of infected aneurysms of the descending thoracic and abdominal aorta: clinicopathologic correlations in 29 cases (1976 to 1999). *Hum Pathol*. 2004;35(9):1112-1120.
85. Stone JR. Aortitis, periaortitis, and retroperitoneal fibrosis, as manifestations of IgG4-related systemic disease. *Curr Opin Rheumatol*. 2011;23(1):88-94.
86. Wilson SK, Hutchins GM. Aortic dissecting aneurysms. Causative factors in 204 subjects. *Arch Pathol Lab Med*. 1982;106:175-180.
87. Fernandez-Moure JS, Vykoukal D, Davies MG. Biology of aortic aneurysms and dissections. *Methodist Debakey Cardiovasc J*. 2011;7(3):2-7. Review.
88. Roberts CS, Roberts WC. Aortic dissection with the entrance tear in the descending thoracic aorta. Analysis of 40 necropsy patients. *Ann Surg*. 1991;213(4):356-368.
89. Matsui H, Adachi I, Uemura H, et al. Anatomy of coarctation, hypoplastic and interrupted aortic arch: relevance to interventional/surgical treatment. *Expert Rev Cardiovasc Ther*. 2007;5(5):871-880.
90. Mathur M, Huda N, Bashir R. Blockage below the belt: Leriche syndrome. *Am J Med*. 2014;127(4):291-294.
91. Lejay A, Ohana M, Delay C, et al. Cystic adventitial pathology as an entity in peripheral arterial disease. *J Cardiovasc Surg (Torino)*. 2016;57(2):282-291.
92. Begelman SM, Olin JW. Fibromuscular dysplasia. *Curr Opin Rheumatol*. 2000;12(1):41-47.
93. Lüscher TF, Lie JT, Stanson AW, et al. Arterial fibromuscular dysplasia. *Mayo Clin Proc*. 1987;62(10):931-952.
94. Flaherty MJ, Lie JT, Haggitt RC. Mesenteric inflammatory veno-occlusive disease. A seldom recognized cause of intestinal ischemia. *Am J Surg Pathol*. 1994;18(8):779-784.
95. Ngo N, Chang F. Enterocolic lymphocytic phlebitis: clinicopathologic features and review of the literature. *Arch Pathol Lab Med*. 2007;131(7):1130-1134.
96. Kurata A, Franke FE, Machinami R, Schulz A. Thromboangitis obliterans: classic and new morphological features. *Virchows Arch*. 2000;436:59-67.
97. Hoffman GS, Weyand CM. *Inflammatory Diseases of Blood Vessels*. New York, NY: Marcel Dekker; 2002.
98. Weyand CM, Goronzy JJ. Medium- and large-vessel vasculitis. *N Engl J Med*. 2003;349:160-169.
99. Allsop CJ, Gallagher PJ. Temporal artery biopsy in giant-cell arteritis. A reappraisal. *Am J Surg Pathol*. 1981;5:317-323.
101. Chang HK, Fernandes J, Nair V. Kawasaki disease: an autopsy case series and review of the literature. *Am J Forensic Med Pathol*. 2016;37(3):183-186.
100. Stone JR, Bruneval P, Angelini A, et al. Consensus statement on surgical pathology of the aorta from the Society for Cardiovascular Pathology and the Association for European Cardiovascular Pathology: I. Inflammatory diseases. *Cardiovasc Pathol*. 2015;24(5):267-278.
102. Guillevin L, Mahr A, Callard P, et al. Hepatitis B virus-associated polyarteritis nodosa: clinical characteristics, outcome, and impact of treatment in 115 patients. *Medicine (Baltimore)*. 2005;84(5):313-322.
103. De Virgilio A, Greco A, Magliulo G, et al. Polyarteritis nodosa: a contemporary overview. *Autoimmun Rev*. 2016;15(6):564-570.
104. Alibaz-Oner F, Koster MJ, Crowson CS, et al. The clinical spectrum of medium-sized vessel vasculitis. *Arthritis Care Res (Hoboken)*. 2016;[Epub ahead of print].
105. Jennette JC, Falk RJ, Bacon PA, et al. 2012 revised International Chapel Hill Consensus Conference Nomenclature of Vasculitides. *Arthritis Rheum*. 2013;65(1):1-11.
106. McLachlin J, Paterson JC. Some basic observations on venous thrombosis and pulmonary embolism. *Surg Gynecol Obstet*. 1951;93:1-8.
107. Malone PC, Agutter PS. Deep venous thrombosis: the valve cusp hypoxia thesis and its incompatibility with modern orthodoxy. *Med Hypotheses*. 2016;86:60-66.
108. Tao MJ, Montbriand JM, Eisenberg N, et al. Temporary inferior vena cava filter indications, retrieval rates, and follow-up management at a multicenter tertiary care institution. *J Vasc Surg*. 2016;16:262-267.
109. Misciali C, Dika E, Baraldi C, et al. Vascular leg ulcers: histopathologic study of 293 patients. *Am J Dermatopathol*. 2014;36(12):977-983.
110. Naik B, Kumar M, Khanna AK, Suman PK. Clinico-histopathological study of varicose vein and role of matrix metalloproteinases-1, matrix metalloproteinases-9 and tissue inhibitor of matrix metalloproteinase-1 in varicose vein formation. *Indian J Pathol Microbiol*. 2016;59(1):25-30.
111. Dandapat MC, Mohapatro SK, Mohanty SS. Filarial lymphoedema and elephantiasis of lower limb. A review of 44 cases. *Br J Surg*. 1986;73:451-453.
112. McLaughlin SA, Wright MJ, Morris KT, et al. Prevalence of lymphedema in women with breast cancer 5 years after sentinel lymph node biopsy or axillary dissection: objective measurements. *J Clin Oncol*. 2008;26(32):5213-5219.
113. Lopez Penha TR, van Roozendaal LM, Smidt ML, et al. The changing role of axillary treatment in breast cancer: who will remain at risk for developing arm morbidity in the future? *Breast*. 2015;24(5):543-547.
114. Ordóñez NG. Podoplanin: a novel diagnostic immunohistochemical marker. *Adv Anat Pathol*. 2006;13(2):83-88.
115. Granzow JW, Soderberg JM, Kaji AH, Dauphine C. Review of current surgical treatments for lymphedema. *Ann Surg Oncol*. 2014;21(4):1195-1201.

For personal use only. No other uses without permission. Copyright ©2017. Elsevier Inc. All rights reserved.

43 Central Nervous System

Arie Perry and Marc K. Rosenblum

CHAPTER CONTENTS

Normal anatomy, *1948*
Developmental abnormalities, *1949*
Craniospinal dysraphism, *1949*
Neuroglial and meningeal heterotopias, *1951*
Choristomas and hamartomas, *1951*
Cysts of the central neuraxis, *1953*
Cerebrovascular disorders, *1955*
Cerebral infarction, *1955*
Intracranial aneurysms, *1955*
Vascular malformations, *1957*
Primary angiitis, *1959*
Cerebral amyloid angiopathy, *1960*
Cerebral autosomal dominant arteriopathy with subcortical infarcts and leukoencephalopathy and the autosomal recessive variant, *1961*
Epidural hematoma, *1961*
Subdural hematoma, *1962*
Inflammatory diseases, *1962*
Demyelinating diseases, *1962*
Noninfectious inflammatory and reactive disorders, xanthomatous lesions, and "histiocytoses", *1964*
Infectious diseases, *1967*
Bacterial infections, *1967*
Mycoses, *1969*
Parasitoses, *1971*
Spirochetal infections, *1972*
Viral infections, *1973*
Prion-associated diseases, *1976*
Primary tumors, *1977*
Glial tumors, *1977*
Choroid plexus tumors, *2007*
Neuronal and glioneuronal tumors, *2009*
Embryonal tumors, *2023*
Medulloblastoma and its variants, *2023*
Pineal parenchymal tumors, *2033*
Papillary tumor of the pineal region, *2035*
Meningiomas, *2036*
Nonmeningothelial mesenchymal tumors, *2044*
Nerve sheath tumors of the craniospinal axis, *2049*
Lymphoproliferative, histiocytic, and myeloproliferative disorders, *2050*
Germ cell tumors, *2054*
Melanocytic tumors, *2055*
Paraganglioma, *2056*
Chordoma, *2057*
Hemangioblastoma (von Hippel–Lindau disease), *2057*
Other primary tumors, *2059*
Secondary/metastatic tumors, *2059*

Normal Anatomy

Dauntingly complex and characterized by extraordinary variation in regional architecture, the gross and microscopic anatomy of the human central nervous system (CNS) cannot be surveyed here in detail. Instead, a brief review of anatomic landmarks and topographic relationships that bear particularly on issues of differential diagnosis is provided.

Confined within the cranium and vertebral canal, the CNS is ensheathed by connective tissue membranes that include a densely collagenous outer covering termed the *pachymeninx* or, more familiarly, *dura mater*, and delicate inner investments known as the *leptomeninges* or *pia-arachnoid*. Under normal circumstances, these are closely apposed and loosely joined by a layer of dural border cells that are easily disrupted (artifactually or by expanding lesions such as hematomas) to yield a "subdural space" that is, in fact, only a potential compartment. A sagittal dural fold referred to as the *falx cerebri* lies between the cerebral hemispheres, and a second such fold—the *tentorium cerebelli*—separates the superior cerebellar surfaces from the overlying temporal lobes of the cerebrum. Enclosed within the cranial dura, in addition to meningeal artery branches, are venous sinuses that serve both to drain the cerebral veins and to carry away cerebrospinal fluid (CSF) transported from the subarachnoid space by arachnoid villi that project into these conduits. Termed *pacchionian granulations,* as they achieve grossly visible proportions with normal aging, these villi are draped by specialized arachnoidal cells of interest to surgical pathologists as the likely progenitors of meningioma. Whereas the dura adheres tightly to the endosteal

For personal use only. No other uses without permission. Copyright ©2017. Elsevier Inc. All rights reserved.

Abstract

The complexity of the central nervous system (CNS) is daunting, particularly to those encountering relatively few CNS biopsies on a weekly basis. Nevertheless, the same basic rules of pathology utilized below the neck apply to diseases of the brain as well. This chapter provides a practical approach to the field of surgical neuropathology, with an emphasis on the common "bread and butter" differential diagnoses. Still, the authors have strived to create a sufficiently comprehensive resource in which rarer disorders encountered by the general pathologist or even the seasoned neuropathologist are also covered. More recently, this subspecialty has seen a dramatic impact on daily practice by molecular diagnostics, as reflected by the extensive changes in the WHO 2016 classification scheme of brain tumors, particularly in reference to gliomas and embryonal neoplasms. As such, there is now a much heavier focus on the use of biomarkers and surrogate immunostains to reach the most accurate "integrated diagnosis" possible. With this in mind, the text and images have been extensively updated for those topics where the greatest advances have been made since the last edition.

Keywords

Brain
central nervous system
malformations
cerebrovascular disorders
CNS infections
brain tumors

For personal use only. No other uses without permission. Copyright ©2017. Elsevier Inc. All rights reserved.

surfaces of the skull, at spinal levels it is attached only anteriorly to the vertebral bodies and is surrounded on its lateral and posterior aspects by a true compartment—the epidural space—which contains segments of the spinal nerve roots, blood vessels, and adipose tissue.

There are several localizing terms used in both clinical and radiographic parlance that may be of potential utility to the pathologist, as they may be encountered in neuroimaging reports and on specimen requisitions. Because the substance of the brain and spinal cord constitutes the central "neuraxis," lesions localized to the neuroparenchyma proper are often described as *intra-axial*, whereas those that simply abut the CNS from a meningeal or juxtameningeal site are said to be *extra-axial*. These qualifiers may be similarly invoked for spinal masses. The brain itself may be broadly but usefully parceled into *supratentorial* and *infratentorial* components, the former situated above and the latter below the tentorium cerebelli. The cerebellum and most of the brainstem, including the pons and medulla in their entirety, are infratentorial structures that may be collectively designated the posterior fossa contents. The supratentorial CNS consists of the cerebrum (subdivided into frontal, parietal, temporal, and occipital lobes) and deep nuclei of the basal ganglia, thalamus, and hypothalamus.

Within the CNS, connective tissue is scant and essentially restricted to the adventitia of blood vessels. There are no resident lymphoid elements. The parenchyma of the brain and spinal cord is composed principally of the bodies and cytoplasmic processes of neuroepithelial cell types, including neurons and various classes of glia. Subsumed under the latter designation are astrocytes, myelinating oligodendrocytes, and ependymal cells that line ventricular surfaces. These all have their neoplastic counterparts, classified generically as gliomas and subclassified as astrocytomas, oligodendrogliomas, and ependymomas, respectively. Close kin of the ependyma are the specialized epithelial elements of the choroid plexus, responsible for CSF production, and represented among brain tumors by papillomas and carcinomas. The neurosecretory parenchymal cells of the pineal gland, situated posterior to the roof (or "tectum") of the midbrain, may also be the targets of transformative events—thus the pineal parenchymal tumors.

On a practical note, there is paramount importance to the location of lesions in the CNS when one is formulating differential clinical and histologic diagnoses, particularly when considering neoplasms. Meningioma, for example, should be a remote consideration when confronted by an intra-axial mass but should loom large if a lesion is dura-based or fills the cerebellopontine angle (where schwannoma might also be reasonably suspected). By contrast, diffuse gliomas and metastatic carcinomas account for most cerebral hemispheric tumors (particularly in adulthood). Pilocytic astrocytomas, which mainly affect the young, exhibit a decided predilection for the cerebellum and third ventricular/hypothalamic region, whereas ependymomas frequent the fourth ventricles of children and the spinal cords of adults (where they constitute the most common intramedullary tumors). Primary CNS lymphomas are most often deep, periventricular white matter or basal ganglia masses, whereas germ cell tumors only exceptionally arise outside of a midline, pineal or suprasellar axis, and central neurocytomas are confined within the lateral ventricles. Similarly, the tapering conus medullaris and filum terminale of the distal spinal cord are the nearly exclusive hosts of myxopapillary ependymomas and CNS paragangliomas. Other neoplasms defined in part by localization include medulloblastoma (posterior fossa), papillary tumor of the pineal region, and chordoid glioma of the third ventricle. Many other such associations are to be found in this chapter. The foregoing should serve to underscore the potential benefits of a dialogue among pathologists, neuroradiologists, and neurosurgeons.

Developmental Abnormalities

Craniospinal Dysraphism

Defective midline closure of the embryonic neural tube or its mesodermally derived coverings accounts for the varied malformations collectively referred to as **dysraphic states**. Expressions of craniospinal dysraphism range from trivial skeletal abnormalities that pass undetected through life to lethal anomalies of the nervous system proper that result in intrauterine fetal demise. Considered here are those representatives of this complex group most likely to be approached by the neurosurgeon.

The large majority of dysraphic malformations occur along the spinal axis, where they are chiefly localized, although by no means restricted, to the lumbosacral region.[1,2] The minimal lesion—simple agenesis of the posterior vertebral arches—ranks among the most prevalent of congenital anomalies and is termed **spina bifida occulta**. Its presence may be suggested in otherwise asymptomatic cases by the finding of an overlying skin dimple or sinus tract, hyperpigmented patch, hairy tuft, angioma, or lipoma. **Spina bifida cystica** or **aperta** refers to the less common situation in which meningeal or neural tissues protrude through an osseous defect. The resulting lesion, generically designated a "**cystocele**," typically bulges from the posterior midline in saccular fashion and is subclassified according to the nature of its herniated elements, the major variants being **meningocele** and **myelomeningocele**. The latter, by definition, contains elements derived from the spinal cord, as well as its ensheathing meninges, and accounts for 80%–90% of cases. Cystoceles may also present as ventrally positioned, pelvic, or laterally situated paravertebral masses. The former are associated with sacral defects, the latter with hemivertebrae. It should be noted, however, that most "lateral meningoceles" are not true dysraphic lesions; instead, they represent arachnoidal diverticula that exit the spinal canal via widened neural foramina. These are most common at thoracic levels and are often encountered in the setting of type 1 neurofibromatosis (NF1). Rarely, meningomyeloceles present as finger- or tail-like appendages in the lumbosacral region.[3,4]

The resected **meningocele** is a discoid mass covered on its external aspect by skin that may be attenuated but that is not usually ulcerated or otherwise disrupted. A narrow pedicle representing the cystocele's attachment to the spinal canal may hang from its smooth, membranous inner surface. The sac proper is composed of collagenous tissue containing meningothelial cells disposed along irregular clefts, around alveolar spaces, in nests and long cords. Distinct dural and arachnoid membranes are not formed. Some examples are associated with tumorous accumulations of mature adipose tissue ("**lipomeningocele**"), and the sac wall may also exhibit a disorganized proliferation of nerve twigs, smooth muscle bundles, and blood vessels. Displaced but otherwise normal spinal nerve roots may lie within the meningocele cavity but can often be successfully repositioned and thus do not usually appear in surgical specimens. The finding of neuroglial tissue in any form converts the diagnosis to **myelomeningocele**. This ranges from microscopic nests of glia embedded in the cystocele wall to recognizable, albeit deformed, spinal cord. Variants include the **lipomeningomyelocele** (which may contain, in addition to mature adipose tissue, skeletal muscle and nephrogenic tissue rests[5]) and the **syringomyelocele** (or **myelocystocele**), the latter characterized by gross distension of its included spinal cord's central canal. Rarely, meningomyeloceles are encountered together with intraspinal cysts lined by enteric epithelium—the so-called **split notochord syndrome**[6]—or complex teratomatous masses regarded by some as bona fide germinal neoplasms and by others as dysembryogenic growths.[7] In any of these guises, the myelomeningocele is often covered by little more than a translucent

For personal use only. No other uses without permission. Copyright ©2017. Elsevier Inc. All rights reserved.

membrane that represents atretic skin and may include plaques of ependymoglial tissue. This is prone to ulceration, and predisposes to bacterial CSF invasion with ascending meningoventricular infection.

The outcome for infants afflicted by spina bifida cystica depends on the size and complexity of the malformation, particularly on the extent to which spinal cord elements participate in its genesis, and is frequently influenced by the presence of associated anomalies involving the spinal cord rostral to the cystocele, the cranium, and brain. Simple meningoceles are often associated with no neurologic impairment or only mild paraparesis; they are generally closed without incident and only exceptionally prove fatal. Unfortunately, the far more common meningomyelocele is usually complicated by significant and irreversible loss of lower extremity and bladder function. Furthermore, nearly all affected children also suffer an associated Arnold–Chiari malformation with hydrocephalus, the main structural features of this second anomaly being caudal displacement of the medulla and cerebellar vermis, kinking of the cervicomedullary junction, widening and shallowing of the posterior fossa, and, in many instances, deformation of the midbrain with aqueductal stenosis. Untreated, few survive childhood and even with aggressive surgical intervention the risk of death is considerable. The leading immediate causes of mortality are meningitis, pyelonephritis, pneumonia, and progressive hydrocephalus. Rarely, squamous carcinomas arise from the chronically irritated epidermis overlying unattended cystoceles.[8]

To the externally evident malformations just described should be added various intraspinal and juxtaspinal anomalies, often referred to as occult or "closed" dysraphisms, which are often imperceptible on physical examination because of their deep location. These, too, exhibit a predilection for the lumbosacral region, where they are typically discovered on neuroradiological evaluation for myelopathy. It is fixation of the filum terminale or spinal roots to these abnormal structures, with resulting traction on the cord (as evidenced by displacement of the conus medullaris below the level of the L2 vertebral body), that is often responsible for their principal neurologic manifestations—disturbed gait, bladder spasticity or hypotonia, and anococcygeal and perineal pain. Maldevelopmental lesions that may present as this "**tethered cord" syndrome** include intraspinal **lipomas**; **dermoid**, **epidermoid**, or **hindgut cysts**; **intrasacral meningeal diverticula** ("**occult meningoceles**"); and cystic intradural masses composed of neuroglial tissue ("**occult myelomeningoceles**"). The dividing collagenous or chondro-osseous septum characteristically present in cases of congenitally split spinal cord (**diastematomyelia**) is yet another potentially tethering anomaly, whereas the offending lesion in some instances is simply a short filum (typically thickened owing to fatty infiltration) or a fibrous band extending into the exposed spinal canal from the sacral subcutis. The latter is often associated with a telltale skin dimple or dermal sinus, can contain ciliated glandular elements as well as components of dermoid or epidermoid cyst, may include CNS tissue, peripheral nerve, ganglion cells, fat and muscle, and rarely exhibits a hamartomatous proliferation of included pacinian corpuscles.[2,9] Sizable **thoracolumbar hamartomas** that may contain nerves, adipose tissue, muscle, cartilage, bone, glandular structures, and primitive urinary tract-type tissues have also been described involving the spinal canal and exerting traction on the spinal cord,[10] as have developmental lesions of müllerian derivation. Fortunately, many of these associated malformations are amenable to surgical correction, and division of the immobilized filum frequently results in substantial neurologic improvement and relief of pain.

A distant second in incidence to the dysraphic cystoceles of the lumbosacral region are those involving the cranium.[1] These, too, hug the midline and, like their spinal counterparts, may contain meningeal derivatives alone or associated neural tissues. The latter, termed **encephaloceles**, vastly predominate. Approximately 80% of encephaloceles exit the cranial cavity in the region of the occiput via defects in the posterior wall of the foramen magnum or occipital bone. These are generally covered by intact scalp, subjacent to which are recognizable dural and leptomeningeal membranes, and may contain choroid plexus, cerebellar, and brainstem elements, in addition to substantial volumes of cerebral hemispheric tissue (Fig. 43.1). The extruded brain, which encloses a central CSF-filled chamber that may communicate freely with the ventricular system, can appear remarkably well formed but commonly exhibits microscopic abnormalities of cortical architecture, if not grossly anomalous gyration, and its covering leptomeninges frequently contain islands of heterotopic neuroglial tissue. Vascular compression at the level of the encephalocele's narrow intraosseous neck may result in secondary alterations such as hemorrhage and infarction. Excision and closure can often be performed without complication, but a regrettably large percentage of occipital encephaloceles are attended by malformations of the intracranial contents, microcephaly, and mental retardation.

Extraoccipital encephaloceles may protrude through defects in other portions of the cranial vault or bulge into the anterior or posterior fontanels but are more commonly of the sincipital or basilar types. Sincipital encephaloceles present as visible facial

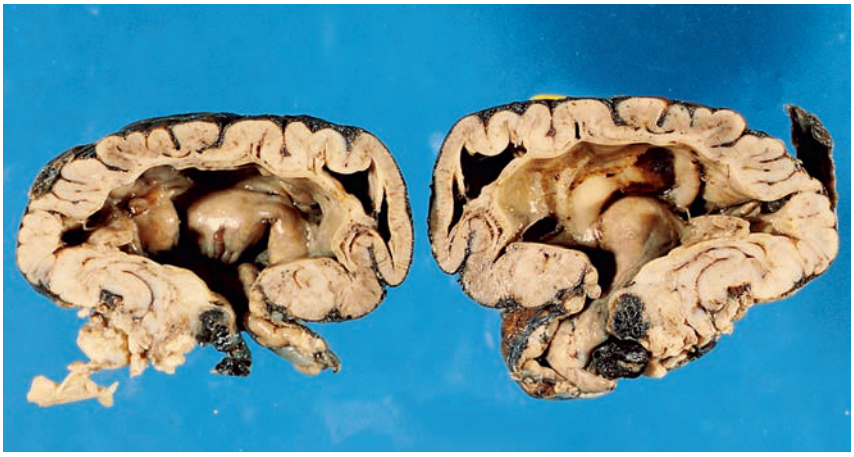

Figure 43.1 Encephalocele. A well-developed, gyriform cortical mantle characterizes this neurosurgical specimen from the occipital region of a newborn. (Courtesy of Dr. Humberto Cravioto, New York.)

For personal use only. No other uses without permission. Copyright ©2017. Elsevier Inc. All rights reserved.

swellings in the region of the forehead, nasal bridge, or orbit, whereas basal variants are situated in the nasal cavity, sphenoid sinus, nasopharynx, or pterygopalatine fossa and therefore are not externally evident. The latter includes transethmoidal encephaloceles that herniate through defects in the cribriform plate and constitute the most common polypoid intranasal masses encountered in the newborn. Prior to biopsy or resection, a congenital subcutaneous or submucosal mass in any of these locations must be carefully evaluated for an intracranial connection. Inasmuch as the encephalocele communicates with the subarachnoid space via its associated osseous defect, intracranial repair with dural closure is required if CSF leakage and meningitis are to be avoided. By contrast, simple neuroglial heterotopias occurring in these same regions (see later) have no intracranial connection and thus may be safely excised transnasally or transorally, depending on their precise situation. Both the heterotopia and true encephalocele often consist solely of aggregated astroglia embedded in fibrous tissue, though either may contain admixed neurons. Heterotopias of the nasal region rarely if ever harbor ependymal elements, a feature of some encephaloceles, but these may be encountered in examples situated in other sincipital or basilar locations. Included meninges are an inconstant feature of specimens derived from extraoccipital encephaloceles but, when identified, exclude heterotopia from further consideration.

Lastly, it should be noted that meningoceles and encephaloceles may also be acquired secondary to trauma or preceding neurosurgical procedures. "Endaural" examples may complicate chronic otitis media or mastoiditis and have been described as a late effect of cranial irradiation in childhood.[11]

Neuroglial and Meningeal Heterotopias

The **neuroglial heterotopia**, introduced in the preceding discussion of cranial dysraphism, is a surgically curable displaced mass of mature central neuroepithelial tissue unconnected to the brain proper. Paracerebral masses of this type only rarely achieve symptomatic size.[12] More common are small leptomeningeal examples that constitute occasional incidental findings on post mortem examination and that are frequently noted in association with major structural anomalies of the underlying nervous system (e.g. craniospinal cystoceles).[1,13] Usually, these are of little clinical import save for their rare roles in epilepsy and as potential progenitors of primary leptomeningeal glial or glioneuronal neoplasms. The heterotopias most likely to engage the surgical pathologist frequent the same locations favored by sincipital and basal encephaloceles—the bridge of the nose and nasal cavity, paranasal sinuses, palatal region, and nasopharynx—and are best regarded as "sequestered" variants of their dysraphic counterparts.[14,15] By far the most common of these maldevelopmental lesions, which have also been termed **glial choristomas**, is the so-called **nasal glioma**, an unfortunately confusing misnomer (Fig. 43.2). Neuroglial heterotopias may also present in the cranial bones, scalp, orbit, and submandibular region. Their structure varies, but most consist solely of solid glial nests embedded in fibrous tissue, and only about 10% contain neurons. Astrocytes usually predominate and are often the only neuroepithelial element present in nasal examples. Pharyngeal lesions are typically more complex, often containing ependyma-lined clefts and choroid plexus–like formations. Pigmented neuroepithelial structures suggesting retinal differentiation may also be rarely encountered. Heterotopias composed of cerebellar tissue have been reported in the anterior cranial fossa and orbit, among other unusual sites.[16]

The neuroglial nature of the lesions under discussion is usually obvious in routinely prepared histologic sections but may be confirmed in questionable cases by glial fibrillary acidic protein (GFAP) immunohistochemistry. The distinction of these rests from

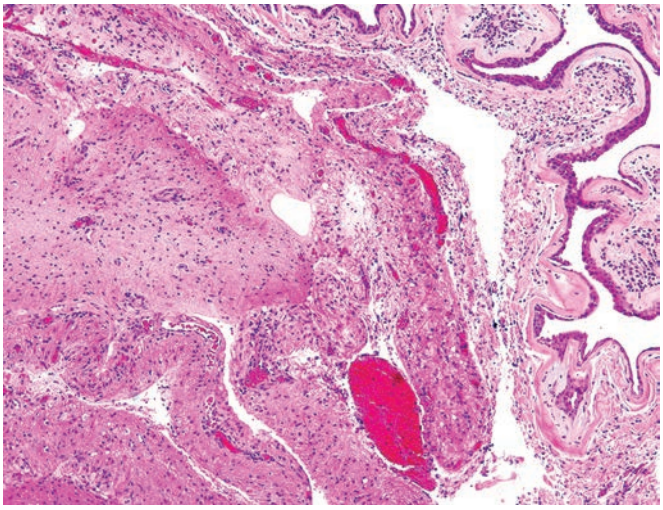

Figure 43.2 Nasal neuroglial heterotopia with fibrillar glial nests *(left)* underlying sinonasal mucosa *(right)*.

encephaloceles, a matter of considerable clinical significance, is addressed earlier. It should be noted that neuroglial heterotopias occasionally exhibit worrisome cytologic abnormalities and troubling hypercellularity, but this is without clinical significance. Rare heterotopias interpreted as having undergone focal neoplastic transformation have been reported, including an oligodendroglioma,[17] an oligoastrocytoma,[18] and a melanotic neuroectodermal tumor of infancy.[19] A probable instance of frontal lobe astrocytoma penetrating the cribriform plate to masquerade as a nasal glial heterotopia has also been described.[20]

In contrast to some sincipital and basal encephaloceles, neuroglial heterotopias do not contain meningeal elements. Displaced meningothelium, however, may be encountered in curious lesions of the scalp variously interpreted as hamartomas or as meningeal dysraphias that have lost their connection to the intracranial compartment in the course of development ("**sequestered meningoceles**").[21] These extracranial meningeal heterotopias are often noted at birth but may not come to surgical attention until adulthood. They are situated most often in the dermis or subcutis of the midline occipital region, at the vertex, in the posterior fontanel, or overlying the lambdoid suture. Regional alopecia is a common associated finding. The lesion consists of collagenous tissue containing irregular slit-like spaces lined by flattened meningothelial cells. These may also form solid cords or, rarely, small nests. Extracranial meningeal heterotopias may be misconstrued as melanocytic lesions, lymphangiomas, or even angiosarcomas[22] but can be distinguished in problematic cases by their immunoreactivity to epithelial membrane antigen (EMA). These maldevelopmental lesions could theoretically serve as precursors to the rare bona fide meningiomas arising in the scalp. Sacrococcygeal myxopapillary ependymal rests and their possible relationship to extramedullary ependymomas are discussed later in the section on ependymal neoplasms.

Choristomas and Hamartomas

Maldevelopmental rests composed of tissues foreign to the nervous system—"choristomas"—are only rarely encountered within the confines of the dura mater (and hardly ever involve the brain proper). An exception to this is the unusual lesion described as **complex choristoma of the gyrus rectus**.[23] Embedded in a gliotic matrix and containing, in addition to mature adipose tissue, benign adenosquamous epithelial components supported by myoepithelium and

For personal use only. No other uses without permission. Copyright ©2017. Elsevier Inc. All rights reserved.

arranged in nests, cords, or tubuloductal structures, this has been likened to the solid cell nests of the thyroid gland and cystic tumor of the atrioventricular node as sharing morphologic features and a potential derivation from neural crest progenitors. We have previously mentioned thoracolumbar hamartomas composed of various mesenchymal and epithelial components in the setting of spinal dysraphism, and note that comparable lesions have rarely been identified as intramedullary growths unaccompanied by dysraphic abnormalities.[24] **Ecchordosis physaliphora** is the term used to describe an intracranial or spinal intradural heterotopia exhibiting the histologic and ultrastructural features characteristic of notochord and its neoplastic counterpart, the chordoma.[25] Ecchordoses are most commonly situated just ventral to the pons, are frequently connected to notochordal remnants in the adjacent clivus via attenuated transdural stalks, and usually take the form of bosselated, gelatinous nodules loosely adherent to the basilar artery. They generally measure no more than 1–2 cm in greatest dimension and, for the most part, are autopsy curiosities. Whether larger, symptomatic examples are best regarded as "giant" ecchordoses or as bona fide intradural chordomas is questionable (see subsequent section on chordoma). Neuroradiologically detected ecchordoses have been described as generally T2 hyperintense and nonenhancing on magnetic resonance imaging (MRI), while chordomas usually exhibit contrast enhancement.[26] **Leptomeningeal rhabdomyomatosis** refers to microscopic aggregates of mature striated myofibers characteristically located in the prepontine region or cerebellopontine angles.[27] These may, in addition, harbor well-differentiated adipocytes, displaced neuroglial tissue, and aberrant peripheral nerve fibers, usually detected in complex with major developmental anomalies of the CNS. Rarely, nodules composed of striated or smooth muscle are encountered in cranial nerve divisions.[28,29] These may contain admixed neuromatous elements and adipose tissue and can achieve considerable size; they have been variously reported as **choristomas**, **neuromuscular** or **ectomesenchymal hamartomas**, **benign triton tumors**, and **rhabdomyomas** (Fig. 43.3), often manifesting with a refractory postoperative fibromatosis and therefore warranting limited surgery when suspected clinically or intraoperatively.[29] Also on record are several **müllerian choristomas of the lumbosacral region** associated with spinal dysraphism, potentially containing endometrium, endocervical glands, and smooth muscle bundles organized in uterus-like fashion.[30] There are also isolated reports of **intracerebral**[31] and **intraspinal**[32] **endometriosis**, although these are properly regarded as acquired, rather than developmental, lesions. Finally, there are the bizarre accounts of a minute adenoid cystic carcinoma arising in a cerebellopontine angle mass otherwise composed of mature salivary gland tissue,[33] and a second salivary heterotopia, also in the cerebellopontine angle, associated with a solitary fibrous tumor (SFT).[34]

Meningioangiomatosis is the designation traditionally applied to what has long been regarded as a hamartomatous or malformative process that usually occurs in sporadic fashion but may be associated with type 2 neurofibromatosis (NF2) as well.[35,36] Sporadic cases are nearly always solitary and present with seizures, whereas NF2-related examples are not infrequently multifocal and typically asymptomatic. The basic lesion (Fig. 43.4) is an en plaque proliferation of small blood vessels that dissects the cerebral cortex, halts abruptly at the gray–white junction, and is often accompanied by a spindle cell proliferation that may be tightly vasocentric or, in exuberantly cellular variants, arrayed in fascicular or storiform patterns. Loose whorling and schwannoma-like nuclear palisading may also be encountered. Extensive psammomatous calcification is common, as is vascular hyalinization and regions of fibrous tissue overgrowth. A curious feature of the lesion is the tendency of entrapped neurons to develop neurodegenerative neurofibrillary tangles.[35] Subcortical presentations are rare. The term meningioangiomatosis notwithstanding, participating spindle cell populations have exhibited a meningothelial immunophenotype (specifically, labeling for EMA) or ultrastructure (e.g. interdigitating cell processes with attaching desmosomes) in only a small minority of cases; they are consistently reactive for vimentin alone, being interpreted as predominantly fibroblastic by some observers.[37]

Meningiomas have been described as occasionally taking root within foci of meningioangiomatosis, but the interpretation of such accounts has been called into question. An analysis of candidate cases for genetic abnormalities commonly associated with meningothelial tumorigenesis found that regions of apparent "meningioangiomatosis" almost invariably shared with their neighboring meningiomas identical patterns of *NF2* and *DAL1* gene deletions,[35] but such deletions (one reported example excepted[38]) are not found in uncomplicated meningioangiomatosis. This would suggest that certain meningiomas spread along the cortical microvasculature in a meningioangiomatosis-like fashion. We have encountered rare

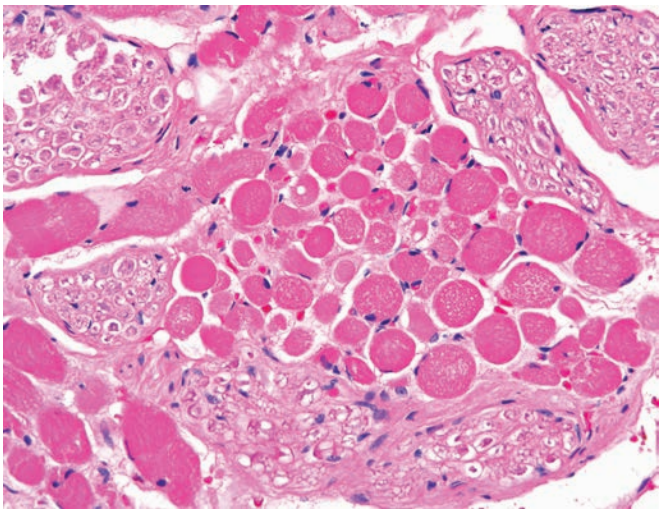

Figure 43.3 Neuromuscular choristoma composed of mixed fascicles containing peripheral nerve and skeletal muscle.

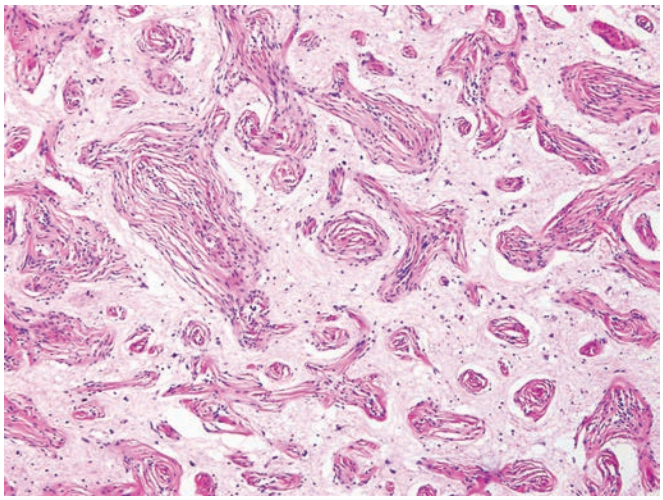

Figure 43.4 Meningioangiomatosis. This typical example exhibits dissection of the cerebral cortex by small blood vessels with accompanying perivascular spindle cells and occasional whorls.

For personal use only. No other uses without permission. Copyright ©2017. Elsevier Inc. All rights reserved.

examples of meningeal SFT/hemangiopericytoma (HPC), other meningeal sarcomas, and other primary and secondary meningeal neoplasms in association with a meningioangiomatosis-like pattern of spread as well.[39] We have also seen vascular lesions indistinguishable from meningioangiomatosis develop within irradiated cerebral cortex. Unusually cellular meningioangiomatoses may also be mistaken for bona fide neoplasms. Simple excision is the treatment of choice, but does not guarantee seizure control since patients with meningioangiomatosis may have complex electroencephalographic abnormalities indicative of multifocal, extralesional epileptogenic pathology.[37]

Cysts of the Central Neuraxis

Considered in this section are various non-neoplastic, developmental, or secondarily acquired lesions, only some of which qualify as "true" (i.e. epithelium-lined) cysts. Chief among the latter are the **colloid cysts of the anterosuperior third ventricle**.[40] These generally present in the third through fifth decades of life with manifestations of ventricular outflow obstruction, a consequence of their intimate relation to the foramen of Monro (Fig. 43.5). Thin-walled and often draped by adherent choroid plexus, colloid cysts are filled with a viscous, mucoid material that rapidly congeals on fixation. Their lining epithelium is prone to a low cuboidal attenuation resulting from pressure exerted by the cyst contents, but when well preserved is found to be of columnar respiratory type and is frequently populated by ciliated and goblet cell elements (Fig. 43.6). Only a basement membrane, inapparent at the light microscopic level, separates these from a delicate, fibrous capsule. The dense proteinaceous cyst contents, which often resemble the colloid of the thyroid, are periodic acid–Schiff (PAS) positive and may include hyphae-like aggregates of degenerate nucleoproteins. An inflammatory reaction to the contents of ruptured colloid cysts is responsible for most, if not all, cases of so-called xanthogranuloma situated in the third ventricle.[41]

Ultrastructural[42] and immunocytochemical[43] investigations of the colloid cyst (as well as Rathke cleft and neuroenteric cysts) support an origin from misplaced endodermal tissues. Its constituent epithelial cell types correspond closely to those typical of respiratory mucosae, sporting an apical glycocalyx coating, and express cytokeratins, EMA, and carcinoembryonic antigen (CEA) but not GFAP or the choroid plexus-associated transthyretin (prealbumin). Their occasional designation as "neuroepithelial" notwithstanding, similar histogenetic considerations apply to rare **endodermal-type cysts** of comparable structure situated within the posterior fossa, supratentorial compartment, optic nerve, and, as discussed later, the spinal canal.[44-48] Adenocarcinomatous transformation of such cysts has rarely been recorded in some of these, as has widespread craniospinal dissemination of histologically benign appearing endodermal-type cysts via the CSF.[46,49] Although also discussed in the context of pituitary disorders (see Chapter 44), the **Rathke cleft cyst**, a lesion having its origin in remnants of the stomodeum, is briefly noted here for the striking resemblance of its lining epithelium to that of the colloid cyst. Curiously, however, the latter rarely contains the metaplastic squamous elements common to Rathke cleft cysts and other cystic intracranial lesions putatively of endodermal lineage.

Intraspinal cysts resulting, in all likelihood, from the incomplete separation of developing endodermal and notochordal tissues in early embryonic life, have been variously designated as "**neurenteric**," "**foregut**," "**enterogenous**," and "**teratomatous**."[46] These intradural endodermal-type cysts are typically situated anterior to the spinal cord, are often associated with local vertebral abnormalities, and may be encountered with other developmental anomalies such as intestinal malformations and dermal sinuses. An intramedullary presentation is well recognized but far less frequently encountered.[50] Most examples exhibit a simple mural structure and columnar epithelial lining similar to that of the colloid cyst, but occasional variants contain specialized respiratory or gastroenteric-type "mucosa"

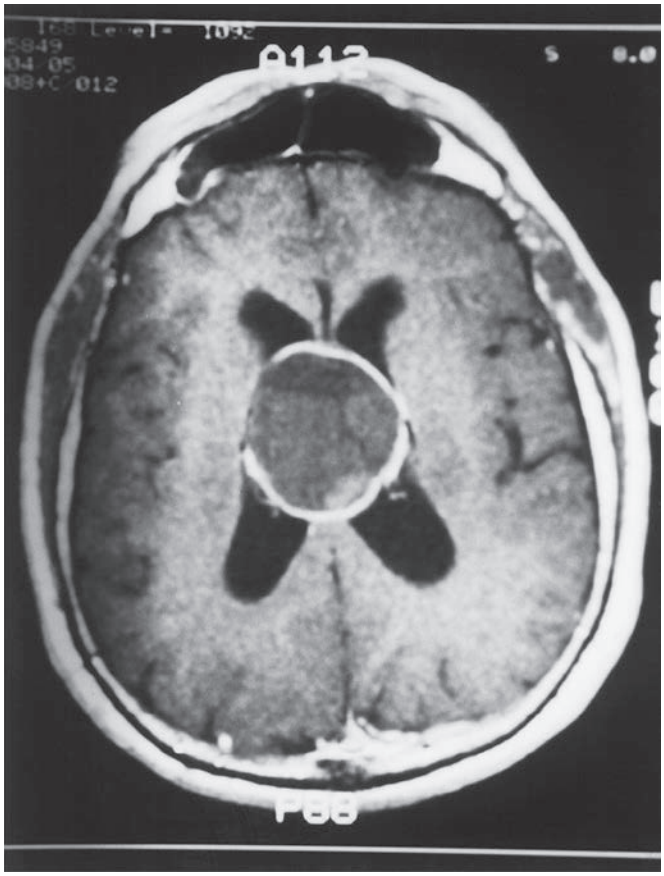

Figure 43.5 Colloid Cyst. The obstructive ventricular dilation (hydrocephalus) associated with this large example is characteristic of these lesions. Note the well-delineated cyst wall, which is bright in this contrast-enhanced magnetic resonance image.

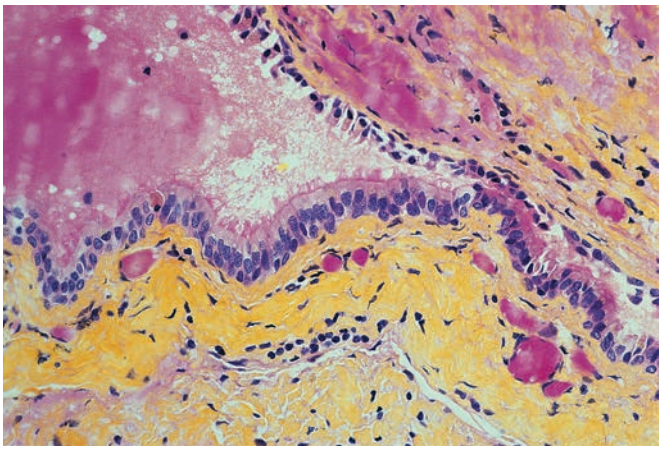

Figure 43.6 Colloid Cyst. A pseudostratified and ciliated columnar epithelium lines well-preserved colloid cysts. Note the supporting collagenous tissue of the cyst wall, *yellow* in this hematoxylin–phloxine–safranin preparation.

For personal use only. No other uses without permission. Copyright ©2017. Elsevier Inc. All rights reserved.

and the organized supporting elements (e.g. seromucinous glands, muscularis, cartilaginous rings, ganglion cells) of the developed alimentary tract or tracheobronchial tree.[51]

Two major variants of ectodermally derived neuraxis cyst are recognized, both lined by keratinizing squamous epithelium.[52] The **epidermoid cyst**, by definition, is devoid of cutaneous-type adnexal structures and filled by friable, often lamellated keratinous debris that radiates a pearly sheen as viewed through the thin, fibrous lesional capsule. **Dermoid cysts**, by contrast, include skin appendages, such as pilosebaceous units, eccrine and, occasionally, apocrine glands, as well as mural adipose tissue foreign to the epidermoid type. They may contain a greasy, yellowish-gray material admixed with hairs or just friable, keratin-rich debris similar to that of their epidermoid counterparts. Cysts of both types are, for the most part, developmental, presumably arising from surface ectodermal elements trapped in association with the developing CNS on closure of the neural groove or formation of the secondary cerebral vesicles. The occurrence of some examples, particularly dermoids, in complex with craniovertebral anomalies (e.g. spina bifida), malformations of the spinal cord, and dermal sinuses attests to their malformative nature. Acquired variants are well recognized; however, most of them are epidermoid and resulting from the traumatic[53] or iatrogenic[54] implantation of cutaneous tissues in the cranial or spinal subdural space.

Epidermoid and dermoid cysts are characterized by distinctive clinical as well as histologic features.[52] The former affect subjects of all ages, most coming to attention in young adulthood or middle age, whereas the latter usually present in childhood or adolescence. Epidermoid cysts are widely distributed, but the great majority are positioned intracranially, most commonly at the cerebellopontine angle. Rarely, posterior fossa examples conspicuously erode into, or lie embedded within, the cerebellum or brainstem. Supratentorial representatives exhibit a predilection for the parasellar region but may also be situated within the ventricular system, in the cerebral hemispheres, and in the suprasellar or pineal regions. Intraspinal epidermoid cysts are typically intradural and extramedullary but may on rare occasion lie entirely within the spinal cord.

Compared with its epidermoid counterpart, the dermoid cyst clings tightly to the midline. It, too, favors the posterior fossa but in this location characteristically occupies the cerebellar vermis or fourth ventricle. When situated above the tentorium, the dermoid cyst tends to a frontal, paramedian position on the skull base. An infantile, subgaleal variant typically resides in the anterior fontanel. Although generally outnumbered by epidermoid cysts, dermoids actually predominate at spinal levels. These exhibit a decided predilection for the lumbosacral region, where they constitute a manifestation of spinal dysraphism.

Although the clinical manifestations of dermoid and epidermoid cysts are principally referable to their local mass effects, either may present with signs and symptoms of "chemical" or infectious meningitis. The former results from cyst rupture and the spillage of irritating keratinous and lipid-rich debris into the ventricular system and subarachnoid space.[55] Repeated episodes of bacterial meningitis are a recognized complication of cysts associated with dermal sinuses offering access to the nervous system. Patients harboring posterior fossa dermoids and occipital sinuses may also suffer cerebellar abscesses. Neoplastic transformation is a well-documented but fortunately rare occurrence. In most cases, the underlying lesion is a cyst of epidermoid type and the secondary cancer a squamous carcinoma.[56] The bizarre phenomenon of an osteogenic sarcoma arising in association with a cerebellar epidermoid cyst has been recorded.[57] A temporal lobe example containing islands of keratinized, anucleate-appearing ("shadow") cells similar to those seen in pilomatricomas has been described.[58] Even histologically conventional cysts can recur following incomplete resection of their walls. Spontaneous seeding of the CSF by apparently benign epidermoid cysts with development of intraventricular or subarachnoid "daughter" lesions is a recorded curiosity.[59]

Inasmuch as epidermoid cysts may arise, albeit rarely, in the suprasellar region, their differential diagnosis includes Rathke cleft cysts with extensive squamous metaplasia and craniopharyngiomas. The former will usually harbor scattered mucicarminophilic goblet cells atop their squamous elements and do not feature the advanced keratinization typical of the epidermoid cyst. The formation of cytoplasmic keratohyaline granules, typical of the epidermoid cyst's maturing squames, is generally foreign to craniopharyngiomas. Furthermore, epidermoid and Rathke cleft cysts lack the latter's islands of "ghost cell" keratinocytes and its "machinery oil"-like contents and do not exhibit the basaloid elements and stellate reticulum of the adamantinomatous craniopharyngioma or the filiform architecture of its papillary variant. As regards further distinction of Rathke cleft cysts from craniopharyngiomas, one study of a limited number of cases found immunolabeling for BRAF V600E mutant protein in papillary craniopharyngioma, but not in Rathke cleft cyst with squamous metaplasia.[60] Cystic craniopharyngiomas of adamantinomatous type, in addition, often manifest foci of aberrant nuclear β-catenin immunoexpression that are not encountered in metaplastic Rathke cleft cysts.[61] The exceptional dermoid cyst presenting in the pineal or suprasellar region should be distinguishable from the mature cystic teratoma by its lack of glandular components (indicative of endodermal differentiation), muscle, or cartilage.

Glioependymal cysts are most commonly situated in the paraventricular white matter of the frontal and parietal lobes but may also lie within the cerebellum, brainstem, or spinal cord.[62-64] A derivation from developmentally displaced ventricular lining seems to explain the majority, while rare cerebellopontine angle and other extra-axial examples conceivably originate from subarachnoid neuroglial heterotopias.[65] Intramedullary glioependymal cysts often involve the conus medullaris, where they may actually represent cystic dilations of the ependyma-lined ventriculus terminalis.[66] As their name implies, they are lined by cells resembling mature ependyma. Like the cells of the more common endodermal type cysts, these may be ciliated but differ in that they do not exhibit goblet cell differentiation, are not coated by an apical glycocalyx, and do not rest on a basal lamina, being directly apposed to fibrillary neuroglial tissue. Representatives presenting in the subarachnoid space may, however, contain "supporting" astrocytic elements that fashion a continuous basement membrane separating them from a delicate fibrous capsule, reminiscent of the normal glia limitans.

The limited immunocytochemical studies reported to date suggest that the lining cells can express GFAP, S-100 protein, and rarely cytokeratin.[67,68] Failure to elaborate CEA or transthyretin (prealbumin) may serve to distinguish these lesions from endodermal or choroid plexus cysts, respectively. By definition, **choroid plexus cysts** are lined by cells with all the microscopic attributes of choroid plexus epithelium.[69]

Rarely, intraparenchymal brain cysts exhibit no specialized lining elements and are not associated with historical or tissue evidence of underlying trauma, hemorrhage, infarction, neoplasia, demyelinating disease, or infection that might account for their genesis. Most numerous are examples termed "**simple**" or "**gliotic**" **cysts**, presenting in the cerebellar hemispheric white matter of middle-aged or elderly adults.[70] That at least some of these clinically benign lesions are not congenital anomalies but represent instead "burnt-out" pilocytic astrocytomas has been suggested in view of the latter tumor's tendency to macrocystic alterations and the presence of a dense mesh of glial processes rich in Rosenthal fibers and scattered atypical astrocytes around many simple cerebellar cysts. Inasmuch as the neoplastic

For personal use only. No other uses without permission. Copyright ©2017. Elsevier Inc. All rights reserved.

components of cerebellar cysts associated with pilocytic astrocytomas and hemangioblastomas may be confined to diminutive mural nodules, careful inspection of cystic lesions in this location is mandatory and biopsy of various portions of their linings is prudent. Exceptional cysts arising outside the cerebellum are lined only by normal or mildly reactive neuroglial tissue, are juxtaventricular in location, and contain a fluid similar in its composition to CSF.[71] These likely derive from ventricular diverticula or represent collections of CSF that have dissected into the neuropil via congenital or acquired breaches in the ependyma. Lesions of macrocystic neuroradiological profile that similarly lack specialized lining elements have been reported to result from marked dilation of perivascular spaces, particularly in the cerebral hemispheric white matter.[72] It is the demonstration of traversing blood vessels that has been taken for evidence of the continuity of these pseudocysts, which are otherwise bordered by rarefied and gliotic neuroparenchyma, with the perivascular compartment.

Particularly prone to cystic change is the normal human pineal gland, but only rarely does this alteration result in a lesion of symptomatic proportions.[73] **Pineal cysts** that come to neurosurgical attention generally do so in the third through fifth decades of life, their presenting manifestations being indistinguishable from those of pineal neoplasms, including obstructive hydrocephalus and disturbances of ocular motility. Like the cerebellar lesions previously described, these are lined by a dense zone of piloid gliosis, rich in Rosenthal fibers and granular bodies but not exhibiting the loose microcystic component or degree of cellularity more typical of pilocytic astrocytomas. A second differential diagnostic consideration is the pineocytoma, as the cysts under discussion regularly contain elements of residual pineal parenchyma within their walls. These usually retain the organoid appearances typical of the normal gland, but in some cases their uniform, telltale lobularity is obscured as a result of longstanding compression. Appreciation of a given lesion's neuroradiological features and appearance at surgery is quite helpful in this regard, as pineocytomas are nearly always solid rather than cystic. Simple excision is curative.

Loculated accumulations of CSF enclosed by fibroconnective tissues derived from the leptomeninges are referred to as **arachnoid cysts**.[74] Etiologically diverse, some arachnoid cysts develop as sequelae of meningitis or trauma and are circumscribed by adhesions traversing the subarachnoid space. Most, however, are considered to begin as maldevelopmental clefts in the arachnoid membrane that subsequently undergo cystic dilation. Lesions of this type are lined by an attenuated meningothelium resting on a layer of supporting fibrous tissue that is macroscopically so thin as to be transparent. These most commonly occupy the Sylvian fissures, followed by the cisterna magna and cerebellopontine angles, but may occur in the suprasellar region and along the spinal neuraxis.[75] Intradiploic[76] and intramedullary[75] presentations have also been recorded. By virtue of their very gradual inflation, such lesions may produce striking deformities in neighboring neural tissues that are often unaccompanied by mass effects such as midline shifts or cerebral herniations. **Dural cysts** (cystically dilated intradural clefts) are rare and described mainly as intraspinal causes of myelopathy.[77] Comparable intracranial lesions have been reported to produce sagittal sinus occlusions.[78]

Most arachnoid "cysts" presenting at spinal levels are actually meningeal diverticula that can be shown to communicate with the subarachnoid space.[79] These may lie within or outside the dural sleeve, are potentially multifocal, and can be lined by meningothelial cells or composed solely of membranous fibrous tissue. Only a minority achieve symptomatic proportions, producing myelopathy or radicular syndromes, at times associated with erosion of adjacent vertebral bodies or the sacrum. Extradural variants arising in association with the posterior spinal roots, typically at lumbosacral levels, are often eponymously designated as **Tarlov perineurial cysts**.[80] Only exceptionally do these prompt neurosurgical intervention by causing perineal pain, sciatica, or bladder or bowel dysfunction. Rarely, cystically dilated or otherwise enlarged arachnoid granulations masquerade as dermoid (or other true) cysts or produce sizable lytic skull defects that arouse suspicion of neoplastic disease.[81]

Yet another cystic lesion that may impinge on the spinal neuraxis is the **juxtafacet** or "**ganglion**" **cyst**, a collection of acellular and often myxoid material bound within a fibrous capsule devoid of specialized lining elements.[82] The term **synovial cyst** has been employed for similar lesions interpreted as containing inflamed synovium.[83] Some examples contain metaplastic chondroid elements and foci of calcification. Cysts of comparable structure may rarely arise within the ligamentum flavum.[84] A degenerative abnormality, the juxtafacet cyst typically presents at lumbar levels in association with osteoarthritic changes of the vertebral column but may rarely occur in the cervical region. Myeloradiculopathy and bony erosion are its principal complications.

Cerebrovascular Disorders

Cerebral Infarction

Characterized by an abrupt loss of neurologic function ("stroke") referable to a circumscribed arterial territory within the affected brain, the common variety of **cerebral infarct**[1] is an ischemic lesion of later adult life confidently diagnosed at the bedside. Occasional examples, however, are silent at onset, evolve in subacute fashion as expansile intracranial "tumors" on conventional neuroradiological assessment, and are consequently sampled by the neurosurgeon. The histology of a given infarct will depend on the stage of development.[85,86] Biopsied tissues generally exhibit a spongy rarefaction reflecting the edema that is largely to blame for these lesions' associated mass effects, commonly evidence of intense vascular congestion, and may also be frankly hemorrhagic. Neurons, if recognizable, persist only in faded "ghost"-like profile or appear shrunken, angulated, and abnormally eosinophilic with a loss of intranuclear detail. Neutrophilic exudates may be apparent early on, but most lesions approached surgically have evolved to the point where mononuclear phagocytes, including lipid-laden foam cells, constitute their principal reactive elements. Organizing infarcts may feature a potentially alarming hypercellularity that is all the more misleading when accompanied, as is often the case, by capillary proliferation and endothelial hypertrophy resembling glioma-associated microvascular hyperplasia. Inasmuch as the cytologic features by which macrophages are recognized tend to be obscured in frozen sections but are immediately apparent in squash and smear preparations, routine use of the latter is recommended for intraoperative consultation. Once a lesion has been identified as being rich in phagocytes, the major differential consideration is demyelinating disease (see later). Nevertheless, demyelinating pseudotumors only exceptionally progress to tissue necrosis, are usually characterized by perivascular lymphoid cuffing and a relative preservation of axons foreign to brain infarcts, and generally afflict patients younger than those at risk for ischemic cerebral events.

Intracranial Aneurysms

The **saccular** or "**berry**" **aneurysm** ranks chief among surgically correctable cerebrovascular abnormalities and is unrivaled as a cause of massive subarachnoid hemorrhage in adults. These common lesions (prevalence of roughly 2%–6%) are somewhat more frequent in women and are encountered at all ages beyond puberty, although symptomatic examples cluster in the fifth through seventh decades

For personal use only. No other uses without permission. Copyright ©2017. Elsevier Inc. All rights reserved.

of life.[87,88] Risk factors include smoking, hypertension, increasing age, and positive family history, with mortality being as high as 50% after rupture. Some 10%–15% of cases have been estimated to occur on a familial basis. The factors critical in initiating the formation of saccular intracranial aneurysms remain undefined, and the majority are unassociated with local or systemic conditions known to promote vascular injury, but hemodynamic stress probably plays the major role in their development. On balance, the weight of evidence supports the hypothesis that these are primarily acquired, degenerative lesions rather than developmental anomalies. Arterial hypertension is widely regarded as playing an aggravating role in their evolution and may underlie an association with the adult form of aortic coarctation, type III polycystic kidney disease, and pheochromocytoma.[89,90] Connective tissue disorders that result in increased vascular fragility have mainly been associated with aneurysms of fusiform type but may also predispose to the development of saccular aneurysms, these having been described in the settings of type III collagen deficiency (Ehlers–Danlos syndrome type IV), pseudoxanthoma elasticum, and Marfan syndrome.[1,89] Aneurysms of the saccular variety occasionally occur together with fibromuscular dysplasia of the renal arteries, intracranial arteriovenous malformations (AVMs) or fistulas, and persistent primitive carotid–basilar anastomoses or other anomalies of the circle of Willis. The latter observations notwithstanding, the localization of most saccular aneurysms (discussed later) is at odds with the theory that they commonly originate in vestigial remnants of the embryonic cerebral vasculature.

Multifocal, saccular intracranial aneurysms usually lie within 3 cm of the internal carotid artery termini at the circle of Willis, and 80% involve divisions of the cerebral vasculature ventral to the posterior communicating arteries.[1] It is clear from autopsy studies that the middle cerebral arteries are most commonly affected, but most clinical series are dominated by anterior communicating and internal carotid artery examples because these are more prone to rupture.[87,91,92] That saccular aneurysms almost invariably bulge from points of acute angle vascular bifurcation has been interpreted by some observers as the natural consequence of increased hemodynamic impact or turbulence at these points and by others as reflecting an inherent vascular weakness secondary to focal gaps in the arterial media known to occur near circulatory forks.[91] Although such "defects" could theoretically influence the localization of some lesions, there actually appears to be little topographic concordance between their major distribution in the human cerebrovascular tree and that of saccular aneurysms.

On histologic examination, the walls of saccular intracranial aneurysms are composed principally of fibrous tissue, the muscular coats, and elastic laminae of parent vessels typically terminating abruptly at the points of aneurysmal outpouching. Atheromatous changes are common and may be florid but are characteristically confined to the aneurysmal sac and thus probably represent superimposed alterations of little direct etiologic significance. Much the same can be said of chronic inflammatory mural infiltration. Other secondary phenomena include partial or, in select instances, complete thrombotic occlusion, the latter presumably accounting for the occasional "disappearance" of untreated aneurysms assessed by periodic angiographic study.

Most saccular aneurysms remain asymptomatic, and even frank rupture may be followed by spontaneous thrombotic closure of the aneurysmal sac and clinical resolution, but should not trivialize the associated risk of catastrophic intracranial hemorrhage. Long-term follow-up studies of patients with angiographically proven saccular aneurysms suggest a 1%–2% annual incidence of rupture; approximately half of these bleeding episodes prove fatal.[87,88] Although subarachnoid hemorrhage alone may be lethal, dissection of blood into the brain proper or ventricular system is more often the cause of death. Massive intraparenchymal hematomas are most often a consequence of middle cerebral artery aneurysms, whereas anterior communicating examples are generally responsible for most episodes of fatal intraventricular hemorrhage (blood usually entering the anterior horn of the lateral ventricle after dissecting through the inferomedial frontal lobe). Another grave complication is cerebral infarction related to postrupture vasospasm, again encountered most commonly in aneurysms of the anterior communicating arteries.

Although most observers have concluded that considerable risk of rupture is attached to saccular aneurysms exceeding 1 cm in diameter and relatively little to examples measuring 5 mm or less,[89] none of these lesions can be regarded as entirely innocent. In fact, nearly 70% of saccular aneurysms that ruptured in the course of one long-term follow-up study measured 6 mm or less in diameter on angiographic assessment.[93] Aneurysms that achieve "giant" proportions (usually defined as having diameters of at least 3 cm) typically present with cranial neuropathies, evidence of ventricular outflow obstruction, or other mass effects, rather than hemorrhage. Rarely, the surgical management of saccular aneurysms is complicated by a local granulomatous response to cotton materials employed as reinforcement following aneurysmal clipping.[94] These "**textilomas**," "**muslinomas**," or "**gauzomas**" can achieve considerable size, presenting as contrast-enhancing masses with significant accompanying edema, and may produce headache, fever, obstructive hydrocephalus, cranial nerve palsies, and endocrinopathy. In some cases a nontumorous optochiasmatic arachnoiditis provoked by these materials causes visual loss.

Although the designation of **mycotic aneurysm** would seem to imply a fungal process, this term has been applied in practice to focal infectious arteritides of diverse cause that have in common only an element of vascular dilation. Most mycotic intracranial aneurysms are, in fact, bacterial in nature and evolve as complications of endocarditis or, less frequently, suppurative pulmonary infection.[1,95] Streptococcal and staphylococcal species are the usual offenders. The resulting lesions, often multifocal, tend to be situated on distal branches of the cerebral vasculature, are more often fusiform or irregular than berry-like in configuration, and are frequently of diminutive proportions. Fungal aneurysms are specifically addressed in the discussion of CNS mycoses. In brief, these are most often caused by *Aspergillus* and *Candida* species, generally involve the large cerebral arteries at the base of the brain, and tend to be larger at presentation than their bacterial counterparts.

Atherosclerotic intracranial aneurysms generally afflict older adults, usually arise in the setting of advanced and generalized cerebrovascular atheromatosis, typically involve supraclinoid portions of the internal carotid arteries or the basilar artery, and may assume saccular, fusiform, cylindrical, or conical configurations.[1] Fusiform lesions of the vertebrobasilar trunk are the single most common variant.[96] Atherosclerotic aneurysms are generally large, and frequently achieve giant proportions. Their presenting manifestations are more often related to compression of neighboring CNS structures or ischemic complications of progressive thrombosis than to hemorrhage, although some observers assert that the associated risk of rupture is underestimated. Far more common than discrete aneurysm formation is atherosclerotic "**dolichoectasia**"—diffuse dilation and tortuous elongation of the basilar or internal carotid arteries—and the two processes may coexist.

Dissecting aneurysms of the intracranial vasculature are rarities.[1] Most documented cases lack an etiologic explanation, although some have been attributed to trauma, syphilis, cystic medionecrosis, arteriosclerosis, fibromuscular dysplasia, or other local abnormalities of vascular structure. α1-Antitrypsin deficiency has also been linked to intracranial arteriopathy potentially complicated by dissection

For personal use only. No other uses without permission. Copyright ©2017. Elsevier Inc. All rights reserved.

or aneurysm formation.[97] Luminal stenosis secondary to the intramural accumulation of blood may result in bulbar or cerebral infarction; rupture typically produces catastrophic subarachnoid hemorrhage. Symptoms referable to mass effect constitute the least frequent manifestation of intracranial arterial dissection.

Exceptionally, tumors metastatic to the CNS present as "spontaneous" intracerebral or subarachnoid hemorrhages that ultimately prove secondary to **neoplastic aneurysm** formation. Most neoplastic intracranial aneurysms result from the embolization of cardiac myxomas to the cerebral vasculature,[98] but examples caused by choriocarcinomas and carcinomas of the lung are also on record.[99,100] The appearance of intracranial aneurysms years following therapeutic irradiation of the brain has also been documented.[101]

Considerable controversy surrounds the incidence of so-called **Charcot–Bouchard** (or "**miliary**") **microaneurysms** and their clinical significance.[1,102] The latter are described as 25–250 μ saccular or fusiform lesions most commonly involving lenticulostriate, perforating pontine, and corticomedullary junction arteries. Said to be particularly prevalent in hypertensive subjects, their rupture is regarded by some as a major cause of basal ganglionic, bulbar, and cerebellar hemorrhages. That aneurysms of Charcot–Bouchard type have received little attention in the surgical pathology literature could reflect the specialized tissue handling requisite to their identification. Studies from Japan, in which surgically evacuated hematomas were subjected to meticulous examination under the dissecting microscope (and serial thin sectioning of suspect lesions), suggest that microaneurysms are underappreciated as a factor predisposing to atraumatic lobar cerebral hemorrhage in both hypertensive and normotensive individuals.[103] Painstaking analysis in white individuals, on the other hand, has demonstrated that most "microaneurysms" actually represent complex vascular tortuosities and failed to establish a link between truly aneurysmal lesions and intracerebral hemorrhage.[104] Whether these discrepancies are simply methodologic or have their basis in genetic or environmental factors is unclear. In practice, it is virtually impossible to conclusively identify microaneurysms in routinely processed paraffin sections.

Vascular Malformations

A variety of non-neoplastic lesions resulting from focal anomalies in the development of the cerebrospinal circulation have been generically designated as vascular malformations. For practical purposes, these are divided into four relatively discrete morphologic categories, namely, capillary telangiectases, angiomas of venous or cavernous type, and AVMs.[1] Transitional or hybrid types, however, may be encountered. Also considered in this section are arteriovenous fistulas, since these are, strictly speaking, malformations, although they are generally regarded as acquired rather than developmental abnormalities.

Capillary telangiectases exhibit a curious predilection for the basis pontis (particularly the region of the median raphe) but are occasionally found to involve the cerebral hemispheres and spinal cord.[1] They usually constitute incidental findings on neuroimaging or autopsy and are only rarely complicated by symptomatic hemorrhage. On record is a massive pontomedullary case associated with a protracted history of bulbar dysfunction.[105] The lesion consists of loosely aggregated and variably ectatic capillary-type vessels (i.e. devoid of elastic or muscular mural elements) separated by normal or only mildly gliotic neuropil. A densely mineralized variant—the "**calcified telangiectatic hamartoma**" or "**hemangioma calcificans**"—is a recognized, albeit rare, cause of epilepsy, particularly of temporal lobe type.[106] Capillary telangiectases of the CNS complicate some examples of hereditary hemorrhagic telangiectasia, also known as Osler–Weber–Rendu disease.[1,107]

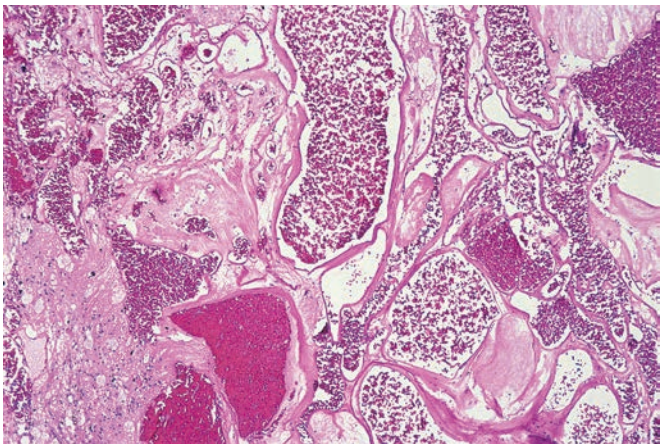

Figure 43.7 Cavernous Angioma. This cavernous angioma consists of ectatic and fibrous-walled vascular channels devoid of intervening neuroglial tissue. Neighboring brain parenchyma is present at the lower left.

The **venous angioma** is a loose collection of dilated veins typically found in the digitate or deep white matter of the cerebral or cerebellar hemispheres.[1] The radial convergence of their ectatic vessels on a central draining varix lends many of these lesions a diagnostic "caput medusae"-like profile on angiography. Although venous angiomas are the most common vascular malformations of the human CNS, it is the exceptional example that is responsible for intracranial hemorrhage or is otherwise symptomatic.[108]

The **cavernous angioma** or "**cavernoma**" differs from all other vascular malformations in that its constituent vessels are fashioned into a compact, globose mass, which is usually devoid of intervening CNS elements.[1] On gross inspection, a spongy core of blood-filled channels is encircled by a thin rind of indurated (gliotic) and rust-colored, hemosiderin-laden parenchyma. Histologic study reveals closely apposed, engorged vessels composed solely of fibrous walls (Fig. 43.7). Secondary alterations such as thrombosis and dystrophic calcification are common, with some lesions undergoing extensive metaplastic ossification as well. The existence of hybrid variants exhibiting in part the structure of capillary telangiectases has fueled speculation that cavernous angiomas may evolve from malformations of the former type,[109] but "mixed" or hybrid lesions remain exceptional. Cavernous angiomas may be situated anywhere along the neuraxis. Most examples lie above the tentorium, often in cerebral white matter subjacent to the motor strip, but the posterior fossa contents and spinal cord are not immune and even the cauda equina, cranial nerves, and epidural compartment may be involved. Multifocal cases are by no means rare. The designation of cavernous angioma has also been extended to certain extra-axial vascular malformations affecting dural venous sinuses, but these depart structurally from their counterparts positioned in the CNS proper in that they contain, in addition to compact cavernous elements, capillaries and muscular vessels of both arterial and venous type.[110] These distinctive lesions usually present as a consequence of cranial nerve compression and are generally mistaken for meningiomas on preoperative neuroimaging.

Cavernous angiomas may become manifest in childhood, but most symptomatic lesions are encountered in the third and fourth decades of life.[111] Familial cases transmitted in autosomal dominant fashion and linked to mutations of the "cerebral cavernous malformation" genes *CCM1*, *CCM2*, and *CCM3* (which are involved in integrin-mediated angiogenesis and programmed cell death) have been reported[1,112,113]; *KRIT1* abnormalities are also responsible for

For personal use only. No other uses without permission. Copyright ©2017. Elsevier Inc. All rights reserved.

an excess of cavernous angiomas among Hispanic–American kindreds of Mexican descent. Such variants may occur together with cavernous angiomas of the retina, hyperkeratotic venous malformations of the skin, vertebral hemangiomas, and café au lait spots.[114-116] The proximity of most cavernous angiomas to epileptogenic cerebrocortical tissues reflects the fact that seizures are their dominant clinical manifestation; less frequent complaints include focal neurologic deficits and headache. Although catastrophic hemorrhage is decidedly rare, cavernous angiomas are a recognized cause of intracranial hematomas, including both acutely symptomatic[117] and "encapsulated" lobar types[118]; the latter result in all likelihood from repeated subclinical episodes of bleeding and subsequent organization. A confident preoperative diagnosis of cavernous angioma may be established by neuroradiological means. The typical lesion, although "angiographically occult" (i.e. not apparent on arteriographic study), appears in T2-weighted magnetic resonance images as an irregularly hyperdense nodule unassociated with significant edema or mass effect but surrounded by a hypodense penumbra resulting from the accumulation of hemosiderin in adjoining neural tissues. Focal vascular lesions having a cavernous angioma-like neuroradiological profile may develop in the brain or spinal cord as a consequence of therapeutic CNS irradiation.[119] These seem slightly more prone to hemorrhage, develop most commonly in pediatric patients (especially when radiation is combined with methotrexate chemotherapy), and may exhibit transitional histologic features with regions of capillary and venous telangiectasis. Of note, both cavernous angiomas and AVMs (discussed later) in the CNS are likely to harbor GLUT1 immunoreactive endothelial cells; therefore, in contrast to cutaneous and soft tissue counterparts, this marker is not useful in their distinction from infantile hemangiomas.[120]

The most threatening of the congenital cerebrovascular anomalies is the **AVM**, a tangle of deformed arterial afferents and draining veins devoid of an interposed capillary bed.[1,121] AVMs may be situated in any region of the brain or spinal cord and can be restricted to the dura or choroid plexus, but most lie within the distribution of the middle cerebral arteries and involve the hemispheric convexities in contiguity with their covering leptomeninges. A majority present in early and mid-adulthood as a consequence of intracranial hemorrhage; other common manifestations include seizures, focal sensorimotor deficits, and headaches that are not clearly referable to episodes of bleeding.[122] Familial cases have been described,[123] and AVMs of the central neuraxis may be encountered in the context of Osler–Weber–Rendu disease (hereditary hemorrhagic telangiectasia).[107] The turbulent shunting of blood through AVMs of the brain is sometimes audible as a cranial or orbital bruit, can often be demonstrated on angiographic study, and may precipitate high output cardiac failure in afflicted infants and children, particularly those harboring extensive lesions drained by aneurysmally dilated galenic veins. Unfortunately, AVMs are complicated by fatal rupture with distressing frequency. Long-term observations suggest that symptomatic examples carry a 2%–4% risk of clinically significant hemorrhage per year and, if left untreated, will result in the deaths of at least one-fourth of affected patients as a direct result of rupture. The greatest risk of bleeding is associated with large size and concurrent saccular aneurysms, the latter of which may also rupture.[122]

AVMs vary in size from cryptic lesions not demonstrable by angiographic means and discovered only on sampling of surgically evacuated hematomas,[124] to enormous lobar examples that may focally span the full thickness of a cerebral hemisphere. Nevertheless, most are readily and accurately diagnosed preoperatively using modern imaging techniques.[125] Because their tortuous, cirsoid vascular components form a complex network of blood-filled channels, the nature of these lesions is often apparent on casual gross inspection. Intervening neural tissues are typically atrophic and gliotic, with evidence of rust-brown discoloration attesting to prior hemorrhage. Involved leptomeninges are thickened, opacified, and frequently siderotic as well. On histologic study (Fig. 43.8), the lesion is composed of variably ectatic and hyalinized veins, abnormally muscularized arteries, and structurally ambiguous vessels formed solely of fibrous tissue or displaying both arterial and venous characteristics.[1,121] Critical to the distinction of the true AVM from normal leptomeningeal vessels that may assume a malformative appearance in neurosurgical material as a result of artefactual compaction are the former's conspicuous mural anomalies, including striking fluctuations in medial thickness, architectural disarray or focal disappearance of the media altogether, or separation of the media into inner and outer coats by a seemingly aberrant elastic lamina. Cushions of fibromuscular tissue may also appear to project in polypoid fashion into the lumens of these abnormal vessels, and focal duplications and disruptions of the internal elastic lamina are common. Superimposed alterations include mural fibroplasia and atheromatosis, aneurysmal dilation, calcification, and thrombosis. Lesions subjected to preoperative embolization in an attempt to minimize blood loss during resection frequently exhibit an intraluminal foreign body response to the occluding material and may undergo focal necrosis,[126] whereas radiosurgical treatment causes fibrointimal hyperplasia with progressive vaso-occlusion.[127] Entrapped neuropil usually shows dense astrogliosis, neuronal depopulation, and ferruginous encrustation of included neuroglial elements. The interstices of select AVMs contain oligodendroglioma-like regions that may be intrinsic to the underlying maldevelopmental process, or the result of abnormal oligodendroglial aggregation caused by the ischemic contraction of entrapped white matter.[128] As noted previously, although systemic AVMs are often GLUT1 immunonegative—a helpful feature in the differential diagnosis with infantile hemangiomas—this marker is often positive in CNS examples.[120] The association of AVMs and bona fide gliomas is discussed under the heading of "Gliosarcoma and other gliomesenchymal tumors," as are malformation-like alterations occurring in the vascular stroma of neuroepithelial tumors.

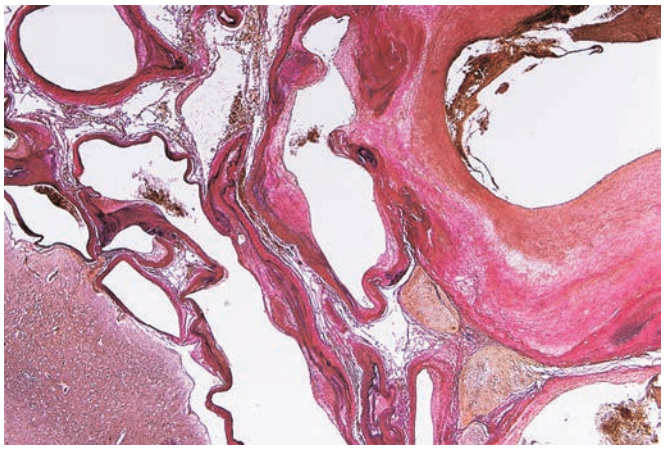

Figure 43.8 Arteriovenous Malformation. Ectatic, variably muscularized blood vessels with interrupted elastic lamina and fibrotic intimal thickening comprise this malformative lesion (van Gieson stain).

To the sporadic and familial malformations mentioned in preceding paragraphs can be added a host of vascular anomalies constituting manifestations of so-called **neurocutaneous syndromes** ("**phakomatoses**"), some clearly inherited while others are the apparent result of spontaneous mutation. The most widely recognized of these disorders is **encephalo-trigeminal angiomatosis**, known by the eponym of **Sturge–Weber syndrome**, defined as a florid

For personal use only. No other uses without permission. Copyright ©2017. Elsevier Inc. All rights reserved.

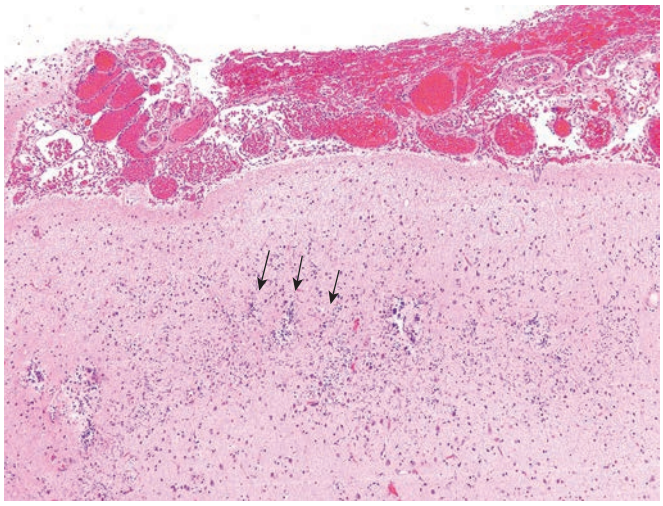

Figure 43.9 Sturge–Weber Syndrome. The cerebral resection specimen shows hemangioma-like venocapillary proliferation involving the leptomeninges, along with "tram-track" like cortical calcifications *(arrows)*.

venocapillary proliferation involving the leptomeninges and cortical mantle of one cerebral hemisphere (Fig. 43.9), in complex with a cutaneous hemangioma ("port-wine stain") lying at least in part in the ophthalmic distribution of the ipsilateral trigeminal nerve. Recent evidence also highlights the frequent association between Sturge–Weber syndrome and somatic *GNAQ* gene mutations.[129] Progressive mineralization of the involved cortex, centered initially on its abnormal perforating vessels, results in a gyriform, "tram-track" profile of radiologically demonstrable intracranial calcifications characteristic of the disease. Atrophy of the affected cerebral hemisphere is the rule, and patients typically suffer contralateral hemiparesis, often attended by motor seizures and mental retardation. The association of unilateral retinal angiomatosis and a cutaneous hemangioma in an ipsilateral trigeminal distribution with an AVM of the midbrain is referred to as **mesencephalo-oculo-facial angiomatosis** (also termed **neuroretinal angiomatosis**, **Bonnet–Dechaume–Blanc syndrome**, or **Wyburn–Mason syndrome**).[1] The generic designation of **cerebrofacial arteriovenous metameric syndrome** has been adopted by some observers to encompass this and other malformative vascular disorders involving the CNS, cutis, and subcutaneous tissues of the face, including rare variants affecting the pons and cerebellum in concert with the skin of the mandibular region and upper neck.[130] Capillary telangiectases and AVMs are also recognized, albeit rare, CNS manifestations of **hereditary hemorrhagic telangiectasia** (**Osler–Weber–Rendu** disease).[107] **Cobb syndrome** or **cutaneomeningospinal angiomatosis** is defined by the association of a dermal angioma (often of port-wine stain type) with an intraspinal hemangioma or AVM at corresponding dermatomal levels.[131]

Arteriovenous fistulas of the craniospinal vasculature are accorded only passing consideration here because their current management—surgical clipping or selective embolic occlusion of the offending communication—does not usually yield specimens for anatomic study, with the rare exception of associated venous aneurysms.[132] It is the absence of a plexiform, angiomatous nidus interposed between its feeding arteries and venous efferents that serves to distinguish the simple fistula from the AVM on angiographic and morphologic evaluation, although the latter's participating vessels may develop fistulous connections. Trauma clearly figures in the genesis of many examples (particularly carotid-cavernous sinus and vertebrovertebral types), as does neurosurgical injury and some associated systemic disorders such as fibromuscular dysplasia, type IV Ehlers–Danlos syndrome, and Osler–Weber–Rendu disease.[1] Many arteriovenous fistulas, however, present in spontaneous fashion. Those involving the cerebral arteries proper typically come to attention in childhood or early adult life, their clinical manifestations including headache, seizures, focal sensorimotor deficits, cardiac decompensation, and intracranial hemorrhage. Catastrophic rupture, however, appears to be exceptional. Fistulas developing below the tentorium are often localized to the dural sheaths of spinal nerve roots in the low thoracic region.[133] Lesions of this sort afflict men far more commonly than women, usually become symptomatic in or beyond middle age, and result in progressive paraparesis, paresthesias of the lower extremities, and sphincter disturbances. Known eponymously as **Foix–Alajouanine syndrome** or as **angiodysgenetic myelomalacia** or **venous congestive myelopathy**, this disorder is typified by serpentine elongation and distension of veins coursing over the dorsal surface of the thoracic spinal cord and is likely the result of protracted local venous hypertension caused by an overlap in the vascular drainage of the adjacent dural fistula and the cord itself. Fistulas involving the perimedullary vascular plexus[134] or distantly situated in the cranial or sacral dura[135] may cause a similar picture. The longstanding hemodynamic alterations in such cases can produce regional expansions of the spinal cord that mimic infiltrative neoplasms and prompt biopsy.[136] Characteristic histopathologic alterations include architectural distortion of the neuroparenchyma with gliosis, thickening and hyalinization of vascular walls, hemosiderin deposition, and varying degrees of myelin loss. Mild glial atypia, sometimes accompanied by Rosenthal fibers (piloid gliosis) may be encountered, and some of these lesions manifest vascular thrombosis and necrosis. Dural arteriovenous fistulas drained by ectatic or aneurysmally dilated cortical veins are particularly prone to hemorrhage.[132] Dural-based arteriovenous fistulas have also been implicated in the pathogenesis of vascular malformations occupying the sigmoid and transverse sinuses.[137]

Primary Angiitis

Among the less common forms of cerebrovascular disease is the idiopathic disorder variously described as "**isolated**," "**granulomatous**," or "**primary**" **angiitis of the CNS (also known as primary CNS vasculitis)**.[138] Inasmuch as many histopathologically confirmed cases do not have overtly granulomatous features, and as autopsy studies have found exceptional instances of extraneural vascular involvement, the last of these designations would seem the most accurate and is adopted here.

Primary angiitis of the CNS can occur at any age but usually afflicts young or middle-aged adults. Its principal clinical manifestations include headache, mental status changes, and focal neurologic deficits (particularly hemiparesis) that may evolve in progressive fashion or present abruptly as "stroke." Signs and symptoms of myelopathy occasionally dominate the clinical picture, but only rarely is there morphologic evidence of vascular injury that is accentuated at, or confined to, spinal levels.[139,140] If not promptly diagnosed and managed, the disorder generally proves progressive and fatal.

Short of biopsy for tissue confirmation, angiography is the most useful investigative procedure, and findings typical of vasculitis—particularly multifocal, segmental stenosis, dilation, or "beading" of small- to medium-caliber leptomeningeal arteries—are considered by some to constitute sufficient grounds for the institution of corticosteroid or cytotoxic therapy in the appropriate setting (i.e. when underlying infection and other systemic processes associated with secondary CNS angiitis have been excluded). However, arteriograms may be negative even in the face of florid vascular disease.[138] Less commonly encountered neuroradiological abnormalities include aneurysm formation and focal "mass" lesions secondary to infarction, which is often hemorrhagic.

For personal use only. No other uses without permission. Copyright ©2017. Elsevier Inc. All rights reserved.

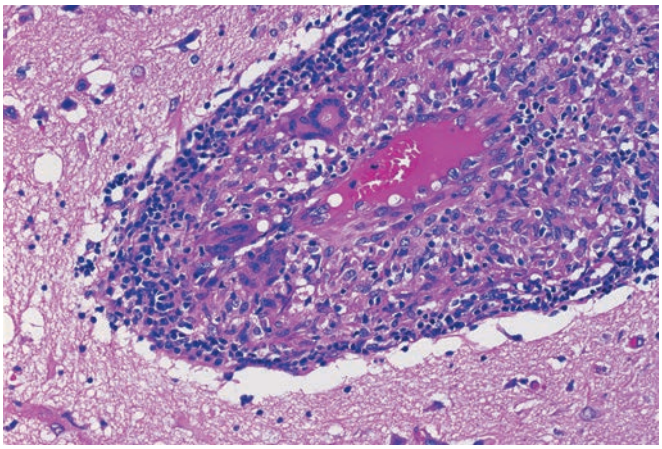

Figure 43.10 Primary Angiitis of the Central Nervous System. A frankly granulomatous inflammatory infiltrate replete with multinucleated giant cells expands the wall of this penetrating cerebrocortical blood vessel, found in biopsy material from a 34-year-old man with progressive encephalopathy.

Most observers regard biopsy as the sole means of confirming a presumptive clinical diagnosis of primary CNS angiitis, although false-negative samplings are a common consequence of the disorder's segmental distribution. Of note, however, biopsies are diagnostic in roughly 65% of cases when a radiographically detectable lesion is targeted, leptomeninges are included, and frozen section confirmation is utilized; in contrast, the majority of "blind biopsies" are nondiagnostic.[138] Small and midsized leptomeningeal and intracortical arteries usually bear the brunt of the injury, but neighboring veins are often involved, and the process may affect the large vessels at the base of the brain as well. Rarely, however, are inflammatory alterations confined to the latter. It should be emphasized that the histologic presentation of primary CNS angiitis is subject to considerable variation. Necrotizing polyarteritis-like or non-necrotizing lymphoplasmacytic variants are frequently encountered. Mural inflammation and vascular damage are definitional of CNS angiitis. Multinucleated giant cells of foreign body and Langhans type characterize the granulomatous examples, which is the most common pattern (Fig. 43.10), followed by lymphocytic forms, with necrotizing vasculitides (transmural fibrinoid necrosis) being the rarest form encountered.[138] When present, giant cells are not strictly associated with the elastic lamina and may lie in any part of the vessel wall. Secondary changes include thrombosis and, in longstanding cases, mural scarring and exuberant fibrointimal hyperplasia. The phenomenon of **"mixed" granulomatous vasculitis and amyloid deposition** is discussed in the "Cerebral Amyloid Angiopathy" section later. Nevertheless, trichrome or pentachrome, elastic, and amyloid stains are amongst the most useful ancillary approaches overall, with beta amyloid immunohistochemistry being more sensitive than a Congo red for amyloid angiopathy.[138]

Notwithstanding the fact that its histologic features are shared by cerebral vasculitides complicating a variety of systemic disorders,[138,141] primary angiitis of the CNS merits distinct nosologic status on clinical grounds. This is not to deny the possibility that this curious process might be triggered by diverse offenses to the cerebrospinal circulation. Although long suspected, an infectious etiology remains unproved. Noteworthy in this regard, however, is the epidemiologic association of primary CNS angiitis with cutaneous varicella-zoster infection and with underlying conditions, chiefly Hodgkin disease and other forms of hematolymphoid neoplasia, that predispose to this and other viral opportunists.[138,142] These observations are especially intriguing in view of the undisputed role of this virus as a cause of large vessel cerebral arteritis that is potentially indistinguishable from primary CNS angiitis.

Cerebral Amyloid Angiopathy

The deposition of amyloid in the walls of cerebral blood vessels is associated with aging and a variety of neurologic disorders, including Alzheimer disease, Down syndrome, dementia pugilistica, and certain types of spongiform encephalopathy. It is the association of this process—**cerebral amyloid angiopathy**—with intracranial hemorrhage that compels the attention of the neurosurgeon and surgical pathologist. Cerebral amyloid angiopathy is the most common nontraumatic cause of lobar cerebral hematoma in elderly subjects (the cohort at greatest risk) and has been estimated to account for some 5%–10% of all primary atraumatic brain hemorrhages, which are also commonly associated with superficial siderosis, microinfarcts, and subcortical small white matter damage, particularly in patients with the *ApoE4* genotype.[1,143] The disorder is not a manifestation of systemic amyloidosis and typically presents in sporadic fashion, although kindreds afflicted by heritable (autosomal dominant) syndromes of florid cerebrovascular amyloidosis and early death due to recurrent intracerebral hemorrhage have been described.[144] Beta amyloid peptide (Aβ), found also in cortical CNS vessels and neuritic plaques of asymptomatic senescence and Alzheimer disease, constitutes the principal amyloid deposited in sporadic cases.[144] Aberrant forms of Aβ, cystatin C, transthyretin, gelsolin, and other proteins resulting from point mutations in their encoding genes are the offending amyloidogenic agents in various heredofamilial types of CNS amyloidosis with vascular involvement. While a substantial proportion of sporadically affected patients have dementia, cerebral amyloid angiopathy, even when severe, is not necessarily associated with cognitive impairment or with Alzheimer disease.

The peripheral, lobar location of amyloid-associated cerebral hematomas contrasts sharply with the basal ganglionic or bulbar situation typical of hypertensive hemorrhages and reflects the particular susceptibility of superficial cortical and leptomeningeal vessels to amyloid-related damage. Chiefly affected are small-caliber arteries and arterioles, but veins may be involved as well. These exhibit mural expansion and, in advanced cases, effacement by acellular, eosinophilic material deposited in the adventitia and media (Fig. 43.11A). By definition, this possesses the histochemical properties and ultrastructural attributes common to all amyloids. This is therefore demonstrable as a dichroic, bluish-green birefringence in Congo red–stained sections viewed under polarized light, although Aβ-amyloid immunoreactivity is considerably more sensitive (see Fig. 43.11B). Amyloid-laden cerebral vessels generally maintain their patency but are subject to a variety of "vasculopathic" alterations. These include "double-barreling" (a targetoid, vessel-within-vessel configuration produced by what would appear to be a circumferential cleft in the media), glomeruloid arteriolar changes, obliterative fibrointimal proliferation, perivascular or intramural lymphocytic infiltration, microaneurysms, and, finally, fibrinoid necrosis. This last abnormality is restricted to vessels bearing a heavy amyloid burden and appears to play a particularly significant role in the pathogenesis of vascular rupture.[145]

As is often the case in extracranial locations, amyloid deposited in the cerebral vasculature occasionally elicits a foreign body–type response replete with multinucleated giant cells that attempt to phagocytize the offending material. Much rarer are examples of cerebral amyloid angiopathy associated with a true vasculitis of necrotizing and/or granulomatous type.[146,147] Such cases have been interpreted to represent, for the most part, idiosyncratic host reactions to the deposited protein ("**Aβ-related angiitis**" or **ABRA**), but it is

For personal use only. No other uses without permission. Copyright ©2017. Elsevier Inc. All rights reserved.

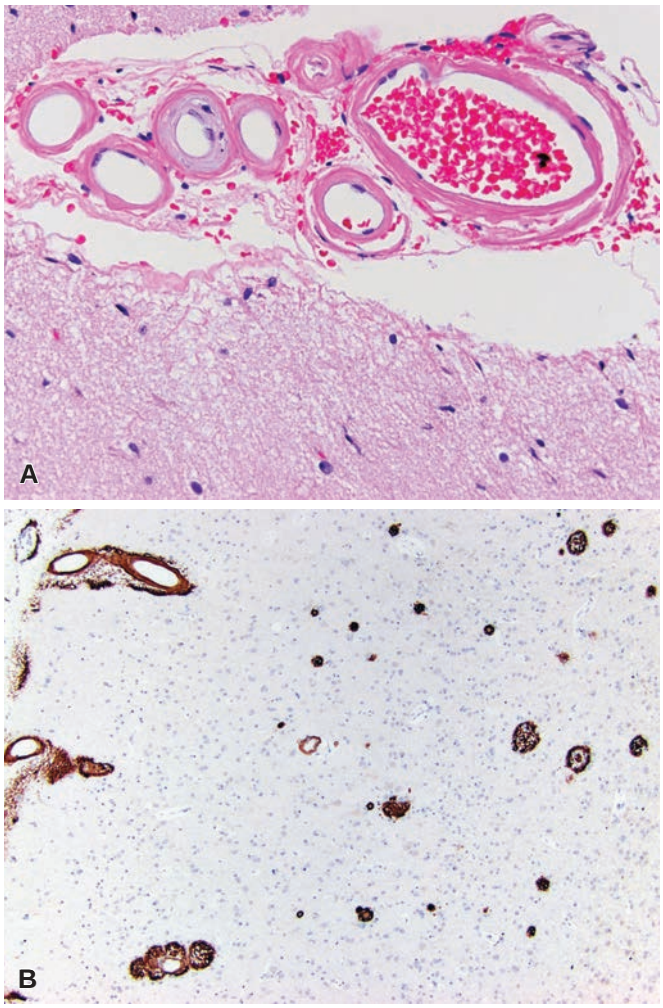

Figure 43.11 Cerebral Amyloid ("Congophilic") Angiopathy. As in extraneural locations, amyloid in the walls of cerebral vessels appears eosinophilic and amorphous **(A)** being further highlighted on immunostains for beta amyloid (often also showing diffuse or neuritic plaques in the cortex) **(B)**.

conceivable that primary cerebral vasculitides might aggravate, if not trigger, local amyloidogenic processes. Interestingly, most examples of angiitic cerebrovascular amyloidosis (including those reported under the rubric of combined granulomatous angiitis and cerebral amyloid angiopathy) do not present with intracerebral bleeding but rather as nonhemorrhagic lesions, some of which are mass forming and radiologically taken for neoplasia. Patients may also present with alterations of mental status, headache, seizures, or focal neurologic deficits of subacutely progressive nature. Sufferers are typically younger than patients with noninflammatory amyloid angiopathy but older than those with primary CNS vasculitis.[147]

Cerebral Autosomal Dominant Arteriopathy With Subcortical Infarcts and Leukoencephalopathy and the Autosomal Recessive Variant

Cerebral autosomal dominant arteriopathy with subcortical infarcts and leukoencephalopathy (CADASIL) and a much rarer autosomal recessive form (CARASIL), as their names imply, are heritable conditions.[1,148] Hundreds of affected CADASIL kindreds have been identified worldwide, whereas only around 50 cases of CARASIL have been reported. CADASIL has been linked to missense mutations or, rarely, small deletions involving the *NOTCH3* gene at chromosome 19p13, the product of which is a transmembrane receptor protein and transcriptional regulator selectively expressed in vascular smooth muscle cells. Isolated nonfamilial cases seemingly due to de novo *NOTCH3* mutations have been described as well. In contrast, CARASIL, like other autosomal recessive disorders, requires biallelic inactivation, in this case of the high-temperature requirement A serine peptidase 1 *(HTRA1)* gene on chromosome 10q, known to be involved in musculoskeletal development.[148] Clinical manifestations of CADASIL include migraine with aura (often the earliest neurologic complaint), subcortical ischemic strokes, psychiatric symptoms, and cognitive deterioration eventuating in dementia. Most patients die within 15–25 years of their initial episodes of stroke. CARASIL follows a similar course but usually starts at an earlier age, with greater severity; it is also associated with low back pain due to disk herniation and spondylosis deformans (reflecting the more generalized connective tissue disorder), as well as premature diffuse baldness in men.[148] Imaging findings are similar in both disorders, though more diffuse in CARASIL. Nodular foci of periventricular T2 hyperintensity are characteristic and early changes seen in MR images are often apparent in presymptomatic individuals. With disease progression, lacunar white matter infarcts develop and confluent zones of increased T2-weighted MRI signal reflect a diffuse leukoencephalopathy, typically with sparing of U-fibers.

CADASIL is a nonarteriosclerotic and nonamyloidotic vasculopathy that principally involves small- and medium-sized arteries in the cerebral hemispheric white matter, but leptomeningeal and even systemic vessels are potentially affected by this generalized disorder.[1,148] Most recorded cases have been identified by brain biopsy, but sampling of skin, skeletal muscle, and peripheral nerve may be informative as well. The hallmark of CADASIL is accumulation of a granular, basophilic, and PAS-positive material in the tunica media of affected vessels with associated loss of medial smooth muscle cells, concentric mural sclerosis, and luminal narrowing. At the ultrastructural level, this distinctive material consists of osmiophilic, electron-dense granules 10–15 mm in size that lie free between degenerating myocytes or cluster within pericellular indentations. These deposits may be labeled by monoclonal antibodies to the NOTCH3 protein extracellular domain, which are specific for CADASIL, and may be identified in the presymptomatic phase of the disease. Accordingly, ultrastructural or immunohistochemical studies of small dermal or subcutaneous arteries in skin biopsy specimens have been advocated as screening procedures for family members at risk as well as in suspect cases. The pathology of CARASIL similarly shows marked arteriolosclerosis but without the characteristic vascular deposits or systemic involvement of CADASIL; in this respect, it overlaps with Binswanger's disease, but patients lack hypertension.[148] Confirmatory genetic assessment (e.g. single-strand conformational polymorphism analysis) is sometimes required for the diagnosis of either disorder.

Epidural Hematoma

The great majority of **epidural hematomas** follow cranial trauma complicated by temporal bone fracture and result from laceration of middle meningeal artery branches that penetrate the skull in the region of the pterion.[1] The accumulation of blood between the calvarium and endosteal surface of the dura mater is typically rapid, associated with acute deterioration of consciousness, and soon eventuates in death as a result of cerebral herniations if not promptly evacuated. Uncommon variants become symptomatic only long after

For personal use only. No other uses without permission. Copyright ©2017. Elsevier Inc. All rights reserved.

their initiating injuries. Delimited by encapsulating neomembranes formed of vascularized fibrous tissue, chronic epidural hematomas of this sort are usually of venous origin.

Subdural Hematoma

Subdural hematomas result from the dissection of blood into the potential space separating the normally apposed arachnoid and dura mater. Most overlie the cerebral convexities in the frontoparietal region and are thought to follow rupture of delicate bridging veins that traverse the arachnoid–dura interface en route to the superior sagittal sinus. These vessels are particularly susceptible to shearing forces generated by sudden angular acceleration of the head, as commonly occurs in the setting of trauma, and many subdural hematomas are clearly associated with cranial injury. Most "spontaneous" examples occur in the elderly, possibly because cerebral atrophy and resultant traction on these bridging vessels reduce their capacity to withstand otherwise trivial stresses. A similar phenomenon may promote the development of subdural hematomas following ventricular decompression for hydrocephalus. Patients who have received anticoagulants, are thrombocytopenic, are alcoholics, or have been treated with long-term hemodialysis are also at increased risk[149] of subdural hemorrhage. A small subset of subdural hematomas result from arterial injury. These are usually associated with major craniocerebral trauma.

The pathology of the subdural hematoma is a function of its age. If evacuated within days of onset, it consists simply of clotted blood. Often, however, the original bleeding episode passes unnoticed, and the hematoma becomes symptomatic only after it has elicited an organizational response resulting in its enclosure within a discoid sac fashioned of grayish-brown, collagenous neomembranes that adhere to the dura but develop no attachments to the underlying arachnoid. The latter feature reflects the fact that the mesenchymal elements responsible for encapsulation of the hematoma derive entirely from the dura, with the leptomeninges remaining curiously unmoved by the presence of blood in the subdural space and playing no part in its organization. Inasmuch as the histologic maturation of these limiting membranes proceeds in temporally predictable fashion, the chronicity of a given lesion may be estimated by thorough assessment of the membranes. Suffice it to say that the outer (juxtadural) membrane, which may attain a thickness of several millimeters, consists in the early stages of proliferating spindle cells and budding capillaries that penetrate the superficial aspect of the hematoma and come to lie in a loose connective tissue matrix containing admixed siderophages, scattered lymphocytes, and, in some cases, extramedullary hematopoietic elements (normoblasts). Infiltration by eosinophils may be striking. The inner membrane, by contrast, has a simpler thinner structure and is relatively avascular. Both membranes undergo progressive hyalinization and, with complete resorption of the hematoma, fuse to form a thin fibrous rind closely resembling the adjacent dura mater on microscopic study. In exceptional instances, the hematoma sac is transformed into a calcific, even ossified, shell.

The capacity of the chronic subdural hematoma to present in clinically delayed fashion as an expanding intracranial mass would seem a paradox. Once completed, the enclosing hematoma sac could conceivably function as a semipermeable membrane and permit the ingress of fluid drawn by osmotic forces from the CSF compartment or the capillary network in its outer lamina. A prosaic (but, perhaps, more likely) explanation would incriminate these delicate newly formed capillaries in episodes of rebleeding. Not infrequently, subdural hematomas that first come to attention in their chronic, encapsulated phases disclose evidence of recent, superimposed hemorrhage.

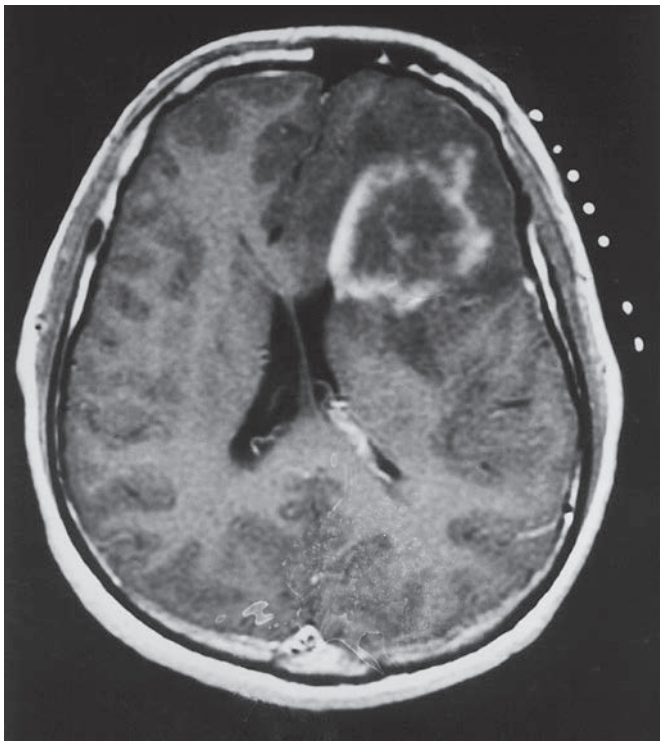

Figure 43.12 Demyelinating Pseudotumor. Taken following administration of a contrast agent that serves to delineate foci of blood–brain barrier breakdown as regions of bright signal, this magnetic resonance image demonstrates a lesion characterized by "ring" enhancement, conspicuous hypodensity of the surrounding white matter (indicative of edema), and mass effect evidenced by obliteration of the ipsilateral ventricular angle and shift of the neighboring cingulate gyrus across the midline. The neuroradiological diagnosis was "probably glioblastoma, abscess also a possibility." The patient, a 32-year-old man with subacutely progressive hemiparesis and somnolence, recovered completely following limited biopsy and a short course of corticosteroids. He remains asymptomatic 15 years after diagnosis.

Inflammatory Diseases

Demyelinating Diseases

The idiopathic demyelinating diseases of the CNS, of which multiple sclerosis is by far the most common, are usually regarded as "medical" disorders diagnosed on clinical grounds or at autopsy. In fact, demyelinating lesions of the cerebral hemispheric white matter and spinal cord may present as space-occupying "tumors" associated with considerable mass effect, edema, and disruption of the blood–brain barrier evidenced, on computed tomography (CT) or MR study, by diffuse or ring-like enhancement following administration of contrast media (Fig. 43.12).[150,151] Especially suspect on neuroradiological grounds is the lesion that exhibits an "open" or "broken ring" profile characterized by the abrupt cessation of rimming contrast enhancement where it abuts a ventricular surface or overlying cortex.[152] Patients may present with symptoms and signs referable to an expanding intracranial mass prior to receiving a diagnosis of a demyelinating disorder. Solitary examples, not surprisingly, prompt consideration of aggressive glial neoplasia or abscess formation, whereas multifocal variants suggest metastatic disease or even cerebral parasitosis when lesions exhibit cystic characteristics on scan. Such **demyelinating "pseudotumors"** understandably occasion neurosurgical intervention for purposes

For personal use only. No other uses without permission. Copyright ©2017. Elsevier Inc. All rights reserved.

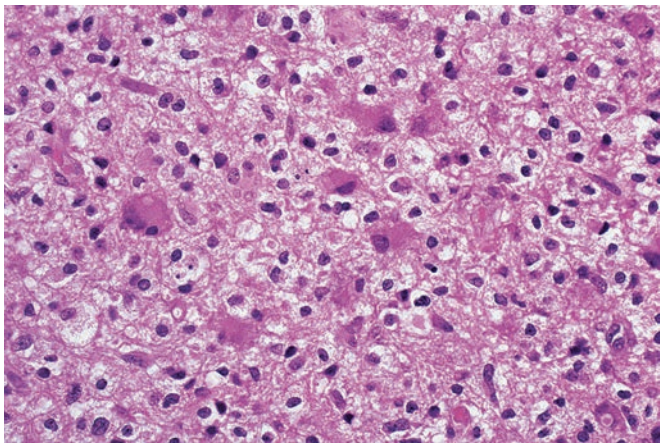

Figure 43.13 Demyelinating Pseudotumor. The hypercellularity of this lesion reflects infiltration by large numbers of macrophages, recognizable on careful study by their granular or foamy cytoplasm. Also apparent are several hyperplastic astrocytes.

of definitive diagnosis and thus enter the domain of the surgical pathologist.

The tumefactive demyelinating lesion shares with the active "plaque" typical of subacute multiple sclerosis a sharp delineation from adjacent, uninvolved white matter evident in biopsy samples that include its perimeter. Affected tissues exhibit diffuse infiltration by foamy, lipid-laden macrophages, reactive astrocytosis of variable intensity, and perivascular aggregates of small B and T lymphocytes (the latter also infiltrating the parenchyma), as well as occasional plasma cells (Fig. 43.13). The definitive characterization of the process as a demyelinating one ultimately requires the demonstration of relative axonal preservation in foci devoid of stainable myelin. This is readily accomplished by comparing serial sections assessed for myelin by a Luxol fast blue (LFB) stain (Fig. 43.14) and axon density using a neurofilament immunostain. In typical cases, large numbers of axons will course uninterrupted through regions in which myelin, if at all demonstrable, persists only as phagocytized debris in the cytoplasm of macrophages. It should be pointed out, however, that a variable element of axonal depopulation is the rule, with some particularly destructive examples causing cavitation.

In our experience, demyelinating pseudotumors are the non-neoplastic lesions most often misinterpreted on biopsy as gliomas, specifically as diffuse fibrillary astrocytomas or as oligodendrogliomas. Unfortunately, the consequences to patients subjected to cerebral irradiation may be devastating[153] and the potential causes for error numerous. A diagnosis of glioma may be prompted by cytologically atypical astrogliosis that characterizes some examples—an impression likely to be reinforced by the finding of scattered mitotic figures, as well as astrocytes that appear to be in atypical mitosis by virtue of a peculiar parcellation of their nuclear material ("granular mitoses") and Creutzfeldt cells forming fragmented micronuclei. Perivascular lymphoid infiltrates are an inconstant feature and, even when conspicuous, do not exclude a glioma. Even in their absence, however, the orderly spacing of gemistocytic astrocytes typical of hyperplastic states should suggest a reactive process.

Especially confounding is failure to distinguish the sheets of macrophages from glioma since their cell borders tend to blend into the fibrillary background, particularly in frozen sections. Therefore, the use of cytologic preparations is strongly advocated for purposes of intraoperative consultation, since the vacuoles and lack of processes are much easier to appreciate on a smear (Fig. 43.15). Immunocytochemical assay for monocyte/macrophage

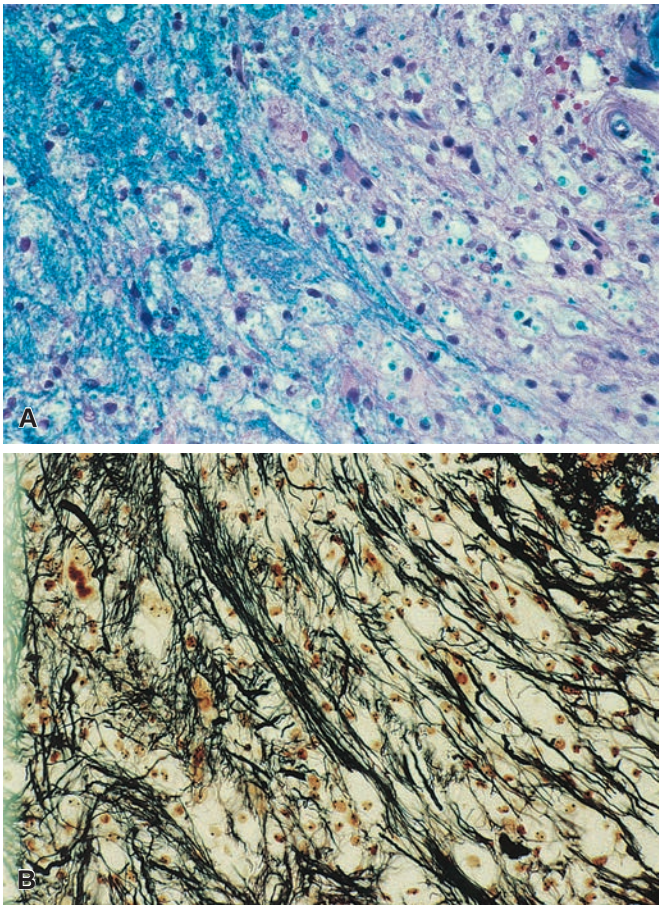

Figure 43.14 Demyelinating Pseudotumor. The interface of a demyelinated plaque *(right)* and normal white matter *(left)* is shown here in serial sections stained for myelin **(A)** and axons **(B)** by the Luxol fast blue and Bielschowsky methods, respectively. Myelin, *blue* in **A**, persists in the plaque only as globules present in the cytoplasm of macrophages. Axons, *stained black* in **B**, course uninterrupted into the region of demyelination.

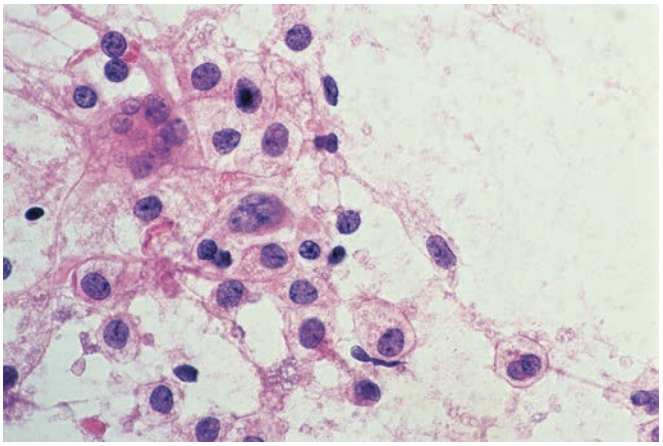

Figure 43.15 Demyelinating Pseudotumor. The presence of foamy macrophages in cytologic preparations argues strongly against a diagnosis of glioma at the time of intraoperative consultation. As shown here, somewhat atypical-appearing, multinucleate astrocytes are not uncommonly encountered in such specimens.

For personal use only. No other uses without permission. Copyright ©2017. Elsevier Inc. All rights reserved.

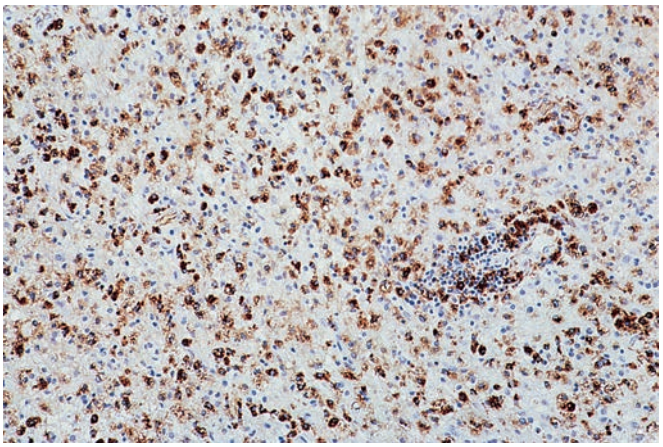

Figure 43.16 Demyelinating Pseudotumor. The density of infiltrating macrophages characteristic of demyelinating lesions is demonstrated in this immunoperoxidase assay for HAM-56.

markers such as HAM-56 (Fig. 43.16) and CD68 may also aid in circumventing problems of cell identification, particularly as applied to neurosurgical specimens exhibiting artefactual distortions. Diffuse infiltration by macrophages in large number is so rarely a feature of the untreated glioma as to virtually exclude this diagnosis. The ready identification of such cells in smears, crush preparations, or tissue sections should instead suggest a non-neoplastic, necrotizing process (such as organizing infarction) or a selectively demyelinating disorder. Primary CNS lymphomas inadvertently treated by the preoperative administration of corticosteroids may vanish on neuroradiological scan and can further simulate demyelinating disease by leaving behind only reactive lymphohistiocytic infiltrates; there should not be truly selective, regionally circumscribed myelin loss in this circumstance (see later discussions). Patients suffering from multiple sclerosis on occasion do develop glial neoplasms,[154] but there is no definite evidence that the incidence of the latter is increased in this population.

Although historically it was thought that tumefactive demyelinating lesions only rarely complicated the course of established multiple sclerosis,[150] more recent data suggest that the majority of patients with tumefactive lesions develop classic features with sufficient follow-up.[151] Lastly, mention is made of a **multifocal inflammatory leukoencephalopathy** described as complicating the chemotherapy of colorectal adenocarcinoma with 5-fluorouracil and levamisole.[155] The lesions in question were demyelinative and morphologically indistinguishable from active multiple sclerosis plaques. Whether one or both of these agents was directly responsible for this condition or somehow precipitated attacks of multiple sclerosis in patients predisposed to the disorder is unclear.

Noninfectious Inflammatory and Reactive Disorders, Xanthomatous Lesions, and "Histiocytoses"

The various oddities collected in this section have little in common beyond their etiologic obscurity and inflammatory or otherwise "reactive" histologic appearances. Many are better known as systemic disorders and are given detailed consideration elsewhere in these volumes. Specific description is here accorded to only those entities unique to the nervous system.

Idiopathic hypertrophic pachymeningitis (IHP) of cranial subtype is, as its name implies, an inflammatory and fibrosing disorder of unknown cause that affects the dura mater. This diagnosis is rendered less and less frequently as other etiologies are increasingly implicated, including intracranial hypotensive, infectious, neoplastic, and autoimmune etiologies, the latter most recently including IgG4 disease (see later).[156,157] Clinical manifestations include headache, progressive cranial neuropathies, and cerebellar ataxia of adult onset occurring in association with radiographically demonstrable thickening and abnormal contrast enhancement of the peribulbar meninges, tentorium, and falx. The process can involve the dura over the cerebral convexities or extend into the cavernous sinus and orbit, causing painful ophthalmoplegia. **Idiopathic hypertrophic spinal pachymeningitis**, a disease of the cervicothoracic region typified by compressive myelopathy, may represent a variant of the same basic disorder.[158] A subset of afflicted patients have extradural abnormalities collected under the rubric of "**multifocal fibrosclerosis**," including inflammatory orbital pseudotumor, idiopathic mediastinal and retroperitoneal fibrosis, sclerosing cholangitis, Riedel stroma, Peyronie disease, Dupuytren contracture, fibrosing orchitis, systemic vasculitis, and fibroinflammatory lesions of the subcutaneous tissues and lungs.

What may represent localized pseudotumoral variants have also been recorded,[159] although it is also important to recognize that IHP is a diagnosis of exclusion, with a subset recently reclassified as pachymeningitis complicating **IgG4-related disease** (Fig. 43.17), a sclerosing autoimmune disorder first described in the pancreas but now recognized almost everywhere in the body, including the pachymeninges and pituitary gland.[157,160,161] Although this diagnosis is made based on increased numbers of IgG4-positive plasma cells and an increased ratio of IgG4- to IgG-positive cells (e.g. >40%), too few cases have been published to establish definitive criteria for these sites.[162] Some also disclose dispersed lymphoplasmacytic infiltrates, exuberant fibroplasia, and, in some instances, necrosis and granuloma formation. Exclusion of tuberculosis, syphilis, mycotic infections, sarcoidosis, Wegener granulomatosis, rheumatoid disease, and other causes of chronic fibrosing meningitis is required. Secondary intracranial extension of inflammatory orbital pseudotumor or IgG4 disease may also produce a similar meningeal picture.[163,164] The clinical course of IHP is variable but often inexorably progressive. Corticosteroid administration and resection of compressing fibroinflammatory meningeal masses are of benefit to some patients. The reader should note that patients undergoing craniotomy, ventricular shunting, or even lumbar puncture alone may occasionally develop neuroradiological evidence of diffuse meningeal thickening and enhancement that is typically asymptomatic and without clinical significance. This is thought to represent a response to intracranial hypotension and may rarely occur spontaneously. Biopsy material in such cases may exhibit subdural fibroplasia, neovascularization, hemosiderin deposition, and meningothelial hyperplasia.[165,166]

Turning from the meninges to the brain proper, we briefly mention a form of chronic encephalitis, known eponymously as **Rasmussen syndrome**, that is characterized by intractable unilateral focal seizures or epilepsia partialis continua of childhood onset, progressive cerebral hemiatrophy with hemiparesis, and cognitive decline.[167] Long suspected (but never convincingly shown) to represent a persistent viral infection, the disorder may have an autoimmune component, as some afflicted patients harbor antibodies to native CNS antigens, including the glutamate GluR3 receptor. The neuropathology is nonspecific, consisting of perivascular and interstitial lymphoid infiltrates involving the cerebral cortex with microglial nodule formation, astrogliosis, and variable neuronal loss.[168] High-dose corticosteroids, intravenous gamma globulins, plasmapheresis, and surgery (including functional or actual hemispherectomy) have all been investigated in the treatment of Rasmussen syndrome and have proven beneficial to some patients. The last of these options is

For personal use only. No other uses without permission. Copyright ©2017. Elsevier Inc. All rights reserved.

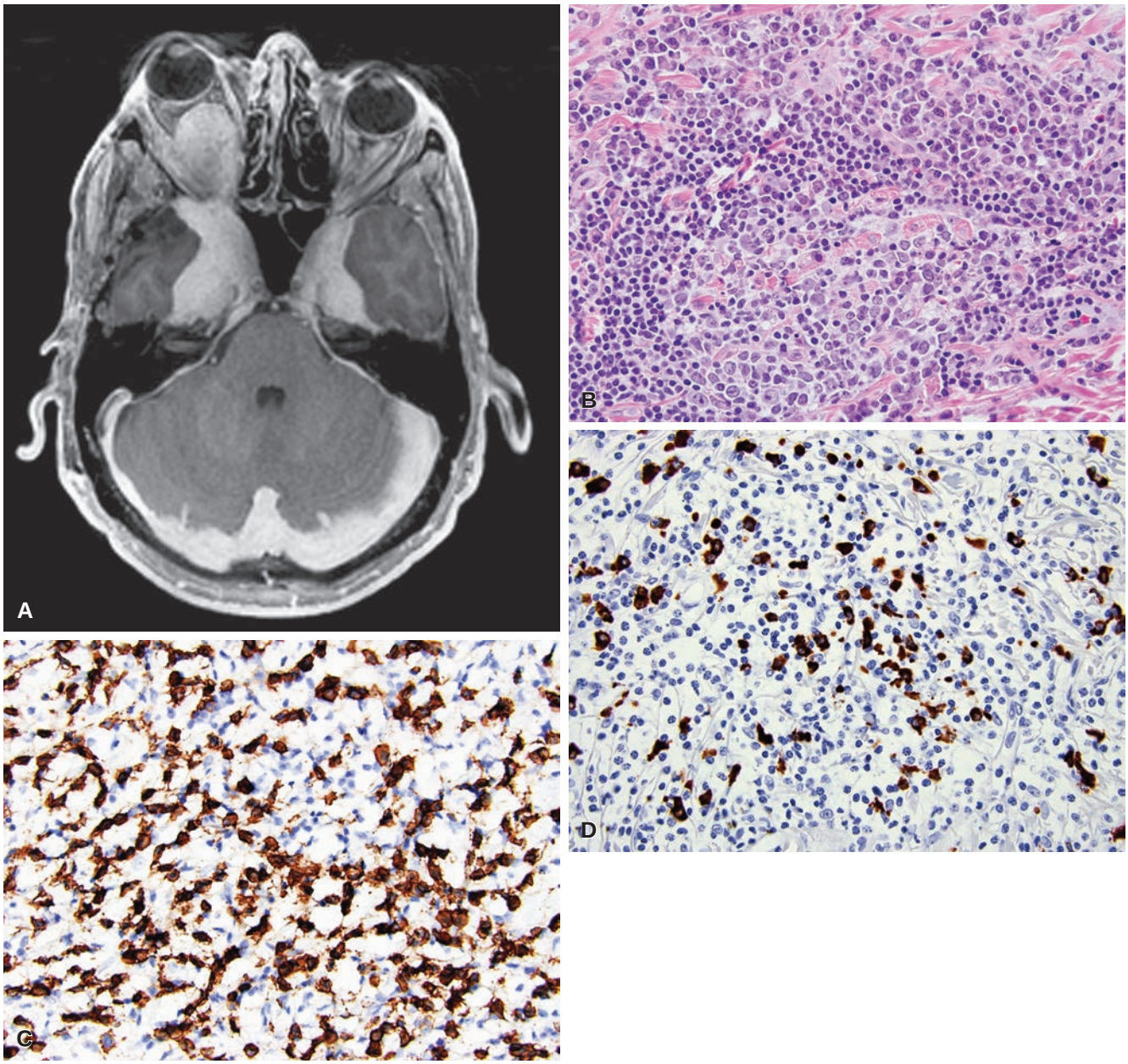

Figure 43.17 IgG4-Associated Pachymeningitis. Note the marked bilateral dural thickening on postcontrast magnetic resonance imaging **(A)**, the lymphoplasmacyte-rich infiltrate and occasional germinal centers on biopsy **(B)**, and the prominence of numerous CD138- **(C)** and IgG4- **(D)** immunoreactive plasma cells.

currently regarded as the approach of choice in typical childhood cases. More localized and clinically benign forms of idiopathic chronic encephalitis have been described, particularly in adolescents and young adults, that may mimic cerebral neoplasms.[169] Whether these represent Rasmussen variants is unclear.

Limbic encephalitis is an amnestic syndrome of adulthood typically encountered as a paraneoplastic phenomenon[170] complicating small cell carcinoma of the lung, but the disorder has also been reported in association with other tumor types (e.g. non-small cell lung cancers, Hodgkin disease, mammary adenocarcinomas, and testicular germ cell tumors) and, rarely, in the absence of demonstrable neoplasia.[171] Due to the latter and the fact that it is not always limited to a limbic distribution, others have advocated the broader term of **autoimmune-mediated encephalitis**.[172] Clinical manifestations progress in subacute fashion and consist principally of short-term memory loss, complex partial or generalized seizures, confusion, and disordered affect. Many examples evolve as one facet of a complex paraneoplastic disease that potentially involves the dorsal root ganglia, brainstem, cerebellum, spinal cord, autonomic ganglia, and myenteric plexi.[173] MRI studies often disclose abnormal T2 hyperintensity of the medial temporal regions (with contrast enhancement in some cases) and may prompt consideration of herpes simplex encephalitis (HSE) or a neoplasm. The brunt of the injury falls on the amygdaloid nuclei, hippocampi, and entorhinal cortices, biopsy material disclosing florid gliosis, perivascular lymphoid cuffing, microglial or "neuronophagia," and, in some cases, conspicuous neuronal depopulation. In contrast to HSE, the process is never overtly necrotizing, hemorrhagic, or attended by viral inclusions.

For personal use only. No other uses without permission. Copyright ©2017. Elsevier Inc. All rights reserved.

Useful in the evaluation of limbic encephalitis (the clinical manifestations of which often herald discovery of otherwise silent, low-stage tumors) are serum and CSF autoantibody studies, including anti-Hu, which is directed against neuronal nucleoproteins in the size range of 35–40 kDa and strongly correlated with the presence of underlying small cell lung cancer.[170,173] Demonstration of this autoantibody constitutes compelling evidence of a paraneoplastic etiology and mandates a search for occult neoplastic disease, especially within the chest cavity. Anti-Hu IgG appears to be elaborated in response to aberrant tumoral expression of this neuron-associated protein, prompting the hypothesis that an immunologic response directed against a triggering neoplasm cross-reacts with the nervous system with devastating neurologic consequences. Another neuronal autoantibody known as anti-Ta or anti-Ma2 is a powerful marker of paraneoplastic limbic encephalitis in the setting of testicular germ cell neoplasia.[170] Tumor localization and treatment may lead to neurologic improvement in patients with limbic encephalitis and is more effective than immune modulation in this regard. Occasional examples remit spontaneously.

The histologically distinctive masses reported as "**fibro-osseous lesions**" or "**calcifying pseudoneoplasms**" **of the neural axis** (Fig. 43.18) are composed principally of nonbirefringent, basophilic materials that may appear amorphous, somewhat chondromyxoid or coarsely fibrillar, ropey, or plate-like.[174,175] Rimming mononuclear and foreign body–type giant cells lend a granulomatous appearance to some examples. Mineralization is at least focally apparent in most cases and many exhibit mature lamellar bone formation as well. Meningioangiomatosis has been found adjacent to rare intracranial examples. These peculiar lesions are usually extra-axial and favor the spinal epidural compartment but may arise from the cranial floor or within the leptomeninges or even the brain. Although non-neoplastic, they may be complicated by considerable neurologic morbidity resulting from spinal cord compression or skull base destruction with cranial nerve and cerebrovascular compromise. Ossified intracranial nodules lacking the defining matrix described above may be formed in nonspecific response to trauma, infection, or hemorrhage and have been termed cerebral calculi or "brain stones." Rarely, symptomatic juxtaneural masses prove to be tophaceous lesions resulting from the crystalline deposition of sodium urate (**gout**), calcium pyrophosphate dihydrate (**pseudogout**), or calcium hydroxyapatite (**tumoral calcinosis**[176]). **Metaplastic hyalinization and ossification** of the leptomeninges is a common asymptomatic finding but may rarely cause progressive myelopathy associated, in some cases, with cavitation of the spinal cord.[177] While the term "**arachnoiditis ossificans**" has been used in such cases and many are clearly the sequelae of mechanical or microbial insults, inflammatory elements are generally lacking and there may be no history of a precipitating condition. Spinal cord injury can similarly be produced by ossification of the ligamentum flavum.[178]

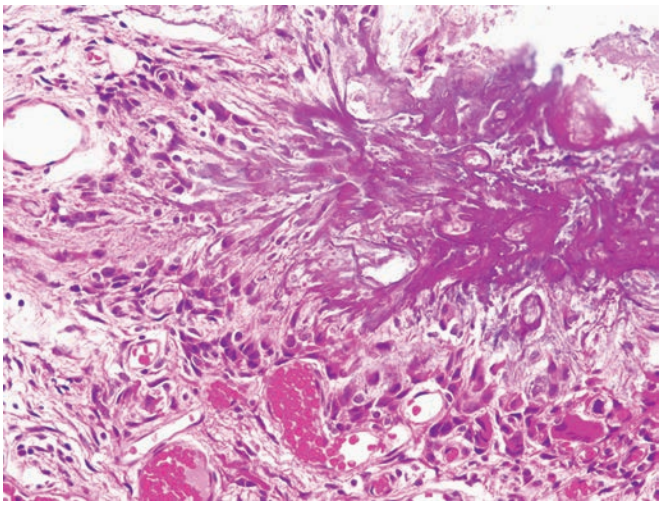

Figure 43.18 Fibro-Osseous Lesion/Calcifying Pseudoneoplasm of the Neuraxis. Fibroplasia and the deposition of a highly characteristic basophilic matrix material in plate-like or ropey masses define this unusual process.

Of those principally extraneural disorders that occasionally undergo surgery, most deserving of mention are Langerhans cell histiocytosis ("eosinophilic granuloma"), sarcoidosis, and sinus histiocytosis with massive lymphadenopathy (SHML) (Rosai–Dorfman disease). CNS involvement in **Langerhans cell histiocytosis** typically follows infiltration of the calvarial floor and exhibits a striking tropism for the region of the hypothalamus and infundibulum, the eponym **Hand–Schüller–Christian disease** being applied to the classic clinical triad of diabetes insipidus, proptosis, and skull base defects on roentgenographic study. While a similar topography is characteristic of those exceptional examples restricted (on presentation, at least) to the nervous system,[179] lesions situated within the meninges, choroid plexus, and brain are on record,[180] as are instances of cerebral invasion from contiguous primary foci in the cranial vault.[181] CD1a and/or langerin immunoreactive Langerhans cells may be only sparsely represented in biopsy material. Of note, both Langerhans cell histiocytosis and another histiocytic disorder that rarely involves the CNS, Erdheim–Chester disease (see later discussion), frequently harbor *BRAF* V600E mutations, which can be targeted therapeutically.[182,183] Xanthomatous masses consisting only of foamy macrophages can also be encountered, possibly representing "burnt-out" lesions, and a nonspecific chronic inflammatory picture with variable loss of myelin and axons may be seen (particularly in the cerebellum and brainstem).

Neurosarcoidosis most commonly assumes the form of a granulomatous basilar meningitis complicated by cranial neuropathies or, with extension of the process to the hypothalamic region, diabetes insipidus and other diencephalic syndromes. An accompanying granulomatous vasculitis may be apparent. While the overwhelming majority of patients have established systemic disease, primary CNS presentations have been described and can include pseudotumoral involvement of the leptomeninges,[184] dura,[185] cranial nerve,[186] and neuroparenchyma proper.[187] An example of necrotizing sarcoid granulomatosis presenting as a mass involving the temporal lobe and cavernous sinus has been depicted.[188] In fact, only a subset of patients evaluated for granulomatous disease of the CNS that is not demonstrably infectious will prove to have clinical manifestations (e.g. interstitial lung involvement, mediastinal lymphadenopathy) or laboratory evidence (elevated serum/CSF angiotensin converting enzyme levels) supporting a diagnosis of sarcoidosis. Unclassifiable, "pathogen-free" granulomatous disorders were found in one study to share a tendency to diffuse neuraxial involvement, combined leptomeningeal and neuroparenchymal (particularly spinal cord) infiltration, attendant angiitis, and a poor prognosis.[189]

Dura-based masses clinically indistinguishable from meningiomas constitute the usual pattern of CNS disease in cases of **Rosai–Dorfman disease** or **extranodal SHML**, though lesions involving the neuroparenchyma have been communicated.[190,191] These can represent the sole manifestations of the disorder and may be multifocal.

A similar predilection for the dura characterizes central neuraxial lesions that have been dubbed **inflammatory pseudotumors** or **plasma cell granulomas**,[192,193] though cerebral and choroid plexus examples have been encountered. There can be little doubt that these designations have been extended through the years to reactive lesions of disparate cause, to cases of extranodal SHML,

For personal use only. No other uses without permission. Copyright ©2017. Elsevier Inc. All rights reserved.

lymphoplasmacyte-rich meningiomas, and low-grade lymphomas of mucosa-associated lymphoid tissue (MALT) type. These terms, furthermore, have been applied indiscriminately to proliferations that should be segregated as **inflammatory myofibroblastic tumors** of the nervous system.[193] The latter are given further consideration in the subsequent discussion of nonmeningothelial mesenchymal tumors. Suffice it to say that diagnoses such as inflammatory pseudotumor and plasma cell granuloma must be rendered with full acknowledgment that they do not carry specific etiologic implications and judiciously reserved for masses harboring polyclonal lymphoplasmacellular populations unaccompanied by the conspicuous spindle cell components, anaplastic lymphoma kinase (ALK) expression, or *ALK* gene (2p23) rearrangements evidenced by tumors of the inflammatory myofibroblastic group. Potentially multifocal, plasma cell granulomas/inflammatory pseudotumors of the nervous system have been described in patients with systemic infections and immunologic disorders such as lupus and relapsing polychondritis.[193,194] IgG4-positive plasma cells may be encountered in the lesions of this group, but a link to IgG4-associated systemic autoimmune disease has not been clearly established.[192] A unique falcine mass possibly analogous to the **hyalinizing plasmacytic granuloma** of pulmonary origin contained "raft-like" islands of acellular, hyaline connective tissue associated with a foreign body-type giant cell response.[195]

Collectively designated as "xanthomatous" are diverse lesions sharing only a conspicuous component of foamy, lipid-laden macrophages. Mention has already been made of **xanthogranulomas** forming in relation to colloid cysts of the third ventricle. Lesions similarly composed of foamy macrophages, foreign body–type giant cells, cholesterol clefts, and reactive lymphoid infiltrates commonly occur in the glomus of the choroid plexus but only rarely attain symptomatic proportions.[196] **Cholesterol granulomas of the petrous apex** that are believed to result from chronically impaired aeration of the petrous air cells may produce headache and palsies of cranial nerves V–VIII, prompting neurosurgical intervention.[197] Dura-based masses described as **xanthomas** or **xanthogranulomas**, some of immense proportions, have been encountered in otherwise healthy subjects,[198] in association with abnormalities of lipid metabolism such as familial hypercholesterolemia,[199] and in the setting of systemic Weber–Christian disease (relapsing nodular nonsuppurative panniculitis[200]). Nevertheless, as already discussed, it remains important to rule out histiocytic disorders, such as Langerhans cell histiocytosis and juvenile xanthogranulomatois.[201] Xanthomatous CNS infiltrates may also complicate **Erdheim–Chester disease**, an enigmatic histiocytosis, the hallmark of which is symmetric and bilateral sclerosis of the long tubular bones with colonization of the marrow spaces by lipid-laden macrophages; *BRAF V600E* and *MAP2K1* mutations are common in this disease.[202,203] On record, in addition, are xanthomas of probable traumatic etiology,[204] arguably neoplastic "**fibroxanthomas**"[205] and **juvenile xanthogranulomas**.[201] CNS infiltration is a recognized complication of "**xanthoma disseminatum**,"[206] a systemic syndrome characterized by the widespread eruption of juvenile xanthogranuloma-like lesions in normolipemic subjects. The development of dura-based masses has also been described in the setting of **necrobiotic xanthogranuloma**,[207] a similarly generalized disorder often associated with plasma cell neoplasia and other lymphoproliferative diseases. Symptomatic leptomeningeal and neuroparenchymal infiltration by foamy macrophages containing intracytoplasmic erythrocytes and lymphocytes frequently complicates the course of **hemophagocytic lymphohistiocytosis**[208] in both its primary (autosomal recessive and infantile-onset) as well as secondary (infection-triggered or paraneoplastic, particularly lymphoma-associated) forms. A possible example restricted to the CNS has been reported.[209]

Reference has been made previously to mass-forming foreign body reactions complicating the surgical management of intracranial aneurysms. Various hemostatic substances placed within neurosurgical beds during resection of neoplasms (and other procedures) may similarly provoke a florid and potentially granulomatous inflammatory response that can mimic tumor recurrence.[210] The cited literature can be consulted for microscopic characteristics of the responsible agents, the reactive masses in such cases being referred to as "**gauzomas**," "**muslinomas**," "**textilomas,**" or "**gossypibomas**" (from the Latin *Gossypium*, the genus of cotton plants, and the Kiswahili *boma*, meaning place of concealment).

Other odd neuropathologic processes that have been documented include **cerebral malakoplakia**[211] and the pseudoparasitic red blood cell alteration known as **myospherulosis**.[212] Lastly, we mention several described complications of systemic autoimmune (collagen vascular) disorders, including **rheumatoid meningeal nodules**,[213] **Wegener granulomatosis** extending to the intracranial dura from the sinonasal compartment[214] or presenting as meninges-restricted disease,[215] and a corticosteroid-responsive meningoencephalitis associated with cognitive impairment in the setting of **Sjögren syndrome**.[216,217] The term **nonvasculitic autoimmune inflammatory meningoencephalitis** has been applied to this non-necrotizing process, which is characterized by perivascular lymphoid cuffing with loose aggregates of microglia in the affected cerebral cortex. This picture, also associated with corticosteroid-reversible encephalopathy, may be encountered in patients without systemic complaints, some of whom have proven to harbor circulating antibodies to Sjögren syndrome antigens, elevated rheumatoid factor, or perinuclear antineutrophil cytoplasmic antibody.[217]

Infectious Diseases

Bacterial Infections

Bacteria are responsible for the overwhelming majority of suppurative infections involving the CNS and its coverings. Of particular concern to surgical pathologists are the common forms of brain and spinal epidural abscesses.

Approximately 20% of **brain abscesses** have no predisposing condition. The remainder arise in patients with established extraneural pyogenic infections, facilitating anatomic anomalies, or prior penetrating cranial trauma or neurosurgery.[218] The demographic features, localization, number, and microbiologic characteristics vary with the risk factors operative in individual cases.

The extraneural bacterial infections predisposing to brain abscess are usefully divided into those involving contiguous meningeal or parameningeal sites versus systemic sources. The fact that cerebral abscesses rarely complicate bacterial meningitis is curious, a notable exception being their significant association with neonatal cases caused by *Proteus mirabilis* and *Citrobacter diversus*.[218,219] More frequently implicated local sources of bacillary invasion are the paranasal sinuses, middle ear cavities, and mastoids.[218] Although the pathogenesis remains imprecisely defined, abscesses associated with these infections are commonly believed to result from the retrograde thrombophlebitic carriage of organisms into the cranial cavity via emissary veins. Typically solitary, these lesions tend to have characteristic topographic presentations. For example, cerebral abscesses related to frontoethmoid sinusitis characteristically settle in the anterobasal frontal lobes, whereas "otitic" examples including chronic mastoiditis are usually encountered in the temporal lobes or cerebellar hemispheres. Lesions complicating sphenoid sinusitis frequent the frontotemporal regions. The organisms most often isolated from brain abscesses in these clinical circumstances include aerobic or microaerophilic streptococci (especially members of the *Streptococcus intermedius "milleri"* group),

For personal use only. No other uses without permission. Copyright ©2017. Elsevier Inc. All rights reserved.

aerobic gram-negative bacilli (*Proteus*, *Escherichia coli*, *Klebsiella–Enterobacter*, and *Haemophilus* species), and *Bacteroides* species. Mixed infections are common. Other local suppurative processes associated with the subsequent development of brain abscess include dental sepsis and pyogenic infections of the face and scalp. Usually frontal in location, "odontogenic" abscesses typically follow tooth extraction or other dental manipulation and harbor mixed aerobic and anaerobic populations dominated by *Fusobacterium*, *Bacteroides*, and *Streptococcus* species. *Staphylococcus aureus* is the main offender with spread of facial or scalp infections; cerebral abscesses in this setting usually occur in cases complicated by cavernous sinus thrombosis. Mandibulofacial **actinomycosis** may also cause a brain abscess.[220] Spinal anomalies predispose to intramedullary abscesses, as do tumors of the spinal neuraxis, but such infections are decidedly rare.[221]

Hematogenous sources of infection usually result in multiple abscesses that commonly lie within the middle cerebral artery territories. Most start at the junction of the cortical mantle and underlying white matter since this is a common site of vascular branching with a filter-like effect, but the cerebellum, basal ganglia, thalami, and brainstem may also be involved. "Metastatic" lesions of this sort most often originate in the thorax, with chronic suppurating pulmonary disorders such as lung abscess and bronchiectasis leading the list of predisposing conditions.[218] Much less common among underlying sources of infection are bacterial endocarditis (characteristically acute), empyema, osteomyelitis, and infections of deep pelvic organs or abdominal viscera. Additional risk factors include various conditions in which the filtering function of the lung's capillary bed is abrogated (e.g. pulmonary arteriovenous fistulas) and cyanotic congenital heart diseases complicated by right-to-left shunts (e.g. tetralogy of Fallot, patent foramen ovale, ventricular septal defect, and transposition of the great vessels). The secondary polycythemia that regularly attends these anomalies may further promote the genesis of abscesses from infective emboli by causing microcirculatory sludging and regional brain hypoxia. Similar mechanisms may account for the significant risk of cerebral abscess in hereditary hemorrhagic telangiectasia (Osler–Weber–Rendu disease); most patients with this complication harbor pulmonary AVMs and exhibit hypoxemia with resultant cyanosis, clubbing, and polycythemia.[222] Iatrogenic causes of metastatic brain abscess include esophageal instrumentation for treatment of caustic strictures, or endoscopic injection of sclerosing agents for treatment of esophageal varices.[223]

The microbiology of the foregoing lesions is complex, but a few generalizations are possible. *Fusobacterium*, *Bacteroides*, and streptococci are most commonly cultured from brain abscesses associated with pulmonary sepsis, while actinomycotic[220] and nocardial[224] lesions (the latter often encountered in debilitated and immunosuppressed subjects) are also common secondary deposits from foci of established lung infection. Streptococci and *Haemophilus* species are the typical offenders in cases related to congenital heart disease, whereas *S. aureus* dominates isolates from examples complicating acute bacterial endocarditis.

Direct bacterial inoculation is probably the least frequent cause of abscess formation from either penetrating cranial trauma or neurosurgery.[218] *S. aureus* is the organism most often recovered from lesions arising in these circumstances, followed by *Streptococcus*, *Enterobacter*, and *Clostridium* species. *Propionibacterium acnes*, a gram-positive, anaerobic rod that causes a syndrome of shunt malfunction and immune-complex nephritis in patients with intraventricular catheters, has also emerged as an agent of traumatically and surgically acquired brain abscesses and epidural infection.[225,226] Trauma and intracranial hematoma accumulation, in addition, predispose to cerebral *Salmonella* abscess.[218] Brain abscesses remain diagnostically challenging from a clinical standpoint because their presenting manifestations and neuroradiological appearances are so nonspecific.

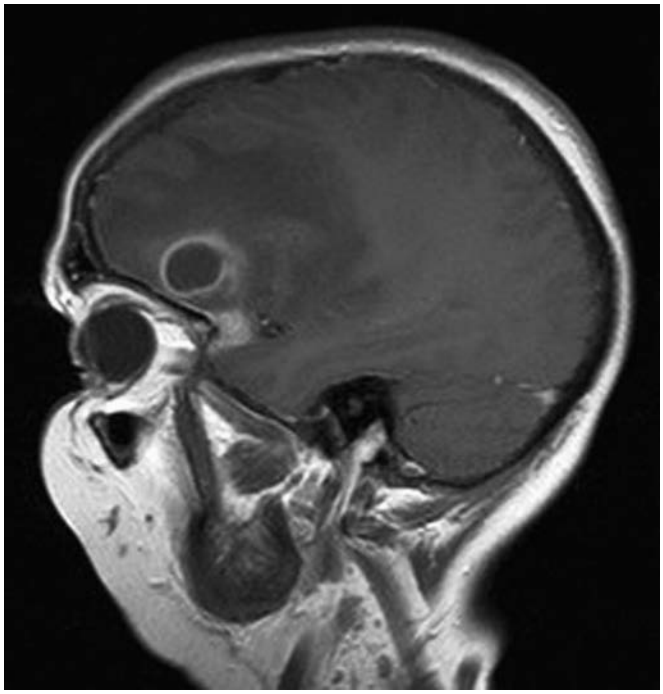

Figure 43.19 Cerebral Abscess. Ring enhancement of their developing pseudocapsules, budding of "daughter" lesions, and marked hypodensity of adjacent white matter reflecting severe edema are all characteristic of cerebral abscesses on postcontrast magnetic resonance imaging. In contrast to most glioblastomas (often a differential consideration), note the relatively thin and uniform rim of enhancement in this example.

It is noteworthy that only 40%–50% of affected patients are febrile. The more common signs and symptoms are those of any expanding intracranial mass: headache, altered mental status, focal sensorimotor deficits, seizure, nausea, and vomiting.[218] Although central hypodensity, rim enhancement, and surrounding edema are characteristic on CT or MRI studies (Fig. 43.19), these appearances may be shared by malignant neoplasms (particularly glioblastomas) and, on occasion, demyelinating disease. The enhancing pseudocapsules of abscesses tend to be thinner and of more uniform profile than in glioblastomas, typically acquire a dark signal on T2-weighted MRI (as they collagenize) that is foreign in neoplasia, and surround contents that are bright on diffusion-weighted imaging in contrast to the centrally necrotic and dark interior of glioblastoma. The apparent budding of smaller, "daughter" lesions from the main mass also suggests abscess.

Experimental, clinical, and histopathologic observations suggest that cerebral abscesses begin as ill-defined zones of bacterial multiplication and polymorphonuclear leukocytic infiltration (cerebritis) most commonly situated in white matter immediately subjacent to the cortical ribbon or at the gray–white junction.[218] With time, proliferating fibroblasts surround a central mass of fibrinopurulent debris and fashion a collagenous capsule resembling the pyogenic membranes formed in suppurative infections outside the nervous system (Fig. 43.20). This, in turn, is bordered by edematous, chronically inflamed, and gliotic brain tissue that may show evidence of acute cerebritis reflecting the host's failure to entirely wall off the primary locus of infection.

The rate and completeness of encapsulation varies considerably. *Nocardia* is especially notorious for poor encapsulation. Capsular organization is typically most advanced along the superficial, juxtacortical perimeter, with "daughter" lesions typically budding from

For personal use only. No other uses without permission. Copyright ©2017. Elsevier Inc. All rights reserved.

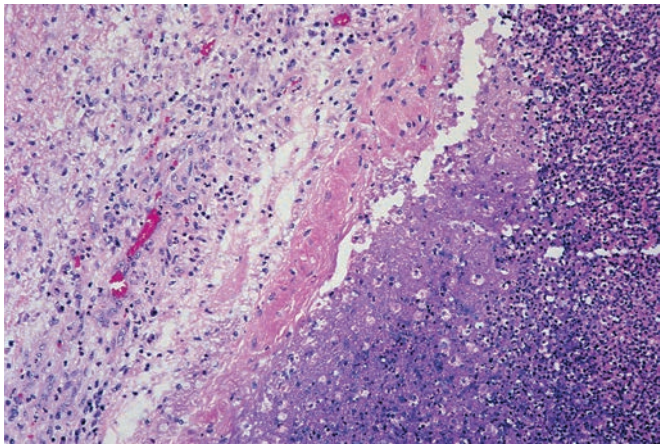

Figure 43.20 Cerebral Abscess. The lesion's purulent contents are separated from neighboring white matter by a granulation tissue–like zone of angioblastic and fibroblastic activity.

the deep aspects with subsequent rupture into the ventricular system rather than subarachnoid space. Because the mesenchymal elements responsible for capsule formation presumably derive from the adventitia of regional blood vessels and require oxygen for collagen fibrillogenesis, the relatively retarded organizational responses of paraventricular, as compared with cortical and paracortical, tissues may be a consequence of their less extensive vasculature. The intraventricular discharge of purulent material is among the most serious complications, often proving fatal.

In contrast to the largely intracranial localization of bacterial abscesses involving the CNS proper, 90% of epidural examples are spinal.[227] This "true" (as opposed to potential) space, containing adipose tissue, nutrient arteries, and an elaborate venous plexus, expands posterior and lateral to the dura mater, whereas above the foramen magnum this fibrous sheath adheres tightly to the inner aspect of the skull. Anterior tethering of the dura to adjacent vertebral bodies presumably accounts for the fact that most **epidural abscesses** of the spinal cord are posteriorly or posterolaterally positioned. Approximately half of these settle in the thoracic, and one-third in the lumbar region. Less accommodating is the epidural space at cervical levels, where the spinal canal is nearly filled by the cord itself, with sacral lesions also being rare.

Roughly 30%–40% of spinal epidural abscesses arise "spontaneously," with the remainder secondarily complicating infections at contiguous or distant sites, trauma, intravenous drug abuse, spinal surgery or other invasive procedures, including epidural catheterization and lumbar puncture. Of particular importance among predisposing infections are contiguous foci of vertebral osteomyelitis, psoas and perinephric abscesses, decubitus ulcers, and other cutaneous and soft tissue suppurations. Diabetes mellitus, alcoholism, and renal failure are also significant risk factors. Presenting clinical manifestations typically include fever, malaise, and backache. If antimicrobial therapy and neurosurgical decompression are delayed, infection may progress in stepwise fashion to radiculopathy, sensorimotor, and sphincter disturbances indicative of spinal cord dysfunction, and, finally, paralysis. *S. aureus* remains the most common culprit, distantly trailed by gram-negative aerobes such as *E. coli* and *Pseudomonas aeruginosa*, streptococci, and various anaerobes.

Although *Mycobacterium tuberculosis* is among the more common agents of spinal epidural abscess,[227,228] especially among intravenous drug abusers, the lesions it produces are typically granulomatous and caseating rather than suppurative. These usually arise in the low thoracic or lumbar region by extension from contiguous foci of tuberculous vertebral osteomyelitis or disk infection, but "primary" examples not associated with osseous, pulmonary, or other extraskeletal disease may be encountered. Diagnosis is complicated by the fact that patients often present with back pain of insidious onset and chronic evolution unattended by fever, leukocytosis, or evidence of tuberculosis on chest film. As with nontuberculous epidural abscesses, the consequence of delayed intervention is progressive neurologic dysfunction culminating in myelopathy or "Pott paraplegia." Other localized forms of mycobacterial CNS infection include **tuberculoma**,[228] **focal tuberculous meningoencephalitis**,[229] and the rare **tuberculous abscess**.[230] **Subdural tuberculous empyema** has also been described.[231] Tuberculoma, defined as an encapsulated, granulomatous, and centrally caseating inflammatory mass, is by far the most common variant of neuroparenchymal tuberculosis. It is usually unaccompanied by evidence of coextant meningeal infection and may settle anywhere along the neuraxis but favors the intracranial contents. An excess of pediatric examples present in the cerebellum, constituting the posterior fossa "tumors" encountered most frequently in some countries (e.g. India) where tuberculosis is rampant. Exceptionally, tuberculomas are dura based,[232] rather than intra-axial, or confined to the spinal cord.[233] Human immunodeficiency virus type 1 (HIV-1)-seropositive subjects[228] are at substantially increased risk of developing both tuberculous meningitis and neuroparenchymal tuberculomas, and instances of CNS infection by nontuberculous mycobacteria have also been documented in this setting.[234] *Mycobacterium avium-intracellulare* complex characteristically evoke a nongranulomatous response that may include conspicuous spindling of infected histiocytic elements—a phenomenon that can be confused with a mesenchymal or meningothelial neoplasm.[235]

Other distinctive bacterial infections of the nervous system proper include a bulbar encephalitis ("rhombencephalitis") caused by *Listeria monocytogenes*,[236] and cerebral Whipple disease, resulting from invasion of the neuropil by *Tropheryma whipplei*.[237] The latter process (which may rarely be confined to the CNS) is characterized in the brain, as elsewhere, by infiltrates of foamy macrophages exhibiting an intense, granular PAS positivity of their cytoplasm (which has a peculiar blue–gray tint in hematoxylin–eosin sections) and containing numerous rod-shaped bacillary forms on ultrastructural study. A florid reactive astrogliosis is the rule. *Bartonella henselae* (agent of cat-scratch disease and bacillary angiomatosis) has been described as causing space-occupying, inflammatory CNS lesions often in association with underlying immunodeficiency.[238]

Mycoses

CNS mycosis is particularly common in immunocompromised patients. Nevertheless, neuroinvasive fungal infection is only exceptionally seen by the surgical pathologist. Most space-occupying intracranial and intraspinal lesions of mycotic etiology develop in association with diffuse meningeal or disseminated systemic infection and, consequently, are diagnosed by study of the CSF or, in the latter scenario, are treated empirically. Many are discovered only at autopsy. *Cryptococcus neoformans*, pathogenic molds, *Candida* species, and the dimorphic and dematiaceous fungi collectively account for the vast majority of lesions encountered in neurosurgical practice.[239]

C. neoformans, the agent of a diffuse leptomeningitis that is the single most common CNS mycosis, occasionally proliferates in localized neuroparenchymal or choroid plexus-based, intraventricular masses known as cryptococcomas.[239] It is noteworthy that fewer than 5% of cryptococcomas arise in the setting of opportunistic infection. Cryptococcal meningitis, by contrast, often afflicts immunosuppressed patients (e.g. HIV, diabetes, organ transplant recipients,

For personal use only. No other uses without permission. Copyright ©2017. Elsevier Inc. All rights reserved.

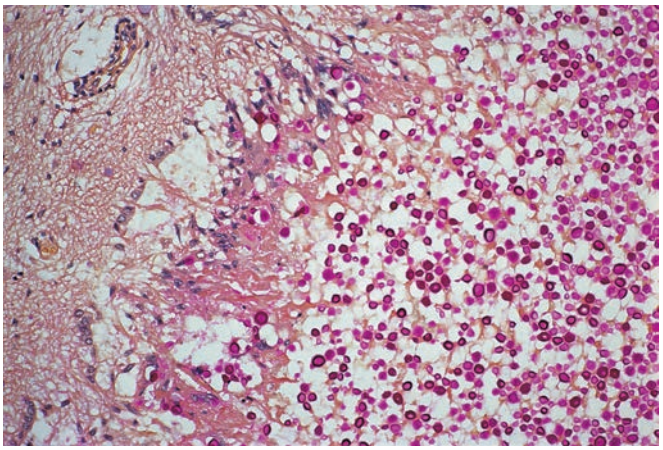

Figure 43.21 Cryptococcoma. This neurosurgical specimen, from a previously healthy 54-year-old man with a "tumor" primarily involving the choroid plexus and wall of the right lateral ventricle, demonstrates numerous yeast forms identifiable as *Cryptococcus neoformans* by their mucicarmine-stained capsules.

and patients being treated for hematologic or lymphoid neoplasia). The appearance of the cryptococcoma varies with the host's reaction and may range from no associated inflammation to necrotizing granulomas and pronounced desmoplasia. When cryptococci hold the advantage, the lesion consists mainly of mucoid or gelatinous material that reflects the conspicuous elaboration of capsular mucopolysaccharides characteristic of these organisms. This is often traversed in honeycomb-like fashion by fibrous connective tissue septa. At the other extreme are sclerotic, granulomatous masses containing only rare yeast forms. Exceptional examples mimic bacterial abscesses, containing purulent debris bound by a well-developed pyogenic membrane. *Cryptococcus* is typically ovoid or spheric in profile, measures 2–15 μm in diameter, replicates by budding from a narrow base, and is reliably distinguished from other yeast by demonstration of its mucicarminophilic capsule (Fig. 43.21) or by the Fontana–Masson stain in the increasingly frequently encountered capsule-deficient variants.

Fungi existing in pure hyphal form at both room temperature and 37°C are termed molds. The major CNS pathogens in this group include *Aspergillus* species, *Mucor* and related species, and *Pseudallescheria boydii* (also referred to as *Scedosporium apiospermum*). *Fusarium*, *Paecilomyces*, and *Penicillium* species, *Streptomyces griseus*, and *Acremonium alabamensis* are also occasionally neuroinvasive.[239] Opportunists all, these ubiquitous organisms only rarely attack otherwise healthy individuals and share a particular predilection for patients receiving maintenance doses of broad-spectrum antibiotics through protracted periods of neutropenia, as commonly occurs in the management of leukemias and lymphomas. CNS infections that occur in such settings result from systemic fungemia, are primarily intraparenchymal and usually multifocal, and are typically accompanied by evidence of systemic mycosis. The development of cerebral aspergillosis in patients treated for hematologic neoplasms, for example, is almost invariably preceded by symptomatic fungal infection of the lungs. Also at risk of blood-borne CNS seeding by pathogenic molds are patients taking corticosteroids, intravenous drug abusers, and, in the case of *P. boydii*,[240] victims of near drowning. Prior to the widespread use of immunosuppressive chemotherapeutic regimens for the treatment of cancer, *Aspergillus* generally invaded the CNS from primary foci of ocular, sinonasal, or middle ear infection. Alcoholic liver disease and Cushing syndrome have also been associated with CNS aspergillosis.[239] A second important form of meningeal and neuroparenchymal mycosis caused by these agents follows their direct intracranial spread from foci of orbital or paranasal sinus infection. This pattern of disease is typified by rhinocerebral mucormycosis, a disorder classically associated with diabetic ketoacidosis but also complicating other acidemic states (e.g. sepsis, profound dehydration, uremia), renal transplantation, and deferoxamine therapy.[239] In addition, skull fracture, penetrating trauma, and craniotomy may set the stage for CNS mycoses.

The neurologic manifestations, distribution, and morphology of CNS lesions caused by these agents vary with the clinical circumstances surrounding infection and the immune status of the host. A syndrome of multifocal stroke that reflects the shared tendency of pathogenic molds to occlude, invade, and trigger thrombosis of the leptomeningeal and perforating cerebral vasculature is particularly characteristic of cerebral disease evolving in the setting of disseminated systemic mycosis. The resulting lesions are basically infarcts, often hemorrhagic, that are secondarily colonized by fungi migrating through damaged blood vessel walls and that frequently exhibit little inflammatory reaction or limited suppuration. These are typically scattered in both cerebral hemispheres and often involve the deep nuclei, cerebellum, and brainstem. Contiguous fungal infiltration of the leptomeninges is common, but infection limited to these tissues is rare. Solitary lesions are exceptional, but examples produced by *Aspergillus* species,[241] *P. boydii*,[240] and other molds[239] are on record. These present with symptoms referable to an expanding intracranial mass, tend to occur in patients whose immune reflexes are relatively preserved, and may assume an abscess-like or even granulomatous character. Of particular note is a distinctive form of localized CNS mucormycosis characterized by a remarkably stereotypic predilection for the basal ganglia of intravenous drug abusers.[242] The more common rhinocerebral infections caused by advancing Mucorales are manifest as poorly delimited, necrotizing lesions again exhibiting the ischemic and hemorrhagic qualities typical of these angioinvasive organisms. True mycotic aneurysm has also been described as a consequence of cerebral aspergillosis.[243]

The definitive taxonomic classification of molds requires their isolation in culture or identification using molecular assays and cannot be accomplished on tissue morphology alone. Of the major CNS pathogens, both *Aspergillus* species and *P. boydii* appear in biopsy material as septate hyphae. *Aspergillus* species are usually somewhat stouter and more frequently branch at acute angles, but these are not reliably distinguishing features. By contrast, *Mucor* is a broad, ribbon-like hyphal organism that is pauciseptate and branches randomly.

Blastomyces dermatitidis, *Histoplasma capsulatum*, *Coccidioides immitis*, and *Paracoccidioides brasiliensis* are traditionally grouped as "dimorphic" fungi because of their growth as filamentous mycelia at room temperature and yeast at 37°C. All are capable of infecting the CNS, usually in the form of a chronic granulomatous meningitis in patients with coextant, active systemic mycoses. Limited extension to the cerebral cortex from contiguous foci of leptomeningeal infection is common but typically of no clinical consequence. Only rarely do neuroparenchymal lesions attain symptomatic proportions.[239] Again, these unusual fungal masses are generally, although not invariably, associated with clinically evident infection of extraneural tissues. Examples have been described both in the obviously immunodeficient and in patients with no clear risk factors for opportunistic disease. It is worth noting that roughly half of the intracranial blastomycomas and a majority of the histoplasmomas reported to date presented as solitary lesions. Brain invasion by *C. immitis* and *P. brasiliensis* is, by contrast, infrequently unifocal. In general, these organisms evoke a necrotizing, granulomatous tissue response replete with multinucleated giant cells and, in cases of blastomycoma and histoplasmoma,

For personal use only. No other uses without permission. Copyright ©2017. Elsevier Inc. All rights reserved.

foci of caseation that may prompt considerations of tuberculous infection. A suppurative/neutrophilic infiltrate is also commonly observed in otherwise granulomatous fungal masses. Cerebral endarteritis and mycotic intracranial aneurysm caused by *C. immitis* infection have been described,[244] as has massive dural and cerebral venous thrombosis associated with coccidioidal meningitis in an AIDS patient.[245]

The dematiaceous (from the genus *Dematium*) fungi are a group of pigmented hyphal yeasts best known as the agents of chronic skin and subcutaneous infections, such as Madura foot and tinea capitis. Extracutaneous disease is exceptional, but the brain is a common target in disseminated mycoses caused by these organisms. One member of the group, *Xylohypha bantiana (Cladosporium trichoides)*, appears to be specifically neurotropic and is responsible for most CNS infections,[246] which are often grouped with other deep mycoses caused by pigmented fungi under the rubric of phaeohyphomycosis. This organism is fully capable of invading the nervous systems of apparently immunocompetent hosts and, in many cases, does so in the absence of demonstrable foci of extraneural infection. Isolated patients have suffered immunosuppressive underlying conditions; have exhibited preexistent phaeohyphomycotic infections of the paranasal sinuses, ear, or lungs; or have apparently acquired the infection through traumatic intracerebral implantation or intravenous drug abuse.[247] Neuroparenchymal lesions consist of necrotizing granulomas, which are multifocal in about 50% of cases. A similar fraction is attended by fungal meningitis. In tissue sections, the agent appears as branching, septate hyphal, and yeast-like structures with a brown or olive-green hue. Culture or PCR testing is required for definite classification. Other pigmented fungi that have also been reported rarely[239] include *Drechslera–Bipolaris–Exserohilum* and *Curvularia* species, *Fonsecaea pedrosoi*, *Wangiella dermatitidis*, *Dactylaria constricta*, *Ramichloridium obovoideum*, and *Scopulariopsis brumptii*.

Cerebral candidiasis has emerged in recent years as one of the most common CNS mycoses encountered in immunosuppressed patients.[239] However, the great majority of cerebral *Candida* infections are discovered only at autopsy, resulting from fungemia in debilitated, moribund patients. The typical lesions are diminutive foci of suppuration scattered widely in the neuropil and associated in some cases with fungal meningitis. The formation of granulomas or macroabscesses, disease limited to the meninges, and vasculitis, with resultant infarction or the development of mycotic aneurysms,[239,243] have also been described, as has the extraordinary presentation of CNS candidiasis as a localized fungal mass.[248]

Parasitoses

The CNS parasitoses include a great variety of protozoal and helminthic infections. This discussion is limited to two representatives of particular importance to the surgical pathologist—neurocysticercosis and toxoplasmosis.

Neurocysticercosis, caused by larvae of the pork tapeworm, *Taenia solium*, is the most common parasitic cerebral infection encountered in worldwide neurosurgical practice.[249] Endemic to nearly all continents, the disease is particularly prevalent in Mexico (where it is the leading cause of space-occupying intracranial lesions), Central and South America, India, Africa, and China. An increasing incidence in the United States is largely attributable to cases occurring in immigrants from these regions. Infection is acquired by ingestion of food or water contaminated by feces containing the cestode's ova. These are partially digested in the host's stomach, evolving to oncospheres and subsequently penetrating the small intestinal mucosa to disseminate throughout the body, preferentially encysting in ocular tissues, striated muscle, and brain. The ensuing clinical disorder is named for the designation given the organism at this larval stage, *Cysticercus cellulosae*.

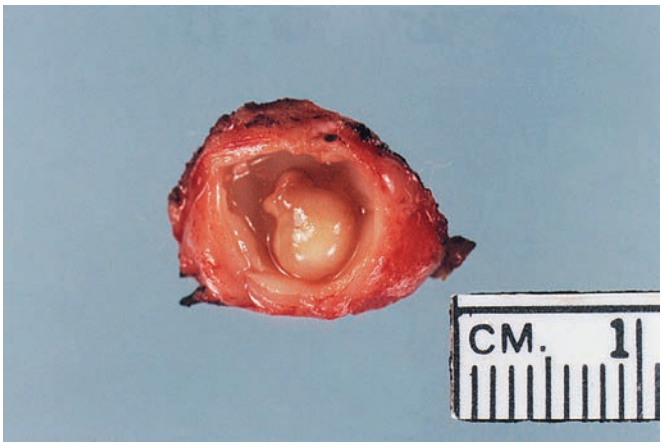

Figure 43.22 Neurocysticercosis. Typical of cerebral *Taenia solium* infestation is the solitary, encysted scolex demonstrated in this neurosurgical specimen from the left frontal cortex of a 32-year-old Haitian man with a history of seizures.

Cysticerci actually persist in parasitized tissues for long periods in asymptomatic form. The active clinical phase is triggered by the host's inflammatory response to the larva's death (~18 months following primary infection). The high incidence of focal or generalized seizures associated with the disorder reflects the fact that oncospheres reaching the CNS settle mainly in the epileptogenic cerebral cortex, but they may also colonize the ventricular system and basal cisterns in a distinctive pattern of infestation ("racemose" cysticercosis) resulting in obstructive hydrocephalus and consequent manifestations of elevated intracranial pressure. The presence of multifocal, rim-enhancing cerebral cysts on neuroimaging study suffices in many cases to prompt a diagnostic as well as therapeutic course of anthelmintic chemotherapy, but a substantial proportion of patients present with solitary lesions, and the host's reaction to the decaying parasite may convert the cyst to a deceptively solid inflammatory pseudotumor. Neurosurgical intervention may be obviated by CSF or serologic assay for specific anticysticercal antibodies or antigens, but false-negative results may be encountered, especially in subjects with unifocal disease.[249]

When not completely obscured by secondary inflammatory changes, the gross appearance of cysticerci excised in toto is virtually pathognomonic (Fig. 43.22). Individual cysts are of small diameter, are circumscribed by a rubbery fibrous pseudocapsule, and contain a single larval scolex represented by a spheric or ovoid grayish-white nodule measuring no more than 3–4 mm in greatest dimension. By contrast, cestode larval cysts produced by the morphologically similar *Multiceps multiceps* contain numerous scolices, and those caused by *Echinococcus granulosus* are considerably larger and endowed with a characteristically laminated wall. On histologic examination, the fibrous pseudocapsule is typically infiltrated by numerous lymphocytes and plasma cells, may contain eosinophils in abundance, and in some cases is the site of an active granulomatous reaction. The mummified remains of the degenerate scolex are covered by a wavy, somewhat refractile cuticle and consist largely of loose, reticular tissue containing numerous calcospherites. Relatively intact scolices possess a discernible subcuticular "pseudoepithelial" layer, small myofiber bundles, and four suckers armed with birefringent hooklets (Fig. 43.23). Racemose cysticerci evacuated from the ventricles or subarachnoid space present as grape-like clusters of interconnected larval "bladders" lacking organized scolices.

For personal use only. No other uses without permission. Copyright ©2017. Elsevier Inc. All rights reserved.

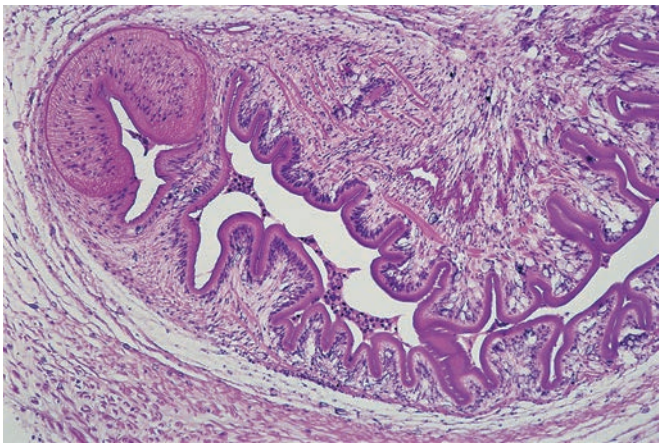

Figure 43.23 Neurocysticercosis. The parasite's main structural features include a prominent investing tegument or "cuticle," aggregated subcuticular cells, smooth muscle fibers, and four suckers, one of which is depicted at upper left.

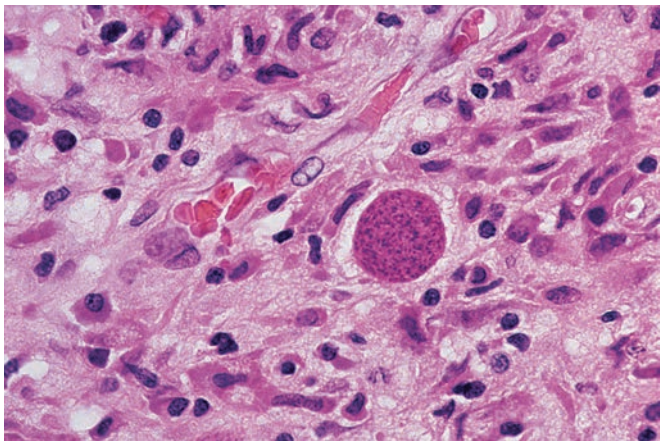

Figure 43.24 Toxoplasmosis. Minute, basophilic structures representing bradyzoites fill a protozoal pseudocyst with associated infiltrating lymphocytes, plasma cells, and macrophages.

Toxoplasmosis is the generic designation applied to localized or systemic infections caused by the obligate intracellular protozoan *Toxoplasma gondii*. CNS involvement may assume a number of distinctive clinicomorphologic guises,[250] but this discussion will focus on a "tumefactive" variant largely confined to immunocompromised hosts that is typically unassociated with clinical manifestations of extraneural parasitosis. Once regarded as rare and encountered principally among patients treated for hematolymphoid neoplasms (Hodgkin disease, particularly), this form of toxoplasmosis is now known to physicians the world over as a common AIDS-defining disorder and is in fact the leading cause of space-occupying intracranial lesions in the HIV-positive patients.[250] Bone marrow transplant recipients have also emerged in recent years as a population prone to CNS infections of this type. Mechanistically, there is a breakdown of cell-mediated immune surveillance, which is thought in most cases to permit reactivation of dormantly parasitized neural tissues. *T. gondii* is noted for its silent persistence in the brain following primary infection, which is usually asymptomatic and acquired by the consumption of inadequately cooked red meats containing encysted organisms, or by the inadvertent ingestion of foodstuffs, soil, or other materials contaminated by protozoal oocytes shed in the feces of domestic cats.

The clinical and neuroradiological features of CNS toxoplasmosis are variable and too nonspecific for definite diagnosis. Because *Toxoplasma* "abscesses" favor neuron-rich gray matter structures such as the cerebral cortex, basal ganglia, and brainstem, it should come as no surprise that seizures, progressive hemipareses, and cranial nerve deficits figure prominently among the initial manifestations. Many patients, however, present without localizing complaints, but rather with fever, headache, lethargy, and a subacute diffuse encephalopathy. Cranial MRI typically discloses multifocal, rim-enhancing nodular lesions with surrounding edema and mass effect, but exceptional examples are nonenhancing, and solitary abscesses are not rare. Isolated involvement of the spinal cord has been described.[251] A negative serum anti-toxoplasma IgG titer is evidence against, but does not entirely exclude, the diagnosis, particularly in severely immunocompromised patients. In the setting of HIV, it has become common practice to institute antimicrobial therapy on empiric grounds in suspect cases and to reserve neurosurgical intervention for patients who do not respond adequately. Most of the latter patients prove to harbor primary CNS lymphomas rather than toxoplasmosis.

The *Toxoplasma* "abscess," as it is commonly called, consists of a central mass of necrotic cellular debris surrounded by edematous and inflamed brain tissue that typically exhibits conspicuous vascular abnormalities. The latter include perivascular and intramural lymphoid infiltration, endothelial swelling, thrombosis, fibrinoid necrosis, and, in longstanding lesions, fibrous obliteration. It is within this perimeter zone that *Toxoplasma* are most numerous, but the necrotic core often lacks identifiable organisms. Two protozoal forms are evident in active lesions. The rapidly proliferating tachyzoite is responsible for tissue injury. These are faintly basophilic, measure approximately 4–8 μm in greatest dimension, and typically have a slightly crescentic or lunate profile (the Greek *toxon* means bow or arc). Because it is often difficult to visualize tachyzoites in routine histologic preparations and to confidently distinguish them from nuclear debris, the screening of suspect biopsy material with *Toxoplasma*-specific antibodies is strongly advised. More readily apparent, although present in less numbers, are intracellular pseudocysts and "true" (i.e. membrane-delimited) cysts that may attain diameters of up to 200 μm (Fig. 43.24). These are filled with minute, PAS-positive bradyzoites (named for their slow replicative cycles), are immunologically inert (i.e. unassociated with an inflammatory response), and represent the form in which *Toxoplasma* chronically persist in brain and other tissues. Within the CNS, bradyzoites appear to collect preferentially within neurons and perivascular macrophages. Again, it is immunodeficiency that somehow triggers their metamorphosis to tachyzoites and subsequent destructive invasion of neural tissues. Careful inspection of active lesions often reveals ruptured cysts as well. Like tachyzoites, bradyzoites are labeled by commercially available *Toxoplasma*-specific antibodies.

Spirochetal Infections

The two major CNS spirochetoses are neurosyphilis,[252] caused by *Treponema pallidum*, and neuroborreliosis, which is caused by the agent of Lyme disease, *Borrelia burgdorferi*.[253] The pathogenesis and varied clinical expressions of these complex syndromes are beyond the scope of this chapter; suffice it to say that intracerebral inflammatory pseudotumors (known as "gummas" in the case of treponemal disease and accompanied by necrosis and fibroplasia) are restricted to the late stages of systemic infection, constitute an uncommon manifestation, and are usually approached surgically only when the diagnosis is not suspected clinically.

For personal use only. No other uses without permission. Copyright ©2017. Elsevier Inc. All rights reserved.

Viral Infections

Herpes Simplex Encephalitis

Herpes viruses are responsible for a wide variety of neurologic infections. Our concern here is with a distinctive form of focal, necrotizing, and hemorrhagic encephalitis caused principally by herpes simplex virus type 1 (HSV1). **HSE** afflicts only 2–4 persons per one million persons a year but leads the list of potentially fatal nonepidemic viral cerebral infections.[254] Individuals of any age may be affected. The disease is often fulminant in its evolution and is characterized by fever, disordered affect, dysphasia, seizure activity, and deterioration of consciousness. CSF pleocytosis is the rule and may be accompanied by xanthochromia. Abnormalities are usually localized to one or both frontotemporal regions on neuroimaging. Brain biopsy has been generally replaced in the appropriate clinical circumstances by the availability of polymerase chain reaction (PCR)-based assays for HSV DNA in the CSF, a diagnostic method with high sensitivity and specificity.[254]

A remarkably stereotypic predilection for the anteromedial temporal lobes, orbitofrontal cortex, insulae, and cingulate gyri typifies HSE.[255,256] Experimental observations support the hypothesis that this "limbic" distribution reflects transolfactory spread of the agent to the CNS and suggest that at least some cases follow activation of virus residing latently in cerebral tissues. The histologic appearance of the disorder varies considerably with the duration of the clinical illness. The earliest appreciable changes, evident prior to the arrival of inflammatory infiltrates, include neuronal shrinkage and eosinophilia accompanied by vascular congestion, spongy cortical rarefaction, and pallor. This picture may closely mimic hypoxic–ischemic brain injury, leading to misdiagnosis as acute cerebral infarction, although close scrutiny of degenerating neurons often reveals a ground-glass viral cytopathic effect. It is during this early phase that careful search for the eosinophilic intranuclear viral inclusions is most likely to be successful (Fig. 43.25). These may be identified in cortical astrocytes and satellite oligodendroglia, as well as neurons, but are an inconstant feature.

The pronounced inflammatory reaction characteristic of fully developed HSE is usually apparent by the second week of clinical disease. Lymphocytes and plasma cells colonize the meninges, cuff penetrating blood vessels, and migrate into damaged cortex. Mononuclear cells may converge on infected neurons to form neuronophagic or so-called microglial nodules. These changes are often accompanied by hemorrhage and, in some cases, thrombosis and even fibrinoid vascular necrosis. Foamy macrophages eventually dominate the cellular infiltrate, ultimately clearing the necrotic debris, leaving only cavitated and gliotic remnants at sites of prior infection.

Immunocytochemistry and molecular genetic techniques may aid in the diagnosis of HSE in select biopsies exhibiting little alteration at the light microscopic level. Commercially available antibodies to HSV are widely available, and immunohistochemical assessment is strongly recommended in all cases of clinically suspected HSE, regardless of whether inspection of biopsy material reveals an inflammatory process (Fig. 43.26). In fact, Esiri's elegant correlative studies indicate that attempts at HSV antigen detection are most likely to succeed during the first week of encephalitic symptoms.[256] Coincident with a mounting inflammatory reaction, antigen expression declines steadily through the second and third weeks of the clinical illness and is not usually demonstrable thereafter. We have noted, however, the unusual persistence of viral antigens beyond this period in cases of HSE involving immunocompromised hosts, including cancer patients and individuals with underlying infection by HIV-1.[257,258] These appeared to be arrested at the noninflammatory, pseudoischemic phase characteristic of early HSE in otherwise normal individuals. HSE has also been documented in patients with primary brain tumors, raising the question of whether a neoplasm, and/or its surgical or adjuvant management, might trigger activation of latent HSV infection.

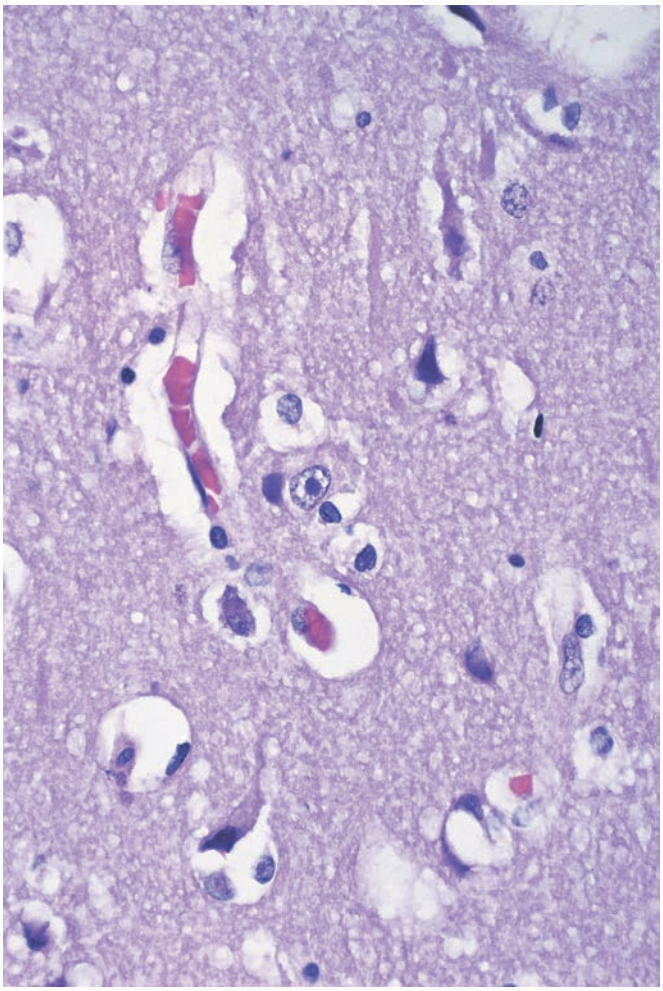

Figure 43.25 Herpes Simplex Encephalitis (HSE). As shown here, HSE may masquerade as a noninfectious, ischemic process (particularly if biopsied early in its clinical evolution). Note the noninflammatory appearance, neuronal shrinkage, pyknosis, and dissolution. The nucleus of a cell in the center of this field contains a well-defined Cowdry A inclusion body.

The reader is referred elsewhere for discussion of relapsing and chronic (including granulomatous) encephalitides that have been attributed to HSV infection.[259]

Progressive Multifocal Leukoencephalopathy

Progressive multifocal leukoencephalopathy (PML) is an opportunistic demyelinating disease caused by DNA viruses of the polyoma group. Nearly all clinical isolates responsible for the disorder have been strains of the ubiquitous **JC virus** (so designated for the initials of the first afflicted patient from whom the agent was recovered), with only exceptional cases linked to the related SV-40. PML is almost always associated with defective cell-mediated immunity and is currently encountered most frequently in the setting of AIDS, where it may be the presenting feature. The disease is characterized by subacutely evolving multifocal neurologic symptoms, chiefly

For personal use only. No other uses without permission. Copyright ©2017. Elsevier Inc. All rights reserved.

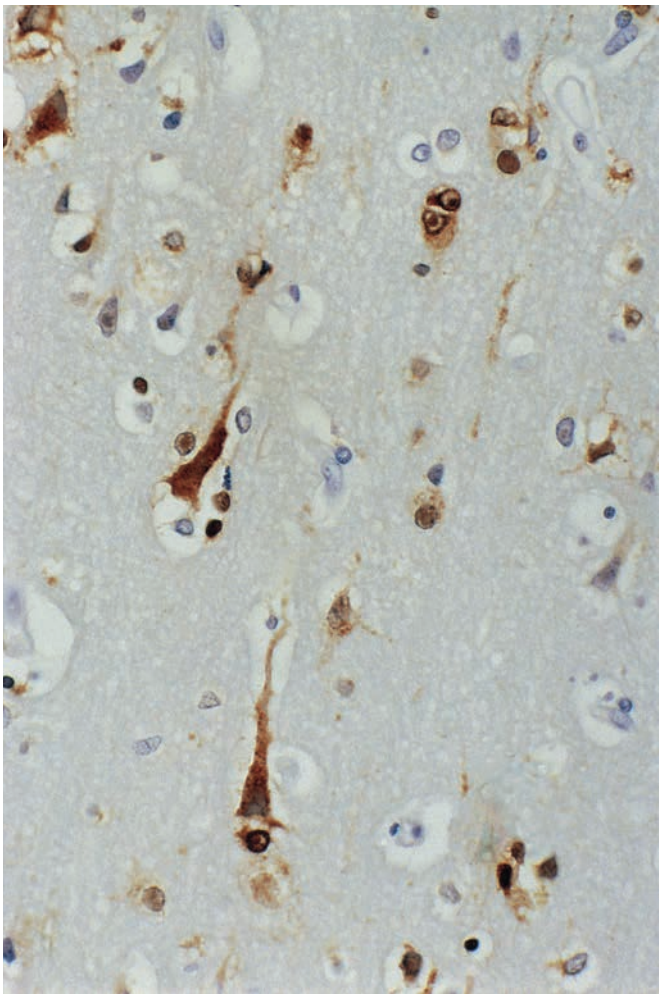

Figure 43.26 Herpes Simplex Encephalitis. In this immunoperoxidase preparation, the cytoplasm of neurons and inclusion bodies within the nuclei of satellite glia are labeled by antibodies to herpes simplex type 1.

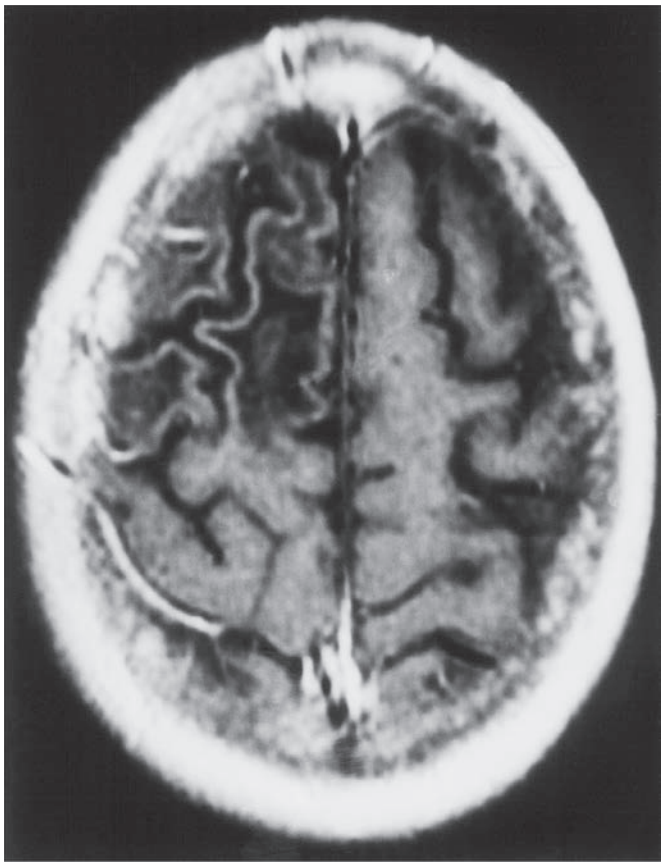

Figure 43.27 Progressive Multifocal Leukoencephalopathy. A postcontrast injection magnetic resonance imaging demonstrates the regional white matter hypodensity, absence of mass effect or abnormal enhancement, and cortical preservation that typify this demyelinating infection.

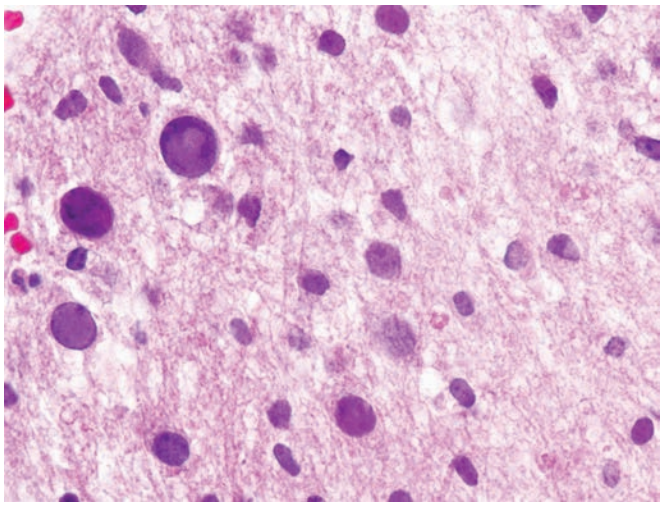

Figure 43.28 Progressive Multifocal Leukoencephalopathy. JC virus–infected oligodendrocytes in the left of this field exhibit the nuclear swelling, chromatin dissolution, and replacement by amphophilic, "ground-glass" inclusion material that is peculiar to this disorder.

motor deficits, cognitive decline, and visual loss. Although tumefactive variants have been described,[260] neuroimaging studies usually provide a clue to the nature of the process by demonstrating scattered white matter hypodensities not associated with mass effect or contrast enhancement (Fig. 43.27). PCR demonstration of JC virus–specific DNA from the CSF has emerged as a useful diagnostic procedure, reducing the need for brain biopsy.

Any level of the central neuraxis may be affected, but the cerebral hemispheric white matter generally bears the brunt of the injury. Cerebellar and bulbar localizations are less common, and the spinal cord is usually spared. It is the remarkable tropism of the JC virus for, and its replication within, oligodendroglia that is responsible for the alterations pathognomonic of PML. Infection of these cells results in progressive nuclear enlargement with plum-colored viral inclusions (Fig. 43.28). Considerably less common are demarcated eosinophilic inclusions of the sort that typify herpes virus infections. At the ultrastructural level, oligodendrocyte nuclei are distended by nonenveloped, spheric, or icosahedral particles measuring 33–45 nm in diameter. These are frequently aggregated in paracrystalline arrays and may be admixed with filamentous viral strands lending an appearance of "spaghetti and meatballs." Although immunocytochemical assays, in situ hybridization, and gene amplification

For personal use only. No other uses without permission. Copyright ©2017. Elsevier Inc. All rights reserved.

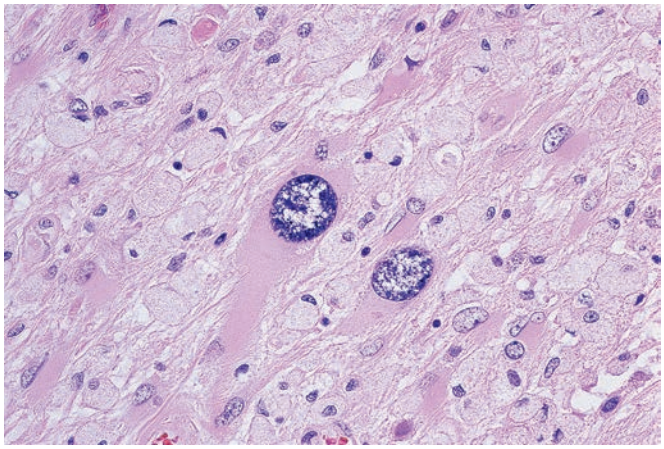

Figure 43.29 Progressive Multifocal Leukoencephalopathy. Grotesque cytologic alterations may result from infection of astrocytes by the JC virus. An accompanying infiltrate of foamy macrophages should militate strongly against the diagnosis of neoplasia, despite the worrisome appearances of these bizarre cells.

techniques may be used to confirm JC virus infection, the highly characteristic histology of PML cannot be overemphasized.[261]

With the ongoing infection and lysis of target cells, PML evolves as centrifugally expanding zones of oligodendroglial depletion and subsequent infiltration by foamy macrophages engaged in the scavenging and digestion of degenerating myelin sheaths. Early on, small plaques tend to cluster at the corticomedullary junction, probably reflecting hematogenous seeding of the CNS following reactivation of the agent in sites of systemic latency. Geographic zones of demyelination, resulting from the coalescence of these small lesions, become grossly evident as regions of white matter retraction, granularity, and yellowish-gray discoloration. In most cases, a relatively undisturbed cortical ribbon will span these devastated areas, although gray matter contributions have been recently emphasized.[261] This, and the characteristic persistence of axons in the face of total demyelination, reflects the resistance of neurons (cerebellar granule cells excepted) to JC virus infection. Some axonal loss, however, is the rule, and PML can progress to extensive white matter cavitation. Particularly widespread and destructive examples have been described in the setting of brain coinfection by HIV-1.[262]

A histologic feature of PML meriting further comment is atypical astrocytic hyperplasia (Fig. 43.29). In addition to florid astrogliosis, greatly enlarged bizarre, astrocytoma-like astrocytes are often found. These cytologic changes (often accompanied by morphologically atypical mitotic activity, Ki-67 expression,[263] and abnormal nuclear immunoreactivity for p53[264]) are believed to reflect a form of infection in which the agent's genome is spliced into that of the host cell.

PML is usually characterized by minimal inflammatory response to the agent; however, some variants exhibit intense perivascular and interstitial lymphoid infiltration. The latter often contain very few oligodendrocytes manifesting the nuclear cytopathic effects typical of JC virus infection and may prompt consideration of primary cerebral lymphoma, another recognized complication in immunosuppressed patients. It is this unusual form of PML that is most likely to present as a space-occupying, contrast-enhancing mass on CT or MRI study, further complicating the clinical delineation of these entities. A conspicuous inflammatory response and accompanying contrast enhancement on neuroradiological study characterize some examples affecting HIV-1–positive patients under highly active antiretroviral therapy (HAART) and typify biopsy material from a subset of AIDS patients surviving for considerably longer than the typical 3- to 6-month interval in which most PML patients progress to death.[265] The rare examples of spontaneously remitting PML have been of this unusually inflammatory type and presumably reflect elimination or immunologic containment of the JC virus following a transitory abrogation of its dormancy. Ironically, HAART-associated restoration of immune function may precipitate exaggerated inflammatory reactions to JC virus (as well as other pathogens, including mycobacteria, cryptococci, cytomegalovirus, and HIV-1) that result in paradoxic clinical deterioration.[266] This sometimes fatal "**immune reconstitution inflammatory syndrome (IRIS)**" is characterized by leptomeningeal and neuroparenchymal lymphoid infiltrates dominated by CD8+ T cells.[267,268]

Varicella-Zoster Virus Encephalitis and Cerebral Vasculitis

Varicella-zoster virus (VZV), the agent of chickenpox and shingles, causes a rare form of encephalitis sharing certain clinical and histologic features with PML.[269,270] The condition has to date been described exclusively in immunocompromised hosts (including patients treated for Hodgkin disease, other cancers, and AIDS) and may present months following resolution of cutaneous zoster or in the absence of a preceding exanthem. Described by some authors as a "leukoencephalitis," this chronic infection can settle anywhere along the central neuraxis but exhibits a striking predilection for the cerebral hemispheric white matter. It is characterized by multifocal, centrifugally expanding, and coalescent foci of demyelination and variable axonal loss with little inflammatory reaction. Many cases also feature small infarcts resulting from VZV-mediated vascular injury as further discussed later. The nuclei of oligodendrocytes situated on the periphery of demyelinating lesions exhibit a ground-glass or basophilic inclusion superficially similar to that of JC virus but without associated nuclear enlargement. Furthermore, neighboring astrocytes (and, in some cases, neurons and ependymal cells) infected by VZV contain well-demarcated Cowdry A-type intranuclear inclusions of the sort that typify herpes virus replication but lacking the atypical hyperplasia of PML. Ultrastructural study will disclose herpes-type nucleocapsids averaging approximately 100 nm in diameter within the nuclei of infected cells. These differ slightly from herpes simplex–type virions in that their core densities tend to be eccentrically positioned, but definite identification of VZV requires immunocytochemical assay, molecular hybridization studies, or culture.

In addition to encephalitis, VZV is recognized as a rare cause of cerebral vasculitis. This may involve large arteries at the base of the brain as well as smaller branches. Like the VZV-associated encephalitis, vasculitic complications typically follow resolution of the cutaneous exanthem. Two major variants have been described. One, a noninflammatory "angiopathy" afflicting immunocompromised hosts and associated in some cases with VZV encephalitis, is characterized by striking fibrointimal proliferation, thrombosis, and, in some cases, disruption of the elastica and thinning of the media without evident necrosis of mural elements.[271] The other is an overtly inflammatory and necrotizing angiitis designated by some observers as "granulomatous" because of the presence of multinucleated histiocytes within damaged vessel walls.[272,273] This often presents as hemiplegic stroke weeks after an episode of contralateral zoster ophthalmicus in a patient with no major evidence of defective immunity.[272] Several cases in HIV patients have shown both angiopathic and angiitic features, depending on the portion of vessel sampled, and there is suspicion that the former simply represents the chronic sequelae of an inflammatory process. In addition to thrombosis with consequent cerebral infarction, VZV angiitis may result in fusiform aneurysmal dilation, mural rupture, and subarachnoid hemorrhage.[273] Diagnosis requires localization of the virus (usually by immunocytochemical

For personal use only. No other uses without permission. Copyright ©2017. Elsevier Inc. All rights reserved.

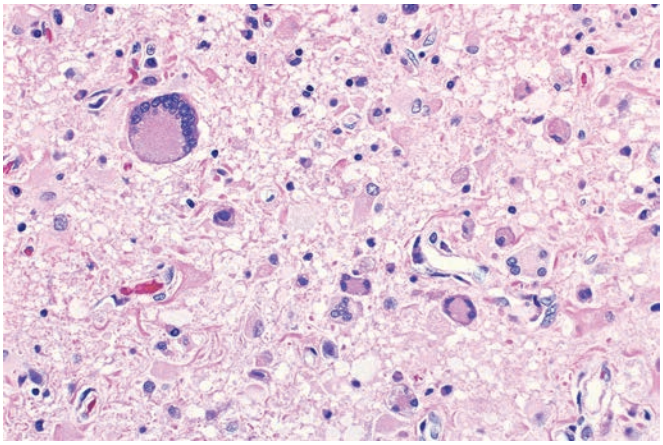

Figure 43.30 Human Immunodeficiency Virus Encephalitis. Non-granulomatous infiltrates centered loosely about blood vessels in the cerebral white matter (shown here) or basal ganglia and dominated by macrophages, including multinucleated forms resulting from retrovirally mediated cell fusion, characterize infection of the central nervous system by this agent. The associated astrogliosis and spongy rarefaction are common accompanying features.

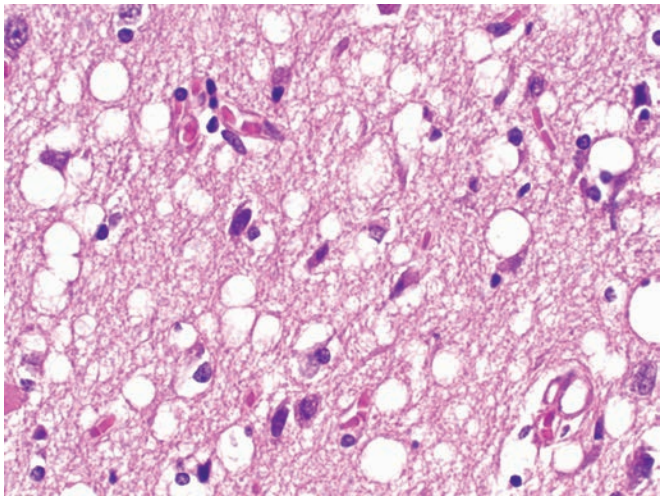

Figure 43.31 Creutzfeldt–Jakob Disease. Noninflammatory vacuolization of the cerebral cortex is the dominant alteration evident in this biopsy specimen from an elderly man with progressive dementia and myoclonus. This change typically precedes conspicuous neuronal dropout and astrogliosis, the other dominant findings in this prion-related disorder.

study) to elements of the vessel wall, typically smooth muscle cells in the media or intimal (myo)fibroblasts. Further consideration of VZV as a cerebrovascular pathogen is discussed earlier in the section on primary angiitis of the nervous system.

Human Immunodeficiency Virus Type 1 Encephalomyelitis

HIV-1 encephalomyelitis is not a disorder likely to engage the surgical pathologist but demands, nevertheless, some consideration in view of the unique nature of the neuropathologic alterations.[274] HIV-1 is alone among viral encephalitis agents in exhibiting no particular tropism for neuroectodermal cell types, as its replication in the nervous system occurs largely within marrow-derived macrophages and microglia. CNS infection is characterized by loosely arrayed, vasocentric, or paravascular inflammatory infiltrates concentrated in the cerebral hemispheric white matter, basal ganglia, and rostral brainstem (Fig. 43.30). These are dominated by mononuclear and multinucleated macrophages, the latter reflecting a process of virally mediated cell fusion that is the characteristic cytopathic effect of this and other members of the lentivirus subfamily of retroviruses. These cells, and their mononuclear precursors, harbor and release fully formed virions, which may be found budding from their plasmalemma, aggregated in membrane-delimited intracytoplasmic vacuoles, or lying free in the cytoplasm. The mature particle is spherical, averages 100–120 nm in diameter, and possesses a cylindrical or bar-shaped nucleoid usually positioned eccentrically and enclosed by a limiting membrane. Attendant changes include diffuse astrogliosis and microglial activation, generalized pallor of the cerebral white matter, and brain atrophy. The precise relationship of local HIV-1 replication to mechanisms of CNS injury remains a subject of active investigation.[274]

Prion-Associated Diseases

Though long ago grouped with the viral disorders, the unusual diseases collectively known as **transmissible spongiform encephalopathies** have resisted classification as conventional contagions and, in fact, occur in heritable and sporadic, as well as clearly infectious (mostly iatrogenically transmitted) forms. The pathogenesis of these rare entities remains a subject of controversy and ongoing investigation, but they clearly share anomalies of a native cell membrane constituent—the prion protein (PrP)—expressed at particularly high levels by central neurons. Conformationally altered, abnormally protease-resistant and amyloidogenic PrP isoforms ("prions") characteristically accumulate in affected tissues, with subsequent propagation sufficing for disease transmission in the absence of associated nucleic acids (i.e. not requiring the usual mechanisms of DNA or RNA replication).[1] Prion-associated illnesses include **kuru** (linked to the practice of ritual cannibalism among the Fore tribespeople of Papua, New Guinea), **Creutzfeldt–Jakob disease (CJD)**, "**variant**" **CJD** (linked to bovine spongiform encephalopathy, or "mad cow" disease), **Gerstmann–Straussler–Scheinker disease**, and **fatal familial insomnia**.[1] The following discussion is essentially limited to practical considerations in the diagnosis of CJD, the variant most commonly encountered in clinical practice.

The iatrogenic transmission of CJD via contaminated neurosurgical instruments, human growth hormone supplements, and a variety of allografts is well documented, but the large majority are sporadic and involve middle-aged or older adults having no evident exposure to contaminated materials or other individuals suffering the disorder. A familial variant associated with *PrP* gene mutations accounts for 10%–15% of cases.[1] The course of most patients is dominated by cognitive decline that progresses relentlessly in subacute fashion to profound dementia. Particularly characteristic accompanying features are generalized myoclonus, an electroencephalographic "burst suppression" pattern of periodic spike and wave complexes, and abnormally increased signal intensity in the basal ganglia and thalami on T2- and diffusion-weighted MRI sequences. The diagnosis is further suggested by appearance of a protein antigen (labeled 14-3-3) on CSF immunoassay. The afflicted are typically left vegetative within 6–8 months of symptom onset and rarely survive longer than a year after diagnosis.

The appearance of brain biopsy material, usually obtained from the nondominant frontal lobe, depends on disease duration and is particularly important for ruling out other disorders, especially the treatable ones.[1,275] The earliest change consists of spongy vacuolization of the cortex most pronounced in deeper laminae (Fig. 43.31). Rare

For personal use only. No other uses without permission. Copyright ©2017. Elsevier Inc. All rights reserved.

vacuoles may be localizable to neuronal perikarya, but most appear randomly scattered in the neuropil. The latter are situated principally within neuronal processes on electron microscopy, are often traversed by membrane-derived septa, and may contain granular or curled membranous profiles. With disease progression, spongiform change becomes increasingly florid and is attended by conspicuous astrogliosis, neuronal shrinkage, and depopulation. The end-stage cortex is left virtually devoid of recognizable neurons and largely replaced by the tangled processes of hyperplastic astrocytes. At no stage of the disorder is there evidence of an inflammatory response, and white matter abnormalities are limited to secondary axonal loss save for rare variants exhibiting spongy leukoencephalopathy.[276] A striking and diagnostic feature of prion-associated diseases, but one evident in only 5% of CJD cases, is the deposition of amyloid in "spiked ball" plaques that display radiate, spicular contours and are strongly PAS positive. Often referred to as "kuru" plaques, these are most often found in the cerebellar cortex (but may also be detected in cerebral gray matter) and are specifically recognized by antibodies to PrP.[1] Cerebrocortical examples may be numerous in familial CJD and are particularly conspicuous in "variant" CJD. Large, clustered deposits of PrP-immunoreactive amyloid in the cerebral and cerebellar cortices typify the dominantly inheritable Gerstmann–Straussler–Scheinker syndrome, also associated with PrP-encoding gene mutations and characterized clinically by a prominent component of progressive cerebellar ataxia.[1]

In the appropriate clinical setting, the presence of spongiform change alone suffices for a diagnosis of "probable" CJD. Definite diagnosis requires satisfaction of any one of the following criteria: (1) finding of spiked ball–type PrP amyloid plaques; (2) demonstration of protease-resistant PrP in biopsy material by specific immunohistochemical or immunoblot methods; (3) detection of a *PrP* gene mutation that is recognized as pathogenic; and (4) transmission of spongiform encephalopathy to an animal host. Readers are referred elsewhere for a fully annotated discussion of these specialized techniques.[1] A diagnosis of "probable" CJD should not be rendered on minimal histologic criteria inasmuch as scattered intracortical vacuoles and neuronal shrinkage are common artifacts of surgical manipulation. Vacuolization that is principally pericellular may also be caused by edema, hypoxia, autolysis, poor fixation, or processing, as well as toxic and metabolic encephalopathies. Furthermore, spongy changes that may mimic CJD (but that are often restricted to the superficial frontotemporal cortex, insula, or amygdala, and unattended by protease-resistant PrP deposition) can be encountered in otherwise typical examples of Alzheimer disease, cerebrocortical Lewy body disease, Pick disease, corticobasal degeneration, aphasic presenile dementia with lower motor neuron disease, and other dementing disorders. Conversely, an ostensibly negative biopsy should not reassure hospital staff handling tissues and fluids from suspect patients. The histopathologic alterations typical of CJD are not uniformly distributed in the involved brain, and methods such as immunohistochemical assessment and Western blot analysis may reveal protease-resistant PrP in neurosurgical specimens with little or no spongiform change.

Biopsy material from patients suspected of having CJD requires cautious handling, as even formalin-fixed and paraffin-embedded archival specimens retain transmissibility. Fixation protocols have been developed that virtually eliminate infectivity while yielding histologic sections of excellent appearance and antigenic integrity (these employ formic acid immersion following initial formalin fixation),[277] but the processing of suspect biopsy material in general surgical pathology laboratories is not recommended. Rather, these should be forwarded in formalin to specialized facilities such as The National Prion Disease Pathology Surveillance Center of the United States (cjdsurv@po.cwru.edu) that can assess specimens for *PrP* gene mutations as well as PrP deposition.

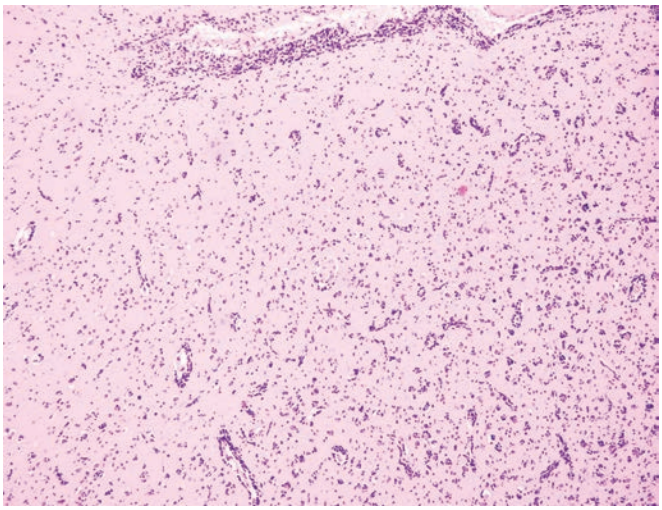

Figure 43.32 Diffuse astrocytoma forming secondary structures of Scherer, including subpial accumulation, perivascular aggregates, and perineuronal satellitosis.

Primary Tumors

Glial Tumors

Diffuse (Astrocytic and Oligodendroglial) Gliomas

The large group of clinically, pathologically, and genetically diverse glial neoplasms designated as diffuse gliomas encompasses those that tend to primarily grow in an infiltrative manner, with individual tumor cells spreading mostly along white matter tracts, perivascular spaces, subpial regions, and surrounding neurons (perineuronal satellitosis), the last three of which are referred to as "secondary structures of Scherer" (Fig. 43.32). Considerable advances have led to a revised World Health Organization (WHO) 2016 classification scheme, with newly incorporated "integrated diagnoses" that combine key morphologic and genetic features in order to establish diagnostic categories that are as biologically uniform as possible (Table 43.1). As a fundamental conceptual shift, for instance, it is now recognized that IDH-mutant diffuse astrocytomas and oligodendrogliomas have considerably more in common with one another than the more disparate entities that were previously lumped together based solely on lineage assumptions, such as diffuse and pilocytic astrocytomas. Although it was initially surprising to find mutations of this Krebs cycle–related gene in 10% of glioblastoma patients (nearly exclusively in the secondary form), this alteration was subsequently demonstrated in roughly 80% of all lower-grade (WHO grade II-III) gliomas, regardless of astrocytic or oligodendroglial lineage. Additional data suggest that further alterations such as *ATRX* and *TP53* mutations drive the precursor cell towards the astrocytoma morphology, whereas 1p19q codeletion with mutations of *TERT*, *CIC*, and *FUBP1* provoke the oligodendroglioma phenotype (Fig. 43.33). In contrast, the most common subtype of primary (de novo) glioblastoma in older adults is IDH-wildtype by definition, typically with associated *TERT* mutations, cytogenetic alterations such as trisomy 7 and monosomy 10, and epidermal growth factor receptor *(EGFR)* gene amplifications in roughly a third of cases. However, even within the overarching category of diffuse gliomas, neoplasms vary considerably in their epidemiologic features, morphologic attributes, growth patterns,

For personal use only. No other uses without permission. Copyright ©2017. Elsevier Inc. All rights reserved.

Table 43.1 Clinicopathologic and molecular features of integrated WHO 2016 glioma diagnoses

WHO 2016 DIAGNOSIS	CLINICAL CORRELATES	HISTOLOGIC CORRELATES	COMMON IHC AND MOLECULAR FEATURES
Diffuse astrocytoma, IDH-mutant, WHO grade II	Mostly young adults with cerebral, nonenhancing T2/FLAIR bright masses	Irregular, hyperchromatic nuclei	IDH1-R132H+ by IHC or *IDH1/2-mutant* by sequencing, p53+, ATRX–*
Gemistocytic variant	Same as above	At least 20% gemistocytes	Same as above
Diffuse astrocytoma, IDH-wildtype, WHO grade II	Same as IDH-mutant counterpart	Must exclude other entities, e.g., undersampled GBM, ganglioglioma, PXA, etc.	IDH-wildtype by IHC and sequencing
Diffuse astrocytoma, NOS, WHO grade II	Same as IDH-mutant counterpart	Same as IDH-mutant counterpart	Diagnosis based on histology alone
Anaplastic astrocytoma (AA), IDH-mutant, WHO grade III	Mostly nonenhancing or focally enhancing cerebral masses	Same as grade II astrocytomas but with mitotic activity	IDH1-R132H+ by IHC or *IDH1/2*-mutant by sequencing, p53+, ATRX–*
Anaplastic astrocytoma, IDH-wildtype, WHO grade III	Same as IDH-mutant counterpart	Must exclude other entities, especially undersampled or early GBM	IDH-wildtype by IHC and sequencing
Anaplastic astrocytoma, NOS, WHO grade III	Same as IDH-mutant counterpart	Same as IDH-mutant counterpart	Diagnosis based on histology alone
Glioblastoma (GBM), IDH-wildtype, WHO grade IV	Mostly older adults with rim-enhancing cerebral masses	Same as AA but with microvascular proliferation and/or necrosis	IDH-wildtype by IHC and sequencing in young patients or by IHC alone in older patients; TERT mutations, *EGFR* amplification/rearrangement, and 10q LOH common
Giant cell GBM variant	Greater tendency to superficial location and sharp demarcation	Predominance of large, bizarre multinucleated cells	Most are p53+ with *TP53* mutations; *EGFR* amplification rare
Gliosarcoma variant	Greater tendency to superficial location and sharp demarcation	Mesenchymal (sarcoma) metaplasia seen either de novo or at recurrence	Reticulin-rich, GFAP-sarcomatous elements; *EGFR* alterations rarer
Epithelioid GBM variant	Mostly children and young adults; greater tendency to superficial location, sharp demarcation, and CSF dissemination	Large melanoma-like cells and relatively sharp interface with brain; may have low-grade precursor, such as PXA	S100+, limited GFAP+ cells, but negative melanoma markers; *BRAF* V600E mutation in ~50%
Small cell GBM pattern	Mostly older adults with rim-enhancing cerebral masses, although roughly one third are nonenhancing initially (early stage)	Monomorphous small rounded to oval nuclei with delicate chromatin and occasional clear haloes, but high mitotic index	IDH-wildtype (100%), monosomy 10 (~95%), *EGFR* amplification (~70%)
GBM with primitive neuronal component pattern	Mostly adults with rim-enhancing masses and foci of markedly restricted diffusion on MRI	Diffuse glioma showing sharply demarcated hypercellular nodules with primitive neuronal features ("small blue cells," mitoses, molding, apoptotic cells, Homer Wright rosettes)	Gain of neuronal (e.g., SYN, NFP, Neu-N) and relative loss of glial (e.g., GFAP, OLIG2) phenotype in primitive foci; IDH-mutant or wildtype, monosomy 10, *MYC* or *MYCN* amplification
Glioblastoma, IDH-mutant, WHO grade IV	Mostly corresponds to "secondary GBM" with history of prior lower-grade astrocytoma; may also appear de novo	Classic GBM histology, including MVP and/or necrosis, often with microcystic foci as well	IDH1-R132H+ by IHC or *IDH1/2*-mutant by sequencing, p53+, ATRX–*, 10q LOH common, but *EGFR* alterations rare

For personal use only. No other uses without permission. Copyright ©2017. Elsevier Inc. All rights reserved.

Table 43.1 Clinicopathologic and molecular features of integrated WHO 2016 glioma diagnoses—cont'd

WHO 2016 DIAGNOSIS	CLINICAL CORRELATES	HISTOLOGIC CORRELATES	COMMON IHC AND MOLECULAR FEATURES
Glioblastoma, NOS, WHO grade IV	Same as IDH-wildtype counterpart	Same as IDH-wildtype counterpart	Diagnosis based on histology alone
Diffuse midline glioma, H3-K27M-mutant, WHO grade IV	Mostly children and young adults with midline (e.g., thalamus, brainstem, spine) gliomas	Wide histologic spectrum and may even appear low-grade; multinucleated cells more common	Mutant H3 K27M+ tumor cells by IHC or mutations of the *H3F3A* or *HIST1H3B/C* genes by sequencing
Oligodendroglioma, IDH-mutant, and 1p/19q-codeleted, WHO grade II	Mostly young to middle-age adults with cerebral nonenhancing masses	Rounded nuclei, delicate chromatin, crisp nuclear membranes, clear haloes, rich chicken-wire capillary network	IDH1-R132H+ by IHC or *IDH1/2*-mutant by sequencing, 1p/19q codeletion by FISH, LOH, or genomic techniques; ATRX-ret, p53 LI <10%‡
Oligodendroglioma, NOS, WHO grade II	Same as IDH-mutant counterpart	Same as IDH-mutant counterpart	Diagnosis based on histology alone
Anaplastic oligodendroglioma, IDH-mutant and 1p/19q-codeleted, WHO grade III	Same as grade II counterpart	Same as grade II cases but often with large epithelioid cells, macronucleoli; high mitotic index, MVP, and/or necrosis	IDH1-R132H+ by IHC or *IDH1/2*-mutant by sequencing, 1p/19q codeletion by FISH, LOH, or genomic techniques
Anaplastic oligodendroglioma, NOS, WHO grade III	Same as IDH-mutant counterpart	Same as IDH-mutant counterpart	Diagnosis based on histology alone
Oligoastrocytoma, NOS, WHO grade II†	Mostly young adults with cerebral, nonenhancing T2/FLAIR bright masses	Diffuse glioma with either mixed or equivocal morphologic features	Diagnosis based on histology alone
Anaplastic oligoastrocytoma, NOS, WHO grade III†	Mostly nonenhancing or focally enhancing cerebral masses	Same as above but with high-grade features	Diagnosis based on histology alone

Italicized entities and variants are currently considered provisional, pending additional scientific validation.
+, positive by IHC; –, negative by IHC. (Diffuse midline gliomas have yet to be assigned a WHO grade but have typically been highly aggressive [GBM-like] in the literature.) GFAP, glial fibrillary acidic protein; MVP, microvascular proliferation; NFP, neurofilament protein; SYN, synaptophysin.
*Tumoral loss of protein expression with retained expression in non-neoplastic cells providing a positive internal control. ATRX-ret, retained expression in tumor cells.
†When ancillary testing is applied, nearly all diffuse gliomas show molecular features of one of the more specific astrocytoma or oligodendroglioma diagnoses listed above; as such, the diagnosis of mixed gliomas (oligoastrocytomas) is limited to cases for which molecular testing is either unavailable or yields nondiagnostic findings. Nevertheless, it should be noted that extremely rare examples have been reported of oligoastrocytomas with discrete areas showing astrocytoma-like integrated morphology/molecular features and other areas showing oligodendroglioma-like integrated features. Similarly, cases that were previously diagnosed as "glioblastoma with an oligodendroglial component" (i.e., grade IV oligoastrocytoma) in the WHO 2007 scheme are now typically reclassified in the WHO 2016 scheme using molecular techniques as: (1) GBM, IDH-wildtype, (2) GBM, IDH-mutant, or (3) anaplastic oligodendroglioma, IDH-mutant, 1p/19q-codeleted.
‡Only rare oligodendrogliomas show strong p53 immunostaining in >10% of tumor cells, but such cases also demonstrate the diagnostic combination of IDH mutation and 1p/19q codeletion.

genetic profiles, and clinical behavior. For example, in addition to the major stratification of IDH-mutant versus IDH-wildtype tumors, there are major genetic and biologic differences in some of the pediatric/young adult counterparts and within different anatomic locations (e.g. pediatric low-grade gliomas with *FGFR1* or *MYB* alterations, H3 K27M-mutant diffuse midline gliomas, *BRAF* V600-mutant epithelioid glioblastomas, and H3 G34R/V-mutant high-grade hemispheric gliomas).

Diffusely Infiltrating Astrocytomas of Either IDH–Mutant Type or IDH–Wildtype

Diffusely infiltrating astrocytomas constitute the largest group, featuring an inherent tendency to biologic progression that reflects a stepwise accumulation of defined genetic abnormalities.[278] The tumor initiating events in the common sporadic forms have yet to be completely elucidated, although spontaneous mutations of the isocitrate dehydrogenase *(IDH)* gene complex, particularly *IDH1*, represent the earliest (possibly initiating) and most common genetic alterations in WHO grade II–III diffuse astrocytomas, secondary glioblastomas arising from these lower-grade precursors, and WHO grade II-III oligodendrogliomas.[279-281] Although traditionally divided on cytologic grounds into **fibrillary**, **gemistocytic**, and **protoplasmic** cell types, only gemistocytic is considered a sufficiently unique variant for inclusion in the 2016 WHO scheme. The fibrillary type, named for the filamentous cytoplasmic processes that lend to their constituent cells a resemblance to non-neoplastic "fibrous" astrocytes, is by far the most frequently encountered; as such, it is considered the de facto subtype when discussing diffuse astrocytomas in general. Nevertheless, the fibrillary processes often blend imperceptibly with background neuropil, such that most display an appearance of "naked nuclei" (Fig. 43.34). The protoplasmic type has never been objectively defined (i.e. the typical "cobweb-like" pattern is also encountered in some oligodendrogliomas and pilocytic astrocytomas), is poorly reproducible among pathologists, and is not known to be associated

For personal use only. No other uses without permission. Copyright ©2017. Elsevier Inc. All rights reserved.

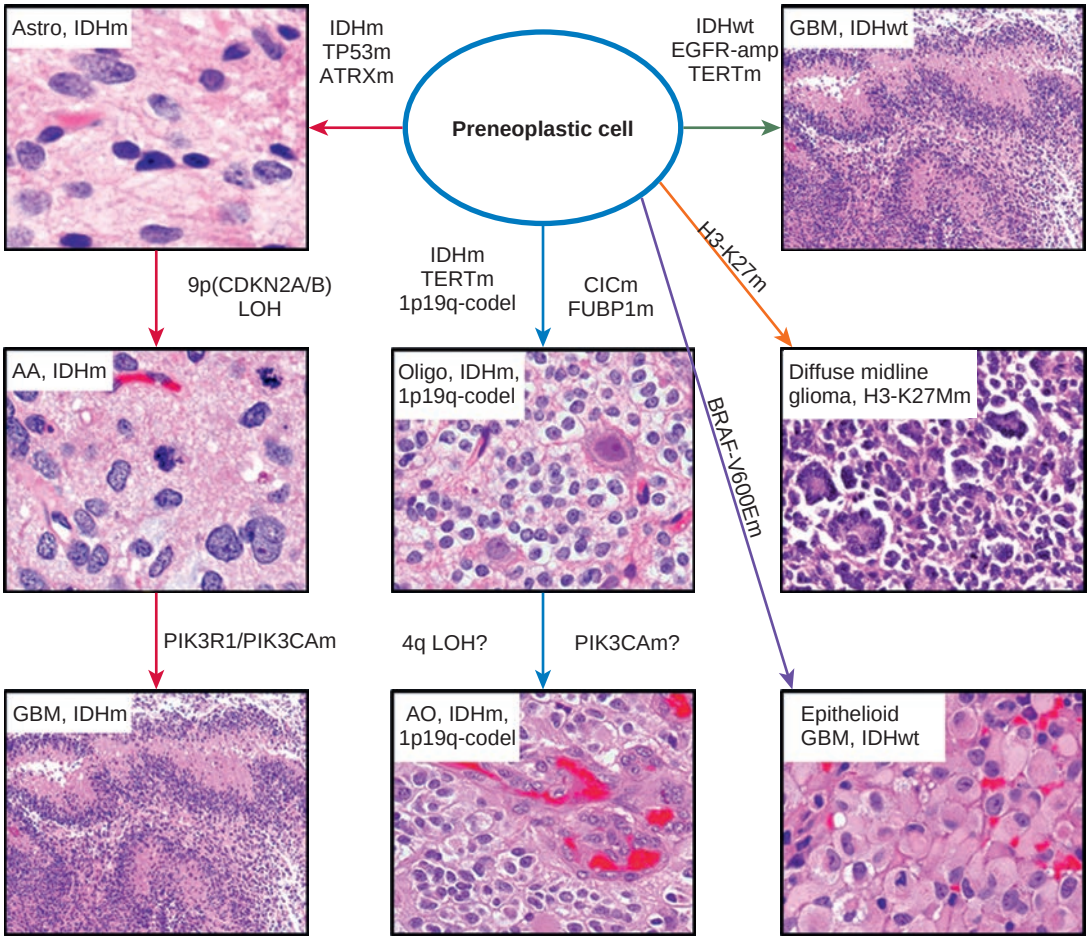

Figure 43.33 Genetic Model of Diffuse Gliomas. The left and middle columns represent the IDH-mutant subtypes, while the right column represents the most common IDH-wildtype categories. m, mutant; wt, wildtype; 1p19q-codel, 1p/19q codeletion

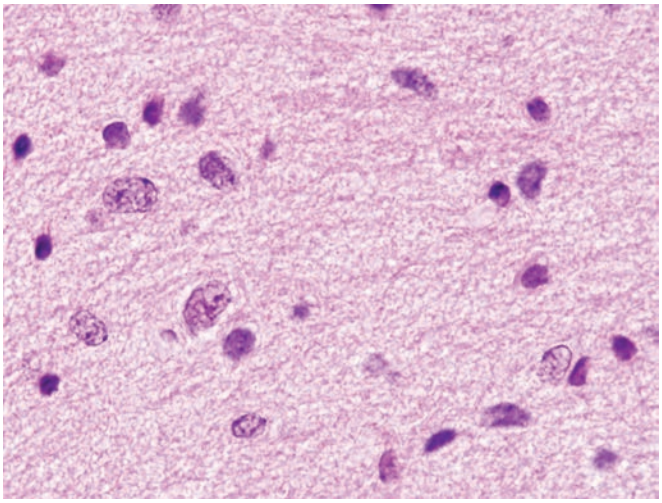

Figure 43.34 Diffuse Astrocytoma With Fibrillary Cytology. Note the appearance of "naked nuclei" with tumor cells seemingly embedded in a fibrillar background but containing irregular hyperchromatic nuclei with no discernable cytoplasm.

with a specific molecular phenotype, and thus it has been discarded from the latest WHO classification.

Diffuse astrocytic neoplasms often contain a minor complement of large tumor cells characterized by eccentric globose "bellies" of glassy eosinophilic cytoplasm and peripherally displaced nuclei that seem on the verge of extrusion from their parent cell bodies (Fig. 43.35). Termed gemistocytes (from the Greek *gemistos* for laden or full), these reflect an accumulation of glial-type intermediate filaments (GFAPs) that form compacted paranuclear whorls and extend into stout cytoplasmic processes. The designation of **gemistocytic astrocytoma** has been subjectively applied to tumors harboring these elements in varying density, but current WHO guidelines endorse the suggestion that gemistocytes constitute at least 20% of the neoplastic population by definition.[278] Gemistocytic astrocytomas are virtually restricted to the cerebral hemispheres of adults. They often exhibit conspicuous perivascular infiltration by lymphocytes and typically contain small, poorly differentiated neoplastic cells that appear more actively proliferative than their large-bodied companions in MIB-1 (Ki-67) immunolabeling studies.[282] Aberrant nuclear immunolabeling for p53 is commonly seen, a phenomenon that reflects the prevalence of *TP53* gene mutations in this variant. Recent studies suggest that they harbor *IDH* mutations slightly less often than fibrillary types (74% vs. 92%) and inactivate the *RRAS* and *ERCC1* genes in subsets of tumors but otherwise show similar genetic patterns to those of lower-grade IDH-mutant astrocytomas.[283]

For personal use only. No other uses without permission. Copyright ©2017. Elsevier Inc. All rights reserved.

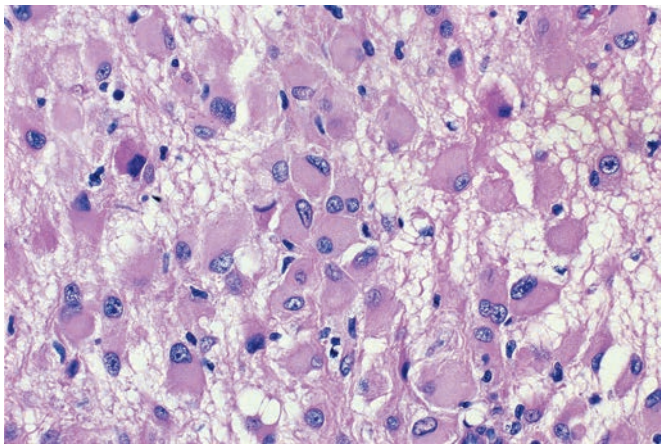

Figure 43.35 Gemistocytic Astrocytoma. Heavily dominated on initial resection by the large gemistocytes shown here, this example recurred 11 months after radiotherapy and chemotherapy. Re-resection demonstrated progression to glioblastoma. Note that these cells retain the oval and somewhat vesicular nuclei of astrocytes. For a comparison with the "minigemistocytic" variant of oligodendroglioma, see Fig. 43.61B.

Gliovascular structuring may be apparent, defined as radially arranged gemistocytes projecting short cytoplasmic processes towards centering blood vessels to form pseudorosettes that may bring ependymoma or astroblastoma to mind. However, the latter tumor types do not permeate neuroparenchyma in the diffuse fashion of gemistocytic astrocytoma. Care must also be taken lest the designation of gemistocytic astrocytoma be applied to oligodendroglial tumors composed of diminutive "mini"-gemistocytes, or to the exceptional oligodendroglioma undergoing macrogemistocytic change with tumor progression. These usually do not manifest perivascular lymphocytic cuffing, may exhibit a distinctively lobular or pavement-like architecture, and almost invariably harbor more classic clear cell features elsewhere. Furthermore, oligodendrogliomas usually display little or no nuclear p53 immunoreactivity (*TP53* mutations being uncommon) and, instead, feature combined chromosomal 1p and 19q deletions.

Gemistocyte-rich astrocytomas are currently graded in the same fashion as conventional astrocytomas. However, while acknowledging that the WHO grade II tumors do not automatically behave aggressively, our experience conforms to that of others who have found that gemistocytic astrocytomas tend to progress more rapidly.[282,284] It is for these reasons that the WHO classifies these as a distinct variant. Nevertheless, the majority of such studies preceded the molecular era, and it is possible that the *IDH* mutation status supersedes the negative prognostic implication when considering the morphology in isolation.

Diffuse (fibrillary) astrocytomas afflict subjects of all ages and may arise at any level of the central neuraxis, but cerebral hemispheric examples in adults are by far the most common. Here, they are characteristically centered in white matter, with a smaller subset of biologically distinct tumors originating in midline structures, such as the basal ganglia, thalami, brainstem, and spinal cord (discussed later under diffuse midline glioma, H3 K27-mutant). Headaches, seizures, focal sensorimotor deficits, and alterations of affect are the principal clinical manifestations of supratentorial lesions. Exceptional variants are situated entirely within the leptomeninges and subarachnoid space, where they may derive from heterotopic neuroglial rests.[285,286]

Neuro-oncologic practice now demands that the diffuse fibrillary astrocytomas be subclassified according to their molecular features and histologic grade. We endorse the three-tiered WHO system, stratifying tumors into **diffuse astrocytoma (WHO grade II)**, **anaplastic astrocytoma (WHO grade III)**, or **glioblastoma (WHO grade IV)**, according to histologic features along with the molecular substratifier of IDH-mutant or IDH-wildtype. Given that the majority of the WHO grade II–III examples are IDH-mutant, one must always consider other diagnostic possibilities for the infrequent IDH-wildtype examples, including early or undersampled glioblastomas, rarer "pediatric" molecular subtypes of diffuse glioma, and more favorable entities, such as pilocytic astrocytoma, pleomorphic xanthoastrocytoma, ganglioglioma, and others. The diagnosis of glioblastoma is generally reserved for astrocytic tumors of the highest grade and not applied to poorly differentiated gliomas of oligodendroglial or ependymal lineage. We would again emphasize the disheartening tendency of the diffuse astrocytoma, however differentiated and indolent at inception, to grow increasingly histopathologically alarming and clinically aggressive with the passage of time. A consequence of this inherent instability that affects diagnosis and management is the resulting regional heterogeneity for which this neoplasm is notorious, and in which zonal variations in histologic appearance and proliferative activity potentially confound the interpretation of limited tissue samples.

Well-differentiated diffuse astrocytomas (WHO grade II) typically present in the third or fourth decade of life and are less common after age 50 (beyond which higher grade forms predominate). A protracted preoperative course characterized by intermittent seizures or headache unassociated with focal neurologic deficits is particularly suggestive of a slowly evolving supratentorial astrocytoma (or other low-grade neoplasm). Complaints referable to such lesions may be present for years prior to their discovery, although the advent of sophisticated neuroradiological techniques has considerably shortened the average predetection interval. As low-grade astrocytomas do not usually provoke significant neovascularization of the infiltrated neural parenchyma, they appear in CT scans and T1-weighted MR images as nonenhancing low-density regions, given that contrast enhancement typically reflects blood–brain barrier disruption (Fig. 43.36). The presence of such enhancement suggests that a lesion shown by biopsy to be an astrocytoma has undergone focal anaplastic progression and should prompt careful review of postoperative neuroradiological studies to ascertain the adequacy of the biopsy (or lack thereof). In other non-enhancing examples, the lesion may best be appreciated on fluid-attenuated inversion recovery (FLAIR) or T2-weighted MR images (Fig. 43.37).

Grossly, WHO grade II astrocytomas are spatially indistinct, producing a diffuse expansion and induration of permeated CNS structures along with a highly characteristic blurring or effacement of gray–white landmarks (Fig. 43.38). They may acquire a somewhat mucoid consistency as a result of myxoid change but are not prone to spontaneous hemorrhage or necrosis. Histologic study typically discloses a cellular infiltrate percolating through recognizable neuropil in a patternless array, or with secondary structure formation (subpial aggregation, perivascular condensation, and/or perineuronal satellitosis) that stands in sharp contrast to the even distribution of hyperplastic astrocytes in reactive glial proliferations (Fig. 43.39). A common architectural feature of immeasurable utility in establishing the neoplastic nature of the process in question is microcystic change (Fig. 43.40), an alteration to which a variety of glial neoplasms (generally low grade) are prone but rarely, if ever, encountered in a reactive setting. A similar, though less specific, significance is attached to the finding of scattered calcospherites. A conspicuous admixture of foamy macrophages, on the other hand, militates strongly against the diagnosis of astrocytoma in the absence of prior therapy, and should instead prompt considerations of demyelinating disease and infarction. Conspicuous lymphocytic cuffing of regional blood vessels,

For personal use only. No other uses without permission. Copyright ©2017. Elsevier Inc. All rights reserved.

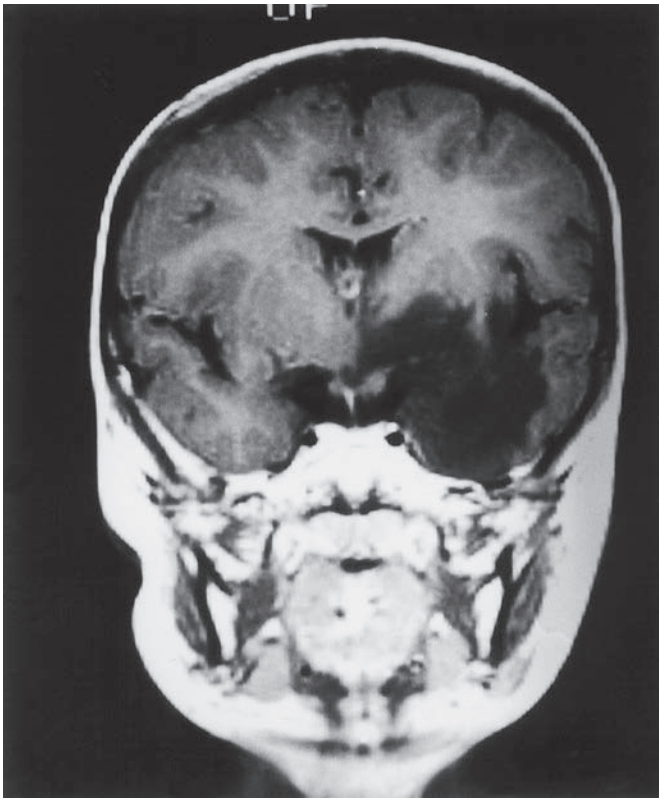

Figure 43.36 Diffuse Astrocytoma. Neuroradiological features common to the low-grade fibrillary astrocytoma in postcontrast magnetic resonance imagings, such as this temporal example, include generalized expansion and hypodensity of infiltrated regions with only modest mass effect, and no foci of bright signal enhancement that would indicate blood–brain barrier disruption.

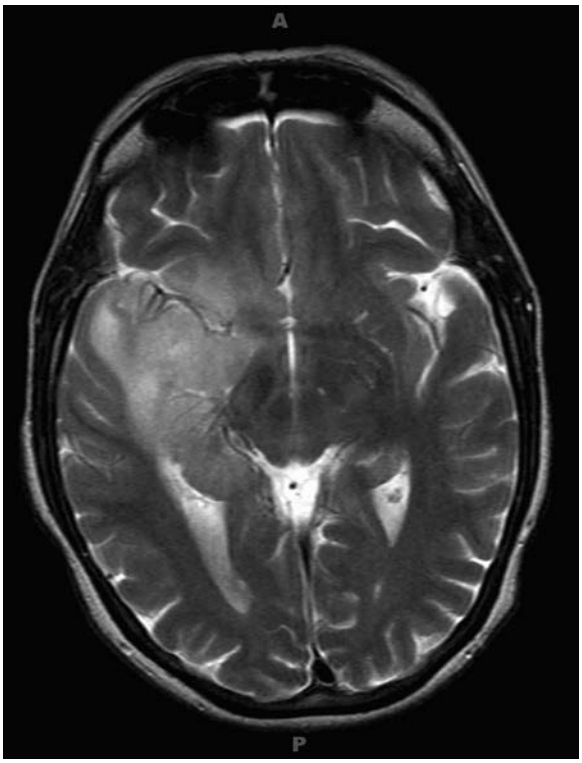

Figure 43.37 Diffuse Astrocytoma. T2-weighted magnetic resonance imaging showing an ill-defined fronto-temporal mass with increased signal intensity.

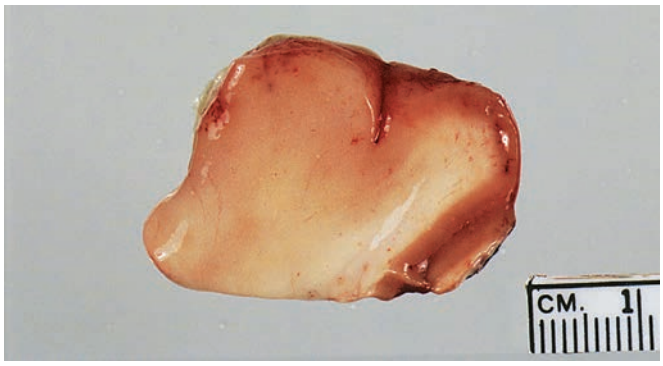

Figure 43.38 Diffuse Astrocytoma. The insidious permeation typical of the fibrillary astrocytoma is illustrated in this anterior temporal lobectomy specimen. The gyrus at right maintains a clearly demarcated cortical ribbon over its digitate white matter. Moving to the left, there is diffuse gyral expansion and effacement of these landmarks, reflecting tumoral infiltration. No discrete mass is formed, and, as is characteristic of low-grade examples, there is no evident hemorrhage or necrosis (see Fig. 43.48 for comparison).

the hallmark of inflammatory CNS disorders, occasionally attends conventional astrocytic neoplasms but among neuroepithelial tumors is most common in gemistocytic astrocytoma, pleomorphic xanthoastrocytoma, and ganglioglioma. Finally, by definition, WHO grade II astrocytoma should not reveal foci of microvascular proliferation (MVP), increased mitotic activity, or zones of necrosis.

At the cytologic level, astrocytomas of fibrillary type are composed, at least in part, of cells invested with delicate processes that taper from a modest perinuclear expanse of eosinophilic cytoplasm or are represented only as a background meshwork in which "naked" nuclei appear to lie embedded (see Figs. 43.34 and 43.39). These may be unipolar or multipolar but, in contrast to the cytoplasmic extensions characteristic of hyperplastic astroglia, do not usually sprout from the cell body in the radial, stellate array for which the astrocyte is named. They are particularly arresting in smear or crush preparations (Fig. 43.41), which are indispensable adjuncts (and expedient alternatives) to frozen section for purposes of intraoperative consultation. On ultrastructural study,[287] these processes contain bundles of 7–11 nm ("intermediate") filaments composed of GFAP, the principal cytoskeletal constituent elaborated by human astrocytes, and vimentin. Nuclei are typically oval in configuration with smooth contours, do not contain conspicuous nucleoli, often have a vesicular quality, but may be somewhat hyperchromatic.

Predisposing Factors. While most diffuse astrocytomas are unassociated with clearly predisposing factors, radiation-related cases are clearly recognized and occasional high-grade examples complicate NF1, the Li–Fraumeni (germline *TP53* gene mutation) syndrome, Turcot (brain tumor-polyposis) syndrome 1 (germline mutations in DNA mismatch repair enzymes), and rarer or less well-characterized familial disorders, including the multiple enchondromatosis syndromes known as Ollier or Maffucci disease.[288]

As mentioned previously, the most common and earliest known genetic alteration in the adult form is a gene mutation of *IDH1* or its homolog, *IDH2*. A single point mutation in codon 132 converting

For personal use only. No other uses without permission. Copyright ©2017. Elsevier Inc. All rights reserved.

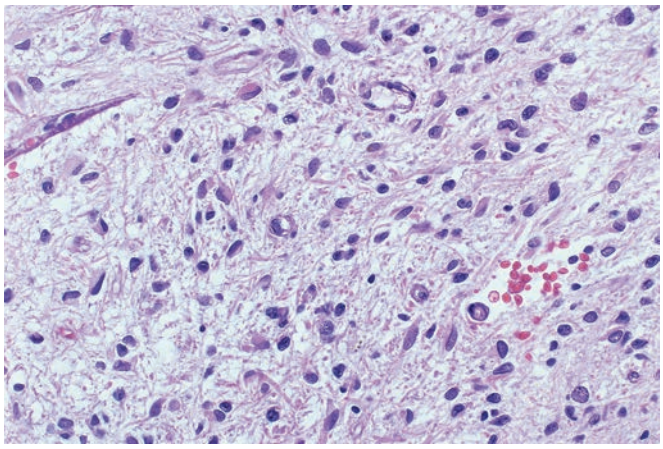

Figure 43.39 Diffuse Astrocytoma. Conspicuous cytoplasmic processes, mild nuclear pleomorphism, and only modest hyperchromasia are evidenced by the cells of this well-differentiated astrocytoma. The absence of mitotic activity supports its classification as a low-grade lesion. Note the dyscohesive growth pattern.

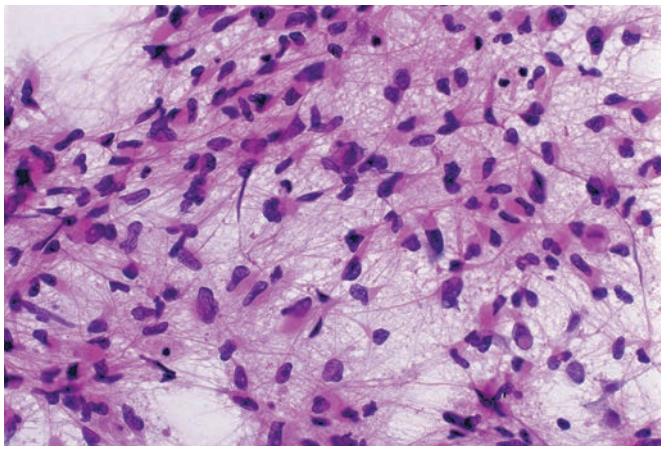

Figure 43.41 Diffuse Astrocytoma. A lack of cellular cohesion and conspicuous cytoplasmic processes—features that serve to distinguish astrocytomas from metastatic carcinomas, lymphomas, and other neoplasms—are apparent in this intraoperative crush preparation.

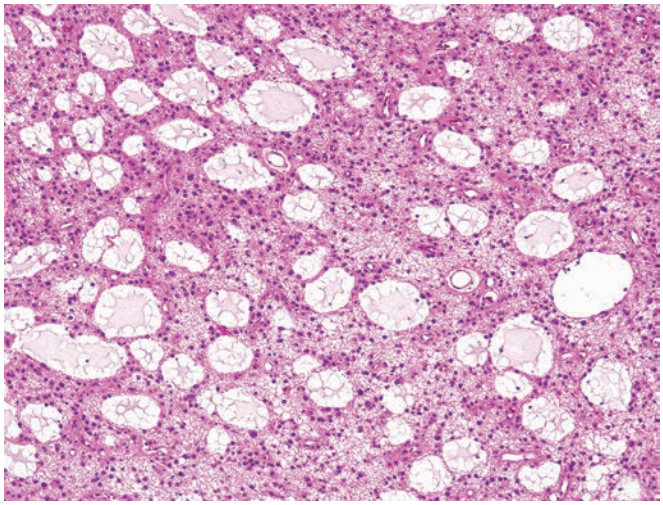

Figure 43.40 Diffuse Astrocytoma. Foreign to reactive astroglial proliferations, microcystic change is a particularly conspicuous feature of some low-grade astrocytomas.

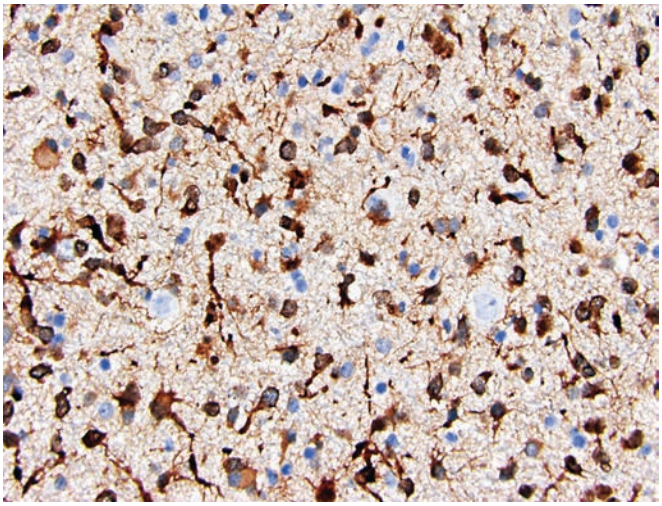

Figure 43.42 Diffuse Astrocytoma, IDH-mutant showing immunoreactivity for the IDH1 R132H mutant protein. Note the immunonegative cortical neurons in the background.

arginine to histidine accounts for up to 90% of all mutations. As such, the R132H mutant–specific immunostain is often used as the initial screening tool to detect this subtype (Fig. 43.42), followed by sequencing of *IDH1* codon 132 and *IDH2* codon 172 (homologous region) to look for rarer mutations in immunonegative examples of appropriately aged patients (most common in older children and adults under 55 years of age). Studies have shown that in most cases of anaplastic astrocytoma, IDH-wildtype tumors behave like primary glioblastoma, suggesting that the majority are either early forms of the latter or simply undersampled. In the case of WHO grade II astrocytomas that are IDH-wildtype, additional differential diagnostic considerations include the pediatric counterpart (more often showing *FGFR1* or *MYB* alterations) and long-term epilepsy-associated tumors (LEATs), such as ganglioglioma, pleomorphic xanthoastrocytoma, and dysembryoplastic neuroepithelial tumor (DNT) (often CD34 and/or BRAF V600E immunoreactive). The great majority of IDH-mutant astrocytomas also harbor mutations of the *ATRX* and *TP53* genes, both of which may be detected, in most cases, using immunohistochemical surrogates. Given its role in chromatin maintenance/remodeling, the alpha-thalassemia mental retardation X-linked (ATRX) protein is ubiquitously expressed in all non-neoplastic nuclei; in contrast, expression is usually lost in astrocytoma cells harboring somatic mutations (Fig. 43.43). In the case of the p53 protein, the half-life is normally so short that *TP53*–wildtype nuclei appear negative, whereas the most common mutations lead to protein stabilization and an "overexpression" pattern (Fig. 43.44). Interpretive care is warranted, however, as there are other scenarios leading to both false-positive and false-negative results by immunohistochemistry alone. One series of 157 diffuse gliomas reported an excellent correlation with *TP53* mutation when there was greater than 10% strong nuclear staining.[289] In terms of a notable example of false positives, JC virus–infected oligodendroglia and astrocytes in PML commonly exhibit strong nuclear p53 expression (as well as MIB-1 reactivity).

The **anaplastic astrocytoma, IDH-mutant (WHO grade III)** often evolves from a well-differentiated precursor lesion of the type just described, a sequence in which deletions of the *CDKN2A/B* genes

For personal use only. No other uses without permission. Copyright ©2017. Elsevier Inc. All rights reserved.

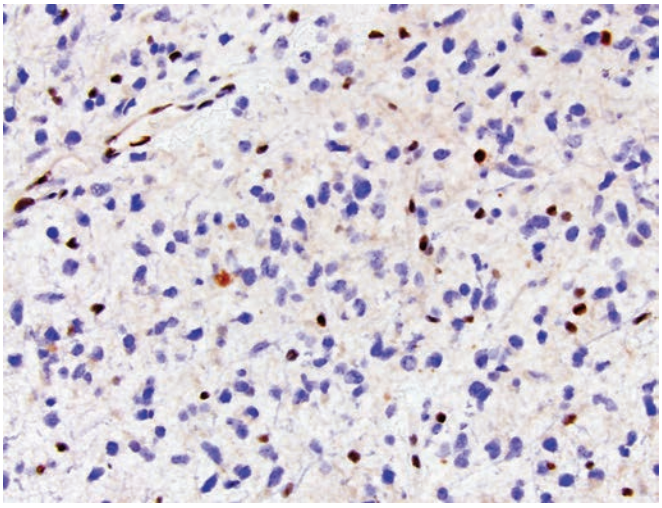

Figure 43.43 Diffuse Astrocytoma, IDH-Mutant. As in this example, most IDH-mutant astrocytomas additionally demonstrate loss of alpha-thalassemia mental retardation X-linked immunoreactivity in tumor nuclei. Note that non-neoplastic cells (endothelial, glial, inflammatory) retain expression serving as an internal positive control.

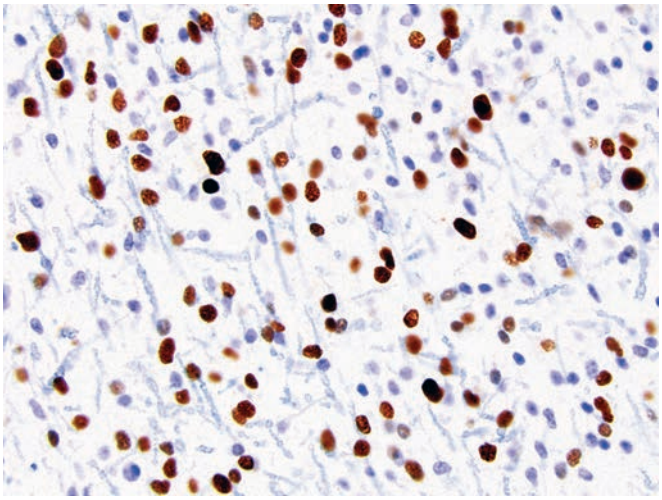

Figure 43.44 Diffuse Astrocytoma, IDH-Mutant. As in this example, most IDH-mutant astrocytomas also show p53 overexpression by immunohistochemistry.

that encode p16, p15, and p14^{ARF}, and others are implicated.[278] In contrast, the IDH-wildtype counterpart most often presents de novo and behaves like a primary glioblastoma in addition to showing the associated genetic alterations of the latter, including *TERT* mutations, monosomy 10/*PTEN* deletions, and *EGFR* amplification, among others. Morphologic evidence of tumor progression from a WHO grade II precursor may constitute a focal finding in what would otherwise qualify as a histologically favorable lesion. Microscopic examination of the prototypical case reveals an infiltrate that is at first glance more alarmingly cellular and cytologically atypical than that of the low-grade astrocytoma (Fig. 43.45), although biopsies derived from the tumor–CNS interface may contain only scattered neoplastic elements. Nuclear alterations commonly include angulation, dense hyperchromasia, and considerable variation in contour and dimension. Mitotic figures can be demonstrated and establish the diagnosis, although the precise cutoff required remains uncertain.

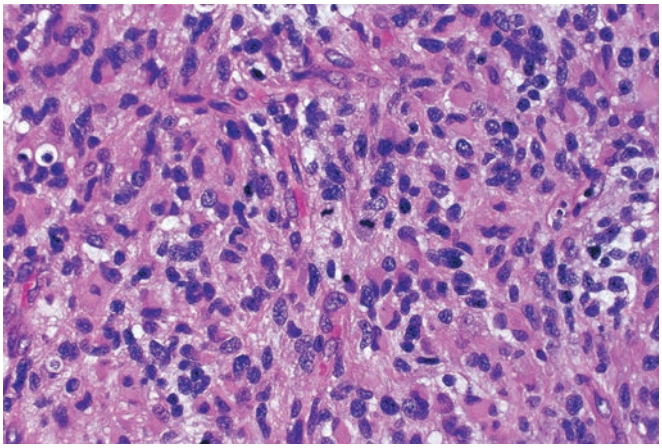

Figure 43.45 Anaplastic Astrocytoma. Compared with its low-grade counterpart (see Fig. 43.39), this lesion exhibits increased cellularity, the cytologic features of a fully malignant neoplasm, and, at center, mitotic figures.

In this regard, we would stress that the solitary mitotic figure found on close scrutiny of a generous biopsy or resection specimen does not an anaplastic astrocytoma make.[290] We will render this diagnosis, however, when confronted by any mitoses in a limited (e.g. stereotactic) neurosurgical sample. Even more importantly, IDH-mutant WHO grade II and III astrocytomas are not always associated with patient survival differences, when applying classically defined grading criteria.[291] As such, it is likely that the mitotic cutoff may ultimately need to be increased in order to avoid overgrading these molecularly defined astrocytomas.

An increase in regional blood vessels is permissible, as is hypertrophy of their lining endothelium, but complex and disorderly proliferation of vasoformative elements or zones of coagulative tumor necrosis in the setting of a diffuse astrocytoma mandate a glioblastoma diagnosis. Glioblastoma-like behavior also characterizes astrocytomas manifesting neither complex MVP nor necrosis, but that are composed predominantly of poorly differentiated and mitotically hyperactive small cell elements.[292] These small cell astrocytomas (covered further later in glioblastoma variants section) are uniformly IDH-wildtype, harbor *EGFR* gene amplification in roughly 70% of cases, and express the glioblastoma-associated mutant *EGFR-vIII* form in about 50%. We report such lesions as "high-grade astrocytomas of small cell type" and, while acknowledging that these fail to satisfy strict histologic criteria for the diagnosis of glioblastoma, comment on their grade IV biologic potential.

Although its unfortunate title would imply a neoplasm of embryonal character, the **glioblastoma (WHO grade IV)** simply represents the most aggressive of the infiltrating astrocytic tumors. "Primary" (mostly IDH-wildtype) and "secondary" (mostly IDH-mutant) variants are recognized, the former occurring de novo (i.e. unassociated with demonstrable precursor lesions), the latter resulting from the expansion of aggressive clones generated within pre-existent WHO grade II or III astrocytomas.[278] Not surprisingly, secondary glioblastomas share the high incidence of *IDH1*, *TP53*, and *ATRX* mutations of their lower-grade precursors.[293] With the exception of *TP53* mutations in roughly a fourth of cases, such abnormalities are rare among primary glioblastomas, these sharing instead a high incidence of *TERT* mutations, allelic losses of chromosome 10/10q, amplification and mutations of the *EGFR* gene on chromosome 7, mutations/deletions of the tumor suppressor *PTEN* gene on chromosome 10q23.3, and *CDKN2A/B* deletions on 9p21.3. *EGFR-vIII*, the major mutant form encountered in glioblastomas, seems highly

For personal use only. No other uses without permission. Copyright ©2017. Elsevier Inc. All rights reserved.

associated with such tumors.[278] Whether predictable differences in prognosis attach to these divergent oncogenetic pathways independent of patient age at diagnosis has been controversial. Secondary glioblastomas tend to affect a significantly younger cohort than primary variants (mean ages at presentation being ~40 vs. 55 years, respectively), and by all accounts advancing age per se is inversely correlated with survival in the setting of diffuse astrocytomas. The presence of *IDH* mutation is a highly favorable prognostic indicator per se in this regard, with studies suggesting that IDH-mutant glioblastoma patients have significantly longer survival times than IDH-wildtype anaplastic astrocytomas.[294]

The comprehensive genomic studies of The Cancer Genome Atlas Network and others have shown that glioblastomas are biologically far more complex than their division into the foregoing types and that there are perhaps at least six molecular subtypes, each with distinct demographic, anatomic, and clinical features.[295] In addition to the IDH-mutant group already discussed, there are two groups with mutations of the histone H3 subsets (*H3F3A* gene encoding H3.3 and less commonly, the *HIST1H3B* encoding H3.1; see Table 43.1 and Fig. 43.32). Whereas K27M mutations of either gene are associated with a highly aggressive new WHO entity, known as "diffuse midline glioma, H3 K27M mutant" (mostly thalamus, brainstem/pontine, and spinal gliomas), G34R/V mutations of the *H3F3A* gene are associated with more laterally localized hemispheric glioblastomas with a somewhat better, intermediate level prognosis.[295-298] Both affect predominantly children and young adults and are associated with relatively wide morphologic spectrums, including overrepresentation of giant cells in the K27M variant and a primitive-appearing subtype mimicking an embryonal neoplasm in the G34R/V subtype.[297,298] Of note, the H3 K27M variant is immunohistochemically detectable using mutant-specific antibodies (Fig. 43.46). Other genomically defined IDH-wildtype molecular subtypes include receptor tyrosine kinase types I (mostly *PDGFRA* amplification/overexpression) and II (mostly *EGFR* amplification/overexpression), as well as a mesenchymal subtype with relatively few copy number alterations.[295] An even rarer form is the epithelioid glioblastoma, which is also associated with younger age, an occasional precursor lesion of pleomorphic xanthoastrocytoma, and an association with *BRAF* V600E mutation (discussed later in greater detail).

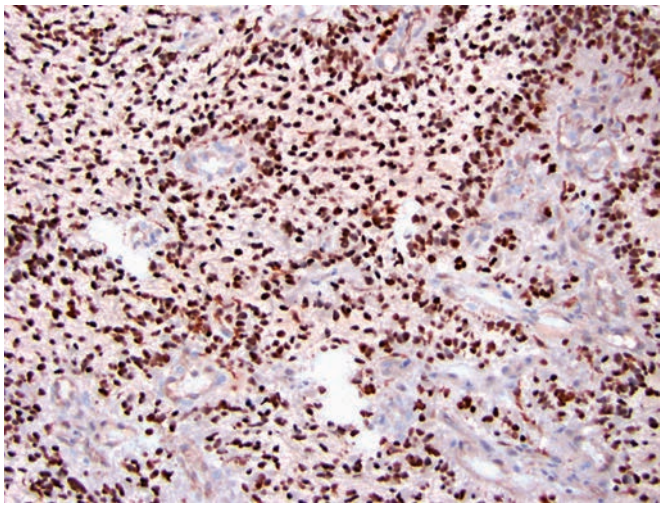

Figure 43.46 Diffuse Midline Glioma (Glioblastoma), H3 K27M-Mutant. This thalamic glioblastoma was characterized as the new WHO entity of "diffuse midline glioma, H3 K27M-mutant" based on immunohistochemical detection of the mutant protein in tumor nuclei.

Like astrocytomas of lower grade, glioblastomas may be discovered on evaluation for seizures or headache but are often attended by subacutely evolving neurologic deficits indicative of their more rapid growth and destructive invasion. A subset present in sudden, stroke-like fashion as a consequence of intratumoral hemorrhage, and occasional examples mimic metastatic disease by virtue of their multifocality.[299] Especially characteristic on CT or MR evaluation is a pattern of ring-like contrast enhancement that reflects their abnormal vascularization and tendency to spontaneous central necrosis (Fig. 43.47). On gross inspection, glioblastomas may seem relatively circumscribed and often appear to be more clearly demarcated from neighboring tissues than their better-differentiated counterparts—deceptively so, inasmuch as neoplastic cells regularly invade neuropil well beyond the apparent tumor perimeter. Hemorrhagic discoloration and foci of yellow softening indicative of coagulative necrosis impart a variegated appearance to most examples that should immediately suggest their virulent nature (Fig. 43.48). Histologically, glioblastoma is a highly cellular and mitotically active neoplasm. Its cytologic makeup is subject to extreme variation (thus the traditional designation of this lesion as glioblastoma "multiforme").

An arresting phenomenon common to many glioblastomas is a complex form of MVP, driven in paracrine fashion by tumor-derived mitogens such as vascular endothelial growth factor (VEGF), in which proliferating blood vessels are lined by hyperplastic (i.e. multilayered) and hypertrophic (i.e. enlarged) cells heaped up in disorderly fashion and sometimes transformed into glomeruloid or solid tufts

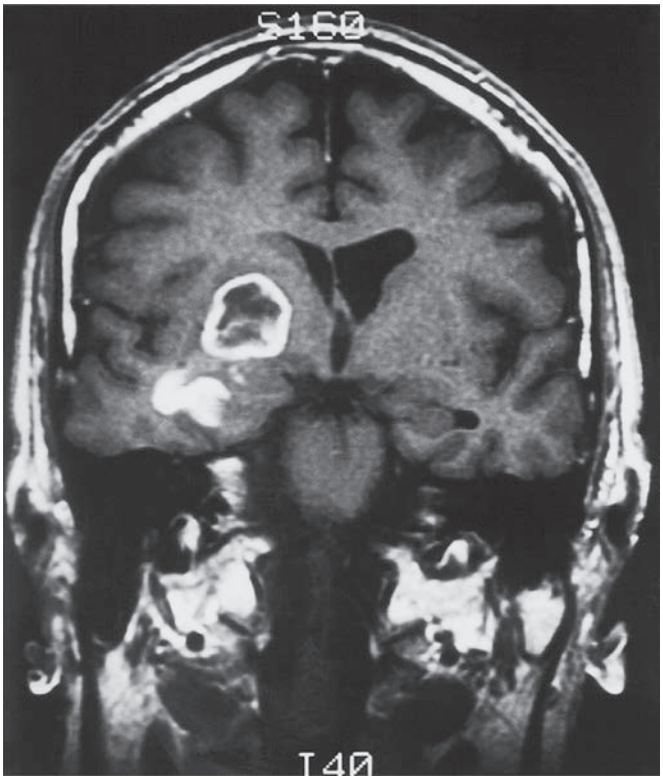

Figure 43.47 Glioblastoma. In postcontrast injection computed tomography or (shown here) magnetic resonance studies, many glioblastomas are characterized by a bright ("enhancing") ring (representing intact, abnormally vascularized tumor tissue in which the blood–brain barrier is disrupted) that surrounds a region of hypodensity (central necrosis). The gyriform temporal lobe enhancement below this basal ganglionic example attests to neoplastic infiltration beyond the deceptively well-delimited ring margin.

For personal use only. No other uses without permission. Copyright ©2017. Elsevier Inc. All rights reserved.

Figure 43.48 Glioblastoma. Foci of hemorrhage and geographic yellow discoloration indicative of necrosis impart a variegated appearance to this example.

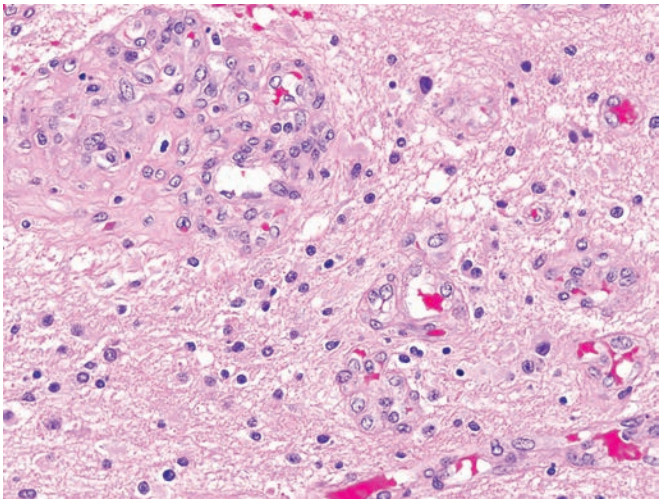

Figure 43.49 Glioblastoma. Note the complex, "glomeruloid" quality of the microvascular proliferation at right. Astrocytic elements are seen at left.

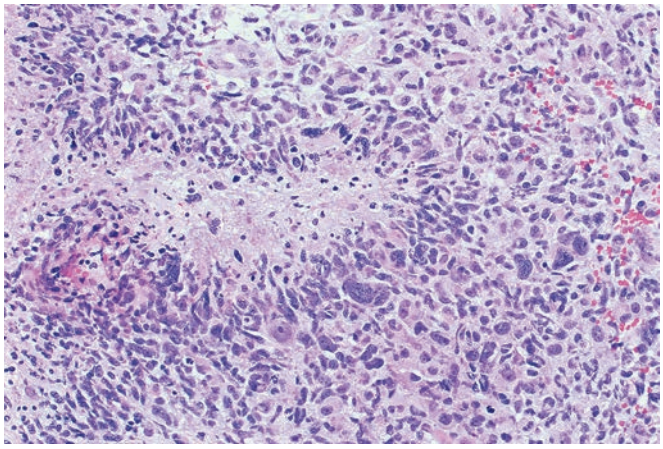

Figure 43.50 Glioblastoma. Dense cellularity, striking pleomorphism, and zones of coagulative necrosis lined by "palisading" tumor cells characterize the prototypical glioblastoma.

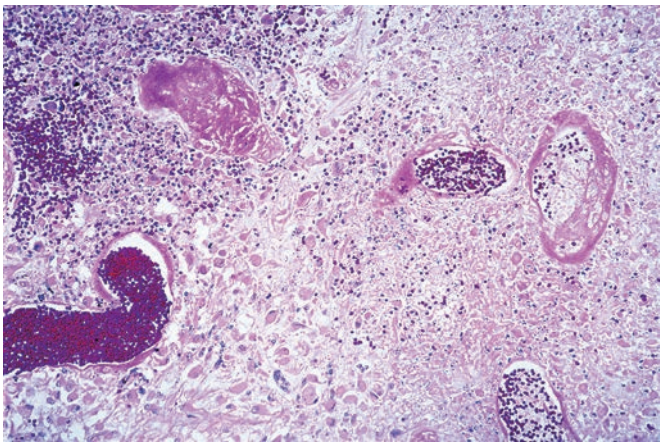

Figure 43.51 Radiation Effects. A marked reduction in cellularity, extensive necrosis, and necrotizing fibrinoid vasculopathy with vascular thrombosis and ectasia typify astrocytic neoplasms injured by irradiation.

(Fig. 43.49). Although often referred to simply as "endothelial" hyperplasia, this process involves a number of vessel-associated cell types, prominent among which are pericytic/myoid elements expressing smooth muscle–related antigens.[300,301] Its identification in neurosurgical material from patients not previously subjected to radiation therapy suffices for a diagnosis of glioblastoma by WHO criteria, as does the finding of focal coagulative tumor necrosis regardless of whether neoplastic cells align themselves about such zones in the prototypical palisades that are a "textbook" feature (Fig. 43.50).

Irradiation induces a variety of morphologic alterations in glioblastomas, the most predictable being widespread necrosis without surrounding increased tumor cell density (usually much reduced) and vasculopathic changes that include ectasia, fibrinoid necrosis, hyalinization, and obliterative mural fibroplasia (Fig. 43.51). Florid astrogliosis and infiltration by macrophages, the latter identifiable by their immunoreactivity for HAM-56, CD68, and other histiocytic markers, may complicate the recognition of neoplastic elements. Some re-resection specimens, in fact, consist solely of necrotic debris or contain only scattered atypical cells, including treatment-related, grotesque cells with karyomegaly, dense hyperchromasia, chromatin smudging and nuclear vacuolization. Although these cells are often neoplastic, albeit damaged, it may be difficult to distinguish them from hyperplastic non-neoplastic astrocytes displaying radiation atypia. From the opposite perspective, residual IDH-mutant astrocytoma cells may appear remarkably similar to reactive astrocytes cytologically (Fig. 43.52). Nevertheless, these elements do not imply disease progression and a need to shift therapy, and we report such specimens as exhibiting treatment effect with only minimal evidence of persistent (albeit "injured") tumor. The diagnosis of progression/recurrence rests on firmest grounds when aggregates of cytologically unaltered and mitotically active tumor cells can be demonstrated, and cellular palisading around foci of necrosis also constitutes unimpeachable testimony to treatment failure. In some instances, the necrotizing and vasculopathic changes described here will be found to involve brain tissue (typically white matter, which is

For personal use only. No other uses without permission. Copyright ©2017. Elsevier Inc. All rights reserved.

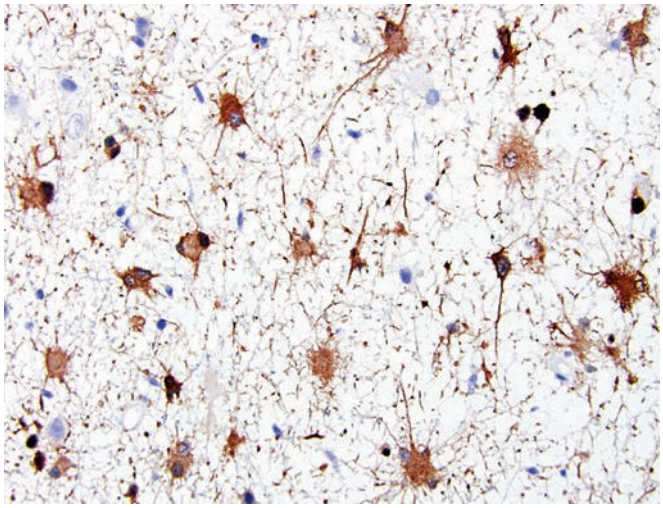

Figure 43.52 Radiation Effects. IDH1 R132H immunohistochemistry highlights residual postradiation astrocytoma cells with radiating processes, resembling reactive astrocytes.

particularly susceptible to ionizing irradiation) manifesting no tumoral infiltration. This toxic process (cerebral radionecrosis) characteristically interrupts a period of apparent remission and neurologic recovery measured in months (or, in some cases, years) and may mimic post-therapy relapse to clinical and neuroradiological perfection.

Gliosarcoma (the GBM Variant) and Other "Gliomesenchymal" Tumors

CNS tumors characterized by mixed neuroepithelial and mesenchymal features are a heterogeneous lot. We have previously alluded to the emergence of sarcomatous elements from neoplasms of the astrocytic, oligodendroglial, and ependymal series. The overwhelming majority of glial tumors manifesting this phenomenon are glioblastomas, and the designation of **gliosarcoma**, employed without qualification, is generally taken to connote a glioblastoma variant[302] (as opposed to "oligosarcoma"[303,304] or "ependymosarcoma"[305]). It has been suggested that approximately 2% of otherwise conventional glioblastomas generate malignant components of mesenchymal type,[278] and only gliosarcomatous neoplasms of this, the most common, type are accorded more extended treatment here. Clinically, some are divided into "primary" or "secondary" forms, based on whether or not they presented as gliosarcoma de novo or the sarcomatous component only arose after recurrence of a classic glioblastoma.[302,306,307] However, this should not be confused with the more common use of the terms primary and secondary in glioblastoma to refer to mostly IDH-wildtype versus IDH-mutant glioblastomas, respectively, the latter of which mostly arise from lower-grade astrocytoma precursors.

The great majority of gliosarcomas correspond clinically and molecularly to the primary or IDH-wildtype glioblastoma variant, with the exception that *EGFR* amplification is rare.[278] Nevertheless, occasional examples arise secondarily from lower-grade IDH-mutant diffuse gliomas.[302,308] Most arise in the absence of recognized predisposing factors, but gliosarcomas have also been associated with prior irradiation, including the intracranial instillation of Thorotrast.[309] At operation, many are initially mistaken for cerebral metastases or (when attached to the dura) meningiomas, errors resulting from their characteristic circumscription and firm textures. These attributes in turn reflect the high content of connective tissue fibers typical of the gliosarcoma but foreign to most other neuroepithelial neoplasms. A marmoreal admixture of gliomatous and sarcomatous tissues lends

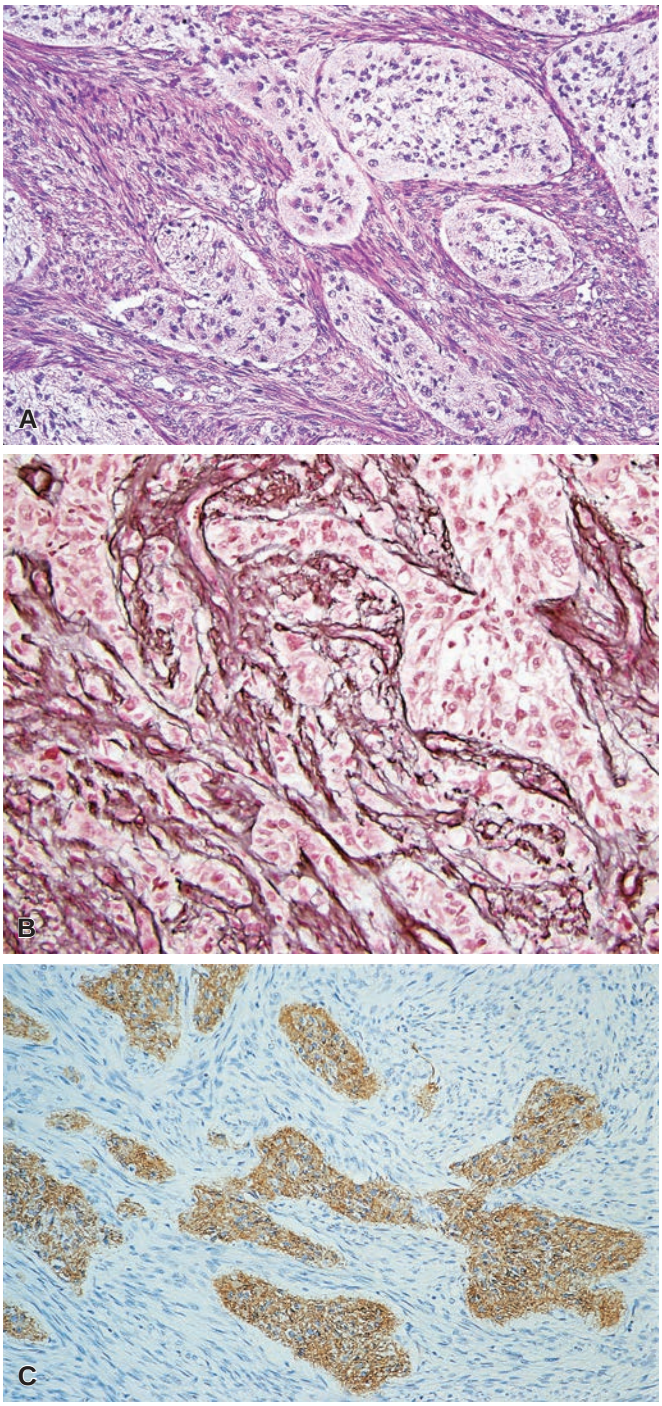

Figure 43.53 Gliosarcoma. A, Islands of astrocytic tumor tissue lie embedded in what otherwise appears to be a spindle cell sarcoma. **B,** Only the sarcomatous regions show dense intercellular reticulin deposition. In contrast, on immunoperoxidase assay **(C)**, only astrocytic elements mark with glial fibrillary acidic protein.

to these tumors a strikingly biphasic architecture on histologic study (Fig. 43.53A). The mesenchymal components would prompt the diagnosis of fibrosarcoma or undifferentiated pleomorphic sarcoma in a soft tissue setting, but chondro-osteogenic and myogenic differentiation may be encountered in this setting, and variants harboring angiosarcomatous, liposarcomatous, and mixed mesodermal-type elements have also been reported.[278,310-313] Squamous differentiation,

For personal use only. No other uses without permission. Copyright ©2017. Elsevier Inc. All rights reserved.

"adenoid" formations, and glandular structures may also be displayed within the glial regions of select cases.[314]

Distinction of the gliosarcoma's dimorphic constituents can be further accomplished using a combination of traditional histochemical and immunocytochemical techniques. Sarcomatous components are richly invested with connective tissue fibers demonstrable by reticulin impregnation methods (see Fig. 43.53B) and preparations for collagen, such as the Mallory trichrome stain, but do not express GFAP, the reverse being true of the glial population (see Fig. 43.53C). The identification of an architecturally and cytologically distinct, GFAP-negative component is requisite to the segregation of the true gliosarcoma from collagenized, spindle cell ("desmoplastic") glioblastomas and gliomas associated with a florid fibroblastic reaction by virtue of meningeal invasion. Similarly distanced from neoplasms of gliosarcomatous character are variants of astrocytoma and ependymoma that give rise to well-differentiated, GFAP-immunoreactive cartilaginous elements,[311] as well as "liposarcomatous,"[315] adipocyte-like constituents that retain GFAP expression.

The "malignant degeneration" of blood vessel–associated stromal elements was first held to account for the genesis of sarcomatous populations within glioblastomas.[316] The latter, as previously discussed, often manifest a florid and complex MVP driven by the tumoral elaboration of mitogens that act on endothelium, pericytes, smooth muscle cells, and fibroblasts. Each of these cell types came to be championed as a target of transformation within evolving gliosarcomas, as did histiocytes, myofibroblasts, and uncommitted adventitial elements. That this autocrine phenomenon could eventuate in sarcomatous outgrowth—a notion originally based on perceived histologic transitions from the hyperplastic to unarguably neoplastic—received only qualified support, however, from immunohistochemical and electron microscopic observations.

A rival histogenetic view of "metaplasia" favored neoplastic glial cells simply undergoing phenotypic shift with tumor progression, losing GFAP expression and assuming mesenchymal attributes.[317] Powerful backing for this scenario derives from molecular genetic studies demonstrating that gliomatous and sarcomatous components may harbor identical *TP53* and *PTEN* mutations, p16 (*CDKN2A*) deletions, and coamplifications of *CDK4* and *MDM2*. Whether a subset of tumors accorded this designation might still represent true composites, as opposed to neometaplastic lesions of clonal character, is arguable. The clonal nature of oligosarcomas and ependymosarcomas is similarly supported by shared patterns of chromosome 1p/19q codeletion[303,304] and of NF2/protein 4.1 gene family alterations,[305] respectively.

The designation "**gliofibroma**" has been extended to a heterogeneous group of neoplasms encountered for the most part in childhood, and having in common a population of astrocytes that may be invested by basal lamina material and that are embedded in a variably collagenized matrix.[318,319] Some appear to represent desmoplastic astrocytomas in which neoplastic glia, unaided by mesenchymal derivatives, are directly responsible for the elaboration of connective tissues, whereas other examples contain a second cellular population interpreted as fibroblastic or, in one study, schwannian.[320] The rarity and disparate morphologic features of the tumors reported under this rubric preclude useful generalizations regarding their histogenesis and clinical biology. A number of recorded cases have evidenced conspicuous cytologic atypia and mitotic activity, pursuing an aggressive course (with CSF-borne metastasis) and ending fatally, the benign connotations of the term "gliofibroma" notwithstanding.[318] A more favorable outcome seems to be attached to those lacking features of histologic anaplasia.

This discussion of gliomesenchymal tumors is concluded with passing reference to the various uses of the term "**angioglioma**." Originally applied to what would now be classified as the cellular variant of cerebellar hemangioblastoma, this designation has been most frequently invoked in reference to gliomas exhibiting degenerative vascular alterations resembling AVMs or cavernous angiomas.[321-323] Slow-growing lesions such as pilocytic astrocytomas, oligodendrogliomas, and gangliogliomas seem especially prone to such changes. These may appear hypervascular on angiographic study, exhibiting a tumoral "blush," but as a rule do not evidence the shunting characteristic of true AVMs. Only exceptionally are the latter found in contiguity with glial neoplasms. Most such lesions are regarded as "collision" tumors in which gliomatous and malformative tissues are fortuitously associated, but isolated reports of glial neoplasms secondarily arising at the sites of pre-existent AVMs and angiomas suggest that the gliotic reaction typical of tissues surrounding such longstanding vascular anomalies may rarely progress to neoplasia. A strikingly increased concentration of oligodendrocytes in and around some AVMs appears to result from "collapse" of chronically edematous and ischemic white matter or to represent part of the malformation process and should not necessarily prompt a diagnosis of oligodendroglioma.[128] Finally, we call attention to a group of exceedingly uncommon tumors interpreted as containing both gliomatous and hemangioblastomatous elements.[323] These, too, have been described as a form of "angioglioma," a nonspecific and potentially misleading term that is best abandoned.

Other Glioblastoma Variants and Patterns

Differentiated elements may be intermingled with bizarre multinucleated tumor giant cells, spindled, epithelioid (including rhabdoid) cells,[324,325] signet ring cells,[326] or small anaplastic forms, altogether devoid of identifying astrocytic features. The last often come to dominate the histologic picture at recurrence, selectively repopulating tumors subjected to therapy, but may also constitute the nearly exclusive elements of select **small cell glioblastomas** at presentation (Fig. 43.54). Given the monomorphism of this subtype and variable presence of arborizing capillaries, microcalcifications, and clear perinuclear haloes, the latter is often mistaken for anaplastic oligodendroglioma but differs from the latter in its lack of IDH1 R132H mutant protein expression and *1p19q* codeletions, as well as frequent chromosome 10 losses and *EGFR* amplification.[292,308]

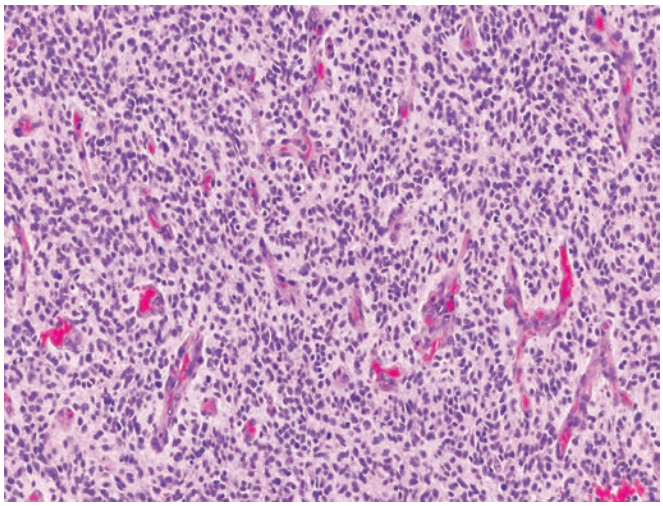

Figure 43.54 Glioblastoma, Small Cell Variant. In contrast to most glioblastomas, the small cell variant is relatively monomorphic with small, round to oval nuclei and minimal discernable cytoplasm. The presence of branching capillaries and clear haloes (not shown here) often invokes a differential diagnosis with anaplastic oligodendroglioma.

For personal use only. No other uses without permission. Copyright ©2017. Elsevier Inc. All rights reserved.

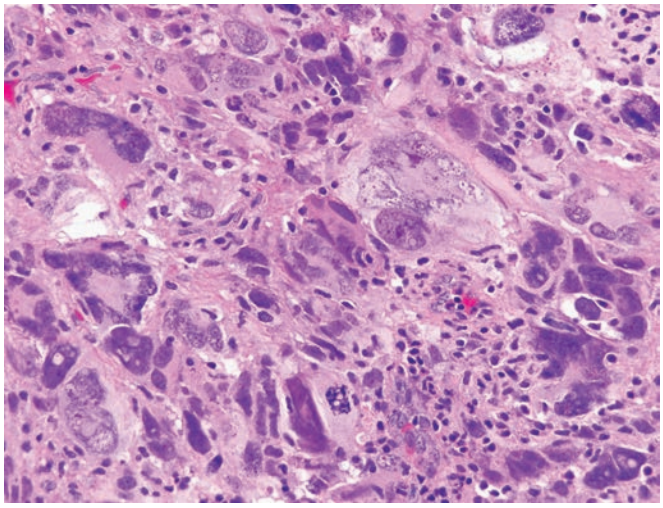

Figure 43.55 Glioblastoma, Giant Cell Variant. This subtype is characterized by numerous bizarre mononucleated and multinucleated giant cells, imparting a marked degree of pleomorphism that often raises a differential with pleomorphic xanthoastrocytoma.

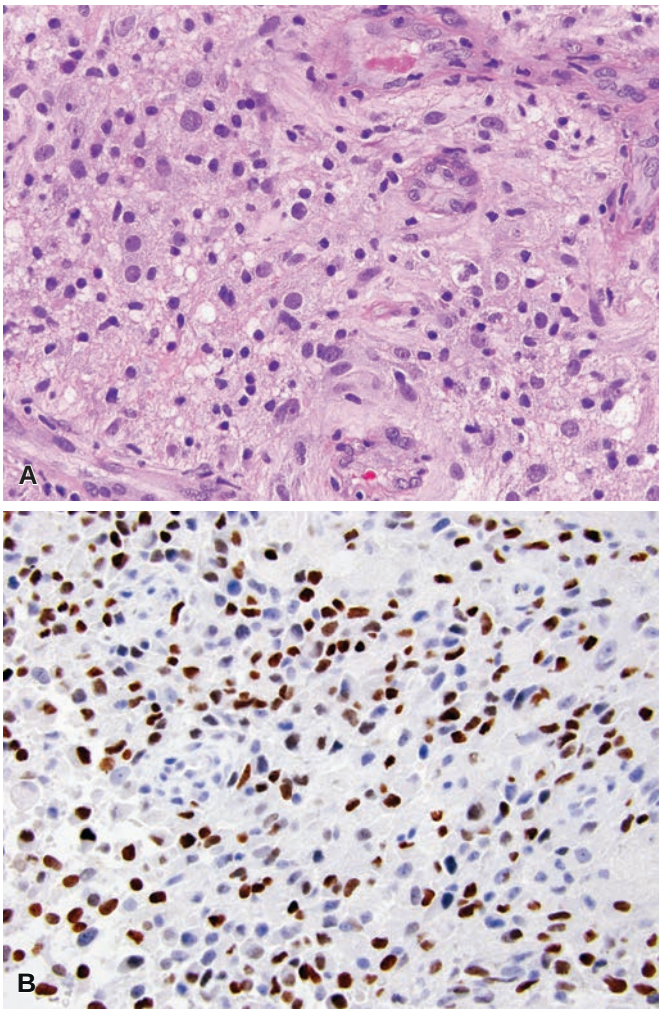

Figure 43.56 Glioblastoma, Granular Cell Variant. Although the granular to vacuolated cytoplasm of tumor cells is reminiscent of macrophages (thus raising a differential diagnosis with demyelinating disease), the larger cell size and presence of microvascular proliferation are clues to its malignant nature **(A)**. Further confirmation of the tumor's glial nature may be established with glial fibrillary acidic protein (not shown) and/or OLIG2 **(B)** immunostains.

Yet another variant, the **giant cell glioblastoma** (Fig. 43.55), shares with the secondary glioblastoma a younger patient age at onset, frequent *TP53* mutation, and lack of *EGFR* amplification and $p16^{INK4a}$ deletion. However, like the primary variant, it arises in the absence of a differentiated precursor lesion, is usually IDH-wildtype, is associated with a brief predetection clinical interval, and often manifests *PTEN/MMAC1* gene mutation.[327] Although most astrocytic neoplasms under discussion are confidently distinguished from primary cerebral sarcomas and tumors metastatic to the CNS by virtue of their characteristic cytologic features and patterns of infiltration, this one is known for its unusual circumscription, sarcomatoid cytologic features, and reticulin-rich matrix. Once regarded as a "monstrocellular" sarcoma, the glial nature is demonstrated by immunolabeling for GFAP and/or OLIG2. The same can be said for spindled and lipid-rich variants of glioblastoma.[328] Some high-grade astrocytic neoplasms have been misclassified as fibrosarcomas or pleomorphic sarcoma when immunohistochemical studies demonstrated cytoplasmic labeling for such nonspecific antigens as vimentin, α1-antitrypsin, or α1-antichymotrypsin but were not examined specifically for glial markers. The emergence of GFAP-negative sarcomatous components within astrocytic and other glial tumors ("gliosarcoma") was discussed previously (see Gliomesenchymal tumors). Still other aggressive and poorly differentiated astrocytic tumors contain glandular or gland-like ("adenoid") formations,[314] undergo squamous metaplasia, or assume clear cell cytologic features (owing to cytoplasmic lipidization) and a cohesive disposition in nests and sheets that bring "balloon cell" melanoma and carcinomas of renal or adrenocortical origin to mind.[329] Immunolabeling for cytokeratin and EMA may further conspire to obscure the glial lineage of these metaplastic elements in other astrocytic neoplasms. We emphasize in this regard the regular labeling of reactive and neoplastic astrocytes with the AE1/3 cytokeratin "cocktail" (thought to represent cross reactivity with GFAP) and the fact that they are usually nonreactive with CAM 5.2, CK7, CK20, and the noncytokeratin epithelial marker Ber-EP4.[330]

We further call the reader's attention to the existence of astrocytic tumors that undergo a striking granular cell metamorphosis resulting from the intracytoplasmic accumulation of engorged secondary lysosomes.[331] While these peculiar neoplasms may exhibit remarkably benign cytologic features (Fig. 43.56A), **granular cell astrocytomas** of this type are characterized as a group by a highly aggressive glioblastoma-like clinical course, even when lacking high-grade features such as high mitotic index, MVP, or necrosis. Immunolabeling of their cytoplasm for CD68 can result in the misidentification of such tumors as reactive histiocytic infiltrates, though the invariably intermixed true macrophages are typically much smaller and more intensely immunoreactive. In contrast, the tumor cells are often positive for glial markers, such as GFAP and OLIG2 (see Fig. 43.56B) but negative for histiocyte lineage-specific markers such as CD163.

Astrocytic neoplasms can contain ganglion cell–like forms or poorly differentiated/primitive elements that raise the question of neuronal or neuroblastic differentiation. While potentially exhibiting immunoreactivity for class III β-tubulin,[332] these constituents (and their patently astroglial neighbors) generally retain at least focal GFAP expression and usually fail to label for more neuron-restricted antigens such as synaptophysin (SYN) and the NeuN[333] and Hu[334] nucleoproteins. This is not to say, however, that the infiltrating astrocytomas are limited in their differentiating potential. Differentiation along neuronal lines, in fact, is now recognized as an occasional

For personal use only. No other uses without permission. Copyright ©2017. Elsevier Inc. All rights reserved.

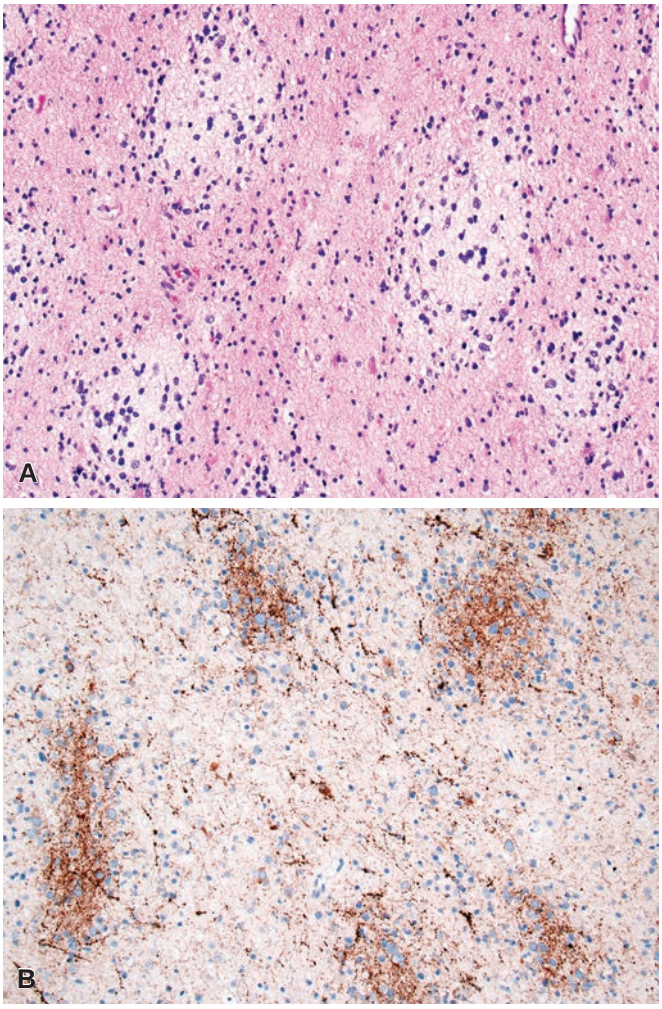

Figure 43.57 "Glioneuronal Tumor With Neuropil Islands." This entity represents a variant of diffuse astrocytoma of any grade with superimposed neuronal/neurocytic differentiation manifesting in pale neuropil-rich islands **(A)** that are synaptophysin immunoreactive **(B)**.

attribute of neoplasms otherwise qualifying as members of the astrocytic, oligodendroglial, and ependymal series. The entity dubbed "**glioneuronal tumor with neuropil-like islands**"[335] can, with much justification, be viewed as a peculiar variant of infiltrating astrocytoma with neuronal/neurocytic differentiation (Fig. 43.57). Typically dominated by fibrillary and gemistocytic astroglial components, at the WHO grade II or III level, this lesion is distinguished by its content of sharply delimited micronodular collections of a delicate meshwork exhibiting intense granular immunolabeling for SYN. These are rimmed in rosetted fashion or internally populated by neurocytic (oligodendrocyte-like) clear cells that often express NeuN and Hu. The diffuse growth pattern of this tumor, its predilection for the cerebral hemispheres of adults, the frequency with which it demonstrates IDH-mutant protein and aberrant p53 expression, and the clinical course (comparable to that of grade-matched infiltrating astrocytomas) are all consonant with the view that the glioneuronal tumor with neuropil-like islands is fundamentally of the conventional astrocytic group.[336]

Similar considerations apply to "**glioblastomas with primitive neuronal (or primitive neuroectodermal tumor [PNET]-like) components**."[337] These harbor relatively well-demarcated nodules of high density, with cellular elements indistinguishable from those characterizing medulloblastomas and other embryonal neoplasms by virtue of their diminutive sizes, undifferentiated cytologic profiles, variable presence of Homer Wright rosettes, loss of GFAP and OLIG2 expression, immunolabeling for SYN (and other neuronal markers), and alarming proliferative activity (Fig. 43.58). Such components may emerge only in recurrent neurosurgical material and usually make their appearance in astrocytic tumors exhibiting the histology and genetic alterations typical of secondary glioblastomas. That this is an unusual form of biologic progression complicating glioblastomas is further suggested by the observation that widespread p53 reactivity and *PTEN* abnormalities (foreign to the great majority of embryonal CNS tumors) are commonly evidenced by both astroglial and primitive-looking populations, whereas the latter may selectively manifest *MYC* or *MYCN* amplifications (a phenomenon rare in astrocytomas, but not uncommon in neuroblastic tumors). A small subset also express mutant IDH1 protein and loss of ATRX expression.[308] The experience communicated to date indicates that a substantially increased risk of CSF dissemination attaches to glioblastomas of this kind, and optimal therapeutic approaches in such patients remain unclear.

Another rare variant is the **epithelioid glioblastoma**, often characterized by a younger age of onset (including pediatric), superficial localization, a surprisingly demarcated interface with adjacent brain, large epithelioid cells with abundant eosinophilic cytoplasm, large macronucleoli, and variable rhabdoid cytology, commonly imparting an initial impression of metastatic melanoma (Fig. 43.59).[324] In common with melanoma and virtually all gliomas, S-100 protein is strongly expressed, SOX10 may be positive, but other, more specific melanocytic markers, such as HMB-45, Melan-A, and MITF are negative. Complicating the differential even further is the fact that most cases show only limited staining for GFAP and OLIG2, while roughly half of cases express the BRAF V600E mutant protein. Of interest, a subset of such tumors arises secondarily from lower-grade precursors, the most common being PXA, another tumor type with frequent *BRAF* V600E mutation. As such, it is not entirely clear whether such examples are best considered a variant of anaplastic PXA (WHO grade III) or an epithelioid glioblastoma (WHO grade IV). In both the de novo and this "secondary" form, the clinical behavior is often highly aggressive, although a subset of long-term survivors have also been encountered. Additionally, dramatic response to BRAF inhibitors has been reported anecdotally in *BRAF* mutant examples.[325] Lastly, *ODZ3* tumor suppressor gene deletion on 4q34.3–q35.1 has been found to be another common alteration.[324]

Prognostic/Predictive Variables. The prognosis of a given fibrillary astrocytic neoplasm is a complex function of clinical, morphologic, and genetic variables, with the IDH status likely representing the most powerful stratifier, as discussed previously. In fact, this one feature often outweighs tumor grading, such that IDH-mutant glioblastoma patients often survive considerably longer than IDH-mutant anaplastic astrocytoma patients.[294] Patient age, functional status on presentation, tumor location, and histology all affect the outcome of supratentorial examples.[278] Faring best are young subjects harboring low-grade, IDH-mutant lesions that are unassociated with focal neurologic deficits and that are situated in the cerebral hemispheres. Follow-up studies of patients identified and managed since the advent of CT and MRI (i.e. in the era of "early" detection) suggest median survivals of up to 10 years under such relatively favorable circumstances, with death typically following tumor progression to glioblastoma.[278] Whether attempted gross total resection, chemotherapy, or radiotherapy prolongs the lives of patients with low-grade cerebral hemispheric astrocytomas is a contentious matter. Many neuro-oncologists elect to simply

For personal use only. No other uses without permission. Copyright ©2017. Elsevier Inc. All rights reserved.

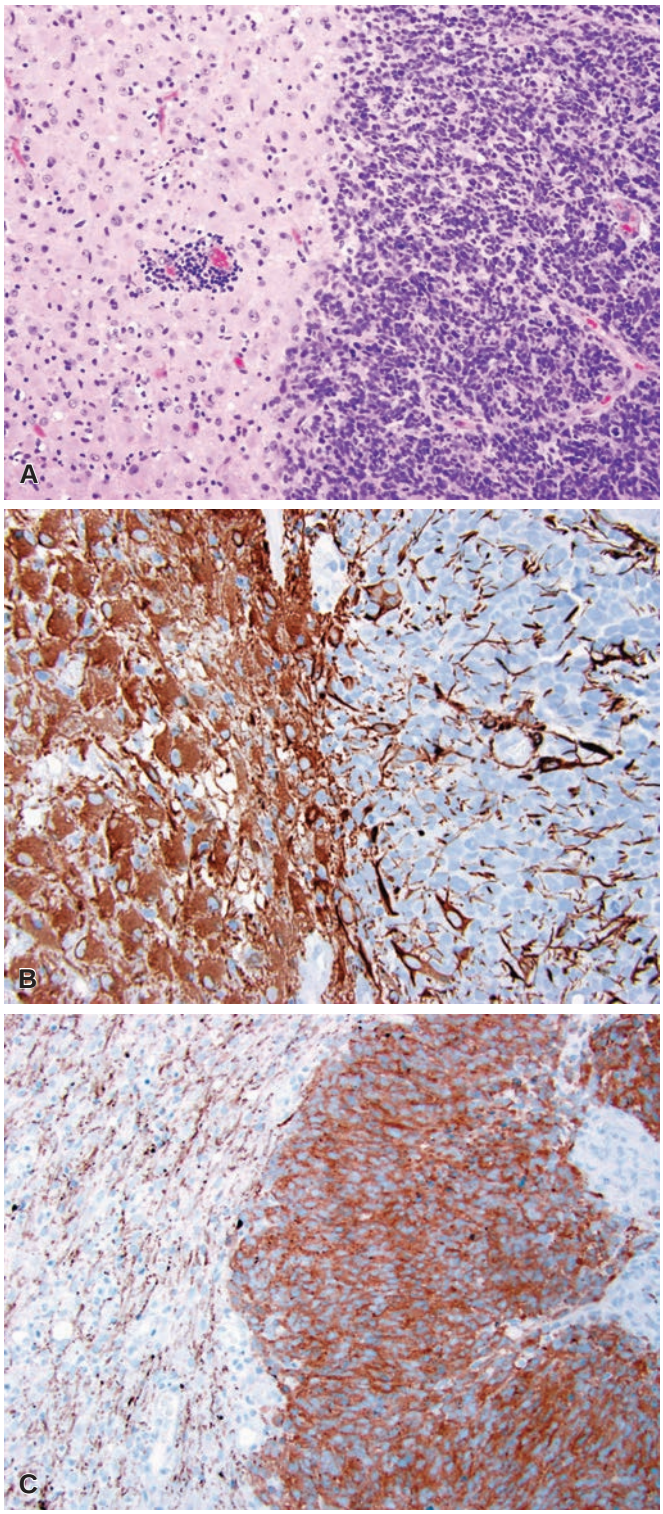

Figure 43.58 Glioblastoma With Primitive Neuronal Component (A, H&E; B, GFAP; C, Synaptophysin). This variant may arise from any diffuse glioma subtype, but astrocytomas are most common. They are characterized by sharp demarcation of a primitive-appearing component with diminished evidence of glial differentiation and increased evidence of neuronal differentiation. In this example, there is a gemistocytic astrocytoma component on the left giving rise to a primitive component on the right.

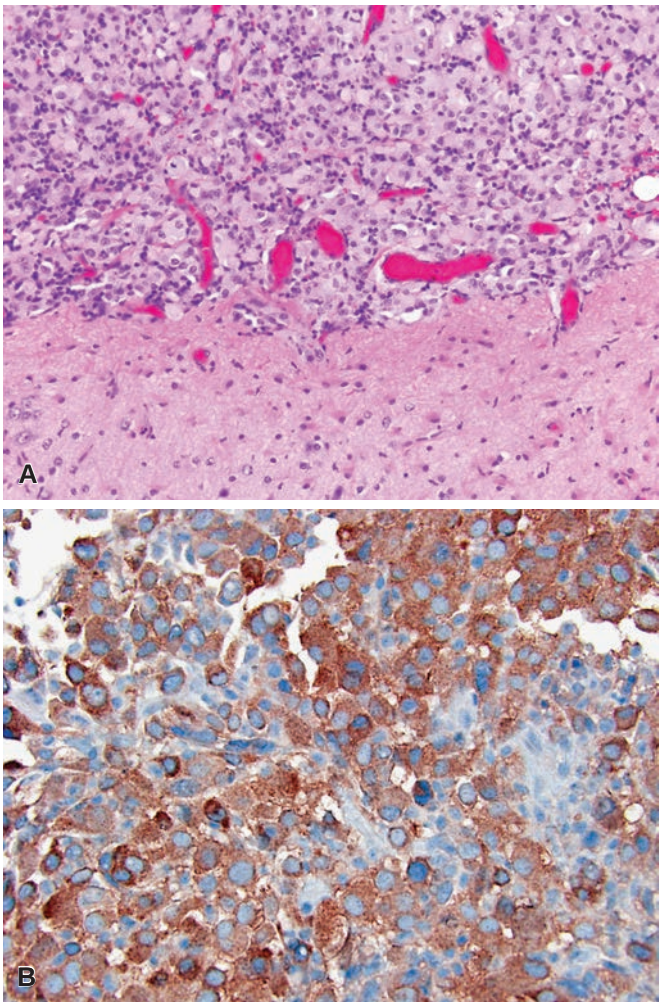

Figure 43.59 Glioblastoma, Epithelioid Variant. A, This variant is often surprisingly demarcated in growth pattern and harbors large epithelioid to rhabdoid glioma cells reminiscent of malignant melanoma. **B,** Roughly half of cases express the BRAF V600E mutant protein by immunohistochemistry.

follow affected individuals until there is compelling clinical or neuroradiological evidence of tumor growth. Comparably situated anaplastic astrocytomas and glioblastomas, by contrast, are unarguably aggressive neoplasms associated with median postoperative survival periods of 24–48 and 12 months, respectively, despite irradiation and adjuvant chemotherapy. Hemispheric H3 G34R/V-mutant examples, occurring primarily in children and young adults, carry an intermediate prognosis,[297,298] while the midline H3 K27M-mutant tumors are amongst the most aggressive (see later). Inactivation of the DNA repair enzyme O^6-methylguanine-DNA methyltransferase (MGMT), usually through promoter hypermethylation of its encoding gene, is emerging both as a predictor of enhanced tumor responsiveness to alkylating agent chemotherapy and generally favorable prognostic marker.[338] Under active investigation in the treatment of glioblastomas are agents against EGFR, its major mutant form *EGFR-vIII*, and downstream targets of these and other kinases. Ultimately, however, the insidious manner in which these lesions permeate brain tissues beyond their neuroradiologically defined and grossly apparent borders, along with their marked genetic heterogeneity, frustrates attempts at local disease control and sets the stage for progressive infiltration of neighboring cerebral parenchyma by

For personal use only. No other uses without permission. Copyright ©2017. Elsevier Inc. All rights reserved.

chemoresistant and, potentially, targeted therapy-resistant clones. This, the primary pattern of treatment failure, is occasionally complicated by the development of CSF-borne neuraxial metastases and, rarely, by spread to somatic sites, such as bone, lung, liver, or lymph node.[339] Most unusual, but well documented, are cases in which systemic metastases have been apparent on initial patient presentation,[339] and the bizarre phenomenon of inadvertent tumor transplantation via solid organ allografts has also been the subject of isolated reports.[340]

Similarly dismal is the prognosis attached to diffusely invasive midline astrocytomas, most of which involve the brainstem, thalamus, or spinal cord and are high grade at diagnosis. Given the predominant mutations in the histone H3 genes, *H3F3A* and *HIST1H3B*, the WHO 2016 scheme has referred to these neoplasms collectively as "**diffuse midline glioma, H3 K27M-mutant**" (see Fig. 43.46). Such tumors predominantly affect children (especially brainstem), although thalamic and spinal tumors are not uncommonly encountered in young adults; they tend to behave aggressively (survival beyond 2 years is rare), even when otherwise appearing lower grade by histology alone.[295-298] These lesions may even mimic pilocytic astrocytomas, gangliogliomas, or ependymomas in limited biopsies, so the index of suspicion should be high and the K27M mutant immunostain applied frequently for such midline gliomas.

Quantifiable methods for the determination of proliferative potential are now in wide use as adjuncts to the conventional morphologic assessment of astrocytic and other primary CNS neoplasms. Immunohistochemical assay for the Ki-67 antigen, a nonhistone nucleoprotein selectively expressed by actively cycling cells and demonstrable in paraffin-embedded material using the MIB-1 monoclonal antibody, has proven especially useful to surgical neuropathologists in this regard. Nevertheless, the performance of this reagent is subject to all the technical vagaries that attend immunohistochemical methods, such that it is often difficult to extrapolate results from one lab to another. General survey discloses a broad correlation of histologic grade and labeling index, but unfortunately reveals overlapping index ranges for low-grade astrocytomas (mostly <5%), anaplastic astrocytomas (mostly 5%–10%), and glioblastomas (mostly >10%). In practice, we employ MIB-1 only in the evaluation of histologically low-grade or "borderline" fibrillary astrocytomas and simply append in our reporting of values above 5% a comment to the effect that such levels suggest a heightened proliferative potential.

Oligodendrogliomas, IDH-Mutant and 1p/19q-Codeleted (and Its Rare Pediatric Counterpart)

Oligodendrogliomas are named for the resemblance of their constituent cells to native oligodendrocytes, although the notion that these neoplasms derive from the latter is unlikely; most recent data favors an origin from oligodendrocyte precursor cells instead of neural stem cells.[341,342] Characteristic clinical features include a predilection for young and middle-aged adults, a cerebral hemispheric localization (the frontal and temporal lobes being principally affected), an often protracted preoperative history of intermittent seizures or headache, and partial calcification on neuroradiological study (Fig. 43.60). Only exceptionally do oligodendroglial neoplasms arise below the tentorium, but no part of the CNS is immune. The literature includes accounts of tumors interpreted as oligodendrogliomas of brainstem, cerebellar, and spinal plus/minus leptomeningeal origin,[343-345] although the latter must be distinguished from a distinctive pediatric neoplasm now known as "diffuse leptomeningeal glioneuronal tumor" (described in greater detail later).[346] In the 2016 WHO scheme,[278] both IDH mutations and chromosome 1p/19q codeletions are required for the diagnosis of the more common adult form of oligodendroglioma.

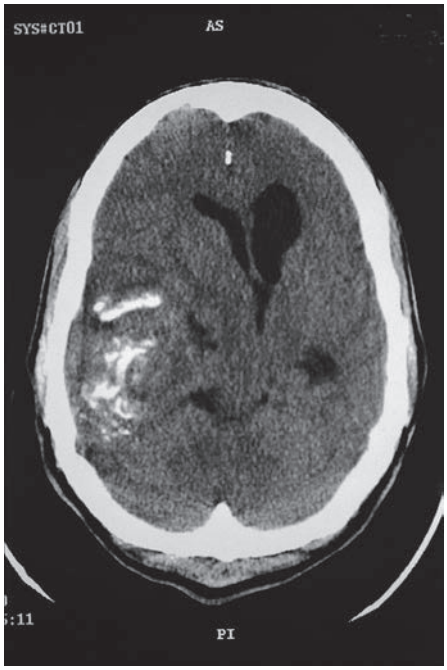

Figure 43.60 Oligodendroglioma. The bright signal abnormalities seen in this nonenhanced computed tomography study of a large right cerebral oligodendroglioma represent foci of intratumoral calcification. While evidenced by only a minority of oligodendroglial neoplasms, linear or plate-like calcifications of this sort are most suggestive of the diagnosis.

Oligodendrogliomas are usually found within white matter at operation, but extension into overlying cortex is the rule. Composed of soft, gray–pink tissue that often acquires a gelatinous consistency due to the accumulation of myxoid matrix materials, these tumors may feature cystic change and can contain foci of dense calcium deposition that are palpably gritty or even rock-hard. A vulnerability to artifactual cytoplasmic dissolution accounts for the classic histologic presentation of oligodendrogliomas as permeative or, in some cases, sheet-like proliferations of uniform rounded nuclei surrounded by optically clear halos (Fig. 43.61A). When well preserved, the nuclei show delicate neuroendocrine-like "salt and pepper" chromatin, small nucleoli, and distinct nuclear membranes. A fusiform spindling of tumor cells is occasionally apparent and some high-grade, "polymorphous" variants harbor markedly pleomorphic, giant cell subpopulations.[347] Oligodendrogliomas often contain scattered calcospherites, which may be clustered in laminar fashion within cerebral cortex along the advancing tumoral perimeter, and many are subtended by a plexiform ("chicken wire") network of thin-walled blood vessels. Of additional diagnostic utility is a tendency to perineuronal tumor cell aggregation ("satellitosis"). Perivascular and subpial growth are also commonly encountered, as are myxoid changes, microcyst formation, and nodular foci of increased cell density. In exceptional instances, tumor cells are segregated into prominent lobules by fibrovascular stromal elements, or stagger across the microscopic field in rhythmic palisades ("spongioblastic" pattern).

It should be emphasized that the "fried egg" cellular profil e of the prototypical oligodendroglioma is an artifact, and thus not seen in conventional frozen sections, intraoperative smears, or crush preparations. The first of these techniques almost invariably produces misleading nuclear angulations, whereas the latter preserve the rounded profiles of tumor cell nuclei which appear either naked or

For personal use only. No other uses without permission. Copyright ©2017. Elsevier Inc. All rights reserved.

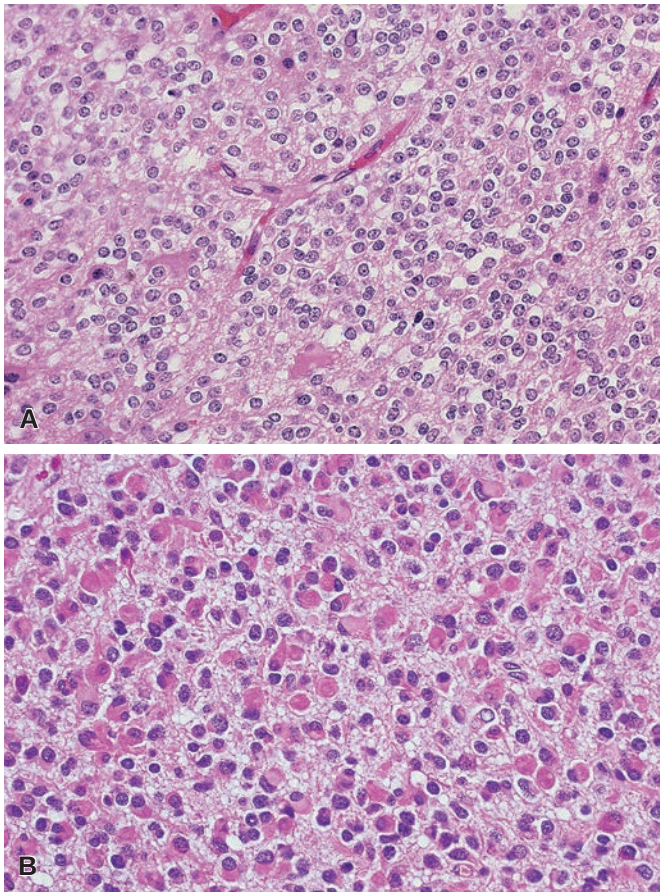

Figure 43.61 Oligodendroglioma. A, Uniform, round nuclei and clear perinuclear halos (artifacts of delayed fixation) typify well-differentiated oligodendrogliomas. "Minigemistocytic" variants **(B)** maintain oligodendroglial nuclear features while amassing globose paranuclear expanses of eosinophilic, hyaline or whorling fibrillar cytoplasm. Compare the size of these cells and their cytologic features with those of the gemistocytic astrocytoma depicted at identical magnification in Fig. 43.35.

irregularly encircled by pale eosinophilic cytoplasm in modest quantity. Distinct cytoplasmic expanses and cell membranes are also less appreciable in paraffin sections prepared from very promptly fixed surgical material. Perinuclear halos, on the other hand, constitute (along with nuclear shrinkage and oligodendrocyte-like rounding) deceptive artifacts potentially imposed on astrocytomas and other nonoligodendroglial neoplasms by the common practice of ultrasonic tumor aspiration.

Oligodendrogliomas often contain intensely GFAP-positive "minigemistocytes"[348,349] that may harbor inclusion-like, whorled intracytoplasmic bodies of filamentous substructure (see Fig. 43.61B). These are of no proven prognostic significance per se but tend to be particularly numerous in high-grade oligodendroglial tumors and may evidence transition to large and pleomorphic gemistocytes of astroglial type. So-called gliofibrillary oligodendrocytes, elements of conventional clear cell type characterized by perinuclear rims of GFAP-immunoreactive cytoplasm that may taper into short, unipolar cell processes, may also be apparent.[349] Other cytologic alterations that may be encountered in oligodendroglial neoplasms include cytoplasmic distension by a PAS-positive mucosubstance, the formation of eosinophilic granular cells stuffed with autophagic vacuoles,[350] and "signet ring" change resulting from the intracytoplasmic accumulation of degenerating mitochondria or from dilated profiles of rough endoplasmic reticulum.[351,352]

Unfortunately, there does not exist at present an immunocytochemical reagent that consistently and specifically identifies neoplastic cells as oligodendroglial. Immunolabeling for S-100 protein, membranous Leu7 (CD57), carbonic anhydrase C, and microtubule-associated protein type 2 (MAP-2) are characteristic but also shared by other glioma types. Cytoplasmic labeling for galactocerebroside and other oligodendrocyte-associated galactolipids is inconstant, and only exceptionally are tumor cells positive for myelin-associated glycoprotein, proteolipid protein, or other differentiation antigens that mark mature oligodendroglia. While oligodendrogliomas commonly display nuclear immunoexpression of the lineage-restricted OLIG1, OLIG2, and SOX10 transcription factors,[353,354] these markers are often positive in other neuroepithelial neoplasms as well, including astrocytomas and, in the case of OLIG2, a subset of neurocytic and embryonal tumors.[355] Of potentially more value may be diffuse cytoplasmic labeling for Nogo-A, a member of the reticulon family, but this antibody also lacks sufficient sensitivity and specificity for clinical utility.[356] In a similar vein, ultrastructural indices of oligodendroglial maturation are lacking in most cases.[357] Microtubules, free ribosomes, and mitochondria constitute the usual cytoplasmic contents and are unaccompanied by any unique organellar structures.

It is, in fact, what the oligodendroglioma fails to accomplish at the ultrastructural level or by way of antigen expression that often proves most useful in its distinction from certain mimickers that may assume astonishingly similar histologic guises. Specifically, it does not fashion the elaborate zonulae adherentes–type intercellular junctions, microlumens, microvillous or ciliary arrays of the clear cell ependymoma, or the clear synaptic or dense-core vesicles that betray the neuronal nature of central and extraventricular neurocytomas. The dot- and ring-like immunolabeling for EMA that corresponds to ependymal microlumen formation is not displayed by oligodendroglial tumors. Neurocytic neoplasms are further (and most efficiently) distinguished by a neuronal immunophenotype that includes diffuse matrix labeling for SYN and, in many instances, widespread immunoreactivity for the neuronal nuclear antigens Hu[334] and NeuN.[358] This is not to dismiss evidence that oligodendrogliomas occasionally exercise a potential for neuronal differentiation. In fact, labeling for a variety of neuron-associated antigens is common,[359] particularly SYN, and there have been notable examples of oligodendrogliomas harboring unarguably neurocytic elements in rosetted array[360] as well as ganglion cell components.[361] We would nevertheless emphasize that close scrutiny is required lest neoplastic infiltration of SYN-rich cortex (a frequent event) be seized upon as evidence of tumoral differentiation along neuronal lines. Again, NeuN assessment is useful in this regard, as immunoreactivity for this protein is foreign to the great majority of oligodendrogliomas,[358] and serves to highlight remaining native neurons in colonized gray matter. The decidedly oligodendroglioma-like dysembryoplastic neuroepithelial tumor departs from the neoplasms under discussion in its predilection for patients younger than 20 years of age, largely cortical topography, content of intracortical nodules with a "patterned" alveolar architecture, lack of *IDH* mutations, and intact chromosome 1p/19q status.

Unlike clear cell meningiomas (usually extra-axial and dura based), oligodendrogliomas are typically EMA negative, are not heavily glycogenated, and lack well-developed intercellular junctions at the electron microscopic level. Similar considerations apply to the identification of clear cell carcinomas, which may also exhibit cytokeratin reactivity.

As with the astrocytomas, by far the most reliable diagnostic aids in the diagnosis of the adult-type oligodendroglioma are molecular markers, including those with immunohistochemical surrogates. By definition, these tumors are IDH-mutant and show chromosome 1p/19q codeletion, the latter typically resulting from a non-balanced

For personal use only. No other uses without permission. Copyright ©2017. Elsevier Inc. All rights reserved.

t(1;19)(q10;p10) translocation[362,363] and associated in smaller subsets with mutations of *CIC* and *FUBP1*.[364,365] In contrast to their astrocytoma counterparts, which promote alternative lengthening of telomeres by *ATRX* mutations, senescence is avoided based on telomerase overexpression resulting from mutations of the *TERT* promoter region; as such, ATRX immunostaining shows retained nuclear expression in all cases.[366-368] Furthermore, oligodendrogliomas may contain minor populations that exhibit nuclear immunoreactivity for p53, but when there is widespread immunoreactivity or strong expression in greater than 10% of tumor nuclei, this phenomenon is far more characteristic of the astrocytoma group, in which it correlates relatively well with the presence of *TP53* mutations and tends to have an inverse correlation to the 1p/19q abnormalities previously mentioned.[289]

A variety of grading strategies have emerged from correlative studies of oligodendroglioma histology and outcome.[369] A two-tiered segregation into low- versus high-grade variants forms the basis of the WHO classification and has found wide application among neuropathologists.[278] Well-differentiated tumors that exhibit little in the way of mitotic activity and are devoid of proliferative microvascular alterations or necrosis are reported as "**oligodendroglioma, IDH-mutant and 1p/19q-codeleted, WHO grade II**." Nodular foci of increased cellularity alone are still compatible with this diagnosis. MVP and conspicuous mitotic activity—joined, in some cases, by necrosis and often accompanied by dense cellularity, enlarged epithelioid cells, and obvious nuclear atypia—are features of the "**anaplastic oligodendroglioma, IDH-mutant and 1p/19q-codeleted, WHO grade III**" (Fig. 43.62). The latter may evolve within an underlying oligodendroglial neoplasm of low-grade character. Other variables associated with an unfavorable clinical course include advancing patient age, contrast enhancement on neuroradiological assessment (a ring-enhancing profile seems especially ominous), and, in some studies, MIB-1 labeling indices in excess of 5%.[370,371]

Median survivals reaching up to nearly 15 years have been reported for 1p/19q-codeleted anaplastic examples in patients treated with adjuvant chemoradiation in clinical trials,[372,373] and survival may be even longer in the low-grade (WHO grade II) cohorts.[374] The *IDH* gene mutations previously mentioned in the discussion of diffuse astrocytic tumors occur at comparably high frequency in both low-grade and anaplastic oligodendrogliomas. In comparison to their adult counterparts however, few pediatric examples harbor IDH mutations and 1p/19q deletions (positive examples seen mostly in adolescent patients), with low-grade examples progressing to anaplastic oligodendrogliomas less often.[365,375,376]

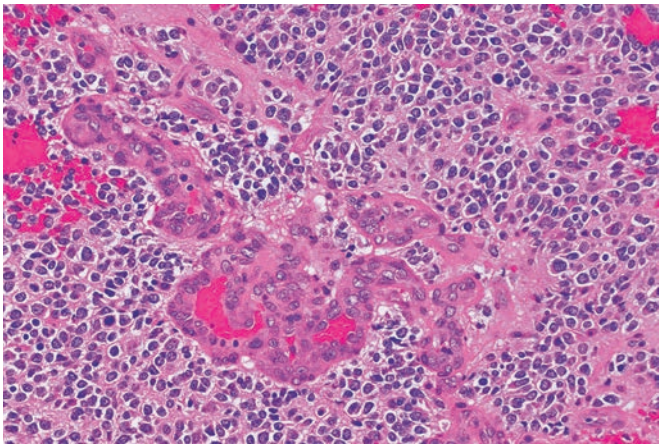

Figure 43.62 Anaplastic Oligodendroglioma. Microvascular proliferation, readily apparent mitotic activity, and cytologic atypism are features of this example.

Oligodendrogliomas usually kill by virtue of progressive neuroparenchymal infiltration following local recurrence. Leptomeningeal dissemination via the CSF is exceptional and distant metastasis rare.[377] Gliosarcomatous transformation has been recorded[303,304] but is exceptional in contrast to their astrocytic counterparts.

Mixed Gliomas

The only "mixed" gliomas broadly recognized by both neuropathologists and the WHO are those manifesting both astrocytic and oligodendroglial features, defined as neoplasms in which elements perceived as astrocytic or oligodendroglial in phenotype are closely and randomly intermingled or in which these components are spatially distinct. These infiltrative lesions most often arise in the cerebral hemispheres of adults (the frontal and temporal lobes are favored) and are termed **oligoastrocytomas** (WHO grade II) or **anaplastic oligoastrocytomas** (WHO grade III). The latter display high cellularity, conspicuous nuclear atypism, readily apparent mitotic activity, and, in some cases, complex microvascular hyperplasia. As noted previously, however, the vast majority of such cases can now be molecularly classified as either astrocytoma or oligodendroglioma, given that no unique oligoastrocytoma-associated molecular signature has been identified. As such, this diagnosis is discouraged in the 2016 WHO scheme, with the rare exceptions being diagnoses made in resource-poor practices on morphology alone (to which a designation of "NOS" for not otherwise specified is appended to the diagnosis), cases where molecular analysis does not clarify the lineage (e.g. rare pediatric counterparts), or exceptional examples wherein the molecular features of astrocytoma are found in one region of the tumor and the genetic signature of oligodendroglioma is encountered in other parts.[378,379] As such, it is expected that the diagnosis of oligoastrocytoma will become vanishingly rare in the near future and, in a similar fashion, the WHO grade IV counterpart of "glioblastoma with oligodendroglioma component" virtually always gets reclassified using molecular studies into one of three integrated diagnoses: (1) glioblastoma, IDH-wildtype with its standard poor prognosis, (2) glioblastoma, IDH-mutant with an intermediate prognosis, and (3) anaplastic oligodendroglioma, IDH-mutant, 1p/19q-codeleted with the most favorable prognosis.[365,380]

As another rare consideration, clear cell components histologically similar to oligodendroglioma may be found within otherwise conventional ependymomas, particularly supratentorial examples. The fact that these elements retain ependymal features at the ultrastructural level, and that some otherwise classic glioblastomas show perivascular pseudorosettes without discernable evidence of ependymal differentiation, calls into question descriptions of either mixed oligodendroglial or astrocytic and ependymal tumors. The diagnosis of "ependymoastrocytoma" should also not be invoked for the common fourth ventricular ependymoma harboring minor components of astrocytic appearance, or the occasional ependymoma that exhibits astrocytoma-like neuroparenchymal permeation along its perimeter.

Gliomatosis Cerebri

Gliomatosis cerebri, as traditionally and stringently defined, is a rare condition in which at least three cerebral lobes are permeated by neoplastic cells without focal mass formation, although genetic studies now suggest that this is simply an exaggeration of the normal diffusely infiltrative growth pattern of astrocytic and oligodendroglial neoplasms, given that all the common molecular subtypes may be represented.[381] As such, this is now considered a radiographically (or autopsy) defined growth pattern rather than a specific clinicopathologic entity in the 2016 WHO scheme.[278] Affected regions

For personal use only. No other uses without permission. Copyright ©2017. Elsevier Inc. All rights reserved.

are typically expanded in nondestructive ("pseudohypertrophic") fashion without formation of appreciable tumor nodules. The process may be remarkably diffuse, often extending from the cerebrum into deep gray matter, as well as brainstem, and potentially involving the entire central neuraxis. Confluent multilobar and bihemispheric zones of signal hyperintensity in T2-weighted and FLAIR studies are characteristic on MRI.[382] A large majority of gliomatoses qualify as WHO grade II or III lesions on histologic grounds, with a small minority presenting with grade IV features such as MVP and necrosis.

Non-Diffuse Astrocytoma Variants

Pilocytic Astrocytomas

Pilocytic astrocytomas typically present in childhood, adolescence, or early adult life—hence their prior designation by the prefacing "juvenile"—and exhibit a decided predilection for the cerebellum, third ventricular/hypothalamic region, and anterior optic pathway.[278] They constitute the great majority of tumors collected under the traditional appellations of "cerebellar astrocytoma" and "optic nerve glioma," including those examples of the latter, often bilateral, complicating NF1. NF1 patients are also at risk of developing cerebellar, and other extraoptic, astrocytomas of pilocytic type. Pilocytic astrocytomas may arise within the cerebral hemispheres, basal ganglia/thalami, or spinal cord and are over-represented within a clinically distinctive subset of bulbar tumors that deviate from the diffuse, fibrillary astrocytic neoplasms typical of the brainstem by virtue of their circumscription, their tendency to bulge into the fourth ventricle in "dorsally exophytic" fashion, and their far more favorable prognosis.[383]

Save for those tumors positioned in the anterior visual pathway, which produce a fusiform, "pseudohypertrophic" expansion of the optic nerve, and a subset of cerebellar examples having diffusely invasive components,[384] pilocytic astrocytomas tend to be relatively demarcated, nodular in contour, and frequently project into sizable cysts that may account for most of their mass effect and associated neurologic symptoms. Homogeneous contrast enhancement typifies the solid elements of the pilocytic astrocytoma, a feature serving, along with the tendency to macrocystic change and the high signal intensity often displayed on both T1- and T2-weighted MRI study, to distinguish this lesion from the diffuse astrocytoma on neuroradiological examination (Fig. 43.63).

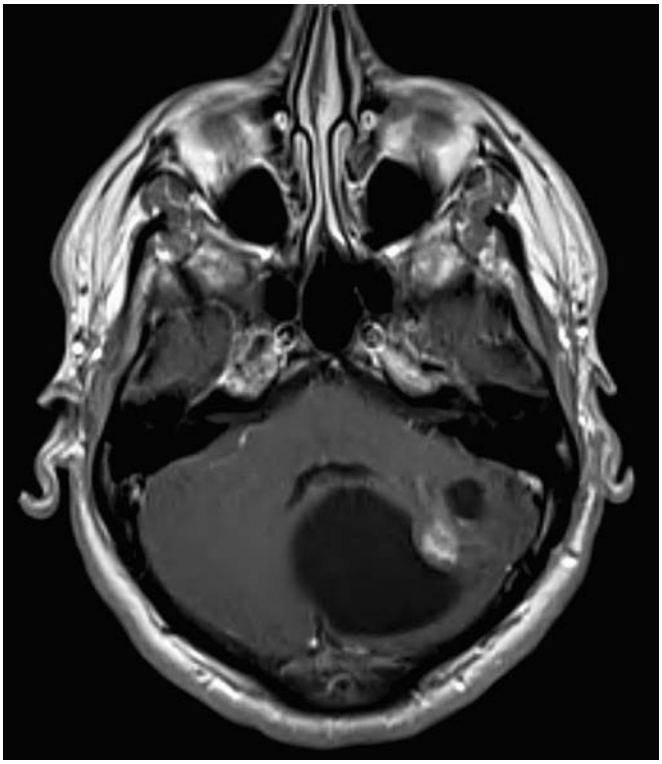

Figure 43.63 Pilocytic Astrocytoma. This typical cerebellar example is characterized by a solid, brightly contrast-enhancing mural component and associated cyst on T1-weighted postcontrast magnetic resonance imaging.

The prototypical pilocytic astrocytoma is an architecturally and cytologically biphasic neoplasm arranged in alternating compact fascicular and loose, microcystic patterns (Fig. 43.64). The former component is fashioned of cells bearing the delicate, bipolar cytoplasmic processes for which the tumor is named (pilo—derives from the Greek root for hair). These are typically woven in a dense fibrillar matrix in which oval or spindly tumor cell nuclei appear to be embedded. The tumor cells' slender and remarkably elongated processes are optimally visualized in intraoperative cytologic preparations. In microcystic regions, neoplastic cells are arranged around, or float suspended in, pools of basophilic, myxoid material. It should be noted that the relative admixture of compact piloid and microcystic elements varies greatly from case to case. The latter are particularly likely to dominate cerebellar examples in children. Other common histologic features include oligodendroglioma-like clear cell foci and an angiomatoid vasculature characterized by complex arborization, hyaline mural fibroplasia, and ectasia. Microcalcifications may be encountered at the histologic level, though neuroradiologically evident tumoral calcification is rare. Mitotic activity is generally low, and MIB-1 labeling indices usually do not exceed 1%–3%, although the significance of focally increased proliferative activity—some of which may reflect inflammatory cells—is often limited in the absence of additional, more overtly malignant features (see later discussion of anaplasia).

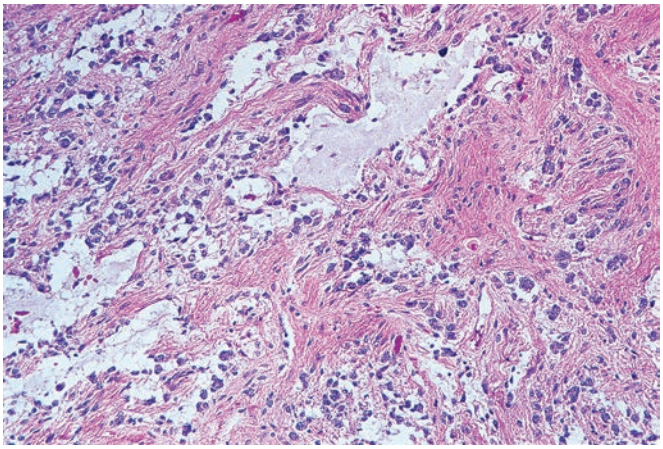

Figure 43.64 Pilocytic Astrocytoma. The biphasic cellular populations and architecture of the classic pilocytic astrocytoma are in evidence. The lesion's process-bearing spindle cell ("piloid") constituents fashion a densely fibrillar matrix, whereas its process-poor elements aggregate in regions of myxoid change that often progress to microcyst formation.

The cytoplasmic structures known as Rosenthal fibers and eosinophilic granular bodies are classically associated with pilocytic astrocytoma. Rosenthal fibers, which are vermiform acidophilic densities typically restricted to the tumor's richly fibrillated regions (Fig. 43.65), represent masses of granular, electron-dense material

For personal use only. No other uses without permission. Copyright ©2017. Elsevier Inc. All rights reserved.

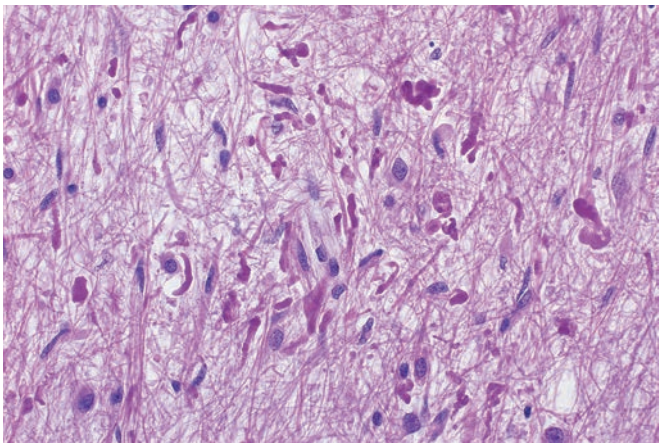

Figure 43.65 Pilocytic Astrocytoma. Varicose Rosenthal fibers lie among the otherwise delicate and hair-like cytoplasmic processes for which the pilocytic astrocytoma is named.

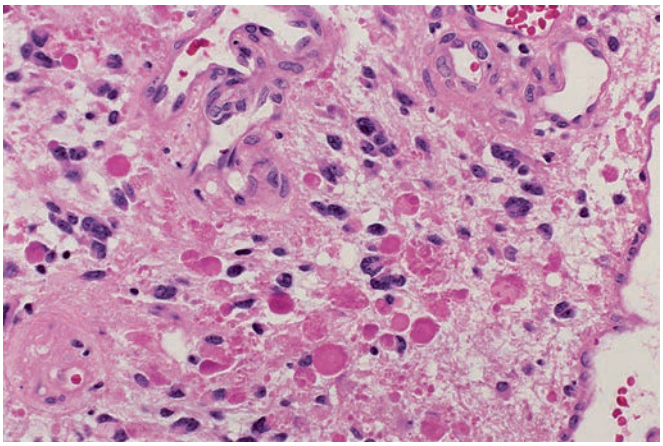

Figure 43.66 Pilocytic Astrocytoma. Eosinophilic granular bodies are typically associated with, although not restricted to, three indolent neuroepithelial tumors: the pilocytic astrocytoma, pleomorphic xanthoastrocytoma, and ganglioglioma.

surrounded by glial filaments. They may be labeled by antisera to alpha B-crystallin and a related 27-kDa heat shock protein, and GFAP positivity is typically restricted to the peripheral rim of Rosenthal fibers.[385] Eosinophilic granular bodies are clustered acidophilic globules (Fig. 43.66) that probably derive from lysosomes and are immunoreactive for α1-antitrypsin, α1-antichymotrypsin, ubiquitin, and alpha B-crystallin.[386] At the ultrastructural level, eosinophilic granular bodies represent membrane-bound collections of amorphous osmiophilic material and myelin-like figures lying within the cytoplasm of tumor cells.[386] It is important to note that neither of these cytoplasmic alterations is invariably present in, or pathognomic of, the pilocytic astrocytoma. Rosenthal fibers, for example, typically abound in the gliotic tissues adjacent to hemangioblastomas and craniopharyngiomas, whereas eosinophilic granular bodies are a conspicuous feature of many gangliogliomas and pleomorphic xanthoastrocytomas.

The exacting histologic indices by which the biologic potential of the diffuse fibrillary astrocytoma is gauged simply cannot be applied to the pilocytic variant, a WHO grade I neoplasm that is among the most indolent of all central neuroepithelial tumors. Isolated mitotic figures, glomeruloid vascular proliferation, multinucleated giant cell formation, and nuclear atypism (at times alarming, particularly in microcystic regions) are divorced, in this setting, from sinister prognostic import, as is the rather common finding of extension into the subarachnoid space. The vast majority of pilocytic astrocytomas are histologically and clinically benign. Rare examples undergo malignant transformation (including some following radiation therapy years before), typically associated with a distinct change in morphology, including focally increased cellularity, nuclear hyperchromasia/atypia, mitotic activity, and infiltrative growth resembling the high-grade diffuse astrocytomas. Nevertheless, it remains difficult to predict clinical behavior in such cases. In one series of 34 "anaplastic pilocytic astrocytomas," the most reliable grading feature was the presence of at least 4 mitoses/10 high-power fields in addition to hypercellularity and moderate-to-severe cytologic atypia; those lacking necrosis had clinical courses similar to WHO grade II astrocytomas, while those with superimposed necrosis were more comparable to WHO grade III counterparts.[387] High Ki-67 labeling index, increased p53 positivity, and loss of p16 expression are more common in such foci of anaplastic transformation.[387,388]

Pilocytic astrocytomas confined to the optic nerve and cerebellum lend themselves to curative neurosurgical resection, as do those arising in accessible cerebral hemispheric sites, though instances of recurrence (even decades) after radical removal are on record.[389] A less favorable prognosis attaches, understandably, to lesions involving the optic chiasm, hypothalamus, and other regions that preclude complete resection, but even in these loci the clinical evolution of subtotally resected pilocytic astrocytomas is typically protracted and may extend over a decade or more. Evidence from bromodeoxyuridine studies suggests that the proliferative activity of pilocytic astrocytomas may actually diminish over time,[390] and rare instances of spontaneous regression are on record.[391] Dissemination via the CSF, principally complicating opticohypothalamic lesions, is exceptional, despite the fact that pilocytic astrocytomas frequently infiltrate the adjacent subarachnoid space and leptomeninges extensively.[392] Metastatic deposits may remain remarkably stable and are not necessarily associated with early death. Radiation therapy may play a role in the development of the latter, as many tumors evidencing such biologic progression were subjected to this treatment years prior to recurring in anaplastic and aggressive form. In fact, some may represent independent, radiation-induced glioblastomas. Extracranial spread of opticohypothalamic pilocytic astrocytoma to the abdominal cavity via a ventriculoperitoneal shunt has been described[393] but is a curiosity. We refer the reader to our discussion of pilomyxoid astrocytomas (see later) for further comments on a potentially aggressive glioma of childhood that has been distinguished from pilocytic astrocytomas of conventional type.

We close this discussion of the clinical biology of pilocytic astrocytomas by emphasizing the importance of segregating these surgically curable neoplasms from diffuse fibrillary astrocytomas, which may arise in the cerebellum. The latter are typically resistant to all forms of therapy and, with rare exception, ultimately prove fatal. Pilocytic astrocytomas of the cerebellum occasionally consist in part of diffusely permeative elements that are indistinguishable from neoplastic cells of fibrillary astrocytic type, but these are noteworthy for their cytologic uniformity, mitotic inactivity, and lack of atypism, often accompanied by a more discrete appearance on neuroimaging despite an invasive growth pattern histologically.[384] The finding of such components, particularly in a pediatric case, should prompt a careful search for piloid or microcystic foci, but even in the absence of such tell-tale pilocytic features, the prognosis of ostensibly infiltrating astrocytomas of this kind in childhood is quite favorable.

Recent investigations of the pilocytic astrocytoma at the molecular genetic level have identified common and in some cases, nearly

For personal use only. No other uses without permission. Copyright ©2017. Elsevier Inc. All rights reserved.

pathognomonic alterations. Upregulation of the mitogen-activated protein kinase (MAPK) pathway, which bears on cell proliferation, differentiation, and apoptosis,[394] is apparently central to the pathogenesis of pilocytic astrocytomas. Whereas this pathway is affected in the setting of NF1 by functional loss of neurofibromin (product of the *NF1* gene and a negative regulator of MAPK pathway signaling through its inhibitory influence on Ras), it is a MAPK activator, *BRAF*, that has been implicated in the causation of most sporadically occurring astrocytomas of pilocytic type. The latter share, as their most common genetic abnormality, tandem duplications at chromosome 7q34 that result in the formation of an oncogenic *KIAA1549-BRAF* fusion gene lacking the autoinhibitory domain of wild-type *BRAF* and producing constitutive MAPK activation.[394,395] These events occur in pilocytic astrocytomas arising in varied CNS sites but seem especially characteristic of cerebellar examples. The observation that *KIAA1549-BRAF* fusions are generally foreign to diffuse astrocytomas, coupled with the immunity of pilocytic lesions to the *IDH1* gene mutations common to the former, allows for a strategy of molecular diagnostic segregation in problematic cases.[396] Other MAPK-activating events that have been detected in pilocytic astrocytomas include *FGFR1*, *BRAF V600E*, and *KRAS* mutations.[394,395]

Pilomyxoid Astrocytoma

Certain tumors historically included in the pilocytic astrocytoma group have garnered attention as a biologically distinct variant or, less likely, a separate entity. **Pilomyxoid astrocytoma** is a morphologically overlapping neoplasm[397,398] that usually arises in the hypothalamus or optic chiasm of an infant or young child but can be encountered in other locations (including the cerebellum). Similar to the classic pilocytic astrocytoma, these tumors contain a population of spindled (though less elongated), bipolar glial cells, but, in contrast, they lack a biphasic solid and microcystic growth pattern, instead exhibiting diffuse and prominent myxomatous change. Pilomyxoid astrocytomas also do not contain Rosenthal fibers and usually lack eosinophilic granular bodies. Many such tumors deviate further from conventional pilocytic histology in containing pseudorosette-like formations of neoplastic cells that appear to radiate from stromal blood vessels (Fig. 43.67). Mitoses are often present, though not numerous, and necrosis (without palisading) may be encountered. Diffuse GFAP and strong OLIG2 expression is the rule, and some examples also stain with SYN. MIB-1 labeling indices are highly variable, but often exceed the 1%–3% levels encountered in pilocytic lesions of the usual type.

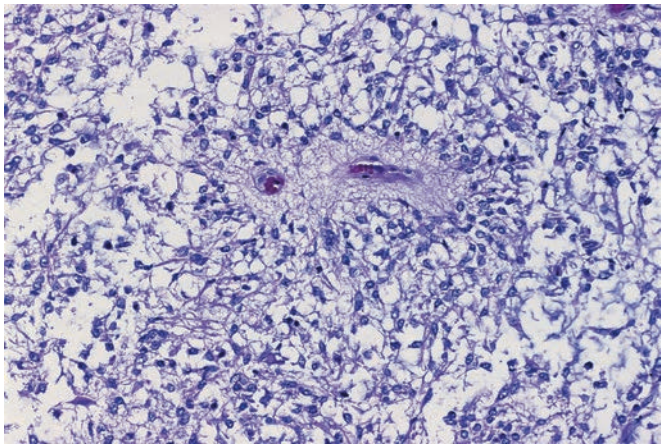

Figure 43.67 Pilomyxoid Astrocytoma. Spindled cytologic features, diffuse myxoid change, and focal perivascular pseudorosetting *(center top)* characterize this variant.

Clarification of whether pilomyxoid astrocytoma is a unique entity or a variant of pilocytic astrocytoma awaits additional study, although the former is currently favored and reflects its current standing in the WHO classification scheme.[278] We and others have encountered tumors manifesting hybrid pilomyxoid/pilocytic features, as well as neoplasms conforming in all respects to the pilomyxoid astrocytoma that have more conventional pilocytic histology upon recurrence.[399] In further attestation to a kinship, a subset of pilomyxoid astrocytomas have evidenced the same type of *BRAF* fusions encountered commonly in classic pilocytic astrocytomas.[400-402] Admittedly, a subset of pilomyxoid suprasellar neoplasms were shown in one study to possess certain fine structural attributes suggesting ependymal differentiation and raising the question of their origin from specialized paraventricular cells known as tanycytes.[403] These features included lengthy, bipolar cytoplasmic extensions with surface microvilli; rare cilia, blebs, coated vesicles and pits; "synaptoid" complexes; intercellular junctions; and foot processes terminating on delimiting, perivascular basement membranes. An origin from radial glia associated with the optic tract has also been proposed.[404] It must be conceded, however, that the diagnosis of pilomyxoid astrocytoma may have been extended to tumors of nonuniform cytogenesis combined with spindle cell morphology and a propensity to myxoid change. Whatever their origins, pediatric neoplasms demonstrating pure pilomyxoid astrocytoma histology carry a higher risk of local progression, symptomatic CSF seeding, and tumor-related death than pilocytic astrocytomas of the usual variety.[397,398] Nevertheless, an official WHO grade has not been assigned in the latest scheme, given the still limited and sometimes inconsistent clinical experiences.[278]

Pleomorphic Xanthoastrocytoma

The **pleomorphic xanthoastrocytoma (WHO grade II)** is a histologically alarming, yet biologically favorable neoplasm that typically presents in later childhood or early adult life and exhibits a predilection for the cerebral hemispheres, particularly the temporal lobes.[405,406] Cerebellar,[407] intramedullary,[408] intrasellar,[409] and retinal[410] examples have been described, as have morphologically similar tumors of the pineal region reported under the rubric of "pleomorphic granular cell astrocytoma."[411] Neuroradiological demonstration of a well-demarcated and partially cystic lesion containing superficially positioned, contrast-enhancing mural components of nodular or plaque-like contour is especially suggestive (Fig. 43.68). Usually unaccompanied by significant mass effect or edema, the latter may adhere to dura and can appear at operation to be predominantly extra-axial.

Evaluation of surgical specimens often shows much of the pleomorphic xanthoastrocytoma to occupy the leptomeninges and subarachnoid space but invariably discloses foci of brain parenchymal invasion in which neoplastic cells permeate Virchow–Robin spaces and the neuropil proper. The tumor is named for its potentially bizarre cytologic characteristics and the tendency of its constituent cells to intracytoplasmic lipid accumulation, although the latter is not a uniformly conspicuous feature. Most examples are composed of spindle-shaped elements in fascicular array admixed with tumor giant cells displaying worrisome, even grotesque, nuclear abnormalities (Fig. 43.69). The abundant cytoplasm of these cells may appear foamy or coarsely vacuolated—attesting to advanced lipidization—but more commonly assumes a ground-glass, finely granular or hyalin quality. Reactive lymphoid infiltrates (at times extensive) and aggregated eosinophilic granular bodies round out the histologic picture. The latter, an important clue to the diagnosis, are shared by certain other slowly growing neuroepithelial neoplasms, notably the pilocytic astrocytoma and ganglioglioma, and so likely reflect a process of cellular senescence. In fact, "composite" tumors harboring

For personal use only. No other uses without permission. Copyright ©2017. Elsevier Inc. All rights reserved.

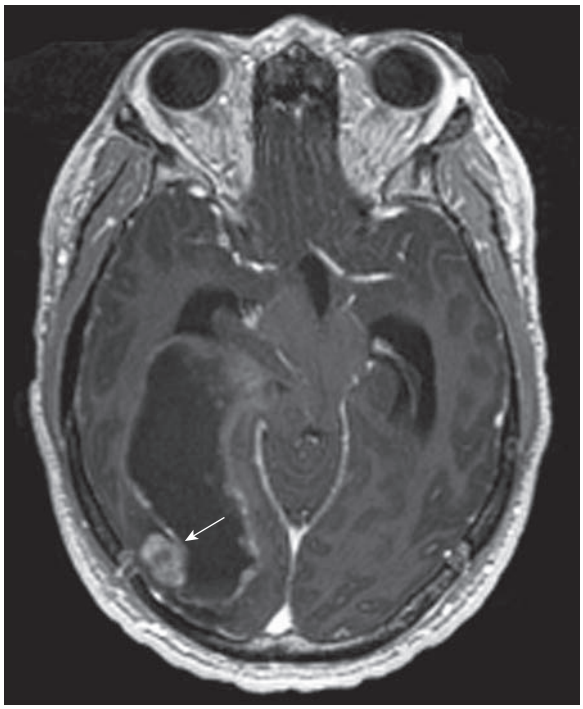

Figure 43.68 Pleomorphic Xanthoastrocytoma. This temporo-occipital example is represented by a sharply delimited, intensely and homogenously contrast-enhancing nodule *(arrow)* that projects into a large cyst on postcontrast magnetic resonance imaging. Pilocytic astrocytomas and gangliogliomas may exhibit identical neuroradiological profiles and are the major differential diagnostic considerations in this setting.

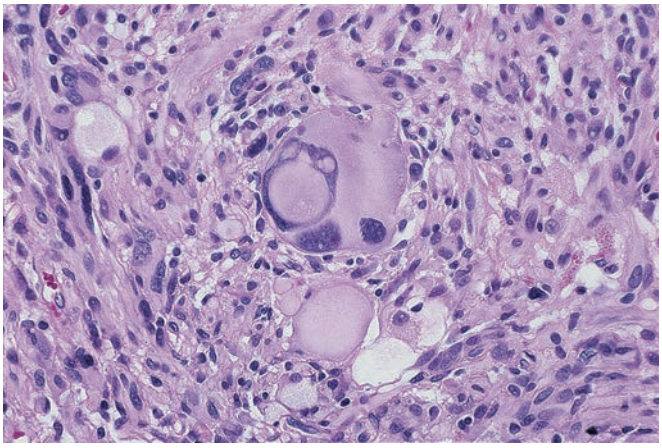

Figure 43.69 Pleomorphic Xanthoastrocytoma. Spindle and giant cells, including bizarre multinucleated forms, combine to give this relatively indolent neoplasm a most disturbing appearance. Note hyaline, granular, and vacuolar cytoplasmic alterations, the last attesting to lipid accumulation.

gangliogliomatous and xanthoastrocytomatous components are on record,[412] and we have rarely encountered cerebral hemispheric astrocytomas of pilocytic type with foci of leptomeningeal spread conforming to the histology of the pleomorphic xanthoastrocytoma in unalloyed form. Additional features described in select cases include a cohesive, nesting or alveolar growth pattern,[413] a hyalinizing, angiomatoid stromal vascular response,[414] and melanotic pigmentation.[415]

The sarcomatoid histologic presentation of the pleomorphic xanthoastrocytoma may be rendered all the more misleading by an intricate pericellular pattern of reticulin deposition, which is in flagrant violation of the neurohistochemical principle that such staining in glial, as opposed to mesodermally derived, neoplasms typically remains confined to supporting vasculature. This feature actually reflects the elaboration of encircling basal lamina material by tumor cells, demonstrable at the ultrastructural level or by collagen type IV or laminin immunostains.[413] This feature has been considered, along with the characteristically superficial location, as evidence of its derivation from a specialized class of subpial astrocytes having radially oriented cytoplasmic processes that are normally invested by basement membranes.[405] GFAP and/or OLIG2 expression, mandatory for definite diagnosis, effectively segregates this tumor from mesenchymal neoplasms,[405,416] though occasionally, typical examples may contain relatively few immunolabeled cells. Diffuse cytoplasmic immunoreactivity for S-100 protein is the rule, and tumor cells may be immunolabeled with α1-antitrypsin, α1-antichymotrypsin, and other "histiocytic markers."[417] The latter reagents stain a variety of neoplastic (including glial) cell types and are of notoriously little discriminatory value when applied to neurosurgical material. It is noteworthy that the tumors under discussion often harbor tumor cells that do not resemble ganglion cells, yet bind antibodies to SYN (among other neuronal antigens) and can exhibit ultrastructural features of neuronal differentiation (including clear [synaptic-type] and dense core vesicles).[418] This would suggest that pleomorphic xanthoastrocytomas are capable of divergent glioneuronal differentiation and would serve, along with shared clinicobiologic features, to further ally these curious neoplasms with gangliogliomas. Noteworthy in this connection (and useful for purposes of diagnosis) is the observation that many pleomorphic xanthoastrocytomas exhibit membranous immunolabeling of tumor cells for CD34, as well as immunoreactive non-neoplastic cells of highly ramified appearance in adjacent cortex (Fig. 43.70).[419] Furthermore, up to two-thirds of cases express the mutant BRAF V600E protein, a feature also seen in related neoplasms such as ganglioglioma and DNT.[420,421] Though not entirely specific, this genetic alteration represents both a diagnostically and potentially therapeutically useful biomarker, which seems to be retained in rare examples that undergo a peculiar form of anaplastic transformation to epithelioid glioblastoma (see glioblastoma variants and patterns).[324] These immunohistochemical features may aid in the distinction of pleomorphic xanthoastrocytomas from giant cell glioblastomas,[422] although care must be exercised since the labeling of giant cell (and other) glioblastomas for neuronal markers, CD34, and/or BRAF V600E have also been occasionally reported.[423]

Despite their disturbing morphology, pleomorphic xanthoastrocytomas tend to behave in relatively benign clinical fashion, and gross total resection usually suffices to achieve long-term tumor control. A closely characterized series of 74 cases with median follow-up of 7.6 years revealed 5-year recurrence-free and overall survivals of 71% and 90% for standard (WHO grade II) tumors versus 49% and 57%, respectively, for the anaplastic (WHO grade III) counterparts, the anaplastic designation defined primarily by the presence of at least 5 mitoses per 10 high-power fields[406]; this criterion has now been similarly adopted by the WHO. Higher-grade examples may assume a number of cytologic patterns (including epithelioid). Ironically, anaplastic foci are often less pleomorphic, yet more cellular and infiltrative, often resembling diffuse astrocytomas (including glioblastoma when accompanied by palisading necrosis). In addition to tumor grade, extent of tumor removal bears critically on both the risk of recurrence and death from disease, while patients with BRAF mutant tumors seemingly enjoy longer survivals than those with wildtype neoplasms.[406] This difference may become even

For personal use only. No other uses without permission. Copyright ©2017. Elsevier Inc. All rights reserved.

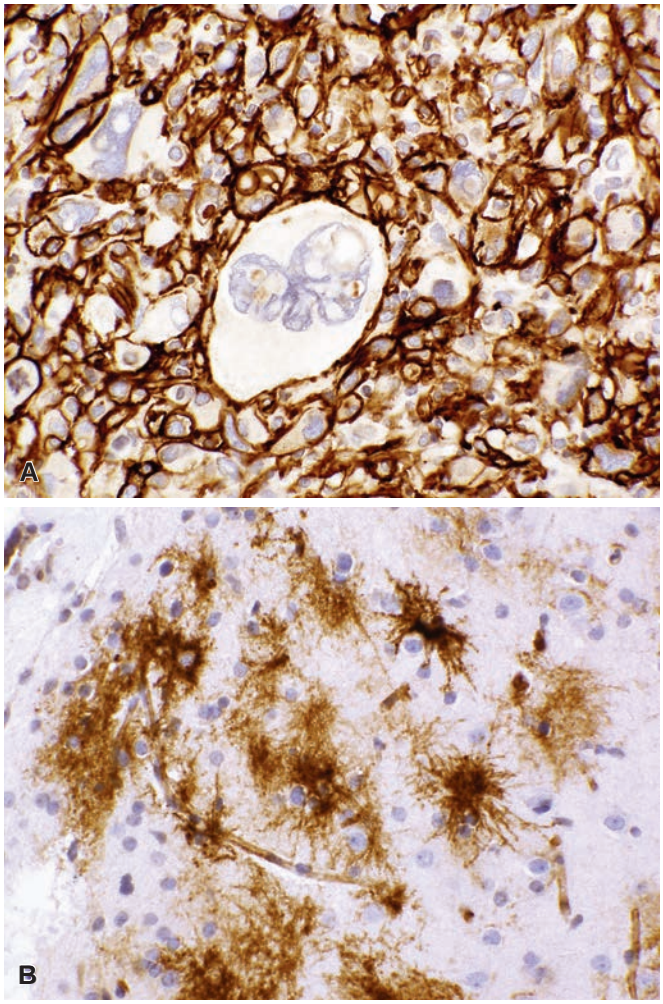

Figure 43.70 Pleomorphic Xanthoastrocytoma. The immunoexpression of CD34 by tumor cells **(A)** and by process-bearing neural cells in adjoining, uninvolved cerebral cortex **(B)** is characteristic. Note the membranous quality of the immunoreactivity.

more exaggerated in the future with increased use of BRAF inhibitors for clinically aggressive BRAF mutant pleomorphic xanthoastrocytomas. A recurring example with histologic evidence of anaplasia and an extensive clear cell component, as well as focally papillary growth, has been recorded.[424] We have encountered an example that developed sarcomatous components (pleomorphic "xanthoastrosarcoma")[419] as well as cases harboring elements morphologically and genetically resembling atypical teratoid/rhabdoid tumor (AT/RT) (including loss of INI1 expression),[425,426] the latter also arising from rare examples of ganglioglioma.[427] Local recurrence is the most common clinical pattern, although CSF-borne spread may also be encountered.[428,429]

Subependymal Giant Cell Astrocytoma (Tuberous Sclerosis)

The **subependymal giant cell astrocytoma** typically presents in the first or second decade of life as an intraventricular mass associated with obstructive hydrocephalus, a consequence of its practically unvarying location near the foramen of Monro (Fig. 43.71).[278,430] Only isolated reports describe extraventricular variants.[431,432] The lesion is virtually restricted to the setting of **tuberous sclerosis**, a disorder transmissible in autosomal dominant fashion via loci on chromosomes 9q34 *(TSC1)* and 16p13.3 *(TSC2)* but often encountered in a nonfamilial form resulting from spontaneous mutation.[278] Traditionally defined by the triad of mental retardation, epilepsy, and midfacial angiofibromatosis ("adenoma sebaceum"), this phakomatosis is named for distinctive foci of gyral expansion ("tubers") that are populated by dysmorphic neurons and giant astrocytes in architectural disarray, and feature an abnormal firmness ("sclerosis") resulting from glial overgrowth. Periventricular "candle gutterings," essentially miniature versions of the tumors under discussion, are also characteristic. Dominant extracranial manifestations of the tuberous sclerosis complex include renal angiomyolipomas, cardiac rhabdomyomas, pulmonary lymphangioleiomyomatosis, fibrous dysplasia of bone, microhamartomatous rectal polyps, and various cutaneous lesions (hypopigmented macules, shagreen patches, subungual fibromas, and, as mentioned, facial angiofibromas). Some afflicted patients also harbor retinal hamartomas similar to the subependymal nodules just described, or larger masses that would qualify as retinal giant cell astrocytomas. A pineal region tumor of this type in a child with tuberous sclerosis has been documented.[432]

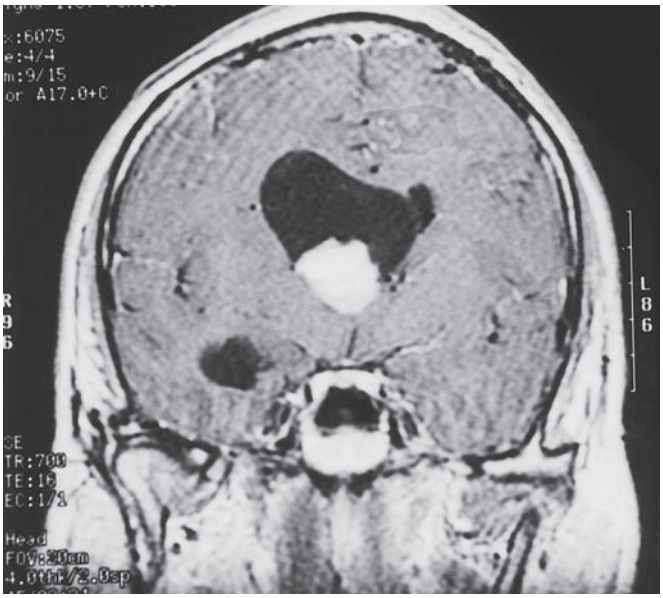

Figure 43.71 Subependymal Giant Cell Astrocytoma. This postcontrast injection magnetic resonance imaging demonstrates the subependymal giant cell astrocytoma's typically intraventricular location near the foramen of Monro (with resulting obstructive hydrocephalus), as well as its characteristic circumscription. This example was not associated with other features of tuberous sclerosis.

The subependymal giant cell astrocytoma is a sharply delineated, spherical or multinodular mass of fleshy, gray–pink tissue that is anchored to the ventricular wall over a broad front. Calcifications are common, and some examples exhibit foci of cystic change. Constituent cells are large, closely apposed, and characterized by polygonal (ganglion cell–like), rounded (gemistocyte-like), or spindled profiles (Fig. 43.72). Their eosinophilic cytoplasm often has a glassy or hyaline appearance, and their eccentrically positioned, vesicular nuclei, and prominent nucleoli distinctly resemble those of large neurons or ganglion cells. An intersecting fibrovascular stroma lends a lobular architecture to many examples, and tumor cell processes often condense about blood vessels in ependymoma-like fashion. A curious feature of many cases is infiltration by mast cells. Immunohistochemical assessment may reveal only few GFAP-positive elements and—designation of this neoplasm as an astrocytoma notwithstanding—may show some tumor cells to colabel for (or

For personal use only. No other uses without permission. Copyright ©2017. Elsevier Inc. All rights reserved.

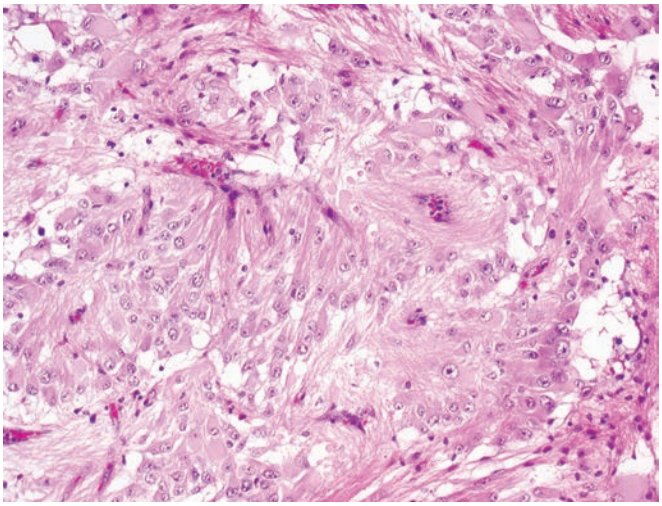

Figure 43.72 Subependymal Giant Cell Astrocytoma. Tumor cells that achieve truly giant proportions, often polygonal in contour and closely apposed in lobular array, are responsible for this neoplasm's name (but not evident in all cases). Note also the spindled elements and perivascular nuclear-free zones resembling the perivascular pseudorosettes of ependymomas.

exclusively express) neuronal antigens, such as class III β-tubulin, neurofilament proteins (NFPs), and, rarely, SYN.[433,434] Ultrastructural studies have demonstrated the presence of dense-core granules and synaptic formations in select cases, confirming the ability of subependymal giant cell astrocytomas to differentiate along neuronal, as well as glial, lines.[433] Accordingly, some neuropathologists prefer to designate these neoplasms simply as subependymal giant cell tumors. Ambiguous glioneuronal features also characterize the morphologically similar "balloon cells" seen in cortical tubers and focal cortical dysplasia type IIb, suggesting a disturbance of normal lineage commitment.[433] Subependymal giant cell astrocytomas do not exhibit immunolabeling for HMB-45, and typically have low MIB-1 indices.[435]

Subependymal giant cell astrocytomas enlarge slowly, rarely invade adjacent cerebral structures, and, isolated examples excepted,[436] have not been reported to exploit the CSF as a means of dissemination. Recurrence following gross total resection is rare, and these indolent neoplasms are not prone to malignant transformation. Although reported examples are few, cases with mitotic activity and foci of necrosis do not appear to behave in a particularly sinister fashion, although highly exceptional examples may manifest frankly anaplastic features with more aggressive clinical behavior.[437]

Desmoplastic Infantile Astrocytoma

The desmoplastic cerebral astrocytoma of infancy or desmoplastic infantile astrocytoma is a rare lesion now recognized as belonging to a tumor family capable of divergent and advanced glioneuronal differentiation. Accordingly, we address this entity along with its variant—the desmoplastic infantile ganglioglioma—in our discussion of neuronal and glioneuronal tumors.

Ependymal Tumors

This section includes those neoplasms that have traditionally been classified as ependymal tumors. Although astroblastoma, chordoid glioma of the third ventricle, angiocentric glioma, and papillary tumor of the pineal region all manifest at least some fine structural and immunohistochemical evidence of ependymal differentiation, they are discussed under separate headings that follow, consistent with the WHO format that segregates these distinctive lesions from the conventional ependymoma group.

Ependymomas constitute no more than 5%–9% of primary CNS neoplasms, their prevalence relative to other tumor types varying considerably with patient age and presenting location.[278] A majority of intracranial examples arise in childhood, whereas intramedullary variants more commonly afflict adults. The incidence of the former peaks in the first decade of life, ependymomas comprising approximately 10% of intracranial neoplasms in the pediatric population and up to 30% of those encountered in children under 3 years of age. At least two-thirds of these childhood tumors are situated within the fourth ventricle and consequently present with evidence of increased intracranial pressure secondary to obstructive hydrocephalus. Supratentorial lesions are more evenly distributed among children and adults and are more likely to be associated with seizures and focal motor deficits.

Ependymomas of the spinal cord (other than those of myxopapillary type) usually arise within cervicothoracic segments and exhibit a predilection for the fourth and fifth decades of life, constituting the most common intramedullary neoplasms of adulthood.[438] Principal clinical manifestations include pain localized to the neck or back, numbness and paresthesias of the distal extremities, atrophy of hand musculature, and gait disturbances. An intramedullary location and multifocality characterize ependymomas complicating NF2, a subset of sporadic spinal cord examples sharing with these predetermined variants alterations of the *NF2* tumor suppressor gene on chromosome 22q12.[278,439] Ependymomas may rarely arise within cranial nerves,[440] the sella turcica,[441,442] and retina[443] and have been reported to originate in the ovary and periadnexal pelvic tissues,[444] abdominal cavity,[445] liver,[446] mediastinum,[447] and lung,[448] though female genital tract and mediastinal cases may well represent "lopsided" (i.e. monodermal) teratomas.

Wherever situated, ependymomas tend to be well circumscribed and contrast enhancing on neuroradiological study. Supratentorial examples are often, but not invariably, found to communicate with or abut the ventricular system, lobar types frequently exhibiting cystic change and focal calcification. The latter is also a relatively common feature of posterior fossa lesions, which tend to be anchored to the floor of the fourth ventricle. Medulloblastomas, by contrast, only exceptionally undergo any appreciable mineralization and usually hang from the fourth ventricular roof when localized to the midline. Ependymomas may exploit CSF exit foramina to escape the restrictive confines of the fourth ventricle and, in so doing, can encircle the medulla and cervical spinal cord. Intramedullary variants produce a fusiform widening of involved segments and commonly precipitate syrinx formation, cystic dissection of the spinal cord usually progressing rostrally. MRI demonstration of a T2-hypointense "hemosiderin cap" atop the rostral pole of a well-delimited and enhancing intramedullary mass is particularly suggestive.

The conventional **ependymoma (WHO grade II)** is typified by a dense meshwork of fibrillary cytoplasmic processes that condense, collar-like, about stromal blood vessels in formations known as perivascular pseudorosettes (Fig. 43.73). These are accompanied in a minority of cases by canals, tubules, or true rosettes lined by epithelioid cells surrounding a rounded gland-like lumen (Fig. 43.74). The term "**cellular ependymoma**" may be used for densely populated examples with relatively narrow pseudorosettes but little mitotic activity, though this conveys no clinically useful information and is no longer considered a WHO sanctioned variant. Tumor cell nuclei are rounded or spindled, characteristically exhibit an evenly granular chromatin distribution, generally lack nucleoli, and may contain invaginated cytoplasmic pseudoinclusions or exhibit longitudinal nuclear grooving.[449] Optimally visualized in cytologic preparations, the last feature—along with the tendency of neoplastic ependymal

For personal use only. No other uses without permission. Copyright ©2017. Elsevier Inc. All rights reserved.

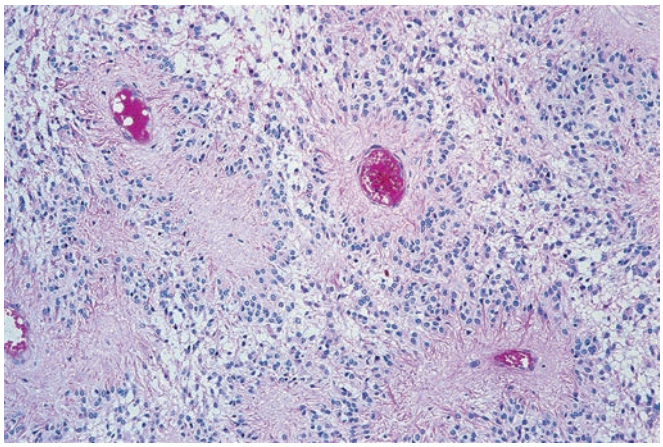

Figure 43.73 Ependymoma. The cytoplasmic processes of ependymal tumor cells condense about blood vessels to form pseudorosettes.

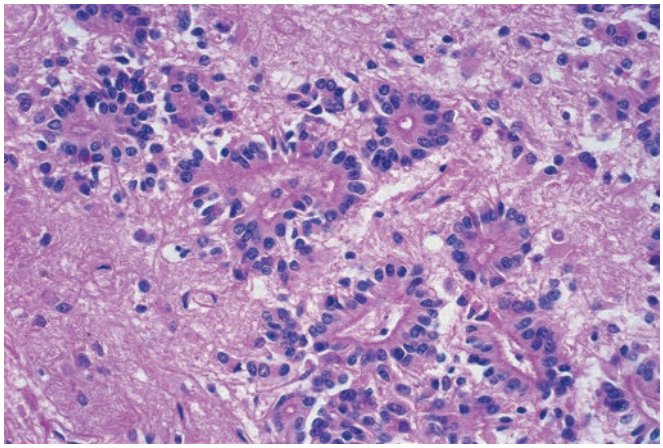

Figure 43.74 Ependymoma. The true ependymal rosette contains a well-defined central lumen. Clustered ciliary basal bodies ("blepharoplasts") are responsible for the enhanced, granular staining of tumor cell apices.

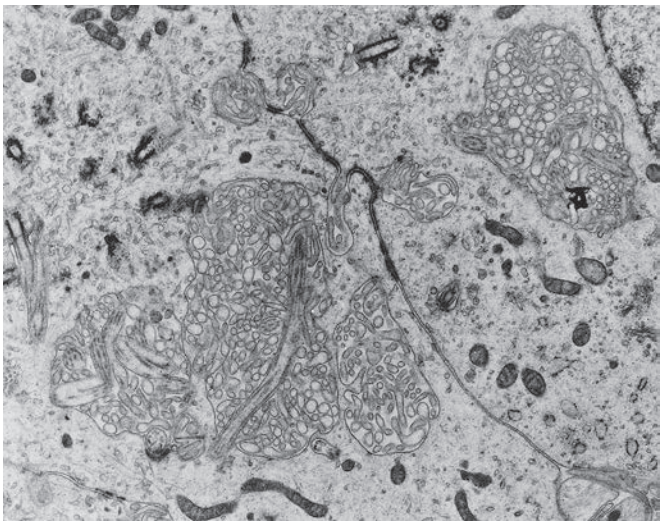

Figure 43.75 Ependymoma. Features indicative of ependymal differentiation at the ultrastructural level include the joining of tumor cells by elongated junctional complexes and the formation of lumens filled with microvilli and, in less number, cilia (×8800).

cells to remain attached to delicate blood vessels in papillary fashion when subjected to smearing or crushing—facilitates intraoperative diagnosis. While nuclear uniformity is the rule, pleomorphic elements may be admixed and "**giant cell**" **ependymomas** have been described within the cranial compartment, spinal cord, and filar region (see discussion of myxopapillary ependymoma later).[450] In the first of these locations, such cytologic changes are often accompanied by elevated mitotic activity and other features indicative of an aggressive biologic potential. Dystrophic calcification is a common finding in ependymomas, and some examples undergo osseous or chondroid metaplasia.[451] Melanotic ependymomas have been depicted,[452-454] as have "xanthomatous" variants containing intracytoplasmic lipid droplets,[455] examples harboring adipocyte-like ("lipomatous") elements,[456] and "epithelioid" subtypes characterized by the tight clustering of tumor cells in a conspicuously myxoid matrix.[457] Gemistocytic change may also be encountered in ependymomas, one report describing a case exhibiting globular, inclusion-like cytoplasmic bodies immunoreactive for GFAP.[457] Sarcomatous transformation ("ependymosarcoma") is exceptional but well documented.[458]

At the ultrastructural level, ependymomas exhibit a number of specialized cytoplasmic features characteristic of non-neoplastic ependyma.[459] Elaborate, zipper-like junctional complexes (zonulae adherentes) bind their constituent cells and are likely responsible in some measure for the cohesive growth pattern and "pushing" margins typical of such tumors. Slender microvilli and (in smaller numbers) cilia sprout into the lumina of rosettes or intercellular clefts, again framed by membrane junctions of zonula adherens type (Fig. 43.75). Intracytoplasmic granules ("blepharoplasts") that are often apprehended by light microscopy along the apices of rosette-forming tumor cells in fact represent anchoring ciliary basal bodies. Also commonly observed on fine structural study is intracytoplasmic lumen formation, a phenomenon responsible in particularly pronounced cases for signet ring cell variants of ependymoma.[460] The phenomenon of microlumen formation by ependymal neoplasms has as its immunohistochemical correlate of dot- and ring-type patterns of cytoplasmic EMA labeling that are of considerable diagnostic value,[461] though not always apparent or entirely specific if displayed by only rare tumor cells (Fig. 43.76). Additional dot-like patterns may be seen with CD99 and/or D2-40 immunostains, which are similarly useful but not entirely specific; nonetheless, these patterns combined with only limited OLIG2 and SOX10 expression nevertheless aid in distinguishing ependymomas from astrocytic and oligodendroglial neoplasms.[462-466] Intermediate filaments composed principally of (and immunoreactive for) vimentin and GFAP are conspicuous in the cell processes (especially those involved in perivascular pseudorosettes), which, in select cases, may be coated by basal lamina material where they abut blood vessel walls.[467]

While maintaining a diagnostic ultrastructural and immunophenotypic fidelity to the ependymal line, a subset of ependymomas exhibit distinctly confounding histologic features. **Tanycytic ependymomas** (from the Greek *tanyos*—to stretch) may be confused with schwannomas, meningiomas, and fibrillary or pilocytic astrocytomas by virtue of their spindled cytology, fascicular growth patterns, and poorly developed, inconspicuous pseudorosettes (Fig. 43.77). Such tumors are typically encountered at spinal levels.[468] Ependymomas commonly contain, in addition to admixed elements of astrocytic appearance, cells characterized by rounded nuclear profiles and perinuclear cytoplasmic clearing. Variants dominated by the latter, **clear cell ependymomas**,[469,470] are practically restricted to the supratentorial compartment and often construed as oligodendroglial,

For personal use only. No other uses without permission. Copyright ©2017. Elsevier Inc. All rights reserved.

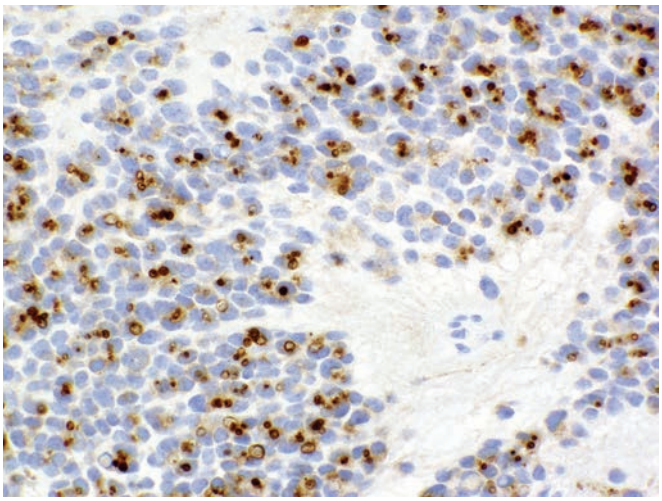

Figure 43.76 Ependymoma. Dot- and ring-type patterns of cytoplasmic immunolabeling for epithelial membrane antigen are diagnostically useful, though inconstant, features of this tumor group.

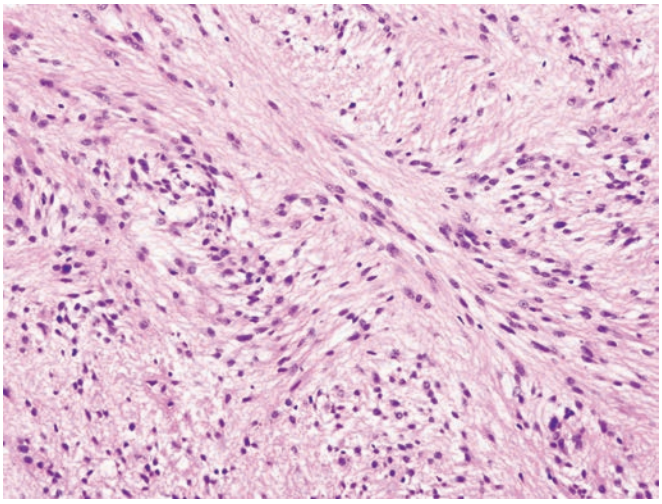

Figure 43.77 Tanycytic Ependymoma. The fascicular pattern and long slender processes of the tanycytic ependymoma often invokes a differential diagnosis with pilocytic astrocytoma and schwannoma. Useful clues in this case included intraparenchymal location, sharp demarcation, vague pseudorosettes, strong glial fibrillary acidic protein expression, and dot-like epithelial membrane antigen positivity (not shown).

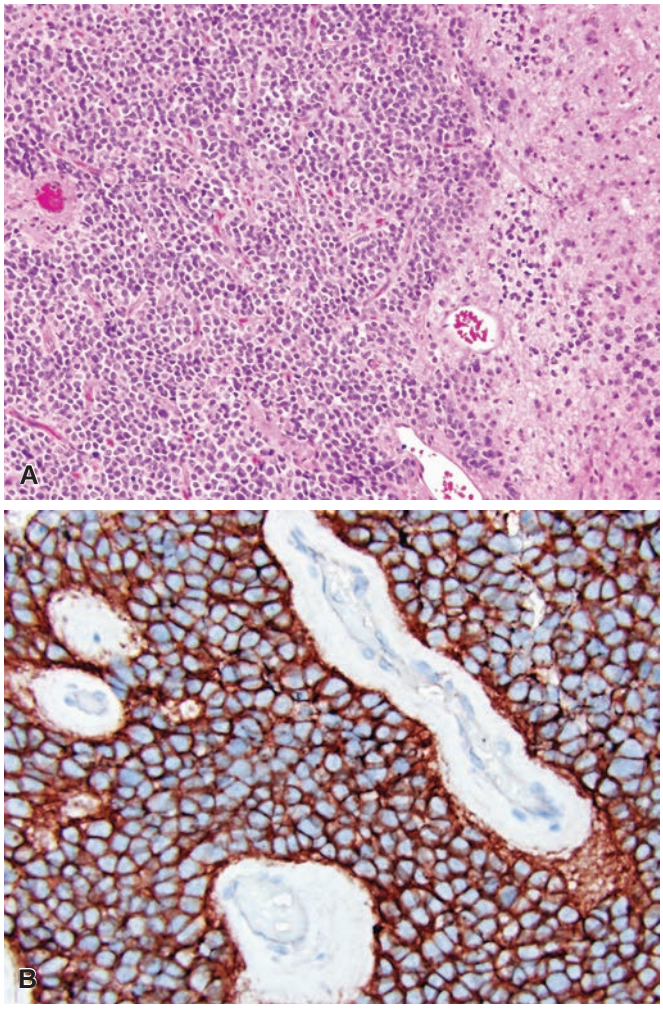

Figure 43.78 Clear Cell (RELA Fusion Positive) Ependymoma. A, The clear cell cytology and branching capillary network often suggests an oligodendroglioma, but note the sharp demarcation from adjacent brain on the right. **B,** Many such cases present as supratentorial masses and show RELA fusion by molecular analysis and L1CAM immunoreactivity.

a mischance made all the more inviting by the frequent presence of intratumoral calcospherules and a plexiform vascular network (Fig. 43.78A). Tumors of this kind often exhibit high-grade histologic features (e.g. high mitotic activity and MVP) and are prone to recur, often after relatively brief postoperative intervals. Again, these retain identifying ependymal attributes at the electron microscopic and immunohistochemical level, typically manifesting at least focal immunoreactivity of truncated perivascular cell processes for GFAP. On careful search they may be found to display dot-type EMA, CD99, and D2-40 expression, combined with no more than sparse OLIG2 expression and a solid rather than infiltrative growth pattern, as evidenced by lack of entrapped neurofilament-positive axons. These attributes permit their segregation from oligodendrogliomas and other potentially clear cell neoplasms, including extraventricular neurocytomas. The odd ependymoma, however, may harbor foci of neuronal differentiation.[471,472] In the latter regard, immunohistochemical labeling of some ependymomas, including clear cell forms, for SYN and the NeuN neuronal nuclear protein should be noted. Exceptional cases even exhibit overt neurocytic differentiation that can be appreciated on light microscopic assessment ("ependymoma with neuropil-like islands"),[472] but this rare phenomenon, like simple labeling for neuron-associated antigens, is typically restricted to minor components and contrasts with the widespread matrix expression of SYN and nuclear NeuN reactivity that characterizes many neurocytomas. Additionally, clear cell ependymomas may have prognostically unfavorable *RELA* gene fusions and L1CAM immunoreactivity (see Fig. 43.78B), characterizing a subset of supratentorial ependymomas (see later molecular features discussion).[473]

True **papillary ependymomas**—that is, tumors in which neoplastic ependymal cells assume a columnar configuration and are supported by fibrovascular cores rather than a fibrillary glial "stroma"—are very rare and need to be distinguished from metastatic papillary carcinomas, choroid plexus papillomas, and papillary meningiomas. Like other ependymomas, however, papillary variants label for S-100 protein, vimentin, EMA, CD99, D2-40, and GFAP. Apical EMA

For personal use only. No other uses without permission. Copyright ©2017. Elsevier Inc. All rights reserved.

reactivity (a feature potentially shared by ependymal rosettes) may be apparent, as may cytoplasmic decoration with the AE1/3 antikeratin "cocktail," but ependymomas usually do not immunolabel for CAM 5.2, CK7, CK20, or CK903.[467] If present at all, cytokeratin-positive tumor cells are typically few. One screening study[474] found 2 of 27 ependymomas to manifest nuclear immunoexpression of thyroid transcription factor (TTF)-1, though neither of these tumors (both localized to the third ventricle) was described as papillary. Epithelial neoplasms of the choroid plexus may show limited GFAP immunoreactive ependymal differentiation, but this phenomenon (which underscores a shared neurocytogenesis), when it occurs, is characteristically focal. Choroid plexus papillomas, furthermore, are generally distinct from intracranial ependymomas in their reactivity for E-cadherin but not neural cell adhesion molecule (NCAM),[475] more diffuse labeling for CAM 5.2 and CK7, expression of transthyretin, Kir 7.1, and stanniocalcin-1, and elaboration of continuous basement membranes demonstrable by immunohistochemical assessment for collagen IV or laminin.[476] Select papillary meningiomas have been described as GFAP immunoreactive (see "Meningothelial Tumors"), but these are extra-axial, dural-based neoplasms that coexpress somatostatin receptor 2a (SSTR2a)[477] and do not show ependymal characteristics by electron microscopy.

Location and extent of resection, along with the molecular phenotype (discussed later), have a significant effect on the prognosis of ependymomas. The intramedullary examples usually encountered in adults often prove amenable to control by surgical means alone in experienced hands.[438] The same cannot be said of tumors located within the cranial compartment. As posterior fossa ependymomas regularly colonize critical bulbar tissues along the floor of the fourth ventricle, few lend themselves to truly complete removal. The large majority recur despite adjuvant treatment, and approximately half kill afflicted children within 5 years of presentation (mortality rates being highest for those below 3 years of age).[278] Supratentorial lesions are also prone to regrowth, though resectable tumors may remain in remission for years after operation. The importance of histology as an independent predictor of prognosis remains controversial.[478] Unfortunately, analysis of this contradictory literature is complicated by the frequent application of nonuniform, highly subjective and consequently irreproducible grading parameters. Poorly differentiated tumors exhibiting dense cellularity and conspicuous mitotic activity (which may be accompanied by complex MVP and necrosis with palisading) merit the designation of **anaplastic ependymoma (WHO grade III)** on morphologic grounds (Fig. 43.79) and have proven more aggressive than their low-grade counterparts in some but not all studies. However, these histologic findings are not consistently predictive of an accelerated course or decreased survival times. The prognostic implications of only regional anaplasia in the form of nodular microscopic foci of increased cellularity and mitotic activity also needs clarifying, though it is likely that future molecular classification will more accurately reflect prognosis and guide patient management.[479] Interestingly, features of anaplasia are especially common in the intracranial ependymomas of young children, and only rarely encountered in adult-onset ependymomas of the spinal cord. Regional necrosis without palisades is a common finding in posterior fossa ependymomas and alone does not brand a lesion as anaplastic. As regards other morphologic features of possible biologic significance, microinvasion of bordering neuroparenchyma by dyscohesive tumor cells presaged recurrence in one study of pediatric ependymomas.[480] Elevated MIB-1 labeling indices have been correlated with aggressive histology and poor outcome, but widely varying "cutoff" values, ranging from 5% to 20% or higher,[481,482] have been reported as significant. Molecular genetic alterations, such as chromosome 1q gains, have been identified in subsets of anaplastic ependymoma but are not currently tested for in routine practice.[278]

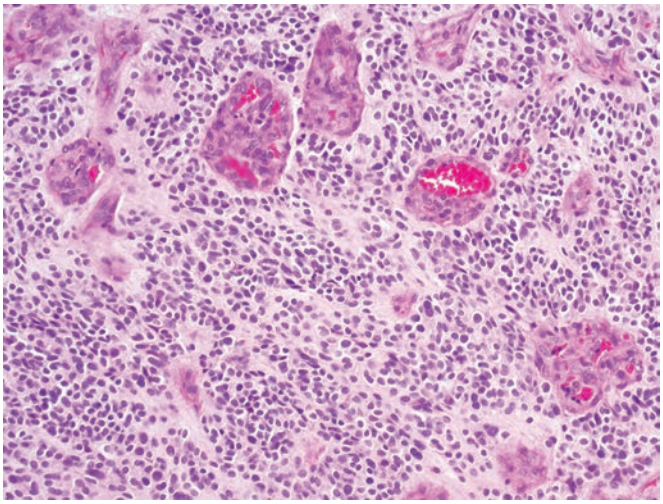

Figure 43.79 Anaplastic ependymoma, associated with hypercellularity, increased mitotic activity, and microvascular proliferation.

Despite their preferential distribution in and around the ventricular system, intracranial ependymomas only occasionally give rise to symptomatic CSF-borne metastasis; the utility of histologic assessment in predicting this complication is, again, open to question. Distant extraneural metastasis is rare, and fatal ependymomas usually kill by uncontrollable progression at the primary site.

The **myxopapillary ependymoma (WHO grade I)** is a morphologically distinctive variant virtually restricted to[483] the region of the conus medullaris and filum terminale. An origin in cervicothoracic segments of the spinal cord is exceptional, and intracranial presentation exceedingly rare.[484,485] Extradural ependymomas that arise in the subcutaneous tissues overlying the sacrococcyx[486,487] or, less often, in the sacrum proper are typically of myxopapillary type.[488] These curious lesions probably originate from ependymal rests representing remnants of the extradural filum terminale or coccygeal medullary vestige, a derivative of the caudal neural tube persisting beneath the skin of the postanal pit as an ependyma-lined cleft. Such rests can exhibit myxopapillary features and should not be construed as neoplastic by sole virtue of this growth pattern.[489] An ependymoma of the broad ligament having myxopapillary components has been recorded,[490] as has a retinal glioma with myxopapillary ependymal features,[491] and a cortical ependymoma with foci resembling angiocentric glioma.[492]

Myxopapillary ependymomas share, along with other intramedullary tumors of the ependymal series, a predilection for adults in the third to fifth decades of life, though nearly one-fifth of those in a large Mayo Clinic series[483] involved patients younger than 20 years of age. Nearly all produce low back pain. Other manifestations include sciatica, sensorimotor deficits, impotence, and urinary and fecal incontinence. Neuroimaging studies usually demonstrate a sharply delimited, contrast-enhancing mass. Surgical exploration typically discloses a highly vascularized, ovoid, or sausage-shaped mass that may be invested by a fibrous pseudocapsule derived from the stroma of the filum. Advanced examples can envelop the cauda equina, erode into neighboring bony structures, and infiltrate paraspinal soft tissues. A gelatinous appearance is characteristic on sectioning, and many examples are hemorrhagic.

The myxopapillary ependymoma is named for the manner in which cuboidal tumor cells drape themselves about a basophilic, mucinous material, which in turn collars stromal blood vessels and collects in microcystic spaces (Fig. 43.80). Many examples contain, in addition, spindled elements that may engage in the formation

For personal use only. No other uses without permission. Copyright ©2017. Elsevier Inc. All rights reserved.

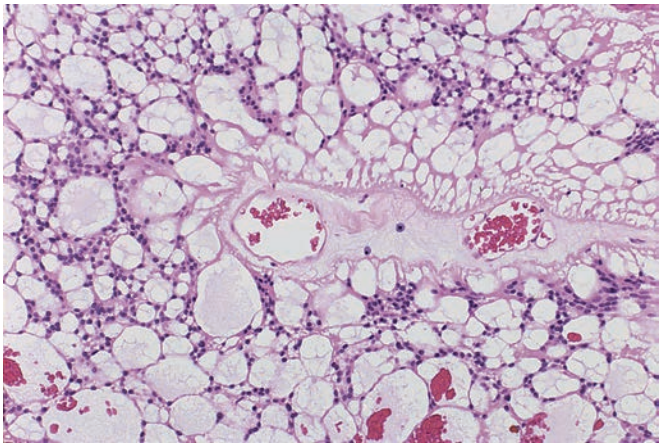

Figure 43.80 Myxopapillary Ependymoma. Note the manner in which mucinous material separates draping tumor cells from a hyalinized vascular core and accumulates in rounded microcysts.

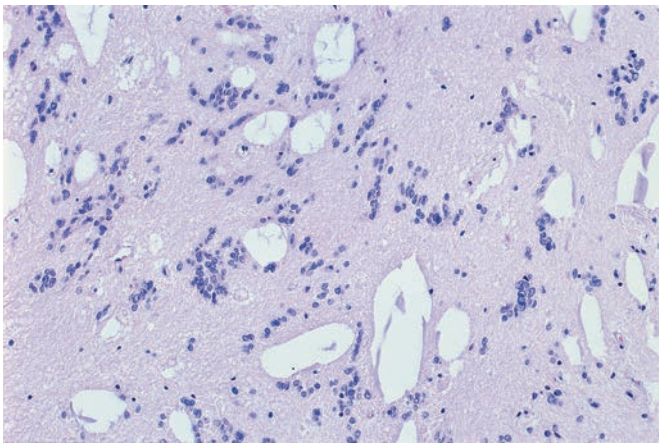

Figure 43.81 Subependymoma. The huddling of small tumor cells in an expansive fibrillar meshwork is characteristic of this entity. Microcystic changes commonly round out the histologic picture.

of gliovascular pseudorosettes. Variants displaying a conspicuous complement of pleomorphic tumor giant cells may be encountered.[493] Select cases feature eosinophilic spherules ("balloons"), possibly representing amalgamated collagen fibrils, as well as myxoid matrix components and basal lamina materials.[483] Common degenerative alterations include vascular sclerosis, hemorrhage, and hemosiderin deposition. Longstanding cases are at times characterized by extensive fibrous tissue overgrowth and virtual obliteration of their neoplastic cellular elements.

The histologic presentation of the myxopapillary ependymoma is in most cases sufficiently distinctive as to render it instantly recognizable to the pathologist familiar with this entity. Particularly myxomatous variants may assume a chordoma-like appearance, whereas examples dominated by spindle cell elements may be mistaken for schwannomas of spinal nerve root origin. A characteristic immunophenotype, as well as a patently ependymal fine structure, distinguishes myxopapillary ependymomas from these neoplasms, from mucinous carcinomas, myxochondroid meningiomas, and paragangliomas of the cauda equina region. The former share the coexpression of vimentin, S-100 protein, and GFAP with other ependymomas, but they do not elaborate chromogranin or CEA, and exhibit little (if any) labeling for CAM 5.2, CK7, or CK20. Tumor labeling by the AE1/3 cytokeratin "cocktail" may be encountered, although the dot and ring patterns of cytoplasmic EMA expression common to conventional ependymomas are usually not manifested by myxopapillary variants. The ultrastructural specializations previously detailed in reference to other ependymomas are faithfully evidenced by the myxopapillary type, though the latter may have less conspicuous cilia and microvilli, consistently elaborates basal lamina material that may invest cells as a continuous basement membrane and may contain a unique and specific ultrastructural marker consisting of microtubules aggregated within cisternae of rough endoplasmic reticulum.[494]

Myxopapillary ependymomas are usually indolent and amenable to surgical cure, but may recur even after ostensibly complete removal, and in some series have even been more aggressive than their WHO grade II ependymoma counterparts.[438] Of 77 patients in a Mayo Clinic series,[483] five (6.5%) died of their disease but did so following repeated local recurrences over periods ranging from 12 to 15 years. The presence of cytologic atypism and modest mitotic activity did not alter the prognosis in this study, whereas lesions amenable only to subtotal resection recurred and progressed more frequently than tumors lending themselves to complete removal. Adjuvant irradiation seems to improve outcome.[495] Frankly anaplastic histology is practically never encountered and is of uncertain significance in the face of gross total excision.[496] Myxopapillary ependymomas can spread via the CSF and rarely metastasize to the lungs, liver, lymph nodes, or bone.[495,497,498] Children seem to be at particular risk for CSF-borne dissemination, which may yet be kept under control for years by surgery and irradiation. Extraneural metastasis typically complicates stubbornly recurring tumors that have gained access to extravertebral soft tissues and is encountered at substantially increased frequency in patients with extradural variants arising in the sacrococcygeal region.[486,488] Neuroradiological survey of the spinal axis is mandatory before a diagnosis of primary intracranial myxopapillary ependymoma can be accepted. We have seen neurosurgical intervention prompted by complaints referable to expanding cerebellopontine angle or suprasellar myxopapillary ependymomas that proved to represent secondary deposits from filar region primaries. As was the case in one reported example,[499] the patients in question only later admitted to years of lower back pain.

We conclude this section with a brief account of the **subependymoma (WHO grade I)**, a lesion named for the resemblance of its constituent cells to, and proposed origin from, subependymal neuroglia distributed along the ventricular system. Most such tumors affect adults, are confined to the fourth ventricle, and are diminutive lesions that may be discovered incidentally; however, they can attain obstructing proportions.[500] Subependymomas situated in the lateral ventricles (particularly tumors originating about the foramen of Monro or from the septum pellucidum), third ventricle, cerebral aqueduct, or spinal cord are more likely to achieve symptomatic size.

Subependymomas are usually well delimited and lobulated. Small examples are typically solid and composed of rubbery or tough white tissue, whereas larger lesions often exhibit cystic change and foci of hemorrhagic discoloration. Calcification is common and may be extensive. Histologic examination discloses a multinodular growth pattern with small aggregates of tumor cells haphazardly disposed in a voluminous, hypovascular fibrillary meshwork that may be densely compacted or show spongy, microcystic rarefaction (Fig. 43.81). Tumor cell nuclei are generally uniform, having delicate oval contours and a punctate chromatin distribution. The occasional formation of ependymal rosettes, the occurrence of transitional or hybrid tumors containing elements of conventional ependymoma, and demonstrable ultrastructural ependymocytic specializations (e.g. zonulae adherentes, ciliary and microvillus arrays) all serve to ally

For personal use only. No other uses without permission. Copyright ©2017. Elsevier Inc. All rights reserved.

these neoplasms with the ependymoma family. These features notwithstanding, many subependymomas contain "astrocytoma-like" elements with fibrillary or gemistocytic profiles, which are devoid of prognostic import. We emphasize that subependymomas may contain a subset of cells with conspicuously enlarged and atypical nuclei, manifest modest mitotic activity, and exhibit foci of coagulative necrosis without palisading, but these findings are not predictive of an aggressive course. A melanotic example has been described,[453] as have cases containing sarcomatous elements.[305,501,502] Immunohistochemistry is rarely necessary, although occasional examples may be difficult to distinguish from pilocytic astrocytoma, especially on small biopsies. The immunoprofile is similar to that of ependymomas in general, including dot-like EMA positivity (though often in fewer cells than ependymoma) and a lack of the more widespread OLIG2- and SOX10-positive nuclei characterizing pilocytic astrocytomas.[465,466]

Excision is the treatment of choice for subependymomas, usually sufficing for control.[500]

Tumors of mixed subependymoma/ependymoma morphology are well recognized. In some studies these carry a higher risk of recurrence and are traditionally graded according to the histology of their conventionally ependymomatous components.[278]

Other Gliomas

Astroblastoma

The **astroblastoma** is a rare glial neoplasm that usually presents as a well-demarcated, contrast-enhancing mass in the cerebral hemisphere of a child, adolescent, or young adult.[503-505] The lesion is characterized by an often papillary or pseudorosetted architecture, with radially arranged cellular elements directing stout unipolar cytoplasmic processes toward centrally placed stromal blood vessels (Fig. 43.82). The latter are prone to progressive collagenous thickening and hyalinization, a striking feature of most cases that may advance to partial fibrous obliteration of the neoplastic tissue. Astroblastomatous cell processes are shorter, stouter, and less tapering than those forming ependymal-type pseudorosettes, differing further in their termination on target vessels as expanded footplates. Whereas ependymal pseudorosettes are generally embedded in a dense fibrillar matrix, the gliovascular structures of the astroblastoma are only tenuously supported by an intervening population of astrocyte-like tumor cells, or appear to float unanchored in tissue sections. Cytoplasmic immunolabeling for vimentin, S-100 protein, and GFAP are the rule, though the latter may be only focally demonstrable, and often highlights epithelioid cells rather than the fibrillar processes of astrocytomas and ependymomas.[503,505] Reactivity for low-molecular-weight cytokeratins and EMA has also been described,[506] but expression of SYN has not been demonstrated. In our experience (similar to ependymomas but unlike diffuse gliomas), neurofilament often highlights a predominantly solid growth pattern with few entrapped axons, while OLIG2 expression is often limited; as expected, IDH mutations are also lacking, though few cases have been studied to date.[507]

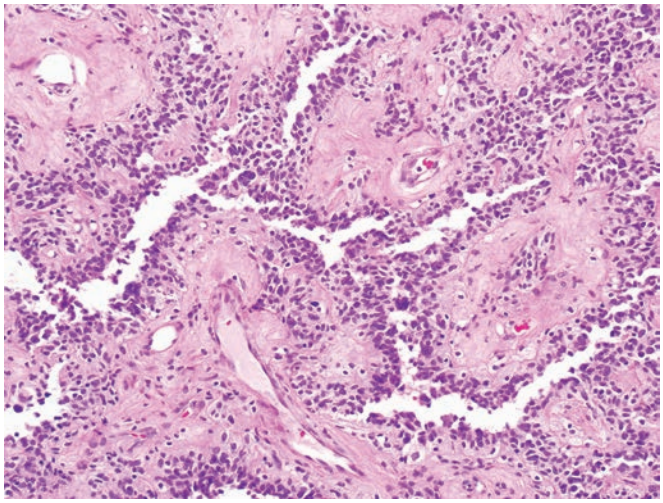

Figure 43.82 Astroblastoma. The stout and non-fibrillar cytoplasmic processes of this papillary neoplasm's constituent cells taper toward markedly hyalinized vascular cores.

Described ultrastructural attributes of the astroblastoma include a rich cytoplasmic complement of intermediate filaments, intercellular junctional complexes that may be well developed but that usually fall short of the elaborate zonulae adherentes characterizing ependymomas, and an investing basal lamina separating polar cell processes from adjoining stromal vessels.[505,508] In select cases, constituent cells have been found to display certain ultrastructural features characteristic of "tanycytes," which are ventricular lining elements that normally extend basal cytoplasmic processes towards regional capillaries. These include "purse string"-like constrictions of cell apices and crowning microvilli, as well as lamellar cytoplasmic interdigitations ("pleats") along lateral cell borders. Evidence of neuronal differentiation has not been detected.

Inasmuch as conventional astrocytomas of diffuse type (particularly gemistocytic variants) may occasionally harbor gliovascular formations comparable to those of the astroblastoma, the latter designation is best reserved for tumors with a pure, or at least dominant, architecture of the type just described, and a circumscribed, compact growth pattern. These may be divided into prognostically favorable and unfavorable types, although the correlation of histology and outcome is, admittedly, imperfect.[503-505] Tumors of orderly histologic aspect throughout and inconspicuous mitotic activity appear to be amenable to long-term control by surgical resection, the role of adjuvant therapy being unclear. Examples featuring regions of solid growth, conspicuous mitotic activity, and cellular atypia (accompanied, in some cases, by MVP and large zones of coagulative necrosis) are over-represented among recurring and fatal cases. These "anaplastic astroblastomas" may develop diffusely infiltrating components, some seeding the CSF. Rare examples may also overlap with other relatively demarcated gliomas such as anaplastic pleomorphic xanthoastrocytoma and epithelioid glioblastoma. That aggressive-looking variants may yet retain the circumscription typical of well-differentiated astroblastomas, rendering operative extirpation feasible, probably accounts for observations of unexpectedly long disease-free survival and cure in this setting, though most recorded cases have also been subjected to irradiation.

Whether astroblastomas constitute an entity sui generis is controversial, and some neuropathologists view these simply as variants of astrocytoma or ependymoma. One study suggests that combined gains of chromosomes 19 and 20q, generally foreign to conventional astrocytic and ependymal neoplasms, are particularly frequent in this rare tumor group.[503] Though this does not speak to the cytogenesis of astroblastomas, it does argue for their being accorded distinct nosologic status. Additionally, a recent genomics study suggests that a subset of these tumors is characterized by gene fusions involving the *MN1* gene on chromosome 22q12.3.[807]

Chordoid Glioma of the Third Ventricle

The rare neoplasms reported as **chordoid gliomas of the third ventricle** have occurred almost exclusively in adults, with a roughly 2:1 female to male ratio.[278,509,510] While tumors of comparable morphology and

For personal use only. No other uses without permission. Copyright ©2017. Elsevier Inc. All rights reserved.

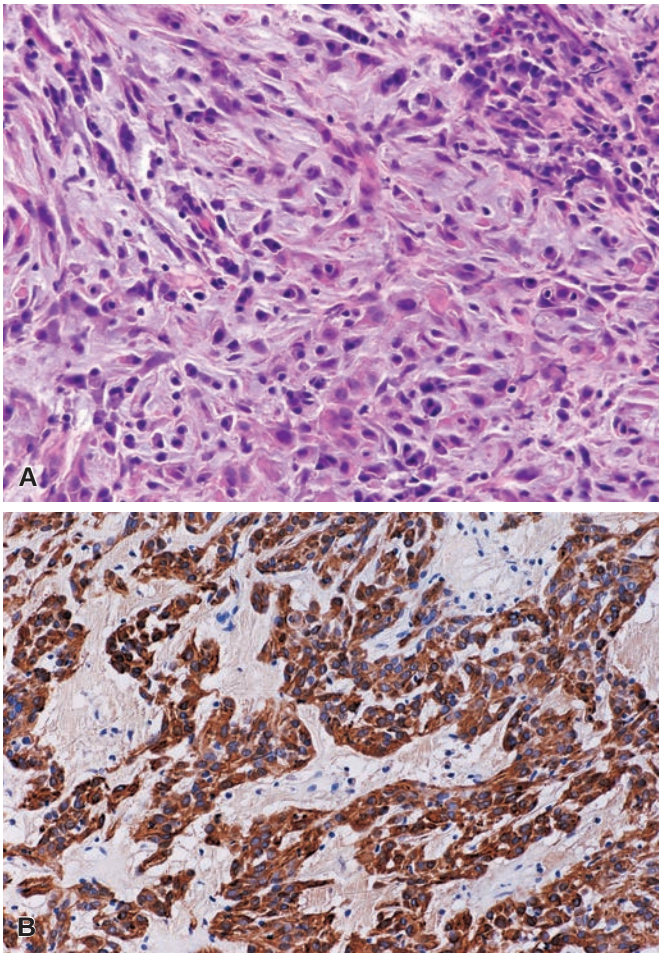

Figure 43.83 Chordoid Glioma of the Third Ventricle. Nests and anastomosing cords of epithelioid tumor cells arrayed against a variably myxoid stromal background typify this lesion **(A)**, which is distinguished from other chordoid neoplasms by its diffuse cytoplasmic immunolabeling for glial fibrillary acidic protein **(B)**. Note also in **A** the presence of plasma cells at upper right. These are often present in conspicuous numbers.

immunophenotype have been encountered in other locations,[511] these peculiar growths (as their name recognizes) have been nearly limited to the third ventricular/suprasellar compartment. MRI typically reveals a large, solid, sharply circumscribed and homogeneously contrast-enhancing mass producing obstructive hydrocephalus, associated with an array of clinical manifestations that potentially include headache, ataxia, visual and endocrine disturbances, marked fluctuations of weight, and psychotic/organic brain syndromes.

The chordoid glioma is noninfiltrative in its growth pattern and composed of epithelioid, oval to polygonal cells disposed as irregular cords or nests within a basophilic, myxoid matrix prone to coarse vacuolation (Fig. 43.83A). The latter may be PAS/PASD positive and faintly mucicarminophilic. Tumor cells possess eosinophilic cytoplasm and round or oval nuclei with finely granular or clumped chromatin and small nucleoli. Cell cords and nests may be outlined by reticulin fibers. A near constant feature of this peculiar neoplasm is interstitial and perivascular infiltration by lymphocytes and Russell body–bearing plasma cells. A unique pediatric example manifesting chondroid metaplasia has been recorded.[512] Pertinent to the differential diagnosis (which includes metastatic carcinoma, intradural chordoma, and chordoid meningioma) is the absence of true gland formation, physaliphorous cells, cellular whorls, intranuclear pseudoinclusions, and psammoma bodies. Mitoses are not found or are rare (MIB-1 labeling indices generally fall in the 0%–1.5% range), and conspicuous pleomorphism, MVP, and necrosis are also foreign to these lesions. Adjacent brain tissue typically manifests reactive gliosis with Rosenthal fiber formation.

A characteristic immunoprofile segregates chordoid gliomas from potential mimickers.[510,513] The former consistently show diffuse cytoplasmic labeling for GFAP (see Fig. 43.83B) as well as vimentin, express CD34 (with cell membrane accentuation), and may be focally S-100 protein positive but are EMA negative or only focally EMA immunoreactive. Limited labeling for a variety of cytokeratins has been reported, though the AE1/3 "cocktail" may yield a pattern overlapping with that of GFAP preparations due to cross reactivity. Along with a few other midline tumors near this region, nuclear TTF-1 expression is frequent, potentially suggesting an origin from the organum vasculosum of the lamina terminalis (see discussion later),[514] although similar expression in unrelated tumors such as pineocytomas and subependymal giant cell astrocytomas suggest that this may be a common feature of periventricular precursor cells in general.[515] Focal SYN expression was reported in select cases,[516] but examples assessed to date have not evidenced reactivity for NFPs, estrogen or progesterone receptors, desmin, chromogranin, or p53.[513] The limited ultrastructural experience communicated thus far suggests that chordoid gliomas differentiate along ependymal lines. While such pathognomonic ependymal specializations as microlumens delimited by intercellular junctional complexes of zonula adherens type have not been depicted, the formation of desmosome-like cytoplasmic attachments, microvilli, partially investing basal lamina, and, in one case,[517] aberrant juxtanuclear cilia would seem to ally these unusual tumors with ependymal neoplasms and to distance them from the astrocytic and oligodendroglial families, the latter further supported by a lack of IDH mutations.[514] In this connection, we would mention personal experience with an example containing papillary perivascular pseudorosettes and alveolus-like structures.[518] Chordoid gliomas have been described in one report[519] as sharing certain ultrastructural properties with specially modified ependymal cells that constitute the subcommissural organ—an ostensibly secretory body, situated in the dorsocaudal aspect of the third ventricle, that develops fully during human embryonic life and undergoes postnatal involution. Common features included zonation of cell bodies into a perinuclear region containing prominent profiles of rough endoplasmic reticulum and Golgi apparatus; an intermediate region occupied principally by mitochondria, smooth endoplasmic reticulum, and secretory-type granules; and an apical zone displaying a rich complement of intermediate filaments and crowning microvilli. An alternative origin from specialized ependyma lining the more rostrally situated lamina terminalis has been proposed,[514] which would account for the localization of relatively small tumors of this type (i.e. those not filling the entire third ventricle) to the latter region. Some workers[516] have found chordoid gliomas to consistently exhibit losses at chromosomes 9q21 and 11q13, the former alterations overlapping with those seen in select supratentorial ependymomas.

Chordoid gliomas of the third ventricle grow slowly, do not invade surrounding tissues, and have not been reported to metastasize via the CSF, but their attachment to hypothalamic/suprasellar structures complicates removal. Curiously, pulmonary thromboembolism has accounted for a disproportionate share of deaths occurring in the immediate postoperative period, a complication which is surprisingly common.[510,513,520] Incompletely resected examples may remain relatively stable but often regrow and can eventually prove fatal. The role of adjuvant therapy is undefined, although some suggest that postoperative radiosurgery is an effective approach when a complete resection cannot be safely achieved.[509]

For personal use only. No other uses without permission. Copyright ©2017. Elsevier Inc. All rights reserved.

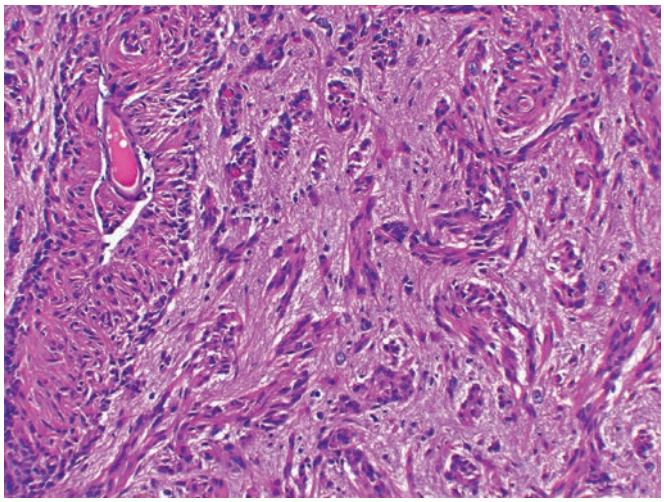

Figure 43.84 Angiocentric Glioma. Tumor cells of monomorphous, spindled profile sheath and collar cerebrocortical blood vessels in this typical example.

Angiocentric Glioma

Angiocentric glioma is a distinctive entity reported as "monomorphous angiocentric glioma" and "angiocentric neuroepithelial tumor" in two defining series.[521,522] Strongly associated with chronic, pharmacoresistant epilepsy having its onset in childhood or adolescence, this rare neoplasm is most often situated in the frontoparietal or temporal lobes, superficially positioned and largely cortical in topography. We have seen a possible example that arose from the tectum of the midbrain.[523] Relative circumscription, hyperintensity on T2-weighted and FLAIR sequences, and lack of contrast enhancement are regular MRI features, some examples manifesting stalk-like extensions of T2/FLAIR-hyperintense signal abnormality towards the underlying ventricular wall and rimming cortical T1 hyperintensity that may suggest the diagnosis.[521,524]

The hallmark of the angiocentric glioma is the manner in which native cerebrocortical blood vessels of all calibers are converted into a scaffolding, along which bipolar spindle cells of uniform cytologic profile are disposed in multilayered sleeves, and about which these neoplastic elements may also be radially arranged in ependymoma-like perivascular pseudorosettes (Fig. 43.84). A granular, stippled chromatin distribution within slender tumor cell nuclei further suggests an ependymocytic character. Spindled cells frequently align in perpendicular palisades beneath the pia and swirl in tight ("schwannoid") micronodules, may freely diffuse into the neuroparenchyma, and can form dense and intersecting fascicles that entirely replace the affected cortex. In some cases, tumor cells of rounded and epithelioid appearance also surround vessels and lie in sheets interrupted by irregular clefts and cavities. Additionally, rare examples include more solid foci with features of typical cortical ependymoma and may even show myxopapillary features.[492,525]

Immunohistochemical and ultrastructural assessments of the angiocentric glioma clearly indicate ependymal differentiation.[521,522,524] Tumor cells exhibit GFAP reactivity (a finding that removes meningioangiomatosis from further diagnostic consideration) and (in contrast to the spindled, bipolar constituents of the pilocytic and diffuse astrocytomas) frequently display dot-like cytoplasmic EMA labeling of the sort correlated with microlumen formation by ependymal neoplasms. EMA expression along cell surfaces may also be evident. The formation of microlumens delimited by zipper-like intercellular junctions has been confirmed at the ultrastructural level, with microvilli and cilia projecting into these structures. In explanation of a consistently extraventricular and cortex-based tumor manifesting these features, it has been proposed[521] that the angiocentric glioma derives from primitive neuroepithelial cells—the radial glia—that span the embryonic neuroepithelium and that may generate ependymocytes.

Angiocentric gliomas are mitotically inactive or display, at most, only rare mitoses. MIB-1 labeling indices are typically low, not exceeding 5% and usually falling below 2%. Clinical indolence is the rule, and these lesions may remain radiologically stable over protracted surveillance intervals, with simple excision generally effecting cure.[278] Malignant progression has been described[522] but is exceptional. Very few angiocentric gliomas have been genetically analyzed, although *MYB* gene alterations (mostly *MYB-QKI* fusion) have been reported, in common with several other low-grade pediatric gliomas.[526]

Choroid Plexus Tumors

The choroid plexus, a secretory organ responsible for the production of CSF, consists of a richly vascularized fibrous stroma draped by an epithelium that derives from neuroectodermal cells abutting the embryonic ventricular system. Only rarely do its specialized epithelial elements give rise to neoplasms, which generally affect children and present in sporadic fashion. Carcinomas (and, rarely, papillomas) of plexus origin, however, may be encountered in the familial Li–Fraumeni (germline *TP53* mutation) syndrome, while papillomas often complicate a complex of infantile flexor spasms, agenesis of the corpus callosum, and chorioretinal anomalies known as Aicardi syndrome, and have been recorded in cases of hypomelanosis of Ito with associated X;17(q12;p13) translocation.[278] As discussed further later, reports linking choroid plexus carcinomas to specific abnormalities of the AT/RT-associated *INI1* gene have been called into serious question.[527]

Tumors derived from the epithelium of the choroid plexus exhibit considerable morphologic and biologic diversity. The great majority, however, are benign neoplasms that replicate the villous architecture of the parent organ and are consequently termed **choroid plexus papillomas (WHO grade I)**.[278] Most of the latter come to attention during early childhood, displaying a predilection for the lateral ventricles. Adult cases, by contrast, are situated more often in the fourth ventricle or its lateral recesses, some presenting as tumors of the cerebellopontine angle. Multifocal presentations are on record,[528] as are ectopic neuroparenchymal,[529] suprasellar,[530] sacral nerve root-associated,[531] and sacral extradural[532] examples. Associated clinical manifestations are largely those of hydrocephalus resulting from ventricular outflow obstruction or the excessive production of CSF by these highly differentiated neoplasms. Rarely, plexus-related hydrocephalus in infancy is caused by villous hyperplasia of this organ.[533] Whether some diffuse lesions of this sort actually represent neoplasms (i.e. bilateral papillomas or papillomatosis) that can be identified by their proliferative activity as assessed in MIB-1 preparations is questionable.[534]

On gross inspection, the choroid plexus papilloma is a friable mass having a villiform or bosselated surface often likened to that of a cauliflower (Fig. 43.85). Lesions described as cystic forms of choroid plexus papilloma are exceptional.[535] Calcification, common to these tumors, imparts to some a gritty consistency or, when extensive, stony hardness that may hinder sectioning in the absence of decalcification. Histologic examination typically discloses a complex array of branching fibrovascular fronds covered by a monolayer of uniform cuboidal or columnar epithelial cells exhibiting minimal nuclear atypism and little, if any, mitotic activity (Fig. 43.86). In contrast to the "cobblestone" pattern of normal choroid plexus, papillomas typically display taller epithelial cells which lack the apical intercellular

For personal use only. No other uses without permission. Copyright ©2017. Elsevier Inc. All rights reserved.



Figure 43.85 Choroid Plexus Papilloma. Note the characteristically bosselated surface of this surgically resected example. Deprived of its blood supply, the tumor tissue loses its normally hyperemic appearance and may assume a tan or golden hue.

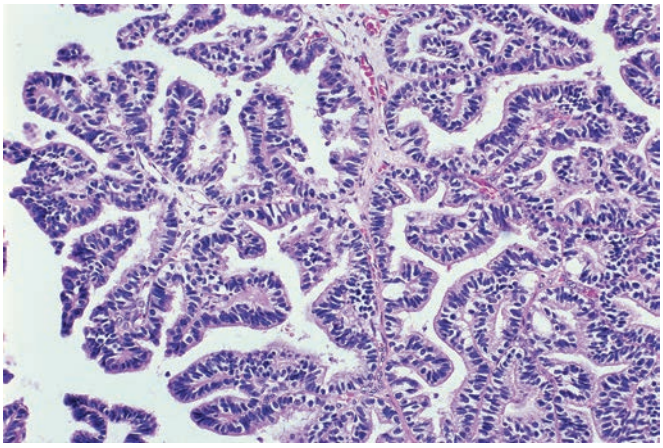

Figure 43.86 Choroid Plexus Papilloma. This example's delicate fibrovascular fronds are covered by an orderly, low columnar epithelium.

separations of their non-neoplastic counterparts. On ultrastructural study these cells rest on an uninterrupted basement membrane, are joined at their apices by elaborate junctional complexes, are crowned by microvilli, and may be ciliated.[536] The tumoral stroma, like that of the normal choroid plexus, may be conspicuously infiltrated by foamy macrophages and is, in select cases, the site of metaplastic bone or cartilage formation. The epithelial elements of some tumors undergo oncocytic change[537] (one reported example progressing to malignant "oncocytoma"[538]), and a rare melanotic variant of the choroid plexus papilloma has also been described.[539] These neoplasms may, in addition, show limited ependymal differentiation, signaled by foci in which tumor cells extend tapering, GFAP-immunoreactive cytoplasmic processes toward their fibrovascular cores. This finding presumably reflects the ontogeny of the plexus epithelium as a form of specialized ependyma, but choroid plexus papillomas do not elaborate the fibrillary glial "stroma" characteristic of ependymomas—an important differential diagnostic feature. Exceptional cases exhibit a gland-like, rather than papillary, growth pattern—an arrangement for which the designations of acinar or tubular choroid plexus adenoma have been invoked.[540] Some of these curious variants have been mucin producing.[541] Most peculiar, but convincingly documented, is the

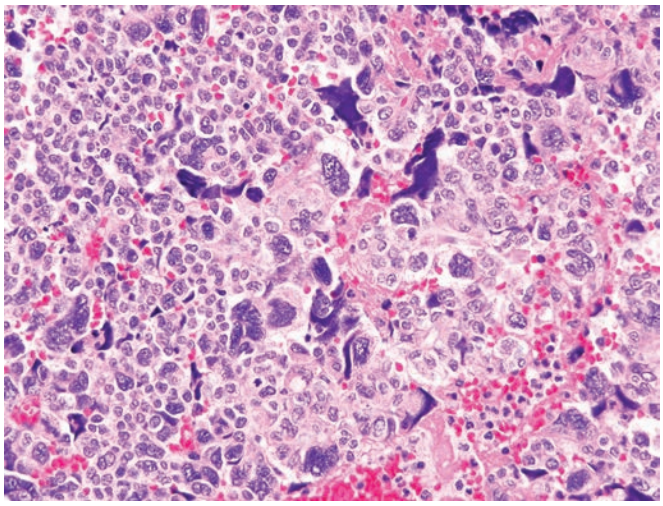

Figure 43.87 Choroid Plexus Carcinoma. In contrast to the choroid plexus papilloma, this tumor shows anaplastic cytology and a more solid growth pattern.

papilloma exhibiting overt neuronal differentiation signaled by micronodular collections of SYN-rich matrix ("choroid plexus papilloma with neuropil-like islands").[542]

The well-differentiated choroid plexus papilloma is usually amenable to curative resection. Regrowth at the primary site may be encountered, particularly after subtotal removal, but progression to carcinoma is rare[543] and focally recurrent lesions often remain surgically controllable. The capacity of otherwise conventional examples to seed the CSF and metastasize along the central neuraxis is a recognized but, fortunately, uncommon phenomenon.[544] More problematic is a subset of tumors, often dubbed **atypical choroid plexus papillomas**, that fall short of overt histologic malignancy but have unexpectedly complex architecture, cytologic atypia, modestly increased mitotic activity, focal necrosis, or penetration of juxtatumoral brain tissue. Some have noted an increased likelihood of recurrence and progression to histologic anaplasia on the part of tumors exhibiting worrisome morphologic traits of this sort, but this remains somewhat controversial.[545] It has been our experience, in fact, that "invasive" tumoral deposits are not infrequently identifiable along the perimeter of perfectly benign-appearing papillomas, where they are typically associated with a Rosenthal fiber–rich pilocytic astrogliosis attesting to a chronic and indolent process. No significance is attached to this finding.[278] The WHO recognizes atypical choroid plexus papillomas as grade II lesions, defining these as exhibiting, at a minimum, increased mitotic activity of two or more mitoses per 10 high-power microscopic fields. However, at least one study suggested that this finding is relevant only in older children.[546] Of note, while some genetic studies support a three-tiered prognostic scale for choroid plexus tumors, correlated in part with patient age, others lump the atypical papillomas squarely along with their WHO grade I counterparts.[547,548]

Choroid plexus carcinoma (WHO grade III) is the appropriate designation for frankly malignant epithelial neoplasms of plexus origin. The overwhelming majority of these rare tumors present in infancy or childhood and are situated in a lateral ventricle.[278] In contrast to their benign counterparts, choroid plexus carcinomas are often overtly anaplastic, highly proliferative, invasive, destructive, and typified by geographic foci of necrosis and hemorrhage (Fig. 43.87). Many, while maintaining a regional fidelity to the villiform architecture of the native plexus, contain foci in which their papillary structure breaks down and is replaced by nests and patternless sheets

For personal use only. No other uses without permission. Copyright ©2017. Elsevier Inc. All rights reserved.

of anaplastic cells exhibiting alarming pleomorphism and mitotic activity. Eosinophilic, PAS-positive and diastase-resistant globules are prominently displayed by some examples, and isolated cases have been described as containing melanotic cytoplasmic pigments.[549] These aggressive neoplasms often prove fatal, some escaping the confines of the ventricular system, seeding the subarachnoid space, and even metastasizing to extraneural sites, but cure of localized examples may be effected by gross total removal and adjuvant treatment.[550]

Application of an appropriate antibody panel can be recommended for purposes of distinguishing choroid plexus tumors from potential mimickers. Choroid plexus tumors often show cytoplasmic colabeling for vimentin, cytokeratins (CAM 5.2 and AE1/3 reactivity are the rule, though CK20 is highly variable in extent, one study[551] describing a CK7+/CK20− or CK7+/CK20+ immunophenotype in most plexus tumors), and S-100 protein (potentially expressed in nuclei as well). Neoplasms of the choroid plexus may, in addition, evidence their neuroepithelial lineage by expressing GFAP (usually in focal fashion), and the labeling of these tumors for SYN has also been described.[552] As previously discussed, intracranial ependymomas (including papillary variants) often exhibit widespread GFAP reactivity, contain few, if any, CAM 5.2− or CK7-positive elements, and are usually SYN negative. As compared to primary choroid plexus tumors, metastatic carcinomas are far more likely to exhibit immunoreactivity for EMA and the surface epithelial antigens identified by monoclonal antibodies HEA125 and Ber-EP4,[553] are less often S-100 protein positive, and (with rare exception) are GFAP negative. Cytoplasmic labeling for transthyretin, a 55-kDa protein involved in thyroxine and retinol transport, is a frequent feature of choroid plexus tumor immunophenotype but is inconstant (~70% of cases prove reactive) and shared by a subset of ependymomas, glioblastomas, and epithelial tumors metastatic to brain.[554]

Additional markers potentially useful in the identification of choroid plexus tumors, but not in general employed by neuropathologists, include antibodies to the excitatory amino acid transporter-1 (EAAT-1),[555] to Kir 7.1 (an inwardly rectifying potassium channel protein), and to stanniocalcin-1 (involved, among other functions, in calcium homeostasis).[554] Membranous EAAT-1 expression characterized 66% (23/35) of choroid plexus tumors but none of 77 metastatic carcinomas (including 64 papillary adenocarcinomas of varied origin) in one study.[555] Nearly 75% (17/23) of choroid plexus neoplasms (including all 5 carcinomas) tested in a second analysis manifested membranous cytoplasmic labeling for Kir 7.1, while 100 other primary and secondary brain tumors (including 19 ependymomas, 44 metastatic carcinomas, 11 glioblastomas, and 6 AT/RTs) proved nonreactive.[554] In the same study, cytoplasmic stanniocalcin-1 expression characterized 83% of choroid plexus tumors (including 3 of 5 malignant lesions) and single examples of DNT (neuronal labeling) and metastatic carcinoma of thyroid origin. Kir 7.1 and stanniocalcin-1 labeling may also distinguish plexus neoplasms from papillary tumors of the pineal region, discussed later in this chapter. EAAT-1 expression has been touted as a feature useful in distinguishing choroid plexus tumors from native choroid plexus,[556] though as stated earlier, this can usually be done morphologically, since choroid plexus tumors lack the normal "cobblestone" appearance of its non-neoplastic counterpart.

The INI1 (BAF47) immunostain is recommended for the purpose of distinguishing anaplastic choroid plexus carcinomas from AT/RTs, which share a predilection for infants and can regionally exhibit somewhat papillary or tubuloglandular growth patterns. This antibody recognizes the product of *SMARCB1*, a gene situated at chromosome band 22q11.2, that encodes a ubiquitously expressed protein active in chromatin remodeling. Whereas AT/RTs are left unlabeled by INI1 in consequence of their consistent association with biallelic gene inactivation, choroid plexus carcinomas regularly retained the expected nuclear reactivity with this reagent in a study of 20 cases classified as such by a group of experienced surgical neuropathologists.[527] Six additional neoplasms carrying referral diagnoses of choroid plexus carcinoma, but reclassified as AT/RTs, proved INI1 negative. While two (of four) plexus carcinomas analyzed exhibited monosomy 22, an abnormality that AT/RTs have in common with varied tumor types (e.g. meningiomas), none of seven assessed manifested mutations specifically involving *INI1*. Thus, the considerable morphologic and immunophenotypic overlap between choroid plexus carcinomas and AT/RTs likely accounted for prior misconception that *INI1* is involved in the carcinogenesis of both tumor types.

We stress that the diagnosis of choroid plexus carcinoma in an adult must be regarded with considerable skepticism (regardless of tumor location, morphology, or immunohistochemical characteristics), as this entity is vanishingly rare beyond childhood, and older patients presenting with intracranial carcinomas, including well-differentiated lesions of papillary configuration, almost invariably prove to have metastases from lung or other systemic primaries. With regard to the prognostic implications of immunophenotype in the setting of choroid plexus neoplasia, we would emphasize that the benign and malignant cannot be reliably distinguished on the basis of antigenic profile, though dampened expression of transthyretin and S-100 protein seems to be more characteristic of choroid plexus carcinomas and of papillomas that recur following resection.[554] Carcinomas may also be somewhat more prone to express CEA, though this is generally foreign to tumors of the choroid plexus family, and are more likely to exhibit widespread nuclear p53 labeling as well as MIB-1 (Ki-67) indices in excess of 5%–10%.[557] In one recent analysis, carcinomas lacking p53 immunoexpression and *TP53* mutations were associated with far more favorable courses than their p53-labeling and *TP53*-mutant counterparts, the latter often suggesting the possibility of Li–Fraumeni syndrome, a hereditary association which should therefore be raised in carcinomas with strong p53 expression.[558]

The reader's attention is called to a report describing as "**pigmented papillary epithelial neoplasm of the pituitary fossa**" a melanotic sellar tumor that underwent anaplastic spindle cell transformation following repeated resections and radiotherapy.[559] As suggested by the authors, this curiosity may represent an ectopic form of choroid plexus neoplasm.

Neuronal and Glioneuronal Tumors

Gangliocytoma and Ganglioglioma

A biologically heterogeneous assortment of CNS tumors, including gliomas and primitive neuroepithelial neoplasms of potentially aggressive character, are capable of neuronal differentiation and may spawn ganglion cell–like forms. The uncommon entities known as **gangliocytoma** and **ganglioglioma** (collectively termed "ganglion cell tumors") share a complement of large and essentially mature neurons unassociated, by definition, with recognizably embryonal elements. Much the more prevalent species, the ganglioglioma harbors an admixed glial population of neoplastic appearance that distinguishes this lesion from the pure gangliocytoma.[560] Ganglion cell tumors usually come to neurosurgical intervention within the first three decades of life[278,561] but may be encountered in older adults. By most accounts, they favor the supratentorial compartment, but examples have been described at all levels of the central neuraxis, and we concur with the observation that gangliogliomas constitute a significant percentage of pediatric tumors presenting in the brainstem and spinal cord.[562-564] Even cranial nerve cases have been depicted,[565,566] and an ectopic intraorbital presentation is also on record.[567] A

For personal use only. No other uses without permission. Copyright ©2017. Elsevier Inc. All rights reserved.

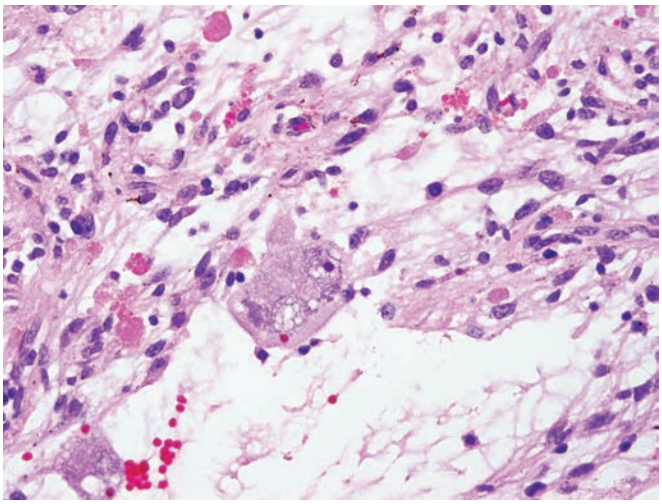

Figure 43.88 Ganglioglioma. The neoplastic nature of the ganglion cell tumor's large neurons is readily apparent from their cytologic abnormalities and multinucleation. Note admixed piloid astrocytic elements, microcystic architecture, and scattered eosinophilic granular bodies.

predilection for the temporal lobes accounts for the discovery of many ganglion cell tumors in the course of evaluation for partial complex epilepsy, often of protracted duration. Albeit nonspecific, neuroradiological presentation as a well-demarcated, partially cystic mass showing contrast enhancement of its solid components and foci of calcification is especially suggestive. The cerebral hemispheric lesion presenting as a discrete mural nodule within a cyst usually proves to be a ganglion cell tumor, pilocytic astrocytoma, or pleomorphic xanthoastrocytoma.

Common to the gangliocytoma and ganglioglioma is the irregular distribution of variably sized neurons, some of ganglion cell–like profile, in a delicate fibrillar matrix that is prone to spongy rarefaction and that often contains scattered calcospherules (Fig. 43.88). Microcystic changes are common in regions of predominantly glial composition. Whereas native neurons trapped in an advancing glial neoplasm generally manifest little cytologic alteration and tend to an even distribution and orderly polarity, the neuronal populace of the ganglion cell tumor often displays, in addition to obvious architectural disarray and anomalous clustering, conspicuous morphologic abnormalities that can include striking pleomorphism, multinucleation, cytoplasmic vacuolization, and gigantism. Some contain Alzheimer disease–type neurofibrillary tangles and other cytoplasmic inclusions seen in neurodegenerative and neuronal storage disorders.[568] Melanotic variants have been described,[569] as have ganglion cell tumors associated with (possibly progenitory) glioneuronal hamartomas,[570] with other maldevelopmental cerebrocortical anomalies,[571] and with the curious lesions known as DNTs (see later discussion).

The glial component of the ganglioglioma is typically astrocytic, GFAP positive, and well differentiated, usually assuming pilocytic or fibrillary guises.[572,573] Gemistocytic elements may be encountered but, if prominent, call the diagnosis into question. Gangliogliomas may contain pleomorphic xanthoastrocytomatous components, reference having previously been made in our discussion of the latter tumor type to "composite" lesions. While gangliogliomas may harbor constituents indistinguishable from conventional oligodendroglioma, the oligodendrocyte-like clear cells present in select ganglion cell tumors usually represent "neurocytes," that is, diminutive neurons.[574] A remarkable example of tanycytic ependymal differentiation on the part of a ganglioglioma is also on record.[575] Only exceptionally do gangliogliomas exhibit high-grade histologic features. This "malignant degeneration" typically involves their astroglial components and potentially results in a glioblastoma-like picture.[576] **Anaplastic ganglioglioma** is the designation appropriate to the tumor densely populated by mitotically active glial cells, and MVP and necrosis may also be encountered; cytologic atypism alone, even if pronounced, does not constitute grounds for this diagnosis. Elements of anaplastic oligodendrogliomatous appearance have exceptionally been observed in malignant ganglioglial tumors.[577] Some cases of this sort, however, may actually represent oligodendrogliomas with ganglion cell components.[361] The recurrence of a ganglioglioma (3 years after subtotal resection and irradiation) as a high-grade neoplasm composed of cells exhibiting a hybrid neuronal/astrocytic phenotype on immunocytochemical and ultrastructural study has also been documented,[578] as have a neuroblastoma-like picture at relapse,[579] the emergence of sarcomatous components,[580] and bizarre examples of AT/RT evolving within gangliogliomas.[427]

Certain recurring histologic features merit emphasis as clues to ganglion cell tumor diagnosis. Eosinophilic granular bodies of lysosomal derivation that appear to aggregate in the matrices of many such tumors are noteworthy in this regard, as only the pilocytic astrocytoma and pleomorphic xanthoastrocytoma exhibit this presumably degenerative alteration with comparable frequency. Lymphoid infiltration can also be of some diagnostic utility to the pathologist not distracted by this common, "pseudoencephalitic" phenomenon. In fact, a florid inflammatory reaction extending into the substance of the lesion (i.e. not simply confined to the perivascular compartment) is only characteristic of gangliogliomas and the pleomorphic xanthoastrocytoma, the more so if plasma cells are found to participate. Desmoplasia, uncommonly associated with neoplasms of neuroepithelial lineage, needs be mentioned as imposing a disfiguring and deceptive spindling and fascicular or vaguely storiform architecture on the constituent cellular elements of some ganglion cell tumors. Stromal blood vessels, often prominent, frequently undergo sclerosis—ganglion cell tumors potentially masquerading as vascular malformations on angiographic and gross neurosurgical assessment.

Given their differentiated appearances, it should come as no surprise that ultrastructural studies have shown the tumoral neurons under discussion to elaborate cytoplasmic processes containing parallel microtubular arrays and clear, synaptic-type vesicles. These neurite-like extensions can terminate in well-developed synaptic complexes.[572] Neoplastic neuronal elements often harbor dense-core neurosecretory granules as well,[572] a feature generally foreign to native cortical neurons, and further depart from the latter in potentially containing spherical protein bodies characteristic of catecholaminergic neuronal populations.[581] While tumors of astrocytic lineage may assume ganglion cell–like cytologic profiles, they manifest none of these specialized neuronal features and in most instances are readily unmasked by their expression of GFAP.

The formation of aberrant axosomatic synapses is apparently responsible for the presence, in many ganglion cell tumors, of large neurons displaying a coarsely granular or linear deposition of reaction product about their perikarya on immunocytochemical assay for SYN (Fig. 43.89), a glycoprotein component of the presynaptic vesicle membrane.[572,574] This phenomenon bears significantly on the problem of distinguishing tumoral and native neurons—a comparable reaction pattern is not observed on immunoassessment of normal cerebral cortex—but must be cautiously interpreted. Circumperikaryal SYN labeling is a recognized attribute of some striatal, cerebellar, bulbar, and intramedullary neurons[582,583]; furthermore, cerebrocortical neurons entrapped within AVMs can evidence this immunoprofile.[582] An identical labeling pattern has been depicted in a lesion of the cerebral cortex reported as postradiation neuronal gigantism,[584] suggesting

For personal use only. No other uses without permission. Copyright ©2017. Elsevier Inc. All rights reserved.

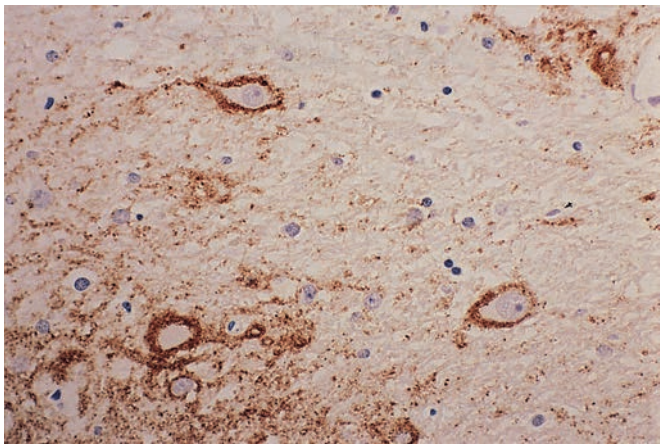

Figure 43.89 Ganglioglioma. Surface perikaryal labeling for synaptophysin characterizes the neuronal elements of some ganglion cell tumors on immunohistochemistry.

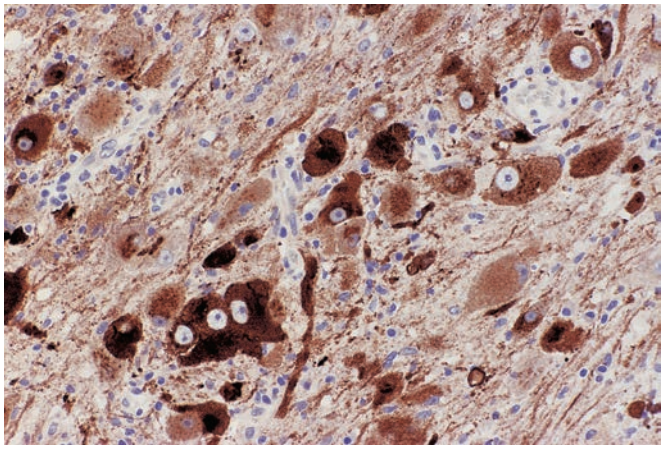

Figure 43.90 Ganglioglioma. Diffuse and strong cytoplasmic immunoreactivity for chromogranin A, a feature foreign to native cerebrocortical neurons, characterizes the neoplastic neuronal perikarya of some ganglion cell tumors.

that chronic, nonspecific neuronal injury may rarely provoke anomalous synaptic remodeling. Additional, and somewhat more specific (albeit inconstant), immunohistochemical evidence for the tumoral nature of a suspect neuronal population is intense and diffuse perikaryal labeling for chromogranin A (Fig. 43.90)—a reflection of the dense core granule formation noted previously.[572] Native CNS neurons outside the brainstem and cerebellum, by contrast, either fail to react (as do glia) or display only punctate and partial labeling of their perikarya for this antigen. Other aberrant immunophenotypic characteristics that can be displayed by the neurons populating ganglion cell tumors include failure to label for NeuN,[358] a nucleoprotein expressed (certain specialized neuronal subclasses, e.g. Purkinje cells, excepted) by their native counterparts throughout the CNS, and reactivity for nestin,[585] a cytoskeletal intermediate filament protein transiently elaborated by multipotent neuroepithelial stem cells but downregulated in differentiated neurons and glia. Nestin labeling may also be observed in astrocytic constituents within these tumors.[585] We do not use nestin immunostaining in clinical practice but can attest to the paradoxically but diagnostically useful (in distinguishing entrapped cortical neurons) NeuN-negative immunoprofile of many gangliogliomas, even when their neuronal components manifest thoroughly mature cytologic features. Some examples, however, retain entirely normal patterns of nuclear (and, at lower intensity, cytoplasmic) NeuN expression.[333] The neuronal constituents of ganglion cell tumors may also exhibit immunoreactivity for NFPs, MAP-2, class III β-tubulin, the neuronal nuclear protein designated as Hu,[334] α-synuclein, various neuropeptides, enzymes integral to catecholamine metabolism, and other neuron-associated antigens.[572,573] Restraint is advised in the interpretation of neuronal "marker" expression limited to minor cell subsets, a phenomenon that can be encountered in otherwise astrocytic, oligodendroglial, and ependymal tumors. In these circumstances, we revert to first principles and render the diagnosis most in accord with the clinical, radiological, and histologic features.

Yet another immunohistochemical feature having some utility in the identification of gangliogliomas is the fact that many exhibit regions of diffuse and intense CD34 reactivity that may include the surface labeling of neuronal perikarya as well as dense decoration of the tumoral matrix.[570,586,587] As mentioned in connection with the frequently CD34-positive pleomorphic xanthoastrocytoma, an entity exhibiting much overlap with gangliogliomas in its clinicobiologic and morphologic profiles, the expression of this antigen has been described as an attribute of neuroepithelial progenitor cells in some mammals (and is, of course, a constant property of endothelium in the CNS as elsewhere) but seems uniformly alien to differentiated neurons and glia in the human neuraxis. Gangliogliomas may further share with pleomorphic xanthoastrocytomas (and with some forms of focal cortical dysplasia) CD34-positive cells of ramified, dendritic appearance that are only apparent in immunohistochemical preparations, and which may be found to populate adjoining, ostensibly uninvolved cerebral cortex in surprising numbers (see Fig. 43.70B).[570,586,587] These distinctive elements are taken by some as evidence that gangliogliomas arise from developmentally dysregulated neural stem cells.[570,586] The reader who consults the references provided on this score will find rather contradictory statements regarding CD34 expression by conventional glial neoplasms, but the demonstration of "dysplastic" neural cells of this type in complex with intratumoral CD34 expression certainly argues against the diagnosis of an infiltrating glioma with entrapped neurons.

A final immunohistochemical characteristic of gangliogliomas that may aid in their identification (and in defining a target of adjuvant therapy for cases that prove refractory to conventional management) is the potential labeling of their neuronal and glial elements for BRAF V600E-mutant protein.[421,588] The most common genetic alteration identified in gangliogliomas to date, *BRAF* V600E mutation has been detected in 11%–60% of cases assessed in various series.[420,421,563,588] This wide variation in reported frequency may reflect diagnostic criteria for case inclusion, as well as the sensitivities of the differing assays employed for detection. Gangliogliomas arising at different levels of the neuraxis may also vary in this regard; for example, the 11% mutation rate quoted above comes from a series of intramedullary tumors,[563] and is well below the rates generally reported in the supratentorial series cited previously. Ganglion cell components may manifest accentuated BRAF V600E reactivity compared to glial populations.[588] A candidate for the diagnosis of ganglioglioma should not have *IDH1* or *IDH2* mutations or immunoreactivity for IDH1 R132H mutant protein, features strongly associated with infiltrating astrocytomas and oligodendrogliomas.[589]

The WHO classifies gangliocytomas and gangliogliomas as grade I lesions and assigns anaplastic gangliogliomas a grade III status in what amounts to a binary formulation.[278] Whether or not there is biologic relevance to the designation of a grade II or "atypical" ganglioglioma (i.e. one falling short of the overtly anaplastic, yet showing increased proliferative activity in complex with conspicuous

For personal use only. No other uses without permission. Copyright ©2017. Elsevier Inc. All rights reserved.

microvascular hyperplasia, unexpectedly high cellularity, or nuclear pleomorphism) is an assertion that awaits validation.[576,590] In practice, few gangliogliomas manifest atypical characteristics of the latter sort (let alone anaplasia). The large majority are characterized by remarkable clinical indolence, and malignant transformation is a decidedly uncommon phenomenon. Supratentorial examples of the usual low-grade type, if accessible, are generally cured by resection alone.[278,590] Bulbar and intramedullary variants are more prone to symptomatic regrowth following operation, possibly owing to surgical limitations imposed by the physical circumstances, but run a protracted clinical course as well.[562-564] Gangliogliomas harboring atypical or patently malignant glial elements have been over-represented among recurrent and fatal cases in some series,[576,590] but repeated observations that even frank anaplasia does not necessarily augur poorly in this setting are noteworthy.[591,592] This happy discrepancy likely reflects the tendency of gangliogliomas to expand in a compact, relatively noninvasive fashion that lends itself to successful neurosurgery. Some observers have suggested that close neuroradiological surveillance alone is reasonable following gross total excision of such tumors, but the optimal management of high-grade gangliogliomas remains in doubt, owing to their rarity. Subtotally resected examples certainly carry a significant risk of fatal progression due to locally aggressive growth and, in some cases, leptomeningeal seeding.[593] One remarkable example of diffuse leptomeningeal gangliogliomatosis may actually have represented advanced glioneuronal maturation of a metastasizing cerebellar medulloblastoma, as noted by the authors.[594] Whether immunohistochemical assessments of proliferative activity or p53 expression independently affect outcome following gross surgical extirpation of gangliogliomas is far from clear.[571,572,595] As a rule, gangliogliomas manifest low MIB-1 labeling indices, reported mean values falling in the 1%–3% range. Histologically anaplastic variants and recurrent lesions have been noted by some observers to evidence higher proliferation indices,[572] but, again, the independent predictive power of proliferation assays is not settled. MIB-1 reactivity is typically restricted to cells of glial appearance though, as previously mentioned, malignant elements of neuronal immunophenotype have been reported to emerge from gangliogliomas.[578,579] One study found *BRAF* V600E-mutant gangliogliomas to have significantly shorter recurrence-free intervals than non-mutant examples.[596]

We briefly call the reader's attention to the occurrence of "intrasellar gangliocytomas"—a heterogeneous collection of benign lesions, most of which arise via neuronal transdifferentiation within growth hormone-producing (or, less commonly, other pituitary) adenomas.[597] A small minority of these curious masses may represent ganglion cell tumors ab initio, or ectopic, hypothalamic-type neuronal hamartomas. Given separate consideration later are the distinctive entities known as desmoplastic infantile ganglioglioma and dysplastic gangliocytoma of the cerebellum (Lhermitte–Duclos disease).

Desmoplastic Infantile Ganglioglioma/Desmoplastic Infantile Astrocytoma

Originally characterized as distinct entities,[598,599] the **desmoplastic infantile astrocytoma** and **desmoplastic infantile ganglioglioma** are allied by common (and stereotypic) clinical, neuroradiological, morphologic, and biologic features.[278] Accordingly, they are given joint treatment in this section. Presentation in the first two years of life is characteristic (mean patient age at tumor discovery being 6 months, though examples in older children and teenagers have been reported), as is supratentorial localization (usually frontoparietal), and associated manifestations of increased intracranial pressure that include irritability, vomiting, macrocephaly, bulging fontanels, and forced downwards deviation of the eyes (the "sunset" sign). CT or

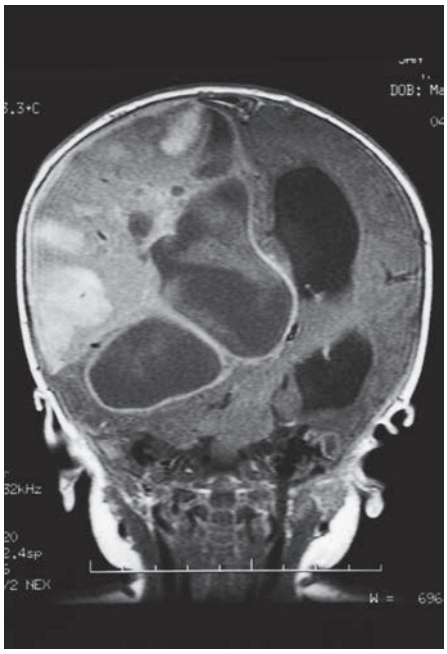

Figure 43.91 Desmoplastic Infantile Ganglioglioma/Astrocytoma. As demonstrated by this example in an 8-week-old boy, tumors of the desmoplastic infantile ganglioglioma/astrocytoma group are typically large cerebral growths exhibiting dural attachment of their superficially located and contrast-enhancing solid components with the formation of prominent underlying cysts.

MR demonstration of a superficially positioned, nodular or plaque-like mass that broadly adheres to the dura, exhibits homogeneous contrast enhancement, and is associated with a prominent subjacent cystic component of unilocular or multilocular aspect (Fig. 43.91) is virtually pathognomonic of this tumor family in the clinical setting just described. Most examples are quite large at operation (often measuring 10 cm or more in greatest span), are composed of tan–white tissue that is rubbery or firm to palpation owing to associated fibroplasia, and appear to lie largely outside the cerebrum proper.

Histologic study of desmoplastic infantile astrocytomas and gangliogliomas generally confirms their dural attachment and predilection for supracerebral growth, while invariably revealing tumor colonization of the adjoining cortex and frequently demonstrating spread along Virchow–Robin spaces. Common to these tumors are collagenized components of pseudomesenchymal appearance, as well as recognizably neuroepithelial elements (Fig. 43.92). The former, usually predominant, are populated by variably pleomorphic spindle cells in loose fascicular or storiform array, these patterns inviting confusion with bona fide fibrohistiocytic neoplasms, intracranial fibromatosis, or fibroblastic meningioma. Immunohistochemical assessment typically discloses a large complement of GFAP-positive astroglial forms within these desmoplastic regions, where they are admixed with nonlabeling elements that have proven on electron microscopic study to include fibroblasts.[598-601] Ultrastructural analyses have further shown that these neoplastic astrocytes are invested by basal lamina material, which accounts for a pericellular, reticulin-impregnable network immunoreactive for basement membrane–associated antigens such as type IV collagen.[600,601] As discussed in connection with the pleomorphic xanthoastrocytoma, this finding may signal differentiation along specialized subpial astrocytic lines.

In addition to sharing collagen-rich zones evidencing astrocytic outgrowth, the desmoplastic infantile astrocytoma and ganglioglioma are also characterized by the regular presence of seemingly

For personal use only. No other uses without permission. Copyright ©2017. Elsevier Inc. All rights reserved.

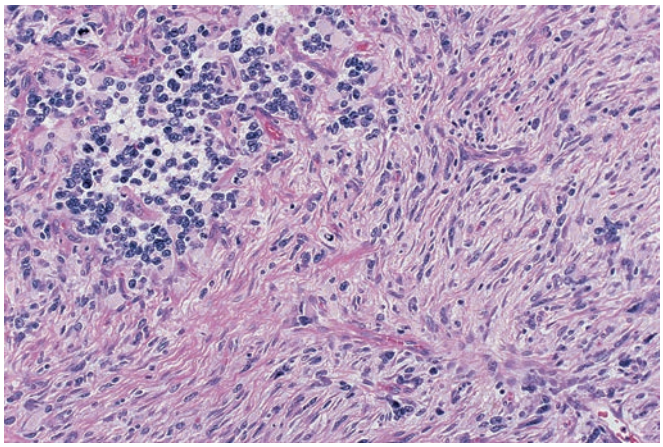

Figure 43.92 Desmoplastic Infantile Ganglioglioma/Astrocytoma. Distinctive features include collagenized regions dominated by spindled astrocytes in fascicular or storiform array and admixed small cells of primitive appearance in nodular aggregates.

undifferentiated small cell populations that inhabit reticulin-free islands or broader tissue expanses (see Fig. 43.92). These may achieve considerable density and can exhibit mitotic activity (usually at low level); however, even in areas dominated by such cells, MIB-1/Ki-67 labeling indices generally remain modest. In fact, most of the tumors under discussion exhibit MIB-1 indices below 5%, and many fall below the 2% level. High mitotic rates, MVP, and necrosis are clearly exceptional but occasionally encountered.[602,603] Small cell components, which appear to be primitive neuroepithelial constituents capable of divergent differentiation, can exhibit cytologic transition to fibrillary astroglial, gemistocytic, or neuronal morphology and may label for GFAP, various neuron-associated antigens (e.g. SYN, class III β-tubulin, NFPs, MAP-2, Hu), and desmin.[598,599] The specific diagnosis of desmoplastic infantile ganglioglioma is reserved for tumors containing recognizable neurons, but the expression of neuron-restricted epitopes by the ostensibly uncommitted small cells populating cases devoid of patently differentiated neuronal elements exposes the artifice in so subclassifying these unusual neoplasms of early life. When present, neuronal forms include mature, atypical, and ganglion cell–sized variants. While most prevalent in noncollagenized regions, these can be detected in desmoplastic areas as well (particularly with the aid of immunoscreening for SYN and neurofilament epitopes). A deep-seated example containing components of conventional ganglioglioma, gangliocytomatous foci, pilocytic astrocytoma-like regions, and elements suggesting Schwann cell differentiation has been recorded.[604] It would appear that only a small minority of these infantile neoplasms harbor the *BRAF* V600E mutations that are more prevalent among gangliogliomas of conventional type.[605]

Desmoplastic infantile gangliogliomas and astrocytomas may represent neoplasms of essentially embryonal character programmed to advanced maturation along glioneuronal lines. Their small cell components notwithstanding, a most favorable prognosis attaches to cases amenable to gross total resection, and thus these peculiar tumors are accorded WHO grade I status. Remarkable instances of their "spontaneous" regression following less than complete excision have been communicated.[606] Even frankly malignant histologic features (e.g. conspicuous mitotic activity and necrosis with palisading) do not necessarily augur an ominous prognosis if surgical removal can be effected,[600,603] but we would caution that very few "anaplastic" cases have been recorded to date. Recurrence following complete excision is exceptional, though subtotally removed examples may occasionally regrow over relatively brief intervals[607] and can prove fatal.[604] CSF-borne metastasis at presentation has been described in an account detailing the virulent behavior of a case that was atypical by virtue of its subcortical, partly intraventricular localization; unusually florid proliferative activity (including a MIB-1/Ki-67 labeling index of 45%); and anaplastic small cell elements that constituted one-third of the tumor bulk.[608] Tumor recurrence and biologic progression in the face of gross total resection, with the emergence of hyperproliferative small cell components and seeding of the ventricular cavities, have also been described,[609] as has transformation to glioblastoma-like histology on relapse.[610,611] It would appear, however, that adjuvant therapy can be reserved for refractory lesions that cannot be extirpated by surgical means alone.[602,603,612] It has been suggested that basal lamina formation by astrocytic elements may exert a restraining influence on the proliferation of these neoplasms, as basement membrane–associated proteins apparently promote cell differentiation and growth arrest when applied to human glioma lines.[601]

Central Neurocytoma and Extraventricular Neurocytic Neoplasms

The **central neurocytoma** is a neoplasm composed of highly differentiated, albeit diminutive, neuronal elements,[278,613] which is characterized by intraventricular location, attendant manifestations of obstructive hydrocephalus, a peak incidence in adults aged 20–40 years, and deceptively oligodendroglioma-like histology. It may be situated anywhere within the ventricular confines, possibly deriving from remnants of the subependymal matrix that retain postnatal proliferative capacity, but most often inhabits anterior portions of the lateral ventricles in the foramen of Monro region. It also frequently involves the septum pellucidum. Common neuroradiological features include cystic change, contrast enhancement of solid components, and conspicuous calcification (Fig. 43.93).

The central neurocytoma is remarkable for the cytologic conformity of its constituent cells (Fig. 43.94), which possess monomorphic nuclei of small diameter, rounded contour, and evenly granular chromatin content. Perinuclear clearing, a plexiform capillary microvasculature, and admixed calcospherules often conspire to render this lesion indistinguishable from the oligodendroglioma, though the central neurocytoma usually differs in its elaboration of a fine, neuropil-like fibrillar matrix that may separate streaming tumor cells, punctuate foci of sheet-like growth as anuclear islands, collar stromal blood vessels in pseudoependymomatous fashion, or constitute the cores of Homer Wright–like rosettes, referred to as "neurocytic rosettes" (although generally a bit larger and more irregular than Homer Wright rosettes, and without the associated primitive appearing nuclei of the latter). This unusual neoplasm can attain dense cellularity, but the typical example is virtually devoid of mitotic activity and does not exhibit MVP or necrosis. Admixed ganglion cell,[614] adipocyte-like,[615,616] and melanotic[617] components have been recorded, as have a case manifesting ependymal (as well as lipomatous) differentiation,[618] an example associated with a fourth ventricular tumor of medulloblastomatous appearance[616] and one interpreted as evidencing ganglioglioma tous differentiation on recurrence.[619]

Cytoplasmic processes replete with parallel microtubular arrays, clear vesicles, and membrane-bound neurosecretory granules (the last typically in small number) attest to the neuronal nature of the central neurocytoma on electron microscopy, synapse formation signaling the particularly advanced maturation of some representatives.[613,614] Such findings effectively distinguish this entity from the oligodendroglioma and clear cell ependymoma, though we note one ultrastructural study depicting an unusual variant with oligodendrocyte-like lamellar cytoplasmic structuring,[620] and a second documenting

For personal use only. No other uses without permission. Copyright ©2017. Elsevier Inc. All rights reserved.

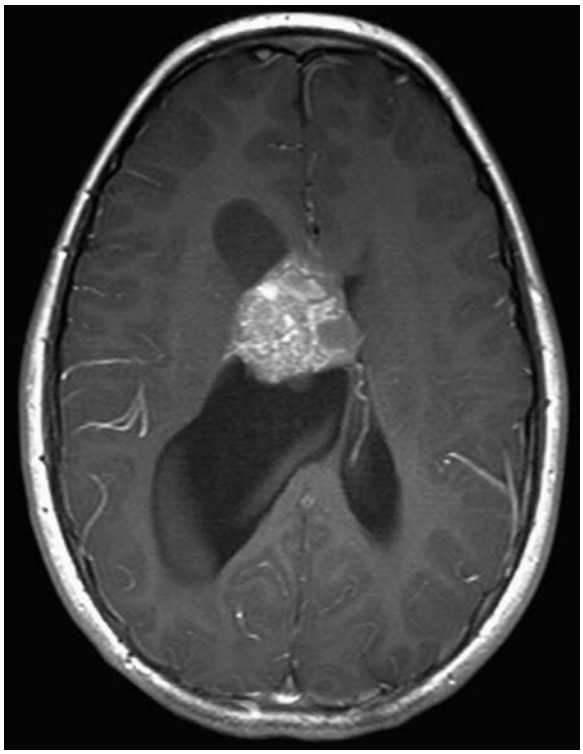

Figure 43.93 Central Neurocytoma. This postcontrast magnetic resonance imaging shows the neurocytoma's predilection for the lateral ventricles, its tendency to be centered about the septum pellucidum, regions of bright enhancement, and associated ventriculomegaly indicative of obstructive hydrocephalus.

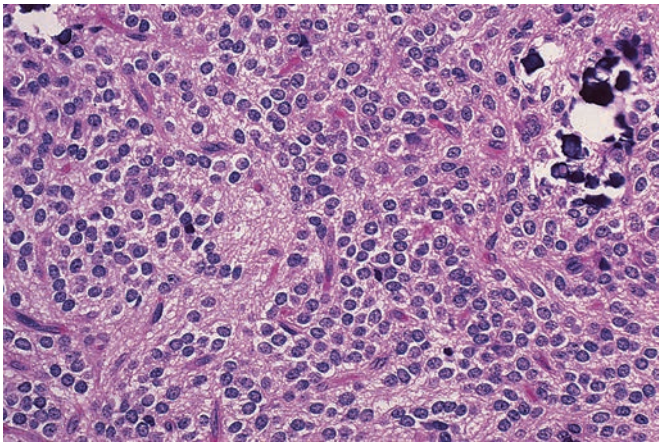

Figure 43.94 Central Neurocytoma. The typical neurocytoma is rather densely populated by small, monomorphous cells embedded in a variably abundant, delicate fibrillar matrix. Rounded nuclear contours, perinuclear clearing, a plexiform capillary arcade, and associated microcalcifications (the basophilic structures present at upper right) impart an oligodendroglioma-like appearance to this small cell neuronal neoplasm.

an intraventricular neoplasm with both neuronal and ependymal specializations.[621] We have also previously alluded to neurocytomatous components within otherwise conventional oligodendrogliomas[360] and to neuronal differentiation within ependymal neoplasms,[471] but these are exceptional (and usually focal) phenomena. The central neurocytoma, unless subjected to prolonged formalin fixation, almost invariably manifests widespread immunolabeling of its fibrillary

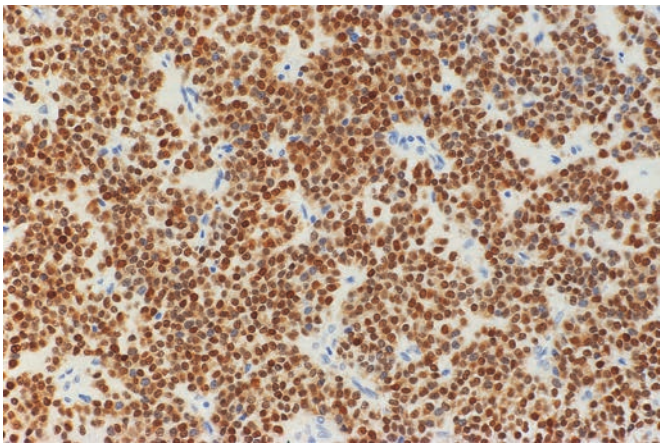

Figure 43.95 Central Neurocytoma. A phenomenon restricted in the normal central nervous system to advanced stages of neuronal maturation, immunolabeling for the NeuN nuclear antigen is shared by many central neurocytomas and attests to their well-differentiated nature.

matrix for SYN, which confirms the diagnosis in the appropriate setting and obviates more costly and time-consuming ultrastructural assessment.[613,614] It is also noteworthy that the chromosome 1p/19q co-deletions and *IDH1* or *IDH2* mutations displayed by canonical oligodendrogliomas are alien to central neurocytic neoplasms.[278,622] Central neurocytomas often exhibit labeling for the Hu[334] and NeuN[333] neuronal nuclear proteins (Fig. 43.95), further evidence of their neuronal character, though chromogranin A and NFP expression seem restricted to the rare variant exhibiting transition to ganglion cell–like morphology.[613,614] Chromogranin A immunoreactivity, by contrast, is a frequent attribute of pineocytomas and of pineal parenchymal tumors of intermediate differentiation that may be difficult to distinguish from central neurocytomas on histologic grounds alone and which share SYN positivity. The reader is referred to the discussion of pineal parenchymal neoplasms for reference to specific ultrastructural features that further segregate such tumors from neoplasms of conventional neuronal type. Central neurocytomas seem capable of glial differentiation,[623-625] but cytoplasmic GFAP immunolabeling is foreign to most and, if present, limited to tumor cells in relatively small number.

Central neurocytomas are classed as grade II lesions in the WHO formulation.[278] The prognosis for patients with resectable tumors is generally favorable, with complete excision alone effecting long-term tumor control in most cases. Tumors that cannot be surgically extirpated generally enlarge slowly and remain confined to the ventricular cavity, but incomplete resection was found to portend a poor outcome in one multicenter analysis.[626] Gross invasion of periventricular structures, dissemination via the CSF, and fatal progression are exceptional[614,627,628] and not necessarily predicted by lesion histology,[626] though "**atypical central neurocytomas**," characterized by features including readily apparent mitotic activity, macronucleoli, MVP, necrosis, and/or elevated MIB-1/Ki-67 labeling indices, have been over-represented among clinically aggressive lesions.[624,629,630] The finding of 3 or more mitoses per 10 high-power microscopic fields has emerged from some studies as indicative of an increased risk of postsurgical recurrence.[626,631] MIB-1/Ki-67 labeling "cutoff" values of 2%[624,629] or 3%[630] have been forwarded as indices of abbreviated recurrence–free survival as well, though these observations have not been borne out in some series.[626] Adjuvant therapy, particularly irradiation, may prove beneficial to some patients with disease refractory to surgical management.[632]

For personal use only. No other uses without permission. Copyright ©2017. Elsevier Inc. All rights reserved.

While the specific diagnosis of central neurocytoma should be reserved for the intraventricular neoplasm described above, tumors of comparable morphology and immunophenotype may arise within the substance of the brain[633,634] or spinal cord.[635] These can harbor admixed ganglion cell and astroglial elements,[633,634] a remarkable cerebellar example exhibiting rhabdomyomatous differentiation.[636] The literature further contains accounts of neurocytomatous tumors arising in a mature cystic teratoma of the ovary[637] and in the pelvis of a young adult male.[638] The clinical biology of these **extraventricular neurocytomas** and "**ganglio/glioneurocytomas**" remains to be fully characterized, but most reported to date have exhibited limited proliferative activity and have behaved in the fashion of benign or low-grade growths.[633,639,640] Gross total resection of these generally demarcated tumors is the treatment of choice. Atypical features (including mitotic activity in excess of 2 mitoses per 10 high-power microscopic fields, geographic necrosis, or MVP) have been correlated with an older age at diagnosis, MIB-1 labeling indices above 5%, tumor unresectability, and an increased risk of recurrence.[633,639,640] The nosology of aggressive, small cell glioblastoma–like neoplasms reported as malignant neurocytic tumors[641] is unclear. Potentially aggressive tumors reported as extraventricular neurocytomas manifesting chromosome 1p/19q co-deletion and t(1;19)(q10;p10) unbalanced translocations[642] are appropriately regarded as oligodendrogliomas evidencing neuronal differentiation. In this vein, we would also stress that *IDH1* and *IDH2* mutations have proven foreign to extraventricular neurocytic neoplasms thus far, as has immunohistochemical expression of the IDH 1 R132H mutant protein.[643,644]

Cerebellar liponeurocytoma is the current and WHO-recognized designation for an unusual lesion previously regarded as embryonal in nature by some observers, and variously termed a "lipomatous" or "lipidized" medulloblastoma, medullocytoma, neurolipocytoma, or lipomatous glioneurocytoma.[278,645-647] To date, it has been encountered only in adults (with a mean age at diagnosis of ~50 years). CT/MRI study typically discloses a relatively well-demarcated, contrast-enhancing cerebellar mass (vermian or hemispheric) with foci of bright signal on precontrast T1-weighted images reflecting the fatty component. The latter, variably represented, consists of lipid-laden neuroepithelial cells that resemble mature or multivacuolated adipocytes grouped within a tumor otherwise of central neurocytoma-like histology, immunophenotype, and fine structure. In fact, cerebellar liponeurocytomas have been found to overexpress, compared to normal adult cerebellum, an adipocyte-associated fatty acid-binding protein[648] and often lose their SYN positivity in comparison to more conventional appearing neurocytic cells (Fig. 43.96A). GFAP-immunoreactive glial elements are often present and concentrated in "lipomatous" regions (see Fig. 43.96B). An example with myoid differentiation is also on record.[649] Mitotic figures are scarce and MIB-1 labeling indices usually fall in the 1%–3% range, though isolated cases that would seem to qualify for the diagnosis have been reported to exhibit more conspicuous proliferative activity as well as MVP and focal necrosis.[650,651] Genetic analyses have not yet shown cerebellar liponeurocytomas to manifest diagnostic abnormalities, but have revealed expression profiles similar to those of the central neurocytoma and have disclosed features distancing these tumors from medulloblastomas.[652] Cerebellar liponeurocytomas have a higher incidence of *TP53* mutation and consistent absence of medulloblastoma-associated alterations such as isochromosome 17q formation or mutations involving Patched *(PTCH)*, adenomatous polyposis coli *(APC)*, or β-catenin *(CTNNB1)*.

An assessment of the literature regarding the prognosis of cerebellar liponeurocytomas is complicated by the inclusion in some reports and reviews, including a retrospective analysis[653] cited by the WHO, of cases that clearly represent medulloblastomas exhibiting tumor cell lipidization[654] or regional infiltration by foamy, CD68-labeling macrophages.[655] These generally have the same predilection for children, primitive appearance, and high (>20%) MIB-1 labeling indices that characterize conventional medulloblastomas as a group, and are predictably aggressive lesions. While conceding the existence of rare tumors that display overlapping histologic features and levels of proliferative activity, it can be said of typical cerebellar liponeurocytomas that most affected patients followed for 5 years or more have remained alive following resection (irrespective of adjuvant radiotherapy) and that seeding of the CSF has not been described. It would appear, however, that the risk of local (particularly late) regrowth following excision was much underestimated in early series (nearly half of reported cases are now known to have recurred), and it has become apparent that even perfectly innocent-looking and hypoproliferative examples can occasionally regrow with unexpected rapidity and prove uncontrollable.[656] Accordingly, the cerebellar liponeurocytoma is designated a grade II lesion in the current WHO classification.[278] Refractory behavior has also been documented on the part of some histologically atypical cases[650] (though these are too few to permit any firm conclusion regarding the impact of increased mitotic activity, elevated MIB-1/Ki-67 labeling or other aberrant features on outcome), as has the emergence of anaplastic

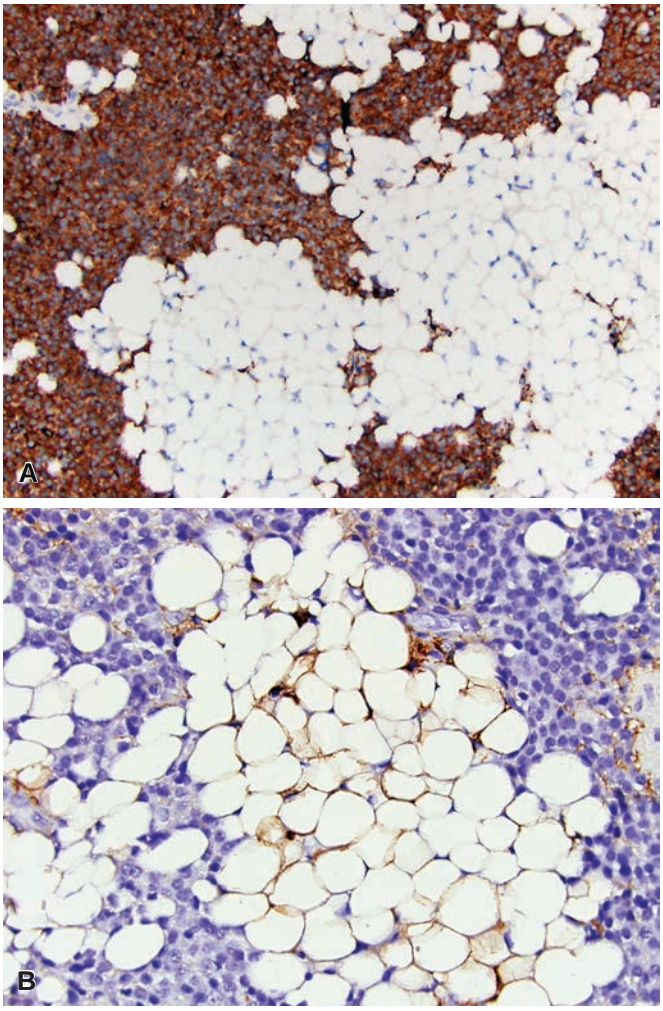

Figure 43.96 Cerebellar Liponeurocytoma. A, As in central neurocytoma, tumor cells are diffusely synaptophysin immunoreactive with the exception of most lipoma-like cells. **B,** In contrast, the latter often express glial fibrillary acidic protein.

For personal use only. No other uses without permission. Copyright ©2017. Elsevier Inc. All rights reserved.

histology and conspicuously increased MIB-1/Ki-67 labeling fractions on recurrence.[657]

Dysembryoplastic Neuroepithelial Tumor

DNTs are strongly associated with pharmacoresistant partial seizures in young subjects and only exceptionally come to attention in patients older than 20 years of age.[278,658-660] While the great majority are supratentorial and cerebral in position, the temporal lobes being particularly prone, lesions of strikingly similar morphology involving the septum pellucidum,[661,662] caudate nucleus,[663] brainstem,[664] and cerebellum[665] have been recorded, although the latter often overlap with rosette-forming glioneuronal tumor (see later discussion). Multifocal presentations have also been described.[666] Neuroradiological features of great utility in suggesting the diagnosis, and in distinguishing DNTs from conventional glial neoplasms (particularly oligodendrogliomas) with which they may be confused histologically, are their tendency to lie largely, if not entirely, within an expanded cortical ribbon (Fig. 43.97) and their multinodular bright signal qualities in T2-weighted MRIs. Examples extending into white matter often taper from a broad cortical base and assume triangular configurations, some seeming to point towards the subjacent ventricle.[667] Remodeling of the adjacent calvarium often attests to the indolent expansion of these unusual lesions, which are typically T1 hypointense (often with isointense rims or septations demarcating multiple hypointense tumor nodules in a bubbly pattern) and devoid of mass effect or associated edema.[667] A minority exhibit discrete foci of nodular or ring enhancement.

"Simple" and "complex" histologic variants of DNT are recognized.[658-660] Common to both and required for morphologic diagnosis is the presence of what has been termed the "specific glioneuronal element"—a proliferation of oligodendrocyte-like cells (OLCs) that appear to be arranged along bundled axons and ramifying capillaries (often coursing perpendicular to the cortical surface) and that are separated by a myxoid matrix in which well-differentiated neurons seem to float (Fig. 43.98). Mitoses are absent or exceedingly rare, and MIB-1 labeling indices do not usually exceed 1%–2%. The specific glioneuronal element colonizes a cortex that may exhibit background architectural disorganization (dysplasia), which is readily appreciated on low-power examination. OLCs can also be arranged around myxoid microcysts in alveolar fashion or about a fine fibrillar meshwork in cribriform, rosetted array. Stellate, GFAP-immunoreactive astrocytes may be found within the specific glioneuronal element of simple DNTs, and complex variants may harbor, in micronodular or more diffuse arrangement, additional glial components that may be indistinguishable from conventional oligodendroglioma, pilocytic, or fibrillary astrocytoma. These can colonize the leptomeninges/subarachnoid space, may exhibit considerable cytologic atypia, and have been described in some cases as manifesting low-level mitotic activity, MVP, and, rarely, necrosis.[659] An anomalous vasculature of hamartomatous aspect may be encountered. Curiosities include examples of DNT admixed with ganglioglioma[668] and a lesion interpreted as a melanotic DNT variant.[669]

The potential association with cortical dysplasia and characteristically young patient age at presentation have been taken as evidence that DNTs are potentially maldevelopmental in origin.[659] Aberrant CD34 expression, a phenomenon (previously discussed in connection with the pleomorphic xanthoastrocytoma and ganglioglioma) that may reflect local developmental dysregulation, may be associated with DNTs as well.[421,586,670] Approximately 30% of DNTs assessed to date, however, have exhibited *BRAF* V600E mutations,[421,671] and the recurrent behavior of some examples further suggests that these are neoplastic in nature (see later). Whether the OLCs that dominate their specific glioneuronal elements actually represent oligodendroglia is unclear. Some observers have found these cells, which are usually S-100 protein and OLIG2 positive but GFAP negative, to be immunoreactive for myelin oligodendrocyte glycoprotein.[672,673] Others have noted minor subsets labeling with such neuron-associated antigens as NeuN and the *N*-methyl-D-aspartate receptor subunit NR1[674] or showing dense core granule and axosomatic synapse formation at the ultrastructural level.[675] These may, then, be capable of divergent differentiation. As previously mentioned, NeuN labeling is typically foreign to oligodendrogliomas (save for rare variants exhibiting neurocytic differentiation).[674] Oligodendroglial tumors, however, may contain trapped, NeuN-positive neurons of small size that complicate segregation of these entities by immunohistochemical

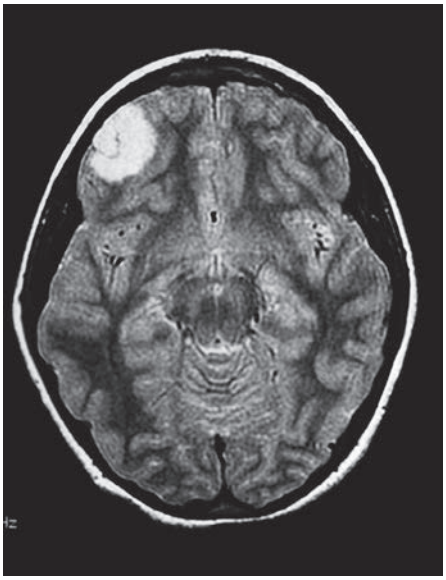

Figure 43.97 Dysembryoplastic Neuroepithelial Tumor. A gyriform focus of increased signal attests to the largely cortical localization of this superficial lesion, seen in a FLAIR MR sequence. Also characteristic is the absence of mass effect or white matter changes indicative of edema.

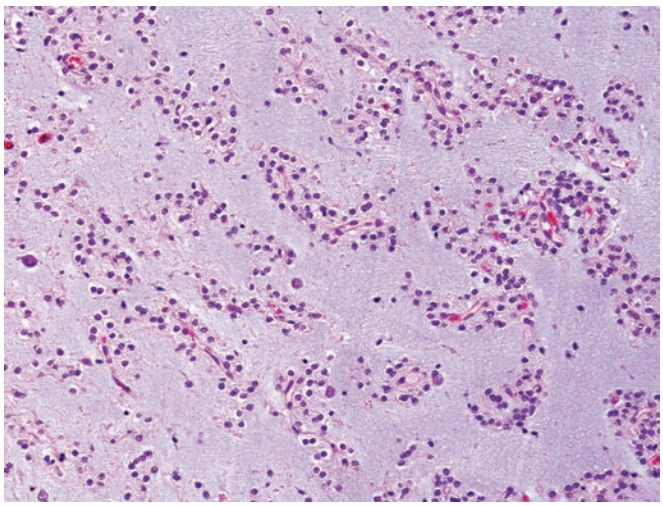

Figure 43.98 Dysembryoplastic Neuroepithelial Tumor. Extensive myxoid change and the disposition of small, oligodendrocyte-like cells along axonal fiber bundles and capillaries lend an alveolar or "patterned" appearance to the specific glioneuronal element of this distinctive lesion. Also present are mature neurons appearing to float in the mucoid matrix.

For personal use only. No other uses without permission. Copyright ©2017. Elsevier Inc. All rights reserved.

means alone. The *IDH1* and *IDH2* mutations,[280] frequent immunoreactivity for IDH1 (R132H) mutant protein,[676] and whole-arm chromosome 1p/19q co-deletions[677] that characterize canonical oligodendrogliomas are foreign to DNTs, but these alterations are rarely encountered in pediatric tumors that would otherwise seem to qualify as oligodendroglial neoplasms.[375] We think that the diagnosis of oligodendroglioma must be approached with considerable skepticism in childhood, particularly when a candidate lesion displays the cortical topography of the DNT. The reader is referred to the section on oligodendrogliomas for further discussion of this differential.

Patients with DNTs of both simple and complex type are usually cured by simple excision alone, and subtotally resected examples generally remain stable on neuroradiological surveillance.[658-660] Local recurrence of histologically typical DNTs following resection does happen but is clearly exceptional.[678,679] While a comparably favorable outcome has been recorded following complete surgical extirpation of complex variants exhibiting mitotic activity, MVP, or necrosis,[659] few such cases have been communicated, and judgment regarding their biologic potential must be reserved. Examples of malignant transformation after excision only[679,680] or following irradiation and chemotherapy[678,681] are extremely rare.

It has been proposed that certain DNT variants show neither a specific glioneuronal element nor a multinodular growth pattern, assuming, instead, the guises of oligodendroglioma, oligoastrocytoma, pilocytic or fibrillary (including high-grade) astrocytoma in unalloyed form.[682] The criteria posited for the identification of such "nonspecific" DNTs, which are said to be clinically benign and nonrecurring after simple removal irrespective of their histologic attributes, are: (1) association with partial seizures (with or without secondary generalization) beginning prior to 20 years of age; (2) absence of associated neurologic deficits or presence of a nonprogressive congenital deficit only; (3) supratentorial localization and cortical topography on CT/MRI; and (4) absence of associated edema or mass effect other than that related to cystic components. This is, understandably, controversial.

Papillary Glioneuronal Tumor

The **papillary glioneuronal tumor** seems to have a predilection for adolescents and young adults and tendency to a subcortical (often paraventricular) cerebral hemispheric localization.[278,683,684] Neuroradiological features include circumscription, contrast-enhancing solid components with associated cysts, and little in the way of accompanying mass effect or edema. A biphasic morphology is characteristic (Fig. 43.99). The glial element, which has papillary architecture, is represented by GFAP-immunolabeling cells of flattened to low cuboidal profile draped in monolayered or pseudostratified fashion over branching, hyalinized vascular cores. SYN-rich, nonpapillary neuronal populations that include neurocytes, large neurons of mature appearance, and intermediate forms are admixed or regionally segregated. These may exhibit nuclear NeuN expression.[685] Solid, nonpapillary regions may also harbor GFAP/NeuN-negative clear cell elements that label for OLIG2 and that may represent oligodendrocytic components[685]; some cases contain, in addition, minigemistocytes and conspicuously granulated cells of the sort found in oligodendrogliomas.[685,686] Myxoid change is common. Mitoses are generally absent or rare, there is typically no MVP or necrosis, and MIB-1/Ki-67 labeling indices usually do not exceed 1%–2%. A novel *SLC44A1-PRKCA* gene fusion seems characteristic of this entity.[687,688] Papillary glioneuronal tumors usually behave in WHO grade I fashion, and simple excision suffices to control most recorded cases.[689] Recurrent examples have exhibited mitotic activity (accompanied, in some cases, by MVP or necrosis) and/or elevated MIB-1 labeling fractions.[683,690,691] The extraneural dissemination of a recurrent, frankly anaplastic example has been communicated.[692] One review found no instances of postoperative tumor regrowth among cases having MIB-1/Ki-67 labeling indices below 5%, whereas one half of lesions with higher labeling fractions eventually recurred or progressed.[691]

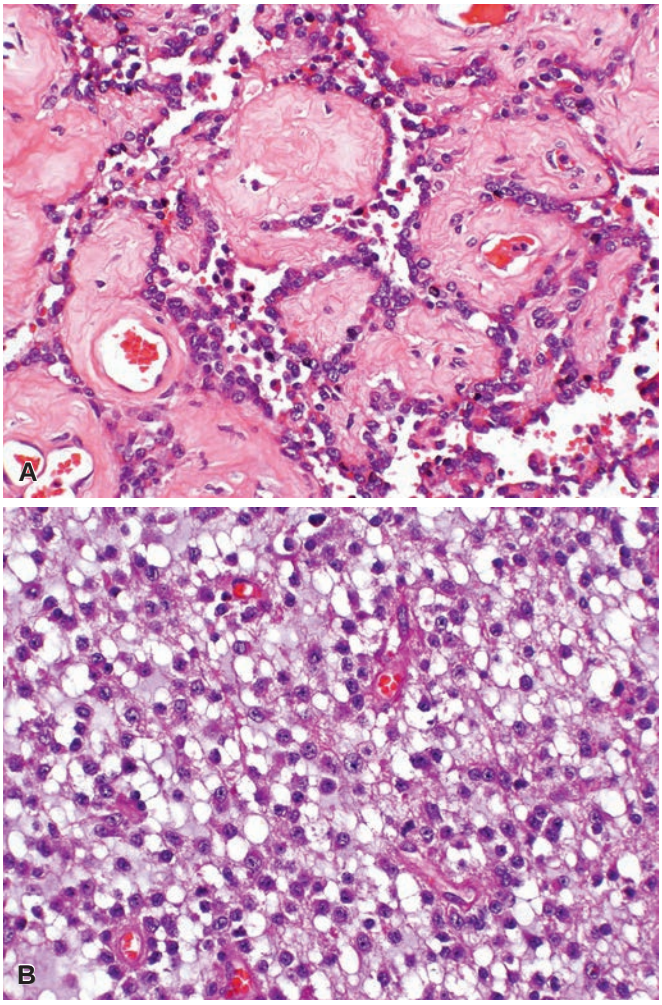

Figure 43.99 Papillary Glioneuronal Tumor. These fields from a single tumor demonstrate papillary **(A)** and nonpapillary **(B)** components. Glial fibrillary acidic protein expression confirmed the glial nature of the former, while the latter (represented in this case by neuronal elements of "intermediate" type) selectively labeled for synaptophysin. The vascular hyalinization in papillary regions **(A)** and bubbly, myxoid alterations in non-papillary foci **(B)** are common accompanying features.

Rosette-Forming Glioneuronal Tumor

Rosette-forming glioneuronal tumors exhibit a decided predilection for the fourth ventricular compartment but commonly involve the adjoining cerebellum, can extend into (or principally occupy) the cerebral aqueduct, and occasionally present as multinodular growths having bulbar components.[278,693,694] Most come to attention in adulthood, causing headache and nausea referable to obstructive hydrocephalus or cerebellar ataxia. Tumors of identical histology have been encountered in the pineal gland and third ventricle,[695] spinal cord,[696] and optic nerve/chiasm,[697] the latter case involving a patient with NF1. Relatively demarcated on MRI evaluation but

For personal use only. No other uses without permission. Copyright ©2017. Elsevier Inc. All rights reserved.

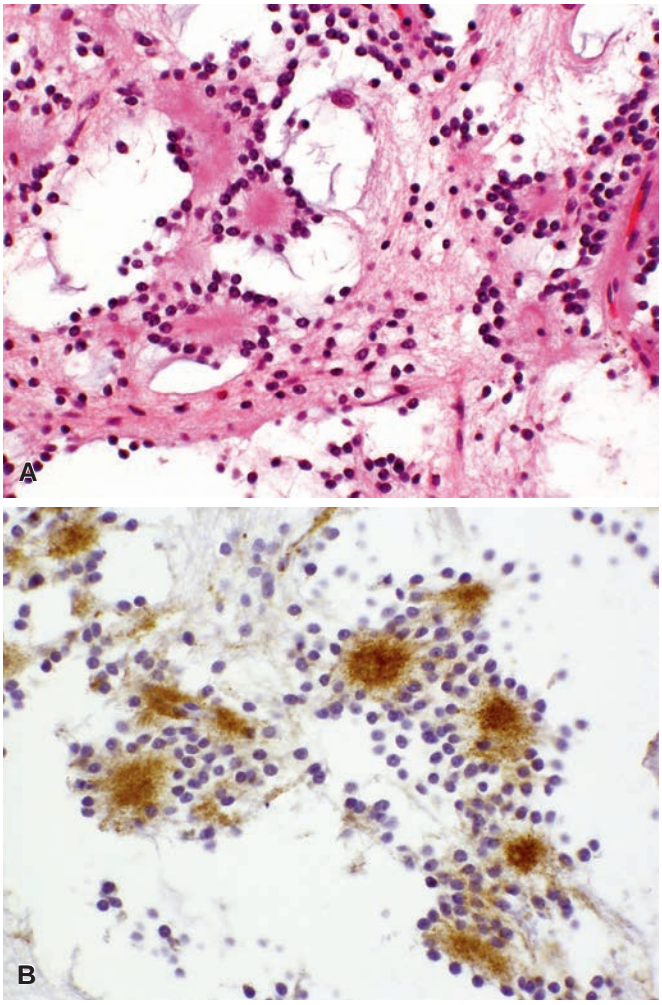

Figure 43.100 Rosette-Forming Glioneuronal Tumor of the Fourth Ventricle. Neurocytic rosettes of small diameter that often appear free floating **(A)** and that exhibit central immunolabeling for synaptophysin **(B)** are defining components of this entity.

Figure 43.101 Diffuse Leptomeningeal Glioneuronal Tumor. This T2-weighted magnetic resonance imaging shows marked expansion of the intracranial and intraspinal subarachnoid spaces, including the basal cisterns.

accompanied in some cases by discrete "satellite" lesions separate from the main mass, these neoplasms are typically T2 bright/T1 hypointense and may exhibit nodular, ring-like or linear patterns of contrast enhancement.[693,694] They are composed in biphasic fashion of glial elements resembling pilocytic astrocytoma (these often hypocellular and associated with vascular hyalinization), and neurocytic populations that engage in the formation of diminutive, SYN-immunoreactive rosettes and narrow perivascular pseudorosettes that may be attended by myxoid alterations and that often seem to float within microcavities (Fig. 43.100). Components indistinguishable from conventional oligodendroglioma and labeling for neither GFAP nor SYN may be encountered. Some cases exhibit complex MVP, but mitotic activity is inapparent, necrosis is not observed, and MIB-1 labeling indices are quite modest (not exceeding 2%–3% and often no higher than 1%). *PIK3CA*[698] and *FGFR1*[699] mutations have been reported. Glioneuronal tumors of the fourth ventricle are indolent, WHO grade I lesions that may remain stable over lengthy periods of neuroradiological surveillance and that can be controlled by surgical means. Aggressive attempts to fully extirpate these neoplasms, however, have been complicated in a substantial number of reported cases by significant neurologic deficits. Late local recurrence following resection has been documented, as have examples evidencing intraventricular dissemination at diagnosis[700] or eventual CSF-borne spread.[689]

Diffuse Leptomeningeal Glioneuronal Tumor

The rare oligodendroglioma-like neoplasms that are now recognized as a distinct entity under the designation of diffuse leptomeningeal glioneuronal tumor typically present in childhood with manifestations of increased intracranial pressure (reflecting obstructive hydrocephalus), cranial neuropathy, or myelopathy.[346,701,702] Only exceptionally are adults affected. Widespread contrast-enhancement and thickening of the leptomeninges on MRI attests to the disseminated nature of this disease at diagnosis. Whereas tumor deposits along the spinal neuraxis commonly assume linear or plaque-like profiles on neuroradiological study, intracranial involvement often presents as a myriad of T2-hyperintense nodules preferentially clustered about the brainstem, in the basilar cisterns, over the cerebellar folia, and in the sylvian fissures (Fig. 43.101).[346] In T1-weighted sequences these hypointense nodules have empty, cyst-like appearances. Imaging studies demonstrate focal intra-axial involvement in 75%–80% of cases, typically quite limited in extent and most often localized within the spinal cord. Examination of the CSF demonstrates increased protein levels and, in some cases, reactive lymphocytosis, but is typically negative for tumor cells.

Diffuse leptomeningeal glioneuronal tumors are typically monomorphous and composed of oligodendrocyte-like clear cells with round nuclei, inconspicuous nucleoli, and perinuclear haloes (Fig. 43.102A). These may be disposed in sheets, irregular nests, or linear files within a collagenous matrix. We would emphasize that obscuring fibroplasia and crush artifact may confound biopsy interpretation, prompting (along with the presence in some cases of reactive lymphohistiocytic infiltrates) primary consideration of chronic arachnoiditis. Myxoid change is common as well and may be especially conspicuous in intracranial samples. Foci in which neoplastic neuronal elements of intermediate to large size lie in a neuropil-like matrix

For personal use only. No other uses without permission. Copyright ©2017. Elsevier Inc. All rights reserved.

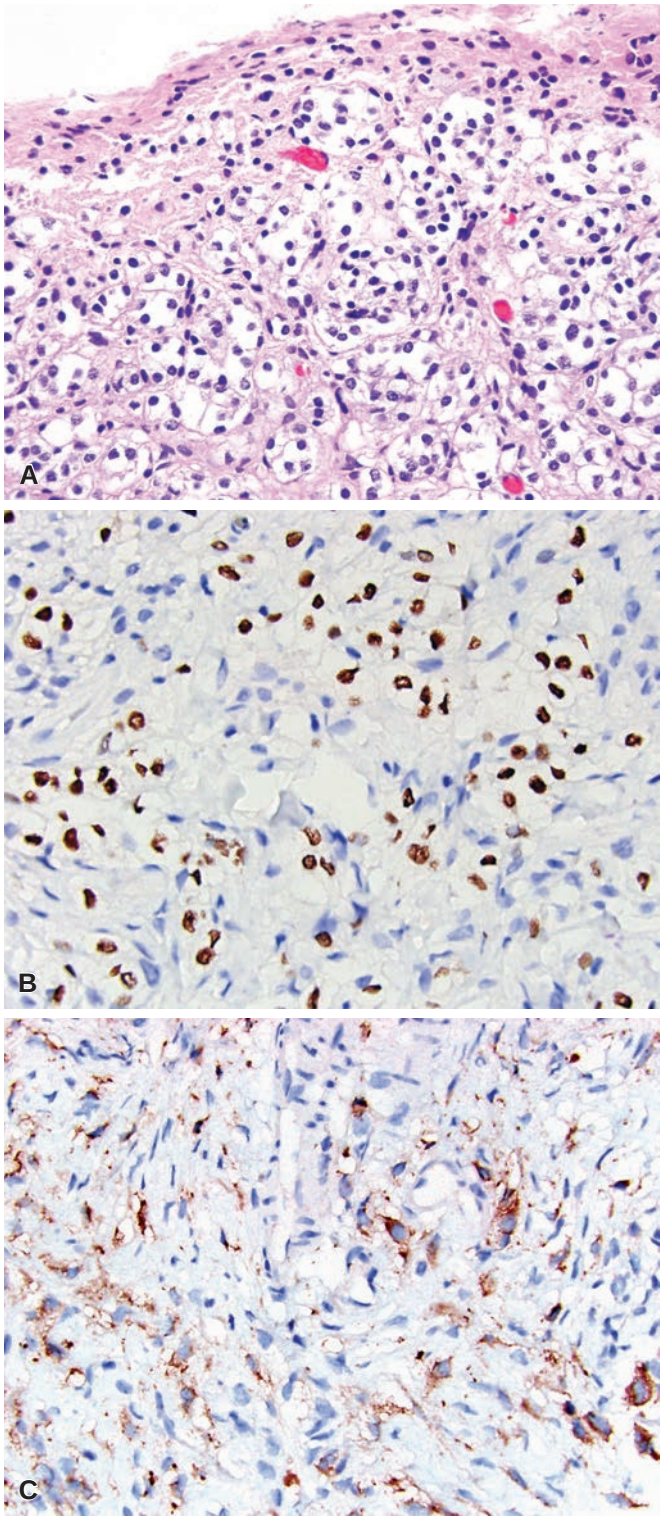

Figure 43.102 Diffuse Leptomeningeal Glioneuronal Tumor. A, Biopsy typically reveals a markedly expanded leptomeningeal layer with tumor cells resembling oligodendroglioma. Immunohistochemistry often reveals strong OLIG2 **(B)** and patchy synaptophysin **(C)** expression.

are occasionally encountered. Neuroparenchymal components often closely resemble infiltrating oligodendrogliomas but may harbor, or even be dominated by, tumor cells of astrocytic appearance. Histologic evidence of anaplasia that includes readily apparent mitotic activity and glomeruloid MVP characterizes a minority of examples at presentation or upon clinical progression,[346,703] necrosis being exceptional and usually encountered only in recurrent biopsy or autopsy material.

Immunohistochemical assessment reveals the neural nature of the leptomeningeal infiltrate. Tumor cells label for S-100 protein, OLIG2 (see Fig. 43.102B), and SYN (see Fig. 43.102C) in upwards of 70% of cases.[346,701,702] GFAP expression characterizes less than 50% of these lesions and is often focal, limited NeuN and NFP labeling have only occasionally been reported,[702] and reactivity for EMA or IDH1 R132H mutant protein is not seen. MIB-1/Ki-67 labeling indices vary greatly, ranging from <1% to 30%, with a median of 1.5% in the largest series on record.[346] Genetic studies have demonstrated BRAF-KIAA1549 fusion[703] and chromosome 1p deletion,[346,701,704] to be common and frequently concurrent events in this setting, occurring in 75% and 59% of cases, respectively, in a recent study.[704] Chromosome 1p/19q co-deletion is far less prevalent, one co-deleted example reportedly demonstrating the oligodendroglioma-associated t(1p; 19q) (q10; p10) translocation on fluorescence in situ hybridization (FISH) study.[705] *BRAF* V600E mutations have not been detected to date.[704]

Diffuse leptomeningeal glioneuronal tumors are often protracted in their clinical evolution and may exhibit stabilization of disease or only slow progression over many years but are associated with significant morbidity and mortality. In the largest reported series,[346] nearly 40% of patients succumbed to disease 3 months to 21 (median = 3) years from diagnosis. Eight of 24 patients with follow-up data lived longer than 10 years with disease. Decreased overall survival in this series was associated with initial biopsies manifesting any mitotic activity, glomeruloid MVP, or MIB-1/Ki-67 labeling indices of 4% or higher. Anaplastic progression with radiological evidence of peritoneal metastases that may have complicated ventriculoperitoneal shunting has been described.[703]

Multinodular and Vacuolating Neuronal Tumor

Whether the recently delineated multinodular and vacuolating neuronal tumor (MVNT), a rare entity, represents an indolent neoplasm, hamartoma, or focal expression of developmentally dysregulated neuronal migration and maturation is unclear. Most recorded cases have affected young to middle-aged adults and have been associated with seizures or seizure equivalents.[706-709] All were cerebral hemispheric and relatively superficial in location, an excess involving the temporal lobes. Particularly suggestive on MRI is the demonstration of small T2- and FLAIR-hyperintense nodules clustered in the digitate white matter and deep cortex. These may coalesce to form lesions several centimeters in size, but there is usually no evidence of associated contrast enhancement, edema, or mass effect. On histologic inspection, the tumor nodules have a variably spongy appearance reflecting vacuolar changes in their neuropil-like matrix and in the bodies of their constituent cells (Fig. 43.103). The latter vary considerably in their dimensions, potentially approaching ganglion cell–like proportions, but most often resemble mid-sized neurons with amphophilic cytoplasm, vesicular nuclei, and distinct nucleoli. Cytologic monomorphism is the rule. Mitotic activity is not seen. An associated astrogliosis is common and apparent disorganization ("dysplasia/microdysgenesis") of the native cortical architecture may be encountered.

MVNTs are characterized by an immature neuronal immunophenotype.[706-709] While GFAP-negative and invariably expressing HuC/HuD and OLIG2, antigens associated with early neuronal lineage

For personal use only. No other uses without permission. Copyright ©2017. Elsevier Inc. All rights reserved.

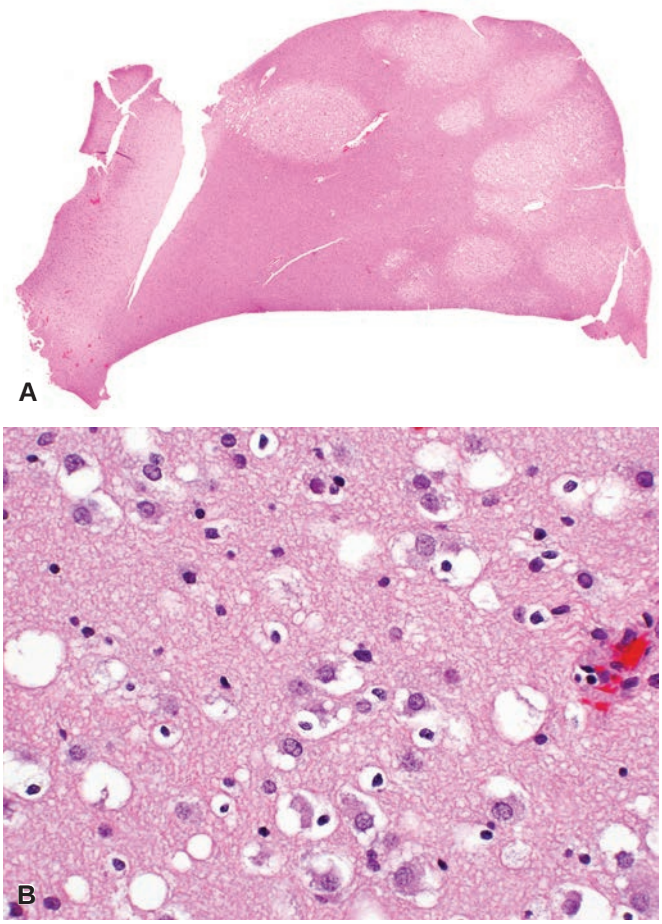

Figure 43.103 Multinodular and vacuolating neuronal tumor with pale nodules **(A)** composed of variably vacuolated neuronal cells **(B)**.

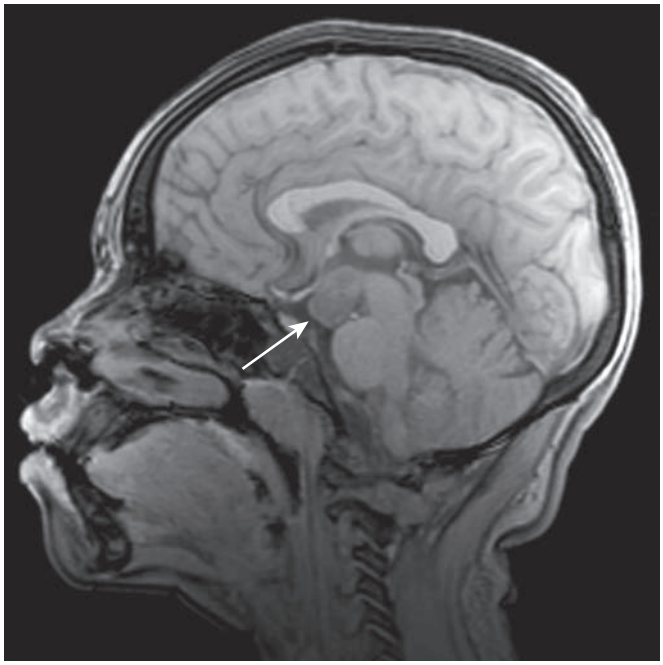

Figure 43.104 Hypothalamic Hamartoma. T1-weighted magnetic resonance image showing sessile hypothalamic mass *(arrow)*.

commitment and differentiation, tumor cells generally fail to label for markers of more advanced neuronal maturation such as NFPs and NeuN. They are chromogranin negative as well. Cytoplasmic SYN labeling is commonly seen but may be faint or undetectable, and the neuropil-like matrix usually manifests a granular reactivity that is much weaker than that of normal cortex. MIB-1/Ki-67 labeling activity is negligible. It is curious that, given their tendency to present in adult life, many MVNTs are associated with ramified, CD34-expressing neural elements in adjoining cortical tissues, which we have previously mentioned in connection with pleomorphic xanthoastrocytoma and ganglioglioma (both more prevalent in the pediatric cohort); this feature has been taken as indicative of local dysontogenesis. In contrast to these entities and to various other glioneuronal neoplasms associated with epilepsy in the young, however, the MVNTs studied to date have not shown evidence of *BRAF* V600E mutation on immunohistochemical[708] or formal molecular profiling,[706,707,709] nor have isolated assessments for BRAF-KIAA1599 or SLC44A1-PRKCA fusions been revealing.[709] In a similar vein, IDH mutations do not play a role in their pathogenesis.[706-709] Whatever the exact nature of the MVNT, it is benign. Simple excision would appear to suffice for control.

Hypothalamic Neuronal Hamartoma

Hypothalamic neuronal hamartomas are usefully subdivided into two basic clinicoanatomic groups.[710] "Parahypothalamic" variants—pedunculated lesions that bulge into the suprasellar cistern from attachments to the tuber cinereum or mammillary bodies—are principally associated with precocious puberty in boys. This may reflect the ectopic secretion of gonadotropic releasing factors by neurons populating hamartomas of this class.[711,712] "Intrahypothalamic" subtypes—sessile growths broadly anchored to the tissues lining the third ventricle—characteristically produce fits of pathologic laughter (known as gelastic seizures) that begin in infancy (Fig. 43.104). The development of more generalized, refractory epileptic syndromes, progressive cognitive impairment, and psychiatric disturbances often complicate lesions of the latter type as well.

Most hypothalamic neuronal hamartomas measure no more than 1–2 cm in maximum dimension, though giant examples may be encountered. Variably sized neurons are the dominant cell population, and these are embedded in a uniformly SYN-positive matrix that is generally indistinguishable from native neuropil and traversed in some cases by bundled axons of myelinated or nonmyelinated type. While large ganglion cell–like elements may be present, small- to mid-sized neuronal forms dominate most lesions (Fig. 43.105).[713] These are given to anomalous nodular clustering. Some cases manifest a gliotic appearance, but astrocytes and oligodendroglia are only minor cellular constituents.

Although most hypothalamic hamartomas present in isolated and sporadic fashion, the association of such lesions with a variety of malformative syndromes has been documented. Chief among the latter is the Pallister–Hall syndrome, linked in its autosomal dominant form to germline *GLI3* gene mutations and characterized by a complex of anomalies that includes imperforate anus, cryptorchidism, polydactyly, pituitary aplasia, hypoplasia of the adrenal and thyroid glands, and various cardiac and renal anomalies.[714,715] In affected infants, the hypothalamic lesion may contain small, immature-appearing neuroepithelial elements and has consequentially been termed a "**hypothalamic hamartoblastoma**,"[714] but the incompletely differentiated profiles of these cells (which may also populate nonsyndromic hamartomas) probably just reflect the very young age of the patients from whom they derive. Resection specimens

For personal use only. No other uses without permission. Copyright ©2017. Elsevier Inc. All rights reserved.

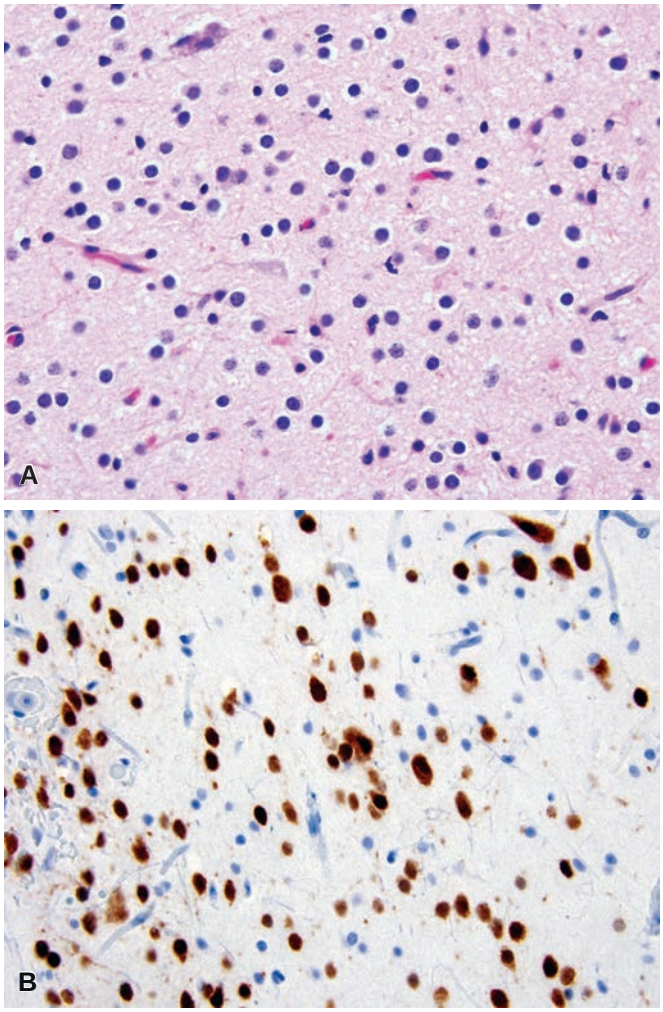

Figure 43.105 Hypothalamic Hamartoma. A, This example was composed of mildly disorganized gray matter composed predominantly of small neurocytic or oligodendrocyte-like neurons. **B,** Their neuronal lineage was confirmed on a Neu-N immunostain.

from affected individuals surviving infancy exhibit more mature neuronal features.[716]

Glioneuronal Hamartomas, Cortical Dysplasias, and Other Epileptogenic Lesions

A number of published series and reviews are recommended to readers interested in the various non-neoplastic lesions associated with refractory seizure disorders that compel neurosurgical intervention.[717-720] Inasmuch as operative approaches to this problem are practiced mainly in specialized referral centers and rarely engage the general surgical pathologist, we specifically consider here only one "tumoral" cause of pharmacoresistant epilepsy not addressed elsewhere in this text, the glioneuronal hamartoma.

Glioneuronal hamartomas figure with special prominence in surgical series addressing chronic temporal lobe epilepsy[717,718] but occur throughout the cerebral hemispheres[719] and may present as intraventricular growths.[721,722] Ranging from microscopic lesions to expansile gray nodules that may be grossly evident on evaluation of lobectomy specimens and visualized by neuroradiographic means, these are sometimes multifocal, are often associated with other features of faulty development (such as patchy cortical dysgenesis and neuronal ectopias in the temporal white matter), and may occur in complex with low-grade neuroepithelial neoplasms of varied type. Whether they serve as the progenitors of select gliomas, gangliogliomas, or DNTs (the more commonly associated lesions) is open to question. As noted previously, gangliogliomas do often share with these dysgenetic lesions expression of CD34, restricted in the developed human CNS to endothelial cells, but displayed by neural progenitors in some species.[723] Populated, in most cases rather sparsely, by neurons of medium to large size and admixed astrocytes that may exhibit hyperplastic features, glioneuronal hamartomas do not evidence the cellularity, pleomorphism, or conspicuous inflammatory infiltration of the bona fide ganglioglioma, nor do they manifest alveolar patterning or the myxoid alterations characteristic of the DNT. Similar to the latter, some glioneuronal hamartomas harbor oligodendrocyte-like clear cell elements (nodular aggregates that constitute microscopic hamartomas or "hamartias" commonly encountered in temporal lobectomies performed for epilepsy control),[717,718] but these are a minor component and further deviate from DNT in evidencing no special relationship to regional axons or the stromal vasculature. Hamartomas composed predominantly or exclusively of astrocytic forms can also be seen.[724] Spongiform change may be apparent within the lesion and can involve associated cortex in patchy fashion, this possibly representing a seizure-induced tissue disturbance. Finally, select variants contain dysmorphic cells of neuronal, astrocytic, or indeterminate lineage resembling those of the cortical tuber (the tuberous sclerosis complex is discussed in relation to subependymal giant cell astrocytomas). These include cells exhibiting a characteristically "ballooned" appearance of their glassy, eosinophilic cell bodies. Such cells are also the hallmark of a form of **focal cortical dysplasia** (**focal cortical dysplasia, type IIb** in the classification of the International League Against Epilepsy[719]) that is strongly associated with refractory seizures in childhood and that appears to represent a disorder of neuronal migration and differentiation.

Dysplastic Gangliocytoma of the Cerebellum (Lhermitte–Duclos Disease)

The **dysplastic gangliocytoma of the cerebellum**, also known by the eponymous **Lhermitte–Duclos disease**, principally affects adults in the third through fifth decades of life and usually comes to attention on evaluation for signs of cerebellar dysfunction, such as progressive ataxia and dysmetria or symptoms of intracranial hypertension reflecting mass effect on the fourth ventricle.[278] A "tiger-striped" alteration of the cerebellar cortex, produced by regionally thickened and abnormally T2-bright cerebellar folia without associated contrast enhancement, is virtually diagnostic on MRI assessment (Fig. 43.106). The histologic substrate of this curious disorder is variable replacement of the internal granule cell layer by an array of large neurons with attendant expansion and aberrant myelination of the overlying molecular layer (Fig. 43.107). The latter is prone to coarse spongy change and dystrophic microcalcification, often blood vessel–associated, while the subjacent folial white matter is thinned, if not cavitated. Neuronal elements are generally well differentiated in appearance, though some cases exhibit nuclear dysmorphism and hyperchromasia in scattered cellular elements.[725] Axons emanating from ganglionic constituents are oriented (relative to the pial surface) in parallel stacks within the deep molecular zone, and in perpendicular array more superficially. The orientation of these axons, their appearances in Golgi preparations,[726] and observed patterns of NFP expression on immunoassay[727] indicate that the abnormal neurons in this disorder are mainly outsized caricatures of the granule cells that they would seem to replace. Immunolabeling for the NeuN neuronal nuclear protein, foreign to Purkinje cells but a consistent

For personal use only. No other uses without permission. Copyright ©2017. Elsevier Inc. All rights reserved.

Figure 43.106 Dysplastic Gangliocytoma (Lhermitte–Duclos Disease). T2-weighted magnetic resonance imaging reveals the typical "tiger-stripe" pattern in the right cerebellar cortex.

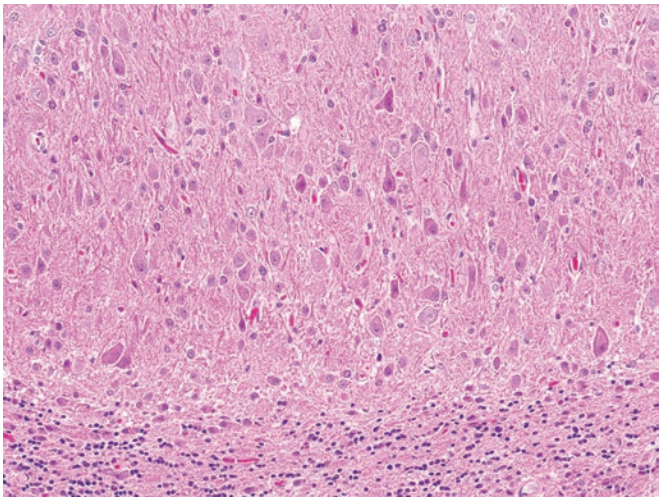

Figure 43.107 Dysplastic Gangliocytoma (Lhermitte–Duclos Disease). This resection specimen reveals replacement of the internal granular layer by large dysmorphic ganglion cells. Note scattered retained internal granular cell neurocytes in lower portion of figure.

feature of granule cell elements, further identifies these large neurons with the latter population.[333] Only minor subsets have been described as manifesting Purkinje cell–like attributes, including immunoexpression of Leu4, PEP-19, L7, and calbindin, as well as surface perikaryal labeling for such synaptic vesicle-associated antigens as SV2 and SYN.[728]

In adult-onset form, the dysplastic gangliocytoma of the cerebellum is now recognized as a lesion virtually pathognomonic of Cowden syndrome, occurring in nearly one-third of affected patients in one series.[729] An autosomal dominant phakomatosis linked to germline mutations of the *PTEN* gene on chromosome 10q23, this disease complex is chiefly characterized by multiple cutaneous tricholemmomas, oral papillomatosis, acral keratoses, macrocephaly/megalencephaly, gastrointestinal polyps of various types, thyroid abnormalities (principally goiter, but including follicular neoplasms), and a substantially increased risk of mammary adenocarcinoma (as well as benign fibroepithelial and papillomatous proliferations of the female breast). Germline mutations and variants of the succinate dehydrogenase B and D genes have been implicated in a similar, if not identical, syndrome.[730] Dysplastic cerebellar gangliocytomas presenting in the adult years regularly display inactivating *PTEN* mutations, irrespective of their association with other manifestations of Cowden syndrome, and underlying germline *PTEN* mutation has been consistently demonstrated in those affected patients studied to date.[731] Pediatric cases, by contrast, seem divorced from these associations.[731]

The linking of dysplastic cerebellar gangliocytomas in adulthood to *PTEN* mutation has done much to clarify the pathogenesis of this entity, which has been historically interpreted as a compensatory hypertrophy of internal granule cells in response to faulty development of the fetal external granular layer from which they derive, as a hamartomatous growth, or as a remarkably orchestrated neoplasm. *PTEN* acts as a regulator of cell size, survival, proliferation, and migration through its inhibitory influence on the phosphatidylinositol 3-kinase (PI3K)/AKT signaling cascade. Studies of both the human disease and murine "knockout" models[732] faithful to the former suggest that abrogated PTEN expression, with resulting activation of AKT and its downstream targets, suffices to produce the alterations characteristic of dysplastic cerebellar gangliocytomas in the absence of transforming events or cellular proliferation.[725,731] In fact, the enlarged internal granule cells persisting in these lesions represent in number a much reduced fraction of the normal populace, are amitotic, and are left unlabeled in MIB-1/Ki-67 preparations (though perivascular elements reasonably interpreted as reactive forms may exhibit immunopositivity).[725] The finding in some cases of what would appear to be granule cells aberrantly situated in the molecular layer attests to impaired migration, as well as compromised survival and dysregulated cell growth, in the evolution of this curious disorder.

Dysplastic gangliocytomas of the cerebellum behave in the manner of WHO grade I tumors, and gross total excision proves curative in most instances. Late local regrowth, however, complicates the course of some patients (particularly after macroscopically incomplete resection) and has been construed as evidence for the neoplastic nature of these lesions. Such "recurrences" may simply reflect the fact that internal granule cells in grossly normal folia remain at risk for gangliocytomatous change due to their *PTEN* mutant status. It is noteworthy that fully developed lesions are often bordered by cerebellar cortex exhibiting subtle enlargement of neurons in the superficial aspect of the internal granule cell layer,[725] a precursor abnormality not appreciable at operation. Given the germline nature of the genetic defect predisposing to dysplastic gangliocytomas, it should not be surprising that patients may develop (and can present with) multifocal cerebellar involvement.

Other Glioneuronal Neoplasms

As we have tried to make plain in the sections devoted to these entities, the neoplasms traditionally placed in the various glioma series can exhibit neuronal "marker" expression on immunohistochemical assessment and may on rare occasion show overt neuronal/neurocytic differentiation. The latter of these unanticipated phenomena merits acknowledging in surgical pathology reports but does not alter the basic classification of such tumors as astrocytic, oligodendroglial, or ependymal. In this connection, we refer readers

For personal use only. No other uses without permission. Copyright ©2017. Elsevier Inc. All rights reserved.

to our discussion of the infiltrating astrocytomas for consideration of the "glioneuronal tumor with neuropil-like islands" (essentially a diffuse, WHO grade II or III astrocytoma harboring micronodular loci of neurocytic differentiation) and "glioblastomas with primitive neuronal components." Oligodendrogliomas, ependymomas, and the odd choroid plexus papilloma containing neuronal populations in SYN-rich, neuropil-like matrices are all cited in our foregoing treatment of these tumor groups. The nosologic status of a recently reported, *BRAF* V600E-mutant neoplasm characterized by an admixture of pleomorphic xanthoastrocytoma-type elements and SYN-labeling cells of epithelioid appearance is unclear.[733]

Embryonal Tumors

Collectively described as "embryonal" are neoplasms sharing, in addition to a postulated derivation from primitive neuroepithelial precursors, a peak incidence in the early years of life and an aggressive clinical biology. Most such tumors are dominated by small, anaplastic cells apparently uncommitted to any particular cytogenetic pathway on conventional histologic assessment, but the capacity of these lesions to differentiate along neuronal, glial, and, on occasion, mesenchymal lines has long been recognized and is manifest in their considerable morphologic and immunophenotypic heterogeneity.

Controversy has long surrounded the nomenclature of these complex neoplasms. Their original designations were predicated on the notion that the histologic appearances of CNS tumors reflect the neoplastic transformation of specific cell types at recognizable stages of neuroembryogenesis.[734] Thus, medulloepithelioma was the name given to a tumor harboring structures resembling, and so presumed to originate from, the primitive medullary epithelium of the neural tube, whereas ependymoblastoma was used for an embryonal neoplasm seemingly committed to differentiation along ependymal lines alone, and so forth. However, the theoretical underpinnings of this scheme have been justly questioned, and an alternative, at least partially molecular-based approach has been adopted by the 2016 WHO scheme. In an attempt to be as precise as possible, the generic "PNET" designation has now been abandoned, although the new term of "embryonal neoplasm, NOS" remains an imprecise compromise for primitive neoplasms that are either not evaluated beyond basic histopathology or defy a more specific designation, even after genetic studies.[735] The remaining categories of medulloblastoma and its variants, atypical teratoid rhabdoid tumor, embryonal tumor with multilayered rosettes (C19MC altered), and CNS neuroblastoma/ganglioneuroblastoma are discussed here, whereas pineoblastoma is covered separately under pineal parenchymal neoplasms.

Medulloblastoma and Its Variants

The anatomic site defining cerebellar and dorsal brainstem tumors termed **medulloblastomas** are the most common of primitive neuroepithelial neoplasms arising in the CNS. They occur throughout life but are characterized by a peak incidence in children between 5 and 10 years of age.[278] Approximately 15%–25% of afflicted patients are beyond their teenage years[278,736,737]; adult-onset cases cluster in the third and fourth decades, and 65% are male. There are four major clinicopathologic and molecular subtypes (discussed later) that vary considerably, based in part on the three major age categories of infancy, childhood, and adolescence/adulthood (Table 43.2). At least 75% of childhood and nearly all infantile medulloblastomas arise in the cerebellar vermis, often expanding to fill the fourth ventricle and thus producing manifestations of obstructive hydrocephalus (lethargy, headache, and morning emesis) in addition to truncal ataxia and disturbed gait. The relative proportion of laterally positioned, hemispheric examples increases with age, with most examples seen in adolescent and young adult patients. In contrast, childhood medulloblastomas localized to the cerebellar peduncle, cerebellopontine angle, or dorsal brainstem are relatively tightly linked with the more favorable WNT subtype,[738-740] covered in greater detail later. Rare medulloblastomas interpreted as primary leptomeningeal growths have also been communicated.[741]

As visualized in CT and MR images, medulloblastomas are usually solid and contrast enhancing. Unlike ependymomas, which are the main differential diagnostic consideration in the fourth ventricular region, they are not prone to calcification and midline examples often appear to hang from the roof of this chamber rather than bulging upwards from its floor. Rare infantile examples corresponding to the extensively nodular variant adopt a grape-like or gyriform configuration based in the vermis or fourth ventricle.[742,743]

While usually sporadic, medulloblastomas are known to complicate certain heritable disorders (see Table 43.2).[278] **Type 2 Turcot syndrome**, an autosomal dominant condition, is defined by the occurrence of medulloblastoma in association with adenomatous polyposis of the colon and germline mutations of the *APC* gene (a negative regulator of the Wnt signaling pathway) on chromosome 5q21. A significantly increased risk of medulloblastoma also characterizes the **nevoid basal cell carcinoma**—or "**Gorlin**"—**syndrome**, an autosomal dominant complex caused by germline mutations of the *PTCH1* gene (chromosome 9q22.3) or less commonly, the *PTCH2* (1p34.1) or *SUFU* (10q24.32) genes, the latter of which is associated with roughly 20-fold increased risk of medulloblastoma over the roughly 2% incidence encountered with germline *PTCH1* mutations.[744] Among its many other manifestations are odontogenic keratocysts, dyskeratotic pitting of the palms and soles, craniomegaly and other skeletal anomalies, lamellar calcium deposition in the falx cerebri and diaphragma sellae, calcifying ovarian fibromas and multifocal basal cell carcinomas notable for their early age at onset, involvement of both sun-exposed and hidden skin, melanotic pigmentation, associated calcifications, and clinical indolence. As these genes are all involved in the Sonic Hedgehog (SHH) signaling pathway, it is not surprising that the majority of tumors are desmoplastic/nodular or extensively nodular SHH-activated medulloblastomas, primarily presenting during infancy. SHH-activated, *TP53*-mutant medulloblastomas arising in the setting of **germline *TP53* gene mutation** (including **Li–Fraumeni syndrome**), previously mentioned as predisposing to astrocytic neoplasms and other tumor types, are also known to complicate subtype D1 **Fanconi anemia**, caused by *BRCA2* (13q12.3) gene mutations (these also put patients at risk for the development of mammary carcinomas, Wilms tumors, and hematologic neoplasms), and may occur at increased frequency (along with oligodendrogliomas and meningiomas) in **Rubinstein–Taybi syndrome**. The latter, due to mutations in the *CREB*-binding protein gene on chromosome 16p13.3, is typified by congenital cognitive impairment, growth retardation, and microcephaly with abnormal facies and broad thumbs and toes. Also on record is the association of medulloblastoma with **Coffin–Siris syndrome** (the complex of mental retardation, postnatal growth impairment, joint laxity, and brachydactyly of the fifth digit with absence of the nailbed) and with germline mutations of a DNA repair protein–encoding gene, designated as *NBN* or *NBS1*, that has been implicated in the cancer predisposition **Nijmegen breakage syndrome**.[745]

Integrated/Molecular Medulloblastoma Diagnoses (Variants)

Suffice it to say for purposes of the present discussion that two main histologic variants are recognized, these being the "classic"

For personal use only. No other uses without permission. Copyright ©2017. Elsevier Inc. All rights reserved.

Table 43.2 Integrated medulloblastoma diagnoses in the 2016 WHO scheme

VARIANT/ SUBVARIANT	PEAK AGE	USUAL LOCALIZATION	HISTOLOGY	USUAL IMMUNOPROFILE	MOLECULAR FEATURES	PROGNOSIS
WNT-activated	Child to young adult	Dorsal BS, CPA, CBL peduncle	Classic	Nuclear β-catenin*	Monosomy 6, *CTNNB1* mutation	Good
SHH-activated and *TP53*-wildtype (infant)	Infant	Vermis	D/N or EN	GAB1+, YAP1+, limited p53	Germline or somatic *PTCH1* or *SUFU* mutations, LOH of 9q, 10q, and 14q	Good to average
SHH-activated and *TP53*-wildtype (adult)	Teen to young adult	Lateral CBL hemisphere	D/N, rare classic	GAB1+, YAP1+, limited p53	Somatic *PTCH1* or *SMO* mutations, LOH of 9q, 10q, and 14q	Average
SHH-activated and *TP53*-mutant	Child	Lateral CBL hemisphere or vermis	D/N, LC/A, rare classic	GAB1+, YAP1+, strong p53+	*PTCH1* or *SUFU* plus *TP53* (+/– germline) and *TERT* mutations, chromothripsis, gene amplifications	Poor
Non-WNT/ non-SHH (group 3)	Child	Vermis	Classic, LC/A	GAB1-, YAP1-	*MYC*-AMP, c-myc overexpression, i17q	Poor
Non-WNT/ non-SHH (group 4)	Child	Vermis	Classic, LC/A	GAB1-, YAP1-	i17q	Average

AMP, gene amplification; BS, brainstem; CBL, cerebellar; CPA, cerebellopontine angle; D/N, desmoplastic/nodular; EN, extensively nodular; LC/A, large cell/anaplastic.
*β-catenin is normally expressed in the cytoplasm of medulloblastomas, but nuclear translocation is relatively specific for WNT activation. Nevertheless, nuclear positivity may be very focal in some examples.

(Fig. 43.108A) and "desmoplastic/nodular" (Fig. 43.109A) subtypes as defined further later. Nevertheless, the WHO now recognizes clinicopathologically relevant molecular subtypes that, together with histology, form integrated diagnostic categories (similar to the approach for diffuse gliomas presented earlier). These are summarized in Table 43.2 and stem from transcriptome, methylome, and microRNA profiling studies showing that there are four major molecular categories (WNT, SHH, group 3, and group 4), with additional clinicopathologically relevant subdivisions within the SHH-activated medulloblastomas.[746-748] Recognizing that there remains great genetic overlap between groups 3 and 4, which also lack easily reproducible immunohistochemical surrogates for their detection, the WHO has also adopted the previously suggested terminology of non-WNT/non-SHH for these 2 subtypes combined.[749] With a diagnostic panel of 3 immunostains, one can now stratify these variants into **WNT-activated** (nuclear β-catenin and YAP1 positive; ~10%; see Fig. 43.108B), **SHH-activated** (cytoplasmic β-catenin, GAB1, and YAP1 positive; ~30%; see Fig. 43.109B), and **non-WNT/non-SHH** (cytoplasmic β-catenin, GAB1, and YAP1 negative; ~60%, with 20% group 3 and 40% group 4) medulloblastomas. By adding p53 as the fourth marker (see Fig. 43.109C), one can also detect the majority of the **SHH-activated and *TP53*-mutant** medulloblastomas with highly aggressive clinical behavior and an association with germline mutations in a subset (Li-Fraumeni syndrome); such cases typically display strong and widespread nuclear p53 positivity in addition to the GAB1 and YAP1 expression.[750-752] Additionally, there are mutational differences within the SHH group, associated with therapeutic implications, such that tumors with a *PTCH1* mutation are most likely to be responsive to Smoothened (SMO) inhibition, whereas tumors harboring a *SUFU* mutation or *MYCN* amplification are likely to be resistant.[753] Lastly, there are major prognostic differences, with the WNT-activated tumors being by far the most favorable (potentially curable with less aggressive/neurotoxic therapies), while the SHH-activated, *TP53*-mutant and the group 3 variants are the most lethal, potentially requiring more aggressive therapeutic strategies. Other unfavorable prognostic variables include individual genetic alterations (e.g. *MYC* amplification) and large cell/anaplastic variant histology, regardless of the underlying molecular subtype. Given that both histopathology (described in greater detail later) and molecular subtype provide independent prognostic information, the 2016 WHO recommendation is to include both within the integrated diagnosis line (e.g. medulloblastoma, *SHH*-activated and *TP53*–wildtype molecular variant, desmoplastic/nodular histology variant). As with the gliomas however, it is recognized that not everyone can provide a molecular characterization, and therefore there remains a fully sanctioned "medulloblastoma, NOS" diagnosis. As regards histogenesis, shared patterns of gene and antigen expression have been forwarded as evidence that the SHH-activated (mostly desmoplastic/nodular histology) medulloblastomas derive from elements of the fetal external granular layer (these migrate to the surface of the embryonic cerebellar cortex from the roof of the fourth ventricle and are the eventual source of internal granular neurons), while the WNT-activated medulloblastomas are thought to arise from precursor cells in the dorsal brainstem arising from the rhombic lip.[738]

For personal use only. No other uses without permission. Copyright ©2017. Elsevier Inc. All rights reserved.

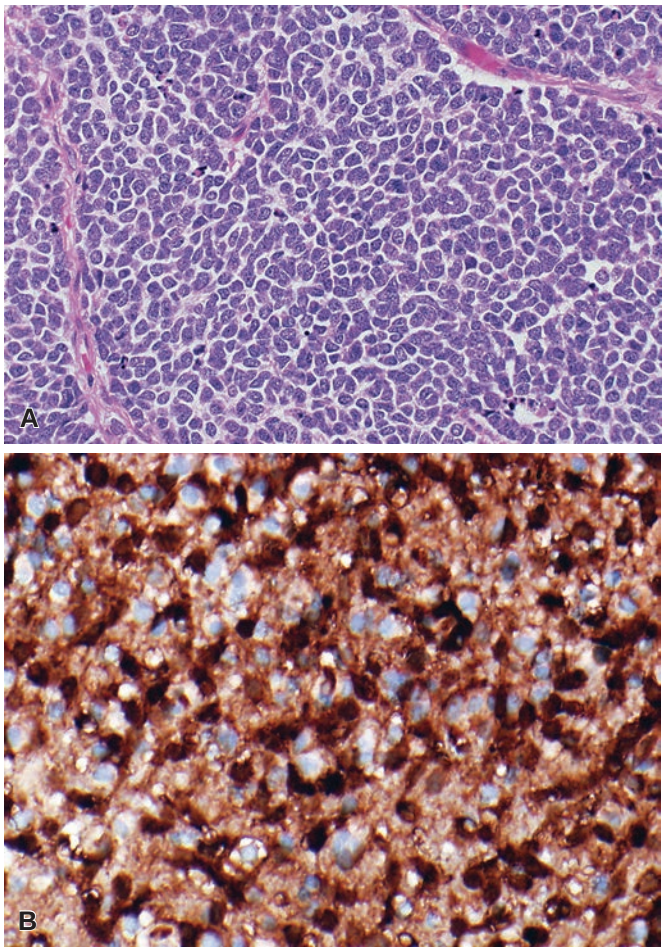

Figure 43.108 Medulloblastoma (Classic and WNT-Activated Subtypes). A, The classic medulloblastoma is a highly cellular neoplasm composed of diminutive, undifferentiated-looking elements possessed of little definable cytoplasm and prone to nuclear molding. **B,** A subset of classic medulloblastomas show evidence of WNT pathway activation, most often detected by the presence of nuclear β-catenin immunoreactivity.

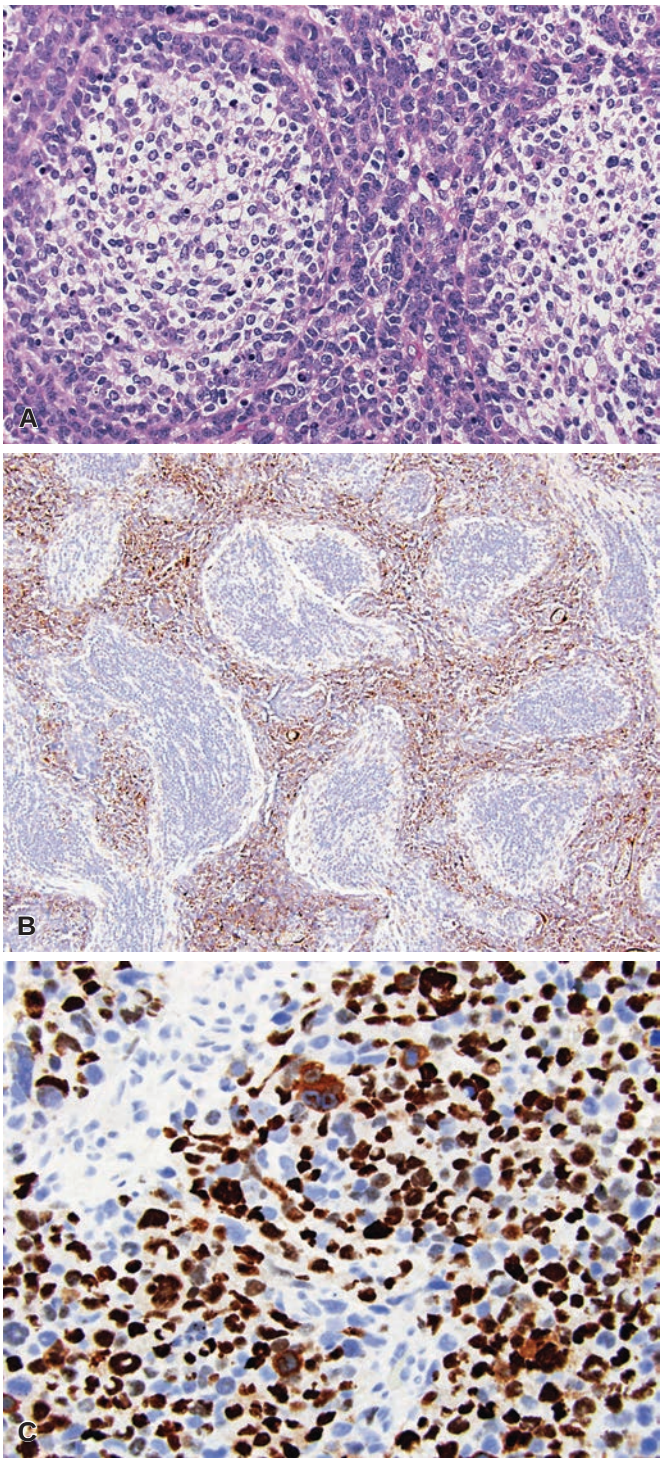

Figure 43.109 Medulloblastoma (Desmoplastic/Nodular and SHH-Activated Subtypes). A, Micronodular zones of reduced cellularity ("pale islands") are a striking feature of this medulloblastoma variant. **B,** Virtually all desmoplastic/nodular (and a smaller subset of classic) medulloblastomas show evidence of SHH pathway activation, including immunoreactivity to GAB1, often with strongest expression in the internodular regions. **C,** A poor prognosis subtype of SHH-activated medulloblastoma features p53 overexpression, often with superimposed anaplastic cytology.

Medulloblastoma Histopathology and Recognized Variants

Medulloblastomas are all classed as WHO grade IV neoplasms and are regarded collectively as potentially aggressive tumors requiring adjuvant treatment as well as surgical attack to prevent local recurrence and metastasis (particularly along CSF pathways). Although both classic and desmoplastic/nodular forms are unarguably capable of differentiating along glial, as well as neuronal, lines, it is the latter option that is far more frequently exercised. While overt ganglion cell maturation is exceptional, the overwhelming majority of medulloblastomas (including those of thoroughly undifferentiated histologic aspect) exhibit at least focal immunolabeling for SYN. Reliable indices of neuronal differentiation that can be appreciated at the light microscopic level include, in addition to the pale islands just described, Homer Wright rosettes, which are radial arrangements of tumor cell nuclei about small tangles of fibrillar material devoid of a centering lumen (Fig. 43.110). Ultrastructural studies have confirmed that the cores of such structures and the neuropil-like matrix of the pale island consist of neuritic cytoplasmic processes laden with microtubules in parallel array and joined by specialized

For personal use only. No other uses without permission. Copyright ©2017. Elsevier Inc. All rights reserved.

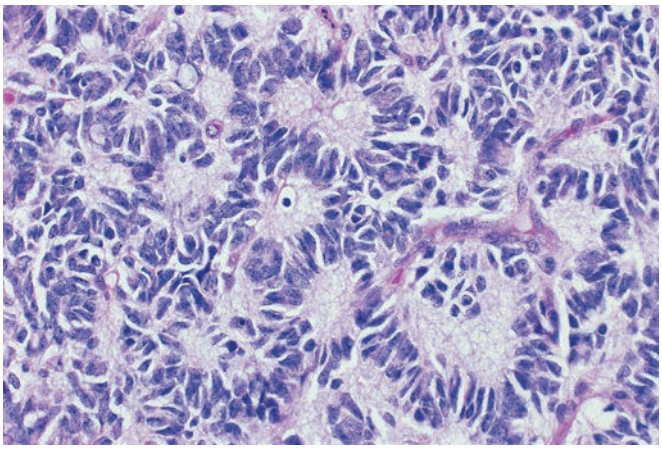

Figure 43.110 Medulloblastoma. Homer Wright rosettes consist of tumor cell nuclei disposed in circular fashion about tangled cytoplasmic processes. These structures are indicative of differentiation along neuronal lines.

adhesion plaques, features restricted in combination to embryonal neurons.[754] Furthermore, both the Homer Wright rosette and pale island constitute loci of concentrated immunoreactivity for SYN and other neuron-associated cytoplasmic antigens, including class III β-tubulin and microtubule-associated protein 2.[755] Pale islands also show upregulated immunoexpression of the TrkA and TrkC neurotrophin receptors.[756] Medulloblastomas may also contain populations immunoreactive for NFPs, as well as the Hu[334] and NeuN[358,756] neuronal nuclear antigens. Labeling for the latter reveals the oligodendrocyte-like elements of the pale island to be diminutive neuronal or "neurocytic" forms.

Classic medulloblastomas are often found on immunohistochemical assessment to be colonized by GFAP-positive elements lying near stromal blood vessels and displaying the stellate cytoplasmic configurations typical of reactive astroglia. These are generally taken to be entrapped, though the identification of similar cells in metastatic deposits raises the possibility that at least some represent neoplastic astrocytes of terminally differentiated nature.[278] GFAP-positive cells of indisputably neoplastic morphology are much less frequently encountered,[757] and glial differentiation sufficiently advanced as to be obvious on routine microscopic inspection is most exceptional. A conspicuous network of tumor cells having GFAP-reactive cytoplasmic rims and processes is often localized about the pale islands of desmoplastic/nodular medulloblastomas, suggesting that these micronodules are organized centers of divergent astroglial, as well as neuronal, outgrowth.[755] We mention in passing the immunolabeling of some medulloblastomas for photoreceptor-associated proteins, including rhodopsin and retinal S-antigen,[758] as well as curious variants containing neurosensory rosettes of Flexner–Wintersteiner type.[759] Shared by retinoblastomas and pineoblastomas, such evidence of photosensory differentiation has been taken to support the unified cytogenesis of these embryonal neoplasms, but this is an embattled hypothesis. The immunophenotypic potential of the medulloblastoma further includes reactivity for vimentin, desmin (typically limited to minor tumor cell subsets), nestin (a class VI intermediate filament protein expressed by many embryonic cell types, including neuroepithelial progenitors in the developing CNS), NCAMs, and nerve growth factors and their receptors.[278] Even cytoplasmic actin labeling has been described,[760] and exceptional cases may show cytokeratin (AE1/3) reactivity. The latter, when present, is usually a focal finding.

Regarding immunophenotype and its bearing on differential diagnosis, as previously emphasized, nearly all medulloblastomas (including those of thoroughly undifferentiated histologic aspect) label for SYN, a property that may be exploited to help exclude such potentially confounding lesions as the poorly differentiated fourth ventricular ependymoma, other anaplastic gliomas, and primary cerebellar lymphoma (typified by a B-cell profile). A pertinent "negative" is the general failure of medulloblastomas to express TTF-1,[474] as SYN-positive metastatic pulmonary small cell carcinoma potentially complicates the diagnostic picture when one is dealing with adult neurosurgical material. We have not encountered a solitary cerebellar metastasis as the presenting manifestation of an otherwise occult small cell carcinoma. The reader should consult the section dealing with AT/RTs for the differential diagnostic discussion of an embryonal neoplasm that often arises in the cerebellum and frequently harbors small cell components that may mimic the medulloblastoma to histologic perfection. Bona fide medulloblastomas do not exhibit anomalies of the rhabdoid tumor-associated *SMARCB1* gene or loss of its protein product on immunoexpression study with the INI1 antibody.[278]

We have elected to cite here only a small sample of the many studies detailing the immunohistochemical profile of medulloblastomas and make no attempt to dissect the conflicting (and, at present, clinically immaterial) data that have emerged from efforts to correlate the expression of neuronal, glial, and photosensory antigens with tumor behavior.[757,761,762] As highlighted previously, the integrated molecular diagnoses have essentially replaced these considerations, and provide a much more reliable scheme for clinical stratification.

Classic medulloblastomas are solid masses of friable, gray–white tissue composed, at their most primitive, of small, ostensibly undifferentiated cells closely arrayed in packed sheets (see Fig. 43.108). Nuclei are often densely hyperchromatic, round or angulated, invested with little or no definable cytoplasm (high nuclear to cytoplasmic [N/C] ratio), and prone to deformation ("molding") by their neighbors. A swirling or fascicular architecture may be encountered, as may nuclei disposed in tight perivascular pseudorosettes or regimented in compact, rhythmic palisades. Stromal elements are typically scant, consisting of small blood vessels that only exceptionally exhibit proliferative changes (only rarely comparable to the glomeruloid alterations characteristic of high-grade gliomas). Mitotic figures may abound, MIB-1 (Ki-67) labeling indices often exceeding 50%, but most medulloblastomas exhibit surprisingly little in the way of geographic necrosis. When present, however, necrotic zones may rarely be rimmed by palisading tumor cells in glioblastoma-like fashion. Patterns of local spread commonly evident in neurosurgical material include diffuse permeation of adjoining neuroparenchyma, arresting subpial accumulations of neoplastic cells that invite comparison to a persistent fetal external granular layer and extension into the subarachnoid compartment, with reinvasion of the underlying cerebellar cortex along a broad front or via penetrating perivascular Virchow–Robin spaces. Contact with the pia-arachnoid may incite considerable fibroplasia, in florid cases forcing tumor cells into single file, trabecular or even storiform arrays. Homer Wright (also known as neuroblastic) rosettes are a common, though not invariable feature of classic medulloblastomas. Rare examples feature pale nodules with neurocytic differentiation, but otherwise lack the reticulin-rich intercellular regions of desmoplastic/nodular medulloblastomas (see later); some have referred to such cases as being "biphasic,"[763] and they typically correspond to non-WNT/non-SHH (group 3 or 4) medulloblastomas molecularly. At the opposite end but similarly a diagnostic pitfall, some classic medulloblastomas show increased intercellular reticulin deposition within foci of leptomeningeal invasion, but otherwise lack the nodularity of desmoplastic/nodular medulloblastomas. It is of note that all WNT-activated medulloblastomas are the classic variant histologically, but classic

For personal use only. No other uses without permission. Copyright ©2017. Elsevier Inc. All rights reserved.

medulloblastomas are also encountered in all of the other molecular variants, such that further testing is needed before an integrated diagnosis is rendered. That said, a childhood onset medulloblastoma involving the dorsal brainstem, cerebellopontine angle, and/or cerebellar peduncle has a high likelihood of being the WNT-activated subtype.

Desmoplastic/nodular medulloblastomas commonly occupy the vermis in infantile examples but are otherwise over-represented among laterally situated, cerebellar hemispheric tumors occurring particularly among older children and adults. At operation, these neoplasms may seem meningeal based and are often lobulated, sharply demarcated, and firm, owing to the associated deposition of reticulin and collagen for which they are named. Desmoplastic/nodular medulloblastomas, however, feature characteristic "pale islands" with micronodular, reticulin-free zones that lend to many a low magnification appearance likened to follicular lymphoid hyperplasia, surrounded by reticulin-rich intercellular regions composed of more primitive appearing cells (see Fig. 43.109). Characterized by reduced cellularity, a rarefied fibrillar matrix, the emergence of an oligodendrocyte-like (but, in fact, neurocytic) populace, and downregulated BCL2 expression with increased apoptosis and a sharp decline in mitotic activity and MIB-1 (Ki-67) immunolabeling, the pale island is not merely free of connective tissues but represents a locus of progressive neuronal maturation and potential glial differentiation (as further addressed later). In recognition of this defining phenomenon (and to avoid confusion with collagenized medulloblastomas of otherwise classic appearance), the WHO specifically endorses the designation of these tumors as "desmoplastic/nodular." The lack of Homer Wright rosettes in most cases also helps distinguish this from the classic subtype. Using the strict diagnostic criteria outlined previously, all desmoplastic/nodular medulloblastomas fall into the SHH-activated molecular group.

Advanced neurocytic maturation also characterizes the rare tumors previously referred to as "**cerebellar neuroblastomas**" or "**neuroblastic medulloblastomas**," but now termed "**medulloblastomas with extensive nodularity**."[278,742] In essence, these are exaggerated forms of the desmoplastic/nodular medulloblastoma, exhibiting an even more strikingly lobular microarchitecture, with outsized reticulin-free zones having unusually elongated profiles, being particularly rich in SYN-immunoreactive fibrillary matrix material and boasting a population of small, amitotic, and uniformly rounded neurocytic cells arrayed in linear streams (Fig. 43.111). In contrast, the reticulin-rich intercellular zones with primitive cells are markedly reduced in comparison to conventional desmoplastic/nodular medulloblastomas. The differentiated neuronal nature of this population is apparent in that such cells elaborate cytoplasmic processes replete with clear and dense-cored secretory vesicles that may terminate in synaptic contacts. Some examples contain recognizable neurons of intermediate to large size, and this embryonal neoplasm may rarely undergo sequential maturation to ganglioneurocytic or gangliogliomatous histology,[764,765] a phenomenon (possibly treatment driven) recorded in isolated cases of conventional medulloblastoma as well.[766] Medulloblastomas of this sort seem to have a predilection for children younger than 3 years of age and to carry a more favorable prognosis than other subtypes (particularly in this age group).[742,767] Though not all such tumors comply, neuroradiological presentation as a cerebellar mass composed of contrast-enhancing nodules clustered in grape-like fashion is virtually diagnostic.[768] In common with their related desmoplastic/nodular medulloblastomas of infancy, this subtype is uniformly SHH activated.

Particularly aggressive behavior and treatment resistance characterize "**large cell**" and "**anaplastic**" **medulloblastomas** (Fig. 43.112).[769-771] The former descriptor has been applied to neoplasms conspicuously or wholly populated by monomorphic cells with large, rounded and vesicular nuclei, prominent nucleoli, and variably abundant eosinophilic cytoplasm. "Anaplastic" tumors exhibit marked variation in nuclear size and contour, multinucleated and bizarre giant cells inhabiting some examples. The cannibalistic wrapping of tumor cells about one another is a striking feature of many cases. In fact, the considerable cytologic overlap evidenced by neoplasms manifesting these alterations has prompted their consideration as a combined category of **large cell/anaplastic medulloblastoma** in the 2016 WHO. High mitotic rates are the rule and apoptotic cellular remains, typically abundant, may form confluent lakes and serpiginous seams. Cytoplasmic immunolabeling for SYN is generally retained (often in dot-like paranuclear form), and reactivity for NFPs and chromogranin may also be demonstrable. Focal GFAP expression has been documented but is uncommon. Of differential diagnostic utility are the observations that large cell/anaplastic medulloblastomas do not manifest the fibrillar to globose eosinophilic paranuclear inclusions, EMA immunoreactivity, chromosome 22 abnormalities, or loss of INI1 protein expression characteristic of the AT/RT.[278] Large cell/anaplastic features may be apparent at presentation or appear only at relapse, are often encountered in medulloblastomas that retain classic or desmoplastic/nodular components, and can emerge within

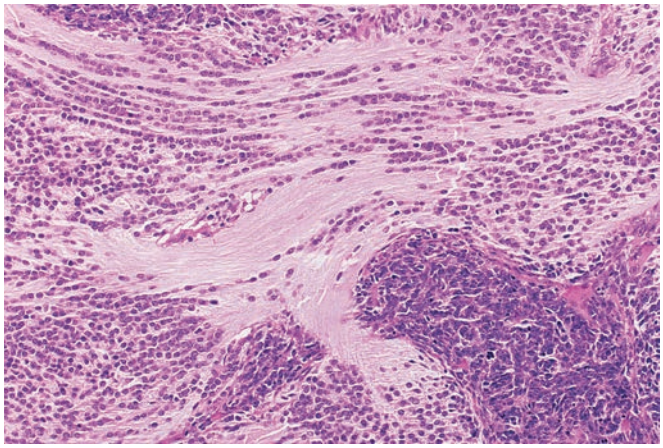

Figure 43.111 Medulloblastoma With Extensive Nodularity. This variant of medulloblastoma is typified by the linear streaming of rounded, "neurocytic" tumor cell nuclei within amassed cytoplasmic processes.

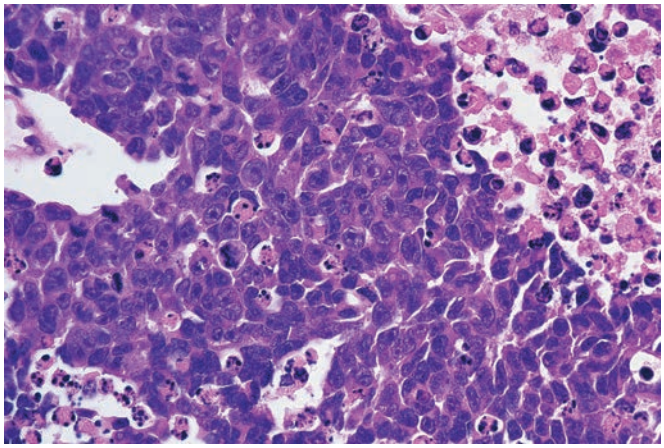

Figure 43.112 Large Cell/Anaplastic Medulloblastoma. Cellular enlargement, often prominent nucleoli, and pronounced mitotic and apoptotic activity are features of this virulent medulloblastoma subtype.

For personal use only. No other uses without permission. Copyright ©2017. Elsevier Inc. All rights reserved.

medulloblastomas with myogenic and/or melanotic differentiation (discussed later).[772,773] These observations, coupled with the demonstration that tumors characterized by large cell or anaplastic morphology may share "background" genetic profiles (e.g. isochromosome 17q formation) with conventional medulloblastomas while harboring many additional genomic aberrations,[746,774] indicate that the representatives of this group can be regarded not as fundamentally distinct medulloblastoma subtypes but as variants exhibiting progression-associated phenomena. Of further support for this notion, large cell/anaplastic medulloblastomas are encountered within all of the molecular classes, albeit with some over-representation in the unfavorable group 3 (non-WNT/non-SHH) subtype. *MYC* oncogene amplifications, previously mentioned as an adverse prognostic indicator, are also especially prevalent in this setting.[775,776]

The virulent clinical biology of large cell/anaplastic medulloblastomas has been acknowledged by some cooperative clinical trial groups in their categorizing of affected patients as "high risk" irrespective of age at presentation, extent of disease, and completeness of resection. In this vein, we mention that the formal grading of medulloblastomas according to the extent and severity of anaplastic alterations has proven clinically relevant and is becoming standard practice.[771] Given that cell size, pleomorphism, mitotic and apoptotic activity constitute continuous variables when medulloblastomas are considered as a class and that reproducible morphologic criteria for identifying such tumors are difficult to define, the WHO nonetheless stresses in their definition that the anaplasia or large cell phenotypes should be "severe" and represented across the majority of the tumor.

Certain rare medulloblastoma patterns merit additional comment. The **melanotic medulloblastoma** or **medulloblastoma with melanotic differentiation** (in suggested WHO parlance[278]) is defined by its content of pigmented cells disposed in tubules, papillae, or nests.[773,777,778] These are stained by conventional histochemical methods for the demonstration of melanin, can be shown to contain melanosomes in varying stages of maturation, label for HMB-45 as well as cytokeratins (AE1/3), and may reflect differentiation along the lines of the retinal pigmented epithelium. Although this lesion bears some histologic resemblance to the indolent melanotic neuroectodermal tumors of infancy that arise in the maxillary and epididymal regions, it is a highly malignant neoplasm prone to early and widespread neuraxis dissemination along CSF pathways. The **medullomyoblastoma** or **medulloblastoma with myogenic differentiation** (the latter being the sanctioned WHO term) is named for its heterologous rhabdomyoblastic elements.[772,779] Medulloblastomas of classic, desmoplastic/nodular, and large cell/anaplastic types may all spawn such components.[772] This curious entity has been variously interpreted as a medulloblastoma evidencing the extreme plasticity of its multipotent neuroepithelial precursors, as a tumor derived from neural crest (ectomesenchymal) progenitors recognized for their ability to differentiate along striated muscle lines, as a composite neoplasm populated by myoblastic constituents that arise via the secondary neoplastic induction of leptomeningeal or stromal elements, and, finally, as a lopsided, bidermal teratoma. Several examples reported under this designation have harbored cystic components with the appearance of mature, tridermal teratoma.[779] Some medullomyoblastomas have been found to harbor an isochromosome 17q, indicating a kinship with the conventional medulloblastoma group.[772] Variants containing both muscular and melanotic elements have also been described,[773] as has **medulloblastoma with chondroid differentiation**,[780] and a cerebellar tumor exhibiting evidence of isochromosome 17q formation and having medulloblastoma-type, ganglion cell, astrocytic, ependymal, cartilaginous, muscular, and glandular components.[781] A group of adult-onset tumors originally characterized as "**lipomatous medulloblastomas**" is now recognized to be more closely allied with neoplasms of neurocytic type. These are termed **cerebellar liponeurocytomas** (see Fig. 43.96) in current WHO nomenclature and are discussed elsewhere under that designation (see "Central neurocytoma and extraventricular neurocytic neoplasms"). Conventional medulloblastomas may rarely contain lipid-laden cells in conspicuous numbers, these usually proving to be foamy macrophages[649] but potentially representing lipidized tumor cells with adipocyte-like or lipoblastic profiles.[654]

Clinical Variables

At present, the therapeutic approach to medulloblastomas is predicated on clinical variables in addition to the integrated histologic and molecular diagnostic category.[278] The "standard risk" patient is generally defined as a subject 3 years of age or older who has undergone complete (or near-total) resection of a tumor confined to the posterior fossa. Protocols combining chemotherapy and whole neuraxis irradiation have achieved 5-year survivals exceeding 80% in this relatively favorable clinical setting, and very few such patients experiencing late relapse. Children below the age of 3 years at diagnosis and individuals of any age with evident CSF dissemination (found in ~30% of cases on initial evaluation), extraneural metastases or bulky (>1.5 cm^2) residual disease after surgery—"high-risk" patients—do not fare as well. Whether the excess mortality noted in the very young reflects intrinsic tumor biology or the reluctance of neuro-oncologists to expose the immature nervous system to the predictably toxic doses of radiation that have been considered requisite to achieving disease control is unclear. Certainly, the price exacted of childhood medulloblastoma survivors by conventional radiotherapy—growth failure, endocrinopathy, significant intellectual impairment, behavioral disturbances, and the induction of secondary neoplasms that include meningiomas, sarcomas, and glioblastomas—has been disheartening and continues to drive investigations aimed at reducing CNS radiation exposure in the pediatric cohort. In this connection, there is evidence to suggest that infants and young children with medulloblastomas of desmoplastic/nodular and extensively nodular type may be spared irradiation and managed with chemotherapy alone following tumor resection.[278] Whereas treatment failure in the posterior fossa or along the craniospinal axis is the rule, medulloblastomas do occasionally travel to more distant sites.[782] Skeletal deposits, often widespread, account for over 90% of systemic metastases, but the liver, lymph nodes, and lungs may be involved, as may the abdominal cavity (via ventriculoperitoneal shunts placed to relieve obstructive hydrocephalus). While medulloblastomas usually conform to the principle (Collins' law) that defines the period of risk for recurrence of embryonal childhood neoplasms as equal to the patient's age at diagnosis plus 9 months, late relapse (including extraneural dissemination) may also be encountered.

Embryonal Tumor With Multilayered Rosettes

This newly sanctioned WHO entity of **embryonal tumor with multilayered rosettes, C19MC-altered** includes most of the cases previously designated as either **embryonal tumor with abundant neuropil and true rosettes** (Fig. 43.113A) or **ependymoblastoma,** as well as subsets of tumors previously classified as either **medulloepithelioma** or "primitive neuroectodermal tumor" with atypical features or divergent differentiation.[278,783,784] Defined by the presence of an amplicon containing a microRNA cluster on chromosome 19, typically in association with LIN28 immunoreactivity (see Fig. 43.113B), cases with classic histology but not undergoing molecular analysis may be designated as **embryonal tumor with multilayered rosettes, NOS.** This highly aggressive lesion of infancy and early childhood has proven more prevalent than previously suspected, accounting for up

For personal use only. No other uses without permission. Copyright ©2017. Elsevier Inc. All rights reserved.

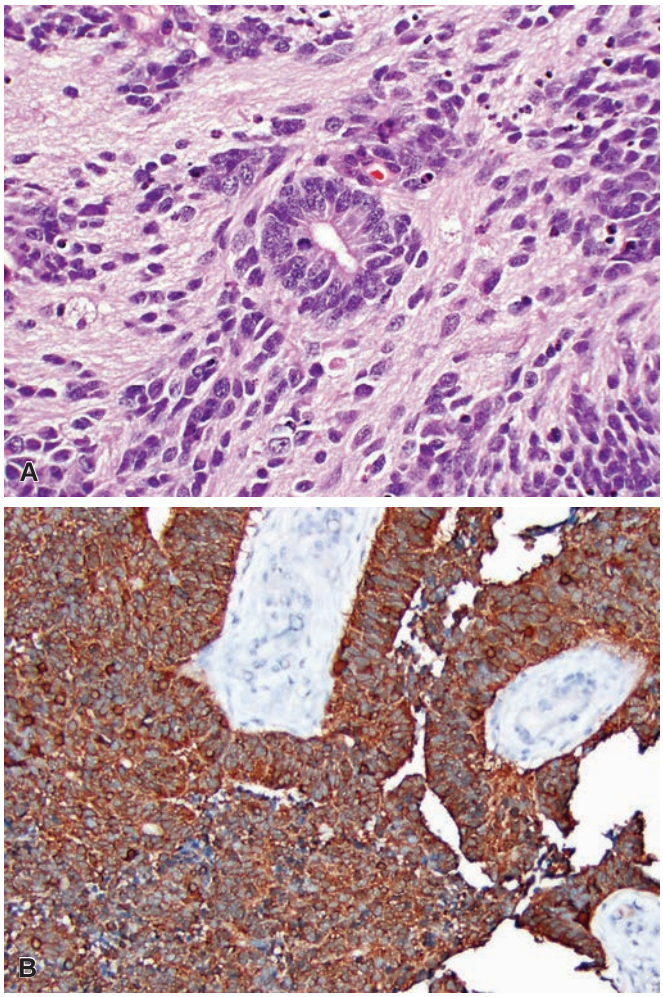

Figure 43.113 Embryonal Tumor With Multilayered Rosettes. A, Typical of the subtype with abundant neuropil and true rosettes is a delicate fibrillar matrix in which primitive neuroepithelial elements and ependymoblastic rosettes *(center)* are arrayed, the latter having well-defined (though often minute) lumens and being composed of mitotically active tumor cells with granular apical stippling. **B,** Immunoreactivity for LIN28 is diagnostically useful, regardless of whether the tumor resembles embryonal tumor with abundant neuropil and true rosettes, ependymoblastoma, or medulloepithelioma.

to a third of all supratentorial primitive neuroectodermal tumors in some series[355] and an even greater fraction of those arising in infants under 4 years of age (the median age in one large series being 29 months[784]). There is a strong predilection for the cerebral hemispheres, although roughly a fourth occur in extra-cerebral sites. In contrast to other CNS neoplasms of embryonal type, this embryonal tumor often displays little to no contrast enhancement on neuroradiological study. The entity often combines features of "ependymoblastoma" and "neuroblastoma" with the embedding of ependymoblastic rosettes in an expansive matrix that is rich in SYN and NFP on immunohistochemical assessment and that commonly exhibits broad zones of strikingly hypocellular neuronal tissue (see Fig. 43.113A). Also populating tumors of this group are undifferentiated and neuroblastic elements, which may form Homer Wright rosettes, and some examples containing ganglion cell components or manifest loci of neurocytic maturation in which tumor cells align in linear streams or aggregate in formations resembling the "pale islands" of the desmoplastic/nodular medulloblastoma. Regions exhibiting large cell/anaplastic medulloblastoma-like histology may be encountered as well. Ependymoblastic rosettes are represented by mitotically active elements in radial, pseudostratified array about central lumens of rounded profile and often diminutive diameter. The juxtaluminal apices of participating cells typically manifest a granular stippling and are joined, at the ultrastructural level, by zonula adherens–type intercellular junctions. MIB-1 labeling activity is high in these formations and in poorly differentiated, nonrosetted components. It should be noted, however, that this feature alone is not specific for this diagnostic entity and is occasionally encountered in other embryonal neoplasms such as AT/RT.[785] High-level genomic amplification at chromosome 19q13.42 (with upregulation of a microRNA cluster including oncomirs miRNA-372 and miRNA-373) is a defining molecular feature, although strong, (albeit often patchy) immunoreactivity for LIN28 serves as a useful and highly sensitive, but not specific, surrogate immunohistochemical marker, although subsets of medulloblastomas, AT/RTs, and high-grade astrocytic or ependymal gliomas can also express this marker.[783,784,786]

The embryonal tumor with multilayered rosettes is a virulent neoplasm that often proves resistant to surgical and adjuvant therapy. In the largest series yet published, 36 of 54 evaluable patients died of progressive disease, with median survival times from diagnosis a mere 13 months with therapy and less than 1 month without therapy.[784] Local failure is the rule, and leptomeningeal dissemination further complicates some cases.

Medulloepithelioma

The **medulloepithelioma**, when not accompanied by C19MC amplification and LIN28 positivity (see previous discussion), is a rare but highly aggressive neoplasm that typically arises in the cerebrum of an infant or child younger than 5 years of age.[787] Particularly characteristic is a deep, paraventricular localization—a topography adduced in support of a postulated origin from the lining germinal matrix of the developing forebrain—but medulloepitheliomas may also originate in the third ventricular/thalamostriate regions, cerebellum, brainstem, cauda equina, optic nerves,[788] and sellar/suprasellar compartments.[789] Ocular neoplasms of comparable morphology are well recognized and rare examples presenting as sciatic nerve[790] or pelvic[791] growths are on record. These extraneural variants are not further considered here.

Often attaining massive proportions, medulloepitheliomas are usually well circumscribed and composed of friable, gray–pink tissue evidencing hemorrhage, necrosis, and, in some cases, cystic change. Their defining feature is the formation of tubules, ribbons, or, less frequently, papillae resembling, and believed to represent a recapitulation of, the medullary epithelial structuring of the primitive neural tube (Fig. 43.114). These are fashioned of pseudostratified columnar cells that rest on a continuous, PAS-positive basement membrane and are sometimes capped by apical cytoplasmic blebs. PAS-positive material may also coat luminal surfaces as an ill-defined, granular pseudomembrane. Mitotic figures are readily identifiable and generally abluminal in location, a pattern reminiscent of the juxtaventricular proliferative activity characterizing early neurocytogenesis. Selective labeling of these inner, mitotically active elements for nestin, and full-thickness immunoreactivity of this neoplastic neuroepithelium for vimentin and microtubule-associated protein type 5 (MAP-5) are additional antigenic features shared with the embryonic neural tube.[792] Some observers have found focal labeling for GFAP, class III β-tubulin, and NFP epitopes within these arrays, but this is exceptional.[793] Also described are instances of apical immunoreactivity for EMA and focal cytoplasmic labeling for NSE and cytokeratins.[792,793] It should be noted that medulloepithelial structures vary greatly in extent from case to case and may constitute only a regionally limited

For personal use only. No other uses without permission. Copyright ©2017. Elsevier Inc. All rights reserved.

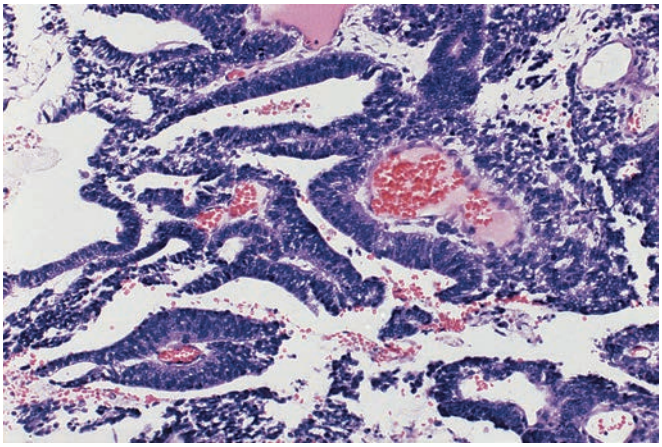

Figure 43.114 Medulloepithelioma. A tubulopapillary disposition of its columnar elements characterizes this primitive neuroepithelial neoplasm.

finding in an otherwise patternless, small cell neoplasm of thoroughly undifferentiated aspect.

In keeping with their proposed stem cell derivation, medulloepitheliomas often manifest divergent differentiation and maturation, at times advanced, along astrocytic, ependymal, neuronal, and, rarely, oligodendroglial lines.[787,793-795] A tubulopapillary, melanotic fourth ventricular neoplasm interpreted as a pigmented medulloepithelioma is on record,[796] as is an example containing chondroid, osseous, and skeletal muscle elements.[797] The exact nosologic position of the latter in relation to the immature teratoma, which may harbor medullary-type neuroepithelial formations, is problematic. Obviously, the presence of admixed nonteratomatous germ cell components and evidence of endodermal or somatic ectodermal differentiation should be sought and excluded before a diagnosis of medulloepithelioma is rendered, particularly if neoplastic mesenchymal tissues are identified.

The differential diagnosis of the medulloepithelioma must also include the embryonal tumor with multilayered rosettes and choroid plexus carcinoma. Medulloepitheliomas may contain ependymoblastic rosettes, but differ in that their neuromedullary components rest on basement membranes and do not fashion at the ultrastructural level such ependymal specializations as crowning cilia, microvilli, or complex intercellular junctions of zonula adherens type.[798] Choroid plexus carcinomas do not manifest divergent differentiation along astrocytic or neuronal lines and tend to a more obviously villiform architecture than is displayed by most medulloepitheliomas; also unlike the latter, they may display widespread immunoreactivity for S-100 protein and cytokeratins.

The medulloepithelioma is highly malignant and typically kills within 1–2 years of diagnosis, though aggressive surgical and adjuvant therapy may save some afflicted children, with age and extent of resection considered the most important prognosticators.[799] Uncontrollable growth at the primary site is the usual cause of death, but widespread leptomeningeal metastasis is frequent as well and may occur early in the disease course.

Central Nervous System Neuroblastic Tumors

The diagnosis of **CNS neuroblastoma** should be reserved for extracerebellar neoplasms of embryonal appearance that can be shown to differentiate solely along neuronal lines. Neuroblastomas of the central neuraxis are typified by a presentation in the first decade of life (usually prior to age 5 years) and localization to the cerebral hemispheres,[800,801] though they may arise within the ventricular system and intraspinal compartment.[802,803]

Consisting of friable gray tissue prone to necrosis, hemorrhage, and cystic change, neuroblastomas often achieve enormous proportions by the time they are discovered but tend to appear relatively circumscribed. Induction of a collagenous stroma lends a firm consistency and unusually lobulated contours to some examples. Although there is no biologic import to this division, several histologic variants are recognized. The "**classic**" **neuroblastoma** is composed of small, mitotically active cells containing densely hyperchromatic nuclei and disposed in highly populous sheets. A delicate fibrillary matrix consisting of tangled cytoplasmic processes is variably present. It is this subtype that is most likely to contain Homer Wright rosettes and large neurons of ganglion cell type. Occasional examples manifest a compact palisading of tumor cell nuclei within their neuropil-like matrices. Tumor cells may also palisade about foci of necrosis, although glioblastoma should always be excluded first when this pattern is encountered. The "**desmoplastic**" **neuroblastoma** is defined by fibrous stroma, most developed where tumor contacts the leptomeninges, that imposes lobular, trabecular, or single-file arrangements on its constituent cells. Larger than classic neuroblasts, the latter are characterized by vesicular nuclei, distinct nucleoli, and, in some cases, a modest paranuclear expanse of basophilic or amphophilic cytoplasm. The "**transitional**" **neuroblastoma** combines features of both the classic and desmoplastic variants. Only exceptionally do central neuroblastic tumors evidence the graded maturational alterations so often displayed by their retroperitoneal and posterior mediastinal counterparts, meriting designation as ganglioneuroblastomas.[804,805]

In the absence of Homer Wright rosettes or an unarguably neoplastic (as opposed to entrapped) neuronal population, the diagnosis of neuroblastoma needs ultrastructural or immunocytochemical support. Neurite-like cytoplasmic processes containing microtubules in parallel array, dense-core, and clear, synaptic-type vesicles signal neuronal differentiation. Attempts at synapse formation, usually abortive, are apparent in only a small minority of cases. Immunohistochemical assessment obviates the need for electron microscopic study if cytoplasmic SYN or NFP labeling can be demonstrated, and nuclear NeuN expression also attests to differentiation along neuronal lines. SYN reactivity is by far the most sensitive, albeit less specific marker, and is typically concentrated in the fibrillar matrix. GFAP expression should primarily be limited to cells reasonably interpreted as reactive astrocytes. These possess stellate cytoplasmic processes, are most numerous at the tumor–brain interface and, when present deeper within a lesion, usually lie near penetrating blood vessels. Some observers have credited central neuroblastic tumors with the capacity to generate GFAP-immunoreactive schwannian elements,[804] but the exact nature of the cells in question is far from clear.[806] Recent genetic studies also suggest rare subtypes, such as CNS neuroblastomas with FOXR2 activation, a Ewing sarcoma family tumor with CIC alterations, those with MN1 alterations, and examples with BCOR alterations.[807] It is therefore likely that this previously vaguely defined category will undergo considerable revisions in future classification schemes.

The interpretation of survival data reported for patients with cerebral neuroblastomas is complicated by the inclusion of cases in some series that would currently be regarded as examples of central neurocytoma or desmoplastic infantile ganglioglioma, both associated with a favorable prognosis, as well as primitive appearing astrocytic and ependymal neoplasms. Still, neuroblastomas seem more amenable to surgical and radiotherapeutic management than other primitive extracerebellar neoplasms.[800] The risks of local regrowth and CSF-borne metastasis, however, are high, and spread to extraneural sites is occasionally seen. Isolated instances of late local recurrence

For personal use only. No other uses without permission. Copyright ©2017. Elsevier Inc. All rights reserved.

in which reoperation has demonstrated maturation of central neuroblastomas to differentiated ganglion cell tumors[808] are noteworthy.

"Polar Spongioblastoma"

It is in deference to a traditional view[809] that the so-called **polar spongioblastoma** represents a primitive neuroepithelial neoplasm of distinctive character that we briefly address it here, but there has been considerable controversy as to whether the peculiar tumors awarded this designation constitute a unified entity,[810] and this diagnosis is no longer recognized in the WHO nosology. A tendency to arise in the walls of the third and fourth ventricles in childhood has been asserted, but no generalizations regarding clinical course emerge from the literature. The tumor is composed of spindled cells with fusiform nuclei that appear suspended in compact palisades between delicate unipolar or bipolar cytoplasmic processes in close parallel array. This arresting disposition has been likened to the radial arrangement of migrating glia ("spongioblasts") that characterizes the 16- to 18-week stage of human neuroembryogenesis.[809] Skeptics point to the fact that a comparably rhythmic architecture may be encountered in neoplasms that otherwise qualify as classic oligodendrogliomas, pilocytic astrocytomas, glioblastomas, ependymomas, neuroblastomas, and medulloblastomas.[810] To believers, however, a frequent admixture of conventional oligodendroglial and astrocytic elements has simply constituted evidence that the polar spongioblastoma derives from embryonic forbears committed to differentiate along glial lines. Uncritical acceptance of this entity is further complicated by its lack of defining immunohistochemical, ultrastructural, or molecular features. It is our view that the diagnosis of polar spongioblastoma, if resorted to at all, should be reserved for neoplasms that exhibit a compact, palisaded growth pattern throughout, and that lack the immunohistochemical or genetic features of better defined diagnostic entities.

Atypical Teratoid/Rhabdoid Tumor

The **AT/RT** is a highly aggressive neoplasm encountered principally in infancy and early childhood.[278,811,812] Adult-onset examples are distinct rareties.[813,814] Over 90% of afflicted patients reported to date have been less than 5 years of age at diagnosis (mean = 20 months), and nearly 50% have harbored tumors of the cerebellum or cerebellopontine angle, often with contiguous brainstem involvement. Supratentorial (cerebral or suprasellar) examples account for at least 40% of recorded cases, trailed distantly by pineal region and intraspinal variants. AT/RTs arising within cranial nerves have been depicted,[815] as have instances in which neoplasms resembling AT/RT have emerged from low-grade neuroepithelial neoplasms (pleomorphic xanthoastrocytoma, ganglioglioma, ependymoma, or DNT) in what apparently represents a bizarre form of tumor progression associated with loss of INI1 expression.[200,426,427,816] MRI typically discloses a bulky and contrast-enhancing mass, cystic and hemorrhagic alterations being common to this entity and its neuroradiological profile indistinguishable from that of medulloblastomas and other CNS embryonal neoplasms. Approximately 20%–25% of patients have evidence of CSF dissemination at diagnosis; many succumb to disease within months of diagnosis, and survival beyond 2 years has been the exception, although intensive adjuvant therapy protocols have been improving this bleak picture more recently.[817]

AT/RTs share with rhabdoid tumors of the infantile kidney and soft tissues a linkage to biallelic inactivation of *SMARCB1/hSNF5/INI1*, a gene mapping to chromosome 22q11.2 and encoding a ubiquitously expressed member of the SWI/SNF chromatin-remodeling complex.[818] Proteins of this family effect conformational alterations in the nucleosome that facilitate or restrict transcription factor access. Most AT/RTs demonstrate a pattern of *SMARCB1* inactivation conforming to the "two-hit" mechanism operative in classic tumor suppressor genes, loss of one copy resulting from partial deletion or monosomy 22 and the second suffering a nonsense or frameshift mutation (often in hotspot exons 5 and 9) that produces a novel stop codon. Also encountered are deletions or mutations involving both gene copies. While the majority of AT/RTs arise in sporadic fashion, germline mutations of *SMARCB1* underlie a familial rhabdoid tumor predisposition syndrome characterized by potentially multifocal, CNS, renal, and other extraneural primaries, mostly presenting in the first year of life.[819] As presently discussed, the loss of INI1 protein product expression that is a consistent feature of AT/RTs can be exploited to facilitate the identification of these neoplasms by immunohistochemical means.

AT/RTs are so designated in acknowledgment of their potentially complex histology. In fact, only a minority consist solely of rhabdoid cells and the latter (characterized in classic form by distinct cell borders, large and vesicular nuclei, macronucleoli, and globose, paranuclear cytoplasmic inclusions of hyalin appearance) may be only sparsely represented (or lacking entirely) among tumor cells with uniformly dense and eosinophilic, finely granular, vacuolated, wispy, or water-clear cytoplasm (Fig. 43.115A). These nonrhabdoid, large cell, mostly epithelioid elements can variably include spindled, polygonal, and bizarre, multinucleated cells disposed in nests or sheets. Bands of hyalinized collagen traverse some examples. Others

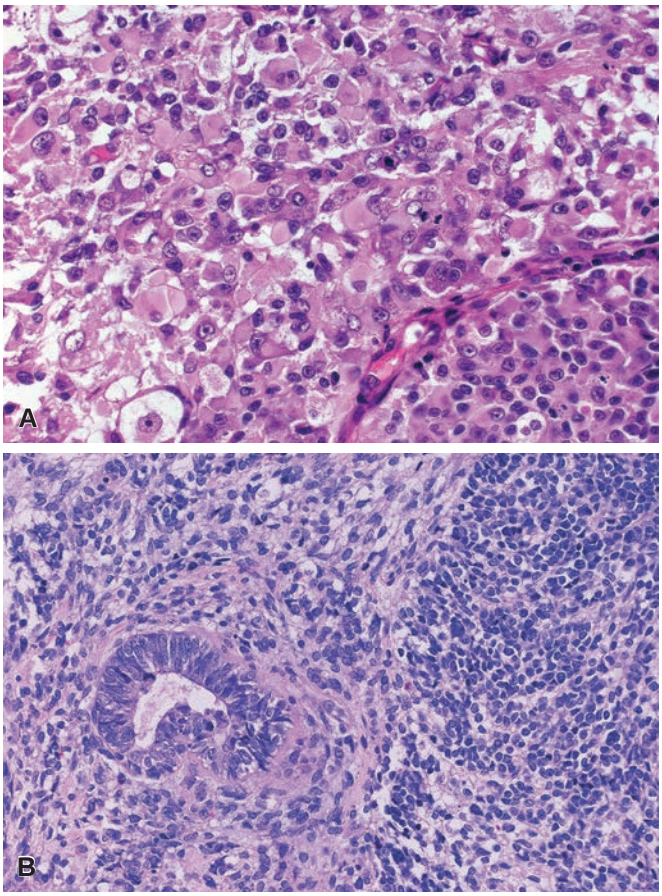

Figure 43.115 Atypical Teratoid/Rhabdoid Tumor. A, Neoplasms of this family typically contain at least some cells of large, rhabdoid phenotype. A second example **(B)** harbors, at right, small cell elements of primitive neuroepithelial appearance and a differentiated glandular structure, at left, embedded in a neoplastic component of mesenchymal appearance.

For personal use only. No other uses without permission. Copyright ©2017. Elsevier Inc. All rights reserved.

exhibit pseudopapillary formations or myxoid change and a chordoid growth pattern. The descriptor "teratoid" reflects the presence, in many tumors of this group, of varied neoplastic tissue components (see Fig. 43.115B). Most prominently represented are small cell elements of embryonal appearance indistinguishable from those that typify the medulloblastomas and other CNS embryonal tumors. The latter, encountered in 60%–70% of cases—and the vastly dominant component in some examples—usually assume an undifferentiated histologic profile but may fashion rosettes of Homer Wright, Flexner–Wintersteiner, or ependymoblastic type, some AT/RTs containing ependymal canal– or neural tube–like structures within their primitive neuroepithelial compartment. Spindle cell mesenchymal components may be present (these often having a fetal mesenchyme-like appearance) and some examples contain epithelial elements that may be represented by cohesive cell nests, adenoid and tubuloglandular structures or keratinizing squamous islands. Differentiation along striated muscle lines has not been reported.

Immunohistochemical assessment is critical to the distinction of AT/RTs from a variety of neoplasms that may assume rhabdoid cytologic features. A complex immunophenotype is the rule.[811,812] Rhabdoid and nonrhabdoid large cell elements invariably display labeling for vimentin (with intense staining of cytoplasmic inclusions, when present), are nearly always immunoreactive for EMA, and commonly label for GFAP and smooth muscle actin (SMA) as well. The percentage of cells reactive for each antigen is highly variable. EMA labeling may be diffuse or confined to cytoplasmic membranes, antibodies to SMA occasionally decorating a peripheral cytoplasmic ring with particular intensity (a pattern encountered in some smooth muscle tumors). In this connection, we would cite gene expression studies confirming the activation of a myogenic differentiation program in AT/RTs.[820] Immunoreactivity of the large cell components for cytokeratins (AE1/3, CAM 5.2) is also common, and some may be decorated by antibodies to NFP and SYN. Desmin reactivity, present in only a minority of cases, is usually restricted to mesenchymal or primitive regions (which may also label for NFP, SYN, and GFAP). Epithelial elements, not surprisingly, label for cytokeratins and, less commonly, EMA.

However, the most significant breakthrough in the immunohistochemical identification of AT/RTs has come with the development and marketing of the monoclonal antibody BAF47 or INI1 that recognizes the protein product of *SMARCB1*. The loss of gene expression at the protein level that regularly results from the *SMARCB1*-inactivating deletions and mutations characteristic of AT/RTs is reflected in a consistent failure of tumor cells to exhibit INI1 reactivity (Fig. 43.116).[821] It is a complete absence of nuclear labeling that must be demonstrated for confirmation of diagnosis (an irrelevant cytoplasmic blush may be observed), as regional loss of INI1 immunoreactivity (e.g. familial schwannomas) or diminished expression (e.g. synovial sarcoma) can be displayed by other tumor types. Results must be considered noninformative if endothelial cells, infiltrating mononuclear elements, and native CNS constituents fail to show the nuclear reactivity expected of these positive internal control populations. An attribute of most neoplasms that can assume strikingly rhabdoid guises, such as meningiomas, glioblastomas, choroid plexus carcinomas, germ cell tumors, large cell/anaplastic medulloblastomas, malignant lymphomas, and other potential mimickers, retained INI1 reactivity nearly excludes AT/RT from further diagnostic consideration in problematic cases. Molecular genetic analysis of *INI1* status may be required in the event of technical failure or equivocal labeling. It should also be noted that rare, mostly infantile examples of AT/RT are caused by inactivating mutations of other SWI/SNF chromatin remodeling complex components, such as the *SMARCA4* gene, encoding the BRG1 protein. Analogous to the more common form, complete loss of BRG1 expression can be detected immunohistochemically and familial examples are also documented.[822] Extremely rare cases showing all the typical clinicopathologic features of AT/RT but lacking demonstrable losses of INI1 or BRG1 may also be seen, though it is unclear whether this is part of the same spectrum or another entity. The WHO now recommends the term "**CNS embryonal tumor with rhabdoid cells**" for such cases and for those where neither immunohistochemical nor other molecular studies were performed.[278]

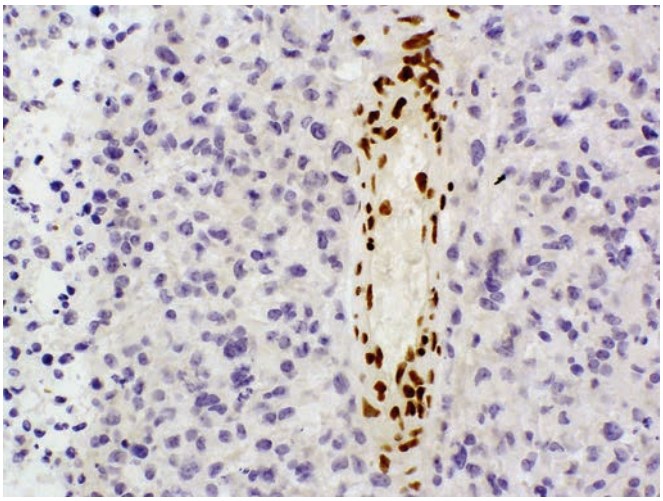

Figure 43.116 Atypical Teratoid/Rhabdoid Tumor. Loss of nuclear INI1 protein expression on immunohistochemical study characterizes this entity. Note retained expression by endothelial cells and perivascular mononuclear cell infiltrate.

Given that AT/RTs frequently harbor small cell components of primitive neuroepithelial appearance and that rare examples lack rhabdoid cells altogether, we also recommend that CNS embryonal tumors (particularly in infancy) be routinely screened for INI1 loss before diagnoses such as medulloblastoma, pineoblastoma, anaplastic choroid plexus carcinoma, or CNS embryonal tumor, NOS are rendered. As previously discussed in our treatment of choroid plexus tumors, suggestions that these are associated with AT/RT-type *SMARCB1* mutations and germline abnormalities of this gene may well reflect histologic misclassification of the tumors in question. We agree that INI1 assessment may be waived in the special circumstance of posterior fossa neoplasms exhibiting desmoplastic/nodular medulloblastoma histology, that is, displaying the "pale islands" that define the latter entity. This distinctive morphologic feature has been consistently correlated with retained INI1 labeling and evidence of SHH activation (see medulloblastoma section); it has never been shown, in our experience or to our knowledge, by a bona fide AT/RT. Readers should note that complete loss of INI1 expression has also been observed in epithelioid sarcomas, medullary carcinomas of the kidney, a novel form of undifferentiated soft tissue sarcoma affecting children, and in isolated examples of rhabdoid leiomyosarcoma.[821] Recently described intraventricular "**cribriform neuroepithelial tumors**" (CRINETs) of the infant CNS have reportedly demonstrated both INI1 silencing and *SMARCB1* abnormalities.[823] Lastly, recent genomic studies suggest that there are at least three molecularly distinct subtypes of AT/RT.[824]

Assorted Primitive Neuronal Tumors

It should be noted that although a peripheral counterpart akin to Ewing sarcoma still exists, the term "**PNET**" has been expunged from

For personal use only. No other uses without permission. Copyright ©2017. Elsevier Inc. All rights reserved.

the WHO 2016 lexicon for CNS tumors, due to the majority of such cases now qualifying for more distinct diagnostic entities. It was originally coined not as a generic appellation for embryonal neoplasms of every stripe, which it was to become, but to designate a cerebral tumor of infancy and childhood characterized by medulloblastoma-like histology and a propensity to disseminate along CSF pathways.

The problems inherent in defining a neoplasm largely on the basis of its undifferentiated appearances should be obvious. The diagnosis of a nonspecific form of "CNS PNET," now replaced by the term **CNS embryonal tumor, NOS** rests on firmest ground when applied to extracerebellar tumors of embryonal aspect, mostly occurring in childhood, exhibiting divergent neuronoglial differentiation and lacking the distinctive molecular features of entities such as the histone H3-associated midline or cerebral glioblastomas, anaplastic ependymoma, AT/RT, and embryonal tumor with multilayered rosettes (see appropriate sections). The demonstration of a polymorphous immunophenotype is useful in this regard, as some CNS embryonal tumors clearly coexpress SYN and multiple intermediate filament proteins (most often the complex of vimentin–GFAP–NFP but, occasionally, cytokeratins and desmin as well). The distinction of putative CNS embryonal tumors evidencing GFAP immunolabeling alone from highly anaplastic gliomas is murky. In practice, we find ourselves applying the former label to largely monomorphic, small cell neoplasms of childhood containing GFAP-positive elements, but manifesting neither the complex MVP nor the perinecrotic cellular palisading that typifies high-grade glial neoplasms (particularly astrocytomas) of conventional type. Immunoreactive cells often huddle in small clusters or aggregate about stromal blood vessels, are poorly fibrillated, and may assume a microgemistocytic appearance. We caution the reader against the low-percentage diagnosis of CNS embryonal tumors in adults, the majority of which end up showing molecular features of a high-grade glioma instead, especially the glioblastoma with primitive neuronal features (see earlier discussion).

CNS embryonal tumors may exhibit large cell/anaplastic features (with particularly unfavorable prognostic implications) of the kind characterizing some medulloblastomas.[825] Tumors of this kind (and their conventional small cell counterparts) must be shown to retain INI1 protein expression in order to exclude AT/RT as an alternative diagnostic possibility.

We have encountered cerebral neoplasms similar to a unique cerebellar lesion descriptively designated as a "**desmoplastic primitive neuroectodermal tumor with divergent differentiation**."[826] The recorded case was characterized by nests and cords of small neuroepithelial cells (some labeling for SYN, NFP epitopes, GFAP, and cytokeratins) embedded in a cellular "stroma" populated by desmin-immunoreactive elements. At recurrence, this exhibited strikingly epithelioid features and overt neuronal (ganglion cell) differentiation. Curiosities that potentially complicate the differential diagnosis of central embryonal neoplasms include intracranial examples of the **melanotic neuroectodermal tumor of infancy**,[827] the **desmoplastic small round-cell tumor** of Gerald and Rosai,[828] and the **Ewing sarcoma/peripheral PNET**.[829] The last two of these entities are characterized by specific t(11;22) chromosomal translocations foreign to embryonal tumors of central neuroepithelial type and critical to definitive tumor classification. Complete membranous immunolabeling for the *MIC2* gene product CD99, a characteristic feature of the Ewing sarcoma/peripheral PNET family, is only exceptionally (and focally) shared by CNS embryonal tumors, though a significant subset of these may exhibit a paranuclear dot-like pattern of reactivity.[825] Genetically confirmed intracranial examples of Ewing sarcoma/peripheral PNET have been described mainly as dura-based lesions. An intramedullary case is also on record.[830]

Pineal Parenchymal Tumors

The pineal gland is populated in the main by specially modified neuronal elements, known as pineal parenchymal cells or "pineocytes," that include among their functions the secretion of melatonin—a potent regulator of gonadotrophic and other endocrine hormonal activity. Tumors of pineal parenchymal lineage include the embryonal pineoblastoma, the mature pineocytoma, and lesions exhibiting mixed histology or intermediate degrees of differentiation.[278,831] As a rule, such neoplasms present as solid, contrast-enhancing masses associated with manifestations of obstructive hydrocephalus owing to aqueductal compression or disturbances of ocular motility (classically including the upwards gaze paresis termed Parinaud syndrome) resulting from pressure on the mesencephalic tectum. While pineal parenchymal tumors usually arise in sporadic fashion, germline mutations of the *RB1* and the *DICER1* genes predispose to pineoblastomas (as further discussed later), which have also been reported in rare association with familial adenomatous colonic polyposis as a possible variant of type 2 Turcot syndrome.[832-834]

The **pineoblastoma** is a WHO grade IV neoplasm characterized by a predilection for children and adolescents, aggressive local growth, and a proclivity for dissemination via the CSF. Primitive in appearance, it is densely populated by diminutive cells with hyperchromatic, round, or variably angulated and molded nuclei. These may exhibit brisk mitotic activity and are disposed in patternless sheets or lobules that are often punctuated by zones of coagulative necrosis and dystrophic calcification. The monotony may be relieved by the formation of Homer Wright rosettes, identical to those of the neuroblastoma and medulloblastoma, that attest (along with frequent tumoral SYN immunoreactivity) to a shared capacity for neuronal differentiation. Rare variants have been described as containing mature ganglion cell and glial elements,[835] and occasional examples evince an atavistic potential for photosensory differentiation that recapitulates the phylogenesis of the pineal gland as the primary photoreceptor of low vertebrates and "third eye" of some mammalian species. The pineoblastoma may thus fashion Flexner–Wintersteiner rosettes and fleurettes a la the retinoblastoma, can elaborate club-shaped cilia with the 9+0 axonemal array characteristic of photosensory cells,[836] and is capable of expressing various genes involved in visual signal transduction.[837] At the immunohistochemical level, they can express retinal phototransduction-associated proteins including the rhodopsin-binding S-antigen or "arrestin."[838]

The vestigial photosensory attributes of the human pineal gland are also obliquely evidenced by the occurrence of particularly aggressive and treatment-resistant pineoblastomas in complex with retinoblastomas. Afflicted patients carry germline mutations of the retinoblastoma *(RB1)* tumor-suppressor gene, and their ocular neoplasms are typically bilateral—hence, designation of this curious phenomenon as the "**trilateral retinoblastoma**" syndrome.[839,840] Rare pineoblastomas actually harbor melanotic elements in tubular array that have been likened to pigmented ciliary or retinal-type epithelium, similar cellular components transiently populating the developing pineal gland in humans.[841-844] That the latter is also home to an enigmatic population of myoid, striated muscle-type cells is noteworthy given the presence of rhabdomyoblastic differentiation in the "**pineal anlage tumor**"—a complex, pineoblastomatous neoplasm that may also contain melanotic and even chondroblastic elements. The similarity of such tumors to neoplasms derived from the primitive medullary epithelium of the optic vesicle (teratoid ocular medulloepitheliomas or "diktyomas") has been noted. An example composed of mature neurons, striated muscle cells, and melanotic components in the absence of primitive neuroepithelial elements is on record.[845] More recently, a subset of pineoblastomas have been noted with

For personal use only. No other uses without permission. Copyright ©2017. Elsevier Inc. All rights reserved.

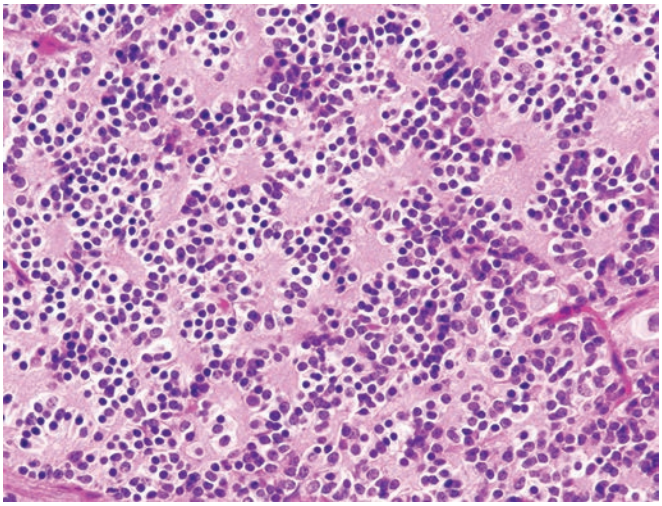

Figure 43.117 Pineocytoma. Shown here are the conspicuous rosettes that constitute a defining feature of this neoplasm. Note the benign oligodendroglioma-like/neurocytoma-like nuclear features, monomorphism, and absence of mitotic activity.

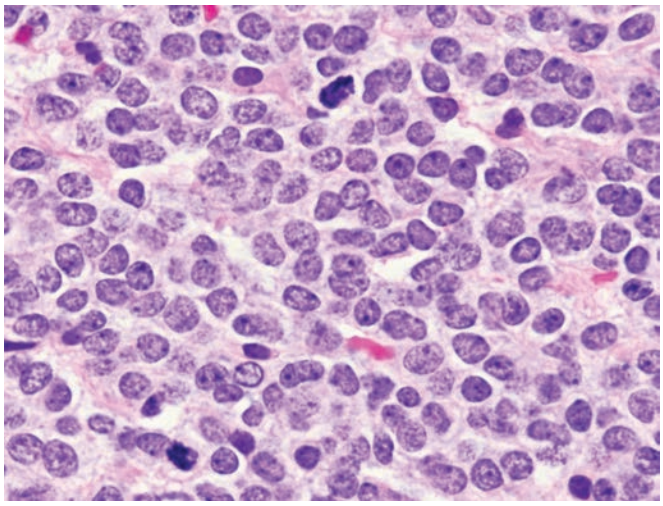

Figure 43.118 Pineal Parenchymal Tumor of Intermediate Differentiation. Note the sheet-like architecture, hypercellularity, lack of pineocytic rosettes, and increased mitotic activity, but the features fall short of the primitive "small blue cell" cytology seen in pineoblastoma.

mutations of the *DICER1* gene, including germline examples,[832] thus expanding the list of DICER1 syndromic manifestations, including pleuropulmonary blastoma, cystic nephroma, ovarian Sertoli–Leydig-type tumors, and many others.

The appellation of **pineocytoma** has been extended over the years to neoplasms of varying histology and disparate biologic potential. We concur in the view that this diagnosis is best reserved for the tumor in which neoplastic cells are arrayed about a conspicuous, anuclear meshwork of delicate, SYN-immunoreactive cytoplasmic processes in formations dubbed "pineocytic" or "pineocytomatous" rosettes.[831,846] Looking virtually identical to "neurocytic rosettes," they resemble outsized versions of the Homer Wright rosette but often have less regular contours (Fig. 43.117) and are frequently found in confluent arrangements alongside regions of uninterrupted, sheet-like or lobular tumor growth. Such lesions are largely devoid of mitotic activity, do not exhibit necrosis, and are typically dominated by monomorphous, cytologically benign-appearing elements with rounded nuclear profiles. They can, however, harbor admixed tumor giant cells with marked degenerative atypia (including hyperchromatic and multinucleated forms) to which no prognostic import attaches.[847] Ganglion cells may be identified within "**pleomorphic pineocytomas**" of the latter type.[848]

The cytoplasmic processes elaborated by pineocytoma cells distinctly resemble those of native pineocytes in the tendency of microtubule-laden, neurite-like cellular extensions to end as bulbous neurofilament immunoreactive expansions, containing clear vesicles of synaptic type, dense core ("neurosecretory") vesicles and vesicle-crowned rodlets ultrastructurally.[836,849] The last, also known as synaptic ribbons and recognized as a distinctive feature of mammalian pineocytes, consist of closely apposed, bar-like osmiophilic densities measuring approximately 700 nm in length by 50 nm in width that are surrounded by clear vesicles 60 nm in diameter. A further specialization shared with pineal parenchymal cells are paired cytoplasmic filaments, 8 nm in diameter, arrayed in helices of 26–30 nm periodicity. Synaptic junctions and such photosensory attributes as annulate lamellae and cilia of 9+0 configuration may also be apparent.

Given the fine structural profile just delineated, it should come as no surprise that the fibrillar matrix of the pineocytoma is GFAP negative but often immunolabels for NFP epitopes, class III β-tubulin, PGP 9.5, chromogranin A, and SYN.[838,846] Rhodopsin and retinal S-antigen immunoreactivity have also been documented[838,846] and further attest (as does expression of several phototransduction-associated genes at the RNA level[837]) to the photosensory differentiating potential of pineal parenchymal tumors. Intriguing in this connection is report of a pineocytoma associated with uveoretinitis.[850] Lastly, the differentiated nature of the pineocytoma is reflected in the observation that its constituent cells may evidence immunoreactivity for, or express messenger RNA encoding, enzymes involved in melatonin synthesis (including tryptophan hydroxylase, serotonin *N*-acetyltransferase, and hydroxyindole-*O*-methyltransferase).[837] While shared by pineoblastomas, the expression of genes encoding these enzymes appears to be comparatively upregulated in tumors of pineocytomatous aspect.

Restriction of the term pineocytoma to the distinctively rosetted neoplasm described above identifies a surgically curable, WHO grade I tumor that typically presents in young or middle-aged adults and that remains confined to the pineal region, expanding slowly and in noninvasive fashion.[278] The same cannot be said for exceedingly rare tumors described as harboring "mixed" pineocytomatous and pineoblastomatous elements,[846,851] these having the potential for aggressive behavior with CSF dissemination.[851] Lesions previously reported as papillary variants of pineocytoma would seem, in fact, to represent examples of the unusual entity discussed under "Papillary Tumor of the Pineal Region."

Falling within an incompletely characterized group now designated as **pineal parenchymal tumors of intermediate differentiation** are certain neoplasms that occupy a rather broad middle ground between the mature and embryonal extremes.[831,846] One variant is characterized by a neuroendocrine histologic profile in which small tumor cells are segregated into lobules subtended by a delicate vasculature, a second by a more sheet-like proliferation of neoplastic elements in a scant fibrillary matrix (Fig. 43.118). Cytoplasmic clearing lends an oligodendroglioma-like aspect to some examples, the differential including third ventricular neurocytoma. A neuronal/neuroendocrine immunoprofile similar to that of the pineocytoma puts the former issue to rest,[846] as neurocytic neoplasms share SYN expression but are usually chromogranin negative (save for examples with ganglion cell components). Some neuropathologists[846] include in this family "transitional" cases in which focal pineocytomatous rosette formation is apparent against a background of solid, lobular, or diffuse

For personal use only. No other uses without permission. Copyright ©2017. Elsevier Inc. All rights reserved.

growth. As a group, these pineocytic neoplasms can achieve relatively dense cellularity, occasionally evidence necrosis, and may exhibit mitotic activity, but fall short of the frank anaplasia and conspicuous proliferative activity that typify pineoblastomas. Many behave in relatively low-grade fashion,[846,851] but some frustrate all attempts at local control, and CSF-borne metastasis has been documented as an exceptional occurrence.[851] The WHO ascribes grade II–III biologic potential to intermediately differentiated pineal parenchymal tumors as a group without providing or endorsing particular criteria for their prognostic subdivision.[278] A four-tiered system has been proposed[846] in which grades 1 and 4 are reserved for the classically rosetted pineocytoma and pineoblastoma, respectively, while neoplasms of the intermediate group are accorded grade 2 status if they exhibit fewer than six mitoses per 10 high-power microscopic fields and retain immunoreactivity for 70- and 200-kDa NFPs, or designated as grade 3 should they fail to label for the latter or manifest higher mitotic indices. Transitional (i.e. focally rosetted) tumors are placed in the grade 2 category, the mixed pineocytoma–pineoblastoma qualifying as grade 3 in this schema. Select studies have demonstrated the ability of this method to stratify affected patients in a hierarchy of increasing risk for recurrence and tumor-related death,[846] but it has not yet found wide application among neuropathologists. As appears to be the case for otherwise conventional pineocytomas, the presence of pleomorphic tumor giant cells does not seem to be of any prognostic import when encountered in lesions of intermediate differentiation.[847]

Papillary Tumor of the Pineal Region

Presenting, on neuroradiological assessment, as a circumscribed and contrast-enhancing mass producing obstructive hydrocephalus (with the expected clinical manifestations), the **papillary tumor of the pineal region** is most often encountered in young or middle-aged adults but can afflict children and adolescents.[852-855] The entity is designated for the radial arrangement of constituent cells about supporting fibrovascular cores (Fig. 43.119A), the latter commonly exhibiting collagenous hyalinization, though regions of solid growth are frequently apparent and may vastly dominate the histologic picture. Papillary formations are composed of epithelial-looking elements, often pseudostratified, with columnar profiles, relatively well-defined cell borders, pale to slightly granular eosinophilic cytoplasm in vasocentric orientation, and peripherally displaced, rounded or oval nuclei manifesting a stippled chromatin distribution. Striking nuclear enlargement and pleomorphism may be displayed by tumor cells in areas of nested and sheet-like architecture, these solid components being punctuated in some cases by perivascular pseudorosettes, as well as true rosettes and tubules, of ependymal type. Mitotic figures are often apparent, though not in large numbers (no more than 10 per 10 high-power fields is the rule), and necrosis is commonly found but unattended by MVP. Neurosurgical specimens that contain adjoining pineal parenchyma or other native tissues typically demonstrate a well-demarcated, "pushing" tumor perimeter. Nevertheless, some show anaplastic features with both grades II and III being possibilities in the most recent WHO scheme.[278] A rare example showing a primitive small round cell component has also been reported, which may overlap with pineoblastoma and other embryonal neoplasms.[856]

Ultrastructural studies have shown the papillary tumor of the pineal region to have ependymocytic characteristics.[852] The latter include the forming of tight junctions and zonulae adherentes that bind cell apices, these crowned by microvilli and punctured by rare cilia. The presence of dense-core cytoplasmic vesicles and parallel paranuclear arrays of rough endoplasmic reticulum with cisternal dilation by granular material attest, however, to neuroendocrine and secretory functions foreign to conventional ependymal cells. These hybrid features, coupled with shared antigenic and gene expression signatures, have been taken as evidence of a tumoral origin from specially modified ependymocytes that are known to colonize the developing pineal parenchyma from the neighboring subcommissural organ.[837,852,853]

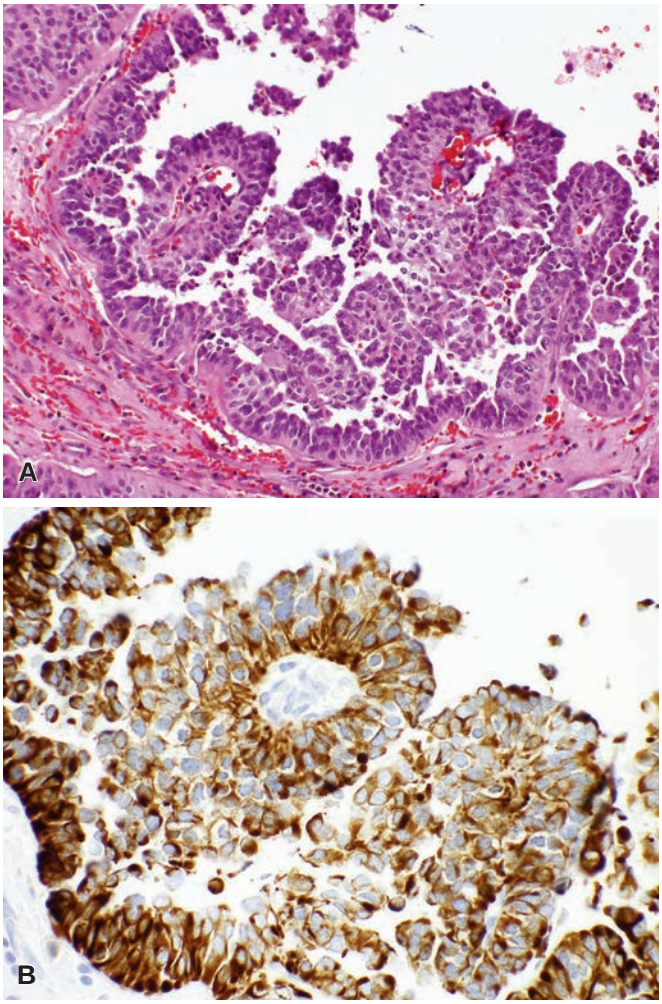

Figure 43.119 Papillary Tumor of the Pineal Region. Perivascular structuring **(A)** and strong immunoexpression of CK18 **(B)** typify the cellular elements of this lesion.

Morphologic evidence of ependymal differentiation notwithstanding, the neoplasms under discussion depart from ependymomas in their general failure to express GFAP (limited immunoreactivity of perivascular cell bodies has been observed in fewer than 10% of recorded cases), by the finding in only exceptional examples of dot- or ring-type EMA labeling (though diffuse and focally membranous cytoplasmic expression can be seen), and in the observation that papillary tumors of the pineal region regularly manifest reactivity for cytokeratins, claudin subtypes, E-cadherin, and NCAM.[852,857] Cytokeratin expression may take the form of generalized cytoplasmic immunopositivity or dot-like intracytoplasmic immunopositivity. Most constant and often diffuse in distribution are CK18 expression (see Fig. 43.119B) and labeling with the KL1 antibody (recognizing acidic and basic keratin proteins 40–68 kDa in size), many examples exhibiting at least regional immunoreactivity with the AE1/3 and CAM 5.2 "cocktails" as well. It is the papillary component that is most likely to prove cytokeratin positive. Only a minority of

For personal use only. No other uses without permission. Copyright ©2017. Elsevier Inc. All rights reserved.

communicated cases have shown focal CK5/6 or CK7 expression and CK20 negativity seems the rule. These curious neoplasms share with choroid plexus papillomas and carcinomas cytoplasmic immunolabeling, frequently widespread, for vimentin and S-100 protein (with regular nuclear expression of the latter antigen) as well as the potential to express transthyretin, but seem far more likely to exhibit MAP-2 reactivity and far less likely to manifest Kir 7.1 or stanniocalcin-1 positivity.[852,854,855] A subset of recorded examples have evidenced SYN and chromogranin A reactivity (usually focal and of weak intensity), a small number of cases demonstrating nestin expression.[854,855,858] Immunolabeling for NSE is constant but of no discriminatory value, while all cases assessed to date have been NFP negative.

Papillary tumors of the pineal region are prone to recurrence and can be fatal. A multicenter, retrospective analysis of 31 affected patients demonstrated 5-year overall and progression-free survival rates of 73% and 27%, respectively.[854] Twenty of 21 recurring tumors did so locally, one also seeding the spinal leptomeninges and a second producing such "drop" metastases in the absence of regrowth at the primary site. Incomplete resection appears to carry a heightened risk of symptomatic relapse. The role of adjuvant therapies in the management of these lesions remains to be defined, as does a prognostically meaningful system of pathologic grading. Molecular studies reveal nearly ubiquitous chromosome 10 deletion, losses of 3 and 22q in subsets, gains of chromosomes 8p and 12, as well as overexpression of SPDEF, the latter of which is in common with the subcommissural organ, a potential site of origin.[853]

We mention a report of **papillary tumors of the spinal cord** that share many histologic, immunophenotypic, and ultrastructural features with the pineal region growths discussed in this section.[857] These, too, demonstrate differentiation along ependymal lines.

Meningiomas

The designation of meningioma has been extended through the years to diverse neoplasms sharing only a tendency to arise within the histogenetically complex tissues of the leptomeninges or dura mater. Thus, such dissimilar entities as the meningeal solitary fibrous tumor/hemangiopericytoma (SFT/HPC) and hemangioblastoma—currently accorded separate nosologic status among tumors of the CNS and its coverings—were once yoked under the regrettable rubric of "angioblastic" meningioma and widely assumed to derive from a common progenitor. In a similar vein, it is recognized that most, if not all, tumors reported as melanotic or pigmented meningiomas actually represent meningeal melanocytomas. Neuropathologists now label as meningiomas only those neoplasms exhibiting morphologic or immunophenotypic evidence of an origin from meningothelial cells, specialized elements that populate the arachnoid membranes and cap the arachnoidal villi associated with intradural venous sinuses and their tributaries.

Meningiomas may make their appearance in childhood or adolescence, but most are encountered in middle or later adult life.[278,859-862] Females are afflicted more commonly than males (especially at spinal levels), and some studies suggest an increased prevalence in women with mammary carcinomas. Rare meningiomas have actually harbored metastatic deposits derived from breast primaries.[863] Coupled with their frequent expression of progesterone (and, less commonly, estrogen as well as androgen) receptors[278] and the rapid enlargement of some examples during pregnancy or the luteal phase of the menstrual cycle, these observations indicate that the growth of meningiomas is subject to hormonal influence. The association of multifocal meningiomas with NF2 is noteworthy, the genetic locus for which resides on chromosome 22q12. Allelic loss involving this band is a frequent feature of meningiomas, including sporadic variants, as are *NF2* gene mutations (particularly common in fibroblastic and transitional variants). The presentation of a meningioma in childhood or adolescence should trigger investigation for underlying NF2.[862] Familial examples occurring outside the setting of classic NF2 have also been described, including rare examples of schwannomatosis with germline *SMARCB1* mutations,[864] although the genetic underpinnings for most remain unclear.[865] Ionizing cranial irradiation, including the low doses previously given for treating tinea capitis or obtaining full mouth dental X-ray series, emerges from a number of epidemiologic studies as conferring significant risk for subsequent meningioma development, radiation-related lesions being more often multiple, histologically atypical, and clinically aggressive than those arising in sporadic fashion.[866-870] Less clear is the etiologic role of craniocerebral trauma,[871] but the presentation of select meningiomas in the immediate vicinity of a prior skull fracture or in close physical association with traumatically implanted foreign bodies has been convincingly documented.[872,873] Also on record are meningiomas found to lie just over glioblastomas or other gliomas.[874] Most "collision" tumors of this sort are undoubtedly fortuitous lesions, but it is conceivable that the occasional meningioma evokes a hyperplastic glial reaction that subsequently progresses to neoplasia. As mentioned in our prior discussion of hamartomatous lesions, tumors interpreted as meningothelial neoplasms originating in foci of meningioangiomatosis have been described but most likely represent meningiomas with unusual patterns of perivascular growth.[35]

Most meningiomas arise within the cranial cavity, are dura based and found in the vicinity of the superior sagittal sinus, over the cerebral convexities, or in contact with the falx cerebri. Basally positioned examples favor the sphenoid ridge, olfactory grooves, tuberculum sellae, and parasellar region. Still others are anchored to the petrous ridge, presenting as cerebellopontine angle tumors when posteriorly situated. Intracranial meningiomas may also originate within the tela choroidea or stroma of the choroid plexus and rest entirely within the ventricular system. At spinal levels, meningiomas clearly favor the thoracic region, cervical examples being uncommon and lumbar lesions rare. Also recognized are epidural and intra-osseous meningiomas as well as variants located entirely outside the craniospinal confines. The latter are usually encountered in the head and neck region and include orbital (i.e. optic sheath), glabellar, sinonasal, oropharyngeal, subgaleal, juxtaparotid, and cutaneous examples.[875-877] Rarely, ectopic meningiomas are situated at even greater removes from the central neuraxis (e.g. in the mediastinum,[878] lung,[879,880] or brachial plexus[881]). As discussed elsewhere in these volumes, the cellular aggregates originally regarded as minute pulmonary "chemodectomas" or meningothelial-like nodules are actually composed of elements having the ultrastructure and immunophenotype of meningothelium.[880,882] Whether these serve as the substrate from which pulmonary meningiomas develop is unknown.

On neuroradiological (Fig. 43.120) and gross assessment (Fig. 43.121), the typical meningioma is a solid, lobulated, or globose mass that is broadly anchored to the dura mater. Cystic variants, although uncommon, are well recognized, and the term meningioma en plaque may be invoked for the occasional lesion that presents (usually over the sphenoid ridge) as a poorly delimited, carpet-like growth. Adjoining neural tissues are generally deflected at the "pushing" perimeters of these tumors, but grossly evident dural infiltration or invasion of nearby venous sinuses is not uncommon. Some examples insidiously permeate the neighboring skull, provoking a highly characteristic form of osteoplastic expansion and bony remodeling known as hyperostosis or, if chronically neglected, come to attention as visible masses in the scalp. None of these findings brand a meningioma as atypical or anaplastic, although involvement of the cranial floor greatly prejudices matters against the neurosurgeon and so predisposes to tumor recurrence and progression following

For personal use only. No other uses without permission. Copyright ©2017. Elsevier Inc. All rights reserved.

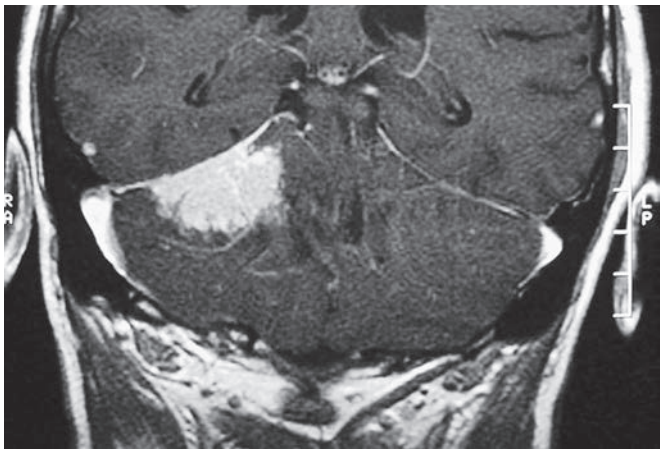

Figure 43.120 Meningioma. Circumscription, homogeneous contrast enhancement and anchorage to the dura (in this case, the tentorium) typify the meningioma. This magnetic resonance imaging also demonstrates thickened and abnormally enhancing dural "tails" extending from the lesional borders—a finding suggestive, though not diagnostic, of this tumor entity.

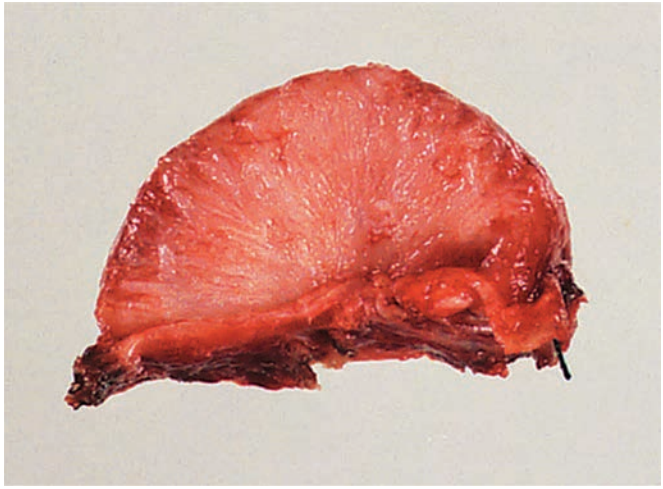

Figure 43.121 Meningioma. The broad dural base depicted here is characteristic.

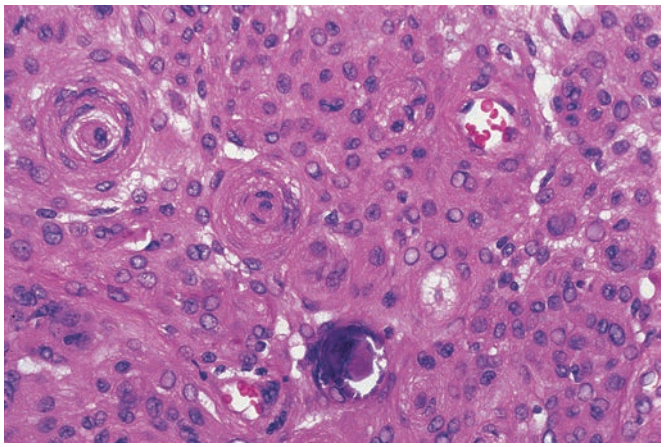

Figure 43.122 Meningioma. Indistinct cytoplasmic boundaries, nuclear clearing ("pseudoinclusions"), cellular whorls, and a psammoma body are all apparent in this view of a meningotheliomatous (syncytial) meningioma.

attempted resection. Highly suspect, however, is the lesion that cannot be easily separated from the adjacent brain or spinal cord, as this may imply transgression of the pia-arachnoid and invasion of the neuroparenchyma proper—nevertheless, the surgeon's gross impression of brain invasion does not correlate well with microscopic confirmation, likely due to some cases adhering to pia rather than truly invading parenchyma.[883] Neuroradiological features that should prompt concern include indistinct tumoral margins, a "mushrooming" growth pattern characterized by multinodular projections from the main mass, foci that fail to enhance on contrast administration (these often representing regions of necrosis), and edema of the neighboring brain on CT or MR study.[884,885] However, some benign meningioma subtypes (e.g. angiomatous, microcystic, secretory, and lymphoplasmacyte-rich variants) are recognized for their regular association with peritumoral cerebral edema. Restricted diffusion on MRI, a finding often associated with increased cellularity, has also been associated with higher-grade histology.[886,887]

On sectioning, most meningiomas are gray-tan and soft, but collagenized examples have a rubbery texture and a whorled or trabeculated cut surface (resembling that of the leiomyoma), whereas variants rich in stromal mucopolysaccharides acquire a somewhat gelatinous consistency. Calcification is often readily apparent and infiltration by foamy macrophages at times results in foci of yellow discoloration, a phenomenon that may also reflect the accumulation of lipids within tumor cells. Grossly apparent regions of gray–black pigmentation characterized a unique example of meningioma colonized by hyperplastic leptomeningeal melanocytes.[888]

Meningiomas are notorious for the variety of their cytologic and histologic presentations, but most assume one of several prototypical guises. **Meningotheliomatous** variants are characterized by a lobular microarchitecture and are populated by cells having delicate round or oval nuclei, inconspicuous nucleoli, lightly eosinophilic cytoplasm, and indistinct cytoplasmic borders (thus their outdated alternate designation of "syncytial" meningiomas). Common to these (and other subtypes) are tumor cells concentrically wrapped in tight whorls, nuclear clearing ("holes") and pale nuclear "pseudoinclusions" consisting of invaginated cytoplasm, and the lamellated calcospherules known as psammoma bodies (Fig. 43.122). While none of these features is pathognomonic of meningioma, their demonstration in the setting of an extra-axial, dura-based mass carries considerable diagnostic weight. In contrast to the epithelioid appearances of meningotheliomatous variants, **fibrous** (or **fibroblastic**) **meningiomas** adopt a mesenchymal profile, being variably collagenized and consisting of spindled tumor cells in fascicular or storiform array (Fig. 43.123). An example containing crystalline structures rich in tyrosine has been described.[889] **Transitional meningiomas**, as their name implies, are hybrids, maintaining a lobular arrangement but having a tendency to cellular elongation and streaming. These are often particularly rich in compact cellular whorls and endowed with psammoma bodies in conspicuous numbers. When the latter are present in profusion, the term **psammomatous meningioma** may be applied. Tumors of this type characteristically occur in middle-aged to elderly women and exhibit a particular predilection for the intraspinal compartment. It should be noted that none of the foregoing growth patterns is of any special biologic significance, and most neuropathologists dispense with these qualifying adjectives in their reports.

To these classic subtypes of meningioma can be added histologic variants too numerous to be accorded detailed discussion or depiction here. Only the more distinctive are acknowledged. Unless otherwise stated, these depart in no way from the benign course pursued by meningiomas of more conventional appearance.

For personal use only. No other uses without permission. Copyright ©2017. Elsevier Inc. All rights reserved.

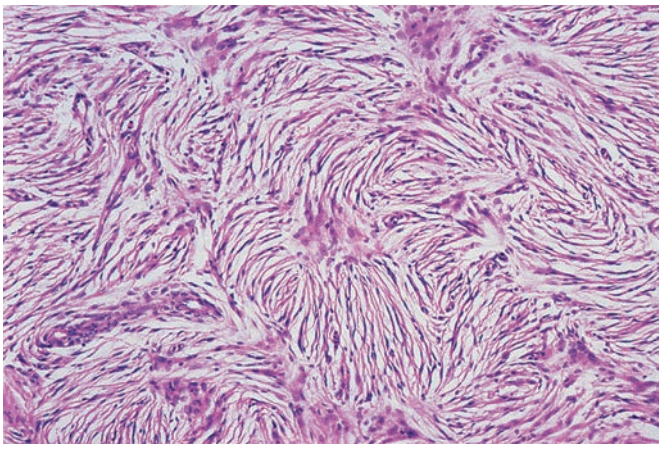

Figure 43.123 Meningioma. Cellular spindling and a fascicular or storiform architecture are evidenced by meningiomas of "fibroblastic" type.

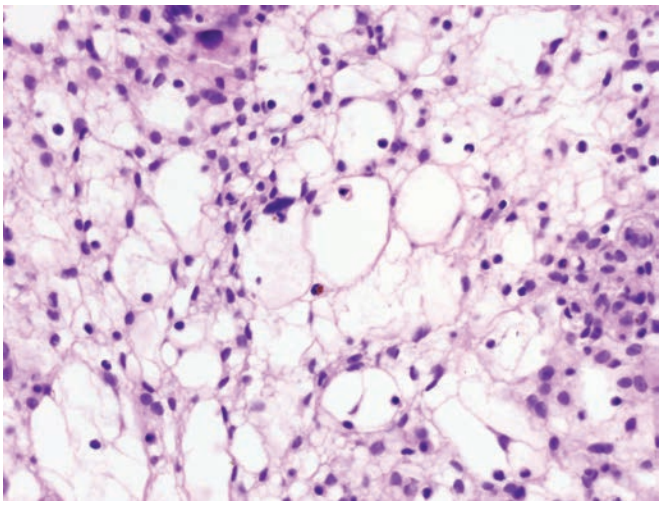

Figure 43.124 Microcystic Meningioma. The wispy "cobweb-like" pattern results from extracellular fluid accumulation and characterizes this variant.

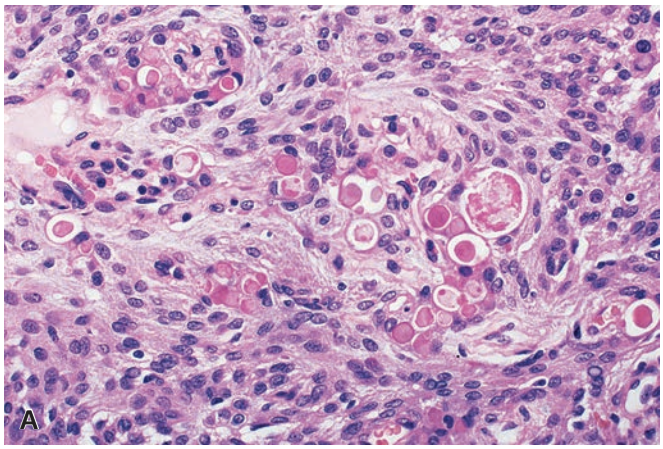

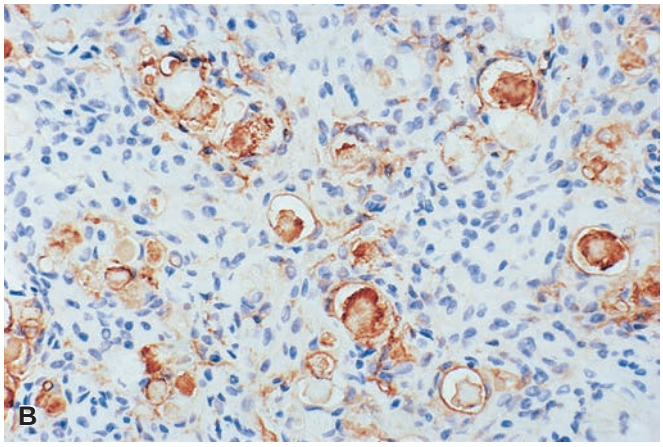

Figure 43.125 Secretory Meningioma. This variant of meningotheliomatous meningioma harbors eosinophilic globules **(A)** that label with antibodies to carcinoembryonic antigen **(B)**.

The **microcystic meningioma**[890,891] is named for its content of variably sized intercellular vacuoles, these often appearing empty but in some instances containing a lightly PAS-positive fluid derived in all likelihood via the transudation of plasma across a characteristically rich, and frequently hyalinized, stromal vasculature. Some examples actually progress to the formation of macrocysts and harbor only minor solid components. Constituent cells may exhibit cytoplasmic clearing due to glycogen (not to be confused with the more diffuse accumulation in the clear cell variant) or lipid accumulation and often assume spindled or stellate profiles that, along with their tendency to disaggregation, can prompt consideration of a low-grade, microcystic astrocytoma in the differential diagnosis (Fig. 43.124). Nuclear pleomorphism, karyomegaly, and a smudgy hyperchromasia are common but are unattended by mitotic activity and are divorced from any sinister prognostic import, as is the common finding of severe peritumoral cerebral edema on preoperative neuroradiological study.

The **secretory meningioma**,[892] a variant of the meningotheliomatous subtype, is distinguished by its content of "pseudopsammoma bodies"—globular hyaline inclusions that are eosinophilic, intensely PAS positive, and diastase resistant (Fig. 43.125A). On ultrastructural study, these can be shown to lie within microvillus-lined intracellular lumina and may be immunolabeled for human secretory component, IgM, IgA, and CEA (see Fig. 43.125B). Nearly always benign, the secretory meningioma may yet masquerade as a malignant neoplasm by virtue of its occasional association with elevated serum CEA levels,[893] an especially confounding phenomenon in the patient with a prior history of systemic cancer, and with subacutely progressive neurologic deficits referable to severe edema of juxtatumoral cerebral tissues.[891] Recent evidence suggests that the majority of secretory meningiomas harbor mutations in the *TRAF7* and *KLF4* genes.[894]

The **lymphoplasmacyte-rich meningioma** is a tumor infiltrated by chronic inflammatory elements, at times so heavily that its meningothelial (and neoplastic) nature is obscured (Fig. 43.126).[895,896] There can be no doubt that at least some reported cases would be better classified as dura-based examples of inflammatory disorders, inflammatory myofibroblastic tumor, or SHML (Rosai–Dorfman disease). An association with hypergammaglobulinemia and/or anemia has been occasionally noted.[896] Peritumoral lymphoplasmacytic infiltrates with germinal center formation are also conspicuous features of a peculiar meningeal tumor noteworthy for its **chordoid histology** and presentation in childhood or adolescence with manifestations of the **Castleman syndrome**—polyclonal dysgammaglobulinemia, iron-refractory anemia, hepatosplenomegaly, and retarded growth and sexual maturation.[897,898] Resection typically effects a remission of the systemic disorder, but this obscure neoplasm may recur and behave in locally aggressive fashion. The relationship

For personal use only. No other uses without permission. Copyright ©2017. Elsevier Inc. All rights reserved.

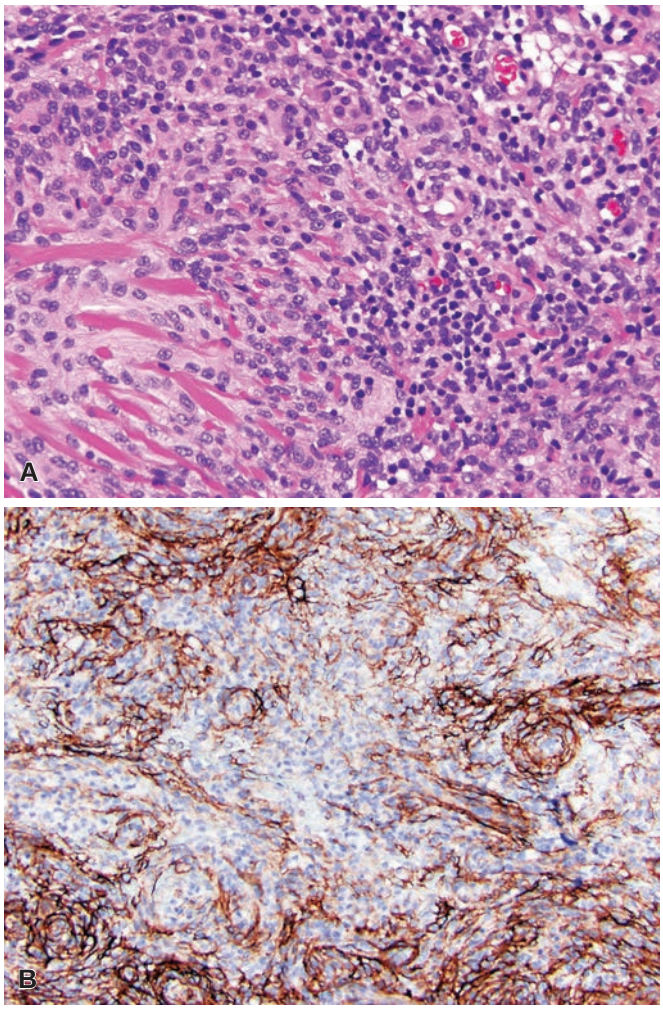

Figure 43.126 Lymphoplasmacyte-Rich Meningioma. The brisk inflammatory infiltrate in this case partially obscures the underlying meningioma **(A)**, the latter of which is highlighted by an immunostain for somatostatin receptor 2a **(B)**.

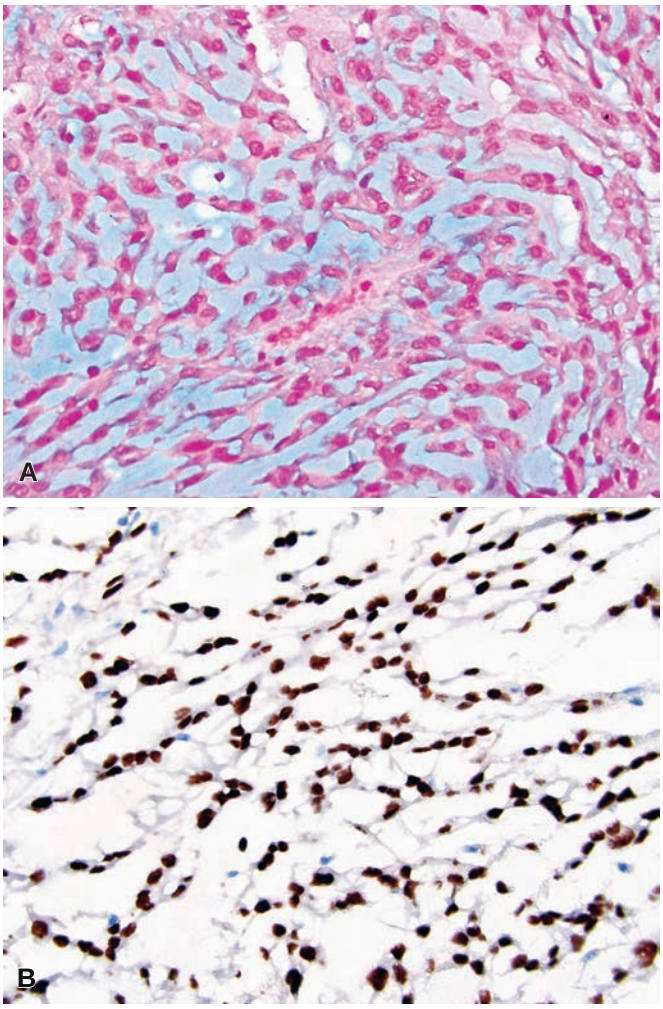

Figure 43.127 Chordoid Meningioma. A, The ribbon-like architecture, vacuolated cytoplasm, and alcian blue–positive mucinous stroma provides a remarkable resemblance to chordoma of the bone. **B,** However, these tumors express the same immunomarkers as conventional meningiomas, often including progesterone receptor.

of this lesion to adult-onset **chordoid meningiomas** (WHO grade II),[899] which are only exceptionally accompanied by conspicuous inflammatory components or indications of Castleman syndrome, and potentially masquerade as chordomas or metastatic mucinous carcinomas, is unclear (Fig. 43.127). The latter, also reported as "myxoid" or "mucinous" meningiomas when otherwise lacking epithelioid cytology, proved in one analysis to be far more prone to local regrowth following subtotal resection than meningothelial tumors of conventional type.[899] We have encountered what appeared to be a primary pulmonary example.[900]

Metaplastic meningiomas can contain bone, cartilage, or adipocytic elements. Progressive xanthomatous change, that is, nonspecific cytoplasmic lipidization, rather than true metaplasia seems to account for so-called **lipomatous meningiomas**.[901] We would call particular attention to rare variants that may be misconstrued as sarcoma owing to potentially lipoblastic cytologic features, and the occurrence in some examples of troubling nuclear abnormalities that are almost certainly degenerative in nature.[902,903] Neoplasms exhibiting meningothelial and rhabdomyosarcomatous[904] or leiomyosarcomatous[905] differentiation are also on record. Still other meningiomas evidence foci of schwannoma-like nuclear palisading; pseudoglandular and rosette-like structures[906]; a nesting arrangement reminiscent of paraganglioma[907]; granular cytoplasmic inclusions[908]; or a hyalinized stromal vasculature so exuberant and domineering as to suggest a malformative process or hemangioblastoma (**angiomatous meningioma**), the latter recently associated with characteristic chromosomal gains (Fig. 43.128).[909,910] The last of these variants shares with microcystic and secretory meningiomas a generally benign clinical profile, despite a tendency to cause conspicuous edema of the adjoining cerebrum and sometimes marked degenerative nuclear atypia. Sclerosing meningiomas that appear to undergo progressive fibrous obliteration are noteworthy for their frequent presentation in the pediatric group and favorable outcome, despite a tendency to foci of disturbing hypercellularity, pleomorphism, and cerebrocortical infiltration.[911-913] Some observers have suggested that at least a subset of sclerosing childhood meningiomas are pseudoinvasive lesions arising within cortical foci of meningioangiomatosis,[914] but whether the latter entity serves as a substrate for the development of meningothelial neoplasms has been called into question.[35]

A subset of meningothelial neoplasms evidence clear cell, oncocytic, or rhabdoid features. The significance of such alterations when partially developed or encountered only focally is unsettled

For personal use only. No other uses without permission. Copyright ©2017. Elsevier Inc. All rights reserved.

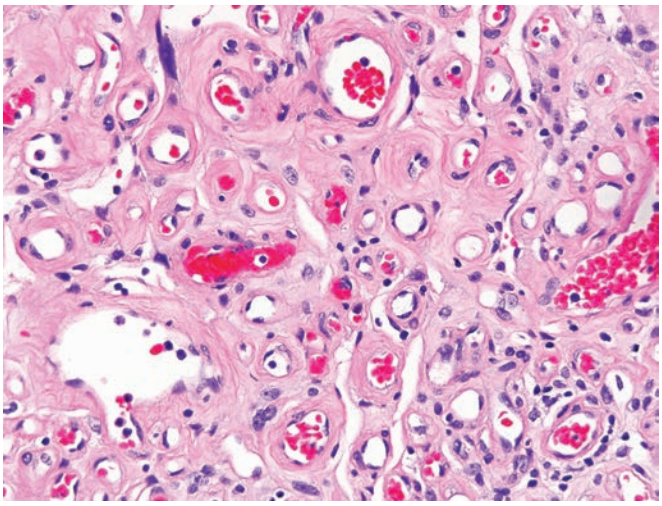

Figure 43.128 Angiomatous (Vascular) Meningioma. The marked hypervascularity (often with hyalinization) and degenerative nuclear atypia may obscure the meningothelial nature of this variant.

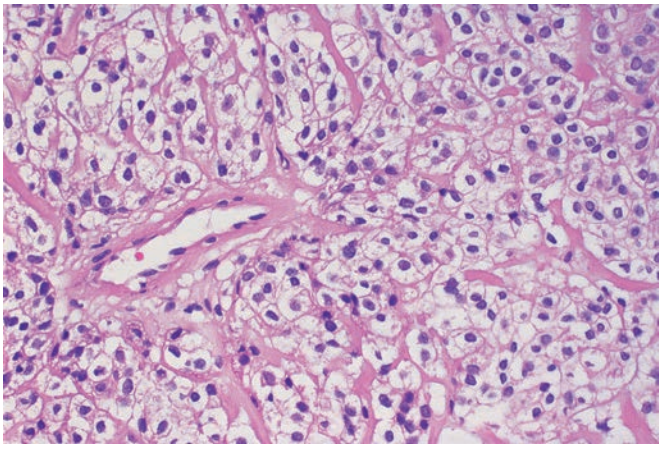

Figure 43.129 Clear Cell Meningioma. The example shown here arose from the filum terminale of a 9-year-old girl. Note cytoplasmic clearing, traversing collagenous bands, and absence of meningothelial-type whorls.

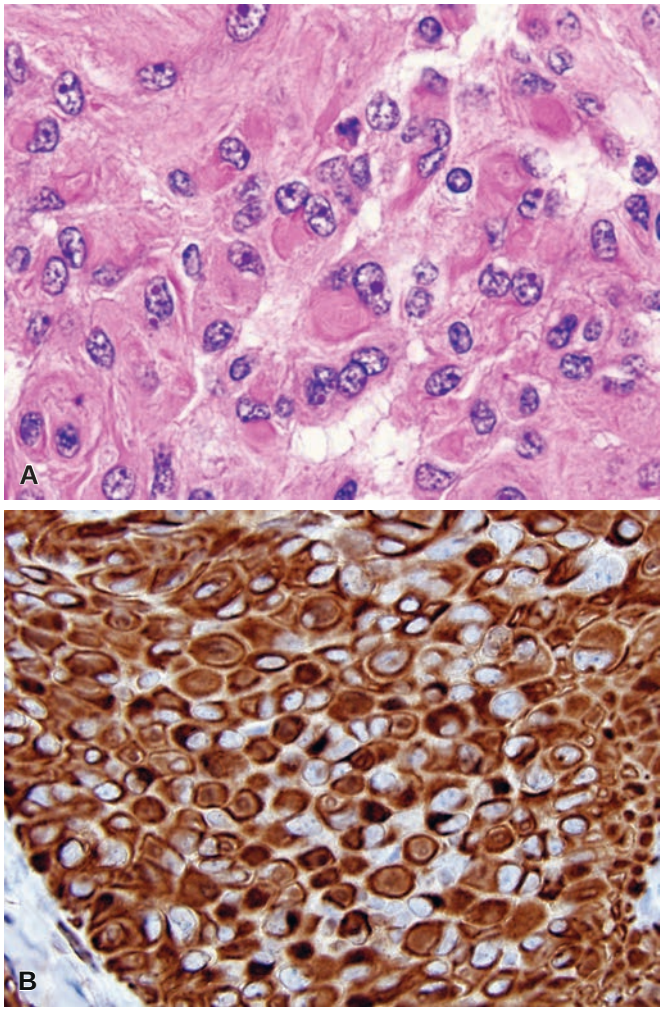

Figure 43.130 Rhabdoid Meningioma. Rhabdoid features include loss of cohesion, large eccentrically placed vesicular nuclei, macronucleoli, and a paranuclear fibrillar to globular eosinophilic inclusion **(A)**, which is often further highlighted on vimentin immunohistochemistry **(B)**.

but probably of lesser significance.[915] In contrast, tumors exhibiting prominent changes of this sort merit distinct designation owing to their potential for a more aggressive biology. **Clear cell meningiomas** (WHO grade II) are the most deceptive of the lot.[916,917] These are characterized by a predilection for young subjects (including children), and are most often found in the spinal canal, cerebellopontine angle, or foramen magnum region. They are usually extra-axial and dura based but may be associated with cranial nerves, spinal roots, or the cauda equina. A fourth ventricular presentation has been described,[918] as has familial occurrence, the latter recently associated with germline *SMARCE1* mutations.[919,920] We have encountered a bulbar example in a 2-year-old child.[921] Composed of glycogen-rich, water-clear cells that are often disposed in patternless sheets traversed by bands of homogeneous to amianthoid-like interstitial and perivascular collagen (Fig. 43.129), these unusual tumors typically manifest little or nothing in the way of classic meningothelial attributes (e.g. whorls or nuclear pseudoinclusions) and may be only focally and faintly immunoreactive for EMA, a marker of specialized arachnoidal cells expressed by most meningiomas in diffuse fashion. High recurrence rates, a potential for CSF-borne spread, and increased mortality characterize this intrinsically aggressive meningioma variant, despite the fact that most examples do not evidence conspicuously increased mitotic activity, necrosis, or other histologic features that would arouse suspicion.

That rhabdoid cytology is, in general, a marker of increased biologic potential is borne out by the discouraging behavior of most meningiomas displaying this profile, which may be evident on initial presentation or appear only in recurrent material.[922] **Rhabdoid meningiomas** (WHO grade III) in fully developed form usually retain meningotheliomatous regions but boast a prominent population of cells with vesicular nuclei, prominent nucleoli, and globose, paranuclear inclusion-like bodies representing compacted cytoplasmic vimentin filaments or rarely other intermediate filaments, such as GFAP (Fig. 43.130). Cells are usually arranged in lobules or sheets, but a papillary growth pattern may also be encountered.[923] Conspicuously increased mitotic activity is the rule, and brain invasion is common; most such tumors qualify as atypical or frankly anaplastic by the WHO/Mayo Clinic criteria presently discussed. In one reported series, 87% of afflicted patients experienced at least one recurrence, and 53% died of tumor progression.[922] The prognosis for cases showing rhabdoid change in the absence of elevated proliferative activity or other malignant indicators does not appear to be nearly

For personal use only. No other uses without permission. Copyright ©2017. Elsevier Inc. All rights reserved.

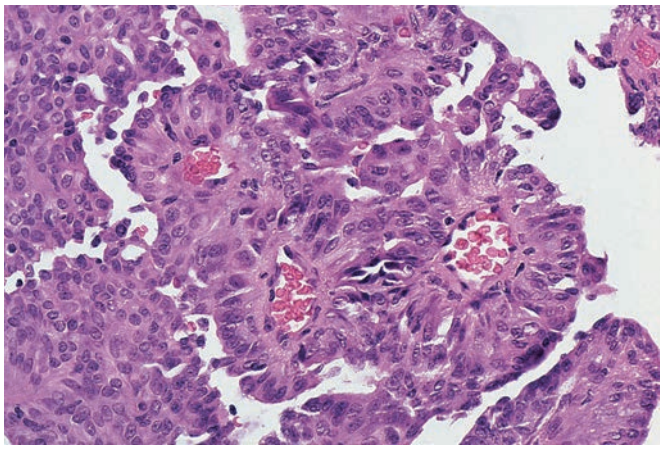

Figure 43.131 Papillary Meningioma. This intraspinal example, which also exhibited features of an atypical meningotheliomatous meningioma with increased mitotic activity and foci of necrosis (not shown here), metastasized to lung, lymph node, and bone.

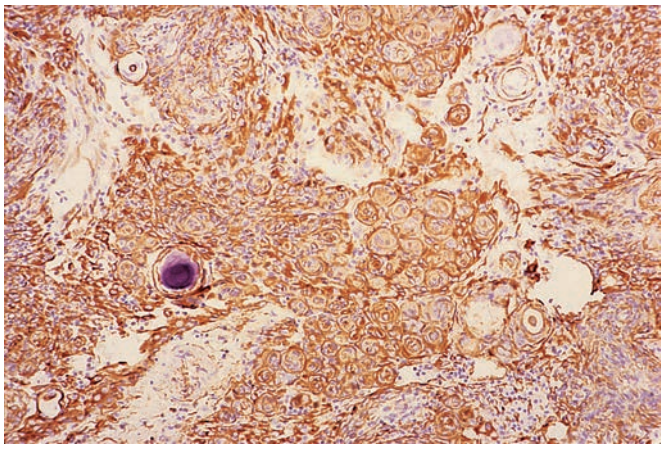

Figure 43.132 Meningioma. Cytoplasmic labeling for epithelial membrane antigen on immunoperoxidase assay, depicted here, characterizes the overwhelming majority of meningiomas, regardless of their histologic subtype.

as poor, but these need close observation nonetheless.[915] Similar considerations seem to apply to oncocytic meningiomas, that is, meningothelial neoplasms demonstrating fine cytoplasmic granularity due to an accumulation of mitochondria.[924] High mitotic rates, necrosis, brain invasion, and recurrence have been over-represented in the few cases recorded to date and in examples that we have encountered in consultation. A series of clinically innocent cases lacking these ominous histologic features has been communicated,[925] though the illustrated example raises questions regarding the criteria for case inclusion in the cited study.

A final variant meriting specific comment in view of its distinctive histology and clinical biology is the **papillary meningioma** (WHO grade III), a tumor characterized by the ependymoma-like perivascular pseudorosetted structuring of its constituent cells.[926,927] The latter can be seen to extend variably elongated cytoplasmic processes toward vessel walls, fashioning structures that disaggregate and come to float unanchored in tissue sections (Fig. 43.131). Regions exhibiting a more conventional meningothelial appearance are nearly always identifiable but usually depart from the typical in evidencing worrisome hypercellularity, mitotic activity, and, in some cases, foci of coagulative necrosis. Stubborn local recurrence, a capacity for extraneural metastasis, and often fatal outcome characterize papillary meningiomas. An excess of reported cases has presented in childhood or adolescence as compared to conventional types of meningioma.

Distinction of the meningioma from potential counterfeits occasionally requires the use of electron microscopy, immunohistochemistry, or genetic analysis. The most constant and distinctive ultrastructural feature of meningothelial neoplasms is the complex interdigitation of tumor cell processes without intervening basal lamina material (elaborated frequently by the meningeal HPC and uniformly by the schwannoma), although fibroblastic variants tend to a more parallel alignment. Intercellular junctional complexes are frequent and include well-developed desmosomes, a conspicuous cytoplasmic complement of intermediate filaments rounding out the ultrastructural picture. The latter consist of vimentin, regularly demonstrable by immunohistochemical methods regardless of tumor subtype. Of particular diagnostic utility is the observation that a large majority of meningiomas exhibit (at least focally) membranous, as well as diffuse, cytoplasmic immunolabeling for EMA (Fig. 43.132),[278] a feature foreign to nerve sheath tumors other than the rare perineurioma and to most HPCs, SFTs, and other fibroblastic neoplasms.[928,929] Expression of claudin-1, though not observed as regularly as labeling for EMA, may also be of discriminatory value in distinguishing meningothelial tumors from these potential mimickers, although claudin-1 positivity is frequently encountered in perineuriomas as well.[930,931] However, an even more sensitive recently identified marker is SSTR2a, which is strongly and diffusely positive in nearly all meningiomas regardless of grade (see Fig. 43.126B).[477] It is not entirely specific and is commonly expressed in a wide variety of neuroendocrine neoplasms, though fortunately, those are not often in the differential diagnosis. Unlike meningeal SFT/HPCs, meningiomas exhibit only weak or focal labeling for CD99 and BCL2.[928] Nuclear immunoreactivity for progesterone receptors is common but inversely associated with grade.[932] Reactivity for S-100 protein, if present, is usually limited to the cytoplasm of a subset of neoplastic cells but may occasionally be encountered in diffuse form (particularly in fibrous/fibroblastic meningiomas). As regards cytokeratin expression, meningiomas often share with native arachnoidal lining cells (and with epithelial cancers) immunolabeling for CK18 but are typically CK20 negative regardless of histologic pattern.[933] Focal reactivity for CK7, CK8 (CAM 5.2), CK19, and AE1/3 may be encountered (and is a consistent feature of the inclusion-bearing elements that define meningiomas of secretory type), but widespread labeling for these antigens suggests that a dura-based mass represents metastatic carcinoma. One study found diffuse AE1/3 and CAM 5.2 expression by 4 of 12 high-grade/anaplastic meningiomas but no labeling of either malignant or benign (n = 20) examples for CEA, Ber-EP4, B72.3, or CD-15 (all commonly expressed by carcinomas).[934] Expression of p63 is also seen in a subset of meningiomas, including higher-grade examples, and this should therefore not be taken as evidence of squamous cell carcinoma.[875,935] GFAP-labeling of papillary,[936] rhabdoid,[922,937] and "whorling–sclerosing"[938] meningiomas have been depicted but are curiosities. Whether this phenomenon always reflects true GFAP expression is open to question. As previously noted, meningiomas rarely exercise an ability to differentiate along myogenic lines, and some otherwise conventional examples focally label for muscle-associated actins.[939] Unlike chordomas, chordoid meningiomas do not exhibit nuclear reactivity for brachyury.[940] Rhabdoid meningioma variants do not manifest the loss of nuclear INI1 protein expression (BAF47 antibody) that is a consistent feature of AT/RTs.[941]

Genetically, biallelic inactivation of the *NF2* gene on chromosome 22 leads to loss of merlin (also known as schwannomin) expression and is the most common alteration in meningiomas, accounting as the

For personal use only. No other uses without permission. Copyright ©2017. Elsevier Inc. All rights reserved.

initial driver mutation in essentially all NF2-associated and up to 60% of sporadic examples.[942,943] The majority of such tumors are convexity or parasagittal transitional and fibrous meningiomas, also representing the subtypes that most frequently undergo progression to atypical or anaplastic meningioma. In contrast, skull base meningiomas are mostly non-NF2 driven, WHO grade I meningothelial variants, with recent studies[944-946] implicating driver mutations of (1) the *TRAF7* gene (mutated in 8%–24% of all cases), almost always in combination with *KLF4* mutations (which are also implicated in 93%–100% of secretory meningiomas[894]); (2) the *AKT1* (*AKT1* E17K) gene in about 13% of cases; and (3) the *SMO* gene in roughly 5% of cases. Rare driver mutations involve the SWI/SNF family members, *SMARCB1* (mostly in schwannomatosis patients), and *SMARCE1* (mostly in familial and sporadic cases of clear cell meningioma).[864] Progression to higher-grade meningiomas is mostly associated with chromosomal losses cytogenetically, though the most strongly implicated candidate tumor suppressor and oncogenes include *CDKN2A/B*, *hTERT*, *NDRG2*, *MEG3*, *RPS6KB1*, *TIMP3*, and *TSLC1*.[947,948]

Meningiomas of conventional histologic type grow slowly and are amenable to surgical cure when complete excision can be effected, as is usually the case for examples arising over the cerebral convexities or along the spinal axis. Even tumors so favorably situated, however, may recur following gross total resection, the magnitude of this risk emerging only on long-term observation. In one study, for example, respective 5-, 15-, and 25-year relapse rates for histologically benign and completely excised intracranial meningiomas were 3%, 15%, and 21%, respectively.[885] By all accounts, the likelihood of regrowth is considerably higher for the less accessible olfactory groove and sphenoid wing meningiomas, with en plaque examples and lesions invasive of the cranial floor proving particularly troublesome.[949] But while there can be no gainsaying the influence of tumor location on outcome in this setting, it is clear that certain morphologic features serve to independently define a subset of high-risk meningiomas to which a substantially increased likelihood of postoperative recurrence attaches. Recognizing that a number of grading strategies have proven useful in the identification of potentially aggressive meningothelial neoplasms, we can endorse with minor reservations a Mayo Clinic proposal,[883,950] adopted with only slight modifications in the last three WHO formulations.[278]

Application of the WHO/Mayo Clinic criteria outlined here broadly stratifies meningothelial tumors into three tiers of increasing biologic potential—**meningioma (WHO grade I)**, **atypical meningioma (WHO grade II)** (Figs. 43.133 and 43.134), and **anaplastic meningioma (WHO grade III)** (Fig. 43.135). The stated criteria are applied whether present as focal findings (often the case) or in more diffuse form. In this scheme, atypical meningiomas are defined as:

1. containing four or more mitotic figures per 10 high-power microscopic fields (0.16 mm^2)
   or
2. brain invasion, with tumor breaching beyond the pia
   or
3. exhibiting at least three of the following features:
   a. hypercellularity
   b. patternless, sheet-like growth
   c. macronucleoli
   d. small cell components with high nuclear:cytoplasmic ratio
   e. zones of spontaneous (i.e. noniatrogenic as seen after embolization) necrosis.

Anaplastic meningiomas are defined as:

1. containing 20 or more mitoses per 10 high-power microscopic fields (0.16 mm^2)
   or
2. exhibiting a loss of differentiated features resulting in carcinoma-, melanoma-, or sarcoma-like appearances.

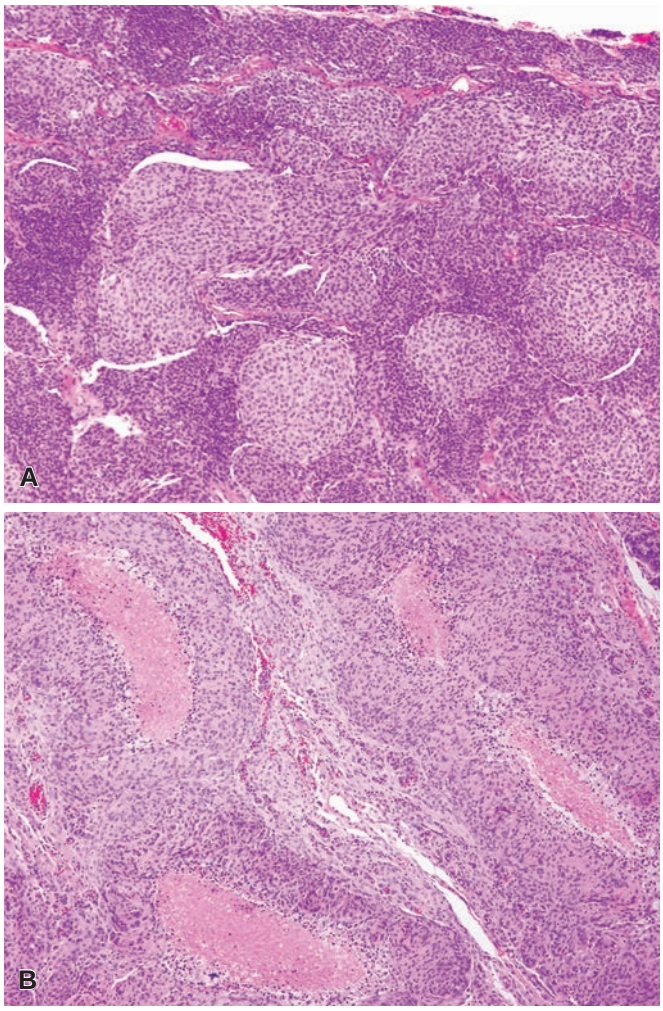

Figure 43.133 Atypical Meningioma. Low-magnification clues include two-dimensional sheeting architecture (loss of whorling and fascicles) and small cell formation (clusters of tumor cells with high N/C ratio) **(A)**, as well as spontaneous (e.g. not embolization-induced) necrosis **(B)**.

Readers should note that WHO grade II status is also accorded to fully developed clear cell and chordoid meningiomas, while papillary and rhabdoid variants are designated as WHO grade III tumors.

We would emphasize that preoperative embolization of meningiomas, undertaken to reduce their blood supplies and facilitate removal, often results in regions of necrosis with evident mitotic activity (and increased MIB-1 reactivity) in adjoining tumor tissue,[951] potentially rendering problematic application of the foregoing criteria. This phenomenon is often, though not invariably, signaled by the presence of clearly foreign material within the tumoral vasculature. The finding of multiple zones of necrosis that appear to be at the same acute stage of development suggests such intervention, but, in any case, pathologists should consult their clinical colleagues on this issue prior to releasing reports. The study cited earlier suggests that WHO/Mayo Clinic mitotic criteria remain valid in these circumstances, but confirmation in additional large series would be reassuring.

Brain invasion is defined as tongue-like extensions of tumor beyond the pial barrier (see Fig. 43.134A), which can often be confirmed with a GFAP stain (see Fig. 43.134B) in equivocal cases,

For personal use only. No other uses without permission. Copyright ©2017. Elsevier Inc. All rights reserved.

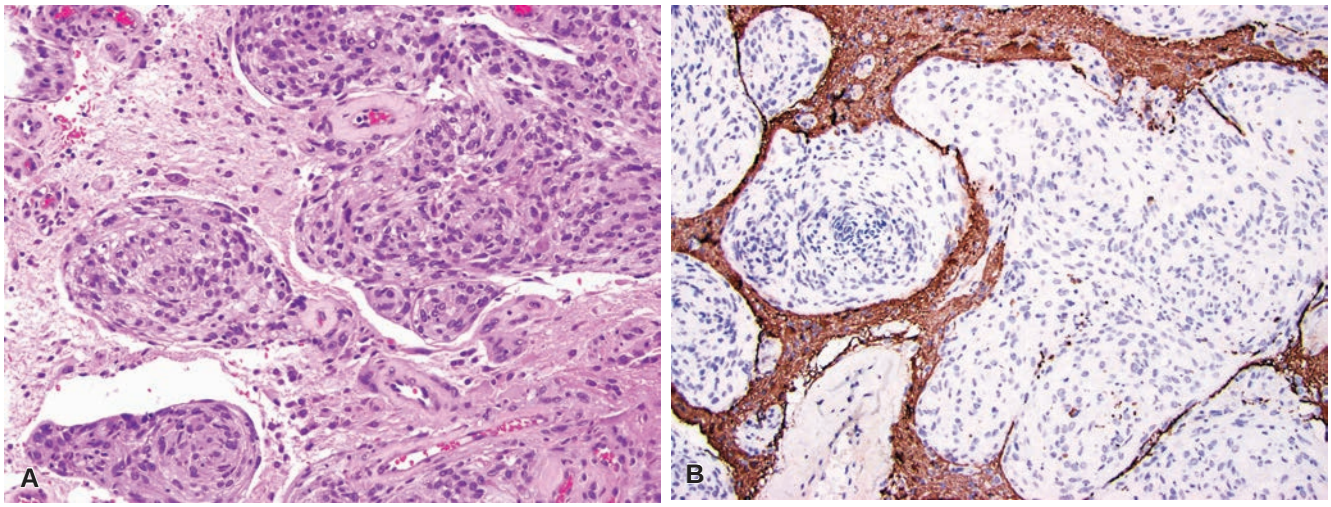

Figure 43.134 Atypical Meningioma. Another criterion for atypical meningioma in the WHO 2016 scheme is brain invasion, characterized by tongue-like protrusions into adjacent gliotic brain **(A)**, which can be further verified using glial fibrillary acidic protein immunohistochemistry **(B)**.

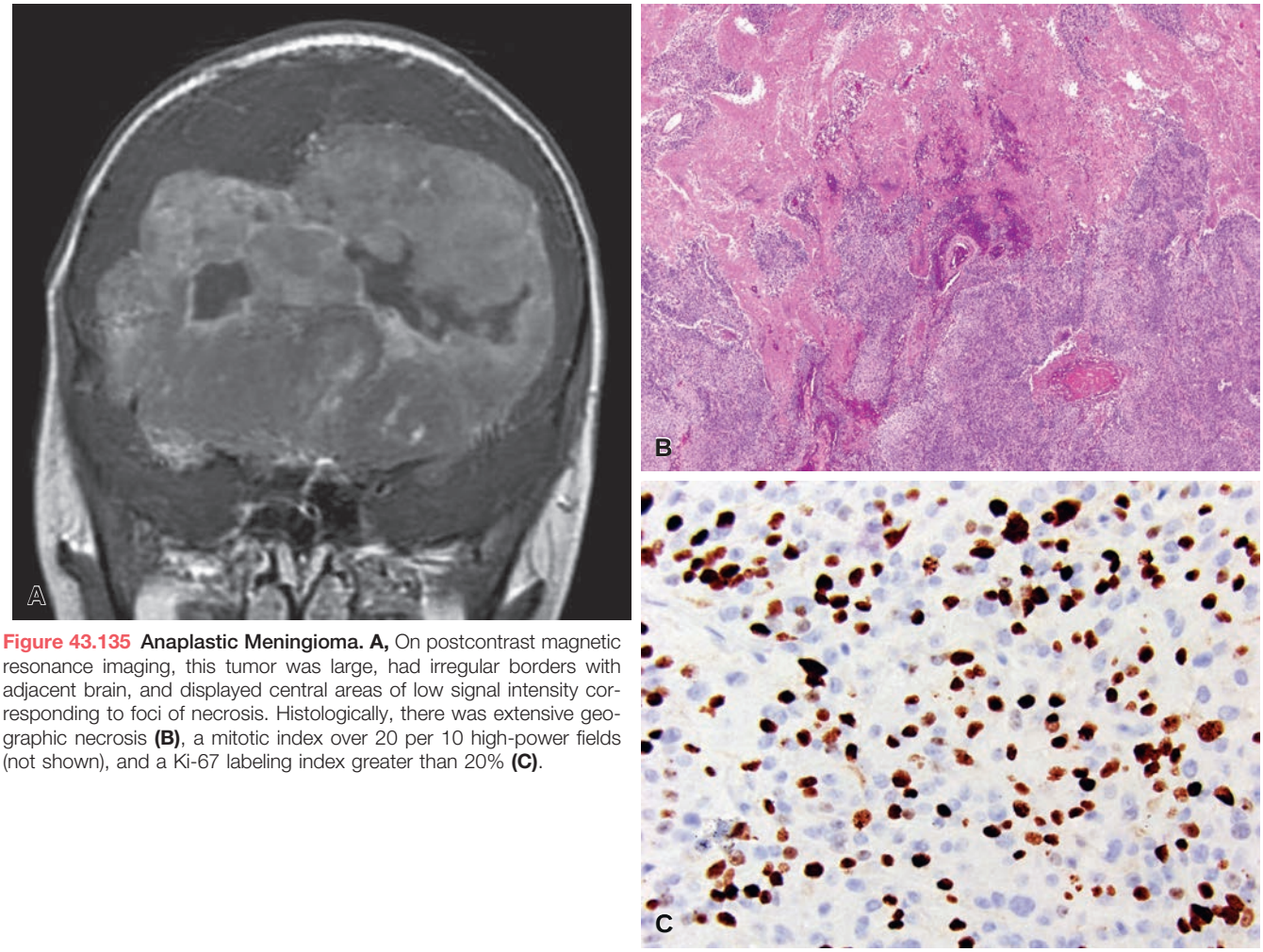

Figure 43.135 Anaplastic Meningioma. A, On postcontrast magnetic resonance imaging, this tumor was large, had irregular borders with adjacent brain, and displayed central areas of low signal intensity corresponding to foci of necrosis. Histologically, there was extensive geographic necrosis **(B)**, a mitotic index over 20 per 10 high-power fields (not shown), and a Ki-67 labeling index greater than 20% **(C)**.

For personal use only. No other uses without permission. Copyright ©2017. Elsevier Inc. All rights reserved.

the latter highlighting entrapped glial nests within the main tumor mass. Such meningiomas, in fact, span the histologic spectrum, some being of otherwise benign appearance, such cases typically showing recurrence-free and overall survival times similar to atypical meningiomas diagnosed by other criteria.[883] For this reason, the 2016 WHO now considers brain invasion as another criterion for atypical meningioma.[278] In contrast, the demonstration of brain invasion per se adds relatively little to the predictive power of the WHO/Mayo Clinic scheme as a prognostic model once a given tumor has satisfied the listed criteria for designation as atypical or anaplastic. As stated earlier, rare meningiomas—especially pediatric examples—may demonstrate extensive perivascular invasion along Virchow–Robin spaces, potentially mimicking meningioangiomatosis and/or brain invasion.[35,914] However, the pia is not actually breached in this scenario and therefore, this pattern alone is insufficient for a WHO grade II designation.

In the experience that served as the basis for these recommendations, respective 5-year recurrence rates for conventional versus atypical meningiomas were 12% and 41% following gross total resection.[883,950] Atypical tumors carried a 5-year mortality rate of approximately 20%. Anaplastic meningiomas, by contrast, recurred in the large majority of cases and were associated with a 68% 5-year mortality rate and a median survival of only 18 months. Nevertheless, patients undergoing complete excision, postoperative radiation therapy, and/or whose tumors lacked *CDKN2A*/p16 losses have considerably better survival times, the first two of these also significantly impacting survival in the atypical meningiomas.[952-955] Other findings that have been correlated with worrisome histology and increased biologic potential in the setting of meningothelial neoplasia include elevated MIB-1 labeling indices and, in some studies, failure to express progesterone receptors.[278] Regarding the former, meningiomas of conventional type and indolent behavior usually have MIB-1 labeling indices below 4%–5%, but there is considerable overlap in the values recorded for benign, atypical, and anaplastic lesions, as well as for recurring versus nonrecurring tumors.[956-958] Consequently, the predictive power of this assessment in the individual case is somewhat compromised. Others have successfully utilized the mitotic index marker pHH3 in a similar fashion.[959] It is noteworthy that disturbing histologic features, including elevated mitotic MIB-1 indices and brain invasion, seem to be over-represented among meningiomas occurring in the pediatric group.[862] As reviewed in the reference just cited, most studies have found these morphologic attributes to correlate with an increased risk of recurrence and fatal outcome in this patient cohort, but, overall, grading is much less predictive in children. Progression-associated genetic markers, such as chromosome 1p and 14q deletions, may also be more prevalent in meningiomas of childhood and adolescence compared to adult-onset examples.

While application of the WHO/Mayo Clinic guidelines discussed previously can be recommended as a means of stratifying affected patients into groups at increasing risk of recurrence and meningioma-related death, pathologists and attending clinicians must realize that prognostic certainty is not to be found in the proposed criteria—particularly in the mitotic thresholds that separate the typical, atypical, and anaplastic. It has long been our practice to specifically comment when confronted by any meningioma containing more than the very occasional mitosis found on careful scrutiny, as close neuroradiological surveillance is prudent in this circumstance even if a gross total excision has been effected. Further supporting this notion, recent studies have shown that meningiomas with one or more atypical features insufficient for a WHO grade II designation, nevertheless have higher recurrence rates than those with none.[956] It also bears emphasizing that within the broad spectrum of meningiomas that qualify as merely "atypical" by WHO/Mayo Clinic criteria are to be found examples (e.g. the tumor exhibiting 14 mitoses per 10 high-power microscopic fields, necrosis, and cerebrocortical invasion) that may not be as predictably virulent as anaplastic variants but that are capable of frankly malignant clinical behavior.

Although local regrowth is the major pattern of treatment failure, aggressive meningioma variants can spread via the CSF and, on occasion, travel to extraneural sites such as the lung, liver, bone, and lymph node.[960] We would point out, however, that an excess of distant metastases recorded in the literature have derived from "angioblastic" variants that would now be classified as meningeal SFT/HPCs. Examples of "**benign metastasizing meningioma**" have been well documented but remain curiosities.[961,962] As noted, venous sinus invasion is a feature of many meningiomas and is not predictive of hematogenous dissemination or germane to the designation of a given lesion as atypical or anaplastic. In a similar vein, little significance attaches to foci of pronounced nuclear pleomorphism associated with "degenerative atypia," provided that nucleolar enlargement, mitotic activity, or other atypical features are not in evidence. X-chromosome inactivation studies and *NF2* gene mutation analyses suggest that the majority of "multifocal" meningioma (particularly those characterized by the presence of three or more spatially distinct tumors) actually represent clonal proliferations with dural spread.[278,963]

Nonmeningothelial Mesenchymal Tumors

Excepting the obscure process known as primary meningeal sarcomatosis and the congenital lipomatous tumors of the lumbosacral spinal canal and cranial cavity, the varied lesions surveyed in this section represent the homologues of neoplasms encountered far more frequently in the somatic soft tissues and bones than along the central neuraxis.[278,964-966] Accordingly, little attempt is made to describe or depict their histopathologic, ultrastructural, and immunophenotypic profiles, all of which are given detailed attention elsewhere in these volumes. However, we would emphasize the hazards in diagnosis occasioned by the existence of both neuroepithelial and meningothelial tumors that mimic the tumors under discussion in this section. Whereas CNS neoplasms exhibiting spindled or bizarre, "monstrocellular" cytologic features were once presumed to be mesodermal in derivation if they could be shown to elaborate an intercellular reticulin network, it is now clear that candidates with this feature must be subjected to immunohistochemistry for evidence of cytoplasmic GFAP expression if entities such as the sarcomatoid or "giant cell" glioblastoma, desmoplastic cerebral astrocytoma/ganglioglioma, and pleomorphic xanthoastrocytoma are to be excluded. In addition, the possibility must always be borne in mind, particularly in adult cases, that the biopsy ostensibly demonstrating a malignant mesenchymal tumor derives, in fact, from a gliosarcoma. Especially suspect in this regard are limited specimens with features of fibrosarcoma or pleomorphic sarcoma, but the gliosarcoma, as already indicated, may also contain angiosarcomatous, osteosarcomatous, chondrosarcomatous, liposarcomatous, and myosarcomatous components. Inasmuch as primitive neuroepithelial neoplasms such as the medulloblastoma with myogenic differentiation and certain variants of pineoblastoma contain striated muscle elements, putative embryonal rhabdomyosarcomas of the CNS must be screened for telltale evidence of neuronal and/or glial differentiation at the ultrastructural or immunohistochemical levels. Finally, electron microscopic study and immunocytochemical assessment for STAT6, SSTR2a, EMA, and CD34 labeling may serve to distinguish the fibrosarcoma-, SFT-, or HPC-like meningioma from the genuine soft tissue neoplasm. These guidelines are offered, of course, with the full realization that poorly differentiated neoplasms may lose expression of key marker antigens or express aberrant antigens.

For personal use only. No other uses without permission. Copyright ©2017. Elsevier Inc. All rights reserved.

Meningeal Solitary Fibrous Tumor/ Hemangiopericytoma

Though long described as separate entities, it is now clear that the **SFT**, WHO grade I, **HPC**, WHO grade II, and **anaplastic HPC**, WHO grade III represent a wide spectrum of histologic appearances within a single biologic entity, which is defined by the same genomic inversion at the 12q13 locus found in the soft tissue SFT counterparts; this alteration fuses the *NAB2* and *STAT6* genes, resulting in nuclear translocation of the STAT6 protein that can be readily identified by immunohistochemistry, thus providing a highly sensitive and specific surrogate biomarker for routine diagnostic practice.[967-969] By far, these are the most common mesenchymal nonmeningothelial neoplasms and virtually always present as dural-based masses mimicking meningioma. Whereas the soft tissue approach has now progressed to a two-tiered scheme of SFT and malignant SFT, the traditional CNS approach has been three-tiered and for now, the WHO 2016 scheme has opted to maintain diagnoses of SFT/HPC of grades I, II, or III based on histologic pattern and mitotic index.[278]

The classic **SFT** diagnosis (now **SFT/HPC, WHO grade I**) is in all respects identical to those originating in the pleura and extrapleural somatic tissues, featuring a haphazard architecture with thick lace-like bands of hyalinized to amianthoid-like collagen and thin-walled branching (staghorn) vessels (Fig. 43.136).[970-972] Usually dura-based (and so taken for meningiomas on preoperative assessment), these may also arise within the lateral ventricles, sellar region, the substance of the spinal cord, or spinal nerve roots.[972] Most such tumors are benign in appearance and clinical behavior, with gross total resection usually proving curative; only exceptional cases showing aggressive morphologic features (e.g. conspicuous mitotic activity) or behavior (local invasion of brain or distant metastasis following repeated local recurrence) are on record.[972] In addition to nuclear STAT6 positivity, neuraxial SFTs share with their systemic counterparts a characteristic immunophenotype, including strong and diffuse cytoplasmic labeling for CD34, frequently intense BCL2 reactivity, and failure to express S-100 protein or EMA, that facilitates their distinction from schwannomas (S-100–protein positive) and fibrous meningiomas (usually both S-100 protein and EMA reactive, while STAT6 is negative or limited to cytoplasmic positivity).

Although their cytogenesis remains a contentious issue, select dura-based tumors once regarded as "angioblastic" variants of meningioma are in fact, distinct entities within the SFT/HPC spectrum. **Meningeal HPC** (now **SFT/HPC, WHO grade II**) are largely tumors of adulthood that do not exhibit the distinct predilection for women characteristic of meningiomas, and that strongly favor the intracranial compartment. Although sharing features of the classic SFT, they tend towards greater cellularity, higher nuclear to cytoplasmic ratio, lesser degree of collagenization, and more prominent staghorn vasculature. Mitotic figures are often found, but maximal indices should not exceed 5 mitoses/10 high-power fields (see anaplastic section later). Their distinction from meningiomas with potentially misleading pericytomatous growth patterns is usually straightforward, as these tumors often contain psammomatous calcospherites and tumor cells concentrically arrayed in tight whorl formations—both foreign to the HPC, as are the intranuclear pseudoinclusions typical of meningothelial elements and their neoplastic derivatives. Also alien to the meningioma, but a feature of many HPCs, is a network of "reticulin" investing individual tumor cells. This appears to represent basal lamina material at the ultrastructural level.[973] The HPC further departs from the meningioma on electron microscopic study in that, although joined by rudimentary junctions, cytoplasmic processes are neither bound by well-developed desmosomes nor intertwined in complex fashion. Serving also to segregate these lesions from neoplasms of meningothelial lineage is an immunophenotype that often includes

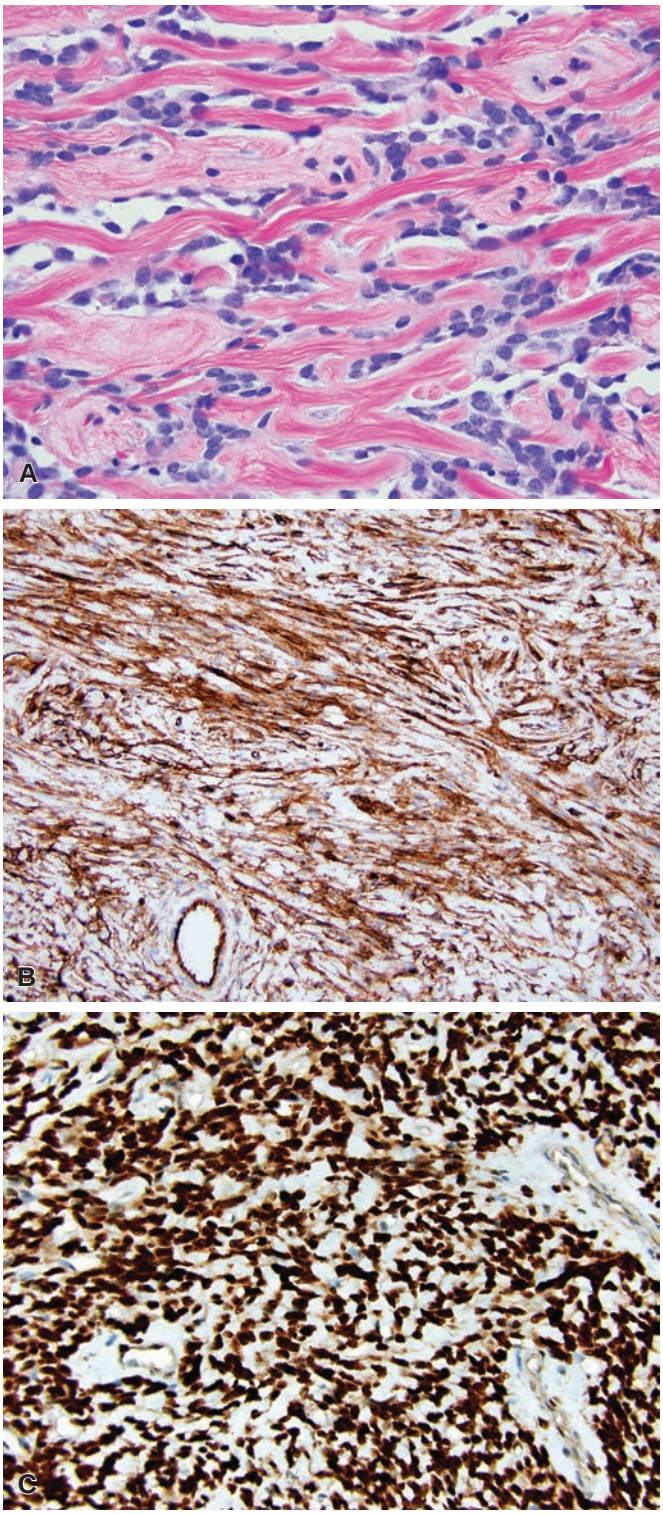

Figure 43.136 Solitary Fibrous Tumor/Hemangiopericytoma, WHO Grade I. A, Demonstrating the classic solitary fibrous tumor histology, this tumor is predominantly spindled and shows lace-like brightly eosinophilic intercellular collagen. Immunohistochemistry reveals diffuse CD34 **(B)** and nuclear STAT6 **(C)** positivity.

For personal use only. No other uses without permission. Copyright ©2017. Elsevier Inc. All rights reserved.

the already mentioned nuclear STAT6 positivity, along with widespread and strong labeling for CD99 and BCL2 but only focal, if any, EMA or claudin-1 expression.[928,931] Mesenchymal chondrosarcomas of dural origin routinely harbor anaplastic small cell elements in pericytomatous architectural array and thus enter the differential diagnosis, but the meningeal HPC lacks chondroid components. As mentioned previously, meningeal HPCs may evidence labeling for CD34, but this is usually weak and patchy as opposed to the diffuse and strong cytoplasmic reactivity typical of SFTs.[278,972] Regrowth at the primary site despite seemingly complete initial resection is commonly seen in the setting of meningeal HPC, although this may take years to become clinically apparent. Even with the addition of postoperative radiotherapy, many afflicted patients die as a direct result of intracranial tumor progression (often after a protracted course characterized by repeated local recurrence) or extracranial metastasis (typically a late complication that develops in at least 20%–25% of cases).[974-976] Most often seeded are the lungs, bones, and liver, but retroperitoneal organs, such as kidney and pancreas, may also be involved.

While all HPCs must be regarded as having the potential to recur locally and disseminate, histologic features may be of some efficacy in identifying the most predictably aggressive variants. Recommendations emerging from a large Armed Forces Institute of Pathology (AFIP) study[975] and adapted in slightly modified format by the WHO are that "**anaplastic HPCs**" (now **SFT/HPC, WHO grade III**) are distinguished from their grade II counterparts by the presence of 5 or more mitoses per 10 high-power fields (Fig. 43.137); necrosis is also commonly found but is not necessary for the diagnosis.[278] In the AFIP series, median overall survival was significantly shorter for patients with anaplastic tumors (62 months) compared to those with lower-grade lesions (144 months).[975] A more recent study of SFTs and HPCs from Marseille, France used similar criteria and suggested two subtypes within the grade II category, though this remains to be validated; it is nevertheless of interest that only the mitotic index was of statistical significance in predicting survival on multivariate analysis.[971] Similar to meningiomas, studies suggest that both complete resection and radiotherapy in the WHO grade II and III categories improve recurrence-free and overall patient survival times.[976-978] Additional experience will be needed to determine whether the current three-tiered approach is best suited for future meningeal SFT/HPC classification and grading or whether the simplified two-tiered approach of SFT versus malignant SFT utilized by soft tissue pathologists is preferable in the CNS as well.

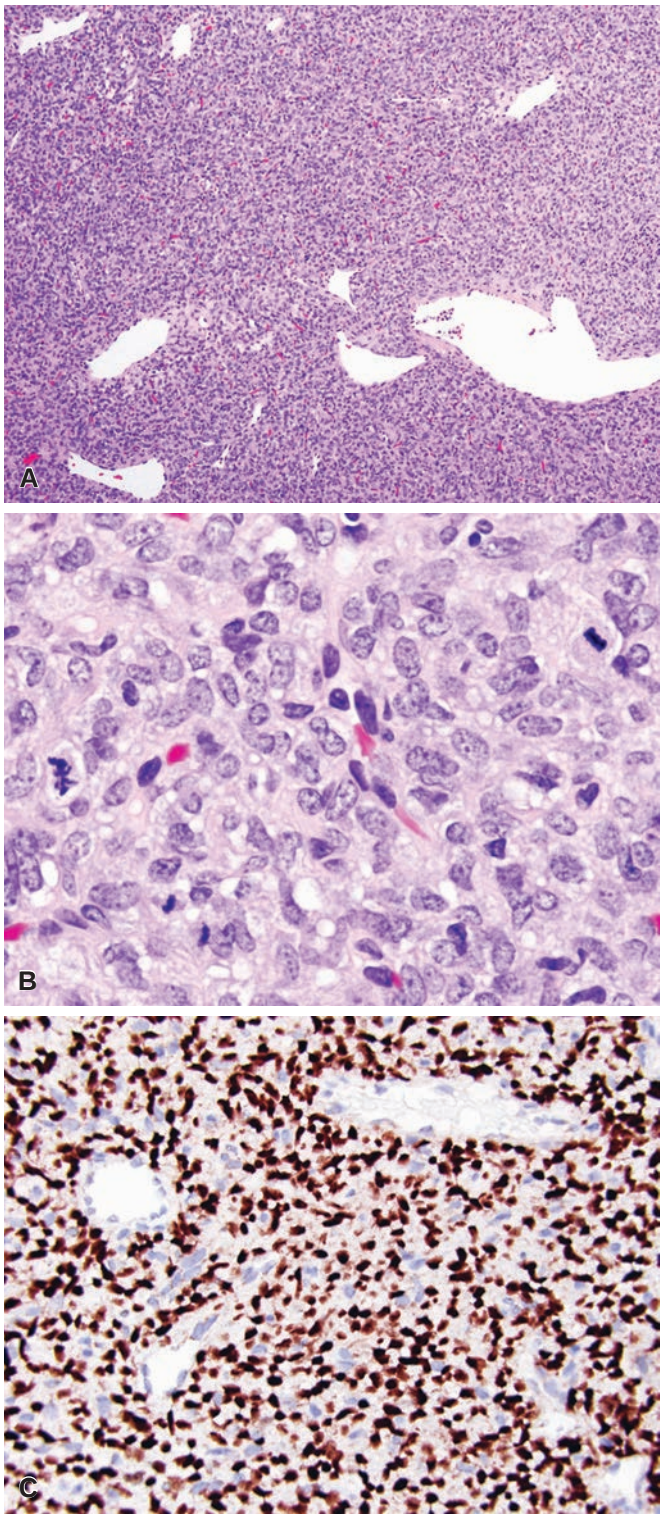

Figure 43.137 Solitary Fibrous Tumor/Hemangiopericytoma, WHO Grade III. In comparison to the case in Fig. 43.136, this one is more cellular, less collagenized, and includes greater than 5 mitoses/10 hpf (**A** and **B**). Note also the typical hypervascularity, including gaping thin walled blood vessels **(A)**. Immunohistochemically, CD34 highlighted the rich vascularity but was negative in tumor cells (not shown), while STAT6 was diffusely expressed in tumor nuclei **(C)**.

Fibroblastic, Myofibroblastic, and "Fibrohistiocytic" Tumors

Benign neuraxial neoplasms of fibroblastic or myofibroblastic type reported under designations other than SFT/HPC are exceedingly rare; whether at least some such cases represent examples of the latter is arguable. The literature thus contains accounts of CNS "**fibroma**"[979] (sometimes referred to as fibromyxoma owing to mucoid stromal alterations) and "**sclerosing fibrous tumor**"[980] as well as **angiofibroma**[981] and **myofibroblastoma**.[982] **Dural fibromatosis (desmoid)**[983] has also been described, in some cases as a complication of neurosurgery, as has the intracranial presentation of **childhood cranial fasciitis**.[984] Fibroblasts additionally participate in the formation of so-called intracranial "**fibroxanthomas**," but these, often dominated by foam cells, may be reactive in nature and are considered under the rubric of xanthomatous lesions.

Fibrosarcomas of the CNS are commonly attached to the dura or leptomeninges, but some examples are situated entirely within the substance of the cerebrum or cerebellum.[965] Radiation is clearly recognized as predisposing,[985,986] especially to sellar fibrosarcoma

For personal use only. No other uses without permission. Copyright ©2017. Elsevier Inc. All rights reserved.

in patients so treated for pituitary adenomas, but a spontaneous counterpart within the sella turcica has also been described.[987] Symptomatic local recurrence is the rule even after gross total resection of circumscribed, superficially positioned lesions, and patients with high-grade lesions usually succumb to their disease within several years of diagnosis, some developing leptomeningeal and distant, extracranial metastases. Low-grade variants seem more amenable to surgical control. Similar considerations apply to the pleomorphic sarcomas previously reported under the rubric of intracranial "**malignant fibrous histiocytoma**" (a nonspecific diagnosis no longer utilized).[965,988] Rare intracerebral **angiomatoid fibrous histiocytomas**, including one with a t(12;22)(q13;q12) translocation resulting in a clear cell sarcoma-like type 1 *EWS/ATF-1* gene fusion, have been documented.[989,990] The spectrum of malignant fibroblastic tumors encountered along the neuraxis includes MUC4 immunoreactive[991] **low-grade fibromyxoid sarcomas** histologically similar to its soft tissue counterpart[992] and **sclerosing epithelioid fibrosarcomas**.[993] The latter may assume a deceptively benign, hypocellular, and amitotic appearance but seems prone to local recurrence and distant metastasis.

Also, the non-neoplastic lesions that can justifiably be regarded as "inflammatory pseudotumors" or "plasma cell granulomas" must be distinguished from bona fide examples of **inflammatory myofibroblastic tumor** involving the CNS.[193] The last of these is a neoplasm, often meningioma-like on neuroradiological study, that departs from the inflammatory pseudotumor group by virtue of its lack of association with underlying systemic infection or immunologic dysfunction, conspicuous content of spindle cells with cytologic atypism, frequent immunoexpression of ALK, and *ALK* gene (2p23) or *ROS1* (6q22.1) rearrangements.[994,995] Gross total resection has been associated with a favorable course in most CNS cases communicated to date.[193]

Lipoma and Liposarcoma

Intradural tumors composed of mature adipose tissue may be encountered anywhere along the neuraxis but are most common at spinal levels, where they can be divided into a congenital, maldevelopmental group situated principally in the lumbosacral region and a smaller, arguably neoplastic subset tending to a thoracic location. The former have already been discussed as manifestations of spinal dysraphism. Commonly occurring in complex with spina bifida and its cutaneous stigmata, "**lipomas**" of this type figure prominently among intraspinal anomalies complicated by fixation of the filum terminale, caudal displacement of the conus medullaris, and the traction-induced myelopathy known as the "tethered cord" syndrome. These malformative lesions not infrequently contain heterotopic components such as smooth and striated muscle ("**myolipoma**"),[996] aberrant peripheral nerve fibers, meningothelial derivatives ("**occult" lipomeningocele**), ependyma, and other neuroglial elements ("**occult" lipomeningomyelocele**).[997] We have encountered an example that harbored mesonephroid tubules and glomeruloid structures lined by an orderly cuboidal epithelium, reference having been made to such "nephrogenic rests" in the discussion of lipomeningomyeloceles complicating spinal dysraphism. Although entrapment of the cauda equina and permeation of the conus usually preclude thorough resection of these intraspinal masses, dramatic neurologic improvement can often be effected by debulking, division of the tethered filum, and dural reconstruction.

In contrast to the congenital lipomatous tumors of the lumbosacral canal, lipomas occurring at higher levels of the spinal axis are typically not associated with regional anomalies of the vertebrae or intraspinal contents and usually consist of mature fat alone. Only rarely are these entirely intramedullary,[998] one report describing a thoracic example with admixed smooth muscle (**leiomyolipoma**).[999] Much more common are **leptomyelolipomas**,[1000] which present as subpial masses plastered over a highly variable length of the spinal cord, incorporating nerve roots and blending into the neuroparenchyma proper. These features frustrate attempts at complete excision, but, again, long-term symptomatic relief is often achieved by simple debulking. Uncommon examples contain conspicuous vascular elements and are dubbed **angiolipomas** or **angiomyolipomas**, but such lesions are more often epidural in location.[1001] An extradural location also characterized an intraspinal example of **osteolipoma** arising in the cervical region.[1002] Symptomatic accumulation of adipose tissue in this compartment is also a recognized, albeit rare, complication of natural obesity and of corticosteroid administration. Known as **spinal epidural lipomatosis**,[1003] this may consist of brown fat ("**hibernoma**").[1004] **Intradural hibernoma** has also been described.[1005]

Intracranial lipomas are usefully segregated into a midline group and laterally situated variants, most of which involve the eighth cranial nerve. The former exhibit a decided predilection for the region of the corpus callosum but may also settle along the tuber cinereum, above the quadrigeminal plate, in the ambient cisterns, and in the third ventricle.[1006] Most are incidentally discovered at autopsy, but epileptogenic callosal examples are well recognized, tuberal variants may eventuate in hypothalamic dysfunction, and lesions impinging on the third ventricle or aqueduct of Sylvius may be complicated by progressive hydrocephalus. Sleep apnea has exceptionally been recorded in association with lipomas involving the mesencephalic tectum and rostral pons.[1007] In any of these locations, the midline lipoma is clearly maldevelopmental, being frequently associated with structural anomalies of neighboring neural tissues (e.g. agenesis of the corpus callosum) and occasionally occurring in complex with cranial defects or congenital intracranial cysts of colloid or epidermoid type. The added presence, in some instances, of cartilage, bone, smooth or striated muscle, heterotopic peripheral nerves, ganglion cells, neuroglia, and choroid plexus further attests to their malformative basis, although some observers have speculated that these more complex lesions may represent teratomas or teratoid neoplasms.[1008] As in the spinal compartment, exceptional variants merit designation as **angiolipomas**[1009] or **osteolipomas**.[1010] The latter preferentially involve the suprasellar/interpeduncular regions and tuber cinereum. A peculiar tentorial tumor having chondromatous, osseous, and lipomatous components ("**osteochondrolipoma**") has been reported.[1011]

Intracranial lipomas situated off the midline tend to present in the cerebellopontine angle or internal auditory canal and are usually mistaken for acoustic schwannomas on clinical evaluation.[1012,1013] The eighth cranial nerve is typically permeated in diffuse fashion, its fibers divided into small fascicles embedded in mature adipose tissue, and other cranial nerves may be engulfed in like manner by large lesions lying adjacent to the brainstem. These may contain dysmorphic vascular elements as well as smooth muscle bundles and striated muscle fibers, suggesting a maldevelopmental etiology ("**lipochoristoma**"). On rare occasions, intracranial lipomas settle in the region of the sylvian fissure, encasing middle cerebral artery branches and infiltrating temporal cortex.[1014] As attempts at en bloc resection may result in severe neurologic injury, it has been suggested that these and cerebellopontine angle examples be subjected to the minimum debulking required to relieve local mass effects. The intrinsically high signal characteristic of fat on T1-weighted MR study may facilitate the accurate preoperative identification of neuraxial masses as lipomas.

Liposarcomas are among the least common of all malignant mesenchymal tumors reported to involve the CNS or its coverings. Only isolated meningeal examples are on record.[965] The reader is reminded that cells resembling lipoblasts or adipocytes may be

For personal use only. No other uses without permission. Copyright ©2017. Elsevier Inc. All rights reserved.

encountered in hemangioblastomas as well as "lipidized" neoplasms of meningothelial and neuroepithelial lineage.

Osseous and Cartilaginous Tumors

Osseous plaques adherent to the falx cerebri and undersurface of the dura in the region of the superior sagittal sinus are common incidental findings at autopsy and are generally asymptomatic. Although termed **osteomas**, these almost certainly represent reactive, metaplastic lesions and may occur with increased frequency in the setting of chronic renal failure.[1015] In a similar vein, the spinal arachnoid frequently undergoes patchy ossification, but only rarely is this process so extensive as to produce myelopathy.[1016] Examples of bona fide **osteogenic sarcoma** arising from the meninges or brain have been depicted but are exceptional.[1017] We have previously mentioned a case of cerebellar osteogenic sarcoma arising in association with an epidermoid cyst.

Bosselated masses of mature hyaline cartilage known as **chondromas** (or **osteochondromas** when they contain bony elements) may bulge into the cranial cavity from its floor or, much less commonly, may arise from the dura.[1018,1019] Examples complicating the generalized skeletal chondromatoses designated as **Maffucci syndrome** and **Ollier disease** have also been depicted.[1020,1021] **Intracranial chondrosarcomas** of conventional type usually originate in the skull base, but meningeal and neuroparenchymal primaries are recognized,[1022] reports including isolated cases following cranial irradiation and evolving from chondromas.[1023,1024] Lack of brachyury positivity distinguishes chondrosarcoma from chondroid chordomas, which are often in the differential.[1025] Curiously, the **mesenchymal chondrosarcoma** seems to have a special predilection for the dura among extraosseous sites.[1026] Examples arising in the leptomeninges and brain[1027] are also on record. Rarest of all cartilaginous intracranial neoplasms is the **extraskeletal myxoid chondrosarcoma**.[1028]

Endothelial Tumors

The overwhelming majority of vasoformative tumors involving the CNS are maldevelopmental anomalies (previously considered in the discussion of vascular malformations). Endothelial neoplasms of the neuraxis[278] include **hemangiomas** (potentially multifocal and typically of capillary type with lobular growth features),[1029-1031] **hemangioendotheliomas** of spindled, epithelioid (recently associated with *WWTR1-CAMTA1* or *YAP1-TFE3* fusions[1032]), and polymorphous types (the first arguably benign and the latter two best regarded as low to intermediate malignant potential lesions),[1033] and aggressive **angiosarcomas** of conventional type.[1034] Also on record is a unique cerebral neoplasm exhibiting hybrid components of "angiogenic" leiomyosarcoma and epithelioid angiosarcoma,[1035] and CNS involvement by AIDS-associated **Kaposi sarcoma** has been documented.[1036] We have not encountered an example of cutaneous or visceral angiosarcoma presenting as a neuraxial mass, but metastatic atrial myxoma may masquerade as intracranial epithelioid hemangioendothelioma.[1037]

The designation of hemangioendothelioma has been extended to certain benign vasogenic meningocerebral lesions that structurally resemble the cellular ("juvenile") capillary hemangiomas encountered as cutaneous "nevi" in infancy.[1031] We have also had the opportunity to study an epileptogenic frontal lobe mass, associated with a history of antecedent cranial trauma, which exhibited the features of lobular capillary hemangioma (or so-called pyogenic granuloma) and are familiar with a case in which morphologically similar, but multifocal cerebral hemispheric lesions regressed after corticosteroid administration.[1038] Multifocal involvement of the spinal cord and cauda equina by lesions having capillary hemangiomatous features has also been described.[1039] Finally, the spectrum of primary endothelial proliferations potentially involving the nervous system includes the process known as **intravascular papillary endothelial hyperplasia** or **Masson vegetant intravascular hemangioendothelioma**.[1040] Intracranial variants, which may evolve from preexisting vascular malformations or develop within dural venous sinuses, can achieve enormous proportions, may regrow if subtotally excised, and have occasionally proved fatal as a result of associated mass effects.

Myogenous Tumors

Embryonal rhabdomyosarcomas account for most primary myogenous neoplasms of the CNS reported to date.[1041-1043] These tend to segregate into a posterior fossa subset, characterized by a presentation in childhood and a predilection for the cerebellum, and a supratentorial group of adult onset typified by a cerebral hemispheric localization. Rare cases of **pleomorphic** and **alveolar rhabdomyosarcoma** have been documented to arise in the cerebrum as well.[1044] The midline, vermal position of many intracranial rhabdomyosarcomas arising in the pediatric population and the recognized capacity of the cerebellar medulloblastoma to differentiate along skeletal muscle lines ("medullomyoblastoma") have prompted speculation that both tumor types might originate from a common, primordial progenitor in the rhombic roof. Whatever their histogenesis, primary rhabdomyosarcomas of the CNS are high-grade neoplasms; few patients remain alive 2 years after diagnosis despite aggressive irradiation and chemotherapy. Neuraxis dissemination and extracranial metastasis may complicate local tumor progression. Mention should be made of a diffuse leptomeningeal variant unassociated with a demonstrable neuroparenchymal component,[1045] but this diagnosis requires rigorous exclusion of an occult primary focus in the orbit, paranasal sinuses, nasopharynx, or middle ear since rhabdomyosarcomas originating in these parameningeal regions frequently seed the subarachnoid space. Non-neoplastic, cranial nerve–associated proliferations of skeletal, and, in some instances, smooth muscle have been variously designated as **rhabdomyomas**, **neuromuscular hamartomas/choristomas**, and **benign ectomesenchymomas/Triton tumors**. These have been previously treated in our discussion of hamartomas and choristomas. **Malignant ectomesenchymoma**, a neoplasm having rhabdomyosarcomatous elements with admixed ganglion cell components, has also been described as originating in the CNS, with a rare example showing transcriptome similarities to malignant peripheral nerve sheath tumor[1046]; however, a more recent study has shown frequent *HRAS* mutations, a feature suggesting a closer genetic link with embryonal rhabdomyosarcomas.[1047]

Sporadic instances of **leiomyoma**[1048] or **leiomyosarcoma**[1049] originating from the meninges or within the neuroparenchyma have been described, these exceedingly rare neoplasms including such oddities as **diffuse leptomeningeal leiomyomatosis**,[1050] **angioleiomyoma**,[1051] **pleomorphic angioleiomyoma**,[1052] and the **composite leiomyosarcoma–epithelioid angiosarcoma**[1035] to which we have previously referred. Intracranial neoplasms interpreted as **myopericytomas** have also been reported and may be associated with *NTRK1* gene fusions.[1053] At special risk of developing neuraxial (as well as systemically situated) smooth muscle tumors are the immunocompromised, particularly patients with AIDS.[1054,1055] Such tumors are usually associated with the dura or situated in juxtaneuraxial sites such as the parasellar region or cavernous sinus but may involve the brain.[1056] They range in appearance from highly differentiated leiomyomas to frank leiomyosarcomas and, in our experience, include epithelioid variants of small, clear cell cytologic type that may be difficult to recognize as being of smooth muscle character. As is the case for their systemic counterparts arising in a background of immunosuppression, neuraxial variants consistently harbor Epstein–Barr virus (EBV) as evidenced by nuclear labeling for EBV-associated

For personal use only. No other uses without permission. Copyright ©2017. Elsevier Inc. All rights reserved.

nuclear antigen 2 (EBNA-2) and EBV-encoded RNA-1 (EBER-1) on immunohistochemical and in situ hybridization assessment, respectively. EBV-associated myopericytomas have rarely been reported to complicate AIDS.[1057]

Other Mesenchymal Tumors

In addition to the various mesenchymal neoplasms of the CNS exhibiting specific diagnostic features, there is a disparate collection of anaplastic tumors to which only descriptive appellations such as high-grade "spindle cell," "pleomorphic," or "undifferentiated" sarcoma can be given.[278] Reported under the rubric of **primary leptomeningeal sarcomatosis** are poorly characterized variants typified by diffuse tumoral proliferation restricted to the subarachnoid space and unaccompanied by dominant foci of bulky disease.[1058] These may present with signs and symptoms of polyradiculopathy, spinal cord compression, or intracranial mass effect and are often misdiagnosed initially as chronic meningitides of infectious etiology or as manifestations of neurosarcoidosis or other inflammatory disorders. The differential diagnosis includes leptomeningeal carcinomatosis, gliomatosis, lymphomatosis, melanomatosis, and medulloblastomatosis. Neoplasms that seem to represent the intracranial equivalents of soft tissue and skeletal **myxomas** have been described,[1059] but myxoid meningioma and metastatic atrial myxoma must be excluded before this diagnosis can be accepted. Also to be found are reports of a dural **epithelioid sarcoma**,[1060] **synovial sarcomas** originating in the dura, spinal nerve roots or nerve plexi,[1061-1063] a peculiar **angiomyxofibromatous tumor** of the falx,[1064] and the bizarre phenomenon of **phosphaturic mesenchymal tumor** (a lesion recognized for its association with paraneoplastic osteomalacia secondary to tumor-induced renal phosphate wasting) masquerading as meningioma[1065] or spinal nerve sheath tumor.[1066] Last, we mention a primary intracranial example of **aneurysmal bone cyst** (with confirmatory 17p13 rearrangement involving the ubiquitin-specific protease 6 [USP6] locus) that presented as a cerebellopontine angle growth.[1067] The **Ewing sarcoma/peripheral primitive neuroectodermal tumor** group has been previously addressed in our discussion of embryonal neoplasms.

Nerve Sheath Tumors of the Craniospinal Axis

Inasmuch as nerve sheath tumors arising within the cranial cavity and spinal canal are the morphologic and biologic homologues of their more common, peripherally situated counterparts, the reader is referred to Chapter 41 of this text for a detailed treatment of their diagnostic, structural, and immunophenotypic features.

Schwannomas are the most frequent variant to abut the central neuraxis, usually presenting in adulthood as tumors of the cerebellopontine angle or lumbosacral spinal extramedullary space.[278] Nearly all cerebellopontine angle tumors originate in the vestibular branch of cranial nerve VIII ("acoustic neuroma" therefore being a misnomer) and produce hearing loss. Schwannomas arising at spinal levels exhibit a similar predilection for sensory divisions of the neuraxis, typically involving the posterior roots. These often assume a "dumbbell" configuration as they squeeze through adjacent intervertebral foramina and expand into the paravertebral soft tissues. Schwannomas may involve cranial nerves other than the eighth nerve and lie within the central neuroparenchyma proper.[1068,1069] Intraventricular[1070] and dura-based[1071] cases have been depicted as well. Bilateral eighth nerve examples are a defining feature of **NF2**, an autosomal dominant disorder linked to inherited or newly acquired mutations involving a gene localized to chromosome 22q12.[278] Affected kindreds are prone to an assortment of neoplasms, all typified in this setting by multifocality, that includes craniospinal schwannomas, meningiomas, and intramedullary ependymomas. Inactivating mutations of the *NF2* gene on chromosome 22 also characterize most acoustic schwannomas occurring in sporadic fashion. Multifocal, nonvestibular schwannomas divorced from other manifestations of NF2 constitute a syndrome known as **schwannomatosis**, although rare familial examples are now known to also include vestibular schwannomas or meningiomas.[1072,1073]

The schwannoma's characteristic Antoni A and B structure, nuclear palisading (Verocay bodies), infiltration by foamy macrophages, and vascular hyalinization usually suffice for its recognition, NF2-associated variants often evidencing a multilobulated growth pattern on gross and microscopic assessment, with recent evidence suggesting that this pattern results from fusion of multiple clonally distinct schwannomas.[1074] Rosenthal fibers and eosinophilic granular bodies may rarely be encountered in vestibular examples,[1075] possibly reflecting chronic stimulation of astrocytes native to the central portion of cranial nerve VIII.[1076] On occasion, meningiomas exhibit schwannoma-like features such as nuclear palisading and are the most frequent mimic. These two tumor types may also collide in patients with NF2, but "composite" lesions of this kind only rarely occur outside this clinical setting.[1077] Immunocytochemical techniques and electron microscopic study may both be usefully applied to distinguishing schwannian from meningothelial neoplasms and to the elimination of SFT/HPC from the differential. Schwannomas are characterized by diffuse cytoplasmic S-100 protein expression and pericellular immunolabeling for laminin and type IV collagen, the latter (and a corresponding reticulin network) reflecting investment of their elongated cellular processes by a continuous basal lamina foreign to the typical meningioma. Most examples also express widespread nuclear SOX10 expression, a useful and more specific marker of either schwannian or melanocytic lineages.[1078-1080] They may also show focal GFAP expression.[1081] Cytoplasmic expression of EMA—a regular feature of meningothelial tumors—is usually absent from the schwannoma or restricted to normal perineurial cells incorporated into the latter's capsule and thus limited to its periphery. Admittedly, however, some observers have described EMA-reactive neoplastic elements in the substance of hybrid nerve sheath tumors with mixed features of schwannoma and perineurioma.[1068] It is worth remembering that meningiomas only rarely present in the lumbosacral regions favored by schwannomas of the spinal roots. SFT/HPCs are typically negative for S-100 protein, instead labeling for nuclear STAT6.[969] Nuclear and cytoplasmic expression of calretinin has been described as a trait segregating schwannomas from neurofibromas, although S-100 and SOX10 is also less widespread in neurofibromas due to the presence of nonschwannian components.[1082]

A small minority of intracranial and intraspinal schwannomas are of the "cellular" type.[1083-1085] In contrast to its histologically conventional counterpart, the **cellular schwannoma** is a densely populated spindle cell tumor, typically devoid of Antoni B areas and Verocay bodies, that may contain foci of mitotic activity and is often misconstrued as a malignant peripheral nerve sheath tumor.[1079] The lesion shares with the classic schwannoma foci of vascular hyalinization, infiltration by lymphocytes and foamy macrophages, widespread S-100, SOX10, and collagen IV immunoreactivity, lack of EGFR expression, and highly differentiated Schwann cell features at the ultrastructural level. Such tumors may be more prone than conventional variants to recur locally following excision, but a metastasizing example has never been described. Finally, **granular cell tumors of schwannian lineage** have been noted to involve cranial and spinal nerves or nerve roots.[1086-1088]

Melanotic schwannoma (malignant melanotic schwannian tumor) is a unique nerve sheath tumor displaying mixed schwannian and melanocytic features, with melanosomal melanin production

For personal use only. No other uses without permission. Copyright ©2017. Elsevier Inc. All rights reserved.

and a decided predilection for the spinal nerve roots.[1089,1090] Rare intramedullary examples have also been recorded.[1091] Given their shared expression of melanocytic markers, such as HMB-45, Melan-A, and SOX10, some of these tumors are extremely difficult to distinguish from meningeal melanocytoma or melanoma, although the latter are characterized by unique *GNAQ* and *GNA11* mutations not encountered in melanotic schwannomas.[1092] A clear neural origin and more nested collagen IV/reticulin-rich patterns are also useful in this distinction, albeit not universal. Most melanotic schwannomas reported to date were stated to evolve in benign fashion, though recorded follow-up intervals for many of these cases were limited. However, the risk of local recurrence is seen in 25%–35%,[1090,1093] and metastases are also common, particularly for spinal examples.[1090,1094] A subset of melanotic schwannomas containing psammomatous concretions and/or lipoma-like fat accumulation constitutes part of the heritable **Carney complex**,[1095,1096] which includes cardiac, cutaneous, and mammary myxomas; spotty pigmentation; large cell calcifying Sertoli cell tumors of the testis; and evidence of endocrine hyperfunction (principally Cushing syndrome and acromegaly, the former associated with primary pigmented nodular adrenocortical disease); however, such **psammomatous melanotic schwannomas** may also be encountered sporadically. Given these unique clinicopathologic associations and frequent loss of PRKAR1A expression (rather than involvement of the *NF2* gene, which is more typical of conventional schwannomas), the alternate term of **malignant melanotic schwannian tumor** has recently been advocated.[1090]

Most craniospinal **neurofibromas** represent manifestations of NF1 ("peripheral" or classic Recklinghausen disease), transmitted in autosomal dominant fashion by a locus on chromosome 17q11.2.[1097] This complex disorder includes, in addition to multifocal cutaneous and more deeply situated plexiform neurofibromas, dermatologic abnormalities (café au lait spots and axillary freckling), pigmented hamartomas of the iris (Lisch nodules), various skeletal defects, and glial neoplasms, chief among which are pilocytic astrocytomas of the anterior optic pathways. Spinal localized intraneural neurofibromas arising in this setting typically do so at multiple levels. Only rarely are cranial nerves involved. Curious lesions interpreted as plexiform neurofibromas of the cauda equina have also been reported in patients without evidence of NF1.[1098]

Well documented, but uncommon, are **malignant nerve sheath tumors** (MPNSTs) originating in cranial or spinal nerve roots.[1099,1100] These may develop de novo or from underlying schwannomas or neurofibromas, can arise spontaneously or complicate NF (particularly NF1), and in roughly 10% of cases, follow local irradiation (including radiosurgery).[1101-1103] Intracerebral[1099,1100] and intraventricular[1104] presentations have been described. Recorded examples include malignant **Triton tumors** (i.e. variants exhibiting rhabdomyoblastic differentiation), which seem to have a somewhat worse prognosis regardless of NF1 status.[1105] A most remarkable instance of intraspinal schwannoma spawning rhabdomyosarcomatous, primitive neuroectodermal, and epithelial elements has also been reported.[1106] Malignant paraspinal nerve sheath tumors that may invade the canal and threaten the spinal cord often originate in neurofibromas, particularly those of plexiform or localized intraneural types, and so are strongly associated with NF1.[1107] Of note, a couple of more diagnostically specific immunohistochemical markers have recently been reported in association with sporadic, NF1 associated, and radiation induced MPNSTs, with supportive findings including the losses of neurofibromin and/or H3K27me3 expression.[1079,1101,1108-1110]

Oddities that round out this brief survey include **neurothekeomas** of the craniospinal neuraxis,[1111,1112] **soft tissue–type perineuriomas** presenting as intraventricular growths,[1113] **intraneural perineuriomas** originating in cranial nerve divisions,[1114] and craniospinal examples of **localized hypertrophic neuropathy**.[1115] Whereas the last of these entities probably represents a reactive hyperplasia characterized by the concentric wrapping of S-100 protein-expressing, EMA-negative Schwann cells about individual axons in formations known as "onion bulbs," the intraneural perineurioma is a bona fide neoplasm in which morphologically similar structures ("pseudo-onion bulbs") reflect concentric periaxonal proliferation by EMAlabeling, S-100 nonreactive elements of perineurial cell type. **Hybrid nerve sheath tumors** combining schwannoma, neurofibroma, and/or perineurioma are also on record, being somewhat over-represented in familial disorders, such as NF1, NF2, and schwannomatosis.[1068] Nevertheless, caution should be exercised to avoid over-interpretation of neurofibroma-like Antoni B areas within a schwannoma as evidence of a hybrid nerve sheath tumor. Last, we mention the occurrence of **traumatic neuromas** in the CNS, most involving the spinal cord and some developing in association with tumors such as intramedullary ependymomas.[1116,1117]

Lymphoproliferative, Histiocytic, and Myeloproliferative Disorders

As secondary spread of systemic lymphoproliferative and myeloproliferative disorders to the CNS does not often occasion neurosurgical intervention for diagnostic purposes, only a few general observations on this problem are offered. At greatest risk of such dissemination are patients suffering from acute leukemias,[1118] particularly of lymphoblastic type; diffuse leptomeningeal infiltration is the dominant pattern of CNS involvement encountered in this setting. In some cases, extensive permeation of cranial and spinal nerve roots accompanies the unrestrained proliferation of leukemic cells in the subarachnoid compartment. Circumscribed, dura-based, or (rarely) intracerebral masses composed of leukemic cells principally complicate the acute myelogenous leukemias but have virtually disappeared from clinical practice since the advent of modern cytoreductive therapy. Variously designated as **chloromas**, **granulocytic sarcomas**, **myeloid sarcomas**, or **myeloblastomas**, these tumors usually develop in subjects who are demonstrably leukemic, but exceptionally constitute the initial manifestation of relapse following apparently successful treatment or arise in otherwise normal individuals as harbingers of subsequent bone marrow and peripheral blood involvement.[1119,1120] Parameningeal masses of **extramedullary hematopoietic** tissue have been reported to produce neurologic dysfunction, mainly as a result of spinal cord compression, in patients with thalassemia or myelofibrosis.[1121,1122]

Involvement of the CNS in the course of node-based non-Hodgkin lymphoma is uncommon and usually limited to permeation of the leptomeninges ("meningeal lymphomatosis") or, less often, infiltration of the spinal epidural space.[1123] Cerebral infiltrates are decidedly unusual in this setting and typically complicate advanced (stage IV) disease, an excess of cases occurring in patients with diffuse large cell or lymphoblastic subtypes and involvement of other extranodal sites. By contrast, patients presenting with non-Hodgkin lymphoma of the eye—an extension of the CNS—frequently develop lymphomatous lesions of the brain proper.[1124] A subset of malignant lymphomas, principally non-Hodgkin variants, are confined at diagnosis to the epidural compartment and paraspinal tissues, usually arising in the midthoracic region and prompting evaluation for compressive myelopathy.[1125] Only exceptionally are the meninges colonized or the neural parenchyma penetrated in the course of systemic **Hodgkin disease**,[1126] **plasma cell myeloma**,[1127] **Waldenström macroglobulinemia**,[1128] or **mycosis fungoides**.[1129]

The designation of **primary central nervous system lymphoma (PCNSL)** is reserved for malignant lymphoid neoplasms restricted at presentation to the brain, spinal cord, or meninges.[1130] Although

For personal use only. No other uses without permission. Copyright ©2017. Elsevier Inc. All rights reserved.

the association of PCNSL with states of diminished immune responsiveness has long been appreciated, and its particular predilection for victims of AIDS firmly established, the majority of afflicted patients suffer no predisposing illness. Sporadic cases most often present in the sixth or seventh decades of life and manifest a 1.5 to 2:1 male/female ratio, whereas immunodeficiency-related examples reflect the demographics of HIV-1 infection, inherited immunologic disorders, diseases prompting organ transplantation, and other conditions necessitating iatrogenic immunosuppression. Most patients suffer the usual symptoms of an expanding intracranial mass, although PCNSLs tend to arise in the deep cerebral hemispheric white matter, corpus callosum, and basal ganglia and thus are not as prone to produce seizures as gliomas or metastatic deposits that involve epileptogenic cortical tissues. Frontocallosal and periventricular examples may prompt evaluation for personality change, depression, progressive psychomotor retardation, or frank psychosis. Rapidly progressing dementia has been associated with a distinctive subset of PCNSLs that diffusely permeate the brain rather than forming bulky masses ("**lymphomatosis cerebri**").[1131] Some tumors are discovered in the course of work-up for persistent uveocyclitides unresponsive to conventional ophthalmologic treatment, a manifestation of ocular involvement that often occurs in complex with cerebral infiltration.[1124]

Suggestive of PCNSL on CT or MR study (Fig. 43.138) are solid, nodular masses displaying hyperdensity in precontrast images, diffuse (as opposed to rim) enhancement on administration of contrast media, evidence of widespread subependymal infiltration, and multifocality. The last is apparent in some 25%–40% of sporadic examples and the majority of HIV-1–associated and post-transplant cases.[1132] Especially suspect in older adults are lesions that regress substantially with corticosteroid administration alone prior to biopsy, as occasional lymphomas disappear (transiently) with such treatment and masquerade as multiple sclerosis. Cases of lymphomatosis cerebri depart from the typical on MR assessment in their failure to form localized masses or enhance, characteristically demonstrating only diffuse, nonspecific white matter hyperintensity on T2-weighted and FLAIR sequences.[1131] Extensive central necrosis, a feature foreign to sporadic examples, lends to many HIV-1–associated or other immunodeficiency-associated PCNSLs a "ring"-enhancing radiological appearance that may be indistinguishable from *Toxoplasma* abscesses. A definite diagnosis of PCNSL usually requires biopsy but may be accomplished by demonstration of malignant lymphoid cells in CSF. Immunocytochemistry (for B-cell "markers"), flow cytometry, and PCR-based molecular assessment (for immunoglobulin heavy chain [IGH] gene rearrangements) have been applied to CSF specimens as methods of facilitating nonsurgical diagnosis.[1133]

PCNSLs may arise anywhere along the neuraxis. Approximately 75% are situated in the supratentorial compartment, these favoring the deep structures enumerated above. Most of the remainder involve the cerebellum or brainstem, with only rare examples isolated to the spinal cord, cauda equina or craniospinal nerve roots.[1134,1135] The designation of "**neurolymphomatosis**" has been applied to cases of the last two types and to lymphomas of nerve that are more peripherally localized.[1134] A small fraction of PCNSLs present as diffuse leptomeningeal infiltrates in the absence of demonstrable intraparenchymal disease,[1136] such as the **human herpesvirus 8–associated** "**primary effusion lymphoma**" of the subarachnoid space as a complication of AIDS.[1137] Dura-based lymphomas are given separate consideration later in this discussion (see later). Grossly, hematolymphoid lesions of the CNS proper are poorly defined in most instances and composed of dry, granular, tan–white, or grayish-pink tissue that may evidence small foci of necrotic softening or hemorrhagic discoloration. Extensive necrosis and conspicuous hemorrhage are most commonly encountered in AIDS-related and other cases associated with immunocompromise, which may closely mimic *Toxoplasma* abscesses on gross examination (particularly after adjuvant treatment), and in lesions complicating transplantation. A striking histologic feature of many PCNSLs is the tendency for tumor cells to aggregate in Virchow–Robin spaces and to infiltrate the walls of cerebral vessels (Fig. 43.139). This is commonly associated

Figure 43.138 Primary Central Nervous System Lymphoma. As demonstrated in this postcontrast injection magnetic resonance imaging, primary cerebral lymphomas exhibit a predilection for the deep, paraventricular white matter and tend to striking and fairly homogeneous enhancement in "sporadic" (as opposed to AIDS-related) cases.

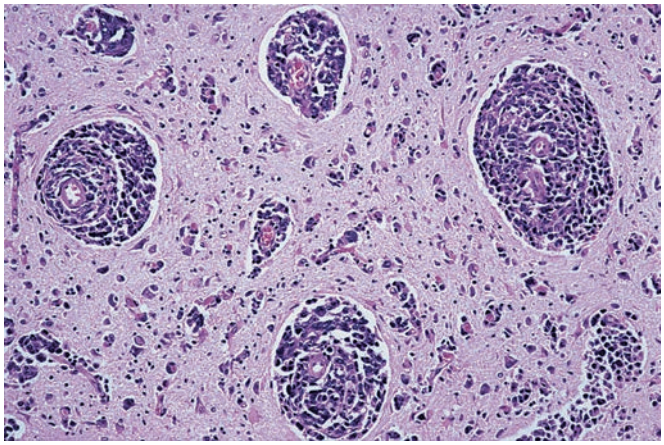

Figure 43.139 Primary Central Nervous System (CNS) Lymphoma. Although not apparent in all cases, a vasocentric growth pattern with tumoral infiltration of blood vessel walls and Virchow–Robin spaces is common to primary CNS lymphomas. Systemic lymphomas secondarily involving the neuroparenchyma may also preferentially grow in this fashion.

For personal use only. No other uses without permission. Copyright ©2017. Elsevier Inc. All rights reserved.

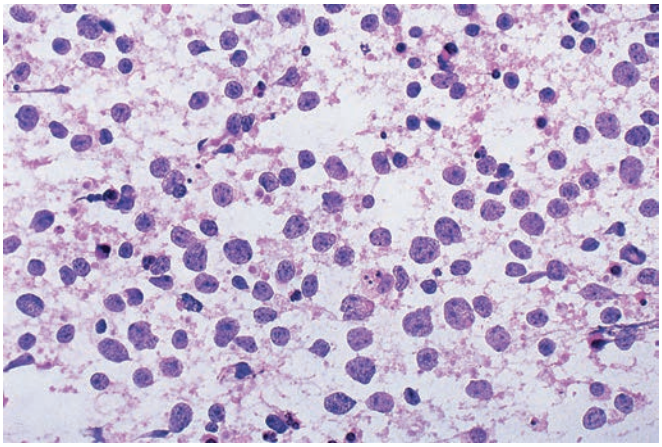

Figure 43.140 Primary Central Nervous System (CNS) Lymphoma. An intraoperative smear preparation demonstrates the large cell cytology and nuclear features characteristic of CNS lymphoma. The lack of cellular cohesion or cytoplasmic processes, respectively, are useful in discriminating this tumor from metastatic carcinoma and glioblastoma multiforme, two neoplasms that commonly enter the clinical differential diagnosis.

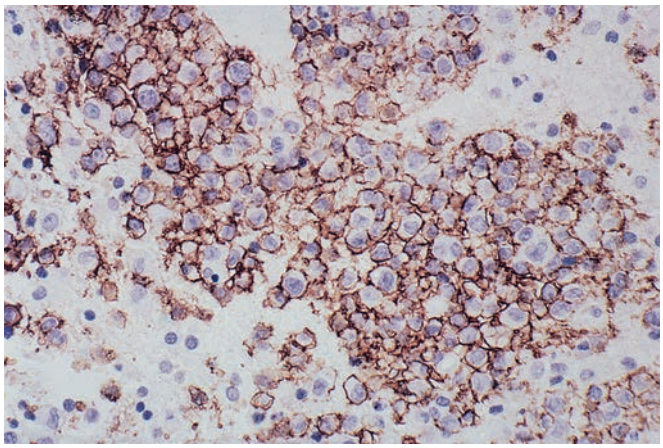

Figure 43.141 Primary Central Nervous System (CNS) Lymphoma. The great majority of lymphomas arising in the CNS are of B-cell type and, as shown here, label for CD20 on immunoperoxidase (L-26) assay.

with reticulin deposition in concentric, ring-like patterns. Most neuroparenchymal PCNSLs are high-grade non-Hodgkin lesions of diffuse large cell type,[1124,1130] but all major cytologic variants have been reported in this location, including low-grade lymphomas of small lymphocytic or lymphoplasmacytic type (sometimes in association with immunoglobulin deposition and/or crystal storing histiocytes),[1138] anaplastic large cell lymphomas,[1139] and such oddities as signet ring cell[1140] and extranodal, choroid plexus-based marginal zone lymphoma.[1141] Follicular (nodular) lymphoid neoplasms, however, are practically never encountered in this setting.[1142] Some observers have noted an over-representation of immunoblastic and small noncleaved Burkitt-like cell types among PCNSLs, particularly those involving AIDS patients and other immunosuppressed hosts, compared with node-based or other extranodal primary tumors.[1143] Regardless of the cytologic variety, touch preparations are useful in establishing the lymphoid nature of a given tumor at the time of intraoperative consultation (Fig. 43.140).

The overwhelming majority of PCNSLs exhibit a B-cell immunophenotype,[278] including labeling for CD20, CD19, PAX5, and CD79a in the absence of CD3 or CD45RO expression (Fig. 43.141). Other evidence of their B-lymphocytic lineage include clonal *IGH* gene rearrangements and certain characteristics shared with germinal center B cells, including recurrent translocations of the *BCL6* gene and BCL6 protein expression in 60%–80% of cases. PCNSLs, however, commonly have "activated" (nongerminal center) B-cell features as well.[1144,1145] Thus, one sizable analysis found an activated B-cell immunophenotype in over 90% of studied examples, these labeling for CD10, BCL6, and MUM1, respectively, in 2.4%, 55.5%, and 92.6% of cases.[1146] There is also evidence of somatic hypermutation, with activating mutations most commonly involving the *IG*, *BCL6*, *BCL2*, *MYC*, *PIM1*, *PAX5*, *RHOH*, *KLHL14*, *OSBPL10*, and *SUSD2* genes.[278,1147] Losses involving chromosome 6p21.32 occur in about 73% of cases, often preventing the expression of HLA class I and II gene products.[278] Epigenetic mechanisms are also important, with hypermethylation leading to inactivation of the *DAPK1* (in 84% of cases), *CDKN2A* (75%), *MGMT* (52%), and *RFC* (30%) genes. Other characteristics shared by PCNSLs and diffuse large cell lymphomas of activated B-cell type arising outside the neuraxis include an IgM phenotype without evidence for immunoglobulin class switch, high-level expression of BCL2 mRNA and protein in the absence of t(14;18)(q32;q21)/*IGH–BCL2* fusion, and frequent gains of chromosome 18q21 that include the *BCL2* and *MALT1* oncogenes.[278] The last of these phenomena constitutes the most common genetic abnormality displayed by PCNSLs and affects (with upregulated expression of other family members, upstream modulators and targets) activation of the nuclear factor kappa B (NFκB) signaling cascade.[1148] Increased NFκB signaling could explain, at least in part, the observations that PCNSLs are highly proliferative (MIB-1/Ki-67 indices regularly exceeding 50%–70% and potentially rising above 90%) while exhibiting relatively low-level apoptotic activity.

It is to be emphasized that PCNSLs often harbor a conspicuous complement of admixed T cells that can confound interpretation of the histologic and immunohistochemical picture, but these reactive elements usually appear as small, well-differentiated lymphocytes that are readily distinguished from the large, atypical B cells on which the diagnosis rests. Particularly deceptive are biopsies derived from the perimeter of PCNSLs, where reactive T lymphocytes often constitute a dominant and obscuring population, or from masses showing regression following preoperative corticosteroid administration. These "sentinel lesions" may be selectively relieved of their neoplastic B-cell components, heavily infiltrated by foamy macrophages, and partially demyelinated, a phenomenon that may prompt, along with their radiological and clinical resolution, misdiagnosis of multiple sclerosis or demyelinating pseudotumor as the primary disease process.[1149] It is worth remembering that multiple sclerosis is, for the most part, a disorder of the young. Furthermore, it has been our experience that inadvertently "treated" lymphomas do not leave behind the sharply demarcated zones of selective and total myelin loss with axonal preservation typical of multiple sclerosis or demyelinating pseudotumors. Clonal B-cell populations have rarely been described as participants in multiple sclerosis,[1150] but atypical B lymphocytes should not be seen in this disorder. **Primary natural killer (NK)/T-cell lymphomas of the CNS** constitute no more than 2%–4% of PCNSLs in series from the West but account for a significantly higher proportion of cases afflicting Japanese and Koreans.[1151,1152] These may be over-represented among leptomeningeal and infratentorial primaries. The spectrum of variants reported to present as CNS primaries includes anaplastic large cell lymphomas.[1136,1153]

Neuroparenchymal PCNSLs of the usual (i.e. diffuse large B-cell) type can be driven into remission by adjuvant means but usually recur (often at CNS sites remote from the initial focus of disease) and prove fatal. High-dose, methotrexate-based chemotherapeutic

For personal use only. No other uses without permission. Copyright ©2017. Elsevier Inc. All rights reserved.

regimens have achieved median survival intervals of 32–60 months.[1130] Although extent of resection has traditionally been considered irrelevant, with aggressive surgeries generally avoided, this concept has recently been challenged.[1154] As toxic leukoencephalopathy has emerged as a frequent complication of combined radiochemotherapeutic approaches, current management strategies and ongoing clinical trials are focused on frontline chemotherapy alone (including potentially promising protocols involving autologous stem cell transplantation), potentially augmented by targeted or immunomodulatory therapies, such as rituximab.[1155] The outlook for patients with intra-axial T-cell PCNSLs is similar or perhaps slightly better at present.[278,1156] Those exceptional examples of low-grade, small lymphocytic or lymphoplasmacytic B-cell lymphoma arising in the central neuraxis seem to be less aggressive and amenable to longer-term control.[1157] A grim prognosis attaches to AIDS-associated PCNSLs, though improvement in survival has been effected since the advent of HAART.[1156] The usual pattern of treatment failure in the setting of PCNSL is progressive, frequently multifocal infiltration of the CNS proper, attended, in some cases, by leptomeningeal dissemination. Ocular involvement is experienced by many patients as the disease evolves, but systemic lymphomatous infiltrates develop in no more than 10% of cases.[1124]

As the central neuraxis normally lacks a resident lymphoid population, the histogenesis of PCNSLs is obscure. Specifically, whether primary neuroparenchymal and leptomeningeal lymphomas actually arise in these locales or are peripherally generated and selectively home to (or opportunistically colonize and, shielded from immune surveillance, persist within) the CNS is unclear. Infections or other inflammatory processes could summon lymphocytes to the CNS and thus set the stage for their subsequent neoplastic transformation (a particularly plausible scenario in the immunodeficient), but only exceptionally has PCNSL been described in patients with proven neurologic infections or other unarguably reactive processes characterized by lymphoid infiltration.[1158] Given the recognized ability of the EBV to immortalize B cells in vitro and to drive a polyclonal, systemic lymphoproliferation that may evolve to frank lymphoma in immunocompromised hosts, it is noteworthy that immunodeficiency-associated PCNSLs, such as AIDS-related examples and post-transplant lymphoproliferative disease involving the CNS regularly harbor this agent, whereas sporadic PCNSLs rarely do, with the exception of **EBV-positive diffuse large B-cell lymphoma of the elderly**, the latter thought to represent an increasing state of systemic "immunosenescence" in patients above the age of 50.[1159-1161] EBV has also been incriminated in a low-grade lymphoproliferative disorder resembling polymorphic B-cell hyperplasia in an HIV-1–infected child[1162] and in a polyclonal cerebellar lymphoproliferation that progressed to lymphoma in an apparently immunocompetent adult.[1163]

Primary lymphoproliferative disorders of the CNS other than non-Hodgkin lymphoma of the neuroparenchyma and leptomeninges merit brief discussion. **Primary dural lymphomas** are uncommon lesions that typically mimic meningiomas and that are usually B-cell tumors of **low-grade, marginal zone (MALT) type**.[1164] These may show intratumoral amyloid deposition, and a subset may be associated with numerous IgG4-positive plasma cells, although systemic evidence of IgG4 disease is typically absent.[1165] Other dural-based variants have been described,[1166] including **T cell–rich B-cell lymphoma**,[1167] small lymphocytic lymphoma, diffuse large B-cell lymphoma, anaplastic large T-cell lymphoma, and low-grade follicular lymphoma of small cleaved type.[1166,1168] Only rarely is **Hodgkin disease** confined, on presentation, to the CNS.[1126,1169,1170] PCNSLs derived from immunodeficient hosts, however, not infrequently harbor pleomorphic cellular elements that may be misconstrued as Reed–Sternberg cells. The peculiar disorder historically described as "neoplastic angioendotheliomatosis," formerly regarded as an intravascular variant of angiosarcoma, is now known to be an unusual form of malignant lymphoma, typically of large B-cell type (though T-cell variants are recognized[1171]), exhibiting a remarkable tropism for blood vessels in the skin, adrenal glands, and CNS, the latter occurring in over 75%–85% of cases; the lack of CD29 and ICAM1(CD54) adhesion molecule expression is thought to preclude transvascular migration in these systemically derived tumor cells.[278,1172] Accordingly, the disorder is now termed **intravascular large B-cell lymphoma**. Patients often present with neurologic dysfunction—progressive encephalopathy, dementia, or stroke—that reflects multifocal cerebral infarction resulting from occlusion of vascular lumina by malignant lymphoid cells (Fig. 43.142). Cerebrovascular aneurysm formation with rupture and intracranial hemorrhage has also been reported to complicate intravascular lymphoma,[1173] as has the development of extravascular lymphomatous masses in the CNS and a rare association with autoimmune hemolytic anemia.[1174,1175] Rare cases have been described as limited to the brain or spinal cord,[1176] one of which occurred in a child with AIDS.[1177]

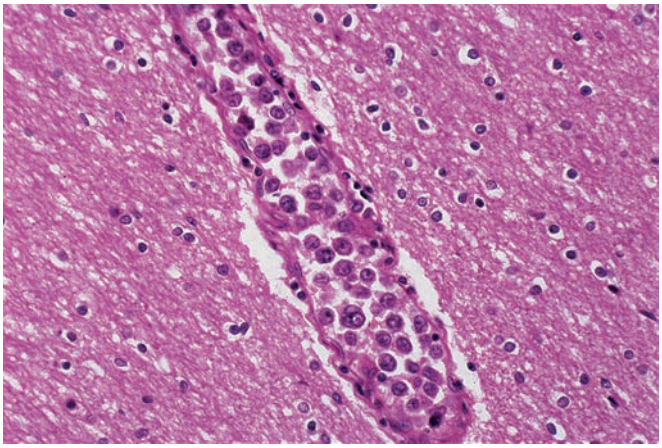

Figure 43.142 Intravascular Large B-Cell Lymphoma. Large, highly atypical cells fill a small blood vessel in the white matter of a 63-year-old woman subjected to brain biopsy for progressive cognitive impairment. Positive immunoassays for leukocyte common antigen and CD20 confirmed their lymphoid nature and B-cell phenotype, respectively.

Other oddities include **Castleman disease** confined to the meninges[1178] or involving spinal nerve roots,[1179] primary **plasmacytoma** of the dura,[1180] brain[1181] or spinal cord[1182] (including cases described as developing against a background of **atypical plasma cell hyperplasia**[1183]), and CNS **amyloidomas**; only rare examples of the latter have been associated with an underlying hematopoietic malignancy, such as low-grade lymphoma.[1138] Amyloidomas of the gasserian ganglion are further recognized as an unusual cause of trigeminal neuropathy, these also representing localized lesions and not complicating or presaging generalized plasma cell dyscrasia.[1184] The vasocentric deposition in brain of type-restricted immunoglobulin light chains (amyloid forming in some cases and accompanied by modest infiltrates of small lymphocytes and mature, but monoclonal, plasma cells) has also been reported under the rubric of **CNS light chain deposition disease**[1138,1185] or as a form of **cerebral amyloid angiopathy**.[1186] The deposits in question have been almost exclusively of lambda light chain type, cerebral and gasserian amyloidomas also being composed of lambda light chain material and harboring clonal lambda-expressing plasma cells,[1138] but an example exhibiting kappa restriction has been communicated.[1187] Tumors interpreted as true **histiocytic sarcoma**,[278] **follicular dendritic cell sarcoma**,[1188] or

For personal use only. No other uses without permission. Copyright ©2017. Elsevier Inc. All rights reserved.

"**microglioma**"[1189] of the brain have been described. The histiocytic sarcomas are rare and highly aggressive but similar to the histiocytic disorders Langerhans cell histiocytosis and Erdheim–Chester disease, they may express BRAF V600E mutation and respond to inhibitors.[1190] Finally, there is so-called **lymphomatoid granulomatosis**, an angiocentric and necrotizing lymphoproliferative disorder historically described as a prelymphomatous condition involving the CNS in association with pulmonary disease but occasionally reported to localize in the brain alone.[1191] Several of these isolated cerebral variants involved patients with AIDS[1192] and a number eventuated in recognizable lymphoma. Arguably, at least some of these cases represented angiocentric forms of malignant lymphoma ab initio. The participation of EBV in this process has been documented.[1191]

Germ Cell Tumors

Whether **germ cell tumors** of the CNS derive, as long presumed, from primordial germ cells that aberrantly migrate to the developing central neuraxis or, as more recently proposed, from native stem cell elements remains a speculative matter, but the fact remains that these uncommon neoplasms are morphologically and immunophenotypically indistinguishable from germinal tumors arising in the gonads (as well as other extragonadal sites), and a subset manifests genetic abnormalities, such as X chromosome gains, increased chromosome 12p copy number, and isochromosome 12p formation, characteristic of testicular (and other extracranial) primaries.[1193] The last genetic lesion, a marker alteration in the setting of testicular germ cell tumorigenesis, does not appear, however, to be as prevalent among intracranial examples. Approximately 90% of CNS germ cell tumors are discovered in the first two decades of life, case rates peaking in 10- to 12-year-olds. In Western series, these account for no more than 0.5% of all primary intracranial neoplasms and 3% of those encountered in children, but their incidence is increased two-fold or more in Japan, Taiwan, and Korea.[1193] Sharing with other extragonadal germ cell tumors a predilection for the midline, at least 80% of CNS examples arise along an axis extending from the suprasellar cistern and infundibulum to the pineal gland (these constituting the most common neoplasms encountered in the latter location). A synchronous suprasellar and pineal region presentation is well recognized, though exceptional, as are cases confined to the cerebral hemispheres, basal ganglia or thalami (these may be bilateral), ventricles, spinal cord, and sella turcica. Metachronous intracranial primaries are on record, but rare.[1194] Males are afflicted more than twice as frequently as females when all sites are considered, but gender distribution varies with tumor localization: the large majority of pineal examples affect boys, but suprasellar lesions occur more often in girls.

CNS germ cell tumors generally arise in sporadic fashion but are recognized to complicate Klinefelter syndrome,[1195] and their incidence may be increased in the setting of Down syndrome as well.[1196] Suprasellar examples produce visual field defects, diabetes insipidus, and hypothalamopituitary failure, whereas pineal region tumors compress the tectal plate and aqueduct, presenting with symptoms and signs of obstructive hydrocephalus that are often accompanied by a vertical gaze paresis, known eponymously as Parinaud syndrome. The secretion of beta human chorionic gonadotropin (β-hCG) by neoplastic syncytiotrophoblast may stimulate testosterone production in boys and result in "precocious puberty" (isosexual pseudoprecocity), as this may release the immature testes from tonic inhibitory controls secondary to pineal and hypothalamic injury. The proposed follicle stimulating hormone–like activity of hCG[1197] or additional elaboration of cytochrome p450 aromatase,[1198] which catalyzes estrogen formation from C19 steroids, could explain the exceptional occurrence of precocious puberty in girls with hCG-producing intracranial germ cell tumors.

The macroscopic features, histologic, and immunohistochemical criteria governing the identification and subclassification of CNS germ cell tumors differ in no way from those previously articulated in discussion of their more common gonadal counterparts and are not reprised here.[1193,1196,1199] **Germinoma** has by far the highest incidence among tumors of this group. This neoplasm is essentially identical to the seminoma in histologic appearance and antigenic profile. While the microscopic diagnosis is usually straightforward, the germinoma that has elicited a florid lymphoplasmacytic and granulomatous reaction may masquerade as tuberculosis, sarcoidosis, or other inflammatory process.[1200] Immunohistochemical screening facilitates the visualization of tumor cells obscured by such an infiltrate and is mandatory when dealing with inflamed biopsy material deriving from the suprasellar–pineal axis (a unique report of apparently **idiopathic** "**pinealitis**" notwithstanding[1201]). D2-40, CD117 (c-kit), and OCT4 antibodies outperform reagents against placental alkaline phosphatase (PLAP) in this regard,[1202] membranous reactivity for the first two being more germinoma-specific than nuclear OCT4 expression (which is shared by embryonal carcinomas). In connection with the CD117/c-kit expression characteristic of germinomas, it is noteworthy that these lesions, in contrast to other intracranial germ cell tumor types, often harbor activating *KIT* gene mutations.[1203,1204] Nuclear immunolabeling for NANOG, a homeodomain transcription factor, is a further feature of germinomas useful in their identification.[1205] These tumors may also express (as can other germ cell neoplasms in varying fashion) the RNA-binding LIN28 protein[1206] and the POU5F1,[1202] HESRG,[1207] UTF1,[1208] and SALL4[1209] transcription factors. We would call the reader's attention to unusual forms of "diffuse" CNS germinoma that permeate the neuroparenchyma in glioma-like fashion rather than forming discrete tumor masses.[1210] A minority of otherwise pure germinomas harbor syncytiotrophoblastic giant cell elements that are β-hCG-immunoreactive and associated with elevated levels of this oncoprotein in serum and CSF. Whether this phenomenon is associated with an increased recurrence risk has been a matter of controversy,[1211] but such tumors clearly do not behave in the highly aggressive fashion of choriocarcinomas.

Apart from germinoma, only CNS germ cell tumors of the teratoma family are likely to be encountered in pure form.[1212] **Teratomas** constitute the majority of congenital CNS germ cell tumors, one account describing the remarkable discovery of a primary intracranial example in the fetus of a woman with an independent ovarian teratoma.[1213] This tumor group includes the **mature teratoma** (composed entirely of adult-type tissues), the **immature teratoma** (defined by a content of incompletely differentiated components exhibiting fetal appearances), and the **teratoma with malignant transformation** (i.e. one spawning a secondary cancer of conventional somatic type). As regards the last entity, sarcomas of undifferentiated or rhabdomyosarcomatous aspect,[1212,1214,1215] leiomyosarcoma,[1216] adenocarcinomas of enteric type,[1217,1218] squamous carcinoma,[1212] and erythroleukemia[1219] have all been reported to arise from intracranial, teratoma-containing germ cell tumors, and we have seen in consultation a mature pineal teratoma partially overgrown by malignant hemangioendothelioma. Whether the account of an intrasellar tumor having components of germinoma and Burkitt-like B-cell lymphoma reflects such somatic malignant change or a collision of unrelated entities is unclear.[1220] A carcinoid has been encountered within a teratomatous tumor of the spinal axis,[1221] though some argue that intraspinal "teratomas" are complex malformations[7] rather than true germinal neoplasms.[1222] Rarely, intracranial teratomas achieve extraordinary degrees of organization and contain fetus-like bodies.[1223] The designation of **intracranial fetus-in-fetu** has been applied to

For personal use only. No other uses without permission. Copyright ©2017. Elsevier Inc. All rights reserved.

these curiosities but is more exactingly restricted by some observers to cases of apparently abortive twinning in which one developing fetus is incorporated into the cranium of the other.[1224] While the spontaneous maturation of teratomas has been recorded,[1225] re-resection specimens composed entirely of fully differentiated somatic tissue elements usually derive from initially immature teratomatous neoplasms or mixed germ cell tumors subjected to adjuvant therapy. The apparent maturation in such circumstances may simply reflect the selective ablation of incompletely differentiated cellular components. The progressive, seemingly paradoxical enlargement of these ostensibly mature neoplasms has been referred to as the "growing teratoma syndrome." The formation and expansion of tumoral cysts may well contribute to this phenomenon, but Ki-67/MIB-1 assessment can demonstrate surprising levels of proliferative activity within the fully differentiated tissues of such recurrent lesions.[1226]

Embryonal carcinoma, **yolk sac tumor**, and **choriocarcinoma** may all arise within the CNS, but only rarely are these encountered in unalloyed form. Far more frequent is their presence within mixed germ cell tumors, which often contain elements of germinoma and teratoma as well. We again emphasize the importance of immunohistochemical assessment in the evaluation of such lesions. Specifically, screening for alpha-fetoprotein is critical if minor components of yolk sac tumor are not to be overlooked (bearing in mind, however, that teratomatous glands of enteric type may also label for this antigen) and assessment for CD30 expression is of great value in distinguishing embryonal carcinomas from other germ cell tumor types. SALL4 expression is also helpful in the identification of yolk sac tumors (as is glypican-3), which is a more sensitive marker than alpha-fetoprotein, but lacks comparable specificity as other germ cell tumors, including germinomas and embryonal carcinomas, also label for this stem cell transcription factor.[1209] The pathologist reporting a mixed germ cell neoplasm should specify the participating tumor types and their relative representation.

Histologic subclassification emerges from a number of multivariate analyses as bearing most heavily on CNS germ cell tumor prognosis.[1212,1227,1228] The best outcomes attach to pure germinomas in localized form (which are radiocurable in over 90% of cases, as well as chemosensitive) and to mature teratomas that can be completely resected. The spontaneous regression of germinoma has been recorded,[1229] a phenomenon that may well be mediated by the tumor-infiltrating lymphocytes characteristic of this neoplasm. Yolk sac tumors, embryonal carcinomas, choriocarcinomas, and mixtures thereof frequently resist both surgery and adjuvant treatment, carrying a high mortality, though aggressive regimens that include vigorous chemotherapy as well as irradiation have achieved survival rates of 60%–70% in this setting.[1211] These virulent lesions destructively infiltrate local structures and may disseminate via the CSF, as can the germinoma. Extraneural spread is a rare complication that includes spontaneous systemic metastasis (mainly to lung and bone) as well as seeding of the peritoneal cavity via ventriculoperitoneal shunts placed for relief of obstructive hydrocephalus. Some observers have found immature teratomas and mixed tumors composed mainly of germinoma and teratomatous elements to be associated with an "intermediate" risk of recurrence and progression.[1212] One analysis could not attach any prognostic significance to chromosome 12p status (either isochromosome formation or polysomy) in the setting of intracranial germ cell neoplasia.[1230]

Melanocytic Tumors

We have previously mentioned melanogenesis as a function occasionally exercised by nerve sheath tumors as well as central neuroepithelial neoplasms of varying types. The CNS and its coverings also host tumors posited to derive from dendritic melanocytes of neural crest origin that normally populate the pia-arachnoid. The latter are especially numerous over the ventral medulla and high cervical spinal cord, regions that often evidence a peppery discoloration on gross inspection, but the growths for which they are held accountable are by no means restricted to these areas and, while largely leptomeninges based, may be anchored to the dura mater or situated in the substance of the brain, spinal cord, or pineal gland. Most such lesions fall into one of several fairly homogeneous diagnostic categories. As described later, these include well-differentiated and relatively indolent tumors that are termed melanocytomas, as well as frankly malignant melanomas, either form occurring in localized mass-like or diffuse leptomeningeal form.[278] They may also constitute manifestations of a generalized neurocristopathy. The syndrome of **neurocutaneous melanosis** (known also as **Touraine syndrome** in its heritable, autosomal dominant form) is defined by the association of giant or multifocal nevi of congenital type with discrete meningeal melanomas or, more commonly, an unrestrained (and ultimately fatal) proliferation of melanocytic elements, often deceptively benign in appearance, throughout the subarachnoid compartment and within Virchow–Robin spaces.[1231,1232] The spread of this process to the abdomen via ventriculoperitoneal shunts placed to relieve obstructive hydrocephalus has been described.[1233] In addition, meningeal melanocytomas and melanomas (including cases with BRAF V600E mutation) have been reported in complex with nevus of Ota, characterized by congenital cutaneous, ocular, and retrobulbar soft tissue hyperpigmentation in a maxillo-ophthalmic trigeminal nerve distribution.[1234-1237] Intracranial melanoma has also been described in the setting of NF1.[1237]

Melanocytomas usually present in middle age or later adult life as circumscribed, extra-axial masses attached to the leptomeninges. Most arise along the spinal neuraxis (some in association with nerve roots), intracranial examples exhibiting a decided predilection for the posterior fossa and Meckel's cave.[278] Only exceptionally do such tumors involve higher levels of the intracranial compartment,[1238] a remarkable case confined to the lateral ventricular system having been described.[1239] Characteristic MRI findings include iso/hyperintensity on T1-weighted images, a hypointense (dark) profile on T2-weighted study—these features reflecting the paramagnetic properties of melanin—and homogeneous contrast enhancement.

Consisting grossly of tan–brown to coal-black tissue, melanocytomas are frequently composed of uniform spindle cells arrayed in fascicles and compact whorled nests (the latter accounting for the once prevalent perception of these tumors as pigmented meningiomas) (Fig. 43.143). Whorling may be centered on delicate stromal blood vessels, and cellular dehiscence often produces a pseudopapillary appearance at low magnification. Epithelioid forms may be admixed, but rarely do these dominate the histologic picture.[1238] Tumor cell nuclei may exhibit longitudinal grooving when spindled and typically contain centrally positioned eosinophilic nucleoli that are easily seen, but of relatively small diameter. Candidates for the diagnosis of melanocytoma should not harbor macronucleoli, evidence conspicuous nuclear atypia or pleomorphism, contain more than the (very) occasional mitotic figure, or exhibit necrosis.[1238] Cytoplasmic melanization is usually advanced, particularly at the periphery of whorled nests (which are often bordered by clustered melanophages), and can obscure all cytologic detail. Virtually amelanotic examples may be encountered but are exceptional. Ultrastructural studies will confirm the presence of mature melanosomes and may show basement membrane material (also demonstrable in type IV collagen immunopreparations) to incompletely invest some cellular processes or to surround groups of neoplastic melanocytes,[1240] though the extensive basal lamina formation about individual cells and complex cytoplasmic interdigitation characteristic of most melanotic schwannomas are foreign to the melanocytoma.

For personal use only. No other uses without permission. Copyright ©2017. Elsevier Inc. All rights reserved.

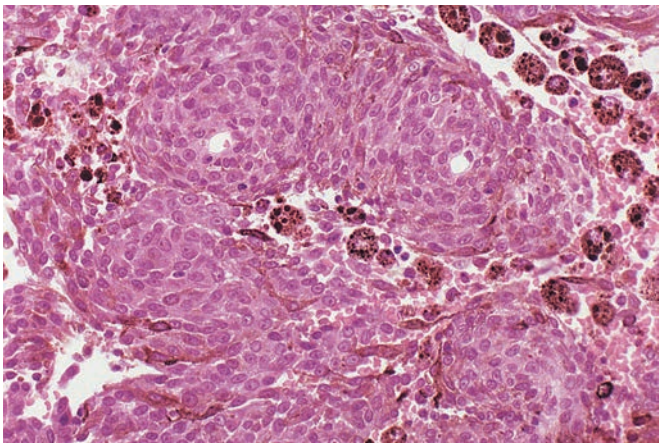

Figure 43.143 Meningeal Melanocytoma. The tendency to cellular whorling manifested by this example, resected from the cervical region of a 34-year-old man with a protracted history of neck pain and gait disturbance, accounts for the potential misclassification of melanocytomas as melanotic meningiomas. Note finely divided brown pigment in the cytoplasm of some tumor cells (as opposed to coarse pigment granules in melanophages), delicate and monomorphous nuclear features, lack of mitotic activity, and absence of necrosis.

Immunoreactivity for vimentin, S-100 protein, SOX10 (personal experience), and HMB-45 is regularly present in melanocytomas—in contradistinction to meningiomas—with melanocytomas also being EMA negative.[1238] Tumor cells may also label for MART-1 (Melan-A/A103), tyrosinase, and microphthalmia transcription factor.[1239,1241] A curious oncocytic (i.e. mitochondrion-rich) neoplasm of apparently melanocytomatous nature has been reported.[1242]

Melanocytomas are slowly expanding and generally amenable to surgical control if gross total removal can be accomplished. They have been reported to recur following resection and to invade adjoining neuroparenchyma, but the literature on this score is difficult to interpret, owing to their rarity and the application of nonuniform diagnostic criteria to these unusual lesions.[1238] The largest and most closely analyzed series to date included, under the rubric of melanocytoma, only well-differentiated leptomeningeal neoplasms with minimal cytologic atypism, small nucleoli, low mitotic counts (maximally one per 10 high-power fields and below this level in most cases), MIB-1 labeling indices not exceeding 2%, and no necrosis or involvement of CNS proper.[1238] None recurred following gross total excision or subtotal resection, irrespective of adjuvant radiotherapy (median follow-up period of 36 months). We have encountered, however, a fatal tumor meeting all of the foregoing criteria that widely seeded the CSF. One report further describes late local recurrence and hepatic metastasis complicating the course of a foramen magnum region melanocytoma.[1243] Neoplasms otherwise acceptable as melanocytomas can partially colonize the spinal cord (extending along perivascular spaces in association with florid Rosenthal fiber formation attesting to their chronicity) or may prove, in the main, to be intramedullary at operation.[1244] The latter, termed "**intermediate grade melanocytic neoplasm**" by some,[1238] may cause debilitating myelopathy and is far more likely than its wholly leptomeningeal counterparts to recur after resection but nonetheless pursue a protracted course. Given the morphologic attributes and relatively favorable clinical biology of most melanocytomas, it should come as no surprise that these have been likened to ocular melanomas of spindle A and B types, as well as to cellular blue nevi.

Malignant melanomas of the CNS may present as diffuse leptomeningeal growths ("**melanomatosis**") or discrete masses.[278] Proliferations of the former sort are particularly characteristic of childhood examples occurring as part of the **neurocutaneous melanosis** complex[1232] but may be encountered at any age and in the absence of unusual dermal nevi. Clinical manifestations of intracranial hypertension, cranial nerve deficits, a meningitic or subarachnoid hemorrhage-like picture, and diffuse leptomeningeal enhancement on CT or MRI are typical of **primary leptomeningeal melanomatosis**, which can be diagnosed by demonstration in CSF samples of tumor cells that are melanin laden or immunoreactive for S-100 protein and HMB-45.[1245] Death within months of diagnosis is the rule. Solitary variants of CNS melanoma (other than those complicating neurocutaneous melanosis) mainly afflict adults and become symptomatic by virtue of their compression or invasion of neural structures. These generally share with melanocytomas an origin in the pia-arachnoid and a predilection for the posterior fossa and intraspinal compartment that stands in contrast to the intracerebral distribution characteristic of melanomas metastatic to the central neuraxis. Still, meticulous search for a cutaneous, mucosal, or ocular primary must prove unrevealing before a malignant melanoma can be accepted as indigenous to the CNS. Spindle cell, epithelioid, and mixed cytologic features may be encountered, with evidence of malignancy including nuclear and nucleolar enlargement, coarse hyperchromatism, readily apparent mitotic activity, necrosis, and neuroparenchymal invasion.

High rates of regional recurrence, a potential for subarachnoid dissemination, and substantial mortality attach to localized CNS melanomas that cannot be surgically extirpated (unfortunately, this comprises a majority of cases). Some observers, however, have found a low incidence of CSF-borne metastasis as well as unexpectedly favorable outcomes following gross total resection in this setting, drawing parallels to the histology and behavior of spindle B, epithelioid, and mixed ocular melanomas.[1238]

It is noteworthy that melanocytic tumors of the central neuraxis occasionally defy ready placement in either the melanocytoma or melanoma camp, maintaining relatively reassuring cytologic profiles while exhibiting modest mitotic activity or invasive growth. These "**atypical**," "**borderline,**" or "**intermediate grade**" **melanocytic neoplasms** are capable of recurrence, but the magnitude of this risk is unclear.[1238] In addition, cases of frankly malignant melanoma apparently evolving from melanocytomas have been communicated.[1246] On record is an intracerebral **balloon cell melanoma** that may have arisen from a meningocortical melanocytic "nevus."[1247]

In terms of genetic work-up, primary melanocytic neoplasms of the CNS, particularly those of the melanocytoma group, may harbor activating somatic mutations of the G alpha q *(GNAQ)* and guanine nucleotide–binding protein, alpha-11 *(GNA11)* genes identical to those that have been identified in uveal melanomas (as well as cellular blue nevi and nevi of Ota[1092,1232,1248]). In further analogy to uveal counterparts, other common alterations include losses of chromosome 3 and 6q, potentially in association with inactivation of *BAP1* (though not yet encountered) or mutations of *SF3B1* or *EIF1AX* genes in those undergoing malignant transformation to melanoma.[1249] Mutations of the *TERT* promoter, *NRAS*, *BRAF*, and *KIT* genes are uncommon in primary CNS melanoma, in contrast to cutaneous and acral counterparts; as such, the finding of such mutations may be useful in suggesting a metastatic deposit, rather than primary disease. Nonetheless, most pediatric CNS melanomas, especially those associated with neurocutaneous melanosis are driven by *NRAS* mutations, with codon 61 as the site of most common involvement.[1250]

Paraganglioma

Primary **paragangliomas** of the craniospinal axis typically arise in either the jugulotympanic area or the region of the cauda equina,

For personal use only. No other uses without permission. Copyright ©2017. Elsevier Inc. All rights reserved.

presenting as delicately encapsulated intradural masses attached to the filum terminale or, less commonly, spinal roots.[278,1251,1252] Afflicted patients are usually in their fifth or sixth decades and commonly complain of either pulsatile tinnitus and/or lower cranial neuropathies for the former location or chronic low back pain that may be accompanied by sciatica, sensorimotor deficits, and sphincter disturbances in the latter. Functional silence is the rule, manifestations referable to the release of biogenic amines being most exceptional. Paragangliomas have also been reported to originate at cervicothoracic levels,[1253] in the pineal region,[1254] cerebellopontine angle,[1255] cerebellum,[1256] cerebrum,[1254] and sellar/suprasellar compartments.[1257] An intrasellar presentation in the setting of von Hippel–Lindau (VHL) disease is on record.[1258] Simple resection usually suffices to cure these uncommon neoplasms, which are generally indolent and noninvasive, but exceptional instances of recurrence in the face of ostensibly complete removal, erosion into neighboring bone, CSF-borne spread, osseous metastasis, and tumor-related death following inadequate excision are well documented.[1253,1259] One paraganglioma of the cauda equina reported for its unusual local regrowth and metastasis to cerebellum 22 years after gross total resection was subsequently found to have occurred in a patient with germline mutation of the succinate dehydrogenase gene-subunit D *(SDHD)*,[1260] an anomaly associated with hereditary paragangliomas of the head and neck. This example of late "recurrence" may have represented the syndromic development of multifocal primaries. Nevertheless, the jugulotympanic and cauda equina paragangliomas are far less likely to be familial than their systemic counterparts.

Apart from a more frequently realized potential to express cytokeratins and to transdifferentiate along ganglion cell and, rarely, schwannian cell lines (phenomena of no clinical import but recognized in the designation of some examples as "gangliocytic" or "ganglioneuromatous," respectively),[1261,1262] paragangliomas of the CNS are histologically, ultrastructurally, and immunophenotypically comparable to their systemic counterparts.[278] Accordingly, we do not describe these neoplasms here other than to emphasize that some depart from the classic arrangement of epithelioid tumor cells in cohesive nests ("Zellballen") and display, instead, spindled cytology and vaguely storiform growth or a vasocentric, pseudopapillary architecture superficially similar to that of the myxopapillary ependymoma but unaccompanied by mucoid change. Paragangliomas are readily distinguished from the latter (and from other tumors that may share a similar intraspinal topography, such as schwannomas and meningiomas) by virtue of their argyrophilia, content of dense-core granules on ultrastructural study, and immunolabeling of chief cells for SYN and chromogranin, while scattered sustentacular cells stain more intensely with S-100 protein than adjacent chief cells. A neoplasm of the cauda equina showing both ependymal and paraganglionic differentiation has been described[1263] but is a curiosity. Paragangliomas have also been reported to variably express NFPs, GFAP, serotonin, somatostatin, and other neuropeptides.[1253] Melanotic and oncocytic examples are on record,[1253,1264] one of the latter exhibiting locally aggressive growth.

Chordoma

Chordomas are familiar to all pathologists (and are given full description and differential diagnostic treatment elsewhere in these volumes) as destructive tumors of the clivus and sacrococcygeum that presumably originate from remnants of the primitive notochord persisting at these sites. Attention is called to entirely extraosseous, intradural variants that typically lie ventral to the brainstem and that present in adulthood by reason of progressive hydrocephalus, bulbar dysfunction, or intratumoral hemorrhage.[25] Chordomas have also been described as originating in the intraspinal compartment (including a remarkable example associated with the filum terminale[1265]), as arising from the tentorium,[1266] and as occupying the anterior third ventricle[1267] (though the actual identity of the last of these reported curiosities in relation to the chordoid glioma of the third ventricle is problematic, to say the least). The relationship of the intradural chordoma to the ecchordosis physaliphora,[1268] a notochordal heterotopia of comparable morphology that also favors the prepontine regions, remains a subject of debate.[1269] Although some lesions designated as intradural chordomas are clearly neoplasms and are likely derived from displaced notochordal remnants, others may simply represent outsized, symptomatic ecchordoses. Ecchordoses have been described as failing to exhibit the contrast enhancement typical of chordomas on neuroradiological assessment,[26] but the number of studied examples has been quite limited. Gross total excision of these circumscribed masses holds the promise of cure, whatever the terminology employed in their designation. Nuclear immunolabeling for brachyury readily distinguishes chordomas from chordoid meningiomas and chordoid gliomas, as well as mucinous adenocarcinomas and chondrosarcomas (including extraskeletal myxoid types).[940] The sections dealing with these entities may be consulted for other patterns of antigen expression useful in this regard, although note is also made of rare pediatric examples featuring anaplastic or poorly differentiated cytology.[1270] Such cases may be more aggressive, including extraneural metastasis. In common with AT/RTs, the *SMARCB1* gene is often inactivated in such cases, leading to loss of INI1 expression, although retained expression of brachyury aids in the diagnostic distinction.[1271,1272]

Hemangioblastoma (von Hippel–Lindau Disease)

Hemangioblastomas are familiar to most physicians as the hallmark of **VHL disease**, variants associated with this heritable condition constituting some 20%–25% of examples encountered in clinical practice.[278,1273] An autosomal dominant disorder caused by germline mutations of a tumor suppressor gene localized to chromosome 3p25–26, the VHL complex classically includes, in addition to hemangioblastomas of the CNS and retina, visceral cysts (particularly of the kidney, liver, and pancreas), renocortical carcinomas of conventional clear cell type, adrenal pheochromocytomas, and papillary cystadenomas of the epididymis. Affected individuals may also develop endolymphatic sac tumors of the inner ear; hepatocellular adenomas and carcinomas; paragangliomas; endocrine tumors of the pancreas, thyroid gland, and gastrointestinal tract; central neuroepithelial neoplasms; visceral angiomas; and papillary cystadenomas of probable mesonephric origin involving the female genital adnexae. Sporadic hemangioblastomas may also exhibit (though less constantly than VHL-associated cases) mutations or other inactivating abnormalities of the *VHL* gene, which appears to be normally involved in aspects of angiogenesis and cell cycle regulation, and share with syndromic examples frequent losses of chromosome 6q.[1274]

The large majority of hemangioblastomas arise within the cerebellum and produce the neurologic manifestations expected of an expanding posterior fossa mass, extracerebellar examples favoring the medulla and spinal cord (including its covering leptomeninges, nerve roots, and cauda equina).[278] No division of the central neuraxis is entirely immune (especially in the setting of VHL), and these curious neoplasms have rarely been documented to originate in the optic nerve, cerebrum, ventricular system, sella turcica, spinal extradural compartment, or at sites considerably further removed from the CNS (e.g. in association with the radial and paraspinal nerves, within the pancreas, kidney, adrenal gland, bladder, retroperitoneum, intestines, soft tissues, orbit, nasal skin, presacral region,

For personal use only. No other uses without permission. Copyright ©2017. Elsevier Inc. All rights reserved.

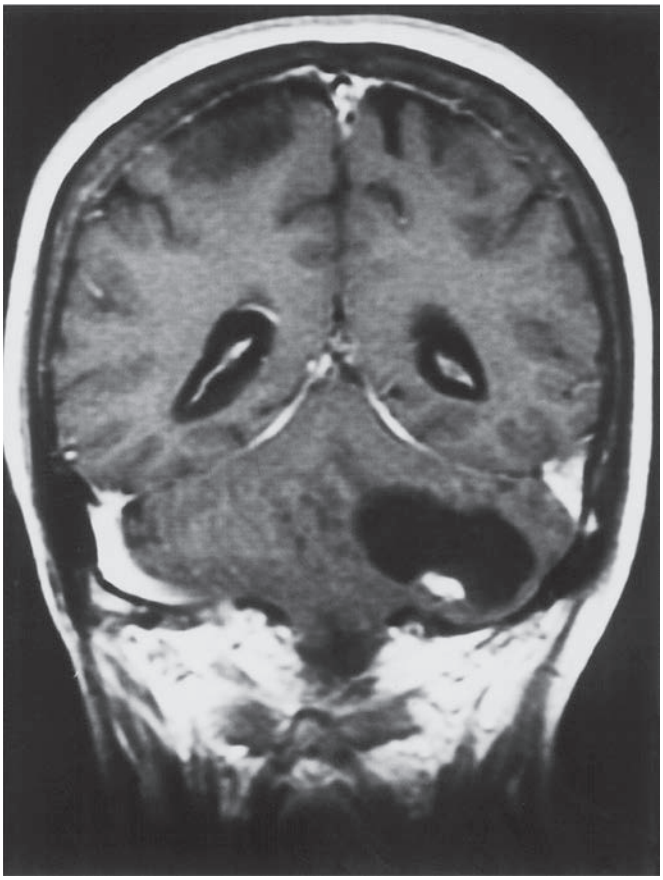

Figure 43.144 Hemangioblastoma. Most hemangioblastomas arise in the cerebellar hemispheres, where, as emphasized in this postcontrast injection magnetic resonance imaging, they present as diminutive, brightly enhancing, and sharply delimited mural nodules projecting into sizable cysts.

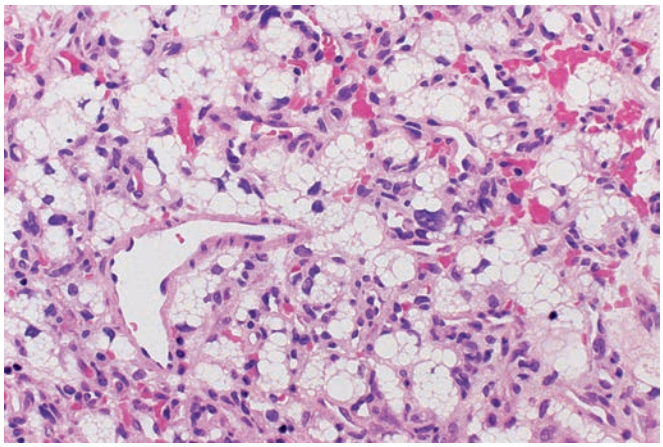

Figure 43.145 Hemangioblastoma. The neoplasm's defining "stromal" cells are most readily visualized when lipid accumulation imparts a foamy or vacuolated quality to their pale cytoplasm.

and maxilla).[1275-1278] Underlying VHL disease carries a special risk of multifocal (including retinal) hemangioblastomas and an increased incidence of extracerebellar primaries. The mean age at diagnosis of VHL disease–associated hemangioblastomas is approximately 30 years, sporadic examples peaking in incidence about a decade later.[278]

The hemangioblastoma often constitutes a sharply circumscribed mural nodule, at times diminutive, in what is otherwise a smooth-walled cyst or, at spinal levels, syrinx (Fig. 43.144). A clear demarcation from adjacent native tissues is typical of the hemangioblastoma, its characteristic reddish-brown and yellow coloration reflecting, respectively, a rich vasculature, and high lipid content. The former component, an anastomosing network of delicate, capillary-like channels supplied by feeding vessels of larger caliber, is responsible for the naming of this entity and its traditional classification as a primary vascular neoplasm. In fact, the sole neoplastic element of the hemangioblastoma—known as the "stromal cell"—inhabits the interstices between ramifying vascular arcades and is recognized by a pale cytoplasm often rich in neutral fats and, as a consequence, vacuolated or foamy in appearance (Fig. 43.145). Aggregation of stromal cells in cohesive nests and lobules lends to "cellular" hemangioblastomas,[1279] an epithelioid histologic presentation that invites confusion with metastatic renocortical carcinoma of clear cell type (these tumors, parenthetically, may collide in the setting of VHL disease[1280]), whereas their paucity in "reticular" variants results in a picture that may be misconstrued as simply angiomatous.

Potentially misleading as well is the tendency of stromal cells to exhibit conspicuous nuclear abnormalities, presumably degenerative, reminiscent of those encountered in neoplasms of neuroendocrine type. These changes, which may include unsettling karyomegaly, pleomorphism, and chromatin smudging, are typically unaccompanied by much, if anything, in the way of mitotic activity and are of no prognostic import. The odd hemangioblastoma will manifest mitoses in more worrisome number, but, again, this finding is not predictive of a malignant course. Regular features of additional note include infiltration by mast cells and, at the tumor–brain interface, a florid piloid astrogliosis replete with Rosenthal fibers but lacking the microcystic elements typical of the juvenile pilocytic astrocytoma. Foci of extramedullary hematopoiesis may be found in hemangioblastomas, some 10% of which present with polycythemia in consequence of erythropoietin production by stromal cells.[1281] Examples of hemangioblastoma arising in association with AVM have been reported[1282] and, as mentioned in our discussion of gliomesenchymal neoplasms, the designation "angioglioma" has been extended to rare tumors interpreted as containing a mixture of hemangioblastomatous and neoplastic glial tissues.

Investigations of stromal cell ultrastructure and immunophenotype have been the basis for widely divergent proposals regarding the cytogenesis of hemangioblastomas. The most recent data suggest a derivation from developmentally arrested cells that normally generate, in embryonic life, the blood islands recognized as loci of early hematopoietic activity (i.e. an origin from true "hemangioblasts"), to some extent vindicating the original name given to this tumor long before the biology was elucidated.[1283,1284] Under appropriate microenvironmental conditions, the cultured stromal cell similarly resembles the multipotent hemangioblast in its reported capacity to spawn erythrocytic, granulocytic, and endothelial elements. In this regard, it is of interest to note the frequent endothelial and sometimes, stromal cell GLUT1 immunoreactivity in hemangioblastomas.[1278,1285] Nonetheless, stromal cells do not label for such endothelial "markers" as CD31 and CD34 and only exceptionally have been described as expressing (and then in small numbers) Factor VIII–related antigen, other endothelium-associated proteins, or lectins.[278]

Additional aspects of hemangioblastoma immunophenotype are of practical significance. GFAP reactivity (a small subset of cellular variants excepted[1279]) is typically restricted to entrapped astrocytes or to stromal cells preferentially distributed along the tumor–neuroparenchymal border, a phenomenon that could well

For personal use only. No other uses without permission. Copyright ©2017. Elsevier Inc. All rights reserved.

reflect nonspecific adsorption or phagocytosis of antigen produced in adjoining gliotic tissues (the occurrence of hemangioblastomas outside the CNS [all GFAP negative] certainly militates against a glial histogenesis[1278]). That stromal cells often label for S-100 protein, NSE, and CD56/NCAM facilitates the distinction of hemangioblastomas from SFTs/HPCs and hemangiomas[1278,1286] (this staining pattern, along with reported immunoreactivity for a variety of neuropeptides[1287] and sightings of dense-core intracytoplasmic granules on ultrastructural study,[1288] have been previously taken as evidence that stromal cells may differentiate along neuroendocrine lines). Particularly important is the observation that stromal cells can exhibit immunolabeling with some anticytokeratins, but most fail to express EMA, the latter further distinguishing the hemangioblastoma from metastatic renocortical carcinoma and lipidized, angiomatous meningiomas. The latter further depart from clear cell carcinomas of renocortical origin in proving CD10 negative, in generally remaining unlabeled by the AE1/3 anticytokeratin "cocktail" and in being far more likely to exhibit widespread immunoexpression of inhibin-alpha, brachyury, and aquaporin 1 (a water channel protein).[1289-1291] While some have found the D2-40 antibody (raised against the M2A fetal gonadal antigen) to label many hemangioblastomas but not metastatic clear cell renal carcinomas,[1292] others have found this reagent lacking in both sensitivity and specificity for purposes of this distinction.[1291]

Hemangioblastomas typically manifest only modest MIB-1/Ki-67 labeling activity, median indices in one large study being less than 1% (range <1%–2%) for reticular and 4% (range <1%–8%) for cellular subtypes.[1279] These differences achieved statistical significance, but proliferative activity as assessed by this immunohistochemical method has not been shown to bear independently on outcome.

Hemangioblastomas are benign (WHO grade I) neoplasms that usually lend themselves to curative resection. Excised tumors may exceptionally recur, however, and patients afflicted with VHL disease are prone to develop additional primaries.[1273] Studies suggesting that cellular variants of hemangioblastoma may be somewhat more prone to recurrence than reticular forms require confirmation.[1279] CSF dissemination by histologically conventional hemangioblastomas ("hemangioblastomatosis") is a rare complication, often occurring years after ostensibly successful resection of cerebellar examples.[1293,1294]

Other Primary Tumors

A unique, **tuberous sclerosis–associated papillary tumor of the hypothalamus** has been reported.[1295] This low-grade lesion expressed cytokeratins 8/18 but not GFAP, SYN, NFPs, NeuN, adenohypophyseal hormones, or choroid plexus–associated antigens such as transthyretin, stanniocalcin-1 or Kir 7.1. The **CRINETS**[823] are intraventricular neoplasms of infancy and early childhood that have ribboned, trabecular, rosetted, and variably dilated tubuloglandular formations composed of poorly differentiated cells with low columnar profiles. Apical EMA labeling as well as immunoreactivity for vimentin, MAP-2C, SYN, and cytokeratins (focal) have been described, but cells do not express GFAP or Kir 7.1. While rhabdoid components have not been identified within these curious lesions, they fail to label for INI1 protein and can exhibit *SMARCB1* gene mutations, but otherwise have relatively stable genomes.[1296] The latter (and conspicuous proliferative activity) notwithstanding, CRINETs seem far more amenable to control by combined surgical and adjuvant means than neoplasms of the AT/RT group. The list of neoplastic oddities that have been encountered along the central neuraxis further includes a **malignant myoepithelioma** of the cranial dura,[1297] a spinal nerve root "**oncocytoma**" of indeterminate lineage,[1298] lumbar intradural masses representing misplaced **adrenocortical neoplasms**,[1299] and a number of **ectopic**, **suprasellar pituitary adenomas** situated in the third ventricle/hypothalamic region.[1300,1301] A survey of intracranial sarcomas previously cited in the discussion of nonmeningothelial, mesenchymal neoplasms includes an example of cerebral **ectomesenchymoma**—a tumor composed of ganglion cell and rhabdomyosarcomatous elements.[966]

Secondary/Metastatic Tumors

Secondary involvement of the CNS by direct extension or hematogenous metastasis is a common complication of systemic cancer and a phenomenon that frequently prompts diagnostic, as well as palliative, neurosurgical intervention. Because we have already touched on this subject in reference to lymphoproliferative and myeloproliferative disorders, this discussion is concerned only with invasion of the central neuraxis by solid tumors.

That neoplasms arising in and around the skeletal confines of the brain and spinal cord often come to impinge on these structures should come as no surprise. Examples include the pituitary adenoma with suprasellar or retrosellar expansion, the jugulotympanic paragangliomas that exploit neighboring foramina of the calvarial floor to present as a mass in the cerebellopontine angle, and sacrococcygeal chordomas that engulf the roots of the cauda equina. Ceruminous gland carcinomas and other neoplasms arising in the ear may occasionally billow into the middle cranial fossa to present as intracranial masses.[1302,1303] A substantial risk of local skull base destruction and invasion of contiguous meninges, potentially complicated by dissemination in the subarachnoid space, is seen in embryonal rhabdomyosarcomas originating in head and neck sites, particularly the nasopharynx, paranasal sinuses, and middle ear.[1041] Similarly situated carcinomas of mucosal or minor salivary gland derivation may behave in like fashion, but some of the latter instead track insidiously along regional nerve fiber bundles to achieve radiologically detectable proportions only within the cranial compartment.[1304,1305] Neglected, basal cell or squamous carcinomas of the face and scalp may also reach the CNS by permeating the calvarium or by propagation within perineurial spaces.[1306] The neurotropic spread of a malignant mesothelioma to the spinal cord via the brachial plexus is also on record.[1307] Cancers arising in more distant sites may secondarily infiltrate the nervous system after first metastasizing to juxtaneural structures, the vertebral column apparently serving as an especially important way station in this regard. Epidural spinal cord compression by malignant tumors, for example, is most frequently caused by carcinomas of pulmonary, prostatic, or mammary origin that have spread to the vertebrae, neoplastic cells commonly entering the spinal canal via the bony foramina traversed by vertebral veins.[1308] A similar sequence of events is postulated to account for the high incidence of vertebral and paravertebral metastases in cancer patients developing diffuse leptomeningeal carcinomatosis, principally a complication of adenocarcinomas derived from the lung and breast.[1309] This diagnosis is usually established by the demonstration of malignant cells on cytologic inspection of the CSF.

More common than instances of secondary CNS infiltration by contiguous malignant tumors are blood-borne neuraxial metastases.[1310] The principal offenders in this regard are carcinomas of the lung and breast, followed by malignant melanomas, renocortical carcinomas, and adenocarcinomas of colorectal origin.[278] Carcinomas of the lung are the systemic cancers most likely to present initially as intracerebral tumors, accounting for roughly half of all such cases and up to 85% of lesions exhibiting adenocarcinomatous histology. Increasingly effective management of systemic disease may account for perceived rises in the incidence of intracranial deposits from ovarian carcinomas[1311] and osseous or soft tissue sarcomas,[1312] but

For personal use only. No other uses without permission. Copyright ©2017. Elsevier Inc. All rights reserved.

the latter remain most uncommon as neurosurgical specimens. Sarcomas typically spread to the lungs en route to the brain but may give rise to isolated cerebral or dura-based metastases that, in exceptional instances, herald discovery of the primary tumor.[1313] The prominence in some series of alveolar soft part sarcoma giving rise to intracranial metastases[1314] is noteworthy, as it is one of the rarest tumor types among mesenchymal neoplasms. Mention should also be made of HIV-1–associated Kaposi sarcoma traveling to the cranial compartment,[1315] but this remains a curiosity even in the presence of widespread cutaneous and visceral involvement. Unusual, but well documented, is the transmission of maternal cancer (particularly melanoma) to the developing fetus via the placenta.[1316]

Although blood-borne tumor emboli may lodge at any level of the central neuraxis, a few useful generalizations can be made regarding the topography of metastatic lesions. Intramedullary metastases (i.e. those involving the spinal cord parenchyma) are rare,[1317] the great majority of metastatic deposits coming to lie in the supratentorial or infratentorial compartments. In general, the distribution of metastases within the latter conforms to their relative volumes and blood supply.[1318,1319] Thus, most lesions settle within frontoparietal cerebral tissues subtended by the middle cerebral artery (the dominant tributary of the circle of Willis); tumor emboli often lodge within the "watershed" zone representing the terminus of this vascular territory. For reasons that are not clear, colorectal, uterine, and renocortical carcinomas are over-represented among cancers seeding the cerebellum.[1319] Prostatic adenocarcinomas also exhibit a curious predilection for this structure when they metastasize to the brain, but their deposits are more typically skull and/or dura-based and only exceptionally involve the neural parenchyma proper.[1320] Dural metastases in women most often derive from mammary carcinomas.[1318,1320] As a rule, those tumors that frequently travel to the CNS (e.g. malignant melanoma and carcinomas of the lung) tend to produce multiple metastases, whereas cancers that only occasionally involve the brain (e.g. gastrointestinal adenocarcinomas) are often represented by solitary deposits. A clinical study in which nearly one-half of cancer patients with brain metastases were found to have unifocal lesions on neuroradiological assessment[1319] is noteworthy. A particularly compelling case for neurosurgical intervention can be made in this setting because metastatic lesions are usually compact in their growth patterns and thus lend themselves to excision. Patients who undergo surgical extirpation of single metastases (usually followed by radiotherapy) may be restored to many months (or even years) of useful function, live longer, and enjoy a better quality of life than those whose tumors are simply irradiated using conventional external beam techniques.[1318] Refined stereotactic and radiosurgical techniques are increasingly employed to address metastases and may improve the outlook for patients with deep-seated or multifocal lesions.

In contrast to the common glial neoplasms of adulthood, metastatic nodules tend to be sharply circumscribed and possessed of "pushing" margins (Fig. 43.146). Much of their mass effect may be derived from edematous expansion of neighboring white matter, often disproportionate to the small size of the offending deposits and usually more pronounced than the edema accompanying primary brain tumors. Most metastases are relatively superficial in location, straddling the gray–white junction to involve both cerebral cortex (thus the high incidence of associated seizures) and digitate white matter. Intralesional hemorrhage occasionally brings brain metastases to light, an especially common phenomenon in the settings of germ cell neoplasia, renocortical carcinomas, and melanomas, although given their higher frequencies overall, lung carcinomas remain in this differential of hemorrhagic metastases.

On histologic examination, most secondary cancers conform to the histology of their donor tumors and are readily distinguished from primary neoplasms of the brain or meninges on casual inspection. Features that aid in the segregation of poorly differentiated carcinomas from anaplastic gliomas include a cohesive architecture, abrupt interface with adjacent neural tissue, "peritheliomatous" pattern of tumor cell preservation about stromal blood vessels in cases evidencing coagulative necrosis, and absence of complex microvascular hyperplasia. The last, however, is an arresting feature of some metastatic small cell carcinomas derived from the lung. A confident diagnosis of metastatic carcinoma can often be made at the time of surgery by examination of smear or crush preparations in which the cellular cohesion of most epithelial neoplasms is preserved (Fig. 43.147). The reader is reminded that glial neoplasms of varied type, including fibrillary astrocytomas, may be labeled by antibodies to cytokeratins (particularly the AE1/3 "cocktail") and, on occasion, EMA.[330,1310,1321] It would appear that CAM 5.2, CK7,

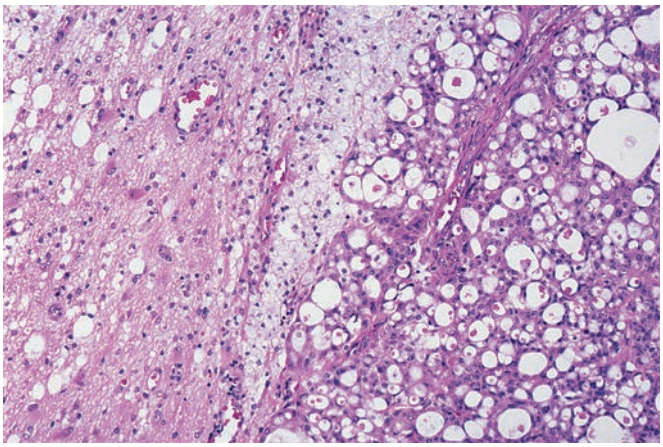

Figure 43.146 Metastatic Carcinoma. A cohesive growth pattern and clearly delimited tumor–central nervous system interface are hallmarks of neoplasms metastatic to the brain. The adenocarcinoma *(right)*, derived from a primary in the left lung, "pushes" against adjacent cerebral white matter.

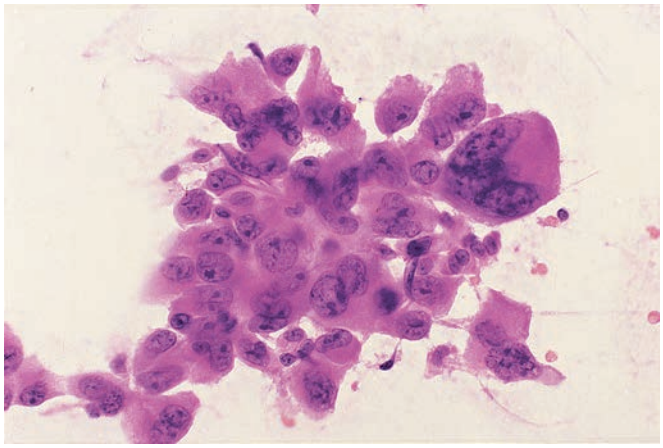

Figure 43.147 Metastatic Carcinoma. The cellular cohesion characteristic of most epithelial neoplasms and foreign to gliomas and lymphomas is generally maintained in cytology preparations, facilitating rapid intraoperative diagnosis. Note also the absence of cytoplasmic processes and presence of conspicuous nucleoli, the latter also alien to most neuroepithelial tumors, in this smear preparation of a poorly differentiated pulmonary adenocarcinoma that presented as a solitary, right frontal lobe brain mass.

For personal use only. No other uses without permission. Copyright ©2017. Elsevier Inc. All rights reserved.

CK20, and Ber-EP4 perform in more discriminating fashion as epithelial markers in this regard. GFAP labeling of metastatic carcinomas, while documented, is an exceptional event.[936,1322] As metastases usually remain faithful to the donor immunophenotype, immunohistochemical algorithms may focus the search for a systemic primary in the patient who does not have a history of cancer.[1310] Nuclear labeling for TTF-1, for example, should raise strong question of a metastatic deposit deriving from a differentiated carcinoma of the thyroid gland or nonsquamous carcinoma of the lung,[1323] although care must be taken regarding which clone is used, since a less specific version may also stain glioblastomas.[1324] Depending on the histologic findings in a given case, the differential diagnosis of a suspected metastasis may include, in addition to an epithelioid or sarcomatoid glioblastoma, the capillary hemangioblastoma, papillary ependymoma, choroid plexus tumor, and meningioma. Each of these is considered separately elsewhere in this chapter.

In closing, mention is made of certain unusual forms or presentations of secondary CNS involvement by malignant neoplasms. These include diffuse seeding of the periventricular tissues by metastatic small cell carcinomas of the lung[1325] (a pattern of spread mimicking the topography of some primary CNS lymphomas), miliary or "encephalitic" cerebral carcinomatosis or melanomatosis with widespread vascular cuffing by tumor cells on microscopic study but no conspicuous mass lesions,[1326] and occlusion of major cerebral vessels by neoplastic emboli resulting in ischemic stroke.[1327] Intracardiac tumors such as myxomas are the lesions most often implicated in cerebral infarcts secondary to neoplastic embolization, but this phenomenon has also been recorded in association with carcinomas arising in the head and neck, lungs, colon, and other visceral sites. As mentioned in the discussion of primary mesenchymal tumors of the CNS, deposits derived from occult atrial myxomas may be misconstrued as cerebral epithelioid hemangioendotheliomas.[1037] Atrial myxomas are also responsible for most neoplastic cerebrovascular aneurysms,[98] a metastatic complication of cancer noted in our prior treatment of vascular disorders. Yet another vascular complication of intracranial metastasis is subdural hemorrhage secondary to dura-based lesions.[1320]

Acknowledgments

Dr. Rosenblum: Dr. Rosemary Purrazzella, my wife, was patience itself and will hopefully find this useful in her own practice of surgical pathology (small reward).

Dr. Perry: Firstly, I am extremely grateful to my coauthor, Marc Rosenblum, for graciously allowing me to update his "baby" from the 9th edition of this text, which was already so beautifully written and illustrated that it made my role remarkably simple and pleasurable. I am also eternally thankful to my wife, Andrea, for her extraordinary patience and support during the many long hours I spent on this and similar projects.

References

1. Love S, Budka H, Ironside JW, Perry A, eds. *Greenfield's Neuropathology*. 9th ed. London, UK: CRC Press, Taylor & Francis Group, LLC; 2015.
2. Bale PM. Sacrococcygeal developmental abnormalities and tumors in children. *Perspect Pediatr Pathol*. 1984;8:9-56.
3. Chakrabortty S, Oi S, Yoshida Y, et al. Myelomeningocele and thick filum terminale with tethered cord appearing as a human tail. Case report. *J Neurosurg*. 1993;78:966-969.
4. Yamada S, Won DJ, Siddiqi J, Yamada SM. Tethered cord syndrome: overview of diagnosis and treatment. *Neurol Res*. 2004;26:719-721.
5. Ibrahim AE, Myles L, Lang DA, Ellison DW. Case of the month: June 1998—2 year old boy with lumbosacral mass. *Brain Pathol*. 1998;8:817-818.
6. Ebisu T, Odake G, Fujimoto M, et al. Neurenteric cysts with meningomyelocele or meningocele. Split notochord syndrome. *Childs Nerv Syst*. 1990;6:465-467.
7. Koen JL, McLendon RE, George TM. Intradural spinal teratoma: evidence for a dysembryogenic origin. Report of four cases. *J Neurosurg*. 1998;89:844-851.
8. Chadduck WM, Uthman EO. Squamous cell carcinoma and meningomyelocele. *Neurosurgery*. 1984;14:601-603.
9. Rajpal S, Salamat MS, Tubbs RS, et al. Tethering tracts in spina bifida occulta: revisiting an established nomenclature. *J Neurosurg Spine*. 2007;7:315-322.
10. Morris GF, Murphy K, Rorke LB, James HE. Spinal hamartomas: a distinct clinical entity. *J Neurosurg*. 1998;88:954-957.
11. Lalwani AK, Jackler RK, Harsh GRt, Butt FY. Bilateral temporal bone encephaloceles after cranial irradiation. Case report. *J Neurosurg*. 1993;79:596-599.
12. Abel TJ, Chowdhary A, Thapa M, et al. Ectopic glioneuronal tissue in the middle cranial fossa region. Report of four cases. *J Neurosurg Pediatr*. 2009;3:188-196.
13. Hirano S, Houdou S, Hasegawa M, et al. Clinicopathologic studies on leptomeningeal glioneuronal heterotopia in congenital anomalies. *Pediatr Neurol*. 1992;8:441-444.
14. Sun LS, Sun ZP, Ma XC, Li TJ. Glial choristoma in the oral and maxillofacial region: a clinicopathologic study of 6 cases. *Arch Pathol Lab Med*. 2008;132:984-988.
15. Penner CR, Thompson L. Nasal glial heterotopia: a clinicopathologic and immunophenotypic analysis of 10 cases with a review of the literature. *Ann Diagn Pathol*. 2003;7:354-359.
16. Matyja E, Grajkowska W, Marchel A, et al. Ectopic cerebellum in anterior cranial fossa: report of a unique case associated with skull congenital malformations and epilepsy. *Am J Surg Pathol*. 2007;31:322-325.
17. Bossen EH, Hudson WR. Oligodendroglioma arising in heterotopic brain tissue of the soft palate and nasopharynx. *Am J Surg Pathol*. 1987;11:571-574.
18. Gold AH, Sharer LR, Walden RH. Central nervous system heterotopia in association with cleft palate. *Plast Reconstr Surg*. 1980;66:434-441.
19. Lee SC, Henry MM, Gonzalez-Crussi F. Simultaneous occurrence of melanotic neuroectodermal tumor and brain heterotopia in the oropharynx. *Cancer*. 1976;38:249-253.
20. Chan JK, Lau WH. Nasal astrocytoma or nasal glial heterotopia? *Arch Pathol Lab Med*. 1989;113:943-945.
21. Bale PM, Hughes L, de Silva M. Sequestrated meningoceles of scalp: extracranial meningeal heterotopia. *Hum Pathol*. 1990;21:1156-1163.
22. Suster S, Rosai J. Hamartoma of the scalp with ectopic meningothelial elements. A distinctive benign soft tissue lesion that may simulate angiosarcoma. *Am J Surg Pathol*. 1990;14:1-11.
23. Abel TW, Curtis M, Lin DD, et al. Complex choristoma of the gyrus rectus: a distinct clinicopathologic entity? *Am J Surg Pathol*. 2006;30:625-629.
24. Abel TJ, Chowdhary A, Jallo G, et al. Thoracic spinal cord compression by intramedullary hamartomatous tissue in a young boy: case report. *Neurosurgery*. 2008;62:E1380-E1381, discussion E1381.
25. Roberti F, Sekhar LN, Jones RV, Wright DC. Intradural cranial chordoma: a rare presentation of an uncommon tumor. Surgical experience and review of the literature. *J Neurosurg*. 2007;106:270-274.
26. Toda H, Kondo A, Iwasaki K. Neuroradiological characteristics of ecchordosis physaliphora. Case report and review of the literature. *J Neurosurg*. 1998;89:830-834.
27. Fix SE, Nelson J, Schochet SS Jr. Focal leptomeningeal rhabdomyomatosis of the posterior fossa. *Arch Pathol Lab Med*. 1989;113:872-873.
28. Thakrar R, Robson CD, Vargas SO, et al. Benign triton tumor: multidisciplinary approach to diagnosis and treatment. *Pediatr Dev Pathol*. 2014;17:400-405.
29. Hebert-Blouin MN, Scheithauer BW, Amrami KK, et al. Fibromatosis: a potential sequela of neuromuscular choristoma. *J Neurosurg*. 2012;116:399-408.
30. Sharma MC, Sarkar C, Jain D, et al. Uterus-like mass of mullerian origin in the lumbosacral region causing cord tethering. Report of two cases. *J Neurosurg Spine*. 2007;6:73-76.
31. Thibodeau LL, Prioleau GR, Manuelidis EE, et al. Cerebral endometriosis. Case report. *J Neurosurg*. 1987;66:609-610.
32. Lombardo L, Mateos JH, Barroeta FF. Subarachnoid hemorrhage due to endometriosis of the spinal canal. *Neurology*. 1968;18:423-426.
33. Curry B, Taylor CW, Fisher AW. Salivary gland heterotopia: a unique cerebellopontine angle tumor. *Arch Pathol Lab Med*. 1982;106:35-38.

For personal use only. No other uses without permission. Copyright ©2017. Elsevier Inc. All rights reserved.

34. Rodriguez F, Scheithauer BW, Ockner DM, Giannini C. Solitary fibrous tumor of the cerebellopontine angle with salivary gland heterotopia: a unique presentation. *Am J Surg Pathol*. 2004;28:139-142.
35. Perry A, Kurtkaya-Yapicier O, Scheithauer BW, et al. Insights into meningioangiomatosis with and without meningioma: a clinicopathologic and genetic series of 24 cases with review of the literature. *Brain Pathol*. 2005;15:55-65.
36. Omeis I, Hillard VH, Braun A, et al. Meningioangiomatosis associated with neurofibromatosis: report of 2 cases in a single family and review of the literature. *Surg Neurol*. 2006;65:595-603.
37. Wiebe S, Munoz DG, Smith S, Lee DH. Meningioangiomatosis. A comprehensive analysis of clinical and laboratory features. *Brain*. 1999;122(Pt 4):709-726.
38. Kim NR, Cho SJ, Suh YL. Allelic loss on chromosomes 1p32, 9p21, 13q14, 16q22, 17p, and 22q12 in meningiomas associated with meningioangiomatosis and pure meningioangiomatosis. *J Neurooncol*. 2009;94:425-430.
39. Lopez JI, Ereno C, Oleaga L, Areitio E. Meningioangiomatosis and oligodendroglioma in a 15-year-old boy. *Arch Pathol Lab Med*. 1996;120:587-590.
40. Desai KI, Nadkarni TD, Muzumdar DP, Goel AH. Surgical management of colloid cyst of the third ventricle—a study of 105 cases. *Surg Neurol*. 2002;57:295-302, discussion 302-304.
41. Montaldi S, Deruaz JP, Cai ZT, de Tribolet N. Symptomatic xanthogranuloma of the third ventricle: report of two cases and review of the literature. *Surg Neurol*. 1989;32:200-205.
42. Ho KL, Garcia JH. Colloid cysts of the third ventricle: ultrastructural features are compatible with endodermal derivation. *Acta Neuropathol*. 1992;83:605-612.
43. Graziani N, Dufour H, Figarella-Branger D, et al. Do the suprasellar neurenteric cyst, the Rathke cleft cyst and the colloid cyst constitute a same entity? *Acta Neurochir (Wien)*. 1995;133:174-180.
44. Wang W, Piao YS, Gui QP, et al. Cerebellopontine angle neurenteric cyst with focal malignant features. *Neuropathology*. 2009;29:91-95.
45. Dunham CP, Curry B, Hamilton M. Malignant transformation of an intraaxial-supratentorial neurenteric cyst—case report and review of the literature. *Clin Neuropathol*. 2009;28:460-466.
46. Takei H, Fuller GN, Powell SZ. Intracranial cysts of endodermal or respiratory epithelioid origin. In: McLendon RE, Rosenblum MK, Bigner DD, eds. *Russell and Rubinstein's Pathology of Tumors of the Nervous System*. 7th ed. London: Hodder Arnold; 2006:591-598.
47. Goel A, Muzumdar D, Chagla A. Endodermal cyst anterior and anterolateral to the brainstem: a report of an experience with seven cases. *Br J Neurosurg*. 2005;19:163-166.
48. Emerson RE, Azzarelli B. Enterogenous cysts of the spinal canal and cerebellopontine angle. *Appl Immunohistochem Mol Morphol*. 2004;12:230-233.
49. Perry A, Scheithauer BW, Zaias BW, Minassian HV. Aggressive enterogenous cyst with extensive craniospinal spread: case report. *Neurosurgery*. 1999;44:401-404, discussion 404-405.
50. Rotondo M, D'Avanzo R, Natale M, et al. Intramedullary neurenteric cysts of the spine. Report of three cases. *J Neurosurg Spine*. 2005;2:372-376.
51. Ho KL, Tiel R. Intraspinal bronchogenic cyst: ultrastructural study of the lining epithelium. *Acta Neuropathol*. 1989;78:513-520.
52. Fuller G, Ribalta T. Dermoid cyst, epidermoid cyst and dermal sinus. In: McLendon RE, Rosenblum MK, Bigner DD, eds. *Russell and Rubinstein's Pathology of Tumors of the Nervous System*. 7th ed. London: Hodder Arnold; 2006:583-590.
53. Smith CM, Timperley WR. Multiple intraspinal and intracranial epidermoids and lipomata following gunshot injury. *Neuropathol Appl Neurobiol*. 1984;10:235-239.
54. Halcrow SJ, Crawford PJ, Craft AW. Epidermoid spinal cord tumour after lumbar puncture. *Arch Dis Child*. 1985;60:978-979.
55. Carvalho GA, Cervio A, Matthies C, Samii M. Subarachnoid fat dissemination after resection of a cerebellopontine angle dysontogenic cyst: case report and review of the literature. *Neurosurgery*. 2000;47:760-763, discussion 763-764.
56. Hamlat A, Hua ZF, Saikali S, et al. Malignant transformation of intra-cranial epithelial cysts: systematic article review. *J Neurooncol*. 2005;74:187-194.
57. Cannon TC, Bane BL, Kistler D, et al. Primary intracerebellar osteosarcoma arising within an epidermoid cyst. *Arch Pathol Lab Med*. 1998;122:737-739.
58. Hitchcock MG, Ellington KS, Friedman AH, et al. Shadow cells in an intracranial dermoid cyst. *Arch Pathol Lab Med*. 1995;119:371-373.
59. Miyagi Y, Suzuki SO, Iwaki T, et al. Magnetic resonance appearance of multiple intracranial epidermoid cysts: intrathecal seeding of the cysts? Case report. *J Neurosurg*. 2000;92:711-714.
60. Kim JH, Paulus W, Heim S. BRAF V600E mutation is a useful marker for differentiating Rathke's cleft cyst with squamous metaplasia from papillary craniopharyngioma. *J Neurooncol*. 2015;123(1):189-191.
61. Hofmann BM, Kreutzer J, Saeger W, et al. Nuclear beta-catenin accumulation as reliable marker for the differentiation between cystic craniopharyngiomas and rathke cleft cysts: a clinico-pathologic approach. *Am J Surg Pathol*. 2006;30:1595-1603.
62. Frazier J, Garonzik I, Tihan T, Olivi A. Recurrent glioependymal cyst of the posterior fossa: an unusual entity containing mixed glial elements. Case report. *J Neurooncol*. 2004;68:13-17.
63. Balasubramaniam C, Balasubramaniam V, Santosh V. Intramedullary glioependymal cyst and tethered cord in an infant. *Childs Nerv Syst*. 2004;20:496-498.
64. Tange Y, Aoki A, Mori K, et al. Interhemispheric glioependymal cyst associated with agenesis of the corpus callosum—case report. *Neurol Med Chir (Tokyo)*. 2000;40:536-542.
65. Ho KL, Chason JL. A glioependymal cyst of the cerebellopontine angle. Immunohistochemical and ultrastructural studies. *Acta Neuropathol*. 1987;74: 382-388.
66. Ciappetta P, D'Urso P I, Luzzi S, et al. Cystic dilation of the ventriculus terminalis in adults. *J Neurosurg Spine*. 2008;8:92-99.
67. Ciricillo SF, Davis RL, Wilson CB. Neuroepithelial cysts of the posterior fossa. Case report. *J Neurosurg*. 1990;72:302-305.
68. Del Bigio MR, Jay V, Drake JM. Prepontine cyst lined by respiratory epithelium with squamous metaplasia: immunohistochemical and ultrastructural study. *Acta Neuropathol*. 1992;83:564-568.
69. Kraus I, Jirasek JE. Some observations of the structure of the choroid plexus and its cysts. *Prenat Diagn*. 2002;22:1223-1228.
70. Weisberg LA. Non-neoplastic gliotic cerebellar cysts: clinical and computed tomographic correlations. *Neuroradiology*. 1982;24:53-57.
71. Wilkins RH, Burger PC. Benign intraparenchymal brain cysts without an epithelial lining. *J Neurosurg*. 1988;68:378-382.
72. Davis G, Fitt GJ, Kalnins RM, Mitchell LA. Increased perivascular spaces mimicking frontal lobe tumor. *J Neurosurg*. 2002;97:723.
73. Patel AJ, Fuller GN, Wildrick DM, Sawaya R. Pineal cyst apoplexy: case report and review of the literature. *Neurosurgery*. 2005;57:E1066, discussion E1066.
74. Ribalta T, Fuller GN. Arachnoid cyst. In: McLendon RE, Rosenblum MK, Bigner DD, eds. *Russell and Rubinstein's Pathology of Tumors of the Nervous System*. 7th ed. London: Hodder Arnold; 2006:607-609.
75. Bond AE, Zada G, Bowen I, et al. Spinal arachnoid cysts in the pediatric population: report of 31 cases and a review of the literature. *J Neurosurg Pediatr*. 2012;9:432-441.
76. Weinand ME, Rengachary SS, McGregor DH, Watanabe I. Intradiploic arachnoid cysts. Report of two cases. *J Neurosurg*. 1989;70:954-958.
77. Hamburger CH, Buttner A, Weis S. Dural cysts in the cervical region. Report of three cases and review of the literature. *J Neurosurg*. 1998;89:310-313.
78. Ojemann JG, Moran CJ, Gokden M, Dacey RG Jr. Sagittal sinus occlusion by intraluminal dural cysts. Report of two cases. *J Neurosurg*. 1999;91:867-870.
79. Nabors MW, Pait TG, Byrd EB, et al. Updated assessment and current classification of spinal meningeal cysts. *J Neurosurg*. 1988;68:366-377.
80. Voyadzis JM, Bhargava P, Henderson FC. Tarlov cysts: a study of 10 cases with review of the literature. *J Neurosurg*. 2001;95:25-32.
81. Rosenberg AE, O'Connell JX, Ojemann RG, et al. Giant cystic arachnoid granulations: a rare cause of lytic skull lesions. *Hum Pathol*. 1993;24:438-441.
82. Sabo RA, Tracy PT, Weinger JM. A series of 60 juxtafacet cysts: clinical presentation, the role of spinal instability, and treatment. *J Neurosurg*. 1996;85:560-565.
83. Almefty R, Arnautović KI, Webber BL. Multilevel bilateral calcified thoracic spinal synovial cysts. *J Neurosurg Spine*. 2008;8(5):473-477.
84. Machino M, Yukawa Y, Ito K, Kato F. Cervical degenerative intraspinal cyst: a case report and literature review involving 132 cases. *BMJ Case Rep*. 2012;2012.
85. Chuaqui R, Tapia J. Histologic assessment of the age of recent brain infarcts in man. *J Neuropathol Exp Neurol*. 1993;52:481-489.
86. Mena H, Cadavid D, Rushing EJ. Human cerebral infarct: a proposed histopathologic classification based on 137 cases. *Acta Neuropathol*. 2004;108:524-530.
87. Serrone JC, Maekawa H, Tjahjadi M, Hernesniemi J. Aneurysmal subarachnoid hemorrhage: pathobiology, current treatment and future directions. *Expert Rev Neurother*. 2015;15:367-380.
88. Tromp G, Weinsheimer S, Ronkainen A, Kuivaniemi H. Molecular basis and genetic predisposition to intracranial aneurysm. *Ann Med*. 2014;46:597-606.
89. Weir B. Unruptured intracranial aneurysms: a review. *J Neurosurg*. 2002;96:3-42.
90. Erbengi A, Inci S. Pheochromocytoma and multiple intracranial aneurysms: is it a coincidence? Case report. *J Neurosurg*. 1997;87:764-767.
91. Love S, Ironside J, Budka H, Perry A. *Greenfield's Neuropathology*. 9th ed. London, UK: CRC Press, Taylor & Francis Group, LLC; 2015.

For personal use only. No other uses without permission. Copyright ©2017. Elsevier Inc. All rights reserved.

92. Inagawa T, Hirano A. Ruptured intracranial aneurysms: an autopsy study of 133 patients. *Surg Neurol*. 1990;33:117-123.
93. Juvela S, Porras M, Poussa K. Natural history of unruptured intracranial aneurysms: probability of and risk factors for aneurysm rupture. *J Neurosurg*. 2000;93:379-387.
94. Chambi I, Tasker RR, Gentili F, et al. Gauze-induced granuloma ("gauzoma"): an uncommon complication of gauze reinforcement of berry aneurysms. *J Neurosurg*. 1990;72:163-170.
95. Bohmfalk GL, Story JL, Wissinger JP, Brown WE Jr. Bacterial intracranial aneurysm. *J Neurosurg*. 1978;48:369-382.
96. Drake CG, Peerless SJ. Giant fusiform intracranial aneurysms: review of 120 patients treated surgically from 1965 to 1992. *J Neurosurg*. 1997;87:141-162.
97. Schievink WI, Puumala MR, Meyer FB, et al. Giant intracranial aneurysm and fibromuscular dysplasia in an adolescent with alpha 1-antitrypsin deficiency. *J Neurosurg*. 1996;85:503-506.
98. Furuya K, Sasaki T, Yoshimoto Y, et al. Histologically verified cerebral aneurysm formation secondary to embolism from cardiac myxoma. Case report. *J Neurosurg*. 1995;83:170-173.
99. Zheng J, Zhang J. Neoplastic cerebral aneurysm from metastatic tumor: a systematic review of clinical and treatment characteristics. *Clin Neurol Neurosurg*. 2015;128:107-111.
100. Chang IB, Cho BM, Park SH, et al. Metastatic choriocarcinoma with multiple neoplastic intracranial microaneurysms: case report. *J Neurosurg*. 2008;108:1014-1017.
101. Sciubba DM, Gallia GL, Recinos P, et al. Intracranial aneurysm following radiation therapy during childhood for a brain tumor. Case report and review of the literature. *J Neurosurg*. 2006;105:134-139.
102. Lammie GA. Hypertensive cerebral small vessel disease and stroke. *Brain Pathol*. 2002;12:358-370.
103. Wakai S, Kumakura N, Nagai M. Lobar intracerebral hemorrhage. A clinical, radiographic, and pathological study of 29 consecutive operated cases with negative angiography. *J Neurosurg*. 1992;76:231-238.
104. Challa VR, Moody DM, Bell MA. The Charcot-Bouchard aneurysm controversy: impact of a new histologic technique. *J Neuropathol Exp Neurol*. 1992;51:264-271.
105. Farrell DF, Forno LS. Symptomatic capillary telangiectasis of the brainstem without hemorrhage. Report of an unusual case. *Neurology*. 1970;20:341-346.
106. Vaquero J, Manrique M, Oya S, et al. Calcified telangiectatic hamartomas of the brain. *Surg Neurol*. 1980;13:453-457.
107. te Veldhuis EC, te Veldhuis AH, van Dijk FS, et al. Rendu-Osler-Weber disease: update of medical and dental considerations. *Oral Surg Oral Med Oral Pathol Oral Radiol Endod*. 2008;105:e38-e41.
108. Naff NJ, Wemmer J, Hoenig-Rigamonti K, Rigamonti DR. A longitudinal study of patients with venous malformations: documentation of a negligible hemorrhage risk and benign natural history. *Neurology*. 1998;50:1709-1714.
109. Rigamonti D, Johnson PC, Spetzler RF, et al. Cavernous malformations and capillary telangiectasia: a spectrum within a single pathological entity. *Neurosurgery*. 1991;28:60-64.
110. Meyer FB, Lombardi D, Scheithauer B, Nichols DA. Extra-axial cavernous hemangiomas involving the dural sinuses. *J Neurosurg*. 1990;73:187-192.
111. Simard JM, Garcia-Bengochea F, Ballinger WE Jr, et al. Cavernous angioma: a review of 126 collected and 12 new clinical cases. *Neurosurgery*. 1986;18:162-172.
112. Laurans MS, DiLuna ML, Shin D, et al. Mutational analysis of 206 families with cavernous malformations. *J Neurosurg*. 2003;99:38-43.
113. D'Angelo R, Marini V, Rinaldi C, et al. Mutation analysis of CCM1, CCM2 and CCM3 genes in a cohort of Italian patients with cerebral cavernous malformation. *Brain Pathol*. 2011;21:215-224.
114. Musunuru K, Hillard VH, Murali R. Widespread central nervous system cavernous malformations associated with cafe-au-lait skin lesions. Case report. *J Neurosurg*. 2003;99:412-415.
115. Dobyns WB, Michels VV, Groover RV, et al. Familial cavernous malformations of the central nervous system and retina. *Ann Neurol*. 1987;21:578-583.
116. Labauge P, Enjolras O, Bonerandi JJ, et al. An association between autosomal dominant cerebral cavernomas and a distinctive hyperkeratotic cutaneous vascular malformation in 4 families. *Ann Neurol*. 1999;45:250-254.
117. Al-Shahi Salman R, Berg MJ, Morrison L, Awad IA. Hemorrhage from cavernous malformations of the brain: definition and reporting standards. Angioma Alliance Scientific Advisory Board. *Stroke*. 2008;39:3222-3230.
118. Roda JM, Carceller F, Perez-Higueras A, Morales C. Encapsulated intracerebral hematomas: a defined entity. Case report. *J Neurosurg*. 1993;78:829-833.
119. Di Giannatale A, Morana G, Rossi A, et al. Natural history of cavernous malformations in children with brain tumors treated with radiotherapy and chemotherapy. *J Neurooncol*. 2014;117(2):311-320.
120. Meijer-Jorna LB, Aronica E, van der Loos CM, et al. Congenital vascular malformations—cerebral lesions differ from extracranial lesions by their immune expression of the glucose transporter protein GLUT1. *Clin Neuropathol*. 2012;31:135-141.
121. Mandybur TI, Nazek M. Cerebral arteriovenous malformations. A detailed morphological and immunohistochemical study using actin. *Arch Pathol Lab Med*. 1990;114:970-973.
122. Abecassis IJ, Xu DS, Batjer HH, Bendok BR. Natural history of brain arteriovenous malformations: a systematic review. *Neurosurg Focus*. 2014;37:E7.
123. Amin-Hanjani S, Robertson R, Arginteanu MS, Scott RM. Familial intracranial arteriovenous malformations. Case report and review of the literature. *Pediatr Neurosurg*. 1998;29:208-213.
124. Lobato RD, Perez C, Rivas JJ, Cordobes F. Clinical, radiological, and pathological spectrum of angiographically occult intracranial vascular malformations. Analysis of 21 cases and review of the literature. *J Neurosurg*. 1988;68:518-531.
125. Mokin M, Dumont TM, Levy EI. Novel multimodality imaging techniques for diagnosis and evaluation of arteriovenous malformations. *Neurol Clin*. 2014;32:225-236.
126. Schweitzer JS, Chang BS, Madsen P, et al. The pathology of arteriovenous malformations of the brain treated by embolotherapy. II. Results of embolization with multiple agents. *Neuroradiology*. 1993;35:468-474.
127. Schneider BF, Eberhard DA, Steiner LE. Histopathology of arteriovenous malformations after gamma knife radiosurgery. *J Neurosurg*. 1997;87:352-357.
128. Nazek M, Mandybur TI, Kashiwagi S. Oligodendroglial proliferative abnormality associated with arteriovenous malformation: report of three cases with review of the literature. *Neurosurgery*. 1988;23:781-785.
129. Wang DD, Blumcke I, Coras R, et al. Sturge-Weber syndrome is associated with cortical dysplasia ILAE type IIIc and excessive hypertrophic pyramidal neurons in brain resections for intractable epilepsy. *Brain Pathol*. 2015;25:248-255.
130. Kang HS, Han MH, Kwon BJ, et al. Cerebellopontomandibular vascular malformation: a rare type of cerebrofacial arteriovenous metameric syndrome. Case report. *J Neurosurg*. 2005;102:156-160.
131. Johnson WD, Petrie MM. Variety of spinal vascular pathology seen in adult Cobb syndrome. *J Neurosurg Spine*. 2009;10:430-435.
132. Hamada J, Yano S, Kai Y, et al. Histopathological study of venous aneurysms in patients with dural arteriovenous fistulas. *J Neurosurg*. 2000;92:1023-1027.
133. Rosenblum B, Oldfield EH, Doppman JL, Di Chiro G. Spinal arteriovenous malformations: a comparison of dural arteriovenous fistulas and intradural AVM's in 81 patients. *J Neurosurg*. 1987;67:795-802.
134. Tomlinson FH, Rufenacht DA, Sundt TM Jr, et al. Arteriovenous fistulas of the brain and the spinal cord. *J Neurosurg*. 1993;79:16-27.
135. Partington MD, Rufenacht DA, Marsh WR, Piepgras DG. Cranial and sacral dural arteriovenous fistulas as a cause of myelopathy. *J Neurosurg*. 1992;76:615-622.
136. Rodriguez FJ, Crum BA, Krauss WE, et al. Venous congestive myelopathy: a mimic of neoplasia. *Mod Pathol*. 2005;18:710-718.
137. Nishijima M, Takaku A, Endo S, et al. Etiological evaluation of dural arteriovenous malformations of the lateral and sigmoid sinuses based on histopathological examinations. *J Neurosurg*. 1992;76: 600-606.
138. Giannini C, Salvarani C, Hunder G, Brown RD. Primary central nervous system vasculitis: pathology and mechanisms. *Acta Neuropathol*. 2012;123:759-772.
139. Caccamo DV, Garcia JH, Ho KL. Isolated granulomatous angiitis of the spinal cord. *Ann Neurol*. 1992;32:580-582.
140. Yoong MF, Blumbergs PC, North JB. Primary (granulomatous) angiitis of the central nervous system with multiple aneurysms of spinal arteries. Case report. *J Neurosurg*. 1993;79:603-607.
141. Scolding NJ. Central nervous system vasculitis. *Semin Immunopathol*. 2009;31:527-536.
142. Yuen RW, Johnson PC. Primary angiitis of the central nervous system associated with Hodgkin's disease. *Arch Pathol Lab Med*. 1996;120:573-576.
143. Esiri M, Chance S, Joachim C, et al. Cerebral amyloid angiopathy, subcortical white matter disease and dementia: literature review and study in OPTIMA. *Brain Pathol*. 2015;25:51-62.
144. Revesz T, Ghiso J, Lashley T, et al. Cerebral amyloid angiopathies: a pathologic, biochemical, and genetic view. *J Neuropathol Exp Neurol*. 2003;62:885-898.
145. Vonsattel JP, Myers RH, Hedley-Whyte ET, et al. Cerebral amyloid angiopathy without and with cerebral hemorrhages: a comparative histological study. *Ann Neurol*. 1991;30:637-649.
146. Danve A, Grafe M, Deodhar A. Amyloid beta-related angiitis—a case report and comprehensive review of literature of 94 cases. *Semin Arthritis Rheum*. 2014;44: 86-92.
147. Salvarani C, Hunder GG, Morris JM, et al. Abeta-related angiitis: comparison with CAA without inflammation and primary CNS vasculitis. *Neurology*. 2013;81:1596-1603.

For personal use only. No other uses without permission. Copyright ©2017. Elsevier Inc. All rights reserved.

148. Tikka S, Baumann M, Siitonen M, et al. CADASIL and CARASIL. *Brain Pathol*. 2014;24:525-544.
149. Wintzen AR. The clinical course of subdural haematoma. A retrospective study of aetiological, chronological and pathological features in 212 patients and a proposed classification. *Brain*. 1980;103:855-867.
150. Kepes JJ. Large focal tumor-like demyelinating lesions of the brain: intermediate entity between multiple sclerosis and acute disseminated encephalomyelitis? A study of 31 patients. *Ann Neurol*. 1993;33:18-27.
151. Lucchinetti CF, Gavrilova RH, Metz I, et al. Clinical and radiographic spectrum of pathologically confirmed tumefactive multiple sclerosis. *Brain*. 2008;131:1759-1775.
152. Kim DS, Na DG, Kim KH, et al. Distinguishing tumefactive demyelinating lesions from glioma or central nervous system lymphoma: added value of unenhanced CT compared with conventional contrast-enhanced MR imaging. *Radiology*. 2009;251(2):467-475.
153. Peterson K, Rosenblum MK, Powers JM, et al. Effect of brain irradiation on demyelinating lesions. *Neurology*. 1993;43:2105-2112.
154. Roemer SF, Scheithauer BW, Varnavas GG, Lucchinetti CF. Tumefactive demyelination and glioblastoma: a rare collision lesion. *Clin Neuropathol*. 2011;30:186-191.
155. Hook CC, Kimmel DW, Kvols LK, et al. Multifocal inflammatory leukoencephalopathy with 5-fluorouracil and levamisole. *Ann Neurol*. 1992;31:262-267.
156. Kupersmith MJ, Martin V, Heller G, et al. Idiopathic hypertrophic pachymeningitis. *Neurology*. 2004;62:686-694.
157. Lindstrom KM, Cousar JB, Lopes MB. IgG4-related meningeal disease: clinico-pathological features and proposal for diagnostic criteria. *Acta Neuropathol*. 2010;120:765-776.
158. Qin LX, Wang CY, Hu ZP, et al. Idiopathic hypertrophic spinal pachymeningitis: a case report and review of literature. *Eur Spine J*. 2015;24(suppl 4):S636-S643.
159. Gilliard C, De Coene B, Lahdou JB, et al. Cervical epidural pseudotumor and multifocal fibrosclerosis. Case report and review of the literature. *J Neurosurg*. 2000;93:152-156.
160. Schubert RD, Wood M, Levin MH, et al. The severe side of the IgG4-related hypertrophic pachymeningitis disease spectrum. *Neurol Neuroimmunol Neuroinflamm*. 2016;3:e197.
161. Bando H, Iguchi G, Fukuoka H, et al. The prevalence of IgG4-related hypophysitis in 170 consecutive patients with hypopituitarism and/or central diabetes insipidus and review of the literature. *Eur J Endocrinol*. 2014;170:161-172.
162. Deshpande V, Zen Y, Chan JK, et al. Consensus statement on the pathology of IgG4-related disease. *Mod Pathol*. 2012;25:1181-1192.
163. Wallace ZS, Khosroshahi A, Jakobiec FA, et al. IgG4-related systemic disease as a cause of "idiopathic" orbital inflammation, including orbital myositis, and trigeminal nerve involvement. *Surv Ophthalmol*. 2012;57:26-33.
164. de Jesus O, Inserni JA, Gonzalez A, Colon LE. Idiopathic orbital inflammation with intracranial extension. Case report. *J Neurosurg*. 1996;85:510-513.
165. Grimaldi D, Mea E, Chiapparini L, et al. Spontaneous low cerebrospinal pressure: a mini review. *Neurol Sci*. 2004;25(suppl 3):S135-S137.
166. Mokri B, Parisi JE, Scheithauer BW, et al. Meningeal biopsy in intracranial hypotension: meningeal enhancement on MRI. *Neurology*. 1995;45:1801-1807.
167. Bien CG, Granata T, Antozzi C, et al. Pathogenesis, diagnosis and treatment of Rasmussen encephalitis: a European consensus statement. *Brain*. 2005;128:454-471.
168. Pardo CA, Vining EP, Guo L, et al. The pathology of Rasmussen syndrome: stages of cortical involvement and neuropathological studies in 45 hemispherectomies. *Epilepsia*. 2004;45:516-526.
169. Hart YM, Andermann F, Fish DR, et al. Chronic encephalitis and epilepsy in adults and adolescents: a variant of Rasmussen's syndrome? *Neurology*. 1997;48:418-424.
170. Gultekin SH, Rosenfeld MR, Voltz R, et al. Paraneoplastic limbic encephalitis: neurological symptoms, immunological findings and tumour association in 50 patients. *Brain*. 2000;123(Pt 7):1481-1494.
171. Bien CG, Schulze-Bonhage A, Deckert M, et al. Limbic encephalitis not associated with neoplasm as a cause of temporal lobe epilepsy. *Neurology*. 2000;55:1823-1828.
172. Jammoul A, Li Y, Rae-Grant A. Autoantibody-mediated encephalitis: not just paraneoplastic, not just limbic, and not untreatable. *Cleve Clin J Med*. 2016;83:43-53.
173. Graus F, Keime-Guibert F, Rene R, et al. Anti-Hu-associated paraneoplastic encephalomyelitis: analysis of 200 patients. *Brain*. 2001;124:1138-1148.
174. Bertoni F, Unni KK, Dahlin DC, et al. Calcifying pseudoneoplasms of the neural axis. *J Neurosurg*. 1990;72:42-48.
175. Qian J, Rubio A, Powers JM, et al. Fibro-osseous lesions of the central nervous system: report of four cases and literature review. *Am J Surg Pathol*. 1999;23:1270-1275.
176. Grant GA, Wener MH, Yaziji H, et al. Destructive tophaceous calcium hydroxyapatite tumor of the infratemporal fossa. Case report and review of the literature. *J Neurosurg*. 1999;90:148-152.
177. Faure A, Khalfallah M, Perrouin-Verbe B, et al. Arachnoiditis ossificans of the cauda equina. Case report and review of the literature. *J Neurosurg*. 2002;97:239-243.
178. Ben Hamouda K, Jemel H, Haouet S, Khaldi M. Thoracic myelopathy caused by ossification of the ligamentum flavum: a report of 18 cases. *J Neurosurg*. 2003;99:157-161.
179. Grois N, Prayer D, Prosch H, Lassmann H. Neuropathology of CNS disease in Langerhans cell histiocytosis. *Brain*. 2005;128:829-838.
180. Rodriguez-Pereira C, Borras-Moreno JM, Pesudo-Martinez JV, Vera-Roman JM. Cerebral solitary Langerhans cell histiocytosis: report of two cases and review of the literature. *Br J Neurosurg*. 2005;19:192-197.
181. Reznik M, Stevenaert A, Bex V, Kratzenberg E. Focal brain invasion as the first manifestation of Langerhans cell histiocytosis in an adult. Case report. *Clin Neuropathol*. 1993;12:179-183.
182. Haroche J, Cohen-Aubart F, Emile JF, et al. Reproducible and sustained efficacy of targeted therapy with vemurafenib in patients with BRAFV600E-mutated Erdheim-Chester disease. *J Clin Oncol*. 2015;33:411-418.
183. Go H, Jeon YK, Huh J, et al. Frequent detection of BRAF(V600E) mutations in histiocytic and dendritic cell neoplasms. *Histopathology*. 2014;65:261-272.
184. Abrey LE, Rosenblum MK, DeAngelis LM. Sarcoidosis of the cauda equina mimicking leptomeningeal malignancy. *J Neurooncol*. 1998;39:261-265.
185. Rodriguez F, Link MJ, Driscoll CL, Giannini C. Neurosarcoidosis mimicking meningioma. *Arch Neurol*. 2005;62:148-149.
186. Quinones-Hinojosa A, Chang EF, Khan SA, McDermott MW. Isolated trigeminal nerve sarcoid granuloma mimicking trigeminal schwannoma: case report. *Neurosurgery*. 2003;52:700-705, discussion 704-705.
187. Graf M, Wakhloo A, Schmidtke K, et al. Sarcoidosis of the spinal cord and medulla oblongata. A pathological and neuroradiological case report. *Clin Neuropathol*. 1994;13:19-25.
188. Strickland-Marmol LB, Fessler RG, Rojiani AM. Necrotizing sarcoid granulomatosis mimicking an intracranial neoplasm: clinicopathologic features and review of the literature. *Mod Pathol*. 2000;13:909-913.
189. Thomas G, Murphy S, Staunton H, et al. Pathogen-free granulomatous diseases of the central nervous system. *Hum Pathol*. 1998;29:110-115.
190. Andriko JA, Morrison A, Colegial CH, et al. Rosai-Dorfman disease isolated to the central nervous system: a report of 11 cases. *Mod Pathol*. 2001;14:172-178.
191. Sandoval-Sus JD, Sandoval-Leon AC, Chapman JR, et al. Rosai-Dorfman disease of the central nervous system: report of 6 cases and review of the literature. *Medicine (Baltimore)*. 2014;93:165-175.
192. Lui PC, Fan YS, Wong SS, et al. Inflammatory pseudotumors of the central nervous system. *Hum Pathol*. 2009;40:1611-1617.
193. Swain RS, Tihan T, Horvai AE, et al. Inflammatory myofibroblastic tumor of the central nervous system and its relationship to inflammatory pseudotumor. *Hum Pathol*. 2008;39:410-419.
194. Sato K, Kubota T, Kitai R, Miyamori I. Meningeal plasma cell granuloma with relapsing polychondritis. Case report. *J Neurosurg*. 2006;104:143-146.
195. Nazek M, Mandybur TI, Sawaya R. Hyalinizing plasmacytic granulomatosis of the falx. *Am J Surg Pathol*. 1988;12:308-313.
196. Miranda P, Lobato RD, Ricoy JR, et al. Xanthogranuloma of the choroid plexus of the third ventricle: case report and literature review. *Neurocirugia (Astur)*. 2005;16:518-522.
197. Eisenberg MB, Haddad G, Al-Mefty O. Petrous apex cholesterol granulomas: evolution and management. *J Neurosurg*. 1997;86:822-829.
198. Koyama S, Tsubokawa T, Katayama Y, Hirota H. A huge intracranial xanthogranuloma in the middle cranial fossa: case report. *Neurosurgery*. 1991;28:436-439.
199. Bonhomme GR, Loevner LA, Yen DM, et al. Extensive intracranial xanthoma associated with type II hyperlipidemia. *AJNR Am J Neuroradiol*. 2000;21:353-355.
200. Nobusawa S, Hirato J, Sugai T, et al. Atypical teratoid/rhabdoid tumor (AT/RT) arising from ependymoma: a type of AT/RT secondarily developing from other primary central nervous system tumors. *J Neuropathol Exp Neurol*. 2016;75(2):167-174.
201. Deisch JK, Patel R, Koral K, Cope-Yokoyama SD. Juvenile xanthogranulomas of the nervous system: a report of two cases and review of the literature. *Neuropathology*. 2013;33:39-46.
202. Chakraborty R, Hampton OA, Shen X, et al. Mutually exclusive recurrent somatic mutations in MAP2K1 and BRAF support a central role for ERK activation in LCH pathogenesis. *Blood*. 2014;124:3007-3015.
203. Haroche J, Charlotte F, Arnaud L, et al. High prevalence of BRAF V600E mutations in Erdheim-Chester disease but not in other non-Langerhans cell histiocytoses. *Blood*. 2012;120:2700-2703.

For personal use only. No other uses without permission. Copyright ©2017. Elsevier Inc. All rights reserved.

204. Kimura H, Oka K, Nakayama Y, Tomonaga M. Xanthoma in Meckel's cave. A case report. *Surg Neurol*. 1991;35:317-320.
205. Usul H, Kuzeyli K, Cakir E, et al. Giant cranial extradural primary fibroxanthoma: a case report. *Surg Neurol*. 2005;63:281-284.
206. Hammond RR, Mackenzie IR. Xanthoma disseminatum with massive intracranial involvement. *Clin Neuropathol*. 1995;14:314-321.
207. Shah KC, Poonnoose SI, George R, et al. Necrobiotic xanthogranuloma with cutaneous and cerebral manifestations. Case report and review of the literature. *J Neurosurg*. 2004;100:1111-1114.
208. Henter JI, Nennesmo I. Neuropathologic findings and neurologic symptoms in twenty-three children with hemophagocytic lymphohistiocytosis. *J Pediatr*. 1997;130:358-365.
209. Shinoda J, Murase S, Takenaka K, Sakai N. Isolated central nervous system hemophagocytic lymphohistiocytosis: case report. *Neurosurgery*. 2005;56:187.
210. Ribalta T, McCutcheon IE, Neto AG, et al. Textiloma (gossypiboma) mimicking recurrent intracranial tumor. *Arch Pathol Lab Med*. 2004;128:749-758.
211. Fudaba H, Ooba H, Abe T, et al. An adult case of cerebral malakoplakia successfully cured by treatment with antibiotics, bethanechol and ascorbic acid. *J Neurol Sci*. 2014;342:192-196.
212. Mills SE, Lininger JR. Intracranial myospherulosis. *Hum Pathol*. 1982;13:596-597.
213. Kim RC, Collins GH. The neuropathology of rheumatoid disease. *Hum Pathol*. 1981;12:5-15.
214. Nishino H, Rubino FA, DeRemee RA, et al. Neurological involvement in Wegener's granulomatosis: an analysis of 324 consecutive patients at the Mayo Clinic. *Ann Neurol*. 1993;33:4-9.
215. Yasuhara T, Fukuhara T, Nakagawa M, et al. Wegener granulomatosis manifesting as meningitis. Case report. *J Neurosurg*. 2002;97:1229-1232.
216. Caselli RJ, Scheithauer BW, Bowles CA, et al. The treatable dementia of Sjogren's syndrome. *Ann Neurol*. 1991;30:98-101.
217. Lyons MK, Caselli RJ, Parisi JE. Nonvasculitic autoimmune inflammatory meningoencephalitis as a cause of potentially reversible dementia: report of 4 cases. *J Neurosurg*. 2008;108:1024-1027.
218. Kastenbauer S, Pfister H-W, Wispelwey B, Scheld WM. Brain abscess. In: Scheld WM, Whitley RJ, Marra CM, eds. *Infections of the Central Nervous System*. 3rd ed. Philadelphia: Lippincott Williams & Wilkins; 2004:479-507.
219. Renier D, Flandin C, Hirsch E, Hirsch JF. Brain abscesses in neonates. A study of 30 cases. *J Neurosurg*. 1988;69:877-882.
220. Smego RA Jr. Actinomycosis of the central nervous system. *Rev Infect Dis*. 1987;9:855-865.
221. Mohindra S, Gupta R, Mathuriya SN, Radotra BD. Intramedullary abscess in association with tumor at the conus medullaris. Report of two cases. *J Neurosurg Spine*. 2007;6:350-353.
222. Ulivieri S, Oliveri G, Filosomi G. Brain abscess and Rendu-Osler-Weber disease. Case report and review of the literature. *J Neurosurg Sci*. 2007;51:77-79.
223. Schlitt M, Mitchem L, Zorn G, et al. Brain abscess after esophageal dilation for caustic stricture: report of three cases. *Neurosurgery*. 1985;17:947-951.
224. Tatti KM, Shieh WJ, Phillips S, et al. Molecular diagnosis of Nocardia farcinica from a cerebral abscess. *Hum Pathol*. 2006;37:1117-1121.
225. Berenson CS, Bia FJ. Propionibacterium acnes causes postoperative brain abscesses unassociated with foreign bodies: case reports. *Neurosurgery*. 1989;25:130-134.
226. Ekseth K, Bostrom S. Late complications of Silastic duraplasty: low-virulence infections. Case report. *J Neurosurg*. 1999;90:559-562.
227. Kastenbauer S, Pfister H-W, Scheld WM. Epidural abscess. In: Scheld WM, Whitley RJ, Marra CM, eds. *Infections of the Central Nervous System*. 3rd ed. Philadelphia: Lippincott Williams & Wilkins; 2004:509-521.
228. Zuger A. Tuberculosis. In: Scheld WM, Whitley RJ, Marra CM, eds. *Infections of the Central Nervous System*. 3rd ed. Philadelphia: Lippincott Williams & Wilkins; 2004:441-459.
229. Trautmann M, Lindner O, Haase C, Bruckner O. Focal tuberculous meningoencephalitis. *Eur Neurol*. 1983;22:417-420.
230. Whitener DR. Tuberculous brain abscess. Report of a case and review of the literature. *Arch Neurol*. 1978;35:148-155.
231. Cayli SR, Onal C, Kocak A, et al. An unusual presentation of neurotuberculosis: subdural empyema. Case report. *J Neurosurg*. 2001;94:988-991.
232. Johnson MD, Powell SZ, Boyer PJ, et al. Dural lesions mimicking meningiomas. *Hum Pathol*. 2002;33:1211-1226.
233. Ratliff JK, Connolly ES. Intramedullary tuberculoma of the spinal cord. Case report and review of the literature. *J Neurosurg*. 1999;90:125-128.
234. Wallace RJ Jr. Infections due to nontuberculosis mycobacteria. In: Scheld WM, Whitley RJ, Marra CM, eds. *Infections of the Central Nervous System*. 3rd ed. Philadelphia: Lippincott Williams & Wilkins; 2004:461-478.
235. Di Patre PL, Radziszewski W, Martin NA, et al. A meningioma-mimicking tumor caused by *Mycobacterium avium* complex in an immunocompromised patient. *Am J Surg Pathol*. 2000;24:136-139.
236. Antal EA, Loberg EM, Dietrichs E, Maehlen J. Neuropathological findings in 9 cases of listeria monocytogenes brain stem encephalitis. *Brain Pathol*. 2005;15:187-191.
237. Arnold CA, Moreira RK, Lam-Himlin D, et al. Whipple disease a century after the initial description: increased recognition of unusual presentations, autoimmune comorbidities, and therapy effects. *Am J Surg Pathol*. 2012;36:1066-1073.
238. George TI, Manley G, Koehler JE, et al. Detection of Bartonella henselae by polymerase chain reaction in brain tissue of an immunocompromised patient with multiple enhancing lesions. Case report and review of the literature. *J Neurosurg*. 1998;89:640-644.
239. Cortez KJ, Walsh TJ. Space-occupying fungal lesions. In: Scheld WM, Whitley RJ, Marra CM, eds. *Infections of the Central Nervous System*. 3rd ed. Philadelphia: Lippincott Williams & Wilkins; 2004:713-734.
240. Kershaw P, Freeman R, Templeton D, et al. Pseudallescheria boydii infection of the central nervous system. *Arch Neurol*. 1990;47:468-472.
241. Kleinschmidt-DeMasters BK. Central nervous system aspergillosis: a 20-year retrospective series. *Hum Pathol*. 2002;33:116-124.
242. Stave GM, Heimberger T, Kerkering TM. Zygomycosis of the basal ganglia in intravenous drug users. *Am J Med*. 1989;86:115-117.
243. Mielke B, Weir B, Oldring D, von Westarp C. Fungal aneurysm: case report and review of the literature. *Neurosurgery*. 1981;9:578-582.
244. Hadley MN, Martin NA, Spetzler RF, Johnson PC. Multiple intracranial aneurysms due to Coccidioides immitis infection. Case report. *J Neurosurg*. 1987;66:453-456.
245. Kleinschmidt-DeMasters BK, Mazowiecki M, Bonds LA, et al. Coccidioidomycosis meningitis with massive dural and cerebral venous thrombosis and tissue arthroconidia. *Arch Pathol Lab Med*. 2000;124:310-314.
246. Revankar SG, Sutton DA, Rinaldi MG. Primary central nervous system phaeohyphomycosis: a review of 101 cases. *Clin Infect Dis*. 2004;38:206-216.
247. Kasantikul V, Shuangshoti S, Sampatanukul P. Primary chromoblastomycosis of the medulla oblongata: complication of heroin addiction. *Surg Neurol*. 1988;29:319-321.
248. Ilgren EB, Westmorland D, Adams CB, Mitchell RG. Cerebellar mass caused by Candida species. Case report. *J Neurosurg*. 1984;60:428-430.
249. Pittella JE. Neurocysticercosis. *Brain Pathol*. 1997;7:681-693.
250. Luft BJ, Sivadas R. Toxoplasmosis. In: Scheld WM, Whitley RJ, Marra CM, eds. *Infections of the Central Nervous System*. 3rd ed. Philadelphia: Lippincott Williams & Wilkins; 2004:755-776.
251. Resnick DK, Comey CH, Welch WC, et al. Isolated toxoplasmosis of the thoracic spinal cord in a patient with acquired immunodeficiency syndrome. Case report. *J Neurosurg*. 1995;82:493-496.
252. Marra CM. Neurosyphilis. In: Scheld WM, Whitley RJ, Marra CM, eds. *Infections of the Central Nervous System*. 3rd ed. Philadelphia: Lippincott Williams & Wilkins; 2004:649-657.
253. Cadavid D. Lyme disease and relapsing fever. In: Scheld WM, Whitley RJ, Marra CM, eds. *Infections of the Central Nervous System*. 3rd ed. Philadelphia: Lippincott Williams & Wilkins; 2004:659-690.
254. Whitley RJ. Herpes simplex virus. In: Scheld WM, Whitley RJ, Marra CM, eds. *Infections of the Central Nervous System*. 3rd ed. Philadelphia: Lippincott Williams & Wilkins; 2004:123-144.
255. Kennedy PG, Adams JH, Graham DI, Clements GB. A clinico-pathological study of herpes simplex encephalitis. *Neuropathol Appl Neurobiol*. 1988;14:395-415.
256. Esiri MM. Herpes simplex encephalitis. An immunohistological study of the distribution of viral antigen within the brain. *J Neurol Sci*. 1982;54:209-226.
257. Graber JJ, Rosenblum MK, DeAngelis LM. Herpes simplex encephalitis in patients with cancer. *J Neurooncol*. 2011;105:415-421.
258. Schiff D, Rosenblum MK. Herpes simplex encephalitis (HSE) and the immunocompromised: a clinical and autopsy study of HSE in the settings of cancer and human immunodeficiency virus-type 1 infection. *Hum Pathol*. 1998;29:215-222.
259. Love S, Koch P, Urbach H, Dawson TP. Chronic granulomatous herpes simplex encephalitis in children. *J Neuropathol Exp Neurol*. 2004;63:1173-1181.
260. McGuire JL, Fridman V, Wuthrich C, et al. Progressive multifocal leukoencephalopathy associated with isolated CD8+ T-lymphocyte deficiency mimicking tumefactive MS. *J Neurovirol*. 2011;17:500-503.
261. Gheuens S, Wuthrich C, Koralnik IJ. Progressive multifocal leukoencephalopathy: why gray and white matter. *Annu Rev Pathol*. 2013;8:189-215.
262. Vazeux R, Cumont M, Girard PM, et al. Severe encephalitis resulting from coinfections with HIV and JC virus. *Neurology*. 1990;40:944-948.

For personal use only. No other uses without permission. Copyright ©2017. Elsevier Inc. All rights reserved.

263. Ariza A, Mate JL, Isamat M, et al. Overexpression of Ki-67 and cyclins A and B1 in JC virus-infected cells of progressive multifocal leukoencephalopathy. *J Neuropathol Exp Neurol*. 1998;57:226-230.
264. Ariza A, Mate JL, Fernandez-Vasalo A, et al. p53 and proliferating cell nuclear antigen expression in JC virus-infected cells of progressive multifocal leukoencephalopathy. *Hum Pathol*. 1994;25:1341-1345.
265. Hoffmann C, Horst HA, Albrecht H, Schlote W. Progressive multifocal leucoencephalopathy with unusual inflammatory response during antiretroviral treatment. *J Neurol Neurosurg Psychiatry*. 2003;74:1142-1144.
266. Di Giambenedetto S, Vago G, Pompucci A, et al. Fatal inflammatory AIDS-associated PML with high CD4 counts on HAART: a new clinical entity? *Neurology*. 2004;63:2452-2453.
267. Bauer J, Gold R, Adams O, Lassmann H. Progressive multifocal leukoencephalopathy and immune reconstitution inflammatory syndrome (IRIS). *Acta Neuropathol*. 2015;130:751-764.
268. Kleinschmidt-Demasters BK, Miravalle A, Schowinsky J, et al. Update on PML and PML-IRIS occurring in multiple sclerosis patients treated with natalizumab. *J Neuropathol Exp Neurol*. 2012;71:604-617.
269. Kleinschmidt-DeMasters BK, Gilden DH. The expanding spectrum of herpesvirus infections of the nervous system. *Brain Pathol*. 2001;11:440-451.
270. Weaver S, Rosenblum MK, DeAngelis LM. Herpes varicella zoster encephalitis in immunocompromised patients. *Neurology*. 1999;52:193-195.
271. Eidelberg D, Sotrel A, Horoupian DS, et al. Thrombotic cerebral vasculopathy associated with herpes zoster. *Ann Neurol*. 1986;19:7-14.
272. Doyle PW, Gibson G, Dolman CL. Herpes zoster ophthalmicus with contralateral hemiplegia: identification of cause. *Ann Neurol*. 1983;14:84-85.
273. Fukumoto S, Kinjo M, Hokamura K, Tanaka K. Subarachnoid hemorrhage and granulomatous angiitis of the basilar artery: demonstration of the varicella-zoster-virus in the basilar artery lesions. *Stroke*. 1986;17:1024-1028.
274. Scaravilli F, Bazille C, Gray F. Neuropathologic contributions to understanding AIDS and the central nervous system. *Brain Pathol*. 2007;17:197-208.
275. Chitravas N, Jung RS, Kofskey DM, et al. Treatable neurological disorders misdiagnosed as Creutzfeldt-Jakob disease. *Ann Neurol*. 2011;70(3):437-444.
276. Cruz-Sanchez F, Lafuente J, Gertz HJ, Stoltenburg-Didinger G. Spongiform encephalopathy with extensive involvement of white matter. *J Neurol Sci*. 1987;82:81-87.
277. Zeitner K. Safe handling of transmissible spongiform encephalopathies specimens in the histopathology laboratory. *J Histotechnol*. 2007;30:81-85.
278. Louis DN, Ohgaki H, Wiestler OD, et al. *WHO Classification of Tumours of the Central Nervous System*. Revised 4th ed. Lyon, France: IARC; 2016.
279. Hartmann C, Meyer J, Balss J, et al. Type and frequency of IDH1 and IDH2 mutations are related to astrocytic and oligodendroglial differentiation and age: a study of 1,010 diffuse gliomas. *Acta Neuropathol*. 2009;118:469-474.
280. Yan H, Parsons DW, Jin G, et al. IDH1 and IDH2 mutations in gliomas. *N Engl J Med*. 2009;360:765-773.
281. Ichimura K, Pearson DM, Kocialkowski S, et al. IDH1 mutations are present in the majority of common adult gliomas but rare in primary glioblastomas. *Neuro Oncol*. 2009;11:341-347.
282. Watanabe K, Tachibana O, Yonekawa Y, et al. Role of gemistocytes in astrocytoma progression. *Lab Invest*. 1997;76:277-284.
283. Ohta T, Kim YH, Oh JE, et al. Alterations of the RRAS and ERCC1 genes at 19q13 in gemistocytic astrocytomas. *J Neuropathol Exp Neurol*. 2014;73:908-915.
284. Tihan T, Vohra P, Berger MS, Keles GE. Definition and diagnostic implications of gemistocytic astrocytomas: a pathological perspective. *J Neurooncol*. 2006;76:175-183.
285. Ng HK, Poon WS. Primary leptomeningeal astrocytoma. Case report. *J Neurosurg*. 1998;88:586-589.
286. Ramsay DA, Goshko V, Nag S. Primary spinal leptomeningeal astrocytoma. *Acta Neuropathol*. 1990;80:338-341.
287. Scheithauer BW, Bruner JM. The ultrastructural spectrum of astrocytic neoplasms. *Ultrastruct Pathol*. 1987;11:535-581.
288. Frappaz D, Ricci AC, Kohler R, et al. Diffuse brain stem tumor in an adolescent with multiple enchondromatosis (Ollier's disease). *Childs Nerv Syst*. 1999;15:222-225.
289. Takami H, Yoshida A, Fukushima S, et al. Revisiting TP53 mutations and immunohistochemistry-A comparative study in 157 diffuse gliomas. *Brain Pathol*. 2015;25:256-265.
290. Giannini C, Scheithauer BW, Burger PC, et al. Cellular proliferation in pilocytic and diffuse astrocytomas. *J Neuropathol Exp Neurol*. 1999;58:46-53.
291. Reuss DE, Mamatjan Y, Schrimpf D, et al. IDH mutant diffuse and anaplastic astrocytomas have similar age at presentation and little difference in survival: a grading problem for WHO. *Acta Neuropathol*. 2015;129:867-873.
292. Perry A, Aldape KD, George DH, Burger PC. Small cell astrocytoma: an aggressive variant that is clinicopathologically and genetically distinct from anaplastic oligodendroglioma. *Cancer*. 2004;101:2318-2326.
293. Reuss DE, Sahm F, Schrimpf D, et al. ATRX and IDH1-R132H immunohistochemistry with subsequent copy number analysis and IDH sequencing as a basis for an "integrated" diagnostic approach for adult astrocytoma, oligodendroglioma and glioblastoma. *Acta Neuropathol*. 2015;129:133-146.
294. Hartmann C, Hentschel B, Wick W, et al. Patients with IDH1 wild type anaplastic astrocytomas exhibit worse prognosis than IDH1-mutated glioblastomas, and IDH1 mutation status accounts for the unfavorable prognostic effect of higher age: implications for classification of gliomas. *Acta Neuropathol*. 2010;120:707-718.
295. Sturm D, Witt H, Hovestadt V, et al. Hotspot mutations in H3F3A and IDH1 define distinct epigenetic and biological subgroups of glioblastoma. *Cancer Cell*. 2012;22:425-437.
296. Castel D, Philippe C, Calmon R, et al. Histone H3F3A and HIST1H3B K27M mutations define two subgroups of diffuse intrinsic pontine gliomas with different prognosis and phenotypes. *Acta Neuropathol*. 2015;130:815-827.
297. Korshunov A, Capper D, Reuss D, et al. Histologically distinct neuroepithelial tumors with histone 3 G34 mutation are molecularly similar and comprise a single nosologic entity. *Acta Neuropathol*. 2016;131(1):137-146.
298. Solomon DA, Wood MD, Tihan T, et al. Diffuse midline gliomas with histone H3-K27M mutation: a series of 47 cases assessing the spectrum of morphologic variation and associated genetic alterations. *Brain Pathol*. 2016;26(5):569-580.
299. Liu Q, Liu Y, Li W, et al. Genetic, epigenetic, and molecular landscapes of multifocal and multicentric glioblastoma. *Acta Neuropathol*. 2015;130:587-597.
300. Haddad SF, Moore SA, Schelper RL, Goeken JA. Vascular smooth muscle hyperplasia underlies the formation of glomeruloid vascular structures of glioblastoma multiforme. *J Neuropathol Exp Neurol*. 1992;51:488-492.
301. Wesseling P, Schlingemann RO, Rietveld FJ, et al. Early and extensive contribution of pericytes/vascular smooth muscle cells to microvascular proliferation in glioblastoma multiforme: an immuno-light and immuno-electron microscopic study. *J Neuropathol Exp Neurol*. 1995;54:304-310.
302. Cachia D, Kamiya-Matsuoka C, Mandel JJ, et al. Primary and secondary gliosarcomas: clinical, molecular and survival characteristics. *J Neurooncol*. 2015;125:401-410.
303. Hiniker A, Hagenkord JM, Powers MP, et al. Gliosarcoma arising from an oligodendroglioma (oligosarcoma). *Clin Neuropathol*. 2013;32:165-170.
304. Rodriguez FJ, Scheithauer BW, Jenkins R, et al. Gliosarcoma arising in oligodendroglial tumors ("oligosarcoma"): a clinicopathologic study. *Am J Surg Pathol*. 2007;31:351-362.
305. Rodriguez FJ, Scheithauer BW, Perry A, et al. Ependymal tumors with sarcomatous change ("ependymosarcoma"): a clinicopathologic and molecular cytogenetic study. *Am J Surg Pathol*. 2008;32:699-709.
306. Han SJ, Yang I, Tihan T, et al. Secondary gliosarcoma: a review of clinical features and pathological diagnosis. *J Neurosurg*. 2010;112:26-32.
307. Han SJ, Yang I, Tihan T, et al. Primary gliosarcoma: key clinical and pathologic distinctions from glioblastoma with implications as a unique oncologic entity. *J Neurooncol*. 2010;96:313-320.
308. Joseph NM, Phillips J, Dahiya S, et al. Diagnostic implications of IDH1-R132H and OLIG2 expression patterns in rare and challenging glioblastoma variants. *Mod Pathol*. 2013;26:315-326.
309. Wargotz ES, Sidawy MK, Jannotta FS. Thorotrast-associated gliosarcoma. Including comments on thorotrast use and review of sequelae with particular reference to lesions of the central nervous system. *Cancer*. 1988;62:58-66.
310. Svajdler M Jr, Rychly B, Gajdos M, et al. Gliosarcoma with alveolar rhabdomyosarcoma-like component: report of a case with a hitherto undescribed sarcomatous component. *Cesk Patol*. 2012;48:210-214.
311. Hayashi K, Ohara N, Jeon HJ, et al. Gliosarcoma with features of chondroblastic osteosarcoma. *Cancer*. 1993;72:850-855.
312. Tyagi I, Majumdar K, Mehta S, Batra VV. Gliosarcoma with osseous tissue: an occasional metaplastic component. *Brain Tumor Pathol*. 2013;30(1):40-44.
313. Shintaku M, Miyaji K, Adachi Y. Gliosarcoma with angiosarcomatous features: a case report. *Brain Tumor Pathol*. 1998;15:101-105.
314. Rodriguez FJ, Scheithauer BW, Giannini C, et al. Epithelial and pseudoepithelial differentiation in glioblastoma and gliosarcoma: a comparative morphologic and molecular genetic study. *Cancer*. 2008;113:2779-2789.
315. Vlodavsky E, Konstantinesku M, Soustiel JF. Gliosarcoma with liposarcomatous differentiation: the new member of the lipid-containing brain tumors family. *Arch Pathol Lab Med*. 2006;130:381-384.

For personal use only. No other uses without permission. Copyright ©2017. Elsevier Inc. All rights reserved.

316. Feigin IM, Allen LB, Lipkin L, Gross SW. The endothelial hyperplasia of the cerebral blood vessels, and its sarcomatous transformation. *Cancer*. 1958;264-277.
317. Actor B, Cobbers JM, Buschges R, et al. Comprehensive analysis of genomic alterations in gliosarcoma and its two tissue components. *Genes Chromosomes Cancer*. 2002;34:416-427.
318. Sharma MC, Gaikwad S, Mehta VS, et al. Gliofibroma: mixed glial and mesenchymal tumour. Report of three cases. *Clin Neurol Neurosurg*. 1998;100:153-159.
319. Prayson RA. Gliofibroma: a distinct entity or a subtype of desmoplastic astrocytoma? *Hum Pathol*. 1996;27:610-613.
320. Vazquez M, Miller DC, Epstein F, et al. Glioneurofibroma: renaming the pediatric "gliofibroma": a neoplasm composed of Schwann cells and astrocytes. *Mod Pathol*. 1991;4:519-523.
321. Kasantikul V, Shuangshoti S, Panichabhongse V, Netsky MG. Combined angioma and glioma (angioglioma). *J Surg Oncol*. 1996;62:15-21.
322. Lombardi D, Scheithauer BW, Piepgras D, et al. "Angioglioma" and the arteriovenous malformation-glioma association. *J Neurosurg*. 1991;75:589-566.
323. Bonnin JM, Pena CE, Rubinstein LJ. Mixed capillary hemangioblastoma and glioma. A redefinition of the "angioglioma". *J Neuropathol Exp Neurol*. 1983;42:504-516.
324. Alexandrescu S, Korshunov A, Lai SH, et al. Epithelioid glioblastomas and anaplastic epithelioid pleomorphic xanthoastrocytomas—same entity or first cousins? *Brain Pathol*. 2016;26(2):215-223.
325. Kleinschmidt-DeMasters BK, Aisner DL, Foreman NK. BRAF VE1 immunoreactivity patterns in epithelioid glioblastomas positive for BRAF V600E mutation. *Am J Surg Pathol*. 2015;39:528-540.
326. Martin SE, Bonnin JM, Hall DC, Hattab EM. Glioblastoma with signet-ring morphology: a case report and review of the literature. *Hum Pathol*. 2010;41:443-446.
327. Homma T, Fukushima T, Vaccarella S, et al. Correlation among pathology, genotype, and patient outcomes in glioblastoma. *J Neuropathol Exp Neurol*. 2006;65: 846-854.
328. Rickert CH, Riemenschneider MJ, Schachenmayr W, et al. Glioblastoma with adipocyte-like tumor cell differentiation—histological and molecular features of a rare differentiation pattern. *Brain Pathol*. 2009;19:431-438.
329. Gokden M, Roth KA, Carroll SL, et al. Clear cell neoplasms and pseudoneoplastic lesions of the central nervous system. *Semin Diagn Pathol*. 1997;14:253-269.
330. Oh D, Prayson RA. Evaluation of epithelial and keratin markers in glioblastoma multiforme: an immunohistochemical study. *Arch Pathol Lab Med*. 1999;123:917-920.
331. Schittenhelm J, Psaras T. Glioblastoma with granular cell astrocytoma features: a case report and literature review. *Clin Neuropathol*. 2010;29:323-329.
332. Katsetos CD, Del Valle L, Geddes JF, et al. Aberrant localization of the neuronal class III beta-tubulin in astrocytomas. *Arch Pathol Lab Med*. 2001;125:613-624.
333. Wolf HK, Buslei R, Schmidt-Kastner R, et al. NeuN: a useful neuronal marker for diagnostic histopathology. *J Histochem Cytochem*. 1996;44:1167-1171.
334. Gultekin SH, Dalmau J, Graus Y, et al. Anti-Hu immunolabeling as an index of neuronal differentiation in human brain tumors: a study of 112 central neuroepithelial neoplasms. *Am J Surg Pathol*. 1998;22:195-200.
335. Teo JG, Gultekin SH, Bilsky M, et al. A distinctive glioneuronal tumor of the adult cerebrum with neuropil-like (including "rosetted") islands: report of 4 cases. *Am J Surg Pathol*. 1999;23:502-510.
336. Huse JT, Nafa K, Shukla N, et al. High frequency of IDH-1 mutation links glioneuronal tumors with neuropil-like islands to diffuse astrocytomas. *Acta Neuropathol*. 2011;122:367-369.
337. Perry A, Miller CR, Gujrati M, et al. Malignant gliomas with primitive neuroectodermal tumor-like components: a clinicopathologic and genetic study of 53 cases. *Brain Pathol*. 2009;19:81-90.
338. Iafrate AJ, Louis DN. "MGMT for pt mgmt": is methylguanine-DNA methyltransferase testing ready for patient management? *J Mol Diagn*. 2008;10:308-310.
339. Kleinschmidt-Demasters BK. Diffuse bone marrow metastases from glioblastoma multiforme: the role of dural invasion. *Hum Pathol*. 1996;27:197-201.
340. Armanios MY, Grossman SA, Yang SC, et al. Transmission of glioblastoma multiforme following bilateral lung transplantation from an affected donor: case study and review of the literature. *Neuro Oncol*. 2004;6:259-263.
341. Persson AI, Petritsch C, Swartling FJ, et al. Non-stem cell origin for oligodendroglioma. *Cancer Cell*. 2010;18:669-682.
342. Lewis KM, Petritsch C. Asymmetric cell division: implications for glioma development and treatment. *Transl Neurosci*. 2013;4:484-503.
343. Guppy KH, Akins PT, Moes GS, Prados MD. Spinal cord oligodendroglioma with 1p and 19q deletions presenting with cerebral oligodendrogliomatosis. *J Neurosurg Spine*. 2009;10:557-563.
344. Gru AA, Fulling K, Perry A. A 39 year-old man with a cerebellar mass and pancytopenia. *Brain Pathol*. 2012;22:251-254.
345. Hewer E, Beck J, Vassella E, Vajtai I. Anaplastic oligodendroglioma arising from the brain stem and featuring 1p/19q co-deletion. *Neuropathology*. 2014;34:32-38.
346. Rodriguez FJ, Perry A, Rosenblum MK, et al. Disseminated oligodendroglial-like leptomeningeal tumor of childhood: a distinctive clinicopathologic entity. *Acta Neuropathol*. 2012;124:627-641.
347. Kros JM, Lie ST, Stefanko SZ. Familial occurrence of polymorphous oligodendroglioma. *Neurosurgery*. 1994;34:732-736, discussion 736.
348. Kros JM, Stefanko SZ, de Jong AA, et al. Ultrastructural and immunohistochemical segregation of gemistocytic subsets. *Hum Pathol*. 1991;22:33-40.
349. Kros JM, Van Eden CG, Stefanko SZ, et al. Prognostic implications of glial fibrillary acidic protein containing cell types in oligodendrogliomas. *Cancer*. 1990;66:1204-1212.
350. Takei Y, Mirra SS, Miles ML. Eosinophilic granular ceels in oligodendrogliomas. An ultrastructural study. *Cancer*. 1976;38:1968-1976.
351. Mikami Y, Shirabe T, Hata S, Watanabe A. Oligodendroglioma with signet-ring cell morphology: a case report with an immunohistochemical and ultrastructural study. *Pathol Int*. 1998;48:144-150.
352. Kros JM, van den Brink WA, van Loon-van Luyt JJ, Stefanko SZ. Signet-ring cell oligodendroglioma—report of two cases and discussion of the differential diagnosis. *Acta Neuropathol*. 1997;93:638-643.
353. Riemenschneider MJ, Koy TH, Reifenberger G. Expression of oligodendrocyte lineage genes in oligodendroglial and astrocytic gliomas. *Acta Neuropathol (Berl)*. 2004;107:277-282.
354. Ligon KL, Alberta JA, Kho AT, et al. The oligodendroglial lineage marker OLIG2 is universally expressed in diffuse gliomas. *J Neuropathol Exp Neurol*. 2004;63:499-509.
355. Picard D, Miller S, Hawkins CE, et al. Markers of survival and metastatic potential in childhood CNS primitive neuro-ectodermal brain tumours: an integrative genomic analysis. *Lancet Oncol*. 2012;13:838-848.
356. Marucci G, Di Oto E, Farnedi A, et al. Nogo-A: a useful marker for the diagnosis of oligodendroglioma and for identifying 1p19q codeletion. *Hum Pathol*. 2012;43:374-380.
357. Min KW, Scheithauer BW. Oligodendroglioma: the ultrastructural spectrum. *Ultrastruct Pathol*. 1994;18:47-60.
358. Preusser M, Laggner U, Haberler C, et al. Comparative analysis of NeuN immunoreactivity in primary brain tumours: conclusions for rational use in diagnostic histopathology. *Histopathology*. 2006;48:438-444.
359. Vyberg M, Ulhoi BP, Teglbjaerg PS. Neuronal features of oligodendrogliomas—an ultrastructural and immunohistochemical study. *Histopathology*. 2007;50:887-896.
360. Perry A, Scheithauer BW, Macaulay RJ, et al. Oligodendrogliomas with neurocytic differentiation. A report of 4 cases with diagnostic and histogenetic implications. *J Neuropathol Exp Neurol*. 2002;61:947-955.
361. Perry A, Burton SS, Fuller GN, et al. Oligodendroglial neoplasms with ganglioglioma-like maturation: a diagnostic pitfall. *Acta Neuropathol*. 2010;120:237-252.
362. Griffin CA, Burger P, Morsberger L, et al. Identification of der(1;19)(q10;p10) in five oligodendrogliomas suggests mechanism of concurrent 1p and 19q loss. *J Neuropathol Exp Neurol*. 2006;65:988-994.
363. Jenkins RB, Blair H, Ballman KV, et al. A t(1;19)(q10;p10) Mediates the combined deletions of 1p and 19q and predicts a better prognosis of patients with oligodendroglioma. *Cancer Res*. 2006;66:9852-9861.
364. Bettegowda C, Agrawal N, Jiao Y, et al. Mutations in CIC and FUBP1 contribute to human oligodendroglioma. *Science*. 2011;333:1453-1455.
365. Wesseling P, van den Bent M, Perry A. Oligodendroglioma: pathology, molecular mechanisms and markers. *Acta Neuropathol*. 2015;129:809-827.
366. Brat DJ, Verhaak RG, Aldape KD, et al. Comprehensive, integrative genomic analysis of diffuse lower-grade gliomas. *N Engl J Med*. 2015;372:2481-2498.
367. Eckel-Passow JE, Lachance DH, Molinaro AM, et al. Glioma groups based on 1p/19q, IDH, and TERT promoter mutations in tumors. *N Engl J Med*. 2015;372:2499-2508.
368. Leeper HE, Caron AA, Decker PA, et al. IDH mutation, 1p19q codeletion and ATRX loss in WHO grade II gliomas. *Oncotarget*. 2015;6:30295-30305.
369. Giannini C, Scheithauer BW, Weaver AL, et al. Oligodendrogliomas: reproducibility and prognostic value of histologic diagnosis and grading. *J Neuropathol Exp Neurol*. 2001;60:248-262.
370. Reis-Filho JS, Faoro LN, Carrilho C, et al. Evaluation of cell proliferation, epidermal growth factor receptor, and bcl-2 immunoexpression as prognostic factors for patients with World Health Organization grade 2 oligodendroglioma. *Cancer*. 2000;88:862-869.
371. Daumas-Duport C, Tucker ML, Kolles H, et al. Oligodendrogliomas. Part II: a new grading system based on morphological and imaging criteria. *J Neurooncol*. 1997;34:61-78.

For personal use only. No other uses without permission. Copyright ©2017. Elsevier Inc. All rights reserved.

372. Cairncross G, Wang M, Shaw E, et al. Phase III trial of chemoradiotherapy for anaplastic oligodendroglioma: long-term results of RTOG 9402. *J Clin Oncol*. 2013;31:337-343.
373. Gorlia T, Delattre JY, Brandes AA, et al. New clinical, pathological and molecular prognostic models and calculators in patients with locally diagnosed anaplastic oligodendroglioma or oligoastrocytoma. A prognostic factor analysis of European Organisation for Research and Treatment of Cancer Brain Tumour Group Study 26951. *Eur J Cancer*. 2013;49:3477-3485.
374. Zhang ZY, Chan AK, Ng HK, et al. Surgically treated incidentally discovered low-grade gliomas are mostly IDH mutated and 1p19q co-deleted with favorable prognosis. *Int J Clin Exp Pathol*. 2014;7:8627-8636.
375. Rodriguez FJ, Tihan T, Lin D, et al. Clinicopathologic features of pediatric oligodendrogliomas: a series of 50 patients. *Am J Surg Pathol*. 2014;38:1058-1070.
376. Raghavan R, Balani J, Perry A, et al. Pediatric oligodendrogliomas: a study of molecular alterations on 1p and 19q using fluorescence in situ hybridization. *J Neuropathol Exp Neurol*. 2003;62:530-537.
377. Jellinger K. Metastatic oligodendrogliomas: a review of the literature and case report. *Acta Neurochir (Wien)*. 2009;151:987.
378. Huse JT, Diamond EL, Wang L, Rosenblum MK. Mixed glioma with molecular features of composite oligodendroglioma and astrocytoma: a true "oligoastrocytoma"? *Acta Neuropathol*. 2015;129:151-153.
379. Wilcox P, Li CC, Lee M, et al. Oligoastrocytomas: throwing the baby out with the bathwater? *Acta Neuropathol*. 2015;129:147-149.
380. Hinrichs BH, Newman S, Appin CL, et al. Farewell to GBM-O: genomic and transcriptomic profiling of glioblastoma with oligodendroglioma component reveals distinct molecular subgroups. *Acta Neuropathol Commun*. 2016;4:4.
381. Herrlinger U, Jones DT, Glas M, et al. Gliomatosis cerebri: no evidence for a separate brain tumor entity. *Acta Neuropathol*. 2016;131(2):309-319.
382. Chen S, Tanaka S, Giannini C, et al. Gliomatosis cerebri: clinical characteristics, management, and outcomes. *J Neurooncol*. 2013;112:267-275.
383. Fisher PG, Breiter SN, Carson BS, et al. A clinicopathologic reappraisal of brain stem tumor classification. Identification of pilocystic astrocytoma and fibrillary astrocytoma as distinct entities. *Cancer*. 2000;89:1569-1576.
384. Hayostek CJ, Shaw EG, Scheithauer B, et al. Astrocytomas of the cerebellum. A comparative clinicopathologic study of pilocytic and diffuse astrocytomas. *Cancer*. 1993;72:856-869.
385. Iwaki T, Iwaki A, Miyazono M, Goldman JE. Preferential expression of alpha B-crystallin in astrocytic elements of neuroectodermal tumors. *Cancer*. 1991;2230-2240.
386. Katsetos CD, Krishna L, Friedberg E, et al. Lobar pilocytic astrocytomas of the cerebral hemispheres: II. Pathobiology—morphogenesis of the eosinophilic granular bodies. *Clin Neuropathol*. 1994;13:306-314.
387. Rodriguez FJ, Scheithauer BW, Burger PC, et al. Anaplasia in pilocytic astrocytoma predicts aggressive behavior. *Am J Surg Pathol*. 2010;34:147-160.
388. Yeo YH, Byrne NP, Counelis GJ, Perry A. Adult with cerebellar anaplastic pilocytic astrocytoma associated with BRAF V600E mutation and p16 loss. *Clin Neuropathol*. 2013;32:159-164.
389. Pagni CA, Giordana MT, Canavero S. Benign recurrence of a pilocytic cerebellar astrocytoma 36 years after radical removal: case report. *Neurosurgery*. 1991;28:606-609.
390. Ito S, Hoshino T, Shibuya M, et al. Proliferative characteristics of juvenile pilocytic astrocytomas determined by bromodeoxyuridine labeling. *Neurosurgery*. 1992;31:413-418.
391. Rozen WM, Joseph S, Lo PA. Spontaneous regression of low-grade gliomas in pediatric patients without neurofibromatosis. *Pediatr Neurosurg*. 2008;44:324-328.
392. Bornhorst M, Frappaz D, Packer RJ. Pilocytic astrocytomas. *Handb Clin Neurol*. 2016;134:329-344.
393. Pollack IF, Hurtt M, Pang D, Albright AL. Dissemination of low grade intracranial astrocytomas in children. *Cancer*. 1994;73:2869-2878.
394. Jones DT, Hutter B, Jager N, et al. Recurrent somatic alterations of FGFR1 and NTRK2 in pilocytic astrocytoma. *Nat Genet*. 2013;45:927-932.
395. Collins VP, Jones DT, Giannini C. Pilocytic astrocytoma: pathology, molecular mechanisms and markers. *Acta Neuropathol*. 2015;129:775-788.
396. Korshunov A, Meyer J, Capper D, et al. Combined molecular analysis of BRAF and IDH1 distinguishes pilocytic astrocytoma from diffuse astrocytoma. *Acta Neuropathol*. 2009;118:401-405.
397. Komotar RJ, Mocco J, Jones JE, et al. Pilomyxoid astrocytoma: diagnosis, prognosis, and management. *Neurosurg Focus*. 2005;18:E7.
398. Tihan T, Fisher PG, Kepner JL, et al. Pediatric astrocytomas with monomorphous pilomyxoid features and a less favorable outcome. *J Neuropathol Exp Neurol*. 1999;58:1061-1068.
399. Johnson MW, Eberhart CG, Perry A, et al. Spectrum of pilomyxoid astrocytomas: intermediate pilomyxoid tumors. *Am J Surg Pathol*. 2010;34:1783-1791.
400. Lin A, Rodriguez FJ, Karajannis MA, et al. BRAF alterations in primary glial and glioneuronal neoplasms of the central nervous system with identification of 2 novel KIAA1549: BRAF fusion variants. *J Neuropathol Exp Neurol*. 2012;71(1):66-72.
401. Colin C, Padovani L, Chappe C, et al. Outcome analysis of childhood pilocytic astrocytomas: a retrospective study of 148 cases at a single institution. *Neuropathol Appl Neurobiol*. 2013;39:693-705.
402. Gierke M, Sperveslage J, Schwab D, et al. Analysis of IDH1-R132 mutation, BRAF V600 mutation and KIAA1549-BRAF fusion transcript status in central nervous system tumors supports pediatric tumor classification. *J Cancer Res Clin Oncol*. 2016;142(1):89-100.
403. Fuller CE, Frankel B, Smith M, et al. Suprasellar monomorphous pilomyxoid neoplasm: an ultastructural analysis. *Clin Neuropathol*. 2001;20:256-262.
404. Chikai K, Ohnishi A, Kato T, et al. Clinico-pathological features of pilomyxoid astrocytoma of the optic pathway. *Acta Neuropathol*. 2004;108:109-114.
405. Kepes JJ, Rubinstein LJ, Eng LF. Pleomorphic xanthoastrocytoma: a distinctive meningocerebral glioma of young subjects with relatively favorable prognosis. A study of 12 cases. *Cancer*. 1979;44:1839-1852.
406. Ida CM, Rodriguez FJ, Burger PC, et al. Pleomorphic xanthoastrocytoma: natural history and long-term follow-up. *Brain Pathol*. 2015;25:575-586.
407. Hamlat A, Le Strat A, Guegan Y, et al. Cerebellar pleomorphic xanthoastrocytoma: case report and literature review. *Surg Neurol*. 2007;68:89-94, discussion 94-95.
408. Nakamura M, Chiba K, Matsumoto M, et al. Pleomorphic xanthoastrocytoma of the spinal cord. Case report. *J Neurosurg Spine*. 2006;5:72-75.
409. Arita K, Kurisu K, Tominaga A, et al. Intrasellar pleomorphic xanthoastrocytoma: case report. *Neurosurgery*. 2002;51:1079-1082, discussion 82.
410. Zarate JO, Sampaolesi R. Pleomorphic xanthoastrocytoma of the retina. *Am J Surg Pathol*. 1999;23:79-81.
411. Snipes GJ, Horoupian DS, Shuer LM, Silverberg GD. Pleomorphic granular cell astrocytoma of the pineal gland. *Cancer*. 1992;70:2159-2165.
412. Perry A, Giannini C, Scheithauer BW, et al. Composite pleomorphic xanthoastrocytoma and ganglioglioma: report of four cases and review of the literature. *Am J Surg Pathol*. 1997;21:763-771.
413. Iwaki T, Fukui M, Kondo A, et al. Epithelial properties of pleomorphic xanthoastrocytomas determined in ultrastructural and immunohistochemical studies. *Acta Neuropathol*. 1987;74:142-150.
414. Sugita Y, Kepes JJ, Shigemori M, et al. Pleomorphic xanthoastrocytoma with desmoplastic reaction: angiomatous variant. Report of two cases. *Clin Neuropathol*. 1990;9:271-278.
415. Sharma MC, Arora R, Khanna N, et al. Pigmented pleomorphic xanthoastrocytoma: report of a rare case with review of the literature. *Arch Pathol Lab Med*. 2001;125:808-811.
416. Tabouret E, Bequet C, Denicolai E, et al. BRAF mutation and anaplasia may be predictive factors of progression-free survival in adult pleomorphic xanthoastrocytoma. *Eur J Surg Oncol*. 2015;41(12):1685-1690.
417. Kros JM, Vecht CJ, Stefanko SZ. The pleomorphic xanthoastrocytoma and its differential diagnosis: a study of five cases. *Hum Pathol*. 1991;22:1128-1135.
418. Giannini C, Scheithauer BW, Lopes MB, et al. Immunophenotype of pleomorphic xanthoastrocytoma. *Am J Surg Pathol*. 2002;26:479-485.
419. Reifenberger G, Kaulich K, Wiestler OD, Blumcke I. Expression of the CD34 antigen in pleomorphic xanthoastrocytomas. *Acta Neuropathol*. 2003;105:358-364.
420. Schindler G, Capper D, Meyer J, et al. Analysis of BRAF V600E mutation in 1,320 nervous system tumors reveals high mutation frequencies in pleomorphic xanthoastrocytoma, ganglioglioma and extra-cerebellar pilocytic astrocytoma. *Acta Neuropathol*. 2011;121:397-405.
421. Chappe C, Padovani L, Scavarda D, et al. Dysembryoplastic neuroepithelial tumors share with pleomorphic xanthoastrocytomas and gangliogliomas BRAF(V600E) mutation and expression. *Brain Pathol*. 2013;23:574-583.
422. Kleinschmidt-Demasters BK, Aisner DL, Birks DK, Foreman NK. Epithelioid GBMs show a high percentage of BRAF V600E mutation. *Am J Surg Pathol*. 2013;37:685-698.
423. Dahiya S, Emnett RJ, Haydon DH, et al. BRAF-V600E mutation in pediatric and adult glioblastoma. *Neuro Oncol*. 2014;16:318-319.
424. Primavera J, Nikas DC, Zamani AA, et al. Clear cell pleomorphic xanthoastrocytoma: case report. *Acta Neuropathol*. 2001;102:404-408.
425. Jeong JY, Suh YL, Hong SW. Atypical teratoid/rhabdoid tumor arising in pleomorphic xanthoastrocytoma: a case report. *Neuropathology*. 2014;34:398-405.
426. Chacko G, Chacko AG, Dunham CP, et al. Atypical teratoid/rhabdoid tumor arising in the setting of a pleomorphic

For personal use only. No other uses without permission. Copyright ©2017. Elsevier Inc. All rights reserved.

xanthoastrocytoma. *J Neurooncol*. 2007;84:217-222.
427. Kleinschmidt-Demasters BK, Birks DK, Aisner DL, et al. Atypical teratoid/rhabdoid tumor arising in a ganglioglioma: genetic characterization. *Am J Surg Pathol*. 2011;35:1894-1901.
428. Delgado-Alvarado M, Gomez-Roman J, Sanchez-Salmon E, et al. Nonanaplastic pleomorphic xanthoastrocytoma with meningeal dissemination presenting with bilateral visual loss. *J Neuroimaging*. 2014;24:533-553.
429. Benjamin C, Faustin A, Snuderl M, Pacione D. Anaplastic pleomorphic xanthoastrocytoma with spinal leptomeningeal spread at the time of diagnosis in an adult. *J Clin Neurosci*. 2015;22:1370-1373.
430. Roth J, Roach ES, Bartels UI, et al. Subependymal giant cell astrocytoma: diagnosis, screening, and treatment. Recommendations from the International Tuberous Sclerosis Complex Consensus Conference 2012. *Pediatr Neurol*. 2013;49(6):439-444.
431. Bollo RJ, Berliner JL, Fischer I, et al. Extraventricular subependymal giant cell tumor in a child with tuberous sclerosis complex. *J Neurosurg Pediatr*. 2009;4:85-90.
432. Dashti SR, Robinson S, Rodgers M, Cohen AR. Pineal region giant cell astrocytoma associated with tuberous sclerosis: case report. *J Neurosurg*. 2005;102:322-325.
433. Hirose T, Scheithauer BW, Lopes MB, et al. Tuber and subependymal giant cell astrocytoma associated with tuberous sclerosis: an immunohistochemical, ultrastructural, and immunoelectron and microscopic study. *Acta Neuropathol*. 1995;90:387-399.
434. Lopes MB, Altermatt HJ, Scheithauer BW, et al. Immunohistochemical characterization of subependymal giant cell astrocytomas. *Acta Neuropathol*. 1996;91:368-375.
435. Gyure KA, Prayson RA. Subependymal giant cell astrocytoma: a clinicopathologic study with HMB45 and MIB-1 immunohistochemical analysis. *Mod Pathol*. 1997;10:313-317.
436. Telfeian AE, Judkins A, Younkin D, et al. Subependymal giant cell astrocytoma with cranial and spinal metastases in a patient with tuberous sclerosis. Case report. *J Neurosurg*. 2004;100:498-500.
437. Grajkowska W, Kotulska K, Jurkiewicz E, et al. Subependymal giant cell astrocytomas with atypical histological features mimicking malignant gliomas. *Folia Neuropathol*. 2011;49:39-46.
438. Tarapore PE, Modera P, Naujokas A, et al. Pathology of spinal ependymomas: an institutional experience over 25 years in 134 patients. *Neurosurgery*. 2013;73(2):247-255.
439. Hagel C, Stemmer-Rachamimov AO, Bornemann A, et al. Clinical presentation, immunohistochemistry and electron microscopy indicate neurofibromatosis type 2-associated gliomas to be spinal ependymomas. *Neuropathology*. 2012;32:611-616.
440. Little NS, Morgan MK, Eckstein RP. Primary ependymoma of a cranial nerve. Case report. *J Neurosurg*. 1994;81:792-794.
441. Parish JM, Bonnin JM, Goodman JM, Cohen-Gadol AA. Intrasellar ependymoma: clinical, imaging, pathological, and surgical findings. *J Clin Neurosci*. 2015;22(4):638-641.
442. Scheithauer BW, Swearingen B, Whyte ET, et al. Ependymoma of the sella turcica: a variant of pituicytoma. *Hum Pathol*. 2009;40:435-440.
443. Tay A, Scheithauer BW, Cameron JD, et al. Retinal ependymoma: an immunohistologic and ultrastructural study. *Hum Pathol*. 2009;40:578-583.
444. Idowu MO, Rosenblum MK, Wei XJ, et al. Ependymomas of the central nervous system and adult extra-axial ependymomas are morphologically and immunohistochemically distinct—a comparative study with assessment of ovarian carcinomas for expression of glial fibrillary acidic protein. *Am J Surg Pathol*. 2008;32:710-718.
445. Mogler C, Kohlhof P, Penzel R, et al. A primary malignant ependymoma of the abdominal cavity: a case report and review of the literature. *Virchows Arch*. 2009;454:475-478.
446. Wiendl H, Feiden W, Scherieble H, et al. March 2003: a 41-year-old female with a solitary lesion in the liver. *Brain Pathol*. 2003;13:421-423.
447. Estrozi B, Queiroga E, Bacchi CE, et al. Myxopapillary ependymoma of the posterior mediastinum. *Ann Diagn Pathol*. 2006;10:283-287.
448. Crotty TB, Hooker RP, Swensen SJ, et al. Primary malignant ependymoma of the lung. *Mayo Clin Proc*. 1992;67:373-378.
449. Craver RD, McGarry P. Delicate longitudinal nuclear grooves in childhood ependymomas. *Arch Pathol Lab Med*. 1994;118:919-921.
450. Li JY, Lopez JI, Powell SZ, et al. Giant cell ependymoma—report of three cases and review of the literature. *Int J Clin Exp Pathol*. 2012;5:458-462.
451. Wang X, Zhang S, Ye Y, et al. Ependymoma with cartilaginous metaplasia might have more aggressive behavior: a case report and literature review. *Brain Tumor Pathol*. 2012;29(3):172-176.
452. Yang C, Li G, Fang J, et al. Clinical analysis of primary melanotic ependymoma in the central nervous system: case series and literature review. *Acta Neurochir (Wien)*. 2013;155:1839-1847.
453. Rosenblum MK, Erlandson RA, Aleksic SN, Budzilovich GN. Melanotic ependymoma and subependymoma. *Am J Surg Pathol*. 1990;14:729-736.
454. Chan AC, Ho LC, Yip WW, Cheung FC. Pigmented ependymoma with lipofuscin and neuromelanin production. *Arch Pathol Lab Med*. 2003;127:872-875.
455. Takahashi H, Goto J, Emura I, et al. Lipidized (foamy) tumor cells in a spinal cord ependymoma with collagenous metaplasia. *Acta Neuropathol*. 1998;95:421-425.
456. Ruchoux MM, Kepes JJ, Dhellemmes P, et al. Lipomatous differentiation in ependymomas: a report of three cases and comparison with similar changes reported in other central nervous system neoplasms of neuroectodermal origin. *Am J Surg Pathol*. 1998;22:338-346.
457. Kleinman GM, Zagzag D, Miller DC. Epithelioid ependymoma: a new variant of ependymoma: report of three cases. *Neurosurgery*. 2003;53:743-747, discussion 747-748.
458. Twiss JL, Anderson LJ, Horoupian DS. Globular glial fibrillary acidic protein-reactive cytoplasmic inclusions in ependymoma: an immunoelectron-microscopic study. *Acta Neuropathol*. 1993;85:658-662.
459. Sara A, Bruner JM, Mackay B. Ultrastructure of ependymoma. *Ultrastruct Pathol*. 1994;18:33-42.
460. Zuppan CW, Mierau GW, Weeks DA. Ependymoma with signet-ring cells. *Ultrastruct Pathol*. 1994;18:43-46.
461. Hasselblatt M, Paulus W. Sensitivity and specificity of epithelial membrane antigen staining patterns in ependymomas. *Acta Neuropathol*. 2003;106:385-388.
462. Choi YL, Chi JG, Suh YL. CD99 immunoreactivity in ependymoma. *Appl Immunohistochem Mol Morphol*. 2001;9:125-129.
463. Ishizawa K, Komori T, Shimada S, Hirose T. Olig2 and CD99 are useful negative markers for the diagnosis of brain tumors. *Clin Neuropathol*. 2008;27:118-128.
464. Ishizawa K, Komori T, Shimada S, Hirose T. Podoplanin is a potential marker for the diagnosis of ependymoma: a comparative study with epithelial membrane antigen (EMA). *Clin Neuropathol*. 2009;28:373-378.
465. Otero JJ, Rowitch D, Vandenberg S. OLIG2 is differentially expressed in pediatric astrocytic and in ependymal neoplasms. *J Neurooncol*. 2011;104:423-438.
466. Kleinschmidt-DeMasters BK, Donson AM, Richmond AM, et al. SOX10 distinguishes pilocytic and pilomyxoid astrocytomas from ependymomas but shows no differences in expression level in ependymomas from infants versus older children or among molecular subgroups. *J Neuropathol Exp Neurol*. 2016;75(4):295-298.
467. Vege KD, Giannini C, Scheithauer BW. The immunophenotype of ependymomas. *Appl Immunohistochem Mol Morphol*. 2000;8:25-31.
468. Kawano N, Yagishita S, Oka H, et al. Spinal tanycytic ependymomas. *Acta Neuropathol*. 2001;101:43-48.
469. Fouladi M, Helton K, Dalton J, et al. Clear cell ependymoma: a clinicopathologic and radiographic analysis of 10 patients. *Cancer*. 2003;98:2232-2244.
470. Min KW, Scheithauer BW. Clear cell ependymoma: a mimic of oligodendroglioma: clinicopathologic and ultrastructural considerations. *Am J Surg Pathol*. 1997;21:820-826.
471. Rodriguez FJ, Scheithauer BW, Robbins PD, et al. Ependymomas with neuronal differentiation: a morphologic and immunohistochemical spectrum. *Acta Neuropathol*. 2007;113:313-324.
472. Gessi M, Marani C, Geddes J, et al. Ependymoma with neuropil-like islands: a case report with diagnostic and histogenetic implications. *Acta Neuropathol*. 2005;109:231-234.
473. Parker M, Mohankumar KM, Punchihewa C, et al. C11orf95-RELA fusions drive oncogenic NF-kappaB signalling in ependymoma. *Nature*. 2014;506:451-455.
474. Zamecnik J, Chanova M, Kodet R. Expression of thyroid transcription factor 1 in primary brain tumours. *J Clin Pathol*. 2004;57:1111-1113.
475. Figarella-Branger D, Lepidi H, Poncet C, et al. Differential expression of cell adhesion molecules (CAM), neural CAM and epithelial cadherin in ependymomas and choroid plexus tumors. *Acta Neuropathol*. 1995;89:248-257.
476. Furness PN, Lowe J, Tarrant GS. Subepithelial basement membrane deposition and intermediate filament expression in choroid plexus neoplasms and ependymomas. *Histopathology*. 1990;16:251-255.
477. Menke JR, Raleigh DR, Gown AM, et al. Somatostatin receptor 2a is a more sensitive diagnostic marker of meningioma than epithelial membrane antigen. *Acta Neuropathol*. 2015;130:441-443.
478. Tihan T, Zhou T, Holmes E, et al. The prognostic value of histological grading of posterior fossa ependymomas in children: a Children's Oncology Group study and a review of prognostic factors. *Mod Pathol*. 2008;21:165-177.
479. Pajtler KW, Witt H, Sill M, et al. Molecular classification of ependymal tumors across all CNS compartments, histopathological

For personal use only. No other uses without permission. Copyright ©2017. Elsevier Inc. All rights reserved.

grades, and age groups. *Cancer Cell*. 2015;27:728-743.
480. Snuderl M, Chi SN, De Santis SM, et al. Prognostic value of tumor microinvasion and metalloproteinases expression in intracranial pediatric ependymomas. *J Neuropathol Exp Neurol*. 2008;67:911-920.
481. Wolfsberger S, Fischer I, Hoftberger R, et al. Ki-67 immunolabeling index is an accurate predictor of outcome in patients with intracranial ependymoma. *Am J Surg Pathol*. 2004;28:914-920.
482. Kurt E, Zheng PP, Hop WC, et al. Identification of relevant prognostic histopathologic features in 69 intracranial ependymomas, excluding myxopapillary ependymomas and subependymomas. *Cancer*. 2006;106:388-395.
483. Sonneland PR, Scheithauer BW, Onofrio BM. Myxopapillary ependymoma. A clinicopathologic and immunocytochemical study of 77 cases. *Cancer*. 1985;56:883-893.
484. Lim SC, Jang SJ. Myxopapillary ependymoma of the fourth ventricle. *Clin Neurol Neurosurg*. 2006;108:211-214.
485. Maruyama R, Koga K, Nakahara T, et al. Cerebral myxopapillary ependymoma. *Hum Pathol*. 1992;23:960-962.
486. Kline MJ, Kays DW, Rojiani AM. Extradural myxopapillary ependymoma: report of two cases and review of the literature. *Pediatr Pathol Lab Med*. 1996;16:813-822.
487. Helwig EB, Stern JB. Subcutaneous sacrococcygeal myxopapillary ependymoma. A clinicopathologic study of 32 cases. *Am J Clin Pathol*. 1984;81:156-161.
488. Miralbell R, Louis DN, O'Keeffe D, et al. Metastatic ependymoma of the sacrum. *Cancer*. 1990;65:2353-2355.
489. Pulitzer DR, Martin PC, Collins PC, Ralph DR. Subcutaneous sacrococcygeal ("myxopapillary") ependymal rests. *Am J Surg Pathol*. 1988;12:672-677.
490. Whittemore DE, Grondahl RE, Wong K. Primary extraneural myxopapillary ependymoma of the broad ligament. *Arch Pathol Lab Med*. 2005;129:1338-1342.
491. Hegyi L, Peston D, Theodorou M, et al. Primary glial tumor of the retina with features of myxopapillary ependymoma. *Am J Surg Pathol*. 2005;29:1404-1410.
492. Hiniker A, Lee HS, Chang S, et al. Cortical ependymoma with unusual histologic features. *Clin Neuropathol*. 2013;32:318-323.
493. Zec N, De Girolami U, Schofield DE, et al. Giant cell ependymoma of the filum terminale. A report of two cases. *Am J Surg Pathol*. 1996;20:1091-1101.
494. Ho KL. Microtubular aggregates within rough endoplasmic reticulum in myxopapillary ependymoma of the filum terminale. *Arch Pathol Lab Med*. 1990;114:956-960.
495. Akyurek S, Chang EL, Yu TK, et al. Spinal myxopapillary ependymoma outcomes in patients treated with surgery and radiotherapy at M.D. Anderson Cancer Center. *J Neurooncol*. 2006;80:177-183.
496. Awaya H, Kaneko M, Amatya VJ, et al. Myxopapillary ependymoma with anaplastic features. *Pathol Int*. 2003;53:700-703.
497. Fassett DR, Pingree J, Kestle JR. The high incidence of tumor dissemination in myxopapillary ependymoma in pediatric patients. Report of five cases and review of the literature. *J Neurosurg*. 2005;102:59-64.
498. Bagley CA, Kothbauer KF, Wilson S, et al. Resection of myxopapillary ependymomas in children. *J Neurosurg*. 2007;106:261-267.
499. al Moutaery K, Aabed MY, Ojeda VJ. Cerebral and spinal cord myxopapillary ependymomas: a case report. *Pathology*. 1996;28:373-376.
500. Rushing EJ, Cooper PB, Quezado M, et al. Subependymoma revisited: clinicopathological evaluation of 83 cases. *J Neurooncol*. 2007;85:297-305.
501. Tomlinson FH, Scheithauer BW, Kelly PJ, Forbes GS. Subependymoma with rhabdomyosarcomatous differentiation: report of a case and literature review. *Neurosurgery*. 1991;28:761-768.
502. Louis DN, Hedley-Whyte ET, Martuza RL. Sarcomatous proliferation of the vasculature in a subependymoma: a follow-up study of sarcomatous dedifferentiation. *Acta Neuropathol*. 1990;80:573-574.
503. Brat DJ, Hirose Y, Cohen KJ, et al. Astroblastoma: clinicopathologic features and chromosomal abnormalities defined by comparative genomic hybridization. *Brain Pathol*. 2000;10:342-352.
504. Thiessen B, Finlay J, Kulkarni R, Rosenblum MK. Astroblastoma: does histology predict biologic behavior? *J Neurooncol*. 1998;40:59-65.
505. Bonnin JM, Rubinstein LJ. Astroblastomas: a pathological study of 23 tumors, with a postoperative follow-up in 13 patients. *Neurosurgery*. 1989;25:6-13.
506. Cabello A, Madero S, Castresana A, Diaz-Lobato R. Astroblastoma: electron microscopy and immunohistochemical findings: case report. *Surg Neurol*. 1991;35:116-121.
507. Fu YJ, Taniguchi Y, Takeuchi S, et al. Cerebral astroblastoma in an adult: an immunohistochemical, ultrastructural and genetic study. *Neuropathology*. 2013;33:312-319.
508. Rubinstein LJ, Herman MM. The astroblastoma and its possible cytogenic relationship to the tanycyte. An electron microscopic, immunohistochemical, tissue- and organ-culture study. *Acta Neuropathol*. 1989;78:472-483.
509. Vanhauwaert DJ, Clement F, Van Dorpe J, Deruytter MJ. Chordoid glioma of the third ventricle. *Acta Neurochir (Wien)*. 2008;150:1183-1191.
510. Brat DJ, Scheithauer BW, Staugaitis SM, et al. Third ventricular chordoid glioma: a distinct clinicopathologic entity. *J Neuropathol Exp Neurol*. 1998;57:283-290.
511. Jain D, Sharma MC, Sarkar C, et al. Chordoid glioma: report of two rare examples with unusual features. *Acta Neurochir (Wien)*. 2008;150:295-300, discussion 300.
512. Castellano-Sanchez AA, Schemankewitz E, Mazewski C, Brat DJ. Pediatric chordoid glioma with chondroid metaplasia. *Pediatr Dev Pathol*. 2001;4:564-567.
513. Reifenberger G, Weber T, Weber RG, et al. Chordoid glioma of the third ventricle: immunohistochemical and molecular genetic characterization of a novel tumor entity. *Brain Pathol*. 1999;9:617-626.
514. Bielle F, Villa C, Giry M, et al. Chordoid gliomas of the third ventricle share TTF-1 expression with organum vasculosum of the lamina terminalis. *Am J Surg Pathol*. 2015;39:948-956.
515. Hewer E, Vajtai I. Consistent nuclear expression of thyroid transcription factor 1 in subependymal giant cell astrocytomas suggests lineage-restricted histogenesis. *Clin Neuropathol*. 2015;34:128-131.
516. Horbinski C, Dacic S, McLendon RE, et al. Chordoid glioma: a case report and molecular characterization of five cases. *Brain Pathol*. 2009;19:439-448.
517. Pasquier B, Peoc'h M, Morrison AL, et al. Chordoid glioma of the third ventricle: a report of two new cases, with further evidence supporting an ependymal differentiation, and review of the literature. *Am J Surg Pathol*. 2002;26:1330-1342.
518. Raizer JJ, Shetty T, Gutin PH, et al. Chordoid glioma: report of a case with unusual histologic features, ultrastructural study and review of the literature. *J Neurooncol*. 2003;63:39-47.
519. Cenacchi G, Roncaroli F, Cerasoli S, et al. Chordoid glioma of the third ventricle: an ultrastructural study of three cases with a histogenetic hypothesis. *Am J Surg Pathol*. 2001;25:401-405.
520. Ampie L, Choy W, Lamano JB, et al. Prognostic factors for recurrence and complications in the surgical management of primary chordoid gliomas: a systematic review of literature. *Clin Neurol Neurosurg*. 2015;138:129-136.
521. Lellouch-Tubiana A, Boddaert N, Bourgeois M, et al. Angiocentric neuroepithelial tumor (ANET): a new epilepsy-related clinicopathological entity with distinctive MRI. *Brain Pathol*. 2005;15:281-286.
522. Wang M, Tihan T, Rojiani AM, et al. Monomorphous angiocentric glioma: a distinctive epileptogenic neoplasm with features of infiltrating astrocytoma and ependymoma. *J Neuropathol Exp Neurol*. 2005;64:875-881.
523. Covington DB, Rosenblum MK, Brathwaite CD, Sandberg DI. Angiocentric glioma-like tumor of the midbrain. *Pediatr Neurosurg*. 2009;45:429-433.
524. Preusser M, Hoischen A, Novak K, et al. Angiocentric glioma: report of clinico-pathologic and genetic findings in 8 cases. *Am J Surg Pathol*. 2007;31:1709-1718.
525. Van Gompel JJ, Koeller KK, Meyer FB, et al. Cortical ependymoma: an unusual epileptogenic lesion. *J Neurosurg*. 2011;114:1187-1194.
526. Qaddoumi I, Orisme W, Wen J, et al. Genetic alterations in uncommon low-grade neuroepithelial tumors: BRAF, FGFR1, and MYB mutations occur at high frequency and align with morphology. *Acta Neuropathol*. 2016;131(6):833-845.
527. Judkins AR, Burger PC, Hamilton RL, et al. INI1 protein expression distinguishes atypical teratoid/rhabdoid tumor from choroid plexus carcinoma. *J Neuropathol Exp Neurol*. 2005;64:391-397.
528. Erman T, Gocer AI, Erdogan S, et al. Choroid plexus papilloma of bilateral lateral ventricle. *Acta Neurochir (Wien)*. 2003;145:139-143, discussion 143.
529. Pillai A, Rajeev K, Chandi S, UNnikrishnan M. Intrinsic brainstem choroid plexus papilloma. Case report. *J Neurosurg*. 2004;100:1076-1078.
530. Kimura M, Takayasu M, Suzuki Y, et al. Primary choroid plexus papilloma located in the suprasellar region: case report. *Neurosurgery*. 1992;31:563-566.
531. Boldorini R, Panzarasa G, Girardi P, Monga G. Primary choroid plexus papilloma of the sacral nerve roots. *J Neurosurg Spine*. 2009;10:51-53.
532. Kurtkaya-Yapicier O, Scheithauer BW, Van Peteghem KP, Sawicki JE. Unusual case of extradural choroid plexus papilloma of the sacral canal. Case report. *J Neurosurg*. 2002;97:102-105.
533. Smith ZA, Moftakhar P, Malkasian D, et al. Choroid plexus hyperplasia: surgical treatment and immunohistochemical results. Case report. *J Neurosurg*. 2007;107:255-262.
534. D'Ambrosio AL, O'Toole JE, Connolly ES Jr, Feldstein NA. Villous hypertrophy versus choroid plexus papilloma: a case report demonstrating a diagnostic role for the proliferation index. *Pediatr Neurosurg*. 2003;39:91-96.
535. Miyagi Y, Natori Y, Suzuki SO, et al. Purely cystic form of choroid plexus papilloma with

For personal use only. No other uses without permission. Copyright ©2017. Elsevier Inc. All rights reserved.

acute hydrocephalus in an infant. Case report. *J Neurosurg*. 2006;105:480-484.
536. Matsushima T. Choroid plexus papillomas and human choroid plexus. A light and electron microscopic study. *J Neurosurg*. 1983;59:1054-1062.
537. Buccoliero AM, Bacci S, Mennonna P, Taddei GL. Pathologic quiz case: infratentorial tumor in a middle-aged woman. Oncocytic variant of choroid plexus papilloma. *Arch Pathol Lab Med*. 2004;128:1448-1450.
538. Diengdoh JV, Shaw MD. Oncocytic variant of choroid plexus papilloma. Evolution from benign to malignant "oncocytoma". *Cancer*. 1993;71:855-858.
539. Hamilton RL. Case of the month. May 1996—hydrocephalus in a 9 month old infant. *Brain Pathol*. 1996;6:533-534.
540. Aquilina K, Nanra JS, Allcutt DA, Farrell M. Choroid plexus adenoma: case report and review of the literature. *Childs Nerv Syst*. 2005;21:410-415.
541. Duckett S, Osterholm J, Schaefer D, et al. Ossified mucin-secreting choroid plexus adenoma: case report. *Neurosurgery*. 1991;29:130-132.
542. Hasselblatt M, Jeibmann A, Guerry M, et al. Choroid plexus papilloma with neuropil-like islands. *Am J Surg Pathol*. 2008;32:162-166.
543. Jeibmann A, Wrede B, Peters O, et al. Malignant progression in choroid plexus papillomas. *J Neurosurg*. 2007;107:199-202.
544. Jinhu Y, Jianping D, Jun M, et al. Metastasis of a histologically benign choroid plexus papilloma: case report and review of the literature. *J Neurooncol*. 2007;83:47-52.
545. Wrede B, Hasselblatt M, Peters O, et al. Atypical choroid plexus papilloma: clinical experience in the CPT-SIOP-2000 study. *J Neurooncol*. 2009;95:383-392.
546. Thomas C, Ruland V, Kordes U, et al. Pediatric atypical choroid plexus papilloma reconsidered: increased mitotic activity is prognostic only in older children. *Acta Neuropathol*. 2015;129:925-927.
547. Thomas C, Sill M, Ruland V, et al. Methylation profiling of choroid plexus tumors reveals 3 clinically distinct subgroups. *Neuro Oncol*. 2016;18(6):790-796.
548. Japp AS, Gessi M, Messing-Junger M, et al. High-resolution genomic analysis does not qualify atypical plexus papilloma as a separate entity among choroid plexus tumors. *J Neuropathol Exp Neurol*. 2015;74(2):110-120.
549. Dobin SM, Donner LR. Pigmented choroid plexus carcinoma: a cytogenetic and ultrastructural study. *Cancer Genet Cytogenet*. 1997;96:37-41.
550. Koh EJ, Wang KC, Phi JH, et al. Clinical outcome of pediatric choroid plexus tumors: retrospective analysis from a single institute. *Childs Nerv Syst*. 2014;30(2):217-225.
551. Ikota H, Tanaka Y, Yokoo H, Nakazato Y. Clinicopathological and immunohistochemical study of 20 choroid plexus tumors: their histological diversity and the expression of markers useful for differentiation from metastatic cancer. *Brain Tumor Pathol*. 2011;28:215-221.
552. Kepes JJ, Collins J. Choroid plexus epithelium (normal and neoplastic) expresses synaptophysin. A potentially useful aid in differentiating carcinoma of the choroid plexus from metastatic papillary carcinomas. *J Neuropathol Exp Neurol*. 1999;58:398-401.
553. Gottschalk J, Jautzke G, Paulus W, et al. The use of immunomorphology to differentiate choroid plexus tumors from metastatic carcinomas. *Cancer*. 1993;72:1343-1349.
554. Hasselblatt M, Bohm C, Tatenhorst L, et al. Identification of novel diagnostic markers for choroid plexus tumors: a microarray-based approach. *Am J Surg Pathol*. 2006;30:66-74.
555. Beschorner R, Schittenhelm J, Schimmel H, et al. Choroid plexus tumors differ from metastatic carcinomas by expression of the excitatory amino acid transporter-1. *Hum Pathol*. 2006;37:854-860.
556. Beschorner R, Pantazis G, Jeibmann A, et al. Expression of EAAT-1 distinguishes choroid plexus tumors from normal and reactive choroid plexus epithelium. *Acta Neuropathol*. 2009;117:667-675.
557. Carlotti CG Jr, Salhia B, Weitzman S, et al. Evaluation of proliferative index and cell cycle protein expression in choroid plexus tumors in children. *Acta Neuropathol*. 2002;103:1-10.
558. Tabori U, Shlien A, Baskin B, et al. TP53 alterations determine clinical subgroups and survival of patients with choroid plexus tumors. *J Clin Oncol*. 2010;28:1995-2001.
559. Fuller CE, Smith M, Miller DC, Schelper R. Pigmented papillary epithelial neoplasm of the pituitary fossa: a distinct lesion of uncertain histogenesis. *Arch Pathol Lab Med*. 2001;125:1242-1245.
560. Felix I, Bilbao JM, Asa SL, et al. Cerebral and cerebellar gangliocytomas: a morphological study of nine cases. *Acta Neuropathol*. 1994;88:246-251.
561. Johnson JH Jr, Hariharan S, Berman J, et al. Clinical outcome of pediatric gangliogliomas: ninety-nine cases over 20 years. *Pediatr Neurosurg*. 1997;27:203-207.
562. Jallo GI, Freed D, Epstein FJ. Spinal cord gangliogliomas: a review of 56 patients. *J Neurooncol*. 2004;68:71-77.
563. Gessi M, Dorner E, Dreschmann V, et al. Intramedullary gangliogliomas: histopathologic and molecular features of 25 cases. *Hum Pathol*. 2016;49:107-113.
564. Constantini S, Houten J, Miller DC, et al. Intramedullary spinal cord tumors in children under the age of 3 years. *J Neurosurg*. 1996;85:1036-1043.
565. Athale S, Hallet KK, Jinkins JR. Ganglioglioma of the trigeminal nerve: MRI. *Neuroradiology*. 1999;41:576-578.
566. Lu WY, Goldman M, Young B, Davis DG. Optic nerve ganglioglioma. Case report. *J Neurosurg*. 1993;78:979-982.
567. Harmon HL, Gossman MD, Buchino JJ, et al. Orbital ganglioglioma arising from ectopic neural tissue. *Am J Ophthalmol*. 2000;129:109-111.
568. Brat DJ, Gearing M, Goldthwaite PT, et al. Tau-associated neuropathology in ganglion cell tumours increases with patient age but appears unrelated to ApoE genotype. *Neuropathol Appl Neurobiol*. 2001;27:197-205.
569. Soffer D, Lach B, Constantini S. Melanotic cerebral ganglioglioma: evidence for melanogenesis in neoplastic astrocytes. *Acta Neuropathol*. 1992;83:315-323.
570. Blumcke I, Wiestler OD. Gangliogliomas: an intriguing tumor entity associated with focal epilepsies. *J Neuropathol Exp Neurol*. 2002;61:575-584.
571. Prayson RA, Khajavi K, Comair YG. Cortical architectural abnormalities and MIB1 immunoreactivity in gangliogliomas: a study of 60 patients with intracranial tumors. *J Neuropathol Exp Neurol*. 1995;54:513-520.
572. Hirose T, Scheithauer BW, Lopes MB, et al. Ganglioglioma: an ultrastructural and immunohistochemical study. *Cancer*. 1997;79:989-1003.
573. Wolf HK, Muller MB, Spanle M, et al. Ganglioglioma: a detailed histopathological and immunohistochemical analysis of 61 cases. *Acta Neuropathol*. 1994;88:166-173.
574. Miller DC, Lang FF, Epstein FJ. Central nervous system gangliogliomas. Part 1: pathology. *J Neurosurg*. 1993;79:859-866.
575. Hayashi S, Kameyama S, Fukuda M, Takahashi H. Ganglioglioma with a tanycytic ependymoma as the glial component. *Acta Neuropathol*. 2000;99:310-316.
576. Majores M, von Lehe M, Fassunke J, et al. Tumor recurrence and malignant progression of gangliogliomas. *Cancer*. 2008;113:3355-3363.
577. Allegranza A, Pileri S, Frank G, Ferracini R. Cerebral ganglioglioma with anaplastic oligodendroglial component. *Histopathology*. 1990;17:439-441.
578. Jay V, Squire J, Becker LE, Humphreys R. Malignant transformation in a ganglioglioma with anaplastic neuronal and astrocytic components. Report of a case with flow cytometric and cytogenetic analysis. *Cancer*. 1994;73:2862-2868.
579. David KM, de Sanctis S, Lewis PD, et al. Neuroblastomatous recurrence of ganglioglioma. Case report. *J Neurosurg*. 2000;93:698-700.
580. Suzuki H, Otsuki T, Iwasaki Y, et al. Anaplastic ganglioglioma with sarcomatous component: an immunohistochemical study and molecular analysis of p53 tumor suppressor gene. *Neuropathology*. 2002;22:40-47.
581. Issidorides MR, Havaki S, Chrysanthou-Piterou M, Arvanitis DL. Ultrastructural identification of protein bodies, cellular markers of human catecholamine neurons, in a temporal lobe ganglioglioma. *Ultrastruct Pathol*. 2000;24:399-405.
582. Quinn B. Synaptophysin staining in normal brain: importance for diagnosis of ganglioglioma. *Am J Surg Pathol*. 1998;22:550-556.
583. Zhang PJ, Rosenblum MK. Synaptophysin expression in the human spinal cord. Diagnostic implications of an immunohistochemical study. *Am J Surg Pathol*. 1996;20:273-276.
584. Caccamo D, Herman MM, Urich H, Rubinstein LJ. Focal neuronal gigantism and cerebral cortical thickening after therapeutic irradiation of the central nervous system. *Arch Pathol Lab Med*. 1989;113:880-885.
585. Duggal N, Hammond RR. Nestin expression in ganglioglioma. *Exp Neurol*. 2002;174:89-95.
586. Blumcke I, Giencke K, Wardelmann E, et al. The CD34 epitope is expressed in neoplastic and malformative lesions associated with chronic, focal epilepsies. *Acta Neuropathol*. 1999;97:481-490.
587. Deb P, Sharma MC, Tripathi M, et al. Expression of CD34 as a novel marker for glioneuronal lesions associated with chronic intractable epilepsy. *Neuropathol Appl Neurobiol*. 2006;32:461-468.
588. Koelsche C, Wohrer A, Jeibmann A, et al. Mutant BRAF V600E protein in ganglioglioma is predominantly expressed by neuronal tumor cells. *Acta Neuropathol*. 2013;125:891-900.
589. Horbinski C, Kofler J, Yeaney G, et al. Isocitrate dehydrogenase 1 analysis differentiates gangliogliomas from infiltrative gliomas. *Brain Pathol*. 2011;21:564-574.
590. Luyken C, Blumcke I, Fimmers R, et al. Supratentorial gangliogliomas: histopathologic grading and tumor recurrence in 184 patients with a median follow-up of 8 years. *Cancer*. 2004;101:146-155.
591. Lang FF, Epstein FJ, Ransohoff J, et al. Central nervous system gangliogliomas. Part 2: clinical outcome. *J Neurosurg*. 1993;79:867-873.
592. Karremann M, Pietsch T, Janssen G, et al. Anaplastic ganglioglioma in children. *J Neurooncol*. 2009;92:157-163.

593. Selch MT, Goy BW, Lee SP, et al. Gangliogliomas: experience with 34 patients and review of the literature. *Am J Clin Oncol*. 1998;21:557-564.
594. Wacker MR, Cogen PH, Etzell JE, et al. Diffuse leptomeningeal involvement by a ganglioglioma in a child. Case report. *J Neurosurg*. 1992;77:302-306.
595. Wolf HK, Müller MB, Spanle M, et al. Ganglioglioma: a detailed histopathological and immunohistochemical analysis of 61 cases. *Acta Neuropathol (Berl)*. 1994;88:166-173.
596. Dahiya S, Haydon DH, Alvarado D, et al. BRAF(V600E) mutation is a negative prognosticator in pediatric ganglioglioma. *Acta Neuropathol*. 2013;125:901-910.
597. Geddes JF, Jansen GH, Robinson SF, et al. 'Gangliocytomas' of the pituitary: a heterogeneous group of lesions with differing histogenesis. *Am J Surg Pathol*. 2000;24:607-613.
598. Taratuto AL, Monges J, Lylyk P, Leiguarda R. Superficial cerebral astrocytoma attached to dura. Report of six cases in infants. *Cancer*. 1984;54:2505-2512.
599. VandenBerg SR, May EE, Rubinstein LJ, et al. Desmoplastic supratentorial neuroepithelial tumors of infancy with divergent differentiation potential ("desmoplastic infantile gangliogliomas"). Report on 11 cases of a distinctive embryonal tumor with favorable prognosis. *J Neurosurg*. 1987;66:58-71.
600. Aydin F, Ghatak NR, Salvant J, Muizelaar P. Desmoplastic cerebral astrocytoma of infancy. A case report with immunohistochemical, ultrastructural and proliferation studies. *Acta Neuropathol*. 1993;86:666-670.
601. Louis DN, von Deimling A, Dickersin GR, et al. Desmoplastic cerebral astrocytomas of infancy: a histopathologic, immunohistochemical, ultrastructural, and molecular genetic study. *Hum Pathol*. 1992;23:1402-1409.
602. Duffner PK, Burger PC, Cohen ME, et al. Desmoplastic infantile gangliogliomas: an approach to therapy. *Neurosurgery*. 1994;34:583-589.
603. Mallucci C, Lellouch-Tubiana A, Salazar C, et al. The management of desmoplastic neuroepithelial tumours in childhood. *Childs Nerv Syst*. 2000;16:8-14.
604. Komori T, Scheithauer BW, Parisi JE, et al. Mixed conventional and desmoplastic infantile ganglioglioma: an autopsied case with 6-year follow-up. *Mod Pathol*. 2001;14:720-726.
605. Gessi M, Zur Muhlen A, Hammes J, et al. Genome-wide DNA copy number analysis of desmoplastic infantile astrocytomas and desmoplastic infantile gangliogliomas. *J Neuropathol Exp Neurol*. 2013;72(9):807-815.
606. Takeshima H, Kawahara Y, Hirano H, et al. Postoperative regression of desmoplastic infantile gangliogliomas: report of two cases. *Neurosurgery*. 2003;53:979-983, discussion 983-984.
607. Fan X, Larson TC, Jennings MT, et al. December 2000: 6 month old boy with 2 week history of progressive lethargy. *Brain Pathol*. 2001;11:265-266.
608. De Munnynck K, Van Gool S, Van Calenbergh F, et al. Desmoplastic infantile ganglioglioma: a potentially malignant tumor? *Am J Surg Pathol*. 2002;26: 1515-1522.
609. Hoving EW, Kros JM, Groninger E, den Dunnen WF. Desmoplastic infantile ganglioglioma with a malignant course. *J Neurosurg Pediatr*. 2008;1:95-98.
610. Loh JK, Lieu AS, Chai CY, Howng SL. Malignant transformation of a desmoplastic infantile ganglioglioma. *Pediatr Neurol*. 2011;45:135-137.
611. Phi JH, Koh EJ, Kim SK, et al. Desmoplastic infantile astrocytoma: recurrence with malignant transformation into glioblastoma: a case report. *Childs Nerv Syst*. 2011;27:2177-2181.
612. Sugiyama K, Arita K, Shima T, et al. Good clinical course in infants with desmoplastic cerebral neuroepithelial tumor treated by surgery alone. *J Neurooncol*. 2002;59:63-69.
613. Figarella-Branger D, Pellissier JF, Daumas-Duport C, et al. Central neurocytomas. Critical evaluation of a small-cell neuronal tumor. *Am J Surg Pathol*. 1992;16:97-109.
614. Robbins P, Segal A, Narula S, et al. Central neurocytoma. A clinicopathological, immunohistochemical and ultrastructural study of 7 cases. *Pathol Res Pract*. 1995;191:100-111.
615. George DH, Scheithauer BW. Central liponeurocytoma. *Am J Surg Pathol*. 2001;25:1551-1555.
616. Horoupian DS, Shuster DL, Kaarsoo-Herrick M, Shuer LM. Central neurocytoma: one associated with a fourth ventricular PNET/medulloblastoma and the second mixed with adipose tissue. *Hum Pathol*. 1997;28:1111-1114.
617. Ng TH, Wong AY, Boadle R, Compton JS. Pigmented central neurocytoma: case report and literature review. *Am J Surg Pathol*. 1999;23:1136-1140.
618. Jouvet A, Lellouch-Tubiana A, Boddaert N, et al. Fourth ventricle neurocytoma with lipomatous and ependymal differentiation. *Acta Neuropathol (Berl)*. 2005;109:346-351.
619. Schweitzer JB, Davies KG. Differentiating central neurocytoma. Case report. *J Neurosurg*. 1997;86:543-546.
620. Park SH, Ostrzega N, Akers MA, Vinters HV. Intraventricular neurocytoma with prominent myelin figures. *Ultrastruct Pathol*. 1999;23:311-317.
621. Mierau GW, Scheithauer BW, Hukee MJ, Orsini EN. Mixed ependymoma-neuroendocrine tumor of the lateral ventricle. *Ultrastruct Pathol*. 1996;20:47-53.
622. Fujisawa H, Marukawa K, Hasegawa M, et al. Genetic differences between neurocytoma and dysembryoplastic neuroepithelial tumor and oligodendroglial tumors. *J Neurosurg*. 2002;97:1350-1355.
623. Ishiuchi S, Tamura M. Central neurocytoma: an immunohistochemical, ultrastructural and cell culture study. *Acta Neuropathol*. 1997;94:425-435.
624. Soylemezoglu F, Scheithauer BW, Esteve J, Kleihues P. Atypical central neurocytoma. *J Neuropathol Exp Neurol*. 1997;56:551-556.
625. Tsuchida T, Matsumoto M, Shirayama Y, et al. Neuronal and glial characteristics of central neurocytoma: electron microscopical analysis of two cases. *Acta Neuropathol*. 1996;91:573-577.
626. Vasiljevic A, Francois P, Loundou A, et al. Prognostic factors in central neurocytomas: a multicenter study of 71 cases. *Am J Surg Pathol*. 2012;36:220-227.
627. Elek G, Slowik F, Eross L, et al. Central neurocytoma with malignant course. Neuronal and glial differentiation and craniospinal dissemination. *Pathol Oncol Res*. 1999;5:155-159.
628. Eng DY, DeMonte F, Ginsberg L, et al. Craniospinal dissemination of central neurocytoma. Report of two cases. *J Neurosurg*. 1997;86:547-552.
629. Mackenzie IR. Central neurocytoma: histologic atypia, proliferation potential, and clinical outcome. *Cancer*. 1999;85: 1606-1610.
630. Rades D, Schild SE, Fehlauer F. Prognostic value of the MIB-1 labeling index for central neurocytomas. *Neurology*. 2004;62:987-989.
631. Leenstra JL, Rodriguez FJ, Frechette CM, et al. Central neurocytoma: management recommendations based on a 35-year experience. *Int J Radiat Oncol Biol Phys*. 2007;67:1145-1154.
632. Patel DM, Schmidt RF, Liu JK. Update on the diagnosis, pathogenesis, and treatment strategies for central neurocytoma. *J Clin Neurosci*. 2013;20:1193-1199.
633. Brat DJ, Scheithauer BW, Eberhart CG, Burger PC. Extraventricular neurocytomas: pathologic features and clinical outcome. *Am J Surg Pathol*. 2001;25:1252-1260.
634. Giangaspero F, Cenacchi G, Losi L, et al. Extraventricular neoplasms with neurocytoma features. A clinicopathological study of 11 cases. *Am J Surg Pathol*. 1997;21:206-212.
635. Tatter SB, Borges LF, Louis DN. Central neurocytomas of the cervical spinal cord. Report of two cases. *J Neurosurg*. 1994;81:288-293.
636. Pal L, Santosh V, Gayathri N, et al. Neurocytoma/rhabdomyoma (myoneurocytoma) of the cerebellum. *Acta Neuropathol*. 1998;95:318-323.
637. Hirschowitz L, Ansari A, Cahill DJ, et al. Central neurocytoma arising within a mature cystic teratoma of the ovary. *Int J Gynecol Pathol*. 1997;16:176-179.
638. Friedrichs N, Vorreuther R, Fischer HP, et al. Neurocytoma arising in the pelvis. *Virchows Arch*. 2003;443:217-219.
639. Furtado A, Arantes M, Silva R, et al. Comprehensive review of extraventricular neurocytoma with report of two cases, and comparison with central neurocytoma. *Clin Neuropathol*. 2010;29:134-140.
640. Kane AJ, Sughrue ME, Rutkowski MJ, et al. Atypia predicting prognosis for intracranial extraventricular neurocytomas. *J Neurosurg*. 2012;116:349-354.
641. Mrak RE. Malignant neurocytic tumor. *Hum Pathol*. 1994;25:747-752.
642. Rodriguez FJ, Mota RA, Scheithauer BW, et al. Interphase cytogenetics for 1p19q and t(1;19)(q10;p10) may distinguish prognostically relevant subgroups in extraventricular neurocytoma. *Brain Pathol*. 2009;19:623-629.
643. Myung JK, Cho HJ, Park CK, et al. Clinicopathological and genetic characteristics of extraventricular neurocytomas. *Neuropathology*. 2013;33:111-121.
644. Agarwal S, Sharma MC, Sarkar C, et al. Extraventricular neurocytomas: a morphological and histogenetic consideration. A study of six cases. *Pathology*. 2011;43:327-334.
645. Nishimoto T, Kaya B. Cerebellar liponeurocytoma. *Arch Pathol Lab Med*. 2012;136:965-969.
646. Giangaspero F, Cenacchi G, Roncaroli F, et al. Medullocytoma (lipidized medulloblastoma). A cerebellar neoplasm of adults with favorable prognosis. *Am J Surg Pathol*. 1996;20:656-664.
647. Soylemezoglu F, Soffer D, Onol B, et al. Lipomatous medulloblastoma in adults. A distinct clinicopathological entity. *Am J Surg Pathol*. 1996;20:413-418.
648. Anghileri E, Eoli M, Paterra R, et al. FABP4 is a candidate marker of cerebellar liponeurocytomas. *J Neurooncol*. 2012;108:513-519.
649. Gonzalez-Campora R, Weller RO. Lipidized mature neuroectodermal tumour of the cerebellum with myoid differentiation. *Neuropathol Appl Neurobiol*. 1998;24: 397-402.

650. Buccoliero AM, Caldarella A, Bacci S, et al. Cerebellar liponeurocytoma: morphological, immunohistochemical, and ultrastructural study of a relapsed case. *Neuropathology*. 2005;25:77-83.
651. Pasquale G, Maria BA, Vania P, et al. Cerebellar liponeurocytoma: an updated follow-up of a case presenting histopathological and clinically aggressive features. *Neurol India*. 2009;57:194-196.
652. Horstmann S, Perry A, Reifenberger G, et al. Genetic and expression profiles of cerebellar liponeurocytomas. *Brain Pathol*. 2004;14:281-289.
653. Aker FV, Ozkara S, Eren P, et al. Cerebellar liponeurocytoma/lipidized medulloblastoma. *J Neurooncol*. 2005;71:53-59.
654. Sharma MC, Agarwal M, Suri A, et al. Lipomedulloblastoma in a child: a controversial entity. *Hum Pathol*. 2002;33:564-569.
655. Giordana MT, Schiffer P, Boghi A, et al. Medulloblastoma with lipidized cells versus lipomatous medulloblastoma. *Clin Neuropathol*. 2000;19:273-277.
656. Jenkinson MD, Bosma JJ, Du Plessis D, et al. Cerebellar liponeurocytoma with an unusually aggressive clinical course: case report. *Neurosurgery*. 2003;53:1425-1427, discussion 1428.
657. Radke J, Gehlhaar C, Lenze D, et al. The evolution of the anaplastic cerebellar liponeurocytoma: case report and review of the literature. *Clin Neuropathol*. 2015;34:19-25.
658. Honavar M, Janota I, Polkey CE. Histological heterogeneity of dysembryoplastic neuroepithelial tumour: identification and differential diagnosis in a series of 74 cases. *Histopathology*. 1999;34:342-356.
659. Daumas-Duport C. Dysembryoplastic neuroepithelial tumours. *Brain Pathol*. 1993;3:283-295.
660. Daumas-Duport C, Scheithauer BW, Chodkiewicz JP, et al. Dysembryoplastic neuroepithelial tumor: a surgically curable tumor of young patients with intractable partial seizures. Report of thirty-nine cases. *Neurosurgery*. 1988;23:545-556.
661. Gessi M, Hattingen E, Dorner E, et al. Dysembryoplastic neuroepithelial tumor of the septum pellucidum and the supratentorial midline: histopathologic, neuroradiologic, and molecular features of 7 cases. *Am J Surg Pathol*. 2016;40(6): 806-811.
662. Baisden BL, Brat DJ, Melhem ER, et al. Dysembryoplastic neuroepithelial tumor-like neoplasm of the septum pellucidum: a lesion often misdiagnosed as glioma: report of 10 cases. *Am J Surg Pathol*. 2001;25:494-499.
663. Cervera-Pierot P, Varlet P, Chodkiewicz JP, Daumas-Duport C. Dysembryoplastic neuroepithelial tumors located in the caudate nucleus area: report of four cases. *Neurosurgery*. 1997;40:1065-1069, discussion 1069-1070.
664. Kurtkaya-Yapicier O, Elmaci I, Boran B, et al. Dysembryoplastic neuroepithelial tumor of the midbrain tectum: a case report. *Brain Tumor Pathol*. 2002;19:97-100.
665. Fujimoto K, Ohnishi H, Tsujimoto M, et al. Dysembryoplastic neuroepithelial tumor of the cerebellum and brainstem. Case report. *J Neurosurg*. 2000;93:487-489.
666. Whittle IR, Dow GR, Lammie GA, Wardlaw J. Dsyembryoplastic neuroepithelial tumour with discrete bilateral multifocality: further evidence for a germinal origin. *Br J Neurosurg*. 1999;13:508-511.
667. Fernandez C, Girard N, Paz Paredes A, et al. The usefulness of MR imaging in the diagnosis of dysembryoplastic neuroepithelial tumor in children: a study of 14 cases. *AJNR Am J Neuroradiol*. 2003;24:829-834.
668. Prayson RA, Napekoski KM. Composite ganglioglioma/dysembryoplastic neuroepithelial tumor: a clinicopathologic study of 8 cases. *Hum Pathol*. 2012;43:1113-1118.
669. Elizabeth J, Bhaskara RM, Radhakrishnan VV, et al. Melanotic differentiation in dysembryoplastic neuroepithelial tumor. *Clin Neuropathol*. 2000;19:38-40.
670. Thom M, Toma A, An S, et al. One hundred and one dysembryoplastic neuroepithelial tumors: an adult epilepsy series with immunohistochemical, molecular genetic, and clinical correlations and a review of the literature. *J Neuropathol Exp Neurol*. 2011;70:859-878.
671. Prabowo AS, Iyer AM, Veersema TJ, et al. BRAF V600E mutation is associated with mTOR signaling activation in glioneuronal tumors. *Brain Pathol*. 2014;24:52-66.
672. Gyure KA, Sandberg GD, Prayson RA, et al. Dysembryoplastic neuroepithelial tumour: an immunohistochemical study with myelin oligodendrocyte glycoprotein. *Arch Pathol Lab Med*. 2000;124:123-126.
673. Komori T, Arai N. Dysembryoplastic neuroepithelial tumor, a pure glial tumor? Immunohistochemical and morphometric studies. *Neuropathology*. 2013;33(4): 459-468.
674. Wolf HK, Buslei R, Blumcke I, et al. Neural antigens in oligodendrogliomas and dysembryoplastic neuroepithelial tumors. *Acta Neuropathol*. 1997;94:436-443.
675. Hirose T, Scheithauer BW, Lopes MB, VandenBerg SR. Dysembryoplastic neuroeptihelial tumor (DNT): an immunohistochemical and ultrastructural study. *J Neuropathol Exp Neurol*. 1994;53:184-195.
676. Capper D, Reuss D, Schittenhelm J, et al. Mutation-specific IDH1 antibody differentiates oligodendrogliomas and oligoastrocytomas from other brain tumors with oligodendroglioma-like morphology. *Acta Neuropathol*. 2011;121:241-252.
677. Prabowo AS, van Thuijl HF, Scheinin I, et al. Landscape of chromosomal copy number aberrations in gangliogliomas and dysembryoplastic neuroepithelial tumours. *Neuropathol Appl Neurobiol*. 2015;41(6):743-755.
678. Ray WZ, Blackburn SL, Casavilca-Zambrano S, et al. Clinicopathologic features of recurrent dysembryoplastic neuroepithelial tumor and rare malignant transformation: a report of 5 cases and review of the literature. *J Neurooncol*. 2009;94:283-292.
679. Chao L, Tao XB, Jun YK, et al. Recurrence and histological evolution of dysembryoplastic neuroepithelial tumor: a case report and review of the literature. *Oncol Lett*. 2013;6:907-914.
680. Heiland DH, Staszewski O, Hirsch M, et al. Malignant transformation of a dysembryoplastic neuroepithelial tumor (DNET) characterized by genome-wide methylation analysis. *J Neuropathol Exp Neurol*. 2016;75(4):358-365.
681. Rushing EJ, Thompson LD, Mena H. Malignant transformation of a dysembryoplastic neuroepithelial tumor after radiation and chemotherapy. *Ann Diagn Pathol*. 2003;7:240-244.
682. Daumas-Duport C, Varlet P, Bacha S, et al. Dysembryoplastic neuroepithelial tumors: nonspecific histological forms—a study of 40 cases. *J Neurooncol*. 1999;41:267-280.
683. Komori T, Scheithauer BW, Anthony DC, et al. Papillary glioneuronal tumor: a new variant of mixed neuronal-glial neoplasm. *Am J Surg Pathol*. 1998;22:1171-1183.
684. Portela-Oliveira E, Torres US, Lancellotti CL, et al. Solid intraventricular papillary glioneuronal tumor: magnetic resonance imaging findings with histopathological correlation. *Pediatr Neurol*. 2014;50:199-200.
685. Tanaka Y, Yokoo H, Komori T, et al. A distinct pattern of Olig2-positive cellular distribution in papillary glioneuronal tumors: a manifestation of the oligodendroglial phenotype? *Acta Neuropathol*. 2005;110:39-47.
686. Ishizawa T, Komori T, Shibahara J, et al. Papillary glioneuronal tumor with minigemistocytic components and increased proliferative activity. *Hum Pathol*. 2006;37:627-630.
687. Bridge JA, Liu XQ, Sumegi J, et al. Identification of a novel, recurrent SLC44A1-PRKCA fusion in papillary glioneuronal tumor. *Brain Pathol*. 2013;23:121-128.
688. Pages M, Lacroix L, Tauziede-Espariat A, et al. Papillary glioneuronal tumors: histological and molecular characteristics and diagnostic value of SLC44A1-PRKCA fusion. *Acta Neuropathol Commun*. 2015;3:85.
689. Schlamann A, von Bueren AO, Hagel C, et al. An individual patient data meta-analysis on characteristics and outcome of patients with papillary glioneuronal tumor, rosette glioneuronal tumor with neuropil-like islands and rosette forming glioneuronal tumor of the fourth ventricle. *PLoS ONE*. 2014;9:e101211.
690. Javahery RJ, Davidson L, Fangusaro J, et al. Aggressive variant of a papillary glioneuronal tumor. Report of 2 cases. *J Neurosurg Pediatr*. 2009;3:46-52.
691. Park CK, Phi JH, Park SH. Glial tumors with neuronal differentiation. *Neurosurg Clin N Am*. 2015;26:117-138.
692. Bourekas EC, Bell SD, Ladwig NR, et al. Anaplastic papillary glioneuronal tumor with extraneural metastases. *J Neuropathol Exp Neurol*. 2014;73:474-476.
693. Komori T, Scheithauer BW, Hirose T. A rosette-forming glioneuronal tumor of the fourth ventricle: infratentorial form of dysembryoplastic neuroepithelial tumor? *Am J Surg Pathol*. 2002;26:582-591.
694. Marhold F, Preusser M, Dietrich W, et al. Clinicoradiological features of rosette-forming glioneuronal tumor (RGNT) of the fourth ventricle: report of four cases and literature review. *J Neurooncol*. 2008;90:301-308.
695. Xu J, Yang Y, Liu Y, et al. Rosette-forming glioneuronal tumor in the pineal gland and the third ventricle: a case with radiological and clinical implications. *Quant Imaging Med Surg*. 2012;2:227-231.
696. Anan M, Inoue R, Ishii K, et al. A rosette-forming glioneuronal tumor of the spinal cord: the first case of a rosette-forming glioneuronal tumor originating from the spinal cord. *Hum Pathol*. 2009;40:898-901.
697. Scheithauer BW, Silva AI, Ketterling RP, et al. Rosette-forming glioneuronal tumor: report of a chiasmal-optic nerve example in neurofibromatosis type 1: special pathology report. *Neurosurgery*. 2009;64:E771-E772, discussion E772.
698. Ellezam B, Theeler BJ, Luthra R, et al. Recurrent PIK3CA mutations in rosette-forming glioneuronal tumor. *Acta Neuropathol*. 2012;123:285-287.
699. Gessi M, Moneim YA, Hammes J, et al. FGFR1 mutations in Rosette-forming glioneuronal tumors of the fourth ventricle. *J Neuropathol Exp Neurol*. 2014;73:580-584.
700. Wang Y, Xiong J, Chu SG, et al. Rosette-forming glioneuronal tumor: report of an unusual case with intraventricular

dissemination. *Acta Neuropathol*. 2009;118:813-819.
701. Schniederjan MJ, Alghamdi S, Castellano-Sanchez A, et al. Diffuse leptomeningeal neuroepithelial tumor: 9 pediatric cases with chromosome 1p/19q deletion status and IDH1 (R132H) immunohistochemistry. *Am J Surg Pathol*. 2013;37:763-771.
702. Cho HJ, Myung JK, Kim H, et al. Primary diffuse leptomeningeal glioneuronal tumors. *Brain Tumor Pathol*. 2015;32:49-55.
703. Kessler BA, Bookhout C, Jaikumar S, et al. Disseminated oligodendroglial-like leptomeningeal tumor with anaplastic progression and presumed extraneural disease: case report. *Clin Imaging*. 2015;39:300-304.
704. Rodriguez FJ, Schniederjan MJ, Nicolaides T, et al. High rate of concurrent BRAF-KIAA1549 gene fusion and 1p deletion in disseminated oligodendroglioma-like leptomeningeal neoplasms (DOLN). *Acta Neuropathol*. 2015;129:609-610.
705. Rossi S, Rodriguez FJ, Mota RA, et al. Primary leptomeningeal oligodendroglioma with documented progression to anaplasia and t(1;19)(q10;p10) in a child. *Acta Neuropathol*. 2009;118:575-577.
706. Huse JT, Edgar M, Halliday J, et al. Multinodular and vacuolating neuronal tumors of the cerebrum: 10 cases of a distinctive seizure-associated lesion. *Brain Pathol*. 2013;23:515-524.
707. Bodi I, Curran O, Selway R, et al. Two cases of multinodular and vacuolating neuronal tumour. *Acta Neuropathol Commun*. 2014;2:7.
708. Fukushima S, Yoshida A, Narita Y, et al. Multinodular and vacuolating neuronal tumor of the cerebrum. *Brain Tumor Pathol*. 2015;32:131-136.
709. Nagaishi M, Yokoo H, Nobusawa S, et al. Localized overexpression of alpha-internexin within nodules in multinodular and vacuolating neuronal tumors. *Neuropathology*. 2015;35(6):561-568.
710. Pati S, Sollman M, Fife TD, Ng YT. Diagnosis and management of epilepsy associated with hypothalamic hamartoma: an evidence-based systematic review. *J Child Neurol*. 2013;28:909-916.
711. Culler FL, James HE, Simon ML, Jones KL. Identification of gonadotropin-releasing hormone in neurons of a hypothalamic hamartoma in a boy with precocious puberty. *Neurosurgery*. 1985;17:408-412.
712. Price RA, Lee PA, Albright AL, et al. Treatment of sexual precocity by removal of a luteinizing hormone-releasing hormone secreting hamartoma. *JAMA*. 1984;251:2247-2249.
713. Coons SW, Rekate HL, Prenger EC, et al. The histopathology of hypothalamic hamartomas: study of 57 cases. *J Neuropathol Exp Neurol*. 2007;66:131-141.
714. Clarren SK, Alvord EC Jr, Hall JG. Congenital hypothalamic hamartoblastoma, hypopituitarism, imperforate anus, and postaxial polydactyly—a new syndrome? Part II: neuropathological considerations. *Am J Med Genet*. 1980;7:75-83.
715. Demurger F, Ichkou A, Mougou-Zerelli S, et al. New insights into genotype-phenotype correlation for GLI3 mutations. *Eur J Hum Genet*. 2015;23:92-102.
716. Squires LA, Constantini S, Miller DC, Wisoff JH. Hypothalamic hamartoma and the Pallister-Hall syndrome. *Pediatr Neurosurg*. 1995;22:303-308.
717. Plate KH, Wieser HG, Yasargil MG, Wiestler OD. Neuropathological findings in 224 patients with temporal lobe epilepsy. *Acta Neuropathol*. 1993;86:433-438.
718. Wolf HK, Campos MG, Zentner J, et al. Surgical pathology of temporal lobe epilepsy. Experience with 216 cases. *J Neuropathol Exp Neurol*. 1993;52:499-506.
719. Blumcke I, Thom M, Aronica E, et al. The clinicopathologic spectrum of focal cortical dysplasias: a consensus classification proposed by an ad hoc Task Force of the ILAE Diagnostic Methods Commission. *Epilepsia*. 2011;52:158-174.
720. Wolf HK, Zentner J, Hufnagel A, et al. Surgical pathology of chronic epileptic seizure disorders: experience with 63 specimens from extratemporal corticectomies, lobectomies and functional hemispherectomies. *Acta Neuropathol*. 1993;86:466-472.
721. Delande O, Rodriguez D, Chiron C, Fohlen M. Successful surgical relief of seizures associated with hamartoma of the floor of the fourth ventricle in children: report of two cases. *Neurosurgery*. 2001;49:726-730, discussion 730-731.
722. Sharma MS, Suri A, Shah T, et al. Intraventricular glioneuronal hamartoma: histopathological correlation with magnetic resonance spectroscopy. *J Neurooncol*. 2005;74:325-328.
723. Blumcke I, Lobach M, Wolf HK, Wiestler OD. Evidence for developmental precursor lesions in epilepsy-associated glioneuronal tumors. *Microsc Res Tech*. 1999;46:53-58.
724. Volk EE, Prayson RA. Hamartomas in the setting of chronic epilepsy: a clinicopathologic study of 13 cases. *Hum Pathol*. 1997;28:227-232.
725. Abel TW, Baker SJ, Fraser MM, et al. Lhermitte-Duclos disease: a report of 31 cases with immunohistochemical analysis of the PTEN/AKT/mTOR pathway. *J Neuropathol Exp Neurol*. 2005;64:341-349.
726. Ferrer I, Isamat F, Acebes J. A Golgi and electron microscopic study of a dysplastic gangliocytoma of the cerebellum. *Acta Neuropathol*. 1979;47:163-165.
727. Yachnis AT, Trojanowski JQ, Memmo M, Schlaepfer WW. Expression of neurofilament proteins in the hypertrophic granule cells of Lhermitte-Duclos disease: an explanation for the mass effect and the myelination of parallel fibers in the disease state. *J Neuropathol Exp Neurol*. 1988;47:206-216.
728. Ferrer I, Isamat F, Lopez-Obarrio L, et al. Parvalbumin and calbindin D-28K immunoreactivity in central ganglioglioma and dysplastic gangliocytoma of the cerebellum. Report of two cases. *J Neurosurg*. 1993;78:133-137.
729. Riegert-Johnson DL, Gleeson FC, Roberts M, et al. Cancer and Lhermitte-Duclos disease are common in Cowden syndrome patients. *Hered Cancer Clin Pract*. 2010;8:6.
730. Ni Y, Zbuk KM, Sadler T, et al. Germline mutations and variants in the succinate dehydrogenase genes in Cowden and Cowden-like syndromes. *Am J Hum Genet*. 2008;83:261-268.
731. Zhou XP, Marsh DJ, Morrison CD, et al. Germline inactivation of PTEN and dysregulation of the phosphoinositol-3-kinase/Akt pathway cause human Lhermitte-Duclos disease in adults. *Am J Hum Genet*. 2003;73:1191-1198.
732. Kwon CH, Zhu X, Zhang J, et al. Pten regulates neuronal soma size: a mouse model of Lhermitte-Duclos disease. *Nat Genet*. 2001;29:404-411.
733. Aisner DL, Newell KL, Pollack AG, et al. Composite pleomorphic xanthoastrocytoma-epithelioid glioneuronal tumor with BRAF V600E mutation—report of three cases. *Clin Neuropathol*. 2014;33:112-121.
734. Rubinstein LJ. Embryonal central neuroepithelial tumors and their differentiating potential. A cytogenetic view of a complex neuro-oncological problem. *J Neurosurg*. 1985;62:795-805.
735. Rorke LB. The cerebellar medulloblastoma and its relationship to primitive neuroectodermal tumors. *J Neuropathol Exp Neurol*. 1983;42:1-15.
736. Remke M, Hielscher T, Northcott PA, et al. Adult medulloblastoma comprises three major molecular variants. *J Clin Oncol*. 2011;29:2717-2723.
737. Kool M, Korshunov A, Pfister SM. Update on molecular and genetic alterations in adult medulloblastoma. *Memo*. 2012;5:228-232.
738. Gibson P, Tong Y, Robinson G, et al. Subtypes of medulloblastoma have distinct developmental origins. *Nature*. 2010;468:1095-1099.
739. Teo WY, Shen J, Su JM, et al. Implications of tumor location on subtypes of medulloblastoma. *Pediatr Blood Cancer*. 2013;60:1408-1410.
740. Perreault S, Ramaswamy V, Achrol AS, et al. MRI surrogates for molecular subgroups of medulloblastoma. *AJNR Am J Neuroradiol*. 2014;35:1263-1269.
741. Mehta RI, Cutler AR, Lasky JL 3rd, et al. "Primary" leptomeningeal medulloblastoma. *Hum Pathol*. 2009;40:1661-1665.
742. Giangaspero F, Perilongo G, Fondelli MP, et al. Medulloblastoma with extensive nodularity: a variant with favorable prognosis. *J Neurosurg*. 1999;91:971-977.
743. Agrawal D, Singhal A, Hendson G, Durity FA. Gyriform differentiation in medulloblastoma—a radiological predictor of histology. *Pediatr Neurosurg*. 2007;43:142-145.
744. Smith MJ, Beetz C, Williams SG, et al. Germline mutations in SUFU cause Gorlin syndrome-associated childhood medulloblastoma and redefine the risk associated with PTCH1 mutations. *J Clin Oncol*. 2014;32:4155-4161.
745. Ciara E, Piekutowska-Abramczuk D, Popowska E, et al. Heterozygous germ-line mutations in the NBN gene predispose to medulloblastoma in pediatric patients. *Acta Neuropathol*. 2010;119:325-334.
746. Taylor MD, Northcott PA, Korshunov A, et al. Molecular subgroups of medulloblastoma: the current consensus. *Acta Neuropathol*. 2012;123:465-472.
747. Northcott PA, Jones DT, Kool M, et al. Medulloblastomics: the end of the beginning. *Nat Rev Cancer*. 2012;12:818-834.
748. Batora N, Sturm D, Jones DT, et al. Transitioning from genotypes to epigenotypes: why the time has come for medulloblastoma epigenomics. *Neuroscience*. 2014;264:171-185.
749. Ellison DW, Dalton J, Kocak M, et al. Medulloblastoma: clinicopathological correlates of SHH, WNT, and non-SHH/WNT molecular subgroups. *Acta Neuropathol*. 2011;121:381-396.
750. Tabori U, Baskin B, Shago M, et al. Universal poor survival in children with medulloblastoma harboring somatic TP53 mutations. *J Clin Oncol*. 2010;28:1345-1350.
751. Rausch T, Jones DT, Zapatka M, et al. Genome sequencing of pediatric medulloblastoma links catastrophic DNA rearrangements with TP53 mutations. *Cell*. 2012;148:59-71.
752. Zhukova N, Ramaswamy V, Remke M, et al. Subgroup-specific prognostic implications of TP53 mutation in medulloblastoma. *J Clin Oncol*. 2013;31:2927-2935.
753. Kool M, Jones DT, Jager N, et al. Genome sequencing of SHH medulloblastoma predicts genotype-related response to

smoothened inhibition. *Cancer Cell*. 2014;25:393-405.
754. Katsetos CD, Liu HM, Zacks SI. Immunohistochemical and ultrastructural observations on Homer Wright (neuroblastic) rosettes and the "pale islands" of human cerebellar medulloblastomas. *Hum Pathol*. 1988;19:1219-1227.
755. Katsetos CD, Herman MM, Frankfurter A, et al. Cerebellar desmoplastic medulloblastomas. A further immunohistochemical characterization of the reticulin-free pale islands. *Arch Pathol Lab Med*. 1989;113:1019-1029.
756. Eberhart CG, Kaufman WE, Tihan T, Burger PC. Apoptosis, neuronal maturation, and neurotrophin expression within medulloblastoma nodules. *J Neuropathol Exp Neurol*. 2001;60:462-469.
757. Janss AJ, Yachnis AT, Silber JH, et al. Glial differentiation predicts poor clinical outcome in primitive neuroectodermal brain tumors. *Ann Neurol*. 1996;39:481-489.
758. Kramm CM, Korf HW, Czerwionka M, et al. Photoreceptor differentiation in cerebellar medulloblastoma: evidence for a functional photopigment and authentic S-antigen (arrestin). *Acta Neuropathol (Berl)*. 1991;81:296-302.
759. Jaffey PB, To GT, Xu HJ, et al. Retinoblastoma-like phenotype expressed in medulloblastomas. *J Neuropathol Exp Neurol*. 1995;54:664-672.
760. Biggs PJ, Powers JM. Neuroblastic medulloblastoma with abundant cytoplasmic actin filaments. *Arch Pathol Lab Med*. 1984;108:326-329.
761. Czerwionka M, Korf HW, Hoffmann O, et al. Differentiation in medulloblastomas: correlation between the immunocytochemical demonstration of photoreceptor markers (S-antigen, rod-opsin) and the survival rate in 66 patients. *Acta Neuropathol*. 1989;78:629-636.
762. Maraziotis T, Perentes E, Karamitopoulou E, et al. Neuron-associated class III beta-tubulin isotype, retinal S-antigen, synaptophysin, and glial fibrillary acidic protein in human medulloblastomas: a clinicopathological analysis of 36 cases. *Acta Neuropathol*. 1992;84:355-363.
763. McManamy CS, Pears J, Weston CL, et al. Nodule formation and desmoplasia in medulloblastomas-defining the nodular/desmoplastic variant and its biological behavior. *Brain Pathol*. 2007;17:151-164.
764. de Chadarevian JP, Montes JL, O'Gorman AM, Freeman CR. Maturation of cerebellar neuroblastoma into ganglioneuroma with melanosis. A histologic, immunocytochemical, and ultrastructural study. *Cancer*. 1987;59:69-76.
765. Geyer JR, Schofield D, Berger M, Milstein J. Differentiation of a primitive neuroectodermal tumor into a benign ganglioglioma. *J Neurooncol*. 1992;14:237-241.
766. Cai DX, Mafra M, Schmidt RE, et al. Medulloblastomas with extensive posttherapy neuronal maturation. Report of two cases. *J Neurosurg*. 2000;93:330-334.
767. Siegfried A, Bertozzi AI, Bourdeaut F, et al. Clinical, pathological, and molecular data on desmoplastic/nodular medulloblastoma: case studies and a review of the literature. *Clin Neuropathol*. 2016;35(3):106-113.
768. Yeh-Nayre LA, Malicki DM, Vinocur DN, Crawford JR. Medulloblastoma with excessive nodularity: radiographic features and pathologic correlate. *Case Rep Radiol*. 2012;2012:310359.
769. Giangaspero F, Rigobello L, Badiali M, et al. Large-cell medulloblastomas. A distinct variant with highly aggressive behavior. *Am J Surg Pathol*. 1992;16:687-693.
770. Brown HG, Kepner JL, Perlman EJ, et al. "Large cell/anaplastic" medulloblastomas: a Pediatric Oncology Group Study. *J Neuropathol Exp Neurol*. 2000;59:857-865.
771. Massimino M, Antonelli M, Gandola L, et al. Histological variants of medulloblastoma are the most powerful clinical prognostic indicators. *Pediatr Blood Cancer*. 2013;60:210-216.
772. Helton KJ, Fouladi M, Boop FA, et al. Medullomyoblastoma: a radiographic and clinicopathologic analysis of six cases and review of the literature. *Cancer*. 2004;101:1445-1454.
773. Polydorides AD, Perry A, Edgar MA. Large cell medulloblastoma with myogenic and melanotic differentiation: a case report with molecular analysis. *J Neurooncol*. 2008;88:193-197.
774. Leonard JR, Cai DX, Rivet DJ, et al. Large cell/anaplastic medulloblastomas and medullomyoblastomas: clinicopathological and genetic features. *J Neurosurg*. 2001;95:82-88.
775. Kaur K, Kakkar A, Kumar A, et al. Integrating molecular subclassification of medulloblastomas into routine clinical practice: a simplified approach. *Brain Pathol*. 2016;26(3):334-343.
776. Ryan SL, Schwalbe EC, Cole M, et al. MYC family amplification and clinical risk-factors interact to predict an extremely poor prognosis in childhood medulloblastoma. *Acta Neuropathol*. 2012;123:501-513.
777. Dolman CL. Melanotic medulloblastoma. A case report with immunohistochemical and ultrastructural examination. *Acta Neuropathol*. 1988;76:528-531.
778. Jimenez CL, Carpenter BF, Robb IA. Melanotic cerebellar tumor. *Ultrastruct Pathol*. 1987;11:751-759.
779. Mahapatra AK, Sinha AK, Sharma MC. Medullomyoblastoma. A rare cerebellar tumour in children. *Childs Nerv Syst*. 1998;14:312-316.
780. Anwer UE, Smith TW, DeGirolami U, Wilkinson HA. Medulloblastoma with cartilaginous differentiation. *Arch Pathol Lab Med*. 1989;113:84-88.
781. Ismail A, Lamont JM, Tweddle AD, et al. A 7-year-old boy with midline cerebellar mass. *Brain Pathol*. 2005;15:261-262, 7.
782. Dufour C, Beaugrand A, Pizer B, et al. Metastatic medulloblastoma in childhood: Chang's classification revisited. *Int J Surg Oncol*. 2012;2012:245385.
783. Korshunov A, Sturm D, Ryzhova M, et al. Embryonal tumor with abundant neuropil and true rosettes (ETANTR), ependymoblastoma, and medulloepithelioma share molecular similarity and comprise a single clinicopathological entity. *Acta Neuropathol*. 2014;128:279-289.
784. Spence T, Sin-Chan P, Picard D, et al. CNS-PNETs with C19MC amplification and/or LIN28 expression comprise a distinct histogenetic diagnostic and therapeutic entity. *Acta Neuropathol*. 2014;128:291-303.
785. Judkins AR, Ellison DW. Ependymoblastoma: dear, damned, distracting diagnosis, farewell!*. *Brain Pathol*. 2010;20:133-139.
786. Korshunov A, Ryzhova M, Jones DT, et al. LIN28A immunoreactivity is a potent diagnostic marker of embryonal tumor with multilayered rosettes (ETMR). *Acta Neuropathol*. 2012;124:875-881.
787. Molloy PT, Yachnis AT, Rorke LB, et al. Central nervous system medulloepithelioma: a series of eight cases including two arising in the pons. *J Neurosurg*. 1996;84:430-436.
788. Chavez M, Mafee MF, Castillo B, et al. Medulloepithelioma of the optic nerve. *J Pediatr Ophthalmol Strabismus*. 2004;41:48-52.
789. Pang LM, Roebuck DJ, Ng HK, Chan YL. Sellar and suprasellar medulloepithelioma. *Pediatr Radiol*. 2001;31:594-596.
790. DiCarlo EF, Woodruff JM, Bansal M, Erlandson RA. The purely epithelioid malignant peripheral nerve sheath tumor. *Am J Surg Pathol*. 1986;10:478-490.
791. Donner LR, Teshima I. Peripheral medulloepithelioma: an immunohistochemical, ultrastructural, and cytogenetic study of a rare, chemotherapy-sensitive, pediatric tumor. *Am J Surg Pathol*. 2003;27:1008-1012.
792. Khoddami M, Becker LE. Immunohistochemistry of medulloepithelioma and neural tube. *Pediatr Pathol Lab Med*. 1997;17:913-925.
793. Caccamo DV, Herman MM, Rubinstein LJ. An immunohistochemical study of the primitive and maturing elements of human cerebral medulloepitheliomas. *Acta Neuropathol*. 1989;79:248-254.
794. Deck JH. Cerebral medulloepithelioma with maturation into ependymal cells and ganglion cells. *J Neuropathol Exp Neurol*. 1969;28:442-454.
795. Scheithauer BW, Rubinstein LJ. Cerebral medulloepithelioma. Report of a case with multiple divergent neuroepithelial differentiation. *Childs Brain*. 1979;5:62-71.
796. Sharma MC, Mahapatra AK, Gaikwad S, et al. Pigmented medulloepithelioma: report of a case and review of the literature. *Childs Nerv Syst*. 1998;14:74-78.
797. Auer RN, Becker LE. Cerebral medulloepithelioma with bone, cartilage, and striated muscle. Light microscopic and immunohistochemical study. *J Neuropathol Exp Neurol*. 1983;42:256-267.
798. Troost D, Jansen GH, Dingemans KP. Cerebral medulloepithelioma—electron microscopy and immunohistochemistry. *Acta Neuropathol*. 1990;80:103-107.
799. Muller K, Zwiener I, Welker H, et al. Curative treatment for central nervous system medulloepithelioma despite residual disease after resection. Report of two cases treated according to the GPHO Protocol HIT 2000 and review of the literature. *Strahlenther Onkol*. 2011;187:757-762.
800. Bennett JP Jr, Rubinstein LJ. The biological behavior of primary cerebral neuroblastoma: a reappraisal of the clinical course in a series of 70 cases. *Ann Neurol*. 1984;16:21-27.
801. Horten BC, Rubinstein LJ. Primary cerebral neuroblastoma. A clinicopathological study of 35 cases. *Brain*. 1976;99:735-756.
802. Sibilla L, Martelli A, Farina L, et al. Ganglioneuroblastoma of the spinal cord. *AJNR Am J Neuroradiol*. 1995;16:875-877.
803. Kepes JJ, Belton K, Roessmann U, Ketcherside WJ. Primitive neuroectodermal tumors of the cauda equina in adults with no detectable primary intracranial neoplasm—three case studies. *Clin Neuropathol*. 1985;4:1-11.
804. Dehner LP, Abenoza P, Sibley RK. Primary cerebral neuroectodermal tumors: neuroblastoma, differentiated neuroblastoma, and composite neuroectodermal tumor. *Ultrastruct Pathol*. 1988;12:479-494.
805. Nishihara H, Ozaki Y, Ito T, et al. A case of cerebral ganglioneuronal tumor in the parietal lobe of an adult. *Brain Tumor Pathol*. 2008;25:45-49.
806. Takahashi M, Ishihara T, Yokota T, et al. A case of cerebral composite ganglioneuroblastoma: an immunohistochemical and ultrastructural study. *Acta Neuropathol*. 1990;80:98-102.

807. Sturm D, Orr BA, Toprak UH, et al. New brain tumor entities emerge from molecular classification of CNS-PNETs. *Cell*. 2016;164:1060-1072.
808. Torres LF, Grant N, Harding BN, Scaravilli F. Intracerebral neuroblastoma. Report of a case with neuronal maturation and long survival. *Acta Neuropathol*. 1985;68:110-114.
809. Russell DS, Rubinstein LJ. *Pathology of Tumours of the Nervous System*. Baltimore: Williams & Wilkins; 1989.
810. Schiffer D, Cravioto H, Giordana MT, et al. Is polar spongioblastoma a tumor entity? *J Neurosurg*. 1993;78:587-591.
811. Burger PC, Yu IT, Tihan T, et al. Atypical teratoid/rhabdoid tumor of the central nervous system: a highly malignant tumor of infancy and childhood frequently mistaken for medulloblastoma: a Pediatric Oncology Group study. *Am J Surg Pathol*. 1998;22:1083-1092.
812. Rorke LB, Packer RJ, Biegel JA. Central nervous system atypical teratoid/rhabdoid tumors of infancy and childhood: definition of an entity. *J Neurosurg*. 1996;85:56-65.
813. Schneiderhan TM, Beseoglu K, Bergmann M, et al. Sellar atypical teratoid/rhabdoid tumours in adults. *Neuropathol Appl Neurobiol*. 2011;37:326-329.
814. Raisanen J, Biegel JA, Hatanpaa KJ, et al. Chromosome 22q deletions in atypical teratoid/rhabdoid tumors in adults. *Brain Pathol*. 2005;15:23-28.
815. Wang X, Liu X, Lin Z, et al. Atypical teratoid/rhabdoid tumor (AT/RT) arising from the acoustic nerve in a young adult: a case report and a review of literature. *Medicine (Baltimore)*. 2015;94:e439.
816. Nadi M, Ahmad T, Huang A, et al. Atypical teratoid rhabdoid tumor diagnosis after partial resection of dysembryoplastic neuroepithelial tumor: case report and review of the literature. *Pediatr Neurosurg*. 2016;51(4):191-198.
817. Lau CS, Mahendraraj K, Chamberlain RS. Atypical teratoid rhabdoid tumors: a population-based clinical outcomes study involving 174 patients from the Surveillance, Epidemiology, and End Results database (1973–2010). *Cancer Manag Res*. 2015;7:301-309.
818. Fruhwald MC, Biegel JA, Bourdeaut F, et al. Atypical teratoid/rhabdoid tumors-current concepts, advances in biology, and potential future therapies. *Neuro Oncol*. 2016;18(6):764-778.
819. Sredni ST, Tomita T. Rhabdoid tumor predisposition syndrome. *Pediatr Dev Pathol*. 2015;18:49-58.
820. Pomeroy SL, Tamayo P, Gaasenbeek M, et al. Prediction of central nervous system embryonal tumour outcome based on gene expression. *Nature*. 2002;415:436-442.
821. Judkins AR. Immunohistochemistry of INI1 expression: a new tool for old challenges in CNS and soft tissue pathology. *Adv Anat Pathol*. 2007;14:335-339.
822. Hasselblatt M, Gesk S, Oyen F, et al. Nonsense mutation and inactivation of SMARCA4 (BRG1) in an atypical teratoid/rhabdoid tumor showing retained SMARCB1 (INI1) expression. *Am J Surg Pathol*. 2011;35:933-935.
823. Hasselblatt M, Oyen F, Gesk S, et al. Cribriform neuroepithelial tumor (CRINET): a nonrhabdoid ventricular tumor with INI1 loss and relatively favorable prognosis. *J Neuropathol Exp Neurol*. 2009;68:1249-1255.
824. Torchia J, Picard D, Lafay-Cousin L, et al. Molecular subgroups of atypical teratoid rhabdoid tumours in children: an integrated genomic and clinicopathological analysis. *Lancet Oncol*. 2015;16(5):569-582.
825. Behdad A, Perry A. Central nervous system primitive neuroectodermal tumors: a clinicopathologic and genetic study of 33 cases. *Brain Pathol*. 2010;20:441-450.
826. Yachnis AT, Rorke LB, Biegel JA, et al. Desmoplastic primitive neuroectodermal tumor with divergent differentiation. Broadening the spectrum of desmoplastic infantile neuroepithelial tumors. *Am J Surg Pathol*. 1992;16:998-1006.
827. Kruse-Losler B, Gaertner C, Burger H, et al. Melanotic neuroectodermal tumor of infancy: systematic review of the literature and presentation of a case. *Oral Surg Oral Med Oral Pathol Oral Radiol Endod*. 2006;102:204-216.
828. Gerald WL, Ladanyi M, de Alava E, et al. Clinical, pathologic, and molecular spectrum of tumors associated with t(11;22)(p13;q12): desmoplastic small round-cell tumor and its variants. *J Clin Oncol*. 1998;16:3028-3036.
829. Dedeurwaerdere F, Giannini C, Sciot R, et al. Primary peripheral PNET/Ewing's sarcoma of the dura: a clinicopathologic entity distinct from central PNET. *Mod Pathol*. 2002;15:673-678.
830. Jia L, Li G, You C, et al. Intramedullary Ewing's sarcoma of the spinal cord associated with hydrocephalus. *Neurol India*. 2009;57:828-829.
831. Han SJ, Clark AJ, Ivan ME, et al. Pathology of pineal parenchymal tumors. *Neurosurg Clin N Am*. 2011;22:335-340, vii.
832. de Kock L, Sabbaghian N, Druker H, et al. Germ-line and somatic DICER1 mutations in pineoblastoma. *Acta Neuropathol*. 2014;128:583-595.
833. Gadish T, Tulchinsky H, Deutsch AA, Rabau M. Pinealoblastoma in a patient with familial adenomatous polyposis: variant of Turcot syndrome type 2? Report of a case and review of the literature. *Dis Colon Rectum*. 2005;48:2343-2346.
834. Ikeda J, Sawamura Y, Meir EV. Pineoblastoma presenting in familial adenomatous polyposis (FAP): random association, FAP variant or Turcot syndrome? *Br J Neurosurg*. 1998;576-578.
835. Sobel RA, Trice JE, Nielsen SL, Ellis WG. Pineoblastoma with ganglionic and glial differentiation: report of two cases. *Acta Neuropathol*. 1981;55:243-246.
836. Min KW, Scheithauer BW, Bauserman SC. Pineal parenchymal tumors: an ultrastructural study with prognostic implications. *Ultrastruct Pathol*. 1994;18:69-85.
837. Fevre-Montange M, Champier J, Szathmari A, et al. Microarray analysis reveals differential gene expression patterns in tumors of the pineal region. *J Neuropathol Exp Neurol*. 2006;65:675-684.
838. Mena H, Rushing EJ, Ribas JL, et al. Tumors of pineal parenchymal cells: a correlation of histological features, including nucleolar organizer regions, with survival in 35 cases. *Hum Pathol*. 1995;26:20-30.
839. Amoaku WM, Willshaw HE, Parkes SE, et al. Trilateral retinoblastoma. A report of five patients. *Cancer*. 1996;78:858-863.
840. Plowman PN, Pizer B, Kingston JE. Pineal parenchymal tumours: II. On the aggressive behaviour of pineoblastoma in patients with an inherited mutation of the RB1 gene. *Clin Oncol (R Coll Radiol)*. 2004;16:244-247.
841. Ahuja A, Sharma MC, Suri V, et al. Pineal anlage tumour—a rare entity with divergent histology. *J Clin Neurosci*. 2011;18:811-813.
842. Olaya JE, Raghavan R, Totaro L, Zouros A. Pineal anlage tumor in a 5-month-old boy. *J Neurosurg Pediatr*. 2010;5:636-640.
843. Min KW, Seo IS, Song J. Postnatal evolution of the human pineal gland. An immunohistochemical study. *Lab Invest*. 1987;57:724-728.
844. Raisanen J, Vogel H, Horoupian DS. Primitive pineal tumor with retinoblastomatous and retinal/ciliary epithelial differentiation: an immunohistochemical study. *J Neurooncol*. 1990;9:165-170.
845. Gudinaviciene I, Pranys D, Zheng P, Kros JM. A 10-month-old boy with a large pineal tumor. *Brain Pathol*. 2005;15:263-264, 7.
846. Jouvet A, Saint-Pierre G, Fauchon F, et al. Pineal parenchymal tumors: a correlation of histological features with prognosis in 66 cases. *Brain Pathol*. 2000;10:49-60.
847. Fevre-Montange M, Szathmari A, Champier J, et al. Pineocytoma and pineal parenchymal tumors of intermediate differentiation presenting cytologic pleomorphism: a multicenter study. *Brain Pathol*. 2008;18:354-359.
848. Kuchelmeister K, von Borcke IM, Klein H, et al. Pleomorphic pineocytoma with extensive neuronal differentiation: report of two cases. *Acta Neuropathol*. 1994;88:448-453.
849. Jouvet A, Fevre-Montange M, Besancon R, et al. Structural and ultrastructural characteristics of human pineal gland, and pineal parenchymal tumors. *Acta Neuropathol*. 1994;88:334-348.
850. Illum N, Korf HW, Julian K, et al. Concurrent uveoretinitis and pineocytoma in a child suggests a causal relationship. *Br J Ophthalmol*. 1992;76:574-576.
851. Schild SE, Scheithauer BW, Schomberg PJ, et al. Pineal parenchymal tumors. Clinical, pathologic, and therapeutic aspects. *Cancer*. 1993;72:870-880.
852. Fevre Montange M, Vasiljevic A, Bergemer Fouquet AM, et al. Histopathologic and ultrastructural features and claudin expression in papillary tumors of the pineal region: a multicenter analysis. *Am J Surg Pathol*. 2012;36:916-928.
853. Heim S, Sill M, Jones DT, et al. Papillary tumor of the pineal region: a distinct molecular entity. *Brain Pathol*. 2016;26(2):199-205.
854. Fevre-Montange M, Hasselblatt M, Figarella-Branger D, et al. Prognosis and histopathologic features in papillary tumors of the pineal region: a retrospective multicenter study of 31 cases. *J Neuropathol Exp Neurol*. 2006;65:1004-1011.
855. Hasselblatt M, Blumcke I, Jeibmann A, et al. Immunohistochemical profile and chromosomal imbalances in papillary tumours of the pineal region. *Neuropathol Appl Neurobiol*. 2006;32:278-283.
856. Heim S, Coras R, Ganslandt O, et al. Papillary tumor of the pineal region with anaplastic small cell component. *J Neurooncol*. 2013;115:127-130.
857. Mobley B, Kalani MY, Harsh GRt, et al. Papillary tumor of the spinal cord: report of 2 cases. *Am J Surg Pathol*. 2009;33:1191-1197.
858. Sharma MC, Jain D, Sarkar C, et al. Papillary tumor of the pineal region—a recently described entity: a report of three cases and review of the literature. *Clin Neuropathol*. 2009;28:295-302.
859. Wiemels J, Wrensch M, Claus EB. Epidemiology and etiology of meningioma. *J Neurooncol*. 2010;99:307-314.
860. Ravindranath K, Vasudevan MC, Pande A, Symss N. Management of pediatric intracranial meningiomas: an analysis of 31 cases and review of literature. *Childs Nerv Syst*. 2013;29:573-582.
861. Thuijs NB, Uitdehaag BM, Van Ouwerkerk WJ, et al. Pediatric meningiomas in The Netherlands 1974-2010: a descriptive

epidemiological case study. *Childs Nerv Syst*. 2012;28:1009-1015.
862. Perry A, Giannini C, Raghavan R, et al. Aggressive phenotypic and genotypic features in pediatric and NF2-associated meningiomas: a clinicopathologic study of 53 cases. *J Neuropathol Exp Neurol*. 2001;60:994-1003.
863. Lanotte M, Benech F, Panciani PP, et al. Systemic cancer metastasis in a meningioma: report of two cases and review of the literature. *Clin Neurol Neurosurg*. 2009;111:87-93.
864. Smith MJ. Germline and somatic mutations in meningiomas. *Cancer Genet*. 2015;208:107-114.
865. Hadfield KD, Smith MJ, Trump D, et al. SMARCB1 mutations are not a common cause of multiple meningiomas. *J Med Genet*. 2010;47:567-568.
866. Ron E, Modan B, Boice JD Jr, et al. Tumors of the brain and nervous system after radiotherapy in childhood. *N Engl J Med*. 1988;319:1033-1039.
867. Yonehara S, Brenner AV, Kishikawa M, et al. Clinical and epidemiologic characteristics of first primary tumors of the central nervous system and related organs among atomic bomb survivors in Hiroshima and Nagasaki, 1958–1995. *Cancer*. 2004;101:1644-1654.
868. Claus EB, Calvocoressi L, Bondy ML, et al. Dental x-rays and risk of meningioma. *Cancer*. 2012;118:4530-4537.
869. Preston DL, Ron E, Yonehara S, et al. Tumors of the nervous system and pituitary gland associated with atomic bomb radiation exposure. *J Natl Cancer Inst*. 2002;94:1555-1563.
870. Sadetzki S, Flint-Richter P, Ben-Tal T, Nass D. Radiation-induced meningioma: a descriptive study of 253 cases. *J Neurosurg*. 2002;97:1078-1082.
871. Phillips LE, Koepsell TD, van Belle G, et al. History of head trauma and risk of intracranial meningioma: population-based case-control study. *Neurology*. 2002;58:1849-1852.
872. Barnett GH, Chou SM, Bay JW. Posttraumatic intracranial meningioma: a case report and review of the literature. *Neurosurgery*. 1986;18:75-78.
873. Saleh J, Silberstein HJ, Salner AL, Uphoff DF. Meningioma: the role of a foreign body and irradiation in tumor formation. *Neurosurgery*. 1991;29:113-118, discussion 118-119.
874. Matyja E, Kuchna I, Kroh H, et al. Meningiomas and gliomas in juxtaposition: casual or causal coexistence? Report of two cases. *Am J Surg Pathol*. 1995;19:37-41.
875. Fox MD, Billings SD, Gleason BC, et al. Cutaneous meningioma: a potential diagnostic pitfall in p63 positive cutaneous neoplasms. *J Cutan Pathol*. 2013;40(10):891-895.
876. Perry A. Ectopic meningioma/meningothelial hamartoma. In: Fletcher CDM, Bridge JA, Hogendoorn PCW, Mertens F, eds. *WHO classification of Tumours of Soft Tissue and Bone*. 4th ed. Lyon, France: IARC; 2013:182-183.
877. Lang FF, Macdonald OK, Fuller GN, DeMonte F. Primary extradural meningiomas: a report on nine cases and review of the literature from the era of computerized tomography scanning. *J Neurosurg*. 2000;93:940-950.
878. Mogi A, Hirato J, Kosaka T, et al. Primary mediastinal atypical meningioma: report of a case and literature review. *World J Surg Oncol*. 2012;10:17.
879. Weber C, Pautex S, Zulian GB, et al. Primary pulmonary malignant meningioma with lymph node and liver metastasis in a centenary woman, an autopsy case. *Virchows Arch*. 2013;462(4):481-485.
880. Masago K, Hosada W, Sasaki E, et al. Is primary pulmonary meningioma a giant form of a meningothelial-like nodule? A case report and review of the literature. *Case Rep Oncol*. 2012;5:471-478.
881. Coons SW, Johnson PC. Brachial plexus meningioma, report of a case with immunohistochemical and ultrastructural examination. *Acta Neuropathol*. 1989;77:445-448.
882. Mizutani E, Tsuta K, Maeshima AM, et al. Minute pulmonary meningothelial-like nodules: clinicopathologic analysis of 121 patients. *Hum Pathol*. 2009;40:678-682.
883. Perry A, Scheithauer BW, Stafford SL, et al. "Malignancy" in meningiomas: a clinicopathologic study of 116 patients, with grading implications. *Cancer*. 1999;85:2046-2056.
884. Lin BJ, Chou KN, Kao HW, et al. Correlation between magnetic resonance imaging grading and pathological grading in meningioma. *J Neurosurg*. 2014;1-8.
885. Jaaskelainen J, Haltia M, Servo A. Atypical and anaplastic meningiomas: radiology, surgery, radiotherapy, and outcome. *Surg Neurol*. 1986;25:233-242.
886. Watanabe Y, Yamasaki F, Kajiwara Y, et al. Preoperative histological grading of meningiomas using apparent diffusion coefficient at 3T MRI. *Eur J Radiol*. 2013;82:658-663.
887. Tan LA, Boco T, Johnson AK, et al. Magnetic resonance imaging characteristics of typical and atypical/anaplastic meningiomas—case series and literature review. *Br J Neurosurg*. 2014;1-5.
888. Nestor SL, Perry A, Kurtkaya O, et al. Melanocytic colonization of a meningothelial meningioma: histopathological and ultrastructural findings with immunohistochemical and genetic correlation: case report. *Neurosurgery*. 2003;53:211-214, discussion 214-215.
889. Couce ME, Perry A, Webb P, et al. Fibrous meningioma with tyrosine-rich crystals. *Ultrastruct Pathol*. 1999;23:341-345.
890. Michaud J, Gagne F. Microcystic meningioma. Clinicopathologic report of eight cases. *Arch Pathol Lab Med*. 1983;107:75-80.
891. Paek SH, Kim SH, Chang KH, et al. Microcystic meningiomas: radiological characteristics of 16 cases. *Acta Neurochir (Wien)*. 2005;147:965-972, discussion 972.
892. Probst-Cousin S, Villagran-Lillo R, Lahl R, et al. Secretory meningioma: clinical, histologic, and immunohistochemical findings in 31 cases. *Cancer*. 1997;79:2003-2015.
893. Louis DN, Hamilton AJ, Sobel RA, Ojemann RG. Pseudopsammomatous meningioma with elevated serum carcinoembryonic antigen: a true secretory meningioma. Case report. *J Neurosurg*. 1991;74:129-132.
894. Reuss DE, Piro RM, Jones DT, et al. Secretory meningiomas are defined by combined KLF4 K409Q and TRAF7 mutations. *Acta Neuropathol*. 2013;125:351-358.
895. Lal A, Dahiya S, Gonzales M, et al. IgG4 overexpression is rare in meningiomas with a prominent inflammatory component: a review of 16 cases. *Brain Pathol*. 2014;24:352-359.
896. Zhu HD, Xie Q, Gong Y, et al. Lymphoplasmacyte-rich meningioma: our experience with 19 cases and a systematic literature review. *Int J Clin Exp Med*. 2013;6:504-515.
897. Kepes JJ, Chen WY, Connors MH, Vogel FS. "Chordoid" meningeal tumors in young individuals with peritumoral lymphoplasmacellular infiltrates causing systemic manifestations of the Castleman syndrome. A report of seven cases. *Cancer*. 1988;62:391-406.
898. Arima T, Natsume A, Hatano H, et al. Intraventricular chordoid meningioma presenting with Castleman disease due to overproduction of interleukin-6. Case report. *J Neurosurg*. 2005;102:733-737.
899. Couce ME, Aker FV, Scheithauer BW. Chordoid meningioma: a clinicopathologic study of 42 cases. *Am J Surg Pathol*. 2000;24:899-905.
900. Rowsell C, Sirbovan J, Rosenblum MK, Perez-Ordonez B. Primary chordoid meningioma of lung. *Virchows Arch*. 2005;446:333-337.
901. Colnat-Coulbois S, Kremer S, Weinbreck N, et al. Lipomatous meningioma: report of 2 cases and review of the literature. *Surg Neurol*. 2008;69:398-402.
902. Lattes R, Bigotti G. Lipoblastic meningioma: "vacuolated meningioma". *Hum Pathol*. 1991;22:164-171.
903. Roncaroli F, Scheithauer BW, Laeng RH, et al. Lipomatous meningioma: a clinicopathologic study of 18 cases with special reference to the issue of metaplasia. *Am J Surg Pathol*. 2001;25:769-775.
904. Jacques TS, Valentine A, Bradford R, McLaughlin JE. December 2003: a 70-year-old woman with a recurrent meningeal mass. Recurrent meningioma with rhabdomyosarcomatous differentiation. *Brain Pathol*. 2004;14:229-230.
905. Sugita Y, Shigemori M, Harada H, et al. Primary meningeal sarcomas with leiomyoblastic differentiation: a proposal for a new subtype of primary meningeal sarcomas. *Am J Surg Pathol*. 2000;24:1273-1278.
906. Liverman C, Mafra M, Chuang SS, et al. A clinicopathologic study of 11 rosette-forming meningiomas: a rare and potentially confusing pattern. *Acta Neuropathol*. 2015;130:311-313.
907. Kepes J. *Meningiomas: Biology, Pathology, and Differential Diagnosis*. New York: Masson; 1982.
908. Alexander RT, McLendon RE, Cummings TJ. Meningioma with eosinophilic granular inclusions. *Clin Neuropathol*. 2004;23:292-297.
909. Abedalthagafi MS, Merrill PH, Bi WL, et al. Angiomatous meningiomas have a distinct genetic profile with multiple chromosomal polysomies including polysomy of chromosome 5. *Oncotarget*. 2014;5:10596-10606.
910. Hasselblatt M, Nolte KW, Paulus W. Angiomatous meningioma: a clinicopathologic study of 38 cases. *Am J Surg Pathol*. 2004;28:390-393.
911. Im SH, Chung CK, Cho BK, et al. Sclerosing meningioma: clinicopathological study of four cases. *J Neurooncol*. 2004;68:169-175.
912. Kim NR, Im SH, Chung CK, et al. Sclerosing meningioma: immunohistochemical analysis of five cases. *Neuropathol Appl Neurobiol*. 2004;30:126-135.
913. Davidson GS, Hope JK. Meningeal tumors of childhood. *Cancer*. 1989;63:1205-1210.
914. Giangaspero F, Guiducci A, Lenz FA, et al. Meningioma with meningioangiomatosis: a condition mimicking invasive meningiomas in children and young adults: report of two cases and review of the literature. *Am J Surg Pathol*. 1999;23:872-875.
915. Vaubel RA, Chen SG, Raleigh DR, et al. Meningiomas with rhabdoid features lacking other histologic features of malignancy: a study of 44 cases and review of the literature. *J Neuropathol Exp Neurol*. 2016;75:44-52.

916. Zorludemir S, Scheithauer BW, Hirose T, et al. Clear cell meningioma. A clinicopathologic study of a potentially aggressive variant of meningioma. *Am J Surg Pathol*. 1995;19:493-505.
917. Wang XQ, Huang MZ, Zhang H, et al. Clear cell meningioma: clinical features, CT, and MR imaging findings in 23 patients. *J Comput Assist Tomogr*. 2014;38(2):200-208.
918. Carlotti CG Jr, Neder L, Colli BO, et al. Clear cell meningioma of the fourth ventricle. *Am J Surg Pathol*. 2003;27:131-135.
919. Smith MJ, O'Sullivan J, Bhaskar SS, et al. Loss-of-function mutations in SMARCE1 cause an inherited disorder of multiple spinal meningiomas. *Nat Genet*. 2013;45:295-298.
920. Gerkes EH, Fock JM, den Dunnen WF, et al. A heritable form of SMARCE1-related meningiomas with important implications for follow-up and family screening. *Neurogenetics*. 2016;17:83-89.
921. Teo JG, Goh KY, Rosenblum MK, et al. Intraparenchymal clear cell meningioma of the brainstem in a 2-year-old child. Case report and literature review. *Pediatr Neurosurg*. 1998;28:27-30.
922. Perry A, Scheithauer BW, Stafford SL, et al. Rhabdoid" meningioma: an aggressive variant. *Am J Surg Pathol*. 1998;22:1482-1490.
923. Wu YT, Ho JT, Lin YJ, Lin JW. Rhabdoid papillary meningioma: a clinicopathologic case series study. *Neuropathology*. 2011;31:599-605.
924. Roncaroli F, Riccioni L, Cerati M, et al. Oncocytic meningioma. *Am J Surg Pathol*. 1997;21:375-382.
925. Gallina P, Buccoliero AM, Mariotti F, et al. Oncocytic meningiomas: cases with benign histopathological features and a favorable clinical course. *J Neurosurg*. 2006;105:736-738.
926. Ludwin SK, Rubinstein LJ, Russell DS. Papillary meningioma: a malignant variant of meningioma. *Cancer*. 1975;36:1363-1373.
927. Pasquier B, Gasnier F, Pasquier D, et al. Papillary meningioma. Clinicopathologic study of seven cases and review of the literature. *Cancer*. 1986;58:299-305.
928. Rajaram V, Brat DJ, Perry A. Anaplastic meningioma versus meningeal hemangiopericytoma: immunohistochemical and genetic markers. *Hum Pathol*. 2004;35:1413-1418.
929. Winek RR, Scheithauer BW, Wick MR. Meningioma, meningeal hemangiopericytoma (angioblastic meningioma), peripheral hemangiopericytoma, and acoustic schwannoma. A comparative immunohistochemical study. *Am J Surg Pathol*. 1989;13:251-261.
930. Agaimy A, Buslei R, Coras R, et al. Comparative study of soft tissue perineurioma and meningioma using a five-marker immunohistochemical panel. *Histopathology*. 2014;65:60-70.
931. Hahn HP, Bundock EA, Hornick JL. Immunohistochemical staining for claudin-1 can help distinguish meningiomas from histologic mimics. *Am J Clin Pathol*. 2006;125:203-208.
932. Perry A, Cai DX, Scheithauer BW, et al. Merlin, DAL-1, and progesterone receptor expression in clinicopathologic subsets of meningioma: a correlative immunohistochemical study of 175 cases. *J Neuropathol Exp Neurol*. 2000;59:872-879.
933. Miettinen M, Paetau A. Mapping of the keratin polypeptides in meningiomas of different types: an immunohistochemical analysis of 463 cases. *Hum Pathol*. 2002;33:590-598.
934. Liu Y, Sturgis CD, Bunker M, et al. Expression of cytokeratin by malignant meningiomas: diagnostic pitfall of cytokeratin to separate malignant meningiomas from metastatic carcinoma. *Mod Pathol*. 2004;17:1129-1133.
935. Mittal S, Jain D, Roy S, Mehta VS. Correlation of p63 protein expression with histological grade of meningiomas: an immunohistochemical study. *Int J Surg Pathol*. 2012;20:349-354.
936. Budka H. Non-glial specificities of immunocytochemistry for the glial fibrillary acidic protein (GFAP). Triple expression of GFAP, vimentin and cytokeratins in papillary meningioma and metastasizing renal carcinoma. *Acta Neuropathol*. 1986;72:43-54.
937. Hojo H, Abe M. Rhabdoid papillary meningioma. *Am J Surg Pathol*. 2001;25:964-969.
938. Haberler C, Jarius C, Lang S, et al. Fibrous meningeal tumours with extensive non-calcifying collagenous whorls and glial fibrillary acidic protein expression: the whorling-sclerosing variant of meningioma. *Neuropathol Appl Neurobiol*. 2002;28:42-47.
939. Tsuchida T, Matsumoto M, Shirayama Y, et al. Immunohistochemical observation of foci of muscle actin-positive tumor cells in meningiomas. *Arch Pathol Lab Med*. 1996;120:267-269.
940. Sangoi AR, Dulai MS, Beck AH, et al. Distinguishing chordoid meningiomas from their histologic mimics: an immunohistochemical evaluation. *Am J Surg Pathol*. 2009;33:669-681.
941. Perry A, Fuller CE, Judkins AR, et al. INI1 expression is retained in composite rhabdoid tumors, including rhabdoid meningiomas. *Mod Pathol*. 2005;18:951-958.
942. Wellenreuther R, Kraus JA, Lenartz D, et al. Analysis of the neurofibromatosis 2 gene reveals molecular variants of meningioma. *Am J Pathol*. 1995;146:827-832.
943. Lekanne Deprez RH, Bianchi AB, Groen NA, et al. Frequent NF2 gene transcript mutations in sporadic meningiomas and vestibular schwannomas. *Am J Hum Genet*. 1994;54:1022-1029.
944. Brastianos PK, Horowitz PM, Santagata S, et al. Genomic sequencing of meningiomas identifies oncogenic SMO and AKT1 mutations. *Nat Genet*. 2013;45:285-289.
945. Clark VE, Erson-Omay EZ, Serin A, et al. Genomic analysis of non-NF2 meningiomas reveals mutations in TRAF7, KLF4, AKT1, and SMO. *Science*. 2013;339:1077-1080.
946. Sahm F, Bissel J, Koelsche C, et al. AKT1E17K mutations cluster with meningothelial and transitional meningiomas and can be detected by SFRP1 immunohistochemistry. *Acta Neuropathol*. 2013;126:757-762.
947. Mawrin C, Perry A. Pathological classification and molecular genetics of meningiomas. *J Neurooncol*. 2010;99:379-391.
948. Sahm F, Schrimpf D, Olar A, et al. TERT promoter mutations and risk of recurrence in meningioma. *J Natl Cancer Inst*. 2016;108.
949. Kallio M, Sankila R, Hakulinen T, Jaaskelainen J. Factors affecting operative and excess long-term mortality in 935 patients with intracranial meningioma. *Neurosurgery*. 1992;31:2-12.
950. Perry A, Stafford SL, Scheithauer BW, et al. Meningioma grading: an analysis of histologic parameters. *Am J Surg Pathol*. 1997;21:1455-1465.
951. Perry A, Chicoine MR, Filiput E, et al. Clinicopathologic assessment and grading of embolized meningiomas: a correlative study of 64 patients. *Cancer*. 2001;92:701-711.
952. Perry A, Banerjee R, Lohse CM, et al. A role for chromosome 9p21 deletions in the malignant progression of meningiomas and the prognosis of anaplastic meningiomas. *Brain Pathol*. 2002;12:183-190.
953. Adeberg S, Hartmann C, Welzel T, et al. Long-term outcome after radiotherapy in patients with atypical and malignant meningiomas—clinical results in 85 patients treated in a single institution leading to optimized guidelines for early radiation therapy. *Int J Radiat Oncol Biol Phys*. 2012;83:859-864.
954. Zhu H, Xie Q, Zhou Y, et al. Analysis of prognostic factors and treatment of anaplastic meningioma in China. *J Clin Neurosci*. 2015;22:690-695.
955. Aizer AA, Bi WL, Kandola MS, et al. Extent of resection and overall survival for patients with atypical and malignant meningioma. *Cancer*. 2015;121:4376-4381.
956. Marciscano AE, Stemmer-Rachamimov AO, Niemierko A, et al. Benign meningiomas (WHO Grade I) with atypical histological features: correlation of histopathological features with clinical outcomes. *J Neurosurg*. 2015;1-9.
957. Abry E, Thomassen IO, Salvesen OO, Torp SH. The significance of Ki-67/MIB-1 labeling index in human meningiomas: a literature study. *Pathol Res Pract*. 2010;206:810-815.
958. Perry A, Stafford SL, Scheithauer BW, et al. The prognostic significance of MIB-1, p53, and DNA flow cytometry in completely resected primary meningiomas. *Cancer*. 1998;82:2262-2269.
959. Olar A, Wani KM, Sulman EP, et al. Mitotic index is an independent predictor of recurrence-free survival in meningioma. *Brain Pathol*. 2015;25:266-275.
960. Surov A, Gottschling S, Bolz J, et al. Distant metastases in meningioma: an underestimated problem. *J Neurooncol*. 2013;112:323-327.
961. Nakayama Y, Horio H, Horiguchi S, Hato T. Pulmonary and pleural metastases from benign meningeal meningioma: a case report. *Ann Thorac Cardiovasc Surg*. 2014;20(5):410-413.
962. Psaras T, Pantazis G, Steger V, et al. Benign meningioma developing late lung metastases: case report and review of the literature. *Clin Neuropathol*. 2009;28:453-459.
963. von Deimling A, Kraus JA, Stangl AP, et al. Evidence for subarachnoid spread in the development of multiple meningiomas. *Brain Pathol*. 1995;5:11-14.
964. Benesch M, von Bueren AO, Dantonello T, et al. Primary intracranial soft tissue sarcoma in children and adolescents: a cooperative analysis of the European CWS and HIT study groups. *J Neurooncol*. 2013;111:337-345.
965. Oliveira AM, Scheithauer BW, Salomao DR, et al. Primary sarcomas of the brain and spinal cord: a study of 18 cases. *Am J Surg Pathol*. 2002;26:1056-1063.
966. Paulus W, Slowik F, Jellinger K. Primary intracranial sarcomas: histopathological features of 19 cases. *Histopathology*. 1991;18:395-402.
967. Robinson DR, Wu YM, Kalyana-Sundaram S, et al. Identification of recurrent NAB2-STAT6 gene fusions in solitary fibrous tumor by integrative sequencing. *Nat Genet*. 2013;45:180-185.
968. Chmielecki J, Crago AM, Rosenberg M, et al. Whole-exome sequencing identifies a recurrent NAB2-STAT6 fusion in solitary fibrous tumors. *Nat Genet*. 2013;45:131-132.
969. Schweizer L, Koelsche C, Sahm F, et al. Meningeal hemangiopericytoma and solitary fibrous tumors carry the NAB2-STAT6 fusion and can be diagnosed by nuclear expression of STAT6 protein. *Acta Neuropathol*. 2013;125:651-658.
970. Carneiro SS, Scheithauer BW, Nascimento AG, et al. Solitary fibrous tumor of the

meninges: a lesion distinct from fibrous meningioma. A clinicopathologic and immunohistochemical study. *Am J Clin Pathol*. 1996;106:217-224.
971. Bouvier C, Metellus P, de Paula AM, et al. Solitary fibrous tumors and hemangiopericytomas of the meninges: overlapping pathological features and common prognostic factors suggest the same spectrum of tumors. *Brain Pathol*. 2012;22:511-521.
972. Bisceglia M, Galliani C, Giannatempo G, et al. Solitary fibrous tumor of the central nervous system: a 15-year literature survey of 220 cases (August 1996–July 2011). *Adv Anat Pathol*. 2011;18:356-392.
973. Dardick I, Hammar SP, Scheithauer BW. Ultrastructural spectrum of hemangiopericytoma: a comparative study of fetal, adult, and neoplastic pericytes. *Ultrastruct Pathol*. 1989;13:111-154.
974. Rutkowski MJ, Sughrue ME, Kane AJ, et al. Predictors of mortality following treatment of intracranial hemangiopericytoma. *J Neurosurg*. 2010;113:333-339.
975. Mena H, Ribas JL, Pezeshkpour GH, et al. Hemangiopericytoma of the central nervous system: a review of 94 cases. *Hum Pathol*. 1991;22:84-91.
976. Ghose A, Guha G, Kundu R, et al. CNS hemangiopericytoma: a systematic review of 523 patients. *Am J Clin Oncol*. 2017;40(3):223-227.
977. Ghia AJ, Allen PK, Mahajan A, et al. Intracranial hemangiopericytoma and the role of radiation therapy: a population based analysis. *Neurosurgery*. 2013;72:203-209.
978. Ghia AJ, Chang EL, Allen PK, et al. Intracranial hemangiopericytoma: patterns of failure and the role of radiation therapy. *Neurosurgery*. 2013;73:624-630, discussion 630-631.
979. Reyes-Mugica M, Chou P, Gonzalez-Crussi F, Tomita T. Fibroma of the meninges in a child: immunohistological and ultrastructural study. Case report. *J Neurosurg*. 1992;76:143-147.
980. Hisaoka M, Furuta A, Rikimaru S. Sclerosing fibrous tumor of the cauda equina: a fibroblastic variant of peripheral nerve tumors? *Acta Neuropathol*. 1993;86:193-197.
981. Iyer GV, Vaishya ND, Bhaktaviziam A, et al. Angiofibroma of the middle cranial fossa. Case report. *J Neurosurg*. 1971;35:90-94.
982. Shinojima N, Ohta K, Yano S, et al. Myofibroblastoma in the suprasellar region. Case report. *J Neurosurg*. 2002;97:1203-1207.
983. Mitchell A, Scheithauer BW, Ebersold MJ, Forbes GS. Intracranial fibromatosis. *Neurosurgery*. 1991;29:123-126.
984. Pagenstecher A, Emmerich B, van Velthoven V, et al. Exclusively intracranial cranial fasciitis in a child. Case report. *J Neurosurg*. 1995;83:744-747.
985. Nishio S, Morioka T, Inamura T, et al. Radiation-induced brain tumours: potential late complications of radiation therapy for brain tumours. *Acta Neurochir (Wien)*. 1998;140:763-770.
986. Gaspar LE, Mackenzie IR, Gilbert JJ, et al. Primary cerebral fibrosarcomas. Clinicopathologic study and review of the literature. *Cancer*. 1993;72:3277-3281.
987. Lopes MB, Lanzino G, Cloft HJ, et al. Primary fibrosarcoma of the sella unrelated to previous radiation therapy. *Mod Pathol*. 1998;11:579-584.
988. Hamlat A, Adn M, Caulet-Maugendre S, Guegan Y. Cerebellar malignant fibrous histiocytoma: case report and literature review. *Neurosurgery*. 2004;54:745-751, discussion 751-752.
989. Hansen JM, Larsen VA, Scheie D, et al. Primary intracranial angiomatoid fibrous histiocytoma presenting with anaemia and migraine-like headaches and aura as early clinical features. *Cephalalgia*. 2015;35:1334-1336.
990. Dunham C, Hussong J, Seiff M, et al. Primary intracerebral angiomatoid fibrous histiocytoma: report of a case with a t(12;22)(q13;q12) causing type 1 fusion of the EWS and ATF-1 genes. *Am J Surg Pathol*. 2008;32:478-484.
991. Doyle LA, Moller E, Dal Cin P, et al. MUC4 is a highly sensitive and specific marker for low-grade fibromyxoid sarcoma. *Am J Surg Pathol*. 2011;35:733-741.
992. Saito R, Kumabe T, Watanabe M, et al. Low-grade fibromyxoid sarcoma of intracranial origin. *J Neurosurg*. 2008;108:798-802.
993. Bilsky MH, Schefler AC, Sandberg DI, et al. Sclerosing epithelioid fibrosarcomas involving the neuraxis: report of three cases. *Neurosurgery*. 2000;47:956-959, discussion 959-960.
994. Hornick JL, Sholl LM, Dal Cin P, et al. Expression of ROS1 predicts ROS1 gene rearrangement in inflammatory myofibroblastic tumors. *Mod Pathol*. 2015;28:732-739.
995. Antonescu CR, Suurmeijer AJ, Zhang L, et al. Molecular characterization of inflammatory myofibroblastic tumors with frequent ALK and ROS1 gene fusions and rare novel RET rearrangement. *Am J Surg Pathol*. 2015;39:957-967.
996. Brown PG, Shaver EG. Myolipoma in a tethered cord. Case report and review of the literature. *J Neurosurg*. 2000;92:214-216.
997. Blount JP, Elton S. Spinal lipomas. *Neurosurg Focus*. 2001;10:e3.
998. Ahmed O, Zhang S, Thakur JD, Nanda A. Nondysraphic intramedullary cervical cord lipoma with exophytic component: case report. *J Neurol Surg Rep*. 2015;76:e87-e90.
999. Arnold PM, Gust TD, Newell K. Intramedullary leiomyolipoma of the thoracic spine. Case report. *J Neurosurg Spine*. 2007;6:438-440.
1000. Harrison MJ, Mitnick RJ, Rosenblum BR, Rothman AS. Leptomyelolipoma: analysis of 20 cases. *J Neurosurg*. 1990;73:360-367.
1001. Preul MC, Leblanc R, Tampieri D, et al. Spinal angiolipomas. Report of three cases. *J Neurosurg*. 1993;78:280-286.
1002. Lin YC, Huang CC, Chen HJ. Intraspinal osteolipoma. Case report. *J Neurosurg*. 2001;94:126-128.
1003. Haddad SF, Hitchon PW, Godersky JC. Idiopathic and glucocorticoid-induced spinal epidural lipomatosis. *J Neurosurg*. 1991;74:38-42.
1004. Perling LH, Laurent JP, Cheek WR. Epidural hibernoma as a complication of corticosteroid treatment. Case report. *J Neurosurg*. 1988;69:613-616.
1005. Chitoku S, Kawai S, Watabe Y, et al. Intradural spinal hibernoma: case report. *Surg Neurol*. 1998;49:509-512, discussion 512-513.
1006. Budka H. Intracranial lipomatous hamartomas (intracranial "lipomas"). A study of 13 cases including combinations with medulloblastoma, colloid and epidermoid cysts, angiomatosis and other malformations. *Acta Neuropathol*. 1974;28:205-222.
1007. Sheridan F, Scharf D, Henderson VW, Miller CA. Lipomas of the mesencephalic tectum and rostral pons associated with sleep apnea syndrome. *Clin Neuropathol*. 1990;9:152-156.
1008. Tresser N, Parveen T, Roessmann U. Intracranial lipomas with teratomatous elements. *Arch Pathol Lab Med*. 1993;117:918-920.
1009. Pirotte B, Krischek B, Levivier M, et al. Diagnostic and microsurgical presentation of intracranial angiolipomas. Case report and review of the literature. *J Neurosurg*. 1998;88:129-132.
1010. Bognar L, Balint K, Bardoczy Z. Symptomatic osteolipoma of the tuber cinereum. Case report. *J Neurosurg*. 2002;96:361-363.
1011. Ahmadi SA, van Landeghem FK, Blechschmidt C, et al. Intratentorial osteochondrolipoma in a 9-year-old boy. *J Neurosurg Pediatr*. 2009;3:386-391.
1012. Bigelow DC, Eisen MD, Smith PG, et al. Lipomas of the internal auditory canal and cerebellopontine angle. *Laryngoscope*. 1998;108:1459-1469.
1013. Wu SS, Lo WW, Tschirhart DL, et al. Lipochoristomas (lipomatous tumors) of the acoustic nerve. *Arch Pathol Lab Med*. 2003;127:1475-1479.
1014. Feldman RP, Marcovici A, LaSala PA. Intracranial lipoma of the sylvian fissure. Case report and review of the literature. *J Neurosurg*. 2001;94:515-519.
1015. Barajas RF Jr, Perry A, Sughrue M, et al. Intracranial subdural osteoma: a rare benign tumor that can be differentiated from other calcified intracranial lesions utilizing MR imaging. *J Neuroradiol*. 2012;39:263-266.
1016. Mello LR, Bernardes CI, Feltrin Y, Rodacki MA. Thoracic spine arachnoid ossification with and without cord cavitation. Report of three cases. *J Neurosurg*. 2001;94:115-120.
1017. Dagcinar A, Bayrakli F, Yapicier O, Ozek M. Primary meningeal osteosarcoma of the brain during childhood. Case report. *J Neurosurg Pediatr*. 2008;1:325-329.
1018. Sugiura Y, Nagaishi M, Takano I, et al. Convexity dural chondroma: a case report with pathological and molecular analysis. *Clin Neuropathol*. 2015;34(1):13-18.
1019. Somerset HL, Kleinschmidt-Demasters BK, Rubinstein D, Breeze RE. Osteochondroma of the convexity: pathologic-neuroimaging correlates of a lesion that mimics high-grade meningioma. *J Neurooncol*. 2010;98(3):421-426.
1020. Chakrabortty S, Tamaki N, Kondoh T, et al. Maffucci's syndrome associated with intracranial enchondroma and aneurysm: case report. *Surg Neurol*. 1991;36:216-220.
1021. Traflet RF, Babaria AR, Barolat G, et al. Intracranial chondroma in a patient with Ollier's disease. Case report. *J Neurosurg*. 1989;70:274-276.
1022. Almefty K, Pravdenkova S, Colli BO, et al. Chordoma and chondrosarcoma: similar, but quite different, skull base tumors. *Cancer*. 2007;110(11):2457-2467.
1023. Amirjamshidi A, Abbassioun K. Radiation-induced tumors of the central nervous system occurring in childhood and adolescence. Four unusual lesions in three patients and a review of the literature. *Childs Nerv Syst*. 2000;16:390-397.
1024. Miyamori T, Mizukoshi H, Yamano K, et al. Intracranial chondrosarcoma—case report. *Neurol Med Chir (Tokyo)*. 1990;30:263-267.
1025. Oakley GJ, Fuhrer K, Seethala RR. Brachyury, SOX-9, and podoplanin, new markers in the skull base chordoma vs chondrosarcoma differential: a tissue microarray-based comparative analysis. *Mod Pathol*. 2008;21:1461-1469.
1026. Rushing EJ, Armonda RA, Ansari Q, Mena H. Mesenchymal chondrosarcoma: a clinicopathologic and flow cytometric study of 13 cases presenting in the central nervous system. *Cancer*. 1996;77:1884-1891.
1027. Yassa M, Bahary JP, Bourguoin P, et al. Intra-parenchymal mesenchymal chondrosarcoma of the cerebellum: case report and review of the literature. *J Neurooncol*. 2005;74:329-331.

1028. Sato K, Kubota T, Yoshida K, Murata H. Intracranial extraskeletal myxoid chondrosarcoma with special reference to lamellar inclusions in the rough endoplasmic reticulum. *Acta Neuropathol*. 1993;86:525-528.
1029. Phi JH, Kim SK, Cho A, et al. Intracranial capillary hemangioma: extra-axial tumorous lesions closely mimicking meningioma. *J Neurooncol*. 2012;109:177-185.
1030. Vassal F, Peoc'h M, Nuti C. Epidural capillary hemangioma of the thoracic spine with proximal nerve root involvement and extraforaminal extension. *Acta Neurochir (Wien)*. 2011;153:2279-2281.
1031. Abe M, Tabuchi K, Tanaka S, et al. Capillary hemangioma of the central nervous system. *J Neurosurg*. 2004;101:73-81.
1032. Antonescu CR, Le Loarer F, Mosquera JM, et al. Novel YAP1-TFE3 fusion defines a distinct subset of epithelioid hemangioendothelioma. *Genes Chromosomes Cancer*. 2013;52:775-784.
1033. Zheng J, Liu L, Wang J, et al. Primary intracranial epithelioid hemangioendothelioma: a low-proliferation tumor exhibiting clinically malignant behavior. *J Neurooncol*. 2012;110:119-127.
1034. Hackney JR, Palmer CA, Riley KO, et al. Primary central nervous system angiosarcoma: two case reports. *J Med Case Rep*. 2012;6:251.
1035. Lach B, Benoit BG. Primary composite angiogenic leiomyosarcoma-epithelioid angiosarcoma of the brain. *Ultrastruct Pathol*. 2000;24:339-346.
1036. Buttner A, Marquart KH, Mehraein P, Weis S. Kaposi's sarcoma in the cerebellum of a patient with AIDS. *Clin Neuropathol*. 1997;16:185-189.
1037. Samaratunga H, Searle J, Cominos D, Le Fevre I. Cerebral metastasis of an atrial myxoma mimicking an epithelioid hemangioendothelioma. *Am J Surg Pathol*. 1994;18:107-111.
1038. Abe M, Tabuchi K, Takagi M, et al. Spontaneous resolution of multiple hemangiomas of the brain. Case report. *J Neurosurg*. 1990;73:448-452.
1039. Roncaroli F, Scheithauer BW, Deen HG Jr. Multiple hemangiomas (hemangiomatosis) of the cauda equina and spinal cord. Case report. *J Neurosurg*. 2000;92:229-232.
1040. Stoffman MR, Kim JH. Masson's vegetant hemangioendothelioma: case report and literature review. *J Neurooncol*. 2003;61:17-22.
1041. Hicks J, Flaitz C. Rhabdomyosarcoma of the head and neck in children. *Oral Oncol*. 2002;38:450-459.
1042. Stein TD, Chae YS, Won N, et al. A 34-year-old man with bitemporal hemianopsia. *Brain Pathol*. 2014;24:107-110.
1043. Dropcho EJ, Allen JC. Primary intracranial rhabdomyosarcoma: case report and review of the literature. *J Neurooncol*. 1987;5:139-150.
1044. Khalatbari MR, Hamidi M, Moharamzad Y. Primary alveolar rhabdomyosarcoma of the brain with long-term survival. *J Neurooncol*. 2013;115:131-133.
1045. Palta M, Riedel RF, Vredenburgh JJ, et al. Primary meningeal rhabdomyosarcoma. *Sarcoma*. 2011;2011:312802.
1046. Kleinschmidt-Demasters BK, Lovell MA, Donson AM, et al. Molecular array analyses of 51 pediatric tumors shows overlap between malignant intracranial ectomesenchymoma and MPNST but not medulloblastoma or atypical teratoid rhabdoid tumor. *Acta Neuropathol (Berl)*. 2007;113:695-703.
1047. Huang SC, Alaggio R, Sung YS, et al. Frequent HRAS mutations in malignant ectomesenchymoma: overlapping genetic abnormalities with embryonal rhabdomyosarcoma. *Am J Surg Pathol*. 2016;40(7):876-885.
1048. Lin SL, Wang JS, Huang CS, Tseng HH. Primary intracerebral leiomyoma: a case with eosinophilic inclusions of actin filaments. *Histopathology*. 1996;28:365-369.
1049. Eckhardt BP, Brandner S, Zollikofer CL, Wentz KU. Primary cerebral leiomyosarcoma in a child. *Pediatr Radiol*. 2004;34:495-498.
1050. Janisch W, Janda J, Link I. [Primary diffuse leptomeningeal leiomyomatosis]. *Zentralbl Pathol*. 1994;140:195-200.
1051. Conner TM, Waziri A, Kleinschmidt-Demasters BK. Angioleiomyomas of the dura: rare entities that lack KRIT1 mutations. *Am J Surg Pathol*. 2012;36:526-533.
1052. Lach B, Duncan E, Rippstein P, Benoit BG. Primary intracranial pleomorphic angioleiomyoma—a new morphologic variant. An immunohistochemical and electron microscopic study. *Cancer*. 1994;74:1915-1920.
1053. Haller F, Knopf J, Ackermann A, et al. Paediatric and adult soft tissue sarcomas with NTRK1 gene fusions: a subset of spindle cell sarcomas unified by a prominent myopericytic/haemangiopericytic pattern. *J Pathol*. 2016;238(5):700-710.
1054. Sivendran S, Vidal CI, Barginear MF. Primary intracranial leiomyosarcoma in an HIV-infected patient. *Int J Clin Oncol*. 2011;16:63-66.
1055. Kleinschmidt-DeMasters BK, Mierau GW, Sze CI, et al. Unusual dural and skull-based mesenchymal neoplasms: a report of four cases. *Hum Pathol*. 1998;29:240-245.
1056. Mierau GW, Greffe BS, Weeks DA. Primary leiomyosarcoma of brain in an adolescent with common variable immunodeficiency syndrome. *Ultrastruct Pathol*. 1997;21:301-305.
1057. Lau PP, Wong OK, Lui PC, et al. Myopericytoma in patients with AIDS: a new class of Epstein-Barr virus-associated tumor. *Am J Surg Pathol*. 2009;33:1666-1672.
1058. Budka H, Pilz P, Guseo A. Primary leptomeningeal sarcomatosis. Clinicopathological report of six cases. *J Neurol*. 1975;211:77-93.
1059. Menon RK, Goel A, Shah A, et al. Primary intracranial myxoma of the parietal region. Illustrated case report. *J Neurooncol*. 2008;88(2):157-160.
1060. Kurtkaya-Yapicier O, Scheithauer BW, Dedrick DJ, Wascher TM. Primary epithelioid sarcoma of the dura: case report. *Neurosurgery*. 2002;50:198-202, discussion 202-203.
1061. Lin YJ, Yang QX, Tian XY, et al. Unusual primary intracranial dural-based poorly differentiated synovial sarcoma with t(X; 18)(p11; q11). *Neuropathology*. 2013;33:75-82.
1062. Peia F, Gessi M, Collini P, et al. Pediatric primitive intraneural synovial sarcoma of L-5 nerve root. *J Neurosurg Pediatr*. 2013;11:473-477.
1063. Keith JL, Bilbao J, Croul S, et al. Clinical Neuropathology practice guide 6-2013: morphology and an appropriate immunohistochemical screening panel aid in the identification of synovial sarcoma by neuropathologists. *Clin Neuropathol*. 2013;32:461-470.
1064. Medeiros F, Scheithauer BW, Oliveira AM, Gregory RS. Angiomyxofibromatous tumor of the falx cerebri. *Am J Surg Pathol*. 2006;30:545-547.
1065. David K, Revesz T, Kratimenos G, et al. Oncogenic osteomalacia associated with a meningeal phosphaturic mesenchymal tumor. Case report. *J Neurosurg*. 1996;84:288-292.
1066. Biernat W, Kaniuka S, Stempniewicz M, et al. Phosphaturic mesenchymal tumor of spinal nerve in a patient with osteomalacia and multiple fractures. *Acta Neuropathol*. 2010;119:379-380.
1067. Fellig Y, Oliveira AM, Margolin E, et al. Extraosseous aneurysmal bone cyst of cerebello-pontine angle with USP6 rearrangement. *Acta Neuropathol*. 2009;118:579-581.
1068. Rodriguez FJ, Folpe AL, Giannini C, Perry A. Pathology of peripheral nerve sheath tumors: diagnostic overview and update on selected diagnostic problems. *Acta Neuropathol*. 2012;123:295-319.
1069. Bristol RE, Coons SW, Rekate HL, Spetzler RF. Invasive intracerebral schwannoma mimicking meningioma in a child. *Childs Nerv Syst*. 2006;22:1483-1486.
1070. Weiner HL, Zagzag D, Babu R, et al. Schwannoma of the fourth ventricle presenting with hemifacial spasm. A report of two cases. *J Neurooncol*. 1993;15:37-43.
1071. Takei H, Schmiege L, Buckleair L, et al. Intracerebral schwannoma clinically and radiologically mimicking meningioma. *Pathol Int*. 2005;55:514-519.
1072. van den Munckhof P, Christiaans I, Kenter SB, et al. Germline SMARCB1 mutation predisposes to multiple meningiomas and schwannomas with preferential location of cranial meningiomas at the falx cerebri. *Neurogenetics*. 2012;13:1-7.
1073. Wu J, Kong M, Bi Q. Identification of a novel germline SMARCB1 nonsense mutation in a family manifesting both schwannomatosis and unilateral vestibular schwannoma. *J Neurooncol*. 2015;125:439-441.
1074. Dewan R, Pemov A, Kim HJ, et al. Evidence of polyclonality in neurofibromatosis type 2-associated multilobulated vestibular schwannomas. *Neuro Oncol*. 2015;17:566-573.
1075. Brown DF, Rushing EJ. Rosenthal fibers and eosinophilic granular bodies in a classic acoustic schwannoma. *Arch Pathol Lab Med*. 1997;121:1207-1209.
1076. Kepes JJ. Rosenthal fibers in a classic acoustic schwannoma. *Arch Pathol Lab Med*. 1998;122:673-674.
1077. Ludemann W, Stan AC, Tatagiba M, Samii M. Sporadic unilateral vestibular schwannoma with islets of meningioma: case report. *Neurosurgery*. 2000;47:451-452, discussion 452-454.
1078. Nonaka D, Chiriboga L, Rubin BP. Sox10: a pan-schwannian and melanocytic marker. *Am J Surg Pathol*. 2008;32:1291-1298.
1079. Pekmezci M, Reuss DE, Hirbe AC, et al. Morphologic and immunohistochemical features of malignant peripheral nerve sheath tumors and cellular schwannomas. *Mod Pathol*. 2015;28:187-200.
1080. Ng J, Celebre A, Munoz DG, et al. Sox10 is superior to S100 in the diagnosis of meningioma. *Appl Immunohistochem Mol Morphol*. 2015;23:215-219.
1081. Kawahara E, Oda Y, Ooi A, et al. Expression of glial fibrillary acidic protein (GFAP) in peripheral nerve sheath tumors. A comparative study of immunoreactivity of GFAP, vimentin, S-100 protein, and neurofilament in 38 schwannomas and 18 neurofibromas. *Am J Surg Pathol*. 1988;12:115-120.
1082. Karamchandani JR, Nielsen TO, van de Rijn M, West RB. Sox10 and S100 in the diagnosis of soft-tissue neoplasms. *Appl Immunohistochem Mol Morphol*. 2012;20:445-450.
1083. Woodruff JM, Godwin TA, Erlandson RA, et al. Cellular schwannoma: a variety of schwannoma sometimes mistaken for a

malignant tumor. *Am J Surg Pathol*. 1981;5:733-744.
1084. White W, Shiu MH, Rosenblum MK, et al. Cellular schwannoma. A clinicopathologic study of 57 patients and 58 tumors. *Cancer*. 1990;66:1266-1275.
1085. Casadei GP, Scheithauer BW, Hirose T, et al. Cellular schwannoma. A clinicopathologic, DNA flow cytometric, and proliferation marker study of 70 patients. *Cancer*. 1995;75:1109-1119.
1086. Cheng RR, Forcucci JA, Kalhorn SP. Intraneural granular cell tumor of a cervical dorsal nerve root: a case report and review of the literature. *World Neurosurg*. 2016;86:511.e5-511.e8.
1087. McRackan TR, Wilkinson EP, Rivas A. Primary tumors of the facial nerve. *Otolaryngol Clin North Am*. 2015;48:491-500.
1088. Miedema J, Solle M, Zanation A, Trembath D. Granular cell tumor of the trigeminal nerve. *Clin Neuropathol*. 2012;31:104-107.
1089. Mennemeyer RP, Hallman KO, Hammar SP, et al. Melanotic schwannoma. Clinical and ultrastructural studies of three cases with evidence of intracellular melanin synthesis. *Am J Surg Pathol*. 1979;3:3-10.
1090. Torres-Mora J, Dry S, Li X, et al. Malignant melanotic schwannian tumor: a clinicopathologic, immunohistochemical, and gene expression profiling study of 40 cases, with a proposal for the reclassification of "melanotic schwannoma". *Am J Surg Pathol*. 2014;38:94-105.
1091. Hoover JM, Bledsoe JM, Giannini C, Krauss WE. Intramedullary melanotic schwannoma. *Rare Tumors*. 2012;4:e3.
1092. Koelsche C, Hovestadt V, Jones DT, et al. Melanotic tumors of the nervous system are characterized by distinct mutational, chromosomal and epigenomic profiles. *Brain Pathol*. 2015;25:202-208.
1093. Killeen RM, Davy CL, Bauserman SC. Melanocytic schwannoma. *Cancer*. 1988;62:174-183.
1094. Vallat-Decouvelaere AV, Wassef M, Lot G, et al. Spinal melanotic schwannoma: a tumour with poor prognosis. *Histopathology*. 1999;35:558-566.
1095. Vezzosi D, Vignaux O, Dupin N, Bertherat J. Carney complex: clinical and genetic 2010 update. *Ann Endocrinol (Paris)*. 2010;71:486-493.
1096. Carney JA. Psammomatous melanotic schwannoma. A distinctive, heritable tumor with special associations, including cardiac myxoma and the Cushing syndrome. *Am J Surg Pathol*. 1990;14:206-222.
1097. Anderson JL, Gutmann DH. Neurofibromatosis type 1. *Handb Clin Neurol*. 2015;132:75-86.
1098. Nadkarni TD, Rekate HL, Coons SW. Plexiform neurofibroma of the cauda equina. Case report. *J Neurosurg*. 1999;91:112-115.
1099. Ren X, Wang J, Hu M, et al. Clinical, radiological, and pathological features of 26 intracranial and intraspinal malignant peripheral nerve sheath tumors. *J Neurosurg*. 2013.
1100. Scheithauer BW, Erdogan S, Rodriguez FJ, et al. Malignant peripheral nerve sheath tumors of cranial nerves and intracranial contents: a clinicopathologic study of 17 cases. *Am J Surg Pathol*. 2009;33:325-338.
1101. Prieto-Granada CN, Wiesner T, Messina JL, et al. Loss of H3K27me3 Expression Is a Highly Sensitive Marker for Sporadic and Radiation-induced MPNST. *Am J Surg Pathol*. 2016;40(4):479-489.
1102. LaFemina J, Qin LX, Moraco NH, et al. Oncologic outcomes of sporadic, neurofibromatosis-associated, and radiation-induced malignant peripheral nerve sheath tumors. *Ann Surg Oncol*. 2013;20:66-72.
1103. Puataweepong P, Janwityanujit T, Larbcharoensub N, Dhanachai M. Radiation-induced peripheral malignant nerve sheath tumor arising from vestibular schwannoma after linac-based stereotactic radiation therapy: a case report and review of literatures. *Case Rep Med*. 2012;2012:648191.
1104. Jung JM, Shin HJ, Chi JG, et al. Malignant intraventricular schwannoma. Case report. *J Neurosurg*. 1995;82:121-124.
1105. Kamran SC, Howard SA, Shinagare AB, et al. Malignant peripheral nerve sheath tumors: prognostic impact of rhabdomyoblastic differentiation (malignant triton tumors), neurofibromatosis 1 status and location. *Eur J Surg Oncol*. 2013;39(1):46-52.
1106. Kurtkaya-Yapicier O, Scheithauer BW, Woodruff JM, et al. Schwannoma with rhabdomyoblastic differentiation: a unique variant of malignant triton tumor. *Am J Surg Pathol*. 2003;27:848-853.
1107. Ducatman BS, Scheithauer BW, Piepgras DG, et al. Malignant peripheral nerve sheath tumors. A clinicopathologic study of 120 cases. *Cancer*. 1986;57:2006-2021.
1108. Reuss DE, Habel A, Hagenlocher C, et al. Neurofibromin specific antibody differentiates malignant peripheral nerve sheath tumors (MPNST) from other spindle cell neoplasms. *Acta Neuropathol*. 2014;127:565-572.
1109. Schaefer IM, Fletcher CD, Hornick JL. Loss of H3K27 trimethylation distinguishes malignant peripheral nerve sheath tumors from histologic mimics. *Mod Pathol*. 2016;29:4-13.
1110. Cleven AH, Sannaa GA, Briaire-de Bruijn I, et al. Loss of H3K27 tri-methylation is a diagnostic marker for malignant peripheral nerve sheath tumors and an indicator for an inferior survival. *Mod Pathol*. 2016;29(6):582-590.
1111. Kaar GF, Bashir SH, N'Dow JM, et al. Neurothekeoma of the cauda equina. *J Neurol Neurosurg Psychiatry*. 1996;61:530-531.
1112. Paulus W, Warmuth-Metz M, Sorensen N. Intracranial neurothekeoma (nerve-sheath myxoma). Case report. *J Neurosurg*. 1993;79:280-282.
1113. Giannini C, Scheithauer BW, Steinberg J, Cosgrove TJ. Intraventricular perineurioma: case report. *Neurosurgery*. 1998;43:1478-1481, discussion 1481-1482.
1114. Almefty R, Webber BL, Arnautovic KI. Intraneural perineurioma of the third cranial nerve: occurrence and identification. Case report. *J Neurosurg*. 2006;104:824-827.
1115. Kretzer RM, Burger PC, Tamargo RJ. Hypertrophic neuropathy of the cauda equina: case report. *Neurosurgery*. 2004;54:515-518, discussion 518-519.
1116. Johnson MW, Burger PC. Intramedullary amputation neuromas associated with spinal ependymomas. *Am J Surg Pathol*. 2009;33:639-643.
1117. Santagata S, Tuli S, Wiese DE 2nd, et al. Intramedullary neuroma of the cervicomedullary junction. Case report. *J Neurosurg Spine*. 2006;5:362-366.
1118. Demopoulos A, DeAngelis LM. Neurologic complications of leukemia. *Curr Opin Neurol*. 2002;15:691-699.
1119. Fukushima S, Terasaki M, Tajima Y, Shigemori M. Granulocytic sarcoma: an unusual complication of acute promyelocytic leukemia causing cerebellar hemorrhage. Case report. *J Neurosurg*. 2006;105:912-915.
1120. Widhalm G, Dietrich W, Mullauer L, et al. Myeloid sarcoma with multiple lesions of the central nervous system in a patient without leukemia. Case report. *J Neurosurg*. 2006;105:916-919.
1121. Ohtsubo M, Hayashi K, Fukushima T, et al. Case report: intracranial extramedullary haematopoiesis in postpolycythemic myelofibrosis. *Br J Radiol*. 1994;67:299-302.
1122. De Klippel N, Dehou MF, Bourgain C, et al. Progressive paraparesis due to thoracic extramedullary hematopoiesis in myelofibrosis. Case report. *J Neurosurg*. 1993;79:125-127.
1123. Herman TS, Hammond N, Jones SE, et al. Involvement of the central nervous system by non-Hodgkin's lymphoma: the Southwest Oncology Group experience. *Cancer*. 1979;43:390-397.
1124. Hoang-Xuan K, Bessell E, Bromberg J, et al. Diagnosis and treatment of primary CNS lymphoma in immunocompetent patients: guidelines from the European Association for Neuro-Oncology. *Lancet Oncol*. 2015;16:e322-e332.
1125. Salvati M, Cervoni L, Artico M, et al. Primary spinal epidural non-Hodgkin's lymphomas: a clinical study. *Surg Neurol*. 1996;46:339-343, discussion 343-344.
1126. Re D, Fuchs M, Schober T, et al. CNS involvement in Hodgkin's lymphoma. *J Clin Oncol*. 2007;25:3182.
1127. Sahin F, Saydam G, Ertan Y, et al. Dural plasmacytoma mimicking meningioma in a patient with multiple myeloma. *J Clin Neurosci*. 2006;13:259-261.
1128. Malkani RG, Tallman M, Gottardi-Littell N, et al. Bing-Neel syndrome: an illustrative case and a comprehensive review of the published literature. *J Neurooncol*. 2010;96:301-312.
1129. Bodensteiner DC, Skikne B. Central nervous system involvement in mycosis fungoides: diagnosis, treatment and literature review. *Cancer*. 1982;50:1181-1184.
1130. Patrick LB, Mohile NA. Advances in primary central nervous system lymphoma. *Curr Oncol Rep*. 2015;17:60.
1131. Rollins KE, Kleinschmidt-DeMasters BK, Corboy JR, et al. Lymphomatosis cerebri as a cause of white matter dementia. *Hum Pathol*. 2005;36:282-290.
1132. Cavaliere R, Petroni G, Lopes MB, Schiff D. Primary central nervous system post-transplantation lymphoproliferative disorder: an International Primary Central Nervous System Lymphoma Collaborative Group Report. *Cancer*. 2010;116:863-870.
1133. Scott BJ, Douglas VC, Tihan T, et al. A Systematic approach to the diagnosis of suspected central nervous system lymphoma. *JAMA Neurol*. 2013;1-9.
1134. Grisariu S, Avni B, Batchelor TT, et al. Neurolymphomatosis: an International Primary CNS Lymphoma Collaborative Group report. *Blood*. 2010;115:5005-5011.
1135. Flanagan EP, O'Neill BP, Porter AB, et al. Primary intramedullary spinal cord lymphoma. *Neurology*. 2011;77:784-791.
1136. Park JS, Park H, Park S, et al. Primary central nervous system ALK positive anaplastic large cell lymphoma with predominantly leptomeningeal involvement in an adult. *Yonsei Med J*. 2013;54:791-796.
1137. Ely SA, Powers J, Lewis D, et al. Kaposi's sarcoma-associated herpesvirus-positive primary effusion lymphoma arising in the subarachnoid space. *Hum Pathol*. 1999;30:981-984.
1138. Rodriguez FJ, Gamez JD, Vrana JA, et al. Immunoglobulin derived depositions in the nervous system: novel mass spectrometry application for protein characterization in formalin-fixed tissues. *Lab Invest*. 2008;88:1024-1037.
1139. Kim MK, Cho CH, Sung WJ, et al. Primary anaplastic large cell lymphoma in the dura of the brain: case report and prediction of a

favorable prognosis. *Int J Clin Exp Pathol*. 2013;6:1643-1651.
1140. Pappas CT, Johnson PC, Sonntag VK. Signet-ring cell lymphoma of the central nervous system. Case report. *J Neurosurg*. 1988;69:789-792.
1141. Kelley TW, Prayson RA, Barnett GH, et al. Extranodal marginal zone B-cell lymphoma of mucosa-associated lymphoid tissue arising in the lateral ventricle. *Leuk Lymphoma*. 2005;46:1423-1427.
1142. Grupka NL, Seinfeld J, Ryder J, et al. Secondary central nervous system involvement by follicular lymphoma: case report and review of the literature. *Surg Neurol*. 2006;65:590-594.
1143. Camilleri-Broet S, Davi F, Feuillard J, et al. AIDS-related primary brain lymphomas: histopathologic and immunohistochemical study of 51 cases. The French Study Group for HIV-Associated Tumors. *Hum Pathol*. 1997;28:367-374.
1144. Montesinos-Rongen M, Brunn A, Bentink S, et al. Gene expression profiling suggests primary central nervous system lymphomas to be derived from a late germinal center B cell. *Leukemia*. 2008;22:400-405.
1145. Hattab EM, Martin SE, Al-Khatib SM, et al. Most primary central nervous system diffuse large B-cell lymphomas occurring in immunocompetent individuals belong to the nongerminal center subtype: a retrospective analysis of 31 cases. *Mod Pathol*. 2010;23:235-243.
1146. Camilleri-Broet S, Criniere E, Broet P, et al. A uniform activated B-cell-like immunophenotype might explain the poor prognosis of primary central nervous system lymphomas: analysis of 83 cases. *Blood*. 2006;107:190-196.
1147. Vater I, Montesinos-Rongen M, Schlesner M, et al. The mutational pattern of primary lymphoma of the central nervous system determined by whole-exome sequencing. *Leukemia*. 2015;29:677-685.
1148. Montesinos-Rongen M, Schmitz R, Brunn A, et al. Mutations of CARD11 but not TNFAIP3 may activate the NF-kappaB pathway in primary CNS lymphoma. *Acta Neuropathol*. 2010;120:529-535.
1149. Deckert M, Brunn A, Montesinos-Rongen M, et al. Primary lymphoma of the central nervous system—a diagnostic challenge. *Hematol Oncol*. 2014;32:57-67.
1150. Young C, Gordon N, Safran HP, et al. Monoclonal B-cell population mimicking lymphoma in a patient with multiple sclerosis. *Arch Pathol Lab Med*. 1996;120:275-278.
1151. Prajapati HJ, Vincentelli C, Hwang SN, et al. Primary CNS natural killer/T-cell lymphoma of the nasal type presenting in a woman: case report and review of the literature. *J Clin Oncol*. 2014;32:e26-e29.
1152. Ogura R, Aoki H, Natsumeda M, et al. Epstein-Barr virus-associated primary central nervous system cytotoxic T-cell lymphoma. *Neuropathology*. 2013;33:436-441.
1153. Kodama K, Hokama M, Kawaguchi K, et al. 1-negative anaplastic large cell lymphoma of the brain: case report and review of the literature. *Neuropathology*. 2009;29:166-171.
1154. Weller M, Martus P, Roth P, et al. Surgery for primary CNS lymphoma? Challenging a paradigm. *Neuro Oncol*. 2012;14:1481-1484.
1155. Rubenstein JL, Hsi ED, Johnson JL, et al. Intensive chemotherapy and immunotherapy in patients with newly diagnosed primary CNS lymphoma: CALGB 50202 (Alliance 50202). *J Clin Oncol*. 2013;31(25):3061-3068.
1156. Lim T, Kim SJ, Kim K, et al. Primary CNS lymphoma other than DLBCL: a descriptive analysis of clinical features and treatment outcomes. *Ann Hematol*. 2011;90:1391-1398.
1157. Villano JL, Koshy M, Shaikh H, et al. Age, gender, and racial differences in incidence and survival in primary CNS lymphoma. *Br J Cancer*. 2011;105:1414-1418.
1158. Aozasa K, Saeki K, Horiuchi K, et al. Primary lymphoma of the brain developing in a boy after a 5-year history of encephalitis: polymerase chain reaction and in situ hybridization analyses for Epstein-Barr virus. *Hum Pathol*. 1993;24:802-805.
1159. Yanagisawa K, Tanuma J, Hagiwara S, et al. Epstein-Barr viral load in cerebrospinal fluid as a diagnostic marker of central nervous system involvement of AIDS-related lymphoma. *Intern Med*. 2013;52: 955-959.
1160. Boersma MN, van der Zanden A, Laverman GD, et al. Epstein-Barr virus-positive post-transplant lymphoproliferative disorder of the central nervous system, after renal transplantation with a discrepancy in viral load between peripheral blood and cerebrospinal fluid. *Transpl Int*. 2012;25(11):e113-e116.
1161. Jamal SE, Li S, Bajaj R, et al. Primary central nervous system Epstein-Barr virus-positive diffuse large B-cell lymphoma of the elderly: a clinicopathologic study of five cases. *Brain Tumor Pathol*. 2014;31:265-273.
1162. Kingma DW, Mueller BU, Frekko K, et al. Low-grade monoclonal Epstein-Barr virus-associated lymphoproliferative disorder of the brain presenting as human immunodeficiency virus-associated encephalopathy in a child with acquired immunodeficiency syndrome. *Arch Pathol Lab Med*. 1999;123:83-87.
1163. Demetrick DJ, Hamilton MG, Curry B, Tranmer BI. Epstein-Barr virus-associated primary B-cell lymphoproliferative disorder of the cerebellum in an immune competent man. *Cancer*. 1992;70:519-528.
1164. Tu PH, Giannini C, Judkins AR, et al. Clinicopathologic and genetic profile of intracranial marginal zone lymphoma: a primary low-grade CNS lymphoma that mimics meningioma. *J Clin Oncol*. 2005;23:5718-5727.
1165. Venkataraman G, Rizzo KA, Chavez JJ, et al. Marginal zone lymphomas involving meningeal dura: possible link to IgG4-related diseases. *Mod Pathol*. 2011;24:355-366.
1166. Miranda RN, Glantz LK, Myint MA, et al. Stage IE non-Hodgkin's lymphoma involving the dura: a clinicopathologic study of five cases. *Arch Pathol Lab Med*. 1996;120:254-260.
1167. Amaker BH, Ghatak NR, Jebraili SA, et al. cell-rich B-cell lymphoma masquerading as a meningioma. *Arch Pathol Lab Med*. 2000;124:1700-1703.
1168. Beriwal S, Hou JS, Miyamoto C, Garcia-Young JA. Primary dural low grade BCL-2 negative follicular lymphoma: a case report. *J Neurooncol*. 2003;61:23-25.
1169. Sapozink MD, Kaplan HS. Intracranial Hodgkin's disease. A report of 12 cases and review of the literature. *Cancer*. 1983;52:1301-1307.
1170. Gerstner ER, Abrey LE, Schiff D, et al. CNS Hodgkin lymphoma. *Blood*. 2008;112:1658-1661.
1171. Cerroni L, Massone C, Kutzner H, et al. Intravascular large T-cell or NK-cell lymphoma: a rare variant of intravascular large cell lymphoma with frequent cytotoxic phenotype and association with Epstein-Barr virus infection. *Am J Surg Pathol*. 2008;32:891-898.
1172. Ponzoni M, Arrigoni G, Gould VE, et al. Lack of CD 29 (beta1 integrin) and CD 54 (ICAM-1) adhesion molecules in intravascular lymphomatosis. *Hum Pathol*. 2000;31:220-226.
1173. Anda T, Haraguchi W, Miyazato H, et al. Ruptured distal middle cerebral artery aneurysm filled with tumor cells in a patient with intravascular large B-cell lymphoma. *J Neurosurg*. 2008;109:492-496.
1174. Alexandrescu S, Orengo JP, Toossi S, et al. CNS intravascular large cell lymphoma in a patient with autoimmune hemolytic anemia. *Neuropathology*. 2015;35:170-174.
1175. Imai H, Kajimoto K, Taniwaki M, et al. Intravascular large B-cell lymphoma presenting with mass lesions in the central nervous system: a report of five cases. *Pathol Int*. 2004;54:231-236.
1176. Dubas F, Saint-Andre JP, Pouplard-Barthelaix A, et al. Intravascular malignant lymphomatosis (so-called malignant angioendotheliomatosis): a case confined to the lumbosacral spinal cord and nerve roots. *Clin Neuropathol*. 1990;9:115-120.
1177. Dozic S, Suvakovic V, Cvetkovic D, et al. Neoplastic angioendotheliomatosis (NAE) of the CNS in a patient with AIDS subacute encephalitis, diffuse leukoencephalopathy and meningo-cerebral cryptococcosis. *Clin Neuropathol*. 1990;9:284-289.
1178. Coca S, Salas I, Martinez R, et al. Meningeal Castleman's disease with multifocal involvement: a case report and review of literature. *J Neurooncol*. 2008;88:37-41.
1179. Finn MA, Schmidt MH. Castleman disease of the spine mimicking a nerve sheath tumor. Case report. *J Neurosurg Spine*. 2007;6:455-459.
1180. Manabe M, Kanashima H, Yoshii Y, et al. Extramedullary plasmacytoma of the dura mimicking meningioma. *Int J Hematol*. 2010;91:731-732.
1181. Wisniewski T, Sisti M, Inhirami G, et al. Intracerebral solitary plasmacytoma. *Neurosurgery*. 1990;27:826-829, discussion 829.
1182. Aizawa T, Sato T, Tanaka Y, et al. Intramedullary plasma cell granuloma in the cervicothoracic spine. Case report. *J Neurosurg*. 2002;97:235-238.
1183. Weidenheim KM, Campbell WG Jr, Goldman HW. Atypical monoclonal plasma cell hyperplasia of the central nervous system: precursor of plasmacytoma with evolutionary considerations. *Neurosurgery*. 1989;429-434.
1184. Laeng RH, Altermatt HJ, Scheithauer BW, Zimmermann DR. Amyloidomas of the nervous system: a monoclonal B-cell disorder with monotypic amyloid light chain lambda amyloid production. *Cancer*. 1998;82:362-374.
1185. Yu JP, Wilson DM, Chang EF, et al. Isolated intracerebral light chain deposition disease: novel imaging and pathologic findings. *Clin Imaging*. 2014;38:868-871.
1186. Schroder R, Deckert M, Linke RP. Novel isolated cerebral ALlambda amyloid angiopathy with widespread subcortical distribution and leukoencephalopathy due to atypical monoclonal plasma cell proliferation, and terminal systemic gammopathy. *J Neuropathol Exp Neurol*. 2009;68:286-299.
1187. Vital A, Ellie E, Loiseau H. A 61-year-old man with instability of gait and right hand clumsiness. *Brain Pathol*. 2010;20:273-274.
1188. Hasselblatt M, Sepehrnia A, von Falkenhausen M, Paulus W. Intracranial follicular dendritic cell sarcoma. Case report. *J Neurosurg*. 2003;99:1089-1090.
1189. Hulette CM. Microglioma, a histiocytic neoplasm of the central nervous system. *Mod Pathol*. 1996;9:316-319.
1190. Idbaih A, Mokhtari K, Emile JF, et al. Dramatic response of a BRAF V600E-mutated primary CNS histiocytic sarcoma to vemurafenib. *Neurology*. 2014;83:1478-1480.

1191. Lucantoni C, De Bonis P, Doglietto F, et al. Primary cerebral lymphomatoid granulomatosis: report of four cases and literature review. *J Neurooncol*. 2009;94:235-242.
1192. Anders KH, Latta H, Chang BS, et al. Lymphomatoid granulomatosis and malignant lymphoma of the central nervous system in the acquired immunodeficiency syndrome. *Hum Pathol*. 1989;20:326-334.
1193. Rosenblum MK, Nakazato M, Matsutani M, et al. Germ cell tumours. In: Louis DN, Ohgaki H, Wiestler OD, Cavenee WK, eds. *WHO Classification of Tumours of the Central Nervous System*. Revised 4th ed. Lyon, France: IARC; 2016.
1194. Kamoshima Y, Sawamura Y, Iwasaki M, et al. Metachronous mature teratoma in the corpus callosum occurring 12 years after a pineal germinoma. *J Neurosurg*. 2008;109:126-129.
1195. Kaido T, Sasaoka Y, Hashimoto H, Taira K. De novo germinoma in the brain in association with Klinefelter's syndrome: case report and review of the literature. *Surg Neurol*. 2003;60:553-558, discussion 559.
1196. Chik K, Li C, Shing MM, et al. Intracranial germ cell tumors in children with and without Down syndrome. *J Pediatr Hematol Oncol*. 1999;21:149-151.
1197. Starzyk J, Starzyk B, Bartnik-Mikuta A, et al. Gonadotropin releasing hormone-independent precocious puberty in a 5 year-old girl with suprasellar germ cell tumor secreting beta-hCG and alpha-fetoprotein. *J Pediatr Endocrinol Metab*. 2001;14:789-796.
1198. O'Marcaigh AS, Ledger GA, Roche PC, et al. Aromatase expression in human germinomas with possible biological effects. *J Clin Endocrinol Metab*. 1995;80:3763-3766.
1199. Rueda-Pedraza ME, Heifetz SA, Sesterhenn IA, Clark GB. Primary intracranial germ cell tumors in the first two decades of life. A clinical, light-microscopic, and immunohistochemical analysis of 54 cases. *Perspect Pediatr Pathol*. 1987;10:160-207.
1200. Kraichoke S, Cosgrove M, Chandrasoma PT. Granulomatous inflammation in pineal germinoma. A cause of diagnostic failure at stereotaxic brain biopsy. *Am J Surg Pathol*. 1988;12:655-660.
1201. Nikas DC, De Girolami U, Zamani AA, et al. Idiopathic pinealitis. Case report. *J Neurosurg*. 1999;91:330-334.
1202. Iczkowski KA, Butler SL, Shanks JH, et al. Trials of new germ cell immunohistochemical stains in 93 extragonadal and metastatic germ cell tumors. *Hum Pathol*. 2008;39:275-281.
1203. Fukushima S, Otsuka A, Suzuki T, et al. Mutually exclusive mutations of KIT and RAS are associated with KIT mRNA expression and chromosomal instability in primary intracranial pure germinomas. *Acta Neuropathol*. 2014;127:911-925.
1204. Wang L, Yamaguchi S, Burstein MD, et al. Novel somatic and germline mutations in intracranial germ cell tumours. *Nature*. 2014;511:241-245.
1205. Santagata S, Hornick JL, Ligon KL. Comparative analysis of germ cell transcription factors in CNS germinoma reveals diagnostic utility of NANOG. *Am J Surg Pathol*. 2006;30:1613-1618.
1206. Cao D, Liu A, Wang F, et al. RNA-binding protein LIN28 is a marker for primary extragonadal germ cell tumors: an immunohistochemical study of 131 cases. *Mod Pathol*. 2011;24:288-296.
1207. Wanggou S, Jiang X, Li Q, et al. HESRG: a novel biomarker for intracranial germinoma and embryonal carcinoma. *J Neurooncol*. 2012;106:251-259.
1208. Pantazis G, Harter PN, Capper D, et al. The embryonic stem cell factor UTF1 serves as a reliable diagnostic marker for germinomas. *Pathology*. 2014;46:225-229.
1209. Mei K, Liu A, Allan RW, et al. Diagnostic utility of SALL4 in primary germ cell tumors of the central nervous system: a study of 77 cases. *Mod Pathol*. 2009;22:1628-1636.
1210. Rushing EJ, Sandberg GD, Judkins AR, et al. Germinoma: unusual imaging and pathological characteristics. Report of two cases. *J Neurosurg*. 2006;104:143-148.
1211. Millard NE, Dunkel IJ. Advances in the management of central nervous system germ cell tumors. *Curr Oncol Rep*. 2014;16:393.
1212. Matsutani M, Sano K, Takakura K, et al. Primary intracranial germ cell tumors: a clinical analysis of 153 histologically verified cases. *J Neurosurg*. 1997;86:446-455.
1213. Poremba C, Dockhorn-Dworniczak B, Merritt V, et al. Immature teratomas of different origin carried by a pregnant mother and her fetus. *Diagn Mol Pathol*. 1993;2:131-136.
1214. Bjornsson J, Scheithauer BW, Okazaki H, Leech RW. Intracranial germ cell tumors: pathobiological and immunohistochemical aspects of 70 cases. *J Neuropathol Exp Neurol*. 1985;44:32-46.
1215. Preissig SH, Smith MT, Huntington HW. Rhabdomyosarcoma arising in a pineal teratoma. *Cancer*. 1979;44:281-284.
1216. Skullerud K, Stenwig AE, Brandtzaeg P, et al. Intracranial primary leiomyosarcoma arising in a teratoma of the pineal area. *Clin Neuropathol*. 1995;14:245-248.
1217. Freilich RJ, Thompson SJ, Walker RW, Rosenblum MK. Adenocarcinomatous transformation of intracranial germ cell tumors. *Am J Surg Pathol*. 1995;19:537-544.
1218. Kim ES, Kwon MJ, Song JH, et al. Adenocarcinoma arising from intracranial recurrent mature teratoma and featuring mutated KRAS and wild-type BRAF genes. *Neuropathology*. 2015;35:44-49.
1219. Heimdal K, Evensen SA, Fossa SD, et al. Karyotyping of a hematologic neoplasia developing shortly after treatment for cerebral extragonadal germ cell tumor. *Cancer Genet Cytogenet*. 1991;57:41-46.
1220. Valdez R, McKeever P, Finn WG, et al. Composite germ cell tumor and B-cell non-Hodgkin's lymphoma arising in the sella turcica. *Hum Pathol*. 2002;33:1044-1047.
1221. Ironside JW, Jefferson AA, Royds JA, et al. Carcinoid tumour arising in a recurrent intradural spinal teratoma. *Neuropathol Appl Neurobiol*. 1984;10:479-489.
1222. al-Sarraj ST, Parmar D, Dean AF, et al. Clinicopathological study of seven cases of spinal cord teratoma: a possible germ cell origin. *Histopathology*. 1998;32:51-56.
1223. Naudin ten Cate L, Vermeij-Keers C, Smit DA, et al. Intracranial teratoma with multiple fetuses: pre- and post-natal appearance. *Hum Pathol*. 1995;26:804-807.
1224. Kim JW, Park SH, Park SS, et al. Fetus-in-fetu in the cranium of a 4-month-old boy: histopathology and short tandem repeat polymorphism-based genotyping. Case report. *J Neurosurg Pediatr*. 2008;1:410-414.
1225. Shaffrey ME, Lanzino G, Lopes MB, et al. Maturation of intracranial immature teratomas. Report of two cases. *J Neurosurg*. 1996;85:672-676.
1226. Oya S, Saito A, Okano A, et al. The pathogenesis of intracranial growing teratoma syndrome: proliferation of tumor cells or formation of multiple expanding cysts? Two case reports and review of the literature. *Childs Nerv Syst*. 2014;30:1455-1461.
1227. Sawamura Y, Ikeda J, Shirato H, et al. Germ cell tumours of the central nervous system: treatment consideration based on 111 cases and their long-term clinical outcomes. *Eur J Cancer*. 1998;34:104-110.
1228. Schild SE, Scheithauer BW, Haddock MG, et al. Histologically confirmed pineal tumors and other germ cell tumors of the brain. *Cancer*. 1996;78:2564-2571.
1229. Ide M, Jimbo M, Yamamoto M, et al. Spontaneous regression of primary intracranial germinoma. A case report. *Cancer*. 1997;79:558-563.
1230. Sukov WR, Cheville JC, Giannini C, et al. Isochromosome 12p and polysomy 12 in primary central nervous system germ cell tumors: frequency and association with clinicopathologic features. *Hum Pathol*. 2010;41:232-238.
1231. Di Rocco F, Sabatino G, Koutzoglou M, et al. Neurocutaneous melanosis. *Childs Nerv Syst*. 2004;20:23-28.
1232. Kusters-Vandevelde HV, Kusters B, van Engen-van Grunsven AC, et al. Primary melanocytic tumors of the central nervous system: a review with focus on molecular aspects. *Brain Pathol*. 2015;25:209-226.
1233. Cajaiba MM, Benjamin D, Halaban R, Reyes-Mugica M. Metastatic peritoneal neurocutaneous melanocytosis. *Am J Surg Pathol*. 2008;32:156-161.
1234. Samadian M, Nejad AM, Bakhtevari MH, et al. Primary meningeal melanocytoma in the left temporal lobe associated with nevus Ota: a case report and review of the literature. *World Neurosurg*. 2015;84(2):567-573.
1235. Munoz-Hidalgo L, Lopez-Gines C, Navarro L, et al. BRAF V600E mutation in two distinct meningeal melanocytomas associated with a nevus of Ota. *J Clin Oncol*. 2014;32:e72-e75.
1236. Theunissen P, Spincemaille G, Pannebakker M, Lambers J. Meningeal melanoma associated with nevus of Ota: case report and review. *Clin Neuropathol*. 1993;12:125-129.
1237. Haddad FS, Jamali AF, Rebeiz JJ, et al. Primary malignant melanoma of the gasserian ganglion associated with neurofibromatosis. *Surg Neurol*. 1991;35:310-316.
1238. Brat DJ, Giannini C, Scheithauer BW, Burger PC. Primary melanocytic neoplasms of the central nervous systems. *Am J Surg Pathol*. 1999;23:745-754.
1239. Tandon N, O'Neill TJ, Vollmer DG, Wang M. Intraventricular occurrence of a melanocytoma. *J Neurosurg*. 2008;109:480-485.
1240. Alameda F, Lloreta J, Galito E, et al. Meningeal melanocytoma: a case report and literature review. *Ultrastruct Pathol*. 1998;22:349-356.
1241. Horn EM, Nakaji P, Coons SW, Dickman CA. Surgical treatment for intramedullary spinal cord melanocytomas. *J Neurosurg Spine*. 2008;9:48-54.
1242. Gelman BB, Trier TT, Chaljub G, et al. Oncocytoma in melanocytoma of the spinal cord: case report. *Neurosurgery*. 2000;47:756-759.
1243. Koenigsmann M, Jautzke G, Unger M, et al. June 2002: 57-year-old male with leptomeningeal and liver tumors. *Brain Pathol*. 2002;12:519-521.
1244. Chacko G, Rajshekhar V. Thoracic intramedullary melanocytoma with long-term follow-up. *J Neurosurg Spine*. 2008;9:589-592.
1245. Tosaka M, Tamura M, Oriuchi N, et al. Cerebrospinal fluid immunocytochemical analysis and neuroimaging in the diagnosis of primary leptomeningeal melanoma. Case report. *J Neurosurg*. 2001;94:528-532.
1246. Wang F, Qiao G, Lou X, et al. Malignant transformation of intracranial meningeal melanocytoma. Case report and review of

the literature. *Neuropathology*. 2011;31:414-420.
1247. Adamek D, Kaluza J, Stachura K. Primary balloon cell malignant melanoma of the right temporo-parietal region arising from meningeal naevus. *Clin Neuropathol*. 1995;14:29-32.
1248. Murali R, Wiesner T, Rosenblum MK, Bastian BC. GNAQ and GNA11 mutations in melanocytomas of the central nervous system. *Acta Neuropathol*. 2012;123:457-459.
1249. Kusters-Vandevelde HV, Creytens D, Grunsven AC, et al. SF3B1 and EIF1AX mutations occur in primary leptomeningeal melanocytic neoplasms; yet another similarity to uveal melanomas. *Acta Neuropathol Commun*. 2016;4:5.
1250. Pedersen M, Kusters-Vandevelde HV, Viros A, et al. Primary melanoma of the CNS in children is driven by congenital expression of oncogenic NRAS in melanocytes. *Cancer Discov*. 2013;3:458-469.
1251. Sonneland PR, Scheithauer BW, LeChago J, et al. Paraganglioma of the cauda equina region. Clinicopathologic study of 31 cases with special reference to immunocytology and ultrastructure. *Cancer*. 1986;58:1720-1735.
1252. Semaan MT, Megerian CA. Current assessment and management of glomus tumors. *Curr Opin Otolaryngol Head Neck Surg*. 2008;16:420-426.
1253. Moran CA, Rush W, Mena H. Primary spinal paragangliomas: a clinicopathological and immunohistochemical study of 30 cases. *Histopathology*. 1997;31:167-173.
1254. Reithmeier T, Gumprecht H, Stolzle A, Lumenta CB. Intracerebral paraganglioma. *Acta Neurochir (Wien)*. 2000;142:1063-1066.
1255. Deb P, Sharma MC, Gaikwad S, et al. Cerebellopontine angle paraganglioma—report of a case and review of literature. *J Neurooncol*. 2005;74:65-69.
1256. Prayson RA, Chahlavi A, Luciano M. Cerebellar paraganglioma. *Ann Diagn Pathol*. 2004;8:219-223.
1257. Naggara O, Varlet P, Page P, et al. Suprasellar paraganglioma: a case report and review of the literature. *Neuroradiology*. 2005;47:753-757.
1258. Scheithauer BW, Parameswaran A, Burdick B. Intrasellar paraganglioma: report of a case in a sibship of von Hippel-Lindau disease. *Neurosurgery*. 1996;38:395-399.
1259. Thines L, Lejeune JP, Ruchoux MM, Assaker R. Management of delayed intracranial and intraspinal metastases of intradural spinal paragangliomas. *Acta Neurochir (Wien)*. 2006;148:63-66, discussion 66.
1260. Masuoka J, Brandner S, Paulus W, et al. Germline SDHD mutation in paraganglioma of the spinal cord. *Oncogene*. 2001;20:5084-5086.
1261. Llena JF, Wisoff HS, Hirano A. Gangliocytic paraganglioma in cauda equina region, with biochemical and neuropathological studies. Case report. *J Neurosurg*. 1982;280-282.
1262. Shankar GM, Chen L, Kim AH, et al. Composite ganglioneuroma-paraganglioma of the filum terminale. *J Neurosurg Spine*. 2010;12:709-713.
1263. Caccamo DV, Ho KL, Garcia JH. Cauda equina tumor with ependymal and paraganglionic differentiation. *Hum Pathol*. 1992;23:835-838.
1264. Gaffney EF, Doorly T, Dinn JJ. Aggressive oncocytic neuroendocrine tumour ('oncocytic paraganglioma') of the cauda equina. *Histopathology*. 1986;10:311-319.
1265. Bayar MA, Erdem Y, Tanyel O, et al. Spinal chordoma of the terminal filum. Case report. *J Neurosurg*. 2002;96:236-238.
1266. Warnick RE, Raisanen J, Kaczmar T Jr, et al. Intradural chordoma of the tentorium cerebelli. Case report. *J Neurosurg*. 1991;74:508-511.
1267. Commins D, Baran GA, Molleston M, Vollmer D. Hypothalamic chordoma. Case report. *J Neurosurg*. 1994;81:130-132.
1268. Ho KL. Ecchordosis physaliphora and chordoma: a comparative ultrastructural study. *Clin Neuropathol*. 1985;4:77-86.
1269. Wolfe JT 3rd, Scheithauer BW. "Intradural chordoma" or "giant ecchordosis physaliphora"? Report of two cases. *Clin Neuropathol*. 1987;6:98-103.
1270. Coffin CM, Swanson PE, Wick MR, Dehner LP. Chordoma in childhood and adolescence. A clinicopathologic analysis of 12 cases. *Arch Pathol Lab Med*. 1993;117:927-933.
1271. Mobley BC, McKenney JK, Bangs CD, et al. Loss of SMARCB1/INI1 expression in poorly differentiated chordomas. *Acta Neuropathol*. 2010;120:745-753.
1272. Choy E, MacConaill LE, Cote GM, et al. Genotyping cancer-associated genes in chordoma identifies mutations in oncogenes and areas of chromosomal loss involving CDKN2A, PTEN, and SMARCB1. *PLoS ONE*. 2014;9:e101283.
1273. Chittiboina P, Lonser RR. Von Hippel-Lindau disease. *Handb Clin Neurol*. 2015;132:139-156.
1274. Lemeta S, Pylkkanen L, Sainio M, et al. Loss of heterozygosity at 6q is frequent and concurrent with 3p loss in sporadic and familial capillary hemangioblastomas. *J Neuropathol Exp Neurol*. 2004;63:1072-1079.
1275. Lonser RR, Huntoon K, Butman JA, et al. 145 Natural history of central nervous system hemangioblastomas in von hippel-lindau disease. *Neurosurgery*. 2013;60(suppl 1):168.
1276. Mills SA, Oh MC, Rutkowski MJ, et al. Supratentorial hemangioblastoma: clinical features, prognosis, and predictive value of location for von Hippel-Lindau disease. *Neuro Oncol*. 2012;14:1097-1104.
1277. Nonaka D, Rodriguez J, Rosai J. Extraneural hemangioblastoma: a report of 5 cases. *Am J Surg Pathol*. 2007;31:1545-1551.
1278. Doyle LA, Fletcher CD. Peripheral hemangioblastoma: clinicopathologic characterization in a series of 22 cases. *Am J Surg Pathol*. 2014;38(1):119-127.
1279. Hasselblatt M, Jeibmann A, Gerss J, et al. Cellular and reticular variants of haemangioblastoma revisited: a clinicopathologic study of 88 cases. *Neuropathol Appl Neurobiol*. 2005;31:618-622.
1280. Polydorides AD, Rosenblum MK, Edgar MA. Metastatic renal cell carcinoma to hemangioblastoma in von Hippel-Lindau disease. *Arch Pathol Lab Med*. 2007;131:641-645.
1281. Glasker S, Kruger MT, Klingler JH, et al. Hemangioblastomas and neurogenic polyglobulia. *Neurosurgery*. 2013;72:930-935, discussion 935.
1282. Medvedev YA, Matsko DE, Zubkov YN, et al. Coexistent hemangioblastoma and arteriovenous malformation of the cerebellum. Case report. *J Neurosurg*. 1991;75:121-125.
1283. Glasker S, Li J, Xia JB, et al. Hemangioblastomas share protein expression with embryonal hemangioblast progenitor cell. *Cancer Res*. 2006;66:4167-4172.
1284. Shively SB, Falke EA, Li J, et al. Developmentally arrested structures preceding cerebellar tumors in von Hippel-Lindau disease. *Mod Pathol*. 2011;24:1023-1030.
1285. North PE, Mizeracki A, Mihm MC Jr, Mrak RE. GLUT1 immunoreaction patterns reliably distinguish hemangioblastoma from metastatic renal cell carcinoma. *Clin Neuropathol*. 2000;19:131-137.
1286. Ishizawa K, Komori T, Hirose T. Stromal cells in hemangioblastoma: neuroectodermal differentiation and morphological similarities to ependymoma. *Pathol Int*. 2005;55:377-385.
1287. Becker I, Paulus W, Roggendorf W. Histogenesis of stromal cells in cerebellar hemangioblastomas. An immunohistochemical study. *Am J Pathol*. 1989;134:271-275.
1288. Ismail SM, Jasani B, Cole G. Histogenesis of haemangioblastomas: an immunocytochemical and ultrastructural study in a case of von Hippel-Lindau syndrome. *J Clin Pathol*. 1985;38:417-421.
1289. Barresi V, Ieni A, Branca G, Tuccari G. Brachyury: a diagnostic marker for the differential diagnosis of chordoma and hemangioblastoma versus neoplastic histological mimickers. *Dis Markers*. 2014;2014:514753.
1290. Rivera AL, Takei H, Zhai J, et al. Useful immunohistochemical markers in differentiating hemangioblastoma versus metastatic renal cell carcinoma. *Neuropathology*. 2010;30:580-585.
1291. Weinbreck N, Marie B, Bressenot A, et al. Immunohistochemical markers to distinguish between hemangioblastoma and metastatic clear-cell renal cell carcinoma in the brain: utility of aquaporin1 combined with cytokeratin AE1/AE3 immunostaining. *Am J Surg Pathol*. 2008;32:1051-1059.
1292. Roy S, Chu A, Trojanowski JQ, Zhang PJ. D2-40, a novel monoclonal antibody against the M2A antigen as a marker to distinguish hemangioblastomas from renal cell carcinomas. *Acta Neuropathol*. 2005;109:497-502.
1293. Weil RJ, Vortmeyer AO, Zhuang Z, et al. Clinical and molecular analysis of disseminated hemangioblastomatosis of the central nervous system in patients without von Hippel-Lindau disease. Report of four cases. *J Neurosurg*. 2002;96:775-787.
1294. Reyes-Botero G, Gallego Perez-Larraya J, Sanson M. Sporadic CNS hemangioblastomatosis, response to sunitinib and secondary polycythemia. *J Neurooncol*. 2012;107:439-440.
1295. Hasselblatt M, Jozwiak J, Mayer K, et al. Hypothalamic papillary tumor in a patient with tuberous sclerosis. *Am J Surg Pathol*. 2008;32:1578-1580.
1296. Gessi M, Japp AS, Dreschmann V, et al. High-resolution genomic analysis of cribriform neuroepithelial tumors of the central nervous system. *J Neuropathol Exp Neurol*. 2015;74:970-974.
1297. Erdogan S, Rodriguez FJ, Scheithauer BW, et al. Malignant myoepithelioma of cranial dura. *Am J Surg Pathol*. 2007;31:807-811.
1298. Kim SH, Paik S, Yoon DH, Kim TS. Oncocytoma of the spinal cord. Case report. *J Neurosurg*. 2001;94:310-312.
1299. Rodriguez FJ, Scheithauer BW, Erickson LA, et al. Ectopic low-grade adrenocortical carcinoma in the spinal region: immunohistochemical and molecular cytogenetic study of a pediatric case. *Am J Surg Pathol*. 2009;33:142-148.
1300. Kleinschmidt-DeMasters BK, Winston KR, Rubinstein D, Samuels MH. Ectopic pituitary adenoma of the third ventricle. Case report. *J Neurosurg*. 1990;72:139-142.
1301. Lindboe CF, Unsgard G, Myhr G, Scott H. ACTH and TSH producing ectopic suprasellar pituitary adenoma of the hypothalamic region: case report. *Clin Neuropathol*. 1993;12:138-141.
1302. Cilluffo JM, Harner SG, Miller RH. Intracranial ceruminous gland adenocarcinoma. *J Neurosurg*. 1981;55:952-956.

1303. Paulus W, Romstock J, Weidenbecher M, et al. Middle ear adenocarcinoma with intracranial extension. Case report. *J Neurosurg*. 1999;90:555-558.
1304. Dolan EJ, Schwartz ML, Lewis AJ, et al. Adenoid cystic carcinoma: an unusual neurosurgical entity. *Can J Neurol Sci*. 1985;12:65-68.
1305. Piepmeier JM, Virapongse C, Kier EL, et al. Intracranial adenocystic carcinoma presenting as a primary brain tumor. *Neurosurgery*. 1983;12:348-352.
1306. Redman BG, Tapazoglou E, Al-Sarraf M. Meningeal carcinomatosis in head and neck cancer. Report of six cases and review of the literature. *Cancer*. 1986;58:2656-2661.
1307. Steel TR, Allibone J, Revesz T, et al. Intradural neurotropic spread of malignant mesothelioma. Case report and review of the literature. *J Neurosurg*. 1998;88:122-125.
1308. Byrne TN. Spinal cord compression from epidural metastases. *N Engl J Med*. 1992;327:614-619.
1309. Kokkoris CP. Leptomeningeal carcinomatosis. How does cancer reach the pia-arachnoid? *Cancer*. 1983;51:154-160.
1310. Pekmezci M, Perry A. Neuropathology of brain metastases. *Surg Neurol Int*. 2013;4:S245-S255.
1311. LeRoux PD, Berger MS, Elliott JP, Tamimi HK. Cerebral metastases from ovarian carcinoma. *Cancer*. 1991;67:2194-2199.
1312. Espat NJ, Bilsky M, Lewis JJ, et al. Soft tissue sarcoma brain metastases. Prevalence in a cohort of 3829 patients. *Cancer*. 2002;94:2706-2711.
1313. Perry JR, Bilbao JM. Metastatic alveolar soft part sarcoma presenting as a dural-based cerebral mass. *Neurosurgery*. 1994;34:168-170.
1314. Portera CA Jr, Ho V, Patel SR, et al. Alveolar soft part sarcoma: clinical course and patterns of metastasis in 70 patients treated at a single institution. *Cancer*. 2001;91:585-591.
1315. Ariza A, Kim JH. Kaposi's sarcoma of the dura mater. *Hum Pathol*. 1988;19:1461-1463.
1316. Trumble ER, Smith RM, Pearl G, Wall J. Transplacental transmission of metastatic melanoma to the posterior fossa. Case report. *J Neurosurg*. 2005;103:191-193.
1317. Costigan DA, Winkelman MD. Intramedullary spinal cord metastasis. A clinicopathological study of 13 cases. *J Neurosurg*. 1985;62:227-233.
1318. Posner JB. *Neurologic Complications of Cancer*. Philadelphia: F.A. Davis; 1995.
1319. Delattre JY, Krol G, Thaler HT, Posner JB. Distribution of brain metastases. *Arch Neurol*. 1988;45:741-744.
1320. Kleinschmidt-DeMasters BK. Dural metastases. A retrospective surgical and autopsy series. *Arch Pathol Lab Med*. 2001;125:880-887.
1321. Cosgrove MM, Rich KA, Kunin SA, et al. Keratin intermediate filament expression in astrocytic neoplasms: analysis by immunocytochemistry, western blot, and northern hybridization. *Mod Pathol*. 1993;6:342-347.
1322. Perry A, Parisi JE, Kurtin PJ. Metastatic adenocarcinoma to the brain: an immunohistochemical approach. *Hum Pathol*. 1997;28:938-943.
1323. Srodon M, Westra WH. Immunohistochemical staining for thyroid transcription factor-1: a helpful aid in discerning primary site of tumor origin in patients with brain metastases. *Hum Pathol*. 2002;33:642-645.
1324. Galloway M, Sim R. TTF-1 staining in glioblastoma multiforme. *Virchows Arch*. 2007;451:109-111.
1325. Vannier A, Gray F, Gherardi R, et al. Diffuse subependymal periventricular metastases. Report of three cases. *Cancer*. 1986;58:2720-2725.
1326. Floeter MK, So YT, Ross DA, Greenberg D. Miliary metastasis to the brain: clinical and radiologic features. *Neurology*. 1987;37:1817-1818.
1327. O'Neill BP, Dinapoli RP, Okazaki H. Cerebral infarction as a result of tumor emboli. *Cancer*. 1987;60:90-95.

44 Pituitary Gland

B.K. Kleinschmidt-DeMasters and Arie Perry

CHAPTER CONTENTS

Overview of sellar region masses, *2086*
Embryologic origins of anterior and posterior pituitary gland, *2086*
Anterior pituitary hormones and transcription factors, *2087*
Normal pituitary cell types, *2089*
Pituitary adenomas, *2090*
General features, *2090*
Grading, Size, Invasiveness, and MIB-1 Labeling Rate (Designation of "Atypical" No Longer Utilized), *2094*
Intraoperative evaluation, immunohistochemistry, and electron microscopy, *2096*
Histologic features of adenoma subtypes, *2098*
Ectopic pituitary adenoma, *2106*
Pituitary apoplexy, *2106*
Mixed pituitary adenoma–gangliocytoma, *2106*
Pituitary carcinoma, *2106*
Rathke cleft cyst, *2106*
Hypophysitis, *2107*
Craniopharyngioma, *2107*
Pituicytoma, spindle cell oncocytoma, and granular cell tumor of neurohypophysis, *2108*
Metastatic tumors, *2110*

Overview of Sellar Region Masses

The overwhelming majority of sellar region masses are pituitary adenomas (85%), followed by craniopharyngioma (3%), Rathke cleft cyst (2%), meningioma (1%), and metastases (0.5%); other lesions such as hypophysitis, pituicytoma, spindle cell oncocytoma, and granular cell tumor of neurohypophysis are rare.[1] However, when these other sellar masses do occur, most so closely mimic pituitary adenoma on neuroimaging studies that the clinical/neuroimaging diagnosis is incorrect and thus, diagnosis falls to the surgical pathologist, necessitating discussion of their histologic features.

Today, immunohistochemistry (IHC) has largely supplanted electron microscopy (EM) for much of general surgical pathology, and while there is still a possible role for the latter in diagnosing very rare subtypes of pituitary adenomas, the chapter will be directed towards practicing surgical pathologists who generally do not have ready access to EM. Previous editions of this book,[2] as well as the World Health Organization (WHO) fascicle,[3] can be consulted for gross and EM images. Antibodies specific for anterior pituitary hormone immunohistochemical antibodies, as well as for those directed against transcription factors (pituitary transcription factor-1 [PIT1] for prolactin [PRL]-, growth hormone [GH]-, and/or thyroid-stimulating hormone [TSH]-immunoreactive tumors, steroidogenic factor-1 [SF1] for gonadotroph adenomas, TPIT for corticotroph adenomas), are becoming more widely utilized. However, not all are readily available, and several recently proposed alternate ways to use these antibodies in smaller panels for pituitary adenoma classification will be discussed.

Embryologic Origins of Anterior and Posterior Pituitary Gland

The anterior lobe (pars distalis) is derived from Rathke pouch, a tube of tissue which invaginates from the fetal oral (stomodeal) ectoderm anterior to the roof of the primitive mouth, forms by the fourth to fifth week of human gestation,[4,5] migrates dorsally towards the base of the brain, and comes in contact with the diencephalon. At the sixth fetal week, a down-pouching of the floor of the third ventricle and diencephalon forms and Rathke pouch detaches from the oral epithelium and becomes a separate structure. Cellular proliferation begins, with the ventral part of Rathke pouch giving rise to the pars distalis and the dorsal part to the pars intermedia.[5] The diencephalic diverticulum thereafter narrows and is obliterated.

The infundibular stalk and posterior gland arise from the infundibular anlage in the floor of the third ventricle.[6] Early in gestation, cells in the infundibular anlage and ependymal and subependymal cells of the fetal third ventricle manifest nuclear immunostaining for TTF1.[6] As early as 12 weeks' gestation, the posterior gland (neurohypophysis) shows nuclear TTF1 immunoreactive pituicytes (Fig. 44.1), and this is retained in adults (Fig. 44.2).[7] In contrast, the immature cerebral cortex and lateral ventricles show no TTF1 immunoreactivity; anterior pituitary (adenohypophysis) cells are

Abstract

The overwhelming majority of sellar region masses are pituitary adenomas (85%), followed by craniopharyngioma (3%), Rathke cleft cyst (2%), meningioma (1%), and metastases (0.5%); other lesions such as hypophysitis, pituicytoma, spindle cell oncocytoma, and granular cell tumor of neurohypophysis are rare. However, when these other sellar masses do occur, most so closely mimic pituitary adenoma on neuroimaging studies that the clinical/neuroimaging diagnosis is incorrect, and thus diagnosis falls to the surgical pathologist, necessitating discussion of their histologic features. Today, immunohistochemistry (IHC) has largely supplanted electron microscopy (EM) for much of general surgical pathology, and while there is still a possible role for the latter in diagnosing very rare subtypes of pituitary adenomas, the chapter is directed toward practicing surgical pathologists who generally do not have ready access to EM. Antibodies specific for anterior pituitary hormone immunohistochemical antibodies usually allow ready subclassification of pituitary adenomas, but subtyping is significantly augmented by the use of IHCs directed against transcription factors (PIT1 [pituitary transcription factor-1] for prolactin, growth hormone, and/or thyroid-stimulating hormone [TSH] immunoreactive tumors, SF1 [steroidogenic factor-1] for gonadotroph adenomas, TPIT for corticotroph adenomas). The terminology of "null cell" adenoma today is restricted to uncommon hormone-negative/transcription-factor negative adenomas. Thyroid transcription factor 1 (TTF1) shows nuclear immunoreactivity in the vast majority of pituicytomas, spindle cell oncocytomas, and granular cell tumors of neurohypophysis and further aids in diagnosis.

Keywords

SF1,
PIT1,
TTF1,
pituitary hormone,
immunohistochemistry,
pituitary adenoma

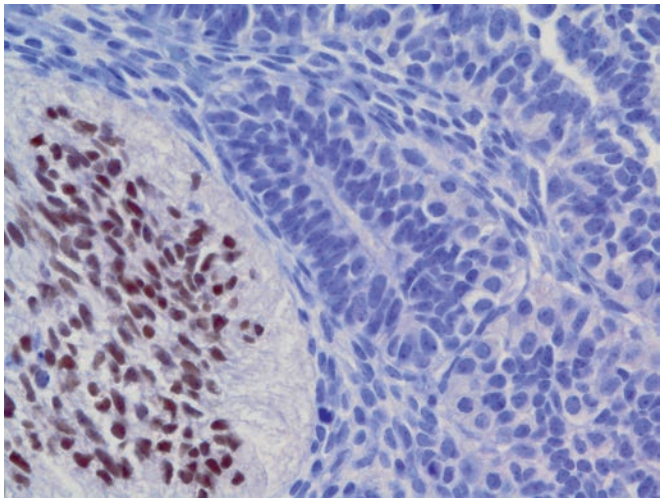

Figure 44.1 Fetal pituitary gland at 12 weeks' intrauterine gestational age shows TTF1 immunoreactive nuclei already identifiable in the posterior gland *(at left)* but not in the anterior gland *(at right)*.

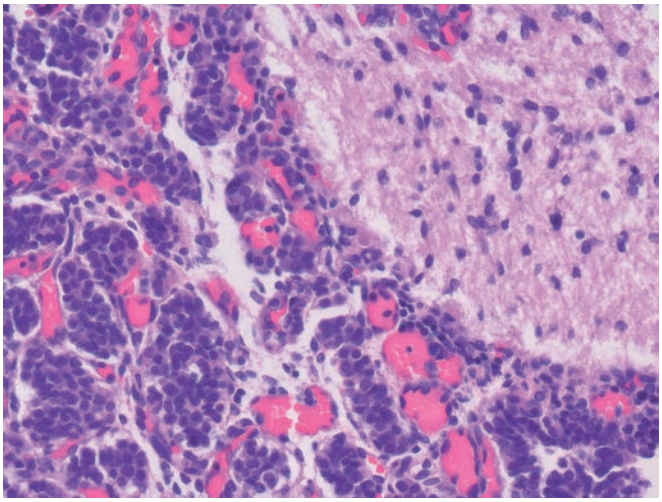

Figure 44.3 Fetal pituitary gland at 22 weeks' intrauterine gestation shows clear distinction between fibrillary posterior *(upper right)* and highly vascular epithelial anterior *(lower left)* portions of the gland.

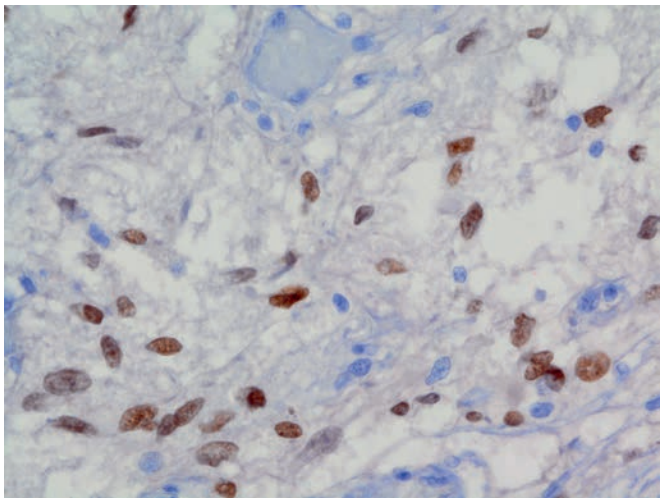

Figure 44.2 Adult posterior pituitary gland with nuclear TTF1 immunoreactivity; TTF1 IHC does not distinguish between normal posterior gland and TTF1 IHC(+) sellar region tumors, such as pituicytoma, spindle cell oncocytoma, and granular cell tumor of the neurohypophysis.

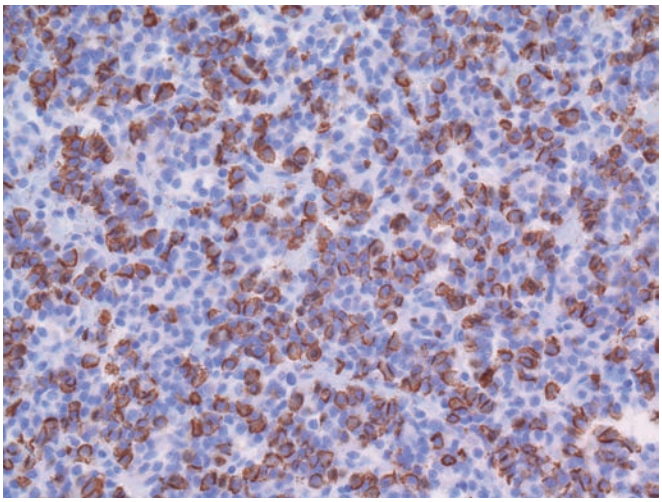

Figure 44.4 Fetal pituitary gland at 22 weeks' intrauterine gestation already shows immunoreactivity for anterior pituitary hormones, with growth hormone from the lateral wings illustrated here.

entirely negative, both embryologically and in adulthood.[6] Today it is recognized that 3 rare neurohypophyseal neoplasms, i.e., pituicytoma, spindle cell oncocytoma, and granular cell tumor, are derived from pituicytes and share this TTF1–positive lineage.[6–8] TTF1 IHC thus serves as an excellent diagnostic tool in differentiating these 3 tumors from TTF1 immunonegative pituitary adenomas, meningiomas, schwannomas, and other spindle cells masses.[9]

By the 14th week of human gestation, pituitary development is essentially complete.[5] The two parts of the pituitary gland are easily distinguished during fetal development (Fig. 44.3) and the anterior gland shows immunoreactivity for specific anterior pituitary hormones (Fig. 44.4). After birth, the gland grows rapidly, reaching a plateau at about 3 years of age; rapid growth again occurs between ages 10 and 13 years.[10] Modern neuroimaging allows distinction between adult anterior (adenohypophysis) and posterior (neurohypophysis) lobes (Fig. 44.5).

Anterior Pituitary Hormones and Transcription Factors

Six distinct hormone-secreting cell types appear during anterior pituitary gland development: the corticotroph (adrenocorticotropic hormone–secreting, ACTH), somatotroph (GH-secreting), lactotroph (PRL-secreting), mammosomatotroph parent cell for GH and PRL, gonadotroph (follicle-stimulating hormone- and luteinizing hormone-secreting, FSH and LH, in a single cell), and thyrotroph (TSH).[11] A number of different pituitary-specific transcription factors also play a role in the determination of pituitary cell lineages.[11,12] Of these, however, only PIT1 (associated with PRL-immunoreactive, GH-immunoreactive, and TSH-immunoreactive adenoma subtypes, Fig. 44.6) and SF1 (associated with gonadotroph lineage tumors, Fig. 44.7) are typically widely available for diagnostic use. Other hormones and transcription factors, such as TPIT, ER, and GATA2,

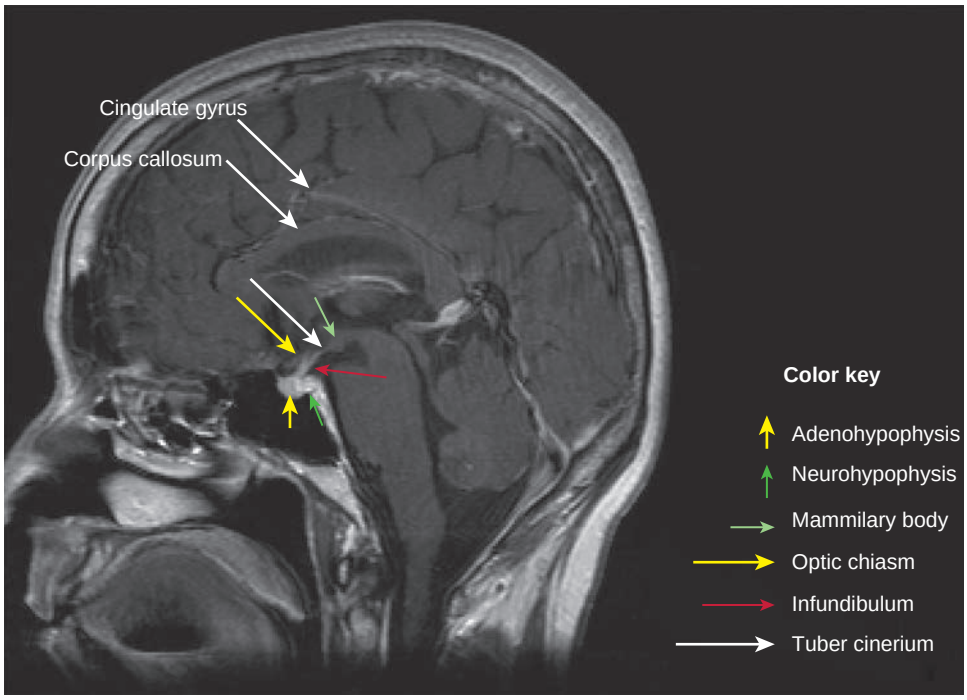

Figure 44.5 Sagittal magnetic resonance imaging (MRI) scan shows normal adult anterior and posterior pituitary and sellar region anatomy. The posterior pituitary "bright spot" is a normal MRI finding, referring to the intrinsically high T1 signal in the posterior pituitary attributed to the storage of vasopressin.

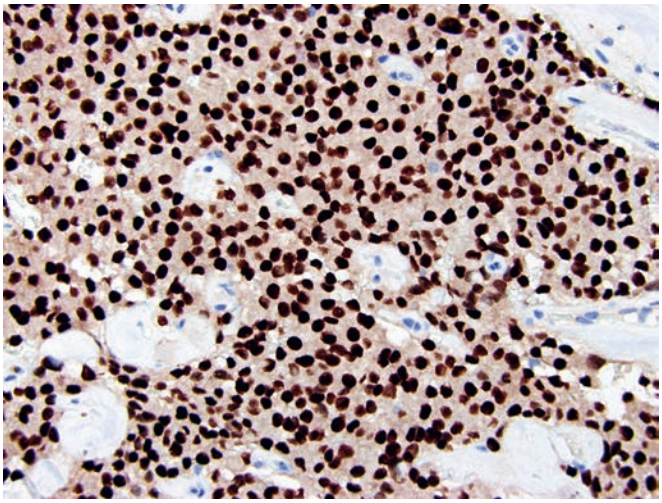

Figure 44.6 Diffuse immunoreactivity with PIT1 transcription factor identifies shared lineage in a large family of adenoma types: sparsely granulated prolactinomas, densely granulated prolactinomas, acidophil stem cell adenomas, densely granulated growth hormone adenomas, sparsely granulated growth hormone adenomas, mixed GH-PRL adenomas, thyrotroph adenomas, and plurihormonal PIT1-positive adenomas, formerly known as "silent type 3 adenomas."

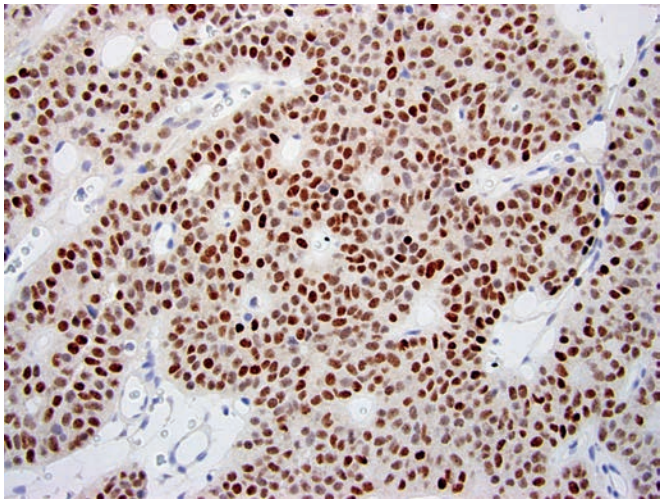

Figure 44.7 Steroidogenic factor-1 (SF1) is the transcription factor associated with gonadotroph adenomas, and the presence of nuclear IHC is the defining feature of this adenoma type, even if follicle-stimulating hormone (FSH) and/or luteinizing hormone (LH) IHC are not present. Null cell adenomas, in contrast, are SF1 negative, as well as negative for PIT1 and adrenocorticotropic hormone (ACTH).

are often only available at laboratories specializing in pituitary adenomas.[13]

Most pituitary adenomas show hormone expression profiles that recapitulate these expected developmental lineage pathways. Corticotrophs and gonadotrophs usually show only lineage-specific, relatively restricted hormonal expression driven by TPIT and SF1, respectively. For example, corticotroph cell adenomas usually show immunoreactivity for ACTH but none of the other hormone types. Thus, given the general unavailability of TPIT IHC in general practice, this family lineage is usually identified by ACTH immunoreactivity. However, a recent study showed that a minority (32/119) of hormone-negative adenomas with only a few (<1%) entrapped ACTH-positive cells were found to be Tpit immunoreactive, identifying them as clinically silent corticotroph adenomas.[14] Clinically, patients with these tumors had demographic and neuroimaging features similar to clinically silent corticotroph adenomas that have larger numbers

of ACTH-positive cells.[14] Thus, future categorization of corticotroph adenomas may require the use of more specific transcription factor immunostaining.

Gonadotroph adenomas manifest immunoreactivity only for FSH-β and/or LH-β, with or without alpha subunit (αSU) (all secreted by the same cell in the normal anterior pituitary gland), but not other hormone types. Estrogen receptor (ER) is also positive in gonadotrophs, but this antibody cannot substitute for FSH and LH in classifying gonadotroph adenomas, due to limited utility because of tissue fixation issues, as well as the fact that PRL-producing adenomas are also ER positive.[13] Currently, by definition, a gonadotroph adenoma must express FSH-β and/or LH-β, or, in the absence of availability of these antibodies, nuclear SF1, in order to distinguish it from other types of hormone-negative adenomas, although the majority of hormone-negative adenomas (i.e., negative for GH, PRL, ACTH, FSH, LH, TSH) are also, in fact, SF1-driven gonadotroph adenomas.[14]

In contrast, GH, PRL, and sometimes αSU and TSH are often coexpressed in PIT1-lineage tumors, due to their common transcription factor and precursor during fetal development—the "parent" mammosomatotroph cell. There is fluidity between four of the cell types (GH, PRL, mammosomatotroph, and TSH cells), which are able to reversibly transdifferentiate under physiologic or disease conditions[11]; this perhaps further explains the wide variation in expression of these hormone types in PIT1-driven adenomas. Table 44.1[13] and WHO 2017 Classification lists the lineages of pituitary adenomas, as driven by PIT1, SF1, and Tpit.

Table 44.1 Pituitary adenoma type by transcription factor family

Pituitary transcription factor (PIT1)	Densely granulated somatotroph (growth hormone) adenoma Sparsely granulated growth hormone adenoma Mixed growth hormone–prolactinoma Mammosomatotroph adenoma Sparsely granulated prolactin secreting (lactotroph) adenoma Densely granulated prolactin secreting (lactotroph) adenoma Acidophil stem cell adenoma Thyrotroph (TSH) adenoma Plurihormonal PIT1-positive adenomas (formerly silent subtype 3 adenoma) Clinically functioning GH/PRL/TSH plurihormonal adenomas with acromegaly and thyroid dysfunction
Steroidogenic factor (SF1)	Gonadotroph adenoma, with or without IHC(+) for FSH, LH*
TPIT	Densely granulated ACTH (corticotroph) adenoma Sparsely granulated ACTH (corticotroph) adenoma Crooke cell adenoma Clinically silent ACTH adenoma (either densely granulated, i.e., subtype I, or sparsely granulated, i.e., subtype II)
Transcription factor negative/unknown	Null cell adenoma†
Unusual plurihormonal types with hormonal combinations not readily explained by cytodifferentiation	Uncertain lineage

*Presence of SF1 defines gonadotroph adenoma even if hormone negative)
†Should be defined as SF1, PIT1, ACTH/TPIT IHC negative (TPIT IHC not as widely available); category severely reduced by use of transcription factor IHCs.
Adapted from Gomez-Hernandez K, Ezzat S, Asa SL, Mete Ö. Clinical implications of accurate subtyping of pituitary adenomas: perspectives from the treating physician. *Turk Patoloji Derg.* 2015;31(suppl 1):4–17 [WHO 2017 Classification].

Normal Pituitary Cell Types

The normal anterior gland is arranged in relatively evenly sized clusters of cells, known as acini, which contain an assortment of cell types (Fig. 44.8) and are outlined by reticulin fibers (Fig. 44.9). Hormone cell types in the anterior gland are not equally distributed, with larger numbers of PRL- and GH-positive cells in the lateral portions (lateral wings) and larger numbers of ACTH-positive cells, and to a lesser extent TSH-positive cells, in the median mucoid wedge. IHC (+) cells are more diffusely distributed.

Anterior pituitary cells are immunoreactive for synaptophysin, and variably with chromogranin A and CAM5.2. Virtually all pituitary adenomas are diffusely synaptophysin positive (Fig. 44.10) but show variable immunoreactivity with the other two antibodies. Box 44.1[15–19] lists the histochemical and IHC profiles of anterior and posterior pituitary gland cells as well as for adenomas in general.

In contrast to the complex anterior pituitary gland, the posterior lobe is more histologically monotonous and composed of unmyelinated axons and specialized glia. The gland has a glial, fibrillary appearance with prominent delicate blood vessels. Small fragments of normal posterior gland are often found in surgical resection specimens of Rathke cleft cysts and occasionally in resection specimens for pituitary adenomas. Swellings of axons that store oxytocin or vasopressin can occasionally be discerned on H&E (Herring bodies) and are normal findings. Anti-neurofilament is the single best stain for confirming the identity of the axon-rich posterior gland (Fig. 44.11) and distinguishes it from other lesions (such as pituicytoma, pilocytic astrocytoma, and meningioma) that might mimic normal posterior gland. Although it may be alarming to the surgical pathologist when these fragments of posterior gland are found within a surgical specimen, it is important to remember that the posterior gland is a storage site, not a synthesis site, for these hormones. Preoperative presentation of pituitary adenomas with diabetes insipidus is distinctly uncommon, and postoperative posterior pituitary gland dysfunction after modern trans-sphenoidal resection is usually limited to transient diabetes insipidus that resolves after several days. Removal of these small fragments of posterior gland appears to have no long-lasting deleterious clinical effects in most patients.

The infundibular stalk is part of the posterior lobe and contains closely juxtaposed, thin-walled blood vessels that transport hypothalamic release and release-inhibiting factors to the anterior gland. When the infundibular stalk is compressed by a mass lesion, or undergoes any traumatic or circulatory disruption, the delicate, thin-walled vessels of the hypothalamic–hypophyseal portal system are pinched off and hypothalamic release and release-inhibiting factors do not reach the pituitary gland. Under normal physiologic conditions, the one anterior pituitary hormone that is more tonically inhibited than stimulated is PRL; the hypothalamic inhibiting factor is dopamine. Interruption of the infundibular stalk by any mass

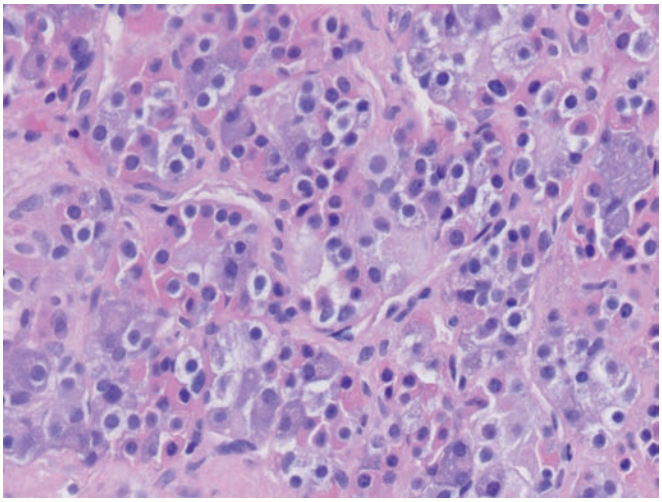

Figure 44.8 Normal anterior pituitary gland shows an assortment of cell types on H&E arranged in clusters known as acini; the different cell types vary in numbers between the lateral wings, where more GH and PRL cells are located, versus the median wedge where more ACTH cells are found.

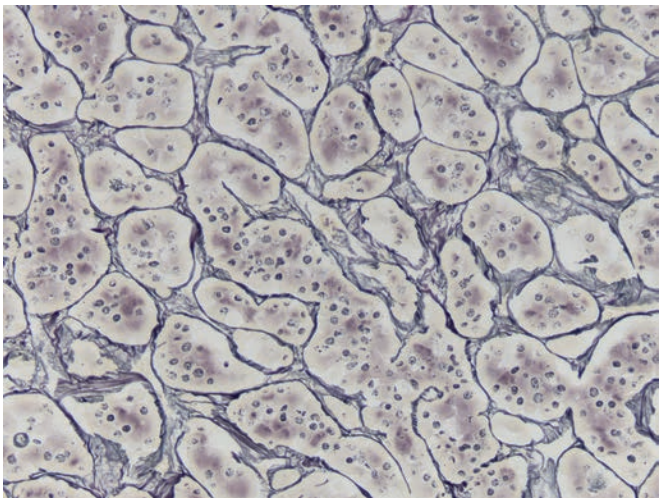

Figure 44.9 Reticulin stain better allows for appreciation of the normal acinar pattern of the anterior pituitary gland than does H&E staining.

lesion will abrogate passage of inhibitory dopamine to the anterior gland and result in hyperprolactinemia of a modest degree (30–200 ng/dL [or 250 ng/dL]).[20]

Pituitary Adenomas

General Features

Adenomas constitute 10%–15% of all intracranial neoplasms in most neurosurgery practices. The vast majority of adenomas are sporadic, and mutations in known oncogenes have little role in the pathogenesis of most sporadic pituitary adenomas.[21] The only somatic mutation that has been identified in a significant proportion of sporadic pituitary tumors is the *GSP* mutation, which causes constitutive activation of the cAMP pathway.[21] This mutation occurs in approximately 30%–40% of sporadic GH-secreting pituitary adenomas but not other adenoma types. Abnormalities in signaling and feedback pathways have been demonstrated in pituitary tumors, but they are unlikely to be the primary events responsible for sporadic tumors.[21] Pituitary adenomas are clonal, but no specific chromosomal alterations are characteristic. Increasing chromosomal imbalances have, however, been demonstrated in recurrent tumors.[22]

Familial adenomas account for 5% or less of all adenomas,[23–25] with germline mutations in the *MEN1* gene associated with multiple

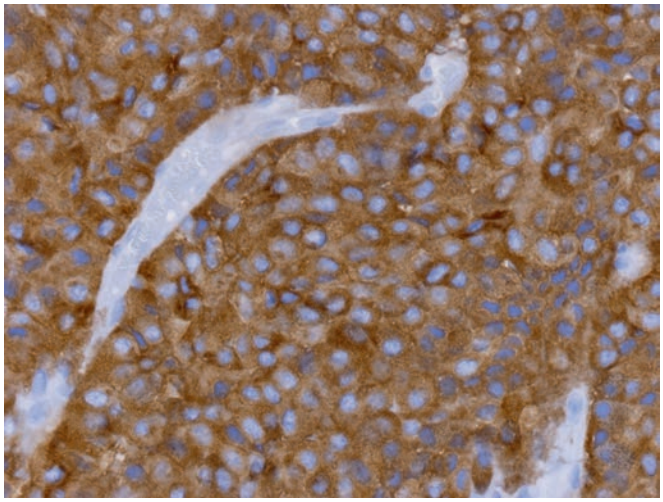

Figure 44.10 All pituitary adenomas, regardless of cell type, are diffusely immunoreactive for synaptophysin; blood vessels show lack of immunostaining in this image.

Box 44.1 Histochemical and general immunohistochemical profile for pituitary adenomas and normal gland

Reticulin: disruption of acinar pattern in all adenomas, expansion in rare hyperplasia

Periodic acid–Schiff (PAS): strongly positive in densely granulated ACTH adenomas

Cytokeratin 7: negative or only rare positive cells in almost all adenomas

Cytokeratin 20: positive in most densely granulated ACTH adenomas, negative in sparsely granulated GH adenomas; positive in all sparsely granulated but not in any densely granulated GH adenomas; positive in nontumorous Crooke cells in patients with hypercortisolism of any etiology

CAM5.2 (keratin 8/18): extensive and diffuse in all densely granulated ACTH adenomas, most densely granulated GH adenomas in perinuclear pattern, all sparsely granulated GH adenomas in a fibrous body pattern, most mixed GH-PRL adenomas, half of all prolactinomas, gonadotroph adenomas, and null cell adenomas

Synaptophysin: positive in normal anterior and posterior gland and all adenomas

Neurofilament: positive in axons in normal posterior pituitary gland

Glial fibrillary acidic protein, S-100: focally present in posterior gland; identifies nonhormone–containing folliculostellate cells in anterior pituitary gland

Chromogranin A: characteristic of gonadotroph adenomas; lacking in both PRL and ACTH functioning adenomas; poorly expressed in GH and GH-PRL functioning adenomas

Estrogen receptor: all prolactin IHC+ adenomas (sparsely, densely granulated lactotroph adenomas, acidophil stem cell, mixed GH-PRL, mammosomatotroph adenomas); gonadotroph adenomas (due to fixation issues can be focal and weakly positive)

Data from references[14–18].

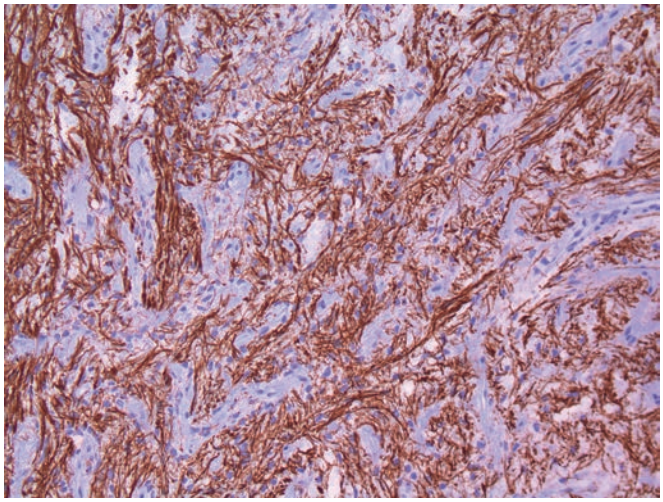

Figure 44.11 Normal posterior gland contains abundant axons, highlighted here by neurofilament immunohistochemistry; this can occasionally be very helpful in distinguishing normal posterior gland from spindle cell tumors such as schwannoma or meningioma that occasionally frequent the sellar region.

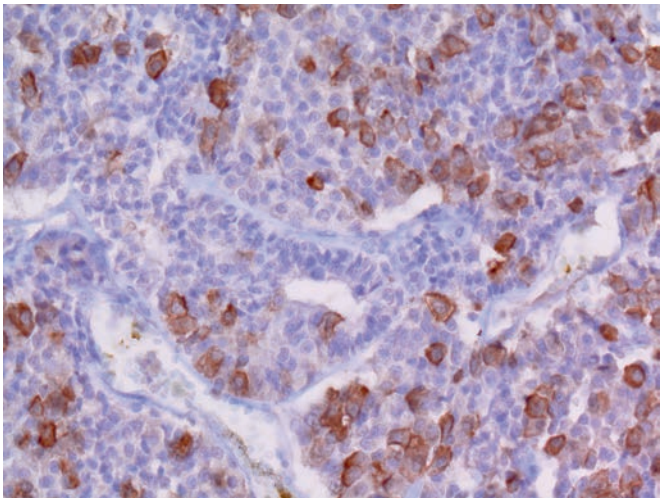

Figure 44.12 Pituitary blastoma is a very rare infantile pituitary tumor that is associated with *DICER1* mutation and is almost inevitably IHC(+) for ACTH, as in this example.

endocrine neoplasia (MEN) type 1 identified in 2.7% of individuals with apparently sporadic pituitary adenomas.[26] Pituitary adenoma predisposition syndromes include MEN 1 (gene *MEN1*, chromosome 11q13, results in all pituitary tumor types),[27] Carney complex (gene *PPKR1A*, chromosome 17q22–24, associated with GH- or PRL-secreting adenomas),[28] MEN 4 (gene *CDKN1B*, chromosome 12p13), and familial isolated pituitary adenomas (FIPA, gene *AIP*, chromosome 11q13.32).[23–25,29]

The practical issue for both pathologist and clinician is when to suspect/advise work-up for genetic mutations in a patient with a pituitary adenoma. While those with known multiple endocrine tumors and/or family history are obvious, it is becoming apparent that young patients with seemingly sporadic pituitary macroadenomas may be candidates for assessment. In one study of 174 macroadenoma patients of at least age 30 years, and without hypercalcemia or MEN 1-associated lesions, 12% had mutations of *AIP* or *MEN1* (8.6% and 3.4%, respectively). However, when pediatric patients (≤18 years old) were assessed, 22% (10/46 patients) had such mutations.[30]

No strong relationship to birth control pill use has been established. Endocrine end-organ failure is not related to pituitary adenoma development either, except in the rare instance of TSH hyperplasia in patients with longstanding hypothyroidism evolving into adenoma. Antecedent or concomitant hyperplasia with adenoma is exceedingly rare. Although hormone receptor mutations in pituitary cells is an attractive hypothesis for adenoma causation, at least in gonadotroph adenomas no activating mutations in the gonadotropin-releasing hormone *(GNRH)* receptor gene have been identified.[31]

Pituitary adenomas usually develop in the third to sixth decades, but pediatric examples certainly occur.[32] Infantile pituitary blastomas, which are rare lesions associated with *DICER1* mutations, are hormonally active and at least focally immunoreactive for ACTH (Fig. 44.12); however, these represent an entity distinct from pediatric pituitary adenomas.[33] Pituitary adenomas are not related to *DICER1* mutations.

Conversely, pituitary adenomas coming to neurosurgical resection at the other extreme of the age spectrum are not rare. In a retrospective study from 1992 to 2002, detailing patients aged 75 years or older who had symptomatic lesions requiring neurosurgical intervention, pituitary adenomas were the third most frequent tumor type.[34]

The relative frequency of the various pituitary adenoma types differs, depending on whether one is looking at autopsy or surgical material (Table 44.2). Ezzat et al. found that 22.5% of persons harbor pituitary lesions on neuroimaging studies, and 14.5% of autopsy pituitary glands contain microadenomas.[35] The most frequently occurring adenoma found as an incidental finding at autopsy is the PRL-secreting adenoma (Fig. 44.13).[36]

As PRL-secreting adenomas are now routinely treated chemically with dopamine agonists such as bromocriptine, Parlodel, or cabergoline, patients no longer come to surgery unless they are drug intolerant or have other mitigating circumstances. In one of the largest series of 3489 pituitary tumors from nine centers in Germany,[1] FSH/LH cell adenomas predominated in surgical material (see Table 44.2); this study, as in most, however, antedates use of SF1 IHC and numbers may actually be even larger. ACTH-producing adenomas were fourth in incidence, and TSH-secreting tumors were very rare. Many clinically nonfunctional/clinically silent adenomas classified in the past as "null cell" are now recognized, with improved IHC, to either show focal individual cells that are immunoreactive for gonadotrophic (FSH, LH) hormones[3] and/or express SF1 (see Fig. 44.7) and thus occur within the same biologic spectrum and lineage pathway as gonadotroph adenomas. Indeed, the majority of both clinically silent/nonfunctioning and hormone-negative adenomas express SF1.[14] As noted above, the use of SF1 IHC divides gonadotroph adenomas from other types of hormone-negative adenomas, and the use of TPIT IHC may further reduce numbers of true null cell adenomas, although reliable commercially available antibodies have been lacking to date.[14] Two or more adenomas arising within the anterior pituitary gland of a single patient have also been reported, but these multiple lesions within the same gland of a patient are more commonly recognized at the time of autopsy when the entire pituitary gland is available for histologic review.[1] Double adenomas within a single patient's pituitary gland are less commonly recognized in surgically resected material.

Particularly complex are those clinically functioning adenomas that result in acromegaly and hyperprolactinemia, as detailed in Table 44.3.[13] Except for dual GH and PRL elevations, generally, only one, or rarely two, hormones are produced in sufficient quantities to result in elevated serum levels and produce clinically discernible endocrinopathies. If the tumor is inefficient at producing hormones,

Table 44.2 Comparison of pituitary adenoma types at surgery and postmortem exam

ADENOMA TYPE	ADENOMAS COMING TO SURGERY (%) (n = 3403)[a]	SUBCLINICAL ADENOMAS POSTMORTEM (%) (n = 334)[b]
Densely granulated GH cell adenoma	9.2	0.90
Sparsely granulated GH cell adenoma	6.3	1.20
Sparsely granulated prolactin cell adenoma	8.9	39.5
Densely granulated prolactin cell adenoma	0.3	—
Mixed bicellular GH/ prolactin cell adenoma	5.2	0.30
Mammosomatotroph adenoma	1.1	—
Acidophil stem cell adenoma	0.2	—
Densely granulated ACTH cell adenoma	7.2	8.08
Sparsely granulated ACTH cell adenoma	7.9	5.69
Crooke cell adenoma	0.03	0.30
TSH cell adenoma	1.5	0.60
FSH/LH (gonadotroph) cell adenoma	25.2	6.6
Null cell adenoma	19.8	23.1
Null cell adenoma, oncocytic variant	5.8	9.3
Plurihormonal adenoma, including plurihormonal PIT1-positive adenoma	1.3	2.7
Unclassified	2.1	1.8

[a]Data from Saeger W, Ludecke DK, Buchfelder M, et al. Pathohistological classification of pituitary tumors: 10 years of experience with the German Pituitary Tumor Registry. *Eur J Endocr.* 2007;156(2):203–216.
[b]Buurman H, Saeger W. Subclinical adenomas in postmortem pituitaries: classification and correlations to clinical data. *Eur J Endocr.* 2006;154(5): 753–758.

the mass effects and hypopituitarism predominate because of compression of the optic chiasm and normal gland.

Necessity of Subtyping of Pituitary Adenomas

Subtyping of pituitary adenomas by hormonal type and subtype is still necessary, as pituitary adenomas are not a homogeneous entity and each subtype has its own clinical presentation, tendency for invasiveness, hormonal secretion pattern, histopathologic features,

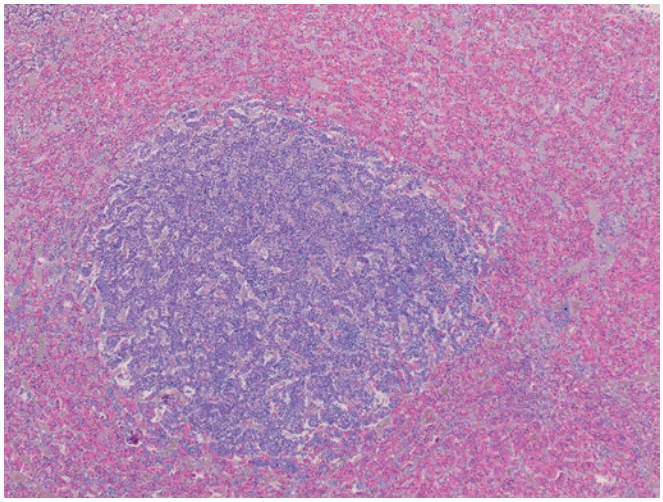

Figure 44.13 Incidental pituitary adenomas are a frequent finding not only on premortem neuroimaging studies but at the time of autopsy; this one was a prolactinoma.

appropriate treatment, and varying response to medical therapies. Some adenomas are well-differentiated tumors that closely mimic their non-neoplastic anterior pituitary counterparts, such as densely granulated GH adenomas or the common sparsely granulated PRL adenomas (which resemble stimulated nontumorous lactotrophs by EM),[37] while others (such as sparsely granulated GH adenomas, acidophil stem cell adenomas, and the rare silent subtype 3, which is still impossible to diagnose confidently without EM) are less differentiated.

Not surprisingly, those adenomas showing advanced differentiation by EM more closely mimicking that of normal nontumorous anterior pituitary cells show greater response to medical therapies (i.e., prolactinomas with dopamine agonists, or densely granulated GH adenomas with somatostatin analogues) than do poorly differentiated tumors (rare densely granulated lactotroph adenomas, acidophil stem cell adenoma, or sparsely granulated GH adenomas).[13] Thus, subtyping predicts which adenomas are likely to be clinically responsive to medical therapy and may direct the use of alternate therapies, based on subtype. An example of the latter is that sparsely granulated GH adenomas that are not controlled with somatostatin analogs consistently respond to the alternate use of, or addition of, a GH receptor antagonist.[38] Subtyping does not usually dictate the use of adjuvant radiation therapy. Instead, recurrent, invasive aggressive adenomas that cannot be completely surgically resected may be candidates for radiation therapy or radiosurgery.[13,39] However, adjuvant radiation is generally not administered after the first resection, or simply because of subtotal resection. For instance, incompletely resected indolent adenomas, such as gonadotroph adenomas, can usually be managed conservatively without adjuvant radiation.[40]

Correlation of Immunohistochemistry With Clinical Features and Serum Hormone Levels

Some adenomas are strongly secretory and produce the hypersecretory syndromes of hyperprolactinemia, acromegaly/gigantism, or Cushing disease (lactotroph, somatotroph, and corticotroph adenomas, respectively [see Table 44.3]), while others are mostly clinically silent/ nonfunctional, such as gonadotroph adenomas and null cell adenomas. Other rare types of silent adenomas (silent corticotroph, somatotroph, lactotroph, and thyrotroph adenomas) and variably

Table 44.3 Pituitary adenomas causing acromegaly or hyperprolactinemia

Pituitary Adenomas Causing Acromegaly/Gigantism, With GH, CAM5.2 Pattern IHC Pattern	
Densely granulated somatotroph (growth hormone) adenoma—**diffuse, strong GH IHC(+)**	**CAM5.2 perinuclear**
Intermediate/mixed/transitional growth hormone adenoma (behaves like densely granulated growth hormone adenoma—**diffuse, strong GH IHC(+)**	**CAM5.2 mostly perinuclear, fibrous bodies less than 70%**
Sparsely granulated growth hormone adenoma—**weak, focal GH IHC(+)**	**CAM5.2 fibrous bodies greater than 70%**
Mixed growth hormone-prolactinoma—**GH IHC(+) in varying degrees and distribution (small groups to scattered admixed cells); Prolactin IHC(+) stronger than in densely or sparsely granulated GH adenoma**	**CAM5.2 pattern depends on whether GH component densely or sparsely granulated. that is, subset of cells perinuclear versus dot-like fibrous body**
Mammosomatotroph adenoma—**diffuse, strong GH IHC(+), often with alpha subunit, PRL, sometimes FSH, LH**	**CAM5.2 mostly perinuclear, fibrous bodies rare if present at all**
Plurihormonal PIT1 positive adenoma**—rare aggressive subtype composed of monomorphic cells diagnosable by electron microscopy only; some being recognized as producing mild acromegaly, less commonly hyperthyroidism or mild hyperprolactinemia**	**CAM5.2 perinuclear in most, occasional fibrous bodies or negative CAM5.2**
Pituitary Adenomas Causing Hyperprolactinemia, With PRL, CAM5.2 Pattern IHC Pattern	
Sparsely granulated prolactin secreting (lactotroph) adenoma—**diffuse strong PRL, Golgi pattern**	**CAM5.2 often moderate, no fibrous bodies**
Densely granulated prolactin secreting (lactotroph) adenoma—**diffuse, strong PRL, may be perinuclear rather than Golgi**	**CAM5.2 no fibrous bodies**
Acidophil stem cell adenoma—**diffuse cytoplasmic PRL IHC(+) except in rare instances where Golgi pattern present; focal GH in approximately ½ of cases**	**CAM5.2 approximately 2/3 with fibrous bodies, usually scattered rather than prominent; sometimes CAM5.2 IHC negative or perinuclear pattern**

Adapted from Gomez-Hernandez K, Ezzat S, Asa SL, Mete Ö. Clinical implications of accurate subtyping of pituitary adenomas: perspectives from the treating physician. *Turk Patoloji Derg.* 2015;(31 suppl 1):4–17.

clinically functional adenomas (acidophil stem cell and plurihormonal adenomas made up of multiple cell types) also exist.[13,41] In some endocrinologically functional adenomas, serum level of hormone strongly parallels the size of the adenoma, as in sparsely granulated PRL adenomas (typical prolactinoma). In others, such as corticotroph adenomas associated with Cushing disease, tumor size does not correlate with severity of clinical features or serum hormone levels.[42] Indeed, florid Cushing disease can be produced by ACTH-secreting adenomas that are only millimeters in size. As is always the case, IHC is a test that is "static" in time, that is, it measures content within the cytoplasm at a singular time point but does not provide information regarding secretory rates of a hormone product, if any. Gonadotroph adenomas, for example, usually show immunoreactivity for FSH and/or LH but almost never produce a clinical hypersecretory condition; these tumors are in fact the most common subtype of clinically nonfunctioning/silent adenomas even if immunoreactive for FSH and/or LH[41] Hormone-negative pituitary adenomas, defined as negative for specific anterior pituitary hormones by IHC, are today recognized to be most commonly of gonadotroph lineage as well, as identified by positive immunostaining for the transcription factor SF1.[14]

At times, discordance between immunoreactivity and clinical features is actually helpful in subtyping. An example of the latter is acidophil stem cell adenomas, which show variable immunopositivity for prolactin and variable elevation in serum levels of prolactin, and almost always show a discordance between tumor size (often large) and serum prolactin levels (typically only modestly elevated) when compared to similarly sized sparsely granulated PRL adenomas (i.e., typical prolactinomas).[13] Correlations between subtypes of adenomas and neuroimaging features also exist.[43]

Clinically Nonfunctional/Clinically Silent Adenoma Versus Hormone-Negative Adenoma

While all hormone-negative adenomas (i.e., negative for the standard anterior pituitary hormones GH, PRL, ACTH, FSH, TSH, +/– LH) are clinically silent/clinically nonfunctional, the reverse is not true. Namely, adenomas may secrete such small amounts of hormone, as in gonadotroph adenomas with focal immunoreactivity for FSH and/or LH, that they are clinically silent. Alternatively, in some instances such as clinically silent ACTH adenomas, the adenoma may show immunoreactivity for ACTH, but the hormone product may be biologically nonfunctional. The most common type of clinically silent adenoma is the gonadotroph adenoma, followed by clinically silent ACTH adenomas. Clinically silent GH, PRL, and TSH adenomas are rare. Hormone-negative adenomas can be further subclassified as to lineage origin by IHC for transcription factors SF1, PTI1, and TPIT. Most hormone-negative adenomas are SF1 driven and are thus classified as gonadotroph adenomas. The second most frequent hormone-negative adenoma type is TPIT driven and

thus they are classified as corticotroph adenomas[14]; PIT1-driven hormone-negative adenomas are very rare.

Grading, Size, Invasiveness, and MIB-1 Labeling Rate (Designation of "Atypical" No Longer Utilized)

World Health Organization grade is not assigned to pituitary adenomas, since numerical grades have historically been utilized by neuroimaging colleagues for assessing CT and resonance MRI extent of disease.

The Hardy system from 1973, utilizing grade as assessed from CT and MRI studies, is as follows:

Grade I: Microadenomas, defined as intrapituitary lesions measuring less than 1 cm in diameter
Grade II: Macroadenomas, defined as at least 1 cm in diameter
Grade III: Locally invasive tumors (small or large) that cause bony erosion of sella turcica
Grade IV: Macroadenomas with invasion of extrasellar structures such as bone, hypothalamus, cavernous sinus.[44]

The Protocol for Primary Pituitary Tumors[44] does not require listing of the specific Hardy system grade but does include in the checklist the "Tumor Size (from imaging)" as microadenoma (<1 cm) or macroadenoma (≥1 cm).

Microadenomas remain confined to the sellar region[2] and may cause some degree of hypofunction of the normal anterior pituitary gland due to compression but seldom result in compromise of posterior pituitary gland function. Indeed, diabetes insipidus is quite uncommon with pituitary adenomas of any size.

Macroadenomas more severely distort adjacent tissues, with traction on the dura of the sellar floor or the dura overlying the sella (the diaphragma sella), causing headaches. Macroadenomas often grow directly upwards (Fig. 44.14), compressing the nearby optic chiasm in its midportion, an area containing crossing axons emanating from retinal cells within the medial retinal fields. Since these medial retinal fields are responsible for lateral visual fields, the classic symptom of optic chiasm midline compression in a pituitary adenoma is bitemporal hemianopsia. Macroadenomas may also extend into the sphenoid sinus and mimic primary nasopharyngeal neoplasms clinically and by neuroimaging features (Fig. 44.15).

As noted by Saeger et al. "hormonally active adenomas are usually diagnosed at an earlier stage than hormonally inactive tumors, the latter being diagnosed mostly due to the effect of local pressure exerted by the already existing large tumor." In the large German registry, 95%–100% of hormonally inactive tumors were macroadenomas.[1] Nearly 100% of gonadotroph, null cell, sparsely granulated GH adenomas, clinically silent ACTH adenomas, TSH adenomas, acidophil stem cell adenomas, and plurihormonal PIT1-positive adenoma are macroadenomas. These are all relatively clinically nonfunctioning (gonadotroph) or aggressive (sparsely granulated GH adenoma, silent ACTH adenoma, acidophil stem cell adenoma, and plurihormonal PIT1-positive adenoma). However, more indolent functioning tumors, such as densely granulated GH adenomas, also present as macroadenomas in more than half of instances, as do prolactinomas in males. Table 44.4 lists which tumor subtypes are usually microadenomas versus macroadenomas.

As previously described, some specific subtypes are more likely to present as microadenomas. Corticotroph adenomas producing Cushing syndrome present as microadenomas in 80% of cases.[1] Also usually presenting as microadenomas are prolactinomas in premenopausal females. As noted by Saeger et al. microprolactinomas, even in patients who refuse therapy, have a low tendency to develop into macroadenomas and therefore may represent a distinct subset of prolactinomas.[1]

Although the protocol for reporting primary pituitary tumors[44] does not require a special designation of giant adenoma, this term has been utilized for adenomas with a maximum size of greater than 4 cm (see Fig. 44.15). Macroadenomas, and especially giant adenomas, often show cysts and hemosiderin pigment either by neuroimaging or in the tumor specimen. Many giant adenomas

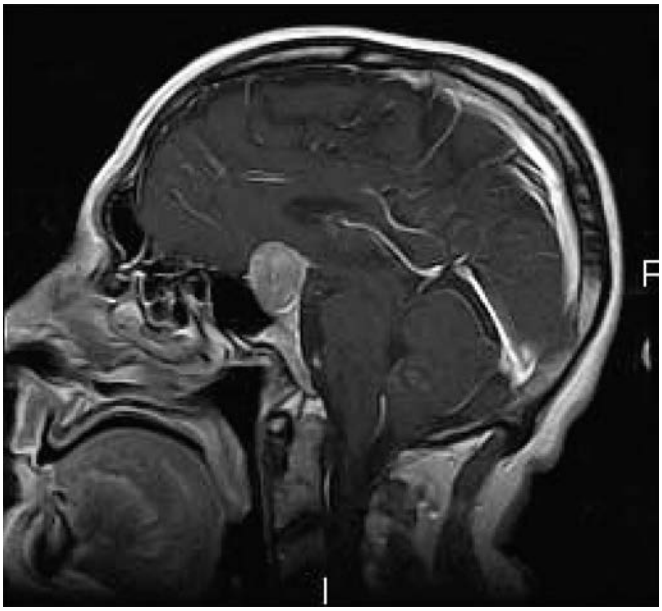

Figure 44.14 Pituitary adenomas more than 1 cm in greatest dimension are termed macroadenomas; compare with the sagittal MRI shown of normal gland in Fig. 44.5.

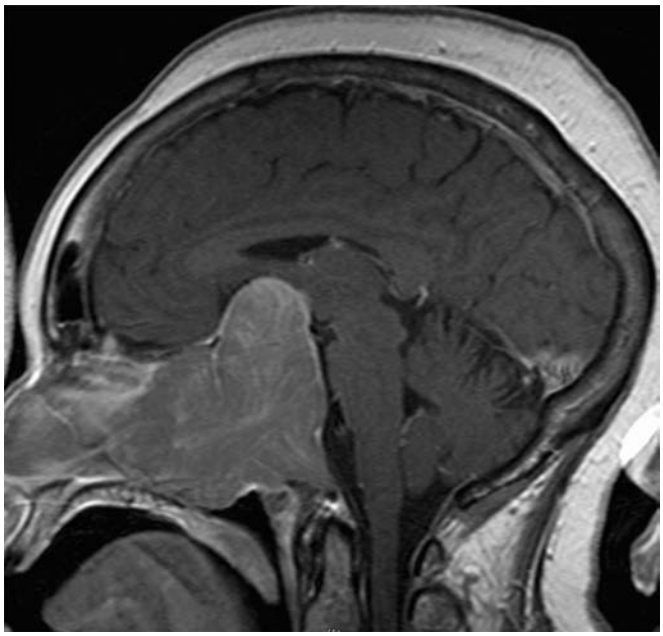

Figure 44.15 Giant pituitary adenomas, defined as greater than 4 cm, sometimes extend into the nasopharyngeal space, mimicking a nasopharyngeal carcinoma.

Table 44.4 Microadenomas versus macroadenomas by subtype

MICROADENOMAS	85% PRESENT AS MACROADENOMAS	NEARLY 100% PRESENT AS MACROADENOMAS
Prolactinomas in females	Densely granulated GH cell adenomas	FSH/LH adenomas
ACTH-secreting adenomas (80% microadenoma)	Sparsely granulated GH cell adenomas Plurihormonal adenomas Mixed GH/PRL tumors Prolactinomas in males	TSH adenomas Acidophil stem cell adenomas Null cell adenomas Silent type 3 adenomas*

*Currently referred to as "plurihormonal PIT1-positive adenoma."
Adapted from Saeger W, Ludecke DK, Buchfelder M, et al. Pathohistological classification of pituitary tumors: 10 years of experience with the German Pituitary Tumor Registry. *Eur J Endocr.* 2007;156(2):203–216.

are gonadotroph adenomas or prolactinomas in males.[45] Clinically silent corticotroph adenomas may also grow to this large size, as well as rarer clinically silent GH, TSH, and PRL+ adenomas.[43] Despite giant size, clinically silent corticotroph adenomas usually manifest a low MIB-1 index, whereas other subtypes producing giant adenomas may show elevated MIB-1 rates.[43] Thus, MIB-1 rates can be different in different subtypes of equal size, and proliferation rate does not parallel adenoma size in either macroadenoma or giant adenoma.

Invasiveness

Local invasion of extrasellar structures does not constitute malignancy in pituitary adenomas; only metastasis is sufficient behavior to connote pituitary carcinoma. Pituitary carcinoma is an exceedingly rare disorder, constituting only 0.12% of all pituitary region masses in the German series.[1]

Nevertheless, invasiveness does preclude gross total resection and therefore affects recurrence. Invasiveness is defined as extension into sellar floor bone, the cavernous sinus, and/or the diaphragma sella,[1] usually as assessed on preoperative neuroimaging studies. However, it differs among studies as to whether "invasion" is judged to be present based on preoperative MRI, intraoperative impression, or histologic features. Macroadenomas are more likely to be invasive than microadenomas.

Studies have verified that invasion is more likely to be identified microscopically by the pathologist than by imaging or by the surgeon intraoperatively.[46,47] Fragments of bone, evidenced as attenuated bone spicules (Fig. 44.16), can be recognized as entrapped within an invasive macroadenoma by the pathologist, and according to the new Protocol for Primary Pituitary Tumors,[44] should be reported. The presence of respiratory epithelium juxtaposed to adenoma tissue is a sign of invasion of the sphenoid sinus (Fig. 44.17). Dural invasion is best assessed by the pathologist when a designated dural sample has been submitted by the surgeon (Fig. 44.18). Invasion of the cavernous sinuses can only be accurately assessed by neuroimaging, since the surgeon avoids entering the cavernous sinuses at the time of surgery and histologic specimens from this area do not come to the pathologist.

The MIB-1 (i.e., Ki-67) labeling index (LI) in noninvasive tumors is typically less than 3%. The LI is generally higher in invasive adenomas but does not correlate perfectly. Invasiveness further correlates with histologic subtype in the sense that it parallels microadenoma versus macroadenoma status.[1] As an example of this correlation between adenoma size and invasive tendencies, ACTH adenomas, which are microadenomas in 80% of cases, are by far the least likely to show invasiveness.[1] Conversely, the majority of macroadenomas are invasive.

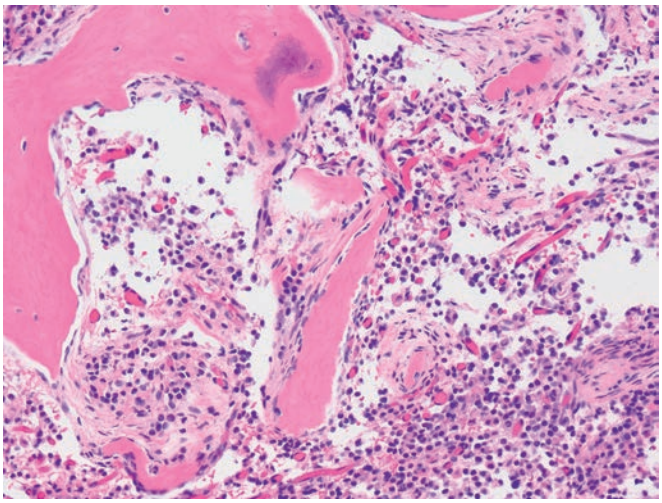

Figure 44.16 The protocol for examination of pituitary tumor specimens suggests that bony invasion seen microscopically should be "included in the protocol when known." This sparsely granulated growth hormone adenoma, a subtype known to be aggressive, encompasses bone spicules from the invaded sellar floor. However, even "benign," less aggressive subtypes may invade the sella.

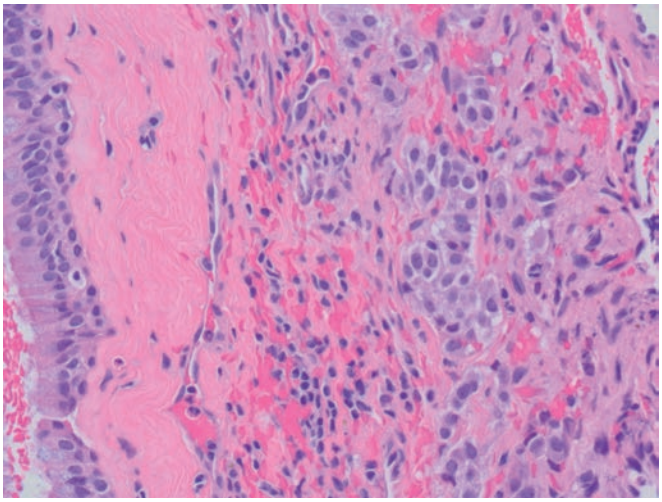

Figure 44.17 The protocol for examination of pituitary tumor specimens suggests that nasal sinus invasion seen microscopically should be "included in the protocol when known." Note the adenoma (at right) immediately adjacent to respiratory mucosa of the sinus *(at extreme left).*

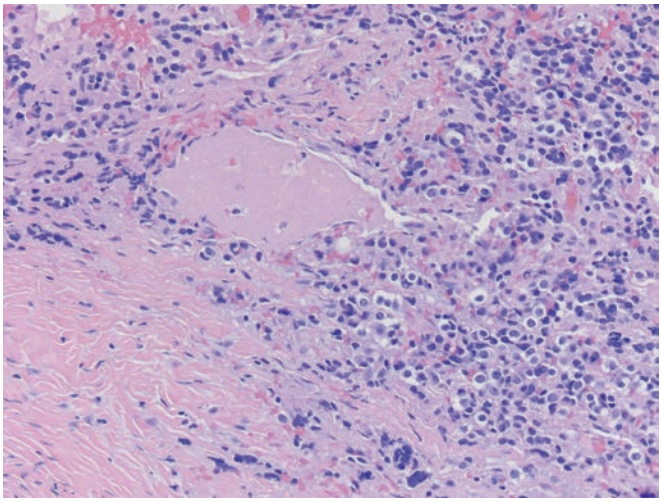

Figure 44.18 Dural invasion is far more commonly identified microscopically when the surgeon specifically submits a specimen of dura for examination; note the hypercellular adenoma *(upper right)* in contrast to the hypocellular dura *(lower left)*.

Designation of Atypical Adenomas No Longer Utilized in WHO 2017

The 2004 WHO Classification of Tumors: Tumors of Endocrine Organs suggested that "atypical adenomas" be defined as "excessive" p53 immunoreactivity, MIB-1 proliferative index greater than 3%, and increased mitotic activity.[3] Since that time, several studies in the past had tried to re-address histologic criteria that correlate with "atypical adenomas."[48–51]

Trouillas proposed a clinicopathologic classification system that combined proliferation rate (defined by 2 of the following 3 features: mitoses >2/10 HPFs; Ki-67 ≥ 3%; or nuclear p53 staining in >10 strongly positive nuclei/10 HPFs) and invasion as assessed by either histologic and/or MRI evidence of cavernous or sphenoid sinus invasion.[16] Of importance, "atypical" histologic features did not correlate tightly with subtype of adenoma, and furthermore, most of these studies looking at "atypical" features lack follow-up for recurrence rates in typical versus atypical adenomas (Table 44.5).

Several workers prior to the WHO 2017 publication called attention to the problems with the use of "atypical adenoma" for pituitary adenomas and suggested, instead, that "pituitary adenoma with elevated MIB-1 index, see comment," could be utilized as the diagnosis. They noted that such a comment should prompt closer clinical follow-up,[9] in order to avoid the automatic administration of radiation therapy after the initial resection. Radiation therapy is a consideration for tumors that recur in a relatively short interval after initial resection ("declare themselves" biologically) and cannot be cured surgically. Adjuvant radiation is especially considered in patients with hypersecretory subtypes where the endocrinologic dysfunction cannot be controlled medically, but that is a clinical decision and should not be based on histology alone.

The new 2017 WHO Classification system acknowledges that parameters in addition to labeling indices may be of prognostic significance in pituitary adenomas, including tumor size, clinical presentation, invasiveness, metastasis, or spinal spread (carcinoma), as well as IHC. The term "atypical" is no longer utilized. They note that Ki-67 labeling still has value and while Ki-67 is usually elevated throughout an adenoma, when focal areas show elevated labeling, those areas should be used for counts.

The use of p53 IHC in pituitary adenomas has been even more controversial than the use of MIB-1, and less standardized (see Table 44.5); some groups do not advocate using p53 IHC at all.[9]

Intraoperative Evaluation, Immunohistochemistry, and Electron Microscopy

If an intraoperative frozen section consultation is requested, work-up starts with choosing the technique that best allows for optimal preservation of material for permanent sections and IHC; freezing of tissue may abrogate some IHC results. Intraoperative touch preparations can be used in most cases instead of actual frozen sections, and demonstrate abundant exfoliation of a monotonous population of cells (Fig. 44.19). Generally, the number of cells shed onto the glass slide roughly parallels the size of the tissue fragment used for the touch imprint. Specifically, if very small amounts of tissue are available for touch preparation, the numbers of cells that will be found on the touch preparation by the pathologist performing the intraoperative consultation will be small, even though the touch preparation has been made from a true adenoma. Cytologic monotony of adenoma cells seen on the touch preparation versus cytologic heterogeneity of cells contrasts presence of adenoma versus nonadenomatous anterior pituitary gland for the pathologist. Diagnosis of pituitary adenoma at the time of touch preparation does not require the presence of mitotic figures, since only occasionally can they be identified (see Fig. 44.19), but accurate subtyping is not possible on touch imprints and awaits permanent sections and IHC. A caveat in using touch imprints is that a large number of cells can be shed onto the slide in instances where the surgeon has been extensively "slicing and dicing" the gland in an attempt to identify the adenoma; in such instances the reticulin investiture that surrounds acini is severely disrupted and a larger number of cells shed onto the slide than would ordinarily be seen with a nontumorous anterior gland. However, the shed population is a heterogeneous, mixed cell population of anterior pituitary gland cells, as noted previously.

If attempting to distinguish a pituitary adenoma from other sellar region masses, including metastases, it is important to remember that all adenomas show diffuse immunopositivity for synaptophysin (see Fig. 44.10). If the issue is normal anterior gland versus adenoma, then the single most informative test is a reticulin stain, since all adenomas show disruption of the normal acinar pattern; however, there can be some variation in the abnormal pattern of reticulin fibers that results (Figs. 44.20–44.22).

Immunohistochemical panels for subtyping adenomas are often utilized on a routine basis once the diagnosis of an adenoma is established. One proposed panel includes synaptophysin and CAM5.2 (for assessment of fibrous bodies, replacing the need for EM identification of fibrous bodies), plus the common specific pituitary antibodies (PRL, GH, FSH, TSH, ACTH). LH and αSU are less critical to assess, since FSH is almost always expressed to a greater degree than LH in gonadotroph adenomas.[9] Even if subtyping beyond this level is desired, EM is only infrequently necessary for classification. Indeed, in the German registry experience, EM had to be utilized in only 22 problem cases out of the total 3489 adenomas.[1] One possible practice is to set aside a small piece of tissue in glutaraldehyde that can be used in the unlikely event that EM becomes necessary.

An alternate, and perhaps more reasonable, panel has been proposed by McDonald et al. using PIT1, SF1, and ACTH IHC as an initial screen for pituitary adenomas.[52] Once the diagnosis of adenoma is established, those adenomas that are SF1 positive would be defined as gonadotroph, and no further testing would be necessary,

Table 44.5 Criteria for atypical adenoma in recent large series

AUTHOR	NUMBER OF ADENOMAS	NUMBER OF ATYPICAL ADENOMAS	SUBTYPES OF ADENOMAS	HISTOLOGIC CRITERIA FOR ATYPICAL DESIGNATION
Miermeister et al.[48]	4232	121 (2.9%)	Prolactin cell adenomas: 32 cases (32.7%) ACTH cell adenomas: 28 cases (28.6%) GH cell adenomas: 14 cases (14.3%) Null cell adenomas: 11 cases (11.2%) Mixed GH/PRL adenomas: 6 cases (6.1%) FSH/LH adenomas: 5 cases (5.1%) TSH adenomas: 2 cases (2.0%)	Minimum of 3 of 4 parameters had to be present: increased p53 IHC, MIB-1 index, mitotic activity, 10 representative high-power fields assessed; invasiveness assessed by combination of preoperative MRI, surgical reports, or confirmed by "clear" histology
Summary: Histologic criteria found to be most information for designation of atypical adenoma of cells (sensitivity for atypical pituitary adenoma 85%, specificity 93%); invasiveness (sensitivity 88%, specificity 53%) [invasiveness not limited to atypical pituitary adenoma and invasive status had lowest specificity for differentiating pituitary adenoma from atypical pituitary adenoma] No clinical follow-up to compare recurrence rates of atypical versus typical adenomas				
Yildirim et al.[49]	133	13 (8.9%)	Nonsecretory adenomas: 9 cases (69.3%) (not further specified as to subtype) Prolactinomas: 3 cases (23.1%) Somatotroph: 1 case (7.6%)	Patients had to have Ki-67 indices above 3% and "increased mitotic activity" to be called atypical pituitary adenoma (those with only elevated Ki-67 indices not called atypical), invasiveness assessed on neuroimaging
Summary: Of adenoma patients with recurrence, 11 were typical adenomas (11/133, 8.2%), 5 were atypical adenomas (5/13, 38.4%)				
Zada et al.[50]	121	18 (15%)	ACTH adenoma: 2 cases (11%) Gonadotroph adenoma: 1 case (6%)	p53 IHC not specified, MIB-1>3%, invasiveness judged by MRI
Summary: No clinical follow-up to compare recurrence rates of atypical versus typical adenomas				
Scheithauer et al.[51]	78 with follow-up	6 (14.7%)	Prolactinomas: 2 cases TSH adenomas: 2 cases GH adenoma: 1 case Silent subtype 3*: 1 case No clinically functional or silent ACTH adenomas or gonadotroph adenomas	
Summary: "MIB-1 and P53 LIs, those parameters related to tumor recurrences in the 2004 who classification of endocrine tumors, were not statistically significant in identifying atypical adenomas, i.e., tumors prone to recur."				

*Currently referred to as "plurihormonal PIT1-positive adenoma."

Data from Miermeister CP, Petersenn S, Buchfelder M, et al. Histological criteria for atypical pituitary adenomas—data from the German pituitary adenoma registry suggests modifications. *Acta Neuropathol Commun.* 2015;19(3):50; Yildirim AE, Divanlioglu D, Nacar OA, et al. Incidence, hormonal distribution and postoperative follow up of atypical pituitary adenomas. *Turk Neurosurg.* 2013;23(2):226–231; Zada G, Woodmansee WW, Ramkissoon S, et al. Atypical pituitary adenomas: incidence, clinical characteristics, and implications. *J Neurosurg.* 2011;114(2):336–344; Scheithauer BW, Gaffey TA, Lloyd RV, et al. Pathobiology of pituitary adenomas and carcinomas. *Neurosurgery.* 2006;59(2):341–353; discussion 341–353.

since the percentage of FSH versus LH positive cells is not clinically relevant. Those with PIT1 immunoreactivity would then be explored further with IHC for GH, PRL, TSH, and CAM5.2. If TPIT becomes more widely available, this would also optimize initial immunohistochemical screening using transcription factors. A third system that blends the two previously discussed panels utilizes a panel containing GH, PRL, CAM5.2, TSH, ACTH, and SF1, avoiding FSH, LH, and αSU. A limitation of classification using any of these systems is the fact that TPIT antibodies are not widely available. Hence, without access to this antibody, a percentage of hormone-negative adenomas that would otherwise be recognized as being TPIT driven—despite having few or no ACTH positive cells—will be missed.[14]

Finally, in more sophisticated laboratories specializing in pituitary adenomas, ER-α and GATA2 can be utilized to further aid subtyping.[19] And while PIT1 lineage tumors may produce GH, PRL, and/or TSH, ER-α coexpression is further characteristic of the subset of PIT1 adenomas with PRL-production, whereas GATA2 coexpression is a feature of the subset of PIT1 adenomas that are thyrotrophs.[19] ER-α expression is also seen in gonadotroph adenomas that are PIT1 negative and SF1 positive. ER-α expression may be affected by tissue

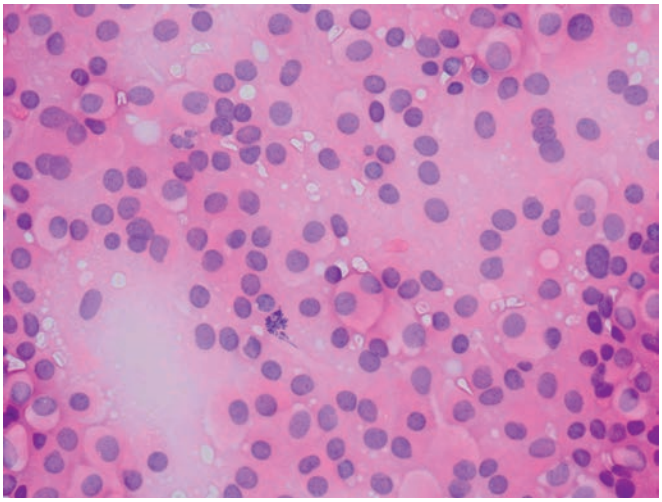

Figure 44.19 Touch preparations at the time of intraoperative consultation show abundant exfoliation of relatively monomorphic adenoma cells onto the slide, with the volume of cells shed roughly proportional to the size of the adenoma tissue fragment. Note the mitotic figure *(central)* in this example, although mitoses are not often identified. Indeed, if several mitoses are found on touch imprint, suspicion for an elevated MIB-1 proliferation index in the adenoma should be raised.

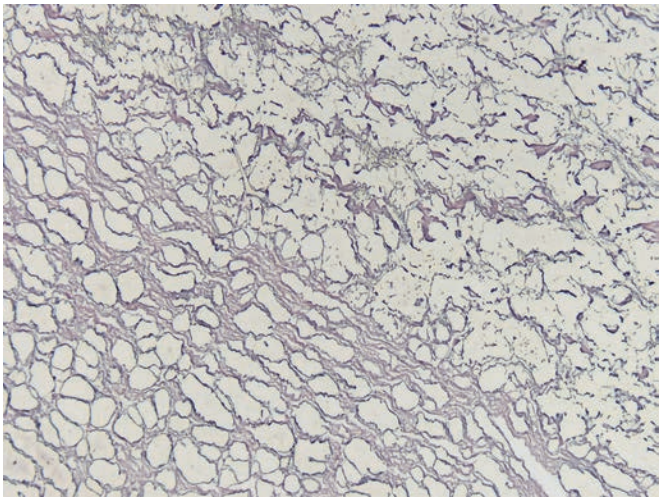

Figure 44.20 Reticulin stain is the single best histochemical stain for confidently identifying adenoma, although there may be some variation in the degree of acinar disruption/dissolution. In this microadenoma, note the disruption of the reticulin pattern *(upper right)* as compared to the sharp demarcation from intact anterior gland *(lower left).*

fixation and thus cannot be substituted for PRL or SF1/FSH/LH IHC in identifying prolactinomas and gonadotroph adenomas, respectively.[18]

Other transcription factors present at even earlier embryologic time periods (Prop-1, Pitx2, and Hesx1) or later stages paralleling that of SF1 (DAX-1) and TPIT (NeuroD1)[40] are used only for research purposes currently. Prop-1 in particular is a transcription factor expressed immediately antecedent to PIT1 and GATA2 expression developmentally and therefore is a common precursor to both GH/PRL/TSH lineage and FSH/LH lineage pituitary cells. This common ancestor to both PIT1 and SF1 lineages may explain why αSU, FSH, and/or LH IHC expression can sometimes be detected in adenomas, such as densely granulated GH adenomas.

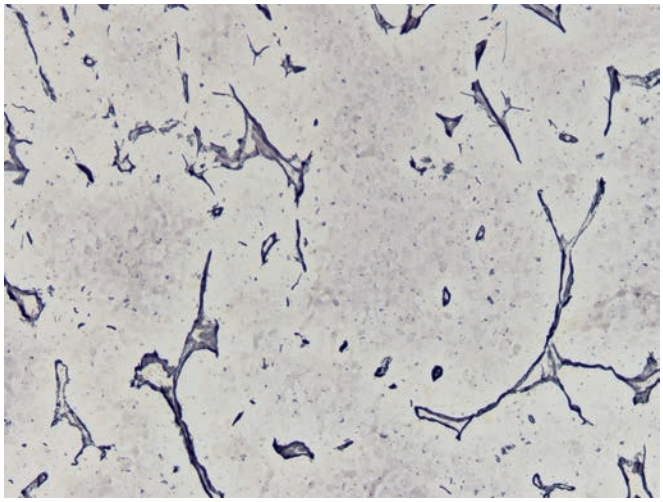

Figure 44.21 Reticulin stain in a macroadenoma usually shows preservation of reticulin fibers only around vascular structures.

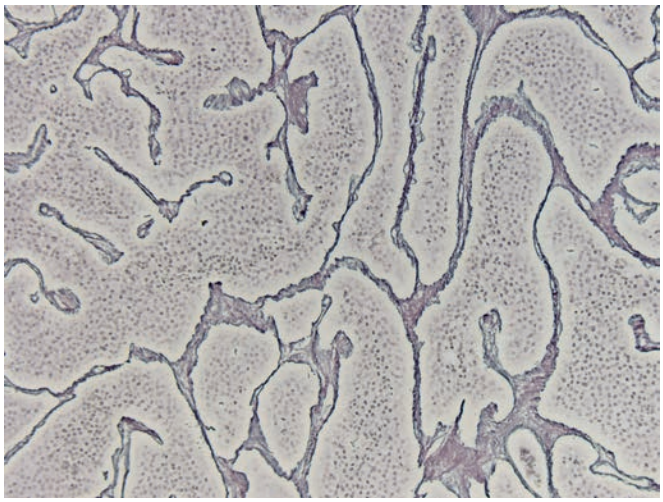

Figure 44.22 A variation of acinar disruption causing a macronodular pattern can be seen in some macroadenomas, especially gonadotroph adenomas; this is still an abnormal pattern (compare with Fig. 44.9).

Histologic Features of Adenoma Subtypes

Older classification systems that specify what percentages of pituitary adenomas are prolactinomas, GH adenomas, etc. are today outmoded since the published percentages antedate the development of IHCs for transcription factors. Specifically, the advent of SF1, PIT1, and, in some laboratories, TPIT, has allowed better lineage classification. For example, today it is recognized that the majority of hormone-negative pituitary adenomas, defined as immunonegative for antibodies directed against specific anterior pituitary hormones, and formerly called "null cell adenomas," are in fact immunoreactive for SF1 (the transcription factor that indicates gonadotroph lineage) while a few are immunoreactive for TPIT (the transcription factor that indicates corticotroph lineage). It is also relevant that the most common pituitary adenoma subtype seen at autopsy is prolactinoma, although with advent of medical therapies which obviate need for surgical intervention and resection of prolactinomas, these are not the most common adenoma type to come to surgery and hence the surgical pathologist. Thus, in surgical practice the most common subtype of adenoma encountered is gonadotroph adenoma–lineage tumors.

This is due to the fact that gonadotroph adenomas (with FSH and/or LH IHC) plus the formerly designated "null cell"/hormone-negative adenomas, and most of the tumors formerly called "oncocytoma," collectively constitute 30%–35%, followed by either prolactinomas or GH adenomas, depending on the surgical practice. Densely and sparsely granulated GH subtypes show near equal numbers. Corticotroph adenomas are fourth in frequency. Importantly, almost all other subtypes are less than 2% each of the total.

Gonadotroph Adenoma

Gonadotroph adenomas are usually clinically silent, indolent tumors found in older adults and are the most likely to come to surgical excision. Histologically, gonadotroph adenomas have a range of cytoarchitectural features, ranging from sheet-like, solid architecture (Fig. 44.23) to a macronodular pattern (Fig. 44.24). There is often focal hemosiderin deposition and cytoplasmic clearing (Fig. 44.25). More abundant eosinophilic cytoplasm or oncocytic change is sometimes seen in a subpopulation of adenoma cells (Fig. 44.26), but this should not be misinterpreted as a separate, so-called double adenoma. A nearly pathognomonic appearance is that of elongated cells surrounding blood vessels in a pseudorosette-like pattern that resembles ependymoma (Fig. 44.27); there may even be discohesion between the cells with preservation around the vessels yielding a pseudopapillary architecture (Fig. 44.28).

Positive immunostaining for nuclear transcription factor SF1 is sufficient to diagnose gonadotroph adenoma (see Fig. 44.7). If additional immunostaining is performed for FSH (Fig. 44.29), LH (Fig. 44.30), and αSU, the positive staining is characteristically quite patchy and focal. FSH IHC is much more likely to be expressed in isolation than LH. This regional diversity for hormone expression in only a subpopulation of cells contrasts with the diffuse immunoreactivity

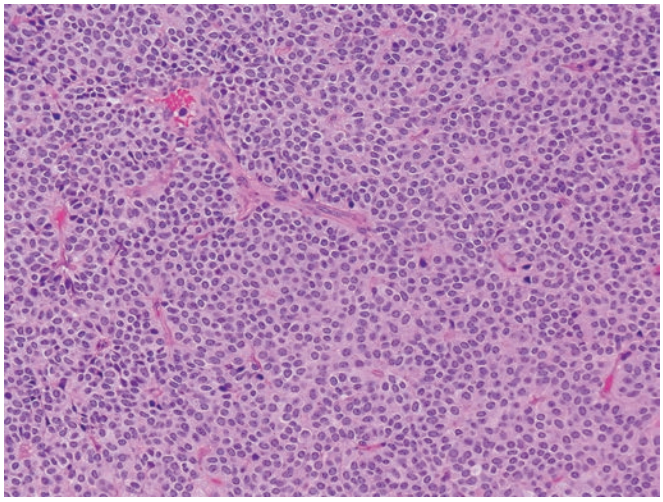

Figure 44.23 Gonadotroph adenomas manifest several different architectural patterns, including the sheet-like arrangement of cells shown here.

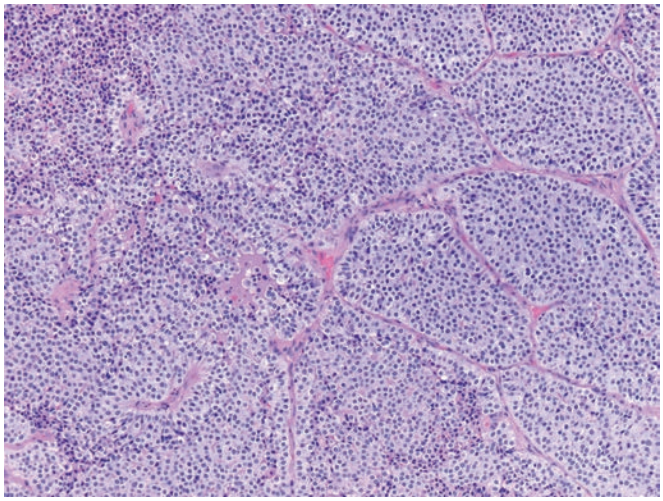

Figure 44.24 Gonadotroph adenomas may show a macronodular pattern; compare this image with the reticulin stain illustrating this pattern in Fig. 44.22.

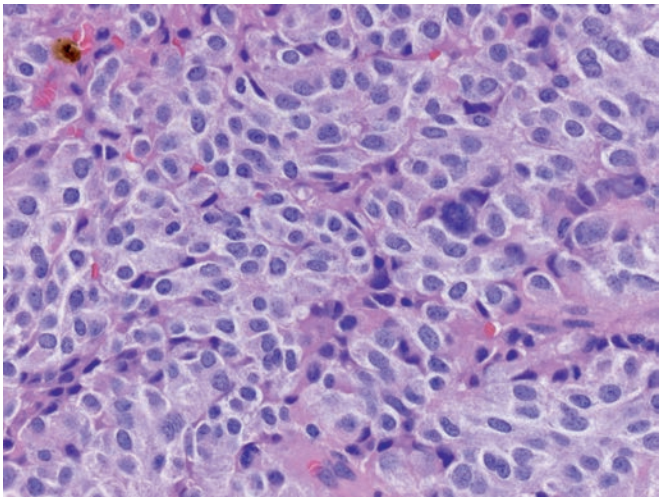

Figure 44.25 Gonadotroph adenomas occasionally have clear cytoplasm. This example has some degree of nuclear pleomorphism; all adenomas can contain occasional cells with nuclear enlargement and hyperchromatism, and this is of no prognostic importance.

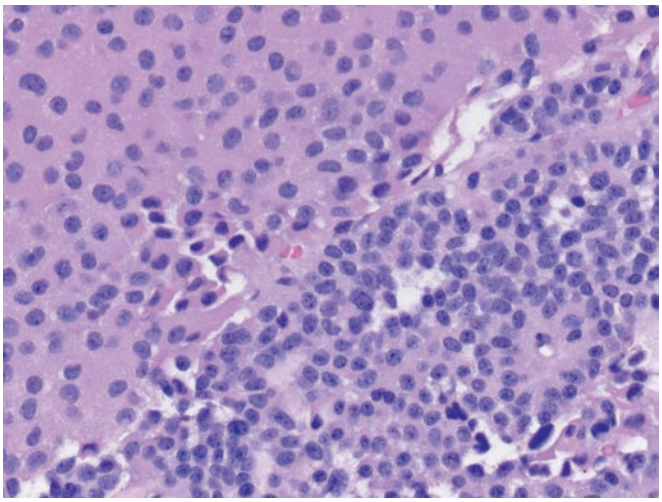

Figure 44.26 Gonadotroph adenomas frequently contain subpopulations of cells with abundant oncocytic cytoplasm *(upper left)* and cells with scant chromophobic cytoplasm *(lower right)*. This dichotomous population should not be misinterpreted as a "double" or "dual" adenoma since the same transcription factor (SF1) and/or FSH/LH immunostaining is seen in both components.

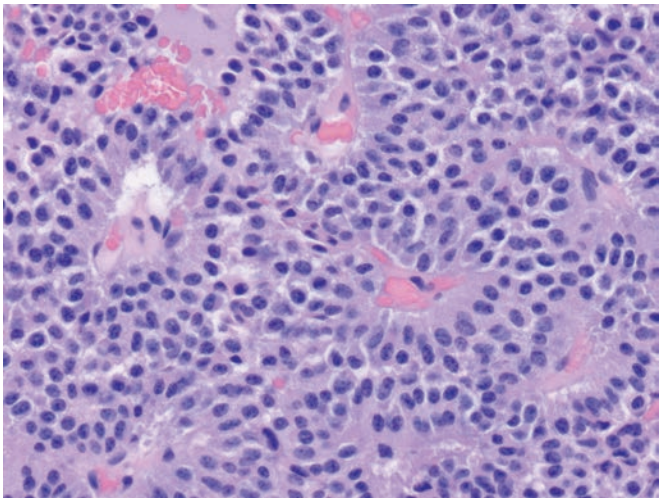

Figure 44.27 Gonadotroph adenoma may mimic ependymoma with perivascular structuring of adenoma cells around blood vessels.

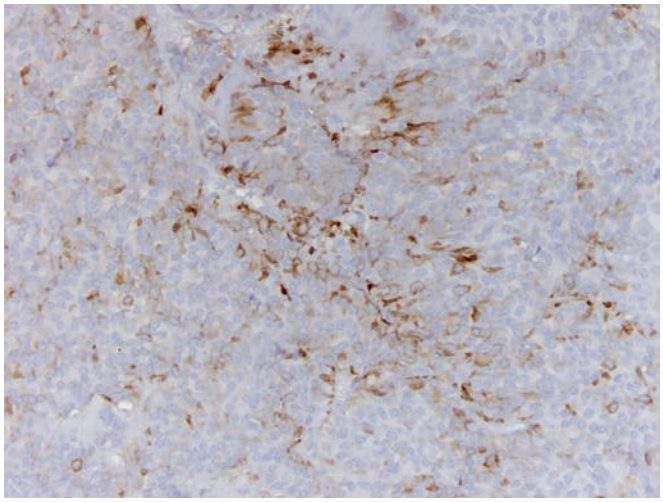

Figure 44.29 Gonadotroph adenomas may show patchy FSH positivity but never diffuse staining as in prolactinomas or densely granulated GH or ACTH adenomas.

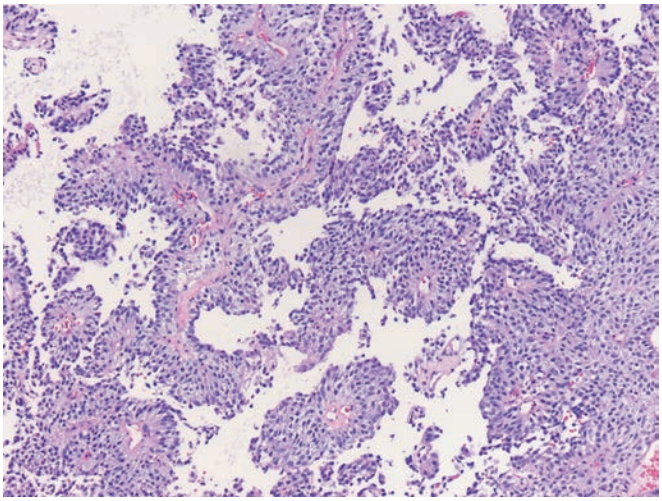

Figure 44.28 Gonadotroph adenoma often shows discohesion of cells, leaving the preserved cells clustered around blood vessels and forming pseudopapillary patterns.

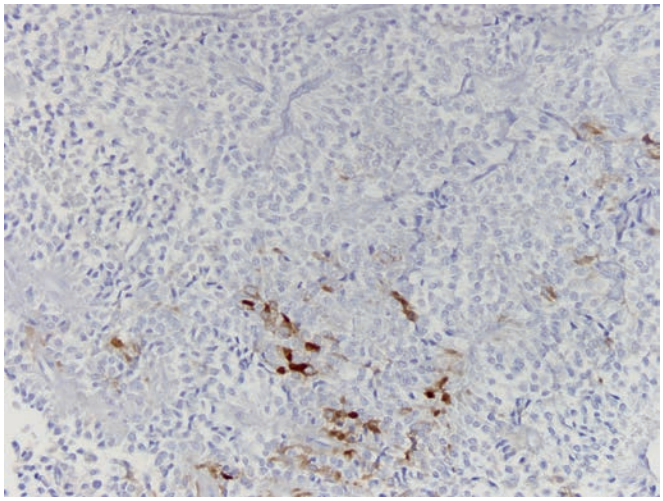

Figure 44.30 Gonadotroph adenoma shows patchy LH IHC(+), but this is usually in a smaller subpopulation of the adenoma cells than is FSH IHC(+), or may not be present at all.

pattern seen in most prolactinomas, densely granulated GH adenomas, and densely granulated ACTH adenomas.

Hormone-Negative Adenoma

Hormone-negative adenomas (i.e., negative for PRL, GH, ACTH, FSH, LH, TSH) are not equivalent to nonfunctioning adenomas, because hormones can be expressed by IHC in several adenoma types, yet the tumors are clinically silent (no hormonal syndrome recognized and/or no elevation of hormone serum levels). The majority of hormone-negative adenomas today have been found to be gonadotroph adenomas, with the advent of SF1 and higher fidelity FSH and LH antibodies. A significant subset of hormone-negative adenomas have been shown to be of TPIT origin (i.e., corticotroph lineage), but few hormone-negative adenomas are PIT1 driven.[14]

Not surprisingly, then, most hormone-negative adenomas show histologic features that are nearly identical to gonadotroph adenomas (Fig. 44.31). Cysts (Fig. 44.32) and hemosiderin pigment deposits are often found in large tumors of both types. Some studies suggest that "null cell adenomas" may have differing biologic behavior than gonadotroph adenomas,[53] but more work needs to be done. Today, "null cell adenoma" is used only for adenomas with no markers for either specific hormones or transcription factors.

Somatotroph Adenoma

GH-producing adenomas are almost always clinically active and, in pure form, exist in two subtypes, densely granulated and sparsely granulated.

Histologically, the densely granulated variant features diffuse growth of a monotonous population of slightly pleomorphic, medium-sized cells, often with an angular profile. There is diffuse, moderate to strong immunostaining for GH, and CAM5.2 shows reactivity throughout the cytoplasm in a perinuclear pattern (Fig. 44.33). Densely granulated GH adenomas may also contain a small percentage of cells that are immunoreactive for αSA or PRL (usually less than 5%).[54]

Sparsely granulated GH tumors also have a diffuse growth pattern, but the cells lack the acidophilia on H&E that is seen in densely

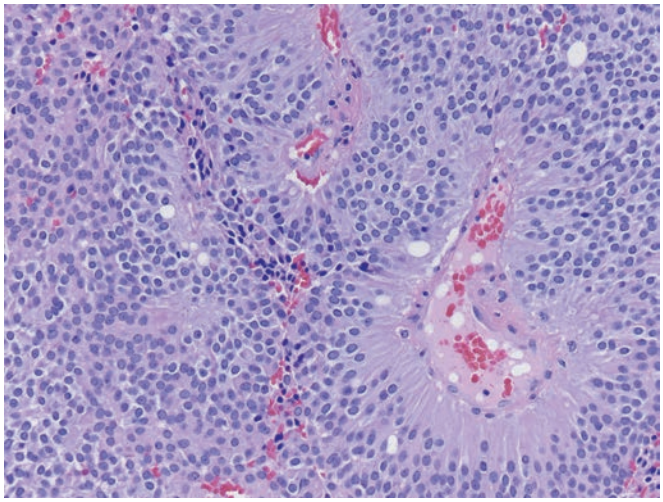

Figure 44.31 Hormone-negative adenomas often show a perivascular "pseudorosette" like pattern identical to that seen in gonadotroph adenomas.

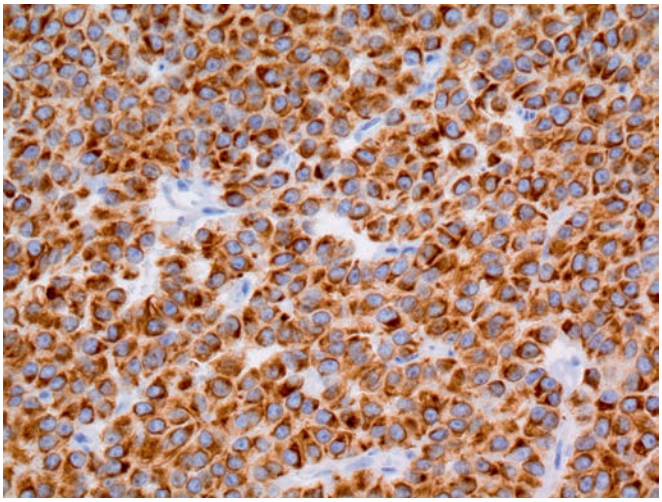

Figure 44.33 Densely granulated growth hormone adenomas show perinuclear keratin that is present throughout the cytoplasm with CAM5.2 immunostaining.

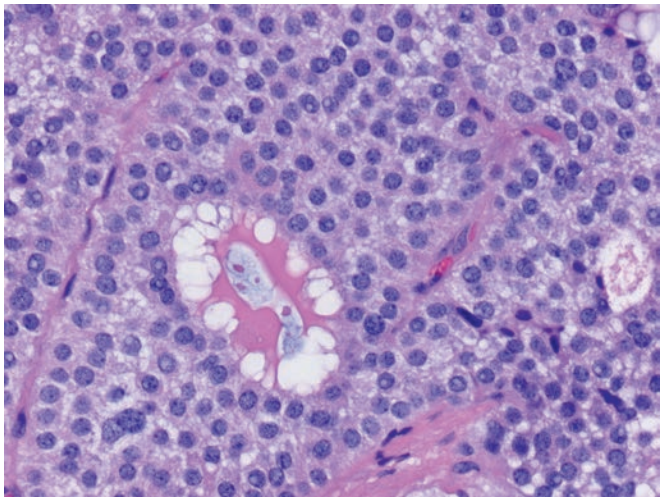

Figure 44.32 Hormone-negative adenomas may be composed of a very monomorphic population of cells, punctuated only by a few mucin-filled microcysts.

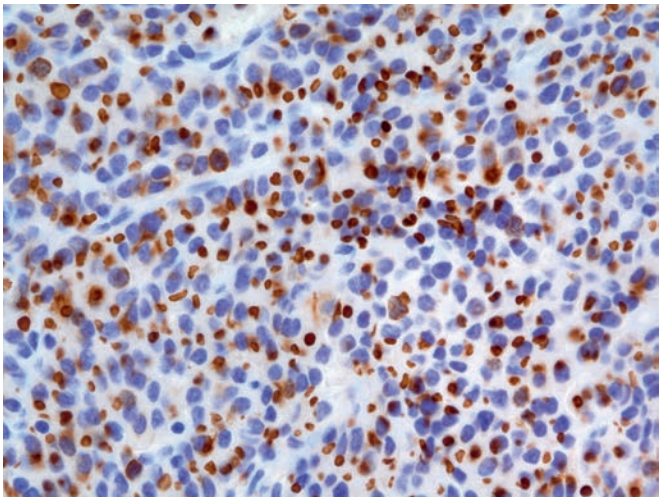

Figure 44.34 Sparsely granulated GH adenomas, by definition, have dot-like cytoplasmic round fibrous bodies in greater than 70% of adenoma cells with CAM5.2 immunostaining.

granulated tumors. Cells of sparsely granulated GH may also have more eccentrically placed nuclei and paranuclear clearing and occasionally may show cellular pleomorphism. These tumors show weaker, patchier GH immunoreactivity, and are usually αSA and PRL negative. The signature feature of sparsely granulated GH adenomas is the finding of widespread, ball-like, cytoplasmic "fibrous bodies" with CAM5.2 immunostaining in greater than 70% of cells (Fig. 44.34).[38,54] CAM5.2 IHC has replaced the need for EM to find fibrous bodies. Sparsely granulated GH adenomas also show down-regulation of E-cadherin, further contrasting them with densely granulated and intermediate/mixed/transitional GH adenomas (see later), which show varying degrees of retained expression.[55]

An intermediate/mixed/transitional form of GH adenomas that produces acromegaly has been increasingly recognized. In these tumors, CAM5.2 IHC shows predominantly perinuclear CAM5.2 cytoplasmic staining but also highlights admixed cells with fibrous bodies or intermediate forms of keratin accumulation; some resemble smaller sized fibrous bodies (Fig. 44.35).[54] The numbers of fibrous bodies seen in sparsely granulated GH adenomas far exceeds that seen in these intermediate/mixed/transitional adenomas. Intermediate/mixed/transitional adenomas behave as densely granulated GH adenomas in terms of good response to somatostatin analogues.[38,55]

Mixed Growth Hormone and Prolactin Adenoma, Mammosomatotroph Cell Adenoma

This group of mixed GH-PRL adenomas totals 6.5% of all adenomas in the German registry.[1] Mixed GH-PRL adenomas are bicellular–bihormonal adenomas that are more frequent (5.2%) than monocellular mammosomatotroph cell adenomas (1.1%), which contain tumor cells that coexpress GH and PRL.[1] Bicellular adenomas contain a combination of sparsely granulated PRL-secreting cells with either densely or sparsely granulated GH-secreting tumor cells.[56] These tumors produce acromegaly, and by IHC most show more GH than PRL expression; clinically, both GH and PRL excess can occur. The

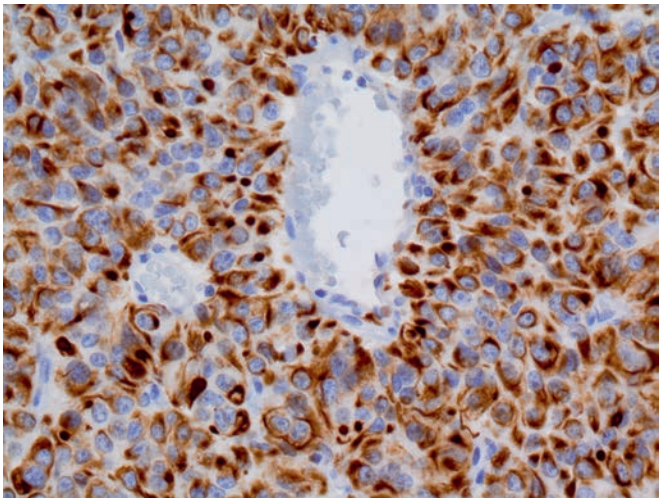

Figure 44.35 Intermediate/mixed/transitional growth hormone adenomas show a predominance of perinuclear CAM5.2 staining but have occasional admixed fibrous bodies or keratin accumulations that are not easily categorized as either perinuclear or fibrous bodies. These adenomas behave like densely granulated growth hormone adenomas, especially in terms of response to somatostatin analogues, and should not be misconstrued as sparsely granulated GH adenomas.

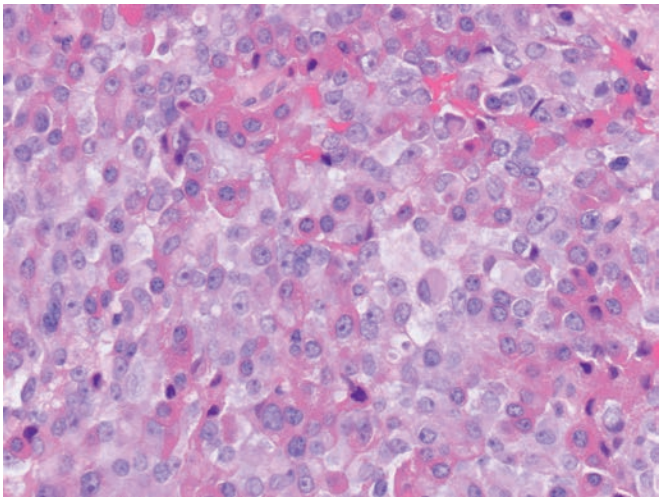

Figure 44.36 This mixed GH-PRL adenoma clearly shows two admixed populations of chromophobic and eosinophilic cells on H&E.

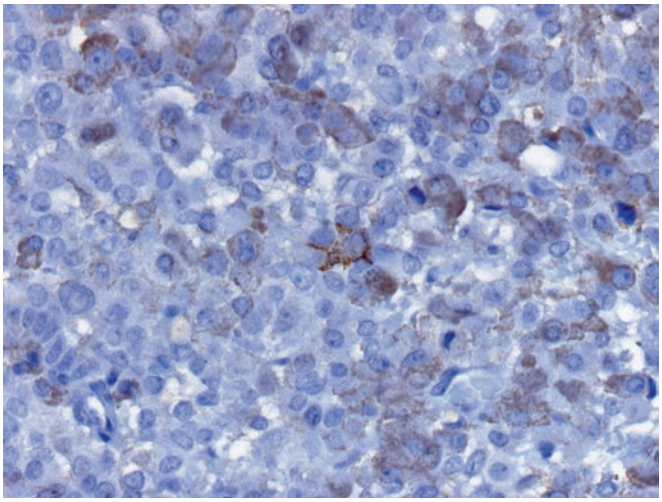

Figure 44.37 Mixed GH-PRL adenomas present with acromegaly, and a significant percentage of the adenoma cells stain with GH.

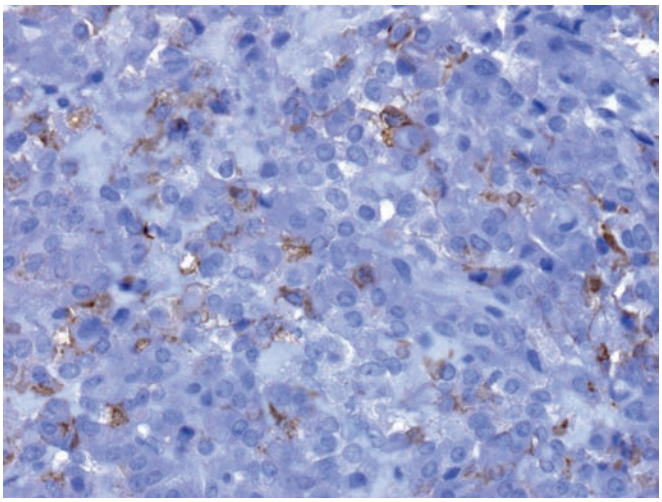

Figure 44.38 Although mixed GH-PRL adenomas present with acromegaly, they are often associated with hyperprolactinemia as well and as shown here contain a higher percentage of PRL+ cells than densely granulated GH adenomas, which should only contain occasional cells that are immunoreactive for PRL.

two cell types can often be identified on H&E (Fig. 44.36), and are paralleled by strong GH (Fig. 44.37) and PRL (Fig. 44.38) expression in tumor subsets. PRL expression is present in a higher percentage of cells than in pure densely granulated GH adenomas (defined by some as less than 5% of cells).[54] Some might prefer to use the term mixed GH-PRL for those adenoma patients with clinical acromegaly but also serum hyperprolactinemia.[56]

Mammosomatotroph adenomas appear identical to densely granulated GH adenomas on light microscopy. They also present with acromegaly and are immunoreactive for GH. They variably express αSU and PRL, and by EM show a single cell type with combined GH and PRL hormone secretion. While confident discrimination between true bicellular mixed GH-PRL adenomas and monocellular mammosomatotroph cell adenomas requires EM, the distinction is considered clinically unimportant by most, but not all workers.[56]

Lactotroph Adenoma

Table 44.3 summarizes the types of tumors that produce prolactin excess, resulting in varying degrees of hyperprolactinemia. Almost all PRL-secreting adenomas are sparsely granulated. Histologically, sparsely granulated PRL-secreting adenomas show diffuse or trabecular growth patterns and demonstrate increased nuclear chromatin content (Fig. 44.39). Diffuse strong immunostaining for PRL is demonstrable in a paranuclear Golgi region pattern (Fig. 44.40). Additional features may include psammomatous calcifications (which are virtually confined to PRL-secreting adenomas), stromal hyalinization (Fig. 44.41) or amyloid derived from PRL. Prolactin secreting adenomas are one of the more common adenoma subtypes in some studies[48] that show increased mitotic rate and MIB-1 indices (Fig. 44.42).

Should patients come to surgical resection after long-term dopamine agonist therapy, specimens will often demonstrate severe cytoplasmic shrinkage with near-naked nuclei and decreased PRL immunoreactivity; this appearance should not be mistaken for

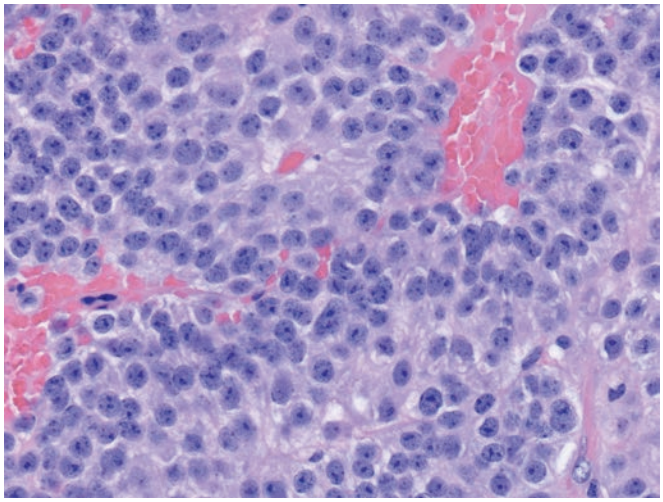

Figure 44.39 Sparsely granulated prolactinomas constitute the overwhelming majority of prolactinomas, and usually feature a sheet-like growth pattern; note the relative prominence of nucleoli (compare with Fig. 44.32).

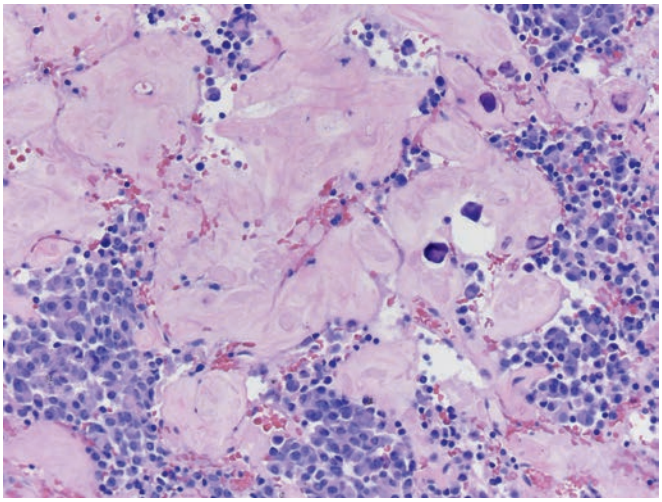

Figure 44.41 Sparsely granulated prolactinomas occasionally show stromal hyalinization and microcalcifications, both of which are pictured here.

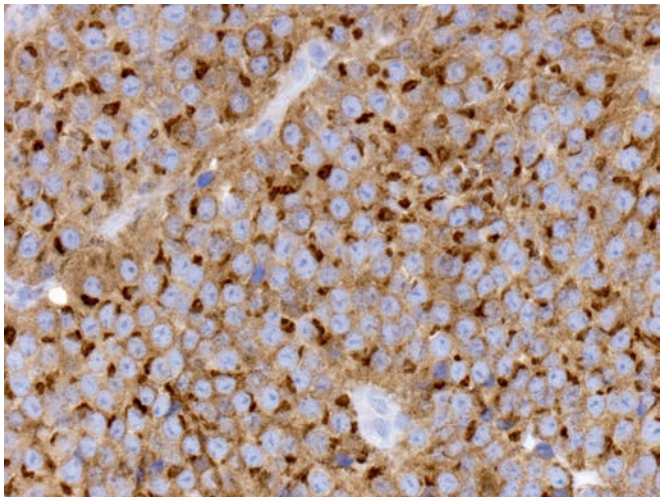

Figure 44.40 Sparsely granulated prolactinomas show PRL positivity in an arc-like cytoplasmic pattern, the so-called Golgi pattern. In contrast, the very rare densely granulated PRL positive adenomas show PRL immunoreactivity throughout the cytoplasm.

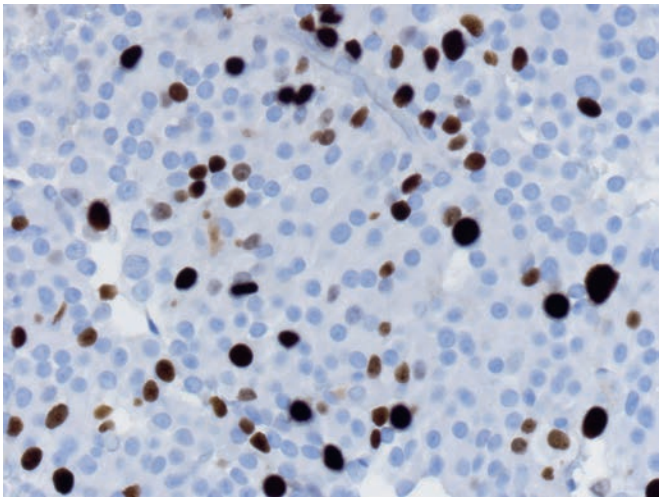

Figure 44.42 Atypical adenomas are defined by an elevated MIB-1 labeling index, although this does not correlate perfectly with adenoma subtype. Indeed, even the well-accepted "aggressive" adenoma subtypes, such as sparsely granulated GH, acidophil stem cell, and silent ACTH adenoma, do not invariably show elevated indices. In some studies, the most common subtype to show elevated MIB-1 is sparsely granulated prolactinoma, as illustrated here. Acidophil stem cell adenoma was excluded in this case by clinical and EM features.

lymphocytes or a small cell neoplasm, such as lymphoma or a metastatic small cell carcinoma. Fibrosis will also be evident in such cases. These changes may not be evident following short-term treatment.

Densely granulated PRL adenomas are exceedingly rare, are PIT1 driven, and show PRL immunoreactivity that fills the cytoplasm of the cell in a diffuse rather than in a Golgi pattern of staining.[13,19] These tumors may behave more aggressively.

Acidophil stem cell adenomas are also rare tumors. They are typically locally invasive macroadenomas that manifest with a relatively short clinical history. The tumor is monomorphous, is chromophobic to slightly acidophilic, contains fibrous bodies by CAM5.2 IHC, and may show large cytoplasmic vacuoles (Fig. 44.43). Mitochondrial accumulation with giant mitochondria is the pathognomonic feature, which imparts an oncocytic change on H&E; identification of this feature has required EM in the past.[57] Whether IHC for mitochondrial antibodies can assist in diagnosis is an unsettled question (Fig. 44.44). Immunostaining shows some reactivity for PRL, with focal GH-positive cells or no GH immunoreactivity at all. This correlates well with clinical features in that this adenoma is usually associated with hyperprolactinemia, but the blood PRL levels are disproportionally low for the size of the lesion, and clinical response to dopamine agonists may be suboptimal. Acromegaly is infrequent and usually mild, if present at all.[58] Finally, a poorly differentiated adenoma, the so-called clinically silent subtype 3 adenoma (currently, "plurihormonal PIT1-positive adenoma"), has recently been recognized to be monomorphous and also of PIT1 lineage.[59]

Corticotroph Adenoma

Corticotroph adenomas are by far the most clinically challenging adenoma type. Because the overwhelming majority of corticotroph

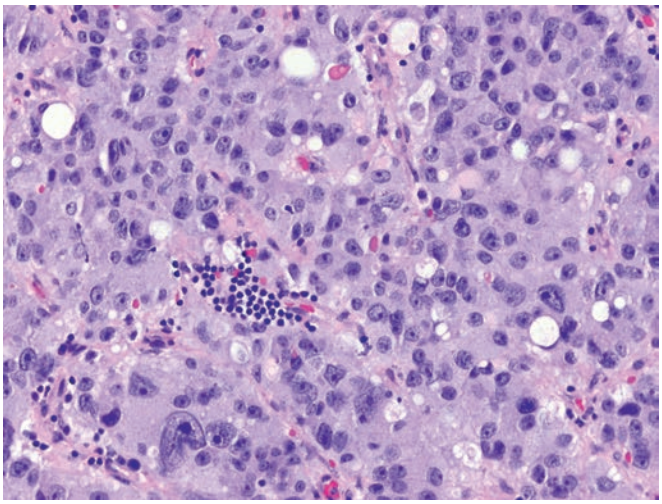

Figure 44.43 Acidophil stem cell adenoma usually presents as a large tumor, with relatively mild hyperprolactinemia for tumor size in comparison to sparsely granulated prolactinomas. Acidophil stem cell adenomas cannot be confidently diagnosed without electron microscopic examination, however. One clue in some cases is the presence of large clear vacuoles corresponding to the giant mitochondria seen on EM.

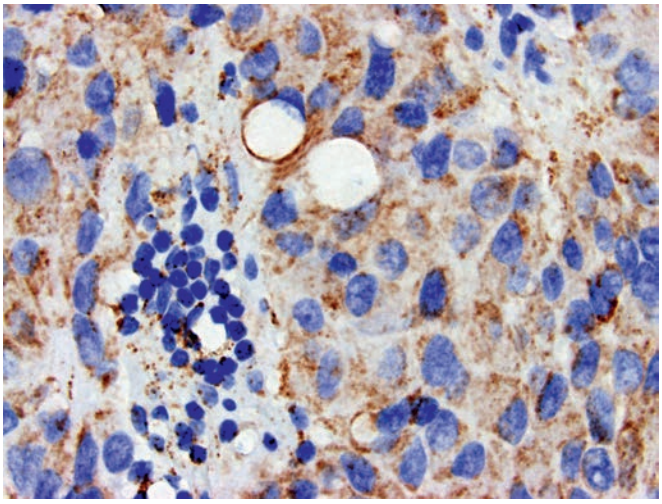

Figure 44.44 Acidophil stem cell adenomas usually require EM for confident diagnosis, but antimitochondrial antibodies are being investigated as possible surrogate IHC markers; note how the immunoreactivity rims the vacuole, indicating that the vacuole is indeed a mitochondrion.

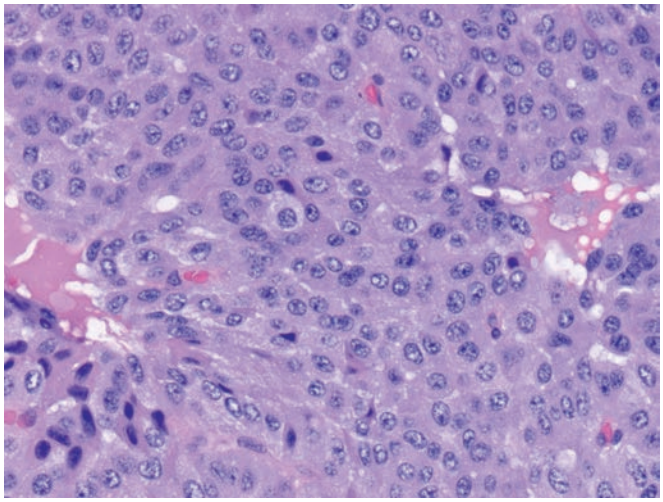

Figure 44.45 This densely granulated corticotroph adenoma is composed of sheets of large cells with basophilic cytoplasm.

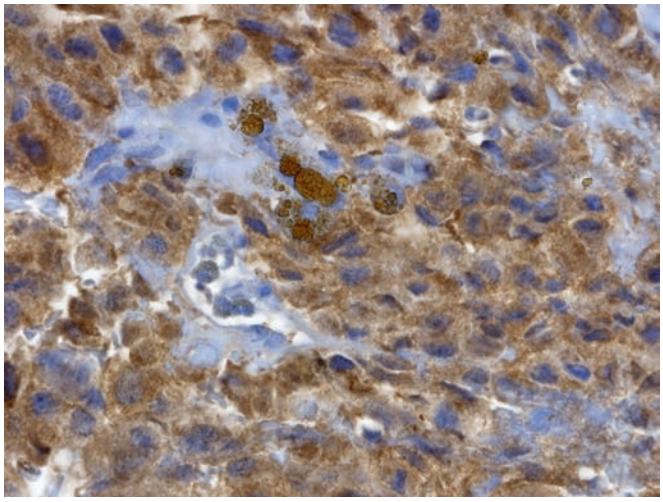

Figure 44.46 Densely granulated corticotroph adenomas show diffuse ACTH immunoreactivity throughout the tumor. Unlike sparsely granulated prolactinomas where adenoma size parallels the serum level of prolactin, minute ACTH adenomas, even millimeters in size, may cause Cushing disease and significantly elevated serum levels.

adenomas (80%) are microadenomas—and 10%–20% are so small that they fall below the resolution level even of modern neuroimaging—petrosal sinus sampling is often necessary to document pituitary gland origin for ACTH excess.

Most ACTH-secreting adenomas occur in women. Clinical features of Cushing disease (i.e., Cushing syndrome caused by a corticotroph pituitary adenoma) may be dramatic, with acquisition of fat in multiple body sites resulting in truncal obesity with thin extremities, and atrophy of the skin with plethora, easy bruisability, and violaceous striae on the abdomen and chest. Additional symptoms include osteoporosis, increased risk of infections, and neuropsychiatric changes.

ACTH-secreting adenomas are equally divided into densely and sparsely granulated types. Densely granulated ACTH adenomas grow as sheets of monotonous round cells, often arranged around blood vessels (Fig. 44.45). Cells show abundant, PAS-positive cytoplasm and strong diffuse immunoreactivity for ACTH only (Fig. 44.46). Sparsely granulated ACTH adenomas show less cytoplasmic volume (Fig. 44.47), are chromophobic to weakly PAS positive, and demonstrate weaker, more focal ACTH positivity (Fig. 44.48).

An interesting aspect to ACTH-secreting adenomas is that, unlike the previously mentioned adenoma subtypes, clinically silent ACTH adenomas are not uncommon, in contrast to the rarity of silent GH- or PRL-positive adenomas. Clinically silent ACTH-secreting adenomas show a range of ACTH immunoreactivity, are histologically identical to their clinically active counterparts, and may include basophilic densely granulated (silent type 1) and chromophobic sparsely granulated (silent type 2) variants. Thus, pathologists cannot distinguish a clinically dramatic tumor from a truly clinically silent ACTH+ adenoma without clinical correlation. Clinically silent ACTH adenomas are generally considered to be one of the aggressive

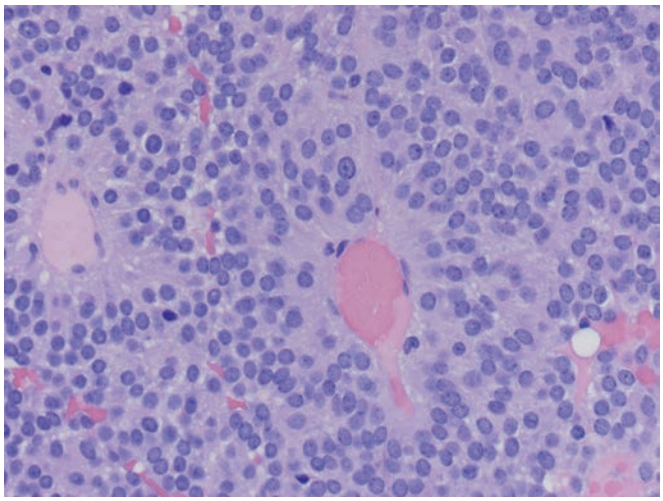

Figure 44.47 Sparsely granulated corticotroph adenomas are usually chromophobic.

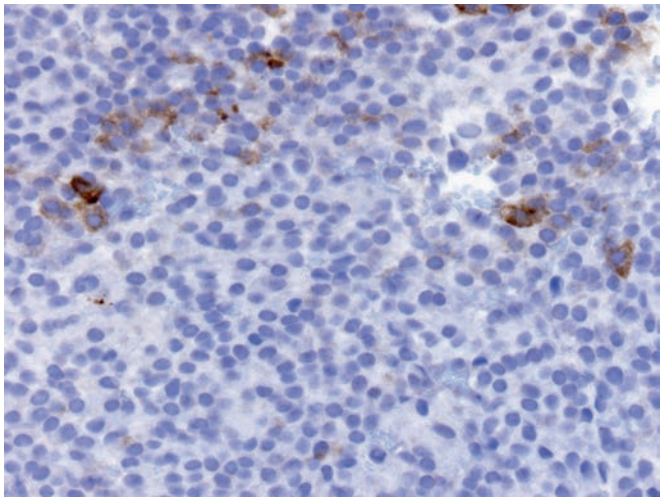

Figure 44.48 Sparsely granulated corticotroph adenomas show focal or patchy ACTH positivity.

adenoma variants,[41] as they have been shown to have an increased frequency of cavernous sinus invasion and progression/recurrence compared to other clinically silent adenomas such as gonadotroph adenomas.[60]

The emergence of clinical symptoms referable to a corticotroph adenoma enlarging after adrenalectomy is known as Nelson's syndrome. Nelson's syndrome occurs when an ACTH adenoma was present but was either so small as to be missed intraoperatively or the patient could not undergo surgical excision for medical reasons in the first place; in either case, the result is the adenoma not being surgically excised. Second line therapy may include a second attempt at surgical removal, medical management, or radiation therapy, but if all that fails, the negative effects of unremitting hypercortisolism may lead to a third line of therapy, bilateral adrenalectomy. Following removal of both adrenals, the corticotroph pituitary adenoma may then eventually enlarge, possibly due to the removal of the negative feedback of cortisol that had been previously produced by the adrenals. The adenoma shows histologic features similar to other ACTH adenomas and variable mitotic activity.

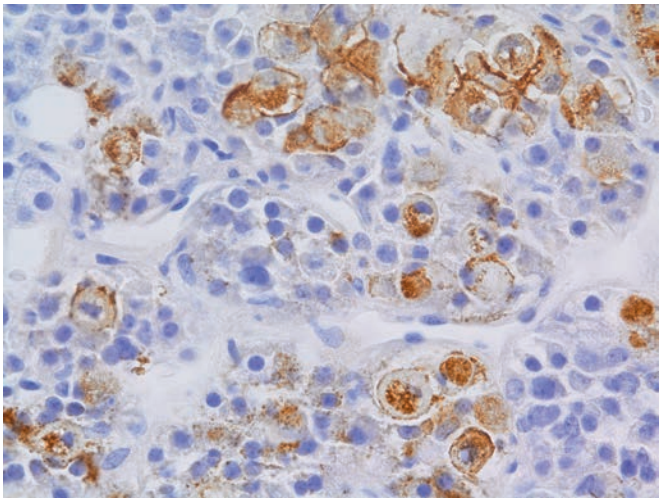

Figure 44.49 Crooke cells in adjacent nontumorous anterior pituitary gland testify to the presence of hypercortisolism, and this change should be sought in any included anterior gland from a corticotroph adenoma resection specimen. Rings of keratin push the ACTH-positive granules close to the nucleus, as well as to submembrane sites.

A specific, albeit uncommon, variant of ACTH-immunoreactive adenoma is the Crooke cell adenoma. In this variant, the cells recapitulate intermediate filament-rich Crooke cells. The ring-like cytoplasmic filament accumulation causes dispersal of secretory granules (and hence the ACTH immunostaining) to the peripheral submembrane region or displaces them internally next to the nucleus. In the largest study to date of 36 cases,[60] only 65% of patients with Crooke cell adenomas manifested Cushing disease (the remainder being silent variants); 81% were macroadenomas and 72% were invasive. All were surgically treated but 60% of patients experienced recurrences, 24% had multiple recurrences, and 12% died; two examples evolved to pituitary carcinoma.[61] Far more frequent than Crooke cell adenoma is the presence of non-neoplastic Crooke cells in the adjacent nontumorous pituitary gland (Fig. 44.49); their presence ensures that functional hypercortisolemia was present, either from an ACTH clinically active adenoma or from iatrogenic steroid administration.

ACTH hyperplasia is an uncommon cause of Cushing syndrome. Diagnosis is predicated on recognizing expansion, rather than destruction, of acini that contain relatively homogeneous populations of ACTH-immunoreactive cells. Given the normal irregular distribution of cell types in the anterior pituitary gland and the normal "basophil" invasion into the posterior pituitary with aging, this diagnosis is often challenging.

Thyroid Stimulating Hormone–Producing Adenoma

Constituting less than 1% of all adenomas, these tumors are macroadenomas and invasive. Hyperthyroidism is usually due to thyroid causes, and a pituitary adenoma is a much rarer explanation. Histologically, these tumors grow in a diffuse pattern and often show a perivascular pseudorosette-like arrangement. Nuclear pleomorphism and spindled morphology is more common in this subtype, and perivascular stromal fibrosis can be encountered. The adenoma cells are chromophobic, may show focal subplasmalemmal dot-like positivity with PAS due to lysosomal accumulation, and are variably immunoreactive for αSU and TSH. Occasional cases develop after longstanding hypothyroidism, but most present without predisposing causes.

Plurihormonal PIT1-Positive Adenoma (Formerly Silent Subtype 3 Adenoma) and Other Unusual Plurihormonal Adenoma Types

The term "plurihormonal" should not be used for adenomas showing combinations of GH/PRL/TSH or GH + FSH/LH/αSU. The new 2017 WHO Classification recognizes plurihormonal PIT1-positive adenomas, clinically functioning adenomas such as GH/prolactin/TSH-producing adenomas when acromegaly and thyroid dysfunction are present, and rare adenoma types with unusual IHC combinations not readily explained by cytodifferentiation/transcription factor histogenesis.

Double or even triple adenomas within a single gland are uncommon but a well-recognized occurrence. The general surgical pathologist should note that if consideration of "plurihormonal adenoma" is raised by IHC, it is far more likely that the rare "aberrant" hormone staining is due to a few entrapped nontumorous anterior pituitary cells encompassed within an adenoma, albeit usually at the edges of tissue fragments.

Ectopic Pituitary Adenoma

The sphenoid sinus and the suprasellar region are the predominant sites for ectopic adenomas;[62,63] less common locations include clivus nasal cavity, cavernous sinus, parasellar region, and sphenoid wing. Rare cases of ectopic adenomas occur in petrous temporal bone, superior orbital fissure, third ventricle,[64] and temporal lobe. Many ectopic adenomas are immunoreactive for ACTH or PRL.[62,63] Ectopic adenomas may cause apoplexy (see later).[65]

Pituitary Apoplexy

Pituitary apoplexy is the sudden onset of clinical symptoms, usually headache, cranial nerve palsy, or visual disturbances, due to a pituitary mass. Pituitary apoplexy usually is due to changes in a pituitary adenoma, not normal gland or other sellar region masses, and corresponds histologically to bland infarction (Fig. 44.50), hemorrhagic infarction, or acute hemorrhage.[66] Pituitary adenomas presenting with clinically evident apoplexy come to surgery because of the need for surgical decompression of the optic chiasm or cavernous sinus. If due to hemorrhage alone, most of the clot may be lost to intraoperative aspiration, and the surgical pathologist would need to correlate the material they receive with preoperative neuroimaging findings and intraoperative impressions. Cases with the greatest interval between symptom onset and surgery show peripheral rim enhancement by preoperative MRI, which can be mistaken for other processes such as pituitary abscess.

Pathologically, this rim enhancement corresponds to granulation tissue, T-cell lymphocytic infiltration, and possible fibrosis at the edge of the infarction or hemorrhage. Occasionally this reaction overshadows the necrotic adenoma and contributes to diagnostic confusion for the pathologist as well. Despite extensive tumor necrosis, reticulin staining usually still allows confident identification of the resected material as an adenoma with a disrupted acinar pattern. Immunohistochemical staining is most informative in cases with necrosis more proximate to the time of surgical intervention. Most apoplexy occurs in macroadenomas such as gonadotroph adenomas, prolactinomas in males, and hormone-negative/null cell macroadenomas.[66]

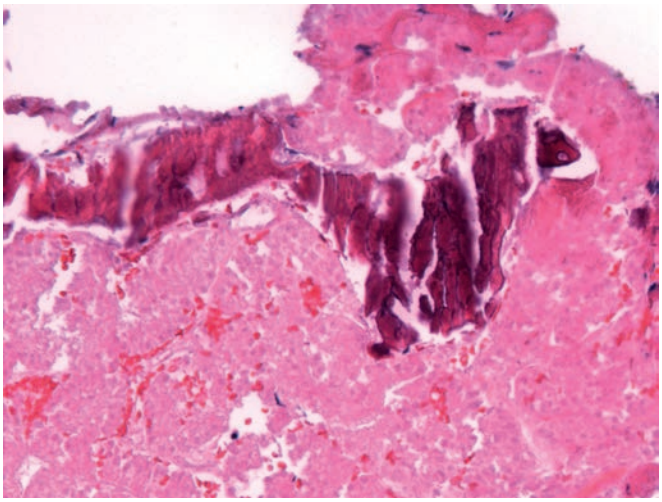

Figure 44.50 Pituitary apoplexy can be seen in several types of adenomas, usually macroadenomas, and may either manifest as bland necrosis, as illustrated here in an adenoma that was present within clival bone, or as acute/subacute hemorrhage.

Mixed Pituitary Adenoma–Gangliocytoma

The entity has appeared in the literature under several names,[67] including pituitary adenoma with neuronal choristoma (PANCH).[68] Several hypotheses have been offered for these lesions, but differentiation of adenoma cells into ganglion cells is favored.

These tumors usually present identically to pituitary adenomas by clinical, neuroimaging, and intraoperative criteria, with the neuronal metaplastic element often representing a surprise of no clinical importance. The pituitary adenoma often predominates, and the two components may be either sharply demarcated from one another or intimately admixed. Most often the adenoma is a GH-secreting type, especially the sparsely granulated subtype. The gangliocytoma portion consists of a neuropil-like, finely fibrillar matrix in which are embedded large, uninucleate or binucleate neurons with normal or even bizarre appearance. The eosinophilic neuropil is hypocellular and composed of ganglion cell processes with the expected reaction for axons with synaptophysin and anti-neurofilament; however, it is usually devoid of a significant glial element and thus is negative for glial fibrillary acidic protein.

Pituitary Carcinoma

Pituitary carcinoma is defined by the presence of cerebrospinal and/or systemic metastases. Vanishingly rare at less than 0.5% of all pituitary region masses,[1] the most important feature to recognize is that these usually evolve from invasive aggressive adenomas over several years, rather than presenting *de novo* as previously undiagnosed metastasizing tumors.[69] Most are invasive macroadenomas at the time of diagnosis and are hormonally active with Cushing syndrome or hyperprolactinemia.

Rathke Cleft Cyst

Symptomatic cysts account for approximately 6%–10% of patients who present in neurosurgical series with sellar and suprasellar lesions. Indications for surgical drainage include headaches, visual disturbances, and/or pituitary hormonal deficiencies. The cyst contains dense eosinophilic amorphous mucin with small strips of simple cuboidal or pseudostratified columnar, ciliated epithelial cyst wall

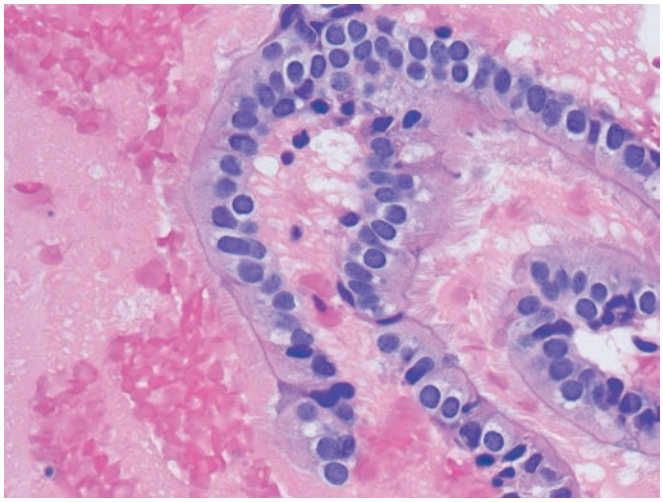

Figure 44.51 Rathke cleft cyst contains variably dense colloid-like proteinaceous contents, usually visible as amorphous eosinophilic material *(left)*. The lining epithelium is often not sent to the pathologist, but, when received, may be columnar ciliated epithelium (as seen here), low cuboidal, or even show squamous metaplasia.

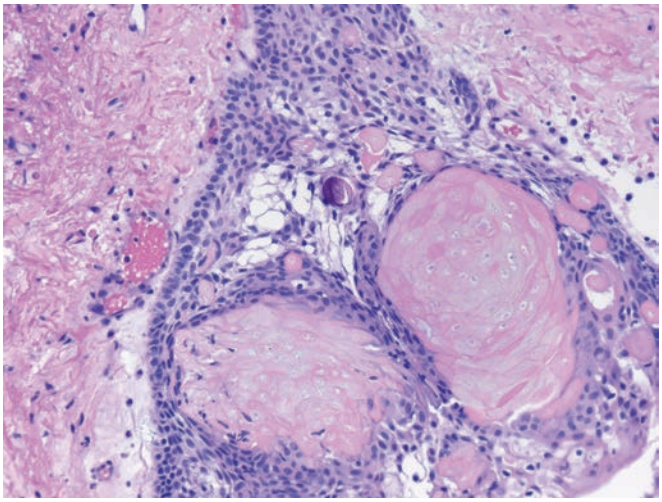

Figure 44.52 Adamantinomatous craniopharyngioma is characterized by peripherally palisaded nuclei, clusters of eosinophilic cells devoid of nuclear staining, so-called ghost cells (also known as wet keratin), focal calcification, and often, surrounding piloid gliosis with Rosenthal fiber formation *(upper right and at left)*.

lining (Fig. 44.51). Squamous metaplasia may correlate with increased incidence of recurrence.

Hypophysitis

Hypophysitis is an inflammatory infiltrate of the pituitary gland but is not a single disorder.[70–76] Secondary hypophysitis is diagnosed when an infectious agent or systemic disease can be identified as affecting the sellar region, such as sarcoidosis, Wegener granulomatosis, Sjögren syndrome, Langerhans cell histiocytosis, and Erdheim–Chester disease. A number of secondary cases currently have been linked with ipilimumab therapy.[74] Germ cell tumors of the central nervous system often involve suprasellar sites and may be accompanied by a profuse lymphocytic or granulomatous reaction that overshadows the neoplastic cells. Lymphoma uncommonly presents as pituitary disease but should be excluded in these cases. Cases in which there is a coexistent pituitary adenoma, craniopharyngioma, or Rathke cleft cyst[73,75] associated with the inflammation can also cause secondary hypophysitis, and these dual pathologies need to be excluded.

Primary hypophysitis was originally thought to occur almost exclusively in young women during late pregnancy or in the early postpartum period, especially the third trimester. More recent series show less association with pregnancy and indicate that males and females are nearly equally affected.[73] Concomitant autoimmune disorders, especially Hashimoto's thyroiditis and Graves' disease,[74] are seen in a significant percentage of cases.[73]

Primary hypophysitis is most commonly divided into lymphocytic, granulomatous, and xanthomatous types, with some workers additionally recognizing mixed xanthogranulomatous and necrotizing forms.[76] Lymphocytic hypophysitis is the most frequent subtype of primary hypophysitis currently encountered by pathologists, followed by granulomatous.[73]

Craniopharyngioma

These tumors have two peaks of occurrence, one in the first to second decade and the second in the fifth decade. The childhood tumors are more often calcified and are almost exclusively of the

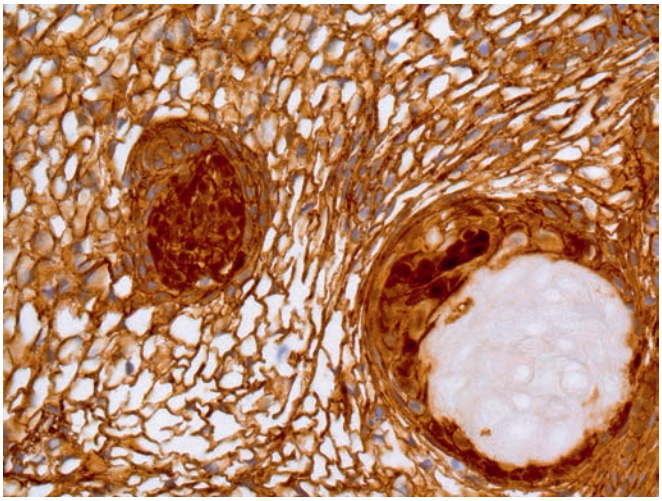

Figure 44.53 Adamantinomatous craniopharyngioma has an underlying mutation in β-catenin and translocation of the protein to the nucleus, which can thus be documented by immunohistochemistry. It should be noted that nuclear β-catenin staining is never seen in all tumor cells, but instead concentrates in cells immediately adjacent to wet keratin or within whorled squamous nests (seen in the plane of section at *lower right*).

adamantinomatous type with peripherally palisaded nuclei, stellate reticulum, ghost cells, focal calcification, and often surrounding piloid gliosis with Rosenthal fiber formation (Fig. 44.52). This type is now known to be associated with beta catenin mutation and WNT pathway activation, with nuclear beta catenin immunoreactivity, although an important point is that positivity is generally confined to cells within squamous morules, sometimes surrounding clumps of wet keratin ("ghost cells") (Fig. 44.53).[77]

Papillary craniopharyngioma is composed of nonkeratinizing stratified squamous epithelium that is devoid of a keratohyalin layer (unlike epidermoid cyst) or wet keratin, ghost cells, or calcification (unlike adamantinomatous craniopharyngioma) (Fig. 44.54). It is

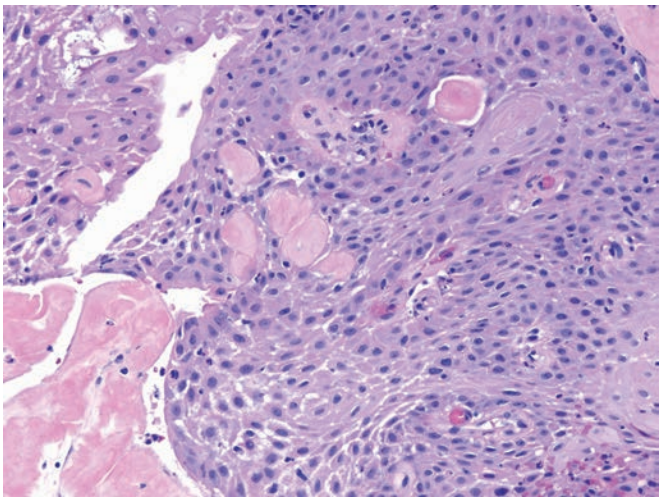

Figure 44.54 Papillary craniopharyngioma lacks the prominent peripheral palisaded nuclei, wet keratin, and calcification of the adamantinomatous variety; note the hyalinized, collagenous whorl-like structures that should not be mistaken for wet keratin.

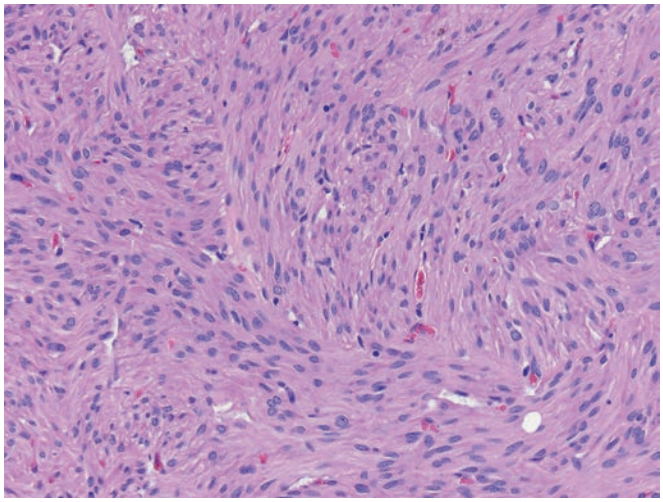

Figure 44.56 Pituicytoma is a spindle cell sellar region mass easily mistaken on light microscopy for meningioma, schwannoma, or even normal posterior pituitary gland.

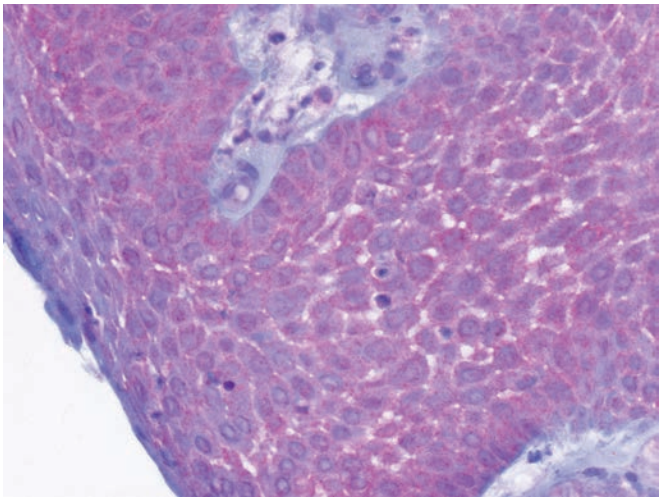

Figure 44.55 Papillary, squamous craniopharyngiomas are composed of benign nonkeratinizing epithelium devoid of a keratohyaline layer, unlike epidermoid cysts. Unlike adamantinomatous craniopharyngioma, papillary craniopharyngioma manifests mutation in *BRAF* V600E, which is paralleled by BRAF VE1 immunoreactivity, as shown here with a red chromogen.

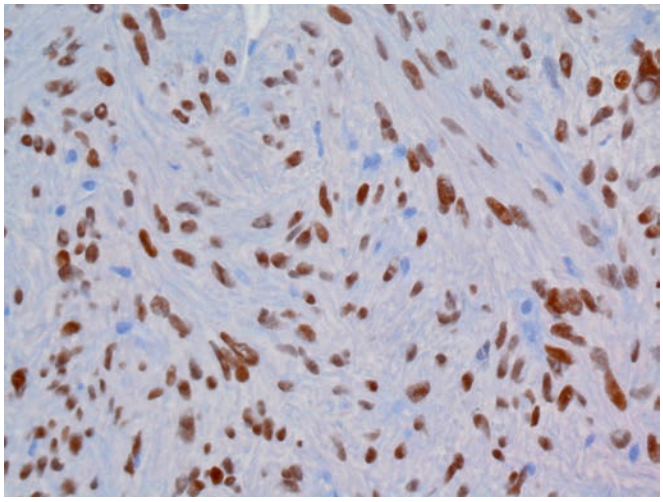

Figure 44.57 Pituicytoma, like the related spindle cell oncocytoma and granular cell tumor of infundibulum, shows nuclear reactivity for TTF1, negating consideration of meningioma, schwannoma, or even pituitary adenoma. The cell density and architectural pattern distinguishes it from TTF1+ normal posterior gland.

almost exclusively seen in adults and is related to mutations in *BRAF* V600E,[78] which is paralleled by BRAF VE1 immunoreactivity (Fig. 44.55). Malignant degeneration is rare in craniopharyngiomas.[79]

Pituicytoma, Spindle Cell Oncocytoma, and Granular Cell Tumor of Neurohypophysis

These three rare entities are WHO grade I sellar masses that clinically and radiographically mimic nonfunctional pituitary adenomas. All three are recognized today to be derivatives of normal posterior gland pituicytes, and share nuclear TTF1 immunoreactivity with the normal posterior gland.[6–8] Pituicytoma is a monomorphic spindle cell tumor composed of plump cells arranged in fascicles (Fig. 44.56), typically with only rare mitoses. Unlike meningioma, the tumor lacks calcification or whorls. Pituicytoma shows strong immunoreactivity for S-100 protein, variable immunoreactivity for glial fibrillary acidic protein, and nuclear TTF1 positivity (Fig. 44.57).[80] Cases have been reported as incidental findings at autopsy, in association with other endocrine neoplasms or presenting with hemorrhage.[7]

Spindle cell oncocytoma is similar, but with epithelioid cells, mild to moderate nuclear atypia (Fig. 44.58), and sometimes a minor lymphocytic infiltrate.[81] EM or mitochondrial IHC (Fig. 44.59) shows numerous mitochondria, which is the feature that distinguishes these lesions from pituicytoma. Recurrence, sometimes after long time periods, has been reported.[7] Granular cell tumor of the neurohypophysis, characterized by lysosomal-rich cytoplasm, is the least

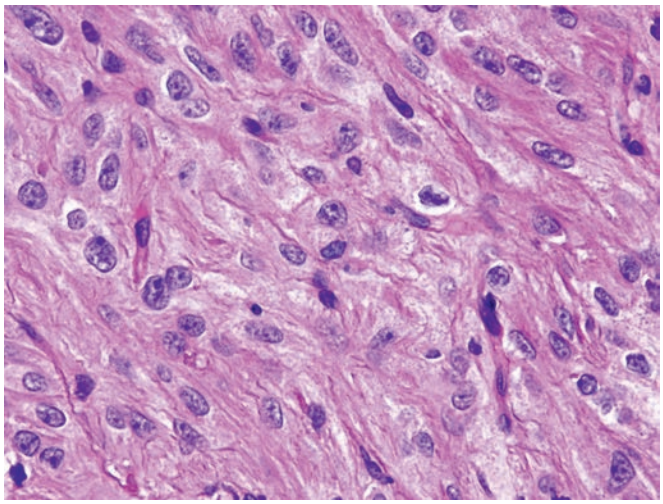

Figure 44.58 Spindle cell oncocytoma is composed of cells with plumper, more epithelioid-appearing eosinophilic cytoplasm but does have overlapping features with pituicytoma, most notably the shared TTF1 immunoreactivity.

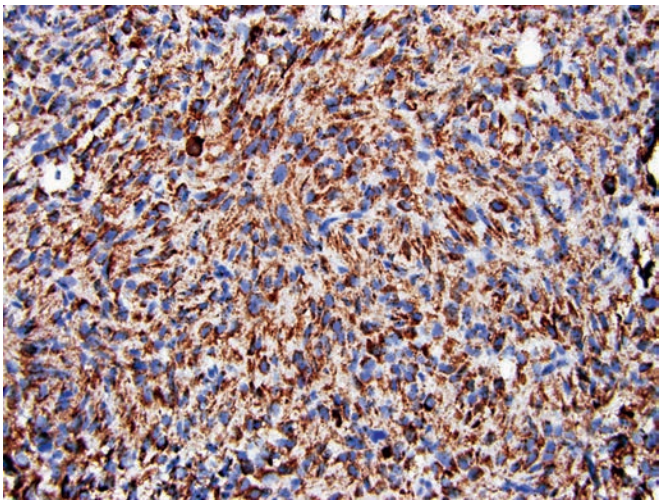

Figure 44.59 Spindle cell oncocytoma is characterized by more abundant cytoplasmic mitochondria than are present in pituicytoma, as seen here on anti-mitochondrial immunohistochemistry.

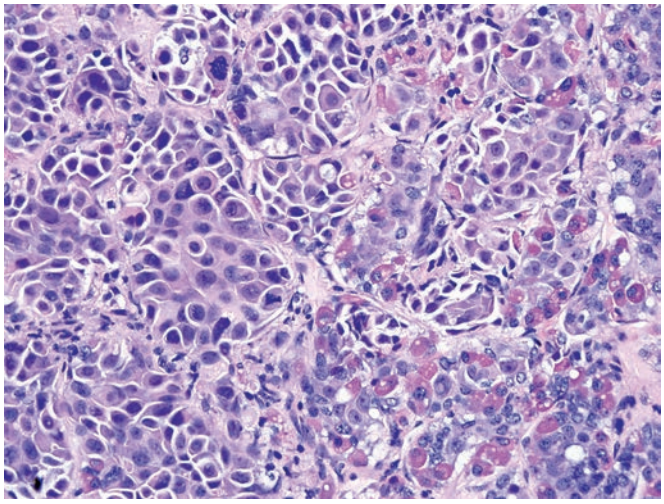

Figure 44.60 Metastases to the pituitary gland usually obliterate or compress the gland, but occasionally the tumor and residual anterior pituitary cells are intimately admixed; compare the metastatic breast carcinoma at left with the normal anterior pituitary gland showing all three cell types (chromophobes, basophils, eosinophils) at right.

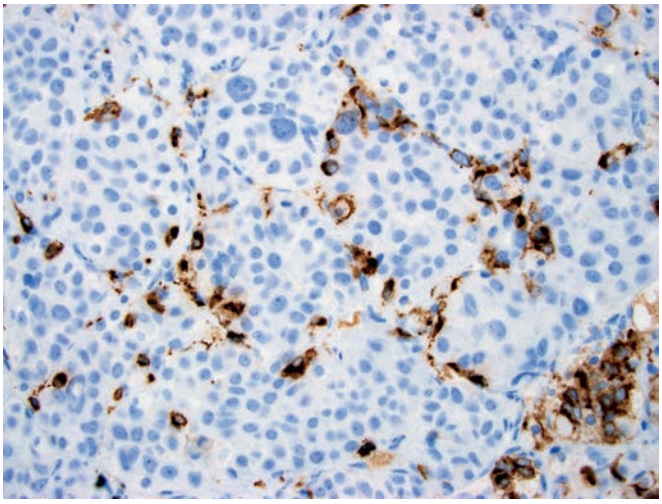

Figure 44.61 Metastatic breast carcinoma to the pituitary gland has so intimately infiltrated the anterior pituitary that acini are not totally destroyed; prolactin-immunoreactive residual normal anterior pituitary cells envelop nests of the metastatic tumor.

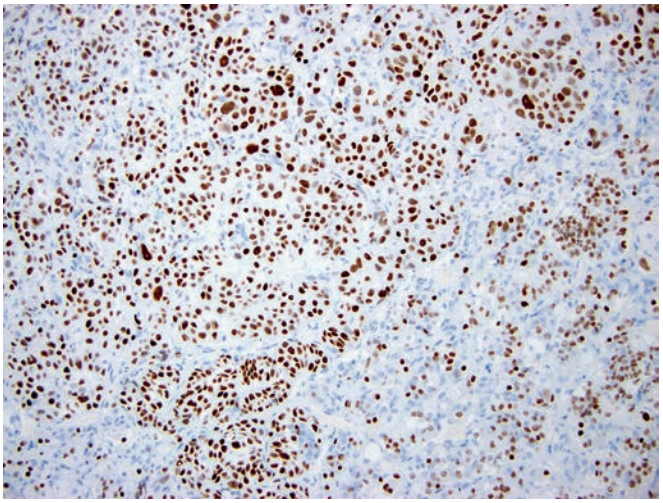

Figure 44.62 In this case the metastatic breast carcinoma shows strong diffuse nuclear immunoreactivity for estrogen receptor. Note, however, that the residual normal anterior pituitary gland, at lower right, also contains a few scattered, smaller-sized nuclei that are also ER positive. These are either gonadotrophs or lactotrophs.

frequent of the three entities, with small incidental tumors predominating over clinically evident examples.

Metastatic Tumors

Pituitary metastases constitute less than 1% of all intracranial metastases premortem, but up to 2% of postmortem cases show pituitary gland involvement.[82] The autopsy incidence is particularly high in patients with breast carcinoma.[82] In clinically evident cases, metastases from breast and lung are the most frequent, followed distantly by prostate and renal cell carcinomas. Metastases to the pituitary gland usually obliterate or compress the gland and therefore usually do not cause significant diagnostic confusion. Occasionally, however, the metastatic tumor is intimately associated with recognizable residual anterior gland (Fig. 44.60). In these instances, pituitary acini may not be totally destroyed and residual normal anterior pituitary cells may envelop nests of the metastatic tumor (Fig. 44.61). IHC may be required to distinguish metastatic cells from residual pituitary cells (Fig. 44.62).

Involvement of the neurohypophysis, extrasellar bone, and dura causes most pituitary metastases to clinically present as diabetes insipidus, in contrast to pituitary adenomas.[82] Meningiomas, and rarely chordomas or other bony neoplasms of the sella, can mimic adenomas by neuroimaging.

Acknowledgments

The authors gratefully acknowledge Mrs. Diane Hutchinson for expert manuscript preparation and Ms. Lisa Litzenberger for photographic expertise.

References

1. Saeger W, Lüdecke DK, Buchfelder M, et al. Pathohistological classification of pituitary tumors: 10 years of experience with the German Pituitary Tumor Registry. *Eur J Endocrinol*. 2007;156(2):203-216.
2. Bilbao JM, Ang LC. Pituitary gland. In: Rosai J, ed. *Rosai and Ackerman's Surgical Pathology*. 9th ed. Edinburgh: Mosby; 2004.
3. Lloyd RV, Kovacs K, Young WF Jr, et al. Tumours of the pituitary. In: DeLellis RA, Lloyd RV, Heitz PU, Eng C, eds. *WHO Classification of Tumours—Tumours of Endocrine Organs*. Lyon: IARC Press; 2004:9-47.
4. Hori A, Schmidt D, Rickels E. Pharyngeal pituitary: development, malformation, and tumorigenesis. *Acta Neuropathol*. 1999;98(3):262-272.
5. Pickett CA, Gutierrez-Hartmann A. Ontogeny of pituitary cell types. In: Wierman MA, ed. *Diseases of the Pituitary*. Totowa, NJ: Humana Press; 1997:1-31.
6. Lee EB, Tihan T, Scheithauer BW, et al. Thyroid transcription factor 1 expression in sellar tumors: a histogenetic marker? *J Neuropathol Exp Neurol*. 2009;68(5):482-488.
7. Kleinschmidt-DeMasters BK, Lopes MB. Update on hypophysitis and TTF-1 expressing sellar region masses. *Brain Pathol*. 2013;23(5):495-514.
8. Mete O, Lopes MB, Asa SL. Spindle cell oncocytomas and granular cell tumors of the pituitary are variants of pituicytoma. *Am J Surg Pathol*. 2013;37(11):1694-1699.
9. Kleinschmidt-DeMasters BK, Lopes MB, Prayson RA. An algorithmic approach to sellar region masses. *Arch Pathol Lab Med*. 2015;139(3):356-372.
10. Konishi Y, Kuriyama M, Sudo M, et al. Growth patterns of the normal pituitary gland and in pituitary adenoma. *Dev Med Child Neurol*. 1990;32(1):69-73.
11. Asa SL. Practical pituitary pathology: what does the pathologist need to know? *Arch Pathol Lab Med*. 2008;132(8):1231-1240.
12. Cohen LE. Genetic regulation of the embryology of the pituitary gland and somatotrophs. *Endocrine*. 2000;12(2): 99-106.
13. Gomez-Hernandez K, Ezzat S, Asa SL, Mete Ö. Clinical implications of accurate subtyping of pituitary adenomas: perspectives from the treating physician. *Turk Patoloji Derg*. 2015;31(suppl 1):4-17.
14. Nishioka H, Inoshita N, Mete O, et al. The complementary role of transcription factors in the accurate diagnosis of clinically nonfunctioning pituitary adenomas. *Endocr Pathol*. 2015;26(4):349-355.
15. Coons SW, Estrada SI, Gamez R, White WL. Cytokeratin CK 7 and CK 20 expression in pituitary adenomas. *Endocr Pathol*. 2005;16(3):201-210.
16. Trouillas J. In search of a prognostic classification of endocrine pituitary tumors. *Endocr Pathol*. 2014;25:124-132.
17. Riva C, Leutner M, Capella C, et al. Different expression of chromogranin A and chromogranin B in various types of pituitary adenomas. *Zentralbl Pathol*. 1993;139(2): 165-170.
18. Lloyd RV, Scheithauer BW, Kovacs K, Roche PC. The immunophenotype of pituitary adenomas. *Endocr Pathol*. 1996;7(2):145-150.
19. Mete Ö, Asa SL. Therapeutic implications of accurate classification of pituitary adenoma. *Semin Diagn Pathol*. 2013;30:158-164.
20. Randall RV, Scheithauer BW, Laws ER Jr, et al. Pituitary adenomas associated with hyperprolactinemia: a clinical and immunohistochemical study of 97 patients operated on transsphenoidally. *Mayo Clin Proc*. 1985;60(11):753-762.
21. Grossman AB. The molecular biology of pituitary tumors: a personal perspective. *Pituitary*. 2009;12(3):265-270.
22. Rickert CH, Dockhorn-Dworniczak B, Busch G, et al. Increased chromosomal imbalances in recurrent pituitary adenomas. *Acta Neuropathol*. 2001;102(6):615-620.
23. Daly AF, Tichomirowa MA, Beckers A. Update on familial pituitary tumors: from multiple endocrine neoplasia type 1 to familial isolated pituitary adenoma. *Horm Res*. 2009;71(suppl 1):105-111.
24. Daly AF, Tichomirowa MA, Beckers A. Genetic, molecular and clinical features of familial isolated pituitary adenomas. *Horm Res*. 2009;71(suppl 2):116-122.
25. Elston MS, McDonald KL, Clifton-Bligh RJ, Robinson BG. Familial pituitary tumor syndromes. *Nat Rev Endocrinol*. 2009;5(8):453-461.
26. Scheithauer BW, Laws ER Jr, Kovacs K, et al. Pituitary adenomas of the multiple endocrine neoplasia type I syndrome. *Semin Diagn Pathol*. 1987;4(3):205-211.
27. Trouillas J, Labat-Moleur F, Sturm N, et al. Pituitary tumors and hyperplasia in multiple endocrine neoplasia type 1 syndrome (MEN1): a case-control study in a series of 77 patients versus 2509 non-MEN1 patients. *Am J Surg Pathol*. 2008;32(4): 534-543.
28. Kurtkaya-Yapicier O, Scheithauer BW, Carney JA, et al. Pituitary adenoma in Carney complex: an immunohistochemical, ultrastructural, and immunoelectron microscopic study. *Ultrastruct Pathol*. 2002;26(6):345-353.
29. Daly AF, Jaffrain-Rea ML, Beckers A. Clinical and genetic features of familial pituitary adenomas. *Horm Metab Res*. 2005;37(6):347-354.
30. Cuny T, Pertuit M, Sahnoun-Fathallah M, et al. Genetic analysis in young patients with sporadic pituitary macroadenomas: besides AIP don't forget MEN1 genetic analysis. *Eur J Endocrinol*. 2013;168(4):533-541.
31. Chanson P, De Roux N, Young J, et al. Absence of activating mutations in the GnRH receptor gene in human pituitary gonadotroph adenomas. *Eur J Endocrinol*. 1998;139(2):157-160.
32. Webb C, Prayson RA. Pediatric pituitary adenomas. *Arch Pathol Lab Med*. 2008;132(1):77-80.
33. de Kock L, Sabbaghian N, Plourde F, et al. Pituitary blastoma: a pathognomonic feature of germ-line DICER1 mutations. *Acta Neuropathol*. 2014;128(1):111-122.
34. Kleinschmidt-DeMasters BK, Lillehei KO, Breeze RE. Neoplasms involving the central nervous system in the older old. *Hum Pathol*. 2003;34(11):1137-1147.
35. Ezzat S, Asa SL, Couldwell WT, et al. The prevalence of pituitary adenomas: a systematic review. *Cancer*. 2004;101(3):613-619.
36. Buurman H, Saeger W. Subclinical adenomas in postmortem pituitaries: classification and correlations to clinical data. *Eur J Endocrinol*. 2006;154(5):753-758.
37. Asa SL. Tumors of the Pituitary Gland. Washington, D.C.: Armed Forces Institute of Pathology, 1998. Print. Ser. 3.
38. Kiseljak-Vassiliades K, Carlson NE, Borges MT, et al. Growth hormone tumor histological subtypes predict response to surgical and medical therapy. *Endocrine*. 2015;49(1):231-241.
39. Lee CC, Vance ML, Lopes MB, et al. Stereotactic radiosurgery for acromegaly: outcomes by adenoma subtype. *Pituitary*. 2015;18(3):326-334.
40. Lillehei KO, Kirshman DL, Kleinschmidt-DeMasters BK, Ridgway EC. Reassessment of the role of radiation therapy in the treatment of endocrine-inactive pituitary macroadenomas. *Neurosurgery*. 1998;43(3):432-438, discussion 438-439.
41. Cooper O, Melmed S. Subclinical hyperfunctioning pituitary adenomas: the silent tumors. *Best Pract Res Clin Endocrinol Metab*. 2012;26(4):447-460.
42. Mathioudakis N, Pendleton C, Quinones-Hinojosa A, et al. ACTH-secreting

pituitary adenomas: size does not correlate with hormonal activity. *Pituitary*. 2012;15(4):526-532.
43. Nishioka H, Inoshita N, Sano T, et al. Correlation between histological subtypes and MRI findings in clinically nonfunctioning pituitary adenomas. *Endocr Pathol*. 2012;23(3):151-156.
44. Nosé V, Ezzat S, Horvath E, et al. Protocol for the examination of specimens from patients with primary pituitary tumors. *Arch Pathol Lab Med*. 2011;135(5):640-646.
45. Madsen H, Borges TM, Knox AJ, et al. Giant pituitary adenomas: pathologic-radiographic correlations and lack of role for p53 and MIB-1 labeling. *Am J Surg Pathol*. 2011;35(8):1204-1213.
46. Selman WR, Laws ER, Scheithauer BW, Carpenter SM. The occurrence of dural invasion in pituitary adenomas. *J Neurosurg*. 1986;63(3):402-407.
47. Meij BP, Lopes MB, Ellegala DB, et al. The long-term significance of microscopic dural invasion in 354 patients with pituitary adenomas treated with transsphenoidal surgery. *J Neurosurg*. 2002;96(2):195-208.
48. Miermeister CP, Petersenn S, Buchfelder M, et al. Histological criteria for atypical pituitary adenomas—data from the German pituitary adenoma registry suggests modifications. *Acta Neuropathol Commun*. 2015;3:50.
49. Yildirim AE, Divanlioglu D, Nacar OA, et al. Incidence, hormonal distribution and postoperative follow up of atypical pituitary adenomas. *Turk Neurosurg*. 2013;23(2):226-231.
50. Zada G, Woodmansee WW, Ramkissoon S, et al. Atypical pituitary adenomas: incidence, clinical characteristics, and implications. *J Neurosurg*. 2011;114(2):336-344.
51. Scheithauer BW, Gaffey TA, Lloyd RV, et al. Pathobiology of pituitary adenomas and carcinomas. *Neurosurgery*. 2006;59(2):341-353, discussion 341-353.
52. McDonald W, Banerji N, McDonald K, et al. Pituitary adenoma immunohistochemical characterization; validating a novel subtyping algorithm. *J Neuropathol Exp Neurol*. 2015;74(6):610.
53. Balogun JA, Monsalves E, Juraschka K, et al. Null cell adenomas of the pituitary gland: an institutional review of their clinical imaging and behavioral characteristics. *Endocr Pathol*. 2015;26(1):63-70.
54. Obari A, Sano T, Ohyama K, et al. Clinicopathological features of growth hormone-producing pituitary adenomas: difference among various types defined by cytokeratin distribution pattern including a transitional form. See comment in PubMed Commons below. *Endocr Pathol*. 2008;19(2):82-91.
55. Fougner SL, Casar-Borota O, Heck A, et al. Adenoma granulation pattern correlates with clinical variables and effect of somatostatin analogue treatment in a large series of patients with acromegaly. *Clin Endocrinol (Oxf)*. 2012;76(1):96-102.
56. Lopes MB. Growth hormone-secreting adenomas: pathology and cell biology. *Neurosurg Focus*. 2010;29(4):E2.
57. Horvath E, Kovacs K, Singer W, et al. Acidophil stem cell adenoma of the human pituitary: clinicopathologic analysis of 15 cases. *Cancer*. 1981;47(4):761-771.
58. Mete O, Gomez-Hernandez K, Ezzat S, Asa SL. Clinicopathologic features of pituitary acidophil stem cell adenomas. Abstract #134, Poster Session VI, USCAP 2015.
59. Mete O, Gomez-Hernandez K, Ezzat S, Asa SL. Pituitary silent type subtype III adenomas are not always silent and represent Pit-1 lineage adenomas. Abstract #135, Poster Session VI, USCAP 2015.
60. Jahangiri A, Wagner JR, Pekmezci M, et al. A comprehensive long-term retrospective analysis of silent corticotrophic adenomas vs hormone-negative adenomas. *Neurosurgery*. 2013;73(1):8-17.
61. George DH, Scheithauer BW, Kovacs K, et al. Crooke's cell adenoma of the pituitary: an aggressive variant of corticotroph adenoma. *Am J Surg Pathol*. 2003;27:1330-1336.
62. Hou L, Harshbarger T, Herrick MK, Tse V. Suprasellar adrenocorticotropic hormone-secreting ectopic pituitary adenoma: case report and literature review. *Neurosurgery*. 2002;50(3):618-625.
63. Seltzer J, Lucas J, Commins D, et al. Ectopic ACTH-secreting pituitary adenoma of the sphenoid sinus: case report of endoscopic endonasal resection and systematic review of the literature. *Neurosurg Focus*. 2015; 38(2):E10.
64. Kleinschmidt-DeMasters BK, Winston KR, Rubinstein D, Samuels MH. Ectopic pituitary adenoma of the third ventricle. *J Neurosurg*. 1990;72:139-142.
65. Mudd PA, Hohensee S, Lillehei KO, et al. Ectopic pituitary adenoma of the clivus presenting with apoplexy: case report and review of the literature. *Clin Neuropathol*. 2012;31(1):24-30.
66. Kleinschmidt-DeMasters BK, Lillehei KO. Pathological correlates of pituitary adenomas presenting with apoplexy. *Hum Pathol*. 1998;29(11):1255-1265.
67. Towfighi J, Salam MM, McLendon RE, et al. Ganglion cell-containing tumors of the pituitary gland. *Arch Pathol Lab Med*. 1996;120(4):369-377.
68. Sato Y, Wada T, Nishikawa Y, et al. Growth hormone-producing pituitary adenoma regrowing as pituitary adenoma with neuronal choristoma 14years after tumor removal. *World Neurosurg*. 2013;80(3-4):436.e11-436.e13.
69. Lopes MB, Scheithauer BW, Schiff D. Pituitary carcinoma, diagnosis and treatment. *Endocrine*. 2005;28:115-121.
70. Carmichael JD. Update on the diagnosis and management of hypophysitis. *Curr Opin Endocrinol Diabetes Obes*. 2012;19:314-321.
71. Cheung CC, Ezzat S, Smyth HA, Asa SL. The spectrum and significance of primary hypophysitis. *J Clin Endocrinol Metab*. 2001;86:1048-1053.
72. Gutenberg A, Hans V, Puchner MJA, et al. Primary hypophysitis: clinical-pathological correlations. *Eur J Endocrinol*. 2006;155:101-107.
73. Leung GK, Lopes MB, Thorner MO, et al. Primary hypophysitis: a single-center experience in 16 cases. *J Neurosurg*. 2004;101:262-271.
74. Honegger J, Schlaffer S, Menzel C, et al. Diagnosis of primary hypophysitis in Germany. *J Clin Endocrinol Metab*. 2015;100(10):3841-3849.
75. Hayashi Y, Oishi M, Kita D, et al. Pure lymphocytic infundibuloneurohypophysitis caused by the rupture of Rathke's cleft cyst: report of 2 cases and review of the literature. *Turk Neurosurg*. 2015;25(2):332-336.
76. Tashiro T, Sano T, Xu B, et al. Spectrum of different types of hypophysitis: a clinicopathologic study of hypophysitis in 31 cases. *Endocr Pathol*. 2002;13(3):183-195.
77. Buslei R, Hölsken A, Hofmann B, et al. Nuclear beta-catenin accumulation associates with epithelial morphogenesis in craniopharyngiomas. *Acta Neuropathol*. 2007;113(5):585-590.
78. Brastianos PK, Taylor-Weiner A, Manley PE, et al. Exome sequencing identifies BRAF mutations in papillary craniopharyngiomas. *Nat Genet*. 2014;46(2):161-165.
79. Rodriguez FJ, Scheithauer BW, Tsunoda S, et al. The spectrum of malignancy in craniopharyngioma. *Am J Surg Pathol*. 2007;31(7):1020-1028.
80. Brat DJ, Scheithauer BW, Staugaitis SM, et al. Pituicytoma: a distinctive low-grade glioma of the neurohypophysis. *Am J Surg Pathol*. 2009;24:362-368.
81. Fuller GN, Scheithauer BW, Roncaroli F, Wesseling P. Spindle cell oncocytoma of the adenohypophysis. In: Louis DN, Ohgaki H, Wiestler OD, Cavenee WK, eds. *WHO Classification of Tumours of the Central Nervous System*. Lyon, France: IARC; 2007:245-246, [Chapter 14].
82. He W, Chen F, Dalm B, et al. Metastatic involvement of the pituitary gland: a systematic review with pooled individual patient data analysis. *Pituitary*. 2015;18(1):159-168.

45 Eye and Ocular Adnexa

Charles G. Eberhart

CHAPTER CONTENTS

Introduction, *2112*
Normal anatomy, *2112*
Eyelids, *2113*
Developmental anomalies, *2113*
Inflammation, *2113*
Cysts, *2114*
Tumors and tumorlike lesions, *2114*
Lacrimal gland, *2117*
Mikulicz disease/IgG4-related disease, *2118*
Sjögren syndrome, *2118*
Tumors and tumorlike conditions, *2118*
Lacrimal passages, *2118*
Canaliculitis and dacryocystitis, *2118*
Mucocele, *2118*
Dacryolithiasis, *2119*
Tumors, *2119*
Orbit, *2120*
Thyroid ophthalmopathy, *2120*
Inflammatory processes, *2120*
Primary tumors, *2122*
Metastatic tumors, *2126*
Conjunctiva, *2126*
Developmental anomalies, *2127*
Cysts, *2127*
Degeneration, *2127*
Graft-versus-host disease, *2128*
Inflammation, *2128*
Tumors and tumorlike conditions, *2128*
Intraocular tissues, *2131*
Malignant melanoma, *2131*
Retinoblastoma and related lesions, *2134*
Lymphoid tumors and tumorlike conditions, *2137*
Other primary tumors, *2137*
Metastatic tumors, *2138*
Cytology, *2138*

Introduction

This chapter will cover primarily those entities that come to the attention of the surgical pathologist; therefore most non-neoplastic entities of the intraocular tissues will be excluded. Dystrophies and degenerative conditions of the cornea also represent a complex subject which will not be covered here. For a more detailed description of these and other diseases, the reader is referred to one of the many specialized textbooks available.[1–7] As with all surgical specimens, a complete description of the lesion and a meaningful clinical history are invaluable. Clinical photographs are especially helpful in ophthalmic pathology.

Normal Anatomy

The *eyelids* are divided into a cutaneous and a conjunctival portion. The former is composed of stratified squamous epithelium and the latter of a much thinner conjunctival epithelium. In addition to standard pilosebaceous units, skin appendages of eyelids include sebaceous glands of Zeis, apocrine glands of Moll, and eccrine sweat glands, as well as the large sebaceous meibomian glands embedded in the thick fibrocellular tarsal plate.

The *lacrimal gland* is largely of serous type, with a minor mucinous component in the ductal portion and a layer of myoepithelial cells in the larger peripheral ducts. In addition to the main lacrimal gland in the orbit, accessary lacrimal glands of Wolfring and Krause are present at the base of the tarsal plate and conjunctival fornix, respectively. The *lacrimal passages* allow tears produced by the lacrimal gland to be transported from the eye into the *nasal cavity*. Tears enter from the ocular surface into upper or lower *punctum* and drain through the *canaliculus* into the *lacrimal sac* and then the *nasolacrimal duct*, which opens in the nasal cavity. The canaliculus is lined by stratified, nonkeratinized epithelium, while both the lacrimal sac and the nasolacrimal duct are lined by *stratified columnar epithelium* containing mucus-secreting goblet cells.

The *orbit* contains, in addition to the ocular globe and the lacrimal gland, the following structures: the optic nerve and its meningeal covering, Tenon's capsule, the extraocular muscles, blood vessels, and a delicate framework of fibroadipose connective tissue.

The *conjunctiva* is a thin mucous membrane that lines the inner surface of the eyelids and most of the anterior surface of the ocular globe. The conjunctival epithelium is composed of two to five layers of columnar cells that rest on a continuous basal lamina. This epithelium contains mucin-secreting goblet cells and melanocytes.

Abstract

The eye and ocular adnexa contain a number of specialized structures, as well as tissues similar to those found at other body sites. Pathology in this region therefore represents a mixture of unique and common entities. This chapter reviews the normal anatomy and histology of the eye, eyelid and orbit, as well as neoplastic and non-neoplastic ophthalmic diseases encountered by surgical pathologists. Some specialized aspects of non-neoplastic ocular pathology, including corneal dystrophies, are not covered.

Keywords

eye
orbit
eyelid

The *caruncle* is a small, fleshy protuberance that fills the triangular space between the medial margins of the upper and lower eyelids. It is covered by epithelium similar to conjunctiva, but contains pilosebaceous units and sweat glands.

The *cornea* consists of six distinct layers: epithelium, epithelial basal lamina, Bowman layer (an acellular structure made up of collagen fibers, which cannot regenerate), stroma, Descemet membrane (a basal lamina produced by the underlying corneal endothelial cells), and a single layer of very flat cells known as "endothelium," but not related to vascular endothelium. A region of epithelial progenitors known as the *limbus* surrounds the cornea.

The thick *sclera* encloses the globe and is mainly composed of a dense collagenous stroma admixed with occasional elastic fibers and scattered fibroblasts.

The *intraocular tissues* comprise the uveal tract (iris, ciliary body, and choroid), the retinal pigment epithelium, the retina, the crystalline lens, and the various intraocular compartments. A detailed description of these structures and how they age is beyond the scope of this book but has recently been reviewed.[8]

Eyelids

Most of the pathologic processes that involve the eyelids are those that affect the skin in general and are considered in detail in Chapters 2 and 3. Some consideration, however, is given in this chapter to those lesions that are either peculiar to the lids or present particular problems in this location.

Developmental Anomalies

Dermoid cysts typically involve the upper eyelid along the lateral brow margin, where ectoderm becomes entrapped during embryologic bony fusion, and often represent forward extension of a mass that is primarily intraorbital (Fig. 45.1). Microscopically, the cysts are lined by well-differentiated epidermal and dermal tissues containing all of the usual skin appendages. The lumen is filled with keratinous debris, sebum, and hairs. In places where these contents have been extruded into the surrounding tissues, a severe foreign body inflammatory reaction may be observed (Fig. 45.2).

Inflammation

Inflammation of the eyelids *(blepharitis)* may be the result of viral, bacterial, rickettsial, mycotic, or parasitic infections; chemical or physical irritants; hypersensitivity states; or systemic dermatologic disorders. These inflammatory processes are rarely biopsied. Eversion or sagging of the eyelid, known as *ectropion*, is often corrected surgically and results in specimens showing conjunctival goblet cell loss and squamous metaplasia (Fig. 45.3).

Granuloma annulare *(Pseudorheumatoid nodule)* can occasionally involve the eyelid and eyebrow and rarely the episcleral and orbital tissues; it generally presents in children and young adults.[9]

Necrobiotic xanthogranuloma with paraproteinemia is characterized by multiple nodules or plaques that involve the periorbital areas (including eyelids) along with other parts of the body. A dysproteinemia is frequently present, and the lesions can also be associated with multiple myeloma. Microscopically, the granulomas are characterized by collagen "necrobiosis" together with foamy macrophages and Touton giant cells.[10]

Chalazion

Chalazion is an extremely common lesion. It represents a lipogranuloma that develops in and about a meibomian gland as a consequence of the effects of obstruction. The sebaceous material discharged into the tarsus provokes an intense granulomatous inflammatory reaction (Fig. 45.4).

Although chalazion begins as a deep-seated process, not infrequently it erupts through the conjunctival surface of the eyelid and

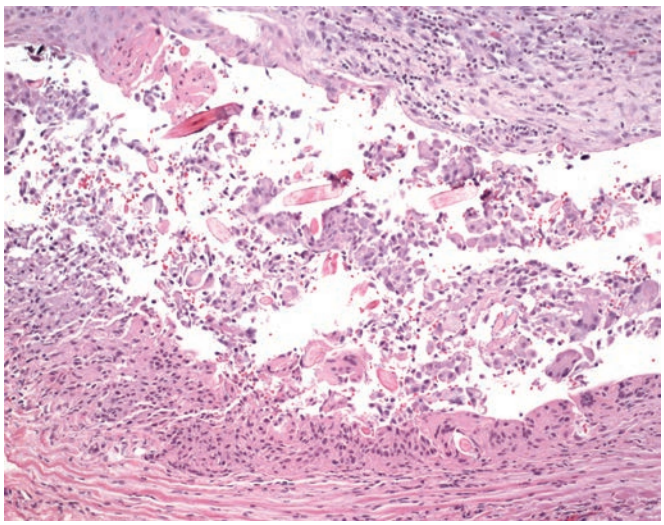

Figure 45.2 Ruptured orbital dermoid cyst containing hair with foreign body reaction.

Figure 45.1 Dermoid cyst of right upper eyelid.

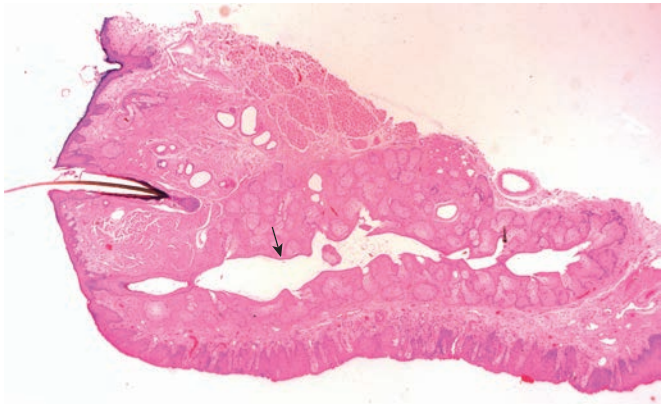

Figure 45.3 **Eyelid Ectropion.** The meibomian gland duct is also dilated *(arrow)*.

can be associated with an overlying pyogenic granuloma. Ordinarily, this lesion is readily recognized and treated; however, if one or more recurrences develop after curettage, sebaceous carcinoma arising from the meibomian gland or other neoplasm must be ruled out.

Microscopically, the typical chalazion reveals multiple foci of granulomatous inflammation (Fig. 45.5). In the center of many of the granulomas there are small globules of fat, which in paraffin sections present as empty, round to ovoid spaces.

Cysts

Benign cysts of the skin of the eyelids and along the lid margins are relatively common, comprising approximately one-third of lesions removed from the lids. The most common of these are the *keratinous cysts* discussed in Chapter 3. Keratinizing intratarsal *Meibomian gland cysts* have recently been described, which arise from ductal epithelium and, in contrast to cutaneous keratinous cysts, are positive for keratin 17 and carcinoembryonic antigen (CEA).[11]

Cysts arising from blocked sweat glands are common in the periocular region and are known as sudoriferous cysts or hidrocystoma. They are filled with a watery fluid and can be multilocular (Fig. 45.6). *Apocrine* and *eccrine hidrocystoma* are differentiated by the tall apical epithelial snouts and "decapitation" secretion in the former, and flatter epithelial profiles in the latter. In one institutional series of 5504 eyelid cases, hidrocystomas represented 8% of all benign lesions.[12]

Tumors and Tumorlike Lesions

Tumors and Tumorlike Lesions of Surface Epithelium

Basal cell carcinoma is by far the most frequent neoplasm arising in any of the palpebral tissues.[13] The overwhelming majority are easily excised without sequelae. On rare occasions, if left untreated for long periods, they may invade the orbit, nose, or both, and exenteration of the orbit may become necessary. Microscopic examination of the margins by frozen section at the time of surgery is a useful technique for ensuring that total removal of the tumor has been achieved.

Basal cell carcinomas arise from the cutaneous surface of the eyelids and rarely, if ever, from the conjunctiva. This point is of some diagnostic significance, for a *papilloma* of the palpebral conjunctiva, or more ominously a *sebaceous carcinoma* involving the conjunctiva and lid margin, may resemble basal cell carcinoma.

Squamous cell carcinoma is responsible for 4%–12% of all malignant epithelial tumors of the eyelid.[14] Most cases are located in the lower lid.[14] A small percentage of these tumors are of the adenoid (pseudoglandular or acantholytic) type.[15] Clear cell or vesicular change can also be seen in squamous carcinoma and can mimic sebaceous carcinoma. Vacuolar adipophilin expression is useful in distinguishing sebaceous carcinoma from basal or squamous cell carcinoma.[16,17]

Figure 45.4 Chalazion of right upper eyelid.

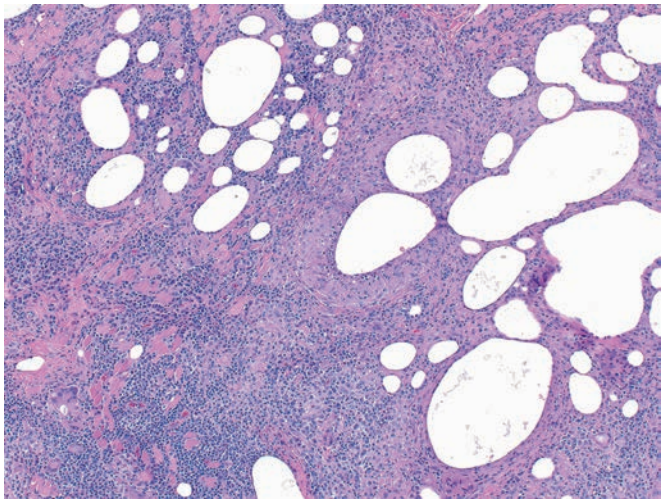

Figure 45.5 Multiple foci of granulomatous inflammation with lipid drop-out spaces in chalazion.

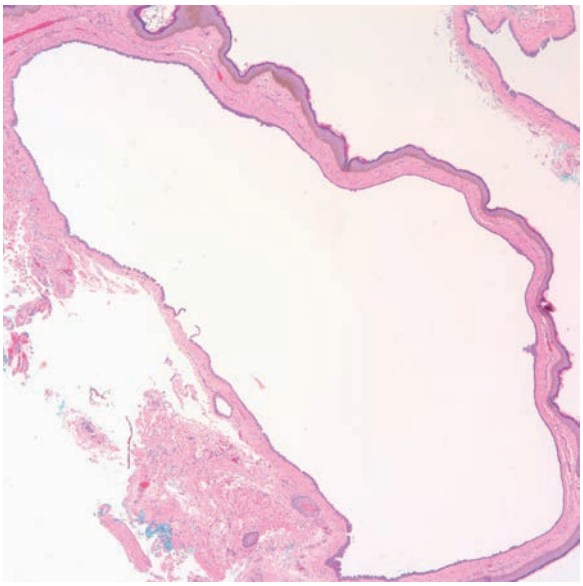

Figure 45.6 Obstruction of outflow from the gland of Moll can lead to apocrine hidrocystoma.

Merkel cell carcinoma can occur in the eyelid, its morphologic appearance being the same as elsewhere in the skin. Most reported cases have been located in the upper eyelid, where they have presented as a large, nontender, red, or violaceous mass.[18]

Non-neoplastic keratotic lesions may closely resemble squamous cell carcinomas. They include such entities as papilloma, pseudoepitheliomatous hyperplasia, keratoacanthoma, inverted follicular keratosis, irritated seborrheic keratosis, actinic keratosis, and cutaneous horns. The histopathologic features of these lesions are described in Chapter 3.

Adnexal Tumors

Sebaceous adenomas and carcinomas may arise from the cutaneous sebaceous glands, the glands of Zeis, or the meibomian glands (Fig. 45.7).[19] They seem to be more common in Asian countries.[20] Muir–Torre syndrome should be considered when sebaceous adenomas or carcinomas are diagnosed around the eye, but the association at this site is not as strong as elsewhere on the skin.[21,22] Some of these carcinomas have been seen as a second malignancy following radiation therapy for retinoblastoma (RB).[23] Periocular sebaceous carcinomas can clinically mimic a range of conditions and are not infrequently misdiagnosed as squamous cell or basal cell carcinomas.[24]

Solitary adenomas of the meibomian and Zeis glands are rarely seen. Indeed, while sebaceous carcinomas can show considerable histologic variation, in the eyelid they tend to be more poorly differentiated that at other cutaneous sites (Fig. 45.8). DNA mismatch repair defects are less common in sebaceous neoplasms arising in the eyelid than elsewhere on the skin.[22]

The most common presentation of sebaceous carcinoma in the eyelid is as round highly cellular nests of poorly differentiated tumor cells in the dermis, sometimes with central necrosis in a comedocarcinoma pattern (see Fig. 45.8). While better-differentiated cells with vacuolated cytoplasm can sometimes be identified, they are generally rare and sometimes completely absent. In such situations immunostains for adipophilin have been used to document sebaceous differentiation.[17] EMA immunostains are generally less useful, as they only highlight well-differentiated sebaceous cells. Oil red O stains for fat can also be helpful but are limited to frozen sections.

Additional valuable clues to the diagnosis can be found in the pattern of tumor dissemination, as intraepithelial spread through the conjunctiva is quite common, and is not seen in basal cell carcinoma (Fig. 45.9). Indeed, sometimes intraepithelial sebaceous carcinoma is encountered in the conjunctiva in the absence of a clear subepithelial tumor mass. This is sometimes referred to as "*in situ*" sebaceous carcinoma, although it is not clear if this represents a true primary conjunctival lesion or spread from an occult site. Pagetoid involvement of the overlying skin can also occur, resulting in a clinical picture of chronic blepharoconjunctivitis, sometimes with no clear mass lesion present.

In the series of sebaceous carcinoma by Rao et al.,[25] 23 out of 104 patients died from metastatic disease, confirming the fact that sebaceous carcinoma is a more aggressive neoplasm when located in the ocular adnexa. Features indicative of a poor prognosis were orbital or vascular invasion, involvement of both eyelids, poor

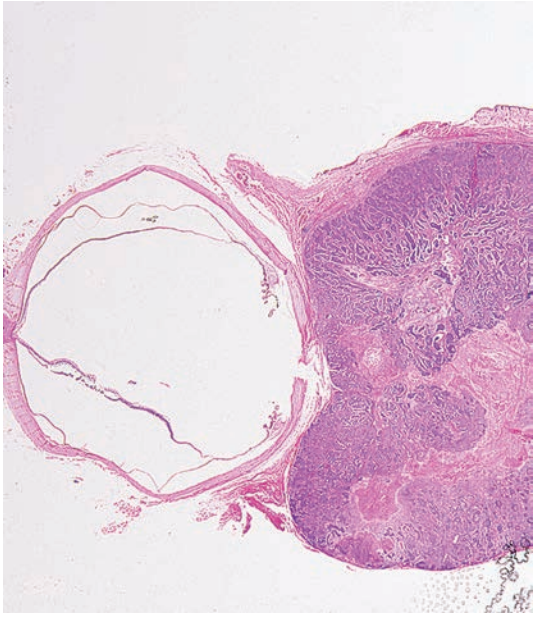

Figure 45.7 Whole mount of sebaceous gland carcinoma compressing but not infiltrating the ocular globe. The tumor is sharply circumscribed and very cellular and has areas of necrosis.

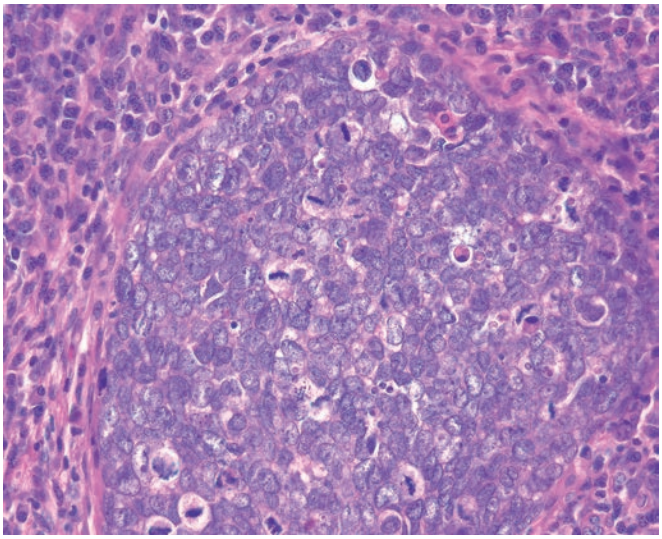

Figure 45.8 Poorly differentiated sebaceous carcinoma.

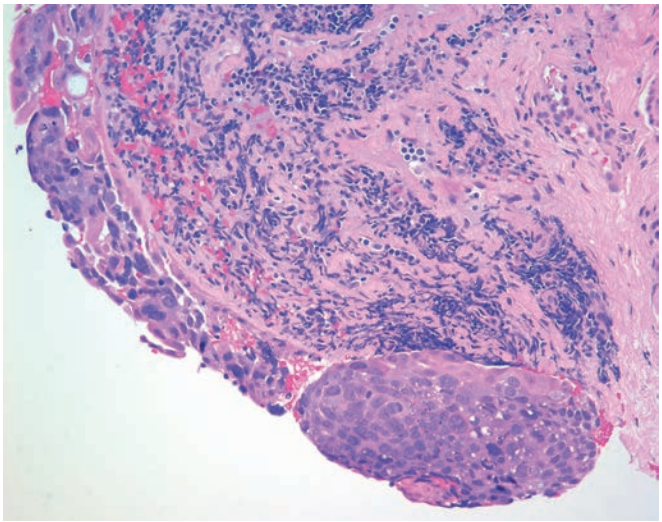

Figure 45.9 Sebaceous carcinoma replacing the majority of the conjunctival epithelium.

differentiation, multicentric origin, large size, a highly infiltrative pattern, and pagetoid spread.[23] Mapping biopsies from multiple sites on the eyelid and ocular surface are sometime taken prior to definitive excision of a sebaceous carcinoma; p16 and p53 immunostains can be useful in highlighting intraepithelial tumor cells in these situations.[24]

Endocrine mucin-producing sweat gland carcinoma (EMPSGC) of the eyelid is composed of bland, round to oval cells with variably solid, cystic, and papillary growth patterns (Fig. 45.10). These lesions are distinctive due to their focal expression of EMA and neuroendocrine markers such as synaptophysin and chromogranin, in conjunction with mucin production (Fig. 45.11). They appear to represent a precursor of invasive mucinous carcinoma of skin, which can also present around the eye.[26,27] Diffuse expression of cytokeratin 7, CEA, estrogen receptor proteins, and other apocrine markers is common and can be useful in distinguishing EMPSGC from other sweat gland tumors.[28] While local recurrence is not uncommon, this group of tumors rarely metastasize or prove fatal, and expression of neuroendocrine markers does not appear to be of prognostic significance.[27]

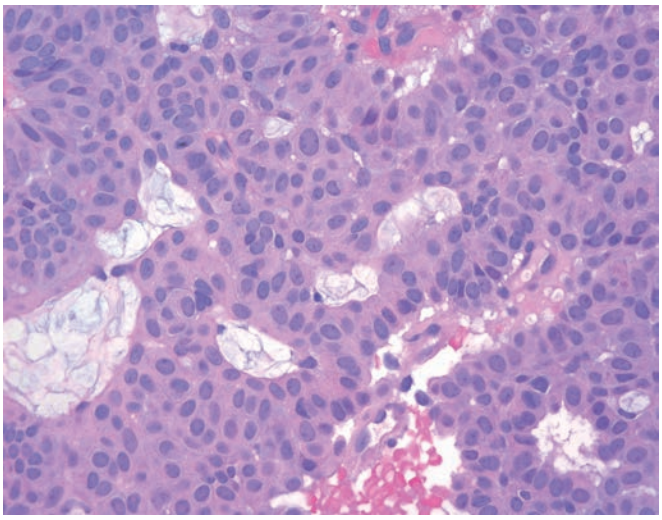

Figure 45.10 Endocrine mucin-producing sweat gland carcinoma showing predominantly solid growth with small mucin-filled cystic spaces.

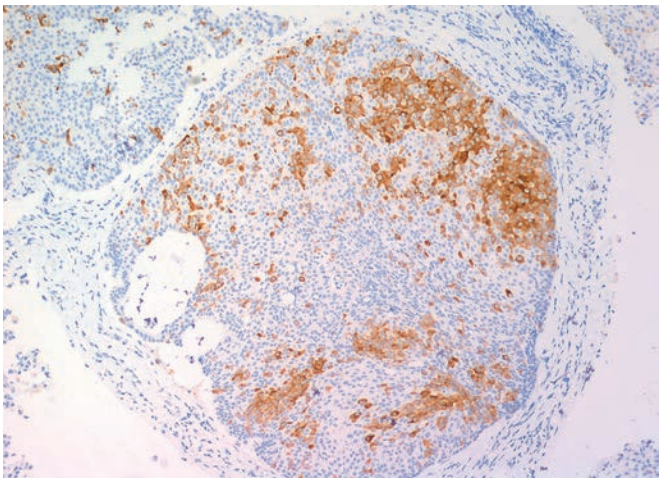

Figure 45.11 Expression of synaptophysin and other neuroendocrine markers is generally focal in endocrine mucin-producing sweat gland carcinoma.

Signet ring/histiocytoid carcinomas morphologically similar to those seen at other sites can arise in the eyelid.[29] Before making the diagnosis of a primary tumor, the possibility of a metastasis from the breast or other organs needs to be ruled out.

Melanocytic Tumors

Melanocytic nevi may be observed in either the cutaneous or the conjunctival surface of the eyelids. The lid margin is a particularly common site, and the divided or "kissing" nevus is a rare but developmentally interesting variant.[30] Most nevi are of the junctional or compound type, but all variants can be encountered at this site, including nevi associated with the Meibomian gland (Fig. 45.12). A more diffuse and deeply situated melanotic lesion of the lids thought to be related to incomplete melanocyte precursor migration is the *nevus of Ota* (congenital oculodermal melanosis). This is a form of extrasacral mongolian spot involving the face in areas supplied by the first and second branches of the trigeminal nerve. This type of nevus occurs more frequently in Asians and blacks than in whites. It is associated with an increased incidence of melanoma and melanocytoma of the eyes, orbit and meninges, with *GNAQ* mutations identified in malignant lesions.[31] *Melanosis oculi* is a related congenital anomaly characterized by variable hyperpigmentation of the conjunctiva, episclera, sclera, uveal tract, and, occasionally, the optic nerve. Patients with this disorder have an increased incidence of ocular malignant melanoma.[32] So-called **acquired melanosis** is a disorder that may involve either surface or both surfaces of the eyelid in association with the conjunctiva and is described in the section on the conjunctiva.

Melanoma of the eyelid is rare.[33] It may originate from a nevus that has been present for many years, from an acquired melanosis of variable duration, or de novo. Nodal metastasis at presentation has been significantly correlated with American Joint Committee on Cancer T category and time to local recurrence or metastasis.[34]

Lymphoid Tumors and Tumorlike Conditions

The morphologic appearances and diagnostic problems presented by these lesions when located in the eyelid are largely similar to those of analogous lesions of the skin, conjunctiva, and orbit; the latter are fully discussed later in this chapter. The only differences of note are that the percentage of malignant tumors seems to be

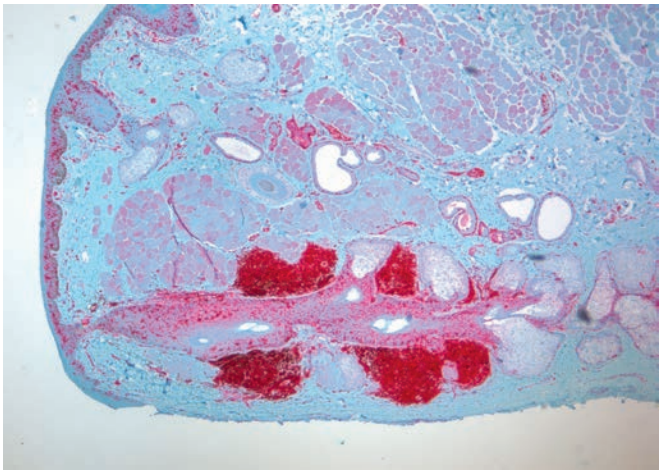

Figure 45.12 MART1 immunohistochemistry highlights a melanocytic nevus associated with the meibomian gland.

higher for lymphoid masses in the eyelid than for those in the other sites, and that the eyelids seem to be the preferential site of involvement for the rare anaplastic large cell lymphoma of the ocular region.[35]

Mesenchymal Tumors and Tumorlike Conditions

Angiomas may present as small lesions confined to the eyelid or extend deep into the orbit.[19] Hemangiomas are more common than lymphangiomas. Their histopathologic characteristics are described in Chapter 3.

The so-called *port-wine stain* (nevus flammeus) is of special interest not only because of its significant cosmetic effect, but also because it may be associated with malformations in other tissues. In the *Sturge–Weber syndrome*, the facial hemangioma may be associated with choroidal hemangioma, glaucoma, and meningeal hemangioma, all on the ipsilateral side (Fig. 45.13).

Masson hemangioma (intravascular papillary endothelial hyperplasia) can develop in the eyelid, either de novo or engrafted on a preexisting vascular lesion. *Hemangiopericytoma* also occurs in the eyelid and orbit, the current interpretation being that it represents a *solitary fibrous tumor* with a hemangiopericytoma-like pattern of growth.[36] Cases have also been reported of *epithelioid hemangioendothelioma*.[37] and *myoepithelioma*.[38]

Neurofibromas can present as isolated lesions or as a component of von Recklinghausen disease. Although believed to be present from birth, these tumors frequently show accelerated growth during childhood or later. **PEComas** (perivascular epithelioid cell tumors) can exceptionally involve the eyelid.[39]

Xanthelasmas are slightly elevated yellow plaques located on the medial aspect of the upper and lower eyelids (Fig. 45.14). They are rarely indicative of any serious systemic disturbance and are usually removed for cosmetic reasons. Most of the patients are in the fifth or sixth decade of life. Patients with familial hypercholesterolemia may develop these lesions at a younger age. Microscopically, these lesions show large, pale-staining, fat-laden histiocytes throughout the subepithelial tissues (Fig. 45.15). If atypia is present, the possibility of primary or metastatic histiocytoid carcinoma should be considered.

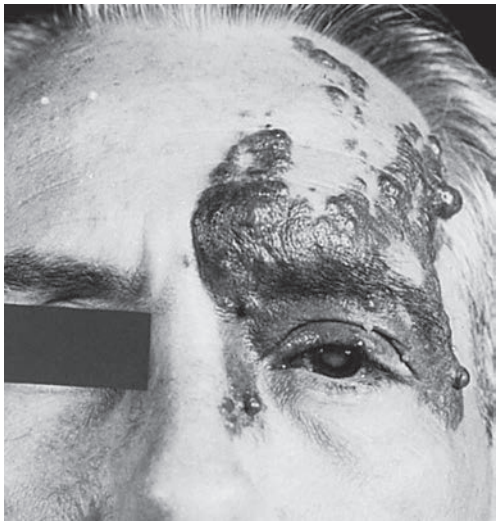

Figure 45.13 Sturge–Weber Syndrome. The patient, a 42-year-old man, had had facial hemangioma all his life and was blind in the ipsilateral eye because of retinal degeneration, glaucoma, and cataract. Choroidal hemangioma was found in the enucleated eye, but clinical study failed to disclose evidence of an intracranial lesion. (Courtesy of the Veterans Administration Hospital, Hines, IL.)

Amyloidosis can occur in the eyelid and conjunctiva as a localized mass. It presents as a chronic painless mass, usually not associated with any systemic disease, although myeloma and related conditions can be present.[40]

Metastatic Tumors

Carcinomas from various sites can metastasize to one or both eyelids, sometimes as the first manifestation of the disease. A notorious diagnostic trap in this area is the mammary lobular carcinoma having striking histiocytoid features and simulating an inflammatory process (Fig. 45.16).[41]

Lacrimal Gland

While most lacrimal gland lesions are orbital, they can extend into the eyelid or arise from accessory lacrimal glands in the eyelid base. Lacrimal gland lesions are divided into nonepithelial and epithelial groups. Among the epithelial tumors, benign mixed cell tumor (pleomorphic adenoma) is the most common. The nonepithelial

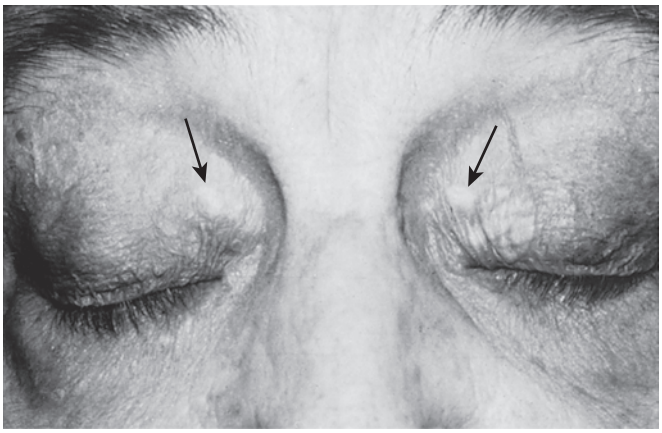

Figure 45.14 Xanthelasma of upper eyelids in a patient who had no systemic findings *(arrows)*.

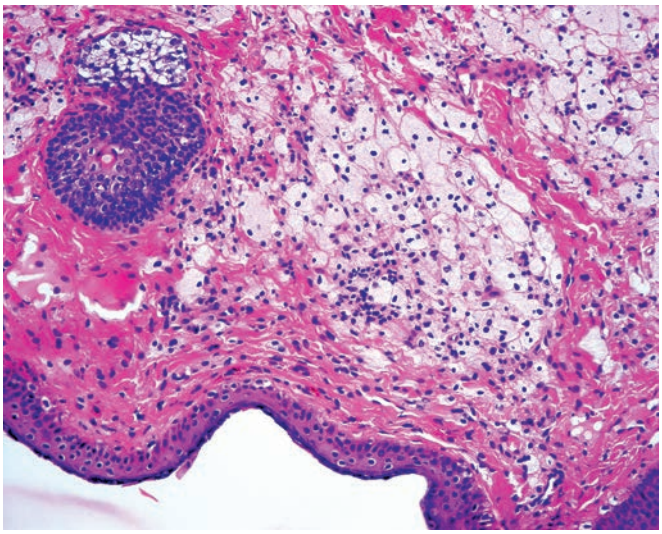

Figure 45.15 Xanthelasma of Eyelid. Clusters of foamy macrophages are seen in the dermis in association with a few lymphocytes.

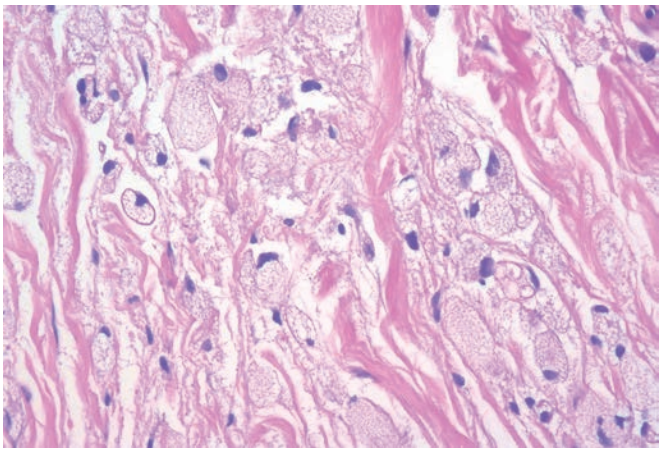

Figure 45.16 Bland histiocytoid metastatic lobular breast carcinoma involving eyelid and orbit.

lesions, which make up over half of the cases, include inflammatory pseudotumor, lymphoid hyperplasia, nonspecific dacryoadenitis, sarcoidosis, Mikulicz disease, Sjögren syndrome, and lymphoma. Nonspecific chronic dacryoadenitis, comprised of patchy or diffuse lymphoplasmacytic infiltrates, is the type the pathologist sees most frequently. However, some specific systemic conditions should be considered.

Mikulicz Disease (IgG4-Related Disease)

When chronic dacryoadenitis is associated with enlargement of the parotid or other salivary glands, it has been referred to as *Mikulicz syndrome*. This may be the result of a variety of specific diseases, including sarcoidosis, tuberculosis, syphilis, mumps, Graves disease, malignant lymphoma, and leukemia, or associated with lymphocytic infiltration and formation of lymphoepithelial lesions historically known as Mikulicz disease. Increased numbers of IgG4-expressing plasma cells are generally found in Mikulicz disease, and it is now thought to represent part of the IgG4-related disease spectrum.[42–44]

Sjögren Syndrome

This chronic autoimmune syndrome occurs most frequently in middle-aged women. Mononuclear cell aggregates are found around the ducts and acini of salivary, lacrimal, and labial glands and result in oral and ocular dryness. However, specific inflammatory cell thresholds of the type used in labial salivary gland biopsy do not exist for lacrimal glands, making it difficult to establish a firm diagnosis based on periocular biopsies.

Tumors and Tumorlike Conditions

Most neoplasms of the lacrimal gland arise in the orbital lobe, where the gland is firmly attached to the orbital rim about the lacrimal fossa. The bone tends to restrict growth in its direction; hence, the enlarging tumor characteristically displaces the eye downward and nasally. A recent study of 702 malignant tumors of the lacrimal gland in the Surveillance, Epidemiology, and End Results (SEER) database identified lymphoma (58%), adenoid cystic carcinoma (13%), adenocarcinoma (4%), and mucoepidermoid carcinoma (4%) as the most common entities.[45]

Epithelial tumors have, on the whole, histopathologic, ultrastructural, and immunohistochemical features very similar to those of the salivary glands (see Chapter 6).[46–49] *Benign mixed tumors* (pleomorphic adenomas) account for approximately 50%–60%, *malignant mixed tumors* (carcinomas ex-pleomorphic adenomas) for 5%–10%, *adenoid cystic carcinomas* for 20%–30%, and other carcinomas for 5%–10%. Many of the mixed tumors have a predominant component of hyaline cells of presumed myoepithelial nature (Fig. 45.17). *Oncocytomas*, *epithelial–myoepithelial carcinomas*, and *myoepithelial carcinomas* have also been reported.[50–53] The carcinomas have a poor prognosis overall, although earlier detection and complete excision has resulted in some long-term survivors.[49]

The appearance of an invasive squamous cell carcinoma of the lacrimal gland can be simulated by *necrotizing sialometaplasia*, in a manner akin to that seen with greater frequency in minor (and sometimes major) salivary glands.[54]

Lymphoid tumors and tumorlike conditions (malignant lymphomas, lymphoid hyperplasias, and chronic inflammatory processes) are important causes of enlargement of the gland. In one orbital series including 114 lacrimal gland lesions, 55% were nonepithelial, with nonspecific chronic dacryoadenitis being most common, followed by malignant lymphoma and reactive lymphoid hyperplasia.[55] Chronic dacryoadenitis, particularly when it is associated with sclerosis, may be part of the spectrum of IgG4-related diseases.[56,57] However, most cases of mild dacryoadenitis lack increased numbers of IgG4-positive cells.[58] Lymphomas of the lacrimal gland are most often MALT or other low-grade B-cell neoplasms; however, more aggressive forms such as mantle cell lymphoma and diffuse large B-cell lymphoma can present at this site as well (Fig. 45.18).

Mesenchymal tumors of the lacrimal gland are exceptional. They comprise a few case reports of solitary fibrous tumor,[59] giant cell angiofibroma (a morphologic variant of solitary fibrous tumor),[60] collagenous fibroma (desmoplastic fibroblastoma),[61] and granular cell tumor.[62,63]

Lacrimal Passages

Diseases of the lacrimal passages that are of importance to the surgical pathologist are characterized by epiphora (the imperfect drainage of tears so that they flow over the lid margin onto the cheek) and by varying degrees of swelling, induration, and inflammation of the lower eyelid at its nasal end. Although inflammatory obstructions of these passages are common, neoplastic lesions are relatively rare.

Canaliculitis and Dacryocystitis

Canaliculitis and *dacryocystitis* may be the result of direct spread of inflammatory processes in neighboring structures such as the conjunctiva or nasal cavity, but more often their pathogenesis is obscure. Acute and chronic types are recognized, and the inflammatory reaction may be suppurative, granulomatous, or necrotizing, with the formation of fistulous tracts to the skin surface below the eyelid near the base of the nose.

The lacrimal passages become filled with purulent exudate in the acute suppurative types, whereas in the chronic forms the passages are narrowed by inflammatory thickening of the walls of the lacrimal canal or sac. Occasionally, there is hyperplasia of the lining epithelium and hypersecretion of mucus. At times, reactive hyperplasia of the sac may be difficult to distinguish squamous or transitional neoplasms.

Sarcoidosis may involve the lacrimal sac as an extension of upper respiratory tract disease.[64]

Mucocele

Lacrimal mucocele is another complication of chronic inflammation of the lacrimal sac. A low-grade obstructive lesion with a relatively

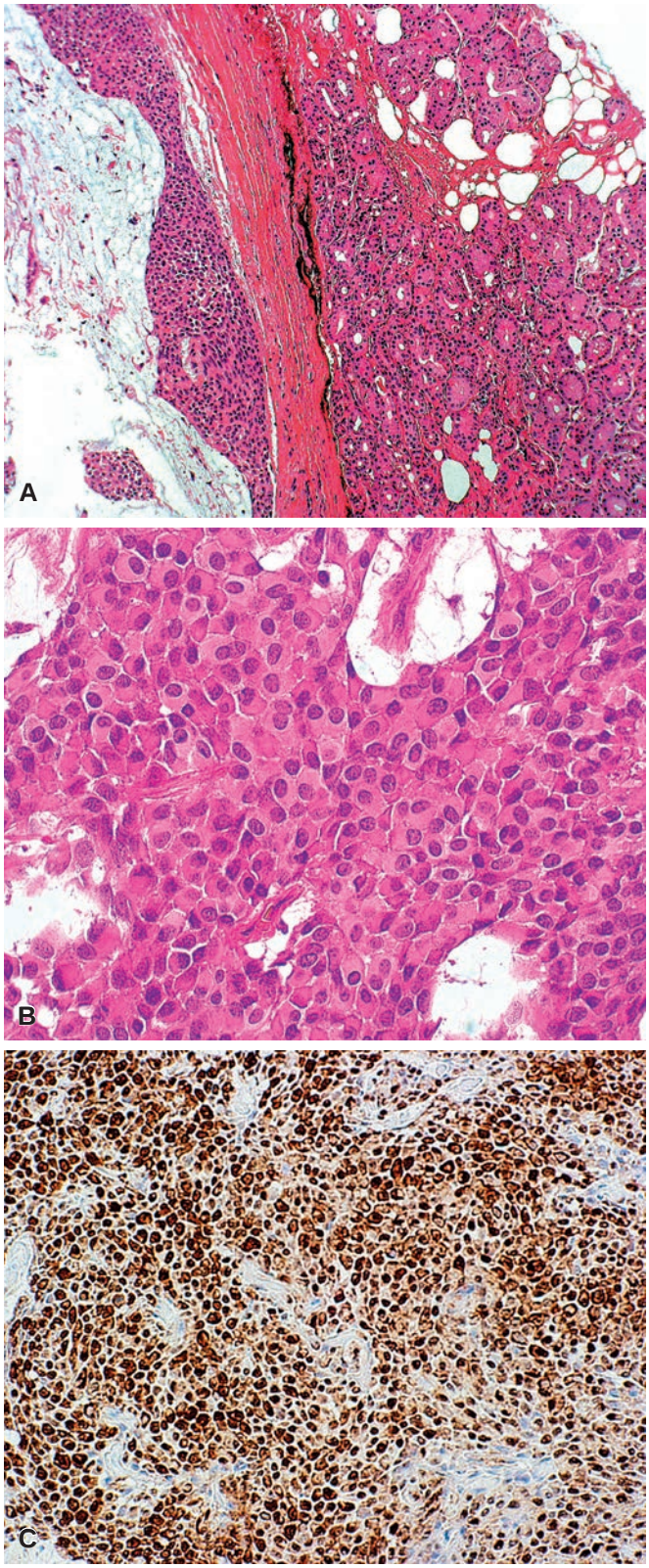

Figure 45.17 Benign mixed tumor of lacrimal gland largely composed of so-called hyaline cells: **A**, low-power view showing encapsulated quality; **B**, high-power view showing a diffuse eosinophilic appearance of the cytoplasm; **C**, strong immunoreactivity for S-100 protein.

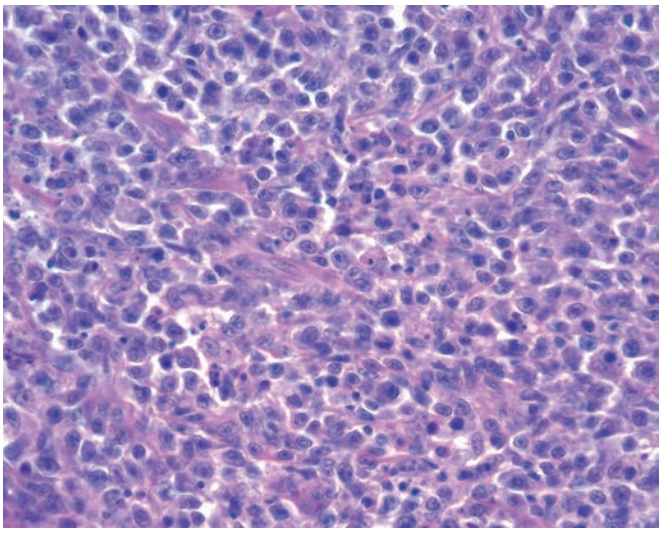

Figure 45.18 Diffuse large B cell lymphoma involving lacrimal gland and orbit.

intact and possibly hypersecreting mucosa may lead to great distention of the sac by accumulated secretions.

The contents of the cyst may be clear or milky, fluid or gelatinous, fibrinous or flocculent, sterile or infected. Microscopically, the cyst wall reveals varying degrees of atrophy, degeneration, hyperplasia, hypersecretion of the mucosa, and chronic inflammation of the subepithelial tissues.

Dacryolithiasis

Dacryolithiasis and concretions in the nasolacrimal duct ("tear stones") are of uncertain pathogenesis, but they are generally believed to be the result of low-grade inflammatory processes, including mycoses. If such concretions are crushed and examined microscopically, they will be seen to contain myriads of mycelial elements embedded in a relatively acellular matrix. Others are laminated, mineralized stones with recognizable fungal or bacterial forms.

Tumors

Neoplasms of the lacrimal passages are relatively rare but must be excluded when any space occupying or obstructive process is encountered. Primary epithelial tumors account for approximately 75% of these, with mesenchymal tumors, lymphoma, melanoma, and other rare lesions comprising the rest.[4] On clinical grounds, it is usually not possible to distinguish malignant tumors of the lacrimal passages from benign neoplasms and pseudotumors of this structure.

Papillomas may form in the punctum, within the nasolacrimal duct, or in the lacrimal sac. Squamous, transitional or mixed histologic features are recognized, and they can grow in an exophytic or inverted pattern.[4,65] Lesions showing inverted growth are more often associated with recurrence and malignant transformation. The microscopic features of *squamous papillomas* are similar to those at other sites, with stratified squamous epithelium and focal dyskeratosis. *Transitional cell papillomas* are composed of cells with features intermediate between columnar and squamous epithelium, including stratified elements and goblet cells or mucin but in general no surface keratin or prominent intercellular bridges (Fig. 45.19).[66] HPV has been identified in both papillomas and carcinomas of the lacrimal sac but not by all investigators.[67]

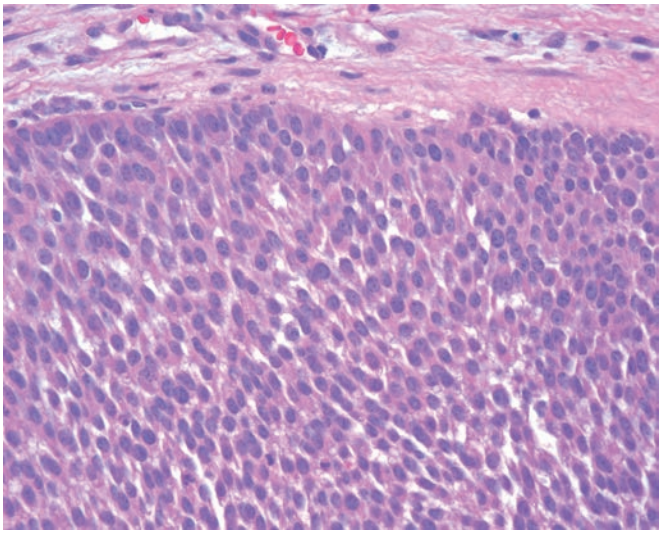

Figure 45.19 Transitional cell papilloma of lacrimal sac with inverted growth pattern. This lesion later recurred as an invasive carcinoma.

Oncocytic tumors may develop in the lacrimal sac but are less common than in the caruncle.[68] Most of the cases are benign oncocytomas, but oncocytic carcinomas have also been reported.[4]

Any malignant tumor of the lacrimal passages except carcinoma is exceedingly rare, and even carcinoma is distinctly uncommon. When they occur, these tumors are usually moderately differentiated **squamous cell carcinomas**, similar in appearance to those arising from the mucosa of the nasal cavity or in the conjunctiva. Transitional cell carcinomas have also been reported and tend to have favorable outcomes.[4,69] Both can form papillary projections into the lumen and spread along natural surfaces, but, as noted previously, often infiltrate directly into adjacent tissues. Foci of carcinoma with increased mitotic rate and cytologic atypia can be found to arise within better-differentiated papillomas, or the entire papillary lesion may be malignant.

Other reported malignant tumors of the lacrimal sac include **mucoepidermoid carcinoma**,[70] **lymphoepithelioma-like carcinoma**,[71] **rhabdomyosarcoma**,[72] **malignant melanoma**,[73] and **malignant lymphoma**.[74] Interestingly, and in contrast to most other periocular sites, the rare lymphomas of the lacrimal sac tend to be of the diffuse large B-cell type.[75]

Orbit

The clinical hallmark of orbital disease is *exophthalmos*. This may not necessarily be caused by a true neoplasm, and therefore the surgical pathologist may never encounter any specimen from the many patients who present with this finding. Indeed, the most common cause of exophthalmos is *thyroid ophthalmopathy*, which is rarely biopsied.

As for the relative frequency of lesions that cause exophthalmos, many of the statistics that have been reported merely reflect the bias of the specialist involved. To the radiologist, for example, one of the most common orbital lesions producing displacement of the eye is a mucocele arising from a paranasal sinus. The ophthalmologist, however, would place mucocele far below such entities as thyroid ophthalmopathy, hemangioma, and inflammatory pseudotumor.[76] Procedures useful for the diagnostic evaluation of orbital masses include computed tomography (CT) scan, magnetic resonance imaging (MRI), and fine-needle aspiration.

Figure 45.20 **A**, Exophthalmos of approximately 10 months' duration in a 65-year-old woman who finally died of congestive heart failure. **B,** At autopsy, extraocular muscles were found to be massively thickened.

Thyroid Ophthalmopathy

A common cause of orbital disease and of exophthalmos is thyroid ophthalmopathy (dysthyroid ophthalmopathy, thyroid eye disease, Graves orbitopathy), in which there is a dysfunction of the pituitary–thyroid axis. Patients with this condition may be hyperthyroid, hypothyroid, or euthyroid. There is often a history of hyperthyroidism or some form of treatment.

Unilateral orbital involvement occurs with sufficient frequency in both forms of dysthyroid ophthalmopathy to warrant this condition always being considered in the differential diagnosis of orbital tumors (Fig. 45.20).

Histopathologic changes observed in severe cases, which are most likely to come to the attention of the surgical pathologist, include widespread edema and chronic inflammation of the orbital tissues. The most striking gross alterations are observed in the extraocular muscles, which may be massively enlarged. Relative sparing of the tendons and orbital fat can help to differentiate thyroid orbitopathy from idiopathic orbital inflammation.[6] Muscle fibers degenerate and become hyalinized. A great increase in the interstitial connective tissue, including both cellular elements and ground substance/glycosaminoglycans, is observed particularly in the muscles.

Inflammatory Processes

Secondary inflammation of the orbit can occur from lesions arising in the face, eyes, nose, sinuses, orbital bones, blood vessels, brain, and meninges. Generally, it is only when such inflammations simulate neoplasms that orbital exploration is undertaken and tissue is obtained for histopathologic diagnosis, although biopsies to diagnose infection are also performed. Both bacterial and fungal orbital disease should be considered when inflamed or necrotic specimens are received. In addition, fungal infection can sometimes result in a fibrosing response, with infectious organisms present in only a small fraction of the tissue.

Granulomatous diseases, including those due to tuberculosis, mycosis, sarcoidosis, and polyangiitis with granulomatosis (Wegener's) are rare (Fig. 45.21). Orbital cholesterol granulomas or cholesteatomas generally involve the superior orbit and frontal bone.[77] It has been suggested that the term cholesteatoma be reserved for cases in which an epithelial lining is identified.[78]

Mucocele is the result of chronic inflammatory disease of the frontal and/or ethmoid sinuses. The lesion erodes through the wall of the sinus to produce an inferolateral displacement of the globe. The onset is usually insidious, and the enlargement is symptomless and slow.

Histopathologically, this cystic mass is lined by mucus-secreting sinus mucosa with variable degrees of inflammation and scarring. Sheets of mucin-containing macrophages can sometimes be found around these lesions.

Rosai–Dorfman disease (sinus histiocytosis with massive lymphadenopathy) can present in the orbit (Fig. 45.22).[79] Children are often affected, and the lacrimal gland can also be involved.[80] The infiltrate is composed of large histiocytes (some exhibiting lymphocytophagocytosis/emperipolesis), lymphocytes, and plasma cells; fibrosis can be very prominent.

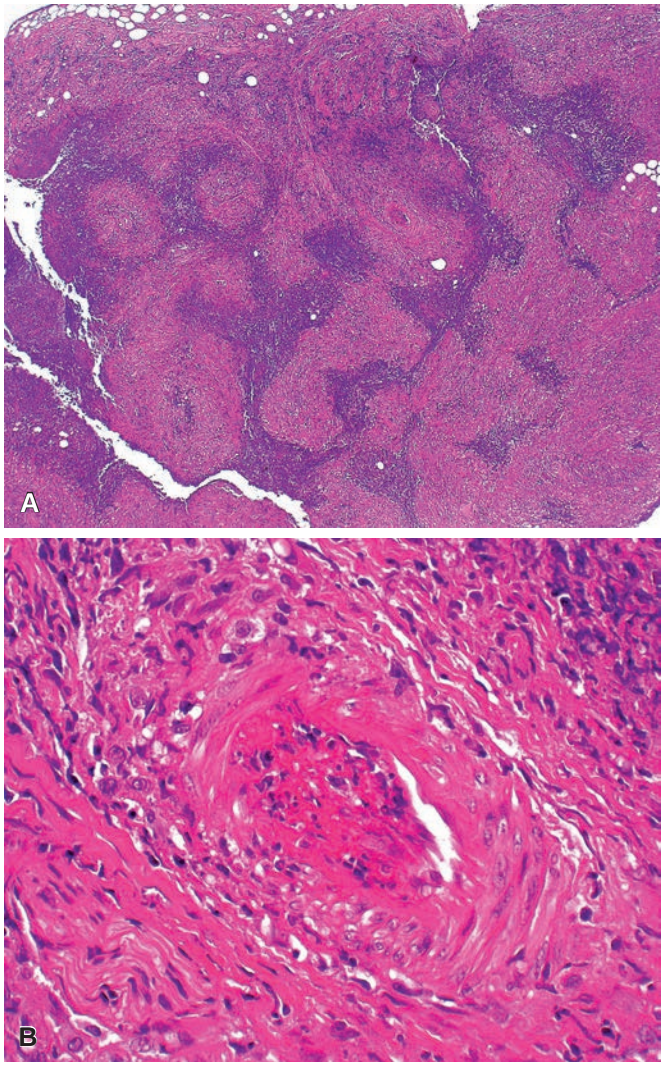

Figure 45.21 Polyangiitis with granulomatosis involving orbit: **A**, multiple confluent granulomas; **B**, vasculitis with thrombosis.

IgG4-related disease can involve all orbital structures, including lacrimal gland, extraocular muscle, and soft tissue (Fig. 45.23).[57] Somewhat increased numbers of IgG4-positive plasma cells can be identified in a range of conditions, including thyroid orbitopathy and granulomatosis with polyangiitis, and diagnostic standards in the orbit are still evolving.[81,82] A consensus group in Japan has proposed criteria, which are somewhat different from those at sites away from the eye, for ophthalmic IgG4-related disease.[44] Fibrosis and phlebitis can be absent in the periocular tissues, and lymphoid follicles with germinal centers are more frequently observed. A ratio of IgG4+ cells to IgG+ cells of 40% or above or more than 50 IgG4+

Figure 45.22 Large intraorbital mass in a case of Rosai–Dorfman disease.

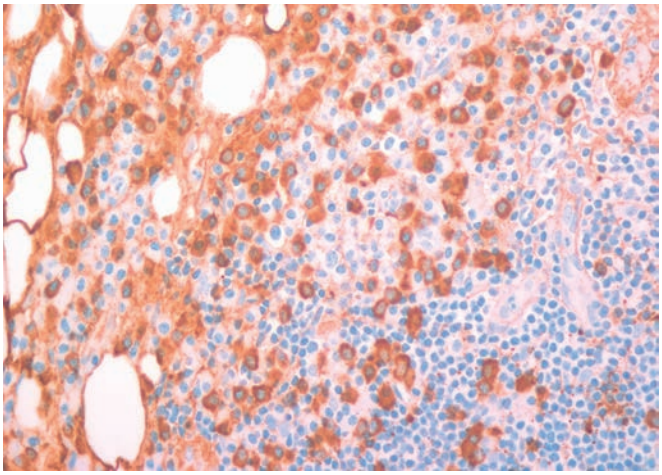

Figure 45.23 Increased numbers of IgG4-positive cells in an inflammatory process involving the lacrimal gland and orbit. The ratio of IgG4/IgG-positive cells was over 60% in this case, and serum IgG4 levels were also greatly elevated.

cells per high-power field was suggested. Xanthogranulomatous inflammation can also be associated with IgG4-related orbital disease.[58]

Inflammatory pseudotumors of the orbit (idiopathic orbital inflammation) are much more frequent than specific infections. These pseudotumors represent an etiologically and pathogenetically heterogeneous group.[6,83,84] In some instances, they have been found associated with involvement of paranasal sinuses.

The pathologic features they share include the following:

1. The formation of an indurated orbital mass often surrounding the optic nerve and incorporating one or more of the extraocular muscles.
2. A tissue reaction that includes exudation of fluid, excessive production of ground substance, mobilization of chronic inflammatory cells, vascular proliferation, and hyperplasia of connective tissue.
3. The absence of demonstrable etiologic agents or of otherwise diagnostic histopathologic alterations indicative of specific disease entities such as lymphoma, vasculitis, infection, or lupus erythematosus. A subset of lesions previously diagnosed as idiopathic orbital inflammation are now thought to represent IgG4-related disease.[82]

This is not to say, however, that the microscopic features are uniform from case to case (Fig. 45.24). In some instances the proliferation of blood vessels and ground substance resembles that of exuberant granulation tissue. At times, there is lymphoid hyperplasia with follicle formation. Other cases with prominent involvement of extraocular muscles suggest the possibility of dysthyroid ophthalmopathy.

A well-developed granulomatous reaction around small pools of fat is observed in certain cases. Such lesions may suggest traumatic fat necrosis. Others containing large numbers of cholesterol clefts and many foamy macrophages and giant cells suggest an area of old suppuration or hemorrhage. Periphlebitis is prominent in certain cases, and some of these may present a significant tissue eosinophilia, suggesting the possibility of a hypersensitivity angiitis, a parasitic infection, or Kimura disease.

Patients with orbital pseudotumors are usually in the third to fifth decade and in good health. The exophthalmos is of relatively sudden onset and in at least one half of the patients is associated with moderate to severe orbital pain and with lid and conjunctival edema. The pain is generally responsive to steroid therapy, although this is less often the case in lesions with prominent sclerosis. Diplopia is often present secondary to limitation of ocular motility in one or more fields of gaze, but visual acuity is usually unimpaired. Intracranial extension can occur.[85]

The lesion often can be palpated through the eyelids; if so, the surgeon may be able to reach it easily for a biopsy. Deeper lesions are not so readily accessible for biopsy, and if the clinical signs and symptoms are characteristic of inflammatory pseudotumor, steroids are often given without a biopsy, especially since systemic steroids often produce dramatic alleviation of signs and symptoms. The CT scan can be helpful in localizing the lesion.

Primary Tumors

Mesenchymal Tumors and Tumorlike Conditions

Rhabdomyosarcoma is the most common soft tissue sarcoma of the orbit in childhood.[55] The types seen in this age group are embryonal and alveolar, the latter being associated with a more aggressive clinical course. Some cases have occurred as a second primary tumor following irradiation for bilateral RB.[86]

Hemangiopericytoma and **solitary fibrous tumor** are closely related and part of a morphologic continuum.[87,88] The former term has been used when the tumor is diffusely hypercellular and vascularity is prominent, while the latter has been generally employed when it contains keloid-like collagen and an alternation of hypercellular and hypocellular areas (Fig. 45.25).[89] Strong immunoreactivity for CD34 and BCL2 is present, particularly in the cases with a solitary fibrous tumor pattern.[90,91] As at other sites, nuclear STAT6 immunostaining is also diagnostically helpful.[92] Rare cases behave in a malignant fashion, particularly when features of hemangiopericytoma are present.

Giant cell angiofibroma is characterized by a richly vascularized proliferation of spindle cells containing pseudovascular spaces and multinucleated giant cells, often of the so-called floret type.[93] CD34 is positive. This lesion, which is not limited to the orbit, is now thought to represent a variant of solitary fibrous tumor rich in giant cells.[88,92,93]

Alveolar soft-part sarcoma can present as a primary orbital tumor.[94] The age of occurrence, microscopic appearance, and evolution are similar to those seen in the other location of this tumor (see

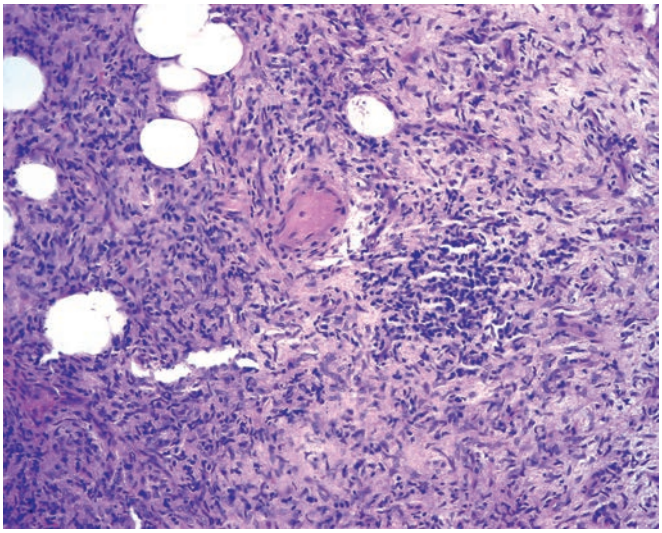

Figure 45.24 Inflammatory Pseudotumor of Orbit. Lymphocytes, plasma cells and spindle cells of fibroblastic/myofibroblastic appearance permeate the adipose tissue of the orbit.

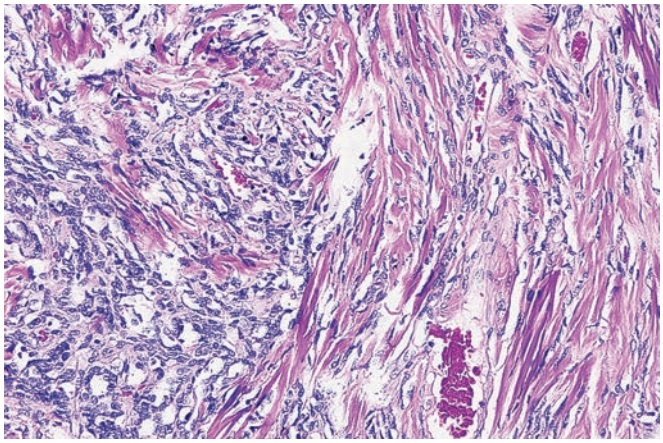

Figure 45.25 Solitary Fibrous Tumor of Orbit. The alternation of hypercellular and hypocellular areas is characteristic. The collagen has a keloid-type quality. This tumor was strongly immunoreactive for CD34.

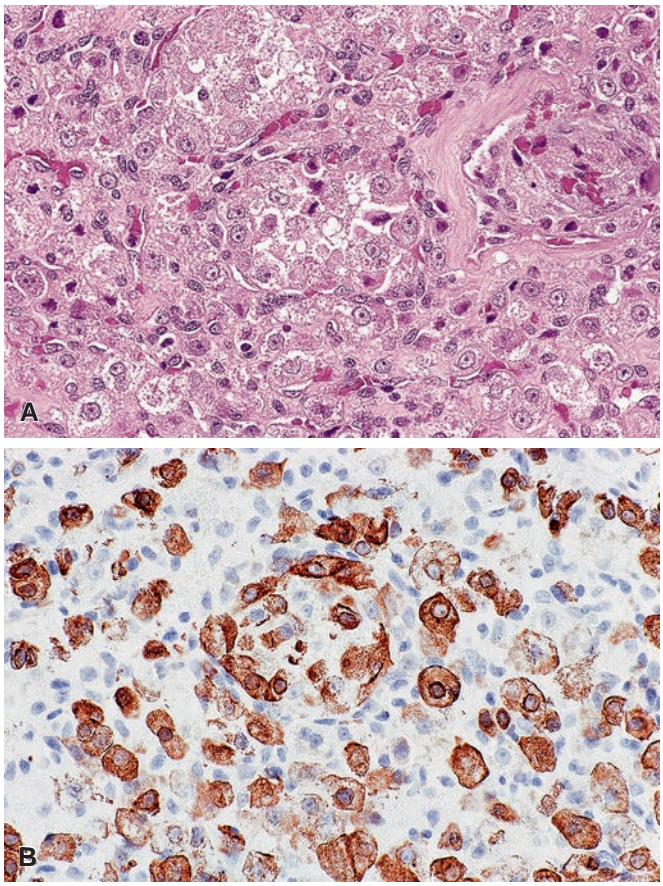

Figure 45.26 **A,** Alveolar soft part sarcoma of orbit. **B,** This degree of desmin immunoreactivity is unusual, but it constitutes strong evidence for muscle differentiation.

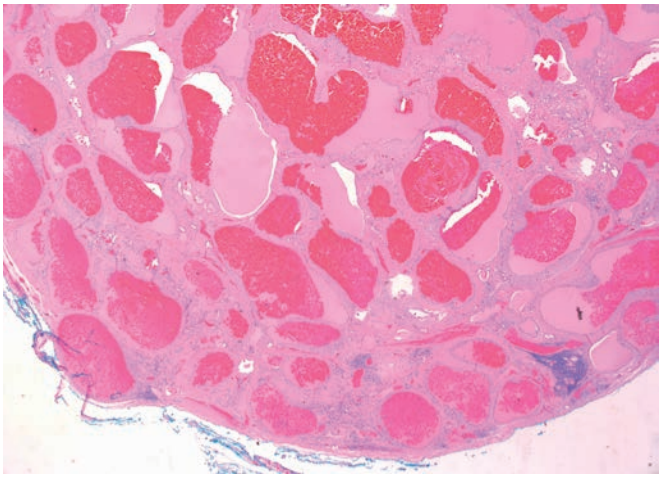

Figure 45.27 A well-circumscribed cavernous hemangioma of the orbit in an adult.

Chapter 25; Fig. 45.26). The clinical course is indolent, distant metastases sometimes occurring 10 years or more after initial therapy.[95]

Osteosarcoma has been reported, sometimes as a late complication of radiation therapy to the area.[96] Other malignant mesenchymal tumors, all extremely rare, include **leiomyosarcoma**,[97] **liposarcoma**,[98] **fibrosarcoma**,[99] **mesenchymal chondrosarcoma**,[100] **angiosarcoma**,[101] and **Ewing sarcoma/PNET**.[102]

Angiomas are relatively common orbital tumors, with hemangiomas occurring much more commonly than lymphangiomas.[103,104] In the infant, these soft, blue, compressible tumors are diffuse throughout the orbit and often extend forward into the eyelids. Surgical removal is difficult; fortunately, however, most hemangiomas spontaneously regress by 4 years of age. If the tumor is so large that the visual axis is covered and the eye is at risk for the development of deprivation amblyopia, such lesions can often be reduced in size using systemic steroids or oral propranolol. In the adult, these tumors are usually encapsulated cavernous hemangiomas situated close to the back of the eye and can be surgically "shelled" out. These tumors rarely present difficulties in histopathologic diagnosis, for they are not significantly dissimilar from angiomas elsewhere. In the infant, the lesion is usually of capillary type (the majority expressing GLUT-1, in contrast to vascular malformation) and in the adult of cavernous type (Fig. 45.27).[105,106]

Schwannoma and **neurofibroma** represent a small percentage of orbital tumors. Almost all orbital schwannomas are well-encapsulated tumors that can be completely removed surgically by orbitotomy; some are cystic.[107] Orbital neurofibromas are usually but not always an expression of von Recklinghausen disease.[108] There may be a gross deformity of the orbit and eyelid and, on palpation, the lid has been referred to as "a bag of worms."

Other benign mesenchymal tumors that have been observed at this site are **lipoma, chondroma**, **orbital infantile myofibroma**,[109] and **osteoma**.

Tumorlike proliferations also occur within the orbit, including **nodular fasciitis**[110] and **intravascular papillary endothelial hyperplasia** (Masson hemangioma).[111] A particularly interesting type of pseudomalignant lesion is seen as a result of prolapse of intraconal orbital fat below the conjunctiva, which can simulate an atypical lipomatous tumor microscopically.[112] This non-neoplastic lesion, known as **subconjunctival herniated orbital fat or "prolapsed orbital fat,"** shows adipocytes with intranuclear vacuoles ("Lochkern"), abundant so-called floret cells (similar to those seen in pleomorphic lipoma), and inflammatory cells, but not cells with large hyperchromatic nuclei within fibrous septa, as regularly seen in true atypical lipomatous tumors.

Langerhans cell histiocytosis can involve the orbit and result in prominent exophthalmos. S-100 and CD1a immunoreactivity is useful in distinguishing these cases from Erdheim–Chester and Rosai–Dorfman disease, which can also occur at this site. As in the CNS, localized disease is generally associated with a good prognosis.[113]

Erdheim–Chester disease of the orbit is generally easily recognized due to presence of systemic disease involving long bones but occasionally has a predominantly periocular presentation.[114] It is characterized microscopically by diffuse xanthogranulomatous inflammation, and S-100 and CD1a are generally not detected. However, as in Langerhans cell histiocytosis, BRAF V600E mutations are commonly identified.[115]

Glioma of Optic Nerve

Gliomas of the optic nerve proper are relatively rare, slow-growing tumors that can arise within the intracranial or orbital segments of the nerve. Because of their indolent behavior and typical radiological appearance, they are biopsied less frequently than in the past.[116] Indeed, tumors limited to the optic nerve sometimes stop growing spontaneously and can require little or no therapy. As these gliomas increase in size, they tend to form a bulbous enlargement of the

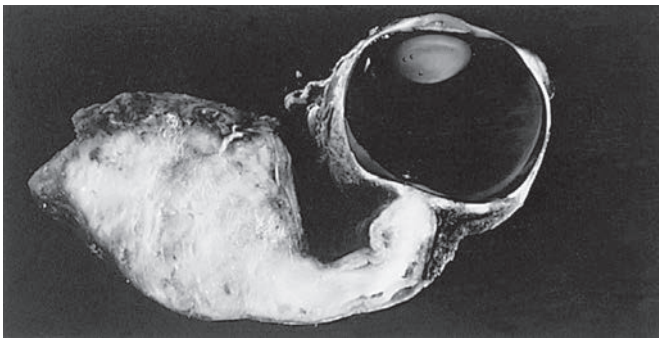

Figure 45.28 Glioma that has produced massive enlargement of the orbital segment of the optic nerve. The tumor has completely effaced characteristic architectural features of the nerve and its meninges.

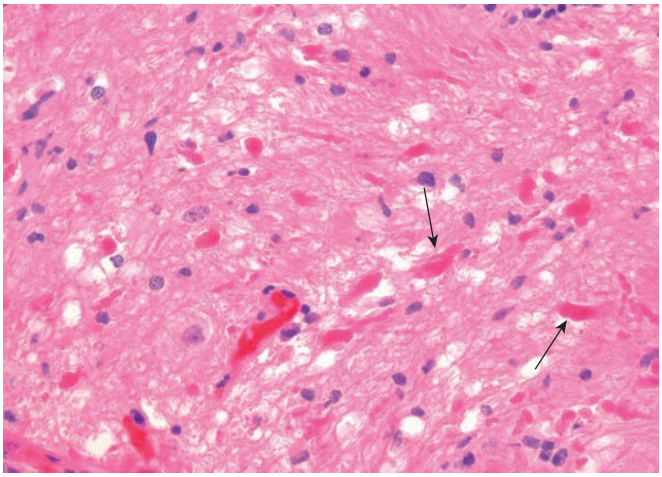

Figure 45.29 Pilocytic astrocytoma with prominent Rosenthal fibers *(arrows)*.

nerve (Fig. 45.28). They also extend along the nerve peripherally toward the eye and centrally toward the brain. Another growth pattern exhibited by a majority of optic nerve gliomas is infiltration through the pia and arachnoid. This leads to significant thickening of the leptomeninges and can include both neoplastic glia and reactive meningothelial cells, although the former generally predominate.

Microscopically, almost all optic gliomas are *pilocytic astrocytomas*, similar to those occurring in the cerebellum and elsewhere in the CNS. Rosenthal fibers and eosinophilic granular bodies are generally present, and florid vascular proliferation is sometimes noted (Fig. 45.29). Microcystic change is also often encountered. Considerable cytologic variation exists, not only from case to case but also in different portions of a given tumor. Varying degrees of cellularity are observed, but generally these neoplasms are characterized by a low degree of anaplasia with bland, round to oval cells showing bipolar hair-like processes. There are sometime areas of myxoid degeneration within the tumor. However, lesions which are monomorphous with a perivascular orientation of bland cells, prominent myxoid changes, and a lack of Rosenthal fibers may represent the somewhat more aggressive *pilomyxoid astrocytoma*. This variant is particularly common in the hypothalamic region but is still thought to form part of the pilocytic astrocytoma spectrum due to its capacity to mature into a classic pilocytic histology.[117]

Gangliogliomas are sometimes encountered in the optic nerve and are also low grade. Malignant astrocytomas, characterized by dense cellularity, high mitotic index, marked pleomorphism, necrosis, and vascular proliferation, are extremely rare in the optic nerve proper.

Figure 45.30 **Meningioma of Optic Nerve.** The meninges are greatly thickened, and the optic nerve reveals severe compression and atrophy *(arrows)*.

One should be consider the possibility of a cellular pilocytic astrocytoma with degenerative or reactive changes before diagnosing a high-grade astrocytoma at this site.

Gliomas of the optic nerve typically make their presence known during the first decade of life, with minimal exophthalmos, optic nerve atrophy, or papilledema and with a characteristic thickening of the nerve on CT or MRI scan. There is a distinct association of these tumors and von Recklinghausen disease, and the presence of bilateral optic nerve astrocytomas is essentially pathognomonic for neurofibromatosis type 1 (NF1). Duplications resulting in *BRAF* gene fusions are identified most optic pathway gliomas not associated with NF1, and identification of this molecular change can be useful in distinguishing these tumors from reactive piloid gliosis or other neoplasms.[116]

Meningioma

Meningiomas of the orbit can be primary (i.e., arising from the meninges of the optic nerve) or secondary lesions that invade into the orbit from the sphenoidal ridge (Fig. 45.30).[118] Occasionally, orbital meningiomas without clear links to either the coverings of the optic nerve or brain are identified. Orbital meningiomas generally produce visual loss, optic atrophy, and sometimes exophthalmos. Those arising from the inner portion of the sphenoidal ridge can cause severe compression of the optic nerve within the optic canal, resulting in papilledema or optic atrophy. CT and MRI scans have facilitated the diagnosis and localization of these tumors, with primary meningioma often showing a "tram-track" extension along the nerve (Fig. 45.31). Microscopically, most orbital meningiomas are of the meningothelial type, although many subtypes are encountered (Fig. 45.32).[118] The differential diagnosis includes exuberant arachnoidal/meningothelial hyperplasia, hemangiopericytoma/solitary fibrous tumor, Rosai–Dorfman disease, and lesions such as metastatic carcinoma with prominent associated desmoplasia.

Lymphoid Tumors and Tumorlike Conditions

Some periocular lymphoid neoplasms develop in the course of a previously recognized malignant lymphoma or leukemia. Others present initially around the eye, and while systemic involvement is eventually documented in a subset of patients, in many disease remains localized to the orbit, conjunctiva, or eyelid.[119]

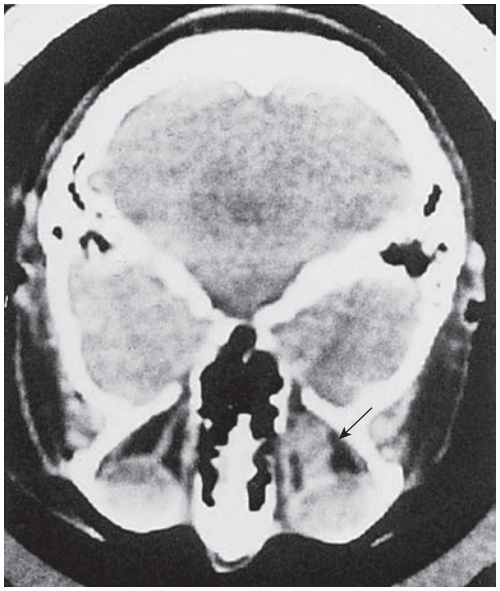

Figure 45.31 CT scan showing perioptic meningioma of left orbit *(arrow)*.

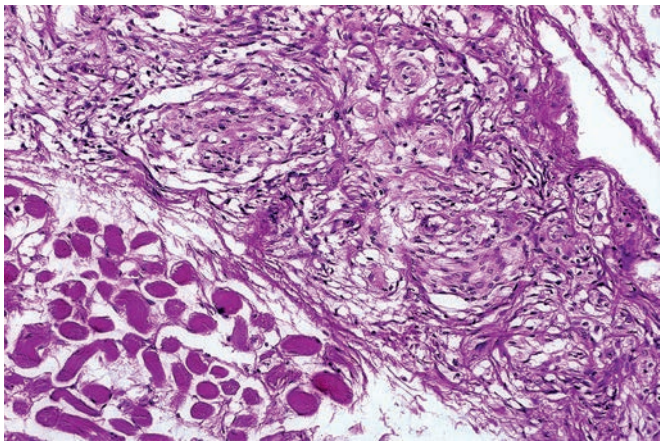

Figure 45.32 **Meningioma of Orbit.** The tumor has a typical meningothelial appearance.

Microscopically, the latter lesions fall into three groups:

1. Lesions that are obviously malignant, usually non-Hodgkin lymphomas. These are quite rare and include diffuse large B-cell lymphomas, including an Epstein–Barr virus–positive subset seen in the elderly[120] and anaplastic large cell lymphoma, which is often located in the eyelid.[35] An international cooperative study including 106 diffuse large B-cell lymphoma patients with disease in the ocular adnexa found that systemic tumor was present in only 43% of cases.[121]
2. Lesions that are fairly obvious examples of reactive hyperplasia with considerable polymorphism, a variety of cell types, vascular proliferation, and prominent follicles with germinal centers. IgG4-related sclerosing disease is one possible cause for the formation of such lesions.[42] As discussed earlier in this section, idiopathic orbital inflammation (orbital pseudotumor) can also present in this fashion, although follicles with germinal centers are generally less common.
3. Lesions that are characterized by a rather uniform and monotonous but widespread proliferation of small lymphocytes, frequently associated with involvement of orbital fat, blood vessels, and nerves (Figs. 45.33 and 45.34). It is this group that presents the most difficult problems in differential diagnosis[122] When neoplastic, most of these lesions belong to the category of extranodal marginal zone lymphoma (MALT lymphoma), however follicular lymphoma, mantle cell lymphoma, and small lymphocytic lymphoma can also be encountered.[122–124] In contrast, diffuse large B cell lymphomas predominate in the lacrimal sac.[75] The microscopic appearance of orbital MALT-type lymphomas is similar to that at other sites, including the inconsistent presence of plasmacytoid cells and the exceptional secondary change known as crystal-storing histiocytosis (although lymphoepithelial lesions are relatively uncommon).[125]

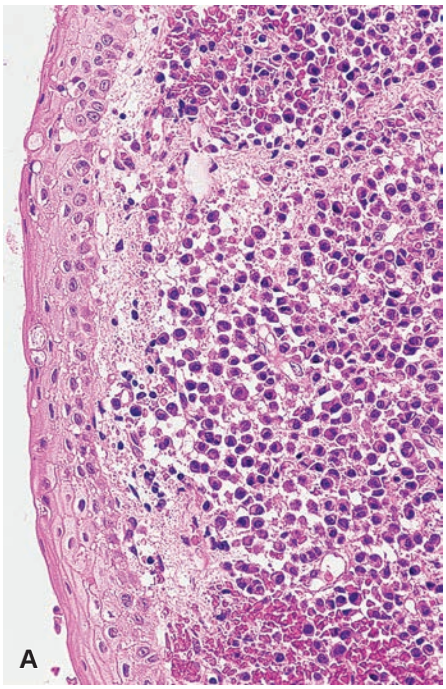

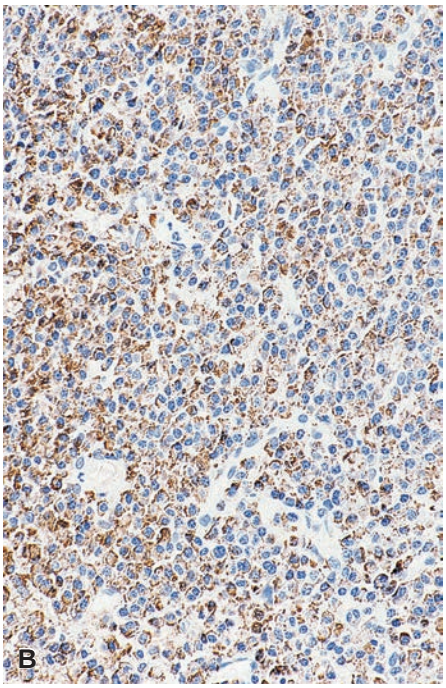

Figure 45.33 **A,** Malignant lymphoid proliferation of conjunctiva composed of small tumor cells with prominent plasmacytoid features. **B,** There is strong immunoreactivity for kappa light chain.

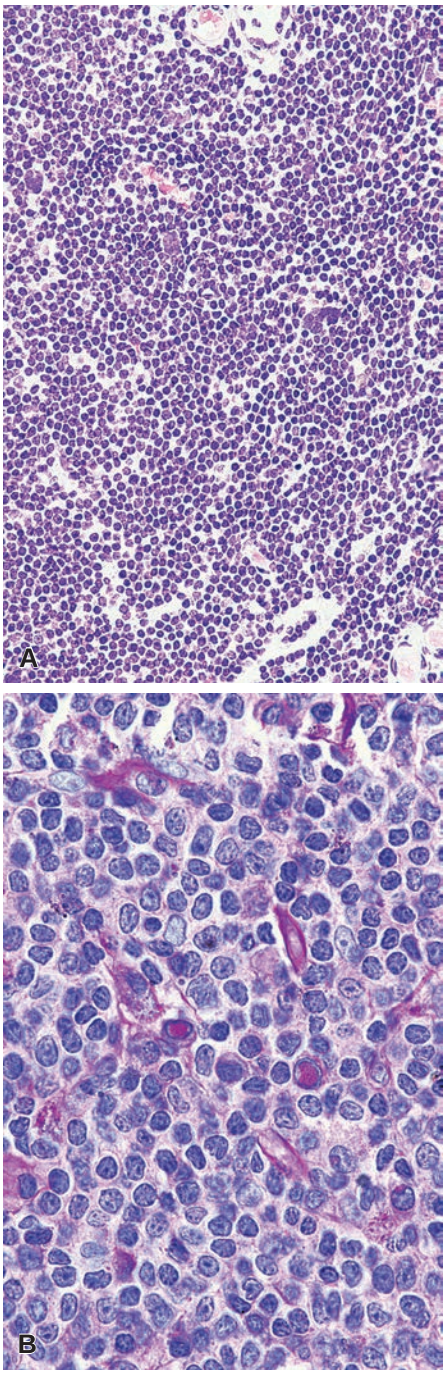

Figure 45.34 Small Lymphocytic Proliferation of Orbit. A, Low-power appearance showing a monotonous infiltrate of small lymphoid cells. **B,** PAS stain in another case, showing PAS-positive intranuclear inclusions composed of inspissated immunoglobulin (Dutcher bodies). The occurrence of these formations favors a neoplastic nature for the proliferation.

Most studies focusing on this third group of lesions have shown that it is very difficult to predict which of them will develop into systemic lymphomas, whether one evaluates them by standard morphologic criteria, by cell marker analysis, or by gene rearrangement techniques.[126,127] Many patients with small lymphocytic proliferations localized to the ocular tissues enjoy a relatively indolent clinical course.[128,129] Lymphoid infiltrates of the conjunctiva are associated with a lower incidence of extraocular lymphoma (20%) than those of the orbit (35%) or eyelid (67%).[130] Overall 5-year survival rates for ocular adnexal lymphoma were 86% in one series, and increased stage may be associated with shorter disease-free survival.[131]

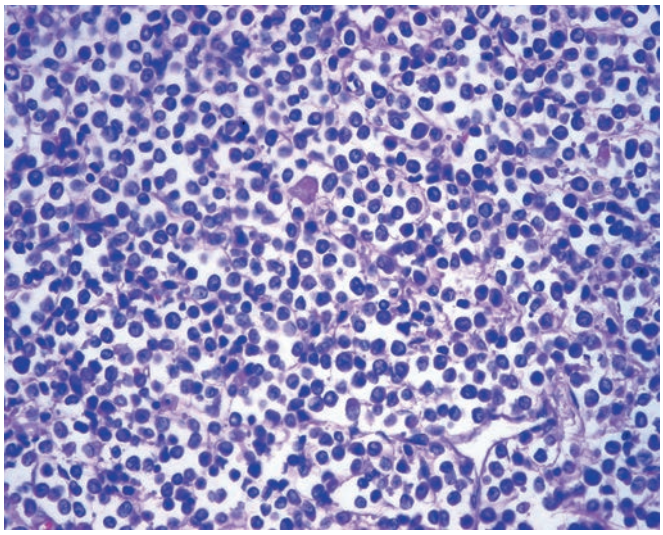

Figure 45.35 So-Called Granulocytic Sarcoma of Orbit. This represents a localized focus of acute myelocytic leukemia.

An Italian group[132] has made a provocative claim that patients with ocular adnexal lymphoma have a high prevalence of *Chlamydia psittaci* (the etiologic agent of psittacosis) infection in both tumor tissue and peripheral blood mononuclear cells, suggesting that this organism may contribute to development of the lymphomas. However, other series from other parts of the world have given very different results.[124] Some cases of ocular lymphoma have been reported as arising against the background of IgG4-related sclerosing disease.[42,133]

Acute myeloid leukemia can involve the orbit as an initially localized lesion (granulocytic sarcoma; Fig. 45.35).

Metastatic Tumors

Direct spread to the orbit from adjacent structures can occur with primary intraocular tumors such as RB or uveal malignant melanomas. Carcinomas of the paranasal sinuses may fail to produce diagnostic symptoms until orbital extension has occurred.

Hematogenous metastases to the orbit may be seen with many different tumors, but only rarely are these the initial manifestations of a carcinoma. Breast cancer represents the commonest distant metastasis in adults, with renal carcinoma representing the second most frequent type in one study.[134] Lobular breast carcinoma often infiltrates through the orbital soft tissue as single cells or in short lines and can be difficult to identify in desmoplastic or inflamed specimens.

In children, neuroblastoma has a notorious reputation for metastasizing to the orbit but rarely does so before other diagnostic signs appear. Primary embryonal rhabdomyosarcoma should not be misinterpreted as a metastatic tumor.

Carcinoid tumors of the lung or small bowel can also metastasize to the orbit or ocular globe[135]; occasionally an orbital carcinoid tumor is found in the absence of any other disease, suggesting the possibility that it may be primary at this site.[136]

Conjunctiva

Specimens from the conjunctiva are thin and tend to fold into distorted patterns when placed into fixative. To prepare the tissue so that it can be oriented properly, the surgeon should spread the

lesion onto a small piece of filter paper and allow it to dry for a few seconds before gently placing the filter paper with the adherent specimen into the jar with the fixative. Specimens should never be put onto sponges because these will expand when placed into the fixative, thus distorting the specimen.

Developmental Anomalies

Dermoid "tumors" of the bulbar conjunctiva are firm, localized, elevated opaque masses that typically occur at the limbus, often encroaching on the cornea (Fig. 45.36). These are solid choristomatous masses, not to be confused with dermoid cysts of the orbit. Over the lesion, the surface epithelium and the subepithelial connective tissue present the histologic features characteristic of epidermis and dermis, respectively. A few hairs typically project from the tumor. The bulk of the mass is composed of thick bundles of collagen. In some lesions, skin appendages are few, and adipose tissue is present; these are known as *dermolipomas* (Fig. 45.37). Additional choristomatous elements including glandular tissue can also sometimes be present. Ocular dermoids may be part of *Goldenhar syndrome*, in which there are frequently bilateral limbal lesions as well as extra-auricular appendages and vertebral abnormalities.

Cysts

Benign epithelium-lined inclusion cysts of the conjunctiva can arise after accidental or surgical trauma or, rarely, de novo. Microscopic identification of goblet cells in the lining and periodic acid–Schiff (PAS)-positive secretions in the lumen are the diagnostic keys, although focal squamous metaplasia in the cyst wall can sometimes obscure the nature of the lesion.

Degeneration

Pinguecula is a common degenerative process affecting primarily the subepithelial connective tissues of the bulbar conjunctiva in the interpalpebral region. This gives rise to an elevated yellowish lesion over which the epithelium may become atrophic or thickened. Since these lesions are not progressive, they are seldom excised. Histologically, the most characteristic feature is actinic elastosis affecting a band-like zone beneath the epithelium, which is highlighted by Verhoeff–van Gieson stains. Secondary hyalinization and calcareous degeneration also may be observed. The epithelium over pingueculae typically becomes atrophic, but at times it becomes acanthotic and dyskeratotic. Intraepithelial dysplasia must be ruled out in pinguecula, as well as in the other lesions discussed later.

Pterygium extend over the cornea and are therefore a clinically more significant lesion than the pinguecula (Fig. 45.38). Microscopically, they represent conjunctival epithelium with variable goblet cell loss and a variably fibrotic underlying stroma (Fig. 45.39). There is usually some stromal actinic elastosis but also a variable amount of acute and chronic inflammation. Reactive atypia is common in the epithelium and should be distinguished from ocular surface squamous dysplasia, which generally features sharper lateral borders.

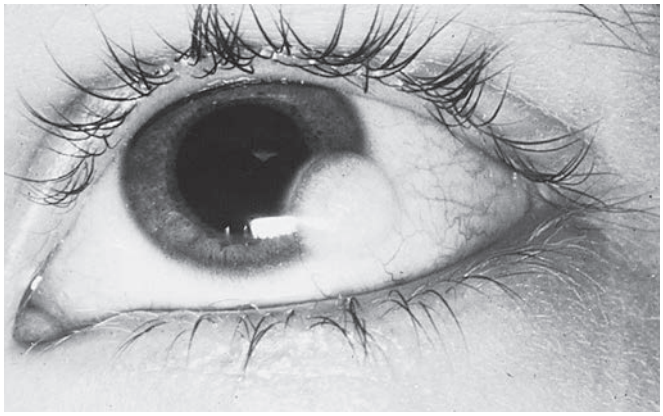

Figure 45.36 Limbal dermoid in a child.

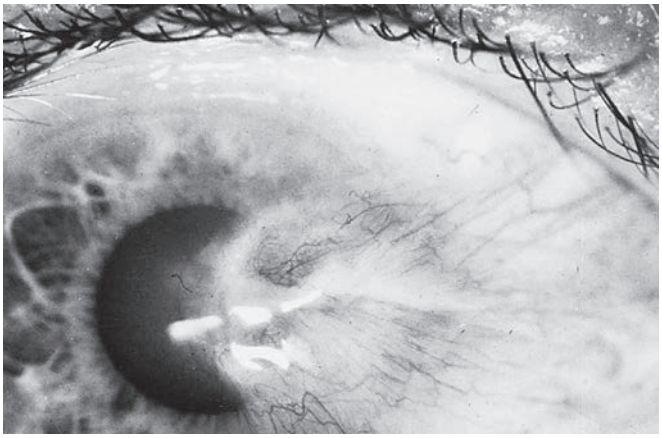

Figure 45.38 Pterygium that has grown over the pupillary axis and has interfered with vision.

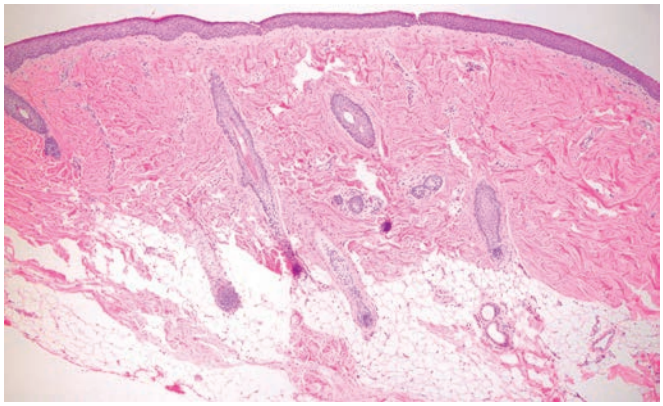

Figure 45.37 Limbal dermolipoma with both hair and adipose tissue in the stroma.

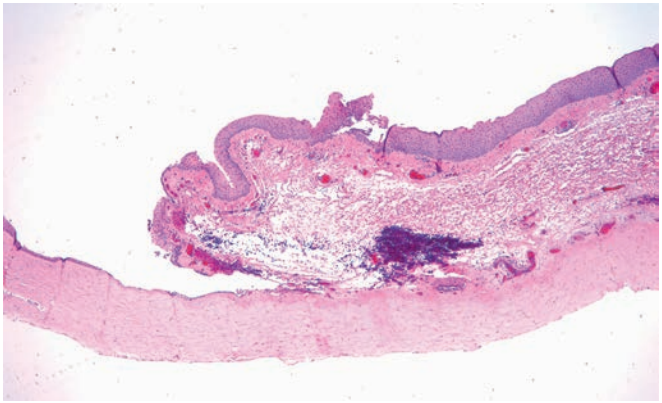

Figure 45.39 Pterygium tissue extends over a cornea.

Graft-Versus-Host Disease

The major histopathologic changes seen in the eyes of patients undergoing bone marrow transplantation involve the conjunctiva, cornea, choroid, and lacrimal gland. The major change in the ocular surface is keratoconjunctivitis.[137]

Inflammation

Scattered lymphocytes and plasma cells are normal components of the conjunctival substantia propria, but prominent inflammatory lesions of the conjunctiva are sometimes biopsied. In many cases only a nonspecific increase in chronic inflammation is present, but some specific non-neoplastic disease patterns can be detected microscopically. Low-grade B-cell lymphomas, generally extranodal marginal zone lymphoma (MALT lymphoma), should also be considered.

Follicular conjunctivitis is characterized clinically by gray-white elevations with avascular centers, representing subepithelial lymphoid follicles, many with well-formed germinal centers.[6] This lymphoid proliferation is often a reaction to viral or bacterial infection. *Chlamydial conjunctivitis*, also known as *trachoma*, is seen in adults as an acute or chronic bilateral keratoconjunctivitis. It can show a microscopic appearance of follicular conjunctivitis indistinguishable from viral infection, and in later stages inflammatory pannus is prominent. The diagnosis is based on the finding of so-called Halberstaedter–Prowazek inclusions in epithelial cells on conjunctival scrapings, or more specific immunoassays.[6,138]

Papillary conjunctivitis (also known as vernal conjunctivitis) is typically seen in the eyelid and is associated with allergic reaction. The raised inflammatory foci have fibrovascular cores and contain lymphocytes and plasma cells with scattered eosinophils. Giant papillary conjunctivitis can also be caused by hypersensitivity reactions to long-term contact lens use.[6]

Sarcoidosis can result in conjunctival noncaseating granulomatous inflammation; these granulomas are generally quite discrete and localized in the substantia propria.

Ligneous conjunctivitis is a peculiar form of chronic pseudomembranous conjunctivitis that presents as a woody induration of the eyelids, together with the formation of a pseudomembrane on the tarsal conjunctiva. The cardinal feature histologically is the presence of large hyaline masses that may simulate amyloid.[139] The disease is thought to be due to plasminogen deficiency.[140]

Actinic granuloma can develop in the bulbar conjunctiva; its microscopic appearance is equivalent to that of its more common cutaneous counterpart, with granulomatous inflammation surrounding a region of elastotic degeneration.[141]

Sjögren syndrome manifests itself in the conjunctiva by a polymorphic inflammatory infiltrate in the stroma, accompanied by metaplasia of the epithelium and a decreased number of goblet cells.[142]

Ocular cicatricial pemphigoid is the name given to mucous membrane pemphigoid involving the ocular surface. Bullae are rare, and diagnosis is based on direct immunofluorescence tests, although these are often negative in patients thought clinically to suffer from the disease.[143]

Tumors and Tumorlike Conditions

Epithelial Tumors

The large majority of epithelial tumors of the conjunctiva arise from the surface epithelium, but a few originate from an accessory lacrimal gland located within the conjunctiva.[144] *Oncocytoma* and other neoplasms can also arise from adnexal structures in the caruncle.[68]

Papillomas are relatively common lesions of the conjunctiva with a tendency for recurrence after apparent complete excision. In children the papillomas are often multiple. The lesions have a typical papillomatous or "mulberry" surface appearance with small vessels coming up to the surface.

Microscopically, the typical papilloma reveals pronounced acanthosis and varying degrees of keratinization, koilocytosis, and nonspecific inflammation. Goblet cells are generally retained at least focally (Fig. 45.40) and can be highlighted using PAS stains. Human papillomavirus (HPV) type 6/11 has been found in these lesions by in situ hybridization or PCR in many cases.[145] Conjunctival papillomas occasionally contain dysplastic foci, although when inflammation is prominent the possibility of reactive atypia should be considered. Papillary carcinomas can arise on the conjunctiva and in many cases represent secondary papillomatous change in a lesion that was originally flat.

Conjunctival intraepithelial neoplasia (CIN) almost always arises on the ocular surface rather than the eyelid and varies considerably in its clinical appearance. They may present clinically as an area of leukoplakia, as a papillomatous growth, or as a complication of pterygium or pinguecula (Fig. 45.41). The incidence of CIN is significantly increased in immunosuppressed patients. The histopathologic characteristics of ocular surface CIN are somewhat similar to those observed elsewhere on mucous membranes, although the degree of dysplasia is often not as pronounced. This is particularly true of lesions which appear papillary clinically, in which microscopic examination can reveal thickening of the epithelium with loss of goblet cells, suprabasal mitoses, disordered growth, and lack of appropriate superficial maturation but only modest cellular enlargement and nuclear atypia. In such cases, the identification of sharp borders at the edges of the lesion can be critical in differentiating it from non-neoplastic reactive changes in the epithelium. Clinically leukoplakic lesions generally show more squamous differentiation and superficial parakeratosis but also have well-defined edges (Fig. 45.42). Koilocytic change is often lacking, and more recent studies suggest that high-risk HPV is generally not present in CIN or conjunctival carcinoma.[146] Some have suggested that cutaneous HPV subtypes may play a role in the development of ocular surface squamous neoplasia, particularly when patients are immunosuppressed due to infection with HIV.[147]

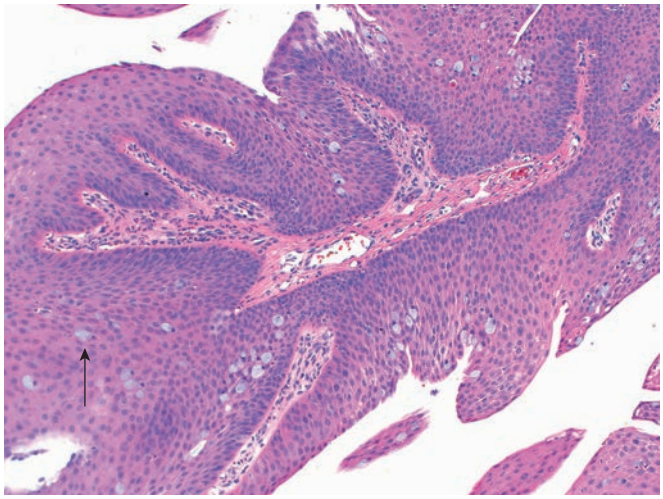

Figure 45.40 Papilloma of bulbar conjunctiva containing pale gray goblet cells *(arrow)*.

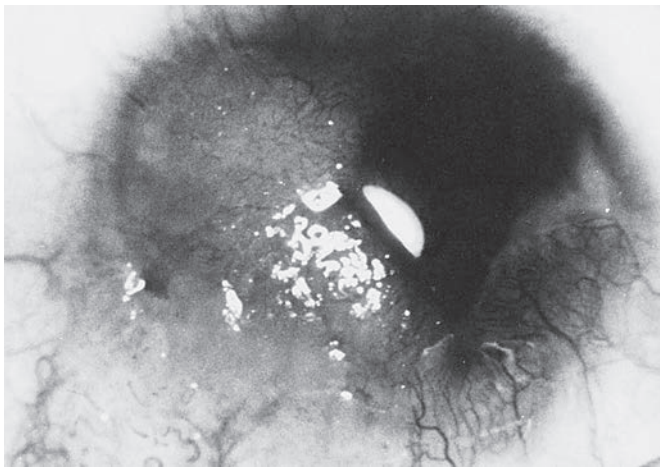

Figure 45.41 CIS of conjunctiva and cornea.

Figure 45.43 Squamous cell carcinoma of conjunctiva growing extensively inside the orbit and compressing the ocular globe.

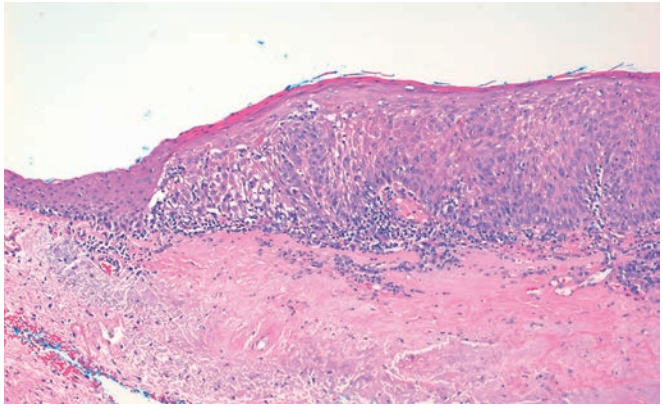

Figure 45.42 Conjunctival intraepithelial neoplasia typically shows sharp peripheral borders with nondysplastic epithelium.

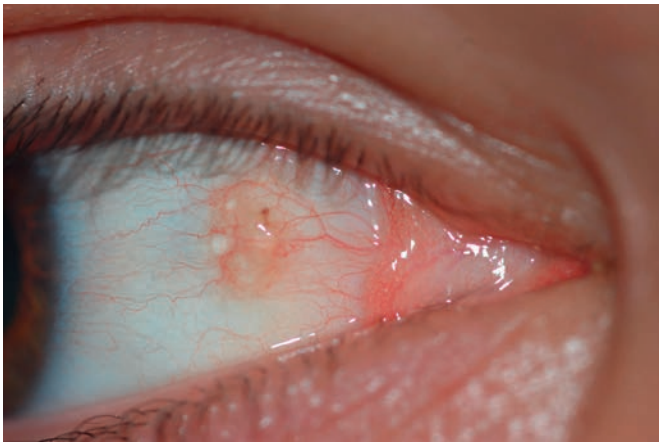

Figure 45.44 Lightly pigmented conjunctival lesion that proved to be a benign nevus.

Dysplasia in CIN is generally classified as mild, moderate, or severe based on the thickness of epithelial involvement.[4] Cases in which essentially the entire epithelium is abnormal, with no normal superficial maturation, are classified as carcinoma in situ (CIS). CIN and conjunctival CIS can both progress in invasive squamous carcinoma.

Hereditary benign intraepithelial dyskeratosis is an autosomal dominant disease characterized by thick leukoplakic lesions that affect the bulbar conjunctiva bilaterally. The acanthosis, dyskeratosis, and parakeratosis can mimic carcinoma, but the condition is benign. It is most frequently encountered in descendants of Native American tribes from North Carolina but can occur in other populations as well.[148]

Invasive squamous cell carcinoma of the conjunctiva generally arises from intraepithelial dysplasia and is relatively rare in regions where early "precancerous" or "in situ cancerous" lesions are efficiently excised. Metastatic spread is uncommon, and even aggressive local disease can often be treated with surgery (Fig. 45.43).[149,150] As for other types of ocular surface squamous neoplasia, sun exposure and immunosuppression due to HIV infection represent major risk factors. Invasive conjunctival carcinomas with *adenosquamous* ("mucoepidermoid") features often behave in a more aggressive fashion.[151] *Spindle cell carcinoma* of conjunctiva is another variant, which can invades more often into the globe and orbit.[152]

Melanocytic Tumors and Tumorlike Conditions

Nevi of the bulbar conjunctiva, like those of the skin, may be observed from birth or first become noticeable at any time during childhood, adolescence, or later. At times a nevus known to have been present since infancy appears to become much larger and more pigmented at puberty. Characteristically, conjunctival nevi are discrete, flat, or slightly elevated lesions located on the globe in the interpalpebral zone, but they vary greatly in size, shape, and position. They also exhibit much variation in degree of pigmentation, with a significant number being essentially amelanotic (Fig. 45.44).

Microscopically, conjunctival nevi are generally of the junctional, compound, or subepithelial varieties, with the latter corresponding to the intradermal nevus of skin. A few are of the Spitz or blue nevus type.[153] Frequently, there are numerous solid and cystic inclusions of conjunctival epithelium intimately incorporated into the subepithelial component of these nevi (Fig. 45.45). At times, the epithelial inclusions may so dominate the clinical and histopathologic picture that the nevoid nature of the lesion is overlooked, and MITF, MART1, or other markers can be useful in highlighting the melanocytic component. The presence of the epithelial inclusions is supportive evidence for benignity, since they are rare in melanomas. Dilatation or proliferation of these cystic epithelial components may also account for clinical growth in lesions that appear nonproliferative microscopically.

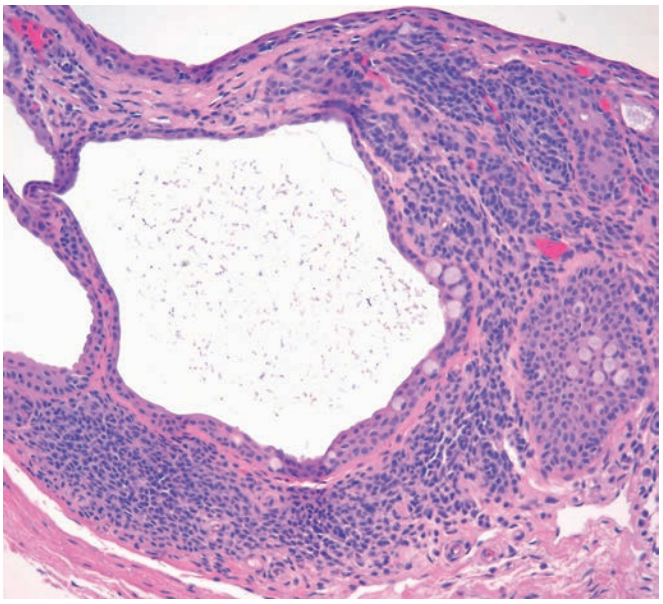

Figure 45.45 Conjunctival nevus with many associated cystic epithelial inclusions. Small round cells about large cysts are not inflammatory cells but nevus cells.

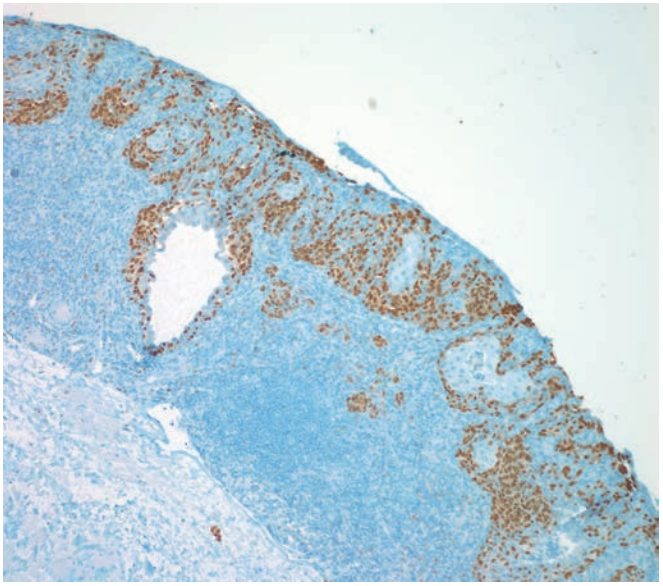

Figure 45.46 An inflamed "juvenile" conjunctival compound nevus in a 10-year-old boy. MITF immunostains highlight melanocytic cells in the conjunctival base and surrounding invaginating epithelial cysts and nests, while deeper region show dense chronic inflammation.

Conjunctival nevi in children, which are usually of junctional or compound types, tend to show a confluent pattern of lentiginous growth and a lack of maturation that may lead to overdiagnosis of melanoma.[154] They can also grow rapidly and show increased cytologic atypia when inflamed, and many regard the *inflamed juvenile conjunctival nevus* as a distinct entity (Fig. 45.46).[155]

Conjunctival melanosis is a confusing term commonly used among ophthalmologists and ophthalmic pathologists to describe a range of entities. Many are benign, such as congenital complexion associated pigmentation, also known as "racial" conjunctival melanosis, which is usually bilateral and does not grow.[156] Primary acquired melanosis (PAM) is the most frequently encountered lesion of clinical

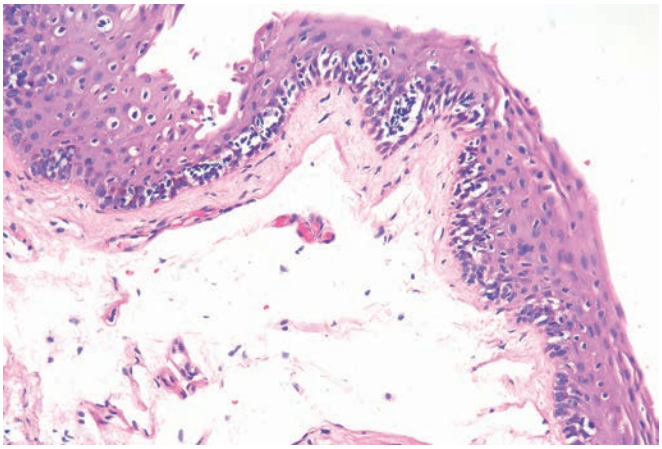

Figure 45.47 Primary acquired melanosis (PAM) with moderate atypia showing lentiginous proliferation of atypical melanocytes in the conjunctival base and some pagetoid spread.

concern, and it has been estimated that approximately 75% of conjunctival melanomas arise from PAM.[157] However, as discussed later, only PAM with severe atypia is thought to commonly give rise to melanomas. PAM has also been referred to as precancerous melanosis, atypical melanocytic hyperplasia, conjunctival melanocytic intraepithelial neoplasia (C-MIN), and malignant melanoma in situ.[158–161] Most cases are seen in the fifth decade of life or later, and the typical presentation is that of a diffuse nonelevated granular pigmentation of the conjunctiva. The most common site is the bulbar conjunctiva, but it can also involve the cornea, caruncle, or palpebral conjunctiva. The extent of the lesion and the degree of pigmentation may fluctuate during the course of the years. PAM is generally divided into lesions without atypia and those with mild, moderate, or severe atypia, although several variations on this general scheme are used.[4,157,162,163] Many now consider lesions in which atypical melanocytes involve more than 75% of the epithelial thickness or slough from the surface to represent melanoma in situ.

Microscopically, PAM without atypia consists of increased conjunctival epithelial pigmentation with little or no increase in melanocytes and an absence of cytologic melanocytic atypia.[157,164] In PAM with atypia, an increase in the number of melanocytes is seen along the basal layer, individually or in clusters, associated with various degrees of atypicality and sometimes pagetoid spread (Fig. 45.47).[160,163,164]

The nature and significance of this lesion have been controversial. It has been postulated that all cases of acquired melanosis exhibiting atypia are malignant melanomas in situ.[158] Most researchers have found that only a subset of lesions with more severe atypia give rise to invasive melanoma, however. In the series of Folberg et al.,[164] none of the lesions without atypia progressed to invasive melanoma, whereas 40% of those with atypia did. Sugiura et al.[165] divided their 29 cases into a *low-risk* and a *high-risk* group based on largely on nuclear morphology and epithelioid features, with the *high-risk group* showing a high association with malignant melanoma. Shields et al. reported on 311 eyes with PAM divided into groups with no atypia, mild atypia, and severe atypia.[157] Progression to melanoma never occurred in cases with no or mild atypia and in only 13% of patients with PAM with severe atypia. Thus it appears that only PAM lesions with prominent melanocytic proliferation and cytologic atypia are likely to progress to invasive melanoma.

Some of the confusion surrounding PAM is due to use of the term "melanosis" to describe both hypersecretion of melanin and melanocytic proliferation. It has therefore been suggested that the

terms *conjunctival hypermelanosis* and C-MIN be used instead of PAM to describe lesions without or with melanocytic proliferation.[160] This system proposed by Damato and Coupland also includes a more standardized system for grading atypia based on radial and vertical melanocyte spread as well as cytologic features.

Malignant melanoma of the conjunctiva, a rare lesion, may arise without an apparent precursor lesion, or it may be the sequela of a nevus or PAM (Figs. 45.48 and 45.49).[157,160] The microscopic appearance is similar to that of its cutaneous counterpart. The prognosis is related to the subsite and size of the primary tumor, which are central to the current American Joint Committee on Cancer staging criteria. The presence of epithelioid cells is also associated with worse clinical outcomes. In the series of 382 cases reported by Shields et al., the 10-year mortality was 9% for tumors arising from PAM or nevus and 35% for those arising de novo.[166] Factors predictive of death on multivariate analysis were de novo origin, fornix location, and nodularity. The treatment varies from local excision to exenteration of the eye, depending on the extent of the disease.

Lymphoid Tumors and Tumorlike Conditions

The morphologic appearances and diagnostic problems posed by lymphoma when they present in the conjunctiva are similar to those of analogous lesions of the eyelid and orbit as discussed previously. The clinical appearance of the conjunctival lymphoma is that of salmon-colored, smooth masses. Most are extranodal marginal zone lymphoma (81%) or follicular lymphoma (8%).[167] **Rosai–Dorfman** disease can also present as fleshy or papillomatous lesions on the conjunctiva, limbus, and cornea.[168]

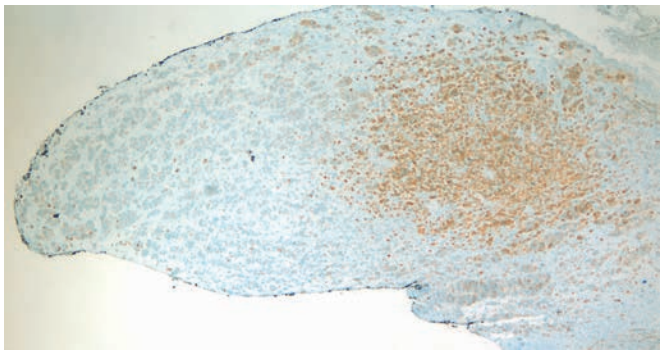

Figure 45.48 Malignant melanoma arising in a conjunctival nevus, with HMB45 negative nevoid nests in the left of the specimen, and more diffuse HMB45-positive cells on the right.

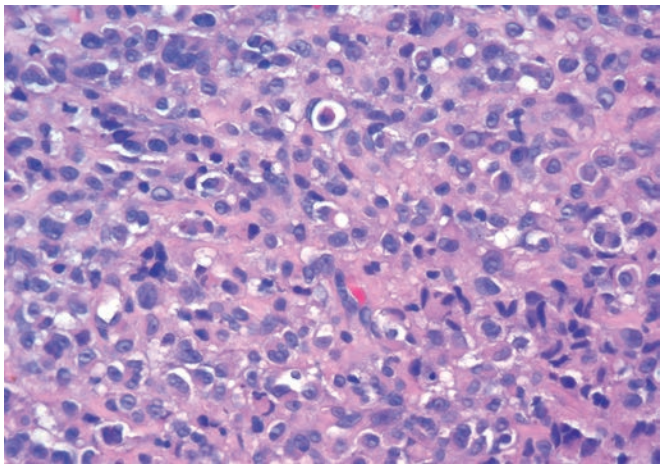

Figure 45.49 Conjunctival melanoma cells corresponding to the HMB45-positive region in Fig. 45.48.

Other Tumors

Myxoma has been reported as a primary tumor in the conjunctiva, cornea, eyelid, and orbit. Grossly, the conjunctival lesions have a smooth, fleshy, gelatinous appearance. Local excision is curative.[169] **Vascular tumors** involving the conjunctiva include hemangioma and Kaposi sarcoma.[170] **Merkel cell carcinoma** has been seen as an apparently primary conjunctival tumor.[171]

Intraocular Tissues

As stated in the Introduction of this chapter, only tumors and tumorlike conditions of these structures will be discussed.

Malignant Melanoma

General and Clinical Features

Melanomas arising from the pigmented or potentially pigment-producing cells of the uvea are the most frequent primary intraocular neoplasms in adults. Rarely, they occur in adolescents and children.[172] Many are thought to arise from preexisting benign nevi, although only a small fraction of uveal nevi progress to melanoma.[2,173] Risk factors for uveal melanoma, in addition to nevi, include a fair complexion, light irides, oculodermal and ocular melanocytosis, and von Recklinghausen disease.[2,174]

Malignant melanoma may be located at any point in the uveal tract, but most arise in the choroid, with less than a quarter found in ciliary body or iris.[2] Melanoma of the iris typically presents as an elevated mass with varying degrees of pigmentation but can also consist of multiple small nodules (tapioca iris melanoma) or generate a broad carpet of growth on the surface (Fig. 45.50). Choroidal melanoma also may vary in pigmentation but characteristically is an irregular, slate-gray, solid, subretinal tumor producing an overlying retinal detachment and decreased vision (Fig. 45.51). They generally appear as a discoid, globular, or mushroom-shaped mass but can

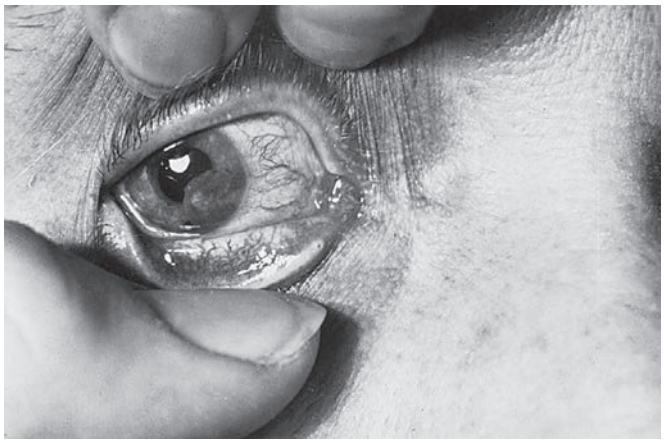

Figure 45.50 Melanoma of iris that had been observed over a period of 10 years, during which time it became progressively larger and encroached on the pupil. Iridectomy revealed it to be of spindle A cell type. The tumor recurred and necessitated enucleation for secondary glaucoma 15 years after iridectomy. (Courtesy of Dr ME Nugent, Bismarck, ND.)



Figure 45.51 Malignant melanoma of choroid that, by erupting through Bruch's membrane, has formed a mushroom-shaped subretinal mass.

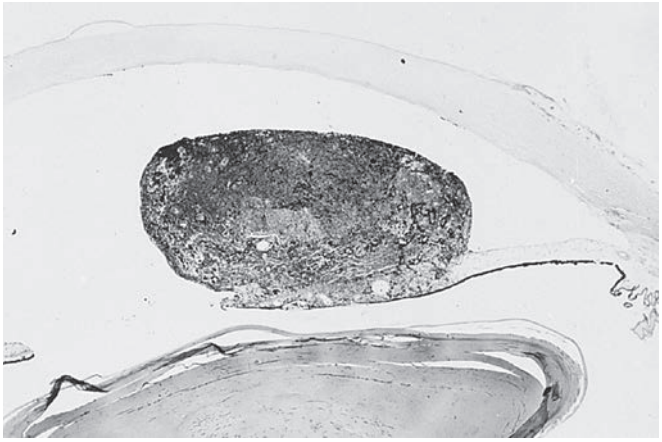

Figure 45.52 Melanomas of iris are frequently visible through the cornea. Hence, their duration and rate of growth are often known by the patient or family long before other subjective or objective manifestations appear.

sometimes spread diffusely or extend out along scleral canals into the orbit. Visual disturbance caused by retinal detachment is one presenting complaint. At times, malignant melanomas of the posterior uvea are not discovered until the enucleated eye is examined in the laboratory.

Diagnosis and staging can be problematic in cases with clinically unsuspected tumors when fragmented specimens are removed by evisceration.[175] Iris tumors are more often recognized early, for they can be seen by the patient and family long before symptoms appear (Fig. 45.52).

Clinically, there are many lesions that simulate uveal malignant melanoma.[176,177] The most important are metastatic carcinoma, localized hemorrhage beneath the retina or between the pigment epithelium and choroid, focal areas of proliferation of the retinal pigment epithelium, posterior scleritis, and benign tumors such as nevi and hemangiomas. Other melanocytic lesions of the choroid which must be distinguished from melanoma include *melanocytoma* and *bilateral diffuse uveal melanocytic proliferation* (BDUMP).

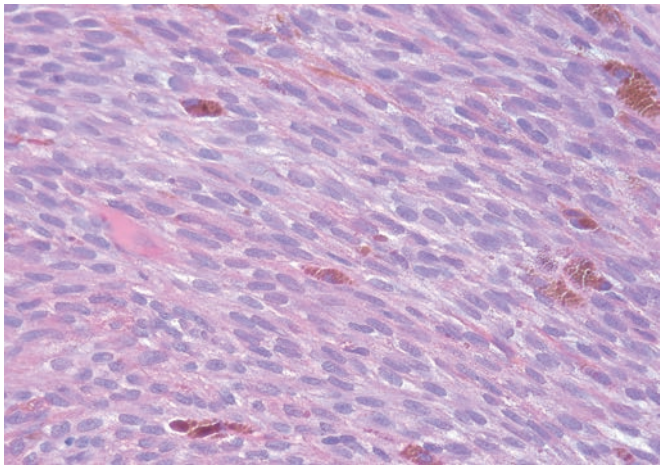

Figure 45.53 A choroidal melanoma comprised predominantly of spindle A cells.

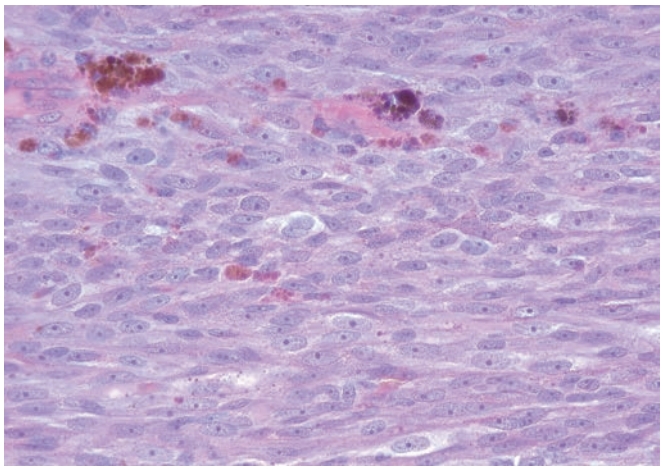

Figure 45.54 A choroidal melanoma comprised predominantly of spindle B cells.

Microscopic Features

Microscopically, uveal melanomas have been traditionally divided into three types: spindle A, spindle B, and epithelioid, which may occur singly or in combination.[2,178] Spindle A cells are slender, benign-appearing cells that have relatively small fusiform nuclei and no nucleoli (Fig. 45.53). Spindle B cells are larger and more pleomorphic, merging on the one hand with spindle A cells and on the other with epithelioid cells. They typically possess large ovoid nuclei containing prominent nucleoli (Fig. 45.54). Both spindle A and spindle B tumors tend to be quite cohesive. Some of these tumors have a distinctly fascicular pattern of growth. Epithelioid cells are still larger and more irregular (Fig. 45.55). They have an abundance of cytoplasm and may be truly gigantic. The nuclei are large, and their nucleoli are often strikingly prominent. Multinucleated forms or balloon cells can be seen. Epithelioid cells are characteristically less cohesive than the spindle cells. It is rather unusual for these tumors to be composed of a single cell type. Mixtures of spindle A and B cells or mixtures of spindle and epithelioid cells are common.

The microscopic differential diagnosis of primary uveal melanoma includes benign pigmented nevi, and it can be difficult to distinguish a small spindled melanoma from a nevus. Iris lesions are particularly problematic, as they are often small and cytologically bland. The

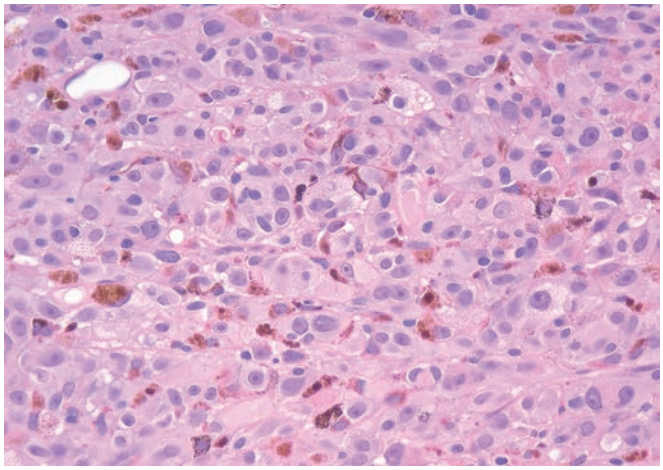

Figure 45.55 A choroidal melanoma comprised predominantly of epithelioid cells.

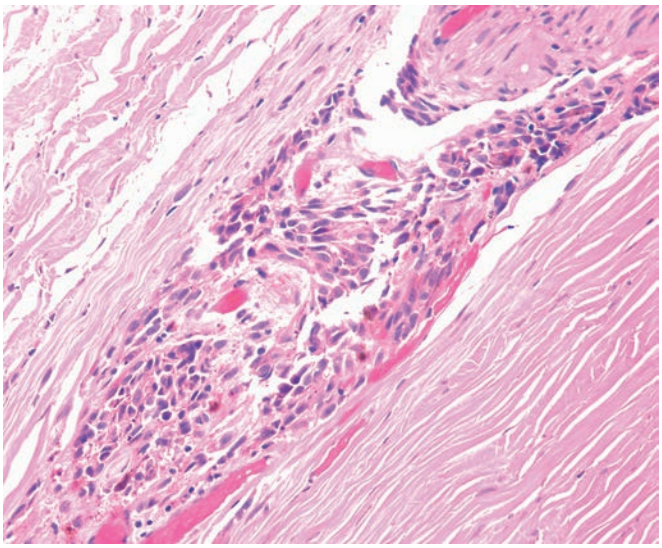

Figure 45.56 Uveal melanoma cells extending through a scleral canal.

presence of nucleoli and signs of proliferation, as well as invasion into adjacent structures, are all helpful in establishing a diagnosis of melanoma. Primary uveal melanomas should also be distinguished from intraocular metastases of cutaneous malignant melanoma. In addition, amelanotic melanomas raise the differential diagnosis with metastatic carcinoma, and spindle cell melanomas with a fascicular pattern of growth may resemble neurofibromas, schwannomas, or leiomyomas. The latter consideration applies particularly to tumors of the ciliary body.

Immunohistochemical and Molecular Genetic Features

Immunohistochemically, malignant melanomas are reactive for S-100 protein, HMB-45, MITF, and Mart-1 (Melan-A).

Cytogenetically, common alterations of clinical significance include chromosome 3 loss, chromosome 6p gain, and chromosome 8q gain.[179,180] Mutations in the *GNAQ* or *GNA11* genes are found in most cases, representing the most common known oncogenic mutation in this cancer, and probably an early event in oncogenesis.[173,181] Mutations in *BAP1* are thought to occur later in tumor progression and are common in lesions which metastasize.[182,183] Immunohistochemical evaluation of BAP1 loss may also have diagnostic utility.[184]

Spread and Metastases

Lymphatic channels are not present in the eye, thus uveal melanoma spread hematogenously, primarily to the liver, lung, and skin.[185] Extraocular extension through scleral canals is rare (Fig. 45.56), but extensive extrascleral growth generally prompts orbital exenteration.[173] Invasion of uveal melanoma along the optic nerve is very rare. Both loss of chromosome 3 (monosomy 3) and specific gene expression profiles have been used to predict metastatic spread and patient survival.[183] Increasingly, FNA is performed to obtain tissue for molecular analysis.[180,183]

Treatment

Uveal melanoma treatment depends on tumor location and multiple clinical factors. Small melanomas of the iris can be treated by iridectomy or iridocyclectomy, while larger or disseminated tumors arising at this site may require radiotherapy or enucleation.[173] Small to moderately sized melanomas of the choroid and ciliary body are general treated by radiotherapy (plaque or proton beam) or less frequently transpupillary thermotherapy. Enucleation of the eye results in better outcomes with larger tumors.[173,176,177] Treatments for metastatic disease are unfortunately of only limited utility.

Prognosis

The overall mortality from metastasis of melanoma of the uveal tract 15 years after enucleation is close to 50%, with only very limited success in treating metastatic disease.[173,176] The prognosis of this tumor depends on multiple clinical, pathologic, and molecular factors, which are summarized here:

1. *Tumor size and proliferation*. Larger tumors have a worse prognosis than smaller ones.[173,179] For choroidal and ciliary body tumors, both the largest basal diameter in contact with the sclera and the thickness should be measured and play a key role in current pathologic staging protocols.[186] Mitotic index should also be reported.
2. *Location*. Tumors located in the iris generally have a better prognosis. In contrast, melanoma involving the ciliary body are associate with shorter survival.[179,186]
3. *Extrascleral extension and growth*. Extrascleral extension only occurs in a minority of patients with uveal melanoma but is associated with worse outcomes, particularly when the tumor forms a large mass outside the confines of the globe.[179]
4. *Cell type*. Spindle A tumors are associated with the best outcomes and epithelioid tumors the worst. Many cases show a mixture of spindled and epithelioid cells.
5. *Lymphocytic infiltration*. The presence of a large number of lymphocytes in the tumor stroma has been found to be significantly associated with decreased survival.[187]
6. *Vascularization*. Specific patterns of "vascular mimicry" by neoplastic cells have been associated with outcome. Melanomas with "closed vascular loops" highlighted on PAS stains behave more aggressively than others.
7. *Chromosome 3 loss*. Loss of chromosome 3 (monosomy 3) is a well-established molecular change strongly associated with metastatic tumor spread.[188]

8. *Gene expression profile.* Gene expression profiling studies have shown that uveal melanomas cluster into two molecular groups—tumors with the class 1 signature rarely metastasize, whereas those with the class 2 signature have a very high rate of metastasis.[189] Low expression of genes on 3p is also associated with a poor prognosis.[190]
9. *BAP1 gene mutation*. Mutations in the *BAP1* gene are also frequent in metastasizing uveal melanoma.[182] Immunohistochemical loss of BAP1 protein detected using immunohistochemistry is also associated with tumor spread and poor outcomes.[184,191]

Melanocytomas are densely pigmented benign tumors that generally arise near the optic nerve head but occasionally develop more anteriorly.[192] On bleach preparations, the cells are epithelioid but have bland nuclei. Because they are benign and very rarely progress, making the distinction between uveal melanocytoma and melanoma is clinically important.

Retinoblastoma and Related Lesions

General Features

RB is the most common intraocular neoplasm of children. It has long been thought to arise from retinal stem or progenitor cells, and recent studies suggest both early progenitors and cone precursors as cells of origin for distinct molecular groups of tumors.[193–195] RBs can present at birth but are usually diagnosed between 1 and 2 years of age, with heritable cases arising in younger infants. Approximately 60% of the cases are unilateral, and the other 40% are bilateral (Fig. 45.57), with all bilateral cases and 15% of unilateral cases representing a heritable form of the disease.[196]

The responsible gene is located at chromosome 13q14 and designated *RB*.[197] Patients with hereditary RB have a germ cell mutation in one allele and develop the RB as a result of a somatic mutation in the second allele, whereas in patients with sporadic RB both mutations are somatic.[198] This model, known as Knudson's "two-hit hypothesis," has become a paradigm of tumorigenesis.[199] The yearly incidence of inherited RB mutations is 1 in 15,000 to 20,000 live births.[196]

Clinical and Gross Features

RBs characteristically present as a leukocoria (white pupillary reflex; Fig. 45.58) or less often as a strabismus. Rarely, extraocular extension with the formation of an orbital mass is the presenting manifestation.

RBs may be flat and diffuse or elevated and may show multicentric foci of origin, especially in the hereditary type. They may protrude into the vitreous (endophytic type; Fig. 45.59), often with vitreous seeding, or they may grow between the retina and the pigment epithelium (exophytic type).[195] Since the tumors tend to outgrow their blood supply, necrosis is often extensive and many minute foci of calcification are often present in these areas of necrosis (Fig. 45.60). In fact, these areas of calcification may be appreciated by x-ray examination prior to enucleation.

Some patients have presented with bilateral RB and a morphologically similar intracranial neoplasm, generally localized in the region

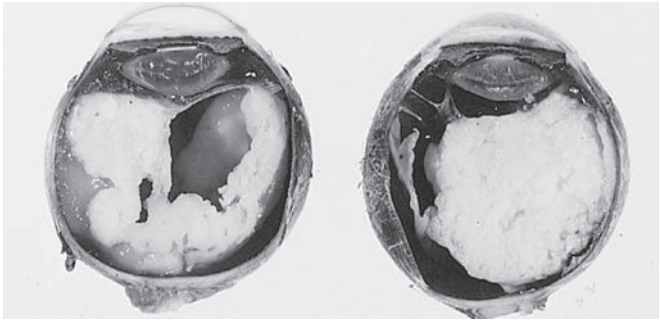

Figure 45.57 Bilateral retinoblastoma showing a white mass consisting of detached retina and neoplastic tissue immediately behind the lens in each eye.

Figure 45.58 Prominent white reflex attributed to retinoblastoma present in the dilated pupil of the left eye.

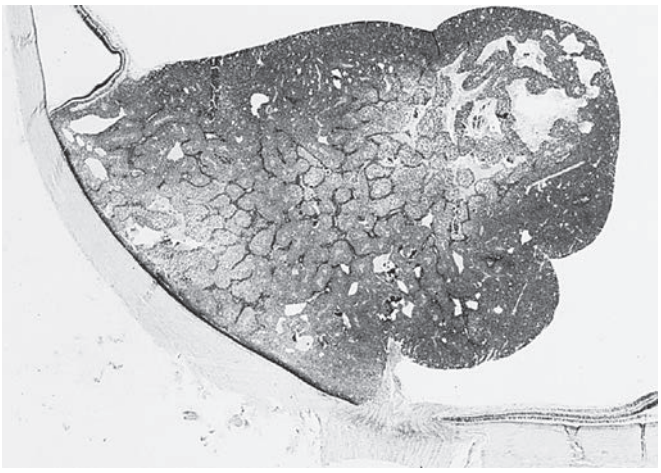

Figure 45.59 Retinoblastoma presenting as a highly cellular neoplasm with scant stroma. The tumor tends to outgrow its blood supply, and irregular areas of necrosis are commonly observed.

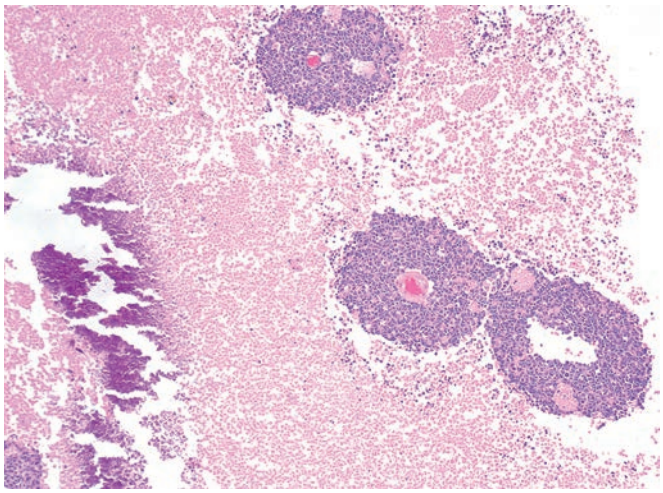

Figure 45.60 Retinoblastoma with a collar of viable cells about nutrient vessels with necrotic cells further away. Calcification is seen on the left.

of the pineal gland, in keeping with the "third eye" nature of the latter structure.[200] These are referred as *trilateral RBs* and are found in 3%–5% of hereditary cases.[201]

The clinical differential diagnosis of RB includes any disease process that leads to retinal detachment or a retrolental mass in a child under 6 years of age.[195] Lesions in this category include traumatic or idiopathic retinal detachments, familial exudative vitreoretinopathy, persistent hyperplastic primary vitreous (persistent fetal vasculature), massive retinal gliosis, coloboma, Coats disease, toxocariasis, astrocytic hamartoma of tuberous sclerosis, and medulloepitheliomas. Some of these disorders are discussed elsewhere in this chapter.

Microscopic Features

Microscopically, RBs are composed of dense masses of small round cells with hyperchromatic nuclei and scanty cytoplasm.[202] Dystrophic calcification and hematoxyphilic DNA deposits in and around blood vessel walls are often seen in necrotic areas. Both neuroblastic Homer Wright rosettes containing a central tangle of processes and Flexner–Wintersteiner rosettes with true lumens can be found, with the latter most common in younger patients (Fig. 45.61). In well-differentiated tumors, "fleurettes" in which cytologically bland cells produce a bouquet of eosinophil processes recapitulating photoreceptor inner segments are seen. Tumors showing an extreme degree of differentiation are designated as *retinocytomas* and regarded as benign (Fig. 45.62).[195,203] These lesions carry the same initiating genetic changes as conventional RBs; they present as small placoid, noninvasive lesions composed entirely of benign-appearing cells with numerous fleurettes, lacking necrosis or mitotic activity.[203] It has also recently been recognized that anaplastic changes similar to those in other embryonal tumors of the brain can be encountered in RB and are associated with worse clinical outcomes (Fig. 45.63).[204]

Electron Microscopic, Immunohistochemical, and Molecular Genetic Features

Ultrastructural evidence of photodifferentiation has been found in the tumor cells of RB (Fig. 45.64).[205,206] Immunohistochemically, there is reactivity for general neuronal proteins such as synaptophysin, as well as markers of retinal differentiation such as retinal-binding protein, retinal S-antigen, interphotoreceptor retinal-binding protein, cone opsin, and rod opsin.[207–209] Interestingly, retinal S-antigen has also been detected in tumors of the pineal gland and in cerebellar medulloblastomas.[209,210] The MIB-1 labeling index is extremely high. Limited p53 immunostaining is present in over half of the cases. In contrast to Ewing sarcoma/PNET, most neuroblastomas are negative for CD99.[211]

Besides loss-of-function mutations in the *RB* gene, other common genetic alterations in RB include gain of 1q, 2p, 6p, and 13q and loss of 16q.[212–215] Some cases also show amplifications of the *NMYC*, *MDMX*, or *MDM2* gene[216] In rare cases, NMYC amplification can substitute for *RB* gene loss as an initiating genetic event, and these tumors tend to be more anaplastic in their microscopic appearance.[217]

Spread and Metastases

RB has a tendency to invade the optic nerve, from which it can extend to the brain or be carried there by the cerebrospinal fluid (Fig. 45.65).[217] Large exophytic tumors with secondary glaucoma

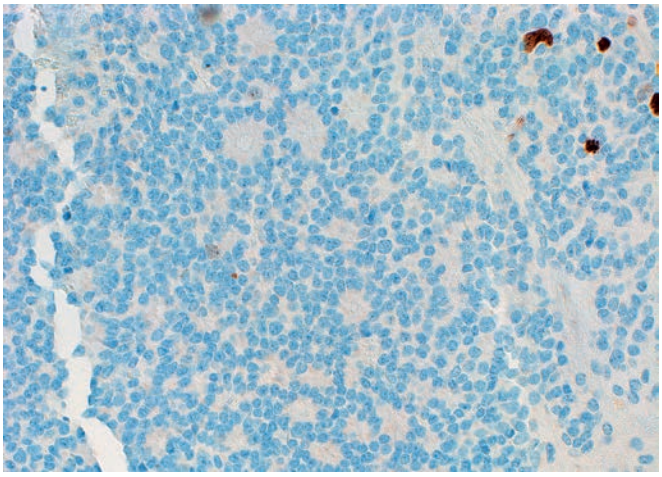

Figure 45.62 Retinocytoma with small bland cells, fleurettes, and a very low Ki67 proliferation index.

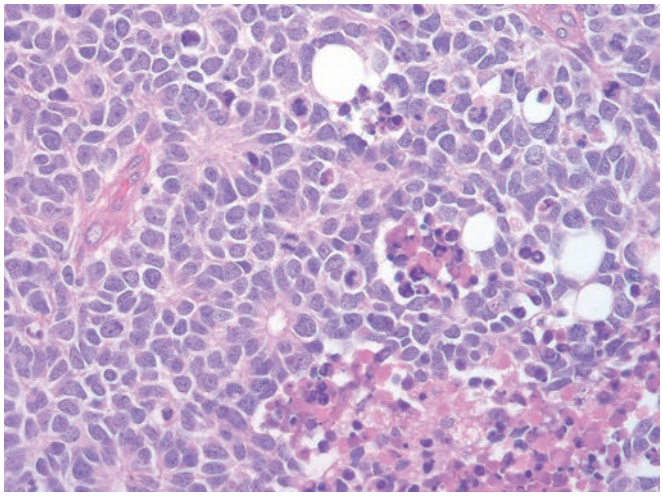

Figure 45.61 Retinoblastoma with a few Flexner–Wintersteiner and Homer Wright rosettes.

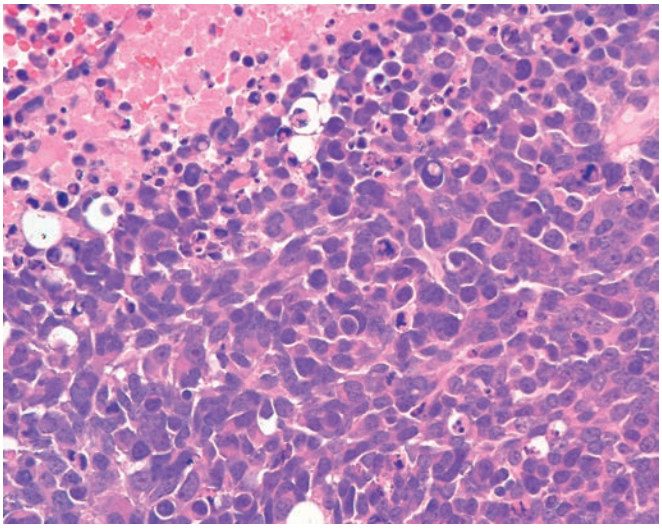

Figure 45.63 Anaplastic retinoblastoma with highly pleomorphic cells showing angular molding and wrapping as well as prominent nucleoli. This lesion was amplified at the NMYC locus.

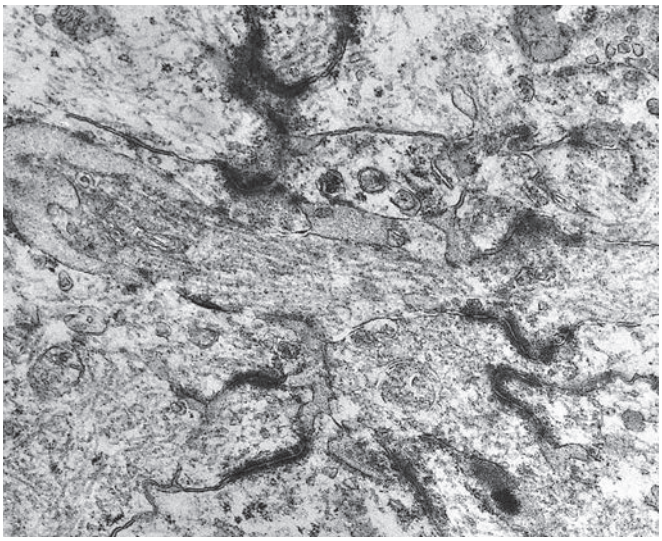

Figure 45.64 Electron micrograph of retinoblastoma. A portion of the center of a rudimentary Flexner–Wintersteiner rosette illustrating a bulbous apical microtubule-containing cytoplasmic process and numerous cell junctions. (Courtesy of Dr Robert A Erlandson, Memorial Sloan Kettering Cancer Center.)

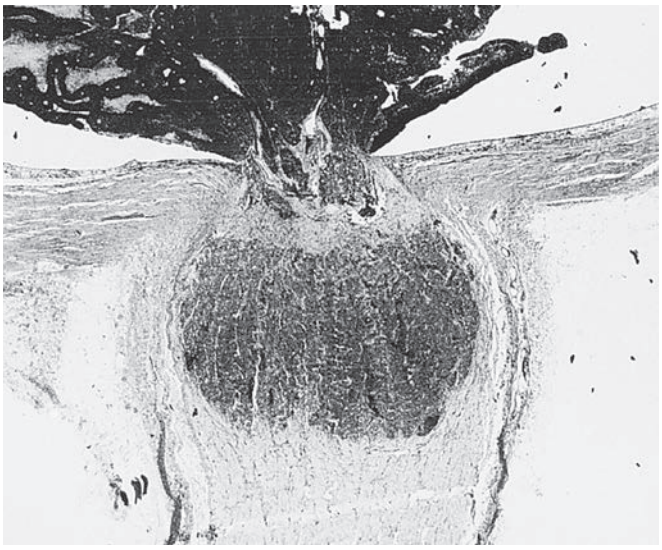

Figure 45.65 Retinoblastomas exhibit a tendency to spread out of the globe by way of the optic nerve *(arrows)*. It is therefore of utmost importance for the surgical pathologist to determine whether such optic nerve extension has occurred and, if it has, to what extent.

are at highest risk for optic nerve invasion. RB can also invade the uveal tract, and "massive" choroidal invasion of over 3 mm is associated with hematogenous metastasis (Fig. 45.66). Vitreous seeding is also associated with chemoresistance and poor outcomes (Fig. 45.67). Distant metastases can be limited to the cranial vault or involve distant sites, particularly the skeletal system.[218]

Treatment

The treatment of RB depends on the extent of the disease, including the presence of bilateral lesions, but has changed significantly over the last decade. Historically, early cases were managed with unilateral radiation, cryopexy, or xenon arc photocoagulation, while larger

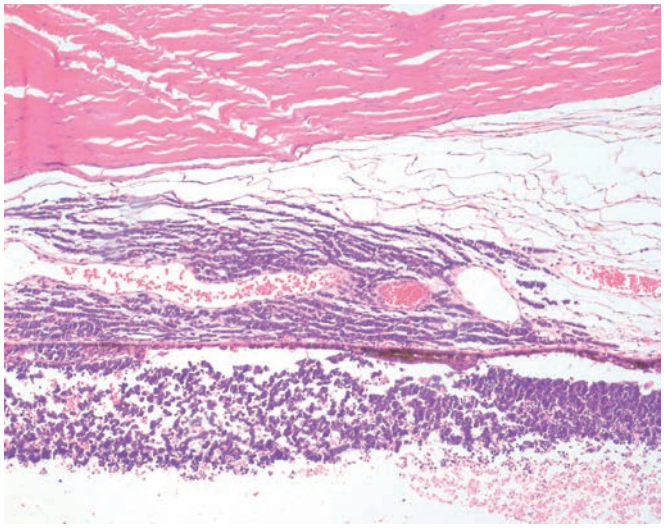

Figure 45.66 Retinoblastoma invades from the subretinal space at the bottom of the image into the overlying choroid *(arrows)*.

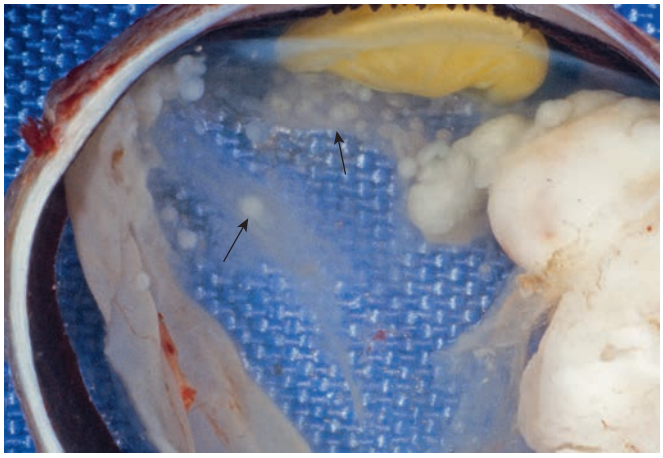

Figure 45.67 Endophytic retinoblastoma on the right with scattered white vitreous seeds *(arrows)* behind the lens, which appears yellow.

lesions were removed by enucleation.[219,220] More recently, increased emphasis has been placed on chemotherapy. Systemic chemoreduction therapy followed by consolidation including cryotherapy for small anterior tumors, thermotherapy/laser photocoagulation for posterior tumors, and plaque radiation/brachytherapy for larger tumors yields very good results.[195] Some centers now use local intraarterial delivery to ameliorate systemic complications.[221] For very large or recurrent lesions, enucleation is still sometimes required. The use of more aggressive treatments can be contingent on pathologic staging.

Prognosis

In developed countries, nearly all children with RB are long-term survivors. Microscopic features that correlate with prognosis and the need for more aggressive treatment in RB, and which therefore need to be carefully analyzed by the pathologist,[195,222] are as follows:

1. *Invasion of optic nerve*. In an operation for suspected neuroblastoma, the surgeon will attempt to obtain a long segment of optic nerve attached to the globe. Transverse sections of this nerve should be examined microscopically at the prelaminar and retrolaminar levels, including the surgical margin.[222] The levels of invasion of the optic nerve by RB have been divided into prelaminar, laminar,

and retrolaminar, the latter further subdivided into lesions with or without resection line involvement.[222] The prognosis decreases with each of these levels.[118,223,224]

2. *Invasion of the choroid*. Massive invasion of the choroid by RB cells, defined as 3 mm or greater in extent, is an unfavorable prognostic sign.[223] Tumor cells must extend through Bruch's membrane and into the choroid, and sub-retinal pigment epithelium spread does not qualify (Fig. 45.68). Scattered clumps of tumor cells carried over the choroid during specimen processing should also not be diagnosed as true tumor invasion.

Long-term survivors have a greater incidence of development of malignant tumors. The incidence has ranged from 6% to 20% after 10 years and in one series has reached 90% at 30 years. The most common types have been osteosarcoma and rhabdomyosarcoma, but several other types have been encountered, including rhabdoid tumors.[225,226] This predisposition for a second malignancy, which should be distinguished from a recurrence of the RB,[227] is seen almost exclusively with the hereditary form of the disease.[228]

Lymphoid Tumors and Tumorlike Conditions

Patients with leukemia can have neoplastic infiltrates in the choroid, retina, vitreous, and anterior chamber, particularly at autopsy, but these are rarely encountered in surgical specimens.

Intraocular **malignant lymphoma** is a relatively rare disease. In contrast to other portions of the ocular apparatus, in which MALT-type lymphomas predominate, most intraocular lymphomas are aggressive diffuse large B-cell lymphomas.[229] In over 90% of the cases the eye lesion heralds the presence or development of extraocular lymphoma in the central nervous system. As in the brain, tumor cells are large with prominent nucleoli and are often surrounded by extensive apoptotic debris, which can obscure the diagnostic component.

Other Primary Tumors

Fuchs adenoma (benign ciliary epithelioma, Fuchs epithelioma) is a benign tumor of the ciliary body usually found incidentally in a surgically enucleated eye or on post mortem examination. Microscopically, it is formed by interlacing trabeculae of uniform, nonpigmented ciliary epithelial cells surrounded by an amorphous, hyaline, PAS-positive material (Fig. 45.69).[230]

Medulloepithelioma, also known as *diktyoma*, is a rare tumor that histologically resembles the embryonal retina or medullary epithelium of the brain. Most cases arise from the ciliary epithelium in children, but a few have been found in the optic nerve or retina. They are composed of tubules and bands of poorly differentiated neuroectodermal cells lining a PAS-positive basement membrane (Fig. 45.70). Teratoid and nonteratoid groups are recognized, with the former containing a variety of heteroplastic elements such as cartilage or muscle. Recent genetic studies indicate that they are distinct from medulloepithelioma of the central nervous system.[231]

Leiomyomas can develop in the ciliary body or the iris. Some of these tumors are regarded as of possible neural crest origin and designated as *mesectodermal leiomyomas.*[232] Epstein–Barr virus–-associated smooth muscle tumors have been reported in immunosuppressed patients.[233]

Hemangioblastomas (generally as a component of von Hippel–Lindau disease) are sometimes found in the retina. The tumors are sometimes called "retinal angiomas" by clinicians but feature the same neoplastic stroma seen in the same entity in the brain (Fig. 45.71). A case of PEComa has been described in the ciliary body.[39]

Astrocytic hamartomas of retina occur in patients with tuberous sclerosis and are similar in appearance to subependymal giant cell astrocytomas in the brain. They are generally benign but occasionally grow in a more aggressive fashion.[234]

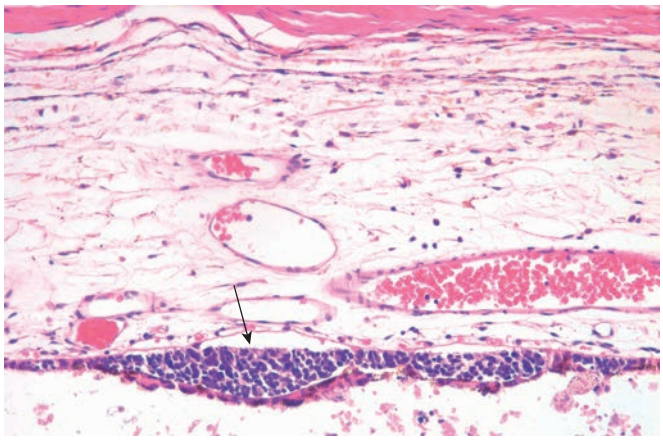

Figure 45.68 Retinoblastoma cells extend under the retinal pigment epithelium but do not invade through Bruch's membrane into the overlying choroid *(arrow)*.

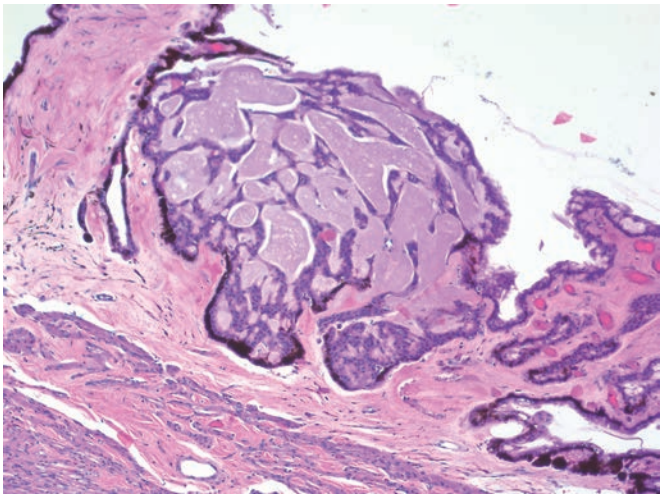

Figure 45.69 Fuchs adenoma are benign, generally incidental lesions comprised of nonpigmented ciliary epithelial cells and amorphous, hyaline material.

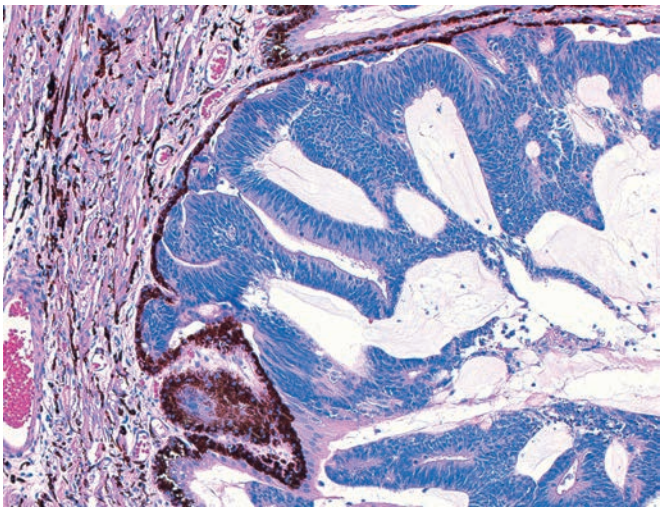

Figure 45.70 Ciliary body medulloepithelioma (non-teratoid) with primitive neuroectodermal cells lining well-defined surfaces.

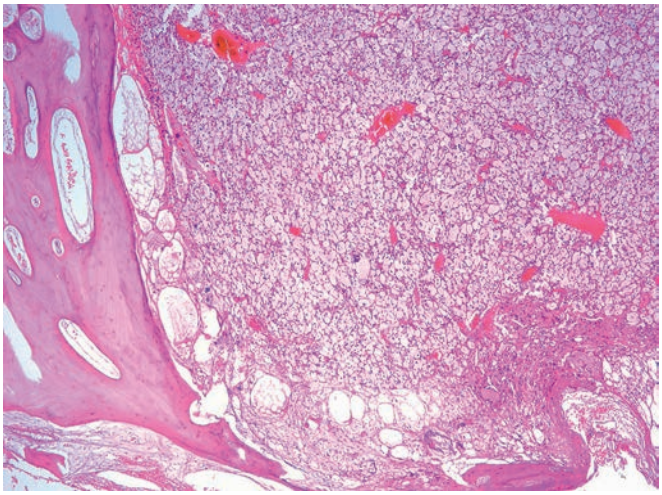

Figure 45.71 This very large hemangioblastoma grew within the eye over several decades. The pale, vacuolated neoplastic cells are interspersed with proliferating vessels. Secondary bone formation is present in the left side of the image.

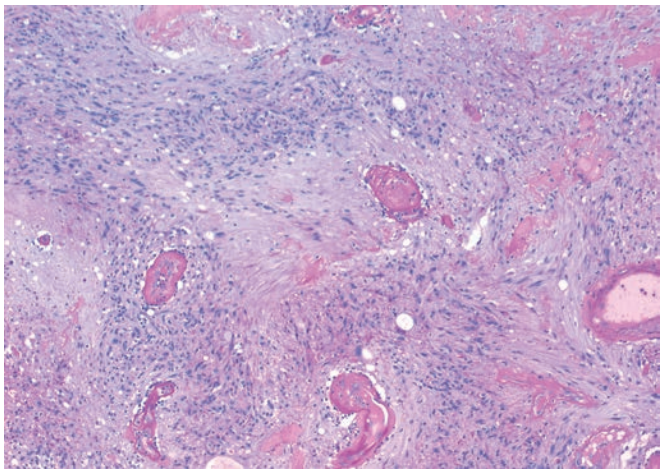

Figure 45.72 A "reactive" retinal astrocytic tumor which grew as a relatively discrete lesion over approximately 1 year. PAS stains highlight the prominent vessels between solid proliferations of spindled glia.

"Reactive" retinal astrocytic tumors can occur following trauma or as an apparently spontaneous finding. They are also sometimes designated *vasoproliferative tumors of retina* when the vascular component is prominent or *massive retinal gliosis* when growth is particularly diffuse. The primary cells within the lesion are spindled GFAP-positive glia (Fig. 45.72). It is unclear if these are clonal neoplasms or purely reactive, but thus far no signature genetic changes have been identified.[235]

Juvenile xanthogranuloma can occur in the iris and result in spontaneous hyphema and/or secondary glaucoma. It occurs almost exclusively in young children and is associated with skin lesions of similar microscopic appearance.[236]

Metastatic Tumors

The intraocular tissues can be involved by metastatic carcinoma and, less commonly, by metastatic cutaneous melanoma and metastatic sarcoma. In fact, if one were to do serial sections routinely on all autopsy eyes, cases of metastatic carcinoma would outnumber the primary tumors. The difference, of course, is that most of the patients were asymptomatic for ocular symptoms while alive. The most common primary lesions involved are in the breast in the female and in the lung in the male, with the gastrointestinal tract next in frequency.[237] The ocular metastasis occasionally may be the initial manifestation of the disease, and the primary lesion is discovered only after the eye has been enucleated. The posterior choroid is the most common site for these metastases.[238] Anterior uveal involvement is much less common, and retinal metastases are rare. Diffuse thickening of the choroid along both sides of the optic nerve is the most common presentation, but bulky tumor masses resembling malignant melanomas also may be observed.

Cytology

In certain cases the pathologist may be called on to examine material that has been aspirated from either the aqueous or the vitreous fluid and processed as cytospins or passed through a Millipore filter. The main differential diagnosis in the vitreous is infection, uveitis, trauma or reactive/degenerative conditions, and diffuse large B cell lymphoma.

References

1. Campbell R. *Histological Typing of Tumours of the Eye and the Adnexa*. London: Springer; 1998.
2. Heergard S, Grossniklaus H. *Eye Pathology, An Illustrated Guide*. Heidelberg: Springer; 2015.
3. Spencer WH. *Ophthalmic Pathology : An Atlas and Textbook*. Philadelphia: Saunders; 1996.
4. Font R, Croxatto J, Rao N. *Tumors of the Eye and Ocular Adnexa (AFIP Atlas of Tumor Pathology)*. Washington, DC: American Registry of Pathology in collaboration with the Armed Forces Institute of Pathology; 2006.
5. Harry JMG. *Clinical Ophthalmic Pathology: Principles of Diseases of the Eye and Associated Structures*. Oxford; Boston: Butterworth Heinemann; 2001.
6. Eagle RC Jr. *Eye Pathology: An Atlas and Text*. 2nd ed. Philadelphia: Lippincott Williams & Wilkins; 2011.
7. Cummings TJ. *Ophthalmic Pathology: A Concise Guide*. New York: Springer; 2013.
8. Grossniklaus HE, Nickerson JM, Edelhauser HF, et al. Anatomic alterations in aging and age-related diseases of the eye. *Invest Ophthalmol Vis Sci*. 2013;54(14):ORSF23-ORSF27.
9. Chiang K, Bhalla R, Mesinkovska NA, et al. Periocular granuloma annulare: a case report and review of literature. *Pediatr Dermatol*. 2014;31(6):722-725.
10. Guo J, Wang J. Adult orbital xanthogranulomatous disease: review of the literature. *Arch Pathol Lab Med*. 2009;133(12):1994-1997.
11. Jakobiec FA, Mehta M, Iwamoto M, et al. Intratarsal keratinous cysts of the Meibomian gland: distinctive clinicopathologic and immunohistochemical features in 6 cases. *Am J Ophthalmol*. 2010;149(1):82-94.
12. Deprez M, Uffer S. Clinicopathological features of eyelid skin tumors. A retrospective study of 5504 cases and review of literature. *Am J Dermatopathol*. 2009;31(3):256-262.
13. Yin VT, Merritt HA, Sniegowski M, Esmaeli B. Eyelid and ocular surface carcinoma: diagnosis and management. *Clin Dermatol*. 2015;33(2):159-169.
14. Donaldson MJ, Sullivan TJ, Whitehead KJ, Williamson RM. Squamous cell carcinoma of the eyelids. *Br J Ophthalmol*. 2002;86(10):1161-1165.
15. Caya JG, Hidayat AA, Weiner JM. A clinicopathologic study of 21 cases of adenoid squamous cell carcinoma of the eyelid and periorbital region. *Am J Ophthalmol*. 1985;99(3):291-297.
16. Ostler DA, Prieto VG, Reed JA, et al. Adipophilin expression in sebaceous tumors and other cutaneous lesions with clear cell histology: an immunohistochemical study of 117 cases. *Mod Pathol*. 2010;23(4):567-573.
17. Milman T, Schear MJ, Eagle RC Jr. Diagnostic utility of adipophilin immunostain in periocular carcinomas. *Ophthalmology*. 2014;121(4):964-971.

18. Merritt H, Sniegowski MC, Esmaeli B. Merkel cell carcinoma of the eyelid and periocular region. *Cancers (Basel)*. 2014;6(2):1128-1137.
19. Hassan AS, Nelson CC. Benign eyelid tumors and skin diseases. *Int Ophthalmol Clin*. 2002;42(2):135-149.
20. Izumi M, Mukai K, Nagai T, et al. Sebaceous carcinoma of the eyelids: thirty cases from Japan. *Pathol Int*. 2008;58(8):483-488.
21. Jagan L, Zoroquiain P, Bravo-Filho V, et al. Sebaceous adenomas of the eyelid and Muir-Torre Syndrome. *Br J Ophthalmol*. 2015;99(7):909-913.
22. Rajan Kd A, Burris C, Iliff N, et al. DNA mismatch repair defects and microsatellite instability status in periocular sebaceous carcinoma. *Am J Ophthalmol*. 2014;157(3):640-647.e1-e2.
23. Howrey RP, Lipham WJ, Schultz WH, et al. Sebaceous gland carcinoma: a subtle second malignancy following radiation therapy in patients with bilateral retinoblastoma. *Cancer*. 1998;83(4):767-771.
24. Rashid A, Jakobiec FA. Avoiding the major complication of ophthalmic pathology: misdiagnosis. A review of three common diagnostic challenges. *Semin Ophthalmol*. 2014;29(5-6):468-474.
25. Rao NA, Hidayat AA, McLean IW, Zimmerman LE. Sebaceous carcinomas of the ocular adnexa: a clinicopathologic study of 104 cases, with five-year follow-up data. *Hum Pathol*. 1982;13(2):113-122. Epub 1982/02/01.
26. Zembowicz A, Garcia CF, Tannous ZS, et al. Endocrine mucin-producing sweat gland carcinoma: twelve new cases suggest that it is a precursor of some invasive mucinous carcinomas. *Am J Surg Pathol*. 2005;29(10):1330-1339.
27. Hoguet A, Warrow D, Milite J, et al. Mucin-producing sweat gland carcinoma of the eyelid: diagnostic and prognostic considerations. *Am J Ophthalmol*. 2013;155(3):585-592.e2.
28. Shon W, Salomao DR. WT1 expression in endocrine mucin-producing sweat gland carcinoma: a study of 13 cases. *Int J Dermatol*. 2014;53(10):1228-1234.
29. Requena L, Prieto VG, Requena C, et al. Primary signet-ring cell/histiocytoid carcinoma of the eyelid: a clinicopathologic study of 5 cases and review of the literature. *Am J Surg Pathol*. 2011;35(3):378-391.
30. Desai SC, Walen S, Holds JB, Branham G. Divided nevus of the eyelid: review of embryology, pathology and treatment. *Am J Otolaryngol*. 2013;34(3):223-239.
31. Shin D, Sinha M, Kondziolka DS, et al. Intermediate-grade meningeal melanocytoma associated with nevus of Ota: a case report and review of the literature. *Melanoma Res*. 2015;25(4):273-278.
32. Shields CL, Kaliki S, Livesey M, et al. Association of ocular and oculodermal melanocytosis with the rate of uveal melanoma metastasis: analysis of 7872 consecutive eyes. *JAMA Ophthalmol*. 2013;131(8):993-1003.
33. Vaziri M, Buffam FV, Martinka M, et al. Clinicopathologic features and behavior of cutaneous eyelid melanoma. *Ophthalmology*. 2002;109(5):901-908.
34. Yin VT, Warneke CL, Merritt HA, Esmaeli B. Number of excisions required to obtain clear surgical margins and prognostic value of AJCC T category for patients with eyelid melanoma. *Br J Ophthalmol*. 2014;98(12):1681-1685.
35. Sanka RK, Eagle RC Jr, Wojno TH, et al. Spectrum of CD30+ lymphoid proliferations in the eyelid lymphomatoid papulosis, cutaneous anaplastic large cell lymphoma, and anaplastic large cell lymphoma. *Ophthalmology*. 2010;117(2):343-351.
36. Kakizaki H, Maden A, Ture M, et al. Hemangiopericytoma-solitary fibrous tumor of the eyelid. *Ophthal Plast Reconstr Surg*. 2010;26(1):46-48.
37. Tsuji H, Kanda H, Kashiwagi H, Mimura T. Primary epithelioid haemangioendothelioma of the eyelid. *Br J Ophthalmol*. 2010;94(2):261-262.
38. Huerva V, Sanchez MC, Egido RM, Matias-Guiu X. Pleomorphic adenoma with extensive myoepithelial component (myoepithelioma) of the lower eyelid. *Ophthal Plast Reconstr Surg*. 2008;24(3):223-235.
39. Furusato E, Cameron JD, Newsom RW, et al. Ocular perivascular epithelioid cell tumor: report of 2 cases with distinct clinical presentations. *Hum Pathol*. 2010;41(5):768-772.
40. Aryasit O, Preechawai P, Kayasut K. Clinical presentation, treatment, and prognosis of periocular and orbital amyloidosis in a university-based referral center. *Clin Ophthalmol*. 2013;7:801-805. Epub 2013/05/10.
41. Tomasini C, Soro E, Pippione M. Eyelid swelling: think of metastasis of histiocytoid breast carcinoma. *Dermatology*. 2002;205(1):63-66.
42. Cheuk W, Chan JK. IgG4-related sclerosing disease: a critical appraisal of an evolving clinicopathologic entity. *Adv Anat Pathol*. 2010;17(5):303-332.
43. Yamamoto M, Takahashi H, Ohara M, et al. A new conceptualization for Mikulicz's disease as an IgG4-related plasmacytic disease. *Mod Rheumatol*. 2006;16(6):335-340.
44. Goto H, Takahira M, Azumi A, Japanese Study Group for Ig GROD. Diagnostic criteria for IgG4-related ophthalmic disease. *Jpn J Ophthalmol*. 2015;59(1):1-7.
45. Andreoli MT, Aakalu V, Setabutr P. Epidemiological trends in malignant lacrimal gland tumors. *Otolaryngol Head Neck Surg*. 2015;152(2):279-283.
46. Bernardini FP, Devoto MH, Croxatto JO. Epithelial tumors of the lacrimal gland: an update. *Curr Opin Ophthalmol*. 2008;19(5):409-413.
47. Paulino AF, Huvos AG. Epithelial tumors of the lacrimal glands: a clinicopathologic study. *Ann Diagn Pathol*. 1999;3(4):199-204.
48. Weis E, Rootman J, Joly TJ, et al. Epithelial lacrimal gland tumors: pathologic classification and current understanding. *Arch Ophthalmol*. 2009;127(8):1016-1028.
49. Shields JA, Shields CL, Epstein JA, et al. Review: primary epithelial malignancies of the lacrimal gland: the 2003 Ramon L. Font lecture. *Ophthal Plast Reconstr Surg*. 2004;20(1):10-21.
50. George E, Swanson PE, Newman BK, Wick MR. Oculocutaneous oncocytic tumors: clinicopathologic and immunohistochemical study of 2 cases with literature review. *Am J Dermatopathol*. 2007;29(3):279-285.
51. Morgan MB, Truitt CA, Romer C, et al. Ocular adnexal oncocytoma: a case series and clinicopathologic review of the literature. *Am J Dermatopathol*. 1998;20(5):487-490.
52. Pecorella I, Garner A. Ostensible oncocytoma of accessory lacrimal glands. *Histopathology*. 1997;30(3):264-270.
53. Wiwatwongwana D, Berean KW, Dolman PJ, et al. Unusual carcinomas of the lacrimal gland: epithelial-myoepithelial carcinoma and myoepithelial carcinoma. *Arch Ophthalmol*. 2009;127(8):1054-1056.
54. Fernando BS, Thaung C, Ataullah S, et al. Necrotizing metaplasia of lacrimal gland/necrotizing dacryometaplasia. *Histopathology*. 2007;51(4):578-580.
55. Shields JA, Shields CL, Scartozzi R. Survey of 1264 patients with orbital tumors and simulating lesions: The 2002 Montgomery Lecture, Part 1. *Ophthalmology*. 2004;111(5):997-1008.
56. Cheuk W, Yuen HK, Chan JK. Chronic sclerosing dacryoadenitis: part of the spectrum of IgG4-related Sclerosing disease? *Am J Surg Pathol*. 2007;31(4):643-645.
57. Ferry JA, Klepeis V, Sohani AR. IgG4-related orbital disease and its mimics in a Western population. *Am J Surg Pathol*. 2015;39:1688-1700.
58. Singh K, Rajan KD, Eberhart C. Orbital necrobiotic xanthogranuloma associated with systemic IgG4 disease. *Ocul Immunol Inflamm*. 2010;18(5):373-378.
59. Cho NH, Kie JH, Yang WI, Jung WH. Solitary fibrous tumour with an unusual adenofibromatous feature in the lacrimal gland. *Histopathology*. 1998;33(3):289-290.
60. Yazici B, Setzen G, Meyer DR, et al. Giant cell angiofibroma of the nasolacrimal duct. *Ophthal Plast Reconstr Surg*. 2001;17(3):202-206.
61. Ahn M, Osipov V, Harris GJ. Collagenous fibroma (desmoplastic fibroblastoma) of the lacrimal gland. *Ophthal Plast Reconstr Surg*. 2009;25(3):250-252.
62. Sabet SJ, Tarbet KJ, Lemke BN, et al. Granular cell tumor of the lacrimal sac and nasolacrimal duct: no invasive behavior with incomplete resection. *Ophthalmology*. 2000;107(11):1992-1994.
63. von Holstein SL, Ostergaard J, Daugaard S, et al. Granular cell tumour of the lacrimal gland. *Acta Ophthalmol*. 2009;87(8):926-927.
64. Harris GJ, Williams GA, Clarke GP. Sarcoidosis of the lacrimal sac. *Arch Ophthalmol*. 1981;99(7):1198-1201.
65. Shields C. *Eyelid Conjuctival and Orbital Tumors: An Atlas and Text*. 2nd ed. Philadelphia: Lippincott Williams & Wilkins; 2007.
66. Heathcote JG. Transitional neoplasms of the naso-lacrimal system: a review of the histopathology and histogenesis. *Saudi J Ophthalmol*. 2012;26(2):125-131.
67. Sjo NC, von Buchwald C, Cassonnet P, et al. Human papillomavirus: cause of epithelial lacrimal sac neoplasia? *Acta Ophthalmol Scand*. 2007;85(5):551-556.
68. Ostergaard J, Prause JU, Heegaard S. Oncocytic lesions of the ophthalmic region: a clinicopathological study with emphasis on cytokeratin expression. *Acta Ophthalmol*. 2011;89(3):263-267.
69. Eweiss AZ, Lund VJ, Jay A, Rose G. Transitional cell tumours of the lacrimal drainage apparatus. *Rhinology*. 2013;51(4):349-354.
70. Yuksel D, Kosker M, Saribas F, Simsek S. Surgical treatment of mucoepidermoid carcinoma of the lacrimal sac. *Semin Ophthalmol*. 2014;29(2):70-72.
71. Keelawat S, Tirakunwichcha S, Saonanon P, et al. Cytokeratin-negative undifferentiated (lymphoepithelial) carcinoma of the lacrimal sac. *Ophthal Plast Reconstr Surg*. 2017;33(1):e16-e18.
72. Neffendorf JE, Bagdonaite L, Mudhar HS, Pearson AR. Adult alveolar rhabdomyosarcoma of the lacrimal sac. *Orbit*. 2014;33(6):468-470.
73. Lee HM, Kang HJ, Choi G, et al. Two cases of primary malignant melanoma of the lacrimal sac. *Head Neck*. 2001;23(9):809-813.
74. Nakamura K, Uehara S, Omagari J, et al. Primary non-Hodgkin's lymphoma of the lacrimal sac: a case report and a review of the literature. *Cancer*. 1997;80(11):2151-2155. Epub 1997/12/10.
75. Sjo LD. Ophthalmic lymphoma: epidemiology and pathogenesis. *Acta Ophthalmol*. 2009;87(Thesis 1):1-20. Epub 2009/01/31.

76. Shields JA, Bakewell B, Augsburger JJ, Flanagan JC. Classification and incidence of space-occupying lesions of the orbit. A survey of 645 biopsies. *Arch Ophthalmol*. 1984;102(11):1606-1611.
77. Rosca T, Bontas E, Vladescu TG, et al. Clinical controversy in orbitary cholesteatoma. *Ann Diagn Pathol*. 2006;10(2):89-94.
78. Jordan DR, Spitellie P, Brownstein S, et al. Orbital cholesterol granuloma and cholesteatoma: significance of differentiating the two. *Ophthal Plast Reconstr Surg*. 2007;23(5):415-417.
79. Foucar E, Rosai J, Dorfman RF. The ophthalmologic manifestations of sinus histiocytosis with massive lymphadenopathy. *Am J Ophthalmol*. 1979;87(3):354-367.
80. Tan JJ, Narang S, Purewal B, et al. Extranodal Rosai-Dorfman disease of the orbit: clinical features of 8 cases. *Ophthal Plast Reconstr Surg*. 2016;32(6):458-461.
81. Wong AJ, Planck SR, Choi D, et al. IgG4 immunostaining and its implications in orbital inflammatory disease. *PLoS ONE*. 2014;9(10):e109847.
82. Andrew NH, Sladden N, Kearney DJ, Selva D. An analysis of IgG4-related disease (IgG4-RD) among idiopathic orbital inflammations and benign lymphoid hyperplasias using two consensus-based diagnostic criteria for IgG4-RD. *Br J Ophthalmol*. 2015;99(3):376-381.
83. Maalouf T, Trouchaud-Michaud C, Angioi-Duprez K, George JL. What has become of our idiopathic inflammatory pseudo-tumors of the orbit? *Orbit*. 1999;18(3):157-166.
84. Lutt JR, Lim LL, Phal PM, Rosenbaum JT. Orbital inflammatory disease. *Semin Arthritis Rheum*. 2008;37(4):207-222.
85. Frohman LP, Kupersmith MJ, Lang J, et al. Intracranial extension and bone destruction in orbital pseudotumor. *Arch Ophthalmol*. 1986;104(3):380-384.
86. Hasegawa T, Matsuno Y, Niki T, et al. Second primary rhabdomyosarcomas in patients with bilateral retinoblastoma: a clinicopathologic and immunohistochemical study. *Am J Surg Pathol*. 1998;22(11):1351-1360.
87. Goldsmith JD, van de Rijn M, Syed N. Orbital hemangiopericytoma and solitary fibrous tumor: a morphologic continuum. *Int J Surg Pathol*. 2001;9(4):295-302.
88. Furusato E, Valenzuela IA, Fanburg-Smith JC, et al. Orbital solitary fibrous tumor: encompassing terminology for hemangiopericytoma, giant cell angiofibroma, and fibrous histiocytoma of the orbit: reappraisal of 41 cases. *Hum Pathol*. 2011;42(1):120-128.
89. Sciot R, Goffin J, Fossion E, et al. Solitary fibrous tumour of the orbit. *Histopathology*. 1996;28(2):188-191.
90. Dorfman DM, To K, Dickersin GR, et al. Solitary fibrous tumor of the orbit. *Am J Surg Pathol*. 1994;18(3):281-287.
91. Westra WH, Gerald WL, Rosai J. Solitary fibrous tumor. Consistent CD34 immunoreactivity and occurrence in the orbit. *Am J Surg Pathol*. 1994;18(10):992-998.
92. Kao YC, Lin PC, Yen SL, et al. Clinicopathological and genetic heterogeneity of the head and neck solitary fibrous tumours: a comparative histological, immunohistochemical and molecular study of 36 cases. *Histopathology*. 2016;68:492-501.
93. Guillou L, Gebhard S, Coindre JM. Orbital and extraorbital giant cell angiofibroma: a giant cell-rich variant of solitary fibrous tumor? Clinicopathologic and immunohistochemical analysis of a series in favor of a unifying concept. *Am J Surg Pathol*. 2000;24(7):971-979.
94. Kim HJ, Wojno T, Grossniklaus HE, Shehata BM. Alveolar soft-part sarcoma of the orbit: report of 2 cases with review of the literature. *Ophthal Plast Reconstr Surg*. 2013;29(6):e138-e142.
95. Font RL, Jurco S 3rd, Zimmerman LE. Alveolar soft-part sarcoma of the orbit: a clinicopathologic analysis of seventeen cases and a review of the literature. *Hum Pathol*. 1982;13(6):569-579.
96. Fan JC, Lamont DL, Greenbaum AR, Ng SG. Primary orbital extraskeletal osteosarcoma. *Orbit*. 2011;30(6):297-299.
97. Yeniad B, Tuncer S, Peksayar G, et al. Primary orbital leiomyosarcoma. *Ophthal Plast Reconstr Surg*. 2009;25(2):154-155.
98. Cai YC, McMenamin ME, Rose G, et al. Primary liposarcoma of the orbit: a clinicopathologic study of seven cases. *Ann Diagn Pathol*. 2001;5(5):255-266.
99. Scruggs BA, Ho ST, Valenzuela AA. Diagnostic challenges in primary orbital fibrosarcoma: a case report. *Clin Ophthalmol*. 2014;8:2319-2323.
100. Jacobs JL, Merriam JC, Chadburn A, et al. Mesenchymal chondrosarcoma of the orbit. Report of three new cases and review of the literature. *Cancer*. 1994;73(2):399-405.
101. Siddens JD, Fishman JR, Jackson IT, et al. Primary orbital angiosarcoma: a case report. *Ophthal Plast Reconstr Surg*. 1999;15(6):454-459.
102. Chokthaweesak W, Annunziata CC, Alsheikh O, et al. Primitive neuroectodermal tumor of the orbit in adults: a case series. *Ophthal Plast Reconstr Surg*. 2011;27(3):173-179.
103. Rosca TI, Pop MI, Curca M, et al. Vascular tumors in the orbit—capillary and cavernous hemangiomas. *Ann Diagn Pathol*. 2006;10(1):13-19.
104. Yamasaki T, Handa H, Yamashita J, et al. Intracranial and orbital cavernous angiomas. A review of 30 cases. *J Neurosurg*. 1986;64(2):197-208.
105. Ahrens WA, Ridenour RV 3rd, Caron BL, et al. GLUT-1 expression in mesenchymal tumors: an immunohistochemical study of 247 soft tissue and bone neoplasms. *Hum Pathol*. 2008;39(10):1519-1526.
106. Leon-Villapalos J, Wolfe K, Kangesu L. GLUT-1: an extra diagnostic tool to differentiate between haemangiomas and vascular malformations. *Br J Plast Surg*. 2005;58(3):348-352.
107. Shields JA, Kapustiak J, Arbizo V, et al. Orbital neurilemoma with extension through the superior orbital fissure. *Arch Ophthalmol*. 1986;104(6):871-873.
108. Krohel GB, Rosenberg PN, Wright JE, Smith RS. Localized orbital neurofibromas. *Am Ophthalmol*. 1985;100(3):458-464.
109. Mynatt CJ, Feldman KA, Thompson LD. Orbital infantile myofibroma: a case report and clinicopathologic review of 24 cases from the literature. *Head Neck Pathol*. 2011;5(3):205-215.
110. Riffle JE, Prosser AH, Lee JR, Lynn JJ. Nodular fasciitis of the orbit: a case report and brief review of the literature. *Case Rep Ophthalmol Med*. 2011;2011:235956.
111. Werner MS, Hornblass A, Reifler DM, et al. Intravascular papillary endothelial hyperplasia: collection of four cases and a review of the literature. *Ophthal Plast Reconstr Surg*. 1997;13(1):48-56.
112. Schmack I, Patel RM, Folpe AL, et al. Subconjunctival herniated orbital fat: a benign adipocytic lesion that may mimic pleomorphic lipoma and atypical lipomatous tumor. *Am J Surg Pathol*. 2007;31(2):193-198.
113. Herwig MC, Wojno T, Zhang Q, Grossniklaus HE. Langerhans cell histiocytosis of the orbit: five clinicopathologic cases and review of the literature. *Surv Ophthalmol*. 2013;58(4):330-340.
114. Arora A, Sharma S, Pushker N, et al. Unusual orbital involvement in Erdheim Chester disease: a radiological diagnosis. *Orbit*. 2012;31(5):338-340.
115. Kim S, Lee M, Shin HJ, et al. Coexistence of intracranial Langerhans cell histiocytosis and Erdheim-Chester disease in a pediatric patient: a case report. *Childs Nerv Syst*. 2016;32:893-896.
116. Rodriguez FJ, Ligon AH, Horkayne-Szakaly I, et al. BRAF duplications and MAPK pathway activation are frequent in gliomas of the optic nerve proper. *J Neuropathol Exp Neurol*. 2012;71:789-794.
117. Johnson MW, Eberhart CG, Perry A, et al. Spectrum of pilomyxoid astrocytomas: intermediate pilomyxoid tumors. *Am J Surg Pathol*. 2010;34(12):1783-1791.
118. Jain D, Ebrahimi KB, Miller NR, Eberhart CG. Intraorbital meningiomas: a pathologic review using current World Health Organization criteria. *Arch Pathol Lab Med*. 2010;134(5):766-770.
119. Peterson K, Gordon KB, Heinemann MH, DeAngelis LM. The clinical spectrum of ocular lymphoma. *Cancer*. 1993;72(3):843-849.
120. Tsuji H, Tamura M, Yokoyama M, et al. Ocular involvement by epstein-barr virus-positive diffuse large B-cell lymphoma of the elderly: a new disease entity in the world health organization classification. *Arch Ophthalmol*. 2010;128(2):258-259.
121. Munch-Petersen HD, Rasmussen PK, Coupland SE, et al. Ocular adnexal diffuse large B-cell lymphoma: a multicenter international study. *JAMA Ophthalmol*. 2015;133(2):165-173.
122. Amin S, Ramsay A, Marafioti T. Diagnostic pitfalls in "low-grade lymphoma" of the orbit and lacrimal gland. *Orbit*. 2015;34(4):206-211.
123. Ferry JA, Fung CY, Zukerberg L, et al. Lymphoma of the ocular adnexa: a study of 353 cases. *Am J Surg Pathol*. 2007;31(2):170-184.
124. Ruiz A, Reischl U, Swerdlow SH, et al. Extranodal marginal zone B-cell lymphomas of the ocular adnexa: multiparameter analysis of 34 cases including interphase molecular cytogenetics and PCR for Chlamydia psittaci. *Am J Surg Pathol*. 2007;31(5):792-802.
125. Kusakabe T, Watanabe K, Mori T, et al. Crystal-storing histiocytosis associated with MALT lymphoma of the ocular adnexa: a case report with review of literature. *Virchows Arch*. 2007;450(1):103-108.
126. Mannami T, Yoshino T, Oshima K, et al. Clinical, histopathological, and immunogenetic analysis of ocular adnexal lymphoproliferative disorders: characterization of malt lymphoma and reactive lymphoid hyperplasia. *Mod Pathol*. 2001;14(7):641-649.
127. White VA, Gascoyne RD, McNeil BK, et al. Histopathologic findings and frequency of clonality detected by the polymerase chain reaction in ocular adnexal lymphoproliferative lesions. *Mod Pathol*. 1996;9(11):1052-1061.
128. Knowles DM 2nd, Jakobiec FA. Cell marker analysis of extranodal lymphoid infiltrates: to what extent does the determination of mono- or polyclonality resolve the diagnostic dilemma of malignant lymphoma v pseudolymphoma in an extranodal site? *Semin Diagn Pathol*. 1985;2(3):163-168.
129. McNally L, Jakobiec FA, Knowles DM 2nd. Clinical, morphologic, immunophenotypic, and molecular genetic analysis of bilateral ocular adnexal lymphoid neoplasms in 17 patients. *Am J Ophthalmol*. 1987;103(4):555-568.
130. Knowles DM, Jakobiec FA, McNally L, Burke JS. Lymphoid hyperplasia and malignant lymphoma occurring in the ocular adnexa

(orbit, conjunctiva, and eyelids): a prospective multiparametric analysis of 108 cases during 1977 to 1987. *Hum Pathol*. 1990;21(9):959-973.
131. Sniegowski MC, Warneke CL, Morrison WH, et al. Correlation of American Joint Committee on Cancer T category for eyelid carcinoma with outcomes in patients with periocular Merkel cell carcinoma. *Ophthal Plast Reconstr Surg*. 2014;30(6):480-485.
132. Ferreri AJ, Guidoboni M, Ponzoni M, et al. Evidence for an association between Chlamydia psittaci and ocular adnexal lymphomas. *J Natl Cancer Inst*. 2004;96(8):586-594.
133. Cheuk W, Yuen HK, Chan AC, et al. Ocular adnexal lymphoma associated with IgG4+ chronic sclerosing dacryoadenitis: a previously undescribed complication of IgG4-related sclerosing disease. *Am J Surg Pathol*. 2008;32(8):1159-1167.
134. Bonavolonta G, Strianese D, Grassi P, et al. An analysis of 2480 space-occupying lesions of the orbit from 1976 to 2011. *Ophthal Plast Reconstr Surg*. 2013;29(2):79-86.
135. Turaka K, Mashayekhi A, Shields CL, et al. A case series of neuroendocrine (carcinoid) tumor metastasis to the orbit. *Oman J Ophthalmol*. 2011;4(3):125-128.
136. Zimmerman LE, Stangl R, Riddle PJ. Primary carcinoid tumor of the orbit. A clinicopathologic study with histochemical and electron microscopic observations. *Arch Ophthalmol*. 1983;101(9):1395-1398.
137. Lin X, Cavanagh HD. Ocular manifestations of graft-versus-host disease: 10 years' experience. *Clin Ophthalmol*. 2015;9:1209-1213.
138. Stenson S. Adult inclusion conjunctivitis. Clinical characteristics and corneal changes. *Arch Ophthalmol*. 1981;99(4):605-608.
139. Hidayat AA, Riddle PJ. Ligneous conjunctivitis. A clinicopathologic study of 17 cases. *Ophthalmology*. 1987;94(8): 949-959.
140. Rodriguez-Ares MT, Abdulkader I, Blanco A, et al. Ligneous conjunctivitis: a clinicopathological, immunohistochemical, and genetic study including the treatment of two sisters with multiorgan involvement. *Virchows Arch*. 2007;451(4):815-821.
141. Mittal R, Meena M, Saha D. Actinic granuloma of the conjunctiva in young women. *Ophthalmology*. 2013;120(9):1786-1789.
142. Raphael M, Bellefqih S, Piette JC, et al. Conjunctival biopsy in Sjogren's syndrome: correlations between histological and immunohistochemical features. *Histopathology*. 1988;13(2):191-202.
143. Goldich Y, Ziai S, Artornsombudh P, et al. Characteristics of patients with ocular cicatricial pemphigoid referred to major tertiary hospital. *Can J Ophthalmol*. 2015;50(2):137-142.
144. Font RL, Del Valle M, Avedano J, et al. Primary adenoid cystic carcinoma of the conjunctiva arising from the accessory lacrimal glands: a clinicopathologic study of three cases. *Cornea*. 2008;27(4):494-497.
145. Sjo NC, von Buchwald C, Cassonnet P, et al. Human papillomavirus in normal conjunctival tissue and in conjunctival papilloma: types and frequencies in a large series. *Br J Ophthalmol*. 2007;91(8):1014-1015.
146. Woods M, Chow S, Heng B, et al. Detecting human papillomavirus in ocular surface diseases. *Invest Ophthalmol Vis Sci*. 2013;54(13):8069-8078.
147. Ateenyi-Agaba C, Franceschi S, Wabwire-Mangen F, et al. Human papillomavirus infection and squamous cell carcinoma of the conjunctiva. *Br J Cancer*. 2010;102(2):262-267.
148. Bui T, Young JW, Frausto RF, et al. Hereditary benign intraepithelial dyskeratosis: report of a case and re-examination of the evidence for locus heterogeneity. *Ophthalmic Genet*. 2016;37:1-5.
149. Ramberg I, Heegaard S, Prause JU, et al. Squamous cell dysplasia and carcinoma of the conjunctiva. A nationwide, retrospective, epidemiological study of Danish patients. *Acta Ophthalmol*. 2015;93(7):663-666.
150. Miller CV, Wolf A, Klingenstein A, et al. Clinical outcome of advanced squamous cell carcinoma of the conjunctiva. *Eye*. 2014;28(8):962-967.
151. Moloney TP, Trinh T, Farrah JJ. A case of conjunctival mucoepidermoid carcinoma in Australia. *Clin Ophthalmol*. 2014;8:11-14.
152. Shields JA, Eagle RC, Marr BP, et al. Invasive spindle cell carcinoma of the conjunctiva managed by full-thickness eye wall resection. *Cornea*. 2007;26(8):1014-1016.
153. Shields CL, Fasiuddin AF, Mashayekhi A, Shields JA. Conjunctival nevi: clinical features and natural course in 410 consecutive patients. *Arch Ophthalmol*. 2004;122(2):167-175.
154. Thiagalingam S, Johnson MM, Colby KA, Zembowicz A. Juvenile conjunctival nevus: clinicopathologic analysis of 33 cases. *Am J Surg Pathol*. 2008;32(3):399-406.
155. Zamir E, Mechoulam H, Micera A, et al. Inflamed juvenile conjunctival naevus: clinicopathological characterisation. *Br J Ophthalmol*. 2002;86(1):28-30.
156. Kurli M, Finger PT. Melanocytic conjunctival tumors. *Ophthalmol Clin North Am*. 2005;18(1):15-24, vii.
157. Shields JA, Shields CL, Mashayekhi A, et al. Primary acquired melanosis of the conjunctiva: risks for progression to melanoma in 311 eyes. The 2006 Lorenz E. Zimmerman lecture. *Ophthalmology*. 2008;115(3):511-519.e2.
158. Ackerman AB, Sood R, Koenig M. Primary acquired melanosis of the conjunctiva is melanoma in situ. *Mod Pathol*. 1991;4(2):253-263.
159. McLean IW. Differential diagnosis of the conjunctival melanoses. *Ann Diagn Pathol*. 1998;2(4):264-270.
160. Damato B, Coupland SE. Conjunctival melanoma and melanosis: a reappraisal of terminology, classification and staging. *Clin Exp Ophthalmol*. 2008;36(8):786-795.
161. Shields CL, Shields JA. Conjunctival primary acquired melanosis and melanoma: tales, fairy tales, and facts. *Ophthal Plast Reconstr Surg*. 2009;25(3):167-172.
162. Guillen FJ, Albert DM, Mihm MC Jr. Pigmented melanocytic lesions of the conjunctiva–a new approach to their classification. *Pathology*. 1985;17(2):275-280.
163. Maly A, Epstein D, Meir K, Pe'er J. Histological criteria for grading of atypia in melanocytic conjunctival lesions. *Pathology*. 2008;40(7):676-681.
164. Folberg R, McLean IW, Zimmerman LE. Primary acquired melanosis of the conjunctiva. *Hum Pathol*. 1985;16(2):129-135.
165. Sugiura M, Colby KA, Mihm MC Jr, Zembowicz A. Low-risk and high-risk histologic features in conjunctival primary acquired melanosis with atypia: clinicopathologic analysis of 29 cases. *Am J Surg Pathol*. 2007;31(2):185-192.
166. Shields CL, Markowitz JS, Belinsky I, et al. Conjunctival melanoma: outcomes based on tumor origin in 382 consecutive cases. *Ophthalmology*. 2011;118(2):389-395.e1-e2.
167. Kirkegaard MM, Coupland SE, Prause JU, Heegaard S. Malignant lymphoma of the conjunctiva. *Surv Ophthalmol*. 2015;60(5):444-458.
168. AlWadani S, Robinson S, Myers R, et al. No increase in IgG4-positive plasma cells in limbal Rosai-Dorfman disease. *Cornea*. 2014;33(8):844-847.
169. Chen CL, Tai MC, Chen JT, et al. A rare case of conjunctival myxoma and a review of the literature. *Ophthalmologica*. 2008;222(2):136-139.
170. Bavishi A, Ashraf A, Lee L. AIDS-associated Kaposi's sarcoma of the conjunctiva in a woman. *Int J STD AIDS*. 2012;23(3):221-222.
171. Kase S, Ishijima K, Ishida S, Rao NA. Merkel cell carcinoma of the conjunctiva. *Ophthalmology*. 2010;117(3):637.e1-637.e2.
172. Sivalingam MD, Hasanreisoglu M, Shields CL. Choroidal melanoma in children: be aware of risks. *J Pediatr Ophthalmol Strabismus*. 2014;51(Online):e85-e88.
173. Shields CL, Kels JG, Shields JA. Melanoma of the eye: revealing hidden secrets, one at a time. *Clin Dermatol*. 2015;33(2):183-196.
174. Mudhar HS, Parsons MA, Sisley K, et al. A critical appraisal of the prognostic and predictive factors for uveal malignant melanoma. *Histopathology*. 2004;45(1):1-12.
175. Eagle RC Jr, Grossniklaus HE, Syed N, et al. Inadvertent evisceration of eyes containing uveal melanoma. *Arch Ophthalmol*. 2009;127(2):141-145.
176. Damato B. Progress in the management of patients with uveal melanoma. The 2012 Ashton Lecture. *Eye*. 2012;26(9):1157-1172.
177. Shields JA, Shields CL, De Potter P, Singh AD. Diagnosis and treatment of uveal melanoma. *Semin Oncol*. 1996;23(6):763-767.
178. McLean IW, Zimmerman LE, Evans RM. Reappraisal of Callender's spindle a type of malignant melanoma of choroid and ciliary body. *Am J Ophthalmol*. 1978;86(4):557-564.
179. Damato BE, Heimann H, Kalirai H, Coupland SE. Age, survival predictors, and metastatic death in patients with choroidal melanoma: tentative evidence of a therapeutic effect on survival. *JAMA Ophthalmol*. 2014;132(5):605-613.
180. Damato B, Dopierala JA, Coupland SE. Genotypic profiling of 452 choroidal melanomas with multiplex ligation-dependent probe amplification. *Clin Cancer Res*. 2010;16(24):6083-6092.
181. Onken MD, Worley LA, Long MD, et al. Oncogenic mutations in GNAQ occur early in uveal melanoma. *Invest Ophthalmol Vis Sci*. 2008;49(12):5230-5234.
182. Harbour JW, Onken MD, Roberson ED, et al. Frequent mutation of BAP1 in metastasizing uveal melanomas. *Science*. 2010;330(6009):1410-1413.
183. Field MG, Harbour JW. Recent developments in prognostic and predictive testing in uveal melanoma. *Curr Opin Ophthalmol*. 2014;25(3):234-239.
184. Kalirai H, Dodson A, Faqir S, et al. Lack of BAP1 protein expression in uveal melanoma is associated with increased metastatic risk and has utility in routine prognostic testing. *Br J Cancer*. 2014;111(7):1373-1380.
185. Kath R, Hayungs J, Bornfeld N, et al. Prognosis and treatment of disseminated uveal melanoma. *Cancer*. 1993;72(7):2219-2223.
186. Kivela T, Kujala E. Prognostication in eye cancer: the latest tumor, node, metastasis classification and beyond. *Eye*. 2013;27(2):243-252.
187. de la Cruz PO Jr, Specht CS, McLean IW. Lymphocytic infiltration in uveal malignant melanoma. *Cancer*. 1990;65(1):112-115.
188. Horsman DE, White VA. Cytogenetic analysis of uveal melanoma. Consistent occurrence of monosomy 3 and trisomy 8q. *Cancer*. 1993;71(3):811-819.
189. Onken MD, Worley LA, Harbour JW. Association between gene expression profile, proliferation and metastasis in uveal melanoma. *Curr Eye Res*. 2010;35(9): 857-863.

190. van Gils W, Lodder EM, Mensink HW, et al. Gene expression profiling in uveal melanoma: two regions on 3p related to prognosis. *Invest Ophthalmol Vis Sci*. 2008;49(10):4254-4262.
191. Shah AA, Bourne TD, Murali R. BAP1 protein loss by immunohistochemistry: a potentially useful tool for prognostic prediction in patients with uveal melanoma. *Pathology*. 2013;45(7):651-656.
192. Kathil P, Milman T, Finger PT. Characteristics of anterior uveal melanocytomas in 17 cases. *Ophthalmology*. 2011;118(9):1874-1880.
193. Xu XL, Singh HP, Wang L, et al. Rb suppresses human cone-precursor-derived retinoblastoma tumours. *Nature*. 2014;514(7522):385-388.
194. Kyritsis AP, Tsokos M, Triche TJ, Chader GJ. Retinoblastoma—origin from a primitive neuroectodermal cell? *Nature*. 1984;307(5950):471-473.
195. Grossniklaus HE. Retinoblastoma. Fifty years of progress. The LXXI Edward Jackson Memorial Lecture. *Am J Ophthalmol*. 2014;158(5):875-891.
196. Theriault BL, Dimaras H, Gallie BL, Corson TW. The genomic landscape of retinoblastoma: a review. *Clin Exp Ophthalmol*. 2014;42(1):33-52.
197. Schubert EL, Hansen MF, Strong LC. The retinoblastoma gene and its significance. *Ann Med*. 1994;26(3):177-184.
198. Gallie BL, Squire JA, Goddard A, et al. Mechanism of oncogenesis in retinoblastoma. *Lab Invest*. 1990;62(4):394-408.
199. Knudson A. Alfred Knudson and his two-hit hypothesis. (Interview by Ezzie Hutchinson). *Lancet Oncol*. 2001;2(10):642-645.
200. Johnson DL, Chandra R, Fisher WS, et al. Trilateral retinoblastoma: ocular and pineal retinoblastomas. *J Neurosurg*. 1985;63(3):367-370.
201. de Jong MC, Kors WA, de Graaf P, et al. The incidence of trilateral retinoblastoma: a systematic review and meta-analysis. *Am J Ophthalmol*. 2015;160(6):1116-1126.e5.
202. Lueder GT, Smith ME. Retinoblastoma. *Semin Diagn Pathol*. 1994;11(2):104-106.
203. Margo C, Hidayat A, Kopelman J, Zimmerman LE. Retinocytoma. A benign variant of retinoblastoma. *Arch Ophthalmol*. 1983;101(10):1519-1531.
204. Mendoza PR, Specht CS, Hubbard GB, et al. Histopathologic grading of anaplasia in retinoblastoma. *Am J Ophthalmol*. 2015;159(4):764-776.
205. Ts'o MO, Fine BS, Zimmerman LE. The nature of retinoblastoma. II. Photoreceptor differentiation: an electron microscopic study. *Am J Ophthalmol*. 1970;69(3):350-359.
206. Ts'o MO, Zimmerman LE, Fine BS. The nature of retinoblastoma. I. Photoreceptor differentiation: a clinical and histopathologic study. *Am J Ophthalmol*. 1970;69(3):339-349.
207. Donoso LA, Hamm H, Dietzschold B, et al. Rhodopsin and retinoblastoma. A monoclonal antibody histopathologic study. *Arch Ophthalmol*. 1986;104(1):111-113.
208. Gonzalez-Fernandez F, Lopes MB, Garcia-Fernandez JM, et al. Expression of developmentally defined retinal phenotypes in the histogenesis of retinoblastoma. *Am J Pathol*. 1992;141(2):363-375.
209. Perentes E, Rubinstein LJ. Recent applications of immunoperoxidase histochemistry in human neuro-oncology. An update. *Arch Pathol Lab Med*. 1987;111(9):796-812.
210. Korf HW, Czerwionka M, Reiner J, et al. Immunocytochemical evidence of molecular photoreceptor markers in cerebellar medulloblastomas. *Cancer*. 1987;60(8):1763-1766.
211. Schwimer CJ, Prayson RA. Clinicopathologic study of retinoblastoma including MIB-1, p53, and CD99 immunohistochemistry. *Ann Diagn Pathol*. 2001;5(3):148-154.
212. Amare Kadam PS, Ghule P, Jose J, et al. Constitutional genomic instability, chromosome aberrations in tumor cells and retinoblastoma. *Cancer Genet Cytogenet*. 2004;150(1):33-43.
213. Corson TW, Gallie BL. One hit, two hits, three hits, more? Genomic changes in the development of retinoblastoma. *Genes Chromosomes Cancer*. 2007;46(7):617-634.
214. Leiderman YI, Kiss S, Mukai S. Molecular genetics of RB1—the retinoblastoma gene. *Semin Ophthalmol*. 2007;22(4):247-254.
215. Lillington DM, Kingston JE, Coen PG, et al. Comparative genomic hybridization of 49 primary retinoblastoma tumors identifies chromosomal regions associated with histopathology, progression, and patient outcome. *Genes Chromosomes Cancer*. 2003;36(2):121-128.
216. Lin P, O'Brien JM. Frontiers in the management of retinoblastoma. *Am J Ophthalmol*. 2009;148(2):192-198.
217. Benavente CA, Dyer MA. Genetics and epigenetics of human retinoblastoma. *Annu Rev Pathol*. 2015;10:547-562.
218. MacKay CJ, Abramson DH, Ellsworth RM. Metastatic patterns of retinoblastoma. *Arch Ophthalmol*. 1984;102(3):391-396.
219. Abramson DH, Marks RF, Ellsworth RM, et al. The management of unilateral retinoblastoma without primary enucleation. *Arch Ophthalmol*. 1982;100(8):1249-1252.
220. Zelter M, Gonzalez G, Schwartz L, et al. Treatment of retinoblastoma. Results obtained from a prospective study of 51 patients. *Cancer*. 1988;61(1):153-160.
221. Houston SK, Lampidis TJ, Murray TG. Models and discovery strategies for new therapies of retinoblastoma. *Expert Opin Drug Discov*. 2013;8(4):383-394.
222. Sastre X, Chantada GL, Doz F, et al. Proceedings of the consensus meetings from the International Retinoblastoma Staging Working Group on the pathology guidelines for the examination of enucleated eyes and evaluation of prognostic risk factors in retinoblastoma. *Arch Pathol Lab Med*. 2009;133(8):1199-1202.
223. Eagle RC Jr. High-risk features and tumor differentiation in retinoblastoma: a retrospective histopathologic study. *Arch Pathol Lab Med*. 2009;133(8):1203-1209.
224. Khelfaoui F, Validire P, Auperin A, et al. Histopathologic risk factors in retinoblastoma: a retrospective study of 172 patients treated in a single institution. *Cancer*. 1996;77(6):1206-1213.
225. Abramson DH, Ellsworth RM, Zimmerman LE. Nonocular cancer in retinoblastoma survivors. *Trans Sect Ophthalmol Am Acad Ophthalmol Otolaryngol*. 1976;81(3 Pt 1):454-457.
226. Walford N, Deferrai R, Slater RM, et al. Intraorbital rhabdoid tumour following bilateral retinoblastoma. *Histopathology*. 1992;20(2):170-173.
227. Dickman PS, Barmada M, Gollin SM, Blatt J. Malignancy after retinoblastoma: secondary cancer or recurrence? *Hum Pathol*. 1997;28(2):200-205.
228. DerKinderen DJ, Koten JW, Nagelkerke NJ, et al. Non-ocular cancer in patients with hereditary retinoblastoma and their relatives. *Int J Cancer*. 1988;41(4):499-504.
229. Faia LJ, Chan CC. Primary intraocular lymphoma. *Arch Pathol Lab Med*. 2009;133(8):1228-1232.
230. Zaidman GW, Johnson BL, Salamon SM, Mondino BJ. Fuchs' adenoma affecting the peripheral iris. *Arch Ophthalmol*. 1983;101(5):771-773.
231. Korshunov A, Jakobiec FA, Eberhart CG, et al. Comparative integrated molecular analysis of intraocular medulloepitheliomas and central nervous system embryonal tumors with multilayered rosettes confirms that they are distinct nosologic entities. *Neuropathology*. 2015;35(6):538-544.
232. Alenda C, Aranda FI, Paya A, Cordoba C. Mesectodermal leiomyoma of ciliary body. *Int J Surg Pathol*. 2002;10(4):309-312.
233. Yu L, Aldave AJ, Glasgow BJ. Epstein-Barr virus-associated smooth muscle tumor of the iris in a patient with transplant: a case report and review of the literature. *Arch Pathol Lab Med*. 2009;133(8):1238-1241.
234. Gunduz K, Eagle RC Jr, Shields CL, et al. Invasive giant cell astrocytoma of the retina in a patient with tuberous sclerosis. *Ophthalmology*. 1999;106(3):639-642.
235. Poole Perry LJ, Jakobiec FA, Zakka FR, et al. Reactive retinal astrocytic tumors (so-called vasoproliferative tumors): histopathologic, immunohistochemical, and genetic studies of four cases. *Am J Ophthalmol*. 2013;155(3):593-608.e1.
236. Zimmerman LE. Ocular lesions of juvenile xanthogranuloma. Nevoxanthoendothelioma. *Trans Am Acad Ophthalmol Otolaryngol*. 1965;69:412-442.
237. Arepalli S, Kaliki S, Shields CL. Choroidal metastases: origin, features, and therapy. *Indian J Ophthalmol*. 2015;63(2):122-127.
238. d'Abbadie I, Arriagada R, Spielmann M, Le MG. Choroid metastases: clinical features and treatments in 123 patients. *Cancer*. 2003;98(6):1232-1238.